Alan W. Partin · Roger R. Dmochowski
Louis R. Kavoussi · Craig A. Peters

Campbell-Walsh-Wein
UROLOGY

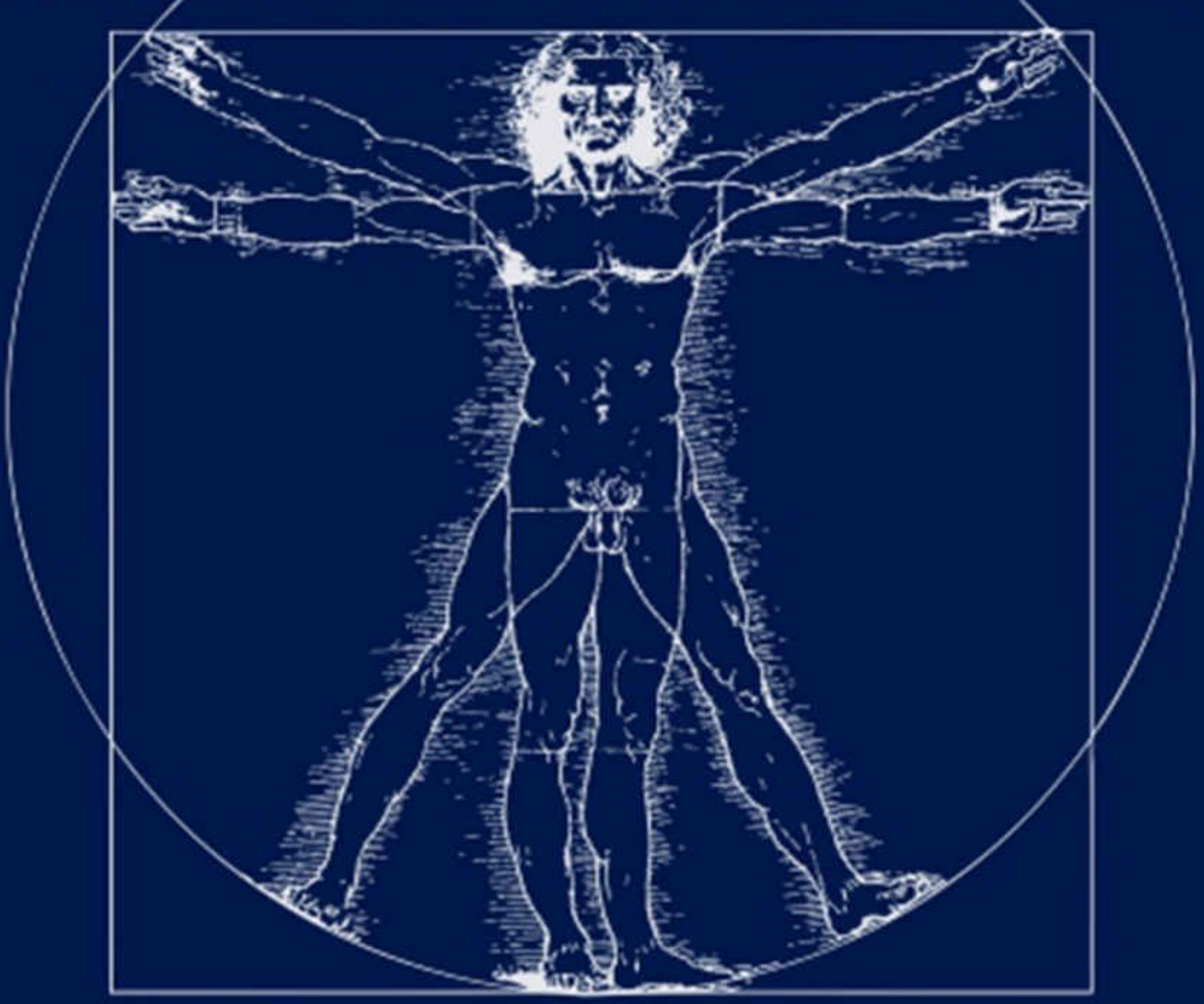

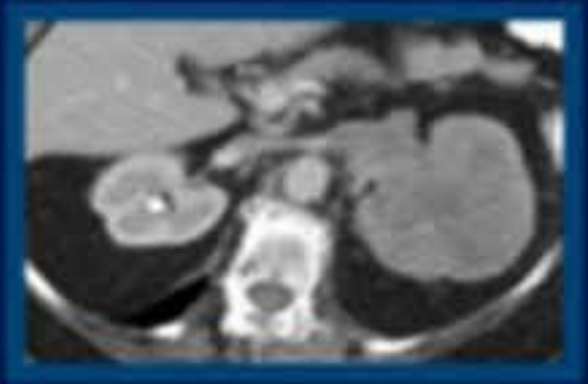

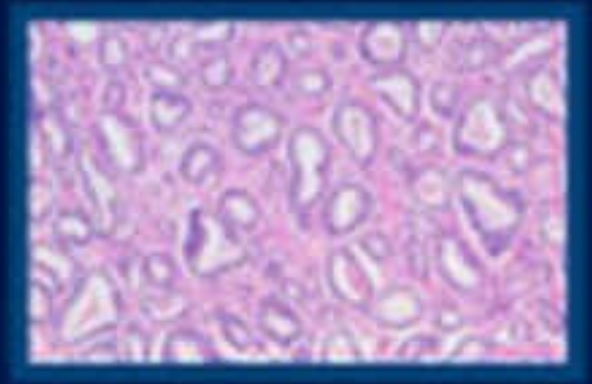

TWELFTH EDITION

ELSEVIER

Campbell-Walsh-Wein Urology

TWELFTH EDITION

Editor-in-Chief

Alan W. Partin, MD, PhD

The Jakurski Family Director, Urologist-in-Chief, Chairman, Department of Urology
Professor, Departments of Urology, Oncology and Pathology, Johns Hopkins Medical Institutions, Baltimore, Maryland
Editors

Roger R. Dmochowski, MD, MMHC, FACS

Professor, Urologic Surgery, Surgery and Gynecology
Program Director, Female Pelvic Medicine and Reconstructive Surgery
Vice Chair for Faculty Affairs and Professionalism, Section of Surgical Sciences
Associate Surgeon-in-Chief, Vanderbilt University Medical Center, Nashville, Tennessee

Louis R. Kavoussi, MD, MBA

Professor and Chair, Department of Urology, Zucker School of Medicine at Hofstra/Northwell, Hempstead, New York;
Chairman of Urology, The Arthur Smith Institute for Urology, Lake Success, New York

Craig A. Peters, MD

Chief, Pediatric Urology, Children's Health System Texas;
Professor of Urology, University of Texas Southwestern, Medical Center, Dallas, Texas

ELSEVIER

Table of Contents

Instructions for online access

Cover image

Title Page

Copyright

Dedication

Preface

Contributors

Video Contents

Volume I

Part I Clinical Decision Making

1 Evaluation of the Urologic Patient

- History
- Physical Examination

Special Populations

Conclusion

References

2 Evaluation of the Urologic Patient

Urinalysis

Chemical Examination of Urine

Summary

References

3 Urinary Tract Imaging

Conventional Radiography

Radiation Management in Uroradiology

Contrast Media

Intravenous Urography

Plain Abdominal Radiography

Retrograde Pyelography

Loopography

Retrograde Urethrography

Static Cystography

Voiding Cystourethrogram

Nuclear Scintigraphy

Computed Tomography

Magnetic Resonance Imaging

Acknowledgments

References

4 Urinary Tract Imaging

Brief History of Ultrasound in Urology

Physical Principles

Modes of Ultrasound

Contrast Agents in Ultrasound

Patient Safety

Clinical Urologic Ultrasound

Practice Accreditation

Suggested Readings

References

5 Urinary Tract Imaging

Principles of Single Photon and PET Imaging

Functional Imaging of the Kidneys

Infection Imaging

Molecular Imaging of Genitourinary Malignancies

- References

6 Assessment of Urologic and Surgical Outcomes

- Establishing a Conceptual Framework for Assessing the Effectiveness of Treatment and Improving Care in Urology
- Long-Term Disease Outcomes That Are Commonly Assessed in Urology
- Commonly Assessed Short-Term Outcomes
- Patient-Reported Outcomes
- Other Outcomes of Interest in Urology
- References

7 Ethics and Informed Consent

- Medical Ethics
- Informed Consent
- References

Part II Basics of Urologic Surgery

8 Principles of Urologic Surgery

- Preoperative Evaluation
- Presurgical Testing
- Preoperative Cardiovascular Evaluation
- Pulmonary Evaluation

Hepatobiliary Evaluation
Special Populations
Preparation for Surgery
Intraoperative Management
Acknowledgments
Suggested Readings
References

9 Principles of Urologic Surgery
Abdominal Incisions
Anterior Approaches to the Kidney and Retroperitoneum
Flank Incisions
Inguinal Incisions
Incisions for Specific Surgeries
Suggested Readings
References

10 Principles of Urologic Surgery
Patient Environment
Blood Products
Drains
Suture Material and Incision Closure

References

11 Lower Urinary Tract Catheterization

History

Anatomic Considerations

Indications for Lower Urinary Tract Drainage

Technique of Urethral Catheterization

Suprapubic Catheterization

Difficult Catheterization

Complications of Lower Urinary Tract Drainage

References

12 Fundamentals of Upper Urinary Tract Drainage

Percutaneous Renal Access and Drainage

Retrograde Renal Access and Drainage

References

13 Principles of Urologic Endoscopy

Introduction

History of Endoscopy

Basic Equipment and Video-Endoscopic Systems

Cystourethroscopy

Upper-Tract Endoscopy

Conclusion

Suggested Readings

References

14 Fundamentals of Laparoscopic and Robotic Urologic Surgery

Preoperative Preparation

Operating Room

Strategic Placement of Operative Team and Equipment

Performing the Procedure

Physiologic Considerations in the Adult

Complications and Troubleshooting in Laparoscopic and Robotic Surgery

Training and Practicing Laparoscopic and Robotic Surgery

Conclusion

Acknowledgment

Suggested Readings

References

15 Basic Energy Modalities in Urologic Surgery

Tissue Dissection and Cauterization

Intracorporeal Lithotripters

- Pneumatic Lithotripsy
- Ultrasonic Lithotripsy
- Holmium:YAG and Erbium:YAG Laser Lithotripsy
- Dual-Modality Lithotripters
- Suggested Readings
- References

16 Evaluation and Management of Hematuria

- Classification and Timing of Hematuria
- Microscopic Hematuria
- Guideline-Based Evaluation of Patients With Microhematuria
- Symptomatic Microscopic Hematuria
- Gross Hematuria
- Hemorrhagic Cystitis
- Hematuria From Prostatic Origin
- Urethral Bleeding
- Hematuria Originating From the Upper Urinary Tract
- Suggested Readings
- References

17 Complications of Urologic Surgery

- Classification of Complications

Physiologic Complications

Positional and Neuromuscular Complications

Urinary Complications

Urine Leaks After Upper Tract Urologic Surgery

Ureteral Injuries

Lower Tract Urinary Complications

Vascular Complications

Bowel Injuries

Conclusion

References

18 Urologic Considerations in Pregnancy

Physiologic Changes During Pregnancy

Physiologic Hydronephrosis of Pregnancy

General Considerations for Imaging of the Pregnant Patient

General Concepts for Surgical Management of the Pregnant Patient

General Concepts of Urologic Medication Administration During Pregnancy

Urolithiasis in Pregnancy

Pregnancy in Women With Congenital Urologic Conditions

Functional and Anatomic Urologic Concerns During Pregnancy

Urologic Malignancy During Pregnancy

Management of Urinary Tract Infections in Pregnancy

Urologic Management of Placental Abnormalities

Acknowledgments

References

19 Intraoperative Consultation

Ethical Considerations

Decision Making

Documentation

Urethral Injury

Bladder Injury

Ureteral Injury

Renal Injury

Placental Cases

References

Part III Pediatric Urology

Section A Development and Prenatal Urology

20 Embryology of the Genitourinary Tract

Development of the External Genitalia

Development of the Female External Genitalia

Development of the Human Prostate

Development of the Human Seminal Vesicle

Development of the Gonads

Müllerian Structures (Female Internal Genitalia)

Development of the Ureter

Kidneys

Acknowledgment

Suggested Readings

References

21 Urologic Aspects of Pediatric Nephrology

Introduction

Renal Function, Fluid, and Electrolyte Homeostasis

Hematuria (Microscopic and Gross)

Proteinuria

Glomerular Disease

Tubulopathies

Cystic Renal Disease

Urolithiasis: Medical Management

Hypertension

Acute Kidney Injury

Chronic Kidney Disease

End-Stage Renal Disease: Dialysis and Renal Transplantation

Summary

Suggested Readings

References

22 Perinatal Urology

Prenatal Imaging

Grading Systems

Prenatal Multidisciplinary Consultations

Urinary Tract Dilation

Postnatal Evaluation and Management

Management Recommendations for Postnatal Urinary Tract Dilation

Key Conditions

Lower Urinary Tract Obstruction (Posterior Urethral Valve, Prune Belly Syndrome, Urethral Stenosis/Atresia)

Kidney Anomalies

Exstrophy (Bladder/Cloacal)

Urogenital Sinus/Congenital Adrenal Hyperplasia

Perinatal Urgencies/Emergencies

References

Section B Basic Principles

23 Urologic Evaluation of the Child

Overview of Pediatric Urology

Imaging

Presentations by Genitourinary Region

Acknowledgments

References

24 Pediatric Urogenital Imaging

Technique

sonography

Magnetic Resonance Imaging

Conventional Radiography

Voiding Cystourethrography/Micturating Cystourethrogram

Computed Tomography

DMSA Renal Cortical Scintigraphy

Diuretic Renal Scintigraphy

Radionuclide Cystography

Radionuclide Testicular Scanning

Suggested Readings

References

25 Infection and Inflammation of the Pediatric Genitourinary Tract

Evaluation and Management of a Child With a Fever

Classification of Pediatric Urinary Tract Infections

Diagnosis of Pediatric Urinary Tract Infection

Management of Pediatric Urinary Tract Infection

Management After Urinary Tract Infection

Sequelae of Pediatric Urinary Tract Infections

Uncommon Pediatric Urinary Tract Infections

Suggested Readings

References

26 Core Principles of Perioperative Management in Children

Pediatric Anesthesia

Preoperative Assessment and Preparation for Surgery

Comorbidities: Perioperative Planning and Postoperative Considerations

ERAS Protocols

Laparoscopic Procedures

Opioid Use in Children

- References

27 Principles of Laparoscopic and Robotic Surgery in Children

- Advantages and Disadvantages of Minimally Invasive Surgery
- Physiology of the Pneumoperitoneum
- Patient Selection for Mimimally Invasive Surgery
- Access
- Approach
- Equipment and Instrumentation
- Complications of Minimally Invasive Surgery
- Simulation Training and Evaluation
- Conclusion
- Suggested Readings
- References

Section C Lower Urinary Tract Conditions

---

28 Clinical and Urodynamic Evaluation of Lower Urinary Tract Dysfunction in Children

- Clinical Evaluation
- Laboratory Testing
- Urodynamic Evaluation

Evaluation Strategies for Specific Clinical Entities

Acknowledgments

Suggested Readings

References

29 Management Strategies for Vesicoureteral Reflux

Historical Perspective

Demographics

Inheritance and Genetics

Embryology of the Ureterovesical Junction

Functional Anatomy of the Antireflux Mechanism

Causes of Vesicoureteral Reflux

Urinary Tract Infection and Reflux

Grading of Reflux

Cortical Defects

Diagnosis and Evaluation of Vesicoureteral Reflux

Assessment of the Lower Urinary Tract

Assessment of the Upper Urinary Tract

Controversies in Usage of Invasive Investigations

Associated Anomalies and Conditions

Natural History and Management

References

30 Bladder Anomalies in Children

Congenital Bladder Anomalies

Acquired Bladder Anomalies in Children

Acknowledgments

References

31 Exstrophy-Epispadias Complex

Historical Aspects

Incidence and Inheritance

Embryology

Classic Bladder Exstrophy

Surgical Reconstruction of Bladder Exstrophy

Modern Initial Repair of Bladder Exstrophy: Outcomes and Results

Other Modern Exstrophy Repairs: Continence Outcomes

Exstrophy Reconstruction Failures and Complications

Transitional Exstrophy Patient: Adolescent and Adult Concerns

Continence

Male Concerns

Female Concerns

Quality of Life

- Long-Term Adjustment Issues
- Epispadias
- Cloacal Exstrophy
- Surgical Reconstruction of Cloacal Exstrophy
- Long-Term Issues in Cloacal Exstrophy
- Summary
- Dedication
- Acknowledgment
- Suggested Readings
- References

32 Prune-Belly Syndrome

- Genetics
- Embryology
- Clinical Features of Prune-Belly Syndrome
- Presentation
- Evaluation and Management
- Long-Term Outlook
- Suggested Readings
- References

33 Posterior Urethral Valves

Background

Epidemiology

Pathophysiology of Posterior Urethral Valves

Diagnosis

Clinical Presentation and Initial Management

Surgical Intervention

Management of Vesicoureteral Reflux

Bladder Dysfunction and Valve Bladder Syndrome

Prognostic Indicators for Renal Function

Transplantation in Valve Patients

Quality of Life With Posterior Urethral Valves

Anterior Urethral Valves

Urethral Atresia

Urethral Duplication

Urethrorrhagia

Urinary Fistula in Boys With Anorectal Malformation

Suggested Readings

References

34 Neuromuscular Dysfunction of the Lower Urinary Tract in Children

Neural Tube Defects

Management of Neuromuscular Dysfunction of the Lower Urinary Tract

Management of Vesicoureteral Reflux in Neuropathic Dysfunction of the Lower Urinary Tract

Lipomeningocele and Other Spinal Dysraphisms

Sacral Agenesis

Conditions of the Pelvis

Central Nervous System Insults

Conditions of the Brain (Tumors/Infarcts/Encephalopathies)

Conditions of the Spinal Cord

Suggested Readings

References

35 Functional Disorders of the Lower Urinary Tract in Children

Clinical Significance

Epidemiology

Self-Esteem and Quality-of-Life Issues

Comorbidities

Terminology

Daytime Urinary Incontinence and Bladder Dysfunction

Enuresis

Suggested Readings

References

36 Management of Defecation Disorders

Epidemiology and Classification of Disorders of Defecation

Management

Suggested Readings

References

37 Lower Urinary Tract Reconstruction in Children

“Functional” Urinary Tract

Patient Evaluation

Patient Preparation

Antireflux

Bladder Neck Reconstruction

Bladder Reconstruction

Augmentation Cystoplasty

Continent Urinary Diversion

Summary

Suggested Readings

References

Section D Upper Urinary Tract Conditions

38 Anomalies of the Upper Urinary Tract
  - Anomalies of Renal Number
  - Anomalies of Renal Ascent
  - Anomalies of Renal Form and Fusion
  - Anomalies of Renal Rotation
  - Anomalies of Renal Vasculature
  - Renal Artery Aneurysm
  - Anomalies of the Renal Collecting System
  - Acknowledgments
  - References

39 Renal Dysgenesis and Cystic Disease of the Kidney
  - Overview of Genetics
  - Renal Agenesis and Dysplasia
  - Hypoplasia and Hypodysplasia
  - Cystic Diseases of the Kidney
  - Autosomal Recessive (Infantile) Polycystic Kidney Disease
  - Autosomal Dominant (Adult) Polycystic Kidney Disease
  - Juvenile Nephronophthisis and Medullary Cystic Disease Complex

Other Inheritable Renal Cystic Diseases (Congenital Nephrosis)

Familial Hypoplastic Glomerulocystic Kidney Disease (Cortical Microcystic Disease)

Multiple Malformation Syndromes With Renal Cysts

Multicystic Dysplastic Kidney

Benign Multilocular Cyst (Cystic Nephroma)

Simple Cysts

Medullary Sponge Kidney

Sporadic Glomerulocystic Kidney Disease

Acquired Renal Cystic Disease

Calyceal Diverticulum (Pyelogenic Cyst)

Parapelvic and Renal Sinus Cysts

Acknowledgment

Suggested Readings

References

40 Pathophysiology of Urinary Tract Obstruction

Prevalence

Clinical Presentation of Obstruction

Progressive Renal Dysfunction

Definition of Obstruction

- Diagnosis and Imaging
- Pathological Changes of Obstruction
- Tubulointerstitial Fibrosis
- Hemodyamic Changes With Obstruction
- Effects of Obstruction on Tubular Function
- Egress of Urine From the Obstructed Kidney
- Clinical Impact of Renal Obstruction
- Treatment of Renal Obstruction
- Suggested Readings
- References

41 Ectopic Ureter, Ureterocele, and Ureteral Anomalies

- Classification and Anatomic Description
- Clinical Presentation
- Evaluation
- Clinical Management
- Other Ureteral Anomalies
- Suggested Readings
- References

42 Surgery of the Ureter in Children

- Ureteropelvic Junction Obstruction

Vesicoureteric Reflux

Endoscopic Treatment of Vesicoureteral Reflux

Megaureter

Suggested Readings

References

43 Management of Pediatric Kidney Stone Disease

Extrarenal Manifestations

Management of Children and Adolescents With Kidney and Ureteral Stones

Shock Wave Lithotripsy

Percutaneous Nephrolithotomy

Laparoscopic and Robotic-Assisted Pyelolithotomy

References

Section E Genitalia

---

44 Management of Abnormalities of the External Genitalia in Boys

Normal Male External Genitalia

Penile Anomalies

Scrotal Anomalies

Vascular Lesions of the Genitalia

Hernia and Hydroceles

Acute Scrotum

Varicocele

Epididymal and Vasal Anomalies

Suggested Readings

References

45 Hypospadias

Embryology

Diagnosis of Hypospadias

Etiology of Hypospadias

Surgical Assessment

Advancement Procedures

Tubularization Techniques

Hypospadias Outcomes

Future

Suggested Readings

References

46 Etiology, Diagnosis, and Management of the Undescended Testis

Introduction

Definitions

- Etiology
- Diagnosis
- General Guidelines for Management
- Medical Management
- Surgical Management
- Prognosis
- Suggested Readings
- References

47 Management of Abnormalities of the Genitalia in Girls

- Female Genital Embryology
- Evaluation and Classification of Female Genital Anomalies
- Congenital Disorders of Female External Genitalia
- Acquired Disorders of the Female External Genitalia
- Suggested Readings
- References

48 Disorders of Sexual Development

- Normal Sexual Development
- Abnormal Sexual Development
- Evaluation and Management of the Newborn With Ambiguous Genitalia

Suggested Readings

References

Section F Reconstruction and Trauma

49 Surgical Management of Differences of Sexual Differentiation and Cloacal and Anorectal Malformations

Classification of Urogenital Sinus and Cloacal Anomalies

Surgical Reconstruction of Disorders of Sex Development and Urogenital Sinus

Surgical Reconstruction for Cloacal Malformations

Summary

Suggested Readings

References

50 Adolescent and Transitional Urology

Definitions

Patient Population

Setting Up a Service

Barriers to Transition

Clinical Delivery

Patient/Parent Preparation for Transition

Clinical Practice: Major Diagnoses

Male

Females Born With Exstrophy

Spina Bifida: the Neuropathic Bladder

Posterior Urethral Valves

Summary

Suggested Readings

References

51 Urologic Considerations in Pediatric Renal Transplantation

Pretransplant Assessment

Pretransplant Preparation

Transplantation

Complications

Summary

Suggested Readings

References

52 Pediatric Genitourinary Trauma

Renal Injuries

Indications for Renal Imaging

Imaging Studies for Diagnosis

Classification and Grading of Renal Injuries

Persistent or Delayed Bleeding

Operative

Ureteral Trauma

Bladder Injuries

Genital Injury in the Pediatric Population

References

Section G Oncology

53 Pediatric Urologic Oncology

Neuroblastoma

Wilms Tumor

References

54 Pediatric Urologic Oncology

Epidemiology and Syndromic Associations

Pathology and Molecular Biology

Presentation, Initial Evaluation and Management, Staging

Other Bladder Tumors

Female Genital Tract

Testicular Tumors

Paratesticular Rhabdomyosarcoma

Perineal Rhabdomyosarcoma

Suggested Readings

References

Volume II
Part IV Infections and Inflammation

55 Infections of the Urinary Tract

Definitions

Incidence and Epidemiology

Pathogenesis

Evaluation

Localization

Imaging

Microbiome

Asymptomatic Bacteriuria

Principles of Antimicrobial Therapy

Bladder Infections

Kidney Infections

Other Infections

Bacteremia, Sepsis, and Septic Shock

Bacteriuria and Urinary Tract Infections in the Elderly

Catheter-Associated Urinary Tract Infection

Management of Urinary Tract Infections in Patients With Spinal Cord Injury

Kidney Transplant Recipients

Antimicrobial Prophylaxis for Common Urologic Procedures

Acknowledgments

References

56 Inflammatory and Pain Conditions of the Male Genitourinary Tract

Prostatitis

Acute and Chronic Orchitis and Orchialgia

References

57 Interstitial Cystitis/Bladder Pain Syndrome and Related Disorders

A Brief History and Overview

Definition, Nomenclature, and Taxonomy

Historical Perspective of Interstitial Cystitis/Bladder Pain Syndrome: Early 1800S to 1970S

Voiding Symptoms and Interstitial Cystitis/Bladder Pain Syndrome

Epidemiology of Interstitial Cystitis/Bladder Pain Syndrome

The Epidemiology of Hunner Lesions

Etiology

Pathology

Beyond the History, Physical Examination, and Urine Studies

Treatment of Interstitial Cystitis/Bladder Pain Syndrome

Final Thoughts

Suggested Readings

References

58 Sexually Transmitted Diseases*

Epidemiology of Sexually Transmitted Diseases

Urethritis

Epididymitis

Genital, Anal, and Perianal Ulcers

Anogenital Warts

Zika Virus

Human Immunodeficiency Virus (HIV) and Acquired Immunodeficiency Syndrome (AIDS)

Viral Hepatitis

Ectoparasitic Infections

Vaginitis

- References

59 Cutaneous Diseases of the External Genitalia

- Introduction to Basic Dermatology
- Dermatologic Therapy
- Allergic Dermatitis
- Papulosquamous Disorders
- Vesicobullous Disorders
- Noninfectious Ulcers
- Infections and Infestations
- Neoplastic Conditions
- Benign Cutaneous Disorders Specific to the Male Genitalia
- Common Miscellaneous Cutaneous Disorders
- Suggested Readings
- References

60 Tuberculosis and Parasitic Infections of the Genitourinary Tract

- Genitourinary Tuberculosis
- Parasitic Infections of the Urogenital Tract
- Suggested Readings
- References

Part V Molecular and Cellular Biology

61 Basic Principles of Immunology and Immunotherapy in Urologic Oncology

- Innate Immune System
- Adaptive Immune System
- Immune Editing Hypothesis
- Chronic Inflammation and the Endogenous Immune Response to Genitourinary Cancers
- Chronic Inflammation and the Immune Response to Bladder Cancer
- Immune Microenvironment in Kidney Cancer
- Chronic Inflammation and the Immune Response to Prostate Cancer
- Immunotherapy for Genitourinary Cancers
- Conclusions
- Suggested Readings
- References

62 Molecular Genetics and Cancer Biology

- Tumor Suppressor Genes and Oncogenes
- Cell Cycle Deregulation
- DNA Methylation
- DNA Damage and Repair
- Genomic Alterations

Telomeres and Telomerase

Apoptosis

Stem Cells and Cancer

Checkpoint Inhibition

Microbiome and Cancer: the Metagenome

Suggested Readings

References

Part VI Reproductive and Sexual Function

63 Surgical, Radiographic, and Endoscopic Anatomy of the Male Reproductive System

Testis

Epididymis

Vas Deferens

Seminal Vesicles and Ejaculatory Ducts

Prostate

Urethra

Penis

Scrotum

Suggested Readings

References

64 Male Reproductive Physiology

- Hypothalamic-Pituitary-Gonadal Axis
- Epididymis
- Ductus (Vas) Deferens
- Seminal Vesicle and Ejaculatory Ducts
- Spermatozoa
- Summary
- Suggested Readings
- References

65 Integrated Men's Health

- Rationale for Integrative Men's Health
- Metabolic Syndrome and Men's Health
- Testosterone Therapy and Cardiovascular Risk: Advances and Controversies
- Association Between Cardiovascular Disease and Erectile Dysfunction
- Mental Health and Opioid Abuse in Men
- Building an Integrative Men's Health Center
- References

66 Male Infertility

Epidemiology

History

Physical Examination

Laboratory Evaluation of Male Infertility

Imaging in the Evaluation of Male Infertility

Testis Histopathology

Assisted Reproduction

Fertility Preservation in Cancer

Suggested Readings

References

67 Surgical Management of Male Infertility

Surgical Anatomy

Testis Biopsy

Vasography

Vasovasostomy

Surgery of the Epididymis

Transurethral Resection of the Ejaculatory Ducts

Electroejaculation

Sperm Retrieval Techniques

Varicocelectomy

Orchiopexy in Adults

Acknowledgments

References

68 Physiology of Penile Erection and Pathophysiology of Erectile Dysfunction

Physiology of Penile Erection

Pathophysiology of Erectile Dysfunction

Perspectives

Suggested Readings

References

69 Evaluation and Management of Erectile Dysfunction

Historical Perspective

Public Health Significance

Management Principles

Diagnostic Evaluation

Specialized Evaluation and Testing

Treatment Considerations

Future Directions

Acknowledgment

References

70 Priapism

- Defining Priapism
- Priapism: Historical Perspectives
- Epidemiology of Priapism
- Molecular Basis of Ischemic and Stuttering Priapism
- Evaluation and Diagnosis of Priapism
- Medical Treatments
- Surgical Management of Ischemic Priapism
- Interventional Angiography in the Management of Arterial (Nonischemic, High-Flow) Priapism
- Surgical Management of Arterial (Nonischemic, High-Flow) Priapism
- Summary
- Suggested Readings
- References

71 Disorders of Male Orgasm and Ejaculation

- Anatomy and Physiology of the Ejaculatory Response
- Premature Ejaculation
- Kate! Delayed Ejaculation, Anejaculation, and Anorgasmia
- Retrograde Ejaculation
- Sperm Retrieval in Men With Anejaculation Pursuing Fertility

Ejaculatory Anhedonia

Post-SSRI Sexual Dysfunction

Orgasmic Headache

Painful Ejaculation

Postorgasmic Illness Syndrome

Conclusion

Suggested Readings

References

72 Surgery for Erectile Dysfunction

Types of Implants Available

Informed Consent

Preoperative Preparation

Incisions

Technique of Device Placement

Intraoperative Troubleshooting

Postoperative Complications

Special Situations

Postoperative Care

Patient and Partner Satisfaction

Suggested Readings

References

73 Diagnosis and Management of Peyronie's Disease

General Considerations

Natural History

Epidemiology

Penile Anatomy and Peyronie's Disease

Etiology of Peyronie's Disease

Symptoms

Evaluation of the Patient

Treatment Protocols

Nonsurgical Treatment of Peyronie's Disease

Surgical Management

Conclusion

Suggested Readings

References

74 Sexual Function and Dysfunction in the Female

Anatomy and Physiology of Female Sexual Organs

Evaluation of Sexual Wellness

Special Populations

Female Sexual Interest Disorder

Female Sexual Arousal Disorder

Pharmacotherapy for Female Sexual Arousal Disorder

Genitopelvic Pain and Penetration Disorder

Lower Urinary Tract Dysfunction and Female Sexual Dysfunction

Lower Urinary Tract Symptoms and Female Sexual Dysfunction: Links and Treatments

Self-Image/Body Image Connected to Female Sexual Dysfunction and Lower Urinary Tract Symptoms

Conclusion

References

Part VII Male Genitalia

75 Surgical, Radiographic, and Endoscopic Anatomy of the Retroperitoneum

Body Surface Landmarks

Posterior Abdominal Wall

Lumbodorsal Fascia

Retroperitoneal Fasciae and Spaces

Gastrointestinal Viscera and Mesentery

Vasculature

Lymphatic System

Nervous Structures

Suggested Readings

References

76 Neoplasms of the Testis

Germ Cell Tumors

Non–Germ Cell Tumors

Tumors of the Testicular Adnexa

Suggested Readings

References

77 Surgery of Testicular Tumors

Management of Testis Mass

Retroperitoneal Lymph Node Dissection

Auxiliary Procedures

Surgical Decision Making

Histologic Findings at Post-Chemotherapy Retroperitoneal Lymph Node Dissection and Survival Outcomes

Post-Chemotherapy Retroperitoneal Lymph Node Dissection in High-Risk Populations

Surgical Outcomes, Functional Considerations, and Complications of Retroperitoneal Lymph Node Dissection

Retroperitoneal Lymph Node Dissection in Unique Situations

Conclusion

References

78 Laparoscopic and Robotic-Assisted Retroperitoneal Lymphadenectomy for Testicular Tumors

Rationale and Evolution

Staging Laparoscopic Retroperitoneal Lymph Node Dissection and Controversy

Duplication of Open Retroperitoneal Lymph Node Dissection

Development of Robotic-Assisted Retroperitoneal Lymph Node Dissection

Surgical Technique

Postoperative Care

Prospective Nerve-Sparing Techniques

Complications

Results and Current Status

Summary

Suggested Readings

References

79 Tumors of the Penis

Premalignant Cutaneous Lesions

Squamous Cell Carcinoma

Surgical Management of the Primary Tumor

Treatment of the Inguinal Nodes
Radiation Therapy
Chemotherapy
Nonsquamous Penile Malignant Neoplasms
References

80 Tumors of the Urethra
Benign Urethral Tumors
Male Urethral Cancer
Female Urethral Cancer
Urethral Recurrence After Radical Cystectomy
Acknowledgments
References

81 Inguinal Node Dissection
Introduction
Anatomic Background
Inguinal Anatomy
Endoscopic Anatomy of Inguinal Area
Imaging Evaluation of Inguinal Area
Penile Cancer: Surgical Management of Regional Lymph Nodes
Penile Cancer: Nonpalpable Inguinal Adenopathy

  - Penile Cancer: Palpable Inguinal Adenopathy or Positive Inguinal Lymph Nodes
  - Preparation of the Patient Before Surgery
  - Postoperative Care of Patients After Inguinal Lymphadenectomy
  - Complications of Inguinal Lymphadenectomy
  - Oncologic Results and Follow-Up After Surgery
  - References

- 82 Surgery for Benign Disorders of the Penis and Urethra
  - Generalities of Reconstructive Surgical Techniques
  - Principles of Reconstructive Surgery
  - Surgical Anatomy of the Penis and Male Perineum
  - Selected Processes
  - Urethral Stricture Disease
  - Pelvic Fracture Urethral Injuries
  - Vesicourethral Distraction Defects (Vesicourethral Stenosis)
  - Complex Fistula of the Posterior Urethra
  - Curvatures of the Penis
  - Penile Transplantation
  - Suggested Readings
  - References

83 Surgery of the Scrotum and Seminal Vesicles

- Surgical Anatomy of the Scrotum
- Preoperative Considerations
- Surgeries of the Scrotum
- Epididymis
- Vas Deferens
- Surgical Management of Chronic Scrotal Pain
- Complications of Scrotal Surgery
- Anatomy and Embryology of Seminal Vesicles
- Surgical Approaches to Seminal Vesicles
- Surgeries of the Seminal Vesicles
- Complications of Seminal Vesicle Surgery
- Suggested Readings
- References

Part VIII Renal Physiology and Pathophysiology

84 Surgical, Radiologic, and Endoscopic Anatomy of the Kidney and Ureter

- Kidneys
- Pelvicalyceal System
- Ureters
- Suggested Readings

- References

85 Physiology and Pharmacology of the Renal Pelvis and Ureter

- Cellular Anatomy
- Development of the Ureter
- Electric Activity
- Contractile Activity
- Role of the Nervous System in Ureteral Function
- Mechanical Properties
- Urine Transport
- Pathologic Processes Affecting Ureteral Function
- Effect of Pregnancy on Ureteral Function
- Effect of Drugs on the Ureter
- Cardiac Glycosides
- Suggested Readings
- References

86 Renal Physiology and Pathophysiology Including Renovascular Hypertension

- Glomerular Filtration
- Pathophysiology and Management of Renovascular Hypertension
- Suggested Readings
- References

87 Renal Insufficiency and Ischemic Nephropathy

- Acute Kidney Injury
- Chronic Kidney Disease
- Suggested Readings
- References

88 Urologic Complications of Renal Transplantation

- Hematuria
- Ureteral Stent Management
- Urinary Leak
- Ureteral Stricture
- Vesicoureteral Reflux
- Lymphocele
- Nephrolithiasis
- Lower Urinary Tract Complications
- Genitourinary Malignancies
- Conclusion
- Suggested Readings
- References

Part IX Upper Urinary Tract Obstruction and Trauma

89 Management of Upper Urinary Tract Obstruction

Evaluation of Upper Tract Obstruction

Ureteropelvic Junction Obstruction

Retrocaval Ureter

Ureteral Stricture Disease

Ureteroenteric Anastomotic Stricture

Retroperitoneal Fibrosis

Suggested Readings

References

90 Upper Urinary Tract Trauma

Renal Injuries

Ureteral Injuries

Suggested Readings

References

Part X Urinary Lithiasis and Endourology

91 Urinary Lithiasis

Epidemiology of Renal Calculi

Physicochemistry and Pathogenesis

Mineral Metabolism

Pathophysiology of Upper Urinary Tract Calculi

Suggested Readings

References

92 Evaluation and Medical Management of Urinary Lithiasis

Evaluation of Urinary Lithiasis

Epidemiology and Morbidity From Urinary Lithiasis

Imaging for Urinary Lithiasis

Metabolic Evaluation

Stone Analysis

Classification of Nephrolithiasis

Calcium-Based Calculi

Hypercalciuria (>200 mg/day)

Hypocitraturia (<550 mg/day Female, <450 mg/day Male)

Hyperoxaluria (>40 mg/day)

Cystinuria

References

93 Strategies for Nonmedical Management of Upper Urinary Tract Calculi

Kidney Calculi

Ureteral Calculi

Rise of Endourology

Renal Calculi

Ureteral Calculi

Suggested Readings

References

94 Surgical Management for Upper Urinary Tract Calculi

Extracorporeal Shock Wave Lithotripsy

Percutaneous Nephrolithotomy

Ureteroscopic Stone Management

Intracorporeal Lithotripsy

Laparoscopic and Robotic Stone Removal

References

95 Lower Urinary Tract Calculi

History

Etiopathogenesis of Bladder Calculi

Presentation of Bladder Stones

Management of Bladder Stones

Lower Tract Calculi in Special Situations

Urethral Calculi

Suggested Readings

References

Part XI Neoplasms of the Upper Urinary Tract

96 Benign Renal Tumors

Diagnosis

Renal Cysts

Oncocytoma

Angiomyolipoma

Papillary Adenoma of the Kidney

Metanephric Adenoma

Mixed Mesenchymal and Epithelial Tumors

Mixed Epithelial and Stromal Tumors

Leiomyoma

Other Benign Renal Tumors

Suggested Readings

References

97 Malignant Renal Tumors

Historical Considerations

Classification

Radiographic Evaluation of Renal Masses

  - Renal Cell Carcinoma
  - Treatment of Localized Renal Cell Carcinoma
  - Treatment of Locally Advanced Renal Cell Carcinoma
  - Other Malignant Renal Tumors
  - Suggested Readings
  - References

- 98 Urothelial Tumors of the Upper Urinary Tract and Ureter
  - Epidemiology
  - Risk Factors
  - Histopathology
  - Diagnosis
  - Staging and Classification
  - Prognosis
  - References

- 99 Surgical Management of Upper Urinary Tract Urothelial Tumors
  - Diagnosis
  - Treatment Algorithm
  - Surgical Management
  - Endourologic Management
  - Follow-Up

References

100 Retroperitoneal Tumors

Overview

Anatomic Considerations of the Retroperitoneum

Initial Evaluation of the Retroperitoneal Mass

Differential Diagnosis

Surgical Management of the Retroperitoneal Tumor

Disease-Specific Neoadjuvant and Adjuvant Therapies

Conclusions

References

101 Open Surgery of the Kidney

Historical Perspective

Preoperative Evaluation and Preparation

Surgical Approaches

Surgery for Benign Diseases

Surgery for Malignancy

Suggested Readings

References

102 Laparoscopic and Robotic Surgery of the Kidney

Patient Evaluation and Preparation

Surgical Approaches and Obtaining Access

Simple Nephrectomy

Surgery for Renal Cystic Disease

Renal Biopsy for Medical Renal Disease

Nephropexy

Calyceal Diverticulectomy

Nephrolysis

Radical Nephrectomy

Partial Nephrectomy

Laparoscopic Ablative Techniques

Laparoendoscopic Single-Site Surgery of the Kidney

Complications ff Laparoscopic Renal Surgery

Minimally Invasive Renal Surgery in Urologic Practice

Summary

Suggested Readings

References

103 Nonsurgical Focal Therapy for Renal Tumors

Cryoablation

Radiofrequency Ablation

Surgical Technique
Treatment Success and Follow-Up Protocol After Tumor Ablation
Oncologic Outcomes
Complications
New Ablation Modalities
Conclusion
Suggested Readings
References

104 Treatment of Advanced Renal Cell Carcinoma

Prognostic Factors
Surgical Management of Metastatic Renal Cell Carcinoma
Immunologic Approaches in the Management of Advanced Clear Cell Renal Cell Carcinoma
Molecular Basis for Targeted Approaches in Clear Cell Renal Cell Carcinoma
Targeted Molecular Agents in Clear Cell Renal Cell Carcinoma
Immune “Checkpoint” Inhibitor–Based Combination Strategies
Other Treatment Options in Patients With Clear Cell Renal Cell Carcinoma
Systemic Therapy for Non–Clear Cell Variants of Renal Cell Carcinoma
Suggested Readings

References

Volume III
Part XII The Adrenals

105 Surgical and Radiographic Anatomy of the Adrenals

- Anatomic Relationships
- Surgical Landmarks
- Adrenal Vasculature
- Adrenal Nerves
- Embryology
- Histology
- Radiology
- Conclusion
- Suggested Readings
- References

106 Pathophysiology, Evaluation, and Medical Management of Adrenal Disorders

- Historical Background
- Adrenal Anatomy and Embryology
- Adrenal Physiology
- Adrenal Disorders

Evaluation of Adrenal Lesions in Urologic Practice

Conclusions

Suggested Readings

References

107 Surgery of the Adrenal Glands

Evolution of Adrenal Surgery

Surgical Anatomy

Clinical Indications for Adrenalectomy

Indications and Contraindications for Laparoscopic Adrenalectomy

Preoperative and Perioperative Management

Open Adrenalectomy

Laparoscopic Adrenalectomy

Robot-Assisted Adrenalectomy

Robot-Assisted Posterior Retroperitoneal Adrenalectomy

Hand-Assisted Surgery

Laparoendoscopic Single-Site Adrenalectomy

Natural Orifice Transluminal Endoscopic Surgery–Assisted Laparoscopic Adrenalectomy

Partial Adrenalectomy

Outcomes

Complications

Ablative Therapy for Adrenal Tumors

Future of Adrenal Surgery

Suggested Readings

References

Part XIII Urine Transport, Storage, and Emptying

108 Surgical, Radiographic, and Endoscopic Anatomy of the Female Pelvis

Surgical Anatomy of the Female Pelvis

Radiographic Anatomy of the Female Pelvis

References

109 Surgical, Radiographic, and Endoscopic Anatomy of the Male Pelvis

Bony Pelvis

Lower Abdominal Wall

Soft Tissues of the Pelvis

Perineum

Pelvic Circulation

Pelvic Viscera

Endoscopic Anatomy

Radiographic Anatomy

References

110 Physiology and Pharmacology of the Bladder and Urethra

Lower Urinary Tract Anatomy

Bladder Compartments

Overview of the Urethra

Urothelial Physiology

Smooth Muscle Physiology

Bladder Mechanics

Neural Control of the Lower Urinary Tract

Pharmacology

Clinical Relevance

Future Research

References

111 Pathophysiology and Classification of Lower Urinary Tract Dysfunction

Normal Lower Urinary Tract Function: Overview

Micturition Cycle: Simplification and Overview

Abnormalities of Filling/Storage and Emptying/Voiding: Overview of Pathophysiology

Classification Systems

Suggested Readings

References

112 Evaluation and Management of Women With Urinary Incontinence and Pelvic Prolapse

Definition and Impact of Pelvic Floor Disorders

Diagnostic Evaluation

Physical Examination

Supplemental Evaluation

Management

Conclusion

Suggested Readings

References

113 Evaluation and Management of Men With Urinary Incontinence

Types of Urinary Incontinence

Evaluation

Principal Methods of Treating Men With Urinary Incontinence

Management of Different Urinary Incontinence Types in Men

Conclusion

Suggested Readings

References

114 Urodynamic and Video-Urodynamic Evaluation of the Lower Urinary Tract

Role of Urodynamics in Clinical Practice

Conducting a Urodynamic Study: Patient and Technical Factors

Components of the Urodynamic Study

Urodynamic Equipment

The Urodynamic Study: Analysis and Interpetation

Videourodynamics

Ambulatory Urodynamics

Clinical Applications of Urodynamic Studies: Evidence-Based Review and Guidelines Pertaining to Urodynamics

Future Directions

References

115 Urinary Incontinence and Pelvic Prolapse

Definition and Classification of Urinary Incontinence

Terminology of Lower Urinary Tract Symptoms and Incontinence

Epidemiology of Urinary Incontinence in Women

Risk Factors for Urinary Incontinence in Women

Epidemiology of Urinary Incontinence in Men

Definitions and Classification of Pelvic Organ Prolapse

Epidemiology of Pelvic Organ Prolapse

Relationship Between Urinary Incontinence and Pelvic Organ

Prolapse

Consequences of Urinary Incontinence and Prolapse

Physiology of Urinary Continence

Pathophysiology of Urinary Incontinence: General Principles

Pathophysiology of Stress Urinary Incontinence in Women

Pathophysiology of Insensible Incontinence

Pelvic Floor Support Mechanism

Pathophysiology of Pelvic Organ Prolapse

Suggested Readings

References

116 Neuromuscular Dysfunction of the Lower Urinary Tract

Objectives

Patterns of Neuropathic Voiding Dysfunction

Diseases at or Above the Brainstem

Diseases Primarily Involving the Spinal Cord

Disease Distal to the Spinal Cord

Miscellaneous Neurologic Diseases Causing Lower Urinary Tract Dysfunction

Miscellaneous Conditions Definitely, Probably, or Possibly Related to Neuromuscular Dysfunction

Treatment of Neurogenic Lower Urinary Tract Dysfunction: Overview

Suggested Readings

References

117 Overactive Bladder

Terminology and Definitions

Epidemiology and Economics

Pathophysiology and Etiology

Clinical Assessment

Management

Suggested Readings

References

118 The Underactive Detrusor

Terminology, Definitions, and Symptoms

Epidemiology

Etiopathogenesis

Diagnosis

Management

Regenerative Medicine

Conclusions

Suggested Readings

References

119 Nocturia

Rationale for Evaluation and Management

Evaluation

Cause and Management

Suggested Readings

References

120 Pharmacologic Management of Lower Urinary Tract Storage and Emptying Failure

Introduction

Pharmacologic Therapy to Facilitate Bladder Filling and Urine Storage

Pharmacologic Therapy to Facilitate Bladder Emptying

Suggested Readings

References

121 Conservative Management of Urinary Incontinence

Indications

Assessment Before Behavioral Treatments

Patient Education

Pelvic Floor Muscle Training

Behavioral Training With Urge Suppression

Role of Biofeedback

Pelvic Floor Muscle Electrical Stimulation

Bladder Training and Scheduled Voiding Regimens

Behavioral Treatment for Voiding and Pelvic Floor Dysfunction

Prevention of Urinary Incontinence

Vaginal and Urethral Mechanical Devices for Incontinence

Models of Delivery

Suggested Readings

References

122 Electrical Stimulation and Neuromodulation in Storage and Emptying Failure

History of Electrical Stimulation

Neurophysiology Relevant to Electrical Stimulation for Storage and Voiding Disorders

Sacral Anterior Root Stimulation and Sacral Dorsal Rhizotomy

Goal and Effect of Dorsal Rhizotomy of the Sacral Nerves

Current and Future Perspectives for Neurostimulation

Working Mechanism of Electrical Stimulation in Non-Neurogenic Storage and Voiding Disorders

Techniques of Electrostimulation of the Lower Urinary Tract

Constant Versus Intermittent Stimulation

Rechargeable Neurostimulator
Other Issues
Suggested Readings
References

123 Retropubic Suspension Surgery for Incontinence in Women

Therapeutic Options
Choice of Surgical Technique
Assessing Outcomes of Therapy
Indications for Retropubic Repair
General Technical Issues
Marshall-Marchetti-Krantz Procedure
Burch Colposuspension
Paravaginal Repair
Vagino-Obturator Shelf Repair
Laparoscopic Retropubic Suspension
Complications of Retropubic Repairs
Comparisons of Incontinence Procedures
World Without Mesh
Suggested Readings
References

124 Vaginal and Abdominal Reconstructive Surgery for Pelvic Organ Prolapse

- Preparing the Patient for Prolapse Surgery
- Use of Mesh in Vaginal Surgery: Current Controversy
- Surgical Management of Pelvic Organ Prolapse
- References

125 Slings

- The Evolution of Slings
- Pathophysiology of Stress Urinary Incontinence and Sling Mechanism of Action
- The Age of the Mid-Urethral Sling
- Preoperative Assessment
- Alternative Treatment Options
- Pubovaginal Sling (PVS)
- Pubovaginal Sling Operative Procedure
- Outcomes of Pubovaginal Slings for Predominantly Stress Urinary Incontinence
- Outcomes of Autologous Pubovaginal Slings for Mixed Urinary Incontinence
- Outcomes of Autologous Pubovaginal Slings for Urethral Reconstruction
- Voiding Dysfunction Secondary to Bladder Outlet Obstruction After Pubovaginal Sling Surgery

Complications of Pubovaginal Slings

Mid-Urethral Slings

Mid-Urethral Sling Operative Procedures

Complications of Retropubic, Transobturator, and Single-Incision Mid-Urethral Slings

Mid-Urethral Sling Trocar Injury to the Urinary Tract

Sexual Dysfunction After Mid-Urethral Sling Surgery

Other Complications After Mid-Urethral Sling Surgery

Suggested Readings

References

126 Complications Related to the Use of Mesh and Their Repair

Mesh and Its Properties

Mesh Slings for Stress Urinary Incontinence

Risk Factors for Mesh Sling Complications

Mesh Complications Among the Three Slings

Male Mesh Slings

References

127 Additional Therapies for Storage and Emptying Failure

Additional Therapies for Storage Failure at the Bladder Level

Additional Therapies for Storage Failure at the Bladder Outlet

Additional Therapies for Emptying

Additional Therapies for Storage and Emptying Failure: Circumventing the Problem

Summary

Suggested Readings

References

128 Aging and Geriatric Urology

Biology and Principles of Aging

Demographics of Aging

Clinical Evaluation of the Geriatric Urology Patient

End-of-Life Care and Urology

Summary

Suggested Readings

References

129 Urinary Tract Fistulae

General Considerations

Vesicovaginal Fistulae

Iatrogenic Fistulae

Ureteric Fistulae

Vesicouterine Fistulae

Urethrovaginal Fistulae

Uroenteric Fistulae

Pyeloenteric Fistulae

Rectourethral Fistulae

Urovascular Fistulae

Renovascular and Pyelovascular Fistulae

Ureterovascular Fistulae

Oncologic and Radiation Fistulae

Cancer Surgery

Radiation Fistulae

Other Urinary Fistulae

Acknowledgments

Suggested Readings

References

130 Bladder and Female Urethral Diverticula

Bladder Diverticula

Female Urethral Diverticula

Urethral Diverticula

Suggested Readings

References

131 Surgical Procedures for Sphincteric Incontinence in the Male

Classification, Pathophysiology, and Etiology

Indications for Surgery

Technique of Device Implantation

Artificial Urinary Sphincter Complications

Long-Term Results of Artificial Urinary Sphincters and Slings

Future Directions

Summary

Acknowledgment

Suggested Readings

References

Part XIV Benign and Malignant Bladder Disorders

132 Bladder Surgery for Benign Disease

Bladder Anatomy and Surgical Considerations

Bladder Diverticulectomy

Ureteral Reimplantation

Psoas Hitch and Boari Flap

Enterocystoplasty

Partial Cystectomy and Urachal Surgery

Bladder Stones and Foreign-Body Removal

References

133 Genital and Lower Urinary Tract Trauma

Injuries of the External Genitalia

Bladder Injury

Urethral Injury

Suggested Readings

References

134 Special Urologic Considerations in Transgender Individuals

Urologic Issues in Gender Nonconforming Youths

Urologic Issues in Male-to-Female Transsexuals (Transwomen)

Urologic Issues in Female-to-Male Transsexuals (Transmen)

Postoperative Care, Follow-Up, and Urethral Complications

Conclusion

Suggested Readings

References

135 Tumors of the Bladder

Epidemiology

Economic Impact

Risk Factors

Detection of Urothelial Carcinoma

Pathology

Histologic Variants of Urothelial Carcinoma

References

136 Management Strategies for Non–Muscle-Invasive Bladder Cancer (Ta, T1, and CIS)

Pathology: Grading and Staging

Endoscopic Surgical Management

Intravesical Therapy

Refractory High-Grade Disease

Surveillance and Prevention

Suggested Readings

References

137 Management of Muscle-Invasive and Metastatic Bladder Cancer

Clinical Presentation, Diagnosis, and Evaluation

Radical Cystectomy and Pelvic Lymph Node Dissection for Muscle-Invasive Bladder Cancer

Neoadjuvant Therapy for Muscle-Invasive Bladder Cancer

Adjuvant Therapy for Muscle-Invasive Bladder Cancer

Prognostic Nomograms for Muscle-Invasive Bladder Cancer

Management of Metastatic Bladder Cancer
Suggested Readings
References

138 Surgical Management of Bladder Cancer

Transurethral Resection of Bladder Tumors
Patient Preparation
Surgical Technique
Pelvic Lymphadenectomy
Radical Cystectomy: Male
Radical Cystectomy: Female
Partial Cystectomy
Robotic Radical Cystectomy
Acknowledgments
Suggested Readings
References

139 Use of Intestinal Segments in Urinary Diversion

Surgical Anatomy
Selecting the Segment of Intestine
Preparing the Bowel for Surgery and Postoperative Recovery
Intestinal Anastomoses

Ureterointestinal Anastomoses

Renal Deterioration

Urinary Diversion

Metabolic and Neurochemical Problems of Urinary Intestinal Diversion

Summary

References

140 Cutaneous Continent Urinary Diversion

General Considerations

Patient Selection

Patient Preparation

Cystectomy

Postoperative Care and Comments

Continent Urinary Diversion

Quality-of-Life Assessments

Variations in Operative Technique

Summary

Suggested Readings

References

141 Orthotopic Urinary Diversion

History of Orthotopic Urinary Diversion
Basic Principles of Continent Orthotopic Urinary Diversion
Patient Selection
Continence Mechanism in Patients Undergoing Orthotopic Diversion
Surgical Techniques for Continence Preservation During Radical Cystectomy
Techniques for Orthotopic Bladder Substitution
Results and Complications of Orthotopic Urinary Diversion
Suggested Readings
References

142 Minimally Invasive Urinary Diversion

Incorporation of Robot-Assisted Approach
Patient Selection
Surgeon Choice
Preoperative Care
Patient Position and Port Placement
Anatomic Considerations in Men
Anatomic Considerations in Women
Ileal Conduit
Intracorporeal Neobladder

- Future Directions
- Suggested Readings
- References

Part XV The Prostate

143 Development, Molecular Biology, and Physiology of the Prostate

- Developmental and Cell Biology
- Endocrine Control of Prostate Growth
- Prostatic Secretions and Proteins
- Suggested Readings
- References

144 Benign Prostatic Hyperplasia

- Etiology of Benign Prostatic Hyperplasia
- Pathophysiology
- Epidemiology and Natural History
- Complications of Benign Prostatic Hyperplasia
- Surgery for Benign Prostatic Hyperplasia
- Suggested Readings
- References

145 Evaluation and Nonsurgical Management of Benign Prostatic Hyperplasia

Diagnostic Evaluation

Management of Lower Urinary Tract Symptoms Caused by Benign Prostatic Enlargement

Androgen Manipulation

Muscarinic Receptor Antagonists

β3-Agonist (Mirabegron)

Phytotherapy

Prognosis of Patients Receiving Medical Treatment for Lower Urinary Tract Symptoms

Acute Urinary Retention

Future Directions in Medical Treatment of Benign Prostatic Hyperplasia

References

146 Minimally Invasive and Endoscopic Management of Benign Prostatic Hyperplasia

Introduction

Epidemiology and Marketshare

Workup

Defining Outcomes

Presurgical Factors

Specific Technologies

Failed, Failing, and Future Directions

Conclusion

Suggested Readings

References

147 Simple Prostatectomy

Indications for Simple Prostatectomy

Preoperative Evaluation

Operating Day Preparation

Surgical Technique

Postoperative Management

Postoperative Management

Complications of Simple Prostatectomy

Summary

Suggested Readings

References

148 Epidemiology, Etiology, and Prevention of Prostate Cancer

Epidemiology

Risk Factors

Etiology and Molecular Genetics

Chemoprevention

Pharmacologic Agents

Vitamins and Micronutrients

Conclusion

References

149 Prostate Cancer Biomarkers

Biomarker Development

Assessment of Biomarker Performance

Blood-Based Biomarkers

Urine-Based Biomarkers

Tissue-Based Biomarkers

Summary

Suggested Readings

References

150 Prostate Biopsy

Ultrasonographic Anatomy of the Prostate

Gray-Scale Transrectal Ultrasonography

Prostate Biopsy: Techniques and Outcomes

Advanced and Investigational Techniques for Prostate Biopsy

Suggested Readings

References

151 Pathology of Prostatic Neoplasia

Prostatic Intraepithelial Neoplasia

Adenocarcinoma

Subtypes of Prostate Adenocarcinoma

Suggested Readings

References

152 Diagnosis and Staging of Prostate Cancer

Diagnosis

Staging

Suggested Readings

References

153 Active Management Strategies for Localized Prostate Cancer

Host Evaluation

Selection of Treatment: Comparative Studies

Patient Counseling: a Stepwise Decision Approach

Conclusion

References

154 Active Surveillance of Prostate Cancer

The Overdiagnosis and Overtreatment Problem

The Natural History of Prostate Cancer

Outcome of Active Surveillance

Other Risk Factors

Magnetic Resonance Imaging

Caveats of Tissue-Based Genomics

Psychological Aspects

Lifestyle Management

Pharmacologic Intervention

Summary

GAP 3

Barriers to Active Surveillance

Research Questions

Conclusion

References

155 Open Radical Prostatectomy

Radical Retropubic Prostatectomy: Surgical Anatomy

Surgical Technique

Complications

Summary of Radical Retropubic Prostatectomy

Suggested Readings

References

156 Laparoscopic and Robotic-Assisted Laparoscopic Radical Prostatectomy and Pelvic Lymphadenectomy

Evolution of Minimally Invasive Laparoscopic Prostatectomy

Patient Selection

Instrumentation

Preoperative Preparation

Surgical Technique

Postoperative Management

Complications of Robotic Prostatectomy

Postoperative Complications

Functional Outcomes

Salvage Robotic-Assisted Radical Prostatectomy

Minimally Invasive Pelvic Lymph Node Dissection

Summary

References

157 Radiation Therapy for Prostate Cancer

Historical Perspective and Technological Advances

External Beam Radiation Treatment (Also See Outcomes for External Beam Radiation)

Brachytherapy

Androgen Suppression Combined With Radiation

Role of Prophylactic Pelvic Nodal Treatment

Treatment Morbidity and Quality-of-Life Outcomes

Evaluating the Response to Radiation Therapy

Treatment Efficacy

Suggested Readings

References

158 Focal Therapy for Prostate Cancer

Introduction

Concepts and Historical Perspective

Biologic Basis for Prostate Focal Therapy

Clinical Applications of Focal Therapy

Patient Selection

Advanced Imaging Techniques in Prostate Cancer

Promising Imaging Modalities

Ablation Patterns and Current Technologies

Conclusions and Areas for Future Research

References

159 Treatment of Locally Advanced Prostate Cancer

Definition

Trends in Incidence and Treatment

Natural History

Radical Prostatectomy

Radiation Therapy

Focal Ablative Therapy

Androgen Deprivation and Its Timing

Management of Delayed Sequelae

Clinical Trials

Suggested Readings

References

160 Management Strategies for Biochemical Recurrence of Prostate Cancer

Radical Prostatectomy

Radiation Therapy

Summary

References

161 Hormonal Therapy for Prostate Cancer

Historical Overview

Molecular Biology of the Androgen Axis

Mechanisms of Androgen Blockade

Clinical Follow-Up on Hormonal Therapy

Combination Therapy

Timing of Therapy

References

162 Treatment of Castration-Resistant Prostate Cancer

Clinical Considerations

Cytotoxic Chemotherapy

Next-Generation Hormonal Therapies

Immunotherapy

Targeted Treatments

Palliative Management

Neuroendocrine Prostate Cancer

Conclusion

Suggested Readings

References

Index

Copyright

Elsevier
1600 John F. Kennedy Blvd.
Ste 1600
Philadelphia, PA 19103-2899

CAMPBELL-WALSH-WEIN UROLOGY, TWELFTH EDITION ISBN: 978-0-323-54642-3
Volume I ISBN: 978-0-323-76066-9
Volume II ISBN: 978-0-323-76067-6
Volume III ISBN: 978-0-323-76068-3
INTERNATIONAL EDITION ISBN: 978-0-323-67226-9
Volume I ISBN: 978-0-323-76005-8
Volume II ISBN: 978-0-323-76006-5
Volume III ISBN: 978-0-323-76007-2
Copyright © 2021 by Elsevier, Inc. All rights reserved.

No part of this publication may be reproduced or transmitted in any form or by any means, electronic or mechanical, including photocopying, recording, or any information storage and retrieval system, without permission in writing from the publisher. Details on how to seek permission, further information about the Publisher's permissions policies and our arrangements with organizations such as the Copyright Clearance Center and the Copyright Licensing Agency, can be found at our website: www.elsevier.com/permissions.

This book and the individual contributions contained in it are protected under copyright by the Publisher (other than as may be noted herein).

Notice
Practitioners and researchers must always rely on their own experience and

knowledge in evaluating and using any information, methods, compounds or experiments described herein. Because of rapid advances in the medical sciences, in particular, independent verification of diagnoses and drug dosages should be made. To the fullest extent of the law, no responsibility is assumed by Elsevier, authors, editors or contributors for any injury and/or damage to persons or property as a matter of products liability, negligence or otherwise, or from any use or operation of any methods, products, instructions, or ideas contained in the material herein.

Previous editions copyrighted 2016, 2012, 2007, 2002, 1998, 1992, 1986, 1978, 1970, 1963, and 1954.

ISBN: 978-0-323-54642-3

Senior Content Strategist: Belinda Kuhn
Senior Content Development Specialist: Jennifer Ehlers
Publishing Services Manager: Catherine Jackson
Senior Project Manager: Kate Mannix
Design Direction: Amy Buxton

Printed in Canada

Last digit is the print number: 9 8 7 6 5 4 3 2 1

ELSEVIER
Book Aid International
Working together
to grow libraries in
developing countries
www.elsevier.com • www.bookaid.org

Dedication

Dedicated to my wife, family, residents, and faculty, all of whom have supported me in this work in various and important ways and helped make this edition of Campbell-Walsh-Wein *possible.*

AP

For this edition of Campbell's *I would like to thank my spouse and my children for their unbelievable support during my career in urology. I would also like to thank my past and present residents and fellows for all that they have taught me about the importance of listening. I would like to recognize a few mentors who have taught me a great deal about the specialty and humanity: Dr. Herb Seybold, Dr. Marty Resnick, Dr. Joe Segura, Dr. Joseph Corriere, Dr. George Benson, Dr. Gerald Jordan, and Dr. Jay Smith.*

RD

To my mentors, whose reassuring voices forever guide me: Bill Catalona, Ralph Clayman, Alan Retik, and Pat Walsh.

LK

The privilege of compiling and editing this book makes us reflect on the vast body of knowledge and experience that makes up the field of urology, and the efforts and dedication of our predecessors and *mentors, to whom I dedicate this work. Without the examples, teaching, and inspiration (with not infrequent cajoling and correction), none of us would have been able to grow into who we are or participate in this textbook. For myself, these mentors have been many and varied, guiding me to this day in areas of clinical care, teaching, research, and mentoring. Some are no longer with us but they all continue to inspire.*

I also include my wife and children, who inspire, teach, and support me in so many ways. Their commitment has meant the world to me.

CP

Preface

Continuing in a great tradition of publishers, editors, and authors, we proudly present to you, our readers, the twelfth edition of the “Bible of Urology”—*Campbell-Walsh-Wein Urology*. Started in 1954 as *Campbell's Urology* and retitled *Campbell-Walsh Urology* in 2012, the present editors felt it was appropriate to honor Alan J. Wein, MD, PhD (Hon) for his many years of dedication to this text by adding his name to the previous chief editors. During his time as chief editor, Dr. Wein was responsible for keeping the textbook in pace with a rapidly growing field in medicine—for this diligence and dedication we are grateful.

As with previous editions, the twelfth edition presents many exciting advances in our use and understanding of technology, physiology, pharmacology, epidemiology, and pathophysiology while maintaining our basic classical urological knowledge.

We are dedicated to keeping the content of this textbook fresh and on the cutting edge of care. *CWW-12* adds 10 novel chapters and more than 150 first-time authors, including several new authors from international sites. *CWW-12* has 3 volumes, 162 chapters, 3706 pages, and more than 3000 illustrations.

The format continues to include color images, Key Points, Suggested Readings, boldfaced important text, and online linkable references to streamline the access and usefulness of the material. Additionally, as in previous editions, a companion Review book with questions and answers for each chapter is available separately under the leadership of Drs. Alan Wein and Thomas F. Kolon.

Volume I (54 chapters) covers basic urological evaluation, imaging and principles and fundamentals of surgery, endourology, and laparoscopy. Also in Volume I is a completely revamped and updated evaluation, the exstrophy-epispadias complex, pediatric stone disease, hypospadias, disorders of sexual development, and many more topics.

Volume II (50 chapters) covers infections within the urinary tract, sexually transmitted diseases, male reproduction, male infertility, erectile dysfunction, neoplasms/management of the testes and penis, medical/surgical management of urological stone disease, and many more topics.

Volume III (58 chapters) covers anatomy, physiology, pharmacology, pathophysiology, oncology, and surgery of the adrenal glands; all chapters covering diagnosis, physiology, and pathophysiology of female and male lower urinary tract disorders; all oncologic aspects (imaging, diagnosis, staging, treatment, and outcomes) of the bladder and prostate; urinary diversion; and physiology, diagnosis, and medical and surgical treatment of benign prostatic hyperplasia.

We all remain extremely proud once again to present you with this textbook and are especially thankful for our spouses and families who have put up with us during the months of review, editing, and proofing. We also give special thanks to the hundreds of authors whose time, expertise, and effort have made all of this possible. We would also like to thank our editorial support staff from Elsevier: Jennifer S. Ehlers (Senior Content Development Specialist) and Belinda Kuhn (Senior Content Strategist), who helped us to coordinate *CWW-12*.

We truly hope you will enjoy reading this textbook.

From the Editors

Alan W. Partin

Roger R. Dmochowski

Louis R. Kavoussi

Craig A. Peters

Contributors

Robert Abouassaly MD, MS
Assistant Professor, Urology
University Hospitals Case Medical Center
Cleveland, Ohio

Ömer Acar MD
Department of Urology
College of Medicine
University of Illinois at Chicago
Chicago, Illinois

Mark C. Adams MD, FAAP
Professor of Urology and Pediatrics
Vanderbilt University
Nashville, Tennessee

Riyad Taher Al-Mousa MBBS, SSCU, FEBU, MSHA
Consultant Urologist/Neuro-urologist
Urology Department
King Fahad Specialist Hospital–Dammam
Dammam, Saudi Arabia

Mohamad E. Allaf MD
Vice Chairman and Professor of Urology, Oncology, and Biomedical Engineering
Director of Minimally Invasive and Robotic Surgery
Department of Urology
Brady Urological Institute
Johns Hopkins University School of Medicine
Baltimore, Maryland

Christopher L. Amling MD, FACS
John Barry Professor and Chair
Department of Urology
Oregon Health & Science University
Portland, Oregon

Christopher B. Anderson MD, MPH
Assistant Professor, Urology
Columbia University Medical Center
New York, New York

Karl-Erik Andersson MD, PhD
Professor
Aarhus Institute for Advanced Studies
Aarhus University
Aarhus, Jutland, Denmark
Professor
Wake Forest Institute for Regenerative Medicine
Wake Forest University School of Medicine
Winston-Salem, North Carolina

Sero Andonian MD, MSc, FRCS(C), FACS
Associate Professor
Department of Urology
McGill University
Montreal, Canada

Emmanuel S. Antonarakis MD
Professor of Oncology and Urology
Johns Hopkins Sidney Kimmel Comprehensive Cancer Center
Baltimore, Maryland

Jodi A. Antonelli MD
Assistant Professor
Department of Urology
University of Texas Southwestern Medical Center
Dallas, Texas

Joshua Augustine MD
Associate Professor of Medicine
Cleveland Clinic Lerner College of Medicine
Cleveland Clinic
Cleveland, Ohio

Paul F. Austin MD
Professor
Division of Urologic Surgery
Washington University School of Medicine
St. Louis, Missouri

Timothy D. Averch MD
Professor and Vice Chair for Quality
University of Pittsburgh Medical Center
Pittsburgh, Pennsylvania

Gina M. Badalato MD
Assistant Professor, Urology
Columbia University Medical Center
New York, New York

Daniel A. Barocas MD, MPH, FACS
Associate Professor, Urologic Surgery
Vanderbilt University Medical Center
Nashville, Tennessee

Julia Spencer Barthold MD
Principal Research Scientist
Nemours Biomedical Research/Division of Urology
Alfred I. duPont Hospital for Children
Wilmington, Delaware
Professor
Urology and Pediatrics
Thomas Jefferson University
Philadelphia, Pennsylvania

Laurence S. Baskin MD

Chief of Pediatric Urology
University of California–San Francisco Benioff Children's Hospital
San Francisco, California

Stuart B. Bauer MD
Professor of Surgery (Urology)
Harvard Medical School
Senior Associate in Urology
Department of Urology
Boston Children's Hospital
Boston, Massachusetts

Mitchell C. Benson MD
Herbert and Florence Irving Professor and Chairman Emeritus
Department of Urology
Columbia University
Attending Physician
Department of Urology
New York Presbyterian Hospital–Columbia
New York, New York

Sara L. Best MD
Associate Professor
Department of Urology
University of Wisconsin School of Medicine and Public Health
Madison, Wisconsin

Lori A. Birder PhD
Professor of Medicine and Pharmacology
Medicine–Renal Electrolyte Division
University of Pittsburgh School of Medicine
Pittsburgh, Pennsylvania

Jay T. Bishoff MD
Director, Intermountain Urological Institute
Intermountain Health Care
Salt Lake City, Utah

Trinity J. Bivalacqua MD, PhD
R. Christian Evenson Professor of Urology
Johns Hopkins University
Baltimore, Maryland

Marc A. Bjurlin DO, MSc
Assistant Professor, Urology
New York University
New York, New York

Brian G. Blackburn MD
Clinical Associate Professor
Internal Medicine/Infectious Diseases and Geographic Medicine
Stanford University School of Medicine
Stanford, California

Bertil Blok MD, PhD
Department of Urology
Erasmus Medical Center
Rotterdam, Netherlands

Michael L. Blute MD
Chief, Department of Urology
Walter S. Kerr, Jr., Professor of Urology
Massachusetts General Hospital
Harvard Medical School
Boston, Massachusetts

Timothy B. Boone MD, PhD
Chairman, Urology
Houston Methodist Hospital
Professor and Associate Dean
Weill Cornell Medical College
Houston, Texas

Stephen A. Boorjian MD, FACS
Carl Rosen Professor of Urology
Mayo Clinic

Rochester, Minnesota

Kristy McKiernan Borawski MD
Clinical Assistant Professor of Urology
Department of Urology
University of North Carolina–Chapel Hill
Chapel Hill, North Carolina

Michael S. Borofsky MD
Assistant Professor, Urology
University of Minnesota
Minneapolis, Minnesota

Steven B. Brandes MD
Department of Urology
Columbia University Medical Center
New York, New York

Michael C. Braun MD
Chief of Renal Service
Texas Children's Hospital
Professor
Renal Section Chief
Department of Pediatrics
Program Director, Pediatric Nephrology Fellowship Program
Baylor College of Medicine
Houston, Texas

Gregory A. Broderick MD
Professor of Urology
Department of Urology
Mayo Clinic College of Medicine
Program Director
Urology Residency Program
Mayo Clinic
Jacksonville, Florida

Elizabeth Timbrook Brown MD, MPH

Assistant Professor, Urology
MedStar Georgetown University Hospital
Washington, DC

Benjamin M. Brucker MD
Assistant Professor, Urology
New York University
New York, New York

Kathryn L. Burgio PhD
Professor of Medicine
Department of Medicine
Division of Gerontology, Geriatrics, and Palliative Care
University of Alabama at Birmingham
Associate Director for Research
Birmingham/Atlanta Geriatric Research, Education, and Clinical Center
Birmingham VA Medical Center
Birmingham, Alabama

Arthur L. Burnett II, MD, MBA
Patrick C. Walsh Distinguished Professor of Urology
Department of Urology
Johns Hopkins School of Medicine
Baltimore, Maryland

Jeffrey A. Cadeddu MD
Professor of Urology and Radiology
University of Texas Southwestern Medical Center
Dallas, Texas

Anne P. Cameron MD, FRCSC, FPMRS
Associate Professor, Urology
University of Michigan
Ann Arbor, Michigan

Steven C. Campbell MD, PhD
Professor of Surgery
Department of Urology

Cleveland Clinic
Cleveland, Ohio

Douglas A. Canning MD
Professor of Surgery (Urology)
Perelman School of Medicine
University of Pennsylvania
Chief, Division of Urology
Children's Hospital of Philadelphia
Philadelphia, Pennsylvania

Paolo Capogrosso MD
Department of Urology
Vita-Salute San Raffaele University
Milan, Italy

Michael A. Carducci MD
AEGON Professor in Prostate Cancer Research
Sidney Kimmel Comprehensive Cancer Center at Johns Hopkins
Johns Hopkins University School of Medicine
Baltimore, Maryland

Maude Carmel MD
Assistant Professor
Department of Urology at University of Texas Southwestern Medical Center
Dallas, Texas

Peter R. Carroll MD, MPH
Professor and Chair, Urology
University of California, San Francisco
San Francisco, California

K. Clint Cary MD, MPH
Assistant Professor
Department of Urology
Indiana University
Indianapolis, Indiana

Erik P. Castle MD
Professor of Urology
Mayo Clinic Arizona
Phoenix, Arizona

Toby C. Chai MD
Professor and Chair, Department of Urology
Boston University School of Medicine
Chief of Urology
Boston Medical Center
Boston, Massachusetts

Charbel Chalouhy MD
Assistant Professor of Urology
Campus des Sciences Médicales
St. Joseph University
Beirut, Lebanon

Alicia H. Chang MD, MS
Instructor
Department of Internal Medicine/Infectious Diseases and Geographic Medicine
Stanford University School of Medicine
Stanford, California
Medical Consultant
Los Angeles County Tuberculosis Control Program
Los Angeles County Department of Public Health
Los Angeles, California

Christopher R. Chapple MD, FRCS (Urol)
Professor and Consultant Urologist
Department of Urology
The Royal Hallamshire Hospital, Sheffield Teaching Hospitals
Sheffield, South Yorkshire, United Kingdom

Thomas Chi MD
Associate Professor
Associate Chair for Clinical Affairs
Department of Urology

University of California–San Francisco
San Francisco, California

John P. Christodouleas MD, MPH
Professor of Radiation Oncology
Urologic Cancer Program
Penn Medicine
Philadelphia, Pennsylvania

Peter E. Clark MD
Professor and Chairman, Urology
Atrium Health
Chair, Urologic Oncology
Levine Cancer Institute
Charlotte, North Carolina

Douglass B. Clayton MD, FAAP
Assistant Professor
Urologic Surgery
Vanderbilt University
Nashville, Tennessee

Joshua A. Cohn MD
Assistant Professor of Urology
Department of Urology
Einstein Healthcare Network
Assistant Professor of Urology
Department of Surgery, Division of Urologic Oncology
Fox Chase Cancer Center
Philadelphia, Pennsylvania

Michael Joseph Conlin MD, MCR
Professor, Urology
Portland VA Medical Center
Professor, Urology
Oregon Health & Sciences University
Portland, Oregon

Christopher S. Cooper MD, FAAP, FACS
Professor
Department of Urology
University of Iowa
Associate Dean, Student Affairs and Curriculum
University of Iowa Carver College of Medicine
Iowa City, Iowa

Kimberly L. Cooper MD
Associate Professor of Urology
Columbia University Medical Center
New York, New York

Lawrence A. Copelovitch MD
Assistant Professor of Pediatrics
Department of Nephrology
The Children's Hospital of Philadelphia
Philadelphia, Pennsylvania

Hillary L. Copp MD
Associate Professor, Pediatric Urology
University of California–San Francisco
San Francisco, California

Nicholas G. Cost MD
Assistant Professor
Department of Surgery
Division of Urology
University of Colorado School of Medicine
Aurora, Colorado

Anthony J. Costello FRACS, MD
Professor, Urology
Royal Melbourne Hospital, Parkville Victoria
Victoria, Australia

Lindsey Cox MD
Assistant Professor of Urology

Medical University of South Carolina
Charleston, South Carolina

Paul L. Crispen MD
Associate Professor
Department of Urology
University of Florida
Gainesville, Florida

Juanita M. Crook MD, FRCPC
Professor, Radiation Oncology
University of British Columbia
Radiation Oncologist
Center for the Southern Interior
British Columbia Cancer Agency
Kelowna, British Columbia, Canada

Gerald Cunha PhD
Professor Emeritus, Urology
School of Medicine
University of California, San Francisco
San Francisco, California

Douglas M. Dahl MD, FACS
Associate Professor of Surgery
Harvard Medical School
Chief, Division of Urologic Oncology
Department of Urology
Massachusetts General Hospital
Boston, Massachusetts

Siamak Daneshmand MD
Associate Professor of Urology (Clinical Scholar)
Institute of Urology
University of Southern California, Los Angeles
Los Angeles, California

Casey A. Dauw MD

Assistant Professor, Urology
University of Michigan
Ann Arbor, Michigan

Shubha K. De MD, FRCSC
Assistant Professor
Department of Surgery
Division of Urology
University of Alberta
Edmonton, Alberta, Canada

Guarionex Joel DeCastro MD, MPH
Assistant Professor, Urology
Columbia University Medical Center;
Department of Urology
New York Presbyterian Hospital/Columbia University
New York, New York

Jean J.M.C.H. de la Rosette MD, PhD
Professor, Urology
AMC University Hospital
Amsterdam, Netherlands

Francisco T. Dénes MD, PhD
Associate Professor, Division of Urology
Chief, Pediatric Urology
University of São Paulo Medical School;
Hospital das Clínicas
São Paulo, Brazil

Dirk J.M.K. De Ridder MD, PhD, FEBU
Professor, Urology
University Hospitals KU Leuven
Leuven, Belgium

Mahesh R. Desai MS, FRCS
Chief Urologist and Managing Trustee
Department of Urology

Muljibhai Patel Urological Hospital, Nadiad
Gujarat, India

David Andrew Diamond MD
Urologist-in-Chief
Department of Urology
Boston Children's Hospital
Professor of Surgery (Urology)
Harvard Medical School
Boston, Massachusetts

Heather N. Di Carlo MD
Director, Pediatric Urology Research
Assistant Professor of Urology
Johns Hopkins Medicine
Baltimore, Maryland

Colin P.N. Dinney MD
Chairman and Professor
Department of Urology
The University of Texas MD Anderson Cancer Center
Houston, Texas

Roger R. Dmochowski MD, MMHC, FACS
Professor, Urologic Surgery, Surgery and Gynecology
Program Director, Female Pelvic Medicine and Reconstructive Surgery
Vice Chair for Faculty Affairs and Professionalism
Section of Surgical Sciences
Associate Surgeon-in-Chief
Vanderbilt University Medical Center
Nashville, Tennessee

Charles G. Drake MD, PhD
Associate Professor of Oncology, Immunology, and Urology
James Buchanan Brady Urological Institute
Johns Hopkins University
Attending Physician
Department of Oncology

Johns Hopkins Kimmel Cancer Center
Baltimore, Maryland

Brian Duty MD
Associate Professor, Urology
Oregon Health & Science University
Portland, Oregon

James A. Eastham MD
Chief, Urology Service
Department of Surgery
Memorial Sloan-Kettering Cancer Center
Professor, Urology
Weill Cornell Medical Center
New York, New York

Scott Eggener MD
Professor, Surgery
University of Chicago
Chicago, Illinois

Mohamed Aly Elkoushy MD, MSc, PhD
Professor, Urology
Faculty of Medicine
Suez Canal University
Ismailia, Egypt

Jonathan Scott Ellison MD
Assistant Professor of Urology
Medical College of Wisconsin
Children's Hospital of Wisconsin
Milwaukee, Wisconsin

Sammy E. Elsamra MD
Assistant Professor of Surgery (Urology)
Department of Urology
Rutgers Robert Wood Johnson Medical School
Director of Robotic Surgical Services

Robert Wood Johnson University Hospital
RWJ-Barnabas Health
New Brunswick, New Jersey

Jonathan I. Epstein MD
Professor of Pathology, Urology, Oncology
The Reinhard Professor of Urological Pathology
Director of Surgical Pathology
The Johns Hopkins Medical Institutions
Baltimore, Maryland

Carlos R. Estrada MD, MBA
Associate Professor, Surgery
Harvard Medical School
Associate in Urology
Boston Children's Hospital
Boston, Massachusetts

Jairam R. Eswara MD
Assistant Surgeon
Division of Urology
Brigham and Women's Hospital
Boston, Massachusetts

Fernando A. Ferrer MD, FACS, FAAP
Professor of Urology
Department of Urology
Mount Sinai School of Medicine
New York, New York

Neil Fleshner MD, MPH, FRCSC
Professor of Surgery and Martin Barkin Chair
Department of Urology
University of Toronto
Surgeon, Uro-Oncology
University Health Network
Toronto, Ontario, Canada

Bryan Foster MD
Associate Professor
Department of Radiology
Oregon Health & Science University
Portland, Oregon

Richard S. Foster MD
Professor, Department of Urology
Indiana University
Indianapolis, Indiana

Pat F. Fulgham MD
Director of Surgical Oncology
Department of Urology
Texas Health Presbyterian Dallas
Dallas, Texas

Arvind P. Ganpule MS, DNB
Department of Urology
Muljibhai Patel Urological Hospital
Nadiad, Gujarat, India

Kris Gaston MD
Carolinas Medical Center
Charlotte, North Carolina

John P. Gearhart MD
The James Buchanan Brady Urological Institute
Johns Hopkins Medical Institutions
Baltimore, Maryland

Matthew T. Gettman MD
Professor and Vice-Chair, Urology
Mayo Clinic
Rochester, Minnesota

Reza Ghavamian MD
Eastern Regional Director of Urology

Department of Urology
Northwell Health
Greenlawn, New York
Professor of Urology
Zucker School of Medicine at Hofstra Northwell
New Hyde Park, New York

Bruce R. Gilbert MD, PhD
Professor of Urology
The Smith Institute for Urology
Zucker School of Medicine of Hofstra/Northwell
New Hyde Park, New York

Timothy D. Gilligan MD, MS, FASCO
Associate Professor of Medicine
Solid Tumor Oncology
Cleveland Clinic Lerner College of Medicine
Program Director, Hematology/Oncology Fellowship
Taussig Cancer Institute
Cleveland Clinic
Cleveland, Ohio

David A. Goldfarb MD
Professor of Surgery, CCLCM
Glickman Urological and Kidney Institute
Cleveland Clinic
Cleveland, Ohio

Marc Goldstein MD, DSc (hon), FACS
Matthew P. Hardy Distinguished Professor of Urology and Male Reproductive Medicine
Department of Urology and Institute for Reproductive Medicine
Weill Medical College of Cornell University
Surgeon-in-Chief, Male Reproductive Medicine, and Surgery
Department of Urology and Institute for Reproductive Medicine
New York Presbyterian Hospital–Weill Cornell Medical Center
New York, New York

Leonard G. Gomella MD, FACS
Professor and Chair
Department of Urology
Thomas Jefferson University
Philadelphia, Pennsylvania

Alex Gomelsky MD
B.E. Trichel Professor and Chairman
Department of Urology
Louisiana State University Health–Shreveport
Shreveport, Louisiana

Mark L. Gonzalgo MD, PhD
Professor and Vice Chairman, Urology
University of Miami Miller School of Medicine
Miami, Florida

Michael A. Gorin MD
Assistant Professor
Department of Urology
Johns Hopkins University School of Medicine
Baltimore, Maryland

Tamsin Greenwell MD, PhD
Consultant Urological Surgeon
University College London Hospitals
London, United Kingdom

Tomas L. Griebling MD, MPH
John P. Wolf 33-Degree Masonic Distinguished Professor of Urology
Department of Urology
The Landon Center on Aging
The University of Kansas
Kansas City, Kansas

Khurshid A. Guru MD
Chair, Department of Urology
Director of Robotic Surgery

Robert P. Huben Endowed Professor of Urologic Oncology
Roswell Park Comprehensive Cancer Center
Buffalo, New York

Thomas J. Guzzo MD, MPH
Assistant Professor of Urology
The Hospital of the University of Pennsylvania
University of Pennsylvania
Philadelphia, Pennsylvania

Jennifer A. Hagerty DO
Attending Physician
Departments of Surgery/Urology
Nemours/Alfred I. duPont Hospital for Children
Wilmington, Delaware
Assistant Professor
Departments of Urology and Pediatrics
Sidney Kimmel Medical College of Thomas Jefferson University
Philadelphia, Pennsylvania

Simon J. Hall MD
Professor
Smith Institute for Urology
Hofstra Northwell School of Medicine
Lake Success, New York

Barry Hallner MD
Associate Program Director, Female Pelvic Medicine & Reconstructive Surgery
Assistant Professor
Departments of OB/GYN and Urology
Louisiana State University Health
New Orleans School of Medicine
New Orleans, Louisiana

Ethan J. Halpern MD, MSCE
Professor of Radiology and Urology
Department of Radiology
Thomas Jefferson University

Philadelphia, Pennsylvania

Misop Han MD, MS
Professor, Urology and Oncology
Johns Hopkins Medicine
Baltimore, Maryland

Philip M. Hanno MD, MPH
Clinical Professor, Urology
Stanford University School of Medicine
Palo Alto, California

Siobhan M. Hartigan MD
Female Pelvic Medicine and Reconstructive Surgery Fellow
Department of Urology
Vanderbilt University Medical Center
Nashville, Tennessee

Christopher J. Hartman MD
Assistant Professor of Urology
The Smith Institute for Urology
Northwell Health System
Long Island City, New York

Hashim Hashim MBBS, MRCS (Eng), MD, FEBU, FRCS (Urol)
Consultant Urological Surgeon
Honorary Professor
Director of the Urodynamics Unit
Bristol Urological Institute
Southmead Hospital
Bristol, United Kingdom

Dorota J. Hawksworth MD, MBA
Director of Andrology and Male Sexual Health
Department of Urology
Walter Reed National Military Medical Center
Bethesda, Maryland

Sarah Hazell MD
Radiation Oncology Resident
Department of Radiation Oncology and Molecular Radiation Sciences
Johns Hopkins University School of Medicine
Baltimore, Maryland

John P.F.A. Heesakkers MD, PhD
Urologist
Radboudumc
Nijmegen, Netherlands

Sevann Helo MD
Southern Illinois University School of Medicine
Division of Urology
Springfield, Illinois

Amin S. Herati MD
Assistant Professor of Urology
Department of Urology
The James Buchanan Brady Urological Institute
Johns Hopkins University School of Medicine
Assistant Professor
Gynecology and Obstetrics
Johns Hopkins University School of Medicine
Baltimore, Maryland

C.D. Anthony Herndon MD, FAAP, FACS
Professor of Surgery
Director of Pediatric Urology
Surgeon-in-Chief, Children's Hospital of Richmond
Department of Urology
Virginia Commonwealth University
Richmond, Virginia

Piet Hoebeke MD, PhD
Professor, Urology
Dean, Faculty of Medicine and Health Sciences
Ghent University

Ghent, Belgium

David M. Hoenig MD
Professor and Chief
North Shore University Hospital
Smith Institute for Urology
North Shore-LIJ-Hofstra University
Lake Success, New York

Michael Hsieh MD, PhD
Stirewalt Endowed Director
Biomedical Research Institute
Rockville, Maryland
Associate Professor, Urology
George Washington University
Washington, DC

Valerio Iacovelli MD
Urology Unit
University of Rome Tor Vergata
San Carlo di Nancy General Hospital
GVM Care and Research
Rome, Italy

Stephen V. Jackman MD
Professor, Urology
University of Pittsburgh
Pittsburgh, Pennsylvania

Joseph M. Jacob MD, MCR
Assistant Professor, Urology
SUNY Upstate Medical Center
Syracuse, New York

Micah A. Jacobs MD, MPH
Department of Urology
University of Texas Southwestern Medical School
Dallas, Texas

Thomas W. Jarrett MD
Professor and Chairman, Urology
George Washington University
Washington, DC

Gerald H. Jordan MD, FACS, FAAP (Hon), FRCS (Hon)
Associate Professor, Urology
Eastern Virginia Medical School
Norfolk, Virginia

Martin Kaefer MD
Professor, Urology
Indiana University School of Medicine
Indianapolis, Indiana

Kamaljot S. Kaler MD
Clinical Assistant Professor
Section of Urology
Department of Surgery
University of Calgary
Calgary, Alberta, Canada

Panagiotis Kallidonis MD, MSc, PhD, FEBU
Consultant Urological Surgeon
Department of Urology
University of Patras
Patras, Greece

Steven Kaplan MD
Professor and Director
The Men's Health Program
Department of Urology
Icahn School of Medicine at Mount Sinai
New York, New York

Max Kates MD
Assistant Professor, Urology
Johns Hopkins Medical Institutions

Baltimore, Maryland

Melissa R. Kaufman MD, PhD
Associate Professor, Urologic Surgery
Vanderbilt University
Nashville, Tennessee

Louis R. Kavoussi MD, MBA
Professor and Chair
Department of Urology
Zucker School of Medicine at Hofstra/Northwell
Hempstead, New York
Chairman of Urology
The Arthur Smith Institute for Urology
Lake Success, New York

Parviz K. Kavoussi MD, FACS
Reproductive Urologist
Department of Urology
Austin Fertility and Reproductive Medicine
Adjunct Assistant Professor
Psychology: Neuroendocrinology and Motivation
University of Texas at Austin
Austin, Texas

Miran Kenk PhD
University Health Network
Toronto, Canada

Mohit Khera MD, MBA, MPH
Professor of Urology
Scott Department of Urology
Baylor College of Medicine
Houston, Texas

Antoine E. Khoury MD, FRCSC, FAAP
Walter R. Schmid Professor of Pediatric Urology
Head of Pediatric Urology

Children's Hospital of Orange County
Orange, California

Eric A. Klein MD
Chairman, Glickman Urological and Kidney Institute
Cleveland Clinic
Cleveland, Ohio

Laurence Klotz MD, FRCSC
Professor, Surgery
University of Toronto
Urologist
Sunnybrook Health Sciences Centre
Toronto, Ontario, Canada

Bodo Egon Knudsen MD, FRCSC
Associate Professor
Vice Chair Clinical Operations
Department of Urology
Wexner Medical Center
The Ohio State University
Columbus, Ohio

Kathleen C. Kobashi MD
Section Head, Urology and Renal Transplantation
Virginia Mason Medical Center
Seattle, Washington

Chester J. Koh MD
Associate Professor of Urology (Pediatric)
TCH Department of Surgery
Scott Department of Urology
Baylor College of Medicine
Texas Children's Hospital
Houston, Texas

Ervin Kocjancic MD
Professor of Urology

Department of Urology
University of Illinois Health and Science
Chicago, Illinois

Badrinath R. Konety MD, MBA
Professor and Chair, Dougherty Family Chair in UroOncology
Associate Director for Clinical Affairs and Clinical Research
Masonic Cancer Center;
Department of Urology
University of Minnesota
Minneapolis, Minnesota

Casey E. Kowalik MD
Department of Urologic Surgery
Vanderbilt University
Nashville, Tennessee

Martin A. Koyle MD, FAAP, FACS, FRCSC, FRCS (Eng)
Division Head, Pediatric Urology
Women's Auxiliary Chair in Urology and Regenerative Medicine
Hospital for Sick Children
Professor of Surgery
University of Toronto
Toronto, Ontario, Canada

Amy E. Krambeck MD
Michael O. Koch Professor of Urology
Indiana University
Indianapolis, Indiana

Jessica E. Kreshover MD, MS
Assistant Professor
Arthur Smith Institute for Urology
Donald and Barbara Zucker School of Medicine at Hofstra-Northwell
Lake Success, New York

Venkatesh Krishnamurthi MD
Director, Kidney/Pancreas Transplant Program

Glickman Urological and Kidney Institute, Transplant Center
Cleveland Clinic Foundation
Cleveland, Ohio

Ryan M. Krlin MD
Assistant Professor of Urology
Department of Urology
Louisiana State University
New Orleans, Louisiana

Alexander Kutikov MD, FACS
Professor and Chief, Urologic Oncology
Fox Chase Cancer Center
Philadelphia, Pennsylvania

Jaime Landman MD
Professor of Urology and Radiology
Chairman, Department of Urology
University of California Irvine
Orange, California

Brian R. Lane MD, PhD
Chief, Urology
Spectrum Health
Associate Professor
Michigan State University College of Human Medicine
Grand Rapids, Michigan

David A. Leavitt MD
Assistant Professor, Urology
Vattikuti Urology Institute
Henry Ford Health System
Detroit, Michigan

Eugene K. Lee MD
Assistant Professor, Urology
University of Kansas Medical Center
Kansas City, Kansas

Gary E. Lemack MD
Professor of Urology and Neurology
University of Texas Southwestern Medical Center
Dallas, Texas

Thomas Sean Lendvay MD, FACS
Professor, Urology
University of Washington
Professor, Pediatric Urology
Seattle Children's Hospital
Seattle, Washington

Herbert Lepor MD
Professor and Martin Spatz Chairman
Department of Urology
NYU School of Medicine
Chief, Urology
NYU Langine Health System
New York, New York

Evangelos Liatsikos MD, PhD
Professor, Urology
University of Patras
Patras, Greece

Sey Kiat Lim MBBS, MRCS (Edinburgh), MMed (Surgery), FAMS (Urology)
Associate Consultant, Urology
Changi General Hospital
Singapore

W. Marston Linehan MD
Chief, Urologic Oncology Branch
National Cancer Institute
National Institutes of Health
Bethesda, Maryland

Richard Edward Link MD, PhD

Carlton-Smith Chair in Urologic Education
Associate Professor of Urology
Director, Division of Endourology and Minimally Invasive Surgery
Scott Department of Urology
Baylor College of Medicine
Houston, Texas

Jen-Jane Liu MD
Director of Urologic Oncology
Assistant Professor
Department of Urology
Oregon Health & Science University
Portland, Oregon

Stacy Loeb MD, MSc
Assistant Professor, Urology and Population Health
New York University and Manhattan Veterans Affairs
New York, New York

Christopher J. Long MD
Assistant Professor of Urology
Department of Surgery
Division of Urology
Children's Hospital of Philadelphia
Philadelphia, Pennsylvania

Roberto Iglesias Lopes MD, PhD
Assistant Professor
Division of Urology
Department of Surgery
University of São Paulo Medical School
São Paulo, Brazil

Armando J. Lorenzo MD, MSc, FRCSC, FAAP, FACS
Staff Paediatric Urologist
Department of Surgery
Division of Urology
Hospital for Sick Children

Associate Professor
Department of Surgery
Division of Urology
University of Toronto
Toronto, Ontario, Canada

Yair Lotan MD
Professor
Department of Urology
University of Texas Southwestern Medical Center
Dallas, Texas

Alvaro Lucioni MD
Department of Urology
Virginia Mason Medical Center
Seattle, Washington

Tom F. Lue MD, ScD (Hon), FACS
Professor of Urology
University of California–San Francisco
San Francisco, California

Nicolas Lumen MD, PhD
Professor, Urology
Ghent University Hospital
Ghent, Belgium

Marcos Tobias Machado MD, PhD
Head, Urologic Oncology Section
Department of Urology
Faculdade de Medicina do ABC, Santo André
São Paulo, Brazil

Stephen D. Marshall MD
Attending Physician
Laconia Clinic Department of Urology
Lakes Region General Hospital
Laconia, New Hampshire

Aaron D. Martin MD, MPH
Associate Professor
Department of Urology
Louisiana State University Health Sciences Center;
Pediatric Urology
Children's Hospital New Orleans
New Orleans, Louisiana

Laura M. Martinez MD
Instructor in Clinical Urology
Houston Methodist
Houston, Texas

Timothy A. Masterson MD
Associate Professor, Urology
Indiana University Medical Center
Indianapolis, Indiana

Surena F. Matin MD
Professor
Department of Urology
The University of Texas M.D. Anderson Cancer Center
Medical Director
Minimally Invasive New Technology in Oncologic Surgery (MINTOS)
The University of Texas M.D. Anderson Cancer Center
Houston, Texas

Brian R. Matlaga MD, MPH
Professor
James Buchanan Brady Urological Institute
Johns Hopkins Medical Institutions
Baltimore, Maryland

Kurt A. McCammon MD, FACS
Devine Chair in Genitourinary Reconstructive Surgery
Chairman and Program Director
Professor
Department of Urology

Eastern Virginia Medical School
Norfolk, Virginia

James M. McKiernan MD
Chairman and Professor, Urology
Columbia University Medical Center/NYPH
New York, New York

Chris G. McMahon MBBS, FAChSHP
Director
Australian Centre for Sexual Health
Sydney, New South Wales, Australia

Kevin T. McVary MD, FACS
Professor and Chairman
Division of Urology
Department ofSurgery
Southern Illinois University School of Medicine
Springfield, Illinois

Luis G. Medina MD
Medical Doctor and Researcher
Department of Urology
University of Southern California
Los Angeles, California

Kirstan K. Meldrum MD
Professor
Department of Surgery
Central Michigan University
Saginaw, Michigan

Matthew J. Mellon MD, FACS
Associate Professor, Urology
Indiana University
Indianapolis, Indiana

Maxwell V. Meng MD

Professor, Urology
Chief, Urologic Oncology
University of California–San Francisco
San Francisco, California

David Mikhail MD, FRCSC
Endourology Fellow
Department of Urology
Arthur Smith Institute for Urology/Northwell Health
New Hyde Park, New York

Nicole L. Miller MD
Associate Professor
Department of Urologic Surgery
Vanderbilt University Medical Center
Nashville, Tennessee

Alireza Moinzadeh MD
Director of Robotic Surgery
Institute of Urology
Lahey Hospital & Medical Center
Burlington, Massachusetts
Assistant Professor, Urology
Tufts University School of Medicine
Boston, Massachusetts

Robert M. Moldwin MD
Professor of Urology
The Arthur Smith Institute for Urology
Hofstra Northwell School of Medicine
Lake Success, New York

Manoj Monga MD, FACS
Director, Stevan Streem Center for Endourology & Stone Disease
Department of Urology
Cleveland Clinic
Cleveland, Ohio

Francesco Montorsi MD, FRCS (Hon)
Professor and Chairman, Urology
Vita-Salute San Raffaele University
Milan, Italy

Daniel M. Moreira MD, MHS
Assistant Professor, Urology
University of Illinois at Chicago
Chicago, Illinois

Allen F. Morey MD, FACS
Professor, Urology
University of Texas Southwestern Medical Center
Dallas, Texas

Todd M. Morgan MD
Associate Professor
Department of Urology
University of Michigan
Ann Arbor, Michigan

John J. Mulcahy MD, PhD, FACS
Clinical Professor, Urology
University of Alabama
Birmingham, Alabama

Ravi Munver MD, FACS
Vice Chairman
Department of Urology
Hackensack University Medical Center
Professor of Surgery (Urology)
Department of Urology
Seton Hall-Hackensack Meridian School of Medicine
Hackensack, New Jersey

Stephen Y. Nakada MD, FACS, FRCS (Glasg.)
Professor and Chairman, The David T. Uehling Chair of Urology
Department of Urology

University of Wisconsin School of Medicine and Public Health
Professor and Chairman
Department of Urology
University of Wisconsin Hospital and Clinics
Madison, Wisconsin

Neema Navai MD
Assistant Professor, Urology
The University of Texas MD Anderson Cancer Center
Houston, Texas

Diane K. Newman DNP, ANP-BC, FAAN
Adjunct Professor of Urology in Surgery
Division of Urology
Perelman School of Medicine
Research Investigator Senior
Perelman School of Medicine
University of Pennsylvania
Philadelphia, Pennsylvania

Craig Stuart Niederberger MD, FACS
Clarence C. Saelhof Professor and Head
Department of Urology
University of Illinois at Chicago College of Medicine
Professor, Bioengineering
University of Illinois at Chicago College of Engineering
Chicago, Illinois

Victor W. Nitti MD
Professor of Urology and Obstetrics & Gynecology
Shlomo Raz Chair in Urology
Chief, Division of Female Pelvic Medicine and Reconstructive Surgery
David Geffen School of Medicine at UCLA
Los Angeles, California

Samuel John Ohlander MD
Assistant Professor, Urology
University of Illinois at Chicago

Chicago, Illinois

L. Henning Olsen MD, DMSc
Professor, Urology
Section of Pediatric Urology
Aarhus University Hospital
Skejby, Denmark
Professor
Institute of Clinical Medicine
Aarhus University
Aarhus, Denmark

Aria F. Olumi MD
Professor of Surgery/Urology
Department of Urologic Surgery
Beth Israel Deaconess Medical Center
Harvard Medical School
Boston, Massachusetts

Nadir I. Osman MBChB (Hons), MRCS
Department of Urology
Royal Hallmashire Hospital
Sheffield, South Yorkshire, United Kingdom

Brandon J. Otto MD
Assistant Professor, Urology
University of Florida
Gainesville, Florida

Priya Padmanabhan MD, MPH
Assistant Professor, Pelvic Reconstruction and Voiding Dysfunction
The University of Kansas
Kansas City, Kansas

Rodrigo Lessi Pagani MD
Assistant Professor, Urology
University of Illinois at Chicago
Chicago, Illinois

Lance C. Pagliaro MD
Professor
Department of Genitourinary Medical Oncology
The University of Texas MD Anderson Cancer Center
Houston, Texas

Ganesh S. Palapattu MD
Chief of Urologic Oncology
Associate Professor, Urology
University of Michigan
Ann Arbor, Michigan

Drew A. Palmer MD
Endourology Fellow
Department of Urology
University of North Carolina at Chapel Hill
Chapel Hill, North Carolina

Jeffrey S. Palmer MD, FACS, FAAP
Director, Pediatric and Adolescent Urology Institute
Cleveland, Ohio

Lane S. Palmer MD, FACS
Professor and Chief, Pediatric Urology
Cohen Children's Medical Center of New York
Zucker School of Medicine of Hofstra/Northwell
Long Island, New York

Meyeon Park MD, MAS
Assistant Professor in Residence, Medicine
University of California–San Francisco
San Francisco, California

William P. Parker MD
Department of Urology
University of Kansas Health System
Kansas City, Kansas

Alan W. Partin MD, PhD
The Jakurski Family Director
Urologist-in-Chief
Chairman, Department of Urology
Professor, Departments of Urology, Oncology and Pathology
Johns Hopkins Medical Institutions
Baltimore, Maryland

Roshan M. Patel MD
Clinical Instructor
Department of Urology
University of California–Irvine
Orange, California

Margaret S. Pearle MD, PhD
Professor, Urology, Internal Medicine
University of Texas Southwestern Medical Center
Dallas, Texas

David F. Penson MD, MPH
Professor and Chair, Urologic Surgery
Vanderbilt University
Director
Center for Surgical Quality and Outcomes Research
Vanderbilt Institute for Medicine and Public Health
Nashville, Tennessee

Craig A. Peters MD
Chief, Pediatric Urology
Children's Health System Texas
Professor of Urology
University of Texas Southwestern Medical Center
Dallas, Texas

Curtis A. Pettaway Sr., MD
Professor
Department of Urology
University of Texas M.D. Anderson Cancer Center

Houston, Texas

Janey R. Phelps MD
Department of Anesthesia
University of North Carolina School of Medicine
Chapel Hill, North Carolina

Ryan Phillips MD, PhD
Resident Physician
Radiation Oncology and Molecular Radiation Sciences
Johns Hopkins University School of Medicine
Baltimore, Maryland

Phillip M. Pierorazio MD
Associate Professor
Urology and Oncology
Brady Urological Institute and Department of Urology
Johns Hopkins University
Baltimore, Maryland

Hans G. Pohl MD, FAAP
Associate Professor, Urology and Pediatrics
Children's National Medical Center
Washington, DC

Thomas J. Polascik MD
Professor, Urologic Surgery
Duke Comprehensive Cancer Center
Duke Cancer Institute
Durham, North Carolina

Michel Pontari MD
Professor and Vice-Chair, Urology
Lewis Katz School of Medicine at Temple University
Philadelphia, Pennsylvania

John C. Pope IV, MD
Professor, Urologic Surgery and Pediatrics

Vanderbilt University Medical Center
Nashville, Tennessee

Jay D. Raman MD, FACS
Professor and Chief, Urology
Penn State Health Milton S. Hershey Medical Center
Hershey, Pennsylvania

Ranjith Ramasamy MD
Director, Reproductive Urology
Department of Urology
University of Miami
Miami, Florida

Ardeshir R. Rastinehad DO, FACOS
Director, Focal Therapy and Interventional Urology
Associate Professor of Radiology and Urology
Icahn School of Medicine at Mount Sinai
New York, New York

Yazan F.H. Rawashdeh MD, PhD
Consultant Pediatric Urologist
Section of Pediatric Urology
Aarhus University Hospital
Aarhus, Denmark

Pramod P. Reddy MD
The Curtis Sheldon and Jeffrey Wacksman Chair of Pediatric Urology
Division of Pediatric Urology
Cincinnati Children's Hospital Medical Center
Professor of Surgery
Division of Urology
University of Cincinnati College of Medicine
Cincinnati, Ohio

W. Stuart Reynolds MD, MPH
Assistant Professor, Urologic Surgery
Vanderbilt University

Nashville, Tennessee

Koon Ho Rha MD, PhD, FACS
Professor
Department of Urology
Urological Science Institute
Yonsei University College of Medicine
Seoul, Republic of Korea

Lee Richstone MD
Chief, Urology
Long Island Jewish Medical Center
Lake Success, New York
System Vice Chairman, Urology
Northwell Health
New York, New York

Stephen Riggs MD
Urologic Oncology
Levine Cancer Institute
Charlotte, North Carolina

Richard C. Rink MD, FAAP, FACS
Emeritus Professor, Pediatric Urology
Riley Hospital for Children Indiana University School of Medicine
Faculty, Pediatric Urology
Peyton Manning Children's Hospital St. Vincent
Indianapolis, Indiana

Michael L. Ritchey MD
Professor, Urology
Mayo Clinic College of Medicine
Phoenix, Arizona

Claus G. Roehrborn MD
Professor and Chairman, Urology
University of Texas Southwestern Medical Center
Dallas, Texas

Ashley Evan Ross MD, PhD
Assistant Professor, Urology
Johns Hopkins Brady Urological Institute
Baltimore, Maryland

Sherry S. Ross MD
Department of Anesthesia
The University of North Carolina at Chapel Hill
Chapel Hill, North Carolina

Christopher C. Roth MD
Associate Professor of Urology
Louisiana State University Health Sciences Center;
Pediatric Urology
Childrens Hospital New Orleans
New Orleans, Louisiana

Kyle O. Rove MD
Urologist
St. Louis Children's Hospital
Washington University
St. Louis, Missouri

Eric S. Rovner MD
Professor
Department of Urology
Medical University of South Carolina
Charleston, South Carolina

Steven P. Rowe MD
Assistant Professor
Department of Radiology
Johns Hopkins University
Baltimore, Maryland

Matthew P. Rutman MD
Associate Professor, Urology
Columbia University College of Physicians and Surgeons

New York, New York

Simpa S. Salami MD, MPH
Assistant Professor
Department of Urology
University of Michigan
Ann Arbor, Michigan

Andrea Salonia MD, PhD
Director, Urological Research Institute
Milan, Italy

Edward M. Schaeffer MD, PhD
Professor and Chair, Urology
Northwestern University
Chicago, Illinois

Bruce J. Schlomer MD
Assistant Professor, Urology
University of Texas Southwestern Medical Center
Dallas, Texas

Michael J. Schwartz MD, FACS
Associate Professor of Urology
The Smith Institute for Urology
Hofstra Northwell School of Medicine
New Hyde Park, New York

Allen D. Seftel MD
Professor of Urology
Department of Surgery
Cooper Medical School of Rowan University
Chief, Division of Urology
Cooper University Health Care
Camden, New Jersey

Rachel Selekman MD, MAS
Instructor, Surgery

Division of Pediatric Urology
Children's National Medical Center
Washington, DC

Abhishek Seth MD
Assistant Professor, Urology
Baylor College of Medicine
Houston, Texas

Karen S. Sfanos PhD
Assistant Professor, Pathology
Johns Hopkins University School of Medicine
Baltimore, Maryland

Paras H. Shah MD
Urologic Oncology
Department of Urology
Mayo Clinic
Rochester, Minnesota

Mohammed Shahait MBBS
Clinical Instructor of Urology
University of Pittsburgh Medical Center
Pittsburgh, Pennsylvania

Robert C. Shamberger MD
Chief of Surgery
Boston Children's Hospital
Robert E. Gross Professor of Surgery
Harvard Medical School
Boston, Massachusetts

Alan W. Shindel MD, MAS
Associate Professor, Urology
University of California, San Francisco
San Francisco, California

Aseem Ravindra Shukla MD

Director of Minimally Invasive Surgery
Department of Pediatric Urology
Children's Hospital of Philadelphia
Philadelphia, Pennsylvania

Jay Simhan MD, FACS
Vice Chairman, Department of Urology
Einstein Healthcare Network
Associate Professor of Urology
Temple Health/Fox Chase Cancer Center
Philadelphia, Pennsylvania

Brian Wesley Simons DVM, PhD
Assistant Professor, Urology
Johns Hopkins University School of Medicine
Baltimore, Maryland

Eila C. Skinner MD
Professor and Chair, Urology
Stanford University
Stanford, California

Armine K. Smith MD
Assistant Professor
Brady Urological Institute
Johns Hopkins University
Assistant Professor, Urology
George Washington University
Washington, DC

Daniel Y. Song MD
Associate Professor, Radiation Oncology and Molecular Radiation Sciences
Johns Hopkins University School of Medicine
Baltimore, Maryland

Rene Sotelo MD
Physician, Surgeon, Urologist
Minimally Invasive and Robotic Surgery Center

Instituto Medico La Floresta, Caracas
Miranda, Venezuela

Michael W. Sourial MD, FRCSC
Assistant Professor, Urology
Wexner Medical Center
The Ohio State University
Columbus, Ohio

Anne-Françoise Spinoit MD, PhD
Pediatric and Reconstructive Urologist
Department of Urology
Ghent University Hospital
Ghent, Belgium

Arun K. Srinivasan MD
Pediatric Urologist
Children's Hospital of Philadelphia
Philadelphia, Pennsylvania

Ramaprasad Srinivasan MD, PhD
Head, Molecular Cancer Section
Urologic Oncology Branch
Center for Cancer Research
National Cancer Institute
National Institutes of Health
Bethesda, Maryland

Irina Stanasel MD
Assistant Professor, Urology
University of Texas Southwestern Medical Center/Children's Health
Dallas, Texas

Andrew J. Stephenson MD, MBA, FRCSC, FACS
Associate Professor of Surgery
Department of Urology
Cleveland Clinic Lerner College of Medicine
Case Western Reserve University

Director, Urologic Oncology
Glickman Urological and Kidney Institute
Cleveland Clinic
Cleveland, Ohio

Julie N. Stewart MD
Assistant Professor
Department of Urology
Houston Methodist Hospital
Houston, Texas

John Stites MD
Minimally Invasive and Robotic Urologic Surgery
Hackensack University Medical Center
Hackensack, New Jersey

Douglas W. Storm MD, FAAP
Assistant Professor
Department of Urology
University of Iowa Hospitals and Clinics
Iowa City, Iowa

Douglas William Strand PhD
Assistant Professor, Urology
University of Texas Southwestern Medical Center
Dallas, Texas

Li-Ming Su MD
David A. Cofrin Professor of Urologic Oncology
Chairman, Department of Urology
University of Florida College of Medicine
Gainesville, Florida

Chandru P. Sundaram MD, FACS, FRCS (Eng)
Professor, Urology
Indiana University School of Medicine
Program Director and Director of Minimally Invasive Surgery
Department of Urology

Indiana University School of Medicine
Indianapolis, Indiana

Samir S. Taneja MD
James M. and Janet Riha Neissa Professor of Urologic Oncology
Departments of Urology and Radiology
NYU Langone Medical Center
New York, New York

Nikki Tang MD
Assistant Professor, Dermatology
Johns Hopkins University
Baltimore, Maryland

Gregory E. Tasian MD, MSc, MSCE
Assistant Professor, Urology and Epidemiology
University of Pennsylvania–Perelman School of Medicine
Attending Physician, Urology
The Children's Hospital of Philadelphia
Philadelphia, Pennsylvania

Kae Jack Tay MBBS, MRCS (Ed), MMed (Surgery), MCI, FAMS (Urology)
Consultant
Department of Urology
Singapore General Hospital
SingHealth Duke-NUS Academic Medical Center
Singapore

John C. Thomas MD, FAAP, FACS
Associate Professor of Urologic Surgery
Division of Pediatric Urology
Monroe Carell Jr. Children's Hospital at Vanderbilt
Nashville, Tennessee

J. Brantley Thrasher MD, FACS
William L Valk Distinguished Professor
Department of Urology
University of Kansas Medical Center

Kansas City, Kansas

Edouard J. Trabulsi MD, FACS
Professor
Department of Urology
Kimmel Cancer Center
Sidney Kimmel Medical College
Thomas Jefferson University
Philadelphia, Pennsylvania

Chad R. Tracy MD
Assistant Professor, Urology
University of Iowa
Iowa City, Iowa

Paul J. Turek MD, FACS, FRSM
Director
The Turek Clinic
San Francisco, California

Mark D. Tyson MD, MPH
Department of Urology
Mayo Clinic College of Medicine and Science
Phoenix, Arizona

Robert G. Uzzo MD, FACS
Professor and Chairman
Department of Surgery
The G. Willing “Wing” Pepper Professor in Cancer Research
Adjunct Professor of Bioengineering
Temple University College of Engineering
Fox Chase Cancer Center–Temple University Health System
Lewis Katz School of Medicine
Philadelphia, Pennsylvania

Brian A. VanderBrink MD
Urologist
Division of Urology

Cincinnati Children's Hospital
Cincinnati, Ohio

Alex J. Vanni MD, FACS
Associate Professor
Department of Urology
Lahey Hospital and Medical Center
Burlington, Massachusetts

David J. Vaughn MD
Professor of Medicine
Division of Hematology/Oncology
Department of Medicine
Abramsom Cancer Center at the University of Pennsylvania
Philadelphia, Pennsylvania

Vijaya M. Vemulakonda MD, JD
Associate Professor of Pediatric Urology
Division of Urology
Department of Surgery
University of Colorado School of Medicine
Aurora, Colorado

Manish A. Vira MD
Vice Chair of Urologic Research
Smith Institute for Urology
Northwell Health
Lake Success, New York
Associate Professor of Urology
Zucker School of Medicine of Hofstra/Northwell
Hempstead, New York

Ramón Virasoro MD
Associate Professor, Urology
Eastern Virginia Medical School
Norfolk, Virginia
Fellowship Director, Urology
Universidad Autonoma de Santo Domingo

Santo Domingo, Dominican Republic

Alvin C. Wee MD
Surgical Director, Kidney Transplantation
Glickman Urological and Kidney Institute
Cleveland Clinic
Cleveland, Ohio

Elias Wehbi MD, FRCSC
Assistant Professor
Department of Urology–Division of Pediatric Urology
University of California Irvine
Orange, California

Alan J. Wein MD, PhD (Hon), FACS
Founders Professor and Emeritus Chief of Urology
Co-Director, Urologic Oncology Program
Co-Director, Voiding Function and Dysfunction Program
Division of Urology
Penn Medicine, Perelman School of Medicine
Philadelphia, Pennsylvania

Dana A. Weiss MD
Assistant Professor, Urology
University of Pennsylvania
Attending Physician, Urology
The Childrens Hospital of Philadelphia
Philadelphia, Pennsylvania

Jeffrey P. Weiss MD, FACS
Professor and Chair
Department of Urology
SUNY Downstate College of Medicine
Brooklyn, New York

Robert M. Weiss MD
Donald Guthrie Professor of Surgery/Urology
Yale University School of Medicine

New Haven, Connecticut

Charles Welliver Jr., MD
Assistant Professor
Division of Urology
Albany Medical College
Albany, New York

Hunter Wessells MD, FACS
Professor and Nelson Chair
Department of Urology
Affiliate Member
Harborview Injury Prevention and Research Center
University of Washington
Seattle, Washington

Duncan T. Wilcox MD, MBBS
Surgeon-in-Chief
Ponzio Family Chair of Pediatric Urology
Department of Pediatric Urology
Children's Hospital Colorado
Aurora, Colorado

Jack Christian Winters MD, FACS
Professor and Chairman, Urology
Louisiana State University Health Sciences Center
New Orleans, Louisiana

Anton Wintner MD
Instructor in Surgery
Harvard Medical School
Assistant in Urology
Massachusetts General Hospital
Boston, Massachusetts

J. Stuart Wolf Jr., MD, FACS
Professor and Associate Chair for Clinical Integration and Operations
Departments of Surgery and Perioperative Care

Dell Medical School
The University of Texas at Austin
Austin, Texas

Christopher E. Wolter MD
Assistant Professor, Urology
Mayo Clinic Arizona
Phoenix, Arizona

Dan Wood PhD
Consultant Urologist in Adolescent and Reconstructive Surgery
The University College Hospitals
London, United Kingdom

Michael E. Woods MD
Associate Professor, Urology
University of North Carolina
Chapel Hill, North Carolina

Hailiu Yang MD
Department of Urology
Cooper Health
New York, New York

Richard Nithiphaisal Yu MD, PhD
Pediatric Urology Attending
Department of Urology
Boston Children's Hospital
Boston, Massachusetts

Joseph Zabell MD
Assistant Professor
Department of Urology
University of Minnesota
Minneapolis, Minnesota

Mark R. Zaontz MD
Professor of Clinical Urology in Surgery

Perelman School of Medicine
University of Pennsylvania
Attending Physician, Urology
Children's Hospital of Philadelphia
Philadelphia, Pennsylvania

Rebecca S. Zee MD, PhD
Chief Resident of Urology
University of Virginia School of Medicine
Charlottesville, Virginia

Video Contents

- PART I **Clinical Decision Making**
  - Chapter 4 **Urinary Tract Imaging: Basic Principles of Urologic Ultrasonography**
    - **Video 4.1 Importance of survey scans.** *Courtesy Bruce R. Gilbert and Pat F. Fulgham*
    - **Video 4.2 Perineal ultrasound.** *Courtesy Bruce R. Gilbert and Pat F. Fulgham*
- PART II **Basics of Urologic Surgery**
  - Chapter 11 **Lower Urinary Tract Catheterization**
    - **Video 11.1 Female urethral catheterization.** *Courtesy Jay Sulek and Chandru Sundaram*
    - **Video 11.2 Male urethral catheterization.** *Courtesy Jay Sulek and Chandru P. Sundaram*
  - Chapter 12 **Fundamentals of Upper Urinary Tract Drainage**
    - **Video 12.1 “Eye-of-the-needle” fluoroscopically guided antegrade access into the upper urinary tract collecting system.** *Courtesy J.*

Stuart Wolf, Jr.

Chapter 13 **Principles of Urologic Endoscopy**

Video 13.1 Ureteroscopy and retrograde ureteral access. *Courtesy Ben H. Chew and John D. Denstedt*

PART III **Pediatric Urology**

SECTION A Development and Prenatal Urology

Chapter 22 **Perinatal Urology**

Video 22.1 Prenatal urinary tract dilation of the fetal kidneys. *Courtesy C.D. Anthony Herndon and Rebecca S. Zee*

Video 22.2 Fetal measurement of amniotic fluid index. *Courtesy C.D. Anthony Herndon and Rebecca S. Zee*

Video 22.3 Fetal ultrasound documenting multicystic dysplastic kidney. *Courtesy C.D. Anthony Herndon and Rebecca S. Zee*

SECTION B Basic Principles

Chapter 23 **Urologic Evaluation of the Child**

Video 23.1 Male examination. *Courtesy Rachel Selekman and Hillary Copp*

Video 23.2 Female examination. *Courtesy Rachel Selekman and Hillary Copp*

Chapter 27 **Principles of Laparoscopic and Robotic Surgery in Children**

Video 27.1 Robotic-assisted ureteral reimplantation. *Courtesy Thomas Sean Lendvay and Jonathan Ellison*
Video 27.2 Robotic-assisted ureteroureterostomy. *Courtesy Thomas Sean Lendvay and Jonathan Ellison*
Video 27.3 Robotic-assisted buccal graft pyeloureteroplasy with omental quilting. *Courtesy Thomas Sean Lendvay and Jonathan Ellison*
Video 27.4 Robotic-assisted ureteral polyp resection. *Courtesy Thomas Sean Lendvay and Jonathan Ellison*
SECTION C Lower Urinary Tract Conditions
Chapter 32 Prune-Belly Syndrome
Video 32.1 Abdominoplasty in prune-belly syndrome. *Courtesy Francisco T. Dénes and Roberto Iglesias Lopes*
Chapter 33 Posterior Urethral Valves
Video 33.1 Cystoscopic incision and ablation of posterior urethral valve. *Courtesy Drs. Long, Shukla, and Srinivasan*
Video 33.2 Repair of Y-configuration urethral duplication. *Courtesy Drs. Srinivasan and Bowen*
Chapter 37 Lower Urinary Tract Reconstruction in Children
Video 37.1 Implanting catheterizable channel into

bladder. *Courtesy John C. Thomas and Mark C. Adams*
Video 37.2 Catheterizable channel (Monti). *Courtesy John C. Thomas and Mark C. Adams*
Video 37.3 Laparoscopic-assisted MACE in children. *Courtesy Steven G. Docimo*

SECTION E Genitalia

Chapter 45 Hypospadias

Video 45.1 First stage proximal hypospadias repair with dermal patch graft correction of ventral penile curvature
Video 45.2 First stage hypospadias repair with dermal graft correction of ventral chordee and free inner preputial graft glansplasty
Video 45.3 Reverse pedicle barrier flap for circumcised boys with hypospadias
Video 45.4 Belman flap
Video 45.5 Meatal advancement glansplasty (MAGPI)
Video 45.6 M inverted V plasty (MIV)
Video 45.7 Thiersch-Duplay
Video 45.8 Thiersch-Duplay without meatoplasty
Video 45.9 Duckett tube
Video 45.10 Second stage urethroplasty with tunica

        - **vaginalis coverage**
        - **Video 45.11 First stage repair of perineal hypospadias with penoscrotal transposition**
        - **Video 45.12 Buccal graft interposition for complex hypospadias reconstruction**
        - **Video 45.13 Closure of urethrocutaneous fistula**
        - **Video 45.14 Repeat Thiersch-Duplay for coronal urethrocutaneous fistula**
        - **Video 45.15 Buccal mucosa graft inlay**
        - **Video 45.16 Urethral diverticulum closure**
    - Chapter 46 **Etiology, Diagnosis, and Management of Undescended Testis**
        - **Video 46.1 Inguinal orchidopexy**
        - **Video 46.2 Transscrotal orchidopexy**
        - **Video 46.3 Laparoscopic orchiopexy**
- PART VI **Reproductive and Sexual Function**
    - Chapter 67 **Surgical Management of Male Infertility**
        - **Video 67.1 General preparation for vasovasostomy.** *Courtesy Marc Goldstein*
        - **Video 67.2 Surgical techniques for vasovasostomy.** *Courtesy Marc Goldstein*
        - **Video 67.3 Microsurgical**

vasovasostomy (microdot suture placements). *Courtesy Marc Goldstein*

Video 67.4 General preparation for vasoepididymostomy. *Courtesy Marc Goldstein*

Video 67.5 Preparation for anastomosis in vasoepididymostomy. *Courtesy Marc Goldstein*

Video 67.6 Varicocelectomy. *Courtesy Marc Goldstein*

Video 67.7 Vasography. *Courtesy Marc Goldstein*

Video 67.8 Vasography and transurethral resection of the ejaculatory ducts. *Courtesy Marc Goldstein*

Chapter 72 Surgery for Erectile Dysfunction

Video 72.1 Implantation of AMS 700 LGX inflatable penile prosthesis. *Courtesy Drogo K. Montague*

Video 72.2 Prosthetic surgery for erectile dysfunction. *Courtesy Drogo K. Montague*

Chapter 73 Diagnosis and Management of Peyronie's Disease

Video 73.1 Reconstruction for Peyronie's disease: incision and grafting. *Courtesy Gerald H. Jordan*

PART VII **Male Genitalia**

- Chapter 75 **Surgical, Radiographic, and Endoscopic Anatomy of the Retroperitoneum**
  - **Video 75.1 Interaortal caval region.** *Courtesy James Kyle Anderson*
  - **Video 75.2 Right retroperitoneum.** *Courtesy James Kyle Anderson*
  - **Video 75.3 Left lumbar vein.** *Courtesy James Kyle Anderson*
  - **Video 75.4 Lumbar artery.** *Courtesy James Kyle Anderson*
- Chapter 77 **Surgery of Testicular Tumors**
  - **Video 77.1 Retroperitoneal lymph node dissection: the split and roll technique.** *Courtesy Kevin R. Rice, K. Clint Cary, Timothy A. Masterson, and Richard S. Foster*
- Chapter 78 **Laparoscopic and Robotic-Assisted Retroperitoneal Lymphadenectomy for Testicular Tumors**
  - **Video 78.1 Laparoscopic retroperitoneal lymph node dissection: patient 1.** *Courtesy Frederico R. Romero, Soroush Rais-Bahrami, and Louis R.*

Kavoussi

- Chapter 79 **Tumors of the Penis**
    - **Video 79.1 Partial penectomy.** *Courtesy Curtis A. Pettaway, Juanita M. Crook, Lance C. Pagliaro*
    - **Video 79.2 Low dose rate brachytherapy.** *Courtesy Curtis A. Pettaway, Juanita M. Crook, Lance C. Pagliaro*
- Chapter 80 **Tumors of the Urethra**
    - **Video 80.1 Male total urethrectomy.** *Courtesy Hadley M. Wood and Kenneth W. Angermeier*

PART VIII **Renal Physiology and Pathophysiology**

- Chapter 84 **Surgical, Radiologic, and Endoscopic Anatomy of the Kidney and Ureter**
    - **Video 84.1 Left gonadal vein.** *Courtesy James Kyle Anderson*
    - **Video 84.2 Left renal hilum.** *Courtesy James Kyle Anderson*
    - **Video 84.3 Right kidney before dissection.** *Courtesy James Kyle Anderson*
    - **Video 84.4 Left lower pole crossing vessel.** *Courtesy James Kyle Anderson*
    - **Video 84.5 Digital nephroscopy: the next step.**

Reproduced with permission from Andonian S, Okeke Z, Anijar M, et al. Digital nephroscopy: the next step. J Endourol Part B Videourology *24, 2010a.*

Video 84.6 Digial ureteroscopy: the next step. *Reproduced with permission from Andonian S, Okeke Z, Smith AD: Digital ureteroscopy: the next step.* J Endourol Part B Videourology *24, 2010b.*

Chapter 88 **Urological Complications of Renal Transplantation**

Video 88.1 Technique of laparoscopic live donor nephrectomy. *Courtesy Michael Joseph Conlin and John Maynard Barry*

Video 88.2 Laparoscopic live donor nephrectomy. *Louis R. Kavoussi*

PART IX **Upper Urinary Tract Obstruction and Trauma**

Chapter 89 **Management of Upper Urinary Tract Obstruction**

Video 89.1 Laparoscopic pyeloplasty. *Courtesy Frederico R. Romero, Soroush Rais-Bahrami, and Louis R. Kavoussi*

Video 89.2 Robotic-assisted laparoscopic pyeloplasty.

Courtesy Sutchin R. Patel and Sean P. Hedican

PART X **Urinary Lithiasis and Endourology**

- Chapter 94 **Surgical Management for Upper Urinary Tract Calculi**
  - **Video 94.1 Blast wave lithotripsy.** *Courtesy Brian R. Matlaga and Amy E. Krambeck*
  - **Video 94.2 Shock wave lithotripsy.** *Courtesy Brian R. Matlaga and Amy E. Krambeck*
  - **Video 94.3 Shockpulse lithotripsy.** *Courtesy Brian R. Matlaga and Amy E. Krambeck*
  - **Video 94.4 Venturi effect.** *Courtesy Brian R. Matlaga and Amy E. Krambeck*

PART XI **Neoplasms of the Upper Urinary Tract**

- Chapter 101 **Open Surgery of the Kidney**
  - **Video 101.1 Patient case study.** *Courtesy Aria F. Olumi and Michael L. Blute*
  - **Video 101.2 Global ischemia.** *Courtesy Aria F. Olumi and Michael L. Blute*
  - **Video 101.3 Regional ischemia.** *Courtesy Aria F. Olumi and Michael L. Blute*
  - **Video 101.4 Vena cava tumor thrombectomy.** *Courtesy Aria*

F. Olumi and Michael L. Blute

Chapter 102 **Laparoscopic and Robotic Surgery of the Kidney**

- **Video 102.1 Laparoscopic partial nephrectomy.** *Courtesy Frederico R. Romero, Soroush Rais-Bahrami, and Louis R. Kavoussi*

Chapter 103 **Nonsurgical Focal Therapy for Renal Tumors**

- **Video 103.1 Percutaneous renal cryoablation.** *Courtesy Arvin K. George, Zhamshid Okhunov, Soroush Rais-Bahrami, Sylvia Montag, Igor Lobko, and Louis R. Kavoussi*

PART XII **The Adrenals**

Chapter 105 **Surgical and Radiographic Anatomy of the Adrenals**

- **Video 105.1 Left adrenal vein.** *Courtesy James Kyle Anderson*
- **Video 105.2 Right adrenal vein.** *Courtesy James Kyle Anderson*

Chapter 107 **Surgery of the Adrenal Glands**

- **Video 107.1 Laparoscopic adrenalectomy.** *Courtesy Frederico R. Romero, Soroush Rais-Bahrami, and Louis R. Kavoussi*

PART XIII **Urine Transport, Storage, and Emptying**

Chapter 110 Physiology and Pharmacology of the Bladder and Urethra

- **Video 110.1 Urothelial cells responding to carbachol, a nonspecific muscarinic agonist.** *Courtesy Toby C. Chai, University of Maryland School of Medicine*
- **Video 110.2 Actin-myosin cross bridge cycling.** *Courtesy Toby C. Chai, Yale School of Medicine*
- **Video 110.3 Digital calcium fluorescent microscopy of a muscle myocyte contraction.** *Courtesy George J. Christ, David Burmeister, and Josh Tan, Wake Forest University School of Medicine*
- **Video 110.4 Calcium spark development in myocyte.** *Courtesy Toby C. Chai, Yale School of Medicine*

Chapter 112 Evaluation and Management of Women With Urinary Incontinence and Pelvic Prolapse

- **Video 112.1 Discussion of normal lower urinary tract function.** *Courtesy Roger Dmochowski*
- **Video 112.2 Live interview of a patient with pelvic floor disorders.** *Courtesy Roger*

Dmochowski

Video 112.3 Case study of a patient with mixed urinary incontinence. *Courtesy Roger Dmochowski*

Video 112.4 Examination of a patient with significant anterior vaginal wall prolapse. *Courtesy Roger Dmochowski*

Video 112.5 Case study of a patient with symptomatic prolapse and incontinence. *Courtesy Roger Dmochowski*

Video 112.6 Demonstration of “eyeball” filling study in a patient with incontinence and prolapse. *Courtesy Roger Dmochowski*

Video 112.7 Q-tip test in a patient with minimal urethral mobility. *Courtesy Roger Dmochowski*

Chapter 114 **Urodynamic and Video-Urodynamic Evaluation of the Lower Urinary Tract**

Video 114.1 Overview of urodynamic studies in female pelvic floor dysfunction. *Courtesy Alan J. Wein, Louis R. Kavoussi, Alan W. Partin, and Craig A. Peters*

Chapter 115 **Urinary Incontinence and**

Pelvic Prolapse: Epidemiology and Pathophysiology
    - **Video 115.1 The Pelvic Organ Prolapse Quantification (POPQ) system.** *Courtesy Jennifer T. Anger and Gary E. Lemack*
- Chapter 125 **Slings: Autologous, Biologic, Synthetic, and Midurethral**
    - **Video 125.1 Distal urethral polypropylene sling.** *Courtesy Shlomo Raz and Larissa Rodriguez*
    - **Video 125.2 Rectus fascia pubovaginal sling procedure.** *Courtesy Alan J. Wein, Louis R. Kavoussi, Alan W. Partin, and Craig A. Peters*
    - **Video 125.3 Top-down retropubic mid-urethral sling: SPARC.** *Courtesy Alan J. Wein, Louis R. Kavoussi, Alan W. Partin, and Craig A. Peters*
    - **Video 125.4 Outside-in transobturator mid-urethral sling: MONARC.** *Courtesy Alan J. Wein, Louis R. Kavoussi, Alan W. Partin, and Craig A. Peters*
    - **Video 125.5 MiniArc single-incision sling system.** *Courtesy Alan J. Wein, Louis*

R. Kavoussi, Alan W. Partin, and Craig A. Peters

Chapter 129 Urinary Tract Fistulae

- **Video 129.1 Robotic-assisted laparoscopic repair of complex vesicovaginal fistula in a patient with failed open surgical and vaginal repair.** *Courtesy Ashok K. Hemal and Gopal H. Badlani*
- **Video 129.2 Martius flap.** *Courtesy Shlomo Raz and Larissa Rodriguez*
- **Video 129.3 Transvaginal repair of a vesicovaginal fistula using a peritoneal flap.** *Courtesy Shlomo Raz and Larissa Rodriguez*
- **Video 129.4 Transvaginal bladder neck closure with posterior urethral flap.** *Courtesy Brett D. Lebed, J. Nathaniel Hamilton, and Eric S. Rovner*

Chapter 131 Surgical Procedures for Sphincteric Incontinence in the Male

- **Video 131.1 Surgical treatment of the male sphincteric urinary incontinence: the male perineal sling and artificial urinary sphincter.** *Courtesy David R. Staskin and Craig V. Comitor*

- **Video 131.2 Male sling.** *Courtesy Hunter Wessells*

PART XIV **Benign and Malignant Bladder Disorders**

- Chapter 133 **Genital and Lower Urinary Tract Trauma**
  - **Video 133.1 Technique demonstrating protection of phallus during removal of penile strangulation device.** *Courtesy Allen F. Morey and Jay Simhan*
- Chapter 134 **Special Urologic Considerations in Transgender Individuals**
  - **Video 134.1 Creation of the neo-urethra**
  - **Video 134.2 Creation of the neoscrotum**
  - **Video 134.3 Procedure for implantation of erectile device**
- Chapter 135 **Tumors of the Bladder**
  - **Video 135.1 Patient case studies using blue light cystoscopy (BLC).** *Courtesy Max Kates and Trinity J. Bivalacqua*
- Chapter 136 **Management Strategies for Non–Muscle-Invasive Bladder Cancer (Ta, T1, and CIS)**
  - **Video 136.1 Demonstration of the technique of en bloc resection of bladder tumor**

completed cystoscopically with a resectoscope and bipolar cutting loop. *Courtesy Giulia Lane*

Chapter 140 **Cutaneous Continent Urinary Diversion**

Video 140.1 Stapled right colon reservoir with appendiceal stoma. *Courtesy Mitchell C. Benson*

Chapter 141 **Orthotopic Urinary Diversion**

Video 141.1 T-pouch ileal neobladder. *Courtesy Eila C. Skinner, Donald G. Skinner, and Hugh B. Perkin*

Video 141.2 The modified Studer ileal neobladder. *Courtesy Siamak Daneshmand*

PART XV **The Prostate**

Chapter 146 **Minimally Invasive and Endoscopic Management of Benign Prostatic Hyperplasia**

Video 146.1 Holmium laser enucleation of the prostate (HoLEP). *Courtesy Mitra R. de Cógáin and Amy E. Krambeck*

Chapter 147 **Simple Prostatectomy: Open and Robot-Assisted Laparoscopic Approaches**

Video 147.1 Robot-assisted laparoscopic simple prostatectomy. *Courtesy*

Misop Han

Chapter 151 **Prostate Biopsy: Techniques and Imaging**

Video 151.1 Images from a transrectal prostate biopsy. *Courtesy Leonard G. Gomella, Ethan J. Halpern, and Edouard J. Trabulsi*

Video 151.2 Ultrasonography and biopsy of the prostate. *Courtesy Daniel D. Sackett, Ethan J. Halpern, Steve Dong, Leonard G. Gomella, and Edouard J. Trabulsi*

Chapter 155 **Open Radical Prostatectomy**

Video 155.1 Radical retropubic prostatectomy. *Courtesy Herbert Lepor and Dmitry Volkin*

Video 155.2 High release of the neurovascular bundle. *Courtesy Patrick C. Walsh*

Video 155.3 Incision on the endopelvic fascia and division of puboprostatic ligaments. *Courtesy Patrick C. Walsh*

Video 155.4 Control of the dorsal vein complex. *Courtesy Patrick C. Walsh*

Video 155.5 Division of the urethra and placement of the urethral sutures. *Courtesy*

Patrick C. Walsh

Video 155.6 Division of the posterior striated sphincter. *Courtesy Patrick C. Walsh*

Video 155.7 Preservation of the neurovascular bundle. *Courtesy Patrick C. Walsh*

Video 155.8 Use of the Babcock clamp during release of the neurovascular bundle. *Courtesy Patrick C. Walsh*

Video 155.9 Wide excision of the neurovascular bundle. *Courtesy Patrick C. Walsh*

Video 155.10 Reconstruction of the bladder neck and vesicourethral anastomosis. *Courtesy Patrick C. Walsh*

Video 155.11 Use of the Babcock clamp during vesicourethral anastomosis. *Courtesy Patrick C. Walsh*

Chapter 156 Laparoscopic and Robotic-Assisted Radical Prostatectomy and Pelvic Lymphadenectomy

Video 156.1 Operating room setup. *Courtesy Li-Ming Su and Jason P. Joseph*

Video 156.2 Vas and seminal vesicle dissection. *Courtesy Li-Ming Su and Jason P. Joseph*

Video 156.3 Posterior

dissection. *Courtesy Li-Ming Su and Jason P. Joseph*

Video 156.4 Entering retropubic space. *Courtesy Li-Ming Su and Jason P. Joseph*

Video 156.5 Endopelvic fascia and puboprostatics. *Courtesy Li-Ming Su and Jason P. Joseph*

Video 156.6 Dorsal venous complex ligation. *Courtesy Li-Ming Su and Jason P. Joseph*

Video 156.7 Anterior bladder neck transection. *Courtesy Li-Ming Su and Jason P. Joseph*

Video 156.8 Posterior bladder neck transection. *Courtesy Li-Ming Su and Jason P. Joseph*

Video 156.9 Bladder neck dissection: anterior approach. *Courtesy Li-Ming Su and Jason P. Joseph*

Video 156.10 Neurovascular bundle dissection. *Courtesy Li-Ming Su and Jason P. Joseph*

Video 156.11 Division of dorsal venous complex and apical dissection. *Courtesy Li-Ming*

Su and Jason P. Joseph

Video 156.12 Pelvic lymph node dissection. *Courtesy Li-Ming Su and Jason P. Joseph*

Video 156.13 Entrapment of prostate and lymph nodes. *Courtesy Li-Ming Su and Jason P. Joseph*

Video 156.14 Posterior reconstruction. *Courtesy Li-Ming Su and Jason P. Joseph*

Video 156.15 Vesicourethral anastomosis. *Courtesy Li-Ming Su and Jason P. Joseph*

Video 156.16 Extraction of specimen. *Courtesy Li-Ming Su and Jason P. Joseph*

Volume I

OUTLINE

Part I Clinical Decision Making
Part II Basics of Urologic Surgery
Part III Pediatric Urology

PART I

Clinical Decision Making

OUTLINE

1 Evaluation of the Urologic Patient History and Physical Examination

2 Evaluation of the Urologic Patient Testing and Imaging

3 Urinary Tract Imaging Basic Principles of CT, MRI, and Plain Film Imaging

4 Urinary Tract Imaging Basic Principles of Urologic Ultrasonography

5 Urinary Tract Imaging Basic Principles of Nuclear Medicine

6 Assessment of Urologic and Surgical Outcomes

7 Ethics and Informed Consent

Evaluation of the Urologic Patient

History and Physical Examination

Sammy E. Elsamra MD

The evaluation of a patient must always begin with a thorough and appropriate history and physical examination. By using an organized system of information accrual, the urologist can gather information pertinent to the cause (or contributing factors) of a disease and obtain information salient to its treatment. To do so reliably for every patient, a reproducible system of history and physical examination has been developed and is taught routinely at all medical schools, usually in the preclinical years. Laboratory and radiologic examinations should be performed based on the findings of history and physical examination to narrow the differential diagnosis and arrive at an accurate diagnosis. A proper history and physical examination also allow for the development of rapport and trust between physician and patient, which can prove invaluable in counseling patients on subsequent diagnostic and treatment decisions.

Often health care providers are tempted to solicit information from the medical record or previously obtained labs and images. Although reviewing such data is critical, the urologist must be careful not to fall into the trap of relying too heavily on this data without input from the patient; chart lore, aberrant labs, and “incidentalomas” encountered may steer subsequent diagnostic evaluations and treatment away from the true illness. In our practice we have encountered patients with hematuria whose penile tumor is identified on physical examination.

This chapter provides a concise yet comprehensive discussion pertinent to the urologist of taking a history and performing a physical exam.

History

Overview

The medical history is the foundation for the evaluation and management of urologic patients. Often a well-obtained history provides the diagnosis or at least properly directs the health care provider to arrive at the correct diagnosis. Establishing several parameters helps to optimize the encounter. First, the environment should be warm, comforting, and nonthreatening for the patient. If the provider has any control over the waiting room or intake process, these should be made as easy as possible for the patient to navigate; this avoids agitating the patient before beginning the provider-patient encounter. Difficulties with parking or with front office staff may upset a patient before meeting the provider. The patient is directed to the examination room; ideally the physician reviews the patient's vitals and prior records before entering this room. A physician's knock before entering the room and an introduction upon entering help to put the patient at ease. If possible, the room should be properly set up for ideal provider-patient positioning, face to face, without any barriers (especially a computer). If a computer is used during the session, the provider ideally should still face the patient and place the computer off to the side so that the patient does not feel secondary to the computer. Although such factors may seem insignificant, it is clear that nonverbal communication is most responsible for communicating emotions, attitudes, and affect (Silverman and Kinnersley, 2010). In fact, studies have shown that patients may reveal more or less information based on level of eye contact and physician posture during the encounter (Byrne and Heath, 1980).

In addition to establishing an optimal setup, the physician must appreciate the patients' level of comprehension. Whether this entails assessing their ability to communicate in interview language or their ability to comprehend complex matters, the physician must assess level of comprehension by reading nonverbal cues or asking patients to summarize the discussion. Further, the patient encounter may be enhanced by the presence of a family member or friend. Often patients may not be as aware of pertinent historical details that family members may be able to supply. Further, when patients are given difficult news (e.g., cancer diagnosis, recommendation to remove an organ), they often cease to listen effectively (Kessels, 2003). The family member or friend may be able to focus, take notes, and relay the information provided by the physician to the patient at a time when the shock of the unfortunate news has passed. Even without shocking news, some instructions or discussions regarding risks, benefits, and alternative treatments may be lengthy and complex, and a second person in audience helps reinforce that information.

A complete history includes the chief complaint, history of present illness (HPI), past medical and surgical history, history of allergic reactions, social and family history, and a review of systems. The surgeon should obtain this information in a direct fashion. Patients should be given the opportunity to express any concerns or pertinent history, but often the physician must focus the conversation to obtain the information necessary to make a diagnosis and avoid pitfalls in treatment.

Chief Complaint

Often patients can identify an issue as urologic. Therefore they may present directly to the urologist with a particular problem or chief complaint. The chief complaint is the reason why the patient is seeking urologic care; this should be the urologist's focus. Although other urologic issues may be identified, the urologist's goal should be to target the chief complaint to allay the patient's immediate concerns. For example, the patient presents with urinary frequency is identified to have a renal mass; addressing the renal mass but not addressing the urinary frequency may be seen as ineffective care by the patient. With a clear chief complaint, the urologist should begin to think of a differential diagnosis and then narrow the possibilities with the HPI.

History of Present Illness

The HPI incorporates questions to identify the timing, severity, nature, and factors that may exacerbate or relieve the issue identified in the chief complaint. For an efficient HPI, the urologist creates a differential diagnosis based on the chief complaint and then asks questions to help support or oppose a diagnosis on the differential list.

The following sections review a variety of typical chief complaints to highlight considerations for the HPI.

Pain

Pain can often be a chief complaint or a factor elicited while obtaining the HPI. The astute clinician must be able to identify the location of pain and characterize its nature; this information will help pinpoint the cause or, at a minimum, direct further examination and testing. It is prudent to assess the onset and duration and to ascertain if this pain episode has occurred previously. In our practice, we have encountered patients with initial obstructive ureteral stones with renal colic (and little experience with kidney stones) who often inappropriately attribute the pain to some gastrointestinal or musculoskeletal cause. However, the same patient will then become very familiar with the nature of this obstructing stone pain and associated symptoms and readily identify the presence of an obstructing stone upon recurrence of such pain.

Often patients can localize pain. While gathering the HPI, the physician should direct patients to point to the site of maximal pain with one finger. An important distinction is made between pain and tenderness. Later in the physical examination, the physician must assess if there is tenderness (pain with palpation) in that location or elsewhere. Although pain and tenderness often overlap in location, a site of pain without tenderness may be the result of referred pain. An example is testicular pain without testicular tenderness; the pain in the testicle can often be referred pain from an obstructing ipsilateral ureteral stone.

The severity of the pain should be assessed and documented. Pain severity can be characterized as mild, moderate, or severe or based on a 1-to-10 scale. This commonly used scale as described by Wong and Baker in 1988 uses face illustrations with increasing appearance of distress/discomfort along a 10-point scale (Wong and Baker, 1988). This scale helps document the severity of pain before and after intervention.

Pain can be due to distention from obstruction or inflammation within the parenchyma of a genitourinary (GU) organ. Obstructive pain results in distention of a hollow organ (or hollow portion) of the organ resulting from some obstruction (e.g., ureteral stone for renal pelvis or ureter and bladder outlet obstruction for bladder). In the kidney, for example, this can result in colicky-type pain, typified by a patient with intermittent pain for which the patient is always moving to seek a position of comfort. This contrasts with parenchymal pain, such as pyelonephritis, which is typified by constant pain and is the result of inflammation, infection, or subcapsular bleeding causing distention within the parenchyma of the GU organ. This pain is typified by a patient who lays still, seeking not to exacerbate the pain with motion.

An understanding of nervous system anatomy can facilitate comprehension of some of the associated signs or symptoms seen with GU pain. For example, the celiac plexus is responsible for the visceral innervation of the foregut and the kidneys. Therefore irritation of the kidneys can result in paroxysmal nausea and vomiting. In addition, irritation of the ureter may result in referred pain to the ipsilateral testicle in men or labium in women because of the common nerve supply to these areas. Rarely pain can be due to tumor infiltration of the periparenchymal nerves. However, often this is a late sign and a manifestation of advanced disease.

Pain of an acute nature often is due to a clear cause. Obstruction or inflammation of an organ causes the release of prostaglandins or chemokines that result in noxious stimulation of nerves. These signals are transmitted from the peripheral nervous system to the central nervous system and perceived as pain. This mechanism is complex, and signals can be amplified or diminished en route to the central nervous system (Urban and Gebhart, 1999). Medications and techniques used to treat pain either target the noxious chemoneural agent (e.g., nonsteroidal anti-inflammatory drugs [NSAIDs] inhibit the production of prostaglandins) or interfere with opioid or other receptors in the brain. Chronic pain can be much more complex with possible signal imprinting within the pain, resulting in the sensation of pain without noxious stimuli, such as in chronic pelvic pain disorder or fibromyalgia (Woolf, 2011). When no clear urologic cause is identified after an appropriately thorough evaluation, referral to a pain specialist should be considered.

Renal Pain.

Renal pain is typified by location in the ipsilateral costovertebral angle just lateral to the vertebral spine and inferior to the 12th rib. It can be due to obstruction of the ipsilateral collecting system (causing colicky-type pain) or inflammation or infection of the renal parenchyma (causing flank pain and costovertebral angle tenderness). The pain may radiate anteriorly across the flank and toward the abdominal midline or down toward the ipsilateral scrotum or labium. Pain in this location also can be from gastrointestinal or musculoskeletal sources. Intraperitoneal causes of pain often are typified by a relationship to food ingestion or irregularity with bowel function. Further, peritoneal irritation causes peritoneal signs on abdominal exam (exquisite tenderness to any abdominal motion). Further tenderness would be most pronounced anteriorly (such as the Murphy sign for acute cholecystitis) as opposed to costovertebral angle tenderness (CVAT). Intraperitoneal pathology may cause ipsilateral shoulder pain from diaphragmatic irritation via the phrenic nerve; renal pain typically does not.

Ureteral Pain.

Ureteral pain typically is due to ureteral obstruction, is acute in onset, and is located to the ipsilateral lower quadrant. The acute distention of the ureter and hyperperistalsis result in pain as prostaglandins accumulate, causing ureteral spasm, which in turn causes increased lactic acid production, which in turn irritates type A and C nerve fibers in the ureteral wall. These nerve fibers conduct signal toward T11-L1 dorsal root ganglia, and this irritation is perceived as pain. Ureteral obstruction of a gradual or partial nature may not cause pain. The point of ureteral obstruction may result in referred pain to the ipsilateral scrotum or penis. Obstruction at the ureterovesical junction also may result in irritative voiding symptoms (with noncommiserate urinary volume).

Vesicle Pain.

If the bladder is inflamed (as in cystitis) or distended because of obstruction (as in acute urinary retention), suprapubic pain may be present. Inflammation of the bladder caused by infection or interstitial cystitis is worst when the bladder is distended, so patients may report improvement in suprapubic pain with voiding. Patients also may describe strangury, a sharp and stabbing pain at the end of urination (presumably resulting from final contraction of the inflamed detrusor). In sensate bladders, acute urinary retention can be easily identified from the history: profound desire to urinate without ability to do so. However, in patients with flaccid atonic bladders, large volumes of urine can be retained without any symptoms.

Prostatic Pain.

Inflammation of the prostate, prostatitis, can result in pain that is located deep within the pelvis. It can be difficult to localize and sometimes is confused with rectal pain. Irritative voiding symptoms (urinary frequency, urgency, and dysuria) are often associated with irritation of the prostate.

Penile Pain.

The differential for penile pain includes paraphimosis, ulcerative penile lesions (e.g., cancer or herpes), or referred pain from cystitis/prostatitis in the flaccid penis. In the rigid penis, Peyronie disease or priapism may be the cause.

Scrotal Pain.

Pain within the scrotum may be due to irritation of the scrotal skin, such as an inflamed pustule from an ingrown hair or from the testicles and cord within. Epididymitis and orchitis are typified by testicular pain that may be relieved by maneuvers that elevate or support the testis. Torsion of the testicle or its appendages result in acute vascular congestion and pain (and in the case of testicular torsion is a surgical emergency). Varicoceles may result in a dull ache particularly toward the end of the day from accumulated vascular congestion. Again, because of common embryologic origins and therefore neurologic pathways, pain within the kidney or ureter may be referred to the ipsilateral scrotum.

Narcotic Considerations.

Currently, the United States is dealing with an alarmingly high rate of opioid abuse. On October 6, 2017, the president of the United States declared a national public health emergency to help curtail opioid abuse and diversion (https://cnn.com, 2018). Diversion, or the exchange of prescription controlled substances for money or illicit substances, has placed physicians in a precarious position. Physicians and pharmaceutical companies have been implicated in contributing to this epidemic by falsely promoting synthetic narcotics as “safer” than natural narcotics or by being complacent in prescribing narcotic pain medication. To this end, many recent studies have sought to identify and quantify the severity of pain of certain urologic diseases and surgery and to assess the utility of nonopioid analgesics for patients. In general, urologic conditions causing pain should be addressed promptly to minimize the need for narcotic use. Non-narcotic analgesia (NSAIDs, physical therapy, neuromodulation, acupuncture) should be used whenever possible to minimize narcotic use. Patients with pain with no identifiable urologic cause should not be offered narcotics and rather should be referred to their primary care physician and/or pain management specialists.

Urologists also should be cognizant of signs for narcotic-seeking behavior and narcotic abuse. All medical students are taught the side effects of narcotics. Besides euphoria, patients often are afflicted with constipation/ileus, dizziness, nausea, vomiting, tolerance, physical dependence, and respiratory depression (Benyamin et al., 2008). Patients seeking narcotics may come from unusual locations, exhibit inconsistent behavior (facile walking in hallway but difficulty walking in examination room), demonstrate noncompliant follow-up, demonstrate disinterest in non-narcotic analgesia, or request specific narcotics by brand name (Pretorius and Zurick, 2008). Clearly, it is important to obtain a thorough HPI seeking any discrepancies and/or rehearsed answers to avoid contributing to this epidemic.

Hematuria

Hematuria, or the presence of blood in the urine, is a concerning urologic sign in adults and must be evaluated because it may signal the presence of a urologic cancer in up to 25% of patients with this complaint. Hematuria comes in two varieties: gross and microscopic. Gross hematuria is often alarming to the patient, whereas microscopic hematuria is unnoticed by the patient until it is detected by a urinalysis. Critical to the HPI for hematuria are the age, presence of irritative voiding symptoms, smoking history, and industrial chemical exposure history because these are risk factors for detecting cancer. Further, exposure to alkylating chemotherapy, analgesic abuse history, or chronic foreign objects in the urinary tract should increase suspicion for GU malignancy.

After excluding urinary tract infection (particularly in young women), history of nephrologic pathology, trauma, or recent urologic manipulation, the physician should give the patient a full urologic evaluation for hematuria according to American Urological Association (AUA) guidelines. Interestingly, several studies demonstrate age as a risk factor for GU malignancy detection on evaluation for hematuria; however, children with GU malignancies have been described (Commander et al., 2017). In fact, the most common cause of gross hematuria in a patient older than 50 years of age is bladder cancer.

Hematuria must be differentiated from pseudohematuria, whereby the urine may appear red because of dehydration or certain medicines or foods (Hubbard and Amin, 1977). The way to differentiate hematuria from pseudohematuria is to obtain a clean midstream urine sample and assess for red blood cells (RBCs) on the microscopic analysis. The urine dipstick alone is not sufficient for determining the presence of true hematuria because it may signal the presence of “hematuria” when no RBCs are present but rather other solutes that discolor the urine. In fact, proceeding with a full hematuria evaluation for dipstick pseudohematuria is associated with unnecessary cost and low yield for detecting malignancy (Rao et al., 2010).

When encountering a patient with hematuria, the physician must ascertain duration of onset and several associated factors. Patients should be queried as to which portion of the urinary stream contains urine: the initial part of the stream, the entire stream, or the terminal portion of the urinary stream. Initial stream hematuria often signifies mild bleeding from a prostatic or urethral source, and terminal hematuria often signifies bladder neck irritation that expresses hematuria upon contraction of the bladder neck at the end of urination. Other helpful clues include any associated pain and clots associated with the hematuria.

Hematuria usually is painless, but pain can occur when clots obstruct the upper urinary tract (see Renal Pain earlier) or cause urinary retention. The shape of clots can help elucidate their origin: clots formed in the upper tract often have a vermiform shape, whereas cuboid clots are likely produced in the bladder.

Lower Urinary Tract Symptoms

Patients often come to the urologist with lower urinary tract symptoms (LUTS). LUTS are symptoms associated with the urinary bladder and its outlet. Such symptoms can be due to any combination of obstructive or irritative causes. Causes of lower urinary tract obstruction include benign prostatic hyperplasia (BPH), obstructive prostate cancer, urethral stricture disease, dysfunctional voiding, detrusor-external sphincter dyssynergia, severe phimosis, and severe meatal stenosis. In short, anything that can obstruct or narrow the caliber of the urethra can cause obstructive LUTS. Although a complete obstruction results in urinary retention, a partial obstruction results in obstructive LUTS (oLUTS); namely sensation of incomplete urinary emptying, urinary frequency (more frequently than every 2 hours), intermittency (intermittent flow of urinary steam), weak urinary stream, and urinary straining (requiring Valsalva maneuver to aid in voiding). In patients with weak detrusor muscle activity, even a minimally obstructive outlet can result in oLUTS or even urinary retention. Therefore it is important to consider causes for hypocontractile or acontractile bladders when evaluating a patient with oLUTS. It is also important to remark that bladder outlet obstruction may result in varying levels of urinary retention. Some patients may urinate their bladder volume incompletely and therefore have an elevated residual volume, whereas other patients may not be able to urinate at all and be in outright urinary retention. Often the progression of obstruction, for instance in BPH, is slow, and therefore changes in urinary stream may not be easily acknowledged by the patient. Further, because of such acclimation and possibly peripheral neuropathy, many patients may not appreciate the level of obstruction they have (which would be evidenced by objective measures of weak urinary stream and elevated residual stream). Oddly enough, chronic bladder outlet obstruction can result in detrusor irritability with irritative voiding symptoms.

Irritative LUTS (iLUTS) include urinary frequency, urgency, and dysuria. Causes of irritative voiding symptoms, other than chronic bladder outlet obstruction, include overactive bladder, cystitis, prostatitis, bladder stones, or bladder cancer. Urinary frequency entails urinary voiding of more than five or six times per day. It is normal to void up to twice per night, but nocturia of more than twice per night merits urologic evaluation. A bladder diary is helpful in determining if the urinary frequency may be due to incomplete bladder emptying, overactive bladder, or polyuria (increased urinary output). Polyuria may be due to polydipsia (behavioral or otherwise), diabetes mellitus, diabetes insipidus, or other reasons.

The rationale for the use of a bladder diary is located elsewhere in the text. A bladder diary, briefly, is a tabulation of all fluid ingested and all urine produced by a patient with associated times and volumes. Preferably patients note sensations of urgency or urinary incontinence on this tabulation. Typically a bladder diary is kept for 48 hours. The bladder diary can help provide insight into the functional capacity of a bladder, which should be around 300 to 400 mL in a normal adult and can help quantify the severity of nocturia. Daytime frequency without nocturia may be due to psychogenic reasons (e.g., anxiety). Nocturia without daytime frequency can be due to increased nighttime polyuria. This can be due to excessive fluid intake before bed (which can be easily elucidated from the bladder diary) or increased intravascular volume resulting from the return of fluid from lower extremity peripheral edema upon elevation of legs for recumbency of sleep. Further, as patients age, renal concentrating ability diminishes, which may result in increased urine production at night when renal blood flow is increased (Weiss and Blaivas, 2000).

Urinary urgency indicates difficulty in postponing urination. Although this sensation may be normal if a patient has held his or her urine for a prolonged period, it should not occur otherwise. Dysuria is painful urination and is typically due to inflammation within the bladder. The pain is often felt along the urethra or referred to the urethral meatus. It is important to highlight that irritative voiding symptoms, particularly in patients older than 50 years and with smoking history, can be the only sign of an occult bladder cancer, particularly carcinoma in situ; therefore a low threshold for cystoscopy should exist for patients presenting with iLUTS.

Urinary hesitancy refers to delay in the start of urination. Typically, micturition occurs a second after the urinary sphincter relaxes. However, in men with bladder outlet obstruction, there may a prolongation of this delay. Postvoid dribbling refers to the loss of a few drops of urine at the end of urination. This is often an early symptom of urethral obstruction related to BPH and is due to the escape of urine into the urethra that is not “milked back” into the bladder at the end of urination (Stephenson and Farrar, 1977). Men may describe shaking the penis to evacuate such residual urine and prevent wetting their clothes. Straining refers to the use of Valsalva maneuver or manual abdominal pressure (i.e., Crede voiding) to help push the urine out and can be easily performed by the patient.

The AUA symptom score was introduced in 1992 and quantifies the presence of many of the symptoms mentioned above onto a scale. The questionnaire assesses whether incomplete emptying, urinary frequency, intermittency, urgency, weak stream, straining, and nocturia were present over the prior month. Answer choices range from 0 to 5 for each question depending on prevalence (not at all, less than 1 time in 5, less than half the time, about half the time, more than half the time, and almost always). Nocturia, however, is not a prevalence over the prior month but rather the typical number of times the patient arises from sleep to urinate (0 to 5; 5 representing 5 times or more per night). The sum of the values indicates the severity of symptoms (0 to 7 is mild, 8 to 19 is moderate, 20 to 35 is severe). The International Prostate Symptom Score (IPSS) is the AUA symptom score with the addition of a quality-of-life score (Barry et al., 1992) (Table 1.1). Although this tool has many limitations (nonspecific, requires sixth-grade reading level, may not be answered by those with neurologic conditions) is very useful in quantifying and standardizing urinary symptoms to help compare patient encounters after intervention (MacDiarmid et al., 1998).

TABLE 1.1

International Prostate Symptom Score

SYMPTOM	NOT AT ALL	<1 TIME IN 5	LESS THAN HALF THE TIME	ABOUT HALF THE TIME	MORE THAN HALF THE TIME
1. INCOMPLETE EMPTYING					

Over the past month, how often have you had a sensation of not emptying your bladder completely after you finished urinating?	0	1	2	3	4
2. FREQUENCY					
Over the past month, how often have you had to urinate again less than 2 hours after you finished urinating?	0	1	2	3	4
3. INTERMITTENCY					
Over the past month, how often have you found you stopped and started again several times when you urinated?	0	1	2	3	4
4. URGENCY					
Over the past month, how often have you found it difficult to postpone urination?	0	1	2	3	4
5. WEAK STREAM					
Over the past month, how	0	1	2	3	4

often have you had a weak urinary stream?					
6. STRAINING					
Over the past month, how often have you had to push or strain to begin urination?	0	1	2	3	4
	NONE	1 TIME	2 TIMES	3 TIMES	4 TIMES
7. NOCTURIA					
Over the past month, how many times did you most typically get up to urinate from the time you went to bed at night until the time you got up in the morning?	0	1	2	3	4
TOTAL INTERNATIONAL PROSTATE SYMPTOM SCORE					
QUALITY OF LIFE DUE TO URINARY SYMPTOMS	DELIGHTED	PLEASED	MOSTLY SATISFIED	MIXED—ABOUT EQUALLY SATISFIED AND DISSATISFIED	MOSTLY DISSATISFIED
If you were to spend the rest of your life with your urinary condition just the way it is now, how would you	0	1	2	3	4

feel about that?					

From Cockett A, Aso Y, Denis L: Prostate symptom score and quality of life assessment. In Cockett ATK, Khoury S, Aso Y, et al., eds: *Proceedings of the Second International Consultation on Benign Prostatic Hyperplasia (BPH); 27-30 June 1993,* Paris, Channel Island, 1994, Jersey: Scientific Communication International, pp 553–555.

Urinary Incontinence.

Urinary incontinence is the involuntary passage of urine. The reasons for urinary incontinence are many and can be due to several pathologies. In general when the pressure within the bladder is greater than the resistance provided by the urethra, or when it is bypassed, urinary incontinence may occur. A thorough differential diagnosis can help the urologist direct the questioning to arrive at the likely diagnosis. It is helpful to understand the eight categories of urinary incontinence.

Stress Incontinence.

Stress urinary incontinence refers to the involuntary passage of urine with any activity that increases intra-abdominal pressure. This is typically indicative of weakness in the urinary sphincter and can be seen in multiparous women, postmenopausal women, and men who have had radical prostatectomy or another procedure affecting the outlet (aggressive transurethral resection of the prostate [TURP]). Patients complain of such loss of urine with Valsalva maneuvers, typically coughing, sneezing, laughing, or heavy lifting. Generally, the treatment for stress urinary incontinence involves exercises or surgeries that increase the resistance of the urinary outlet (e.g., Kegel exercises, urethral sling, artificial urinary sphincters, urethral bulking).

Urge Incontinence.

Urinary urgency, described previously, may be due to a myriad of reasons. This occurs when a patient experiences involuntary passage of urine coincident with sensation of urinary urgency. This is often a symptom of severe overactive bladder, cystitis, or neurogenic bladder or may occur in patients with poorly compliant bladders. Just as with urinary urgency, urge incontinence may be a sign of occult bladder cancer, and this diagnosis must be considered. Treatment for urge incontinence is distinct from that of stress urinary incontinence in that treatment focuses on measures to relax the bladder (e.g., anticholinergic medical therapy, intravesical Botox, neuromodulation).

Mixed Urinary Incontinence.

Patients often may have urinary urgency with loss of urine and loss of urine with Valsalva maneuvers. These patients should be characterized as having mixed incontinence, and their treatments should reflect both processes; the treatment of one cause of incontinence but not the other may result in exacerbation of symptoms.

Continuous Incontinence.

Patients with continuous urinary incontinence complain of constant wetness in the perineum that is independent of the urge to urinate or maneuvers associated with increased intra-abdominal pressure. Typical of continuous incontinence are processes that bypass the bladder outlet; mainly urinary fistulas. In women, a urinary fistula between the urinary bladder or ureter and the vaginal vault may result in continuous incontinence. Patients complaining of continuous incontinence should be asked about a history of gynecologic surgery, radiation, or traumatic childbirth. Continuous incontinence can be congenital. Such is the case with an ectopic ureter, in which the typically dysplastic upper pole moiety of a duplicated kidney drains into the vaginal or perineum, bypassing the external urinary sphincter. The parents of juvenile patients with ectopic ureters may report unsuccessful toilet training. As adults such patients may complain of urinary incontinence continuously during the day, which may be less severe at night. The absence of urinary incontinence at night may reflect the collection of urine in the saccular upper pole moiety, which is more dependent when the patient is in the recumbent position.

Pseudoincontinence.

Some female patients may experience symptoms similar to continuous urinary incontinence but fail to demonstrate true urinary incontinence. Patients with chronic vaginal discharge may complain of continuous perineal wetness, which may be confused with continuous urinary incontinence. Also, severe labial fusions may result in retention of urine within the vaginal vault and mimic continuous incontinence (Palla et al., 2010). Clearly, a thorough pelvic examination may help identify such causes.

Overflow Incontinence.

Often referred to as paradoxic incontinence, overflow incontinence occurs when the urinary volume within the bladder approaches and exceeds bladder capacity, resulting in an increase in intravesicle pressure greater than urethral outlet resistance. The pressure is released by the decrease in urinary bladder volume associated with incontinence. This is likely to occur at night when the patient is less likely to guard against this incontinence. Guarding is voluntary contraction of the pelvic floor muscles in an attempt to prevent urinary incontinence and can occur with any cause of urinary incontinence. Overflow incontinence can be resolved by treating the outflow obstruction, hence the paradoxic nature of this incontinence. Overflow incontinence is usually present in male patients with prolonged history of bladder outlet obstruction. Because of the gradual progression of symptoms, such patients may not be aware of their obstructive symptoms (as noted earlier).

Functional Incontinence.

Patients with limited mobility or limited access to a toilet or urinal may experience urinary incontinence. Such patients may have intact bladder-outlet anatomy and physiology but may simply be unable to move in time to void in a urinal or toilet. Therefore the urologist must assess mobility in the elderly patient with urinary incontinence.

Elderly patients also may have diminishment of their cognitive abilities and awareness and may lose the social inhibition to soil oneself. Therefore an assessment of cognitive ability should be considered in elderly patients with what ultimately may be volitional urination.

Enuresis.

Urinary incontinence during sleep, known as enuresis, is normal in children up to 3 years of age. It persists in about 15% of children up to 5 years of age and in up to 1% of adolescents up to 15 years of age (Forsythe and Redmond, 1974). Primary enuresis (enuresis that has always been present) persistent beyond 6 years of age should be evaluated by a urologist as ectopic ureter in the female patient. Secondary enuresis (enuresis with onset after child has ceased bedwetting) may be associated with child abuse and bullying (Zhao et al., 2015).

Sexual Dysfunction

Patients with sexual dysfunction often are referred to the urologist. Although sexual dysfunction often is encountered in women with LUTS (Elsamra et al., 2010), the urologist also must be familiar with the different components of sexual dysfunction in men. Men may complain of erectile dysfunction or impotence, when this is merely a symptom of another problem.

Erectile Dysfunction.

The AUA and National Institutes of Health (NIH) Consensus Conference on Impotence in 1993 have defined erectile dysfunction (ED) as the inability to attain and/or maintain penile erection sufficient for satisfactory intercourse. Incidence of ED is significant and can affect more than 50% of men over the age of 40 years. The basic causes of ED (vasculogenic, neurogenic, psychogenic, endocrinologic, and medication side effect) help direct the medical interview. For instance, poorly controlled diabetes mellitus (DM) may result in peripheral neuropathy or vasculopathy, which can affect erectile quality. Antihypertensives, antidepressants, antipsychotic medications, and medications that directly or indirectly affect testosterone levels may all potentially contribute to ED. Therefore a thorough history should explore whether the patient is taking such medications or is afflicted with such ailments that are known to cause ED. Understanding the timing and situational nature of erections in the patient complaining of ED may help identify the cause. For instance, patients who experience situational ED (can have erections with one partner but not another or can attain sufficient erection with visual or manual stimulation) or those who have adequate nocturnal tumescence may have a psychogenic cause. Further, ED can be a harbinger of occult coronary artery disease and should merit consultation to a cardiologist (Nehra, 2012).

Because much of the assessment of ED is subjective, a questionnaire may be a useful tool to quantify and monitor the level of ED. The International Index of Erectile Function (IIEF) and the abbreviated IIEF-6 (also known as the Sexual Health Index for Men [SHIM]) are validated questionnaires often used to quantify and monitor erectile function, orgasmic function, sexual desire, intercourse, and overall satisfaction (Kriston et al., 2008).

Loss of Libido.

ED can be the result of hypogonadism. Hypogonadism can be primary or secondary, and if a low serum testosterone is identified, evaluation of serum prolactin and gonadotropins should be performed. Symptoms of hypogonadism include change in sleep patterns, emotional changes, decreased strength, weight gain, infertility, and ED. The amount of testosterone necessary to maintain libido is usually less than that required for full stimulation of the prostate and seminal vesicles. Therefore patients with adequate ejaculatory volume are unlikely to have hypogonadism severe enough to cause loss of libido. Depression, several medications, or severe medical illnesses (e.g., cancer) can result in loss of libido.

Because libido is a subjective measure, clinical questionnaires may be the best tool to quantify and monitor a patient's sexual desire. Several validated questionnaires have been produced to aid in the evaluation for hypogonadism: the Androgen Deficiency in Aging Questionnaire (ADAM), the Aging Male Survey, and the Massachusetts Male Aging Study Questionnaire (Wiltink, 2009). Although these surveys may not correlate with serologic hypogonadism, the Hypogonadism Related Symptom Scale may offer greater sensitivity and specificity based on serum testosterone levels (Wiltink, 2009).

Premature Ejaculation.

According to the International Society of Sexual Medicine Guidelines, premature ejaculation is either less than 1 minute (if lifelong) or 3 minutes (if acquired) and must be associated with inability to delay ejaculation and with negative personal consequence (Althof et al., 2014). Unfortunately, many patients presenting with the complaint of premature ejaculation often have unrealistic expectations for intravaginal ejaculatory latency time. Intravaginal ejaculatory latency time (IELT) was evaluated in five countries, and median time to ejaculation was 5.4 minutes in one study published in 2005. Further, a survey of sexual therapists supported IEJT of 1 to 2 minutes as too short but 3 to 7 minutes as adequate and 7 to 12 minutes as desirable (Corty and Guardiani, 2008). In patients with true premature ejaculation, vaginal quieting or sexual counseling should be offered. Although possibly helpful, treatment with a serotonin reuptake inhibitor should be offered infrequently (Montague et al., 2010). Because of latency to erectile function postejaculation, some patients with erectile dysfunction actually may have normal latency in attaining erections postejaculation.

Failure to Ejaculate.

Several causes exist for anejaculation. Androgen deficiency, sympathetic denervation, use of pharmacologic agents, and a history of bladder neck/prostate surgery can result in decreased volume of ejaculation or anejaculation. Therefore the patient should be assessed for hypogonadism. Systemic hypogonadism (see earlier) or local decreased stimulation of prostate and seminal vesicles as seen with 5-alpha-reductase inhibitor administration often used for alopecia or enlarged prostate can result in lower volume ejaculate. A history of retroperitoneal surgery, especially retroperitoneal lymphadenectomy, as is done for testicular cancer, should be established because transection of the sympathetic nerve fibers results in anejaculation. Alpha-adrenergic antagonists (e.g., tamsulosin) and surgeries that affect the bladder neck (e.g., TURP) may result in retrograde ejaculation. Patients with advanced diabetes also may experience anejaculation.

Anorgasmia.

Orgasm is the euphoria associated with a series of muscular contractions in the genital region and the release of endorphins. It usually is associated with ejaculation in men. Orgasm can occur without erection or ejaculation in men (e.g., postprostatectomy). Absence of orgasm can be due to psychogenic causes and several medications used to treat psychiatric ailments. In cases of impaired pudendal nerve function (e.g., diabetic peripheral neuropathy) anorgasmia can occur as well. Such patients may benefit from neurologic evaluation (e.g., vibratory testing to assess penile sensation) or referral to a sexual counselor.

Hematospermia

Hematospermia is the presence of blood in the ejaculate. With rare exception it is due to nonspecific inflammation of the prostate or seminal vesicles and usually resolves spontaneously. This can be associated with ejaculation after a long duration of sexual abstinence. If blood is persistent beyond several weeks, the urologist should consider an evaluation including a genital examination, digital rectal examination, prostate specific antigen, cystoscopy, and urine cytology to exclude GU tuberculosis or cancer.

Pneumaturia

Pneumaturia is the passage of gas within the urine. This can sometimes be an alarming finding for the patient because this may interrupt the urinary flow and sound like flatus from the urethra. Pneumaturia is most commonly due to a fistula between the gastrointestinal system and the bladder. Therefore such patients should be screened for Crohn disease, enteritis, or history of recent intra-abdominal surgery or radiation. Rarely, pneumaturia may be due to gas-forming bacteria within the urinary tract. Therefore patients also should be screened for history of severe urinary tract infections or immunocompromised states.

Urethral Discharge

This is the most common symptom of sexually transmitted infection (STI). Patients should be screened for high-risk sexual behavior. Bloody discharge may be concerning for urethral carcinoma.

Fevers and Chills

It should be determined, in a patient who reports fevers, if the fevers are subjective or if they were measured objectively with a thermometer. The method by which the temperature was obtained (thermometer used orally vs. rectally vs. auricular or temporal scanner) can affect the accuracy of the measured temperature compared with the core temperature and may be important to note in pediatric patients. Rigors (or chills) may or may not be associated with fevers but can be independently concerning for bacteremia or other severe infection. The severity and site of infection may affect whether a patient will have fevers or chills. For example, cystitis rarely causes fever, but the diagnosis of pyelonephritis often requires presence of a fever. A patient with fevers and chills may signal a systemic response to an infectious process or sepsis and merit further evaluation or even possibly hospitalization. Fevers and chills in the elderly or immunocompromised should be especially concerning.

Constitutional Symptoms

Constitutional symptoms are fevers, chills, night sweats, anorexia, weight loss, fatigue, or lethargy. Sometimes these are referred to as B symptoms, borrowed from non-Hodgkin lymphoma staging. Such symptoms can signal the presence of advanced inflammatory, infectious, or malignant processes such as GU tuberculosis or advanced bladder cancer.

Medical History

It is incumbent upon the urologist to obtain an accurate medical history because many of the patients’ medical problems may have urologic implications. Moreover, it is important to understand the severity of the medical illness and the compliance with treatment. For instance, knowing that patients are afflicted with

DM is important, but so is knowing if their glucose is well controlled with or without insulin and if they have peripheral neuropathy associated with their diabetes. (A good question to ask is, “Is a recent HgbA1C available?”)

Patients often may not be aware of all their medical conditions. Soliciting input from a family member or reviewing a recent note from the primary care provider also may help. A good place to start is to assess the patient's medication list and determine medical illnesses based on that. However, this can be misleading because several medications may be administered for different reasons (e.g., hydrochlorothiazide for hypercalciuria vs. hypertension) and patients may not be compliant with all their medications.

Even though the patient, family member, or recent medical documentation may not mention a medical illness, the urologist must remain vigilant to ensure there are no undiagnosed medical conditions that can adversely affect the patient or any subsequent urologic treatment. The classic example of this is occult coronary artery disease in the urologic patient who may require surgery soon. Although patients may have never had a “heart attack,” they may, if prompted, report shortness of breath or chest pain with activity, and this may be a signal of undiagnosed coronary artery disease. Another example is a large patient with a large collar size who does not provide a medical history of obstructive sleep apnea, but, if prompted, his spouse may report nighttime snoring and irregular breathing or daytime fatigue in the patient. Clearly, the diagnosis of coronary artery disease and obstructive sleep apnea, among others, can have implications for treatment.

Performance Status

The functional ability of patients is a testament to their overall health and their ability to withstand challenging treatments such as invasive surgery or chemotherapy. At the most basic level, the activities of daily living (ADLs), which include dressing, eating, ambulating, toileting, and hygiene, and the instrumental ADLs, which include cleaning and maintaining a house, managing money, preparing meals, shopping, and community participation, can be easily assessed during the perioperative setting to help determine risk for surgery. Levitt et al. evaluated nearly 200 patients who underwent percutaneous nephrolithotomy, identified deficiency in ADLs in 16% of patients, and identified deficit in ADLs as an independent predictor of complications better than Charlson Comorbidity Index or the American Society of Anesthesiology Score (Leavitt et al., 2014).

Several performance status scales have been developed and are used mostly for oncologic purposes. These scales include the Eastern Cooperative Oncology Group score and Karnofsky performance status grade, which classify patients according to their ability to perform physical activity of a strenuous or nonstrenuous nature, ability to self-care, ability to stay out of bed, or moribund status. Using such scales may be beneficial particularly in transmitting an impression of overall health to another provider; they are a clear factor in health assessment.

Past Surgical History

Prior surgery in a patient may have clear impact on the patient's assessment and subsequent treatment options. Prior surgeries, related to GU anatomy of interest or not, may indicate additional adhesions or obliteration of surgical planes, which can render subsequent surgery difficult. For example, a patient with extensive intra-abdominal surgery undergoing subsequent laparoscopic surgery may benefit from Hasson technique or visual port access as opposed to Veress needle access (Gaunay, 2016). Further, abstracting surgical anatomic details in a prior operative report may help the surgeon ascertain the utility of a subsequent procedure. For instance, a patient who underwent a prior TURP may have an operative report that includes TURP, but the operative details may reveal that only a channel TURP was performed, therefore opening the possibility that a subsequent TURP may be beneficial. Further, a prior operative report may provide vital information regarding anatomy or other difficulties encountered.

Medications

A thorough knowledge of medications can provide information regarding the presence and severity of a medical illness, possible cause for urologic complaints from medication side effects, and a target for cessation or adjustment in the perioperative period. Several examples to highlight these principles are as follows:

1. A patient with diabetes on several medications and large doses of insulin may have severe diabetes and be more likely to have peripheral neuropathy, even if he or she is not on a medication for peripheral neuropathy.
2. A patient on tamsulosin may complain of anejaculation or

lightheadedness, not knowing the side effect profile of this medication.

3. A patient with hematuria on anticoagulation or antiplatelet therapy may benefit from temporary cessation (in addition to a full evaluation).

This last example can be used to highlight several pitfalls with poor medical history taking and its impact. For example, a patient on baby aspirin may be taking this for primary coonary artery disease prophylaxis or for prevention of coronary artery stent thrombosis. Clearly this would have consequence regarding when and if such medications should be ceased. See Table 1.2 for a list of drugs associated with urologic side effects.

TABLE 1.2

Drugs Associated With Urologic Side Effects

UROLOGIC SIDE EFFECTS	CLASS OF DRUGS	SPECIFIC EXAMPLES
Decreased libido	Antihypertensives	Hydrochlorothiazide
Erectile dysfunction	Psychotropic drugs	Propranolol
		Benzodiazepines
Ejaculatory dysfunction	α-Adrenergic antagonists	Prazosin
		Tamsulosin
		α-Methyldopa
	Psychotropic drugs	Phenothiazines
		Antidepressants
Priapism	Antipsychotics	Phenothiazines
	Antidepressants	Trazodone
	Antihypertensives	Hydralazine
		Prazosin
Decreased spermatogenesis	Chemotherapeutic agents	Alkylating agents
	Drugs with abuse potential	Marijuana
		Alcohol
		Nicotine
	Drugs affecting endocrine function	Antiandrogens
		Prostaglandins
Incontinence or impaired voiding	Direct smooth muscle stimulants	Histamine
		Vasopressin
	Others	Furosemide
		Valproic acid
	Smooth muscle relaxants	Diazepam

	Striated muscle relaxants	Baclofen
Urinary retention or obstructive voiding symptoms	Anticholinergic agents or musculotropic relaxants	Oxybutynin
		Diazepam
		Flavoxate
	Calcium channel blockers	Nifedipine
	Antiparkinsonian drugs	Carbidopa
		Levodopa
	α-Adrenergic agonists	Pseudoephedrine
		Phenylephrine
	Antihistamines	Loratadine
		Diphenhydramine
Acute renal failure	Antimicrobials	Aminoglycosides
		Penicillins
		Cephalosporins
		Amphotericin
	Chemotherapeutic drugs	Cisplatin
	Others	Nonsteroidal anti-inflammatory drugs
		Phenytoin
Gynecomastia	Antihypertensives	Verapamil
	Cardiac drugs	Digoxin
	Gastrointestinal drugs	Cimetidine
		Metoclopramide
	Psychotropic drugs	Phenothiazines
	Tricyclic antidepressants	Amitriptyline
		Imipramine

Allergies

Patients must be asked about allergies during the initial encounter, and allergy lists should be verified for accuracy on subsequent encounters. The inciting medication and the reaction should be written because many patients confuse allergy with side effect (e.g., red-man syndrome for vancomycin or upset stomach with antibiotics). Such medical allergies should be highlighted in the electronic medical record (EMR) to prevent inadvertent prescription or administration of such medication.

Social History

The social history includes an evaluation of tobacco, alcohol, and illicit drug consumption. The agent and the method of use have medical implications. Tobacco can be chewed, smoked, or vaped. A patient who chews tobacco may still benefit from a nicotine patch during a hospitalization but may not necessarily have the urothelial cancer risk associated with smoking. Vaping, which may not have many of the carcinogens associated with combustion, may still provide derivatives of nicotine that promote malignant changes in urothelial and lung cell lines (Lee et al., 2018), although the long-term effect is still unknown.

Alcohol use should be evaluated because it may increase oncologic risk and risk for liver disease, which have clear implications for patient care. Alcohol use also can affect LUTS and sexual function. More acutely, a patient who ingests significant amounts of alcohol and is hospitalized may suffer from life-threatening withdrawal if a prophylactic measure such as Clinical Institute Withdrawal Assessment for Alcohol (CIWA) or alcohol replacement is not ordered. Patients with heavy alcohol ingestion often understate the amount of alcohol consumed. Anticipating this can allow for the provider to better order prophylactic measures.

Illicit Drug Use

There are many classes of illicit drugs (e.g., cocaine, narcotics, methamphetamines), all of which can be consumed via a myriad of modes. Knowing the agent used and the mode can prepare the provider for anticipating challenges in subsequent care in addition to the risk for communicable diseases if the intravenous mode is used. Because of the illicit nature and social stigma of such drugs, many patients may not be forthright about use; therefore the provider may need to establish high levels of trust to encourage the patient to divulge such information. Alternatively, review of prior medical records can help ascertain these risky habits.

Sexual Relations

Patients may engage in sexual behavior with a single person or multiple people of the same or different gender. The physician should not presume a monogamous, heterosexual relationship. Nonaccusatory questions such as, “Do you partake in sexual relations with men, women, or both? A single partner or many?” may allow the patient to provide an accurate answer without being defensive regarding alternative lifestyle. Clearly such information is important to assess for risk for STI and to assess social support structure.

Domestic Station

Typically patients are asked if they are married or single and who lives in the home with them. It is also beneficial to understand if the patient has family or friends who live nearby. Assessing where the patient lives and with whom is important for planning subsequent care. A patient with little or no social support may not fare well after a complex, life-altering surgery. Further, this information may provide insight regarding what treatment options a patient may find unacceptable (e.g., an elderly man who is the sole caretaker of an elderly handicapped woman may not be willing to undergo major surgery with long convalescence). Screening for domestic violence or other unsafe domestic situation should be completed at this time as well.

Occupation

Understanding the patient's current or prior occupations provides the urologist with greater insight into the patient's world-view and socioeconomic status as well as possible industrial exposure to possible carcinogenic agents.

Family History

Many diseases with urologic manifestations have a clear genetic component, and their mode of transmission (e.g., autosomal dominant) is well defined. Examples include adult polycystic kidney disease, tuberous sclerosis, von Hippel-Lindau disease, renal tubular acidosis, and cystinuria. Other diseases, such as prostate cancer or urolithiasis, have a well appreciated familial component, although the precise pattern of inheritance is not understood. Often the age at diagnosis of the family member can direct screening age. A recent study by Bratt et al. evaluated nearly 52,000 Swedish men with fathers or brothers with prostate cancer and identified an increased risk of prostate cancer incidence with a brother diagnosed (30% vs. 13% in the general population) and a father and a brother diagnosed (48% vs. 13% in the general population) (Bratt et al., 2016; Nordström, 2016). Therefore identifying not only the presence of disease in the family but also the frequency within the family may be important in screening such patients for disease.

Review of Systems

A review of systems is a comprehensive system-based checklist to determine if there are any other complaints or ailments that the patient may have. This may be a valuable opportunity to identify important issues that may not be related to the chief complaint.

Physical Examination

A complete and thorough physical examination is essential for any patient encounter. It often allows the urologist to select the most appropriate next step.

Vital Signs

Physical examination should start with a general set of vital signs. The objectively measured temperature, heart rate, blood pressure, respiratory rate, and pain rating can identify immediately the critically ill patient who may not necessarily be best served by waiting for an appointment. In the office setting, a defined normal range should be established, with patients beyond this acceptable range referred to the physician immediately to triage. All office staff should be assigned a role in assessing patients for critical illness or severe distress. In my clinical practice, we have encountered such patients who are profoundly hypotensive or tachycardic who benefited from rapid transportation to the emergency room.

Some have advocated for a rapid screening tool used to assess distress and measures set in place to provide such patients with prompt attention from social worker, mental health professional, or pastoral care (JNCCN, 2003). Such a tool can be considered a sixth vital sign and can help decrease the anxiety and distress within an already stressful waiting room.

General Appearance

Every medical student is instructed regarding the four modes of physical examination: inspection, auscultation, percussion, and palpation. Inspection is the first mode and can be applied to the entire patient at the onset of the encounter. Several general observations should be made, including level of pain or emotional distress, nutritional status, socioeconomic status and appropriateness in dress, overall strength or mobility of patient, appearance of skin quality, and quality of dentition. Often patients' appearance is compared with the stated age and noted accordingly (e.g., an ill patient or one with poor self-care may appear much older than stated age). Several diseases may have stigmata, such as jaundice with advanced liver disease, buffalo hump or skin striae with Cushing disease, exophthalmos with Graves disease, fibrofolliculomas in patients with Birt-Hogg-Dube syndrome, cogwheel rigidity in Parkinson disease, and apparent erection with priapism.

A preliminary assessment of frailty and nutritional status can be made upon general inspection. Frailty has been defined as the “excess vulnerability to stressors, with a reduced ability to maintain or regain homeostasis after a destabilizing event” by the American Geriatric Society (Xue, 2011). Several simple tools have been established and validated as markers for frailty. The gait speed (Dudzińska-Griszek et al., 2017) and get-up-and-go test (Pamoukdjian et al., 2015) as well as grip strength can be obtained easily as part of the standard encounter. Calf circumference (Landi et al., 2014) also has been assessed with an inverse relationship with frailty.

Many other clues can be obtained from the general physical examination. The quality of the dentition or moist mucous membranes can be a sign of health and hydration, respectively. For morbidly obese patients or patients with skeletal deformities, I have found that positioning the patient in the anticipated operative position while in the office prevents any surprises in the operating room.

Kidneys

The kidneys are located in the retroperitoneum and surrounded by the psoas muscle, diaphragm, oblique muscles, and the peritoneum with its contents. Aside from very large renal masses in small children or very thin adults, the kidneys should not be visible. In fact, the kidneys may be difficult to palpate under normal conditions. Because of the location of the liver, the right kidney may be inferior to the level of the left kidney, and palpation of the lower pole can be appreciated on deep inspiration.

The overlying skin in the upper quadrant and the costovertebral angle should be inspected, however, for any superficial lesions that may be causing “flank pain.” Assessment of the skin sensation for pain, temperature, and light touch can be performed with a spoke-wheel or pin, cool object, and fine brush, respectively. Patients with herpes zoster may experience prodromal hyperesthesia before eruption of vesicles.

Bimanual examination, or renal ballottement, can be performed by placing the nonexamining hand posteriorly at the costophrenic angle and palpating for the kidney with the examining hand through the anterior abdominal wall (Fig. 1.1). Deep inspiration can help inferiorly displace the kidney to aid in exposure. In neonates and infants, ballottement can be performed between the thumb, placed anteriorly on the abdomen, and remaining four fingers, placed posteriorly at the costovertebral angle. Often large flank masses originate from the kidney in neonates, and transillumination may be feasible. If such a mass is fluid filled (cyst or hydronephrosis), then a dull reddish glow can be appreciated. However, if the flank mass is from a solid process (tumor or polycystic kidney), then no glow will be appreciated.

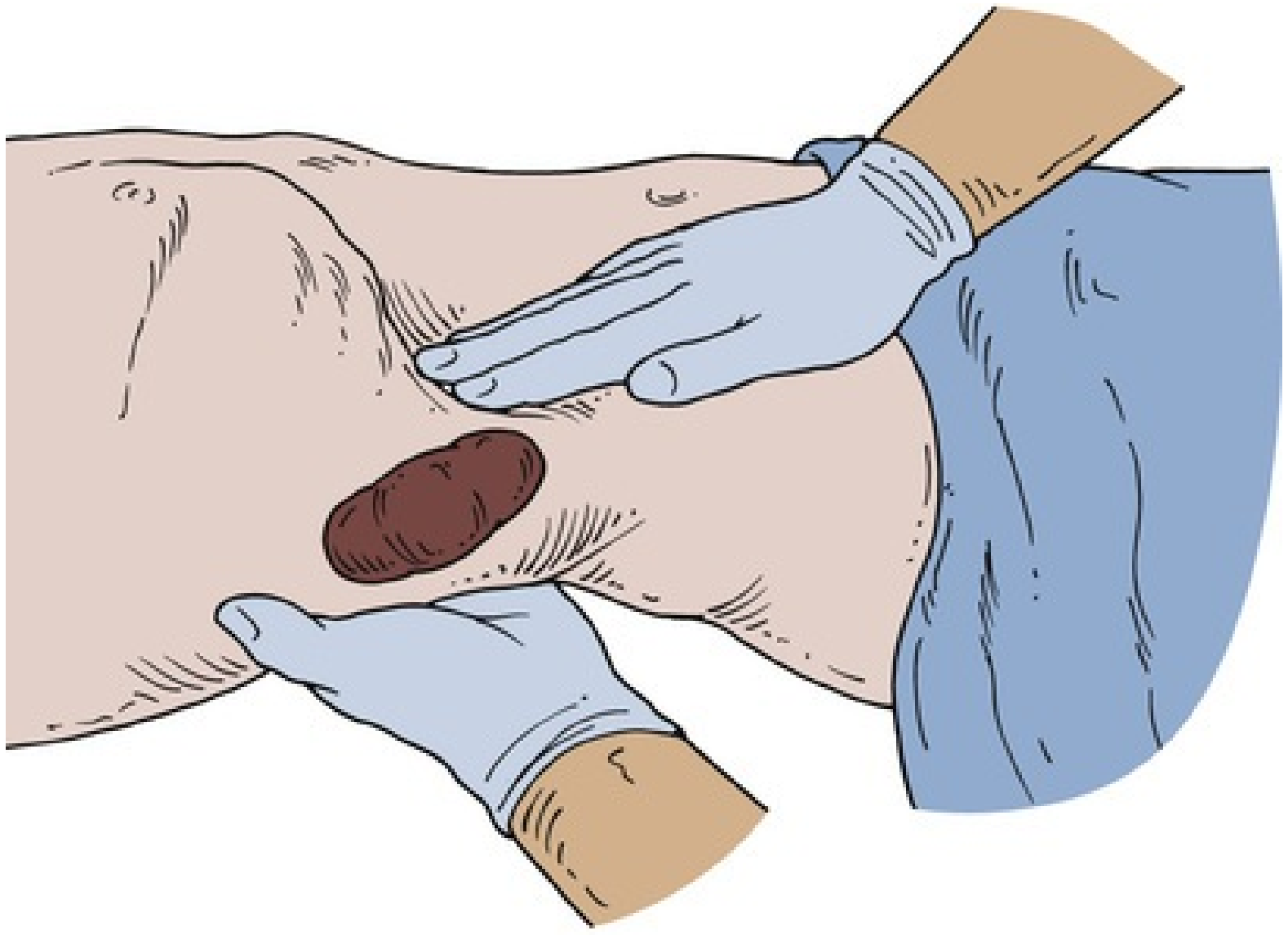

FIG. 1.1 Bimanual examination of the kidney.

Turbulent vascular flow within the renal artery, suggestive of renal artery stenosis or large renal arteriovenous fistula, theoretically can be observed with auscultation. However, if such a bruit is appreciated, it is nonspecific for renal artery source and should be evaluated further with appropriate imaging (ultrasound with Doppler or angiography). Percussion of the kidneys often refers to the assessment of pain when the base of a closed hand of the examiner contacts the costovertebral angle. The examiner should approach this examination technique gently and avoid using excessive force because a simple tap may elicit the positive sign.

Bladder

The bladder is located within the pelvis and can be palpable only as the bladder distends to a level above the pubis, typically greater than 150 mL. At a volume of approximately 500 mL, the bladder may be visible as a lower midline abdominal mass in thin patients. Percussion starting at the level of the pubic symphysis and ascending toward the umbilicus can help determine the level of distention because the pitch may change from dull to resonant beyond the bladder. Ballottement also can aid in palpation of the bladder.

A bimanual examination (Figs. 1.2 and 1.3) is performed to assess the mobility of the bladder and is the standard of care for examination of patients with large bladder tumors postresection (Chang et al., 2016). Even in the era of CT and MRI, a bimanual examination can improve upon the performance of these images for the prediction of pT3 disease (Rozanski et al., 2015) and was found to be an independent predictor of pT3 disease on multivariate analysis.

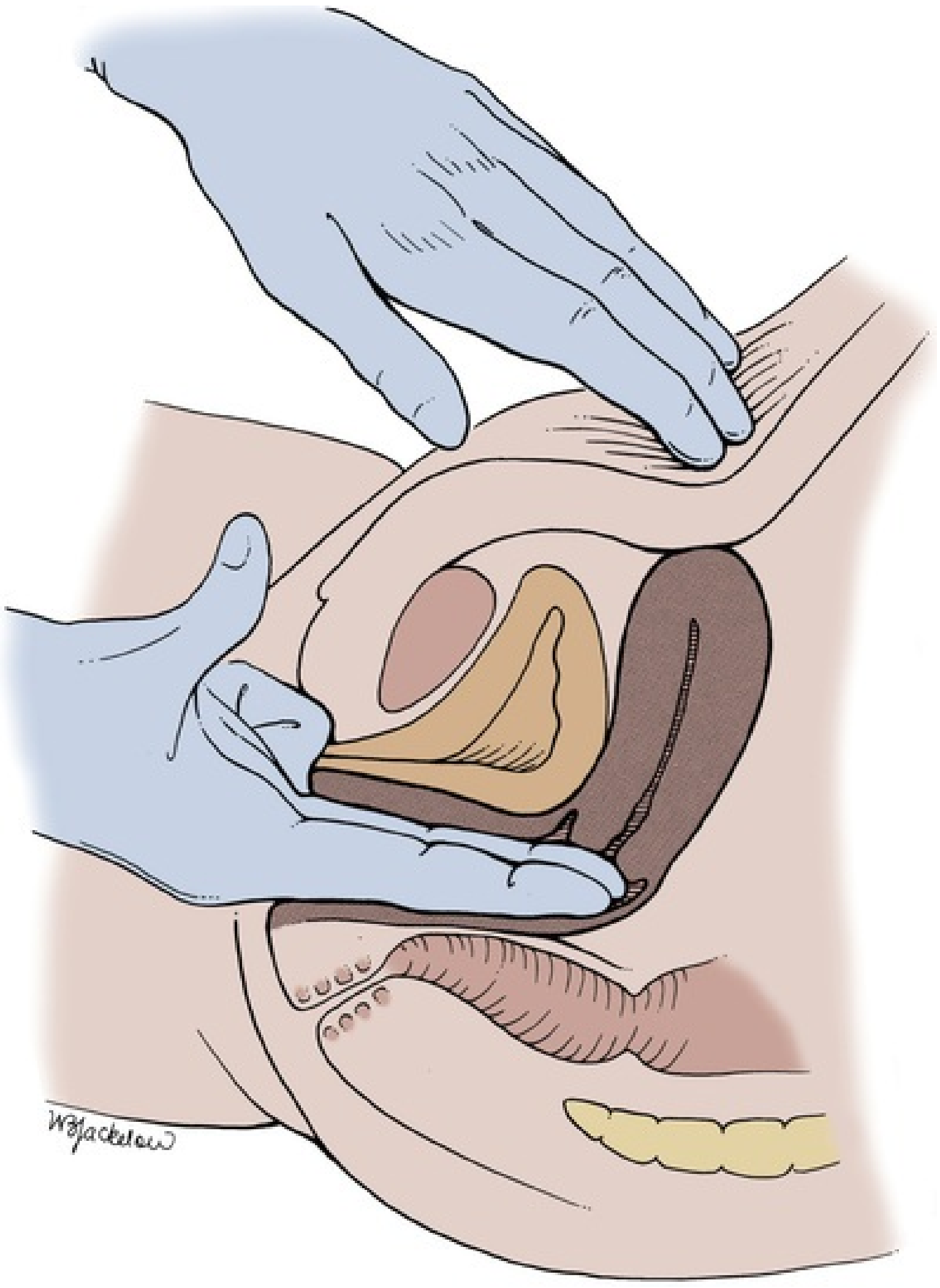

FIG. 1.2 Bimanual examination of the bladder in the female. (From Swartz MH: *Textbook of physical diagnosis*, Philadelphia, 1989, Saunders, p 405.)

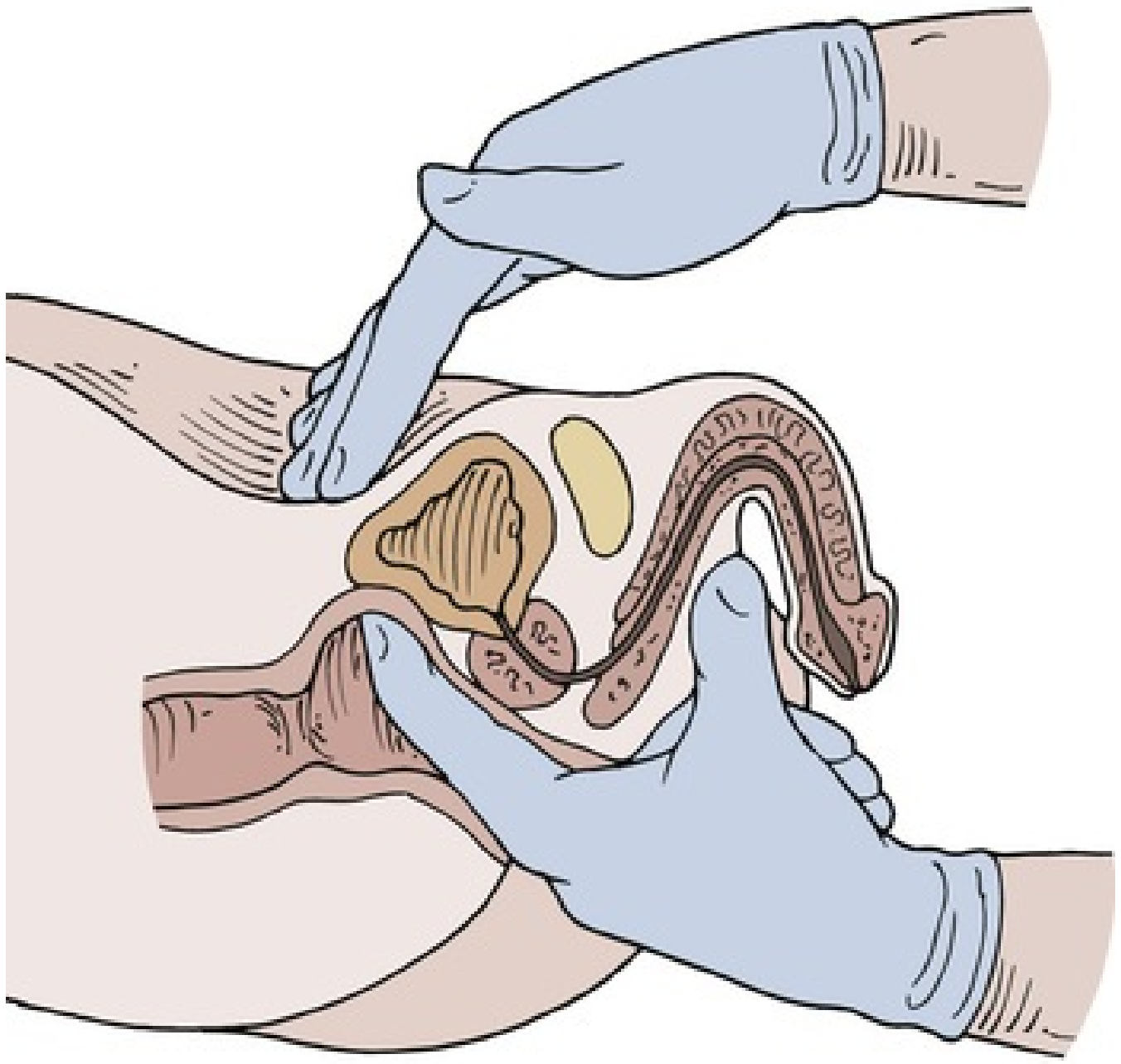

FIG. 1.3 Bimanual examination of the bladder in the male.

Penis

The phallus should be inspected for hair distribution, lesions on the skin, and the presence or absence of a foreskin. In the pediatric population, Tanner stage should be noted. Lesions on the penile skin can include superficial vesicles suggestive of herpes simplex or ulcerative lesions concerning for other sexually transmitted diseases or squamous cell carcinoma of the penis or venereal warts (condyloma acuminata) concerning for human papillomavirus (HPV) infection. Often patients may inquire about prominent vasculature on the phallus, particularly in children, and this is often normal.

The foreskin, if present, should be retracted to ensure that there are no penile tumors; most penile tumors involve the prepuce or the glans penis. The urethra should be inspected for location and absence of stenosis and presence of urethral discharge. Discharge, if present, should be characterized, and ideally a sample should be obtained if there is concern for STI. If hypospadias (ectopic location of urethral meatus on ventral aspect of penis) is identified, location and caliber of urethral meatus are noted (e.g., mega-meatus). A rare finding would be epispadias, in which the meatus is located on the dorsal aspect of the penis, although this is often seen with other profound GU anomalies such as bladder exstrophy. Palpation of the phallus can reveal dense subcutaneous plaques on the underlying fascia, which is concerning for Peyronie disease, which may also be demonstrated as curvature in the erect penis. Palpation of the urethra, if tender, is suggestive of periurethritis. Spongiofibrosis, which has implications for urethral reconstruction, can be palpated along the corpora spongiosum only if it is severe.

Scrotum and Contents

The scrotum contains the testicles and spermatic cord structures. The scrotal skin, which has hair and sebaceous glands, should be assessed for infectious processes (e.g., tinea cruris, cellulitis, pustules), which are more common, and malignant processes (squamous cell carcinoma typical of chimney sweeps), which are rare. Often such infectious processes are of minimal clinical consequence. Tinea cruris and cellulitis may be manifested by erythema and tenderness, whereas an abscess may demonstrate an area of fluctuance or purulent drainage. In the immunocompromised patient or in patients with limited capacity for self care, such infections can progress to Fournier gangrene, which is typified by necrotic “black” skin, foul odor, dishwater discharge, and crepitus.

The impression of the testicles should be assessed for their size and orientation. Although one testicle may be slightly inferior to the other, they should be of similar size and in the vertical orientation. However, in a patient with unilateral testicular pain, the testicle with a foreshortened cord and a horizontal lie can be concerning for testicular torsion. The absence of a cremasteric reflex (light touch to inner thigh resulting in cremasteric muscle contraction and ascension of the ipsilateral testicle) is a very specific sign for testicular torsion in pediatric patients.

Palpation of the testicles, epididymi, and spermatic cords should begin with the normal testicle. The testicles have a firm, rubbery consistency with a smooth ovoid surface. Typical size is 6 cm in length and 4 cm in width with variation seen among different races. Testicular size can be better assessed with an orchiometer (goniometer). Gliding the testicles between the examiner's fingers of both hands allows for palpation of the contour of the surface. A testicle that is small can be suggestive of prior infarct, surgery, hypogonadism, or endocrinopathy such as Klinefelter disease. Tenderness of the testis or the epididymis may indicate orchitis or epididymitis, respectively. Masses in the testes are hard and obliterate the smooth contour of the testis and should be considered testicular cancer till proven otherwise. Epididymal masses, on the other hand, which obliterate the distinct ridge of tissue posterior to the testis, are almost always benign. The vas deferens should be palpable bilaterally on each cord, high in the scrotum, and feel like a thick al dente linguini. Transillumination can be performed in the scrotal mass to assess for fluid content (e.g., hydrocele). To accentuate a varicocele, typically described as a "bag of worms," inspection and palpation of the scrotum should be performed with the patient supine, standing, and standing with Valsalva.

Examination for hernia can be performed by placing the examiner's index finger over the testis and invaginating the scrotum up toward the external ring (Fig. 1.4). The other hand is used to palpate over the internal ring and Hesselbach triangle (bordered by the inferior epigastric artery, the inguinal ligament, and the midline). The patient is instructed to perform Valsalva maneuver at that point, and the examiner assesses for a hernia as a distinct bulge that descends against the tip of the index finger. In children, the presence of a hernia can be appreciated by assessing for the "silk glove" sign. The potential space within the hernia sac allows for the hernia sac to roll over itself, resembling the sensation of rolling over the finger of a silk glove.

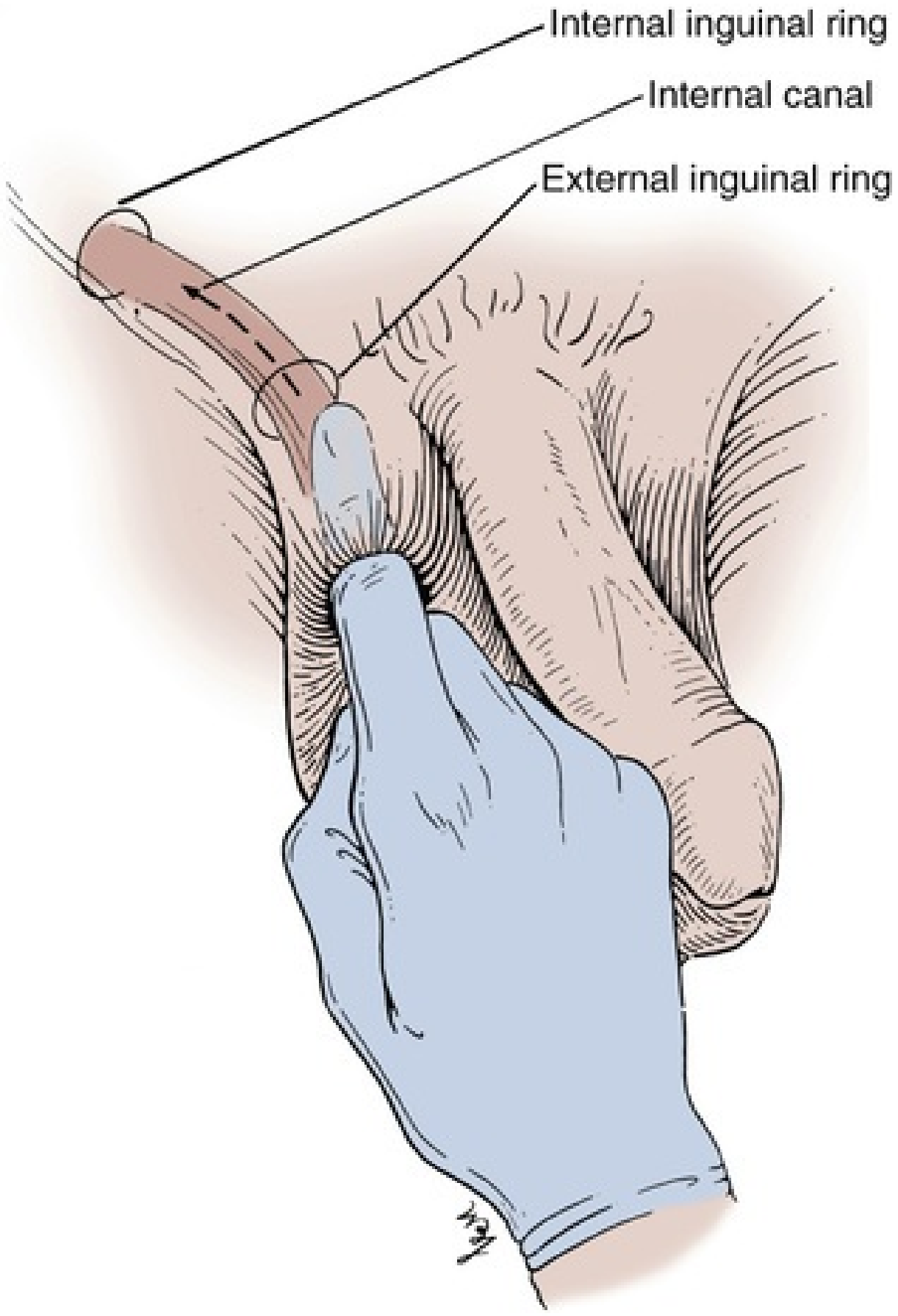

FIG. 1.4 Examination of the inguinal canal. (From Swartz MH: *Textbook of*

physical diagnosis, Philadelphia, 1989, Saunders, p 376.)

Digital Rectal Examination

The digital rectal examination (DRE) can be performed for assessment of prostate size, detection or provocation of prostatitis, and screening for prostate cancer. A DRE with a concurrent lower abdominal exam (bimanual examination) typically is performed in a patient who has undergone a transurethral resection of bladder tumor while still anesthetized. A gentle DRE also can be performed in neonates with disorders of sexual differentiation to evaluate for internal müllerian structures (e.g., uterus). Although prior recommendations included DRE for men ages 40 and older, current AUA guidelines state that prostate cancer screening should be offered in men of average risk from the age of 55 to 69 at an interval of every 2 years.

To have a DRE, the patient should be standing with feet shoulder width apart and bent nearly 90 degrees at the waist. The patient can benefit from using the table to support this position by placing his hand or elbows on the table. Alternatively, the patient may be in a lateral decubitus position, flexed at the hips and knees, on the examining table. The patient is to be reassured throughout this part of the examination. The examiner's nondominant hand is used to spread the gluteal folds and expose the anus, which should be inspected for hemorrhoids or other lesions. The examiner's gloved finger with adequate lubrication then is advanced gently through the anus with the nondominant hand placed on the patient's anterior thigh or lower abdomen to provide gentle counter-traction. The finger is advanced until the prostate is palpable. The normal prostate is the size of a chestnut and should feel soft, similar to that of the contracted thenar eminence. Nodular firmness (which feels like a flexed knuckle) is concerning for prostate cancer and should merit biopsy. Adequate supplies to allow for the patient to cleanse himself and privacy should be provided before concluding the encounter.

Pelvic Examination in the Female

The female pelvic exam is performed by the urologist to evaluate for pelvic organ prolapse, urinary incontinence, dyspareunia, blood per urethra or vagina, and anterior vaginal masses. The patient should be instructed to disrobe from the waist down and wear an examining gown and then is placed on the examining table. Footrests (stirrups) are used to flex and abduct the thighs and flex the knees. If a male urologist is to perform a pelvic examination, this must be done with the presence of a female chaperone (nurse or medical assistant).

Visual inspection of the external genitalia and introitus should evaluate for atrophic changes, erosions, ulcers, discharge, or genital warts. The labia should be separated, and the urethra inspected for prolapse, caruncle, hyperplasia, or cysts. Ideally with a full bladder, the patients should be instructed to perform Valsalva maneuver to elicit stress urinary incontinence. The insertion of a half of a speculum may allow for appropriate visualization of one wall of the vagina. With Valsalva, the examiner can evaluate for prolapse from the bladder, apex, or rectum. Palpation of the urethra can reveal a mass or promote a discharge, which may raise suspicion for urethral diverticulum. Bimanual examination should be performed by placing two of the examiner's fingers of the dominant hand into the vaginal vault (one finger if the introitus is small) and placing the nondominant hand over the lower abdomen and palpating for pelvic mass or tenderness. The female pelvic exam is intrusive and should be performed based on clinical suspicion and not for screening. For screening examinations the patient should be referred to the gynecologist. Children, adolescents, and young women should rarely need a pelvic examination from the urologist.

Neurologic Examination

A sensory dermatome map can help localize the location of a neurologic deficit (Fig. 1.5). Most sensory deficits of the genitalia and perianal area indicate a lesion in the sacral nerves or their root. Evaluation of bulbocavernosal reflex can indicate whether this reflex arc is intact. This reflex tests the integrity of the spinal cord–mediated reflex arc involving S2-S4. Squeezing the glans penis or clitoris should result in immediate contraction of the anal sphincter muscles, which can be appreciated during a DRE. Alternatively, in patients with a Foley catheter indwelling, tugging on the Foley catheter can elicit this response.

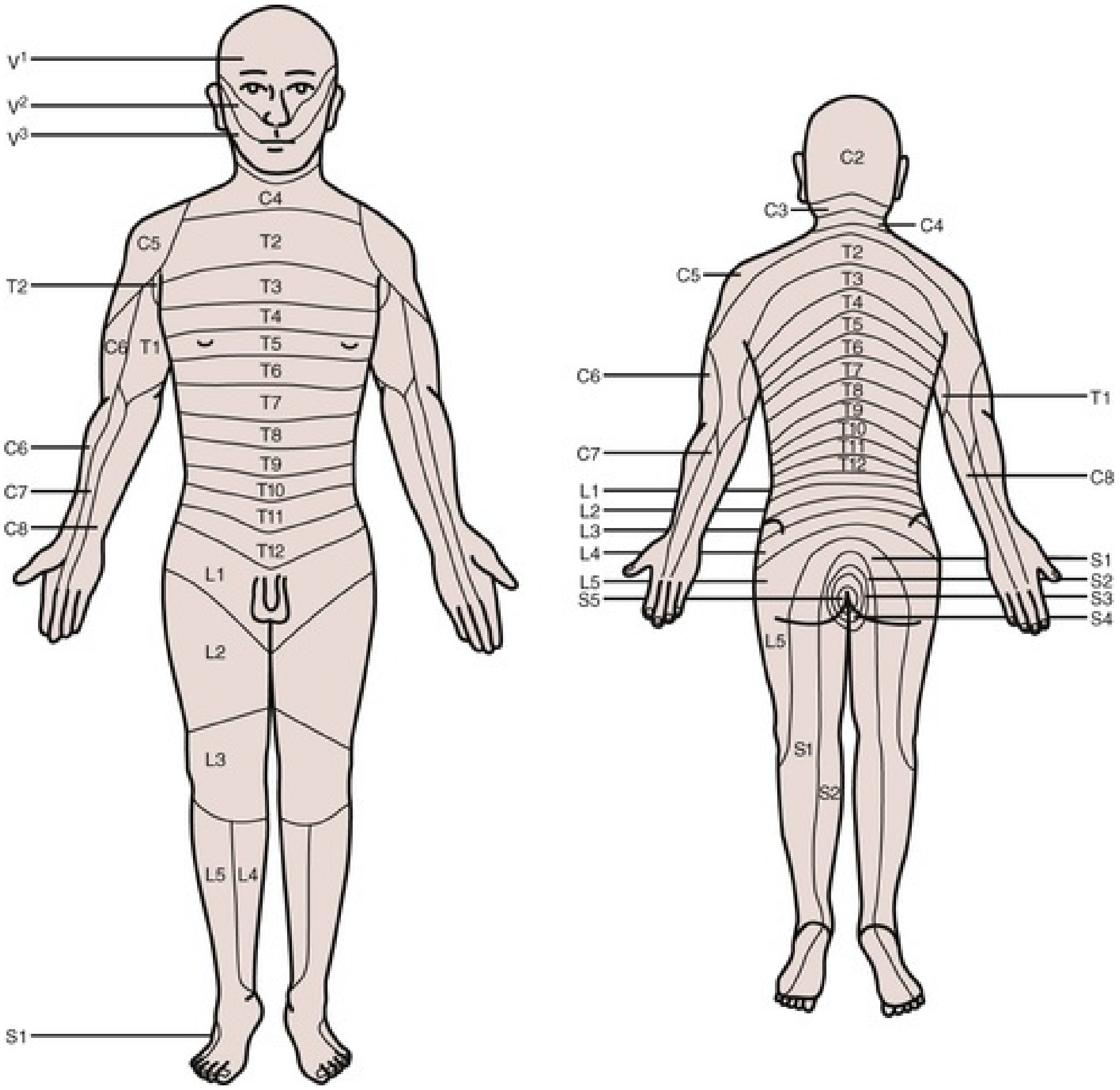
V1
V2
V3
C4
C5
T2
T2
T3
T4
T5
C6
T1
T6
T7
T8
C6
T9
C7
T10
C8
T11
T12
L1
L2
L3
L5
L4
S1
C2
C3
C4
T2
C5
T3
T4
T5
T6
C6
T7
T1
T8
T9
T10
C7
T11
T12
C8
L1
L2
L3
L4
S1
L5
S2
S5
S3
S4
L5
S1
S2

FIG. 1.5 Sensory dermatome maps used to help localize the level of neurologic deficit.

Special Populations

Children

Although pediatric urology practice includes the care of infants, toddlers, children, adolescents, and young adults (sometimes up to age 26 years), the needs of each of these subgroups of pediatrics may be very different. Infants and toddlers may not be able to provide an HPI; therefore any clinical questions are directed toward the parents or guardians. Adolescents and young adults likely require some input from the parent or guardian but will also require some privacy. Questions pertinent to social history (alcohol, smoking, drugs, sexual activity) should be directed to the patient in private. The examination of infants, toddlers, and children should include a comfortable, nonthreatening environment. Often pediatric urologists do not wear a white coat because of the association of white coats with painful doctor's visits and immunizations. The examination ideally should be performed with the help of the family member to decrease the child's distress with the exam. Children are particularly sensitive to the cold and pain, and maneuvers resulting in this should be reserved for the end of the visit.

Elderly

Geriatric patients require much care and attention because they may not have the same physical and cognitive ability as younger patients. Again, a comfortable, nonthreatening environment should be provided. As with pediatric patients, input from the family member or caretaker may be invaluable; however, privacy should not be compromised. Elderly patients may have decreased mobility, and the examination room should be set up for this: lower examination tables, possibly Hoyer lifts for those who are wheelchair bound, blankets and pillows to facilitate comfortable position. Elderly patients can have pseudodementia, which is depression of cognitive affect and ability related to an illness. Therefore it is very important that baseline physical and cognitive abilities be assessed and occult illness be considered.

Transgender and Gender Nonbinary People

It is estimated that 5 in 1000 persons in the United States are transgender or gender nonbinary. These people may have reluctance to seek medical care because of the social stigma associated with their lifestyle. Regardless of the caretaker's belief system, such people should still be offered compassionate medical care as would be afforded to any other person. Caretakers should demonstrate cultural humility and meet their patients without preconceptions.

A few definitions are beneficial to help standardize documentation and communication. Sex often refers to chromosomal or gonadal sex, which is assigned from birth, whereas gender (or gender identity) is a person's perceived internal self. A transgender person's gender is different from the sex attributed at birth. A transgender woman is a male at birth but has a female gender identity. A transgender man is a female at birth but has a male gender identity. Transgender masculine or feminine connotates a directionality and not a full conversion, towards the gender identity. Patients who do not identify with a single gender are referred to as nonbinary. The patient's name, the term “the patient,” or neutral pronouns (*they, them,* or *their* instead of *he/she* or *his/hers*) are used in such patients. Cross-dressing refers to patients who wear clothing of the opposite sex assigned to them at birth for entertainment, self-expression, or sexual pleasure. Sexual orientation is independent of all these prior definitions and is not related to gender identity.

Currently many offices may not be set up ideally to treat transgender patients in a culturally neutral way. Office staff should be educated regarding proper terminology and refrain from expressing judgment. The electronic medical record ideally should have gender identity as a two-step question: gender identity and assigned sex at birth. Further, the presence of gender-neutral bathrooms can decrease some of the tensions associated with caring for transgender and non-transgender patients.

Secondary sexual characteristics should be identified and noted. Patients should be asked what steps they have taken toward their gender, restricted to cross-dressing, hormonal therapy, or gender-affirming surgery (and its extent). Examination of gender-sensitive areas (breasts and genitalia) should be reserved for purpose, as they should in non-transgender patients. Explaining the anatomy and the steps for each exam may help decrease the anxiety associated with a pelvic exam. Establishing a trusting physician-patient relationship before delving into a pelvic exam also may prove beneficial. Pharmaceutical adjuncts include the administration of a benzodiazepine before exam to help decrease anxiety associated with the exam or administration of topical estrogen creams for 1 to 2 weeks before the exam to help counter the effect of exogenous androgens.

Conclusion

The history and physical examination are the foundation of any urologic encounter. Obtaining a thorough history and performing a proper physical examination can help detect urologic issues that are not detectable by other means (laboratory or radiology). Having a broad differential diagnosis can help direct the HPI. Understanding nuances associated with elderly, pediatric, and transgender patients can help the practitioner offer urologic care to a wider population.

Key Points

- The urologist should perform a history and physical examination in a systematic approach, such that pertinent information can be obtained in a reliable fashion to help ascertain diagnosis or at least direct subsequent laboratory and/or radiographic evaluations.
- A broad differential diagnosis is beneficial and can help direct the history of present illness.
- Several disease states and medications have urologic side effects and can have implications for subsequent urologic surgery.
- Physical examination should be thorough but not unnecessarily invasive.
- Special considerations must be made for children, the elderly, and transgender patients.

References

Althof S, McMahon C, Waldinger M, et al. An update of the International Society of Sexual Medicine's guidelines for the diagnosis and treatment of premature ejaculation (PE). *J Sex Med*. 2014;11(6):1392–1422.

Barry MJ, Fowler FJ Jr, O'Leary MP, et al. The American urological association symptom index for benign prostatic hyperplasia. *J Urol*. 1992;148:1549.

Benyamin R, Trescot A, Datta S, et al. Opioid complications and side effects. *Pain Physician*. 2008;11:S105–S120.

Byrne P, Heath C. Practitioners' use of non-verbal behaviour in real consultations. *J R Coll Gen Pract*. 1980;30:327–331.

Chang SS, Boorjian SA, Chou R, et al. Diagnosis and treatment of non-muscle invasive bladder cancer: AUA/SUO guideline. *American Urological Association Education and Research, Inc*. 2016.

Commander C, Johnson D, Raynor M, et al. Detection of upper tract urothelial malignancies by computed tomography urography in patients referred for hematuria at a large tertiary referral center. *Urology*. 2017;102:31–37.

Corty E, Guardiani JM. Canadian and American sex therapists' perceptions of normal and abnormal ejaculatory latencies: how long should intercourse last? *J Sex Med*. 2008;5:1251.

Dudzińska-Griszek J, Szuster K, Szewieczek J. Grip strength as a frailty diagnostic component in geriatric inpatients. *Clin Interv Aging*. 2017;12:1151–1157.

Elsamra S, Nazmy M, Shin D, et al. Female sexual dysfunction in urological patients: findings from a major metropolitan area in the USA. *BJU Int*. 2010;106(4):524–526.

Forsythe WI, Redmond A. Enuresis and spontaneous cure rate: study of 1129 enuretics. *Arch Dis Child*. 1974;49:259.

Gaunay GS, Elsamra SE, Richstone L. Trocars: site selection, instrumentation, and overcoming complications. *J Endourol*. 2016;30(8):833–843.

Hubbard J, Amin M. Pseudohematuria. *Urology*. 1977;10(3):190.

Kessels RP. Patients' memory for medical information. *J R Soc Med*. 2003;96:219–222.

Kriston L, Gunzler C, Harms A, et al. Confirmatory factor analysis of the German version of the international index of erectile function (IIEF): A comparison of four models. *J Sex Med*. 2008;5:92.

Landi F, Onder G, Russo A, et al. Calf circumference, frailty and physical performance among older adults living in the community. *Clin Nutr*. 2014;33:539–544.

Leavitt DA, Theckumparampil N, Moreira DM, et al. Continuing aspirin therapy during percutaneous nephrolithotomy: unsafe or underutilized. *J Endourol*. 2014;28(12):1399–1403.

Lee H, Parka S, Wenga M, et al. E-cigarette smoke damages DNA and reduces repair activity in mouse lung, heart, and bladder as well as in human lung and bladder cells. *Proc Natl Acad Sci U S A*. 2018;115(7):E1560–E1569.

MacDiarmid S, Goodson T, Holmes T, et al. An assessment of the comprehension of the American urological association symptom index. *J Urol*. 1998;159:873.

Montague D, Jarow J, Broderick G, et al. Pharmacologic management of premature ejaculation. *AUA Guidelines*. 2010.

National Comprehensive Cancer Network: Distress management. Clinical practice guidelines. *J Natl Compr Canc Netw*. 2003;1(3):344–374.

Nehra A, Jackson G, Miner M, et al. The Princeton III Consensus recommendations for the management of erectile dysfunction and cardiovascular disease. *Mayo Clin Proc*. 2012;87(8):766–778.

Nordström T, Bratt O, Örtegren J, et al. A population-based study on the association between educational length, prostate-specific antigen testing, and use of prostate biopsies. *Scand J Urol*. 2016;50(2):104–109.

Opioid crisis fast facts. https://www.cnn.com/2017/09/18/health/opioid-crisis-fast-facts/index.html; 2018.

Palla L, De Angelis B, Lucarini L, et al. A case of labial fusion and urinary pseudo-incontinence in an elderly woman. A surgical treatment and a review. *Eur Rev Med Pharmacol Sci*. 2010;14(5):491–493.

Pamoukdjian F, Paillaud E, Zelek L, et al. Measurement of gait speed in older adults to identify complications associated with frailty: a systematic review. *J Geriatr Oncol*. 2015;6:484–496.

Pretorius R, Zurick G. A systematic approach to identifying drug-seeking patients. *Fam Pract Manag*. 2008;15:A3–A5.

Rao PK, Gao T, Phol M, et al. Dipstick pseudohematuria: unnecessary consultation and evaluation. *J Urol*. 2010;183:560–565.

Rozanski A, Benson C, McCoy JA, et al. Is exam under anesthesia still necessary for the staging of bladder cancer in the era of modern imaging? *Bladder Cancer*. 2015;1:91–96.

Silverman J, Kinnersley P. Doctors' non-verbal behaviour in consultations: look at the patient before you look at the computer. *Br J Gen Pract*. 2010;76–78.

Stephenson TP, Farrar DJ. Urodynamic study of 15 patients with postmicturition dribble. *Urology*. 1977;9:404.

Urban M, Gebhart G. Supraspinal contributions to hyperalgesia. *Proc Natl Acad Sci U S A*. 1999;96(14):7687–7692.

Weiss J, Blaivas J. Nocturia. *J Urol*. 2000;163:5.

Wiltink J, Beutel ME, Brahler E, et al. Hypogonadism-related symptoms: development and evaluation of an empirically-derived self-rating instrument (HRS ‘Hypogonadism Related Symptom Scale’). *Andrologia*. 2009;41:297–304.

Wong D, Baker CM. Pain in children: comparison of assessment scales. *Pediatr Nurs*. 1988;14:9–17.

Woolf CJ. Central sensitization: implications for the diagnosis and treatment of pain. *Pain*. 2011;152(Suppl 3):S2–S15.

Xue Q-L. The fraility syndrome: definiton and natural history. *Clin Geriatr Med*. 2011;27(2):1–15.

Zhao P, Velez D, Faiena I, et al. Bullying has a potential role in pediatric lower urinary tract symptoms. *J Urol*. 2015;193:1743–1748.

Evaluation of the Urologic Patient

Testing and Imaging

Erik P. Castle MD, Christopher E. Wolter MD, Michael E. Woods MD

The urologist has various serum, urinary, and radiologic studies available to complement the physical examination and perform a thorough and comprehensive evaluation of the urologic patient. Knowing when to order these studies based on the history and physical findings is crucial to identifying underlying pathology. Urinalysis is one of the more commonly performed laboratory studies, and in some cases the urologist will perform the urinary dipstick and microscopy analysis in the office during the evaluation. Furthermore, many office procedures such as uroflowmetry and cystourethroscopy may be incorporated into the evaluation. It is these laboratory and office studies that may be combined with radiologic testing during the evaluation of the urologic patient.

Urinalysis

The urinalysis is a fundamental test that should be performed in all urologic patients presenting with urinary symptoms and complaints. **Evaluation of voided urine includes gross examination, dipstick chemical analysis, and microscopic analyses.**

Collection of Urinary Specimens

Males

To avoid contamination in the male patient**, a midstream urine sample is obtained.** Retraction of the foreskin and cleansing of the glans and urethral meatus is performed. The male patient begins urinating into the toilet and then places a wide-mouth sterile container under his penis to collect a midstream sample.

A variety of methods are available to identify a potential source of infection if not clearly from the bladder. One traditional test is the use of four aliquots to differentiate bacteria from the bladder, urethra, and prostate. **These aliquots can be designated Voided Bladder 1, Voided Bladder 2, Expressed Prostatic Secretions, and Voided Bladder 3 (VB1, VB2, EPS, and VB3).** The VB1 specimen is the initial 5 to 10 mL of urine voided, whereas the VB2 specimen is the midstream urine. The EPS is the secretions obtained after gentle prostatic massage, and the VB3 specimen is the initial 2 to 3 mL of urine obtained after prostatic massage. The value of these cultures for localization of urinary tract infections (UTIs) is that the VB1 sample represents urethral flora, the VB2 sample represents bladder flora, and the EPS and VB3 samples represent prostatic flora. The VB3 sample is particularly helpful when little or no prostatic fluid is obtained by massage. The four-part urine sample is particularly useful in evaluating men with suspected bacterial prostatitis (Meares and Stamey, 1968). An alternative is to obtain two aliquots of urine, one before prostatic massage and one following prostatic massage (Nickel et al., 2006). The two-aliquot technique may be easier in some cases and has been demonstrated in one study to show concordance with the four-aliquot test described by Meares and Stamey.

Females

Obtaining a sterile voided urine collection can be a challenge in the female patient. The standard midstream urinalysis in the female patient should be obtained after separating the labia and cleansing the vaginal introitus and external urethral meatus. This is an appropriate method for the routine collection. However, **in the female patient with suspected recurrent UTIs or a history of antibiotic-resistant infections, a catheterized urine sample should always be obtained.**

Neonates and Infants

The usual way to obtain a urine sample in a neonate or infant is to place a sterile plastic bag with an adhesive collar over the infant's genitalia. However, these devices may not be able to distinguish contamination from true UTI. Whenever possible, **all urine samples should be examined within 1 hour of collection and plated for culture and sensitivity if indicated.** If urine is allowed to stand at room temperature for longer periods, bacterial overgrowth may occur, the pH may change, and red and white blood cell casts may disintegrate. If it is not possible to examine the urine promptly, it should be refrigerated at 5°C. When appropriate, a collection of urine via suprapubic aspiration may be obtained.

Physical and Gross Examination of Urine

The visual and physical examination of the urine includes an evaluation of color and turbidity.

Color

Typical, normal urine color is pale yellow as a result of the presence of the pigment urochrome. **Urine color varies most commonly because of concentration, but many foods, medications, metabolic products, and infections may produce abnormal urine color.** It is important for the urologist to be aware of the common causes of abnormal urine color, and these are listed in Table 2.1. For example, bright red color or pink suggests blood that may be active bleeding, and purple or brown urine may indicate an old hemorrhage or a retained clot in the bladder. Brown or cola-colored urine can be a sign of glomerular bleeding and disease. Often, the urine color is an important adjunct to the workup and management of the urologic patient.

TABLE 2.1

Common Causes of Abnormal Urine Color

COLOR	CAUSE
Colorless	Very dilute urine
	Overhydration
Cloudy/milky	Phosphaturia
	Pyuria
	Chyluria
Red	Hematuria
	Hemoglobinuria/myoglobinuria
	Anthocyanin in beets and blackberries
	Chronic lead and mercury poisoning
	Phenolphthalein (in bowel evacuants)
	Phenothiazines (e.g., Compazine)
	Rifampin
Orange	Dehydration
	Phenazopyridine (Pyridium)
	Sulfasalazine (Azulfidine)
Yellow	Normal
	Phenacetin
	Riboflavin
Green-blue	Biliverdin
	Indicanuria (tryptophan indole metabolites)
	Amitriptyline (Elavil)
	Indigo carmine
	Methylene blue
	Phenols (e.g., IV cimetidine [Tagamet], IV promethazine [Phenergan])
	Resorcinol
	Triamterene (Dyrenium)
Brown	Urobilinogen
	Porphyria
	Aloe, fava beans, and rhubarb
	Chloroquine and primaquine
	Furazolidone (Furoxone)
	Metronidazole (Flagyl)
	Nitrofurantoin (Furadantin)
Brown-black	Alcaptonuria (homogentisic acid)
	Hemorrhage
	Melanin

	Tyrosinosis (hydroxyphenylpyruvic acid)
	Cascara, senna (laxatives)
	Methocarbamol (Robaxin)
	Methyldopa (Aldomet)
	Sorbitol

IV, Intravenous.

From Hanno PM, Wein AJ. *A clinical manual of urology.* Norwalk, CT: Appleton-Century-Crofts; 1987:67.

Turbidity

Cloudy urine is commonly caused by phosphaturia, a benign process in which excess phosphate crystals precipitate in alkaline urine. Phosphaturia is often intermittent and may occur after meals, and many patients are otherwise asymptomatic. The diagnosis of phosphaturia can be accomplished either by acidifying the urine with acetic acid, which will result in immediate clearing, or by performing a microscopic analysis, which will reveal large amounts of amorphous phosphate crystals.

Pyuria is another common cause of cloudy urine. The large numbers of white blood cells cause the urine to become turbid. Pyuria is readily distinguished from phosphaturia either by smelling the urine (infected urine has a characteristic pungent odor) or by **urine dipstick or microscopic examination.** The presence of leukocyte esterase or identification of leukocytes on microscopic analysis is diagnostic of pyuria. In patients with indwelling tubes such as catheters or percutaneous nephrostomy tubes, the smell and turbidity of the urine may often be a contributing deciding factor in determining treatment. For example, in a patient with a **long-term indwelling nephrostomy tube and worsening cloudy, smelly urine, the urologist may choose to give both an antibiotic and an antifungal before any manipulation or procedures** while awaiting the results of a urinalysis and culture.

Rare causes of cloudy urine include chyluria (in which there is an abnormal communication between the lymphatic system and the urinary tract resulting in lymph fluid being mixed with urine), lipiduria, hyperoxaluria, and hyperuricosuria.

Chemical Examination of Urine

The chemical examination of the urine involves the assessment of various characteristics of the urine via a urine dipstick. Urine dipsticks provide a quick and inexpensive method for detecting abnormal substances within the urine. Dipsticks are short, plastic strips with small marker pads that are impregnated with different chemical reagents that react with abnormal substances in the urine to produce a colorimetric change. **Dipstick tests include those for specific gravity, pH, blood, protein, glucose, ketones, urobilinogen, leukocyte esterase, and nitrites.**

Substances listed in Table 2.1 that produce an abnormal urine color may interfere with appropriate color development on the dipstick. A common medication that may interfere with the dipstick analysis is phenazopyridine (Pyridium). Phenazopyridine turns the urine bright orange and makes dipstick evaluation of the urine unreliable.

The technique of obtaining an accurate dipstick determination includes completely immersing it in a fresh uncentrifuged urine specimen and then withdrawing it quickly while drawing the edge along the rim of the container to remove excess urine. The dipstick should be held horizontally until the appropriate time for reading and then compared with the color chart. **Excess urine on the dipstick or holding the dipstick in a vertical position will allow mixing of chemicals from adjacent reagent pads on the dipstick, resulting in a faulty diagnosis.** False-negative results for glucose and bilirubin may be seen in the presence of elevated ascorbic acid concentrations in the urine. However, increased levels of ascorbic acid in the urine do not interfere with dipstick testing for hematuria. Highly buffered alkaline urine may cause falsely low readings for specific gravity and may lead to false-negative results for urinary protein. **Other common causes of false results with dipstick testing are outdated test strips and exposure of the sticks**, leading to damage to the reagents. Alterations in the color of the pads before immersing the sticks should be a sign of an outdated or exposed stick.

Specific Gravity and Osmolality

Specific gravity of urine is easily determined from a urinary dipstick and usually varies from 1.001 to 1.035. Specific gravity usually reflects the patient's state of hydration but may also be affected by abnormal renal function, the amount of material dissolved in the urine. A specific gravity less than 1.008 is regarded as dilute, and a specific gravity greater than 1.020 is considered concentrated. Acute or chronic renal insufficiency can be associated with a specific gravity of 1.010.

In general, specific gravity reflects the state of hydration but also affords some idea of renal concentrating ability. Conditions that decrease specific gravity include diuretics, increased fluid intake, diabetes insipidus, and other causes of decreased renal concentrating ability. Conversely, specific gravity can be increased with uncontrolled diabetes mellitus caused by glycosuria, inappropriate secretion of antidiuretic hormone, and any condition causing dehydration. It should be noted that intravenous injection of some iodinated contrasts and administration of dextran can cause a rise in specific gravity above 1.035.

Osmolality is a measure of the amount of material dissolved in the urine and usually varies between 50 and 1200 mOsm/L. Urine osmolality most commonly varies with hydration, and the same factors that affect specific gravity will also affect osmolality. Urine osmolality can be an indicator of renal function, and any abnormal value should be further investigated with additional testing for renal compromise. Furthermore, with alterations in urine osmolality such as very dilute urine (below 308 mOsm), reliable assessment of red blood cells in urine can be compromised due to lysis (Vaughan and Wyker, 1971).

pH

The dipstick test strip incorporates two colorimetric indicators, methyl red and bromothymol blue, which yield clearly distinguishable colors over the pH range from 5 to 9. Urinary pH may vary from 4.5 to 8; the average pH varies between 5.5 and 6.5. A urinary pH between 4.5 and 5.5 is considered acidic, whereas a pH between 6.5 and 8 is considered alkaline.

In general, the urinary pH reflects the pH in the serum. In patients with metabolic or respiratory acidosis, the urine is usually acidic; conversely, in patients with metabolic or respiratory alkalosis, the urine is alkaline. Renal tubular acidosis (RTA) presents an exception to this rule. In patients with both type I and II RTA, the serum is acidemic, but the urine is alkalotic because of continued loss of bicarbonate in the urine. In severe metabolic acidosis in type II RTA, the urine may become acidic, but in type I RTA, the urine is always alkaline, even with severe metabolic acidosis (Morris and Ives, 1991). Urinary pH determination is used to establish the diagnosis of RTA; **inability to acidify the urine below a pH of 5.5 after administration of an acid load is diagnostic of RTA**.

Urine pH determinations are also useful in the diagnosis and treatment of UTIs and urinary calculus disease. **In patients with a presumed UTI, an alkaline urine with a pH greater than 7.5 suggests infection with a urea-splitting organism, most commonly *Proteus*.** Urease-producing bacteria convert ammonia to ammonium ions, markedly elevating the urinary pH and causing precipitation of calcium magnesium ammonium phosphate crystals. Crystallization may result in staghorn calculi.

Urinary pH is usually acidic in patients with uric acid and cystine lithiasis. Alkalinization of the urine is an important feature of therapy in both conditions, and frequent monitoring of urinary pH is necessary to ascertain adequacy of therapy.

Blood/Hematuria

Normal urine should contain less than 3 erythrocytes per HPF. A positive dipstick for blood in the urine indicates either hematuria, hemoglobinuria, or myoglobinuria. **The chemical detection of blood in the urine is based on the peroxidase-like activity of hemoglobin.** When in contact with an organic peroxidase substrate, hemoglobin catalyzes the reaction and causes subsequent oxidation of a chromogen indicator, which changes color according to the degree and amount of oxidation. The degree of color change is directly related to the amount of hemoglobin present in the urine specimen. Dipsticks frequently demonstrate both colored dots and field color change. If present, free hemoglobin and myoglobin in the urine are absorbed into the reagent pad and catalyze the reaction within the test paper, thereby producing a field change effect in color. Intact erythrocytes in the urine undergo hemolysis when they come in contact with the reagent test pad, and the localized free hemoglobin on the pad produces a corresponding dot of color change. The greater the number of intact erythrocytes in the urine specimen, the greater the number of dots that will appear on the test paper, and a coalescence of the dots occurs when there are more than 250 erythrocytes/mL.

Hematuria can be distinguished from hemoglobinuria and myoglobinuria by microscopic examination of the centrifuged urine; the presence of a large

number of erythrocytes establishes the diagnosis of hematuria. If erythrocytes are absent, examination of the serum will distinguish hemoglobinuria and myoglobinuria. A sample of blood is obtained and centrifuged. In hemoglobinuria, the supernatant will be pink. This is because free hemoglobin in the serum binds to haptoglobin, which is water insoluble and has a high molecular weight. This complex remains in the serum, causing a pink color. Free hemoglobin will appear in the urine only when all of the haptoglobin-binding sites have been saturated. In myoglobinuria, the myoglobin released from muscle is of low molecular weight and water soluble. It does not bind to haptoglobin and is therefore excreted immediately into the urine. Therefore in myoglobinuria the serum remains clear.

The sensitivity of urinary dipsticks in identifying microscopic hematuria, defined as greater than or equal to 3 erythrocytes per HPF of centrifuged sediment examined microscopically, is higher than 90%. Conversely, the specificity of the dipstick for hematuria compared with microscopy is somewhat lower, reflecting a higher false-positive rate with the dipstick (Shaw et al., 1985). Things to consider when considering the possibility of a false positive include: contamination of the urine in females when they may be menstruating; significant dehydration, which can result in a higher concentration of erythrocytes; and vigorous exercise, which has been reported to result in clinically significant hematuria (Akiboye and Sharma, 2018). The normal individual excretes about 1000 erythrocytes/mL of urine, with the upper limits of normal varying from 5000 to 8000 erythrocytes/mL (Kincaid-Smith, 1982). Therefore, examining urine of high specific gravity such as the first-void specimen increases the likelihood of a false-positive result.

The efficacy of hematuria screening using the dipstick to identify patients with significant urologic disease is somewhat controversial. Because of the risk for false positives that may lead one to order additional costly and invasive testing, **the dipstick result should be confirmed with a microscopic examination of the centrifuged urinary sediment**. Several societies including the American Urological Association (AUA) have released guidelines (https://www.auanet.org/guidelines/asymptomatic-microhematuria-(2012-reviewed-for-currency-2016) or consensus statements and agree that a urinary dipstick alone is inadequate to confirm the diagnosis of hematuria.

Differential Diagnosis and Evaluation of

Hematuria

One of the early signs and symptoms of nephrologic or urologic disease is microscopic or gross hematuria. Interpreting the microscopic findings of the urinalysis can be helpful in working through the differential diagnosis. Differentiating between nephrologic and urologic causes is critical when deciding what additional tests may need to be ordered. **Identifying the hematuria as nephrologic versus urologic and glomerular versus nonglomerular is one of the first steps in the analysis.**

Hematuria of nephrologic origin is frequently associated with casts in the urine and almost always associated with significant proteinuria. Significant gross hematuria of urologic origin is unlikely to elevate the protein concentration in the urine into the 100 to 300 mg/dL or 2+ to 3+ range on dipstick, and proteinuria of this magnitude almost always indicates glomerular or tubulointerstitial renal disease prompting a consultation with nephrology. Morphologic evaluation of erythrocytes in the centrifuged urinary sediment also helps localize their site of origin. **Erythrocytes arising from glomerular disease are typically dysmorphic and show a wide range of morphologic alterations. Conversely, erythrocytes arising from tubulointerstitial renal disease and of urologic origin have a uniformly round shape;** these erythrocytes may or may not retain their hemoglobin (“ghost cells”), but the individual cell shape is consistently round.

Glomerular Hematuria

Glomerular hematuria is suggested by the presence of dysmorphic erythrocytes, RBC casts, proteinuria, and brown or cola-colored urine. Of those patients with glomerulonephritis proven by renal biopsy, however, about 20% will have hematuria alone without RBC casts or proteinuria (Fassett et al., 1982).

The glomerular disorders associated with hematuria are listed in Table 2.2. Further evaluation of patients with glomerular hematuria should begin with a thorough history and possibly a consultation with nephrology. Hematuria in children and young adults, usually males, associated with low-grade fever and an erythematous rash suggests a diagnosis of immunoglobulin A (IgA) nephropathy (Berger disease). A family history of renal disease and deafness suggests familial nephritis or Alport syndrome. Hemoptysis and abnormal bleeding associated with microcytic anemia are characteristic of Goodpasture syndrome, and the presence of a rash and arthritis suggest systemic lupus erythematosus. Finally, poststreptococcal glomerulonephritis should be suspected in a child with a recent streptococcal upper respiratory tract or skin infection.

TABLE 2.2

Glomerular Disorders in Patients With Glomerular Hematuria

DISORDER	PATIENTS
IgA nephropathy (Berger disease)	30
Mesangioproliferative GN	14
Focal segmental proliferative GN	13
Familial nephritis (e.g., Alport syndrome)	11
Membranous GN	7
Mesangiocapillary GN	6
Focal segmental sclerosis	4
Unclassifiable	4
Systemic lupus erythematosus	3
Postinfectious GN	2
Subacute bacterial endocarditis	2
Others	4
Total	100

GN, Glomerulonephritis; *IgA,* immunoglobulin A.

Modified from Fassett RG, Horgan BA, Mathew TH. Detection of glomerular bleeding by phase-contrast microscopy. *Lancet.* 1982;1(8287):1432–1434.

Further laboratory evaluation often includes measurement of serum creatinine, creatinine clearance, and a 24-hour urine protein determination. Although these tests will quantitate the specific degree of renal dysfunction, further tests are usually required to establish the specific diagnosis and particularly to determine whether the disease is caused by an immune or a nonimmune etiology. **Frequently, a renal biopsy is necessary to establish the precise diagnosis, and biopsies are particularly important if the result will influence subsequent treatment of the patient.** Renal biopsies are extremely informative when examined by an experienced pathologist using light, immunofluorescence, and electron microscopy.

An algorithm for the evaluation of glomerular hematuria is shown in Fig. 2.1.

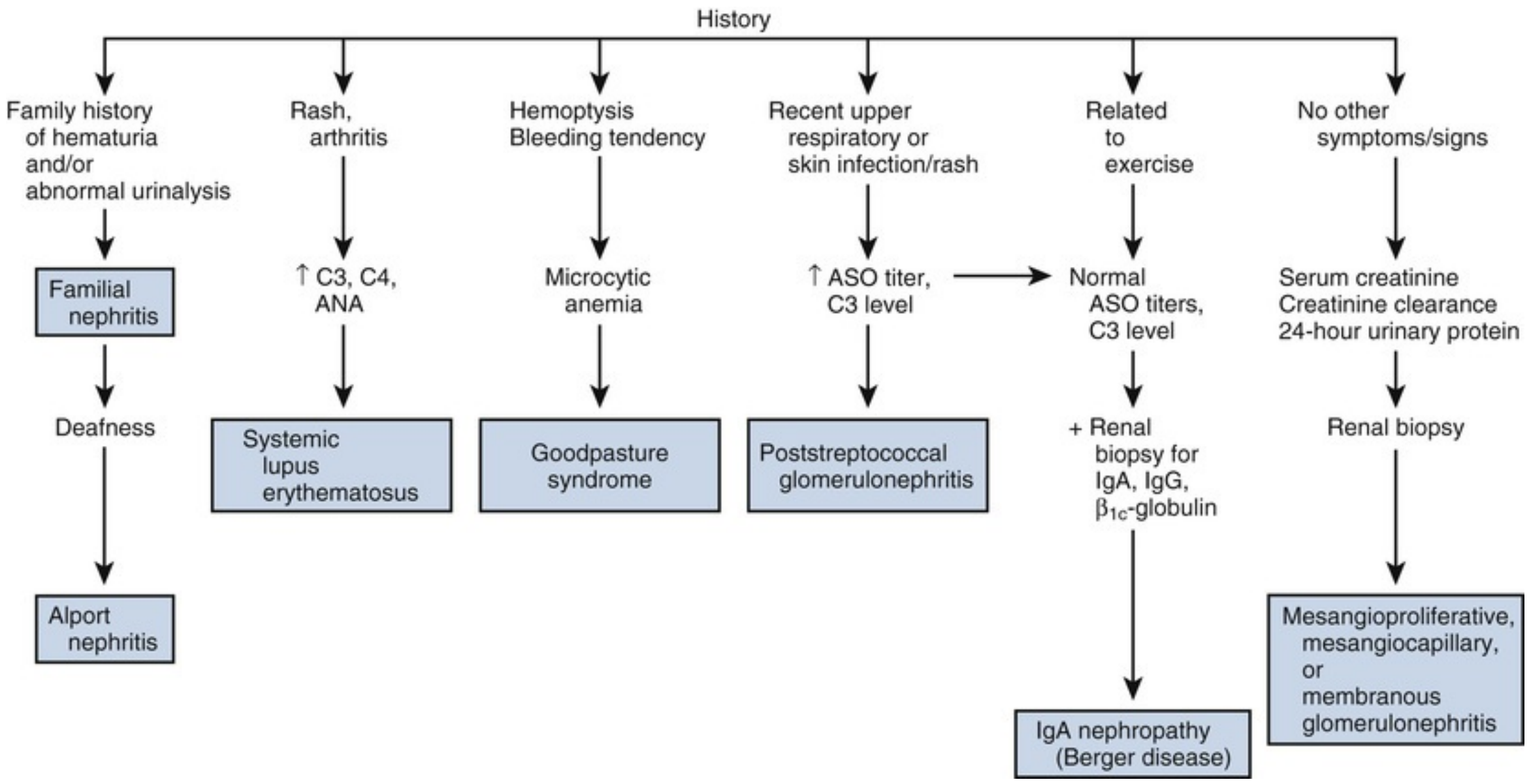
History
Family history of hematuria and/or abnormal urinalysis
Familial nephritis
Deafness
Alport nephritis
Rash, arthritis
↑ C3, C4, ANA
Systemic lupus erythematosus
Hemoptysis Bleeding tendency
Microcytic anemia
Goodpasture syndrome
Recent upper respiratory or skin infection/rash
↑ ASO titer, C3 level
Poststreptococcal glomerulonephritis
Related to exercise
Normal ASO titers, C3 level
+ Renal biopsy for IgA, IgG, β1c-globulin
IgA nephropathy (Berger disease)
No other symptoms/signs
Serum creatinine Creatinine clearance 24-hour urinary protein
Renal biopsy
Mesangioproliferative, mesangiocapillary, or membranous glomerulonephritis

FIG. 2.1 Evaluation of glomerular hematuria (dysmorphic erythrocytes, erythrocyte casts, and proteinuria). *ANA,* Antinuclear antibody; *ASO,* antistreptolysin O; *Ig,* immunoglobulin.

IgA Nephropathy (Berger Disease)

IgA nephropathy, or Berger disease, is the most common cause of glomerular hematuria, accounting for about 30% of cases (Fassett et al., 1982). Therefore it is described in greater detail in this section. IgA nephropathy occurs most commonly in children and young adults, with a male predominance (Berger and Hinglais, 1968). Patients typically present with hematuria after an upper respiratory tract infection or exercise. Hematuria may be associated with a low-grade fever or rash, but most patients have no associated systemic symptoms. Gross hematuria occurs intermittently, but microscopic hematuria is a constant finding in some patients. The disease is chronic, but the prognosis in most patients is excellent. Renal function remains normal in the majority, but about 25% will subsequently develop renal insufficiency. Older age at onset, initial abnormal renal function, consistent proteinuria, and hypertension are indicators of a poor prognosis (D'Amico, 1988).

The pathologic findings in Berger disease are limited to either focal glomeruli or lobular segments of a glomerulus. The changes are proliferative and usually confined to mesangial cells (Berger and Hinglais, 1968). Renal biopsy reveals deposits of IgA, IgG, and β_{1c}-globulin, although IgA and IgG mesangial deposits are found in other forms of glomerulonephritis as well. The role of IgA in the disease remains uncertain, although the deposits may trigger an inflammatory reaction within the glomerulus (van den Wall Bake et al, 1989). Because gross hematuria frequently follows an upper respiratory tract infection, a viral etiology has been suspected but not established. The frequent association between hematuria and exercise in this condition remains unexplained.

The clinical presentation of IgA glomerulonephritis is alarming and similar to certain systemic diseases, including Schönlein-Henoch purpura, systemic lupus erythematosus, bacterial endocarditis, and Goodpasture syndrome. Therefore a careful clinical and laboratory evaluation is indicated to establish the correct diagnosis. The presence of RBC casts establishes the glomerular origin of the hematuria. In the absence of casts, a urologic evaluation is indicated to exclude the urinary tract as a source of bleeding and to confirm that the hematuria is arising from both kidneys. The diagnosis of IgA nephropathy is confirmed by renal biopsy demonstrating the classic deposits of immunoglobulins in mesangial cells, as described earlier in this chapter. Once the diagnosis has been established, repeat evaluations for hematuria are generally not indicated. Although there is no effective treatment for this condition, renal function remains stable in most patients, and there are no other known long-term complications.

Nonglomerular Hematuria

Medical/Nonsurgical

Medical causes of nonglomerular hematuria of renal origin are secondary to either tubulointerstitial, renovascular, or systemic disorders. **The urinalysis in nonglomerular hematuria is distinguished from that of glomerular hematuria by the presence of circular erythrocytes and the absence of erythrocyte casts.** It is frequently associated with significant proteinuria, which distinguishes these nephrologic diseases from urologic diseases in which the degree of proteinuria is usually minimal, even with heavy bleeding.

As with glomerular hematuria, a careful history frequently helps establish the diagnosis. A family history of hematuria or bleeding tendency suggests the diagnosis of a blood dyscrasia, which should be investigated further. A family history of urolithiasis associated with intermittent hematuria may indicate inherited stone disease, which should be investigated with serum and urine measurements of calcium and uric acid. A family history of renal cystic disease should prompt further radiologic evaluation for medullary sponge kidney and adult polycystic kidney disease. **Papillary necrosis as a cause of hematuria should be considered in diabetics, African-Americans (secondary to sickle cell disease or trait), and suspected analgesic abusers.**

Medications may induce hematuria, particularly anticoagulants. **Anticoagulation at normal therapeutic levels, however, does not predispose patients to hematuria.** In one study, the prevalence of hematuria was 3.2% in anticoagulated patients versus 4.8% in a control group. Urologic disease was identified in 81% of patients with more than one episode of microscopic hematuria, and the cause of hematuria did not vary between groups (Culclasure et al., 1994). Thus anticoagulant therapy per se does not appear to increase the risk for hematuria unless the patient is excessively anticoagulated. Therefore, in patients on anticoagulation, hematuria should not be attributed to the medication, and a proper thorough workup should be performed as it would in any other patient that is not anticoagulated.

Exercise-induced hematuria can be observed in patients with a recent history of vigorous exercise such as extreme or long-distance running (Akiboye and Sharma, 2018). In long-distance runners (>10 km), it is usually noted at the conclusion of the run, and rapidly disappears with rest. The hematuria may be of renal or bladder origin. An increased number of dysmorphic erythrocytes have been noted in some patients, suggesting a glomerular origin. Exercise-induced hematuria may be the first sign of underlying glomerular disease such as IgA nephropathy. Conversely, cystoscopy in patients with exercise-induced hematuria frequently reveals punctate hemorrhagic lesions in the bladder, suggesting that the hematuria is of bladder origin.

Vascular disease may also result in nonglomerular hematuria. Renal artery embolism and thrombosis, arteriovenous fistulae, and renal vein thrombosis may all result in hematuria. Physical examination may reveal severe hypertension, a flank or abdominal bruit, or atrial fibrillation. In such patients, further evaluation for renal vascular disease should be undertaken. Microscopic hematuria has also been reported in Nutcracker syndrome associated with pelvic congestion (Chau et al., 2018; Gulleroglu et al., 2014).

Surgical

Nonglomerular hematuria caused by surgical and urologic causes includes pathology of the collecting system of the urinary tract. Common causes include urologic tumors, stones, benign prostatic hyperplasia, and urinary tract infections.

The urinalysis in both nonglomerular medical and surgical hematuria is similar in that both are characterized by circular erythrocytes and the absence of erythrocyte casts. Essential hematuria is suggested, however, by the absence of significant proteinuria usually found in nonglomerular hematuria of renal parenchymal origin. It should be remembered, however, that proteinuria is not always present in glomerular or nonglomerular renal disease.

Asymptomatic microscopic hematuria (AMH) "is defined as three or greater RBC/HPF on a properly collected urinary specimen in the absence of an obvious benign cause" (Davis et al., 2012, reviewed and validated 2016). The AUA guideline on the diagnosis, evaluation, and follow-up of AMH in adults provides 19 guideline statements and an algorithm for AMH (https://www.auanet.org/guidelines/asymptomatic-microhematuria-(2012-reviewed-for-currency-2016)).

Proteinuria

Healthy adults excrete 80 to 150 mg of protein in the urine daily. The qualitative detection of proteinuria in the urinalysis should raise the suspicion of underlying renal disease. **Proteinuria may be the first indication of renovascular, glomerular, or tubulointerstitial renal disease, or it may represent the overflow of abnormal proteins into the urine in conditions such as multiple myeloma.** Proteinuria can also occur secondary to nonrenal disorders and in response to various physiologic conditions such as strenuous exercise.

The protein concentration in the urine depends on the state of hydration, but it seldom exceeds 20 mg/dL. In patients with dilute urine, however, significant proteinuria may be present at concentrations less than 20 mg/dL. **Normally, urine protein is about 30% albumin, 30% serum globulins, and 40% tissue proteins, of which the major component is Tamm-Horsfall protein.** This profile may be altered by conditions that affect glomerular filtration, tubular reabsorption, or excretion of urine protein. Determination of the urine protein profile by such techniques as protein electrophoresis may help determine the etiology of proteinuria.

Pathophysiology

Most causes of proteinuria can be categorized into one of three categories: glomerular, tubular, or overflow. Glomerular proteinuria is the most common type of proteinuria and results from increased glomerular

capillary permeability to protein, especially albumin. Glomerular proteinuria occurs in any of the primary glomerular diseases such as IgA nephropathy or in glomerulopathy associated with systemic illness such as diabetes mellitus. Glomerular disease should be suspected when the 24-hour urine protein excretion exceeds 1 g and is almost certain to exist when the total protein excretion exceeds 3 g.

Tubular proteinuria results from failure to reabsorb normally filtered proteins of low molecular weight such as immunoglobulins. In tubular proteinuria, the 24-hour urine protein loss seldom exceeds 2 to 3 g, and the excreted proteins are of low molecular weight rather than albumin. Disorders that lead to tubular proteinuria are commonly associated with other defects of proximal tubular function such as glycosuria, aminoaciduria, phosphaturia, and uricosuria (Fanconi syndrome).

Overflow proteinuria occurs in the absence of any underlying renal disease and is caused by an increased plasma concentration of abnormal immunoglobulins and other low–molecular-weight proteins. The increased serum levels of abnormal proteins result in excess glomerular filtration that exceeds tubular reabsorptive capacity. The most common cause of overflow proteinuria is multiple myeloma, in which large amounts of immunoglobulin light chains are produced and appear in the urine (Bence Jones protein).

Detection

Qualitative detection of abnormal proteinuria is most easily accomplished with a dipstick impregnated with tetrabromophenol blue dye. The color of the dye changes in response to a pH shift related to the protein content of the urine, mainly albumin, leading to the development of a blue color. Because the background of the dipstick is yellow, various shades of green will develop, and the darker the green, the greater the concentration of protein in the urine. The minimal detectable protein concentration by this method is 20 to 30 mg/dL. **False-negative results can occur in alkaline urine, dilute urine, or when the primary protein present is not albumin.** Nephrotic range proteinuria in excess of 1 g/24 h, however, is seldom missed on qualitative screening. Precipitation of urinary proteins with strong acids such as 3% sulfosalicylic acid will detect proteinuria at concentrations as low as 15 mg/dL and is more sensitive at detecting other proteins and albumin. Patients whose urine is negative on dipstick but strongly positive with sulfosalicylic acid should be suspected of having multiple myeloma, and the urine should be tested further for Bence Jones protein.

If qualitative testing reveals proteinuria, this should be quantitated with a 24-hour urinary collection. Further qualitative assessment of abnormal urinary proteins can be accomplished by either protein electrophoresis or immunoassay for specific proteins. **Protein electrophoresis is particularly helpful in distinguishing glomerular from tubular proteinuria. In glomerular proteinuria, albumin makes up about 70% of the total protein excreted, whereas in tubular proteinuria, the major proteins excreted are immunoglobulins, with albumin making up only 10% to 20%. Immunoassay is the method of choice for detecting specific proteins such as Bence Jones protein in multiple myeloma.**

Evaluation

Proteinuria should first be classified by its timing into transient, intermittent, or persistent. Transient proteinuria occurs commonly, especially in the pediatric population, and usually resolves spontaneously within a few days (Wagner et al., 1968). It may result from fever, exercise, or emotional stress. In older patients, transient proteinuria may be caused by congestive heart failure. If a nonrenal cause is identified and a subsequent urinalysis is negative, no further evaluation is necessary. If proteinuria persists, it should be evaluated further.

Proteinuria may also occur intermittently, and this is frequently related to postural change (Robinson, 1985). Proteinuria that occurs only in the upright position is a frequent cause of mild, intermittent proteinuria in young males. Total daily protein excretion seldom exceeds 1 g, and urinary protein excretion returns to normal when the patient is recumbent. Orthostatic proteinuria is thought to be secondary to increased pressure on the renal vein while standing. It resolves spontaneously in about 50% of patients and is not associated with morbidity. Therefore if renal function is normal in patients with orthostatic proteinuria, no further evaluation is indicated.

Persistent proteinuria requires further evaluation, and most cases have a glomerular etiology. A quantitative measurement of urinary protein should be obtained through a 24-hour urine collection, and a qualitative evaluation should be obtained to determine the major proteins excreted. The findings of greater than 2 g of protein excreted per 24 hours, of which the major components are high-molecular-weight proteins such as albumin, establish the diagnosis of glomerular proteinuria. Glomerular proteinuria is the most common cause of abnormal proteinuria, especially in patients presenting with persistent proteinuria. If glomerular proteinuria is associated with hematuria characterized by dysmorphic erythrocytes and erythrocyte casts, the patient should be evaluated as outlined earlier for glomerular hematuria (see Fig. 2.1). Patients with glomerular proteinuria who have no or little associated hematuria should be evaluated for other conditions, of which the most common is diabetes mellitus. Other possibilities include amyloidosis and arteriolar nephrosclerosis.

In patients in whom total protein excretion is 300 to 2000 mg/day, of which the major components are low–molecular-weight globulins, further qualitative evaluation with immunoelectrophoresis is indicated. This will determine whether the excess proteins are normal or abnormal. Identification of normal proteins establishes a diagnosis of tubular proteinuria, and further evaluation for a specific cause of tubular dysfunction is indicated.

If qualitative evaluation reveals abnormal proteins in the urine, this establishes a diagnosis of overflow proteinuria. Further evaluation should be directed to identify the specific protein abnormality. The finding of large quantities of light-chain immunoglobulins or Bence Jones protein establishes a diagnosis of multiple myeloma. Similarly, the finding of large amounts of hemoglobin or myoglobin establishes the diagnosis of hemoglobinuria or myoglobinuria. An algorithm for the evaluation of proteinuria is shown in Fig. 2.2.

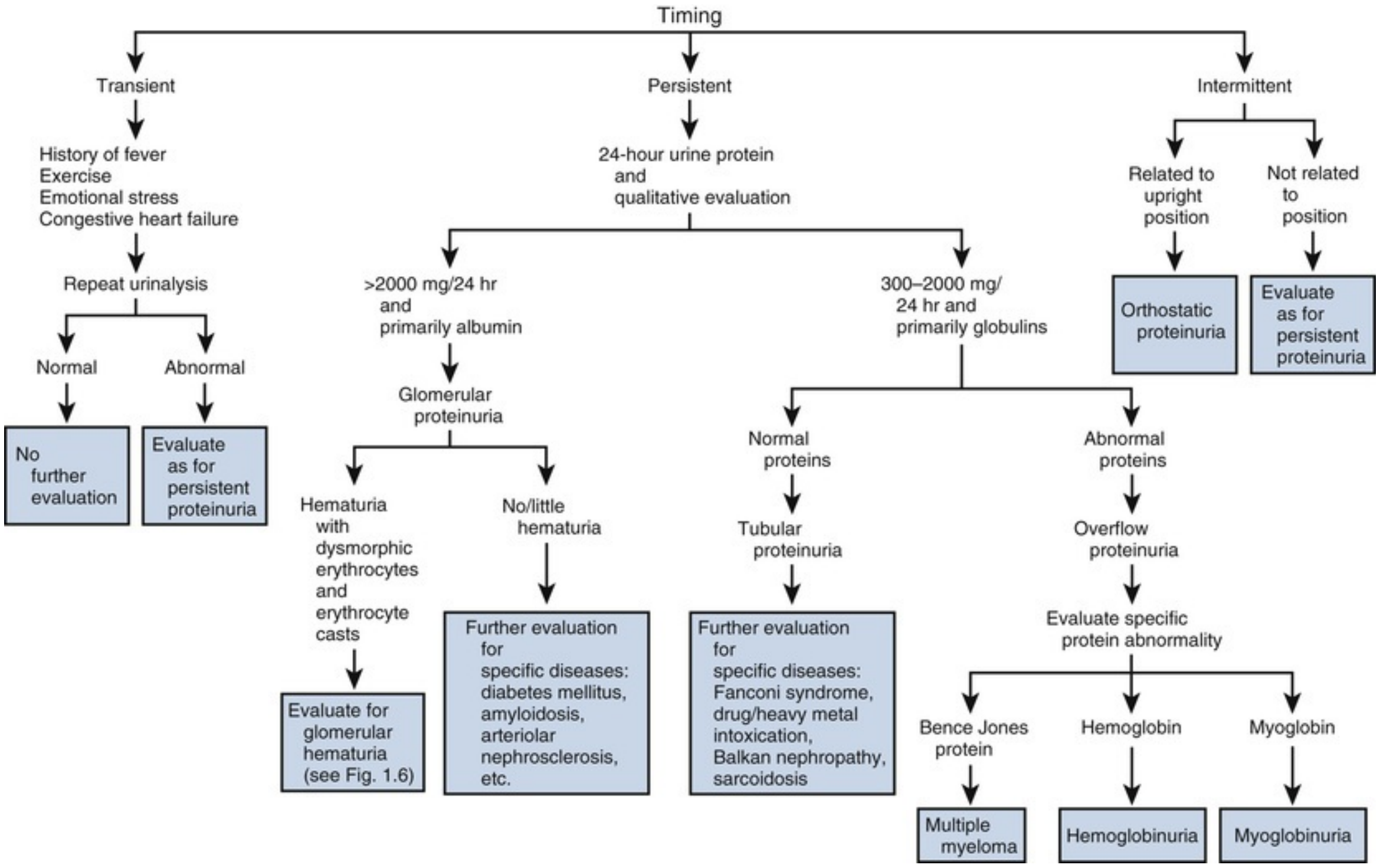
Timing
Transient
Persistent
Intermittent
History of fever
Exercise
Emotional stress
Congestive heart failure
Repeat urinalysis
Normal
Abnormal
No further evaluation
Evaluate as for persistent proteinuria
24-hour urine protein and qualitative evaluation
>2000 mg/24 hr and primarily albumin
Glomerular proteinuria
Hematuria with dysmorphic erythrocytes and erythrocyte casts
Evaluate for glomerular hematuria (see Fig. 1.6)
No/little hematuria
Further evaluation for specific diseases: diabetes mellitus, amyloidosis, arteriolar nephrosclerosis, etc.
300–2000 mg/ 24 hr and primarily globulins
Normal proteins
Tubular proteinuria
Further evaluation for specific diseases: Fanconi syndrome, drug/heavy metal intoxication, Balkan nephropathy, sarcoidosis
Abnormal proteins
Overflow proteinuria
Evaluate specific protein abnormality
Bence Jones protein
Multiple myeloma
Hemoglobin
Hemoglobinuria
Myoglobin
Myoglobinuria
Related to upright position
Orthostatic proteinuria
Not related to position
Evaluate as for persistent proteinuria

FIG. 2.2 Evaluation of proteinuria.

Glucose and Ketones

Urine testing for glucose and ketones is useful in screening patients for diabetes mellitus. Normally, almost all of the glucose filtered by the glomeruli is reabsorbed in the proximal tubules. Although small amounts of glucose may normally be excreted in the urine, these amounts are not clinically significant and are below the level of detectability with the dipstick. If, however, the amount of glucose filtered exceeds the capacity of tubular reabsorption, glucose will be excreted in the urine and detected on the dipstick. **This so-called *renal threshold* corresponds to serum glucose of about 180 mg/dL; above this level, glucose will be detected in the urine.**

Glucose detection with the urinary dipstick is based on a double sequential enzymatic reaction yielding a colorimetric change. In the first reaction, glucose in the urine reacts with glucose oxidase on the dipstick to form gluconic acid and hydrogen peroxide. In the second reaction, hydrogen peroxide reacts with peroxidase, causing oxidation of the chromogen on the dipstick, producing a color change. **This double-oxidative reaction is specific for glucose, and there is no cross-reactivity with other sugars.** The dipstick test becomes less sensitive as the urine increases in specific gravity and temperature.

Ketones are not normally found in the urine but will appear when the carbohydrate supplies in the body are depleted and body fat breakdown occurs. This happens most commonly in diabetic ketoacidosis but may also occur during pregnancy and after periods of starvation or rapid weight reduction. **Ketones excreted include acetoacetic acid, acetone, and β-hydroxybutyric acid. With abnormal fat breakdown, ketones will appear in the urine before the serum.**

Dipstick testing for ketones involves a colorimetric reaction: Sodium nitroprusside on the dipstick reacts with acetoacetic acid to produce a purple color. **Dipstick testing will identify acetoacetic acid at concentrations of 5 to 10 mg/dL but will not detect acetone or β-hydroxybutyric acid.** A dipstick that tests positive for glucose should also be tested for ketones, and diabetes mellitus is suggested. False-positive results, however, can occur in acidic urine of high specific gravity, in abnormally colored urine, and in urine containing levodopa metabolites, 2-mercaptoethane sulfonate sodium, and other sulfhydryl-containing compounds (Csako, 1987).

Bilirubin and Urobilinogen

Normal urine contains no bilirubin and only small amounts of urobilinogen. There are two types of bilirubin: direct (conjugated) and indirect. Direct bilirubin is made in the hepatocyte, where bilirubin is conjugated with glucuronic acid. **Conjugated bilirubin has a low molecular weight, is water soluble, and normally passes from the liver to the small intestine through the bile ducts, where it is converted to urobilinogen. Therefore conjugated bilirubin does not appear in the urine except in pathologic conditions in which there is intrinsic hepatic disease or obstruction of the bile ducts.**

Indirect bilirubin is of high molecular weight and bound in the serum to albumin. It is water insoluble and therefore does not appear in the urine, even in pathologic conditions.

Urobilinogen is the end product of conjugated bilirubin metabolism. Conjugated bilirubin passes through the bile ducts, where it is metabolized by normal intestinal bacteria to urobilinogen. Normally, about 50% of the urobilinogen is excreted in the stool, and 50% is reabsorbed into the enterohepatic circulation. A small amount of absorbed urobilinogen, about 1 to 4 mg/day, will escape hepatic uptake and be excreted in the urine. Hemolysis and hepatocellular diseases that lead to increased bile pigments can result in increased urinary urobilinogen. Conversely, obstruction of the bile duct or antibiotic usage that alters intestinal flora, thereby interfering with the conversion of conjugated bilirubin to urobilinogen, will decrease urobilinogen levels in the urine. In these conditions, serum levels of conjugated bilirubin rise.

There are different dipstick reagents and methods to test for both bilirubin and urobilinogen, but the basic physiologic principle involves the binding of bilirubin or urobilinogen to a diazonium salt to produce a colorimetric reaction. False-negative results can occur in the presence of ascorbic acid, which decreases the sensitivity for detection of bilirubin. False-positive results can occur in the presence of phenazopyridine because it colors the urine orange and, similar to the colorimetric reaction for bilirubin, turns red in an acid medium.

Leukocyte Esterase and Nitrite Tests

Leukocyte esterase activity indicates the presence of white blood cells in the urine. The presence of nitrites in the urine is strongly suggestive of bacteriuria. Thus both tests have been used to screen patients for UTIs. The most accurate method to diagnose infection is by microscopic examination of the urinary sediment to identify pyuria and subsequent urine culture**. If the dipstick is positive for leukocyte esterase but negative for nitrites, noninfectious causes of inflammation should be considered and a microscopic analysis and urine culture should be obtained before any empirical antibiotic therapy should be prescribed.**

Leukocyte esterase is produced by neutrophils and catalyzes the hydrolysis of an indoxyl carbonic acid ester to indoxyl (Gillenwater, 1981). The indoxyl formed oxidizes a diazonium salt chromogen on the dipstick to produce a color change. It is recommended that leukocyte esterase testing be done 5 minutes after the dipstick is immersed in the urine to allow adequate incubation (Shaw et al., 1985). The sensitivity of this test subsequently decreases with time because of lysis of the leukocytes. Leukocyte esterase testing may also be negative in the presence of infection because not all patients with bacteriuria will have significant pyuria. Therefore if one uses leukocyte esterase testing to screen patients for UTI, it should always be done in conjunction with nitrite testing for bacteriuria (Pels et al, 1989).

Other causes of false-negative results with leukocyte esterase testing include increased urinary specific gravity, glycosuria, presence of urobilinogen, medications that alter urine color, and ingestion of large amounts of ascorbic acid. **The major cause of false-positive leukocyte esterase tests is specimen**

contamination.

Nitrites are not normally found in the urine, but many species of gram-negative bacteria can convert nitrates to nitrites. Nitrites are readily detected in the urine because they react with the reagents on the dipstick and undergo diazotization to form a red azo dye. The specificity of the nitrite dipstick for detecting bacteriuria is higher than 90% (Pels et al., 1989). The sensitivity of the test, however, is considerably less, varying from 35% to 85%. The nitrite test is less accurate in urine specimens containing fewer than 10^5 organisms/mL (Kellogg et al., 1987). As with leukocyte esterase testing, the major cause of false-positive nitrite testing is contamination.

A protocol combining the visual appearance of the urine with leukocyte esterase and nitrite testing has been proposed when in-office microscopy is not available (Fig. 2.3). It reportedly detects 95% of infected urine specimens and decreases the need for microscopy by as much as 30% (Flanagan et al., 1989). Other studies, however, have shown that dipstick testing is not an adequate replacement for microscopy (Propp et al., 1989). As stated earlier, any dipstick test that is positive for only one without the other should be confirmed with microscopy and culture before prescribing any treatment. In summary, it has not been demonstrated conclusively that dipstick testing for UTI can replace microscopic examination of the urinary sediment.

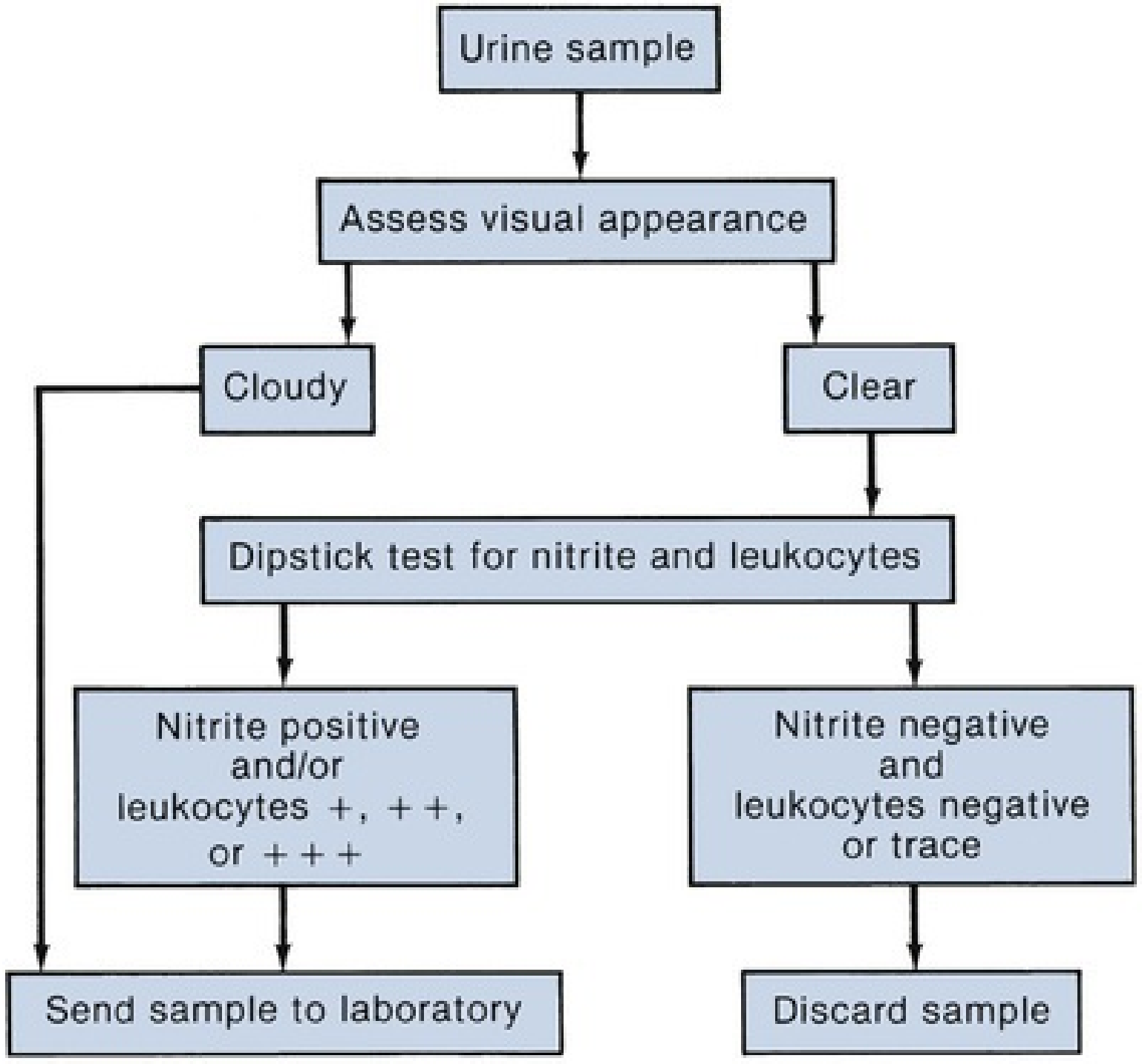
Urine sample
Assess visual appearance
Cloudy
Clear
Dipstick test for nitrite and leukocytes
Nitrite positive and/or leukocytes +, ++, or +++
Nitrite negative and leukocytes negative or trace
Send sample to laboratory
Discard sample

FIG. 2.3 Protocol for determining the need for urine sediment microscopy in an asymptomatic population. (From Flanagan PG, Rooney PG, Davies EA, et al. Evaluation of four screening tests for bacteriuria in elderly people. *Lancet.* 1989;1(8647):1117–1119. © by The Lancet Ltd., 1989.)

Urinary Sediment

Obtaining and Preparing the Specimen

A clean-catch midstream urine specimen should be obtained. As described earlier, uncircumcised men should retract the prepuce and cleanse the glans penis before voiding. It is more difficult to obtain a reliable clean-catch specimen in females because of contamination with introital leukocytes and bacteria. **If there is any suspicion of a UTI in a female, a catheterized urine sample should be obtained for culture and sensitivity**.

If possible, **the first-void urine specimen is the specimen of choice and should be examined within 1 hour.** A standard procedure for preparation of the urine for microscopic examination has been described (Cushner and Copley, 1989). Ten to 15 milliliters of urine should be centrifuged for 5 minutes at 3000 rpm. The supernatant is then poured off, and the sediment is resuspended with 0.3 mL of saline in the centrifuge tube by gently tapping the bottom of the tube. Although the remaining small amount of fluid can be poured onto a microscope slide, this usually results in excess fluid on the slide. It is better to use a small pipette to withdraw the residual fluid from the centrifuge tube and to place it directly on the microscope slide. This usually results in an ideal volume of between 0.01 and 0.02 mL of fluid deposited on the slide. The slide is then covered with a coverslip. The edge of the coverslip should be placed on the slide first to allow the drop of fluid to ascend onto the coverslip by capillary action. The coverslip is then gently placed over the drop of fluid, and this technique allows for most of the air between the drop of fluid and the coverslip to be expelled. If one simply drops the coverslip over the urine, the urine will disperse over the slide and there will be a considerable number of air bubbles that may distort the subsequent microscopic examination.

Microscopy Technique

Microscopic analysis of urinary sediment should be performed with both low-power (×100 magnification) and high-power (×400 magnification) lenses. At least 10 to 20 microscopic fields should be analyzed. The use of an oil immersion lens for higher magnification is seldom, if ever, necessary. Under low power, the entire area under the coverslip should be scanned. **Particular attention should be given to the edges of the coverslip, where casts and other elements tend to be concentrated.** Low-power magnification is sufficient to identify erythrocytes, leukocytes, casts, cystine crystals, oval fat macrophages, and parasites such as *Trichomonas vaginalis* and *Schistosoma hematobium*.

High-power magnification is necessary to distinguish circular from dysmorphic erythrocytes, to identify other types of crystals, and, particularly, to identify bacteria and yeast. In summary, **the urinary sediment should be examined microscopically for (1) cells, (2) casts, (3) crystals, (4) bacteria, (5) yeast, and (6) parasites.**

Cells

Erythrocyte morphology may be determined under high-power magnification. Although phase contrast microscopy has been used for this purpose, circular (nonglomerular) erythrocytes can generally be distinguished from dysmorphic (glomerular) erythrocytes under routine brightfield high-power magnification (Figs. 2.4 to 2.8). **This is assisted by adjusting the microscope condenser to its lowest aperture, thus reducing the intensity of background light. This**

allows one to see fine detail not evident otherwise and also creates the effect of phase microscopy because cell membranes and other sedimentary components stand out against the darkened background.

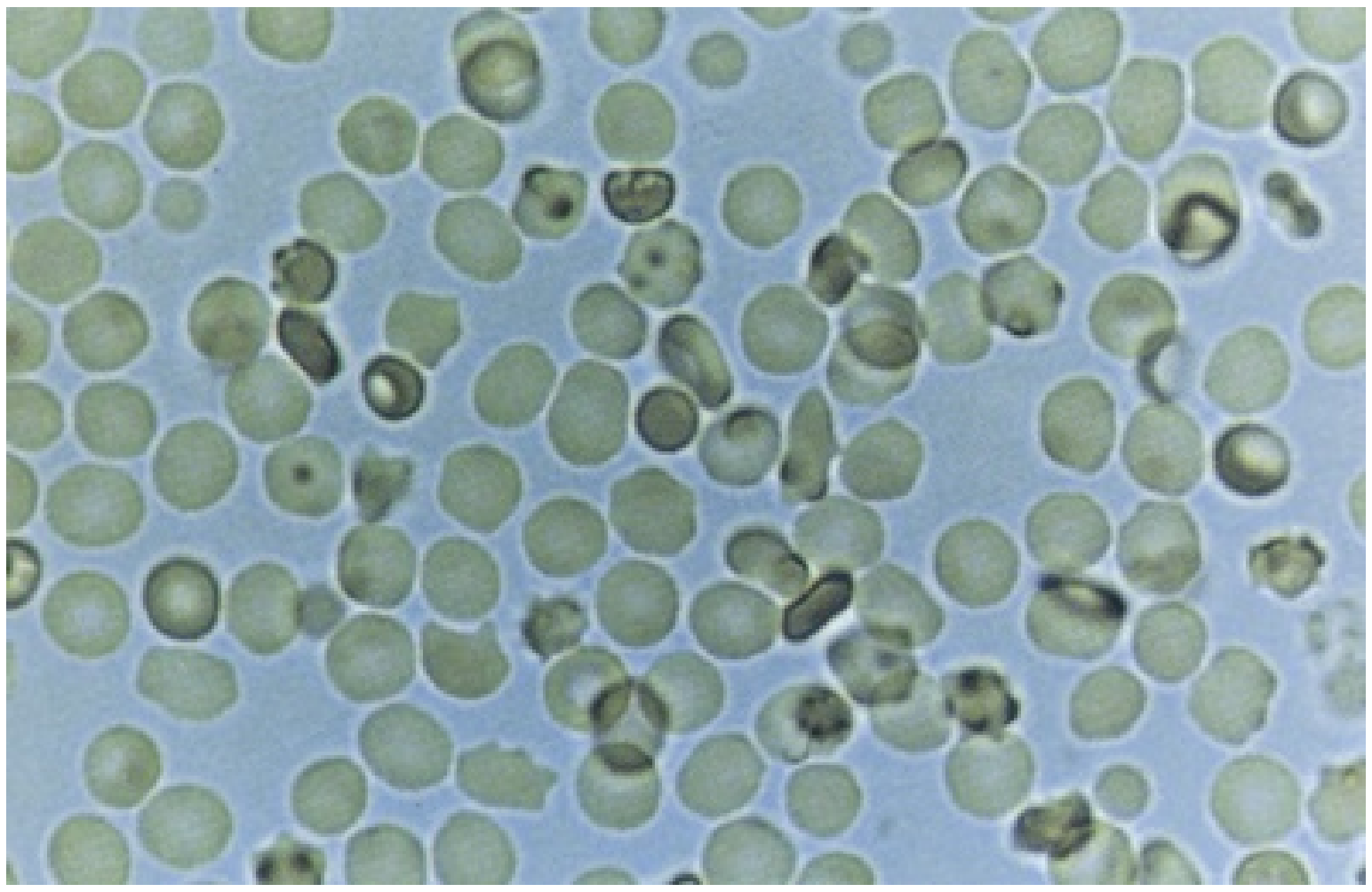

FIG. 2.4 Red blood cells, both smoothly rounded and mildly crenated, typical of epithelial erythrocytes.

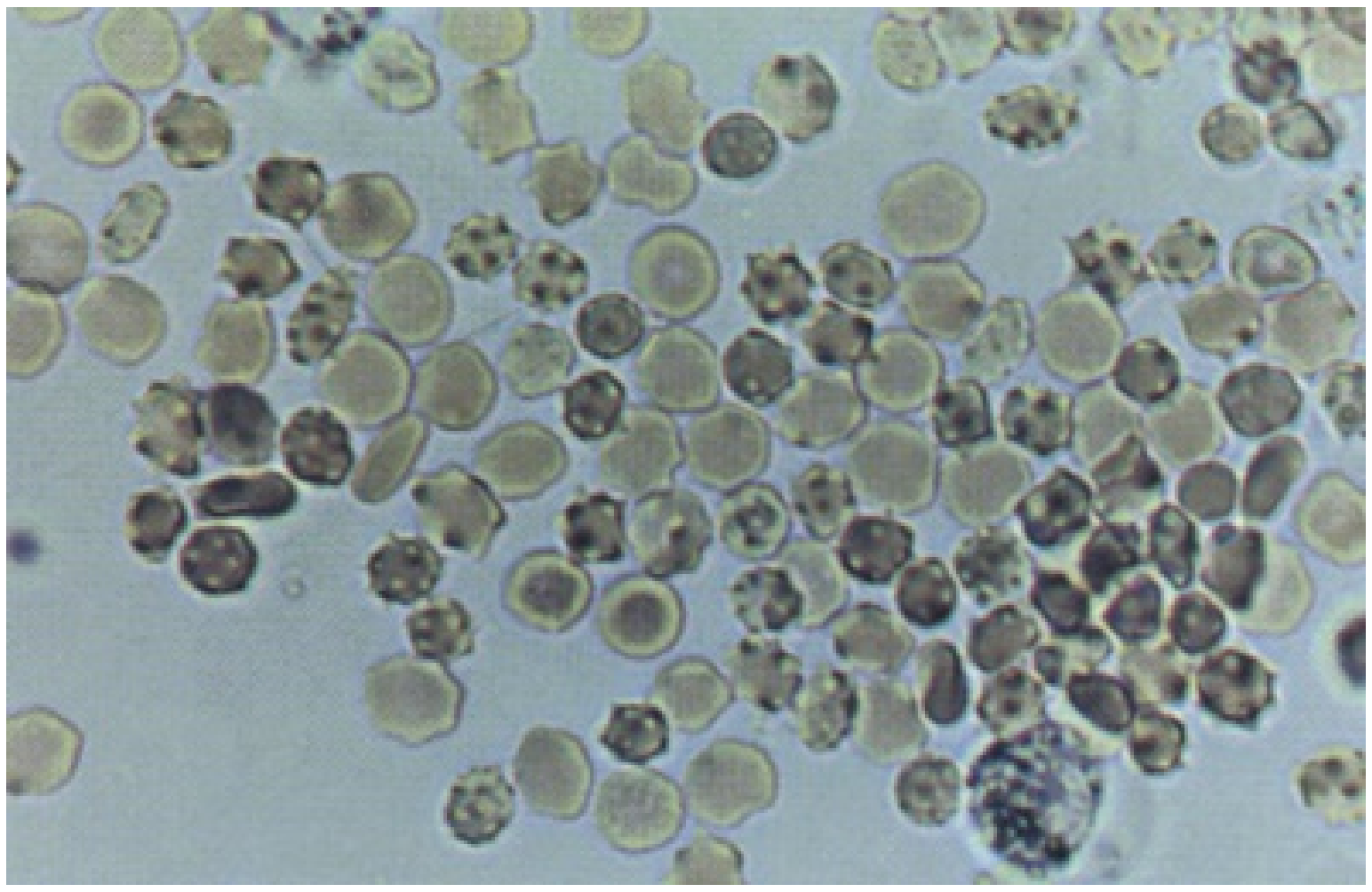

FIG. 2.5 Red blood cells from a patient with a bladder tumor.

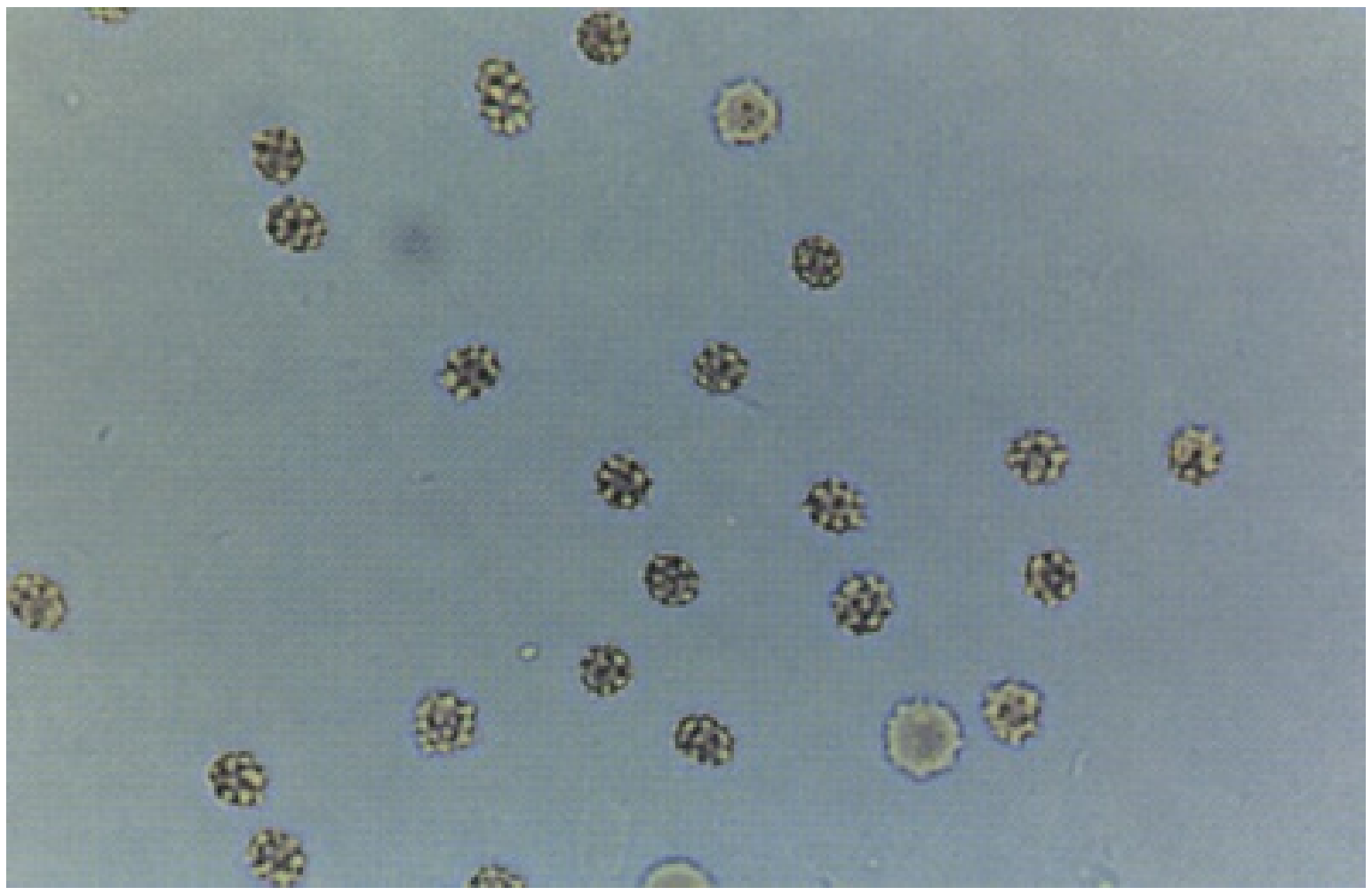

FIG. 2.6 Red blood cells from a patient with interstitial cystitis. Cells were collected at cystoscopy.

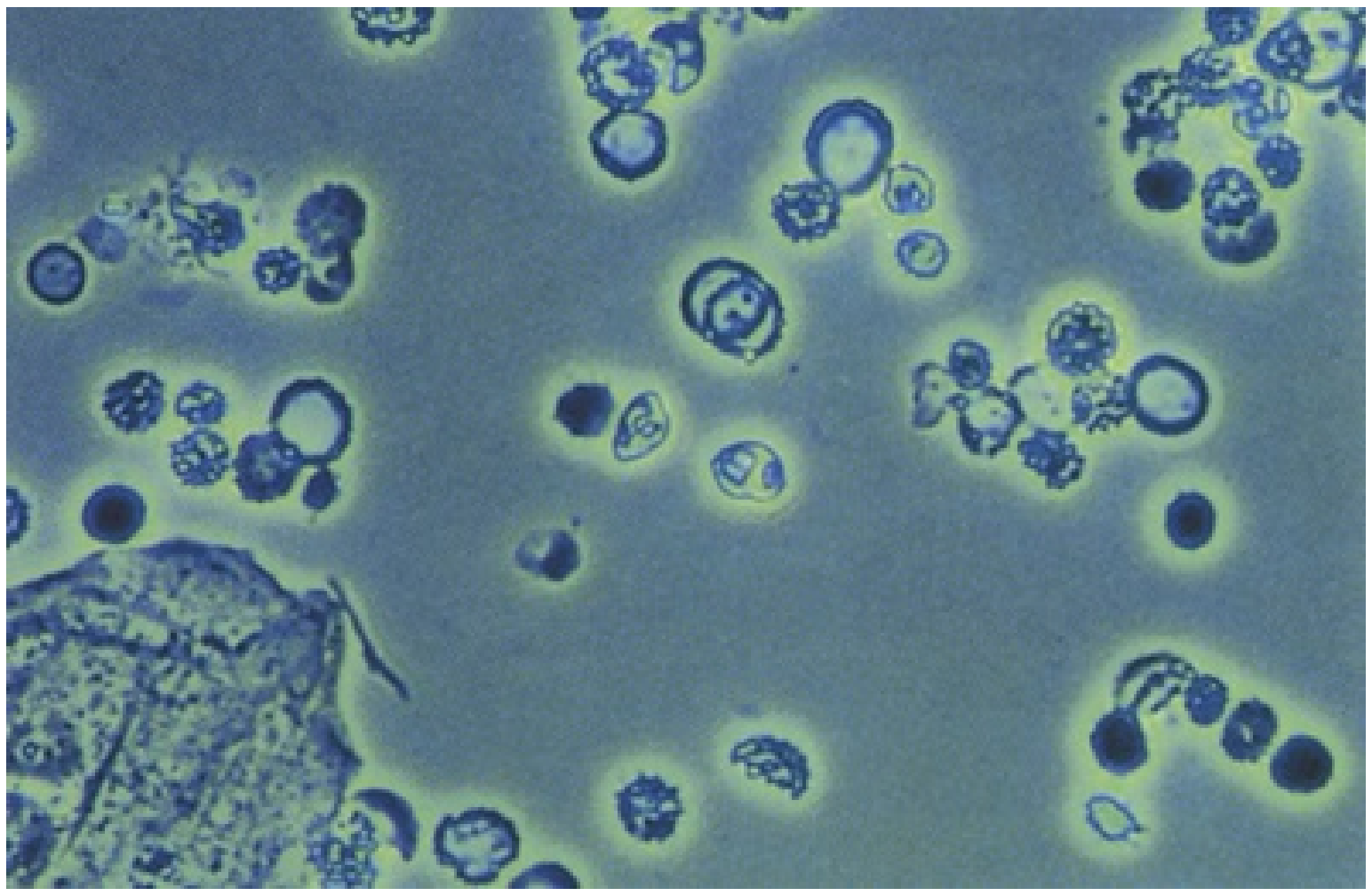

FIG. 2.7 Red blood cells from a patient with Berger disease. Note variations in membranes characteristic of dysmorphic red blood cells.

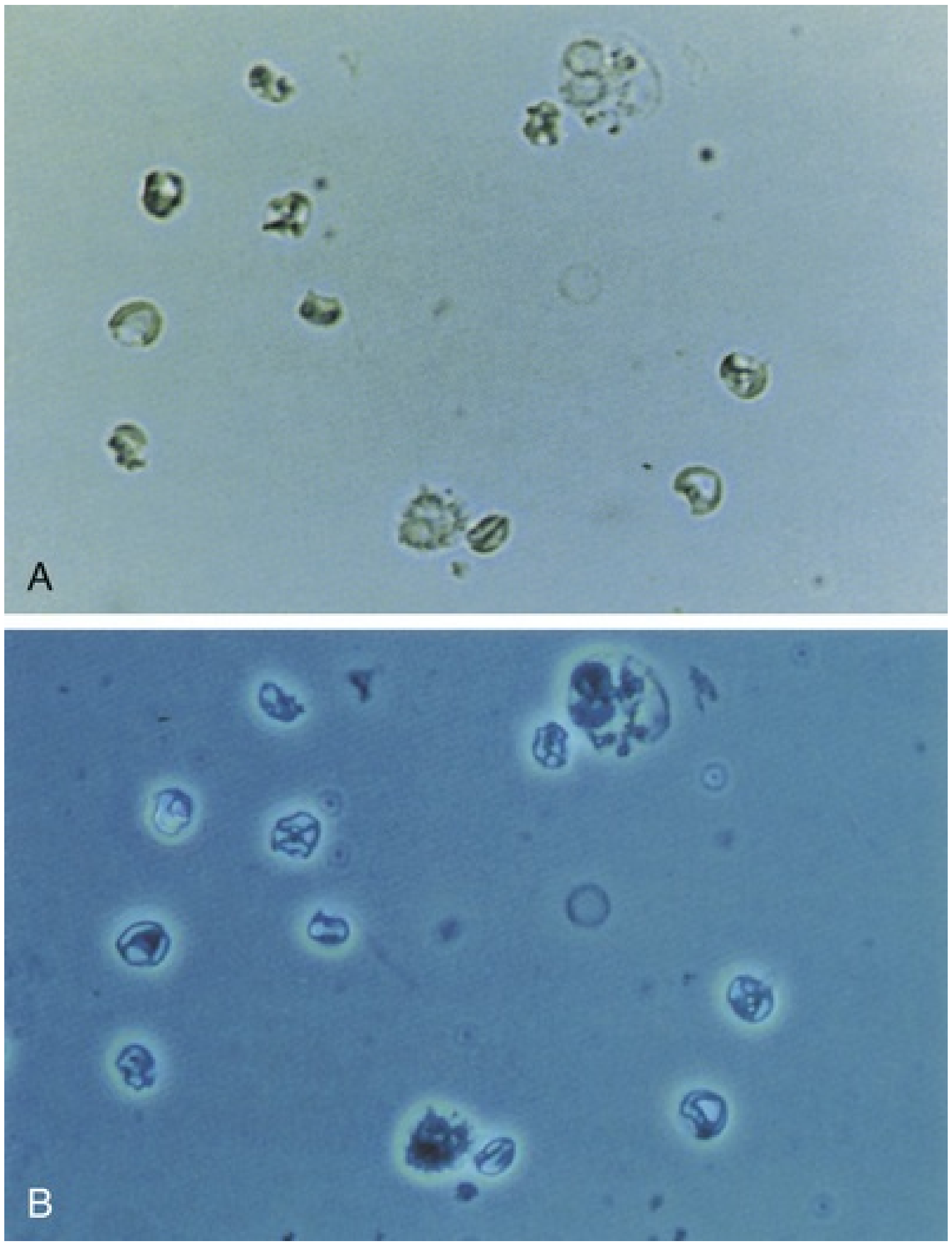

FIG. 2.8 Dysmorphic red blood cells from a patient with Wegener granulomatosis. (A) Brightfield illumination. (B) Phase illumination. Note irregular deposits of dense cytoplasmic material around the cell membrane.

Circular erythrocytes generally have an even distribution of hemoglobin with either a round or crenated contour, whereas dysmorphic erythrocytes are irregularly shaped with minimal hemoglobin and irregular distribution of cytoplasm. Automated techniques for performing microscopic analysis to distinguish the two types of erythrocytes have been investigated but have not yet been accepted into general urologic practice and are probably unnecessary. In one study using a standard Coulter counter, microscopic analysis was found to be 97% accurate in differentiating between the two types of erythrocytes (Sayer et al., 1990). **Erythrocytes may be confused with yeast or fat droplets** (Fig. 2.9). Erythrocytes can be distinguished, however, because yeast will show budding, and oil droplets are highly refractile.

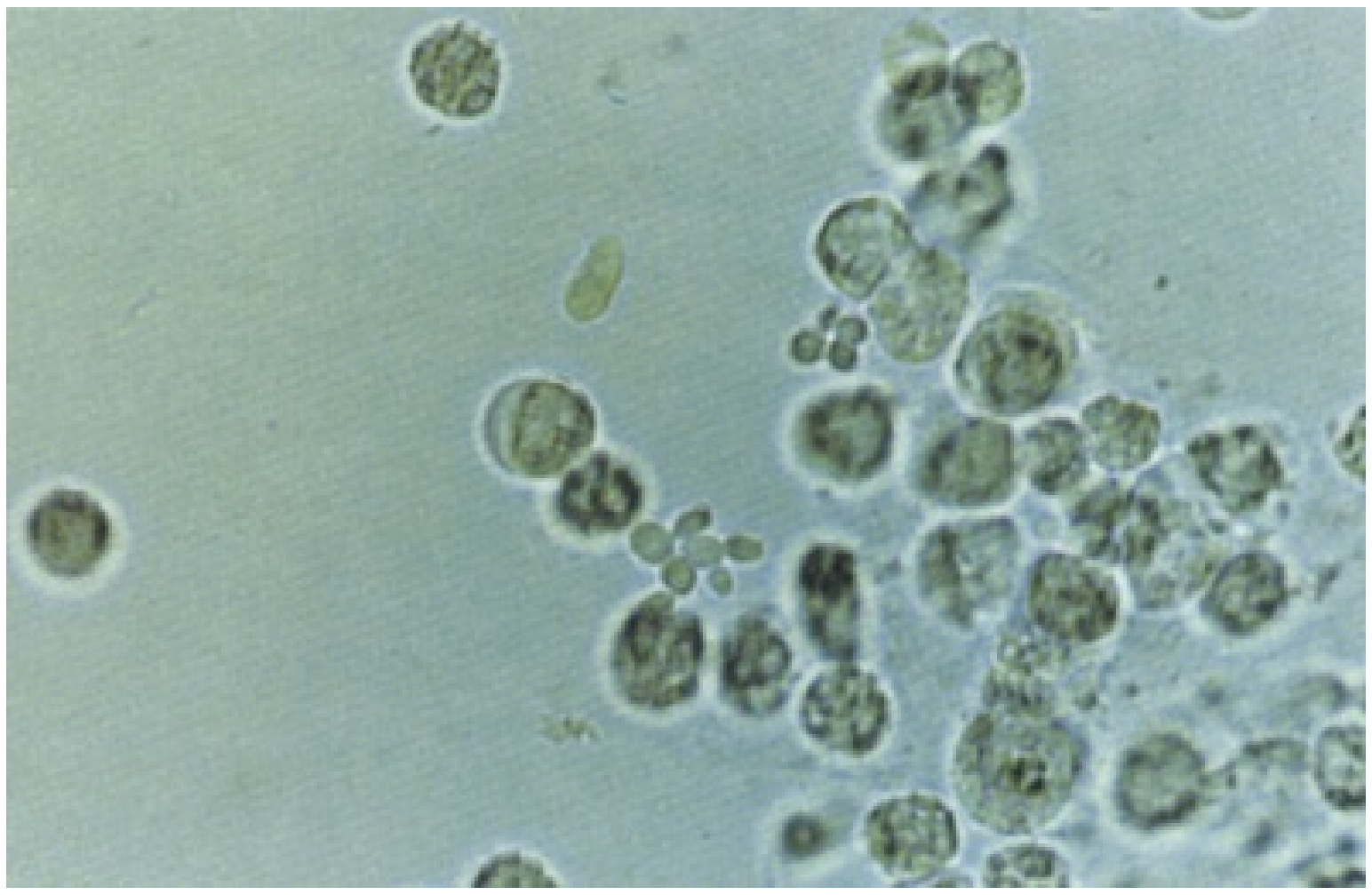

FIG. 2.9 *Candida albicans.* Budding forms surrounded by leukocytes.

Leukocytes can generally be identified under low-power magnification and definitively diagnosed under high-power magnification (Figs. 2.10 and 2.11; see Fig. 2.9). It is normal to find 1 or 2 leukocytes per HPF in men and up to 5 per HPF in women in whom the urine sample may be contaminated with vaginal secretions. A greater number of leukocytes generally indicates infection or inflammation in the urinary tract. It may be possible to distinguish **old leukocytes, which have a characteristic small and wrinkled appearance** and which are commonly found in the vaginal secretions of normal women, from fresh leukocytes, which are generally indicative of urinary tract pathology. Fresh leukocytes are generally larger and rounder, and, when the specific gravity is less than 1.019, the granules in the cytoplasm demonstrate glitterlike movement, so-called *glitter cells.*

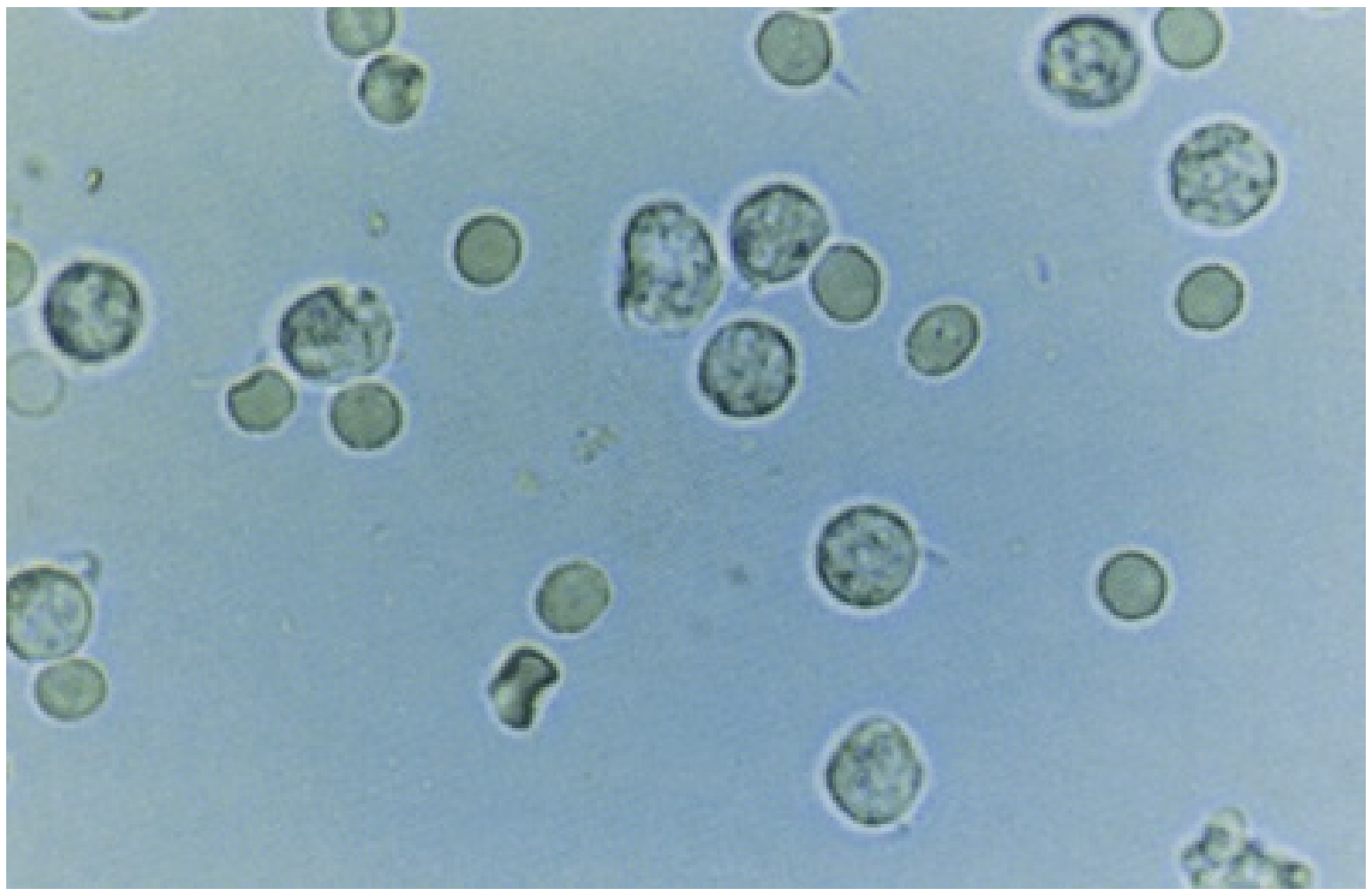

FIG. 2.10 Old leukocytes. Staghorn calculi with Proteus infection.

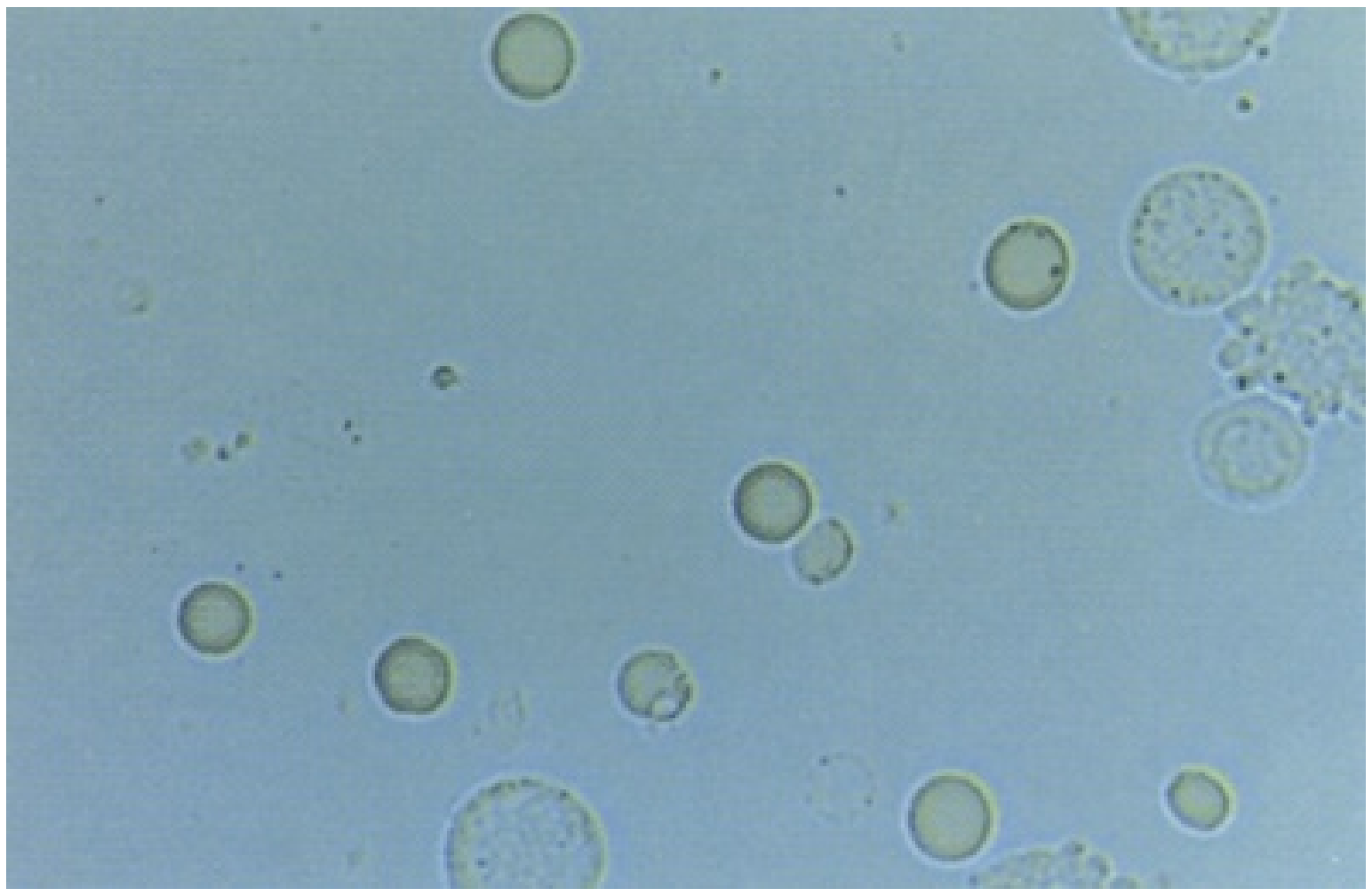

FIG. 2.11 Fresh “glitter cells” with erythrocytes in background.

Epithelial cells are commonly observed in the urinary sediment. Squamous cells are frequently detected in female urine specimens and are derived from the lower portion of the urethra, the trigone of postpubertal females, and the vagina. **Squamous epithelial cells are large, have a central small nucleus about the size of an erythrocyte, and have an irregular cytoplasm with fine granularity.** Transitional epithelial cells may arise from the remainder of the urinary tract (Fig. 2.12). Transitional cells are smaller than squamous cells, have a larger nucleus, and demonstrate prominent cytoplasmic granules near the nucleus. Malignant transitional cells have altered nuclear size and morphology and can be identified with either routine Papanicolaou staining or automated flow cytometry.

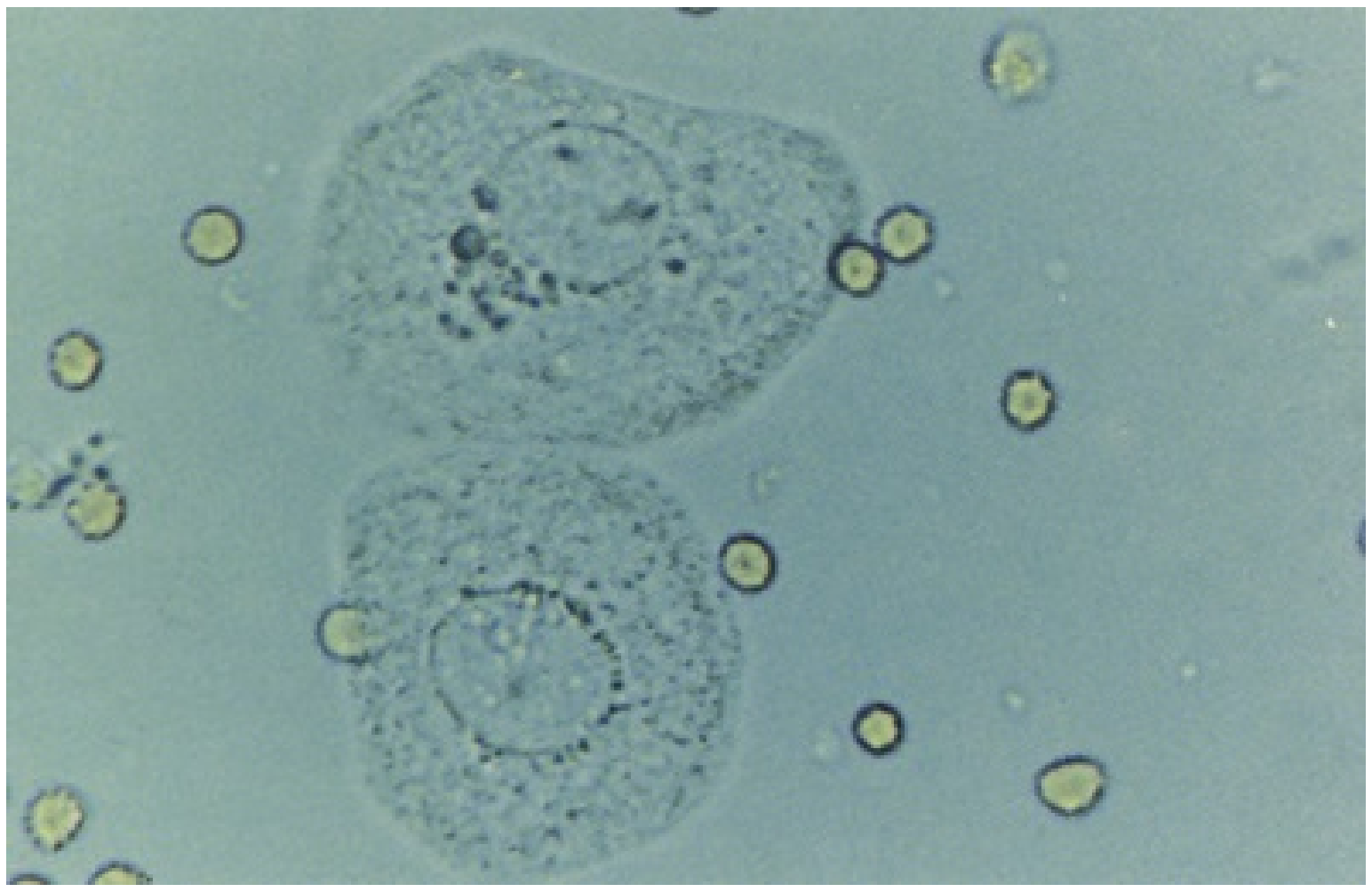

FIG. 2.12 Transitional epithelial cells from bladder lavage.

Renal tubular cells are the least commonly observed epithelial cells in the urine but are most significant because their presence in the urine is always indicative of renal pathology. Renal tubular cells may be difficult to distinguish from leukocytes, but they are slightly larger.

Casts

A cast is a protein coagulum that is formed in the renal tubule and traps any tubular luminal contents within the matrix. **Tamm-Horsfall mucoprotein is the basic matrix of all renal casts; it originates from tubular epithelial cells and is always present in the urine.** When the casts contain only mucoproteins, they are called *hyaline casts* and may not have any pathologic significance. Hyaline casts may be seen in the urine after exercise or heat exposure but may also be observed in pyelonephritis or chronic renal disease.

RBC casts contain entrapped erythrocytes and are diagnostic of glomerular bleeding, most likely secondary to glomerulonephritis (Figs. 2.13 and 2.14). White blood cell casts are observed in acute glomerulonephritis, acute pyelonephritis, and acute tubulointerstitial nephritis. Casts with other cellular elements, usually sloughed renal tubular epithelial cells, are indicative of nonspecific renal damage (Fig. 2.15). Granular and waxy casts result from further degeneration of cellular elements. Fatty casts are seen in nephrotic syndrome, lipiduria, and hypothyroidism.

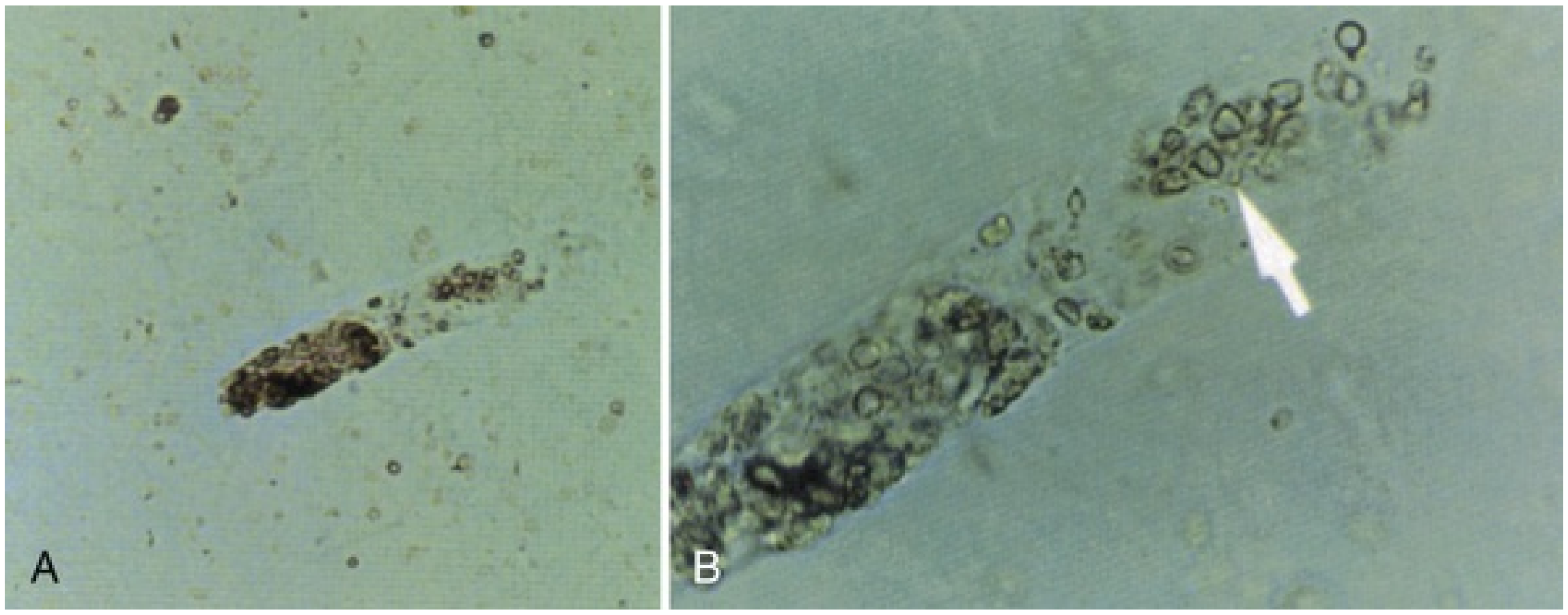

FIG. 2.13 Red blood cell cast. (A) Low-power view demonstrates distinct border of hyaline matrix. (B) High-power view demonstrates the sharply defined red blood cell membranes *(arrow).*

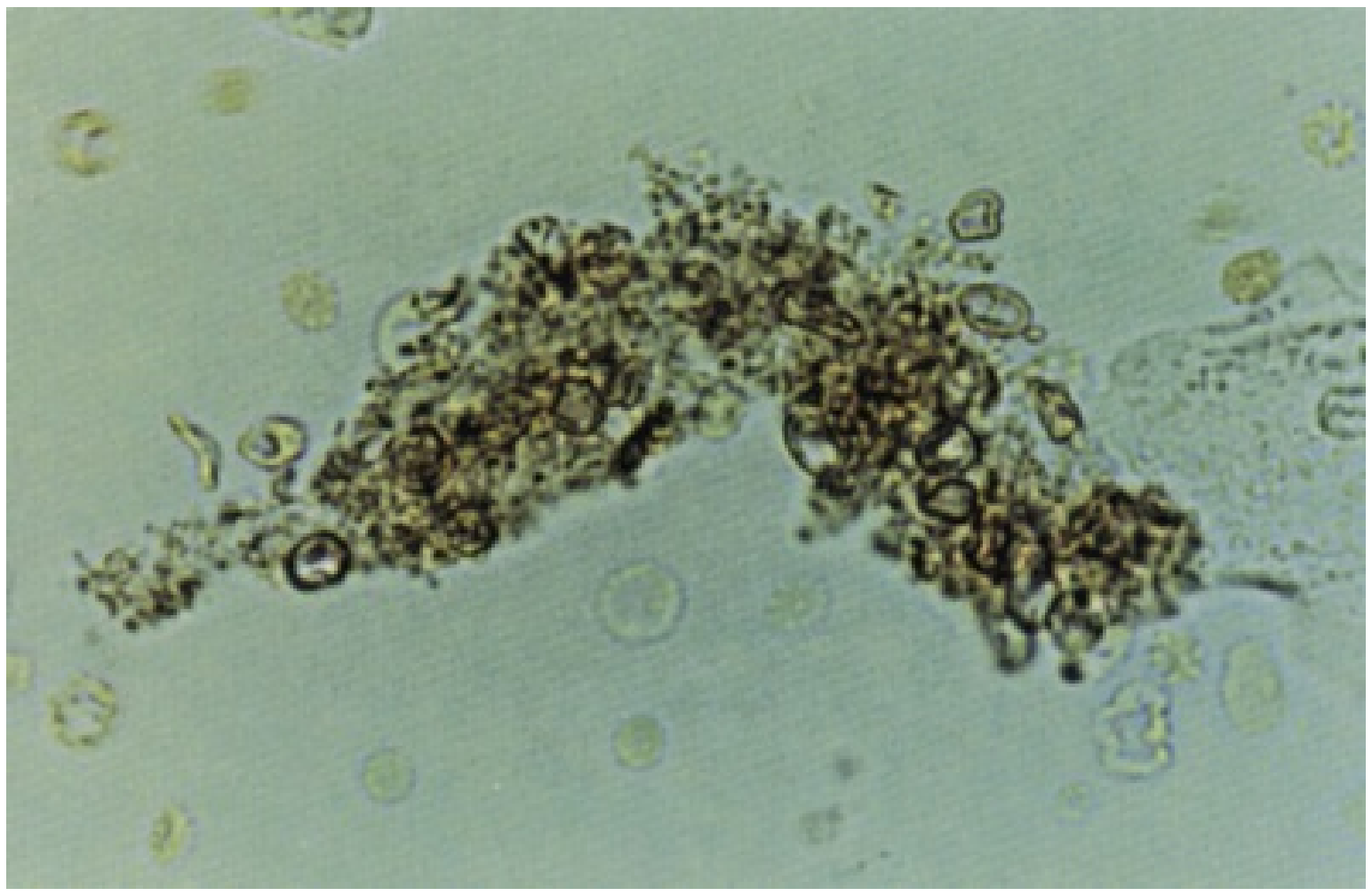

FIG. 2.14 Red blood cell cast.

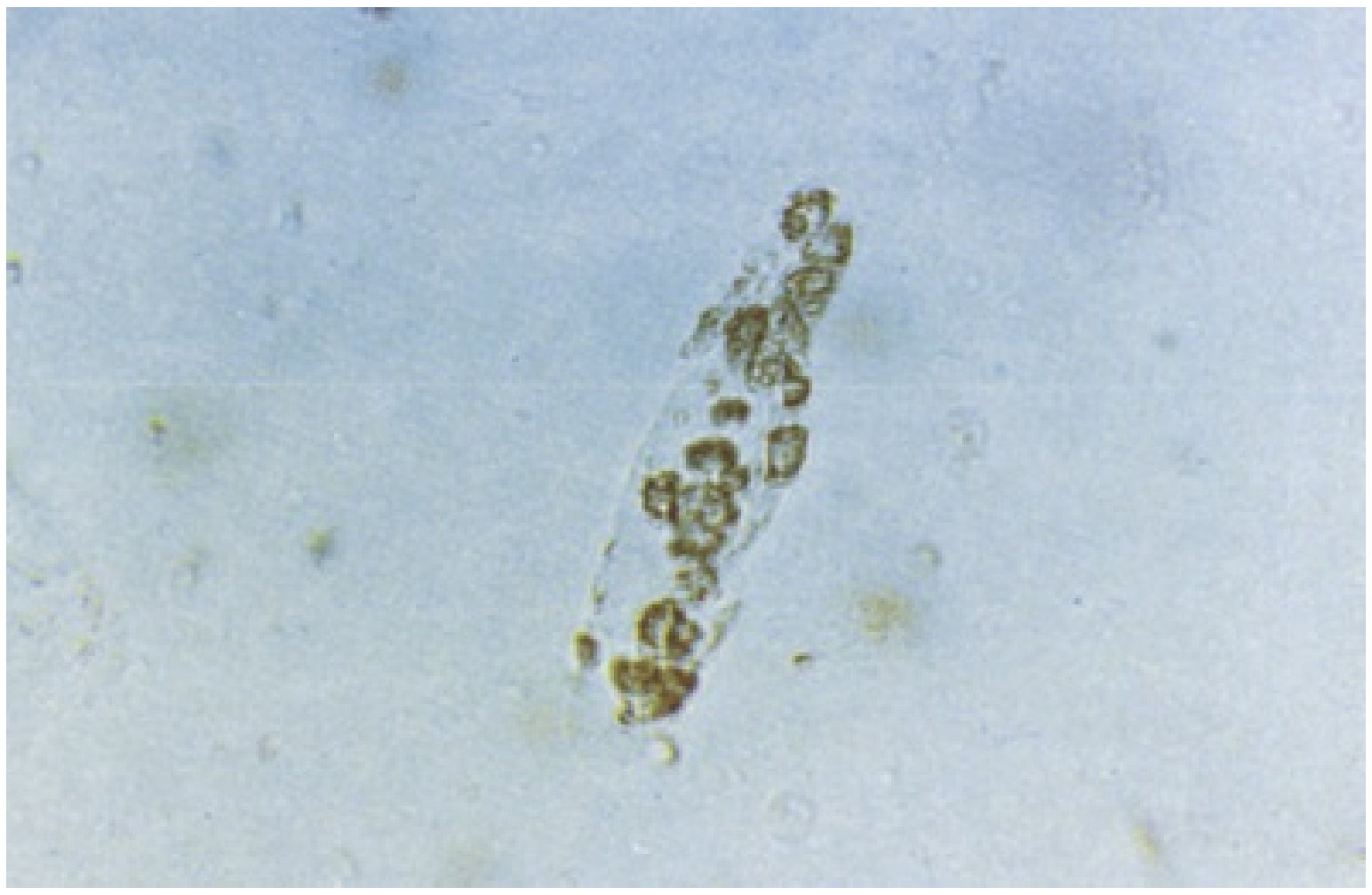

FIG. 2.15 Cellular cast. Cells entrapped in a hyaline matrix.

Crystals

Identification of crystals in the urine is particularly important in patients with stone disease because it may help determine the etiology (Fig. 2.16). Although other types of crystals may be seen in normal patients, **the identification of cystine crystals establishes the diagnosis of cystinuria.** Crystals precipitated in acidic urine include calcium oxalate, uric acid, and cystine. Crystals precipitated in an alkaline urine include calcium phosphate and triple-phosphate (struvite) crystals. Cholesterol crystals are rarely seen in the urine and are not related to urinary pH. They occur in lipiduria and remain in droplet form.

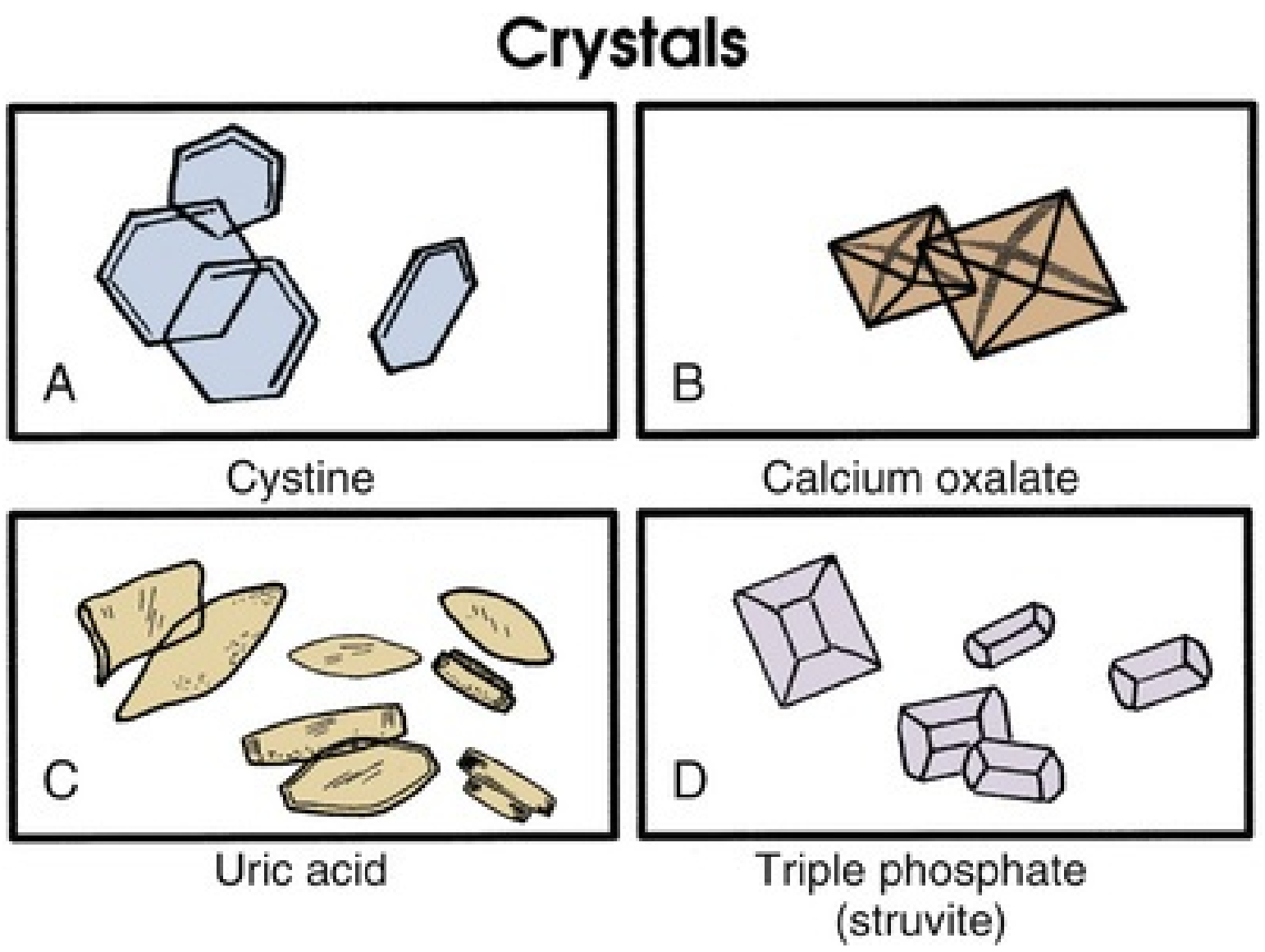

FIG. 2.16 Urinary crystals. (A) Cystine. (B) Calcium oxalate. (C) Uric acid. (D) Triple phosphate (struvite).

Bacteria

Normal urine should not contain bacteria; in a fresh uncontaminated specimen, the finding of bacteria is indicative of a UTI. Because each HPF views between 1/20,000 and 1/50,000 mL, each bacterium seen per HPF signifies a bacterial count of more than 30,000/mL. Therefore, **5 bacteria per HPF reflects colony counts of about 100,000/mL.** This is the standard concentration used to establish the diagnosis of a UTI in a clean-catch specimen. This level should apply only to women, however, in whom a clean-catch specimen is frequently contaminated. The finding of any bacteria in a properly collected midstream specimen from a male patient should be further evaluated with a urine culture.

Under high power, it is possible to distinguish various bacteria. Gram-negative rods have a characteristic bacillary shape (Fig. 2.17), whereas streptococci can be identified by their characteristic beaded chains (Figs. 2.18 and 2.19) and staphylococci can be identified when the organisms are found in clumps (Fig. 2.20).

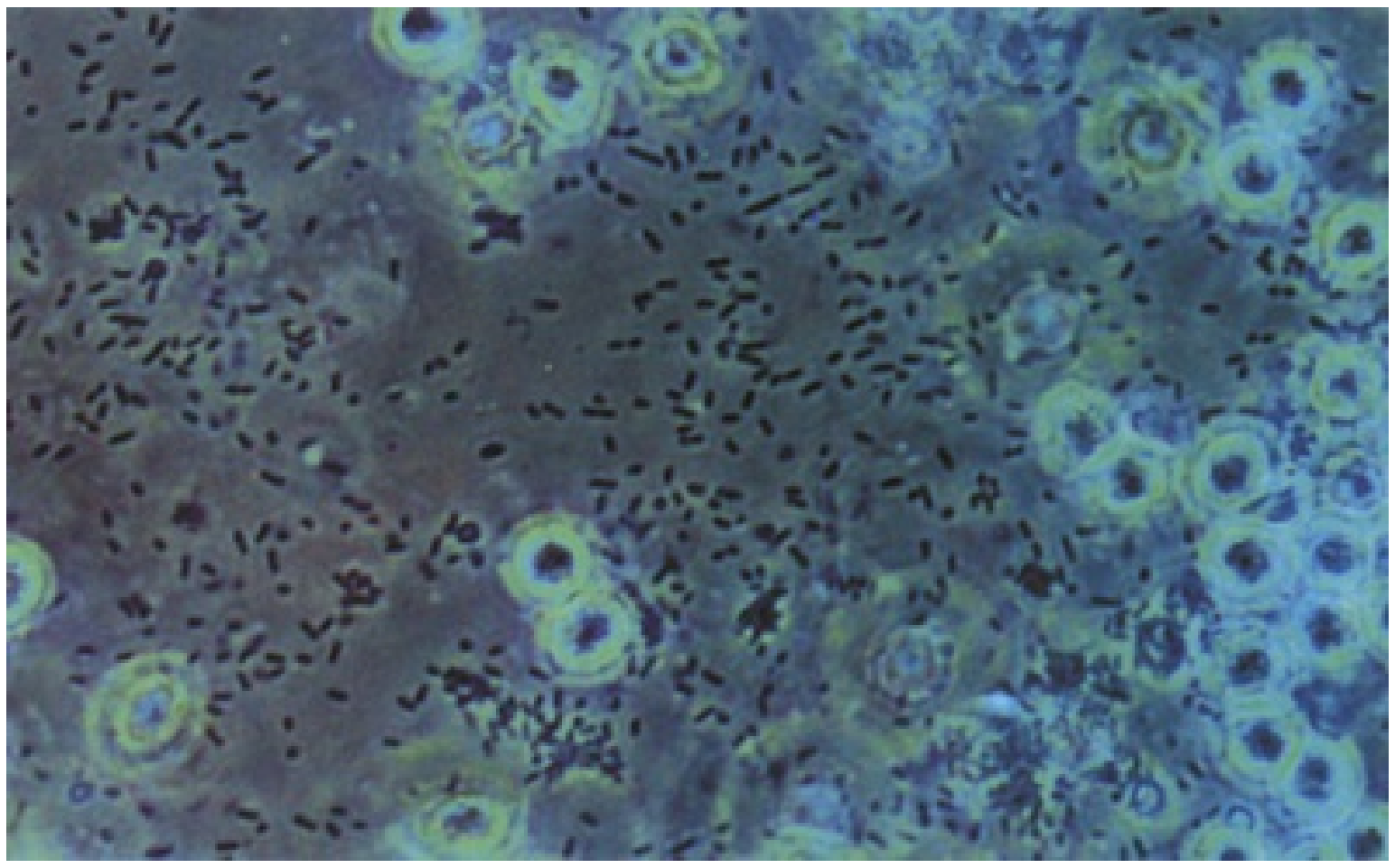

FIG. 2.17 Gram-negative bacilli. Phase microscopy of *Escherichia coli.*

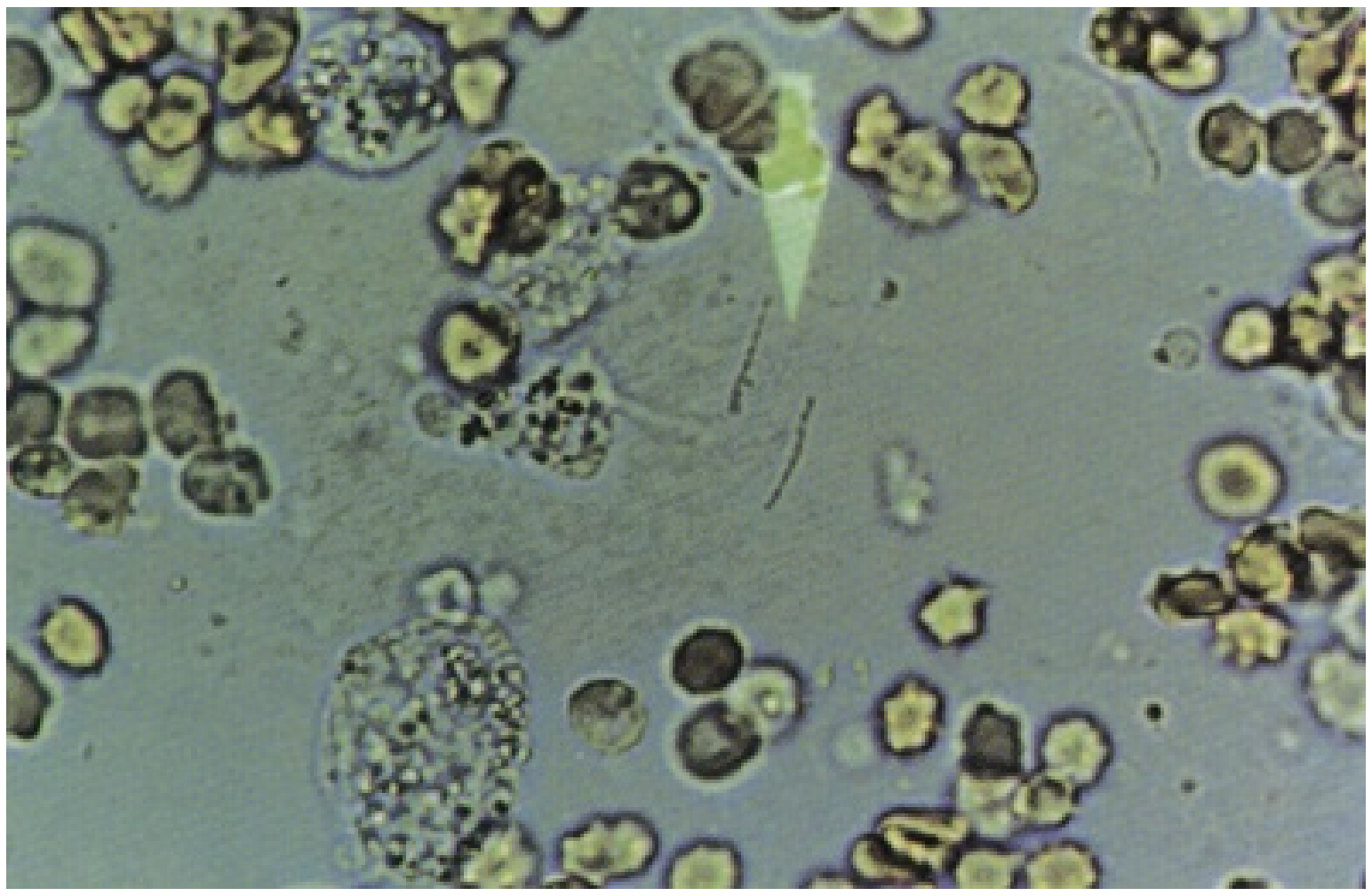

FIG. 2.18 Streptococcal urinary tract infection with typical chain formation *(arrow).*

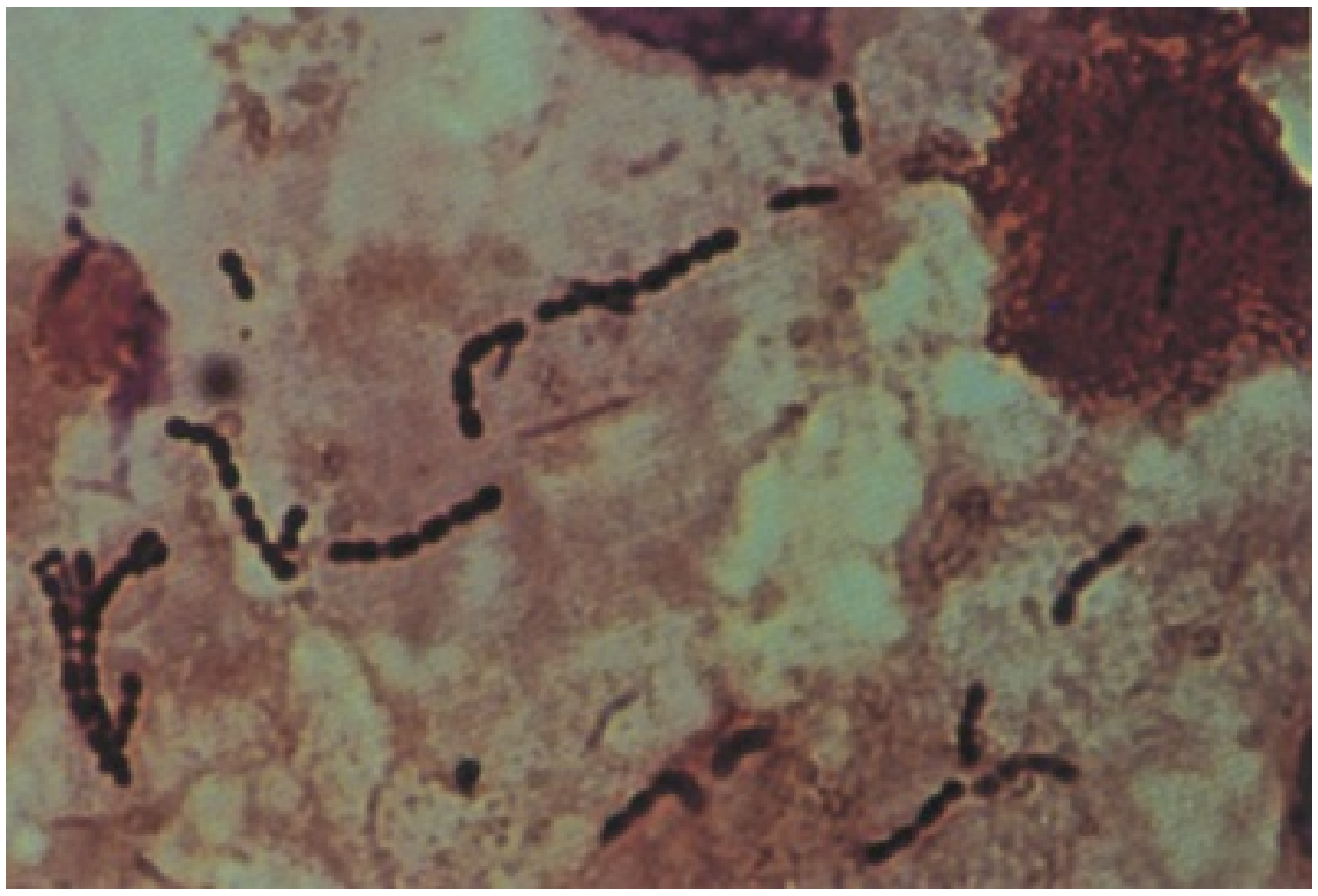

FIG. 2.19 Streptococcal urinary tract infection (Gram stain).

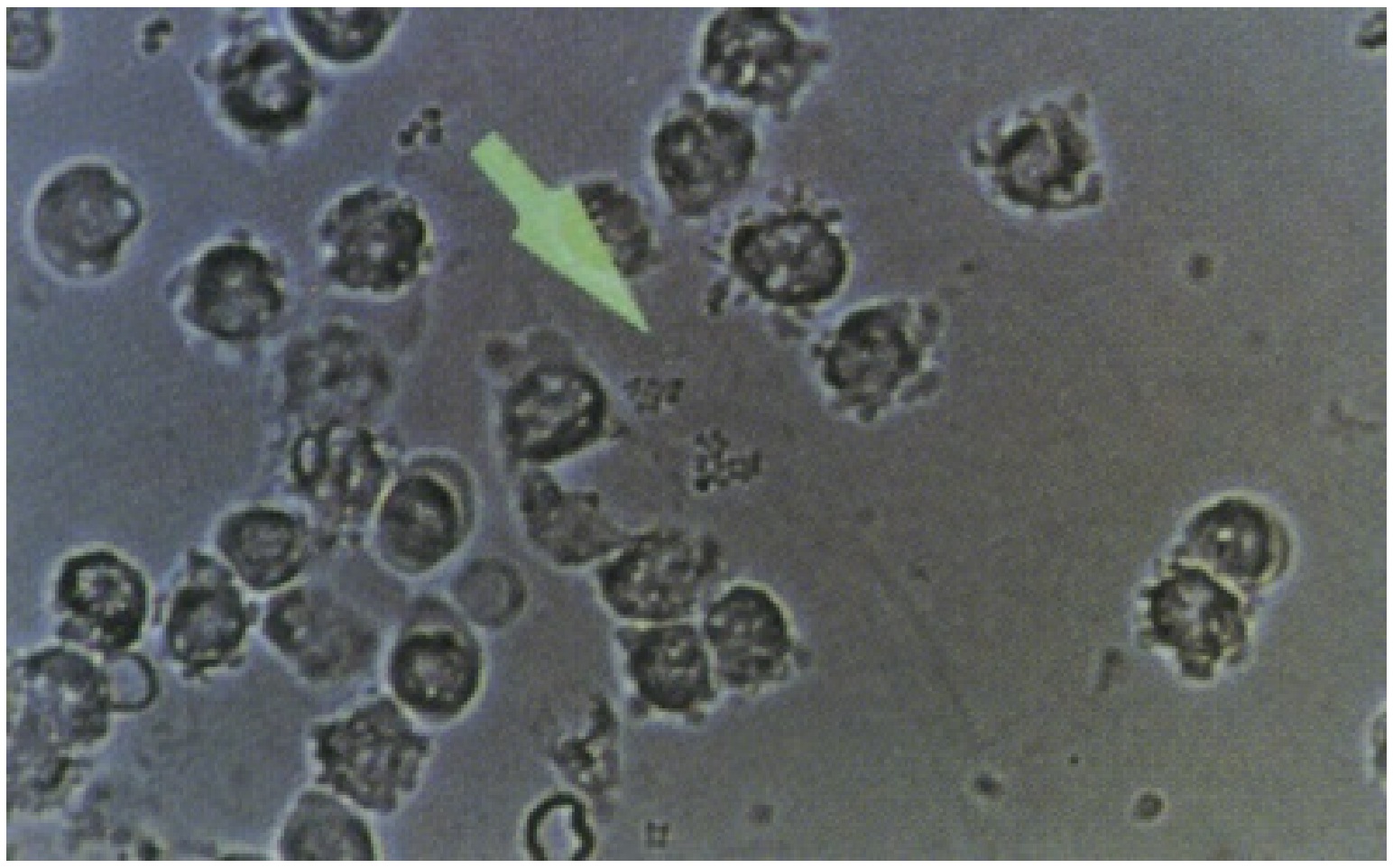

FIG. 2.20 *Staphylococcus aureus* in typical clumps *(arrow).*

Yeast

The most common yeast cells found in urine are *Candida albicans*. The biconcave oval shape of yeast can be confused with erythrocytes and calcium oxalate crystals, but **yeasts can be distinguished by their characteristic budding and hyphae** (see Fig. 2.9). Yeasts are most commonly seen in the urine of patients with diabetes mellitus or as contaminants in women with vaginal candidiasis.

Parasites

***Trichomonas vaginalis* is a frequent cause of vaginitis in women and occasionally of urethritis in men.** Trichomonads can be readily identified in a clean-catch specimen under low power (Fig. 2.21). Trichomonads are large cells with rapidly moving flagella that quickly propel the organism across the microscopic field.

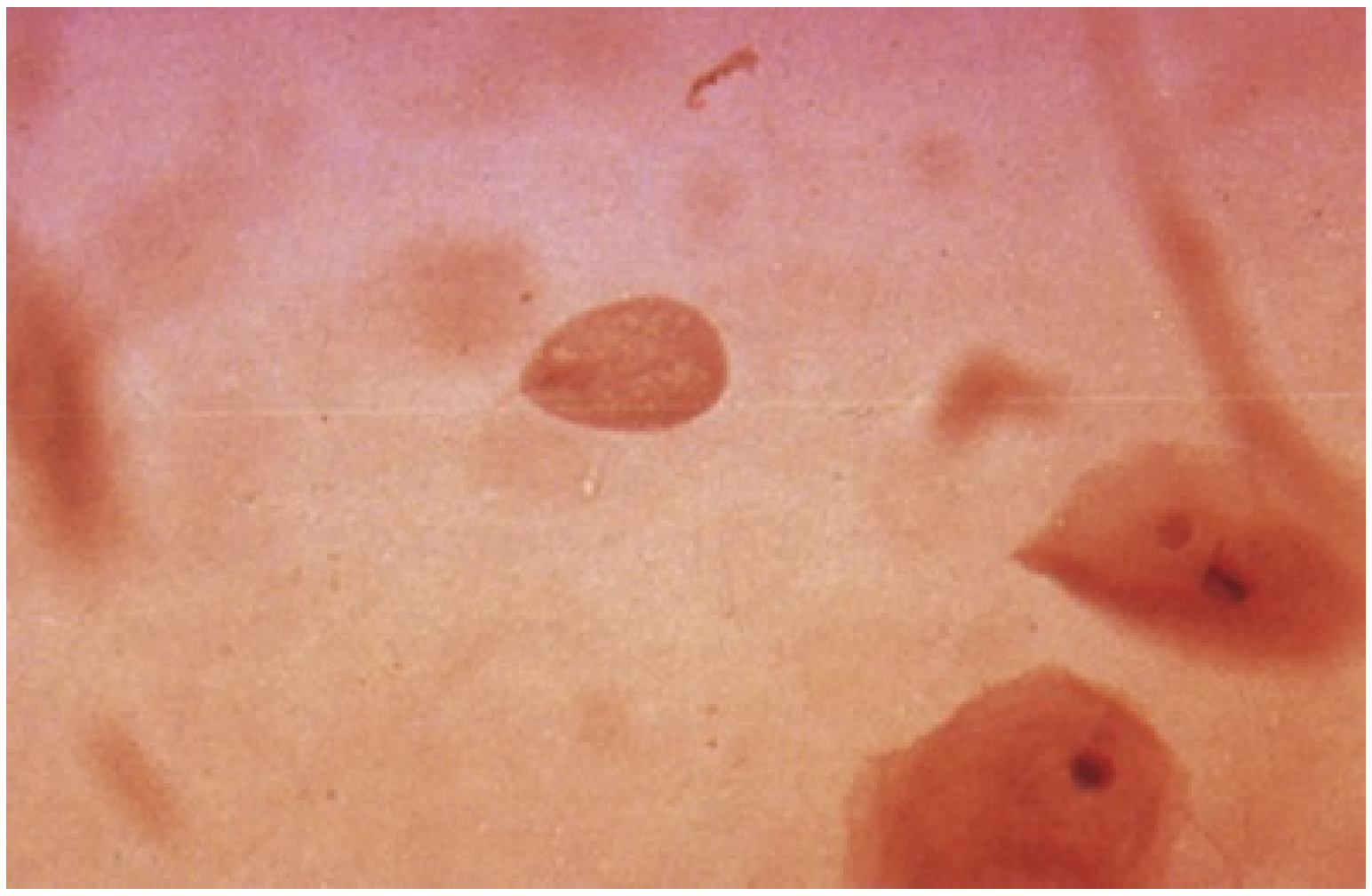

FIG. 2.21 Trichomonad with ovoid shape and motile flagella.

***Schistosoma hematobium* is a urinary tract pathogen that is not found in the United States but is extremely common in countries of the Middle East and North Africa. Examination of the urine shows the characteristic parasitic ova with a terminal spike.**

Expressed Prostatic Secretions

Although not strictly a component of the urinary sediment, the expressed prostatic secretions should be examined in any male patient suspected of having prostatitis. Normal prostatic fluid should contain few, if any, leukocytes, and the presence of a larger number or clumps of leukocytes is indicative of prostatitis. **Oval fat macrophages are found in postinfection prostatic fluid** (Figs. 2.22 and 2.23). Normal prostatic fluid contains numerous secretory granules that resemble but can be distinguished from leukocytes under high power because they do not have nuclei.

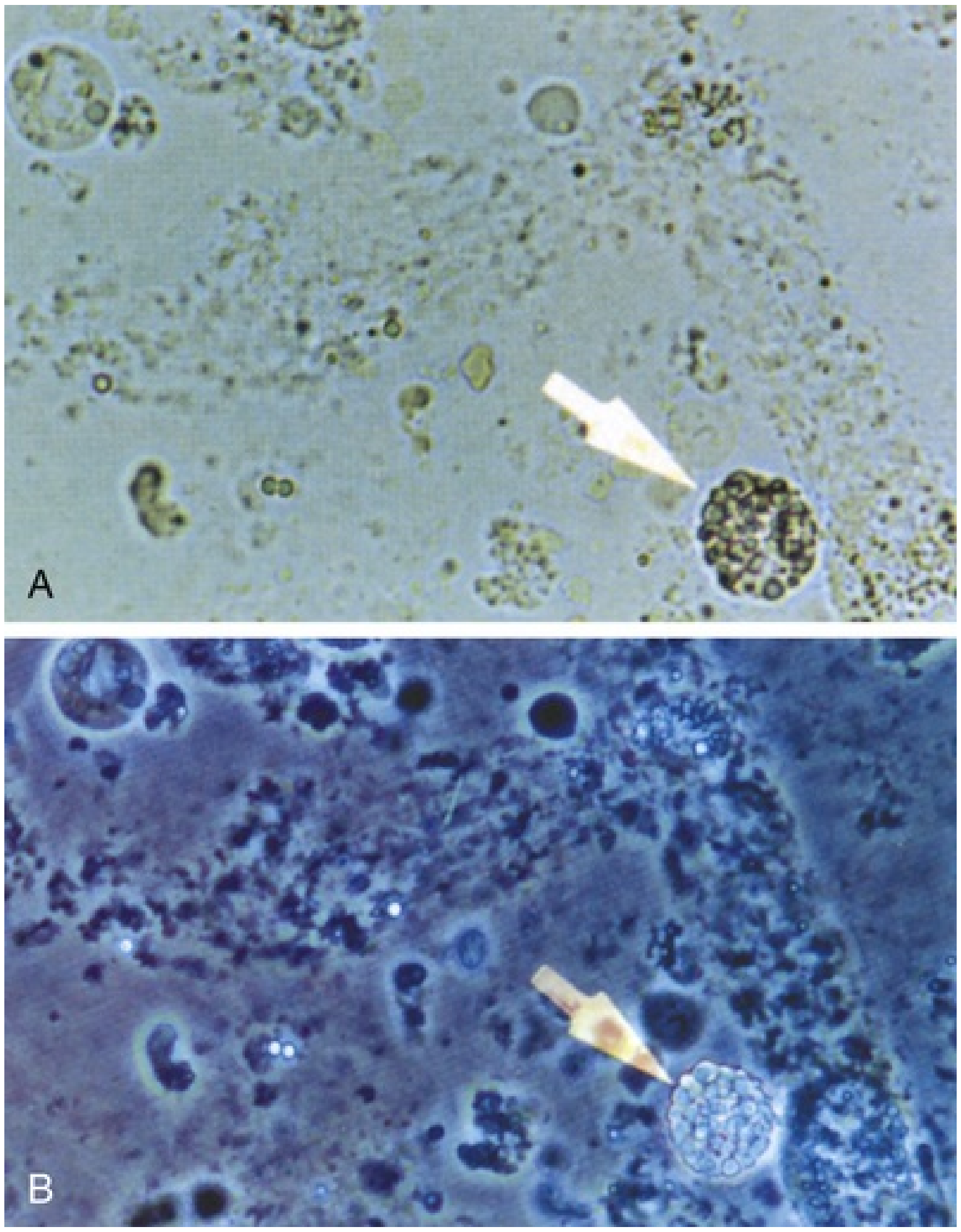

FIG. 2.22 Oval fat macrophage. (A) High-power view showing doubly refractile fat particles *(arrow).* (B) Phase microscopy of the same specimen *(arrow).*

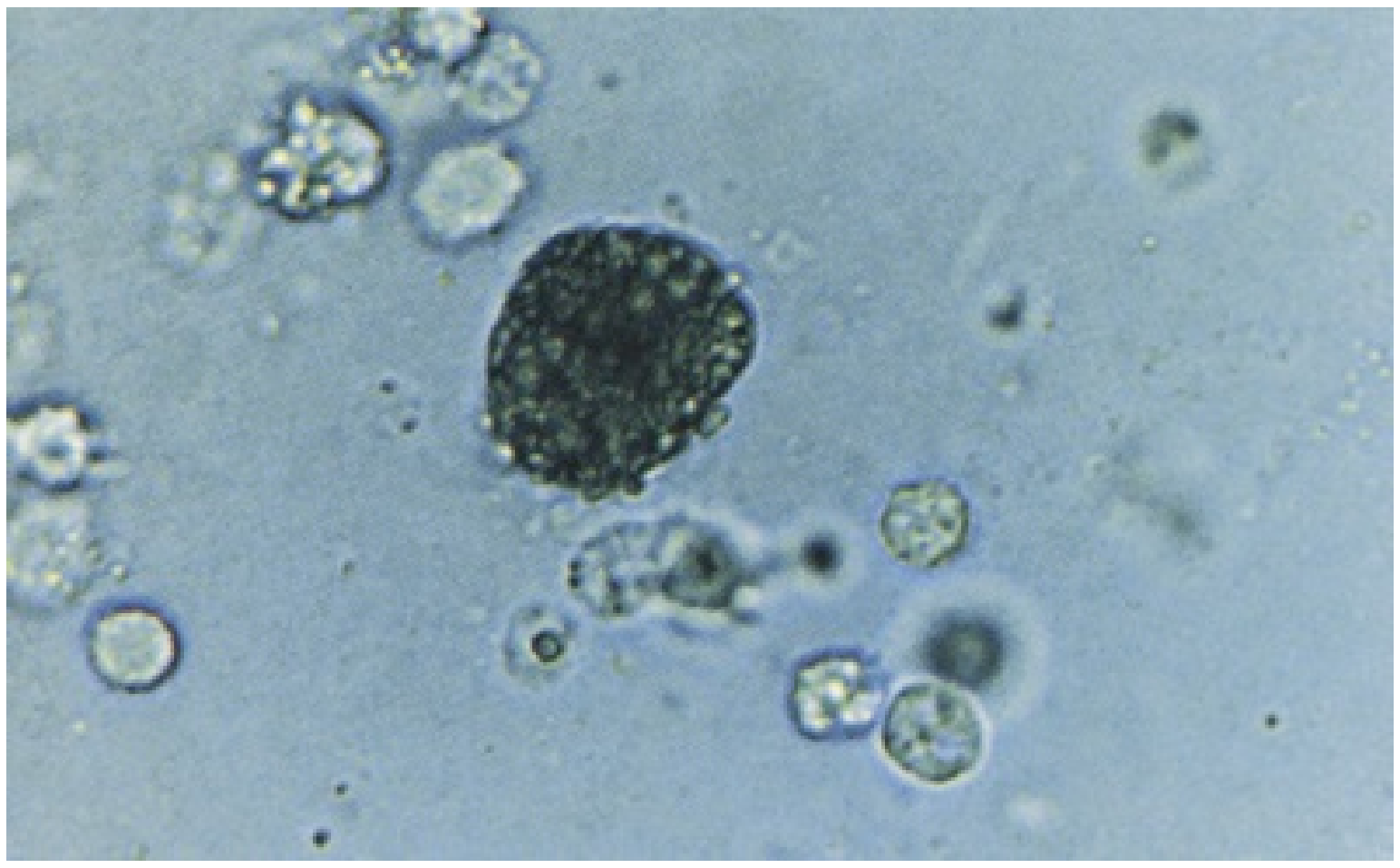

FIG. 2.23 Oval fat macrophage, high-power view. Note the fine secretory granules in the prostatic fluid.

Key Points

- A catheterized urine specimen should be obtained in the female patient with a history of recurrent UTIs or suspected contaminated specimen.
- Hematuria should be stratified into glomerular, nonglomerular, medical, and surgical causes.
- A dipstick alone is inadequate for the diagnosis of microscopic hematuria.
- AMH is defined as greater than or equal to 3 erythrocytes per HPF on a properly collected urinary specimen in the absence of an obvious benign cause.
- A urine dipstick that is positive for only leukocyte esterase or nitrites but not both should be confirmed with microscopic analysis and urine culture.

Serum Laboratory Studies

In some cases, assessing for metabolic function is incorporated in the evaluation of the urologic patient. A serum creatinine and calculated glomerular filtration rate (GFR) is often used to assess baseline or current renal function. Identifying any compromise of renal function may be useful when investigating lower or upper tract obstruction or any contributing medical renal disease. **Urgency of intervention and treatment of obstruction will be influenced by renal function.** Furthermore, the presence or history of renal disease is also used in the evaluation of conditions such as hematuria, proteinuria, and anatomic pathology as described earlier. In some cases, additional laboratory values such as serum potassium, CO_2, and liver transaminases are part of the diagnostic evaluation of malignancy or metabolic derangement seen with conditions affecting multiple organ systems including the urinary tract. A complete blood count (CBC) includes a white blood cell count, hemoglobin, hematocrit, and platelet count and may be ordered with or without a differential. This test may be ordered for perioperative purposes, during routine follow-up of patients with malignancy, and in the workup for an infectious process. A CBC may provide useful information to the urologist during evaluation of the urologic patient and help guide additional testing and workup when findings on history and physical examination suggest significant pathology within the urinary tract.

Prostate-Specific Antigen

One of the most important and controversial tumor markers identified is prostate-specific antigen (PSA). It is used by the urologist in the diagnostic evaluation of prostate pathology including cancer, benign prostatic hyperplasia (BPH), and inflammatory conditions of the prostate (prostatitis). **PSA, also known as *human kallikrein peptidase 3(hK3)*, is a serine protease and a member of the kallikrein gene family. It is produced by prostatic luminal epithelial cells.** Although there is significant disagreement across disciplines regarding its use for the detection of prostate cancer, it is a particularly useful tool for the assessment of BPH and prostatitis because of its sensitivity for the detection of prostatic pathology. The PSA level often directly correlates to prostate volume and any significant inflammatory process within the prostate gland. It is also one of the most reliable laboratory tests used when following patients with prostate cancer, particularly following treatment including radiation, radical prostatectomy, and hormonal therapy. **This test may be ordered when evaluating the male patient for prostatic diseases including prostate cancer, urinary obstruction, and symptoms caused by BPH and prostatitis**. Indications, algorithms, and implications for ordering PSA for specific pathology are covered in depth later in this text.

Urinary Markers

Urinary cytology is ordered when urothelial malignancy is suspected. Although in the past it was considered a standard part of the screening for urothelial cell carcinoma (UCC), deciding to order it in the initial evaluation is tailored to other aspects of the patient's history. Routine use as a screening tool or in the initial evaluation of AMH is not recommended and is more often used to follow patients with a known history of UCC (Davis et al., 2012, reviewed and validated 2016). However, it may be useful in patients with suspicious radiologic abnormalities or in cases in which a high-grade malignancy is suspected. **Urine cytology is highly specific for high-grade UCC, but sensitivity decreases for low-grade UCC ranging from 15.8% to 54.5%** (Steiner et al., 2008). Additional urinary markers including NMP22, BTA stat, and UroVysion FISH are available but are not recommended for routine use or for routine screening for bladder cancer (Davis et al., 2012, reviewed and validated 2016). In select cases and patients, the urologist may order one or more these tests but generally not during the initial evaluation of the urologic patient.

Additional Serum Studies

Some additional serum testing that may be ordered during the initial evaluation of the urologic patient includes serum markers for other urologic malignancies and endocrinologic studies. Examples include the standard markers for testicular cancers: alpha-fetoprotein (AFP), human chorionic gonadotropin (HCG), and lactate dehydrogenase (LDH). These are ordered during the initial evaluation of the scrotal mass or tumor that has been diagnosed on imaging such as testicular ultrasonography. Endocrinologic studies including total testosterone, free testosterone, luteinizing hormone (LH), follicle-stimulating hormone (FSH), prolactin (PRL), and thyroxine T4 may be ordered in the workup of the male patient with suspected hypogonadism. Additional serum endocrinologic studies may be ordered in the patient suspected of having endocrine disorders such as Cushing's syndrome or parathyroid disorders, and during the workup of adrenal pathology.

Key Points

- Serum creatinine and glomerular filtration rate should be ordered when renal obstruction of nephrologic disease is suspected.
- Prostate-specific antigen is a very sensitive test for prostate conditions such as BPH and prostatitis and correlates most often with prostate volume.
- Urine cytology is not recommended during the initial evaluation and screening for AMH.
- Urine cytology is very specific for high-grade urothelial carcinoma.

Office Diagnostic Procedures

Uroflowmetry and Ultrasound for Postvoid Residual

Two very common noninvasive tests performed in the urologist's office are uroflowmetry and assessment of postvoid residual (PVR). These are useful tests to obtain some basic information of the voiding status of the patient. Uroflowmetry is performed in the office with the patient voiding either in a standing or seated position. A multiple array of uroflowmeters are available on the market. In general, a peak or maximum flow rate (Qmax), mean flow rate, voided volume is obtained along with a voiding curve/pattern. This information is used to assess the patient for bladder outlet obstruction (BOO) and provide some insight as to the degree of obstruction in the male patient with suspected BPH. **If the Qmax is greater than 20 mL/s, there is a low probability of BOO. Rates between 15 mL/s and 20 mL/s indicate a low probability of BOO, but patients with significant symptomatic complaints may warrant further workup. Rates between 10 mL/s and 15 mL/s are equivocal, and rates less than 10 mL/s are often the result of BOO, urethral stricture, or detrusor impairment (Kelly, 2004).** It is recommended to interpret abnormally low flow rates with caution if the voided volume is less than 100 mL.

A PVR can be obtained as well to assess residual urine in the bladder and can complement the findings of the flow study to provide basic information about voiding. Modern office PVR is determined with a handheld bladder scanner, but if not available, a sterile catheter can be inserted. Using a sterile catheter has the disadvantage of being somewhat invasive and can cause discomfort, trauma, or infection. Threshold values of PVR are not well defined, but volumes less than 100 mL are generally considered within the acceptable range, especially in the older male patient. Conditions that can result in high PVRs include BOO, BPH, detrusor hypocontractility, neurogenic bladder, bladder diverticula, and urethral stricture disease. Further studies and testing based on results of uroflowmetry and PVR should be ordered based on the complete examination of the patient.

Cystometrography and Multichannel Urodynamic Studies

Urodynamic testing is the study of the transport, storage, and evacuation of urine. Testing is performed when a patient is in need of a more comprehensive workup of storage and voiding dysfunction that is not sufficiently diagnosed with history and physical examination. These studies are performed in the office setting, and ambulatory urodynamic studies can be obtained in select cases. **Components of more complex urodynamic studies include cystometrography, electromyography, urethral pressure profile, and**

pressure flow studies. Voiding and storage disorders and its workup are covered thoroughly later in this text.

Cystourethoscopy

Office cystourethroscopy is ordered when direct visualization and evaluation of the lower urinary tract is required. It can be performed in the office with modern flexible cystoscopic equipment. Rigid cystoscopy may be performed at the discretion of the urologist in female patients, but most often flexible cystoscopy is better tolerated. Direct examination of the urethra, bladder, and prostatic urethra in male patients can be performed for diagnostic and screening purposes, and in some cases treatments can be administered. The most common reasons office cystourethroscopy is performed is for diagnosis of lower urinary tract malignancy, urinary obstruction, or in some cases to assist with insertion of a urethral catheter. For patients with a urinary diversion such as an ileal conduit, office looposcopy can be performed to assess for pathology within the ilial conduit. This is performed with a flexible cystoscope and is generally well tolerated with only a mild amount of patient discomfort if there is significant pressure and reflux into the upper tracts. **It should be noted that use of antimicrobial prophylaxis during simple diagnostic cystourethroscopy without manipulation is not recommended as per the AUA best practice statement on urologic surgery antimicrobial prophylaxis and should only be used in patients with the risk factors listed in Table 2.3** (Wolf et al, 2008).

TABLE 2.3

Risk Factors Associated With Increased Risk for Infection Following Urologic Procedure

Advanced age
Anatomic anomalies of the urinary tract
Poor nutritional status
Smoking
Chronic corticosteroid use
Immunodeficiency
Externalized catheters
Colonized endogenous/exogenous material

Distant coexistent infection

Prolonged hospitalization

Key Points

- Uroflowmetry and assessment of PVR should be ordered when lower urinary tract obstruction is suspected.
- Urodynamic studies provide information on disorders of storage and voiding.
- Routine use of antimicrobial prophylaxis is not recommended for office cystourethroscopy, urodynamics, or cystography in the patient without risk factors.

Radiologic Imaging

During the evaluation of the urologic patient, information obtained with the history and findings on physical examination may prompt the need for radiologic testing. Although the details on the principles of imaging studies are covered in depth in later chapters, basic imaging that may be ordered for specific findings are briefly reviewed in the following section. Some imaging studies may be obtained in urology offices equipped to perform the studies, but more complex imaging such as computed tomography (CT), magnetic resonance imaging (MRI), and nuclear imaging is most often obtained at a formal radiologic facility.

Ultrasonography

Most urologists should be familiar with the indications for ordering ultrasonography of the kidneys, bladder, and prostate. In fact, more and more urologists are performing basic renal ultrasonography in the office setting. **Renal ultrasonography is ordered to obtain information on the size and shape of the kidneys, the presence or absence of hydronephrosis, anatomic abnormalities such as cysts and masses, echogenicity, and vasculature**. Medical renal disease should be suspected if there is increased cortical echogenicity relative to the liver or spleen (O'Neill, 2014). Patients with a history of stones or symptoms of flank pain may benefit from renal ultrasonography to assess for possible obstruction. However, the need for more detailed information from other studies such as CT should be weighed against the ease and convenience of performing an office ultrasonography of the kidneys. **Renal ultrasonography is not sufficient as a stand-alone imaging study for the workup of hematuria, and other cross-sectional abdominal imaging should be considered for this diagnosis.** Urologists rarely order ultrasonography of the bladder as a diagnostic study, but the bladder is often assessed during abdominal and renal ultrasonography. Large masses, large stones, and volume can be assessed by basic ultrasonography of the bladder, but limited information is provided by formal ultrasonography of the bladder. It should be noted that ultrasonography of the ureters is very difficult and should not be used as a method to diagnose conditions of the ureter such as stones or malignancy, although routine ultrasonography may be used to detect severe hydroureter.

Ultrasonography of the prostate is ordered and obtained most often in conjunction with prostate biopsy. More recently, prostate ultrasonography is being used along with MRI for the detection and diagnosis of prostate cancer (Moore and Taneja, 2016). Technology to fuse images from the MRI can be used in real-time during ultrasound-guided biopsy to target lesions within the prostate, or cognitive fusion may be used. More detailed analysis on the technology and indications for its use in the diagnosis of prostate cancer will be covered later in this text. A urologist may also order ultrasonography of the prostate without biopsy when assessing volume during the workup of BPH and/or obstruction. Information on the seminal vesicles and ejaculatory duct patency may be acquired for the assessment of ejaculatory and fertility disorders. The presence of full seminal vesicles along with a dilated ejaculatory duct may help the urologist to decide of additional testing or treatment is indicated.

Computed Tomography and Magnetic Resonance Imaging

Cross-sectional abdominal and pelvic imaging may be obtained either with CT or MRI. Both studies can be obtained with or without contrast. The principles on these more complex imaging studies will be covered later in this text, but the basic indications for ordering them in patients are when conditions of the upper tracts and bladder are suspected. The workup of microscopic and gross hematuria includes CT with contrast or MRI if there is a significant contraindication to iodinated contrast. Noncontrast CT is the most sensitive test and the gold standard for the detection of urinary stones. A history of nephrolithiasis with the onset of flank pain should prompt the ordering of a noncontrast CT of the abdomen and pelvis to assess for the presence of urinary stones. **MRI is not useful in the diagnosis and follow-up of urinary stones.** MRI is more useful in the diagnosis and evaluation of soft tissue abnormalities such as renal malignancies, tumor thrombus within the vasculature, pathology of the adrenal glands, cystic structures within the kidneys and urinary tract, and other soft tissue disorders of the abdomen, pelvis, and retroperitoneum.

Intravenous Pyelogram and Plain Radiographs

Intravenous pyelogram (IVP) and standard plain radiographs such as nephrograms have been largely eclipsed by CT and MRI. Nevertheless, there are select indications for these radiographic studies. Although IVP has been replaced by CT for the workup of urinary stones and upper tract abnormalities, especially with low-dose CT protocols that result in lower radiation exposure, one may order an IVP when dynamic imaging of upper tract excretion and obstruction is required and CT with contrast is not available. The urologist should not underestimate the usefulness of a plain radiography of the kidneys, ureters, and bladder (KUB). **A KUB may be ordered in the initial evaluation and follow-up of the nonemergent patient with a urinary stone in the ureter and/or kidneys**. As more than 70% of urinary stones are generally radio-opaque, a KUB can be useful when conservative management of urolithiasis is being pursued. For example, if a patient presents with a ureteral stone that is nonemergent and subsequent imaging may be needed for follow-up, an initial KUB may be obtained, and if the stone is visible then follow-up imaging may consist of a simple KUB rather than CT. Furthermore, patients with nonobstructing kidney stones may be successfully followed with KUB imaging if surveillance is the primary management strategy. Ultimately, patient symptoms may be used to decide if more complex imaging is warranted.

Key Points

- Renal ultrasonography can provide basic screening information on the presence of hydronephrosis and medical renal disease but is not an adequate stand-alone study for the workup of hematuria.
- CT without contrast of the abdomen and pelvis is the gold standard for detecting urinary stones.

- A KUB is a useful and easy test for the follow-up of existing nonemergent radio-opaque urinary stones.

Summary

This chapter provides an overview of the standard testing and imaging that may be part of the initial evaluation of the urologic patient. There are numerous diagnostic modalities within the urologic armamentarium, and a fundamental understanding of when to order these tests is critical when evaluating the urologic patient. The history and physical examination along with a properly collected urinalysis will help develop a differential diagnosis and direct which additional laboratory testing, office procedures, and imaging should be ordered.

References

Akiboye RD, Sharma DM. Haematuria in sport. *Eur Urol Focus*. 2018 [S2405–S4569(18)30070-1].

Berger J, Hinglais N. Les depots intercapillaires d'IgA-IgG. *J Urol Nephrol (Paris)*. 1968;74(9):694–695.

Chau AH, Abdul-Muhsin H, Peng X, et al. Robotic-assisted left renal vein transposition as a novel surgical technique for the treatment of renal nutcracker syndrome. *J Vasc Surg Cases Innov Tech*. 2018;4(1):31–34.

Culclasure TF, Bray VJ, Hasbargen JA. The significance of hematuria in the anticoagulated patient. *Arch Intern Med*. 1994;154(6):649–652.

Csako G. False-positive results for ketone with the drug mesna and other free-sulfhydryl compounds. *Clin Chem*. 1987;33(2 Pt 1):289–292.

Cushner HM, Copley JB. Back to basics: the urinalysis: a selected national survey and review. *Am J Med Sci*. 1989;297(3):193–196.

D'Amico G. Clinical features and natural history in adults with IgA nephropathy. *Am J Kidney Dis*. 1988;12(5):353–357.

Davis R, Jones JS, Barocas DA, et al. Diagnosis, evaluation and follow-up of asymptomatic microhematuria (AMH) in adults: AUA guideline. *J Urol*. 2012;188(6 Suppl):2473–2481.

Fassett RG, Horgan BA, Mathew TH. Detection of glomerular bleeding by phase-contrast microscopy. *Lancet*. 1982;1(8287):1432–1434.

Flanagan PG, Rooney PG, Davies EA, et al. Evaluation of four screening tests for bacteriuria in elderly people. *Lancet*. 1989;1(8647):1117–1119.

Gillenwater JY. Detection of urinary leukocytes by chemstrip-l. *J Urol*. 1981;125(3):383–384.

Gulleroglu K, Gulleroglu B, Baskin E. Nutcracker syndrome. *World J Nephrol*. 2014;3(4):277–281.

Kellogg JA, Manzella JP, Shaffer SN, et al. Clinical relevance of culture versus screens for the detection of microbial pathogens in urine specimens. *Am J Med*. 1987;83(4):739–745.

Kelly CE. Evaluation of voiding dysfunction and measurement of bladder volume. *Rev Urol*. 2004;6(Suppl 1):S32–S37.

Kincaid-Smith P. Haematuria and exercise-related haematuria. *Br Med J*. 1982;285(4):1595–1597.

Meares EM, Stamey TA. Bacteriologic localization patterns in bacterial prostatitis and urethritis. *Invest Urol*. 1968;5(5):492–518.

Moore CM, Taneja SS. Integrating MRI for the diagnosis of prostate cancer. *Curr Opin Urol*. 2016;26(5):466–471.

Morris RC, Ives HE. *Inherited disorders of the renal tubule*. ed 4. Saunders: Philadelphia, PA; 1991:1596.

Nickel JC, Shoskes D, Wang Y, et al. How does the pre-massage and post-massage 2-glass test compare to the Meares-Stamey 4-glass test in men with chronic prostatitis/chronic pelvic pain syndrome? *J Urol*. 2006;176(1):119–124.

O'Neill CW. Renal relevant radiology: use of ultrasound in kidney disease and nephrology procedures. *Clin J Am Soc Nephrol*. 2014;9(2):373–381.

Pels RJ, Bor DH, Woolhandler S, et al. Dipstick urinalysis screening of asymptomatic adults for urinary tract disorders. II: bacteriuria. *JAMA*. 1989;262(9):1221–1224.

Propp DA, Weber D, Ciesla ML. Reliability of a urine dipstick in emergency department patients. *Ann Emerg Med*. 1989;18(5):560–563.

Robinson RR. Clinical significance of isolated proteinuria. Avram MM. *Proteinuria*. Plenum Medical Book: New York, NY; 1985:67–82.

Sayer J, McCarthy MP, Schmidt JD. Identification and significance of dysmorphic versus isomorphic hematuria. *J Urol*. 1990;143(3):545–548.

Shaw ST, Poon SY, Wong ET. Routine urinalysis: is the dipstick enough? *JAMA*. 1985;253(11):1596–1600.

Steiner H, Bergmeister M, Verdorfer I, et al. Early results of bladder-cancer screening in a high-risk population of heavy smokers. *Brit J Urol*. 2008;102(3):291–296.

van den Wall Bake AW, Daha MR, van Es LA. Immunopathogenetic aspects of IgA nephropathy. *Nephrologie*. 1989;10(3):141–145.

Vaughan ED Jr, Wyker AW Jr. Effect of osmolality on the evaluation of microscopic hematuria. *J Urol*. 1971;105(5):709–711.

Wagner MG, Smith FG Jr, Tinglof BO Jr, et al. Epidemiology of proteinuria: a study of 4807 school children. *J Pediatr*. 1968;73(6):825–832.

Wolf JS, Bennett CJ, Dmochowski RR, et al: Urologic Surgery Antimicrobial Prophylaxis. AUA Best Practice: Reviewed and Validity Confirmed 2011; Amended 2012.

Urinary Tract Imaging

Basic Principles of CT, MRI, and Plain Film Imaging

Jay T. Bishoff MD, Ardeshir R. Rastinehad DO, FACOS

With advances in all of the imaging modalities, imaging continues to play an indispensable role in the diagnosis and management of urologic diseases. Because many urologic conditions cannot be assessed by physical examination, conventional radiography has long been critical to the diagnosis of conditions of the adrenals, kidneys, ureters, and bladder. The development of new computed tomography (CT) imaging techniques, three-dimensional (3D) reconstruction, improved ultrasound modalities, advances in magnetic resonance imaging (MRI), new radiotracers for positron emission tomography (PET), and the use of intravenous contrast agents provide detailed anatomic, functional, and physiologic information about urologic conditions and are required for accurate and appropriate urologic care. With so many different imaging options available, it is important for the urologist to be familiar with different options and their correct implementation. In this chapter we discuss the indications for imaging in urology, with an emphasis on the underlying physical principles of the imaging modalities. The strengths and limitations of each modality and the techniques necessary to maximize image quality and minimize the risks and harms to urologic patients are discussed.

Conventional Radiography

Conventional radiography has largely been replaced by CT and MRI for many evaluations but remains useful for preoperative diagnosis and postoperative evaluation in a variety of different urologic conditions. Conventional radiography includes abdominal plain radiography, intravenous excretory urography, retrograde pyelography, loopography, retrograde urethrography, and cystography. Urologists frequently perform and interpret conventional radiography examinations, including fluoroscopic examinations, in the office and operating room environments.

Physics

Urologists should be familiar with the physics of conventional radiography and fluoroscopy, as well as the implications and dangers of radiation exposure to the patient and the operator. The underlying physical principles of conventional radiography involve emitting a stream of photons from an x-ray source. These photons travel through the air and strike tissue, imparting energy to that tissue. Some of the photons emerge from the patient with varying amounts of energy attenuation and strike an image recorder such as a film cassette or the input phosphor of an image-intensifier tube, thus producing an image (Fig. 3.1).

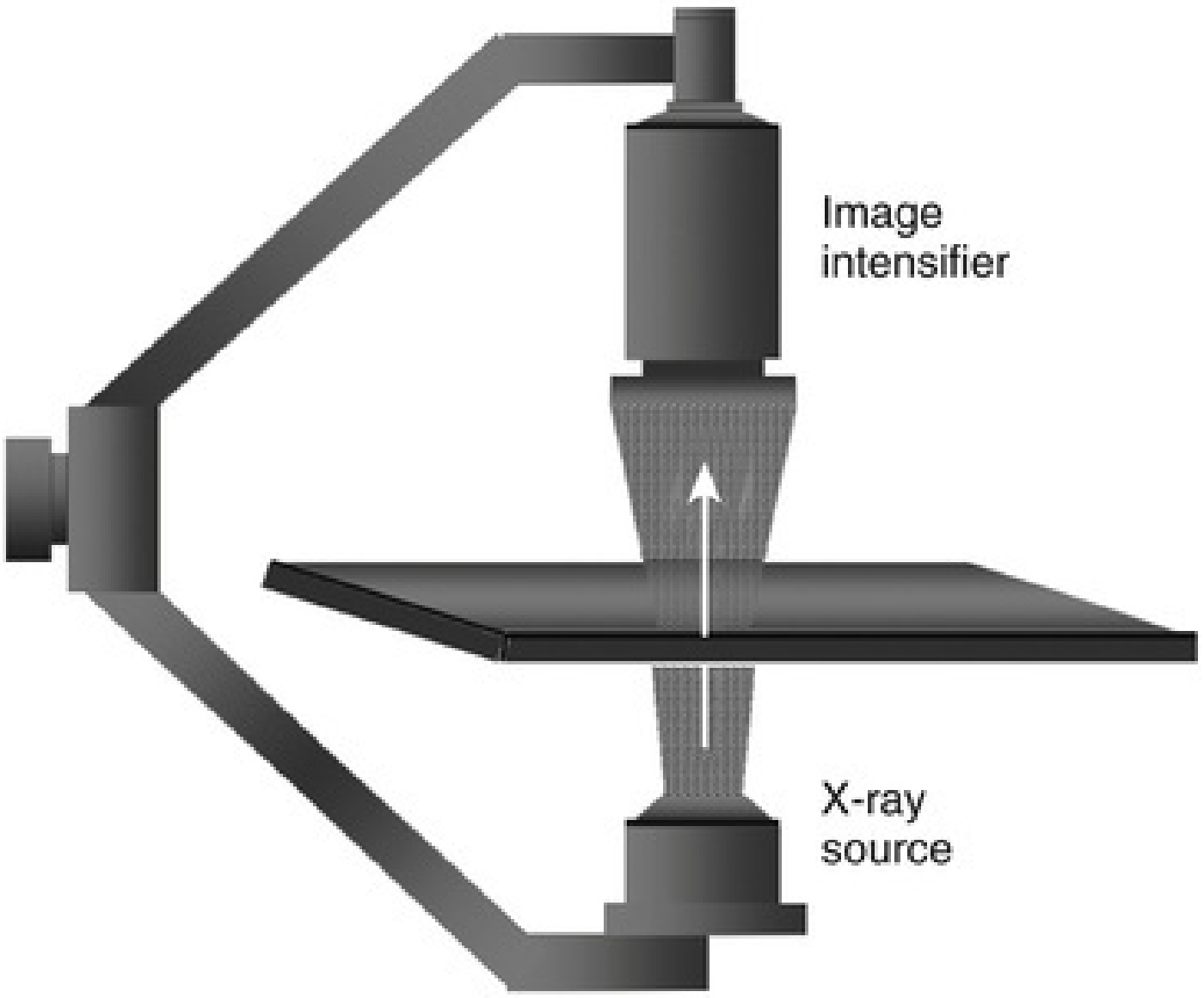

FIG. 3.1 **Recommended equipment setup for fluoroscopy.** The x-ray source located beneath the table reduces the radiation exposure to the urologist. Locating the image intensifier as close to the patient as feasible reduces scatter radiation. Equipment setup will vary based on application.

Radiation Management in Uroradiology

When diagnostic radiation passes through tissue, it creates ion pairs. The resultant charge per unit mass of air is referred to as the **radiation exposure**. The current unit of radiation exposure is measured in coulombs (C)/kg. **Absorbed dose** is the energy absorbed from the radiation exposure and is measured in units called gray (Gy). The older unit of absorbed dose was called the rad (1 rad = 100 Gy).

Because different types of radiation have different types of interaction with tissue, a conversion factor is applied to better express the amount of energy absorbed by a given tissue. The application of this conversion factor to the **absorbed dose** yields the **equivalent dose** measured in sieverts (Sv). For diagnostic x-rays the conversion factor is 1, so the absorbed dose is the same as the equivalent dose. When the amount of radiation energy absorbed by patients during therapeutic radiation is discussed, the dose is given in gray. When exposure to patients or medical personnel resulting from diagnostic ionizing radiation procedures is discussed, the dose is given in sieverts.

The distribution of energy absorption in the human body is different based on the body part being imaged and a variety of other factors. The most important risk of radiation exposure from diagnostic imaging is the development of cancer. The **effective dose** is a quantity used to denote the radiation risk (expressed in **sieverts**) to a population of patients from an imaging study. See Table 3.1 for a description of the relationship between these measures of radiation exposure.

TABLE 3.1

Units of Radiation Exposure and the Clinical Relevance of the Measures

---

RADIATION QUANTITY	TRADITIONAL UNIT	SI UNIT	CONVERSION	CLINICAL RELEVANCE
Exposure	roentgen (R)	coulomb (C)/kg	1 C/kg = 3876 R	Charge per unit mass
Absorbed dose	rad	gray (Gy)	1 Gy = 100 rad	Energy absorbed by tissue
Equivalent dose	rem	sievert (Sv)	1 Sv = 100 rem	Absorbed energy based on tissue type
Effective dose	rem	sievert		Biologic risk

		(Sv)		associated with absorbed energy

Modified from Geise RA, Morin RL: Radiation management in uroradiology. In Pollack HM, McClennan BL, ed: *Clinical urography,* ed 2, Philadelphia, 2000, Saunders, p 13.

The average person living in the United States is exposed to 6.2 mSv of radiation per year from ambient sources, such as radon and cosmic rays, and medical procedures, which account for 36% of the annual radiation exposure (National Council on Radiation Protection and Measurements [NCRP], 2012). The recommended occupational exposure limit to medical personnel is 50 mSv per year (NCRP, 2012). Exposure to the eyes and gonads has a more significant biologic impact than exposure to the extremities, so recommended exposure limits vary according to the body part. The linear no-threshold model (LNT) used in radiation protection to quantify exposition and to set regulatory limits assumes that the long-term biologic damage caused by ionizing radiation is directly proportional to the dose. **Based upon the LNT there is no safe dose of radiation.** An effective radiation dose of as little as 10 mSv may result in the development of a malignancy in 1 of 1000 individuals exposed (National Research Council of the National Academies, 2006).

Relative Radiation Levels

The assessment of biologic risk from radiation exposure is complex. Estimating the range of effective doses for various imaging modalities allows assignment of a **relative radiation level (RRL)** (Table 3.2). The effective dose from a three-phase CT of the abdomen and pelvis without and with contrast may be as high as 25 to 40 mSv. Another often-overlooked source of significant radiation exposure is seen in the use of fluoroscopy. Fluoroscopy for 1 minute results in a radiation dose to the skin equivalent to 10 times that of a single radiograph of the same anatomic area (Geise and Morin, 2000).

TABLE 3.2

Radiation Exposure From Common Urologic Imaging Procedures

RELATIVE RADIATION LEVEL (RRL)	EFFECTIVE DOSE ESTIMATED RANGE	EXAMPLE EXAMINATIONS
None	0	Ultrasound, MRI

Minimal	<0.1 mSv	Chest radiographs
Low	0.1–1.0 mSv	Lumbar spine radiographs, pelvic radiographs
Medium	1–10 mSv	Abdomen CT without contrast, nuclear medicine, bone scan, ^{99m}Tc-DMSA renal scan, IVP, retrograde pyelograms, KUB, chest CT with contrast
High	10–100 mSv	Abdomen CT without and with contrast, whole-body PET

Modified from American College of Radiology: *ACR Appropriateness Criteria Radiation Dose Assessment Introduction*. http://www.acr.org/SecondaryMainMenuCategories/quality_safety/app_criteria/RRLInformation.asp 2008.

Radiation Protection

The cumulative dose of radiation to patients increases relatively rapidly with repeated CT imaging studies or procedures guided by fluoroscopy. Certain patient populations such as those with recurrent renal calculus disease or those with a urologic malignancy may be at increased risk of developing cancer because of repeated exposures to ionizing radiation. Attempts should be made to limit axial imaging studies to the anatomic area of interest and to substitute imaging studies not requiring ionizing radiation when feasible. The cumulative dose of radiation to medical personnel (including physicians) may increase relatively rapidly in circumstances in which fluoroscopy is used.

Reduction in radiation exposure to medical personnel is achieved by three major mechanisms: (1) limiting the time of exposure; (2) maximizing distance from the radiation source; and (3) shielding. Radiation dose during fluoroscopy is directly proportional to the **time of exposure** and to the **number of exposures**. The exposure time during fluoroscopy should be minimized by using short bursts of fluoroscopy and using the “last image hold” feature of the fluoroscopy unit. Radiation beams diverge with distance, and therefore radiation exposure diminishes as the square of the distance from the radiation source. Maintaining the maximum practical distance from an active radiation source significantly decreases exposure to medical personnel. Positioning the image intensifier as close to the patient as feasible substantially reduces scatter radiation. Standard aprons, thyroid shields, radiation-resistant eye protection, and leaded gloves provide significant shielding for medical personnel and should be worn by all personnel involved in the use of fluoroscopy. **A practice of**

routinely collimating to the minimum required visual fluoroscopy field results in significant reductions in radiation exposure when compared with a usual approach to collimation. This may have important implications for decreasing the risk of malignancy in patients and operators.

Key Points: Conventional Radiography/Radiation Management in Uroradiology

- The effective radiation dose describes the potential for adverse health effects from ionizing radiation.
- The effective dose is a quantity used to denote the radiation risk (expressed in sieverts) to a population of patients from an imaging study. See Table 3.1 for a description of the relationship between these measures of radiation exposure.
- Based upon the LNT model, there is no safe dose of radiation.
- RRLs categorize diagnostic imaging studies by their estimated effective dose of radiation.
- Radiation protection for medical personnel includes (1) limiting time of exposure, (2) maximizing distance from radiation source, and (3) shielding.
- Collimating to the minimum required visual fluoroscopy field reduces exposure to the patient and operator.

Contrast Media

The urologist ordering a radiographic evaluation on a patient must consider the risks and benefits associated with a contrast-enhanced imaging study as well as alternative imaging modality that could provide the same information without the need for contrast exposure.

Many different types of contrast media have been used to enhance medical imaging and thus improve diagnostic and therapeutic decisions made by urologists. These agents are used daily throughout the world with great safety and efficacy. However, like all other pharmaceuticals, there are inherent risks associated with the use of contrast media. Adverse side effects and adverse reactions (ARs) can be a direct result from the use of contrast media and vary from minor disturbances to severe, life-threatening situations. Imaging centers must be prepared with trained personnel, readily available medications, equipment, and an ongoing system to educate clinic personnel on the recognition and treatment of ARs associated with contrast media.

Adverse Reactions to Intravascular Contrast Media

The urologists ordering a radiographic study of a patient first must consider the risks and benefits associated with a contrast-enhanced imaging study as well as alternative imaging modalities that could provide the same information without the need for radiation or contrast exposure.

ARs associated with current intravenous contrast media are uncommon: iodinated: 0.6% aggregate and 0.04% severe (Wang et al., 2008); gadolinium (Gd) based: 0.01% to 0.22% aggregate and 0.008% severe.

Low-osmolality contrast media (LOCM) are associated with low incidence of ARs, and most are not life threatening. Reports of the overall acute AR rates for allergic-like and physiologic reactions (PRs) for nonionic LOCM is 0.2% to 0.7% (Cochran et al., 2001; Mortele et al., 2005; Wang et al., 2008). Serious acute reactions have an incidence of 0.04% (4/10,000) (Katayama et al., 1990). The mortality associated with LOCM injections was reported by the USFDA and drug manufacturers' data from 1990 to 1994 to be 2.1 fatalities per 1 million contrast-enhanced studies using LOCM (Lasser et al., 1987).

The American College of Radiology has divided AR contrast agents into two categories: allergic-like reactions (ALRs) or PRs, and each is subdivided into three categories: mild, moderate, or severe (Table 3.3) (ACR Manual on Contrast Media, 2017).

TABLE 3.3

Types of Acute Reactions to Contrast Medium

MILD REACTIONS	
Self-limiting signs or symptoms	
Allergic-Like	**Physiologic**
Limited urticaria/pruritus	Limited nausea/emesis
Limited edema	Transient flushing/warm/chills
Limited throat irritation	Headache/dizziness/anxiety/altered taste
Nasal congestion	Mild hypertension
Sneezing, eye irritation, rhinorrhea	Vasovagal but resolves spontaneously
MODERATE REACTIONS	
Commonly require medical management and may become severe if not treated	
Allergic-Like	**Physiologic**
Diffuse urticaria/pruritus	Protracted nausea/emesis
Diffuse erythema	Hypertension
Facial edema	Chest pain
Throat tightness	Vasovagal responds to treatment
Wheezing/bronchospasm mild	
SEVERE REACTIONS	
Life-threatening, may result in morbidity or mortality if not treated. Cardiac arrest may occur from allergic-like as well as physiologic adverse reactions	
Allergic-Like	**Physiologic**
Diffuse edema/facial edema/shortness of breath	Vasovagal reaction resists treatment
Diffuse erythema and hypotension	Arrhythmia
Laryngeal edema with hypoxia	Seizures
Wheezing/bronchospasm with hypoxia	Hypertensive emergency
Anaphylactic shock/hypotension/tachycardia	

Data from *ACR Manual on Contrast Media,* Version 10.3, 2017.

Allergic-Like Reactions

ALRs manifest in a similar manner to allergic reactions and are now termed “allergic-like” because they are usually idiosyncratic and usually differ immunologically from true ARs. Given that an antigen-antibody response is rarely identified, allergic-like contrast medium reactions are classified as “anaphylactoid,” “allergic-like,” or “idiosyncratic” (Brockow, 2005; Bush and Swanson, 1991; Cohan and Dunnick, 1987; Dunnick and Cohan, 1994).

The exact mechanism of ALRs is not known but is thought to be a combination of systemic effects (Lasser et al., 1987, 2000)**. ALRs have not been shown to result from a true IgE antibody immunologic reaction to the contrast media** (Dawson et al.,1999). At least four mechanisms may play a role in ALRs: (1) release of vasoactive substances including histamine; (2) activation of physiologic cascades, including complement, kinin, coagulation, and fibrinolytic systems; (3) inhibition of enzymes including cholinesterase, which may cause prolonged vagal stimulation; and (4) the patient's own anxiety and fear of the actual procedure. **ALRs are not dose dependent. Severe reactions have been reported after only 1 cc was injected at the beginning of the procedure and have also occurred after completion of a full dose despite no reaction to the initial test dose** (ACR, 2017; Nelson et al., 1988; Thomsen et al., 1999).

The PRs are not allergic like and represent a physiologic response to the contrast medium molecular properties creating chemotoxicity, effects resulting from hyperosmolality, or binding of specific contrast molecules to activators. Their reactions are often dose and concentration dependent (Bush and Swanson, 1991; Cohan and Dunnick, 1987; Dunnick and Cohan, 1994; Lieberman and Seigle, 1999).

Vasovagal reactions are common PRs, characterized by hypotension and bradycardia and usually self-limiting. These reactions can be related to anxiety and have been known to occur when obtaining consent for the imaging procedure, during venous cannulation, or during administration of contrast medium.

Treatment of Contrast Reactions

Severe contrast reactions are rare but may require immediate treatment. In the case of severe reactions the patient will need emergency care and attention to respiratory and cardiovascular systems. A moderately severe reaction may progress to be severe and life threatening. To reduce the chance of significant morbidity and mortality, a plan and protocol must be in place with trained staff who are trained to recognize, assess, and treat contrast reactions. The evaluation of a patient experiencing a possible reaction includes the following:

- General appearance
- Ability to speak and characterization of the voice
- Respiratory status and oxygen saturation
- Pulse rate and characterization
- Blood pressure

Treatment: Mild Allergic-Like and Physiologic Reactions.

Observation and reassurance are often all that is needed. Usually, no intervention or medication is required. If needed, an H1-receptor blocker such as diphenhydramine (Benadryl) PO/IM/IV 1 to 2 mg/kg up to 50 mg may be helpful in this patient population. Caution is advised: these reactions may progress into a more severe category. Consequently these patients should be observed for 20 to 30 minutes. If necessary, administer chlorpheniramine 4 to 10 mg orally, intravenously, or intramuscularly and diazepam 5 mg for anxiety. For bronchospasm, oxygen 6 to 10 L/min should be administered and a β-agonist inhaler used at 2 puffs (90 mcg/puff) for a total of 180 mcg; this can be repeated up to three times.

Treatment: Moderate Allergic-Like and Physiologic Reactions.

Moderate ARs occur in 0.5% to 2% of patients and require treatment but are not immediately life threatening. These reactions are usually transient and require treatment with close observation, using hydrocortisone 100 to 500 mg IM or IV, or β-agonist inhalation for bronchospasm bronchiolar dilators (metaproterenol [Alupent], terbutaline [Brethaire], or albuterol [Proventil or Ventolin]) 2 to 3 puffs; repeat as necessary. For bronchospasm, oxygen 6 to 10 L/min should be administered and a β-agonist inhaler used at 2 puffs (90 mcg/puff) for a total of 180 mcg; this can be repeated up to three times. Epinephrine can be added to moderate or severe bronchospasm (see the following for epinephrine dosing).

Treatment: Severe Allergic-Like and Physiologic Reactions.

Life-threatening reactions occur in approximately 1/1000 uses for high osmolar agents and are far less frequent for LOCM, with both types of agents resulting in mortality rates of 1/170,000 uses (Spring et al., 1997). Immediate treatment is required. The patient usually requires emergency care, involving particular attention to the respiratory and cardiovascular systems. If bronchospasm is severe and not responsive to inhalers, or if an upper airway edema (including laryngospasm) is present, epinephrine should be used promptly. **Rapid administration of epinephrine is the treatment of choice for severe contrast reactions. Epinephrine can be administered IV in the dose of 0.1 mL/kg of 1:10,000 dilution or (0.01 mg/kg) slowly into a running IV infusion of saline and can be repeated every 5 to 15 minutes as needed. The maximum single dose is 1.0 mL (0.1 mg) and can be repeated as needed to a total dose of 1 mg.**

If no IV access is available, the recommended intramuscular dose of epinephrine is 0.01 mg/kg of 1:1000 dilution (0.01 mL/kg) to a maximum of 0.15 mg of 1:1000 if less than 30 kg (0.3 mg if weight is >30 kg) is injected intramuscularly in the lateral thigh. This can be repeated every 5 to 15 minutes up to 1 mL (1 mg) total dose. Subcutaneous injection is much less effective (ACR Manual, 2017; Lightfoot et al., 2009). Epinephrine must be administered with care to patients who have cardiac disease or those who are taking beta-blockers because the unopposed alpha effects of epinephrine in these patients may cause severe hypertension or angina.

Antihistamines do not have a major role in the treatment of severe reactions. Careful monitoring of patient vital signs is paramount; the presence of both hypotension and tachycardia indicates a higher likelihood of anaphylactic reaction. Bradycardia is a sign of vasovagal reaction and therefore the use of beta-blockers is to be avoided. Hypotension resulting from an anaphylactic reaction can be treated with intravenous iso-osmolar fluids (e.g., 0.9% normal saline or Ringer's lactate solution): several liters of fluid may be needed before obtaining a significant hemodynamic response. If fluid and oxygen are unsuccessful in reversing the patient's hypotension, the use of vasopressors is indicated. The most effective vasopressor is dopamine. Dopamine should be used at infusion rates between 2 and 10 mcg/kg/min.

Premedication

There is no known premedication strategy that will eliminate the risk of a severe adverse reaction to contrast media. The regimens suggested in the literature include the use of corticosteroids, antihistamines, H_1 and H_2 antagonists, and ephedrine. Patients at high risk should be premedicated with corticosteroids and possibly with antihistamines 12 to 24 hours before and after use of intravenous radiographic contrast media (IRCM). LOCM should be used in these patients. Several premedication regimens have been proposed to reduce the frequency and/or severity of reactions to contrast media. Two frequently used regimens are outlined in Box 3.1.

Box 3.1

Premedication Strategies to Reduce Severity of Reactions to Contrast Media

1. Prednisone: 50 mg by mouth at 13 hours, 7 hours, and 1 hour before contrast media injection
   Plus diphenhydramine (Benadryl) 50 mg intravenously, intramuscularly, or by mouth 1 hour before contrast medium injection
2. Methylprednisolone (Medrol): 32 mg by mouth 12 hours and 2 hours before contrast media injection
   Plus diphenhydramine (Benadryl): 50 mg intravenously, intramuscularly, or by mouth 1 hour before contrast medium injection

From *American College of Radiology Manual on Contrast Media*, version 9, 2013. http://www.acr.org/SecondaryMainMenuCategories/quality_safety/contrast_manu

Corticosteroid Premedication.

Corticosteroid administered before contrast imaging is used to lower the likelihood of an ALR in patients thought to be at risk for a reaction. It has been demonstrated that the use of nonionic contrast media combined with a premedication strategy including corticosteroids results in a reduction in reaction rates compared to other protocols for patients who have experienced a prior contrast media–induced reaction. A randomized trial of premedication for average-risk patients before high-osmolality iodinated contrast medium showed a reduction in mild, intermediate, and severe reactions (Lasser et al., 1987). However, high-osmolality agents are no longer used for intravascular purposes. Another small, randomized trial reported decreased reactions in premedicated patients receiving low-osmolality iodinated contrast medium (O'Malley et al., 2011).

Because severe reactions are rare events, it is difficult to design a study that would be adequately powered to measure a difference. It is estimated that the number of patients needed to premedicate to prevent one reaction in high-risk patients was 69 for avoidance of any reaction, and 569 patients to prevent a severe reaction (Mervak et al., 2015). It is estimated that the number needed to treat to prevent a lethal reaction in high-risk patients would be approximately 50,000 patients (Davenport et al., 2016).

There are no published studies addressing the use of premedication strategies before oral contrast or gadolinium-based intravenous contrast medium in high-risk patients. The current premedication recommendations in these patients are extrapolated from patients receiving intravascular iodinated contrast media.

The risks to patients for premedication with corticosteroids are small and include leukocytosis, asymptomatic hyperglycemia, and possible infection risk (Davenport et al., 2011; Davenport et al., 2016; Lasser, 1988). Diphenhydramine may result in drowsiness.

Premedication Strategies.

Oral administration of steroids seems preferable to intravascular administration, with prednisone and methylprednisolone being equally effective. If the patient is unable to take oral medication, 200 mg of hydrocortisone intravenously may be substituted for oral prednisone. **One consistent finding is that steroids should be given at least 6 hours before the injection of contrast media regardless of the route of steroid administration. It is clear that administration for 3 hours or less before contrast does not decrease the incidence of ARs** (Greenberger et al., 1984; Greenberger et al., 1985; Lasser, 1988; Lasser et al., 1987; O'Malley et al., 2011). The minimum duration of premedication is not known. Most studies show that 32 mg of oral methylprednisolone 2 hours before IV use of high-osmolality iodinated contrast in average-risk patients was not effective at prevention of AR, whereas two doses of 32 mg of oral methylprednisolone, one taken 12 hours before contrast and the second taken 2 hours before contrast, was effective (O'Malley et al., 2011).

Supplemental administration of an H_1 antihistamine (e.g., diphenhydramine), orally or intravenously, may reduce the frequency of urticaria, angioedema, and respiratory symptoms.

In emergency situations, intravenous corticosteroid (e.g., 200 mg hydrocortisone) every 4 hours plus an H_1 antihistamine (e.g., 50 mg diphenhydramine) 1 hour before the procedure has been used. In patients who have a prior documented contrast reaction, the use of a different contrast agent has been advocated and may be protective. Switching to a different agent should be in combination with a premedication regimen.

Although rare, ARs have been reported after extravascular instillation of contrast agents (e.g., retrograde pyelography). **In patients with a positive history of previous severe reactions to contrast agents undergoing a nonvascular study, premedication with corticosteroids should be considered.**

Premedication Regimens.

Elective premedication with 12 to 13 hours before administration of contrast medium is as follows:

Prednisone: 50 mg oral prednisone at 13 hours, 7 hours, and 1 hour before contrast medium administration, plus 50 mg diphenhydramine IV, IM, or PO 1 hour before contrast administration

or

Methylprednisolone: 32 mg orally 12 hours and again 2 hours before contrast medium administration, plus 50 mg diphenhydramine IV, IM, or PO 1 hour before contrast administration

For patients unable to take oral medication, substitute 200 mg IV hydrocortisone for each does of the or prednisone may be used (Lasser et al., 1987; Mervak et al., 2017).

Accelerated IV Premedication.

Premedication regimens less than 4 to 5 hours before administration of contrast medium, with oral or IV medications, have not been shown to be effective. The accelerated 4- to 5-hour regimen is supported by a case series and a retrospective cohort study of 828 patients (Mervak et al., 2017).

1. Methylprednisolone sodium succinate (e.g., Solu-Medrol) 40 mg IV or hydrocortisone sodium succinate (e.g., Solu-Cortef) 200 mg IV immediately and then every 4 hours until contrast medium administration, plus diphenhydramine 50 mg IV 1 hour before contrast medium administration. This regimen usually lasts 4 to 5 hours.
2. Dexamethasone sodium sulfate (e.g., Decadron) 7.5 mg IV immediately and then every 4 hours until contrast medium administration, plus diphenhydramine 50 mg IV 1 hour before contrast medium

administration. This regimen may be useful in patients with an allergy to methylprednisolone and usually lasts 4 to 5 hours.

3. Methylprednisolone sodium succinate (e.g., Solu-Medrol) 40 mg IV or hydrocortisone sodium succinate (e.g., Solu-Cortef) 200 mg IV, plus diphenhydramine 50 mg IV, each 1 hour before contrast medium administration. This regimen, and all other regimens with a duration less than 4 to 5 hours, has no evidence of efficacy. It may be considered in emergent situations when there are no alternatives (ACR, 2017).

Delayed Contrast Reactions

Delayed contrast reactions can occur from 3 hours to 7 days after the administration of contrast. These reactions are identified in as many as 14% to 30% of patients after the injection of ionic monomers and in 8% to 10% of patients after the injection of nonionic monomers. The most common of delayed reactions are allergic-like and cutaneous reactions with reported incidence of 0.5% to 9%. The most common reactions include a cutaneous xanthem or pruritis without urticaria. Nausea, vomiting, drowsiness, headache, and flulike symptoms also may occur. These signs and symptoms typically resolve spontaneously (Loh et al., 2010).

Specific Contrast Considerations

Allergy.

Patients who have had a prior ALR to contrast medium have a fivefold increased risk for developing a future ALR if exposed to the same class of contrast agent (Jung et al., 2012; Katayama et al., 1990). Patients who have allergies unrelated to contrast are at a two to three times increased risk for an ALR to contrast. Patients with shellfish or iodine allergies are at no greater risk from iodinated contrast medium than are patients with other allergies (Beaty et al., 2008; Boehm, 2008). Patients who have had a reaction to one class of contrast medium are not at higher risk or chance of having a reaction to another type of contrast medium.

Anxiety.

Contrast reactions are more common in patients with anxiety and may need reassurance but do not require premedication (Lalli, 1974).

Asthma.

A history of asthma increases the chance of an ALR and bronchospasm. Notwithstanding, premedicating based on the history of asthma alone is not recommended (Shehadi, 1975).

Beta-Blockers.

It has been suggested that the use of beta-blockers can lower the threshold for contrast reactions, reduce the response to treatment, and increase the risk of more severe contrast reactions (Lane et al., 1993). This risk is modest and consequently premedication and cessation of beta-blockers are not recommended before use of contrast medium.

Cardiac Abnormalities.

Patients with underlying severe cardiac disease, including chest pain and cardiac arrest, have an increased incidence and/or severity of cardiovascular side effects. Pulmonary angiography and intracardiac and coronary artery injections carry the highest degree of risk. Possible reactions include hypotension, tachycardia, and arrhythmias. More severe, but uncommon, reactions include congestive heart failure, pulmonary edema, and cardiac arrest. Premedication is not recommended based solely upon cardiac status.

Hyperthyroidism.

Iodinated contrast media does not affect thyroid function in patients with a normal functioning thyroid. Patients with hyperthyroidism may develop thyrotoxicosis after exposure to an iodinated contrast medium, but this is a rare event (van der Molen et al., 2004). During acute thyroid storm, iodinated contrast can potentiate thyrotoxicosis and should be avoided in these patients. Iodinated contrast medium can interfere with patients undergoing radioactive iodine therapy or radioactive iodine imaging of the thyroid, and a washout period is recommended after imaging with iodinated contrast medium of 3 to 6 weeks (ACR, 2017; Silberstein et al., 2012).

Myasthenia Gravis.

The use of intravenous iodinated contrast medium causing an exacerbation of symptoms in patients with myasthenia gravis (MG) is controversial. Myasthenic exacerbation occurs in approximately 6% of patients with MG exposed to iodinated contrast compared with 1% of patients with MG undergoing contrast

CT imaging. Premedication is not recommended solely based on the history of MG (Mehrizi and Pascuzzi, 2014; Somashekar et al., 2013).

Pheochromocytoma.

There is no evidence that the use of currently available iodinated or gadolinium contrast medium will induce a hypertensive crisis in patients with pheochromocytoma (Mukherjee et al., 1997).

Sickle Cell Trait and Disease.

It has been suggested that contrast medium in sickle cell disease or trait patients may increase the risk of sickle crisis. This has not been seen with the use of current iodinated or gadolinium contrast medium (Morcos, 2005).

Extravasation of Contrast Material.

Large volume extravasation can be seen with power injections not monitored with electrical skin impedance devices that detect extravasation and arrest the injection process. When large volume extravasation of IRCM occurs, the result can be swelling, edema, erythema, pain, and cellulitis. The most severe consequences may not be manifest immediately, and the inflammatory reaction usually reaches a maximum in 24 to 48 hours. The primary underlying mechanism is believed to be the hyperosmolality of the contrast agent. Mechanical compression resulting from a compartment syndrome may also occur, leading to tissue necrosis. Management steps are immediate cessation of injection, notification of responsible and referring physicians, and elevation of the affected extremity above the level of the heart. If large volume of extravasate occurs, it is recommended to manually massage to promote drainage. If the patient becomes symptomatic, plastic surgery consultation may also be needed. Admission to the hospital for observation or frequent follow-up in clinic may be necessary in some cases of large volume extravasation.

Postcontrast Acute Kidney Injury.

Postcontrast acute kidney injury (PC-AKI) is a nonspecific term assigned to an acute, sudden deterioration in kidney function within 48 hours after IV administration of contrast medium. Contrast-induced nephropathy (CIN) is specific for a sudden decrease in kidney function caused by IV administration of iodinated contrast medium.

The precise pathophysiology is not entirely understood, and many different factors have been implicated: vasoconstriction, direct tubular toxicity, osmotic mechanisms, and chemotoxic mechanisms (Heinrich et al., 2005; Liu et al., 2012).

When used at FDA-recommended doses, gadolinium-based contrast media either do not cause CIN or the incidence is extremely low. However, if administered at higher than FDA-approved doses, gadolinium-based contrast media (GBCM) are more nephrotoxic than isoattenuating doses of iodinated contrast media (Briguori et al., 2006).

Although there are no standard criteria for CIN, the diagnosis can be made if one of the following occurs within 48 hours after administration of iodinated contrast medium: increase in serum creatinine of >0.3 mg/dL, >50% increase in serum creatinine from baseline, or urine output reduced to <0.5 mL/kg/h for at least 6 hours (Mehta et al., 2007).

Four large studies of more than 40,000 patients have addressed CIN, and all four studies have shown that CIN is less common than previously reported. For patients with a stable baseline estimated glomerular filtration rate (eGFR) of at least 45 mL/min/1.73 m^2 IV, iodinated contrast media are not an independent risk for CIN, and in patients with a eGFR 30 to 44 mL/min/1.73 m^2, IV iodinated contrast media are either not nephrotoxic or rarely the cause of CIN (Davenport et al., 2013a; Davenport et al., 2013b; McDonald et al., 2013; McDonald et al., 2014). IV iodinated contrast material appears to be an independent risk factor for CIN in patients with stage IV and stage V chronic kidney disease whose eGFR is less than 30 mL/min/1.73 m^2.

High doses of IRCM can impair renal function in some patients for 3 to 5 days, and the creatinine level usually returns to baseline in 10 to 14 days. The incidence of contrast agent–related nephropathy is estimated to be 2% to 5%, and of those with CIN, up to 25% have persistent renal dysfunction. Clinical manifestations are highly variable and may be absent or proceed to oliguria. CIN in patients with normal kidney function is rare (Kelly et al., 2008; Pannu et al., 2006). CIN is the third most common cause of acute kidney failure in hospitalized patients (Nash et al., 2002).

Isolating specific risk factors for CIN have proven to be difficult to determine. There is general consensus that the most important preexisting risk factor for CIN is severe renal insufficiency. Other risk factors that have been suspected to lead to CIN include diabetes mellitus, dehydration, cardiovascular disease, diuretic use, advanced age, multiple myeloma, hypertension, hyperuricemia, and repeated doses of iodinated contrast in a short period of time.

The most common patient-related risk factors for CIN are chronic kidney disease (creatinine clearance <60 mL/min), diabetes mellitus, dehydration, diuretic use, advanced age, congestive heart failure, age, hypertension, low hematocrit, and ventricular ejection fraction less than 40%. The patients at highest risk for developing CIN are those with both diabetes *and* preexisting renal insufficiency. Other risk factors are concomitant exposure to chemotherapy, aminoglycoside or nonsteroidal anti-inflammatory agents, hyperuricemia, and diseases that affect renal hemodynamics, such as end-stage liver disease and nephrotic syndrome. Patients with a diagnosis of a paraproteinemia syndrome/disease (e.g., multiple myeloma) or a history of a kidney transplant, renal tumor, renal surgery, or single kidney may also be at higher risk of CIN.

The most common non–patient-related causes are high osmolar contrast agents, ionic contrast, increased contrast viscosity, and multiple contrast-enhanced studies performed within a short period and large contrast volume infused (Pannu et al., 2006).

Despite significant discussion on the part of radiologists and urologists, the literature does not support an absolute serum creatinine level that prohibits the use of contrast media. Prevention of CIN has been the subject of many research studies, and the results have been summarized by several different meta-analyses. In these meta-analyses the baseline serum creatinine of study participants ranged from 0.9 to 2.5 mg/dL. In one survey the policies regarding the cutoff value for serum creatinine varied widely among radiology practices: 35% of respondents used 1.5 mg/dL, 27% used 1.7 mg/dL, and 31% used 2.0 mg/dL (mean 1.78 mg/dL) as a cutoff value in patients with no risk factors other than elevated creatinine; threshold values were slightly lower in people with diabetes (mean 1.68 mg/dL). Patients in end-stage renal disease who have no remaining natural renal function are no longer at risk for CIN and may receive LOCM or iso-osmolar contrast medium (IOCM) (Elicker et al., 2006).

Some radiologists prefer to stratify patients by eGFR instead of serum creatinine, and several studies support this practice. One report showed no risk of CIN from IV iodinated contrast regardless of baseline eGFR (McDonald et al., 2014). Another report identified patients with an eGFR less than 30 mL/min/1.73 m^2 were at significant risk of CIN, and patients with an eGFR 30 to 44 mL/min/1.73 m^2 were at some risk for CIN but not statistically significant risk (Davenport et al., 2013). One report showed that a higher percentage of patients presenting for contrast-enhanced CT had an eGFR less than 60 mL/min/1.73 m^2 than had a serum creatinine greater than 1.4 mg/dL, favoring the use of eGFR instead of serum creatinine (Herts et al., 2008). Presently, there is minimal evidence to suggest that IV iodinated contrast material acts as an independent risk factor for CIN in patient with an eGFR of more than 30 mL/min/1.73 m^2. Therefore it seems that this threshold is supported by the greatest amount of evidence.

The American College of Radiology recommends a baseline serum creatinine level before receiving IV iodinated contrast medium if one or more of the following risk factors are present (ACR Manual on Contrast Media, 2017):

- Age >60 years
- History of renal disease:
    - Dialysis
    - Kidney transplant
    - Solitary kidney
    - Renal cancer
    - Renal surgery
    - Hypertension requiring medical management
    - History of diabetes mellitus
    - Metformin drug combinations

Prevention of CIN is of great concern and has been a subject of many different studies. Hydration is the major preventative action against CIN. Periprocedural IV hydration with 0.9% saline at 100 mL/h 12 hours before to 12 hours after has been shown to decrease the incidence of CIN after intravenous contrast use (Solomon et al., 2007). **The use of sodium bicarbonate has not been definitively shown to prevent CIN in patients receiving IV iodinated contrast material. (The use of *N*-acetylcysteine for the prevention of CIN is controversial** [Safirestein et al., 2000].**) Currently there is insufficient evidence to make a definitive recommendation for its use, and therefore it should not be considered a substitute for appropriate screening and hydration** (Newhouse and RoyChoudhury, 2013; Zoungas et al., 2009). Furosemide was found to increase the risk of developing CIN (Kelly et al., 2008; Pannu et al., 2006).

Metformin and Iodinated Contrast.

Metformin, an oral antihyperglycemic drug used to treat diabetes, is eliminated unchanged through the kidneys, most likely by glomerular filtration and tubular excretion. As a biguanide, it stimulates intestinal production of lactic acid. Some conditions can reduce metformin excretion or increase serum lactate. Such conditions include renal disease (decreases metformin excretion), liver disease (decreases lactic acid metabolism), and cardiac disease (increases anaerobic metabolism). **Patients with type 2 diabetes mellitus on metformin may have an accumulation of the drug after administering IRCM, resulting in biguanide lactic acidosis; they experience vomiting, diarrhea, and somnolence. This condition is fatal in approximately 50% of cases** (Wiholm and Myrhed, 1993). **Biguanide lactic acidosis is rare in patients with normal renal function. Consequently, in patients with normal renal function and no known comorbidities, there is no need to discontinue metformin before IRCM use, nor is there a need to check creatinine after the imaging study. However, in patients with renal insufficiency, metformin should be discontinued the day of the study and withheld for 48 hours. Postprocedure creatinine should be measured at 48 hours and metformin started once kidney function is normal** (Bailey and Turner, 1996). **It is not necessary to discontinue metformin before gadolinium-enhanced magnetic resonance (MR) studies when the amount of gadolinium administered is in the usual dose range of 0.1 to 0.3 mmol per kg of body weight.**

Metformin is an antihyperglycemic agent used to treat diabetes mellitus and other conditions that is excreted in the kidneys by glomerular filtration and tubular excretion. The most significant adverse effect of metformin therapy is the possibility of developing metformin-associated lactic acidosis, which is rare (0.084 cases per 1000 patient-years) but has a mortality of 50% in susceptible patients.

The management of patients taking metformin should include the following information. Patients taking metformin are not at higher risk for CIN than other patients. Iodinated contrast is a potential concern for furthering renal damage in patients with acute kidney injury and those with chronic (stage IV or stage V) kidney disease. There have been no reports of lactic acidosis after IV iodinated contrast medium in patients properly selected for metformin considerations.

Recommendations[a] for patients taking metformin are classified into two categories:

1. Patients with no evidence of acute kidney injury (AKI) and eGFR ≥ 30

mL/min/1.73 m^2 do not need to discontinue metformin before or after IV administration of iodinated contrast media and do not need assessment of renal function after imaging.

2. Patients with AKI or CKD (stage IV, stage V, eGFR < 30 mL/min/1.73 m^2) or are having arterial catheter studies that may result in emboli of any type to the kidneys should have their metformin temporarily discontinued before the procedure for 48 hours and then restarted only after renal function has been revaluated and found to be normal.

Metformin and Gadolinium.

It is not necessary to discontinue metformin before contrast medium administration when the amount of gadolinium contrast material is in the normal and usual dose range of 0.1 to 0.3 mmol/kg body weight.

Magnetic Resonance Imaging Contrast Agents

Because MRI offers previously unseen detailed soft tissue imaging compared with CT, it was initially believed that MRI would not require contrast enhancement. However, by 2005, almost 50% of MRI studies were being performed with contrast media. Extracellular MRI contrast agents contain paramagnetic metal ions. Copper, manganese, and gadolinium were the potential paramagnetic ions for use with MRI. Gadolinium, however, is the most powerful, having seven unpaired electrons, but its toxicity required encapsulation by a chelate. Paramagnetic agents such as gadolinium are positive enhancers, reducing the T1 and T2 relaxation times and increasing tissue signal intensity on T1-weighted images, while having little effect on T2-weighted images.

Gadolinium

Acute adverse reactions are encountered less frequently with GBCM than after administration of iodinated contrast media. The frequency of all acute adverse events after an injection of 0.1 or 0.2 mmol/kg of gadolinium chelate ranges from 0.07% to 2.4%. The vast majority of these reactions are mild, including coldness at the injection site, nausea, emesis, headache, warmth or pain at the injection site, paresthesias, dizziness, and itching. Reactions resembling an ALR occur in 0.004% to 0.7% of cases. Reactions consisting of rash, hives, or urticaria are most frequent; the patient rarely develops bronchospasm. The severe, life-threatening anaphylactoid or nonallergic anaphylactic reactions are exceedingly rare (0.0001% to 0.001%). In a meta-analysis of 687,000 gadolinium doses for MRI, there were only 5 severe reactions. In another survey based on 20 million administered doses there were 55 cases (0.0003%) of severe reactions. Fatal reactions to gadolinium chelate agents have been reported, but they are extremely rare events. There have been no documented vaso-occlusive or hemolytic complications when administering GBCM to patients with sickle cell disease (Dillman et al., 2011; Elicker et al., 2006). Gadolinium agents are considered to have no nephrotoxicity at approved doses for MRI. However, because of the risk of nephrogenic systemic fibrosis (NSF) in patients with severe renal dysfunction, its use in this patient population requires some precaution and a review of the current recommendations.

Extracellular MRI agents are known to interfere with some serum chemistry assays. For example, serum calcium tests often are measured as a false reading of hypocalcemia for 24 hours after MRI with gadolinium enhancement, even though serum calcium is actually in the normal range. Other tests, including iron, magnesium, iron-binding capacity, and zinc, may also have spurious results. Biochemical assessment is more reliable when performed 24 hours after exposure to GBCM.

Nephrogenic Systemic Fibrosis

NSF is a fibrosing disease of the skin, subcutaneous tissues, lungs, esophagus, heart, and skeletal muscles. Initial symptoms typically include skin thickening and/or pruritus. Symptoms and signs may develop and progress rapidly, with some affected patients developing contractures and joint immobility within days of exposure. Death may result in some patients, presumably as a result of visceral organ involvement.

In 1997 NSF was described in dialysis patients who had not been exposed to GBCM. The condition was previously known as nephrogenic fibrosing dermopathy. In 2006 and again in 2007 independent reports surfaced defining a strong association with GBCM in patients with advanced renal disease (Grobner, 2006; Mackerman et al., 2007). **It is now accepted that GBCM exposure is a necessary factor in the development of NSF. Onset of NSF varies between 2 days and 3 months, with rare cases appearing years after exposure** (Shabana et al., 2008). **Early manifestations include subacute swelling of distal extremities, followed by severe skin induration and later even organ involvement.** In a 2007 survey performed by the American College of Radiology, 156 cases of NSF were reported by 27 responding institutions; 140 of these 156 patients were known to have received GBCM. In 78 patients, the specific GBCM was known: 45 of them received gadodiamide, 17 gadopentetate dimeglumine, 13 gadoversetamide, and 3 gadobenate dimeglumine. NSF after gadoteridol administration has also been reported. Many of the cases in which agents other than gadodiamide and gadopentetate dimeglumine were used are confounded by the fact that affected patients were injected with other agents as well (ACR, 2017). Between 12% and 20% of confirmed cases of NSF have occurred in patients with acute kidney injury. Patients with end-stage kidney disease and eGFR less than 15 mL/min/1.73 m^2 and severe CKD and eGFR 15 to 29 mL/min/1.73 m^2 have a 1% to 7% chance of developing NSF after MRI with gadolinium agents (Todd et al., 2007).

Patients with glomerular filtration rate (GFR) less than 30 mL/min/1.73 m^2 not on chronic dialysis are the most difficult patient population in terms of choosing imaging modality. They are at risk for CIN if exposed to iodinated contrast media for CT imaging and are at significant risk of developing NSF if exposed to GBCM during MRI. Recent data suggest that the risk of NSF may be greatest in patients with a GFR of less than 15 mL/min/1.73 m^2 who have a 1% to 7% chance of developing NSF after GBCM MRI, with the incidence being much less in patients with GFRs that are higher (Kanal et al., 2008). There is a single report of NSF in a patient with eGFR greater than 30 mL/min/1.73 m^2. In the chronic kidney disease patient population, it is recommended that contrast media be avoided if possible. If MRI contrast media is absolutely essential, use of the lowest possible doses (needed to obtain a diagnostic study) of selected GBCM is recommended. In this setting, the patient should be informed of the risks of GBCM administration and must give their consent to proceed. There is no proof that any GBCM is completely safe in this patient group; however, some have suggested avoiding gadodiamide and considering use of macrocyclic agents (Kanal et al., 2008). Patients with CKD but GFR exceeding 30 mL/min/1.73 m^2 are considered to be at extremely low or no risk for developing NSF if a dose of GBCM of 0.1 mmol/kg or less is used. Patients with GFR greater than 60 mL/min/1.73 m^2 do not appear to be at increased risk of developing NSF; the current consensus is that all GBCM can be administered safely to these patients.

The exact mechanism causing NSF is not known. It is believed, but not definitely proven, that gadolinium ions dissociate from the chelates in gadolinium-based contrast agent (GBCA) patients with poor renal clearance. The free gadolinium binds with anions such as phosphate, and the result is an insoluble precipitate that becomes deposited in different tissues with subsequent fibrotic reaction (Abraham et al., 2008; Collidge et al., 2007).

The ACR Committee on Drugs and Contrast Media (ACR Manual on Contrast Media, 2017) has concluded that patients considered to be at risk for NSF and who should have precontrast renal function testing include patients with a history of the following:

- Renal disease:
    - Dialysis
    - Severe or end-stage CKD (eGFR <30 mL/min/1.73 m^2) without dialysis
    - AKI
    - Solitary kidney
    - Known kidney cancer
- Hypertension requiring medical therapy
- Diabetes mellitus

Key Points: Contrast Media

- People with type II diabetes with renal insufficiency on oral metformin biguanide hyperglycemic therapy are at risk for developing biguanide lactic acidosis after exposure to intravascular radiologic contrast media and should stop metformin the day before the procedure and restart 48 hours after if they have a normal or baseline serum creatinine.
- Patients at risk for adverse reaction to contrast include patients with previous adverse reaction, history of asthma, severe cardiac disease, renal insufficiency, dehydration, sickle cell anemia, anxiety, apprehension, hyperthyroidism, and presence of adrenal pheochromocytoma.
- Epinephrine can be administered IV in the dose of 0.01 mg/kg of 1:10,000 dilution or 0.1 mL/kg slowly into a running IV infusion of saline and can be repeated every 5 to 15 minutes as needed. If no IV access is available, the recommended intramuscular dose of epinephrine is 0.01 mg/kg of 1:1000

dilution (or 0.01 mL/kg to a maximum of 0.15 mg of 1:1000 if <30 kg; 0.3 mg if weight is >30 kg) injected intramuscularly in the lateral thigh.

- Patients at greatest risk for contrast-induced nephropathy are those with diabetes mellitus and dehydration.
- Steroids given to prevent adverse contrast agents should be given at least 6 hours before injection.

Intravenous Urography

Once the mainstay of urologic imaging, the intravenous excretory urographic (IVU) study has almost been replaced by CT and MRI imaging. With the ability of new scanners to perform axial, sagittal, and coronal reconstruction of the upper tract urinary system, practically all of the data and information obtained by traditional IVU can be realized with CT. In addition, some parenchymal defects, cysts, and tumors can be better delineated with CT than IVU.

Technique

Bowel prep may help to visualize the entire ureters and upper collecting systems. Patients with chronic constipation may benefit most from complete bowel prep with clear liquids for 12 to 24 hours and an enema 2 hours before the procedure.

Before injection of contrast, a scout radiograph or KUB (kidneys, ureters, bladder) film is taken demonstrating the top of the kidneys and the entire pelvis to the pubic symphysis. This allows determination of adequate bowel prep, confirms correct positioning, and exposes kidney stones or bladder stones.

Contrast is injected as a bolus of 50 to 100 cc of contrast. The nephrogenic phase is captured with a radiograph immediately after injection. In the past, tomograms were used to look for parenchymal defects, but now CT or MRI imaging is preferred. A film is taken at 5 minutes and then additional films at 5-minute intervals until the question that prompted the IVU is answered. Abdominal compression may be used to better visualize the ureters. Occasionally oblique films are used to better define the course of the ureter in the bony pelvis and to precisely differentiate ureteral stones from pelvic calcifications.

Upright films may be helpful in certain situations. In the rare case of suspected symptomatic renal ptosis, IVU can be particularly helpful (Fig. 3.2). Supine films are compared with upright films to measure the degree of ptosis. Such a comparison cannot be made with MRI or CT imaging. In the case of calyceal stones or milk of calcium stones, layering of the contrast can be helpful to evaluate the anatomy of the calyx harboring the stones.

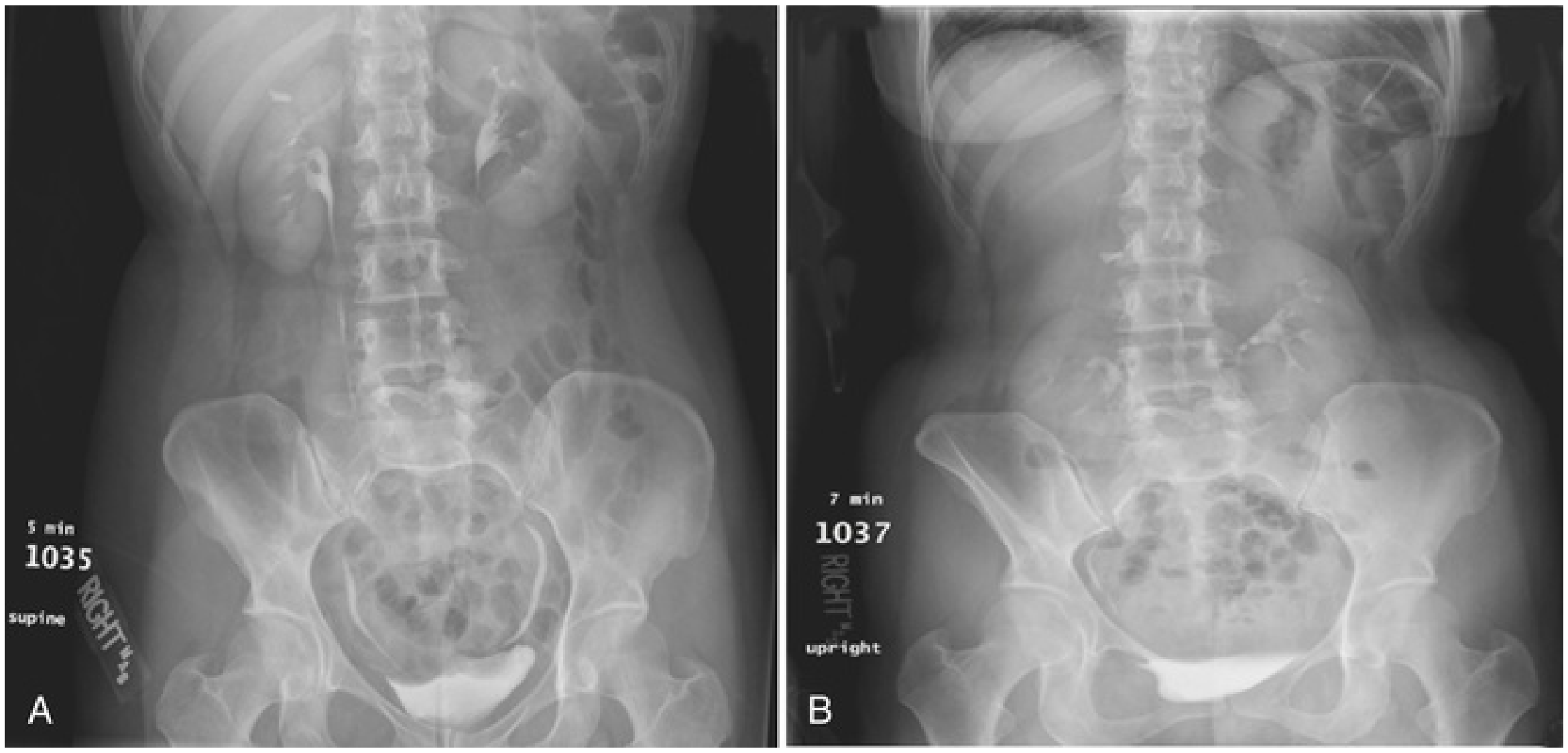

FIG. 3.2 Intravenous excretory urogram (IVU) in a 40-year-old woman with the complaint of a mobile mass in the right lower quadrant with standing associated with bilateral flank and back pain that resolved in the supine position. (A) Supine IVU shows kidneys in the normal position, with normal ureters and proximal collecting systems. (B) Standing film shows significant displacement of both kidneys with the right kidney moving onto the pelvis as described by the patient.

Postvoid films are obtained to evaluate the presence of outlet obstruction, prostate enlargement, and bladder-filling defects, including stones and urothelial cancers.

Indications

1. Demonstration of the renal collecting systems and ureters
2. Investigation of the level of ureteral obstruction
3. Intraoperative opacification of collecting system during extracorporeal shock wave lithotripsy or percutaneous access to the collecting system
4. Demonstration of renal function during emergent evaluation of unstable patients
5. Demonstration of renal and ureteral anatomy in special circumstances (e.g., ptosis, after transureteroureterostomy, and after urinary diversion)

Plain Abdominal Radiography

The plain abdominal radiograph is a conventional radiography study, which is intended to display the KUB. The plain abdominal radiograph may be employed (1) as a primary study or (2) as a scout film in anticipation of contrast media. Plain films are widely used in the management of renal calculus disease. Plain radiography is also useful in evaluation of the trauma patient because it can be performed as a portable study in the trauma unit. Secondary findings on plain radiography such as rib fractures, fractures of the transverse processes of the vertebral bodies, and pelvic fractures may indicate serious associated urologic injuries.

Technique

An abdominal plain radiograph is obtained with the patient in the supine position, using an anterior to posterior exposure. The study typically includes that portion of the anatomy from the level of the diaphragm to the inferior pubic symphysis. It may occasionally be necessary to make two exposures to cover the desired anatomic field. Depending on the indication for the study oblique films are obtained to clarify the position of structures in relation to the urinary tract. If small bowel obstruction or free peritoneal air is suspected, upright films will be obtained.

Indications

1. Preliminary film in anticipation of contrast administration
2. Assessment of the presence of residual contrast from a previous imaging procedure
3. Pre- and post-treatment assessment of renal calculus disease
4. Assessment of the position of drains and stents
5. Adjunct to the investigation of blunt or penetrating trauma to the urinary tract

Limitations

Although plain film radiography is often used in the evaluation of renal colic, it is unreliable in the demonstration of calculus disease for a variety of reasons: (1) overlying stool and bowel gas may obscure small calculi; (2) stones may be obscured by other structures such as bones or ribs (Fig. 3.3); (3) calcifications in pelvic veins or vascular structures may be confused with ureteral calculi; and (4) stones that are poorly calcified or composed of uric acid may be radiolucent. Nevertheless, plain film radiography is valuable in assessing the suitability of a patient for extracorporeal shock wave lithotripsy because the ability to identify the stone on fluoroscopy is critical to targeting. Furthermore, a KUB is very cost effective for monitoring residual stone burden after treatment (Fig. 3.4). For complex pathology of the urinary tract, plain abdominal radiography has been supplanted by axial imaging. Plain radiography has a very limited role in evaluating soft tissue abnormalities of the urinary tract.

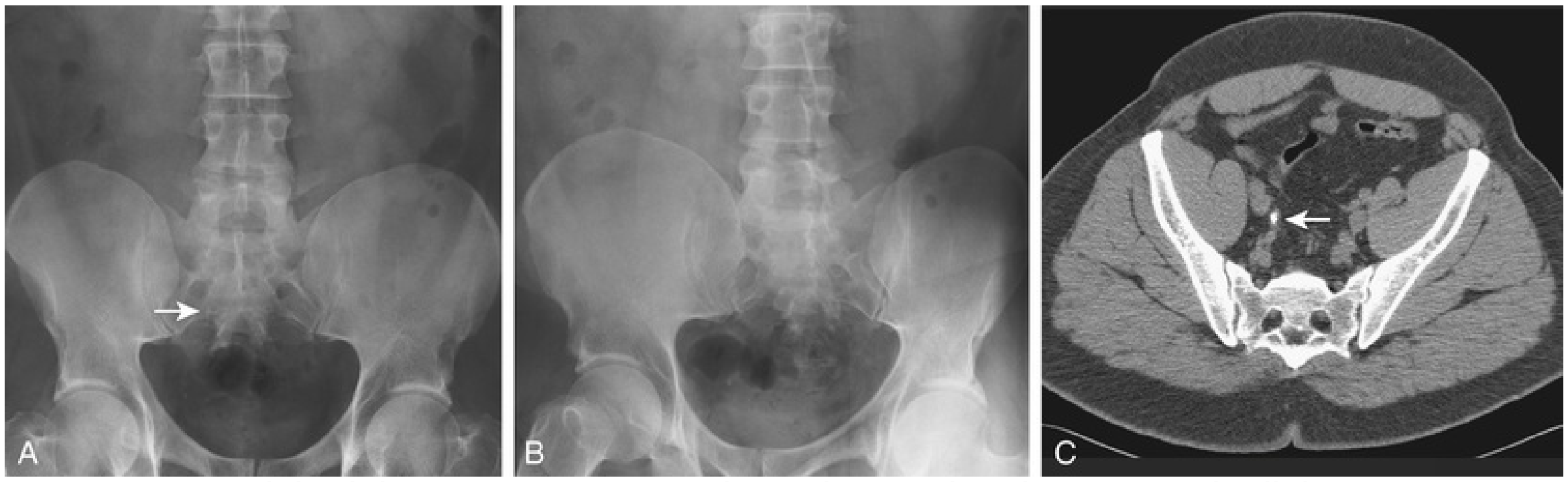

FIG. 3.3 (A) Right ureteral calculus *(arrow)* overlying the sacrum is difficult to visualize on the plain film. (B) The right posterior oblique study fails to confirm the location of the ureteral calculus. (C) CT confirms this 6-mm calculus in the right ureter at the level of the third sacral segment.

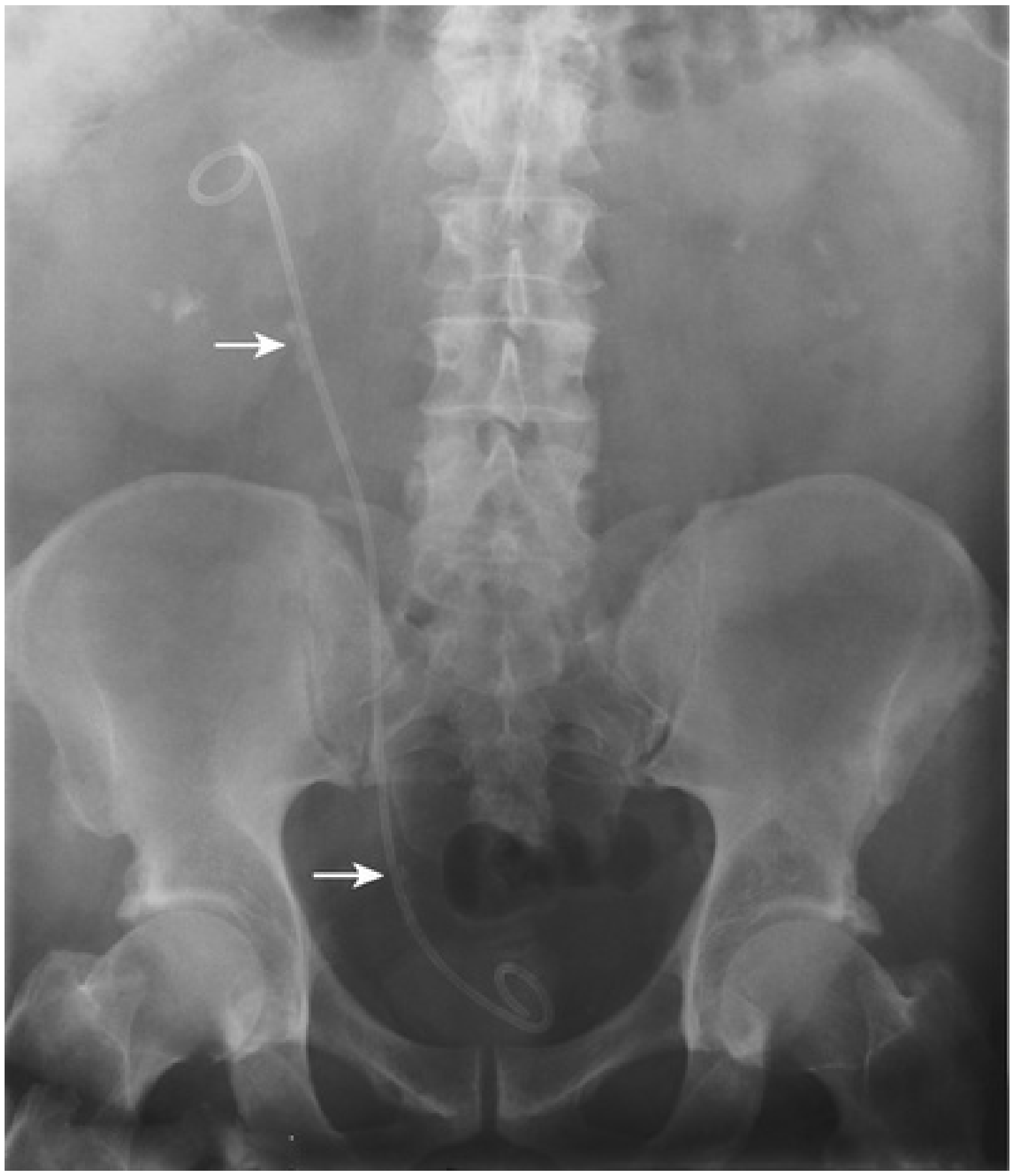

FIG. 3.4 KUB demonstrating residual stone fragments *(arrows)* adjacent to a right ureteral stent 1 week after right extracorporeal shock wave lithotripsy.

Retrograde Pyelography

Retrograde pyelograms are performed to opacify the ureters and intrarenal collecting system by the retrograde injection of contrast media. Any contrast media that can be used for excretory urography is also acceptable for retrograde pyelography. Attempts should be made to sterilize the urine before retrograde pyelography because there is a risk of introducing bacteria into the upper urinary tracts or into the bloodstream. Although many studies are able to document the presence or absence of dilation of the ureter, retrograde pyelography has the unique ability to document the normalcy of the ureter distal to the level of obstruction and to better define the extent of the ureteral abnormality.

Technique

Retrograde pyelography usually is performed with the patient in the dorsal lithotomy position. An abdominal plain radiograph (scout film) is obtained to ensure that the patient is in the appropriate position to evaluate the entire ureter and intrarenal collecting system. Cystoscopy is performed and the ureteral orifice is identified.

Contrast may be injected through either a nonobstructing catheter or an obstructing catheter. Nonobstructing catheters include whistle-tip, spiral-tip, or open-ended catheters. Use of nonobstructing catheters allows passage of the catheter into the ureter and up to the collecting system, over a guidewire if necessary. Contrast then can be introduced directly into the upper collecting system and the ureters visualized by injection of contrast as the catheter is withdrawn.

The other commonly employed method is the use of an obstructing ureteral catheter such as a bulb-tip, cone-tip, or wedge-tip catheter. These catheters are inserted into the ureteral orifice and then pulled back against the orifice to effectively obstruct the ureter. Contrast is then injected to opacify the ureter and intrarenal collecting system. Depending on the indication for the study, it is useful to dilute the contrast material (to 50% or less) with sterile fluid. This prevents subtle filling defects in the collecting system or ureter from being obscured. Care should be taken to evacuate air bubbles from the syringe and catheter before injection. Such air bubble artifacts could be mistaken for stones or tumors.

After air is expelled from the catheter into the bladder, the ureteral orifice is intubated. Contrast is injected slowly, usually requiring from 5 to 8 cc to completely opacify the ureter and intrarenal collecting system in adults (Fig. 3.5). More or less contrast may be required depending on the size of the patient and the capaciousness of the collecting system. Limited use of fluoroscopy while injecting helps prevent overdistension of the collecting system and reduces the risk of extravasation of contrast.

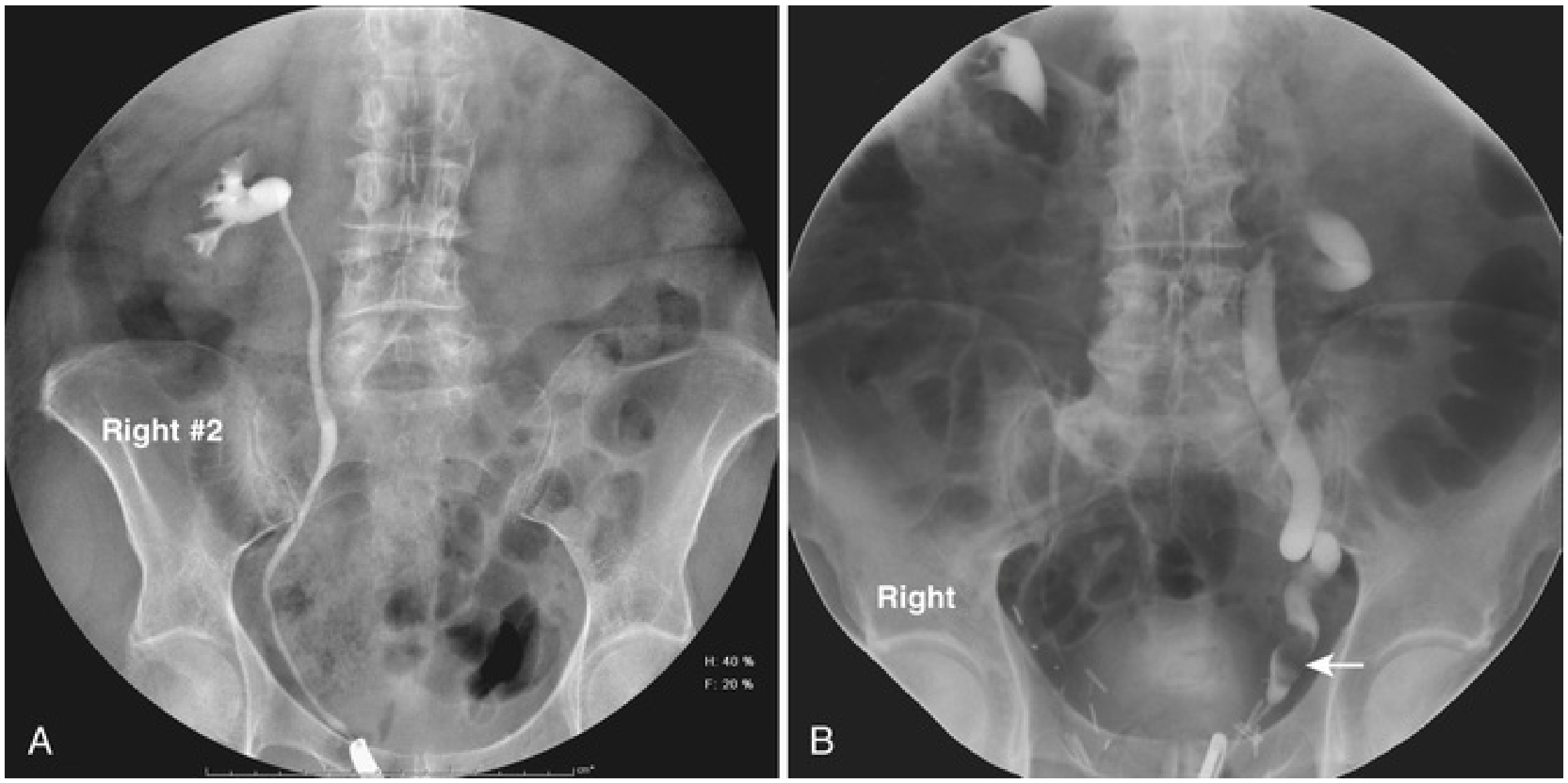

FIG. 3.5 (A) Right retrograde pyelogram performed using an 8-Fr cone-tipped ureteral catheter and dilute contrast material. The ureter and intrarenal collecting system are normal. (B) Left retrograde pyelogram using an 8-Fr cone-tipped ureteral catheter. A filling defect in the left distal ureter *(arrow)* is a low-grade transitional cell carcinoma. The ureter demonstrates dilation, elongation, and tortuosity, the hallmarks of chronic obstruction.

Historically, when a retrograde pyelogram consisted of a series of radiographs taken at intervals, it was important to document various stages of filling and emptying of the ureter and collecting systems. Because of peristalsis the entire ureter will often not be seen on any given static exposure or view. With current equipment, including tables that incorporate fluoroscopy, it is possible to evaluate the ureter during peristalsis in real time, thus reducing the need for static image documentation. Documentary still images or “spot films” may be saved for future comparison. Urologists interpret retrograde pyelograms in real time as they are performed.

Indications

1. Evaluation of congenital ureteral obstruction
2. Evaluation of acquired ureteral obstruction
3. Elucidation of filling defects and deformities of the ureters or intrarenal collecting systems
4. Opacification or distention of collecting system to facilitate percutaneous access
5. In conjunction with ureteroscopy or stent placement
6. Evaluation of hematuria
7. Surveillance of transitional cell carcinoma
8. In the evaluation of traumatic or iatrogenic injury to the ureter or collecting system

Limitations

Retrograde pyelography may be difficult in cases in which the bladder is involved with diffuse inflammation or neoplastic changes, especially when bleeding is present. Identification of the ureteral orifices may be facilitated by the intravenous injection of indigotindisulfonate sodium or methylene blue in such cases. Changes associated with bladder outlet obstruction may result in angulation of the intramural ureters. This may make cannulation with an obstructing catheter difficult. Attempts to cannulate the ureteral orifice may result in trauma to the ureteral orifice and extravasation of contrast material into the bladder wall. The potential for damage to the intramural ureter must be weighed against the potential information to be obtained by the retrograde pyelogram.

Complications

Backflow occurs during retrograde pyelography when contrast is injected under pressure and escapes the collecting system. Contrast may escape the collecting system by one of four routes: **Pyelotubular backflow** occurs when contrast fills the distal collecting ducts producing opacification of the medullary pyramids (Fig. 3.6A). **Pyelosinus backflow** occurs when a tear in the calyces at the fornix allows contrast to leak into the renal sinus (Fig. 3.6B). **Pyelolymphatic backflow** is characterized by opacification of the renal lymphatic channels (Fig.

3.6C). **Pyelovenous backflow** is seen when contrast enters the venous system, resulting in visualization of the renal vein.

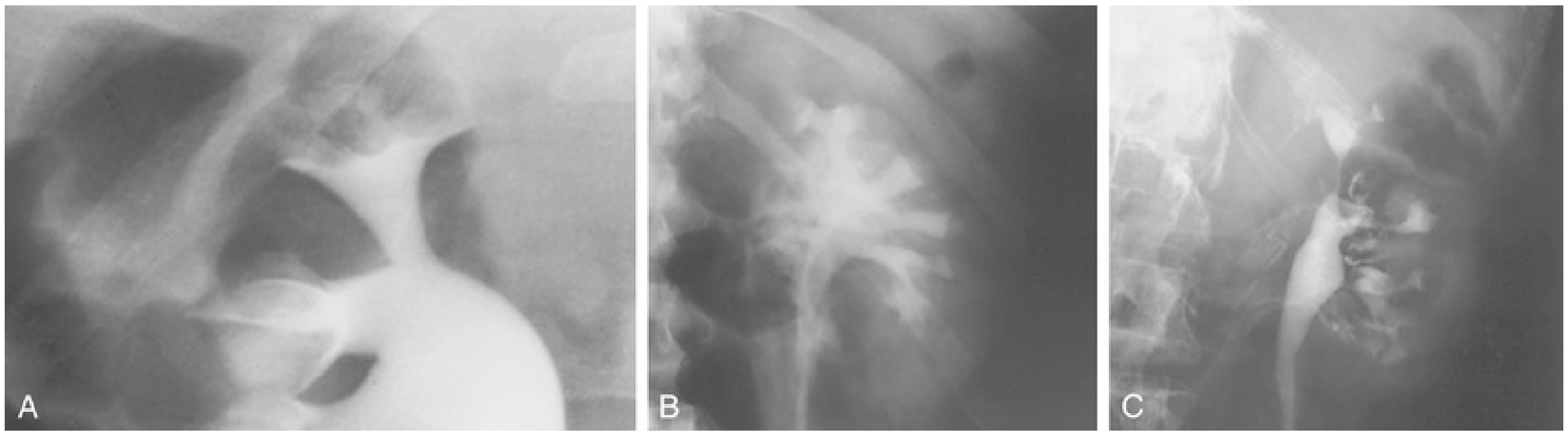

FIG. 3.6 Patterns of backflow during retrograde pyelography. (A) Pyelotubular backflow. (B) Pyelosinus backflow. (C) Pyelolymphatic backflow.

Although backflow does not usually cause measurable clinical harm, the potential implications of backflow include (1) introduction of bacteria from infected urine into the vascular system and (2) the absorption of contrast media, which could result in adverse reactions in susceptible patients. It has been demonstrated that the risk of significant urinary tract infection is only about 10% and the risk of sepsis is low when antibiotic prophylaxis therapy is administered before endoscopic procedures (including retrograde pyelography) (Christiano et al., 2000). Although contrast reactions are rare with retrograde pyelography, they have been reported (Johenning, 1980; Weese et al., 1993). In patients with documented severe contrast allergy, prophylactic pretreatment may be appropriate. In those patients considered at risk, care should be taken to inject under low pressures to minimize the probability of backflow and absorption of the contrast into the vasculature system.

Loopography

Loopography is a diagnostic procedure performed in patients who have undergone urinary diversion. Historically the term “loopogram” has been associated with ileal conduit diversion but may be used in reference to any bowel segment serving as a urinary conduit. When imaging patients with a continent diversion involving a reservoir or neobladder, “pouch-o-gram” would be more accurately descriptive. Because an ileal conduit urinary diversion usually has freely refluxing ureterointestinal anastomoses, the ureters and upper collecting systems may be visualized. In other forms of diversion, the ureterointestinal anastomoses may be purposely nonrefluxing. In such circumstances, when opacification of the upper urinary tract is desirable, antegrade ureteral imaging such as IVU, CT, or MR urography or antegrade nephrostography may be required. When the patient has compromised renal function or is allergic to iodinated contrast material, loopogram can be performed with a low risk of systemic absorption (Hudson et al., 1981).

Technique

The patient is positioned supine. An abdominal plain radiograph is obtained before the introduction of contrast material (Fig. 3.7A). A commonly employed technique is to insert a small-gauge catheter into the ostomy of the loop, advancing it just proximal to the abdominal wall fascia. The balloon on such a catheter can then be inflated to 5 to 10 cc with sterile water. By gently introducing contrast through the catheter, the loop can be distended, usually producing bilateral reflux into the upper tracts. Oblique films should be obtained to evaluate the entire length of the loop (see Fig. 3.7). Because of the angle at which many loops are constructed, a traditional anteroposterior (AP) view often shows a foreshortened loop and could miss a substantial pathology. A drain film should be obtained (see Fig. 3.7). This may demonstrate whether there is obstruction of the conduit.

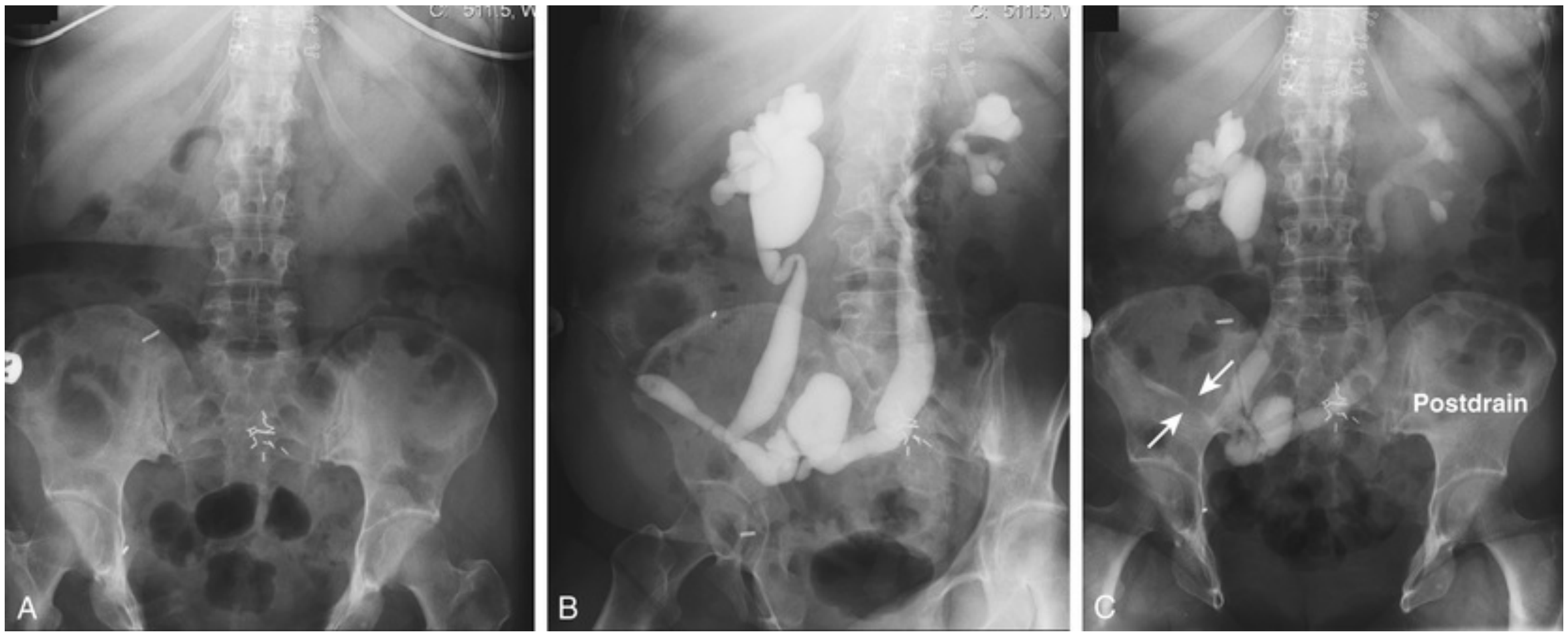

FIG. 3.7 Loopogram in a patient with epispadius/exstrophy and ileal conduit urinary diversion. The plain film (A) shows wide diastasis of the pubic symphysis. After contrast administration via a catheter placed in the ileal conduit, free reflux of both ureterointestinal anastomoses is demonstrated (B). (C) A postdrain radiograph demonstrates persistent dilation of the proximal loop indicating mechanical obstruction of the conduit *(arrows).*

Indications

1. Evaluation of infection, hematuria, renal insufficiency, or pain after urinary diversion
2. Surveillance of upper urinary tract for obstruction
3. Surveillance of upper urinary tract for urothelial neoplasia
4. Evaluation of the integrity of the intestinal segment or reservoir

Retrograde Urethrography

A retrograde urethrogram is a study meant to evaluate the anterior and posterior urethra. Retrograde urethrography may be particularly beneficial in demonstrating the total length of a urethral stricture, which cannot be negotiated by cystoscopy. Retrograde urethrography also demonstrates the anatomy of the urethra distal to a stricture, which may not be assessable by voiding cystourethrography. Retrograde urethrography may be performed in the office or in the operating room before performing visual internal urethrotomy or formal urethroplasty.

Technique

A plain film radiograph is obtained before injection of contrast. The patient usually is positioned slightly obliquely to allow evaluation of the full length of urethra. The penis is placed on slight tension. A small catheter may be inserted into the fossa navicularis with the balloon inflated to 2 cc with sterile water. Contrast then is introduced via a catheter-tipped syringe. Alternatively, a penile clamp (e.g., Brodney clamp) may be used to occlude the urethra around the catheter (Fig. 3.8).

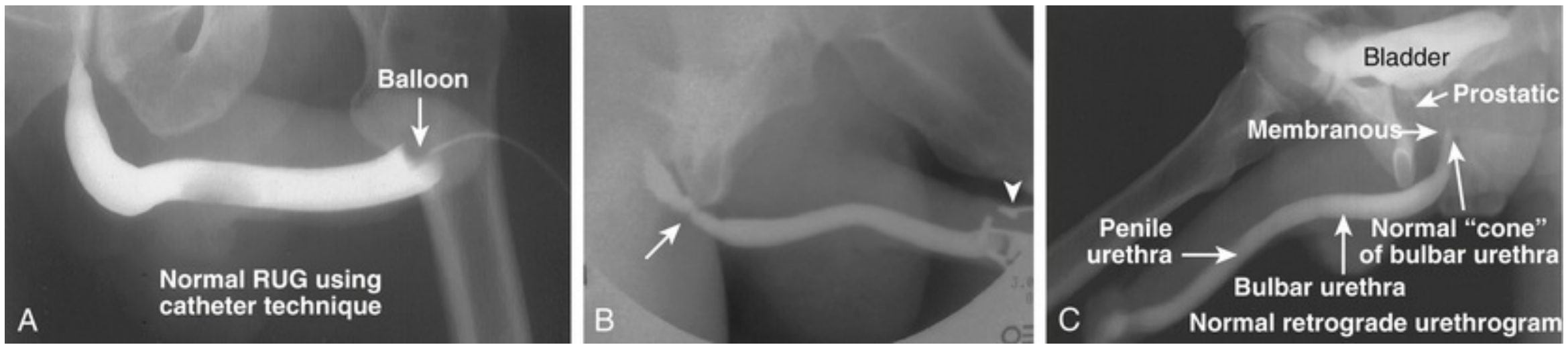
Balloon
Normal RUG using catheter technique
A
B
Bladder
Prostatic
Membranous
Penile urethra
Normal "cone" of bulbar urethra
Bulbar urethra
C
Normal retrograde urethrogram

FIG. 3.8 Normal retrograde urethrogram demonstrating (A) the balloon technique for retrograde urethrography, (B) Brodney clamp *(arrowhead)* technique; note the bulbar urethral stricture *(arrow)*, and (C) normal structures of the male urethra.

Indications

1. Evaluation of urethral stricture disease

    a. Location of stricture
    b. Length of stricture
2. Assessment for foreign bodies
3. Evaluation of penile or urethral penetrating trauma
4. Evaluation of traumatic gross hematuria

Static Cystography

Static cystography is employed primarily to evaluate the structural integrity of the bladder. The shape and contour of the bladder may give information about neurogenic dysfunction or bladder outlet obstruction. Filling defects such as tumors and stones may be appreciated.

Technique

The patient is positioned supine. A plain radiograph is performed to evaluate for stones and residual contrast and to confirm position and technique. The bladder is filled under gravity with 200 to 400 cc of contrast depending on bladder size and patient comfort. Adequate filling is important to demonstrate intravesical pathology or bladder rupture. Oblique films should be obtained because posterior diverticula or fistulae may be obscured by the full bladder. A postdrainage film completes the study (Fig. 3.9).

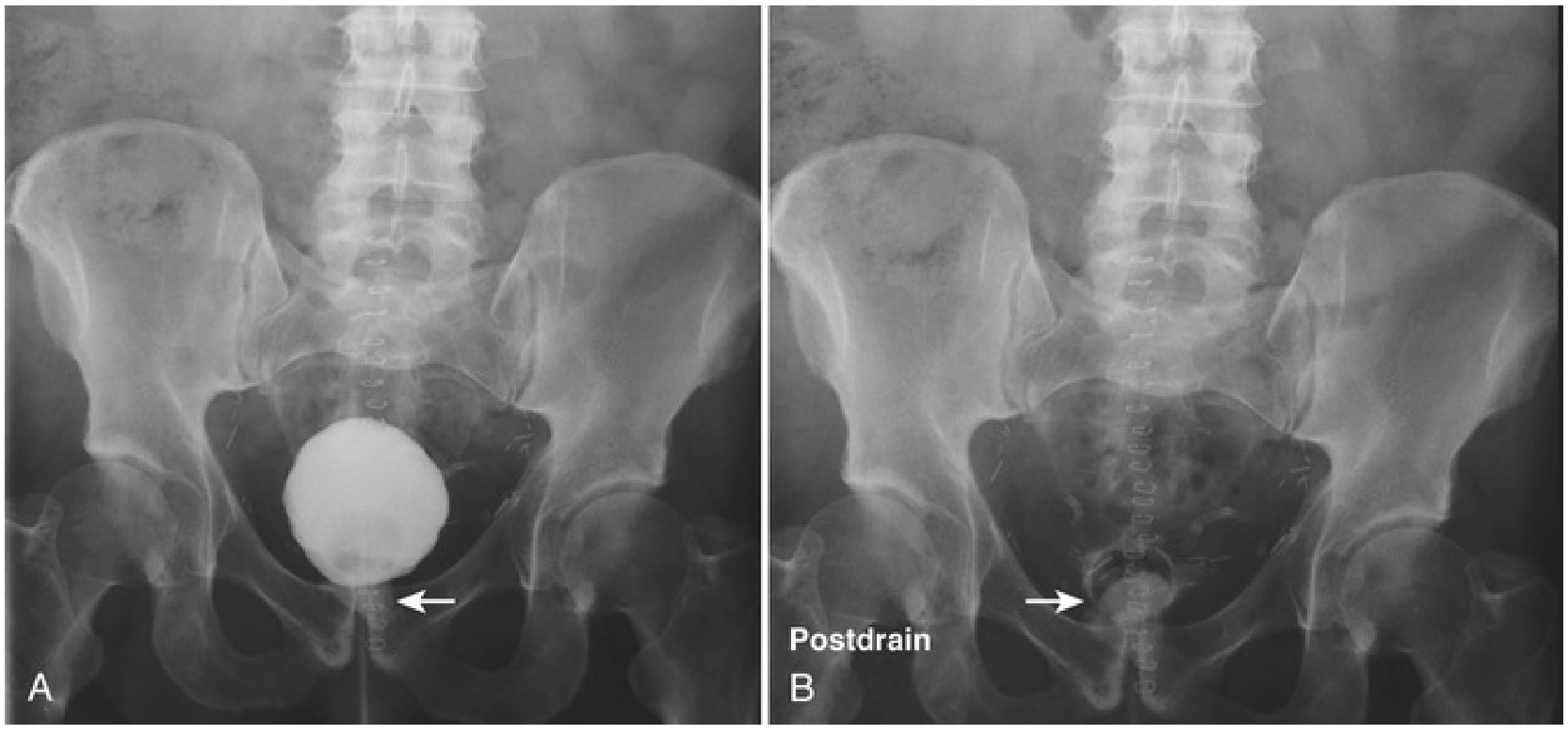

FIG. 3.9 The patient has undergone radical retropubic prostatectomy. (A) During bladder filling, contrast is seen adjacent to the vesicoureteral anastomoses *(arrow).* (B) The postdrain film clearly demonstrates a collection of extravasated contrast *(arrow).*

Indications

1. Evaluation of intravesical pathology
2. Evaluation of bladder diverticula
3. Evaluation of inguinal hernia involving the bladder
4. Evaluation of colovesical or vesicovaginal fistulae
5. Evaluation of bladder or anastomotic integrity after surgical procedure
6. Evaluation of blunt or penetrating trauma to the bladder

Limitations

Abdominal and pelvic CT are so commonly used in the evaluation of blunt or penetrating trauma to the abdomen that CT cystography is often performed in conjunction with the trauma evaluation. However, studies have shown that conventional static cystography is as sensitive as CT cystography in detecting bladder rupture (Broghammer and Wessells, 2008; Quagliano et al., 2006).

Voiding Cystourethrogram

A voiding cystourethrogram (VCUG) is performed to evaluate the anatomy and physiology of the bladder and urethra. The study provides valuable information regarding the posterior urethra in pediatric patients. VCUG has long been used to demonstrate vesicoureteral reflux.

Technique

The study may be performed with the patient supine or in a semi-upright position using a table capable of bringing the patient into the full upright position. A preliminary pelvic plain radiograph is obtained. In children, a 5- to 8-Fr feeding tube is used to fill the bladder to the appropriate volume. Patient comfort should be taken into account when determining the appropriate volume. In the adult population a standard catheter may be placed and the bladder filled to 200 to 400 cc. The catheter is removed and a film is obtained. During voiding, AP and oblique films are obtained. The bladder neck and urethra may be evaluated by fluoroscopy during voiding. Bilateral oblique views may demonstrate low-grade reflux, which cannot be appreciated on the AP film. In addition, oblique films demonstrate bladder or urethral diverticula, which are not always visible in the straight AP projection. Postvoiding films should be performed (Fig. 3.10).

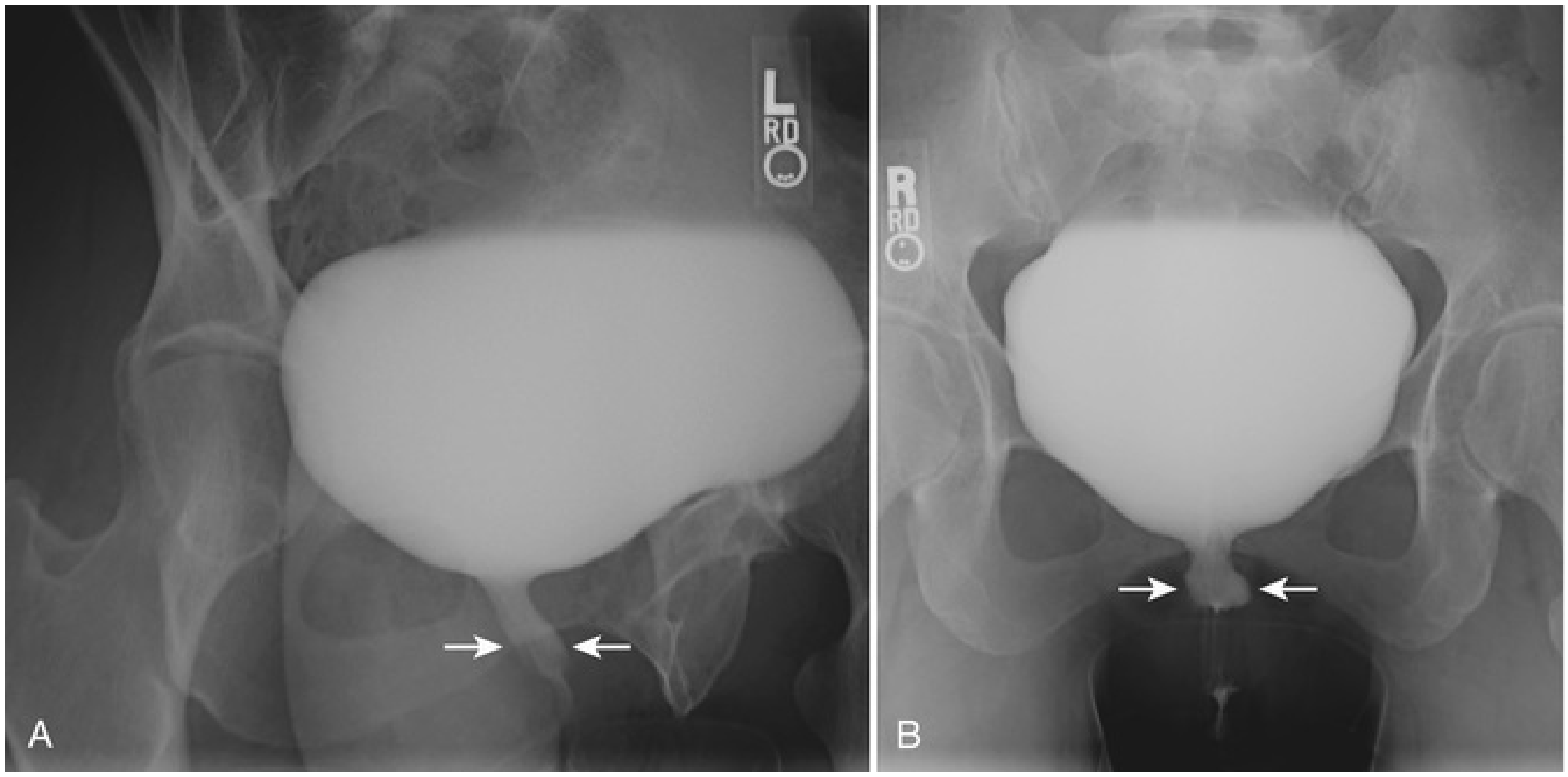

FIG. 3.10 **A voiding cystourethrogram performed for the evaluation of recurrent urinary tract infection in this female patient.** (A) An oblique film during voiding demonstrates thickening of the midureteral profile *(arrows).* (B) After interruption of voiding a ureteral diverticulum is clearly visible extending posteriorly and to the left of the midline *(arrows).*

Indications

1. Evaluation of structural and functional bladder outlet obstruction
2. Evaluation of reflux
3. Evaluation of the urethra in males and females

Limitations

This study requires bladder filling using a catheter. This may be traumatic in children and difficult in some patients with anatomic abnormalities of the urethra or bladder neck. Filling of the bladder may stimulate bladder spasms at low volumes, and some patients are unable to hold adequate volumes for investigation. **Bladder filling in patients with spinal cord injuries higher than T6 may precipitate autonomic dysreflexia** (Barbaric, 1976; Fleischman and Shah, 1977; Linsenmeyer et al., 1996).

Nuclear Scintigraphy

Radionuclide imaging is the procedure of choice to evaluate renal obstruction and function. It is very sensitive to changes that induce focal or global changes in kidney function. Because neither gadolinium or iodinated intravenous contrast agents are used, scintigraphy does not damage the kidney, has no lingering toxicity, results in minimal absorbed radiation, and is free from allergic reactions. Compared with other diagnostic imaging studies such as retrograde pyelogram, renal scintigraphy is noninvasive, has minimal risk and minimal discomfort, and allows determination of the function of the kidney.

Once the agent is intravenously injected, gamma scintillation cameras measure radiation emitted from the radioisotope and digital work stations gather, process, and display the information. There is an extensive list of radiopharmaceuticals used for renal scintigraphy. This section is limited to those agents most commonly used in urologic practice.

Technetium^{99m}–diethylenetriamine pentaacetic acid (^{99m}Tc-DTPA) is primarily a glomerular filtration agent (Gates, 2004; Peters, 1998). It is most useful for evaluation of obstruction and renal function. Because it is excreted through the kidney and dependent on GFR, it is less useful in patients with renal failure because impaired GFR may limit adequate evaluation of the collecting system and ureters. It is readily available and relatively inexpensive (Klopper et al., 1972).

Technetium^{99m}-dimercaptosuccinic acid (^{99m}Tc-DMSA) is cleared by filtration and secretion.

^{99m}Tc-DMSA localizes to the renal cortex with very little accumulation in the renal papilla and medulla (Lin et al., 1974). Therefore it is most useful for identifying cortical defects or ectopic or abhorrent kidneys. With these properties, ^{99m}Tc-DMSA can distinguish a benign functioning abnormality in the kidney from a space-occupying malignant lesion, which would not have normal renal function. No valuable information on the ureter or collecting system can be obtained with ^{99m}Tc-DMSA but remains a standard for renal cortical imaging.

Technetium^{99m}-mercaptoacetyltriglycine (^{99m}Tc-MAG3) is an excellent agent for imaging because of its photon emission, 6-hour half-life, and ease of preparation. It is cleared mainly by tubular secretion (Fritzberg et al., 1986). A small amount, approximately 10%, of MAG3 is excreted by extrarenal means, and most of this is hepatobiliary excretion (Eshima et al., 1990; Itoh, 2001). Because it is bound extensively to protein in plasma, it is limited in its ability to measure GFR but is an excellent choice for patients with renal insufficiency and urinary obstruction. The tracer is well suited for evaluation of renal function and diuretic scintigraphy. It is also an excellent tracer to evaluate renal plasma flow.

Diuretic Scintigraphy

Nuclear medicine imaging plays a crucial role unmet by CT, MRI, or ultrasound in the diagnosis of upper tract obstruction, and its unique characteristics provide noninvasive information regarding dynamic renal function. The diuretic renal scan using ^{99m}Tc-MAG3 can provide differential renal function and clearance time comparing right and left kidneys, which is pivotal in patient management. The initial phase is the flow phase, in which 2-second images are gathered for 2 minutes and then 1-second images for 60 seconds. The flow phase shows renal uptake, background clearance, and abnormal vascular lesions, which may indicate arteriovenous malformations, tumors, or active bleeding. In the second phase, the renal phase, time to peak uptake is typically between 2 and 4 minutes. The renal phase is the most sensitive indicator of renal dysfunction; 1-minute images are taken for 30 minutes. In the final phase, the excretory phase, 1-minute images are taken for 30 minutes. **A diuretic (usually furosemide 0.5 mg/kg) is administered when maximum collecting system activity is visualized. The $T_{1/2}$ is the time it takes for collecting system activity to decrease by 50% from that at the time of diuretic administration. This is highly technician dependent because the diuretic must be given when the collecting system is displaying maximum activity. Transit time through the collecting system in less than 10 minutes is consistent with a normal, nonobstructed collecting system. $T_{1/2}$ of 10 to 20 minutes shows mild to moderate delay and may be a mechanical obstruction. The patient's perception of pain after diuretic administration can be helpful for the treating urologist to consider when planning surgery in the patient with middle to moderate obstruction. A $T_{1/2}$ of greater than 20 minutes is consistent with a high-grade obstruction. The level of obstruction usually can be determined as can abnormalities such as ureteral duplication** (Ell and Gambhir, 2004). A normal renal scan is shown in Fig. 3.11.

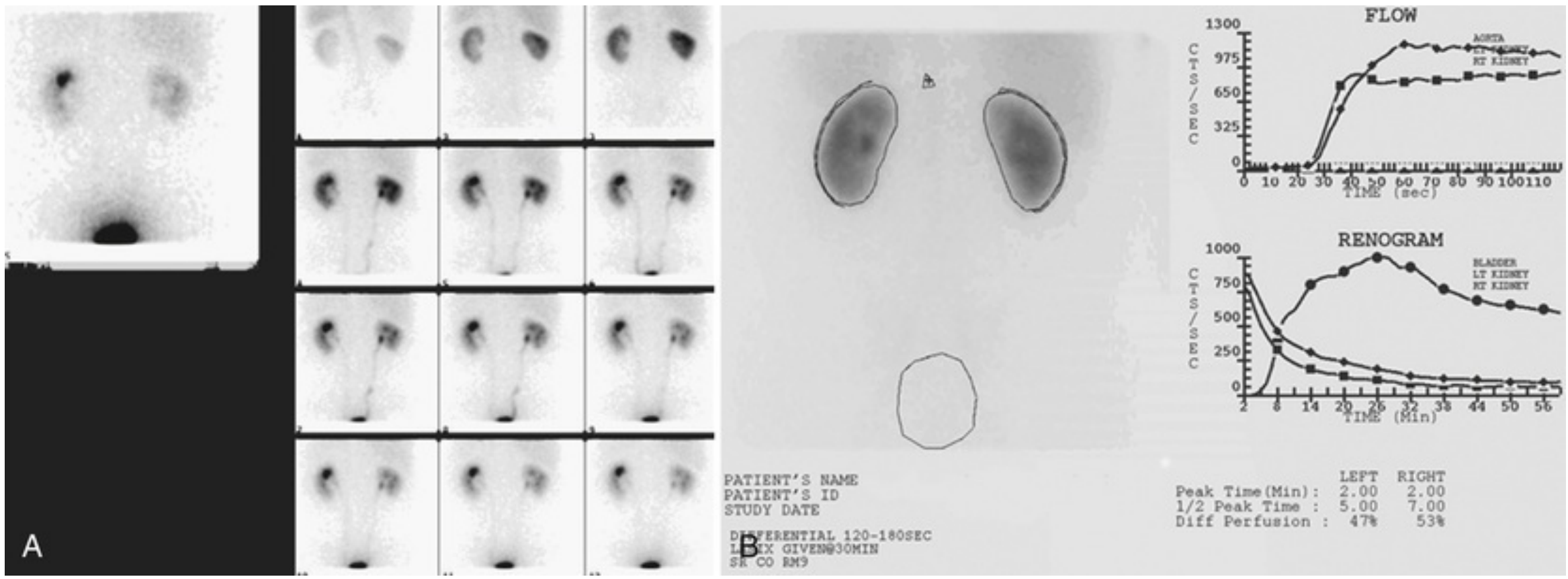
A
B
FLOW
1300
975
650
325
0
CTS/SEC
0 10 20 30 40 50 60 70 80 90 100 110
TIME (sec)
AORTA
LT KIDNEY
RT KIDNEY
RENOGRAM
1000
750
500
250
0
CTS/SEC
2 8 14 20 26 32 38 44 50 56
TIME (Min)
BLADDER
LT KIDNEY
RT KIDNEY
PATIENT'S NAME
PATIENT'S ID
STUDY DATE
DIFFERENTIAL 120-180SEC
LASIX GIVEN@30MIN
SR CO RM9

	LEFT	RIGHT
Peak Time(Min) :	2.00	2.00
1/2 Peak Time :	5.00	7.00
Diff Perfusion :	47%	53%

FIG. 3.11 (A) Technetium^{99m}-mercaptoacetyltriglycine (^{99m}Tc-MAG3) perfusion images demonstrate normal, prompt, symmetric blood flow to both kidneys. (B) Perfusion time-activity curves demonstrating essentially symmetric flow to both kidneys. Note the rising curve typical of ^{99m}Tc-MAG3 flow studies. Dynamic function images demonstrate good uptake of tracer by both kidneys and prompt visualization of the collecting systems. This renogram demonstrates prompt peaking of activity in both kidneys. The downslope represents prompt drainage of activity from the kidneys. Printout of quantitative data shows the differential renal function to be 47% on the left, 53% on the right. The normal half-life for drainage is less than 20 minutes when ^{99m}Tc-MAG3 is used. The $T_{1/2}$ is 5 min on the left and 7 min on the right, consistent with both kidneys being unobstructed.

Hepatobiliary excretion can cause false-positive readings if the area of intestinal activity or gallbladder activity is included in the area of interrogations during the study (Fig. 3.12).

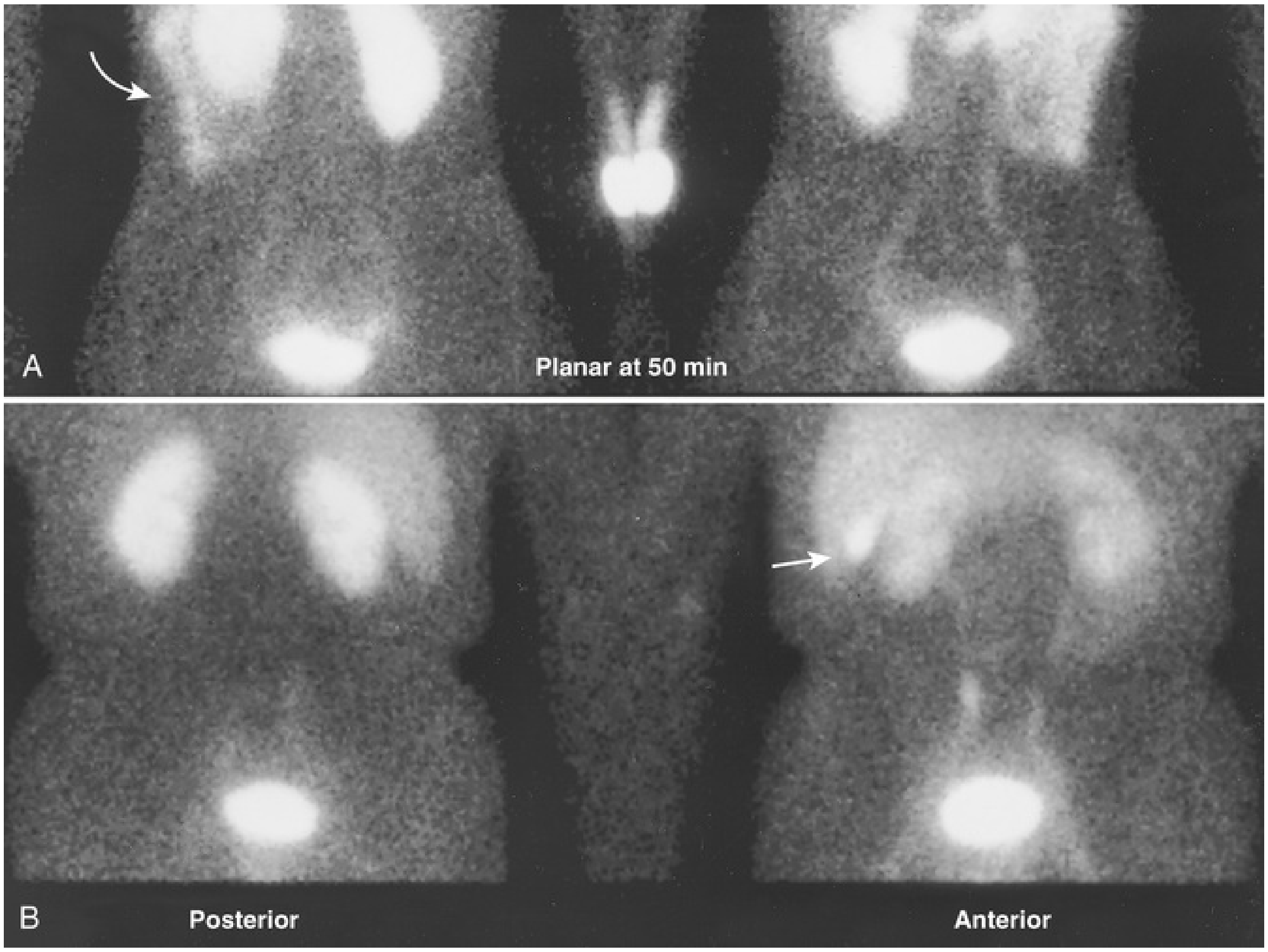

FIG. 3.12 Delayed static images in the posterior and anterior projections demonstrate intestinal activity (*arrow* in A) and gallbladder activity (*arrow* in B), reflecting a normal mode of excretion of ^{99m}Tc-MAG3. Gallbladder activity, in particular, can cause false-positive interpretation when it overlies activity in the renal collecting system or is inappropriately included in the area of interrogation. Liver activity is variable and tends to be more pronounced in children and patients with renal insufficiency.

The diuretic renal scan is another imaging study in which communication with the interpreting physician is vital for correct performance of the test as well as appropriate interpretation. For example, there are times when patients with unilateral or bilateral ureteral stents are sent for diuretic scintigraphy to determine differential renal function. If a bladder catheter is not placed and is open to drainage during the diuretic renal scan, the radiopharmaceutical excreted from the healthy kidney may wash up into or back flow via the ureteral stent into the stented kidney, giving the false-positive appearance to have more function than is physiologically present. This false-positive test may lead to inappropriately reconstructing a kidney that has little or insufficient function.

Nuclear Medicine in Urologic Oncology

Whole-Body Bone Scan

Conventional radionuclide imaging in urologic malignancy has long been the standard for detecting bone metastasis. The whole-body bone scan, or skeletal scintigraphy, is the most sensitive method for detecting bone metastasis (Narayan et al., 1988). A “positive” bone scan is not specific for cancer and may require plain film radiography, CT, or MRI to confirm as well as correlation with prior history of bone fractures, trauma, surgery, or arthritis. In patients with diffuse metastatic bone involvement, the bone scan can be mistaken for normal because there is uniformly increased uptake in the bony structures (Kim et al., 1991).

Positron Emission Tomography

One of the most rapidly changing areas of imaging in urologic oncology is in the use of PET/CT and PET/MRI. Depending on the radiotracer used, PET offers diagnostic information based on glucose, choline, or amino acid metabolism and has been applied to imaging tumor cell proliferation and tissue hypoxia in urologic malignancies. PET with 2-[^{18}F]fluoro-2-deoxy-D-glucose (^{18}F-FDG), available since the late 1990s, exploits the increased use and high uptake of glucose by malignant cells and provides new imaging opportunities in urology. The radiopharmaceutical most commonly used for PET in oncology is ^{18}F-FDG, an analog of glucose that is preferentially taken up and trapped inside malignant cells. For more than a decade, integrated PET/CT, in which a full-ring-detector clinical PET scanner and multidetector-row helical CT scanner are combined, has made it possible to acquire metabolic and anatomic imaging data using a single device in a single diagnostic session and provides precise anatomic localization of suspicious areas of increased ^{18}F-FDG uptake.

In urologic oncology, the use of ^{18}F-FDG has been limited by low tumor uptake and physiologic excretion of ^{18}F-FDG through the urinary system masking ^{18}F-FDG uptake by the primary urologic carcinoma. **The diagnostic performance of FDG-PET is hampered by the renal excretion of FDG and by the low metabolic activity often seen in tumors such as prostate cancer. However, new PET tracers, including radiolabeled choline, acetate, and others may offer alternatives with improved diagnostic abilities. There is consistent evidence that FDG-PET provides important diagnostic**

information in detecting metastatic and recurrent testicular germ cell tumors, and it may offer additional information in the staging and restaging of bladder and renal cancer (Kitajima et al., 2014, 2016; Powles et al., 2011; Rioja et al., 2010).

Molecular imaging with PET is showing promise to individualize the surgical and medical care of urologic oncology patients. PET provides unique insights into molecular pathways of diseases. PET using [F-18]-fluorodeoxyglucose (FDG) has gained increasing acceptance for the diagnosis, staging, and treatment monitoring of some genitourinary (GU) tumor types.

Kidney Cancer

Contrast-enhanced CT provides accurate information for detection and staging of renal cell carcinoma (RCC). Extrarenal metastatic disease is more easily detected by ^{18}F-FDG PET/CT and is useful for staging, restaging, and treatment of advanced RCC. A meta-analysis of 14 studies included 517 patients, demonstrated a pooled sensitivity of ^{18}F-FDG PET or PET/CT to be 79% for intrarenal tumors and 84% for extrarenal metastases, and that ^{18}F-FDG PET/CT increased the pooled sensitivity to 91% (Ferda et al., 2013; Wang et al., 2012). Other investigators have evaluated the clinical impact of ^{18}F-FDG PET/CT for restaging renal cancer in 104 patients after surgery and demonstrated that the sensitivity and specificity were 74% and 80%, respectively (Alongi et al., 2016).

Bladder Cancer

For localized bladder cancer, ^{18}F-FDG PET has not been widely used because its physiologic activity excreted through the urinary system interferes with visualization of the primary bladder cancer and locoregional lymph nodes (LNs). A meta-analysis showed that the sensitivity and specificity of ^{18}F-FDG PET/CT for detecting bladder cancer was 80% (95% CI 71%–87%) and 84% (95% CI 69%–93%), respectively (Wang et al., 2014).

In patients with metastatic disease ^{18}F-FDG PET/CT is useful for staging and restaging (detection of metastatic lesions) of bladder cancer. A systematic review and meta-analysis of 6 studies involving 236 patients showed that the pooled sensitivity and specificity for staging and restaging (metastatic lesions) were 82% (95% CI 0.72–0.89) and 89% (95% CI 0.81–0.95), respectively (Lu et al., 2012).

Prostate Cancer

Many different PET tracers are being actively investigated for use in PET/CT imaging for prostate cancer. It is well known that the ability of ^{18}F-FDG PET to detect cancer is based on increased expression of cellular membrane glucose transporter 1 (GLUT1) and enhanced hexokinase II enzyme activity within tumor cells. Preclinical studies have examined the expression of GLUT1 in prostate cancer cell lines and found that it is higher in those that are poorly differentiated in comparison with well-differentiated hormone-sensitive cell lines (Jadvar et al., 2005). This suggests that GLUT1 transporter expression increases with increasing disease grade and may explain the higher ^{18}F-FDG accumulation in castration-resistant than in castration-sensitive tumors and the modulatory effect of androgen on the glucose metabolism of castration-sensitive tumors.

^{18}F-FDG PET/CT is of limited value for detection and localization of primary prostate cancer and initial staging of disease because most primary tumors are slow growing, well differentiated, multiple, and small, with tumor uptake levels that can overlap with those of normal tissue, prostatitis, or benign prostatic hyperplasia (BPH).

^{11}C-choline and ^{18}F-fluorocholine are well-established tracers routinely employed at some PET centers for imaging of prostate cancer. Focal choline uptake in the prostate could arouse suspicion of prostate cancer, but nonmalignant causes, such as high-grade prostatic intraepithelial neoplasia, prostatitis, BPH, and normal tissue, also can be sources of false-positive focal activity (Reske et al., 2006).

In the largest preoperative series (n = 210) of intermediate- and high-risk patients who had undergone radical prostatectomy (RP) with surgical LN dissection, the sensitivity and specificity for detection of pelvic LN metastases were 73% and 88%, with a node-based sensitivity and specificity of 56% and 94%, respectively (Poulsen et al., 2012).

Choline PET/CT is a useful modality for detection of bone metastasis. In a patient-based analysis of patients with prostate-specific antigen (PSA) progression after primary treatment, comparing ^{11}C-choline PET/CT and bone scintigraphy for detection of bone metastasis, ^{11}C-choline PET/CT had better sensitivity and specificity (Picchio et al., 2012). Choline PET/CT can be useful in restaging of biochemically recurrent prostate cancer, particularly when the PSA level becomes significantly elevated. Many reports have discussed the usefulness of choline PET/CT for detecting sites of recurrence in patients with

PSA failure, and choline PET/CT is employed routinely for this purpose at a number of PET centers (Picchio et al., 2012).

^{11}C-acetate PET/CT has also been used for identification of recurrent prostate cancer in the setting of PSA failure, with a reported sensitivity of 59% to 83% (Kitajima et al., 2014).

PET with ^{18}F-sodium fluoride (^{18}F-NaF) is a highly sensitive radiotracer for skeletal metastases whose uptake reflects the increased regional blood flow, and bone turnover in malignant bone lesions has been reported to be more sensitive for detection of skeletal metastases than bone scintigraphy (Even-Sapir et al., 2006). The combined administration of ^{18}F-NaF and ^{18}F-FDG in a single PET/CT scan for cancer detection has been advocated for detection of extraskeletal and skeletal lesions. It has been reported that ^{18}F-NaF/FDG PET/CT is superior to whole-body MRI and bone scintigraphy for evaluating the extent of skeletal disease (Minamimoto et al., 2015).

Prostate-specific membrane antigen (PSMA) has been used as a relevant target for imaging of prostate cancer. PSMA is a cell-surface protein expressed at higher levels in prostate carcinoma tissue than in other tissues, and its expression is associated with tumor aggressiveness, androgen independence, metastatic disease, and disease recurrence. Mainly available in Europe, PSMA-targeting ligands have been labeled with ^{68}Ga for PET imaging, and this approach shows some promise for detection of prostate carcinoma recurrence. The use of ^{68}Ga-PSMA PET/CT in 248 patients (PSA 0.2–59.4 ng/mL, median 1.99 ng/mL) treated with RP demonstrated that the patient-based detection rate was 89.5%; the detection rates for PSA levels of ≥2, 1 to <2, 0.5 to <1, and 0.2 to <0.5 ng/mL were 96.8%, 93.0%, 72.7%, and 57.9%, respectively. ^{68}Ga-PSMA PET/CT reveals a high degree of positivity within the clinically important range of low PSA values (<0.5 ng/mL), which in many cases can substantially influence further clinical management (Eiber et al., 2015). It has been demonstrated that ^{68}Ga-PSMA PET/CT may be superior to ^{18}F-choline PET/CT and conventional imaging modalities (bone scintigraphy and contrast-enhanced CT of the chest, abdomen, and pelvis) or identification of disease recurrence in the setting of biochemical failure (Morigi et al., 2015). Fig. 3.13 shows different PET images.

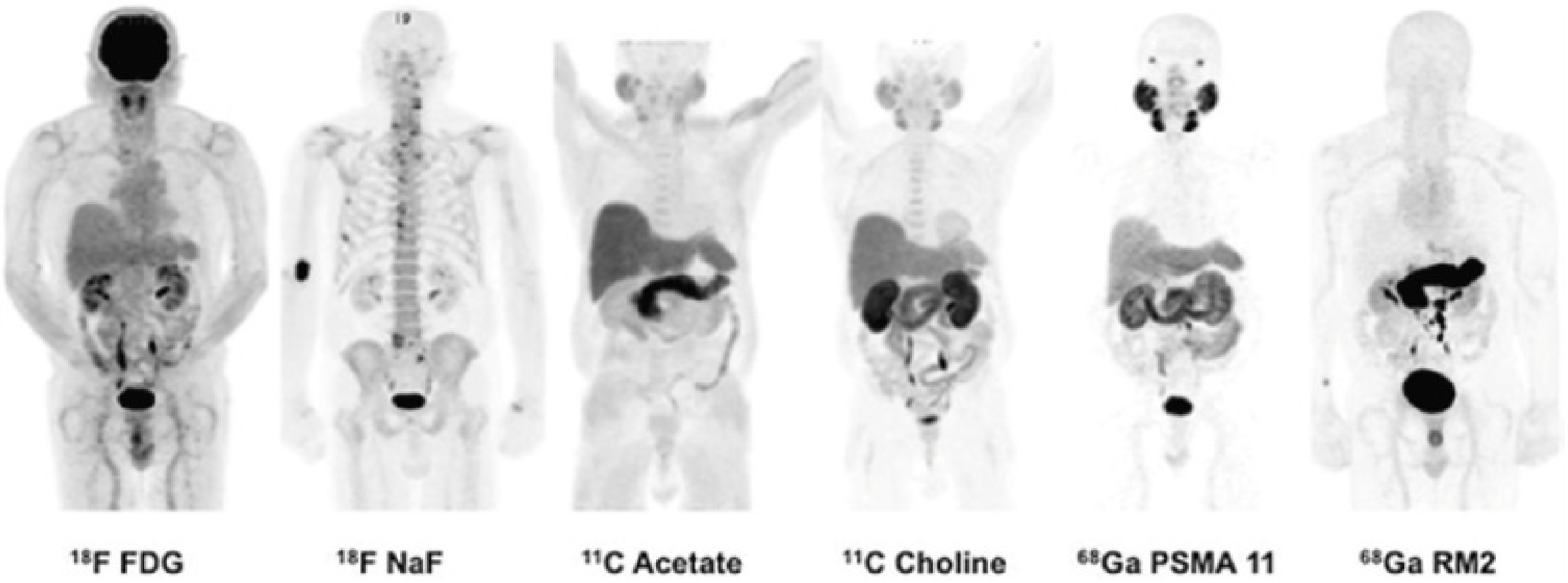

FIG. 3.13 Six different PET tracers used to evaluate an 83-year-old man with a T2b nodule and a prostate-specific antigen (PSA) level of 5.4, confirmed Gleason 5+4 prostate adenocarcinoma, and treated with intensity-modulated pelvic radiotherapy and androgen blockade. After PSA nadir of 0.11, biochemical recurrence occurred with PSA of 1.83 and negative conventional imaging. Patient was followed for 40 months under watch-and-wait strategy due to no identification of sites of recurrent disease despite increasing PSA up to 18.7 at the time of positive Ga-68 PSMA 11 and Ga-68 RM2 (both show retroperitoneal lymph nodes whereas all other studies are negative). (Image courtesy of Andrei Iagaru, MD, Stanford University.)

Adrenal Cancer

Malignant adrenal disease tends to have higher ^{18}F-FDG uptake compared with benign adrenal lesions. A meta-analysis, including 21 selected studies with a total of 1391 lesions (824 benign, 567 malignant) in 1217 patients revealed a pooled sensitivity of 97% (95% CI 93%–98%) and specificity of 91% (95% CI 87%–94%) of ^{18}F-FDG PET/CT (SUV_{max} or standard uptake ratio) for differentiating between malignant and benign adrenal disease (Boland et al., 2011). A multicenter study demonstrated that ^{18}F-FDG PET/CT showed the better diagnostic accuracy of diagnosing primary adrenal malignancy (adrenocortical carcinoma, malignant pheochromocytoma, neuroblastoma, and lymphoma) than contrast-enhanced CT (Cistaro et al., 2015). The diagnostic performance of ^{18}F-FDG PET/CT for differentiating metastatic adrenal tumors from adrenal adenoma is high (sensitivity, specificity, and accuracy are 82%, 92%, and 90%) as well as adrenal protocol CT (unenhanced early and delayed contrast-enhanced CT) and, moreover, the combination of ^{18}F-FDG PET/CT and adrenal protocol CT can improve the ^{18}F-FDG PET/CT or adrenal protocol CT diagnostic accuracy for differentiation of metastatic adrenal tumors from adrenal adenoma, reducing false-positive cases (Ardito et al., 2015; Park et al., 2014).

Testis Cancer

^{18}F-FDG PET/CT is useful for initial staging of testicular cancer and determining the viability of residual masses after completion of treatment, especially in patients with seminoma. The clinical impact of ^{18}F-FDG PET/CT for staging and restaging of testicular tumors was evaluated in 51 cases of seminoma and 70 cases of nonseminoma. PET/CT showed good sensitivity and specificity for detection of seminoma lesions (92% and 84%, respectively), but its sensitivity was lower for nonseminoma forms (77% and 95%, respectively); it influenced the clinical management of 47 out of 51 (92%) seminomas and 59 out of 70 (84%) nonseminomas (Ambrosini et al., 2014). A meta-analysis including four selected studies with a total of 130 patients evaluated the diagnostic accuracy of ^{18}F-FDG PET/CT for prediction of viable residual tumors after chemotherapy in patients with metastatic seminoma and demonstrated that it was superior to CT for determining tumor size and predicting tumor viability: sensitivity was 72% versus 63%, specificity was 92% versus 59%, positive predictive value (PPV) was 70% versus 28%, and negative predictive value (NPV) was 93% versus 86%, respectively (Müller et al., 2011). Another review and meta-analysis including nine selected studies with a total of 375 patients showed that ^{18}F-FDG PET/CT had a pooled sensitivity of 78% (95% CI: 67%–87%), a specificity of 86% (95% CI 81%–89%), a PPV of 58% (95% CI 48%–68%), an NPV of 94% (95% CI 90%–96%), and an accuracy of 84% (95% CI 80%–88%) (Treglia et al., 2014). These results mean that negative ^{18}F-FDG PET/CT findings warrant follow-up if only to avoid inappropriate subsequent treatment (surgery, chemotherapy, or radiotherapy), whereas positive ^{18}F-FDG PET/CT findings suggest a high possibility of residual seminoma, although a false-positive result cannot be excluded in view of the low PPV.

Several limitations of PET imaging for testis cancer should be noted when considering ^{18}F-FDG PET: (1) Lesions of less than 1 cm are often not detected because of the limited spatial resolution of PET. (2) Mature teratoma has variable low ^{18}F-FDG uptake or no uptake and cannot be distinguished from necrosis or fibrosis, and therefore ^{18}F-FDG PET is not recommended for characterization of residual masses after therapy for nonseminomatous germ cell cancers, which frequently harbor residual foci of mature teratoma. (3) There should be a minimum of 6 weeks between the end of chemotherapy and acquisition of an ^{18}F-FDG PET/CT scan to avoid any false-positive findings resulting from chemotherapy-induced inflammatory and granulomatous tissues or false-negative results resulting from temporary suppression of tumor cell activities (Bachner et al., 2012; Kazuhiro et al., 2016; Oechsle et al., 2008). Fig. 3.14 shows testis PET/CT before and after chemotherapy.

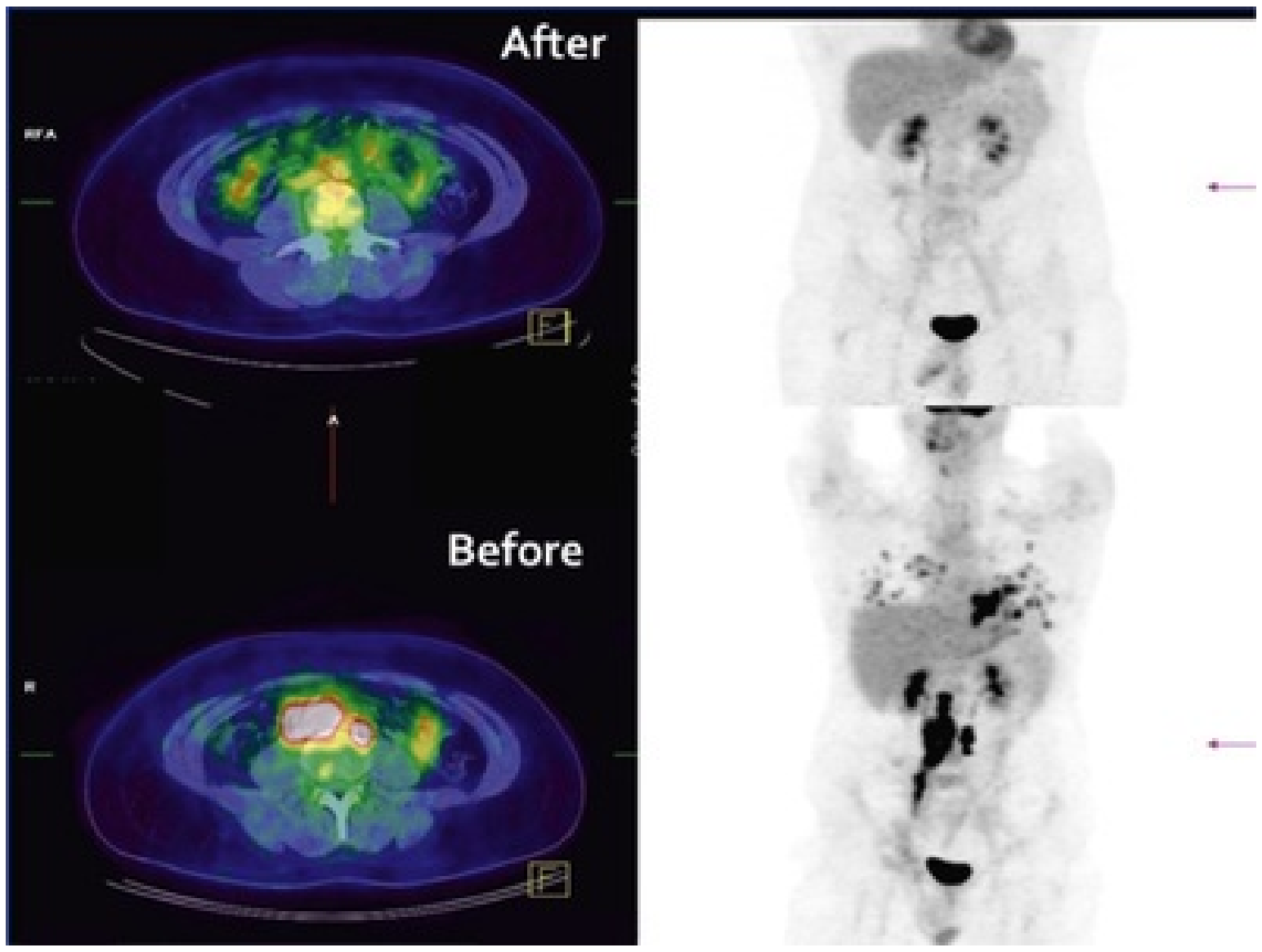

FIG. 3.14 Fluorine-18 fluorodeoxyglucose (^{18}F-FDG) PET/CT is useful for staging and restaging of seminoma in patients treated with chemotherapy. This patient presented with a right-sided seminoma with bulky right-sided retroperitoneal lymph nodes. PET/CT after chemotherapy shows no uptake in the previously positive nodal region.

Positron Emission Tomography Magnetic Resonance Imaging

There is increasing interest in the integration of PET/MRI systems because PET/MRI would have advantages over PET/CT, including improved soft-tissue contrast, the possibility of performing simultaneous instead of sequential acquisitions, and the availability of sophisticated MRI sequences (diffusion and perfusion imaging, functional MRI, and MR spectroscopy) while offering a significant decrease in radiation exposure. Its use had been demonstrated in patients with RCC, bladder cancer, prostate cancer, and pheochromocytoma, which is of foremost importance for serial follow-up and pediatric imaging (Table 3.4).

TABLE 3.4

PET Tracer in Urologic Oncology

BIOLOGIC ANALOG	PROCESS TARGETED	EFFECT
^{18}F-FDG Glucose	Glucose transporters and hexokinases	Aerobic and anaerobic glycolysis, glucose consumption
^{11}C-choline Choline	Choline kinase	Cell membrane metabolism, tumor proliferation
^{18}F-choline Choline	Choline kinase	Cell membrane metabolism, tumor proliferation
^{11}C-acetate Acetate	Tricarboxylic acid cycle and fatty acid synthase	Lipid synthesis
^{18}F-FDHT Testosterone	Androgen receptor	Measures androgen receptor
^{18}F-NaF Fluoride	Hydroxyl and bicarbonate ions of bone hydroxyapatite	Measures bone status
^{18}F-FMISO NA	Measures hypoxia	Tumor hypoxia
^{18}F-FLT NA	Thymidine kinase	Nucleic acid synthesis, tumor proliferation
^{18}F-FACBC Amino-fluorocyclobutane-carboxylic acid	Neutral A–A type amino acid uptake and protein synthesis	Protein synthesis
^{68}Ga-PSMA Prostate-specific membrane antigen	Prostate cell surface protein	Tumor aggressiveness, androgen independence

Data from Kazuhiro K, Shingo Y, Kazuhito F, et al: Update on advances in molecular PET in urological oncology. *Jpn J Radiol* 34:470–485, 2016.

Key Points: Nuclear Scintigraphy

- During diuretic renal scan, the diuretic must be given when maximum activity is seen in the kidney.
- An elimination $T_{1/2}$ less than 10 minutes is an unobstructed system, and a $T_{1/2}$ greater than 20 minutes is consistent with high-grade obstruction.
- If ureteral stents are in place, patients undergoing diuretic renal scan should

have an unclamped bladder catheter in place during the study.

- Technetium^{99m}-mercaptoacetyl triglycerine (MAG3) is the agent of choice for diuretic renal scan to determine differential renal function and obstruction.

Computed Tomography

The 1979 Nobel Prize in Medicine and Physiology was awarded to Allan M. Cormack and Sir Godfrey N. Hounsfield for the development of computer-assisted tomography. Although basic principles remain the same, significant advances have resulted in the development of multidetector CT devices, improving soft-tissue detail and allowing the possibility of rapid 3D reconstruction of the entire genitourinary system.

CT has become one of the most integral parts of urologic practice, and the CT urogram (CTU) has replaced IVU as the imaging modality of choice in modern urology for the workup of hematuria, urologic malignancies, detection of kidney stones, and preoperative planning. As in the case of conventional radiographic imaging, the basis for CT imaging is the attenuation of x-ray photons as they pass through the patient. Tomography is an imaging method that produces 3D images of internal structures by recording the passage of x-rays as they pass through different body tissues. In the case of CT, a computer reconstructs cross-sectional images of the body based upon measurements of x-ray transmission through thin slices of the body tissue (Brant, 1999). A collimated x-ray beam is generated on one side of the patient and the amount of transmitted radiation is measured by a detector placed on the opposite side of the x-ray beam. These measurements are then repeated systematically while a series of exposures from different projections is made as the x-ray beam rotates around the patient. The result is production of a 3D image of internal structures in the human body by recording the passage of different energy waves through various internal structures. Data collected by the detectors are reconstructed by computerized algorithms to result in a viewable tomographic display.

There are several different imaging variables that are adjusted to allow adequate, detailed image resolution, while minimizing the time on the scanner and limiting exposure to radiation. The variable application of pitch, beam collimation, detector size, and tube voltage are used by the radiologist and imaging technologist for ideal image requisition. A detailed description of each of these variables is beyond the scope of this chapter.

Perhaps the greatest recent advancement in CT is the use of helical image acquisition techniques with multichannel or multidetectors (MDCTs). In a helical CT the patient moves through a continuously rotating gantry. The helical raw images are processed using interpolation algorithms to visualize the internal structures as sagittal, coronal, or axial reconstructed images. The “single-slice spiral CT,” introduced in 1988, had a single row of detectors and required multiple passes to visualize a small area of interrogation. The standard scanners in use today have between 64 and 320 rows of detectors, which allow the patient's entire body to be imaged during a single breath hold, with few or no motion artifacts, more precise diagnostic accuracy, increased concentration of contrast material, shorter scanning time, less radiation exposure, and significant increase in anatomic coverage with a single scan. CT scanners with 750 rows of detectors are currently being developed. For example, a 640-slice CT scanner with a gantry rotation of 0.275 seconds can image 16 cm (6.3 inches) in a single rotation with 0.5-mm slices and some scanners can capture 73 cm/s (28 inches/s), capturing all of the body's organs in a single rotation of the central x-ray–emitting gantry (Mahesh, 2002; Wang and Vannier, 1994) (Fig. 3.15).

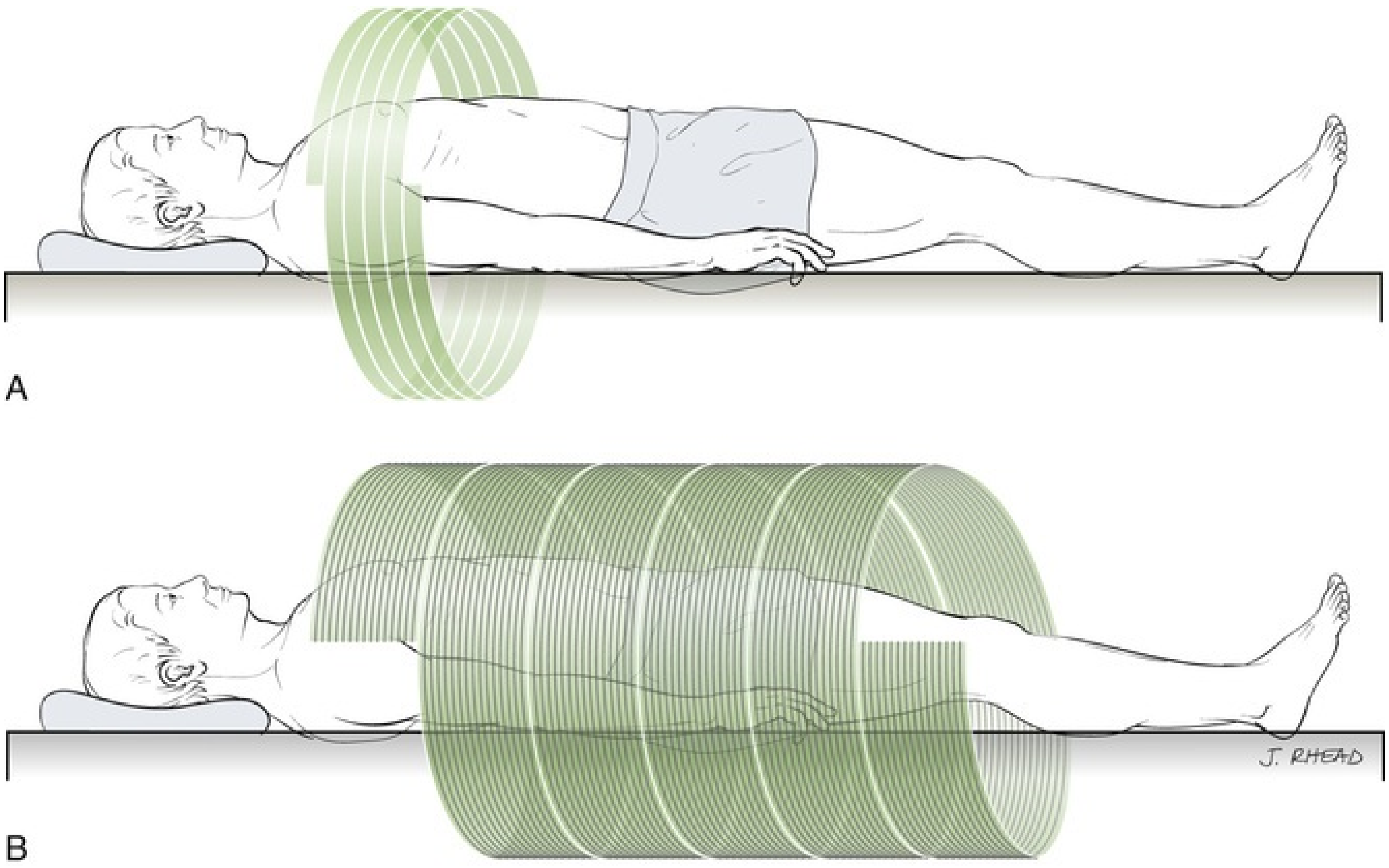

FIG, 3.15 (A) CT scanner with a single-row detector requires five circular passes around the patient to image a small area of the patient's body. (B) With a 16-slice, multirow detector, the chest, abdomen, and pelvis can be imaged with five circular passes, easily obtained during a single breath hold. The thin slices offered by the 16-slice detector offer much greater detail of internal structures.

Readily available software is capable of complex and accurate 3D processing of CT images to recreate the urinary system. These 3D images offer improved preoperative planning, appreciation of proximity to adjacent organs, and the ability to define vasculature and improve communication with patients who can now easily see their particular pathology and better appreciate the challenges faced by their surgeon. These images are often used for printing of 3D organ models. In some complex urology cases, the segmentation and formatting of CT images to create 3D renderings can be more useful during surgery than 3D printed organs (Christiansen et al., 2018) (Fig. 3.16).

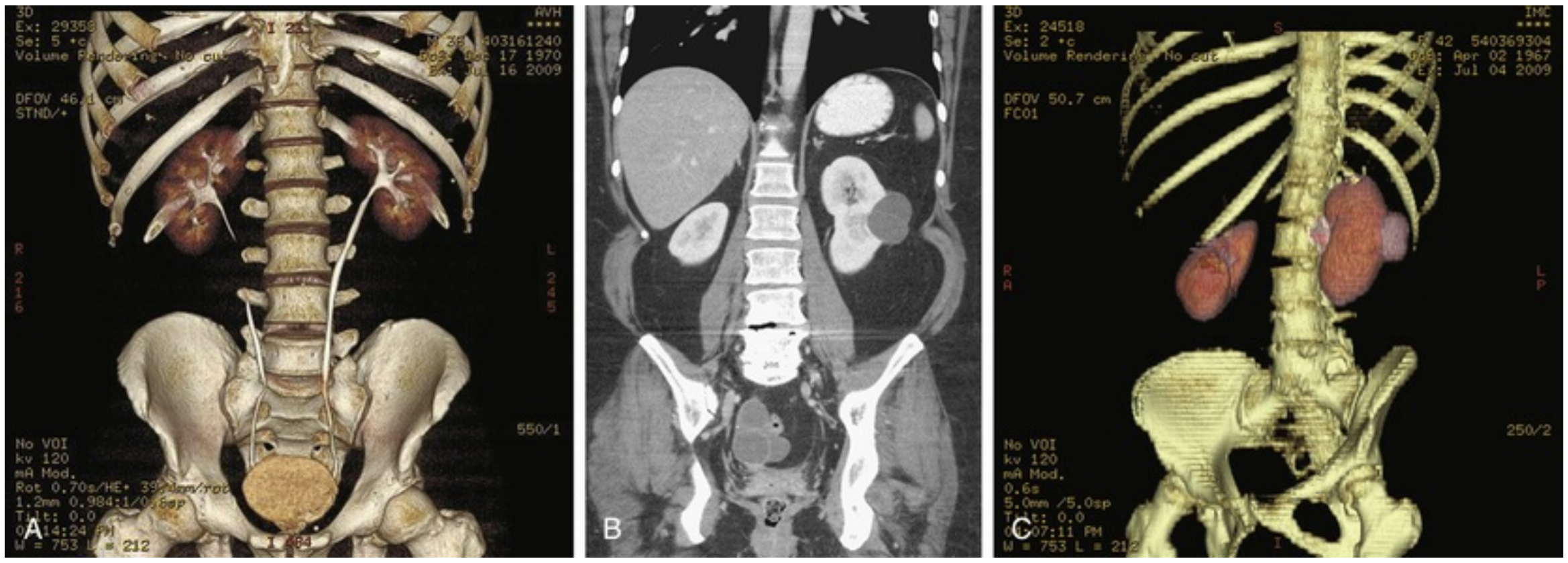

FIG. 3.16 (A) 3D colored reconstruction of the kidneys ureter and bladder from CT urogram. (B) Coronal reconstruction in a patient with a clear cell renal cell carcinoma in a complex renal cystic mass and enhancing mural nodule. (C) 3D reconstruction of the same patient with slight posterior rotation.

Dual-source CT (DSCT) is a relatively new technique used for diagnostic imaging, using two rotating tubes to acquire high- and low-voltage images, allowing tissue differentiation, visualization of tendons and ligaments, improved CT angiography, and differentiation of kidney stones based upon stone composition (Coursey, 2010). Use of DSCT helps make a reliable distinction between uric acid and calcium oxalate and between brushite and uric acid stones (Botsikas, 2013; Ferrandino, 2010).

Real-time CT fluoroscopy is available as an option on new CT imaging equipment. CT fluoroscopy gives a 3D CT image that is much more detailed and offers greater soft-tissue contrast and resolution than conventional CT. The most common use in urology is for biopsy of the kidney. CT fluoroscopy helps to overcome movement of the kidney during respiratory variation. It also has been used for fluid aspiration, drain placement, catheter placement, percutaneous cryoablation, and radiofrequency ablation of renal tumors. **One significant disadvantage of CT fluoroscopy is the increased radiation exposure to the patient and radiologist or surgeon performing the procedure** (Daly et al., 1999; Gupta et al., 2006; Keat, 2001).

The CT urogram (CTU) is an excretory urography in which the MDCT is used for imaging of the urinary tract. It is indicated in the workup of hematuria, kidney stones, renal masses, renal colic, and urothelial tumors. The CT scan examination starts with the physician's request for imaging. Radiologists around the world appreciate, from the urologist, a brief description of the question to be answered by the CT scan. Equipped with a better understanding of why the CT scan was ordered, the radiologist and the CT technician can adjust different CT variables and choose the appropriate contrast media needed to deliver a valuable report to the ordering urologist.

Urologists often request a CT evaluation of the abdomen and pelvis. An abdominal CT scan starts at the diaphragm and ends at the iliac crest. If the pelvis is to be imaged, a separate request usually is required. The pelvic CT scan begins at the iliac crest and terminates at the pubis symphysis. Intravenous contrast may be required for better delineation of soft tissue. Oral contrast is not commonly used in urology but may be helpful in certain cases to differentiate bowel from lymph nodes, scar, or tumor (Fig. 3.17).

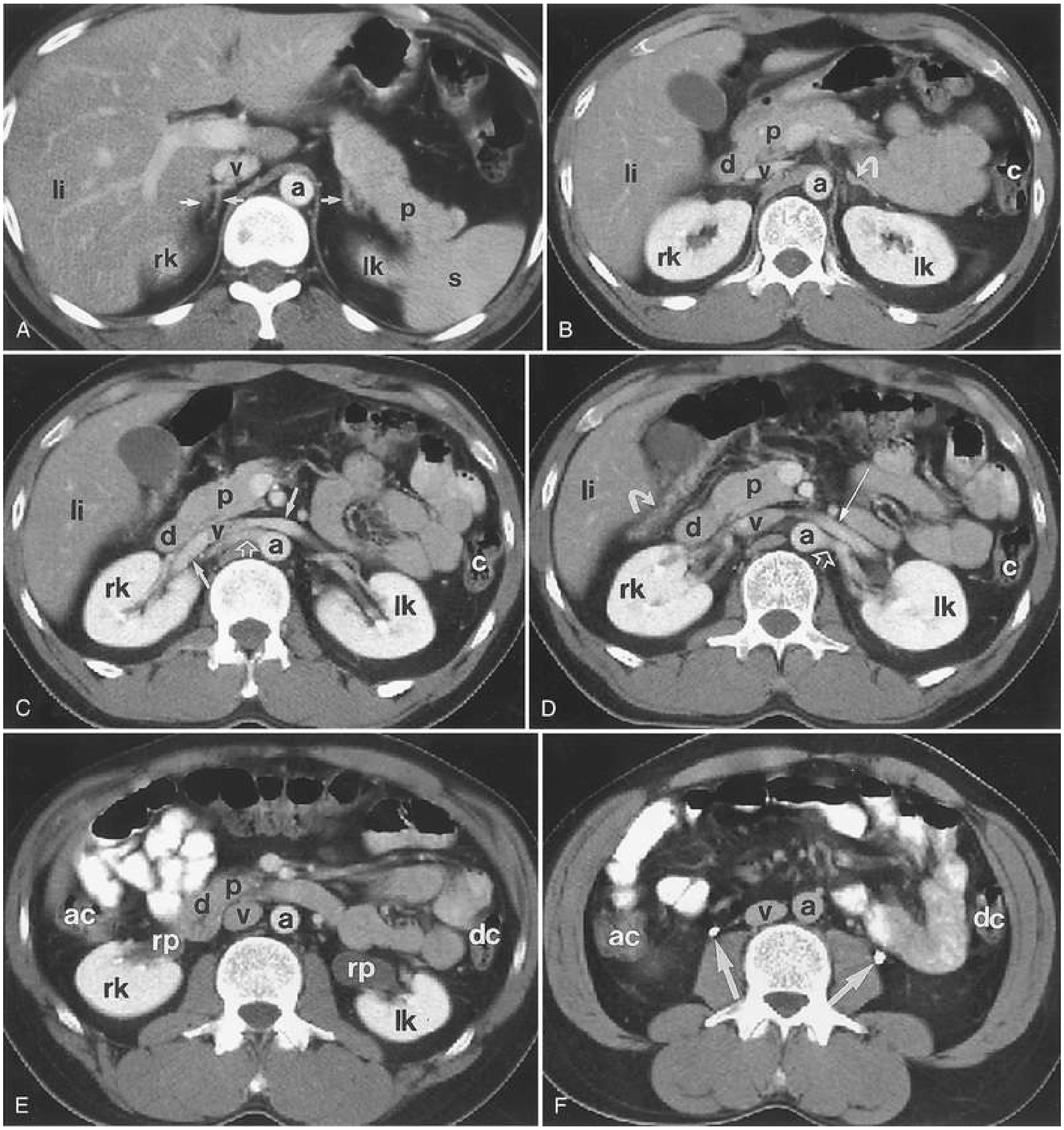
v
a
li
p
rk
lk
s
A
p
d
v
a
li
c
rk
lk
B
p
li
d
v
a
rk
c
lk
C
li
p
d
v
a
rk
c
lk
D
p
ac
d
v
a
dc
rp
rk
rp
lk
E
v
a
dc
ac
F

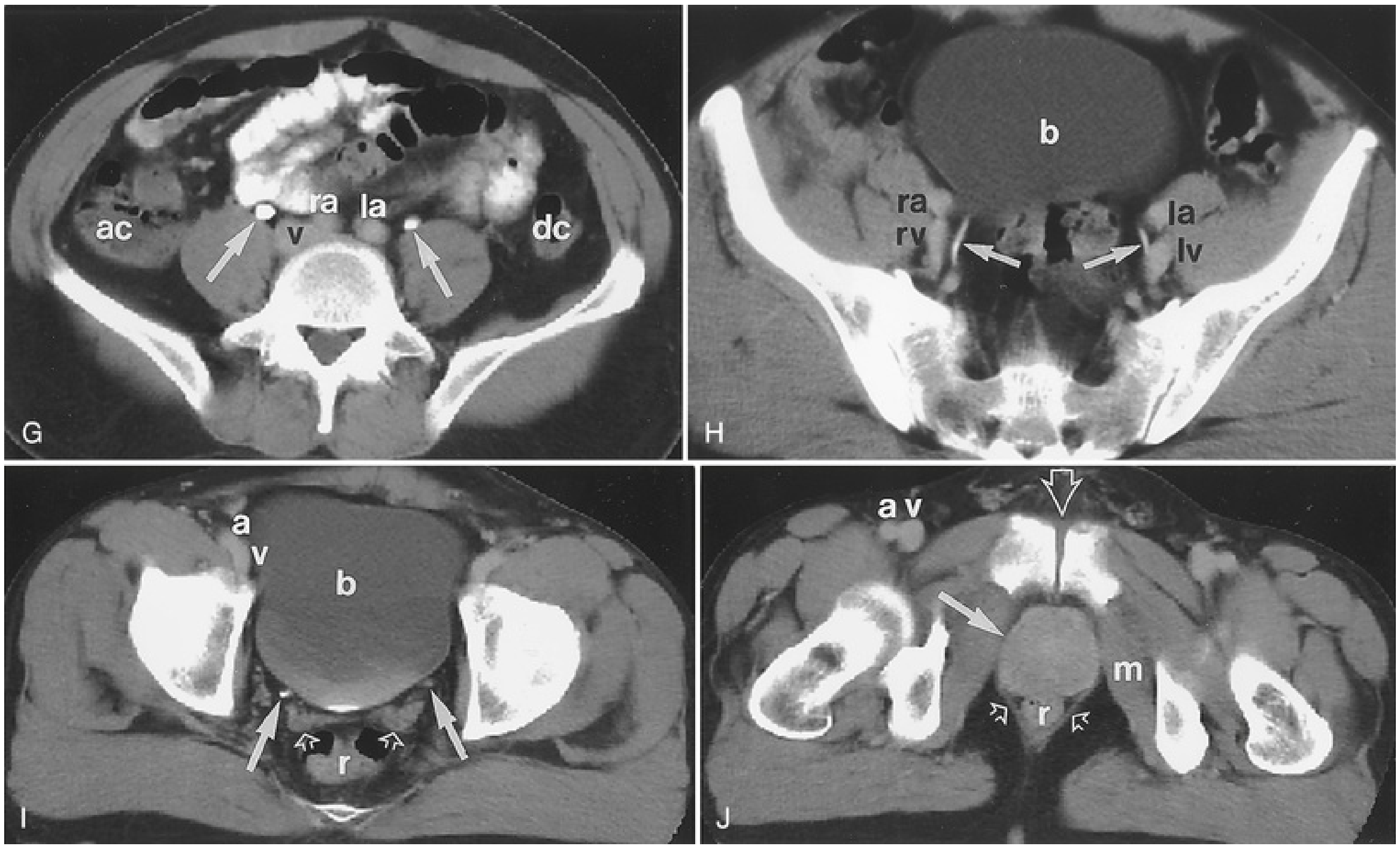

FIG. 3.17 CT of the abdomen and pelvis demonstrating normal genitourinary anatomy. (A) The adrenal glands are indicated with *arrows.* The upper pole of the right and left kidneys is indicated with *rk* and *lk,* respectively. *a,* aorta; *li,* liver; *p,* pancreas; *s,* spleen; *v,* inferior vena cava. (B) Scan through the upper pole of the kidneys. The left adrenal gland is indicated with an *arrow. a,* aorta; *c,* colon; *d,* duodenum; *li,* liver; *lk,* left kidney; *p,* pancreas; *rk,* right kidney; *v,* inferior vena cava. (C) Scan through the hilum of the kidneys. The main renal veins are indicated with *solid arrows,* and the right main renal artery is indicated with an *open arrow. a,* aorta; *c,* colon; *d,* duodenum; *li,* liver; *lk,* left kidney; *p,* pancreas; *rk,* right kidney; *v,* inferior vena cava. (D) Scan through the hilum of the kidneys slightly caudal to C. The left main renal vein is indicated with a *solid straight arrow,* and the left main renal artery is indicated with an *open arrow.* The hepatic flexure of the colon is indicated with a *curved arrow. a,* Aorta; *c,* colon; *d,* duodenum; *li,* liver; *lk,* left kidney; *p,* pancreas; *rk,* right kidney; *v,* inferior vena cava. (E) Scan through the mid to lower polar region of the kidneys. *a,* Aorta; *ac,* ascending colon; *d,* duodenum; *dc,* descending colon; *lk,* left kidney; *p,* pancreas; *rk,* right kidney; *rp,* renal pelvis; *v,* inferior vena cava. (F) CT scan obtained below the kidneys reveals filling of the upper ureters *(arrows).* The wall of the normal ureter is usually paper thin or not visible on CT. *a,* aorta; *ac,* ascending colon; *dc,* descending colon; *v,* inferior vena cava. (G) Contrast filling of the midureters *(arrows)* on a scan obtained at the level of the iliac crest and below the aortic bifurcation. *ac,* Ascending colon; *dc,* descending colon; *la,* left common iliac artery; *ra,* right common iliac artery; *v,* inferior vena cava. (H) The distal ureters *(arrows)* course medial to the iliac vessels on a scan obtained below the promontory of the sacrum. *b,* urinary bladder; *la,* left external iliac artery; *lv,* left external iliac vein; *ra,* right external iliac artery; *rv,* right external iliac vein. (I) Scan through the roof of the acetabulum reveals distal ureters

(solid arrows) near the ureterovesical junction. The bladder *(b)* is filled with urine and partially opacified with contrast material. The normal seminal vesicle *(open arrows)* usually has a paired bow-tie structure with slightly lobulated contour. *a,* Right external iliac artery; *r,* rectum; *v,* right external iliac vein. (J) Scan at the level of the pubic symphysis *(open arrow)* reveals the prostate gland *(solid arrow). a,* Right external iliac artery; *m,* obturator internus muscle; *r,* rectum; *v,* right external iliac vein.

Hounsfield Units

A single CT image generated by the scanner is divided into many tiny blocks of different shades of black and white called pixels. The actual gray scale of each pixel on a CT depends upon the amount of radiation absorbed at that point, which is termed an *attenuation value*. **Attenuation values are expressed in Hounsfield units (HU). The Hounsfield units scale or attenuation value is based upon a reference scale in which air is assigned a value of −1000 HU and dense bone is assigned the value of +1000 HU. Water is assigned 0 HU.**

Urolithiasis

Patients in the emergency department with abdominal pain or renal colic are frequently evaluated with CT imaging. The use of nonenhanced CT imaging to identify urolithiasis was first reported in 1995 (Smith et al., 1995) and has become the standard diagnostic tool to evaluate renal colic. It offers the advantage over IVU of avoiding contrast and has the ability to diagnose other abdominal abnormalities that can also cause abdominal pain. MDCT can readily diagnose radiolucent stones that may not have been seen on IVU, as well as small stones even in the distal ureter (Federle et al., 1981). **With the exception of some indinavir stones, all renal and ureteral stones can be detected on helical CT scan** (Schwartz et al., 1999). In the workup of urolithiasis, the unenhanced CT has a sensitivity ranging between 96% and 100% and specificity ranging between 92% and 100% (Memarsadeghi et al., 2005). **Stones in the distal ureter can be difficult to differentiate between pelvic calcifications. In these cases, the urologist needs to look for other signs of obstruction that indicate the presence of a stone, including ureteral dilation, inflammatory changes in the perinephric fat, hydronephrosis, and a soft-tissue rim surrounding the calcification within the ureter. The soft-tissue rim around a stone represents irritation and edema in the ureteral wall** (Dalrymple et al., 2000; Heneghan et al., 1997) (Fig. 3.18).

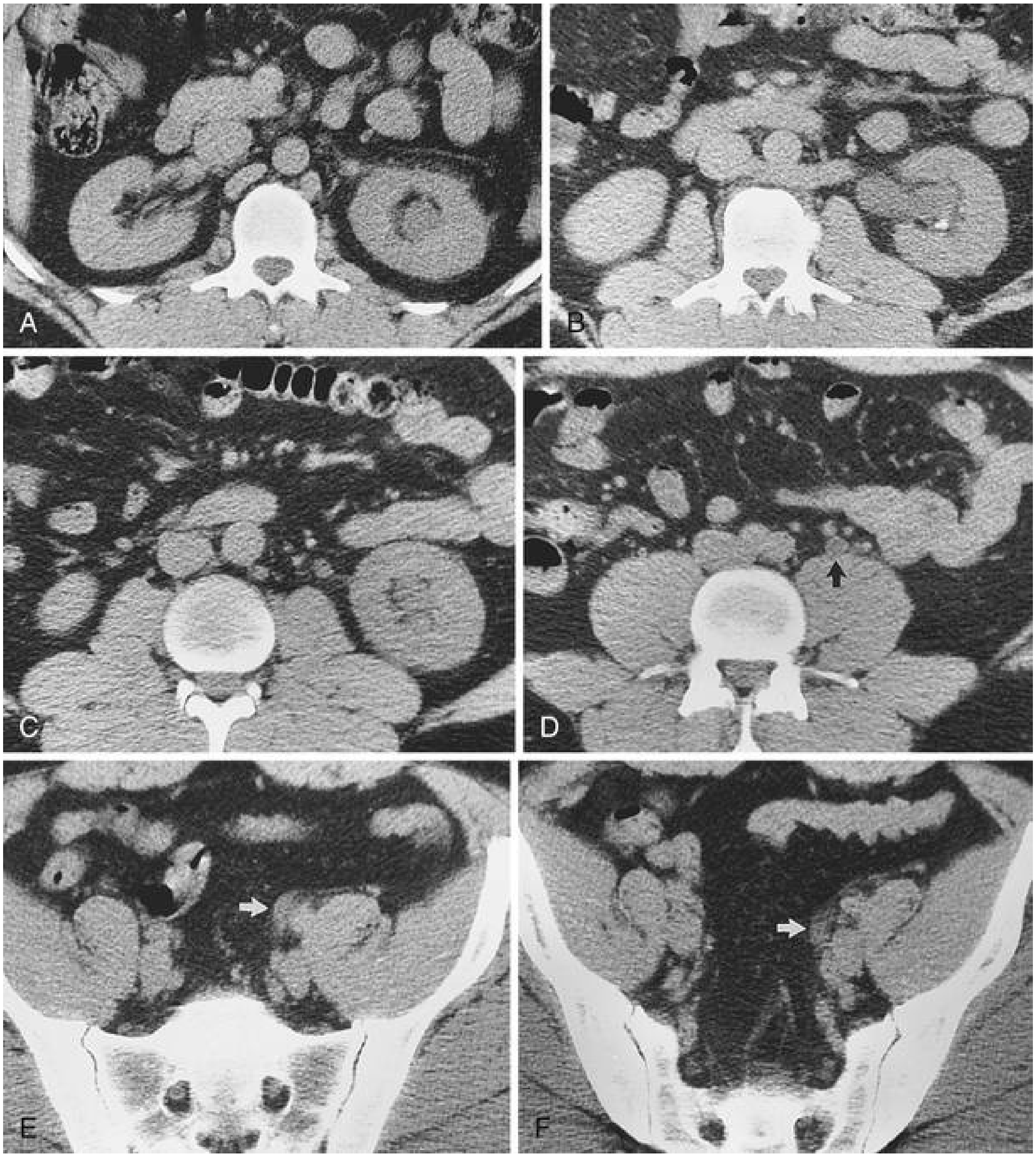

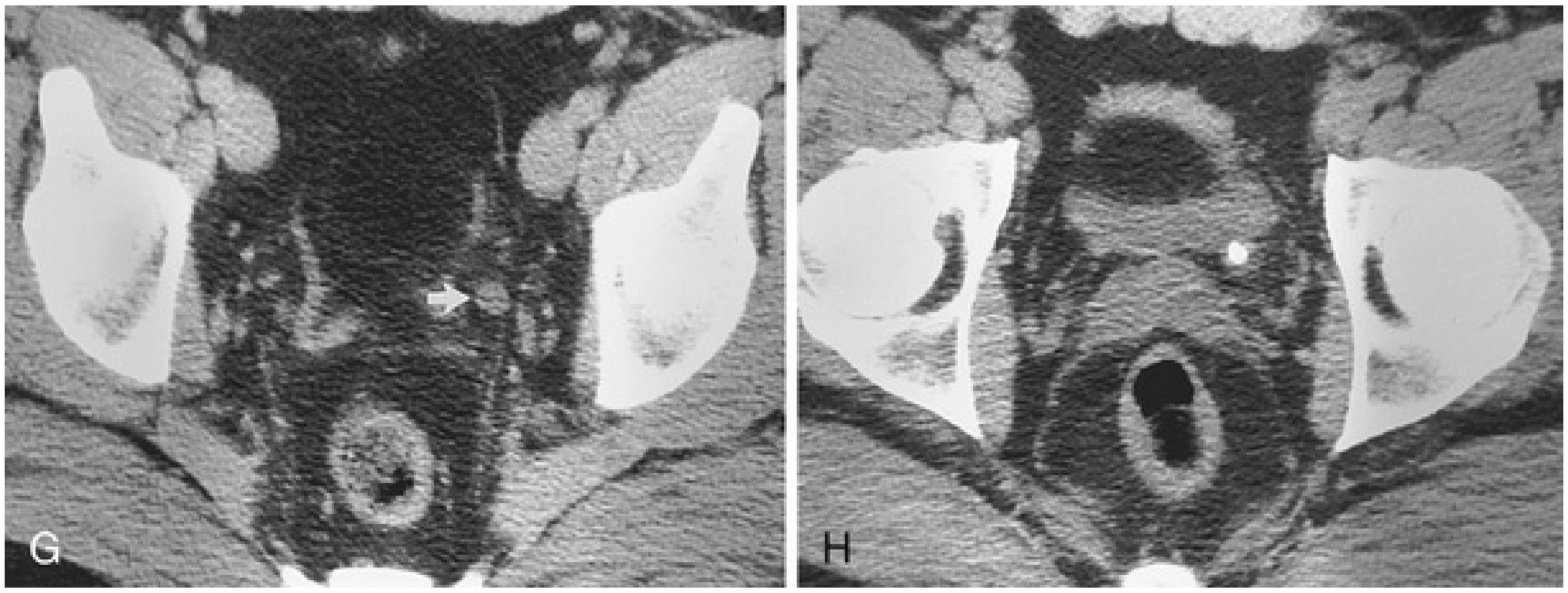

FIG. 3.18 CT of the abdomen and pelvis in patient with an obstructing ureteral stone at the level of the ureterovesicle junction. (A) Level of the left upper pole. Mild renal enlargement, caliectasis, and perinephric stranding are apparent. (B) Level of the left renal hilum. Left pyelectasis with a dependent stone, mild peripelvic and perinephric stranding, and a retroaortic left renal vein are shown. (C) Level of the left lower pole. Left caliectasis, proximal ureterectasis, and mild periureteral stranding are present. (D) Level of the aortic bifurcation. The dilated left ureter *(arrow)* has lower attenuation than do nearby vessels. (E) Level of the upper portion of the sacrum. A dilated left ureter *(arrow)* crosses anteromedial to the common iliac artery. (F) Level of the midsacrum. A dilated left ureter *(arrow)* is accompanied by periureteral stranding. (G) Level of the top of the acetabulum showing a dilated pelvic portion of the left ureter *(arrow).* (H) Level of the ureterovesical junction. The impacted stone with a “cuff” or “tissue rim” sign that represents the edematous wall of the ureter. (Reprinted from Talner LB, O'Reilly PH, Wasserman NF: Specific causes of obstruction. In Pollack HM, et al., eds: *Clinical urography,* ed 2, Philadelphia, 2000, Saunders.)

Stone patients are frequently subjected to radiation exposure as part of diagnosis, treatment, and follow-up. Increasing awareness of the potential long-term adverse effects of radiation exposure has encouraged urologists and radiologists to discover means to decrease the amount of radiation exposure. The low-dose unenhanced helical CT scan is gaining increasing popularity for initial diagnosis of renal colic suspected to be due to urolithiasis and for follow-up in stone patients. Using low-dose CT protocols, the specificity and sensitivity of unenhanced low-dose helical CT scan are approximately 96% and 97%, respectively. Low-dose techniques offer a 99% positive and 90% negative predictive value for urolithiasis. The end result is a 50% to 75% decrease in the patient's total radiation exposure for each CT obtained (Hamm et al., 2002; Kalra et al., 2005; Liu et al., 2000).

Cystic and Solid Renal Masses

The frequent CT imaging in emergency room patients has resulted in an increase in the detection of incidental renal masses. With use of CT imaging, the mass can be characterized as a simple or complex cyst or a solid mass. Based upon the Hounsfield unit attenuation scale, we would expect simple cysts to have Hounsfield units near zero (Fig. 3.19).

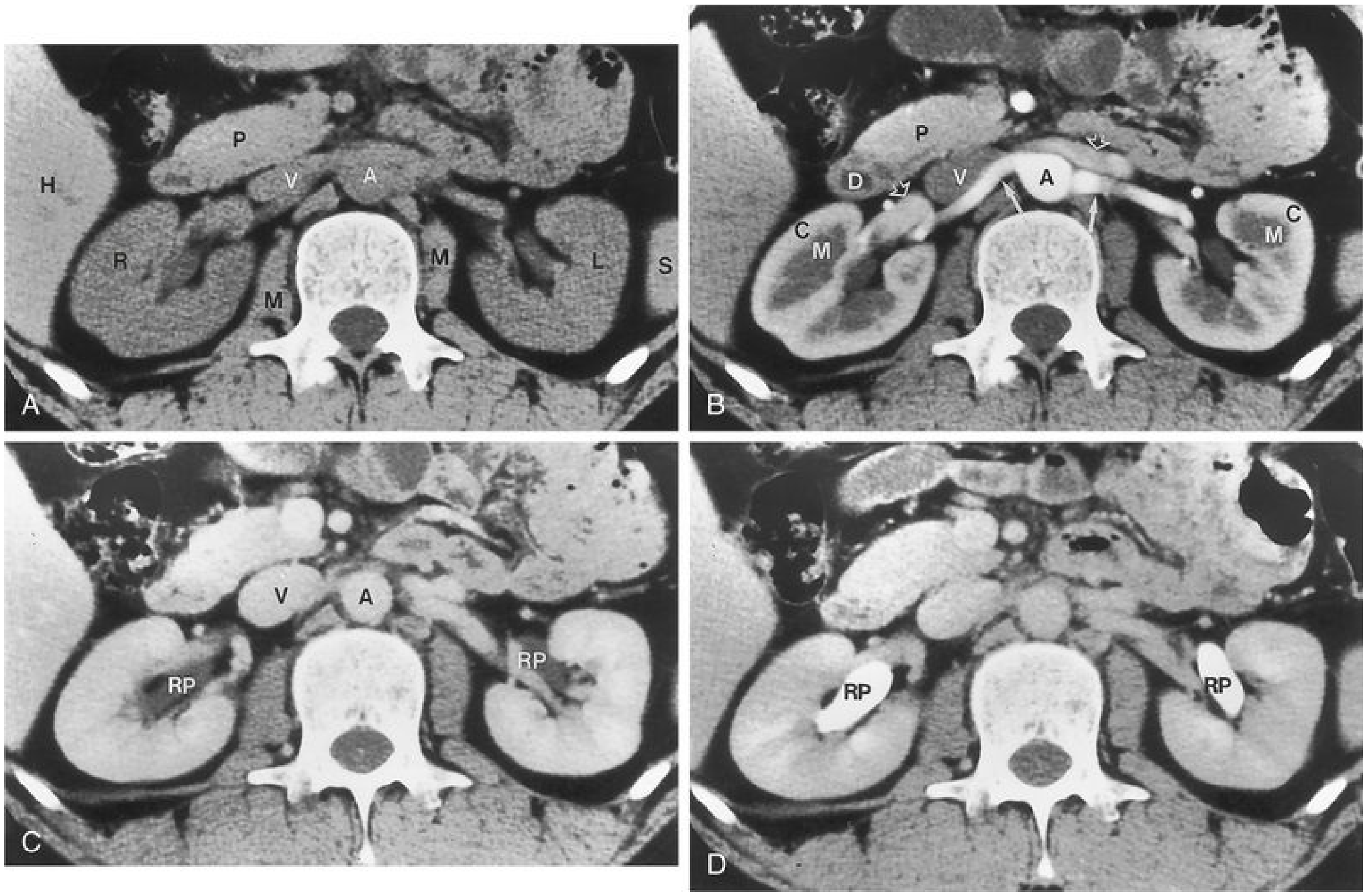

FIG. 3.19 **Renal CT demonstrating normal nephrogenic progression.** (A) Unenhanced CT scan obtained at the level of the renal hilum shows right *(R)* and left *(L)* kidneys of CT attenuation values slightly less than those of the liver *(H)* and pancreas *(P). A,* Abdominal aorta; *M,* psoas muscle; *S,* spleen; *V,* inferior vena cava. (B) Enhanced CT scan obtained during a cortical nephrographic phase, generally 25 to 80 seconds after contrast medium injection, reveals increased enhancement of the renal cortex *(C)* relative to the medulla *(M).* The main renal artery is indicated with *solid arrows* bilaterally. Main renal veins *(open arrows)* are less opacified with respect to the aorta *(A)* and arteries. *D,* Duodenum; *P,* pancreas; *V,* inferior vena cava. (C) CT scan obtained during the homogeneous nephrographic phase, generally between 85 and 120 seconds after contrast medium administration, reveals a homogeneous, uniform, increased attenuation of the renal parenchyma. The wall of the normal renal pelvis *(RP)* is paper thin or not visible on the CT scan. *A,* Abdominal aorta; *V,* inferior vena cava. (D) CT scan obtained during the

excretory phase shows contrast medium in the RP bilaterally; this starts to appear approximately 3 minutes after contrast medium administration.

When the unenhanced CT images of a renal mass are compared with the enhanced images obtained in the cortical medullary or nephrogenic phase, an increase in Hounsfield units (measured in the area of the renal mass) by 15 to 20 HU confirms the presence of a solid enhancing mass, which is usually renal cancer. Pseudoenhancement is maximal when small (≤1.5-cm) intrarenal cysts are scanned during maximal levels of renal parenchymal enhancement. The magnitude of this effect varies with scanner type but may be large enough to prevent accurate lesion characterization, despite use of a thin-section helical CT data acquisition technique (Birnbaum et al., 2002). **The presence of fat, which should enhance less than 10 HU, is diagnostic for angiomyolipoma. A hyperdense cyst shows no change in density between the postcontrast and delayed phase images.**

Complex cystic masses are usually characterized based upon the Bosniak classification system. The most important criterion used to differentiate a lesion that should be considered for surgery versus a nonsurgical lesion is the presence or absence of tissue vascularity or enhancement. Bosniak category I, II, and IIF lesions do not enhance to any measurable degree. Category I lesions are simple cysts and considered to be benign. Category II lesions are more complicated and may have calcifications, high attenuation fluid, and several thin septae. Category III lesions are more complex, have small areas of calcification, and may also have irregular walls or septate where there is measurable enhancement. Cystic lesions discovered on CT scan that are difficult to categorize as either II or III are now currently categorized as IIF. **Bosniak III lesions have been reported to be malignant renal cell carcinoma in 60% of cases and require close follow-up or surgical extirpation. Bosniak category IV lesions are cystic masses that meet all the criteria of category III but also have enhancing soft-tissue components adjacent or independent of the wall or septum of the cyst and have been reported to be malignant RCC in 100% of cases** (Bosniak, 1997; Curry, 2000; Israel and Bosniak, 2005).

Hematuria

The CTU is one of the most common studies ordered for the workup of gross or microscopic hematuria. With MDCT it is possible to perform a comprehensive evaluation of the patient with a single examination (Chai et al., 2001). The study images the abdomen and pelvis and typically includes four different phases. The first scan is an unenhanced CT to distinguish between different masses that can be present in the kidney and uncover kidney stones that would later be obscured by the excretion of contrast into the renal collecting system. At 30 to 70 seconds after contrast injection, the corticomedullary phase is captured with another pass through the MDCT, helping to define vasculature and perfusion. The nephrogenic phase occurs between 90 to 180 seconds after injection of contrast and, when compared with the nonenhanced images, allows sensitive detection and characterization of renal masses. The final phase is the excretory phase, imaged approximately 3 to 5 minutes after injection of contrast. The excretory phase allows complete filling of the collecting system and usually allows visualization of the ureter (Joudi et al., 2006).

CTU has been shown to be sensitive in detecting upper tract urothelial cancers. In one series of 57 patients with hematuria, 38 were found to have urothelial carcinoma. CT urography detected 37/38 urothelial cancers for a sensitivity of 97%, compared with retrograde pyelogram, which detected 31/38 lesions and had a sensitivity of 82%. Approximately 90% of malignant upper tract lesions can be detected with CT urography (Caoili et al, 2005; Lang et al., 2003; McCarthy and Cowan, 2002). CT urography is not as sensitive as cystoscopy for the detection of urothelial tumors in the bladder. Only large bladder tumors are visualized with CT imaging studies as filling defect in the lumen of the bladder. Carcinoma in situ cannot be visualized on CT scanning and therefore cystoscopy is still an important part of a comprehensive hematuria workup.

Key Points: Computed Tomographic Imaging

- The CTU is an excellent imaging choice to evaluate the kidney, upper tract collecting system, and ureter.
- The CTU is highly sensitive and specific for upper tract urothelial carcinoma.
- A renal mass in the kidney seen on CTU that enhances more than 15 to 20 HU is most likely a renal cancer.
- With the exception of indinavir stones, all urolithiasis is visible on unenhanced CT of the abdomen and pelvis.

Magnetic Resonance Imaging

CT imaging remains the mainstay of urologic cross-sectional imaging. Continued technologic improvements in MRI is narrowing the overall resolution quality gap between these two techniques. A significant advantage of MRI is the excellent signal contrast resolution of soft tissue without the need for intravenous contrast in many situations.

To obtain MRIs, the patient is placed on a gantry that passes through the bore of a magnet. When exposed to a magnet field of sufficient strength, the free water protons in the patient orient themselves along the magnetic field's z-axis. This is the head-to-toe axis, straight through the bore of the magnet. A radiofrequency (RF) antenna or “coil” is placed over the area of interest. It is the coil that transmits the RF pulses through the patient. When the RF pulse stops, protons release their energy, which is detected and processed to obtain an MRI. An MR sequence exploits the body's different tissue characteristics and the manner that each type of tissue absorbs and then releases this energy. Currently, most coils can transmit and receive signal, which is referred to as dual-channel RF.

Weighting of the image depends on how the energy is imparted through the physics of the pulse sequence and whether the energy is released quickly or slowly. Images are described as T1 or T2 weighted. The T1-weighted images are generated by the time to return to equilibrium in the z-axis. The T2-weighted images are generated by the time required to return to equilibrium in the xy-axis. **On T1-weighted MRIs, fluid has a low signal intensity and appears dark. T2-weighted MRIs have a high signal intensity and appear bright. In the kidney this translates into the cortex having a higher signal intensity or being brighter than the medulla, which gives off a lower signal and is darker.**

MRI has significant advantages over other imaging modalities. First, and most importantly, there are no risks associated with secondary malignancies from radiation exposure (Berrington de González and Darby, 2004). It is the modality of choice in patients who are pregnant, suffer from renal insufficiency, and/or have an iodine contrast allergy.

The contrast agents in MRI are noniodinated compounds. Iodinated compounds as used in CT imaging function by absorbing x-rays. **GBCAs shorten the relaxation times of water** (Lin and Brown, 2007). This results in an increase in signal intensity (enhancement), most commonly assessed in a T1 sequence. Gadolinium is a toxic heavy metal that is chelated to prevent cellular absorption and any associated toxicities (Lin and Brown, 2007). The dose of gadolinium is nontoxic for almost all patients, except ones with *severe* renal insufficiency.

Nephrogenic systemic fibrosis (NSF) occurs in patients with acute or chronic renal insufficiency with a GFR less than 30 mL/min/1.73 m^2 and was first described in 2000 (Cowper et al., 2000). Gadolinium is deposited in skin and muscle as an insoluble precipitate, which leads to the systemic fibrosis (Grobner, 2006). In response, the FDA has issued warnings regarding the association between NSF and GBCAs because there is no effective treatment available (US Food and Drug Safety Communication, 2010). The current guidelines are available at the FDA.gov official website and the US Food and Drug Administration website. In addition, there have been documented cases of gadolinium deposition (linear > macrocyclic) within deep brain tissue. However, the clinical significance of deposition is unknown, and no adverse events have been documented. Current recommendations include favoring the use of macrocyclic agents over linear GBCAs well as a continued analysis of possible future risks associated with GBCAs as the data continue to evolve (Gulani et al., 2017).

Adrenal Magnetic Resonance Imaging

One of the key differences between MRI and other imaging modalities is the ability of MRI to characterize soft tissues without the use of intravenous contrast. In the adrenal gland minute quantities of lipids can help differentiate between malignancies and benign adenomas. Most adrenal masses are identified incidentally and are nonfunctioning.

Adrenal adenomas are usually less than 3 cm and nonfunctional (Boland and Blake, 2008). Adrenal adenomas have a high lipid content (74%), which makes them more readily differentiated from malignant processes (Dunnick and Korobkin, 2002).

Inversion-recovery imaging, chemical shift imaging (CSI), and fat saturation imaging are three approaches to assess lipid content on masses. These approaches use the differences in the behavior of fat protons and water protons within the magnetic field. CSI is the most commonly used technique for urologic patients. Spectral presaturation with inversion recovery (SPIR) and spectral presaturation attenuated inversion recovery (SPAIR) can also be used to detect fat via selective excitation of the fat protons and T1 relation techniques (Ünal et al., 2016).

Adrenal Adenoma

Adrenal adenomas are characterized by assessing the lipid content within the cells. CSI uses the difference in the behavior of water protons (H_2O) versus fat protons ($-CH_2-$). The oxygen atom in water pulls on the electron cloud surrounding the hydrogen atom, whereas the carbon atom in fat is less electronegative and has a decreased effect on the hydrogen electron cloud (Pokharel and Macura, 2013). This difference in the magnetic field (shielding) for these two types of protons is the precession frequencies or the CSI (Pokharel and Macura, 2013).

CSI obtains images “in-phase” (IP) and “out-of-phase” (OP) regarding the water and fat protons. The signals detected for a given voxel can be additive or canceled out. The IP imaging refers to the contribution of fat and water, or additive, to the signal at a given voxel. This occurs when the echo time (TE) is set to align the fat and water protons.

In the OP imaging the TE is set to cancel the signals obtained, thus the subtraction of the protons results in a decrease, or canceling, in signal at that given voxel and produces a lower signal intensity if fat and water are present.

The next step is to compare the two data sets (IP and OP) obtained to determine if there is a loss of signal (decrease) on the OP images, which is indicative of intracytoplasmic fat (Fig. 3.21). If there is no change between the two data sets, then there is a lower probability that fat is present within the mass. This was initially determined on a qualitative basis by visually comparing signal intensities between the two sequences (Korobkin and Giordano, 1996). The loss of signal on CSI MRI is 92% sensitive and has a limited specificity of 17% for adrenal adenoma (Boland and Blake, 2008).

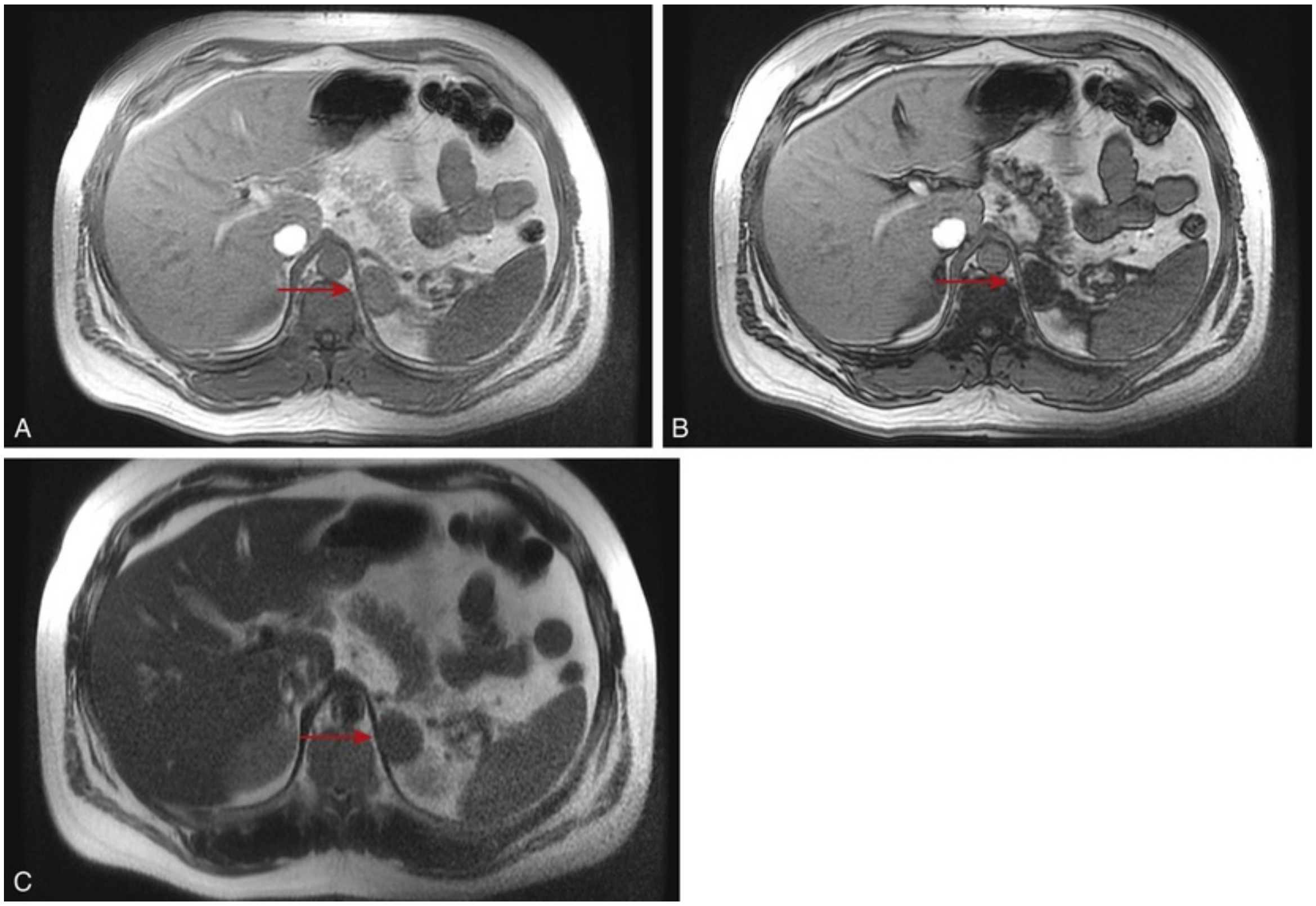

FIG. 3.21 A 45-year-old man underwent a 1.5T MRI with chemical shift imaging, which was consistent with left adrenal adenoma *(red arrow).* (A) In-phase (IP) T1-weighted image demonstrates a left adrenal mass with signal isointense to muscle. (B) Out-of-phase T1-weighted imaging shows drop out of signal in a left adrenal mass relative to the IP imaging. (C) Single-shot T2-weighted spin echo image reveals a left adrenal nodule with low signal intensity.

Other authors have attempted to determine signal intensity (SI) index by quantitatively comparing the IP and OP images. Nakamura and Namimoto (2012) reported that using a 5% SI yielded an accuracy of 100% (3 Tesla) in determining if intracytoplasmic lipid was present and thus a diagnosis of an adenoma. Although there are currently no set thresholds, cutoff ranges are reported to be between 1.7% and 20% (Nakamura and Namimoto, 2012). The limited specificity reported by the qualitative approach (17%) was increased to 100% specificity using the quantitative SI index (Nakamura and Namimoto, 2012).

$$\text{Signal intensity (SI) index (\%)} = (\text{SI in-phase} - \text{SI out-of-phase}) / \text{SI in-phase} \times 100$$

In some clinical situations, lipid-poor adenomas (10%–30% incidence) can result in an indeterminate study (Elsayes and Mukundan, 2004). The typical washout of an adrenal cortical carcinoma is slow. Therefore an enhanced CT with washout may be a better study to differentiate lipid-poor adrenal adenomas from other adrenal masses (Park and Kim, 2007). In cases of unilateral adenomas data suggest there are limitations associated with localization using CT/MRI and adrenal vein sampling may be a useful adjunct to the diagnostic pathway (Ladurner et al., 2017).

Adrenal Cortical Carcinoma

An adrenal cortical carcinoma (ACC) diagnosis is obtained using a combination of clinical factors and imaging characteristics (Fig. 3.20). In a review by Ng and Libertino, ACC is hormonally active in 62% of cases (Ng and Libertino, 2003). **The incidence of ACC is related to size and adrenal lesions equal to or less than 4 cm represented 2% of all ACC diagnosed. The incidence of ACC increased to 6% for lesions 4 to 6 cm and to 25% for lesions greater than 6 cm** (Mansmann and Lau, 2004). T2-weighted and T1-weighted images with Gd are usually heterogeneous with a high signal intensity and a heterogeneous enhancement, respectively. CSI exhibits a low signal (Bharwani and Rockall, 2011). **ACC also is associated with local vascular thrombosis, which can be detected on MRI** (Mezhir and Song, 2008). ACC has an increased metabolic activity and can be visualized on FDG-PET imaging, and this can differentiate ACC from adenomas with 100% sensitivity and 88% specificity (Groussin and Bonardel, 2009).

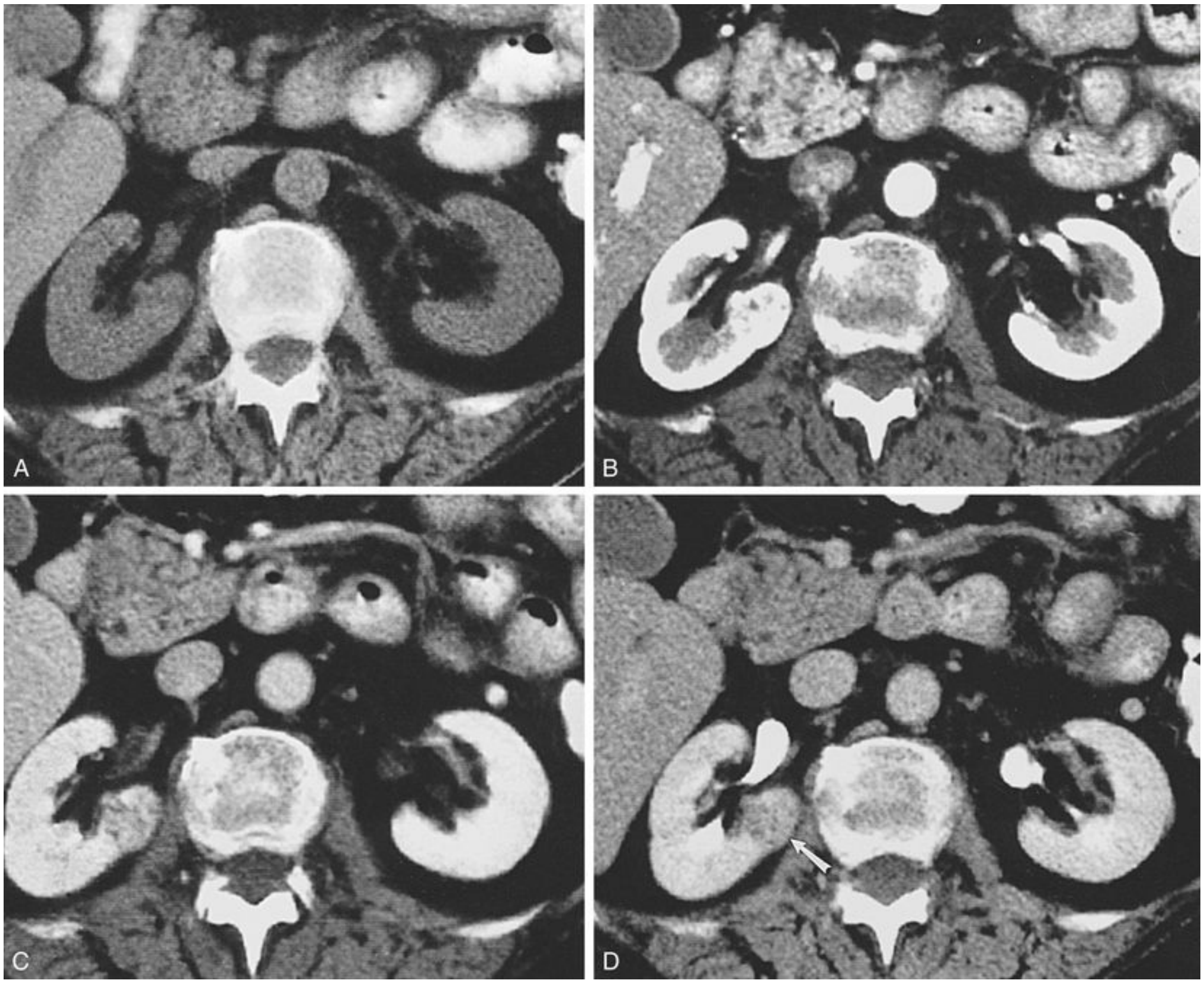

FIG. 3.20 Small renal cell carcinoma in the infrahilar lip of the right kidney is not easily seen on unenhanced image (A). On corticomedullary phase image (B), the lesion is subtly visible as a hyperenhancing focus within the renal medulla. On nephrographic (C) and pyelographic phase (D) images, the full extent of the lesion *(arrow)* within the medulla and cortex is depicted. (Reprinted from Brink JA, Siegel CL: Computed tomography of the upper urinary tract. In Pollack HM, et al., eds: *Clinical urography,* ed 2, Philadelphia, 2000, Saunders.)

Myelolipoma

Myelolipoma is a benign adrenal mass that consists of mature fatty tissues and bone marrow elements. Myelolipoma occurs in approximately 6.5% of patients with incidentally detected adrenal masses (Song and Chaudhry, 2008). The complicating issues with myelolipomas is that the size of the mass can be greater than 4 cm, and this carries significant overlap with malignant adrenal lesions (Meyer and Behrend, 2005). On MRI a myelolipoma has a high signal intensity on T1-weighted imaging, suppressed signal on frequency selective fat suppression, and an India ink artifact (Figs. 3.22 and 3.23) (Taffel and Haji-Momenian, 2012). India ink artifact appears as a dark line around the lesion and/or organs and is the result of a voxel containing fat and water on CSI OP images.

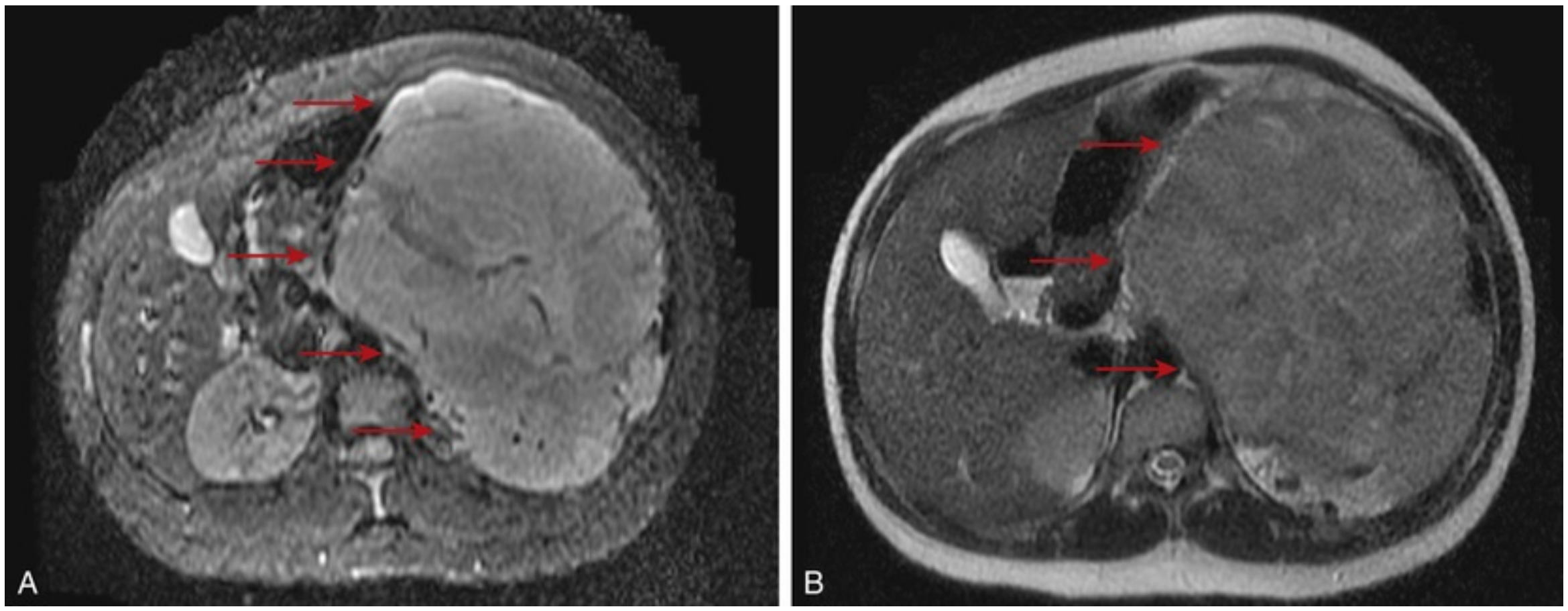

FIG. 3.22 A 65-year-old woman with left side heterogeneous enhancing suprarenal lesion (ACC) with select images from a 1.5T abdominal MRI. (A) Moderately weighted T2 STIR images with a hyperintense signal *(red arrow).* (B) Heavily weighted T2 single shot fast spin echo isointense signal. These findings are all dependent on the degree of T2 weighting.

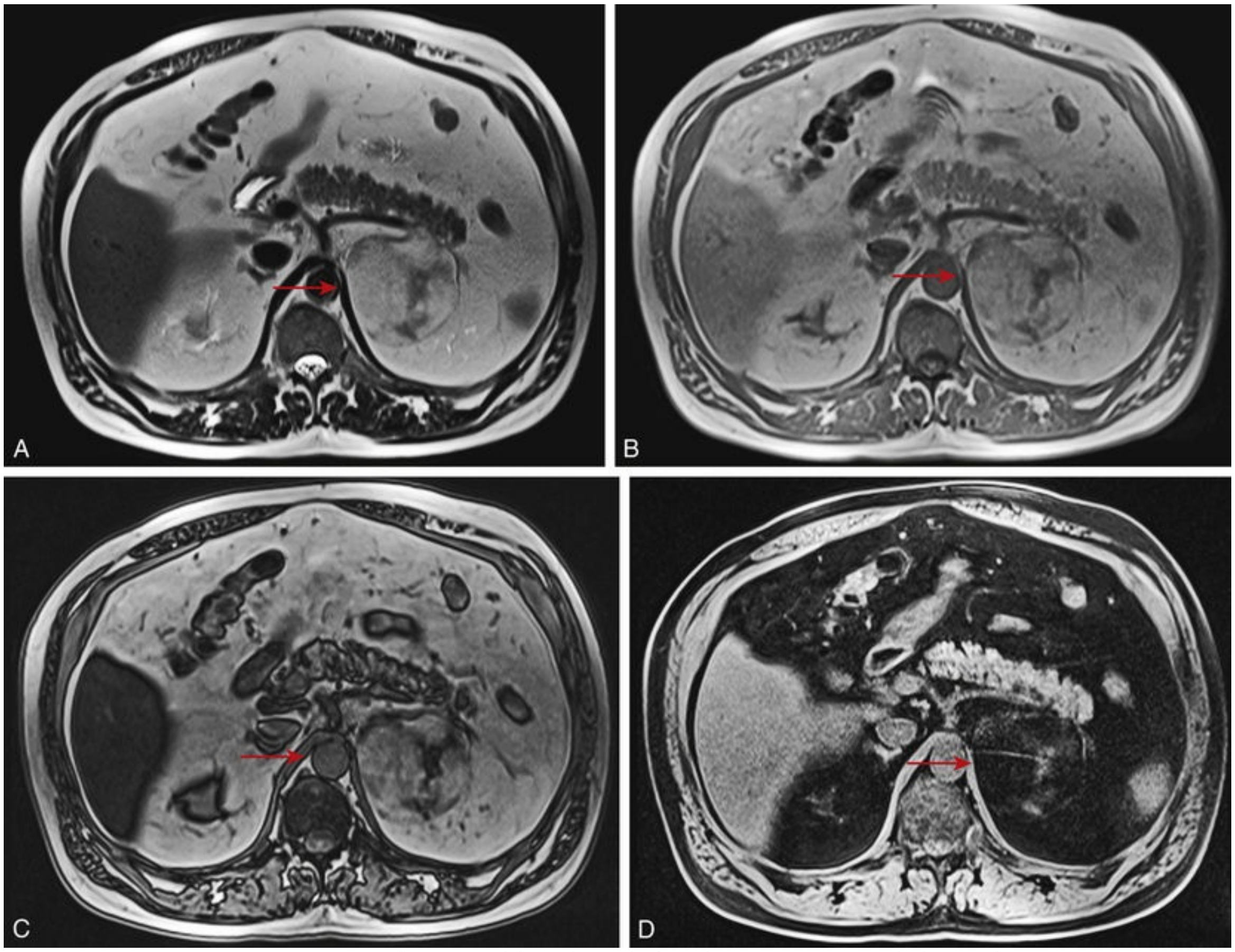

FIG. 3.23 A 44-year-old man with prior abdominal ultrasound detecting an indeterminate renal mass underwent a 1.5T MRI with chemical shift imaging, which was consistent with left adrenal myelolipoma *(red arrow).* (A) T2 single-shot spin echo demonstrates a large left adrenal mass with signal isointense to abdominal fat. (B) T1 in-phase (IP) imaging demonstrates a left adrenal mass, which signals similar to the abdominal fat. (C) T1 out-of-phase imaging shows no drop of signal compared with IP imaging. (D) T1 fat-suppressed precontrast imaging shows loss of signal within the mass consistent with gross fat.

Metastasis

An adrenal mass is considered to be metastatic in the setting of a known primary malignancy. The MRI findings are consistent with a large, irregular, heterogeneous mass with occasional necrosis present on imaging. Metastasis have a high signal on T2-weighted images secondary to higher fluid content compared with adrenal adenoma (Shadev, 2010). Gadolinium enhancement on T1-weighted images demonstrates heterogeneous enhancement with a delayed peak enhancement (65 seconds) when compared with adrenal adenomas (40 seconds) (Inan and Arslan, 2008). Using a time to peak enhancement cutoff of

53 seconds or greater resulted in 87.5% sensitivity and 80% specificity in characterizing metastatic adrenal lesions (Inan and Arslan, 2008).

Patients with primary lesions known to contain intracytoplasmic fat may require additional imaging to better differentiate an adrenal gland lesion. The metastatic sites often carry the same histologic features as the primary tumor. This can result in a false positive for adrenal adenomas if the primary contains intracytoplasmic lipids content (chemical shift MRI positive) (Fig. 3.24) (Krebs and Wagner, 1998). This has been reported in liposarcoma, renal cell carcinoma, and hepatocellular carcinoma (Krebs and Wagner, 1998; Sydow and Rosen, 2006).

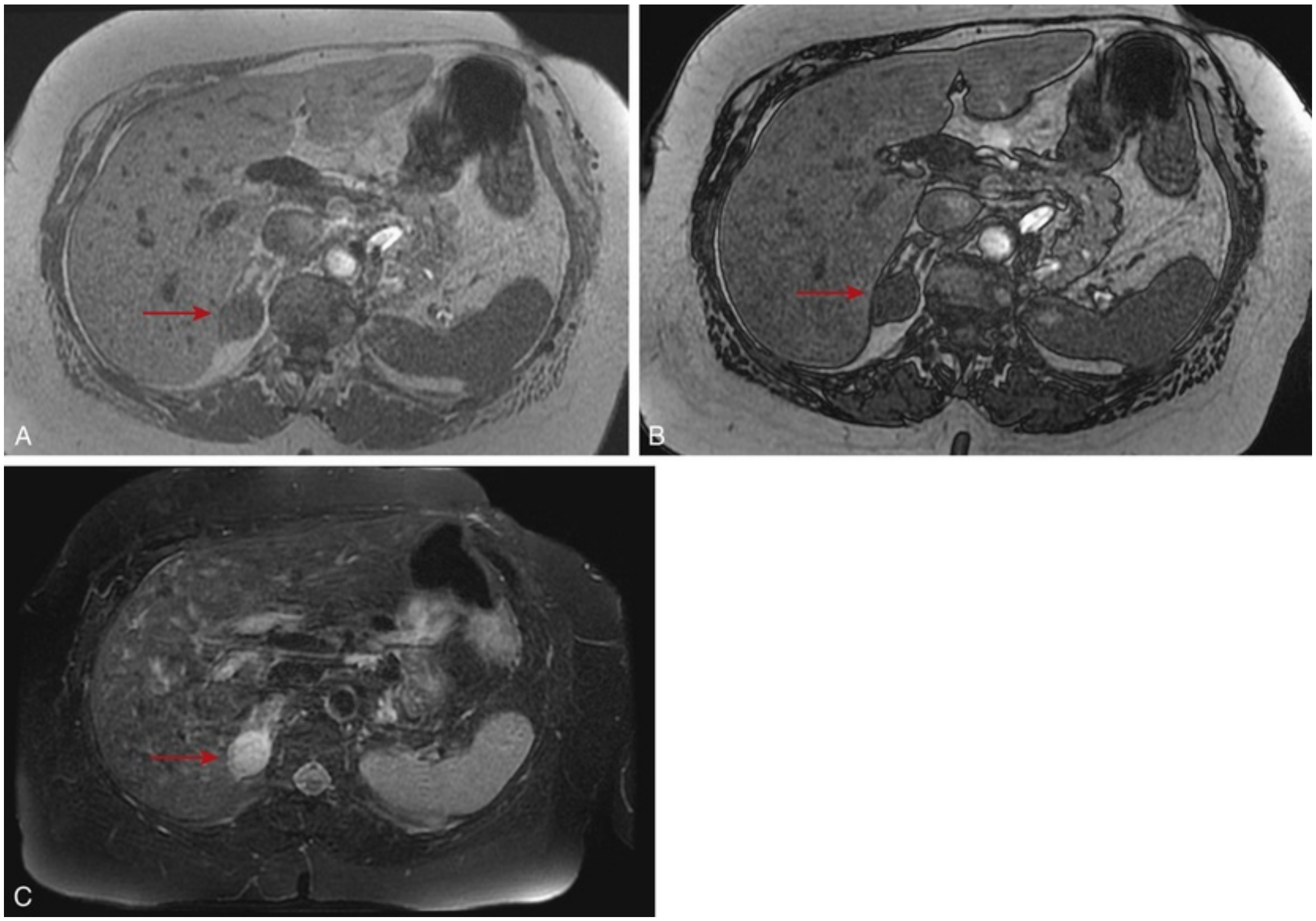

FIG. 3.24 A 63-year-old female s/p right nephrectomy for clear cell carcinoma with a metachronous right adrenal metastasis. (A) T1 in-phase imaging of the right adrenal mass *(red arrow).* (B) T1 out-of-phase imaging with drop in signal *(red arrow)* consistent with microscopic fat. (C) Fat-suppressed fast relaxation fast spin echo moderately weighted T2 image with hyperintense signal *(red arrow).*

Pheochromocytoma

Pheochromocytoma traditionally was considered to be diagnostic if on T2-weighted images the lesion demonstrated an increased signal intensity (Fig. 3.25). However, Varghese and Hahn reported that 35% of pheochromocytomas demonstrated low T2 signal contrary to conventional teaching (Varghese and Hahn, 1997). **Pheochromocytoma, adrenal cortical carcinoma, and metastatic lesions to the adrenal gland can exhibit a hyperintense signal intensity or "bright" on T2-weighted images.** It is important to understand that the signal intensity can vary because of the degree of weighting of the T2 signal and would not exhibit the traditional findings of "being bright" on T2-weighted images (see Figs. 3.21 to 3.23). The pheochromocytoma may be characterized by MRI without the need for contrast enhancement.

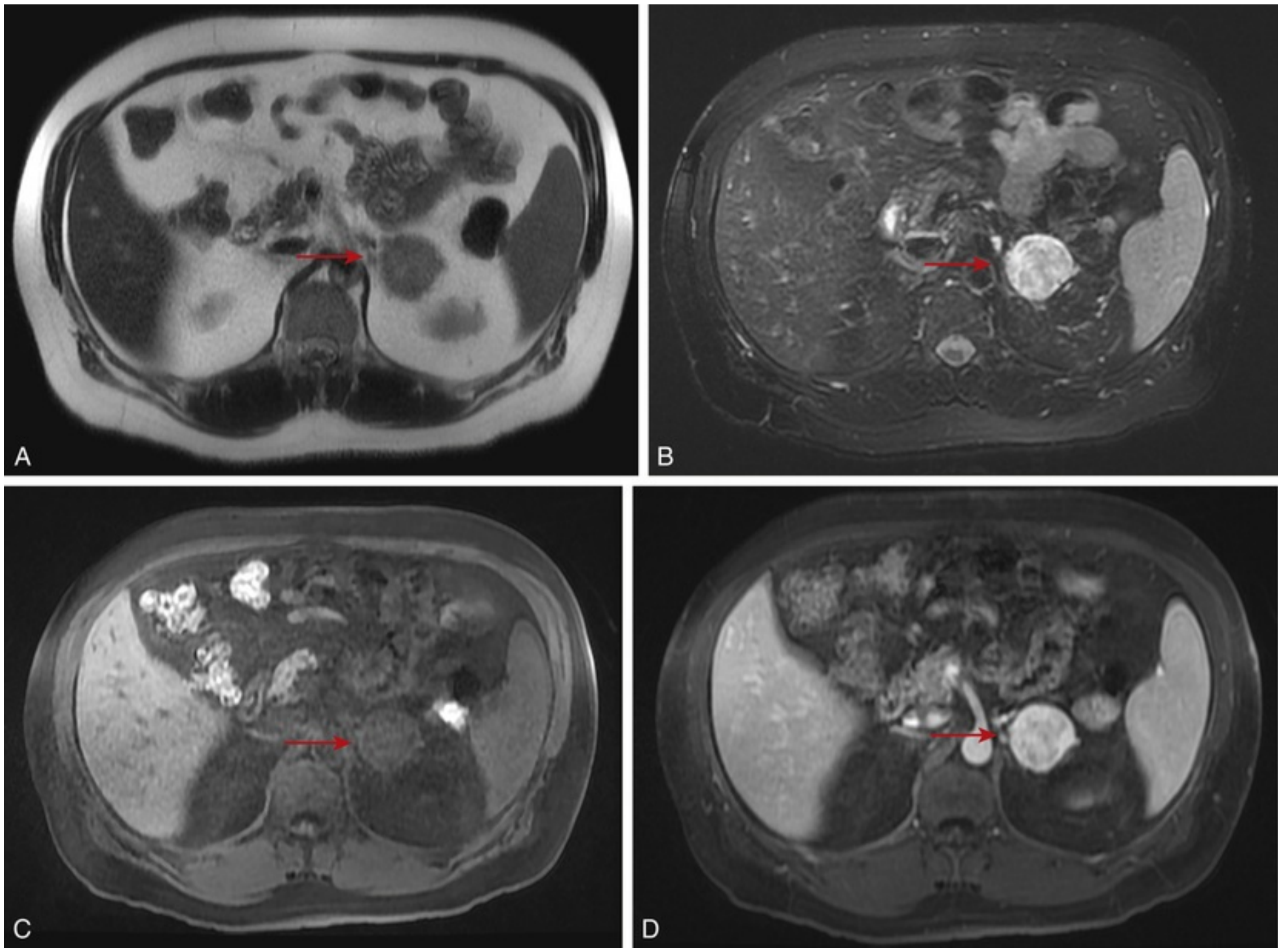

FIG. 3.25 A 50-year-old man with a left side pheochromocytoma and select images from a 1.5T MRI. (A) Heavily weighted T2 single-shot fast spin echo with an isointense signal (not bright). (B) Moderately weighted T2 fat-suppressed fast recovery fast spin echo with hyperintense signal (bright). (C) T1-weighted precontrast images. (D) T1-weighted postcontrast images with marked early enhancement.

Other Adrenal Lesions

Lymphoma, neuroblastoma, ganglioneuroma, hemangioma, and granulomatous diseases of the adrenal gland have an intermediate SI index on chemical shift MRI and other imaging findings (Table 3.5).

TABLE 3.5

Morphologic and Imaging Characteristics of Incidental Adrenal Lesions

IAL	SIZE (cm)	SHAPE	TEXTURE	UNENHANCED CT ATTENUATION (HU)	15-MINUTE CT WASHOUT (%)
Adrenal metastasis	Variable	Variable	Heterogeneous when larger	>10	RPW < 40
Adrenal cortical carcinoma	> 4 cm	Variable	Variable	>10	RPW < 40
Pheochromocytoma	Variable	Variable	Variable	>10 rarely <10	RPW < 40
Cyst	Variable	smooth, Round	Smooth	<10	does not enhance
Adenoma	1–4 cm	Smooth, round	Homogeneous	<10 in 70%	RPW > 40; APW > 60
Myelolipoma	1–5 cm	Smooth, round	Variable with macroscopic fat	<0, often <-50	No data
Lymphoma	Variable	Variable	Variable	>10	RPW < 40
Hematoma	Variable	Smooth	Variable	>10, sometimes >50	No data
Neuroblastoma	Variable	Variable	smooth, Round	>10	RPW < 40
Ganglioneuroma	Variable	Variable	Variable	>10	No data
Hemangioma	Variable	Variable	Variable	>10	No data
Granulomatous	1–5 cm	Smooth	Usually Homogeneous	>10	No data

APW, Absolute percentage washout; *MIBG,* m-iodobenzylguanidine; *OP,* out-of-phase; *RPW,* relative percentage washout; *SI,* signal intensity.

Data from Boland and Blake, 2008 and Taffel and Haji-Momenian, 2012.

Adrenal hematomas have variable imaging characteristics on MRI because of changes in the hematoma from initial acute bleeding to breakdown products of red blood cells with deposition of hemosiderin within the hematoma. This progresses from an iso-intense to hypointense signal on T1 and low signal on T2 to hyperintense on T1 fat-suppressed sequences and T2 sequences at 1 to 7 weeks. A low signal rim is present on T1 and T2 sequences because of hemosiderin deposits (Taffel and Haji-Momenian, 2012).

Renal Magnetic Resonance Imaging

Simple cysts have similar characteristics on ultrasound, CT, and MRI. Complex cysts can be differentiated or characterized using MRI. Hemorrhage within a cyst results in a high signal on T1-weighted images because of the paramagnetic effects of the byproducts from the breakdown of blood (hemosiderin) (Fig. 3.26) (Roubidoux, 1994).

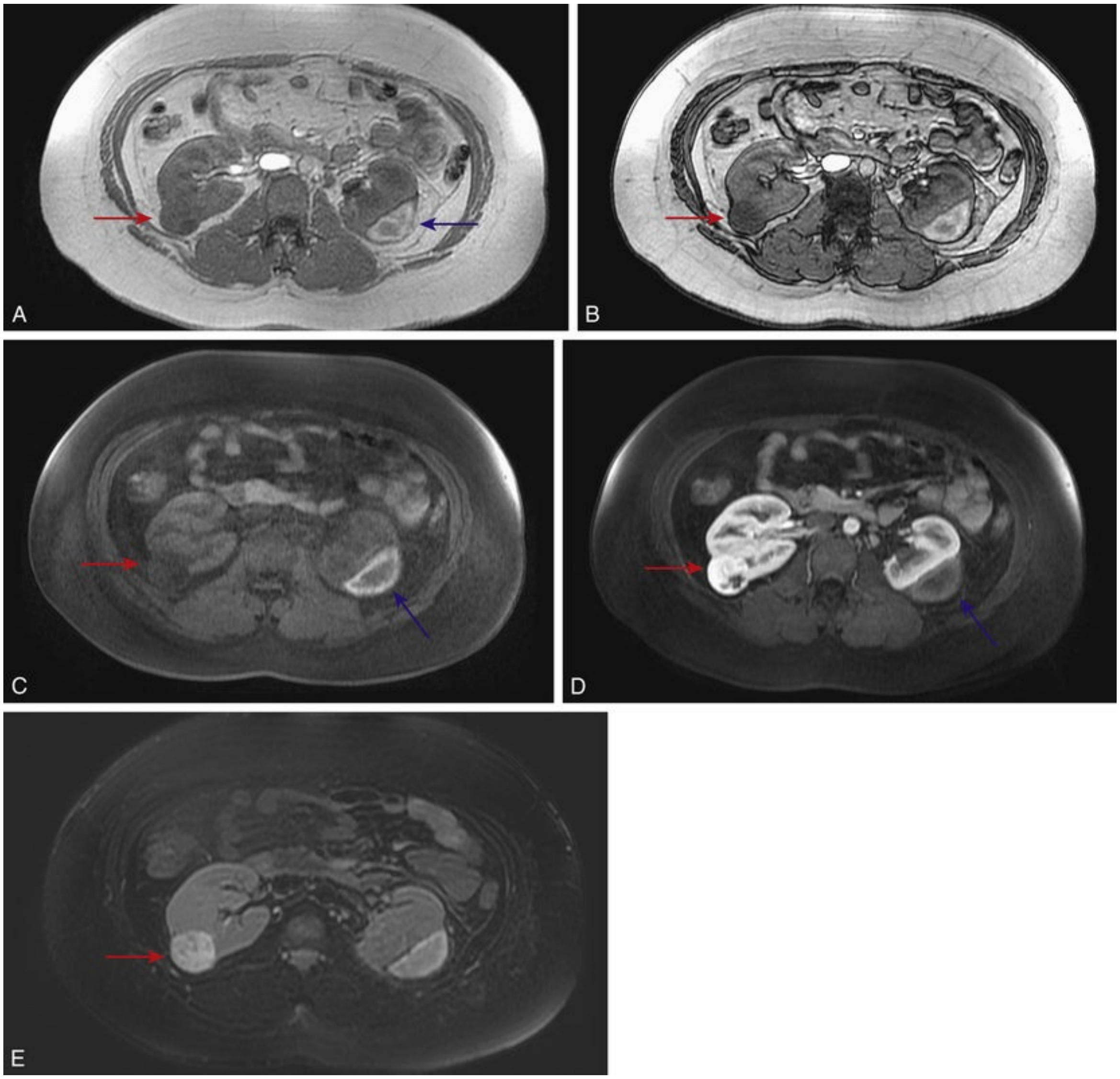

FIG. 3.26 A 31-year-old woman after left extracorporeal shock wave lithotripsy with a subcapsular hematoma and right-side pathology confirmed 3.5-cm clear cell carcinoma underwent a 1.5T MRI of the abdomen. (A) T1-weighted in-phase (IP) imaging of a right renal nodule with mild heterogeneity *(red arrow)* but primarily isointense signal intensity. Left kidney subcapsular hematoma with a rim of high signal intensity *(blue arrow).* (B) T1-weighted out-of-phase (OP) image shows diffuse signal dropout within the renal nodule consistent with microscopic fat. (C) T1-weighted fat-suppressed precontrast image with a low signal intensity of the right renal nodule *(red arrow)* and high signal intensity of the left subcapsular hematoma *(blue arrow)*. Blood is high signal intensity on precontrast T1-weighted images. (D) T1 fat-suppressed postcontrast images of the right renal nodule with avid heterogeneous enhancement. Nonenhancing left subcapsular hematoma. (E) Diffusion-weighted imaging b-1000 demonstrates high signal intensity throughout the right renal nodule.

Proteinaceous contents within a cyst demonstrate high signal on T1-weighted images. Chronic hemorrhage results in a black ring along the cyst wall on T2-weighted images. **For benign and complex cysts there should be no enhancement** (Israel and Hindman, 2004).

When independent risk factors were evaluated for RCC, enhancement of the cyst wall had higher sensitivity and specificity than calcifications on the cyst wall. Calcifications can cause artifacts that may decrease the ability to appreciate enhancement of small nodules within the wall of a complex cyst on CT imaging. MRI has the advantage of not being influenced by calcifications within the wall of a complex cyst. Calcifications appear as a void on MRI. Therefore MRI is more likely to detect enhancement of a renal cell carcinoma in the wall of a complex cyst compared with CT imaging when mural calcifications are present (Israel and Bosniak, 2003).

MRI offers a distinct advantage over CT imaging in the evaluation of the pseudocapsule, which appears on T1- and T2-weighted images as a low signal surrounding the lesion. The lack of pseudocapsule surrounding a renal mass had an accuracy of 91% in predicting pT3a disease (Roy and El Ghali, 2005).

MRI allows differentiation of different subtypes of RCC by using a multiparametric approach. These sequences can include T1-weighted images, multiplanar T2-weighted sequences (with and without fat suppression), dynamic contrast-enhanced (DCE) sequences (with arterial, corticomedullary, nephrogenic, and excretory phases), diffusion-weighted images (DWIs) (with corresponding apparent diffusion coefficient [ADC] maps), and CSI. Using these unique features, we are better able to differentiate the subtypes of renal masses compared with CT imaging.

Renal cell carcinoma clear cell type (ccRCC) is the most common type of RCC. It is characterized by a heterogeneous high signal on T2-weighted sequences because of the presence of hemorrhage, necrosis, and/or cysts (Pedrosa and Chou, 2008). Papillary RCC (pRCC), when compared with ccRCC, exhibits a homogenous lower signal intensity on T2-weighted images, which is secondary to hemosiderin deposition (histiocytes) within the tumor (Pedrosa and Chou, 2008) (Fig. 3.27). Hemorrhagic cysts with an enhancing peripheral wall growth and/or a solid hypoenhancing mass with low signal intensity (SI) on T2-weighted images resulted in 80% sensitivity and 94% specificity in differentiating pRCC from other types of RCC (Fig. 3.28) (Pedrosa and Chou, 2008).

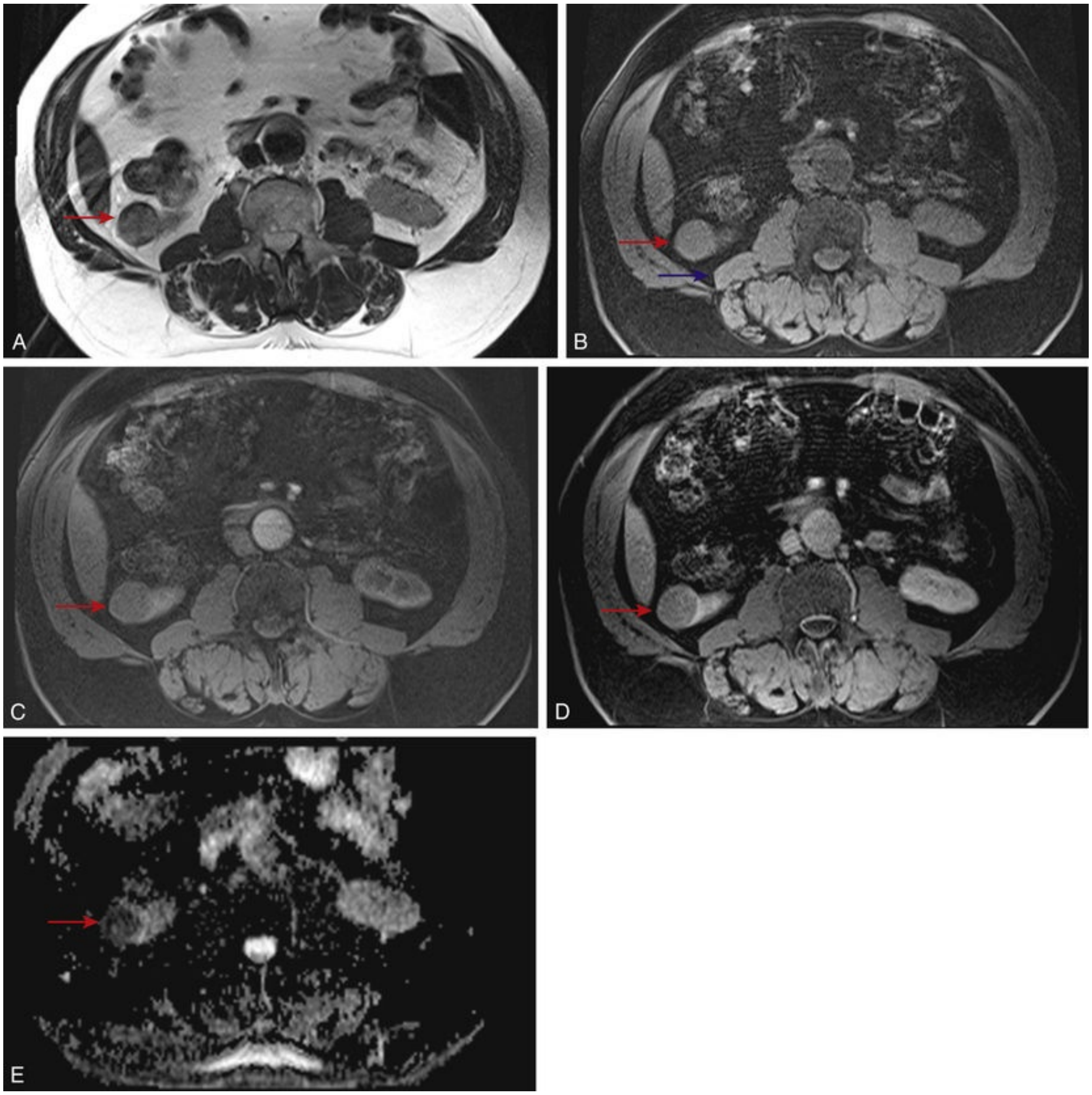

FIG. 3.27 A 72-year-old man with papillary renal cell carcinoma underwent a 1.5T MRI of the abdomen. (A) T2-weighted single-shot fast spin echo image reveals a heterogeneous but primarily low signal intensity of the right renal nodule *(red arrow).* (B) T1 fat-suppressed precontrast images of the right renal nodule with signal isointense to muscle *(blue arrow).* (C) T1 fat-suppressed postcontrast cortical medullary phase with no significant enhancement. (D) T1 fat-suppressed postcontrast nephrogenic phase demonstrates minimal central enhancement. (E) Apparent diffusion coefficient map with low signal intensity of the renal nodule.

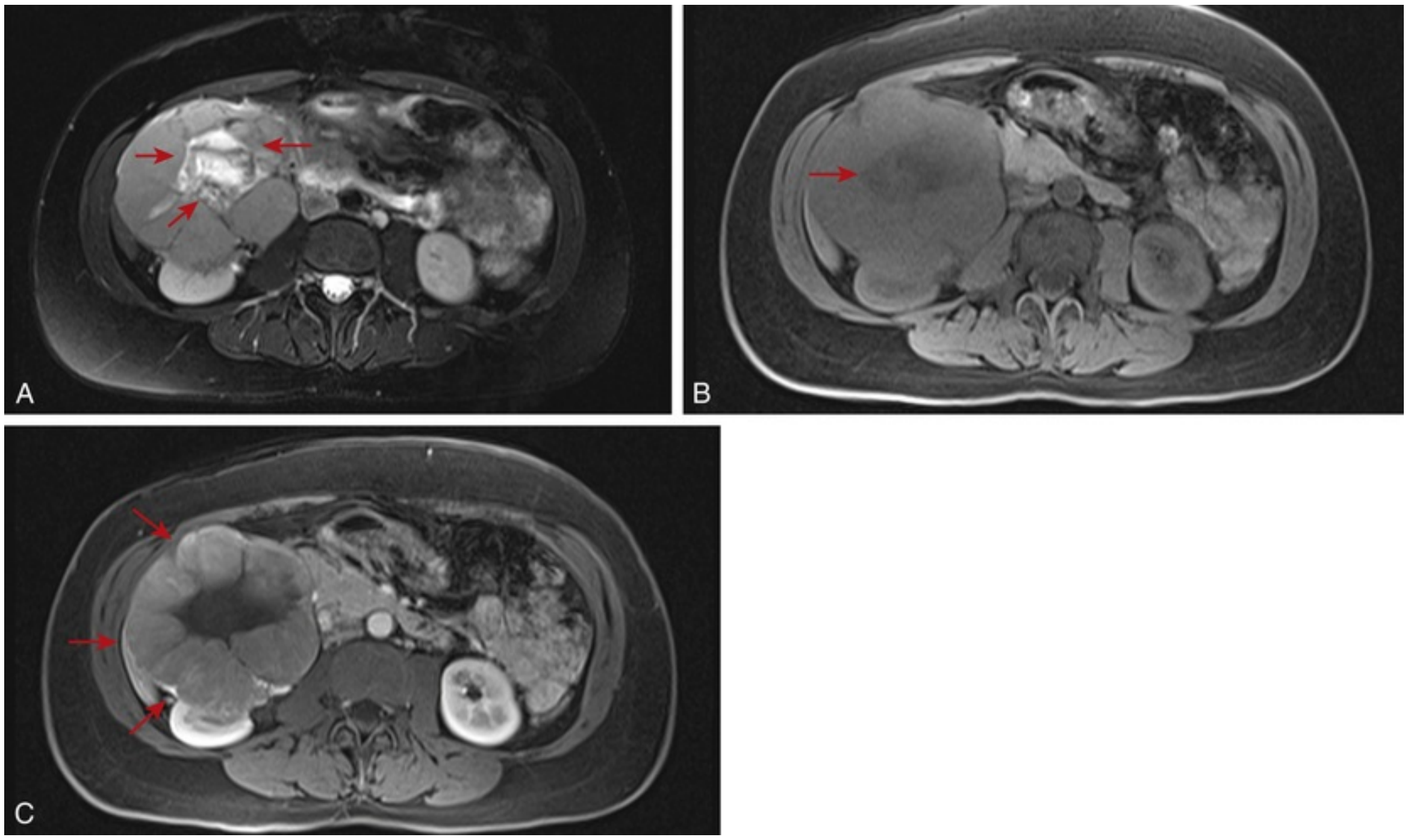

FIG. 3.28 A 45-year-old woman with chromophobe carcinoma with select images from 1.5T MRI of the abdomen. (A) T2-weighted images demonstrate a heterogeneous right renal mass with a high signal intensity centrally *(red arrows).* (B) T1-weighted fat-suppressed precontrast image reveals a central low signal intensity *(red arrow)* and peripheral iso-intensity. (C) T1-weighted fat-suppressed postcontrast image demonstrates peripheral enhancement of the renal mass *(red arrows)* with lack of enhancement centrally.

Similar to adrenal MRI, CSI can detect intracytoplasmic lipids and aid in the differentiation of ccRCC from other RCC subtypes (see Fig. 3.26). Microscopic intracytoplasmic lipids have been found in 59% of clear cell carcinomas (Outwater and Bhatia, 1997). Karlo and Donati reported that once angiomyolipomas (AMLs) have been ruled out using standard MRI techniques (Fig. 3.29) in which macroscopic fat has been detected, chemical shift MR sequences with a 25% decrease in SI can be considered diagnostic for ccRCC from other renal tumors (Karlo and Donati, 2013). Pedrosa and Chou (2008) reported the sensitivity and specificity CSI for ccRCC were 42% and 100%, respectively. There are rare cases of RCC with macroscopic fat; however, if calcifications are also present, this would favor the diagnosis of RCC over AML (Wasser and Shyn, 2013).

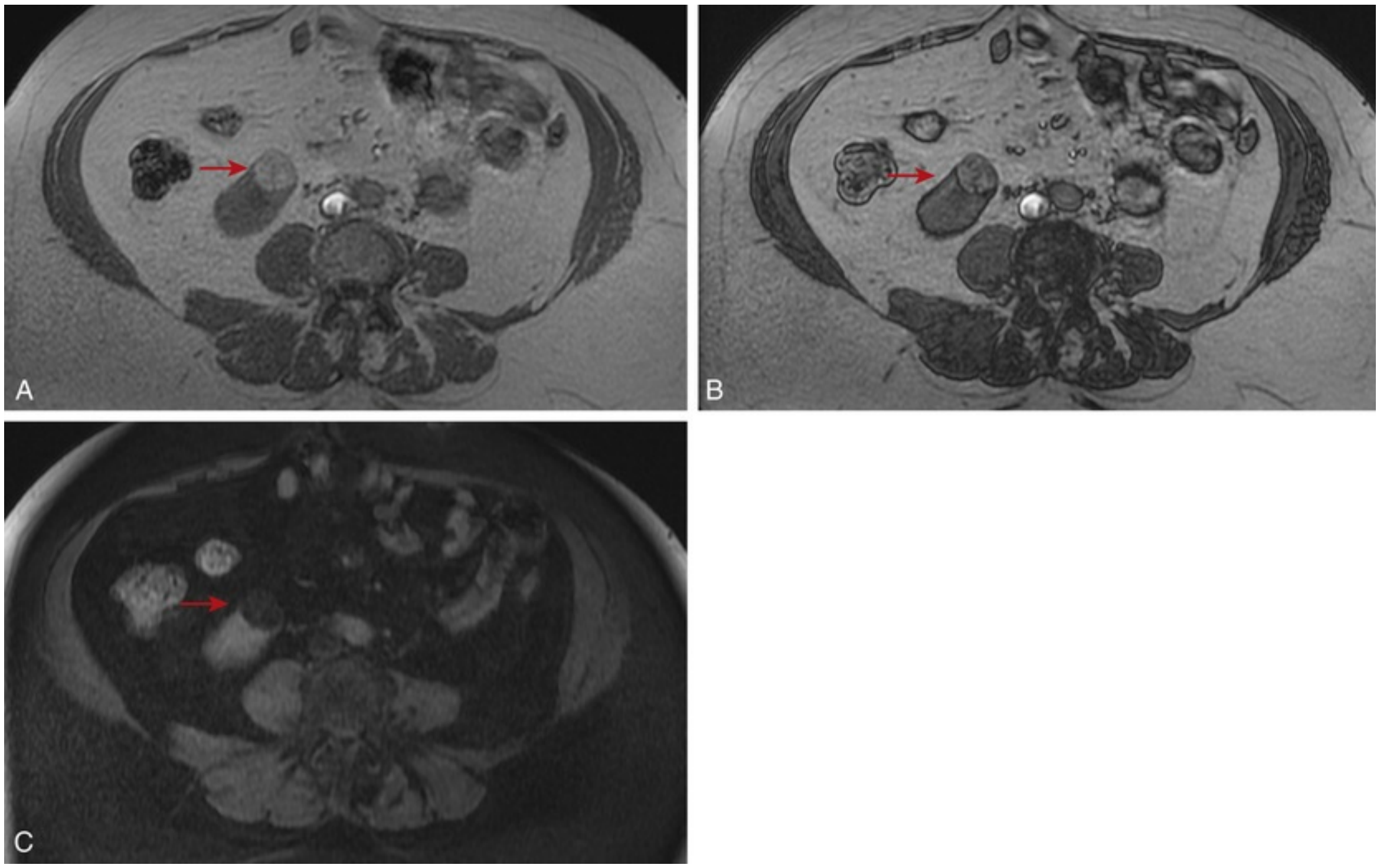

FIG. 3.29 A 78-year-old woman with a 2.5-cm angiomyolipoma with select images from a 1.5T MRI of the abdomen. (A) T1 in-phase right renal nodule *(red arrow).* (B) T1 out-of-phase imaging demonstrating no drop in signal intensity *(red arrow).* (C) T1 fat-suppressed precontrast demonstrates drop in signal intensity within the lesion consistent with macroscopic fat.

Gd-enhanced T1-weighted images with a relative signal intensity increase of 15% is considered to be positive for enhancement, which results in a 100% sensitivity in differentiation cysts from renal cell carcinoma with peak enhancement occurring at 2 to 4 minutes (Ho and Allen, 2002). Using the specific characteristics of DCE MR sequences, Vargas and Chaim assessed the enhancement characteristics of ccRCC, pRCC, AML, and chromophobe carcinoma in the corticomedullary, nephrogenic, and excretory phases (Vargas and Chaim, 2012). Clear cell demonstrated greater than 200% signal intensity increase in all three contrast phases, which was significantly higher than chromophobe and papillary carcinoma (Table 3.6). AML was the only renal mass to demonstrate a decrease in signal intensity from the corticomedullary phase to the nephrogenic phase. Because of a high degree of overlap it is difficult to assign cutoff points. It was not possible to find characteristics to differentiate oncocytoma from ccRCC (Vargas and Chaim, 2012).

TABLE 3.6

MRI Characteristics of Renal Masses

	SIGNAL INTENSITY % CHANGE			AD B VA 0 A 800 s/m 10^{-6} mm
	CORTICOMEDULLARY PHASE	**NEPHROGENIC PHASE**	**EXCRETORY PHASE**	
Clear cell	230%	250%	227%	169
Papillary Carcinoma	49%	92%	88%	884
Chromophobe Carcinoma	98%	183%	159%	113
Oncocytoma	208%	265%	237%	
Angiomyolipoma	353%	285%	222%	
Renal parenchyma				230
TCC				<45

ADC, Apparent diffusion coefficient; *TCC,* transitional cell carcinoma.

Data from Vargas and Chaim, 2012 and Wang et al., 2010.

Oncocytoma typically is described with a central scar, which is observed as a high signal intensity on T2-weighted images. However, this is present in only 54% to 80% of cases (Cornelis and Lasserre, 2013). Unfortunately, a central scar also has been reported in 37% of chromophobe carcinomas (see Fig. 3.28) (Rosenkrantz, 2010). Oncocytoma and chromophobe carcinomas are usually peripheral and are hypovascular compared with the renal cortex (Rosenkrantz, 2010). Necrosis has a high SI on T2-weighted images and low SI on T1-weighted images, which is the same for the central scar associated with oncocytoma (Harmon and King, 1996).

Diffusion-weighted imaging (DWI) detects the restricted movement of water protons within the intra- and extracellular spaces. Wang et al. reported on using an ADC map threshold of 1281×10^{-6} mm^2/s and above for differentiating ccRCC from non-clear cell carcinomas with a 95.9% sensitivity and 94.4% specificity (Table 1 in Wang et al., 2010). Central RCC can be differentiated from transitional cell carcinoma (TCC) of the renal pelvis by setting a threshold of 451×10^{-6} mm^2/s and below on normalized ADC values, resulting in an 83% sensitivity and 71% specificity for detecting TCC (Wehrli and Kim, 2013). It is important to be aware that the calculated ADC map values can vary depending on b-values and TE used for calculation during a specific study (Schmidt et al., 2015). Therefore individual institutional validation of cutoffs may be necessary.

Historically, MRI has been reported superior to earlier CT imaging techniques when attempting to assess if tumor thrombus is present within the renal vein or inferior vena cava. Currently, MRI and CT have the same performance when evaluating for tumor thrombus (Hallscheidt and Fink, 2005). **GBCA is used to differentiate tumor thrombus, which exhibits enhancement, compared with a bland thrombus (clot) which exhibits no enhancement.**

MR and CT can be used to detect and assess lymphadenopathy. Several investigators have been evaluating the use of nanoparticles that are composed of supraparamagnetic iron oxide in the evaluation of lymphadenopathy (Eisner and Feldman, 2009). Normal lymph nodes take up the iron oxide particles via phagocytosis, which results in a signal loss on T2-weighted sequences. Overall, multiparametric MRI (mpMRI) can add important information regarding the tumor microenvironment, which may improve the diagnostic process in evaluating renal masses (see Table 3.6).

Upper Tract and Lower Tract Magnetic Resonance Imaging for Transitional Cell Carcinoma

TCC of the upper tract can be assessed by an MR urogram in addition to the standard renal mass MRI techniques. MR urography (MRU) can be used in patients for whom other imaging modalities are contraindicated. MRU is accomplished by using heavily weighted T2 sequences in which fluid/urine have a high signal intensity or T1-weighted images with gadolinium (Chahal and Taylor, 2005). MRU and CTU have the same accuracy in assessing renal obstruction (Silverman and Leyendecker, 2009). Nephrolithiasis/calcification on

MRI has no signal characteristics; therefore it appears as a signal void on imaging. Urothelial tumors, blood clots, gas, or sloughed renal papilla may exhibit a low signal or signal voids on T2-weighted images secondary to the high signal of urine (Kawashima and Glockner, 2003). Short acquisition times (approximately 2 seconds per image) can be used to differentiate areas of pathology versus ureteral peristalsis (de Leon et al., 2016).

MRI is advantageous over CT imaging of the bladder because of the increased signal contrast between the layers of the bladder. This allows for differentiation between invasive and superficial bladder cancer with an accuracy of 85% (Fig. 3.30) (Tekes and Kamel, 2005). However, bladder underdistention can lead to false negatives during imaging.

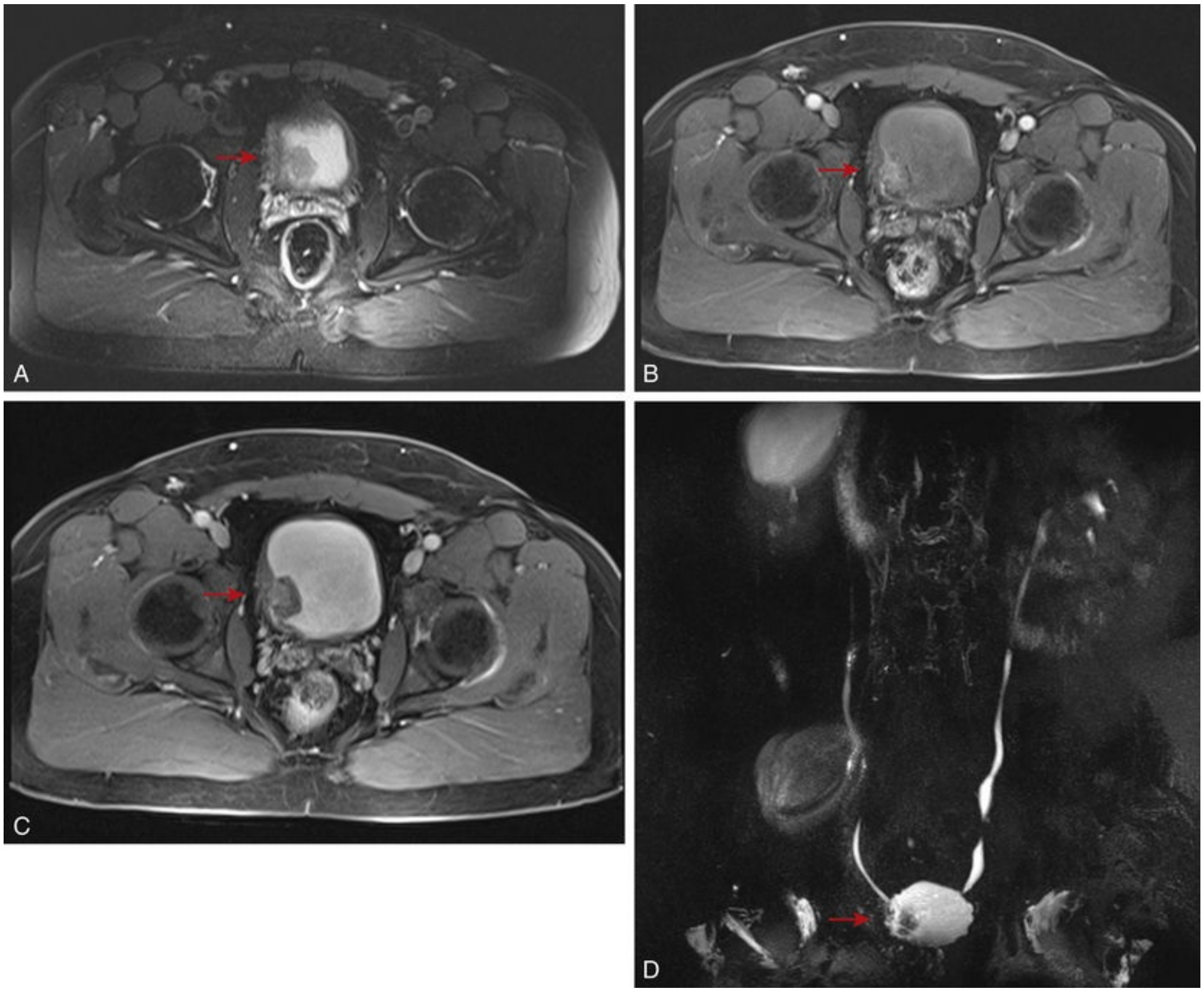

FIG. 3.30 A 51-year-old man with a history of gross hematuria underwent a 1.5T MR urogram. (A) T2 fat-saturated sequence with high T2 signal in bladder (urine). Right bladder wall low signal intensity filling defect *(red arrow).* (B) Fat-suppressed T1 postcontrast arterial phase shows

enhancing right bladder wall polypoid mass and is without bladder wall invasion. (C) Fat-suppressed T1 delayed contrast imaging shows high signal in bladder consistent with IV contrast excretion. Mild persistent signal in right bladder wall mass. (D) Heavily weighted T2 MRI urogram selectively demonstrates high signal of fluid within the ureters and bladder. Right wall bladder filling defect is evident. TURBT confirmed no bladder wall invasion of a high-grade papillary urothelial carcinoma.

Prostate Magnetic Resonance Imaging

Prostate cancer (CaP) is one of the last solid organ malignancies lacking reliable and reproducible imaging, thus leaving urologists to rely on ultrasound as the primary imaging modality and an extended sextant (12 to 14 core) biopsy as the standard of care when assessing a man's risk of CaP. In the last 15 years, several developments have led to the integration of MRI for the detection of CaP. Some of these advances include an increase in the field strength (Tesla) of magnets from 1.0 Tesla (T) to 3T, improved imaging protocols, and surface coils, which resulted in an increase in signal contrast (signal-to-noise ratio [SNR]), allowing for improved visualization and differentiation of normal versus abnormal prostate tissue. The PROMIS study (2017) reported level 1b evidence supporting the use of MRI as a screening tool to be used before prostate biopsies in patients with an elevated PSA (Ahmed et al., 2017). A follow-up study demonstrated that this new approach could be cost effective (Faria, 2018). This was followed by the Goteborg Swedish screening study demonstrating an approximate 50% decrease in biopsies if prostate MRI was used in a screening protocol with a PSA threshold of 2.8 ng/mL. However, even with this supporting data and advances in MRI technology, mpMRI is still not considered a standard of care and therefore not always covered by insurance carriers. The AUA issued guidance (2017) on the use of mpMRI and reported that the evidence available did not fully support the use of mpMRI in all men with an elevated PSA. The current recommendations are reserved for staging a known CaP and patients with a prior negative prostate biopsy (Fulgham, 2017).

Several authors have reported on varying standards that should be used for prostate imaging. The currency in MRI is signal. Signal detection is optimized by using external surface coils and/or an endorectal coil (ERC) and therefore leads to improved image quality. The National Institutes of Health (NIH) completed a study comparing the diagnostic accuracy at 3T with and without ERC in the same patients and compared findings with whole mount histopathology. Results indicated a 36% decrease in sensitivity in detecting CaP when the ERC was not used (Turkbey and Mani, 2013). Follow-up studies by the ACR demonstrated that not all radiology practices have integrated the standards set forth by the PIRAD v2 document (Weinreb and Barentsz, 2016). Urologists must become more informed and ask their radiology partners to optimize imaging and use standardized reporting to improve patient care.

Prostate MRI usually is referred to as an mpMRI, which consists of anatomic and functional imaging techniques. Anatomic imaging should include T1- and T2-weighted images. Functional imaging includes DWI with ADC maps, DCE sequences, and possibly spectroscopy. MR spectroscopy is not always included in the standard mpMRI sequences. MR spectroscopy takes approximately 15 minutes to perform, is labor intensive, and may not add additional information to affect the clinical interpretation of the study.

Initial T1-weighted sequences are obtained to determine if hemorrhage is present within the prostate and, if present, may limit the diagnostic interpretation of the study. If hemorrhage is present, it can lead to false positives on T2-weighted sequences, DWI/ADC, and DCE images, although some authors report no difference in diagnostic accuracy with or without hemorrhage present (Rosenkrantz, 2010). There is debate regarding the time between biopsy and the prostate MRI. A prostate MRI can be performed 3 to 8 weeks after a biopsy to optimize intraprostatic anatomy (Ikonen, 2001; Muller, 2014; Qayyum and Coakley, 2004). The wait period is not required for presurgical staging to determine if there is extraprostatic extension (EPE) and/or seminal vesicle invasion (SVI).

The AUA guidance on mpMRI of the prostate does recommend a minimum exam should be a 1.5T MRI with an ERC or a 3T with or without an ERC and a multiparametric approach (Fulgham, 2017). The use of external phased array coils increases signal detection and therefore improves image quality. A 3T mpMRI with a minimum of 16 to 32 channels phased array coil and an ERC detects the highest signal and therefore provides the highest-quality images (spatial and temporal resolution). However, it is unclear if a radiologist needs this level of quality to make a diagnostic impression. An ERC should never be filled with air or water (Rosen and Bloch, 2007). This causes a decrease in the performance of the T2, DWI, and MR spectroscopy. The most optimal fluids are diamagnetic and proton neutral (Rosen and Bloch, 2007). In patients with metallic implants, alternative scanning protocols may be used, which includes the use of 1.5T scanners or specific 3T protocols for patients with pacemakers.

T2-Weighted Imaging

T2-weighted sequences of the prostate provide anatomic information and should include a triplanar (axial, coronal, and sagittal) or comparable sequence (Fig. 3.31). These images provide a detailed anatomic assessment of the gland. The normal peripheral zone appears as an area of high signal intensity. The central gland with BPH appears as areas of well-demarcated nodules with a heterogeneous signal intensity. Areas of low signal intensity on T2-weighted sequences can represent CaP or prostatitis, atrophy, scars, postprostate biopsy hemorrhage, and/or BPH nodules (Barentsz and Richenberg, 2012). BPH nodules (stromal proliferation) can also be observed within the peripheral zone and can result in a false-positive MRI for cancer (see Fig. 3.31).

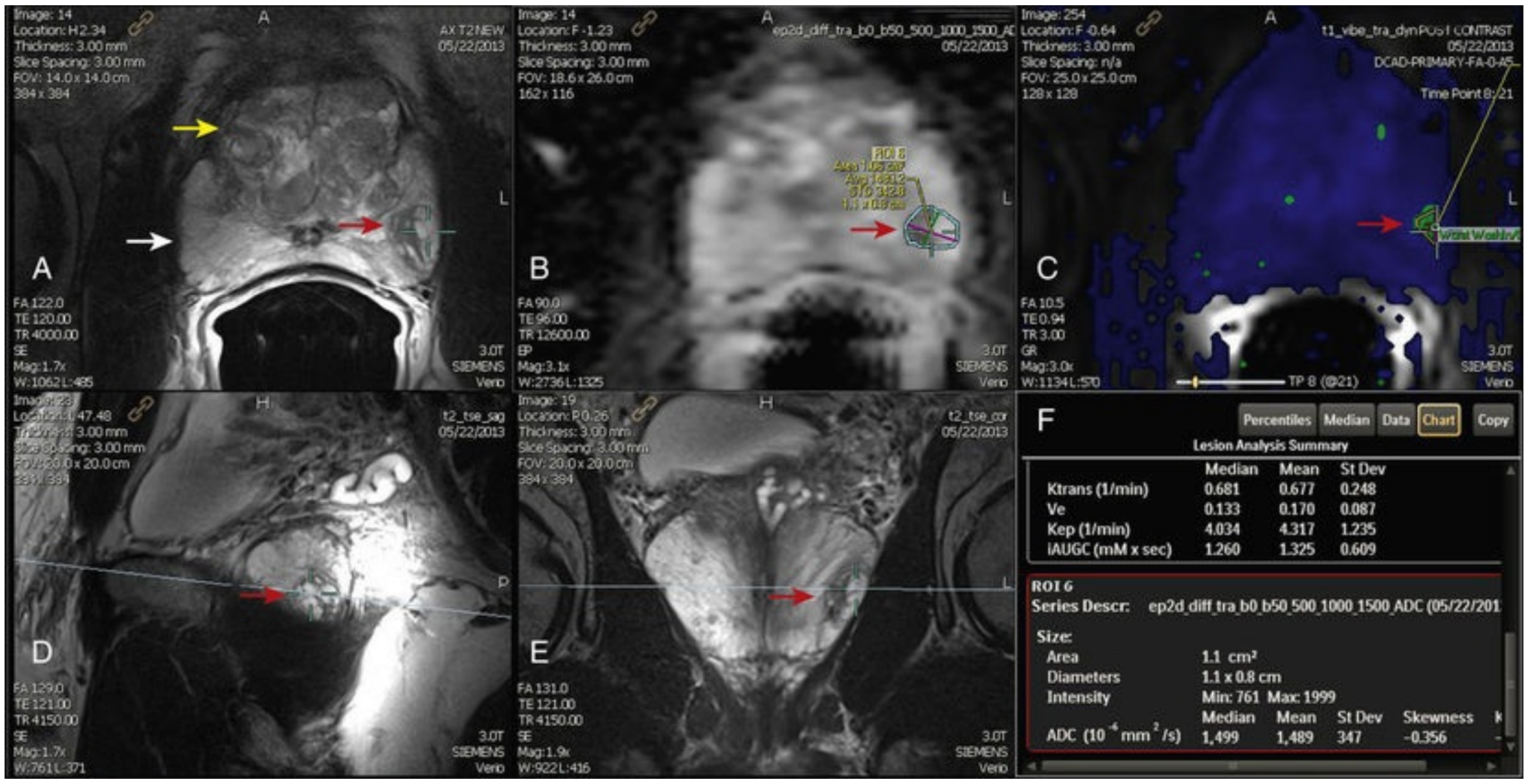

Lesion Analysis Summary

	Median	Mean	St Dev
Ktrans (1/min)	0.681	0.677	0.248
Ve	0.133	0.170	0.087
Kep (1/min)	4.034	4.317	1.235
iAUGC (mM x sec)	1.260	1.325	0.609

ROI 6
Series Descr: ep2d_diff_tra_b0_b50_500_1000_1500_ADC (05/22/201

Size:

Area	1.1 cm²			
Diameters	1.1 x 0.8 cm			
Intensity	Min: 761 Max: 1999			
	Median	Mean	St Dev	Skewness
ADC (10^{-6} mm^2/s)	1,499	1,489	347	-0.356

FIG. 3.31 A 66-year-old African-American man with a prostate-specific antigen (PSA) of 7.0 and two prior negative biopsies. A 3T mpMRI with an endorectal coil of the prostate was obtained. There were two suspicious areas. A, D, and E are the triplanar axial, sagittal, and coronal plane images. The peripheral zone *(blue line)* and the central gland *(yellow arrow)* are well visualized. The *red arrow* represents a well-circumscribed heterogeneous BPH nodule (11 mm × 11 mm × 14 mm) within the peripheral zone with no communication to the central gland. The corresponding apparent diffusion coefficient map (B) demonstrates areas of heterogeneous restriction (761 × 10^{-6} mm^2/s). The lesion on the dynamic contrast-enhanced (DCE) image (C) exhibits focal type 2 and 3 enhancement curves. (F) The DCE quantitative analysis is listed. The patient underwent a fusion biopsy. The lesion was also appreciated on US and no cancer was detected.

T2-weighted imaging alone results in a 58% sensitivity and 93% specificity for detecting CaP within the gland at 3T with an ERC (Turkbey and Mani, 2011). These limitations reinforce the need to perform a multiparametric assessment that incorporates functional imaging and increases the NPV and PPV of the exam to greater than 90% (Turkbey and Mani, 2011). T2-weighted sequences are used to assess EPE and SVI. These areas are represented by low signal intensity. mpMRI at 3T with an ERC has an approximate 90% accuracy when assessing extraprostatic extension on a per-lesion analysis. At the patient level, comparing the accuracy of staging, including microscopic EPE, overall accuracy decreased to 78.5% (Turkbey and Mani, 2011). The use of ERC improves the accuracy of detecting EPE and SVI (Heijmink and Fütterer, 2007).

Diffusion-Weighted Imaging/Apparent Diffusion Coefficient Maps

Diffusion-weighted imaging (DWI) assesses the diffusion of water (Brownian motion) within the magnetic field. The MR magnet detects the phase shift changes in the motion of the water protons. The more cellular a tissue is, the closer the cells are together, which results in a limited motion of water that is reflected as a high signal intensity on DWIs (Manenti, 2006).

As with all MR sequences there are several details that warrant observation. Most important are the b-values associated with DWI. b-Values represent threshold for detecting restriction. As a b-value is increased, less restricted tissues do not exhibit a high signal on DWI. DWI can include multiple b-values, and it is recommended to include at least one b-value greater than 1000 (Rosenkrantz and Minnelli, 2011). The ADC is a quantitative assessment of the DWI. This is represented by an area of low signal on the images (dark spot) (Fig. 3.32D). Some authors recommend including a b-2000 sequence on DWI; it has been shown that CaP exhibits a high signal intensity compared with the rest of the gland (Fig. 3.32F) (Ueno and Kitajima, 2013). There has been interest in shortening the image acquisition time by discontinuing DCE from the standard protocol (Jambor, 2017; Scialpi et al., 2016). Rosenkrantz et al. replied to these suggestions and highlighted the pitfalls that could arise with this approach. They recommended against discontinuing the DCE sequence because it can aid in the detection of small lesions, lesions with poor signal contrast with adjoining tissues, and overcome possible artifacts limiting T2 and DWI sequences (Rosenkrantz et al., 2016).

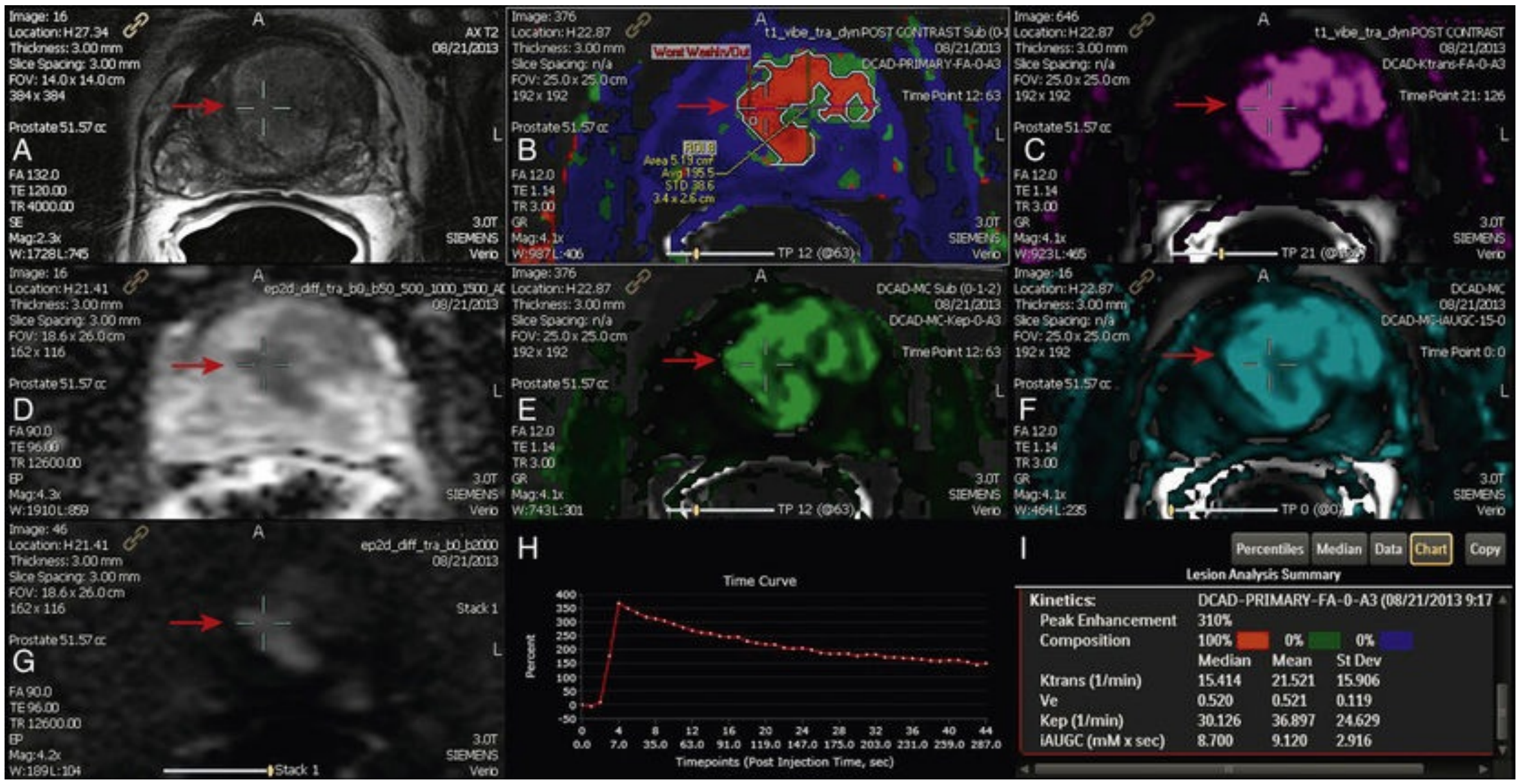

Lesion Analysis Summary

Kinetics:	DCAD-PRIMARY-FA-0-A3 (08/21/2013 9:17		
Peak Enhancement	310%		
Composition	100% 🟥	0% 🟩	0% 🟦
	Median	Mean	St Dev
Ktrans (1/min)	15.414	21.521	15.906
Ve	0.520	0.521	0.119
Kep (1/min)	30.126	36.897	24.629
iAUGC (mM x sec)	8.700	9.120	2.916

FIG. 3.32 A 65-year-old African-American man with a prostate-specific antigen (PSA) of 38.9 and 16 prior negative biopsies with MR US fusion biopsy proven Gleason 4+4 prostate cancer. (A) T2-weighted image with an anterior lesion within the central gland, 3.5 cm × 2.7 cm × 3.5 cm *(red arrow).* (B and H) Dynamic contrast-enhanced MR sequence with color mapping exhibiting a focal type 3 enhancement curve. (C) Elevated K_{trans}. (D) Apparent diffusion coefficient map with low signal. (E) Elevated K_{ep}. (F) Area under the curve (AUC). (G) b-2000 Diffusion-weighted sequence with an area of high signal intensity. (I) Quantitative summary of the large anterior central gland lesion.

The ADC value computed from the DWI has been shown to correlate directly with the Gleason score (Turkbey and Mani, 2011). Intuitively this makes sense, as an increase in cellularity results in an increase in the Gleason score. The extracellular/intracellular spaces between the cells are decreased and therefore reflected as areas of increased restriction.

Dynamic Contrast-Enhanced Magnetic Resonance Imaging

DCE MRI is T1-weighted imaging with Gd-based contrast agents. DCE is not a simple assessment of enhancement versus no enhancement. DCE MRI assesses vascular permeability and perfusion of the prostate by obtaining multiple image acquisitions over 5 to 10 minutes at a temporal resolution of less than or equal to 5 seconds (Verma and Turkbey, 2012). The 5-second temporal resolution requires a decrease in the size of the imaging matrix, resulting in a “lower-resolution image.” DCE MRI is not meant to obtain clear anatomic images, and it is used to assess the blood flow and vascular permeability throughout the gland over time.

DCE provides qualitative, semiquantitative, and quantitative information regarding enhancement within the prostate. A qualitative approach consists of visually assessing early enhancement and early washout within the prostate. The use of computer-aided diagnostic systems provides specific information regarding enhancement characteristics. A semiquantitative approach assesses enhancement over time (Verma and Turkbey, 2012). There are three distinct curves associated with prostate imaging (Fig. 3.33). Because of the overlap of all three curve types with benign conditions, it is useful to combine these approaches in mpMRI. A quantitative assessment for cancer was first proposed by Tofts and Wicks observing the pharmacokinetics of the contrast within the gland (Tofts and Wicks, 1991). K_{trans} (transfer constant) represents the transfer rate (permeability) of contrast between the intravascular space and the extracellular space (or blood flow) to the tissues depending on the hemodynamics at the time of the study (Tofts and Brix, 1999). K_{ep} (rate constant) is the rate of efflux of contrast back into the vascular space (Tofts and Brix, 1999). These quantitative metrics have not been incorporated in the daily work flow of most radiologists; however, they are being evaluated for possible decision analysis software (see Fig. 3.32C, D, E, and H).

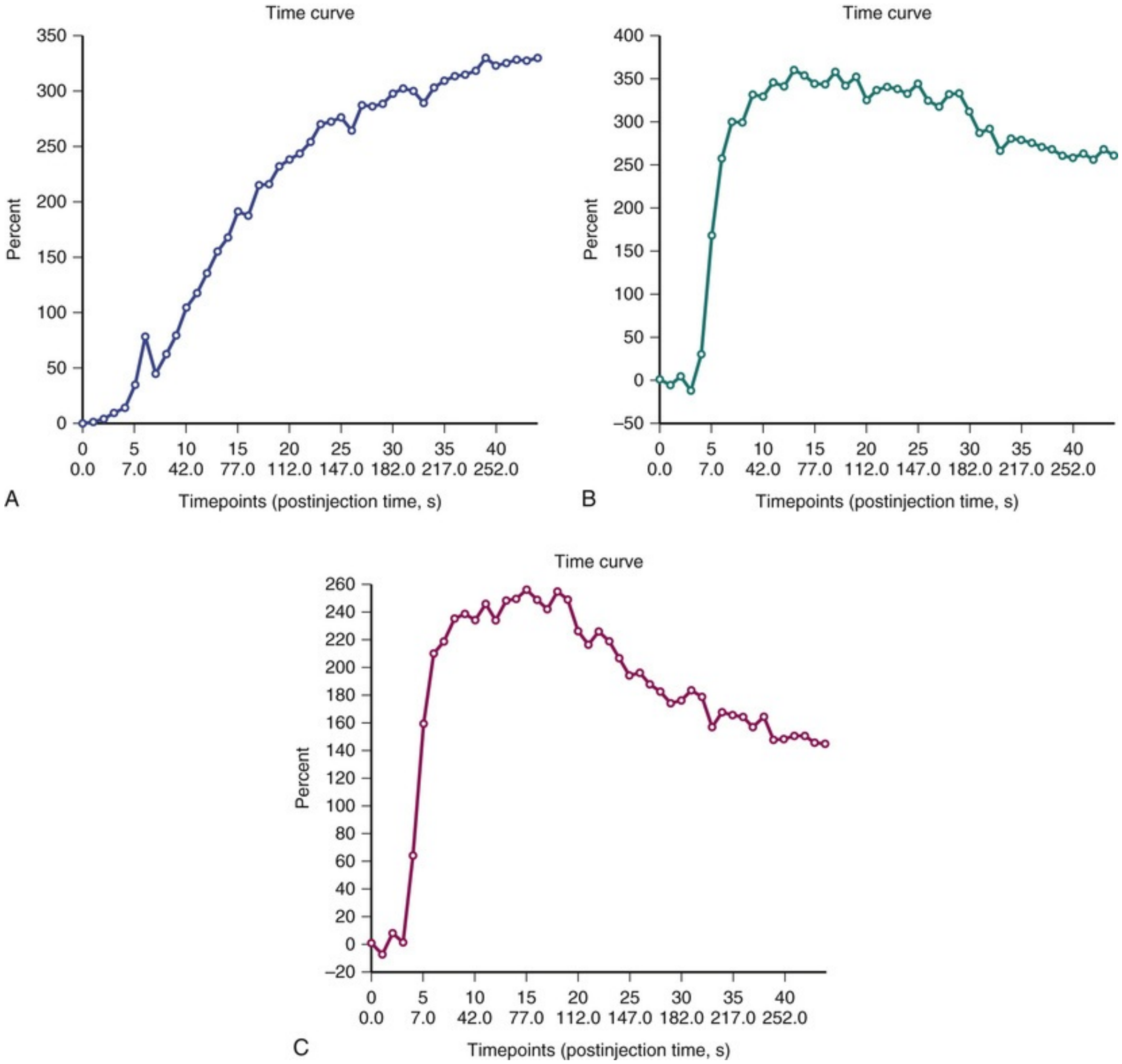

FIG. 3.33 (A) Type 1 curve is normal enhancement with persistent increase in enhancement over time. (B) Type 2 curve is early enhancement with a plateau (no washout). (C) Type 3 curve, which is the most indicative of prostate cancer, can overlap with inflammation and this is characterized by early enhancement with an early washout of contrast.

DCE MRI has a reported 46% to 96% sensitivity and 74% to 96% specificity for detecting CaP. These large ranges can be due to the high variability resulting from patient selection, MRI technique, and pathology correlation and reader experience (Verma and Turkbey, 2012).

Magnetic Resonance Spectroscopy

Proton MR spectroscopic imaging (MRSI) detects the concentration of citrate, choline, and creatine within the prostate. As cells go through malignant transformation, citrate decreases, and creatine and choline levels increase secondary to increased cellular turnover (Choi, 2007). An increase of 2 standard deviations of choline-to-citrate ratio is indicative of cancer (Kurhanewicz, 1996). This process is time consuming (15 minutes) and has fallen out of favor when used in a nonresearch setting. Turkbey and Mani reported only a 7% increase in PPV and NPV using MRSI (Turkbey and Mani, 2011). Therefore the additional time may not clinically affect cancer detection rates. There is still a significant research potential associated with MRSI. Some authors are using MRSI assessment cellular metabolism (choline, creatine, and citrate) to evaluate biochemical recurrence after radiation therapy (Zhang and Westphalen, 2014).

Multiparametric Magnetic Resonance Imaging

The combination of T2, DCE, and DWI has yielded NPV and PPV greater than 90% (Abd-Alazeez and Kirkham, 2014; Turkbey and Mani, 2011). It is important to understand that high-quality MRI requires tuning of the MR magnets, a dedicated staff to perform the studies, and pathology correlation for the urologists/radiologists. There are thousands of adjustable settings to obtain high-quality images. It is important to start with the basics, which are outlined in the most recent *Prostate Imaging: Reporting and Data System V2* from the ACR (Weinreb and Barentsz, 2016). If an ERC is used during the study, an antispasmodic agent should be used to decrease the artifact created by rectal spasms. The MR technologist should actively review images during the study and adjust or repeat sequences as needed. Using newer magnets with higher field strength, external coils, and an ERC can decrease image acquisition time and may improve image quality (Fig. 3.34) (Heijmink, 2011).

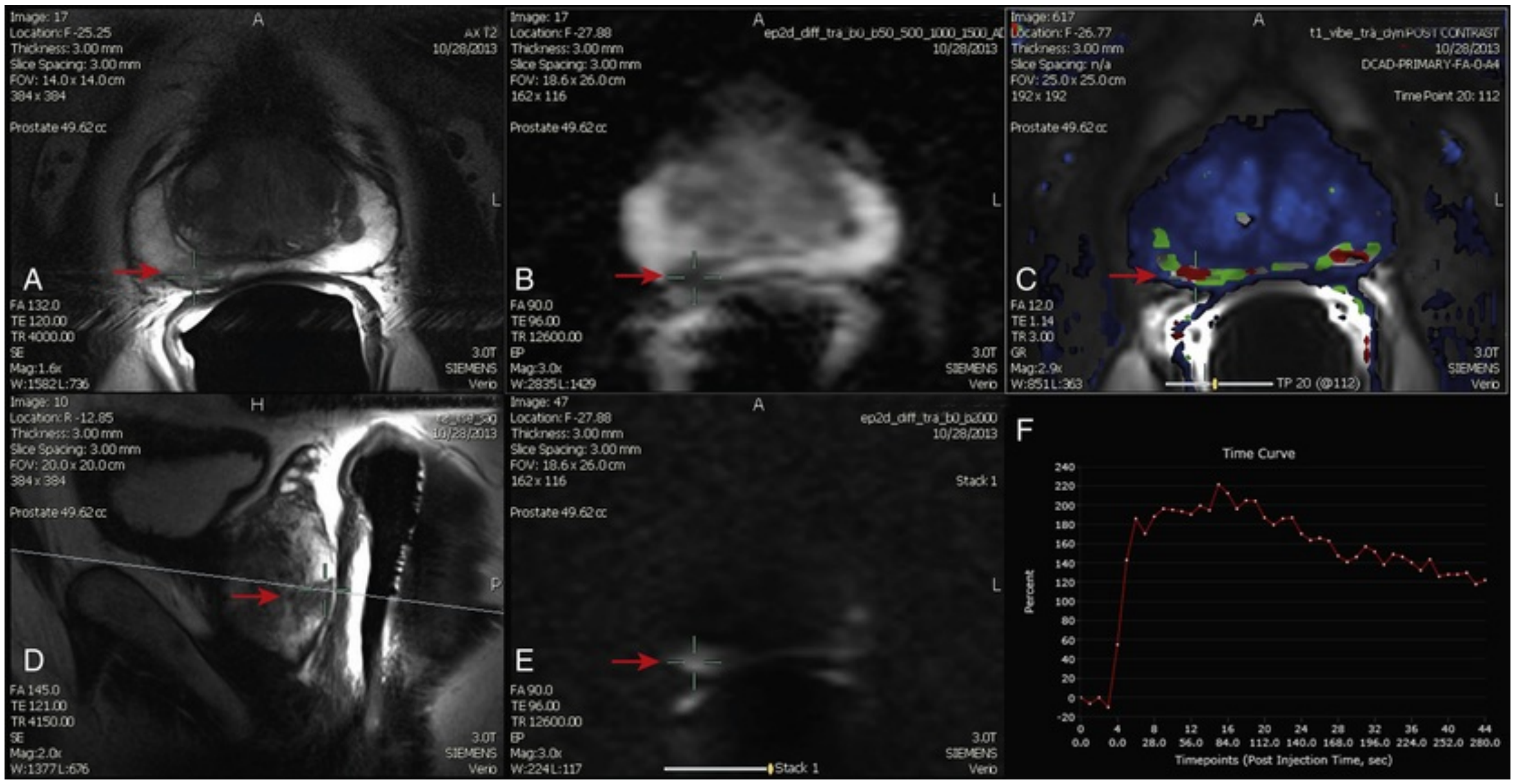

FIG. 3.34 A 61-year-old Caucasian man with an increasing prostate-specific antigen (4.65 ng/mL) after a prior negative biopsy 1 year ago. 3T mpMRI of the prostate with an endorectal coil was obtained. (A) T2-weighted image with a homogeneous low signal intensity lesion within the right posterior peripheral zone *(red arrow).* (B) Apparent diffusion coefficient (ADC) map with a corresponding low signal intensity to the T2 sequence. (C) Dynamic contrast-enhanced **(**DCE) MRI with color mapping exhibiting a focal type 3 enhancement curve. (D) Sagittal T2 sequence with a low signal lesion within the peripheral zone. (E) b-2000 Diffusion-weighted image with high signal corresponding to T2, ADC, DCE abnormalities. (F) Type 3 enhancement curve. The pathology was Gleason 3+4 prostate cancer, zone 3L, volume was 0.3 cc (9 × 8 × 9 mm).

As more and more physicians begin to use mpMRI of the prostate (Fig. 3.35), maintaining quality and improving interpretation is extremely important. Each center should have designated readers. Prostate MRI is like no other study in radiology and can benefit from consensus reading and pathology correlation, especially when an imaging program is established (Muller, 2013). The PIRADS v2 has given guidance to standardize zonal reporting, which helps urologists use information from the report regarding slice #2 on T2-weighted sequence and zonal location to identify suspicious areas (Table 3.7).

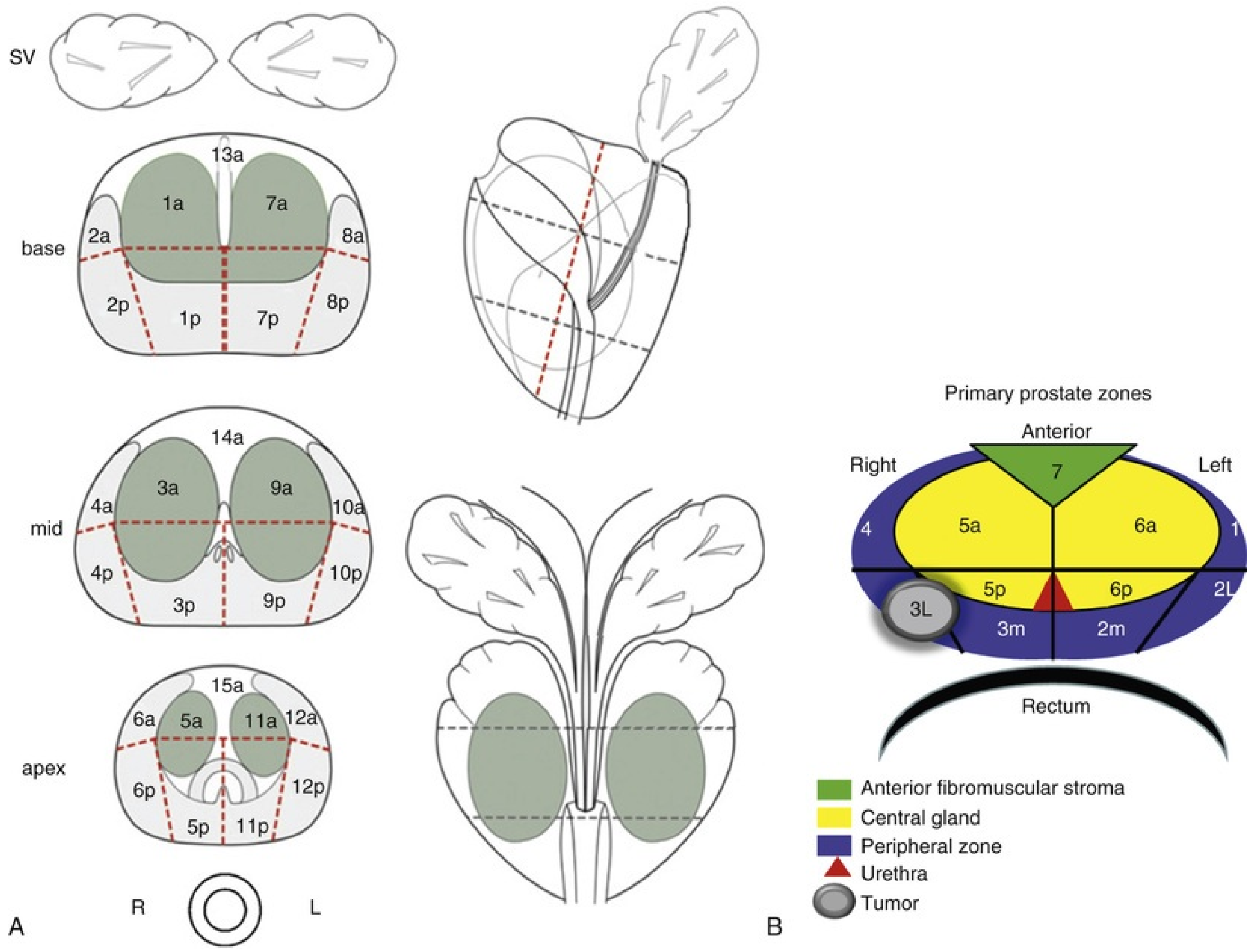
SV
base
13a
1a
7a
2a
8a
2p
1p
7p
8p
mid
14a
3a
9a
4a
10a
4p
10p
3p
9p
apex
15a
6a
5a
11a
12a
6p
12p
5p
11p
R
L
A
B
Primary prostate zones
Anterior
Right
Left
7
4
5a
6a
1
5p
6p
2L
3L
3m
2m
Rectum
🟩 Anterior fibromuscular stroma
🟨 Central gland
🟦 Peripheral zone
▲ Urethra
● Tumor

FIG. 3.35 **PIRADS v2 zonal anatomy.** Recommendations are to include zone as well as slice number(s) for the areas considered suspicious on mpMRI of the prostate.

TABLE 3.7

PIRADS v2 Assessment Categories

1 **Very Low**: Clinically significant disease is highly unlikely to be present.

2 **Low:** Clinically significant disease is unlikely to be present.

3 **Intermediate**: Clinically significant disease is equivocal.

4 **High**: Clinically significant disease is likely to be present.

5 **Very High**: Clinically significant disease is highly likely to be present.

From Barentsz JO, Weinrebb JC, Verma S, et al: Synopsis of the PI-RADS v2 Guidelines for Multiparametric Prostate Magnetic Resonance Imaging and

Recommendations for Use, *Eur Urol* 69(1):41–49, 2016.

In summary, mpMRI of the prostate is a potential new tool that can detect, quantify, stage, and influence treatment planning for patients with CaP. mpMRI has also been shown to correctly select patients with low-grade/low-volume disease for active surveillance with an accuracy of 92% (Turkbey and Mani, 2013). mpMRI of the prostate also provides information on possible bone involvement or lymphadenopathy at the time of diagnosis. The accuracy of MRI detecting lymphadenopathy has a sensitivity up to 86% and specificity of 78% to 90% (Talab and Preston, 2012). It is important that scanning parameters and updates from the American College of Radiology are observed and integrated as best as possible.

Magnetic Resonance Fusion-Guided Prostate Biopsy

MR US fusion-guided prostate biopsy is the next step in the integration of high-quality intraprostatic imaging in the urologist armamentarium for screening and diagnosing CaP. There are multiple fusion biopsy systems on the market. The performance of these systems does differ slightly from one vendor to the other. However, the most important factor is the quality of the mpMRI and abilities of the imaging team. These two factors have been shown to result in increased cancer detection rates in patients undergoing targeted biopsies (Pinto and Chung, 2011; Siddiqui et al., 2015; Sonn and Natarajan, 2013).

Currently, a targeted biopsy or mpMRI alone is not an alternative to the standard of care in screening men for CaP. mpMRI offers a distinct advantage when selecting men to undergo a biopsy with an elevated PSA. PSA is not CaP-specific and can be elevated because of numerous reasons, including inflammation/infection, BPH, and/or physical manipulation. The MRI can assess BPH and inflammation before a biopsy; this may allow men with a persistently elevated PSA and an initial negative 12-core biopsy to avoid undergoing a second biopsy. In addition, mpMRI of the prostate can detect intermediate and high-risk disease but has difficulty detecting low-grade/low-volume cancers, which may decrease overdiagnosis and overtreatment of clinically insignificant disease. Moore et al. reported that 38% of men with an elevated PSA did not have any visible lesions on mpMRI. In this study, a 12-core biopsy only detected clinically significant cancer for 2.3% of the patients (Gleason ≥7 or a core length of >5 mm) (Moore, 2013).

The MR US fusion-guided biopsy has the advantage of using the MRI to target specific areas (i.e., anterior or central gland lesions) within the prostate that may be missed or undersampled on a standard systematic 12-core biopsy. In addition, the 12-core biopsy may miss many lesions within the peripheral zone.

The cancer detection rates for targeted biopsies is superior compared with a cognitive biopsy in which one uses the information from the MRI for freehand targeting (Wysock, 2014). The CDR rate for fusion-targeted biopsies with moderate to high suspicion on mpMRI is approximately 50% to 72% (Pinto and Chung, 2011; Rastinehad and Turkbey, 2014; Sonn and Natarajan, 2013).

For more information, see Chapter 151.

Key Points: Magnetic Resonance Imaging

- When a renal mass is seen on MRI, the most important characteristic indicating the presence of a malignancy is enhancement of the mass.
- NSF is seen in patients with severe renal insufficiency who are exposed to gadolinium contrast media.
- Pheochromocytoma, metastatic lesion to the adrenal gland, and primary adrenal cortical carcinoma are bright on T2-weighted images.

Acknowledgments

Thank you to the Drs. Ben-Levi, Villani, and Friedman for their help acquiring and reviewing images.

References

Radiation Management in Uroradiology

Geise RA, Morin RL. Radiation management in uroradiology. Pollack HM, McClennan BL. *Clinical urography*. ed 2. Saunders: Philadelphia; 2000:13–14.

National Council on Radiation Protection and Measurements (NCRP). *Report No. 160 - Limitation of Exposure to Ionizing Radiation. Bethesda*. 2012.

National Research Council of the National Academies. *Board on radiation effects research: health risks from exposure to low levels of ionizing radiation, BEIR VII phase 2*. National Academies Press: Washington, DC; 2006 http://www.nap.edu.

Contrast Media

Abraham JL, Thakral C, Skov L, et al. Dermal inorganic gadolinium concentrations: evidence for in vivo transmetallation and long-term persistence in nephrogenic systemic fibrosis. *Br J Dermatol*. 2008;158(2):273–280.

American College of Radiology (ACR). *Manual on contrast media, ed 10.3*. http://www.acr.org/SecondaryMainMenuCategories/quality_s 2017.

Bailey CJ, Turner RC. Metformin. *N Engl J Med*. 1996;334:574–579.

Beaty AD, Lieberman PL, Slavin RG. Seafood allergy and radiocontrast media: are physicians propagating a myth? *Am J Med*. 2008;121(2):158 e1–158 e4 [PMID] 18261505.

Boehm I. Seafood allergy and radiocontrast media: are physicians propagating a myth? *Am J Med*. 2008;121(8):e19

[PMID] 18691465.

Briguori C, Colombo A, Airoldi F, et al. Gadolinium-based contrast agents and nephrotoxicity in patients undergoing coronary artery procedures. *Catheter Cardiovasc Interv*. 2006;67(2):175–180.

Brockow K. Contrast media hypersensitivity–scope of the problem. *Toxicology*. 2005;209:189–192.

Bush WH, Swanson DP. Acute reactions to intravascular contrast media: types, risk factors, recognition, and specific treatment. *AJR Am J Roentgenol*. 1991;157:1153–1161.

Cochran ST, Bomyea K, Sayre JW. Trends in adverse events after IV administration of contrast media. *AJR Am J Roentgenol*. 2001;176:1385–1388.

Cohan RH, Dunnick NR. Intravascular contrast media: adverse reactions. *AJR Am J Roentgenol*. 1987;149:665–670.

Collidge TA, Thomson PC, Mark PB, et al. Gadolinium-enhanced MR imaging and nephrogenic systemic fibrosis: retrospective study of a renal replacement therapy cohort. *Radiology*. 2007;245(1):168–175.

Davenport MS, Cohan RH, Khalatbari S, et al. Hyperglycemia in hospitalized patients receiving corticosteroid premedication before the administration of radiologic contrast medium. *Acad Radiol*. 2011;18(3):384–390 [PMID] 21215661.

Davenport MS, Khalatbari S, Cohan RH, et al. Contrast material-induced nephrotoxicity and intravenous low-osmolality iodinated contrast material: risk stratification by using estimated glomerular filtration rate. *Radiology*. 2013;268(3):719–728.

Davenport MS, Khalatbari S, Dillman JR, et al. Contrast material-induced nephrotoxicity and intravenous low-osmolality iodinated contrast material. *Radiology*. 2013;267(1):94–105.

Davenport MS, Mervak BM, Ellis JH, et al. Indirect cost and harm attributable to oral 13-hour inpatient corticosteroid prophylaxis before contrast-enhanced CT. *Radiology*. 2016;279(2):492–501 [PMID] 26536404.

Dawson P, Cosgrove DO, Grainger RG. *Textbook of contrast media*. Isis Medical Media: Oxford; 1999.

Dillman JR, Ellis JH, Cohan RH, et al. Safety of gadolinium based contrast material in sickle cell disease. *J Magn Reson Imaging*. 2011;34:917–920.

Dunnick NR, Cohan RH. Cost, corticosteroids, and contrast media. *AJR Am J Roentgenol*. 1994;162:527–529.

Elicker BM, Cypel YS, Weinreb JC. IV contrast administration for CT: a survey of practices for the screening and prevention of contrast nephropathy. *AJR Am J Roentgenol*. 2006;186:1651–1658.

Greenberger PA, Patterson R, Radin RC. Two pretreatment regimens for high-risk patients receiving radiographic contrast media. *J Allergy Clin Immunol*. 1984;74(4 Pt 1):540–543 [PMID] 6491099.

Greenberger PA, Patterson R, Tapio CM. Prophylaxis against repeated radiocontrast media reactions in 857 cases. Adverse experience with cimetidine and safety of beta-adrenergic antagonists. *Arch Intern Med*. 1985;145(12):2197–2200 [PMID] 2866755.

Grobner T. Gadolinium: a specific trigger for the development of nephrogenic fibrosing dermopathy and nephrogenic systemic fibrosis? *Nephrol Dial Transplant*. 2006;21:1104–1108.

Heinrich MC, Kuhlmann MK, Grgic A, et al. Cytotoxic effects of ionic high-osmolar, nonionic monomeric, and nonionic iso-osmolar dimeric iodinated contrast media on renal tubular cells in vitro. *Radiology*. 2005;235(3):843–849.

Herts BR, Schneider E, Poggio ED, et al. Identifying outpatients with renal insufficiency before contrast-enhanced CT by using estimated glomerular filtration rates versus serum creatinine levels. *Radiology*. 2008;248(1):106–113.

Jung JW, Kang HR, Kim MH, et al. Immediate hypersensitivity reaction to gadolinium-based MR contrast media. *Radiology*. 2012;264(2):414–422 [PMID] 22550309.

Kanal E, Broome DR, Martin DR, et al. Response to the FDA's May 23, 2007, nephrogenic systemic fibrosis update. *Radiology*. 2008;246:11–14.

Katayama H, Yamaguchi K, Kozuka T, et al. Adverse reactions to ionic and nonionic contrast media. A report from the Japanese committee on the safety of contrast media. *Radiology*. 1990;175:621–628 [PMID] 2343107.

Kelly AM, Dwamena B, Cronin P, et al. Meta-analysis: effectiveness of drugs for preventing contrast-induced nephropathy. *Ann Intern Med*. 2008;148(4):284–294.

Lalli AF. Urographic contrast media reactions and anxiety. *Radiology*. 1974;112(2):267–271 [PMID] 4600651.

Lane DM, Alpern MB, Visintainer PF, et al. Elevated risk of anaphylactoid reaction from radiographic contrast media is associated with both beta-blocker exposure and cardiovascular disorders. *Arch Intern Med*. 1993;153(17):2033–2040 [PMID] 8102844.

Lasser EC. The multipotential pseudoantigenicity of x-ray contrast media. Pseudoantigen excess may downregulate the release of hypotensive mediators. *Int Arch Allergy Immunol*. 2000;123(4):282–290 [PMID] 11146385.

Lasser EC. Pretreatment with corticosteroids to prevent reactions to IV contrast material: overview and implications. *AJR Am J Roentgenol*. 1988;150:257–259.

Lasser EC, Berry CC, Talner LB, et al. Pretreatment with corticosteroids to alleviate reactions to intravenous contrast material. *N Engl J Med*. 1987;317(14):845–849 [PMID]

3627208.

Lieberman PL, Seigle RL. Reactions to radiocontrast material. Anaphylactoid events in radiology. *Clin Rev Allergy Immunol*. 1999;17:469–496.

Lightfoot CB, Abraham RJ, Mammen T, et al. Survey of radiologist's knowledge regarding the management of severe contrast material induced allergic reactions. *Radiology*. 2009;251:691–696.

Liu ZZ, Viegas VU, Perlewitz A, et al. Iodinated contrast media differentially affect afferent and efferent arteriolar tone and reactivity in mice: a possible explanation for reduced glomerular filtration rate. *Radiology*. 2012;265(3):762–771 [22].

Loh S, Bagheri S, Katzberg RW, et al. Delayed adverse reaction to contrast-enhanced CT: a prospective single center study comparison to control group without enhancement. *Radiology*. 2010;255:764–771.

Marckmann P, Skov L, Rossen K, et al. Nephrogenic systemic fibrosis: suspected causative role of gadodiamide used for contrast-enhanced magnetic resonance imaging. *J Am Soc Nephrol*. 2006;17:2359–2362.

McDonald JS, McDonald RJ, Carter RE, et al. Risk of intravenous contrast material mediated acute kidney injury: a propensity score-matched study stratified by baseline-estimated glomerular filtration rate. *Radiology*. 2014;271(1):65–73.

McDonald RJ, McDonald JS, Bida JP, et al. Intravenous contrast material-induced nephropathy: causal or coincident phenomenon? *Radiology*. 2013;267(1):106–118.

Mehrizi M, Pascuzzi RM. Complications of radiologic contrast in patients with myasthenia gravis. *Muscle Nerve*. 2014;50(3):443–444 [PMID] 24677227.

Mehta RL, Kellum JA, Shah SV, et al. Acute kidney injury network: report of an initiative to improve outcomes in acute kidney injury. *Crit Care*. 2007;11:R31.

Mervak BM, Cohan RH, Ellis JH, et al. 5-hour intravenous corticosteroid premedication has a breakthrough reaction rate that is non-inferior to that of a traditional 13-hour oral regimen. *Radiology*. 2017;285(2):425–433.

Mervak BM, Davenport MS, Ellis JH, et al. Rates of breakthrough reactions in inpatients at high risk receiving premedication before contrast-enhanced CT. *AJR Am J Roentgenol*. 2015;205(1):77–84 [PMID] 26102383.

Morcos SK. Review article: acute serious and fatal reactions to contrast media: our current understanding. *Br J Radiol*. 2005;78(932):686–693 [PMID] 16046418.

Mortele KJ, Oliva MR, Ondategui S, et al. Universal use of nonionic iodinated contrast medium for CT: evaluation of safety in a large urban teaching hospital. *AJR Am J Roentgenol*. 2005;184:31–34.

Mukherjee JJ, Peppercorn PD, Reznek RH, et al. Pheochromocytoma: effect of nonionic contrast medium in CT on circulating catecholamine levels. *Radiology*. 1997;202(1):227–231.

Nash K, Hafeez A, Hou S. Hospital-acquired renal insufficiency. *Am J Kidney Dis*. 2002;39:930–936.

Nelson RC, Anderson FA Jr, Birnbaun BA, et al. Contrast media extravasation during dynamic CT: detection with an extravasation detection accessory. *Radiology*. 1988;209:837–843.

Newhouse JH, RoyChoudhury A. Quantitating contrast medium–induced nephropathy: controlling the controls. *Radiology*. 2013;267:4–8.

O'Malley RB, Cohan RH, Ellis JH, et al. A survey on the use of premedication prior to iodinated and gadolinium-based contrast material administration. *J Am Coll Radiol*.

2011;8(5):345–354.

Pannu N, Wiebe N, Tonelli M, et al. Prophylaxis strategies for contrast-induced nephropathy. *J Am Med Assoc*. 2006;295(23):2765–2779.

Safirstein R, Andrade L, Vieira JM. Acetylcysteine and nephrotoxic effects of radiographic contrast agents-a new use for an old drug. *N Engl J Med*. 2000;343:210–212.

Shabana WM, Cohan RH, Ellis JH, et al. Nephrogenic systemic fibrosis: a report of 29 cases. *AJR Am J Roentgenol*. 2008;190:736–741.

Shehadi WH. Adverse reactions to intravascularly administered contrast media. A comprehensive study based on a prospective survey. *Am J Roentgenol Radium Ther Nucl Med*. 1975;124(1):145–152 [PMID] 1170768.

Silberstein EB, Alavi A, Balon HR, et al. The SNMMI practice guideline for therapy of thyroid disease with 131i 3.0. *J Nucl Med*. 2012;53(10):1633–1651 [PMID] 22787108.

Solomon RJ, Natarajan MK, Doucet S, et al. Cardiac angiography in renally impaired patients (CARE) study: a randomized double blinded trial of contrast induced nephropathy in patients with chronic kidney disease. *Circulation*. 2007;115:3189–3196.

Somashekar DK, Davenport MS, Cohan RH, et al. Effect of intravenous low-osmolality iodinated contrast media on patients with myasthenia gravis. *Radiology*. 2013;267(3):727–734.

Spring DB, Bettman MA, Barkan HE. Deaths related to iodinated contrast media reported spontaneously to US food and drug administration 1978-1994: effect of the availability of low-osmolality contrast media. *Radiology*. 1997;204:333–337.

Thomsen HS, Muller RN, Mattrey RF. *Trends in contrast media*. Springer-Verlag: Germany; 1999.

Todd DJ, Kagan A, Chibnik LB, et al. Cutaneous changes of nephrogenic systemic fibrosis: predictor of early mortality and association with gadolinium exposure. *Arthritis Rheum*. 2007;56:3433–3441.

van der Molen AJ, Thomsen HS, Morcos SK. Effect of iodinated contrast media on thyroid function in adults. *Eur Radiol*. 2004;14(5):902–907 149973340.

Wang CL, Cohan RH, Ellis JH, et al. Frequency, outcome, and appropriateness of treatment of nonionic iodinated contrast media reactions. *AJR Am J Roentgenol*. 2008;191(2):409–415.

Wiholm BE, Myrhed M. Metformin-associated lactic acidosis in Sweden 1977-1991. *Eur J Clin Pharmacol*. 1993;44:589–591.

Zoungas S, Ninomiya T, Huxley R, et al. Systematic review: sodium bicarbonate treatment regimens for the prevention of contrast induced nephropathy. *Ann Intern Med*. 2009;151:631–638.

Retrograde Pyelography

Christiano AP, Hollowell CM, Kim H, et al. Double-blind randomized comparison of single-dose ciprofloxacin versus intravenous cefazolin in patients undergoing outpatient endourologic surgery. *Urology*. 2000;55:182–185.

Johenning PW. Reactions to contrast material during retrograde pyelography. *Urology*. 1980;16:442–443.

Weese DL, Greenberg HM, Zimmern PE. Contrast media reactions during voiding cystourethrography or retrograde pyelography. *Urology*. 1993;41:81–84.

Loopography

Hudson HC, Kramer SA, Anderson EE. Identification of ureteroileal obstruction in retrograde loopogram. *Urology*. 1981;17:147–148.

Static Cystography

Broghammer J, Wessells H. Acute management of bladder and urethral trauma. *AUA Update Series*. 2008;27(24):221–231.

Quagliano PV, Delair SM, Malhotra AK. Diagnosis of blunt bladder injury: a prospective comparative study of computed tomography cystography and conventional retrograde cystography. *J Trauma*. 2006;61:410–421.

Voiding Cystourethrogram

Barbaric ZL. Autonomic dysreflexia in patients with spinal cord lesions: complication of voiding cystourethrography and ileal loopography. *AJR Am J Roentgenol*. 1976;127:93–295.

Fleischman S, Shah P. Autonomic dysreflexia: an unusual radiologic complication. *Radiology*. 1977;124:695–697.

Linsenmeyer TA, Campagnolo DI, Chou I. Silent autonomic dysreflexia during voiding in men with spinal cord injuries. *J Urol*. 1996;155:519–522.

Nuclear Scintigraphy

Ell PJ, Gambhir SS. *Nuclear medicine in clinical diagnosis and treatment*. ed 3. Churchill-Livingston: London; 2004.

Eshima D, Fritzberg AR, Taylor A Jr. 99mTc renal tubular function agents: current status. *Semin Nucl Med*. 1990;20:28–40.

Fritzberg AR, Kasina S, Echima D. Synthesis and biological evaluation of technetium-99m MAG3 as a hippuran replacement. *J Nucl Med*. 1986;27:111–116.

Gates GF. Filtration fraction and its implications for radionuclide renography using diethylenetriaminepentaacetic acid and mercaptoacetyltriglycine. *Clin Nucl Med*. 2004;29:231–237.

Itoh K. 99mTc-MAG3: review of pharmacokinetics, clinical application to renal diseases and quantification of renal function. *Ann Nucl Med*. 2001;15:179–190.

Kim SE, Kim DY, Lee DS, et al. Absent or faint uptake on bone scan-etiology and significance in metastatic bone disease. *Clin Nucl Med*. 1991;16:545–550.

Klopper JF, Hauser W, Atkins HL. Evaluation of 99mTc-DTPA for the measurement of glomerular filtration rate. *J Nucl Med*. 1972;13:107–110.

Lin TH, Khentigan A, Winchell HS. A 99mTc-chelate substitute for organoradiomercurial renal agents. *J Nucl Med*. 1974;15:34–35.

Narayan P, Lillian D, Hellstrom W, et al. The benefits of combining early radionuclide renal scintigraphy with routine bone scans in patients with prostate cancer. *J Urol*. 1988;140:1448–1553.

Peters AM. Scintigraphic imaging of renal function. *Exp Nephrol*. 1998;6:391–397.

Positron Emission Tomography (PET)

Alongi P, Picchio M, Zattoni F, et al. Recurrent renal cell carcinoma: clinical and prognostic value of FDG PET/CT. *Eur J Nucl Med Mol Imaging*. 2016;43:464–473.

Ambrosini V, Zucchini G, Nicolini S, et al. ^{18}F-FDG PET/CT impact on testicular tumours clinical management. *Eur J Nucl Med Mol Imaging*. 2014;41:668–673.

Ardito A, Massaglia C, Pelosi E, et al. ^{18}F-FDG PET/CT in the post-operative monitoring of patients with adrenocortical carcinoma. *Eur J Endocrinol*. 2015;173:749–756.

Bachner M, Loriot Y, Gross-Goupil M, et al. 2-^{18}fluoro-deoxy-D-glucose positron emission tomography (FDG-PET) for postchemotherapy seminoma residual lesions: a retrospective validation of the SEM-PET trial. *Ann Oncol*. 2012;23:59–64.

Boland GW, Dwamena BA, Jagtiani Sangwaiya M, et al. Characterization of adrenal masses by using FDG PET: a systematic review and meta-analysis of diagnostic test performance. *Radiology*. 2011;259:117–126.

Cistaro A, Niccoli Asabella A, Coppolino P, et al. Diagnostic and prognostic value of ^{18}F-FDG PET/CT in comparison with morphological imaging in primary adrenal gland malignancies—a multicenter experience. *Hell J Nucl Med*. 2015;18:97–102.

Eiber M, Maurer T, Souvatzoglou M, et al. Evaluation of hybrid ^{68}Ga-PSMA ligand PET/CT in 248 patients with biochemical recurrence after radical prostatectomy. *J Nucl Med*. 2015;56(5):668–674.

Even-Sapir E, Metser U, Mishani E, et al. The detection of bone metastases in patients with high-risk prostate cancer: 99mTc-MDP planar bone scintigraphy, single- and multi-field-of-view SPECT, 18F-fluoride PET, and 18F-fluoride PET/CT. *J Nucl Med*. 2006;47(2):287–297.

Ferda J, Ferdova E, Hora M, et al. 18F-FDG-PET/CT in potentially advanced renal cell carcinoma: a role in treatment decisions and prognosis estimation. *Anticancer Res*. 2013;33(6):2665–2672.

Jadvar H, Xiankui L, Shahinian A, et al. Glucose metabolism of human prostate cancer mouse xenografts. *Mol Imaging*. 2005;4(2):91–97.

Kitajima K, Murphy RC, Nathan MA, et al. Review update on positron emission tomography for imaging of prostate cancer. *Int J Urol*. 2014;21(1):12–23.

Kitajima Kazuhiro, Yamamoto Shingo, Fukushima Kazuhito, et al. Update on advances in molecular PET in urological oncology. *Jpn J Radiol*. 2016;34:470–485.

Lu YY, Chen JH, Liang JA, et al. Review clinical value of FDG PET or PET/CT in urinary bladder cancer: a systemic review and meta-analysis. *Eur J Radiol*. 2012;81(9):2411–2416.

Minamimoto R, Loening A, Jamali M, et al. Prospective comparison of 99mTc-MDP scintigraphy, combined 18f-NaF and 18F-FDG PET/CT, and whole-body MRI in patients with breast and prostate cancer. *J Nucl Med*. 2015;56(12):1862–1868.

Morigi JJ, Stricker PD, van Leeuwen PJ, et al. Prospective comparison of 18F-fluoromethylcholine versus 68ga-PSMA PET/CT in prostate cancer patients who have rising PSA after curative treatment and are being considered for targeted therapy. *J Nucl Med*. 2015;56(8):1185–1190.

Müller J, Schrader AJ, Jentzmik F, et al. Assessment of residual tumours after systemic treatment of metastatic seminoma: ^{18}f-2-fluoro-2-deoxy-D-glucose positron emission tomography—meta-analysis of diagnostic value. *Urologe A*. 2011;50:322–327.

Oechsle K, Hartmann M, Brenner W, et al. [^{18}F]fluorodeoxyglucose positron emission tomography in nonseminomatous germ cell tumors after chemotherapy: the german multicenter positron emission tomography study group. *J Clin Oncol*. 2008;26:5930–5935.

Park SY, Park BK, Kim CK. The value of adding ^{18}F-FDG PET/CT to adrenal protocol CT for characterizing adrenal metastasis (≥10 mm) in oncologic patients. *AJR Am J Roentgenol*. 2014;202:W153–W160.

Picchio M, Spinapolice EG, Fallanca F, et al. [^{11}C]choline PET/CT detection of bone metastases in patients with PSA progression after primary treatment for prostate cancer: comparison with bone scintigraphy. *Eur J Nucl Med Mol*

Imaging. 2012;39:13–26.

Poulsen MH, Bouchelouche K, Hoilund-Carlsen PF, et al. [^{18}F]-fluorocholine positron-emission/computed tomography for lymph node staging of prostate cancer: a prospective study of 210 patients. *BJU Int*. 2012;110:1666–1671.

Powles T, Blank C, Chowdhury S, et al. The outcome of patients treated with sunitinib prior to planned nephrectomy in metastatic clear cell renal cancer. *Eur Urol*. 2011;60:448–454.

Reske SN, Blumstein NM, Neumaier B, et al. Imaging prostate cancer with ^{11}c-choline PET/CT. *J Nucl Med*. 2006;47:1249–1254.

Rioja J, Rodriguez-Fraile M, Lima-Favaretto R, et al. Role of positron emission tomography in urological oncology. *BJU Int*. 2010;106:1578–1593.

Treglia G, Sadeghi R, Annunziata S, et al. Diagnostic performance of fluorine-18-fluorode- oxyglucose positron emission tomography in the postchemotherapy management of patients with seminoma: systematic review and meta-analysis. *Biomed Res Int*. 2014;2014:852681.

Wang HY, Ding HJ, Chen JH, et al. Review meta-analysis of the diagnostic performance of [18f]FDG-PET and PET/CT in renal cell carcinoma. *Cancer Imaging*. 2012;12:464–474.

Wang N, Jiang P, Lu Y. Is fluorine-18 fluorodeoxyglucose positron emission tomography useful for detecting bladder lesions? A meta-analysis of the literature. *Urol Int*. 2014;92(2):143–149.

Computed Tomography

Birnbaum B, Maki D, Chakraborty D, et al. Renal cyst pseudoenhancement: evaluation with an anthropomorphic body CT phantom. *Radiology*. 2002;225(1):83–90.

Bosniak MA. Diagnosis and management of patients with complicated cystic lesions of the kidney. *AJR Am J Roentgenol*. 1997;169(3):819–821.

Botsikas D, Hansen C, Stefanelli S, et al. Urinary stone detection and characterization with dual energy CT urography after furosemide intravenous injection: preliminary results. *Eur Radiol*. 2013;2 [epub].

Brant W. Basic principles. Brant WE, Helms CA. *Fundamentals of diagnostic radiology*. ed 2. Williams and Wilkins: Baltimore, Maryland; 1999:3–21.

Caoili EM, Coahn RH, Inampudi P, et al. MDCT urography of upper tract urothelial neoplasms. *AJR Am J Roentgenol*. 2005;184(6):1873–1881.

Chai RY, Jhaveri K, Saini S, et al. Comprehensive evaluation of patients with hematuria on multi-slice computed tomography scanner: protocol design and preliminary observations. *Australas Radiol*. 2001;45(4):536–538.

Christiansen AR, Shorti RM, Smith CD, et al. Intraoperative utilization of advanced imaging modalities in a complex kidney stone case: a pilot case study. *World J Urol*. 2018 https://doi.org/10.1007/s00345-018-2260-4.

Coursey CA, Nelson RC, Boll DT, et al. Dual energy multidetector CT: how does it work, what can it tell us, and when can we use it in abdominopelvic imaging? *Radiographics*. 2010;30:1037–1055.

Curry NS, Cochran ST, Bissada NK. Cystic renal masses: accurate bosniak classification requires adequate renal CT. *AJR Am J Roentgenol*. 2000;175:339–342.

Dalrymple NC, Casford B, Raiken DP, et al. Pearls and pitfalls in the diagnosis of ureterolithiasis with unenhanced helical CT. *Radiographics*. 2000;20:439–447.

Daly B, Krebs TL, Wong-You-Cheong JJ, et al. Percutaneous abdominal and pelvic interventional procedures using CT fluoroscopy guidance. *AJR Am J Roentgenol*. 1999;173(3):637–644.

Federle MP, McAninch JW, Kaiser JA, et al. Computed tomography of urinary calculi. *AJR Am J Roentgenol*. 1981;136(2):255–258.

Ferrandino MN, Pierre SA, Simmons WN, et al. Dual energy computed tomography with advanced post image acquisition data processing: improved determination of urinary stone composition. *J Endourol*. 2010;24:347–354.

Gupta A, Allaf ME, Kavoussi LR, et al. Computerized tomography guided percutaneous renal cryoablation with the patient under conscious sedation: initial clinical experience. *J Urol*. 2006;175:447–452.

Hamm M, Knoplfe E, Wartenberg S, et al. Low dose unenhanced helical computerized tomography for the evaluation of acute flank pain. *J Urol*. 2002;167(4):1687–1691.

Heneghan JP, Dalrymple NC, Verga M, et al. Soft tissue “rim” sign in the diagnosis of ureteral calculus with the use of unenhanced helical CT. *Radiology*. 1997;202(3):709–711.

Israel GM, Bosniak MA. An update of the Bosniak renal cyst classification system. *Urology*. 2005;66(3):484–488.

Joudi FN, Kuehn DM, Willimas RD. Maximizing clinical information obtained by CT. *Urol Clin North Am*. 2006;33:287–300.

Kalra MK, Maher MM, D'Souza RV, et al. Detection of urinary tract stones at low-radiation-dose CT with z-axis automatic tube current modulation: phantom and clinical studies. *Radiology*. 2005;235(2):523–529.

Keat N. Real-time CT and CT fluoroscopy. *Br J Radiol*. 2001;74:1088–1090.

Lang EK, Macchia RJ, Thomas R. Improved detection of renal pathologic features on multi-phasic helical CT compared with

IVU in patients presenting with microscopic hematuria. *Urology*. 2003;61(3):528–532.

Liu W, Esler SJ, Kenny BJ, et al. Low dose nonenhanced helical CT of renal colic: assessment of ureteric stone detection and measurement of effective dose equivalent. *Radiology*. 2000;215(1):51–54.

Mahesh M. Search for isotropic resolution in CT from conventional through multiple-row detector. *Radiographics*. 2002;22:949–962.

McCarthy CL, Cowan NC. Multidetector computed tomography urography for a urothelial imaging. *Radiology*. 2002;225:137.

Memarsadeghi M, Heinz-Peer G, Helbich TH, et al. Unenhanced multi-detector row CT in patients suspected of having urinary stone disease: effect of section width on diagnosis. *Radiology*. 2005;235(2):530–536.

Schwartz BF, Schenkman N, Armenakas NA, et al. Imaging characteristics of indinavir calculi. *J Urol*. 1999;161:1085–1087.

Smith RC, Rosenfield AT, Choe KA. Acute flank pain: comparison of the non-contrast- enhanced CT and intravenous urography. *Radiology*. 1995;194(3):789–794.

Wang G, Vannier MW. Longitudinal resolution in volumetric x-ray CT: analytic comparison between conventional and helical CT. *Med Phys*. 1994;421:433.

MRI Introduction

Berrington de González A, Darby S. Risk of cancer from diagnostic x-rays: estimates for the UK and 14 other countries. *Lancet*. 2004;363(9406):345–351.

Cowper SE, Robin HS, Steinberg SM, et al. Scleromyxoedema-like cutaneous diseases in renal-dialysis patients. *Lancet*. 2000;356(9234):1000–1001.

FDA Drug Safety Communication. *New warnings for using gadolinium-based contrast agents in patients with kidney dysfunction*. http://www.fda.gov/Drugs/DrugSafety/ucm223966.htm; 2010.

Grobner T. Gadolinium–a specific trigger for the development of nephrogenic fibrosing dermopathy and nephrogenic systemic fibrosis? *Nephrol Dial Transplant*. 2006;21(4):1104–1108 [Epub 2006 Jan 23].

Gulani V, Calamante F, Shellock FG, et al. International society for magnetic resonance in medicine. Gadolinium deposition in the brain: summary of evidence and recommendations. *Lancet Neurol*. 2017;16(7):564–570.

Lin SP, Brown JJ. MR contrast agents: physical and pharmacologic basics. *J Magn Reson Imaging*. 2007;25(5):884–899.

Adrenal MRI

Bharwani N, Rockall AG. Adrenocortical carcinoma: the range of appearances on CT and MRI. *AJR Am J Roentgenol*. 2011;196(6):W706–W714.

Boland GW, Blake MA. Incidental adrenal lesions: principles, techniques, and algorithms for imaging characterization. *Radiology*. 2008;249(3):756–775.

Dunnick NR, Korobkin M. Imaging of adrenal incidentalomas: current status. *AJR Am J Roentgenol*. 2002;179(3):559–568.

Elsayes KM, Mukundan G. Adrenal masses: MR imaging features with pathologic correlation. *Radiographics*. 2004;24(Suppl 1):S73–S86.

Groussin L, Bonardel G. 18F-fluorodeoxyglucose positron emission tomography for the diagnosis of adrenocortical tumors: a prospective study in 77 operated patients. *J Clin*

Endocrinol Metab. 2009;94(5):1713–1722.

Inan N, Arslan A. Dynamic contrast enhanced MRI in the differential diagnosis of adrenal adenomas and malignant adrenal masses. *Eur J Radiol*. 2008;65(1):154–162.

Israel GM, Hindman N. Evaluation of cystic renal masses: comparison of CT and MR imaging by using the bosniak classification system. *Radiology*. 2004;231(2):365–371.

Korobkin M, Giordano TJ. Adrenal adenomas: relationship between histologic lipid and CT and MR findings. *Radiology*. 1996;200(3):743–747.

Krebs TL, Wagner BJ. MR imaging of the adrenal gland: radiologic-pathologic correlation. *Radiographics*. 1998;18(6):1425–1440.

Ladurner R, Sommerey S, Buechner S, et al. Accuracy of adrenal imaging and adrenal venous sampling in diagnosing unilateral primary aldosteronism. *Eur J Clin Invest*. 2017;47(5):372–377.

Mansmann G, Lau J. The clinically inapparent adrenal mass: update in diagnosis and management. *Endocr Rev*. 2004;25(2):309–340.

Meyer A, Behrend M. Presentation and therapy of myelolipoma. *Int J Urol*. 2005;12(3):239–243.

Mezhir JJ, Song J. Adrenocortical carcinoma invading the inferior vena cava: case report and literature review. *Endocr Pract*. 2008;14(6):721–725.

Nakamura S, Namimoto T. Characterization of adrenal lesions using chemical shift MRI: comparison between 1.5 tesla and two echo time pair selection at 3.0 tesla MRI. *J Magn Reson Imaging*. 2012;35(1):95–102.

Ng L, Libertino JM. Adrenocortical carcinoma: diagnosis, evaluation and treatment. *J Urol*. 2003;169(1):5–11.

Park BK, Kim CK. Comparison of delayed enhanced CT and chemical shift MR for evaluating hyperattenuating incidental adrenal masses. *Radiology*. 2007;243(3):760–765.

Pokharel SS, Macura KJ. Current MR imaging lipid detection techniques for diagnosis of lesions in the abdomen and pelvis. *Radiographics*. 2013;33(3):681–702.

Sahdev A, Willatt J. The indeterminate adrenal lesion. *Cancer Imaging*. 2010;10:102–113.

Song JH, Chaudhry FS. The incidental adrenal mass on CT: prevalence of adrenal disease in 1,049 consecutive adrenal masses in patients with no known malignancy. *AJR Am J Roentgenol*. 2008;190(5):1163–1168.

Sydow BD, Rosen MA. Intracellular lipid within metastatic hepatocellular carcinoma of the adrenal gland: a potential diagnostic pitfall of chemical shift imaging of the adrenal gland. *AJR Am J Roentgenol*. 2006;187(5):W550–W551.

Taffel M, Haji-Momenian S. Adrenal imaging: a comprehensive review. *Radiol Clin North Am*. 2012;50(2):219–243.

Ünal E, Karaosmanoğlu AD, Akata D, et al. Invisible fat on CT: making it visible by MRI. *Diagn Interv Radiol*. 2016;22(2):133–140.

Varghese JC, Hahn PF. MR differentiation of phaeochromocytoma from other adrenal lesions based on qualitative analysis of T2 relaxation times. *Clin Radiol*. 1997;52(8):603–606.

Renal MRI

Cornelis F, Lasserre AS. Combined late gadolinium-enhanced and double-echo chemical-shift MRI help to differentiate renal oncocytomas with high central T2 signal intensity from renal cell carcinomas. *AJR Am J Roentgenol*. 2013;200(4):830–838.

Eisner BH, Feldman AS. Nanoparticle imaging for genitourinary cancers. *Cancer Biomark*. 2009;5(2):75–79.

Hallscheidt PJ, Fink C. Preoperative staging of renal cell carcinoma with inferior vena cava thrombus using multidetector CT and MRI: prospective study with histopathological correlation. *J Comput Assist Tomogr*. 2005;29(1):64–68.

Harmon WJ, King BF. Renal oncocytoma: magnetic resonance imaging characteristics. *J Urol*. 1996;155(3):863–867.

Ho VB, Allen SF. Renal masses: quantitative assessment of enhancement with dynamic MR imaging. *Radiology*. 2002;224(3):695–700.

Israel GM, Bosniak MA. Calcification in cystic renal masses: is it important in diagnosis? *Radiology*. 2003;226(1):47–52.

Israel GM, Hindman N. Evaluation of cystic renal masses: comparison of CT and MR imaging by using the bosniak classification system. *Radiology*. 2004;231(2):365–371.

Karlo CA, Donati OF. MR imaging of renal cortical tumours: qualitative and quantitative chemical shift imaging parameters. *Eur Radiol*. 2013;23(6):1738–1744.

Outwater EK, Bhatia M. Lipid in renal clear cell carcinoma: detection on opposed-phase gradient-echo MR images. *Radiology*. 1997;205(1):103–107.

Pedrosa I, Chou MT. MR classification of renal masses with pathologic correlation. *Eur Radiol*. 2008;18(2):365–375.

Rosenkrantz AB, Hindman N. MRI features of renal oncocytoma and chromophobe renal cell carcinoma. *AJR Am J Roentgenol*. 2010;195(6):W421–W427.

Roubidoux MA. MR imaging of hemorrhage and iron deposition in the kidney. *Radiographics*. 1994;14(5):1033–1044.

Roy C Sr, El Ghali S. Significance of the pseudocapsule on MRI of renal neoplasms and its potential application for local staging: a retrospective study. *AJR Am J Roentgenol*. 2005;184(1):113–120.

Schmidt H, Gatidis S, Schwenzer NF, et al. Impact of measurement parameters on apparent diffusion coefficient quantification in diffusion-weighted-magnetic resonance imaging. *Invest Radiol*. 2015;50(1):46–56.

Vargas HA, Chaim J. Renal cortical tumors: use of multiphasic contrast-enhanced MR imaging to differentiate benign and malignant histologic subtypes. *Radiology*. 2012;264(3):779–788.

Wang H, Cheng L, Zhang X, et al. Renal cell carcinoma: diffusion-weighted MR imaging for subtype differentiation at 3.0 T. *Radiology*. 2010;257(1):135–143.

Wasser EJ, Shyn PB. Renal cell carcinoma containing abundant non-calcified fat. *Abdom Imaging*. 2013;38(3):598–602.

Wehrli NE, Kim MJ. Utility of MRI features in differentiation of central renal cell carcinoma and renal pelvic urothelial carcinoma. *AJR Am J Roentgenol*. 2013;201(6):1260–1267.

Upper and Lower Tract MRI

Chahal R, Taylor K. Patients at high risk for upper tract urothelial cancer: evaluation of hydronephrosis using high resolution magnetic resonance urography. *J Urol*. 2005;174(2):478–482 [quiz 801].

de Leon AD, Costa D, Pedrosa I. Role of multiparametric MR imaging in malignancies of the urogenital tract. *Magn Reson Imaging Clin N Am*. 2016;24(1):187–204.

Kawashima A, Glockner JF. CT urography and MR urography. *Radiol Clin North Am*. 2003;41(5):945–961.

Silverman SG, Leyendecker JR. What is the current role of CT urography and MR urography in the evaluation of the urinary tract? *Radiology*. 2009;250(2):309–323.

Tekes A, Kamel I. Dynamic MRI of bladder cancer: evaluation of staging accuracy. *AJR Am J Roentgenol*. 2005;184(1):121–

127.

Prostate MRI

Abd-Alazeez M, Kirkham A. Performance of multiparametric MRI in men at risk of prostate cancer before the first biopsy: a paired validating cohort study using template prostate mapping biopsies as the reference standard. *Prostate Cancer Prostatic Dis*. 2014;17(1):40–46.

Ahmed HU, El-Shater Bosaily A, Brown LC, et al. Diagnostic accuracy of multi-parametric MRI and TRUS biopsy in prostate cancer (PROMIS): a paired validating confirmatory study. PROMIS study group. *Lancet*. 2017;389(10071):815–822.

Barentsz JO, Richenberg J. European society of urogenital radiology. ESUR prostate MR guidelines 2012. *Eur Radiol*. 2012;22(4):746–757.

Berrington de González A, Darby S. Risk of cancer from diagnostic x-rays: estimates for the UK and 14 other countries. *Lancet*. 2004;363(9406):345–351.

Bharwani N, Rockall AG. Adrenocortical carcinoma: the range of appearances on CT and MRI. *AJR Am J Roentgenol*. 2011;196(6):W706–W714.

Boland GW, Blake MA. Incidental adrenal lesions: principles, techniques, and algorithms for imaging characterization. *Radiology*. 2008;249(3):756–775.

Choi YJ, Kim JK. Functional MR imaging of prostate cancer. *Radiographics*. 2007;27(1):63–75 [discussion 75–7].

Cornelis F, Lasserre AS. Combined late gadolinium-enhanced and double-echo chemical-shift MRI help to differentiate renal oncocytomas with high central T2 signal intensity from renal cell carcinomas. *AJR Am J Roentgenol*. 2013;200(4):830–838.

Cowper SE, Robin HS, Steinberg SM, et al. Scleromyxoedema-like cutaneous diseases in renal-dialysis patients. *Lancet*. 2000;356(9234):1000–1001.

Dunnick NR, Korobkin M. Imaging of adrenal incidentalomas: current status. *AJR Am J Roentgenol*. 2002;179(3):559–568.

Eisner BH, Feldman AS. Nanoparticle imaging for genitourinary cancers. *Cancer Biomark*. 2009;5(2):75–79.

Elsayes KM, Mukundan G. Adrenal masses: MR imaging features with pathologic correlation. *Radiographics*. 2004;24(Suppl 1):S73–S86.

Faria R, Soares MO, Spackman E, et al. Optimising the diagnosis of prostate cancer in the era of multiparametric magnetic resonance imaging: a cost-effectiveness analysis based on the prostate MR imaging study (PROMIS). *Eur Urol*. 2018;73(1):23–30.

FDA Drug Safety Communication. *New warnings for using gadolinium-based contrast agents in patients with kidney dysfunction*. http://www.fda.gov/Drugs/DrugSafety/ucm223966.htm; 2010.

Fulgham PF, Rukstalis DB, Turkbey IB, et al. AUA policy statement on the use of multiparametric magnetic resonance imaging in the diagnosis, Staging and management of prostate cancer. *J Urol*. 2017;198(4):832–838.

Grobner T. Gadolinium–a specific trigger for the development of nephrogenic fibrosing dermopathy and nephrogenic systemic fibrosis? *Nephrol Dial Transplant*. 2006;21(4):1104–1108.

Groussin L, Bonardel G. 18F-fluorodeoxyglucose positron emission tomography for the diagnosis of adrenocortical tumors: a prospective study in 77 operated patients. *J Clin Endocrinol Metab*. 2009;94(5):1713–1722.

Hallscheidt PJ, Fink C. Preoperative staging of renal cell carcinoma with inferior vena cava thrombus using multidetector CT and MRI: prospective study with histopathological correlation. *J Comput Assist Tomogr*. 2005;29(1):64–68.

Harmon WJ, King BF. Renal oncocytoma: magnetic resonance imaging characteristics. *J Urol*. 1996;155(3):863–867.

Heijmink SW, Fütterer JJ. Prostate cancer: body-array versus endorectal coil MR imaging at 3 T–comparison of image quality, localization, and staging performance. *Radiology*. 2007;244(1):184–195.

Ho VB, Allen SF. Renal masses: quantitative assessment of enhancement with dynamic MR imaging. *Radiology*. 2002;224(3):695–700.

Ikonen S, Kivisaari L. Optimal timing of post-biopsy MR imaging of the prostate. *Acta Radiol*. 2001;42(1):70–73.

Inan N, Arslan A. Dynamic contrast enhanced MRI in the differential diagnosis of adrenal adenomas and malignant adrenal masses. *Eur J Radiol*. 2008;65(1):154–162.

Israel GM, Bosniak MA. Calcification in cystic renal masses: is it important in diagnosis? *Radiology*. 2003;226(1):47–52.

Jambor I, Boström PJ, Taimen P, et al. Novel biparametric MRI and targeted biopsy improves risk stratification in men with a clinical suspicion of prostate cancer (IMPROD trial). *J Magn Reson Imaging*. 2017;46(4):1089–1095.

Karlo CA, Donati OF. MR imaging of renal cortical tumours: qualitative and quantitative chemical shift imaging parameters. *Eur Radiol*. 2013;23(6):1738–1744.

Korobkin M, Giordano TJ. Adrenal adenomas: relationship between histologic lipid and CT and MR findings. *Radiology*. 1996;200(3):743–747.

Krebs TL, Wagner BJ. MR imaging of the adrenal gland: radiologic-pathologic correlation. *Radiographics*. 1998;18(6):1425–1440.

Kurhanewicz J, Vigneron DB. Three-dimensional H-1 MR spectroscopic imaging of the in situ human prostate with high (0.24-0.7-cm3) spatial resolution. *Radiology*. 1996;198(3):795–805.

Lin SP, Brown JJ. MR contrast agents: physical and pharmacologic basics. *J Magn Reson Imaging*. 2007;25(5):884–899.

Manenti G, Squillaci E. In vivo measurement of the apparent diffusion coefficient in normal and malignant prostatic tissue using thin-slice echo-planar imaging. *Radiol Med*. 2006;111(8):1124–1133.

Mansmann G, Lau J. The clinically inapparent adrenal mass: update in diagnosis and management. *Endocr Rev*. 2004;25(2):309–340.

Meyer A, Behrend M. Presentation and therapy of myelolipoma. *Int J Urol*. 2005;12(3):239–243.

Mezhir JJ, Song J. Adrenocortical carcinoma invading the inferior vena cava: case report and literature review. *Endocr Pract*. 2008;14(6):721–725.

Moore CM, Robertson NL. Image-guided prostate biopsy using magnetic resonance imaging-derived targets: a systematic review. *Eur Urol*. 2013;63(1):125–140.

Muller BG, Fütterer JJ. The role of magnetic resonance imaging in focal therapy for prostate cancer: recommendations from a consensus panel. *BJU Int*. 2014;113(2):218–227.

Ng L, Libertino JM. Adrenocortical carcinoma: diagnosis, evaluation and treatment. *J Urol*. 2003;169(1):5–11.

Outwater EK, Bhatia M. Lipid in renal clear cell carcinoma: detection on opposed-phase gradient-echo MR images. *Radiology*. 1997;205(1):103–107.

Park BK, Kim CK. Comparison of delayed enhanced CT and chemical shift MR for evaluating hyperattenuating incidental adrenal masses. *Radiology*. 2007;243(3):760–765.

Pedrosa I, Chou MT. MR classification of renal masses with pathologic correlation. *Eur Radiol*. 2008;18(2):365–375.

Pinto PA, Chung PH. Magnetic resonance imaging/ultrasound fusion guided prostate biopsy improves cancer detection following transrectal ultrasound biopsy and correlates with multiparametric magnetic resonance imaging. *J Urol*. 2011;186(4):1281–1285.

Qayyum A, Coakley FV. Organ-confined prostate cancer: effect of prior transrectal biopsy on endorectal MRI and MR spectroscopic imaging. *AJR Am J Roentgenol*. 2004;183(4):1079–1083.

Rastinehad AR, Turkbey B. Improving detection of clinically significant prostate cancer: MRI/TRUS fusion-guided prostate biopsy. *J Urol*. 2014;191(6):1749–1754.

Rosen Y, Bloch BN. 3T MR of the prostate: reducing susceptibility gradients by inflating the endorectal coil with a barium sulfate suspension. *Magn Reson Med*. 2007;57(5):898–904.

Rosenkrantz AB, Hindman N. MRI features of renal oncocytoma and chromophobe renal cell carcinoma. *AJR Am J Roentgenol*. 2010;195(6):W421–W427.

Rosenkrantz AB, Kopec M. Prostate cancer vs. post-biopsy hemorrhage: diagnosis with T2- and diffusion-weighted imaging. *J Magn Reson Imaging*. 2010;31(6):1387–1394.

Rosenkrantz AB, Mannelli L. Prostate cancer: utility of fusion of T2-weighted and high b-value diffusion-weighted images for peripheral zone tumor detection and localization. *J Magn Reson Imaging*. 2011;34(1):95–100.

Rosenkrantz AB, Oto A, Turkbey B, et al. Reply to “standardizing biparametric MRI to simplify and improve prostate imaging reporting and data system, Version 2, in prostate cancer management.”. *AJR Am J Roentgenol*. 2016;6:W1.

Roubidoux MA. MR imaging of hemorrhage and iron deposition in the kidney. *Radiographics*. 1994;14(5):1033–1044.

Roy C Sr, El Ghali S. Significance of the pseudocapsule on MRI of renal neoplasms and its potential application for local staging: a retrospective study. *AJR Am J Roentgenol*. 2005;184(1):113–120.

Scialpi M, Martorana E, D'Andrea A. Standardizing biparametric MRI to simplify and improve prostate imaging reporting and data system, Version 2, in prostate cancer management. *AJR Am J Roentgenol*. 2016;207(4):W74–W75.

Siddiqui MM, Rais-Bahrami S, Turkbey B, et al. Comparison of MR/ultrasound fusion-guided biopsy with ultrasound-guided biopsy for the diagnosis of prostate cancer. *J Am Med Assoc*. 2015;313(4):390–397.

Song JH, Chaudhry FS. The incidental adrenal mass on CT: prevalence of adrenal disease in 1,049 consecutive adrenal masses in patients with no known malignancy. *AJR Am J Roentgenol*. 2008;190(5):1163–1168.

Sonn GA, Natarajan S. Targeted biopsy in the detection of prostate cancer using an office based magnetic resonance ultrasound fusion device. *J Urol*. 2013;189(1):86–91.

Sydow BD, Rosen MA. Intracellular lipid within metastatic hepatocellular carcinoma of the adrenal gland: a potential diagnostic pitfall of chemical shift imaging of the adrenal gland. *AJR Am J Roentgenol*. 2006;187(5):W550–W551.

Taffel M, Haji-Momenian S. Adrenal imaging: a comprehensive review. *Radiol Clin North Am*. 2012;50(2):219–243.

Talab SS, Preston MA. Prostate cancer imaging: what the urologist wants to know. *Radiol Clin North Am*. 2012;50(6):1015–1041.

Tofts PS, Brix G. Estimating kinetic parameters from dynamic contrast-enhanced T(1)-weighted MRI of a diffusable tracer:

standardized quantities and symbols. *J Magn Reson Imaging*. 1999;10(3):223–232.

Tofts PS, Wicks DA. The MRI measurement of NMR and physiological parameters in tissue to study disease process. *Prog Clin Biol Res*. 1991;363:313–325.

Turkbey B, Mani H. Multiparametric 3t prostate magnetic resonance imaging to detect cancer: histopathological correlation using prostatectomy specimens processed in customized magnetic resonance imaging based molds. *J Urol*. 2011;186(5):1818–1824.

Turkbey B, Mani H. Prostate cancer: can multiparametric MR imaging help identify patients who are candidates for active surveillance? *Radiology*. 2013;268(1):144–152.

Turkbey B, Shah VP. Is apparent diffusion coefficient associated with clinical risk scores for prostate cancers that are visible on 3-T MR images? *Radiology*. 2011;258(2):488–495.

Ueno Y, Kitajima K. Ultra-high b-value diffusion-weighted MRI for the detection of prostate cancer with 3-T MRI. *J Magn Reson Imaging*. 2013;38(1):154–160.

Vargas HA, Chaim J. Renal cortical tumors: use of multiphasic contrast-enhanced MR imaging to differentiate benign and malignant histologic subtypes. *Radiology*. 2012;264(3):779–788 [Epub 2012 Jul 24].

Varghese JC, Hahn PF. MR differentiation of phaeochromocytoma from other adrenal lesions based on qualitative analysis of T2 relaxation times. *Clin Radiol*. 1997;52(8):603–606.

Verma S, Turkbey B. Overview of dynamic contrast-enhanced MRI in prostate cancer diagnosis and management. *AJR Am J Roentgenol*. 2012;198(6):1277–1288.

Wang H, Cheng L. Renal cell carcinoma: diffusion-weighted MR imaging for subtype differentiation at 3.0 T. *Radiology*. 2010;257(1):135–143.

Wasser EJ, Shyn PB. Renal cell carcinoma containing abundant non-calcified fat. *Abdom Imaging*. 2013;38(3):598–602.

Wehrli NE, Kim MJ. Utility of MRI features in differentiation of central renal cell carcinoma and renal pelvic urothelial carcinoma. *AJR Am J Roentgenol*. 2013;201(6):1260–1267.

Weinreb JC, Barentsz JO. PI-RADS Prostate Imaging-Reporting and Data System: 2015, Version 2. *Eur Urol*. 2016;69(1):16–40.

Wysock JS, Rosenkrantz AB. A prospective, blinded comparison of magnetic resonance (MR) imaging-ultrasound fusion and visual estimation in the performance of MR-targeted prostate biopsy: the PROFUS trial. *Eur Urol*. 2014;66(2):343–351.

Zhang VY, Westphalen A. The role of metabolic imaging in radiation therapy of prostate cancer. *NMR Biomed*. 2014;27(1):100–111.

---

[a] Recommendations from American College of Radiology: *ACR Manual on Contrast Media,* Version 10.3, 2017, p 48.

Urinary Tract Imaging

Basic Principles of Urologic Ultrasonography

Bruce R. Gilbert MD, PhD, Pat F. Fulgham MD

Ultrasound has often been referred to as the urologist's stethoscope because much of the genitourinary system is not easily evaluated by physical examination and requires imaging for diagnosis. Therein lies one of the unique aspects of ultrasound studies performed and interpreted by urologists. The mandate to examine the patient, coupled with the urologist's experience in surgical and medical treatment, engenders an unparalleled ability to meld the healer's art with advanced imaging technology. In addition, ultrasonography is a versatile and relatively inexpensive imaging modality that has the unique feature of being the only imaging modality to provide real-time evaluation of urologic organs and structures without the need for ionizing radiation. For urologists to best use this technology on behalf of their patients, they must have a mature understanding of the underlying physical principles of ultrasound. They must also understand how the manipulation of ultrasound equipment can affect the quality of ultrasound images. The technical skills required to perform and interpret urologic ultrasonography represent a combination of practical scanning ability and knowledge of the underlying disease process in organs being imaged. To communicate the findings appropriately, urologists should understand the nomenclature of ultrasonography and have a specific plan for documentation of each type of study. Understanding how ultrasonography interacts with human tissues allows urologists to use this modality effectively, appropriately, and safely. It is our fervent hope that this chapter may encourage many urologists to embrace the art and science of ultrasound in their mission to provide excellence in patient care (▶Video 4.1).

Brief History of Ultrasound in Urology

In 1963 Japanese urologists Takahashi and Ouchi became the first to attempt ultrasonic examination of the prostate. However, the resulting image quality was not interpretable and thus carried little medical utility (Takahashi and Ouchi, 1963). Wild and Reid (1955) also attempted transrectal ultrasound but met with the same result. Progress was not made until Watanabe et al. demonstrated radial scanning that could adequately identify prostate and bladder pathology. Using a purpose-built device modeled after a museum sculpture entitled “Magician's Chair,” Watanabe seated his patients on a chair with a hole cut in the center such that the transducer tube could be passed through the hole and into the rectum of the seated patient (Fig. 4.1A; Watanabe et al., 1974). It is evident in Figs. 4.1B (demonstrating an area of circumscribed symmetric echogenicity representing benign prostatic hyperplasia [BPH]) and 4.1C (demonstrating an asymmetric area of hyperechogenicity, representing prostate cancer) that resolution was poor and images displayed extreme contrast. Subsequent development of biplane, high-frequency probes has created increased resolution and has allowed for transrectal ultrasound to become the standard for diagnosis of prostatic disease.

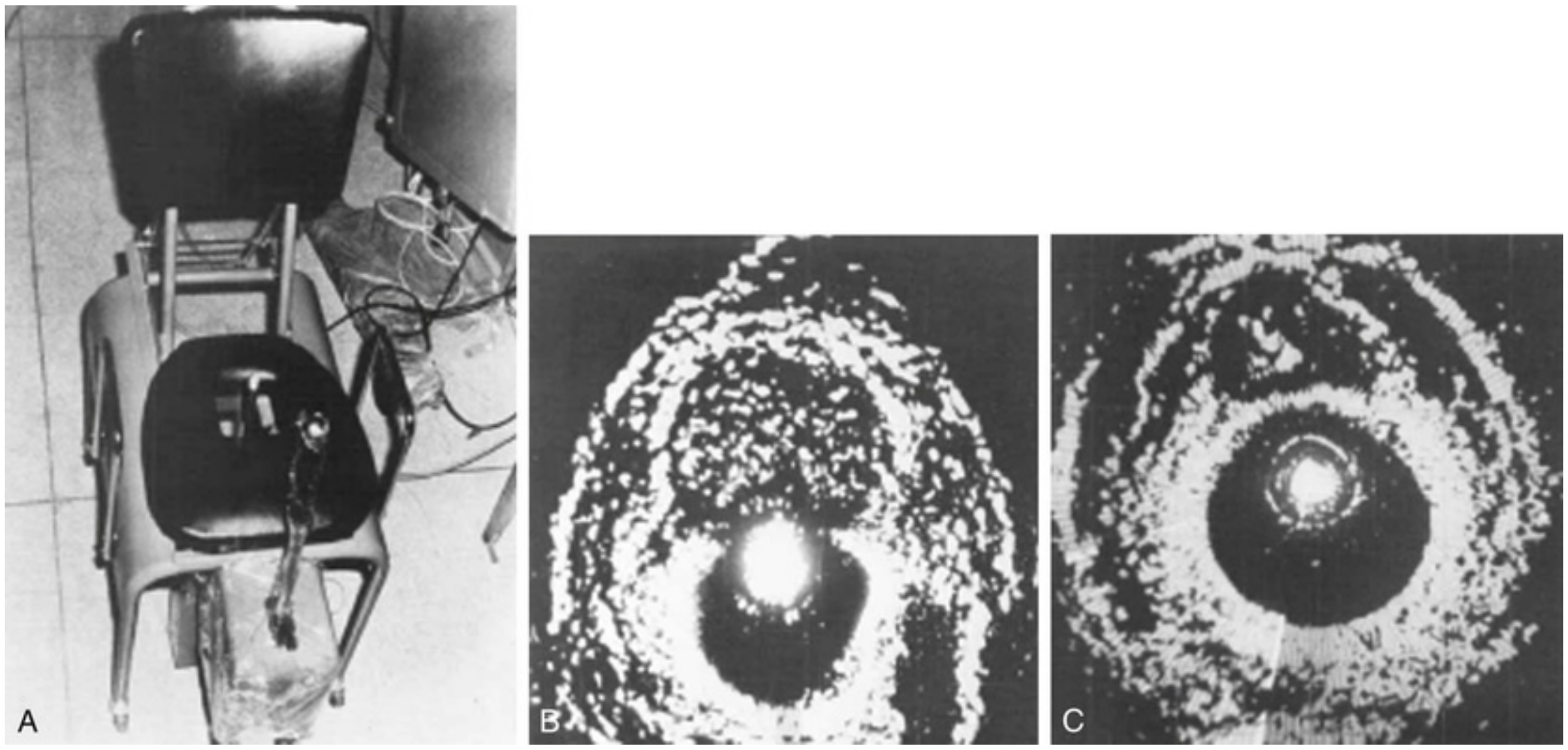

FIG. 4.1 (A) Watanabe's chair; (B) display of patient with BPH; (C) display of prostate cancer. (From Watanabe H et al.: Development and application of new equipment for transrectal ultrasonography. *J Clin Ultrasound* 2[2]:91–98, 1974.)

In 1971 Goldberg and Pollack, frustrated with the inability of intravenous pyelogram (IVP) to differentiate benign from malignant lesions, turned to A-mode ultrasound in the evaluation of the kidney. In their report on “nephrosonography,” they demonstrated in a series of 150 patients the capability of ultrasound to discern solid, cystic, and complex masses with an accuracy of 96%. The diagrammatic representation of the three ultrasound patterns they found are depicted in Fig. 4.2 (Goldberg and Pollack, 2002). In cystic lesions, the first spike represents the striking of the front wall of the cyst, and the second spike represents the striking of the back wall. More complex lesions therefore have return of more spikes.

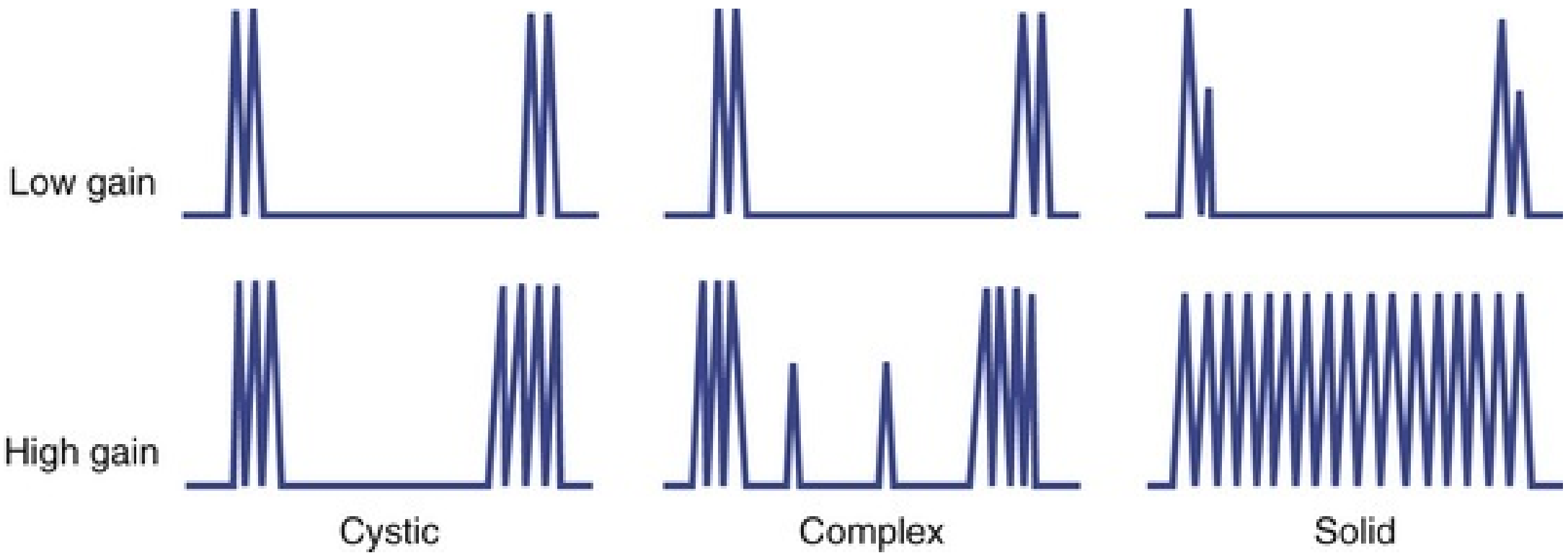

FIG. 4.2 Goldberg and Pollack were the first to differentiate among solid, complex, and cystic masses by ultrasound. In cystic lesions, the first spike represents the striking of the front wall of the cyst, and the second spike represents the striking of the back wall. More complex lesions therefore have return of more spikes. (From Goldberg B, Pollack H: Differentiation of renal masses using A-mode ultrasound. *J Urol* 167[2]:1022–1026, 2002.)

In 1974 Holm and Northeved introduced a transurethral ultrasonic device that would be interchangeable with conventional optics during cystoscopy for the purpose of imaging the prostate and bladder. Their other goals for this device included the ability to determine depth of bladder tumor penetration, prostatic volume, evaluation of prostatic tumor progression, and to assist with transurethral resection of prostate (Holm and Northeved, 1974).

Perri et al. were the first to use Doppler as a sonic “stethoscope” in their workup of patients with an acute scrotum in 1976. Although they were able to identify patients with epididymitis and torsion of the appendix testis as having increased flow and patients with spermatic cord torsion as having no blood flow, they also reported that false negatives in cases of torsion could result from increased flow secondary to reactive hyperemia (Perri et al., 1976).

Watanabe et al., pioneers in the use of ultrasound in urology, demonstrated that Doppler could be used to identify the renal arteries in a noninvasive way in 1976 (Watanabe et al., 1976). Five years later, Greene et al. documented that Doppler could adequately differentiate stenotic from normal renal arteries (Greene et al., 1981). In 1982 Arima et al. used Doppler to differentiate acute from chronic rejection in renal transplant patients, noting that acute rejection is characterized by the disappearance of diastolic phase, with reappearance being indicative of recovery from rejection. The authors concluded that Doppler could guide the management of rejection as an index for steroid therapy (Arima et al., 1982).

In the early 1990s a number of authors investigated the therapeutic uses of high-intensity focused ultrasound (HIFU). After prior reports of histologic changes after HIFU (Burgess, Iwamoto, and Coleman, 1987), Madersbacher et al. were the first to report the safety and efficacy of HIFU in patients with symptomatic BPH (Madersbacher et al., 1993). Its utilities in the treatments of testicular cancer (Madersbacher et al., 1998), early prostate cancer (Chapelon et al., 1999), recurrent prostate cancer (Berge, Baco, and Karlsen, 2010), and renal cell cancer transcutaneously (Köhrmann, Michel, and Gaa, 2002) and laparoscopically (Margreiter and Marberger, 2010) were soon explored.

Novel uses for ultrasound technology continue to be demanded and discovered in the field of urology. Chen et al. (2010) used transrectal ultrasound guidance to inject botulinum toxin into the external urethral sphincters of a series of patients with detrusor external sphincter dyssynergia. Ozawa et al. used perineal ultrasound video-urodynamics to accurately diagnose bladder outlet obstruction in a new, noninvasive method (Ozawa, Igarashi, and Uematsu, 2010). The possibilities for the application of ultrasound in diagnosing or treating urologic patients are endless.

Urologic ultrasound continues to evolve with the use of contrast agents and new modalities (e.g., sonoelastography), which include groundbreaking discoveries and new applications of basic physical principles. This homage to the innovators of the past recognizes prior achievements and acknowledges that future work in the development of new applications for ultrasound will always be needed.

Physical Principles

All ultrasound imaging is the result of the interaction of sound waves with tissues and structures within the human body. Ultrasound waves are produced by applying short bursts of alternating electrical current to a series of crystals housed in the transducer. Alternating expansion and contraction of the crystals via the piezoelectric effect creates a mechanical wave that is transmitted through a coupling medium to the skin and then into the body. The waves that are produced are longitudinal waves. In a longitudinal wave the particle motion is in the same direction as the propagation of the wave (Fig. 4.3). This motion produces areas of rarefaction and compression of tissue in the direction of travel of the ultrasound wave (Fig. 4.4). A portion of the wave is reflected toward the transducer. The transducer then serves as a receiver and "listens" for the returning sound wave reconverting the mechanical to electrical energy. The transducer must be in direct, secure contact with the subject to transmit and receive the reflected sound waves.

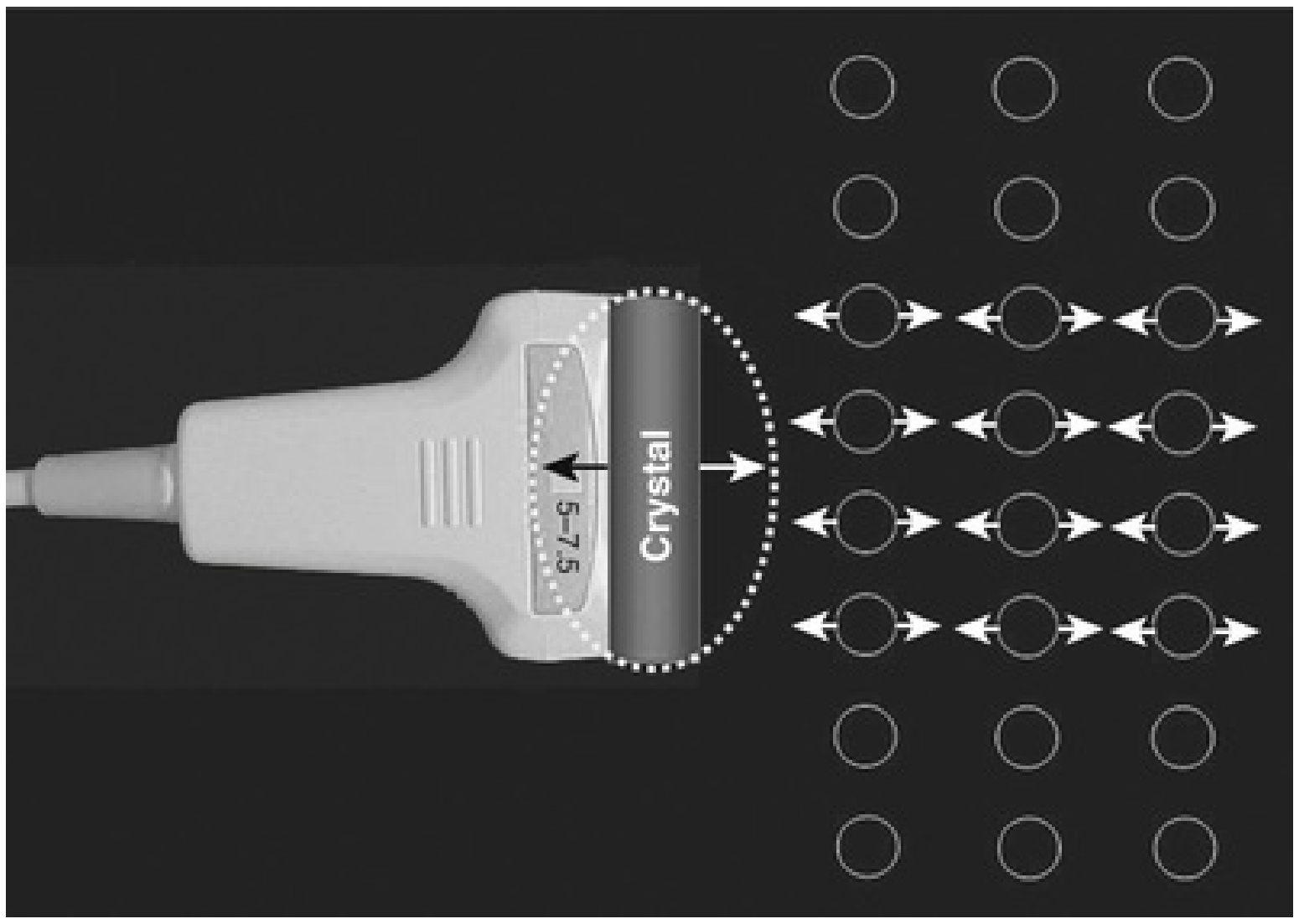

FIG. 4.3 The alternating expansion and contraction of the crystal produces longitudinal mechanical waves. In this simplified schematic drawing, the individual molecules *(depicted as circles)* are displaced in the direction of the propagated wave.

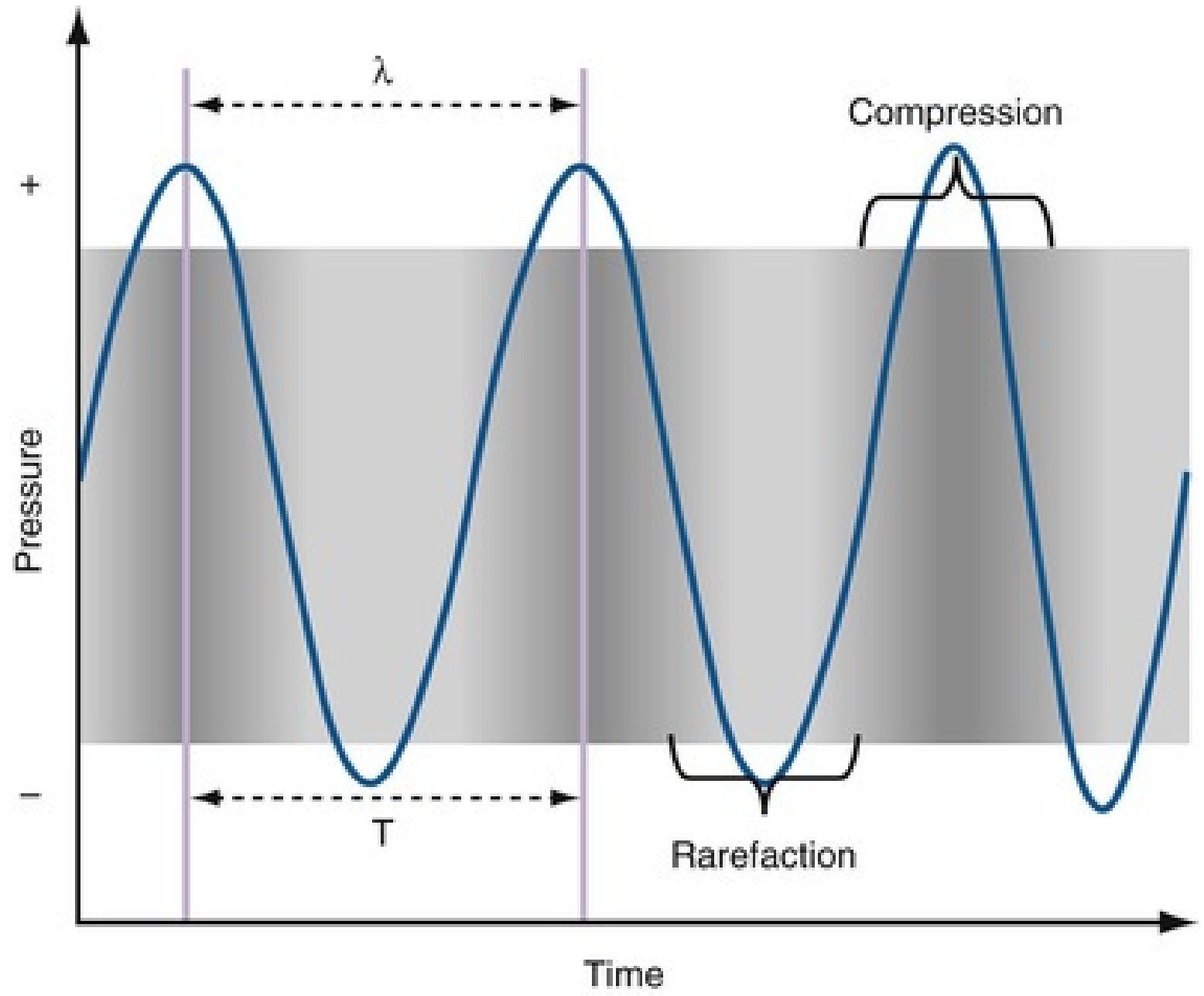

FIG. 4.4 Areas of compression alternating with areas of rarefaction are depicted as a sine wave. The wavelength *(λ)* is the length from peak compression to peak compression in this drawing. This graphic depiction is critical to the understanding of the behavior of sound waves in the human body and of how ultrasound images are generated. (From Merritt CRB: Physics of ultrasound. In Rumack C, Wilson S, eds: *Diagnostic ultrasound,* ed 3, St. Louis, 2005, Elsevier.)

The appearance of the image produced by ultrasonography is the result of the interaction of mechanical ultrasound waves with biologic tissues and materials. Because ultrasound waves are transmitted and received at frequent intervals, the images can be rapidly reconstructed and refreshed, providing a real-time image. The frequencies of the sound waves used for urologic ultrasound imaging are in the range of 3.5 to 20 MHz.

Mechanical waves are represented graphically as a sine wave alternating between a positive and negative direction from the baseline. In the case of ultrasound, the amplitude of the sine wave describes differences in pressure. Ultrasound waves are described using the standard nomenclature for sine waves. A wavelength (λ) is described as the distance between one peak of the wave and the next peak. The complete path traveled by the wave from one peak to the next is called a *cycle*. One cycle per second is known as *1 hertz* (Hz). The "period" is the time it takes for one complete cycle of the wave.

The "amplitude" of a wave is the maximal excursion in the positive or negative direction from the baseline. Amplitude corresponds to the mechanical energy associated with the sound wave and is a key property in assigning pixel brightness to a gray-scale ultrasound image. The greater the amplitude is, the brighter the corresponding pixel.

Ultrasound Image Generation

The image produced by an ultrasound machine begins with the transducer. In ultrasound imaging, the transducer has a dual function as a sender and receiver. Sound waves are created in short pulses and transmitted into the body and are then at least partially reflected. Reflected mechanical sound waves are received by the transducer and converted back into electrical energy. The transducer acts as a receiver more than 99% of the time. The electrical energy is converted by the ultrasound instrument to an image displayed on a monitor (Fig. 4.5).

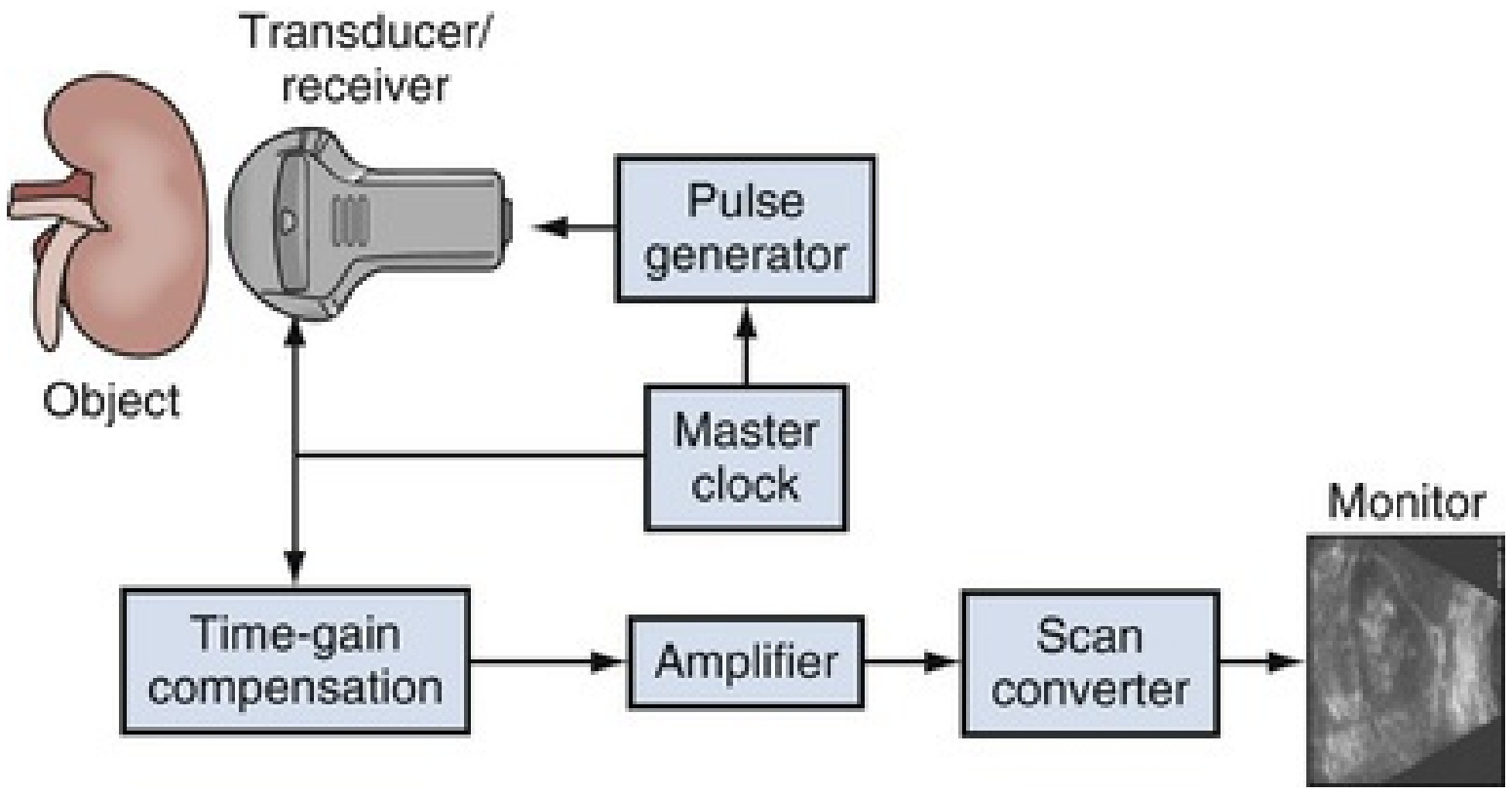

FIG. 4.5 In this simplified schematic diagram of ultrasound imaging, the ultrasound wave is produced by a pulse generator controlled by a master clock. The reflected waves received by the transducer are analyzed for amplitude and transit time within the body. The scan converter produces the familiar picture seen on the monitor. The actual image is a series of vertical lines that are continuously refreshed to produce the familiar real-time, gray-scale image.

Resolution

The resolution of an ultrasound image refers to the ability to discriminate between two objects that are close to one another. **Axial resolution** refers to the ability to identify as separate two objects in the direction of the traveling sound wave. Axial resolution is directly dependent on the frequency of sound waves. The higher the sound wave's frequency is, the better the axial resolution. **Lateral**

resolution refers to the ability to identify separately objects that are equidistant from the transducer. Lateral resolution is a function of the focused width of the ultrasound beam and is a characteristic of the transducer. The location of the narrowest beam width can be adjusted by the user. The more focused the beam is, the better the lateral resolution at that location. Thus image quality can be enhanced by locating the narrowest beam width (focus or focal zone) at the depth of the object or tissue of interest (Fig. 4.6). Continued improvements in transducer design and software allow for near-simultaneous beam steering, multiple foci, and focusing in the azimuthal plane.

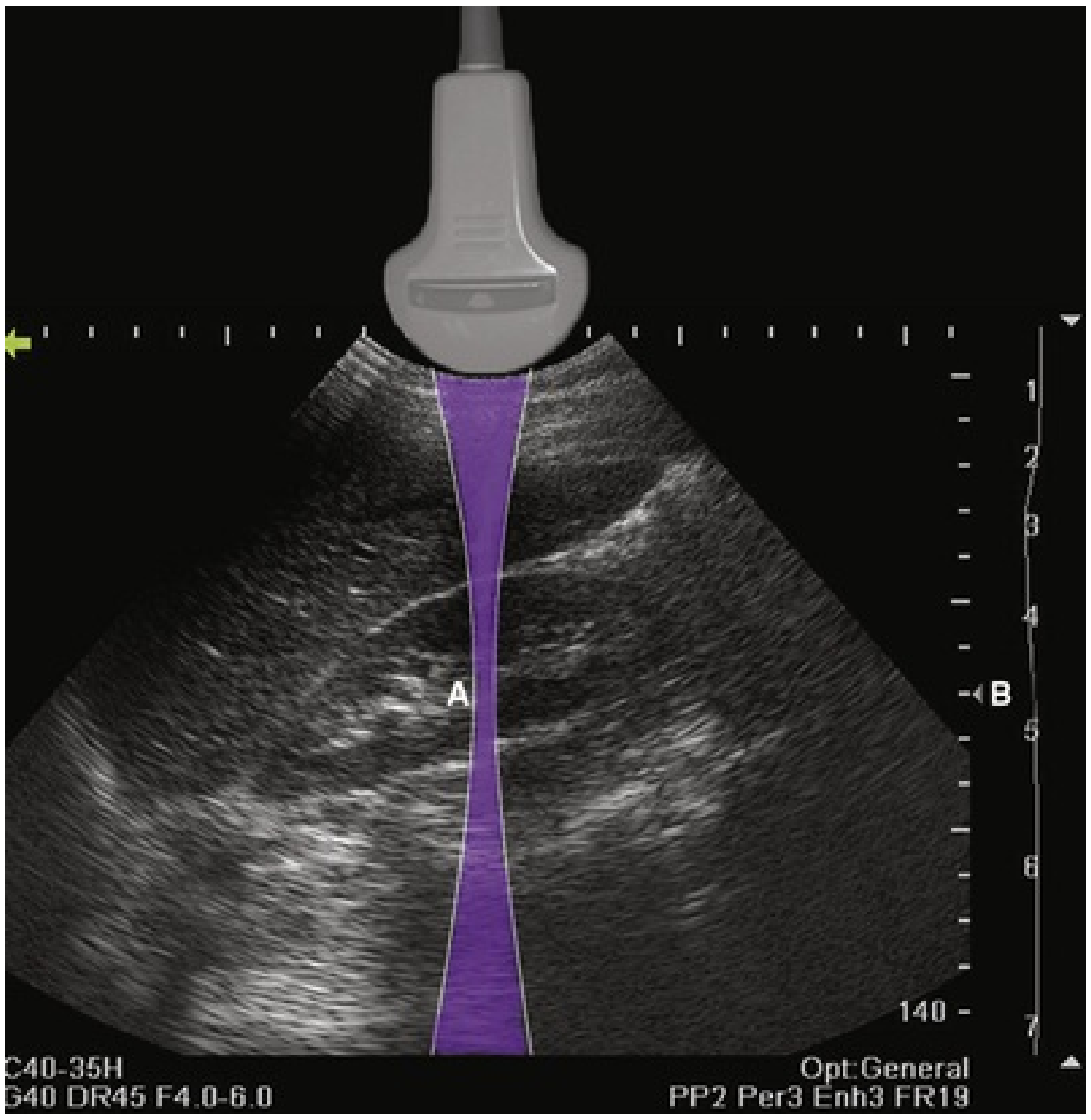

FIG. 4.6 The shape of the ultrasound beam is simulated in this drawing *(purple).* The focal zone *(A)* is located to produce the best lateral resolution of the medial renal cortex. The location of the focal zone is designated by the caret *(B).* The location of the focal zone can be adjusted by the operator.

The velocity with which a sound wave travels through tissue is a product of its frequency and wavelength (Fig. 4.7). The **average velocity of sound in human tissues is 1540 meters per second.** Because the average velocity of sound in tissue is a constant, changes in frequency result in changes in wavelength.

$$v = f \times \lambda$$

$$\text{velocity} = \text{frequency} \times \text{wavelength}$$

FIG. 4.7 The relationship among velocity, frequency, and wavelength of sound waves in tissue. Wavelength and frequency vary in an inverse relationship.

The optimal ultrasound image requires trade-offs between resolution and depth of penetration. High-frequency transducers of 7 to 18 MHz may be used to image structures near the surface of the body (e.g., testis, pediatric kidney) with excellent resolution. Consequently, images of deeper structures acquired at lower frequencies have poorer axial resolution than images of more superficial structures obtained at higher frequencies.

Mechanisms of Attenuation

As sound waves transit tissues, energy is lost or attenuated. Mechanisms of attenuation include **reflection, scattering, interference, and absorption**. Reflection is the key physical phenomenon that allows for information to return to the transducer as mechanical energy. Reflection occurs when ultrasound waves strike an object, a surface, or a boundary (called an **interface**) between unlike tissues. The shape and size of the object and the angle at which the advancing wave strikes the object are critical determinants of the amount of energy reflected. The amount of energy reflected from an interface is also influenced by the **impedance** of the two tissues at the interface. Impedance is a property that is influenced by tissue stiffness and density. It is the difference in impedance that allows an appreciation of interfaces between different types of tissue (Table 4.1).

TABLE 4.1

Density and Impedance of Tissues Encountered During Urologic Ultrasound

	DENSITY (kg/m^3)	IMPEDANCE (kg/m^{2}s)
Air and other gases	1.2	0.0004
Fat tissue	952	1.38
Water and other clear liquids	1000	1.48
Kidney (average of soft tissue)	1060	1.63
Liver	1060	1.64
Muscle	1080	1.70

Bone and other calcified objects	1912	7.80

The impedance difference between perinephric fat and the kidney allows a sharp visual distinction at the interface. If the impedance difference between tissues is small (such as that between the liver and kidney), the interface between the tissues will be more difficult to see (Fig. 4.8A). If impedance differences are large, there will be significant reflection of the sound wave producing an acoustical shadow distal to the interface (Fig. 4.8B).

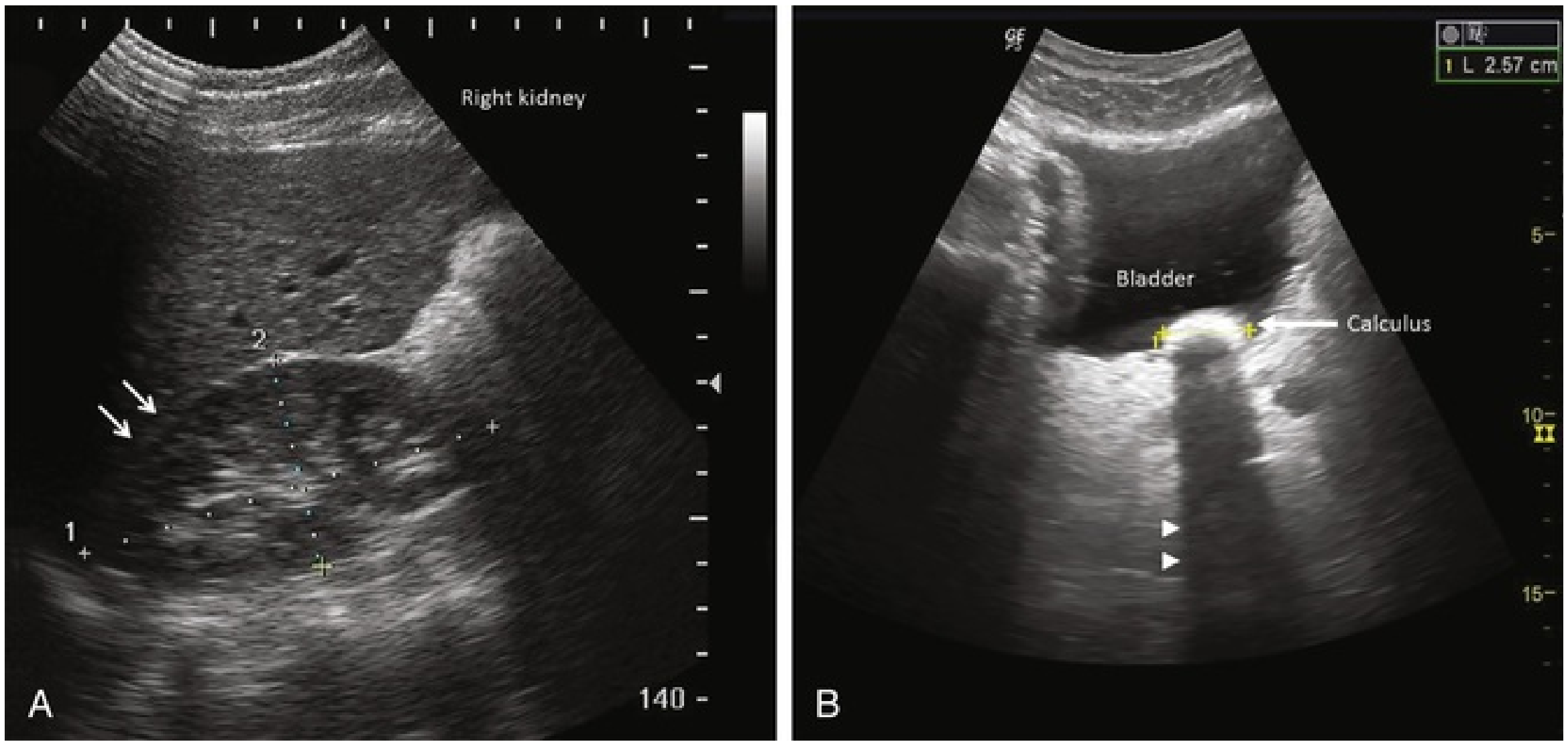

FIG. 4.8 (A) In this sagittal view of the right kidney, the paucity of perinephric fat and the small impedance difference make it difficult to distinguish the interface between the kidney and the liver *(arrows).* (B) The large impedance difference at the interface between urine and this bladder stone *(arrow)* results in significant reflection and attenuation of the sound wave. An acoustic shadow is seen distal to the stone *(arrowheads).*

Scattering occurs when sound waves strike a small or irregular object. The resulting spheric wave overlaps those of surrounding scattering objects (Fig. 4.9).

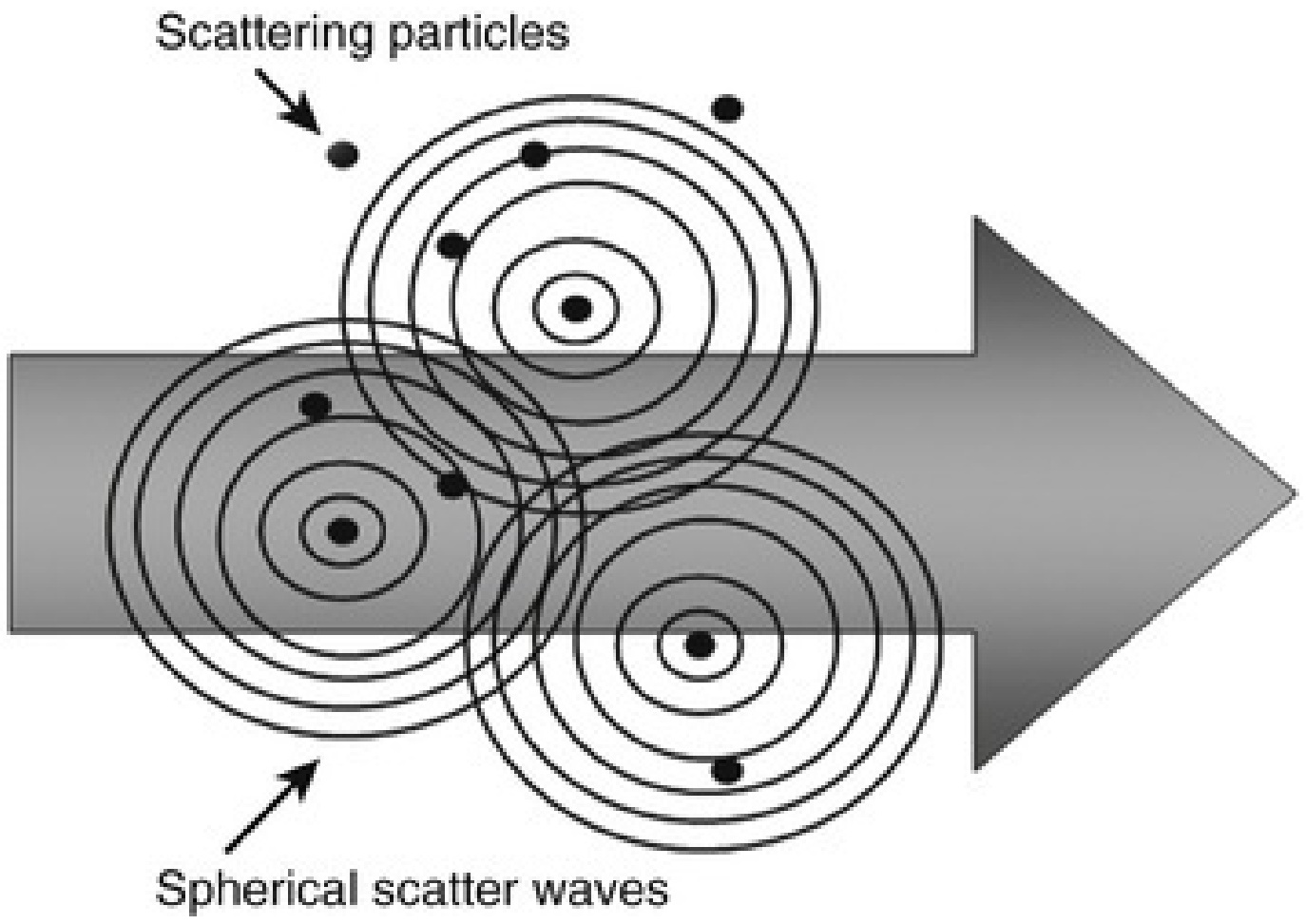

FIG. 4.9 Scattering is a phenomenon that occurs when sound waves strike small objects. The resulting pattern of energy dispersal often results in interference.

When interacting sound waves are in phase or out of phase, their amplitude will be enhanced or diminished. This **pattern of interference** is partially responsible for the echo architecture or texture of organs. One pattern of interference, commonly called **"speckling"** (Fig. 4.10), is seen in organs with fine, internal histology (i.e., reflectors) such as the testis.

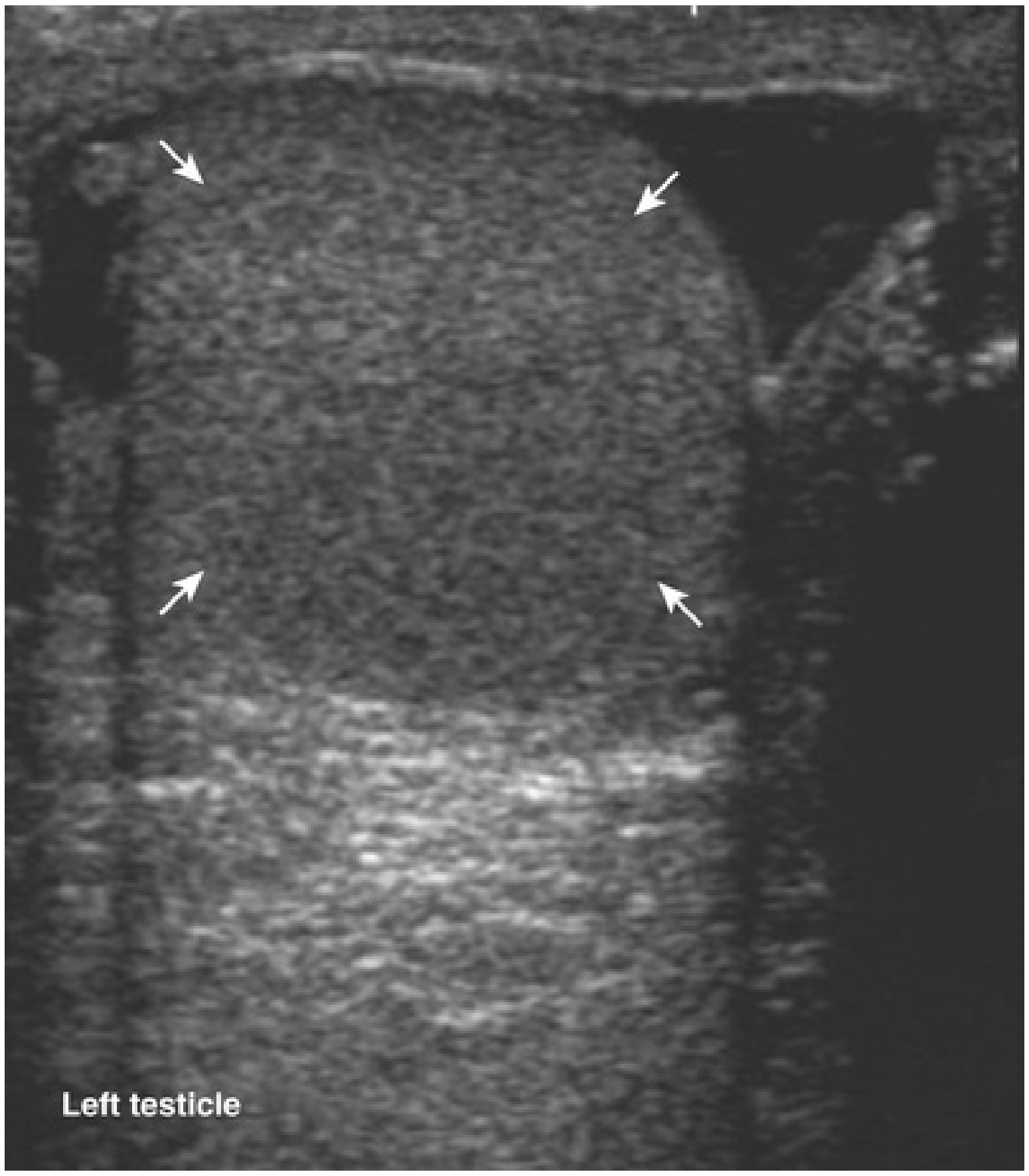

FIG. 4.10 Fine internal echogenicity called "speckle" is caused by scattering of sound waves and the resultant pattern of interference. Note the resulting finely granular, homogenous echogenicity *(arrows)* of the testicular parenchyma.

Absorption occurs when the mechanical energy of the ultrasound waves is converted to heat. Absorption is directly proportional to frequency. Therefore the higher the frequency of the incident wave is, the greater will be the absorption of energy and the more tissue heating that will result. Higher-frequency waves are more rapidly attenuated and therefore have a limited depth of penetration (Fig. 4.11).

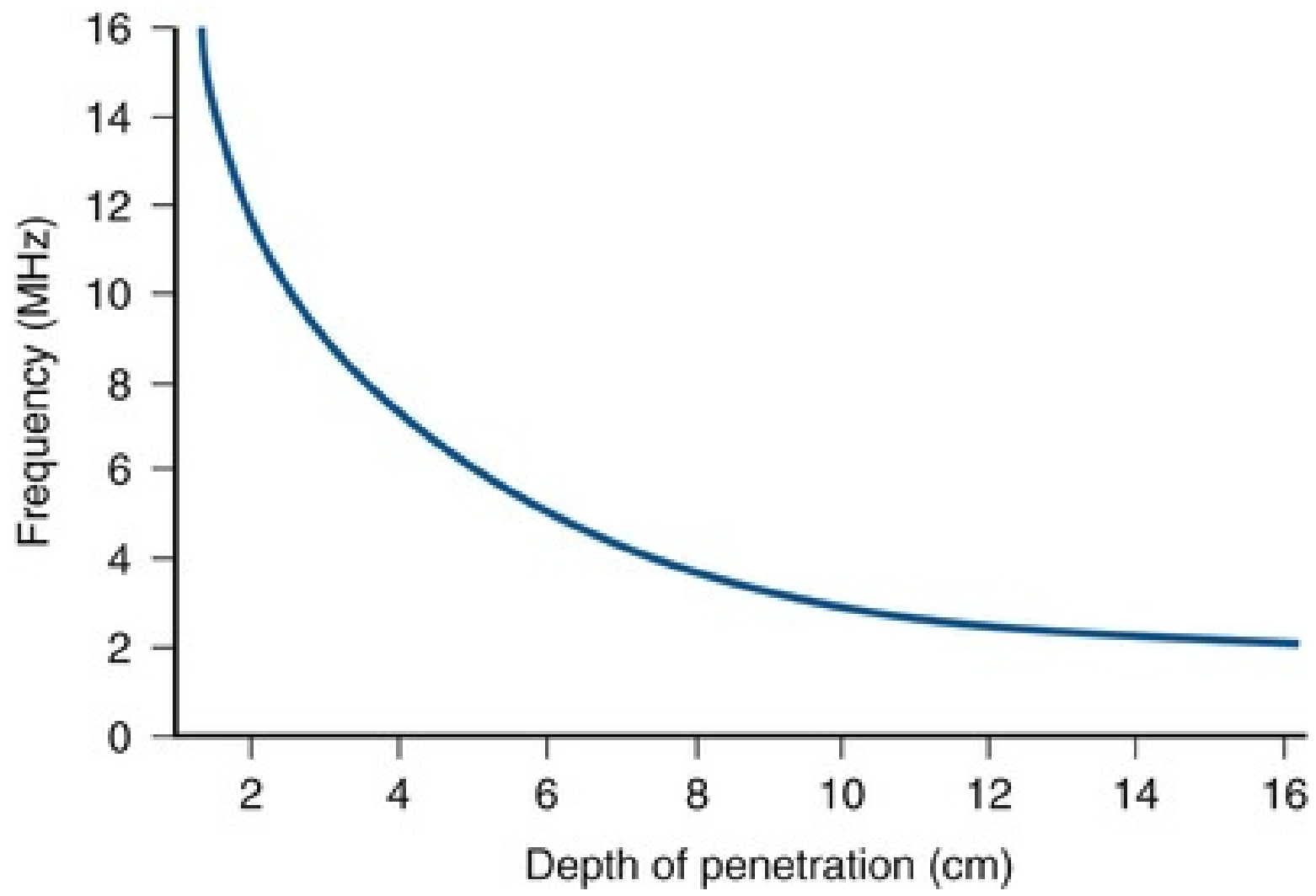

FIG. 4.11 The relationship between frequency and tissue penetration. High-frequency sound waves are rapidly attenuated and are unable to penetrate deeply. Conversely, low-frequency waves are less attenuated and able to penetrate deeply to internal structures.

Artifacts

The interaction of ultrasound waves with tissues may produce images that do not reflect the true underlying anatomy. These misrepresentations are called "artifacts." Artifacts may be misleading but, if recognized, may also assist in diagnosis. **Acoustic shadowing** occurs when there is significant attenuation or reflection of sound waves at a tissue interface. Echo information posterior to the interface may be obscured or lost. An anechoic or hypoechoic "shadow" is produced. Under these conditions, three-dimensional (3D) objects such as stones may appear as crescentic objects, making it difficult to obtain accurate measurements (Fig. 4.12). Important pathology posterior to such an interface may be missed. This problem may often be overcome or mitigated by changing the angle of insonation, changing the frequency of the transducer, or changing the focal zone of the transducer.

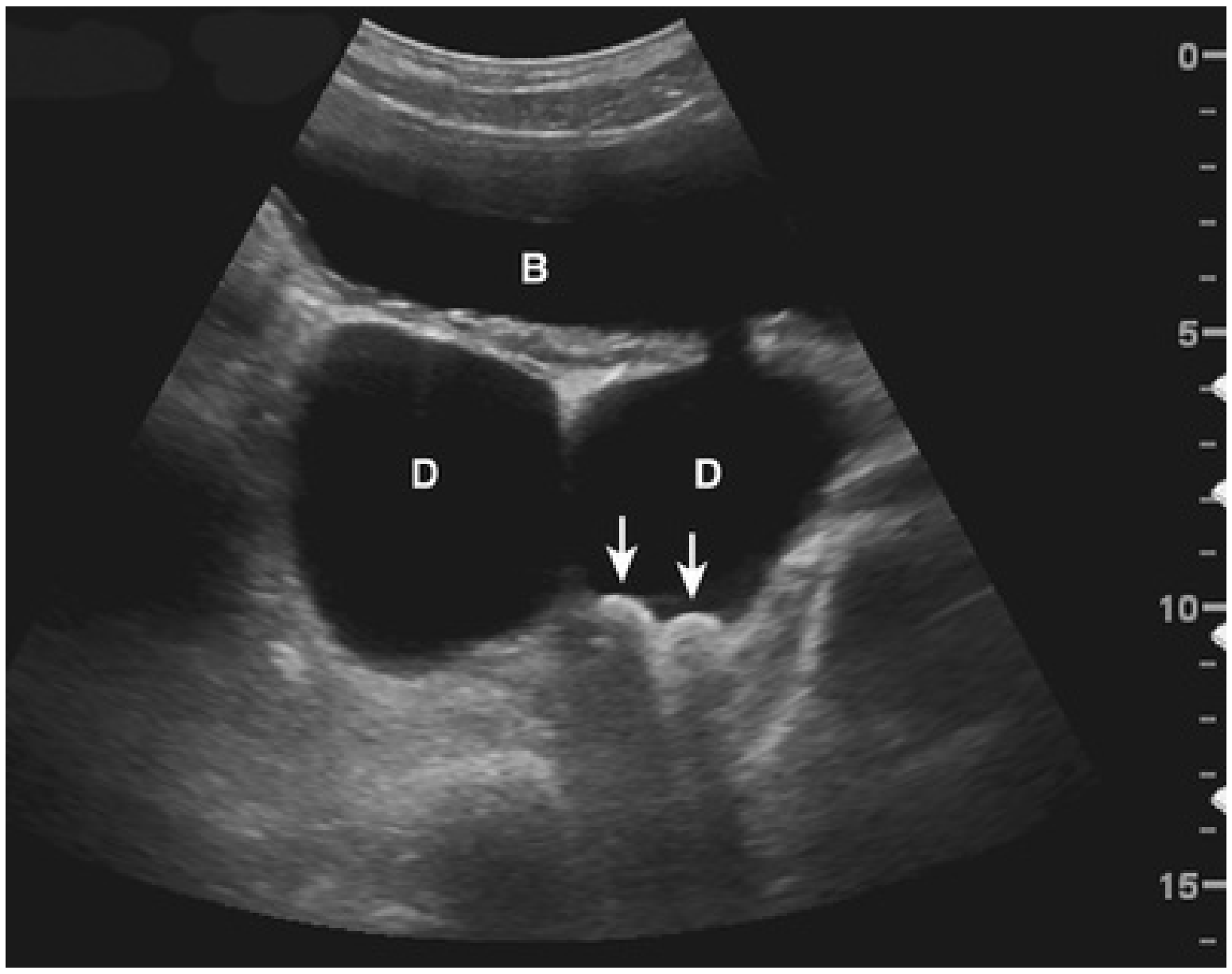

FIG. 4.12 In this transverse view of the urinary bladder *(B),* there are two large bladder diverticula *(D).* Two stones *(arrows)* strongly reflect and attenuate the incident sound wave, producing an acoustic shadow. Note that the stones appear crescentic even though they are ovoid.

Increased through transmission is observed when sound waves are less attenuated while passing through a given structure or tissue than by the surrounding tissues. For example, when a simple cyst of the kidney is imaged, sound waves passing through the cyst are less attenuated than those passing through the surrounding renal cortex and renal sinus. When the waves transiting the cyst strike the back wall of the cyst and posterior renal tissue, the waves are more energetic on arrival to these tissues. The reflected sound waves are also more energetic and less attenuated as they return to the transducer. The result is that tissue posterior to the cyst appears hyperechoic compared with the surrounding renal tissue, even though the tissues are histologically identical (Fig. 4.13). The effect of this artifact can be mitigated by changing the angle of insonation or adjusting the time-gain compensation (TGC) settings.

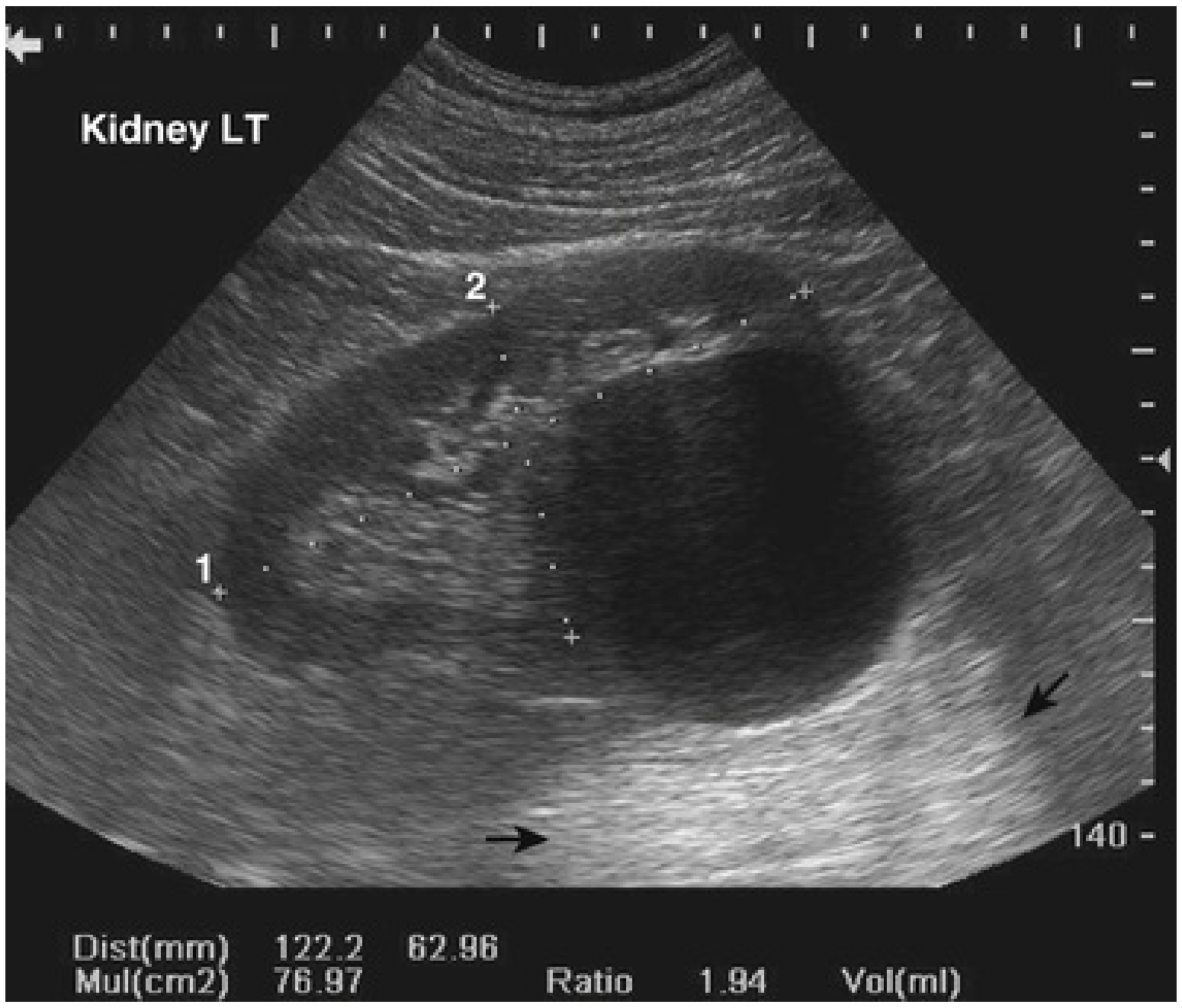
Kidney LT
2
1
140
Dist(mm) 122.2 62.96
Mul(cm2) 76.97
Ratio 1.94
Vol(ml)

FIG. 4.13 Increased through transmission (also called *distal enhancement*) is demonstrated in this longitudinal view of the left kidney. The tissue distal to the cyst appears hyperechoic (indicated by *arrows*) compared with adjacent tissue.

An **edging artifact** occurs when sound waves strike a curved surface or interface at an incident angle, resulting in refraction of the wave along the plane of the interface (Fig. 4.14).

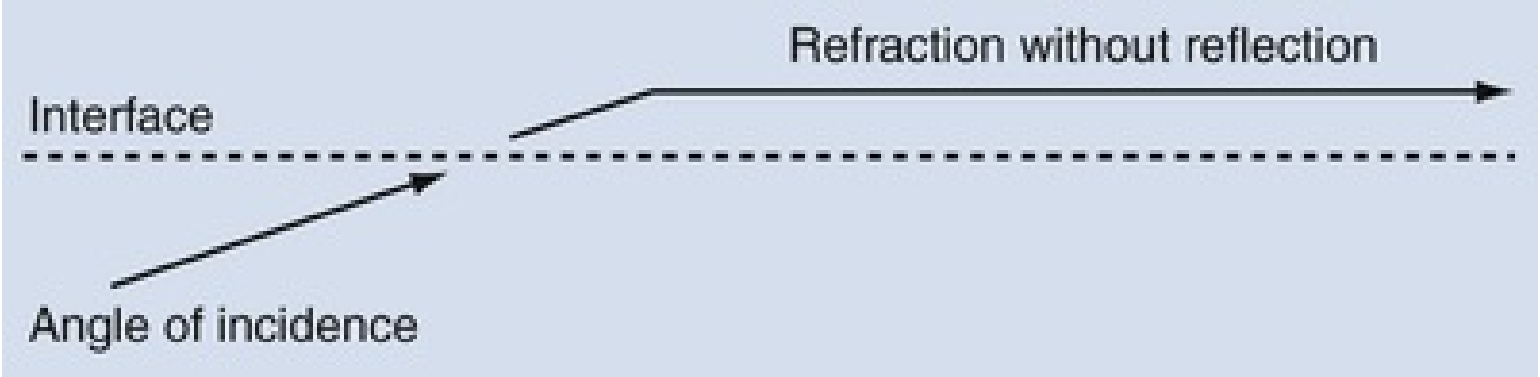
Refraction without reflection
Interface
Angle of incidence

FIG. 4.14 When sound waves strike a surface or interface at a “critical angle,” the wave is refracted without significant reflection.

An incident wave at this angle (the critical angle) will not be directly reflected to the transducer, resulting in a hypoechoic “shadow.” This artifact is commonly seen in testicular ultrasonography and transrectal ultrasonography (Fig. 4.15). It can be overcome by changing the angle of insonation.

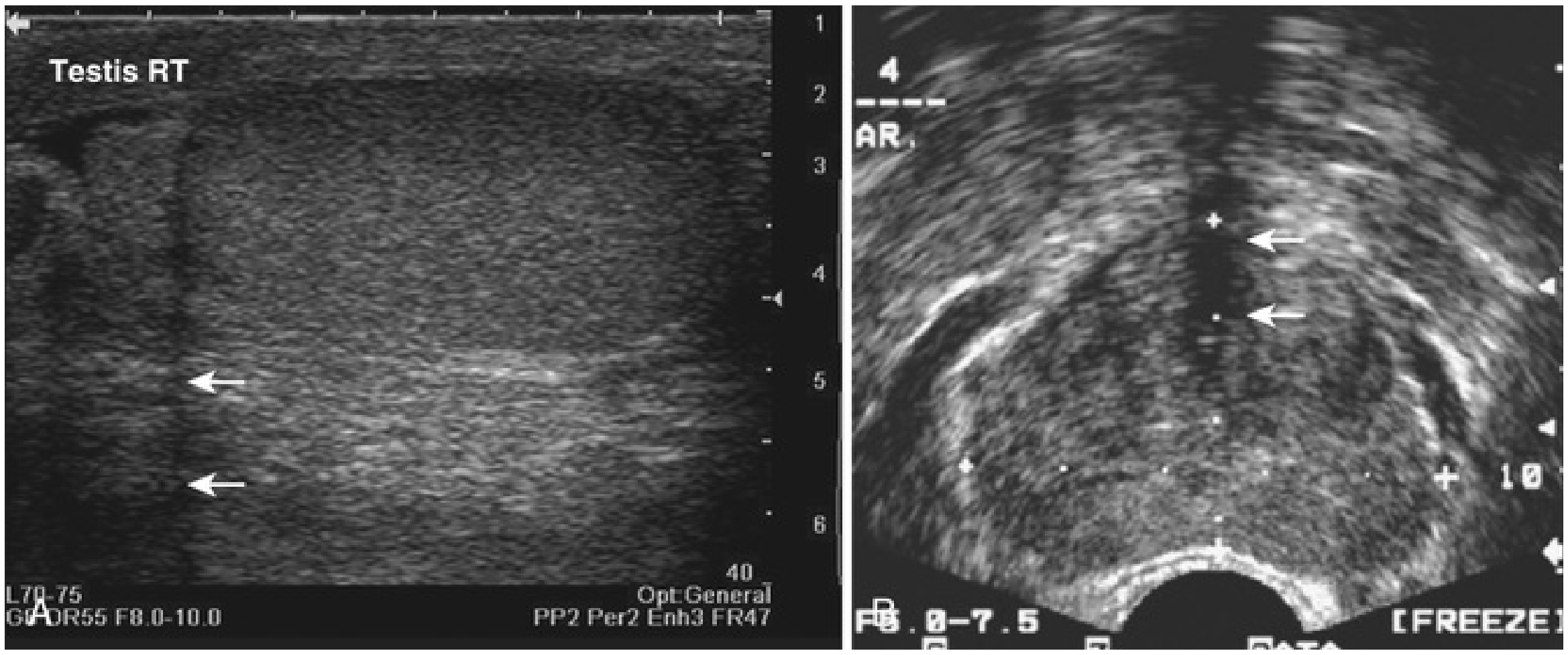

FIG. 4.15 (A) The curved surface of the tunica albuginea of the upper pole of testis creates a critical angle edging artifact *(arrows).* (B) The rounded surfaces of the lateral lobes of the prostate as they meet in the prostatic urethra create an edging artifact *(arrows)* in this transverse image of the prostate.

A **reverberation artifact** results when there are large differences in impedance between two adjacent tissues or surfaces with a strong reflection of the incident wave. The ultrasound wave bounces back and forth (reverberates) between the reflective interfaces. With the second transit of the sound wave, the ultrasound equipment interprets a second object that is twice as far away as the first. There is ongoing attenuation of the sound wave with each successive reverberation, resulting in a slightly less echoic image displayed on the screen. Therefore images are produced, spaced at equal intervals from the transducer but progressively less echoic (Fig. 4.16).

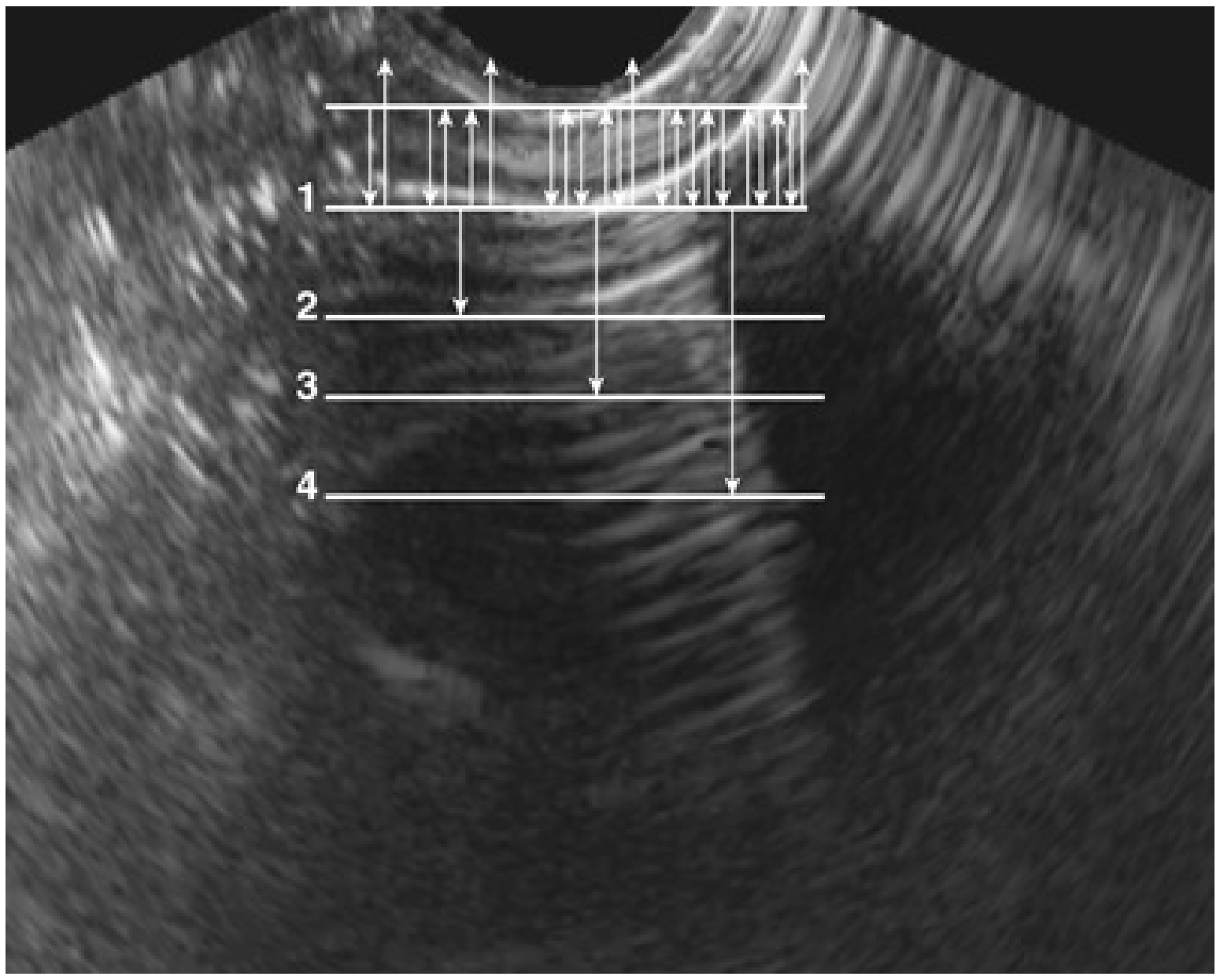

FIG. 4.16 Reverberation artifact. The strongly reflective interface is projected with decreasing amplitude as the incident sound wave makes multiple round trips.

The reverberation artifact can also be seen in cases in which the incident sound wave strikes a series of smaller reflective objects (such as the gas-fluid mixture in the small bowel), which results in multiple reflected sound waves of various angles and intensity (Fig. 4.17). The resultant echo pattern is a collection of hyperechoic artefactual reflections distal to the structure with progressive attenuation of the sound wave.

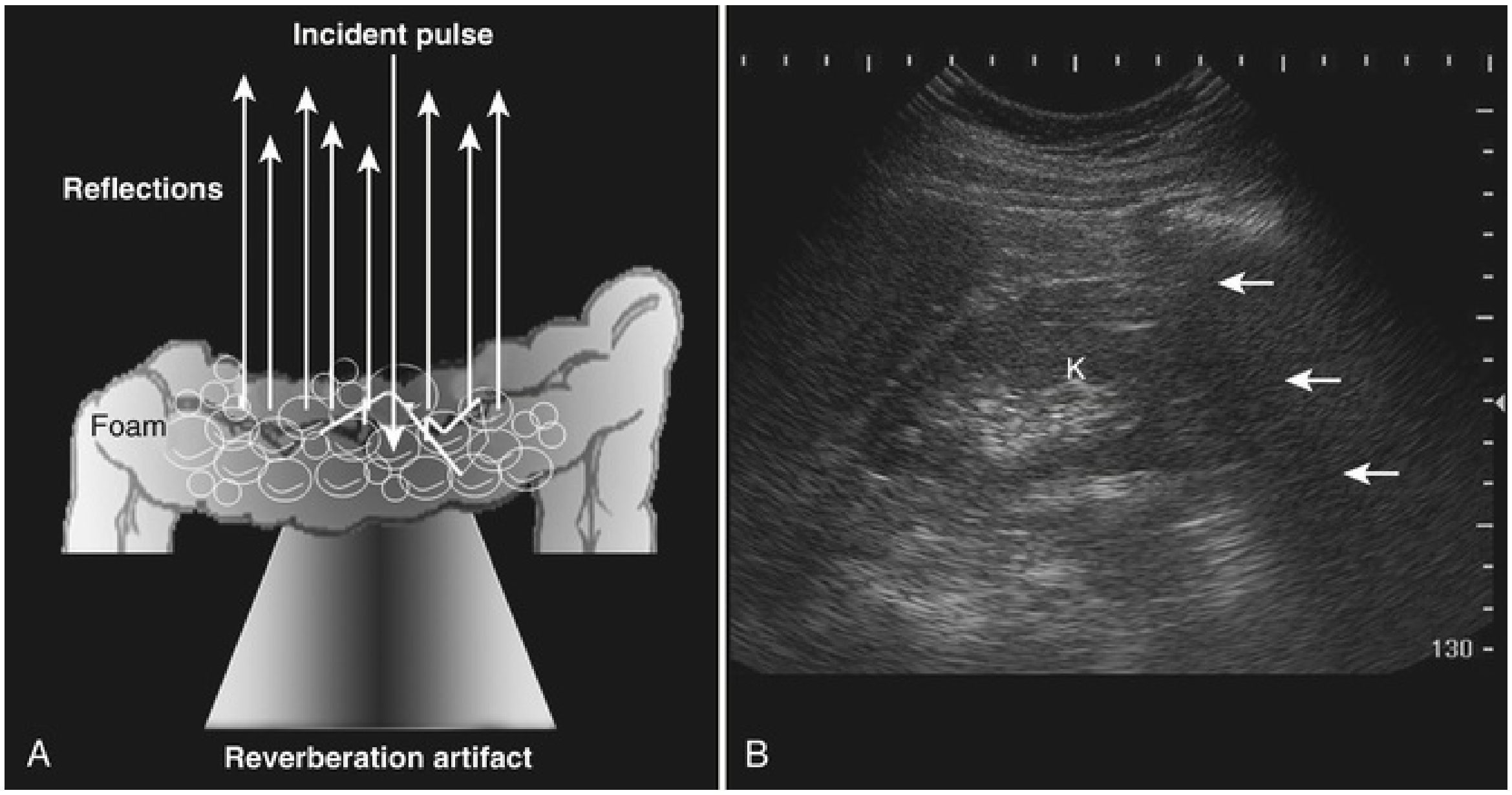
Incident pulse
Reflections
Foam
Reverberation artifact
A
B
K
130

FIG. 4.17 When ultrasound strikes a structure such as bowel, which contains gas bubbles (A), the resultant reverberation artifact has a characteristic appearance sometimes called a “comet tail.” (B) A comet tail artifact produced by bowel gas *(arrows)* obscures the lower pole of the kidney.

Modes of Ultrasound

Gray-Scale Ultrasound

Gray-scale B-mode ultrasonography is the most commonly employed mode of ultrasound. This pulsed-wave technique produces real-time two-dimensional (2D) images consisting of shades of gray. The generation of this image involves assigning a pixel brightness to the amplitude of the returning sound waves received by the transducer. The position of the pixel is determined by the duration of the round trip of the sound wave. Individual lines of data are displayed sequentially on the monitor to produce a continuous or real-time image. Evaluation of gray-scale imaging requires the ability to recognize normal patterns of echogenicity from anatomic structures. Variations from these expected patterns of echogenicity indicate disorders of anatomy or physiology.

Doppler Ultrasound

The Doppler ultrasound mode depends on the physical principle of frequency shift when sound waves strike a moving object. The basic principle of Doppler ultrasound is that sound waves of a certain frequency will be shifted or changed on the basis of the direction and velocity of the moving object as well as the angle of insonation. This phenomenon allows for the characterization of motion, most commonly the motion of blood through vessels, but it may also be useful for detecting the flow of urine.

Color Doppler ultrasonography allows for evaluation of the velocity and direction of motion. A color map may be applied to direction with the most common assignation of the color blue to motion away from the transducer and red to motion toward the transducer. The velocity of motion is designated by the intensity of the color; thus the brighter the color, the greater the velocity. Color Doppler may be used to evaluate the presence or absence of blood flow in the kidney, testes, penis, and prostate. It also may be useful in the detection of ureteral “jets” of urine emerging from the ureteral orifices.

Color flow with spectral display is a mode that allows the interrogation of particular areas within an ultrasound field for flow and displays the flow as a continuous wave form. This mode is commonly used to evaluate the pattern and velocity of blood flow in the intrarenal or penile vasculature. The waveform provides information about peripheral vascular resistance in the tissues. The most commonly used index of these velocities is the resistive index. The **resistive index** is a ratio of peak systolic velocity minus the end-diastolic velocity over the peak systolic velocity. This index is helpful in characterizing a number of clinical conditions, including renal artery stenosis, ureteral obstruction, and penile arterial insufficiency.

Power Doppler ultrasonography is a mode that assigns the amplitude of frequency change to a color map. This does not permit evaluation of velocity or direction of flow but is less affected by back-scattered waves and therefore a more sensitive mode for detecting blood flow. Power Doppler is less angle dependent than color Doppler and is three to five times as sensitive as color Doppler ultrasound for detecting flow. Therefore it may be useful for evaluating testicular torsion.

Harmonic Scanning

Harmonic scanning makes use of aberrations related to the nonlinear propagation of sound waves within tissue. These asymmetrically propagated waves generate fewer harmonics, but those that are generated have greater amplitudes. Because these harmonics are not subject to scattering at the frequency associated with the incident wave, there is less noise associated with the signal. Concentrating on the harmonic frequencies produced within the body and reflected to the transducer allows production of an image with less artifact and greater resolution (Fig. 4.18).

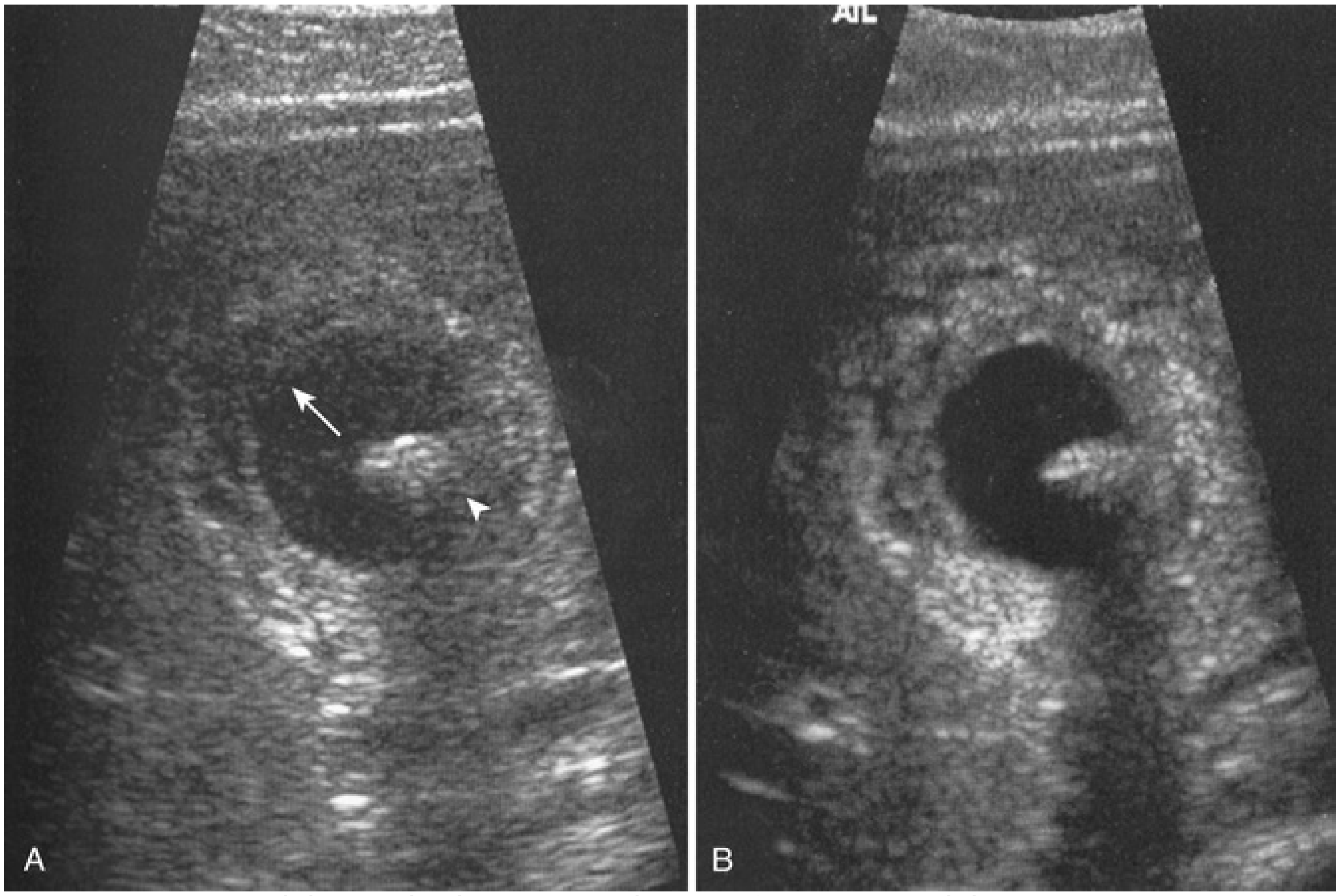

FIG. 4.18 (A) Standard gray-scale image of a cyst containing a mural nodule *(arrowhead).* Note the artifactual echogenicity within the cyst *(arrow).* (B) The same structure on harmonic scanning is more clearly seen. There is less artifact within and distal to the cyst. (From Merritt CRB: Physics of ultrasound. In Wilson S, Rumack C, eds: *Diagnostic ultrasound,* ed 3, St. Louis, 2005, Elsevier.)

Spatial Compounding

Spatial compounding is a scanning mode whereby the direction of insonation is electronically altered and a composite image is generated. This technique reduces the amount of artifact and noise, producing a scan of better clarity.

Sonoelastography

The ability to access pathology by palpation has long been a key part of a physician's physical examination. Hard lesions are often a sign of pathology. Sonoelastography (tissue elasticity imaging) is an ultrasound modality that adds the ability to evaluate the elasticity (compressibility and displacement) of biologic tissues. Essentially, it gives a representation, using color, of the softness or hardness of the tissue of interest. But how do we use ultrasound to "palpate" an organ? To do so requires a compressing mechanical wave to be produced in the tissue of interest. Presently, there are two ways to produce this mechanical wave: real-time elastography (RTE) and shear wave elastography (SWE).

In RTE, as in standard diagnostic, an external, nonquantifiable mechanically produced compression wave travels in tissue (1540 m/s). These waves successively compress tissue layers, producing backscattered reflected waves that are received and processed by the ultrasound equipment producing an image. Because the stress producing the mechanical compression wave cannot be directly measured, only a relative elasticity can be determined.

With RTE (Fig. 4.19) deformation is induced by manually pressing on the anatomy with the transducer and is measured using ultrasound. RTE is a qualitative technique and highly user dependent. Because of the requirement of manual displacement, RTE cannot measure absolute tissue stiffness as currently employed. Its major benefits are that it has a high spatial resolution, is a real-time measurement, and does not require any modifications to conventional ultrasound hardware. Spatial resolution is the ability to distinguish two separate objects that are close together and encompasses axial resolution and lateral resolution as defined previously.

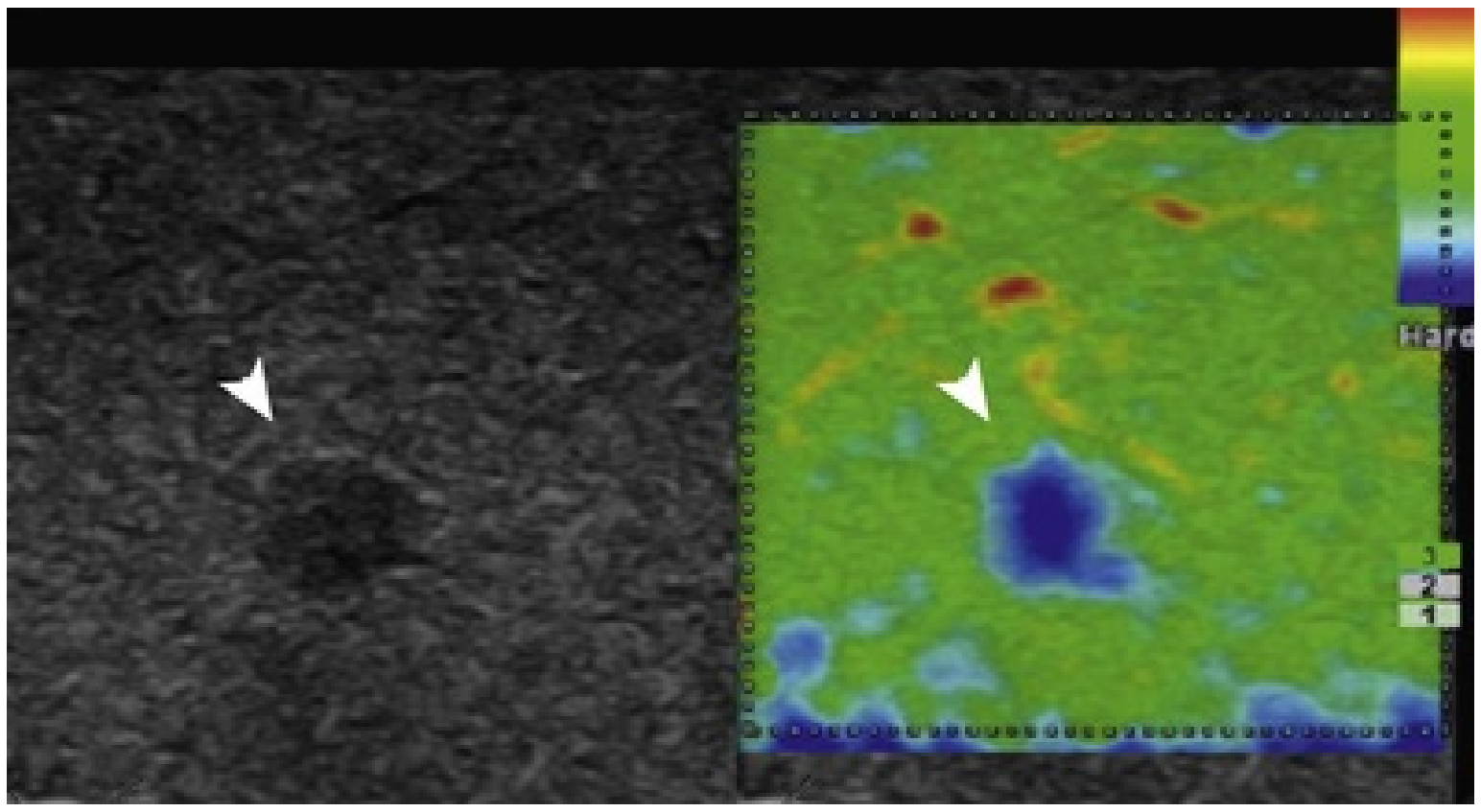

FIG. 4.19 Real-time elastography. A 4-mm hypoechoic nodule *(arrowhead, left panel)* was found with Doppler ultrasound with vascular flow internally. Real-time sonoelastography suggested a hard nodule (with this equipment blue is hard, not soft). Close follow-up with ultrasound every 3 months found no increase in size of the nodule. It was therefore considered “probably” benign. (From Goddi A et al: Real-time tissue elastography for testicular lesion assessment. *Eur Radiol* 22[4]:721–730, 2012.)

In SWE the shear wave produced can be measured precisely and travels more slowly (1 to 10 m/s). The shear wave is propagated by a tangential “sliding” force between tissue layers. The elasticity (E), density of the tissue (p, kg/m^2), and shear wave propagation speed (c) are directly related through the following equation:

$$E = 3pc^2$$

Therefore, by measuring the shear wave propagation speed, practitioners can directly determine the elasticity of the tissue.

With SWE (Figs. 4.20A and 4.20B), low-frequency (~100-Hz) pulses are rapidly transmitted into the tissue to induce a vibration in the tissue. Depending on the manufacturer's implementation, the vibrations can be induced in a single area or in a vertical plane by rapidly altering focal depth. Subsequently the observation of the propagation velocity of the resultant transient shear waves determines the viscoelastic properties of the tissues. Two typical limitations of generated shear waves are that (1) they are very weak, resulting in only a few millimeters of propagation and (2) detection of shear wave propagation requires very rapid acquisition speeds (pulse repetition frequency is >5000 Hz), which may limit the area of detection. However, some new-generation ultrasound systems have overcome these obstacles and allow large areas of interest to be displayed at near real-time imaging frame rates.

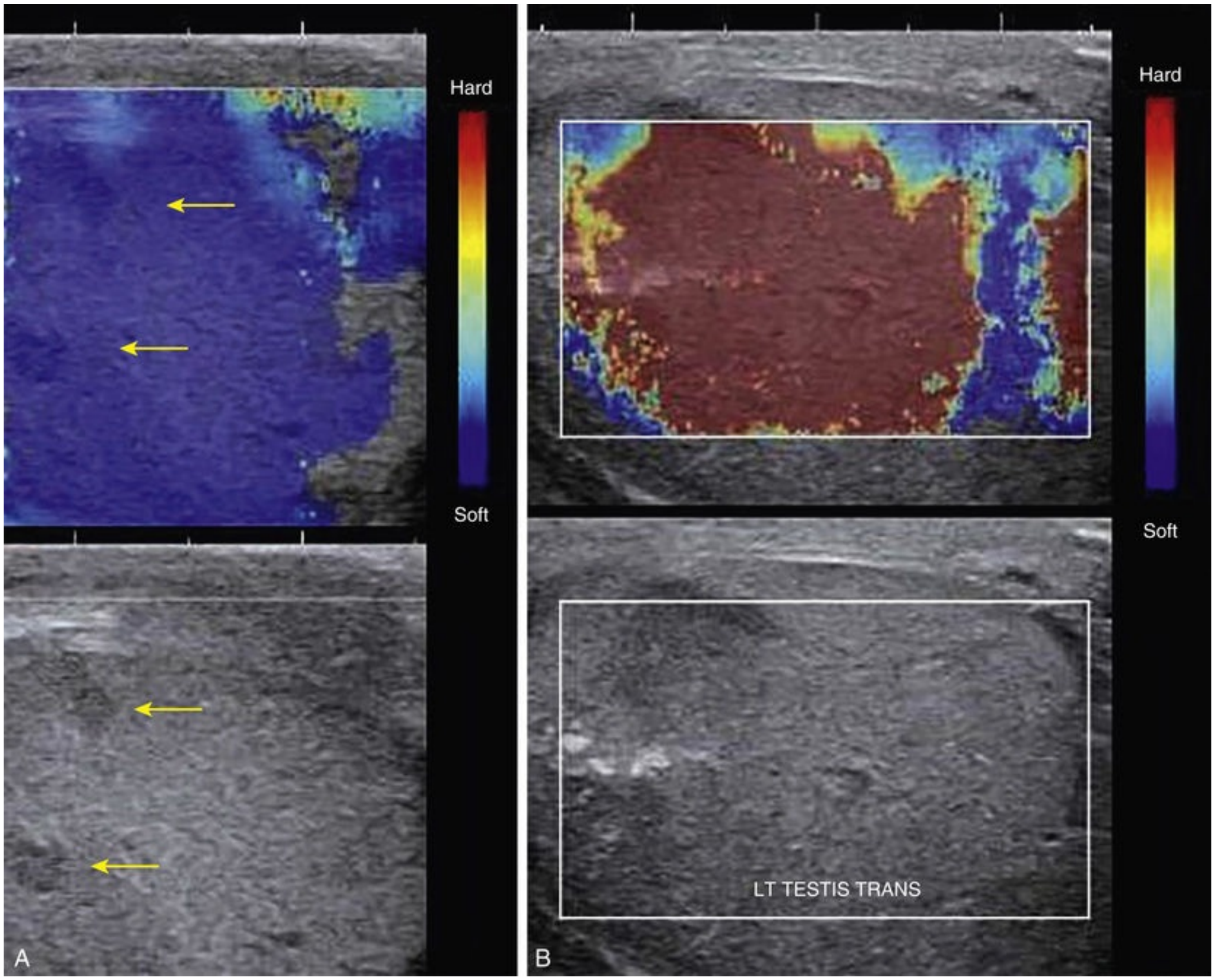

FIG. 4.20 Shear wave elastography. (A) Two small hypoechoic vascular lesion *(arrows, lower panel)* found with B-mode ultrasound is shown in the upper panel to be a soft *(blue)* lesion with shear wave elastography ultrasound. Biopsy confirmed a Sertoli cell nodule. (B) A larger lesion with heterogeneous echogenicity on B-mode ultrasound *(lower panel)* demonstrates diffuse "hardness" on shear wave elastography *(upper panel)*. Pathology demonstrated a nonseminomatous germ cell tumor.

Several approaches for elastography have been introduced. All of them have three common steps:

1. The sonographer manually compresses (in RTE) or the machine automatically generates (in SWE) a low-frequency vibration in tissue to induce stress.
2. The tissue is imaged with the goal of analyzing the resulting strain.
3. Parameters are defined related to tissue stiffness.

The principle of elastography is based on the concept that a given force applied to softer tissue results in a larger displacement than the same force applied to harder tissue. Measuring the tissue displacement induced by compression allows estimation of the tissue hardness and differentiation between benign (soft) from malignant (hard) lesions. This relationship between stress (s) and strain (e) is given by Young's modulus of elasticity (E):

$$E = s/e$$

E is larger in hard tissues and lower in soft tissues.

Visually, the elasticity of a tissue is represented by color spectrum. Be aware that the color given to hard lesions is determined by the manufacturer of the equipment and can be set by the user. Therefore, just as in using color Doppler, the user needs to look at the color bar (see Figs. 4.19 and 4.20) to know what color represents a “hard” and “soft” lesion.

Three-Dimensional Scanning

Three-dimensional (3D) scanning has been used extensively in obstetrics and gynecology but so far has limited application in urology. 3D scanning produces a composite of images (data set), which can then be manipulated to generate additional views of the anatomy in question (Fig. 4.21). 3D rendering may be important in procedural planning and precise volumetric assessments (Ghani et al., 2008a; Ghani et al., 2008b). 3D scanning may allow the recognition of some tissue patterns that would otherwise be inapparent on 2D scanning (Mitterberger et al., 2007b; Onik and Barzell, 2008).

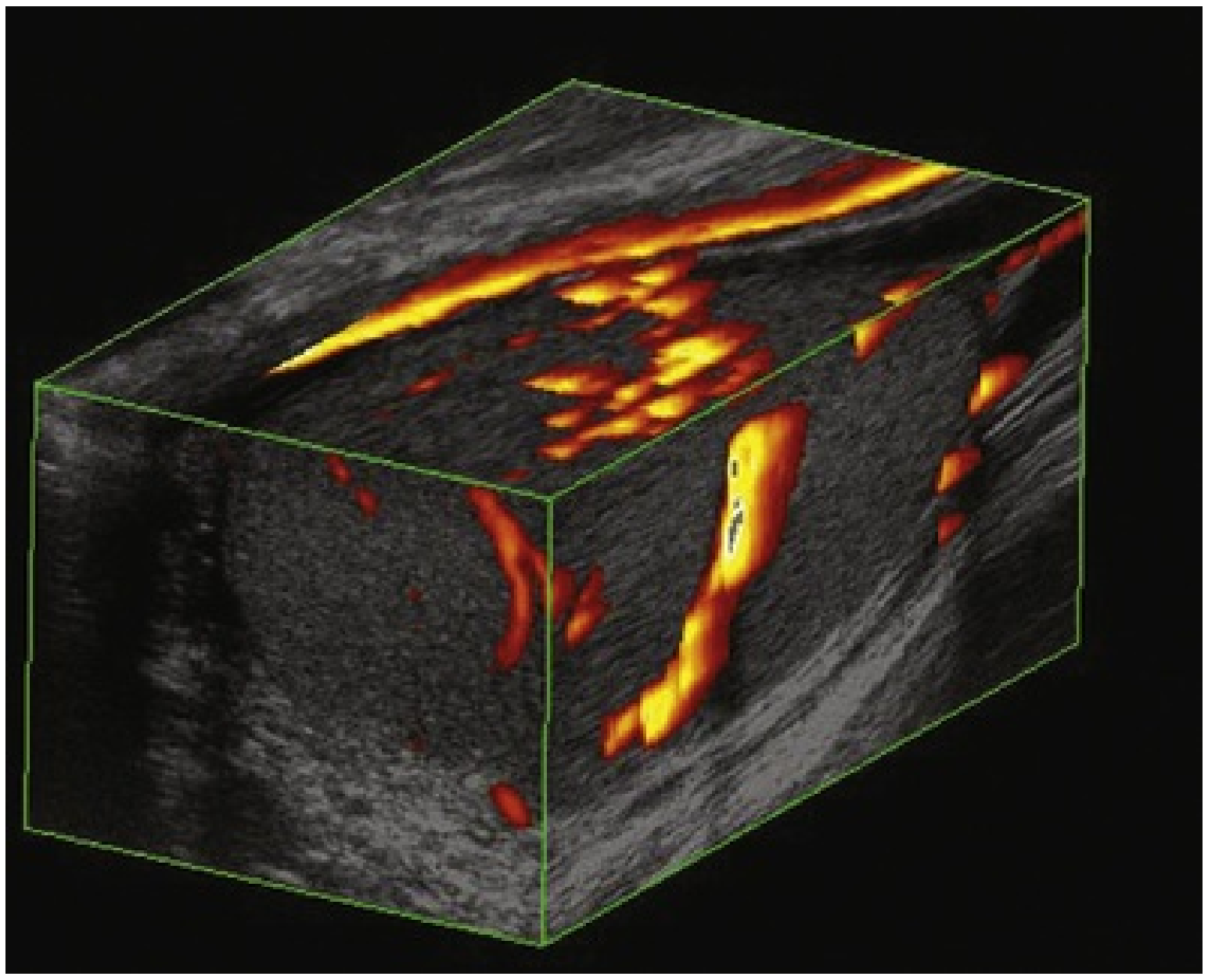

FIG. 4.21 A three-dimensional image of the testis demonstrating intratesticular blood flow on power Doppler. The image can be virtually rotated and manipulated to produce unique anatomic perspectives. (Used with permission by BK Medical.)

Multiparametric Ultrasound

The emergence of multiple modalities of ultrasound, including gray-scale, Doppler, elastography, contrast-enhancement, and computer-enhanced imaging, has given rise to the concept of multiparametric ultrasound (mpUS). Just as multiparametric MRI (mpMRI) offers excellent anatomic resolution with T2-weighted imaging, ultrastructural histology with water diffusion, and vascularity with contrast enhancement, mpUS is able to address all of those tissue properties in real time. mpUS is already used in transrectal ultrasound of the prostate and is finding many applications in nonprostate ultrasound (Fig. 4.22).

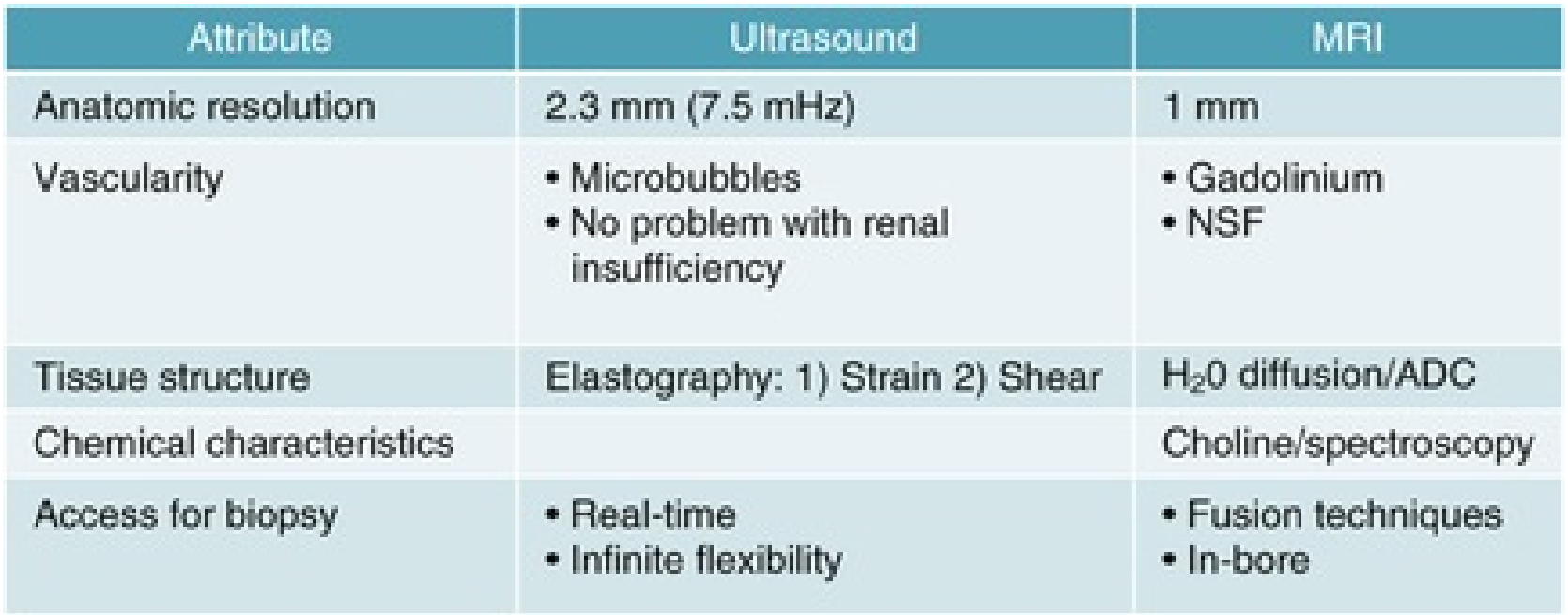

Attribute	Ultrasound	MRI
Anatomic resolution	2.3 mm (7.5 mHz)	1 mm
Vascularity	• Microbubbles • No problem with renal insufficiency	• Gadolinium • NSF
Tissue structure	Elastography: 1) Strain 2) Shear	H_20 diffusion/ADC
Chemical characteristics		Choline/spectroscopy
Access for biopsy	• Real-time • Infinite flexibility	• Fusion techniques • In-bore

FIG. 4.22 Multiparametric ultrasound is compared with MRI. *ADC,* Apparent diffusion coefficient; *SNF,* systemic nephrogenic fibrosis.

Contrast Agents in Ultrasound

Intravenous compounds that contain microbubbles have been used for enhancing the echogenicity of blood and tissue. The addition of targeting ligands attached to the microbubble allows the microbubble complex to selectively accumulate in diseased or abnormal tissues. Microbubbles are distributed in the vascular system and create strong echoes with harmonics when struck by sound waves. The bubbles are rapidly degraded by their interaction with the sound waves. Contrast agents may be useful in prostatic ultrasonography by enhancing the ability to recognize areas of increased vasculature. Several intravenous ultrasound contrast agents have been approved by the US Food and Drug Administration (FDA) as of this writing. They have a good safety profile and have found use in a number of urologic scanning situations (Auer et al., 2017; Mitterberger et al., 2007a; Wildeboer et al., 2017; Wink et al., 2008).

Documentation and Image Storage

Documentation is essential for ensuring high-quality patient care. Proper documentation includes the production a permanent record of the ultrasound examination and interpretation of the examination. This documentation is inclusive of the report and acquired images (American Institute of Ultrasound in Medicine, 2014). All documentation must be retrievable and comply with local, state, and federal requirements.

Report

The report should include specific identifiers, including the patient identification, the date of the examination, the measurement parameters, and a description of findings of the examination. Ideally the report should also include specifics of how the evaluation was performed, which would detail the transducer used, machine used, and settings employed. However, most of these should be on the recorded image that is also stored with the report. The report must be signed by the physician who performed the ultrasound examination, and prominently displayed at the top of the report should be the indications for performing the examination.

When urologists perform and interpret ultrasound studies, it is important that appropriate nomenclature be used to describe the objects imaged (Fig. 4.23). By convention, the liver is used as a benchmark for echogenicity. If a structure is hypoechoic, it means it is darker than the surrounding tissues. If it is hyperechoic, it means it is brighter than the surrounding tissues. Isoechoic means it is similar to the surrounding tissues. Structures that do not generate echoes are called *anechoic*. A simple cyst is an example of a structure with an anechoic interior. In general, a high water content causes tissue to appear hypoechoic. In general, a high fat content causes tissue to appear hyperechoic.

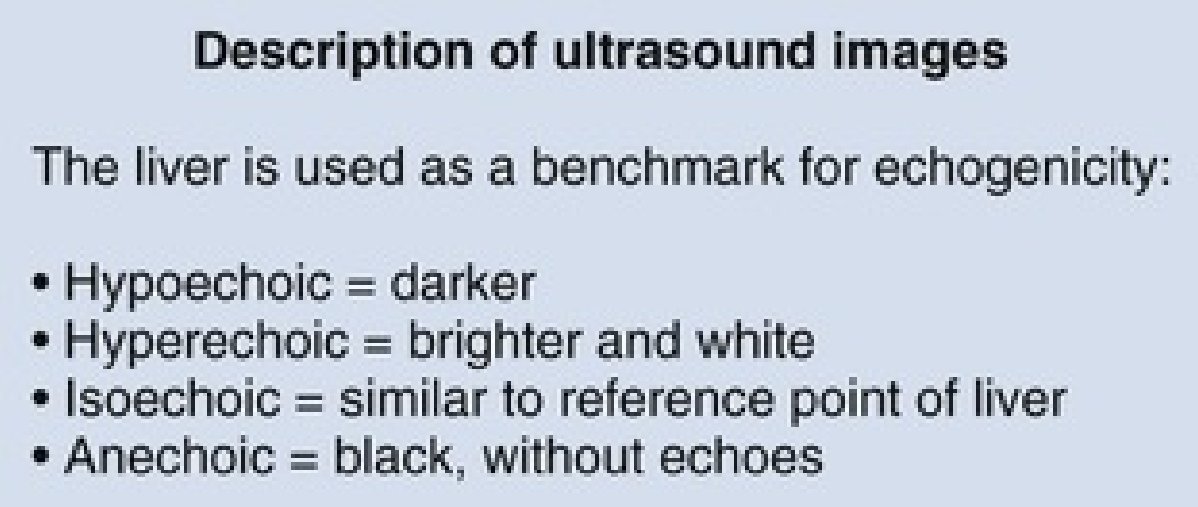

Description of ultrasound images

The liver is used as a benchmark for echogenicity:

- Hypoechoic = darker
- Hyperechoic = brighter and white
- Isoechoic = similar to reference point of liver
- Anechoic = black, without echoes

FIG. 4.23 The nomenclature for describing the appearance of ultrasound images.

Images

Images should include the patient identification, the date and time of each image, and clear image orientation. Measurements should also be clearly identified, and anatomy and any abnormalities should be labeled. The image should be interpretable by any appropriately trained sonographer and demonstrate a clear, unimpeded ultrasound image of the anatomy of interest. Images should always be attached to the report or be easily accessible from the report.

By convention, structures imaged by ultrasonography should be oriented so that the superior aspect of the structure is to the left as the image is viewed and the inferior aspect of the structure to the right. With paired structures, it is critically important to document right or left. It is useful to use equipment-generated icons to illustrate patient position and the orientation of insonation (Fig. 4.24).

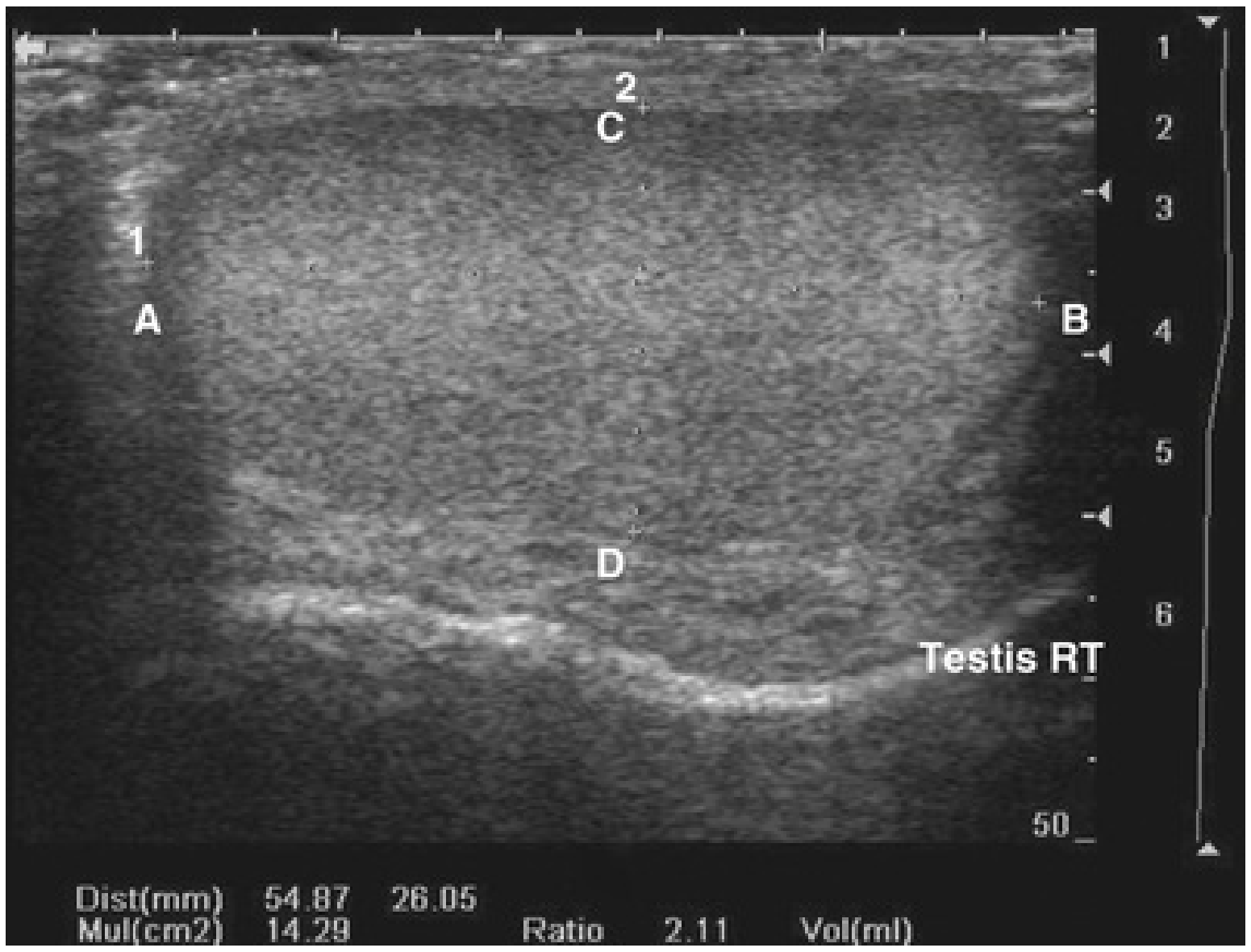

FIG. 4.24 In this sagittal image of the right testis, the superior pole of the testis *(A)* is to the left, and the inferior pole of the testis *(B)* is to the right. The anterior aspect of the testis *(C)* is at the top of the image and the posterior aspect *(D)* at the bottom. Without the label, there would be no way to distinguish the right from the left testis.

The appropriate number of images to be captured for documentation is the number necessary to document a systematic and complete examination and to document relevant pathology.

Report and Image Storage

The use of electronic medical records has made the documentation of ultrasound examinations somewhat easier. However, it has also created challenges in the archiving of images for easy reviewing. These images can occupy large portions of digital storage and, because they are part of the medical record and contain protected health information (PHI), must comply with local, state, and federal regulations. The widespread use of cloud storage has created an opportunity for many vendors as well as challenges regarding how to secure this information. Fortunately, there are many validated systems available for small and large practices that meet current regulatory requirements.

Patient Safety

Diagnostic ultrasonography transmits energy into the patient that has the potential to produce biologic effects. The two main categories of biologic effects are **mechanical effects** and **thermal effects.**

The mechanical effects of ultrasonography are torque and streaming. The mechanical effects of an acoustic field may produce a phenomenon called *cavitation.* **Cavitation** occurs when small gas-filled bubbles form and then collapse. These collapsing bubbles liberate a large amount of energy, which may cause damage to tissue in certain circumstances. Mechanical effects are most likely to be observed around gas-containing structures such as lung and bowel.

The thermal effects of ultrasonography are primarily the result of tissue heating resulting from the absorption of energy. The amount of tissue heating is influenced by several factors, including beam focusing, transducer frequency, exposure time, scanning mode, and tissue density.

To assist the sonographer in monitoring the bioeffects of ultrasound, the ultrasonography community has adopted the **output display standard (ODS).** Two values are typically displayed: the **mechanical index (MI)** and the **thermal index (TI).** These indices are calculated **estimates** of the potential for bioeffects of ultrasonography based on the mode of ultrasonography being used, frequency, power output, and time of insonation. The MI indicates the probability that cavitation will occur. For tissues not containing stabilized gas bodies (lung and intestine), the risk of cavitation is low as long as the MI is less than or equal to 0.7. For structures adjacent to lung or intestine, scanning time should be limited if the MI exceeds 0.4. The TI indicates the probability that tissue temperature within the sonographic field will be increased by 1°C. The precise consequences of tissue heating are not completely understood, but even tissue temperature elevations of up to 6°C are not likely to be dangerous unless exposure time exceeds 60 seconds. TI values should be less than 2 for most urologic ultrasound studies (Nelson et al., 2009). The MI and TI typically are displayed on the monitor during ultrasound examinations, and all practitioners should be familiar with the location. **These indices are not safety limits.**

In general, ultrasonography performed by urologists has a low risk for patient harm as long as standard protocols are followed (Rumack and Wilson, 2005). Although tissue heating may occur, there are no confirmed biologic effects of tissue heating in nonfetal scanning except when they are sustained for extended periods. Users should be aware that for soft tissues not known to contain gas bodies, there is no basis in present knowledge to suggest an adverse nonthermal bioeffect from current diagnostic instruments not exceeding the FDA output limits (Rumack and Wilson, 2005). Nevertheless, all urologists should endeavor to follow the principles of **ALARA,** which stands for **"As Low As Reasonably Achievable."** The ALARA principle is intended to limit the total energy imparted to the patient during an examination. This can be accomplished by (1) keeping power outputs low, (2) using appropriate scanning modes, (3) limiting examination times, (4) adjusting focus and frequency, and (5) using the cine function during documentation.

In summary, ultrasound scanning offers an excellent, cost-effective modality for diagnosing and treating urologic conditions. **The most important factor in ultrasound safety is the informed operator.** Urologists should endeavor to perform limited examinations using consistent technique for specific indications. Patient safety and equipment maintenance should be emphasized in all the environments where ultrasound technology is used.

Clinical Urologic Ultrasound

The use of ultrasonography in urology has expanded dramatically because of its profound utility in the clinic and operating room. In addition to being the mainstay of the diagnosis of prostatic disease, ultrasonography is increasingly being used by urologists in the clinical environment for initial diagnosis, interventional management, and longitudinal follow-up of urologic diseases.

Renal Ultrasound

Urologists, because of their intimate knowledge of surgical anatomy of the kidneys and retroperitoneum, are uniquely qualified to perform and interpret selected ultrasound examinations of the abdomen. These skills are relevant in the office and the operating room environment. Urologists generally perform abdominal ultrasonography for a specific clinical indication and less often for general screening of the abdominal contents. Therefore, in most clinical situations, a limited retroperitoneal examination is used in urologic practice.

Technique

The transducer normally used for renal ultrasonography is a curved array transducer of 3.5 to 5.0 MHz. Transducers of a higher frequency may be used for pediatric patients. For intraoperative and laparoscopic renal ultrasonography, a linear array transducer of 6 to 10 MHz is typically employed.

Scanning of the right kidney is performed with the patient supine. The kidney is located by beginning in the midclavicular line in the right upper quadrant. In the sagittal plane the transducer is moved laterally until the midsagittal plane of the kidney is imaged. Once the kidney has been imaged anteriorly and posteriorly in the sagittal plane, the probe is rotated 90 degrees counterclockwise. The midtransverse plane will demonstrate the renal hilum containing the renal vein. The kidney is scanned from the upper pole to the lower pole.

The technique and documentation for left renal ultrasonography is identical to that of the right side. However, the left kidney is slightly more cephalad than the right kidney. Bowel gas is more problematic on the left because of the position of the splenic flexure of the colon. Visualization of the left kidney often requires the patient to be turned into a lateral position. Ultrasound imaging of the left kidney lacks the liver as an acoustic window, and it is sometimes more difficult to image the left kidney in a true sagittal plane.

Indications

1. Assessment of renal and perirenal masses
2. Assessment of the dilated upper urinary tract
3. Assessment of flank pain during pregnancy
4. Evaluation of hematuria in patients who are not candidates for IVP, CT, or MRI because of renal insufficiency, contrast allergy, or physical impediment
5. Assessment of the effects of voiding on the upper urinary tract
6. Evaluation for and monitoring of urolithiasis
7. Intraoperative renal parenchyma and vascular imaging for ablation of renal masses
8. Percutaneous access to the renal collecting system
9. Guidance for transcutaneous renal biopsies, cyst aspiration, or ablation of renal masses
10. Postoperative evaluation of patients after renal and ureteral surgery
11. Postoperative evaluation of renal transplant patients

Normal Findings

It is helpful during scanning of the kidney to understand its anatomic position within the retroperitoneum. This assists in identifying the midsagittal plane, which serves as a reference point for a complete examination (Fig. 4.25).

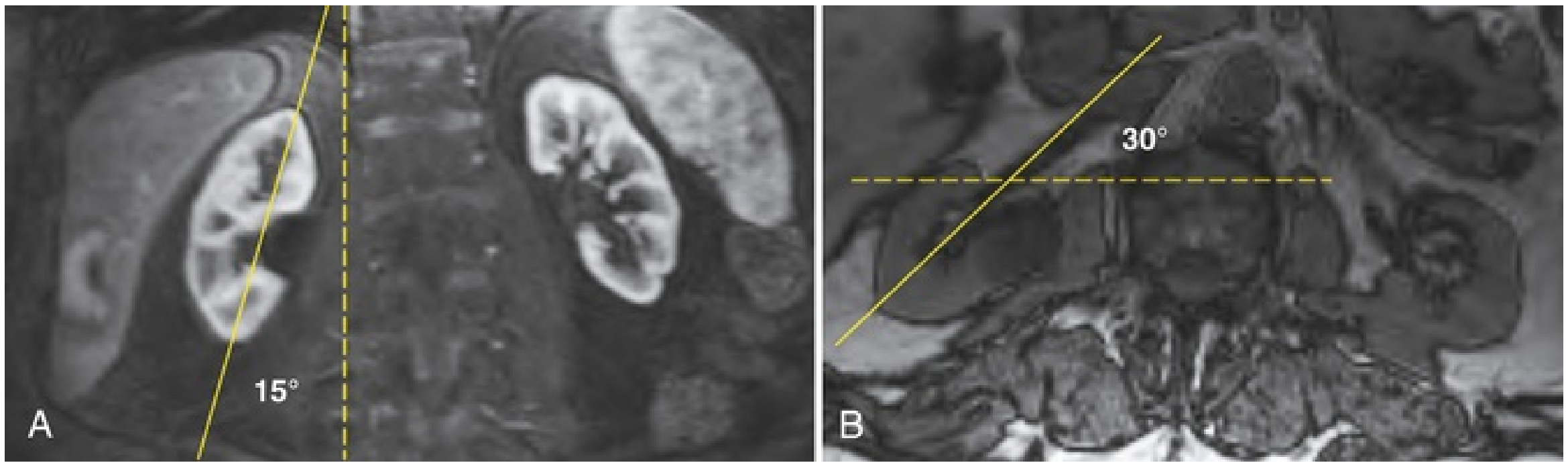

FIG. 4.25 The lower pole of the kidney is displaced 15 degrees laterally compared with the upper pole (A). The kidney is rotated 30 degrees

posterior to the true coronal plane (B). The lower pole of the kidney is slightly anterior compared with the upper pole.

The adult right kidney in the sagittal view demonstrates a cortex that is usually hypoechoic with respect to the liver. The central band of echoes in the kidney is a hyperechoic area that contains the renal hilar adipose tissue, blood vessels, and collecting system. Acoustic shadowing from ribs overlying the inferior pole can be eliminated by moving the probe to a more lateral position or into the intercostal space. By having the patient take a deep breath, the kidney can be moved inferiorly to assist complete imaging (Fig. 4.26).

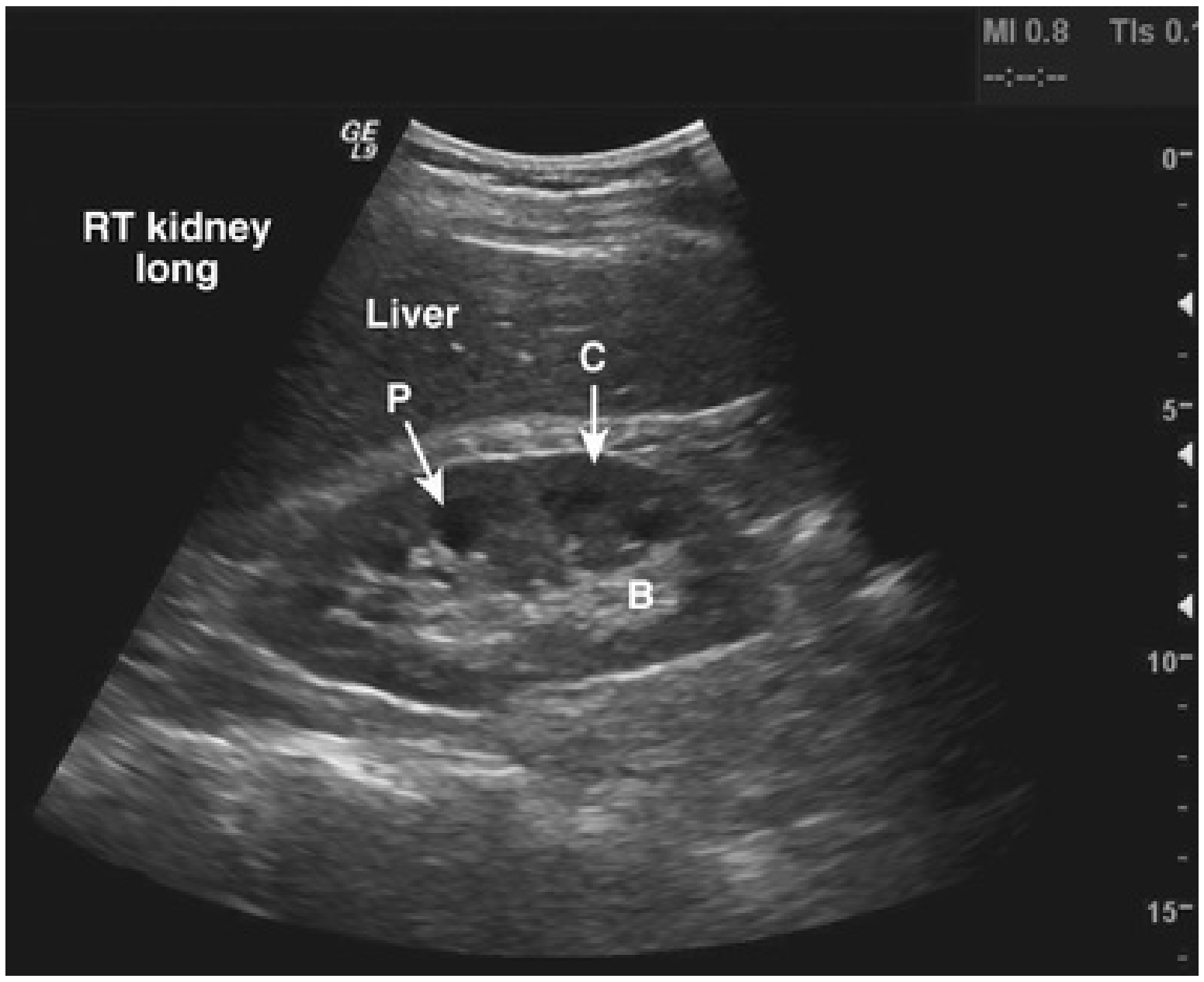

FIG. 4.26 Midsagittal plane of the kidney. Note the relative hypoechogenicity of the renal pyramids *(P)* compared with the cortex *(C).* The central band of echoes *(B)* is hyperechoic compared with the cortex. The midsagittal plane will have the greatest length measurement pole to pole. A perfectly sagittal plane will result in a horizontal long axis of the kidney.

The echogenicity of the kidney varies with age. The renal cortex of an infant is relatively hyperechoic compared with that of an adult. In addition, there is a smaller and less apparent central band of echoes in the infant. In the adult, the echogenicity of the renal cortex is usually hypoechoic with respect to the liver (Emamian et al., 2013). In patients with chronic medical renal diseases the renal cortex is often thinned and isoechoic or hyperechoic with respect to the liver (O'Neill, 2001).

Renal size changes over the lifetime of an individual. Nomograms for pediatric renal size should be consulted. These are based on age, height, and weight of the patient. The average adult kidney measures 10 to 12 cm in length and 4 to 5 cm in width. Measurements of renal volume may be appropriate in cases of severe renal impairment. Renal measurements should be obtained in the midsagittal plane and midtransverse plane. Measurements taken in other than the midsagittal plane and midtransverse may be spuriously low. The thickness of the parenchyma is the average distance between the renal capsule and the central band of echoes. The precise location for making this measurement is somewhat subjective. The midlateral renal parenchyma in the sagittal view is a common choice for obtaining this measurement (Fig. 4.27). Although there is no universal standard, the renal cortical thickness should be greater than 7 mm (Roger et al., 1994), and the renal parenchymal thickness should be greater than 15 mm in adults (Emamian et al., 2013).

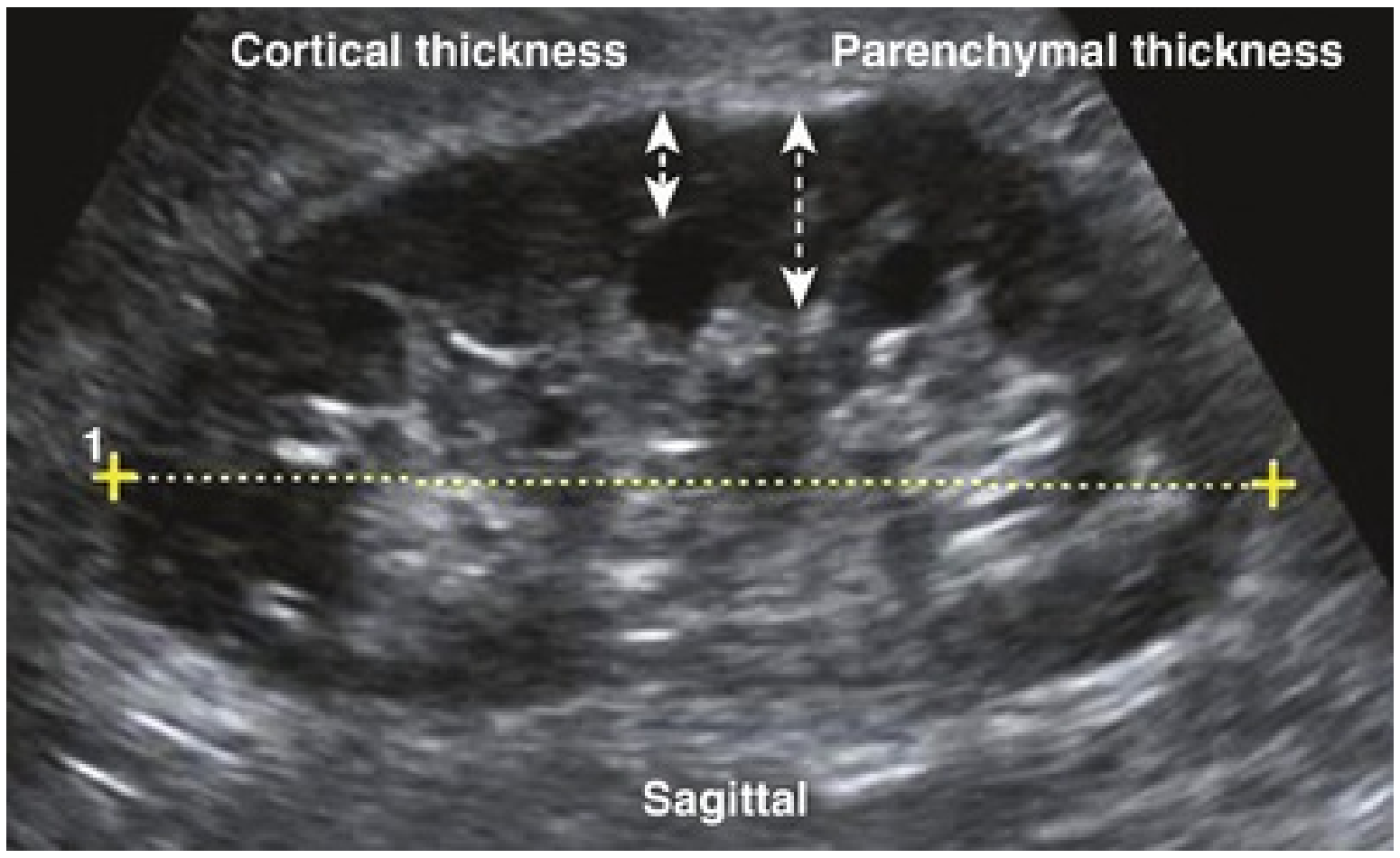

FIG. 4.27 The distinction between renal cortical thickness and renal parenchymal thickness is that the renal parenchyma is measured from the central band of echoes to the renal capsule. The renal cortex is measured from the outer margin of the medullary pyramid to the renal capsule.

Doppler ultrasound may be helpful in evaluating the renal artery and renal vein and assessing the vascular resistance in the kidney. Doppler modes may also be useful in evaluating neovascularity associated with renal tumors and in correctly characterizing hypoechoic structures in the renal pelvis such as a parapelvic cyst, the renal vein, or the dilated collecting system.

Procedural Applications

Percutaneous renal biopsy as an office procedure has been used by several groups for the past two decades and found to be a safe and effective procedure (Christensen et al., 1995; Fraser and Fairley, 1995; Hergesell, 1998). In a series of 131 ultrasound-guided biopsies by Christensen et al. (1995), complication occurred in 21% of patients with 18% considered minor and 3% major. In their series, increasing the number of biopsy passes did not increase the complication rate, but severe hypertension did. Fraser and Fairley (1995) compared 118 outpatient ultrasound-guided biopsies with 232 inpatient procedures and found no difference in complication rate. Hergesell et al. (1998) reviewed their series of 1090 percutaneous biopsies performed with local anesthesia and ultrasound guidance. They had only one case requiring interventional radiology for persistent blood loss, 2.2% with minor hematoma conservatively treated (25/1090), and self-limited macrohematuria in 0.8% (9/1090). They did note in a subset of their population evaluated by Doppler ultrasound hemodynamically irrelevant AV fistula in 9% (48/533). Sufficient tissue was obtained in 98.8%.

More recently Al-Hweish (Al-Hweish and Abdul-Rehaman, 2007) followed two groups. Group I (N = 22) had a 24-hour hospital admission after the biopsy, and group II (N = 22) was observed for 6 hours after the biopsy and then discharged. A small perinephric hematoma as observed in a single patient in group II and resolved spontaneously. Gross hematuria (13.6% and 9.1%, respectively) was the only significant complication they observed and occurred in all cases within 6 hours.

Safety and efficacy has also been found for pediatric (Davis et al., 1998; Hussain et al., 2003; Kamitsuji et al., 1999) and elderly patients (Kohli et al., 2006; Moutzouris et al., 2009; Stratta et al., 2007).

Limitations

Some patients are not favorable candidates for renal ultrasonography. Obesity, intestinal gas, and physical deformity may be impediments to complete renal evaluation. Renal ultrasonography has poor sensitivity for renal masses less than 2 cm (Warshauer, McCarthy, and Street, 1988). There is a lack of specificity for renal tumor type except for angiomyolipoma. Angiomyolipoma has characteristics that are distinctive on ultrasonography (highly echoic), but some small renal cell carcinomas have been shown to be indistinguishable from angiomyolipoma by ultrasound criteria (Forman, Middleton, and Melson, 1993; Yamashita, Takahashi, and Watanabe, 1992).

Transabdominal Pelvic Ultrasound

Transabdominal pelvic ultrasonography is a tremendously versatile tool for the urologist. It is a noninvasive method for evaluating the lower urinary tract and prostate in men and the bladder in women. A curved array transducer of 3.5 to 5 MHz is most commonly employed to perform transabdominal ultrasonography. In pediatric patients, a higher-frequency transducer may be used. For determining only a residual urine or bladder volume, an automated bladder scanner is often employed.

Technique

Bladder ultrasonography is most commonly performed with the patient supine and the sonographer on the patient's right side. The scan should be performed in a warm room and the patient draped to provide for comfort and privacy. If necessary, a roll may be placed beneath the patient's hips. Scanning technique depends on the circumstances and the reason for the examination but in general should be performed with a moderately full bladder. The bladder should be scanned in a sagittal and transverse manner, angling the probe into the pelvis so that the bladder can be visualized beneath the pubic bone. Although the prostate cannot be imaged with the same resolution achieved during transrectal scanning, the size and morphology of the prostate can be demonstrated. Although transabdominal scanning is the most common means of evaluating the bladder, the bladder may also be assessed via a transvaginal and transrectal approach. These approaches are useful in patients who are obese or who are not suitable candidates for transabdominal scanning.

Indications

1. Measurement of bladder volume or postvoid residual urine
2. Assessment of prostate size and morphology
3. Demonstration of secondary signs of bladder outlet obstruction
4. Evaluation of bladder wall configuration and thickness
5. Evaluation of hematuria of lower urinary tract origin
6. Detection of ureteroceles
7. Assessment for ureteral obstruction
8. Detection of perivesical fluid collections
9. Evaluation of clot retention

10. Confirmation of catheter position
11. Removal of retained catheter
12. Guidance of suprapubic tube placement
13. Establishment of bladder volume before and after flow rate determination

Normal Findings

Transabdominal pelvic ultrasonography should include evaluation of the lumen of the bladder, as well as bladder wall configuration and thickness. The presence of specific lesions such as stones or tumors should be documented. The structures immediately surrounding the bladder may also be evaluated including the distal ureters, the prostate in men, and the uterus and ovaries in women (Fig. 4.28). The emergence of urine from the ureteral orifices (ureteral jets) can be demonstrated. The clinical value of demonstrating ureteral jets has been questioned. Up to 10 minutes of continuous observation may be required to verify the absence of a ureteral jet (Fig. 4.29) (Delair and Kurzrock, 2006).

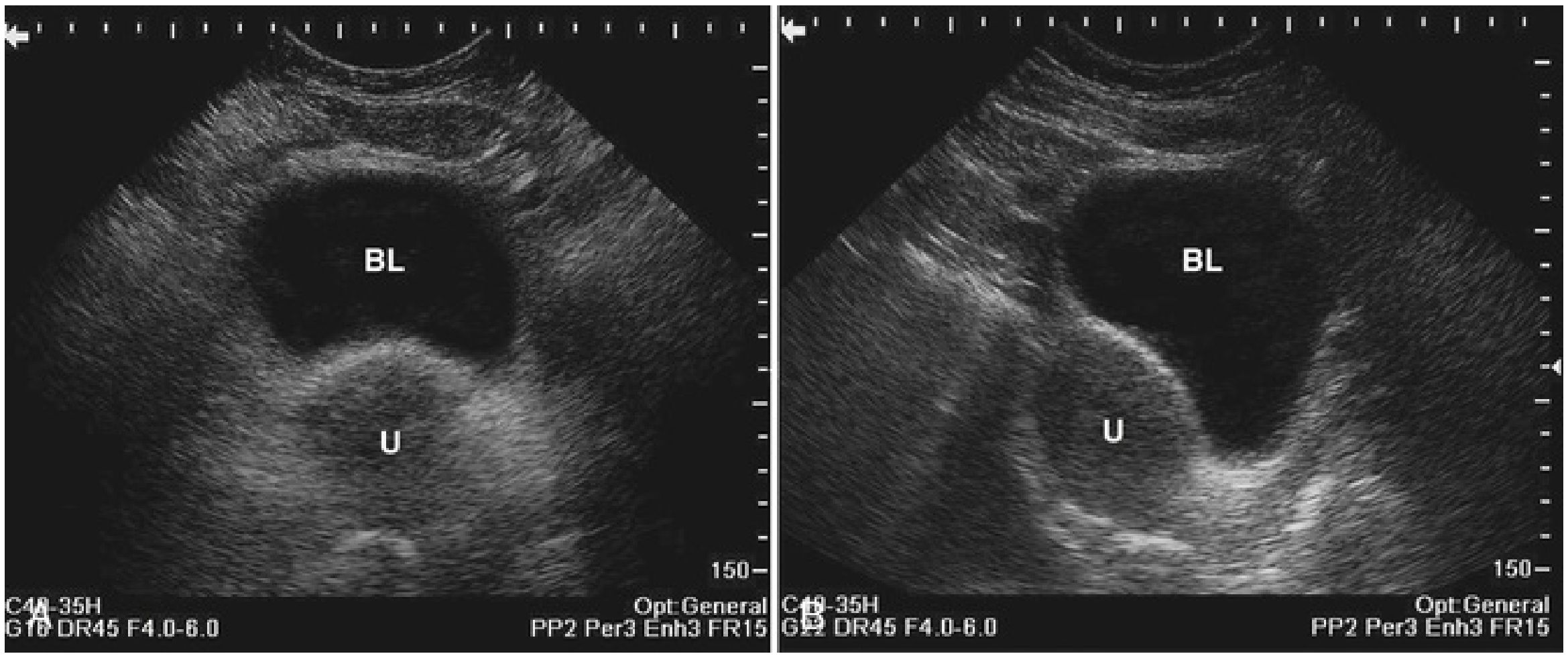
BL
U
150
C40-35H
G16 DR45 F4.0-6.0
A
Opt:General
PP2 Per3 Enh3 FR15
BL
U
150
C40-35H
G22 DR45 F4.0-6.0
B
Opt:General
PP2 Per3 Enh3 FR15

FIG. 4.28 (A) Transverse view of the bladder *(BL)* in this female patient demonstrates the uterus *(U)*. (B) Sagittal view of the bladder shows the uterus posterior to the bladder.

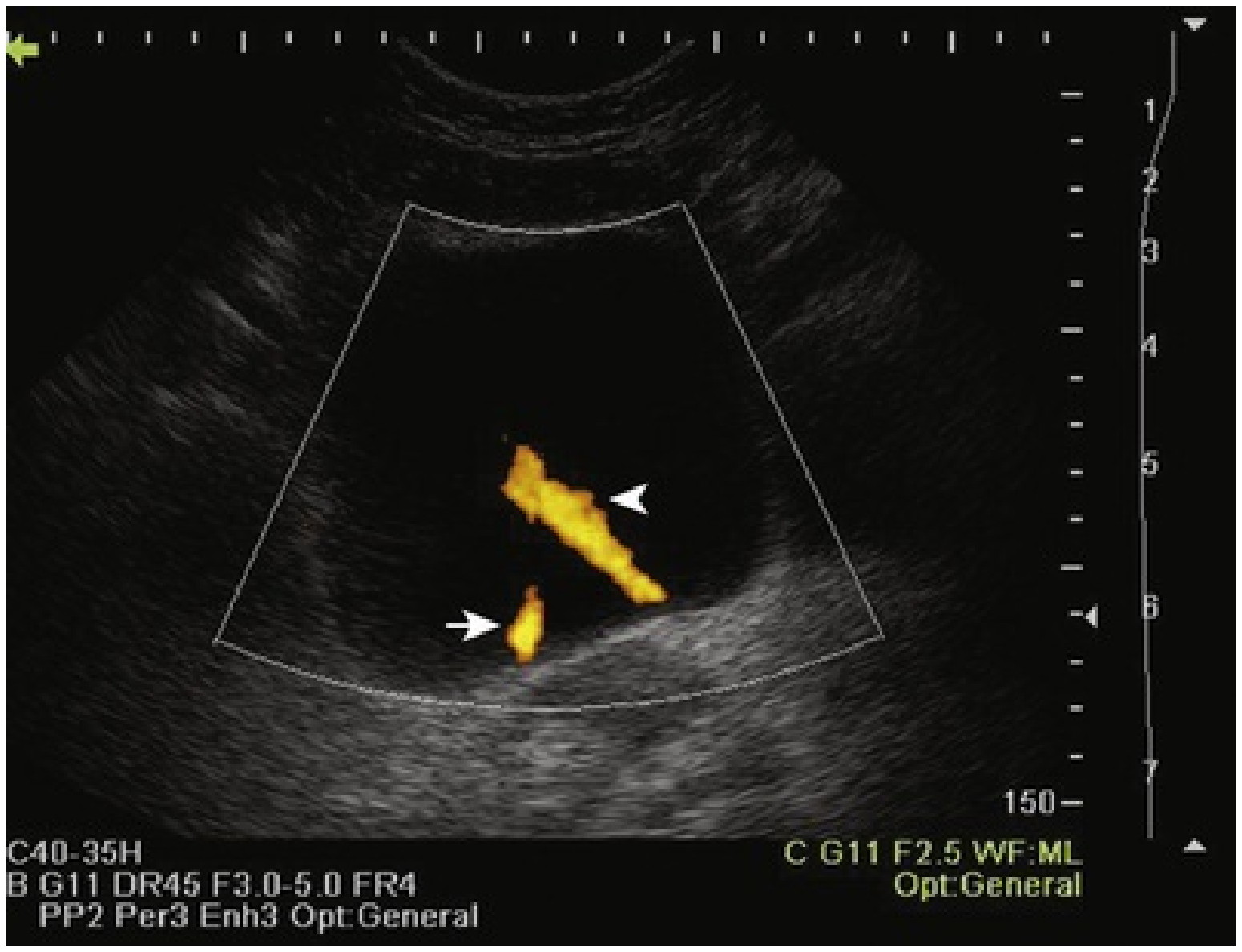

FIG. 4.29 In this transverse view of the bladder, ureteral "jets" emerging from the left *(arrow)* and right *(arrowhead)* ureteral orifices are demonstrated by power Doppler.

Bladder volume can be calculated manually by obtaining measurements in the midtransverse and midsagittal planes (Fig. 4.30). Numerous studies have shown that for bladder volumes between 100 and 500 mL, such calculated volumes are within 10% to 20% of the actual bladder volume (Ghani et al., 2008b; Park, Ku, and Oh, 2011; Simforoosh et al., 1997). Measuring bladder wall thickness may assist the clinician in understanding the degree of bladder outlet obstruction (Fig. 4.31). Bladder wall thickness varies depending on the volume of urine in the bladder and on which part of the bladder wall is measured. It has been shown that measuring bladder wall thickness may predict bladder outlet obstruction with greater accuracy than free uroflowmetry, postvoid residual urine, and prostate volume (Oelke et al., 2007).

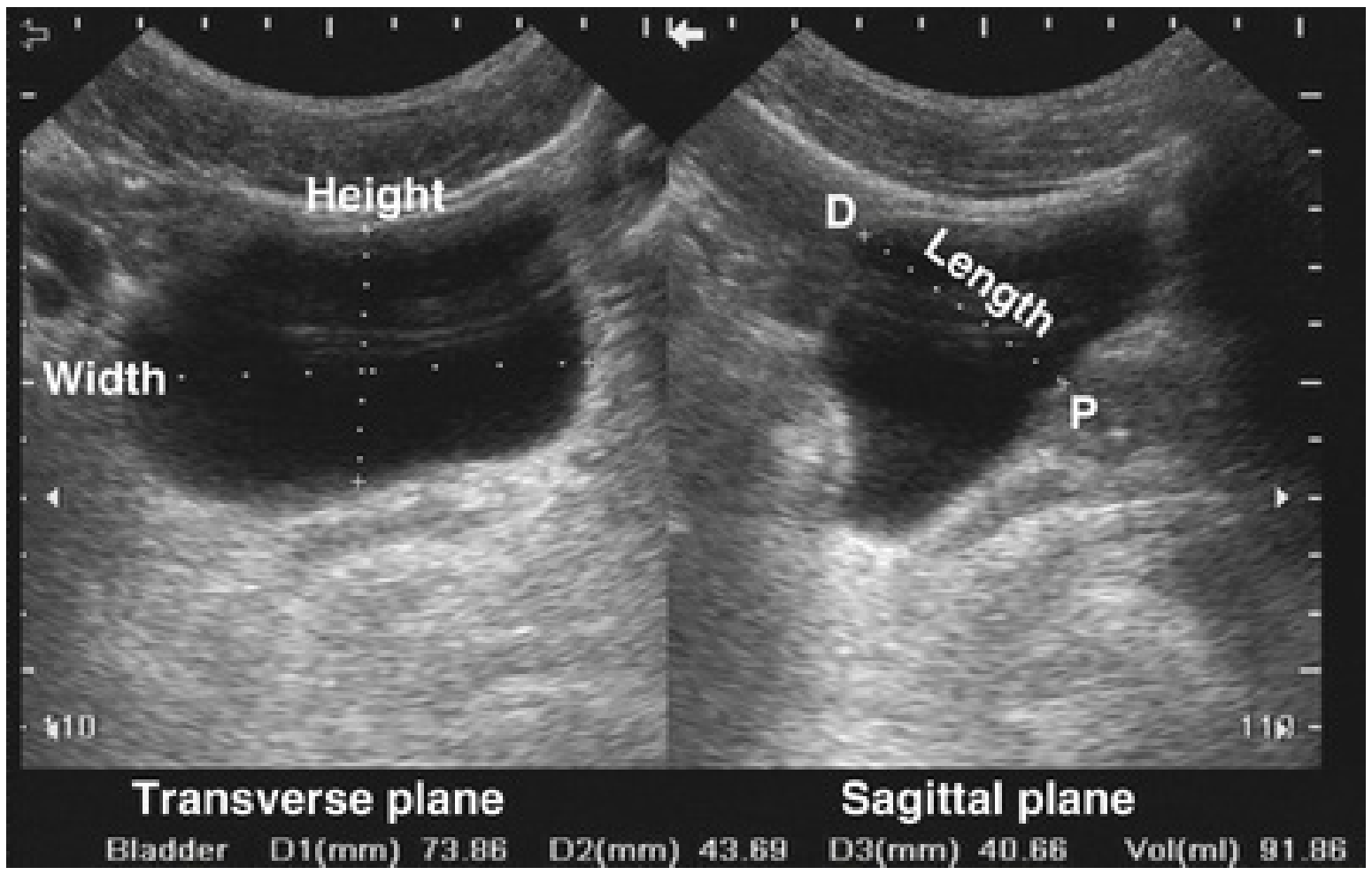
Height
Width
D
Length
P
110
110
Transverse plane
Sagittal plane
Bladder D1(mm) 73.86 D2(mm) 43.69 D3(mm) 40.66 Vol(ml) 91.86

FIG. 4.30 Measurement of bladder volume using this formula: bladder volume = width (transverse plane) × height (transverse plane) × length (midsagittal plane) × 0.625. In the sagittal plane, the dome *(D)* of the bladder is to the left and the prostate *(P)* to the right.

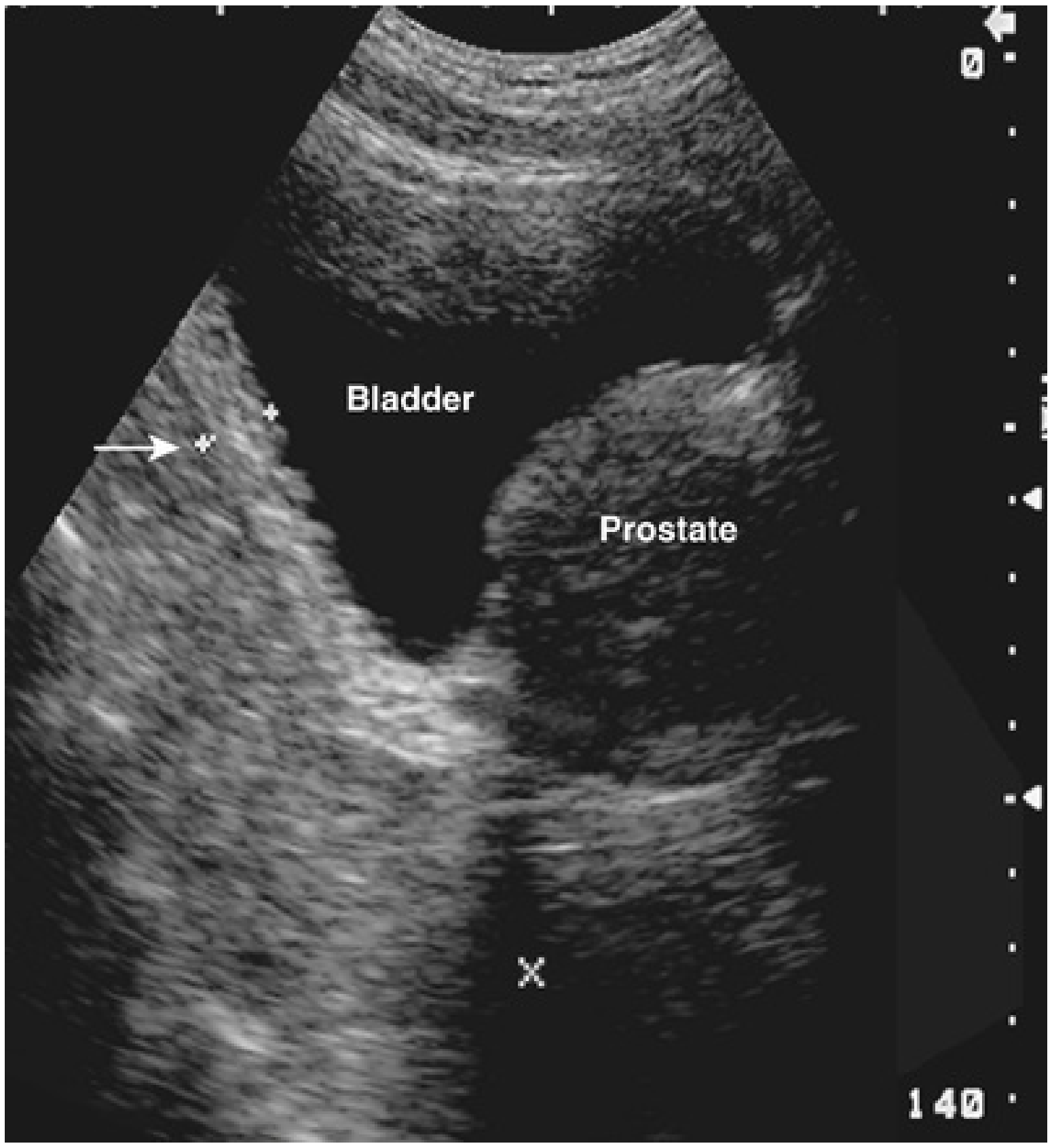
0
Bladder
Prostate
140

FIG. 4.31 Bladder wall thickness may provide information about bladder outlet obstruction. In this sagittal view, bladder wall thickness is measured posteriorly *(arrow)* near the midline. Note the trabeculation of the relatively

hyperechoic bladder wall.

Transabdominal prostatic ultrasonography requires angling the probe beneath the pubic bone. In the transverse plane the transducer is fanned inferiorly until the largest transverse diameter of the prostate is identified. Measurements of the transverse width and height are obtained (Fig. 4.32A). The transducer is then rotated 90 degrees clockwise to produce a true sagittal image of the prostate. The transducer is fanned until the midline is identified. This is recognized by a V-shaped indentation at the bladder neck (Fig. 4.32B). Depending on the degree of prostatic hypertrophy and the presence or absence of a middle lobe, this “V” may be more or less apparent and more or less anterior or posterior in its position. A sagittal measurement is made from the bladder neck to the apex of the prostate. The apex of the prostate may be identified by using the hypoechoic urethra as a guide.

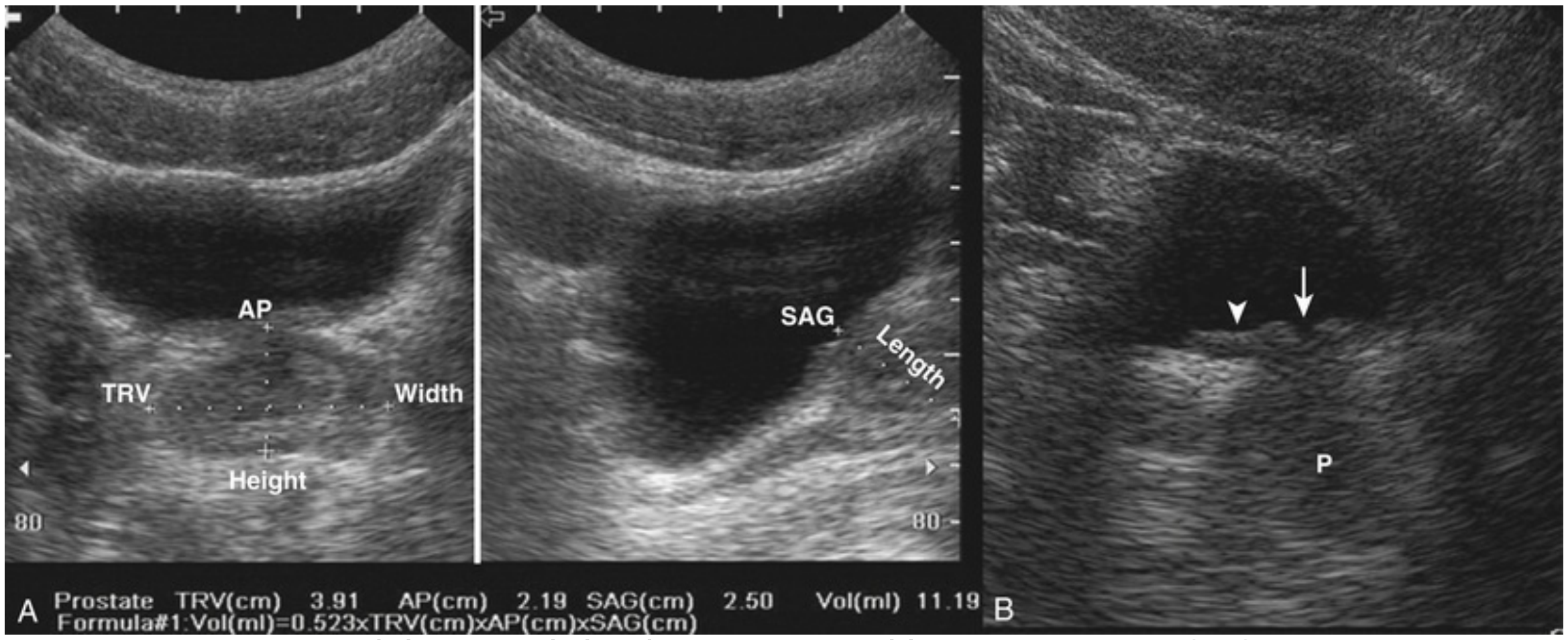
AP
TRV
Width
Height
80
SAG
Length
80
P
A
Prostate TRV(cm) 3.91 AP(cm) 2.19 SAG(cm) 2.50 Vol(ml) 11.19
Formula#1:Vol(ml)=0.523xTRV(cm)xAP(cm)xSAG(cm)
B

FIG. 4.32 (A) Transabdominal ultrasound is extremely useful for measuring prostatic volume and evaluating prostatic morphology. The volume of the prostate can be calculated using this formula: prostate volume (mL) = width (cm) × height (cm) × length (cm) × 0.523. (B) In this midsagittal view of the prostate, the bladder neck is identified as a V-shaped indentation *(arrow)*. Note the characteristically hyperechoic trigone *(arrowhead).*

The degree of protrusion of the prostate into the bladder may have some predictive value for bladder outlet obstruction. It has been shown that intravesical prostatic protrusion correlates relatively well with formal urodynamic evaluation of bladder outlet obstruction (Chia et al., 2003; Keqin et al., 2007). The measurement is obtained by drawing a line corresponding to the bladder base on sagittal scan and measuring the perpendicular distance from the bladder base to the greatest protrusion of the prostate into the bladder (Fig. 4.33).

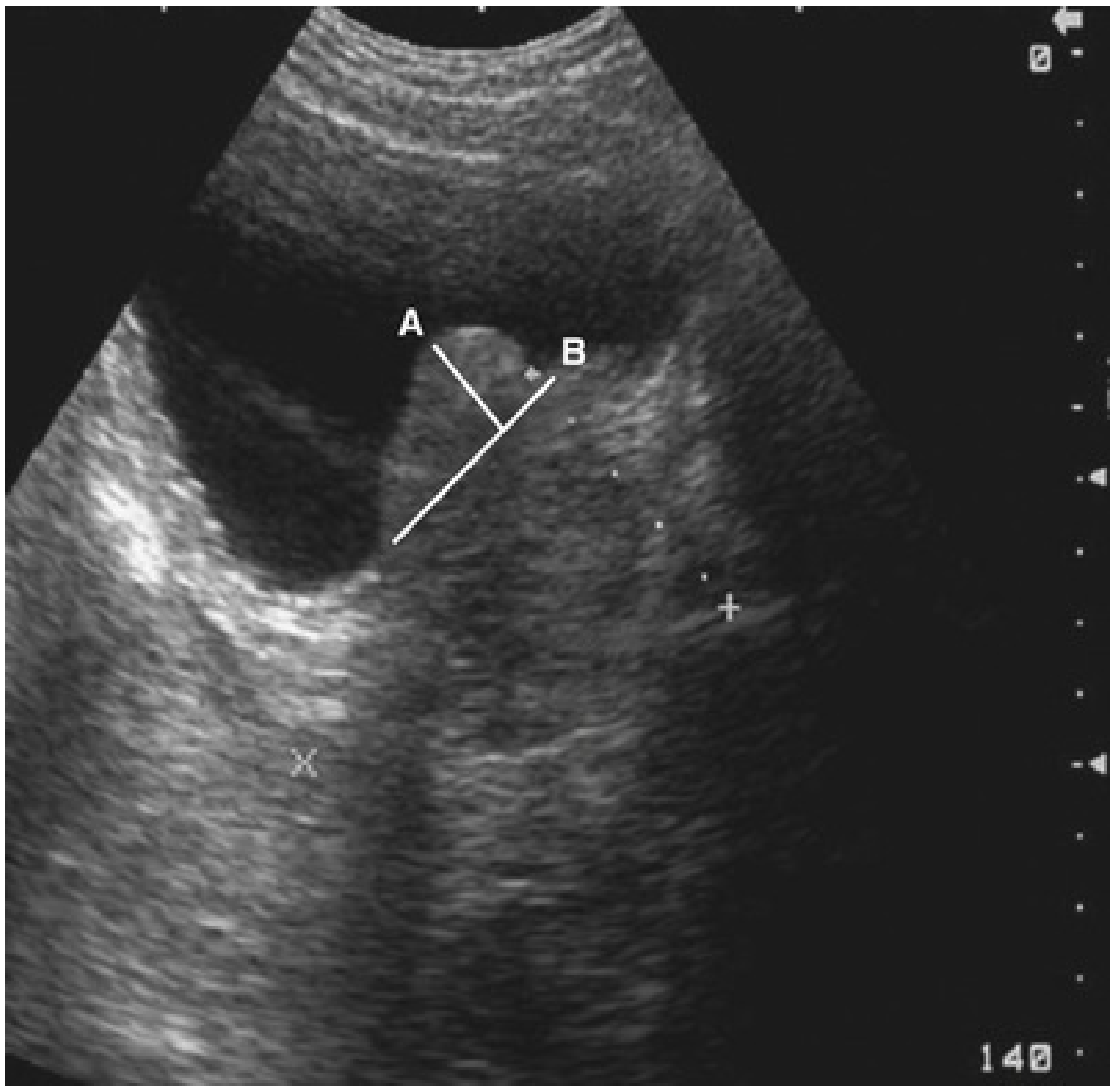

FIG. 4.33 In this sagittal view of the prostate, the middle lobe extends into the bladder *(A)*. The bladder base is defined by *line B*. The length of *line A* is the intravesical prostatic protrusion (IPP).

Transabdominal ultrasonography of the prostate is useful in characterizing prostatic urethral length, the size and configuration of the middle lobe of the prostate, and some secondary information about the physiology of bladder outlet obstruction. This information is valuable in treatment planning for bladder outlet obstruction.

Procedural Applications

Transabdominal ultrasound-guided percutaneous bladder aspiration with or without catheter placement has been successfully used in neonates, children, and adults (Gochman et al., 1991; Wilson and Johnson, 2003). It has also been employed for treatment of bladder stones (Ikari et al., 1993; Sofer et al., 2004). Ultrasound-guided aspiration has also been used for peritoneal drainage after bladder perforation (Manikandan et al., 2003).

Limitations

Transabdominal pelvic ultrasonography yields limited information in patients with an empty bladder. The ability to identify distal ureteral obstruction, bladder stones, and bladder tumors requires a full bladder. Although prostatic morphology and volume can be assessed with an empty bladder, it is much easier when the bladder is full. Pelvic structures may be difficult to evaluate in patients with a protuberant abdomen or panniculus. **Automated measurement of bladder volume or residual urine, although using ultrasonography, is not an imaging study.** Lack of imaging confirmation can lead to inaccurate residual urine determinations in patients with obesity, clot retention, ascites, bladder diverticulum, or perivesical fluid collection (e.g., urinoma, lymphocele).

Ultrasonography of the Scrotum

No aspect of urologic care is better suited to the use of ultrasonography than evaluation of the scrotum. Urologists have a surgical understanding of the anatomy and extensive experience with the diagnosis and treatment of disorders that affect the scrotum. Because the scrotum and its contents are superficial, high-frequency transducers may be employed to yield excellent and detailed anatomic and physiologic information. Imaging information can be correlated with findings on direct physical examination.

Technique

Sound technique is critical to performing adequate ultrasonography of the scrotum. In general, the examination should be carried out in a quiet room that is adequately warm for patient comfort. The patient should be supine with the scrotum supported on a towel or on the anterior thighs. The patient should be draped in such a way as to hold the penis out of the way and to ensure patient privacy. Copious amounts of conducting gel should be used to provide a good interface between the transducer and the scrotal skin because air trapping by scrotal hair results in unwanted artifacts. Complete but gentle contact between skin and transducer is essential because excessive pressure results in movement of testis or compression of the testis. Compression may change echogenicity and obscure fine anatomic detail. In addition, compression may significantly alter volume measurements.

Scrotal ultrasonography is performed with a high-frequency linear array transducer, generally in the range of 7 to 18 MHz. Transducers may be 4 to 7.5 cm in width. Some sonographers prefer the maneuverability of a 4-cm transducer, whereas others prefer the longer 7.5-cm transducer for its ability to simultaneously image the entire testis in the sagittal plane. Imaging should be done in a systematic fashion and should include sagittal and transverse views of the testis. The sagittal view should proceed from the midline medially and then laterally and from the midtransverse section of the testis to the upper pole and the lower pole of the testis. In addition to the testis, the epididymis and entire scrotal contents should be imaged.

Indications

1. Assessment of scrotal and testicular mass
2. Assessment of scrotal and testicular pain
3. Evaluation of scrotal trauma
4. Evaluation of infertility
5. Follow-up after scrotal surgery
6. Evaluation of the empty or abnormal scrotum

Normal Findings

It is important to document the size and, if appropriate, the volume of the testes. The echo architecture of the testis should be described (Fig. 4.34). It is important to compare the testes for echogenicity because some infiltrative processes may result in diffuse changes in a testis that would be noticed only when that testis is compared with its contralateral mate (Fig. 4.35). For example, lymphomatous or leukemic involvement of the testis may result in a diffusely hypoechoic and homogeneous appearance, which may be unilateral (Mazzu et al., 1995). If paratesticular fluid is present, the epididymis and the testicular and epididymal appendages are more easily identified (Fig. 4.36).

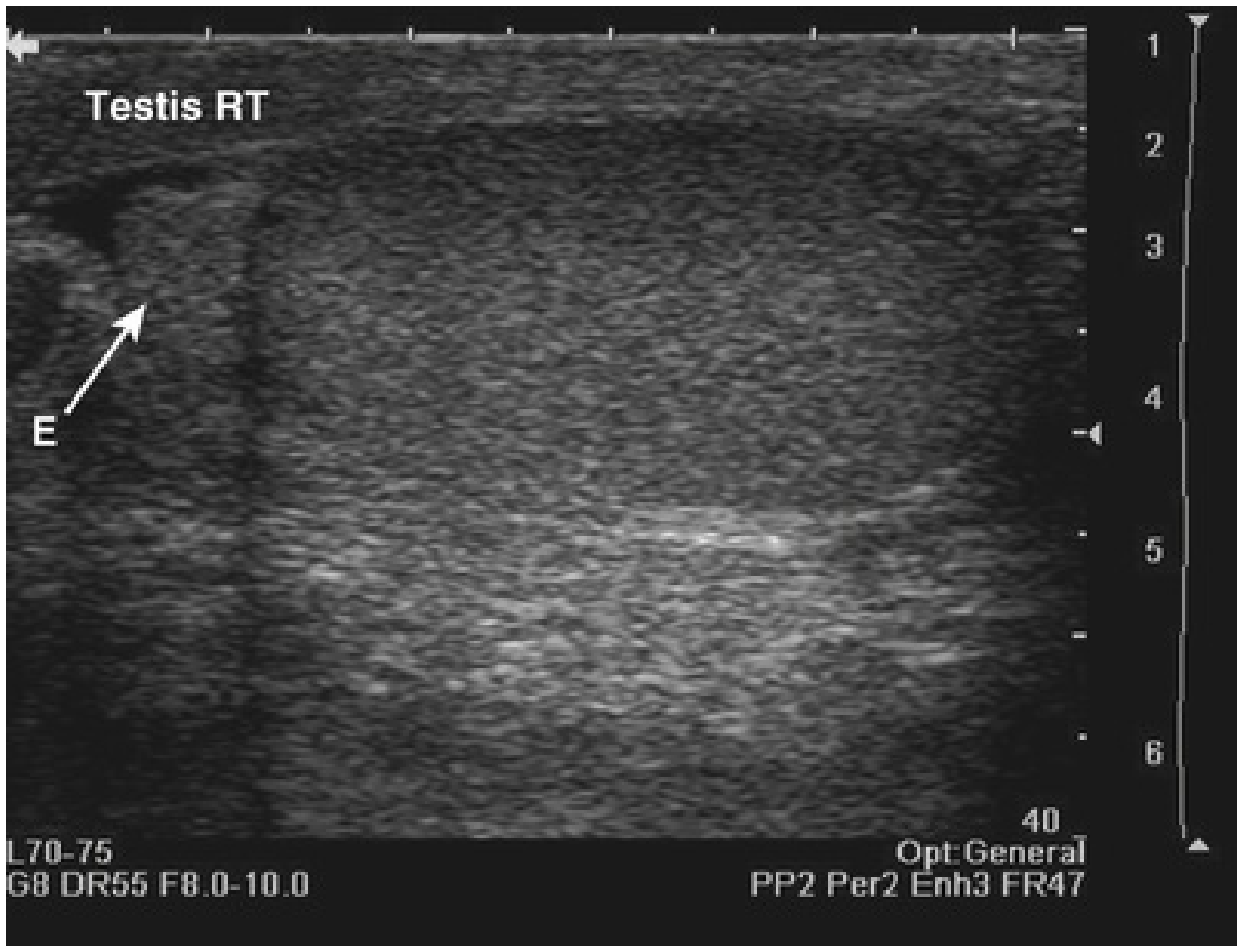
Testis RT
E
1
2
3
4
5
6
40
L70-75
G8 DR55 F8.0-10.0
Opt:General
PP2 Per2 Enh3 FR47

FIG. 4.34 In this longitudinal view the head of the epididymis *(E)* is seen to the left, and the lower pole of the testis is to the right. Normal testicular sonographic anatomy is characterized by a homogeneous finely granular appearance of the testis.

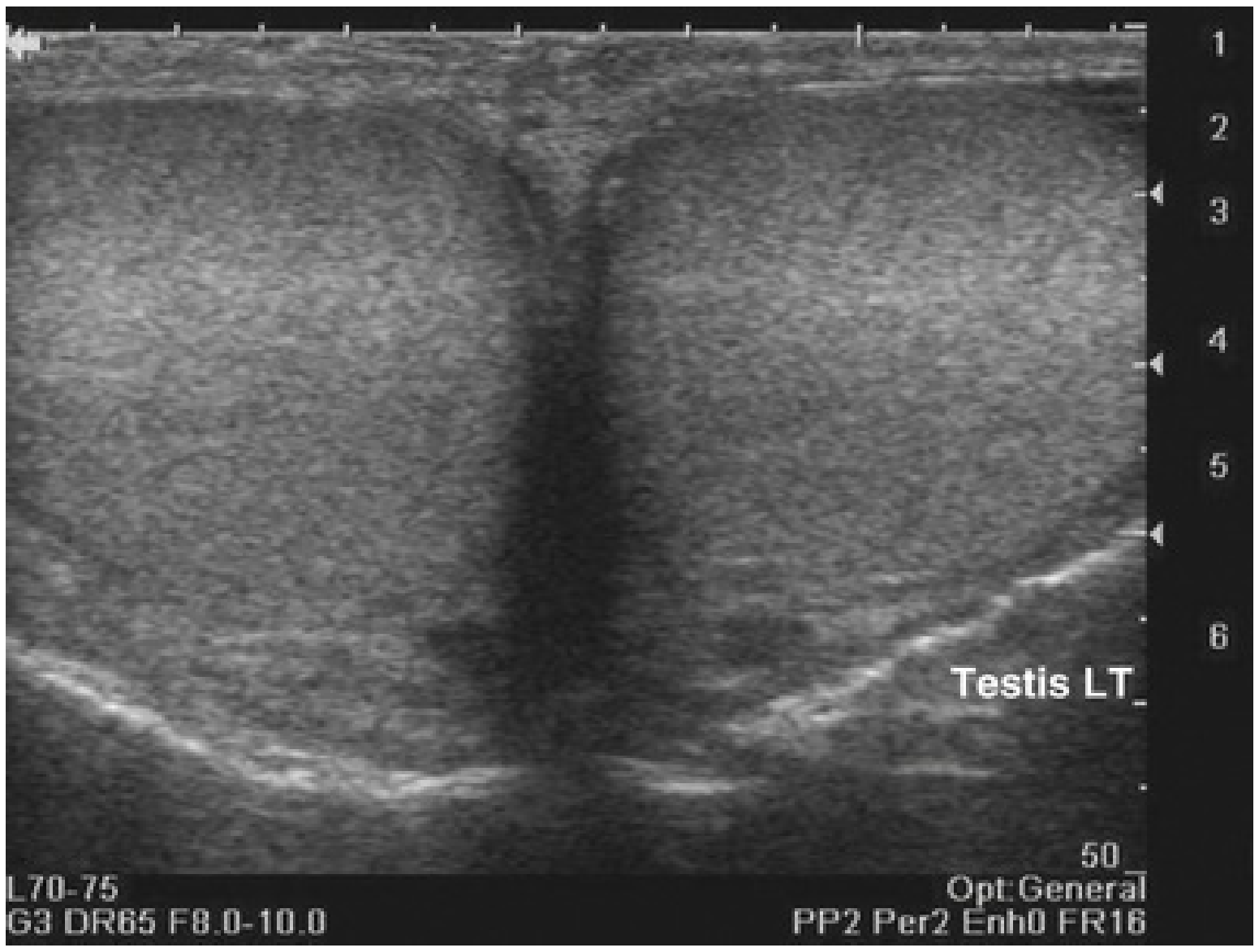
Testis LT
1
2
3
4
5
6
50
L70-75
G3 DR65 F8.0-10.0
Opt:General
PP2 Per2 Enh0 FR16

FIG. 4.35 Simultaneous bilateral views are important to rule out a diffuse infiltrative process such as lymphoma. A diffuse and homogenous change in echogenicity in one testis could otherwise be unappreciated. In this example, the testes are symmetric and normal. This view is also required to document the presence of two testes.

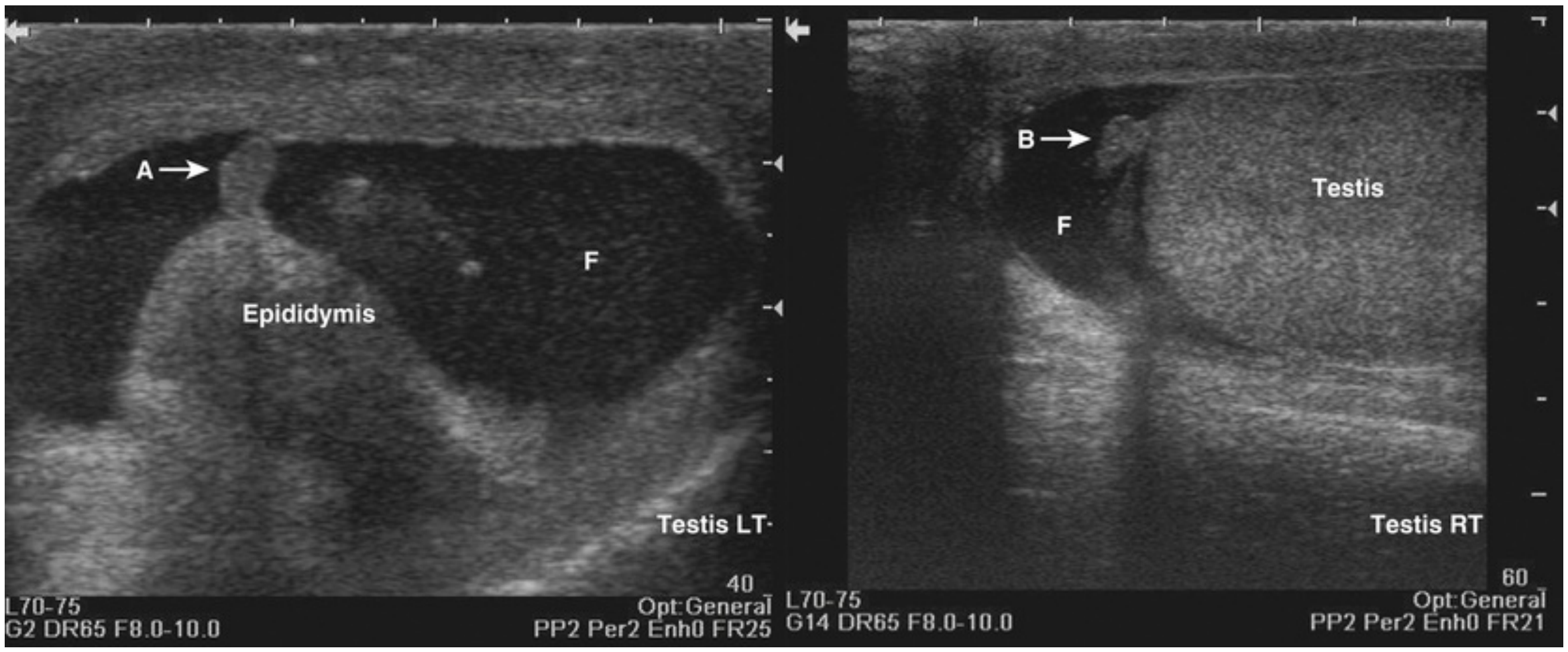
A
Epididymis
F
Testis LT
B
F
Testis
Testis RT
L70-75
G2 DR65 F8.0-10.0
40
Opt:General
PP2 Per2 Enh0 FR25
L70-75
G14 DR65 F8.0-10.0
60
Opt:General
PP2 Per2 Enh0 FR21

FIG. 4.36 The presence of paratesticular fluid *(F)* permits the identification of the appendix epididymis *(A)* and the appendix testis *(B)*.

Normal testicular blood flow may be demonstrated with color or power Doppler (Barth and Shortliffe, 1997) (Fig. 4.37). Intratesticular blood flow is low velocity with the average peak systolic velocity (PSV) of less than 10 cm/s (Middleton and Thorne, 1989). Intratesticular blood flow is primarily supplied by the testicular artery, which ultimately divides to supply the individual testicular septa. The fibrous septa coalesce to form the mediastinum testis, which is a hyperechoic linear structure seen in the sagittal plane (Fig. 4.38).

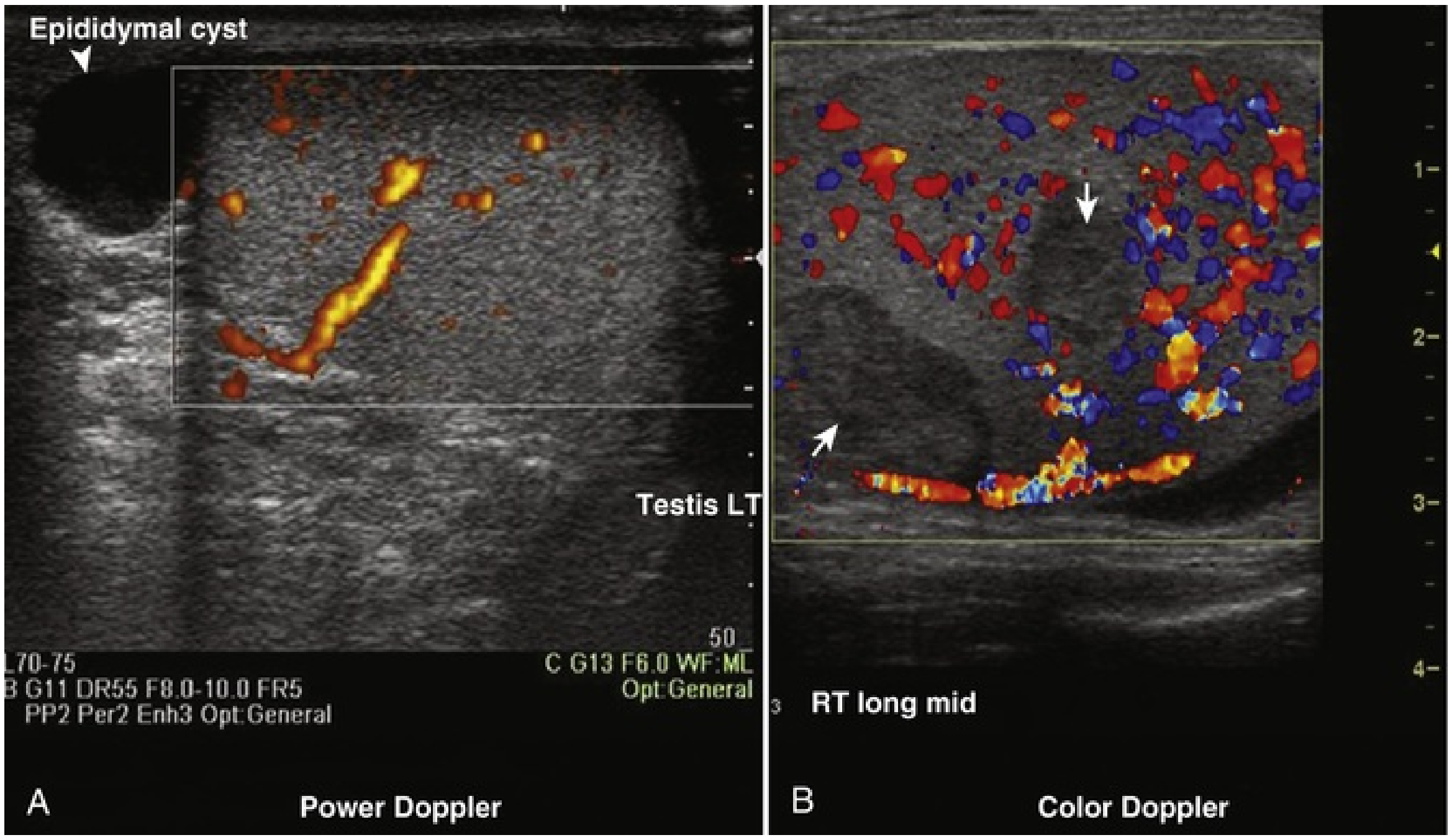
Epididymal cyst
Testis LT
L70-75
B G11 DR55 F8.0-10.0 FR5
PP2 Per2 Enh3 Opt:General
50
C G13 F6.0 WF:ML
Opt:General
A
Power Doppler
RT long mid
1
2
3
4
B
Color Doppler

FIG. 4.37 (A) Normal intratesticular blood flow by power Doppler; note the epididymal cyst *(arrowhead).* (B) Increased blood flow in an irregular pattern demonstrated by color Doppler was associated with necrotizing vasculitis; note the relatively hypoechoic areas of decreased vascularity *(arrows).*

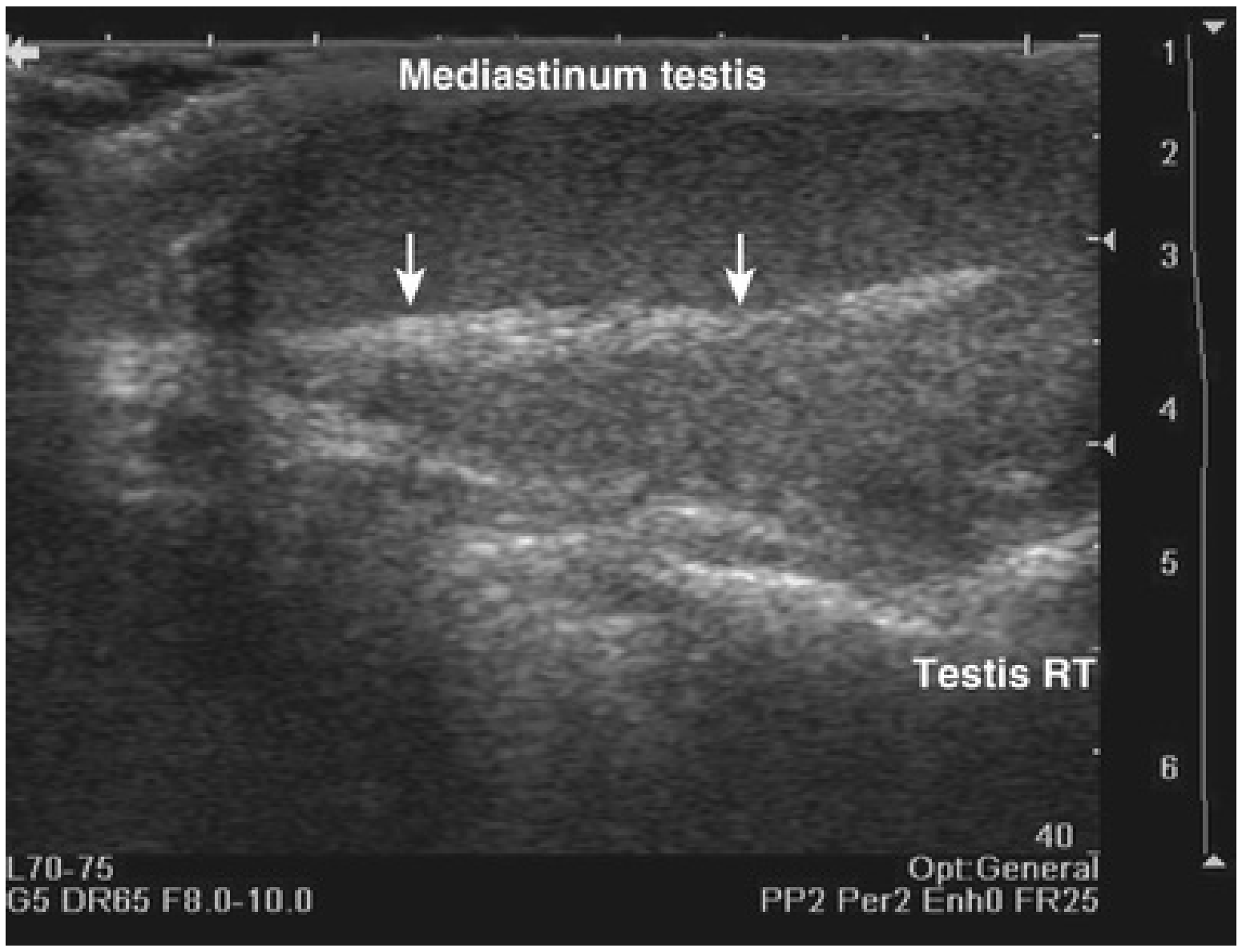
Mediastinum testis
Testis RT
1
2
3
4
5
6
40
L70-75
G5 DR65 F8.0-10.0
Opt:General
PP2 Per2 Enh0 FR25

FIG. 4.38 The sagittal image of this testis demonstrates a common anatomic finding, the hyperechoic mediastinum testis *(arrows).* The mediastinum testis is a normal structure resulting from the coalescence of the fibrous septa of the testis.

Spectral Doppler can be used to evaluate the intratesticular blood flow: elevated resistive index (RI) greater than 0.6 suggests impaired spermatogenesis (Fig. 4.39) (Biagiotti et al., 2002; Hillelsohn et al., 2013; Pinggera et al., 2008).

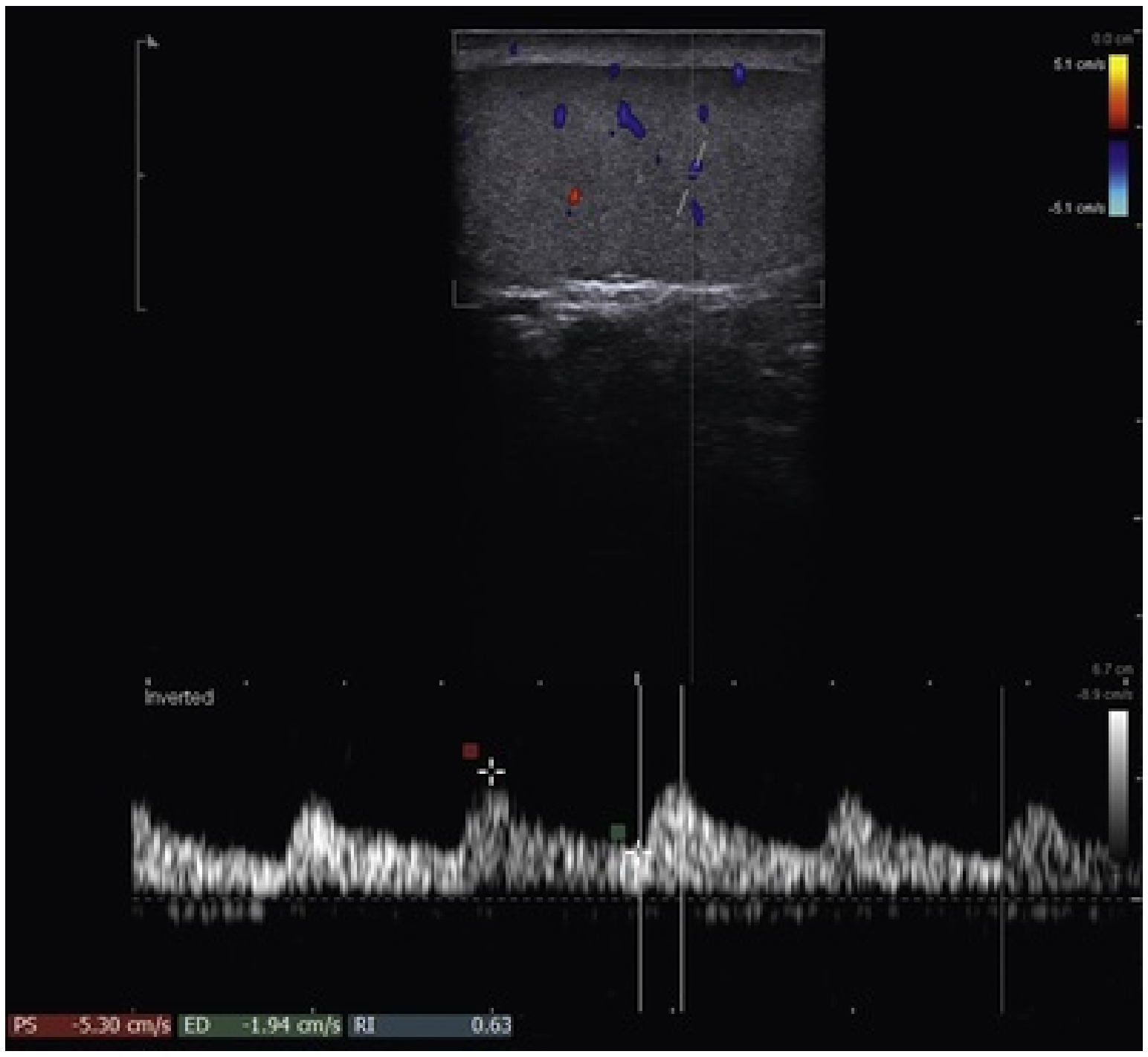

FIG. 4.39 Spectral Doppler analysis of an intratesticular artery demonstrating a peak systolic velocity (PSV) of 5.3 cm/s, an end diastolic velocity of 1.94 cm/s, and a calculated resistive index of 0.63 in a patient with dyspermia.

Procedural Applications

The testis provides easy access for ultrasound localization of internal structures and therefore for percutaneous access. In particular, small nonpalpable lesions can be localized by ultrasound, guiding placement of a needle for percutaneous biopsy or injection of a dye for localization during open biopsy (Buckspan et al., 1989).

Current therapeutic applications using ultrasound guidance include percutaneous testicular sperm aspiration (TESA) (Belker et al., 1998; Friedler et al., 1997; Khadra et al., 2003) or from percutaneous epididymal sperm aspiration (PESA) (Belker et al., 1998; Craft et al., 1995; Lin et al, 2000; Meniru et al., 1998a; 1998b; Pasqualotto et al., 2003; Rosenlund et al., 1998).

Future ultrasound-guided applications may include spermatogonia stem cell transfer to testes devoid of germ cells after gonadotoxic therapies.

Sonoelastography

Two recent studies have used real-time elastography to differentiate benign from malignant testicular lesions because it is postulated that malignant lesions have an increased stiffness resulting from a higher concentration of vessels and cells compared with surrounding tissues. Goddi et al. (2012) assessed 88 testes with 144 lesions and found a 93% positive predictive value, 96% negative predictive value, and 96% accuracy rate (see Fig. 4.19). Aigner et al. (2012) assessed 50 lesions and found a 92% positive predictive value, 100% negative predictive value, and 94% accuracy rate in differentiating malignant from benign lesions. In addition, Li et al. (2012) found that men with nonobstructive azoospermia had a significantly different testicular elasticity compared with patients with obstructive azoospermia and healthy controls with a normal semen analysis. Sonoelastography (see Figs. 4.19 and 4.20) is an exciting innovation in assessing abnormalities on scrotal examination; however, more data are necessary before ruling out surgical intervention based on the findings.

Limitations

Caution should be used when interpreting Doppler flow studies in the evaluation of suspected testicular torsion. The hallmark of testicular torsion is the absence of **intratesticular** blood flow (Fig. 4.40). Paratesticular flow in epididymal collaterals may appear within hours of torsion. Comparison with the contralateral testis should be performed to ensure that the technical attributes of the study are adequate to demonstrate intratesticular blood flow.

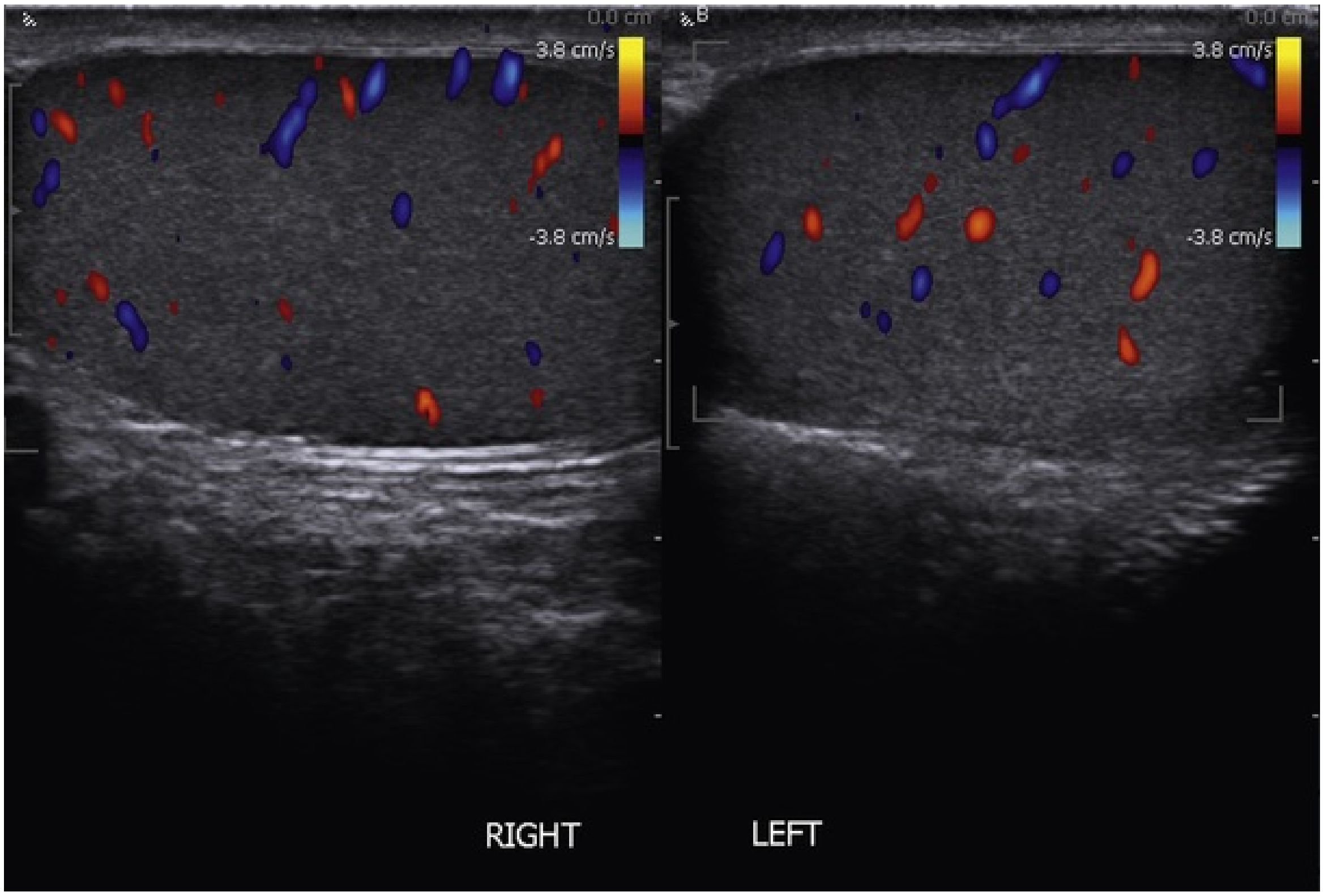

FIG. 4.40 Demonstration of normal bilateral intratesticular blood flow by color Doppler.

Ultrasonography of the Penis and Male Urethra

Ultrasonography of the penis and male urethra provides exquisite anatomic detail and may be used in many cases in lieu of studies requiring ionizing radiation.

Technique

Penile and urethral ultrasonography is best performed with a 12- to 18-MHz linear array transducer for optimum resolution. The technique for penile and urethral ultrasonography includes imaging the phallus in the longitudinal and transverse plane. Ventral and dorsal surfaces of the phallus can be interrogated. As for scrotal ultrasound, the examination is best carried out in a quiet room that is adequately warm for patient comfort. Draping is done to ensure patient privacy. The examination is performed in a systematic fashion beginning at the base of the penis and proceeding distally to the glans. It is possible to get an image of the proximal urethra and corporal bodies by scanning through the scrotum or the perineum.

It may be helpful when evaluating the penile urethra, especially for stricture disease, to inject a sterile gel into the urethra in a retrograde fashion. This distends the urethra and allows better identification of urethral anatomy and the anatomy of the corpus spongiosum.

Indications

1. Evaluation of penile vascular dysfunction
2. Documentation of fibrosis of the corpora cavernosa
3. Localization of foreign body
4. Evaluation of urethral stricture
5. Evaluation of urethral diverticulum
6. Assessment of penile trauma or pain

Normal Findings

Scanning of the external portion of the phallus can be performed either from the dorsal or ventral surface (Fig. 4.41). Transverse scanning of the phallus reveals the two corpora cavernosa dorsally and the urethra ventrally (Fig. 4.42A). The sagittal view of the phallus demonstrates the corpora cavernosa with a hyperechoic, double linear structure representing the cavernosal artery (Fig. 4.42B). The corpus spongiosum is isoechoic to slightly hypoechoic and contains the coapted urethra. The urethra is collapsed except during voiding.

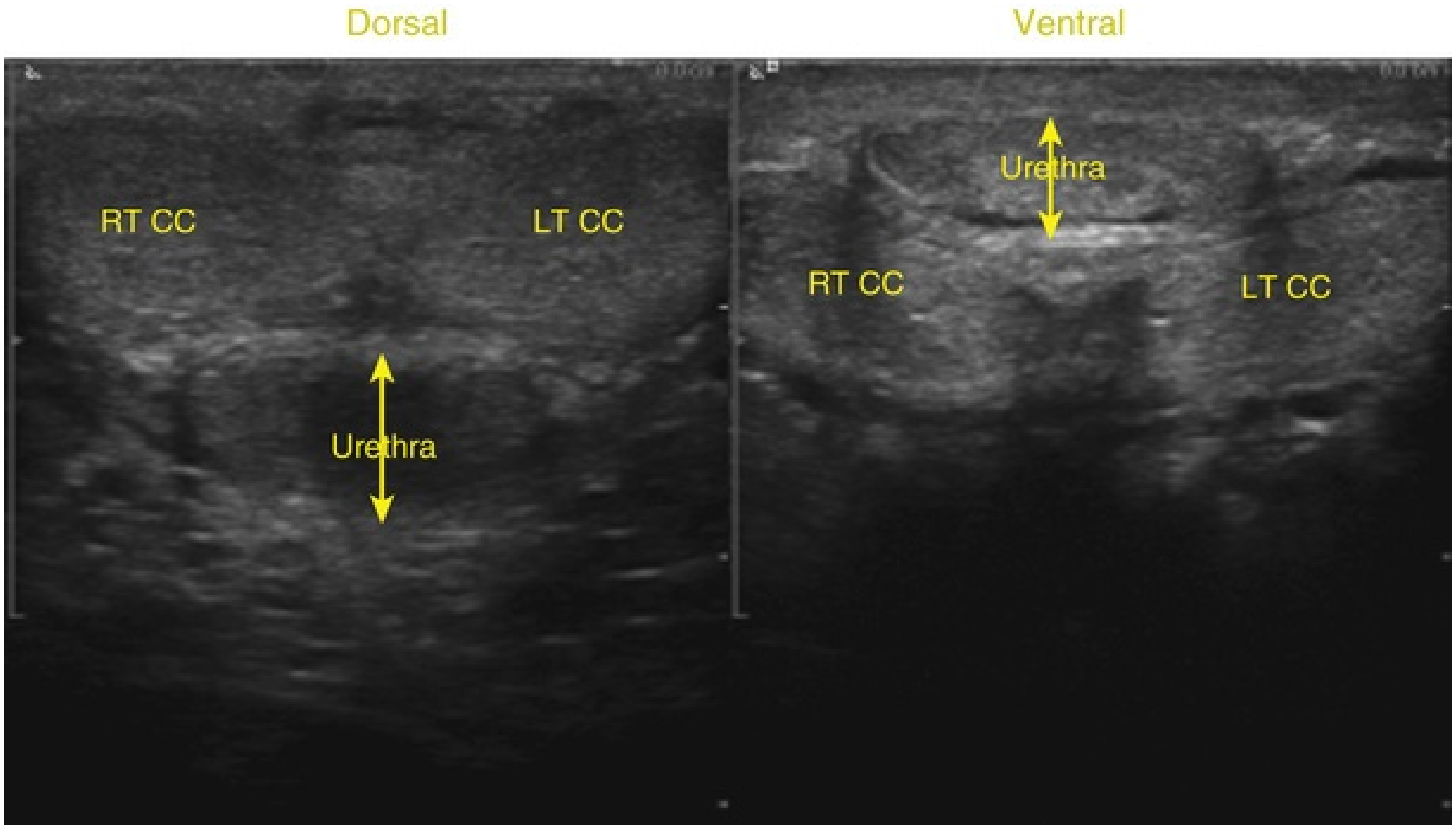
Dorsal
Ventral
RT CC
LT CC
Urethra
Urethra
RT CC
LT CC

FIG. 4.41 A transverse view of the phallus with the transducer placed either on the dorsal or ventral surface. Note the compression of the urethra and corporal spongiosum compression in the ventral projection with minimal pressure applied to the phallus.

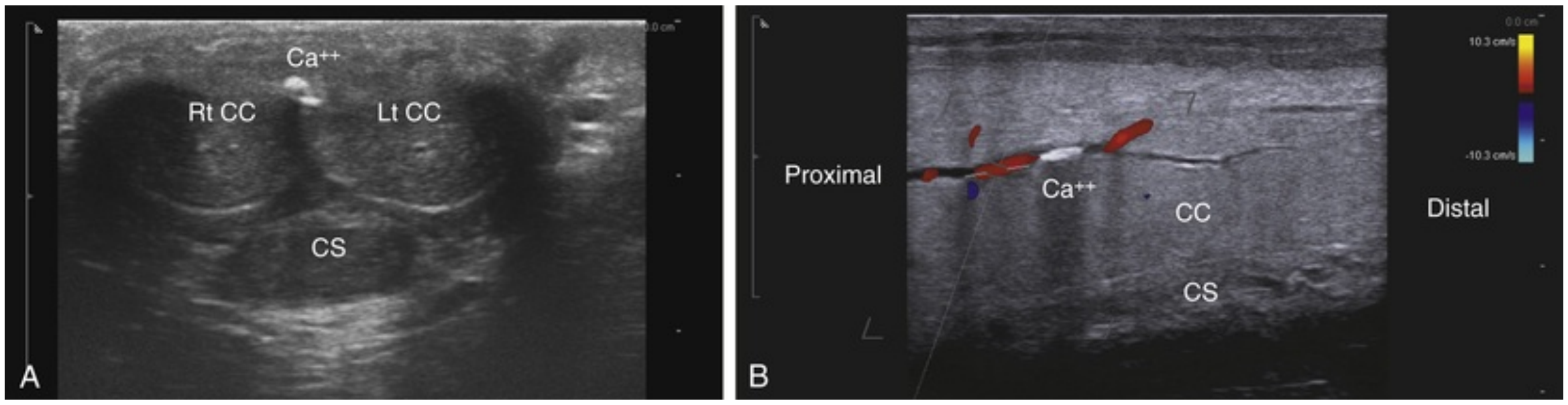
Ca++
Rt CC
Lt CC
CS
A
Proximal
Ca++
CC
CS
Distal
B
10.3 cm/s
-10.3 cm/s

FIG. 4.42 (A) In the transverse plane scanning from the dorsal surface of the midshaft of the penis, the corpora cavernosa *(CC)* are paired structures seen dorsally whereas the corpus spongiosum *(CS)* is seen ventrally in the midline. A calcification (Ca++) is seen between the two CC with posterior shadowing. (B) In the parasagittal plane the CC is dorsal with the relatively hypoechoic CS seen ventrally. Within the CC the cavernosal artery is shown with a Ca++ in the wall of the artery and posterior shadowing.

Perineal Ultrasound

The more proximal aspects of the urethra and corpora cavernosa are best assessed through a perineal approach by placement of the transducer on the perineum (▶Video 4.2). The bulbar urethra with the bulbar branch of the pudendal artery as well as the proximal cavernosal bodies and the cavernosal branch of the pudendal artery can be visualized (Fig. 4.43A).

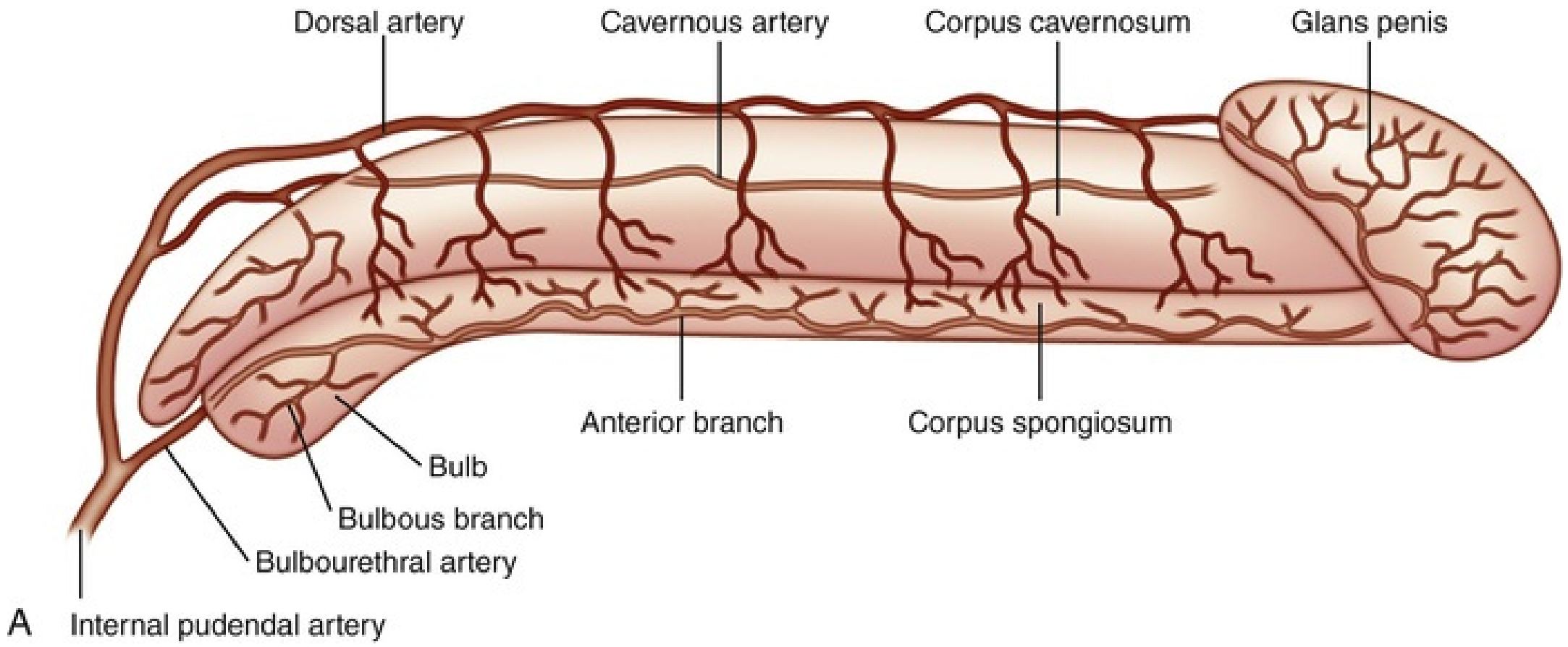
Dorsal artery
Cavernous artery
Corpus cavernosum
Glans penis
Anterior branch
Corpus spongiosum
Bulb
Bulbous branch
Bulbourethral artery
A
Internal pudendal artery

(A) The internal pudendal artery gives rise to the bulbourethral artery, dorsal artery, and cavernosal artery. The most proximal aspect of the cavernosal artery is best imaged through the perineum. (From Gilbert BR: *Ultrasound of the male genitalia,* New York, 2014, Springer.)

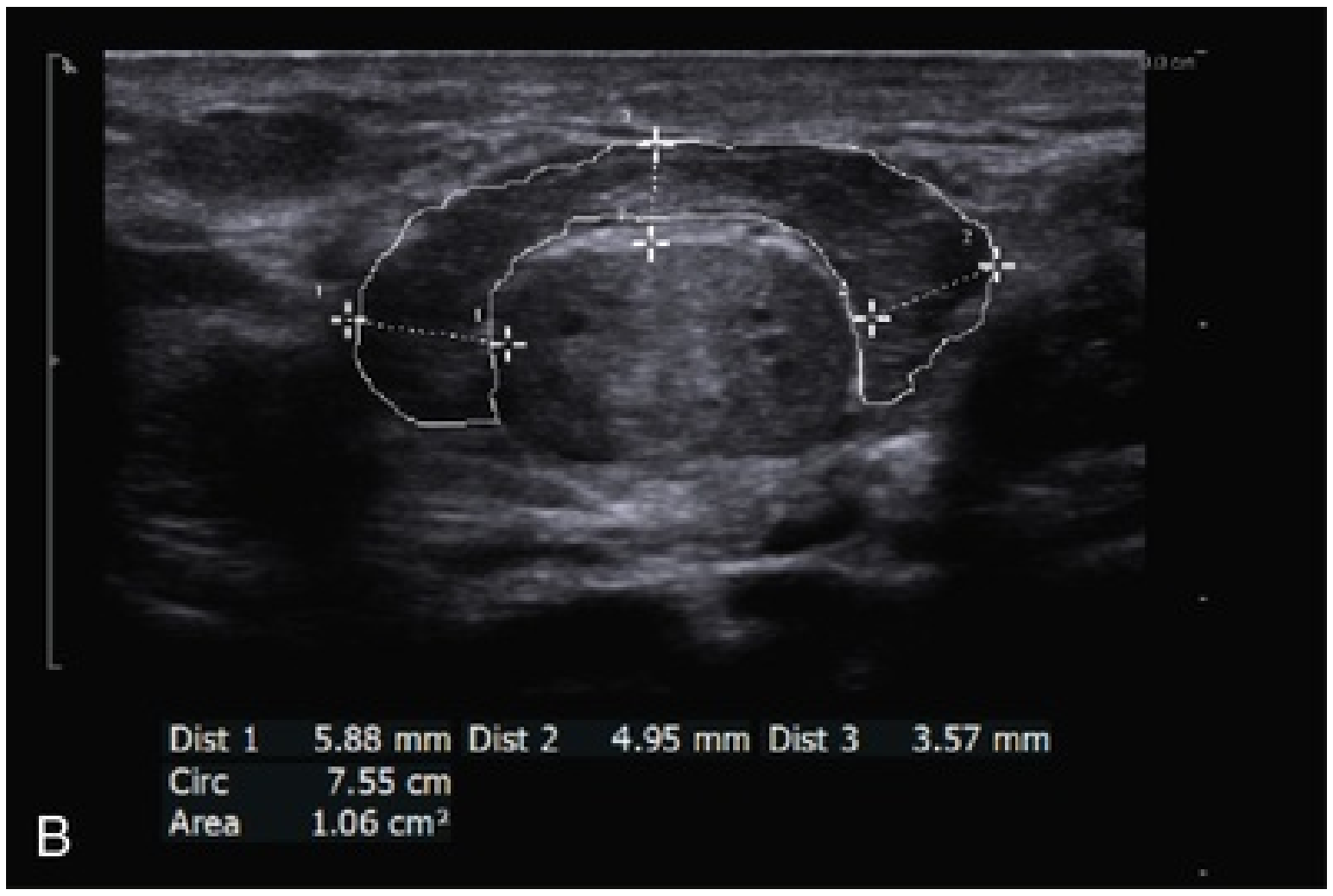
Dist 1 5.88 mm Dist 2 4.95 mm Dist 3 3.57 mm
Circ 7.55 cm
Area 1.06 cm²
B

(B) In this schematic the bulbocavernosus muscle, also known as the bulbospongiosus muscle, is red (*Gray's anatomy of the human body,* ed 20, Philadelphia, 1918, Lea &

Febiger.).

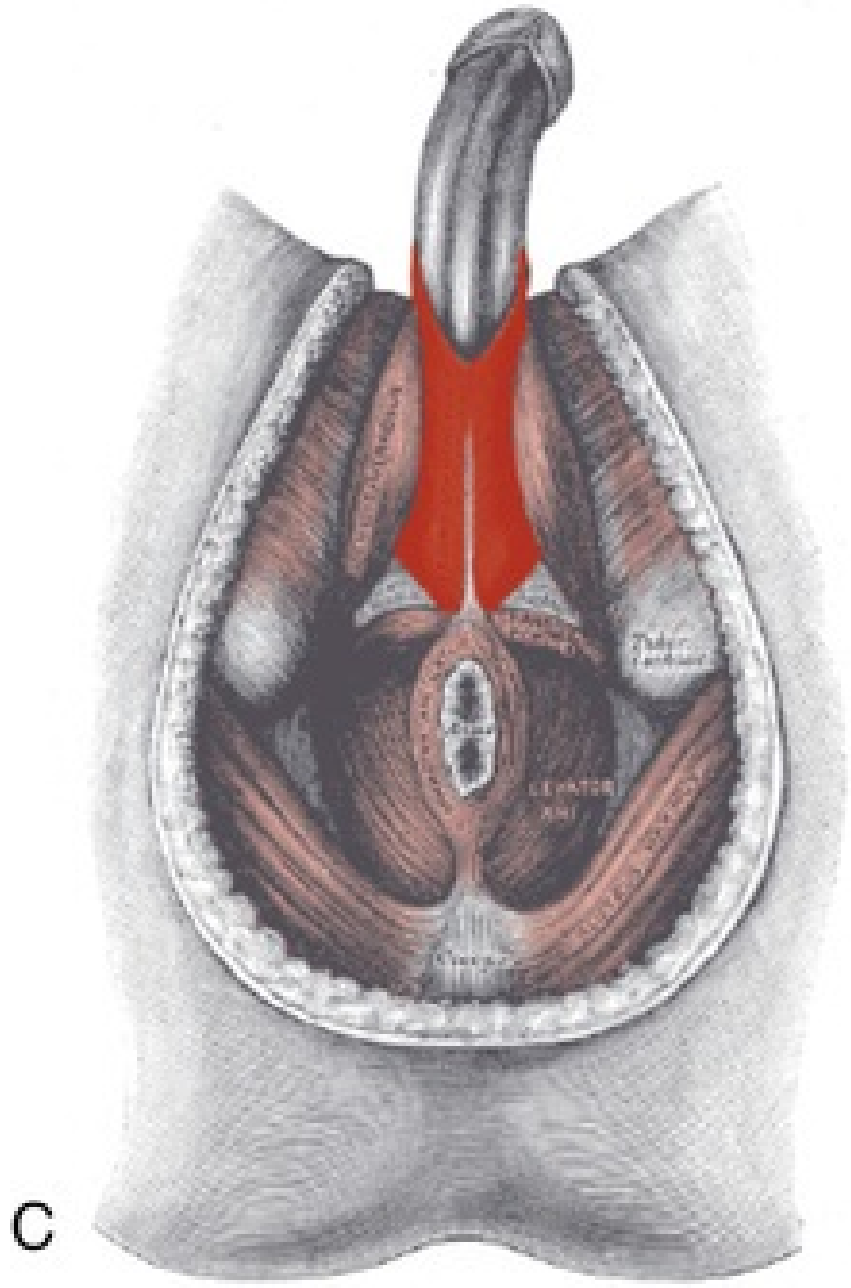

(C) Freehand measurement of the area of the bulbocavernosus muscle.

FIG. 4.43

Measurement of the bulbocavernosal (also known as bulbospongiosus) muscle (BCM) through a perineal approach (Fig. 4.43B) is a novel way of assessing androgen receptor sensitivity (Dabaja et al., 2014). The cross-sectional BCM area (Fig. 4.43C) is inversely related to the number of cytosine, adenine, guanine (CAG) repeats. The BCM area has also been shown to be directly related to total testosterone, free testosterone, and bone density as measured by dual-energy x-ray absorptiometry (DEXA) (Gupta et al, 2017).

Transperineal Ultrasound

Transperineal and translabial ultrasound have also been used for evaluation of the pelvic floor for diagnostic and postprocedural follow-up. The anterior, central, and posterior compartments are well visualized. Further, in contrast to a transvaginal approach, they are noninvasive and do not distort the pelvic anatomy (Baxter and Firoozi, 2013).

Excellent visualization of the female bladder, urethra, and pelvic floor can also be obtained via translabial ultrasound. This minimally invasive technique is performed by placing a 5-mHz curved array probe between the labia majora. This allows direct visualization of the urethra, including presence of urethral diverticula, tumors, or foreign bodies. The three compartments of the female pelvis can be examined (Fig. 4.44) with 2D and 3D ultrasound. The relationship between the bladder, urethra, and pelvic musculature can be assessed in real-time in cases of stress urinary incontinence and pelvic organ prolapse.

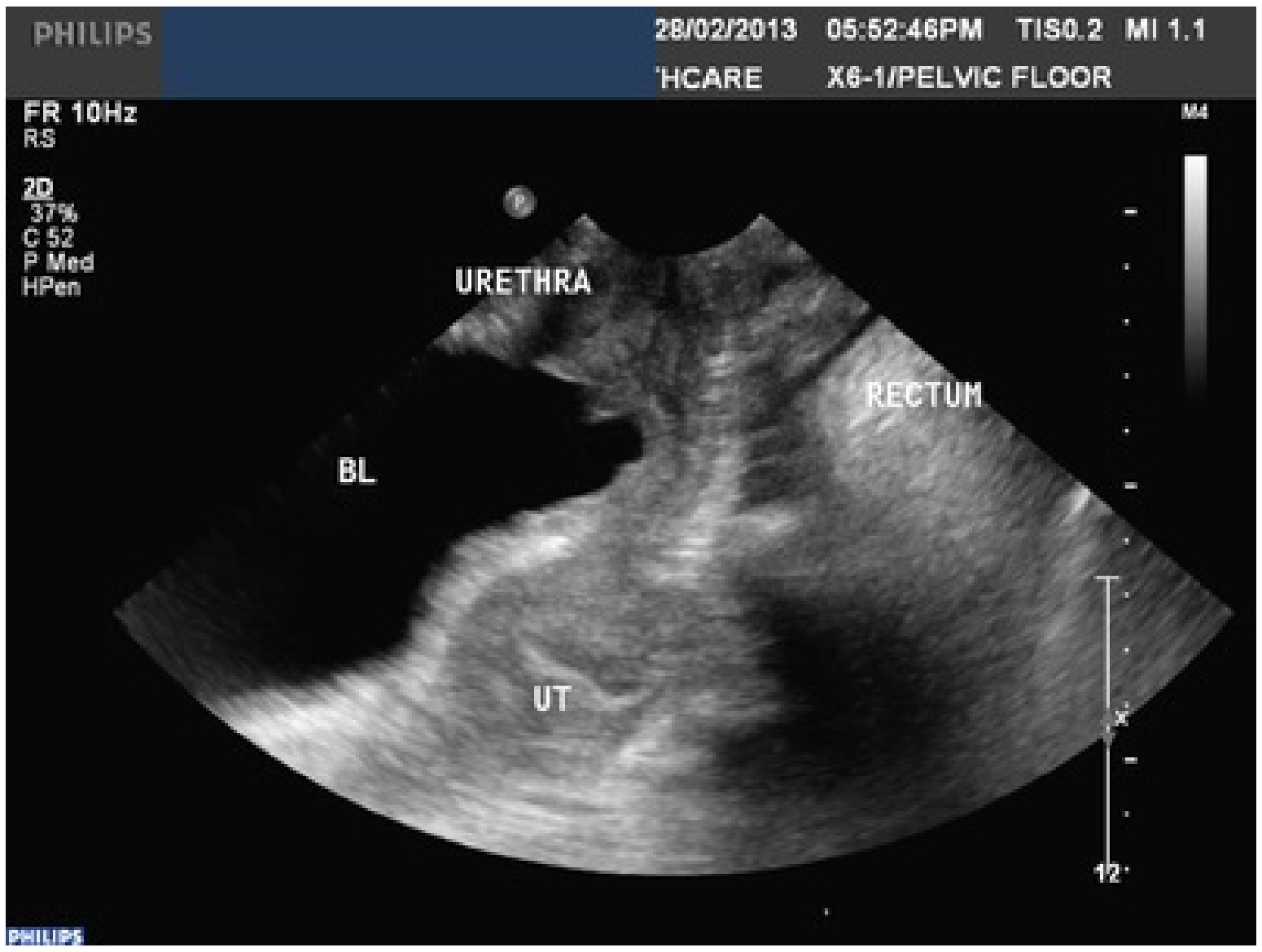

FIG. 4.44 Normal transperineal ultrasound of the female pelvis in the midsagittal plane. The anterior compartment comprises the bladder *(BL)* and urethra, apical compartment comprises the vagina and uterus *(UT),* posterior compartment is the rectum. (Image courtesy Lewis Chan, MD.)

This technique is also useful in assessing complications of urethral slings and pelvic reconstruction. The echogenicity of synthetic sling and meshes makes transperineal ultrasound perfectly well suited to identifying location of a midurethral sling and other meshes in patients with complications such as sling failure, erosion, and de-novo voiding dysfunction (Fig. 4.45).

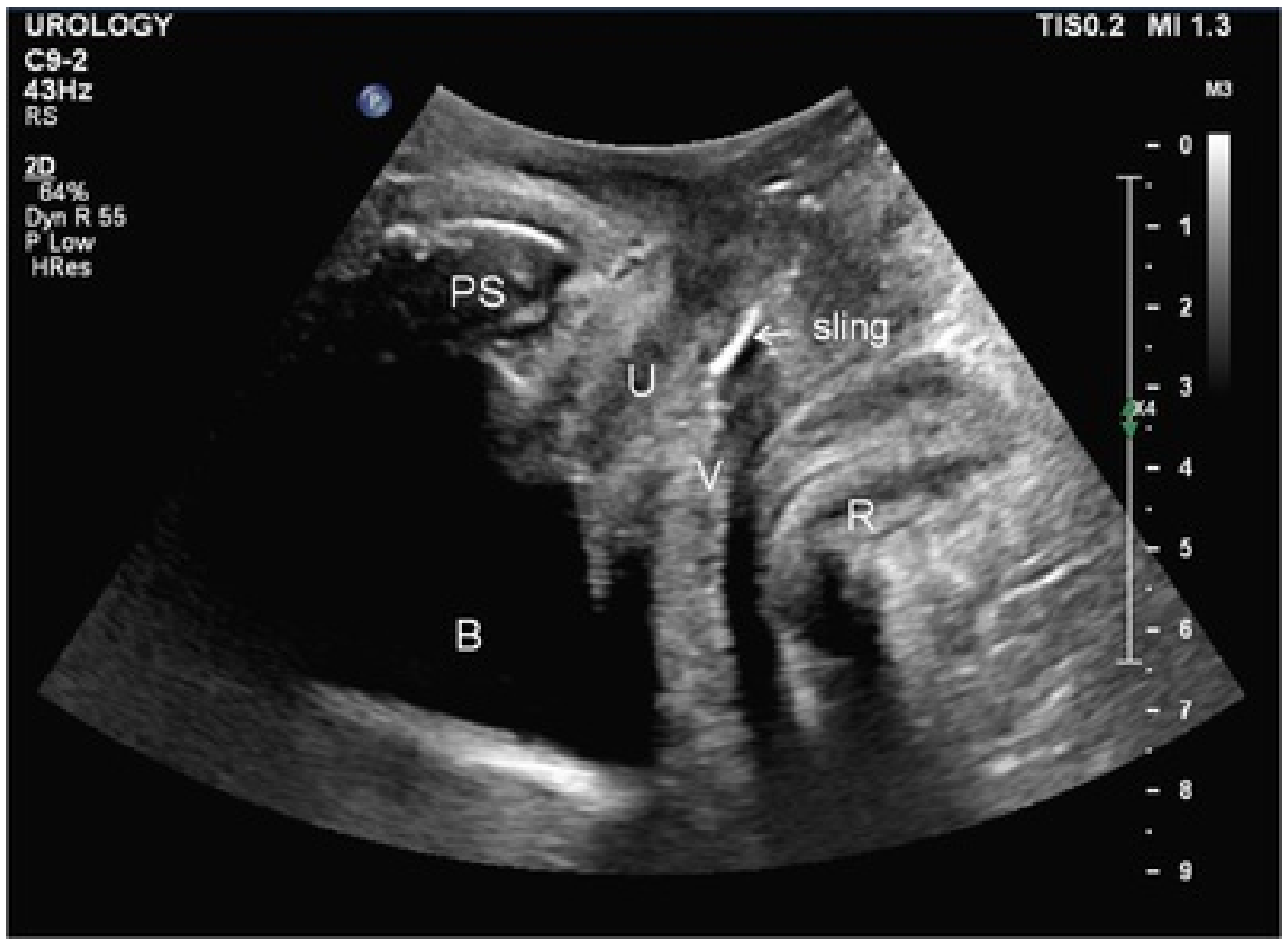

FIG. 4.45 Transperineal ultrasound demonstrating mid-urethral sling *(arrow and label). B,* Bladder; *PS,* pubic symphysis; *R,* rectum; *U,* urethra; *V,* vagina. (Image courtesy Lewis Chan, MD.)

Procedural Applications

The most common application of penile ultrasound is in the evaluation of erectile dysfunction (ED) and penile curvature. Pharmacostimulation provides quantification of cavernosal artery blood flow velocity (Fig. 4.46). Primary criteria for arteriogenic ED include a PSV less than 25 cm/s, cavernosal artery dilation less than 75%, and acceleration time more than 110 msec. Cases of equivocal PSV measurements, particularly when PSV is between 25 and 35 cm/s, included asymmetry of greater than 10 cm/s in PSV between the two cavernosal arteries, focal stenosis of the cavernosal artery, cavernosal artery, and cavernosal-spongiosal flow reversal (Benson et al., 1993).

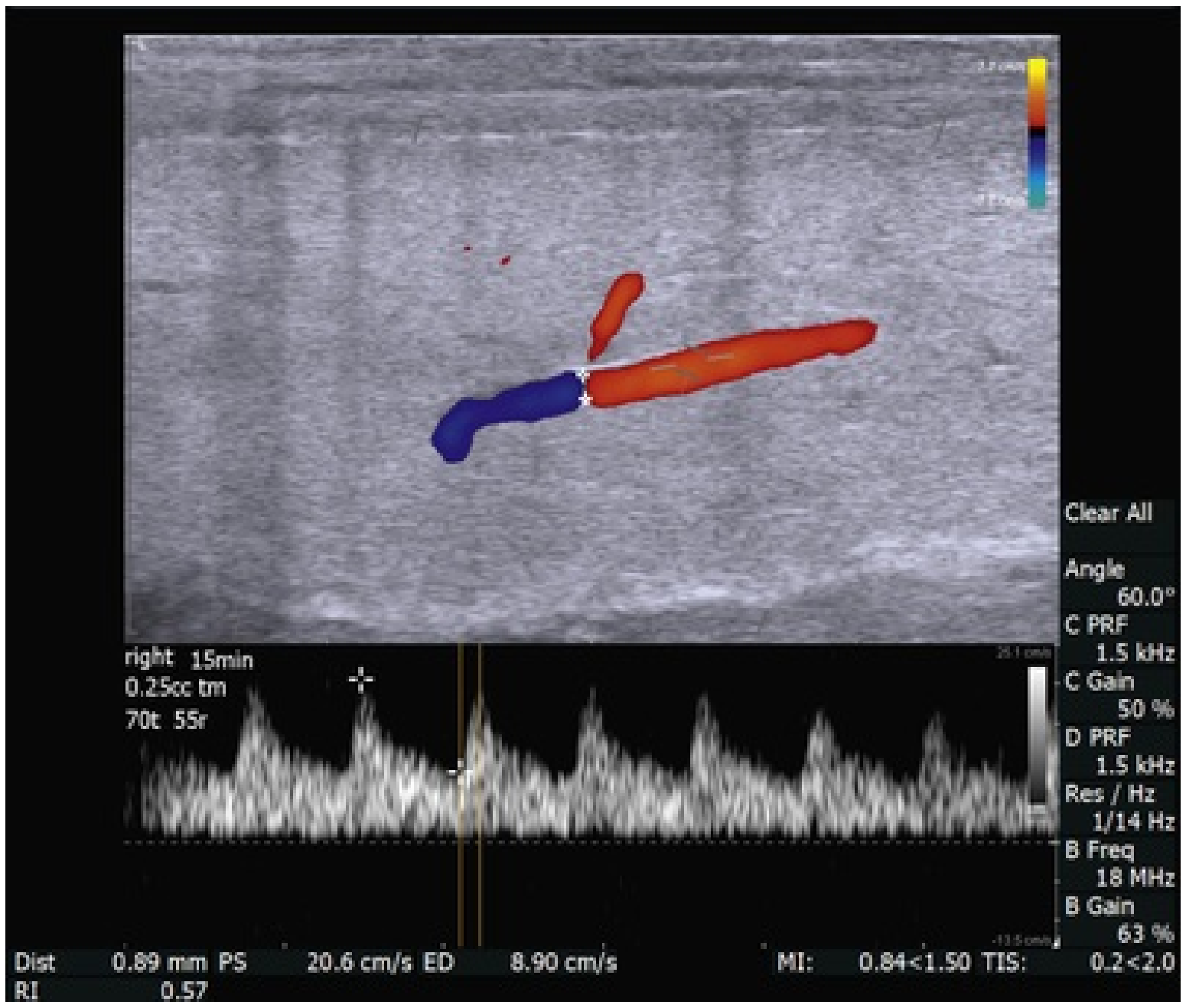

FIG. 4.46 Longitudinal view of the right corpora cavernosa demonstrating peak systolic (PS) and end diastolic (ED) flow velocity in the right cavernosal artery, which measures 0.89 mm in diameter.

In addition, arteriogenic ED has been found to correlate directly with other systemic cardiovascular diseases, coronary artery disease (CAD), and peripheral vascular disease (PVD) in a number of population studies. PSV is the most accurate measure of arterial disease as the cause of ED. The average PSV after intracavernosal injection of vasoactive agents in healthy volunteers without ED ranges from 35 to 47 cm/s, with a PSV of 35 cm/s or greater signifying arterial sufficiency after pharmacostimulation (Broderick and Lue, 1991; Lue et al., 1985; Mueller and Lue, 1988; Pescatori et al., 1994; Schaeffer et al., 2006; "Sexual impotence caused by vascular disease," 1990; Shabsigh et al., 1990). Penile cavernosal artery internal diameter less than 1 mm can often be the first indication of vascular disease. The finding of arteriogenic dysfunction can often provide a window of opportunity (Miner, 2011) to identify and potentially alter the progressive nature of systemic vascular disease (Gazzaruso et al., 2008; Montorsi et al., 2006; Seftel, 2011).

Assessment of penile curvature most often involves palpation and ultrasound interrogation of the pharmacostimulated phallus. However, a palpable plaque is not easily identified (Kalokairinou et al., 2012; Prando, 2009). Often, in many cases, standard B-mode and color Doppler ultrasound does not localize pathology. Sonoelastography (tissue elasticity imaging) is an emerging ultrasound modality that evaluates the stiffness of biologic tissues and localizes these nonpalpable, nonultrasound visualized lesions for potential treatment (Fig. 4.47) (Richards et al., 2013).

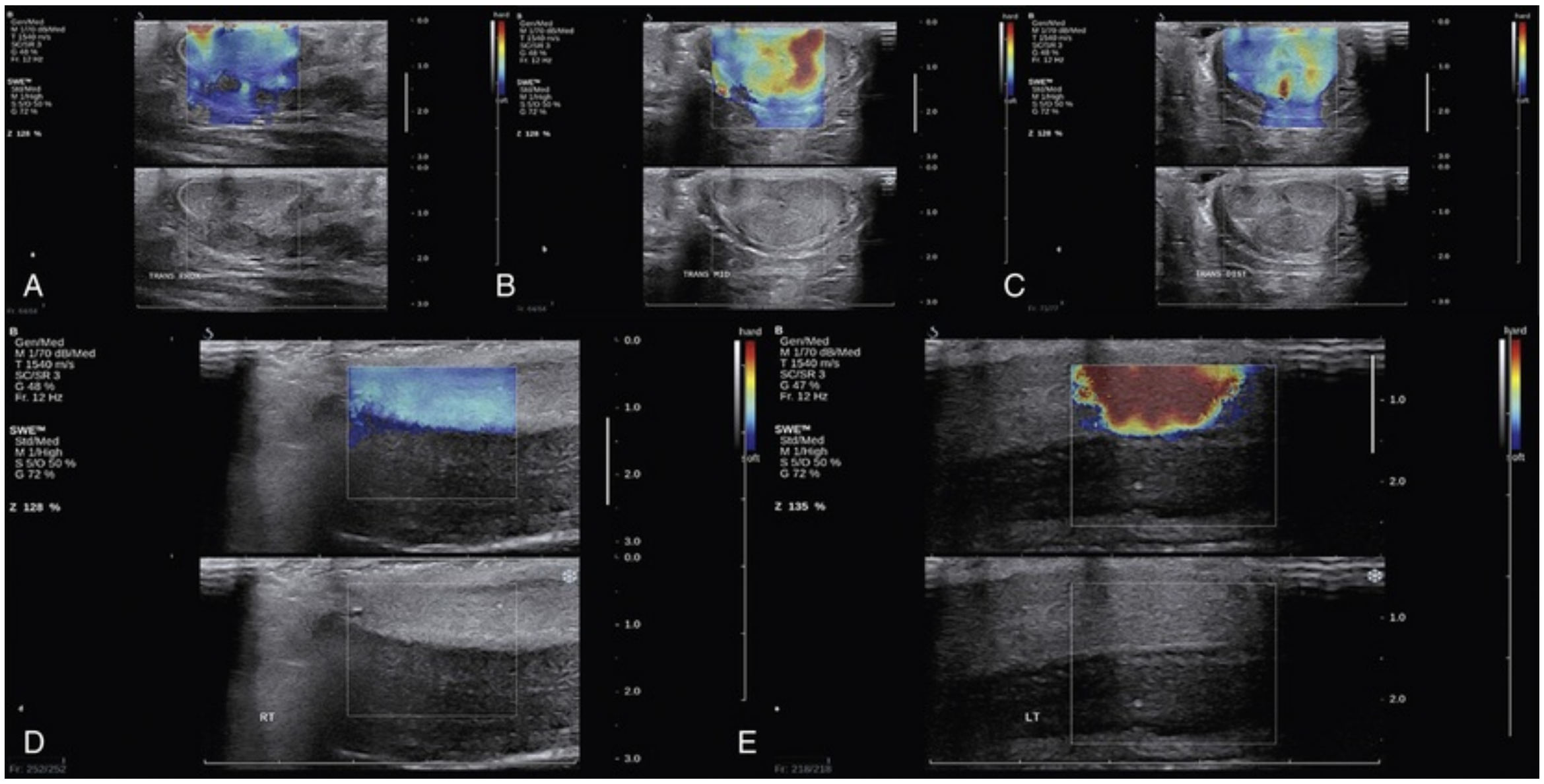

FIG. 4.47 Sonoelastograms (scaled with red more firm and blue less firm) superimposed over transverse B-mode ultrasound images of the (A) proximal, (B) mid, and (C) distal phallus. Sonoelastograms superimposed over parasagittal views of the (D) right and (E) left cavernosal bodies. (From Richards G, Goldenberg E, Pek H, Gilbert BR: Penile sonoelastography for the localization of a non-palpable, non-sonographically visualized lesion in a patient with penile curvature from Peyronie's disease. *J Sex Med* 11:516–520, 2014.)

Limitations

The complete evaluation of the penile urethra, corpora cavernosa, and corpora spongiosum requires a dorsal or ventral interrogation of the exposed phallus as well as a perineal approach to the nonexposed portions of the phallus. This is particularly important in evaluation of the bulbourethra and proximal corpora. In addition, the evaluation of ED requires qualitative and quantitative measurements of blood flow in the penile arteries. Such evaluation requires blood flow measurements before and after the intracavernosal injection of vasoactive substances.

Transrectal Ultrasonography of the Prostate

Transrectal ultrasonography of the prostate (TRUS) is the sonographic imaging procedure most commonly performed by urologists (Trabulsi et al., 2013). It is minimally invasive and provides exquisite anatomic detail of the prostate and periprostatic tissues. Presented here is an overview of transrectal prostate imaging. A comprehensive discussion can be found in Chapter 109. TRUS performed by the urologist enhances patient care by providing a minimally invasive procedure that gives real-time information for a rapid and accurate diagnosis.

Technique

A systematic scan will ensure that a comprehensive examination is performed and appropriately documented. A high-frequency 7.5- to 10-MHz transducer is usually used. This can be a biplane or single-plane transducer (i.e., “end fire” or “side fire”).

It is essential to perform a digital rectal exam **before** inserting the ultrasound probe. Pain or tenderness, rectal stricture, mass, lesion, and/or bleeding that is encountered when performing the rectal exam or when inserting the probe may preclude the TRUS.

After probe insertion, perform a “survey” scan of the prostate from base to apex, including the seminal vesicles and rectal wall. The seminal vesicles are then examined in the transverse plane for comparative evaluation of echogenicity and measurements of seminal vesicle height and ampulla (vas deferens) diameter. Next the midsagittal transverse and longitudinal image of the prostate is examined and the AP, height, and length measurements are taken. Prostate volume, predicted prostate-specific antigen (PPSA) and PSA density (PSAD) can then be calculated usually by formulas already programmed in the ultrasound machine. As in many urologic applications of sonography, color Doppler can add valuable information.

The rectal wall thickness must be evaluated and documented as well as any other notable findings (Trabulsi et al., 2017). Rectal cancer, polyps, and inflammatory processes require further evaluation. The appearance of rectal abnormalities should be documented and possibly a referral made.

Indications

1. Measurement of prostate volume for determination of PSAD
2. Abnormal digital rectal exam

3. Prostatic assessment with sonographic-controlled biopsy
4. Cysts
5. Evaluation for and aspiration of prostate abscess
6. Assessment for suspected congenital abnormality
7. Lower urinary tract symptoms
8. Pelvic pain
9. Prostatitis/prostadynia
10. Hematospermia
11. Infertility (e.g., azoospermia)
    a. Low volume or poorly motile specimen
    b. Cysts
    c. Hypoplastic or dilated seminal vesicle
    d. Impaired motility
    e. Antisperm antibodies

Normal Findings

Echogenicity is best evaluated by comparing the left and right side of the prostate (Fig. 4.48). In the young male, TRUS is often indicated in the evaluation of the subfertile male. The young male prostate is homogenous with zones often difficult to visualize. The “sonographic capsule” can be identified because of the impedance difference between the prostate and surrounding fat. The prominence of the urethra (u) is related to the surrounding low reflectivity of urethral muscles.

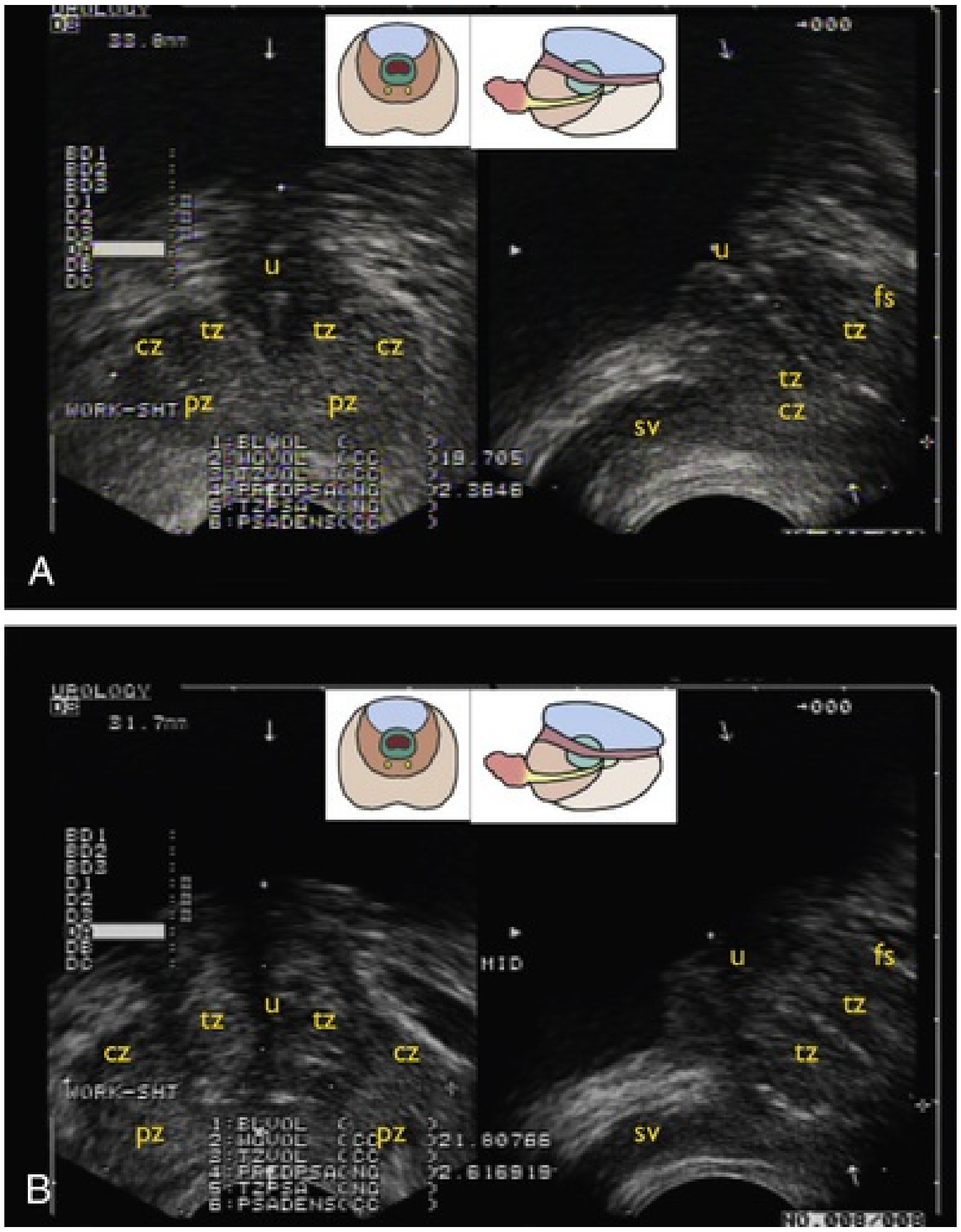

FIG. 4.48 (A) Young male prostate. The peripheral zone *(pz)* is often hyperreflective to the central *(cz)* and transition *(tz)* zones. The cz and tz are difficult to differentiate from each other, and the fibromuscular stroma *(fs)* is positioned anterior to the urethra. (B) Older male prostate. The glandular and stromal elements enlarge, increasing the size of the tz and occasionally the pz. The tz is seen independent of other zones, and the cz is difficult to visualize.

In the young male the peripheral zone (pz) is often hyperreflective to the central zone (cz) and transition zone (tz), although the cz and tz are difficult to differentiate from each other and the fibromuscular stroma (fs) is positioned anterior to the urethra.

In the older male the glandular and stromal elements enlarge, increasing the size of the tz and occasionally the pz. The tz is seen independent of other zones and the cz is difficult to visualize.

The base of the prostate is located at the superior aspect of the prostate contiguous with the base of the bladder. The apex of the prostate is located at the inferior aspect of the prostate continuous with the striated muscles of the urethral sphincter.

Procedural Applications

Transrectal ultrasound-guided biopsy (TRUS/BX) of the prostate is most often initially performed for a specific clinical indication, such as an elevation or change in the PSA or in an abnormal digital rectal examination (Porter, 2013). High-grade prostatic intraepithelial neoplasia (HGPIN) and atypical small acinar proliferation (ASAP) on initial biopsy are considered by some to be indications for immediate or planned repeat biopsy. TRUS/BX may be performed for a rising PSA after initial therapy. In the case of a patient with a rising PSA after radical retropubic prostatectomy, ultrasound and biopsy of the prostatic fossa and vesicourethral anastomosis may be used to diagnose local recurrence. After radiation therapy or cryotherapy, TRUS/BX is employed to diagnose local treatment failure.

Prostatic cyst aspiration is a therapeutic procedure easily performed in the office with minimal patient discomfort. It is often indicated when a large midline cyst obstructs the ejaculatory duct, resulting in dilation of the ejaculatory ducts and/or seminal vesicles. However, refilling of the cyst is common.

Limitations

Bowel preparation is sometimes necessary for imaging. In addition, the patient's body habitus may make it difficult to adequately image the base of the prostate, seminal vesicles, and bladder. Also, current technology limits the diagnostic capabilities of TRUS to anatomic anomalies.

Practice Accreditation

In performing office ultrasound, urologists are committed to ensure that the equipment, sonographers, and protocols provide high-quality diagnostic information. Likewise, patients rightfully expect that the ultrasound exam performed uses equipment that is safe and can effectively image the organ of interest. In addition, third-party payers have, for a multitude of reasons, instituted requirements for practices, including urology practices, to follow to be compensated for their work in providing ultrasound imaging services. How does the urologist sonographer then ensure that the ultrasound exam is compliant with current standards and protocols? One way is through practice accreditation. There are presently two acknowledged accrediting agencies: the American College of Radiology (ACR) and the American Institute for Ultrasound in Medicine (AIUM). The American Urological Association (AUA) and the AIUM have partnered to develop a pathway whereby urology practices can obtain accreditation that is recognized by regulatory authorities and third-party payers.

There are few laws regulating the performance and interpretation of ultrasound examinations. Any licensed physician may purchase an ultrasound machine and begin performing and interpreting sonograms. When an ultrasound exam is indicated, how can patients and their referring physicians be assured of quality?

In 1995 the American College of Radiology (ACR) and the American Institute for Ultrasound in Medicine began to develop programs to accredit ultrasound practices, and the two organizations accredited their first ultrasound practices in 1996. The ACR and AIUM both have pathways to accredit urology practices. The AIUM has worked together with the AUA to develop training guidelines for Urologists and practice parameters for urology practices.

The ACR offers ultrasound practice accreditation in breast, general, gynecologic, obstetric, and vascular ultrasound. The AIUM offers ultrasound practice accreditation in abdominal/general, breast, dedicated musculoskeletal, dedicated thyroid/parathyroid, gynecologic, fetal echocardiography, obstetric, and recently urologic ultrasound.

How does ultrasound practice accreditation differ from AUA board certification? Certification is granted to an individual who has demonstrated a level of knowledge and who continues to meet the requirements necessary to maintain the certification. The individual remains certified regardless of where he or she works. Accreditation is granted to a practice (which may be the practice of a solo practitioner) that demonstrates that all of the individuals in the practice, all the relevant policies and procedures, and equipment and maintenance meet certain requirements. Practices must continue to demonstrate compliance at regular intervals, regardless of whether there are changes in personnel, policies, or equipment. An individual who works in an accredited practice cannot go to another practice and claim that the services provided at the second facility are accredited.

The process of practice accreditation is not without challenges to the urologists and the urology practice. Urologists have traditionally viewed imaging as a tool, very much like a stethoscope, that assists them in providing care for their patients. The process of accreditation changes this by requiring the urologist and the urology practice to expend resources to meet the requirements of accreditation.

However, the accreditation process helps organize the approach to the ultrasound examination and markedly improves quality. This translates into improved diagnostic ultrasound examinations and, in turn, patient satisfaction (Abuhamad and Benacerraf, 2004).

Key Points: Ultrasonography

- An ultrasound wave is a mechanical wave creating alternating areas of compression and rarefaction in tissue.
- Axial resolution improves with increasing frequency of the ultrasound wave.
- Depth of ultrasound penetration decreases with increasing frequency.
- Optimal ultrasound imaging requires trade-offs between resolution and depth of penetration.
- Artifacts may be helpful in the diagnosis of certain conditions.
- The appropriate number of images to be captured for documentation is the number necessary to document a systematic and complete examination and to document relevant pathology.
- The mechanical index and the thermal index are not safety limits.
- The ALARA principle is intended to limit the total energy imparted to the patient during an examination.

- The most important factor in ultrasound safety is the informed operator.
- Angiomyolipoma has a characteristic hyperechoic appearance, but some renal cell carcinomas are also hyperechoic.
- Automated measurement of bladder volume or residual urine, although using ultrasonography, is not an imaging study.
- Sonoelastography extends the ability of ultrasound to detect “hardness” of a lesion.
- The hallmark of testicular torsion is the absence of intratesticular blood flow. However, ultrasound cannot diagnose torsion, only the surgeon (or the pathologist) can.

Suggested Readings

Fulgham PF. *Abdominal ultrasound DVD*. Urologic Ultrasound DVD Series, American Urological Association: Linthicum, MD; 2008.

Fulgham PF. *Basic ultrasound DVD*. Urologic Ultrasound DVD Series, American Urological Association: Linthicum, MD; 2007.

Fulgham PF, Gilbert BR. *Practical urological ultrasound*. ed 2. Humana Press; 2017.

Gilbert BR. *Ultrasound of the male genitalia*. Springer; 2015.

Gilbert BR. *Ultrasound of the male genitalia DVD*. Urologic Ultrasound DVD Series, American Urological Association: Linthicum, MD; 2008.

Holland CK, Fowlkes JB. Biologic effects and safety. Rumack CM, Wilson SR, Charboneau JW, et al. *Diagnostic ultrasound*. ed 3. Elsevier Mosby: St. Louis; 2005:35–53.

Merritt CRB. Physics of ultrasound. Rumack CM, Wilson SR, Charboneau JW, et al. *Diagnostic ultrasound*. ed 3. Elsevier Mosby: St. Louis; 2005:3–34.

O'Neill WC. *Atlas of renal ultrasonography*. Saunders: Philadelphia; 2001.

Rifkin MD, Cochlin MD, Goldberg BB. *Imaging of the scrotum and contents*. Martin Dunitz Ltd: London; 2002.

Scoutt LM, Burns P, Brown JL, et al. Ultrasound evaluation of the urinary tract. *Clinical urography*. ed 2. Saunders: Philadelphia; 2000:388–472.

Thurston W, Wilson SR. The urinary tract. Rumack CM, Wilson SR, Charboneau JW, et al. *Diagnostic ultrasound*. ed 3. Elsevier: St. Louis; 2005:321–393.

References

Abuhamad AZ, Benacerraf BR. The accreditation of ultrasound practices: impact on compliance with minimum performance guidelines. *J Ultrasound Med*. 2004;23(8):1023–1029.

Aigner F, De Zordo T, Pallwein-Prettner L, et al. Real-time sonoelastography for the evaluation of testicular lesions. *Radiology*. 2012;263(2):584–589.

Al-Hweish AK, Abdul-Rehaman IS. Outpatient percutaneous renal biopsy in adult patients. *Saudi J Kidney Dis Transpl*. 2007;18(4):541–546.

American Institute of Ultrasound in Medicine. AIUM practice parameter: documentation of an ultrasound examination. *J Ultrasound Med*. 2014.

Arima M, Takahara S, Ihara H, et al. Predictability of renal allograft prognosis during rejection crisis by ultrasonic Doppler flow technique. *Urology*. 1982;19(4):389–394.

Auer T, De Zordo T, Dejaco C, et al. Value of multiparametric US in the assessment of intratesticular lesions. *Radiology*. 2017;285(2):640–649.

Barth RA, Shortliffe LD. Normal pediatric testis: comparison of power Doppler and color Doppler US in the detection of blood flow. *Radiology*. 1997;204(2):389–393.

Baxter C, Firoozi F. Pelvic floor ultrasound. *Practical urological ultrasound*. Springer: New York; 2013:143–153.

Belker AM, Sherins RJ, Dennison-Lagos L, et al. Percutaneous testicular sperm aspiration: a convenient and effective office procedure to retrieve sperm for in vitro fertilization with intracytoplasmic sperm injection. *J Urol*. 1998;160(6 Pt 1):2058–2062.

Benson CB, Aruny JE, Vickers MA Jr. Correlation of duplex sonography with arteriography in patients with erectile dysfunction. *Am J Roentgenol*. 1993;160(1):71–73.

Berge V, Baco E, Karlsen SJ. A prospective study of salvage high-intensity focused ultrasound for locally radiorecurrent prostate cancer: early results. *Scand J Urol Nephrol*. 2010;44(4):223–227.

Biagiotti G, Vitali G, Cavallini G. Dyspermia and testicular artery peak systolic velocity. *Arch Ital Urol Androl*. 2002;74(4):243–246.

Broderick GA, Lue TF. The penile blood flow study: evaluation of vasculogenic impotence by duplex ultrasonography. *Erectile dysfunction*. Springer: Berlin, Heidelberg; 1991:126–136.

Buckspan MB, Klotz PG, Goldfinger M, et al. Intraoperative ultrasound in the conservative resection of testicular neoplasms. *J Urol*. 1989;141(2):326–327.

Burgess SE, Iwamoto T, Coleman DJ. Histologic changes in porcine eyes treated with high-intensity focused ultrasound. *Ann Opthalmol*. 1987;19(4):133–138.

Chapelon JY, Ribault M, Vernier F, et al. Treatment of localised prostate cancer with transrectal high intensity focused ultrasound. *J Eur Ultrasound*. 1999;9(1):31–38.

Chen SL, Bih LI, Chen GD, et al. Transrectal ultrasound–guided transperineal botulinum toxin A injection to the external urethral sphincter for treatment of detrusor external sphincter dyssynergia in patients with spinal cord injury. *Arch Phys Med Rehabil*. 2010;91(3):340–344.

Chia SJ, Heng CT, Chan SP, et al. Correlation of intravesical prostatic protrusion with bladder outlet obstruction. *BJU Int*. 2003;91(4):371–374.

Christensen J, Lindequist S, Knudsen DU, et al. Ultrasound-guided renal biopsy with biopsy gun technique—efficacy and complications. *Acta Radiol*. 1995;36(3):276–279.

Craft I, Tsirigotis M, Bennett V, et al. Percutaneous epididymal sperm aspiration and intracytoplasmic sperm injection in the management of infertility due to obstructive azoospermia. *Fertil Steril*. 1995;63(5):1038–1042.

Dabaja AA, et al. Bulbocavernosus muscle area measurement: a novel method to assess androgenic activity. *Asian J Androl*. 2014;16:618–622.

Davis ID, Oehlenschlager W, O'Riordan MA, et al. Pediatric renal biopsy: should this procedure be performed in an outpatient setting? *Pediatr Nephrol*. 1998;12(2):96–100.

Delair SM, Kurzrock EA. Clinical utility of ureteral jets: disparate opinions. *J Endourol*. 2006;20(2):111–114.

Emamian SA, Nielsen MB, Pedersen JF, et al. Kidney dimensions at sonography: correlation with age, sex, and habitus in 665 adult volunteers. *AJR Am J Roentgenol*. 2013;160(1):83–86.

Forman HP, Middleton WD, Melson GL, et al. Hyperechoic renal cell carcinomas: increase in detection at US. *Radiology*. 1993;188(2):431–434.

Fraser IR, Fairley KF. Renal biopsy as an outpatient procedure. *Am J Kidney Dis*. 1995;25(6):876–878.

Friedler S, Raziel A, Strassburger D, et al. Testicular sperm retrieval by percutaneous fine needle sperm aspiration compared with testicular sperm extraction by open biopsy in men with non-obstructive azoospermia. *Hum Reprod*. 1997;12(7):1488–1493.

Gazzaruso C, Solerte SB, Pujia A, et al. Erectile dysfunction as a predictor of cardiovascular events and death in diabetic patients with angiographically proven asymptomatic coronary artery disease. *J Am Coll Cardiol*. 2008;51(21):2040–2044.

Ghani KR, Pilcher J, Patel U, et al. Three-dimensional ultrasound reconstruction of the pelvicaliceal system: an in-vitro study. *World J Urol*. 2008;26(5):493–498.

Ghani KR, Pilcher J, Rowland D, et al. Portable ultrasonography and bladder volume accuracy—a comparative study using three-dimensional ultrasonography. *Urology*. 2008;72(1):24–28.

Gochman RF, Karasic RB, Heller MB. Use of portable ultrasound to assist urine collection by suprapubic aspiration. *Ann Emerg Med*. 1991;20(6):631–635.

Goddi A, Sacchi A, Magistretti G, et al. Real-time tissue elastography for testicular lesion assessment. *Eur Radiol*. 2012;22(4):721–730.

Goldberg BB, Pollack HM. Differentiation of renal masses using A-mode ultrasound. *J Urol*. 2002;167(2):1022–1026.

Greene ER, Venters MD, Avasthi PS, et al. Noninvasive characterization of renal artery blood flow. *Kidney*. 1981.

Gupta N, Carvajal M, Jurewicz M, et al. Bulbocavernosus muscle area as a novel marker for hypogonadism. *Asian J Urol*. 2017;4(1):3–9.

Hergesell O. Safety of ultrasound-guided percutaneous renal biopsy-retrospective analysis of 1090 consecutive cases. *Nephrol Dial Transplant*. 1998;13(4):975–977.

Hillelsohn JH, Chuang KW, Goldenberg E, et al. Spectral Doppler sonography: a noninvasive method for predicting dyspermia. *J Ultrasound Med*. 2013;32(8):1427–1432.

Holm HH, Northeved A. A transurethral ultrasonic scanner. *J Urol*. 1974;111(2):238–241.

Hussain F, Watson A, Hayes J, et al. Standards for renal biopsies: comparison of inpatient and day care procedures. *Pediatr Nephrol*. 2003;18(1):53–56.

Ikari O, Netto NR, D'Ancona CA, et al. Percutaneous treatment of bladder stones. *J Urol*. 1993;149(6):1499–1500.

Kalokairinou K, Konstantinidis C, Domazou M, et al. US imaging in Peyronie's disease. *J Clin Imag Sci*. 2012;2(1):63.

Kamitsuji H, Yoshioka K, Ito H. Percutaneous renal biopsy in children: survey of pediatric nephrologists in Japan. *Pediatr*

Nephrol. 1999;13(8):693–696.

Keqin Z, Zhishun X, Jing Z, et al. Clinical significance of intravesical prostatic protrusion in patients with benign prostatic enlargement. *Urology*. 2007;70(6):1096–1099.

Khadra AA, Abdulhadi I, Ghunain S, et al. Efficiency of percutaneous testicular sperm aspiration as a mode of sperm collection for intracytoplasmic sperm injection in nonobstructive azoospermia. *J Urol*. 2003;169(2):603–605.

Kohli HS, Jairam A, Bhat A, et al. Safety of kidney biopsy in elderly: a prospective study. *Int Urol Nephrol*. 2006;38(3–4):815–820.

Köhrmann K, Michel MS, Gaa J, et al. High intensity focused ultrasound as noninvasive therapy for multilocal renal cell carcinoma: case study and review of the literature. *J Urol*. 2002;167(6):2397–2403.

Li M, Du J, Wang Z, et al. The value of sonoelastography scores and the strain ratio in differential diagnosis of azoospermia. *J Urol*. 2012;188(5):1861–1866.

Lin YM, Hsu CC, Kuo TC, et al. Percutaneous epididymal sperm aspiration versus microsurgical epididymal sperm aspiration for irreparable obstructive azoospermia—experience with 100 cases. *J Formos Med Assoc*. 2000;99(6):459–465.

Lue TF, Hricak H, Marich KW, et al. Vasculogenic impotence evaluated by high-resolution ultrasonography and pulsed Doppler spectrum analysis. *Radiology*. 1985;155(3):777–781.

Madersbacher S, Kratzik C, Susani M, et al. Transcutaneous high-intensity focused ultrasound and irradiation: an organ-preserving treatment of cancer in a solitary testis. *Eur Urol*. 1998;33(2):195–201.

Madersbacher S, Kratzik C, Szabo N, et al. Tissue ablation in benign prostatic hyperplasia with high-intensity focused ultrasound. *Eur Urol*. 1993;23(Suppl 1):39–43.

Manikandan R, Lynch N, Grills RJ. Percutaneous peritoneal drainage for intraperitoneal bladder perforations during transurethral resection of bladder tumors. *J Endourol Soc*. 2003;17(10):945–947.

Margreiter M, Marberger M. Focal therapy and imaging in prostate and kidney cancer: high-intensity focused ultrasound ablation of small renal tumors. *J Endourol*. 2010;24(5):745–748.

Mazzu D, Jeffrey RB Jr, Ralls PW. Lymphoma and leukemia involving the testicles: findings on gray-scale and color Doppler sonography. *Am J Roentgenol*. 1995;164(3):645–647.

Meniru GI, Gorgy A, Batha S, et al. Studies of percutaneous epididymal sperm aspiration (PESA) and intracytoplasmic sperm injection. *Hum Reprod Update*. 1998;4(1):57–71.

Meniru GI, Gorgy A, Batha S, et al. Successful sperm retrieval by percutaneous epididymal and testicular sperm aspiration. *Hum Reprod Update*. 1998;4(1):57–71.

Middleton WD, Thorne DA. Color Doppler ultrasound of the normal testis. *AJR Am J Roentgenol*. 1989;152(2):293–297.

Miner MM. Erectile dysfunction: a harbinger or consequence: does its detection lead to a window of curability? *J Androl*. 2011;32(2):125–134.

Mitterberger M, Pinggera GM, Horninger W, et al. Comparison of contrast enhanced color Doppler targeted biopsy to conventional systematic biopsy: impact on gleason score. *J Urol*. 2007;178(2):464–468.

Mitterberger M, Pinggera GM, Pallwein L, et al. The value of three-dimensional transrectal ultrasonography in staging prostate cancer. *BJU Int*. 2007;100(1):47–50.

Montorsi P, Ravagnani PM, Galli S, et al. Association between erectile dysfunction and coronary artery disease. Role of coronary clinical presentation and extent of coronary vessels involvement: the COBRA trial. *Eur Heart J*. 2006;27(22):2632–2639.

Moutzouris DA, Herlitz L, Appel GB, et al. Renal biopsy in the very elderly. *Clin J Am Soc Nephrol*. 2009;4(6):1073–1082.

Mueller SC, Lue TF. Evaluation of vasculogenic impotence. *Urol Clin North Am*. 1988;15(1):65–76.

Nelson TR, Fowlkes JB, Abramowicz JS, et al. Ultrasound biosafety considerations for the practicing sonographer and sonologist. *J Ultrasound Med*. 2009;28(2):139–150.

Oelke M, Höfner K, Jonas U, et al. Diagnostic accuracy of noninvasive tests to evaluate bladder outlet obstruction in men: detrusor wall thickness, uroflowmetry, postvoid residual urine, and prostate volume. *Eur Urol*. 2007;52(3):827–834.

O'Neill WC. *Atlas of renal physiology*. Saunders: Philadelphia; 2001.

Onik G, Barzell W. Transperineal 3D mapping biopsy of the prostate: an essential tool in selecting patients for focal prostate cancer therapy. *Urol Oncol*. 2008;26(5):506–510.

Ozawa H, Igarashi T, Uematsu K. The future of urodynamics: non-invasive ultrasound videourodynamics. *J Urol*. 2010.

Park YH, Ku JH, Oh S-J. Accuracy of post-void residual urine volume measurement using a portable ultrasound bladder scanner with real-time pre-scan imaging. *Neurourol Urodyn*. 2011;30(3):335–338.

Pasqualotto FF, Rossi-Ferragut LM, Rocha CC, et al. The efficacy of repeat percutaneous epididymal sperm aspiration procedures. *J Urol*. 2003;169(5):1779–1781.

Perri AJ, Morales JO, Feldman AE, et al. Necrotic testicle with increased blood flow on Doppler ultrasonic examination. *Urology*. 1976;8(3):265–267.

Pescatori ES, Hatzichristou DG, Namburi S, et al. A positive intracavernous injection test implies normal veno-occlusive but not necessarily normal arterial function: a hemodynamic study. *J Urol*. 1994;151(5):1209–1216.

Pinggera GM, Mitterberger M, Bartsch G, et al. Assessment of the intratesticular resistive index by colour Doppler ultrasonography measurements as a predictor of spermatogenesis. *BJU Int*. 2008;101(6):722–726.

Porter CR. Ultrasound for prostate biopsy. *Practical urological ultrasound*. Springer: New York; 2013.

Prando D. New sonographic aspects of peyronie disease. *J Ultrasound Med*. 2009;28(2):217–232.

Richards G, Goldenberg E, Pek H, et al. Penile sonoelastography for the localization of a non-palpable, non-sonographically visualized lesion in a patient with penile curvature from Peyronie's disease. *J Sex Med*. 2013;11(2):516–520.

Roger SD, Beale AM, Cattell WR, et al. What is the value of measuring renal parenchymal thickness before renal biopsy? *Clin Radiol*. 1994;49(1):45–49.

Rosenlund B, Westlander G, Wood M, et al. Sperm retrieval and fertilization in repeated percutaneous epididymal sperm aspiration. *Hum Reprod*. 1998;13(10):2805–2807.

Rumack C, Wilson S. *Diagnostic ultrasound*. Mosby: St Louis; 2005.

Schaeffer EM, Jarow JP, Vrablic J, et al. Duplex ultrasonography detects clinically significant anomalies of penile arterial vasculature affecting surgical approach to penile straightening. *Urology*. 2006;67(1):166–169.

Seftel A. Re: erectile dysfunction and later cardiovascular disease in men with type 2 diabetes: prospective cohort study based on the ADVANCE (action in diabetes and vascular disease: preterax and diamicron Modified-release controlled evaluation) trial. *J Urol*. 2011;186(1):238–239.

Sexual impotence caused by vascular disease: diagnosis with duplex sonography. *J Diagn Med Sonogr*. 1990;6(2):121–

122.

Shabsigh R, Fishman IJ, Shotland Y, et al. Comparison of penile duplex ultrasonography with nocturnal penile tumescence monitoring for the evaluation of erectile impotence. *J Urol*. 1990;143(5):924–927.

Simforoosh N, Dadkhah F, Hosseini SY, et al. Accuracy of residual urine measurement in men: comparison between real-time ultrasonography and catheterization. *J Urol*. 1997;158(1):59–61.

Sofer M, Kaver I, Greenstein A, et al. Refinements in treatment of large bladder calculi: simultaneous percutaneous suprapubic and transurethral cystolithotripsy. *Urology*. 2004;64(4):651–654.

Stratta P, Canavese C, Marengo M, et al. Risk management of renal biopsy: 1387 cases over 30 years in a single centre. *Eur J Clin Invest*. 2007;37(12):954–963.

Takahashi H, Ouchi T. [CITATION][C]. *Proc Jpn Soc Ultrasonics Med*. 1963.

Trabulsi EJ, Liu XS, Smith WR, Das AK. Transrectal ultrasound. *Practical Urological Ultrasound*. 2nd ed. Springer: New York; 2017:183–195.

Warshauer DM, McCarthy SM, Street L. Detection of renal masses: sensitivities and specificities of excretory urography/linear tomography, US, and CT. *Radiology*. 1988;493–498.

Watanabe H, Igari D, Tanahasi Y, et al. Development and application of new equipment for transrectal ultrasonography. *J Clin Ultrasound*. 1974;2(2):91–98.

Watanabe H, Saitoh M, Igari D, et al. Non-invasive detection of ultrasonic Doppler signals from renal vessels. *Tohoku J Exp Med*. 1976;118(4):393–394.

Wild J, Reid J. *4th Annual Conference in Ultrasound Therapy*. 1955.

Wildeboer RR, Postema AW, Demi L, et al. Multiparametric dynamic contrast-enhanced ultrasound imaging of prostate cancer. *Eur Radiol*. 2017;27(8):3226–3234.

Wilson RD, Johnson MP. Prenatal ultrasound guided percutaneous shunts for obstructive uropathy and thoracic disease. *Sem Pediatr Surg*. 2003;12(3):182–189.

Wink M, Frauscher F, Cosgrove D, et al. Contrast-enhanced ultrasound and prostate cancer; a multicentre European research coordination project. *Eur Urol*. 2008;54(5):982–993.

Yamashita Y, Takahashi M, Watanabe O. Small renal cell carcinoma: pathologic and radiologic correlation. *Radiology*. 1992;184(2):493–498.

Urinary Tract Imaging

Basic Principles of Nuclear Medicine

Michael A. Gorin MD, Steven P. Rowe MD

Nuclear medicine is a branch of radiology that utilizes pharmaceutical agents labeled with radionuclides to visualize organ function, treat disease, and characterize molecular processes within cells (Society of Nuclear Medicine and Molecular Imaging, 2018). The last of these applications is commonly referred to as *molecular imaging*. Imaging agents used in nuclear medicine, known as *radiotracers,* are generally administered in subpharmacologic quantities such that they do not perturb the processes that they are being used to measure. Radiotracers emit radioactivity that can be detected by an external sensor unit. Data received by the sensor can then be formatted as an image for interpretation by a nuclear medicine specialist. In contrast, anatomic imaging techniques, such as plain film radiography, computed tomography (CT), magnetic resonance imaging (MRI), and ultrasonography all require an external energy source to generate structural images of the body.

In the field of urology, there are many applications of nuclear imaging. In this chapter, we review the basic principles of nuclear medicine and explore ways in which this specialized form of diagnostic imaging can be used to evaluate the genitourinary tract.

Principles of Single Photon and PET Imaging

Radionuclides that emit low energy gamma photons in the range of 100 to 300 keV can be detected with a gamma camera operating in either planar or tomographic mode (Zanzonico, 2012). The gamma camera itself is composed of several key components: a scintillation crystal (usually made of NaI) that absorbs gamma photons and emits light, photomultiplier tubes that collect and amplify the light emitted by the scintillation crystal, and circuitry that integrates the output from the photomultiplier tubes into information that can be reconstructed as an image. To encode spatial information, a device called a *collimator* is generally placed between the patient and the scintillation crystal. The collimator has a specific geometry that allows gamma photons traveling only in a certain direction to reach the scintillation crystal. When operated in planar mode, photons are detected by the gamma camera at a single angle to the patient. The resulting image from a planar acquisition is a two-dimensional representation of the detected radioactivity.

Three-dimensional images can also be acquired with single-photon imaging. This requires the gamma camera to be slowly rotated around the patient so that photons can be detected at multiple angles of incidence. This is often referred to as *single-photon emission computed tomography (SPECT).* A noncontrast CT scan is typically acquired at the time of SPECT imaging and is used for anatomic localization of the detected radioactivity and for signal attenuation correction (i.e., correction for the fact that signal generated more deeply within the patient is attenuated as photons travel through the body). SPECT may be included as a standard part of an imaging protocol or can be used for problem solving when two-dimensional planar images are inadequate to completely understand a pathologic process. Commonly used radionuclides for single-photon imaging include technetium-99m (^{99m}Tc) and indium-111 (^{111}In) (Table 5.1).

TABLE 5.1

Physical Characteristics of Single-Photon Emitting Radionuclides Mentioned in the Chapter

RADIONUCLIDE	HALF-LIFE (hours)	POSITRON ENERGY IN keV (%)

^{67}Ga	78.3	93 (37), 185 (20), 300 (17), 395 (5)
^{111}In	67.3	171 (90), 245 (94)
^{99m}Tc	6.0	140 (89)

Data from Ziessman HA, O'Malley JP, Thrall JH. *Nuclear medicine: the requisites.* 4th ed; 2013.

Radionuclides that emit positrons can be detected with positron emission tomography (PET) (Basu et al. 2011; Zanzonico, 2012). Emitted positrons travel a short distance before colliding with a nearby electron, causing an annihilation event that leads to the release of two 511 keV photons traveling 180 degrees apart. Images are constructed after the coincident detection of these two high-energy photons. Like SPECT imaging, PET is acquired tomographically and is typically performed in combination with a noncontrast CT, allowing anatomic localization and attenuation correction. Alternatively, an MRI can be acquired at the time of PET imaging in specially designed PET/MRI scanners, which are becoming more common in many large specialty centers (Mannheim et al., 2018). Radionuclides used for PET imaging include carbon-11 (^{11}C), iodine-124 (^{124}I), fluorine-18 (^{18}F), and gallium-68 (^{68}Ga) (Table 5.2).

TABLE 5.2

Physical Characteristics of Positron-Emitting Radionuclides Mentioned in the Chapter

RADIONUCLIDE	HALF-LIFE	POSITRON ENERGY (keV)	RANGE IN SOFT TISSUE (mm)	PRODUCTION SOURCE
^{11}C	20.3 minutes	960	3.9	Cyclotron
^{18}F	109.8 minutes	634	2.3	Cyclotron
^{68}Ga	68.0 minutes	1899	8.9	Generator
^{124}I	4.17 days	1525 (50%) and 2138 (50%)	6.9 and 10.2	Cyclotron
^{89}Zr	78.4 hours	896	3.6	Cyclotron

Data from Serdons K, Verbruggen A, Bormans GM. Developing new molecular imaging probes for PET. *Methods* 2009;48(2):104-111.

Among the described nuclear imaging techniques, PET offers the highest level of spatial resolution (~5 mm vs. ~10 mm for SPECT and ~20 mm for scintigraphy). Additionally, depending on the radiotracer administered, PET typically offers the highest degree of visual conspicuity. This is because the PET detector can filter out photons that lack a coincidentally detected partner, thus minimizing noise. In contrast, any photon passing through the collimator of a gamma camera is assumed to be a true signal. Another relative strength of PET imaging is the ability to quantify the degree of radiotracer uptake within areas of interest through the measurement of standardized uptake values (SUVs) which take into account the total dose of injected radiotracer and patient body mass (Boellaard, 2009). In contrast, single-photon imaging, as currently used clinically, only allows for semiquantitation. A notable limitation of PET is the relatively high cost of this technology, limiting access in many parts of the world. At the present time, the majority of functional imaging tests in urology are performed with scintigraphy, and cancer imaging is most often performed with PET in combination with CT or MRI.

Functional Imaging of the Kidneys

Over the past half century, a number of radiopharmaceutical agents have been developed to allow for the functional assessment of the kidneys (Taylor 2014a, 2014b). Common applications for these agents include measurement of renal blood flow, determination of differential renal function, evaluation for the presence and degree of renal obstruction, and assessment of renal scarring. Accurate interpretation of imaging results relies on a firm understanding of renal physiology and the properties of the available imaging agents.

Relevant Renal Physiology

On average, the kidneys receive 20% of cardiac output. For a healthy individual weighing approximately 70 kg, cardiac output averages 5 L/min, making the total blood volume received by the kidneys equal to approximately 1 L/min. With 60% of blood volume composed of plasma (the liquid component of blood that contains water, glucose, proteins, and electrolytes), renal plasma blood flow (RPF) to the kidneys occurs at a rate of approximately 600 mL/min. It is the job of the kidneys to clear plasma of waste products and to maintain electrolyte balance. Approximately 20% of plasma clearance occurs by passive glomerular filtration, and the remaining 80% occurs by active tubular secretion. The kidneys have the ability to reclaim free water and various electrolytes from fluid in the renal tubules depending on the physiologic needs of the body. The mechanism of clearance from the blood and the timing of excretion from the kidney determines the clinical information that each radiotracer can provide. Although a number of agents have been investigated for functional renal imaging, the radiotracers most commonly used in current clinical practice are technetium-99m diethylenetriaminepentaacetic acid (^{99m}Tc-DTPA), technetium-99m mercaptoacetyltriglycine (^{99m}Tc-MAG3), and technetium-99m dimercaptosuccinic acid (^{99m}Tc-DMSA).

Technetium-99m Diethylenetriaminepentaacetic Acid (^{99m}Tc-DTPA)

DTPA, also known as pentetic acid, is a heavy metal chelator with multiple industrial and medical applications. When radiolabeled with ^{99m}Tc, the resulting compound can be used to evaluate relative RPF to the kidneys and to assess for functional renal obstruction. Upon injection into the bloodstream, ^{99m}Tc-DTPA is extracted by the kidneys entirely through glomerular filtration (Reba et al., 1968). The drug then quickly moves through the renal tubules and is excreted in the urine without being reabsorbed. Because of this agent's mechanism of renal clearance, ^{99m}Tc-DTPA can be used to calculate glomerular filtration rate. This same property, however, leads to high background activity and poor image quality in patients with impaired renal function.

Technetium-99m Mercaptoacetyltriglycine (^{99m}Tc-MAG3)

Similar to ^{99m}Tc-DTPA, ^{99m}Tc-MAG3 is a radiotracer that is excreted in the urine and can be used to determine renal split function and to assess for functional obstruction. However, unlike ^{99m}Tc-DTPA, which is cleared from the plasma via glomerular filtration, ^{99m}Tc-MAG3 is protein bound in circulation and undergoes clearance nearly entirely through tubular secretion (Fritzberg et al., 1986). ^{99m}Tc-MAG3 is therefore not impacted by impaired glomerular filtration and has a higher extraction efficiency than ^{99m}Tc-DTPA. This property results in improved image quality and lower radiation doses to nontarget organs. Additionally, the cost of ^{99m}Tc-MAG3 is considerably less than that of ^{99m}Tc-DTPA. In light of these advantages, ^{99m}Tc-MAG3 has largely become the agent of choice for measuring differences in RPF and to asses for functional obstruction.

Technetium-99m Dimercaptosuccinic Acid (^{99m}Tc-DMSA)

A third commonly used radiotracer for assessment of renal function is ^{99m}Tc-DMSA. After intravenous injection, ^{99m}Tc-DMSA is cleared from the plasma primarily by glomerular filtration (Peters et al., 1988). Once within the lumina of the renal tubules, ^{99m}Tc-DMSA undergoes receptor-mediated endocytosis by the proximal tubular cells. The receptors responsible for the endocytosis of ^{99m}Tc-DMSA are megalin and cubilin (Weyer et al., 2013). Because ^{99m}Tc-DMSA is retained by the proximal tubular cells, this imaging agent is ideally suited for imaging cortical processes such as acute pyelonephritis and renal scarring.

Dynamic Renal Imaging With ^{99m}Tc-MAG3 and ^{99m}Tc-DTPA

As mentioned earlier, both ^{99m}Tc-MAG3 and ^{99m}Tc-DTPA can be used to assess differential renal function and to evaluate for the presence of renal obstruction. This requires imaging to be performed in a dynamic fashion over a period of time. This is in contrast with most anatomic imaging techniques in which a static image is commonly acquired at a single time point. Although the details of a given dynamic imaging protocol may vary by clinical indication, the radiotracer administered, or even institutional practices, a number of common principles apply. Using ^{99m}Tc-MAG3 renal scintigraphy as an example, the basics for acquiring and interpreting dynamic imaging data are reviewed.

Patient Preparation

It is important for patients to be well hydrated on the day of the examination. This will ensure the optimal delivery of radiotracer to the kidneys. Before the examination, one should take note of any medications that the patient may be taking that can impact performance and interpretation of the examination. For example, it is important to note if the patient is taking any blood pressure medications such as diuretics. It is also important to note any known or suspected anatomic abnormalities that may impact patient positioning, setup of the gamma camera, or interpretation of the study. For example, it should be noted if the patient has a horseshoe kidney, renal transplant, or duplication of the urinary tract. Finally, it is important to note whether the patient has a history of neurogenic bladder or bladder outlet obstruction, as this may necessitate the placement of a Foley catheter to decrease retrograde pressure to the kidneys. Similarly, for patients with percutaneous nephrostomy tubes, the tubes are often capped so that the patency of the native ureters can be evaluated.

Dosing and Pharmacokinetics

A dose of 2 to 5 mCi (74 to 185 MBq) of ^{99m}Tc-MAG3 is administered by intravenous push (5 to 10 mCi for ^{99m}Tc-DTPA). With an extraction efficiency of nearly 60%, the peak cortical uptake of the ^{99m}Tc-MAG3 radiotracer is typically observed 3 to 5 minutes after intravenous injection (Eshima and Taylor, 1992). Shortly thereafter, the radiotracer is seen within the renal collecting system. By 10 to 15 minutes, the bladder can be visualized as the radiotracer is excreted in the urine. The typical time from the peak activity to half of the radiotracer being cleared from the collecting system (also known as the *half-clearance time*) is 15 to 20 minutes for a nonobstructed renal unit.

Image Acquisition and Interpretation

Dynamic renal imaging is performed in two phases. In the first phase, known as the *perfusion phase*, RPF to each individual renal unit is measured and compared with flow within the aorta. During this phase, images are acquired every 1 to 2 seconds starting immediately after radiotracer administration. Images are generally collected over a 1-minute period. Regions of interest are drawn over the aorta and each renal unit. Additional regions of interest are drawn just outside of each kidney allowing for background subtraction. Data are recorded as the number of total photon counts, also known as activity, per unit time. These data are plotted on a time activity curve (TAC), with time on the *x*-axis and total activity on the *y*-axis. Activity should be detected in the regions of interest overlying the kidneys within several seconds of detection in the aorta. The shape of the curve for each kidney should roughly match that of the aorta (i.e., brisk upstrokes). A curve with a slow rise to peak suggests poor flow to the kidney and likely underlying poor renal function.

The second phase of dynamic renal imaging is known as the functional phase. During this phase, images are acquired at a slower rate, commonly 1 frame per minute. A comparison of the individual renal curves allows for the determination of relative RPF or renal function. The relative function of each kidney is determined by measuring the area under the TACs between 1 and 3 minutes postinjection of the radiotracer. Fig. 5.1 includes the TACs of a patient with normal split renal function. The curves for each kidney are roughly parallel in both shape and magnitude between 1 and 3 minutes postinjection. Typically, a split function difference of up to 10% is considered to be within normal limits.

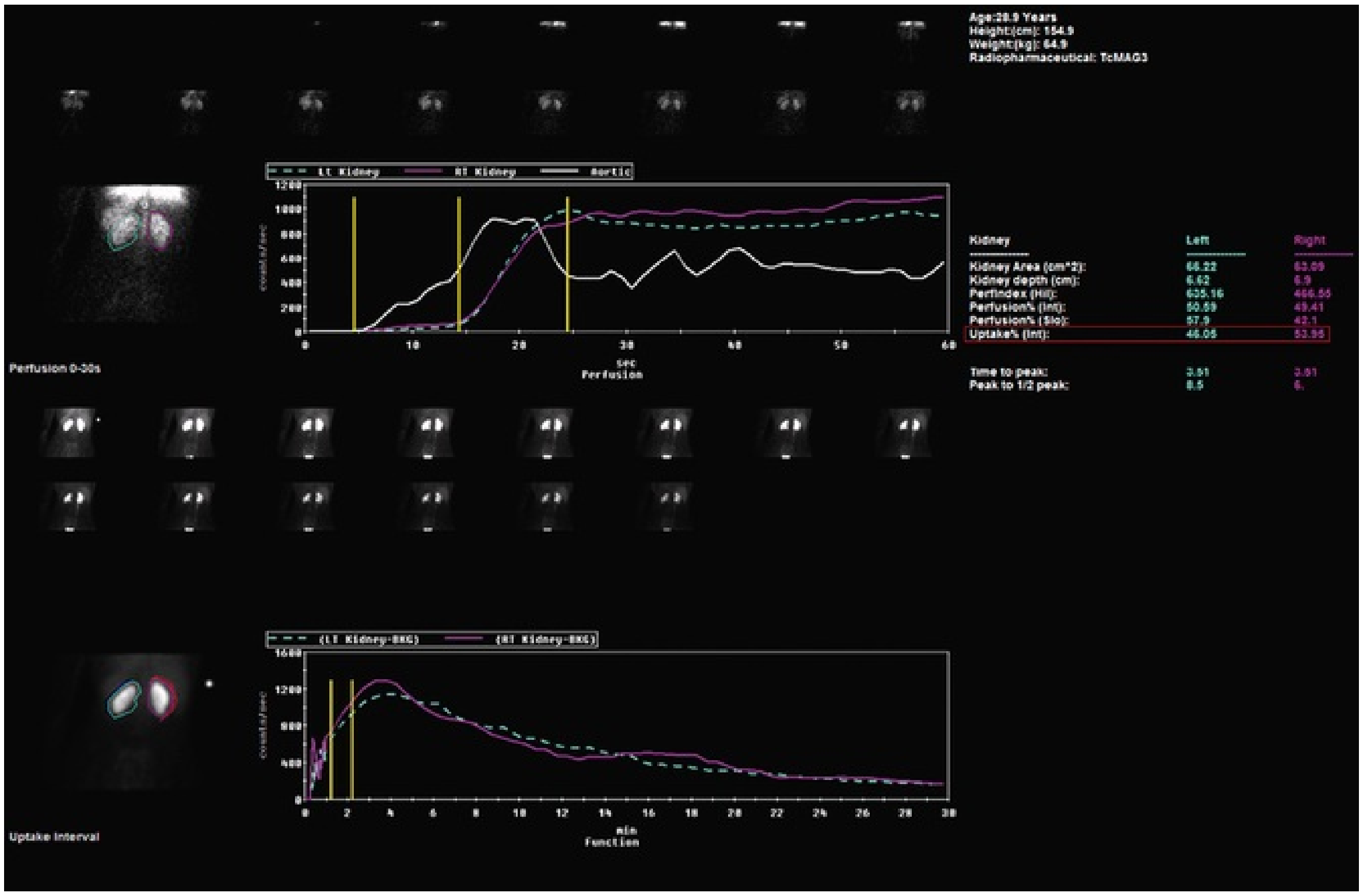
Age:28.9 Years
Height:(cm): 154.9
Weight:(kg): 64.9
Radiopharmaceutical: TcMAG3

Kidney	Left	Right
Kidney Area (cm^2):	66.22	63.09
Kidney depth (cm):	6.62	6.9
Perfindex (Hil):	635.16	466.55
Perfusion% (Int):	50.59	49.41
Perfusion% (Slo):	57.9	42.1
Uptake% (Int):	46.05	53.95
Time to peak:	3.01	3.01
Peak to 1/2 peak:	8.5	6.

FIG. 5.1 Normal ^{99m}Tc-MAG3 renogram of a patient with history of hydronephrosis being evaluated for obstruction. In the upper portion of the figure, a series of 2-second–per–frame flow images demonstrate the movement of radiotracer from the site of injection, to the heart, aorta/renal arteries, and kidneys. A corresponding time-activity curve is shown. The *white curve* reflects activity in the aorta, and the *purple* and *teal curves* reflect radiotracer activity in the kidneys. Note the sharp upstroke of all three lines and that activity in the aorta precedes activity in the kidneys by several seconds. In the lower half of the figure, a series of 2-minute–per–frame images depicts radiotracer activity within the kidneys as it transitions bilaterally into the collecting systems, and then drains down the ureters. In the corresponding time-activity curve, activity within the kidneys peaks at approximately 3 to 4 minutes and then washes out, reaching half-peak approximately 6 to 9 minutes later. The split function of the kidneys is within normal limits, measuring 46% on the left and 54% on the right *(red rectangle).* No evidence of obstruction was present, and no furosemide was administered.

With good function, a healthy kidney will spontaneously clear the radiotracer within 15 minutes of initial injection. In contrast, an obstructed renal unit will show retention of radiotracer in the collecting system. This retention will lead to a gradually upsloping TAC with no peak during the acquisition. It is important to note that some patients may experience delayed clearance of radiotracer from the renal pelvis although they do not have a truly obstructed system. In many of these patients, the collecting system and ureter are patulous as a result of a previously repaired obstructive process such as a ureteropelvic junction obstruction. To differentiate these patients from those with obstruction, the diuretic furosemide can be administered. The recommended dose of intravenous furosemide in adults is 0.5 mg/kg body weight to a maximum of 40 mg, although higher doses can be used in patients with impaired renal function who may not respond to a 40-mg dose. A post-furosemide half-clearance time of less than 10 minutes is consistent with a patulous nonobstructed system, whereas a half-clearance time of more than 20 minutes is generally consistent with obstruction. A half-clearance time between 10 to 20 minutes is considered indeterminate, and further evaluation is warranted. Although these values are fairly well agreed on, currently there is little consensus as to the most appropriate timing of furosemide administration (O'Reilly, 2003; Durand et al., 2008). At our institution, furosemide is given 15 minutes after radiotracer injection. Others, however, administer the diuretic at the start of, or 15 minutes before, image acquisition. It is critical for the urologist to review the report that accompanies any ^{99m}Tc-MAG3 or ^{99m}Tc-DTPA study to understand if and when a diuretic was administered.

Figs. 5.1, 5.2, and 5.3 include example TACs for patients imaged with ^{99m}Tc-MAG3. The legend for each figure includes a detailed interpretation of the test.

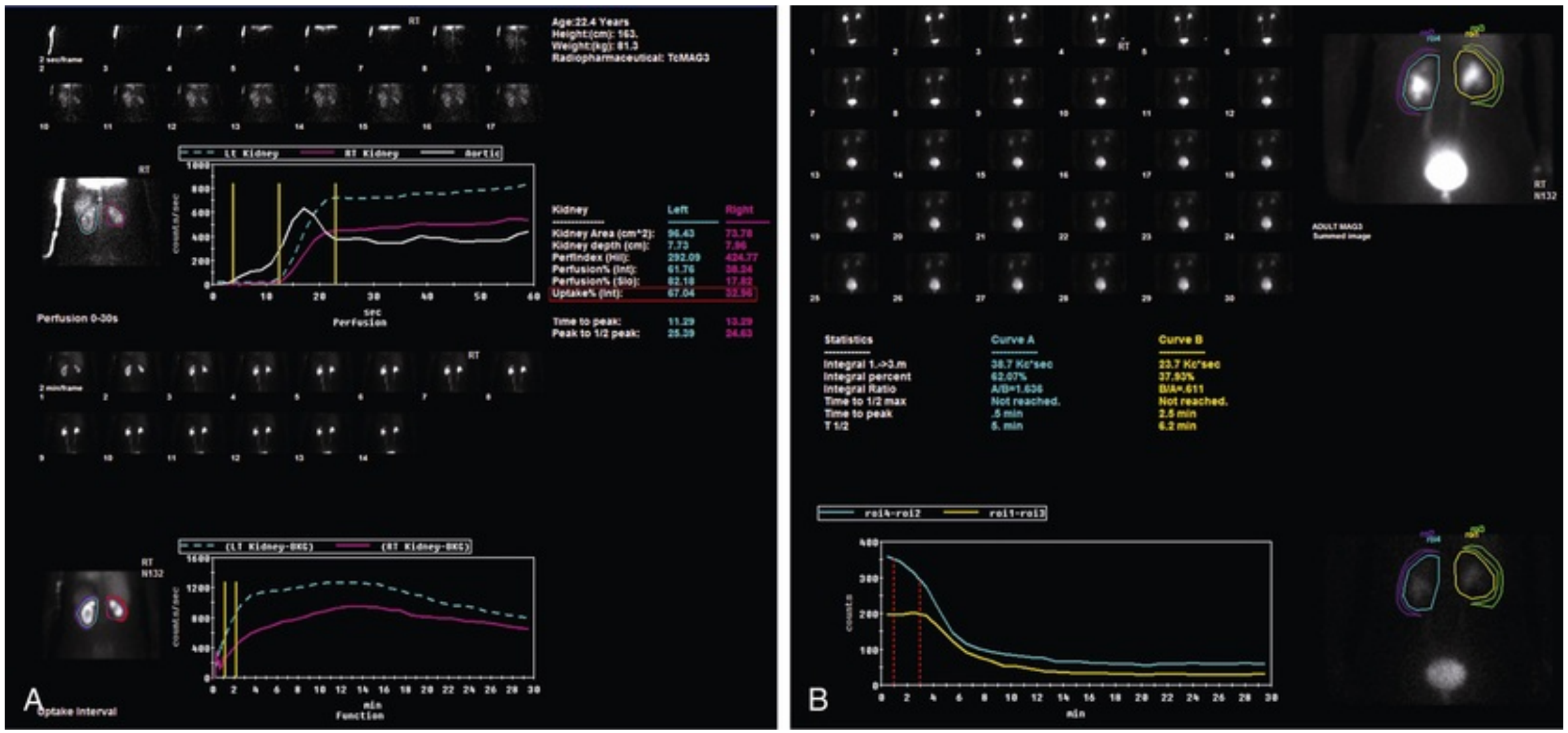

Age:22.4 Years
Height:(cm): 163.
Weight:(kg): 81.3
Radiopharmaceutical: TcMAG3

Kidney	Left	Right
Kidney Area (cm^2):	96.43	73.78
Kidney depth (cm):	7.73	7.96
PerfIndex (Hil):	292.09	424.77
Perfusion% (Int):	61.76	38.24
Perfusion% (Slo):	82.18	17.82
Uptake% (Int):	67.04	32.96
Time to peak:	11.29	13.29
Peak to 1/2 peak:	25.39	24.63

Statistics	Curve A	Curve B
Integral 1.->3.m	38.7 Kc*sec	23.7 Kc*sec
Integral percent	62.07%	37.93%
Integral Ratio	A/B=1.636	B/A=.611
Time to 1/2 max	Not reached.	Not reached.
Time to peak	.5 min	2.5 min
T 1/2	5. min	6.2 min

FIG. 5.2 ^{99m}Tc-MAG3 renogram of a patient with a history of bilaterally repaired ureteroceles and persistent hydronephrosis without functional obstruction. (A) In the upper portion of the panel, a series of 2-second–per–frame flow images demonstrate the movement of radiotracer from the site of injection, to the heart, aorta/renal arteries, and kidneys. A corresponding

time-activity curve is shown. Note that the *purple curve,* representing the right kidney, has less brisk upstroke than the *teal curve* of the left kidney, suggesting decreased function on the right. In the lower half of the figure, a series of 2-minute–per–frame images depicts radiotracer activity within the kidneys as it transitions bilaterally into the collecting systems, and then drains down the ureters. In the corresponding time-activity curve, peak radiotracer uptake in the kidneys is shown to be significantly delayed up to approximately 11 to 14 minutes. Washout is also delayed, with curves for both kidneys slowly decreasing over time. Obstructed systems will often show continued increase in uptake throughout the initial 30 minutes of the examination, so this pattern is perhaps more typical of a patulous but nonobstructed system. The split function of the kidneys is also abnormal, measuring 67% on the left and 33% on the right *(red rectangle)*. (B) Given the delayed washout, 40 mg of intravenous furosemide was administered. In the upper portion of the panel, the 1-minute–per–frame images demonstrate significant washout after administration of furosemide. This is confirmed in the time-activity curve, where both collecting systems drain promptly (half-clearance time of 5 minutes on the left and 6.2 minutes on the right). Less than 10 minutes is diagnostic of a nonobstructed system.

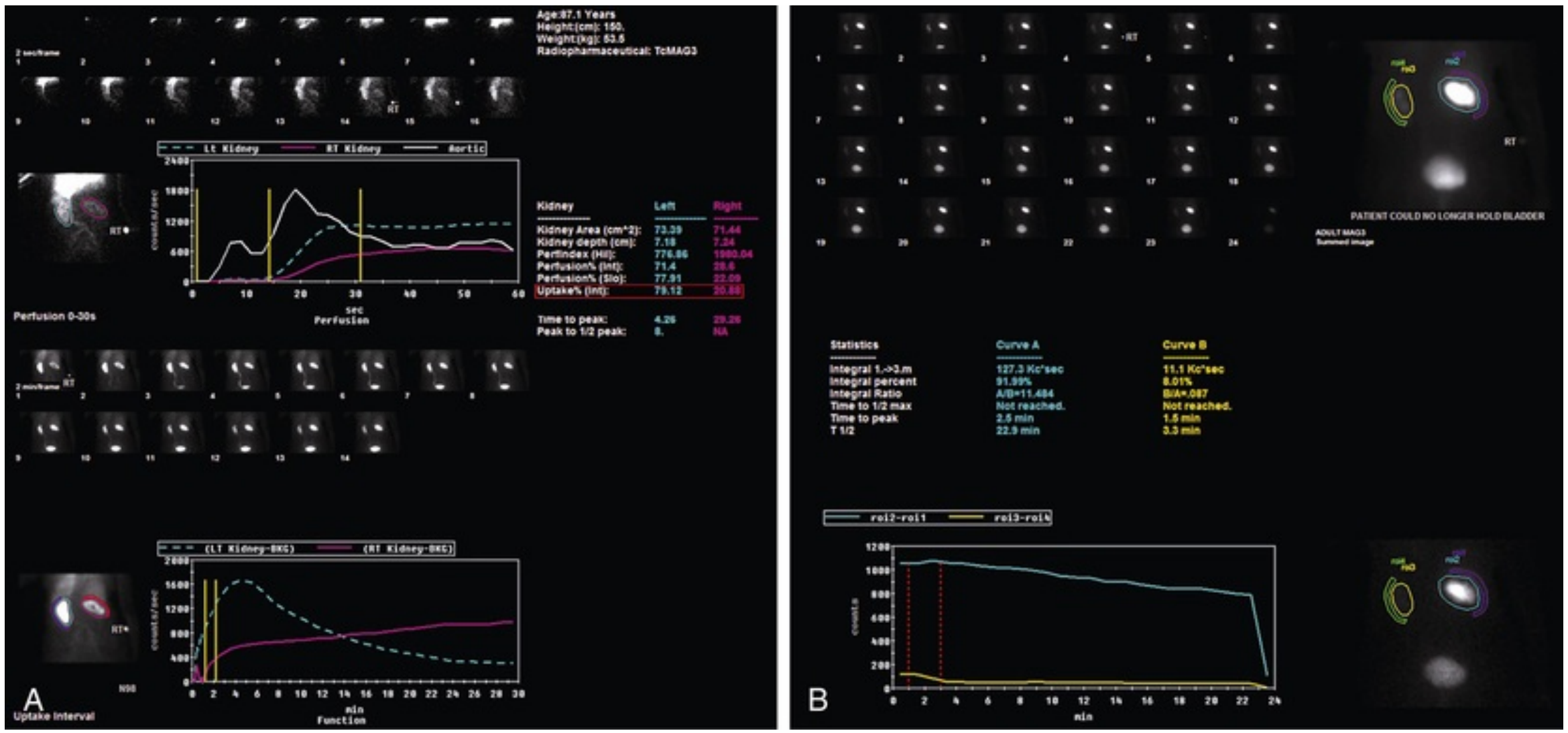
Age:87.1 Years
Height(cm): 150.
Weight(kg): 53.5
Radiopharmaceutical: TcMAG3
2 sec/frame
RT
Lt Kidney
RT Kidney
Aortic
counts/sec
sec
Perfusion
Perfusion 0-30s
Kidney
Left
Right
Kidney Area (cm^2): 73.29 71.44
Kidney depth (cm): 7.18 7.24
PerfIndex (Hil): 776.86 1980.04
Perfusion% (Int): 71.4 28.6
Perfusion% (Slo): 77.91 22.09
Uptake% (Int): 79.12 20.88
Time to peak: 4.26 29.26
Peak to 1/2 peak: 8. NA
2 min/frame
(LT Kidney-BKG)
(RT Kidney-BKG)
min
Function
A
Uptake Interval
RT
PATIENT COULD NO LONGER HOLD BLADDER
ADULT MAG3
Summed image
Statistics
Curve A
Curve B
Integral 1.->3.m 127.3 Kc*sec 11.1 Kc*sec
Integral percent 91.99% 8.01%
Integral Ratio A/B=11.484 B/A=.087
Time to 1/2 max Not reached. Not reached.
Time to peak 2.5 min 1.5 min
T 1/2 22.9 min 3.3 min
roi2-roi1
roi3-roi4
counts
min
B

FIG. 5.3 ^{99m}Tc-MAG3 renogram of a patient with right-sided renal obstruction. (A) In the 2-second–per–frame flow images at the top of the panel, the left kidney appears much better perfused than the right kidney. This is borne out in the time-activity curve in the upper half of the panel in which the *teal curve* representing the left kidney has a significantly sharper upstroke relative to the *purple curve* of the right kidney. The *white curve* of the aorta is irregular and unreliable because of the abnormal course of the aorta caused by the patient's scoliosis. In the bottom half of the panel, the 2-minute–per–frame images demonstrate normal transit of radiotracer through the left kidney parenchyma and into the collecting system, with drainage to the bladder. This is shown by the *teal curve* of the left kidney on the time-activity curve. The right kidney, which appears smaller and has a central photopenic area corresponding to a dilated renal pelvis, demonstrates increasing uptake throughout the study with very slow transit into the collecting system. This is shown by the *purple curve* of the right kidney in the time-activity curve. A markedly abnormal split function is present, measuring 79% on the left and 21% on the right *(red rectangle).* (B) Given the obstructive pattern of the right kidney, 40 mg of intravenous furosemide was administered. The 1-minute–per–frame images in the upper portion of the panel demonstrate no significant clearing of radiotracer from the left renal collecting system after furosemide administration. This is also seen in the time-activity curve, where the *teal curve* representing the left kidney is nearly horizontal. The lack of response to furosemide is diagnostic of an obstructed collecting system.

Additional Applications of ^{99m}Tc-MAG3 and ^{99m}Tc-DTPA Scintigraphy

Evaluation of Renal Vascular Hypertension

To maintain a near-constant rate of glomerular filtration, the kidneys employ a system of vascular autoregulation that is modulated by release of renin from the juxtaglomerular cells of the nephron (Beevers et al., 2001). In cases in which arteriole blood flow is perceived as low, renin acts to convert the protein angiotensinogen to angiotensin I. This peptide hormone is further converted by angiotensin-converting enzyme in the lung to angiotensin II, which stimulates the release of aldosterone from the adrenal glands and acts on the efferent arterioles of the glomerulus to raise filtration pressure. Additionally, angiotensin II causes peripheral vasoconstriction resulting in increased systemic blood pressure. In individuals with renal artery stenosis, the renin-angiotensin-aldosterone system is in a state of constant activation resulting in hypertension and, with time, glomerular sclerosis (Safian and Textor, 2001; Dworkin and Cooper, 2009). Renal scintigraphy can be used to differentiate between renal vascular hypertension and essential hypertension. Clues to the presence of renal vascular hypertension include early age of onset, hypertension that is resistant to multiple medical therapies, and a bruit on physical examination.

When evaluating for renal vascular hypertension, dynamic imaging with either ^{99m}Tc-MAG3 or ^{99m}Tc-DTPA can be performed. ^{99m}Tc-DTPA, however, is typically used for this application, as it is cleared from the blood exclusively by glomerular filtration. During the course of this evaluation, patients are imaged using a 2-day protocol. On the first day of imaging, patients are administered a dose of oral captopril, an angiotensin-converting enzyme inhibitor, and then undergo standard dynamic renal scintigraphy. In cases of renal artery stenosis, one will observe slow uptake and low peak activity after captopril administration. For those with an abnormal curve, a second study is performed 1 to 2 days later, with the patient holding any angiotensin-converting enzyme inhibitors or calcium channel blockers. An improvement in renal function by 10% is associated with a high probability of renal vascular hypertension, and these patients would likely be best served by angioplasty or other surgical intervention (Mann et al., 1991; Bubeck, 1993). With the widespread availability of cross-sectional imaging, including CT angiography, MR angiography, and ultrasonography with Doppler, the use of captopril scintigraphy has decreased over time.

Renal Transplant Evaluation

Dynamic renal scintigraphy with either ^{99m}Tc-MAG3 or ^{99m}Tc-DTPA can also be used to evaluate renal transplant patients for acute rejection or delayed graft function secondary to prolonged ischemia during organ harvesting (Dubovsky et al., 1999). It is critical to differentiate between these two processes, as their management differs considerably. Although renal biopsy is the best differentiator of the two, dynamic renal imaging can be used to gain clues as to the underlying pathology. More specifically, acute rejection is characterized by decreased renal perfusion, and for delayed graft function normal perfusion is maintained. Additionally, on serial imaging, acute rejection will worsen with time, whereas in delayed graft function longitudinal improvement is typically observed. A challenge of using dynamic renal imaging in this context is the fact that transplant patients often have overlapping causes of renal failure. Furthermore, some patients with renal ischemia will progress to chronic impairment of the kidney, in which case serial imaging can be misleading. Thus, it is important to understand the full clinical context of a patient being imaged for this indication. One additional use of dynamic renal imaging in transplant patients is to evaluate for an anastomotic leak, which on delayed imaging can be seen as a collection of radioactivity outside of the kidney. This is particularly helpful in this patient population who are often unable to receive iodinated contrast.

Assessment of Vesicoureteral Reflux

Vesicoureteral reflux (VUR) is a condition in which urine flows in a retrograde fashion from the bladder to the upper urinary tracts (Peters et al., 2010; Tekgul et al., 2012). This occurs commonly in children and can result in ascending infections of the kidneys and eventual loss of renal function. The presence and degree of reflux can be monitored with renal scintigraphy (Piepsz, 2002). This can be performed by administering ^{99m}Tc-MAG3 or ^{99m}Tc-DTPA and then asking the patient to void once the radiotracer has accumulated in the bladder. Alternatively, and more commonly, a solution of ^{99m}Tc-sulfur colloid can be instilled directly into the bladder. It is important to note that fluoroscopic voiding cystourethrography, and not nuclear scintigraphy, should be used in the initial screening for VUR (Tekgul et al., 2012). The reason for this is that scintigraphy provides little anatomic information, and children with a history of urinary tract infections should also be evaluated for posterior urethral valves (in males) and bladder diverticula, conditions that can only be detected with the combined anatomic and functional information from a fluoroscopic voiding cystourethrogram. Nuclear voiding cystography should be used instead to follow patients with reflux. Indeed, this imaging test is often preferred over contrast cystography because of its higher sensitivity for detecting subtle VUR and its lower associated radiation doses (Lebowitz, 1992).

Renal Cortical Imaging With ^{99m}Tc-DMSA

As noted earlier, ^{99m}Tc-DMSA is retained by proximal tubular cells of the kidney allowing for visualization of the renal cortex. Patients undergoing this examination should be prepared in a manner similar to the earlier description for dynamic renal imaging. A dose of the radiotracer in the amount of 50 μCi/kg for children or 5 mCi for adults is then administered intravenously, and images are acquired 2 hours later with either a pinhole collimator or gamma camera operating in SPECT mode. Because ^{99m}Tc-DMSA clearance is dependent on glomerular filtration, the imaging time may need to be modified in patients with renal failure.

Renal cortical imaging is mainly used to evaluate for suspected pyelonephritis and to detect renal scarring. In a normal ^{99m}Tc-DMSA study, the renal parenchyma should appear homogeneous and smooth. Areas with acute inflammation or infection will appear as defects with low levels of radiotracer uptake. Similarly, renal scarring will also appear as areas without radiotracer uptake. However, areas of scarring will typically have sharper borders and are commonly seen in small atrophic kidneys. Although clinical context is the best way to differentiate between acute inflammation and scarring, serial imaging can be helpful in discerning between these two processes. In cases of pyelonephritis, one can often see resolution of the photopenic area, whereas with scar the area devoid of radiotracer uptake will persist. A period of typically 6 months is recommended between scans.

Key Points

- The most commonly used radiopharmaceutical agents for nuclear imaging of the kidneys are technetium-99m diethylenetriaminepentaacetic acid (^{99m}Tc-DTPA), technetium-99m mercaptoacetyltriglycine (^{99m}Tc-MAG3), and technetium-99m dimercaptosuccinic acid (^{99m}Tc-DMSA).
- ^{99m}Tc-DTPA and ^{99m}Tc-MAG3 are used to measure renal blood flow, determine differential renal function, and evaluate for the presence and degree of renal obstruction.
- ^{99m}Tc-DTPA is cleared by glomerular filtration, whereas ^{99m}Tc-MAG3 is cleared by tubular secretion.
- ^{99m}Tc-MAG3 is preferred at most centers over ^{99m}Tc-DTPA because it has a higher extraction efficiency and is less affected by changes in renal function.
- ^{99m}Tc-DMSA is retained by cells of the proximal renal tubules and is used to evaluate for infection and the presence renal scarring.
- ^{99m}Tc-DTPA and ^{99m}Tc-MAG3 can also be used to evaluate renovascular hypertension, transplant graft function, and vesicoureteral reflux.

Infection Imaging

Although infections of the genitourinary tract can often be readily identified on the basis of clinical signs, symptoms, and localizing culture data, this is not always the case. Pediatric patients and individuals with neurologic disorders or compromised immunity potentially pose a challenge in this regard. Within the field of nuclear medicine, a host of radiopharmaceuticals have been developed to aid with the identification and localization of infectious and inflammatory processes.

^{99m}Tc-DMSA is the most widely used radiopharmaceutical agent for imaging infections of the kidney, although its role has decreased with the widespread availability of CT. As previously noted, this radiotracer will show decreased uptake in areas of active pyelonephritis. On follow-up imaging, these areas will show resolution with homogeneous uptake. In contrast, areas of renal scarring will have continued photopenia that corresponds to alterations in the renal contour compatible with thinned cortex. These foci can also be found in patients with a history of VUR who may have never had a documented bout of pyelonephritis. Identification of cortical scarring is important as it predisposes patients to the development of hypertension and chronic kidney disease (Fillion et al., 2014).

Leukocytes labeled with ^{111}In-oxine can also be used for imaging infections of the kidney. Oxine is a lipid-soluble complex that chelates ^{111}In and passively diffuses into leukocytes. For this test, white blood cells are first collected from the patient by drawing approximately 50 mL of venous whole blood. Erythrocytes are then removed from the collected blood sample, and the remaining white blood cells are labeled with ^{111}In-oxine under a laminar flow hood. After labeling, the cells are injected back into the patient. The labeled white blood cells will normally accumulate in the liver, spleen, and bone marrow, with other sites of uptake generally indicating the presence of active infection. Blood pool activity clears with a half-life of ~7.5 hours, and so it is recommended that whole-body scintigraphy be performed approximately 24 hours after ^{111}In-oxine-tagged white blood cell injection. Given the long decay half-life of ^{111}In (67.3 hours), imaging at 24 hours is very feasible.

Alternatively, leukocytes can be labeled with ^{99m}Tc-hexamethyl-propyleneamine oxime (^{99m}Tc-HMPAO), a lipid-soluble neutral complex that rapidly diffuses into cells. The use of ^{99m}Tc as the radionuclide results in improved image quality over ^{111}In. ^{99m}Tc-HMPAO can be seen, however, being cleared in urine and the hepatobiliary system, and this property makes use of this imaging agent challenging when evaluating for sites of infection in close proximity to the genitourinary tract (versus ^{111}In-oxine-labeled white blood cells, which have no normal uptake anywhere in the lower abdomen) (Brown et al., 1994; Forstrom et al., 1995). Imaging with ^{99m}Tc-HMPAO–tagged white blood cells is typically undertaken at 1 to 2 hours postreinfusion to minimize the amount of interfering radioactivity in the bowel, renal collecting system, ureters, and bladder. Despite the potential disadvantages, ^{99m}Tc-HMPAO–tagged white blood cells are preferred for pediatric patients because of more favorable dosimetry (Brown et al., 1994). It is worth noting that regardless of the radiolabeling method, tagged leukocyte imaging cannot be used when assessing a transplant kidney because a large fraction of the white blood cells will accumulate in the renal graft, which is seen as non-self by the white blood cells.

Another application of infection imaging in the urologic patient is the evaluation of intra-abdominal infections. This is particularly helpful for patients without localizing symptoms or convincing findings of a collection on conventional imaging. In this situation, radiolabeled white blood cells labeled with ^{111}In-oxine are particularly helpful. Intra-abdominal signal with this test has a high specificity for a true infection (Mountford et al., 1990).

One last radiopharmaceutical agent worthy of mention that can be used for the applications mentioned earlier is ^{67}Ga-citrate. This radiotracer binds to transferrin and is transported to areas of inflammation in the body (Ohkubo et al., 1989). Sites of inflammation can then be identified with single-photon imaging. Shortcomings of this radiotracer are its high level of nonspecific accumulation in soft tissues, need for delayed imaging up to 48 to 72 hours, and high cost. Like many radiotracers based on a metabolic process in the body, ^{67}Ga-citrate lacks specificity, and uptake can be seen in many neoplastic processes in addition to infection.

Molecular Imaging of Genitourinary Malignancies

Within the field of oncology, molecular imaging is most commonly performed using the PET radiotracer 2-deoxy-2-[^{18}F]fluoro-D-glucose (^{18}F-FDG) (Farwell et al., 2014). ^{18}F-FDG is a glucose analogue that is taken up by metabolically active cells via GLUT transporters (Brown et al., 1996). Once within the cell, ^{18}F-FDG is phosphorylated by the glycolytic enzyme hexokinase, preventing diffusion back across the cell membrane. The trapped ^{18}F-FDG molecules, which are missing a 2-hydroxyl group, cannot undergo further metabolism and remain intact allowing for their detection with PET imaging.

^{18}F-FDG accumulates in cells of metabolically active organs including the brain and kidneys. Additionally, ^{18}F-FDG is taken up by malignant cells, which commonly shunt energy production from oxidative phosphorylation to lactic acid fermentation, a phenomenon referred to as the *Warburg effect* or *aerobic glycolysis* (Bensinger and Christofk, 2012). A number of genitourinary malignancies can be successfully imaged with ^{18}F-FDG PET including urothelial carcinoma, renal cell carcinoma (RCC), squamous cell carcinoma of the penis, and testicular germ cell tumors. Because the genitourinary tract is partially obscured by urinary excretion of ^{18}F-FDG, imaging with this radiotracer is typically reserved for the detection of distant sites of disease. Of note, prostate cancer, the most common genitourinary malignancy, is unique in that it uncommonly shunts energy production toward aerobic glycolysis and therefore is poorly visualized with ^{18}F-FDG PET (Zadra et al., 2013; Jadvar, 2013).

A multitude of other PET radiotracers have been developed for cancer imaging, including additional agents that accumulate on the basis of increased cellular metabolism and compounds that target specific cancer-associated proteins. The use of ^{18}F-FDG and other PET radiotracers for imaging genitourinary malignancies is reviewed.

Bladder Cancer

^{18}F-FDG is the most widely studied PET radiotracer for imaging urothelial carcinoma of the bladder (Fig. 5.4). In a meta-analysis that included data from

14 studies, the pooled sensitivity of ^{18}F-FDG PET for preoperative lymph node staging was 57% (95% CI, 49% to 64%), with a pooled specificity of 92% (95% CI, 87% to 95%) (Ha et al., 2018). Current guidelines, however, do not support the routine use of ^{18}F-FDG PET in patients with otherwise clinically localized bladder cancer, as it remains unclear if the detection of extravesical disease on molecular imaging alone changes outcomes in these patients (Chang et al., 2017; Alfred Witjes et al., 2017). According to guidelines from the American Urological Association, PET imaging of bladder cancer is only indicated in cases of equivocal conventional imaging or as a confirmatory test when biopsy of a conventional imaging finding is not possible (Chang et al., 2017). Additionally, available data suggest that MRI may provide a higher level of sensitivity for detecting lymph node metastases, while also maintaining the ability to accurately visualize localized disease within the bladder (Crozier et al., 2018). Indeed, multiparametric MRI is increasingly being used to image bladder cancer (Woo et al., 2017; van der Pol et al., 2018; Panebianco et al., 2018).

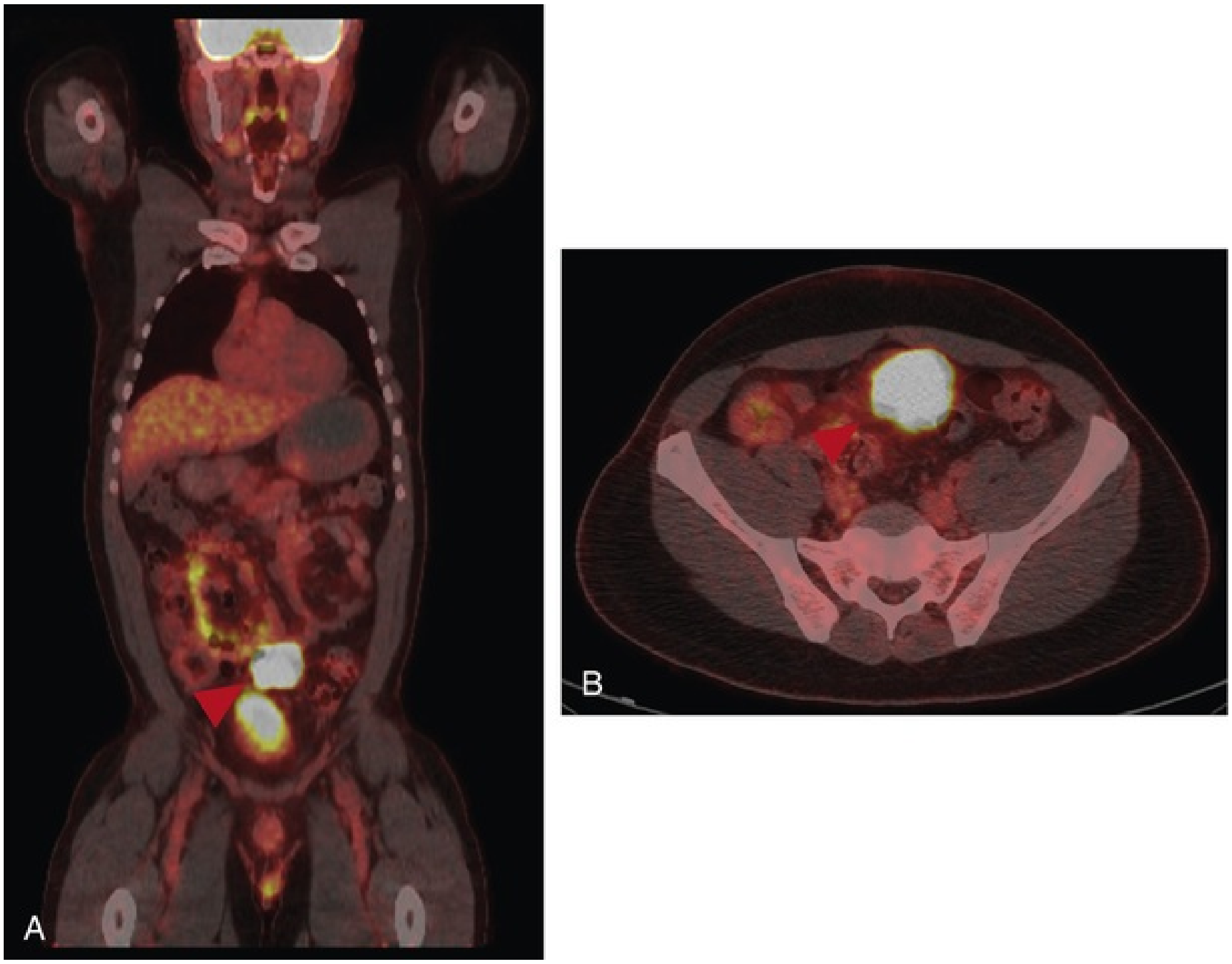

FIG. 5.4 ^{18}F-FDG PET/CT of a patient with metastatic urothelial carcinoma of the bladder. Coronal (A) and axial (B) fused PET/CT images. The *red arrowheads* point to a large FDG-avid soft tissue mass within the anterior pelvis.

^{18}F-FDG PET can also be used to image urothelial carcinoma of the upper urinary tract (Asai et al., 2015; Tanaka et al., 2016). As with bladder cancer, this imaging modality appears to be most useful for detecting distant sites of disease. Current guidelines state that the mainstay of imaging localized upper tract urothelial carcinoma is CT urography; however, little guidance is provided on imaging distant sites of disease (Roupret et al., 2018). Because of the rare nature of upper tract urothelial carcinoma, large studies evaluating the clinical utility of ^{18}F-FDG PET imaging of this malignancy are limited. Thus, ^{18}F-FDG PET should be used sparingly in cases of upper tract urothelial carcinoma, and guidelines for imaging bladder cancer should likely be applied (Chang et al., 2017).

Although the use of ^{18}F-FDG PET for imaging of urothelial carcinoma is limited at the current time, emerging data suggest a potential role for this imaging modality to aid in disease prognostication. For example, Vind-Kezunovic et al. found that SUV_{max} on preoperative ^{18}F-FDG PET/CT was independently associated with the risk for bladder cancer recurrence after radical cystectomy with extended lymph node dissection (Vind-Kezunovic et al., 2017). Additionally, several studies have shown the potential for ^{18}F-FDG PET to predict histologic response to induction or neoadjuvant chemotherapy (Kollberg et al., 2017; Soubra et al., 2018). Additional work, however, is required to more fully understand the clinical benefits of ^{18}F-FDG imaging as a tool for disease prognostication.

Other PET radiotracers have been studied for imaging urothelial carcinoma. Two particularly promising agents are ^{11}C-chole and ^{11}C-acetate, which are positron-emitting radiolabeled cell membrane building blocks that localize to rapidly dividing cells (Kim et al. 2018). Both of these radiotracers have shown potentially higher levels of sensitivity than ^{18}F-FDG; however, neither is currently approved for imaging urothelial carcinoma, and their adoption has been hampered by the short 20.9-minute half-life of ^{11}C.

Kidney Cancer

Like urothelial carcinoma, metastatic RCC can be successfully imaged with ^{18}F-FDG PET, albeit with limited gains beyond anatomic imaging techniques. A meta-analysis of 14 studies reported an overall sensitivity of 86% (95% CI, 88% to 93%) and a specificity of 88% (95% CI, 84% to 91%) for ^{18}F-FDG PET to detect sites of recurrent or metastatic RCC (Ma et al., 2017). This imaging test appears to have the highest level of sensitivity for detecting sites of extrarenal disease in cases of type II papillary RCC (Nakatani et al., 2011; Shuch et al., 2014). Current guidelines, however, recommend against the routine use of ^{18}F-FDG PET for staging or follow-up of RCC, as the clinical benefits remain unclear, and most cases of RCC are the clear cell subtype which shows lower levels of ^{18}F-FDG uptake (Donat et al., 2013; Ljungberg et al., 2015).

Novel radiotracers targeting the cell surface protein carbonic anhydrase IX (CAIX)—a molecule that is near universally expressed by clear cell RCC but not by other renal tumor histologies—are likely in the future to play a large role in molecular imaging of RCC. To date, the most promising agent targeting CAIX is the monoclonal antibody girentuximab, also known as G250. The application of CAIX-based PET imaging that has been most actively pursued is the differentiation of localized clear cell RCC apart from other renal tumor histologies (Divgi et al., 2007, 2013). In a large phase III trial, PET imaging with ^{124}I-girentuximab PET/CT had a sensitivity of 86.2% (95% CI, 75.3% to 97.1%) and a specificity of 85.9% (95% CI, 69.4% to 99.9%) for differentiating localized clear cell RCC from other renal tumor histologies (Divgi et al., 2013). This outperformed contrast-enhanced CT, which had a sensitivity of 75.5% (95% CI, 62.6% to 88.4%) and a specificity of 46.8% (95% CI, 18.8% to 74.7%). Despite these promising results, girentuximab is not yet approved for routine human use, as the results of a confirmatory phase III trial are pending.

While the urologic community awaits the approval of a PET radiotracer to aid in the histologic characterization of localized renal tumors, the SPECT imaging agent ^{99m}Tc-sestamibi is already available off-label for this application. This radiotracer, which is a lipophilic cation that binds to cells with high mitochondrial content, is approved by the United States Food and Drug Administration (FDA) for breast and myocardial imaging (Travin and Bergmann, 2005; Schillaci et al., 2013). Additionally, ^{99m}Tc-sestamibi is widely used for imaging parathyroid adenomas (Judson and Shaha, 2008) and has recently been shown to accumulate in oncocytic renal tumors with high levels of mitochondrial content such as benign oncocytomas (Fig. 5.5) (Gormley et al., 1996; Rowe et al., 2015; Gorin et al., 2016b; Tzortzakakis et al., 2017). In the largest study to date evaluating this imaging modality, Gorin et al. found a sensitivity of 87.5% (95% CI, 47.4% to 99.7%) and a specificity of 95.2% (95% CI, 83.8 to 99.4%) for differentiating benign renal oncocytomas and hybrid oncocytic/chromophobe tumors from other renal tumor histologies (Gorin et al., 2016b). Although these results are promising, the worldwide literature on ^{99m}T-sestamibi SPECT/CT imaging of renal tumors remains small, and the clinical adoption of this test has been rather limited to date.

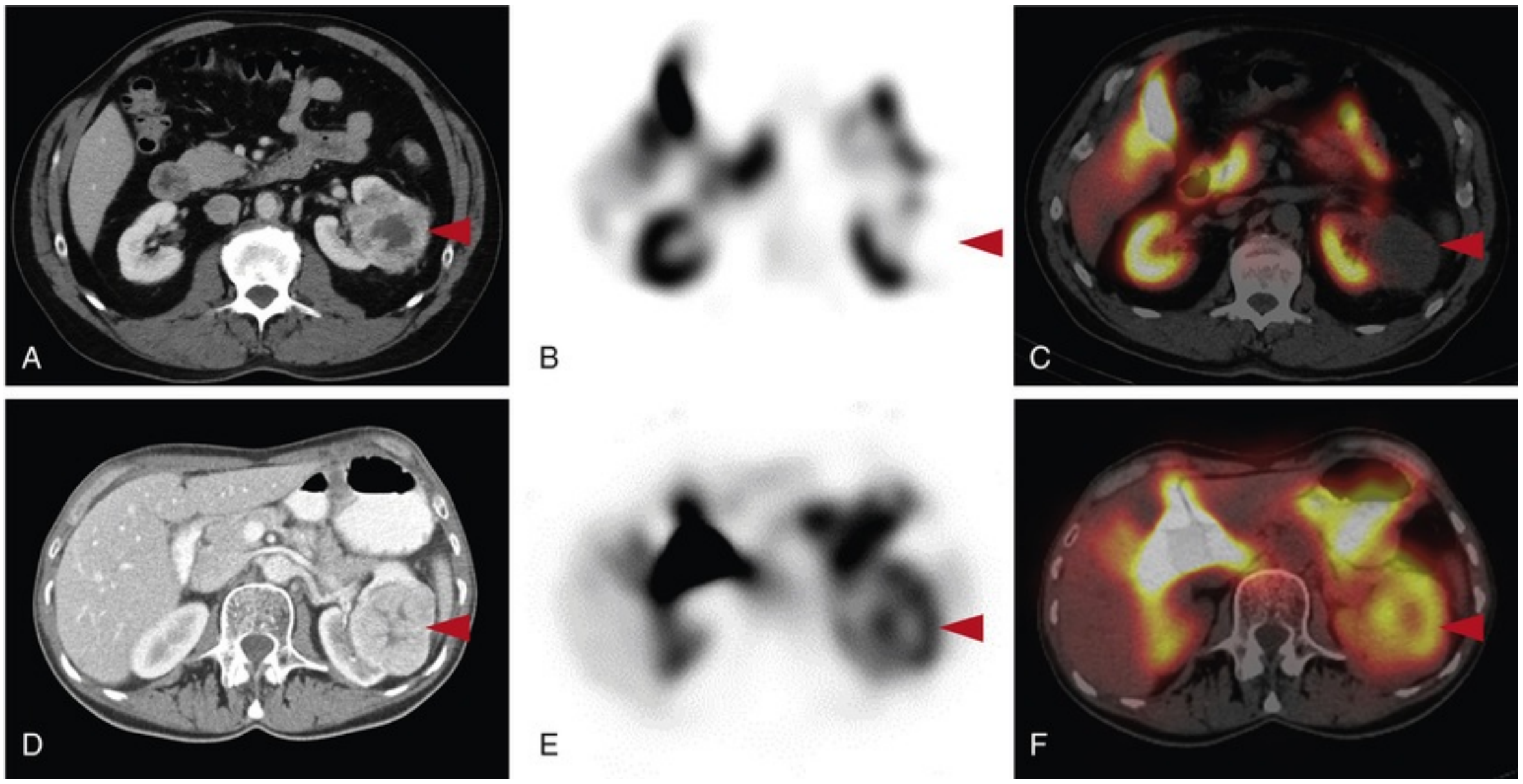

FIG. 5.5 Differentiation of a localized clear cell RCC (A to C) from a benign renal oncocytoma (D to F) using ^{99m}Tc-sestamibi SPECT/CT. (A) Axial, contrast-enhanced CT image demonstrates a heterogeneous mass in the left kidney *(red arrowhead).* Axial ^{99m}Tc-sestamibi SPECT (B) and axial ^{99m}Tc-sestamibi SPECT/CT (C) images show no evidence of radiotracer uptake in the tumor *(red arrowheads).* The mass was resected and was found to be a clear cell RCC. (D) Axial, contrast-enhanced CT image showing another left-sided heterogeneous renal mass *(red arrowhead).* Axial ^{99m}Tc-sestamibi SPECT (E) and axial ^{99m}Tc-sestamibi SPECT/CT (F) images show that the mass has intrinsic radiotracer uptake, with the highest uptake in those parts of the mass with the most avid enhancement *(red arrowheads).* A subsequent renal mass biopsy confirmed the mass to be most consistent with a renal oncocytoma.

Prostate Cancer

As noted earlier, ^{18}F-FDG has little role in imaging prostate cancer. Instead imaging is most commonly performed with a combination of contrast-enhanced CT, MRI, and bone scintigraphy with ^{99m}Tc-methylene diphosphonate, a compound that has affinity for hydroxyapatite crystals in areas of increased osteoid formation. PET imaging with Na^{18}F does offer a more sensitive alternative to bone scan; however, this radiotracer suffers in terms of specificity because of its similar mechanism of uptake to ^{99m}Tc-methylene diphosphonate (Langsteger et al., 2016). Overall, the available combination of traditional modalities for prostate cancer imaging lacks the required sensitivity and specificity for detecting small volume sites of disease. As a result, a number of targeted radiotracers have been developed for PET imaging of prostate cancer (Table 5.3).

TABLE 5.3

PET Radiotracers Used for Prostate Cancer Imaging

NAME OF AGENT	MECHANISM OF UPTAKE	FDA APPROVED?	APPROVED INDICATION
Na^{18}F	Exchanges with hydroxyl groups on hydroxyapatite at areas of bone turnover	Yes	Imaging of bone to define areas of altered osteogenic activity
^{18}F-FDG	Glucose analogue that is taken up by glycolytically active cells	Yes	Assessment of abnormal glucose metabolism to assist in the evaluation of malignancy in patients with known or suspected abnormalities found by other testing modalities, or in patients with an existing diagnosis of cancer
^{11}C-choline	Choline analogue that is taken up by metabolically active cells undergoing phospholipid synthesis	Yes	Imaging of men with suspected prostate cancer recurrence and noninformative bone scintigraphy, CT, or MRI
^{18}F-FACBC	Amino acid analogue that is taken up by metabolically active	Yes	Imaging of men with suspected prostate cancer recurrence based on an elevated PSA level after prior

	cells undergoing protein synthesis		treatment
^{68}Ga-PSMA-11	Small molecule inhibitor of PSMA	No	N/A
^{18}F-DCFPyL	Small molecule inhibitor of PSMA	No	N/A
^{68}Ga-RM2	Synthetic gastrin-releasing peptide receptor antagonist	No	N/A

Data from Joice GA, Rowe SP, Pienta KJ, Gorin MA. Oligometastatic prostate cancer: shaping the definition with molecular imaging and an improved understanding of tumor biology. *Curr Opin Urol* 2017;27(6):533–541.

The first radiotracer to be approved by the FDA specifically for prostate cancer imaging was ^{11}C-choline. This agent has been shown to provide added value over conventional imaging in the detection of otherwise-occult pelvic lymph nodes in patients undergoing radical prostatectomy (Mapelli and Picchio, 2015; Castellucci et al., 2017). One study reported a sensitivity of 70% and specificity of 90% when a maximum SUV cutoff of 2.5 was used to identify disease-involved lymph nodes (Vag et al., 2014). In the context of biochemical recurrence, ^{11}C-choline allows for the reliable detection of sites of disease, with increasing sensitivity at higher prostate-specific antigen (PSA) levels (Krause et al., 2008). In one meta-analysis, the pooled detection rate of ^{11}C-choline PET across 16 studies of men with biochemically recurrent prostate cancer was 62.2% (95% CI, 48.9% to 74.4%) (Sathianathen et al., 2018). There are a number of mechanistically similar radiotracers to ^{11}C-choline that have been studied for prostate cancer imaging, including ^{18}F-fluorocholine, ^{18}F-fluoromethylcholine, and ^{11}C-acetate (Brogsitter et al., 2013). None of these agents, however, have gained FDA approval. Of note, ^{11}C-choline and its related radiotracers do not appear to have a role in characterizing primary prostate cancer, as uptake can be seen in areas of inflammation within the prostate, thereby providing false-positive results (Farsad et al., 2005).

The next radiotracer to be granted FDA approval for prostate cancer imaging was the synthetic amino acid ^{18}F-FACBC (also known as ^{18}F-fluciclovine). ^{18}F-FACBC functions as a substrate for the amino acid transporters LAT1 and ASCT2, which are overexpressed by multiple malignancies including prostate cancer (Oka et al., 2012). The longer half-life of ^{18}F (109.7 minutes) in comparison to ^{11}C (20.3 minutes) has allowed ^{18}F-FACBC to be made widely available to most centers in the United States. As a metabolism-based radiotracer, the diagnostic performance of ^{18}F-FACBC somewhat parallels that of ^{11}C-choline. For instance, ^{18}F-FACBC also has limited diagnostic use in primary prostate cancer, as uptake in sites of cancer is quite similar to benign prostatic hyperplasia (Turkbey et al., 2014). Additionally, in the context of preoperative staging, ^{18}F-FACBC performs similar to ^{11}C-choline; however, no direct comparison between the two radiotracers has been performed in this setting (Zarzour et al., 2017). In terms of imaging biochemical recurrence, comparative studies suggest that ^{18}F-FACBC offers slightly improved sensitivity and specificity over ^{11}C-choline across a wide range of serum PSA values (Nanni et al. 2014, 2015, 2016).

An additional class of radiotracers for prostate imaging are the prostate-specific membrane antigen (PSMA)-targeted agents. PSMA is a type II transmembrane glycoprotein that is highly expressed by prostate cancer epithelial cells (Wright et al., 1995; Sweat et al., 1998). Compounds targeting PSMA are increasingly being used throughout the world and appear poised to become the dominant means by which prostate cancer is imaged. As of yet, these agents are not FDA approved, but are nonetheless considered by many practitioners outside of the United States as a new standard of care. The majority of small-molecule PET radiotracers targeting PSMA are negatively charged urea-based small molecules that have a very high affinity for the PSMA active site (Rowe et al., 2016). Much of the early clinical work with PSMA-targeted radiotracers was carried out with ^{68}Ga-labeled agents (e.g., ^{68}Ga-PSMA-11 and ^{68}Ga-PSMA-I&T), although there is a trend toward adoption of ^{18}F-labeled compounds (e.g., ^{18}F-DCFPyL and ^{18}F-PSMA-1007) that take advantage of this radionuclide's longer half-life and superior imaging characteristics (Fig. 5.6) (Sanchez-Crespo, 2013; Gorin et al., 2016a).

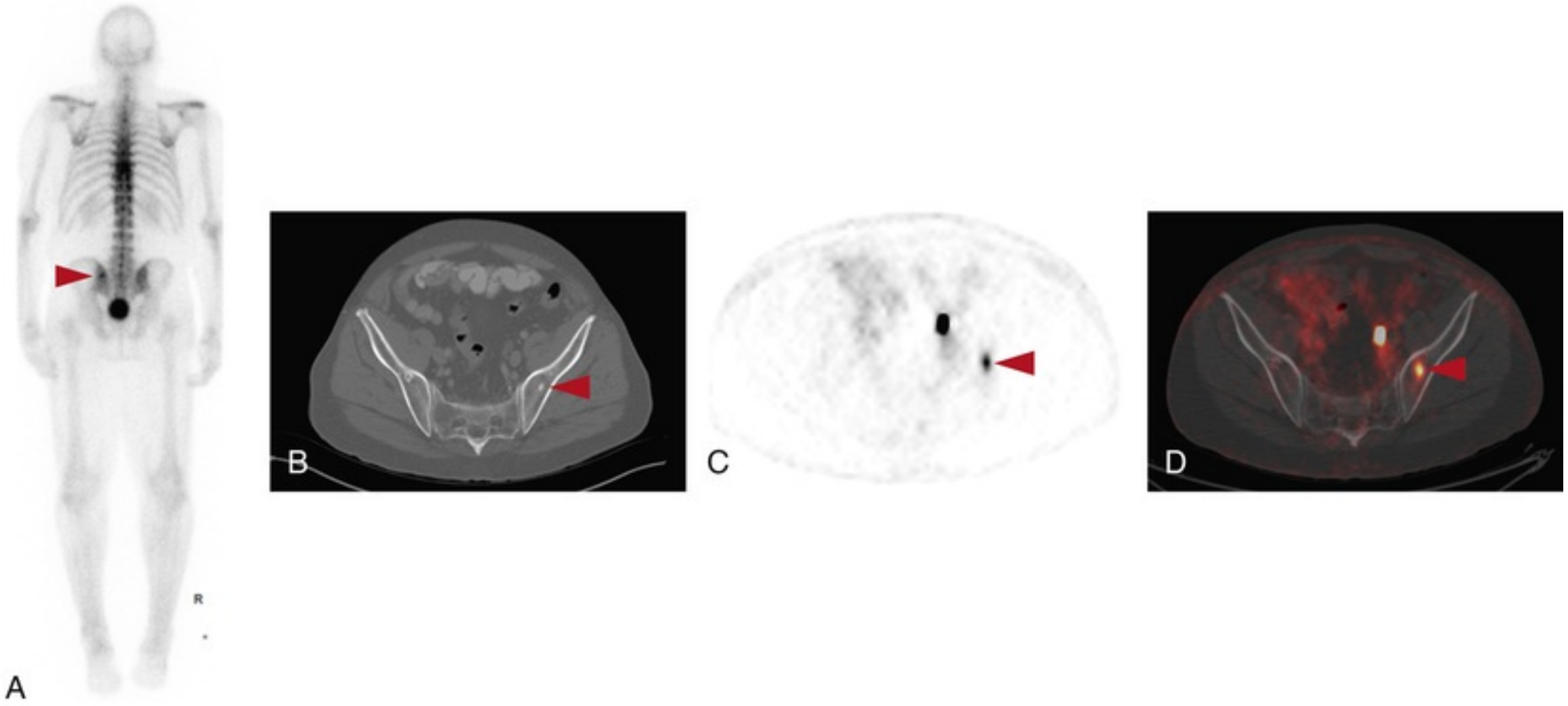

FIG. 5.6 Imaging studies of a patient with metastatic prostate cancer. (A) Posterior projection of a whole-body ^{99m}Tc-MDP planar bone scan demonstrates intense radiotracer uptake at a focus near the left sacroiliac joint *(red arrowhead).* (B) Axial, contrast-enhanced CT image through the pelvis in the same patient shows a sclerotic lesion in the left iliac that corresponds to the site of uptake on the bone scan *(red arrowhead).* (C) Axial ^{18}F-DCFPyL PSMA-targeted PET and (D) ^{18}F-DCFPyL PET/CT fusion images demonstrate intense radiotracer uptake at the same location *(red arrowheads),* corroborating the findings on bone scan and CT.

For preoperative staging, PSMA-targeted agents have the moderate-to-high sensitivity of ^{11}C-choline and ^{18}F-FACBC, but offer higher specificity (overall sensitivity 60% to 70% and specificity >90%) (Gorin et al., 2018). The detection of lesions in patients with biochemical recurrence has been the most commonly studied indication for PSMA-targeted PET radiotracers (Perera et al. 2016; von Eyben et al., 2018). In terms of patient-level detection, PSMA-targeted radiotracers have consistently been found to have higher sensitivity than choline-based radiotracers and ^{18}F-FACBC, an observation that is accentuated at lower PSA values (Afshar-Oromieh et al., 2014; Morigi et al., 2015; Schwenck et al., 2017; Alonso et al., 2018; Calais et al., 2018). As of this writing, the roles of PSMA-targeted agents in guiding metastasis-directed therapy in patients with oligometastatic prostate cancer and imaging response to therapy remain controversial (Murphy et al., 2017; Zukotynski et al., 2018). A final note regarding PSMA-targeted diagnostic radiotracers is that patients with high-volume disease and high uptake may be eligible for PSMA-targeted endoradiotherapies with β- or α-emitting agents that deliver lethal doses of radioactivity to sites of prostate cancer (Kulkarni et al., 2018).

One final class of prostate cancer–targeted radiotracers deserving of mention are those targeting the gastrin-releasing peptide receptor (GRPR), which is overexpressed in many human malignancies including prostate cancer (Ananias et al., 2009). Both agonist and antagonist peptide derivatives of bombesin bind to GRPR with high affinity, and a number of different radionuclides have been used to label bombesin derivatives, including ^{18}F, ^{68}Ga, and ^{64}Cu (Mansi et al., 2016). The GRPR antagonist ^{68}Ga-RM2 appears to have similar sensitivity for detection of sites of putative disease in biochemical recurrence as a ^{68}Ga-labeled PSMA-targeted agent (Minamimoto et al., 2016).

The increasing number of prostate cancer PET agents has the potential to cause confusion in the field, and it remains necessary to standardize the manner in which these agents are used to best take advantage of the relative merits of the various imaging agents. This level of guidance is currently absent from prostate cancer guidelines, as is how molecular imaging should be used in concert with traditional imaging techniques (Mottet et al., 2017; Cornford et al., 2017; Sanda et al., 2018a, 2018b). Further data—particularly those collected in clinical trials and well-designed prospective studies—are needed to better define the role of molecular imaging of prostate cancer.

Penile Cancer

Squamous cell carcinoma of the penis shows high levels of ^{18}F-FDG uptake (Ottenhof and Vegt, 2017). One application of ^{18}F-FDG imaging in patients with penile cancer is inguinal lymph node staging. More specifically, ^{18}F-FDG PET offers a reliable method for confirming the presence of metastatic disease and determining the relative extent of nodal involvement in patients with palpable inguinal lymph nodes. A meta-analysis by Saeghi et al. reported a sensitivity of 96.4% for detecting nodal metastases among patients with palpable groin nodes (95% CI, 81.7% to 99.9%) (Sadeghi et al., 2012). Thus, in this high-risk population, ^{18}F-FDG is useful for assessing extent of disease and steering patients with large-volume nodal involvement toward neoadjuvant chemotherapy. In contrast, the utility of ^{18}F-FDG PET for primary tumor staging and the evaluation of patients with nonpalpable inguinal lymph nodes is somewhat limited. More specifically, in the meta-analysis by Saeghi et al. the pooled sensitivity of ^{18}F-FDG PET for detecting otherwise clinically occult lymph node metastases was only 56.5% (95% CI, 34.5% to 76.8%) (Sadeghi et al., 2012). It is worth noting that although ^{18}F-FDG PET can be used to detect distant sites of penile cancer, the literature on this topic is somewhat scarce, and little is known regarding the clinical benefits of this practice (Ottenhof and Vegt, 2017).

Testis Cancer

Molecular imaging with ^{18}F-FDG PET has had a long-standing application in the evaluation of patients with metastatic tesitular seminoma. Current guidelines from the European Association of Urology endorse the use of this imaging modality for men with a residual mass after treatment with chemotherapy (Albers et al., 2015). Using ^{18}F-FDG PET in this manner helps differentiate fibrosis from residual active tumor. A meta-analysis that included data from 9 studies found that ^{18}F-FDG PET had a pooled sensitivity of 78% (95% CI, 67% to 87%) and a specificity of 86% (95% CI, 81% to 89%) for detecting residual tumor after chemotherapy (Treglia et al., 2014). For patients with nonseminomatous germ cell tumors, ^{18}F-FDG PET imaging is not indicated, as there appears to be no clinical benefit for PET in the detection of viable tumor over the combination of CT and serum markers (Oechsle et al., 2008). The development of a PET radiotracer capable of detecting residual tumor in patients with nonseminomatous germ cell tumors is a critical need, as the current standard of care is retroperitoneal lymph node dissection for postchemotherapy tumors greater than 1 cm in diameter (Albers et al., 2015).

Key Points

- Molecular imaging of cancer is most commonly performed using the PET radiotracer 2-deoxy-2-[^{18}F]fluoro-D-glucose (^{18}F-FDG).
- A number of genitourinary malignancies can be successfully imaged with ^{18}F-FDG PET albeit with varying degrees of clinical utility beyond conventional anatomic imaging techniques.
- Because ^{18}F-FDG is excreted in the urine, imaging with this radiotracer is typically performed to detect distant sites of disease.
- ^{18}F-FDG has little role in imaging prostate cancer, and a number of other radiotracers have been developed for this purpose.

- Radiotracers targeting PSMA are the most promising class of agents for prostate cancer imaging and in many parts of the world have become the new standard of care for imaging this malignancy.
- One of the most well established indications for ^{18}F-FDG PET imaging is in the detection of residual seminomatous germ cell tumors after chemotherapy.

References

Afshar-Oromieh A, Zechmann CM, Malcher A, et al. Comparison of PET imaging with a ^{68}Ga-labelled PSMA ligand and ^{18}F-choline-based PET/CT for the diagnosis of recurrent prostate cancer. *Eur J Nucl Med Mol Imaging*. 2014;41:11–20.

Albers P, Albrecht W, Algaba F, et al. Guidelines on testicular cancer: 2015 Update. *Eur Urol*. 2015;68:1054–1068.

Alfred Witjes J, Lebret T, Comperat EM, et al. Updated 2016 EAU guidelines on muscle-invasive and metastatic bladder cancer. *Eur Urol*. 2017;71:462–475.

Alonso O, Dos Santos G, Garcia Fontes M, et al. ^{68}Ga-PSMA and ^{11}C-choline comparison using a tri-modality PET/CT-MRI (3.0 T) system with a dedicated shuttle. *Eur J Hybrid Imaging*. 2018;2:9.

Ananias HJ, van den Heuvel MC, Helfrich W, et al. Expression of the gastrin-releasing peptide receptor, the prostate stem cell antigen and the prostate-specific membrane antigen in lymph node and bone metastases of prostate cancer. *Prostate*. 2009;69:1101–1108.

Asai S, Fukumoto T, Tanji N, et al. Fluorodeoxyglucose positron emission tomography/computed tomography for diagnosis of upper urinary tract urothelial carcinoma. *Int J Clin Oncol*. 2015;20:1042–1047.

Basu S, Kwee TC, Surti S, et al. Fundamentals of PET and PET/CT imaging. *Ann N Y Acad Sci*. 2011;1228:1–18.

Beevers G, Lip GY, O'Brien E. ABC of hypertension: the pathophysiology of hypertension. *BMJ*. 2001;322:912–916.

Bensinger SJ, Christofk HR. New aspects of the Warburg effect in cancer cell biology. *Semin Cell Dev Biol*. 2012;23:352–361.

Boellaard R. Standards for PET image acquisition and quantitative data analysis. *J Nucl Med*. 2009;50(Suppl 1):11S–20S.

Brogsitter C, Zophel K, Kotzerke J. ^{18}F-choline, ^{11}C-choline and ^{11}C-acetate PET/CT: comparative analysis for imaging prostate cancer patients. *Eur J Nucl Med Mol Imaging*. 2013;40(Suppl 1):S18–S27.

Brown ML, Hung JC, Vetter RJ, et al. The radiation dosimetry and normal value study of ^{99m}Tc-HMPAO-labeled leukocytes. *Invest Radiol*. 1994;29:443–447.

Brown RS, Leung JY, Fisher SJ, et al. Intratumoral distribution of tritiated-FDG in breast carcinoma: correlation between Glut-1 expression and FDG uptake. *J Nucl Med*. 1996;37:1042–1047.

Bubeck B. Captopril scintigraphy: procedure, results, and theoretical evaluation of validity. *J Nucl Biol Med*. 1993;37:249–258.

Calais J, Fendler WP, Herrmann K, et al. Comparison of ^{68}Ga-PSMA-11 and ^{18}F-fluciclovine PET/CT in a case series of 10 patients with prostate cancer recurrence. *J Nucl Med*. 2018;59:789–794.

Castellucci P, Ceci F, Fanti S. Imaging of prostate cancer using ^{11}C-choline PET/computed tomography. *PET Clin*. 2017;12:137–143.

Chang SS, Bochner BH, Chou R, et al. Treatment of non-metastatic muscle-invasive bladder cancer: AUA/ASCO/ASTRO/SUO guideline. *J Urol*. 2017;198:552–559.

Cornford P, Bellmunt J, Bolla M, et al. EAU-ESTRO-SIOG guidelines on prostate cancer. Part II: treatment of relapsing, metastatic, and castration-resistant prostate cancer. *Eur Urol*. 2017;71:630–642.

Crozier J, Papa N, Perera M, et al. Comparative sensitivity and specificity of imaging modalities in staging bladder cancer prior to radical cystectomy: a systematic review and meta-analysis. *World J Urol*. 2018 [in press].

Divgi CR, Pandit-Taskar N, Jungbluth AA, et al. Preoperative characterisation of clear-cell renal carcinoma using iodine-124-labelled antibody chimeric G250 (^{124}I-cG250) and PET in patients with renal masses: a phase I trial. *Lancet Oncol*. 2007;8:304–310.

Divgi CR, Uzzo RG, Gatsonis C, et al. Positron emission tomography/computed tomography identification of clear cell renal cell carcinoma: results from the REDECT trial. *J Clin Oncol*. 2013;31:187–194.

Donat SM, Diaz M, Bishoff JT, et al. Follow-up for clinically localized renal neoplasms: AUA guideline. *J Urol*. 2013;190:407–416.

Dubovsky EV, Russell CD, Bischof-Delaloye A, et al. Report of the Radionuclides in Nephrourology Committee for evaluation of transplanted kidney (review of techniques). *Semin Nucl Med*. 1999;29:175–188.

Durand E, Blaufox MD, Britton KE, et al. International Scientific Committee of Radionuclides in Nephrourology (ISCORN) consensus on renal transit time measurements. *Semin Nucl Med*. 2008;38:82–102.

Dworkin LD, Cooper CJ. Clinical practice. renal-artery stenosis. *N Engl J Med*. 2009;361:1972–1978.

Eshima D, Taylor A Jr. Technetium-99m (^{99m}Tc) mercaptoacetyltriglycine: update on the new ^{99m}Tc renal tubular function agent. *Semin Nucl Med*. 1992;22:61–73.

Farsad M, Schiavina R, Castellucci P, et al. Detection and localization of prostate cancer: correlation of ^{11}C-choline PET/CT with histopathologic step-section analysis. *J Nucl Med*. 2005;46:1642–1649.

Farwell MD, Pryma DA, Mankoff DA. PET/CT imaging in cancer: current applications and future directions. *Cancer*. 2014;120:3433–3445.

Fillion ML, Watt CL, Gupta IR. Vesicoureteric reflux and reflux nephropathy: from mouse models to childhood disease. *Pediatr Nephrol*. 2014;29:757–766.

Forstrom LA, Dunn WL, Rowe FA, et al. ^{111}In-oxine-labelled granulocyte dosimetry in normal subjects. *Nucl Med Commun*. 1995;16:349–356.

Fritzberg AR, Kasina S, Eshima D, et al. Synthesis and biological evaluation of technetium-99m MAG3 as a hippuran replacement. *J Nucl Med*. 1986;27:111–116.

Gorin MA, Pomper MG, Rowe SP. PSMA-targeted imaging of prostate cancer: the best is yet to come. *BJU Int*. 2016;117:715–716.

Gorin MA, Rowe SP, Baras AS, et al. Prospective evaluation of ^{99m}Tc-sestamibi SPECT/CT for the diagnosis of renal oncocytomas and hybrid oncocytic/chromophobe tumors. *Eur Urol*. 2016;69:413–416.

Gorin MA, Rowe SP, Patel HD, et al. Prostate specific membrane antigen targeted ^{18}F-DCFPyL positron emission tomography/computerized tomography for the preoperative staging of high risk prostate cancer: results of a prospective, phase II, single center study. *J Urol*. 2018;199:126–132.

Gormley TS, Van Every MJ, Moreno AJ. Renal oncocytoma: preoperative diagnosis using technetium 99m sestamibi imaging. *Urology*. 1996;48:33–39.

Ha HK, Koo PJ, Kim SJ. Diagnostic accuracy of F-18 FDG PET/CT for preoperative lymph node staging in newly diagnosed bladder cancer patients: a systematic review and meta-analysis. *Oncology*. 2018;95:31–38.

Jadvar H. Imaging evaluation of prostate cancer with ^{18}F-fluorodeoxyglucose PET/CT: utility and limitations. *Eur J Nucl Med Mol Imaging*. 2013;40(Suppl 1):S5–S10.

Judson BL, Shaha AR. Nuclear imaging and minimally invasive surgery in the management of hyperparathyroidism. *J Nucl Med*. 2008;49:1813–1818.

Kim SJ, Koo PJ, Pak K, et al. Diagnostic accuracy of C-11 choline and C-11 acetate for lymph node staging in patients with bladder cancer: a systematic review and meta-analysis. *World J Urol*. 2018;36:331–340.

Kollberg P, Almquist H, Blackberg M, et al. [^{18}F]Fluorodeoxyglucose-positron emission tomography/computed tomography response evaluation can predict histological response at surgery after induction chemotherapy for oligometastatic bladder cancer. *Scand J Urol*. 2017;51:308–313.

Krause BJ, Souvatzoglou M, Tuncel M, et al. The detection rate of [^{11}C]choline-PET/CT depends on the serum PSA-value in patients with biochemical recurrence of prostate cancer. *Eur J Nucl Med Mol Imaging*. 2008;35:18–23.

Kulkarni HR, Singh A, Langbein T, et al. Theranostics of prostate cancer: from molecular imaging to precision molecular radiotherapy targeting the prostate specific membrane antigen. *Br J Radiol*. 2018;91:20180308.

Langsteger W, Rezaee A, Pirich C, et al. ^{18}F-NaF-PET/CT and ^{99m}Tc-MDP bone scintigraphy in the detection of bone metastases in prostate cancer. *Semin Nucl Med*. 2016;46:491–501.

Lebowitz RL. The detection and characterization of vesicoureteral reflux in the child. *J Urol*. 1992;148:1640–1642.

Ljungberg B, Bensalah K, Canfield S, et al. EAU guidelines on renal cell carcinoma: 2014 update. *Eur Urol*. 2015;67:913–924.

Ma H, Shen G, Liu B, et al. Diagnostic performance of ^{18}F-FDG PET or PET/CT in restaging renal cell carcinoma: a systematic review and meta-analysis. *Nucl Med Commun*. 2017;38:156–163.

Mann SJ, Pickering TG, Sos TA, et al. Captopril renography in the diagnosis of renal artery stenosis: accuracy and limitations. *Am J Med*. 1991;90:30–40.

Mannheim JG, Schmid AM, Schwenck J, et al. PET/MRI hybrid systems. *Semin Nucl Med*. 2018;48:332–347.

Mansi R, Minamimoto R, Macke H, et al. Bombesin-targeted PET of prostate cancer. *J Nucl Med*. 2016;57:67S–72S.

Mapelli P, Picchio M. Initial prostate cancer diagnosis and disease staging—the role of choline-PET-CT. *Nat Rev Urol*. 2015;12:510–518.

Minamimoto R, Hancock S, Schneider B, et al. Pilot comparison of ^{68}Ga-RM2 PET and ^{68}Ga-PSMA-11 PET in patients with biochemically recurrent prostate cancer. *J Nucl Med*. 2016;57:557–562.

Morigi JJ, Stricker PD, van Leeuwen PJ, et al. Prospective comparison of ^{18}F-fluoromethylcholine versus ^{68}Ga-PSMA PET/CT in prostate cancer patients who have rising PSA after curative treatment and are being considered for targeted therapy. *J Nucl Med*. 2015;56:1185–1190.

Mottet N, Bellmunt J, Bolla M, et al. EAU-ESTRO-SIOG guidelines on prostate cancer. part 1: screening, diagnosis, and local treatment with curative intent. *Eur Urol*. 2017;71:618–629.

Mountford PJ, Kettle AG, O'Doherty MJ, et al. Comparison of technetium-99m-HM-PAO leukocytes with indium-111-oxine leukocytes for localizing intraabdominal sepsis. *J Nucl Med*. 1990;31:311–315.

Murphy DG, Sweeney CJ, Tombal B. “Gotta catch 'em all”, or do we? Pokemet approach to metastatic prostate cancer. *Eur Urol*. 2017;72:1–3.

Nakatani K, Nakamoto Y, Saga T, et al. The potential clinical value of FDG-PET for recurrent renal cell carcinoma. *Eur J Radiol*. 2011;79:29–35.

Nanni C, Schiavina R, Brunocilla E, et al. ^{18}F-FACBC compared with ^{11}C-choline PET/CT in patients with biochemical relapse after radical prostatectomy: a prospective study in 28 patients. *Clin Genitourin Cancer*. 2014;12:106–110.

Nanni C, Schiavina R, Brunocilla E, et al. ^{18}F-fluciclovine PET/CT for the detection of prostate cancer relapse: a comparison to ^{11}C-choline PET/CT. *Clin Nucl Med*. 2015;40:e386–e391.

Nanni C, Zanoni L, Pultrone C, et al. ^{18}F-FACBC (anti1-amino-3-^{18}F-fluorocyclobutane-1-carboxylic acid) versus ^{11}C-choline PET/CT in prostate cancer relapse: results of a prospective trial. *Eur J Nucl Med Mol Imaging*. 2016;43:1601–1610.

O'Reilly PH. Standardization of the renogram technique for investigating the dilated upper urinary tract and assessing the results of surgery. [for the Consensus Committee of the Society of Radionuclides in Nephrourology] *BJU Int*. 2003;91:239–243.

Oechsle K, Hartmann M, Brenner W, et al. [^{18}F]Fluorodeoxyglucose positron emission tomography in nonseminomatous germ cell tumors after chemotherapy: the German multicenter positron emission tomography study group. *J Clin Oncol*. 2008;26:5930–5935.

Ohkubo Y, Shibuya A, Kohno H, et al. Involvement of transferrin in the uptake of ^{67}Ga in inflammatory and normal tissues. *Int J Rad Appl Instrum B*. 1989;16:337–341.

Oka S, Okudaira H, Yoshida Y, et al. Transport mechanisms of trans-1-amino-3-fluoro[1-^{14}C]cyclobutanecarboxylic acid in prostate cancer cells. *Nucl Med Biol*. 2012;39:109–119.

Ottenhof SR, Vegt E. The role of PET/CT imaging in penile cancer. *Transl Androl Urol*. 2017;6:833–838.

Panebianco V, Narumi Y, Altun E, et al. Multiparametric magnetic resonance imaging for bladder cancer: development of VI-RADS (Vesical Imaging-Reporting And Data System). *Eur Urol*. 2018;74:294–306.

Perera M, Papa N, Christidis D, et al. Sensitivity, specificity, and predictors of positive ^{68}Ga-prostate-specific membrane antigen positron emission tomography in advanced prostate cancer: a systematic review and meta-analysis. *Eur Urol*. 2016;70:926–937.

Peters AM, Jones DH, Evans K, et al. Two routes for ^{99m}Tc-DMSA uptake into the renal cortical tubular cell. *Eur J Nucl Med*. 1988;14:555–561.

Peters CA, Skoog SJ, Arant BS Jr, et al. Summary of the AUA guideline on management of primary vesicoureteral reflux in children. *J Urol*. 2010;184:1134–1144.

Piepsz A. Radionuclide studies in paediatric nephro-urology. *Eur J Radiol*. 2002;43:146–153.

Reba RC, Hosain F, Wagner HN Jr. Indium-113m diethylenetriaminepentaacetic acid (DTPA): a new radiopharmaceutical for study of the kidneys. *Radiology*. 1968;90:147–149.

Roupret M, Babjuk M, Comperat E, et al. European Association of Urology guidelines on upper urinary tract urothelial carcinoma: 2017 update. *Eur Urol*. 2018;73:111–122.

Rowe SP, Drzezga A, Neumaier B, et al. Prostate-specific membrane antigen-targeted radiohalogenated pet and therapeutic agents for prostate cancer. *J Nucl Med*. 2016;57:90S–96S.

Rowe SP, Gorin MA, Gordetsky J, et al. Initial experience using ^{99m}Tc-MIBI SPECT/CT for the differentiation of oncocytoma from renal cell carcinoma. *Clin Nucl Med*. 2015;40:309–313.

Sadeghi R, Gholami H, Zakavi SR, et al. Accuracy of ^{18}F-FDG

PET/CT for diagnosing inguinal lymph node involvement in penile squamous cell carcinoma: systematic review and meta-analysis of the literature. *Clin Nucl Med*. 2012;37:436–441.

Safian RD, Textor SC. Renal-artery stenosis. *N Engl J Med*. 2001;344:431–442.

Sanchez-Crespo A. Comparison of Gallium-68 and Fluorine-18 imaging characteristics in positron emission tomography. *Appl Radiat Isot*. 2013;76:55–62.

Sanda MG, Cadeddu JA, Kirkby E, et al. Clinically localized prostate cancer: AUA/ASTRO/SUO guideline. Part I: risk stratification, shared decision making, and care options. *J Urol*. 2018;199:683–690.

Sanda MG, Cadeddu JA, Kirkby E, et al. Clinically localized prostate cancer: AUA/ASTRO/SUO guideline. Part II: recommended approaches and details of specific care options. *J Urol*. 2018;199:990–997.

Sathianathen NJ, Butaney M, Konety BR. The utility of PET-based imaging for prostate cancer biochemical recurrence: a systematic review and meta-analysis. *World J Urol*. 2018 [in press].

Schillaci O, Spanu A, Danieli R, et al. Molecular breast imaging with gamma emitters. *Q J Nucl Med Mol Imaging*. 2013;57:340–351.

Schwenck J, Rempp H, Reischl G, et al. Comparison of ^{68}Ga-labelled PSMA-11 and ^{11}C-choline in the detection of prostate cancer metastases by PET/CT. *Eur J Nucl Med Mol Imaging*. 2017;44:92–101.

Shuch B, Stamatakis L, Chen C, et al. Utility of 2-(^{18}F) fluoro-2 deoxy-D-glucose PET/CT in advanced papillary renal cell carcinoma. *J Clin Oncol*. 2014;32:419.

SNMMI. *Fact sheet: what is nuclear medicine and molecular imaging?*. http://www.snmmi.org/AboutSNMMI/Content.aspx?

ItemNumber=15627.

Soubra A, Gencturk M, Froelich J, et al. FDG-PET/CT for assessing the response to neoadjuvant chemotherapy in bladder cancer patients. *Clin Genitourin Cancer*. 2018;16:360–364.

Sweat SD, Pacelli A, Murphy GP, et al. Prostate-specific membrane antigen expression is greatest in prostate adenocarcinoma and lymph node metastases. *Urology*. 1998;52:637–640.

Tanaka H, Yoshida S, Komai Y, et al. Clinical Value of ^{18}F-fluorodeoxyglucose positron emission tomography/computed tomography in upper tract urothelial carcinoma: impact on detection of metastases and patient management. *Urol Int*. 2016;96:65–72.

Taylor AT. Radionuclides in nephrourology, Part 1: radiopharmaceuticals, quality control, and quantitative indices. *J Nucl Med*. 2014;55:608–615.

Taylor AT. Radionuclides in nephrourology, Part 2: pitfalls and diagnostic applications. *J Nucl Med*. 2014;55:786–798.

Tekgul S, Riedmiller H, Hoebeke P, et al. EAU guidelines on vesicoureteral reflux in children. *Eur Urol*. 2012;62:534–542.

Travin MI, Bergmann SR. Assessment of myocardial viability. *Semin Nucl Med*. 2005;35:2–16.

Treglia G, Sadeghi R, Annunziata S, et al. Diagnostic performance of fluorine-18-fluorodeoxyglucose positron emission tomography in the postchemotherapy management of patients with seminoma: systematic review and meta-analysis. *Biomed Res Int*. 2014;2014:852681.

Turkbey B, Mena E, Shih J, et al. Localized prostate cancer detection with ^{18}F FACBC PET/CT: comparison with MR imaging and histopathologic analysis. *Radiology*. 2014;270:849–856.

Tzortzakakis A, Gustafsson O, Karlsson M, et al. Visual evaluation and differentiation of renal oncocytomas from renal cell carcinomas by means of ^{99m}Tc-sestamibi SPECT/CT. *EJNMMI Res*. 2017;7:29.

Vag T, Heck MM, Beer AJ, et al. Preoperative lymph node staging in patients with primary prostate cancer: comparison and correlation of quantitative imaging parameters in diffusion-weighted imaging and ^{11}C-choline PET/CT. *Eur Radiol*. 2014;24:1821–1826.

van der Pol CB, Chung A, Lim C, et al. Update on multiparametric MRI of urinary bladder cancer. *J Magn Reson Imaging*. 2018;48:882–896.

Vind-Kezunovic S, Bouchelouche K, Ipsen P, et al. Detection of lymph node metastasis in patients with bladder cancer using maximum standardised uptake value and ^{18}F-fluorodeoxyglucose positron emission tomography/computed tomography: results from a high-volume centre including long-term follow-up. *Eur Urol Focus*. 2019;5:90–96.

von Eyben FE, Picchio M, von Eyben R, et al. ^{68}Ga-Labeled prostate-specific membrane antigen ligand positron emission tomography/computed tomography for prostate cancer: a systematic review and meta-analysis. *Eur Urol Focus*. 2018;4:686–693.

Weyer K, Nielsen R, Petersen SV, et al. Renal uptake of ^{99m}Tc-dimercaptosuccinic acid is dependent on normal proximal tubule receptor-mediated endocytosis. *J Nucl Med*. 2013;54:159–165.

Woo S, Suh CH, Kim SY, et al. Diagnostic performance of MRI for prediction of muscle-invasiveness of bladder cancer: a systematic review and meta-analysis. *Eur J Radiol*. 2017;95:46–55.

Wright GL Jr, Haley C, Beckett ML, et al. Expression of prostate-specific membrane antigen in normal, benign, and malignant prostate tissues. *Urol Oncol*. 1995;1:18–28.

Zadra G, Photopoulos C, Loda M. The fat side of prostate cancer. *Biochim Biophys Acta*. 2013;1831:1518–1532.

Zanzonico P. Principles of nuclear medicine imaging: planar, SPECT, PET, multi-modality, and autoradiography systems. *Radiat Res*. 2012;177:349–364.

Zarzour JG, Galgano S, McConathy J, et al. Lymph node imaging in initial staging of prostate cancer: an overview and update. *World J Radiol*. 2017;9:389–399.

Zukotynski KA, Valliant J, Benard F, et al. Flare on serial prostate-specific membrane antigen-targeted ^{18}F-DCFPyL PET/CT examinations in castration-resistant prostate cancer: first observations. *Clin Nucl Med*. 2018;43:213–216.

Assessment of Urologic and Surgical Outcomes

David F. Penson MD, MPH, Mark D. Tyson MD, MPH

Over the past 25 years, there has been increased focus on "outcomes research" in urology. Unfortunately, outcomes research is an umbrella term without consistent definition. Jefford et al. noted that outcomes research tends to describe the effectiveness of public health interventions and health services on patient outcomes (Jefford et al., 2003). Others, however, have described it differently. **The US Agency for Healthcare Research and Quality (AHRQ) defined outcomes research as "research [that] seeks to understand the end results of particular health care practices and interventions.** End results include effects that people experience and care about, such as change in the ability to function. In particular, for individuals with chronic conditions—where cure is not always possible—end results include quality of life as well as mortality. By linking the care that people get to the outcomes they experience, outcomes research has become the key to developing better ways to monitor and improve the quality of care" (AHRQ, 2000). People with urologic conditions, however, care about any number of end results, which underscores the difficulty of accurately defining "outcomes research" in urology. Some endpoints that matter in urology include quality of life, clinical effectiveness, cost, quality of care, patient preferences, appropriateness, access, and health status, just to name a few (Jefford et al., 2003).

Some might use the terms *outcomes research* and *health services research* interchangeably. This is not entirely unreasonable, as health services research constitutes a major portion of what urologists think of when they are referring to outcomes research. Health services research has been defined as "the multidisciplinary field of scientific investigation that studies how social factors, financing systems, organizational structures and processes, health technologies, and personal behaviors affect access to health care, the quality and cost of health care, and ultimately our health and well-being" (Lohr and Steinwachs, 2002).

Although this definition captures much of what urologists think of when speaking of outcomes research, it fails to capture the often clinical nature of the research. **To this end, urologic outcomes research not only includes health services research—it also includes clinical epidemiology, comparative effectiveness research, and, to some degree, traditional clinical trials research.**

Establishing a Conceptual Framework for Assessing the Effectiveness of Treatment and Improving Care in Urology

Implicit in the name "outcomes research" is a focus on improving the end results of urologic interventions. This has led to an increased focus on improvement in the quality of care delivered. The Institute of Medicine (IOM) has defined quality of care as "the degree to which health services for individuals and populations increase the likelihood of desired health outcomes and are consistent with current professional knowledge" (IOM, 2001). The IOM notes that quality can be affected by various elements of care including access, clinical effectiveness, integration of services such as care coordination and continuity, cultural competence, and comprehensiveness (IOM, 2001). As such, there is a pressing need for a conceptual model to guide quality improvement and optimize end results.

The most commonly accepted framework through which quality is measured is the model proposed by Avedis Donabedian (Donabedian, 1966, 1978, 1988). **The Donabedian model is a conceptual framework for examining health services and assessing quality in health care. The model consists of three dimensions in which the quality of care can be measured: structure, process, and outcomes.** Importantly, it is possible (and desirable) to measure specific elements of each of these dimensions to assess the overall quality of care.

***Structure* consists of the factors that affect the context in which the care is delivered.** Examples of measurable elements of structure include procedure volume, subspecialty training, nurse-to-bed ratios, or the presence of specific amenities such as "closed" intensive care units or certain types of technology and equipment (Brook et al., 1996; Donabedian, 1986; Luft et al., 1987). Structural quality of care measures are usually easily and inexpensively obtained from administrative databases and other publicly available sources (Donabedian, 1996; Liu et al., 2006). Although structural measures may be more relevant in complex health care systems, they often fail to capture the quality of care actually delivered at the provider level and tend to be nonmodifiable. That being said, there is little doubt that they influence the quality of care and clinically relevant endpoints, so they need to be considered.

***Process* refers to specific activities carried out by health care professionals and health care systems to deliver services** (Brook and Appel, 1973). Examples of measurable processes include the appropriate use of radiographic and laboratory testing, assessment of types of medication prescribed (i.e., the use of antibiotics before a procedure or deep venous thrombosis prophylaxis), specific technical processes performed in the completion of a surgical procedure, and so on. There is enthusiasm for process measures because of a clearly established link between process measures and improved outcomes where the evidence is robust (e.g., preoperative heparin for DVT prophylaxis in major cancer cases) (Guyatt et al., 2012). An additional advantage to process measures is that quality problems can usually be detected long before demonstrable outcome differences become evident (Mant and Hicks, 1995, 1996). Evidence-based practice guidelines, like those generated by the American Urological Association (AUA) or the European Association of Urology (EAU), have greatly facilitated the development of quality-of-care process measures. For example, the AUA guidelines strongly recommend the use of 24 to 36 months of androgen deprivation therapy as an adjunct to external beam radiotherapy in localized prostate cancer (Sanda et al, 2018a; 2018b). This, in turn, has been used as a quality-of-care process measure in a number of programs, including Medicare's physician quality reporting system and by numerous private payors (Spencer et al., 2003a, 2003b). Donabedian suggested that measurement of the processes of care may be the most reflective measurement of overall quality of care because process contains all of the elements of health care delivery (Donabedian, 1980). Compared with outcome measures, process measures are easier and less costly to measure, and, unlike outcome measures, are less influenced by case-mix or risk adjustment when carefully specified (Mant, 2001).

***Outcomes* measures refer to the effects of health care on patients or populations.** Whereas structural measures focus on the infrastructure of health care delivery and process measures focus on how health care is delivered, outcome measures focus on the effect of health care on patients, which many feel is the most important indicator of quality of care. A few examples of commonly used outcomes measures include mortality rates, length of stay, readmission rates, patient satisfaction, quality of life, cost-effectiveness, and utilization. Although some have advocated that outcomes should be the primary (and perhaps only) focus of quality improvement efforts (McAuliffe, 1979), others have noted problems with using these measures, primarily resulting from confounding by patient-level factors such as age and comorbidity (Lilford et al., 2007; Rademakers et al., 2011). **There is certainly a pressing need for proper risk adjustment when assessing outcomes.** If studies do not include proper case-mix adjustment, they might find that providers who treat high-risk patients have poorer outcomes, not necessarily because of poorer quality of care, but because of underlying differences in patient populations. This, in turn, could create an economic disincentive to treat these patients and negatively affect their health.

Long-Term Disease Outcomes That Are Commonly Assessed in Urology

Although structure and process contribute to overall quality of care, patients and urologists tend to focus mostly on outcomes, as having “good” clinical results and/or stable or improved day-to-day health is usually the primary goal of the treatment of any urologic condition. In many regards, this is why the term *outcomes research* has become so prevalent. That being said, there are a myriad of outcomes that can be studied in urologic research. It is important to understand the strengths and weaknesses of the various types of outcomes if one is to undertake research in this space. Surgeons tend to be most concerned with morbidity and mortality, as these are the “hardest” endpoints and, at least in theory, are easiest to assess. Patients and other stakeholders are also interested in these endpoints but may have additional focus on other “softer” endpoints, including patient-reported outcomes (such as symptoms and bother), economic endpoints, and satisfaction with care. The variety of outcomes that can be assessed in urologic research are discussed in the following sections with attention to how to measure these endpoints and some of the strengths and weaknesses of each.

Overall Mortality

Mortality refers to “death” and, in many regards, it is the most objective of all endpoints one can measure. After all, there is usually no argument regarding whether or not a patient is alive or dead. **Overall (or all-cause) mortality is a key endpoint in epidemiology that can be assessed in larger population-based studies in the United States by querying the National Death Index (NDI), which is maintained by the National Center for Health Statistics (NCHS) within the Centers for Disease Control and Prevention (CDC)** (CDC, 2019). Data are obtained from the vital statistics office from each of the 50 states and are then stored centrally. The NDI is updated annually, and the information contained within the dataset tends to lag behind 1 calendar year. Researchers are requested to submit as much identifying information as possible, including the subject's name, Social Security number, date of birth, race, sex, marital status, state of residence, and state of birth. If the subject has died, the

NDI will provide the location and date of death and the corresponding death certificate number. The NDI can also provide the cause of death as listed on the death certificate. Numerous studies have demonstrated that the NDI has an accuracy rate of 96% or higher (Boyle and Decouflé, 1980; Stampfer et al., 1984). Unfortunately, the NDI only contains data on deaths that occurred after 1979 in the United States. For information on deaths that occurred before this time in the United States, the researcher can query the Social Security Administration (SSA), which maintains a mechanism for researchers to determine vital status (SSA, n.d.). The SSA dataset is less accurate than the NDI; researchers were only able to document an 83% accuracy rate (Boyle and Decouflé, 1980; Curb et al., 1985). One last option that may also contain international options involves the use of records from the various credit reporting agencies (Equifax, Experian, and TransUnion) or other Internet databases to ascertain vital status (Sesso et al., 2000). This approach, however, may not be as comprehensive as the NDI.

Once ascertained, mortality (or its reciprocal, survival) can be assessed as a simple count, a ratio, a proportion, or a rate. For most clinical studies in urology, the use of a proportion or a rate is most appropriate. For example, if one were comparing overall mortality between two arms of a clinical trial, one could simply calculate the proportion of participants in each study arm who died (or were alive if the researchers wished to focus on survival) over the total number of study participants in each arm. Although this simple approach has face validity, it fails to account for the element of time, which is usually of significance. To this end, the preferred approach is usually to calculate a mortality *rate*, defined as the proportion of dying in a population *over a specified period* (Last, 2001). Expanding on the earlier example, assume the randomized clinical trial is comparing second- or third-line treatments for castrate-resistant metastatic prostate cancer. In this setting, one would likely expect all of the study participants to die within the study period. To this end, comparing mortality rates at the conclusion of the study would be less meaningful. Researchers, therefore, might compare 1-, 2-, and 5-year mortality rates between two treatments in a randomized clinical trial to assess the comparative effectiveness of each therapy.

Comparing mortality (or its reciprocal, survival) endpoints over time is facilitated by using time-to-event analyses (commonly referred to as *survival analyses,* although any binary endpoint can be used with these methods) (Feinstein, 2002). **One of the unique advantages of survival analyses is that**

they allow researchers to account for situations in which there is varying or loss to follow-up among subjects. For example, assume that a researcher is analyzing clinical trial data at the conclusion of a study. The majority of the participants were followed for 3 years, but a significant proportion were only followed for 1 to 2 years, and others were lost to follow-up well before the end of the 3-year study. Survival or time-to-event analyses allow researchers to include all participants, even if they do not have complete data. This is accomplished through censoring of participants (Feinstein, 1985). Effectively, if we know that a study participant did not experience the outcome of interest up to the point when there is no additional follow-up (either resulting from the participant being lost to follow-up or the study ending) or another endpoint occurring making it impossible for the outcome of interest to occur (such as a patient dying of an unrelated heart attack before experiencing a disease recurrence), the patient is considered to have "survived" up to that point and is then censored. The use of censoring is critical to the construction of Kaplan-Meier curves, which graphically illustrate survival (time-to-event) analyses and provide survival estimates at various timepoints during a study that incorporate both clinical outcome and censoring events (Rich et al., 2010).

Although overall mortality is a relatively easy endpoint to assess in individual patients and is not really subject to interpretation bias, it does not mean that studies that use this endpoint may not be susceptible to various forms of bias, often related to study design. Two examples of this are lead-time and length-time bias. **Lead-time bias is most likely to occur in studies of screening tests and other novel diagnostic modalities.** Lead time is defined as the period from detection of disease (which is intimately related to novel screening and detection modalities) and the disease's clinical presentation and diagnosis (Feinstein, 1987; Gordis, 2008). The goal of a screening test is usually to allow clinicians to detect a condition earlier in the disease course. In the absence of a screening test, the disease would not be diagnosed until symptoms appeared. **This ability to detect the disease earlier may give the appearance that survival is prolonged, despite the fact that it is not. Rather, it is simply identified earlier.** This is represented graphically in Fig. 6.1. There are numerous examples of lead-time bias in urology, although the best one may be kidney cancer. Over the past 30 years, the incidence rate of kidney cancer has doubled (presumably caused by increased use of abdominal computed tomography (CT) scanning, which results in increased detection of asymptomatic renal masses). Population-based studies have shown that the 5-year survival rate in kidney cancer has increased from

50% to 75%. During the same time, however, the mortality rate from kidney cancer has remained stable, implying that the survival benefit is likely caused by lead-time bias (Welch and Fisher, 2015). Similarly, claims of improved survival as a result of prostate-specific antigen (PSA) testing in prostate cancer (Bokhorst et al., 2015) have been attributed to lead-time bias by some researchers (Carlsson and Albertsen, 2015).

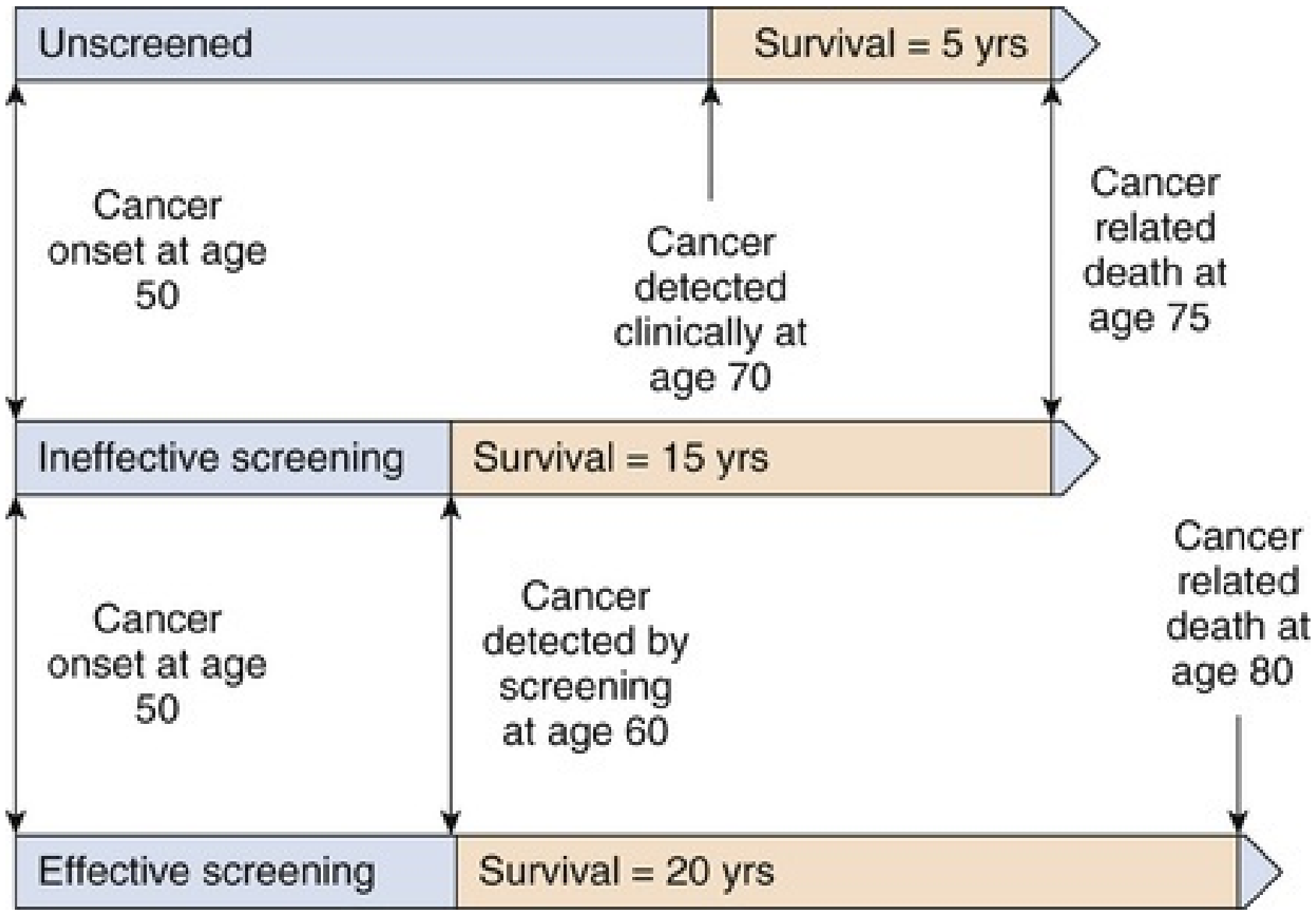

Unscreened
Survival = 5 yrs
Cancer onset at age 50
Cancer detected clinically at age 70
Cancer related death at age 75
Ineffective screening
Survival = 15 yrs
Cancer onset at age 50
Cancer detected by screening at age 60
Cancer related death at age 80
Effective screening
Survival = 20 yrs

FIG. 6.1 Lead-time bias related to screening. In the unscreened patient, survival is 5 years. In the screened patient, the cancer is detected 10 years before it would have presented clinically. In the setting of an ineffective screening intervention, survival appears longer (15 years), but in reality, the 10-year survival difference is caused by lead-time bias. Conversely, in the setting of effective screening, the cancer is still detected 10 years before it would have presented clinically, but the patient's survival is prolonged by an additional 5 years, making the overall survival 20 years total.

Length-time bias can also give the appearance of improved survival as a result of screening when, in fact, no advantage actually exists (Feinstein, 1985; Gordis, 2008; Last, 2001). Consider the example of prostate cancer. Each PSA screening test occurs at a single point in time that is relatively random in the disease course. It is known that higher-grade, more aggressive cancers have a faster disease course, and lower-grade more indolent cancers have a slower disease course (D'Amico et al., 1998). **As illustrated in Fig. 6.2, slower-growing tumors usually have a much longer asymptomatic phase, and, to this end, they are more likely to be detected by screening tests than fast-**

growing tumors. Assuming that these slower-growing tumors are less likely to be fatal, it may appear that patients whose tumors are detected by screening have a longer survival, even though there is no true survival benefit to catching the tumor earlier. Lead- and length-time bias underscore the observation that even the most objective endpoint in urology, mortality, may be subject to problems in interpretation, and, as such, researchers must be aware of this when comparing outcomes after treatment of urologic diseases.

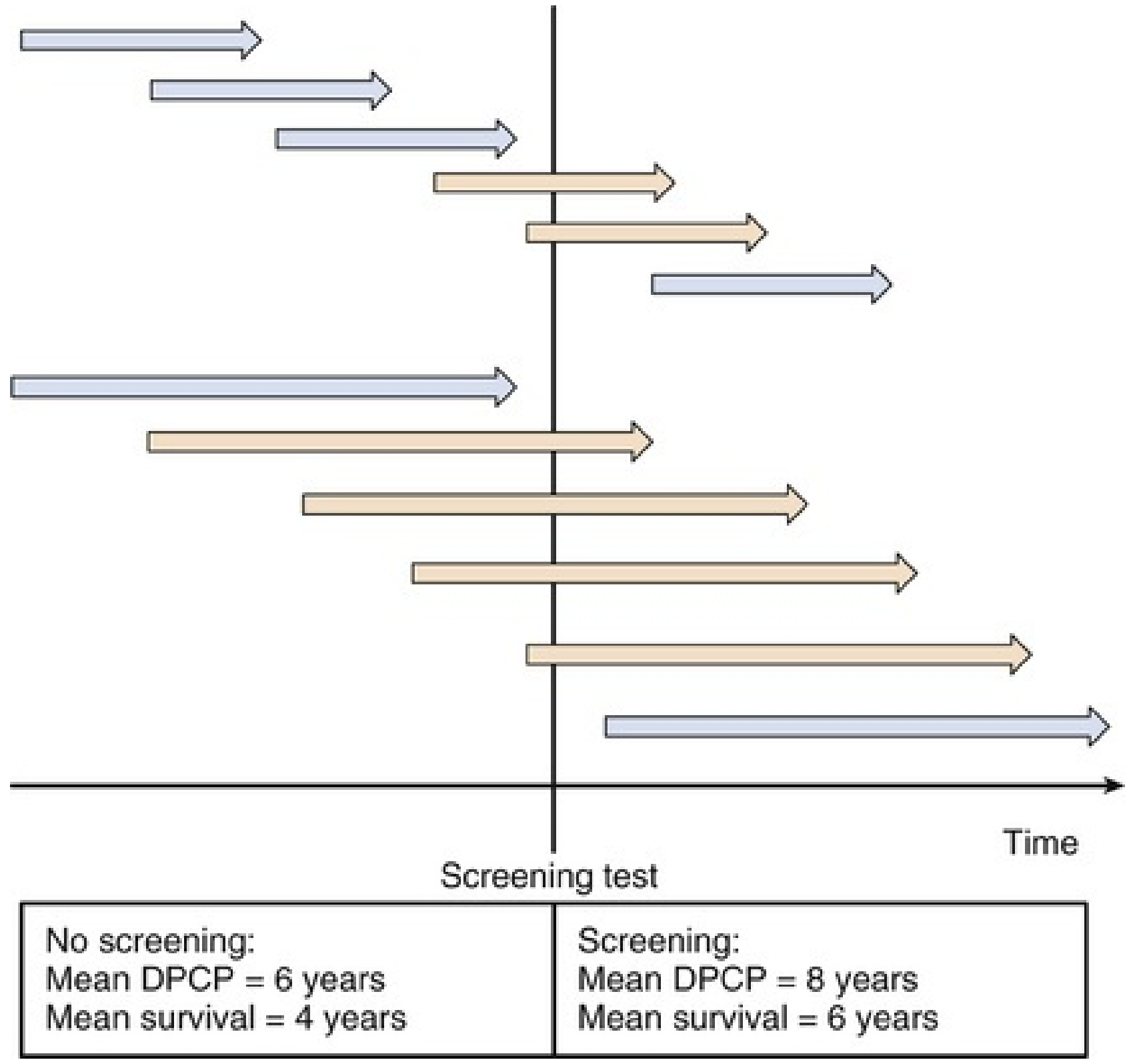

FIG. 6.2 Length-time bias in screening. Cancers can have varying degrees of clinical growth. Those that are slower growing and less aggressive will have longer detectable preclinical periods (DPCP), and those that are faster growing and more aggressive will have shorter DPCPs. It is also safe to assume that the slower growing tumors would have a longer period from clinical detection to cancer-related death (assuming the patient does not succumb to a non–cancer-related mortality beforehand). Each *arrow* represents a single patient with onset of cancer on the left and clinical presentation in the absence of screening on the right. *Red arrows* represent cases that would be detected with a screening intervention, and *blue arrows* represent cases that would not be detected by screening. Screening appears to prolong survival because screening detects more slower growing, less-aggressive cancers.

Disease-Specific Mortality

Although overall mortality is the “hardest” endpoint one can measure in urology, it is also the crudest in many regards. It fails to account for other intercurrent illnesses that may result in mortality. It is also not always the most germane endpoint, particularly in benign diseases or those with relatively low mortality rates. To this end, disease-specific mortality is often used in urology to assess the effectiveness of treatment.

Disease-specific mortality is defined as deaths attributed directly to the disease under study (Gordis, 2008). Although many urologists believe that this is easy to define, it is actually considerably more complicated than one might appreciate, particularly in the setting of “benign” disease. Many urologic conditions are primarily treated via a surgical approach, yet if there is a mortality event within the immediate postoperative period, one's immediate inclination is not to attribute the death to the urologic condition. That being said, one could make a strong argument that the mortality event is directly related to the urologic disease and its treatment and should be considered a disease-specific mortality event. To test this, Welch and Black used data from the Surveillance, Epidemiology, and End Results (SEER) database from 1994 to 1998 and noted that 75% of deaths reported within 1 month of surgery for prostate cancer were attributed to a cause other than prostate cancer (Welch and Black, 2002). Had these deaths been attributed to prostate cancer, disease-specific mortality would be increased by 1% to 2%, in a condition that already has a relatively low mortality rate (Hoffman et al., 2013). Clearly, these data are taken from early in the PSA era before the introduction of robotic surgery, but they illustrate some of the nuances of defining disease-specific mortality, even when all of the data are properly collected and available.

This extends to medical treatment as well. Consider the patient who is on long-term androgen deprivation therapy (ADT) for metastatic prostate cancer. Numerous studies have documented an increased risk for cardiovascular disease and death presumably related to changes in the hormonal milieu related to ADT (Nguyen et al., 2015; Keating et al., 2006; Nguyen et al., 2011). If this patient dies of a cardiac event, is this related to the treatment of his prostate cancer? By extension, could he have avoided this event if he never had prostate cancer and did not receive ADT? Similarly, this same patient could have been admitted to the hospital with pneumonia and ultimately experience overwhelming sepsis, vascular collapse, and cardiac arrest. One could argue that metastatic prostate cancer caused the patient to become immobile and may have contributed to the development of pneumonia, which in turn, led to sepsis and death. Alternatively, one could argue that older patients are prone to pneumonia and that the death had nothing to do with the underlying prostate cancer, as he would have died of infection regardless of malignancy. To this end, disease-specific mortality is subject to interpretation and may be prone to "attribution bias" (Feinstein, 1987; Sackett et al., 1991).

Attribution bias is the greatest limitation of using disease-specific mortality as an outcome. When patients are diagnosed with an underlying urologic malignancy, this is usually well-documented in the medical record, even if the patient is hospitalized for unrelated reasons. If the patient expires during the hospital admission, the malignancy is often recorded on the death certificate, which sometimes results in the cause of death being attributed to the cancer, even if the death really is not related (Mackenbach et al., 1997; Maudsley and Williams, 1994).

This has been documented in various urologic cancers. In prostate cancer, for example, there have been a number of studies that have examined the ability of clinicians to accurately ascribe cause of death on the death certificate. Albertsen et al. abstracted the inpatient medical records of 201 men who died with prostate cancer in Connecticut in either 1985 or 1995 (Albertsen et al., 2000). The researchers then performed a medical record review and independently assigned cause of death, which was then compared with the cause of death recorded on the death certificate. Although agreement was fairly high (87%), there were still discrepancies in nearly 1 of 10 cases, indicating that although the risk for attribution bias is not overwhelming, the cause of death is still open to interpretation at least 10% of the time. Penson et al. and Hoffman et al. noted similar findings in their review of subjects from Seattle and New Mexico, respectively (Penson et al., 2001; Hoffman et al., 2003).

Attribution bias is not limited to prostate cancer. Chow and Devesa studied a population of deceased patients with urinary tract tumors identified through the Surveillance, Epidemiology and End Results (SEER) program (Chow and Devesa, 1996). Tumors were classified as arising from the bladder, kidney, renal pelvis, or other site in the urologic tract. Cause of death in a significant number of these cases was ascribed to nonurologic conditions and varied by site of the primary cancer (48% of bladder, 28% of kidney, 37% of renal pelvis, and 38% of other urinary site cases). Not surprisingly, the more advanced the disease stage at diagnosis, the more likely the cause of death was ascribed to cancer. However, site of the primary tumor did affect whether or not the cause of death was related to cancer. Comparing similar-stage renal pelvic tumors to kidney tumors, 5.5% of renal pelvic tumor cases were recorded in the death certificate as death caused by cancer compared with 33.7% in kidney cancer cases. It is worth noting that all of these studies tend to focus on in-hospital deaths only. It is even more difficult to determine cause of death for individuals who die at home or in a nursing facility**. In summary, although disease-specific mortality rates are commonly used in many urologic studies and are usually relatively reliable, there may be some attribution bias and misclassification that can affect the conclusions.**

Other Binary “Survival” Outcomes

Effectively, any definable binary outcome can be converted into a survival endpoint and assessed using Kaplan-Meier curves and proportional hazards analysis (Rich et al., 2010; Feinstein et al., 1990). Examples of these types of endpoints include metastatic-free survival, radiologic progression-free survival, symptom-free survival, and biochemical-free survival, just to name a few. Binary nonmortality endpoints are commonly used in benign conditions (Tasian et al., 2017) and in malignancies like prostate cancer (Jhaveri et al., 1999; Prada et al., 2012), where mortality events may be rare or take a long-time to occur. **Because each urologic disease is somewhat unique, clinically relevant outcomes of interest vary from condition to condition.** It is important to recognize that some clinical outcomes are easier to measure and more objective than others. As such, many clinical endpoints are subject to an array of biases that may affect their validity. For example, results of urodynamic evaluation have been used as an endpoint in studies of urinary incontinence, but studies have shown that stress or urge incontinence cannot always be reproduced during urodynamics (Nygaard, 2004). Furthermore, even if incontinence is noted on urodynamics, there is no general agreement concerning how to define what degree of leakage is required for a patient to be considered incontinent. Some have suggested that patient-reported outcomes, such as pad use or symptom scores, should be used as endpoints (Carmel et al., 2016), but these are far less “objective” than radiologic tests or serum assays commonly used in other conditions (Naughton et al., 2004).

Proxy Endpoints

Although mortality endpoints represent the “hardest” outcomes we can measure, they often can take many years to occur. Furthermore, mortality may be almost irrelevant in benign conditions, such as incontinence or stone disease. To this end, there is often a need for other outcomes to assess the effectiveness of therapies for urologic conditions. These alternate outcomes may be clinically relevant or may be proxy endpoints for survival. **Prentice** (1989) **defined the four requirements for a valid surrogate end point as: (1) treatment is associated with the true end point (overall or disease-specific survival); (2) treatment is also associated with the surrogate end point; (3) the surrogate end point is associated with the true end point; and (4) the full effect of the treatment on the true end point is explained by the surrogate end point. There are few proxy endpoints for mortality in urology that meet all four criteria.**

Disease Progression/Recurrence

Progression-free survival is a common proxy endpoint in urologic oncology studies. Although progression is often easily defined in clinical practice, there is a need for more standardized definitions of radiologic change in tumor burden if this endpoint is to be used in research settings. Responding to this need, the World Health Organization (WHO) first introduced a set of radiologic tumor response criteria in 1981 (Miller et al., 1981). Over time, researchers modified the criteria for individual studies, which lead to confusion and studies of the same drugs with conflicting results (Baar and Tannock, 1989). This lead the European Organization for Research and Treatment of Cancer, the US National Cancer Institute, and the National Cancer Institute of Canada to convene an international working group to standardize and simplify tumor response criteria. This working group developed the RECIST criteria (Response Evaluation Criteria In Solid Tumors) in 2000 (Therasse et al., 2000). These original criteria defined the minimum size of measurable lesions, suggested guidelines on how many lesions to follow (up to ten, five per organ site) and established standardized unidimensional measures of overall tumor burden. After the original RECIST criteria had been used in the field for a number of years, several limitations of the criteria were noted including: (1) RECIST's limited ability to measure disease progression (the original RECIST criteria were focused on tumor response to therapy exclusively); (2) RECIST's need to incorporate novel imaging technologies such as magnetic resonance imaging and positron emission tomography into the criteria; (3) RECIST's inability to incorporate lymph node involvement into the criteria (as the original RECIST were focused primarily on organ site involvement; and (4) RECIST's inability to assess response to targeted noncytotoxic drugs. In response to this, the working group issued a new set of guidelines, RECIST version 1.1 (Eisenhauer et al., 2009).

RECIST 1.1 defines a measurable lesion as having a unidimensional size of 10 mm or larger on CT scan, 20 mm on chest radiograph, or 10 mm on clinical examination (measured with calipers). For a lymph node to be considered pathologically enlarged and measurable, it must be at least 15 mm in the short axis on CT scan. RECIST 1.1 advises against the use of ultrasonography to assess lesion size. It also advises against the use of tumor markers *alone* to assess tumor response, although the RECIST guidelines specifically mention the PSA response in advanced prostate cancer, as defined by the Prostate Cancer Clinical Trials Working Group (Scher et al., 2016) as a tumor marker that could be used in combination with the RECIST criteria.

RECIST 1.1 directs researchers to document at least one and up to five measurable lesions as “target lesions” to be measured at baseline and followed for the course of any study. The largest lesions should be selected as target lesions and should be selected in a way that they are both representative of all involved organs and should lend themselves to repeated measurement. The sum of the diameters of all the target lesions is measured at baseline and is then followed during the study to assess tumor response or progression. The exact criteria to define complete and partial response, stable disease, and progressive disease are presented in Table 6.1. These definitions can now be used to calculate outcomes including radiologic progression-free survival, duration of response, and overall response rate, just to name a few.

TABLE 6.1

RECIST Criteria

EVALUATION OF TARGET LESIONS	
Complete response (CR)	Disappearance of all target lesions. Any pathologic lymph nodes (whether target or nontarget) must have a reduction in short axis to <10 mm
Partial response (PR)	At least a 30% decrease in the sum of diameters of target lesions, taking as reference the baseline sum diameters.
Progressive	At least a 20% increase in the sum of diameters of target lesions, taking as

disease (PD)	a reference the smallest sum on study (this includes the baseline sum if this is the smallest on study). In addition to the relative increase of 20%, the sum must also demonstrate an absolute increase of at least 5 mm. The appearance of new lesions is considered progression.
Stable disease (SD)	Neither sufficient shrinkage to qualify for PR nor sufficient increase to qualify for PD, taking as reference the smallest sum diameters while on study.
EVALUATION OF NONTARGET LESIONS	
Complete response (CR)	Disappearance of all nontarget lesions and normalization of any tumor marker levels. All lymph nodes must be <10 mm in size along short axis.
Non-CR/Non-PD	Persistence of one or more nontarget lesion(s) and/or maintenance of tumor marker level above normal limits.
Progressive disease (PD)	Unequivocal progression of existing nontarget lesions and/or the appearance of new lesions.

From Eisenhauer EA, Therasse P, Bogaerts J, et al. New response evaluation criteria in solid tumours: revised RECIST guideline (version 1.1). *Eur J Cancer* 45(2):228–247, 2009.

Although the RECIST criteria standardize the definition of radiologic disease progression, they do not eliminate the risk for detection bias**. Detection bias occurs when one group of patients in a study is more likely to have a progression detected than the other, perhaps as a result of increased imaging or closer clinical follow-up** (Feinstein, 1987)**. Although this is less likely to occur in the setting of a prospective clinical trial (where follow-up is usually dictated by study protocol and should be similar between the two arms of the study), it is not uncommon in observational and/or retrospective studies and must be considered when reviewing the literature** (Feinstein, 1985).

Another important consideration is variation in radiologist interpretation of imaging studies. Take the example of renal calculus disease, where stone burden is relatively easily assessed with computerized tomography. There can be differences in study interpretation among radiologists and even by the same radiologist reading the study at a different date (interobserver and intraobserver variability, respectively). To quantify the degree of variability, Jewett et al had three different radiologists review post–shock wave lithotripsy CT scans of 58 patients (Jewett et al., 1992). The reviewers disagreed with each other 24% of the time and with themselves 16% of the time. This study clearly documents that radiographic outcomes after stone treatment are far less objective than one might imagine. There is no reason to believe that this is not true for other urologic conditions in which radiographic imaging is used to define outcomes. This is why many prospective clinical trials will have central review of imaging (or pathology for that matter).

Receipt of Secondary Therapy

Rates of secondary therapy are often reported as an outcome in studies of malignant urologic conditions (Grossfeld et al., 2002; Lu-Yao et al., 1996) and nonmalignant urologic conditions (McConnell et al., 2003). Although receipt of secondary therapy may seem quite easy to measure and objective at first glance, it is, in fact, subject to considerable bias. For example, consider secondary therapies for prostate cancer. If a patient undergoes surgery and is found to have high-risk disease, he may receive additional radiotherapy or hormonal ablation therapy (Thompson et al., 2006). Is this considered a secondary therapy or an adjuvant to primary treatment? **Furthermore, secondary therapies are often initiated for subjective reasons. Men who experience a biochemical recurrence after radical prostatectomy will often elect to receive hormone ablation or radiotherapy, although this “recurrence” may not be clinically meaningful** (Freedland et al., 2005). **Some researchers have referred to this as “discretionary” treatment** (Shahinian et al., 2010). Although all therapies are presumably given at the discretion of the provider, it is also assumed that the treatments given are medically necessary. In situations in which this is not clear, subjectivity and bias can come into play.

Commonly Assessed Short-Term Outcomes

Assessing Surgical Complications

One of the most commonly studied outcomes in urology is postoperative complications. A complication can be broadly defined as any occurrence that deviates from the "normal" or expected course of events after surgery. That being said, there are differing degrees of complications, and some complications may be more unexpected than others. There have been a number of standardized systems proposed for classifying surgical complications that can be used in both clinical and research settings.

Common Terminology Criteria for Adverse Events

The Common Terminology Criteria for Adverse Events (CTCAE) system was developed in the early 1980s to classify complications after treatment for cancer. It is now broadly accepted and used by the National Cancer Institute cooperative groups and industry to assess complications in clinical trials. Now in its fifth iteration, Common Terminology Criteria for Adverse Events (CTCAE) Version 5.0 uses a grading scale for each of the various organ systems from 1 to 5 to classify complications, from "mild" to "death" (U.S. Department of Health and Human Services, 2017) (Table 6.2). The system is relatively simple, which makes it well-suited for trials involving novel agents and therapies in which there is an increased risk for unexpectedly serious or life-threatening complications. That being said, it is a relatively unrefined grading system that is not specific to surgical treatment and does not have the granularity required for many comparative effectiveness studies.

TABLE 6.2

CTCAE System for Classification of Surgical and Medical Procedures

1	Asymptomatic or mild symptoms; clinical or diagnostic observations only; intervention not required
2	Moderate; minimal, local, or noninvasive intervention indicated; limiting age-appropriate instrumental ADLs
3	Severe or medically significant but not immediately life-threatening; hospitalization

	or prolongation of existing hospitalization indicated; disabling; limiting self-care ADLs
4	Life-threatening consequences; urgent intervention indicated
5	Death

ADLs, Activities of daily living; *CTCAE,* Common Terminology Criteria for Adverse Events.

Clavien-Dindo System of Classifying Complications

In 1992, Clavien et al. proposed a new grading system for the severity of complications specifically related to surgical treatments. This new framework was centered around the risk and invasiveness of the therapy required to address or treat the complication (Table 6.3). They posited that by focusing on the therapy required to treat the unexpected event, the system minimized the influence of subjective interpretation of the severity of the complication. In 2004, Dindo et al. proposed modifications of the original system, expanding it from 4 to 5 grades that contained a total of 7 possible strata (Dindo et al., 2004). This modification allowed more precise classification by capturing whether the intervention in response to the complication required the use of general anesthesia for administration and whether the complication itself led to organ failure and/or admission to an intensive care unit. This reporting system, known as the Clavien-Dindo classification system, has been extensively validated and evaluated for interobserver variability (Clavien et al., 2009).

TABLE 6.3

Clavien-Dindo Classification of Complications

GRADE	DEFINITION	EXAMPLE
I	Any deviation from the normal postoperative course without the need for pharmacologic treatment or surgical, endoscopic, or radiologic intervention. Allowed therapeutic regimens include antiemetics, antipyretics, analgesics, diuretics, and so on. This grade also includes wound infections opened at the bedside.	Prolonged postoperative ileus after cystectomy managed with observation and normal IV fluids (not total parental nutrition).
II	Any deviation from the normal postoperative course requiring pharmacologic treatment with medications/pharmacologic interventions other than those allowed for grade I	Perioperative bleeding after nephrectomy requiring blood transfusion and continued monitoring of serum

	complications.	hemoglobin without admission to an intensive care unit.
IIIa	Any deviation from the normal postoperative course requiring surgical, endoscopic, or radiologic intervention WITHOUT the need for general anesthesia.	Pelvic fluid collection after prostatectomy requiring placement of percutaneous drain in interventional radiology with local anesthesia and mild sedation only.
IIIb	Any deviation from the normal postoperative course requiring surgical, endoscopic, or radiologic intervention WITH the need for general anesthesia.	Any unplanned takeback to the operating room for any reason that requires general anesthesia.
IVa	Any life-threatening complication (including central nervous system [CNS] complications)[a] that require intermediate care/intensive care unit management. IVa is defined a single-organ dysfunction only.	Patient has an isolated myocardial infarction immediately after percutaneous nephrolithotomy that requires transfer to cardiac intensive care unit for observation and pharmacologic management.
IVb	Any life-threatening complication (including CNS complications)[a] that require intermediate care/intensive care unit management. IVb is defined a multi-organ dysfunction only.	Patient has myocardial infarction and hypotension after partial nephrectomy that results in renal failure and acute respiratory distress syndrome and is transferred to ICU for intubation, pressors, and dialysis.
V	Death of a patient.	Postoperative mortality of any type.

[a] Brain hemorrhage, ischemic stroke, subarachnoid bleeding. This excludes transient ischemic attacks (TIAs).

Modified from Dindo D, Demartines N, Clavien PA. Classification of surgical complications: a new proposal with evaluation in a cohort of 6336 patients and results of a survey, *Ann Surg* 240(2):205–213, 2004.

Although the Clavien-Dindo system, as it has come to be known, has been widely used and accepted in the past decade, it still has a number of limitations that should be acknowledged. **First, there is still an element of subjective interpretation of the severity of complications, which may introduce**

variability within the grading assignments. For example, urologists may grade a recognized rectal injury during a radical prostatectomy differently: grade 1 for prolonged hospital stay versus grade 3 for intraoperative repair under general anesthesia (Morgan et al., 2009). **Second, some interventions may be performed under local anesthesia at one institution but general anesthesia at another, which introduces interrater variability within grades 3 and 4** (Rassweiler et al., 2012)**. Third, this system may fail to capture the increased severity when two complications of the same grade occur in the same patient. Lastly, two patients with the same complication may be managed differently at two separate institutions (e.g., IVC filter vs. heparinization alone for DVT).**

Assessing Risk for Surgical Complications

A goal of many quality improvement initiatives is to identify patients at greater risk for surgical complications so one can potentially make perioperative interventions to reduce complication rates. To do this, it is critical to understand risk factors for postoperative complications. Although specific procedures carry specific risk factors, there are several clinical characteristics that apply across all surgical procedures and can predict the risk for surgical complications. These include functional status, comorbidity, and frailty (Fried et al., 2001; 2004).

Functional Status

Functional status is defined as an individual's ability to perform normal daily activities required to meet basic needs, fulfill usual roles, and maintain health and well-being (Leidy, 1994a; 1994b; Wilson and Cleary, 1995). Effectively, functional status reflects an individual's ability to perform routine activities of daily living (ADLs). The six essential ADLs include the ability to eat independently; dress; walk or transfer from one place to another; bathe; use the bathroom for toileting; and maintain good continence (Edemekong and Levy, 2019). There are a number of established tools available for determining functional status by assessing a patient's ability to perform ADLs (Buurman et al., 2011).

Assessment of functional status is of particular importance in urologic oncology trials, as it affects both inclusion criteria and outcomes (Atkinson et al., 2015). The Karnofsky Performance Scale (KPS), first developed in 1949, has been widely used in cancer studies (Karnofsky and Burchanel, 1949). Relatively simple, the KPS is scored by the treating health professional and generates a score from 100% to 0% that incorporates ADLs and overall functional status. A score of 100% represents a normal ability to work and care for one's self with no special care, and a score of 0% represents death. In between, the observer gives the patient a score based on a taxonomy that accounts for issues such as need for assistance, physical disability, hospitalization for acute illness, and so on. The KPS has been shown to perform relatively well with acceptable interobserver and intraobserver reliability (Schaafsma and Osoba, 1994; Schag et al., 1984).

Another well-known scale that is commonly used in cancer trials is the Eastern Cooperative Oncology Group (ECOG) performance scale. This scale is scored from 0 to 5, with 0 being perfectly active and 5 being dead (Oken et al., 1982). The ECOG scale has been compared with the KPS, and both perform well (Verger et al., 1992). Table 6.4 compares the elements and scoring of the KPS to the ECOG scale. In the future, wearable technologies may provide real-time data regarding functional status that could be incorporated into outcome assessment (Kelly and Shahrokni, 2016).

TABLE 6.4

Comparison of Karnofsky Performance Score to ECOG Grade

KARNOFSKY STATUS	KARNOFSKY SCORE	ECOG GRADE	ECOG STATUS
Normal, no complaints	100	0	Fully active and able to carry out all predisease performance without restriction
Able to carry on normal activities. Minor signs or symptoms of disease.	90	1	Restricted in physically strenuous activity but ambulatory and able to carry out light work/activity
Normal activity with effort	80	1	Restricted in physically strenuous activity but ambulatory and able to carry out light work/activity
Can care for self but unable to carry on normal activity or to do active work	70	2	Ambulatory and capable of all self care but unable to carry out work activities. Up and about for more than 50% of waking hours.
Requires occasional	60	2	Ambulatory and capable of all

assistance but able to care for most of one's own needs			self care but unable to carry out work activities. Up and about for more than 50% of waking hours.
Requires considerable assistance and frequent medical care	50	3	Capable of only limited self care. Confined to bed or chair more than 50% of waking hours.
Disabled. Requires special care and assistance.	40	3	Capable of only limited self-care. Confined to bed or chair more than 50% of waking hours.
Severely disabled. Hospitalization may be indicated although death not imminent.	30	4	Completely disabled. Cannot carry out self care. Totally confined to bed or chair.
Very sick. Hospitalization required. Active supportive treatment necessary.	20	4	Completely disabled. Cannot carry out self care. Totally confined to bed or chair.
Moribund	10	4	Completely disabled. Cannot carry out self care. Totally confined to bed or chair.
Dead	0	5	Dead

Modified from Oken MM, Creech RH, Tormey DC, et al. Toxicity and response criteria of the Eastern Cooperative Oncology Group, *Am J Clin Oncol* 5(6):649–655, 1982.

Comorbidity

The term *comorbidity* was originally defined by Alvan Feinstein in 1970 (Feinstein, 1970). **It refers to any coexisting ailments that may be present in addition to the disease being studied. Assessment of comorbidity is of profound importance in the study of urologic disease, as comorbid conditions are often confounding variables (as they affect treatment choice), and failure to account for them may lead to selection bias.** One of the best examples of this in urologic literature relates to transurethral resection of the prostate (TURP). Roos et al. (1989) used administrative data in the late 1980s to compare mortality after either open prostatectomy or TURP. With data from roughly 50,000 subjects and 8 years of follow-up data, they noted that men undergoing TURP were 1.45 times more likely to die in the follow-up period than those undergoing open surgery. The Roos study, however, failed to control for comorbidity in the analysis, which might have biased the findings. To address this shortcoming, Concato et al. (1992) meticulously reviewed the charts of 252 men who underwent either TURP or open prostatectomy at a single institution. They used a validated scale to collect detailed comorbidity information from the medical record and included this in their analysis. When they controlled for age and comorbidity at the time of surgery, they noted no differences in 5-year mortality between TURP and open prostatectomy. Other authors have since confirmed the findings of the Concato study (Crowley et al., 1995).

There are many standardized tools available to assess comorbid disease. The best known of these is the Charlson Combined Comorbidity Index (Charlson et al., 1987, 1994). The original Charlson Comorbidity Score was calculated as a total of the patients comorbid conditions, with some conditions being more weighted than others. Conditions that had a weight of one included: myocardial infarction, congestive heart failure, peripheral vascular disease, cerebrovascular disease, dementia, chronic pulmonary disease, connective tissue disease, peptic ulcer disease, mild liver disease, and diabetes. Conditions that had a weight of two included: hemiplegia, moderate or severe renal disease, diabetes with end organ damage, and any malignancy. Moderate to severe liver disease was given a weight of three, and metastatic cancer or full-blown acquired immunodeficiency syndrome was given a weight of six. The scale was developed to predict 1-year mortality in patients to an inpatient medical service (Charlson et al., 1987) but later was shown to predict 3- to 5-year mortality outcomes in patients undergoing general surgery procedures (Charlson et al., 1994). The scale has since been modified into a short-form (Dell'Oglio et al., 2017) and into a scale that can be used in administrative datasets (Deyo et al., 1992). In addition to the Charlson scale, a number of other validated and reliable comorbidity scales have been used in urologic disease (Klabunde et al., 2000; Litwin et al., 2007; Stier et al., 1999).

Frailty

Frailty is a clinically recognizable state of increased vulnerability resulting from an aging-associated decline in reserve and function across multiple physiologic systems (Xue, 2011). Frailty is associated with increased falls, hospitalization, disability, and mortality (Bandeen-Roche et al., 2006; 2015; Fried et al., 2001; Gill et al., 2006).

Fried et al. operationally defined frailty as a condition in which three of the five following criteria are present: low grip strength, low energy, slowed walking speed, low physical activity, and/or unintentional weight loss (Fried et al., 2001, 2004). Using this definition, they showed that frailty was independently predictive of incident falls, declining functional status, hospitalization, and death in a cohort of patients in the Cardiovascular Health study followed for 3 years (Fried et al., 2001). The Fried definition has since been shown to predicted postoperative complications, length of stay, and discharge to a skilled nursing facility in a cohort of 594 patients presenting for elective surgery (Makary et al., 2010). Frailty has been shown to correlate with surgical outcomes after various urologic procedures including cystectomy (Pearl et al., 2017; Sathianathen et al., 2018), prostatectomy (Levy et al., 2017), and surgery for pelvic organ prolapse (Suskind et al., 2017). As such, it should be controlled for in nonrandomized studies of urologic diseases.

Pain

Postoperative pain is a common endpoint in surgical trials. There are three approaches to pain assessment in research and/or clinical practice. First, one can obtain verbal or written descriptions of the pain. Another approach is to rate the pain via its effect on the observable behavior of the person experiencing it. This can be done by the patient or by an observer. The third approach, which is done almost exclusively in the laboratory setting, is to have the patient compare the pain from his or her condition to an experimentally induced pain stimulus of a known intensity. Most pain assessment in urology is performed using the first approach, that is, having the patient provide a verbal or written description or rating of his or her pain. In the research setting, it is desirable to use one of the many established and validated instruments to capture the patients pain experience, as the findings can be used in statistical analysis.

One way to assess pain is to measure the number of pain pills a patient takes and convert this into “oral morphine equivalents” (McDowell and Newell, 1996). Although this may seem quite objective and unlikely to be subject to bias, further review reveals that this is not the case. Some patients may have a higher “pain tolerance” and will be reluctant to take pain medications, despite considerable discomfort. To this end, it is probably best to directly query patients regarding the severity of the pain they are experiencing. On approach is to ask patients to rate their pain using a series of subjective expressions varying from “no pain at all” to “worst pain imaginable” (McDowell and Newell, 1996). Although this is often enough for clinical care, it is difficult to incorporate this into research. One of the simplest yet most effective ways of capturing pain levels in both the research and the clinical setting is to use of a visual analog scale (VAS). A VAS is usually portrayed as a straight line (usually 10 cm long) which represents a continuum on which the pain is rated. The two ends are usually anchored with one end being “pain as bad as it could be” and the other being “no pain.” The subject marks a spot on the line, and the distance from one end to this mark is measured in millimeters and recorded from 0 to 100, which is then considered the pain score (Scott and Huskisson, 1976). Other authors have used variations of this grading system, providing a numerical scale from 0 to 10 (Downie et al., 1978) or inserting descriptive terms such as *severe, moderate*, or *mild* along the line (Scott and Huskisson, 1976). In addition to the VAS, there are a number of multiple-item pain questionnaires that can be used in the study of urologic conditions. These include the 20-item McGill Pain Questionnaire (Melzack, 1975) and the 20-item Brief Pain Inventory (Cleeland and Ryan, 1994; Cleeland et al., 1994). More recently, the National Institutes of Health PROMIS program also developed a validated and reliable item bank of pain-related questions (Revicki et al., 2009). These questionnaires capture the pain experience in much greater detail and lend themselves to use in clinical research.

Patient-Reported Outcomes

The goal of many urologic interventions is to relieve symptoms caused by benign or malignant conditions. **Although symptoms can affect quality of life, symptom assessment is inherently different than health-related quality-of-life assessment** (Gill and Feinstein, 1994)**. Health-related quality of life (HRQoL) is a patient-reported outcome that encompasses the global impact of disease and disease treatment on a patient's well-being and his or her ability to function in daily life** (Wan et al., n.d.). A key element of HRQoL that distinguishes it from a symptom scale is the inclusion of function and bother elements. In other words, the survey captures not only the degree of symptoms a patient has, but also how much of a problem this is for the individual (Gill and Feinstein, 1994). HRQoL is discussed in much greater detail later in this chapter. When specifically assessing patient-reported symptoms, it is important to remember that symptoms are the physical manifestations of a condition or disease. To this end, they can be assessed a variety of ways, depending on the condition of interest and the nature of the symptom.

One common error that clinicians make is to believe that they can assess patient-centered outcomes from their clinical interaction with the patient. This often leads to unreliable results and introduces considerable bias into any study, as patients often minimize their symptoms to please their treating physicians and/or physicians fail to capture the true severity of the patient's symptoms. To document this, Litwin et al. compared patient report of symptoms using a well-known validated and reliable survey tool to their physician's estimates of the patient's symptoms (Litwin et al., 1998a, 1998b). The treating physicians consistently underestimated the degree of urinary, sexual, and bowel dysfunction the patient experienced, in addition to underestimating the degree of fatigue and bony pain. This study and others (Bennett et al., 1997) underscore the need to collect these data directly from the patient.

Methods of Assessing Patient-Reported Outcomes

There are generally two methods for assessing patient-reported outcomes: patient-completed questionnaires and researcher-administered interviews.

Because interviews are time and labor intensive, questionnaires (also referred to as *surveys* or *instruments*) are typically preferred. Instruments are usually inexpensive, practical, and easy to administer. That being said, these instruments require a rigorous process of development and implementation to ensure they accurately capture what the researchers intend to capture.

Instrument development is a multistep process that begins by determining what patient-reported outcomes the developers wish to measure, then generating and assembling questions into a single instrument and finally performing a psychometric analysis (Vickery et al., 2001). Question, or item, development ideally involves input from multiple perspectives, such as physicians, patients, epidemiologists, and psychologists and usually includes a literature review of existing tools to identify if validated surveys already exist in the space. Initial pilot testing of proposed surveys is also performed to identify readability and redundancy of the new tool (Sung et al., 2016).

Item responses are recorded on either a Likert scale, in which several answer options are presented in a categorical fashion, or a visual analog scale, where patients mark their answer along a continuum between two ends of a spectrum (Voutilainen et al., 2016). Most patient-reported outcomes tools use Likert scales because of easier data capture and simplicity of answering. There are several factors to consider in instrument development. Each item must be written below an eighth-grade reading level, free of abbreviations and complex terms, and contain only one question to ensure patient comprehension (Paasche-Orlow et al., 2003). There is generally a trade-off between breadth (number of domains) and depth (number of items) of assessment. To minimize patient burden, a balance must be struck between the two, with a possible bias toward breadth given the uncertainty of the impact of a disease or treatment (Ware, 1984).

Traditionally, once a preliminary tool has been created, it undergoes psychometric analysis to assess its measurement properties (Nunnally, 1978; Rothrock et al., 2011). **Instruments are tested for the psychometric properties of reliability and validity. Reliability refers to the instrument's precision, or freedom from measurement error.** A number of different measures of reliability are usually assessed. The two most common are internal consistency and test-retest. Internal consistency reliability is the amount of internal agreement among items (Streiner, 2003). For instance, all items intended to measure functional status should score similarly and correlate highly. The goal is to strike a balance between precise measurement of a particular concept without too many items assessing the same theme. Internal consistency reliability is quantified with Cronbach's coefficient alpha (Cronbach, 1951). A value of greater than 0.7 indicates good reliability; however, if it is too high (>0.9), the instrument may have excessive homogeneity suggesting item redundancy. Test-retest reliability represents how reproducible an instrument's results are over time (Litwin, 1995). It is usually measured by administering the instrument to the same subject within a relatively short time span, often a matter of weeks. The time span should be short enough so it is unlikely for the patient's experience to change but long enough so that the instrument seems “fresh” to the patient. Test-retest reliability is quantified using the correlation coefficient statistic, with greater than 0.7 considered highly reliable (Litwin, 1995).

If reliability assesses how reproducible an instrument's results are, validity assesses how well an instrument measures the patient experience it is intended to measure (Nunnally, 1978). Because validity varies based on the context and population for which it is used, it must be assessed separately for different clinical scenarios. For example, an instrument validated to measure incontinence symptoms in neurogenic bladder patients may not accurately measure the same symptoms in prostate cancer patients and, to this end, it should be validated in this second population before it is used in prostate cancer studies (Reeve et al., 2007). There are three types of validity: face, construct, and criterion. Face validity, also known as *content validity,* is a subjective assessment of how well the instrument measures the outcome it is designed to assess. It represents the general impression of experts in the field as to whether the instrument includes necessary items and does not include irrelevant ones (Gill and Feinstein, 1994). Criterion validity is best defined as the correlation between the instrument’s results and those of an accepted “gold standard” or “objective” measure (American Psychological Association, 1974). For example, one might correlate the findings of a new instrument to assess bladder outlet obstruction symptoms with uroflowmetry results. An instrument is highly valid if it scores similarly and correlates highly (r >0.7) with the gold standard. Finally, construct validity is a retrospective assessment of how well an instrument measures what it was designed to measure. Construct validity represents a “gestalt” around instrument performance and can be difficult to assess and often takes years of instrument use before establishing. Two methods for evaluating construct validity are convergent and divergent validity (Parkinson and Konety, 2004). Convergent validity is established when different instruments designed to theoretically measure the same concept are compared and obtain similar results. Conversely, divergent validity is established when instruments measuring unrelated concepts have opposite results. Correlation coefficients are usually used to assess construct validity (Litwin, 1995).

A key characteristic of patient-reported outcomes tools that is often poorly assessed is instrument responsiveness, or how well it detects a clinically meaningful change over time. For some commonly used instruments in urology, this has been studied and is well documented. For example, the smallest clinically meaningful difference in American Urological Association-Symptom Index scores has been studied has was noted to be 3.1 points (Barry et al., 1995b). For many other commonly used instruments in urology, clinically meaningful differences have not been studied or clearly determined. In these cases, although there is no number universally regarded as clinically meaningful, setting the clinically meaningful difference to at least one-half the instrument's standard deviation is a good rule of thumb (Norman et al., 2003).

Specific Symptom Scales

Lower Urinary Tract Symptoms

Valid assessment of lower urinary tract symptoms (LUTS) is critical as these symptoms are seen in many urologic conditions. As such, there are a number of symptom indices that have been shown to be valid and reliable for the assessment of LUTS. Although many of these scales were originally developed for use in men with benign prostatic hyperplasia, they have since been used in women with LUTS and have been found to be valid in both genders (Zhang et al., 2017). **The best LUTS symptom scale is the I-PSS (International Prostate Symptom Score), also know is the American Urological Association (AUA) Symptom Score** (Barry, et al., 1992). The I-PSS is a seven-item survey designed to assess symptom severity in patients with benign prostatic hyperplasia (BPH) (Barry et al., 1992a, 1992b). Although the tool is quite effective in capturing the objective degree of LUTS severity, (Barry, et al., 1995b), it does not really capture the impact of symptoms on quality of life. To this end, the I-PSS is often given in conjunction with the BPH impact index (BII), which consists of four items designed to measure the specific impact of LUTS on general HRQoL (Barry et al., 1995a). The BII has been shown to correlate with a number of general HRQoL instruments, including the general health index and the mental health index of the SF-36 HRQoL instrument (Barry, et al., 1992b).

Although these instruments are the most commonly used LUTS scales and have been used in a number of large, well-known randomized clinical trials to assess the response of LUTS to therapy (Lepor et al., 1996; McConnell et al., 1998, 2003), there are a number of other questionnaires that have been shown to function well in patients with lower urinary tract symptoms. The International Continence Society (ICS) short form ICSmale questionnaire consists of 11 questions (Donovan et al., 1996, 2000). It has the advantage of generating separate voiding and continence summary scores, which may be useful to some researchers. Finally, the DAN-PSS-I (Danish Prostatic Symptom Score) is a 12-item questionnaire that assesses function and bother related to a series of urinary symptoms (Meyhoff et al., 1993). This instrument is unique in that the final score is weighted by the degree of dysfunction and patient-perceived bother. The choice of which symptom scale to use is best driven by the research questions under study. A brief description of the available instruments to assess LUTS specifically in men is presented in Table 6.5.

TABLE 6.5

Selected Patient-Reported Outcomes Tools for Use Primarily in Men With Lower Urinary Tract Symptoms

INSTRUMENT	LEAD AUTHOR, YEAR	NUMBER OF ITEMS	DESCRIPTION
International Prostate Symptom Score (I-PSS)	Barry et al., 1992a	7	Also known as the AUA symptom score, functional scale scored from 0–35; gold standard for patient-reported outcomes in BPH
BPH Impact Index (BII)	Barry et al., 1995a	4	Assesses impact of BPH on quality of life
ICSmale questionnaire	Donovan et al., 2000	11	Assesses voiding and continence separately
Danish Prostatic Symptom Score (DAN-PSS-I)	Meyhoff et al., 1993	12	Generates a weighted score that accounts for urinary function and personal preferences
ICIQ-Nocturia Quality of Life Question (ICIQ-Nqol)	Mock et al., 2008	12	Tested in both men and women. Focuses on two thematic areas only. There is also a single item (in addition to the 12 in the primary instrument) that addresses bother caused by nocturia.

Urinary Incontinence

Although incontinence is certainly a lower urinary tract symptom in and of itself, there are a number of symptom scales designed specifically to assess this common constellation of symptoms in urologic patients. Incontinence can sometimes be documented in the office setting and/or during urodynamics, but this is not always feasible. Furthermore, assessment of incontinence in these settings often does not capture the severity of symptoms to the degree required in the research setting. The clinic and/or urodynamics suite is a somewhat artificial environment, and the fact that incontinence cannot be documented in the clinic does not mean that the patient does not experience leakage at home, work, and so on.

Some researchers have suggested the use of a pad test as a more objective way to assess the severity of urinary incontinence during the usual ADLs (Nygaard, 2004). The patient weighs pads over the course of a day and reports this back to the clinician giving a more quantifiable and objective measure of the degree of incontinence. Although this may be the case, there may also be differences in the way patients use pads, leakage around the pads, and other factors that influence the results of a pad test. In addition, the optimal duration of the pad test to reliably capture the degree of incontinence is unclear. Studies have shown that there is no correlation between 1-hour and 48-hour pad tests. It is clear that longer pad tests produce more reproducible results. In one study, the correlation coefficient between leakage observed in two 24-hour pad tests was 0.66 (Victor et al., 1987). This increased to 0.90 when two 48-hour tests were compared, supporting the need for a longer duration for pad testing (Jorgensen et al., 1987). **It is important to note that the pad test neither distinguishes between urge and stress incontinence nor captures the degree of bother experienced by patients. Two patients may have equal degrees of leakage, yet one is much more limited and bothered by the incontinence than the other. To this end, patient-reported measures are really required to comprehensively understand outcomes related to urinary incontinence.**

There are numerous instruments available for use in incontinence, many of which are geared toward use in women, but some can be used in both genders. The BFLUTS (Bristol Female Lower Urinary Tract Symptoms) instrument is a modified version of the ICSmale survey questionnaire (Jackson et al., 1996, Brookes et al., 2004), The BFLUTS contains 33 items that address urinary incontinence, voiding symptoms in the voiding and storage phases, sexual function, and other aspects of quality of life. The BFLUTS tool goes beyond simple symptom assessment as it captures both function and bother in the urinary domain, making it more of a disease-specific HRQoL tool. It, however, has been used sparingly in men (Heidler et al., 2010).

Similar to the BFLUTS instrument, The IIQ (Incontinence Impact Questionnaire) and the UDI (Urogenital Distress Inventory) are two of the common questionnaires for use in incontinence that, when used together, capture disease-specific HRQoL in this condition (as they capture both function and bother). Developed in the mid-1990s, the original versions of these questionnaires were specifically designed for use in women and were relatively long (roughly 53 items combined) (Shumaker et al., 1994). This was remedied with the development of short-form versions of these questionnaires, the IIQ-7 and the UDI-6 (Uebersax et al., 1995). The shortened surveys focus specifically on the severity and impact of urinary urgency, frequency, and incontinence. Although not originally developed for men, the IIQ-7 and UDI-6 have since been used in a population of older men and performed well (Beaulieu et al., 1999; Coyne et al., 2006; Moore and Jensen, 2000; Moore et al., 1999). These tools have also been modified to focus more on urge incontinence. Lubeck et al. developed modified versions of the IIQ and UDI, known as the U-IIQ (Urge-Incontinence Impact Questionnaire) and the U-UDI (Urge-Urinary Distress Inventory) for use in patients with overactive bladder (OAB) and predominantly urge incontinence (Lubeck et al., 1999). The U-IIQ and the U-UDI are longer (42 items) than the IIQ-7 and UDI-6 and comprehensively capture the severity of urge symptoms and their impact on travel, feelings, physical activities, relationships, and sexual function. The instrument has good psychometric properties and appears to capture most of the psychosocial concerns of patients with urge incontinence and overactive bladder.

Other surveys for use in incontinence tend to focus less on symptoms and functional status and more on the impact of urinary symptoms on quality of life and daily activities. For example, Kelleher et al. developed a 21-item survey, known as the King's Health Questionnaire, to assess HRQoL in incontinent women (Kelleher et al., 1997). Although this questionnaire assesses urinary symptoms and severity of incontinence, it also focuses on general health, incontinence impact, role limitations, physical limitations, social limitations, personal limitations, emotional problems, and sleep disturbances. This makes it more of a HRQoL instrument than a simple symptom scale. It has been shown to be valid and reliable, and it correlates well with outcomes from the SF-36 (Kelleher et al., 1997).

Finally, in the area of urinary incontinence, there are tools that focus exclusively on disease impact and quality of life and do not capture symptoms at all. For example, Patrick et al. (1999) developed the I-QOL (Incontinence Quality of Life), a 22-item questionnaire that assesses avoidance and limiting behavior because of incontinence, social embarrassment, and psychosocial impact of incontinence. This instrument has been tested in both sexes and has been cross-culturally adapted for use in numerous countries in various languages. It does not capture symptom severity, and this should be captured using an additional method (e.g., pad tests, voiding diaries, or symptom scales). A general overview of available patient surveys for assessing urinary incontinence outcomes is presented in Table 6.6.

TABLE 6.6

Selected Patient-Reported Outcomes Tools for Use Primarily in Women With Urinary Incontinence

INSTRUMENT	LEAD AUTHOR(S), YEAR(S)	NUMBER OF ITEMS	DESCRIPTION
Bristol Female Lower Urinary Tract Symptoms (BFLUTS) Questionnaire	Jackson et al., 1996	33	Designed specifically for female incontinence; assesses numerous domains included quality of life.
International Consultation on Incontinence Questionnaire-Female Lower Urinary Symptoms (ICIQ-FLUTS)	Brookes et al., 2004	12	Modified from the BFLUTS. The instrument was reduced to 12 items and also contains an additional 7 items, 2 of which deal with sexual function and 5 of which deal with quality of life.
Incontinence Impact Questionnaire (IIQ) and Urogenital Distress Inventory (UDI)	Uebersax et al., 1995; Shumaker et al., 1994	53	Captures function and bother caused by incontinence and other voiding problems, originally intended for use by females only, shortened versions (IIQ-7 and UDI-6) are available.
Urge-Incontinence	Lubeck et al.,	42	Similar to the IIQ and UDI but heavily

Impact Questionnaire (U-IIQ) and Urge-Urinary Distress Inventory (U-UDI)	1999		weighted to assess the impact of urgency and overactive bladder symptoms on urinary function and quality of life.
King's Health Questionnaire	Kelleher et al., 1997	21	Assesses outcomes in 10 domains and has been used in numerous clinical trials.
Incontinence Quality of Life (I-QOL) Instrument	Patrick et al., 1999; Wagner et al., 1996	22	Assesses impact of incontinence on health-related quality of life (HRQoL) in 3 domains, does not assess function.
Overactive Bladder Questionnaire (OAB-Q)	Coyne et al., 2004	32	Includes an 8-item symptoms bother scale and 25 health-related quality-of-life items. Generates 6 subscale scores from 0–100, with 100 being better quality of life/outcomes.
International Consultation on Incontinence Questionnaire (ICIQ)	Avery et al., 2004	4	Consists of 3 scored items that assess how often the subject experiences urinary leakage, how much leakage the patient thinks she experiences, and how much it interferes with everyday life. The fourth item is descriptive and attempts to determine what activities cause leakage.
Symptom Severity Index (SSI) and Symptom Impact Index (SII)	Black et al., 1996	16	Primarily designed for women with stress incontinence. The SSI consists of 13 items designed to assess symptom severity, including how often the subject leaks and what activities they were doing when they did leak. The SII includes 3 items that assess the amount of bother and worry the symptoms cause.
CONTILIFE	Amarenco et al., 2003	28	Validated in women with incontinence in 5 languages. Generates a global HRQoL score and 6 subscale scores from 0–100, with 100 being poorer quality of life.

Sexual Dysfunction

Assessing sexual function outcomes is particularly challenging for a number of reasons. First, there are obvious gender differences that often prevent researchers from using the same end point when assessing response to treatment. Beyond the obvious gender differences, there are numerous additional issues that make outcomes assessment challenging. First, many individuals judge sexual function in the context of relations with a partner. This can make outcomes assessment difficult in patients who do not have a regular partner or voluntarily choose to be sexually inactive. Even when researchers use outcomes that are not dependent on the presence of a partner, subjects may be reluctant to honestly report their function for fear of embarrassment. Importantly, sexual function is multidimensional and encompasses libido, arousal, erection (men), and ejaculation/orgasm. A problem in any of these areas can be perceived as sexual dysfunction and can cause bother for patients.

One might suggest that the best way to assess sexual function outcomes is to use "objective" physiologic tests, such as nocturnal penile tumescence or duplex Doppler ultrasonography (at least in male sexual dysfunction). Unfortunately, these objective studies can also be problematic, as they are usually performed in "clinical" environments, which may not reflect what the patient is experiencing at home on a daily basis. In addition, they may not accurately assess the degree of dysfunction in subjects with psychogenic etiologies (Blander et al., 1999). **To this end, patient-reported outcomes are crucial when assessing sexual function. Although this also has its problems, when done properly, patient survey instruments for use in sexual dysfunction can be expected to obtain valid and reliable outcomes.**

There are more than 20 validated instruments for male sexual dysfunction in addition to a number of additional questionnaires for which there are no published psychometric data available, most of which focus on sexual dysfunction as it relates to both the patient and his partner (Arrington et al., 2004). This may affect the utility of many of these tools when patients do not have a partner. There are few tools that assess sexual function outcomes independent of the role of the partner. One, the EDITS (Erectile Dysfunction Inventory of Treatment Satisfaction) (Althof et al., 1999) does not require a partner and may be useful for assessing response and satisfaction with treatment. EDITS, however, is not intended for use in patients before they are treated or if they elect no therapy, which may limit its utility. In summary, there is no perfect tool of outcomes assessment in male sexual dysfunction, and clinicians and researchers should choose instruments based on the particular clinical setting of

interest and the question they wish to answer.

To comprehensively capture outcomes in male sexual dysfunction, instruments should assess results in various domains, including libido, erection, and orgasm/ejaculation. The International Index of Erectile Dysfunction assesses outcomes in all of these domains and has become the gold standard instrument for assessing outcomes in male erectile dysfunction. This questionnaire includes 15 items, has been shown to be psychometrically sound, and has been used in numerous clinical trials (Rosen et al., 1997). The five items that deal specifically with erectile dysfunction (ED) have been separately validated and are often referred to as SHIM (Sexual Health Inventory for Men) (Cappelleri and Rosen, 2005; Cappelleri et al., 2000). This shortened instrument has also been used in numerous studies, as have some of the individual items from the questionnaire (Barqawi et al., 2005; Mulhall et al., 2004).

Although the SHIM is a concise measure of erectile function that can be successfully used to assess potency in clinical studies, it fails to capture the bother associated with erectile dysfunction, and, as such, it does not truly assess HRQoL changes related to erectile dysfunction. There are, however, a number of instruments that more comprehensively capture HRQoL outcomes in this common condition (Latini et al., 2002; Wagner et al., 1996). An overview of commonly used instruments for assessment of outcomes in male sexual dysfunction is presented in Table 6.7.

TABLE 6.7

Selected Patient-Reported Outcomes Tools for Use in Men With Sexual Dysfunction

INSTRUMENT	LEAD AUTHOR, YEAR	NUMBER OF ITEMS	DESCRIPTION
International Index of Erectile Function (IIEF)	Rosen et al., 1997	15	Gold standard for patient reported outcomes in male sexual dysfunction; generates scores in erection, libido, and orgasm domains.
Sexual Health Inventory for Men (SHIM)	Cappelleri et al., 2005	5	Consists of the 5 IIEF items that address erection.
QOL-MED	Wagner et	18	Assesses HRQoL impact of erectile

	al., 1996		dysfunction (ED) but assumes a partner is present and that the subject is heterosexual.
Psychological Impact of Erectile Dysfunction (PIED) scale	Latini et al., 2002	16	Examines impact of ED on sexual life and overall emotional state; function not assessed.
Index of Premature Ejaculation (IPE)	Althof et al., 2006	10	Focused on ejaculatory function. Generates scores in three domains: control, sexual satisfaction, and distress.
Sexual Quality of Life for Men (SQOL-M)	Abraham et al., 2008	11	Addresses ejaculatory and ED but not libido issues. Correlates well with the overall satisfaction domain of the IIEF.

In contrast with male sexual dysfunction, there are considerably fewer tools for assessing outcomes in female sexual dysfunction (FSD). The BISF-W (Brief Index of Sexual Function for Women) is a 22-item self-report questionnaire (Taylor et al., 1994). The three domains assessed are sexual interest/desire, sexual activity, and sexual satisfaction. When originally developed, there was no single summary score. However, Mazer et al. modified the BISF-W to provide an overall composite score to facilitate use of the instrument in clinical trials (Mazer et al., 2000). The Female Sexual Function Inventory is a 19-item questionnaire that generates scores in the six domains of lubrication, arousal, desire, pain, orgasm, and satisfaction (Meston, 2003; Rosen et al., 2000). It also creates a summary score that can be used in clinical trials. This instrument has been used in a number of studies to date (Padma-Nathan et al., 2003; Salonia et al., 2004).

The DISF (Derogatis Interview for Sexual Functioning) is a unique tool that combines an interview and a self-report questionnaire to evaluate female sexual function (Derogatis, 1997). Each part takes about 15 to 20 minutes to administer. A total of 25 questions in the two parts assess the five domains of sexual cognition and fantasy, sexual arousal, sexual behavior and experiences, orgasm, and sexual drive and relationship. Because of the interview component, this tool has not been widely used and probably is not of value in the clinical urology setting. However, it also provides a more comprehensive portrait of the psychosocial aspects of FSD and may be useful for assessing outcomes in the research setting. In summary, the DISF is probably not needed for most simple studies of FSD. A summary of the available patient-reported measures for use in female sexual function is presented in Table 6.8.

TABLE 6.8

Selected Patient-Reported Outcomes Tools for Use in Females With Sexual Dysfunction (FSD)

INSTRUMENT	LEAD AUTHOR, YEAR	NUMBER OF ITEMS	DESCRIPTION
Brief Index of Sexual Function for Women (BISF-W)	Taylor et al., 1994	22	Assesses female sexual function in 3 domains of interest, activity, and satisfaction
Female Sexual Function Inventory (FSFI)	Rosen et al., 2000	19	Measures outcomes in 6 domains and generates a summary score, becoming the most widely accepted tool in FSD
Derogatis Interview for Sexual Functioning (DISF)	Derogatis, 1997	25	Incorporates an interview and a questionnaire; assesses outcomes in 5 domains

Health-Related Quality of Life

The primary goal of many urologic interventions is to improve patients' quality of life. To this end, researchers need to be able to assess this outcome objectively and accurately. Advances in the assessment of HRQoL over the past three decades have made this possible. HRQoL refers specifically to the elements of a patient's life and existence that are specifically affected by their health status**. It is a broad and multidimensional construct that is difficult to define. HRQoL has been described as a "patient's appraisal of and satisfaction with their current level of functioning as compared to what they perceive to be possible or ideal," and the extent to which "medical interventions impact the functional, psychological, social and economic life" of a patient** (Aaronson et al., 1986; Cella and Tulsky, 1990). In fact, Calman simply defined HRQoL as the gap between a patient's expectations and experiences (Calman, 1984). Components of HRQoL include health perceptions, function, patient preferences, and overall patient satisfaction with care received. Many elements of human experience affect well-being and quality of life, including access to adequate food and shelter, personal responses to illness, and activities associated with professional responsibilities (Patrick and Erickson, 1993).

As mentioned earlier, any assessment of HRQoL should include both a relatively objective assessment of a patient's function coupled with the amount of bother a patient experiences caused by any decrements in their functional status (Gill and Feinstein, 1994). HRQoL instruments can be general or disease-specific in nature (Patrick and Deyo, 1989). General HRQoL instruments assess domains of quality of life that are common in all patients, regardless of the disease process (e.g., functional well-being, emotional well-being, overall health status). Disease-specific HRQoL instruments focus on domains of quality of life that are highly relevant to individuals who suffer from the particular disease process being studied. For example, patients with invasive bladder cancer may be concerned with body image, and sexual and urinary function, and a bladder cancer–specific HRQoL instrument would assess these areas. A listing of some of the available general and disease-specific HRQoL instruments that have been used in studies of urologic conditions is included in Table 6.9.

TABLE 6.9

Selected Health-Related Quality of Life Instruments That Have Been Used in Urologic Diseases

INSTRUMENT	LEAD AUTHOR, YEAR	NUMBER OF ITEMS
GENERAL (GENERIC) HRQoL MEASURES		
Medical Outcomes Study (MOS) SF-36	Ware et al., 1992	36
Medical Outcomes Study (MOS) SF-12	Ware et al., 1996	12
Nottingham Health Profile (NHP)	Moinpour et al., 1989	38
Quality of Well-being Scale	Kaplan et al., 1976	24
Sickness Impact Profile	Bergner et al., 1981	136
EuroQol EQ-5D	Brazier et al, 1993	5 (and VAS)
CANCER-SPECIFIC HRQoL MEASURES		
Functional Assessment of Cancer Therapy—General (FACT-G)	Cella et al., 1993	28
European Organization for Research and Treatment of Cancer Quality of Life Questionnaire (EORTC-QLQ)-C30	Aaronson et al., 1993	30
Functional Living Index-Cancer (FLIC)	Schipper et	22

	al., 1984	
Cancer Rehabilitation Evaluation System—Short Form (CARES-SF)	Ganz et al, 1992	59
PROSTATE CANCER–SPECIFIC MEASURES		
FACT-Prostate (FACT-P)	Esper et al., 1997	47
University of California, Los Angeles (UCLA) Prostate Cancer Index	Litwin et al., 1998a	20
Prostate Cancer Specific Quality of Life Instrument (PROSQOLI)	Stockler et al., 1999	10
Prostate Cancer Treatment Outcome Questionnaire (PCTO-Q)	Shrader-Bogen et al., 1997	41
Expanded Prostate Index Composite (EPIC)	Wei et al., 2000	36
Patient ORiented Prostate Utility Scales (PORPUS)	Krahn et al., 2013	10
BLADDER CANCER–SPECIFIC MEASURES		
FACT-Vanderbilt Cystectomy Index (FACT-VCI)	Anderson et al., 2012	17
Bladder Cancer Index (BCI)	Gilbert et al., 2007	34
FACT-BL	Månsson et al., 2002	40
European Organization for Research and Treatment of Cancer Quality of Life Questionnaire—Muscle Invasive Bladder Cancer (EORTC QLQ-BLM-30)	Pavone-Macaluso et al., 1997	30
European Organization for Research and Treatment of Cancer Quality of Life Questionnaire—Superficial Bladder Cancer (EORTC QLQ-BLM-24)	Pavone-Macaluso et al., 1997	24
SELECTED OTHER UROLOGIC DISEASE-SPECIFIC MEASURES		
National Institutes of Health Chronic Prostatitis Symptom Index (NIH-CPSI)	Litwin et al., 1999	9
O'Leary-Sant Interstitial Cystitis Symptom Index and Problem Index (OSICSI-PI)	O'Leary et al., 1997	23
Wisconsin Stone QOL	Penniston et al., 2017	28
European Organization for Research and Treatment of Cancer Quality of Life Questionnaire—Renal Cell Carcinoma (EORTC QLQ-RCC10)	Beisland et al., 2016	10
Functional Assessment of Cancer Therapy—Kidney	Cella et al.,	15

Symptoms Index (FKSI-15)	2006	

Other Outcomes of Interest in Urology

Patient Satisfaction

Over the past decades, there has been increased focus on patient satisfaction with their health care. General patient satisfaction with health care has been used as an outcome in various studies of urologic disease (Kaye et al., 2017; Schoenfelder et al., 2014; Shirk et al., 2016). Perhaps more importantly, however, patient satisfaction scores on the Hospital Consumer Assessment of Healthcare Providers and Systems (HCAHPS) has been tied to hospital reimbursement by Medicare, with hospitals realizing or losing up to 1.5% of their Medicare reimbursements based on these scores. The HCAHPS survey contains 27 items that query recently discharged patients about their hospital stay. The survey contains 18 core questions about critical aspects of patients' hospital experiences (communication with nurses and doctors, responsiveness of hospital staff, cleanliness and quietness of the hospital environment, pain management, communication about medicines, discharge information, overall rating of hospital, and if they would recommend the hospital). The survey also includes four items to direct patients to relevant questions, three items to adjust for the mix of patients across hospitals, and two items that support Congressionally-mandated reports (Centers for Medicare and Medicaid Services, n.d.). There are a number of general patient-satisfaction surveys available for research use, although few if any are focused specifically on urologic disease (Ware and Hays, 1988; Wiggers et al., 1990; Woodward et al., 2000).

Health Care Costs

There is increased focus on the economic costs of health care, as demand for health care outstrips available resources. Accurate cost data have proven difficult to collect because of differences in prices across countries and within regions of the same country, the proprietary nature of economic data, and the fact that different elements of health care costs are borne by different entities (i.e., the patient, the insurer, the employer, the government). Acknowledging this, it is possible to divide the cost of a health care intervention into three components: direct costs, indirect costs, and intangible costs.

Direct costs consist of the actual costs of delivering the intervention. These include inpatient and outpatient services (which includes professional fees, staffing costs, equipment costs, and so on), pharmaceuticals, and other expenses directly related to the delivery of health care. These costs are often difficult to ascertain as mentioned earlier. Traditionally, these costs have been gleaned from administrative databases and/or hospital chargemasters, which may not be accurate (Brill, 2013). One approach to assessing direct costs is to use time-driven activity-based costing (TDABC). This was originally proposed for use in health care by Kaplan and Porter. TDABC consists of identifying the potential clinical path a patient can take during his or her care and then meticulously identifying both the costs of all health care resources consumed and the amount of time spent at each step in pathway (Kaplan and Porter, 2011; Porter, 2010). Although this technique may seem difficult (and perhaps it is), it has already been successfully employed in urology to identify the cost of delivering prostate cancer care (Laviana et al., 2016).

Indirect costs include lost wages to the patient and his or her caregivers and other potential opportunity costs. This is obviously dependent on the age of the patient and his or her social support status, in addition to the severity and length of the condition the patient is suffering from (Finkelstein and Corso, 2003; Gold et al., 1996). Finally, intangible costs consist of the monetary value of pain and suffering, anxiety, and costs to society. These are very difficult to measure and are not usually included as endpoints in clinical research studies.

Key Points

- The effectiveness of health services delivery and treatment can be measured across three distinct dimensions: structure, process, and outcomes. Structure and process measures are easier to assess, but outcomes tend to be most meaningful to clinicians and patients.
- Mortality is the “hardest” endpoint one can assess in urology. That being said, it can be subject to bias. Specifically, studies using overall mortality can still be subject to lead- and length-time bias, and studies using disease-specific mortality may be subject to attribution bias.
- Although there are many proxy endpoints in urology, few meet all four requirements for being a valid surrogate endpoint. Despite this, urologists routinely use proxy endpoints in research and clinical practice.

- There are a number of published and widely accepted criteria for defining disease progression and surgical complications in urology. Although urologists should use these reporting systems whenever possible, they should also remember that use of these systems does not completely eliminate the potential for bias in research because of study design and other factors.
- Frailty, functional status, and comorbidity are important potential confounders that should be considered in urologic research. There are numerous standardized tools available to capture these variables.
- There are numerous patient-reported outcomes tools available to assess symptoms and quality of life in patients with urologic diseases. Physicians and researchers should always use validated and reliable patient-centered tools when possible.

References

Aaronson NK, Calais da Silva F, Yoshida O, et al. Quality of life assessment in bladder cancer clinical trials: conceptual, methodological and practical issues. *Prog Clin Biol Res*. 1986;221:149–170.

Aaronson NK, Ahmedzai S, Bergman B, et al. The European Organization for Research and the treatment of Cancer QLQ-C30: a quality of life instrument for use in international clinical trials in oncology. *J Natl Cancer Inst*. 1993;85(5):356–365.

Abraham L, Symonds T, Morris MF. Psychometric validation of a sexual quality of life questionnaire for use in men with premature ejaculation or erectile dysfunction. *J Sex Med*. 2008;5(3):595–601.

Agency for Healthcare Research and Quality. *Outcomes research fact sheet*. Agency for Healthcare Research and Quality: Rockville; 2000.

Albertsen PC, Walters S, Hanley JA. A comparison of cause of death determination in men previously diagnosed with prostate cancer who died in 1985 or 1995. *J Urol*. 2000;163(2):519–523.

Althof S, Rosen R, Symonds T, et al. Development and validation of a new questionnaire to assess sexual satisfaction, control, and distress associated with premature ejaculation. *J Sex Med*. 2006;3(3):465–475.

Althof SE, Corty EW, Levine SB, et al. EDITS: development of questionnaires for evaluating Satisfaction with treatment for erectile dysfunction. *Urology*. 1999;53(4):793–799.

Amarenco G, Arnould B, Carita P, et al. European psychometric validation of the CONTILIFE: a Quality of Life questionnaire for urinary incontinence. *Eur Urol*. 2003;43(4):391–404.

American Psychological Association. *Standards for educational and psychological tests*. American Psychological Association: Washington, DC; 1974.

Anderson CB, Feurer ID, Large MC, et al. Psychometric characteristics of a condition-specific, health-related quality-of-life survey: the FACT-Vanderbilt Cystectomy Index. *Urology*. 2012;80(1):77–83.

Arrington R, Cofrancesco J, Wu AW. Questionnaires to measure sexual quality of life. *Qual Life Res*. 2004;13(10):1643–1658.

Atkinson TM, Andreotti CF, Roberts KE, et al. The level of association between functional performance status measures and patient-reported outcomes in cancer patients: a systematic review. *Support Care Cancer*. 2015;23(12):3645–3652.

Avery K, Donovan J, Peters TJ, et al. ICIQ: a brief and robust measure for evaluating the symptoms and impact of urinary incontinence. *Neurourol Urodyn*. 2004;23(4):322–330.

Baar J, Tannock I. Analyzing the same data in two ways: a demonstration model to illustrate the reporting and misreporting of clinical trials. *J Clin Oncol*. 1989;7(7):969–978.

Bandeen-Roche K, Xue Q-L, Ferrucci L, et al. Phenotype of frailty: characterization in the women's health and aging studies. *J Gerontol A Biol Sci Med Sci*. 2006;61(3):262–266.

Bandeen-Roche K, Seplaki CL, Huang J, et al. Frailty in older adults: a nationally representative profile in the United States. *J Gerontol A Biol Sci Med Sci*. 2015;70(11):1427–1434.

Barqawi A, O'Donnell C, Kumar R, et al. Correlation between LUTS (AUA-SS) and erectile dysfunction (SHIM) in an age-matched racially diverse male population: data from the Prostate Cancer Awareness Week (PCAW). *Int J Impot Res*. 2005;17(4):370–374.

Barry MJ, Fowler FJ, O'Leary MP, et al. The American Urological Association symptom index for benign prostatic hyperplasia. The Measurement Committee of the American Urological Association. *J Urol*. 1992;148(5):1549–1557 [discussion 1564].

Barry MJ, Fowler FJ Jr, O'Leary MP, et al. Correlation of the American Urological Association symptom index with self-administered versions of the Madsen-Iversen, Boyarsky and Maine Medical Assessment Program symptom indexes. Measurement Committee of the American Urological Association. *J Urol*. 1992;148(5):1558–1563 [discussion 1564].

Barry MJ, Fowler FJ, O'Leary MP, et al. Measuring disease-specific health status in men with benign prostatic hyperplasia. Measurement Committee of The American Urological Association. *Med Care*. 1995;33(4 Suppl):AS145–AS155.

Barry MJ, Williford WO, Chang Y, et al. Benign prostatic hyperplasia specific health status measures in clinical research: how much change in the American Urological Association symptom index and the benign prostatic hyperplasia impact index is perceptible to patients? [see comments]. *J Urol*. 1995;154(5):1770–1774.

Beaulieu S, Collet JP, Tu LM, et al. Performance of the Incontinence Impact Questionnaire in Canada. *Can J Urol*. 1999;6(1):692–699.

Beisland E, Aarstad HJ, Aarstad AK, et al. Development of a disease-specific health-related quality of life (HRQoL) questionnaire intended to be used in conjunction with the general European Organization for Research and Treatment of Cancer (EORTC) Quality of Life Questionnaire (QLQ) in renal cell carcinoma patients. *Acta Oncol*. 2016;55(3):349–356.

Bennett CL, Chapman G, Elstein AS, et al. A comparison of perspectives on prostate cancer: analysis of utility assessments of patients and physicians. *Eur Urol*. 1997;32(Suppl 3):86–88.

Bergner M, Bobbitt RA, Carter WB, et al. The Sickness Impact Profile: development and final revision of a health status measure. *Med Care*. 1981;19(8):787–805.

Black N, Griffiths J, Pope C. Development of a symptom severity index and a symptom impact index for stress incontinence in women. *Neurourol Urodyn*. 1996;15(6):630–640.

Blander DS, Sanchez-Ortiz RF, Broderick GA. Sex inventories: can questionnaires replace erectile dysfunction testing? *Urology*. 1999;54(4):719–723.

Bokhorst LP, Kranse R, Venderbos LD, et al. Differences in treatment and outcome after treatment with curative intent in the screening and control arms of the ERSPC Rotterdam. *Eur Urol*. 2015;68(2):179–182.

Boyle CA, Decouflé P. National Sources of Vital Status information: extent of coverage and possible selectivity in reporting. *Am J Epidemiol*. 1980;131(1):160–168.

Brazier J, Jones N, Kind P. Testing the validity of the Euroqol and comparing it with the SF-36 health survey questionnaire. *Qual Life Res*. 1993;2(3):169–180.

Brill S. Bitter pill: how outrageous pricing and egregious profits are destroying our health care. *Time*. 2013;181(8):16–24 [26, 28 passim].

Brook RH, Appel FA. Quality-of-care assessment: choosing a method for peer review. *N Engl J Med*. 1973;288:1323–1329.

Brook RH, McGlynn EA, Cleary PD. Quality of health care. Part 2:measuring quality of care. *N Engl J Med*. 1996;335(13):966–970.

Brookes ST, Donovan JL, Wright M, et al. A scored form of the Bristol Female Lower Urinary Tract Symptoms questionnaire: data from a randomized controlled trial of surgery for women with stress incontinence. *Am J Obstet Gynecol*. 2004;191(1):73–82.

Buurman BM, van Munster BC, Korevaar JC, et al. Variability in measuring (instrumental) activities of daily living functioning and functional decline in hospitalized older medical patients: a systematic review. *J Clin Epidemiol*. 2011;64(6):619–627.

Calman KC. Quality of life in cancer patients—an hypothesis. *J Med Ethics*. 1984;10(3):124–127.

Cappelleri JC, Siegel RL, Osterloh IH, et al. Relationship between patient self-assessment of erectile function and the erectile function domain of the international index of erectile function. *Urology*. 2000;56(3):477–481.

Cappelleri JC, Rosen RC. The Sexual Health Inventory for Men (SHIM): a 5-year review of research and clinical experience. *Int J Impot Res*. 2005;17(4):307–319.

Carlsson SV, Albertsen PC. Better survival after curative treatment for screen-detected prostate cancer compared with clinical diagnosis: a real effect or lead-time bias? *Eur Urol*. 2015;68(2):183–184 [discussion 184–185].

Carmel ME, Deng DY, Greenwell TJ, et al. Definition of success after surgery for female stress incontinence or voiding dysfunction: an attempt at standardization. *Eur Urol Focus*. 2016;2(3):231–237.

Cella DF, Tulsky DS. Measuring quality of life today. *Oncology (Williston Park)*. 1990;4(5):29–38.

Cella DF, Tulsky DS, Gray G, et al. The functional assessment of cancer therapy scale: development and validation of the general measure. *J Clin Oncol*. 1993;11(3):570–579.

Cella D, Yount S, Du H, et al. Development and validation of the Functional Assessment of Cancer Therapy-Kidney Symptom Index (FKSI). *J Support Oncol*. 2006;4(4):191–199.

Centers for Disease Control and Prevention. *National Death Index*. [Available at] https://www.cdc.gov/nchs/ndi/index.htm; 2019.

Centers for Medicare and Medicaid Services. *Hospital Consumer Assessment of Healthcare Providers and Systems: Patients' Perspectives of Care Survey*. [Available at] https://www.cms.gov/Medicare/Quality-Initiatives-Patient-Assessment-instruments/hospitalqualityinits/hospitalHCAHPS.html.

Charlson ME, Pompei P, Ales KL, et al. A new method of classifying prognostic comorbidity in longitudinal studies: development and validation. *J Chronic Dis*. 1987;40(5):373–383.

Charlson M, Szatrowski TP, Peterson J, et al. Validation of a combined comorbidity index. *J Clin Epidemiol*. 1994;47(11):1245–1251.

Chow WH, Devesa SS. Underreporting and misclassification of urinary tract cancer cases on death certificates. *Epidemiology*. 1996;7(5):517–520.

Clavien PA, Sanabria JR, Strasberg SM. Proposed classification of complications of surgery with examples of utility in cholecystectomy. *Surgery*. 1992;111(5):518–526.

Clavien PA, Barkun J, de Oliveira ML, et al. The Clavien-Dindo classification of surgical complications: five-year experience. *Ann Surg*. 2009;250(2):187–196.

Cleeland CS, Gonin R, Hatfield AK, et al. Pain and its treatment in outpatients with metastatic cancer. *N Engl J Med*. 1994;330(9):592–596.

Cleeland CS, Ryan KM. Pain assessment: global use of the Brief Pain Inventory. *Ann Acad Med Singapore*. 1994;23(2):129–138.

Concato J, Horwitz RI, Feinstein AR, et al. Problems of comorbidity in mortality after prostatectomy. *JAMA*.

1992;267(8):1077–1082.

Coyne KS, Payne C, Bhattacharyya SK, et al. The impact of urinary urgency and frequency on health-related quality of life in overactive bladder: results from a national community survey. *Value Health*. 2004;7(4):455–463.

Coyne KS, Tubaro A, Brubaker L, et al. Development and validation of patient-reported outcomes measures for overactive bladder: a review of concepts. *Urology*. 2006;68(2 Suppl):9–16.

Cronbach LJ. Coefficient alpha and the internal structure of tests. *Psychometrika*. 1951;16(3):297–334.

Crowley AR, Horowitz M, Chan E, et al. Transurethral resection of the prostate versus open prostatectomy: long-term mortality comparison. *J Urol*. 1995;153(3 Pt 1):695–697.

Curb JD, Ford CE, Pressel S, et al. Ascertainment of vital status through the National Death Index and the Social Security Administration. *Am J Epidemiol*. 1985;121(5):754–766.

D'Amico AV, Desjardin A, Chen MH, et al. Analyzing outcome-based staging for clinically localized adenocarcinoma of the prostate. *Cancer*. 1998;83(10):2172–2180.

Dell'Oglio P, Tian Z, Leyh-Bannurah SR, et al. Short-Form Charlson Comorbidity Index for assessment of perioperative mortality after radical cystectomy. *J Natl Compr Canc Netw*. 2017;15(3):327–333.

Derogatis LR. The Derogatis Interview for Sexual Functioning (DISF/DISF-SR): an introductory report. *J Sex Marital Ther*. 1997;23(4):291–304.

Deyo RA, Cherkin DC, Ciol MA. Adapting a clinical comorbidity index for use with ICD-9-CM administrative databases. *J Clin Epidemiol*. 1992;45(6):613–619.

Dindo D, Demartines N, Clavien PA. Classification of surgical complications: a new proposal with evaluation in a cohort of

6336 patients and results of a survey. *Ann Surg*. 2004;240(2):205–213.

Donabedian A. Evaluating the quality of medical care. *Milbank Mem Fund Q*. 1966;44(3) [Suppl:166–206].

Donabedian A. The quality of medical care. *Science*. 1978;200(4344):856–864.

Donabedian A. Health Administration Press: Ann Arbor, MI; 1980. *The definition of quality and approaches to its assessment. explorations in quality assessment and monitoring*. vol 1.

Donabedian A. Criteria and standards for quality assessment and monitoring. *QRB Qual Rev Bull*. 1986;12(3):99–108.

Donabedian A. The quality of care. How can it be assessed? *JAMA*. 1988;260(12):1743–1748.

Donabedian A. The effectiveness of quality assurance. *Int J Qual Health Care*. 1996;8(4):401–407.

Donovan JL, Abrams P, Peters TJ, et al. The ICS-“BPH” Study: the psychometric validity and reliability of the ICSmale questionnaire. *Br J Urol*. 1996;77(4):554–562.

Donovan JL, Peters TJ, Abrams P, et al. Scoring the short form ICSmaleSF questionnaire. International Continence Society. *J Urol*. 2000;164(6):1948–1955.

Downie WW, Leatham PA, Rhind VM, et al. Studies with pain rating scales. *Ann Rheum Dis*. 1978;37(4):378–381.

Edemekong PF, Levy SB. *Activities of daily living (ADLs). StatPearls*. StatPearls Publishing: Treasure Island, FL; 2019.

Eisenhauer EA, Therasse P, Bogaerts J, et al. New response evaluation criteria in solid tumours: revised RECIST guideline (version 1.1). *Eur J Cancer*. 2009;45(2):228–247.

Esper P, Mo F, Chodak G, et al. Measuring quality of life in men with prostate cancer using the functional assessment of cancer therapy-prostate instrument. *Urology*. 1997;50(6):920–928.

Feinstein AR. The Pre-therapeutic classification of co-morbidity in chronic disease. *J Chronic Dis*. 1970;23(7):455–468.

Feinstein A. *Clinimetrics*. Yale University Press: New Haven, CT; 1987.

Feinstein AR. *Clinical epidemiology: the architecture of clinical research*. Saunders: Philadelphia, PA; 1985.

Feinstein A. *Principles of medical statistics*. CRC Press: Boca Raton, FL; 2002.

Feinstein AR, Wells CK, Walter SD. A comparison of multivariable mathematical methods for predicting survival—I. Introduction, rationale, and general strategy. *J Clin Epidemiol*. 1990;43(4):339–347.

Finkelstein E, Corso P. Cost-of-illness analyses for policy making: a cautionary tale of use and misuse. *Expert Rev Pharmacoecon Outcomes Res*. 2003;3(4):367–369.

Freedland SJ, Humphreys EB, Mangold LA, et al. Risk of prostate cancer-specific mortality following biochemical recurrence after radical prostatectomy. *JAMA*. 2005;294(4):433–439.

Fried LP, Tangen CM, Walston J, et al. Frailty in older adults: evidence for a phenotype. *J Gerontol A Biol Sci Med Sci*. 2001;56(3):M146–M156.

Fried LP, Ferrucci L, Darer J, et al. Untangling the concepts of disability, frailty, and comorbidity: implications for improved targeting and care. *J Gerontol A Biol Sci Med Sci*. 2004;59(3):255–263.

Ganz PA, Schag CAC, Lee JJ, et al. The CARES: a generic measure of health related quality of life for patients with cancer. *Qual Life Res*. 1992;1(1):19–29.

Gilbert SM, Wood DP, Dunn RL, et al. Measuring health-related quality of life outcomes in bladder cancer patients using the Bladder Cancer Index (BCI). *Cancer*. 2007;109(9):1756–1762.

Gill TM, Gahbauer EA, Allore HG, et al. Transitions between frailty states among community-living older persons. *Arch Intern Med*. 2006;166(4):418–423.

Gill TM, Feinstein AR. A critical appraisal of the quality-of-life measurements. *JAMA*. 1994;272(8):619–626.

Gold MR, Patrick DL, Torrance GW, et al. Identifying and valuing outcomes. Gold MR, Siegel JE, Russell LB, et al. *Cost effectiveness in health and medicine*. Oxford University Press: New York, NY; 1996:82–134.

Gordis L. *Epidemiology*. Saunders: Philadelphia, PA; 2008.

Grossfeld GD, Li YP, Lubeck DP, et al. Predictors of secondary cancer treatment in patients receiving local therapy for prostate cancer: data from cancer of the prostate strategic urologic research endeavor. *J Urol*. 2002;168(2):530–535.

Guyatt GH, Akl EA, Crowther M, et al. American College of Chest Physicians Antithrombotic Therapy and Prevention of Thrombosis Panel. Executive summary: antithrombotic therapy and prevention of thrombosis, 9th ed: American College of Chest Physicians Evidence-Based Clinical Practice Guidelines. *Chest*. 2012;141(2 Suppl):7S–47S.

Heidler S, Mert C, Wehrberger C, et al. Impact of overactive bladder symptoms on sexuality in both sexes. *Urol Int*. 2010;85(4):443–446.

Hoffman RM, Koyama T, Fan K-H, et al. Mortality after radical prostatectomy or external beam radiotherapy for localized prostate cancer. *J Natl Cancer Inst*. 2013;105(10):711–718.

Hoffman RM, Stone SN, Hunt WC, et al. Effects of misattribution in assigning cause of death on prostate cancer mortality rates. *Ann Epidemiol*. 2003;13(6):450–454.

Institute of Medicine. *Crossing the quality chasm: a new health system for the 21st century*. National Academies Press: Washington DC; 2001.

Jackson S, Donovan J, Brookes S, et al. The Bristol Female

Lower Urinary Tract Symptoms questionnaire:development and psychometric testing. *Br J Urol*. 1996;77(6):805–812.

Jefford M, Stockler MR, Tattersall MH. Outcomes research: what is it and why does it matter? *Intern Med J*. 2003;33(3):110–118.

Jewett MA, Bombardier C, Caron D, et al. Potential for inter-observer and intra-observer variability in x-ray review to establish stone-free rates after lithotripsy. *J Urol*. 1992;147(3):559–562.

Jhaveri FM, Zippe CD, Klein EA, et al. Biochemical failure does not predict overall survival after radical prostatectomy for localized prostate cancer: 10-year results. *Urology*. 1999;54(5):884–890.

Jorgensen L, Lose G, Andersen JT. One-hour pad-weighing test for objective assessment of female urinary incontinence. *Obstet Gynecol*. 1987;69(1):39–42.

Kaplan RM, Bush JW, Berry CC. Health status: types of validity and the index of well-being. *Health Serv Res*. 1976;11(4):478–507.

Kaplan RS, Porter ME. How to solve the cost crisis in health care. *Harv Bus Rev*. 2011;89(9):46–52 [54, 56–61 passim].

Karnofsky DA, Burchanel JH. The clinical evaluation of chemotherapeutic agents in cancer. MacLeod CM. *Evaluation of chemotherapeutic agents*. Columbia University Press: New York, NY; 1949:199–205.

Kaye DR, Richardson CR, Ye Z, et al. Association between patient satisfaction and short-term outcomes after major cancer surgery. *Ann Surg Oncol*. 2017;24(12):3486–3493.

Keating NL, O'Malley AJ, Smith MR. Diabetes and cardiovascular disease during androgen deprivation therapy for prostate cancer. *J Clin Oncol*. 2006;24(27):4448–4456.

Kelleher CJ, Cardozo LD, Khullar V, et al. A new questionnaire to assess the quality of life of urinary incontinent women. *Br*

J Obstet Gynaecol. 1997;104(12):1374–1379.

Kelly CM, Shahrokni A. Moving beyond Karnofsky and ECOG performance status assessments with new technologies. *J Oncol*. 2016;2016:6186543.

Klabunde CN, Potosky AL, Legler JM, et al. Development of a comorbidity index using physician claims data. *J Clin Epidemiol*. 2000;53(12):1258–1267.

Krahn MD, Bremner KE, Alibhai SMH, et al. A reference set of health utilities for long-term survivors of prostate cancer: population-based data from Ontario, Canada. *Qual Life Res*. 2013;22(10):2951–2962.

Last JM. *A dictionary of epidemiology*. ed 4. Oxford University Press: Oxford, UK; 2001.

Latini DM, Penson DF, Colwell HH, et al. Psychological impact of erectile dysfunction: validation of a new health related quality of life measure for patients with erectile dysfunction. *J Urol*. 2002;168(5):2086–2091.

Laviana AA, Ilg AM, Veruttipong D, et al. Utilizing time-driven activity-based costing to understand the short- and long-term costs of treating localized, low-risk prostate cancer. *Cancer*. 2016;122(3):447–455.

Leidy NK. Functional status and the forward progress of merry-go-rounds: toward a coherent analytical framework. *Nurs Res*. 1994;43(4):196–202.

Leidy NK. Using functional status to assess treatment outcomes. *Chest*. 1994;106(6):1645–1646.

Lepor H, Williford WO, Barry MJ, et al. The efficacy of terazosin, finasteride, or both in benign prostatic hyperplasia. Veterans Affairs Cooperative Studies Benign Prostatic Hyperplasia Study Group. *N Engl J Med*. 1996;335(8):533–539.

Levy I, Finkelstein M, Bilal KH, et al. Modified frailty index associated with Clavien-Dindo IV complications in robot-assisted radical prostatectomies: a retrospective study. *Urol Oncol*. 2017;35(6):425–431.

Lilford RJ, Brown CA, Nicholl J. Use of process measures to monitor the quality of clinical practice. *BMJ*. 2007;335:648–650.

Litwin MS. *How to measure survey reliability and validity*. Sage Publications: Thousand Oaks, CA; 1995.

Litwin MS, Greenfield S, Elkin EP, et al. Assessment of prognosis with the total illness burden index for prostate cancer: aiding clinicians in treatment choice. *Cancer*. 2007;109(9):1777–1783.

Litwin MS, Hays RD, Fink A, et al. The UCLA Prostate Cancer Index: development, reliability, and validity of a health-related quality of life measure. *Med Care*. 1998;36(7):1002–1012.

Litwin MS, Lubeck DP, Henning JM, et al. Differences in urologist and patient assessments of health related quality of life in men with prostate cancer: results of the CaPSURE database. *J Urol*. 1998;159(6):1988–1992.

Litwin MS, McNaughton-Collins M, Fowler FJ Jr, et al. The National Institutes of Health Chronic Prostatitis Symptom Index: development and validation of a new outcome measure. Chronic Prostatitis Collaborative Research Network. *J Urol*. 1999;162(2):369–375.

Liu JH, Zingmond DS, McGory ML, et al. Disparities in the utilization of high-volume hospitals for complex surgery. *JAMA*. 2006;296(16):1973–1980.

Lohr KN, Steinwachs DM. Health services research: an evolving definition of the field. *Health Serv Res*. 2002;37(1):15–17.

Lubeck DP, Prebil LA, Peeples P, et al. A health related quality of life measure for use in patients with urge urinary incontinence: a validation study. *Qual Life Res*.

1999;8(4):337–344.

Luft HS, Hunt SS, Maerki SC. The volume-outcome relationship: practice-makes-perfect or selective-referral patterns? *Health Serv Res*. 1987;22(2):157–182.

Lu-Yao GL, Potosky AL, Albertsen PC, et al. Follow-up prostate cancer treatments after radical prostatectomy: a population-based study. *J Natl Cancer Inst*. 1996;88(3–4):166–173.

Mackenbach JP, Kunst AE, Lautenbach H, et al. Competing causes of death: a death certificate study. *J Clin Epidemiol*. 1997;50(10):1069–1077.

Makary MA, Segev DL, Pronovost PJ, et al. Frailty as a predictor of surgical outcomes in older patients. *J Am Coll Surg*. 2010;210(16):901–908.

Mansson A, Davidsson T, Hunt S, et al. The quality of life in men after radical cystectomy with a continent cutaneous diversion or orthotopic bladder substitution: is there a difference? *BJU Int*. 2002;90(4):386–390.

Mant J. Process versus outcome indicators in the assessment of quality of health care. *Int J Qual Health Care*. 2001;13(6):475–480.

Mant J, Hicks N. Detecting differences in quality of care: the sensitivity of measures of process and outcome in treating acute myocardial infarction. *BMJ*. 1995;311(7008):793–796.

Mant J, Hicks NR. Assessing quality of care: what are the implications of the potential lack of sensitivity of outcome measures to differences in quality? *J Eval Clin Pract*. 1996;2(4):243–248.

Maudsley G, Williams L. Death certification—a sad state of affairs. *J Public Health Med*. 1994;16(3):370–371.

Mazer NA, Leiblum SR, Rosen RC. The brief index of sexual functioning for women (BISF-W): a new scoring algorithm and comparison of normative and surgically menopausal populations. *Menopause*. 2000;7(5):350–363.

McAuliffe WE. Measuring the quality of medical care: process versus outcome. *Milbank Mem Fund Q Health Soc*. 1979;57(1):118–152.

McConnell JD, Bruskewitz R, Walsh P, et al. The effect of finasteride on the risk of acute urinary retention and the need for surgical treatment among men with benign prostatic hyperplasia. Finasteride Long-Term Efficacy and Safety Study Group. *N Engl J Med*. 1998;338(9):557–563.

McConnell JD, Roehrborn CG, Bautista OM, et al. The long-term effect of doxazosin, finasteride, and combination therapy on the clinical progression of benign prostatic hyperplasia. *N Engl J Med*. 2003;349(25):2387–2398.

McDowell I, Newell C. Pain measurements. *Measuring health: a guide to rating scales and questionnaires*. ed 2. Oxford University Press: New York, NY; 1996:335–379.

Melzack R. The McGill Pain Questionnaire: major properties and scoring methods. *Pain*. 1975;1(3):277–299.

Meston CM. Validation of the Female Sexual Function Index (FSFI) in women with female orgasmic disorder and in women with hypoactive sexual desire disorder. *J Sex Marital Ther*. 2003;29(1):39–46.

Meyhoff HH, Hald T, Nordling J, et al. A new patient weighted symptom score system (DAN-PSS-1). Clinical assessment of indications and outcomes of transurethral prostatectomy for uncomplicated benign prostatic hyperplasia. *Scand J Urol Nephrol*. 1993;27(4):493–499.

Miller AB, Hoogstraten B, Staquet M, et al. Reporting results of cancer treatment. *Cancer*. 1981;47(1):207–214.

Mock LL, Parmelee PA, Kutner N, et al. Content validation of symptom-specific nocturia quality-of-life instrument developed in men: issues expressed by women, as well as men. *Urology*. 2008;72(4):736–742.

Moinpour CM, Feigl P, Metch B, et al. Quality of life end points in cancer clinical trials: review and recommendations. *J Natl Cancer Inst*. 1989;81(7):485–495.

Moore KN, Jensen L. Testing of the Incontinence Impact Questionnaire (IIQ-7) with men after radical prostatectomy. *J Wound Ostomy Continence Nurs*. 2000;27(6):304–312.

Moore KN, Griffiths D, Hughton A. Urinary incontinence after radical prostatectomy: a randomized controlled trial comparing pelvic muscle exercises with or without electrical stimulation. *BJU Int*. 1999;83(1):57–65.

Morgan M, Smith N, Thomas K, et al. Is Clavien the new standard for reporting urological complications? *BJU Int*. 2009;104(4):434–436.

Mulhall JP, Creech SD, Boorjian SA, et al. Subjective and objective analysis of the prevalence of Peyronie's disease in a population of men presenting for prostate cancer screening. *J Urol*. 2004;171(6 Pt 1):2350–2353.

Naughton MJ, Donovan J, Badia X, et al. Symptom severity and QOL scales for urinary incontinence. *Gastroenterology*. 2004;126(1 Suppl 1):S114–S123.

Nguyen PL, Je Y, Schutz FA, et al. Association of androgen deprivation therapy with cardiovascular death in patients with prostate cancer: a meta-analysis of randomized trials. *JAMA*. 2011;306(21):2359–2366.

Nguyen PL, Alibhai SMH, Basaria S, et al. Adverse effects of androgen deprivation therapy and strategies to mitigate them. *Eur Urol*. 2015;67(5):825–836.

Norman GR, Sloan JA, Wyrwich KW. Interpretation of changes in health-related quality of life: the remarkable universality of half a standard deviation. *Med Care*. 2003;41(5):582–592.

Nunnally JC. *Psychometric theory*. ed 2. McGraw-Hill: New York, NY; 1978.

Nygaard I. Physiologic outcome measures for urinary incontinence. *Gastroenterology*. 2004;126(1 Suppl 1):S99–S105.

Oken MM, Creech RH, Tormey DC, et al. Toxicity and response criteria of the Eastern Cooperative Oncology Group. *Am J Clin Oncol*. 1982;5(6):649–655.

O'Leary MP, Sant GR, Fowler FJ Jr, et al. The interstitial cystitis symptom index and problem index. *Urology*. 1997;49(5A Suppl):58–63.

Paasche-Orlow MK, Taylor HA, Brancati FL. Readability standards for informed-consent forms as compared with actual readability. *N Engl J Med*. 2003;348:721–726.

Padma-Nathan H, Brown C, Fendl J, et al. Efficacy and safety of topical alprostadil cream for the treatment of female sexual arousal disorder (FSAD): a double-blind, multicenter, randomized, and placebo-controlled clinical trial. *J Sex Marital Ther*. 2003;29(5):329–344.

Parkinson JP, Konety BR. Health related quality of life assessments for patients with bladder cancer. *J Urol*. 2004;172(6 Pt 1):2130–2136.

Patrick DL, Deyo RA. Generic and disease-specific measures in assessing health care status and quality of life. *Med Care*. 1989;27(3 Suppl):S217–S232.

Patrick DL, Erickson P. Assessing health-related quality of life for clinical decision-making. [Chapter 19] Walker SR, Rosser RM. *Quality of life assessment: key issues in the 1990s*. Kluwer Academic Publishers: Dordrecht, Netherlands; 1993.

Patrick DL, Martin ML, Bushnell DM, et al. Cultural adaptation of a quality-of-life measure for urinary incontinence. *Eur Urol*. 1999;36(5):427–435.

Pavone-Macaluso M, Corselli G, Ingargiola GB, et al. The Urologic Cooperative Group of the EORTC. Structure, scope, research, results. *Arch Ital Urol Androl*. 1997;69(4):209–215.

Pearl JA, Patil D, Filson CP, et al. Patient frailty and discharge disposition following radical cystectomy. *Clin Genitourin Cancer*. 2017;15(4):e615–e621.

Penniston KL, Antonelli JA, Viprakasit DP, et al. Validation and reliability of the Wisconsin Stone Quality of Life Questionnaire. *J Urol*. 2017;197(5):1280–1288.

Penson DF, Albertsen PC, Nelson PS, et al. Determining cause of death in prostate cancer: are death certificates valid? *J Natl Cancer Inst*. 2001;93(23):1822–1823.

Porter ME. What is value in health care? *N Engl J Med*. 2010;363(26):2477–2481.

Prada PJ, González H, Fernández J, et al. Biochemical outcome after high-dose-rate intensity modulated brachytherapy with external beam radiotherapy: 12 years of experience. *BJU Int*. 2012;109(12):1787–1793.

Prentice RL. Surrogate endpoints in clinical trials: definition and operational criteria. *Stat Med*. 1989;8(4):431–440.

Rademakers J, Delnoij D, de Boer D. Structure, process or outcome: which contributes most to patients’ overall assessment of healthcare quality? *BMJ Qual Saf*. 2011;20(4):326–331.

Rassweiler JJ, Rassweiler MC, Michel MS. Classification of complications: is the Clavien-Dindo classification the gold standard? *Eur Urol*. 2012;62(2):256–258 [discussion 259–260].

Reeve BB, Hays RD, Bjorner JB, et al. Psychometric evaluation and calibration of health-related quality of life item banks: plans for the Patient-Reported Outcomes Measurement Information System (PROMIS). *Med Care*. 2007;45(5 Suppl 1):S22–S31.

Revicki DA, Chen WH, Harnam N, et al. Development and psychometric analysis of the PROMIS pain behavior item bank. *Pain*. 2009;146(1–2):158–169.

Rich JT, Neely JG, Paniello RC, et al. A practical guide to understanding Kaplan-Meier curves. *Otolaryngol Head Neck Surg*. 2010;143(3):331–336.

Roos NP, Wennberg JE, Malenka DJ, et al. Mortality and reoperation after open and transurethral resection of the prostate for benign prostatic hyperplasia. *N Engl J Med*. 1989;320(17):1120–1124.

Rosen RC, Riley A, Wagner G, et al. The International Index of Erectile Function (IIEF): a multidimensional scale for assessment of erectile dysfunction. *Urology*. 1997;49(6):822–830.

Rosen R, Brown C, Heiman J, et al. The Female Sexual Function Index (FSFI): a multidimensional self-report instrument for the assessment of female sexual function. *J Sex Marital Ther*. 2000;26(2):191–208.

Rothrock NE, Kaiser KA, Cella D. Developing a valid patient-reported outcome measure. *Clin Pharmacol Ther*. 2011;90(5):737–742.

Sackett DL, Haynes RB, Guyatt GH, et al. *Clinical epidemiology: a basic science for clinical medicine*. Little Brown: Boston, MA; 1991.

Salonia A, Zanni G, Nappi RE, et al. Sexual dysfunction is common in women with lower urinary tract symptoms and urinary incontinence: results of a cross-sectional study. *Eur Urol*. 2004;45(5):642–648 [discussion 648].

Sanda MG, Cadeddu JA, Kirkby E, et al. Clinically localized prostate cancer: AUA/ASTRO/SUO Guideline. Part I: risk stratification, shared decision making, and care options. *J Urol*. 2018;199(3):683–690.

Sanda MG, Cadeddu JA, Kirkby E, et al. Clinically localized prostate cancer: AUA/ASTRO/SUO Guideline. Part II: recommended approaches and details of specific care options. *J Urol*. 2018;199(4):990–997.

Sathianathen NJ, Jarosek S, Lawrentschuk N, et al. A simplified frailty index to predict outcomes after radical cystectomy. *Eur Urol Focus*. 2018 [pii: S2405-4569(18)30002-6].

Schaafsma J, Osoba D. The Karnofsky performance status scale re-examined: a cross-validation with the EORTC-C30. *Qual Life Res*. 1994;3(6):413–424.

Schag CC, Heinrich RL, Ganz PA. Karnofsky performance status revisited: reliability, validity, and guidelines. *J Clin Oncol*. 1984;2(3):187–193.

Scher HI, Morris MJ, Stadler WM, et al. Trial design and objectives for castration-resistant prostate cancer: updated recommendations from the Prostate Cancer Clinical Trials Working Group 3. *J Clin Oncol*. 2016;34(12):1402–1418.

Schipper H, Clinch J, McMurray A, et al. Measuring the quality of life of cancer patients: the functional living index—cancer: development and validation. *J Clin Oncol*. 1984;2(5):472–483.

Schoenfelder T, Schaal T, Klewer J, et al. Patient satisfaction in urology: effects of hospital characteristics, demographic data and patients' perceptions of received care. *Urol J*. 2014;11(4):1834–1840.

Scott J, Huskisson EC. Graphic representation of pain. *Pain*. 1976;2(2):175–184.

Sesso HD, Paffenbarger RS, Lee IM. Comparison of National Death Index and World Wide Web death searches. *Am J Epidemiol*. 2000;152(2):107–111.

Shahinian VB, Kuo Y-F, Gilbert SM. Reimbursement policy and androgen-deprivation therapy for prostate cancer. *N Engl J Med*. 2010;363(19):1822–1832.

Shirk JD, Tan HJ, Hu JC, et al. Patient experience and quality of urologic cancer surgery in US hospitals. *Cancer*. 2016;122(16):2571–2578.

Shrader-Bogen CL, Kjellberg JL, McPherson CP, et al. Quality of life and treatment outcomes: prostate carcinoma patients' perspectives after prostatectomy or radiation therapy. *Cancer*. 1997;79(10):1977–1986.

Shumaker SA, Wyman JF, Uebersax JS, et al. Health-related quality of life measures for women with urinary incontinence: the incontinence impact questionnaire and the urogenital distress inventory. *Qual Life Res*. 1994;3(5):291–306.

Social Security Administration. *Research, Statistics & Policy Analysis*. [Available at] https://www.ssa.gov/policy/about/epidemiology.html.

Spencer BA, Steinberg M, Malin J, et al. Quality-of-care indicators for early-stage prostate cancer. *J Clin Oncol*. 2003;21(10):1928–1936.

Spencer BA, Steinberg M, McGlynn EA, et al. Quality of care indicators for conventional and conformal external-beam radiation therapy in the treatment of early stage prostate cancer. *Int J Radiat Oncol Biol Phys*. 2003;57(2):S420–S421.

Stampfer MJ, Willett WC, Speizer FE, et al. Test of the National Death Index. *Am J Epidemiol*. 1984;119(5):837–839.

Stier DM, Greenfield S, Lubeck DP, et al. Quantifying comorbidity in a disease-specific cohort: adaptation of the total illness burden index to prostate cancer. *Urology*. 1999;54(3):424–429.

Stockler MR, Osoba D, Corey P, et al. Convergent discriminative, and predictive validity of the Prostate Cancer Specific Quality of Life Instrument (PROSQOLI) assessment and comparison with analogous scales from the EORTC QLQ-C30 and a trial-specific module. European Organisation for Research and Treatment of Cancer. Core Quality of Life Questionnaire. *J Clin Epidemiol*. 1999;52(7):653–666.

Streiner DL. Starting at the beginning:an introduction to coefficient alpha and internal consistency. *J Pers Assess*. 2003;80(1):99–103.

Sung VW, Griffith JW, Rogers RG, et al. Item bank development, calibration and validation for patient-reported outcomes in female urinary incontinence. *Qual Life Res*. 2016;25(7):1645–1654.

Suskind AM, Jin C, Walter LC, et al. Frailty and the role of obliterative versus reconstructive surgery for pelvic organ prolapse: a national study. *J Urol*. 2017;197(6):1502–1506.

Tasian GE, Kabarriti AE, Kalmus A, et al. Kidney stone recurrence among children and adolescents. *J Urol*. 2017;197(1):246–252.

Taylor JF, Rosen RC, Leiblum SR. Self-report assessment of female sexual function:psychometric evaluation of the Brief Index of Sexual Functioning for Women. *Arch Sex Behav*. 1994;23(6):627–643.

Therasse P, Arbuck SG, Eisenhauer EA, et al. New guidelines to evaluate the response to treatment in solid tumors. European organization for research and treatment of cancer, National Cancer Institute of the United States, National Cancer Institute of Canada. *J Natl Cancer Inst*. 2000;92(3):205–216.

Thompson IMJ, Tangen CM, Paradelo J, et al. Adjuvant radiotherapy for pathologically advanced prostate cancer: a randomized clinical trial. *JAMA*. 2006;296(19):2329–2335.

Uebersax JS, Wyman JF, Shumaker SA, et al. Short forms to assess life quality and symptom distress for urinary incontinence in women: the incontinence impact questionnaire and the urogenital distress inventory. *Neurourol Urodyn*. 1995;14(2):131–139.

U.S. Department of Health and Human Services. National Institutes of Health. National Cancer Institute. *Common Terminology Criteria for Adverse Events (CTCAE), Version 5.0*. [Available at] https://ctep.cancer.gov/protocoldevelopment/electronic_appli
2017.

Verger E, Salamero M, Conill C. Can Karnofsky performance status be transformed to the Eastern Cooperative Oncology Group scoring scale and vice versa? *Eur J Cancer*. 1992;28A(8–9):1328–1330.

Vickery CW, Blazeby JM, Conroy T, et al. Development of an EORTC disease-specific quality of life module for use in patients with gastric cancer. *Eur J Cancer*. 2001;37(8):966–971.

Victor A, Larsson G, Asbrink AS. A simple patient-administered test for objective quantitation of the symptom of urinary incontinence. *Scand J Urol Nephrol*. 1987;21(4):277–279.

Voutilainen A, Pitkäaho T, Kvist T, et al. How to ask about patient satisfaction? The visual analogue scale is less vulnerable to confounding factors and ceiling effect than a symmetric Likert scale. *J Adv Nurs*. 2016;72(4):946–957.

Wagner TH, Patrick DL, McKenna SP, et al. Cross-cultural development of a quality of life measure for men with erection difficulties. *Qual Life Res*. 1996;5(4):443–449.

Wan GJ, Counte MA, Cella DF A new paradigm for assessing health-related quality of life: a social-clinical model [abstract]. Abstract Book/Association for Health Services Research;15:304.

Ware JE Jr. Methodology in behavioral and psychosocial cancer research. Conceptualizing disease impact and treatment outcomes. *Cancer*. 1984;53(10 Suppl):2316–2326.

Ware JE, Hays RD. Methods for measuring patient satisfaction with specific medical encounters. *Med Care*. 1988;26(4):393–402.

Ware JE Jr, Sherbourne CD. The MOS 36-item short-form health survey (SF-36). I. Conceptual framework and item selection. *Med Care*. 1992;30(6):473–483.

Ware J Jr, Kosinski M, Keller SD. A 12-item short-form health survey: construction of scales and preliminary tests of reliability and validity. *Med Care*. 1996;34(3):220–233.

Wei JT, Dunn RL, Litwin MS, et al. Development and validation of the expanded prostate cancer index composite (EPIC) for comprehensive assessment of health-related quality of life in men with prostate cancer. *Urology*. 2000;56(6):899–905.

Welch HG, Black WC. Are deaths within 1 month of cancer-directed surgery attributed to cancer? *J Natl Cancer Inst*. 2002;94(14):1066–1070.

Welch HG, Fisher ES. *Revisiting mortality versus survival in international comparisons of cancer care*. [Available at] https://www.healthaffairs.org/do/10.1377/hblog20150401.04 2015.

Wiggers JH, Donovan KO, Redman S, et al. Cancer patient satisfaction with care. *Cancer*. 1990;66(3):610–616.

Wilson IB, Cleary PD. Linking clinical variables with health-related quality of life. A conceptual model of patient outcomes. *JAMA*. 1995;273(1):59–65.

Woodward CA, Ostbye T, Craighead J, et al. Patient satisfaction as an indicator of quality care in independent health facilities: developing and assessing a tool to enhance public accountability. *Am J Med Qual*. 2000;15(X):94–105.

Xue QL. The frailty syndrome: definition and natural history. *Clin Geriatr Med*. 2011;27(1):1–15.

Zhang HL, Huang ZG, Qiu Y, et al. Tamsulosin for treatment of lower urinary tract symptoms in women: a systematic review and meta-analysis. *Int J Impot Res*. 2017;29(4):148–156.

Ethics and Informed Consent

Vijaya M. Vemulakonda MD, JD

As clinical urologic practice continues to become more complex, the ethical and legal implications of practice become more profound. The purpose of this chapter is to provide a brief history of the origins of medical ethics and legal principles of informed consent, to define key ethical principles and their application to clinical decision making, and to consider the ethical and legal requirements for informed consent in both the clinical and surgical settings.

Medical Ethics

History of Medical Ethics

The origins of medical ethics are thought to be rooted in the writings of Hippocrates, considered to be the “father of medicine.” Foremost among his contributions to medicine is the Hippocratic oath (Box 7.1), considered the cornerstone of ancient Greek medical ethics, which postulated that the primary goal of medicine is to protect the patient's interests. **The oath establishes the moral framework governing the physician-patient relationship and introduces the ethical principles of beneficence, nonmaleficence, confidentiality, and accountability to the medical profession** (Antoniou et al., 2010).

Box 7.1

Translation of the Original Hippocratic Oath

I swear by Apollo the physician, and Aesculapius, and Health, and All-heal, and all the gods and goddesses, that, according to my ability and judgment, I will keep this Oath and this stipulation: to reckon him who taught me this Art equally dear to me as my parents, to share my substance with him, and relieve his necessities if required; to look upon his offspring in the same footing as my own brothers, and to teach them this Art, if they shall wish to learn it, without fee or stipulation; and that by precept, lecture, and every other mode of instruction, I will impart a knowledge of the Art to my own sons, and those of my teachers, and to disciples bound by a stipulation and oath according to the law of medicine, but to none others.

I will follow that system of regimen which, according to my ability and judgment, I consider for the benefit of my patients, and abstain from whatever is deleterious and mischievous. I will give no deadly medicine to anyone if asked, nor suggest any such counsel; and in like manner I will not give to a woman a pessary to produce abortion. With purity and with holiness will I pass my life and practice my Art.

I will not cut persons labouring under the stone, but will leave this to be done by men who are practitioners of this work. Into whatever houses I enter, I will

> go into them for the benefit of the sick, and will abstain from any voluntary act of mischief and corruption; and, further, from the seduction of females or males, of freemen and slaves.
>
> Whatever, in connection with my professional practice, or not in connection with it, I see or hear, in the life of men, which ought not to be spoken of abroad, I will not divulge, as reckoning that all such should be kept secret. While I continue to keep this Oath unviolated, may it be granted to me to enjoy life and the practice of the Art, respected by all men, in all times! But should I trespass and violate this Oath, may the reverse be my lot!
>
> From *The Genuine Works of Hippocrates,* translated from the Greek by Francis Adams, Surgeon, volume 2, London, 1849.

However, in the 20th century, the traditional values embodied by the oath were challenged by prominent ethicists such as Robert Veatch. In this view, the oath relies on the physician to make judgments about diagnosis and treatment because of the patient's inability to understand the information needed for decision making. As a result, the oath undermines the growing respect for patient autonomy that emerged during the late 20th century (Veatch, 1991; Veatch, 2009). Additionally, the oath has been criticized for not addressing issues surrounding justice in the allocation of medical resources, instead focusing on the individual outside of the social context of his care (Veatch, 1991).

As criticism of the Hippocratic oath grew, the interdisciplinary field of bioethics emerged. During the 1960s, physicians first began to discuss the impact of technology, such as antibiotics and genetic testing, on medical care (Jonsen, 2001). In 1970 Van Rensselaer Potter first coined the term *bioethics* to describe “the study of the moral relationship between humans and their social and physical world (Jonsen, 2001; Potter, 1970).” Concerns over the eugenic experiments of the Nazis during World War II strengthened the focus on patient autonomy and patient rights to protect their medical and genetic information (Jonsen, 2001). This focus on respect for patient autonomy and informed consent was reinforced in the research realm as information about the Tuskegee syphilis studies became public in the early 1970s (Jonsen, 2001). In 1979 the “Four Principles” framework for addressing ethical issues in medicine was first described by Beauchamp and Childress. This approach remains the cornerstone of modern medical ethics (Beauchamp and Childress, 1979).

The Four-Principles Framework

The four principles delineated by Beauchamp and Childress were developed to help provide a common set of moral commitments and language with which to address ethical issues (Gillon, 1994). **The principles include autonomy, beneficence, nonmaleficence, and justice.** These principles are considered equal in weight and should be considered *prima facie* binding unless in conflict, leading to ethical dilemmas in circumstances in which the physician and patient must prioritize among conflicting principles (Gillon, 1994).

***Autonomy,* described as respect for the "deliberated self-rule" of individuals, includes an obligation to respect that patients are able to make their own choices even if the outcomes of those choices do not coincide with the physician's calculation of maximal benefit and minimal harm** (Gillon, 1994). This principle is grounded in the Kantian "categorical imperative" that people be considered ends in themselves rather than a means to an end. Although some have postulated that autonomy should be prioritized when in conflict with other principles, it is also considered bound by justice or the consideration of autonomy of others in addition to the individual patient (Gillon, 1994). Respect for autonomy provides the foundation for several physician obligations, including informed consent, confidentiality, and avoidance of deceit. Importantly, communication is essential to providing the physician with the information about patient preferences and attitudes needed to guide discussions of options and to frame medical decision making in a way that is respectful of the patient (Gillon, 1994).

Beneficence and nonmaleficence are grounded in the Hippocratic oath's dictum to protect the patient's best interests (Antoniou et al., 2010). ***Beneficence* refers to the physician's obligation to optimize benefit to the patient and should be considered through the prism of the patient's values and preferences *(autonomy)*. *Nonmaleficence* is grounded in the Hippocratic dictum *primum non nocere* (first do no harm) and refers to the obligation to avoid or minimize harm to the patient**. These principles mean that (1) we must be able to provide the benefits we promise, through adequate training, education, and professional standards and (2) we must be clear about the probability and magnitude of risk and benefit associated with treatment to ensure that we are able to optimize the patient's understanding (Gillon, 1994). As a result, the complementary principles of beneficence and nonmaleficence can be seen as an obligation not only to provide training to the individual clinician but also to conduct research to ensure that the information we offer is as accurate as possible. Finally, the weighing of risks and benefits should be considered both at the individual and at the population level *(justice)* to ensure that risks and benefits are equally shared among patients.

***Justice* refers to the obligation to seek and achieve fairness in the distribution of resources, benefits, and risks across patients.** Although equality and justice share many traits, they are not equivalent; “people may be treated unjustly even if they are treated equally” (Gillon, 1994). At the individual patient level, justice means that the physician should try to minimize the effect of self-interest or personal preferences on patient decisions and should respect the patient's right to self-determination. Additionally, the physician should try to minimize waste of resources when possible. At the societal level, determination of justice may be more difficult. Competing values in justice may lead to different outcomes: does just distribution require equal access to care, provision to those who need it most, advocacy by physicians to maximize the benefit for their patients, limitation of societal costs (via taxes or insurance deductibles), or respect for patient choice? Although all of these values have merit, how do we as physicians and as a society determine which should have priority (Gillon, 1994)?

Medical Ethics in Clinical Practice

Despite the focus on these four principles in medical society codes of ethics and in training, the translation of these principles to specific medical care may not always be clear (Page, 2012). To address this issue, Jonsen et al. recommend use of the “Four-Box” technique to provide a more systematic method to consider and apply ethical principles to medical cases (Table 7.1) (Jonsen et al., 1998). The four topics to be considered include the following:

TABLE 7.1

The Four-Box Method to Application of Ethics in Clinical Practice

Medical Indications	Patient Preferences
1. What is the patient's medical problem? History? Diagnosis? Prognosis? 2. Is the problem acute? Chronic? Critical? Emergent? Reversible? 3. What are the goals of treatment? 4. What are the probabilities of success?	1. What has the patient expressed about treatment preferences? 2. Has the patient been informed of benefits and risks, demonstrated understanding, and given consent? 3. Is the patient mentally capable and

5. What are plans in cases of therapeutic failure? 6. In sum, how can this patient be benefited by medical and nursing care and how can harm be avoided?	legally competent? What evidence is there of incapacity? 4. Has the patient expressed prior preferences (e.g., advance directives)? 5. If incapacitated, who is the appropriate surrogate? Is the surrogate using appropriate standards? 6. Is the patient unwilling or unable to cooperate with medical treatment? If so, why? 7. In sum, is the patient's right to choose being respected to the extent possible in ethics and law?
Quality of Life 1. What are the prospects, with or without treatment, for a return to the patient's normal life? 2. Are there biases that might prejudice the provider's evaluation of the patient's quality of life? 3. What physical, mental, and social deficits is the patient likely to experience if treatment succeeds? 4. Is the patient's present or future condition such that continued life might be judged undesirable by him or her? 5. Is there a plan and rationale to forego treatment? 6. What are plans for comfort/palliative care?	Contextual Features 1. Are there family issues that might influence treatment decisions? 2. Are there provider issues that might influence treatment decisions? 3. Are there financial and economic factors? 4. Are there religious or cultural factors? 5. Is there any justification to breach confidentiality? 6. Are there problems of resource allocation? 7. What are the legal implications of treatment decisions? 8. Is clinical research or teaching involved? 9. Are there any provider or institutional conflicts of interest?

Modified from Jonsen AR, Siegler M, Winslade WJ. *Clinical ethics: a practical approach to ethical decisions in clinical medicine.* 4th ed. McGraw-Hill; 1998.

***Medical Indications* include the general goals of medical treatment (prevention and care of illness) and are grounded in the principles of beneficence and nonmaleficence** (Jonsen et al., 1998). In addition to discussion of clinical issues and potential treatment options, this discussion should extend to the goals of intervention. To act ethically, the physician must use his or her clinical judgment to evaluate the potential risks and benefits of treatment, to make a recommendation based on this assessment, and to identify the patient's preferences regarding treatment choice. The physician should consider and discuss with the patient potential clinical uncertainty both in terms of suspected diagnosis and outcomes. Additionally, when the risks and benefits of treatment appear to be equivocal, the physician should defer to the patient's stated preferences (Schumann and Alfandre, 2008).

***Patient Preferences* refer to the patient's values and assessment of relative benefits of treatment alternatives and are grounded in the ethical principle of autonomy** (Schumann and Alfandre, 2008). To ensure adequate consideration of patient preferences, the provider must ensure the patient has sufficient information and comprehension to weigh treatment options. Additionally, the provider should ensure that the patient has a clear understanding of the uncertainty in outcome and the potential range of treatment choices and outcomes. Finally, it is essential to ensure the patient's choice is voluntary. In the setting of lack of adequate capacity, the physician should ensure that the appropriate person has been identified to act as the patient's surrogate and is acting in accordance with the patient's beliefs and wishes when possible (Schumann and Alfandre, 2008).

***Quality of Life* is the most ephemeral of the factors to be considered in practice and stems from the principles of autonomy, beneficence, and nonmaleficence** (Schumann and Alfandre, 2008). As a result of the variable understanding of this term, it may be difficult for the provider to intuit the impact of treatment on the patient's perceived quality of life. As a result, the substitution of the provider's views for the patient's raises concerns about potential bias that should be considered in the decision-making process, and the provider should try to elicit from the patient his or her values and preferences to guide assessment of quality of life (Jonsen et al., 1998).

***Contextual Features* allow for consideration of a patient-physician partnership within the greater framework of personal, institutional, legal, and social relationships and is grounded in the ethical principle of justice**. This may include family dynamics, patient socioeconomic circumstances, as well as religious beliefs (Schumann and Alfandre, 2008). Additionally, this topic includes the dynamics of the treatment team, the need for coordination of care among multiple providers, as well as potential physician biases or interests that may affect treatment decisions (Jonsen et al., 1998).

Although the Four-Box framework allows for a systematic approach to assessing clinical conundrums by providing an easy-to use-technique for organizing conflicting priorities in patient care and for discussing areas of conflict with the patient and family, it may also lead to oversimplification of ethical issues and may not always clearly guide clinical decision making within the context of identified ethical concerns. **As a result, this framework (or any ethical model) should be used in conjunction with the surgeon's assessment of reasonable alternatives for treatment as a vehicle to guide discussion of the relative benefits of each alternative through the prism of the patient's preferences.**

Informed Consent

History of Informed Consent

Although now considered within the scope of negligence, the legal concept of informed consent originated in early 20th century battery law. From 1905 to 1914, state courts identified a right to bodily integrity that required physicians to obtain informed consent before performing a procedure. They found that patients have the right to decide their course of treatment, and as part of that right, they are entitled to be informed about the risks associated with the procedure and to evaluate those risks before coming to a decision (Faden and Beauchamp, 1986). Patients also may limit the consent provided. For example, consent for an examination under anesthesia does not extend to a consent to surgery (Schloendorff, 1914). Furthermore, consultation for medical advice from a physician does not imply consent (Mohr vs. Williams, 1905). Although the courts did acknowledge the potential for implied consent, this was limited to emergency situations or to cases in which a life-threatening condition was identified and the patient was not capable of consent (Faden and Beauchamp, 1986; Luka vs. Lowrie, 1912).

In 1957 the term *informed consent* was coined and included that physicians provide "any facts which are necessary to form the basis of an intelligent consent by the patient to the proposed treatment" (Salgo vs. Leland, 1957). Under this new standard, physicians faced a heightened responsibility to provide information about the risks, benefits, and alternatives to a procedure to facilitate an informed decision by the patient. The Kansas Supreme Court in 1960 found that physician liability for failure to adequately inform a patient about the risks associated with treatment fell within the scope of negligence. As a result, the legal standard for violating informed consent required both establishing that a physician's actions fell outside of the scope of what a "reasonable and prudent" physician would do and that these actions were the "proximate cause" of the subsequent harm (Katz, 1977). This standard was expanded in 1972 by the DC Court of Appeals, which found that the disclosure should fit within what a "reasonable person" would want to know rather than deferring to what a "reasonable physician" would disclose (Canterbury vs Spence, 1972).

Elements of Informed Consent

Informed consent refers to the process by which a patient and medical provider discuss a proposed medical treatment, its anticipated consequences, potential risks and benefits, and alternatives. This process allows for open discussion between the provider and the patient and may theoretically help reduce medical errors, improve patient outcomes, and increase patient empowerment (Cordasco, 2013).

A comprehensive informed consent consists of four basic elements: (1) description of the clinical problem, the proposed treatment, and alternatives including no treatment; (2) discussion of the risks and benefits of the proposed treatment with comparisons to the risks and benefits of alternatives, and discussion of medical/clinical uncertainties regarding the proposed treatment; (3) assessment of the patient's understanding of the information provided by the medical provider; and (4) solicitation of the patient's preference and consent for treatment (Cordasco, 2013).

The extent of information to be provided is generally based on the physician's assessment of what information may impact diagnosis and treatment planning. Extraneous information that is unlikely to impact the patient's decision may be withheld. Additionally, to the extent possible, information should be provided in a way that is understandable to the average layperson and facilitates his or her meaningful participation in treatment planning. By discussing options before making a recommendation, the surgeon may reduce undue influence on the patient's decision (McCullough et al., 1986).

To ensure adequate information for consent, patients must understand the “material risks” and expected benefits of treatment. However, there is no clear consensus on what constitutes a material risk. Some have proposed a 1% risk cutoff, with lower risk considered based on the severity of harm (Adams and Smith, 2001). Additionally, there are several limitations to patient understanding of risks. First, patients often use shortcuts to simplify the decision-making process, often leading to misunderstanding of the risks posed by a treatment (Lloyd, 2001). Second, patients may underestimate their own risks compared with other people's (Weinstein, 1989). Third, patients are influenced by the way in which risks are presented (e.g., likelihood of survival versus likelihood of death) (Lloyd, 2001). Counterintuitively, information about clinical uncertainty in the probability of risk improves understanding of risk and also elicits more trust in the information provided (Johnson and Slovic, 1995).

Patients often idealize surgeons and accept surgical recommendations without meaningful participation in the decision-making process (McNeally and Martin, 2000). As a result, the surgeon has a heightened responsibility to solicit patient feedback during the consent process. By empowering the patient to both ask questions and to authorize surgical intervention, the surgeon also strengthens their relationship with the patient, opening the door to an ongoing process of communication before, during, and after treatment (Jones et al., 2007). Substantively, the physician should ensure that the patient understands the goals of treatment, the general nature of the procedure to be performed, as well as expected outcomes including what to expect in the immediate postoperative period.

The last element of the informed consent process is explicit consent or refusal of treatment based on the information and recommendations provided by the surgeon. The surgeon should help the patient understand the potential future implications of his or her decisions. The extent to which the surgeon directs the conversation regarding treatment alternatives may depend on how active the patient chooses to be in the decision-making process (Fig. 7.1). Regardless of the patient's role in the process, the surgeon should at least ensure patient understanding of the potential outcomes, risks, and benefits associated with the procedure before obtaining consent. To facilitate the patient's judgments about the relative risks and benefits of treatment, the surgeon may ask the patient about what elements of treatment are most important to him or her, such as impact on job performance, sexual function, continence, or ability to pursue leisure activities.

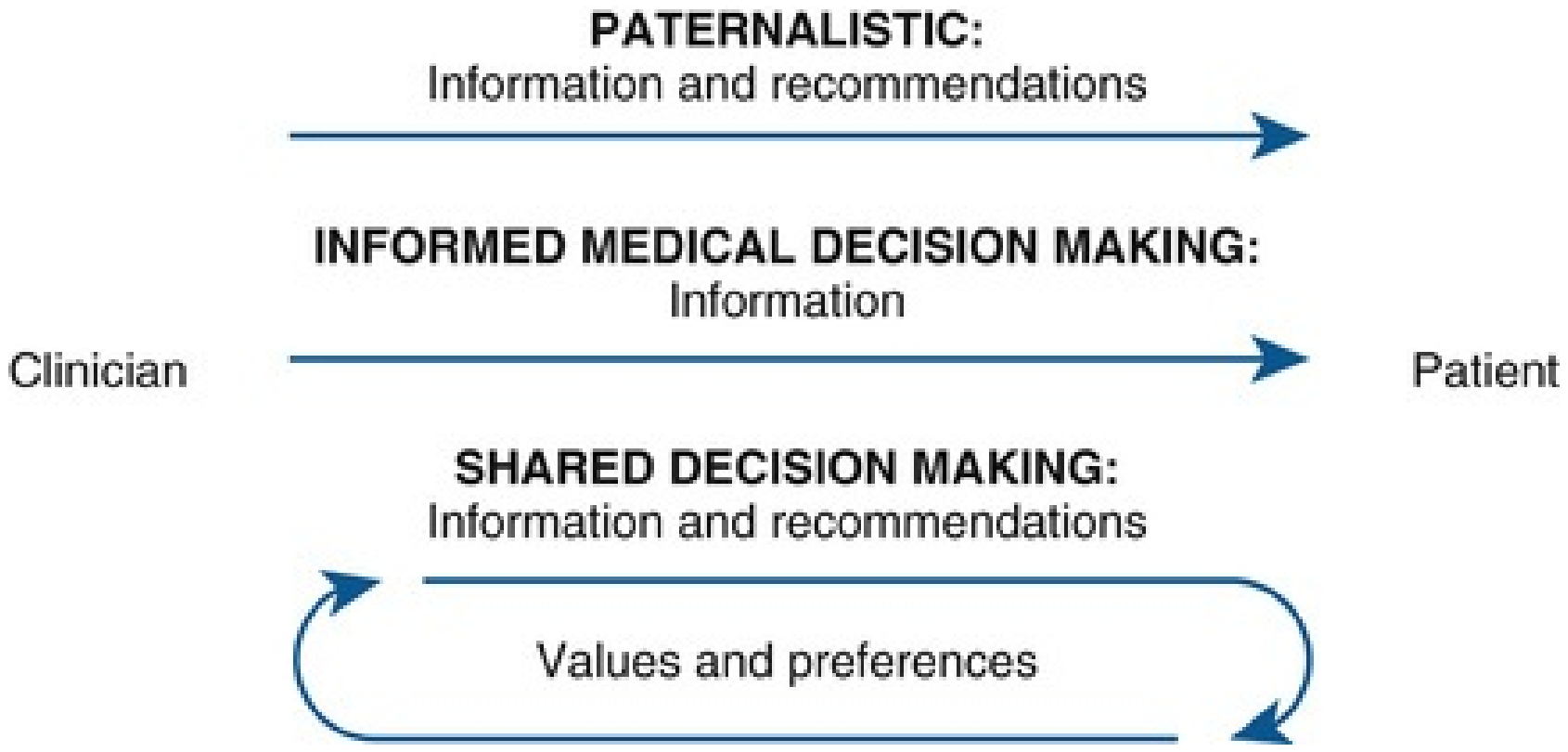
PATERNALISTIC:
Information and recommendations
INFORMED MEDICAL DECISION MAKING:
Information
Clinician
Patient
SHARED DECISION MAKING:
Information and recommendations
Values and preferences

FIG. 7.1 Models of patient decision making. (From Schrager S, Phillips G, Burnside E. A simple approach to shared decision making in cancer screening. *Fam Pract Manag* 2017;24(3):5–10.)

Exceptions to the Informed Consent Requirement

Emergency situations: One of the well-established exceptions to informed consent is in the emergency setting. **In this setting, where there is a significant threat to patient's well-being or life, consent is presumed** (Hartman and Liang, 1999). In unconscious patients in need of emergent medical care, the responsibility of disclosure is waived because of the potential irreparable harm that may result (Barnett vs. Bachrach, 1943). Similarly, in the pediatric setting, informed consent from the parents may be waived if the patient is at risk for “immediate injury or death (Hartman and Liang, 1999).” However, this waiver does not extend to the conscious patient, who may refuse treatment even if to do so would be life-threatening (In re Quackenbush, 1978) or to children where obtaining parental consent does not constitute an immediate threat of harm (Rogers vs Sells, 1936).

Patients without decision-making capacity: **In patients who are unable to participate in the decision-making process, often family members are empowered by law to make decisions for them** (Areen, 1987). The goal is for the family to assess what the patient would consider most important (“substituted judgment”) rather than for the family to make decisions based on their own values. In cases in which the family is unable to achieve substituted judgment, they should instead act in the best interest of their loved one. When the surgeon does not believe that the surrogate decision maker is adequately pursuing the patient's wishes, he or she should then consult with the institutional ethics board or hospital administration to determine whether petitioning the court for a conservator is warranted (McCullough et al., 1986).

Pediatric patients: **Although by law parents are considered surrogate decision makers for minor children (younger than 18 years of age), children should participate in the decision-making process to the extent that they are able** (Committee on Bioethics, American Academy of Pediatrics, 1995). When parents and their children disagree about the best treatment decision, the surgeon should offer to facilitate discussion to help them reach a common decision. Additionally, providing information about the process, including providing families with the opportunity to visit perioperative spaces before surgery, may help improve understanding and alleviate anxiety about the process (Ziegler and

Prior, 1994).

Quality of Informed Consent

In assessing the quality of consent, two questions must be answered: (1) Did the physician provide the patient with enough information about the diagnosis and treatment and (2) Did the patient consent to treatment based on this information (Jones et al., 2007)? **The standard by which to judge the adequacy of information should be based on what a reasonable person (patient) needs for a meaningful decision** (Canterbury vs. Spence, 1972) **and includes a responsibility for the physician to respect the patient's perspective of his or her interests whether or not the physician agrees** (Jones et al., 2007).

Despite the need for effective consent, most informed consent processes are incomplete, with the most common missed element being assessment of patient understanding of the information provided by the physician (Cordasco, 2013). The information provided in consent forms often is above the 12th-grade level, although the majority of patients have reading levels well below that (Hopper et al., 1998). Whether because of the difficulty of understanding or recalling the information in informed consent documents, patients who report reading consent forms do not demonstrate better understanding of the procedure and its risks than those who do not (Cassileth et al., 1980). This lack of understanding is even more pronounced in patients with limited English proficiency (Cordasco, 2013).

To address these limitations, several techniques have been tried to improve the informed consent process. Simplifying consent forms alone has had mixed results in improving patient understanding (Cordasco, 2013). Supplemental written materials providing information about the procedure in more simplified language than the consent form has had a more significant impact on patient recall of information (Cordasco, 2013). Similarly, decision aids with more detailed information about options and potential outcomes have improved knowledge about procedures, reduced decisional conflict, improved patient participation in the decision, and improved risk assessment (O'Connor et al., 2009). Finally, use of “repeat-back” methods in which the patient is asked to explain what he or she has been told and the provider then clarifies the information provided with subsequent repeat assessments of patient knowledge has been found to be effective in improving comprehension but also adds significant time to the patient-provider encounter, limiting its potential feasibility

(Fink et al., 2010).

Key Points

- Although the scope of medical ethics continues to evolve, the basic ethical principles of autonomy, beneficence, nonmaleficence, and justice remain the foundation of ethical medical practice.
- Informed consent is essential to the practice of surgery with limited exceptions.
- Despite the goal of ensuring adequate understanding of the nature, risks, benefits, and alternatives of surgery to facilitate a meaningful decision, the informed consent process is often incomplete. It is therefore the responsibility of the surgeon to make every effort to facilitate patient understanding and participation in the decision-making process.

References

Adams AM, Smith AF. Risk perception and communication. *Anaesthesia*. 2001;56:745–755.

Antoniou SA, Antoniou GA, Granderath FA, et al. Reflections of the hippocratic oath in modern medicine. *World J Surg*. 2010;34(12):3075–3079.

Areen J. The legal status of consent obtained from families of adult patients to withhold or withdraw treatment. *JAMA*. 1987;258:229–235.

Barnett vs. Bachrach. 34 A.2d 626, 1943.

Beauchamp TL, Childress JF. *Principles of biomedical ethics*. Oxford University Press; 1979.

Canterbury vs Spence, 464 F 2d 772, 778, 1972.

Cassileth BR, Upkis RV, Sutton-Smith K, et al. Informed consent-why are its goals imperfectly realized? *N Engl J Med*. 1980;302(16):896–900.

Committee on Bioethics, American Academy of Pediatrics. Informed consent, parental permission, and assent in pediatric practice. *Pediatrics*. 1995;95:314–317.

Cordasco KM. Obtaining informed consent from patients: brief update review. *Making health care safer II: an updated critical analysis of the evidence for patient safety practices*. Agency for Healthcare Research and Quality (US); 2013.

Faden RR, Beauchamp TR. *A history and theory of informed consent*. Oxford University Press; 1986.

Fink AS, Prochazka AV, Henderson WG, et al. Enhancement of surgical informed consent by addition of repeat back: a multicenter, randomized controlled clinical trial. *Ann Surg*. 2010;252(1):27–36.

Gillon R. Medical ethics: four principles plus attention to scope. *BMJ*. 1994;309(6948):184–188.

Hartman KM, Liang BA. *Exceptions to informed consent in emergency medicine*. Hosp Physician. 1999:53–59 [March].

Hopper KD, TenHave TR, Tully DA, et al. The readability of currently used surgical/procedure consent forms in the United States. *Surgery*. 1998;123(5):496–503.

In re Quackenbush, 156 NJ Super 282, 383 A 2d 785, 1978.

Johnson BB, Slovic P. Presenting uncertainty in health risk assessment: initial studies of its effects on risk perception and trust. *Risk Anal*. 1995;15:485–494.

Jones JW, McCullough LB, Richman BW. A comprehensive primer of surgical consent. *Surg Clin North Am*. 2007;87:903–918.

Jonsen AR. Social responsibilities of bioethics. *J Urban Health*. 2001;78(1):21–28.

Jonsen AR, Siegler M, Winslade WJ. *Clinical ethics: a practical approach to ethical decisions in clinical medicine*. 4th ed. McGraw-Hill; 1998.

Katz J. Informed consent—a fairy tale? Law's vision. *University Pittsburg Law Rev*. 1977;137.

Lloyd AJ. The extent of patients' understanding of the risk of treatments. *Qual Health Care*. 2001;10(Suppl 1):i14–i18.

Luka vs Lowrie, 136 NW 1106, 1912.

McCullough L, Jones JW, Brody BA. Informed consent: autonomous decision making of the surgical patient. McCullough LB, Jones JW, Brody BA. *Surgical ethics*. Oxford University Press: New York; 1986.

McNeally MF, Martin DK. An entrustment model of consent for surgical treatment of life-threatening illness: perspective of patients requiring esophagectomy. *J Thorac Cardiovasc Surg*. 2000;120:264–269.

Mohr vs Williams, 96 Minn 261, 104 NW 12, 1905.

O'Connor AM, Bennet CL, Stacey D, et al. Decision aids for people facing health treatment or screening decisions.

Cochrane Database Syst Rev. 2009;(3) [CD001431].

Page K. The four principles: can they be measured and do they predict ethical decision making? *BMC Med Ethics*. 2012;13:10.

Potter VR. Bioethics, the science of survival. *Perspect Biol Med*. 1970;14(1):127–153.

Rogers vs Sells, 178 Okla 103, 1936.

Salgo vs Leland Stanford Jr University Board of Trustees, 317 P 2d 170, 173, 1957.

Schloendorff vs Society of New York Hospital, 211 NY 125, 105 NE 92, 93, 1914.

Schumann JH, Alfandre D. Clinical ethical decision making: the four topics approach. *Semin Med Pract*. 2008;11:36–42.

Veatch RM. *Patient, heal thyself: how new medicine puts the patient in charge*. Oxford University Press; 2009.

Veatch RM. *The patient-physician relation: the patient as partner*. Indiana University Press; 1991.

Weinstein ND. Optimism biases about personal risks. *Science*. 1989;246:1232–1233.

Ziegler DB, Prior MM. Preparation for surgery and adjustment to hospitalization. *Nurs Clin North Am*. 1994;29(4):655–659.

PART II

Basics of Urologic Surgery

OUTLINE

8 Principles of Urologic Surgery Perioperative Care
9 Principles of Urologic Surgery Incisions and Access
10 Principles of Urologic Surgery Intraoperative Technical Decisions
11 Lower Urinary Tract Catheterization
12 Fundamentals of Upper Urinary Tract Drainage
13 Principles of Urologic Endoscopy
14 Fundamentals of Laparoscopic and Robotic Urologic Surgery
15 Basic Energy Modalities in Urologic Surgery
16 Evaluation and Management of Hematuria
17 Complications of Urologic Surgery
18 Urologic Considerations in Pregnancy
19 Intraoperative Consultation

Principles of Urologic Surgery

Perioperative Care

Simpa S. Salami MD, MPH

The perioperative care of the urology patient continues to evolve as newer tools and techniques are introduced and as the population ages. Over the past two decades, the economics of health care have added increasing pressure for more outpatient surgery, decreased hospital stays, and decreased complication rates. It has become the standard of care for patients undergoing even the most sophisticated and complex urologic procedures to be admitted on the same day as the surgery and discharged to home the day after surgery. Further, although the practice of urology continues to move toward office-based and nonsurgical treatments, the diversity of genitourinary disease requires that the practicing urologist be familiar with perioperative surgical principles to improve clinical care and outcomes. This chapter provides the reader with basic tools to understand the preoperative assessment and optimization, intraoperative and postoperative management approaches necessary to promote a culture of patient safety and effective and efficient clinical care, and to ensure optimal surgical outcomes.

Preoperative Evaluation

The acuity of surgical patients is increasing as the population ages and as patients present with more significant comorbidities. **The urologic surgeon is responsible for ensuring that the patient has been thoroughly evaluated by the other physicians on the health care team and arrives in and leaves the operating room in the most optimized medical condition.** The preoperative use of appropriate medical specialist consultations not only will result in improved patient safety and outcomes but will also obviate the need for unnecessary cancelled surgeries resulting from the inadequacy of medical optimization.

Presurgical Testing

The goal of presurgical testing is to identify an undiagnosed comorbidity, an undertreated pre-existing medical problem, or a significant exacerbation of existing comorbid illness that may affect the operative course and/or outcome (Townsend et al., 2015). Ideally, the preoperative evaluation should be individualized on the basis of age, history, physical examination findings, and the surgical procedure to be performed. Although most hospitals or ambulatory surgery centers have requirements for baseline evaluation, routine testing in addition to history and physical examination has never been shown to be cost-effective. In fact, the results of routine testing are less predictive of perioperative morbidity than the American Society of Anesthesiologists (ASA) status or the American Heart Association (AHA) and American College of Cardiology (ACC) guidelines for surgical risk. A recent systematic review found no evidence to support routine preoperative testing in patients undergoing noncardiac elective surgery (Johansson et al., 2013). Most commonly, presurgical testing includes complete blood count (CBC); basic metabolic panel (BMP); prothrombin time (PT), partial thromboplastin time (PTT), and international normalized ratio (INR) (controversial); electrocardiogram (ECG); ABO/Rh blood typing and antibodies screen; and chest radiograph. The routine ordering of a PT/PTT in a patient not currently on anticoagulation or in a patient without a prior history of a bleeding disorder or increased bleeding with other surgical procedures is controversial, and these tests can be omitted in the majority of patients. **Any woman of childbearing age, unless the ovaries or uterus have been previously surgically removed, must undergo a urine pregnancy test on the morning of surgery** (Halaszynski et al., 2004). The value of a preoperative ECG in identification of underlying acute cardiac disease and prediction of perioperative cardiac morbidity is also controversial. Some studies have shown that ECG abnormalities have no significant added predictive value (van Klei et al., 2007; Liu et al., 2002), whereas others found that an abnormal ECG preoperatively is a predictor of an adverse cardiac event in patients undergoing noncardiac surgery (Noordzij et al., 2006; Biteker et al., 2012; Shoyeb et al., 2006). Nonetheless, current recommendations, in general, suggest that a preoperative ECG be obtained from patients older than 40 years of age or those with a history of cardiac disease. Similarly, the routine preoperative use of a chest radiograph, in the absence of preexisting cardiopulmonary disease, is not indicated. Overall, even an ASA Task Force on Pre-anesthesia Evaluation could not make firm recommendations other than “preoperative tests may be ordered, required, or *performed on a selective basis* for purposes of guiding or optimizing perioperative management” (Committee on Standards and Practice Parameters et al., 2012).

American Society of Anesthesiologists Classification and Risk

Approximately 27 million patients undergo surgery each year in the United States, and 8 million (30%) have significant coronary artery disease or other cardiac comorbidities. Appropriately, the cardiovascular system is targeted during the preoperative assessment of patients. The ASA classification was first developed in 1961 and has been revised to categorize risk into six stratifications (Box 8.1).

Box 8.1

American Society of Anesthesiologists (ASA) Classification

1	ASA Class I	Normal healthy patient
2	ASA Class II	Patient with mild systemic disease
3	ASA Class III	Patient with severe systemic disease that limits activity but is not incapacitating
4	ASA Class IV	Patient with incapacitating disease that is a constant threat to life
5	ASA Class V	Moribund patient not expected to survive 24 hours with or without an operation
6	ASA Class VI	A declared brain-dead patient whose organs are being removed for donor purposes
7	ASA Class E	In the event of emergency surgery, an E is added after the Roman numeral (in I through V classes)

The goal of the classification system is to assess the overall physical status of the patient before surgery (not to assess surgical risk), and although quite subjective, it remains a significant independent predictor of mortality (Davenport et al., 2006). Other tools to assess the preoperative risks were developed by multivariate statistical analysis of patient-related factors correlated with surgical outcomes. One such scoring system, Goldman's criteria (Table 8.1), assigns points to easily reproducible characteristics. The points are then added to compute the perioperative risk for cardiac-related complications. Another system, the Cardiac Risk Index, simplified this concept; it uses only six predictors to estimate cardiac complication risk in noncardiac surgical patients (Table 8.2) (Akhtar and Silverman, 2004).

TABLE 8.1

Goldman's Cardiac Risk Index

PATIENT RISK FACTORS	POINTS
Third heart sound or jugular venous distention	11
Recent myocardial infarction	10
Nonsinus rhythm or premature atrial contraction on electrocardiogram	7
More than five premature ventricular contractions	7
Age older than 70 years	5
Emergency operations	4
Poor general medical condition	3
Intrathoracic, intraperitoneal, or aortic surgery	3
Significant valvular aortic stenosis	3
For noncardiac surgery, the risk for cardiac complications is: 6–12 points = 7% risk 13–25 points = 14% risk >26 points = 78% risk	

Modified from Akhtar S, Silverman DG. Assessment and management of patients with ischemic heart disease. *Crit Care Med 2004*;32(4 Suppl):S126–S136.

TABLE 8.2

Modified Cardiac Risk Index

PATIENT RISK FACTORS	POINTS
Ischemic heart disease	11
Congestive heart failure	10
Cerebral vascular disease	7

High-risk surgery	7
Preoperative insulin treatment for diabetes	5
Preoperative creatinine ≥2 mg/dL	4
Each increment in point increases the risk for perioperative cardiovascular morbidity.	

Modified from Akhtar S, Silverman DG. Assessment and management of patients with ischemic heart disease. *Crit Care Med.* 2004;32(4 Suppl):S126–S136.

Preoperative Cardiovascular Evaluation

The preoperative cardiac evaluation, which consists of an initial history, physical examination, and ECG, attempts to identify potential serious cardiac disorders such as coronary artery disease, heart failure, symptomatic arrhythmias, the presence of a pacemaker or implantable defibrillator, or a history of orthostatic hypotension (Eagle et al., 1996, 2002). Furthermore, it is essential to define the severity and stability of existing cardiac disease before surgery. Cardiac-specific risk is also altered by the patient's functional capacity, age, and other comorbid conditions such as diabetes, peripheral vascular disease, renal dysfunction, and chronic obstructive pulmonary disease (COPD). The ACC and AHA recently collaborated to develop guidelines regarding perioperative cardiac evaluation before surgery (Fleisher et al., 2007a). In general, the guidelines use three categories of clinical risk predictors: *clinical markers*, *functional capacity*, and *type of surgical procedure* (Eagle et al., 2002).

Clinical Markers

The need for a general medical or cardiac evaluation before surgery is dependent on patients’ comorbid condition and overall perioperative risk. The *major* clinical predictors of increased perioperative cardiovascular risk includes a documented acute myocardial infarction less than 7 days previously, a recent myocardial infarction (defined as at least 7 days but less than 1 month before surgery), unstable angina, evidence of any ischemic burden by clinical symptoms or noninvasive testing, decompensated heart failure, significant arrhythmias, and severe valvular disease. *Intermediate* predictors include mild angina, previous myocardial infarction by history or pathologic Q waves on ECG, compensated heart failure, diabetes, or renal insufficiency (creatinine >2 mg/dL). *Minor* predictors of risk are advanced age, abnormal ECG, rhythms other than sinus (e.g., atrial fibrillation), history of stroke, or uncontrolled systemic hypertension. The historical dictum suggesting that elective surgery after myocardial infarction be performed after a 3- to 6-month interval is now currently avoided (Tarhan et al., 1972). **The ACC cardiovascular database committee stratifies risk on the basis of the severity of the myocardial infarction and the likelihood of reinfarction based on a recent exercise stress**

test. However, in the absence of adequate clinical trials on which to base firm recommendations, it is reasonable to wait 4 to 6 weeks after myocardial infarction to perform elective surgery, keeping in mind the kind of cardiac intervention (stents or bypass grafting) and the need for antiplatelet therapy (see later).

Functional Capacity

Functional capacity, or one's ability to meet aerobic demands for a specific activity, is quantified as metabolic equivalents of the task (METs). For example, a 4-MET demand is comparable with a patient's ability to climb two flights of stairs. This simple measurement continues to be an easy and inexpensive method to determine a patient's cardiopulmonary functional capacity (Biccard, 2005). **The Duke Activity Status Index (Table 8.3), which has been validated in several studies, allows the physician to easily determine a patient's functional capacity** (Hlatky et al., 1989; Carter et al., 2002; Coutinho-Myrrha et al., 2014; Wu et al., 2016). **In general, a capacity of 4 METs indicates no further need for invasive cardiac evaluation.**

TABLE 8.3

Duke Activity Status Index[a]

ACTIVITY	YES	NO
Can you take care of yourself such as eating, dressing, bathing, or using the toilet?	2.75	0
Can you walk indoors such as around your house?	1.75	0
Can you walk a block or two on level ground?	2.75	0
Can you climb a flight of stairs or walk up a hill?	5.50	0
Can you run a short distance?	8.00	0
Can you do light work around the house such as dusting or washing dishes?	2.70	0
Can you do moderate work around the house such as vacuuming, sweeping floors, or carrying in groceries?	3.50	0
Can you do heavy work around the house such as scrubbing floors or lifting and moving heavy furniture?	8.00	0
Can you do yardwork such as raking leaves, weeding, or pushing a power mower?	4.50	0
Can you have sexual relations?	5.25	0
Can you participate in moderate recreational activities such as golf, bowling, dancing, doubles tennis, or throwing a baseball or football?	6.00	0

Can you participate in strenuous sports such as swimming, singles tennis, football, basketball, or skiing?	7.50	0

[a] The most widely recognized measure of cardiorespiratory fitness is maximal oxygen consumption (VO_2peak) measured in mL/kg/min. The Index score correlates directly with VO_2peak and therefore is an indirect measure of maximal METs.

Duke activity status index (DASI) = Sum of values for all 12 questions

Estimated peak oxygen uptake (VO_2peak) in mL/min = (0.43 × DASI) + 9.6

METs (metabolic equivalents of the task) = VO_2peak × 0.286 $(\text{mL/kg/min})^{-1}$

Modified from Hlatky MA, Boineau RE, Higginbotham MB, et al. A brief self-administered questionnaire to determine functional capacity (the Duke Activity Status Index). *Am J Cardiol.* 1989;64(10):651–654.

Surgery-Specific Cardiac Risk

Two important factors determine the surgery-specific cardiac risk: the type of surgery and the degree of hemodynamic stress. Surgery-specific risk is stratified into high-, intermediate-, and low-risk procedures. High-risk procedures include both major emergent surgeries, particularly in the elderly, and surgery associated with increased operative time resulting in large fluid shifts or blood loss. Intermediate risk procedures include intraperitoneal surgery, laparoscopic procedures, and robotic-assisted laparoscopic surgeries. Low-risk procedures include endoscopic procedures or superficial surgeries (i.e., not involving entrance into a body cavity) (Eagle et al., 2002).

Pulmonary Evaluation

Preoperative pulmonary evaluation is important in all urologic procedures but critical in those surgeries involving the thoracic or abdominal cavities. These procedures, which include intra-abdominal, laparoscopic, or robotic surgeries, can decrease pulmonary function during the operation or postoperatively and predispose to pulmonary complications. Accordingly, it is prudent to consider pulmonary functional assessment in patients who have significant underlying pulmonary disorder, significant smoking history, or overt pulmonary symptoms. Pulmonary function tests that include a forced expiratory volume in 1 second (FEV_1), forced vital capacity, and the diffusing capacity of carbon monoxide are quite easily performed and provide a preoperative baseline. **Patients with an FEV_1 of less than 0.8 L/sec or 30% of predicted are at high risk for complications** (Arozullah et al., 2003). Specific pulmonary risk factors include COPD, smoking, preoperative sputum production, pneumonia, dyspnea, and obstructive sleep apnea. **It has been shown that smokers have a fourfold increased risk for postoperative pulmonary morbidity and as high as a 10-fold higher mortality rate** (Fowkes et al., 1982). In general, it is interesting to note that patients with restrictive pulmonary disease fare better than those with obstructive pulmonary disease because the former group maintains an adequate maximal expiratory flow rate, which allows for a more effective cough with less sputum production (Pearce and Jones, 1984). In addition to the specific pulmonary risk factors, general factors contribute to increased pulmonary complications such as increased age, lower serum albumin levels, obesity, impaired sensorium, previous stroke, immobility, acute renal failure, and chronic steroid use.

Hepatobiliary Evaluation

Survival of patients with advanced liver disease has improved over the past decade, thus surgery is being performed more frequently in these patients. Furthermore, patients with mild to moderate hepatic disease are often asymptomatic. These patients need to be identified and evaluated before surgery. Patients are usually aware of a prior diagnosis of hepatitis, and they should be questioned regarding the timing of diagnosis and the precipitating factors. This history is particularly important if a member of the health care team is inadvertently stuck with a needle or cut with a scalpel during the surgical procedure. A review of systems should include questions regarding pruritus, excessive bleeding, abnormal abdominal distention, and weight gain. On physical examination, jaundice and scleral icterus may be evident with serum bilirubin levels higher than 3 mg/dL. Skin changes such as caput medusae, palmar erythema, spider angiomas, and clubbing all indicate hepatic dysfunction. Severe manifestations include abdominal distention, encephalopathy, asterixis, or cachexia. Again, identification of underlying hepatic illness is important in the preoperative risk assessment of the patient. Although the estimation of perioperative mortality is limited by the lack of high-quality clinical studies, the use of the Child classification and model for end-stage liver disease (MELD) score offers a reasonable estimation.

The Child classification assesses perioperative morbidity and mortality in patients with cirrhosis and is based on the patient's serum markers (bilirubin, albumin, PT) and severity of clinical manifestations (i.e., encephalopathy and ascites). **Mortality risk for patients undergoing surgery stratified by Child class is as follows: Child Class A—10%, Child Class B—30%, and Child Class C—76% to 82%.** The Child classification also correlates with the frequency of complications such as liver failure, encephalopathy, bleeding, infection, renal failure, hypoxia, and intractable ascites. Independent risk factors other than the Child class that can increase the mortality rate in patients with liver disease include emergency surgery and COPD (Pearce and Jones, 1984; O'Leary et al., 2009; O'Leary and Friedman, 2007).

The MELD score is perhaps a more accurate assessment of perioperative mortality in patients with hepatic dysfunction. The score is derived from a linear regression model based on serum bilirubin, creatinine levels, and the INR. It is more accurate than the Child classification in that it is objective, gives weights to each variable, and does not rely on arbitrary cutoff values (Teh et al., 2007). **Clinicians can use a website (http://mayoclinic.org/meld/mayomodel9.html) to calculate the 7-day, 30-day, 90-day, 1-year, and 5-year surgical mortality risk on the basis of the patient's age, ASA class, INR, serum bilirubin, and creatinine levels.** A recent study also found that the MELD score was tightly correlated with 30-day mortality risk in all patients undergoing colorectal surgery regardless of the presence of liver disease (Hedrick et al., 2013). Taken together, the Child classification and the MELD score complement each other and provide an important assessment of the risk associated with surgery in cirrhotic patients (O'Leary and Friedman, 2007; O'Leary et al., 2009).

Special Populations

Elderly

It is estimated that by 2050 the number of Americans older than 65 years of age will more than double to 89 million individuals, with more than 20% older than 85 years of age (Jacobson et al., 2011). Accordingly, octogenarians and nonagenarians are undergoing an increasing number of surgeries annually. Because of elderly patients' special physiologic, pharmacologic, and psychological needs, a unique set of health care challenges is encountered. It is still unclear whether advanced age independently predicts surgical risk or whether it is coexisting medical conditions that adversely affect surgical outcomes. However, in a large study published by Turrentine, the authors showed that increased age independently predicted morbidity and mortality (Turrentine et al., 2006). This confirmed the study by Vemuri, who also found increased age to be an independent risk factor for morbidity and mortality in patients undergoing aneurysm surgery (Vemuri et al., 2004). Within the urologic literature, Liberman et al. reported 90-day mortality rates after radical cystectomy in patients younger than 70 years, 70 to 80 years, and older than 80 years of 2%, 5.4%, and 9.2%, respectively (Liberman et al., 2011). The studies suggest that independent of comorbidities, perhaps the elderly patient cannot meet the increased functional demand required during the perioperative and postoperative periods. Notably, hypertension and dyspnea were the most frequently seen comorbid risk factors in patients older than 80 years of age, and preoperative transfusion history, emergency operation, and weight loss best predicted postoperative morbidity. Additionally, each 30-minute increment of operative time increased the odds of mortality by 17% in octogenarians (Turrentine et al., 2006). A unique and important factor in the perioperative care of the elderly is in the identification and prevention of delirium. Often overlooked as "sundowning," delirium can be the first clinical sign of metabolic and infectious complications (Townsend et al., 2015).

Morbid Obesity

The careful selection of the morbidly obese patient for elective surgery is of paramount importance. With the rising incidence of obesity, one must carefully weigh and balance the risk associated with any surgical procedure with the natural history of the disease when deciding the optimal time of the surgery in the morbidly obese. **It is estimated that patients with a body mass index (BMI) of 45 kg/m^2 or higher may lose anywhere from 8 to 13 years of life expectancy** (Fontaine et al., 2003). Cardiac symptoms such as exertional dyspnea and lower extremity edema are nonspecific in morbidly obese patients, and many of these patients have poor functional capacity. The physical examination often underestimates cardiac dysfunction in the severely obese patient. Severely obese patients with more than three coronary heart disease risk factors may require noninvasive cardiac evaluation (Poirier et al., 2009). Obesity is associated with a vast array of comorbidities. Morbidly obese patients often have atherosclerotic cardiovascular disease, heart failure, systemic hypertension, pulmonary hypertension related to sleep apnea and obesity, hypoventilation, cardiac arrhythmias, deep vein thrombosis, history of pulmonary embolism, and poor exercise capacity. There are also numerous pulmonary abnormalities that result in a ventilation perfusion mismatch and alveolar hypoventilation. Obesity is a risk factor for postoperative wound infections, and, when appropriate, laparoscopic surgery should be considered.

Pregnancy

Urologic surgery in the pregnant woman is most commonly related to the management of renal colic and urinary tract stones. The stones can be discovered during the sonographic evaluation of the fetus in an asymptomatic pregnant woman or during the evaluation of the pregnant woman who is experiencing renal colic. **The fetus is at the highest risk from radiation exposure from the preimplantation period to approximately 15 weeks' gestation.** Because the radiation dose that is associated with congenital malformations is 10 cGy, the evaluation of renal colic in the pregnant patient is performed usually with sonography (radiation dose with abdominal computed tomography [CT]—1 cGy; intravenous pyelogram—0.3 cGy). **In general, a surgical procedure in the pregnant woman should be delayed, if at all possible, until the baby is mature enough for delivery unless significant harm to the mother or fetus will result.** The indications for operative intervention in the pregnant patient are discussed elsewhere in this book. Anesthetic risks during pregnancy concern both the mother and the fetus. During the first trimester, the fetus may be directly exposed to the teratogenic effects of certain anesthetic agents. Later in pregnancy, anesthesia places the mother at risk for preterm labor and the fetus at risk for hypoxemia secondary to changes in uterine blood flow and maternal acid-base imbalance. These risks seem to be greatest during the first and third trimesters. **For semi-elective procedures, an attempt should be made to delay surgery until after the first trimester.** However, one must consider the continued exposure of the underlying condition in relation to the operative risks to both the mother and fetus. **The second trimester is the safest time to perform surgery because organ system differentiation has occurred and there is almost no risk for anesthetic-induced malformation or spontaneous abortion.** When one is contemplating surgery on a pregnant patient, consultation with the obstetrician, perinatologist, and anesthesiologist is essential (Kizer and Powell, 2011). These specialists will help determine the optimum technique to monitor the status of the fetus. Fetal heart rate monitors and tocometer monitoring for uterine activity are used before and after the procedure. Postoperative pain is best managed with narcotic analgesics because they have not been shown to cause birth defects in humans when used in normal dosages. Nonsteroidal anti-inflammatory medication should be avoided because of the risk for premature closure of the ductus arteriosus. Chronic use of narcotics during pregnancy may cause fetal dependency, and it is recommended that the pregnant postsurgical patient be weaned off narcotic use as soon as possible.

Nutritional Status

Malnutrition compromises host defenses and increases the risk for perioperative morbidity and mortality. Adequate nutritional status is essential for proper wound healing, mounting appropriate immune response to infections, return of bowel activity, and maintenance of vital organ function (Evans et al., 2014). The preoperative evaluation and classification of the patient's nutritional status typically consist of assessment of any recent weight loss and measurement of laboratory values, such as lymphocyte count and serum albumin. A 20-pound weight loss in the preceding 3 months before surgery is considered to be a reflection of severe malnutrition. The lymphocyte count and serum albumin level reflect visceral protein status, with lower levels indicating malnutrition (Reinhardt et al., 1980). Several assessment tools have been validated to quantitate nutritional status, including the Subjective Global Assessment (http://subjectiveglobalassessment.com).

There are two methods for nutritional support. **Total parenteral nutrition**

(TPN) is used for patients who are severely malnourished and who have a nonfunctioning gastrointestinal (GI) tract. Several studies have shown that 7 to 10 days of preoperative parenteral nutrition improves postoperative outcome in undernourished patients (Von Meyenfeldt et al., 1992). However, its use in well-nourished or mildly undernourished patients either is of no benefit or increases the risk for sepsis (Veterans Affairs Total Parenteral Nutrition Cooperative Study Group, 1991). **Enteral nutrition,** on the other hand, has fewer complications than TPN and can provide a more balanced physiologic diet. Enteral nutrition is accomplished via a feeding tube, gastrostomy, or feeding jejunostomy. Enteral nutrition has the added benefits of maintaining the gut-associated lymphoid tissue, enhancing mucosal blood flow, and maintaining the mucosal barrier. There are hundreds of enteral products on the market, and most have a caloric density of 1 to 2 kcal/mL. These formulas are also lactose free and provide the recommended daily allowances of vitamins and minerals in less than 2 L/day. Patients receiving enteral feedings must be monitored for improvement in nutritional status, GI intolerance, and fluid and electrolyte imbalance. **Preoperative enteral feedings can decrease postoperative complication rates by 10% to 15% when used for 5 to 20 days before surgery** (ASPEN Board of Directors and the Clinical Guidelines Task Force, 2002). **The guidelines recommend postoperative parenteral nutrition in patients who are unable to meet their caloric requirements within 7 to 10 days.** Just as in the perioperative state, enteral feedings are preferred over parenteral nutrition when feasible (Sigalet et al., 2004). Moreover, the routine use of postoperative TPN has not proven useful in well-nourished patients or in those with adequate oral intake within 1 week after surgery.

Complications can occur with either enteral nutrition or parenteral nutrition. Dislodgement of nasoenteral tubes and percutaneous enteral catheters can result in pulmonary and peritoneal complications. Adynamic ileus may also occur because of decreased splanchnic perfusion, sympathetic tone, or opiate use. With regard to TPN, establishing central access is associated with a significant risk for complications. These include pneumothorax or hemothorax secondary to poor line placement and chylothorax secondary to thoracic duct injury. Line sepsis is the most common complication of indwelling central catheters and necessitates catheter removal. Venous thrombosis with associated thrombophlebitis and extremity edema has been reported. Catheter thrombosis has also been reported and can be treated with thrombolytic agents (ASPEN Board of Directors and the Clinical Guidelines Task Force, 2002).

Preparation for Surgery

Management of Medications

Preoperative Optimization Strategies

Optimization of Comorbid Illness.

Just as adequate preoperative evaluation is important, optimization of comorbid illness is critical in improving surgical outcomes and in reducing perioperative morbidity and mortality. With regard to cardiac disease, many studies have evaluated the prophylactic use of nitrates, calcium-channel blockers, and β-blockers for patients who are at risk for perioperative myocardial ischemia. Only β-blockade has been shown to improve outcomes (Pearse et al., 2004). In a landmark study, Mangano et al. reported that there was an improvement in outcomes with the prophylactic use of atenolol in patients undergoing vascular surgery (Mangano et al., 1996). Similarly, a retrospective, cooperative group study of more than one-half million patients showed that perioperative β-blockade is associated with a reduced risk for death among high-risk patients undergoing major noncardiac surgery (Lindenauer et al., 2005). In addition to β-blockade, the concept of goal-directed therapy, employing the judicious use of fluids, inotropes, and oxygen therapy to achieve therapeutic goals may further reduce perioperative risk (Pearse et al., 2004). This concept was validated by Shoemaker, who reported an impressive reduction in mortality from 28% to 4% ($P < .02$) when goal-directed therapy was used (Shoemaker et al., 1988).

Specific preoperative interventions can decrease pulmonary complications. **Smoking must be discontinued at least 8 weeks before surgery to achieve a risk reduction.** Patients who discontinue smoking less than 8 weeks before surgery may actually have a higher risk for complications because the acute absence of the noxious effect of cigarette smoke decreases postoperative coughing and pulmonary toilet (Pearce and Jones, 1984). **However, patients who stop smoking at least 8 weeks preoperatively will significantly lower their complication rate, and patients who have ceased smoking for more than 6 months have a pulmonary morbidity comparable with that of nonsmokers** (Warner et al., 1989). The use of preoperative bronchodilators in COPD patients can dramatically reduce postoperative pulmonary complications. Aggressive treatment of preexisting pulmonary infections with antibiotics and the pretreatment of asthmatic patients with steroids are essential in optimizing pulmonary performance. Likewise, the use of epidural and regional anesthetics, vigorous pulmonary toilet, rehabilitation, and continued bronchodilation therapy is all beneficial (Arozullah et al., 2003).

As with cardiopulmonary comorbidities, the preoperative management and optimization of diabetic patients are quite important. Perioperative hyperglycemia can lead to impaired wound healing and a higher incidence of infection (Golden et al., 1999). Hypoglycemia in an anesthetized or sedated diabetic patient may be unrecognized and carries its own significant risks. **Non–insulin-dependent diabetic patients may need to discontinue long-acting hypoglycemics because of this risk for intraoperative hypoglycemia. Shorter-acting agents or sliding-scale insulin regimens are preferable, in general.** It is recommended that blood glucose levels be controlled between 80 and 250 mg/dL. Frequent fingerstick glucose checks and a sliding scale short-acting insulin regimen are used in the postoperative period. Once the patient is eating, the usual insulin regimen can be resumed. Patients who manage their diabetes with the use of insulin pumps should continue their basal insulin infusions on the day of surgery. The pump is then used to correct the glucose level as it is measured. It is important to know the sensitivity factor that corrects the glucose so that the patient's sugars can be managed in the operating room (Townsend et al., 2015).

Patients with either hyperthyroidism or hypothyroidism should be evaluated by an endocrinologist, and surgery should be deferred until a euthyroid state has been achieved. **The greatest risk in the hypothyroid patient is thyrotoxicosis, or thyroid storm, which can manifest with fevers, tachycardia, confusion, and cardiovascular collapse.** Atrial fibrillation may also be present in 20% of hyperthyroid patients (Klein and Ojamaa, 2001). With regard to hyperthyroidism, careful attention should be given to the airway because the trachea can be compressed or deviated by a large goiter. In general, antithyroid medications such as propylthiouracil or methimazole, as well as β-blockers, are continued on the day of surgery. In the event of thyroid storm, iodine and steroids may be necessary (Schiff and Welsh, 2003). Hypothyroidism is usually associated with an increased sensitivity to medications such as anesthetic agents and narcotics. Severe hypothyroidism can be associated with myocardial dysfunction, coagulopathy, electrolyte imbalance, and a decreased GI motility. Symptoms include lethargy, cold intolerance, hoarseness, constipation, dry skin, and apathy. The decrease in metabolic rate produces periorbital edema, thinning of the eyebrows, brittle hair, dry skin, hypothermia, bradycardia, and a prolonged relaxation of the deep tendon reflexes (Murkin, 1982). Once the diagnosis has been confirmed by a low thyroxine level and an elevated thyroid stimulating hormone level, thyroid replacement with levothyroxine can be initiated (Schiff and Welsh, 2003).

The evaluation of the patient either taking corticosteroids or suspected of having an abnormal response of the hypothalamic-pituitary-adrenal (HPA) axis is also important. There is a wide variability in HPA suppression in patients receiving exogenous steroids. Nonetheless, it seems clear that the administration of oral steroids equivalent to less than 5 mg of prednisone for any duration of time does not cause clinically significant suppression of the HPA axis. **By contrast, any patient taking more than 20 mg of prednisone or its equivalent per day for more than 3 weeks or who is clinically cushingoid has probable HPA axis suppression** (LaRochelle et al., 1993). HPA suppression can occur even in patients using potent topical steroids at doses of 2 g/day and in patients using inhaled corticosteroids at doses of 0.8 mg/day. Although the duration of functional HPA axis suppression after glucocorticoids have been stopped is debatable, perioperative supplemental steroids are recommended for patients who have received HPA axis–suppressive doses within 1 year of surgery. A low-dose adrenocorticotropic hormone (ACTH) stimulation test can be used to assess the HPA axis and the need for stress steroids. For patients who take 5 mg of prednisone or the equivalent each day, no supplemental steroids are necessary, and the usual daily glucocorticoid dose may be given in the perioperative period. **For those in whom the HPA axis is presumed to be suppressed or is documented to be suppressed, then 50 to 100 mg of intravenous hydrocortisone is given before the induction of anesthesia, and 25 to 50 mg of hydrocortisone is given every 8 hours thereafter for 24 to 48 hours until the usual steroid dose can be resumed.** Minor procedures under local anesthesia do not require stress-dose steroids (Schiff and Welsh, 2003).

Antithrombotic Therapy

Most urologic patients have medical comorbidities; urologists frequently encounter patients on chronic vitamin K antagonist therapy (e.g., warfarin) or antiplatelet therapy for the management of atrial fibrillation, mechanical heart valves, or coronary artery disease. Perioperative management including interruption of this antithrombotic therapy can be a challenging problem. Unlike venous thromboembolism (VTE) pharmacologic prophylaxis, warfarin and antiplatelet therapies have been shown to be associated with significant bleeding complications after surgery. Therefore, urologists must carefully consider and balance the risks and benefits of interruption of chronic anticoagulation to determine the best course of perioperative management of these medications.

Chronic anticoagulation with warfarin is most frequently encountered in patients with atrial fibrillation, mechanical heart valves, or prior VTE. **The pharmacologic half-life of warfarin is 36 to 42 hours, and therefore most guidelines recommend cessation of therapy 5 days before surgery to ensure an INR less than 1.5.** Recently, several new oral anticoagulants (e.g., apixaban, dabigatran, and rivaroxaban), have been introduced to improve efficacy, decrease patient variability, and improve patient convenience. Each of the new medications has different pharmacologic properties, and therefore it is imperative for the surgeon to be familiar with these medications to properly advise the patient (Douketis et al., 2012; Douketis, 2010). The larger issue is whether patients require a bridge with short-term anticoagulation between the time of subtherapeutic INR and surgery. The decision is based on risk for a thrombotic event. Regarding atrial fibrillation, clinical scoring systems such as congestive heart failure, hypertension, age, diabetes, stroke (CHADS2) stratify patients into risk groups that predict risk for stroke while patients are not undergoing anticoagulation therapy. Patients with mechanical heart valves can also be stratified into risk groups according to the location (mitral vs. aortic) and type of valve used. Similarly, patients with a prior history of VTE are stratified according to duration since the last VTE and the patient's risk for recurrent VTE (Table 8.4). **In general, the 2012 American College of Chest Physicians (ACCP) guidelines recommends that patients in the moderate- and high-risk groups undergo bridging anticoagulation with therapeutic-dose subcutaneous low–molecular-weight heparin or intravenous unfractionated heparin** (Douketis et al., 2012).

TABLE 8.4

Risk Stratification for Arterial or Venous Thromboembolism Events During Perioperative Period in Patients on Chronic Anticoagulant Therapy

RISK	INDICATIONS FOR ANTICOAGULANT THERAPY

STRATUM	MECHANICAL HEART VALVE	ATRIAL FIBRILLATION	VTE
Low	Bileaflet aortic valve prosthesis without atrial fibrillation and no other risk factors for stroke	CHADS2 score of 0–2 (and no prior stroke or transient ischemic attack)	Single VTE occurred >12 mo ago and no other risk factors
Moderate	Bileaflet aortic valve prosthesis plus one or more of the following: atrial fibrillation, prior stroke or transient ischemic attack, hypertension, diabetes, congestive heart failure, age above 75 yr	CHADS2 score of 3–4	VTE within the past 3–12 mo Nonsevere thrombophilic conditions (e.g., heterozygous factor V Leiden mutation, heterozygous factor II mutation) Recurrent VTE Active cancer (treated within 6 mo or palliative)
High	Any mitral valve prosthesis Any caged-ball or tilting disc aortic valve prosthesis Recent (within 6 mo) stroke or transient ischemic attack	CHADS2 score of 5–6 Recent (within 3 mo) stroke or transient ischemic attack Rheumatic valvular heart disease	Recent (within 3 mo) VTE Severe thrombophilia (e.g., deficiency of protein C, protein S, or antithrombin; presence of antiphospholipid antibodies; multiple abnormalities)

CHADS2, Congestive heart failure, hypertension, age, diabetes, stroke; *mo,* months; *VTE,* venous thromboembolism; *yr,* year.

Modified from Douketis JD, Spyropoulos AC, Spencer FA, et al. Perioperative management of antithrombotic therapy: Antithrombotic Therapy and Prevention of Thrombosis, 9th ed: American College of Chest Physicians evidence-based clinical practice guidelines. *Chest.* 2012;141(2 Suppl):e326S–e350S.

An increasing number of patients are receiving chronic antiplatelet therapy in the prevention of cardiovascular events and, more important, in the prevention of coronary stent thrombosis. Although the former indication poses little controversy for the urologist, the latter indication presents a significant and complex clinical challenge in which the urologist must weigh the risk for bleeding with the potentially devastating risk for perioperative stent thrombosis. Aspirin and clopidogrel are the two most commonly used antiplatelet drugs and are frequently used together. Both are irreversible inhibitors of platelet function and therefore need to be stopped 7 to 10 days before surgery to minimize bleeding risk. **Current recommendations require dual antiplatelet therapy for 6 weeks after bare metal coronary stents and 12 months for drug-eluting stents. Premature interruption of antiplatelet therapy has been associated with a 25% to 50% risk for significant myocardial infarction with resultant increased perioperative mortality** (O'Riordan et al., 2009). In most patients, urologists should defer elective surgery until after antiplatelet therapy can be safely interrupted. In a review of the literature, Gupta et al. recommended delay of elective urologic surgery for at least 30 days for bare metal stents and, if possible, longer than 1 year for drug-eluting stents (Gupta et al., 2012). Even then, because acute stent thrombosis has been described with drug-eluting stents after 12 months, urologists should strongly consider at least single-agent antiplatelet therapy in these patients. Given the current lack of clinically useful alternatives to antiplatelet therapy, when surgery cannot be delayed (e.g., because of malignancy), the ACCP strongly recommends continuing aspirin and clopidogrel during the perioperative period in patients with drug-eluting stents (Douketis et al., 2012). Nevertheless, communication between the urologist and the cardiologist throughout the perioperative period is essential to minimize complications and maximize outcomes.

Bowel Preparation

Since antibiotics were first shown to reduce infectious complications in GI surgery, mechanical and antibiotic bowel preparation has been a mainstay of urologic surgery employing intestinal segments. The rationale for bowel preparation before intestinal surgery is to decrease intraluminal feces and decrease bacterial colony counts to decrease the rate of anastomotic leak, intra-abdominal abscesses, and wound infections. The bacterial flora in the bowel consists of aerobic organisms, the most common of which are *Escherichia coli* and *Enterococcus faecalis*, and anaerobic organisms, the most common of which are *Bacteroides* species and *Clostridium* species. **The bacterial concentration**

ranges from 10 to 10^5 organisms per gram of fecal content in the jejunum, 10^5 to 10^7 in the distal ileum, 10^6 to 10^8 in the ascending colon, and 10^{10} to 10^{12} in the descending colon. The preparation itself consists of two components: antibiotic preparation and mechanical preparation. Because there are only a few small series in the urologic literature, the rationale for each must be inferred from the general surgery literature—specifically, from colorectal surgery literature.

Although preoperative parenteral antibiotic prophylaxis before intestinal surgery is well established and widely used, oral antibiotic preparation is still somewhat controversial. Several oral antibiotic regimens are used today. The most commonly used regimen, oral neomycin and erythromycin, first became established in 1977 with the landmark study by Clark et al. (Clarke et al., 1977). In a double-blind, placebo-controlled study, 167 patients undergoing elective colonic surgery were randomized to receive mechanical bowel preparation with or without oral neomycin and erythromycin. The overall rates of septic complications were 43% with mechanical-only preparation and 9% with antibiotic plus mechanical preparation ($P = .001$). However, with current standards of the use of preoperative *parenteral* antibiotics, the benefit of oral antibiotic preparation was debated. Several older studies reported decreased infectious complications; however, these studies were small, and there have been no randomized controlled trials (RCTs) to document the benefit. **The disadvantage of oral antibiotic preparation is primarily related to increased incidence of pseudomembranous colitis secondary to *Clostridium difficile* infection.** In a retrospective analysis of 304 patients, Wren et al. reported a significantly decreased incidence of *C. difficile* colitis in patients who did not receive oral antibiotics before elective colorectal surgery (2.6% vs. 7.2%, $P = .03$) (Wren et al., 2005). Inferring from the colorectal literature, most current guidelines and a 2014 Cochrane review recommend that **antibiotics covering aerobic and anaerobic bacteria delivered orally or intravenously (or both) before elective colorectal surgery reduce the risk for surgical wound infection by as much as 75%** (Nelson et al., 2014). Despite the lack of level 1 evidence in the literature, a recent survey of colorectal surgeons revealed that up to 87% of surgeons continue to administer oral antibiotic bowel preparation before elective surgery (Zmora et al., 2003). In the 2014 Cochrane review, however, it was acknowledged that it is unknown whether oral antibiotics would have any beneficial effect in reducing surgical wound infection when the colon is not empty (Nelson et al., 2014).

Mechanical bowel preparation predates the use of antibiotics in intestinal surgery and was thought to decrease the rate of anastomotic complications. Before the development of nonabsorbable liquids, patients underwent several days of oral laxatives, bowel irrigations via nasogastric tubes, and repeat enemas. These regimens were associated with significant patient discomfort and clinical morbidity caused by electrolyte imbalances. The development of polyethylene glycol solution (GoLYTELY) and sodium phosphate solution (Fleet Phospho-soda) reduced much of the electrolyte disturbance and allowed for mechanical bowel preparation to be done in the outpatient setting. **Both regimens are suitable for most patients; however, polyethylene glycol is preferred in the elderly and in patients with renal insufficiency, congestive heart failure, existing electrolyte disturbances, and cirrhosis because it is completely nonabsorbable.**

The benefit of mechanical bowel preparation has been assumed for decades as evidenced by 99% positive response by colorectal surgeons when asked if mechanical preparation is routinely used (Zmora et al., 2003). However, RCTs have called into doubt the true benefit. Slim et al. published a meta-analysis of RCTs including a total of 4859 patients (Slim et al., 2009). The analysis included 14 trials including two large trials from the Netherlands and Sweden (Contant et al., 2007; Jung et al., 2007). **Overall, the analysis revealed that mechanical bowel preparation provided no benefit for anastomotic leak (odds ratio [OR] 1.12, 95% confidence interval [CI], 0.82 to 1.53, *P* = .46); abdominal or pelvic abscess (OR 0.90, 95% CI 0.47 to 1.72, *P* = .75); or mortality (OR 0.91, 95% CI 0.57 to 1.45, *P* = .70).** In fact, when overall surgical site infection (SSI) was considered, mechanical bowel preparation was associated with a significantly increased risk (OR 1.40, 95% CI 1.05 to 1.87, *P* = .02). These results were reiterated in an updated Cochrane review, which found no significant differences in anastomotic leak rate or wound infection, need for reoperation, and mortality rates (Güenaga et al., 2011). The authors concluded that there was no evidence that mechanical bowel preparation improves patient outcomes after elective colorectal surgery. Although similar studies have not been done in patients undergoing elective urologic surgery, urologists can make inferences from the colorectal literature and should reevaluate the common practice of mechanical bowel preparation before urologic intestinal surgery. To date, there have been multiple single-institution reports suggesting equivalent SSI outcomes with or without bowel preparation before radical cystectomy and urinary diversion (Zaid et al., 2013). Two specific exceptions are transrectal ultrasound-guided prostate needle biopsy and laparoscopic urologic surgery. Given the portal of entry and subsequent risk for bacteremia, most urologists have advocated for mechanical rectal cleansing with an enema before transrectal ultrasound-guided prostate needle biopsy. With regard to laparoscopy, surgeons who perform minimally invasive procedures have long believed that preoperative bowel preparation improves operative exposure because of bowel decompression and decreases the incidence of postoperative ileus. However, to date there have been no trials to support this assertion.

In the early postoperative period, most patients experience some degree of primary ileus and delayed GI activity. Any patient with ileus lasting more than 72 to 96 hours after surgery should be evaluated for a mechanical bowel obstruction secondary to adhesions, an intra-abdominal pathologic process, or a retroperitoneal hemorrhage. Given that return of GI function is often the rate-limiting factor for hospital discharge, efforts to reduce ileus including minimization of parenteral or oral opioid use, selective use of nasogastric tubes, and correction of electrolyte imbalances should be employed. More recently, methods to accelerate GI recovery have been investigated. Gum chewing—that is, sham feeding—was evaluated and reported to be associated with improvements in GI recovery and reduction in length of stay in patients undergoing colorectal surgery (Ho et al., 2014). Alvimopan (Entereg) is a peripherally acting opioid antagonist that was approved by the U.S. Food and Drug Administration (FDA) in 2008 to help restore bowel function after surgery. With the validation of alvimopan established in the colorectal literature, there have been several studies performed in patients undergoing cystectomy including a phase 4 trial whose findings were recently published. Use of alvimopan compared with placebo resulted in decreased length of stay of 2.6 days in patients undergoing radical cystectomy (Kauf et al., 2014). Many high-volume centers are now incorporating both strategies into enhanced recovery after surgery (ERAS) clinical pathways to reduce postoperative ileus and reduce hospital stays.

Intraoperative Management

Patient Environment

Maintaining an optimal patient environment is critical for the overall outcome of the patient. Although hypothermia can be therapeutic in certain situations of trauma and brain injury, for elective surgical procedures, hypothermia is associated with significantly increased morbidity to the patient. **There are two primary reasons for hypothermia to develop in the operating room. Anesthetic agents induce peripheral vasodilation, redistributing heat from the core (trunk, head) with a resultant drop in immediate core temperature after induction. Throughout the rest of the surgical procedure, radiation and conductive heat loss account for most of the heat loss.** *Normothermia* is defined as a core temperature between 36°C and 38°C, and hypothermia of even 1°C to 2°C results in adverse effects. **Rajagopalan et al. performed a meta-analysis of RCTs and reported that mild hypothermia (decrease of 1°C) resulted in a 16% increase in estimated blood loss and a 22% increase in transfusion requirements** (Rajagopalan et al., 2008). The increased bleeding risk is thought to result from a hypothermia-associated decrease in clotting cascade enzymatic function and platelet aggregation. Even more significant is the increase in the risk for SSI associated with mild hypothermia (34°C to 36°C). Hypothermia increases the risk for SSI by impairing immune mechanisms and vasoconstriction, resulting in regional tissue hypoxia. In a landmark study, Kurz et al. with the Study of Wound Infection and Temperature Group tested in 200 patients undergoing elective colorectal surgery the hypothesis that hypothermia increases the rate of wound infection and hospital stay (Kurz et al., 1996). **Hypothermia was associated with a three times increased risk for wound infection and a 2.6-day increase in hospitalization.** More recent studies have confirmed these findings in general in other series of surgical patients (Mauermann and Nemergut, 2006). In its overall goal of reducing SSI, the SCIP has also included perioperative normothermia as one of its guidelines. Strategies to improve maintenance of normothermia include regular use of warming blankets, warmed intravenous fluids, warmed irrigation fluids (especially during transurethral resection of the prostate [TURP] and other prolonged endoscopic procedures), warmed humidified CO_2 gas during laparoscopy, and increase in ambient operating room temperature. Although there have been few studies in the urologic literature, the findings can be generalized to all surgical patients.

Patient Safety

In 1991, Brennan et al. published their seminal work describing adverse events, defined as injuries caused by medical management in hospitalized patients, revealing that 48% of the events accompanied a surgical operation (Brennan et al., 1991; Leape et al., 1991). This important study inspired the publication of “To Err Is Human: Building a Safer Health System,” a comprehensive study by the Institute of Medicine on medical errors. Regarding surgical patients, the most frequent venue of preventable injuries is the operating room. **Although the surgeon is the “captain of the ship” and ultimately responsible, it takes cognizance and attention to detail from each member of the operating room team to prevent iatrogenic injuries to the patient.** Three causes of immediately preventable injuries are retractor-associated injuries, thermal injuries, and patient position–related injuries. There are several reports in the literature documenting an increased rate of neuropathy (especially femoral nerve) after laparotomy with self-retaining retractors versus without self-retaining retractors (Irvin et al., 2004). Careful attention to be certain that the lateral blades do not directly compress the psoas muscle and only cradle the rectus abdominal muscles will ensure avoidance of femoral neuropathy. Furthermore, periodic reinspection of the retractor blades is also warranted. Many devices used in urologic surgery employ thermal energy for desired effect and therefore can result in thermal injury to the patient. These include Bovie cautery, the argon beam coagulator, bipolar devices, and lasers. In both endoscopic and laparoscopic surgery, high-wattage light sources are used to illuminate the operative field. Although it is illuminated, the ends of the light cords can result in burns when in direct contact with the patient (even through draping). These light sources should be turned off or placed on standby at all times when not in use. Special mention is deserved for the morbidly obese patient. The operating room should be equipped with a hydraulic table, extra-long instruments, additional padding, wide venous compression devices, and side extensions to the operating table to ensure a safe operating room environment for the patient.

Patient Positioning

Although often given only a cursory evaluation, proper patient positioning in the operating room can prevent potentially devastating complications. Ultimately, proper positioning is the shared responsibility of each member of the operating room team. Much of the knowledge and guidelines for avoidance of position-related injury are drawn from the anesthesia literature. In fact, based on a 1999 study of the ASA Closed Claims Database, which found neuropathy as second-leading cause of liability, the ASA published a practice advisory for the prevention of perioperative peripheral neuropathies (American Society of Anesthesiologists, 2018). The recommendations are listed in Box 8.2. **Although the exact mechanisms of peripheral neuropathy are not always known, the cause of position-related neuropathy is usually secondary to excessive stretch, prolonged compression, or ischemia.** Given the variety of different patient positions used in urologic surgery, it is critical for the urologist to be an active participant in the positioning of the patient and to understand the potential patient compromise that accompanies each position.

Box 8.2

American Society of Anesthesiologists Task Force Recommendations on the Prevention of Perioperative Peripheral Neuropathies

Preoperative Assessment

- When judged appropriately, it is helpful to ascertain that patients can comfortably tolerate the anticipated operative position.

Upper Extremity Positioning

- Arm abduction should be limited to 90 degrees in supine patients; patients who are positioned prone may comfortably tolerate arm abduction greater than 90 degrees.
- Arms should be positioned to decrease pressure on the post-condylar groove of the humerus (ulnar groove). When arms are tucked at the side, a neutral forearm position is recommended. When arms are abducted on arm boards, either supination or a neutral forearm position is acceptable.

- Prolonged pressure on the radial nerve in the spiral groove of the humerus should be avoided.
- Extension of the elbow beyond a comfortable range may stretch the median nerve.

Lower Extremity Positioning

- Lithotomy positions that stretch the hamstring muscle group beyond a comfortable range may stretch the sciatic nerve.
- Prolonged pressure on the peroneal nerve at the fibular head should be avoided.
- Neither extension nor flexion of the hip increases the risk for femoral neuropathy.

Protective Padding

- Padded arm boards may decrease the risk for upper extremity neuropathy.
- The use of chest rolls in laterally positioned patients may decrease the risk for upper extremity neuropathies.
- Padding at the elbow and at the fibular head may decrease the risk for upper and lower extremity neuropathies, respectively.

Equipment

- Properly functioning automated blood pressure cuffs on the upper arms do not affect the risk for upper extremity neuropathies.
- Shoulder braces in steep head-down positions may increase the risk for brachial plexus neuropathies.

Postoperative Assessment

- A simple postoperative assessment of extremity nerve function may lead to early recognition of peripheral neuropathies.

Documentation

- Charting specific positioning actions during the care of patients may result in improvements of care by (1) helping practitioners focus attention on relevant aspects of patient positioning and (2) providing information that continuous improvement processes can use to effect refinements in patient care.

Modified from American Society of Anesthesiologists Task Force on Prevention of Perioperative Peripheral Neuropathies. Practice advisory for the prevention of perioperative peripheral neuropathies: a report by the American Society of Anesthesiologists Task Force on Prevention of Perioperative Peripheral Neuropathies. *Anesthesiology*. 2000;92(4):1168–1182.

The supine position, used in abdominal, pelvic, and penile procedures, is in general considered the safest patient position. However, several specific issues should be considered. **Excessive upper extremity abduction (>90 degrees) can lead to tension on the brachial plexus, causing upper extremity neuropathy.** The arm board should be padded to avoid excessive pressure on the ulnar groove and spiral groove of the humerus (radial nerve injury). In cases in which the arms are tucked at the patient's side, care must be taken to avoid excessive pressure on the hand and forearm. Moreover, peripheral intravenous catheter infiltration must be identified quickly because forearm compartment syndrome may develop.

One of the most frequent positions used in urology is the lithotomy position. Improper positioning can lead to transient and occasionally prolonged lower extremity neuropathy. In a retrospective evaluation of more than 190,000 cases from 1957 to 1991 involving the lithotomy position, persistent neuropathy was found in 0.03%; however, the same group in a prospective study of 991 patients reported an incidence of 1.5% (15 patients), with resolution of symptoms by 6 months in all but one patient (Warner et al., 1994, 2000). **The basic principle of positioning involves manipulation of both lower extremities *simultaneously* with flexion of the hips at 80 to 100 degrees with 30- to 45-degree abduction.** The legs should be padded to avoid excessive compression against the stirrup. Particular caution should be given to the patient's hands to avoid entrapment within the moving parts of the stirrups.

For most open and laparoscopic upper urothelial tract and renal procedures, the patient is placed in some degree of lateral decubitus position. Proper padding of the patient is important, with appropriate anterior and posterior support to maintain the decubitus position. The most frequent focus of compromise involves positioning of the arms and the potential for brachial plexus injury. The ipsilateral arm should be placed on the chest or an elevated arm rest or gel pad, or pillow (s) avoiding abduction of more than 90 degrees and excessive stretch on the shoulder. The contralateral arm should be placed on an arm board with ulnar padding. Furthermore, in patients in full flank position, an axillary roll should be placed just caudal to the axilla (not in the axilla) to avoid compression of the contralateral brachial plexus. Finally, after the patient has been positioned and before sterile draping, the operating table should be fully rotated to ensure that the patient is adequately secured in all positions.

Two patient positions used in specific urologic cases deserve attention: the prone position for percutaneous nephroscopy and the full Trendelenburg position for robotic-assisted laparoscopic procedures in the pelvis. In the prone position, special care should be taken to pad the torso, elbows, hips, and legs. The anesthesiologist should ensure that the endotracheal tube and all vascular accesses are properly secured. Coordination of the entire team is required during transfer from the supine position on the stretcher to the prone position on the operating room table. A stretcher should always be available immediately in case of airway compromise and the need for rapid transfer to the supine position. Regarding the full Trendelenburg position for minimally invasive pelvic procedures, the primary issues involve the physiologic changes in respiratory function, cardiovascular function, and increases in central venous and intracranial pressures. **Patient positioning should focus on properly padding and securing the patient to the operating table to prevent cephalad sliding. Although fixed shoulder braces will undoubtedly prevent patient movement, these braces should be avoided because of the risk for brachial plexus compression and resultant neuropathy.**

Antibiotic Prophylaxis

In 1999 the Centers for Disease Control and Prevention (CDC) issued its third report on the prevention of SSI, highlighting the importance of standardization of prophylactic treatment to prevent this universal surgical complication (Mangram et al., 1999). **The report indicated that SSIs account for approximately 40% of nosocomial infections in surgical patients and potentially prolong hospital stay by 7 to 10 days.** A study of national SSIs from the 2005 Healthcare Cost and Utilization Project National Inpatient Sample

(HCUP NIS) calculated an increase in hospital stay of 9.7 days and in per-patient cost of $20,892 (de Lissovoy et al., 2009). This translated nationally into an additional 1 million inpatient hospital days and additional health care cost of $1.6 billion. Bowater et al. published a systematic review of meta-analyses (level 1 evidence) and concluded that there was substantial evidence that antibiotic prophylaxis was an effective prevention for SSI over a wide variety of surgical procedures (Bowater et al., 2009). **Given both the ethical responsibility of the surgeon to decrease surgical morbidity and the recent policy shift by the Centers for Medicare and Medicaid Services to withhold reimbursement for hospital admissions secondary to specific SSI, it is mandatory for urologists to understand the principles behind and to practice SSI prevention.**

Along with antibiotic prophylaxis, proper hand washing and scrubbing and sterile preparation of the operative field have always been central to the prevention of SSI. For procedures involving the GI tract, mechanical and oral antibiotic bowel preparation had been standard practice until more recent literature, calling into question its usefulness (discussed later). Preoperative hair removal has not been associated with a decrease in SSI, but if performed, use of mechanical clippers or depilatory creams as opposed to razors is associated with a decreased risk for SSI (Wolf et al., 2008).

The risk for SSI and therefore the recommendation for antibiotic prophylaxis is composed of three factors: the patient's susceptibility to and ability to respond to localized and systemic infection, the procedural risk for infection, and the potential morbidity of infection. First, patient-related factors, listed in Box 8.3, increase risk by decreasing natural defense mechanisms, increasing the local bacterial concentration, and/or altering the spectrum of bacterial flora. Second, surgical procedure–specific factors can affect the route of entry, site of infection, and pathogen involved. This idea was first described in the landmark study from the National Research Council and later formalized by the CDC; specifically, surgical wounds are now classified by degree of contamination (i.e., the inoculum of potential pathogen) (Box 8.4; Hart et al., 1968). To predict the risk for SSI, several scoring systems have been developed incorporating patient-related factors with wound classification. Finally, the risk to the patient from SSI is an important consideration in determining the need for prophylaxis. For example, routine cystoscopy in the evaluation of microhematuria in an otherwise young, healthy patient may not warrant prophylaxis; however, the same procedure in an elderly, insulin-dependent diabetic (immunocompromised) does warrant prophylaxis given the high likelihood that a postprocedural urinary tract infection would result in a significant deterioration in the patient's overall health. Understanding the three factors together then allows the urologist to make a rational decision regarding the risks and benefits of antibiotic prophylaxis.

Box 8.3

Patient Factors That Increase the Risk for Infection

- Advanced age
- Anatomic anomalies
- Poor nutritional status
- Smoking
- Chronic corticosteroid use
- Immunodeficiency
- Chronic indwelling hardware
- Infected endogenous or exogenous material
- Distant coexistent infection
- Prolonged hospitalization

Data from Cruse PJ. Surgical wound infection. In: Wonsiewicz MJ. ed. Infectious disease. Philadelphia, PA: Saunders; 1992:758–764; Mangram AJ, Horan TC, Pearson ML, et al. Guideline for prevention of surgical site infection, 1999. Hospital Infection Control Practices Advisory Committee. *Infect Control Hosp Epidemiol*. 1999;20(4):250–278; quiz 279–280.

Box 8.4

Surgical Wound Classification

Clean

- Uninfected wound without inflammation or entry into the genital, urinary, or alimentary tract
- Primary wound closure, closed drainage

Clean Contaminated

- Uninfected wound with controlled entry into the genital, urinary, or alimentary tract
- Primary wound closure, closed drainage

Contaminated

- Uninfected wound with major break in sterile technique (gross spillage from gastrointestinal tract or nonpurulent inflammation)
- Open fresh accidental wounds

Dirty Infected

- Wound with preexisting clinical infection or perforated viscera
- Old traumatic wounds with devitalized tissue

Data from Garner JS. CDC guideline for prevention of surgical wound infections, 1985. Supersedes guideline for prevention of surgical wound infections published in 1982. (Originally published in 1995.) Revised. *Infect Control.* 1986;7(3):193–200; Simmons BP. Guideline for prevention of surgical wound infections. *Infect Control.* 1982;2:185–196.

Once the decision for antibiotic prophylaxis has been made, the keys to successful prevention are the proper choice of antibiotic for the particular procedure and proper timing and administration of the antibiotic. The first key to successful prevention is the proper choice of antibiotic for the procedure in question. As mentioned earlier, surgery-specific factors affect the type of pathogen, route of entry, and likelihood of systemic infection. For example, the choice of antibiotic is different for TURP (need coverage for common urinary tract pathogens) than for a cystectomy with planned sigmoid colon urinary diversion (need coverage for anaerobic bacteria). Another important consideration is the rate of antibiotic resistance in the community**. Although there is level 1 evidence for the use of fluoroquinolones as prophylaxis for urologic endoscopic procedures, the emerging *Escherichia coli* resistance in the community is changing practice patterns in many practices and high-resistance hospitals.** One resource that is particularly useful is the hospital antibiogram. These reports are published monthly at most major hospitals and quantify the susceptibility and resistance of common organisms to a wide variety of antibiotics. A summary of the recent American Urological Association (AUA) best practice statement on antibiotic prophylaxis is shown in Table 8.5. In 2012, the AUA issued an amendment to the best practice statement with regard to prostate biopsy, acknowledging the emerging resistance to fluoroquinolones and recommending cephalosporins and/or aminoglycosides in certain communities.

TABLE 8.5

American Urological Association Best Practice Statement on Recommended Antimicrobial Prophylaxis for Urologic Procedures

PROCEDURE	ORGANISM	PROPHYLAXIS INDICATED	ANTIMICROBIALS OF CHOICE	ALTER ANTIM
LOWER URINARY TRACT INSTRUMENTATION				
Removal of external urinary catheter	GU tract	If risk factors	Fluoroquinolone TMP-SMX	Ami ampi First- gene ceph Amo
Cystography, urodynamic study, or simple cystoscopy	GU tract	If risk factors	Fluoroquinolone TMP-SMX	Ami ampi First- gene ceph Amo
Cystoscopy with manipulation	GU tract	All	Fluoroquinolone TMP-SMX	Ami ampi First- gene ceph Amo
Prostate brachytherapy or cryotherapy	Skin	Uncertain	First-generation cephalosporin	Clindam
Transrectal prostate needle biopsy	Intestine	All	Fluoroquinolone Second- or third-generation cephalosporin	Aminogl metronid clindamy

UPPER URINARY TRACT INSTRUMENTATION				
Shock wave lithotripsy	GU tract	All	Fluoroquinolone TMP-SMX	Ami ampi First- gene ceph Amo
Percutaneous renal surgery	GU tract Skin	All	First- or second-generation cephalosporin Aminoglycoside + metronidazole or clindamycin	Amp Fluo
Ureteroscopy	GU tract	All	Fluoroquinolone TMP-SMX	Ami ampi First- gene ceph Amo
OPEN OR LAPAROSCOPIC SURGERY				
Vaginal surgery (including urethral sling procedures)	GU tract Skin Group B Streptococcus	All	First- or second-generation cephalosporin Aminoglycoside + metronidazole or clindamycin	Amp Fluo
Open or laparoscopic surgery without entering GU tract	Skin	If risk factors	First-generation cephalosporin	Clindam
Surgery involving entry into GU tract	GU tract Skin	All	First- or second-generation cephalosporin Aminoglycoside + metronidazole or clindamycin	Amp Fluo
Intestinal surgery	GU tract Skin Intestinal flora	All	Second- or third-generation cephalosporin Aminoglycoside + metronidazole	Amp Tica Pipe Fluo

			or clindamycin	
Implanted prosthesis	GU tract Skin	All	Aminoglycoside + first- or second-generation cephalosporin or vancomycin	Amp Tica Pipe

GU, Genitourinary; *hr,* hour; *TMP-SMX,* trimethoprim-sulfamethoxazole.

Modified from Wolf JS Jr, Bennett CJ, Dmochowski RR, et al.; Urologic Surgery Antimicrobial Prophylaxis Best Practice Policy Panel. Best practice policy statement on urologic surgery antimicrobial prophylaxis. *J Urol*. 2008;179(4):1379–1390.

Since the pivotal study by Classen et al., particular emphasis has been placed on the timing of prophylaxis to be given within 2 hours of incision (Classen et al., 1992). This emphasis was exemplified by the Joint Commission's Surgical Care Improvement Project (SCIP) guideline for administration of antibiotic prophylaxis 60 minutes before incision in a broader effort to decrease overall surgical complications by 25% by 2010. A multi-institutional trial involving more than 4400 patients at 29 institutions reported results of their analysis on the optimal timing of antibiotic prophylaxis (Steinberg et al., 2009). **The results suggested an improvement in prevention of SSI when antibiotics were administered within 30 minutes of incision as compared with 31 to 60 minutes (adjusted odds ratio [OR] 1.48, *P* = .06).** More importantly, this larger study confirmed the significantly increased risk for SSI when antibiotics were administered at the time of or after incision, with an adjusted OR of 2.20, *P* = .02. The duration of antibiotic prophylaxis is more controversial; however, **most recommendations advocate no more than 24 hours in a patient without an established infection.** Routine antibiotic use beyond 24 hours increases the risk for *C. difficile* colitis, increases the development of antibiotic resistance, and increases costs. Along with timing and duration, proper administration of antibiotics implies proper dosage. Antibiotic dose is dependent on the patient's body weight, renal function and hepatic function, and duration of procedure (re-administration is required if longer than 4 hours). A recent analysis of the Premier Perspectives Database encompassing urologic procedures performed between 2007 and 2012 revealed that compliance with AUA Best Practices increased with time, but overall rates remain less than 60% (Mossanen et al., 2015). **A practicing urologist must be familiar with best practice guidelines and hospital policies to avoid underuse, overuse, or misuse of antimicrobial prophylaxis.**

Venous Thromboembolic Prophylaxis

Venous thromboembolic complications are a major cause of potentially preventable morbidity and mortality among surgical patients in the United States. A recent study from the Center for Quality Improvement and Patient Safety and the Agency for Healthcare Research and Quality found postoperative VTE to be the second most common cause of excess length of stay, charges, and mortality among surgical patients discharged from acute care hospitals (Zhan and Miller, 2003). Urology patients in particular have an increased incidence of VTE, estimated to be 10% to 40% in patients without any prophylaxis (Geerts et al., 2008). Although these estimates are based on historical studies conducted before the routine use of mechanical prophylaxis and the recognition of the benefits of early ambulation, the increased risk persists, with more recent studies reporting incidences of 1% to 5%. Urologic patients followed prospectively in the European @RISTOS study developed VTE in 1.9% undergoing open surgery despite a high rate of prophylaxis (Scarpa et al., 2007). For patients in the United Kingdom undergoing urologic procedures, Dyer et al. reported an overall incidence of 0.66% including a 2.8% incidence among patients undergoing radical cystectomy (Dyer et al., 2013). Overall, VTE is the most important cause of nonsurgical mortality among urology patients (Forrest et al., 2009).

Although the use of perioperative mechanical prophylaxis (pneumatic compression stockings or sequential compressive device) is fairly universal, pharmacologic prophylaxis is administered only after weighing the risk for VTE versus the risk for perioperative bleeding complications (Table 8.6). Leonardi et al. reviewed and analyzed 33 RCTs to assess the incidence of bleeding complications in general surgery patients receiving pharmacologic prophylaxis (Leonardi et al., 2006). **Although there was a significantly higher rate of minor complications (injection site bruising and wound hematoma), there was no significant difference in major complications (e.g., GI tract bleeding [0.2%] or retroperitoneal bleeding [<0.1%]).** Although these results are applicable in general to urology patients, certain urologic procedures, such as TURP and partial nephrectomy, have a specifically higher rate of bleeding complications. Regarding an individual's risk for VTE, both surgery-related risk factors and patient-related risk factors must be considered. Surgical factors specific to urologic surgery to be weighed include general versus neuraxial anesthesia, supine versus dorsal lithotomy positioning, abdominal versus pelvic surgery with or without lymphadenectomy, and open versus laparoscopic approach. Patient-related risk factors are listed in Box 8.5, with increasing age, malignancy, history of cancer therapy, and others being fairly common among urology patients. In fact, both the @RISTOS study and a recent report on minimally invasive radical prostatectomy confirmed several of these factors as being associated with increased risk for VTE in urologic patients (Scarpa et al., 2007; Secin et al., 2008). In 2008, the ACCP issued guidelines on the prevention of VTE with a strong recommendation that hospitals develop a formal, active strategy to address VTE prevention. **Although prior recommendations from the ACCP advocated individualized risk assessment models to guide therapy, the current recommendations advocate implementation of group-specific thromboprophylaxis routinely for all patients who belong to each of the major surgical groups (e.g., urologic surgery)** (Geerts et al., 2008). The AUA has published a best practice statement on the use of VTE prophylaxis in urologic patients (Forrest et al., 2009). These recommendations combine an individualized risk assessment model with each type of urologic surgery. For example, a high-risk patient (multiple patient risk factors) undergoing low-risk surgery may require pharmacologic prophylaxis, as might a low-risk patient undergoing high-risk surgery. The recommendations are summarized in Table 8.7.

TABLE 8.6

Mechanical and Pharmacologic Venous Thromboembolism Prophylaxis

PROPHYLAXIS	DOSE	ADVANTAGES	DISADVANTAGES
Pneumatic compression stockings	N/A	Can be used in patients with high bleeding risk Easily standardized for all patients Studied in multiple patient groups	No standards for size, pressure Individual models not specifically studied Less effective than pharmacologic prophylaxis in high-risk groups
Low–molecular-weight heparin	40 mg SC once daily	Once-daily administration Less risk for heparin-induced thrombocytopenia No blood monitoring necessary	Not reversible High cost Relative contraindication in patients with renal insufficiency

Low-dose unfractionated heparin	5000 units SC q8h	Reversible Can be used safely in patients with renal insufficiency Relatively inexpensive	Needs readministration q8-12h Heparin-induced thrombocytopenia

Box 8.5

Patient-Related Factors Increasing Risk for Venous Thromboembolism

- Surgery
- Trauma (major trauma or lower extremity injury)
- Immobility, lower extremity paresis
- Cancer (active or occult)
- Cancer therapy (hormonal, chemotherapy, angiogenesis inhibitors, radiotherapy)
- Venous compression (tumor, hematoma, arterial abnormality)
- Previous venous thromboembolism
- Increasing age
- Pregnancy and the postpartum period
- Estrogen-containing oral contraceptives or hormone replacement therapy
- Selective estrogen receptor modulators
- Erythropoiesis-stimulating agents
- Acute medical illness
- Inflammatory bowel disease
- Nephrotic syndrome
- Myeloproliferative disorders
- Paroxysmal nocturnal hemoglobinuria
- Obesity
- Central venous catheterization
- Inherited or acquired thrombophilia

Modified from Geerts WH, Bergqvist D, Pineo GF, et al. Prevention of venous thromboembolism: American College of Chest Physicians evidence-based clinical practice guidelines (8th edition). *Chest*. 2008;133(6 Suppl):381S–453S.

TABLE 8.7

Patient Risk Assessment Model and American Urological Association Best Practice Recommendations

PATIENT RISK STRATIFICATION	
Low risk	Minor surgery in patients younger than 40 yr with no additional risk factors
Moderate risk	Minor surgery in patients with additional risk factors Surgery in patients 40–60 yr with no additional risk factors
High risk	Surgery in patients older than 60 yr Surgery in patients 40–60 yr with additional risk factors (see Box 8.4)
Highest risk	Surgery in patients with multiple risk factors (e.g., age older than 40 yr, cancer, prior venous thromboembolism)
LEVEL OF RISK	RECOMMENDATIONS
Low risk	No prophylaxis other than early ambulation
Moderate risk	Heparin 5000 units q12h SC starting after surgery or Enoxaparin 40 mg (for CrCl <30 mL/min, use 30 mg) SC daily or Pneumatic compression device if risk for bleeding is high
High risk	Heparin 5000 units q12h SC starting after surgery or Enoxaparin 40 mg (for CrCl <30 mL/min, use 30 mg) SC daily or Pneumatic compression device if risk for bleeding is high
Highest risk	Enoxaparin 40 mg (for CrCl <30 mL/min, use 30 mg) SC daily and adjuvant pneumatic compression device or Heparin 5000 units q8h SC starting after surgery and adjuvant pneumatic compression device

CrCl, Creatinine clearance; *yr,* year.

Modified from Forrest JB, Clemens JQ, Finamore P, et al. AUA Best Practice Statement for the prevention of deep vein thrombosis in patients undergoing urologic surgery. *J Urol*. 2009;181(3):1170–1177.

Anesthetic Considerations

The basic tenet of anesthesia is to deliver hypnosis, amnesia, and analgesia while maintaining satisfactory operating conditions. An understanding of the basic pharmacologic principles, anesthetic equipment and monitoring, and patient analgesia is important to any surgeon including the urologist for successful operative outcomes and avoidance of surgical complications. Although urologists are performing increasingly more procedures in the office, the bulk of urologic surgery occurs in the operating room under monitored anesthesia care, regional anesthesia, or general anesthesia. Current practice in operative anesthesia employs a combination of inhalational agents and intravenous medications along with analgesics (for pain control) and benzodiazepines (for anxiolysis and amnesia). Of course, improved presurgical evaluation, pharmacologic drugs, and perioperative monitoring have dramatically decreased the risks associated with anesthesia. A recent study of New York hospital-based and freestanding ambulatory surgical centers reported the risk for all-cause mortality to be 1 in 49,012 and the rate of immediate admission to an inpatient facility to be 0.6% (Fleisher et al., 2007b).

Selection of Mode of Anesthesia

An important role of the urologist in the anesthetic evaluation is to determine what mode of anesthesia is best for the particular patient and surgical procedure. The choice depends on patient-related factors including comorbidities, airway, and patient preference and procedural factors including complexity, duration, anatomic location, and expected fluid and blood loss. A basic understanding of each method of anesthesia and the pharmacologic principles will aid the urologist in making recommendations to the anesthesiologist.

Monitored Anesthesia Care

Although *monitored anesthesia care* is defined as conscious sedation under the care of an anesthesiologist in a monitored situation, it encompasses a wide range of levels of anesthesia from minimal sedation to brief intervals of unconscious general anesthesia. Most commonly, anesthesiologists combine intravenous opioid analgesics and benzodiazepines to maintain a sufficient level of patient comfort and anxiolysis. Monitored anesthesia care is widely used in urology in the ambulatory setting and is suitable for short-duration endoscopic procedures, transrectal ultrasound-based procedures, and, when combined with a local anesthetic, superficial procedures of the external genitalia. Conscious sedation can be administered in the office setting, but only with proper monitoring of the patient during and after the procedure. **The Joint Commission has strict guidelines to ensure that the patients receive the same level of monitoring as if under the care of an anesthesiologist including a requirement for a trained monitoring assistant, immediate access to airway and resuscitation equipment, and specific preprocedure and postprocedure evaluations.**

Regional Anesthesia

Regional anesthesia incorporates different levels of anesthesia directed toward the surgical site, including local anesthesia, spinal anesthesia, and epidural anesthesia. The use of local anesthetics is typically combined with monitored anesthesia care for superficial procedures in an isolated anatomic location. The keys to proper local anesthetic administration are avoidance of intravascular injection and knowledge of pharmacology. The two most commonly used drugs are lidocaine and bupivacaine, with the primary differences being the onset and duration of action. Infiltration of local anesthetics before surgical incision decreases nociceptor sensitization and conduction and results in decreased postoperative pain and analgesic requirements.

Spinal and epidural anesthesia involves injection of anesthetic (most commonly lidocaine or bupivacaine) into the subarachnoid space or epidural space with direct effect on the spinal cord, resulting in sensory, motor, and sympathetic blockade. In urologic procedures, epidural anesthesia is most useful for postoperative pain management for major abdominal procedures, thereby avoiding the adverse effects of high doses of intravenous opioids (i.e., respiratory depression, GI dysfunction). Spinal anesthesia is suitable for most urologic endoscopic procedures and lower abdominal surgical procedures and is limited only by the duration of anesthesia required. Spinal anesthesia avoids the cardiopulmonary effects and complications of general anesthesia. Several factors affect the spinal level and efficacy of administration. In general, larger volume and increased doses result in longer duration and increased cephalad migration. The addition of low-dose opioids and/or vasoconstrictors prolongs the duration of analgesia while reducing the dose of anesthetic. The anesthetic-related adverse effect is hypotension as a result of sympathetic blockade and occurs in 10% to 40% of patients (Di Cianni et al., 2008). **The primary technique-related complication is post–dural puncture headache (results from cerebrospinal fluid leak) with an incidence of less than 2% with currently**

used 29-gauge pencil-tipped needles (Turnbull and Shepherd, 2003). **Overall, spinal anesthesia has become safe, with the incidence of serious neurologic deficits being 0.05%.**

General Anesthesia

Inhalational General Anesthesia.

Inhalational drug development has emphasized inhalational agents that facilitate rapid induction and emergence and are nontoxic. **Two of the most important characteristics of inhalational anesthetics are the blood/gas solubility coefficient (B/G) and the minimum alveolar concentration (MAC). The B/G refers to the serum uptake of the inhaled agent, and the MAC is a measure of the potency of a volatile anesthetic (i.e., the serum level required to prevent movement in response to a skin incision in 50% of patients).** The various inhalational agents differ not only in the B/G and MAC but also in their cardiopulmonary effects. Obviously, a basic understanding of these properties is important for the urologic surgeon, especially during instances of surgical complication.

Nitrous oxide (NO) is one of the most commonly used agents because of its propensity for rapid induction and emergence; however, because of its low potency, it is often combined with other agents. **Because of NO's high B/G and tendency to increase the volume and pressure of closed spaces, its use is contraindicated in certain clinical situations such as small bowel obstruction and pneumothorax. During laparoscopic abdominal procedures, surgeons often prefer to avoid the use of NO because of resultant bowel distention and subsequent interference in the operative field.** Although this effect is debated in the surgical literature, El-Galley et al. reported significantly increased bowel distention and surgical interference with NO use in patients undergoing laparoscopic donor nephrectomy (El-Galley et al., 2007).

Once introduced in the 1950s, halothane rapidly became one of the most commonly used anesthetic agents because of its high potency. **However, halothane has several important risks that have since limited its use. It has significant cardiac effects and can precipitate failure in patients with left ventricular dysfunction. Furthermore, it sensitizes the myocardium to the effects of catecholamines (relevant for local anesthetics injected into the surgical site).** Finally, there is a 1 in 35,000 incidence of fulminant hepatitis, which can be lethal as a result of overaccumulation of toxic metabolites. More recent advancements in inhalational agents have focused on reduction in toxicity while maintaining the potency and rapidity of halothane. **Three of the most commonly used current agents are isoflurane, sevoflurane, and desflurane**. Isoflurane, less expensive than the other agents because of the availability of generic equivalents, is widely used as a result of its low cardiac depression, lower myocardial sensitization to catecholamines, and minimal metabolism. The primary unique toxicity is a variable response to tachycardia, which can lead to significantly increased myocardial oxygen consumption. Unlike isoflurane, which has a putrid odor, sevoflurane is often used for inhalation induction (odorless) because of its rapid induction and emergence, decreased incidence of postoperative nausea (important in outpatient surgery), and minimal cardiac toxicity. It is, in general, the preferred agent for difficult airways requiring mask induction and in patients with severe bronchospastic disease. Desflurane, like isoflurane, has a pungent odor and is not used for inhalational induction. Its primary advantage over isoflurane is a more rapid recovery in patients requiring anesthesia for more than 3 hours.

Intravenous General Anesthesia.

Intravenous anesthesia consists of a combination of induction agent, opioid, and neuromuscular relaxant. Anesthesiologists often prefer intravenous induction with a combination of inhalational and intravenous agents for maintenance of anesthesia. Intravenous induction offers several advantages in that it is rapid, minimizes patient discomfort, and is preferred by children and most adults. Thiopental, the oldest and least expensive agent, is a suitable choice for uncomplicated situations but is limited in more complex cases because of its significant vasodilation, cardiac depression, and risk for bronchospasm, especially in patients with reactive airway disease. Ketamine is a preferred choice for procedures that are brief and superficial because of its profound amnesia and somatic analgesia. It is associated with increased arteriolar and bronchomotor tone and is advantageous during induction for hypovolemic and asthmatic patients. **Propofol is among the most commonly used anesthetic agents, especially in outpatient surgery. It has a rapid onset, produces excellent bronchodilation in patients with reactive airway disease, and, perhaps most important, is associated with smooth, nausea-free emergence from anesthesia.** Its primary adverse effect is significant blood pressure reduction. Midazolam, never used as a single agent, produces profound amnesia and anxiolysis while having a rapid onset and short duration and producing minimal cardiac side effects. Although these agents induce unconsciousness and amnesia, opioids have become an integral component to all forms of anesthesia. Opioids result in significant analgesia without an increase in cardiac side effects. Opioids also results in decreased requirements of other agents when used in combination, thus reducing the overall cardiopulmonary side effects of anesthesia. Opioids themselves are differentiated in their potency, onset of action, duration of action, and metabolism and excretion. **Fentanyl (synthetic opioid) is probably the most widely used because of its potency (100 to 150 times that of morphine), rapid onset, and short duration of action.** Newer synthetics are geared toward shorter duration and more rapid metabolism.

For major operative cases, complete neuromuscular relaxation is required for sufficient exposure and successful outcome. Although full relaxation can be achieved with intravenous and inhalational agents, the dose required is extremely high. The use of intravenous neuromuscular blockers allows for neuromuscular relaxation and minimization of inhalational and intravenous drugs. **There are two types of neuromuscular blockers: depolarizing drugs, which depolarize the plasma membrane of skeletal muscle fibers, making the fibers resistant to further stimulation by acetylcholine, and nondepolarizing drugs, which block the binding of acetylcholine to cholinergic receptors on the presynaptic and postsynaptic membrane.** Succinylcholine, the only depolarizing drug on the market, is chosen for its rapid onset (used in rapid induction sequences), relatively short duration (around 5 minutes), and rapid metabolism. Its use is limited because of the risk for malignant hyperthermia (when used in combination with volatile inhalational agents), hyperkalemia, and bradycardia in children. When succinylcholine is contraindicated, nondepolarizing agents are used. Several nondepolarizing drugs are available and differ in routes of metabolism and adverse effects. Furthermore, multiple medications including desflurane can alter the metabolism of these drugs and potentiate their actions. The most important consideration in the use of neuromuscular blockers is the assessment of adequate return of neuromuscular function after withdrawal of the drug.

The most common complication of neuromuscular-blocking drugs is inadequate reversal resulting in respiratory failure and reintubation. Numerous reports in the literature correlate residual neuromuscular blockade with increased postoperative pulmonary complications in the postanesthesia care unit (PACU) and in the postoperative period. **The concept of train-of-four fade ratio (TOF) was developed to devise an objective measure of adequate neuromuscular**

function. This concept refers to the magnitude of the fourth of four twitches in response to maximal stimuli to the ulnar nerve delivered at 0.5-second intervals. Historically, a TOF of 0.7 (meaning that the fourth twitch was 70% the magnitude of the first twitch) correlated with adequate return of neuromuscular function; however, more recent standards have raised the threshold to 0.9 as an indicator of complete return of neuromuscular function (Kopman et al., 1997). Currently, anesthesiologists use several clinical assessments including head lift, tongue depressor test, and hand grip to estimate a TOF of 0.9. A recent study revealed that with use of clinical assessments alone, 16% and 45% of patients 2 hours after a single intubating dose of neuromuscular blocker had a TOF of less than 0.7 and less than 0.9, respectively, in the PACU (Debaene et al., 2003). As such, quantitative TOF measurement (acceleromyography) should be combined with clinical assessments before extubation in the operating room.

Skin Preparation

Sterile skin preparation is fundamental in the prevention of SSI for any procedure. Currently the most commonly used skin antiseptics are alcohol, povidone-iodine, or chlorhexidine based. Whichever antiseptic is chosen, the solution should be applied in concentric circles from the center of the surgical site and allowed to dry before incision. **The Cochrane Wound Study group recently published their updated analysis on various preoperative skin preparations. The authors found some evidence that preoperative skin preparation with 0.5% chlorhexidine in methylated spirits was associated with lower rates of SSI after clean surgery than alcohol-based povidone iodine paint but were unable to report conclusive evidence of superior efficacy of one particular skin preparation** (Dumville et al., 2013). Furthermore, although the CDC clearly recommends preoperative showering or bathing to reduce SSI, **there is no evidence that bathing with an antiseptic solution reduces the rate of infection** (Webster and Osborne, 2015). Regarding hair removal, the CDC recommends that if hair removal is performed, it should be performed immediately before the surgical procedure and performed with clippers (rather than shaving) to avoid breakage in the continuity of the integument and the resulting bacterial colonization (Mangram et al., 1999).

Transfusion Considerations

Given the vascular nature of urologic organs, the urologist often confronts the issue of blood loss in the perioperative period. Therefore, it is imperative that the urologist understand the implications and risks associated with blood product transfusion. Additionally, the urologist should be familiar with transfusion alternatives for patients who will not accept blood transfusions, such as Jehovah's Witnesses.

Before the acquired immunodeficiency syndrome (AIDS) epidemic, blood transfusion was liberally administered, often for any patient with a hematocrit less than 30%. However, fear and concern about the infectious risk led to the convening of a National Institutes of Health (NIH) panel to develop consensus recommendations for the indication of blood product transfusion (National Institutes of Health, 1988). The principles in these guidelines are reflected by the ASA practice guidelines issued in 2006 (American Society of Anesthesiologists Task Force on Perioperative Blood Transfusion and Adjuvant Therapies, 2006). **To summarize, the guidelines indicate that transfusion is rarely indicated with hematocrit greater than 30% and often indicated for a hematocrit less than 21%. For levels between 21% and 30%, clinical factors such as risk for complications from inadequate oxygenation should guide the need for transfusion, balancing the risks and benefits.** In general, patients with relatively minor comorbidities can tolerate hematocrit of greater than 21%. Patients with moderate to severe comorbidity (e.g., significant pulmonary compromise, coronary artery disease, or vascular insufficiency, or with signs or symptoms of hypovolemic, hemorrhagic shock) may not tolerate a hematocrit less than 30%. Ultimately, until technology is available to directly measure inadequate oxygen-carrying capacity, the urologist should individualize each patient's management based on the clinical situation.

A major advancement in blood banking and product transfusion has been the development of component therapy allowing for administration of specific fractions of whole blood. Packed red blood cells (PRBCs) are equivalent to whole blood minus the plasma component. Whereas the hematocrit in whole blood is 40%, it is 70% in PRBC units. These units are reconstituted and administered with crystalloid. Given the lack of the remaining components, in instances of massive PRBC transfusions and associated bleeding, platelets and occasionally fresh frozen plasma (FFP) are given to avoid dilutional coagulopathy. Platelet transfusion is rarely given empirically except in patients with significant thrombocytopenia ($<50,000/mm^3$) and a planned surgical procedure or with moderate thrombocytopenia ($50,000$ to $100,000/mm^3$) and either a high-risk procedure or evidence of platelet dysfunction. Similarly, empirical transfusion with FFP for massive transfusion is not standard practice. **The current indications for FFP transfusion are immediate reversal of warfarin-induced coagulopathy, replacement in patients with specific clotting factor deficiencies, and evidence of bleeding and INR greater than 1.5. According to ASA guidelines, in patients with massive transfusion and no INR readily available, FFP should be given after replacement of 1 blood volume.**

There are well-documented risks associated with blood transfusion, and these risks should always be discussed with the patient before administration. Hemolytic transfusion reactions occur as a result of incompatibility between donor and recipient (either ABO or non-ABO incompatibility). Transfusion reactions occur relatively frequently and, if identified early, can be treated with rare catastrophic events. The early signs and symptoms include fever, chills, chest pain, hypotension, and bleeding diathesis occurring during or immediately after transfusion. Reactions may also occur in a delayed fashion, characterized by significant intravascular hemolysis secondary to recipient antibodies. The treatment of transfusion reaction is centered on fluid resuscitation, cessation of the transfusion, and alkalinization of the urine to prevent renal failure. **The most common cause of transfusion-related fatality is transfusion-related acute lung injury (TRALI). This entity accounted for 55% of transfusion mortality from 2005 to 2007. The injury is characterized by noncardiogenic pulmonary edema and manifests 1 to 2 hours after transfusion.** Although no specific treatment other than supportive measures is indicated, most patients recover without significant sequelae.

Finally, one of the most feared complications (at least in the public eye) is the transmission of bacterial or viral infection. Although the risk for hepatitis virus and human immunodeficiency virus (HIV) transmission was unacceptably high in the 1970s and 1980s, the initiation of more stringent screening procedures for high-risk populations and the development of nucleic acid amplification technology (polymerase chain reaction [PCR] and transcription-mediated amplification) have resulted in dramatically reduced risk and incidence of viral transmission. **Currently, the risk for HIV and hepatitis C transmission is approximately 1 in 2 million cases, whereas the risk for hepatitis B transmission is 1 in 200,000.** The highest risk for infectivity occurs with platelet transfusion, in which bacterial contamination develops at a rate of 1 in 5000 units (Eder et al., 2007).

Given the proximity of major vascular structures to several genitourinary organs, occasionally the urologist is faced with a clinical situation in which a large-volume blood loss occurs, although very high–blood loss procedures in urology are uncommon. Traditionally, component transfusion would not begin until more than 6 units of PRBCs had been given to the patient. More recently, evidence from the trauma literature supports the use of an increased ratio of platelets to FFP to red blood cells (RBCs)—that is, massive transfusion protocol. The protocol is triggered in the anticipation of greater than 10 units of PRBCs per 24 hours and mobilizes blood bank and hospital resources to provide an adequate supply of RBCs and component transfusion. A study from Ball et al. demonstrated improved abdominal wall closure rates among patients with high-grade liver injuries when a massive transfusion protocol was used (Ball et al., 2013).

Several management strategies and transfusion alternatives are available for the management of patients with religious or other obligations not to accept blood transfusion. Contrary to popular beliefs, Jehovah's Witnesses’ refusal of blood transfusion does not indicate or translate to refusal of medical care. Importantly, they have respect for life and seek the best (bloodless) medical and surgical care available. Although *all* will not accept the four major blood components (RBCs, white blood cells, platelets, and plasma), some may accept minor blood fractions such as albumin, immunoglobulins, and clotting factors. A detailed discussion should be held with the patient, in conjunction with the anesthesiologist, to determine what is acceptable and what is not before initiating treatment. In the surgical patient, acceptable strategies include the use of electrocautery, cell salvage, intraoperative hemodilution, high-dose erythropoietin, and iron. Major surgical procedures have been performed with success without the use of blood transfusion, and some studies indicate that patients managed without blood had better outcome compared with those who received blood transfusion. Although there is currently no substitute for blood transfusion, several hemoglobin-based blood substitutes have been evaluated in various trials, but translation into routine clinical practice has been hindered by side effects or complications resulting from their use (Natanson et al., 2008).

Pain Management

Equally important to intraoperative anesthetic considerations, proper pain management after surgery is crucial to minimizing postoperative complications and delayed recovery. **Untreated acute pain not only is unacceptable for the patient, but also may increase the risk for complications by causing increased physiologic stress in the recovery period.** The neural process, referred to as *nociception,* involves signal transduction from noxious stimuli via sensory afferent nerves to the spinal cord and cerebral cortex, resulting in the perception of pain. Analgesia aims to block the pain sensation along various points of this signal transduction pathway.

Opioids are perhaps the most commonly used analgesic medications in the immediate postoperative period. These drugs primarily act in the central nervous system (CNS) at both the dorsal root ganglion and the cerebral cortex to modulate the perception of pain. Administration can be oral, intravenous, neuraxial, or transdermal. In general, the choice of route of administration is dependent on the patient's severity of pain and ability to take oral medications. Although typically very effective for providing analgesia, opioids can cause decreased GI activity resulting in ileus, respiratory depression, sedation, and mental confusion. Weaker (less potent) opioids such as hydrocodone and codeine may minimize these adverse effects but are often combined with acetaminophen and should be used with caution in patients with hepatic insufficiency. Additionally, opioid (mis)use has resulted in addiction and opioids epidemics in the United States (Jalal et al., 2018).

Physicians have a tremendous role to play in curbing the opioid crisis currently plaguing the United States (Waljee et al., 2017). In an effort to improve pain control and thus quality of care, advanced practice providers and surgeons often prescribe large amounts of narcotics, the majority of which are not used by the patients, and this contributes to dispersion of opioids into the community, misuse, abuse, and addiction (Lee et al., 2017; Theisen et al., 2018a, 2018b; Fujii et al., 2018; Cron et al., 2018). To underscore the significance of opioid overprescription, new persistent opioid use in patients undergoing minor and major surgeries has been reported to be up to 5.9% and 6.5%, respectively (Brummett et al., 2017). Thus, there are ongoing efforts to evaluate the judicious use of narcotic pain medicines in patients undergoing urologic surgery. For kidney stone management, for example, a recent analysis of 22,609 patients demonstrated a wide variation in opioid-prescribing patterns (Leapman et al., 2018). In a retrospective analysis of 104 patients undergoing ureteroscopy, 10% (5/52) of patients managed initially without narcotics and 17% (9/52) of patients managed initially with narcotics but sought additional medical care because of inadequate pain control, suggesting that patients undergoing ureteroscopy can be safely managed without narcotic pain pills (Large et al., 2018). Ongoing studies at various institutions will provide insight into the judicious use of narcotic analgesia after urologic surgeries.

Nonsteroidal anti-inflammatory drugs (NSAIDs) are being employed in the postoperative setting more frequently now to avoid the unwanted effects of opioids. These medications act by inhibition of cyclooxygenase enzyme activity, resulting in decreased prostaglandin production. Prostaglandins are the primary mediators of nociceptor activation at the tissue level. **Multiple studies have demonstrated that the appropriate use of NSAIDs can result in decreased use of opioid analgesics and decreased nausea and vomiting after anesthesia** (Rawlinson et al., 2012). In a randomized study of patients undergoing laparoscopic colon surgery, the use of intravenous ketorolac was associated with improved pain scores and reduced postoperative ileus (Schlachta et al., 2007). NSAIDs are usually very well tolerated but should be avoided in patients with renal insufficiency and used with caution in patients with a history of esophageal reflux or peptic ulcer disease.

For major abdominal surgery in which prolonged opioid use is expected, neuraxial analgesia (i.e., epidural) can provide significant patient benefits. Epidural analgesia is administered and monitored by the anesthesia or pain management team. Both opioids and local anesthetic medications are infused in the epidural space via catheter and are given as a continuous infusion and/or patient-controlled infusion. Epidural analgesia has the advantage of improved pain control while minimizing the CNS and GI adverse effects of intravenous opioid medications. Block et al. performed a meta-analysis of randomized trials to review the efficacy and concluded that epidural analgesia, regardless of agent or location of catheter placement, provided better pain control than parenteral opioids (Block et al., 2003). **In fact, a recent review of RCTs found that in patients undergoing general anesthesia, the use of concomitant epidural analgesia resulted in decreased perioperative mortality and improved comorbidity end points across multiple organ systems** (Pöpping et al., 2014).

Key Points

- Proper preoperative evaluation of the patient will prevent unanticipated cancellations and decrease the risk for postoperative complications.
- The indications for preoperative cardiac testing depend on three groups of

factors: the functional capacity of the patient, cardiac risk factors, and surgery-specific risk factors.

- SSIs are one of the leading causes of perioperative complications and increased hospital stay. Antibiotic prophylaxis is indicated in virtually all surgical procedures.
- VTE is a common complication of urologic procedures, and the AUA recommends either mechanical or pharmacologic prophylaxis (or both for patients at highest risk) for all urologic procedures.
- Proper understanding of the pharmacologic principles of anesthesia will allow the urologist to actively participate in the decision-making process of choosing which mode of anesthesia will be appropriate for a particular patient and procedure.
- Current guidelines advocate blood product transfusion for a hematocrit less than 21% in most patients unless there are specific cardiopulmonary risk factors.
- Perioperative hypothermia of even 1°C to 2°C is associated with increased estimated blood loss and increased risk for SSI.

Acknowledgments

Thanks to Manish A. Vira, MD, and Joph Steckel, MD, FACS, who wrote the previous version of this chapter.

Suggested Readings

American Society of Anesthesiologists Task Force on Perioperative Blood Transfusion and Adjuvant Therapies. Practice guidelines for perioperative blood transfusion and adjuvant therapies: an updated report by the American Society of Anesthesiologists Task Force on Perioperative Blood Transfusion and Adjuvant Therapies. *Anesthesiology*. 2006;105(1):198–208.

Brennan TA, Leape LL, Laird NM, et al. Incidence of adverse events and negligence in hospitalized patients. Results of the Harvard Medical Practice Study I. *N Engl J Med*. 1991;324(6):370–376.

Douketis JD, Berger PB, Dunn AS, et al. The perioperative management of antithrombotic therapy: American College of Chest Physicians evidence-based clinical practice guidelines (8th edition). *Chest*. 2008;133(6 Suppl):299S–339S.

Eagle KA, Berger PB, Calkins H, et al. ACC/AHA guideline update for perioperative cardiovascular evaluation for noncardiac surgery—executive summary: a report of the American College of Cardiology/American Heart Association Task Force on Practice Guidelines (Committee to Update the 1996 Guidelines on Perioperative Cardiovascular Evaluation for Noncardiac Surgery). *J Am Coll Cardiol*. 2002;39(3):542–553.

Geerts WH, Bergqvist D, Pineo GF, et al. Prevention of venous thromboembolism: American College of Chest Physicians evidence-based clinical practice guidelines (8th edition). *Chest*. 2008;133(6 Suppl):381S–453S.

Wolf JS Jr, Bennett CJ, Dmochowski RR, et al. Best practice policy statement on urologic surgery antimicrobial prophylaxis. *J Urol*. 2008;179(4):1379–1390.

References

Akhtar S, Silverman DG. Assessment and management of patients with ischemic heart disease. *Crit Care Med*. 2004;32(4 Suppl):S126–S136.

Liberman D, Lughezzani G, Sun M. Perioperative mortality is significantly greater in septuagenarian and octogenarian patients treated with radical cystectomy for urothelial carcinoma of the bladder. *Urology*. 2011;77(3):660–666.

American Society of Anesthesiologists Task Force on Perioperative Blood Transfusion and Adjuvant Therapies. Practice guidelines for perioperative blood transfusion and adjuvant therapies: an updated report by the American Society of Anesthesiologists Task Force on Perioperative Blood Transfusion and Adjuvant Therapies. *Anesthesiology*. 2006;105(1):198–208.

American Society of Anesthesiologists Task Force on Prevention of Perioperative Peripheral Neuropathies. Practice advisory for the prevention of perioperative peripheral neuropathies: an updated report by the American Society of Anesthesiologists Task Force on Prevention of Perioperative Peripheral Neuropathies. *Anesthesiology*. 2018;128(1):11–26.

Arozullah AM, Conde MV, Lawrence VA. Preoperative evaluation for postoperative pulmonary complications. *Med Clin North Am*. 2003;87(1):153–173.

ASPEN Board of Directors and the Clinical Guidelines Task Force. Guidelines for the use of parenteral and enteral nutrition in adult and pediatric patients. *JPEN J Parenter Enteral Nutr*. 2002;26(1 Suppl):1SA–138SA.

Ball CG, Dente CJ, Shaz B, et al. The impact of a massive transfusion protocol (1:1:1) on major hepatic injuries: does it increase abdominal wall closure rates? *Can J Surg*.

2013;56(5):E128–E134.

Biccard BM. Relationship between the inability to climb two flights of stairs and outcome after major non-cardiac surgery: implications for the pre-operative assessment of functional capacity. *Anaesthesia*. 2005;60(6):588–593.

Biteker M, Duman D, Tekkeşin AI. Predictive value of preoperative electrocardiography for perioperative cardiovascular outcomes in patients undergoing noncardiac, nonvascular surgery. *Clin Cardiol*. 2012;35(8):494–499.

Block BM, Liu SS, Rowlingson AJ, et al. Efficacy of postoperative epidural analgesia: a meta-analysis. *JAMA*. 2003;290(18):2455–2463.

Bowater RJ, Stirling SA, Lilford RJ. Is antibiotic prophylaxis in surgery a generally effective intervention? Testing a generic hypothesis over a set of meta-analyses. *Ann Surg*. 2009;249(4):551–556.

Brennan TA, Leape LL, Laird NM, et al. Incidence of adverse events and negligence in hospitalized patients. Results of the Harvard Medical Practice Study I. *N Engl J Med*. 1991;324(6):370–376.

Brummett CM, Waljee JF, Goesling J, et al. New persistent opioid use after minor and major surgical procedures in US adults. *JAMA Surg*. 2017;152(6):e170504.

Carter R, Holiday DB, Grothues C, et al. Criterion validity of the Duke Activity Status Index for assessing functional capacity in patients with chronic obstructive pulmonary disease. *J Cardiopulm Rehabil*. 2002;22(4):298–308.

Clarke JS, Condon RE, Bartlett JG, et al. Preoperative oral antibiotics reduce septic complications of colon operations: results of prospective, randomized, double-blind clinical study. *Ann Surg*. 1977;186(3):251–259.

Classen DC, Evans RS, Pestotnik SL, et al. The timing of prophylactic administration of antibiotics and the risk of surgical-wound infection. *N Engl J Med*. 1992;26(5):281–286.

Committee on Standards and Practice Parameters, Apfelbaum JL, Connis RT, et al. Practice advisory for preanesthesia evaluation: an updated report by the American Society of Anesthesiologists Task Force on Preanesthesia Evaluation. *Anesthesiology*. 2012;116(3):522–538.

Contant CM, Hop WC, van't Sant HP, et al. Mechanical bowel preparation for elective colorectal surgery: a multicentre randomised trial. *Lancet*. 2007;370(9605):2112–2117.

Coutinho-Myrrha MA, Dias RC, Fernandes AA, et al. Duke Activity Status Index for cardiovascular diseases: validation of the Portuguese translation. *Arq Bras Cardiol*. 2014;102(4):383–390.

Cron DC, Lee JS, Dupree JM, et al. Provider characteristics associated with outpatient opioid prescribing after surgery. *Ann Surg*. 2018; 10.1097/SLA.0000000000003013 [Epub ahead of print].

Davenport DL, Bowe EA, Henderson WG, et al. National Surgical Quality Improvement Program (NSQIP) risk factors can be used to validate American Society of Anesthesiologists Physical Status Classification (ASA PS) levels. *Ann Surg*. 2006;243(5):636–641 [discussion 641–644].

de Lissovoy G, Fraeman K, Hutchins V, et al. Surgical site infection: incidence and impact on hospital utilization and treatment costs. *Am J Infect Control*. 2009;37(5):387–397.

Debaene B, Plaud B, Dilly MP, et al. Residual paralysis in the PACU after a single intubating dose of nondepolarizing muscle relaxant with an intermediate duration of action. *Anesthesiology*. 2003;98(5):1042–1048.

Di Cianni S, Rossi M, Casati A, et al. Spinal anesthesia: an evergreen technique. *Acta Biomed*. 2008;79(1):9–17.

Douketis JD. Pharmacologic properties of the new oral anticoagulants: a clinician-oriented review with a focus on perioperative management. *Curr Pharm Des*. 2010;16(31):3436–3441.

Douketis JD, Spyropoulos AC, Spencer FA, et al. Perioperative management of antithrombotic therapy: antithrombotic therapy and prevention of thrombosis, 9th ed: American College of Chest Physicians evidence-based clinical practice guidelines. *Chest*. 2012;141(2 Suppl):e326S–e350S.

Dumville JC, McFarlane E, Edwards P, et al. Preoperative skin antiseptics for preventing surgical wound infections after clean surgery. *Cochrane Database Syst Rev*. 2013;(3) [CD003949].

Dyer J, Wyke S, Lynch C. Hospital Episode Statistics data analysis of postoperative venous thromboembolus in patients undergoing urological surgery: a review of 126,891 cases. *Ann R Coll Surg Engl*. 2013;95(1):65–69.

Eagle KA, Berger PB, Calkins H, et al. ACC/AHA guideline update for perioperative cardiovascular evaluation for noncardiac surgery–executive summary: a report of the American College of Cardiology/American Heart Association Task Force on Practice Guidelines (Committee to Update the 1996 Guidelines on Perioperative Cardiovascular Evaluation for Noncardiac Surgery). *J Am Coll Cardiol*. 2002;39(3):542–553.

Eagle KA, Brundage PH, Chaitman BR, et al. Guidelines for perioperative cardiovascular evaluation for noncardiac surgery. Report of the American College of Cardiology/American Heart Association Task Force on Practice Guidelines. Committee on Perioperative Cardiovascular Evaluation for Noncardiac Surgery. *Circulation*. 1996;93(6):1278–1317.

Eder AF, Kennedy JM, Dy BA, et al. Bacterial screening of apheresis platelets and the residual risk of septic transfusion reactions: the American Red Cross experience (2004–2006). *Transfusion*. 2007;47(7):1134–1142.

El-Galley R, Hammontree L, Urban D, et al. Anesthesia for laparoscopic donor nephrectomy: is nitrous oxide contraindicated? *J Urol*. 2007;178(1):225–227 [discussion 227].

Evans DC, Martindale RG, Kiraly LN, et al. Nutrition optimization prior to surgery. *Nutr Clin Pract*. 2014;29(1):10–21.

Fleisher LA, Beckman JA, Brown KA, et al. ACC/AHA 2007 guidelines on perioperative cardiovascular evaluation and care for noncardiac surgery: a report of the American College of Cardiology/American Heart Association Yask Force on Practice Guidelines (Writing Committee to Revise the 2002 Guidelines on Perioperative Cardiovascular Evaluation for Noncardiac Surgery) developed in collaboration with the American Society of Echocardiography, American Society of Nuclear Cardiology, Heart Rhythm Society, Society of Cardiovascular Anesthesiologists, Society for Cardiovascular Angiography and Interventions, Society for Vascular Medicine and Biology, and Society for Vascular Surgery. *Circulation*. 2007;116(17):e418–e499.

Fleisher LA, Pasternak LR, Lyles A. A novel index of elevated risk of inpatient hospital admission immediately following outpatient surgery. *Arch Surg*. 2007;142(3):263–268.

Fontaine KR, Redden DT, Wang C, et al. Years of life lost due to obesity. *JAMA*. 2003;289(2):187–193.

Forrest JB, Clemens JQ, Finamore P, et al. AUA best practice statement for the prevention of deep vein thrombosis in patients undergoing urologic surgery. *J Urol*. 2009;181(3):1170–1177.

Fowkes FG, Lunn JN, Farrow SC, et al. Epidemiology in anaesthesia. III: mortality risk in patients with coexisting physical disease. *Br J Anaesth*. 1982;54(8):819–825.

Fujii MH, Hodges AC, Russell RL, et al. Post-discharge opioid prescribing and use after common surgical procedure. *J Am Coll Surg*. 2018;226(6):1004–1012.

Geerts WH, Bergqvist D, Pineo GF, et al. Prevention of venous thromboembolism: American College of Chest Physicians evidence-based clinical practice guidelines (8th edition). *Chest*. 2008;133(6 Suppl):381S–453S.

Golden SH, Peart-Vigilance C, Kao WH, et al. Perioperative glycemic control and the risk of infectious complications in a cohort of adults with diabetes. *Diabetes Care*. 1999;22(9):1408–1414.

Güenaga KF, Matos D, Wille-Jørgensen P. Mechanical bowel preparation for elective colorectal surgery. *Cochrane Database Syst Rev*. 2011;(9) [CD001544].

Gupta AD, Streiff M, Resar J, et al. Coronary stent management in elective genitourinary surgery. *BJU Int*. 2012;110(4):480–484.

Halaszynski TM, Juda R, Silverman DG. Optimizing postoperative outcomes with efficient preoperative assessment and management. *Crit Care Med*. 2004;32(4 Suppl):S76–S86.

Hart D, Postlethwait RW, Brown IW Jr, et al. Postoperative wound infections: a further report on ultraviolet irradiation with comments on the recent (1964) national research council cooperative study report. *Ann Surg*. 1968;167(5):728–743.

Hedrick TL, Swenson BR, Friel CM. Model for End-Stage Liver Disease (MELD) in predicting postoperative mortality of patients undergoing colorectal surgery. *Am Surg*. 2013;79(4):347–352.

Hlatky MA, Boineau RE, Higginbotham MB, et al. A brief self-administered questionnaire to determine functional capacity (the Duke Activity Status Index). *Am J Cardiol*. 1989;64(10):651–654.

Ho YM, Smith SR, Pockney P, et al. A meta-analysis on the effect of sham feeding following colectomy: should gum chewing be included in enhanced recovery after surgery protocols? *Dis Colon Rectum*. 2014;57(1):115–126.

Irvin W, Andersen W, Taylor P, et al. Minimizing the risk of neurologic injury in gynecologic surgery. *Obstet Gynecol*. 2004;103(2):374–382.

Jacobson LA, Kent M, Lee M, et al. America's aging population. *Popul Bull*. 2011;66(1).

Jalal H, Buchanich JM, Roberts MS, et al. Changing dynamics of the drug overdose epidemic in the United States from 1979 through 2016. *Science*. 2018;361(6408) [pii: eaau1184].

Johansson T, Fritsch G, Flamm M, et al. Effectiveness of non-cardiac preoperative testing in non-cardiac elective surgery: a systematic review. *Br J Anaesth*. 2013;110(6):926–939.

Jung B, Påhlman L, Nyström PO, et al. Multicentre randomized clinical trial of mechanical bowel preparation in elective colonic resection. *Br J Surg*. 2007;94(6):689–695.

Kauf TL, Svatek RS, Amiel G, et al. Alvimopan, a peripherally acting μ-opioid receptor antagonist, is associated with reduced costs after radical cystectomy: economic analysis of a phase 4 randomized, controlled trial. *J Urol*. 2014;191(6):1721–1727.

Kizer NT, Powell MA. Surgery in the pregnant patient. *Clin Obstet Gynecol*. 2011;54(4):633–641.

Klein I, Ojamaa K. Thyroid hormone and the cardiovascular system. *N Engl J Med*. 2001;344(7):501–509.

Kopman AF, Yee PS, Neuman GG. Relationship of the train-of-four fade ratio to clinical signs and symptoms of residual paralysis in awake volunteers. *Anesthesiology*. 1997;86(4):765–771.

Kurz A, Sessler DI, Lenhardt R. Perioperative normothermia to reduce the incidence of surgical-wound infection and shorten hospitalization. [for the; Study of Wound Infection and Temperature Group] *N Engl J Med*. 1996;334(19):1209–1215.

Large T, Heiman J, Ross A, et al. Initial experience with narcotic-free ureteroscopy: a feasibility analysis. *J Endourol*. 2018;32(10):907–911.

LaRochelle GE Jr, LaRochelle AG, Ratner RE, et al. Recovery of the hypothalamic-pituitary-adrenal (HPA) axis in patients with rheumatic diseases receiving low-dose prednisone. *Am J Med*. 1993;95(3):258–264.

Leape LL, Brennan TA, Laird N, et al. The nature of adverse events in hospitalized patients. Results of the Harvard Medical Practice Study II. *N Engl J Med*. 1991;324(6):377–384.

Leapman MS, DeRycke E, Skanderson M, et al. Variation in national opioid prescribing patterns following surgery for kidney stones. *Pain Med*. 2018;19(suppl_1):S12–S18.

Lee JS, Hu HM, Brummett CM, et al. Postoperative opioid prescribing and the pain scores on hospital consumer assessment of healthcare providers and systems survey. *JAMA*. 2017;317(19):2013–2015.

Leonardi MJ, McGory ML, Ko CY. The rate of bleeding complications after pharmacologic deep venous thrombosis prophylaxis: a systematic review of 33 randomized controlled trials. *Arch Surg*. 2006;141(8):790–797 [discussion 797–799].

Lindenauer PK, Pekow P, Wang K, et al. Perioperative beta-blocker therapy and mortality after major noncardiac surgery. *N Engl J Med*. 2005;353(4):349–361.

Liu LL, Dzankic S, Leung JM. Preoperative electrocardiogram abnormalities do not predict postoperative cardiac complications in geriatric surgical patients. *J Am Geriatr Soc*.

2002;50(7):1186–1191.

Mangano DT, Layug EL, Wallace A, et al. Effect of atenolol on mortality and cardiovascular morbidity after noncardiac surgery. Multicenter Study of Perioperative Ischemia Research Group. *N Engl J Med*. 1996;335(23):1713–1720.

Mangram AJ, Horan TC, Pearson ML, et al. Guideline for prevention of surgical site infection, 1999. Hospital Infection Control Practices Advisory Committee. *Infect Control Hosp Epidemiol*. 1999;20(4):250–278 [quiz 279–280].

Mauermann WJ, Nemergut EC. The anesthesiologist's role in the prevention of surgical site infections. *Anesthesiology*. 2006;105(2):413–421 [quiz 439–440].

Mossanen M, Calvert JK, Holt SK, et al. Overuse of antimicrobial prophylaxis in community practice urology. *J Urol*. 2015;193(2):543–547.

Murkin JM. Anesthesia and hypothyroidism: a review of thyroxine physiology, pharmacology, and anesthetic implications. *Anesth Analg*. 1982;61(4):371–383.

Natanson C, Kern SJ, Lurie P, et al. Cell-free hemoglobin-based blood substitutes and risk of myocardial infarction and death: a meta-analysis. *JAMA*. 2008;299(19):2304–2312.

National Institutes of Health. NIH consensus statement available on perioperative red cell transfusion. *Am J Public Health*. 1988;78(12):1588.

Nelson RL, Gladman E, Barbateskovic M. Antimicrobial prophylaxis for colorectal surgery. *Cochrane Database Syst Rev*. 2014;(5) [CD001181].

Noordzij PG, Boersma E, Bax JJ, et al. Prognostic value of routine preoperative electrocardiography in patients undergoing noncardiac surgery. *Am J Cardiol*. 2006;97(7):1103–1106.

O'Leary JG, Friedman LS. Predicting surgical risk in patients with cirrhosis: from art to science. *Gastroenterology*.

2007;132(4):1609–1611.

O'Leary JG, Yachimski PS, Friedman LS. Surgery in the patient with liver disease. *Clin Liver Dis*. 2009;13(2):211–231.

O'Riordan JM, Margey RJ, Blake G, et al. Antiplatelet agents in the perioperative period. *Arch Surg*. 2009;144(1):69–76 [discussion 76].

Pearce AC, Jones RM. Smoking and anesthesia: preoperative abstinence and perioperative morbidity. *Anesthesiology*. 1984;61(5):576–584.

Pearse RM, Rhodes A, Grounds RM. Clinical review: how to optimize management of high-risk surgical patients. *Crit Care*. 2004;8(6):503–507.

Poirier P, Alpert MA, Fleisher LA, et al. American Heart Association Obesity Committee of the Council on Nutrition, Physical Activity and Metabolism, Council on Cardiopulmonary Perioperative and Critical Care, Council on Cardiovascular Surgery and Anesthesia, Council on Cardiovascular Disease in the Young, Council on Cardiovascular Nursing, and Council on Clinical Cardiology. Cardiovascular evaluation and management of severely obese patients undergoing surgery: a science advisory from the American Heart Association. *Circulation*. 2009;120(1):86–95.

Pöpping DM, Elia N, Van Aken HK, et al. Impact of epidural analgesia on mortality and morbidity after surgery: systematic review and meta-analysis of randomized controlled trials. *Ann Surg*. 2014;259(6):1056–1067.

Rajagopalan S, Mascha E, Na J, et al. The effects of mild perioperative hypothermia on blood loss and transfusion requirement. *Anesthesiology*. 2008;108(1):71–77.

Rawlinson A, Kitchingham N, Hart C, et al. Mechanisms of reducing postoperative pain, nausea and vomiting: a systematic review of current techniques. *Evid Based Med*.

2012;17(3):75–80.

Reinhardt GF, Myscofski JW, Wilkens DB, et al. Incidence and mortality of hypoalbuminemic patients in hospitalized veterans. *JPEN J Parenter Enteral Nutr*. 1980;4(4):357–359.

Scarpa RM, Carrieri G, Gussoni G, et al. Clinically overt venous thromboembolism after urologic cancer surgery: results from the @RISTOS Study. *Eur Urol*. 2007;51(1):130–135 [discussion 136].

Schiff RL, Welsh GA. Perioperative evaluation and management of the patient with endocrine dysfunction. *Med Clin North Am*. 2003;87(1):175–192.

Schlachta CM, Burpee SE, Fernandez C, et al. Optimizing recovery after laparoscopic colon surgery (ORAL-CS): effect of intravenous ketorolac on length of hospital stay. *Surg Endosc*. 2007;21(12):2212–2219.

Secin FP, Jiborn T, Bjartell AS, et al. Multi-institutional study of symptomatic deep venous thrombosis and pulmonary embolism in prostate cancer patients undergoing laparoscopic or robot-assisted laparoscopic radical prostatectomy. *Eur Urol*. 2008;53(1):134–145.

Shoemaker WC, Appel PL, Kram HB, et al. Prospective trial of supranormal values of survivors as therapeutic goals in high-risk surgical patients. *Chest*. 1988;94(6):1176–1186.

Shoyeb A, Weinstein H, Roistacher N, et al. Preoperative exercise echocardiography and perioperative cardiovascular outcomes in elderly patients undergoing cancer surgery. *Am J Geriatr Cardiol*. 2006;15(6):338–344.

Sigalet DL, Mackenzie SL, Hameed SM. Enteral nutrition and mucosal immunity: implications for feeding strategies in surgery and trauma. *Can J Surg*. 2004;47(2):109–116.

Slim K, Vicaut E, Launay-Savary MV, et al. Updated systematic review and meta-analysis of randomized clinical trials on the role of mechanical bowel preparation before colorectal surgery. *Ann Surg*. 2009;249(2):203–209.

Steinberg JP, Braun BI, Hellinger WC, et al. Timing of antimicrobial prophylaxis and the risk of surgical site infections: results from the Trial to Reduce Antimicrobial Prophylaxis Errors. *Ann Surg*. 2009;250(1):10–16.

Tarhan S, Moffitt EA, Taylor WF, et al. Myocardial infarction after general anesthesia. *JAMA*. 1972;220(11):1451–1454.

Teh SH, Nagorney DM, Stevens SR, et al. Risk factors for mortality after surgery in patients with cirrhosis. *Gastroenterology*. 2007;132(4):1261–1269.

Theisen K, Jacobs B, Macleod L, et al. The United States opioid epidemic: a review of the surgeon's contribution to it and health policy initiatives. *BJU Int*. 2018;122(5):754–759.

Theisen KM, Myrga JM, Hale N, et al. Excessive opioid prescribing after major urologic procedures. *Urology*. 2018;(18):30890–30892 [pii: S0090-4295].

Townsend CM Jr, Beauchamp RD, Evers BM, et al. *Sabiston textbook of surgery E-Book*. Elsevier Health Sciences; 2015.

Turnbull DK, Shepherd DB. Post-dural puncture headache: pathogenesis, prevention and treatment. *Br J Anaesth*. 2003;91(5):718–729.

Turrentine FE, Wang H, Simpson VB, et al. Surgical risk factors, morbidity, and mortality in elderly patients. *J Am Coll Surg*. 2006;203(6):865–877.

van Klei WA, Bryson GL, Yang H, et al. The value of routine preoperative electrocardiography in predicting myocardial infarction after noncardiac surgery. *Ann Surg*. 2007;246(2):165–170.

Vemuri C, Wainess RM, Dimick JB, et al. Effect of increasing patient age on complication rates following intact abdominal aortic aneurysm repair in the United States. *J Surg Res*. 2004;118(1):26–31.

Veterans Affairs Total Parenteral Nutrition Cooperative Study

Group. Perioperative total parenteral nutrition in surgical patients. *N Engl J Med*. 1991;325(8):525–532.

Von Meyenfeldt MF, Meijerink WJ, Rouflart MM, et al. Perioperative nutritional support: a randomised clinical trial. *Clin Nutr*. 1992;11(4):180–186.

Waljee JF, Li L, Brummett CM, et al. Iatrogenic opioid dependence in the United States: are surgeons the gatekeepers? *Ann Surg*. 2017;265(4):728–730.

Warner MA, Martin JT, Schroeder DR, et al. Lower-extremity motor neuropathy associated with surgery performed on patients in a lithotomy position. *Anesthesiology*. 1994;81(1):6–12.

Warner MA, Offord KP, Warner ME, et al. Role of preoperative cessation of smoking and other factors in postoperative pulmonary complications: a blinded prospective study of coronary artery bypass patients. *Mayo Clin Proc*. 1989;64(6):609–616.

Warner MA, Warner DO, Harper CM, et al. Lower extremity neuropathies associated with lithotomy positions. *Anesthesiology*. 2000;93(4):938–942.

Webster J, Osborne S. Preoperative bathing or showering with skin antiseptics to prevent surgical site infection. *Cochrane Database Syst Rev*. 2015;(2) [CD004985].

Wolf JS Jr, Bennett CJ, Dmochowski RR, et al. Best practice policy statement on urologic surgery antimicrobial prophylaxis. *J Urol*. 2008;179(4):1379–1390.

Wren SM, Ahmed N, Jamal A, et al. Preoperative oral antibiotics in colorectal surgery increase the rate of Clostridium difficile colitis. *Arch Surg*. 2005;140(8):752–756.

Wu JR, Lennie TA, Frazier SK, et al. Health-related quality of life, functional status, and cardiac event-free survival in patients with heart failure. *J Cardiovasc Nurs*. 2016;31(3):236–244.

Zaid HB, Kaffenberger SD, Chang SS. Improvements in safety and recovery following cystectomy: reassessing the role of pre-operative bowel preparation and interventions to speed return of post-operative bowel function. *Curr Urol Rep*. 2013;14(2):78–83.

Zhan C, Miller MR. Excess length of stay, charges, and mortality attributable to medical injuries during hospitalization. *JAMA*. 2003;290(14):1868–1874.

Zmora O, Wexner SD, Hajjar L, et al. Trends in preparation for colorectal surgery: survey of the members of the American Society of Colon and Rectal Surgeons. *Am Surg*. 2003;69(2):150–154.

Principles of Urologic Surgery

Incisions and Access

David Mikhail MD, FRCSC, Simon J. Hall MD

In the era of expanding experience, training, and indications for surgical robotics and laparoscopy, urologists are experiencing less exposure to traditional surgical techniques. Open incisions remain unpopular when there are minimally invasive alternatives and are associated with higher rates of unscheduled clinical encounters (phone calls, office visits) related to patient anxiety compared with endoscopic procedures (Arpey et al., 2018). However, there remain indications for open surgery based on patient driven characteristics, such as prior abdominal surgeries, use of prior abdominal mesh or size, and complexity of pathology (e.g., renal mass with a caval thrombus). Alternatively, and perhaps most importantly, the skill, experience, and comfort level of the individual surgeon and team may dictate an open versus minimally invasive procedure in more challenging cases. Furthermore, larger specimens such as polycystic kidneys, donor kidneys, or retroperitoneal sarcomas need to be extracted following a minimally invasive approach via an incision. Therefore, all operative urologists need to have a basic understanding of the various types of open incisions.

Abdominal Incisions

Midline Incision

Midline incisions are a commonly used abdominal incision. Through the midline, the extraperitoneal, peritoneal, and retroperitoneal spaces can be accessed.

The lower midline incision, also known as *infraumbilical*, provides access to the pelvic organs via the extraperitoneal, retropubic space (Space of Retzius) and intraperitoneal access when desired. There are multiple indications including radical retropubic prostatectomy, simple prostatectomy, pelvic lymph node dissection, radical cystectomy, partial cystectomy, diverticulectomy, enteric cystoplasty, and urinary diversions. This is also a common incision for extraction of specimens such as kidneys after laparoscopic surgery (Lee et al., 2017).

An upper midline incision can be utilized to access retroperitoneal structures bilaterally including the adrenal glands, kidneys, ureters, retroperitoneal lymph nodes, and great vessels. Procedures include retroperitoneal lymph node dissections, bilateral simple nephrectomies, and resection of retroperitoneal masses.

Various lengths are used depending on the procedure; as small as 2 to 3 cm for a suprapubic cystolithotomy. Either of the midline incisions can be extended (inferiorly or superiorly) past the umbilicus to allow improved exposure and access to abdominal and retroperitoneal organs as required. Procedures that could be done through a complete midline incision include retroperitoneal lymph node dissection, bilateral nephrectomy for polycystic kidneys, large retroperitoneal mass resection, nephroureterectomy or reconstruction requiring a significant amount of bowel for reconstruction (Indiana Pouch). This is also the approach in trauma nephrectomies (Carroll et al., 1989).

One should identify by palpation the linea alba, the aponeuroses of the abdominal wall muscles in the midline, and incise along it to avoid cutting through the rectus abdominus muscle. This becomes more challenging in patients who are obese, have had multiple abdominal surgeries, or have abdominal wall hernias. Avoiding the musculature decreases the risk for bleeding from the incision as it will avoid the vessels that run deep to and perforate the muscles (Fig. 9.1AB). With the lower midline incision, the extraperitoneal space is accessed by opening the posterior fascia as low as possible near the pubic bone to enter and then bluntly expand into this space. Alternatively, entrance into the peritoneal space can be made by opening the posterior fascia followed by the peritoneum.

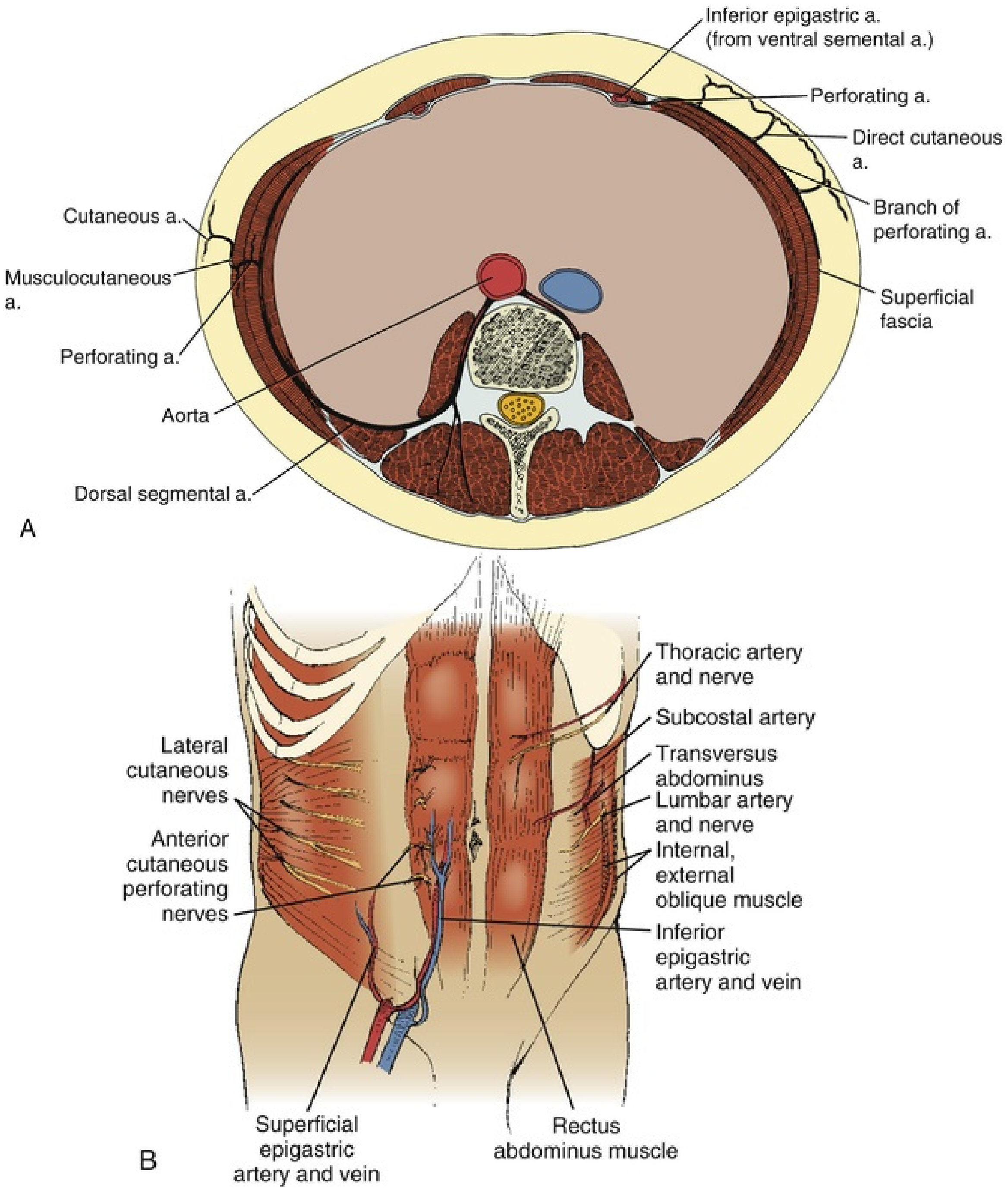
Inferior epigastric a.
(from ventral semental a.)
Perforating a.
Direct cutaneous a.
Branch of perforating a.
Superficial fascia
Cutaneous a.
Musculocutaneous a.
Perforating a.
Aorta
Dorsal segmental a.
A
Thoracic artery and nerve
Subcostal artery
Transversus abdominus
Lumbar artery and nerve
Internal, external oblique muscle
Inferior epigastric artery and vein
Lateral cutaneous nerves
Anterior cutaneous perforating nerves
Superficial epigastric artery and vein
Rectus abdominus muscle
B

FIG. 9.1 Cross-sectional and anterior abdominal wall anatomy. (A and B) Cross-sectional and anterior abdominal wall anatomy shown here is important to recognize when making abdominal incisions. Every attempt

should be made to avoid important vessels and nerves and to avoid direct incisions into the musculature when possible. (From Smith JA Jr, Howards SS, Preminger GM, Dmochowski RR. *Hinman's atlas of urologic surgery,* 4th ed. Philadelphia, PA: Elsevier, 2018; Figs. 3.1 and 8.1.)

Midline incisions are usually closed in one layer, keeping in mind that these will have more tension across the incision than those that conform to Langer's lines. Closure of fascial layers can be done in a running or interrupted figure-of-eight fashion with strong 2-0 synthetic monofilament absorbable sutures, such as Polydioxanone or braided Polyglycolide. Careful surgical technique is critical to avoid injury to abdominal structures and to ensure strength of the wound. Sutures should be 1 cm from midline and 1 cm apart (Figs. 9.2 and 9.3). There appears to be no evidence that one method is superior in terms of failure or subsequent incisional hernias (Patel et al., 2017), although one should avoid continuous closure technique if using any rapidly absorbable suture because this has been linked to higher hernia rates (Van ’t et al., 2002).

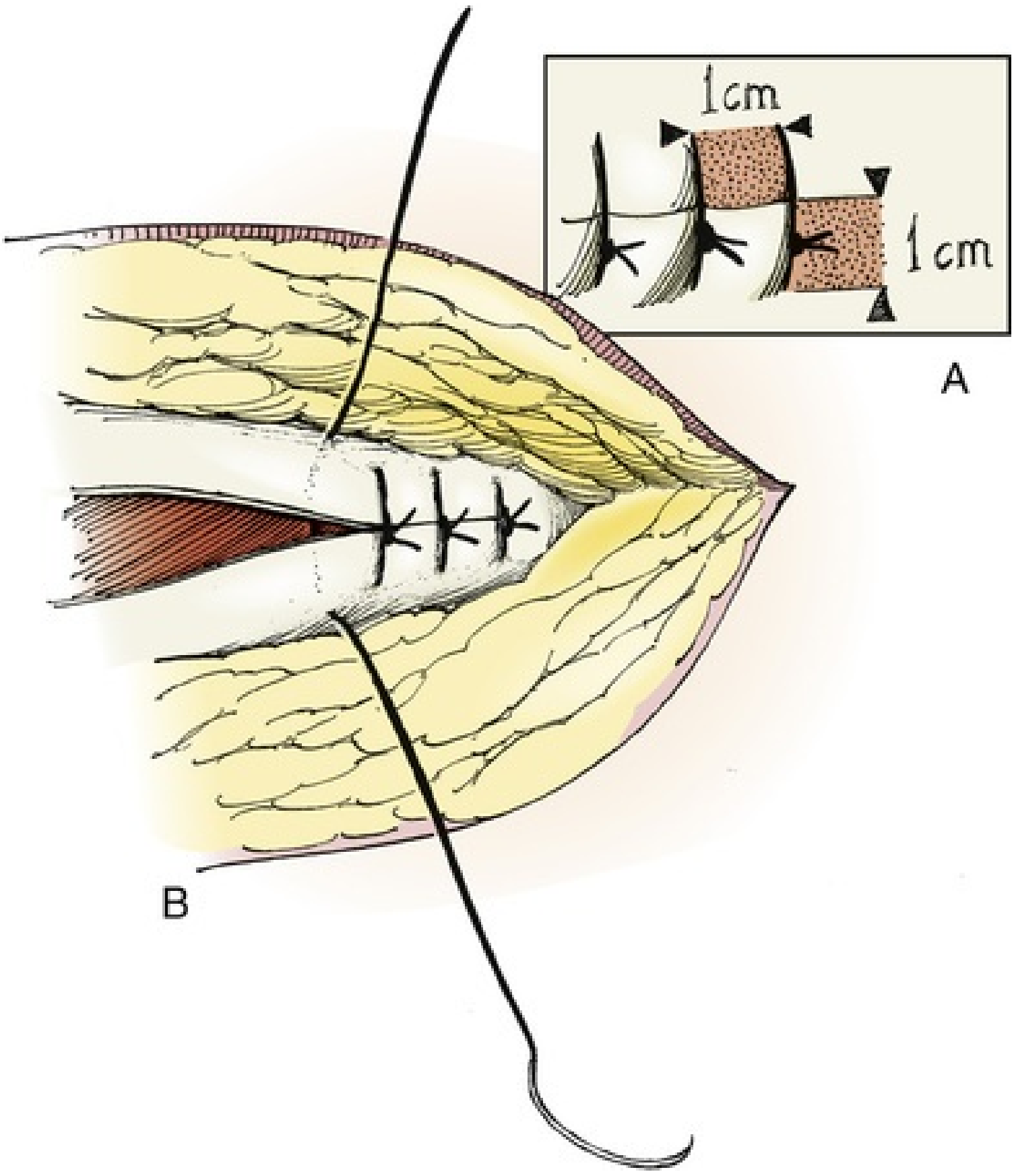

FIG. 9.2 Fascial closure technique. (A and B) Strong fascial closure is important in abdominal incisions. 2-0 non-absorbable sutures are usually

used and should be placed 1 cm from edge and 1 cm apart, as shown here. This can be done in an interrupted fashion (shown here) or running fashion. (From Smith JA Jr, Howards SS, Preminger GM, Dmochowski RR. *Hinman's atlas of urologic surgery,* 4th ed. Philadelphia, PA: Elsevier, 2018; Fig. 2.5AB.)

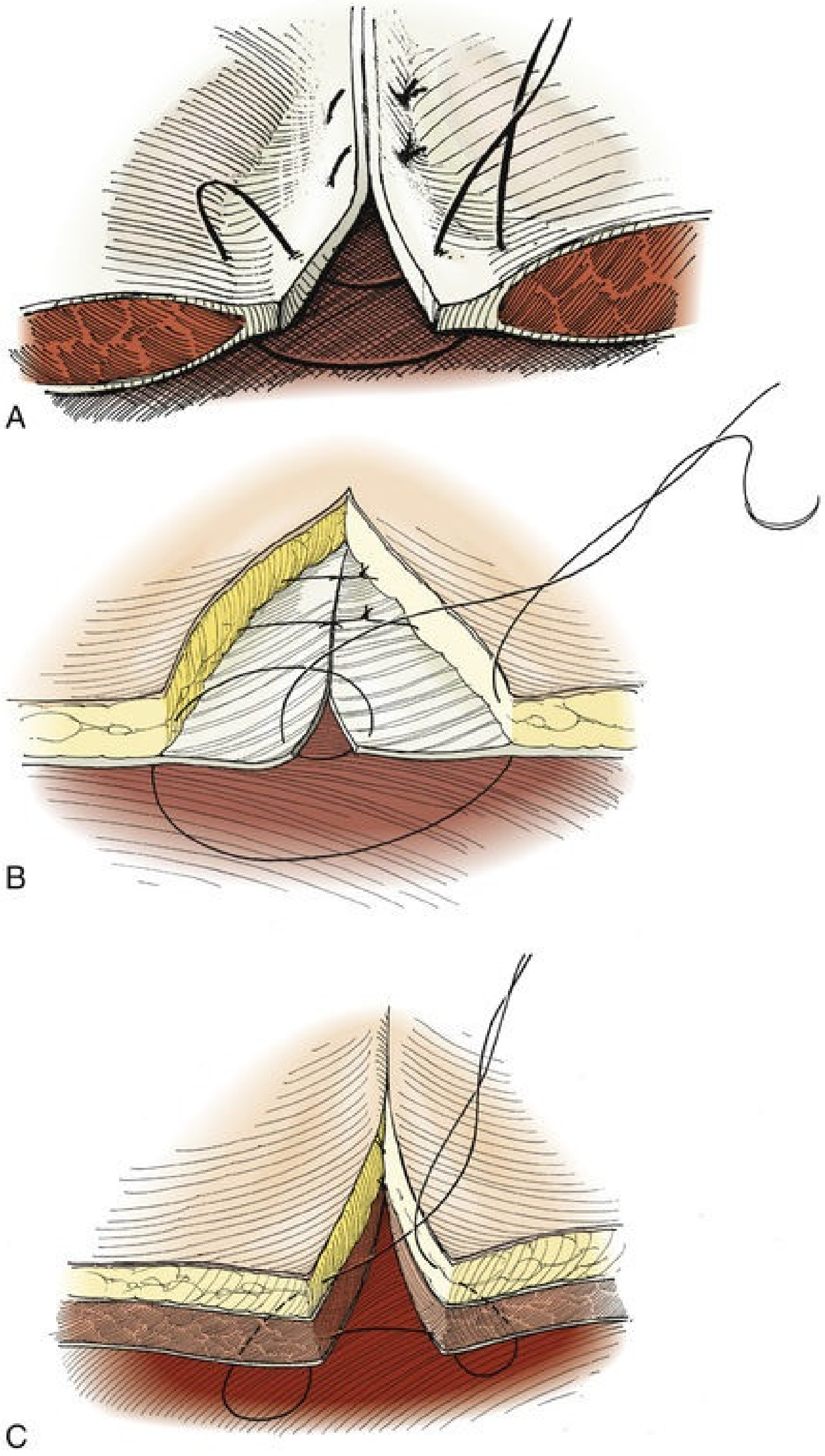

FIG. 9.3 Other fascial closure techniques. Different fascial closure techniques have been described but are less commonly used by urologists. In this figure, we see (A) near-and-far suture for mass closure, (B) Smead-Jones technique in which sutures are 2 cm apart with near and far figure-eight bites, and (C) a Gambee stitch or vertical mattress that incorporates both fascial layers. (From Smith JA Jr, Howards SS, Preminger GM,

Dmochowski RR. *Hinman's atlas of urologic surgery*, 4th ed. Philadelphia, PA: Elsevier, 2018: Fig 2.7A–C.)

Pfannenstiel Incision

This incision is utilized by both adult and pediatric urologists and may be suitable for both extraperitoneal and intraperitoneal pelvic surgeries. It also serves well as a specimen-extraction site postnephrectomy (Matin and Gill, 2003) and may have lower rates of morbidity and incisional hernias than a midline or extension of a port site approach (Binsaleh et al., 2015; Lee et al., 2017).

A transverse semilunar incision is made two fingerbreadths above the pubic bone (Fig. 9.4). The anterior rectus sheath is opened transversely, and the muscle above and below either side of the midline is bluntly separated from the sheath. Using cautery or scissors, the linea alba attachment to the anterior sheath is taken down both inferiorly and superiorly. The midline is then opened to either expand into the extraperitoneal space (Space of Retzius) or enter the peritoneum. The incision can be extended laterally for more exposure and can be extended into a Gibson incision if one needs more access to the lower ureter, for example. For specimen extraction, it can be modified slightly toward the side of surgery (Matin and Gill, 2003). For closure, the peritoneum and muscle are reapproximated, and the fascia is closed with a running or figure-of-eight absorbable suture.

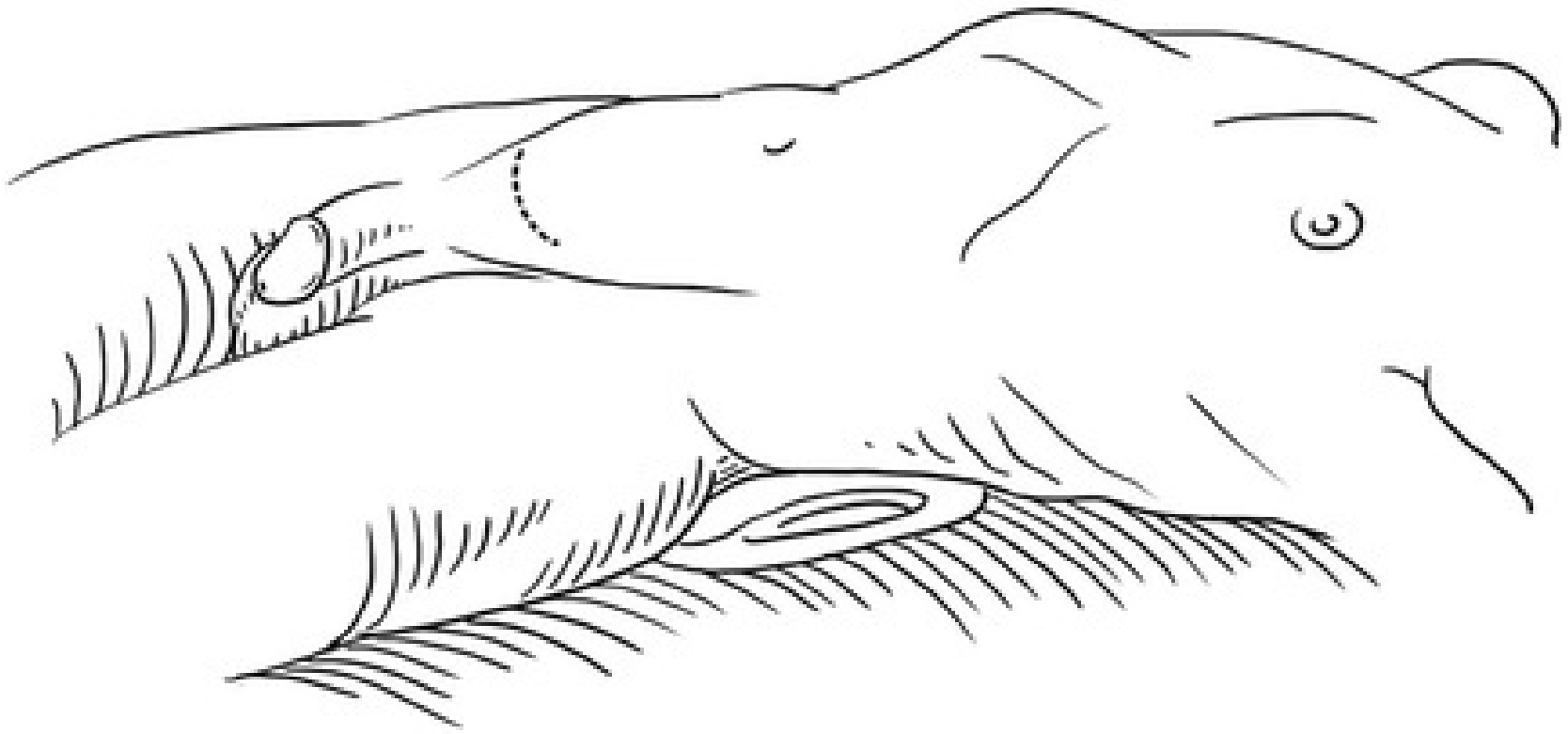

FIG. 9.4 Pfannenstiel incision. A Pfannenstiel is most commonly used by urologists for benign and malignant pelvic organ procedures in pediatric and adult populations. It can also be used for donor nephrectomy and specimen extractions. It heals well cosmetically and has decreased pain

postoperatively because it is a muscle-splitting procedure. (From Smith JA Jr, Howards SS, Preminger GM, Dmochowski RR. *Hinman's atlas of urologic surgery,* 4th ed. Philadelphia, PA: Elsevier, 2018; Fig. 69.1.)

Gibson Incision

The Gibson incision is the traditional approach for renal transplant and transplant nephrectomy (Wagenaar et al., 2017). This muscle-splitting incision provides great extraperitoneal access to pelvic vessels, the lower ureter, and the bladder for benign and malignant disease and is also utilized as part of minimally invasive nephrectomy for specimen extraction or use of a hand port (Yang and Ou, 2012).

The traditional pelvic Gibson incision is an oblique or curvilinear incision from a few centimeters medial to the anterior superior iliac spine (ASIS) extending down toward the inguinal fold and terminating just lateral to the rectus muscle or continued to above the symphysis pubis (Graybar and Tarpey, 1987; Kahan, 2000). Recently, this incision has been modified to be more *J*-shaped or “hockey-stick” shaped (Fig. 9.5), although some retrospective comparisons have found this leads to higher hernia rates (Nanni et al., 2005). The external oblique muscle is split, followed by the internal oblique and transversus abdominus muscles in the same fashion. These can be incised if needed for further exposure. The peritoneum is then identified and mobilized medially to maintain an extraperitoneal approach. The ureter can be then identified crossing the iliac artery. Alternatively, the peritoneum can be opened if this incision is being used for a hand port in a laparoscopic procedure. This incision is usually closed in two layers with running absorbable sutures.

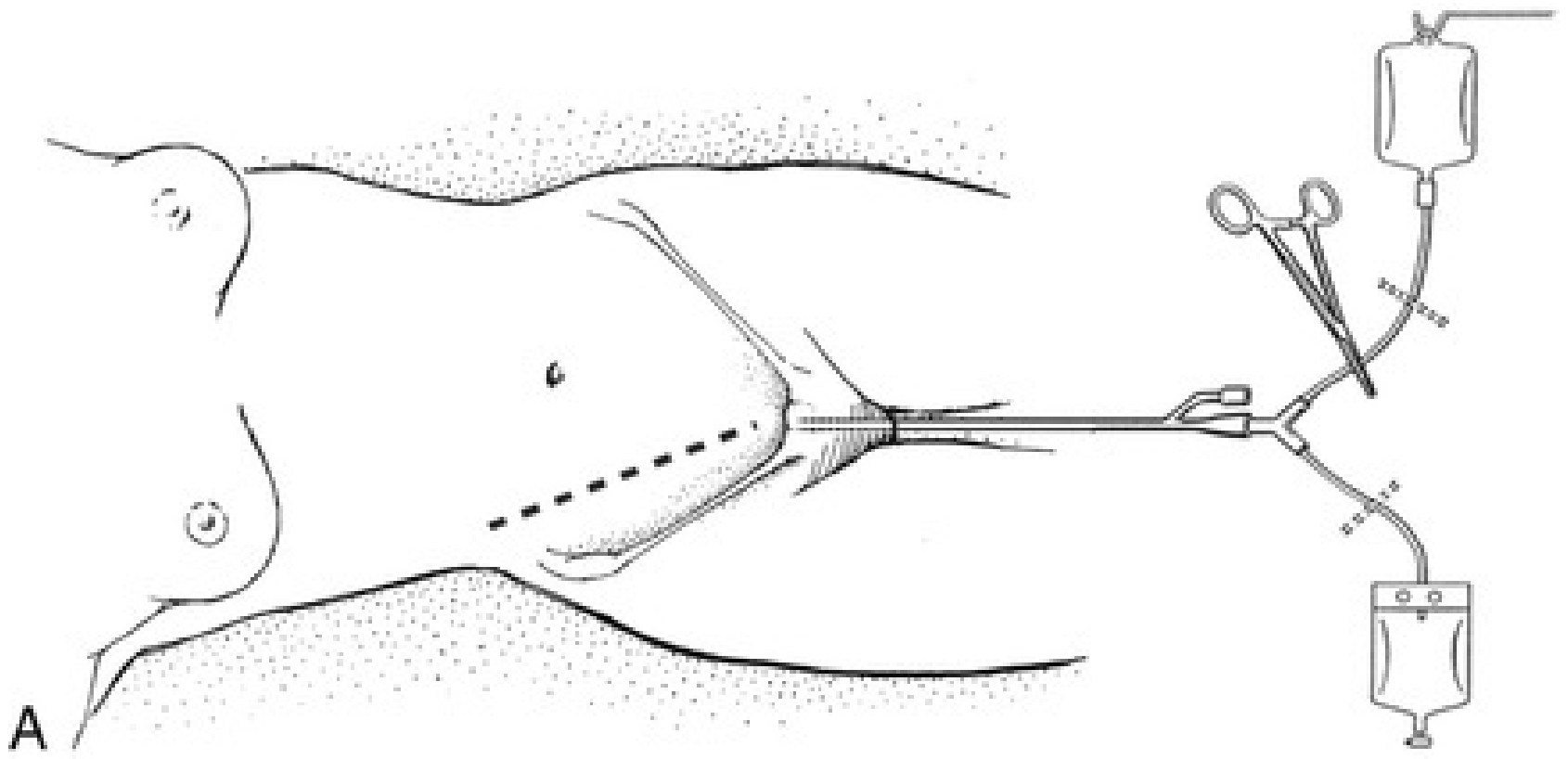

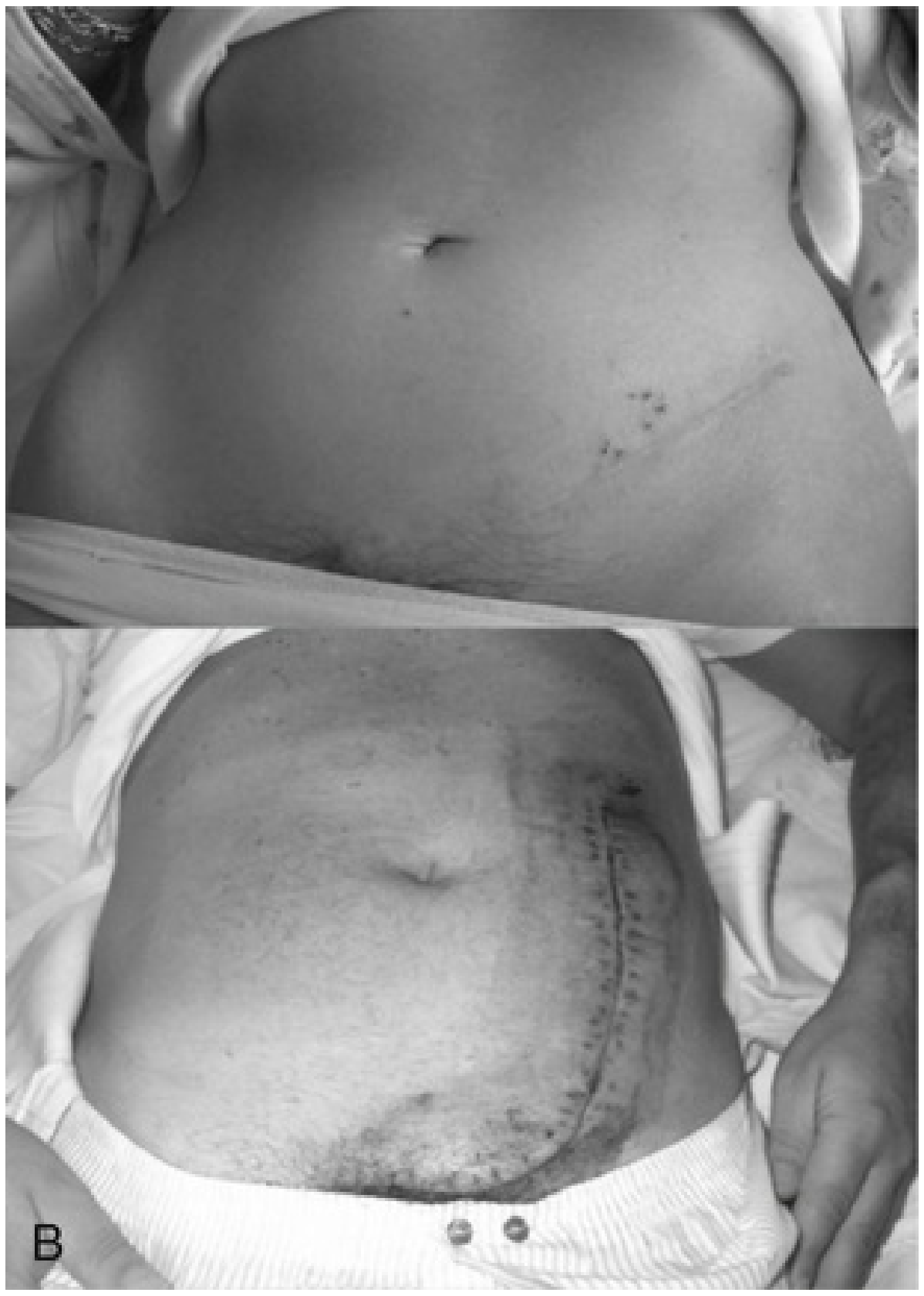

FIG. 9.5 (A) Traditional oblique Gibson incision. The traditional Gibson incision is shown here. This incision is used for renal transplantation and allograft nephrectomy as well as access to the lower ureter and bladder. (B) Traditional oblique Gibson vs. "hockey-stick" incision. The modern Gibson incision has become practically more "*J*-shaped," now also called a "hockey-stick" incision by some. Both incisions serve a similar purpose, with the *J*-incision able to be extended more superiorly if needed. (A, From Smith JA Jr, Howards SS, Preminger GM, Dmochowski RR. *Hinman's atlas of urologic surgery,* 4th ed. Philadelphia, PA: Elsevier, 2018; B, From Nanni G, Tondolo V, Citterio F, et al. Comparison of oblique versus hockey-stick surgical incision for kidney transplantation. *Transplant Proc.* 2005;37(6):2479–2481.)

Anterior Approaches to the Kidney and Retroperitoneum

Fig. 9.6 illustrates various midline and anterior incisions that are discussed in this chapter. These all provide access to the kidney or retroperitoneum with their own advantages and disadvantages (Table 9.1). The decision on which incision to use is based on oncologic and patient factors as well as surgeon preference.

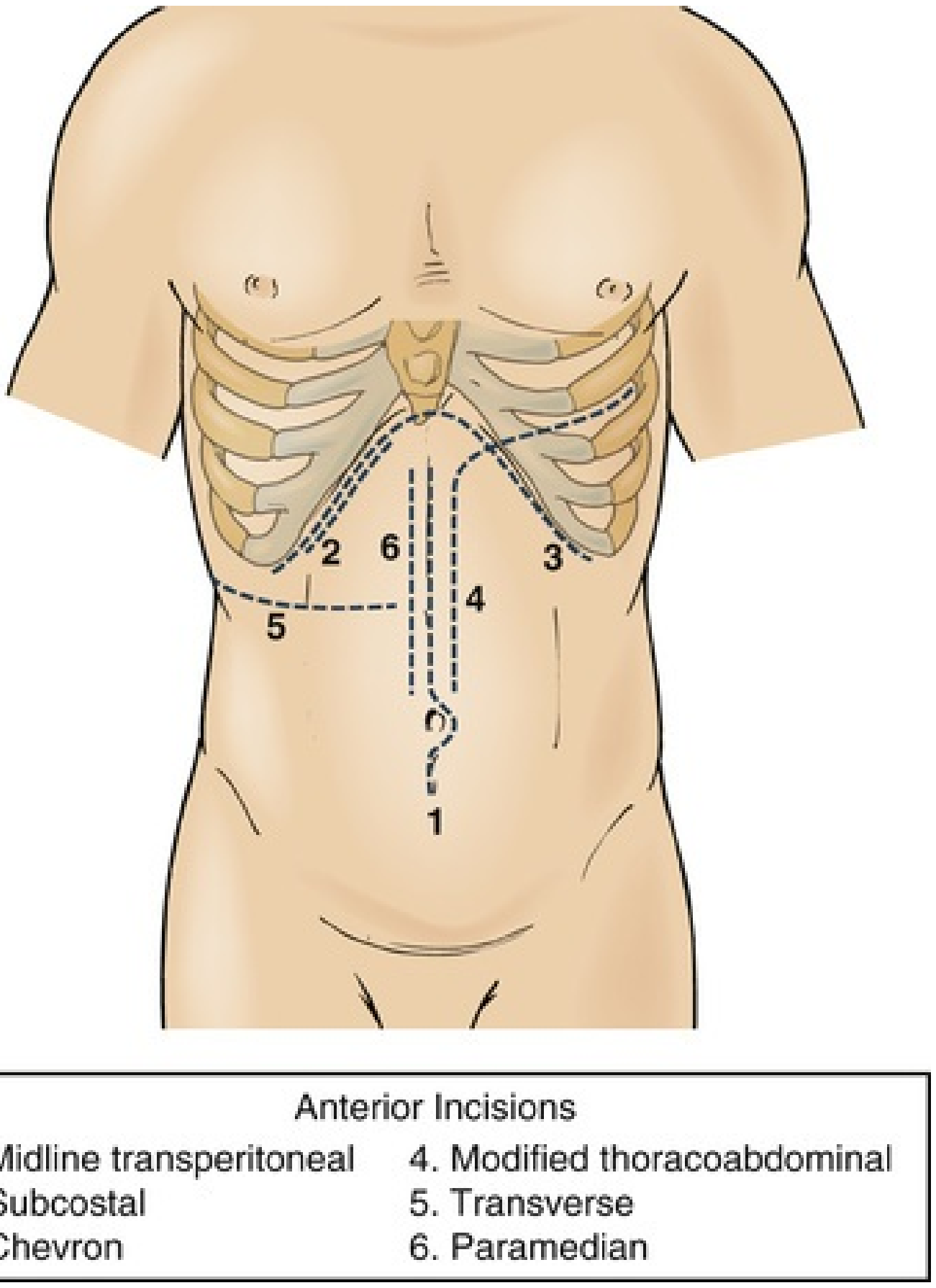
2
6
3
4
5
1
Anterior Incisions
1. Midline transperitoneal
2. Subcostal
3. Chevron
4. Modified thoracoabdominal
5. Transverse
6. Paramedian

FIG. 9.6 Anterior approaches to kidney and retroperitoneum. In a supine position, or modified oblique position, there are multiple approaches to the kidney and retroperitoneum anteriorly. These each have different benefits and disadvantages, which can be found in Table 9.1. (From Smith JA Jr, Howards SS, Preminger GM, Dmochowski RR. *Hinman's atlas of urologic surgery,* 4th ed. Philadelphia, PA: Elsevier, 2018; Fig. 8.4.)

TABLE 9.1

Open Approaches to the Kidney

APPROACH	INCISION	INDICATIONS	BENEFITS	LIMITATION
Anterior	Midline Transperitoneal	Trauma, IVC thrombus, bilateral renal or ureteral disease, horseshoe kidney	Rapid, less painful, can access both kidneys, early vascular control	Limited exposure to the upper retroperitoneu bowel complications, wound complications
	Subcostal	Radical nephrectomy, UPJO	Incision can be extended to chevron or flank, early vascular control	Bowel complications
	Chevron	Bilateral renal tumor, IVC thrombus, polycystic bilateral nephrectomy, local tumor extension or invasion	Excellent bilateral exposure, early vascular control	Injury to liver and spleen, transection of large muscles
	Transverse Abdominal	Pediatric Wilms tumor, pediatric pyeloplasty	Easy access to the renal pedicle and retroperitoneal nodes	Unfamiliar incision in adults
	Paramedian	Avoidance of another structure (e.g., colostomy)	Facilitates development of the preperitoneal space in the extraperitoneal approach	Risks injury to superior epigastric arter thoracic nerve hernia risk
	Modified Thoracoabdominal	Radical nephrectomy, lymphadenectomy, retroperitoneal mass	Versatile, exposure of large upper pole or adrenal masses	Bowel complications, transection of large muscles, painful, wound complication risk

Flank	11th or 12th Rib Supracostal	Partial nephrectomy, simple nephrectomy, simple adrenalectomy	Extraperitoneal with good renal and retroperitoneal exposure; avoids cutting rib	Pleural injury
	11th Rib Transcostal	Partial nephrectomy, simple nephrectomy, simple adrenalectomy	Good renal and retroperitoneal exposure	Pleural injury, flank bulge
	Thoracoabdominal	Large renal mass, IVC thrombus, adrenal mass, involvement of surrounding structures, lymphadenectomy	Excellent exposure, can approach completely extraperitoneally	Pleural injury, transection of large muscles, bowel complications intraperitoneal

IVC, Inferior vena cava; *UPJO,* ureteropelvic junction obstruction.

(Modified from Gregg JR, Scarpato KR. Surgical approaches for open renal surgery, including open radical nephrectomy. In: Smith JA Jr, Howards SS, Preminger GM, Dmochowski RR. *Hinman's atlas of urologic surgery*, 4th ed. Philadelphia, PA: Elsevier, 2018:61–75; Table 8.1.)

The transverse upper abdominal incision (incision 5 in Fig. 9.6) is more commonly used in pediatric renal surgery either for resection (e.g., Wilms tumor) or open reconstruction (e.g., pyeloplasty). Another incision less commonly used in the adult population is the paramedian incision. Although it has been described as an extraperitoneal approach for nephroureterectomy (Tessler et al., 1975) and pediatric bladder augmentation (Talic, 2000), a paramedian incision lateral to the rectus can risk injury to nerves within the rectus and predispose to ventral hernia (Chung et al., 2016), and it is therefore not performed often unless the surgeon would like to avoid entering midline because of a complex abdomen.

Thoracoabdominal Incision

With early incidental detection and nephron-sparing approaches becoming the norm, the indications for a thoracoabdominal incision have decreased. At the cost of a large and more morbid incision, it provides excellent exposure to the adjacent thorax, retroperitoneum, and great vessels, which allows for early vascular control (Buse et al., 2006). It can be utilized for more complex oncologic procedures, such as level III caval thrombus, T4 renal tumors, large upper pole tumors, adrenal tumors, and retroperitoneal masses (Parekh et al., 2005; Cooper et al., 1950). Somewhat contrary to what we believe as surgeons, a study comparing thoracoabdominal incisions with flank incisions found no difference in pain levels when patients were surveyed at different points within the first month of surgery (Kumar et al., 1999).

The patient is placed in an exaggerated flank position with the arm of the side being operated on elevated and secured to a mayo stand or trapeze. The incision is usually made above the 9th to 10th rib bed depending on the pathology, either supracostal or removing a section of rib and extended onto the abdomen. It can be extended to the midline in continuity if needed. Alternatively, a modified thoracoabdominal incision can be done by performing the thoracotomy through the 8th rib bed and combining a subcostal incision with the standard longitudinal abdominal incision (Merrill, 1977). The muscles are incised and the pleura opened with care not to injure the underlying lung. The diaphragm can then be opened to conjoin the thoracic and abdominal cavities and the costochondral junction cut (Chute et al., 1949).

The chest incision is closed after placement of a chest tube encompassing all the layers and reapproximating the cut edges of the costal cartilage, although some advocate that a chest tube can be omitted if there is no parietal pleural injury (Rosser et al., 2000). As part of this closure, the diaphragmatic incision is also closed in two layers with a running absorbable suture. Use of a nonabsorbable mesh (Marlex) with anchoring figure-of-eight sutures has been described to decrease costochondral displacement and discomfort (Stein and Skinner, 2002), although we have not adopted this in our practice. The abdominal wall is then closed.

Chevron and Subcostal Incisions

Use of a subcostal transperitoneal approach to the kidney can be utilized for addressing kidney masses with associated caval thrombus (Parekh et al., 2005). Alternatively, a supine subcostal incision may be used to address larger, more anterior tumors where access to the hilum may be better controlled than via a flank subcostal approach (Caraballo et al., 2018). A subcostal incision may be extended at the midline toward the xiphoid for better exposure of the suprahepatic vena cava or extended to incorporate a sternotomy if the thrombus has extended to the heart (Wotkowicz et al., 2006). This can further be extended across the midline as a full-chevron incision when a larger area of exposure is needed, such as with a caval thrombus extending from the left kidney or locally invading tumors (Pouliot et al., 2010) (Fig. 9.7).

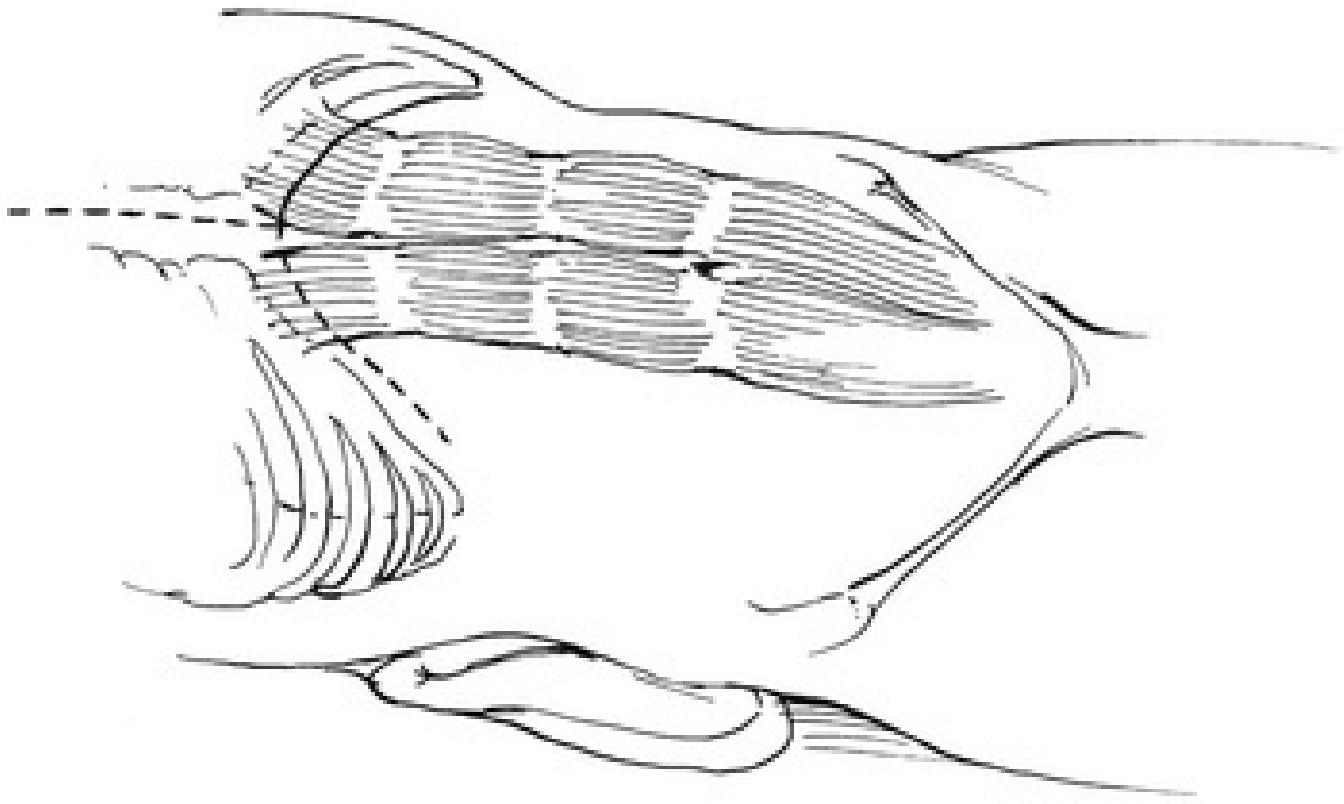

FIG. 9.7 Subcostal incision and extensions. The subcostal incision *(bold black line)* is shown on the left side. It can be used for renal access in the supine or flank position. *Dashed lines* represent possible extension across the midline to a "three-quarters" incision or complete subcostal "Chevron" incision. Further extension to include a sternotomy (shown with *dashed lines* as well) is rarely ever used by urologists. (From Smith JA Jr, Howards SS, Preminger GM, Dmochowski RR. *Hinman's atlas of urologic surgery,* 4th ed. Philadelphia, PA: Elsevier, 2018; Fig. 8.8.)

The patient may be in the supine or modified flank position. The incision is generally made from the midline two fingerbreadths below the costal margin extending laterally as far as the tip of the 11th rib. The anterior rectus sheath is incised, and the muscle is cut with electrocautery, while laterally the muscle layers are divided in sequence. This may be both an extraperitoneal or intraperitoneal incision, though generally the exposure is better with the latter. The retroperitoneum is exposed by incising along the white line of Toldt up to either the hepatic or splenic flexure and mobilizing the colon medially (Gregg and Scarpato, 2018). A self-retaining retractor such as a Bookwalter can be used to facilitate retraction and exposure, with care not to injure the liver or spleen. These incisions are closed in two layers with running absorbable sutures.

Flank Incisions

There are multiple flank and modified flank incisions used by urologists (Novick et al., 1998). Although careful technique can avoid the long-term complications and the postoperative pain traditionally associated with these incisions, they often still involve incision of muscles and/or removal of parts of ribs. Interestingly, some older comparisons have not shown them to be more painful than the thoracoabdominal approach (Kumar et al., 1999). Subsequently, in the era of minimally invasive surgery, they are commonly reserved for larger or complex oncologic resections. Based on surgeon skill and preference, these are still used around the world for benign renal surgery as well, including donor nephrectomy and simple nephrectomy for xanthogranulomatous pyelonephritis (XGP).

These incisions require dissection through three muscle/fascial layers: external oblique, internal oblique, and transversalis muscles. Muscle fibers are usually separated with electrosurgical cautery.

True Flank Incisions

Flank incisions are usually performed with the patient in the flank position, which is a lateral recumbent position with the lower leg flexed and upper leg extended, creating a convex extension of the upper side (operative side) of the body. The area of incision is placed over the break in the table to better “open” this area. Based on the target location and size of the renal or retroperitoneal mass, the traditional flank incision can be either 12th rib supracostal, 11th rib transcostal, or subcostal (Fig. 9.8). One usually begins anterior to the 12th rib laterally until no further than the medial edge of the rectus muscle medially (Gregg and Scarpato, 2018).

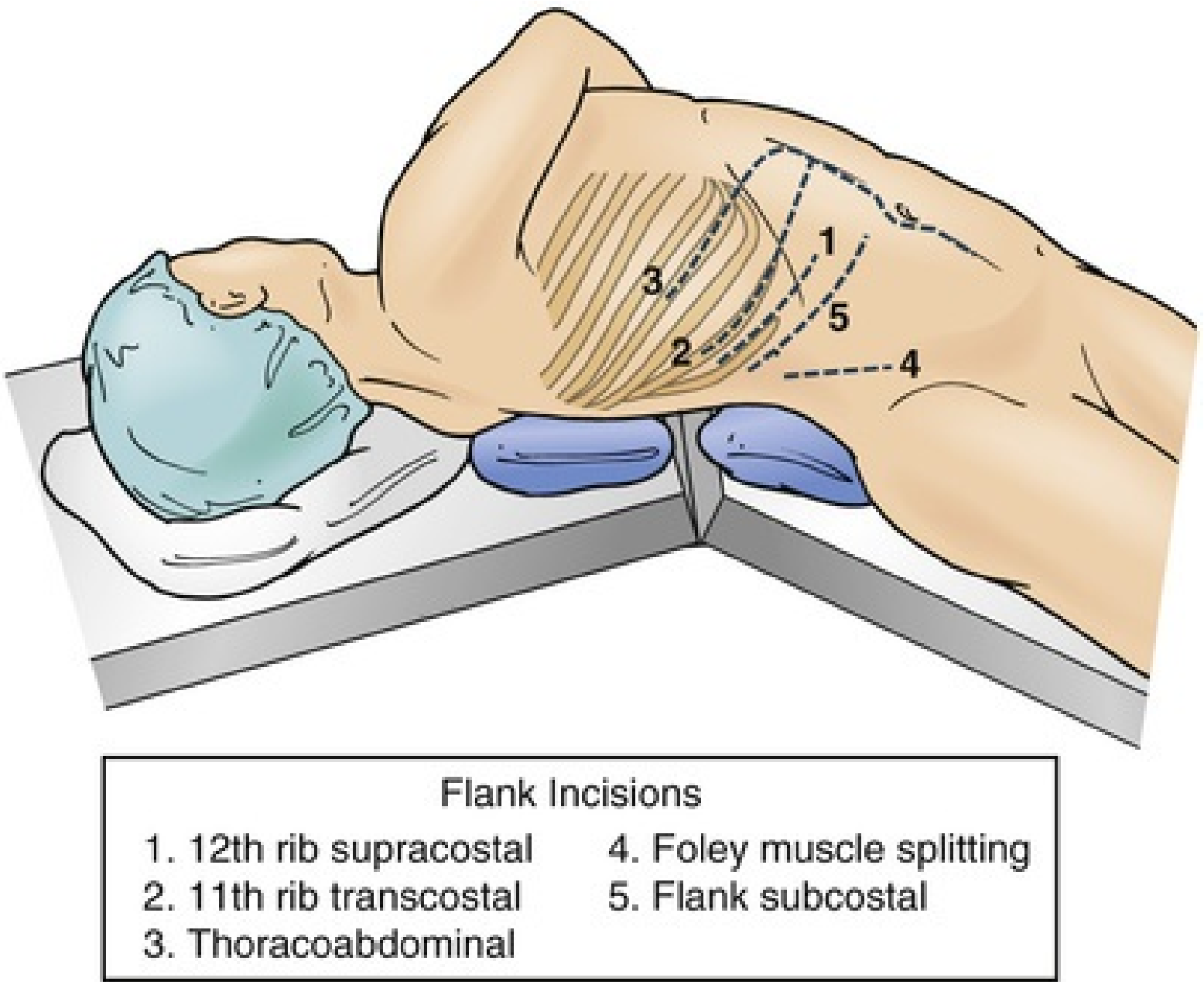

FIG. 9.8 Flank incisions for renal and retroperitoneal access. Commonly used incisions for renal and retroperitoneal access in the flank position. These incisions can be used for benign and malignant conditions. (From Smith JA Jr, Howards SS, Preminger GM, Dmochowski RR. *Hinman's atlas of urologic surgery,* 4th ed. Philadelphia, PA: Elsevier, 2018; Fig. 8.5.)

12th Rib Supracostal and 11th Rib Transcostal

These are the traditional flank incisions that often require taking the tip of the ribs using a rib cutter. They allow for more comfortable retroperitoneal access posteriorly, therefore decreasing the risk for associated bowel complications. However, they inherently increase the risk for thoracic complications including pleural injuries. Given the resection of the tip of the rib, patients will often have significant postoperative pain and a risk for a flank bulge if one goes as high as the 11th rib (Gregg and Scarpato, 2018).

The skin is incised over the rib and extended medially. Using electrocautery, the external oblique and latissimus dorsi are incised, centered over the rib to be extended past the tip of the rib onto the abdominal wall. Using a periosteal elevator, the muscle and the periosteum are stripped from the rib anteriorly and along the superior and inferior edges; a Doyen rib stripper is then passed posteriorly to free the rib, which can then be excised using a rib cutter. Sharp edges can be blunted with a the rib cutter or heavy scissors and sealed with bone wax. The rib bed is then divided, followed by the lumbodorsal fascia, and the pleura can then be identified by having the anesthesiologist give a series of larger-volume breaths. The retroperitoneum is then entered as posterior as possible with the peritoneum bluntly pushed medially as the remaining muscle layers are opened. The neurovascular bundle from either rib should be identified between the second and third layers and dissected free if possible. Retractors can then be placed.

The incision is traditionally closed in two layers with a running absorbable suture. In the event of a pleural injury, a red rubber catheter is placed through the injury, which is closed with a running absorbable suture. The diaphragmatic muscle layers are then closed. The catheter is placed in a bowl of water, and the anesthesiologist gives a series of high-volume breaths to force the air out of the pleural space. Once there are no more air bubbles, the red rubber tube is slowly removed. In the instance of a larger injury, a formal chest tube can be placed. A chest radiograph should be obtained postoperatively if a pleural tear was recognized and repaired, however it is not needed after every open nephrectomy as yield for pneumothorax is very low without clinical suspicion (Latchamsetty et al., 2005).

Alternatively, the incision can be made above the 11th rib or between the 11th and 12th ribs (Diblasio et al., 2006) and not excise the rib at all. This would avoid the complications and pain associated with rib resection and still allow for adequate exposure to the kidney and hilum (Fig. 9.9) (Gregg and Scarpato, 2018).

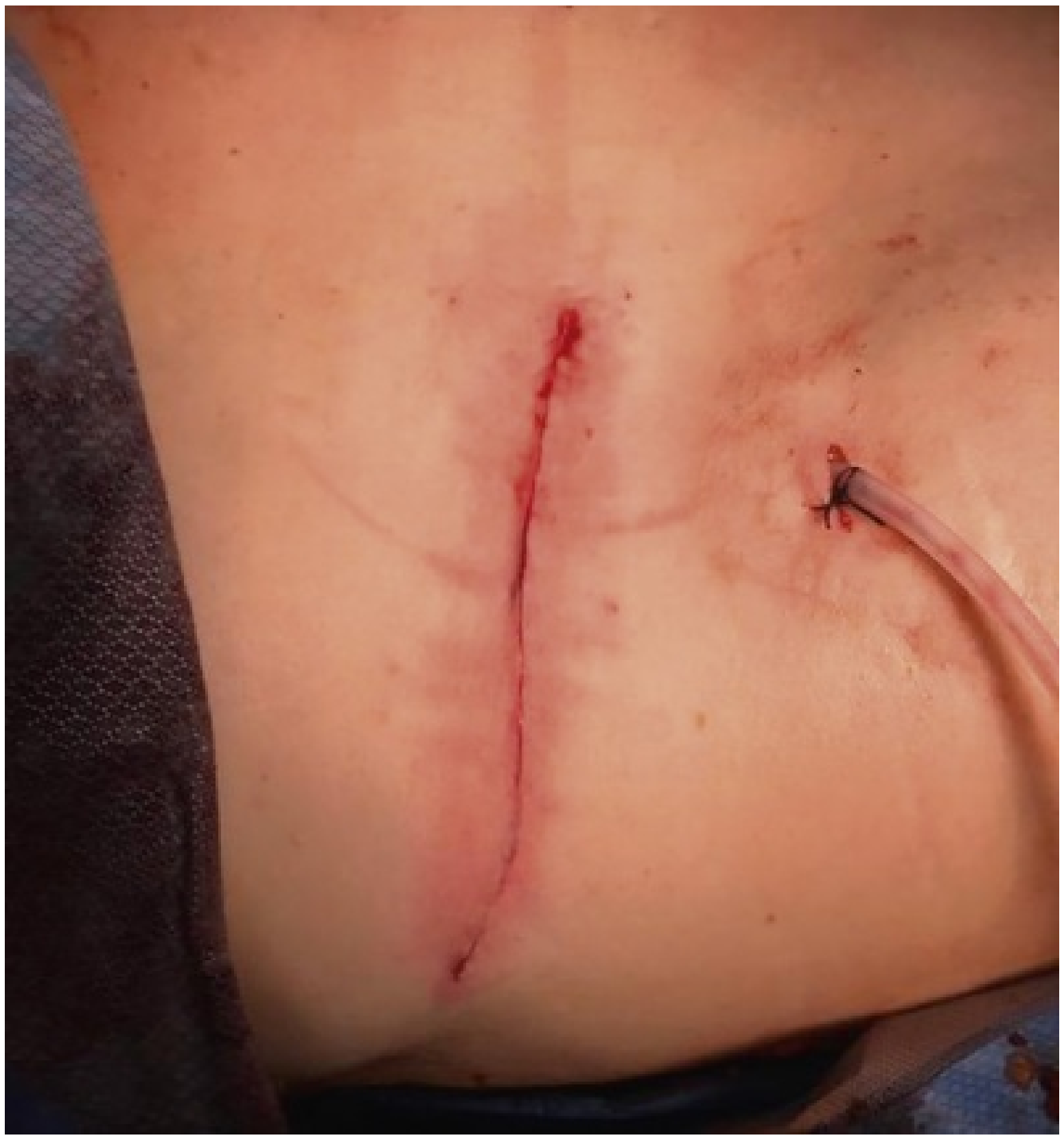

FIG. 9.9 Infra–11th rib incision with drain placement. This patient had a large right renal mass and our flank incision below the 11th rib. Use of a drain is not often required except when intra-operative findings mandate drainage of the nephrectomy site. Common scenarios would include partial nephrectomies or simple nephrectomies for XGP. By going supracostal (between 12th and 11th ribs), one can avoid cutting the rib tips and remain extraperitoneal.

Inguinal Incisions

There are multiple indications for utilizing inguinal incisions in both pediatric and adult patients. These procedures usually require access to the spermatic cord whether for the management of cryptorchidism and synchronous hernia repair or oncologic procedures such as partial or radical orchiectomy (Rice et al., 2016).

Incisions Above the Inguinal Ligament

The inguinal incision (Fig. 9.10) is used most commonly for radical orchiectomy in the adult population. A 5- to 7-cm curvilinear or transverse incision is made beginning 2 cm cephalad and lateral to the pubic tubercle. The angle can be made more oblique and extended toward the scrotum for larger scrotal masses.

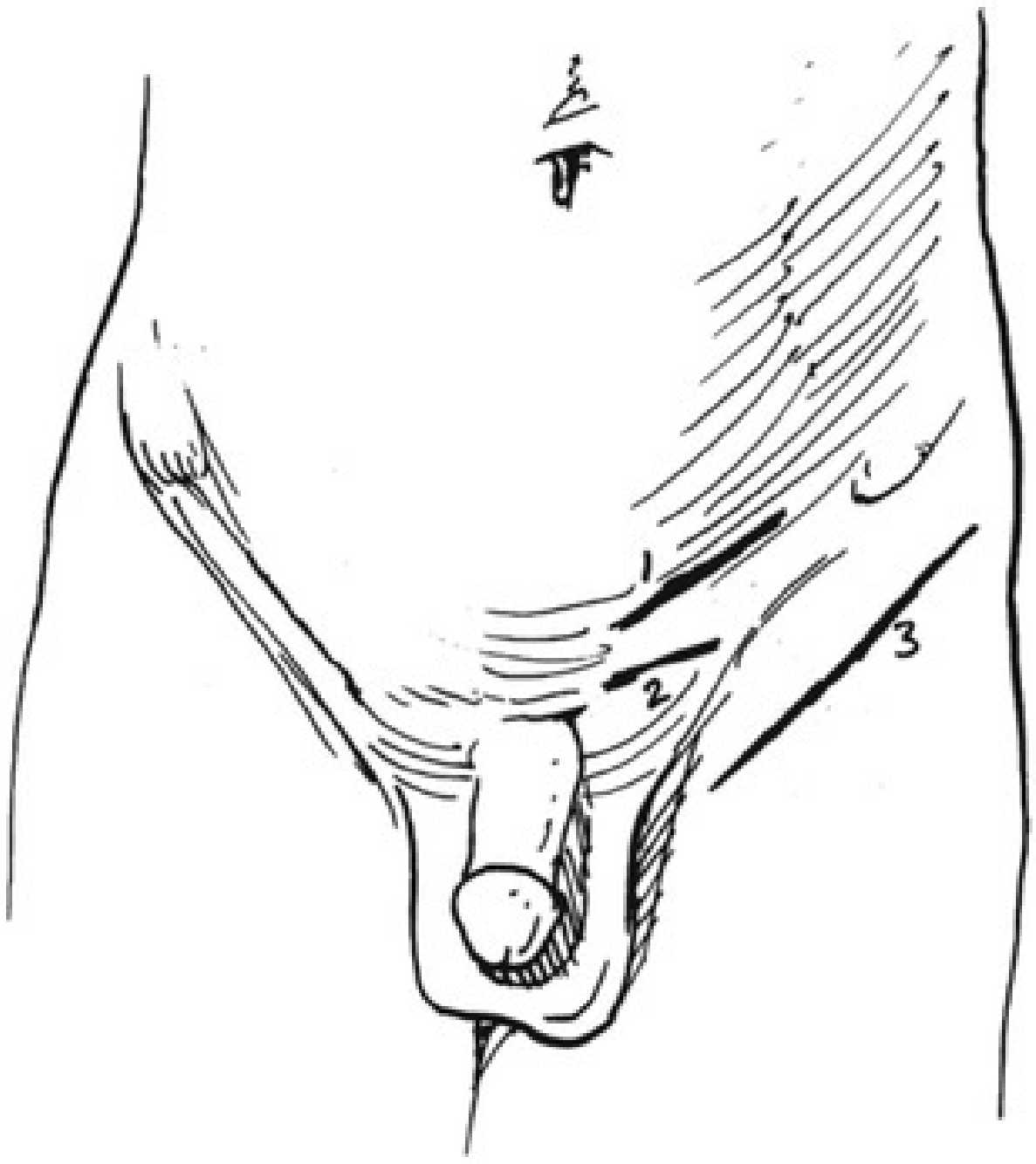

FIG. 9.10 Inguinal incisions. Incision 1: Curvilinear incision for radical orchiectomy and suspected malignancies. Incision 2: Inguinal incision above external inguinal ring for cryptorchidism or inguinal approach to varicocelectomy. Incision 3: Subinguinal incision for inguinal lymphadenectomy for penile cancer. (Modified from Smith JA Jr, Howards SS, Preminger GM, Dmochowski RR. *Hinman's atlas of urologic surgery,* 4th ed. Philadelphia, PA: Elsevier, 2018; Fig. 117.1.)

A similar incision can be used for inguinal varicocelectomies (especially in prepubertal children) and exploration for cryptorchidism (orchidopexy and hernia repair). For benign disease, the incision is usually smaller (2 to 3 cm) and begins two fingerbreadths above the symphysis pubis starting at the lateral aspect of the scrotum obliquely along the course of the inguinal canal. The goal in these benign operations is to enter just below the external inguinal ring, which can often be palpated externally in thinner patients and children (Marmar et al., 1985). A subinguinal approach can used in obese men or those with prior inguinal surgeries (Goldstein, 2016).

For incisions above the inguinal ligament, careful dissection is essential to avoid injury to the ilioinguinal nerve and spermatic cord structures (Goldstein, 2016). When closing these incisions, the internal and external oblique muscles should be reapproximated to close the inguinal canal and create a new external ring. One must be careful not to make the closure too tight, especially at the external ring, to ensure cord structures are not compromised (Turek, 2018).

Incisions for Inguinal and/or Pelvic Lymphadenectomy in Penile Cancer

Multiple incisions have been described for this purpose (Fig. 9.11). Extent of positive disease or desired dissection will determine which incision is performed. They can be used unilaterally for an extended or modified inguinal lymphadenectomy. The standard is a much larger incision and is associated with significant complications, including wound infection and lymphoceles (Protzel et al., 2009). Although other incisions are used for inguinal and pelvic lymphadenectomies (Gibson, *S*-shaped, *T*-shaped, elliptical), the basic subinguinal incision parallel to the inguinal ligament (Fig. 9.12) is most common and is used exclusively in urology for lymph node dissection and extensive penile cancer metastasis (Horenblas, 2001; Loughlin, 2006).

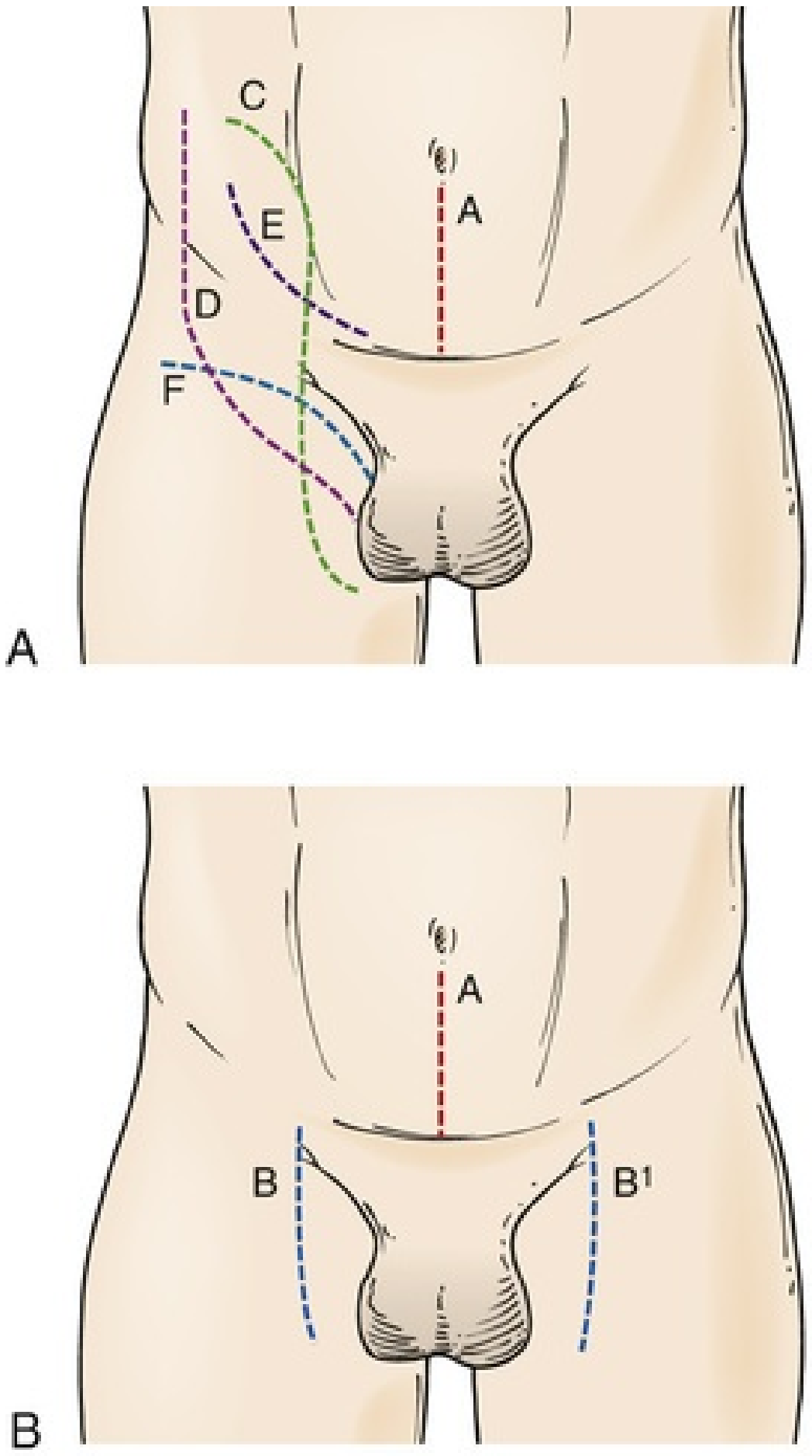

FIG. 9.11 (A) Various incisions described for ILND/PLND in penile cancer. *A*, Midline incision for bilateral PLND. *B*, Vertical incision allowing for access to superficial and deep ILND. *C, S*-shaped incision described for access to complete ILND and ipsilateral pelvic nodes. *D*, *L*-shaped incision for palpable disease, similar access to *C*. *E*, Gibson incision for ipsilateral pelvic node access. *F*, Common subinguinal incision for ipsilateral nodes. (B) Another approach for bilateral complete inguinal and pelvic lymphadenectomy. (Modified from Loughlin KR. Surgical atlas. Surgical management of penile carcinoma: the inguinal nodes. *BJU Int*. 2006;97(5):1125–1134.)

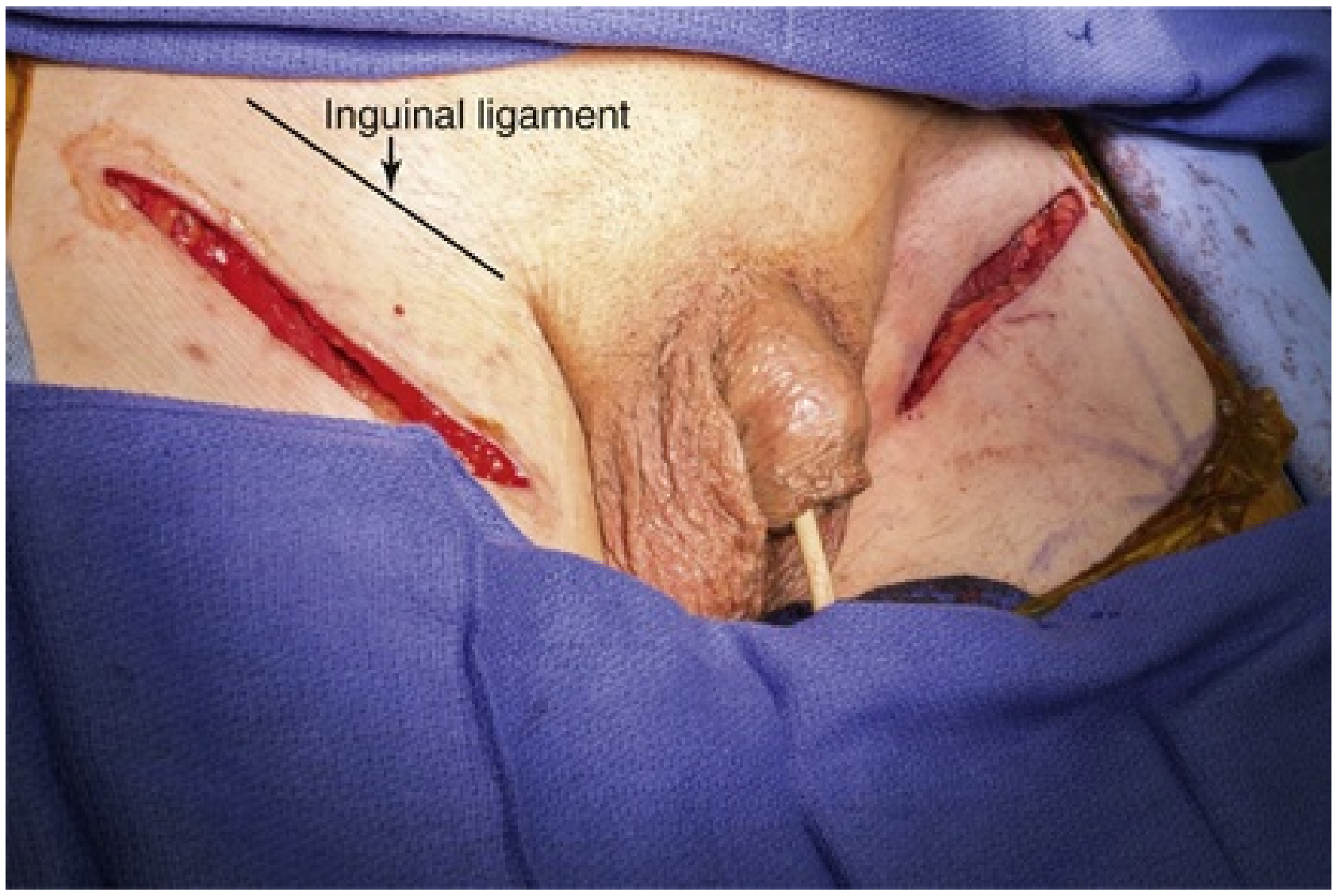

FIG. 9.12 Bilateral ilioinguinal lymph node dissection through subinguinal incision. This is the most common approach to an ilioinguinal lymph node dissection for penile cancer as it allows for a modified or complete lymphadenectomy. (From Smith JA Jr, Howards SS, Preminger GM, Dmochowski RR. *Hinman's atlas of urologic surgery,* 4th ed. Philadelphia, PA: Elsevier, 2018; Fig. 133.3.)

Typically, the skin is incised obliquely from the ASIS to the pubic tubercle 2 cm below the inguinal ligmanet parallel to the groin crease. The incision can be made elliptical if there is palpable or extensive disease superficially. Subcutaneous flaps are then developed below Scarpa's fascia to allow for the dissection of all the nodes in the region. Depending on the extent of disease and resection, closure may require a myocutaneous flap. The dissection and creation of flap are beyond the scope of this chapter. Fig. 9.12 shows bilateral inguinal node dissection incisions.

Incisions for Specific Surgeries

Posterior Lumbodorsal Incision or Dorsal Lumbotomy

Traditionally, the lumbodorsal approach to the kidney was used as it had multiple benefits over the flank incision (lack of muscle or rib distortion) and the anterior transabdominal approaches (faster convalescence and decreased intraperitoneal complications). Simon performed the first planned nephrectomy through this incision in 1870 (Hudnall et al., 1988).

Prior to the adoption of minimally invasive approaches, this incision allowed for good exposure, less postoperative pain, decreased hospitalization, more rapid convalescence, and ease of closure—advantages now boasted by laparoscopy and robotic surgery. The major disadvantages were the limited surgical exposure, which resulted in difficult access for vascular control of the kidney. Classically this incision was used for benign surgeries in adult and pediatric populations such as open upper tract urolithiasis, open renal biopsy, and pre-transplant nephrectomies. In modern times, this incision is mostly used for pediatric (Kumar and Smith, 1999) and sometimes adult (Troxel et al., 2006) pyeloplasty, although some advocate it is underutilized and can be modified for complex benign renal, adrenal, and renovascular surgery (Wollin and Menon, 1991). The incision itself is muscle sparing and has minimal risk for complications. Traditional contraindications to this incision included malrotation of the kidney, renal fusion abnormalities, severe spinothoracic deformities, and malignancy (Wollin and Menon, 1991). However, with recent emphasis on nephron-sparing surgery for renal masses, some groups have explored this incision for partial nephrectomies, boasting shorter operative times and reasonable surgical success, although oncologic outcomes were not assessed (Tennyson et al., 2016).

The lumbodorsal region is bordered between the 12th rib superiorly, iliac crest inferiorly, spinous processes of the vertebral column medially and laterally to an imaginary line between the ASIS and the costal margin (Wollin and Menon, 1991). Appropriate positioning for this procedure is essential with a laterolateral axis of 45 degrees and muscles relaxed to allow for easier retraction (Fig. 9.13).

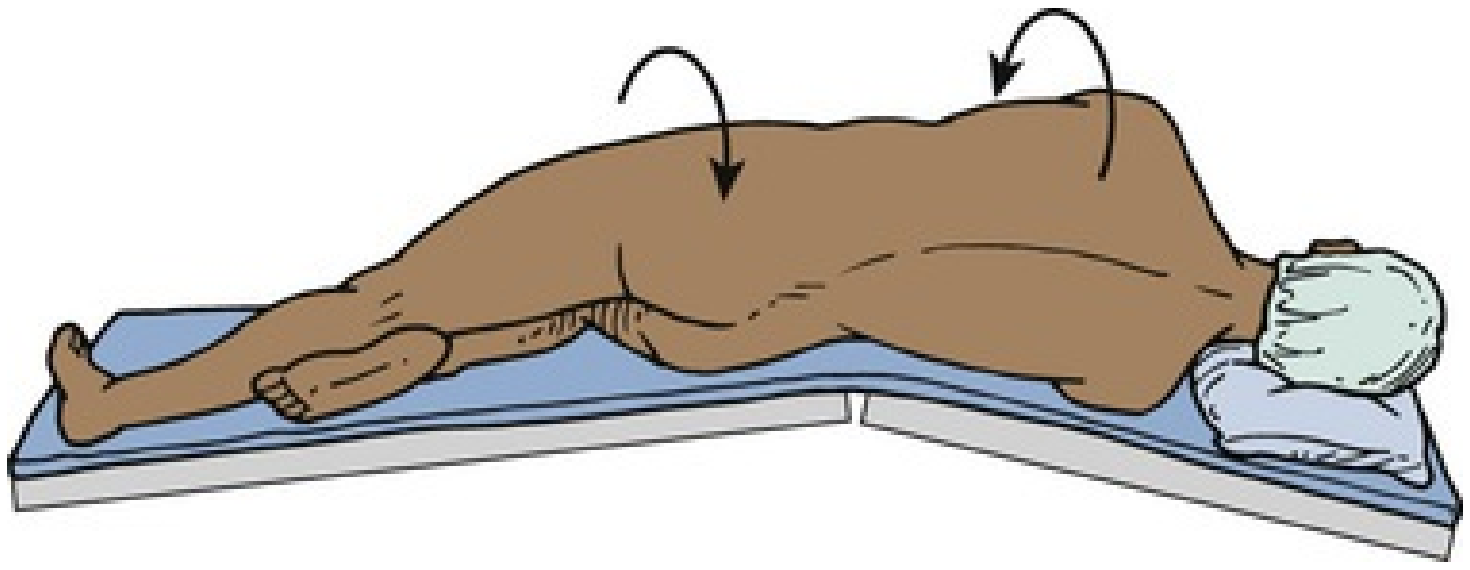

FIG. 9.13 Positioning for dorsal lumbotomy position. The position of the patient on the operating table is important and is characterized by three main features. The laterolateral axis makes a 45-degree angle with the operating table. It is not necessary for the table to be bent too much because the muscles do not need to be stretched; on the contrary, it is better if they are relaxed to allow easier retraction. The thorax is turned ventrally and the pelvis dorsally to allow a better opening of the dorsolumbar space. The legs and the upper arm are positioned as usual for a flank incision. (Modified from Pansadoro V. Surgery illustrated: Surgical atlas: The posterior lumbotomy. *BJU Int.* 2005;95[7]:1121–1131.)

Multiple incisions have been described (Hudnall et al., 1988; Pansadoro, 2005). The general approach is to start two to three fingerbreadths lateral to the spine with a 3- to 5-cm incision starting at the costovertebral angle or as high as the 11th rib. The incision is made directly over the quadratus lumborum muscle over the lateral part of the sacrospinalis muscle slightly obliquely toward the iliac crest or sacroiliac joint (Fig. 9.14). The superficial muscles encountered are the sacrospinalis (medially), latissimus dorsi (posteriorly), and external oblique (anteriorly). The incision is deepened through the lumbodorsal fascia, where the sacrospinalis muscle is encountered, and a “Y” should be made around it. This incision can be extended by transsecting the costovertebral ligament, mobilizing the 12th rib, and removing a 2-cm section of the 12th rib as needed.

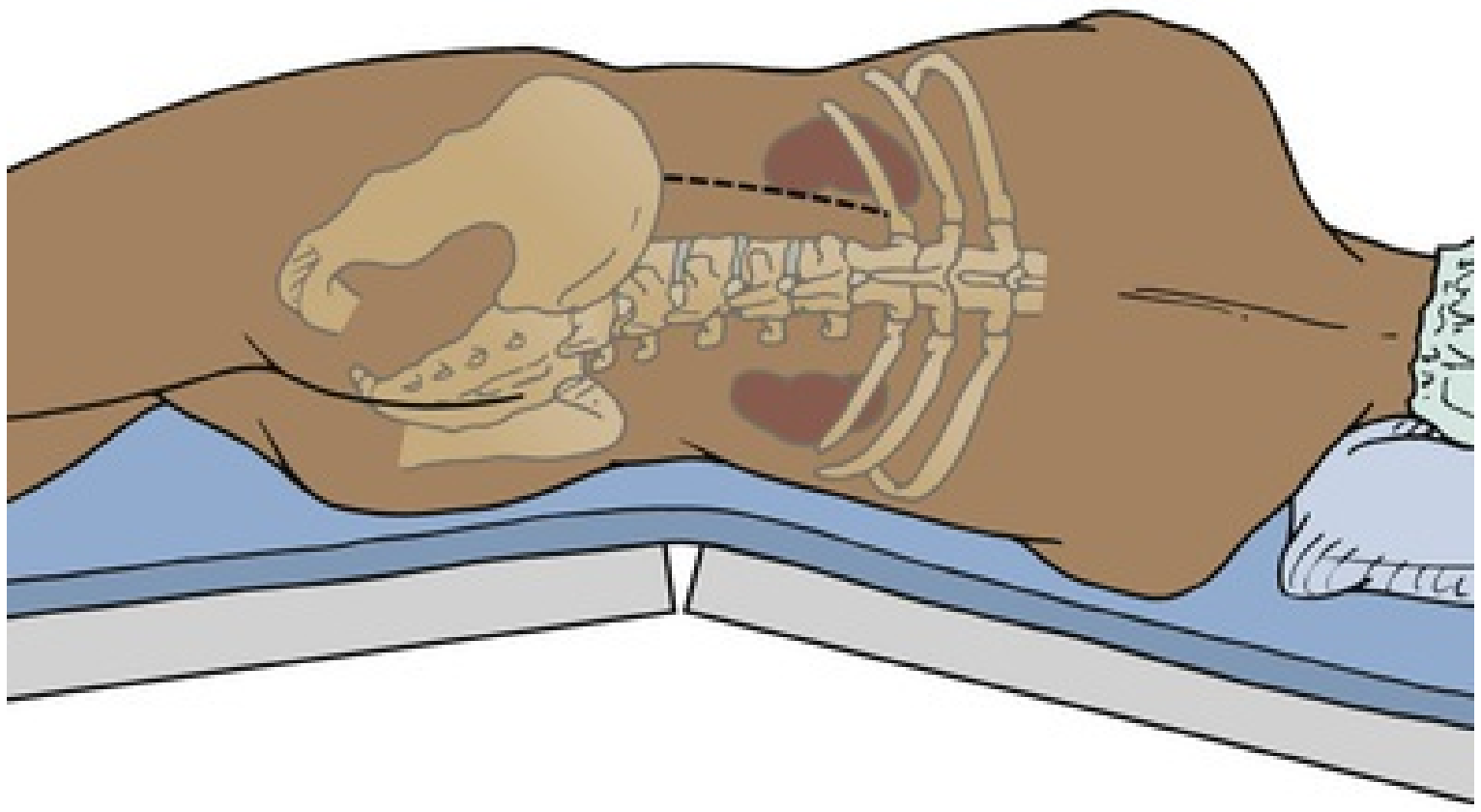

FIG. 9.14 Lumbodorsal incision. Once the iliac crest, the 12th rib, and the spinal processes have been located, the sacrospinalis muscle can be identified easily and the surgeon can then locate the quadratus lumborum. This muscle goes from the medial part of the 12th rib to the middle third of the iliac crest; its upper third is under the sacrospinalis muscle. The skin incision is made over the quadratus lumborum muscle and begins at the costovertebral angle, over the lateral part of the sacrospinalis muscle, and with a slightly oblique course extends down to the iliac crest, 3 to 5 cm in front of the anterior margin of the sacrospinalis muscle. (Modified from Pansadoro V. Surgery illustrated: Surgical atlas: The posterior lumbotomy. *BJU Int.* 2005;95[7]:1121–1131.)

Although largely replaced by abdominal or flank approaches, the posterior lumbodorsal approach to the adrenal glands can also be achieved in a similar fashion in a prone position. These can be used for bilateral extraperitoneal access to the adrenal glands (Young, 1936) or unilateral access through an incision over the 12th rib, the 11th rib, or the classic lumbodorsal incision (Vaughan and Phillips, 1987; Vaughan, 1991) (Fig. 9.15).

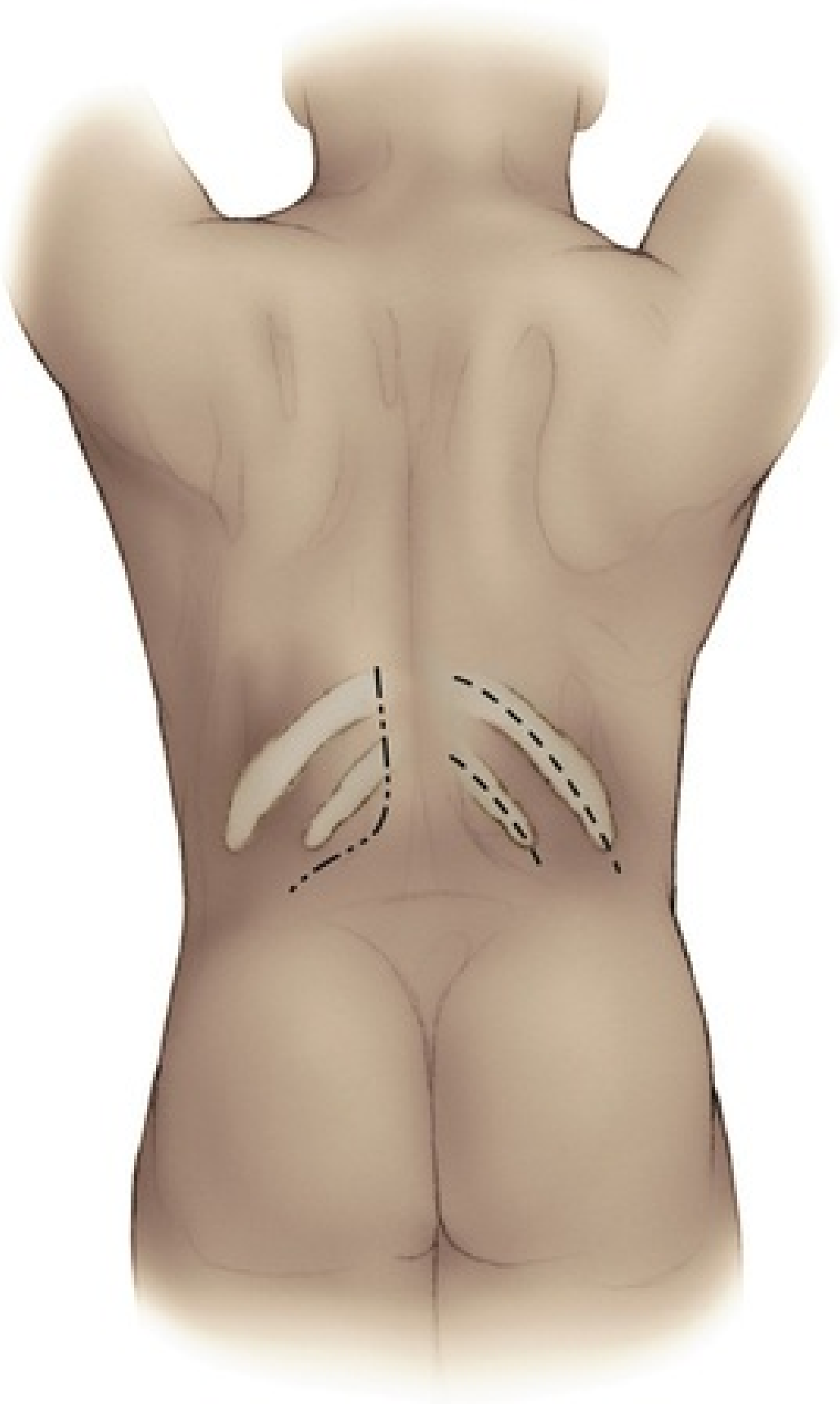

FIG. 9.15 Unilateral or bilateral posterior lumbodorsal incisions. These incisions can be performed in a prone position to access the adrenal glands unilaterally or bilaterally.

Scrotal Incisions

There are various approaches to scrotal procedures. Scrotal skin is quite elastic, and incisions are easy to close. The only contraindication to a scrotal incision is presumed testicular or intrascrotal malignancy, which should be approached through an inguinal incision (Rice et al., 2016). Depending on the indication, a unilateral incision can be used in a transverse or vertical approach on the ipsilateral side. If there is desire to operate on both sides of the scrotum, then a midline vertical incision is made in the median raphe. Common indications include varicocelectomy, hydrocelectomy, spermatocelectomy, vasectomy, scrotal exploration for testicular torsion, and orchidopexy (Dayanç et al., 2004). One can also reach the base of the penis to insert an inflatable penile prosthesis or artificial urinary sphincter through a scrotal incision (Rolle et al., 2012).

Given the elasticity and rich blood supply of the scrotum and scrotal structures, usually an effort is made to close dead space to prevent swelling/hematoma formation. Alternatively, a Penrose drain can be left in temporarily. Closures usually involve one or two layers involving the dartos layer with an absorbable suture. The skin is closed in an interrupted or horizontal mattress fashion.

Penile Incisions

Penile incisions are usually performed electively for correction of Peyronie disease and are beyond the scope of this chapter. However, every urologist should have an approach to circumcision, penile fractures, and distal shunts for priapism.

Pediatric circumcision is discussed later in this text. There are many approaches to circumcision, with the most common in adults being the two-incision “sleeve” technique (Fig. 9.16). First, retract the foreskin and mark out your first incision circumferentially about 5 to 10 mm from the edge of the glans, being careful not to be too close to the glans. Then replace the prepuce over the glans, and mark your second incision circumferentially on the prepuce at the coronal sulcus (visible through the prepuce) (Wan and Kraft, 2018). Check both of these markings again, and then very carefully cut both incisions using a #15 blade or preferred scalpel with extra caution around the frenular vessels. Either incision can be cut first, however we usually cut the prepucial incision (around the coronal sulcus) first. A space is then developed between the prepuce and the dartos/penile shaft, and the prepuce is cut longitudinally and removed. Hemostasis is of utmost importance given the rich blood supply and potential for significant hematomas and complications. Closure is usually done in a simple interrupted fashion with a 3-0 or 4-0 absorbable suture such as chromic gut. A continuous closure can also be performed with the same suture, but extreme care must be taken to not strangulate the tissue.

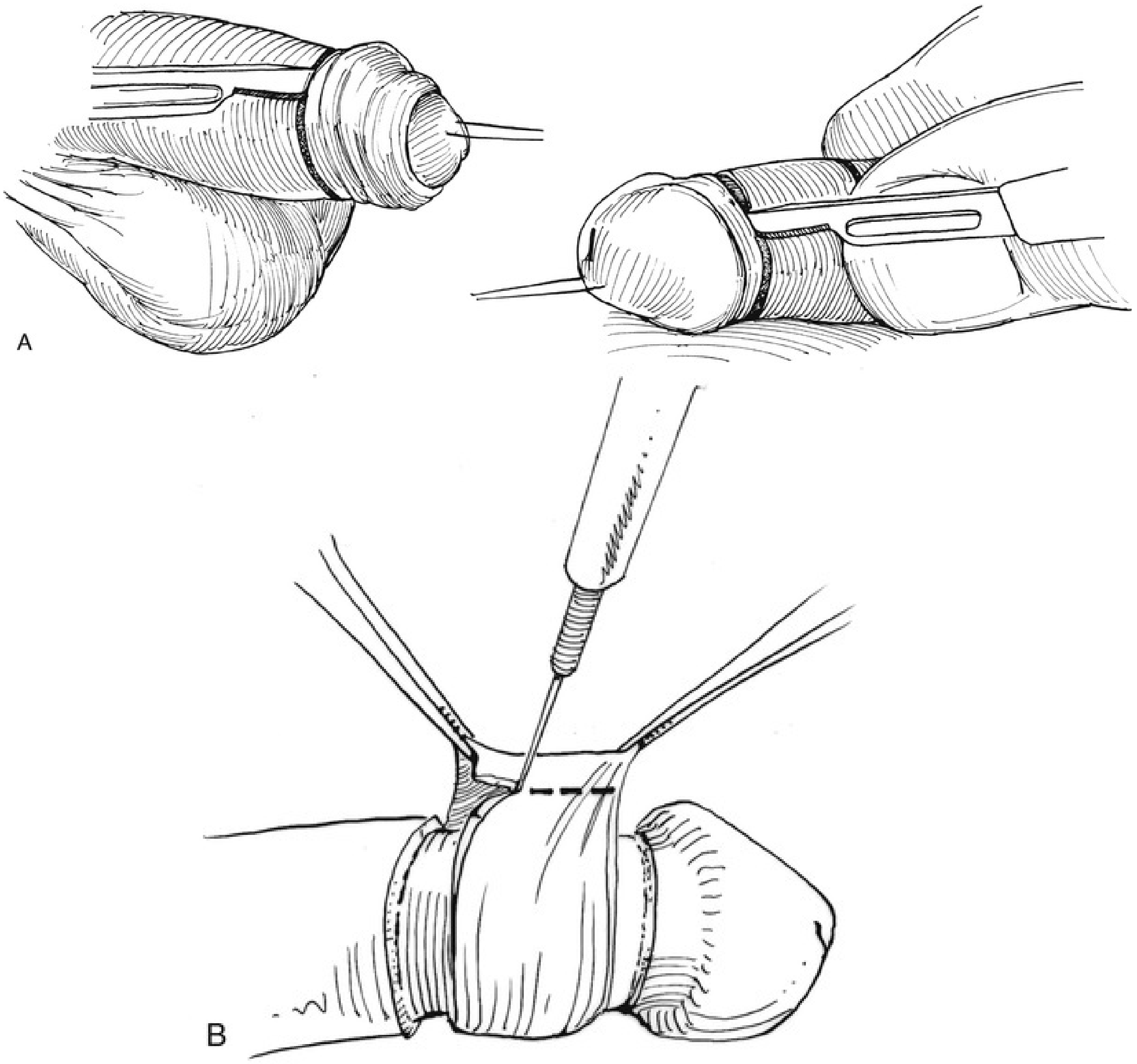
A
B

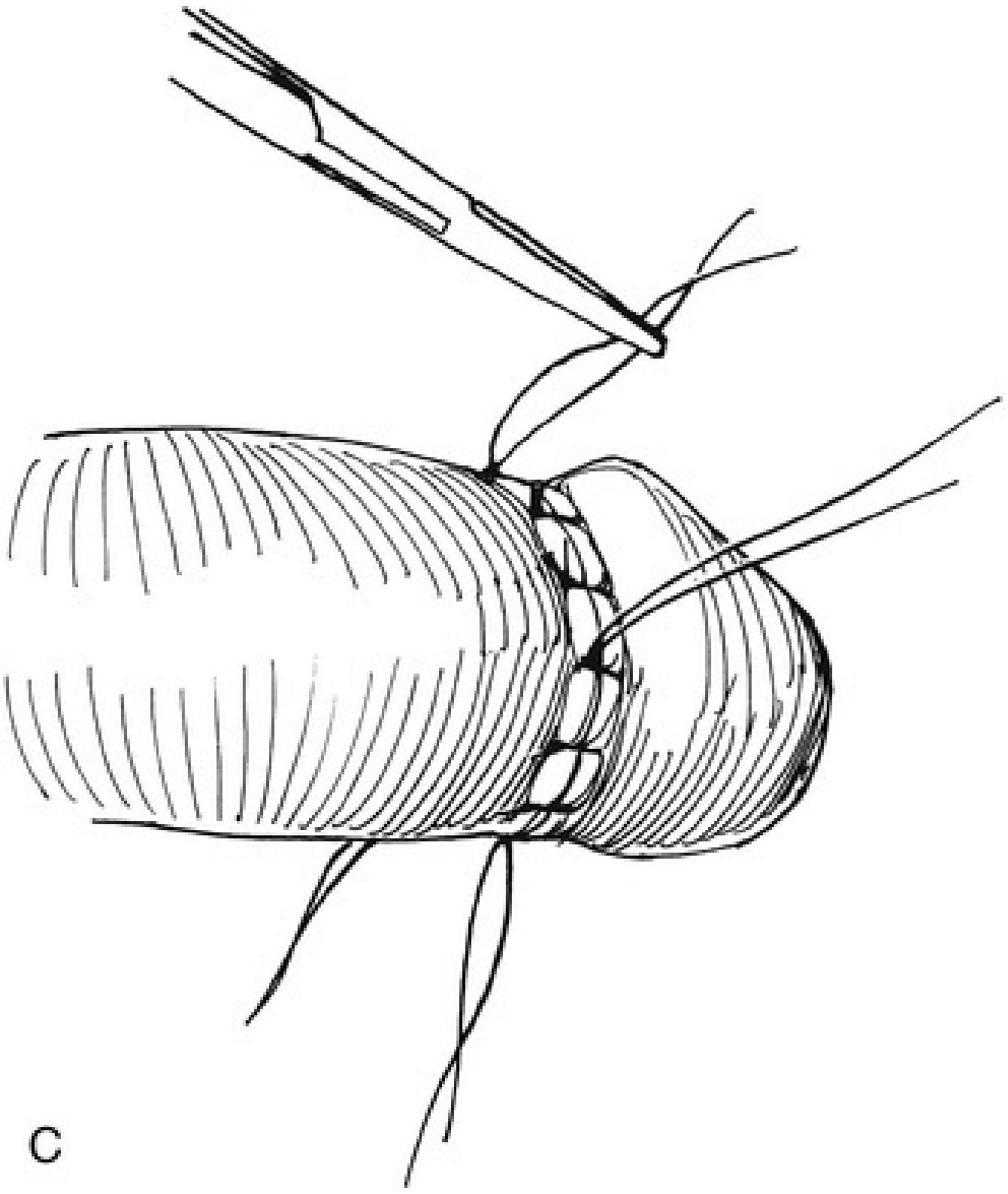

FIG. 9.16 (A to C) Circumcision. Adult circumcisions are most commonly done through the two-incision “sleeve” technique. Circumferential incisions are shown here on either side of the prepuce. The collar of skin is then isolated and cut longitudinally. Closure is performed in an interrupted fashion after hemostasis is achieved. (From Smith JA Jr, Howards SS, Preminger GM, Dmochowski RR. *Hinman's atlas of urologic surgery,* 4th ed. Philadelphia, PA: Elsevier, 2018; Figs. 120.1, 120.2, and 120.3.)

Suspected penile fractures and injuries are usually explored via a “degloving” approach. This approach begins with a circumferential subcoronal incision, similar to that in a circumcision or plication surgery for Peyronie disease (Reed-Maldonado and Lue, 2018). The penile skin is then carefully peeled back to expose the corporal bodies and allow for exploration for the suspected defect. The direct longitudinal incision might become more popular in the future compared with the degloving approach. A direct incision requires preidentification of the defect with imaging and was recently shown to have advantage over degloving in return to sexual function (Xu et al., 2016). Further details and images can be found in Chapter 133 of this text. The approach to distal penile shunts for priapism can be found in Chapter 70.

Perineal Incisions

Perineal incisions are most commonly used as an approach to the proximal urethra and base of the penis. Common indications include urethroplasties, perineal urethrostomy, male urethral slings, inflatable penile prostheses, and artificial urethral sphincters. Although rarely performed in modern times, this would also be the approach for radical perineal prostatectomy.

For urethral procedures, an 8- to 10-cm incision is performed vertically beginning at the perineoscrotal junction. An inverted-Y, or Lambda incision is also an option, however, this was recently shown to be associated with higher 90-day wound complication rates compared with a standard midline (Bascom et al., 2016). Closure is usually multilayer depending on the extent of dissection and mobilization. The Colles fascia should be closed before the skin closure, usually in a continuous fashion, to close the dead space and approximate the skin. Skin closure is usually in an interrupted mattress-type closure for approximation and to prevent opening of the incision given the location.

The radical perineal prostatectomy is done through a large inverted horseshoe incision. The apex of the incision is about 2 cm from the anal verge, and the ischial tuberosities are used as landmarks. Largely replaced by the retropubic prostatectomy, the details of the this approach are beyond the scope of this chapter. For more details, refer to *Hinman's Atlas of Urologic Surgery,* 4th edition, Chapter 77: Radical Perineal Prostatectomy (Smith et al., 2018). Interestingly, with the dawn of single-port robotic devices, this incision has recently been used to revisit the radical perineal prostatectomy and other urologic procedures (e.g., cystectomy, pelvic lymph node dissection) robotically through a perineal incision and might regain popularity in our careers (Akca et al., 2015; Kaouk et al., 2016; Maurice and Kaouk, 2017).

Key Points

- There remain several indications for open surgical approaches in urology. Decisions regarding open versus minimally invasive approaches depend on complexity/size of pathology, patient preference, and the surgeon's skill set.
- Knowledge of the abdominal wall musculature and anatomy are important to avoid key vessels and nerves when making incisions. These can usually be avoided by staying in the midline.
- Anterior abdominal incisions can be used to access pelvic, intraperitoneal,

retroperitoneal, and extraperitoneal structures. Urologists most commonly use a lower midline incision for access to the bladder and prostate.

- There are many open approaches to the kidney, each with their own advantages and disadvantages. Usually the kidney is approached via an anterior or flank incision, however dorsal incision was a traditional approach that is being explored again by some groups.
- Inguinal incisions can be above or below the inguinal ligament depending on the indication. They give access to contents of the spermatic cord, testicle, and ilioinguinal lymph nodes.
- Adult circumcisions are commonly performed through a two-incision technique on either side of the prepuce.
- Meticulous hemostasis is necessary for scrotal and penile incisions as one can have significant bruising and bleeding complications.
- Perineal incisions might become more common for various pelvic procedures with the development of new robotic technology.

Suggested Readings

Pansadoro V. Surgery illustrated: surgical atlas: the posterior lumbotomy. *BJU Int*. 2005;95(7):1121–1131.

Smith JA Jr, Howards SS, Preminger GM, et al. *Hinman's atlas of urologic surgery*. ed 4. Elsevier: Philadelphia, PA; 2018.

References

Akca O, Zargar H, Kaouk JH. Robotic surgery revives radical perineal prostatectomy. *Eur Urol*. 2015;68(2):340–341.

Arpey N, Sloan M, Hahn A, et al. Unscheduled clinical encounters in the post-operative period after adult and pediatric urologic surgery. *Urology*. 2018 [pii: S0090-4295(18)31097-5].

Bascom A, Ghosh S, Fairey AS, et al. Assessment of wound complications after bulbar urethroplasty: the impact of a lambda perineal incision. *Urology*. 2016;90:184–188.

Binsaleh S, Madbouly K, Matsumoto ED3, et al. A prospective randomized study of Pfannenstiel versus expanded port site incision for intact specimen extraction in laparoscopic radical nephrectomy. *J Endourol*. 2015;29(8):913–918.

Buse S, Gilfrich C, Wagener N, et al. Thoraco-abdominal approach to large retroperitoneal tumours. *BJU Int*. 2006;98(5):969–972.

Caraballo ER, Palacios DA, Suk-Ouichai C, et al. Open partial nephrectomy when a non-flank approach is required: indications and outcomes. *World J Urol*. 2018; 10.1007/s00345-2414-4 [Epub ahead of print].

Carroll PR, Klosterman P, McAninch JW. Early vascular control for renal trauma: a critical review. *J Urol*. 1989;141(4):826–828.

Chung BI, Sommer G, Brooks JD. Surgical, radiographic, and endoscopic anatomy of the male pelvis. Wein AJ, Kavoussi LR, Partin AW, et al. *Campbell-Walsh urology*. ed 11. Elsevier: Philadelphia, PA; 2016:1611–1630.

Chute R, Shutter L, Kerr WS. Value of thoracoabdominal incision in removal of kidney tumors. *N Engl J Med*. 1949;241(24):951–960.

Cooper JF, Leadbetter WF, Chute R. The thoracoabdominal approach for retroperitoneal gland dissection: its application to testis tumors. *Surg Gynecol Obstet*. 1950;90:486.

Dayanç M, Kibar Y, Tahmaz L, et al. Scrotal incision orchiopexy for undescended testis. *Urology*. 2004;64(6):1216–1218.

Diblasio CJ, Snyder ME, Russo P. Mini-flank supra-11th rib incision for open partial or radical nephrectomy. *BJU Int*. 2006;97(1):149–156.

Goldstein M. Surgical management of male infertility. Wein AJ, Kavoussi LR, Partin AW, et al. *Campbell-Walsh urology*. ed 11. Elsevier: Philadelphia, PA; 2016:580–611.

Graybar GB, Tarpey M. Kidney transplantation. Gelman S. *Anesthesia and organ transplantation*. Saunders: Philadelphia, PA; 1987:61.

Gregg JR, Scarpato KR. Surgical approaches for open renal surgery, including open radical nephrectomy. Smith JA Jr, Howards SS, Preminger GM, et al. *Hinman's atlas of urologic surgery*. ed 4. Elsevier: Philadelphia, PA; 2018:61–75.

Horenblas S. Lymphadenectomy for squamous cell carcinoma of the penis. Part 2: the role and technique of lymph node dissection. *BJU Int*. 2001;88:473–483.

Hudnall CH, Kirk JF, Radwin HM. The role of posterior lumbotomy in the management of surgical stone disease. *J Urol*. 1988;139:704.

Kahan B. Surgical principles of the operation. Kahan B, Ponticelli C. *Principles and practice of renal transplantation*. C. Martin Dunitz: London; 2000:191.

Kaouk JH, Akca O, Zargar H, et al. Descriptive technique and initial results for robotic radical perineal prostatectomy. *Urology*. 2016;94:129–138.

Kumar R, Smith G. Dorsal lumbotomy incision for pediatric pyeloplasty—a good alternative. *Pediatr Surg Int*.

1999;15(8):562–564.

Kumar S, Duque JL, Guimaraes KC, et al. Short and long-term morbidity of thoracoabdominal incision for nephrectomy: a comparison with the flank approach. *J Urol*. 1999;162(6):1927–1929.

Latchamsetty K, Rochelle J, Hoeksema J, et al. Is routine postoperative chest radiography needed after open nephrectomy? *Urology*. 2005;65(2):256–259.

Lee L, Abou-Khalil M, Liberman S, et al. Incidence of incisional hernia in the specimen extraction site for laparoscopic colorectal surgery: systematic review and meta-analysis. *Surg Endosc*. 2017;31(12):5083–5093.

Loughlin KR. Surgical atlas. Surgical management of penile carcinoma: the inguinal nodes. *BJU Int*. 2006;97(5):1125–1134.

Marmar JL, DeBenedictis TJ, Praiss D. The management of varicoceles by microdissection of the spermatic cord at the external inguinal ring. *Fertil Steril*. 1985;43(4):583–588.

Matin S, Gill I. Modified Pfannenstiel incision for intact specimen extraction after retroperitoneoscopic renal surgery. *Urology*. 2003;61(4):830–832.

Maurice MJ, Kaouk JH. Robotic radical perineal cystectomy and extended pelvic lymphadenectomy: initial investigation using a purpose-built single-port robotic system. *BJU Int*. 2017;120(6):881–884.

Merrill DC. Modified thoracoabdominal approach to the kidney and retroperitoneal tissue. *J Urol*. 1977;117(1):15–18.

Nanni G, Tondolo V, Citterio F, et al. Comparison of oblique versus hockey-stick surgical incision for kidney transplantation. *Transplant Proc*. 2005;37(6):2479–2481.

Novick AC, Streem SB. Surgery of the kidney. Walsh PC, Retik AB, Vaughan ED Jr, et al. *Campbell's urology*. ed 7. Saunders: Philadelphia, PA; 1998:2973–3061.

Pansadoro V. Surgery illustrated: surgical atlas: the posterior lumbotomy. *BJU Int*. 2005;95(7):1121–1131.

Parekh DJ, Cookson MS, Chapman W, et al. Renal cell carcinoma with renal vein and inferior vena caval involvement: clinicopathological features, surgical techniques and outcomes. *J Urol*. 2005;173(6):1897–1902.

Patel SV, Paskar DD, Nelson RL, et al. Closure methods for laparotomy incisions for preventing incisional hernias and other wound complications. *Cochrane Database Syst Rev*. 2017;(11) [CD005661].

Pouliot F, Shuch B, Larochelle JC, et al. Contemporary management of renal tumors with venous tumor thrombus. *J Urol*. 2010;184(3):833–841 [quiz 1235].

Protzel C, Alcaraz A, Horenblas S, et al. Lymphadenectomy in the surgical management of penile cancer. *Eur Urol*. 2009;55(5):1075–1088.

Reed-Maldonado AB, Lue TF. Procedures for Peyronie disease. Smith JA Jr, Howards SS, Preminger GM, et al. *Hinman's atlas of urologic surgery*. ed 4. Elsevier: Philadelphia, PA; 2018:892–899.

Rice KR, Carey CK, Masterson TA, et al. Surgery of testicular tumors. Wein AJ, Kavoussi LR, Partin AW, et al. *Campbell-Walsh urology*. ed 11. Elsevier: Philadelphia, PA; 2016:815–837.

Rolle L, Ceruti C, Sedigh O, et al. Surgical implantation of artificial urinary device and penile prosthesis through trans-scrotal incision for postprostatectomy urinary incontinence and erectile dysfunction: synchronous or delayed procedure? *Urology*. 2012;80(50):1046–1050.

Rosser CJ, McCullough DL, Hall MC. Thoracoabdominal radical nephrectomy: is a postoperative thoracostomy tube necessary? *Urology*. 2000;55(6):847–851.

Stein J, Skinner D. Simple technique to stabilize the costochondral junction using synthetic mesh after a thoracoabdominal incision. *Urology*. 2002;59(5):768–770.

Troxel S, Das S, Helfer E, et al. Laparoscopy versus dorsal lumbotomy for ureteropelvic junction obstruction repair. *J Urol*. 2006;176(3):1073–1076.

Talic RF. Paramedian extraperitoneal approach for combined nephrectomy and augmentation ureterocystoplasty in children with neurovesical dysfunction. *Eur Urol*. 2000;38(6):762–765.

Tennyson LE, Lyon TD, Farber NJ, et al. Dorsal lumbotomy incision for partial nephrectomy in patients with small posterior renal masses. *Urology*. 2016;87:120–124.

Tessler AN, Yuvienco F, Farcon E. Paramedian extraperitoneal incision for total nephroureterectomy. *Urology*. 1975;05(3):397–398.

Turek PJ. Varicocele ligation. Smith JA Jr, Howards SS, Preminger GM, et al. *Hinman's atlas of urologic surgery*. ed 4. Elsevier: Philadelphia, PA; 2018:794.

van ‘t Riet M, Steyerberg EW, Nellensteyn J, et al. Meta-analysis of techniques for closure of midline abdominal incisions. *Br J Surg*. 2002;89(11):1350–1356.

Vaughan ED Jr, Phillips H. Modified posterior approach for right adrenalectomy. *Surg Gynecol Obstet*. 1987;165(5):453–455.

Vaughan ED Jr. Adrenal surgery. Marshall F. *Operative urology*. Saunders: Philadelphia, PA; 1991:3–13.

Wagenaar S, Nederhoed JH, Hoksbergen AWJ, et al. Minimally invasive, laparoscopic, and robotic-assisted techniques versus open techniques for kidney transplant recipients: a systematic review. *Eur Urol*. 2017;72(2):205–217.

Wan J, Kraft K. Circumcision and dorsal slit or preputioplasty circumcision. *Hinman's atlas of urologic surgery*. ed 4. Elsevier: Philadelphia, PA; 2018:864–871.

Wollin M, Menon M. The lumbodorsal approach to the kidney. Marshall F. *Operative urology*. Saunders: Philadelphia, PA; 1991:89–94.

Wotkowicz C, Libertino J, Sorcini A, et al. Management of renal cell carcinoma with vena cava and atrial thrombus: minimal access vs median sternotomy with circulatory arrest. *BJU Int*. 2006;98(2):289–297.

Xu MX, Zhou Z, Yao HJ, et al. Comparison of different approaches to the surgical treatment of penile fractures: quicker return to sexual function with longitudinal incisions. *Int J Impot Res*. 2016;28(4):155–159.

Yang WH, Ou CH. A muscle-sparing modified Gibson incision for hand-assisted retroperitoneoscopic nephroureterectomy and bladder cuff excision—an approach through a window behind the rectus abdominis muscle. *Urology*. 2012;79(2):470–474.

Young HH. A technique for simultaneous exposure and operation on the adrenals. *Surg Gynecol Obstet*. 1936;54:179.

10

Principles of Urologic Surgery

Intraoperative Technical Decisions

Manish A. Vira MD, Christopher J. Hartman MD

The perioperative management of patients undergoing urologic surgery continues to evolve. Over the past two decades, the economics of health care has added increasing pressure for more outpatient surgery, decreased hospital stays, and most importantly decreased complication rates. At the same time, the acuity of surgical patients has increased with patients who are older with more significant comorbidities. **The modern urologic surgeon is responsible for ensuring not only that the patient enters the operating room in the most optimized medical condition but also that the intraoperative decision making results in the best possible outcomes.**

Patient Environment

Patient Temperature

Although hypothermia can be therapeutic in certain situations of trauma and brain injury, for elective surgical procedures, hypothermia is associated with significantly increased morbidity to the patient. There are two primary reasons for hypothermia to develop in the operating room. First, anesthetic agents induce peripheral vasodilation redistributing heat from the core (trunk, head) with a resultant drop in immediate core temperature after induction. Second, heat loss occurs through radiation and conduction/convection throughout the procedure as the body interacts with air environment in the operating room. **Normothermia is defined as core temperature between 36°C and 38°C, and even changes of 1°C to 2°C can result in adverse effects.** Rajagopalan et al. (2008) performed a meta-analysis of randomized controlled trials (RCTs) and reported that mild hypothermia (decrease of 1°C) resulted in a 16% increase in estimated blood loss and a 22% increase in transfusion requirements. The increased bleeding risk is thought to result from a hypothermia-associated decrease in clotting cascade enzymatic function and platelet aggregation. Even more significant is the increase in the risk of surgical site infections (SSIs) associated with mild hypothermia (34°C to 36°C). Hypothermia increases the risk of SSI by impairing immune mechanisms and vasoconstriction, resulting in regional tissue hypoxia. In a landmark study, Kurz et al. (1996) with the Study of Wound Infection and Temperature Group tested the hypothesis that hypothermia increases the rate of wound infection and hospital stay in 200 patients undergoing elective colorectal surgery. **Hypothermia was associated with a three times increased risk of wound infection and a 2.6-day increase in hospitalization.** Subsequent studies have generally confirmed these findings in other series of surgical patients (Mauermann and Nemergut, 2006). In its overall goal of reducing SSI, the Surgical Care Improvement Project has also included perioperative normothermia as one of its guidelines. Strategies to improve maintenance of normothermia include regular use of warming blankets, warmed intravenous fluids, warmed irrigation fluids (especially during transurethral resection of the prostate [TURP] and other prolonged endoscopic procedures), warmed/humidified CO_2 gas during laparoscopy, and an increase in ambient operating room temperature. A recent Cochrane review confirmed the benefits of active body surface warming systems, citing beneficial effects of reduced rate of SSI, reduced major cardiovascular complications, decreased blood loss, and improved patient comfort (Madrid et al., 2016).

Skin Preparation

Sterile skin preparation is fundamental in the prevention of SSI for any procedure. Currently, the most commonly used skin antiseptics are alcohol, povidone-iodine, or chlorhexidine-based. Whichever antiseptic is chosen, the solution should be applied in concentric circles from the center of the surgical site and be allowed to dry before incision. The Cochrane Wound Study Group recently published their updated third analysis on various preoperative skin preparations (Dumville et al., 2015). The authors again were unable to report conclusive evidence of superior efficacy of one particular skin preparation. Furthermore, although the Centers for Disease Control and Prevention (CDC) clearly recommends preoperative showering/bathing to reduce SSI, there is no evidence that bathing with an antiseptic solution reduces the rate of infection (Webster and Osborne, 2007). Regarding hair removal, the CDC recommends that if hair removal is performed, it should be performed immediately before the surgical procedure and performed with clippers (rather than shaving) (Mangram et al., 1999).

Patient Safety

In 1991 Brennan et al. published their seminal work describing adverse events, defined as injuries caused by medical management in hospitalized patients, revealing that 48% of the events accompanied a surgical operation (Brennan et al., 1991; Leape et al., 1991). This important study inspired the publication of “To Err Is Human, Building a Safer Health System,” a comprehensive study by the Institute of Medicine on medical errors. Regarding surgical patients, the most frequent venue of preventable injuries is the operating room. Although the surgeon is the “captain of the ship” and ultimately responsible, it takes awareness of and attention to detail from each member of the operating room team to prevent iatrogenic injuries to the patient. **Three causes of immediately preventable injuries are retractor-associated injuries, thermal injuries, and patient position–related injuries.** There are several reports in the literature documenting increased rate of neuropathy (especially femoral nerve) after laparotomy with self-retaining retractors versus without self-retaining retractors (Irvin et al., 2004). **Careful attention to be certain that the lateral blades do not directly compress the psoas muscle and only cradle the rectus abdominal muscles ensures avoidance of femoral neuropathy.** Furthermore, periodic reinspection of the retractor blades is also warranted. Many devices used in urologic surgery employ thermal energy for desired effect and therefore can result in thermal injury to the patient. These include Bovie cautery, argon beam coagulator, bipolar devices, and laser. **In endoscopic and laparoscopic surgery, high-wattage light sources are used to illuminate the operative field. While illuminated, the ends of the light cords can result in burns when in direct contact with the patient (even through draping).** These light sources should be turned off at all times when not in use. Special mention is deserved for the morbidly obese patient. The operating room should be equipped with a hydraulic table, extra-long instruments, additional padding, wide venous compression devices, and side extensions to ensure a safe operating room environment for the patient.

Patient Positioning

Although often given only a cursory evaluation, proper patient positioning in the operating room can prevent potentially devastating complications. **Ultimately, proper positioning is the shared responsibility of each member of the operating room team.** Much of the knowledge and guidelines for avoidance of position-related injury are drawn from the anesthesia literature. In fact, in response to a 1999 study of the American Society of Anesthesiologists (ASA) Closed Claims Database, which found neuropathy as the second-leading cause of liability, the ASA published a practice advisory for the prevention of perioperative peripheral neuropathies (Practice advisory, 2000). The recommendations are listed in Table 10.1. **Although the exact mechanisms of peripheral neuropathy are not always known, the cause of position-related neuropathy is generally secondary to excessive stretch, prolonged compression, or ischemia.** Given the variety of different patient positions used in urologic surgery, it is critical for the urologist to be an active participant in the positioning of the patient and to understand the potential patient compromise that accompanies each position.

TABLE 10.1

American Society of Anesthesiologists Task Force Recommendation on the Prevention of Perioperative Peripheral Neuropathies

Preoperative assessment	• When judged appropriate, it is helpful to ascertain that patients can comfortably tolerate the anticipated operative position.
Upper extremity positioning	• Arm abduction should be limited to 90 degrees in supine patients; patients who are positioned prone may comfortably tolerate arm abduction greater than 90 degrees. • Arms should be positioned to decrease pressure on the postcondylar groove of the humerus (ulnar groove). When arms are tucked at the side, a neutral forearm position is recommended. When arms are abducted on armboards, either supination or a neutral forearm position is acceptable. • Prolonged pressure on the radial nerve in the spiral groove of the humerus should be avoided. • Extension of the elbow beyond a comfortable range may stretch the median nerve.
Lower extremity positioning	• Lithotomy positions that stretch the hamstring muscle group beyond a comfortable range may stretch the sciatic nerve. • Prolonged pressure on the peroneal nerve at the fibular head should be avoided. • Neither extension nor flexion of the hip increases the risk of femoral neuropathy.
Protective padding	• Padded armboards may decrease the risk of upper extremity neuropathy. • The use of chest rolls in laterally positioned patients may decrease the risk of upper extremity neuropathies. • Padding at the elbow and at the fibular head may decrease the risk of upper and lower extremity neuropathies, respectively.
Equipment	• Properly functioning automated blood pressure cuffs on the upper arms do not affect the risk of upper-extremity neuropathies. • Shoulder braces in steep head-down positions may increase the risk of brachial plexus neuropathies.
Postoperative assessment	• A simple postoperative assessment of extremity nerve function may lead to early recognition of peripheral neuropathies.
Documentation	• Charting specific positioning actions during the care of patients may result in improvements of care by (1) helping practitioners focus attention on relevant aspects of patient positioning and (2) providing information that continuous improvement processes can use to effect refinements in patient care.

The supine position, used in abdominal, pelvic, and penile procedures, is generally considered the safest patient position. However, several specific issues should be considered. Excessive upper extremity abduction (>90 degrees) can lead to tension on the brachial plexus, leading to upper extremity neuropathy. The armboard should be padded to avoid excessive pressure on the ulnar groove and spiral groove of the humerus (radial nerve injury). In cases in which the arms are tucked at the patient's side, care must be taken to avoid excessive pressure on the hand and forearm. Moreover, peripheral intravenous catheter infiltration must be identified quickly because forearm compartment syndrome may develop.

One of the most frequent positions used in urology is the lithotomy position. Improper positioning can lead to transient and occasionally prolonged lower extremity neuropathy. In a retrospective evaluation of more than 190,000 cases from 1957 to 1991 involving the lithotomy position, persistent neuropathy was found in 0.03%; however, the same group in a prospective study of 991 patients reported an incidence of 1.5% (15 patients) with resolution of symptoms by 6 months in all but one patient (Warner et al., 1994, 2000). **The basic principle of lithotomy position involves manipulation of both lower extremities simultaneously with flexion of the hips at 80 to 100 degrees with 30- to 45-degree abduction.** The legs should be padded to avoid excessive compression against the stirrup. Particular caution should be given to the patient's hands to avoid entrapment within the moving parts of the stirrups.

For most open and laparoscopic upper urothelial tract and renal procedures, the patient is placed in some degree of lateral decubitus position. Proper padding of the patient is important with appropriate anterior and posterior support to maintain the decubitus position. **The most frequent focus of compromise involves positioning of the arms and potential for brachial plexus injury.** The ipsilateral arm should be placed on an elevated arm rest or gel pad, avoiding abduction more than 90 degrees and excessive stretch on the shoulder. The contralateral arm should be placed on an armboard with ulnar padding. Furthermore, in patients in full flank position, an axillary roll should be placed just caudal to the axilla (not in the axilla) to avoid compression of the contralateral brachial plexus. Finally, after the patient is positioned and before sterile draping, the operating table should be fully rotated to ensure that the patient is adequately secured in all positions.

Two patient positions used in specific urologic cases deserve attention: the prone position for percutaneous nephroscopy and the full Trendelenburg position for robotic-assisted laparoscopic procedures in the pelvis. In the prone position, special care should be taken to pad the torso, elbows, hips, and legs. The anesthesiologist should ensure that the endotracheal tube and all vascular access are properly secured. Coordination of the entire team is required during transfer from the supine position on the stretcher to the prone position on the operating room table. A stretcher should always be available immediately in case of airway compromise and the need for rapid transfer to the supine position. Regarding the full Trendelenburg position for minimally invasive pelvic procedures, the primary issues involve the physiologic changes in respiratory function, cardiovascular function, and increases in central venous and intracranial pressures. **Patient positioning should focus on properly securing and padding the patient to the operating table to prevent cephalad sliding. Although fixed shoulder braces undoubtedly prevent patient movement, these braces should be avoided because of the risk of brachial plexus compression and resultant neuropathy.**

Blood Products

Packed Red Blood Cells

Given the vascular nature of urologic organs, the urologist often confronts the issue of indication and necessity of transfusion in the perioperative period. Therefore it is important that the urologist understand the indications, implications, and risks associated with blood product transfusion. Before the acquired immunodeficiency syndrome (AIDS) epidemic, blood transfusion was liberally administered often for any patient with hematocrit less than 30%. However, fear and concern about the infectious risk led to the convening of a National Institutes of Health (NIH) panel to develop consensus recommendations for the indication of blood product transfusion (NIH Consensus Statement, 1988). The principles in these guidelines remain current, as reflected by the ASA practice guidelines issued in 2006 (Practice guidelines, 2006) and updated in 2015 (Practice guidelines, 2015). **To summarize, the guidelines indicate that transfusion is rarely indicated with hematocrit greater than 30% and often indicated for hematocrit less than 21%. For levels between 21% and 30%, clinical factors such as risk of complications from inadequate oxygenation should guide the need for transfusion, balancing the risks and benefits.** In general, patients with relatively minor comorbidities can tolerate hematocrit of greater than 21% before transfusion is indicated. Patients with moderate to severe comorbidity (i.e., with significant pulmonary compromise, coronary artery disease, or vascular insufficiency or with signs/symptoms of hypovolemic or hemorrhagic shock) warrant transfusion to achieve hematocrit greater than 30%. The guidelines updated in 2015 included recommendations to consider intraoperative antifibrinolytic therapy (tranexamic acid, epsilon aminocaproic acid) in situations with anticipated excessive blood loss such as cardiac and liver surgery.

Component Therapy

A major advance in blood banking and product transfusion has been the development of component therapy, allowing for administration for specific fractions of whole blood. Packed red blood cells (PRBCs) are equivalent to whole blood minus the plasma component. Whereas the hematocrit in whole blood is 40%, it is 70% in PRBC units. These units are reconstituted and administered with crystalloid. Given the lack of the remaining components, in instances of massive PRBC transfusions and associated bleeding, platelets and occasionally fresh frozen plasma (FFP) should be given to avoid dilutional coagulopathy. **Platelet transfusion is rarely indicated empirically except in patients with significant thrombocytopenia (<50,000/mm^3) and planned surgical procedure or with moderate thrombocytopenia (50,000–100,000/mm^3) and either high-risk procedure or evidence of platelet dysfunction.** Similarly, empiric transfusion with FFP for massive transfusion is not indicated. With the development of component therapy, the use of FFP increased dramatically, leading to consensus statements from the NIH and the ASA to guide practitioners (Consensus conference, 1985; Practice guidelines, 2006). **The current indications for FFP transfusion are immediate reversal of anticoagulant medication-induced coagulopathy, replacement in patients with specific clotting factor deficiencies, and evidence of bleeding and international normalized ratio (INR) greater than 1.5.** According to the ASA guidelines, in patients with significant blood loss and no INR readily available, FFP should be given after replacement of 1 blood volume.

Massive Transfusion Protocol

Although very high blood loss procedures in urology are uncommon, given the proximity of major vascular structures to several genitourinary organs, occasionally the urologist is faced with a clinical situation in which transfusion of a large amount of blood is necessary. Traditionally, component transfusion would not begin until more than 6 units of PRBC had been given to the patient. **More recently, evidence from the trauma literature supports the use of increased ratio of platelet:FFP:RBC ratio (i.e., massive transfusion protocol). The protocol is triggered in the anticipation of greater than 10 units of PRBC in 24 hours and mobilizes blood bank and hospital resources to provide adequate supply of red blood cell and component transfusion.** There are multiple reports of improved survival of trauma patients managed with massive transfusion protocols. A study from Ball et al. (2013) demonstrated improved abdominal wall closure rates among patients with high-grade liver injuries when massive transfusion protocol was used.

Hemostatic Agents

Numerous different agents have been developed to aid in surgical hemostasis. These may be categorized as being derived from human-, animal-, or plant-based sources and may occur in either a dry or liquid form. In most cases, hemostatic agents act by enhancing local clotting factors and promoting blood clotting. They are not a substitute for good surgical hemostasis and typically do not seal large vascular defects, but they may be especially helpful as an adjunct in controlling slow bleeding from raw tissue surfaces.

Dry Matrix Agents

Dry matrix agents may be broadly categorized as oxidized regenerated cellulose, microfibrillar collagen, absorbable gelatin matrix, and microporous polysaccharide spheres. In general, they are less expensive than biologically active agents, typically costing between $50 and $100 per use, as compared with $300 to $750 for biologically active agents.

Oxidized regenerated cellulose agents (Fibrillar [Ethicon, Neuchâtel, Switzerland], Surgicel [Ethicon, Neuchâtel, Switzerland], Nu-Knit [Ethicon, Neuchâtel, Switzerland]), are plant-derived agents supplied as a mesh sheet. They work by activating the body's natural clotting cascade, thereby aiding in natural blood clotting. Placed directly on an area of bleeding, they may serve as a substrate on which a thrombus can form. Because of the pliable nature of the material, they are easily placed through laparoscopic ports and therefore can be used in open and laparoscopic surgeries. These agents typically dissolve within 1 to 2 weeks (Mannucci, 1998).

Microfibrillar collagen (Avitene [BD/C.R. Bard, Flanklin Lakes, NJ]), as its name suggests, is a bovine-derived collagen agent that is supplied in either a sheet of material or dense powdered form. When placed directly on a site of bleeding, it stimulates blood clotting by allowing proteins of the clotting cascade and platelets to adhere to it. **Because it works by enhancing platelet aggregation, its efficacy is decreased in patients with thrombocytopenia.** Microfibrillar collagen is completely absorbed within 12 weeks (Peralta, 2018).

Absorbable gelatin matrix agents (Surgifoam [Ethicon, Neuchâtel, Switzerland], Gelfoam [Pfizer, New York, NY]) are porcine-derived collagen agents packaged as a dry, pliable foam material. They are typically moistened with saline before use and are easily molded to conform to small

spaces. In addition, they can be placed through laparoscopic port sites during minimally invasive surgeries. Similar to other dry matrix agents, they promote the clotting cascade and act as a substrate on which a thrombus can form. They typically dissolve in 4 to 6 weeks and have been suggested to increase the risk of infection at the surgical site, possibly before their prolonged dissolution time and favorable substrate for bacterial adherence (Hong and Loughlin, 2006; Mannucci, 1998).

Microporous polysaccharide spheres (Arista [BD/C.R. Bard, Flanklin Lanks, NJ]) are derived from plant-based starch material and are available as a fine powder. This allows for broad coverage of the operative site by spraying the powder onto the field through an accordion-type bulb. Applicators can be either short or long and therefore can be placed through laparoscopic port sites. **Microporous polysaccharide spheres work by absorbing blood, thereby concentrating platelets and proteins of the clotting cascade.** They typically dissolve within 1 to 2 days of application (Ereth et al., 2008).

Biologically Active Agents

Biologically active agents can be characterized as topical thrombin agents, fibrin sealants, and tissue adhesives. They are usually delivered via a syringe and needle type applicator and may have to be mixed before application. In addition, they may be combined with a gelatin matrix to aid in hemostasis.

Topical thrombin agents (Thrombin-JMI [Pfizer, New York, NY], Evithrom [Ethicon, Neuchâtel, Switzerland], Recothrom [Malinckrodt Pharmacetuicals, Bedminster, NJ]) are human- or bovine-derived liquid agents that are applied directly to a site of bleeding. Floseal (Baxter, Deerfield, IL) and Surgiflo (Ethicon, Neuchâtel, Switzerland) are commonly used preparations of thrombin sealants that are combined with a gelatin matrix. **These hemostatic agents have the advantages in urologic surgery of not being inhibited by urine and of resisting stone formation within the urinary tract; therefore they are used commonly in urologic surgery** (Bak et al., 2004; Uribe et al., 2005).

Fibrin sealants (Tisseel [Baxter, Deerfield, IL], Evicel [Ethicon, Neuchâtel, Switzerland], Evarrest [Ethicon, Neuchâtel, Switzerland]) are human-derived liquid preparations of fibrinogen, factor XII, thrombin, and calcium. They are stored frozen and are thawed before use. A two-syringe system allows a preparation of fibrinogen and factor XII to be stored in one syringe, while thrombin and calcium are stored in another. When mixed via an applicator that combines the two solutions, a fibrin-based clot is formed over a site of bleeding. These agents are absorbed immediately and therefore pose a very low risk of infection at the surgical site (Mannucci, 1998; Peralta, 2018; Spotnitz and Burks, 2008).

Tissue adhesives (Bioglue) are bovine albumin-derived liquid agents that are effective for mild to moderate bleeding. **When administered over a site of bleeding, they form an adhesive matrix that causes hemostasis and may be effective when bleeding does not respond to other hemostatic agents.** They can be used to control bleeding from moderate-sized vessels (Chao and Torchiana, 2003; Pursifull and Morey, 2007).

Drains

A controversial issue in the prevention of organ and space infections is the routine placement of surgical drains at the time of an initial operative procedure. A wide variety of surgical drains are available. Drains are broadly categorized as open nonsuction, closed nonsuction, and closed suction drains. Open nonsuction drains are employed when accurate quantification of drainage amount is not necessary. These drains are associated with less patient discomfort and are the easiest to remove. Closed drains are chosen if quantification of drainage amounts or characterization of drainage fluid is necessary. The use of suction or negative pressure in closed drainage systems is preferred if immediate recognition of small amounts of drainage is important (e.g., a drain around the ureterointestinal anastomosis). **Although drains continue to be widely used in various urologic procedures, several prospective studies in the general surgical literature have failed to show significant benefit; therefore most experts caution against their routine use (unless strong indication exists)** (Barie, 2002).

Penrose

Penrose drains are soft, flexible latex or silicone rubber drains that allow passive drainage of fluid from a surgical site. They are available in a variety of sizes, typically ranging from ¼ inch to 1 inch in diameter, and can be cut to a desired length. Penrose drains are typically sutured to the skin to prevent drain migration either into or out of the wound. Penrose drains do not contain a collection system and therefore drain into the dressing material placed over an incision. Because of this, they may allow for an increased risk of infection at the surgical site and are therefore typically removed sooner than other closed drainage systems. Penrose drains are commonly used in scrotal surgery or may be placed in the subcutaneous tissue during wound closure to prevent fluid accumulation.

Jackson-Pratt

A Jackson-Pratt (JP) drainage system represents a closed drainage system. It consists of a grenade–shaped bulb that is connected to a flat or round perforated internal tubing system. The internal component of the tubing usually sits at the surgical site and can be tailored to the length and shape needed for a particular application. The external bulb is compressed to create negative pressure that draws fluid from the surgical site. **JP drains are commonly used during intra-abdominal urologic surgeries because they effectively remove blood, urine, and other fluids from the surgical field in the postoperative period.** As a closed drainage system, they minimize the risk of infection introduced by other open drainage systems. These drains are usually placed through a separate small incision away from the primary surgical site and are sutured in place to the skin. Removal of JP drains may cause discomfort because the perforated, collecting portion of the tubing is typically larger than the remainder of the drainage tubing.

Blake

Blake drains are similar to JP drains in that they are commonly used during intra-abdominal procedures to prevent postoperative fluid accumulation, contain a grenade-type external drainage bulb that creates negative pressure, and contain an internal tubing component that can be trimmed. **In contrast to JP drains, Blake drains consist of a continuous diameter tubing system that may minimize discomfort during removal.** In addition, as opposed to perforations that allow fluid entry into the tubing system, Blake drains contain channels that run the length of the collecting portion of the tube and allow fluid to enter via capillary action and negative pressure.

Pigtail

Pigtail drains are closed drainage systems that allow for drainage of a surgical site, abscess cavity, or organ space. They may be connected either to a negative pressure bulb, such as when draining an abscess cavity or surgical site, or to a drainage bag, as is common for nephrostomy tubes and suprapubic tubes. Pigtail drains contain a curled inner portion of tubing that is deployed by tightening a suture after placement. This curled portion contains small perforations for fluid removal and allows the drain to remain in position. Removal of a pigtail drain requires the suture to be loosened or the drain to be transected to unfurl the inner curled portion of the drain.

Suture Material and Incision Closure

Knowledge of the basic principles of wound healing is important to properly assess incision closure and its associated complications. **All cutaneous wounds progress stepwise through a series of events toward complete wound repair; in a particular wound, different phases of events may occur simultaneously. This series of steps can be divided broadly into three stages: reactive phase, proliferative phase, and maturational phase.** The reactive phase occurs immediately with the two primary responses of hemostasis and inflammation. Disruption of vascular membranes results in platelet activation and aggregation, which in turn initiate the inflammatory response. During this stage of wound healing, inflammatory cells, including polymorphonuclear cells, macrophages, and lymphocytes, migrate into the wound and become activated, leading to cytokine activation and secretion of various growth factors. The second stage, proliferative, results in the formation of granulation tissue. The stage is characterized by proliferation of endothelial cells and fibroblasts, leading to angiogenesis and epithelialization, which eventually results in growth of immature blood vessels and deposition of extracellular matrix and early collagen scaffolding. Finally, the maturation stage occurs with further deposition of collagen and wound contraction. **The maturational phase begins approximately 1 week after injury and progresses rapidly over 6 weeks, with increasing wound strength over the next 12 months.** The scar regains approximately 3% strength after 1 week, 20% after 3 weeks, and 80% after 3 months (Witte and Barbul, 1997).

Proper incision closure is necessary to avoid surgical complications, including wound infection, hernia formation, and fascial dehiscence. In general, there are three types of wound closure: primary, secondary, and tertiary (or delayed primary closure). In the majority of elective procedures, the urologist should attempt a permanent closure after the operation (primary closure). **Secondary closure is reserved for heavily contaminated wounds for which the fascia is closed primarily, but the skin and subcutaneous tissues are allowed to heal via re-epithelialization and contraction.** Tertiary closures are reserved for patients with abdominal compartment syndrome or patients requiring re-explorations, in whom temporary closure is initially performed with intention of future permanent closure. Unless the procedure involves heavy contamination, incision closure involves reapproximation of the fascia (in one or multiple layers) and the skin. **Choice of suture type by the urologist depends on preferences of braided versus nonbraided, monofilament versus multifilament, and absorbable versus nonabsorbable. A description of different suture types and their properties is listed in Table 10.2.**

TABLE 10.2

Properties of Suture Materials

SUTURE	ORIGIN	TISSUE ABSORPTION	PHYSICAL CONFIGURATION	TENSILE STRENGTH	COMMEN
Vicryl	Synthetic	Absorbable	Braided	65% 2 wk 40% 4 wk	Slower los function an higher kno breaking strength compared polyglycol acid (Dexo
Dexon	Synthetic	Absorbable	Braided	63% 2 wk 17% 3 wk	Lubricant coating decreases coefficient friction
Monocryl	Synthetic	Absorbable	Monofilament	30%–40% 2 wk (dyed) 25% 2 wk (undyed)	Excellent tensile strength allows use smaller sutures for skin closur
PDS	Synthetic	Delayed absorbable	Monofilament	74% 2 wk 50% 4 wk 25% 6 wk	No absorpt until after days; low reactivity, tends to maintain strength in presence o infection; newer barb version is

					knotless
Maxon	Synthetic	Delayed absorbable	Monofilament	81% 2 wk 59% 4 wk 30% 6 wk	
Chromic gut	Natural	Absorbable	Monofilament	0% 3 wk	Can also be found as pl gut (untrea for faster absorption
Nylon	Synthetic	Nonabsorbable	Monofilament	50% 1–2 yr	Very low tissue reactivity
Prolene	Synthetic	Nonabsorbable	Monofilament	No significant loss over time	High plasticity, extremely smooth surface (requires e knot throw
Silk	Natural	Nonabsorbable	Braided	Degraded over time	Braided fo easier handling; c be prone to infection
Mersilene	Synthetic	Nonabsorbable	Braided or monofilament	No significant loss over time	Braided should not used in infection

PDS, Polydioxanone suture.

An additional suture design developed in recent years is that of barbed sutures. These sutures contain small barbs that allow for increased tissue holding strength and prevent the suture from slipping backward in tissue. Barbed sutures are available as many different primary suture types, including Vicryl, polydioxanone suture (PDS), and Monocryl. They can therefore be used to reapproximate various different types of tissue, including skin, fat, fascia, and organs, and have been increasingly used in urologic surgery (e.g., vesicourethral anastomosis during prostatectomy).

Absorbable Sutures

Absorbable suture material has the advantage of providing sufficient tensile strength for wound closure, while dissolving over time. This latter property minimizes the amount of foreign body material in a wound, thereby decreasing the risk of infection. In general, absorbable sutures produce a greater inflammatory response than nonabsorbable sutures but do not need to be removed and therefore minimize additional wound trauma. The following is a brief review of commonly used absorbable sutures in urologic surgery.

Plain Gut and Chromic Gut

This suture material is made from the serosal lining of bovine or sheep intestine. Chromic gut suture is additionally processed with a chromium salt solution, which prolongs its tensile strength and reduces its rate of absorption. **Although these sutures are constructed as a monofilament, they have a much higher degree of friction than other synthetic monofilament sutures and therefore do not pass through tissue as easily. This allows the suture material to hold securely in tissue, as well as prevent it from unraveling in surgical knots.** Although chromic gut suture retains its tensile strength for 3 to 4 weeks, plain gut is restricted to 7 to 10 days, limiting its utility in most applications. These suture materials may be used to reapproximate the skin edges in areas of low tension in an interrupted fashion, such as that of the scrotal or penile skin.

Poliglecaprone (Monocryl), Biosyn, Caprosyn

These sutures are used primarily for subcuticular skin suturing and create minimal tissue reaction. Constructed as a monofilament, they create minimal trauma when passed through tissue. Monocryl creates acceptable tensile strength for 14 days, whereas Biosyn extends this time period slightly longer. **Caprosyn suture provides acceptable tensile strength for approximately 10 days, although it is absorbed in nearly half the time of the other two sutures and therefore theoretically reduces the risk of infection.**

Polyglactin 910; Vicryl

Vicryl suture is one of the most commonly used suture materials in intra-abdominal surgery and therefore should be familiar to urologists. This suture uses a braided design, although it easily passes through tissue and minimizes unraveling in surgical knots. Vicryl is commonly used to reapproximate subcutaneous tissue such as fat, muscle, and fascia and to create ureteroileal, ureterovesical, and other anastomoses.

Polydioxanone and Polyglyconate (Maxon)

PDS and Maxon suture are commonly used when an extended period of tensile strength is needed. Both sutures are constructed as a monofilament design and are available in a looped configuration for abdominal fascia closure. **PDS typically takes approximately 8 months to be fully absorbed, whereas Maxon is usually absorbed in approximately 6 months.**

Nonabsorbable Sutures

Nonabsorbable suture material has the advantage of retaining tensile strength for a longer period of time as compared with absorbable sutures. These sutures are not degraded by the body over time and therefore can act as a nidus for infection and stone formation. **For this reason, nonabsorbable sutures are not used when contact with urine is anticipated, such as during urinary tract anastomosis or repair of a genitourinary organ injury.** Although most nonabsorbable sutures provide an indefinite length of tensile strength, some nonabsorbable sutures, such as nylon and silk, gradually lose tensile strength over time. **In general, nonabsorbable sutures provoke less of an inflammatory reaction than absorbable sutures and therefore result in less discomfort when being removed.**

Polypropylene (Prolene)

Constructed as a monofilament suture, Prolene easily passes through tissue and creates minimal tissue reaction as it does. As compared with other nonabsorbable sutures, Prolene does not lose tensile strength over time and is therefore very well suited for areas where maximal strength is necessary, such as the abdominal fascia. **Because of its smooth surface and high plasticity, it has a tendency to unravel more than other suture types, and additional knot throws are necessary to ensure knot integrity.**

Polyester (Mersilene)

Similar to Prolene, Mersilene provides excellent tensile strength that does not degrade over time. As opposed to Prolene, it is constructed as a braided suture and therefore maintains better knot hold. **Because of this characteristic, however, it also allows for increased bacterial adherence and should not be used when concern for infection exists.**

Polyamide (Nylon)

Although nylon is a nonabsorbable suture, it does lose strength over time. It is commonly used as a drain suture because the smooth monofilament design passes easily through tissue and creates a minimal tissue reaction, therefore reducing pain as it is removed.

Silk

Constructed in a braided configuration, silk suture is effective at ligating large vessels. It provides a long duration of tensile strength and is not absorbed. This latter property makes it a favored suture type for cases in which wound reentry and easy suture location may be necessary, such as during inguinal orchiectomy.

Fascial Closure Techniques

Although numerous different abdominal fascial closure techniques have been described, a definitive, superior method has not been universally agreed upon. Most commonly studied has been closure in an interrupted fashion with absorbable suture, such as Vicryl, compared with closure in a continuous fashion with a slowly absorbing or nonabsorbable suture material, such as PDS, Maxon, or Prolene. van't Reit et al. (2002) performed a meta-analysis of available RCTs examining different fascial closure techniques. In all, 6566 patients from 15 studies were included; the primary outcome measure was incidence of incisional hernia. **The analysis demonstrated that between slowly absorbable and nonabsorbable suture material there was no difference in risk of incisional hernia in continuous versus interrupted fascial closures, although closure with nonabsorbable suture material was associated with increased wound pain and sinus formation.** For rapidly absorbable suture types, continuous fascial closure was significantly associated with an increased risk of incisional hernias. The authors therefore concluded that wound closure with slowly absorbable suture in a continuous fashion may be the preferred method of fascial closure. To address limitations encountered in previous meta-analyses, Seiler et al. (2009) performed an RCT of 625 patients undergoing surgery requiring fascial closure. Patients were categorized to one of three arms: interrupted fascial closure with rapidly absorbable suture or continuous closure with one of two different slowly absorbable sutures. They found no significant difference in the rate of incisional hernia formation (15.9% vs. 8.4% vs. 12.2%, $P = 0.09$), fascial dehiscence, wound infection, or serious adverse events between the groups. **In conclusion, although incisions may be closed in an interrupted fashion with more rapidly absorbable suture material or in a continuous fashion with slowly absorbable suture or nonabsorbable suture, careful attention should be paid to the technique of closure, given the relatively high incidence of incisional hernia formation.**

Perhaps the most dreaded complication of surgical incisions is acute wound failure (or fascial dehiscence). Overall the incidence of fascial dehiscence is 1% to 2%, and the complication usually occurs approximately 1 week after surgery (although it may occur up to 30 days postoperatively). Risk factors for dehiscence include patient-related factors (advanced age, malnutrition, corticosteroid use, obesity, and prior history of radiotherapy), SSI, and technical errors at the time of wound closure. **The most common technical errors associated with wound failure are placing sutures too close to the fascial edge, knot slippage, and excessive suture tension.** Multiple studies have investigated the type of fascial closure and have demonstrated that there is no difference in the risk of dehiscence between interrupted and continuous closures, as long as rapidly absorbable sutures are not used with the latter.

When acute wound failure does occur, it is usually immediately preceded by a sudden gush of serosanguineous fluid from the wound. **Some small fascial disruptions can be managed conservatively with wound packing and close observation, but the majority of disruptions, particularly in the setting of bowel evisceration, mandate urgent return to the operating room.** At the bedside, a sterile, saline-moistened towel should be placed over the eviscerated components while the patient is being prepared for the operating room. At the time of reoperation, the fascial edges are inspected for the cause of the disruption. In the case of a technical error or fascial tearing, in which the fascial edges are healthy and can be brought together without tension, a primary closure is appropriate. In all other cases, the fascial edges are debrided and the wound is closed with absorbable mesh or biologic prosthetic grafts. A full discussion of the different materials is beyond the scope of this chapter, but strong consideration should be given to an intraoperative general surgical consultation.

Skin Closure

The choice of how to close a skin incision depends on a number of factors, including the length of the incision, tensile strength the incision will be subjected to postoperatively, location of the incision, and need to reopen the incision in the future. Whereas Monocryl, Biosyn, and Caprosyn sutures are preferred for subcuticular suturing because of their ease of handling, minimal tissue reaction, and adequate strength to oppose wound edges, chromic sutures are often used to reappose the cut edges of skin after a circumcision or scrotal surgery because of its rapid time to dissolution and firm knot strength.

When a large abdominal or flank incision is closed, skin stapling offers an alternative to suturing an incision closed. Stapling an incision has the advantages of reduced time and effort to close an incision and the ability to open small areas of a wound should the need arise in the future, such as in the case of infection, while maintaining integrity of the remainder of the incision. Surgical staples, however, create a greater inflammatory tissue reaction and may cause more pain than subcuticular sutures. In addition, the need to remove staples and the discomfort at the time of their removal are averted when using absorbable suture material. **A recent meta-analysis involving 2111 patients comparing surgical staples with sutures for wound closure found that stapling an incision was, on average, 5.56 minutes faster than suturing an incision (Iavazzo et al., 2011). In addition, the authors found that wound infections were significantly more likely in incisions closed with suture than in those closed with staples (odds ratio 2.06).** Interestingly, the authors reported nonsignificant differences in cosmetic outcomes and patient satisfaction with wound appearance after closure with staples compared with sutures. These study results suggest that, although there is not a distinct advantage to closing skin incisions with either staples or suture, neither is inferior to the other, and the decision regarding the appropriate method of skin closure should be individualized on a case-by-case basis.

Retention Sutures

Historically, in high-risk patients retention sutures were strongly advocated and widely used as a preventive measure for wound dehiscence. Literature evidence, however, was primarily retrospective**. Subsequent prospective trials have since shown mixed evidence of benefit for preventing wound dehiscence (Carlson, 1997; Khorgami et al., 2013; Rink et al., 2000).** Specifically, Rink et al. (2000)

randomized 95 high-risk patients to retention sutures versus standard closure; the researchers reported that although no difference in wound failure rates was seen, retention sutures were associated with a significantly increased rate of patient morbidity, primarily discomfort. Alternatively, a recent RCT by Khorgami et al. (2013) randomized 300 patients undergoing midline laparotomy who were deemed to be high risk for wound dehiscence to fascial closure with and without retention sutures. In these patients, they found a significantly greater rate of wound dehiscence in patients undergoing fascial closure without retention sutures as compared with those who also had retention sutures placed (13.3% vs. 4%, $P = 0.007$). However, the rates of evisceration (2.7% vs. 0.7%, $P = 0.371$), wound infection, and incisional hernia did not differ between the groups (Khorgami et al., 2013). Given the mixed study results and potential for patient morbidity, recent surgical trends suggest a movement away from the routine use of retention sutures and reserving the technique for patients at high risk of fascial dehiscence.

Wound Dressing

Sterile dressings protect surgical wounds from infection and abrasion from clothing and the environment. In addition, they collect blood and fluid that drain from the wound and provide a more socially acceptable cosmetic appearance of the surgical wound for the patient. Typically, Steri-Strips are placed over an abdominal wound to provide extra tensile strength to the suture line. Alternatively, skin glue may be applied to small incisions to protect and reinforce the wound. Certain dressing supplies that contain antimicrobial properties, such as Xeroform, may be used to further protect the incision from infection. Dressings are typically removed within 24 to 48 hours to inspect the wound and redress if necessary.

Perhaps the most important recent advancement in wound closure has been development of negative-pressure wound vacuum-assisted closure (VAC) systems. There are three separate types of wound VAC systems intended to aid in closure of three types of wounds, and each has the potential to provide distinct advantages over wound healing without the aid of a VAC device.

Standard wound VAC systems were developed to aid in the closure of complex surgical wounds. **As opposed to primary closure of a grossly infected wound, placement of a foam pad into the wound and providing negative pressure allow for several important benefits that aid in wound closure: passive wound debridement, active fluid removal from the wound, and**

protection from environmental factors. Proposed secondary effects include increased cell proliferation, improved formation of granulation tissue, and reduced inflammation (Orgill and Bayer, 2013). Standard wound VAC systems have been increasingly used in the treatment of Fournier's gangrene.

Open abdomen wound VAC systems (Abthera) allow for temporary abdominal wall closure with a wound VAC when primary closure is otherwise not possible or is impractical. Used in critically ill patients with an open abdomen, this allows a sterile wound VAC to be placed in the wound, protecting the open abdomen from the environment and removing excess fluid as well. **Use of a wound VAC in the open abdomen has been shown to improve rates of eventual fascial closure and decrease mortality (Bruhin et al., 2014; Cheatham et al., 2013).**

Closed-incision negative-pressure wound VAC systems have also recently gained popularity. These systems are typically battery-powered disposable devices that are placed directly over a closed incision. They can be left in place for up to 1 week postoperatively and have been shown in numerous studies to reduce the risk of SSIs, decrease the rate of seroma formation, and increase blood flow to the surgical incision (Blackham et al., 2013; Bonds et al., 2013; Pachowsky et al., 2012; Semsarzadeh et al., 2015).

Key Points

- Proper attention to the operating room and patient environment can decrease the rate of intraoperative preventable complications.
- Perioperative hypothermia of even 1°C to 2°C is associated with increased estimated blood loss and increased risk of SSI.
- Current guidelines advocate restriction of blood product transfusion for hematocrit greater than 21% in most patients unless there are specific cardiopulmonary risk factors.
- Understanding the mechanisms of dry matrix and biologically active hemostatic agents ensures the appropriate application to augment surgical hemostasis.
- Current literature suggests that closure with continuous, slowly absorbing suture results in the lowest risk of incisional-related complication.

References

American Society of Anesthesiologists Task Force on Perioperative Blood Management. Practice guidelines for perioperative blood management: an updated report by the American Society of Anesthesiologists Task Force on Perioperative Blood Management. *Anesthesiology*. 2015;122:241–275.

Bak JB, Singh A, Shekarriz B. Use of gelatin matrix thrombin tissue sealant as an effective hemostatic agent during laparoscopic partial nephrectomy. *J Urol*. 2004;171(2 Pt 1):780–782.

Ball CG, Dente CJ, Shaz B, et al. The impact of a massive transfusion protocol (1:1:1) on major hepatic injuries: does it increase abdominal wall closure rates? *Can J Surg*. 2013;56:E128–E134.

Barie PS. Are we draining the life from our patients? *Surg Infect (Larchmt)*. 2002;3(3):159–160.

Blackham AU, Farrah JP, McCoy TP, et al. Prevention of surgical site infections in high-risk patients with laparotomy incisions using negative-pressure therapy. *Am J Surg*. 2013;205(6):647–654.

Bonds AM, Novick TK, Dietert JB, et al. Incisional negative pressure wound therapy significantly reduces surgical site infection in open colorectal surgery. *Dis Colon Rectum*. 2013;56(12):1403–1408.

Brennan TA, Leape LL, Laird NM, et al. Incidence of adverse events and negligence in hospitalized patients. Results of the Harvard Medical Practice Study I. *N Engl J Med*. 1991;324:370–376.

Bruhin A, Ferreira F, Chariker M, et al. Systematic review and evidence based recommendations for the use of negative pressure wound therapy in the open abdomen. *Int J Surg*. 2014;12(10):1105–1114.

Carlson MA. Acute wound failure. *Surg Clin North Am*. 1997;77(3):607–636.

Chao HH, Torchiana DF. BioGlue: albumin/glutaraldehyde sealant in cardiac surgery. *J Card Surg*. 2003;18(6):500–503.

Cheatham ML, Demetriades D, Fabian TC, et al. Prospective study examining clinical outcomes associated with a negative pressure wound therapy system and Barker's vacuum packing technique. *World J Surg*. 2013;37(9):2018–2030.

Consensus conference. Fresh-frozen plasma. Indications and risks. *J Am Med Assoc*. 1985;253:551–553.

Dumville JC, McFarlane E, Edwards P, et al. Preoperative skin antiseptics for preventing surgical wound infections after clean surgery. *Cochrane Database Syst Rev*. 2015;(4) [CD003949].

Ereth MH, Schaff M, Ericson EF, et al. Comparative safety and efficacy of topical hemostatic agents in a rat neurosurgical model. *Neurosurgery*. 2008;63(4 Suppl 2):369–372 [discussion 72].

Hong YM, Loughlin KR. The use of hemostatic agents and sealants in urology. *J Urol*. 2006;176(6 Pt 1):2367–2374.

Iavazzo C, Gkegkes ID, Vouloumanou EK, et al. Sutures versus staples for the management of surgical wounds: a meta-analysis of randomized controlled trials. *Am Surg*. 2011;77(9):1206–1221.

Irvin W, Andersen W, Taylor P, et al. Minimizing the risk of neurologic injury in gynecologic surgery. *Obstet Gynecol*. 2004;103:374–382.

Khorgami Z, Shoar S, Laghaie B, et al. Prophylactic retention sutures in midline laparotomy in high-risk patients for wound dehiscence: a randomized controlled trial. *J Surg Res*. 2013;180(2):238–243.

Kurz A, Sessler DI, Lenhardt R. Perioperative normothermia to reduce the incidence of surgical-wound infection and shorten hospitalization. Study of wound infection and temperature group. *N Engl J Med*. 1996;334:1209–1215.

Leape LL, Brennan TA, Laird N, et al. The nature of adverse events in hospitalized patients. Results of the Harvard Medical Practice Study II. *N Engl J Med*. 1991;324:377–384.

Madrid E, Urrútia G, Roqué I, Figuls M, et al. Active body surface warming systems for preventing complications caused by inadvertent perioperative hypothermia in adults. *Cochrane Database Syst Rev*. 2016;(4) [CD009016].

Mangram AJ, Horan TC, Pearson ML, et al. Guideline for prevention of surgical site infection, 1999. Hospital infection control practices advisory committee. *Infect Control Hosp Epidemiol*. 1999;20:250–278 [quiz 279–80].

Mannucci PM. Hemostatic drugs. *N Engl J Med*. 1998;339(4):245–253.

Mauermann WJ, Nemergut EC. The anesthesiologist's role in the prevention of surgical site infections. *Anesthesiology*. 2006;105:413–421 [quiz 439–40].

NIH consensus statement available on perioperative red cell transfusion. *Am J Public Health*. 1988;78:1588.

Orgill DP, Bayer LR. Negative pressure wound therapy: past, present and future. *Int Wound J*. 2013;10(Suppl 1):15–19.

Pachowsky M, Gusinde J, Klein A, et al. Negative pressure wound therapy to prevent seromas and treat surgical incisions after total hip arthroplasty. *Int Orthop*. 2012;36(4):719–722.

Peralta E. *Overview of topical hemostatic agents and tissues adhesives used in surgery*. UpToDate. 2018 [website] https://www.uptodate.com/contents/overview-of-topical-hemostatic-agents-and-tissue-adhesives.

Practice advisory for the prevention of perioperative peripheral neuropathies: a report by the American Society of

Anesthesiologists Task Force on Prevention of Perioperative Peripheral Neuropathies. *Anesthesiology*. 2000;92:1168–1182.

Practice guidelines for perioperative blood transfusion and adjuvant therapies: an updated report by the American Society of Anesthesiologists Task Force on Perioperative Blood Transfusion and Adjuvant Therapies. *Anesthesiology*. 2006;105:198–208.

Pursifull NF, Morey AF. Tissue glues and nonsuturing techniques. *Curr Opin Urol*. 2007;17(6):396–401.

Rajagopalan S, Mascha E, Na J, et al. The effects of mild perioperative hypothermia on blood loss and transfusion requirement. *Anesthesiology*. 2008;108:71–77.

Rink AD, Goldschmidt D, Dietrich J, et al. Negative side-effects of retention sutures for abdominal wound closure: a prospective randomised study. *Eur J Surg*. 2000;166(12):932–937.

Seiler CM, Bruckner T, Diener MK, et al. Interrupted or continuous slowly absorbable sutures for closure of primary elective midline abdominal incisions: a multicenter randomized trial (INSECT: ISRCTN24023541). *Ann Surg*. 2009;249(4):576–582.

Semsarzadeh NN, Tadisina KK, Maddox J, et al. Closed incision negative-pressure therapy is associated with decreased surgical-site infections: a meta-analysis. *Plast Reconstr Surg*. 2015;136(3):592–602.

Spotnitz WD, Burks S. Hemostats, sealants, and adhesives: components of the surgical toolbox. *Transfusion*. 2008;48(7):1502–1516.

Uribe CA, Eichel L, Khonsari S, et al. What happens to hemostatic agents in contact with urine? An in vitro study. *J Endourol*. 2005;19(3):312–317.

van't Riet M, Steyerberg EW, Nellensteyn J, et al. Meta-analysis of techniques for closure of midline abdominal incisions. *Br J Surg*. 2002;89(11):1350–1356.

Warner MA, Martin JT, Schroeder DR, et al. Lower-extremity motor neuropathy associated with surgery performed on patients in a lithotomy position. *Anesthesiology*. 1994;81:6–12.

Warner MA, Warner DO, Harper CM, et al. Lower extremity neuropathies associated with lithotomy positions. *Anesthesiology*. 2000;93:938–942.

Webster J, Osborne S. Preoperative bathing or showering with skin antiseptics to prevent surgical site infection. *Cochrane Database Syst Rev*. 2007;(2) [CD004985].

Witte MB, Barbul A. General principles of wound healing. *Surg Clin North Am*. 1997;77(3):509–528.

11

Lower Urinary Tract Catheterization

Joseph M. Jacob MD, MCR, Chandru P. Sundaram MD, FACS, FRCS (Eng)

History

The earliest known record of catheterization is from 1500 BCE. Ancient Egyptians recorded the use of transurethral bronze tubes, reeds, straws, and curled up palm trees. There are references in the writings of Hippocrates (400 BCE) to the use of malleable lead tubes used for catheterization. An S-shaped silver tube used for the treatment of urinary retention was found in the ruins of Pompeii (CE 79) (Feneley et al., 2015). A fourth-century Byzantine medical anthology includes several indications for catheterization of bladder, including fistula repair surgery, urinary retention, and kidney “inflammation.” In the fifth century, Latin authors mention catheter placement in paralyzed patients (Moog et al., 2005). Catheter use was recorded in the middle ages in Spain as well as China. In the 16th century, the use of an indwelling wax and cloth catheter was documented. Benjamin Franklin used a silver wire catheter to treat his brother's urinary retention from a bladder calculus. He later used this catheter on himself when he developed a bladder calculus. In our opinion, one of the most important advances in catheterization was Jean Francois Reybard's invention of the self-retaining catheter in 1855. He developed a catheter with two channels, one for urine drainage and the other to inflate a balloon. In 1929 Dr. Frederic Foley developed the modern balloon-based rubber catheter with an inflatable rubber balloon. This catheter was originally designed for postprostatectomy hemostasis, but soon after production, its use was widely applied. Silicone catheters were developed in 1968, which reduced urethritis, encrustation, and infection (Feneley et al., 2015). Not unexpectedly, the simple concept of lower urinary drainage via catheterization has withstood the test of time and has remained an invaluable aspect of urologic care.

Anatomic Considerations

Male Urethra

The male urethra is about 18 to 20 cm long. The anterior urethra, which is surrounded by the corpus spongiosum, is approximately 16 cm and lies within the penis distally and the perineum proximally. The anterior urethra can be further subdivided into the pendulous or penile urethra; the bulbar urethra, which is surrounded by the bulbospongiosus muscle; and the fossa navicularis. The posterior urethra is 4 cm long and lies within the pelvis proximal to the corpus spongiosum. It can be further subdivided into the preprostatic or bladder neck, prostatic, and membranous urethra (Standring, 2015). The average normal male meatus should accommodate a 24-Fr instrument or catheter. The prostatic urethra should accommodate a 32-Fr instrument and the bladder neck a 28-Fr catheter or instrument (Davis, 1918; Kohler et al., 2008).

Female Urethra

The female urethra is approximately 4 cm in length and is present within the anterior vagina (Standring, 2015). The normal caliber of a female urethra is 22 Fr (Uehling, 1978).

Indications for Lower Urinary Tract Drainage

Diagnostic

There are multiple diagnostic indications for lower urinary tract drainage. Patients, especially children or females, may require catheterization of the urinary bladder for sterile acquisition of urine for culture. This can be important in cases in which there is a suspicion for contamination of the urine with clean-catch specimens. Often, when patients are admitted to the hospital for varying diagnoses such as acute kidney injury or sepsis, catheterization is indicated for urine output monitoring. When lower urinary tract trauma is expected, catheterization may be required for diagnosis of a urethral or bladder injury. A cystogram requires the insertion of a catheter into the bladder, whereas a retrograde urethrogram requires insertion of the catheter into the fossa navicularis. Flexible and rigid cystoscopy are a form of lower urinary catheterization and are used to diagnose various lower urinary tract pathologies. The performance of urodynamics studies requires catheterization of the bladder to measure postvoid residual, to fill the bladder during measurement, and to insert the sensor catheter to measure detrusor pressure. Finally, catheterization may be required to collect cytology when there is a suspicion of urothelial cancer.

Therapeutic

Lower urinary catheterization has remained an essential part of urologic therapy. Urinary catheterization for urinary retention is a simple yet extremely important urologic treatment. Many causes of urinary retention including benign prostatic hyperplasia (BPH), clot retention, and urethral strictures can be temporarily treated with catheterization. In these situations, catheterization allows the urologist to temporize the emergent situation and permits the clinician to offer definitive therapy in a planned and controlled environment. Long-term urethral catheterization is used for selected patients with urinary retention and urinary incontinence when other definitive treatment options are not possible. It may also be indicated in the setting of hematuria if continuous bladder irrigation is required. Intravesical treatments such as Bacillus Calmette-Guérin vaccine or mitomycin for bladder cancer or dimethyl sulfoxide for interstitial cystitis necessitate the catheterization of the bladder. Catheterization or dilation of the urethra can be used to treat urethral strictures. Lower urinary tract catheterization is also performed during major surgery to drain the bladder and monitor urine output. Extraperitoneal bladder injury and selected cases of intraperitoneal bladder injury are managed with urethral catheterization. Small vesicovaginal fistulas can also be managed conservatively with urethral catheterization.

Contraindications

The only absolute contraindication to urethral catheterization is a suspected or confirmed urethral injury or a history of bladder neck closure or repair. Relative contraindications include recent urethral surgery or urethral stricture (Thomsen and Setnik, 2006). Urethral catheterization should not be placed in a patient with an artificial urinary sphincter (AUS) without the consultation of a urologist. The technique for catheter placement in patients with an AUS is described later in this chapter.

Technique of Urethral Catheterization

Preparation for Catheterization

Before placement of any type of lower urinary catheter, the clinician must prepare all the necessary supplies. These supplies vary based on the situation; however, in most cases, all the required supplies will be packaged in a catheter kit or tray. These trays usually include sterile gloves, a catheter, sterile lubricant, antiseptic solution, sterile drapes, sterile water, and a collection bag with tubing (Thomsen and Setnik, 2006). Based on the indication for catheterization, the clinician must decide whether more supplies or special catheters are needed. Before catheterization, the catheter tray or supplies should be opened sterilely and sterile gloves should be placed. The catheter balloon should be tested by inflating and deflating it with sterile water, and the antiseptic solution placed on cotton balls or swabs. The sterile field should be established with sterile drapes, and the external genitalia should be properly prepared with antibacterial solution.

Urethral Catheterization in Men

The male patient should be in a supine position. If the penis is uncircumcised, the foreskin should be retracted and the glans should be sterilized. Ten to fifteen mL of sterile lubricant are slowly injected directly into the meatus, then the distal glans is pinched to prevent the reflux of lubricant from the meatus. At this point, the nondominant hand is considered not sterile and the remainder of the procedure should be performed with the other hand. The catheter is gently inserted into the meatus while the penis is pulled straight and taut. It is not uncommon to feel slight resistance at the urinary sphincter or prostate. Slow, steady pressure is continued until the catheter is completely positioned and the balloon port is at the level of the meatus**. It is essential that the catheter be inserted completely before filling the balloon, even though the return of urine may be seen before this.** Some urine return may be encountered before passing the catheter passed the bladder neck. Then the balloon is filled with sterile water and the catheter pulled distally to ensure proper placement. The balloon should not be inflated until flow of urine through the catheter is confirmed. If it appears that the catheter is beyond the bladder neck and there is no return of urine, the catheter may be obstructed by the lubrication. In this case, the catheter is irrigated with sterile water or saline. If the foreskin was retracted, the clinician must ensure that the foreskin is replaced over the glans to prevent paraphimosis (Thomsen and Setnik, 2006). Sterile 2% lidocaine jelly may be used instead of lubricant jelly in patients who are apprehensive or if initial attempts at catheterization have failed.

Urethral Catheterization in Women

In most circumstances, catheterization of the female urethra should be less difficult than catheterization in the male. The patient should be in a supine frog-legged position. The thumb, pointer, and middle finger of the nondominant hand are used to spread the labia before sterilization of the meatus. Lifting anteriorly while spreading the labia may help improve visualization. The catheter is lubricated with sterile lubricant, then the catheter is inserted gently into the meatus. Very little or no resistance should be encountered. Once urine return is noticed, the balloon port is filled with sterile water. If visualization of the meatus is difficult, the patient may be placed in Trendelenburg position, and more assistance may be needed for retraction (Manzano and Lacroix, 2014).

Urethral Catheterization of Children

Catheterization of the urethra in a male and female child should follow the same principles as discussed earlier. However, there are a few important considerations when catheterizing the lower urinary tract of a child. Male children may have physiologic phimosis, which should not be forced to retract (Lacroix et al., 2010). In this circumstance, the foreskin can be gently moved ventrally or dorsally to identify the meatus. Male children may exhibit an intense urinary sphincter contraction in response to manipulation of the urethra. In this case, steady pressure is held at the sphincter without forcing until the resistance is released. Usually resistance abates once the child takes a deep breath. Clinicians should also ensure that the catheter size is appropriate for the age of the child (Table 11.1).

TABLE 11.1

Recommended Size of Pediatric Catheters According to Age

TYPE OF CATHETER	AGE OF CHILD					
	NEWBORN	**1–11 MO**	**12–23 MO**	**2–6 YR**	**7–12 YR**	**>12 YR**
Straight—French gauge	4.0–6.0	6.0–8.0	8.0	10.0	10.0–12.0	14.0
Balloon—French gauge	6.0	6.0–8.0	8.0	8.0–10.0	12.0–14.0	14.0–16.0

Types of Urethral Catheters

Urethral catheters can vary by size, shape, number of ports, and material. Catheters either have a straight tip or a coudé tip. A council tip catheter can be passed over a wire because it has an opening at the distal tip, unlike a typical catheter, which is blind-ending. Council catheters are available with either a straight or coudé tip. Catheters are available with either one, two, or three ports. A one-port catheter can be effective in drainage of the bladder because its lumen is greatest in diameter. However, a one-port catheter cannot be anchored because of lack of a balloon port. A two-port catheter is the most common type and is effective for anchoring because a balloon can be filled with sterile water to prevent the catheter from migrating distally. A three-port catheter is used for bladder irrigation, most commonly in patients with hematuria. The extra port is usually connected to a saline bag and fluid is continuously infused. Many types of materials and coatings are used for different types of catheters. Catheters can be manufactured from latex, rubber, silicone, or polyvinylchloride (PVC). They can be manufactured with hydrophilic, antibiotic, or antiseptic coatings.

Numerous studies have been performed attempting to compare patient outcomes based on catheter material or coating. Three trials compared standard catheters with silver oxide impregnated catheters. Pooling these trials together still does not provide enough evidence to recommend silver oxide catheters over the standard. Several trials comparing silver alloy catheters to the standard did show a significant decrease in asymptomatic bacteriuria defined as greater than 10^5 colony-forming units (Schumm and Lam, 2008). However, when using symptomatic urinary tract infections (UTIs) as the primary endpoint, no difference was found (Pickard et al., 2012). A small trial compared minocycline- and rifampicin-impregnated with the standard catheter in men after prostatectomy. The risk of asymptomatic bacteriuria was decreased; however, there was no significant difference in symptomatic bacteriuria (Darouiche et al., 1999). No difference in asymptomatic bacteriuria was found in multiple trials comparing different types of standard catheters, including silicone, latex, hydrophilic polymer-coated latex, and PVC catheters (Chene et al., 1990; Nickel et al., 1989; Tidd et al., 1976). One trial showed that silicone catheters had a lower incidence of reported urethral symptoms compared with nonsilicone catheters (Kalambaheti, 1965), and another showed a decrease in urethritis diagnosed on urethral swab when comparing silicone with latex (Nacey et al., 1985).

Catheter Sizing

The clinician should first determine the indication for catheterization and understand the anatomy of the patient's urethra based on age and history. Based on these factors, the clinician should then choose the most appropriate catheter for the specific patient. For example, a 30-year-old man with spinal cord injury likely requires a different size catheter than a 75-year-old man with urinary retention. This is discussed later. Also, some patients may have a latex allergy, and therefore a silicone or PVC catheter should be used. French (Fr) is the accepted measurement unit for urinary catheters along with other types of catheters such as coronary catheters. **To convert French to millimeters, the number in French is divided by 3. As the French size increases, the diameter of the catheter lumen increases** (Table 11.2). **The sizing units describe the diameter of the lumen.**

TABLE 11.2

Approximate Conversion From French to Millimeters[a]

FRENCH	MILLIMETERS
3	1
4	1.33
5	1.67
6	2
7	2.33
8	2.67
9	3
10	3.33
11	3.67

12	4
13	4.33
14	4.67
15	5
16	5.33
17	5.67
18	6
19	6.33
20	6.67
21	7
22	7.33
23	7.67
24	8
25	8.33
26	8.67
27	9
28	9.33
29	9.67
30	10
31	10.33
32	10.67
33	11

[a] These are approximate measurements.

Double-Lumen Catheters

Double-lumen catheters are likely the most prevalent and are used commonly for simple catheterization of patients in the hospital setting. Intraoperatively, anchoring a catheter may be necessary, and usually double-lumen catheters are used with a temperature-sensing probe built into the lumen. This aids the anesthesiologist to monitor the temperature of the patient intraoperatively. Double-lumen catheters may be made with latex, silicone, or PVC. They also may have a straight tip or a coudé tip.

Single-Lumen Catheters

Single-lumen catheters are usually indicated in patients who require intermittent catheterization. This can be in the setting of urethral catheterization in patients with a catheterizable channel. Typically, a catheterizable channel can accommodate a 12- or 14-Fr catheter. As the diameter increases, usually the rigidity of the catheter increases. **Catheter type or material also influences rigidity.** Red rubber catheters are soft and are less likely to create a false passage. However, they may not be rigid enough to traverse an obstructing prostate or a valve mechanism such as in an ileocecal valve in an Indiana pouch or a valve created at the anastomosis between the orthotopic bladder and a catheterizable channel.

Hematuria Catheter

A hematuria catheter can be extremely helpful in patients with significant hematuria with clots. These catheters usually have three lumens to initiate continuous bladder irrigation. They are also made with PVC, which does not compress. Alternatively they are made of latex along with a metal spring, which prevents the catheter from compressing. This allows the clinician to irrigate without the lumen of the catheter narrowing as negative pressure from a syringe is used to remove clots. These catheters also usually have a large drainage eye at the tip, which aids the extraction of thick material (Fig. 11.1).

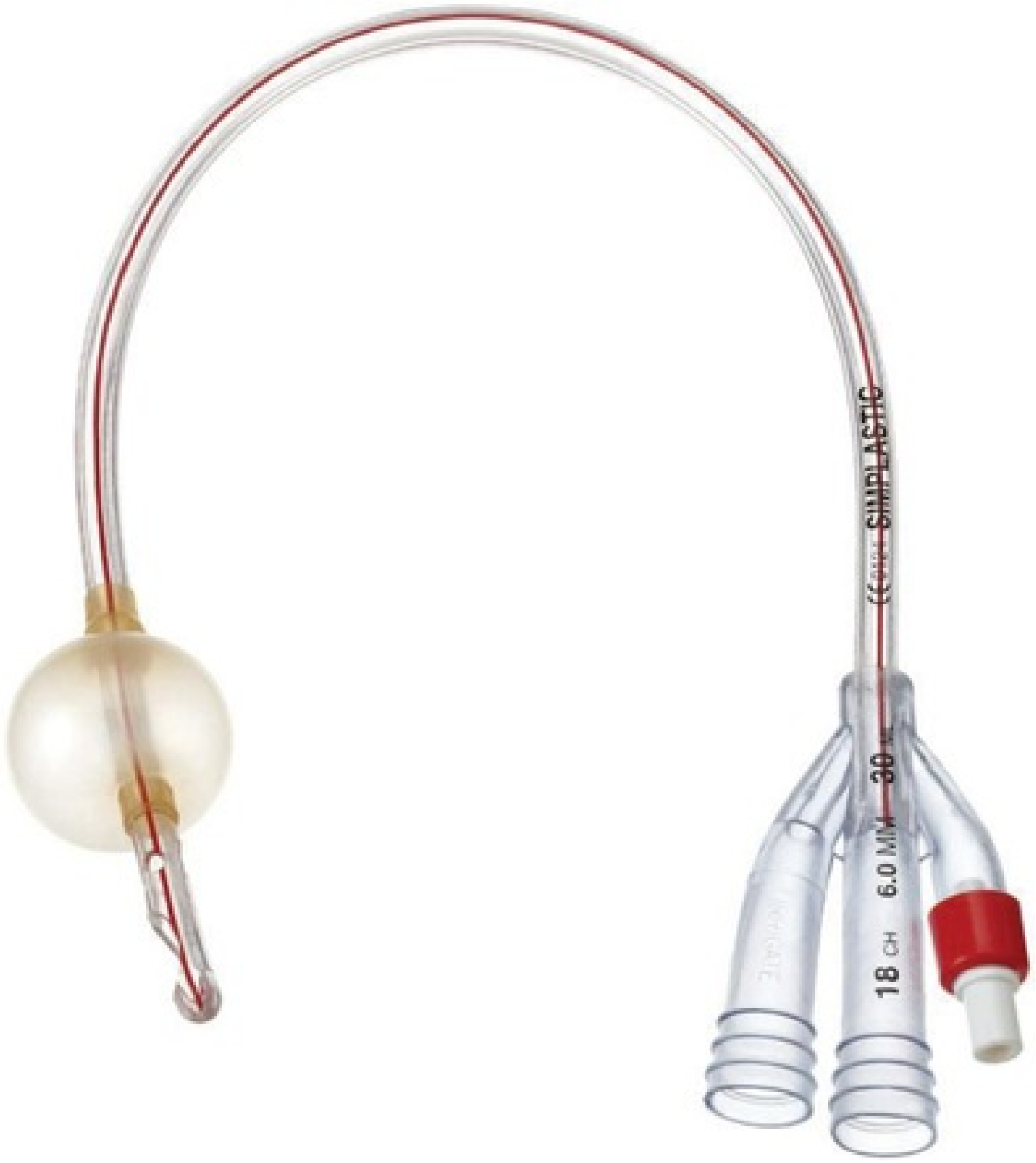

FIG. 11.1 Three-way hematuria catheter. (**Image courtesy of Teleflex Incorporated. © 2019 Teleflex Incorporated.** All rights reserved.)

Another type of hematuria catheter is a four-lumen catheter. One lumen is for the balloon, one for continuous flow, one for drainage, and the fourth for simultaneous irrigation when needed (Fig. 11.2).



FIG. 11.2 Four-way catheter. (From https://www.crbard.com/medical/en-US/Products/4-Way-Infection-Control-Specialty-Foley-Catheters.)

Diagnostic Catheters

The Lapides Diagnostic Foley catheter has five radiopaque rings, each 1 cm apart for calibration of female urethra length. The Davis and Trattner Diagnostic Foley catheters were used to diagnose urethral diverticula in females. These catheters have two balloons, one for the bladder neck and one to seal the meatus so that contrast can be instilled in the urethra. Currently, MRI technology has likely replaced the diagnostic method using these specialty catheters (Fig. 11.3).

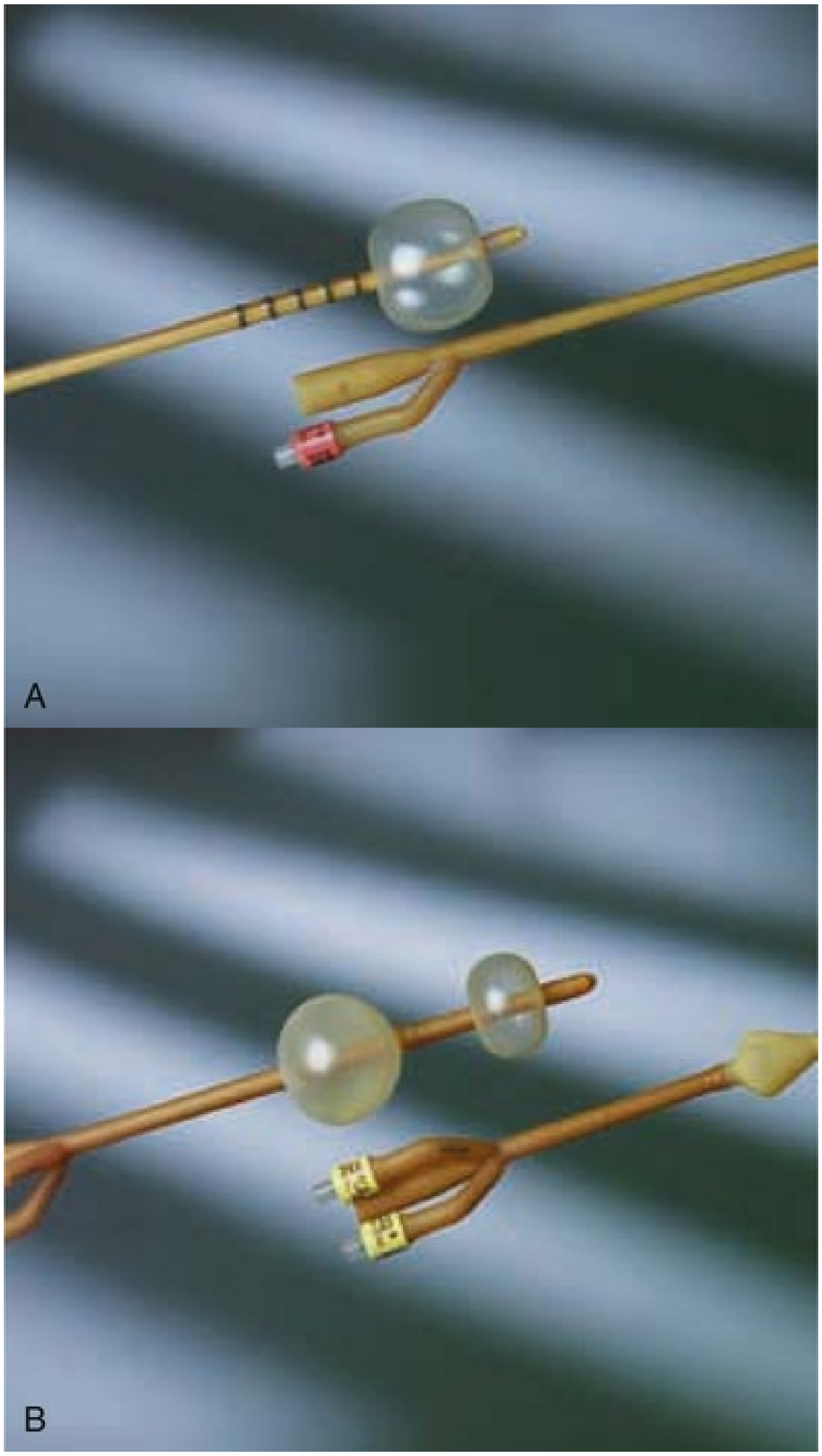

FIG. 11.3 Diagnostic catheters. (A) Lapides diagnostic catheter. (B) Davis and Trattner diagnostic catheters. (From https://www.crbard.com/medical/en-US/Products/Diagnostic-Foley-Catheters.)

Urodynamic catheters are essential for diagnoses of many different bladder pathologies. The catheter has three ports, one is a pressure sensor, one is for filling, and the other is a balloon port.

Drain Catheters

Malecot catheters are used primarily postsurgically for optimal drainage. There is no balloon port, but instead the tip has four small arms that can be compressed for insertion but hold the catheter in place (Fig. 11.4). These can be used as nephrostomy tubes or suprapubic (SP) tubes after a simple prostatectomy or are commonly placed intraoperatively during Indiana pouch creation. A Pezzer tube is similar with a slightly different configuration (Fig. 11.5).



FIG. 11.4 Malecot tube. (From https://www.crbard.com/medical/en-US/Products/Malecots.)



FIG. 11.5 Pezzer tube. (From https://www.crbard.com/medical/en-US/Products/Pezzers.)

Condom Catheters

Condom catheters are a type of external urinary drainage. They are typically used for male patients who have mobility issues with no concern for bladder outlet obstruction (Fig. 11.6).



FIG. 11.6 Condom catheter. (From https://www.coloplast.us/freedom-cath-en-us.aspx#.)

Key Points: Catheters

- There are many indications for urethral catheterization and many sizes and types of catheters that can be used.
- As the French size increases, the diameter of the catheter lumen increases (see Table 11.2).
- Catheter rigidity varies by material.
- Three-way hematuria catheters should be used if clot retention is suspect.

Suprapubic Catheterization

Indications

SP catheterization is indicated in many situations and may even be necessary in situations in which the urethra is inaccessible. Patients with a urethral disruption from trauma may require temporary placement of an SP catheter for bladder drainage. This access may then be used to fill the bladder with contrast and perform a voiding urethrogram to aid in visualization of the proximal urethra. Patients may also have a urethral stricture or multiple strictures that are too dense to dilate without general anesthesia. Recent urethral or bladder neck reconstruction may also preclude the use of a urethral catheter. SP catheterization can be an invaluable procedure in scenarios such as these especially when the patient urgently requires bladder drainage.

In patients requiring long-term catheterization, an SP tube may be more comfortable and has the potential to avoid certain complications such as urethral erosion or stricture. Although long-term catheterization is not recommended, some patients may require it. For example, there are patients that may be too unhealthy to undergo major urologic procedures such as simple prostatectomy, urinary diversion, bladder augmentation, urethroplasty, or even transurethral resection of the prostate. If these patients have significant retention or urinary incontinence, SP catheterization may be considered.

Techniques

There are various techniques to place an SP catheter, which include open cystotomy, trocar technique, Seldinger technique, and Seldinger technique with ultrasound guidance. Occasionally, SP drainage is indicated without placement of a catheter. In this case, once the bladder is palpated, a 21-gauge needle can be inserted and urine can be aspirated. This can be done under ultrasound guidance if the bladder is not easily palpated, such as in an obese person or if there is a history of prior abdominal or pelvic surgery. **The needle should be placed in a vertical plane 1 fingerbreadth cephalad to the pubic symphysis** (Harrison et al., 2011). The clinician should aspirate as the needle is inserted in an anterior to posterior direction. Once urine is confirmed, the needle is advanced slightly and the bladder continues to drain.

Open Cystotomy

Open cystotomy can be performed in various ways. Usually this procedure is performed under general anesthesia or sedation. The bladder is distended to capacity. A small incision is made in the skin, and retractors are used to expose the rectus fascia. The fascia is incised and the rectus muscle is spread. Once the bladder is palpated, stay stitches can be placed to lift the bladder toward the incision. A small incision is made in the bladder, and any catheter can be placed and anchored in the bladder. Hemostasis is achieved and the catheter is then secured to the skin with permanent suture. Alternatively, after incising the skin, a trocar, usually stainless steel, can be placed into the bladder under cystoscopic vision. A catheter can then be placed through the outer sheath once the obturator is removed (Fig. 11.7).



FIG. 11.7 Stainless steel obturator and outer sheath. (From Goyal NK, Goel A, Sankhwar SN: Safe percutaneous suprapubic catheterization. *Ann R Coll Surg Engl* 94:597–600, 2012.)

Another method uses an adapted urethral sound, referred to as the Lowsley retractor. The Lowsley retractor is advanced into the bladder through the urethra. It is then pushed anteriorly toward the abdominal wall. A skin incision is made, and electrocautery is used to cut down onto the tip of the retractor. The retractor is then exposed up into the incision. A catheter is then secured to the retractor usually with a 2-0 silk tie. The Lowsley and catheter are then pulled back through the urethra and out the meatus. The tie is cut and the retractor is released from the catheter. Cystoscopy is used to guide the catheter back proximally into the urethra and safely in the bladder. The balloon port is then filled and the catheter secured to the SP skin with permanent suture (Edokpolo and Foster, 2011; Zeidman et al., 1988).

Placement With a Guidewire and the Seldinger Technique

These techniques are most commonly used under local anesthesia. Usually the skin and the future SP tract are injected with lidocaine after the skin is prepped. The site of puncture is usually 2 to 4 cm cephalad to the pubic symphysis. A small incision is made in the skin, and a 21-gauge needle is advanced in a vertical direction similar to aspiration described earlier. This can be performed under ultrasound guidance to ensure the bladder is distended and the tract is free of bowel. If the bladder is not distended, the clinician should either fill the bladder or wait until the bladder is eventually distended. The ultrasound probe can be placed transversely, and the probe should be angled slightly toward the needle. The needle is then advanced until urine is returned. Advance the needle slightly further posterior and then place a super stiff guidewire into the bladder. Once the needle is removed, various kits are available to advance a catheter over the wire. Some kits include a peel-away sheath that can be inserted over a wire. Care must be taken as to not advance the catheter too far and into the bladder neck (Jacob et al., 2012; Martino et al., 2017; Mohammed et al., 2008). The catheter is then secured by filling the balloon or deploying the pigtail. The clinician can also place a council tip catheter over a wire after dilation or after incising the fascia.

Difficult Catheterization

Prostatic Obstruction

Likely the most common cause of difficulty with lower urinary tract catheterization is BPH with obstruction. The prostatic adenoma causes a narrowing of the prostatic urethra. The narrowing combined with the angle of the male urethra can lead to the inability to advance the catheter or the unfortunate iatrogenic creation of a false passage posterior to the prostatic urethra. Usually, smaller catheters such as 14 or 16 Fr will not pass through the prostatic urethra. An 18-Fr catheter has more rigidity and the tip has more surface area, which may aide in advancing past the prostatic urethra. **If BPH is suspected, ideally the clinician should use at least an 18-Fr catheter with a coudé tip**. The coudé tip was developed to follow the angle of the male urethra. There is a small raised marker on the end of the coudé catheter that shows the orientation of the tip. The clinician should ensure this mark is always anterior, which will point the coudé tip anteriorly. Usually the combination of a coudé tip and at least an 18-Fr catheter is sufficient to advance a catheter in a man with prostatic obstruction. If a false passage has been created, cystoscopy is indicated to not exacerbate the extent of the false passage. If blood is noticed in the catheter port or at the tip of the catheter once removed after difficulty with passage, a false passage should be suspected. Using cystoscopy allows the clinician to visually traverse a false passage, usually by angling the camera anteriorly, and a guidewire can be placed once the bladder is entered. A council tip catheter may then be used, which is passed over the wire.

Urethral Stricture

Urethral strictures can occur at any position in the urethra. The clinician can estimate the location of the stricture based on the amount of catheter that is passed before feeling resistance. Occasionally, gentle pressure may dilate a soft stricture, and the catheter may pass beyond the stricture. Strictures at the membranous urethra are more likely to lead to a false passage because of the angle of the urethra. However, a false passage may occur anywhere in the urethra. If a stricture is suspected, the clinician may attempt to pass an atraumatic guidewire, which is usually a hydrophilic wire, past the stricture and into the bladder. Most efficiently, a cystoscope is used to pass the wire under direct vision. An atraumatic wire can be exchanged for a more rigid guidewire through a 5-Fr catheter. Urethral dilators can be passed over the wire. Usually dilation is stepwise, starting from a small dilator size and progressively increasing the dilator sizes. Care must be taken not to pass the dilator too far, causing a puncture in the posterior wall of the bladder. Typically, the clinician must dilate one size larger than the catheter because of the decreased rigidity of the catheter compared with the dilator. For example, if a 16-Fr catheter is planned, dilation should be performed until at least 18 Fr. A balloon dilator may be used instead of urethral dilators (Giesy et al., 1984). Alternatively, filiform dilators can be used. In some circumstances, a stricture may be too dense or too long, and dilation may not be possible. Emergently, an SP tube can be placed. If it is not an emergent situation, operative management such as direct vision urethrotomy or urethral reconstruction may be preferred before dilation.

Urethral Trauma

Urethral trauma can lead to partial or complete urethral injuries. **In posterior urethral injuries, one gentle passage of a catheter may be attempted.** If resistance is noticed, the clinician should immediately remove the catheter. Primary endoscopic realignment can be attempted depending on the stability of the patient (Herschorn et al., 1992). An SP catheter may be required. Urethral trauma is discussed in further detail in Chapter 133.

Abnormal Anatomy

Posterior Urethral Valves

Newborn males born with posterior urethral valves may require urgent catheterization. A blunt-tip 5-Fr catheter can be placed in ice and then shaped with an anterior curve to allow the catheter to pass anterior to the valves. Alternatively, one can place the fourth finger in the newborn's rectum and guide the catheter anteriorly past the valves. If a urethral catheter is unsuccessful, ultrasound-guided SP tube placement is required (Fig. 11.8).

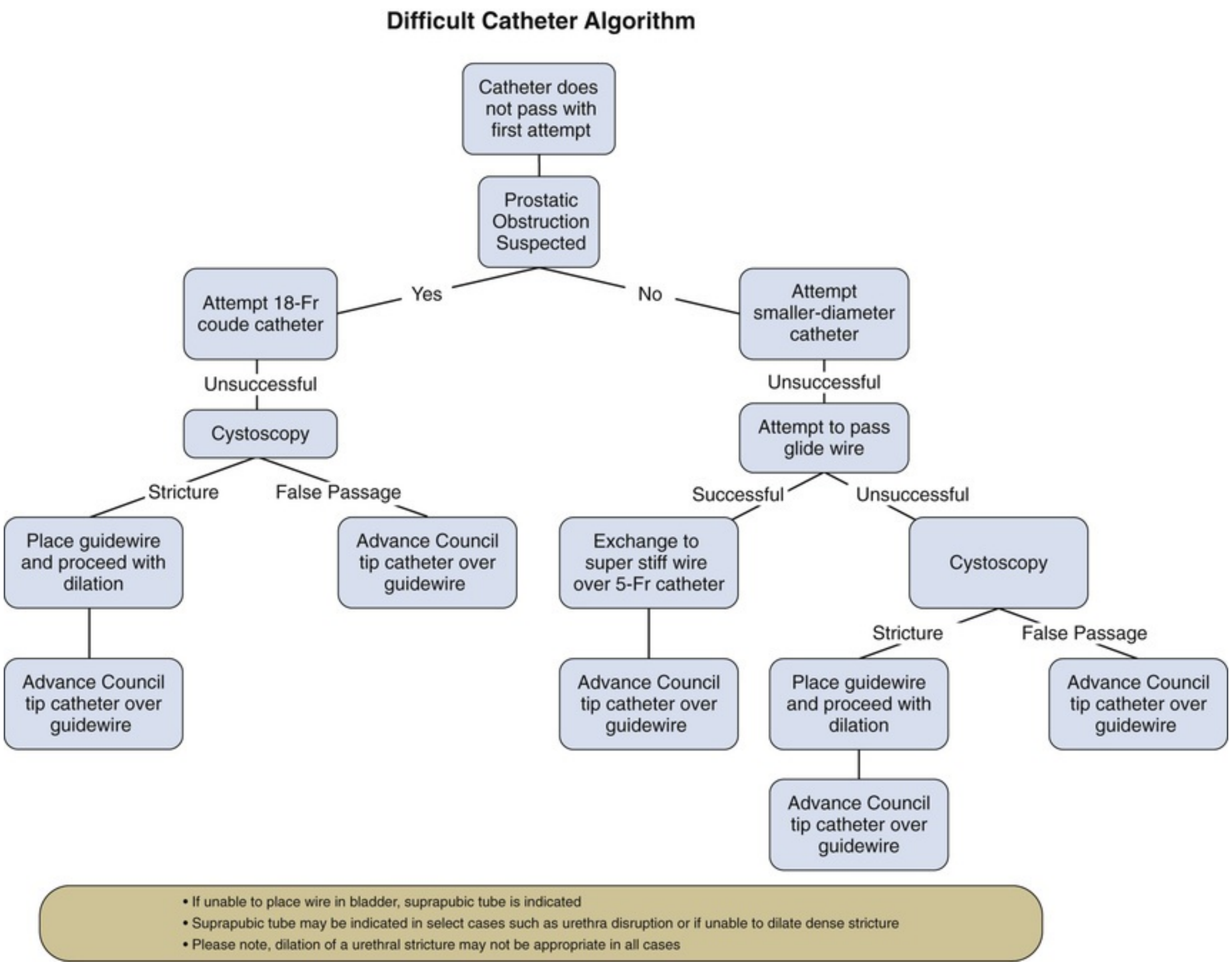

Difficult Catheter Algorithm
Catheter does not pass with first attempt
Prostatic Obstruction Suspected
Yes
No
Attempt 18-Fr coude catheter
Attempt smaller-diameter catheter
Unsuccessful
Unsuccessful
Cystoscopy
Attempt to pass glide wire
Stricture
False Passage
Successful
Unsuccessful
Place guidewire and proceed with dilation
Advance Council tip catheter over guidewire
Exchange to super stiff wire over 5-Fr catheter
Cystoscopy
Stricture
False Passage
Advance Council tip catheter over guidewire
Advance Council tip catheter over guidewire
Place guidewire and proceed with dilation
Advance Council tip catheter over guidewire
Advance Council tip catheter over guidewire

- If unable to place wire in bladder, suprapubic tube is indicated
- Suprapubic tube may be indicated in select cases such as urethra disruption or if unable to dilate dense stricture
- Please note, dilation of a urethral stricture may not be appropriate in all cases

FIG. 11.8 Algorithm for difficult catheter placement.

Obesity

Obese patients, especially with a large amount of infrapubic adipose, can present a challenge in catheter placement. In a female, exposure can be attained with the help of others to provide adequate retraction. The bed can be placed in Trendelenburg as well. If the urethra is still difficult to visualize, the clinician can place two fingers in the vagina and pass the catheter while guiding it anteriorly with the fingers. In obese males with a buried penis, usually applying posterior force to the infrapubic area allows the clinician to identify the meatus. Often phimosis is encountered because of the irritation from poor hygiene or urine incontinence. In this case, a dorsal incision in the foreskin may be necessary.

Reconstruction of the Lower Urinary Tract

In patients with a history of urologic surgery, lower urinary catheterization may be extremely difficult or may not be possible. **The clinician should obtain a thorough history and all prior operative records before instrumentation.** If a bladder neck closure has been performed, obviously urethral catheterization should be avoided. Similarly, urethral catheterization in patients with continent or incontinent diversions after cystectomy should not be attempted except in the case of an orthotopic bladder replacement.

Bladder Replacement or Neobladder

A bladder replacement should be easily catheterizable through the urethra as long as there are no anastomotic issues or tumor recurrence. If catheterizing the urethra is unsuccessful, clinicians must take great caution in placing an SP tube. Usually the ileum falls into the pelvis after cystectomy and can easily be injured during SP tube placement. SP tube placement should be performed with ultrasound guidance. If an SP catheter was placed during the cystectomy and creation of the bladder placement, often a scar from the old SP site can be identified on examination. This old tract can be used to guide the placement of a needle because this theoretically was the location that was pulled toward the abdominal wall by the catheter. Most likely the old SP site is scarred and therefore safe from bowel injury. However, caution should still be emphasized. If emergent decompression is required, likely the bladder replacement will be palpable in the pelvis. The old SP site, if present, should be a safe location to insert a needle. The needle should be inserted with a syringe drawn back to identify urine once the bladder replacement is entered. If succus is visualized in the syringe, the clinician should obviously remove the needle and choose a different location. A single puncture with a 21-gauge needle should not cause significant injury to the small bowel. Once access is obtained into the bladder replacement and urine return is visualized, any of the various SP tube techniques described earlier can then be used.

Continent Urinary Reservoir or Indiana Pouch

Postcystectomy patients with a continent urinary reservoir or an Indiana pouch should not be catheterized per urethra except in certain circumstances such as a pelvic abscess that requires drainage. The reservoir is usually placed in the right lower quadrant with a catheterizable channel most commonly in the right lower quadrant. Occasionally, patients are unable to catheterize through the channel for various reasons. **Most commonly, if the reservoir becomes overly distended,**

the channel will kink and will not accommodate the passage of a catheter. Forcing a catheter should not be attempted because of the risk of channel perforation. Also, patients may inadvertently create a false passage in the channel or may be unable to catheterize because of severe stomal stenosis. If a false passage is suspected, the clinician may use a flexible cystoscope or ureteroscope to traverse the false passage and gain access to the reservoir with a guidewire. A council tip catheter can be placed over the wire. Leaving the catheter in place for 1 to 2 weeks is usually sufficient for the channel to heal. If the reservoir is overdistended, the clinician must use a 21-gauge needle to decompress it. If available, ultrasound guidance should be used. If an SP tube was used perioperatively and an SP site scar is identified, the clinician should advance the needle at this location as described earlier. Usually, in this situation, placement of an SP tube is not necessary because once the reservoir is decompressed, the catheter should pass smoothly through the catheterizable channel because the kinking has been released. If stomal stenosis is the issue, likely an office stomal revision will resolve difficulty with catheterization.

Urinary Conduit

Postcystectomy patients with a urinary conduit also should not be catheterized per urethra except for special situations. Occasionally, a urinary conduit may require catheterization. Patients with severe stomal stenosis may need temporary placement of a catheter to keep the stoma open. Catheter placement may also be indicated in situations such as a parastomal hernia causing obstruction, urine extravasation from the conduit, or conduit stenosis. The clinician should place the catheter in the stoma and then beyond the level of the fascia. The balloon can be filled gently. Usually the balloon is not filled completely to theoretically prevent obstruction of the ureters. Alternatively, the clinician can use a permanent stitch to secure the catheter to the stoma.

Bladder Neck Reconstruction or Closure

An absolute contraindication to urethral catheter placement is a history of bladder neck reconstruction or closure. Severe harm can result from urethra catheterization such as urinary incontinence or urinary fistula. Patients with a bladder neck reconstruction in urgent need of catheterization should have an SP tube placed. Patients with a bladder neck closure will have a catheterizable channel that should be catheterized. If there is a false passage in the channel, which is usually created from appendix or ileum, the clinician may use a flexible cystoscope or ureteroscope to find the correct lumen and place a guidewire into the bladder. Catheter placement over the wire should be performed, and the catheter should be secured to the skin and remain in place to allow for healing of the false passage. If this is unsuccessful, then SP catheterization should be performed with great caution.

Artificial Urinary Sphincter

A relative contraindication to urethral catheterization is a history of AUS placement. Clinicians should avoid urethral catheterization in these patients if at all possible. **If catheterization is required, the sphincter should be completely deactivated before placement. After deactivation, a 12-Fr catheter should be placed.** This catheter should be removed as soon as possible to prevent the possibility of urethral erosion.

Key Points

- The urologist should be prepared to attain lower urinary drainage in almost all situations.
- The clinician should closely review the patient's history and prior operative reports before instrumenting the lower urinary tract.
- If BPH is expected, the practitioner should use an 18-Fr coudé catheter for lower urinary tract drainage.
- A history of bladder neck repair or closure is a contraindication to urethral catheterization.
- Catheter placement should be avoided in patients with an AUS. A 12-Fr catheter should be used after deactivation of the sphincter if necessary.

Complications of Lower Urinary Tract Drainage

Infection

UTIs and catheter-associated infections are discussed in great detail in Chapter 55. According to the Centers for Disease Control and Prevention (CDC), **UTIs are the most common type of health care–associated infections. Most health care–associated UTIs are attributable to urinary instrumentation** (see https://www.cdc.gov/infectioncontrol/guidelines/cauti/). Evidence-based guidelines on the prevention and treatment of catheter associated UTI have been published by the CDC and the Infectious Diseases Society of America (Hooten et al., 2010 and https://www.cdc.gov/infectioncontrol/guidelines/cauti/).

Iatrogenic Trauma

Catheterization of the urethra, especially in men, can cause significant trauma to the urethra. A false passage may be created or even significant gross hematuria from the bladder, urethra, or prostate may result. Patients with spinal cord injury were found to have a 13.5% incidence of gross hematuria (Hollingsworth et al., 2013). A single institution during a 7-month period reported an incidence of iatrogenic urethral injuries of 3.2 per 1000 male admissions. Penile bleeding occurred in 86% of males with iatrogenic urethral injury. In this institution, catheter safety training was implemented and a significant decrease in iatrogenic injuries was reported (Kashefi et al., 2008). This shows that urethral injury from catheterization is a preventable complication. In hospitalized patients, approximately 0.3% experience iatrogenic urethral trauma. Iatrogenic trauma may occur during catheter insertion, balloon inflation, or catheter removal if the balloon is not fully deflated. Education is the most important intervention to prevent iatrogenic urethral trauma (Simhan, 2015).

Stricture

The incidence of urethral strictures from catheterization is estimated to be 3.4% (Hollingsworth et al., 2013).

Erosion

Erosion of the urethra causing iatrogenic hypospadias has been described (Andrews et al., 1998).

Malignancy

The incidence of bladder cancer in spinal cord patients with long-term catheterization is estimated to be 1% (Hollingsworth et al., 2013). This is thought to be related to chronic inflammation because up to half of spinal cord patients with bladder cancer in a large series used external catheters (Kalisvaart et al., 2010). There are no clear guidelines on the frequency and timing of surveillance cystoscopy in patients with spinal cord injuries. Some advocate initiating yearly cystoscopy after 8 years with an indwelling catheter (Stonehill et al., 1996). Urologists must use their best judgment based on the available literature. If long-standing chronic bladder inflammation is suspected, surveillance cystoscopy may be indicated. Theoretically this has the potential to diagnose bladder tumors at an earlier stage; however, there are no prospective data to guide us.

Catheter Knotting and Balloon Malfunction

Pushing a catheter in too far in a child or female can result in the rare complication of catheter knotting. This can prevent the balloon mechanism from deflating and can result in extreme difficulty with catheter removal. Occasionally the balloon malfunctions for unknown reasons. Cystoscopy alongside the catheter may be required with use of a cystoscopic needle or syringe to puncture the balloon (Arena et al., 2002; Jallad et al., 2017). The clinician may attempt to cut the balloon port and place the stiff end of a guidewire through the port to attempt to puncture the balloon before cystoscopy. Alternatively, under ultrasound guidance the catheter can be punctured with a spinal needle. If the balloon is successfully punctured, cystoscopy should be considered to be sure all pieces of the balloon are retrieved.

Key Points

- Catheter-associated UTIs are the most common hospital-acquired infection.
- Catheters may lead to trauma, stricture, and erosion.
- Chronic catheterization can lead to bladder inflammation and increase the risk of bladder cancer.

See Videos 11.1 and 11.2 for urethral catherization procedures.

References

Andrews HO, Nauth-Misir R, Shah PJ. Iatrogenic hypospadias—a preventable injury? *Spinal Cord*. 1998;36:177–180.

Arena B, McGillivray D, Dougherty G. Urethral catheter knotting: be aware and minimize the risk. *CJEM*. 2002;4(2):108–110.

Chene G, Boulard G, Gachie JP. A controlled trial of a new material for coating urinary catheters. *Agressologie*. 1990;31:499–501.

Darouiche RO, Smith JA Jr, Hanna H, et al. Efficacy of antimicrobial-impregnated bladder catheters in reducing catheter-associated bacteriuria: a prospective, randomized, multicenter clinical trial. *Urology*. 1999;54:976–981.

Davis G. *Applied anatomy: the construction of the human body considered in relation to its functions; diseases and injuries*. JB Lippincott: Philadelphia; 1918.

Edokpolo LU, Foster HE. Suprapubic cystostomy for neurogenic bladder using lowsley retractor method: a procedure revisited. *Urology*. 2011;78:1196–1198.

Feneley R, Hopley I, Wells P. Urinary catheters: history, current status, adverse events and research agenda. *J Med Eng Technol*. 2015;39:459–470.

Giesy JD, Finn JC, Hermann GD, et al. Coaxial balloon dilation and calibration of urethral strictures. *Am J Surg*. 1984;147:611–614.

Harrison S, Lawrence W, Morley R, et al. British association of urological Surgeons’ suprapubic catheter practice guidelines. *BJU Int*. 2011;107:77–85.

Herschorn S, Thijssen A, Radomski SB. The value of immediate or early catheterization of the traumatized posterior urethra. *J Urol*. 1992;148:1428–1431.

Hollingsworth JM, et al. Determining the noninfectious complications of indwelling urethral catheters: a systematic review and meta-analysis. *Ann Intern Med*. 2013;159:401–410.

Hooten TM, et al. Diagnosis, prevention, and treatment of catheter-associated urinary tract infection in adults: 2009 international clinical practice guidelines from the infectious diseases society of America. *Clin Infect Dis*. 2010;50:625–663.

Jacob P, Rai B, Todd A. Suprapubic catheter insertion using an ultrasound-guided technique and literature review. *BJU Int*. 2012;110:779–784.

Jallad S, Shah A, Bhardwa J. Knotted urethral catheter: an unusual complication in adults. *BMJ Case Rep*. 2017.

Kalambaheti K. Siliconized foley catheters. *Am J Surg*. 1965;110:935–936.

Kalisvaart JF, Katsumi HK, Ronningen LD, et al. Bladder cancer in spinal cord injury patients. *Spinal Cord*. 2010;48:257–261.

Kashefi C, Messer K, Barden R, et al. Incidence and prevention of iatrogenic urethral injuries. *J Urol*. 2008;179:2254–2257 [discussion 2257–8].

Kohler T, Yadven M, Manvar A, et al. The length of the male urethra. *Int Braz J Urol*. 2008;34:451–454 [discussion 455–6].

Lacroix L, Vunda A, Bajwa NM, et al. Catheterization of the urethra in male children. *N Engl J Med*. 2010;363:e19.

Manzano S, Lacroix L. Catheterization of the urethra in girls. *N Engl J Med*. 2014;371:1849–1850.

Martino P, Forte S, Martino D, et al. Interventional ultrasound: US-guided puncture of the bladder. Martino P, Galosi A. *Atlas of ultrasonography in urology, andrology, and nephrology*. Springer: Switzerland; 2017.

Mohammed A, Khan A, Shergill IS, et al. A new model for suprapubic catheterization: the MediPlus seldinger suprapubic catheter. *Expert Rev Med Devices*. 2008;5:705–707.

Moog F, Karenberg A, Moll F. The catheter and its use in late antiquity and the early middle ages. *J Urol*. 2005;174:439–441.

Nacey JN, Tulloch AG, Ferguson AF. Catheter-induced urethritis: a comparison between latex and silicone catheters in a prospective clinical trial. *Br J Urol*. 1985;57:325–328.

Nickel JC, Feero P, Costerton JW, et al. Incidence and importance of bacteriuria in postoperative, short-term urinary catheterization. *Can J Surg*. 1989;32:131–132.

Pickard R, Lam T, MacLennan G, et al. Antimicrobial catheters for reduction of symptomatic urinary tract infection in adults requiring short-term catheterisation in hospital: a multicentre randomised controlled trial. *Lancet*. 2012;380:1927–1935.

Schumm K, Lam TB. Types of urethral catheters for management of short-term voiding problems in hospitalised adults. *Cochrane Database Syst Rev*. 2008;(2) [CD004013].

Simhan J. Reducing iatrogenic urethral trauma. *J Urol*. 2015;194:871–872.

Standring S. *Gray's anatomy: the anatomical basis of clinical practice*. Elsevier: Philadelphia; 2015.

Stonehill WH, Dmochowski RR, Patterson AL, et al. Risk factors for bladder tumors in spinal cord injury patients. *J Urol*. 1996;155:1248–1250.

Thomsen TW, Setnik SG. Male urethral catheterization. *N Engl J Med*. 2006;354:e22 http://nejm.org/cgi/content/short/354/21/e22.

Tidd MJ, Gow JG, Pennington JH, et al. Comparison of hydrophilic polymer-coated latex, uncoated latex and PVC indwelling balloon catheters in the prevention of urinary

infection. *Br J Urol*. 1976;48:285–291.
Uehling DT. The normal caliber of the adult female urethra. *J Urol*. 1978;120:176–177.
Zeidman EJ, Chiang H, Alarcon A, et al. Suprapubic cystostomy using lowsley retractor. *Urology*. 1988;32:54–55.

12

Fundamentals of Upper Urinary Tract Drainage

Casey A. Dauw MD, J. Stuart Wolf Jr., MD, FACS

Percutaneous Renal Access and Drainage

History

Commonly ascribed to Goodwin and colleagues (1955), the first therapeutic percutaneous nephrostomy actually was performed by Thomas Hillier in 1865 (Bloom et al., 1989). Hillier, at the Hospital for Sick Children at Great Ormond Street, repeatedly aspirated the hydronephrotic kidney of a young boy for symptom relief over a 4-year period until his death at 8 years of age. Subsequently there were a few reports of diagnostic percutaneous renal aspirations, but it was not until Goodwin and colleagues published their landmark report in 1955 that therapeutic percutaneous nephrostomy was rediscovered. Even then, the utility of percutaneous access to the upper urinary tract collecting system was limited to drainage of obstructed kidneys until Fernström and Johansson (1976) described the percutaneous removal of renal calculi, termed *percutaneous pyelolithotomy.*

Subsequently, many procedures have been performed via the percutaneous route to the upper urinary tract collecting system including drainage of an obstructed kidney, nephrolithotomy, endopyelotomy, and resection of urothelial tumors. More recently, percutaneous access to portions of the kidney other than the collecting system has been introduced (addressed in Chapter 84). Specific aspects of the procedures performed through the percutaneous access are covered in Chapters 42, 86, and 99.

Indications

Simple Drainage

Percutaneous renal drainage is effective for most, if not all, obstructions including those in intrarenal, ureteropelvic junction, or ureteral locations. Although lower urinary tract obstruction is best treated by bladder drainage via a catheter, secondary supravesical obstruction can be managed by percutaneous nephrostomy tube placement if other measures have failed to provide adequate drainage. An alternative to percutaneous drainage is drainage through a ureteral catheter or stent placed in a retrograde fashion (later in this chapter). The choice of antegrade or retrograde drainage of the upper urinary tract collecting system depends on the indication, the patient's medical condition and anatomy, and preferences of both the patient and physician.

Generally, a retrograde route to drainage is preferred over the antegrade route. This includes most cases of acute and chronic ureteral obstruction without infection (Rosevear et al., 2007). In the setting of upper urinary tract collecting system obstruction complicated by infection, however, drainage is an emergency and in many such cases, percutaneous rather than retrograde drainage may be best (Ng et al., 2002) unless retrograde drainage can be obtained expeditiously and assuredly. Percutaneous nephrostomy tubes and retrograde ureteral stents are generally equivalent in their capacity to resolve fever in patients with upper urinary tract obstruction and fever (Goldsmith et al., 2013; Pearle et al., 1998), but in a given patient circumstances may dictate preference for one access over the other. Retrograde ureteral stent placement often requires regional or general anesthesia, whereas a percutaneous nephrostomy tube can be inserted under local anesthesia; this is an important consideration in an ill patient. Because the percutaneous route has a greater initial success rate than the retrograde one in cases in which the collecting system is dilated, it might be preferred in a patient who needs rapid intervention. This is especially true when the ureteral obstruction is long, severe, or involving the ureteral orifice—which can retrograde access more difficult. Conversely, untreated coagulopathy is a contraindication to percutaneous access, but ureteral stents can be placed safely in an anticoagulated patient. A final consideration is patient preference. Studies using a validated questionnaire in a population of patients after percutaneous nephrolithotomy suggest that a temporary nephrostomy tube, though equivalent to a ureteral stent in terms of effectiveness of renal drainage, may actually be associated with improved health-related quality of life (Jiang et al., 2017; Zhao et al., 2016).

Diagnostic Studies

In rare instances, percutaneous renal access is necessary solely for diagnostic purposes, such as the Whittaker test, which is an invasive but highly accurate study to differentiate obstructive from nonobstructive hydronephrosis (Jaffe and Middleton, 1980). After obtaining percutaneous access into the kidney, the upper urinary tract is perfused at a constant rate and pressures are transduced in the renal pelvis and urinary bladder. The finding of a pressure differential above 12 cm of water across the ureteropelvic junction or ureter indicates urinary obstruction. For a more detailed description of this test, refer to Chapter 89.

Therapeutic Instillations

Percutaneous renal access can be performed to facilitate instillations of chemotherapeutic agents for upper-tract urothelial lesions or agents for chemolysis of renal stones. For a more comprehensive description of these topics, refer to Chapters 43 and 99.

Percutaneous Renal Surgery

Percutaneous renal access facilitates surgery for upper tract calculi, urothelial tumors, obstruction, and calyceal diverticulae and hydrocalyces. For a more comprehensive description of these surgical procedures, refer to Chapters 42, 43, and 99.

Anatomic Considerations

With limited visualization of the kidney and surrounding structures during standard percutaneous entry guided by fluoroscopy or ultrasonography, understanding renal and perirenal anatomy is critical.

Perirenal Anatomy

The kidneys are well-protected, situated in the retroperitoneum, and surrounded by adipose tissue. The mobility of the kidneys is limited by short renal hilar vessels, although nephroptosis can occur, especially in thin women with a paucity of perirenal fat. In such cases, the kidney not only descends but also rotates anteriorly. This can be troublesome during percutaneous punctures with the patient in a prone position.

The kidneys lie adjacent to the vertebral bodies, usually extending from the 11th or 12th thoracic to the 2nd or 3rd lumbar vertebrae (Fig. 12.1). The right kidney is displaced a few centimeters inferior to the left kidney. The longitudinal axis of the kidneys parallels the lateral edges of the psoas muscles, about 30 degrees from vertical, with the lower poles lateral to the upper poles. The kidneys are also tilted 30 degrees off the frontal plane, with the lower poles anterior to the upper poles. Finally, the kidneys are rotated out of the frontal plane as well, with the lateral aspect of the kidney posterior to the medial aspect, such that each kidney is rotated 30 degrees posteriorly from the renal hilum. This brings the upper pole calyces medial and superficial (dorsal) in relation to the lower pole calyces, which can have important implications for successful renal access.

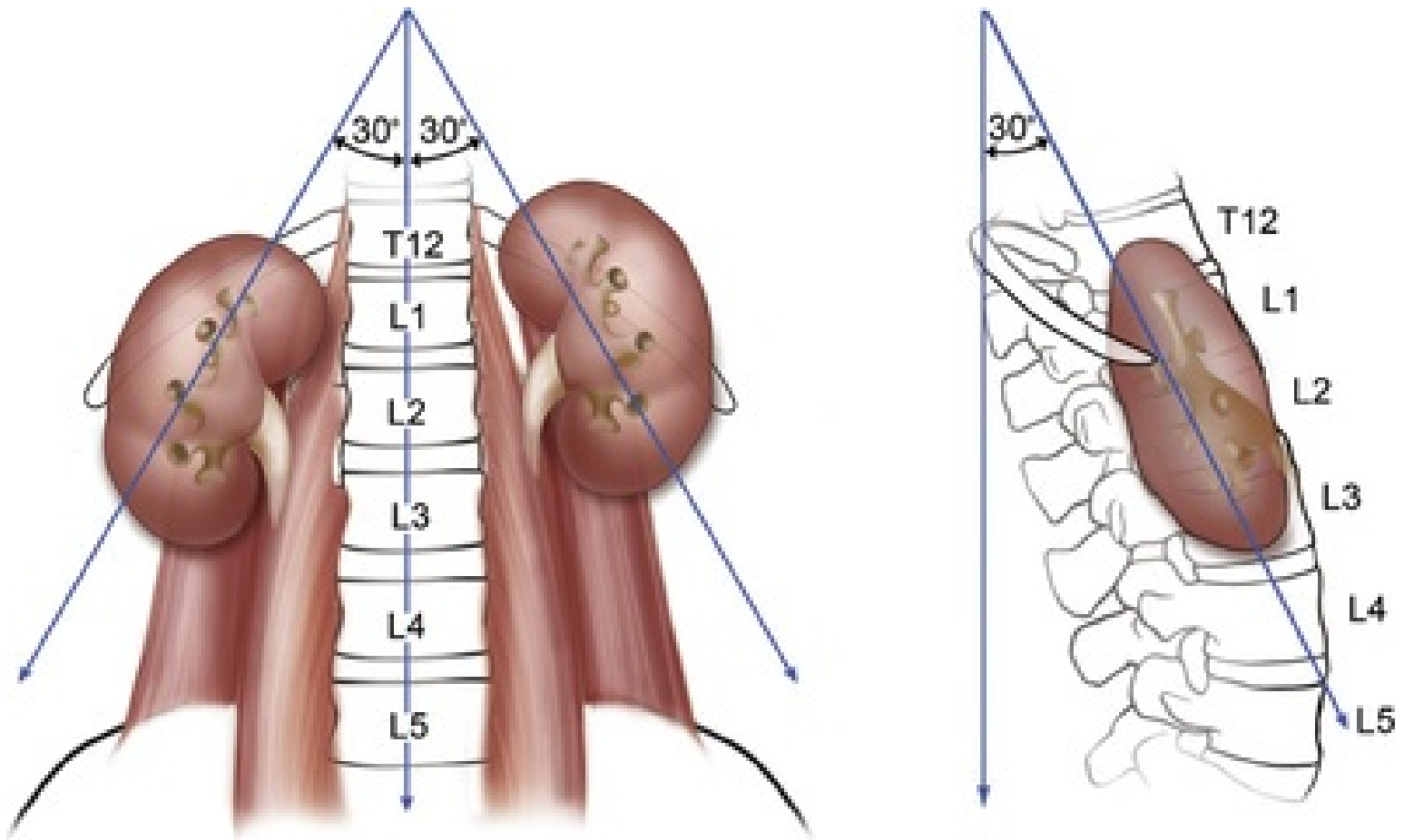

FIG. 12.1 Location of kidneys in the retroperitoneum.

Immediately posterior to the kidneys are the quadratus lumborum and psoas muscles, except at the upper poles where the diaphragm is posterior (Fig. 12.2). **The pleura can be violated during percutaneous entry into the upper pole of the kidney. This risk is greater with more cephalad access.** The lung is above the 11th rib, so direct lung injury is unlikely unless the 10th intercostal space (superior to the 11th rib) is used as the entry site. The ribs curve inferiorly from medial to lateral, such that more portions of the kidney can be approached subcostally with a medial as opposed to a lateral access site.

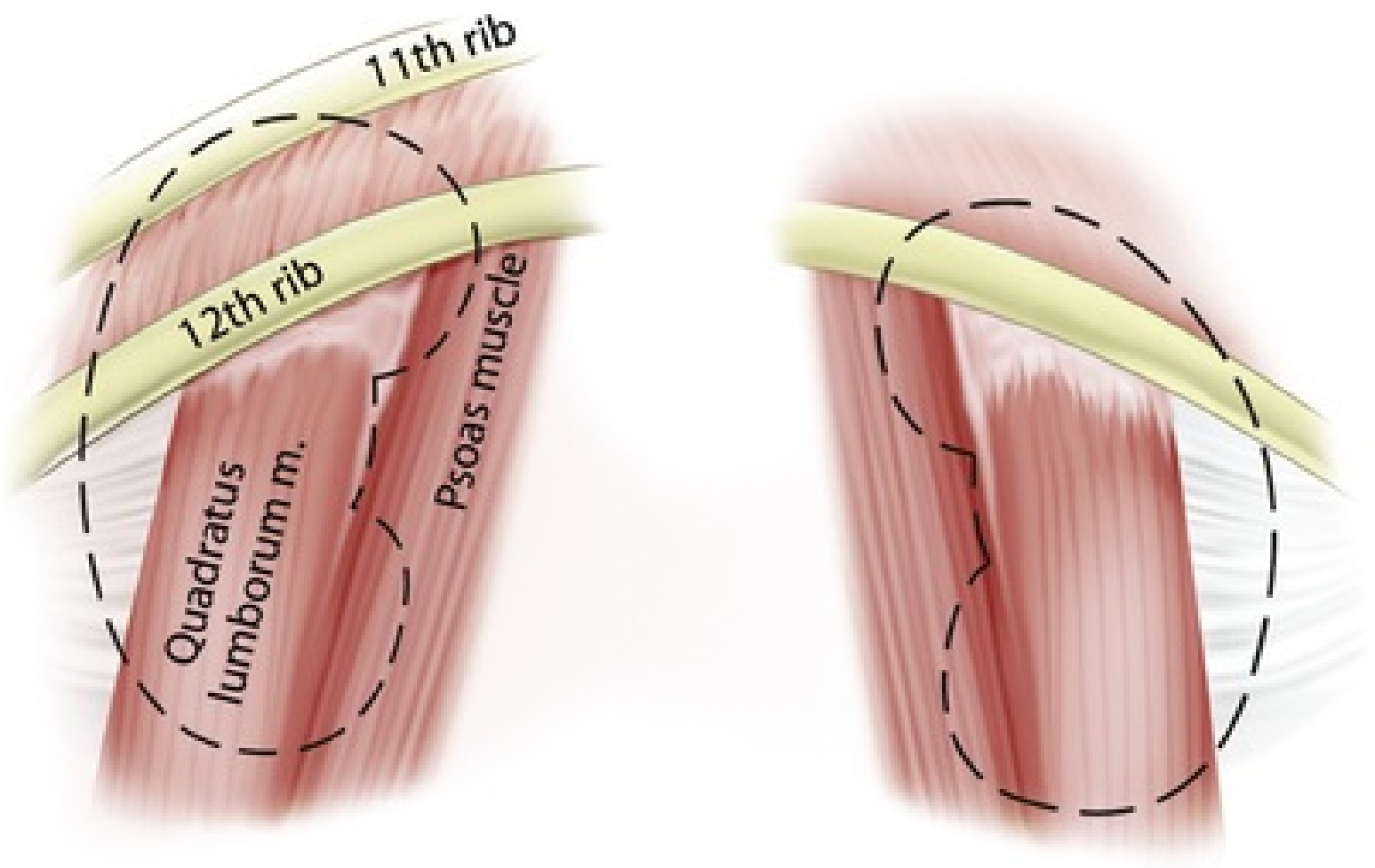

FIG. 12.2 Muscles and ribs posterior to the kidneys.

The lateral, anterior, and medial perirenal relationships are more varied than the posterior ones (Fig. 12.3). On the right side, the liver is anterior to the upper pole of the kidney and can extend in some individuals to cover the entire anterior surface. On the left, the spleen covers less of the kidney anteriorly. Both the liver and spleen can extend lateral to the kidneys and are therefore at risk for injury with a lateral puncture into the kidney. This is especially true in situations in which the liver or spleen are enlarged because of other medical conditions. **The ascending and descending colon can be lateral or even posterior to the right and left kidneys, respectively. The apposition of the colon to the kidney varies with location; it is greatest on the left side and at the lower pole.** In one CT-based study, the left colon was posterior in 16.1% of cases, and the right colon was posterior in 9% of cases at the level of the lower pole. At the mid-portion of the kidney, the colon was posterior in 5.2% and 2.8%, respectively, and at the upper pole 1.1% and 0.4%, respectively (Boon et al., 2001). The relationship of the kidney and the colon vary not only by cranial-caudal location and laterality but also by patient positioning. In a study of 75 patients undergoing CT for non-neurologic indications, retrorenal colon was identified in 2% of patients in the supine position versus 6.8% of patients in the prone position (Sharma et al., 2015). Additional visceral relations to the kidney include the adrenal glands (medial to the upper pole of both kidneys), the duodenum and gallbladder (anterior and medial to the right kidney), and the tail of the pancreas (anterior and medial to the left kidney). These structures can be injured with a misdirected or excessively deep puncture.

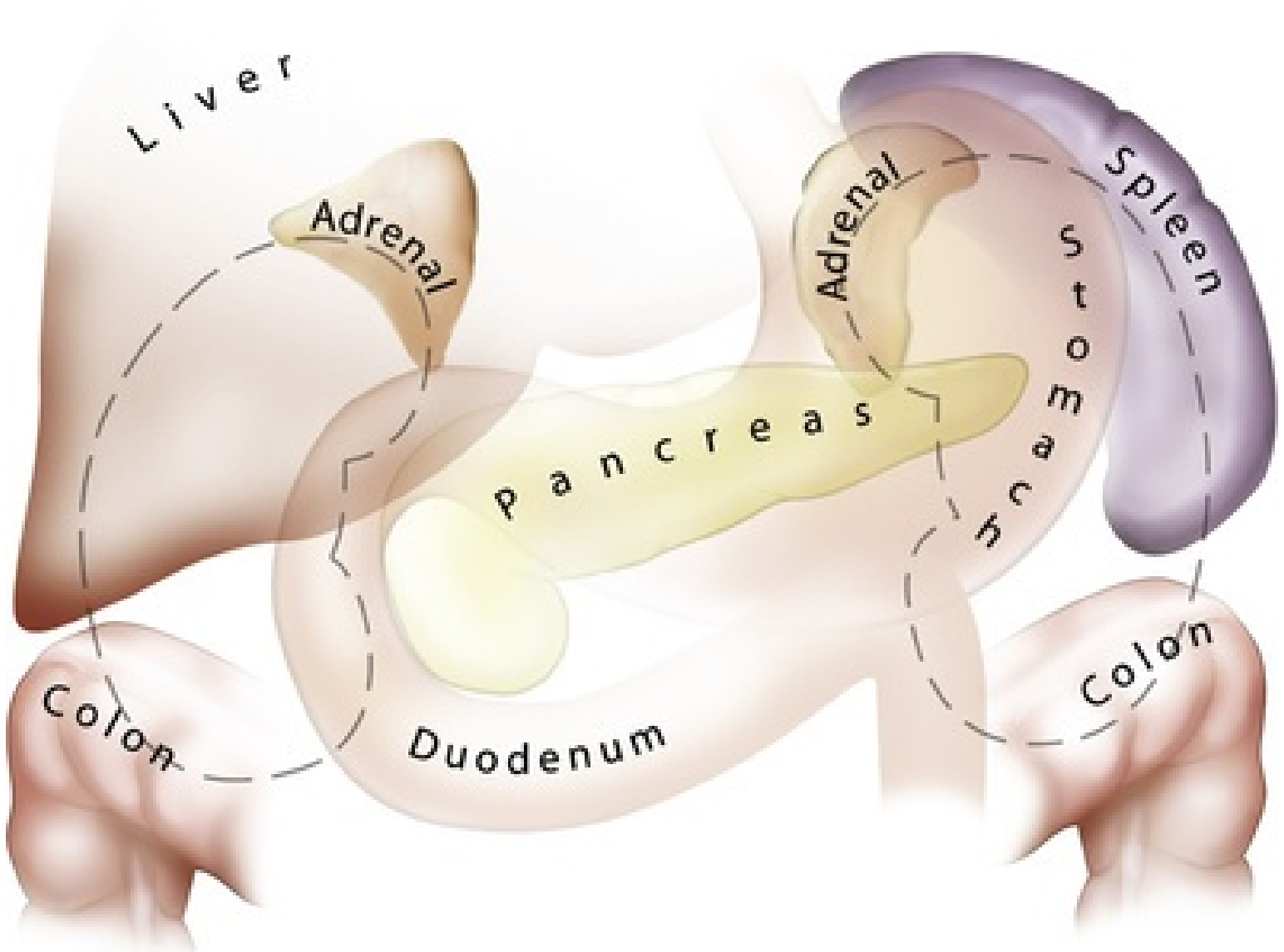

FIG. 12.3 Viscera lateral, anterior, and medial to the kidneys.

Renal Parenchyma and Collecting System

The renal parenchyma is composed of the cortex and the medulla. The cortex, outermost, contains the glomeruli and proximal and distal convoluted tubules. The more interior medulla contains the renal pyramids. These are inverted cones (the base of which is superficial and the apex is deep) that comprise the loops of Henle and the collecting ducts, which coalesce at the apex of the pyramid into papillary ducts that open on the surface of the renal papillae. There are approximately 20 papillary ducts draining into each papilla. The columns of Bertin are invaginations of cortical tissue that surround the renal pyramids except at their apices.

The renal papillae drain into the minor calyces, which are the most peripheral portions of the intrarenal collecting system. If only one papilla drains into a minor calyx, it is described as a simple calyx. When there are two or more papillae entering the calyx, it is termed a *compound calyx*. The outermost wall of the calyx, into which the papilla is set, is the calyceal fornix. **There are 5 to 14 minor calyces in each kidney (mean of 8, with 70% of kidneys having 7 to 9 minor calyces)** (Sampaio and Mandarim-de-Lacerda, 1988). **There are three calyceal groups: the upper, middle, and lower. Compound calyces are the rule in the upper calyceal group, are common in the lower calyceal group, and are rare in the middle calyceal group.** The minor calyces, either directly or after coalescing into major calyces, drain by infundibula into the renal pelvis

(Fig. 12.4). Occasionally a minor calyx will open directly into the renal pelvis without an intervening infundibulum.

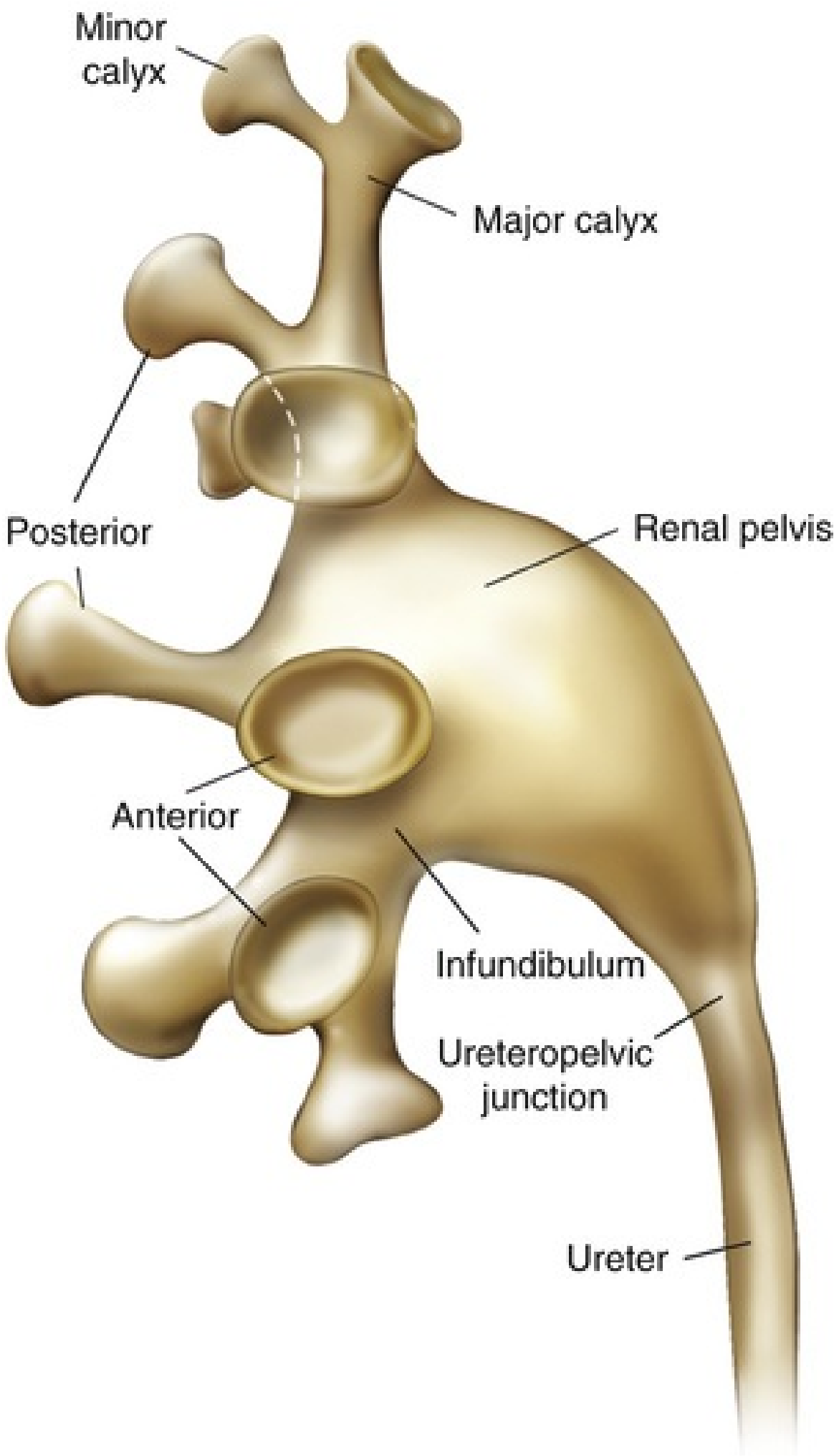
Minor calyx
Major calyx
Posterior
Renal pelvis
Anterior
Infundibulum
Ureteropelvic junction
Ureter

FIG. 12.4 Upper urinary tract collecting system.

The compound calyces of the poles of the kidney are oriented facing their respective poles. The simple calyces usually come in pairs, one facing anteriorly and one facing posteriorly (Fig. 12.5). Drainage of the upper pole into the renal pelvis is by a single midline infundibulum in most kidneys. Drainage from the lower pole is via a single infundibulum in about one half of kidneys and otherwise via a series of paired anterior and posterior calyces. The middle calyces typically are arranged in a series of paired anterior and posterior calyces. In about two thirds of kidneys, there are two major calyceal systems—an upper and lower one—and the middle calyces drain into either or both systems. In the other one third of kidneys, the middle calyceal system is distinct from the upper and lower systems, coalescing either into a middle major calyx before emptying into the renal pelvis or with drainage of the middle minor calyces directly into the renal pelvis through short infundibula.

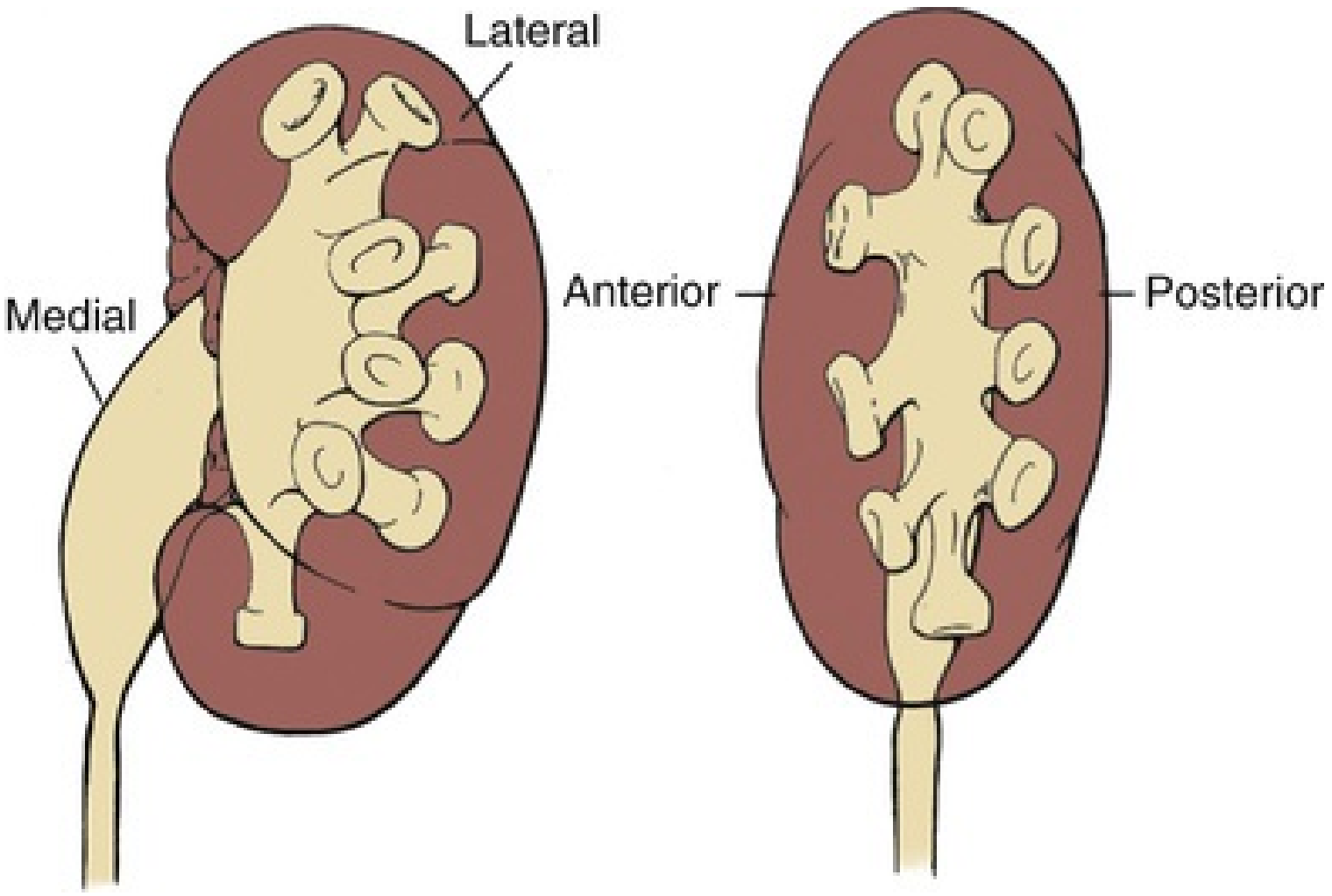

FIG. 12.5 Calyceal orientation of polar and middle calyces. (From Smith AD: *Controversies in endourology.* Philadelphia, 1995, Saunders.)

An important consideration for percutaneous renal surgery is determining the anterior-posterior orientation of the calyces because access (from the typical posterior or posterolateral approach) into a posterior calyx allows relatively straight entry into the rest of the kidney, whereas percutaneous puncture of an anterior calyx requires an acute angulation to enter the renal pelvis, which may not be possible with rigid instrumentation (Fig. 12.6). Efforts have been made to determine which calyces are likely to be anterior and which are likely to be posterior based on their medial-lateral position on anterior-posterior radiography. The distinction pertains to the middle and lower calyceal system, which contains (in almost all middle systems and approximately one half of the lower system) paired anterior and posterior minor calyces. The upper-pole system, with its almost uniformly compound calyceal system, is less problematic in this regard. Paired anterior and posterior calyces usually enter at about 90 degrees from each other. As such, the relative medial-lateral orientation (on anterior-posterior radiography) is determined by the relationship of this 90-degree unit to the frontal plane of the kidney. In a Brödel-type kidney, this unit is rotated anteriorly, such that the posterior calyces are about 20 degrees behind the frontal plane and the anterior calyces are 70 degrees in front of the frontal plane. The posterior calyces are lateral, and the anterior calyces are medial in this case. The Hodson-type kidney is the opposite; the calyceal pairs are rotated posteriorly, with the posterior calyces 70 degrees behind the frontal plane and appearing medial and the anterior calyces 20 degrees in front of the frontal plane and appearing lateral (see Fig. 12.6). Most right kidneys have a Brödel-type orientation (posterior calyces are lateral), and most left kidneys have a Hodson-type orientation (posterior calyces are medial). One group found that, in the lower calyceal system, the medial calyces are anterior and the lateral ones are posterior most of the time (Eisner et al., 2009). **Because variation is considerable, the mediolateral orientation of the calyces on anteroposterior radiography cannot be used to reliably determine the optimal calyx for entry, and additional maneuvers are required to determine the exact calyceal anatomy.** One reliable anatomic distinction is that the upper calyceal group is situated in a mediolateral orientation in 95% of kidneys, in contrast with the anteroposterior orientation of the middle and lower calyceal groups in 100% and 95% of kidneys, respectively (Miller et al., 2013). This means that **most calyces of the upper pole are suitable for percutaneous access from the posterior approach, whereas care must be taken to select a posterior minor calyx in the middle and lower groups.** Within the lower calyceal group, the most inferior calyx is usually anterior, but the next most cephalad calyx is usually posterior.

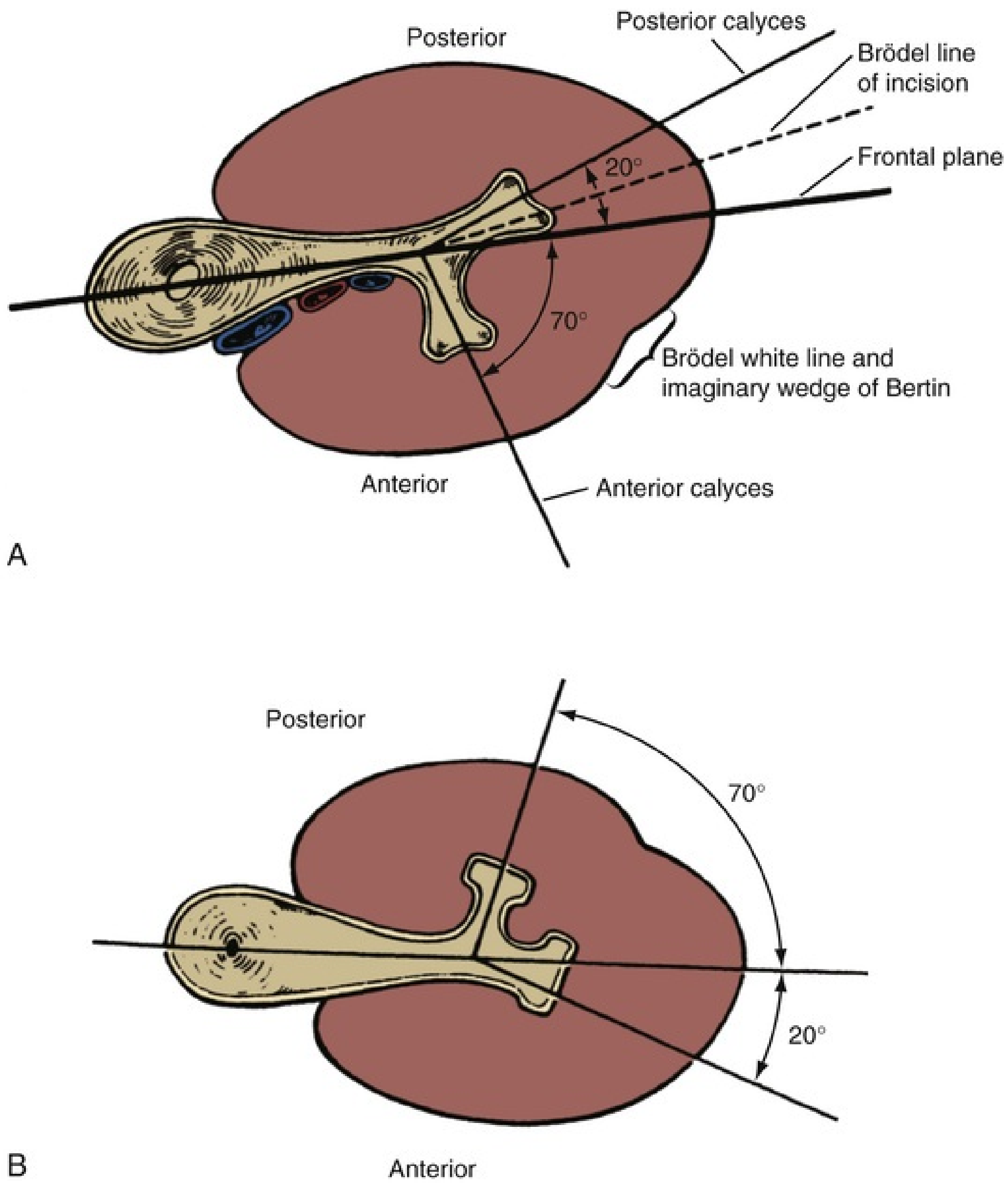
Posterior
Posterior calyces
Brödel line
of incision
20°
Frontal plane
70°
Brödel white line and
imaginary wedge of Bertin
Anterior
Anterior calyces
A
Posterior
70°
20°
B
Anterior

FIG. 12.6 Relation of anterior and posterior calyces to renal parenchyma in Brödel-type kidney (A) and Hodson-type kidney (B). The optimal site of percutaneous entry from the posterior aspect of the kidney is into a posterior calyx because the path into the renal pelvis is fairly straight. If entry is into an anterior calyx (from the posterior aspect of the kidney), then an acute angulation must be made to enter the renal pelvis, which may not be possible with rigid instrumentation. (From Smith AD: *Controversies in endourology.* Philadelphia, 1995, Saunders.)

Intrarenal Vasculature

Although the renal arterial anatomy is variable, in general the main renal artery divides into an anterior and a posterior branch. The former then divides within or before the renal sinus into four anterior segmental arteries: the apical and lower segmental arteries (which supply the tip of the upper pole and the entire lower pole, respectively) and the upper and middle segmental arteries (which supply the remainder of the anterior half of the kidney). The posterior branch of the renal artery supplies the remainder of the posterior half of the kidney (Fig. 12.7). Once the arteries enter the renal parenchyma, they divide into interlobar (infundibular) arteries. At the cortico-medullary junction, near the base of the renal pyramids, each interlobar artery usually divides into two arcuate arteries that run along the renal pyramid. The next division is into the interlobular arteries, which run along the outer surface of the renal pyramids and are derived at right angles from the arcuate arteries. The final divisions, the afferent arterioles of the glomeruli, come off the interlobular arteries in the peripheral renal cortex. Each renal arteriole is an “end-artery,” meaning that each cell in the kidney derives blood supply from one arteriole. For this reason, renal arterial vascular injury must be avoided to prevent loss of renal function. The potential for arterial injury is least in Brödel's line, an avascular plane approximately at the lateral margin of the kidney, extending from the superior apex of the kidney (limited by the circulation of the apical anterior segmental artery) to the lower pole of the kidney (limited by the circulation of the lower anterior segmental artery). Although anatomically it seems that percutaneous access into the kidney would be safest in a forniceal or papillary location because of avoidance of the interlobar and arcuate arteries, a recent trial refutes this notion. Kallidonis et al. performed a randomized controlled clinical trial of patients undergoing percutaneous nephrolithotomy using either a papillary or infundibular puncture location. There was no difference in hemoglobin change, 30-day complication rate, or length of stay between the two groups (Kallidonis et al., 2017).

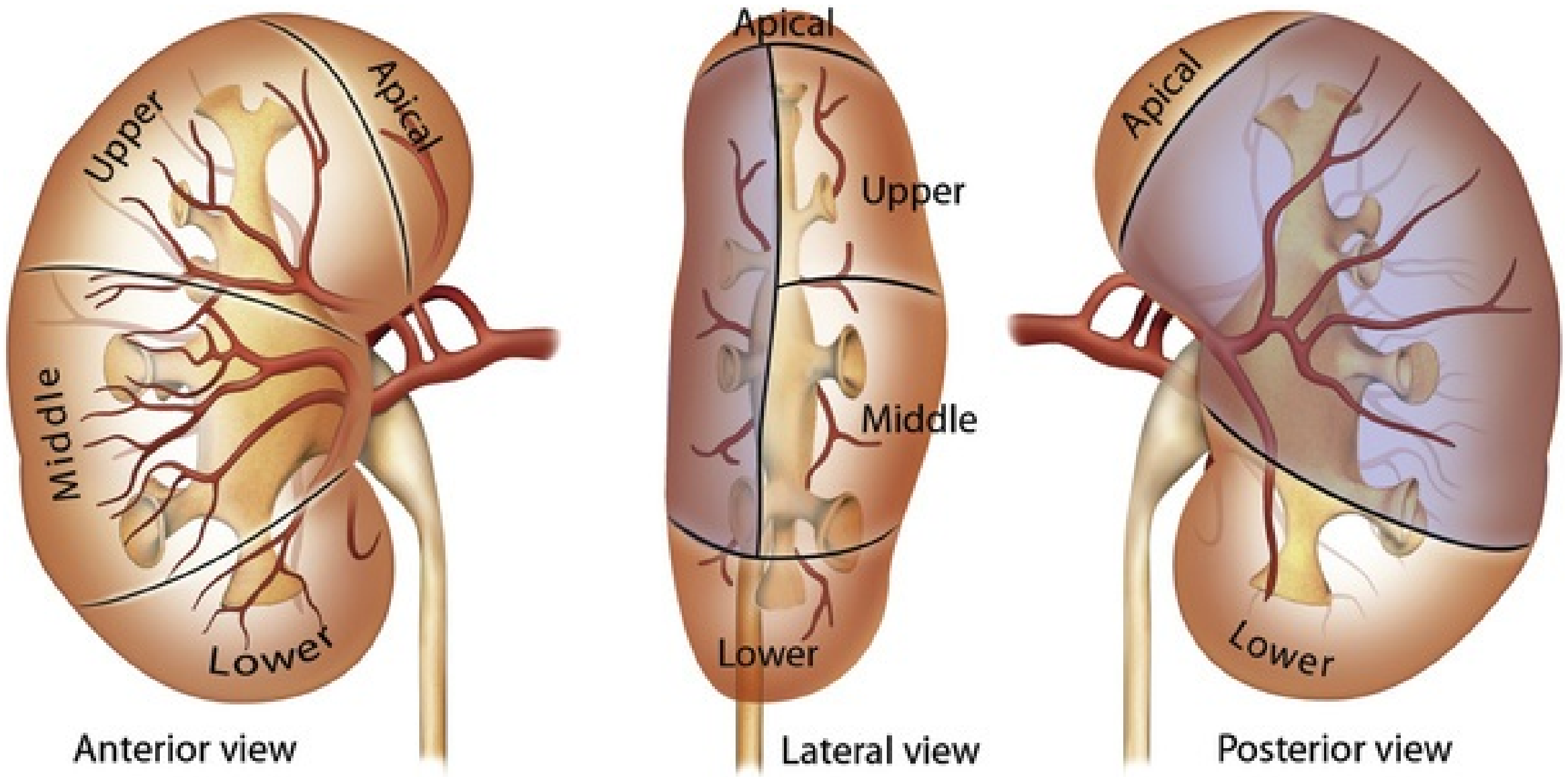

FIG. 12.7 Arterial supply to the kidney. The kidney is supplied by the anterior and posterior branches of the main renal artery. The anterior branch supplies both the anterior half of the kidney and the polar regions via four segmental branches. The posterior branch of the renal artery supplies the posterior aspect of the kidney (represented by the shaded region). An avascular plane, known as the Brödel line, separates the anterior and posterior circulations.

The venous anatomy of the kidney does not have the same defined structure as the arteries. Moreover, there is free cross-circulation among the intrarenal veins via arcades. This enhances vascular outflow from the kidneys, reduces the risk for venous congestion, and makes renal venous injury less damaging to renal function than arterial injury.

Surgical Technique

Provider Obtaining Access

Although some urologists in the United States are trained to obtain percutaneous renal access (Spann et al., 2011), only a minority translate this skill into routine practice (Bird et al., 2003; Lee et al., 2004). Registry data from the United Kingdom indicates that the relative proportion of urologists who obtain percutaneous renal access is higher than that in the United States, but interventional radiologists still obtain access most often (Armitage et al., 2017). **Although rates of successful access and complications differ inconsistently between urologists and interventional radiologists** (El-Assmy et al., 2007; Speed et al., 2017; Tomaszewski, et al., 2010a; Watterson et al., 2006), **it is clear**

that the most vital aspect for a successful procedure is not who performs the puncture, but that the urologist is directly involved in access planning. Ideally, if it is not the urologist who is obtaining renal access, they should be present at the time of percutaneous access to explicitly direct the interventional radiologist as to the appropriate site of puncture for the planned procedure. When access is gained without input of the urologist, the access site is not acceptable for the subsequent percutaneous procedure in a large portion of cases (Tomaszewski et al., 2010a).

Antimicrobial Prophylaxis

Urosepsis is one of the most feared complications after percutaneous access into the renal collecting system. Risk can be mitigated in several ways. Obtain a screening urinalysis, and if there are concerns for infection, then submit for urine culture (Assimos et al., 2016). In patients with risk factors for infection, such as prior history of urinary tract infection, prior history of or current suspicion for struvite stones, anatomic abnormalities (e.g. ureteropelvic junction obstruction or ureteral stricture), or presence of urinary tract reconstruction (e.g. urinary diversion or bladder augmentation), routinely obtain urine culture. Rivera et al. evaluated a large cohort of patients undergoing percutaneous nephrolithotomy and found that only presence of a staghorn calculus was associated with a threefold increase in sepsis (Rivera et al., 2016). The authors suggest that urologists consider a preoperative course of antibiotics in such patients. Special attention should be paid to patients with indwelling foreign bodies such as nephrostomy tubes, ureteral stents, or externalized urinary catheters (suprapubic tube or urethral catheter) as these patients are colonized with bacteria and are at higher risk for postoperative infection. Collecting a urine culture from an externalized drain, though interpretation can be challenging because of potential contamination, is a reasonable practice to tailor preoperative antibiotic choice.

If a preoperative urine culture is positive, treatment with culture-directed antibiotics is imperative. Ideally, a posttreatment urine culture should be obtained to document resolution of bacteriuria, though this is often not practical. For patients with suspected or known struvite stones, those with urinary diversions or reconstructions, and those with externalized drains, it is often impossible to completely eradiate infection and thus the goal should be to suppress bacterial counts before surgery. This can be achieved with culture-directed antibiotics for a duration leading up to any proposed surgical intervention.

The American Urological Association (AUA) recommends periprocedural antimicrobial prophylaxis for all cases of percutaneous renal surgery (Wolf et al., 2008). Although no randomized controlled trials exist to support this recommendation, in a large retrospective but matched case-control study comparing 162 patients with and 162 patients without antimicrobial prophylaxis undergoing percutaneous nephrolithotomy, the rate of fever and other postoperative complications was 3- to 10-fold greater in the group without antimicrobial prophylaxis (Gravas et al., 2012). The need for antimicrobial coverage for simple percutaneous drainage of the upper urinary tract collecting system is not certain.

Antimicrobial coverage should include organisms common to the urinary tract and the skin. Recommended agents include first- and second-generation cephalosporins; aminoglycosides (or aztreonam in patients with renal insufficiency) plus either metronidazole or clindamycin; ampicillin/sulbactam; or a fluoroquinolone. Although there are some series that suggest that administration of antimicrobials for the week before percutaneous nephrolithotomy reduces the risk for infectious complications (Bag et al., 2011; Mariappan et al., 2006), the preponderance of evidence suggests that **when the antimicrobial is being administered only for prophylaxis (i.e., not treatment of known or presumed infection), immediate perioperative treatment for percutaneous nephrolithotomy (24 hours or less) is just as effective as a longer course and is therefore preferred** (Demirtas et al., 2012; Deshmukh et al., 2015; Dogan et al., 2002; Seyrek et al., 2012; Tuzel et al., 2013). A short (≤24 hours) course of antimicrobials at the time of nephrostomy tube removal also can be considered (Wolf et al., 2008).

Management of Anticoagulation

It is important to perform a detailed appraisal of medications that a patient is taking before undertaking percutaneous renal access. Medications such as nonsteroidal anti-inflammatory drugs (NSAIDs), antiplatelet agents, and anticoagulants, with few exceptions, should be discontinued before planned surgery as follows: aspirin, 1 week; warfarin, 1 week; clopidogrel, 5 days; and NSAIDs, 3 to 5 days. Because novel antiplatelet and anticoagulation drugs are rapidly being developed, and this list is not exhaustive, consult with the prescribing physician or a clinical pharmacist as recommended by the ICUD/AUA review paper on this topic (Culkin et al., 2014). The use of perioperative aspirin deserves special mention. Although patients electively taking aspirin for the purpose of primary prevention of cardiovascular disease without coronary artery disease should be counseled to stop aspirin 7 days before surgery. Those with preexisting heart disease or at high risk for heart disease or cerebrovascular disease can continue this medication safely in the perioperative period. Leavitt et al. retrospectively analyzed a large group of patients undergoing percutaneous nephrolithotomy and found that uninterrupted use of aspirin was not associated with greater blood loss or need for transfusion, even when evaluating a subset of high–cardiovascular risk patients (Leavitt et al., 2014).

Diagnostic Imaging

The type of preoperative imaging performed before percutaneous renal access is often determined by the pathology to be treated. For simple decompression in the setting of presumed distal obstruction, preoperative ultrasonography may suffice. **For percutaneous nephrolithotomy, the AUA guidelines on the surgical management of kidney stones recommends preoperative noncontrast CT for access and treatment planning** (Assimos et al., 2016). In cases in which ipsilateral renal function is uncertain, obtain a nuclear medicine renal scan.

Patient Positioning

There are a variety of positions in which patients can be placed for percutaneous access to the kidney. For practical purposes, the most common positions are prone, supine, and modifications of these positions. What follows is a description of the described positions for percutaneous renal access and a general comparison of the advantages and disadvantages of each. Comparisons particular to percutaneous nephrolithotomy are described in Chapter 94.

Prone Position

The prone position for percutaneous renal access, first described by Goodwin and colleagues in 1955, is the most commonly used position (Valdivia et al., 2011). In general, patients are positioned with the chest supported by either a single horizontal chest roll across the nipple line or two vertical rolls positioned along the mid-clavicular line. It is important to elevate the legs to prevent pressure injury of the lower extremities. Typically, the ipsilateral arm relative to the side of the procedure is positioned toward the head in a modified swimmers position, and the contralateral arm is tucked at the side. Meticulous padding of all pressure points is vital to prevent injury.

The prone position affords direct access into the favorably located posterior renal calyces. Any polar location can also be accessed (upper, mid, or lower). In particular, the upper pole calyx is anatomically closest to the skin in the prone position and offers ready access to the proximal ureter and in some cases, the entire collecting system (Ray et al., 2009). Prone positioning allows bilateral percutaneous procedures without any repositioning (Desai et al., 2007). Finally, if the chest is padded in such a way to allow free abdominal excursion (Fig. 12.8), prone positioning is associated with increased pulmonary capacity and no difference in peak inspiratory pressures relative to supine positioning (Edgcombe et al., 2008; Siev et al., 2015). Despite these benefits, there are several disadvantages to the prone position. From an anesthesia perspective, access to the airway is more challenging in the prone position. It is also associated with a decrease in cardiac index (Hatada et al., 1991). Although uncommon, there are extreme circumstances in which patients with spinal deformity or super morbid obesity cannot be safely positioned prone. Care must be taken when the patient is positioned prone to avoid pressure injuries, which in extreme situations can lead to rhabdomyolysis or neuraxial injury. In particular, ocular injuries resulting from insufficient padding are unique to the prone position (Ghani et al., 2016). Finally, prone positioning requires the surgeon to stand and work with outstretched arms, which can contribute to surgeon fatigue.

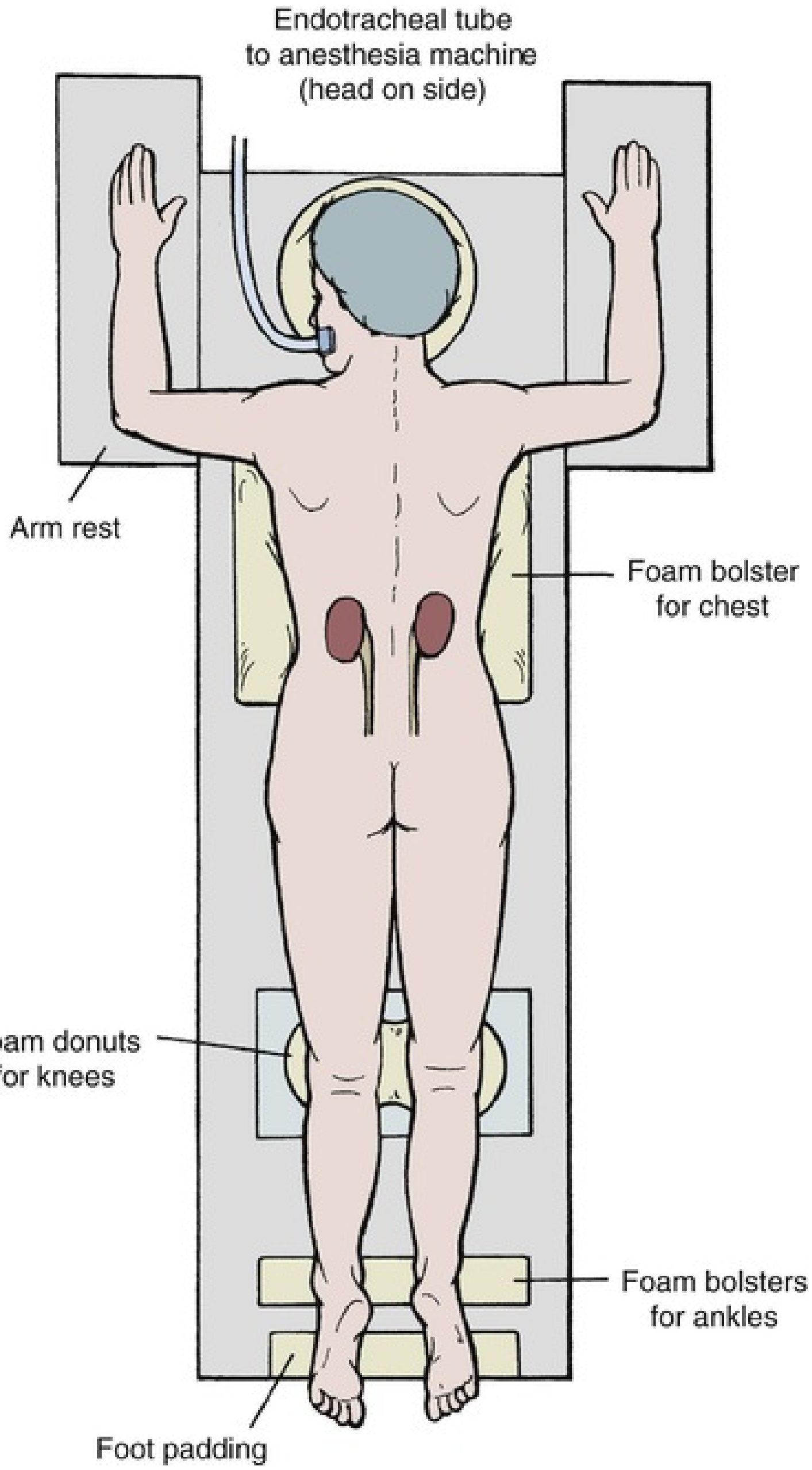
Endotracheal tube
to anesthesia machine
(head on side)
Arm rest
Foam bolster
for chest
Foam donuts
for knees
Foam bolsters
for ankles
Foot padding

FIG. 12.8 Padding for prone positioning.

Supine Position

First described by Valdivia Uria and colleagues in 1987, the supine position is an alternative to traditional prone positioning (Valdivia Uria et al., 1987). As originally described, the patient is positioned with the ipsilateral side toward the most lateral aspect of the table and the flank elevated with a bolster or 3-liter bag of saline underneath the lumbar fossa. The ipsilateral arm is positioned across the chest, and padding is applied to limit pressure to the elbow and wrist. There have been several modifications to the prone position including the Galdakao-modified supine position (Scoffone et al., 2008) and the complete supine position (Falahatkar et al., 2011), among others.

Benefits of the supine position include easy access to the airway and optimization of cardiopulmonary function in patients. Because patients do not need to be repositioned after induction of anesthesia, randomized controlled trials indicate that supine positioning is associated with faster operative times (Al-Dessoukey et al., 2014), at least in the setting of percutaneous nephrolithotomy. Finally, radiation exposure to the physician's hands is minimized, and the surgeon can perform the procedure in the seated position, limiting fatigue. Drawbacks to the supine approach include limited surface area for renal puncture, difficulty accessing the upper pole, and lower intrarenal pressures caused by the downward orientation of the access sheath, which may impair visualization.

Modifications to Prone or Supine Positioning

From either position, better access to the urethra can be facilitated by positioning the patient with the legs spread in the prone split leg position (Grasso et al., 1993) or in a modified lithotomy position while in supine position. These modifications allow for a combined antegrade and retrograde approach at the time of percutaneous renal surgery. The clinical benefits of these modifications are unclear.

Anesthetic Considerations

Choice of anesthetic is typically left to the anesthesiology team and should be dictated by patient characteristics such as cardiopulmonary comorbidity and body mass index. In general, general endotracheal anesthesia is required to maintain a secure airway in the prone position, whereas laryngeal mask airway can be considered when the patient is positioned supine. Regardless of what primary anesthesia is used for percutaneous renal surgery, the addition of local and regional anesthesia may be beneficial. A meta-analysis of six randomized trials revealed reduced analgesia requirement and 24-hour pain scores in the patients receiving tract infiltration with local anesthetic (vs. placebo) (Wang et al., 2016). Additionally, intercostal nerve blocks and thoracic paravertebral block with long-acting local anesthetics have provided similar benefit in randomized controlled trials (Ak et al., 2013; Honey et al., 2013; Ozkan et al., 2013).

Choice of Calyx for Access

Choice of calyx for access is dictated by patient positioning; If the patient is prone, then the posterior calyces are most accessible, whereas if the patient is supine, then the anterior ones are preferred. In special circumstances (i.e., calyceal diverticulum), anterior or posterior calyces can be approached from any position. Access should never be directly through the renal pelvis, and caution should be exercised when puncturing in a location with atrophic renal parenchyma as sealing of the tract can be compromised.

Upper Pole Calyx

Puncture into the upper pole calyx provides the most versatile access. The renal pelvis, proximal ureter, lower pole, and in some cases, interpolar calyces can be accessed with a combination of rigid and flexible instruments with a well-placed upper-pole puncture. This site often requires supracostal (above the 12th rib) access leading to an increased risk for pleural morbidity. **Nonetheless, if entry directly above the 12th rib (11th intercostal space) provides the best access to the optimal calyx, then the benefit generally exceeds the risk** (Fig. 12.9). Entry above the 11th rib, however, has a greater potential for pleural and even lung injury, so when the best access calls for a direct puncture above the 11th rib, additional maneuvers should be considered to displace the kidney inferiorly. These include cephalad tilt of a subcostal access sheath or access needle placed into a lower calyx (Karlin and Smith, 1989; Lezrek et al., 2011); gentle traction on a through-and-through guidewire placed through a lower-pole access (Goyal et al., 2012); and attaining access during full inspiration (Falahatkar et al., 2010). Another alternative is to angle the access tract cephalad from a subcostal entry site (Liatsikos et al., 2005; Rehman et al., 2008). This approach provides limited access to the rest of the kidney. All of these alternatives can damage the kidney if excessive force is applied. Access above the 10th rib is associated with a high incidence of pleural violation and lung injury and should be avoided unless absolutely necessary. Thorascopically guided access superior to the 10th rib can be performed to reduce the risk for lung injury (Finelli and Honey, 2001).

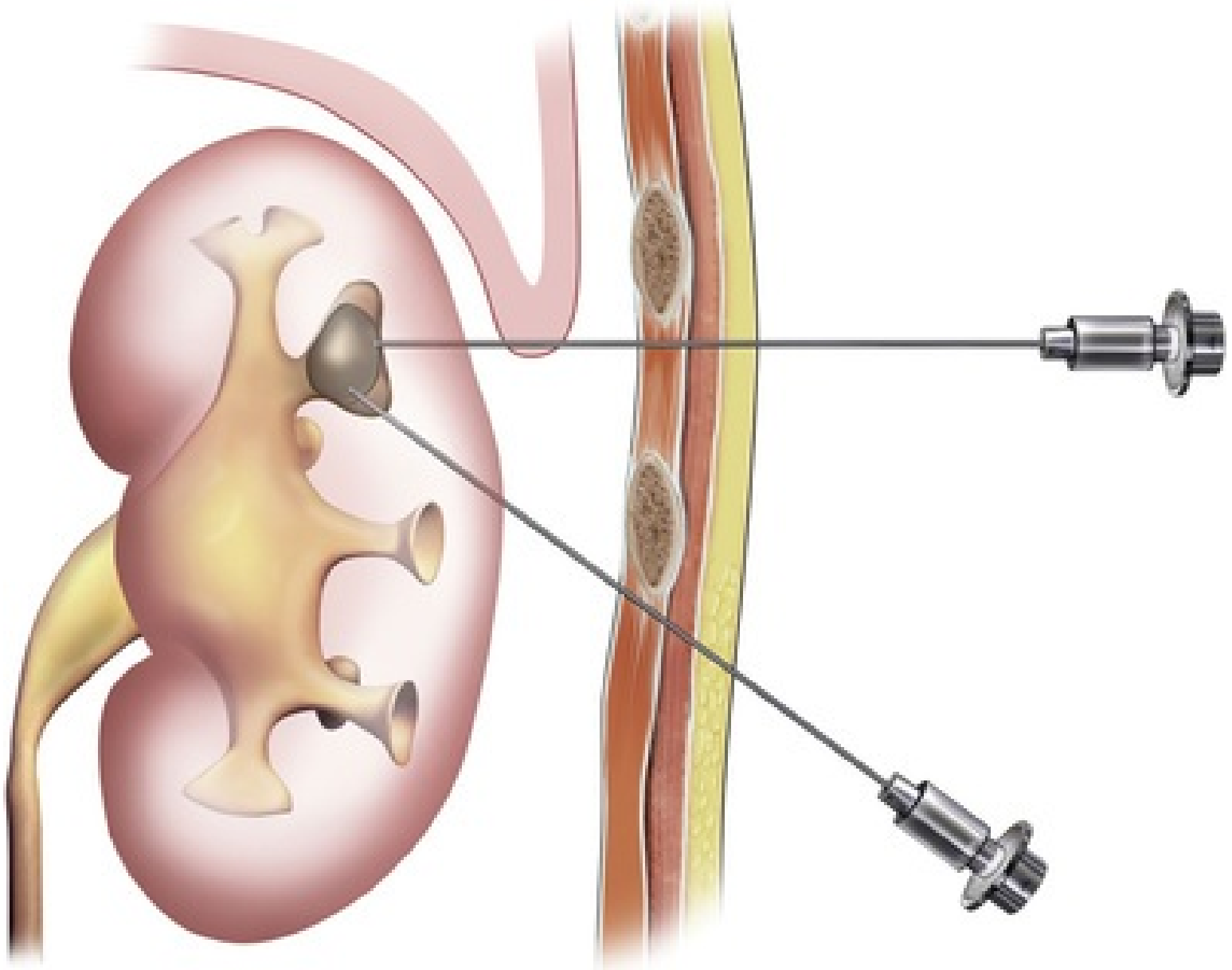

FIG. 12.9 Subcostal and supracostal percutaneous access to an upper pole calyx. The supracostal approach provides more direct access and provides a better angle for endoscopy of the rest of the kidney.

Interpolar Calyx

Interpolar calyceal access likely is the least versatile. Although it does afford ready access for procedures in the renal pelvis or upper ureter, it is nearly impossible to navigate a rigid instrument into the upper or lower pole calyces, so it otherwise should be reserved only for procedures limited to the interpolar region.

Lower Pole Calyx

Though not as versatile as the upper pole access, puncture into the lower pole calyx affords the surgeon ready access to the majority of the kidney while essentially eliminating the possibility of pulmonary morbidity with upper-pole access. A rigid instrument can often be navigated to the renal pelvis without much difficulty, though other bodily landmarks such as the iliac crest may limit upward deflection of the scope. With the use of a flexible scope, access to most calyces can be achieved.

Image Guidance for Puncture

Fluoroscopic-Guided Access.

Fluoroscopic guidance is one of the most commonly employed techniques for antegrade access into the renal collecting system. **Fluoroscopy provides excellent delineation of the intrarenal collecting system anatomy and pathology (when contrast-enhanced), a wide field of view (that can be collimated down to reduce radiation exposure), and the ability to monitor all steps of the procedure. Although retrograde instillation of air and/or contrast material is not absolutely essential** (Tabibi et al., 2007), **most urologists find that it enhances fluoroscopically guided percutaneous access** (eFigs. 12.10 and 12.11).

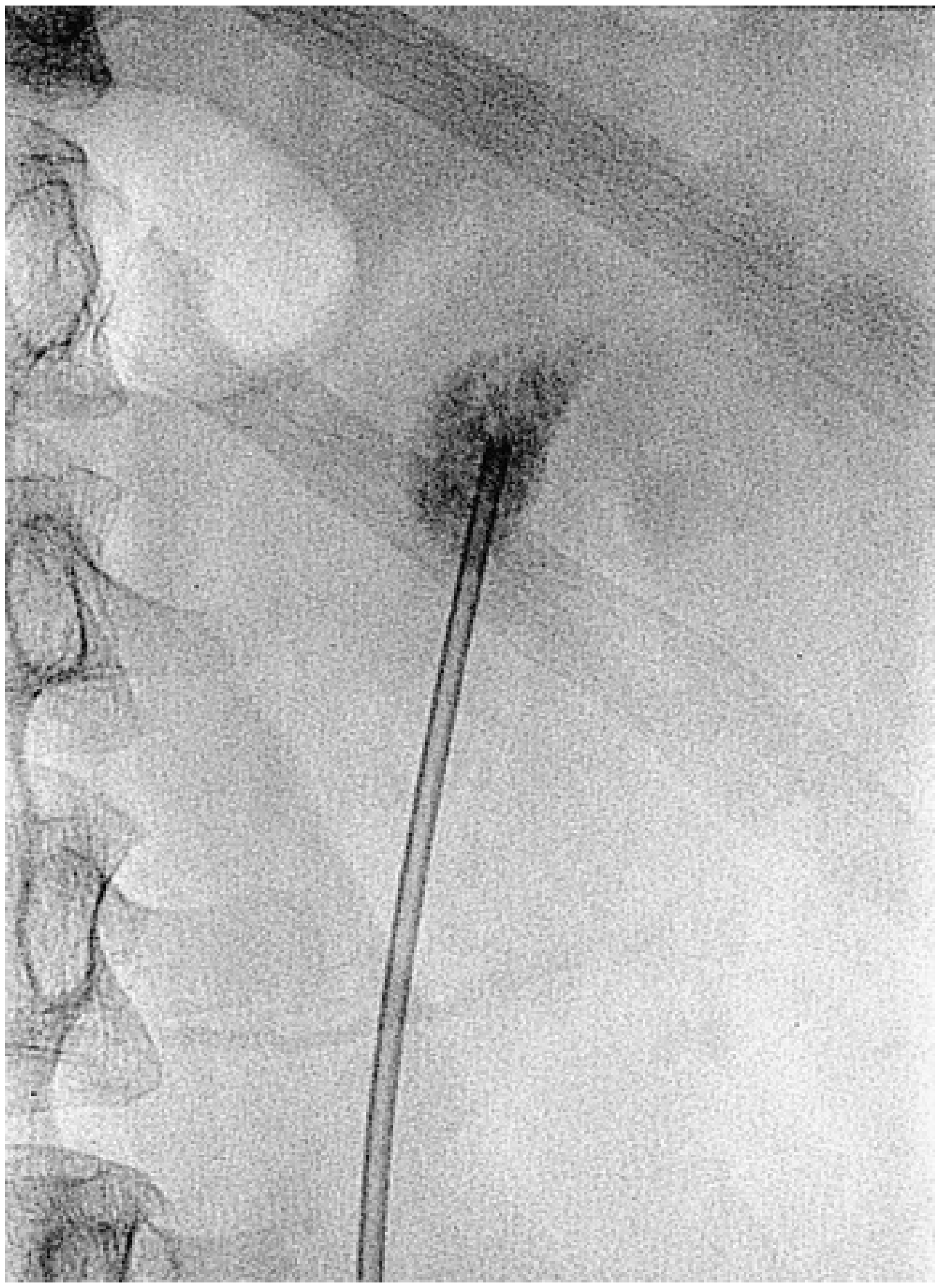

EFIG. 12.10 Straight ureteral catheter has been passed up into stone-containing renal pelvis.

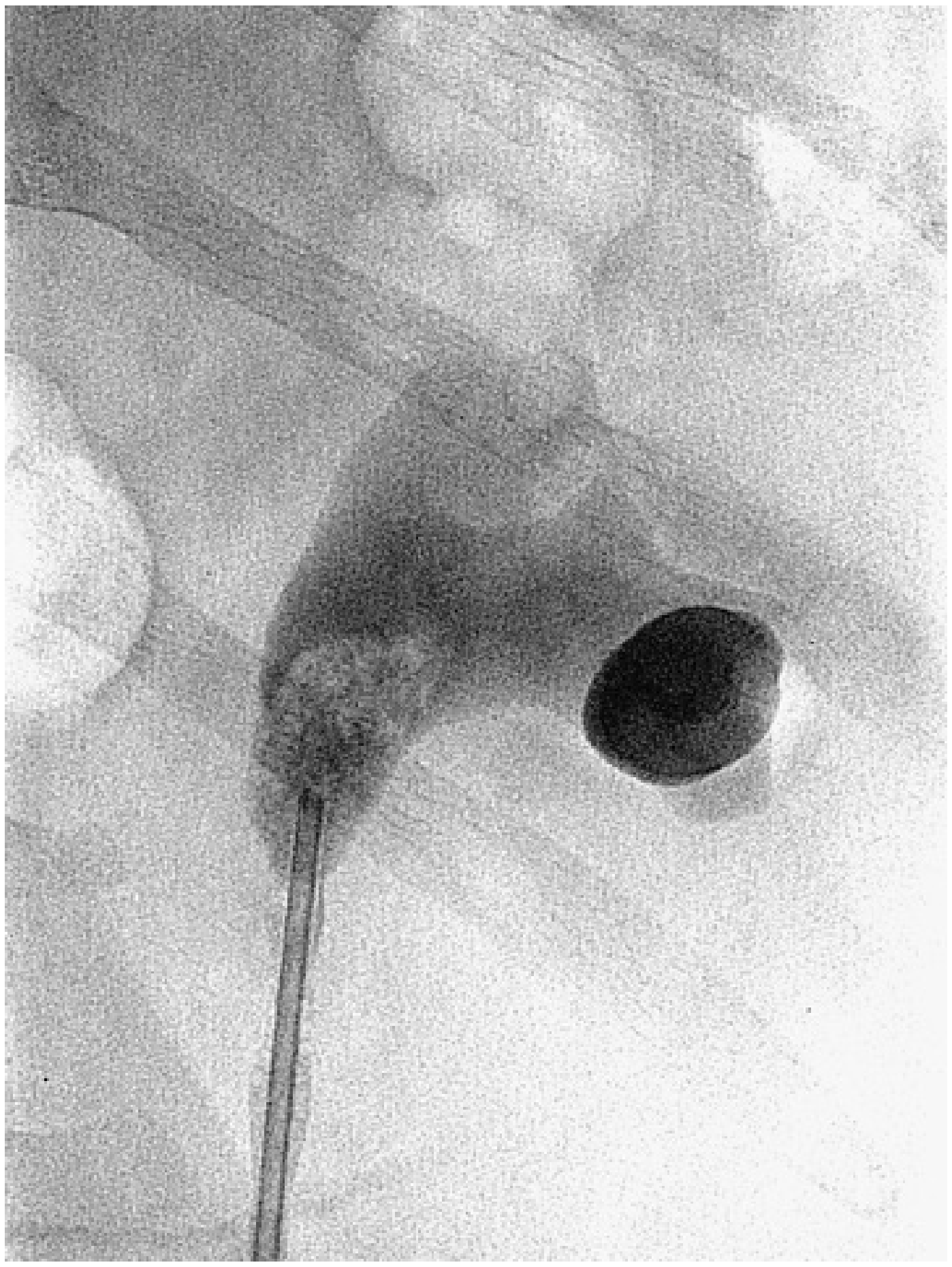

EFIG. 12.11 Retrograde pyelogram with air and contrast shows air in upper pole compound calyx and posterior lower pole calyx.

There are two well-described methods of fluoroscopic guidance for antegrade percutaneous access into the upper urinary tract collecting system: the "eye-of-the-needle" technique (Video 12.1▶) **and the "triangulation" technique** (Miller et al., 2007). Both have their proponents, and there is no clear advantage of one over the other, as confirmed by one randomized controlled trial (Tepeler et al., 2012).

In the remainder of this section, the descriptions are for percutaneous access in the prone position. Slight modifications are made for the supine position. First, place a retrograde ureteral catheter through which contrast material is instilled after obtaining an initial radiograph to delineate any pathology that may become obscured with contrast material. Combining the original noncontrasted images with the postinjection images is usually sufficient to identify an appropriate calyx for puncture. In some cases, it may be useful to perform an "air pyelogram" as an adjunct to retrograde pyelography by injecting a bolus of air to delineate the posterior calyces (in the prone position) (Fig. 12.12).

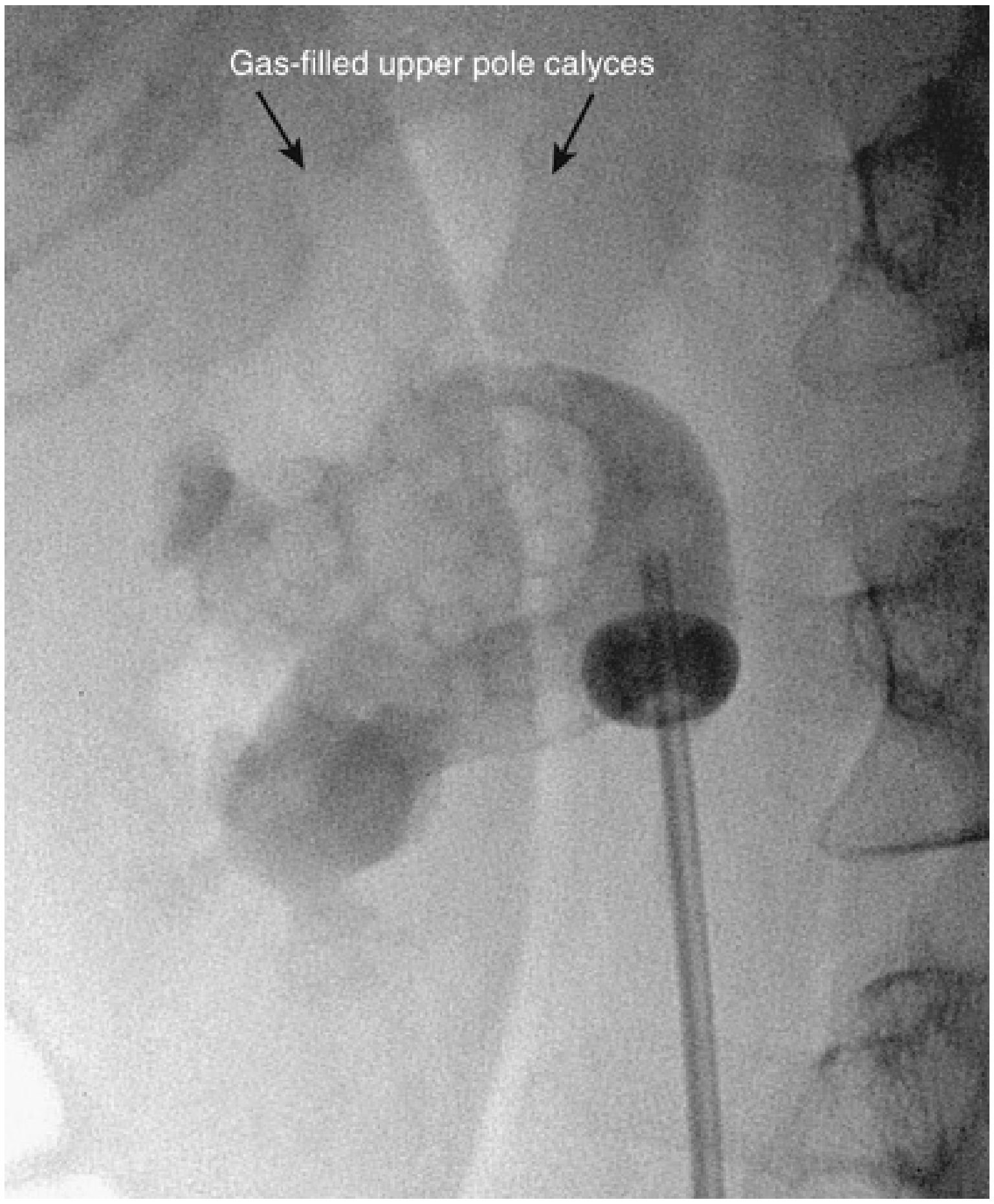

FIG. 12.12 Injection of air into contrast-filled upper tract collecting system shows posterior calyces, in this case most clearly the upper pole calyces.

To perform the “eye-of-the-needle” technique, first inspect the kidney with the fluoroscopy unit directly above the patient (directed vertically) and select the desired calyx. Next, rotate the top of the fluoroscopic unit 30 degrees toward the operator, which brings the fluoroscopic view approximately in line with the posterior calyces. The unit can be additionally rotated slightly cephalad or caudad to correspond more exactly with the calyx. Place the tip of a hemostat on the skin, and move it until it is directly over the desired calyx. Mark this site, and make an incision large enough to accept the needle and initial dilators. Place the tip of the access needle into this incision, and then move the shaft of the needle while keeping the tip in place until the needle is directly in line with the axis of the fluoroscopy unit; doing so gives the appearance of a “bull's eye” with the hub of the needle (which appears as a circle) around the shaft (which appears as a dot). The fluoroscopic view is as if the operator is looking down the shaft of the needle at the targeted calyx—thus the term *eye of the needle* (Fig. 12.13A). Advance the needle straight in while checking with fluoroscopy and adjusting the angle of the needle as needed to maintain the “bull's-eye” appearance. If the needle is more than a few centimeters deep and readjustment is necessary, the needle may have to be withdrawn before a new trajectory can be followed. The 21-gauge needle can be difficult to control during this step. If this occurs, substitute the more easily passed 18-gauge needle. Once the needle's axis is fixed and it is thought that the needle is approaching or is in the kidney (typically a “pop” can be felt when the renal capsule is punctured), then rotate the fluoroscopy unit away from the operator, back to vertical or even 10 to 15 degrees beyond vertical. Now the needle appears “in profile” as a straight line. With the cephalo-caudad and medial-lateral axes of the needle now fixed, advance or withdraw the needle to change its anterior-posterior position (depth) to get the tip of the needle into the desired calyx (see Fig. 12.13B). Aspiration of urine or air after removing the obturator confirms entry. Instillation of contrast material can be used to confirm entry as well, but if the needle is misplaced, the extravasated contrast material can obscure subsequent fluoroscopic visualization. If a gently passed guidewire stays within the contours of the collecting system, then this confirms proper entry without risking the troublesome extravasation of contrast material.

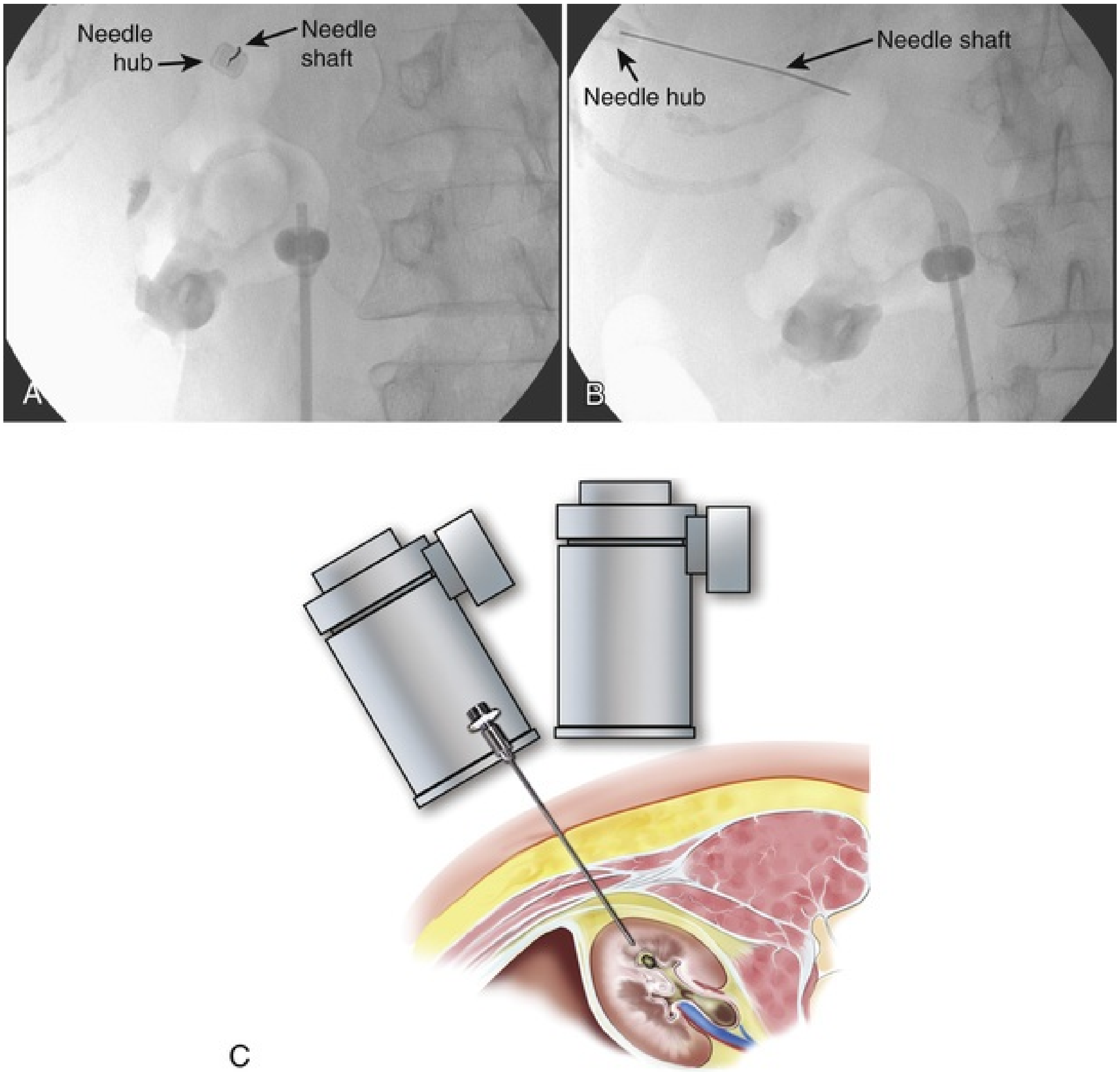

FIG. 12.13 “Eye-of-the-needle” fluoroscopic guidance. (A) With the top of the fluoroscopic unit rotated 30 degrees toward the operator, the needle is lined up directly over the intended calyx of entry. (B) With the fluoroscopy unit rotated away from the operator, the needle is now seen in profile and in (C) has already been advanced under fluoroscopic control to achieve collecting system entry.

To use the triangulation technique, inspect the kidney with the fluoroscopy unit directly above the patient to select the desired calyx, and hold the needle in the approximate position of the desired angle of entry. For puncture into a lower pole calyx, angle the fluoroscopy unit caudally to get the operator's hands outside of the radiation field. Triangulation relies on two distinct fluoroscopy unit positions to address both medial-lateral orientation of the needle and depth. First, with the unit rotated 20 to 30 degrees toward the operator, adjust the needle in the medial-lateral plane relative to the patient until the desired calyx is targeted (Fig. 12.14A). Once this orientation is satisfactory, rotate the unit away from the operator 20 to 30 degrees (toward a true anterior-posterior orientation). In this plane, adjust the needle in the cephalo-caudal plane relative to the patient until the desired calyx is targeted (see Fig. 12.14B). Move the needle only in the medial-lateral or cephalo-caudal plane in each projection, otherwise targeting will be compromised. Resting the forearm on the patient's back helps stabilize the needle in one plane while moving in the other. Once targeting is complete, advance the needle with the fluoroscopy in the anterior-posterior orientation to allow monitoring of needle depth. Assess the medial-lateral orientation of the needle with the fluoroscopy unit tilted toward the surgeon 20 to 30 degrees when the needle tip depth has reached the renal capsule to ensure that targeting is still appropriate. Confirm final entry into the collecting system in the anterior-posterior orientation.

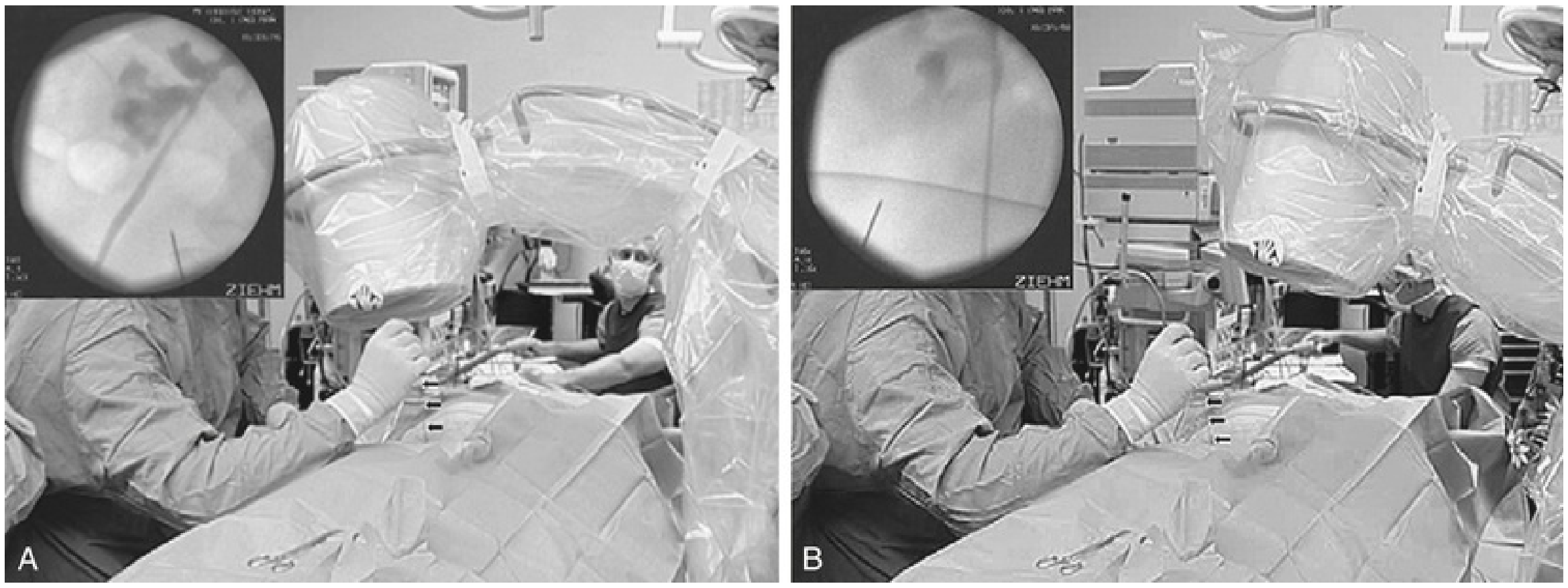

FIG. 12.14 Triangulation fluoroscopic guidance. (A) With the top of the fluoroscopy unit rotated laterally and cephalad, adjust the access needle *(arrows)* to a mediolateral orientation of the needle. (B) After rotating the top of the fluoroscopy unit medially, and while keeping mediolateral orientation of the needle constant, move the needle in the cephalo-caudad plane until the needle is again aimed toward the desired calyx. (From Miller NL, Matlaga BR, Lingeman JE: Techniques for fluoroscopic percutaneous renal access. *J Urol* 178:15–23, 2007.)

With the “eye-of-the-needle” technique, the proper cephalo-caudad and medial-lateral axes of the needle are verified and maintained on a single fluoroscopic view, and the confirmatory view is necessary only to confirm the depth of the needle tip. For the triangulation technique, one fluoroscopic view is used to assess the medial-lateral axis and another is used to assess the cephalo-caudal axis, with the depth of the needle tip being assessed on both views (Miller et al., 2007). The advantages of the triangulation technique over the eye-of-the-needle technique is that the needle cannot be passed too deeply because the depth of advancement is monitored continuously, and the tract is often oriented favorably in relation to the calyx of the puncture, avoiding excess torque on the kidney when working with rigid instruments. The disadvantage of the triangulation technique is that maintaining both the medial-lateral and cephalo-caudad planes is difficult because neither are monitored at the same time as in the eye-of-the-needle technique. Use of the 18-gauge rather than a 21-gauge needle is recommended with the triangulation technique to help maintain the angle of entry. Mechanical devices that stabilize the needle during insertion might be helpful as well (Lazarus and Williams, 2011).

Ionizing radiation presents a small but real risk. When the operator must grasp the access needle within the fluoroscopy field, it is best to hold the needle with a hemostat, sponge forceps, or purpose-built needle holder to reduce radiation exposure to the operator's hand. Collimating the field down as much as possible while still maintaining an adequate field of view reduces radiation exposure to the patient and all personnel in the room. Moving a collimated field around to maintain the object of interest in the field is preferable to maintaining a wide field that includes the operator's hands and unnecessary body parts of the patient. Increased body mass index, greater stone burden, nonbranched stones, greater number of access sites, and use of air rather than contrast during initial retrograde pyelography are associated with an increased radiation dose (Lipkin et al., 2011; Mancini et al., 2010). For additional information about radiation safety, see Chapter 157.

Ureteroscopic-Assisted Fluoroscopic Access.

As detailed earlier, placement of a ureteral catheter facilitates antegrade fluoroscopic access by allowing the surgeon to instill contrast material or air into the collecting system to choose a suitable target. Adaptations to this approach include placement of a ureteral access sheath through which a ureteroscope is introduced directly into the collecting system. This serves two purposes. First, the improved drainage afforded by the ureteral access sheath allows any stone fragments that may be generated during lithotripsy to flush down the ureter and out of the body (Landman et al., 2003). Second, a ureteroscope passed retrograde can greatly facilitate percutaneous entry into the intrarenal collecting system (Grasso et al., 1995; Kidd and Conlin, 2003; Patel et al., 2008) by allowing the surgeon to observe and correct the percutaneous placement of a needle into the desired calyx. A basket can then be passed through the ureteroscope to grasp the end of the percutaneous guidewire; pulling this out, the urethra provides through-and-through access (Fig. 12.15). Furthermore, tract dilation can be observed in real time, ensuring accurate working sheath placement. Moreover, the ureteroscope may have better access to some sites in the kidney than the nephroscope and can be used to assist in the procedure (e.g., fragment or relocate stones, fulgurate small tumors). Retrospective nonrandomized comparisons of ureteroscopic assistance versus solely fluoroscopic guidance for access during percutaneous nephrolithotomy suggest that the former may be associated with a lower transfusion rate (Sountoulides et al., 2009) and a decreased need for fluoroscopy time, multiple accesses, and early termination of the procedure resulting from hemorrhage (Isac et al., 2013).

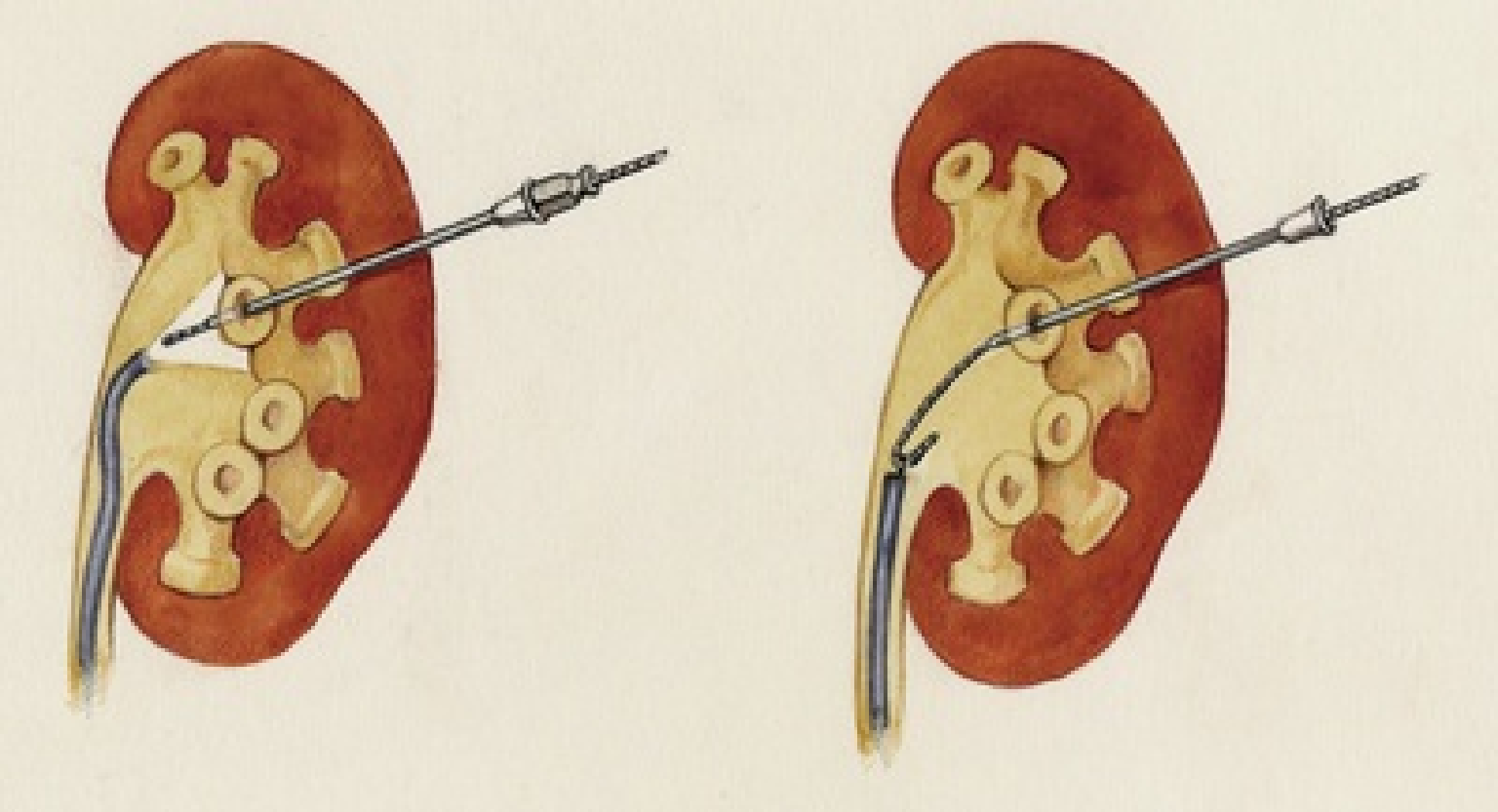

FIG. 12.15 Ureteroscope retrograde assistance. The needle can be directly visualized entering the calyx, and a wire can be grasped and pulled down the ureter and out the urethra.

More recently, use of the holmium laser to provide retrograde-assisted percutaneous renal access has been described. In a small study, investigators positioned a ureteroscope into the most posterior upper-pole calyx (confirmed by air bubble location) and used a 365-micron holmium laser fiber with settings of 1 Joule and 10 Hertz to bore directly through the desired calyx until the laser fiber was seen exiting the flank. At this time, a skin incision was made and an 18-gauge needle was advanced coaxially over the laser fiber until it was seen under direct vision to be entering the calyx. The laser fiber was then withdrawn and a guidewire was advanced antegrade, grasped with the ureteroscope, and withdrawn to secure through-and-through access (Kaler et al., 2018).

Ultrasound-Guided Access.

Although not as commonly performed as fluoroscopic guidance in the United States, ultrasound-guided renal access is widely practiced among the international urologic community. **Benefits of the ultrasound-guided approach include decreased ionizing radiation exposure, potential for decreased costs** (Hudnall et al., 2017), **ability to identify and potentially avoid adjacent viscera, and clear delineation of anterior versus posterior renal calyces.** It has been successfully performed in a variety of clinical situations including the pediatric population, those with obesity, and those with renal anatomic abnormalities (Penbegul et al., 2013; Usawachintachit et al., 2016; Xiao et al., 2016). Unlike fluoroscopically guided renal access, which is dependent on placement of a retrograde ureteral catheter for instillation of contrast, ultrasound-guided access can be performed in nearly any clinical situation. It is particularly useful in the setting of prior urinary reconstruction like ileal conduit or orthotopic urinary diversion, where access to the ureter may be impossible. A curved array ultrasound transducer, typically 3.5 MHz, is often utilized (Fig. 12.16). It is important to use an etched needle, which is more visible sonographically, to allow continuous visualization of the needle tip. The procedure begins with careful sonography of the kidney to determine appropriate access location. In a nondilated system, placement of a ureteral catheter allows for saline injection to distend the collecting system and facilitate accurate entry. Several techniques for ultrasound-guided access have been described, but in general, can be broken down simply into whether the ultrasound probe is oriented in a transverse or longitudinal orientation to the kidney. In the transverse orientation, orient the probe perpendicular to the paraspinous muscle. After selecting a target calyx, insert the needle orthogonally to the probe and track the needle continuously by sweeping the probe along the axis of the kidney. For the longitudinal approach, orient the probe cephalocaudally approximately parallel to the paraspinous muscle along the axis of the kidney. Insert the needle above or below the probe, and again track the needle until entry into the target calyx (Chu et al., 2016). Once entry into the collecting system is confirmed, fluoroscopy can be used for safety wire placement and tract dilation. A “fluoroscopy-free” approach wherein safety wire placement and tract dilation are conducted exclusively with ultrasonography has been described (Sharifiaghdas et al., 2015).

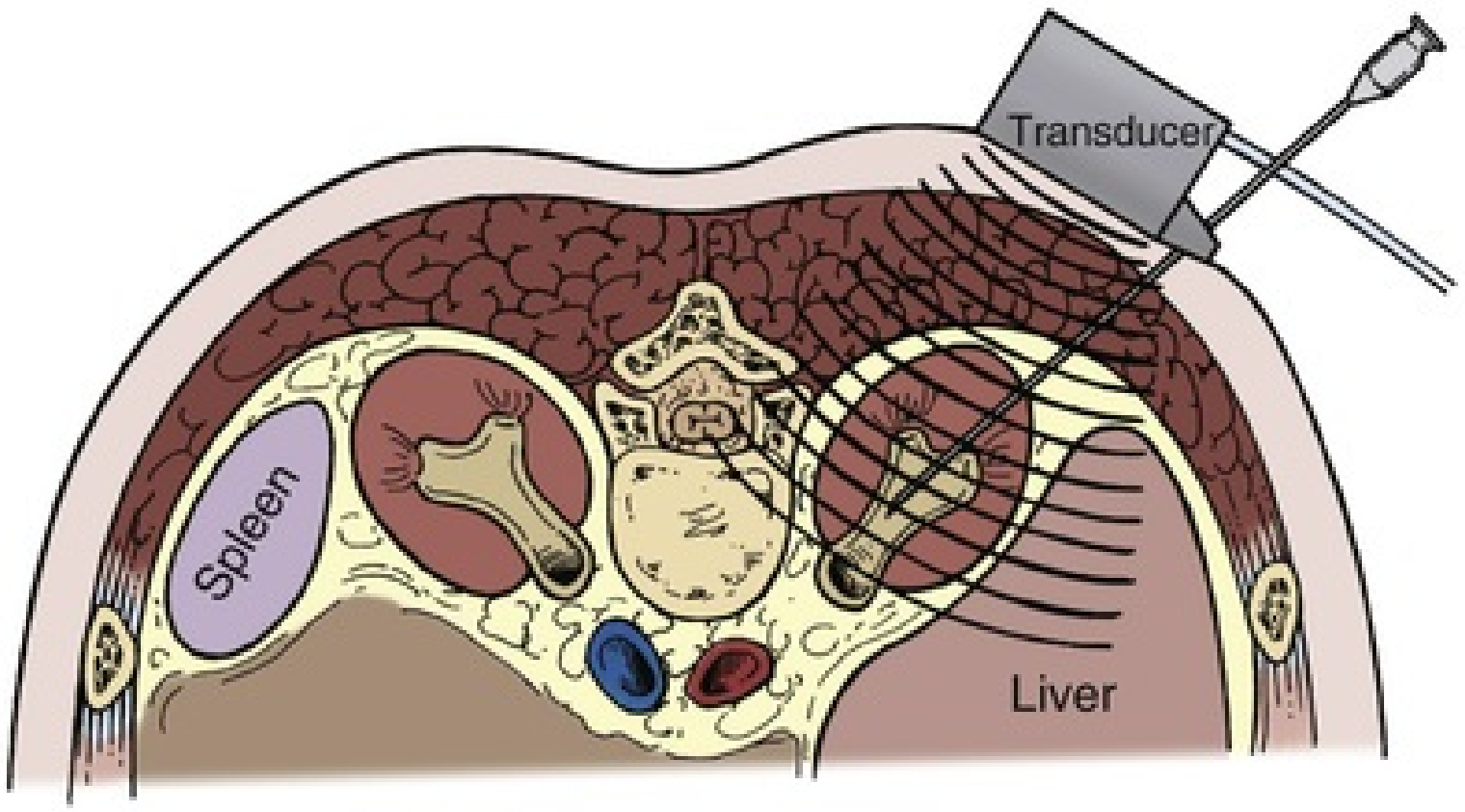

FIG. 12.16 Ultrasonographic guidance of puncture needle.

Advanced Guidance Techniques

In some complex cases, percutaneous access into the kidney guided by CT or MRI might be considered. The initial access is obtained into the desired calyx with the patient on the CT or MRI table, like the techniques used for needle biopsy (Barbaric et al., 1997; Hagspiel et al., 1998; Thanos et al., 2006). Bowel and other viscera can be imaged to protect against their injury, and this approach is especially useful in cases of anatomic abnormalities (LeMaitre et al., 2000; Matlaga et al., 2003; Srivastava et al., 2010).

“Blind” Access.

The upper urinary tract collecting system can also be accessed “blindly,” without any imaging guidance (Chien and Bellman, 2002). The only situation in which this should be considered is if sonography is not available and there is complete ureteral obstruction (precluding retrograde instillation of contrast material or opacification of the collecting system with intravenous contrast). The lumbar notch, also known as the *superior lumbar triangle* or *Grynfeltt lumbar triangle,* has been reported to be a reliable landmark for blind percutaneous renal access (Fig. 12.17). The lumbar notch is an area of muscular insufficiency through which hernias can occur. It is located posteriorly below the 12th rib. The superior border is the 12th rib and latissimus dorsi muscle, the lateral border is the transversus abdominis and external oblique muscles, the medial border is the quadratus lumborum and sacrospinalis muscles, and the inferior border is the internal oblique muscle. Insert a needle 3 to 4 cm deep into the notch at a 30-degree cephalad angle to enter the collecting system. Another blind approach to the collecting system is to insert a needle directly perpendicular to the body surface 1 to 1.5 cm lateral to the L1 vertebral body, which will lead directly to the renal pelvis if anatomy is normal. If fluoroscopy is available, then air and contrast material can be injected through a blindly placed needle to fluoroscopically assess its position and guide another needle if needed. In the only randomized clinical trial comparing “blind” access to image-guided access, entry into the collecting system was successful in 50% and 90% of cases, respectively (Basiri et al., 2007). Use of the technique is not recommended in most settings.

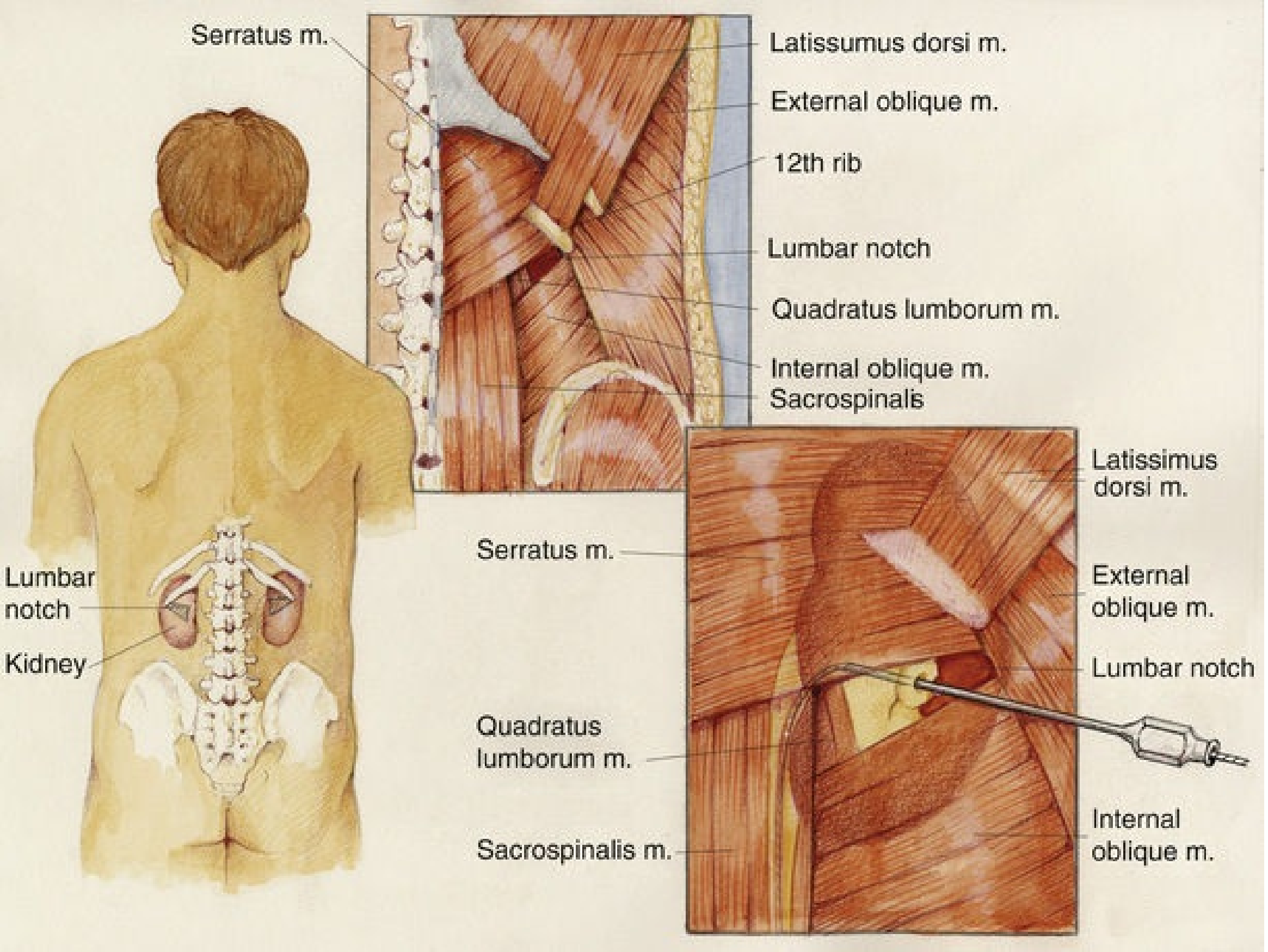
Serratus m.
Latissumus dorsi m.
External oblique m.
12th rib
Lumbar notch
Quadratus lumborum m.
Internal oblique m.
Sacrospinalis
Latissimus dorsi m.
Serratus m.
External oblique m.
Lumbar notch
Lumbar notch
Kidney
Quadratus lumborum m.
Sacrospinalis m.
Internal oblique m.

FIG. 12.17 The lumbar notch is a useful anatomic landmark for blind percutaneous access to the renal collecting system. It is bounded superiorly by the latissimus dorsi muscle and the 12th rib, medially by the sacrospinalis and quadratus lumborum muscles, laterally by the transversus abdominis and external oblique muscles, and inferiorly by the internal oblique muscle.

Key Points: Obtaining Percutaneous Renal Access

- Whether the interventional radiologist or urologist obtains percutaneous renal access, it is imperative that the urologist is present to clearly define the best location for puncture.
- Fluoroscopy and ultrasonography are well-described techniques to guide percutaneous renal access. In some cases, advanced techniques are required to safely obtain renal access.
- Upper-pole access is often the most versatile location for percutaneous renal surgery as all calyceal groups are typically able to be reached. Upper-pole access must be balanced with the risk for pleural morbidity.

Access Needles.

The general scheme of antegrade access is to place a needle through the skin into the upper urinary tract collecting system. A guidewire is placed through the needle, and then catheters and other devices are placed over the guidewire, eventually enlarging the tract until the desired lumen is obtained. This is the Seldinger technique, described (for vascular access) by Sven-Ivar Seldinger (Seldinger, 1953). The standard choices for the needle are a 21-gauge needle through which is passed a 0.018-inch guidewire or an 18-gauge needle through which is passed a standard 0.035-inch guidewire. Both needles have a blunt sheath and a sharp obturator (Fig. 12.18). The 21-gauge needle has the advantage of causing relatively minor injury as it is passed through tissue. Multiple passes can generally be made with little risk for hemorrhage from the needle itself. The 18-gauge needle is more traumatic, and multiple passes should be avoided. The advantage of the 18-gauge needle is that it is stiffer. In many circumstances, the 21-gauge needle does not adequately maintain trajectory (e.g., scarred kidney, obese patient), and the 18-gauge needle is more effective. In addition, the 0.018-inch guidewire that passes through the 21-gauge needle must be exchanged for a standard 0.035-inch guidewire for subsequent tract dilation or catheter placement. This requires an extra step, which adds to the complexity of the procedure and increases the risk for access loss. Balancing the reduced efficacy of the 21-gauge needle and its increased potential for loss of access versus the increased risk for trauma with the 18-gauge needle, it is recommended that the 21-gauge needle be used when the operator is less experienced or if minimizing trauma is paramount. The 18-gauge needle should be used when an experienced operator is confident that the tip of the needle can be placed within the desired calyx with just a few attempts.



FIG. 12.18 Percutaneous access needle, with a blunt sheath and a sharp obturator.

Two methods can be used to exchange the 0.018-inch for a 0.035-inch guidewire. A coaxial introducer incorporates a small catheter within a slightly larger catheter. After inserting the 0.018-inch guidewire and removing the needle, advance the coaxial introducer over the guidewire until the end is within the renal collecting system. Remove the inner catheter and 0.018-inch guidewire, and then advance a 0.035-inch guidewire through the outer catheter into the collecting system. The second method is the use of a graduated introducer, which fits over the 0.018-inch guidewire at its tip but then enlarges to a lumen that will accept the 0.035-inch guidewire. A few centimeters back from the tip there is a hole through which the 0.035-inch guidewire can pass. After inserting the 0.018-inch guidewire and removing the needle, pass the graduated introducer over the guidewire until it is a few centimeters inside the kidney, such that the side hole is within the renal collecting system. Remove the 0.018-inch guidewire and then insert an angled or *J*-tipped 0.035-inch guidewire through the introducer until the end of the wire exits the catheter within the collecting system. With either the coaxial or graduated introducer, a stiffener can be used to assist in passing the device over the relatively insecure 0.018-inch guidewire.

Guidewires.

The safest initial 0.035-inch guidewire to use for upper urinary tract percutaneous access is a polytetrafluoroethylene (PTFE)-coated *J*-wire or *C*-wire. The curved tip makes the guidewire unlikely to perforate out of the collecting system. This guidewire will not easily pass down the ureter, however, which is more easily done with a floppy-tip PTFE-coated guidewire or a hydrophilic guidewire with a straight or angled tip. There are many options available to the surgeon to facilitate passage of the wire down the ureter and into the bladder. With an upper-pole calyceal puncture, the trajectory of access is often in line with the ureter, thus the wire may pass without assistance. In the case of a lower-pole calyx or when initial access to the ureter is not achieved, use of a torque-stabilized angled-tip catheter allows the surgeon to change the trajectory of the wire such that the ureter can be cannulated. Once a wire has been negotiated down the ureter, it is often exchanged for a stiffer wire (i.e., Amplatz super stiff wire) over which dilation is more readily achieved. In most situations, it is best to place a second safety wire down the ureter. This can be achieved by positioning either a dual-lumen catheter or larger coaxial catheter with an inner lumen sufficient to pass a second guidewire down the ureter. There are instances in which placement of a second guidewire is challenging such as complete staghorn calculi, calyceal diverticulae, and impacted infundibular stones. In these cases, working with just a single guidewire is appropriate, but attempts should be made to secure access down the ureter if ever feasible as the case progresses to avoid losing access.

Tract Dilation.

Once there is adequate wire access into the upper urinary tract collecting system, dilate the tract to allow insertion of working instruments. In most cases, the goal of dilation for percutaneous renal surgery is to place a 30-Fr inner-diameter/34-Fr outer-diameter plastic access sheath. In some cases, a smaller sheath with an inner diameter measuring 12 to 24 Fr is adequate. Renal access sheaths generally have a beveled tip, such that one side of the sheath extends farther than the other part. This bevel is used to maintain access into part of the collecting system on one side of the sheath while allowing extra mobility on the other side. Sheath repositioning is facilitated by the bevel. In cases of pathology at the edge of the collecting system, however, the bevel is a disadvantage because the entire tip of the sheath cannot be placed into the collecting system. Both opaque and clear sheaths are available; some prefer the clear sheaths because structures next to the sheath can be visualized.

In the early years of therapeutic percutaneous renal procedures, the tract was dilated gradually over the course of many days by placing sequentially larger tubes. Acute dilation of the tract was first reported by Castañeda-Zúñiga and associates in 1982 (Castañeda-Zúñiga et al., 1982). There are several dilator systems available. **Regardless of the method used, is it imperative that the dilator does not pass too far into the collecting system.** If this occurs, an infundibulum, the renal pelvis, or the ureteropelvic junction can be torn or perforated, either directly by the dilator or indirectly by a stone pushed aside by the dilator. Pass the dilator just into the calyx. It is better to dilate a bit “short” of the targeted calyx than to dilate too far and create trauma. If on initial nephoscopy the sheath is not deep enough, then simply replace the dilating device and redilate after advancing it. Dilators should not be used to dilate the skin; incise the skin to allow entry of the final sheath without pressure on skin edges.

Sequential rigid metal dilators, introduced by Alken (1985), are a series of progressively enlarging coaxial stainless steel rods that pass over an 8-Fr guide rod. The first step in tract dilation is to pass the 8-Fr guide rod over a 0.035-inch guidewire. The end of the guide rod has a ball that prevents advancement of the first dilating rod beyond the tip. The ball is positioned at the intended depth of the dilation (Fig. 12.19). After passing the first rod, each successive metal rod is passed sequentially over the former until the desired tract is achieved, up to a 30-Fr rod over which is passed a 30/34-Fr plastic sheath. **The advantages of the rigid metal dilator system are that it is the most effective dilator, that it is able to dilate even when there is dense perirenal scarring from prior procedures, and that it is inexpensive on a per-case basis because it is reusable. The disadvantage is that, for the same reason they are so effective, the rigid metal dilators can do considerable damage.** The depth of the dilation can be hard to maintain accurately, especially when pushing against tough scar tissue. One group has modified the rigid metal rods, tapering the ends and adding centimeter markings (Shen et al., 2007).

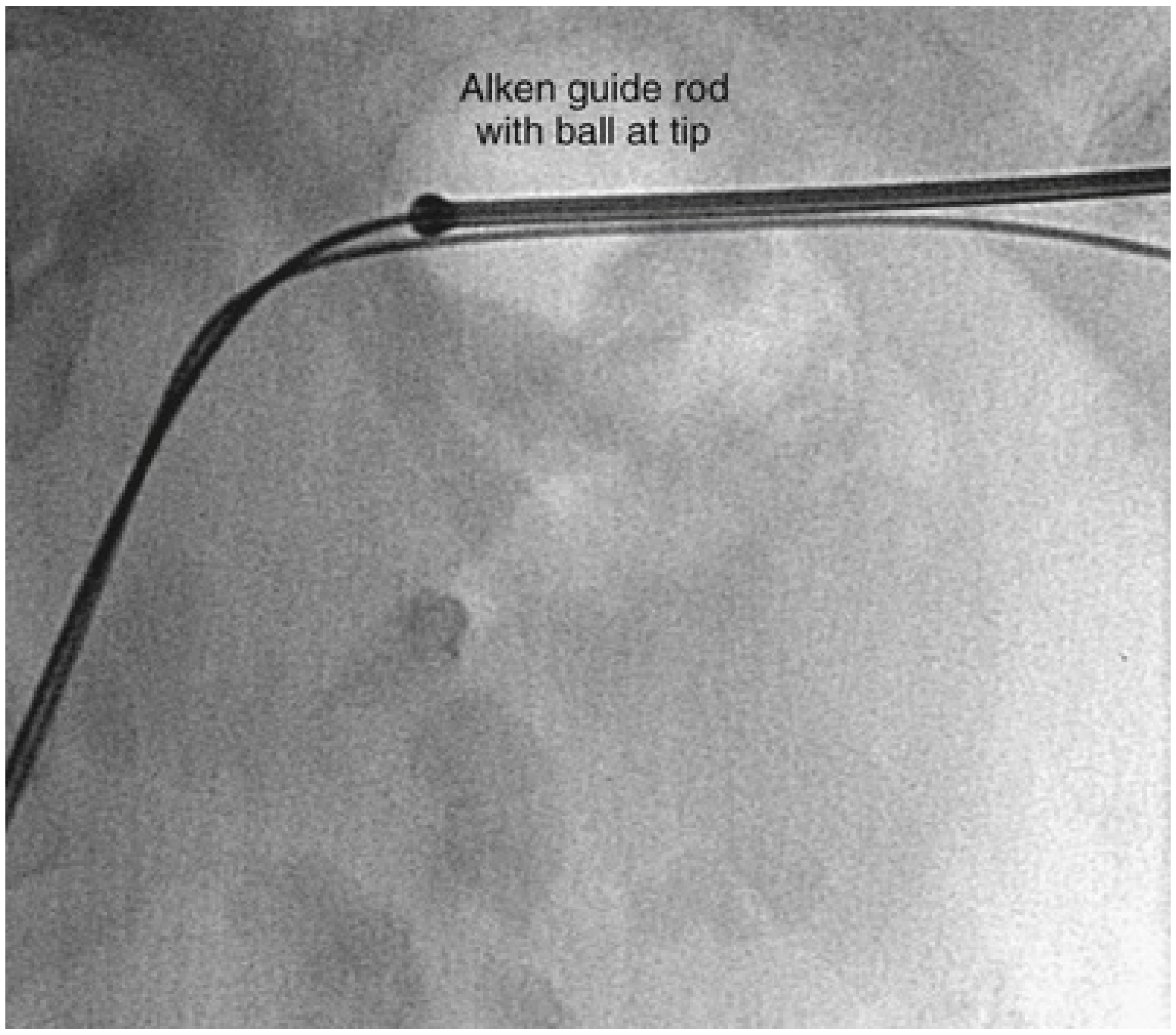

FIG. 12.19 Alken guide rod is positioned with the ball at the tip of the rod positioned at the intended depth of the dilation.

Progressive semirigid plastic dilation sets, often referred to as “Amplatz” dilators, after Kurt Amplatz, the senior author in the initial publication (Rusnak et al., 1982), consist of progressively larger firm polyurethane dilators that are passed over an 8-Fr PTFE guiding catheter that fits over a 0.035-inch guidewire (Fig. 12.20). The dilators are passed one after the other, not coaxially like the rigid metal dilators but progressively, advancing one dilator, removing it, advancing the next largest dilator, and so on until the final tract diameter is achieved. The working sheath is passed over the final dilator, and then the dilator and 8-Fr catheter are removed, leaving the working wire and sheath in place. The dilators are made in increments of 2 Fr, but if the tissue being dilated is soft, then not every dilator needs to be used. **The advantages of the semirigid plastic dilation system are that trauma to the collecting system is theoretically less likely than with the rigid metal dilators (although experienced urologists have found no difference between the two systems in terms of safety), but the disadvantage is that hemorrhage can occur each time a dilator is withdrawn.** Current semirigid plastic dilators are sold as disposable devices, so they are more expensive on a per-case basis than rigid metal dilators. One retrospective comparison of the two techniques found no other differences (Ozok et al., 2012).

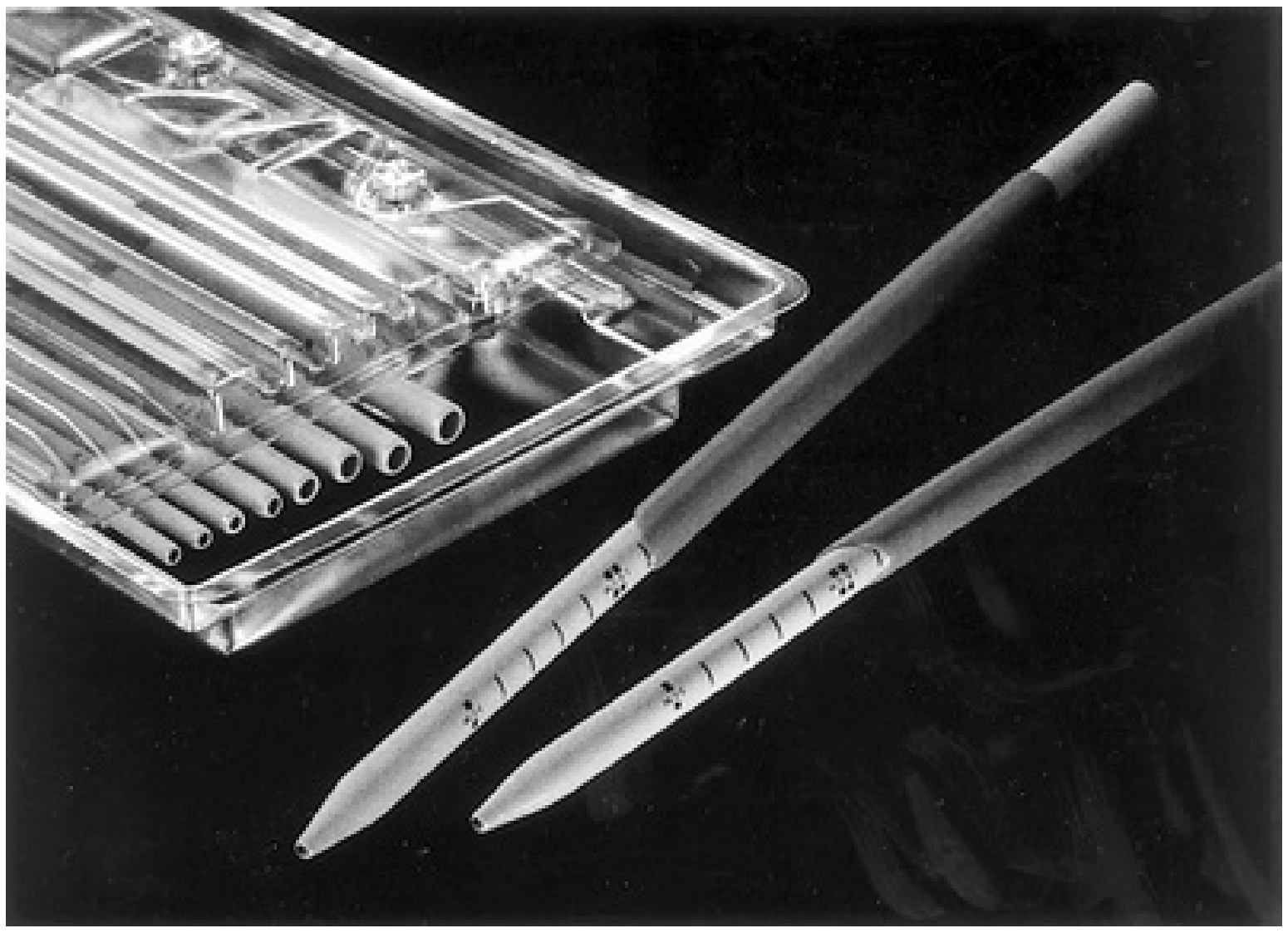

FIG. 12.20 Amplatz dilators with sheaths.

Balloon dilators (Fig. 12.21) do not require the repetitive passes of the rigid metal and semirigid plastic dilation systems. This is the most common dilation method for percutaneous renal surgery today (Benway and Nakada, 2008). The appropriate working sheath is backloaded onto the balloon dilation catheter, which is passed over the working wire until the radiopaque marker is at the intended depth of dilation (Fig. 12.22A). The dilating balloon is then inflated with a pressure syringe. A "waist" appears at the site(s) of greatest resistance, usually the abdominal wall fascia and the renal capsule (see Fig. 12.22B). Once the balloon is fully expanded (see Fig. 12.22C), the working sheath is advanced over the balloon (see Fig. 12.22D). The balloon catheter has a "shoulder," which is the portion between the end of the balloon and the point at which the maximal diameter is achieved. Passing the sheath beyond the maximal diameter of the balloon risks significant injury. **Balloon dilators, which are expensive one-time-use devices, are less effective than rigid metal and semirigid plastic dilation systems in densely scarred tissue but are more effective when the kidney is hypermobile** (Kumar and Keeley, 2008), though novel PTFE-reinforced balloons offering increased burst pressures may be useful in this setting. Most (Davidoff and Bellman, 1997; Heggagi et al., 1991; Kukreja et al., 2004; Safak et al., 2003) but not all (Gonen et al., 2008a; Wezel et al., 2009) single-series reports have suggested that hemorrhage and transfusion rates are less with the balloon dilators compared with rigid metal and semirigid plastic dilators. In a large multi-institutional study, however, balloon dilators were associated with longer operative time and greater bleeding and transfusion rates compared with rigid metal and semirigid plastic dilators (Lopes et al., 2011). Baseline differences between the groups, including more stones per kidney and more frequent treatment of staghorn calculi in the balloon dilation, may have been biased against balloon dilation.

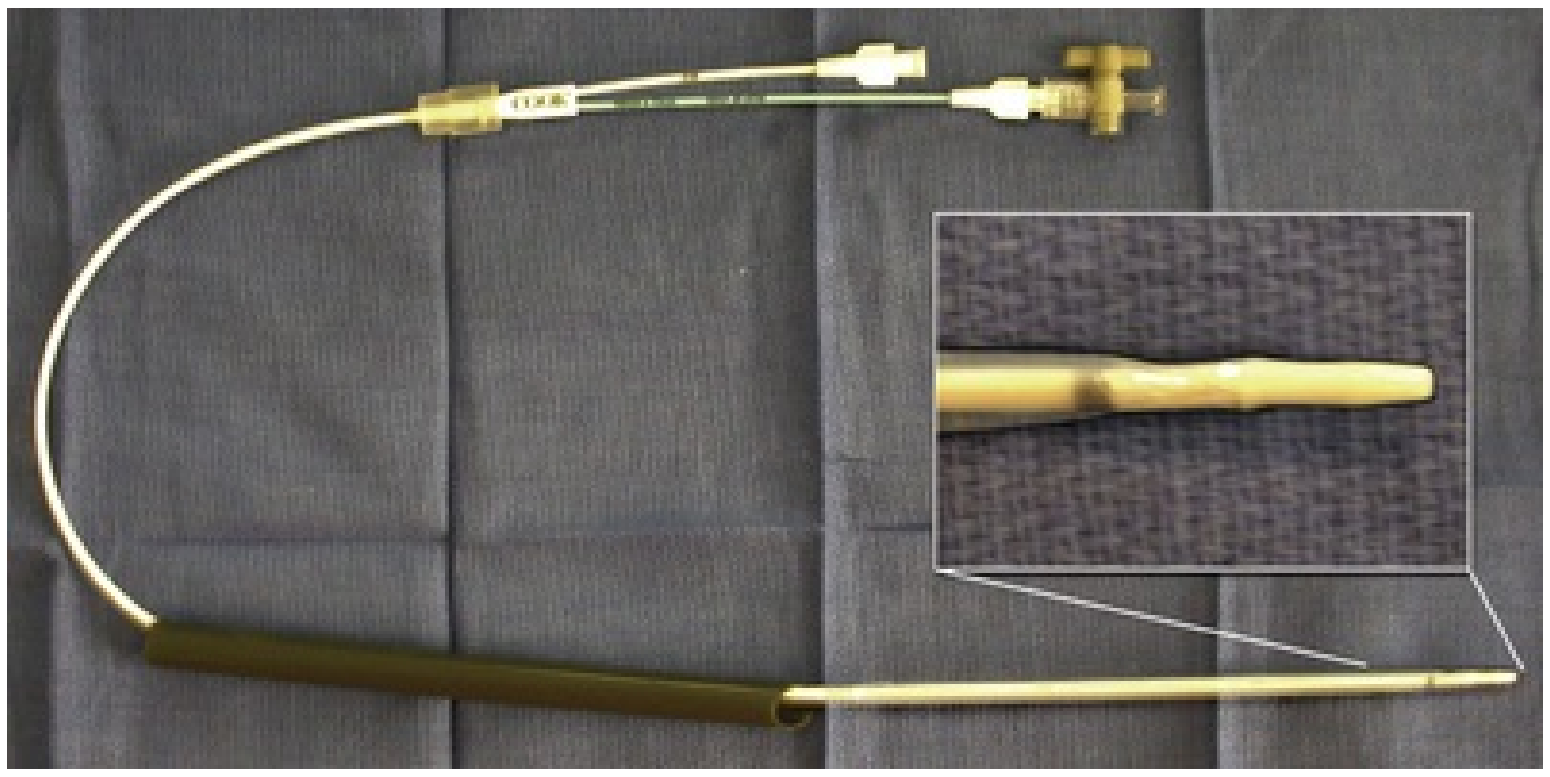

FIG. 12.21 Balloon dilation catheter with preloaded sheath.

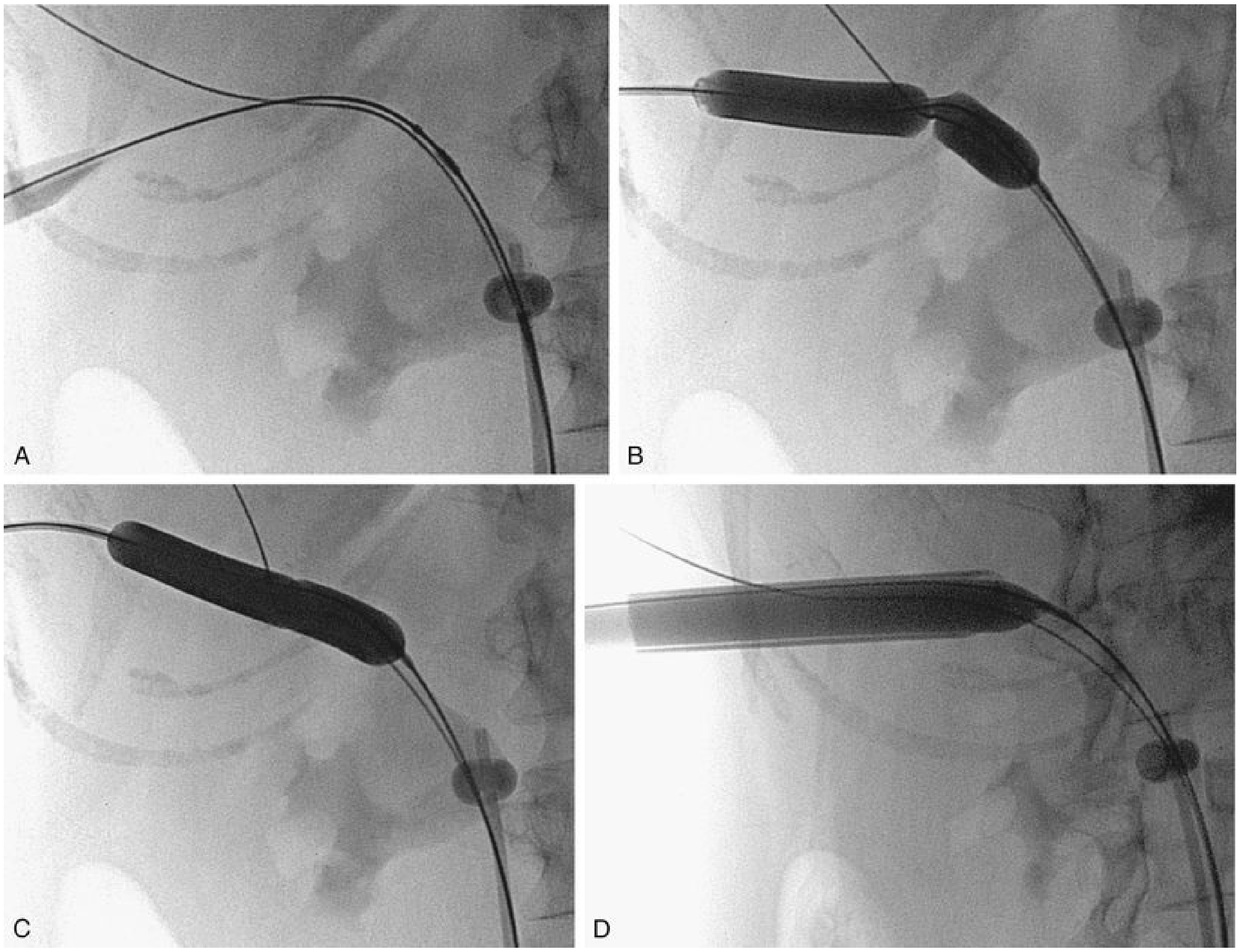

FIG. 12.22 Balloon dilation of tract and placement of working sheath. (A) Balloon catheter is inserted over wire, with distal radiopaque marker at the intended depth of dilation. (B) "Waist" appears as balloon is inflated. (C) Balloon is fully expanded. (D) Sheath is passed over balloon, taking care not to advance it beyond the point of maximal diameter of the balloon.

In an effort to further simplify dilation of the renal access tract, a number of single-step techniques have been described. The simplest is passage of the final semirigid plastic dilator without prior dilation by the smaller dilators (Frattini et al., 2001). A meta-analysis of four randomized controlled trials comparing single plastic dilators with sequential rigid metal dilators suggested that the former was associated with reduced access and fluoroscopy times without increased complications (Li et al., 2013c). Devices designed specifically for single-step dilation include a balloon dilator with an expandable sheath (Baldwin et al., 2006; Kalpee et al., 2012; Maynes et al., 2008; Pathak and Bellman, 2005) and a rigid dilator with an expandable sheath (Goharderakhshan et al., 2001). In the only randomized trial to compare all four dilation methods (balloon, rigid metal, semirigid plastic, and single-step), authors found no difference in access time, hemoglobin decrease, complication rates, or success, though fluoroscopy time was significantly decreased in the balloon-dilation and one-step-dilation groups (Srivastava et al., 2017).

The most common cause of difficult tract dilation is prior renal surgery (Joel et al., 2005). If even semirigid plastic or rigid metal dilators fail, novel uses of devices such as Collings knives, atherotomy cutting balloons, or fascial incising needles can be employed (Davis et al., 1991; Williams et al., 2008). One group has reported using a bipolar resectoscope with a plasma vaporization electrode to enlarge the percutaneous tract, and in their randomized controlled trial there were some advantages over balloon dilation (Chiang and Su, 2013). Though densely scarred kidneys such as those in the setting of repeat percutaneous renal surgery, present challenges, they are often not insurmountable, and surgery can be successfully performed in most cases (Borofsky et al., 2016).

Postprocedural Drainage

After percutaneous renal access and surgery, the surgeon must consider what, if any, means of drainage to employ.

Balloon Catheters.

The Foley and Council catheters used for transurethral drainage can be used as nephrostomy tubes as well (Fig. 12.23). These tubes come in a range of diameters; typically, 16- to 24-Fr catheters are used for postoperative nephrostomy drainage. **The 5-mL retention balloon might be too large for some collecting systems and does not need to be completely inflated.** The balloon can cause calyceal obstruction if it is pulled into an infundibulum. **Saline or water should be used to inflate the balloon because viscous contrast material might hinder emptying of the balloon when removal is attempted.** An advantage of the Council catheter is the ability to pass a small-caliber catheter through the end hole and down the ureter, providing more secure access to the upper urinary tract collecting system and maintaining ureteral patency. **All nephrostomy tubes, even ones with robust internal retention devices, should be fixed to the skin externally with a suture or other mechanism.** External fixation of a tube, however, does not necessarily prevent internal dislodgement of the tube. Especially in a large patient, the distance from the skin to the collecting system can change with patient movement, and the tube (fixed at the skin) can pull out of the kidney. **The potential for tube dislodgement is one of the best arguments in favor of nephrostomy tubes that have some extension down the ureter to maintain a conduit to the upper urinary tract collecting system even if the renal pelvic portion of the tube is pulled out of the kidney.**

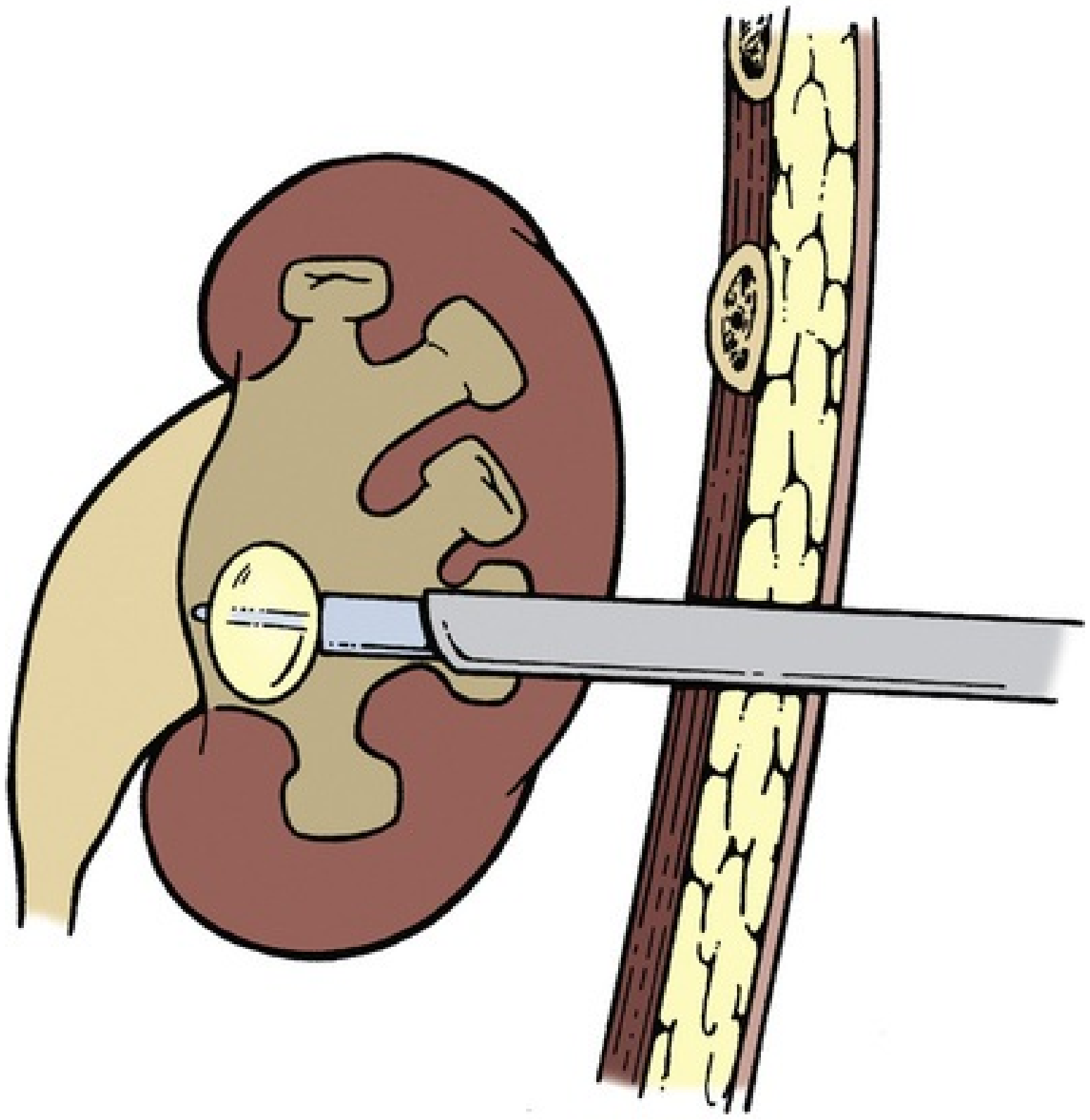

FIG. 12.23 Council catheter.

Cope Catheter.

A more secure retention mechanism is provided by Cope nephrostomy tubes. **A string exits the catheter a few centimeters from the distal tip and then re-enters the catheter near the tip** (Fig. 12.24). **Pulling on the string forms a secure coil that is not easily dislodged from the renal pelvis.** The string is fixed at the external end of the tube with a locking mechanism or by wrapping it around the tube and fixing it in place with a rubber cuff. Cope catheters employ the same coil shape used in pigtail ureteral stents. The active reinforcement of the coil strength by the string is thought to provide more secure retention than the passive coil of a pigtail, although one comparative study did not confirm this (Chuang et al., 2011). Cope nephrostomy tubes, ranging from 6 to 14 Fr in diameter, can be used for simple upper urinary tract drainage and instillation procedures and after percutaneous surgery. Care should be taken when placing a small-bore cope nephrostomy tube (8-10 Fr) after percutaneous renal surgery in which a large tract is dilated such as in percutaneous nephrolithotomy as the tube can become dislodged. The main risk factors for dislodgement is increased body mass index (Bayne et al., 2015). Risk for dislodgement can be reduced by placing the retention loop in a polar calyx rather than in the renal pelvis and by using a nephrostomy tube with extension down the ureter (see later).



FIG. 12.24 Cope catheter with the retention string loosened for demonstration.

Malecot Catheter.

The wings of the Malecot catheter expand when the catheter is at rest, providing a modest but atraumatic and nonobstructive retention mechanism (Fig. 12.25A). When the catheter is being placed or removed, a stiffener is inserted through it to push on the distal end of the Malecot tip and straighten the wings. During removal, this stiffener can misalign with the Malecot tip if the tube is not straight; pulling the catheter back until the tube is straight helps the stiffener line up properly. **The Malecot catheter is also available with an extension that is directed down the ureter. This modification is called a "re-entry" catheter because it simplifies placing a guidewire through the Malecot catheter and down the ureter into the bladder** (see Fig. 12.25B). The extension is long enough (18 cm) so that in most patients the Malecot tube can be withdrawn until the wings are externalized and a guidewire can be placed into the ureter. Malecot catheters for renal use are large-bore catheters, ranging from 16 to 30 Fr, although Malecot catheters as small as 8 Fr are available.

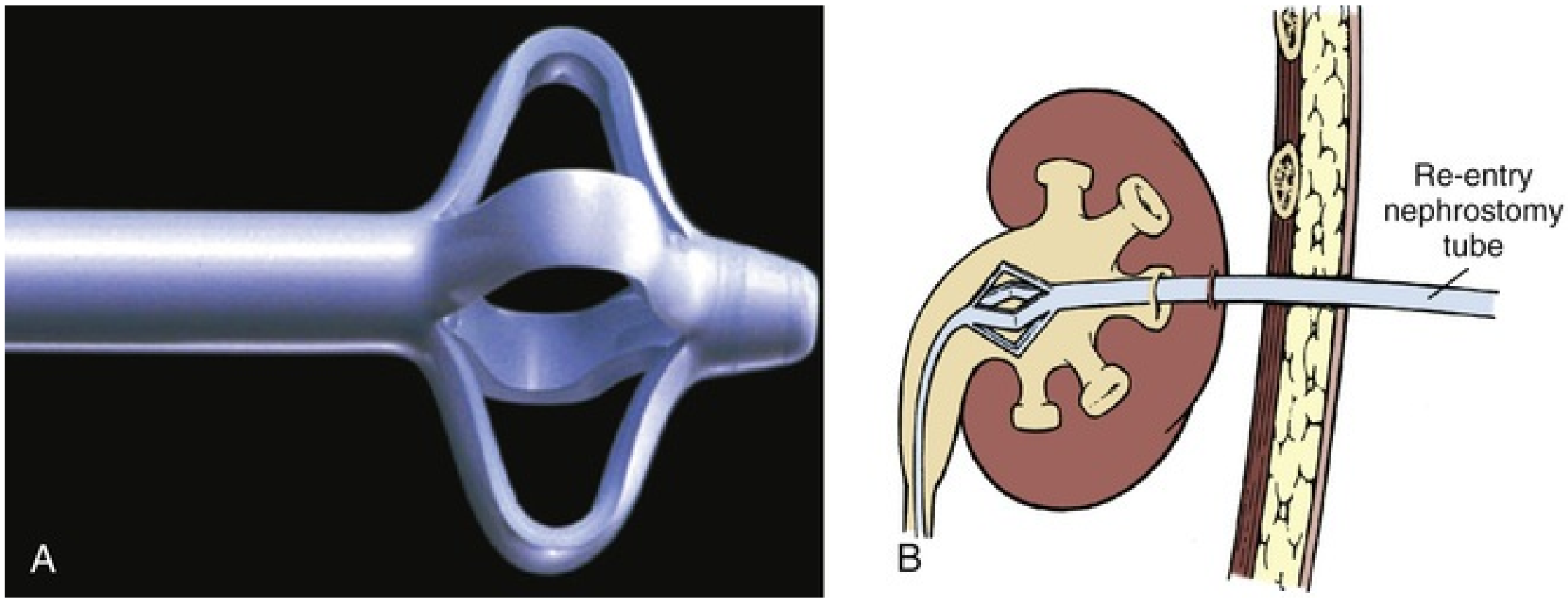

FIG. 12.25 (A) Malecot catheter. (B) Malecot catheter with ureteral extension (“re-entry” catheter).

Nephroureteral Stent.

The Cope retention mechanism is also used in nephroureteral stents. A nephroureteral stent has a renal coil like that of a Cope nephrostomy tube, but the tube continues to a ureteral extension that travels down the ureter to end in a passive pigtail that rests in the bladder (Figs. 12.26A, B). The ureteral portion can be the same diameter as the nephrostomy portion, or it can be narrower. A nephroureteral stent is passed percutaneously over a wire that ends in the bladder. Once the end is coiled generously in the bladder, careful inspection of the fluoroscopy image reveals the location of the side holes in the renal coil. By moving the catheter in and out while pulling on the string and rotating the external portion of the tube clockwise, the Cope retention coil is formed in the renal pelvis. **A nephroureteral stent offers excellent control of the entire upper urinary tract, from renal pelvis to bladder, and is unlikely to become dislodged.** Nephroureteral stents are available in diameters of 8 to12 Fr, and the standard lengths (from renal to bladder coil) are 20 to 28 cm.

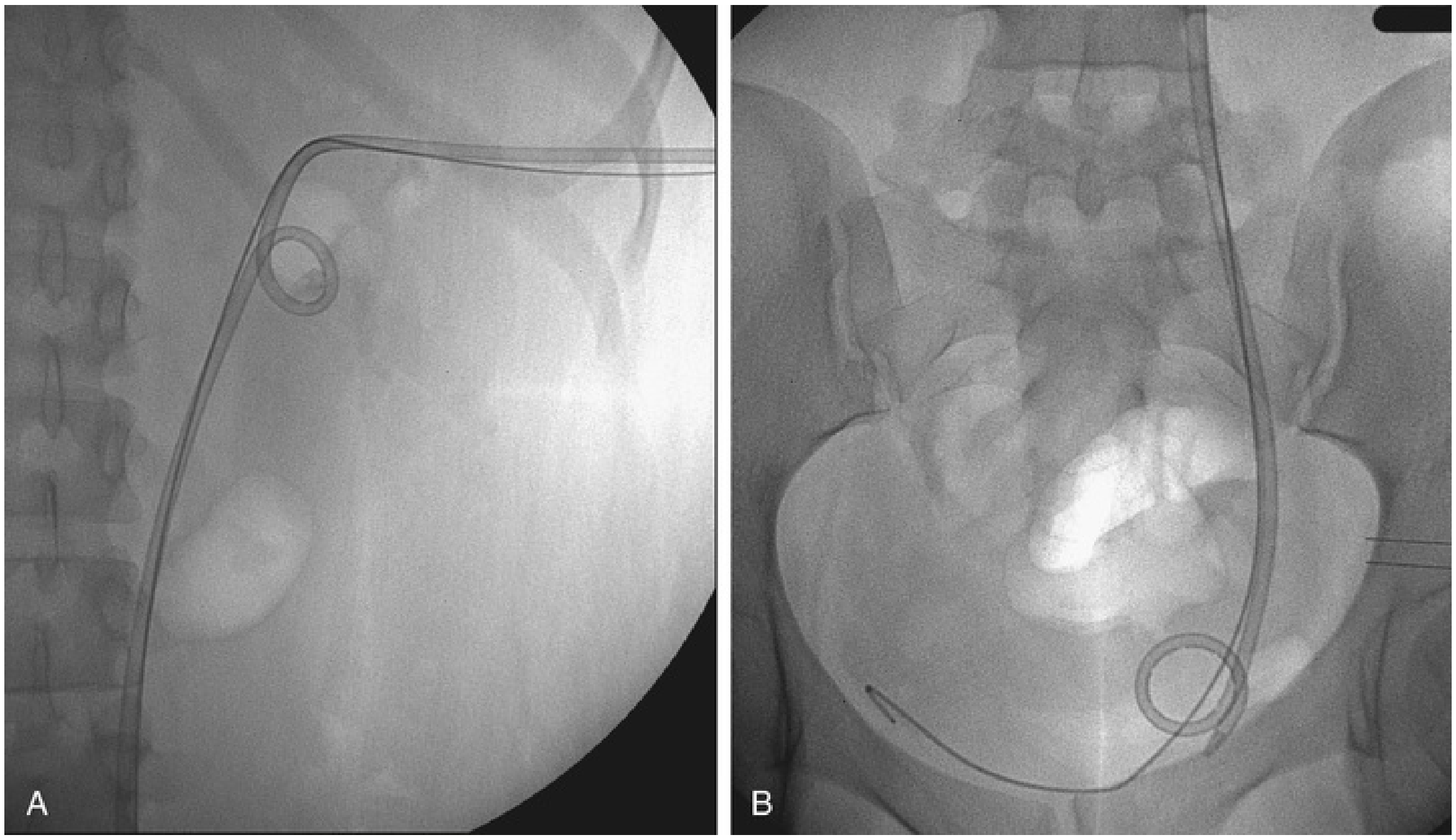

FIG. 12.26 Nephroureteral stent. (A) Renal coil. (B) Bladder coil.

Circle Catheter.

A final type of nephrostomy tube is the circle nephrostomy tube (Fig. 12.27), **which is secure, easily exchanged, causes little trauma, rarely occludes, and provides excellent drainage and an avenue for irrigation of the renal pelvis.** The circle nephrostomy tube requires two percutaneous access sites to the kidney, and this tube is most useful when maintenance of two tracts is desired, such as for irrigation of the renal pelvis or if more than one access is necessary for second-look nephroscopy (Kim et al., 2005). After obtaining access at two distant calyces, a flexible nephroscope or flexible ureteroscope passed over one wire is used to grasp the wire coming from the other site. When the endoscope is withdrawn, the wire is now in position to guide placement of the circle nephrostomy tube. Radiopaque markers on the tube delineate the location of the drainage holes, which should be maintained within the intrarenal collecting system. External drainage of the circle nephrostomy tube requires a Y-connector. Achieving repeat access into the kidney for second look nephroscopy is straightforward. A PTFE-coated wire is introduced into one end of the circle catheter until resistance is met or it exits through the other limb of the tube. If resistance is met, this is typically caused by the wire exiting through one of the side holes of the catheter. In this instance, the tube and wire are advanced together until the wire emanates from the other point of renal access (El Tayeb et al., 2017). Once through-and-through renal access is reestablished, tract dilation can be performed and second-look nephroscopy completed.

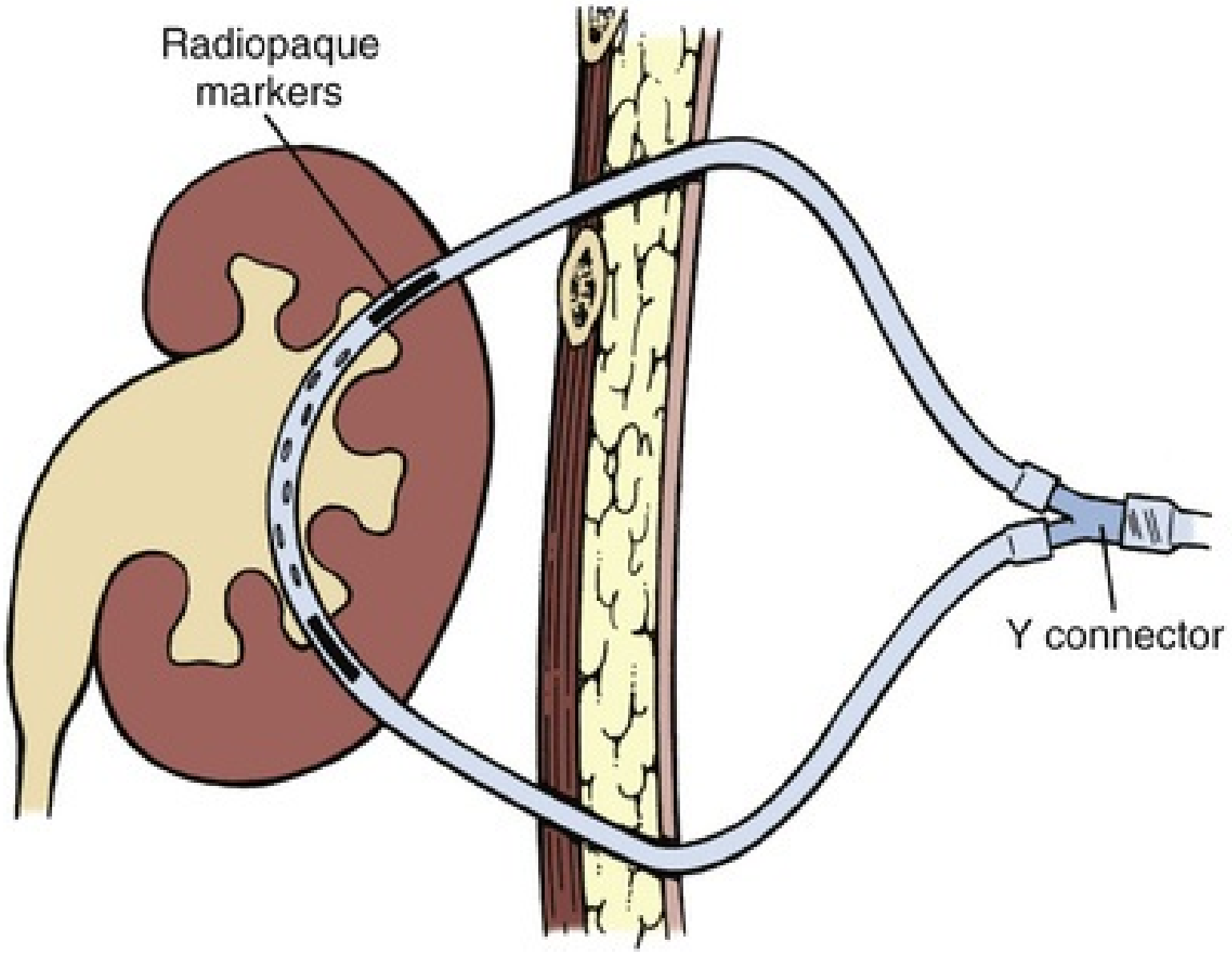

FIG. 12.27 Circle nephrostomy tube.

General Considerations.

The advantages of a postoperative nephrostomy tube include good drainage and control of the upper urinary tract and maintenance of percutaneous access for additional procedures. It was initially thought that a postoperative nephrostomy served to tamponade the nephrostomy tract and reduce hemorrhage, but subsequent studies have suggested this is not the case. When hemorrhage does occur, however, the larger caliber of a nephrostomy tube provides better drainage of the upper urinary tract collecting system than an internal ureteral stent. In addition, if a large perforation has occurred during the procedure, the additional diversion of urine away from the site might be advantageous. When a nephrostomy tube is left in place after percutaneous renal surgery, it is usually in the dilated access site. At least one group has attempted to reduce the discomfort associated with supracostal percutaneous renal surgery by placing a small-caliber postoperative nephrostomy tube in a new subcostal site and leaving the dilated supracostal access site without a nephrostomy tube (although there was no control cohort for comparison) (Kim et al., 2006).

Including, along with the nephrostomy, a tube that goes down the ureter provides the greatest control and assurance of drainage. Because entry of a tube into the bladder is associated with additional symptoms, such a tube should only be used when needed. Considerations include the size of the patient (which determines to a large extent the risk for tube dislodgement), the importance of maintaining drainage, and the desire for ureteral intubation (e.g., ureteral obstruction that might resolve if intubated, ureteral injury that should be bypassed). Aside from the choice of retention mechanism, the main remaining consideration is the diameter of the nephrostomy tube.

A number of studies have compared the impact of nephrostomy tube diameter after percutaneous renal surgery including two nonrandomized prospective trials (De Sio et al., 2011; Maheshwari et al., 2000) and four randomized controlled trials comparing large-caliber tubes (20 to 24 Fr) to small-caliber tubes (8 to 18 Fr) (Desai et al., 2004; Liatsikos et al., 2002; Marcovich et al., 2004; Pietrow et al., 2003). **Among the six studies comprising a total of 215 patients with nephrostomy tubes, five revealed less pain and two reported less urinary leakage in the patients with smaller tubes. Bleeding was not increased in the groups with smaller tubes in any of the studies.** Only one study found no benefit to the smaller tube (Marcovich et al., 2004). Although tube diameter is not related to bleeding overall, the removal of larger tubes occasionally can be followed by immediate hemorrhage; this is rare with smaller tubes. As such, large-caliber nephrostomy tubes should be removed in a radiology suite where there is the opportunity for immediate replacement of the tube. Small-caliber tubes can be removed safely at the bedside after a period of clamping to assess clinically for distal ureteral obstruction.

“Tubeless” With Ureteral Stent.

A “tubeless” percutaneous procedure—one that omits the postoperative nephrostomy tube—was initially proposed by Wickham and colleagues (1984). This practice never met with widespread acceptance, especially after Winfield and colleagues (1986) reported disastrous outcomes with this technique. The concept was revived in 1997 by Bellman and colleagues (1997) with the addition of an internal ureteral stent left in place for 1 or 2 weeks. Since then, many studies have evaluated the practice of omitting the nephrostomy tube after percutaneous renal surgery. Although this technique is called “tubeless,” most series employ a ureteral stent for a short period postoperatively.

Options for ureteral stenting without a nephrostomy tube after percutaneous renal surgery include an internal ureteral stent that is removed cystoscopically, an internal ureteral stent with an attached string that exits out the flank to allow removal of the ureteral stent without cystoscopy, and an externalized (out the urethra) ureteral stent that is removed along with the urethral catheter to which it is attached. The potential advantages of omitting the nephrostomy tube after percutaneous renal surgery include decreased pain and analgesic use, avoidance of an external drainage device, abbreviated hospital stay, and decreased health care costs (secondary to shortening the duration of hospitalization). Since the report of Bellman and colleagues (1997), many studies, including several randomized controlled trials, have evaluated omission of the nephrostomy tube postoperatively with placement of an internal ureteral stent. It is important to note that most of these studies patients were excluded if they had significant bleeding or perforation or if a second percutaneous procedure was anticipated.

A meta-analysis of tubeless percutaneous nephrolithotomies published in 2012 included nine randomized controlled trials involving 547 patients (Shen et al., 2012). The results were stratified into four groups with regard to postprocedure drainage: tubeless with internal ureteral stent, small nephrostomy tube (8 to 9 Fr), medium nephrostomy tube (16 to 18 Fr), and large nephrostomy tube (20 to 24 Fr). The meta-analysis demonstrated that hospital stay and postoperative pain were reduced in the tubeless group compared with the medium- and large-tube groups, but were similar in the tubeless and small-tube groups. There were no significant differences between the tubeless group and any of the nephrostomy tube groups with regard to fever/infection, transfusion, or operative time. In two earlier meta-analyses that combined the nephrostomy groups into two instead of three groups, 4 to 10 Fr versus 14 to 24 Fr (Yuan et al., 2015) and 8 to 9 Fr versus 14 to 26 Fr (Ni et al., 2011), shorter hospital stay and reduced postoperative pain were noted in the tubeless group even in comparison to the small nephrostomy group. Thus the preponderance of evidence suggests **that tubeless percutaneous nephrolithotomy leads to shorter hospital stay and reduced postoperative pain in comparison to the use of large postprocedure nephrostomy tubes but that these benefits are less certain in comparison to small nephrostomy tubes.** A subsequent meta-analysis (Xun et al., 2017) and one large multi-institutional matched case-control study involving 488 patients (Cormio et al., 2013b) have yielded similar results. The tubeless approach appears to be safe even when supracostal access is used (Duty et al., 2013; Jun-

Ou and Lojanapiwat, 2010; Shah et al., 2006b) and in the setting of bilateral simultaneous procedures (Gupta et al., 2003; Shah et al., 2005).

There are some disadvantages to using an internal ureteral stent as an alternative to a nephrostomy tube, however, including loss of the percutaneous tract for a secondary procedure and the cost, inconvenience, and discomfort associated with an internal ureteral stent that requires cystoscopic removal. The discomfort of the ureteral stent is significant; in two randomized trials that used the Wisconsin Stone Quality of Life (WiSQoL) questionnaire, participants managed with an internal ureteral stent reported poorer scores than did those with nephrostomy tubes (Jiang et al., 2017; Zhao et al., 2016). To obviate the need for cystoscopic removal of the ureteral stent, several groups have offered alternatives including insertion of an externalized ureteral stent or insertion of an internal stent with an attached string that exits out the flank. In both cases, the stent can then be removed before hospital discharge without an additional procedure. Goh and Wolf first reported in 1999 the use of an externalized ureteral stent (single pigtail) as an alternative to a postoperative nephrostomy tube (Goh and Wolf, 1999). Since then, there have been a number of reports of this option (Abou-Elela et al., 2007; Al-Ba'adani et al., 2008; Karami et al., 2007; Lojanapiwat et al., 2001; Rana and Mithani, 2007) including three randomized controlled trials, one comparing an externalized ureteral stent to a large-caliber nephrostomy tube, which suggested a benefit in terms of reduced narcotic use and length of hospital stay (Tefekli et al., 2007). A meta-analysis including 863 patients from five randomized trials and two other studies compared internal and external ureteral stents and revealed no difference between the two techniques except for more stent-related symptoms in the internal stent group (Chen et al., 2018). Shpall and colleagues (2007) described the modification of leaving the attached string on the stent and placing the stent “upside down” so that the string can exit the flank. They described removing the stent as an outpatient 3 and 12 days postoperatively, but since then, others have reported removing the stent at the bedside on the first postoperative day (Berkman et al., 2008). One randomized trial has confirmed the safety of this approach (with stent removal 10 to 14 days postoperatively), compared with postoperative nephrostomy tube (removed on the second or third postoperative day) (Agrawal et al., 2014). Use of a Polaris Loop stent (Boston Scientific, Marlborough, MA) placed “upside down” offers less resistance at the time of removal (Fig. 12.28).

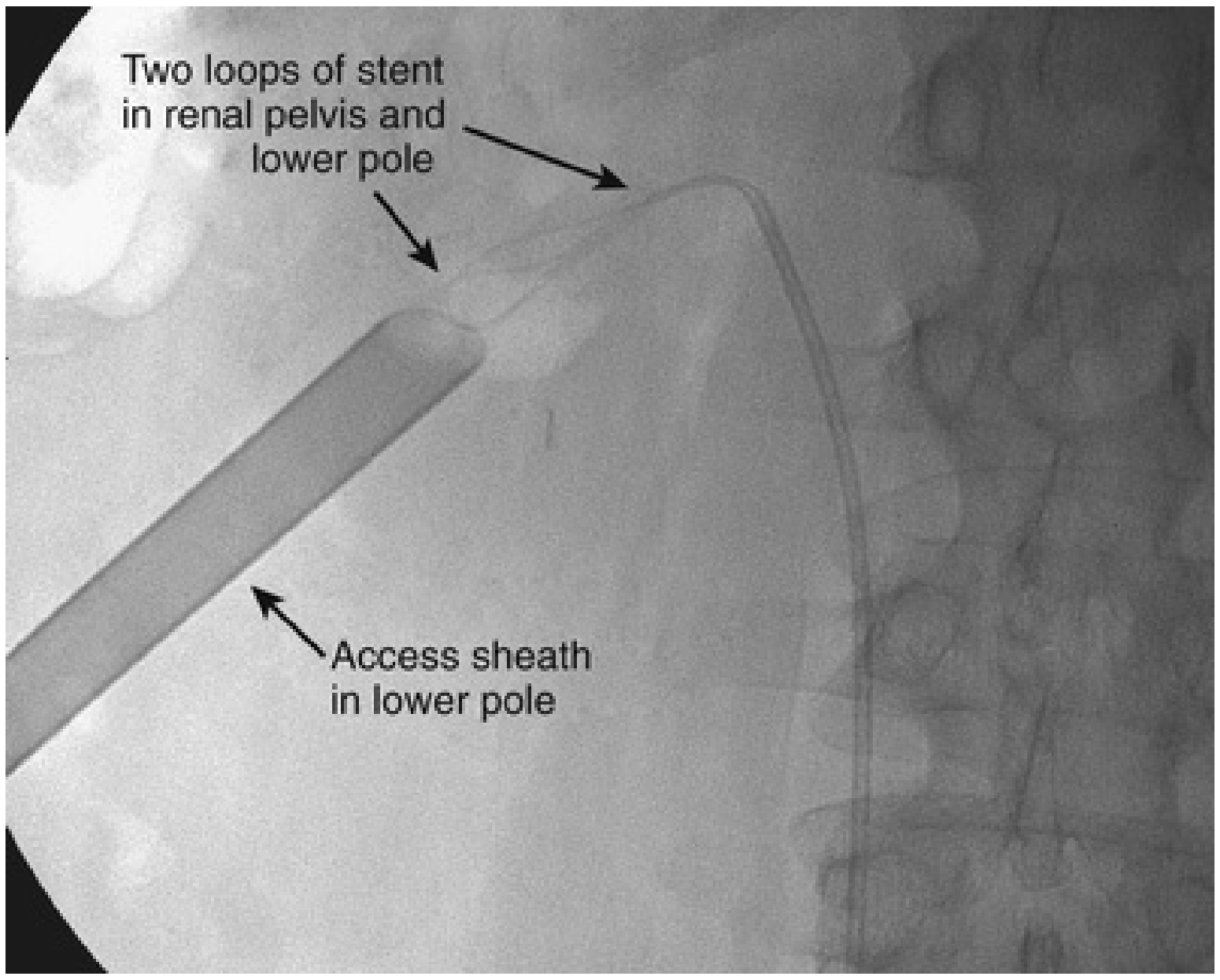
Two loops of stent in renal pelvis and lower pole
Access sheath in lower pole

FIG. 12.28 Use of a Polaris Loop stent (Boston Scientific, Marlborough, MA) placed "upside down." An attached string is left exiting the flank, which allows removal of the stent without an additional procedure.

These modifications of nephrostomy tube omission avoid many of the disadvantages of an internal ureteral stent but still leave the problem of loss of access in case a secondary procedure is required. With improved endoscopes, better ancillary tools, and growing experience with percutaneous surgery, the need for secondary procedures is declining. In properly selected patients including those who do not need external drainage (e.g., pyonephrosis, significant bleeding, significant collecting system injury) and those who are unlikely to need a secondary procedure, omission of the postoperative nephrostomy tube appears to be safe and effective.

No Drainage Tube

More recently, the idea of a "totally tubeless" percutaneous renal surgery, omitting both the nephrostomy tube and ureteral catheter, has been reintroduced. This can be considered in selected patients with low-volume stones, atraumatic single access, and no hemorrhage, perforation, or obstruction. A meta-analysis of five randomized controlled trials and four nonrandomized comparative studies comparing "totally tubeless" percutaneous nephrolithotomy to percutaneous nephrolithotomy with a postprocedure nephrostomy tube suggests that the "totally tubeless" approach reduces hospital stay, analgesic requirement, and time to return to normal activity without increasing complications (Zhong et al., 2013). These outcomes have been mirrored in a single, small randomized controlled trial conducted in the pediatric population (Aghamir et al., 2012). Total health care expenditures are also decreased in the setting of a totally tubeless approach (Choi et al., 2014).

Tract Sealants.

One of the concerns with any approach that omits the nephrostomy tube after percutaneous renal surgery is that of hemorrhage from the tract. **Although the evidence from randomized controlled trials suggests that the size or presence of the nephrostomy tube does not affect the degree of postoperative bleeding, there is still a potential for dramatic bleeding after any percutaneous procedure—and such bleeding would be more problematic without a nephrostomy tube in place.** Several groups have described adjuncts intended to enhance hemostasis of the percutaneous tract including placing a fascial suture (Li et al., 2011), direct monopolar cauterization of the tract (Chang et al., 2011; Mouracade et al., 2008), cryotreatment of the tract (Okeke et al., 2009), and insertion/instillation of hemostatic agents into the tract including oxidized cellulose (Aghamir et al., 2006), gelatin sponge (Singh et al., 2008), gelatin granules plus thrombin (Lee et al., 2004; Li et al., 2011; Nagele et al., 2006), fibrin glue (Gudeman et al., 2012; Noller et al., 2004), collagen matrix coated with fibrin glue (Cormio et al., 2012), and temporary compression with nonabsorbable surgical gauze impregnated with kaolin (Koo et al., 2015). Randomized studies have failed to show an impact on postoperative bleeding with the use of tract-sealing agents, thus their utility in routine practice remains questionable (Aghamir et al., 2006; Cormio et al., 2012; Istanbulluoglu et al., 2013; Shah et al., 2006b; Singh et al., 2008; Wang et al., 2014; Yu et al., 2014; Ziaee et al., 2013).

Key Points: Postprocedural Nephrostomy Drainage

- The advantages of a postoperative nephrostomy tube include good drainage and control of the upper urinary tract and maintenance of percutaneous access for additional procedures. Inclusion of an extension down the ureter provides the greatest control and assurance of drainage.
- Small-caliber nephrostomy tubes are associated with less pain than large-caliber nephrostomy tubes and are not associated with any increased

hemorrhage.

- Use of a ureteral stent instead of a large-caliber nephrostomy tube is associated with reduced narcotic use and decreased length of hospitalization. The benefit of nephrostomy omission is less apparent when compared with a small-caliber nephrostomy tube. In properly selected patients, use of a ureteral stent instead of a nephrostomy tube does not affect stone-free or complication rates.
- Options for ureteral stenting without using a nephrostomy tube afterward include an internal ureteral stent that is removed cystoscopically, an internal ureteral stent that is removed by string exiting the flank, and an externalized ureteral stent that is removed along with the urethral catheter to which it is taped.
- After straightforward procedures with atraumatic single access and no hemorrhage, perforation, or obstruction, some patients can be managed without a nephrostomy tube or a ureteral stent.
- The utility of adjuncts for tract hemostasis is uncertain.

Training

Efforts to enhance training for percutaneous surgery of the upper urinary tract have focused on obtaining percutaneous access. Summarizing their own experience and other reports (Allen et al., 2005; Tanriverdi et al., 2007), de la Rosette and colleagues estimated that a trainee must perform approximately 24 percutaneous nephrolithotomies to attain proficiency, whereas competence is not achieved until the experience includes 60 cases, and excellence is not obtained until more than 100 cases have been performed (de la Rosette et al., 2008). Training during residency is the most effective way to develop the skills, but maintenance of skills requires ongoing experience. In a survey of urologists who completed a single-residency program, those trained in percutaneous access were more likely to perform percutaneous surgical procedures than those not trained in percutaneous access (92% vs. 33%). Of those who performed percutaneous surgery, urologists with training did more procedures than those without training (14.0 vs. 3.3 procedures annually). However, only about one third of respondents in both groups continued to attain their own percutaneous access (27% vs. 11%) (Lee et al., 2004).

The most advanced trainer is the PERC Mentor (Simbionix Ltd., Lod, Israel), a computer-assisted simulator for percutaneous access procedures guided by fluoroscopy (Fig. 12.29). The PERC Mentor has undergone preclinical validation, confirming that training on the PERC Mentor improves performance on the PERC Mentor (Knudsen et al., 2006; Zhang et al., 2013) and that trained individuals more proficiently attain percutaneous renal access in a porcine in-vivo model (Margulis et al., 2005), but validation of the impact on performance in the human operating room is lacking (Stern et al., 2007). Other novel trainers for percutaneous renal access includes one that incorporates simulated fluoroscopic imaging (Veneziano et al., 2015) and the use of patient-specific three-dimensional modeling of anatomy (Li et al., 2013a). At the least, these trainers can serve as an introduction for trainees by orienting them to the necessary anatomic considerations and familiarizing them with the physical movements of the procedure. It is unknown if these or other devices can be used to validate the skills of trainees and clinicians.

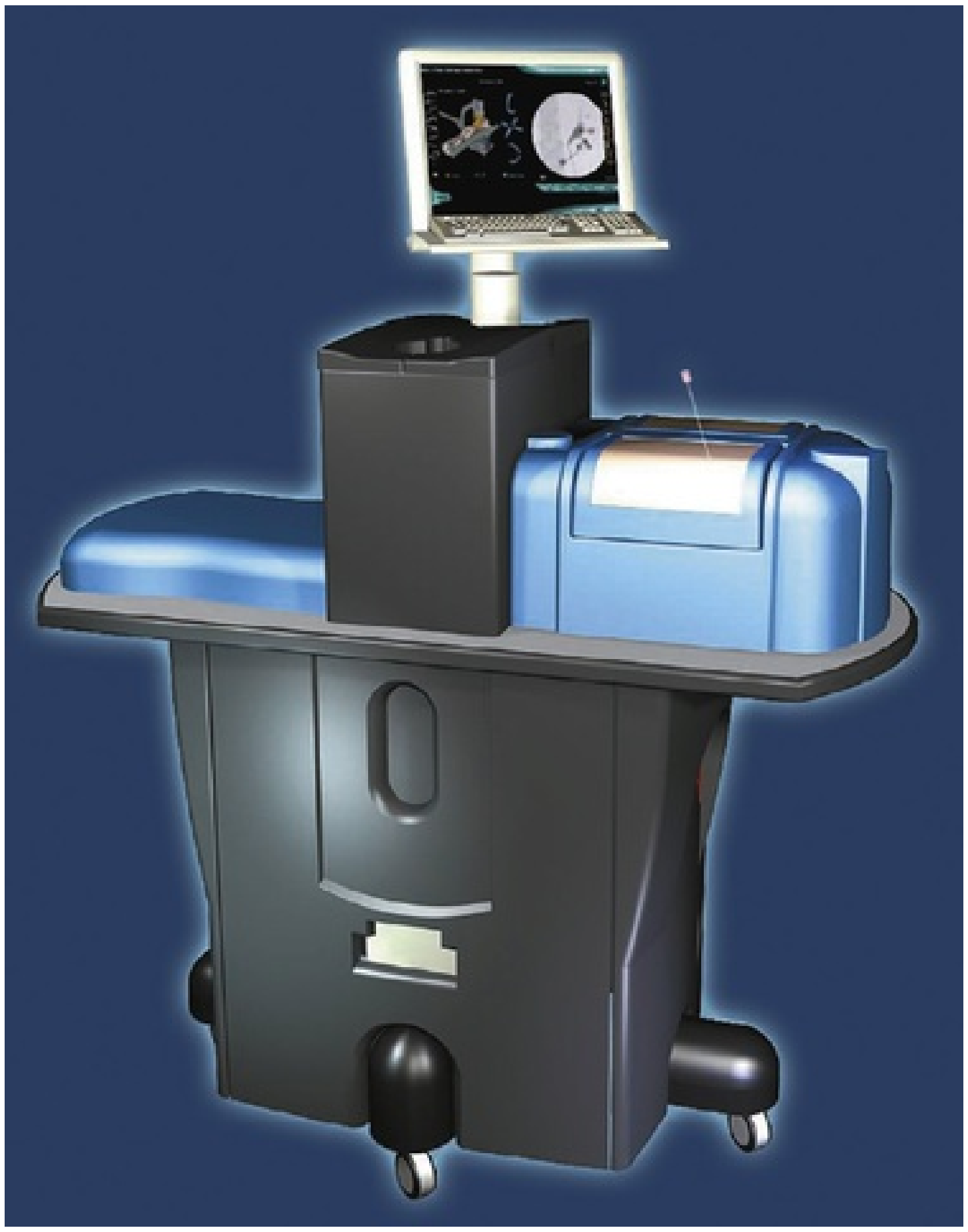

FIG. 12.29 PERC Mentor (Simbionix Ltd., Lod, Israel).

Special Situations

Horseshoe Kidney

Although antegrade access into horseshoe kidneys is somewhat different than into normal kidneys, standard techniques can generally still be used. CT or MRI should be considered for preoperative assessment of horseshoe kidneys, both to assess for the possibility of retro-renal colon (Skoog et al., 1985) and to assess the vasculature and relationship of the calyces to the anticipated puncture site. In a series of 12 patients undergoing percutaneous nephrolithotomy in horseshoe kidneys, 5 had bowel posterior to the kidney on CT (Al-Otaibi and Hosking, 1999). Horseshoe kidneys often have extra and eccentric calyces that can be difficult to access. In other ways, however, percutaneous access to a horseshoe kidney is more favorable than in normal kidneys. The anteroposterior tilt of the kidney is prominent, which makes the upper pole the most superficial and posterior aspect of the horseshoe kidney. In addition, the upper pole is usually inferior to the ribs. **Upper-pole access is useful in horseshoe kidneys because this is the easiest calyx to enter, the puncture rarely needs to be supracostal, and it provides excellent access to most of the kidney and the ureter because of alignment of the long axis of the moiety** (Fig. 12.30). The initial entry into a horseshoe kidney is more medial than in normal kidneys and can pass through the paraspinous musculature. The distance to the lower pole and ureter can be great in an obese or muscular patient, such that extra-long rigid nephroscopes or flexible nephroscopy may be necessary. In some cases, middle calyceal access is preferred because the upper pole is so far away from the pathology, but lower-pole calyces are usually not safely accessible with direct percutaneous puncture. The vasculature of horseshoe kidneys is aberrant, but vessels enter and exit the kidney in an anteromedial location (except for some at the isthmus), so direct vessel injury is rare with well-planned access (Janetschek and Kunzel, 1988). Overall, among a total of 309 percutaneous procedures (primarily nephrolithotomy) reported in horseshoe kidneys, there were 12 (3.9%) major hemorrhagic complications and only 1 (~0.3%) colon injury (Al-Otaibi and Hosking, 1999; Darabi Mahboub et al., 2007; Etemadian et al., 2013; Gupta et al., 2009; Lojanapiwat, 2005; Majidpour and Yousefinejad, 2008; Miller et al., 2008; Mousavi-Bahar et al., 2007; Purkait and Goel, 2015; Shokeir et al., 2004; Symons et al., 2008; Viola et al., 2007; Wu et al., 2014).

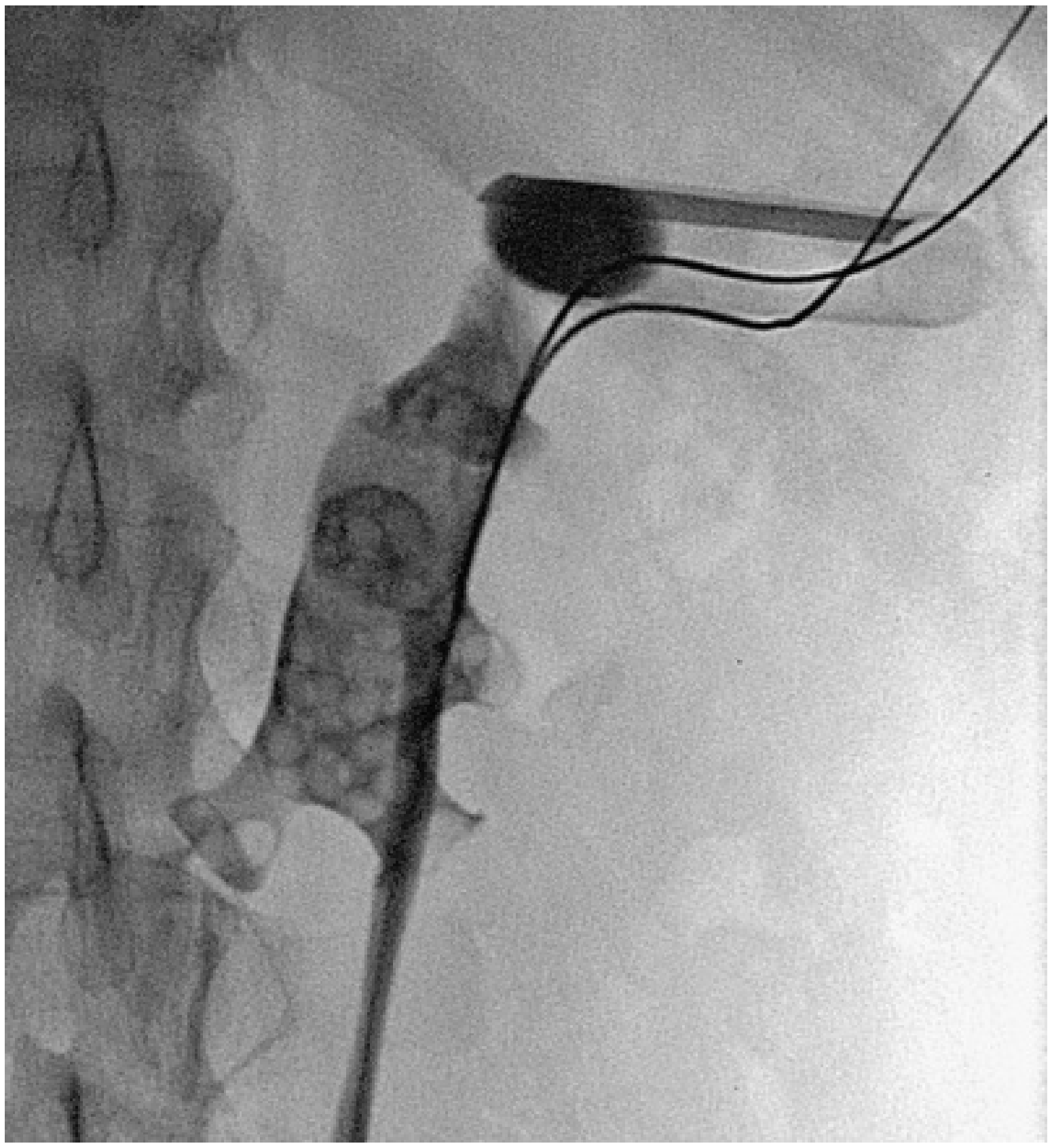

FIG. 12.30 Percutaneous access sheath (radiolucent except for a radiopaque stripe) in upper pole of horseshoe kidney. Note medially directed lower pole calyx. Although not apparent from this radiograph, the access site is subcostal.

Pelvic/Ectopic Kidney

Ectopic kidneys can range in location from the pelvis to the thorax. Pelvic kidneys are often difficult to access through a posterior approach, so supine positioning and transabdominal access may be necessary if permitted by overlying bowel. In some cases, advanced guidance techniques such as CT or MRI may be needed for safe access. Rarely, laparoscopic or robotic assistance may be required to mobilize overlying bowel such that the kidney can be safely punctured. In 12 series of laparoscopically directed antegrade percutaneous nephrolithotomy into pelvic kidneys published since 2001 that described a total of 35 patients, all procedures were reported to be successful and without complications (Aquil et al., 2006; Aron et al., 2005a; El-Kappany et al., 2007; Goel et al., 2006; Gupta et al., 2009; Maheshwari et al., 2004; Matlaga et al., 2006; Mousavi-Bahar et al., 2008; Santos et al., 2004; Tahmaz et al., 2009;

Tepeler et al., 2013; Troxel et al., 2002). As a simpler alternative to laparoscopic assistance, anterior percutaneous access into pelvic kidneys using a supine oblique position with a pad under the ipsilateral hemipelvis and using ultrasonography to assess for intervening bowel has been reported to be a safe technique in selected patients (Desai and Jasani, 2000; Mousavi-Bahar et al., 2007). If bone does not intervene between the appropriate calyx and the skin, then a posterior approach can be used just above the iliac bone (Atmaca et al., 2007) or through the greater sciatic foramen via a transgluteal approach (Mullins et al., 2015; Watterson et al., 2001).

Transplant Kidney

Approaching a transplant kidney percutaneously presents several challenges. First, retrograde access with a ureteral catheter is often challenging because of the anterior location of the ureteroneocystotomy and short ureteral length, which makes durable purchase with a guidewire difficult. When retrograde access cannot be achieved to facilitate contrast opacification of the collecting system, the initial puncture is best guided by ultrasound. In addition, the pelvic location of the transplant kidney almost always mandates an anterior approach with the patient in supine position. Fortunately, the extraperitoneal location of most renal transplants limits the likelihood of intervening bowel. Finally, there is typically a dense fibrosis surrounding the transplant kidney, which may be resistant to standard balloon tract dilation. In these cases, use of a fascial incising needle coupled with balloon dilation or use of telescoping metal dilators may be necessary. Of 81 percutaneous procedures in transplant kidneys reported in 11 series using ultrasonographically and/or fluoroscopically directed percutaneous access, all but six were technically successful, and there were no major complications (Challacombe et al., 2005; Francesca et al., 2002; Klingler et al., 2002; Krambeck et al., 2008b; Oliveira et al., 2011; Rifaioglu et al., 2008; Stravodimos et al., 2012; Verrier et al., 2012; Wyatt et al., 2009; Yuan et al., 2015).

Complications

Among more than 5000 patients undergoing percutaneous renal surgery, slightly more than 10% experienced major complications based on the modified Clavien-Dindo system (Labate et al., 2011).

Acute Hemorrhage

Acute hemorrhage is the most common significant complication of percutaneous access into the upper urinary tract collecting system. **Percutaneous nephrostomy alone results in hemorrhage requiring transfusion in 0.5% to 4% of procedures** (ACR, 2007; Radecka and Magnusson, 2004; Rana et al., 2007; Wah et al., 2004)**. With the addition of percutaneous nephrolithotomy, likely caused by the larger caliber of the percutaneous tract and increased intrarenal manipulation, the incidence of hemorrhage requiring blood transfusion rises to 0.8% to 20% depending on what series is reviewed** (Akman et al., 2011; Chew et al., 2009; Duvdevani et al., 2007; Kamphuis et al., 2015; Keoghane et al., 2012; Kukreja et al., 2004; Labate et al., 2011; Muslumanoglu et al., 2006; Netto et al., 2005; Preminger et al., 2005; Tomaszewski et al., 2010b). **Factors associated with hemorrhage during percutaneous renal surgery include patient characteristics, multiple access sites, supracostal access, increasing tract size, tract dilation with methods other than balloon dilation, prolonged operative time, and renal pelvic perforation** (Akman et al., 2011; Hegarty and Desai, 2006; Keoghane et al., 2012; Kukreja et al., 2004; Lee et al., 2013; Martin et al., 1999; Netto et al., 2005; Rastinehad et al., 2009; Stoller et al., 1994).

Most hemorrhage occurs from the renal parenchyma, and in most cases this hemorrhage is not significant. Parenchymal bleeding is minimized by proper entry and dilation and by careful manipulation of the sheath. **The access sheath provides intraoperative tamponade of parenchymal bleeding. Postoperatively, hemostasis is achieved by collapse of the parenchyma onto itself.** Unless the postoperative nephrostomy tube is as large as or larger than the sheath used during the procedure, it likely does not contribute to hemostasis. There is no difference in measures of postoperative bleeding between small (8- to 18-Fr) and large (20- to 28-Fr) tubes (Desai et al., 2004; De Sio et al., 2011; Liatsikos et al., 2002; Maheshwari et al., 2000; Marcovich et al., 2004; Pietrow et al., 2003), and some work suggests less postoperative bleeding with smaller-caliber nephrostomy tubes (Cormio et al., 2013a). In fact, hemorrhage is no greater when the nephrostomy tube is omitted altogether (Shen et al., 2012). **If there is noticeable bleeding from the tract after sheath removal following an otherwise unremarkable procedure, this suggests bleeding from intraparenchymal vessels.** Hemostatic maneuvers such as cauterization or placement of hemostatic material can be considered**, but in general the best management is to insert and occlude a nephrostomy tube, apply pressure to**

the incision, and let the collecting system clot off. A tubeless approach is not advised in such cases because maintenance of percutaneous access to the upper tract might facilitate management. Nephrostomy tubes should not be irrigated the day or evening of the procedure if they are not draining; it is best to let the collecting system remain occluded to tamponade bleeding. By the next morning, it is safe to gently irrigate the tube because hemostasis is more certain.

If the procedure was not complicated by bleeding but severe hemorrhage occurs after sheath removal and is refractory to the hemostatic measures described earlier, then use of a Kaye Nephrostomy Tamponade Balloon (Cook Urological, Spencer, IN) should be considered. This is a nephrostomy tube surrounded by a balloon (Fig. 12.31) (Kaye and Clayman, 1986), which is inflated up to 36 Fr to tamponade the parenchymal bleeding just as the sheath did intraoperatively. This device should be removed under fluoroscopic guidance with guidewire access down the ureter in case tube reinsertion is required for recurrent bleeding.



FIG. 12.31 Kaye Nephrostomy Tamponade Balloon.

Intraoperative hemorrhage from an injured vein or artery within the collecting system mandates cessation of the procedure if vision is lost. In most cases, especially if the injury appears to be venous, then placing a nephrostomy tube and letting the collecting system clot off is effective. If this is not effective, then Gupta and colleagues (2002) have described inserting a Council catheter as a nephrostomy tube, with the balloon inflated slowly at the site where contrast material enters into the venous system until repeated nephrostography reveals no more extravasation of contrast material. A hole should be cut into the tube proximal to the balloon to provide drainage of calyces obstructed by the balloon. Millard and associates (2010) have reported an addition to this technique, in which gelatin matrix hemostatic sealant is injected into the tract peripheral to the balloon occluding the renal injury and then a second catheter is inserted with the balloon placed just underneath the skin surface, such that the tract is occluded and the gelatin matrix hemostatic sealant contributes to hemostasis. Another alternative, described in one case of a large venous injury, is to place a large-bore catheter through the injury site into the main renal vein and then back it out several days later (Shah et al., 2005). A small arterial injury can sometimes be addressed with fulguration under direct vision, but if this is not successful and bleeding does not cease with pressure, or in cases of significant arterial hemorrhage, then selective angioembolization will likely be required (see later).

Delayed Hemorrhage

Postoperative hemorrhage can occur with the nephrostomy tube in place, at time of tube removal, or after discharge from the hospital. **Less than 1% of major percutaneous procedures are complicated by delayed hemorrhage requiring treatment** (El Tayeb et al., 2015; Keoghane et al., 2012; Kessaris et al., 1995; Martin et al., 2000; Richstone et al., 2008; Tomaszewski et al., 2010b). **Delayed hemorrhage is usually caused by arteriovenous fistulas or arterial pseudoaneurysms, with the latter being more common.** Arteriovenous fistulas occur when a paired set of artery and vein are injured, and arterial blood enters directly into the vein (Fig. 12.32). The weak vein wall cannot sustain the high arterial pressure and ruptures. An arterial pseudoaneurysm occurs when an artery is injured, clots off, and then intermittently ruptures, often clotting off again at variable intervals (Fig. 12.33A). Any report of bright-red blood in the urine or nephrostomy tube after surgery should raise clinical suspicion for either of these entities. In most instances, bleeding occurs approximately 1 week after surgery (El Tayeb et al., 2015). The patient may complain of flank pain associated with hematuria if the bleeding is associated with clot formation, which can cause obstruction and mimic renal colic. Cases of suspected arteriovenous fistula or pseudoaneurysm should be promptly evaluated with angiography, which is diagnostic in more than 90% of cases and allows for subsequent treatment in the same setting in most instances (Richstone et al., 2008). Both arteriovenous fistulae and pseudoaneurysms are treated with selective angioembolization, which is usually effective (Jain et al., 2009; Ji et al., 2012; Martin et al., 2000; Patterson et al., 1985; Richstone et al., 2008). Nonetheless, in one multicenter study embolization failure (occurring in 10% of cases), was more common in patients with multiple percutaneous access sites, more than two bleeding sites on angiography, and when gelatin only was used as the embolic material (Zeng et al., 2013). Moreover, angioembolization can be associated with partial or total renal loss if it is not selective enough (Fig. 12.33B). An alternative is placement of a covered stent to occlude the site of arterial injury, which has the benefit of preserving downstream renal parenchyma because renal blood flow is preserved (Areste et al., 2005; Sprouse and Hamilton, 2002).

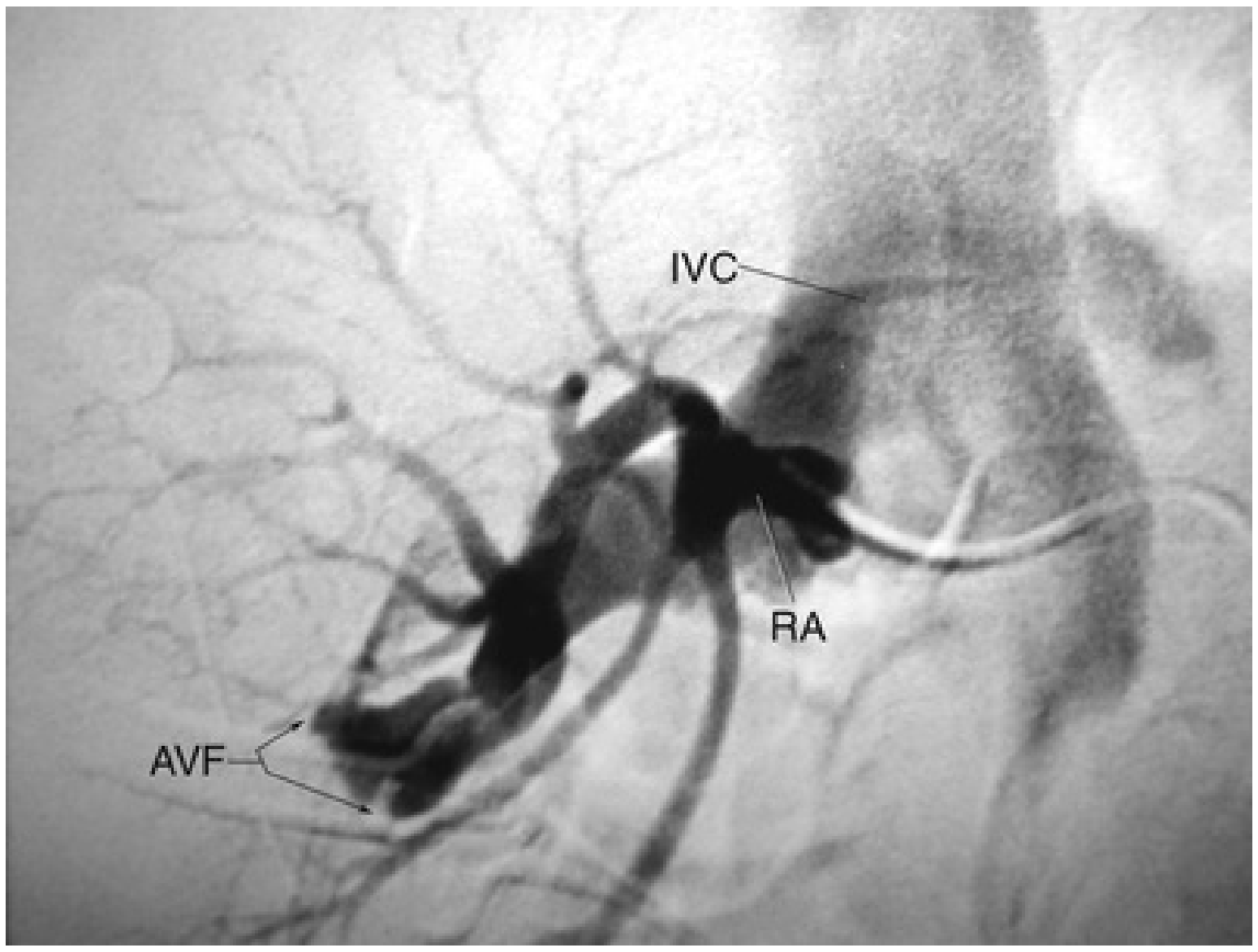

FIG. 12.32 Angiography of the renal artery *(RA)* is followed promptly by contrast material appearing in the inferior vena cava *(IVC),* suggesting the presence of an arteriovenous fistula *(AVF).*

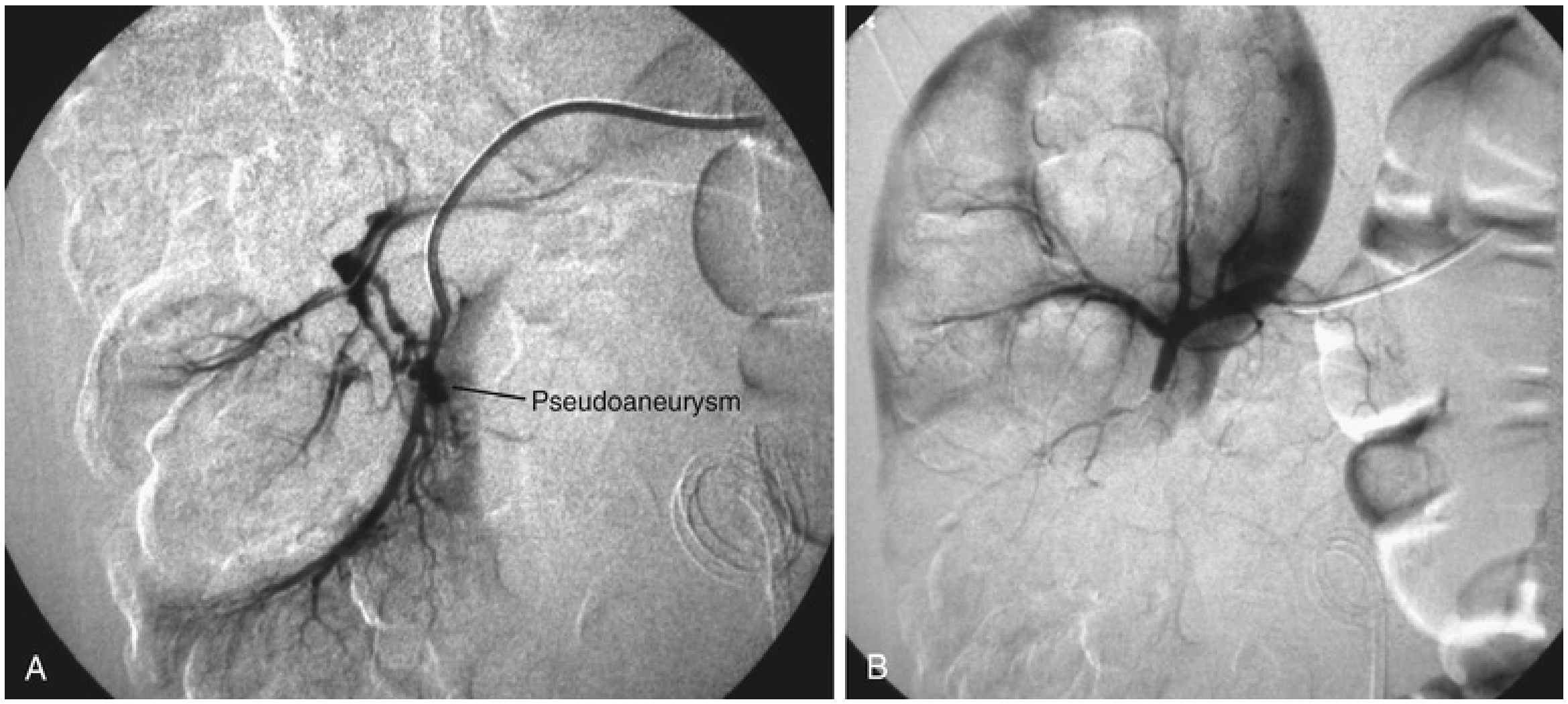

FIG. 12.33 (A) Angiography demonstrates a pseudoaneurysm in the lower pole of the right kidney. (B) Angioembolization was successful at occluding the pseudoaneurysm, but it also devascularized a large portion of the lower pole.

Collecting System Injury

Tears in the infundibulum are not uncommon during percutaneous surgery of the upper urinary tract collecting system. They generally do not cause problems intraoperatively as long as there is no hemorrhage. Ureteral injuries are rare but can occur as a result of inflating the ureteral balloon occlusion catheter in the ureter or during other ureteral manipulation. These injuries generally will heal over a ureteral stent. Renal pelvic perforation can occur during initial access or during dilation. Pushing on a renal pelvic stone too hard during lithotripsy or misusing a lithotripter or resectoscope can also perforate the renal pelvis. **Renal pelvic perforation is usually recognized intraoperatively** (Fig. 12.34). **Collapse of a previously distended renal pelvis is a usual sign if the perforation is not visualized directly at first.** A perforation that has not been recognized intraoperatively might be heralded by postoperative abdominal distention, ileus, and/or fever. **If noted intraoperatively, abort the procedure unless it is near completion, in which case the task can be completed at lower irrigation pressure if the patient is doing well clinically. At the completion of a case in which renal pelvic perforation has been noted, insert a nephroureteral stent or a nephrostomy tube plus an internal ureteral stent to optimize drainage, and then wait 2 to 7 days before nephrostography and tube removal, depending on the severity of the injury.** If renal pelvic perforation is detected postprocedure despite adequate drainage of the collecting system, then placement of a percutaneous drain into the urinoma might be required. There have been reports of massive intra-abdominal collection of extravasated fluid after percutaneous renal surgery (Etemadian et al., 2012; Ghai et al., 2003; Peterson et al., 1985; Pugach et al., 1999).

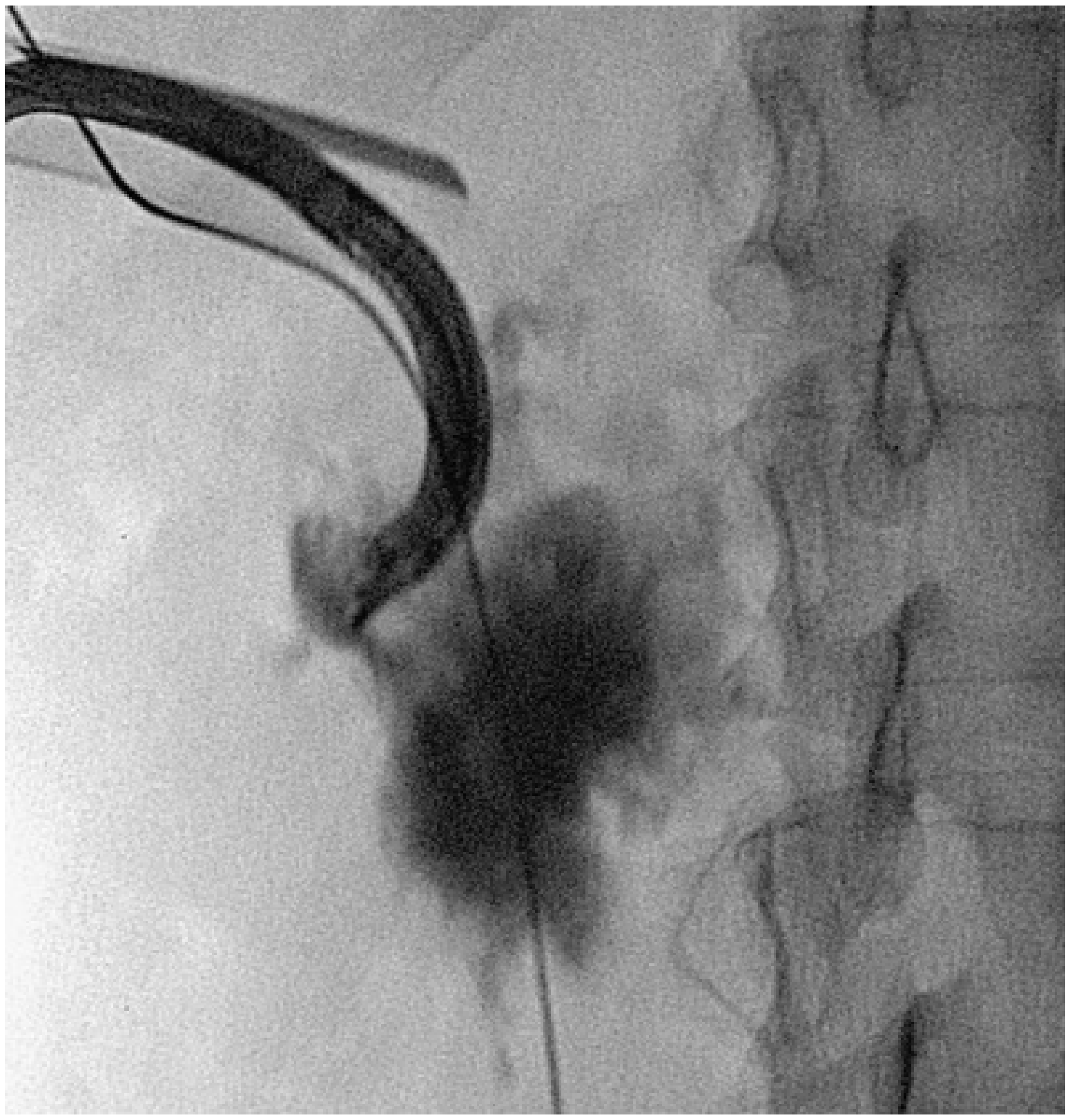

FIG. 12.34 Renal pelvic perforation confirmed with injection of contrast material through flexible nephroscope.

Visceral Injury

Any abdominal organ close to the kidney can be injured during percutaneous renal surgery including the colon, duodenum, jejunum, spleen, liver, and biliary system. Thankfully, injury to adjacent viscera at the time of percutaneous renal access or surgery is exceedingly rare. **Two recent large studies including more than 16,000 patients undergoing percutaneous nephrolithotomy indicate the incidence of colon injury to be around 0.1%** (AslZare et al., 2014; Kachrilas et al., 2012). **As would be expected on the basis of the anatomy, with the apposition of the colon to the kidney being greatest on the left side and at**

the lower pole, the left colon is injured twice as often as the right colon, and the majority of colon injuries involve access to the lower pole (El-Nahas et al., 2006). Additional risk factors include advanced patient age, dilated colon, prior colon surgery or disease, thin body habitus, and the presence of a horseshoe kidney (El-Nahas et al., 2006; Goswami et al., 2001; Korkes et al., 2009; Michel et al., 2007). Injury might be less likely with the patient in the supine position; one study reported a retrorenal colon on CT in 1.9% of patients in the supine position versus 10% in prone patients (Hopper et al., 1987). An additional study based on CT-measured distance from a hypothetical puncture location to the colon favored supine versus prone positioning (Desoky et al., 2018).

Intraoperative detection of colonic injury confers easier management. If not determined intraoperatively, colon injury should be considered postoperatively if a patient develops unexplained fever, prolonged ileus, unexplained leukocytosis, rectal bleeding, evidence of peritoneal inflammation, or fecaluria or pneumouria. Clinically apparent nephrocolonic fistula may be the presenting sign, or the injury may not be noted until the time of postoperative nephrostogram. **Most colon injuries are extraperitoneal and can be managed conservatively** (El-Nahas et al., 2006; Gerspach et al., 1997; Goger et al., 2012; Kachrilas et al., 2012; Korkes et al., 2009; Traxer, 2009). **The traditional principle of care is prompt and separate drainage of the colon and urinary collecting system,** although some authors report that internal urinary tract drainage alone is adequate (Maghsoudi et al, 2017). Give nothing by mouth for a few days, and then start clear liquids and advance diet as tolerated. If the injury is intraperitoneal, or if the patient develops peritonitis or sepsis, then open surgical repair may be required.

Small bowel injuries are even less common than colonic injury, described in only a few cases reports (Ahmed and Reeve, 1995; Al-Assiri et al., 2005; Culkin et al., 1985; Lopes-Neto et al., 2000; Morris et al., 1991; Kumar et al., 1994; Ricciardi et al., 2007; Santiago et al., 1998; Traxer, 2009; Winer et al., 2009). Detection is by clinical signs and symptoms of peritonitis or by noting a nephroenteric fistula during postoperative nephrostography. Although open surgery may be required, conservative management using percutaneous intraduodenal catheterization or simple nasogastric or nasoduodenal drainage, combined with drainage of the upper urinary tract, fasting, and parenteral feeding, has been successful.

Studies based on CT and MRI have suggested that splenic and hepatic injuries should be unlikely unless the kidney is accessed above the 10th rib,

although access above the 11th or 12th rib might traverse these organs in rare cases (Hopper and Yakes, 1990; Robert et al., 1999). These relationships change when splenomegaly or hepatomegaly is present, and access guided by CT is recommended. Splenic or hepatic injuries to orthotopic and normal-sized organs occur almost exclusively with supracostal upper-pole renal access. Splenic injury can often be managed conservatively with careful serial abdominal examinations and complete blood count measurement (Carey et al., 2006; Desai et al., 2010; Goldberg et al., 1989; Santiago et al., 1998; Schaeffer et al., 2008; Thomas et al., 2009), but it rarely requires laparotomy and potentially splenectomy because of hemorrhage (Kondas et al., 1994; Shah et al., 2007). Liver injury is less likely to be associated with significant hemorrhage—indeed the liver can be traversed percutaneously to obtain biliary access (Nadler et al., 2002), and purposeful transhepatic percutaneous renal surgery has been reported (Matlaga et al., 2006). As such, liver injuries during percutaneous renal surgery can be managed conservatively (El-Nahas et al., 2008).

There have been a few reported cases of biliary peritonitis caused by injury of the gallbladder or biliary tree, which require exploratory laparotomy/laparoscopy and cholecystectomy because of the high mortality rate of bile peritonitis (Fisher et al., 2004; Kontothanassis and Bissas, 1997; Martin et al., 1996; Patel and Nakada, 2010; Ricciardi et al., 2007; Saxby, 1996). Postoperative pancreatitis, without evidence of direct pancreatic injury, has been described as well (Chitale et al., 2005).

Pleural Injury

Hydrothorax, and occasionally pneumothorax, is a risk for percutaneous access to the upper urinary tract–collecting system. Supracostal access is the main risk factor; access below the 12th rib rarely results in hydrothorax or pneumothorax (Lojanapiwat and Prasopsuk, 2006; Maheshwari et al., 2009; Munver et al., 2001; Radecka et al., 2003). The incidence of pleural complications with punctures above the 12th rib (the 11th intercostal space) is generally considered an acceptable risk if that approach provides optimal access to the upper urinary tract. Access above the 11th rib or higher carries a much greater risk for pleural injury. **Among 16 reports that distinguished between access above the 12th rib and access above the 11th rib, reporting a total of 1384 supracostal percutaneous accesses, the incidence of hydrothorax/pneumothorax that required intervention varied from 0% to 18% for access superior to the 12th rib (weighted mean of 4.6%) and from**

0% to 100% for access superior to the 11th rib (weighted mean of 24.6%) (Aron et al., 2005b; Golijanin et al., 1998; Gupta et al., 2002; Kekre et al., 2001; Lojanapiwat and Prasopsuk, 2006; Munver et al., 2001; Muzrakchi et al., 2003; Narasimham et al., 1991; Picus et al., 1986; Radecka et al., 2003; Shaban et al., 2008; Sukumar et al., 2008; Wong and Leveillee, 2002; Yadav et al., 2006; Yadav et al., 2008; Young et al., 1985).

Nephropleural fistula (urinothorax) is a direct and persistent communication between the intrarenal collecting system and the intrathoracic cavity (Handa et al., 2007; Ray et al., 2003; Shleyfer et al., 2006). It can follow percutaneous renal access of the upper urinary tract in the setting of pleural transgression. Some degree of distal ureteral obstruction usually contributes to the problem. Most commonly, nephropleural fistula is diagnosed after the percutaneous tube is removed, but it can occur in the setting of a recognized hydrothorax when the persistent communication is documented on nephrostography at the time of intended tube removal. Lallas and colleagues (2004) reported that nephropleural fistula never occurred in association with subcostal access but did complicate 2.3% of punctures superior to the 12th rib and 6.3% of punctures superior to the 11th rib.

Pleural complications of supracostal percutaneous access can often be detected with chest fluoroscopy during or at the conclusion of the procedure. Fluid can be seen tracking along the lateral borders of the chest cavity and compressing the ipsilateral lung. Although postoperative chest radiography is more sensitive than intraoperative fluoroscopy, some authors report that thoracostomy was never required on the basis of postoperative chest radiography when intraoperative chest fluoroscopy was negative (Bjurlin et al., 2012; Ogan et al., 2003).

Thoracostomy is not necessary for all patients with hydrothorax. If hydrothorax is noted intraoperatively, then insert a small-caliber (8-Fr to 12-Fr) Cope nephrostomy tube as the thoracostomy (Fig. 12.35), using fluoroscopic guidance and the same general techniques as for antegrade percutaneous renal access (Ogan and Pearle, 2002). A Heimlich valve, rather than water seal drainage, is all that is necessary in the absence of lung injury. If a hydrothorax is noted on the postoperative chest radiograph, then place a small-caliber tube only if the effusion is large or there is evidence of respiratory compromise or hemodynamic instability. A large-bore thoracostomy tube as for lung injury is rarely required.

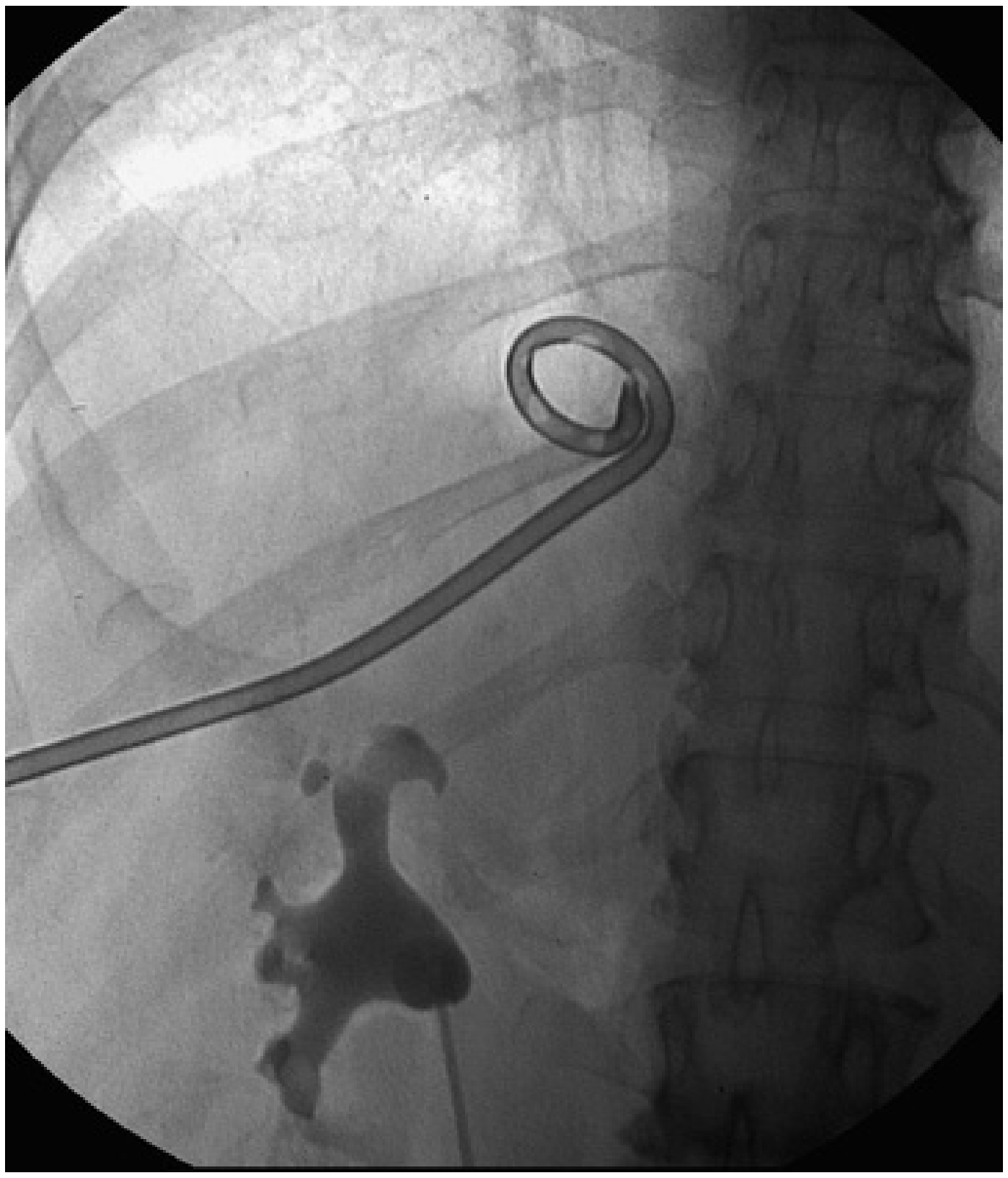

FIG. 12.35 A 12-Fr Cope catheter placed into the chest when a large hydrothorax was noted intraoperatively on fluoroscopy.

Metabolic and Physiologic Complications

Normal saline should be the irrigant for percutaneous renal surgery, with the exception of glycine or similar nonelectrolytic isotonic fluids when monopolar electrocautery is used. Irrigation with water during percutaneous renal surgery risks intravascular hemolysis, which can be fatal. At least one death associated with water irrigation during percutaneous nephrolithotomy has been described (Bennett et al., 1984), and the author is aware of an unreported case. Intravascular or extravascular extravasation of nonelectrolytic isotonic fluid from continued irrigation in the setting of a large venous injury or collecting system perforation, respectively, can result in hyponatremia and other electrolyte abnormalities, renal or hepatic dysfunction, and mental status changes. When normal saline is used in uncomplicated cases, the amount of fluid absorption is generally clinically insignificant (Köroğlu et al., 2003; Kukreja et al., 2002), although in one study 28% of patients absorbed more than 1 liter (Malhotra et al., 2001). A large amount of saline extravasation can lead to clinically significant respiratory distress or cardiac failure caused by volume overload.

Venous gas embolism is a rare but potentially fatal complication of percutaneous renal surgery. The gas (in this case, air) enters the venous system and passes through the right heart into the pulmonary circulation, blocking the output of the right heart, which results in hypoxemia, hypercapnia, and depressed cardiac output. Gas can also pass through a patent foramen ovale to enter the arterial system, which can result in neurologic deficits. Among six reported cases of venous gas embolism in association with percutaneous renal surgery, three were associated with air pyelography in combination with percutaneous access of the kidney (Cadeddu et al., 1997; Droghetti et al., 2002; Miller et al., 1984), one involved percutaneous surgery without air pyelography (Turillazzi et al., 2009), and two occurred after retrograde injection of air into the renal pelvis but before percutaneous puncture (Song et al., 2007; Varkarakis et al., 2003). Venous gas embolism is indicated by hypoxemia, evidence of pulmonary edema, increased airway pressure, hypotension, jugular venous distention, facial plethora, dysrhythmias, and auscultation of a mill-wheel cardiac murmur and/or the appearance of a widened QRS complex with right heart strain patterns on electrocardiography. The most sensitive measure is a sudden decrease in capnometry reading of the P(end-tidal)CO_2. Swift response is required and includes rapid ventilation with 100% oxygen, positioning the patient head down with the right side up, and general resuscitative maneuvers.

Postoperative Fever and Sepsis

After percutaneous nephrolithotomy, 15% to 30% of patients have a fever. Risk factors for fever/infectious complications after percutaneous nephrolithotomy include diabetes mellitus, paraplegia, indwelling ureteral stent or nephrostomy tube, prior percutaneous nephrolithotomy, multiple access tracts, infection stone, staghorn stone, positive preoperative urine culture, larger stones, and hydronephrosis (Aghdas et al., 2006; Charton et al., 1986; Draga et al., 2009; Gutierrez et al., 2013; Korets et al., 2011; Kumar et al., 2012; Lojanapiwat and Kitirattrakarn, 2011; Rivera et al., 2016; Troxel and Low, 2002). **Most patients with fever after percutaneous nephrolithotomy, assuming appropriate antimicrobial prophylaxis, do not have infection** (Cadeddu et al., 1998). Rather, the majority suffer from systemic inflammatory response syndrome (SIRS), a nonspecific immune response defined by hyperthermia/hypothermia, leukocytosis/leukopenia, tachycardia, and tachypnea, which can be caused by either infectious or noninfectious insults**.** Self-limited fever after percutaneous interventions without associated hemodynamic compromise can often be managed expectantly. Indeed, most patients in this setting can be routinely discharged without intervention or risk for unplanned readmission (Moses et al., 2017).

Sepsis, differentiated from SIRS alone in that an identifiable infectious source (i.e., positive urine or blood culture) can be identified, occurs in 0.5% to 2.5% of patients after percutaneous nephrolithotomy (Dogan et al., 2007; Duvdevani et al., 2007; Gonen et al., 2008b; Labate et al., 2011; Li et al., 2013b; Lojanapiwat and Kitirattrakarn, 2011; Seitz et al., 2012). Positive preoperative urine cultures should be treated. Even if bacteriologic cure is not possible (e.g., infectious stone, indwelling nephrostomy tube), bacterial counts should be suppressed as much as possible to reduce the risk for infectious complications. Nonetheless, a negative urine culture does not guarantee against sepsis because the voided urine culture may not reflect the intrarenal urine (Korets et al., 2011; Lojanapiwat and Kitirattrakarn, 2011; Mariappan et al., 2005; Rao et al., 1991). **If pus is aspirated upon initial percutaneous entry to the upper urinary tract, the safest measure is to abort the procedure and leave a nephrostomy tube for drainage.**

Neuromusculoskeletal Complications

Prone positioning for percutaneous renal surgery has the potential for a number of neuromusculoskeletal injuries (Edgcombe et al., 2008; Shermak et al., 2006). **Excessive pressure on neural and vascular structures, whether directly from the operative table or indirectly through the positioning of limbs, may lead to short- or long-term disability.** Most reported injuries associated with prone positioning are related to the head and neck region including ocular injury resulting in visual loss, facial nerve injury or necrosis over facial bones or the tip of the nose, and cerebrovascular accident caused by carotid or vertebrobasilar artery dissection. Careful padding of the head, in a neutral and nonextended position, is important. Malpositioning of the extremities can lead to peripheral nerve injury (Winfree and Kline, 2005). The shoulder and elbow should not be abducted more than 90 degrees, to prevent brachial plexopathy, and generous padding at the elbow and forearm reduces the risk for nerve compression. Knees need to be padded. Ankles should be elevated to reduce pressure on the dorsum of the foot.

Venous Thromboembolism

The incidence of venous thromboembolism with percutaneous renal surgery is low (<3% in older series of percutaneous nephrolithotomy) (Lee et al., 1987; Segura et al., 1985), but there are no recent data. **The American Urological Association's Best Practice Statement for the prevention of deep vein thrombosis in patients undergoing urologic surgery does not include percutaneous renal surgery among procedures for which prophylaxis against venous thromboembolism is recommended** (Forrest et al., 2009). Early ambulation is the best measure to reduce the already low risk for venous thromboembolism.

Collecting System Obstruction

Transient ureteral obstruction caused by ureteral edema or blood clot occurs commonly. To assess for this, nephrostomy tubes should be removed after nephrostography or after a period of clamping to assess clinically for distal ureteral obstruction. Much more uncommon is stricture formation, which can occur in the ureter, at the ureteropelvic junction, or in an infundibulum. If the stricture occurs early in the postprocedure course, then a nephrocutaneous fistula will develop. If it develops late, then hydronephrosis or hydrocalyx will occur. **In one large series, there was a 2% rate of infundibular stenosis after percutaneous nephrolithotomy** (Parsons et al., 2002). The obstructions developed in the areas that had been accessed percutaneously. Predisposing factors in this and other smaller reports (Ballanger et al., 1987; Buchholz, 2001; Weir and Honey, 1999) include large stone burden requiring multiple or long procedures and prolonged nephrostomy tube drainage, previous open stone surgery, diabetes mellitus, and obesity. The ureter (Culkin et al., 1987; Lopes-Neto et al., 2008) and the ureteropelvic junction (Ben Slama et al., 2005; Green et al., 1987) are smaller in caliber than the intrarenal collecting system and are therefore also susceptible to trauma.

Obstruction after percutaneous renal surgery should respond to endoscopic treatment in most cases, but open surgical reconstruction or excision with partial nephrectomy or total nephrectomy may be required.

Loss of Renal Function

Despite the direct puncture of renal parenchyma and enlargement of sometimes multiple tracts to up to 34 Fr, the kidney suffers little permanent damage after uncomplicated percutaneous renal surgery. Renal function does decrease slightly immediately after percutaneous renal surgery, reaching a nadir 48 hours postprocedure (Nouralizadeh et al., 2011), but long-term there is negligible loss of function (Chen et al., 1992; Ekelund et al., 1986; Kilic et al., 2006; Saxby, 1997), and in one study there appeared to be less damage to the kidney after percutaneous nephrolithotomy than after shock-wave lithotripsy (LeChevallier et al., 1993). In the setting of impaired function, especially caused by obstructing calculi, percutaneous surgery will often improve renal function (Bilen et al., 2008; Chandhoke et al., 1992; Chatham et al., 2002). Percutaneous renal surgery also causes no significant change in function of solitary kidneys (Canes et al., 2009; Jones et al., 1991; Liou and Streem, 2001). In one study of patients surveyed a mean of 19 years after treatment, there was no difference between shock-wave lithotripsy and percutaneous nephrolithotomy in the development of renal insufficiency or hypertension (Krambeck et al., 2008a).

When there is renal loss after percutaneous renal surgery, it usually is a result of disastrous vascular injury or the angioembolization used to treat hemorrhage.

Death

Death after percutaneous renal surgery is extremely rare, and when it occurs it is usually caused by underlying cardiovascular conditions (Labate et al., 2011; Seitz et al., 2012).

Key Points: Complications of Percutaneous Renal Access

- Patients should be clearly counseled before any percutaneous renal intervention regarding possible complications of the procedure.
- The most common complications after percutaneous renal access are bleeding and infection.
- Pleural injury or parenchymal lung injury is uncommon after percutaneous renal access but increases with supracostal punctures.
- Solid visceral injury is uncommon. Hepatic and splenic injury can often be managed conservatively. Injury to the small or large bowel requires prompt recognition and separation of renal and bowel drainage. Laparotomy may

be required in severe cases.

- Death after percutaneous renal access is exceedingly uncommon.

Retrograde Renal Access and Drainage

History

Although interest in ureteral catheterization has been documented for centuries, it was not until the development of the first cystoscopes that modern ureteral catheterization was possible. The first reported successful ureteral catheterization came in 1893 when Dr. James Brown, the head of the department of urology at Johns Hopkins, introduced a small catheter into each ureteral orifice for urine sampling in a paraplegic patient with persistent pyuria (Arcadi, 1999). It was not until the 1930s and 1940s and the development of pliable plastics that stents were manufactured that combined flexibility with sufficient rigidity. In the ensuing decades, a variety of reports indicate use of ureteral stents for ureteral injuries and malignant ureteral obstruction (Tulloch, 1952; Zimskind et al., 1967). Early stent design did not allow for stent retention, thus migration was a common problem. This was first addressed in 1974 with a self-retaining “Gibbons stent,” which featured sharp barbs along its length to prevent migration. The design was imperfect, however, and the stent itself was quite large at 11 Fr, thus limiting its use (Gibbons et al., 1974). The first double pigtail, self-retaining ureteral stent was developed in 1978 and serves as the predecessor to most commonly available modern ureteral stents used today (Finney, 1978).

Indications

The indications for retrograde renal drainage are vast, and roughly parallel those for percutaneous renal drainage (i.e., for renal obstruction). In addition, stents are often placed after routine ureteroscopy for stone disease. Drainage via ureteral stent placement is also important after a multitude of reconstructive surgeries to allow for ureteral healing, though these indications are beyond the scope of this chapter and are discussed elsewhere in this text. Specific scenarios in which retrograde versus antegrade renal drainage are preferred are outlined earlier in this chapter.

Surgical Technique

Before retrograde renal drainage, obtain urinalysis to evaluate for pyuria, and treat any infection before intervention. The AUA Guidelines recommend antibiotic prophylaxis in all patients undergoing cystoscopy with ureteral instrumentation (Wolf et al., 2008). Choice of anesthesia is dependent on the indication for which ureteral stent placement is being considered. Although ureteral stent placement can be performed in the awake patient with only local anesthesia (Sivalingam et al., 2013), in most cases, general anesthesia or sedation is preferable. Dorsal lithotomy position affords the surgeon ready access to the external genitalia and perineum and facilitates cystoscopy, although positioning can be modified to account for patient factors. A ureteral catheter introduced through the working channel of the cystoscope is used to intubate the ureteral orifice, with or without a leading guidewire. Retrograde pyelography delineates the ureteral and collecting system anatomy.

Guidewire Placement

There are numerous types of ureteral catheters and guidewires for ureteral stent placement. In most cases, a straight, open-ended ureteral catheter, typically 5 or 6 Fr, is used to stabilize and introduce a working guidewire. In challenging cases, the surgeon may choose an angled tip or torque stabilized angiographic catheter to further facilitate guidewire placement. Initial choice of guidewire is based on surgeon experience and preference. Guidewires for retrograde ureteral access have straight or curved tips and are available in a variety of materials such as PTFE, hydrophilic coated nitinol, or hybrid wires composed of a hydrophilic nitinol tip and PTFE body. Guidewires also vary in their stiffness, ranging from standard to stiff to super-stiff. Regardless of the guidewire chosen, the first objective is to successfully place the wire into the renal collecting system.

Stent Placement

The ureteral stent should be passed in a coaxial fashion over the working wire and into the renal collecting system. This can be accomplished by placement through the cystoscope working channel under direct vision using the supplied pusher. While monitoring the progress of the distal end of the stent in the bladder under direct vision, the proximal extent of the stent can be monitored using fluoroscopy until satisfied with the position. At this point, the guidewire is slowly removed to allow the proximal renal curl to form. The cystoscope is then positioned at the bladder neck, and the pusher is advanced until it is just within the field of view. The wire can then be completely withdrawn, which facilitates distal stent curl formation in the bladder. Advantages of stent placement under direct vision are the ability to monitor the distal extent of stent advancement to avoid overpassing the stent up the ureter and to potentially decrease fluoroscopy use. In addition, the added stability of a cystoscope is beneficial in settings in which stent passage may be challenging such as ureteral stricture or impacted stone, where the stent may otherwise tend to buckle rather than advance. Alternatively, the ureteral stent can be placed using fluoroscopic guidance only. In this situation, the cystoscope is removed and the pusher is used to advance the stent directly over the guidewire (Fig. 12.36A). It is typically best to position the fluoroscope over the pubic symphysis and monitor the radiopaque marker at the distal tip of the pusher (see Fig. 12.36B). Once this marker has been positioned at the mid-symphysis, the fluoroscope can be positioned over the ipsilateral renal location and the guidewire removed partially to form the proximal renal curl. After confirming good proximal position, the fluoroscope is repositioned over the pubic symphysis and the guidewire is completely withdrawn to form the distal curl of the stent (see Fig. 12.36C).

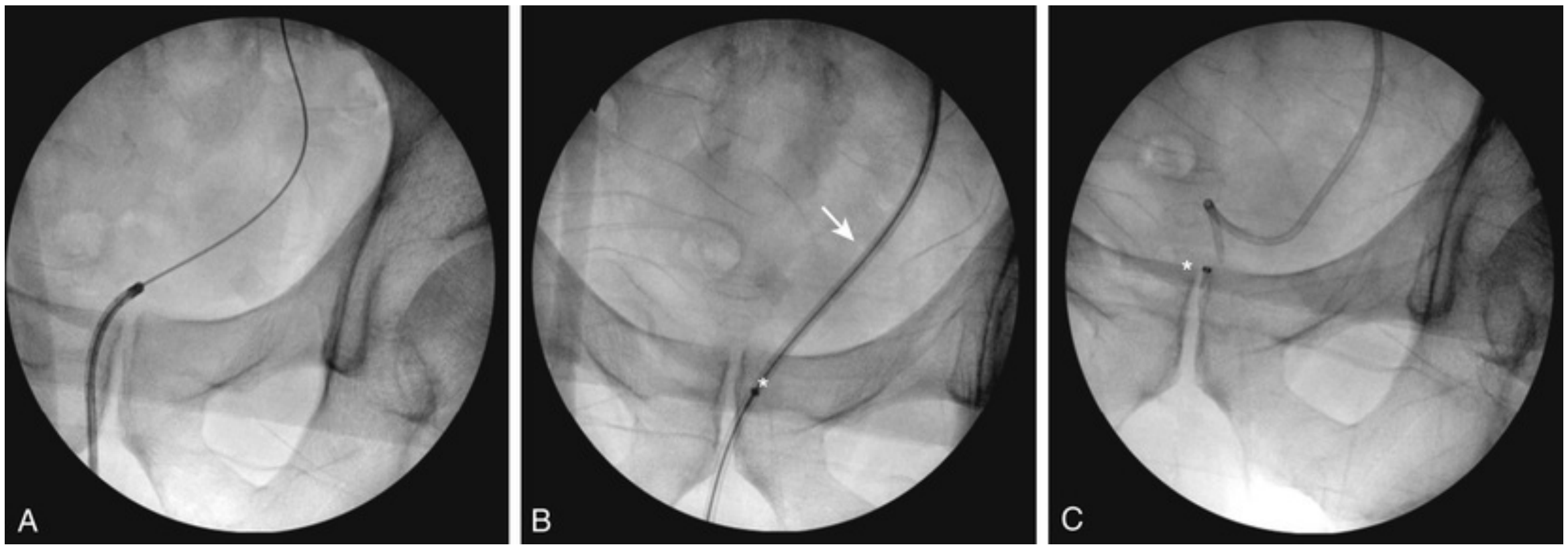

FIG. 12.36 (A) Cystoscope in bladder plus guidewire in ureter. (B) Stent placed in ureter through 10-Fr sheath (*asterisk* indicates radiopaque marker of pusher; *arrow* indicates 10-Fr sheath). (C) Guidewire and 10-Fr sheath removed; distal stent section coiled in bladder.

Stent Varieties

Materials

Most ureteral stents are composed of flexible polymers such as polyurethane, silicone, or others. In an effort to increase resistance to radial compression, such as in cases of malignant ureteral obstruction, metallic stents are available. The Wallstent is a self-expandable, metallic stent first developed for the management of extrinsic ureteral obstruction and refractory ureteral strictures (Pauer and Lugmayr, 1992; Reinberg et al., 1994). Though it does exhibit substantial resistance to compressive forces, the tendency for ureteral tissue ingrowth causing obstruction requiring ancillary endoscopic procedures has limited its widespread use (Lang et al., 2013). The Resonance stent (Cook Medical, Bloomington, IN) is constructed of tightly coiled metal alloy, which is also quite resistant to external compressive forces. First employed in 2006 for refractory ureteral obstruction caused by retroperitoneal fibrosis (Borin et al., 2006), longer-term data indicates primary ureteral patency rates of 72% with acceptable tolerability (Kadlec et al., 2013). More recently, hybrid ureteral stents with hydrophilic polymer coating reinforced by metallic coils have been developed (Silhouette stent: Applied Medical, Rancho Santa Margarita, CA; Passage/Snake stent: ProSurg, San Jose, CA). *In vitro* testing indicates high resistance to extrinsic compression, though *in vivo* reports as to their clinical effectiveness are limited (Dauw et al., 2015; Hendlin et al., 2012).

Design

Self-retaining, double pigtail ureteral stents are ubiquitous (Fig. 12.37). Single pigtail urinary diversion catheters are also available and typically employed in cases of lower urinary tract diversion in which the distal end can emanate from the body into an ostomy. Open-ended, spiral-tipped, or whistle-tipped ureteral catheters are typically reserved for temporary ureteral catheterization as an aid to ureteral identification in radial abdominal or pelvic surgery. In an effort to increase patient tolerability, stents have been designed with novel distal ends to minimize bladder irritation. One such example is the Polaris Loop ureteral stent (Boston Scientific, Marlborough, MA). However, a randomized controlled trial comparing this stent to a traditional double pigtail ureteral stent failed to show any symptomatic benefit using a validated questionnaire (Davenport et al., 2011; Park et al., 2015).

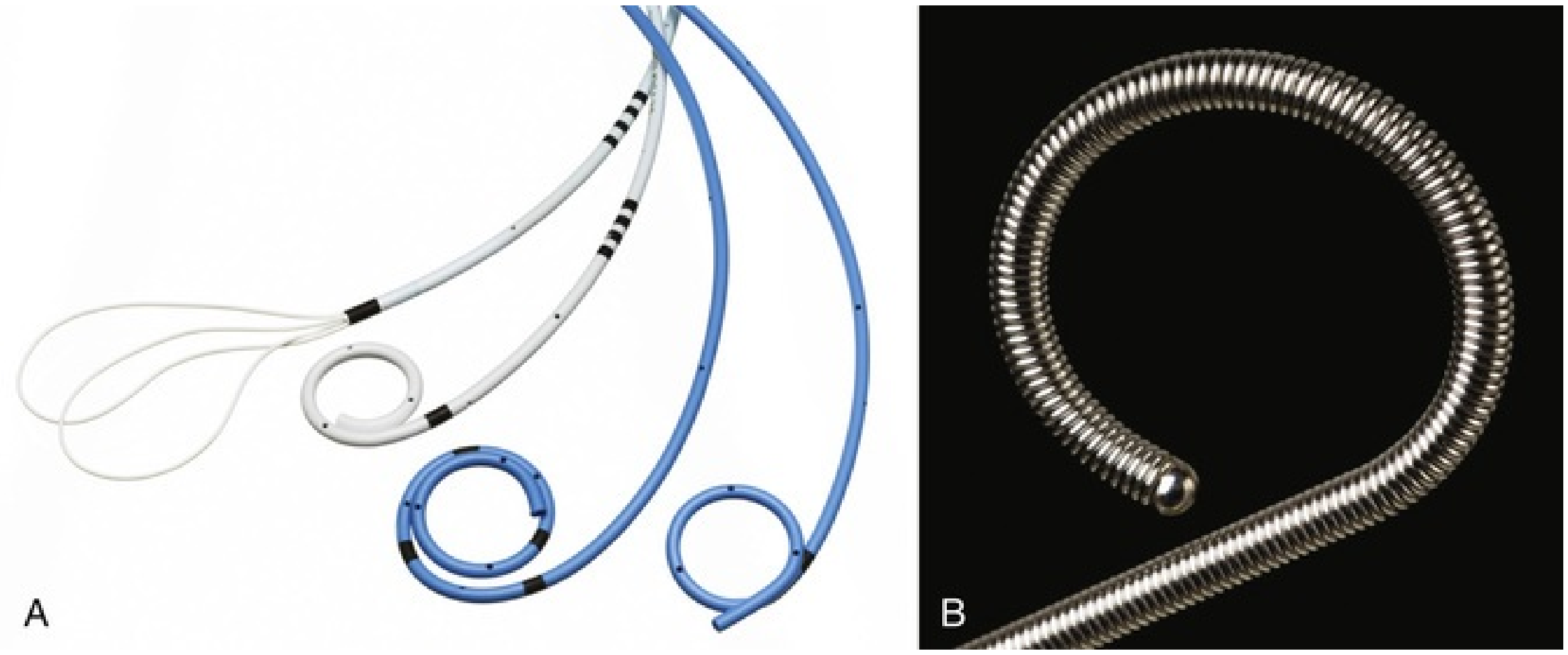

FIG. 12.37 Different stent designs. (A) Polaris Loop stent, Polaris Ultra stent, Percuflex Plus stent, and Contour VL stent. (B) Resonance metal stent. (A, Courtesy Boston Scientific, Marlborough, MA; B, Courtesy Cook Medical, Bloomington, IN.)

Stent Tolerance

Symptoms associated with ureteral stents are often quite bothersome to patients. The validated ureteral stent symptom questionnaire (USSQ), which can be used to measure the impact of ureteral stents on patient quality of life, is composed of 6 distinct domains addressed by 38 questions regarding urinary symptoms, pain, general health, work performance, sexual function, and additional problems (Joshi et al., 2003a). Using data from the initial cohort of patients completing the USSQ, urinary symptoms were present in 78% of patients, 80% felt that pain limited daily activities, 32% reported some degree of sexual dysfunction, and more than 50% reported decreased ability to work (Joshi et al., 2003b).

In an effort to reduce patient discomfort related to ureteral stents, investigators have evaluated a multitude of stent-specific factors such as stent length and diameter and a variety of pharmacologic agents. In a study evaluating patients with either a 22-, 24-, or 26-cm ureteral stent, bladder symptoms, notably urinary urgency and frequency, were more common as stent length increased, yet there was no difference in flank discomfort (Ho et al., 2008). One marker of stent length is the position of the distal (bladder) curl of the ureteral stent. Although an initial study suggested that extension of the distal curl of the ureteral stent across the midline of the urinary bladder was associated with significant urinary symptoms but no appreciable difference in flank pain (Al-Kandari et al., 2007), in a recent large randomized controlled trial evaluating stent length using the validated USSQ questionnaire, the authors found no difference in urinary symptoms or flank pain in longer versus shorter ureteral stents (Calvert et al., 2013). Studies evaluating stent diameter and its association with pain have shown no association of stent-related discomfort with stent diameter (Damiano et al., 2005; Erturk et al., 2003; Lamb et al., 2011; Yakoubi et al., 2011; Zhou et al., 2015).

One of the major symptoms associated with ureteral stents is bladder discomfort presumed to be caused by interaction of the distal curl of the ureteral stent with the bladder mucosa. Systematic reviews and meta-analyses indicate that both alpha blockers and antimuscarinic medications are associated with improvement of bladder symptoms such as urgency and frequency associated with ureteral stents, though the individual randomized controlled trials are quite small (Kwon et al., 2015; Lamb et al., 2011; Yakoubi et al., 2011; Zhou et al., 2015).

Key Points: Retrograde Renal Drainage

- In general, the indications for retrograde renal drainage mirror those for antegrade renal drainage.
- Stent architecture (material, tip configuration) has not been shown to increase stent tolerability.
- Stent length and position have been associated with decreased bladder discomfort such as urgency and frequency of urination.
- Alpha blockers and antimuscarinic medications have been associated with improved stent tolerability.

References

Abou-Elela A, Emran A, Mohsen MA, et al. Safety and efficacy of tubeless percutaneous renal surgery. *J Endourol*. 2007;21:977–984.

ACR. Practice guideline for the performance of percutaneous nephrostomy. *ACR practice guidelines and technical standards*. American College of Radiology: Reston, VA; 2007.

Aghamir SM, Salavati A, Aloosh M, et al. Feasibility of totally tubeless percutaneous nephrolithotomy under the age of 14 years: a randomized clinical trial. *J Endourol*. 2012;26:621–624.

Aghamir SMK, Khazaeli MH, Meisami A. Use of surgicel for sealing nephrostomy tract after totally tubeless percutaneous nephrolithotomy. *J Endourol*. 2006;20:293–295.

Aghdas FS, Akhavizadegan H, Aryanpoor A, et al. Fever after percutaneous nephrolithotomy: contributing factors. *Surg Infect (Larchmt)*. 2006;7:367–371.

Agrawal MS, Sharma M, Agarwal K. Tubeless percutaneous nephrolithotomy using antegrade tether: a randomized study. *J Endourol*. 2014;28:644–648.

Ahmed M, Reeve R. Iatrogenic duodeno-cutaneous fistula at percutaneous nephrolithotomy managed conservatively. *Br J Urol*. 1995;75:416–418.

Ak K, Gursoy S, Duger C, et al. Thoracic paravertebral block for postoperative pain management in percutaneous nephrolithotomy patients: A randomized controlled clinical trial. *Med Princ Pract*. 2013;22:229–233.

Akman T, Binbay M, Sari E, et al. Factors affecting bleeding during percutaneous nephrolithotomy: single surgeon experience. *J Endourol*. 2011;25:327–333.

Al-Assiri M, Binsaleh S, Libman J, et al. Jejunal perforation during percutaneous nephrolithotrypsy. *ScientificWorldJournal*. 2005;5:496–499.

Al-Ba'adani TH, Al-Kohlany KM, Al-Adimi A, et al. Tubeless percutaneous neprolithotomy: the new gold standard. *Int Urol Nephrol*. 2008;40:603–608.

Al-Dessoukey AA, Moussa AS, Abdelbary AM, et al. Percutaneous nephrolithotomy in the oblique supine lithotomy position and prone position: a comparative study. *J Endourol*. 2014;28:1058–1063.

Al-Kandari AM, Al-Shaiji TF, Shaaban H, et al. Effects of proximal and distal ends of double-J ureteral stent position on postprocedural symptoms and quality of life: a randomized clinical trial. *J Endourol*. 2007;21:698–702.

Al-Otaibi K, Hosking DH. Percutaneous stone removal in horseshoe kidneys. *J Urol*. 1999;162:674–677.

Alken P. The telescope dilators. *World J Urol*. 1985;3:7–10.

Allen D, O'Brien T, Tiptaft R, et al. Defining the learning curve for percutaneous nephrolithotomy. *J Endourol*. 2005;19:279–282.

Aquil S, Rana M, Zaidi Z. Laparoscopic assisted percutaneous nephrolithotomy (PCNL) in ectopic pelvic kidney. *J Pak Med Assoc*. 2006;56:381–383.

Arcadi JA. Dr. James brown and catheterization of the male ureter: June 9, 1893. *Urology*. 1999;54:188–192.

Areste N, Moyano MJ, Naranjo D, et al. Endovascular treatment with “covered stent” of arteriovenous fistula secondary to percutaneous renal biopsy. *Nefrologia*. 2005;25:449–450.

Armitage JN, Withington J, Fowler S, et al. Percutaneous nephrolithotomy access by urologist or interventional radiologist: practice and outcomes in the UK. *BJU Int*. 2017;119:913–918.

Aron M, Gupta NP, Goel R, et al. Laparoscopy-assisted percutaneous nephrolithotomy (PCNL) in a previously operated ectopic pelvic kidney. *Surg Laparosc Endosc Percutan Tech*. 2005;15:41–43.

Aron M, Yadav R, Goel R, et al. Multi-tract percutaneous nephrolithotomy for large complete staghorn calculi. *Urol Int*. 2005;75:327–332.

AslZare M, Darabi Mahboub MR, Shakiba B, et al. Colonic perforation during percutaneous nephrolithotomy: an 18-year experience. *Can Urol Assoc J*. 2014;8:E323.

Assimos D, Krambeck A, Miller NL, et al. Surgical management of stones: American urological Association/endourological society guideline, Part I. *J Urol*. 2016;196:1153–1160.

Atmaca AF, Akbulut Z, Altinova S, et al. Standard percutaneous nephrolithotomy on a pelvic kidney without any ancillary modalities. *Int Urol Nephrol*. 2007;39:723–725.

Bag S, Kumar S, Taneja N, et al. One week of nitrofurantoin before percutaneous nephrolithotomy significantly reduces upper tract infection and urosepsis: a prospective controlled study. *Urology*. 2011;77:45–49.

Baldwin DD, Maynes LJ, Desai PJ, et al. A novel single step percutaneous access sheath: the initial human experience. *J Urol*. 2006;175:156–161.

Ballanger P, Baron JC, Teillac P, et al. Acquired stenosis of the upper urinary tract after percutaneous nephrolithotomy. *Ann Urol (Paris)*. 1987;21:296–299.

Barbaric ZL, Hall T, Cochran ST, et al. Percutaneous nephrostomy: placement under CT and fluoroscopy guidance. *AJR Am J Roentgenol*. 1997;169:151–155.

Basiri A, Mehrabi S, Kianian H, et al. Blind puncture in comparison with fluoroscopic guidance in percutaneous nephrolithotomy: a randomized controlled trial. *Urol J*. 2007;4:79–83.

Bayne D, Taylor ER, Hampson L, et al. Determinants of nephrostomy tube dislodgment after percutaneous nephrolithotomy. *J Endourol*. 2015;29:289–292.

Bellman GC, Davidoff R, Candela J, et al. Tubeless percutaneous renal surgery. *J Urol*. 1997;157:1578–1582.

Ben Slama MR, Zaafrani R, Ben Mouelli S, et al. Ureterocalicostomy: last resort in the treatment of certain forms of ureteropelvic junction stenosis. Report of 5 cases. *Prog Urol*. 2005;15:646–649.

Bennett MJ, Smith RW, Fuchs E. Sudden cardiac arrest during percutaneous ultrasonic nephrostolithotomy. *Anesthesiology*. 1984;60:245–246.

Benway BM, Nakada SY. Balloon dilation of nephrostomy tracts. *J Endourol*. 2008;22:1875–1876.

Berkman DS, Lee MW, Landman J, et al. Tubeless percutaneous nephrolithotomy (PCNL) with reversed polaris loop stent: reduced postoperative pain and narcotic use. *J Endourol*. 2008;22:2245–2249.

Bilen CY, Inci K, Kocak B, et al. Impact of percutaneous nephrolithotomy on estimated glomerular filtration rate in patients with chronic kidney disease. *J Endourol*. 2008;22:895–900.

Bird VG, Fallon B, Winfield HN. Practice patterns in the treatment of large renal stones. *J Endourol*. 2003;17:355–363.

Bjurlin MA, O'Grady T, Kim R, et al. Is routine postoperative chest radiography needed after percutaneous nephrolithotomy? *Urology*. 2012;79:791–795.

Bloom DA, Morgan RJ, Scardino PL. Thomas Hillier and percutaneous nephrostomy. *Urology*. 1989;33:346–350.

Boon JM, Shinners B, Meiring JH. Variations of the position of the colon as applied to percutaneous nephrostomy. *Surg Radiol Anat*. 2001;23:421–425.

Borin JF, Melamud O, Clayman RV. Initial experience with full-length metal stent to relieve malignant ureteral obstruction. *J Endourol*. 2006;20:300–304.

Borofsky MS, Wollin DA, Reddy T, et al. Salvage percutaneous nephrolithotomy: analysis of outcomes following initial treatment failure. *J Urol*. 2016;195:977–981.

Buchholz NP. Double infundibular obliteration with abscess formation after percutaneous nephrolithotomy. *Urol Int*. 2001;66:46–48.

Cadeddu JA, Arrindell D, Moore RG. Near fatal air embolism during percutaneous nephrostomy placement. *J Urol*. 1997;159.

Cadeddu JA, Chen R, Bishoff J, et al. Clinical significance of fever after percutaneous nephrolithotomy. *Urology*. 1998;52:48–50.

Calvert RC, Wong KY, Chitale SV, et al. Multi-length or 24 cm ureteric stent? A multicentre randomised comparison of stent-related symptoms using a validated questionnaire. *BJU Int*. 2013;111:1099–1104.

Canes D, Hegarty NJ, Kamoi K, et al. Functional outcomes following percutaneous surgery in the solitary kidney. *J Urol*. 2009;181:154–160.

Carey RI, Siddiq FM, Guerra J, et al. Conservative management of a splenic injury related to percutaneous nephrostolithotomy. *JSLS*. 2006;10:504–506.

Castañeda-Zúñiga WR, Smith AD, Rusnak B, et al. Single-step dilation of nephrostomy tract. *J Urol*. 1982;127:341.

Challacombe B, Dasgupta P, Tiptaft R, et al. Multimodal management of urolithiasis in renal transplantation. *BJU Int*. 2005;96:385–389.

Chandhoke PS, Albala DM, Clayman RV. Long-term comparison of renal function in patients with solitary kidneys and/or moderate renal insufficiency undergoing extracorporeal shock wave lithotripsy or percutaneous nephrolithotomy. *J Urol*. 1992;147:1226–1230.

Chang C-H, Wang C-J, Huang S-W. Totally tubeless percutaneous nephrolithotomy: a prospective randomized controlled study. *Urol Res*. 2011;39:459–465.

Charton M, Vallancien G, Veillon B, et al. Urinary tract infection in percutaneous surgery for renal calculi. *J Urol*. 1986;135:15–17.

Chatham JR, Dykes TE, Kennon WG, et al. Effect of percutaneous nephrolithotomy on differential renal function as measured by mercaptoacetyl triglycine nuclear renography. *Urology*. 2002;59:522–525.

Chen KK, Chen MT, Yeh SH, et al. Radionuclide renal function study in various surgical treatments of upper urinary stones. *Zhonghua Yi Xue Za Zhi (Taipei)*. 1992;49:319–327.

Chen Y, Feng J, Yue Y, et al. Externalized ureteral catheter versus double-J stent in tubeless percutaneous nephrolithotomy for upper urinary stones: a systematic review and meta-analysis. *J Endourol*. 2018;32:581–588.

Chew BH, Chiu RYW, Hamidizadeh R, et al. Success and complication rates in 729 percutaneous nephrolithotomies at a single centre (abstract #1381). *J Urol*. 2009;181(Suppl):493–494.

Chiang PH, Su HH. Randomized and prospective trial comparing tract creation using plasma vaporization with balloon dilatation in percutaneous nephrolithotomy. *BJU Int*. 2013;112:89–93.

Chien GW, Bellman GC. Blind percutaneous renal access. *J Urol*. 2002;16:93–96.

Chitale S, Mbakada R, Burgess N. Pancreatitis following percutaneous nephrolithotomy. *Scand J Urol Nephrol*. 2005;39:251–253.

Choi SW, Kim KS, Kim JH, et al. Totally tubeless versus standard percutaneous nephrolithotomy for renal stones:

analysis of clinical outcomes and cost. *J Endourol*. 2014;28:1487–1494.

Chu C, Masic S, Usawachintachit M, et al. Ultrasound-guided renal access for percutaneous nephrolithotomy: a description of three novel ultrasound-guided needle techniques. *J Endourol*. 2016;30:153–158.

Chuang M-T, Lu C-H, Tsai Y-S, et al. Comparative study of percutaneous nephrostomy using catheters with and without locking strings. *Clin Nephrol*. 2011;76:226–232.

Cormio L, Preminger G, Saussine C, et al. Nephrostomy in percutaneous nephrolithotomy (PCNL): does nephrostomy tube size matter? Results from the global PCNL study from the clinical research office endourology society. *World J Urol*. 2013;31:1563–1568.

Cormio L, Gonzalez GI, Tolley D, et al. Exit strategies following percutaneous nephrolithotomy (PCNL): A comparison of surgical outcomes in the clinical research office of the endourological society (CROES) PCNL global study. *World J Urol*. 2013;1239-44.

Cormio L, Perrone A, Di Fino G, et al. TachoSil® sealed tubeless percutaneous nephrolithotomy to reduce urine leakage and bleeding: outcome of a randomized controlled study. *J Urol*. 2012;188:145–150.

Culkin DJ, Exaire EJ, Green D, et al. Anticoagulation and antiplatelet therapy in urological practice: ICUD/AUA review paper. *J Urol*. 2014;192:1026–1034.

Culkin DJ, Wheeler JS Jr, Canning JR. Nephro-duodenal fistula: a complication of percutaneous nephrolithotomy. *J Urol*. 1985;134:528–530.

Culkin DJ, Wheeler JS Jr, Canning JR. Distal ureteral obstruction complicating percutaneous nephrolithotomy. *Urology*. 1987;30:364–368.

Damiano R, Autorino R, De Sio F, et al. Does the size of ureteral stent impact urinary symptoms and quality of life? A prospective randomized study. *Eur Urol*. 2005;48:673–678.

Darabi Mahboub MR, Zolfaghari M, Ahanian A. Percutaneous nephrolithotomy of kidney calculi in horseshoe kidney. *Urol J*. 2007;4:147–150.

Dauw CA, Faerber GJ, Hollingsworth JM 3rd, et al. Wire-reinforced ureteral stents to rescue from nephrostomy tube in extrinsic ureteral obstruction. *Can J Urol*. 2015;22:7806–7810.

Davenport K, Kumar V, Collins J, et al. New ureteral stent design does not improve patient quality of life: a randomized, controlled trial. *J Urol*. 2011;185:175–178.

Davidoff R, Bellman GC. Influence of technique of percutaneous tract creation on incidence of renal hemorrhage. *J Urol*. 1997;157:1229–1231.

Davis BE, Noble MJ, Mebust WK. Use of the collings knife electrode for percutaneous access in difficult endourology cases. *J Urol*. 1991;145:257–261.

de la Rosette JJ, Laguna MP, Rassweiler JJ, et al. Training in percutaneous nephrolithotomy—a critical review. *Eur Urol*. 2008;54:994–1001.

De Sio M, Autorino R, Quattrone C, et al. Choosing the nephrostomy size after percutaneous nephrolithotomy. *World J Urol*. 2011;29:707–711.

Demirtas A, Yildirim YE, Sofikerim M, et al. Comparison of infection and urosepsis rates of ciprofloxacin and ceftriaxone prophylaxis before percutaneous nephrolithotomy: A prospective and randomised study. *ScientificWorldJournal*. 2012;2012:916381.

Desai AC, Jain S, Benway BM, et al. Splenic injury during percutaneous nephrolithotomy: a case report with novel management technique. *J Endourol*. 2010;24:541–545.

Desai M, Grover R, Manohar T, et al. Simultaneous bilateral percutaneous nephrolithotomy: a single-center experience. *J Endourol*. 2007;21:508–514.

Desai MR, Jasani A. Percutaneous nephrolithotripsy in ectopic kidneys. *J Endourol*. 2000;14:289–292.

Desai MR, Kukreja RA, Desai MM, et al. A prospective randomized comparison of type of nephrostomy drainage following percutaneous nephrostolithotomy: large bore versus small bore versus tubeless. *J Urol*. 2004;172:565–567.

Deshmukh S, Sternberg K, Hernandez N, et al. Compliance with American urological association guidelines for post-percutaneous nephrolithotomy antibiotics does not appear to increase rates of infection. *J Urol*. 2015;194:992–996.

Desoky EAE, Eliwa AM, Fawzi AM, et al. Radiologic relation of the colon to the trajectory of percutaneous nephrolithotomy access in prone versus flank free modified supine position: a prospective study of intra- and inter-individual influencing factors. *Urology*. 2018;115:71–75.

Doğan HS, Sahin A, Cetinkaya Y, et al. Antibiotic prophylaxis in percutaneous nephrolithotomy: prospective study in 81 patients. *J Endourol*. 2002;16:649–653.

Dogan HS, Guliyev F, Cetinkaya YS, et al. Importance of microbiological evaluation in management of infectious complications following percutaneous nephrolithotomy. *Int Urol Nephrol*. 2007;39:737–742.

Draga RO, Kok ET, Sorel MR, et al. Percutaneous nephrolithotomy: factors associated with fever after the first postoperative day and systemic inflammatory response syndrome. *J Endourol*. 2009;23:921–927.

Droghetti L, Giganti M, Memmo A, et al. Air embolism: diagnosis with single-photon emission tomography and successful hyperbaric oxygen therapy. *Br J Anaesth*. 2002;89:775–778.

Duty B, Conlin M, Wagner M, et al. Supracostal tubeless percutaneous nephrolithotomy: a retrospective cohort study. *J Endourol*. 2013;27:294–297.

Duvdevani M, Razvi H, Sofer M, et al. Third prize: contemporary percutaneous nephrolithotripsy: 1585 procedures in 1338 consecutive patients. *J Endourol*. 2007;21:824–829.

Edgcombe H, Carter K, Yarrow S. Anaesthesia in the prone position. *Br J Anaesth*. 2008;100:165–183.

Eisner BH, Cloyd J, Stoller ML. Lower-pole fluoroscopy-guided percutaneous renal access: which calix is posterior? *J Endourol*. 2009;23:1621–1625.

Ekelund L, Lindstedt E, Lundquist SB, et al. Studies on renal damage from percutaneous nephrolitholapaxy. *J Urol*. 1986;135:682–685.

El Tayeb MM, Borofsky MS, Lingeman JE. The circle nephrostomy tube: an attractive nephrostomy drainage system following complex percutaneous nephrolithotomy. *Urology*. 2017;103:251–255.

El Tayeb MM, Knoedler JJ, Krambeck AE, et al. Vascular complications after percutaneous nephrolithotomy: 10 years of experience. *Urology*. 2015;85:777–781.

El-Assmy AM, Shokeir AA, Mohsen T, et al. Renal access by urologist or radiologist for percutaneous nephrolithotomy—is it still an issue? *J Urol*. 2007;187:916–920.

El-Kappany HA, El-Nahas AR, Shoma AM, et al. Combination of laparoscopy and nephroscopy for treatment of stones in pelvic ectopic kidneys. *J Endourol*. 2007;21:1131–1136.

El-Nahas AR, Mansour AM, Ellaithy R, et al. Case report: conservative treatment of liver injury during percutaneous nephrolithotomy. *J Endourol*. 2008;22:1649–1652.

El-Nahas AR, Shokeir AA, El-Assmy AM, et al. Colonic perforation during percutaneous nephrolithotomy: study of risk factors. *Urology*. 2006;67:937–941.

Erturk E, Sessions A, Joseph JV. Impact of ureteral stent diameter on symptoms and tolerability. *J Endourol*. 2003;17:59–62.

Etemadian M, Maghsoudi R, Abdollahpour V, et al. Percutaneous nephrolithotomy in horseshoe kidney: our 5-year experience. *Urol J*. 2013;10:856–860.

Etemadian M, Shadpour P, Haghighi R, et al. A rare, but life-threatening complication of percutaneous nephrolithotomy: massive intra-abdominal extravasation of irrigation fluid. *Urol J*. 2012;9:614–616.

Falahatkar S, Asli MM, Emadi SA, et al. Complete supine percutaneous nephrolithotomy (csPCNL) in patients with and without a history of stone surgery: safety and effectiveness of cspcnl. *Urol Res*. 2011;39:295–301.

Falahatkar S, Enshaei A, Afsharimoghaddam A, et al. Complete supine percutaneous nephrolithotomy with lung inflation avoids the need for a supracostal puncture. *J Endourol*. 2010;24:213–218.

Fernström I, Johansson B. Percutaneous pyelolithotomy: a new extraction technique. *Scand J Urol Nephrol*. 1976;10:257–259.

Finelli A, Honey RJ. Thoracoscopy-assisted high intercostal percutaneous renal access. *J Endourol*. 2001;15:581–585.

Finney RP. Experience with new double J ureteral catheter stent. *J Urol*. 1978;120:678–681.

Fisher MB, Bianco FJ Jr, Carlin AM, et al. Biliary peritonitis complicating percutaneous nephrolithomy requiring laparoscopic cholecystectomy. *J Urol*. 2004;171:791–792.

Forrest JB, Clemens JQ, Finamore P, et al. AUA best practice statement for the prevention of deep vein thrombosis in patients undergoing urologic surgery. *J Urol*. 2009;181:1170–1177.

Francesca F, Felipetto R, Mosca F, et al. Percutaneous nephrolithotomy of transplanted kidney. *J Endourol*. 2002;16:225–227.

Frattini A, Barbieri A, Salsi P, et al. One shot: a novel method to dilate the nephrostomy access for percutaneous lithotripsy. *J Endourol*. 2001;15:919–923.

Gerspach JM, Bellman GC, Stoller ML, et al. Conservative management of colon injury following percutaneous renal surgery. *Urology*. 1997;49:831–836.

Ghai B, Dureja GP, Arvind P. Massive intraabdominal extravasation of fluid: a life threatening complication following percutaneous nephrolithotomy. *Int Urol Nephrol*. 2003;35:315–318.

Ghani KR, Andonian S, Bultitude M, et al. Percutaneous nephrolithotomy: update, trends, and future directions. *Eur Urol*. 2016;70:382–396.

Gibbons RP, Mason JT, Correa RJ Jr. Experience with indwelling silicone rubber ureteral catheters. *J Urol*. 1974;111:594–599.

Goel R, Yadav R, Gupta NP, et al. Laparoscopic assisted percutaneous nephrolithotomy (PCNL) in ectopic kidneys: two different techniques. *Int Urol Nephrol*. 2006;38:75–78.

Goger E, Guven S, Gurbuz R, et al. Management of a colon perforation during pediatric percutaneous nephrolithotomy. *J Endourol*. 2012;26:1118–1120.

Goh M, Wolf JS Jr. Almost totally tubeless percutaneous nephrostolithotomy: further evolution of the technique. *J Endourol*. 1999;13:177–180.

Goharderakhshan RZ, Schwartz BF, Rudnick DM, et al. Radially expanding single-step nephrostomy tract dilator. *Urology*. 2001;58:693–696.

Goldberg SD, Gray RR, St Louis EL, et al. Nonoperative management of complications of percutaneous renal nephrostomy. *Can J Surg*. 1989;32:192–195.

Goldsmith ZG, Oredein-McCoy O, Gerber L, et al. Emergent ureteric stent vs percutaneous nephrostomy for obstructive urolithiasis with sepsis: patterns of use and outcomes from a 15-year experience. *BJU Int*. 2013;112:E122–E128.

Golijanin D, Katz R, Verstandig A, et al. The supracostal percutaneous nephrostomy for treatment of staghorn and complex kidney stones. *J Endourol*. 1998;12:403–405.

Goodwin WE, Casey WC, Woolf W. Percutaneous trocar (needle) nephrostomy in hydronephrosis. *JAMA*. 1955;157:891–894.

Gonen M, Istanbulluoglu OM, Cicek T, et al. Balloon dilatation versus amplatz dilatation for nephrostomy tract dilatation. *J Endourol*. 2008;22:901–904.

Gonen M, Turan H, Ozturk B, et al. Factors affecting fever following percutaneous nephrolithotomy: a prospective clinical study. *J Endourol*. 2008;22:2135–2138.

Goswami AK, Shrivastava P, Mukherjee A, et al. Management of colonic perforation during percutaneous nephrolithotomy in horseshoe kidney. *J Endourol*. 2001;15:989–991.

Goyal A, Mukerjee K, Karaolides T, et al. Inferior distraction of the kidney to aid upper pole and supracostal punctures during supine percutaneous renal access. *Urol J*. 2012;9:706–710.

Grasso M, Lang G, Taylor FC. Flexible ureteroscopically assisted percutaneous renal access. *Tech Urol*. 1995;1:39–43.

Grasso M, Nord R, Bagley DH. Prone split leg and flank roll positioning: simultaneous antegrade and retrograde access to the upper urinary tract. *J Endourol*. 1993;7:307–310.

Gravas S, Montanari E, Geavlete P, et al. Postoperative infection rates in low risk patients undergoing percutaneous nephrolithotomy with and without antibiotic prophylaxis: a matched case control study. *J Urol*. 2012;188:843–847.

Green DF, Lytton B, Glickman M. Ureteropelvic junction obstruction after percutaneous nephrolithotripsy. *J Urol*.

1987;138:599–602.

Gudeman SR, Stroup SP, Durbin JM, et al. Percutaneous stone surgery using a tubeless technique with fibrin sealant: report of our first 107 cases. *BJU Int*. 2012;110:E1048–E1052.

Gupta NP, Kumar P, Aron M, et al. Bilateral simultaneous tubeless percutaneous nephrolithotomy. *Int Urol Nephrol*. 2003;35:313–314.

Gupta NP, Mishra S, Seth A, et al. Percutaneous nephrolithotomy in abnormal kidneys: single-center experience. *Urology*. 2009;73:710–714.

Gupta R, Kumar A, Kapoor R, et al. Prospective evaluation of safety and efficacy of the supracostal approach for percutaneous nephrolithotomy. *BJU Int*. 2002;90:809–813.

Gutierrez J, Smith A, Geavlete P, et al. Urinary tract infections and post-operative fever in percutaneous nephrolithotomy. *World J Urol*. 2013;31:1135–1140.

Hagspiel KD, Kandarpa K, Silverman SG. Interactive MR-guided percutaneous nephrostomy. *J Magn Reson Imaging*. 1998;8:1319–1322.

Handa A, Agarwal R, Aggarwal AN. Urinothorax: an unusual cause of pleural effusion. *Singapore Med J*. 2007;48:e289–e292.

Hatada T, Kusunoki M, Sakiyama T, et al. Hemodynamics in the prone jackknife position during surgery. *Am J Surg*. 1991;162:55–58.

Hegarty NJ, Desai MM. Percutaneous nephrolithotomy requiring multiple tracts: comparison of morbidity with single-tract procedures. *J Endourol*. 2006;20:753–760.

Heggagi MA, Karsza A, Szüle E Jr. Use of different types of dilator systems in the prevention of complications of percutaneous (PC) renal surgery. *Acta Chir Hung*. 1991;32:365–369.

Hendlin K, Korman E, Monga M. New metallic ureteral stents:

improved tensile strength and resistance to extrinsic compression. *J Endourol*. 2012;26:271–274.

Ho CH, Chen SC, Chung SD, et al. Determining the appropriate length of a double-pigtail ureteral stent by both stent configurations and related symptoms. *J Endourol*. 2008;22:1427–1431.

Honey RJ, Ghiculete D, Ray AA, et al. A randomized, double-blinded, placebo-controlled trial of intercostal nerve block after percutaneous nephrolithotomy. *J Endourol*. 2013;27:415–419.

Hopper KD, Sherman JL, Luethke JM, et al. The retrorenal colon in the supine and prone patient. *Radiology*. 1987;162:443–446.

Hopper KD, Yakes WE. The posterior intercostal approach for percutaneous renal procedures: risk of puncturing the lung, spleen, and liver as determined by CT. *AJR Am J Roentgenol*. 1990;154:115–117.

Hudnall M, Usawachintachit M, Metzler I, et al. Ultrasound guidance reduces percutaneous nephrolithotomy cost compared to fluoroscopy. *Urology*. 2017;103:52–58.

Isac W, Rizkala E, Liu X, et al. Endoscopic-guided versus fluoroscopic-guided renal access for percutaneous nephrolithotomy: a comparative analysis. *Urology*. 2013;81(2):251–256.

Istanbulluoglu MO, Kaynar M, Cicek T, et al. A new hemostatic agent (ankaferd blood Stopper®) in tubeless percutaneous nephrolithotomy: a prospective randomized study. *J Endourol*. 2013;27:1126–1130.

Jaffe RB, Middleton AW Jr. Whitaker test: differentiation of obstructive from nonobstructive uropathy. *AJR Am J Roentgenol*. 1980;134:9–15.

Jain V, Ganpule A, Vyas J, et al. Management of non-neoplastic renal hemorrhage by transarterial embolization. *Urology*.

2009;74:522–526.

Janetschek G, Kunzel KH. Percutaneous nephrolithotomy in horseshoe kidneys: applied anatomy and clinical experience. *Br J Urol*. 1988;62:117–122.

Ji W-B, Wang W-Z, Sun S, et al. Interventional therapy for renal artery pseudoaneurysms. *Asian Pac J Cancer Prev*. 2012;13:1595–1598.

Jiang H, Huang D, Yao S, et al. Improving drainage after percutaneous nephrolithotomy based on health-related quality of life: a prospective randomized study. *J Endourol*. 2017;31:1131–1138.

Joel AB, Rubenstein JN, Hsieh MH, et al. Failed percutaneous balloon dilation for renal access: incidence and risk factors. *Urology*. 2005;66:29–32.

Jones DJ, Kellett MJ, Wickham JE. Percutaneous nephrolithotomy and the solitary kidney. *J Urol*. 1991;145:477–479.

Joshi HB, Newns N, Stainthorpe A, et al. Ureteral stent symptom questionnaire: development and validation of a multidimensional quality of life measure. *J Urol*. 2003;169:1060–1064.

Joshi HB, Stainthorpe A, MacDonagh RP, et al. Indwelling ureteral stents: evaluation of symptoms, quality of life and utility. *J Urol*. 2003;169:1065–1069 [discussion 69].

Jun-Ou J, Lojanapiwat B. Supracostal access: does it affect tubeless percutaneous nephrolithotomy efficacy and safety? *Int Braz J Urol*. 2010;36:171–176.

Kachrilas S, Papatsoris A, Bach C, et al. Colon perforation during percutaneous renal surgery: a 10-year experience in a single endourology centre. *Urol Res*. 2012;40:263–268.

Kadlec AO, Ellimoottil CS, Greco KA, et al. Five-year experience with metallic stents for chronic ureteral obstruction. *J Urol*. 2013;190:937–941.

Kaler KS, Parkhomenko E, Okunohov Z, et al. Ureteroscopic holmium laser-assisted retrograde nephrostomy access: a novel approach to percutaneous stone removal. *World J Urol*. 2018;36:963–969.

Kallidonis P, Kyriazis I, Kotsiris D, et al. Papillary vs nonpapillary puncture in percutaneous nephrolithotomy: a prospective randomized trial. *J Endourol*. 2017;31:S4–S9.

Kalpee AR, Venter R, Fourie T. Single-centre comparison of a novel single-step balloon inflation device and amplatz sheath dilatation during percutaneous nephrolithotomy: A pilot study. *S Afr J Surg*. 2012;50:79–81.

Kamphuis GM, Baard J, Westendarp M, et al. Lessons learned from the CROES percutaneous nephrolithotomy global study. *World J Urol*. 2015;33:223–233.

Karami H, Jabbari M, Arbab AH. Tubeless percutaneous nephrolithotomy: 5 years of experience in 201 patients. *J Endourol*. 2007;21:1411–1413.

Karlin GS, Smith AD. Approaches to the superior calix: renal displacement technique and review of options. *J Urol*. 1989;142:774–777.

Kaye KW, Clayman RV. Tamponade nephrostomy catheter for percutaneous nephrostolithotomy. *Urology*. 1986;27:441–445.

Kekre NS, Gopalakrishnan GG, Gupta GG, et al. Supracostal approach in percutaneous nephrolithotomy: experience with 102 cases. *J Endourol*. 2001;15:789–791.

Keoghane SR, Cetti RJ, Rogers AE, et al. Blood transfusion, embolisation and nephrectomy after percutaneous nephrolithotomy (PCNL). *BJU Int*. 2012;111:628–632.

Kessaris DN, Bellman GC, Pardalidis NP, et al. Management of hemorrhage after percutaneous renal surgery. *J Urol*. 1995;153:604–608.

Kidd CR, Conlin MJ. Ureteroscopically assisted percutaneous renal access. *Urology*. 2003;61:1244–1245.

Kilic S, Altinok T, Altunoluk B, et al. Long-term effects of percutaneous nephrolithotomy on renal morphology and arterial vascular resistance as evaluated by color Doppler ultrasonography: preliminary report. *Urol Res*. 2006;34:178–183.

Kim SC, Ng JC, Matlaga BR, et al. Use of lower pole nephrostomy drainage following endorenal surgery through an upper pole access. *J Urol*. 2006;175:580–584.

Kim SC, Tinmouth WW, Kuo RL, et al. Using and choosing a nephrostomy tube after percutaneous nephrolithotomy for large or complex stone disease: a treatment strategy. *J Endourol*. 2005;19:348–352.

Klingler HC, Kramer G, Lodde M, et al. Urolithiasis in allograft kidneys. *Urology*. 2002;59:344–348.

Knudsen BE, Matsumoto ED, Chew BH, et al. A randomized, controlled, prospective study validating the acquisition of percutaneous renal collecting system access skills using a computer based hybrid virtual reality surgical simulator: phase I. *J Urol*. 2006;176:2173–2178.

Kondas J, Szentgyorgyi E, Vaczi L, et al. Splenic injury: a rare complication of percutaneous nephrolithotomy. *Int Urol Nephrol*. 1994;26:399–404.

Kontothanassis D, Bissas A. Biliary peritonitis complicating percutaneous nephrostomy. *Int Urol Nephrol*. 1997;29:529–531.

Koo KC, Park SU, Jang HS, et al. Tubeless percutaneous nephrolithotomy with non-absorbable hemostatic sealant (Quikclot®) versus nephrostomy tube placement: a propensity score-matched analysis. *Urolithiasis*. 2015;43:527–533.

Korets R, Graversen JA, Kates M, et al. Post-percutaneous nephrolithotomy systemic inflammatory response: a prospective analysis of preoperative urine, renal pelvic urine and stone cultures. *J Urol*. 2011;186:1899–1903.

Korkes F, Neto ACL, Lucio J 2nd, et al. Management of colon injury after percutaneous renal surgery. *J Endourol*. 2009;23:569–573.

Köroğlu A, Toğal T, Cicek M, et al. The effects of irrigation fluid volume and irrigation time on fluid electrolyte balance and hemodynamics in percutaneous nephrolithotripsy. *Int Urol Nephrol*. 2003;35:1–6.

Krambeck AE, LeRoy AJ, Patterson DE, et al. Long-term outcomes of percutaneous nephrolithotomy compared to shock wave lithotripsy and conservative management. *J Urol*. 2008;179:2233–2237.

Krambeck AE, LeRoy AJ, Patterson DE, et al. Percutaneous nephrolithotomy success in the transplant kidney. *J Urol*. 2008;180:2545–2549.

Kukreja R, Desai M, Patel S, et al. Factors affecting blood loss during percutaneous nephrolithotomy: prospective study. *J Endourol*. 2004;18:715–722.

Kukreja RA, Desai MR, Sabnis RB, et al. Fluid absorption during percutaneous nephrolithotomy: does it matter? *J Endourol*. 2002;16:221–224.

Kumar A, Banerjee GK, Tewari A, et al. Isolated duodenal injury during relook percutaneous nephrolithotomy. *Br J Urol*. 1994;74:382–383.

Kumar S, Bag S, Ganesamoni R, et al. Risk factors for urosepsis following percutaneous nephrolithotomy: role of 1 week of nitrofurantoin in reducing the risk of urosepsis. *Urol Res*. 2012;40:79–86.

Kumar V, Keeley FX Jr. Percutaneous nephrolithotomy: why do we use rigid dilators? *J Endourol*. 2008;22:1877–1879.

Kwon JK, Cho KS, Oh CK, et al. The beneficial effect of alpha-blockers for ureteral stent-related discomfort: systematic review and network meta-analysis for alfuzosin versus tamsulosin versus placebo. *BMC Urol*. 2015;15:55.

Labate G, Modi P, Timoney A, et al. The percutaneous nephrolithotomy global study: classification of complications. [on behalf of the; CROES PCNL Study Group de la Rosette, J] *J Endourol*. 2011;25:1275–1280.

Lallas CD, Delvecchio FC, Evans BR, et al. Management of nephropleural fistula after supracostal percutaneous nephrolithotomy. *Urology*. 2004;64:241–245.

Lamb AD, Vowler SL, Johnston R, et al. Meta-analysis showing the beneficial effect of alpha-blockers on ureteric stent discomfort. *BJU Int*. 2011;108:1894–1902.

Landman J, Venkatesh R, Lee DI, et al. Combined percutaneous and retrograde approach to staghorn calculi with application of the ureteral access sheath to facilitate percutaneous nephrolithotomy. *J Urol*. 2003;169:64–67.

Lang EK, Winer AG, Abbey-Mensah G, et al. Long-term results of metallic stents for malignant ureteral obstruction in advanced cervical carcinoma. *J Endourol*. 2013;27:646–651.

Lazarus J, Williams J. The locator: novel percutaneous nephrolithotomy apparatus to aid collecting system puncture—a preliminary report. *J Endourol*. 2011;25:747–750.

Leavitt DA, Theckumparampil N, Moreira DM, et al. Percutaneous nephrolithotomy during uninterrupted aspirin therapy in high-cardiovascular risk patients: preliminary report. *Urology*. 2014;84:1034–1038.

LeChevallier E, Siles S, Ortega JC, et al. Comparison by SPECT of renal scars after extracoporeal shock wave lithotripsy and percutaneous nephrolithotomy. *J Endourol*. 1993;7:465–467.

Lee CL, Anderson JK, Monga M. Residency training in percutaneous renal access: does it affect urological practice? *J Urol*. 2004;171:592–595.

Lee DI, Uribe C, Eichel L, et al. Sealing percutaneous nephrolithotomy tracts with gelatin matrix hemostatic sealant: initial clinical use. *J Urol*. 2004;171:575–578.

Lee JK, Kim BS, Park YK. Predictive factors for bleeding during percutaneous nephrolithotomy. *Korean J Urol*. 2013;54:448–453.

Lee WJ, Smith AD, Cubelli V, et al. Complications of percutaneous nephrolithotomy. *AJR Am J Roentgenol*. 1987;148:177–180.

LeMaitre L, Mestdagh P, Marecaux-Delomez J, et al. Percutaneous nephrostomy: placement under laser guidance and real-time CT fluoroscopy. *Eur Radiol*. 2000;10:892–895.

Lezrek M, Bazine K, Ammani A, et al. Needle renal displacement technique for the percutaneous approach to the superior calix. *J Endourol*. 2011;25:1723–1726.

Li H, Chen Y, Liu C, et al. Construction of a three-dimensional model of renal stones: comprehensive planning for percutaneous nephrolithotomy and assistance in surgery. *World J Urol*. 2013;31:1587–1592.

Li K, Liu C, Zhang X, et al. Risk factors for septic shock after mini-percutaneous nephrolithotripsy with holmium laser. *Urology*. 2013;81:1173–1176.

Li R, Louie MK, Lee HJ, et al. Prospective randomized trial of three different methods of nephrostomy tract closure after percutaneous nephrolithotripsy. *BJU Int*. 2011;107:1660–1665.

Li YT, Yang L, Xu P, et al. One-shot versus gradual dilation technique for tract creation in percutaneous nephrolithotomy: a systematic review and meta-analysis. *Urolithiasis*. 2013;41:443–448.

Liatsikos EN, Hom D, Dinlenc CZ, et al. Tail stent versus re-entry tube: a randomized comparison after percutaneous stone extraction. *Urology*. 2002;59:15–19.

Liatsikos EN, Kapoor R, Lee B, et al. Angular percutaneous renal access: multiple tracts through a single incision for staghorn calculous treatment in a single session. *Eur Urol*. 2005;48:832–837.

Liou LS, Streem SB. Long-term renal functional effects of shock wave lithotripsy, percutaneous nephrolithotomy and combination therapy: a comparative study of patients with solitary kidney. *J Urol*. 2001;166:33–37.

Lipkin ME, Mancini JG, Zilberman DE, et al. Reduced radiation exposure with the use of an air retrograde pyelogram during fluoroscopic access for percutaneous nephrolithotomy. *J Endourol*. 2011;25:563–567.

Lojanapiwat B. Percutaneous nephrolithotomy (PCNL) in kidneys with fusion and rotation anomalies. *J Med Assoc Thai*. 2005;88:1426–1429.

Lojanapiwat B, Kitirattrakarn P. Role of preoperative and intraoperative factors in mediating infection complication following percutaneous nephrolithotomy. *Urol Int*. 2011;86:448–452.

Lojanapiwat B, Prasopsuk S. Upper-pole access for percutaneous nephrolithotomy: comparison of supracostal and infracostal approaches. *J Endourol*. 2006;20:491–494.

Lojanapiwat B, Soonthornphan S, Wudhikarn S. Tubeless percutaneous nephrolithotomy in selected patients. *J Endourol*. 2001;15:711–713.

Lopes T, Sangam K, Alken P, et al. The clinical research office of the endourological society percutaneous nephrolithotomy global study: tract dilation comparisons in 5537 patients. [on behalf of the; Clinical Research Office of the Endourological Society Percutaneous Nephrolithotomy Study Group de la Rosette, J] *J Endourol*. 2011;25:755–762.

Lopes-Neto AC, de Mattos MH, da Silva MN, et al. Extensive ureteral stricture after percutaneous nephrolithotomy. *Arch*

Esp Urol. 2008;61:559–561.

Lopes-Neto AC, Tobias-Machado M, Juliano RV, et al. Duodenal damage complicating percutaneous access to kidney. *Sao Paulo Med J*. 2000;118:116–117.

Maghsoudi R, Etemadian M, Kashi AH, et al. Management of colon perforation during percutaneous nephrolithotomy: 12 years of experience in a referral center. *J Endourol*. 2017;31(10):1032–1036.

Maheshwari PN, Andankar MG, Bansal M. Nephrostomy tube after percutaneous nephrolithotomy: large bore or pigtail catheter? *J Endourol*. 2000;14:735–737.

Maheshwari PN, Bhandarkar DS, Andankar MG, et al. Laparoscopically guided transperitoneal percutaneous nephrolithotomy for calculi in pelvic ectopic kidneys. *Surg Endosc*. 2004;18:1151.

Maheshwari PN, Mane DA, Pathak AB. Management of pleural injury after percutaneous renal surgery. *J Endourol*. 2009;23:1769–1772.

Majidpour HS, Yousefinejad V. Percutaneous management of urinary calculi in horseshoe kidneys. *Urol J*. 2008;5:188–191.

Malhotra SK, Khaitan A, Goswami AK, et al. Monitoring of irrigation fluid absorption during percutaneous nephrolithotripsy: the use of 1% ethanol as a marker. *Anaesthesia*. 2001;56:1103–1106.

Mancini JG, Raymundo EM, Lipkin M, et al. Factors affecting patient radiation exposure during percutaneous nephrolithotomy. *J Urol*. 2010;184:2373–2377.

Marcovich R, Jacobson AI, Singh J, et al. No panacea for drainage after percutaneous nephrolithotomy. *J Endourol*. 2004;18:743–747.

Margulis V, Matsumoto ED, Knudsen BE, et al. Percutaneous renal collecting system access: can virtual reality shorten the learning curve? *J Urol*. 2005;173(Suppl):315.

Mariappan P, Smith G, Bariol SV, et al. Stone and pelvic urine culture and sensitivity are better than bladder urine as predictors of urosepsis following percutaneous nephrolithotomy: a prospective clinical study. *J Urol*. 2005;173:1610–1614.

Mariappan P, Smith G, Moussa SA, et al. One week of ciprofloxacin before percutaneous nephrolithotomy significantly reduces upper tract infection and urosepsis: a prospective controlled study. *BJU Int*. 2006;98:1075–1079.

Martin E, Lujan M, Paez A, et al. Puncture of the gall bladder: an unusual cause of peritonitis complicating percutaneous nephrostomy. *Br J Urol*. 1996;77:464–465.

Martin X, Murat F-J, Feitosa LC, et al. Severe bleeding after nephrolithotomy: results of hyperselective embolization. *Eur Urol*. 2000;37:136–139.

Martin X, Tajra LC, Gelet A, et al. Complete staghorn stones: percutaneous approach using one or multiple percutaneous accesses. *J Endourol*. 1999;13:367–368.

Matlaga BR, Kim SC, Watkins SL, et al. Percutaneous nephrolithotomy for ectopic kidneys: over, around, or through. *Urology*. 2006;67:513–517.

Matlaga BR, Shah OD, Zagoria RJ, et al. Computerized tomography guided access for percutaneous nephrostolithotomy. *J Urol*. 2003;170:45–47.

Maynes LJ, Desai PJ, Zuppan CW, et al. Comparison of a novel one-step percutaneous nephrolithotomy sheath with a standard two-step device. *Urology*. 2008;71:223–237.

Michel MS, Trojan L, Rassweiler JJ. Complications in percutaneous nephrolithotomy. *Eur Urol*. 2007;51:899–906.

Millard WW, Jellison FC, Tenggardjaja C, et al. Hemostatic sandwich to control percutaneous nephrolithotomy tract bleeding. *J Endourol*. 2010;24:1415–1419.

Miller J, Durack JC, Sorensen MD, et al. Renal calyceal anatomy characterization with 3-dimensional in vivo computerized tomography imaging. *J Urol*. 2013;189:562–567.

Miller NL, Matlaga BR, Handa SE, et al. The presence of horseshoe kidney does not affect the outcome of percutaneous nephrolithotomy. *J Endourol*. 2008;22:1219–1225.

Miller NL, Matlaga BR, Lingeman JE. Techniques for fluoroscopic percutaneous renal access. *J Urol*. 2007;178:15–23.

Miller RA, Kellett MJ, Wickham JE. Air embolism, a new complication of percutaneous nephrolithotomy. What are the implications? *J Urol (Paris)*. 1984;90:337–339.

Morris DB, Siegelbaum MH, Pollack HM, et al. Renoduodenal fistula in a patient with chronic nephrostomy drainage: a case report. *J Urol*. 1991;146:835–837.

Moses RA, Agarwal D, Raffin EP, et al. Postpercutaneous nephrolithotomy systemic inflammatory response syndrome is not associated with unplanned readmission. *Urology*. 2017;100:33–37.

Mouracade P, Spie R, Lang H, et al. Tubeless percutaneous nephrolithotomy: what about replacing the double-J stent with a ureteral catheter? *J Endourol*. 2008;22:273–275.

Mousavi-Bahar SH, Amir-Zargar MA, Gholamrezaie HR. Laparoscopic assisted percutaneous nephrolithotomy in ectopic pelvic kidneys. *Int J Urol*. 2008;15:276–278.

Mousavi-Bahar SH, Amirzargar MA, Rahnavardi M, et al. Percutaneous nephrolithotomy in patients with kidney malformations. *J Endourol*. 2007;21:520–524.

Mullins RJ, Dauw CA, Borofsky MS, et al. Transgluteal CT-guided percutaneous renal access for percutaneous nephrolithotomy in a pelvic horseshoe kidney. *J Endourol Case Rep*. 2015;1:27–29.

Munver R, Delvecchio FC, Newman GE, et al. Critical analysis of supracostal access for percutaneous renal surgery. *J Urol*. 2001;166:1242–1246.

Muslumanoglu AY, Tefekli A, Karadag MA, et al. Impact of percutaneous access point number and location on complication and success rates in percutaneous nephrolithotomy. *Urol Int*. 2006;77:340–346.

Muzrakchi AA, Szmigielski W, Omar AJS, et al. Is the 10th and 11th intercostal space a safe approach for percutaneous nephrostomy and nephrolithotomy? *Cardiovasc Intervent Radiol*. 2003;27:503–506.

Nadler RB, Rubenstein JN, Kim SC, et al. Percutaneous hepatolithotomy: the Northwestern University experience. *J Endourol*. 2002;16:293–297.

Nagele U, Schilling D, Anastasiadis AG, et al. Closing the tract of mini-percutaneous nephrolithotomy with gelatine matrix hemostatic sealant can replace nephrostomy tube placement. *Urology*. 2006;68:489–493.

Narasimham DL, Jacobsson B, Vijayan P, et al. Percutaneous nephrolithotomy through an intercostal approach. *Acta Radiol*. 1991;32:162–165.

Netto NR Jr, Ikonomidis J, Ikari O, et al. Comparative study of percutaneous access for staghorn calculi. *Urology*. 2005;65:659–662.

Ng CK, Yip SKH, Sim LSJ, et al. Outcome of percutaneous nephrostomy for the management of pyonephrosis. *Asian J Surg*. 2002;25:215–219.

Ni SB, Qiyin C, Tao W, et al. Tubeless percutaneous nephrolithotomy is associated with less pain and shorter hospitalization compared with standard or small bore drainage: a meta-analysis of randomized, controlled trials. *Urology*. 2011;77:1293–1298.

Noller MW, Baughman SM, Morey AF, et al. Fibrin sealant enables tubeless percutaneous stone surgery. *J Urol*. 2004;172:166–169.

Nouralizadeh A, Sichani MM, Kashi AH. Impacts of percutaneous nephrolithotomy on the estimated glomerular filtration rate during the first few days after surgery. *Urol Res*. 2011;39:129–133.

Ogan K, Corwin TS, Smith T, et al. Sensitivity of chest fluoroscopy compared with chest CT and chest radiography for diagnosing hydropneumothorax in association with percutaneous nephrostolithotomy. *Urology*. 2003;62:988–992.

Ogan K, Pearle MS. Oops we got in the chest: fluoroscopic chest tube insertion for hydrothorax after percutaneous nephrostolithotomy. *Urology*. 2002;60:1098–1099.

Okeke Z, Andonian S, Srinivasan A, et al. Cryotherapy of the nephrostomy tract: a novel technique to decrease the risk of hemorrhage after tubeless percutaneous renal surgery. *J Endourol*. 2009;23:417–420.

Oliveira M, Branco F, Martins L, et al. Percutaneous nephrolithotomy in renal transplants: a safe approach with a high stone-free rate. *Int Urol Nephrol*. 2011;43:329–335.

Ozkan D, Akkaya T, Karakoyunlu N, et al. Effect of ultrasound-guided intercostal nerve block on postoperative pain after percutaneous nephrolithotomy. *Anaesthesist*. 2013;1-6.

Ozok HU, Sagnak L, Senturk AB, et al. A comparison of metal telescopic dilators and amplatz dilators for nephrostomy tract dilation in percutaneous nephrolithotomy. *J Endourol*. 2012;26:630–634.

Park HK, Paick SH, Kim HG, et al. The impact of ureteral stent type on patient symptoms as determined by the ureteral stent symptom questionnaire: a prospective, randomized, controlled study. *J Endourol*. 2015;29:367–371.

Parsons JK, Jarrett TW, Lancini V, et al. Infundibular stenosis after percutaneous nephrolithotomy. *J Urol*. 2002;167:35–38.

Patel B, Mason BM, Hoenig DM. Retrograde endoscopic-assisted percutaneous renal access: a novel “lasso” technique to achieve rapid secure access to the collecting system. *J Endourol*. 2008;22:591–596.

Patel SR, Nakada SY. Biliary peritonitis after percutaneous nephrolithotomy: case studies and management concerns. *J Endourol*. 2010;24:1729–1731.

Pathak AS, Bellman GC. One-step percutaneous nephrolithotomy sheath versus standard two-step technique. *Urology*. 2005;66:953–957.

Patterson DE, Segura JW, LeRoy AJ, et al. The etiology and treatment of delayed bleeding following percutaneous lithotripsy. *J Urol*. 1985;133:447–451.

Pauer W, Lugmayr H. Metallic wallstents: a new therapy for extrinsic ureteral obstruction. *J Urol*. 1992;148:281–284.

Pearle MS, Pierce HL, Miller GL, et al. Optimal method of urgent decompression of the collecting system for obstruction and infection due to ureteral calculi. *J Urol*. 1998;160:1260–1264.

Penbegul N, Hatipoglu NK, Bodakci MN, et al. Role of ultrasonography in percutaneous renal access in patients with renal anatomic abnormalities. *Urology*. 2013;81:938–942.

Peterson GN, Krieger JN, Glauber DT. Anaesthetic experience with percutaneous lithotripsy. A review of potential and actual complications. *Anaesthesia*. 1985;40:460–464.

Picus D, Weyman PJ, Clayman RV, et al. Intercostal-space nephrostomy for percutaneous stone removal. *AJR Am J Roentgenol*. 1986;147:393–397.

Pietrow PK, Auge BK, Lallas CD, et al. Pain after percutaneous nephrolithotomy: impact of nephrostomy tube size. *J Endourol*. 2003;17:411–414.

Preminger GM, Assimos DG, Lingeman JE, et al. Chapter 1:

AUA guideline on management of staghorn calculi: diagnosis and treatment recommendations. *J Urol*. 2005;173:1991–2000.

Pugach JL, Moore RG, Parra RO, et al. Massive hydrothorax and hydro-abdomen complicating percutaneous nephrolithotomy. *J Urol*. 1999;162:2110.

Purkait B, Goel A. Factors affecting outcomes of percutaneous nephrolithotomy in horseshoe kidneys. *Urology*. 2015;85:1523–1524.

Radecka E, Brehmer M, Holmgren K, et al. Complications associated with percutaneous nephrolithotripsy: supra- versus subcostal access. A retrospective study. *Acta Radiol*. 2003;44:447–451.

Radecka E, Magnusson A. Complications associated with percutaneous nephrostomies. A retrospective study. *Acta Radiol*. 2004;45:184–188.

Rana AM, Mithani S. Tubeless percutaneous nephrolithotomy: call of the day. *J Endourol*. 2007;21:169–172.

Rana AM, Zaidi Z, El-Khalid S. Single-center review of fluoroscopy-guided percutaneous nephrostomy performed by urologic surgeons. *J Endourol*. 2007;21:688–691.

Rao PN, Dube DA, Weightman NC, et al. Prediction of septicemia following endourological manipulation for stones in the upper urinary tract. *J Urol*. 1991;146:955–960.

Rastinehad AR, Andonian S, Smith AD, et al. Management of hemorrhagic complications associated with percutaneous nephrolithotomy. *J Endourol*. 2009;23:1763–1767.

Ray AA, Chung DG, Honey RJ. Percutaneous nephrolithotomy in the prone and prone-flexed positions: anatomic considerations. *J Endourol*. 2009;23:1607–1614.

Ray K, Rattan S, Yohannes T. Urinothorax: unexpected cause of a pleural effusion. *Mayo Clin Proc*. 2003;78:1433–1434.

Rehman J, Chughtai B, Schulsinger D, et al. A percutaneous subcostal approach for intercostal stones. *J Endourol*. 2008;22:497–502.

Reinberg Y, Ferral H, Gonzalez R, et al. Intraureteral metallic self-expanding endoprosthesis (Wallstent) in the treatment of difficult ureteral strictures. *J Urol*. 1994;151:1619–1622.

Ricciardi S, Sallustio P, Troisi R. Life-threatening biliary complications after percutaneous nephro-lithotomy: a case report. *Acta Chir Belg*. 2007;107:336–337.

Richstone L, Reggio E, Ost MC, et al. Hemorrhage following percutaneous renal surgery: characterization of angiographic findings. *J Endourol*. 2008;22:1129–1135.

Rifaioglu MM, Berger AD, Pengune W, et al. Percutaneous management of stones in transplanted kidneys. *Urology*. 2008;72:508–512.

Rivera M, Viers B, Cockerill P, et al. Pre- and postoperative predictors of infection-related complications in patients undergoing percutaneous nephrolithotomy. *J Endourol*. 2016;30:982–986.

Robert M, Maubon A, Roux JO, et al. Direct percutaneous approach to the upper pole of the kidney: MRI anatomy with assessment of the visceral risk. *J Endourol*. 1999;13:17–20.

Rosevear HM, Kim SP, Wenzler DL, et al. Retrograde ureteral stents for extrinsic ureteral obstruction: 9 years of experience at the University of Michigan. *Urology*. 2007;70:846–850.

Rusnak B, Castañeda-Zúñiga W, Kotula F, et al. An improved dilator system for percutaneous nephrostomies. *Radiology*. 1982;144:174.

Safak M, Gogus C, Soygur T. Nephrostomy tract dilation using a balloon dilator in percutaneous renal surgery: experience with 95 cases and comparison with the fascial dilator system. *Urol Int*. 2003;71:382–384.

Sampaio FJB, Mandarim-de-Lacerda CA. 3-Dimensional and radiological pelviocaliceal anatomy for endourology. *J Urol*.

1988;140:1352–1355.

Santiago L, Bellman GC, Murphy J, et al. Small bowel and splenic injury during percutaneous renal surgery. *J Urol*. 1998;159:2071–2072.

Santos ARD, Rocha Filho DCB, Tajra LCF. Management of lithiasis in pelvic kidney through laparoscopy-guided percutaneous transperitoneal nephrolithotripsy. *Int Braz J Urol*. 2004;30:32–34.

Saxby MF. Biliary peritonitis following percutaneous nephrolithotomy. *Br J Urol*. 1996;77:465–466.

Saxby MF. Effects of percutaneous nephrolithotomy and extracorporeal shock wave lithotripsy on renal function and prostaglandin excretion. *Scand J Urol Nephrol*. 1997;32:141–144.

Schaeffer AJ, Handa SE, Lingeman JE, et al. Transsplenic percutaneous nephrolithotomy. *J Endourol*. 2008;22:2481–2484.

Scoffone CM, Cracco CM, Cossu M, et al. Endoscopic combined intrarenal surgery in Galdakao-modified supine valdivia position: a new standard for percutaneous nephrolithotomy? *Eur Urol*. 2008;54:1393–1403.

Segura JW, Patterson DE, LeRoy AJ, et al. Percutaneous removal of kidney stones: review of 1000 cases. *J Urol*. 1985;134:1077–1081.

Seitz C, Desai M, Häcker A, et al. Incidence, prevention, and management of complications following percutaneous nephrolitholapaxy. *Eur Urol*. 2012;61:146–158.

Seldinger S-I. Catheter replacement of the needle in percutaneous arteriography; a new technique. *Acta Radiol*. 1953;39:368–376.

Seyrek M, Binbay M, Yuruk E, et al. Perioperative prophylaxis for percutaneous nephrolithotomy: randomized study concerning the drug and dosage. *J Endourol*. 2012;26:1431–

1436.

Shaban A, Kodera A, El Ghoneimy MN, et al. Safety and efficacy of supracostal access in percutaneous renal surgery. *J Endourol*. 2008;22:29–34.

Shah HN, Hegde SS, Mahajan AP, et al. Splenic injury: rare complication of percutaneous nephrolithotomy: report of two cases with review of literature. *J Endourol*. 2007;21:919–922.

Shah HN, Hegde SS, Shah JN, et al. Safety and efficacy of supracostal access in tubeless percutaneous nephrolithotomy. *J Endourol*. 2006;20:1016–1021.

Shah HN, Kausik VB, Hegde SS, et al. Safety and efficacy of bilateral simultaneous tubeless percutaneous nephrolithotomy. *Urology*. 2005;66:500–504.

Sharifiaghdas F, Tabibi A, Nouralizadeh A, et al. Our experience with totally ultrasonography-guided percutaneous nephrolithotomy in children. *J Endourol*. 2015 [Epub ahead of print].

Sharma G, Jangid DK, Yadav SS, et al. Retro-renal colon: role in percutaneous access. *Urolithiasis*. 2015;43:171–175.

Shen CH, Cheng MC, Lin CT, et al. Innovative metal dilators for percutaneous nephrostomy tract: report on 546 cases. *Urology*. 2007;70:418–421.

Shen P, Liu Y, Wang J. Nephrostomy tube-free versus nephrostomy tube for renal drainage after percutaneous nephrolithotomy: a systematic review and meta-analysis. *Urol Int*. 2012;88:298–306.

Shermak M, Shoo B, Deune EG. Prone positioning precautions in plastic surgery. *Plast Reconstr Surg*. 2006;117:1584–1588.

Shleyfer E, Nevzorov R, Jotkowitz AB, et al. Urinothorax: an unexpected cause of pleural effusion. *Eur J Intern Med*. 2006;17:300–302.

Shokeir AA, El-Nahas AR, Shoma AM, et al. Percutaneous nephrolithotomy in treatment of large stones within horseshoe kidneys. *Urology*. 2004;64:426–429.

Shpall AI, Parekh AR, Bellman GC. Tubeless percutaneous nephrolithotomy with antegrade stent tether: clinical experience. *J Endourol*. 2007;21:973–976.

Siev M, Motamedinia P, Leavitt D, et al. Does peak inspiratory pressure increase in the prone position? An analysis related to body mass index. *J Urol*. 2015;194:1302–1306.

Singh I, Saran RN, Jain M. Does sealing of the tract with absorbable gelatin (Spongostan) facilitate tubeless PCNL? A prospective study. *J Endourol*. 2008;22:2485–2493.

Sivalingam S, Tamm-Daniels I, Nakada SY. Office-based ureteral stent placement under local anesthesia for obstructing stones is safe and efficacious. *Urology*. 2013;81:498–502.

Skoog SJ, Reed MD, Gaudier FA Jr, et al. The posterolateral and the retrorenal colon: implication in percutaneous stone extraction. *J Urol*. 1985;134:110–112.

Song SH, Hong B, Park HK, et al. Paradoxical air embolism during percutaneous nephrolithotomy: a case report. *J Korean Med Sci*. 2007;22:1071–1073.

Sountoulides PG, Kaufmann OG, Louie MK, et al. Endoscopy-guided percutaneous nephrostolithotomy: benefits of ureteroscopic access and therapy. *J Endourol*. 2009;23(10):1649–1654.

Spann A, Poteet J, Hyatt D, et al. Safe and effective obtainment of access for percutaneous nephrolithotomy by urologists: the Louisiana State University experience. *J Endourol*. 2011;25:1421–1425.

Speed JM, Wang Y, Leow JJ, et al. The effect of physician specialty obtaining access for percutaneous nephrolithotomy on perioperative costs and outcomes. *J Endourol*. 2017;31:1152–1156.

Sprouse LR 2nd, Hamilton IN Jr. The endovascular treatment of a renal arteriovenous fistula: placement of a covered stent. *J*

Vasc Surg. 2002;36:1066–1068.

Srivastava A, Gupta P, Chaturvedi S, et al. Percutaneous nephrolithotomy in ectopically located kidneys and in patients with musculoskeletal deformities. *Urol Int*. 2010;85:37–41.

Srivastava A, Singh S, Dhayal IR, et al. A prospective randomized study comparing the four tract dilation methods of percutaneous nephrolithotomy. *World J Urol*. 2017;35:803–807.

Stern J, Zeltser IS, Pearle MS. Percutaneous renal access simulators. *J Endourol*. 2007;21:270–273.

Stoller ML, Wolf JS Jr, St Lezin MA. Estimated blood loss and transfusion rates associated with percutaneous nephrolithotomy. *J Urol*. 1994;152:1977–1981.

Stravodimos KG, Adamis S, Tyritzis S, et al. Renal transplant lithiasis: analysis of our series and review of the literature. *J Endourol*. 2012;26:38–44.

Sukumar S, Nair B, Kumar PG, et al. Supracostal access for percutaneous nephrolithotomy: less morbid, more effective. *Int Urol Nephrol*. 2008;40:263–267.

Symons SJ, Ramachandran A, Kurien A, et al. Urolithiasis in the horseshoe kidney: a single-centre experience. *BJU Int*. 2008;102:1676–1680.

Tabibi A, Akhavizadegan H, Nouri-Mahdavi K, et al. Percutaneous nephrolithotomy with and without retrograde pyelography: a randomized clinical trial. *Int Braz J Urol*. 2007;33:19–24.

Tahmaz L, Ozgok Y, Zor M, et al. Laparoscopy-assisted tubeless percutaneous nephrolithotomy in previously operated ectopic pelvic kidney with fragmented J–J stent. *Urol Res*. 2009;37:257–260.

Tanriverdi O, Boylu U, Kendirci M, et al. The learning curve in the training of percutaneous nephrolithotomy. *Eur Urol*.

2007;52:206–211.

Tefekli A, Altunrende F, Tepeler K, et al. Tubeless percutaneous nephrolithotomy in selected patients: a prospective randomized comparison. *Int Urol Nephrol*. 2007;39:57–63.

Tepeler A, Armağan A, Akman T, et al. Impact of percutaneous renal access technique on outcomes of percutaneous nephrolithotomy. *J Endourol*. 2012;26:828–833.

Tepeler A, Silay MS, Armagan A, et al. Laparoscopic-assisted “microperc” of a stone in a pelvic kidney of a 3-year-old girl. *J Laparoendosc Adv Surg Tech A*. 2013;23:174–176.

Thanos L, Mylona S, Stroumpouli E, et al. Percutaneous CT-guided nephrostomy: a safe and quick alternative method in management of obstructive and nonobstructive uropathy. *J Endourol*. 2006;20:486–490.

Thomas AA, Pierce G, Walsh RM, et al. Splenic injury during percutaneous nephrolithotomy. *JSLS*. 2009;13:233.

Tomaszewski JJ, Ortiz TD, Gayed BA, et al. Renal access by urologist or radiologist during percutaneous nephrolithotomy. *J Endourol*. 2010;24:1733–1737.

Tomaszewski JJ, Smaldone MC, Schuster T, et al. Factors affecting blood loss during percutaneous nephrolithotomy using balloon dilation in a large contemporary series. *J Endourol*. 2010;24:207–211.

Traxer O. Management of injury to the bowel during percutaneous stone removal. *J Endourol*. 2009;23:1777–1780.

Troxel SA, Low RK. Renal intrapelvic pressure during percutaneous nephrolithotomy and its correlation with the development of postoperative fever. *J Urol*. 2002;168:1348–1351.

Troxel SA, Low RK, Das S. Extraperitoneal laparoscopy-assisted percutaneous nephrolithotomy in a left pelvic kidney. *J Endourol*. 2002;16:655–657.

Tulloch WS. Restoration of the continuity of the ureter by means of polythene tubing. *Br J Urol*. 1952;24:42–45.

Turillazzi E, Pomara C, Bisceglia R, et al. Vascular air embolism complicating percutaneous nephrolithotomy: medical malpractice or fatal unforeseeable complication? *Urology*. 2009;73:e1–e4.

Tuzel E, Aktepe OC, Akdogan B. Prospective comparative study of two protocols of antibiotic prophylaxis in percutaneous nephrolithotomy. *J Endourol*. 2013;27:172–176.

Usawachintachit M, Masic S, Chang HC, et al. Ultrasound guidance to assist percutaneous nephrolithotomy reduces radiation exposure in obese patients. *Urology*. 2016;98:32–38.

Valdivia JG, Scarpa RM, Duvdevani M, et al. Supine versus prone position during percutaneous nephrolithotomy: a report from the clinical research office of the endourological society percutaneous nephrolithotomy global study. *J Endourol*. 2011;25:1619–1625.

Valdivia Uria JG, Lachares Santamaria E, Villarroya Rodriguez S, et al. Percutaneous nephrolithectomy: simplified technic (preliminary report). *Arch Esp Urol*. 1987;40:177–180.

Varkarakis J, Su LM, Hsu TH. Air embolism from pneumopyelography. *J Urol*. 2003;169:267.

Veneziano D, Smith A, Reihsen T, et al. The SimPORTAL fluoro-less C-arm trainer: an innovative device for percutaneous kidney access. *J Endourol*. 2015;29:240–245.

Verrier C, Bessede T, Hajj P, et al. Decrease in and management of urolithiasis after kidney transplantation. *J Urol*. 2012;187:1651–1655.

Viola D, Anagnostou T, Thompson TJ, et al. Sixteen years of experience with stone management in horseshoe kidneys. *Urol Int*. 2007;78:214–218.

Wah TM, Weston MJ, Irving HC. Percutaneous nephrostomy insertion: outcome data from a prospective multi-operator study at a UK training centre. *Clin Radiol*. 2004;59:255–261.

Wang J, Zhang C, Tan D, et al. The effect of local anesthetic infiltration around nephrostomy tract on postoperative pain control after percutaneous nephrolithotomy: a systematic review and meta-analysis. *Urol Int*. 2016;97:125–133.

Wang J, Zhang C, Tan G, et al. The use of adjunctive hemostatic agents in tubeless percutaneous nephrolithotomy: a meta-analysis. *Urolithiasis*. 2014;42:509–517.

Watterson JD, Cook A, Sahajpal R, et al. Percutaneous nephrolithotomy of a pelvic kidney: a posterior approach through the greater sciatic foramen. *J Urol*. 2001;166:209–210.

Watterson JD, Soon S, Jana K. Access related complications during percutaneous nephrolithotomy: urology versus radiology at a single academic institution. *J Urol*. 2006;176:142–145.

Weir MJ, Honey JD. Complete infundibular obliteration following percutaneous nephrolithotomy. *J Urol*. 1999;161:1274–1275.

Wezel F, Mamoulakis C, Rioja J, et al. Two contemporary series of percutaneous tract dilation for percutaneous nephrolithotomy. *J Endourol*. 2009;23:1655–1661.

Wickham JE, Miller RA, Kellett MJ, et al. Percutaneous nephrolithotomy: one stage or two? *Br J Urol*. 1984;56:582–585.

Williams SK, Bird VG, Maurici G, et al. Borrowing from interventional radiology: novel technique to dilate scarred nephrostomy tract. *Urology*. 2008;72:1156–1158.

Winer AG, Hyams ES, Shah O. Small bowel injury during percutaneous nephrostomy tube placement causing small bowel obstruction. *Can J Urol*. 2009;16:4950.

Winfield HN, Weyman P, Clayman RV. Percutaneous nephrostolithotomy: complications of premature nephrostomy tube removal. *J Urol*. 1986;136:77–79.

Winfree CJ, Kline DG. Intraoperative positioning nerve injuries. *Surg Neurol*. 2005;63:5–18.

Wolf JS Jr, Bennett CJ, Dmochowski RR, et al. Best practice policy statement on urologic surgery antimicrobial prophylaxis. *J Urol*. 2008;179:1379–1390.

Wong C, Leveillee RJ. Single upper-pole percutaneous access for treatment of > or = 5-cm complex branched staghorn calculi: is shockwave lithotripsy necessary? *J Endourol*. 2002;16:477–481.

Wu W, Zhao Z, Zhu H, et al. Safety and efficacy of minimally invasive percutaneous nephrolithotomy in treatment of calculi in horseshoe kidneys. *J Endourol*. 2014;28:926–929.

Wyatt J, Kolettis PN, Burns JR. Treatment outcomes for percutaneous nephrolithotomy in renal allografts. *J Endourol*. 2009;23:1821–1824.

Xiao B, Hu W, Zhang X, et al. Ultrasound-guided mini-percutaneous nephrolithotomy in patients aged less than 3 years: the largest reported single-center experience in China. *Urolithiasis*. 2016;44:179–183.

Xun Y, Wang Q, Hu H, et al. Tubeless versus standard percutaneous nephrolithotomy: an update meta-analysis. *BMC Urol*. 2017;17:102.

Yadav R, Aron M, Gupta NP, et al. Safety of supracostal punctures for percutaneous renal surgery. *Int J Urol*. 2006;13:1267–1270.

Yadav R, Gupta NP, Gamanagatti S, et al. Supra-twelfth supracostal access: when and where to puncture? *J Endourol*. 2008;22:1209–1212.

Yakoubi R, Lemdani M, Monga M, et al. Is there a role for alpha-blockers in ureteral stent related symptoms? A systematic review and meta-analysis. *J Urol*. 2011;186:928–934.

Young AT, Hunter DW, Castaneda-Zuniga WR, et al. Percutaneous extraction of urinary calculi: use of the intercostal approach. *Radiology*. 1985;154:633–638.

Yu C, Xu Z, Long W, et al. Hemostatic agents used for nephrostomy tract closure after tubeless PCNL: a systematic review and meta-analysis. *Urolithiasis*. 2014;42:445–453.

Yuan HJ, Yang DD, Cui YS, et al. Minimally invasive treatment of renal transplant nephrolithiasis. *World J Urol*. 2015;33:2079–2085.

Zeng G, Zhao Z, Wan S, et al. Failure of initial renal arterial embolization for severe post-percutaneous nephrolithotomy hemorrhage: a multicenter study of risk factors. *J Urol*. 2013;190:2133–2138.

Zhang Y, Yu CF, Liu JS, et al. Training for percutaneous renal access on a virtual reality simulator. *Chin Med J*. 2013;126:1528–1531.

Zhao PT, Hoenig DM, Smith AD, et al. A randomized controlled comparison of nephrostomy drainage vs ureteral stent following percutaneous nephrolithotomy using the Wisconsin stone QOL. *J Endourol*. 2016;30:1275–1284.

Zhong Q, Zheng C, Mo J, et al. Total tubeless versus standard percutaneous nephrolithotomy: a meta-analysis. *J Endourol*. 2013;27:420–426.

Zhou L, Cai X, Li H, et al. Effects of alpha-blockers, antimuscarinics, or combination therapy in relieving ureteral stent-related symptoms: a meta-analysis. *J Endourol*. 2015;29:650–656.

Ziaee SA, Sarhangnejad R, Abolghasemi H, et al. Autologous fibrin sealant in tubeless percutaneous nephrolithotomy; a prospective study. *Urol J*. 2013;10:999–1003.

Zimskind PD, Fetter TR, Wilkerson JL. Clinical use of long-term indwelling silicone rubber ureteral splints inserted cystoscopically. *J Urol*. 1967;97:840–844.

13

Principles of Urologic Endoscopy

Brian Duty MD, Michael Joseph Conlin MD, MCR

Introduction

The development of endoscopic tools and techniques has transformed many areas of medical and surgical care—perhaps none more than urology. Bladder outlet obstruction, urothelial tumors, ureteral obstruction, and nephrolithiasis are just a few of the urologic conditions revolutionized by endoscopic procedures.

This chapter will highlight significant events in the history of modern endoscope development, then describe contemporary video-endoscopic equipment. We will then explain in detail the indications, patient preparation, and techniques of cystourethroscopy and ureteropyeloscopy.

History of Endoscopy

Attempts to look inside the human body date back to antiquity. Little progress was made until 1806, when Philipp Bozzini developed the first “modern” endoscope (Engel, 2003). The Lichtleiter or “Light Conductor” used angled mirrors to conduct candlelight from a sharkskin-covered box into the body through aluminum tubing. In 1853, the French urologist Antonin Jean Desormeaux introduced a smaller profile endoscope with improved mirrors that utilized a kerosene lamp for illumination (Shah, 2002). He excised a urethral papilloma through this instrument, and he became the first individual to perform a therapeutic endoscopic procedure.

In 1877, Max Nitze moved the source of illumination (water-cooled electric platinum filament) to the end of the instrument and utilized a series of optical lenses placed at precise distances along the length of a hollow, air-filled scope to conduct and magnify the image (Herr, 2006). Few design improvements occurred—save development of the Amici prism in 1906, which allowed 90-degree offset images to maintain correct orientation—until 1966, when Harold Hopkins developed his rod-lens system (Gow, 1998). By abandoning hollow-chamber optical relay lenses for a series of glass rods with only short gaps of air between them, Hopkins was able to improve light transmission and decrease scope size. Hopkins’ rod-lens paved the way for contemporary rigid cystoscopes and the first rigid ureteroscope in 1979 (Lyon et al., 1979).

In 1854, John Tyndall demonstrated that light could travel through a curved stream of water by internal reflection (Whewell et al., 1854). This finding led to drawing molten glass into flexible, small-diameter fibers for light transmission. The development of fiber optics made possible the creation of flexible endoscopes. In 1964, Marshall reported the first application of flexible ureteroscopy (Marshall, 1964). However, the utility of flexible ureteroscopes was severely limited until the addition of a working channel and active tip deflection in the early 1980s (Bagley et al., 1983).

Although still widely used, fiber-optic endoscopes are fragile and have limited optical resolution. In 1970, Boyle and Smith developed the charge-coupled device (CCD), a sensor with the ability to convert photons into a digital image (Samplaski and Jones, 2009). Technical advances over the past three decades allowed placement of CCD sensors onto the distal tip of scopes. Introduced in 2005, the ACMI DCN-2010 flexible cystoscope was the first commercially available digital endoscope (Natalin and Landman, 2009). **Compared with rod-lens and fiber-optic bundle systems, digital sensor technology offers improved image resolution and durability without the need for a separate light cable and camera** (Quayle et al., 2005).

Basic Equipment and Video-Endoscopic Systems

At minimum, cystourethroscopy requires irrigation fluid, a light source, and an endoscope. Irrigation fluid should be normal saline routinely or a solution free from electrolytes such as glycine or mannitol when *monopolar* electrocautery is required. Using *bipolar* electrocautery permits the use of normal saline for transurethral surgical procedures, avoiding the potential complications of these other solutions. Sterile water should be avoided because of the small risk for absorption, electrolyte disturbance, and hemolysis.

A high-intensity xenon or halogen external light source delivers white light through a fiber-optic cable and endoscope to the field of view. Modern light source units feature light-level detection and automatic light-output adjustment to provide constant illumination.

First introduced into urologic practice in 2007, narrow-band imaging utilizes only blue (415 nm) and green (540 nm) wavelengths to image the urothelium (Bryan et al., 2008). These wavelengths are strongly absorbed by hemoglobin, enhancing the visibility of urothelial capillaries, small papillary lesions, and carcinoma in-situ. A meta-analysis of 8 studies including 1022 patients found that narrow-band imaging improves detection accuracy of noninvasive lesions, including carcinoma in situ (Zheng et al., 2012). These findings were supported by a more recent randomized multicenter study, which found narrow-band imaging to be superior to white-light cystoscopy for detecting non–muscle-invasive bladder cancer (Ye et al., 2015).

Although it is possible to view the image through the optical eyepiece of the endoscope, a camera is commonly used that allows the image to be displayed on a monitor that is part of a dedicated fixed or mobile video-endoscopic tower (Fig. 13.1). Video-endoscopic units have several advantages including better visualization, which enhances patient safety and surgical training; decreased risk for bodily fluid exposure; and improved surgeon ergonomics.



FIG. 13.1 Videoendoscopic unit consisting of a fixed tower, monitor, light source, image processor, video-recording device, and printer.

Traditional video-endoscopic systems consist of a light source, endoscope camera, image processor/recorder, and monitor. Newer digital endoscopes eliminate the need for an external camera and incorporate the light source and video cable into a single, built-in housing (Fig. 13.2). In the traditional system, a series of glass rods or fiber-optic bundles transmits the endoscopic image to the eyepiece. The external camera's CCD chip receives the optical image and produces an electrical charge (voltage waveform). The unit's video processor then converts the analog voltage waveform into a digital video signal that is sent to the monitor. In contrast, digital endoscope systems have the CCD chip located at the distal end of the endoscope. The image is immediately converted into an electrical signal that is managed by the video processor without the need for internal optics or an external CCD camera.

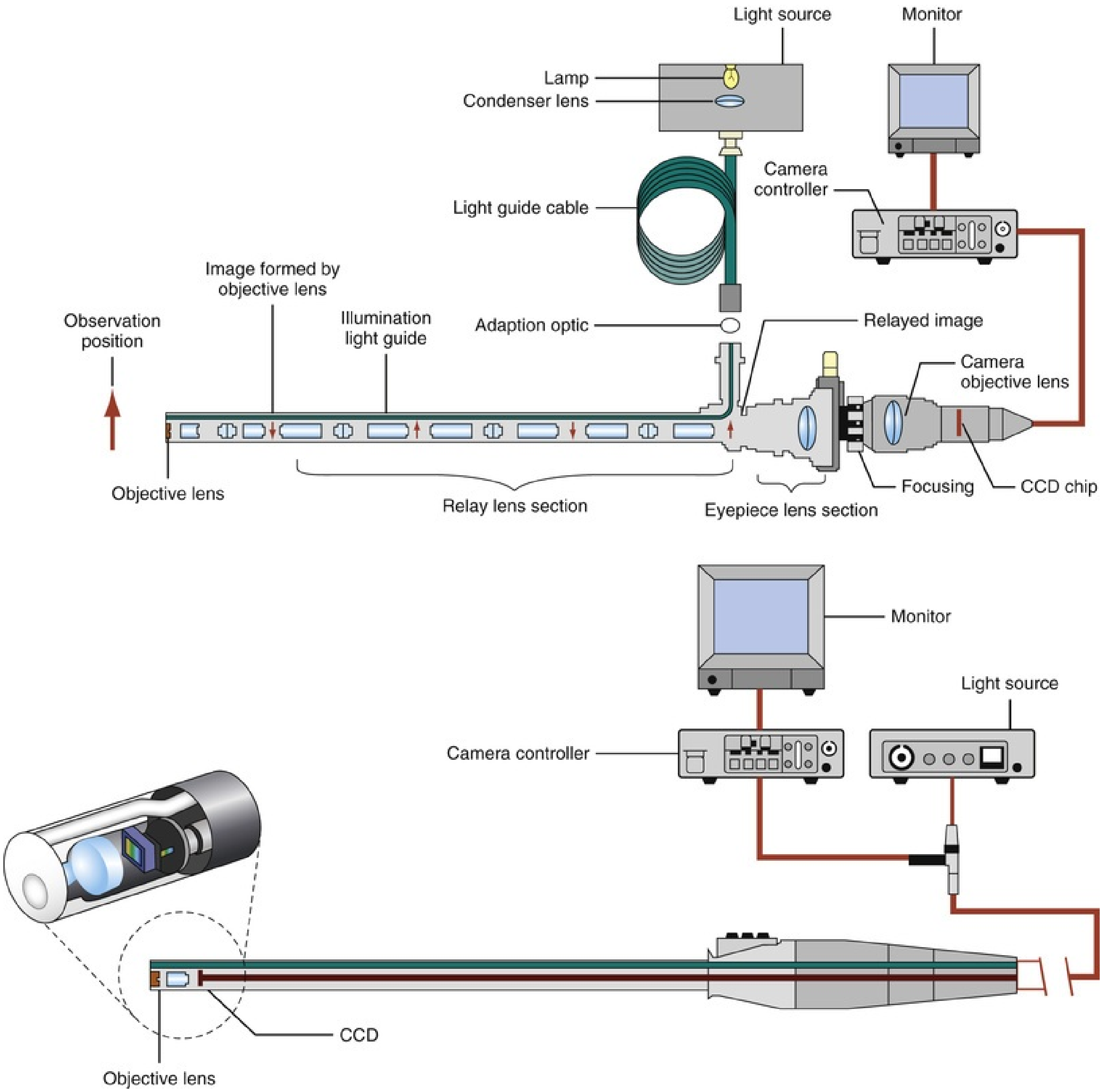
Light source
Monitor
Lamp
Condenser lens
Camera controller
Light guide cable
Image formed by objective lens
Observation position
Illumination light guide
Adaption optic
Relayed image
Camera objective lens
Objective lens
Relay lens section
Eyepiece lens section
Focusing
CCD chip
Monitor
Light source
Camera controller
CCD
Objective lens

FIG. 13.2 Traditional rod lens optical system compared with digital sensor videoendoscopes. *CCD,* Charge-coupled device. (Photo courtesy of Olympus, Center Valley, PA.)

Cystourethroscopy

Indications

Cystourethroscopy is the most common office-based procedure in urology (Lee et al., 2002). Routinely performed in both the office and operating room, cystourethroscopy provides direct visualization of the urethra and bladder. Table 13.1 summarizes the indications for office-based cystourethroscopy. Most are for diagnostic purposes, but transurethral therapeutic procedures may also be performed. A frequent reason for cystourethroscopy is the evaluation of microscopic or gross hematuria. Besides direct inspection of the lower urinary tract, cystourethroscopy permits collection of cytologic specimens and retrograde pyelography in patients who are not candidates for intravenous contrast.

TABLE 13.1

Indications for Outpatient Cystourethroscopy

Hematuria	Gross
	Microscopic
Malignancy	Urethral cancer
	Bladder cancer
	Atypical cytology
	Upper tract transitional cell carcinoma surveillance
Lower Urinary Tract Symptoms	Recurrent urinary tract infections Obstructive voiding symptoms
	Irritative voiding symptoms
	Urinary incontinence
	Chronic pelvic pain syndrome
	Urethral stricture disease
Miscellaneous	Trauma
	Bladder abnormalities seen on imaging
	Removal of foreign bodies and small bladder stones
	Hematospermia
	Obstructive azoospermia

Urothelial carcinoma surveillance is another routine indication for cystourethroscopy. Small urothelial lesions may be biopsied and fulgurated in clinic. Upper tract surveillance may be accomplished by selective ureteral catheterization with retrograde pyelography, upper-tract washes for cytology, and brush biopsies for histologic evaluation.

Cystoscopy may be used in the assessment of lower urinary tract complaints such as recurrent infections, voiding dysfunction, and chronic pelvic pain. In select cases, urethral strictures, bladder stones, and foreign bodies may be treated in the office. Ureteral stents can also be placed or exchanged in clinic with fluoroscopic assistance.

Equipment

Cystourethroscopes are available in a variety of sizes and come in both rigid and flexible models. Sizes are expressed in French (Fr) gauge. **Devised by French instrument designer Joseph-Frédéric-Benoît Charrière (1803 to 1876), a 1-Fr device has a circumference of $\frac{1}{3}$ of a millimeter** (Osborn and Baron, 2006).

Rigid cystoscopes utilize the Hopkins rod-lens optical system, which provides improved optical clarity compared with the fiber-optic bundles used in flexible endoscopes (Lyon et al., 1979). Rigid cystourethroscopes have larger working channels than flexible scopes, resulting in increased irrigation flow and the ability to use a greater variety of working instruments. Rigid scopes are also easier to control with one hand, freeing the surgeon's second hand to manipulate ancillary tools.

In contrast, the smaller size of flexible cystourethroscopes improves patient comfort, making them ideal for office-based procedures. Endoscope passage does not require the patient to be in the frog-leg or lithotomy position. Their active tip deflection makes it easier to thoroughly inspect the bladder and negotiate an elevated bladder neck or median lobe of the prostate.

Rigid Cystourethroscopes

Rigid cystourethroscopes are manufactured in sets consisting of an optical lens, bridge, sheath, and obturator (Fig. 13.3). Configurations differ by vendor (Table 13.2). Optical lenses come with tip angles ranging from 0 to 120 degrees. Visualization of the urethra is best performed with a 0- or 12-degree lens. A 25- or 30-degree lens is commonly used for therapeutic purposes. A 70- or 120-degree lens may be required to thoroughly inspect the anterior and inferolateral walls, dome, and neck of the bladder.

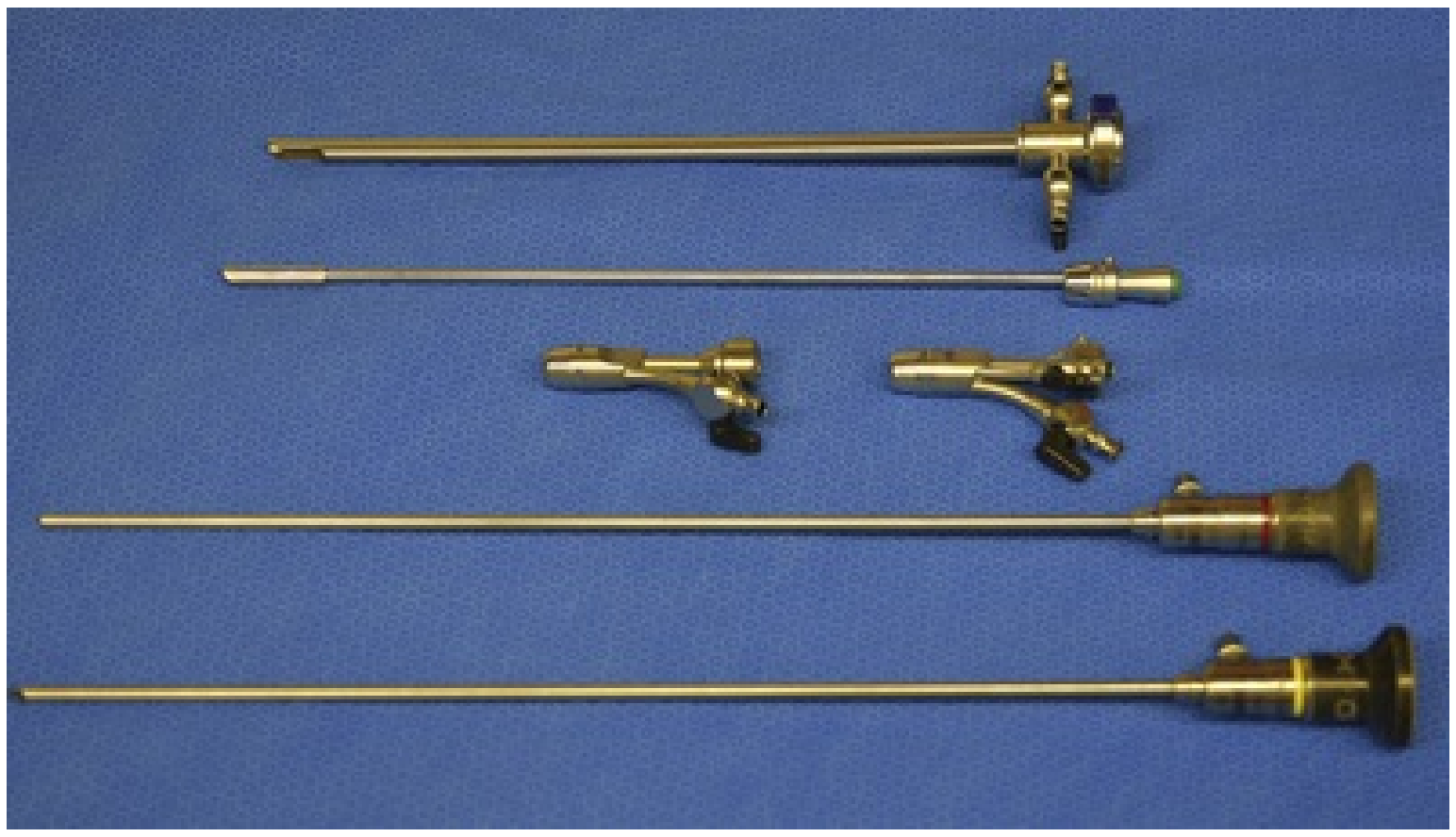

FIG. 13.3 Rigid cystourethroscope set consisting of sheath, obturator, bridges, and lenses *(from top to bottom)*.

TABLE 13.2

Adult Rigid Cytourethroscopes

	KARL STORZ	OLYMPUS	GYRUS/ACMI	WOLF
Lenses	0, 12, 30, 70, 120 degrees • Diameter: 4 mm • Length: 30 cm	0, 12, 30, 70, 110 degrees • Diameter: 4 mm • Length: 28 cm	0, 12, 30, 70, 110 degrees • Diameter: 4 mm • Length: 28 cm	0, 12, 30, 70 degrees • Diameter: 4 mm • Length: 30 cm
Bridges	Telescopic • Diagnostic • Single- and dual-channel	Telescopic • Diagnostic • Single- and dual-channel	Telescopic • Diagnostic • Single- and dual-channel	Telescopic • Diagnostic • Single- and dual-channel
	Deflecting (Albarran lever) • Single- and dual-channel	Deflecting (Albarran lever) • Single- and dual-channel	Deflecting (Albarran lever) • Single- and dual-channel	Deflecting (Albarran lever) • Single- and dual-channel
Sheaths/Working Channels		15 Fr • SB: none • DB: none		16 Fr • SB: 5 Fr • DB: none
	17 Fr • SB: 5 Fr • DB: 5 Fr × 1	17 Fr • SB: none • DB: none	17 Fr • SB: 5 Fr • DB: 4 Fr × 2	17.5 Fr • SB: 5 Fr • DB: 4 Fr × 2
	19 Fr • SB: 6 Fr	19.8 Fr • SB: 6 Fr		19.5 Fr • SB: 7 Fr

	• DB: 5 Fr × 2	• DB: 5 Fr, 6 Fr		• DB: 5 Fr × 2
	20 Fr • SB: 7 Fr • DB: 6 Fr × 2	21 Fr • SB: 8 Fr • DB: 6 Fr, 7 Fr	21 Fr • SB: 9 Fr • DB: 6 Fr × 2	21 Fr • SB: 10 Fr • DB: 6 Fr × 2
	22 Fr • SB: 10 Fr • DB: 7 Fr × 2	22.5 Fr • SB: 10 Fr • DB: 8 Fr × 2	23 Fr • SB: 10 Fr • DB: 8 Fr × 2	23 Fr • SB: 12 Fr • DB: 7 Fr × 2
	25 Fr • SB: 12 Fr • DB: 8 Fr × 2	25 Fr • SB: 12 Fr • DB: 8 Fr × 2	25 Fr • SB: 12 Fr • DB: 8 Fr × 2	25 Fr • SB: 15 Fr • DB: none

Fr, French; *SB,* single bridge; *DB,* dual bridge.

The bridge connects the optical lens to the sheath. Diagnostic bridges do not have a working channel. Therapeutic bridges have one or two working channels. Patients with an elevated bladder neck, large median lobe of the prostate, or ureteroneocystostomy may require use of an Albarran's bridge. This specialized bridge contains a lever that deflects wires and catheters passed through the working channel to facilitate ureteral orifice canalization (Fig. 13.4).



FIG. 13.4 Albarran's bridge, which is used to deflect wires and catheters passed through the rigid cystoscope working channel.

Cystourethroscope sheaths come in a variety of sizes. Most have markings indicating the size of the sheath and associated working channels (Fig. 13.5). Smaller sheaths (15 and 17 Fr) are ideal for diagnostic cystoscopy, with larger models being used for therapeutic procedures requiring improved irrigant flow and larger working channels. Each sheath has an associated obturator that blunts the distal end of the sheath for passage into the bladder without visual assistance. In most cases, "blind" endoscope passage should only be performed in women.



FIG. 13.5 Markings on rigid cystoscope sheath. The largest number on the base of the scope indicates the outer diameter (17.5 Fr). The numbers on the side of the sheath indicate the maximum working channel size when a dual bridge is used (4 Fr for both lumens) or when a single bridge is employed (5 Fr).

Flexible Cystourethroscopes

Flexible cystourethroscopes range between 16 and 17 Fr. Models differ with regard to tip deflection, direction of view, field of view, working channel size, illumination, and optics (Table 13.3). Most models have an "inline" eyepiece lens and produce a field of view of approximately 120 degrees. Tip deflection ranges between 120 and 210 degrees and is either intuitive (same direction as lever deflection) or counterintuitive (opposite direction of lever deflection). Irrigation and instrument passage occurs through the same working channel. Photodynamic and narrow-band imaging capabilities are increasingly common.

TABLE 13.3

Flexible Cytourethroscopes

MANUFACTURER	OPTICS	DEFLECTION	DIRECTION OF VIEW	FIELD OF VIEW	WORK LENG
Karl Storz	Fiber-optic • Multiple models	Up 210 degrees Down 140 degrees	0 degrees	110 degrees	37 cm
	Digital (standard-definition) • Multiple models	Up 210 degrees Down 140 degrees	0 degrees	120 degrees	37 cm
Olympus	Fiber-optic • Model CYF-5	Up 210 degrees Down 120 degrees	0 degrees	120 degrees	38 cm
	Digital (standard-definition) • Model CYF-V2	Up 210 degrees Down 120 degrees	0 degrees	120 degrees	38 cm
	Digital (high-definition) • Model CYF-VH	Up 210 degrees Down 120 degrees	0 degrees	120 degrees	38 cm
Wolf	Fiber-optic • Model 7305	Up 210 degrees Down 150 degrees	0 degrees	120 degrees	40 cm

Flexible cystourethroscopes are available in fiber-optic and digital models. Digital scopes do not require focusing or white balancing. They are now available in high-definition (1920 × 1080 pixels) and standard-definition (720 × 480 pixels) models. An *in vitro* study compared the resolution, contrast evaluation, depth of field, color representation, and illumination of fiber-optic, standard-definition, and high-definition flexible cystoscopes (Lusch et al., 2013). All three scopes were manufactured by Olympus (Olympus; Center Valley, PA). Compared with the fiber-optic and standard-definition models, the high-definition scope had a significantly higher resolution and depth of field. The high-definition scope's resolution was five times greater and had a 37% larger image than the standard-definition model. Color representation was only slightly better, and there was no difference in contrast evaluation among the three models. Illumination was significantly better in the fiber-optic model compared with both digital cystoscopes.

A randomized study of 1022 flexible cystoscopy cases compared optics, performance, and durability of fiber-optic and standard-definition digital scopes (Okhunov et al., 2009). There was a trend toward improved mean surgeon optical ranking in favor of the digital scopes ($p = 0.076$). There was no difference in durability between the models. Only two cystoscopes required repair (0.2% incidence rate), and both were damaged when the endoscope was placed in a storage case rather than during usage.

Data from an independent endoscope repair company found that flexible cystoscopes require less than one repair every 2 years (Canales et al., 2007). The most common repair was to the rubber overlying the distal flexible segment. Unlike flexible ureteroscopes, flexible cystourethroscopes are robust, likely making the optical mechanism a lesser determinant of scope durability.

Patient Preparation

Informed consent must be obtained before performing any cystoscopic procedure. A urinalysis and urine culture, if indicated, should be completed before cystoscopy. All urinary tract infections must be treated given the risk for bacteremia and sepsis after lower urinary tract manipulation.

Both the American Urological Association (AUA) and European Association of Urology (EAU) have published recommendations regarding periprocedural antibiotics. The AUA's Best Practice Policy Statement on Urologic Surgery Antimicrobial Prophylaxis was originally published in 2008 and was most recently amended in 2012 (Wolf et al., 2008). The EAU's Urological Infections guidelines were first published in 2001 and have been updated through 2017

(Bonkat et al., 2017).

Neither organization recommends antimicrobial prophylaxis for routine diagnostic cystoscopy in the absence of patient-related risk factors (Table 13.4). **The AUA recommends prophylaxis lasting less than 24 hours for therapeutic lower urinary tract procedures such as transurethral resection of the bladder and prostate.** This recommendation is largely based on a meta-analysis of 32 randomized controlled trials evaluating antimicrobial prophylaxis before transurethral resection of the prostate, which showed a decrease in bacteriuria, bacteremia, symptomatic urinary tract infection, and high-grade fever (Berry and Barratt, 2002). Given a lack of controlled trials pertaining to transurethral bladder procedures, the EAU guidelines leave prophylaxis at the provider's discretion.

TABLE 13.4

Patient Risk Factors Precluding Simple Cystoscopy Without Antimicrobial Prophylaxis

AUA BEST PRACTICE POLICY STATEMENT	EAU UROLOGICAL INFECTIONS GUIDELINES
Advanced age Anatomic anomalies of the urinary tract Poor nutritional status Smoking Chronic corticosteroid use Immunodeficiency Externalized catheters Colonized endogenous/exogenous material Distant coexistent infection	Older age Diabetes mellitus Impaired immune system Malnutrition Extreme weight History of urinary tract infectionVIndwelling catheters/bacterial burden Previous instrumentation Genetic factors
Prolonged hospitalization	

AUA, American Urological Association; *EAU,* European Association of Urology.

The AUA recommends either a fluoroquinolone or trimethoprim-sulfamethoxazole as the prophylactic agent of choice. Alternative agents include an aminoglycoside with or without ampicillin, a first- or second-generation cephalosporin, or amoxicillin/clavulanate. However, the Best Practice Policy has not been updated since 2012, and there are increasing concerns about the rising incidence of fluoroquinolone resistance (Marino Sabo and Stern, 2014). Consequently, the EAU guidelines state, “knowledge of the local pathogen profiles, susceptibility and virulence is mandatory.”

Before cystourethroscopy, the skin is prepared with an antiseptic agent. Most commercially available agents contain iodophors or chlorhexidine gluconate in either an aqueous or alcohol-based solution. **Both chlorhexidine gluconate and alcohol-based solutions can damage mucous membranes and therefore are not recommended on the genitalia. Aqueous-based iodophor-containing products such as Betadine are safe on all skin surfaces regardless of patient age.**

After application of an antiseptic agent, lubricating gel is instilled into the urethra of patients undergoing flexible cystourethroscopy. Either a plain or lidocaine gel may be used. **A meta-analysis of four randomized trials involving 411 patients found that patients receiving lidocaine gel were 1.7 times less likely to experience moderate to severe pain during the procedure** (Aaronson et al., 2009). **However, only one of the four trials showed a statistical benefit to lidocaine gel, which is consistent with a larger meta-analysis involving 817 patients from 9 randomized trials that showed no difference in procedure tolerance** (Patel et al., 2008a).

Other techniques have been employed to improve patient comfort during flexible cystourethroscopy. For most men, the least comfortable portion of the procedure is during scope passage through the membranous urethra (Taghizadeh et al., 2006). In an attempt to improve tolerance, a randomized trial was performed to evaluate the effectiveness of increased hydrostatic pressure of the irrigation solution (Gunendran et al., 2008). Manual compression of the irrigation bag during passage of the scope through the membranous urethra was compared with gravity irrigation alone in 151 men undergoing flexible cystourethroscopy. A significant improvement on an analog pain scale was noted (1.38 vs. 3.00, $p < 0.001$) in the manual compression group.

The impact of being allowed to observe the procedure has also been evaluated. One hundred male patients undergoing flexible cystourethroscopy were randomized; one-half of the subjects were allowed to watch the procedure on a video monitor, and the remaining patients were not (Patel et al., 2007). **Men who viewed the procedure had significantly less pain on a 100-mm visual analog pain scale (14 vs. 23, $p = 0.02$). These findings were confirmed by another randomized study of 76 male patients** (Soomro et al., 2011). **Men in the observation group had less pain and lower postprocedure pulse rates.** In contrast, a randomized study on 100 women undergoing office-based cystoscopy with a 17-Fr rigid scope found no difference in procedural pain (Patel et al., 2008b).

The potentially calming effect of music has also been examined. Seventy men undergoing flexible cystoscopy were randomized to either no music or classical music played during the procedure (Yeo et al., 2013). Patients listening to classical music had significantly less pain, higher satisfaction, lower postprocedure pulse rates, and lower systolic blood pressures.

Technique

Before inserting the cystourethroscope, the external genitalia is inspected for cutaneous lesions and anatomic abnormalities. Mild meatal stenosis may be addressed with sequential metal dilators. Dilation should be performed to at least 2 Fr wider than the intended endoscope size.

In women, rigid cystourethroscope insertion is safest using the sheath obturator. The scope will often need to be directed anteriorly as it is advanced into the bladder. Flexible cystourethroscopes can often be inserted into the bladder like a Foley catheter with active deflection being used as needed.

In men, the penis is placed on maximal stretch to straighten the urethra. When passing a rigid cystourethroscope, the penis is typically grasped with all five digits of the surgeon's nondominant hand. With flexible cystourethroscopy, the penis is pinched between the third and fourth digits of the nondominant hand at the corona while the thumb and index finger help advance and direct the scope into the urethra (Fig. 13.6). In morbidly obese patients, it is often easier to lay the scope down, retract the pannus with the nondominant hand, and direct the tip of the flexible scope into the urethra like a Foley catheter. Once in the mid-penile urethra, the scope is placed in the dominant hand and advanced as usual.

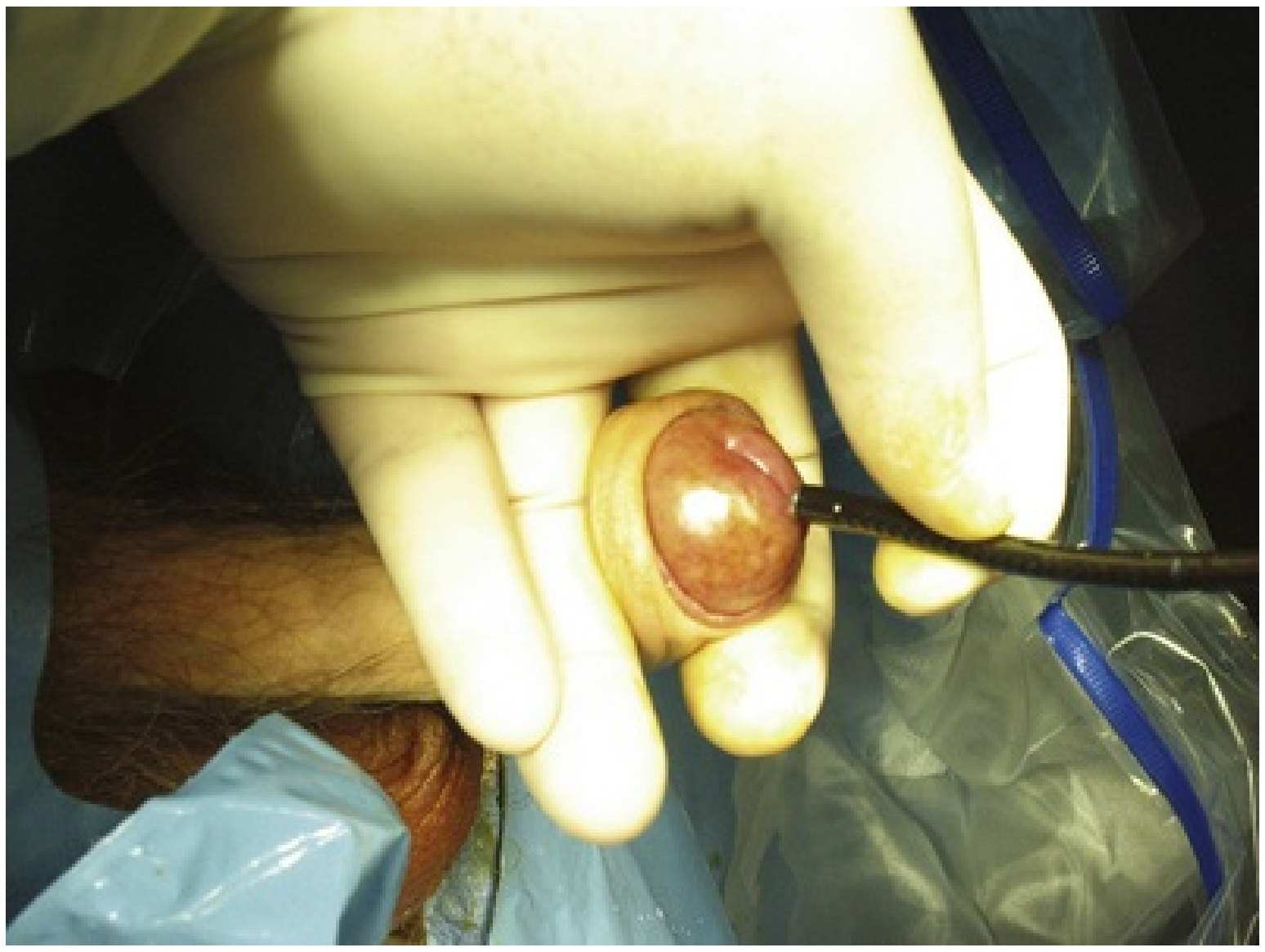

FIG. 13.6 During flexible cystoscopy, the distal penis is grasped between the surgeon's third and fourth fingers and placed on stretch while the thumb and index finger advance the cystoscope into the urethral meatus.

The penis should be angled 45 to 90 degrees relative to the abdominal wall while passing the scope through the anterior urethra. Once beyond the membranous urethra, the cystoscope is directed anteriorly to enter the bladder. With flexible cystoscopes, this is accomplished by active upward deflection, and with rigid cystoscopes by dropping the distal end of the scope toward the operative table.

The lower urinary tract is systematically evaluated under maximal irrigation as the scope is advanced. The penile and bulbar urethra are inspected for strictures. The periurethral glands of Littre should be noted as they drain into the urethra dorsally. Patients, in particular young men, should be encouraged to relax as much as possible as the scope is advanced through the membranous urethra. Once in the prostatic urethra, the verumontanum and utricle are identified posteriorly. The length of the posterior urethra is measured, and the size of the prostatic lobes are evaluated.

Once in the bladder, the mucosa is carefully inspected. Rigid cystoscopy is usually begun with a 25- or 30-degree lens. The floor of the bladder and trigone are surveyed. The number, location, and configuration of the ureteral orifices are noted. Efflux from each ureter should be observed for the presence of gross blood. The remainder of the bladder is inspected for stones, trabeculation, cellules, diverticula, erythematous patches, and papillary and sessile lesions. Visualization of the lateral walls is accomplished by rotating the cystoscope while keeping the camera orientation fixed. The dome, anterior and posterolateral walls are inspected with a 70- or 120-degree lens. After completing the procedure, the bladder is emptied, and the endoscope is withdrawn. If a Foley catheter is to be placed after the cystoscopy, it is best to leave the bladder at least partially full before removing the cystoscope.

Special Circumstances

Suprapubic Cystostomy

The indications for cystoscopy in patients with suprapubic cystostomy tubes are the same as those without chronic indwelling catheters. However, these individuals are at increased risk for infection, bladder calculi, and bladder cancer (El Masri et al., 2014; Subramonian et al., 2004; Welk et al., 2013). There is no level-one data showing that use of surveillance cystoscopy improves survival in patients with long-term indwelling catheters. As a result, controversy exists regarding the utility of surveillance cystoscopy in patients with neurogenic bladder and long-term indwelling catheters (Vince and Klausner, 2017).

Cystoscopy may be performed through the urethra or the patient's suprapubic tract. However, many patients with long-term suprapubic tubes suffer from urethral stricture disease, making the suprapubic tract the only feasible route to the bladder. Every effort should be made to avoid endoscopy through a suprapubic tract until it has had time to mature, which usually takes several weeks from the time of creation. There will be occasions when endoscopy through an immature suprapubic tract is required. When needed, it is helpful to place a wire through the suprapubic tube before removal. This safety wire helps maintain access to the bladder and can serve to guide placement of the endoscope. This technique is also helpful in morbidly obese patients with long, often tortuous tracts.

Ureteral access is often challenging during rigid cystoscopy through the cystostomy tract because of the acute angle required to cannulate the ureteral orifice. Angled catheters such as the Kumpe catheter (Cook Medical; Bloomington, IN) or use of an Albarran's deflector may facilitate ureteral access. Using a flexible cystoscope will often overcome these problems. Alternatively, patients with low-grade urethral strictures may be able to accommodate transurethral passage of a semirigid ureteroscope facilitating standard ureteral access. Lastly, the ureteral orifices may be difficult to identify because of edema caused by the chronic suprapubic tube. Administering intravenous indigo carmine or methylene blue early in the procedure may help visualize the ureteral orifices.

Continent Urinary Diversions

There are two general classes of continent urinary diversions after cystectomy. Orthotopic urinary diversions are anastomosed to the urethra and rely on the striated urinary sphincter to maintain continence. Continent cutaneous reservoirs utilize a catheterizable channel spanning from the diversion to the anterior abdominal wall. The catheterizable channel may be composed of the appendix (Mitrofanoff), tapered/imbricated terminal ileum and ileocecal valve, or an intussuscepted nipple valve.

Before undertaking any endoscopic procedure involving a continent urinary diversion, it is imperative to obtain the operative note. It's important to know the bowel segment used, type and location of the ureteroenteric anastomoses, continence mechanism employed, and if an afferent limb was created.

Transurethral access to orthotopic diversions is often straightforward and can be accomplished using a rigid cystoscope. If a urethral anastomotic contracture is noted and the patient is not suffering from outlet obstruction, then it is advisable to use the smallest scope possible rather than dilate or incise the stricture to prevent worsening urinary incontinence.

Diagnostic endoscopy of continent cutaneous reservoirs is best accomplished using a flexible cystoscope through the catheterizable channel. All but the most straightforward therapeutic procedures should be performed percutaneously given the continence mechanisms are often fragile and excess manipulation may result in either stomal stenosis or urinary incontinence (L'Esperance et al., 2004). Preoperative computed tomography or intraoperative ultrasound should be used to minimize the risk for bowel injury during percutaneous access.

Once within the diversion, visualization is often challenging because of mucus, mucosal folds, bowel peristalsis, and, if present, tortuous afferent limb. Begin by irrigating out all of the mucus. Irrigation should then be used judiciously. Too little irrigation will make mucosal folds more prominent and impair visualization, but overdistention will prevent access to the afferent limb and will often result in troublesome retroflexion of flexible cystoscopes. Once again, ancillary techniques such as using angled catheters and indigo carmine or methylene blue may be required.

Key Points: Cystourethroscopy

- Rigid cystourethroscopes are manufactured in sets consisting of an optical lens, bridge, sheath, and obturator.
- Flexible cystourethroscopes are available in fiber-optic, standard-definition, and high-definition digital models.
- Cystourethroscope sizes are expressed using the French gauge system with 1 Fr equaling one-third of a millimeter in circumference.
- The smallest-diameter cystourethroscope that can be used to perform the procedure should be selected to decrease the risk for genitourinary tract trauma.
- Antimicrobial prophylaxis is not recommended for diagnostic cystourethroscopy unless patient-related risk factors are present.
- Increasing the hydrostatic pressure during scope passage and allowing men to observe the procedure have been prospectively shown to improve patient comfort during flexible cystourethroscopy.

Upper-Tract Endoscopy

Indications

Urolithiasis

Surgical treatment of nephrolithiasis is the most common indication for upper-tract endoscopy. The AUA/Endourological Society guidelines on surgical management of stones recommend either shock wave lithotripsy (SWL) or ureteroscopy for ureteral calculi (Assimos et al., 2016). Clinicians are encouraged to discuss with their patients the higher stone-free rate but greater morbidity associated with ureteroscopy compared with SWL. The EAU guidelines on urolithiasis also indicate that ureteroscopy and SWL are appropriate modalities for smaller ureteral stones, but ureteroscopy is preferred for calculi larger than 10 mm because of its higher stone-free rate (Türk et al., 2017).

Per the AUA/Endourological Society guidelines, non–lower-pole intrarenal stones measuring less than 20 mm may be treated with either SWL or ureteroscopy. Stones larger than 20 mm should be managed with percutaneous nephrolithotomy (PCNL). **However, patients with comorbidities making percutaneous treatment prohibitively dangerous have been successfully managed with ureteroscopy. Two studies have reported stone-free rates of 91% and 93% for ureteroscopic treatment of patients with stones larger than 2 cm** (Grasso et al., 1997; Breda et al., 2008). Lower-pole stones less than 10 mm can be managed with either SWL or ureteroscopy. Consideration for PCNL should be given to stones larger than 10 mm in the lower pole given its superior stone-free rate. The EAU guidelines are very similar in their recommendations regarding intrarenal stone management. However, they do indicate that SWL for lower-pole stones between 10 and 20 mm may be considered as long as there are no unfavorable factors, such as the presence of shock wave–resistant stones (calcium oxalate monohydrate, brushite, or cystine), a steep infundibular-pelvic angle, a long lower-pole calyx (>10 mm), a narrow infundibulum (<5 mm), or a skin-to-stone distance exceeding 10 cm.

Upper Urinary Tract Urothelial Carcinoma

The EAU guidelines on upper urinary tract urothelial carcinoma recommend performing diagnostic ureteroscopy when imaging is equivocal or conservative management is being considered (Keeley et al., 1997). Despite yielding only a small amount of material for evaluation, ureteroscopic biopsy has been shown to accurately predict final pathologic grade in approximately 90% of patients (Rojas et al., 2013). Diagnostic ureteroscopy has not been shown to negatively impact long-term or disease-specific survival in patients undergoing extirpative therapy (Ishikawa et al., 2010). However, a recent study reported an increased risk for intravesical recurrence, highlighting the need for long-term bladder surveillance (Yoo et al., 2017).

In the past, urologists reserved endoscopic treatment of upper tract urothelial tumors for compelling indications such as solitary kidney, renal insufficiency, bilateral upper tract urothelial cell carcinoma, or significant medical comorbidities. However, with improvements in instrumentation and technique, endoscopic treatment of low-grade disease has been reported to be a reasonable option without compromising survival (Cutress et al., 2012; Grasso et al., 2012). Larger tumors can be challenging to fully ablate in one session, prompting reports of percutaneous nephroscopy with electroresection (Cutress et al., 2012; Irwin et al., 2010; Motamedinia et al., 2016; Strijbos and van der Heij, 2016). Nevertheless, when feasible, ureteroscopy is preferable because it avoids the small, but reported risk for seeding the percutaneous tract and retroperitoneum with tumor (Sengupta and Harewood, 1998; Sharma et al., 1994).

Ureteropelvic Junction Obstruction and Ureteral Stricture

Despite the widespread adoption of laparoscopic and robotic-assisted pyeloplasty, endopyelotomy remains a common treatment for patients with ureteropelvic junction (UPJ) obstruction (Jacobs et al., 2018). Endopyelotomy can be performed percutaneously or ureteroscopically. The ureteroscopic approach has the advantage of avoiding the potential morbidity of percutaneous renal access, allowing the procedure to be performed in an outpatient setting.

There are two situations in which ureteroscopic endopyelotomy may not be the preferred approach. Patients with concomitant renal calculi should be treated percutaneously to allow simultaneous stone removal and endopyelotomy. Also, several studies have demonstrated a decreased success rate with endopyelotomy in patients who have vessels crossing at the UPJ (Bagley et al., 1995; Conlin and Bagley, 1998; Tawfiek et al., 1999; Van Cangh et al., 1994). **It may be best to limit ureteroscopic endopyelotomy to those patients with a documented absence of crossing vessels and to treat those with crossing vessels using**

laparoscopic ureteropyeloplasty.

Patients with ureteral strictures can also be managed from a ureteroscopic approach. The technique is nearly identical to the ureteroscopic endopyelotomy technique. Endoureterotomy is less successful in patients with ureteral strictures longer than 1.5 cm, allograft ureters, previously irradiated ureters, ureters draining poorly functioning kidneys, and ureteral-enteral anastomotic strictures (Wolf et al., 1997). Ureteroscopic incision of short ureteral strictures in otherwise healthy ureters is a reasonably successful treatment option (Emiliani and Breda, 2015).

Other Indications for Ureteroscopy

Diagnostic ureteroscopy can be performed for persistent, unexplained positive cytology, filling defects noted on excretory urography, and recurrent urinary tract infections localized to a single renal unit. With the miniaturization of flexible ureteroscopes, the safety of flexible ureteroscopy has increased significantly. Rather than relying on ureteropyelography alone, we can now safely and easily perform diagnostic ureteroscopy. Ureteroscopy has also been used for removal of foreign bodies including suture, proximally migrated ureteral stents, balloon catheters, and other fractured working instruments.

Benign essential hematuria can be diagnosed and treated with flexible ureteroscopy. This condition is defined as unilateral gross hematuria for which there is no radiographically defined cause (Bagley et al., 1987; Lano et al., 1979). These patients frequently have had studies including excretory urography, renal sonography, arteriography, or a combination of these. Flexible ureteroscopic inspection of the involved kidney usually results in diagnosis and successful treatment. The most common finding in patients with benign essential hematuria is a small hemangioma, which can often be fulgurated. Other endoscopic findings in patients with benign essential hematuria include small venous ruptures, papillary tumors, varices, and calculi (Dooley and Pietrow, 2004).

Equipment

Semirigid Ureteroscopes

Successful ureteroscopy (▶Video 13.1) requires a variety of instrumentation, most importantly suitable, modern ureteroscopes. Although larger rod lens rigid ureteroscopes are still available in some operating rooms, the smaller-diameter fiber-optic ureteroscopes are less traumatic, require ureteral dilation less often, and are equally capable.

Semirigid ureteroscopes are smaller in diameter because of the incorporation of fiber optics into their construction. Fiber-optic bundles consist of multiple glass fibers. Each fiber is coated with a cladding; an additional layer of glass with a different refractive index. This cladding improves the internal reflection, light transmission, and durability of the fiber-optic bundle. When the fibers are grouped randomly, such as those within a light bundle, they transmit light for illumination but no image. When the fibers are arranged coherently, the light from each fiber within the bundle will coalesce to transmit images.

Small lenses are attached to both ends of the image bundle to create a telescope. The number of fibers in the bundle and the type and orientation of the lenses determine the degree of image magnification, the field of view, and focusing ability for different fiber-optic endoscopes. For example, by changing the axis of the lens at the distal tip of the image bundle, the angle of view of the ureteroscope can be changed to improve the visibility of working instruments passed out of the working channel (Higashihara et al., 1990).

Improvements in image bundle construction allow closer packing of more fibers, resulting in improved image transmission, smaller outer diameters, and larger working channels in both rigid and flexible ureteroscopes. Manufacturers have also replaced the single-light bundle with two smaller bundles permitting a more centrally placed working channel and better distribution of the light within the field of view (Conlin et al., 1997).

Most current semirigid ureteroscopes have tip diameters of 7 Fr or less and working channels larger than 3 Fr. Semirigid ureteroscopes have either a large single or two smaller individual working channels. **An advantage of the separate working channels is improved irrigation through one open channel while a working instrument occupies the other. Independent working channels also permit passage of a lithotripsy device through one channel to fracture a trapped stone stuck in a basket in the other channel**. With a single channel, this may be impossible because of entanglement between the two working instruments. For these reasons, semirigid ureteroscopes with two separate working channels are preferred.

Eyepieces are commonly “in line” with the ureteroscope for a more natural insertion and use of the scope (Fig. 13.7). The offset eyepiece design makes possible a straight working channel, needed for less flexible working instruments like rigid biopsy forceps or pneumatic lithotripsy probes (Fig. 13.8). Increased availability and use of the holmium laser for ureteroscopic lithotripsy has decreased the need for ureteroscopes with offset eyepieces.



FIG. 13.7 Semirigid ureteroscope with an "in-line" eyepiece.



FIG. 13.8 Semirigid ureteroscope with an offset eyepiece, which has a straight working channel permitting passage of rigid instruments.

In the past, some urologists preferred larger ureteral resectoscopes (11.5 Fr) for large distal ureteral tumor resection and ureteroscopic endopyelotomies (Thomas et al., 1996). Preoperative ureteral stenting was necessary to allow passage of the larger-diameter ureteral resectoscope, especially to the UPJ. By using laser energy for tissue ablation and incision, urologists can avoid the more significant trauma of these ureteral resectoscopes.

Currently available semirigid ureteroscopes and their characteristics are listed in Table 13.5.

TABLE 13.5

Rigid Ureteroscopes

MODEL	EYEPIECE	DIAMETER (Fr)	WORKING LENGTH (cm)	NUMBER OF CHANNELS	SIZE OF CHANNELS (Fr)
OLYMPUS (WHITE PLAINS, NY)					

MR-6A	Straight	6.9/8.2/10.2	33	2	2.3; 3.4
MR-6LA	Straight	6.9/8.2/10.2	43	2	2.3; 3.4
MRO-733A	Angled offset	7.7/9.2/10.8	33	1	5.4
MRO-742A	Angled offset	7.7/9.2/10.8	42	1	5.4
WA29040A; WA29041A	Angled	6.4/7.8/12	43 (WA29040A); 33 (WA29041A)	1	4.2
WA29042A	Angled	8.6/9.8/13.5	43	1	6.4
WA29048A; WA29049A	Straight	6.4/7.8/12	43 (WA29048A); 33 (WA29049A)	1	4.2
WA02943A	Angled	7.5	43	2	2.4; 3.4
WA02944A	Straight	7.5	43	2	2.4; 3.4
WA02946A	Straight	7.5	33	2	2.4; 3.4
KARL STORZ ENDOSCOPY (CULVER CITY, CA)					
27001KA/LA	Angled	7/8/12	34 (KA)/43 (LA)	1	5
27002KA/LA	Angled	8/9.5/12	34 (KA)/43 (LA)	1	6
27003KA/LA	Angled	9/9.5/12	34 (KA)/43 (LA)	2	3.8; 5
27000KA/LA	Angled	6/7/9.9	34 (KA)/43 (LA)	1	4.8
27010KA/LA	Straight	7/8.4/9.9	34 (KA)/43 (LA)	2	2.4; 3.4
RICHARD WOLF MEDICAL INSTRUMENTS (VERNON HILLS, IL)					
8701.517; 8701.518	Straight	4.5/6	33 (517); 43 (518)	2	2.5; 3
8701.533; 8701.534	Angled	4.5/6	31.5 (533); 43 (534)	2	2.5; 3
8702.517; 8702.518	Straight	6/7.5	33 (517); 43 (518)	1	4.2 × 4.6 (oval)
8702.523; 8702.524	Offset	6/7.5	31.5 (523); 43 (524)	1	4.2 × 4.6 (oval)
8702.533;	Angled	6/7.5	31.5	1	4.2 × 4.6

8702.534			(533); 43 (534)		(oval)
8703.517, 8703.518	Straight	8/9.8	33 (517); 43 (518)	1	5.2 × 6.2 (oval)
8704.523; 8704.524	Offset	8.5/11.5	31.5 (523); 43 (524)	1	6.2 × 8.2 (oval)
8708.517; 8708.518	Straight	6.5/8.5	33 (517); 43 (518)	2	2.55; 4.2
8708.533; 8708.534	Angled	6.5/8.5	31.5 (517); 43 (518)	2	2.55; 4.2

Flexible Ureteroscopes

The fundamental components of flexible ureteroscopes include the optical system, deflection mechanism, and working channel. The nondigital optical system consists of flexible fiber-optic image and light bundles. Improvements in the fiber-optic image bundles are similar to those in semirigid ureteroscopes, as discussed in the preceding section.

Active deflection of the flexible ureteroscope permits complete maneuverability within the intrarenal collecting system (Bagley, 1989). The deflecting mechanism control wires run the length of the ureteroscope from a manually operated lever mechanism, through moveable metal rings, to the distal end of the scope where they are fixed. Moving the lever up or down will pull the control wire through these rings and deflect the tip. When the tip moves in the same direction as the lever, the deflection is said to be “intuitive” (i.e., down is down, and up is up). Modern flexible ureteroscopes allow both up and down deflection in a single plane (Grasso and Bagley, 1994). **The plane of deflection is designated by the reticle seen as a notch within the field of view of the ureteroscope (Fig. 13.9). When maneuvering the flexible ureteroscope, it must be rotated to align the plane of deflection with the intended target.** The active deflection mechanism eventually “wears out” with repeated use, requiring repair or replacement of the ureteroscope. Improvements in the construction of the deflecting mechanism with each new generation of flexible ureteroscope continue to improve durability.

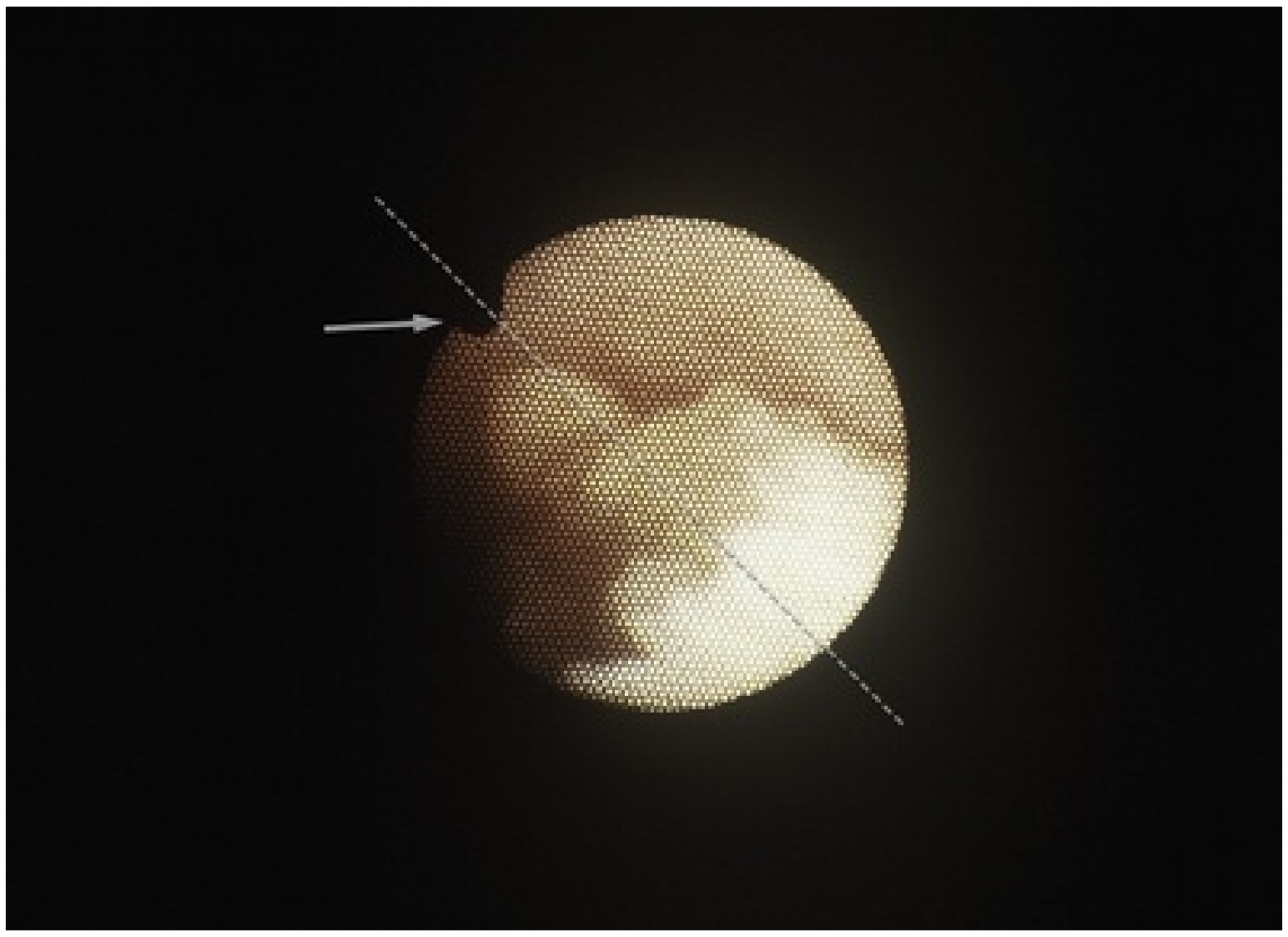

FIG. 13.9 Flexible ureteroscopic image showing the reticle *(arrow),* which designates the plane of deflection *(dotted line).*

Current flexible ureteroscopes permit more than 180 degrees of deflection. The amount of deflection necessary to reach the lower pole of the kidney varies among different patients. One group of investigators measured ureteroinfindibular angle (between the major axis of the ureter and the lower pole infundibulum) in 30 patients. They determined an average angle of 140 degrees with a maximum of 175 degrees (Bagley and Rittenberg, 1987). Active deflection of the ureteroscope of 180 degrees should allow visualization of the lower pole in most patients. However, reaching into the lower-pole calyx with the tip of the ureteroscope in a fashion that allows endoscopic work to be done can still be challenging.

Active deflection occurs only at the distal tip of the ureteroscope, and the deflected segment may not be long enough to reach the lower-pole calyx. Previous flexible ureteroscopes incorporated a flexible section of the ureteroscope just proximal to the point of active deflection. This secondary, passive deflection mechanism addressed the difficulty of reaching the lower pole in some patients. By passively bending the tip of the ureteroscope off of the superior margin of the renal pelvis, the point of deflection was moved proximally on the ureteroscope, effectively extending the tip of the ureteroscope. When passive deflection is used, the lower-pole calyx can be reached in most patients. Many of the failures to reach the lower pole will be in patients with significant hydronephrosis, which can limit the ability to engage passive secondary deflection.

Two recent innovations in ureteroscope deflection have improved ureteroscopic access to the lower pole. These are active secondary deflection and “exaggerated” deflection. The first ureteroscope incorporating active secondary deflection, the DUR-8 Elite, was developed by Circon-ACMI, now part of Olympus (Center Valley, PA). In addition to the primary deflection mechanism, there is a second control lever for active secondary deflection of 165 degrees at a more proximal location on the shaft, which extended the length of the deflected segment into the lower pole. This ureteroscope can assist the urologist to reach the lower pole even under conditions in which access with passive secondary deflection is not possible (Fig. 13.10). Locking the secondary deflection in place simplifies the use of primary deflection for manipulation of the tip within the lower-pole calyces. The usefulness of active secondary deflection was evaluated by Ankem et al. (2004), who found it helpful in cases in which the single deflection flexible instruments fail to access and treat upper urinary tract pathology. Despite these advantages, and because of more significant improvements in ureteroscope primary deflection, there is currently no available flexible ureteroscope with active secondary deflection.

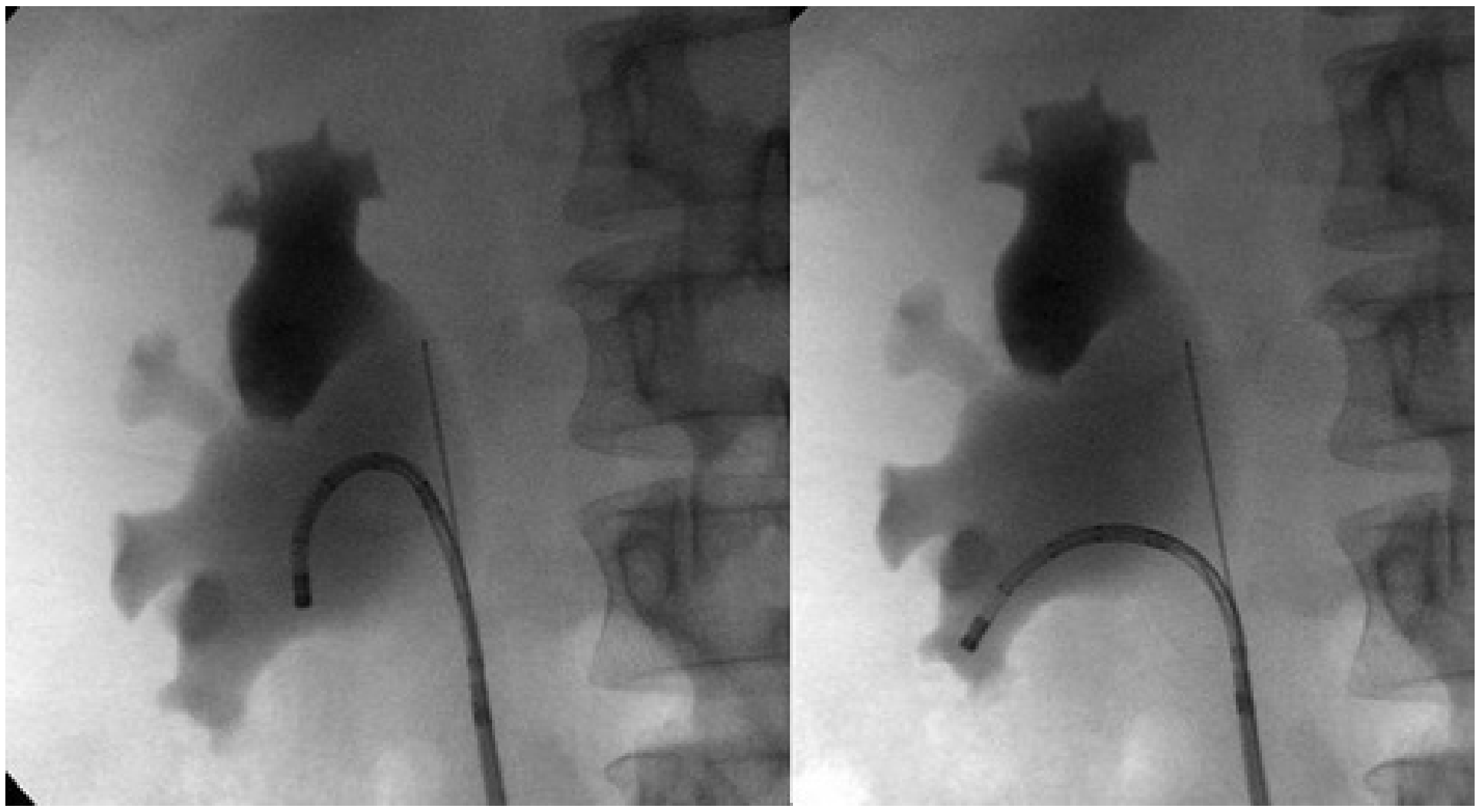

FIG. 13.10 Inability to access the lower-pole calyx with typical primary deflection *(left).* Successful access of the lower pole using active secondary deflection *(right).*

Karl Storz Endoscopy (Tuttlingen, Germany) introduced “exaggerated deflection” with their Flex-X model flexible ureteroscope (Johnson and Grasso, 2004). This modification of the deflection mechanism permits active primary deflection to greater than 300 degrees (Fig. 13.11). When approaching the lower-pole calyx, the deflected segment of the ureteroscope will effectively lengthen as it is deflected against the lower-pole infundibulum. This improvement of the deflection mechanism results in easier lower-pole access and improved deflection when using working instruments. Most modern ureteroscopes now incorporate similar enhancements in primary deflection that have significantly improved the ease of reaching the lower-pole calyces.

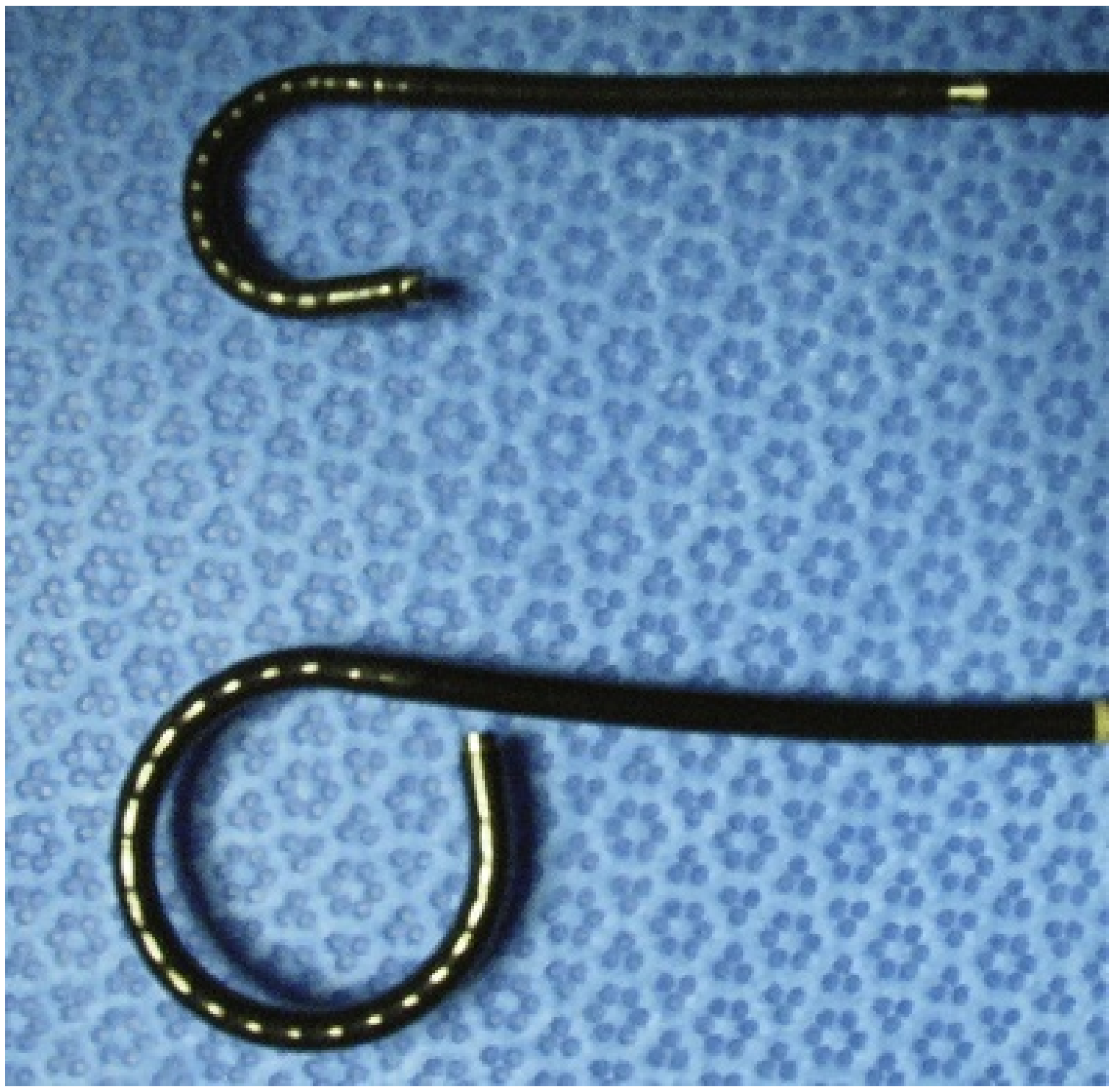

FIG. 13.11 Flexible ureteroscopes with standard primary deflection *(top)* and exaggerated primary deflection *(bottom).*

All currently available flexible ureteroscopes have working channels of 3.6 Fr diameter. Adequate irrigation is possible, even when using working devices up to 3 Fr. Higher-pressure irrigation will be necessary, especially when devices are present within the working channel (Bach et al., 2011). This higher-pressure irrigation can be delivered using a pressurized irrigation bag, roller pump, or handheld devices. The development of a dual-channel flexible ureteroscope, the Cobra from Richard Wolf (Vernon Hills, IL), is an innovation that can improve irrigation through the ureteroscope. The dual 3.3-Fr channels will permit unimpeded irrigation through one channel while the working instrument occupies the other (Haberman et al., 2011). One may also use both channels for working instruments, such as a laser and a basket, if necessary.

Digital Ureteroscopes

Digital flexible ureteroscopes have become the preferred upper tract endoscope for most urology services. Like digital flexible cystoscopes described earlier in this chapter, these ureteroscopes integrate the digital camera and light source within the endoscope. A separate camera head is unnecessary because the digital camera chip (CCD or CMOS) is incorporated into the tip of the endoscope. Because these devices do not require a fiber-optic image bundle, separate light cord, or camera head, they may be less prone to damage and have a longer lifespan.

Digital flexible ureteroscopes are larger in diameter than the smallest fiber-optic flexible ureteroscopes. One group of investigators prospectively compared digital and fiber-optic ureteroscopes to determine the influence of these larger-diameter digital scopes on patient outcomes. They found more frequent use of ureteral access sheaths and related complications in those patients undergoing ureteroscopy with a digital ureteroscope (Bach et al., 2012). In another analysis of the efficacy of digital and flexible ureteroscopes, investigators determined a statistically equivalent stone-free rate but a significantly shorter operative time in the digital group (Somani et al., 2013). The quicker procedures were likely caused by the improved visibility of the digital ureteroscopes (Fig. 13.12). Future digital ureteroscopes may advance miniaturization, optimize digital resolution, and improve durability.

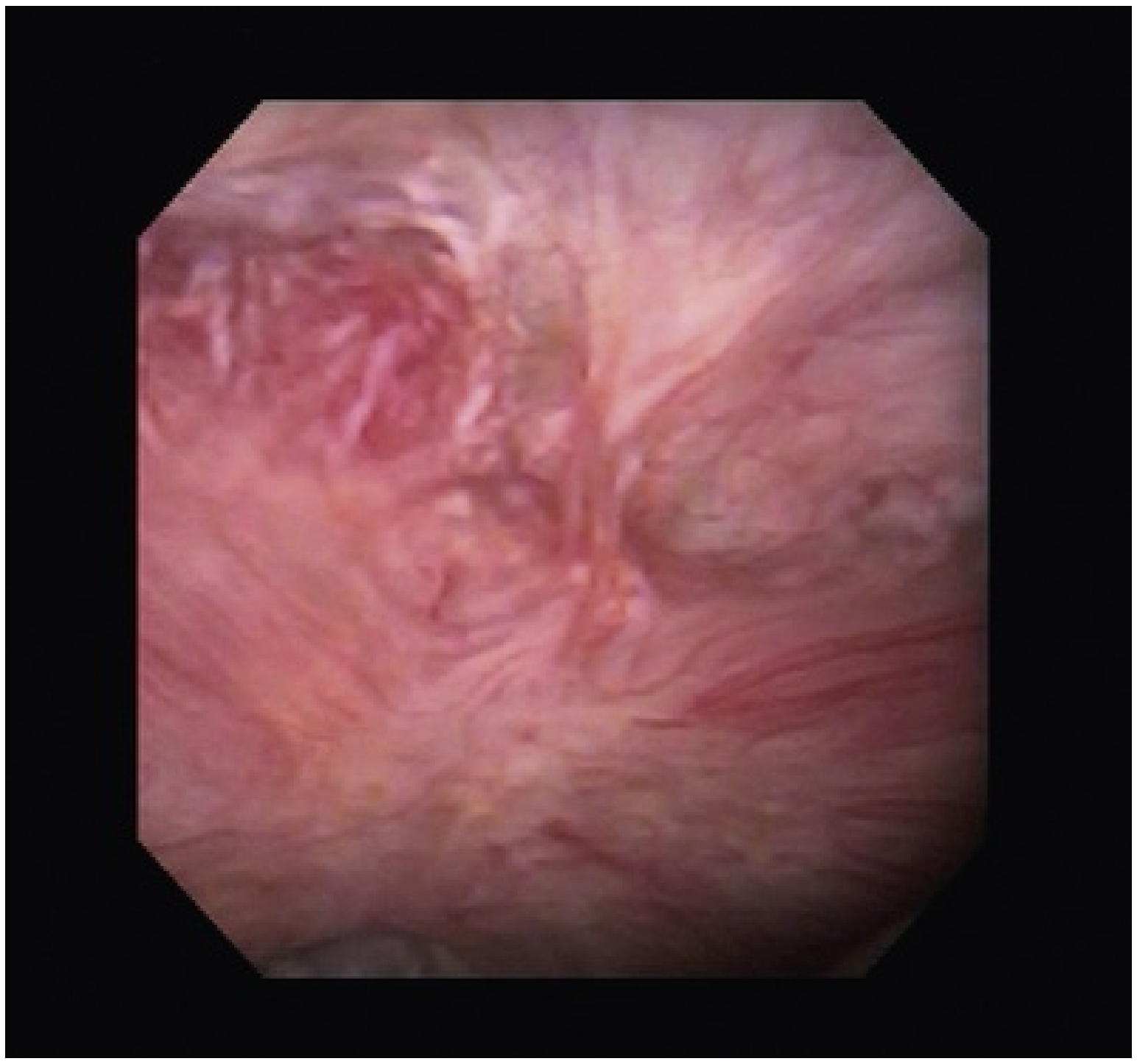

FIG. 13.12 Excellent optical clarity of a digital ureteroscope image of a compound calyx.

In 2015, Boston Scientific (Marlborough, MA) introduced the LithoVue, the first single-use flexible ureteroscope. The rationale for a single-use ureteroscope is to avoid the high cost associated with maintaining and repairing reusable endoscopes. Although the durability of flexible ureteroscopes varies in the literature, some studies have reported repair needed after an average of only three to five cases (Knudsen et al., 2010; Monga et al., 2006). Furthermore, refurbished scopes appear to be more prone to damage than new scopes (Carey et al., 2014). One study estimated that repair costs add $355 to each case (Kramolowsky et al., 2016).

The LithoVue ureteroscope has an LED light source at the tip and a digital CMOS sensor that provides a depth of field between 2 mm and 50 mm. The tip diameter is 7.7 Fr, and the shaft has a maximal outer diameter of 9.5 Fr. The scope contains a single working channel of 3.6 Fr and has 270-degree active deflection in both directions.

A cadaveric study comparing the LithoVue to nondisposable fiber-optic and digital ureteroscopes found the LithoVue to be comparable in visibility and scope maneuverability (Proietti et al., 2016). A prospective case-control study comparing the LithoVue to a reusable fiber-optic scope found that the LithoVue was associated with shorter procedure duration and comparable failure rates

(4.4% LithoVue vs. 7.7% reusable scope; *p* = 0.27) (Usawachintachit et al., 2017).

The economic impact of the LithoVue has not been definitively determined. Some studies report comparable costs associated with the LithoVue (Taguchi et al., 2017), and others report an economic benefit in select situations such as low-volume centers (Martin et al., 2017) or larger stones in the lower pole (Ozimek et al., 2017).

Given the potential advantages of disposable ureteroscopes, several companies are in the process of bringing competing products to the market. These include the Pusen (Zhuhai Pusen Medical Technology Company Limited, China), the YC-FR-A (YouCare Tech, China), and the NeoFlex (Neoscope, Inc.).

The specifications of currently available flexible ureteroscopes are detailed in Table 13.6.

TABLE 13.6

Flexible Ureteroscopes

	BOSTON SCIENTIFIC	**OLYMPUS**				**KARL STORZ**	
CHARACTERISTIC	**LITHOVUE**	**URF-V**	**URF-V2**	**URF-P5**	**URF-P6**	**FLEX-XC**	**FLEX-X2S**
Digital or fiber-optic?	Digital	Digital	Digital	Fiber-optic	Fiber-optic	Digital	Fiber-optic
Tip diameter (Fr)	7.7	8.5	8.4	5.3	4.9	8.5	7.5
Shaft diameter (Fr)	9.5	9.9	8.5	8.4	7.9	8.5	7.5
Working length (cm)		67	67	70	67	70	67
Channel size (Fr)	3.6	3.6	3.6	3.6	3.6	3.6	3.6
Up deflection (degrees)	270	180	275	180	275	270	270
Down deflection (degrees)	270	275	275	275	275	270	270
Direction of view (degrees)	0	0	0	0	0	0	0
Field of view (degrees)	85	90	80	90	90	90	88
Depth of field (mm)	2–50	2–50	1.5–50	2–50	2–50	4–60	2–40
Magnification (×)	Digital zoom	Digital zoom	Digital zoom	52	52	Digital zoom	50
Chip type	CMOS	CCD	CCD			CMOS	

Comments	Disposable						

Care and Sterilization

Rigid and flexible ureteroscopes are delicate instruments that need to be handled accordingly. Damage to the working channel, deflecting mechanism, or fibers within the image bundle can render the ureteroscope useless. One series reported that repairs of flexible ureteroscopes were necessary after only 3 to 13 hours of use (Afane et al., 2000). The repairs were usually caused by deterioration of the deflecting mechanism.

The working channels of flexible ureteroscopes are also easily damaged. This primarily occurs during passage of a small (200-micron) holmium laser fiber. **When inserting a fiber into a flexible ureteroscope that is even minimally deflected, the tip of the fiber may scrape the inner working channel. This can raise a small irregular area of the channel that will be more prone to damage.** With each subsequent pass of laser fibers or other working instruments, the channel is increasingly damaged and eventually perforated. Once perforated, sterilization of the flexible ureteroscope will result in fluid damage to the imaging system of the scope, making the scope unusable. **Firing the fiber within the working channel will also result in scope injury. The holmium laser may damage the working channel when the tip is very near the end of the working channel** (Fig. 13.13). Keeping the tip of the fiber within the central portion of the field of view when firing the laser should prevent collateral damage to the ureteroscope. **The "golden rule" of safe holmium laser lithotripsy is, "do not step on the pedal if you cannot see the tip of the fiber in contact with the stone." This will prevent injury to the ureter and damage to the ureteroscope**.



FIG. 13.13 Image of the tip of a flexible ureteroscope that has been damaged by firing of the holmium laser within the working channel *(arrow).*

Ureteroscopes, including the working channel, should be cleaned with warm water and a nonabrasive detergent after each use. Sterilization of ureteroscopes can be performed by using gas (ethylene oxide), soaking in a glutaraldehyde solution, or using the Steris system (Mentor, OH) (Gregory et al., 1988). The Steris system provides automated washing and rinsing of the endoscopes in a peracetic acid solution.

Guidewires

Guidewires are essential to urologic endoscopy. We use them for many portions of these procedures—the establishment of percutaneous or ureteroscopic access, straightening of the ureter, a guide for dilation of the ureter or percutaneous tract, and stent placement. Many types of guidewires are available differing in diameter, rigidity, tip design, materials, and coating. The choice of the most appropriate wire depends on the present task, the patient's anatomy, and upper urinary tract problem being confronted.

The most common design is a solid stainless steel core around which an outer wire is wrapped. Nitinol (nickel-titanium) can be used for inner core construction, and this gives guidewires a kink-resistant, slightly stiffer property. Some newer wires (Zebra wire; Boston Scientific, Natick, MA, and Roadrunner wire, Cook Urological, Spencer, IN) have a nitinol core wire and polyurethane outer layer. These wires are well suited for passage of the ureteroscope as there is less friction of the ureteroscope over the polyurethane, and the stiffer core allows more reliable transmission of the "push" from the urologist to the tip of the ureteroscope. Angling of the wire tip is also possible because of the "memory" quality of the nitinol material. When the outer polyurethane layer is coated with a hydrophilic polymer, these wires become exceptionally slippery. These "glide wires" are incredibly adept at negotiating around impacted ureteral calculi, tortuous ureters, and ureteral strictures. **Hydrophilic-coated wires are too slippery to be reliable safety wires because they can easily slide out of the patient. When these wires are used for initial access, they are exchanged for a standard safety wire through an open-ended catheter.** A new hybrid designed wire (Sensor; Boston Scientific, Natick, MA) incorporating a hydrophilic tip with a polytetrafluoroethylene (PTFE)-coated shaft may serve as both an access and safety wire for difficult access cases.

Guidewires for urology range in diameter from 0.018 to 0.038 inches, the most commonly used being 0.038 inches. Lengths vary from 80 to 260 cm. The most useful length for endourology is 145 cm. The tips of these wires are generally "floppy" for 1 to 3 cm. Bentson and Newton wire designs have flexible tips of up to 15 cm and are seldom used today. Some wires have a movable core that can be partially withdrawn to increase the length of the flexible tip. Other variable characteristics in guidewire construction include the distal tip design and the wire stiffness. The distal tip can be straight, angled, or "J" tipped. The rigidity of the wires can be varied by changing the diameter and design of the inner core wire. Stiffer wires can be useful for straightening out tortuous ureters or displacing a sizeable prostatic lobe.

The choice of the most appropriate guidewire for the current endourologic mission can be the difference between failure and success. Despite all of these advances in wire design and construction, a 0.038-inch–diameter straight, flexible-tip, Teflon-coated stainless steel wire is still an excellent choice for most cases.

Dilation Devices

Ureteral dilation is less necessary for ureteroscopy with the advent of smaller-diameter ureteroscopes. Hudson et al. (2005) determined that the need for dilation was directly related to the diameter of the ureteroscope and was as low as 0.9% for 7.4-Fr diameter scopes. When needed, ureteral dilation can be accomplished passively with indwelling stent placement or actively with dilating catheters or balloons. Ureteral dilating catheters are hydrophilic-coated polyurethane catheters tapered from a 6-Fr tip to 12-Fr shaft and are passed over a wire to dilate the ureter (Gaylis et al., 2000). Ureteral balloon dilators are also passed over a wire, have a low profile of 3 to 8 Fr, and have dilation diameters of 12 to 30 Fr. **Dilation of the ureter beyond 15 Fr is rarely necessary for routine ureteroscopy.** Balloons can have maximum inflation pressures of 8 to 20 atmospheres depending on the design and the balloon material. Zero-tip design ureteral balloon dilators are useful for dilating immediately adjacent to an impacted ureteral calculus. Ureteroscopic balloon dilators are 3 Fr in size, can be inflated to 12 Fr, and are passed directly through the ureteroscope. They are used to dilate under direct vision such as dilation of stenotic infundibula or calyceal diverticular necks. Once inflated, these ureteroscopic balloons cannot be removed through the ureteroscope but must be removed together with the ureteroscope.

Intraluminal Lithotripsy Devices

Intraluminal lithotripsy can be performed with several different modalities. Electrohydraulic lithotripsy (EHL) is widely available worldwide and is cost-effective. Fragmentation of calculi is produced by shock waves from an electric spark generated on the tip of the electrode (Denstedt and Clayman, 1990). Fragmentation of most calculi is good but is less effective for denser calculi compositions such as cystine or calcium oxalate monohydrate. The small, flexible EHL probes can be used with both rigid and flexible ureteroscopes. EHL can cause ureteral trauma because the energy is poorly focused. Although this rarely results in stricture formation, it can hinder visibility. It is also alarmingly easy to damage the ureteroscope when using EHL. For all of these problems, EHL is now rarely used.

Pneumatic lithotripsy devices fragment calculi using mechanical ("jackhammer") energy (Schulze et al., 1993). Fragmentation is very good, and the potential for ureteral injury is low. Unfortunately, the mechanical energy can produce significant stone retropulsion. The rigid probes are limited to use with rigid scopes. There are flexible probes available that can be used with flexible ureteroscopes, but they significantly restrict scope deflection (Zhu et al., 2000).

The pulsed dye laser was the first laser successfully used for intraluminal lithotripsy. This energy is no longer used because of the inability to fragment specific compositions of calculi and the high cost of purchase and maintenance. **The holmium:YAG laser has become the intraluminal lithotripsy energy of choice. It has a wavelength of 2100 nanometers, which is absorbed in 3 millimeters of water, making it very safe for use in urology** (Blomley et al., 1995). Fragmentation is produced by a photothermal reaction with the crystalline matrix of calculi and produces stone dust rather than fragments, effectively removing a moderate volume of the stone (Zagone et al., 2002). The flexible quartz fibers can be used with both rigid and flexible ureteroscopes and are reusable. The holmium laser is effective for any composition of calculi (Bagley and Erhard, 1995; Denstedt et al., 1995; Erhard and Bagley, 1995; Grasso, 1996).

Stone-Retrieval Devices

The essential components of stone-retrieval devices include the control handle, the control wire, the sheath, and the device itself. These instruments have shaft diameters that vary in size from 1.9 to 7.0 Fr. Devices for ureteroscopy are 3.0 Fr or smaller to fit in the working channel while leaving enough room for adequate irrigation. Larger-diameter devices are used for cystoscopic or percutaneous procedures.

Three-pronged grasping forceps are the safest instruments for removing calculi with the flexible ureteroscope. They reliably release stones that are too large to retrieve from the ureter safely. The weaker grasp will merely release the stone if too much force is applied, preventing damage to the ureter. Care not to basket an irretrievable-sized stone is critical when using a flexible ureteroscope without a second working channel. A second working channel permits fragmentation of an unyielding stone trapped within a basket in the other channel. Rigid ureteroscopes with two working channels have this additional degree of safety, allowing the more routine use of baskets for removal of ureteral calculi. Although three-pronged graspers are the safest devices for ureteroscopic stone removal, they are seldom used because of improvements in the design and safety of stone baskets.

Stone baskets are available in helical, flat-wire, and other shapes. Baskets can also vary in the number and type of wires used. Two sheathing materials—PTFE and polyimide—are commonly used for working instruments including stone baskets. A sheath made of polyimide is durable but stiff and limits deflection of the flexible ureteroscope. PTFE does not limit deflection as much as polyimide but is less durable and prone to stretching. Hybrid sheath designs incorporate Teflon at the tip and polyimide in the shaft, maximizing the advantages of each material. Helical baskets can be made with three, four, or double-wire designs with six or more wires. The double-wire designs have improved opening strength, which may facilitate removal of impacted calculi. Other basket designs unwind the dual wires, exposing more wires on the distal end of the basket, making them useful for removing multiple small fragments. Helical baskets have round wires and, unlike flat wire baskets, are safe to rotate within the ureter. They are opened above the stone and pulled down while rotating the basket to engage the stone.

Flat wire baskets are nonhelical and are designed to have larger spaces between the four wires to allow engagement of larger stones. They were initially designed for percutaneous use, where, by filling the calyx when opened, they could more easily engage calyceal stones. They are also useful for biopsy of papillary ureteral tumors (Bagley, 1998).

Several basket designs attempt to combine the safety of three-prong graspers with the solid grasp of baskets, the Graspit and Dakota from Boston Scientific (Natick, MA) and NGage from Cook Urological (Spencer, IN). These tipless devices open at the distal end like three-pronged graspers and are advanced onto the stone, permitting easier disengagement of a calculus that is too large to withdraw from the ureter safely.

The most recent material innovation is the use of nitinol for the basket wires. The soft nitinol wires have memory, maintain their shape, resist kinking, and therefore open more safely and allow disengagement of stones more reliably than stainless steel baskets. The unique qualities of nitinol also enable basket construction in a tipless fashion. These tipless baskets are soft and safe for use in the ureter and can be more fully deployed in a calyx without the interference from the tip, unlike stainless steel baskets.

Retropulsion Prevention Devices

Intraluminal lithotripsy within the ureter can propel the stone proximally (“retropulsion”). The amount of retropulsion depends on the size and location of the stone, the degree of ureteral dilation, and the lithotripsy energy used. Retropulsion of a stone back into the kidney is not a problem and is sometimes desirable. The now renal calculus can be treated with a flexible ureteroscope. However, prevention of retropulsion may be more expeditious and is particularly important for situations in which no flexible ureteroscope is available.

There are several devices designed to prevent retropulsion of ureteral stones (Fig. 13.14): The Stone Cone and LithoCatch (Boston Scientific, Natick, MA), the NTrap (Cook Urological, Spencer, IN), and the Accordian and CoAx (Accordian Medical, Indianapolis, IN) (Eisner and Dretler, 2009; Wang et al., 2011; Wu et al., 2013). The Stone Cone is a 3-Fr device with a distal coil that can be deployed above the stone before fragmentation to help prevent stone migration. After fragmentation of the stone, it can be withdrawn to remove fragments. Any fragments too large to safely remove are left behind because the coil simply unravels around the stone. The NTrap device is a 2.8-Fr device with a meshlike wire basket that deploys perpendicular to the shaft, preventing migration of all but the smallest stone fragments. A unique solution to prevent stone retropulsion was the use of a reverse-thermosensitive gel (Rane et al., 2010). The gel was injected above the stone, conforming to and completely occluding the ureter. The deployment catheter was removed after injection of the gel, preventing hindrance of the ureteroscopic procedure. The gel could then be dissolved by irrigating with cold saline solution. This gel is no longer available, but other similar approaches may be developed in the future.



FIG. 13.14 Stone migration devices designed to prevent stone retropulsion during lithotripsy. *From left to right:* NTrap (Cook Medical, Bloomington, IN), Accordion (PercSys, Palo Alto, CA), and Stone Cone (Boston Scientific, Natick, MA).

Miscellaneous Devices

Other devices are available for use during ureteroscopy. Small 3-Fr cup biopsy forceps can be used for biopsy of sessile tumors. A larger biopsy forceps, the

BIGopsy (Cook Urological, Spencer, IN) provides a much more substantial biopsy specimen, which may improve diagnostic yield (Wason et al., 2012). The large forceps requires backloading of the device into the ureteroscope, and it must be removed together with the ureteroscope after the biopsy. Electrodes are available in various shapes including pencil-tip, ball-tip, angled-tip, and straight-tip. These can be used for fulguration and incisional procedures such as endoureterotomy and endopyelotomy.

Ureteral Access Sheaths

Ureteral access sheaths allow repeated access to the intrarenal collecting system without having to replace the working guidewire with each passage of the endoscope (Fig. 13.15). They are available in 11- to 16-Fr sheath outer diameters. Table 13.7 lists the currently available ureteral access sheaths.

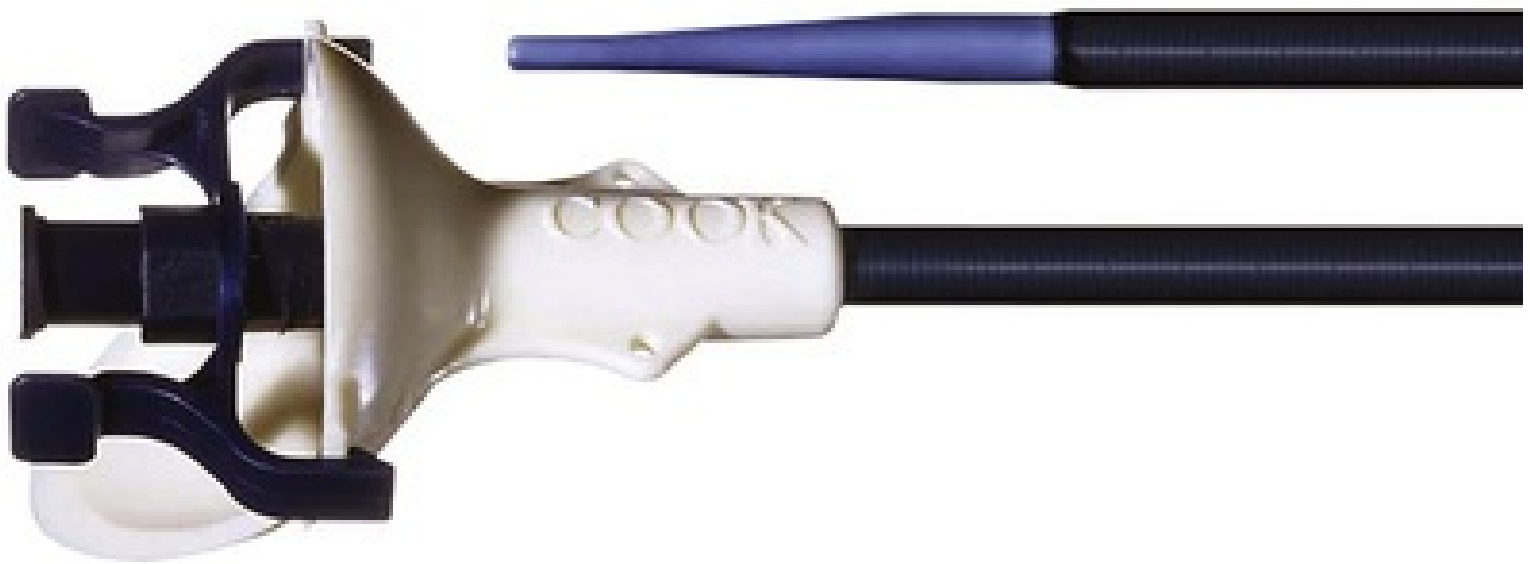

FIG. 13.15 The distal *(top)* and proximal *(bottom)* portions of a typical ureteral access sheath. The distal portion of the internal obturator *(blue)* is tapered. The access sheath is placed over a super-stiff guidewire and the internal obturator is removed before ureteroscope insertion. The proximal end of the obturator accepts a Luer-Lock syringe, facilitating retrograde pyelography.

TABLE 13.7

Characteristics of Currently Available Ureteral Access Sheaths

MANUFACTURER	SHEATH NAME	DILATOR/SHEATH (Fr)	LENGTHS (cm)	UNIQUE FEATURES
Boston Scientific	Navigator	11/13 13/15	28, 36, 46	
	Navigator HD	11/13 12/14 13/15	28, 36, 46	

Applied	Forte (AxP and HD)	10/12–16; 12/14–18; 14/16–18	20, 28, 35, 45, 55	
	Forte Plus	10/14	35, 55	Active deflecting mechanism
Bard	Proxis	10/12 12/14	25, 35, 45	
Cook	Flexor	9.5/11; 12/13.7; 14/16	13, 20, 28, 35, 45, 55	
	Flexor DL	9.5/14; 12/16.7	13, 20, 28, 35, 45, 55	Dual-lumen design
	Flexor Parallel	9.5/11; 12/13.7; 14/16	13, 20, 28, 35, 45, 55	Rapid release design for single wire external to sheath
Olympus	UroPass	10/12 11/13 12/14 13/15	24, 38, 46, 54	

In addition to facilitating stone fragment retrieval, access sheaths have been shown to decrease the intrapelvic pressure during ureteroscopy, which may reduce the risk for infectious complications from pyelovenous backflow (Auge et al., 2004). Their primary disadvantage is related to their size and their (small) potential for ureteral injury (Delvecchio et al., 2003; Traxer and Thomas, 2013). Furthermore, the majority of intrarenal stones only require a single passage of the ureteroscope to access and completely fragment the calculi. For these cases, an access sheath is usually unnecessary.

Fluoroscopy Equipment

Fluoroscopy is used for ureteroscopic procedures and is helpful for initial ureteral access, monitoring during endoscopy, and stent placement. Although tables designed for urologic endoscopy with fixed fluoroscopy units are available, mobile C-arm fluoroscopy units are preferable. **C-arm fluoroscopy units allow greater mobility, improved image quality, and less scatter radiation exposure to the surgeon because the x-ray source is below the patient.** Modern C-arm fluoroscopy units incorporate digital enhancement of the image and “last image hold” technology to minimize radiation exposure.

Exposure can also be decreased by using image collimation and pulsed fluoroscopy. The urologist should control the fluoroscopy unit with foot pedal control, which will facilitate the speed of the case and minimize excessive fluoroscopy time. When possible, collimation and pulsed fluoroscopy should be employed to further limit exposure. Several recent "fluoroless" ureteroscopy series have been published calling into question the need for imaging during routine cases (Hsi and Harper, 2013; Olgin et al., 2015).

Ureteroscopy Technique

Preparation for Ureteroscopy

As with cystoscopy, a urinalysis, and urine culture if indicated, should be performed before performing upper-tract endoscopy. Urinary tract infections are treated preoperatively with culture-specific antibiotics. According to the AUA Best Practice Policy Statement, **all patients undergoing upper-tract endoscopy should receive antibiotic prophylaxis. Agents of choice include a fluoroquinolone or trimethoprim-sulfamethoxazole with an aminoglycoside plus or minus ampicillin; a first- or second-generation cephalosporin; or amoxicillin/clavulanate** (Wolf et al., 2008). First- and second-generation cephalosporins are also considered first-line agents in patients undergoing PCNL. In contrast, the EAU's Urological Infections guidelines cite a lack of controlled trials on ureteroscopy (Bonkat et al., 2017). As a result, prophylaxis for low-risk procedures (e.g., simple diagnostic ureteroscopy and treatment of distal ureteral stones) are left to clinician discretion. The EAU recommends prophylaxis with trimethoprim plus or minus sulfamethoxazole; amoxicillin/clavulanate; or a second- or third-generation cephalosporin in patients undergoing percutaneous stone extraction.

Anesthesia can be general (endotracheal or laryngeal mask), regional, or local with sedation (Hosking and Bard, 1996; Vögeli et al., 1993). It is essential to inform the anesthesia provider about the need for the patient to remain still throughout the procedure. Significant patient movement during rigid ureteroscopy can result in ureteral injury or perforation.

Endourologic procedures should be performed in a fully equipped operating room. The urologist should be prepared for any unanticipated problem encountered. In addition to conventional Teflon-coated stainless steel guidewires, angled hydrophilic, nitinol core, and extra-stiff guidewires should be readily available. Dilation devices including dilating catheters, high-pressure balloon catheters, and zero-tipped balloon catheters are standard. Angled catheters that can be reliably rotated or “torqued” are very useful for gaining access beyond impacted calculi, strictures, or tortuous ureters. These include the Imager II catheter (Boston Scientific, Natick, MA) and the Kumpe catheter (Cook Urological, Spencer, IN). The urologist should be very familiar with the endoscopes available and the size of their working channels to choose appropriately sized working instruments when needed (see Tables 13.5 and 13.6). The largest working channels of most of the fiber-optic rigid ureteroscopes are just over 3 Fr, so devices 3 Fr or less are appropriate. A variety of additional flexible and semirigid ureteroscopes should also be kept ready to ensure availability of appropriately functioning endoscopic equipment to treat pathology regardless of location in the upper urinary tract. Table 13.8 lists items commonly needed items for successful ureteroscopy.

TABLE 13.8

Common Supplies for Ureteroscopy

URETEROSCOPES

- Rigid
  - 7 Fr or smaller semirigid ureteroscope
  - Larger ureteroscope with straight working channel (optional)
- Flexible
  - 7.5 Fr
  - 8.6 Fr or larger
  - Secondary deflection or exaggerated deflection–capable ureteroscope

DISPOSABLE SUPPLIES

- Guidewires
  - 0.038 Angled hydrophilic
  - 0.038 Straight Teflon coated
  - 0.038 Nitinol core, polyurethane coated
  - 0.038 Extra-stiff
- Irrigation
  - Power irrigation device
  - High-pressure working port seal
- Stone-retrieval devices (3.0 Fr or smaller)
  - Helical basket
  - Tipless basket
  - Three-prong grasping forceps or equivalent
- Catheters
  - Dual-lumen catheter

- 6- to 12-Fr Dilating catheter
- 5-Fr Open-ended catheter
- 5-Fr Angled-tip torque-able catheter

Dilation devices
- High-pressure ureteral dilating balloons (5–7 mm)
- “Zero-tip” ureteral dilating balloon

Biopsy devices
- 3-Fr Cup biopsy
- Flat-wire basket
- BIGopsy (optional)

Ureteral stents
- 5- to 7-Fr, 20- to 28-cm, double-pigtail

INTRALUMINAL LITHOTRIPSY DEVICES

Holmium laser
Pneumatic (optional)
Electrohydraulic (optional)

Accessing the Ureter

The patient is placed in the cystolithotomy position. If a longer rigid ureteroscope is being used, the contralateral leg is elevated to allow for the easier introduction of the ureteroscope. With the advent of improved flexible ureteroscopes, most rigid ureteroscopy is confined to the ureter below the iliac vessels, and shorter rigid ureteroscopes can be routinely used decreasing interference from the contralateral leg.

Cystoscopy is performed to inspect the bladder fully and place a safety guidewire. Usually, a simple 0.038-inch–diameter flexible-tip Teflon-coated guidewire is sufficient. A safety wire is useful during rigid ureteroscopy, to maintain access and allow placement of a ureteral stent if any problems are encountered. Care must be taken when trying to gain access around an impacted stone as you can easily perforate the ureter. Manipulation of the wire around the stone may require the use of an angled hydrophilic-coated wire, an angled torquable catheter, or both. If a guidewire cannot be safely passed beyond the stone, direct inspection of the ureter up to the stone with the rigid ureteroscope will permit passage of the wire under direct vision. Once access above the stone is achieved, the hydrophilic wire is exchanged for a more secure standard 0.038-inch diameter Teflon-coated guidewire. If there is any suspicion about possible infection above the stone, an open-ended catheter should be passed over the wire to aspirate the renal pelvis. The hydronephrosis can be decompressed to permit irrigation, and if the fluid appears turbid, a stent is placed and the ureteroscopy postponed until treatment of the infection. Before proceeding with the ureteroscopy, the bladder is drained to permit the accumulation of irrigation fluid during ureteroscopy and minimize buckling of the flexible ureteroscope into the bladder (Fig. 13.16).

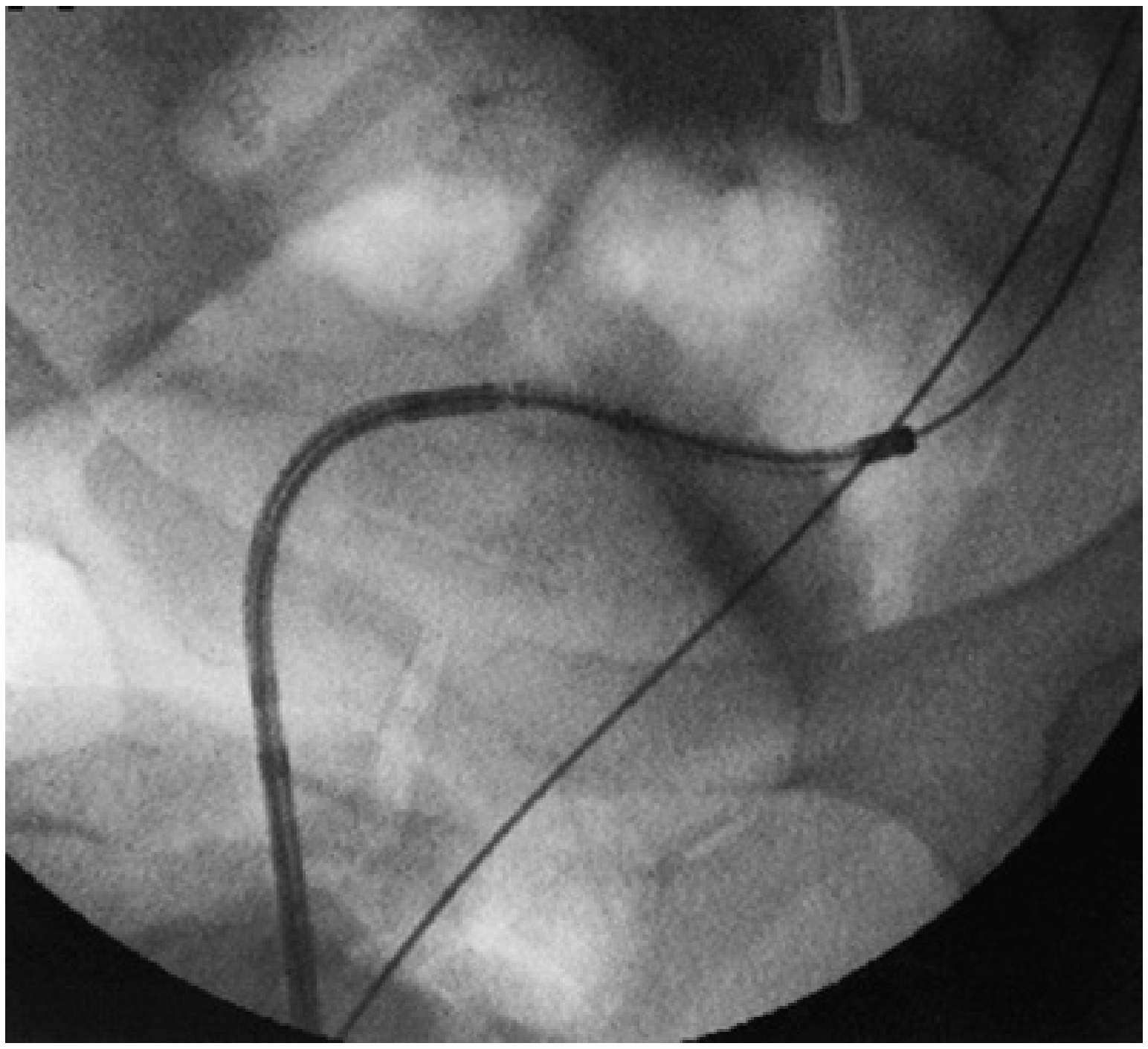

FIG. 13.16 The bladder should be emptied before flexible ureteroscope passage to prevent buckling of the instrument within the bladder if resistance is met at the ureteral orifice.

Semirigid Ureteroscopy Technique

Flexible ureteroscopes better accommodate the natural tortuosity of the ureter, and their deflection provides better access to the intrarenal collecting system than semirigid ureteroscopes. For these reasons, semirigid ureteroscopy is generally limited to the ureter distal to the iliac vessels.

Semirigid ureteroscopy begins with cystoscopic placement of a safety guidewire in the ureter. The ureteroscope is then introduced through the urethra, into the bladder under direct vision usually with the aid of the video camera. By visually following the guidewire, the ureteral orifice is easily identified. By maneuvering the tip of the ureteroscope next to the guidewire posterolaterally, the wire can be elevated, thereby propping the ureteral orifice open to allow scope passage. If necessary, an additional wire can be passed through the ureteroscope into the ureter just beyond the intramural segment. The ureteroscope is then rotated until it is directly between the two wires, which will hold the orifice widely open for entry of the scope (Fig. 13.17). Once the ureteroscope is through the intramural ureter, the additional guidewire can be removed. This technique is also useful when negotiating through tortuous segments of the ureter and above the iliac vessels.

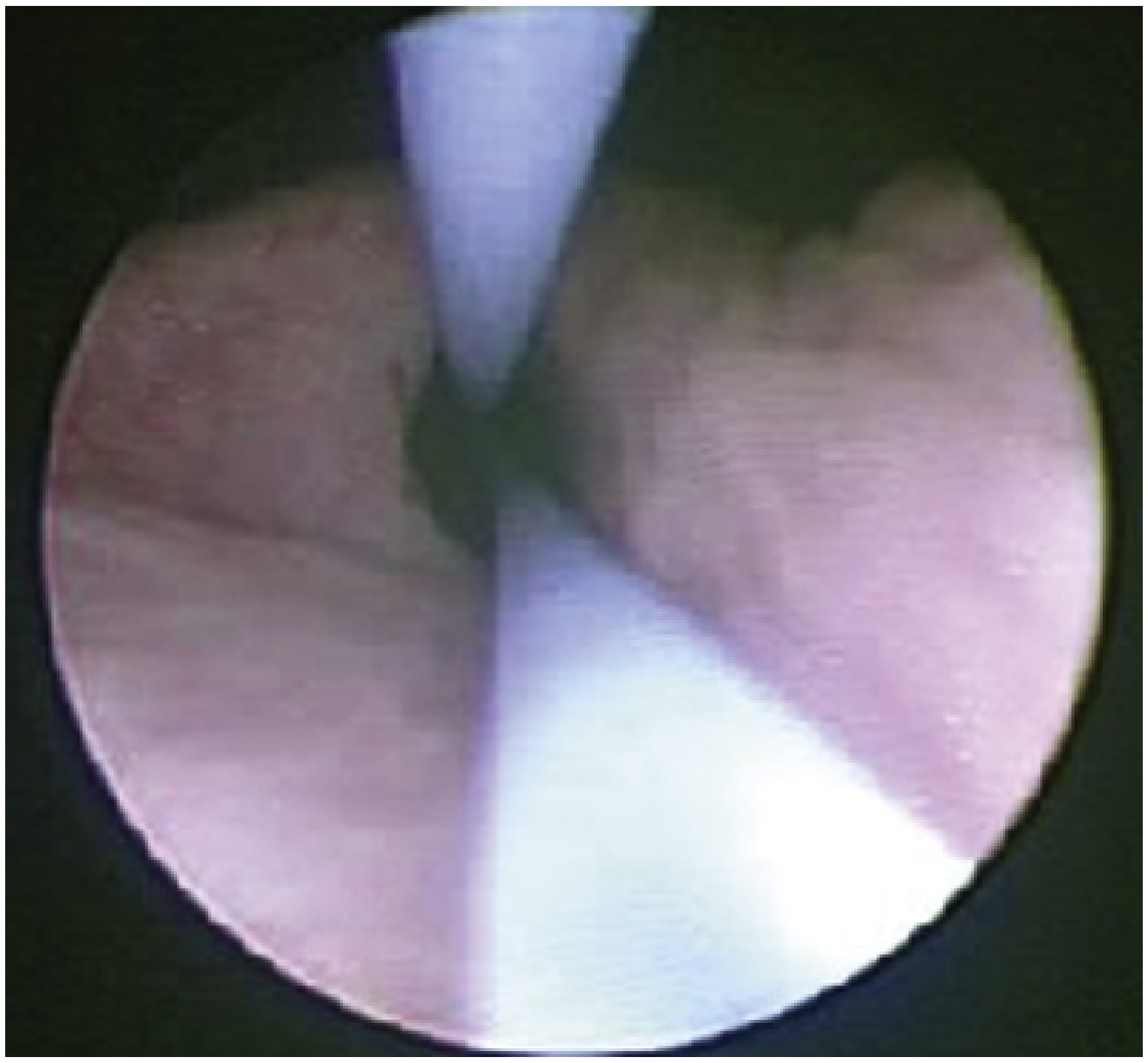

FIG. 13.17 Semirigid ureteroscope passage between two wires. After safety wire placement *(bottom wire)*, a second wire *(top wire)* is passed through the working channel and up the ureter using fluoroscopic guidance to “tent open” the ureteral orifice. The ureteroscope is then gently advanced between the wires until ureteral access is achieved.

If the intramural ureter is too tight to allow safe passage of the ureteroscope, a balloon catheter can be used to dilate the orifice. A 4-mm–diameter balloon is sufficient. If there is a stricture beneath a stone that prevents safe visualization and lithotripsy, dilation beneath the stone is performed with a zero-tip balloon catheter. This catheter can be passed over the safety wire immediately below the stone so dilation of the stenotic segment can be achieved. The ureteroscope can then be safely introduced and the stone visualized. If a ureteral stone is impacted, it can be helpful to gently manipulate it with the tip of the ureteroscope proximally out of the traumatized area of ureter for improved visibility and safer lithotripsy. If this is not possible, the holmium laser energy can be used in a “drill and core” technique. Using this method, we ablate the central portion of the stone, and the outer shell of the stone will partially protect the ureteral wall. The later collapsed outer shell can then be safely fragmented. Ureteral stones can be “dusted” until no fragments are greater than 2 mm or cleaved until the fragments are small enough to be easily removed with a helical basket. A stent is placed and generally left for 3 to 7 days.

Flexible Ureteroscopy Technique

After the guidewire is placed in the ureter, the cystoscope is removed, and a dual-lumen catheter is passed over the wire. This catheter is 10 Fr, which will gently dilate the ureteral orifice and allow placement of a second, working wire. The flexible ureteroscope is then passed in a monorail fashion over the taut working wire to the point of the pathology. Dilation of the ureteral orifice with the dual-lumen catheter is usually sufficient to permit passage of the flexible ureteroscope.

The working channel of flexible ureteroscopes is not centrally located, so the tip of the ureteroscope will be eccentrically positioned relative to the guidewire. If the flexible ureteroscope does not pass the ureteral orifice, it should be rotated 90 to 180 degrees on the guidewire to better position the tip of the ureteroscope relative to the ureteral orifice. If difficulty passing the flexible ureteroscope through the ureteral orifice is still encountered, a dilating catheter (Nottingham) or a dilating balloon catheter can be used to dilate the ureteral orifice. **Formal ureteral dilation is reported in most ureteroscopy series to be needed in 8% to 25% of patients and has decreased with the advent of smaller-diameter flexible ureteroscopes** (Elashry et al., 1997; Grasso and Bagley, 1998; Tawfiek and Bagley, 1999). However, a more recent study of 11,885 patients at 114 centers in 32 countries found a ureteral dilation rate of 33.7%, indicating it remains a common practice worldwide (de la Rosette et al., 2014).

Traditionally, a safety wire has been used during upper-tract endoscopy to maintain access throughout the procedure, allowing for ureteral stent placement should injury to the ureter occur. However, with continued miniaturization of ureteroscopes and more widespread adoption of upper-tract endoscopic techniques, the utility of the safety wire has been called into question (Dutta et al., 2016).

If the passage of the flexible ureteroscope is difficult in the absence of any significant ureteral stricture or another source of obstruction, the use of a nitinol core polyurethane-coated guidewire may be helpful. As previously discussed, these stiffer, smoother wires enable more efficient transmission of the push from the urologist to the tip of the ureteroscope.

The basic movements of the flexible ureteroscope include deflection, rotation, and advancing and retreating the ureteroscope. The reticle of the flexible ureteroscope marks the plane of deflection, and rotation of the ureteroscope is often necessary to align this plane of deflection in the direction desired. **Failure to adequately rotate the ureteroscope is the most common mistake of the novice ureteroscopist.** Irrigation through the ureteroscope should be provided with a pressurized irrigation bag, pump, or handheld syringe. Irrigation must be well controlled and only delivered when needed to clear the visual field. **Normal saline should be used to prevent accumulation and absorption of a hypotonic solution and resultant "TUR syndrome."**

When using the holmium laser, it is essential to pass the laser fiber through a straightened flexible ureteroscope—confirmed fluoroscopically—to prevent damage to the working channel. Once the fiber is advanced beyond the tip, the ureteroscope can be deflected appropriately. The most commonly used sizes of holmium laser fibers include the 365-micron fiber and the 200-micron fiber. When significant deflection of the ureteroscope is needed, the more flexible 200-micron fiber is preferred, as it limits the deflection of the ureteroscope less than larger fibers. The tip of the fiber must be in contact with the stone during treatment because the holmium laser energy is absorbed in 3 mm of water. **The holmium laser can damage the ureteroscope, the guidewire, and the ureteral wall. These problems can be avoided by not activating the laser unless the tip of the fiber is seen in contact with the stone** (Beaghler et al., 1998). Additionally, if the helium-neon aiming beam is not visible, the laser should not be activated, as this may be an indication of fiber damage. Firing the holmium laser through a broken fiber can cause significant damage to the ureteroscope.

Once the pathology has been adequately addressed, a ureteral stent is usually placed and left indwelling for 3 to 5 days. Postoperative pain management can be facilitated with the use of a COX-2 inhibitor, an alpha-adrenergic blocker, or both (Nazim and Ather, 2012).

Key Points: Ureteroscopy

- Semirigid ureteroscopy is used below the iliac vessels and flexible ureteroscopy above.
- Semirigid ureteroscopes with two working channels permit better irrigation and the added safety of being able to pass a lithotripsy device through one channel when needing to fragment a stone engaged in a basket in the other channel.
- Flexible ureteroscopes must be straight when passing a laser fiber, or the working channel will be damaged.
- The golden rule of safe laser lithotripsy: “Do not step on the pedal if you cannot see the tip of the fiber in contact with the stone.”
- Stone baskets made of nitinol maintain their shape, resist kinking, and allow disengagement of stones more reliably than stainless steel baskets.
- Ureteral access sheaths facilitate repeated passage of flexible ureteroscopes and decrease the intrapelvic pressure during ureteroscopy.
- Mobile C-arm fluoroscopy is preferred because of greater mobility, improved image quality, and less scatter radiation exposure to the surgeon compared with urology tables with fixed fluoroscopy units.
- A routine preoperative antibiotic should be given to all patients undergoing ureteroscopy.
- Normal saline should be used as irrigation during ureteroscopy to prevent absorption of a hypotonic solution.

Conclusion

Over the past 150 years, tremendous advances have been made in endoscope design revolutionizing urologic surgery. Visualization of both the upper and lower urinary tracts is now routinely performed with rigid and flexible endoscopes. A variety of urologic conditions can be evaluated efficiently with minimal discomfort in the office by flexible cystoscopy. A wide array of benign and malignant pathologies affecting the bladder and urethra can be managed transurethrally with rigid cystourethroscopes in the operating room with limited morbidity. Improvements in flexible ureteroscopes, working instruments, and endoscopic techniques have significantly improved our ability to effectively treat upper urinary tract problems as well. With continued innovation and refinement, the role of ureteroscopy in the treatment of complex intrarenal calculi, ureteral obstruction, and upper-tract tumors should continue to grow.

Suggested Readings

Bonkat G, Pickard R, Bartoletti R, et al. *Urologic Infections. In European Association of Urology [Internet]*. http://uroweb.org/guideline/urological-infections/#1_4; 2017.

Natalin RA, Landman J. Where next for the endoscope? *Nat Rev Urol*. 2009;6:622–628.

Patel AR, Jones JS, Babineau D. Lidocaine 2% gel versus plain lubricating gel for pain reduction during flexible cystoscopy: a meta-analysis of prospective, randomized, controlled trials. *J Urol*. 2008;179:986–990.

Proietti S, Laurian D, Wilson M, et al. Comparison of new single-use digital flexible ureteroscope versus nondisposable fiber optic and digital ureteroscope in a cadaveric model. *J Endourol*. 2016;30(6):655–659.

Somani BK, Al-Qahtani SM, de Medina SD, et al. Outcomes of flexible ureterorenoscopy and laser fragmentation for renal stones: comparison between digital and conventional ureteroscope. *Urology*. 2013;82:1017–1019.

Wolf JS Jr, Bennett CJ, Dmochowski RR, et al. Best practice policy statement on urologic surgery antimicrobial prophylaxis. *J Urol*. 2008;179:1379–1390.

References

Aaronson DS, Walsh TJ, Smith JF, et al. Meta-analysis: does lidocaine gel before flexible cystoscopy provide pain relief? *BJU Int*. 2009;104:506–509 [discussion 509–10].

Afane JS, Olweny EO, Bercowsky E, et al. Flexible ureteroscopes: a single center evaluation of the durability and function of the new endoscopes smaller than 9Fr. *J Urol*. 2000;164:1164–1168.

Ankem MK, Lowry PS, Slovick RW, et al. Clinical utility of dual active deflection flexible ureteroscope during upper tract ureteropyeloscopy. *Urology*. 2004;64:430–434.

Assimos D, Krambeck A, Miller NL, et al. Surgical Management of Stones: American Urological Association/Endourological Society Guideline, Part II. *J Urol*. 2016;196:1161–1169.

Auge BK, Pietrow PK, Lallas CD, et al. Ureteral access sheath provides protection against elevated renal pressures during routine flexible ureteroscopic stone manipulation. *J Endourol*. 2004;18:33–36.

Bach C, Nesar S, Kumar P, et al. The new digital flexible ureteroscopes: ‘size does matter’—increased ureteric access sheath use!. *Urol Int*. 2012;89:408–411.

Bach T, Netsch C, Herrmann TRW, et al. Objective assessment of working tool impact on irrigation flow and visibility in flexible ureterorenoscopes. *J Endourol*. 2011;25:1125–1129.

Bagley D, Erhard M. Use of the holmium laser in the upper urinary tract. *Tech Urol*. 1995;1:25–30.

Bagley DH. Flexible ureteroscopy. *Semin Urol*. 1989;7:7–15.

Bagley DH. Ureteroscopic laser treatment of upper urinary tract tumors. *J Clin Laser Med Surg*. 1998;16:55–59.

Bagley DH, Huffman JL, Lyon ES. Combined rigid and flexible ureteropyeloscopy. *J Urol*. 1983;130:243–244.

Bagley DH, Huffman JL, Lyon ES. Flexible ureteropyeloscopy: diagnosis and treatment in the upper urinary tract. *J Urol*. 1987;138:280–285.

Bagley DH, Liu JB, Goldberg BB, et al. Endopyelotomy: importance of crossing vessels demonstrated by endoluminal ultrasonography. *J Endourol*. 1995;9:465–467.

Bagley DH, Rittenberg MH. Intrarenal dimensions. Guidelines for flexible ureteropyeloscopes. *Surg Endosc*. 1987;1:119–121.

Beaghler M, Poon M, Ruckle H, et al. Complications employing the holmium:YAG laser. *J Endourol*. 1998;12:533–535.

Berry A, Barratt A. Prophylactic antibiotic use in transurethral prostatic resection: a meta-analysis. *J Urol*. 2002;167:571–577.

Blomley MJ, Nicholson DA, Bartal G, et al. Penetration of the holmium:YAG laser through fluid. *J Vasc Interv Radiol*. 1995;6:903–910.

Bonkat G, Pickard R, Bartoletti R, et al. Urologic Infections [Internet]. *European Association of Urology*. 2017 http://uroweb.org/guideline/urological-infections/#1_4.

Breda A, Ogunyemi O, Leppert JT, et al. Flexible ureteroscopy and laser lithotripsy for single intrarenal stones 2 cm or greater—is this the new frontier? *J Urol*. 2008;179:981–984.

Bryan RT, Billingham LJ, Wallace DMA. Narrow-band imaging flexible cystoscopy in the detection of recurrent urothelial cancer of the bladder. *BJU Int*. 2008;101:702–705 [discussion 705–6].

Canales BK, Gleason JM, Hicks N, et al. An independent analysis of flexible cystoscope repairs and cost. *J Urol*. 2007;178:2098–2101 [discussion 2102].

Carey RI, Martin CJ, Knego JR. Prospective evaluation of refurbished flexible ureteroscope durability seen in a large public tertiary care center with multiple surgeons. *Urology*. 2014;84:42–45.

Conlin MJ, Bagley DH. Ureteroscopic endopyelotomy at a single setting. *J Urol*. 1998;159:727–731.

Conlin MJ, Marberger M, Bagley DH. Ureteroscopy. Development and instrumentation. *Urol Clin North Am*. 1997;24:25–42.

Cutress ML, Stewart GD, Wells-Cole S, et al. Long-term endoscopic management of upper tract urothelial carcinoma: 20-year single-centre experience. *BJU Int*. 2012;110:1608–1617.

Delvecchio FC, Auge BK, Brizuela RM, et al. Assessment of stricture formation with the ureteral access sheath. *Urology*. 2003;61:518–522 [discussion 522].

Denstedt JD, Clayman RV. Electrohydraulic lithotripsy of renal and ureteral calculi. *J Urol*. 1990;143:13–17.

Denstedt JD, Razvi HA, Sales JL, et al. Preliminary experience with holmium: YAG laser lithotripsy. *J Endourol*. 1995;9:255–258.

Dooley RE, Pietrow PK. Ureteroscopy for benign hematuria. *Urol Clin North Am*. 2004;31:137–143.

Dutta R, Vyas A, Landman J, et al. Death of the Safety Guidewire. *J Endourol*. 2016;30:941–944.

Eisner BH, Dretler SP. Use of the Stone Cone for prevention of calculus retropulsion during holmium:YAG laser lithotripsy: case series and review of the literature. *Urol Int*. 2009;82:356–360.

El Masri YWS, Patil S, Prasanna KV, et al. To cystoscope or not to cystoscope patients with traumatic spinal cord injuries managed with indwelling urethral or suprapubic catheters? That is the question!. *Spinal Cord*. 2014;52:49–53.

Elashry OM, Elbahnasy AM, Rao GS, et al. Flexible ureteroscopy: Washington University experience with the

9.3F and 7.5F flexible ureteroscopes. *J Urol*. 1997;157:2074–2080.

Emiliani E, Breda A. Laser endoureterotomy and endopyelotomy: an update. *World J Urol*. 2015;33:583–587.

Engel RME. Philipp Bozzini—the father of endoscopy. *J Endourol*. 2003;17:859–862.

Erhard MJ, Bagley DH. Urologic applications of the holmium laser: preliminary experience. *J Endourol*. 1995;9:383–386.

Gaylis F, Bastuba M, Bidair M, et al. Ureteral dilation using a tapered dilator: a cost-effective approach. *J Endourol*. 2000;14:447–449.

Gow JG. Harold Hopkins and optical systems for urology—an appreciation. *Urology*. 1998;52:152–157.

Grasso M. Experience with the holmium laser as an endoscopic lithotrite. *Urology*. 1996;48:199–206.

Grasso M, Bagley D. A 7.5/8.2 F actively deflectable, flexible ureteroscope: a new device for both diagnostic and therapeutic upper urinary tract endoscopy. *Urology*. 1994;43:435–441.

Grasso M, Bagley D. Small diameter, actively deflectable, flexible ureteropyeloscopy. *J Urol*. 1998;160:1648–1653 [discussion 1653–4].

Grasso M, Conlin M, Bagley D. Ureteroscopic treatment of large (> 2 cm) upper urinary tract calculi: multicenter experience. *J Endourol*. 1997;11:S97.

Grasso M, Fishman AI, Cohen J, et al. Ureteroscopic and extirpative treatment of upper urinary tract urothelial carcinoma: a 15-year comprehensive review of 160 consecutive patients. *BJU Int*. 2012;110:1618–1626.

Gregory E, Simmons D, Weinberg JJ. Care and sterilization of endourologic instruments. *Urol Clin North Am*. 1988;15:541–546.

Gunendran T, Briggs RH, Wemyss-Holden GD, et al. Does increasing hydrostatic pressure (“bag squeeze”) during flexible cystoscopy improve patient comfort: a randomized, controlled study. *Urology*. 2008;72:255–258 [discussion 258–9].

Haberman K, Ortiz-Alvarado O, Chotikawanich E, et al. A dual-channel flexible ureteroscope: evaluation of deflection, flow, illumination, and optics. *J Endourol*. 2011;25:1411–1414.

Herr HW. Max Nitze, the cystoscope and urology. *J Urol*. 2006;176:1313–1316.

Higashihara E, Minowada S, Kameyama S, et al. Angled Optical Axis for Central Viewing of Endoscopic Accessories. *J Endourol*. 1990;4:361–364.

Hosking DH, Bard RJ. Ureteroscopy with intravenous sedation for treatment of distal ureteral calculi: a safe and effective alternative to shock wave lithotripsy. *J Urol*. 1996;156:899–901 [discussion 902].

Hsi RS, Harper JD. Fluoroless ureteroscopy: zero-dose fluoroscopy during ureteroscopic treatment of urinary-tract calculi. *J Endourol*. 2013;27:432–437.

Hudson RG, Conlin MJ, Bagley DH. Ureteric access with flexible ureteroscopes: effect of the size of the ureteroscope. *BJU Int*. 2005;95:1043–1044.

Irwin BH, Berger AK, Brandina R, et al. Complex percutaneous resections for upper-tract urothelial carcinoma. *J Endourol*. 2010;24:367–370.

Ishikawa S, Abe T, Shinohara N, et al. Impact of diagnostic ureteroscopy on intravesical recurrence and survival in patients with urothelial carcinoma of the upper urinary tract. *J Urol*. 2010;184:883–887.

Jacobs BL, Lai JC, Seelam R, et al. The comparative effectiveness of treatments for ureteropelvic junction obstruction. *Urology*. 2018;111:72–77.

Johnson GB, Grasso M. Exaggerated primary endoscope deflection: initial clinical experience with prototype flexible ureteroscopes. *BJU Int*. 2004;93:109–114.

Keeley FX, Kulp DA, Bibbo M, et al. Diagnostic accuracy of ureteroscopic biopsy in upper tract transitional cell carcinoma. *J Urol*. 1997;157:33–37.

Knudsen B, Miyaoka R, Shah K, et al. Durability of the next-generation flexible fiberoptic ureteroscopes: a randomized prospective multi-institutional clinical trial. *Urology*. 2010;75:534–538.

Kramolowsky E, McDowell Z, Moore B, et al. Cost analysis of flexible ureteroscope repairs: evaluation of 655 procedures in a community-based practice. *J Endourol*. 2016;30:254–256.

Lano MD, Wagoner RD, Leary FJ. Unilateral essential hematuria. *Mayo Clin Proc*. 1979;54:88–90.

Lee F, Patel HRH, Emberton M. The “top 10” urological procedures: a study of hospital episodes statistics 1998-99. *BJU Int*. 2002;90:1–6.

L'Esperance JO, Sung J, Marguet C, et al. The surgical management of stones in patients with urinary diversions. *Curr Opin Urol*. 2004;14:129–134.

Lusch A, Liss MA, Greene P, et al. Comparison of optics and performance of a distal sensor high definition cystoscope, a distal sensor standard definition cystoscope, and a fiberoptic cystoscope. *Urology*. 2013;82:1226–1230.

Lyon ES, Banno JJ, Schoenberg HW. Transurethral ureteroscopy in men using juvenile cystoscopy equipment. *J Urol*. 1979;122:152–153.

Marino Sabo E, Stern JJ. Approach to antimicrobial prophylaxis for urology procedures in the era of increasing fluoroquinolone resistance. *Ann Pharmacother*. 2014;48:380–386.

Marshall VF. Fiber optics in urology. *J Urol*. 1964;91:110–114.

Martin CJ, McAdams SB, Abdul-Muhsin H, et al. The economic implications of a reusable flexible digital ureteroscope: a cost-benefit analysis. *J Urol*. 2017;197:730–735.

Monga M, Best S, Venkatesh R, et al. Durability of flexible ureteroscopes: a randomized, prospective study. *J Urol*. 2006;176:137–141.

Motamedinia P, Keheila M, Leavitt DA, et al. The expanded use of percutaneous resection for upper tract urothelial carcinoma: a 30-year comprehensive experience. *J Endourol*. 2016;30:262–267.

Natalin RA, Landman J. Where next for the endoscope? *Nat Rev Urol*. 2009;6:622–628.

Nazim SM, Ather MH. Alpha-blockers impact stent-related symptoms: a randomized, double-blind, placebo-controlled trial. *J Endourol*. 2012;26:1237–1241.

Okhunov Z, Hruby GW, Mirabile G, et al. Prospective comparison of flexible fiberoptic and digital cystoscopes. *Urology*. 2009;74:427–430.

Olgin G, Smith D, Alsyouf M, et al. Ureteroscopy without fluoroscopy: a feasibility study and comparison with conventional ureteroscopy. *J Endourol*. 2015;29:625–629.

Osborn NK, Baron TH. The history of the “French” gauge. *Gastrointest Endosc*. 2006;63:461–462.

Ozimek T, Schneider MH, Hupe MC, et al. Retrospective cost analysis of a single-center reusable flexible ureterorenoscopy program: a comparative cost simulation of disposable fURS as an alternative. *J Endourol*. 2017;31:1226–1230.

Patel AR, Jones JS, Angie S, et al. Office based flexible cystoscopy may be less painful for men allowed to view the procedure. *J Urol*. 2007;177:1843–1845.

Patel AR, Jones JS, Babineau D. Lidocaine 2% gel versus plain lubricating gel for pain reduction during flexible cystoscopy: a meta-analysis of prospective, randomized, controlled trials.

J Urol. 2008;179:986–990.

Patel AR, Jones JS, Babineau D. Impact of real-time visualization of cystoscopy findings on procedural pain in female patients. *J Endourol*. 2008;22:2695–2698.

Proietti S, Dragos L, Molina W, et al. Comparison of New Single-Use Digital Flexible Ureteroscope Versus Nondisposable Fiber Optic and Digital Ureteroscope in a Cadaveric Model. *J Endourol*. 2016;30:655–659.

Quayle SS, Ames CD, Lieber D, et al. Comparison of optical resolution with digital and standard fiberoptic cystoscopes in an in vitro model. *Urology*. 2005;66:489–493.

Rane A, Bradoo A, Rao P, et al. The use of a novel reverse thermosensitive polymer to prevent ureteral stone retropulsion during intracorporeal lithotripsy: a randomized, controlled trial. *J Urol*. 2010;183:1417–1421.

Rojas CP, Castle SM, Llanos CA, et al. Low biopsy volume in ureteroscopy does not affect tumor biopsy grading in upper tract urothelial carcinoma. *Urol Oncol*. 2013;31:1696–1700.

de la Rosette J, Denstedt J, Geavlete P, et al. The clinical research office of the endourological society ureteroscopy global study: indications, complications, and outcomes in 11,885 patients. *J Endourol*. 2014;28:131–139.

Samplaski MK, Jones JS. Two centuries of cystoscopy: the development of imaging, instrumentation and synergistic technologies. *BJU Int*. 2009;103:154–158.

Schulze H, Haupt G, Piergiovanni M, et al. The Swiss lithoclast: a new device for endoscopic stone disintegration. *J Urol*. 1993;149:15–18.

Sengupta S, Harewood L. Transitional cell carcinoma growing along an indwelling nephrostomy tube track. *Br J Urol*. 1998;82:591.

Shah J. Endoscopy through the ages. *BJU Int*. 2002;89:645–652.

Sharma NK, Nicol A, Powell CS. Track infiltration following percutaneous resection of renal pelvic transitional cell carcinoma. *Br J Urol*. 1994;73:597–598.

Somani BK, Al-Qahtani SM, de Medina SDG, et al. Outcomes of flexible ureterorenoscopy and laser fragmentation for renal stones: comparison between digital and conventional ureteroscope. *Urology*. 2013;82:1017–1019.

Soomro KQ, Nasir AR, Ather MH. Impact of patient's self-viewing of flexible cystoscopy on pain using a visual analog scale in a randomized controlled trial. *Urology*. 2011;77:21–23.

Strijbos WE, van der Heij B. Percutaneous resection of upper tract urothelial cell carcinoma: when, how, and is it safe? *Asian J Urol*. 2016;3:134–141.

Subramonian K, Cartwright RA, Harnden P, et al. Bladder cancer in patients with spinal cord injuries. *BJU Int*. 2004;93:739–743.

Taghizadeh AK, El Madani A, Gard PR, et al. When does it hurt? Pain during flexible cystoscopy in men. *Urol Int*. 2006;76:301–303.

Taguchi K, Usawachintachit M, Tzou DT, et al. Micro-costing analysis demonstrates comparable costs for LithoVue^{TM} compared to reusable flexible fiberoptic ureteroscopes [Internet]. *J Endourol*. 2017 http://dx.doi.org/10.1089/end.2017.0523.

Tawfiek ER, Bagley DH. Management of upper urinary tract calculi with ureteroscopic techniques. *Urology*. 1999;53:25–31.

Tawfiek ER, Liu J-B, Bagley DH. Ureteroscopic treatment of ureteropelvic junction obstruction. *J Urol*. 1999;160:1643–1647.

Thomas R, Monga M, Klein EW. Ureteroscopic retrograde endopyelotomy for management of ureteropelvic junction obstruction. *J Endourol*. 1996;10:141–145.

Traxer O, Thomas A. Prospective evaluation and classification of ureteral wall injuries resulting from insertion of a ureteral access sheath during retrograde intrarenal surgery. *J Urol*. 2013;189:580–584.

Türk C, Neisius A, Petrik A, et al. Urolithiasis [Internet]. *European Association of Urology*. 2017 http://uroweb.org/guideline/urolithiasis/.

Usawachintachit M, Isaacson DS, Taguchi K, et al. A prospective case-control study comparing LithoVue, a single-use, flexible disposable ureteroscope, with flexible, reusable fiber-optic ureteroscopes. *J Endourol*. 2017;31:468–475.

Van Cangh PJ, Wilmart JF, Opsomer RJ, et al. Long-term results and late recurrence after endoureteropyelotomy: a critical analysis of prognostic factors. *J Urol*. 1994;151:934–937.

Vince RA Jr, Klausner AP. Surveillance strategies for neurogenic lower urinary tract dysfunction. *Urol Clin North Am*. 2017;44:367–375.

Vögeli TA, Mellin HE, Hopf B, et al. Ureteroscopy under local anaesthesia with and without intravenous analgesia. *Br J Urol*. 1993;72:161–164.

Wang C-JJ, Huang S-WW, Chang C-HH. Randomized trial of NTrap for proximal ureteral stones. *Urology*. 2011;77:553–557.

Wason SEL, Seigne JD, Schned AR, et al. Ureteroscopic biopsy of upper tract urothelial carcinoma using a novel ureteroscopic biopsy forceps. *Can J Urol*. 2012;19:6560–6565.

Welk B, McIntyre A, Teasell R, et al. Bladder cancer in individuals with spinal cord injuries. *Spinal Cord*. 2013;51:516–521.

Whewell W, Faraday M, Latham RG, et al. Lectures on education, delivered at the Royal Institution of Great Britain.

JW Parker & Son. 1854.

Wolf JS, Bennett CJ, Dmochowski RR, et al. Best practice policy statement on urologic surgery antimicrobial prophylaxis. *J Urol*. 2008;179:1379–1390.

Wolf JS, Elashry OM, Clayman RV. Long-term results of endoureterotomy for benign ureteral and ureteroenteric strictures. *J Urol*. 1997;158:759–764.

Wolf JS Jr, Bennett CJ, Dmochowski RR, et al. Urologic Surgery Antimicrobial Prophylaxis [Internet]. *American Urological Association*. 2012 https://www.auanet.org/guidelines/antimicrobial-prophylaxis-(2008-reviewed-and-validity-confirmed-2011-amended-2012.

Wu JA, Ngo TC, Hagedorn JC, et al. The accordion antiretropulsive device improves stone-free rates during ureteroscopic laser lithotripsy. *J Endourol*. 2013;27:438–441.

Ye Z, Hu J, Song X, et al. A comparison of NBI and WLI cystoscopy in detecting non-muscle-invasive bladder cancer: a prospective, randomized and multi-center study. *Sci Rep*. 2015;5:10905.

Yeo JK, Cho DY, Oh MM, et al. Listening to music during cystoscopy decreases anxiety, pain, and dissatisfaction in patients: a pilot randomized controlled trial. *J Endourol*. 2013;27:459–462.

Yoo S, You D, Song C, et al. Risk of intravesical recurrence after ureteroscopic biopsy for upper tract urothelial carcinoma: does the location matter? *J Endourol*. 2017;31:259–265.

Zagone RL, Waldmann TM, Conlin MJ. Fragmentation of uric acid calculi with the holmium:YAG laser produces cyanide. *Lasers Surg Med*. 2002;31:230–232.

Zheng C, Lv Y, Zhong Q, et al. Narrow band imaging diagnosis of bladder cancer: systematic review and meta-analysis. *BJU*

Int. 2012;110:E680–E687.

Zhu S, Kourambas J, Munver R, et al. Quantification of the tip movement of lithotripsy flexible pneumatic probes. *J Urol*. 2000;164:1735–1739.

14

Fundamentals of Laparoscopic and Robotic Urologic Surgery

Roshan M. Patel MD, Kamaljot S. Kaler MD, Jaime Landman MD

More than 100 years ago the “father of modern medicine,” Sir William Osler, challenged surgeons to perpetually refine their craft, stating, “Diseases that harm require treatments that harm less.” In pursuit of this noble goal, the urologists of the 20th century brought us great achievements in our field; however, in the past 30 years, in particular, the specialty of minimally invasive urology has become predominant. The earliest techniques that laid the foundation for modern laparoscopic and robotic urologic procedures were developed at academic institutions throughout the world and have continuously been validated and improved. Subsequently, an increasing number of multi-institutional studies have emerged comparing laparoscopic and robotic procedures with their open surgical counterparts and showing equivalent efficacy and acceptable efficiency as well as the distinct advantages of decreased postoperative pain, improved cosmesis, expedited recovery, a shorter hospital stay, and, as techniques evolve and mature, in many cases, lower cost. Indeed, it has become increasingly clear that the objectives of many open urologic surgeries even for the most complex cases, be it of the adrenal gland, kidney, ureter, bladder, prostate, or lymph nodes, can now be achieved with minimally invasive surgery with less patient injury and suffering. Therefore, whereas open surgery has had a steadily diminishing role in the treatment of urologic diseases, laparoscopic and robotic surgery have moved into the mainstream of urologic surgery. Knowledge of the required principles and techniques is essential for the practicing urologist. This chapter provides a basic foundation of knowledge on which the aspiring minimally invasive urologist can build.

Preoperative Preparation

Patient Selection and Contraindications

Careful patient selection and identification of possible relative and absolute contraindications to laparoscopic and robotic procedures are vital to a successful outcome. A meticulous history, focusing on prior surgeries, and physical examination, detailing the location and extent of all abdominal scars, are the initial steps in patient evaluation.

Age- and health-based laboratory studies, an electrocardiogram, and a chest radiograph should be obtained according to the same criteria established for any other significant surgical procedure undertaken with general anesthesia.

In patients with severe chronic obstructive pulmonary disease (COPD), further studies (i.e., arterial blood gases and pulmonary function tests) are required because of the physiologic effects of the CO_2 pneumoperitoneum. Cardiac arrhythmias should be evaluated and treated preoperatively because hypercarbia and the resulting acidosis from the pneumoperitoneum may have adverse effects on the myocardium, thereby exacerbating any preexisting myocardial instability.

Contraindications to laparoscopic surgery include uncorrectable coagulopathy, intestinal obstruction unless there is an intention to treat, significant abdominal wall infection, massive hemoperitoneum or hemoretroperitoneum, generalized peritonitis, and suspected malignant ascites. Select circumstances in which laparoscopic and robotic procedures are being contemplated necessitate careful risk-benefit analysis and detailed and specific informed consent with the patient. The following conditions may portend potential difficulties with a laparoscopic or robotic approach.

Morbid Obesity

Laparoscopic and robotic procedures in morbidly obese patients are technically challenging. Difficulties may include inadequate length of instruments, decreased range of motion of trocars and instruments, need for higher pneumoperitoneum pressures to elevate the abdominal wall, and poor anatomic orientation owing to excessive amounts of adipose tissue. Traditionally, these difficulties translated into a higher rate of associated complications (Aboumarzouk et al., 2012; Anast et al., 2004; Mendoza et al., 1996; Parker et al., 2008). However, in comparison with open surgery, it has been found that the laparoscopic approach to renal and adrenal procedures actually has several advantages. Studies have shown for laparoscopic adrenalectomy and nephrectomy in obese patients that the laparoscopic group had significantly superior outcomes regarding blood loss, resumption of oral intake and ambulation, narcotic analgesic requirements, median hospital stay, and convalescence compared with the open approach (Fazeli-Matin et al., 1999; Fugita et al., 2004; Kapoor et al., 2004; Shuford et al., 2004). These findings have been confirmed for complicated procedures such as laparoscopic and robotic partial nephrectomy (Colombo et al., 2007; Isac et al., 2012; Romero et al., 2008) and laparoscopic nephroureterectomy (Brown et al., 2008).

With regard to laparoscopic and robotic radical prostatectomy in obese men, it has been found that, although the operation can be performed without compromising pathologic outcomes, obese patients have a greater risk of perioperative complications (26% vs. 5%) (Ahlering et al., 2005). Similarly, with robotic cystectomy there was found to be a small but statistically significant risk of complication in those with a body mass index (BMI) over 30 (Johar et al., 2013). Surgeon and institutional experience should guide patient selection in morbidly obese patients because laparoscopic and robotic procedures in morbidly obese patients are certainly more challenging and should be performed later in the surgeon's career.

Extensive Prior Abdominal or Pelvic Surgery

When extensive intra-abdominal or pelvic adhesions are suspected, careful consideration must be given to the possible site of Veress needle insertion as well as to obtaining open access with a Hasson-style cannula. **The Palmer point (subcostal in the midclavicular line on the left side) is the preferred site for Veress needle insertion when extensive intra-abdominal adhesions are suspected** (Palmer, 1974). Alternatively, in patients with suspected adhesions, a retroperitoneal approach may be preferable to a transperitoneal approach, or the procedure can be initiated retroperitoneally and the peritoneum entered via the retroperitoneal access (Cadeddu et al., 1999).

Pelvic Fibrosis

Pelvic fibrosis caused by previous peritonitis, pelvic surgery, or extensive endometriosis may constitute a severe technical challenge to the laparoscopic and robotic surgeon when surgery of the lower urinary tract is indicated. Similar problems may be encountered when trying to perform pelvic lymph node dissection in patients who have a hip prosthesis; leakage of the polymethyl methacrylate cement can create a dense inflammatory reaction and fibrosis in the adjacent pelvis (Cooper et al., 1997).

Organomegaly

Known or preoperatively diagnosed organomegaly (e.g., hepatomegaly or splenomegaly) necessitates a cautious approach when obtaining the pneumoperitoneum. The site of Veress needle insertion must be chosen at a safe distance from any enlarged organs, or, preferably, open access with the Hasson cannula may be considered.

Ascites: Benign Cause

Patients with severe ascites are under increased risk of injury to the bowel because of closer proximity of bowel loops to the anterior peritoneum. In addition, a watertight wound closure is required, and a firm wound dressing should be applied to prevent prolonged postoperative leakage.

Pregnancy

Any surgery in the gravid female should be carefully considered with regard to the overall risk/benefit ratio. If surgery is indicated, initial access to the abdomen must be obtained at a safe distance from the fundus of the gravid uterus. Therefore trocar placement is usually performed more cephalad on the abdominal wall, depending on the fundus of the uterus. The left upper quadrant in the subcostal midclavicular line (i.e., Palmer point) is often the preferred site of access. Prolonged intra-abdominal pressures of 15 mm Hg or greater may result in hypotension because of significantly reduced venous return because the vena cava is already mechanically compromised by the enlarged uterus. Prolonged CO_2 pneumoperitoneum, which may result in maternal hypercarbia and acidosis with subsequent adverse effects on the fetus, should be avoided. Accordingly, a working pneumoperitoneum of 8 to 12 mm Hg is recommended in the pregnant patient. **The second trimester is a preferred time for necessary surgery, given the completion of fetal organogenesis and reduced chance of inducing labor.**

As pregnancy progresses beyond the 20th week, the possibility of performing laparoscopic procedures decreases significantly, correlating with the increasing size of the gravid uterus. Laparoscopic nephrectomy and adrenalectomy have been successfully accomplished in pregnant women (Nezhat et al., 1997; O'Connor et al., 2004; Sainsbury et al., 2004).

Hernia

A diaphragmatic hernia may result in leakage of a significant amount of CO_2 into the mediastinum, which, although rarely noted, may eventually result in clinical problems such as respiratory compromise or cardiac tamponade (e.g., pneumopericardium) (Knos et al., 1991).

Any evidence of uncorrected or surgically corrected umbilical hernia or abdominal wall hernia should rule out these sites for obtaining a pneumoperitoneum.

Iliac or Aortic Aneurysm

Significant aneurysms warrant evaluation by the vascular surgeon. If the aneurysm does not require immediate surgical correction, insertion of the Veress needle should be performed in the left upper quadrant to stay well away from the area of the aneurysm. Of course, open access with the Hasson technique can be used alternatively. Insertion of accessory trocars must be done under strict endoscopic control to avoid the area of the aneurysm.

Bowel Preparation

For extraperitoneoscopy and retroperitoneoscopy, no bowel preparation is typically necessary. Similarly, for transperitoneal laparoscopic or robotic procedures *not* involving the use of bowel segments for urinary tract reconstruction, a mechanical bowel preparation is typically not necessary. A recent large-scale propensity score-matched analysis demonstrated no benefit for mechanical bowel preparation in operative time, postoperative stay, or overall complications for patients undergoing laparoscopic nephrectomy (Sugihara et al., 2013a). Likewise, the same group found no benefit to mechanical bowel preparation in patients undergoing laparoscopic radical prostatectomy in terms of complications, operative time, and postoperative length of stay (Sugihara et al., 2013b).

The need for a full mechanical and antibiotic bowel preparation is subject to question and becomes an issue only if one anticipates encountering dense intra-abdominal adhesions or if the surgery involves entering the bowel. However, emerging literature suggests no benefit to a full mechanical bowel preparation for patients undergoing radical cystectomy with creation of ileal conduit or orthotopic neobladder (Hashad et al., 2012; Large et al., 2012; Raynor et al., 2013).

Enhanced Recovery After Surgery Protocols

Enhanced recovery after surgery (ERAS) was developed in Europe in 2001 by a group of academic surgeons (Fearon et al., 2005). It is a multimodal and multidisciplinary approach to resolve issues that delay recovery and cause complications. Elements of ERAS programs include guidelines based on evidence-based modern care changes from overnight fasting to avoiding solid food 6 hours before surgery, carbohydrate drinks 2 hours before surgery, management of fluids to seek balance rather than large volumes of intravenous fluids, early removals of drains and tubes, early mobilization, and the consumption of food and drink on the day of operation. These protocols have resulted in shorter hospital stays by 30%, a reduction in complications by 50%, and a decrease in readmission rates, thus reducing healthcare costs (Lemanu et al., 2014; Ljungqvist et al., 2017). There is accumulating evidence supporting the use of ERAS programs in cystectomy patients, and further high-quality prospective multicenter studies to tailor different elements of ERAS protocols in minimally invasive urologic surgery are necessary (Azhar et al., 2016). Importantly, as changes to existing protocols are made, a key emphasis should be placed on the collaboration between surgery and anesthesia.

Preparation of Blood Products

Serum type and screen are sufficient for laparoscopic and robotic procedures with a low chance of major hemorrhage. Procedures such as laparoscopic radical nephrectomy and nephroureterectomy have a low rate of transfusion (3% to 12%), with an estimated average blood loss in the range of 106 to 255 mL (Dunn et al., 2000; Jeschke et al., 2000; Ono et al., 1999; Shalhav et al., 2000). Similarly, the transfusion rate with laparoscopic or robotic radical prostatectomy is low (2.5% at experienced centers) (Ahlering et al., 2004; Guillonneau and Vallancien, 2000).

More extensive laparoscopic robotic procedures (e.g., partial nephrectomy, radical cystectomy, radical nephrectomy with inferior vena cava thrombectomy), especially early in one's experience, should be managed like any other major open surgical procedure, with packed red blood cells available before surgery. With greater experience, a type and screen may suffice for certain more extensive procedures (e.g., partial nephrectomy) because the risk for transfusion is low (6% to 7%) (Ghani et al., 2014).

Key Points: Preoperative Preparation

- Careful patient selection and identification of contraindications for laparoscopic and robotic procedures are vital for successful outcomes. A meticulous past history, focusing on prior surgeries, and physical examination, detailing the location and extent of all abdominal scars, are the initial steps in patient evaluation for minimally invasive surgery.
- Contraindications to laparoscopic or robotic surgery include uncorrectable coagulopathy, intestinal obstruction unless treatment is intended, significant abdominal wall infection, massive hemoperitoneum or hemoretroperitoneum, generalized peritonitis, and suspected malignant ascites.

Operating Room

Setup of the Operating Room

The operating room has to provide enough space to accommodate all necessary personnel and the equipment required by the surgeon and the anesthesiologist. Positioning of equipment, surgeon, assistants, nurses, anesthesiologist, and other support staff should be clearly defined and established for each laparoscopic or robotic case. All equipment must be fully functional and in operating condition before any laparoscopic or robotic procedure is started (Box 14.1). A separate tray with open laparotomy instruments must be ready for immediate use in the event of complications or problems necessitating emergent open surgery.

Box 14.1

Instrumentation Checklist for Making a Skin Incision for Obtaining the Pneumoperitoneum

1. Irrigation-aspiration unit is working.
2. Electrosurgical unit is working.
3. CO_2 tank is full, with extra CO_2 tank in the room.
4. Camera is white balanced, and light source is working.
5. Insufflation is checked for flow and response to kinking of the tubing.
6. Veress needle is checked for flow and proper tip retraction.

Patient Positioning

Positioning of the patient depends primarily on the procedure to be performed. In the supine position the arms can be tucked snugly at the sides or rest on specially designed sleds. In the Trendelenburg or lateral position, tape and security belts applied across the chest and thighs provide safe and stable positioning of the patient. In the lateral position, all bony prominences in contact with the table must be carefully padded; likewise, the point of contact between any of the positioning straps and the hip or shoulder should be padded. In the lateral position, the bottom leg is flexed approximately 45 degrees while the upper leg is kept straight; pillows are placed between the legs as a cushion and to elevate the upper leg so that it lies level with the flank, thereby obviating any undue stretch on the sciatic nerve. Pads should be placed between the table and the knee and ankle of the lower leg because these are high-pressure areas. In the lateral decubitus position an axillary roll should be used. Application of an active warming system may prevent hypothermia if a lengthy laparoscopic procedure is anticipated.

A host of new advances in padding and table-mounted accessories are now available, but none has been conclusively demonstrated to significantly reduce pressure on the patient's flank in the lateral position. Researchers at the University of California, Irvine, showed that women have significantly lower interface pressures than men (Deane et al., 2008). A BMI greater than or equal to 25, use of a kidney rest, and full-table flexion as opposed to half-table flexion were associated with increases in interface pressure; of these, **use of the kidney rest was believed to be the most detrimental, and its use beyond 20 to 30 minutes was discouraged.** Therefore male patients with a BMI of 25 or higher undergoing laparoscopic surgery in the lateral position with the kidney rest elevated and the table completely flexed are at highest risk of developing rhabdomyolysis from flank pressure. In this study the unaugmented operating table mattress was superior to egg crate or gel padding as an augmenting surface material; egg crate padding was equal or superior to the more expensive gel padding.

Table-mounted accessories for all major commercial operating room tables aid in safely and effectively positioning patients in the lateral decubitus position and in the prone position. For laparoscopic or robotic procedures on the pelvis, the patient can be placed in Trendelenburg position with the legs on split-leg positioners (Fig. 14.1A) or in Allen stirrups (Fig. 14.1B). **Shoulder supports or braces should never be used in this position because of the risk of brachial nerve injury.**

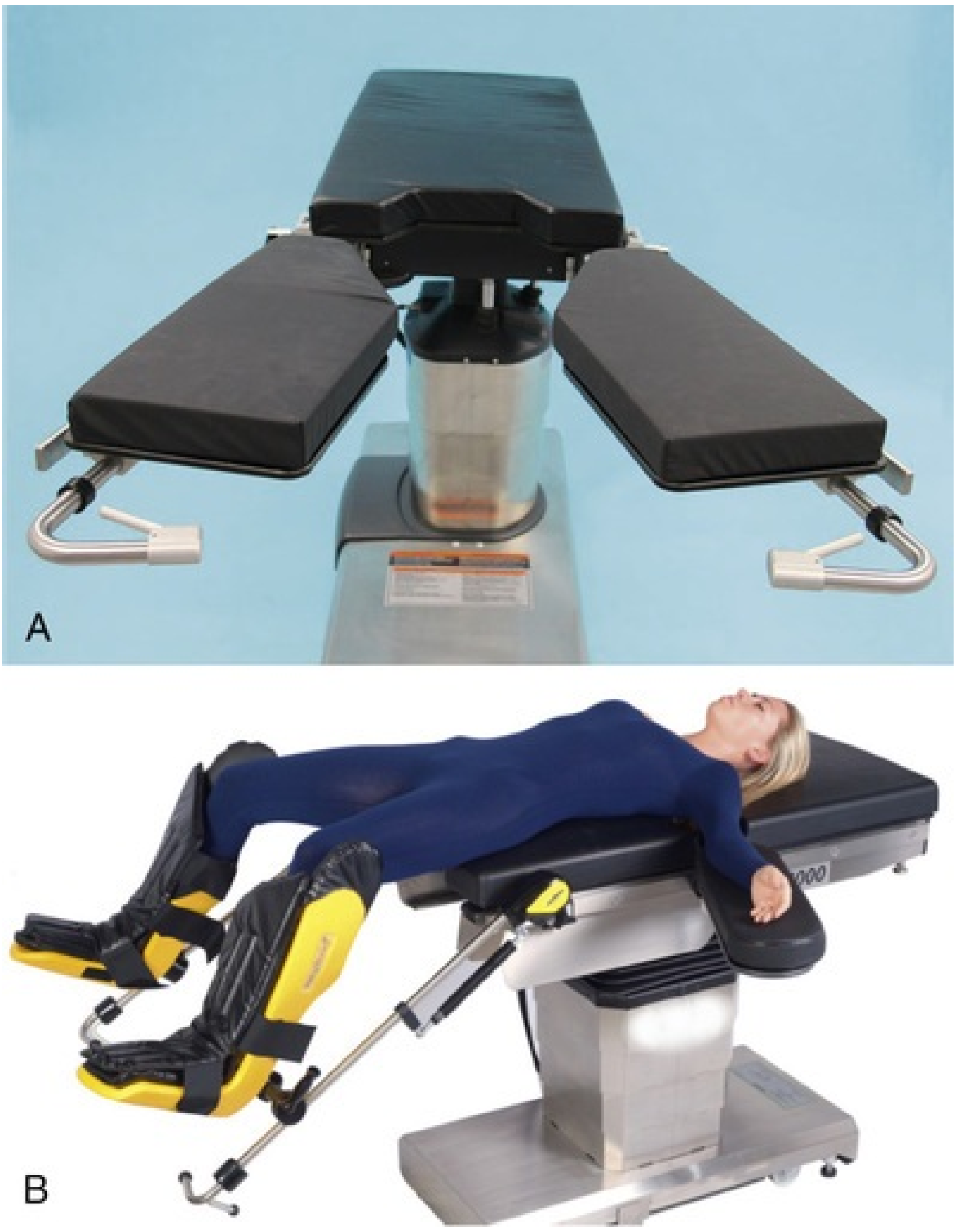

FIG. 14.1 (A) Split-leg positioners. (B) Allen stirrups.

Prophylaxis and Other Preparations

Pneumatic compression stockings can be applied for antiembolic prophylaxis. In addition, the administration of 5000 units of subcutaneous heparin preoperatively is an option. In higher-risk patients, such as the morbidly obese, both may be considered and their use can be continued postoperatively (see the discussion of early postoperative complications). Before laparoscopic or robotic procedures, placement of a Foley catheter allows for accurate measurement of urine output, decompresses the bladder to improve visibility and working space, and reduces the risk of injury with pelvic procedures. Similarly, when needed, a nasogastric or orogastric tube can be inserted to improve the working space available in the upper abdomen.

Strategic Placement of Operative Team and Equipment

Standard Laparoscopic Carts

Traditionally, the mandatory hardware for laparoscopic procedures (monitor, light source, insufflator) is located on carts or towers that are built in the operating room and adapted to various types of surgical procedures and approaches (eFig. 14.2A). The main laparoscopic cart should contain the insufflator, light source, camera controls, and any recording device. Ideally, the insufflator should be placed at the surgeon's eye level to allow continuous monitoring of the CO_2 pressure.

EFIG. 14.2 (A) A standard laparoscopic cart. (B) An integrated laparoscopic vision system.

Integrated Endoscopy Systems

More recently, most major manufacturers of endoscopy equipment offer “integrated” systems that consist of flat panel displays and equipment towers mounted on adjustable ceiling booms (eFig. 14.2B). This allows the mobile display monitors to be suspended over the patient and placed directly in front of the surgeon at any height or angle. This feature may reduce eye and body strain. Furthermore, the tower containing the light source, camera system, and insufflator can be placed in any area around the patient depending on the operation at hand.

Robotic Systems

Currently the only robotic surgical system in widespread use for laparoscopic surgery is the da Vinci Robotic System (Intuitive Surgical, Sunnyvale, CA; Rassweiler et al., 2017). The three major components of the system are the robotic tower (i.e., patient-side cart) to which are attached the instruments that are mechanically manipulated within the patient; a surgeon's console, which is the workstation at which the surgeon sits to manipulate the robotic instruments; and finally the ancillary vision cart, which supports a flat screen monitor, an insufflator, a light source, and components of the camera system (eFig. 14.3). Additional monitors can be linked with the robotic system and used for the assistant and support staff image viewing. The newest generation of the robotic surgical system (da Vinci Xi) offers several advantages over the older Si system. First, the da Vinci Xi uses an 8-mm HD camera that can be placed in any of the four ports, which is important for multiquadrant procedures. Second, the boom-mounted system allows the surgical cart to be placed at any position around the patient, and optimal configuration is achieved with the laser targeting system. Third, the redesigned arms are much finer, which allows for more flexible port placement with less arm collisions during the procedure. Last, updated robotic technology also allows for the use of single-port platforms (e.g., SP 1098 platform), which can overcome the suboptimal ergonomics with clashing instruments in single-site surgery.

EFIG. 14.3 The da Vinci Xi Robotic System (Intuitive Surgical, Sunnyvale, CA) with dual surgeon console. (Copyright 2018 Intuitive Surgical, Inc.)

Placement of the Operative Team for Laparoscopic Procedures

Transperitoneal Procedures in the Upper Abdomen

Laparoscopic.

For transperitoneal laparoscopic renal and adrenal surgical procedures, the patient is positioned in a modified lateral decubitus position. The surgeon and assistant usually stand in front of the abdomen with the patient in the lateral decubitus position (i.e., for a left nephrectomy the surgeon and assistant stand on the right side of the operating table). The instrument table and the scrub nurse are best located on the opposite side of the patient near the foot of the bed so that instruments can be handed to the surgeon over the table (Fig. 14.4A). Incoming lines from insufflators, suction and irrigation, and electrosurgical devices enter from the contralateral side of the table or from the ipsilateral head of the table. Additional instruments (e.g., laparoscopic ultrasound probe) may be moved to the operating table depending on the surgeon's needs, as well as on the availability of space.

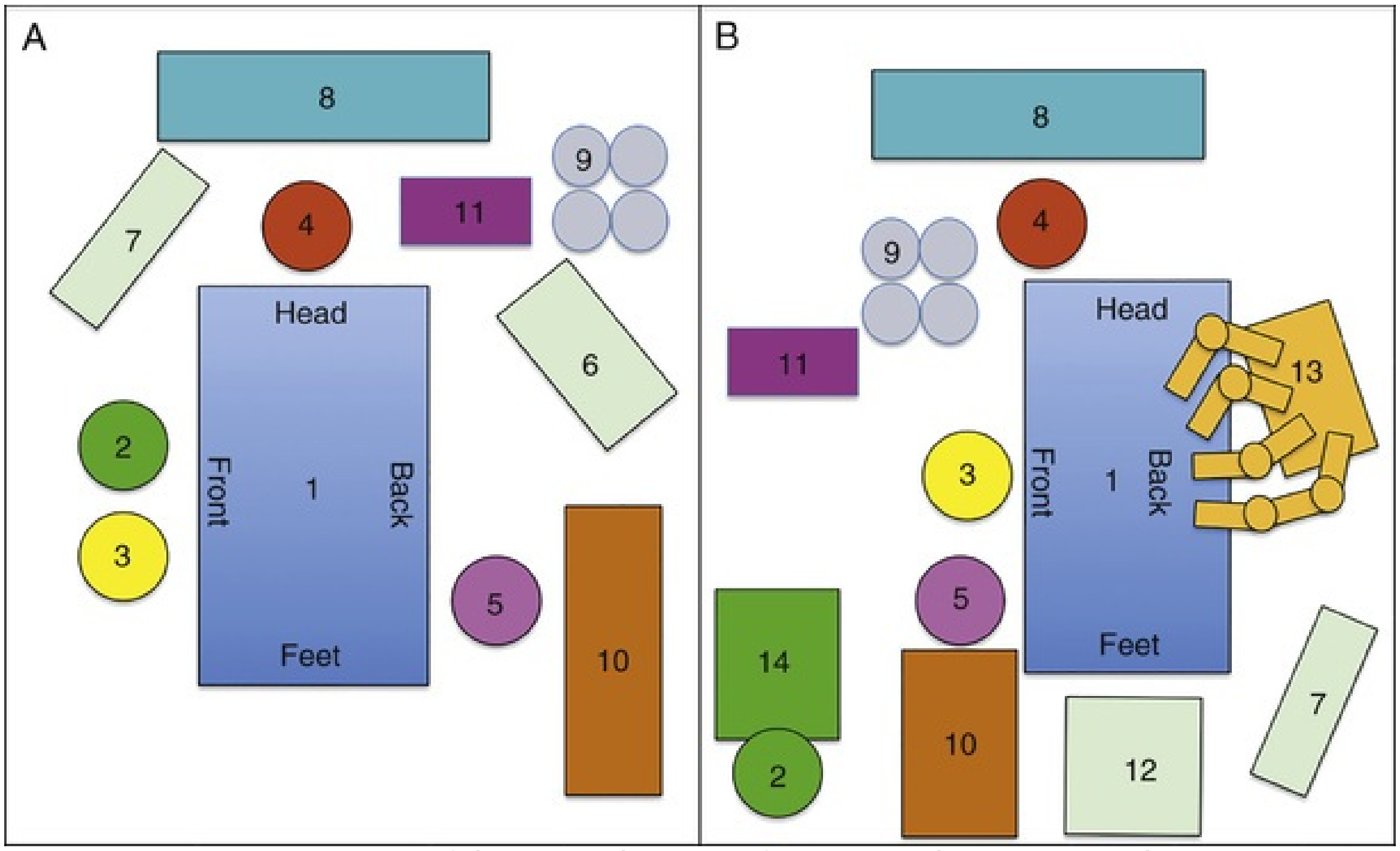

FIG. 14.4 Placement of the operative team for transperitoneal procedures in the upper abdomen. (A) Laparoscopic procedure. (B) Robotic procedure. *1,* Operating table; *2,* surgeon; *3,* assistant; *4,* anesthesiologist; *5,* scrub assistant; *6,* laparoscopic cart or tower; *7,* auxiliary video monitor; *8,* anesthesia equipment; *9,* suction and irrigation unit; *10,* scrub assistant's instrument table; *11,* electrocautery unit; *12,* ancillary vision cart; *13,* robotic tower; *14,* surgeon's console.

To provide more comfortable positioning of the surgeon's arms, a 6- × 4-foot, 6-inch platform can be used when the operating table cannot be lowered sufficiently to allow the surgeon to hold the laparoscopic instruments with his or her elbows held comfortably at the side rather than extended laterally. This configuration is helpful during suturing because it allows for more natural ergonomics.

Robotic.

For transperitoneal robotic-assisted laparoscopic renal and adrenal surgical procedures, the patient is again positioned in a modified lateral decubitus position. The assistant usually stands in front of the abdomen with the patient in the lateral decubitus position (i.e., for a left nephrectomy the assistant stands on the right side of the operating table). The robotic arms (i.e., patient-side cart) are brought in from the opposite side (i.e., facing the back with the patient in the lateral decubitus position) so that the robotic arms stretch over the patient and can then be docked to the preplaced ports. In general, it is best to angle the robot slightly so that the camera is pointing directly toward the site of interest. Accordingly, depending on the exact port placement, the robotic arms may be brought in at an angle toward the head of the patient, as opposed to perpendicular to the operating table, to minimize clashing of the robotic arms once docked (eFig. 14.5). The instrument table and the scrub nurse are best located at the foot of the bed on the same side of the patient as the surgical assistant so that instruments can be easily handed to the surgical assistant (see Fig. 14.4B). The robotic console can be placed anywhere in the room remote from the operating table and instrument table so that it is out of the way but in view of the patient and anesthetic monitors. All incoming lines from insufflators, suction and irrigation, and electrosurgical devices enter either from the contralateral foot side of the table or the ipsilateral head of the table.

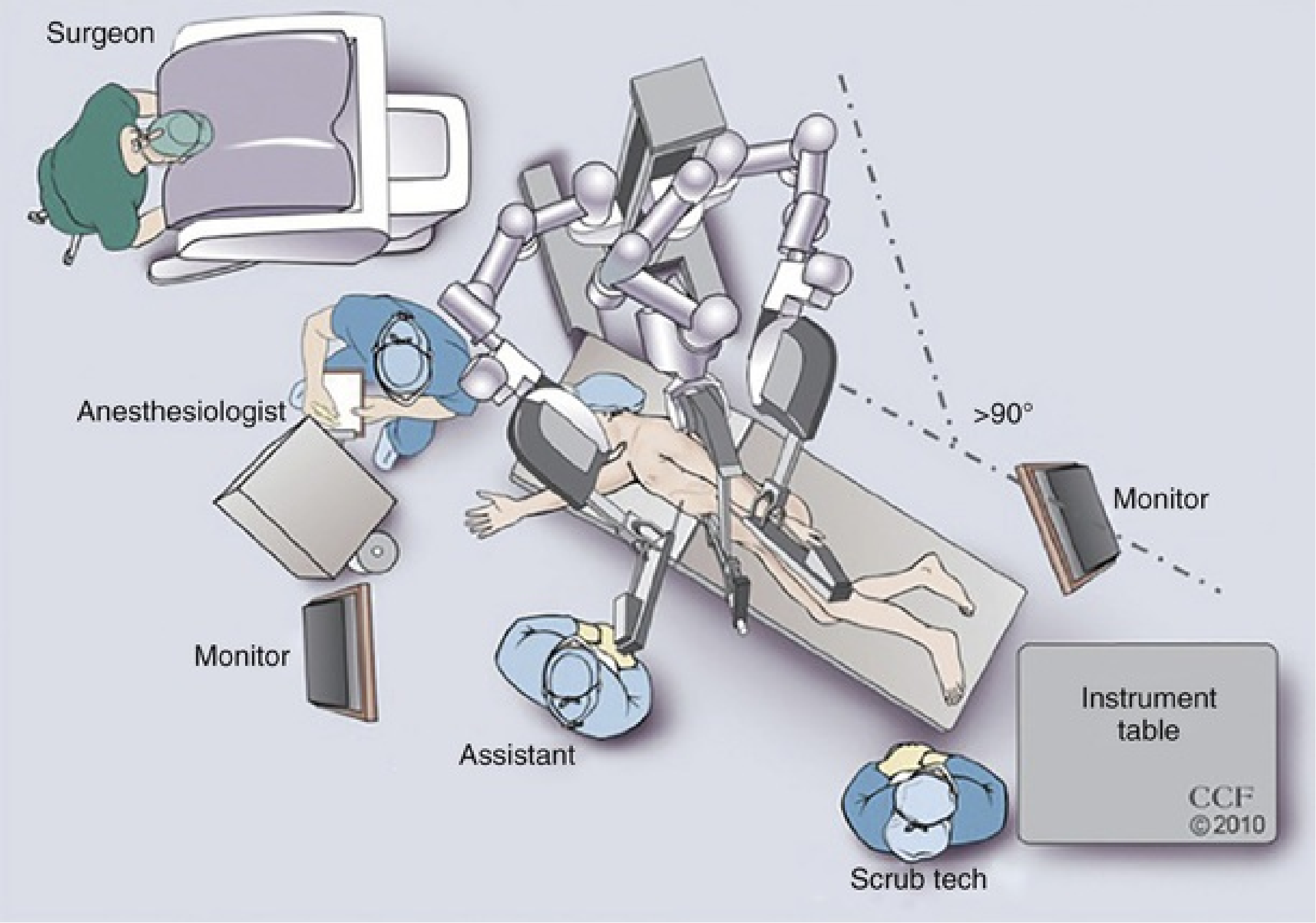

EFIG. 14.5 Angulated placement of the robotic tower to minimize clashing of the robotic arms during transperitoneal (i.e., renal and adrenal) upper abdominal procedures.

Retroperitoneal Procedures in the Upper Abdomen

Laparoscopic.

For retroperitoneal renal and adrenal procedures, the patient is placed in the true 90-degree lateral decubitus position with the body at a right angle to the table. All of the proper steps for padding in this position should be followed (see previously). **The table is angled at the hip to accentuate and increase the distance between the 12th rib and the iliac crest. Maximizing this distance is paramount with regard to port placement.** The primary surgeon and the camera assistant stand facing the patient's back (Fig. 14.6A). The scrub nurse or technician stands facing the patient's front, and instruments are handed across the patient accordingly.

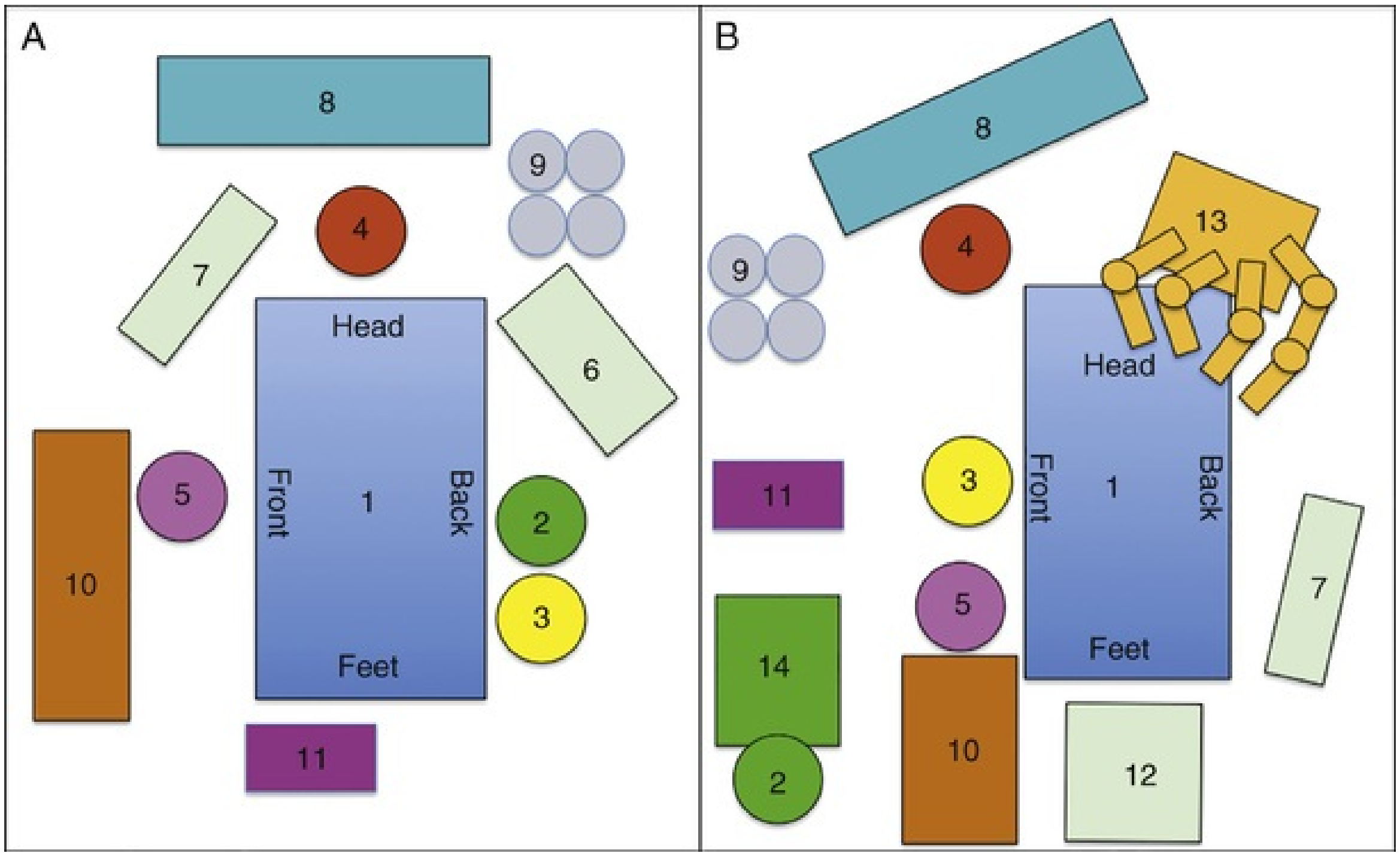

FIG. 14.6 Placement of the operative team for retroperitoneal procedures in the upper abdomen. (A) Laparoscopic procedure. (B) Robotic procedure. *1,* Operating table; *2,* surgeon; *3,* assistant; *4,* anesthesiologist; *5,* scrub assistant; *6,* laparoscopic cart or tower; *7,* auxiliary video monitor; *8,* anesthesia equipment; *9,* suction and irrigation unit; *10,* scrub assistant's instrument table; *11,* electrocautery unit; *12,* ancillary vision cart; *13,* robotic tower; *14,* surgeon's console.

Robotic.

For retroperitoneal robotic-assisted renal and adrenal procedures, the patient is similarly placed in the true 90-degree lateral decubitus position. The surgical assistant can stand facing either the patient's abdomen or his or her back depending on the surgeon's preference for port placement. The instrument table and scrub nurse are best placed on the same side as the assistant near the foot of the table. The robotic arms are brought in over the head of the patient (Fig. 14.6B). Because the robotic arms are positioned over the patient's head, the anesthesiologist and the anesthetic cart and monitors should be positioned off to the side, in front of the patient, at the head of the bed.

Transperitoneal and Extraperitoneal Pelvic Procedures

Laparoscopic.

The patient is positioned in the supine position with the legs on split-leg positioners or elevated in stirrups that have knee and leg supports to avoid perineal nerve injury. The table is angled (flexed) slightly at the hip to accentuate the pelvis. The patient's arms are tucked at the sides; plastic sleds can be used to support the arms. A slightly snug chest strap should be placed directly across the patient's chest. The table is placed in the 30-degree Trendelenburg position. The surgeon stands on the side of the table where he or she is comfortable, and the assistant stands on the opposite side (Fig. 14.7A).

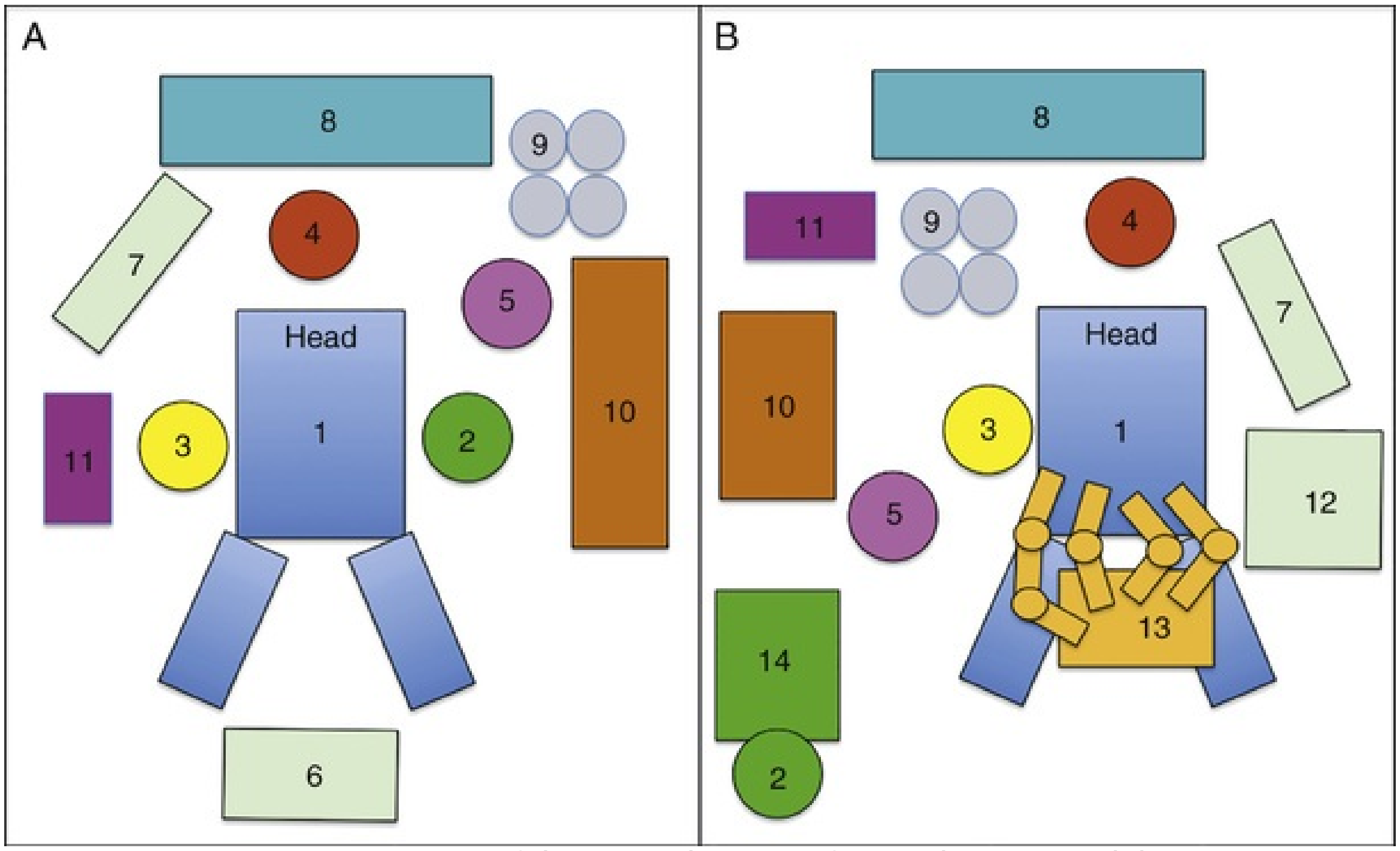

FIG. 14.7 Placement of the operative team for pelvic surgery. (A) Laparoscopic procedure. (B) Robotic procedure. *1,* Operating table; *2,* surgeon; *3,* assistant; *4,* anesthesiologist; *5,* scrub assistant; *6,* laparoscopic cart or tower; *7,* auxiliary video monitor; *8,* anesthesia equipment; *9,* suction and irrigation unit; *10,* scrub assistant's instrument table; *11,* electrocautery unit; *12,* ancillary vision cart; *13,* robotic tower; *14,* surgeon's console.

Robotic.

For robotic procedures on the pelvis the patient is positioned exactly as described previously for laparoscopic pelvic procedures when using the da Vinci S or SI systems. After port placement, the robot is positioned between the patient's legs, and the assistant can remain on either side of the table depending on surgeon preference (Fig. 14.7B). The scrub nurse or technician can be positioned on the same side as the assistant to facilitate passing instruments because passing instruments across the robotic arms can be cumbersome. A benefit of using the da Vinci Xi system is that the robot can be positioned on either side of the table as the mobile boom-mounted system can be configured for pelvic cases and that it eliminates the need to place the patient in stirrups.

Performing the Procedure

Before the Initial Incision

A checklist ensuring that all essential equipment is present and operational should be completed just before initiation of the pneumoperitoneum (see Box 14.1).

Additional items to check when using the da Vinci Robotic System include ensuring that all plugs for the console, vision cart, and patient-side cart are plugged into different circuits and that all cables connecting these carts are connected properly. The system should be turned on, and the self-test and homing routine should be complete. The three-dimensional (3D) camera and endoscopes should be calibrated, the image black and white balanced, and target alignment performed according to the manufacturer's instructions. The patient-side cart should be draped and ready.

Achieving Transperitoneal Access and Establishing the Pneumoperitoneum

Achieving transperitoneal access is the first step before establishing a pneumoperitoneum. This can be done using either a closed (i.e., Veress needle) or open (i.e., Hasson cannula) technique.

Closed Techniques

Veress Needle.

A disposable (70- or 120-mm, 14-gauge, and 2-mm outer diameter) or nondisposable Veress needle can be used. Proper needle function should be ensured before the procedure. Specifically, the blunt tip of the needle is tested to make sure the spring retracts easily and the needle is connected to the CO_2 line to ensure that there is no resistance to gas inflow (i.e., at 2-L/min flow, pressure remains at ≤2 mm). Last, saline is flushed through the needle with the tip manually occluded to make sure there is no leakage at the juncture between the shaft and the hub of the needle.

For proper placement the Veress needle is grasped at midshaft and is passed perpendicularly through skin using a gentle, steady pressure. Two points of resistance are traversed: the abdominal wall fascia and the peritoneum.

Sites for Needle Passage.

With the patient in the supine position, the head of the bed is lowered 10 to 20 degrees; insertion of the Veress needle is commonly accomplished at the superior border of the umbilicus. There are certain advantages to choosing the umbilical area as the site for initial trocar placement: the abdominal wall is thinnest, and postoperative cosmesis is excellent. However, this point of entry is fraught with the potential for injury to a major vessel, in particular the left common iliac vessels, aorta, or vena cava. In consideration of the umbilical area as the site for Veress needle placement, body habitus influences the relative location of the umbilicus to underlying vascular structures. In obese patients, the umbilicus tends to migrate inferiorly, whereas in nonobese patients the umbilicus lies in its commonly described position, directly above the bifurcation of the aorta and vena cava. Thus, for umbilical access in nonobese patients, the Veress needle should be passed through the abdominal wall angled toward the pelvis to avoid injury to the bowel and great vessels that lie directly beneath. In more obese patients, because the umbilicus lies more caudad, less angulation is needed and the Veress needle should be passed perpendicular to the umbilical incision (Loffer and Pent, 1976).

The right or left lower quadrant can also be used with the patient in the supine position, decreasing the likelihood of vascular injury. However, surgeons must be cognizant of risk for colonic injury with this site. If the patient is in a lateral decubitus position, then the Veress needle can be passed two fingerbreadths medial and two fingerbreadths superior to the anterior superior iliac spine.

Other potential insertion sites when the patient is either supine or in a lateral decubitus position are at the Palmer point (i.e., subcostal in the midclavicular line on the left side) and at the corresponding site on the right side. The Palmer point is the preferred site when extensive intra-abdominal adhesions are suspected (Palmer, 1974). With either of these insertion sites care must be exercised; if the needle is inserted too deeply, there is the potential to hit the liver on either side or, rarely, the spleen on the left side. Alternatively, in the abdomen that has previously been operated on, insertion should be performed in an unscarred quadrant of the abdomen. If there is no scar-free area, then an open technique (see following) should be used.

The safety of the Veress needle technique has been demonstrated in numerous studies, including a study by Chung et al. (2003) that examined the outcome of 622 consecutive cases with Veress needle insertion. Prior abdominal surgery had been performed in 192 patients (31%), and the BMI was 30 or greater in 98 patients. Blind Veress needle placement was successful in 579 (93%), and outcome was not associated with laterality, type of surgery, or prior surgery. In 34 cases (5%), a minor laceration to the liver was managed conservatively without sequelae; and in 21 cases (3%), the omentum or falciform ligament was traversed without significant injury. No major complications, such as vascular or hollow-organ perforation, were caused by either the Veress needle or trocar.

Assessment of Proper Needle Placement.

First the aspiration-irrigation-aspiration test is performed. With the use of a 10-mL syringe containing 5 mL of saline, the Veress needle is aspirated to check for blood or bowel contents. Blood is easily discerned by the color, but bowel contents often appear as just small particulate matter and do require close attention on the part of the surgeon to discern. If this test result is negative, then the saline is injected into the abdominal cavity; this should occur without any resistance. Next, the plunger of the syringe is again withdrawn; no fluid should return into the barrel of the syringe. An additional injection of 2 to 3 mL of saline helps to expel any omentum that may have been sucked into the needle tip with the original aspiration technique. Last, the syringe is detached from the Veress needle and any fluid left in the hub of the needle should fall swiftly into the peritoneal cavity (i.e., **the "drop" test**).

Second, the advancement test can be performed. If the needle has truly just entered the peritoneal cavity, then the surgeon ought to be able to advance the needle 1 cm deeper without the tip meeting any resistance. Resistance at this stage usually means the needle is still in the preperitoneal space and must be advanced through the remaining peritoneum.

Insufflation should never be initiated unless *all* the signs for proper peritoneal entry (negative aspiration, easy irrigation of saline, negative aspiration of saline, positive drop test, and normal advancement test) have been confirmed. Once proper needle placement is verified, insufflation is started up to a maximal capacity of 9 L/min with the abdominal pressure set at 15 mm Hg. Free flow of CO_2 is confirmed if intra-abdominal pressure remains below 10 mm Hg, and free flow of CO_2 stops as soon as the preset limit of 15 mm Hg of intra-abdominal pressure is reached.

Stabilization of the abdominal wall fascia with towel clips or Allis clamps at the time of Veress needle puncture may help in stabilizing the fascia; however, the surgeon should not lift up on the fascia because this will only increase the space between the fascia and the peritoneum and will not change the intra-abdominal space.

Open Access Techniques

Hasson Technique.

The pneumoperitoneum can be more easily, and in a surgeon's early experience, more safely established using the open Hasson technique; however, its use involves making a larger incision and increases the chances of port-site gas leakage during the procedure. **The open technique is recommended specifically when extensive adhesions are anticipated. Studies have shown the open technique to be as efficient as the closed approach and may be safer in patients with prior abdominal surgery** (Bonjer et al., 1997).

In the unscarred abdomen, with the patient in the supine position, a 2-cm semicircular incision is made at the lower edge or slightly below the umbilicus. The fascia and peritoneum are opened individually with a transverse incision, sufficient to accommodate the surgeon's index finger. After visual and digital confirmation of entry into the peritoneal cavity, two 0 silk traction sutures are placed on either edge of the fascia. Next, the Hasson cannula is advanced through the incision with the blunt tip protruding (Fig. 14.8). The funnel-shaped adapter of the Hasson cannula is advanced until it rests firmly in the incision, and it is then tightened onto the cannula with the attached screw; fixation to the abdominal wall is provided with the fascial sutures that are wrapped around the struts on the funnel-shaped adapter of the Hasson cannula, thereby anchoring it in place. After removal of the obturator, free flow of CO_2 into the peritoneal cavity is achieved by attaching the CO_2 tubing to the cannula. The insufflator can be set at maximum inflow, thereby creating the pneumoperitoneum quickly.



FIG. 14.8 Various reusable Hasson-type trocars.

Hand Port Access.

The pneumoperitoneum can be obtained before or after making the hand port incision. If the surgeon has little experience with achieving a pneumoperitoneum, the safest maneuver is to use an open technique and place the hand port into a 6.5- to 7.5-cm open incision and then create the pneumoperitoneum through the hand port (i.e., hand port access). For this technique, the procedure begins with making a standard midline or lower quadrant incision at the planned hand-assist site. The peritoneal cavity is entered in the standard open surgical fashion, after which the hand-assist device is placed according to the manufacturer's instructions. Next, a blunt cannula is passed through the hand-assist device and a pneumoperitoneum is established. Additional 5-mm or 10- to 12-mm ports can be placed rapidly under manual control with the surgeon's intra-abdominal hand being used to guide the additional trocars through the abdominal wall. Alternatively, a laparoscope can be placed through the port placed in the hand-assist device for insufflation, and the rest of the trocars can then be placed under direct vision.

Laparoendoscopic Single-Site Surgery

Advances in abdominal access technology combined with the development of curved and articulating laparoscopic instrumentation have made it possible to perform selected procedures through a single incision (typically a 2.5-cm transumbilical incision); using three access ports through this incision, the laparoscope and two working instruments can be introduced.

Much the same as for hand port access, the incision can be made before or after obtaining a pneumoperitoneum depending on surgeon preference. Typically, the incision is made periumbilically for cosmetic purposes. **The size of the skin incision should correspond to the surgical task at hand. If the procedure does not require removal of a large intact specimen, then the incision should be minimized to as little as 2.5 cm. If the procedure requires large intact specimen removal (as in donor nephrectomy), then the incision should be large enough to extract the specimen.** Once the incision has been made, several ports side by side or a single triport access device (see the following) can be placed and a pneumoperitoneum is reestablished at high flow.

After the first reports of laparoendoscopic single-site surgery (LESS) nephrectomy (Raman et al., 2007; Rane and Rao, 2008), this technique was refined for use across a broad spectrum of benign and urologic oncology procedures. **The theoretical advantages of LESS over standard multi-incision laparoscopy are improved cosmesis, decreased pain, and faster recovery time** (Merseburger et al., 2013; Raman et al., 2008). However, enthusiasm for this technique has precipitously declined because it is associated with a steep learning curve biased toward skilled laparoscopic surgeons (Sorokin et al., 2017). When surgeons approach LESS, the transition from standard laparoscopy to LESS should occur in a stepwise fashion by gradually decreasing the number of ports used until the procedure can be performed through a single incision. **Conversely, with difficulty performing a procedure using LESS, the surgeon should not hesitate to place one or more extra trocars at separate incision sites to improve triangulation and thereby ensure safety and a high-quality result.**

Robotic Laparoendoscopic Single-Site Surgery

Robotic laparoendoscopic single-site surgery (R-LESS) addressed numerous issues associated with LESS with significant enhancement in optics and ergonomics (Kaouk et al., 2009). At present R-LESS has been used for nephrectomy (partial, simple, and radical), pyeloplasty, nephroureterectomy, prostatectomy, and sacrocolpopexy. The recent development of a single-port (SP) robotic platform has allowed for continued evolution and advancement of this technique, and there is promise in the extraperitoneal and perineal approaches. A next-generation single-port robotic platform developed by Intuitive (SP1098) to be used for the Si and Xi systems is promising and allows for intercorporal triangulation while eliminating instrument clashing as seen with prior methods. Further studies are needed to better define its role in minimally invasive surgery.

Retroperitoneal Access and the Retroperitoneal Space

Technique for Balloon or Self-Styled Dilator Placement: Open (Hasson) Technique

The Hasson technique is the most commonly used technique because it affords the greatest precision during development of the retroperitoneal space (Gill, 1998). Initial access is obtained through a 2.0- to 2.5-cm transverse incision in the midaxillary line, just below the tip of 12th rib. The wound is opened with a pair of S-retractors. Under direct vision, the posterior layer of the lumbodorsal fascia is incised and muscle fibers are split or divided. The retroperitoneal space is entered **under direct vision** by making a small incision in the anterior thoracolumbar fascia with an electrocautery blade or, less commonly, by bluntly piercing the fascia digitally or with a hemostat. This fascial opening must be snug around the index finger and no larger so that intraoperative air leak is minimized. Index finger palpation of the belly of the psoas muscle posteriorly and the Gerota fascia–covered inferior pole of the kidney anteriorly confirms proper entry into the retroperitoneal space (Fig. 14.9A). The index finger is used to digitally create a space in this precise location for placement of the balloon dilator; two inflations of the balloon are then done—one directed cephalad and the second directed caudad to fully dilate the retroperitoneal space (Fig. 14.9B). Thus balloon dilation is performed anterior to the psoas muscle and fascia and outside and posterior to the Gerota fascia. In cases involving definitive ureteric mobilization (e.g., retroperitoneoscopic donor nephrectomy, nephroureterectomy), additional balloon dilation may be performed more caudad to the primary site of dilation (Gill et al., 1995). Similarly, during a retroperitoneoscopic adrenalectomy, it is helpful after the initial balloon dilation to move the balloon up higher in the retroperitoneum and perform a second, even more cephalic balloon dilation along the undersurface of the diaphragm (Sung and Gill, 2000).

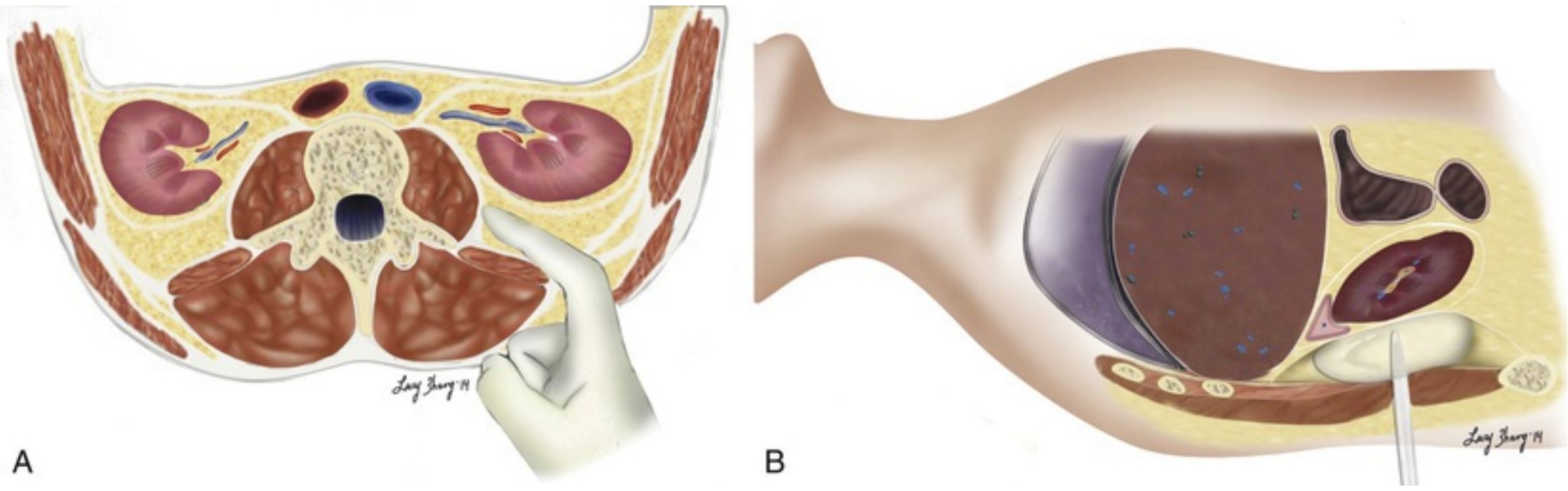

FIG. 14.9 (A) Access into the right retroperitoneum. Through the primary port incision at the tip of the lowest (12th) rib, open access is gained into the retroperitoneum after piercing the thoracolumbar fascia. Finger dissection is performed anterior to the psoas muscle and fascia to create a space for insertion of the balloon dilator. Confirmation that the finger dissection is indeed being performed in the proper plane is obtained by palpating the psoas and erector spinae muscles between the retroperitoneally located index finger and the fingertips of the opposite hand positioned on the patient's back. The fat-covered lower pole of the kidney can be palpated in a cephalad direction by turning the finger clockwise in the retroperitoneum on the right side. (B) Balloon dilation in the posterior pararenal space facilitates the creation of a working space for retroperitoneal laparoscopic nephrectomy *(coronal view).*

Balloon Dilation.

Gradual distention of a balloon dilator in the retroperitoneal space atraumatically displaces the mobile fat and moves the peritoneum forward relative to the immobile body musculature. This device thus creates a working space equivalent to the size of the balloon. Either commercially available balloon dilators or a self-styled dilator can be used.

Commercially Available Balloons.

Commercially available trocar-mounted preperitoneal balloon dissectors (PBDs) (e.g., Medtronic, Minneapolis, MN) are typically a transparent, high–tensile strength silicone balloon that is inflated with a sphygmomanometer bulb insufflator using room air (Fig. 14.10). The balloon has a maximum capacity of 800 mL (40 pumps of the inflating bulb). A primary advantage of commercially available balloons is that the balloon is affixed to the end of a stiff, hollow, transparent plastic shaft. This shaft allows precisely directed placement of the balloon dilator. Furthermore, because the laparoscope can actually be inserted into the shaft of the balloon dilator during the inflation process, it provides the capability for endoscopic confirmation of the proper positioning of the transparent balloon and of the adequacy of the controlled radial dilation of the extraperitoneal area. Balloon dilators are commercially available in two different shapes: a round balloon for dilation of the pelvic extraperitoneal space and a horizontally oriented, oblong balloon for dilation of the retroperitoneal space.

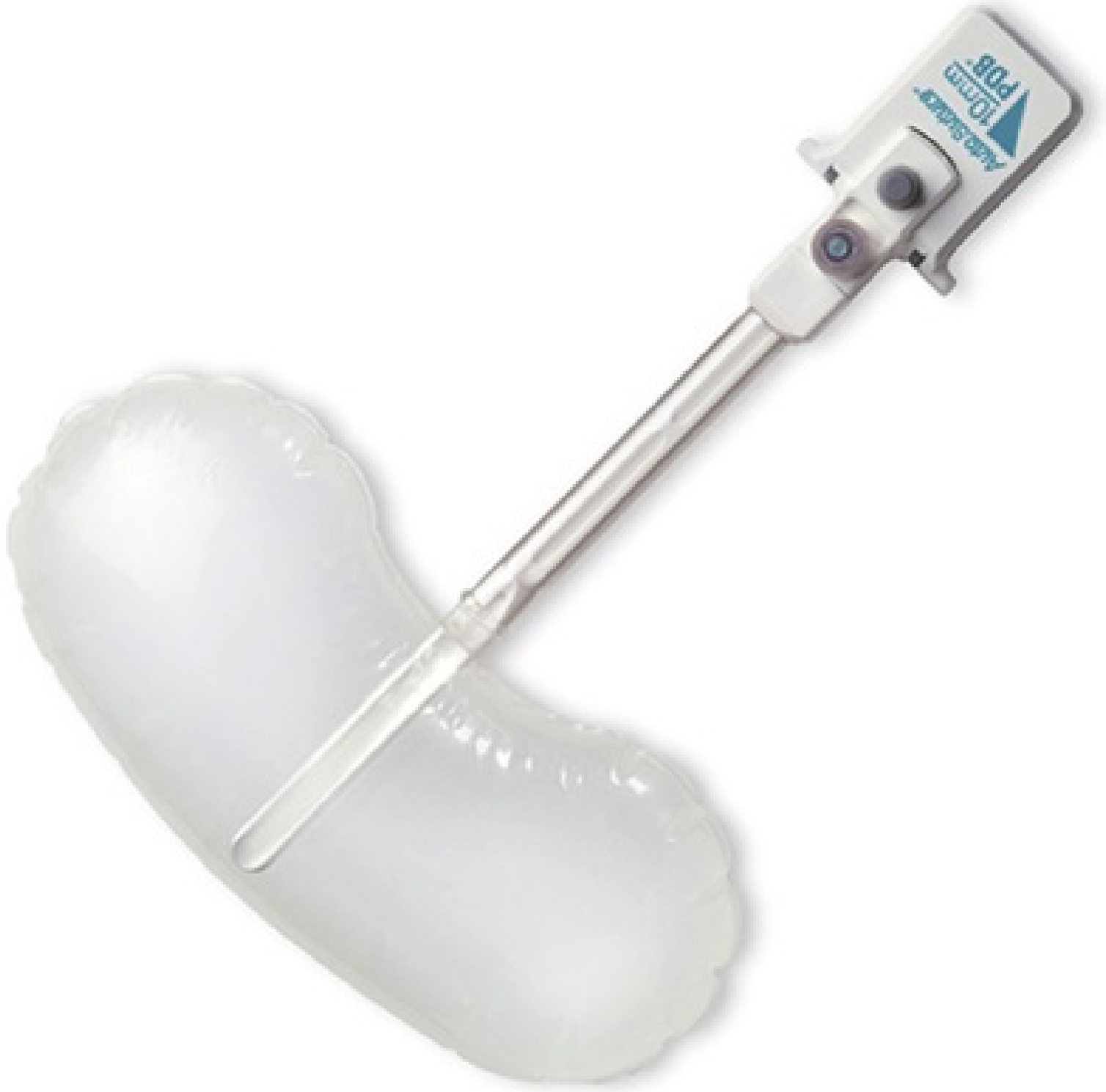

FIG. 14.10 Example of a commercially available balloon dilator for creating space in the retroperitoneum: preperitoneal balloon dissector. (Courtesy Medtronic, Minneapolis, MN.)

Self-Styled Dilators.

Gaur's original (Gaur, 1992) version of the balloon dilator was a size 7 surgeon's glove mounted on a No. 8 red rubber catheter. The external end of the catheter was connected to a sphygmomanometer bulb insufflator, and the balloon was insufflated to 110 mm Hg. After this initial description, several other self-styled dilators were described: the middle finger of a size 7 to 8 glove, two fingers of a size 7 to 8 glove tied over each other for additional strength, a sterile condom, and the cot of an O'Connor-style drape mounted on a 16- or 18-Fr red rubber or whistle-tip catheter (Chiu et al., 1995; Webb et al., 1993). For the balloons made from the middle finger of a surgeon's glove, the finger is affixed to the rubber catheter with two 0 silk sutures. These self-styled dilators were filled with saline rather than air. The device may be back-loaded into a well-lubricated (i.e., K-Y Jelly) 30-Fr Amplatz sheath to facilitate introduction through a laparoscopic port. Although it is economically advantageous, drawbacks of the self-styled balloon include the lack of a stiff shaft to manually direct the balloon into a specific location for precise dilation and the inability to endoscopically monitor the dilation process from within the balloon. In addition, the latex balloon has a tendency to rupture into multiple pieces, whereas the Silastic balloon usually leaves only one large fragment, making retrieval an easier task.

Complications associated with balloon dilation stem from improper balloon placement or balloon rupture. Intramuscular dilation may result in hernia formation, or inadvertent peritoneal disruptions may occur (Adams et al., 1996; Gaur, 1992).

Manual Dilation.

Creation of a working space within the retroperitoneum may also be achieved exclusively with a combination of digital and laparoscopic instrument dissection (Kerbl et al., 1993). After access to the extraperitoneal area is gained, to-and-fro movements of the laparoscope are performed to create a working space (McKernan, 1995). This technique has been used to perform various simple and advanced procedures in the retroperitoneum (Abbou et al., 1999; Rassweiler et al., 1998a). Although it is effective, potential disadvantages of this technique include frequent cleaning of the laparoscope and the lack of clear landmarks initially as a result of the smaller, undeveloped working space.

Extraperitoneal Access and the Extraperitoneal

Space

Technique for Balloon or Self-Styled Dilator Placement: Open (Hasson) Technique

A 1.5- to 2-cm curvilinear incision is made along the inferior umbilical crease. The anterior rectus sheath is incised vertically for 1.5 cm, and the rectus muscle is separated in the midline to expose the posterior rectus sheath. With the surgeon's index finger positioned posterior to the rectus muscle and anterior to the posterior rectus sheath, gentle tunneling motions are made in a caudal direction until the area of the symphysis pubis is reached. At this distal location, the fascia transversalis is punctured with the fingertip, and gentle side-to-side digital dissection is performed in the prevesical space, posterior to the pubic bone. Into this predeveloped space, a balloon dilator or self-styled dilator (see previous) is inserted and distended to create an adequate working space. Balloon dilation or self-styled dilation effectively displaces the prevesical fat and reflects the peritoneum cephalad. The balloon is initially inflated in the midline and then reinflated on either side to further expand the working area (Meraney and Gill, 2001).

Caveat: In earlier studies of retroperitoneoscopy, excessive subcutaneous emphysema and higher carbon dioxide levels were the norm because of the use of the standard Hasson cannula (Ng et al., 1999; Wolf et al., 1995); this situation was rectified with the introduction of the open access blunt balloon port, which has a balloon to secure it against the underside of the abdominal wall and a soft foam cuff to secure it to the outer abdominal wall, creating an airtight seal (Ng et al., 1999).

Limitations and Advantages of Transperitoneal Versus Extraperitoneal Approach to the Flank and Pelvis

Transperitoneal Versus Retroperitoneal Renal and Adrenal Surgery.

The transperitoneal and retroperitoneal approaches to the upper abdomen offer advantages and disadvantages. Retroperitoneoscopy is associated with unique anatomic orientation with limited anatomic landmarks, except for the psoas muscle. In comparison, the transperitoneal approach offers a very familiar anatomic approach with a number of landmarks (e.g., liver, spleen, large bowel). Retroperitoneal laparoscopy is also associated with a relatively restricted working space compared with transperitoneal laparoscopy. This results in a steeper learning curve with the retroperitoneal approach. Moreover, the fact that a comparatively limited space is available necessitates precise accuracy regarding the strategic placement of ports.

The degree of technical difficulty of the retroperitoneal approach increases in the presence of large specimens, including entrapment of these larger specimens, which may be very difficult. The latter problem of entrapment can be overcome by laparoscopically creating an intentional peritoneotomy at the end of the procedure to allow entrapment of the specimen within the larger peritoneal cavity.

Laparoscopic reconstruction and intracorporeal suturing are technically demanding procedures regardless of the approach. However, in the retroperitoneal space, reconstruction can be more challenging compared with transperitoneal laparoscopy because of suboptimal instrument angulation and a smaller working space. One potential way to overcome some of these limitations is to use a robotic approach to the retroperitoneum (Kaouk et al., 2008c).

Offsetting the limitations of retroperitoneoscopy are some distinct advantages. First, the risks of inadvertent bowel injury and postoperative ileus are minimized, although not eliminated (Kavoussi et al., 1993). This results in a slightly more rapid postoperative recovery compared with the transperitoneal approach. During retroperitoneoscopy and extraperitoneoscopy the bowel can be effectively and safely retracted within its peritoneal cover. Although out of sight, the bowel should never be out of mind, because bowel injuries can still occur.

Transperitoneal laparoscopy may be associated with an increased incidence of postoperative shoulder-tip pain, a feature rarely associated with retroperitoneoscopy. In addition, **extraperitoneoscopy and retroperitoneoscopy are associated with a significantly lower incidence of postoperative trocar site hernias.**

Another significant benefit of the retroperitoneal approach is the rapid and direct access to the renal hilum; the renal artery is the first hilar structure encountered and controlled. Furthermore, **if a partial nephrectomy is planned, it may be more effective to approach a posterior tumor from the retroperitoneal approach, whereas anterior tumors are often more easily approached from the transperitoneal approach**.

Contrary to common conception, the occurrence of an inadvertent peritoneotomy during retroperitoneoscopy does not usually interfere with the subsequent steps of the procedure, and conversion to a transperitoneal laparoscopic technique is not mandatory (Gill et al., 2000).

Although a retroperitoneal approach may not be advantageous for every surgery, there are certain instances in which this approach may be more appropriate, as in the case of multiple prior transabdominal surgeries. Conversely, a history of prior retroperitoneal surgery increases the difficulty of re-entering the retroperitoneal space and therefore should be approached with caution. Subsequent attempts at extraperitoneoscopy or retroperitoneoscopy should be ventured only by individuals with considerable experience and comfort with this approach. In our experience, prior percutaneous renal procedures do not necessarily constitute a contraindication to subsequent retroperitoneoscopy, provided that entry is away from the area of the prior nephrostomy tube placement.

Transperitoneal Versus Extraperitoneal Pelvic Surgery.

As with the upper abdomen, the transperitoneal and extraperitoneal approaches to the pelvis offer distinct advantages and disadvantages. The transperitoneal approach to the pelvis offers easy access to all areas of the pelvic cavity once the space of Retzius, iliac and obturator fossa, or the rectovesical space has been entered directly through the peritoneum. The working space is maximized because the peritoneum does not limit camera or instrument motion. However, potential limitations associated with this approach as compared with the extraperitoneal approach include the possibility of causing mechanical or thermal injury to the bowel, the necessity to use more extreme Trendelenburg positioning or additional retraction of the bowel, and the possibility of prolonged ileus. Overall, in large prospective studies the only significant difference between the extraperitoneal and transperitoneal approaches is that the extraperitoneal approach is associated with shorter operative times (Erdogru et al., 2004; Madi et al., 2007; Ruiz et al., 2004).

One undeniable advantage of the extraperitoneal approach is that it avoids the necessity of lysis of adhesions in patients who have had prior abdominal surgery. In contrast, for patients who have had prior laparoscopic inguinal hernia repair, a transperitoneal approach is more advantageous.

Unlike with retroperitoneoscopy, the occurrence of a peritoneotomy during extraperitoneoscopy may interfere with the performance of subsequent extraperitoneal dissection, and conversion to a transperitoneal technique may be required (Meraney and Gill, 2001).

In summary, for most cases there does not seem to be a clear advantage to use of a transperitoneal versus extraperitoneal approach for laparoscopic and robotic pelvic surgery. In selected cases described earlier there may be advantages of one approach over the other.

Access Technology: Trocars, Hand Ports, and Single-Port Access

Trocars

Trocars enable the laparoscopist to introduce working instruments into the gas-filled abdomen or retroperitoneum. They also maintain the pneumoperitoneum by conveying the insufflant and may serve as pathways for delivering small amounts of dissected tissue from the surgical area. Typically a trocar consists of an outer hollow sheath (also called a *cannula* or *port*) and an inner obturator, which is removed as soon as the outer sheath has entered the peritoneal cavity.

A variety of nondisposable and disposable trocars are available (Fig. 14.11) with one-way valves and multiseal valves. Standard models range from 3 to 20 mm in diameter and 5 to 20 cm in length. One-way valves within the trocar allow the surgeon to exchange instruments through the port without the escape of significant amounts of gas. Multiseal-type valves accommodate the passage of 5-mm and larger instruments without any air leak occurring; if large amounts of tissue are to be withdrawn, removal of the outer seal or of the entire valve is necessary for this procedure. The outer seal and valve can then be replaced before reinsertion of instruments.

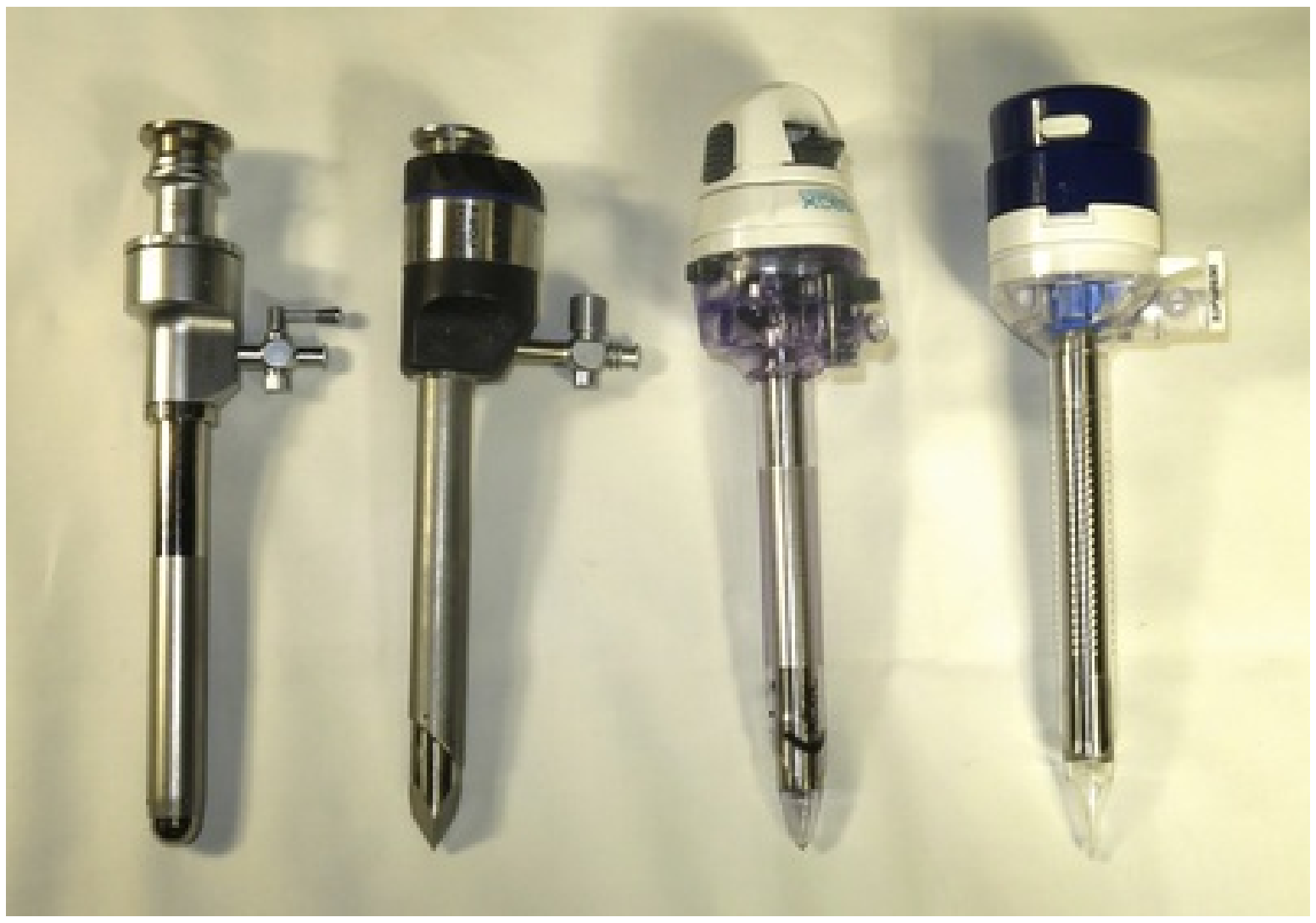

FIG. 14.11 Various trocar designs showing *(left to right)* reusable blunt-

tipped, reusable bladed, and two disposable visual obturator fascial dilating designs.

Initially, only “cutting,” sharp-tipped or bladed, trocars were available. On these trocars a blade on the obturator incised the various layers of tissue as it entered the peritoneal cavity. To protect the underlying viscera from the sharp tip of these trocars, a plastic safety shield was later incorporated into the disposable trocars that would spring forward to shield the blade once the trocar entered the gas-filled abdomen. **However, bladed trocars should be only of historical interest because they have been superseded by safer noncutting dilating trocars (i.e., blunt), which no longer require a safety shield.** These trocars enter the abdomen by spreading the abdominal wall musculature rather than cutting it. Therefore there is less chance of injuring an abdominal wall vessel, and the resulting entry site is less prone to subsequent herniation. Indeed, studies have shown the risk of inferior epigastric injury or port site herniation is fivefold less with blunt versus sharp trocars (Hashizume and Sugimachi, 1997; Thomas et al., 2003). In addition, a recent meta-analysis demonstrated a lower relative risk of trocar site bleeding (3% vs. 9%) and overall complications (3% vs. 10%) with blunt compared with bladed trocars (Antoniou et al., 2013).

Other blunt-tipped trocars are produced by all of the major trocar manufacturers. These devices have a variety of tips that enable their placement by spreading the tissues; some also have a clear plastic tip (i.e., optical trocar) so that the surgeon can pass an endoscope into the trocar to endoscopically monitor its passage through the abdominal wall and its entry into the gas-filled abdomen.

For the da Vinci Robotic System the trocar type that will accommodate the camera lens depends on whether the Si or Xi system is used. The Xi camera fits through any of the 8-mm trocars, whereas the Si camera requires a 12-mm trocar for use. The instruments fit through proprietary reusable 8-mm trocars that couple directly with the robotic arms. These reusable metal trocars have disposable valves that must be changed with each new case and the option of a reusable blunt inner cannula or a bladeless disposable inner cannula for use during placement.

In traditional flap-valve or trap door ports, a reducer is necessary to allow downsizing of working channels in 10-mm or larger trocars to accommodate smaller, 5-mm working instruments without any leakage of CO_2. However, the development of multiseal technology and the even newer AirSeal technology (CONMED, Utica, NY; discussed later) has resulted in valves that can accommodate 5- to 12-mm instruments without the need for a reducer, which can save significant time during a long procedure.

Retention of the cannula at the port site is essential to decrease air leak and subcutaneous emphysema and facilitate the timely completion of a procedure. In the past it was necessary to affix a suture to the insufflation side port and the skin to secure the trocar. At present, myriad retention mechanisms prevent dislocation of cannulae, such as threaded sleeves, adjustable threaded sleeves, expandable arms, and inflatable balloons. The Blunt Tip Trocar (Medtronic, Minneapolis, MN) (eFig. 14.12) has a retention balloon that can be inflated in the peritoneal cavity and then drawn up tightly against the peritoneal side of the abdominal wall; an outer foam or rubber sealing ring can then be advanced down the extra-abdominal shaft of the cannula, thereby sandwiching the abdominal wall between the inflated balloon and the foam or rubber seal, effectively precluding any leakage of gas during the case. **Use of this device minimizes CO_2 leakage around the primary port incision, thus reducing the incidence of subcutaneous emphysema and hypercarbia.** This is especially effective when doing retroperitoneoscopic procedures.

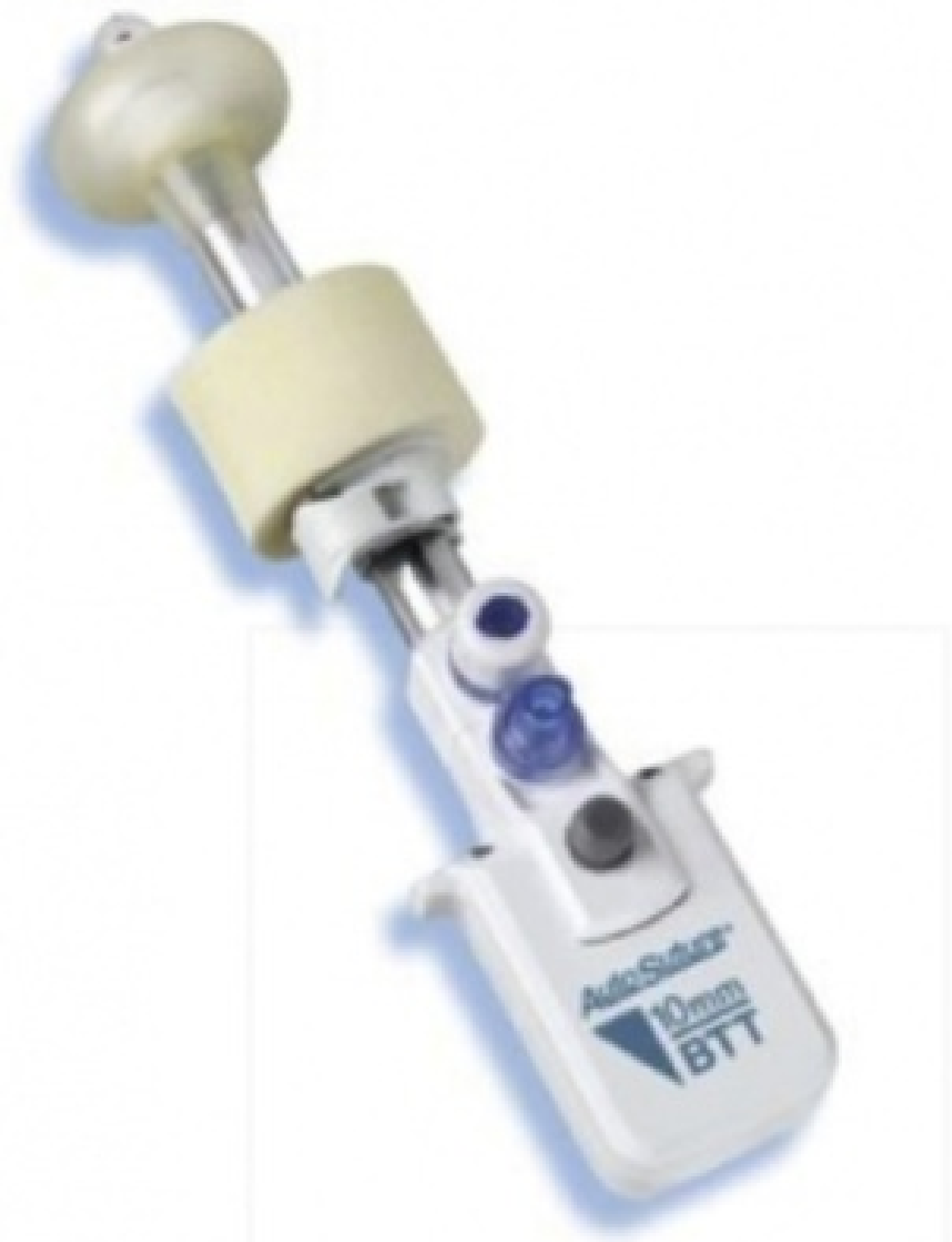

EFIG. 14.12 Blunt-tipped trocar with balloon tip.

A technologic advance in trocar and insufflation technology has addressed some of the limitations of existing trocar systems including air leak, need for reducers, and specimen removal. The AirSeal System (CONMED, Utica, NY) consists of a specialized Intelligent Flow System insufflator (eFig. 14.13A) featuring a circulatory flow design, a valve-free Access Port (eFig. 14.13B and C), and a Tri-Lumen filtered tube set (eFig. 14.13D). This system has the ability to provide a substantially more stable pneumoperitoneum (Bucur et al., 2016) despite continuous high-flow suction, trocar dislodgment, or excessive port-side leakage. The stable pneumoperitoneum allows for procedures to be routinely performed at lower insufflation pressures (i.e., 8–12 mm Hg) in the majority of cases. The valve-free design of the Access Port allows smudge-free scope insertion, intact specimen removal, and easy insertion and withdrawal of instruments of varying sizes. The AirSeal System also provides continuous smoke evacuation without the fear of venting surgical smoke and plume into the operating room.


AirSeal i FS
Intelligent Flow System
AirSeal Mode
Smoke Evacuation Mode
Standard Insufflation Mode
MENU
SURGIQUEST
A
B
SURGIQUEST
12
12
AIRSEAL
C
D

EFIG. 14.13 AirSeal System (CONMED, Utica, NY). (A) Intelligent flow system insufflator. (B) Trocar. (C) Valve-free access port. (D) Tri-Lumen filtered tube set.

Hand-Assist Devices

The most common hand-assist devices available are the GelPort (Applied Medical Resources, Rancho Santa Margarita, CA) and the Endopath Dextrus (Ethicon, Somerville, NJ) (Fig. 14.14). An important caveat with using hand-assist devices is the impact on the surgeon. Studies have shown that compared with standard laparoscopy, pain and numbness of the surgeon's hand, wrist, and forearm and, to a lesser extent, overall fatigue are much greater with use of a hand-assist device (Gofrit et al., 2008; Monga et al., 2004). Both devices maintain peritoneal gas pressure while allowing for insertion of the surgeon's hand or surgical instruments into the abdominal cavity.



FIG. 14.14 Hand port devices. (A) GelPort. (Courtesy Applied Medical Resources, Rancho Santa Margarita, CA.) (B) Endopath Dextrus. (Courtesy Ethicon, Somerville, NJ.)

Laparoendoscopic Single-Site Surgery Access Devices

Two basic methods are used to perform LESS. One technique is to make a 2.5-cm incision, typically periumbilical or transumbilical (although an alternate site may be necessary), through which a skin flap can be raised off the abdominal wall fascia. Then, through this single incision, several (two to four) standard 5-mm laparoscopic ports can be placed in proximity to one another. A laparoscope and working instruments can then be placed through these ports. This is obviously the most cost-effective technique.

Alternatively, a commercially available single-site surgery device can be used. These devices currently require a single incision that is typically placed periumbilically or transumbilically unless the procedure dictates an alternate site. Currently the most popular devices that are available for commercial use are the TriPort15/TriPort+ (Olympus, Center Valley, PA) and the SILS Port (Medtronic, Minneapolis, MN).

The TriPort15 contains three instrument ports and two insufflation valves (eFig. 14.15A), whereas the TriPort+ contains four instrument ports and two insufflation valves. Both accommodate different sizes of laparoscopic instruments and feature duckbill/lipseal valves that allow for the introduction and removal of instruments while maintaining pneumoperitoneum. The same manufacturer also makes a five-port model called the QuadPort+ that contains five instrument ports and two insufflation valve sites and can be easily introduced through a 2.0-cm incision.

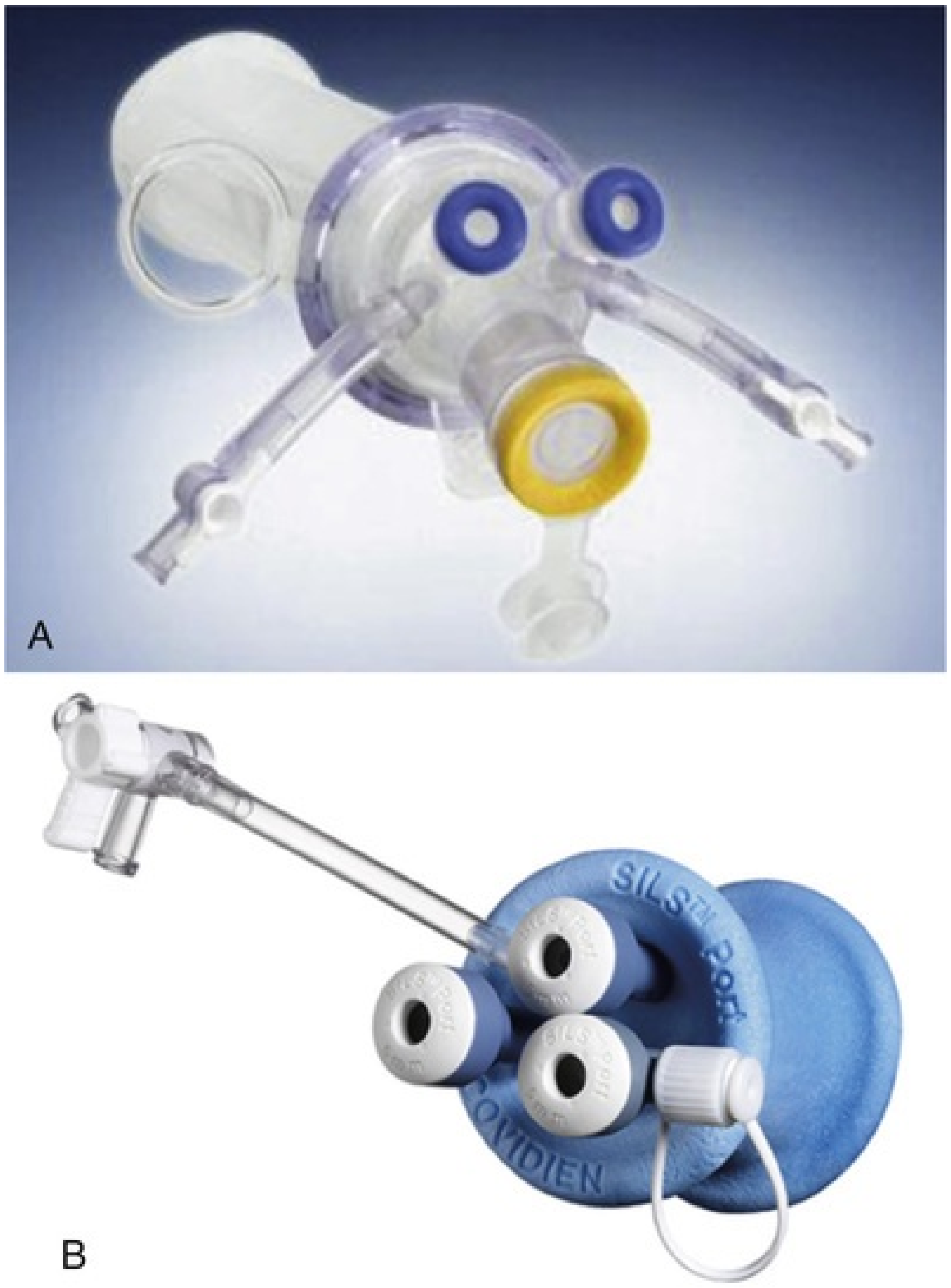

EFIG. 14.15 Commercially available ports for laparoendoscopic single-site surgery. (A) TriPort15. (B) SILS Port.

The third available device is the SILS Port, which can be placed into a 2-cm incision and can house three 5-mm ports or two 5-mm ports and a 5- to 10-mm port (eFig. 14.15B).

Robotic Laparoendoscopic Single-Site Surgery Devices.

Intuitive Surgical has developed a single-site platform for both the da Vinci Systems. The da Vinci single-site port system is a five-lumen port that provides access for two single-site instruments, the 8.5-mm endoscope, a 5- or 10-mm accessory port, and an insufflation adaptor (eFigs. 14.16A and B). The port has a pliable architecture that enables simple and safe entry into a 2.0- to 2.5-cm incision. Curved 5-mm instrument cannulae and trocars have been designed for specific use with the single-site port and are meant to optimize triangulation toward the target anatomy and provide an unobstructed view of the surgical field (eFig. 14.16C). More recently, a complete change in the platform for R-LESS has been developed to overcome the challenges of instrument clashes and improve triangulation of the arms. The novel da Vinci SP 1098 platform uses EndoWrist technology to avoid difficulties with instrument triangulation and is currently in the preclinical research phase.

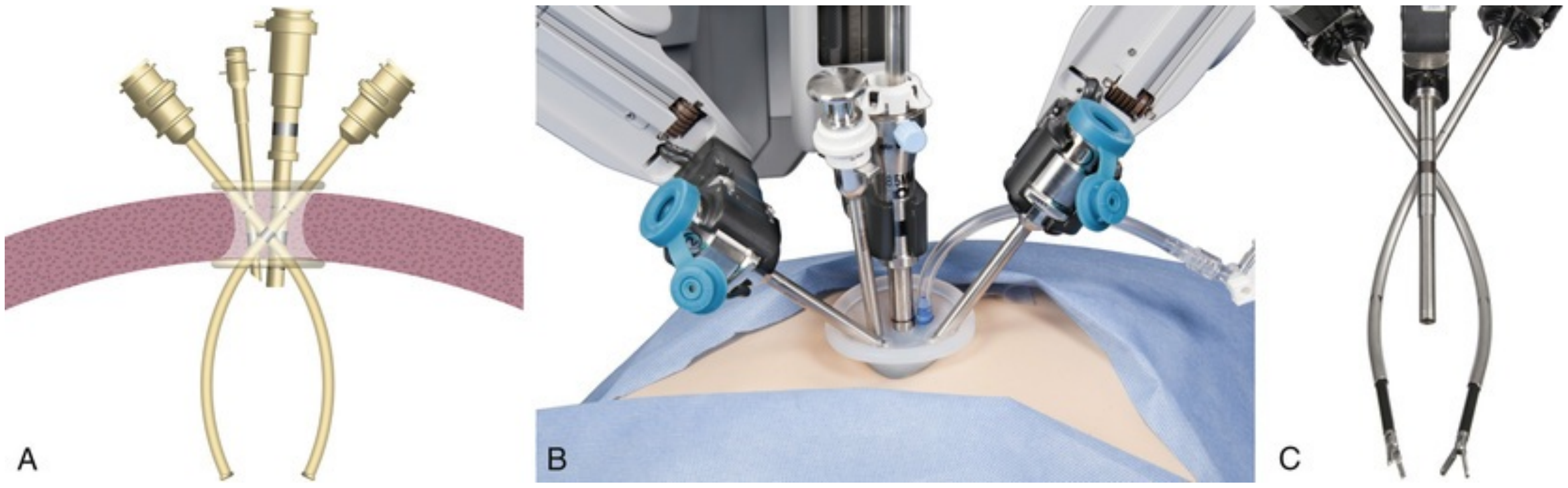

EFIG. 14.16 Single-site platform for the da Vinci Si System. (A) Schematic diagram of access port with curved trocars. (B) Robotic arms docked to single-site platform. (C) Curved robotic instruments within trocars with camera. (Copyright 2015 Intuitive Surgical, Inc. Used with permission.)

Trocar Placement

Placement of Initial Trocar

When the Veress needle technique is used after establishment of the pneumoperitoneum, an incision is made for placement of the initial trocar. Alternatively, if an incision was made for placement of the Veress needle, the edges of the wound and subcutaneous tissue are spread with blunt forceps. Next, the trocar is held in the dominant hand with the middle finger extending along the shaft, and the trocar is inserted using a twisting downward motion. The nondominant hand can be placed at the level of the skin, gently holding the trocar to stabilize it and prevent a sudden advancement. If the surgical site is in the mid to upper abdomen, then the trocar is passed perpendicular to the umbilical incision; however, for pelvic procedures, the trocar is directed 70 degrees caudad. Proof of entering the gas-filled intraperitoneal cavity is the sound of CO_2 escaping from the open sidearm. After the sidearm is closed, the obturator is removed and the CO_2 insufflation line is connected to the side port of the trocar. Alternatively, if a clear blunt port (i.e., optical trocar) is used, a 0-degree laparoscopic lens is placed within the port so that the entire entry of the trocar is endoscopically monitored.

Some advocate for increasing the pneumoperitoneum after achieving access with the Veress needle in preparation for initial trocar placement to decrease the risk of underlying vascular or visceral injury with trocar insertion (Vilos et al., 2007). It is recommended to increase the pressure to 20 mm Hg. However, some data suggest this may not increase the volume of the pneumoperitoneum or ease of trocar insertion (McDougall et al., 1994).

When an **open technique** is performed to obtain the pneumoperitoneum, the Hasson-style cannula used to obtain access to the abdomen also serves as the initial trocar.

Hand-Assist Placement

The hand-assist device can be placed either as an initial “port,” described earlier, or as a secondary port depending on the surgeon's preference. When placed as a secondary port, a Veress or Hasson pneumoperitoneum is initially established and the hand-assist device is then placed under endoscopic monitoring. Establishing the pneumoperitoneum before hand port placement can help to minimize the size of skin incision for the hand port, as the skin is on stretch. The surgeon should carefully plan out the hand port entry site as well as the additional instrument and camera port sites. Every hand port device has a “footprint” that can be drawn on the abdominal wall; that footprint varies depending on the diameter of the external appliance. **Care should be taken to plan out the additional trocar sites carefully to avoid interference between the hand port and the instrument ports;** this is most easily done once the pneumoperitoneum has been established. After the footprint has been traced, the hand port incision site is marked; the length of the incision should correspond to the surgeon's glove size (e.g., 7 glove size = 7-cm incision). The skin is incised, and the fascia is divided. The peritoneum is entered, and the insufflation is temporarily stopped. The hand port device is then placed according to the manufacturer's instructions.

Before initiating a hand-assist procedure, the surgeon is advised to wrap the arm-glove seam on the hand that is to be used through the hand port either with a 1010 drape or an Ioban (3M, St. Paul, MN) “sticky drape” to waterproof his or her arm. **Last, the use of a brown glove on the intra-abdominal hand is recommended because it does not reflect the light from the laparoscope and thus reduces glare** (Wolf, 2005).

Secondary Trocar Placement

After obtaining access, the first step before secondary trocar placement is to inspect the entire abdomen systematically to rule out any injury to the underlying viscera that may have occurred during access or placement of the initial trocar. After this, the surgeon can proceed with secondary port placement.

Number, size, and exact location of secondary trocars depend largely on the intended laparoscopic procedure. Their configuration should be planned so that neither the tips nor handles of the cannulas cross or come into close contact with one another (a problem termed *crossing swords* and *rollover,* respectively) so that adequate working space is provided for all instruments to be used during a particular procedure and allowing for effective triangulation at the surgical site by the endoscope and two working ports. In general, it is reasonable to place the ports in a four-point diamond pattern so that the site of the operation is encircled within the diamond. **This is particularly important when considering reconstructive renal procedures, because the angle between the horizontal plane and the needle drivers should be less than 55 degrees, whereas the angle between the surgeon's suturing instruments should be in the 25- to 45-degree range** (Rassweiler and Frede, 2002).

It is also important to place each port so that it is pointing toward the surgical field to avoid continued forceful redirection of the port during the procedure that may result in widening of the tissue tract around the port and development of subcutaneous emphysema.

Standard Approach.

Secondary trocars are placed under direct optical control. The 30-degree lens is ideal for this portion of the procedure because turning the lens 180 degrees away from the surgical site provides the surgeon with a panoramic view of the anterior abdominal wall. The operative lights are dimmed, and the tip of the laparoscope is moved upward toward the intended site of port placement, thereby, in the thin patient, transilluminating any superficial blood vessels that must be avoided while passing the trocar. With a blade, a skin incision is made just wide enough to accept the selected cannula. When placing secondary ports, the surgeon should direct them toward the intended surgical field to provide tension-free maneuverability of the laparoscopic instruments. This is especially important in obese patients because the errant port will provide resistance to the surgeon throughout the rest of the procedure. Similar to placement of the initial port, all secondary ports are advanced through the abdominal wall using a slow, twisting motion and constant pressure. Each secondary port is passed into the peritoneal cavity under meticulous endoscopic monitoring. To prevent dislocation, ports that do not possess self-retaining mechanisms may be anchored to the skin using No. 2 nonabsorbable sutures. **In this regard, the laparoscopist should never use a metal trocar in conjunction with an outer plastic retaining ring because stray current can no longer be harmlessly dissipated through the metal cannula directly to the surrounding peritrocar abdominal wall. Therefore any juxtaposed visceral structure may be damaged in an area remote to the laparoscopist's vision.**

Hand-Assist Approach.

When the hand-assist device is in place, then secondary trocars can be placed with digital guidance. After inspection of the abdomen rules out any potentially interfering adhesions, the surgeon's index finger is placed on the underside of the abdominal wall at the planned site of trocar placement. A skin incision is made over the surgeon's index finger, and the nonbladed trocar is passed with the other hand and guided by the surgeon's finger into the abdominal cavity. This is a very rapid and safe way to place all of the secondary nonbladed trocars.

Trocar Configuration

A number of different trocar configurations exist for transperitoneal or retroperitoneal upper abdominal laparoscopy and robotics. Details and diagrams of these configurations can be found in Chapter 103. Similarly, a number of trocar configurations exist for transperitoneal and extraperitoneal laparoscopic and robotic pelvic procedures, which are detailed in Chapter 157. Most important, regardless of the configuration chosen, is to ensure meticulous placement of the ports to minimize instrument clashing intracorporeally and extracorporeally.

Robotic Considerations

If a robotic procedure is planned, then the camera port is either an 8-mm (Xi) or 12-mm (Si) trocar site depending on the da Vinci system used and the two (or three if the fourth arm is used) auxiliary ports are 8 mm. **All the ports must be placed 8 to 10 cm apart to reduce the possibility of the robotic arms clashing with each other.** In addition, if the patient is in a flank position, then the lowest port placement should not be inferior to the umbilicus or the arm may be blocked from a full range of motion by the patient's upside leg. An assistant's port is placed on a line either caudal or inferior to the robotic arms; placement of the assistant's port between the arms of the robot makes it awkward for the assistant to work and limits the range of motion of the assistant's instrument because of clashing with the arms of the robot. All 8-mm robotic ports must be advanced to ensure that the thick black marking on the shaft of the trocar is below the abdominal wall.

Laparoscopic Instrumentation

Instruments for Visualization

To create a laparoscopic image, four components are required: the laparoscope, light source, camera, and monitor. To record the image, video recorders, digital video discs, and video printers are available.

Laparoscope and Camera

Standard Systems.

The most commonly used laparoscopes have 0- or 30-degree lenses (range, 0 to 45 degrees) and are available in sizes from 2.7 to 10 mm. Typically, the 30-degree lens provides the surgeon with a more complete view of the surgical field than the 0-degree lens, allowing the surgeon to peer around vascular structures by rotating the lens. Deflectable laparoscopes have been developed in which the tip of the endoscope can deflect in four directions up to 100 degrees (EndoEYE Deflectable-Tip Video Laparoscope [Olympus, Center Valley, PA]), which offers many potential angles from which to view a structure but requires an adept assistant. Another endoscope design is the EndoCAMeleon (Karl Storz, Tuttlingen, Germany). This scope maintains the familiar feel of a standard rigid laparoscope but has a variable-view swing prism that enables the surgeon to change viewing angles from 0 to 120 degrees. An advantage of the EndoCAMeleon is that it has a standard eyepiece, allowing it to be used with most camera systems.

With standard laparoscopes, image transmission uses an objective lens, a rod-lens system with or without an eyepiece, and a fiberoptic cable. From the eyepiece, the optical image is magnified and transferred to the camera and onto the monitor. Light is transmitted from the light source through the fiberoptic cable onto the light post of the laparoscope (eFig. 14.17A). Some laparoscopes have a miniature charge-coupled device (CCD) camera mounted at the tip (EndoEYE [Olympus, Center Valley, PA]), which improves image quality and avoids the need for an external light cord that can sometimes impede the movement of other instruments (eFig. 14.17B).



EFIG. 14.17 (A) Standard rod and lens laparoscope and camera. (B) Laparoscope with a mini–charge-coupled device camera mounted at the tip.

The most vexing problem with any laparoscope is fogging of the lens. To prevent fogging of the laparoscope after insertion into the warm intraperitoneal cavity, the laparoscope should be warmed before passing it into the abdomen. Several methods for this include using a container holding warm saline or using a warming thermos (Applied Medical Resources). In addition, wiping the tip with a commercial defogging fluid or with povidone-iodine solution is also recommended. Alternatively, an all-in-one visualization system cleans and defogs the camera simultaneously (Medtronic, Minneapolis, MN). Should moisture buildup occur between the eyepiece and the camera, both components must be disconnected and carefully cleansed with a dry gauze pad; this is not a problem with the digital endoscopes because the only connection is from the endoscope directly into the display box. A final important note is to ensure that the sterile scope is white balanced.

The **camera system** consists of a camera and a video monitor. All currently made cameras can be gas or liquid sterilized, thereby facilitating their use and limiting possible intraoperative contamination. For standard laparoscopes the camera is attached directly to the end of the laparoscope and transfers the view of the surgical field through a cable to the camera box unit. After reconstruction of the optical information, the image is displayed on one or two video monitors.

Three-Dimensional Systems.

3D laparoscopic systems offer the surgeon the distinct advantage of depth perception. Optimal 3D laparoscopy is performed with a two-lens system that duplicates the two-eye perception of 3D. In this way binocular vision is maintained. The most commonly used 3D vision system currently in use is the InSite Vision System (Intuitive Surgical), which provides vision for the da Vinci Robotic System. The laparoscope and high-definition camera are controlled by a robotic arm that is under direct control of the surgeon from the ergonomic console. The surgeon maintains a steady, magnified 3D view of the surgical field. Zero- and 30-degree lenses are currently available.

Instrumentation for Grasping and Blunt Dissection

Most graspers and dissectors are used in their 5-mm size but are available in a range from 3 to 12 mm in predominantly reusable forms. Grasping instruments have either single-action (only one jaw moves during opening) or double-action (both jaws move) tip design.

Wide variations exist with regard to configuration of tip, surface characteristics of jaws, handle design, and possible electrosurgical properties. Tip designs include blunt-coarse, pointed (dolphin), straight (duckbill), curved (Maryland), and angled. The surface of the jaws may be atraumatic or traumatic. Serrated or smooth surfaces allow gentle tissue manipulation in atraumatic graspers (e.g., bowel forceps with a 3-cm long grasping jaw). Traumatic graspers have toothed or clawed surfaces on their jaws to allow them to grasp and hold tissues firmly. In addition, each of these instruments may be equipped with tip-rotation and/or articulating features. Reusable and disposable instruments are available.

Depending on the design of the handle, grasping instruments may be locking or nonlocking. Most nonlocking forceps have a scissor-type handle. Different designs allow for locking capabilities; in particular, bar-type and spring-loaded locking handles are convenient when prolonged grasping of tissue is required, whereas other dissectors offer additional degrees of freedom by means of an articulating joint activated through wrist movements of the surgeon.

In addition to standard dissecting instruments, the laparoscopic suction apparatus and the “heel” of the hook electrode can be used for effective and rapid blunt dissection. Along these same lines, laparoscopic “peanuts” or Kittners (i.e., 5- and 10-mm gauze-tipped disposable dissectors) have been most helpful. These dissectors can be moved side to side or up and down in an area of adipose tissue to rapidly tease away the fat surrounding vital structures such as the renal hilum or the adrenal gland. In addition, the device can be used to raise an entire “line” of tissue (e.g., pararenal fat), allowing for its rapid and safe division because neither the shaft nor the tip of the Kittner will conduct electrosurgical current.

Instrumentation for Incising and Hemostasis

Laparoscopic scissors, scalpels, electrocautery, ultrasonic devices, and lasers (CO_2, neodymium:yttrium-aluminum-garnet [Nd:YAG], or potassium titanyl phosphate [KTP]) are used to incise or cut tissue during laparoscopic surgery. Cutting of tissue with electrocautery and lasers is achieved when the cell temperature is elevated until the concomitant gas pressure causes the cells to explode. Conversely, with ultrasonic devices the cutting mechanism is a relatively sharp blade, vibrating at 25 kHz to 55 kHz over an excursion distance of up to 100 µm.

Monopolar and bipolar electrocautery and other technologies exist for achieving hemostasis. The basic mechanism for coagulating bleeding vessels is similar among the various modalities in that vessels are sealed and occluded with denatured protein; however, the manner in which protein is denatured is different for each modality. Electrosurgery and lasers denature protein by heating the tissues with electric current in the former and light in the latter at a very high temperature. Conversely, ultrasonic devices denature protein by transferring mechanical energy to ultrasonic high-frequency vibration (25 kHz to 55 KHz).

Sharp Dissectors.

Laparoscopic scissors are available in disposable and nondisposable forms. The blades of laparoscopic scissors are shorter than their open surgical counterparts. The configuration of the tip may be useful for selected situations: hooked tips for cutting sutures, microscissors for spatulating the ureter during a pyeloplasty, and curved tips for dissection. The scissors may come with either permanent blades or with replaceable tips; use of the latter ensures "sharp" scissors for each procedure. In addition, the shaft of the scissors may rotate and, in some disposable scissors, even articulate up to 90 degrees.

Monopolar Electrosurgical Devices.

For **electrosurgical incision** of tissue, a selection of different electrodes are available. Needle electrodes (Corson type) produce fine cuts useful in making peritoneal incisions. Spatula electrodes are used in blunt dissection and cutting. Hook electrodes (J and L configurations) are of particular value during dissection of vessels because tissue can be pulled away from delicate structures before the cutting current is activated. **The thinner the metal tip of the probe is, the higher the density of the electrical current, and the greater the tissue vaporization and apparent "cutting" power.**

As with all insulated instruments, certain precautions must be followed during monopolar electrosurgery to avoid local or distant transmitted thermal injury. Consequently, **the electrosurgical probe should not be activated unless the metal part is in complete view. The insulation of the electrosurgical instrument should be carefully checked for any damage. The probe should not be activated unless it is in direct contact with the tissue to be incised.**

To avoid the potential dangers of stray current from use of monopolar electrosurgical equipment, the surgeon can use monopolar current in conjunction with active electrode monitoring (Encision, Boulder, CO). This instrumentation is constructed so that there is ongoing feedback during activation of the electrosurgical current; therefore any break in the insulation of the shaft results in immediate deactivation of the instrument.

Bipolar Electrosurgical Devices.

The laparoscopic surgeon can also use bipolar electrosurgical devices that require less energy for performance than their monopolar counterparts. There is also a decreased likelihood of injury to surrounding tissue for a couple of important reasons. First, because the **electrical current is only passing from**

one jaw of the instrument to the other, it precludes the potential problem of capacitive coupling, common with monopolar electrosurgical current. Second, **with bipolar current, the extent of coagulative damage is less than with monopolar electrosurgery**: 1 to 6 mm versus 5 to 7 mm with monopolar current (Landman et al., 2003a).

One of the currently available bipolar electrosurgical devices is the LigaSure vessel-sealing system (Medtronic, Minneapolis, MN). It consists of a 5- or 10-mm grasper-dissector connected to a bipolar radiofrequency generator. When the vascular structure is grasped by the instrument, the tissue is evaluated by an impedance-based feedback-response system that subsequently delivers the optimal energy required to seal the vessel effectively. Because of the high-current and low-voltage output, the vascular structure enclosed by the jaws of the instrument degrades quickly, and a protein-based seal is presumably created. This mechanism of electrical current delivery to the tissues results in less charring and less collateral thermal damage (1–3 mm) (Landman et al., 2003a). Indeed, use of this instrument during partial nephrectomy does not compromise the ability of the pathologist to read the surgical margin (Phillips et al., 2008). An audible signal alerts the surgeon that the sealing of the vessel is complete; the instrument has a trigger-activated blade that the surgeon can then use to cut the sealed tissue. Vessels up to and including 7 mm in diameter appear to be effectively occluded to above-normal physiologic pressures with this device (Carbonell et al., 2003; Landman et al., 2003a). However, only one LigaSure application to the structure being sealed is recommended, because multiple applications may weaken the seal (Truong et al., 2008). An alternative to the LigaSure is the EnSeal G2 (Ethicon, Somerville, NJ), which is also a vessel-sealing and cutting device. This is a 5-mm instrument that can also act as a grasper-dissector and be used to seal vessels up to 7 mm.

In a recent study, surgical metrics including transection time, vessel-sealing time, thermal spread, and seal burst pressures were compared using five contemporary energy-based vessel-sealing devices (Okhunov et al., 2018). In their porcine model the Caiman 5 (Aesculap, Center Valley, PA) outperformed all devices tested. The Caiman 5 is a novel device that uses advanced bipolar technology with a pivoting jaw design and closing mechanism with the sealing electrodes distributed in the upper and lower jaws of the instrument (eFigs. 14.18A and B). This mechanism allows for a more homogenous pressure distribution in the jaws.

EFIG. 14.18 (A) Example of a Caiman 5 vessel-sealing system. (B) Caiman 5 tip. (Courtesy Aesculap, Center Valley, PA.)

Laser Instrumentation.

Lasers are most frequently used through the working channel of an operating laparoscope. The CO_2 laser provides excellent cutting and vaporization of surface lesions and requires a rigid hand piece and probe. In contrast, the 400- and 600-µm KTP fibers are flexible and allow for noncontact cutting and fulguration. Nd:YAG laser fibers are also flexible and allow noncontact fulguration and contact cutting. Holmium laser fibers are also flexible and are used in a contact mode for cutting. Typically, lasers are not used in urologic laparoscopy, where they have largely been supplanted by electrosurgical instruments. Only in gynecology is the CO_2 laser used extensively, generally in the treatment of endometriosis.

Ultrasound Instrumentation.

Ultrasonic technology (Harmonic scalpel [Ethicon, Sommerville, NJ]; Sonicbeat [Olympus, Center Valley, PA]; Sonicision [Medtronic, Minneapolis, MN]) is another option for cutting and hemostasis in endoscopic surgery. It provides an especially attractive alternative to monopolar electrosurgery for working around particularly delicate tissues or operating on patients with an implanted pacemaker or cardioverter defibrillator (Gossot et al., 1999; Strate et al., 1999). In ultrasonic devices, electrical energy is transformed into mechanical energy by the use of a piezoelectric crystal system. Specifically, electrical energy is produced by a power-supply generator and transformed into mechanical vibration at the tip of the instrument through a piezoelectric crystal interface (Gossot et al., 1999; Suzuki et al., 1995; Takeda et al., 1997). Mechanical vibrations produced by this system in the tip of the instrument are capable of causing cavitation, coaptation, coagulation, and cutting in the targeted tissue (Strate et al., 1999). There are several important benefits to the ultrasonic system. These include the absent risk of local thermal damage and tissue charring because of a working temperature lower than 80°C. Subsequently, reduced tissue charring may result in a reduced rate of postoperative adhesions (Amaral and Chrotstek, 1997). A second benefit is that the depth of penetration is limited to the targeted tissue within a diameter of 1 mm, so there is minimal lateral thermal spread and potential for tissue damage (Landman et al., 2003a). Ultrasonic devices also minimize smoke for improved visibility in the surgical field. In addition, the ultrasonic systems eliminate other problems associated with monopolar electrosurgery, specifically problems of remote site tissue damage caused by capacitive coupling, insulation defects in the instrumentation, and direct coupling. As with bipolar energy, use of ultrasonic energy during partial nephrectomy does not compromise the ability of the pathologist to read the surgical margin (Phillips et al., 2008). Last, cordless versions of these devices (e.g., Sonicision), although heavier, reduce the number of cords in the operative field.

Potential disadvantages of ultrasonic technology include slower vessel sealing (Lamberton et al., 2008) and the fact that the metal portion of the shears becomes hot during activation (often more than 200°C compared with the bipolar energy–based devices, which stay below 100°C) and must not come into direct contact with any bowel surrounding the area of dissection. In fact, the harmonic shears take roughly twice as long to cool to a “safe” temperature after firing (often up to 45 seconds) compared with the LigaSure device (Medtronic, Minneapolis, MN) (Kim et al., 2008).

Combined Devices and Other Instrumentation.

The Thunderbeat (Olympus, Center Valley, PA) combines ultrasonic and advanced bipolar energies into a single multifunctional instrument, allowing surgeons to seal and cut vessels up to and including 7 mm in size with minimal thermal spread. Initial studies have shown promising results, with the Thunderbeat surpassing the dissection speed of ultrasonic devices while having the sealing efficacy of bipolar devices (Milsom et al., 2012; Milsom et al., 2015; Seehofer et al., 2012).

The **argon beam coagulator** provides a noncontact form of electrocoagulation. Electrical current originating from a monopolar electrosurgical generator is conducted to the tissue through an ionized argon gas stream. The gas stream blows away blood from the tissue, resulting in better exposure of the bleeding site and therefore more effective delivery of the electrosurgical current. Argon is a colorless, odorless, inert gas that clears the body within one respiratory cycle (Quinlan et al., 1992). Holding the hand piece at an oblique 60-degree angle within 1 cm of the surface of the target tissue provides optimal coagulation effects. During argon beam coagulation, the sidearm on one of the laparoscopic ports must be opened to prevent buildup of excessive intra-abdominal pressures. Because argon beam coagulation has its major advantage when hemostasis must be achieved over a diffusely bleeding surface, its most practical indication in laparoscopic urologic surgery is during partial nephrectomy or for control of small liver or spleen lacerations.

Surgical Pharmaceuticals

Recently, a vast array of topical hemostatic agents and sealants that can be used for a variety of surgical tasks have entered the surgical realm and have become valuable additions to the surgeon's tray.

Fibrin-Based Glue.

Fibrin glue has been used to promote hemostasis in parenchymal beds, in particular after partial nephrectomy or to seal a liver laceration. The two components of the fibrin glue, fibrinogen and thrombin, are delivered through separate channels and then combine at the tip of the delivery system during application to the tissue. Fibrin glue provides topical hemostasis and has sealant and adhesive qualities once dry; it essentially hardens into a rubbery coagulum.

Tisseel VH Fibrin Sealant (Baxter, Glendale, CA) has the maximum concentration of human fibrinogen available (75–115 mg/mL). It can be delivered by means of a laparoscopic applicator in liquid form or in an aerosolized form. One disadvantage of Tisseel is that it requires 15 minutes to prepare before the surgeon can apply it. If immediate application is required (e.g., because of bleeding), then fibrin glue is not a viable option unless it has been prepared in anticipation of possible hemorrhage. Once prepared, Tisseel is available for use for 4 hours.

Another fibrin-based sealant that can be delivered as a spray is Evicel (Johnson & Johnson, New Brunswick, NJ). This agent contains no bovine serum components (e.g., aprotinin) and can be used in individuals with allergies to bovine-derived products. Another advantage of this sealant is it comes frozen and thus requires no reconstitution. It can be thawed in the hand in 5 minutes and available in another minute. Once thawed, Evicel has a shelf life of 1 month under refrigeration (Tredree et al., 2006). This product can also be applied laparoscopically or robotically with an available applicator.

Relatively new on the market is Evarrest (Ethicon, Somerville, NJ), a fibrin sealant patched embedded with human biologics. This product does not require preparation, mixing, moistening with saline, or refrigeration and has a shelf life of 30 months. Randomized control trials have shown superiority over topical absorbable hemostat agents (Fischer et al., 2013); however, as with most new agents, cost remains a concern.

Non–Fibrin-Based Surgical Hemostats.

In contrast to the fibrin-based agents, other hemostatic agents such as thrombin-soaked oxidized cellulose particles (Floseal [Baxter, Glendale, CA]; Surgiflo [Johnson & Johnson, New Brunswick, NJ]) have no adhesive capability but are excellent hemostatic agents in the presence of active bleeding from parenchymal surfaces such as a partial nephrectomy bed, a liver or spleen laceration, or an oozing adrenal bed. These agents are composed of human-derived thrombin and bovine- or porcine-derived gelatin matrix. The gelatin granules swell 10% to 20% to produce a tamponade effect, whereas the high concentration of thrombin promotes conversion of fibrinogen to fibrin, as well as activating platelets and several coagulation factors. This agent is also prepared by the scrub assistant; it takes 2 minutes to prepare and is usable for 2 hours. It is applied through a tube applicator with a syringe. It is most effective when pressure is applied after its delivery; this can be done either with an instrument (e.g., 10-mm gauze-tipped dissector) or with a bolster.

The Avitene microfibrillar collagen hemostat (Davol, Cranston, RI) is an active collagen hemostat that accelerates clot formation by enhancing platelet aggregation and the release of fibrin. Similar to Floseal, it has no tissue sealing capability but is useful for counteracting parenchymal bleeding. EndoAvitene is available for use in endoscopic procedures. EndoAvitene comes prepared in a preloaded endoscopic delivery system developed to easily pass through standard trocars and cannulae. It is available in 5- and 10-mm diameters.

Chemical-Based Sealants.

BioGlue (CryoLife, Kennesaw, GA) is a two-component adhesive composed of purified bovine serum albumin (BSA) and glutaraldehyde. The solutions are mixed during application from a controlled delivery system. The glutaraldehyde then cross-links the BSA molecules to one another and then to the tissue protein at the site of use. Once applied, the agent polymerizes within 20 to 30 seconds and reaches its full bonding strength within 3 minutes. The delivery system comes ready for immediate use. BioGlue is a sealant and must be applied to a dry field and allowed to dry. Thus it cannot be used to counteract active bleeding but can be used to seal a raw, nonbleeding surface.

Coseal (Baxter, Glendale, CA) and AdvaSeal-S (Genzyme, Cambridge, MA) are completely synthetic products composed of two distinct polyethylene glycol polymers that chemically bond together to form a hydrogel that seals tissue surfaces, suture lines, and synthetic grafts. It does not require thawing, heating, or light activation and therefore can be ready in 1 minute. It must be applied to a dry (nonbloody) surface because it does not interact with the clotting cascade and therefore is not useful in the setting of active hemorrhage.

Now that the benefits of such substances have come into the spotlight in surgery, it is important for the surgeon to be familiar with the properties of these various agents and thereby able to choose one that is most appropriate for the job at hand.

Instrumentation for Suturing and Tissue Anastomosis

Needle Drivers.

Suturing and knot tying are among the most difficult tasks in laparoscopic surgery. A significant amount of practice is needed to achieve a sufficient level of proficiency. **Laparoscopic needle holders** have one fixed jaw and one jaw that opens by squeezing the spring-loaded handle of the instrument. They all have a locking mechanism to secure the needle in their jaws; this is done with a ratchet, spring-loaded, or Castroviejo-type mechanism. Some needle holders also possess a feature that allows the jaws to rotate around the main axis relative to the handle. The handles may be straight or provide a pistol-type grip (eFig. 14.19). In addition to standard rigid needle drivers, some companies have recently developed articulating needle drivers that aid in obtaining more optimal suturing angles with the needle. The actuation of the articulation mechanism is controlled by the surgeon's wrist motion (Laparo-Angle, Cambridge Endoscopic Devices, Framingham, MA).

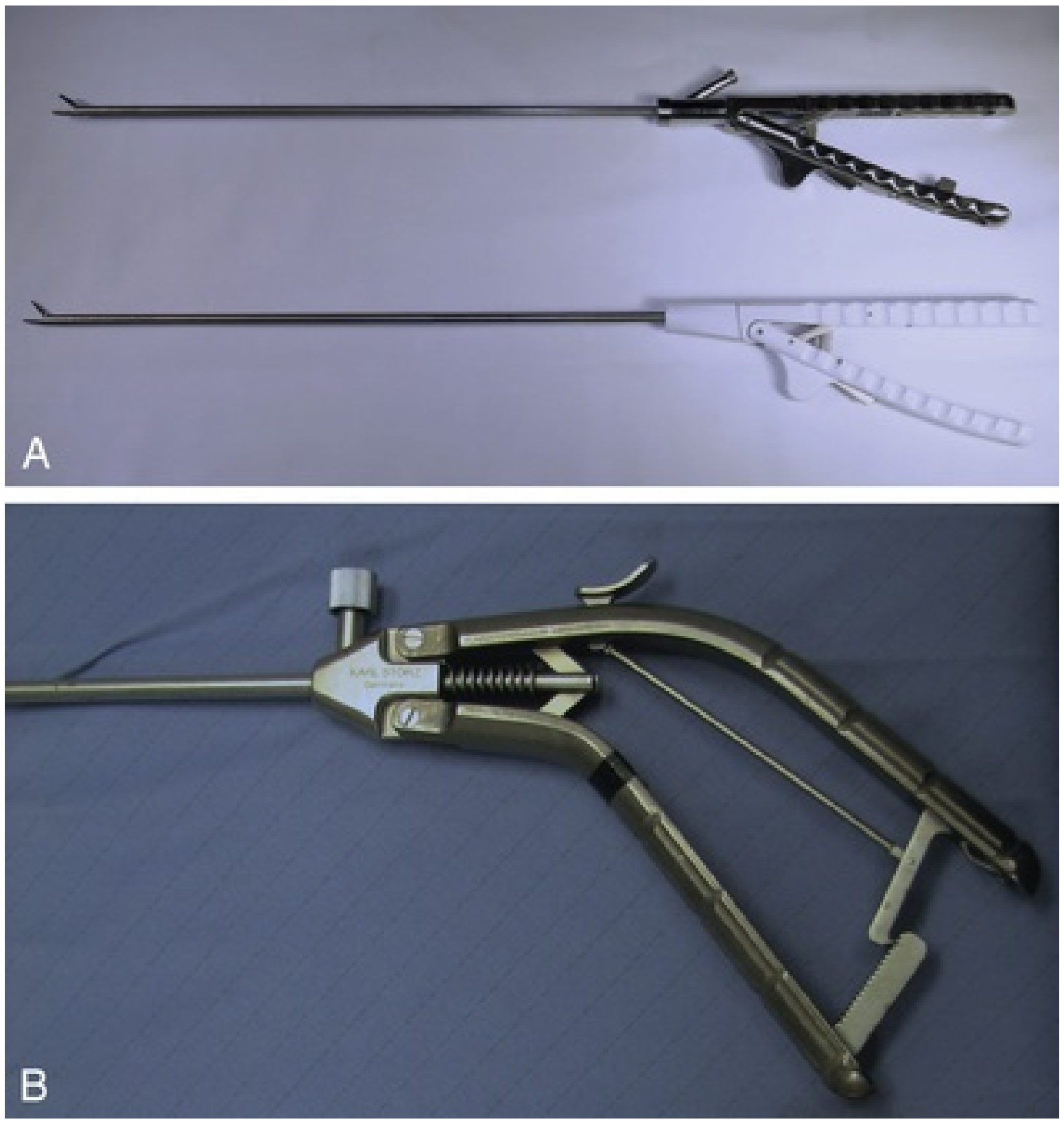

EFIG. 14.19 Different handle designs for commonly used laparoscopic needle drivers. (A) Straight-handled reusable *(top)* and disposable *(bottom)* drivers. (B) Pistol-type grip.

Endo Stitch.

The Endo Stitch (Medtronic, Minneapolis, MN) device is a disposable, 10-mm instrument that facilitates laparoscopic suture placement and knot tying (Adams et al., 1995). With increased experience with standard laparoscopic needle holders and especially with the advent of robotic-assisted procedures, use of the Endo Stitch has become less common.

The suture is secured to the center of a straight needle with two pointed ends, thereby allowing tissue penetration in either direction. The needle is shuttled back and forth between the jaws of the instrument after each passage through the tissue, applying a long-known principle used in sewing machines. In this way, passing the needle through the tissue and regrasping the needle after it has traversed the tissue become simple tasks because they are done by a one-handed squeeze of the handle and a flip of the needle-securing lever, respectively. Use of this sewing apparatus has had a major impact on decreasing operative times, especially in laparoscopic pyeloplasty (Chen et al., 1998).

Lapra-Ty Clips.

Lapra-Ty clips (Ethicon, Somerville, NJ) are a very useful adjunct to suturing and knot tying. **The clip acts as a knot, thereby precluding time-consuming intracorporeal laparoscopic knot tying** (Fig. 14.20). These 3.5-mm clips are made of absorbable polydioxanone and are designed to provide secure anchoring of sutures for up to 14 days in low-tension to mid-tension environments (Ames et al., 2005). According to the manufacturer, these suture anchors can be secured to the end of a single strand of polyglactin 910 (Vicryl) suture as fine as 4-0. Experimental models from two different laboratories have shown that these clips are least likely to fall off polyglactin 910 sutures from size 1-0 to 3-0 (Ames et al., 2005; Weld et al., 2008). In the laboratory environment Lapra-Ty clips have been shown to be slip resistant with 2-0 Monocryl and polydioxanone suture. In multiple test trials for each suture type, a percentage of monofilament sutures size 3-0 and smaller as well as 4-0 suture of any type had slippage of the clip. Therefore it seems logical to avoid Lapra-Ty use with 4-0 suture and to avoid excessive tension when using these clips with 3-0 monofilament suture. Lapra-Ty clips can be used to secure a single suture or a running suture and for anchoring bolsters during renorrhaphy for laparoscopic or robotic partial nephrectomy (Orvieto et al., 2004).



FIG. 14.20 (A) Tip of a laparoscopic device for applying a Lapra-Ty clip (Ethicon, Somerville, NJ). (B) Lapra-Ty clip affixed to a suture.

Barbed Suture.

The knotless barbed suture (V-loc; Medtronic, Minneapolis, MN) is an innovative type of suture that can accelerate the placement of sutures and eliminate knot tying (Fig. 14.21). The specifically designed monofilament suture with barbs orientated in the opposite direction of the needle allow the suture to grab the tissue without allowing the suture to slide back. The use of barbed suture was initially popularized for use during the vesicourethral anastomosis during robotic prostatectomy (Zorn et al., 2011); however, given the versatility of the suture, its use has expanded across the range of urologic surgery. A recent meta-analysis indicates that the vesicouretheral anastomosis using barbed suture was associated with a shorter operative time, comparable complication rate, and convenience of manipulation (Bai et al., 2015).

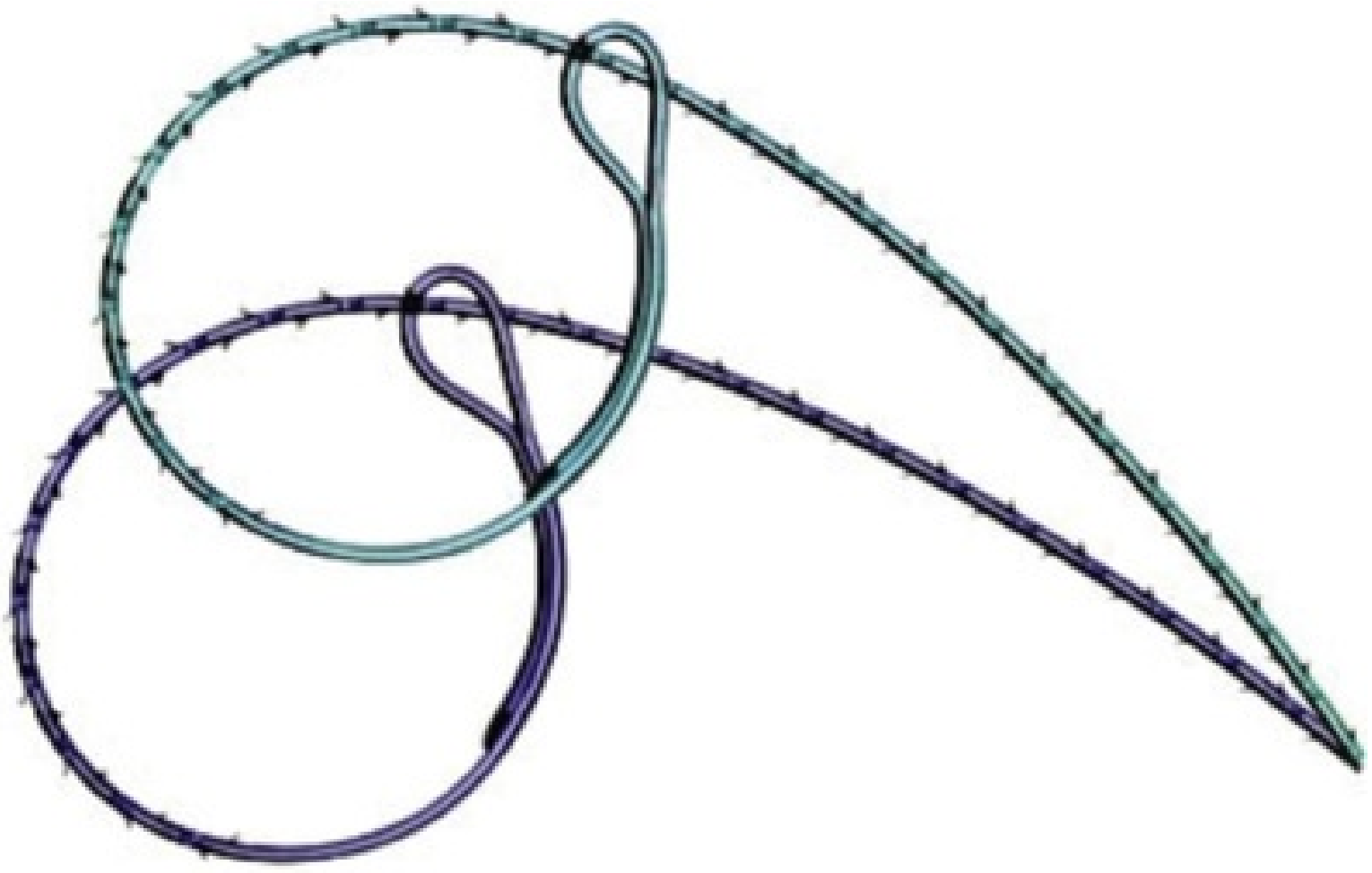

FIG. 14.21 Knotless barbed suture. (Courtesy Medtronic, Minneapolis, MN.)

Instrumentation for Stapling and Clipping

Stapling Devices.

Various stapling devices are available for tissue occlusion and division. The Endo GIA Universal 12-mm stapler and linear cutting device (Medtronic, Minneapolis, MN) requires a 12-mm port and delivers two triple-staggered rows of staples and simultaneously cuts between the rows (Fig. 14.22). The Universal stapler can be loaded with a variety of 30-, 45-, or 60-mm loads and fired any number of times. Similarly, the ETS-Flex 45 stapler (Ethicon, Somerville, NJ) also requires a 12-mm port and delivers two triple rows of staples while cutting between rows 3 and 4. This stapler has a maximum fire limit of eight staple loads. Articulating and roticulating staplers that enable the surgeon to properly align the instrument with the tissue to be occluded and divided are available from both companies. **Each staple load cartridge is color coded depending on the size of the staples: 2.0-mm staples (gray) or 2.5-mm staples (white) are preferred for vascular (renal vein or renal artery) stapling, whereas 3.8-mm (blue) and 4.8-mm (green) staples are used in thicker tissues (ureter, bowel, bladder).** In addition, for laparoscopic live donor nephrectomy, a single Endo-

TA (linear noncutting) stapler can be used to secure the patient's side of the renal vein, thereby providing a longer donor renal vein, because there is no need to trim staples from the vessels before anastomosis in the recipient (Meng et al., 2003). Linear noncutting staplers deliver either three or four staple rows 30 or 60 mm long. These staplers can also be used to close an enterotomy after a side-to-side bowel anastomosis. **When laparoscopic staplers are used, special attention must be paid to the markers on the cartridge to ensure that all the targeted tissue is properly situated proximal to the markers before the cartridge is fired. The stapler should not be fired across any previously placed clips because this is thought to possibly cause stapler malfunction.** Indeed, in a 9-year review of stapler use (1992 to 2001), Brown and Woo (2004) noted US Food and Drug Administration–recorded reports of 112 mortalities and 2180 injuries attributed to use of the stapler; overall, malfunctions were reported 22,804 times.

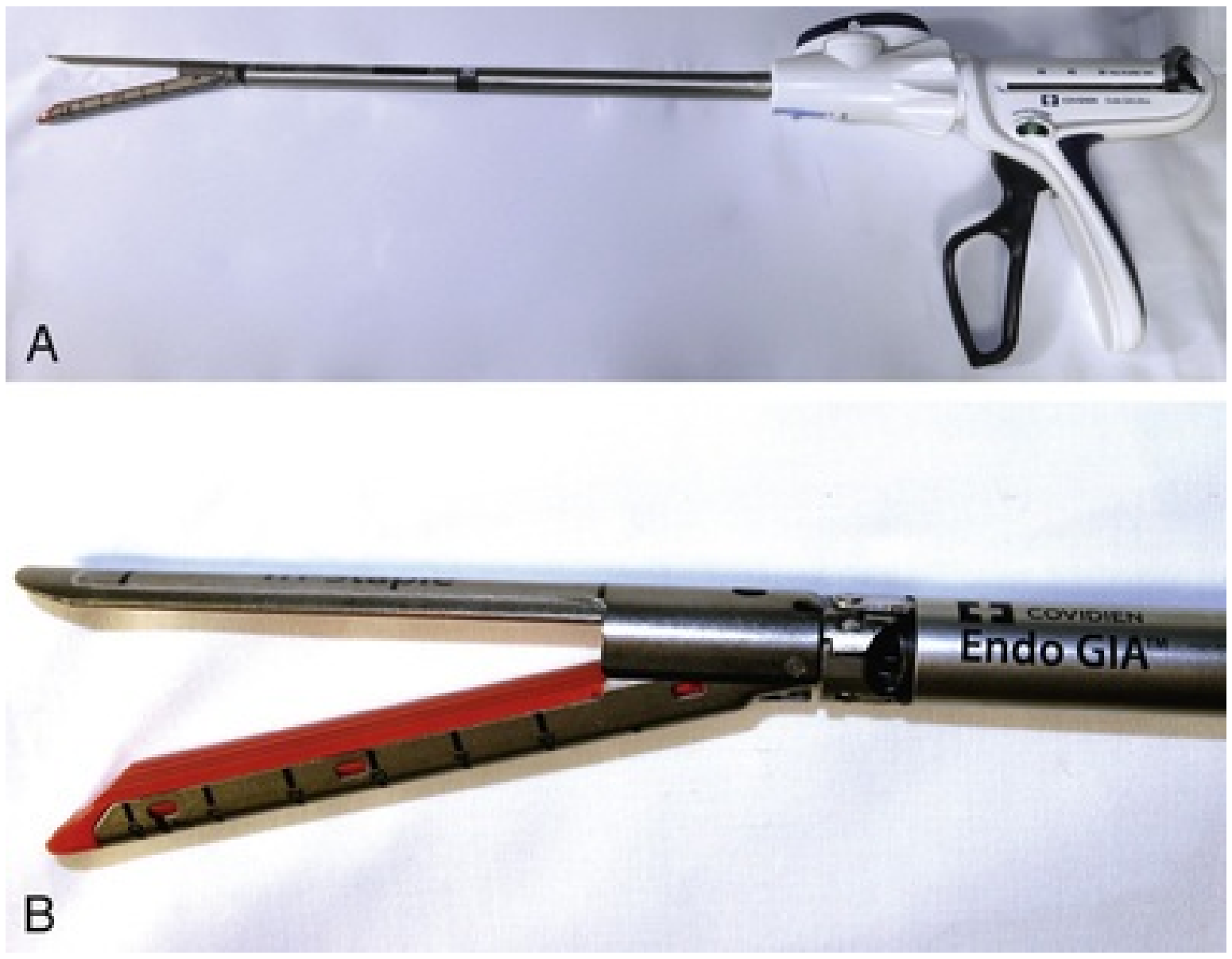

FIG. 14.22 (A) Example of Endo GIA laparoscopic stapling device. (B) Stapling device tip. (A, Courtesy Medtronic, Minneapolis, MN.)

The first powered stapler was introduced in 2010. Currently the iDrive Ultra (Medtronic, Minneapolis, MN) and the Echelon Flex GST System (Ethicon, Somerville, NJ) are the most widely available (Fig. 14.23). Powered staplers are thought to increase the stability and enable more precise stapling relative to manual staplers. In a large-study retrospective review in bariatric surgery, better economic outcomes and a lower rate of bleeding was noted in the powered staplers group (Roy et al., 2017). Further, prospective, randomized trials are needed to support these findings.



FIG. 14.23 (A) Example of iDrive Ultra-powered laparoscopic stapling system. (Courtesy Medtronic, Minneapolis, MN.) (B) Echelon Flex GST System. (Courtesy Ethicon, Somerville, NJ.)

Clipping Devices.

Disposable and nondisposable clip appliers are available from different manufacturers and require 5-, 10-, or 12-mm laparoscopic ports. In general, they contain occlusive clips ranging in size from 6 to 11 mm. Disposable clip appliers possess a rotating shaft and multifire, self-reloading features, whereas nondisposable instruments have to be reloaded for each clip to be deployed at the site of surgery.

Electrocoagulation must be avoided in the vicinity of clips placed for occlusion of vessels to prevent conductive tissue necrosis and subsequent clip dislocation. To ensure reliable function, the closed ends of the occlusive clips must be seen extending slightly beyond the targeted vessel and should be placed perpendicular to the longitudinal axis of the vessel.

In addition to titanium clips, polymer clips that completely encircle and lock down around a vessel are available (Weck Hem-o-lok polymer ligation clip system [Teleflex, Research Triangle Park, NC]) (Fig. 14.24). They are available in four sizes (M, ML, L, and XL). Up to 10 mm of tissue can be ligated through a 5-mm trocar, and up to 16 mm of tissue can be ligated through a 10-mm trocar. Because of results from a survey put forth by the American Society of Transplant Surgeons in which use of these clips was associated with hemorrhage from the renal artery stump, the company producing the clips put forth a statement contraindicating their use for securing the renal artery during laparoscopic live donor nephrectomies (Friedman et al., 2006). Subsequently, a multi-institutional study of 1695 patients from 9 different institutions undergoing laparoscopic donor nephrectomy with ligation of the renal artery with Hem-o-lok clips concluded that the clips were safe to use because in this review there were no adverse bleeding events (Ponsky et al., 2008a). **The authors did acknowledge, however, that proper technique of application must be strictly adhered to, including application of at least two clips on the stump of the artery and that a 2-mm cuff of artery should be left distal to the clips** (Box 14.2). Removal of a Hem-o-lok clip is possible using the specified removal instrument should a structure be clipped in error.

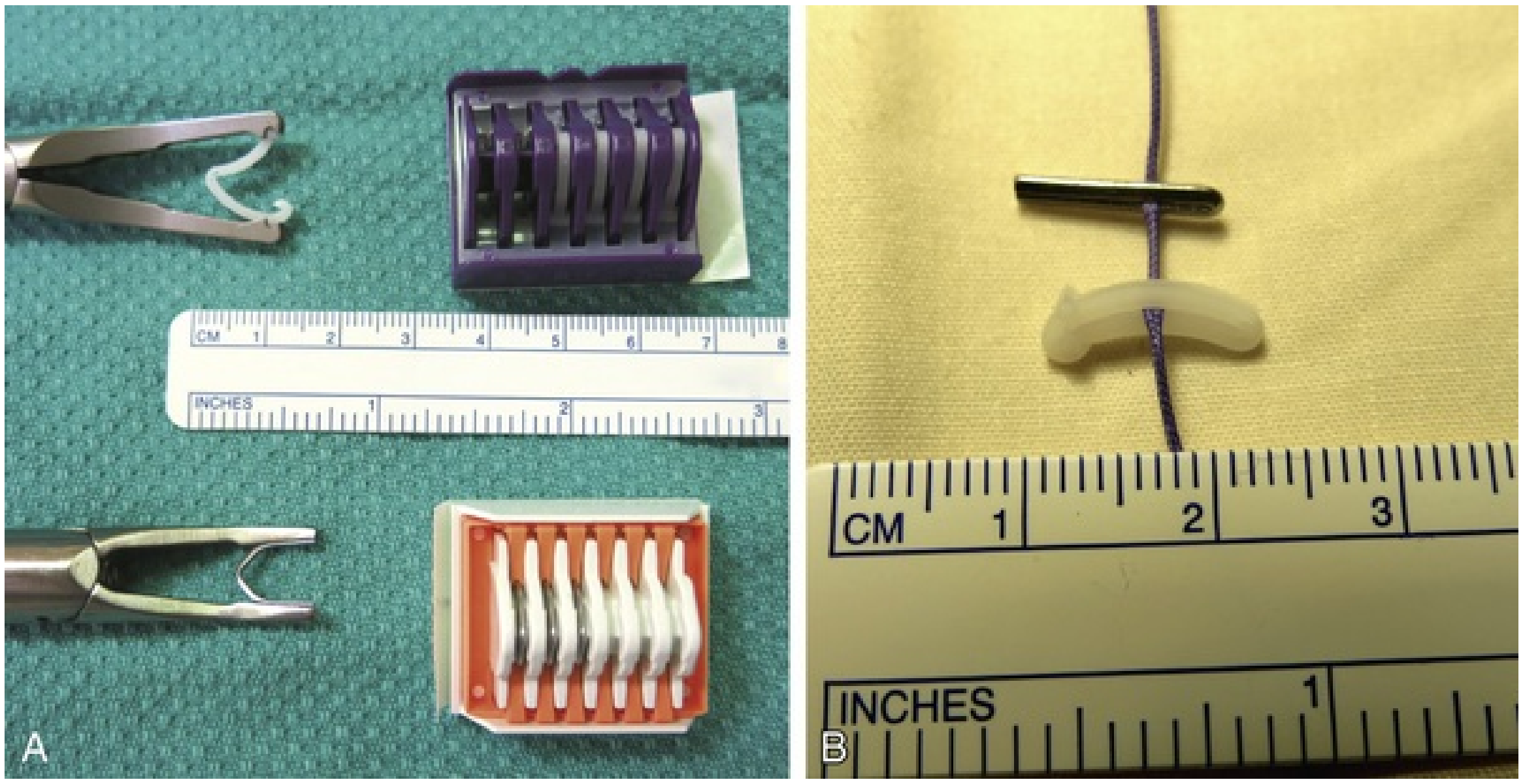

FIG. 14.24 (A) Weck Hem-o-lok clip and tip of laparoscopic applier *(top)* (Teleflex, Research Triangle Park, NC) and metal clip and tip of laparoscopic applier *(bottom).* (B) Metal clip *(top)* and Weck Hem-o-lok clip *(bottom)* affixed to a suture.

Box 14.2

Basic Principles of Hem-o-lok Clip Placement

- Complete circumferential dissection of the vessel
- Visualization of the curved tip of the clip around and beyond the vessel, often with the curved end of the clip placed between the artery and vein
- Confirmation of the tactile snap when the clip engages
- No cross-clipping
- Not squeezing the clip handles too hard (compared with the application of metal clips)
- Careful removal of the applier after application is given; the tips are sharp and can cause a laceration of nearby vessels (e.g., renal vein)
- During transaction of vessels, only a partial division is performed initially to confirm hemostasis before complete transaction
- Minimum of two clips are placed on the patient side of the renal hilar vessel

From Ponsky L, Cherullo E, Moinzadeh A, et al.: The Hem-o-lok clip is safe for laparoscopic nephrectomy: a multi-institutional review. *Urology* 71:593–596, 2008.

Instrumentation for Specimen Entrapment

Various organ entrapment and retrieval systems are available. Depending on the size of the tissue and on whether in situ morcellation or intact organ retrieval is planned, the laparoscopic surgeon can choose among different-sized sacks, materials, and designs. Studies have been conducted to test organ retrieval bags for permeability to tumor cells and bacteria before and after morcellation, as well as for stability during morcellation and resistance to tearing forces (Rassweiler et al., 1998b; Urban et al., 1993). The originally designed (1990) LapSac (Cook Urological, Spencer, IN), which is made of nylon with a polyurethane inner coating and a polypropylene drawstring, is the entrapment sack least susceptible to tearing (Eichel et al., 2004) or leakage of cells. Up to a 2-kg specimen can be secured within the LapSac; however, deployment of the LapSac and subsequent organ entrapment are challenging.

Other entrapment sacks offer marked advantages when the only goal is organ entrapment and intact removal rather than morcellation. These sacks have spring wires that, when activated by the surgeon, deploy the bag after its introduction into the abdomen; this facilitates tissue entrapment because the broad wire supports stabilize the opened sack, thereby allowing the surgeon to scoop the specimen into the sack (Fig. 14.25). The entrapped specimen can easily be withdrawn through a hand-assist site or by enlarging a laparoscopic port site, usually to 5 to 7 cm for most specimens.



FIG. 14.25 Example of an organ retrieval bag. (Courtesy Medtronic, Minneapolis, MN).

Instrumentation for Morcellation

Various techniques of tissue morcellation have been used in laparoscopic surgery. The simplest method for fragmentation of tissue within the entrapment sack is use of the index finger, ring forceps, or Kelly clamp. The ring forceps are the preferred instrument for manual morcellation because they are less likely to puncture the entrapment sack (Eichel et al., 2004).

If morcellation is performed intracorporeally, the entrapment sack should be a LapSac; however, a variation reported by Landman et al. (2003b) for morcellation uses one of the plastic entrapment sacks. In this method, the morcellation is performed above the abdominal wall by extending the extraction site incision to 3 cm in length. **All tissue is fragmented and removed under direct vision above the abdominal surface; at no time is the morcellating instrument out of the direct vision of the surgeon.** With this approach, specimens could be morcellated rapidly, with the entire entrapment and morcellation process taking only 13 minutes for clinical specimens as large as 700 g; also fragment size increased from 1.5 to 4.5 g, which may afford better tissue assessment with regard to capsular, vascular, or renal sinus fat invasion (Landman et al., 2003b).

For morcellation of a renal malignancy, the neck of the sack is triply draped to preclude any contamination: a towel drape, Ioban (3M, St. Paul, MN), and nephrostomy drape can be used. At the end of the morcellation procedure, the surgeon and assistants regown and glove.

The use of an entrapment sac is important because wound seeding with tumor has been reported with intact specimen extraction without entrapment (Iwamura et al., 2004). In contrast, there has been only one noted wound seeding with morcellation in a LapSac (Fentie et al., 2000). A multi-institutional study comprising 2064 radical nephrectomies, among which 826 were removed by entrapment and morcellation, showed no instance of a wound seeding with tumor (Micali et al., 2004).

Instrumentation for Retraction

Many varieties of retractors with different features are available.

The simplest retractor is a metal bar with an atraumatic tip or a curved saddle shape; the latter is helpful for retracting a vessel during lymph node dissection. Similarly, the disposable laparoscopic "peanut," in either its 5- or 10-mm rendition, is very helpful because it can dissect and atraumatically retract tissue.

However, the most useful retractors are the expanding types: fan retractors with three or four atraumatic fingerlike extensions, fan retractors with V-hinge joints, balloon retractors, and kite-style instruments (e.g., Padron endoscopic exposing retractor) (Jarit, Hawthorne, NY) (Brooks, 1993). The 5-mm kite style retractor provides a 2- × 3-cm retracting area, whereas the 10-mm version provides a 4- × 3-cm retracting area. This type of retractor is very helpful for firm retraction, such as on the kidney to put the renal hilum on stretch.

Another type of retractor is malleable and thus can be shaped to the needs of the surgeon. The Diamond-Flex angled 80-mm triangular retractor (Snowden-Pencer Instrumentation, Carefusion, Waukegan, IL) can be adapted to many different angles, curves, and shapes, and the surgeon can lock in its particular configuration. This feature is of particular value when retraction of a delicate organ such as the liver is required. This instrument forms a broad retracting surface 8 cm in length.

Retraction of tubelike structures (e.g., vessels, ureter) can also be achieved by placing a suture, a vessel loop, or an umbilical tape around the tissue and applying traction either with a grasper inside the abdomen or by pulling the ends of the retraction loop out of the abdomen through a small stab incision using a Carter-Thomason device (Carter, 1994) or by encircling the structure with a suture affixed to a Keith needle, which can be passed across the abdominal wall, around the structure to be retracted, and then back out the abdominal wall (see following discussion of exiting the abdomen). The retraction loop can then be secured under slight tension on the surface of the abdomen with a small hemostat. Care should be taken during the use of this technique because excessive tension may injure the structure being retracted.

Mechanical Assistants.

External mechanical devices such as the EndoHolder (Codman, Raynham, MA) or the Laparostat (Civco, Kalona, IA) can be used to keep grasping forceps or locking retractors in position, thereby taking the place of a tableside assistant. This device is usually mounted on the side of the table opposite the surgeon. The malleable-free arm is then affixed to the shaft of a grasping forceps or laparoscopic retractor. When the surgeon has used the retractor for its given purpose, the malleable arm of the external mechanical device is locked in place, thereby providing reliable, continued traction.

Robotic Instrumentation

For the da Vinci Robotic System (Intuitive Surgical, Sunnyvale, CA), a wide variety of articulating instruments are available. The proprietary EndoWrist (Intuitive Surgical, Sunnyvale, CA) technology offers articulation at the tip of the instruments with 7 degrees of freedom and 90 degrees of articulation, mimicking the wrist movements of the surgeon at the robotic console (Fig. 14.26). A full line of 8-mm EndoWrist instruments are available, but most robotic instruments for the da Vinci Surgical System (except the laparoscopes) have a 10-case limit before they must be replaced. The number of “lives” left on each instrument should be recorded with each case.

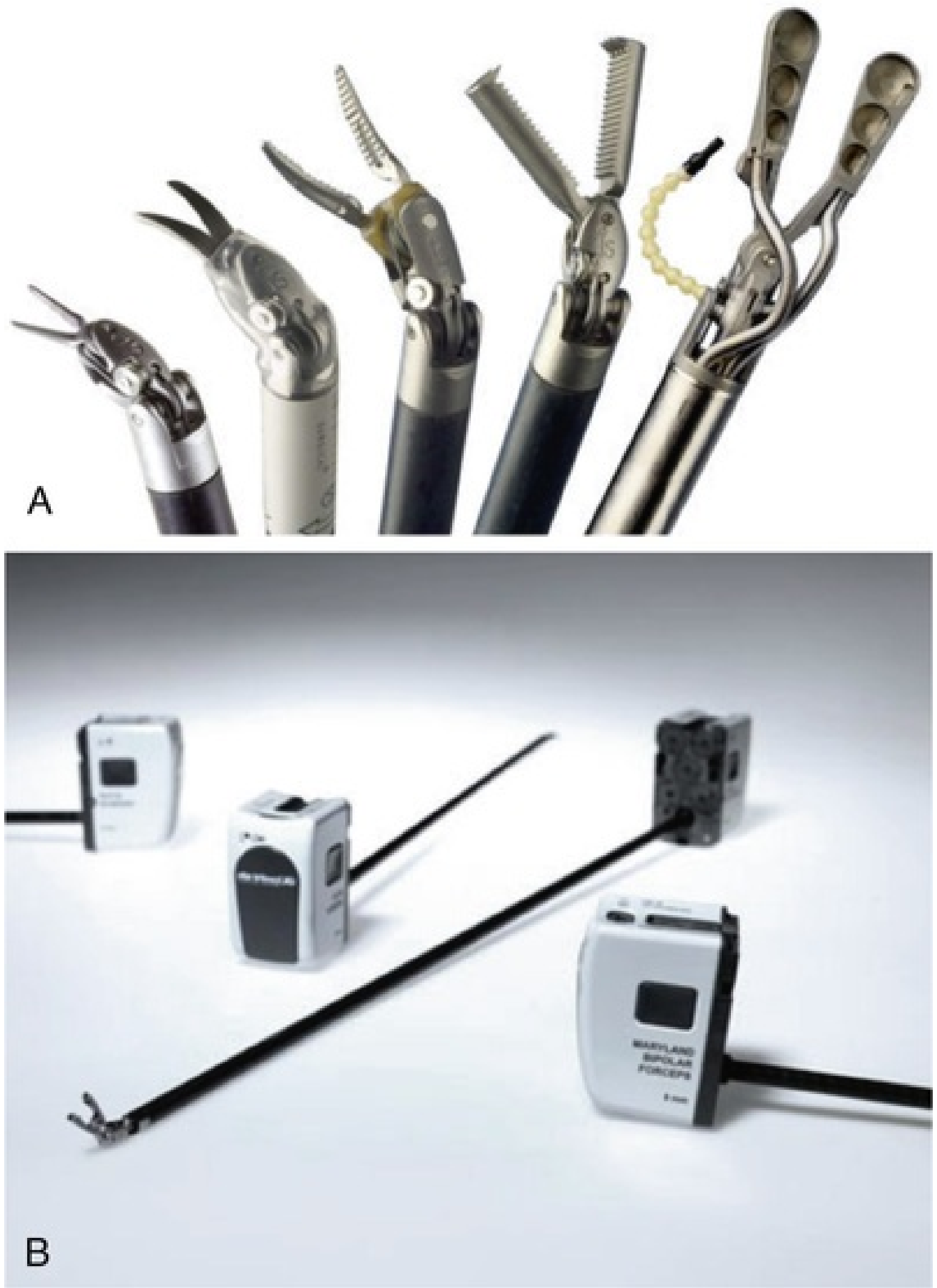

FIG. 14.26 A and B, Examples of 8-mm interchangeable instruments for the da Vinci Robotic System. (Copyright 2018 Intuitive Surgical, Inc. Used with permission.)

Instrumentation for Incising and Hemostasis

EndoWrist scissors for incising tissue include the round tip and Potts scissors. EndoWrist monopolar and bipolar electrocautery instruments are available for incision, dissection, and hemostasis during procedures. Monopolar instruments include the HotShears curved scissors, cautery hook, and spatula. Bipolar instruments include the Maryland, fenestrated, curved, micro, long, and vessel sealer. An ultrasonic device (Harmonic ACE curved shears, Ethicon, Somerville, NJ) is also available for dissection and hemostasis.

Instrumentation for Grasping and Blunt Dissection

A large array of EndoWrist graspers exist, including Prograsp, tenaculum, long-tip, tip-up fenestrated, small grasping retractor Cadiere forceps, Cobra grasper, dual-blade and resano forceps, for use in varying situations. The most commonly used grasper in urologic procedures is the ProGrasp blunt forceps.

A safety feature on all robotic grasping devices is a small Allen bolt that can manually open the jaws of the instrument in the case of a robotic arm malfunction or loss of power in which the grasper is locked onto tissue or a needle at the time of failure. Robot failure is rare. In the series from the University of Chicago, a robot failure was recorded in less than 1% of cases, and half of these problems (e.g., failure to power up, optical malfunction) were discovered before the patient entered the operating room. In addition, in the few instances in which there was a system malfunction (e.g., loss of 3D vision, robotic arm failure) during the case (0.4%), the procedure could still be completed without converting to an open procedure (Zorn et al., 2007).

Instrumentation for Suturing and Tissue Anastomosis

Four different EndoWrist needle drivers are available for suturing. There are two sizes of needle drivers available in the standard and SutureCut design. The SutureCut design allows the surgeon to be able to cut the suture material using the crotch of the instrument.

Other Available 8-mm and 5-mm Instruments

A number of other robotic instruments are also available. EndoWrist clip appliers exist for small titanium clips and medium-large and large Weck Hem-o-lok polymer clips (Teleflex Medical, Research Triangle Park, NC). In addition, an articulating suction device and irrigator, a probe stabilizer, and specialty retractors exist.

A 5-mm line of instruments is also available that is slightly more limited but still offers a relatively complete line of instruments. However, the 5-mm robotic laparoscope offers a 2D, not 3D, image.

Instrumentation for Single-Site Surgery

A detailed description of access devices for LESS such as the TriPort15/TriPort+ and SILS has previously been presented in this chapter. By definition, in LESS, all of the instrumentation for the case, including a camera and lens for visualization and the working instruments to perform the procedure, must be placed though a single incision. This creates ergonomic challenges with regard to instrument collisions inside and outside the abdominal cavity. Furthermore, the typical trocar arrangement for laparoscopy, which affords one the ability to "triangulate," is largely lost with LESS. Much of the emphasis on instrumentation for LESS, therefore, centers on minimizing instrument collisions outside the abdominal cavity and recreating the "triangulation" necessary to approach the surgical site safely (eFig. 14.27).

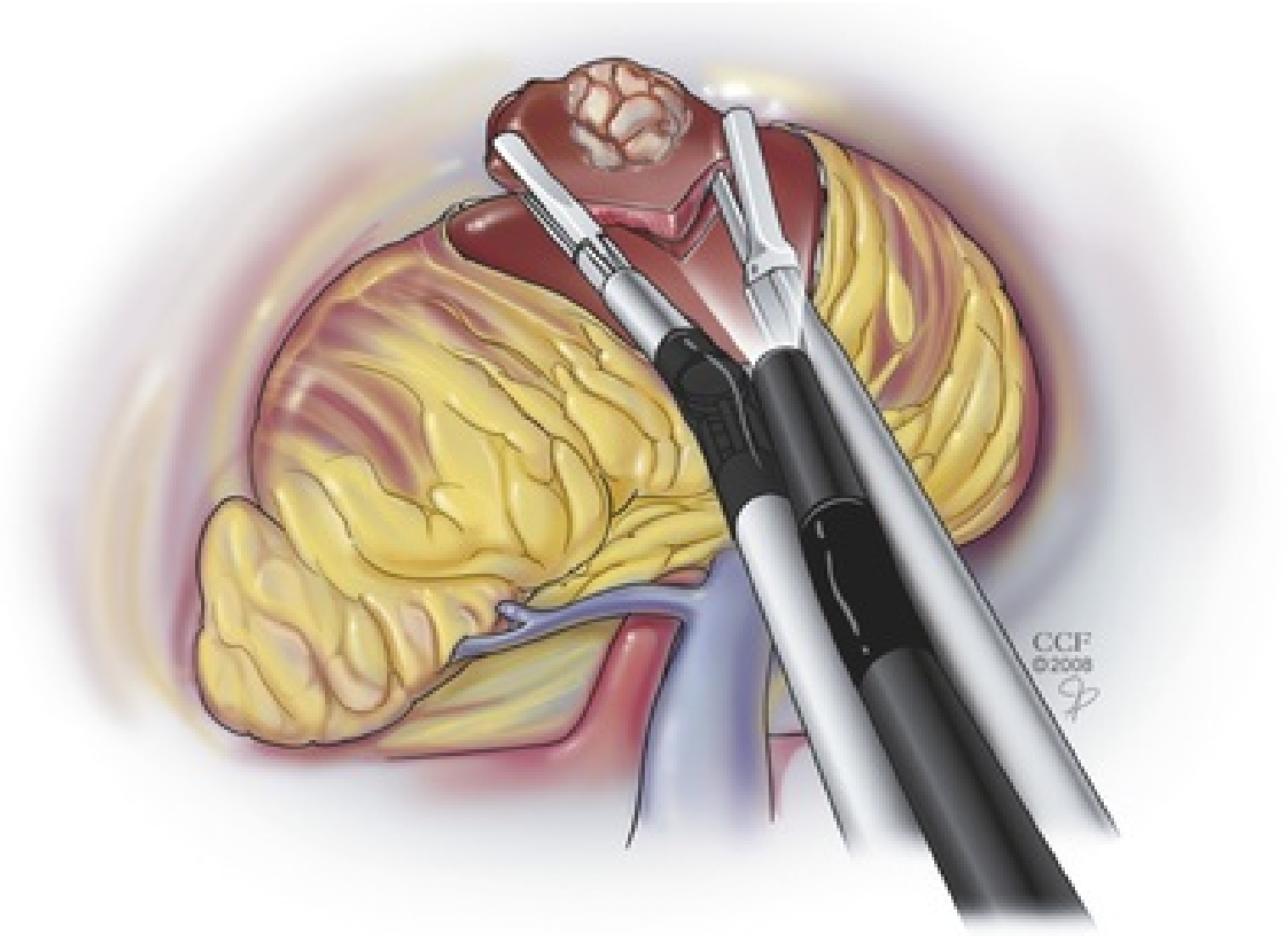

EFIG. 14.27 Deflecting laparoscopic instrumentation can be used to maintain triangulation during laparoendoscopic single-site surgery. (Reprinted with permission, Cleveland Clinic Center for Medical Art & Photography, copyright 1998–2011. All rights reserved.)

With regard to endoscope choice, one issue encountered is that the light cord often attaches to the telescope at a 90-degree angle and can thus hinder the movement of the lens or other instruments. To avoid this problem the surgeon can use an endoscope that has the light cord attached end-on from the back directly into the endoscope (Karl Storz, Tuttlingen, Germany) or a one-piece endoscope that already has an end-on integrated light cord (EndoEYE, Olympus, Center Valley, PA). Alternatively, an extra-long laparoscopic lens can be used to keep the light cord away from the shorter standard working laparoscopic instruments. Similarly, use of laparoscopic instruments of different lengths can help keep the handles from clashing with one another.

With regard to overcoming the parallel nature of the instrument paths and reestablishing a triangular arrangement of instrumentation, several technologic advances have been developed so far with endoscopes and instruments. In terms of endoscopes, a laparoscope with a deflecting tip (EndoEYE Flex [Olympus, Center Valley, PA]) or adjustable angle tip (EndoCAMeleon [Karl Storz, Tuttlingen, Germany]) should be used because these telescope designs offer the greatest adjustability for optimal viewing. At the very least an angled lens (30- or 45-degree fixed angle) should be used. In terms of instruments, the use of articulating or curved instrumentation is essential to avoid instrument collision outside the abdomen and to achieve proper triangulation for tissue retraction, exposure, and dissection. Curved reusable laparoscopic instruments are also available (Karl Storz-Tuttlingen, Germany; Sklar Instruments, West Chester, PA) and provide a nondisposable alternative to the articulating instruments, which are one-time-use items. Single-curved and double-curved reusable instruments exist.

Finally, robotic laparoendoscopic single-site is currently being used for nephrectomy (partial, simple, and radical), pyeloplasty, nephroureterectomy, prostatectomy, and sacrocolpopexy (Nelson et al., 2017). Unfortunately, the robotic arms using the Gelport still resulted in limited triangulation angles, and this spurred the development of the new SP1098 platform, which is in the preclinical testing phase (Ramirez et al., 2016).

Instrumentation for Natural Orifice Transluminal Endoscopic Surgery

The concept of natural orifice transluminal endoscopic surgery (NOTES) is not truly new; indeed, the first NOTES procedure would have been Philipp Bozzini's cystoscopy in 1804. What is new is the use of flexible endoscopic technology to perform procedures heretofore unthinkable with a transgastric (e.g., appendectomy in 2004 by Rao and Reddy) or transvaginal approach (e.g., appendectomy in 2004 and cholecystectomy in 2007 independently by Bressler and then Marescaux). Over time these increasingly complex endoscopes have developed from purely diagnostic instruments for visualization of intraluminal surfaces to highly functional endoscopes capable of carrying therapeutic tools that can be used to treat visualized problems. Further advances in this type of technology have led to the development of endoscopes specifically for transluminal surgery. The potential advantages of transluminal endoscopic surgery are better cosmesis, less pain, elimination of the risk for wound infection and hernias, and a reduction in adhesions (Swanstrom et al., 2008a, 2008b).

Exiting the Abdomen

Port Removal and Fascial Closure

Port removal and fascial closure are key elements of the procedure that, if not performed in a step-by-step, organized fashion, can result in major, possibly fatal, complications. Herniation, possible bowel incarceration, and postoperative hemorrhage are the results of a poorly performed or haphazard, overly rapid exiting of the abdomen.

Before port removal is initiated, the operative site and the intra-abdominal entry sites of each cannula must be carefully inspected with the intra-abdominal pressure lowered to 5 mm Hg. After achievement of perfect hemostasis, removal of all laparoscopic ports must be undertaken strictly under laparoscopic visual control to avoid any possible acute herniation of intra-abdominal contents into the previous port sites.

Presently, with the shift away from bladed to nonbladed trocars, the need for fascial closure for even 12-mm ports has come into question. Most will recommend that **on removal of any of the blunt-tipped ports, the fascia does not have to be sutured, except for ports larger than 10 mm placed in the midline. However, a report has shown that 12-mm ports, regardless of site (i.e., midline vs. transmuscular), do not require fascial closure, provided that postoperative palpation of the entry site reveals a small defect** (Siqueira et al., 2004). **In the literature, the switch from bladed to blunt trocars has resulted in a marked decrease in abdominal wall bleeding (from 0.83% to only 0.16%) and in port site hernia formation (1.83% to 0.19%)** (Hashizume and Sugimachi, 1997; Thomas et al., 2003).

In the rare case in which bladed trocars are used, the fascia at all 10- to 12-mm port sites should be closed. After inspection at 5 mm Hg, the first 10- or 12-mm port is removed and the fascia at the entry site is secured with 0-0 Vicryl either by direct placement of a fascial suture or use of a suture-passing device (see following). **Five-millimeter ports are not closed in the adult but are closed in the pediatric patient with a single absorbable suture.** Ideally, each fascial suture will be placed under direct endoscopic vision before definitive port removal. In this manner, each port is visually assessed for any bleeding at 5 mm Hg, thereby precluding the possibility of removing a port and missing an injured vessel. After removal of all ports, the CO_2 is allowed to pass out passively through the 5-mm port sites.

The hand-assist device should be removed before removal of the other port sites. The hand-assist device wound is then closed as one would close a typical abdominal wound. After closure, the pneumoperitoneum is reestablished and the other port sites are closed as previously described. Proceeding in this fashion precludes the chance of injuring the bowel or omentum beneath the hand-port site and ensures an airtight closure.

Instrumentation for Port Site Closure

Several possibilities for fascial closure of port sites exist. The **simplest method** is retracting the skin with retractors, grasping the fascia, and suturing it with absorbable 0-0 suture. However, in patients with a BMI above 30, securely accessing the fascia is very difficult to accomplish.

Fortunately, several devices for complete en bloc closure of fascia, muscle, and peritoneum under direct vision have been developed (Carter, 1994; Elashry et al., 1996; Garzotto et al., 1995; Monk et al., 1994). These work well in patients of all sizes.

The **Carter-Thomason needle-point suture passer** (CooperSurgical, Pleasanton, CA) consists of a 5-, 10-, or 12-mm cone that has two integrated, hollow, angled, cylindric passages located 180 degrees opposite each other (Fig. 14.28). With the sharp needle-point, single-action grasper, the 0-0 Vicryl suture is inserted through one of the cylinders in the metal or plastic cone, thereby traversing muscle, fascia, and peritoneal layers in an ever-widening angle. The end of the suture is grasped with a 5-mm grasper through one of the other ports. The needle-point grasper is reintroduced through the other cylinder of the cone, and the intraperitoneal end of the suture is grasped by the needle-point grasper and pulled out of the abdomen. The cone is slid off both ends of the suture. Subsequently, closure of the fascia, muscle layer, and peritoneum is accomplished by tying the suture. **The Carter-Thomason needle-point device not only is helpful for wound closure but also can be used as a fifth port during nephrectomy to help hold the sack open or to encircle the ureter with a vessel loop through a small stab incision.**

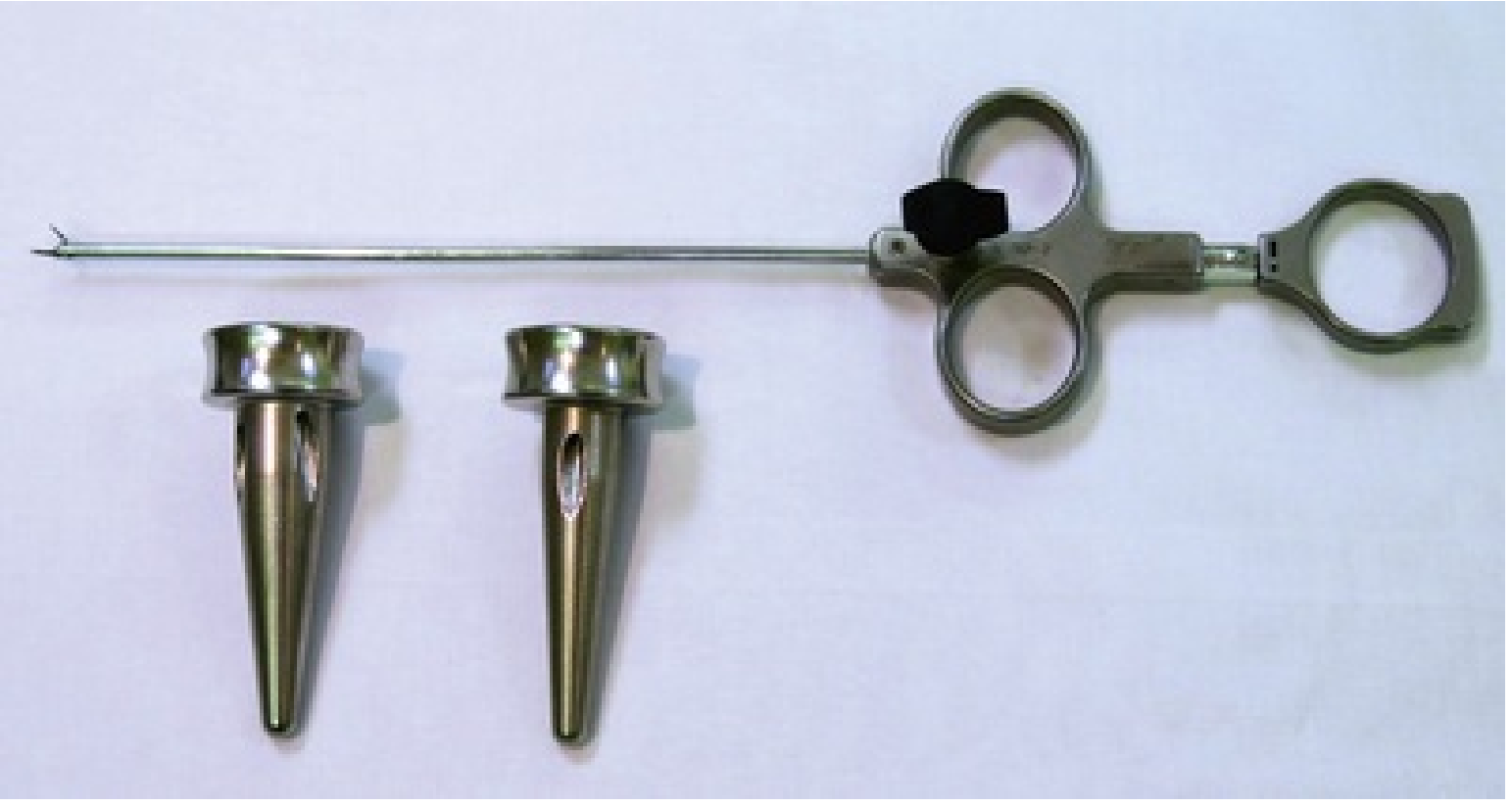

FIG. 14.28 Carter-Thomason device. Cone and needle-point single-action grasper in open position.

The disposable Endo Close suture carrier (Medtronic, Minneapolis, MN) is a device with a spring-loaded suture carrier at its tip. Loaded with a suture, the device traverses fascia, muscle, and peritoneum alongside the port. After reinsertion on the opposite side of port entry, it is reloaded with the suture, aided by a 5-mm grasper, and is pulled out again so that the suture can then be tied.

A far simpler, less expensive, homemade solution is available to all surgeons for closing ports in a large patient. This **angiocatheter technique** applies the previously described principles. A 14-gauge, sheathed needle is passed alongside the port through the abdominal layers. After removal of the needle, a 0-0 Vicryl suture is inserted through the angiocatheter sheath until it is deep inside the peritoneal cavity. After the sheath is removed, the same maneuver is repeated on the opposite side, but this time a 30-inch 0-0 Prolene suture folded in half is passed into the peritoneal cavity through the sheath to act as a retrieving loop. A 5-mm grasper passed through another port is then passed through the loop of 0-0 Prolene suture and used to grasp the end of the 0-0 Vicryl suture. The 0-0 Vicryl suture is pulled through the Prolene loop and released. By pulling the Prolene loop upward through the angiocatheter sheath, the surgeon then retrieves the entrapped 0-0 Vicryl suture from the abdomen. After the angiocatheter sheath is removed, the two ends of the suture can be tied.

Closure of the Skin

The skin of all 10-mm port sites is closed with subcuticular 4-0 absorbable suture. Adhesive strips are applied to all port sites to close (for incisions <10 mm) or to further approximate (for incisions ≥10 mm) the skin. As an alternative, the skin can be closed using octylcyanoacrylate glue. This has been found to speed closure time and provide an equivalent cosmetic result compared with suturing (Sebesta and Bishoff, 2004).

Key Points: Performing the Procedure

- A checklist ensuring that all essential equipment is present and operational should be completed just before initiating the pneumoperitoneum. Additional items to check when using the da Vinci Robotic System include ensuring that all plugs for the console, vision cart, and patient-side cart are plugged into different circuits and that all cables connecting these carts are connected properly.
- After placement of the Veress needle, insufflation should never be initiated unless all of the signs for proper peritoneal entry (negative aspiration, easy irrigation of saline, negative aspiration of saline, positive drop test result, and normal advancement test) have been confirmed.
- The open technique is recommended specifically when extensive adhesions are anticipated.
- Noncutting dilating trocars have superseded bladed trocars because they are safer. These trocars enter the abdomen by spreading the abdominal wall musculature, rather than cutting it, and therefore there is less chance of injuring an abdominal wall vessel, and the resulting entry site is less prone to subsequent herniation.

Physiologic Considerations in the Adult

Almost 30 years have passed since Clayman et al. performed the first laparoscopic nephrectomy. Since that time laparoscopy and robotics have become common in operative urology; therefore it is important to be familiar with physiology and the potential complications related to the pneumoperitoneum and patient positioning.

Choice of Insufflant

Carbon Dioxide

CO_2 is the most commonly used insufflant for laparoscopic and robotic surgery and is favored by most minimally invasive surgeons thanks to its properties (colorless, noncombustible, very soluble in blood, and inexpensive). Prolonged postoperative distention of the abdomen does not occur because CO_2 is quickly absorbed (Wolf and Stoller, 1994). It is highly soluble in water and easily diffuses in body tissues. It readily moves out of the peritoneal cavity as a result of a high diffusion gradient caused by the difference in concentration of CO_2 between the intraperitoneal space and the surrounding components (e.g., blood). However, the characteristic of rapid absorption, which lessens the chance of a CO_2 gas embolus, may also lead to potential problems (e.g., hypercapnia, hypercarbia, associated cardiac arrhythmias). In particular, patients with COPD may not be able to compensate for the absorbed CO_2 by increased ventilation; this may result in dangerously elevated levels of CO_2 in these patients, thereby necessitating the direct testing of arterial blood gases during laparoscopy or robotics in the pulmonary compromised patient. Carbon dioxide also stimulates the sympathetic nervous system, which results in an increase in heart rate, cardiac contractility, and vascular resistance. Last, CO_2 is also stored in various body compartments (e.g., viscera, bones, muscles). After prolonged laparoscopic or robotic procedures it may take hours before the patient has eliminated the extra CO_2 that has accumulated in these storage areas; again, this is more often the case and a problem in patients with pulmonary compromise (Lewis et al., 1972; Puri and Singh, 1992; Tolksdorf et al., 1992; Wolf and Stoller, 1994). Therefore, as previously noted, all patients, and in particular those with pulmonary disease, must be closely monitored after a lengthy laparoscopic or robotic procedure for possible signs or symptoms of hypercarbia; indeed, their greatest chance of compromise as a result of hypercarbia may occur after extubation in the postanesthesia recovery room.

Alternative Gases

Nitrous oxide is less irritating to the peritoneum and causes fewer acid-base changes and cardiovascular adverse effects (e.g., arrhythmias) than CO_2 (El-Minawi et al., 1981; Minoli et al., 1982; Scott and Julian, 1972; Sharp et al., 1982). However, some studies have shown that nitrous oxide insufflation reduces cardiac output and increases mean arterial pressure (MAP), heart rate, and central venous pressure (Marshall et al., 1972; Shulman and Aronson, 1984). Because nitrous oxide supports combustion, it can be used only during laparoscopic procedures that do not involve the use of electrosurgical instruments.

Helium is an inert and noncombustible insufflant. Initial studies performed in various animal models showed favorable effects on arterial partial pressure of CO_2 and pH with **no evidence of hypercarbia** (Fitzgerald et al., 1992; Leighton et al., 1993; Rademaker et al., 1995). These results were corroborated by clinical studies (Bongard et al., 1991; Fitzgerald et al., 1992; Jacobi et al., 1997; Leighton et al., 1993; Neuberger et al., 1994; Rademaker et al., 1995). **Therefore helium is particularly useful for the patient with pulmonary disease in whom hypercarbia would be poorly tolerated.** In a study from Johns Hopkins University, 10 patients at high risk for hypercarbia underwent laparoscopic renal surgery with helium insufflation. These patients were successfully managed, with only one patient developing an end-tidal CO_2 over 45 mm Hg (Makarov et al., 2007). **Likewise, if hypercarbia develops during a laparoscopic procedure with CO_2, rather than aborting the procedure or converting to an open approach, the surgeon can change the insufflant to helium and usually salvage the case** (Brackman et al., 2003). There is also evidence that the use of helium may cause a decrease in tumor cell growth and inflammatory reactions within the peritoneal cavity (Dahn et al., 2005; Jacobi et al., 1997, 1999). Helium insufflation can be used for laparoscopic procedures (e.g., cholecystectomy, appendectomy, hernia repair) performed with local and regional anesthesia in high-risk patients not only because of its favorable metabolic features but also because of its lack of peritoneal irritation and its association with decreased postoperative pain (Crabtree and Fishman, 1999). **However, laparoscopic surgeons must remember that helium may be associated with a higher risk of gas embolism because of its lower blood solubility.** When helium is going to be used, it is advised to initially obtain the pneumoperitoneum with CO_2 and then change to helium, thereby lowering the chances of a helium gas embolus. Also, helium is significantly more expensive than CO_2. Last, with use of helium a separate "yoke" (i.e., line from the gas tank to the insufflator) is needed; accordingly, surgeons must make sure that a "helium yoke" is available in the operating room or make arrangements to have one provided when performing laparoscopy on patients with severe pulmonary compromise. In practice, the use of helium may be difficult; however, argon may also be used in circumstances when hypercarbia occurs. Indeed, the gas from the argon beam coagulator can be used to maintain the pneumoperitoneum. However, with argon being an inert gas, like helium, the same precautions apply (Badger et al., 2008).

Other insufflants (e.g., room air, oxygen) have been used to establish a pneumoperitoneum in the past. However, possible serious side effects (e.g., air embolus, intra-abdominal explosion, combustion with oxygen and room air) have terminated their clinical use. Other options for insufflants include some of the other noble gases (e.g., xenon, argon, and krypton), which are inert and nonflammable; however, their widespread clinical use has not been adopted because of their high cost and poor solubility in blood.

Choice of Pneumoperitoneum Pressure

Overall, the most commonly selected pressure for performing laparoscopy or robotics is 15 mm Hg; however, studies support a pressure of 12 mm Hg as more optimal because this results in no perturbations in cardiac parameters (i.e., no change in stroke volume) versus a pressure of 15 mm Hg (Mertens zur Borg et al., 2004). Working at lower pneumoperitoneum pressures has also been found to reduce postoperative pain (Sarli et al., 2000). Using an even lower working pressure of 10 mm Hg has been shown to result in a marked reduction in oliguria (McDougall et al., 1994), and the authors routinely use a pressure of 8 mm Hg during renal surgery when using a valve-free trocar system with an Intelligent Flow System insufflator (AirSeal System, CONMED, Utica, NY). Conversely, a pressure of 20 mm Hg has been noted to produce a 22% increase in insufflant filling volume and possibly less venous bleeding during the procedure (Adams et al., 1999). However, the absolute benefit of increased insufflant filling is debatable; McDougall et al. (1994) noted that, despite the increased volume, there was only a very small increase in abdominal girth at higher pressures.

Various cardiovascular, renal, and respiratory effects seen during different intra-abdominal pressures in the supine state are summarized in Table 14.1. These physiologic parameters may be further altered (i.e., overridden or reversed) as a result of the health of the individual patient and changes in the patient's position.

TABLE 14.1

Pressure Effects: 5, 10, 20, and 40 mm Hg

EFFECTS	5 mm Hg	10 mm Hg	20 mm Hg	40 mm Hg
CARDIOVASCULAR				
Heart rate	↑	↑	↑	↓
Mean arterial pressure	↑	↑	↑	↑
Systemic vascular resistance	↑	↑	↑	↑
Venous return	→/↓	↓ ↑	↓ ↑	↓
Cardiac output	→/↓	→/↑	→/↓	↓
RENAL				
Glomerular filtration rate	→	↓	↓ ↓	↓ ↓
Urine output	→	↓	↓ ↓	↓ ↓
RESPIRATORY				
End-tidal CO_2	→	→/↑	→/↑	↑
P_{CO_2}	→	↑	↑	↑
Arterial pH	→	→/↓	↓	↓

CO_2, Carbon dioxide; P_{CO_2}, partial pressure of carbon dioxide.

Cardiovascular Effects of the Pneumoperitoneum

Venous Flow

Animal studies have shown that the effects of the pneumoperitoneum on venous return depend on atrial pressures, which, in turn, are a reflection of the hydration state of the subject (Diamant et al., 1978; Ivankovich et al., 1975; Kashtan et al., 1981). If atrial pressures are low (normal or hypovolemic state), then, during a pneumoperitoneum of up to 20 mm Hg, venous return is reduced because of increased compression of the vena cava from the pneumoperitoneum. If atrial pressures are high (hypervolemic state), the vena cava resists elevated intra-abdominal pressure and venous return is actually enhanced. However, these principles apply only to an intra-abdominal pressure of up to 20 mm Hg. By further increasing pneumoperitoneum pressures, especially to 40 mm Hg and above, capacitance vessels are collapsed, vascular resistance increases, blood flow decreases markedly, and venous return is significantly reduced. Lower extremity venous return is also reduced by elevated intra-abdominal pressures. Reduced venous blood flow in the lower extremities could facilitate deep vein thrombosis; however, this remains a rare clinical complication of laparoscopy (Jorgensen et al., 1993).

These pathophysiologic insights, gained through animal experiments, have been corroborated by clinical studies (Jorgensen et al., 1993; Kelman et al., 1972; Lee, 1975; Motew et al., 1973). As a result of these trials, intra-abdominal pressures during laparoscopy and robotics should not be allowed to exceed 20 mm Hg over extended periods (Arthur, 1970; Lee, 1975; Seed et al., 1970), and a working pressure of 10 to 12 mm Hg is recommended.

Cardiac Arrhythmias

Tachycardia and ventricular extrasystoles may be seen as results of hypercapnia (Scott and Julian, 1972). Peritoneal irritation may lead to vagal stimulation and subsequently to bradyarrhythmias (Doyle and Mark, 1989). Also, dysrhythmias can serve as clinical warning signs for the occurrence of pneumothorax, hypoxia, and gas embolism (Wolf and Stoller, 1994).

Unreliability of Central Venous Pressure Readings

As previously noted, intravenous pressures may actually rise with low intra-abdominal pressures. In addition, increasing intra-abdominal pressures may artificially elevate central venous pressure readings owing to an increase in intrathoracic pressure. Therefore the anesthetist must *not* rely on central venous pressure readings for any clinical decision making.

Respiratory Effects of the Pneumoperitoneum

Pressure-Mediated Effects

Because of increased intra-abdominal pressure, diaphragmatic motion is limited.

Pulmonary dead space remains unchanged, but functional reserve capacity decreases (Wolf and Stoller, 1994). The average peak airway pressure needed to keep up a constant tidal volume increases parallel to the increasing intra-abdominal pressure (Alexander et al., 1969; Motew et al., 1973; Wolf and Stoller, 1994).

Although usually not of great clinical importance in a healthy patient population, it is advisable to use positive end-expiratory pressure techniques when patients with lung disease undergo general anesthesia for a laparoscopic procedure (Ekman et al., 1988; Hazebroek et al., 2002; Wolf and Stoller, 1994).

Non–Pressure-Related Respiratory Effects

The head-down position, commonly used in laparoscopic and robotic procedures, has an adverse effect on respiration. It elevates the diaphragm and decreases vital capacity. It can also lead to a dislocation of the endotracheal tube that, in turn, may cause right main bronchus intubation. Although of little clinical significance in healthy patients, the head-down position may cause pulmonary edema in patients with increased left-sided heart pressures (Prentice and Martin, 1987). Also, during lengthy procedures performed with the patient in the head-down position, it is useful to limit fluid administration if possible because it will minimize facial swelling postoperatively.

Renal Effects of the Pneumoperitoneum

Increased intra-abdominal pressure was found to be associated with a significant decrease in urinary output. A number of investigators, with the oldest study dating back to 1923, have observed **oliguria** and anuria associated with an ongoing increase in intra-abdominal pressure (Harmann et al., 1982; Richards et al., 1983; Thorington and Schmidt, 1923). Decreased renal vein blood flow and direct renal parenchymal compression, rather than marked hormonal changes or ureteral compression, have been shown to be the likely reasons for the oliguric state (Chiu et al., 1994; McDougall et al., 1996). Renal cortical blood flow decreases with increasing intra-abdominal pressures, whereas renal medullary blood flow increases up to pressures of 20 mm Hg; above this level, medullary blood flow also decreases (Chiu et al., 1994).

In general, to avoid an oliguric state during a laparoscopic procedure, a pressure of 10 mm Hg or less is recommended. In addition, clinically the use of furosemide (Lasix), mannitol (12.5 to 25 g), and dopamine at 2 μg/kg/min can help overcome oliguria. With this regimen and judicious fluid administration, the patient can usually be maintained with a urine output in excess of 100 mL/h. The key is to use these pharmaceutical modalities in lieu of excessive hydration and fluid boluses (Perez et al., 2002), which may lead to significant fluid overload and edema.

Effects of the Pneumoperitoneum on Mesenteric Blood Flow and Intestinal Motility

Decreased blood flow during laparoscopic procedures was found not only in the kidney but also in mesenteric vessels and other organs (e.g., liver, pancreas, stomach, spleen, small and large intestines) (Caldwell and Ricotta, 1987; Hashikura et al., 1994; Ishizaki et al., 1993). This may rarely lead to mesenteric thrombosis with catastrophic results. This complication may take days to develop (Schorr, 1998).

Open, incisional abdominal surgery usually results in some postoperative impairment of gastric and intestinal emptying because of intestinal paralysis (physiologic ileus) (Kemen et al., 1991). Clinical observation and studies undertaken during laparoscopic and open surgical cholecystectomy have shown that laparoscopic surgery causes less significant disturbances of the gastrointestinal motility pattern, therefore resulting in no postoperative physiologic ileus or less than occurs with open surgery (Halevy et al., 1994; Sezeur et al, 1993). The exact mechanisms responsible for this difference have yet to be defined; however, it is postulated that perhaps it is related to the hypercarbia (Aneman et al., 2000). In addition, intestinal perfusion does not change significantly during prolonged pneumoperitoneum at a pressure of 15 mm Hg with CO_2 or helium (Goitein et al., 2005); however, at least in the rat model, there does seem to be an increase in bacterial translocation that is proportional to the pneumoperitoneum pressure (Sukhotnik et al., 2006).

Also, despite the increased intra-abdominal pressures associated with laparoscopy, there has been no increased incidence of gastroesophageal reflux and regurgitation in patients undergoing laparoscopic procedures (Schippers et al., 1992).

Acid-Base Metabolic Effects of Pneumoperitoneum

Animal and human studies have demonstrated that prolonged laparoscopic procedures may result in hypercarbia and respiratory acidosis (Motew et al., 1973). Because there is no increase in ventilatory dead space during laparoscopy, the resulting respiratory acidosis has been attributed to transperitoneal absorption of CO_2 during establishment and maintenance of the pneumoperitoneum (Leighton et al., 1993; Motew et al., 1973). Although the resulting mild respiratory acidosis does not adversely affect otherwise normal patients and can be corrected by increasing the minute ventilation, increased absorption of CO_2 can become dangerous in patients with COPD because of their impaired ability to release pulmonary CO_2. **To ensure proper monitoring of acid-base status, intermittent arterial blood gas sampling should be performed in patients with COPD during any laparoscopic or robotic procedure that requires more than 1 hour of CO_2 insufflation. In patients with COPD, arterial blood gas sampling should continue in the postanesthesia recovery area because after extubation these patients may be at risk of significant hypercarbia as a result of subsequent mobilization of procedurally absorbed CO_2.**

The potential for developing hypercarbia exists during transperitoneal and preperitoneal laparoscopy. CO_2 is absorbed from the peritoneal membrane during transperitoneal laparoscopy and from preperitoneal adipose and connective tissue during retroperitoneoscopy and extraperitoneoscopy (Collins, 1981). Others have also implicated the disrupted microvascular and lymphatic channels for CO_2 absorption during preperitoneal laparoscopy (Glascock et al., 1996). Several studies have demonstrated that CO_2 absorption during either transperitoneal or retroperitoneal laparoscopy increases significantly during the initial 30 to 60 minutes of the procedure and reaches a steady-state plateau thereafter (Ng et al., 1999; Wolf et al., 1995). Which one of the two approaches is associated with greater CO_2 absorption remains a debated issue. Although some studies have demonstrated greater absorption during transperitoneal laparoscopy (Giebler et al., 1997), others have demonstrated greater absorption during retroperitoneal laparoscopy using a standard Hasson cannula (Wolf et al., 1995). However, in another study, no significant clinical difference was seen (Ng et al., 1999), as long as a balloon tip–type cannula was used that tightly sealed the site of entry between the balloon and soft cuff carried on the shaft of the cannula.

Although transperitoneal and retroperitoneoscopic approaches are routinely used safely at numerous centers worldwide, vigilant perioperative anesthetic management is essential to prevent the development of potential complications related to CO_2 buildup, particularly in patients with preexisting airway and cardiovascular compromise. End-tidal CO_2 and O_2 saturation should be monitored intraoperatively with a capnometer. Furthermore, arterial blood gases are obtained during prolonged laparoscopic procedures and in patients with increased risk of developing hypercarbia (because of airway disease, renal failure, congestive heart failure, or advanced age). **A rise in end-tidal CO_2 should prompt the anesthesiologist to adjust the respiratory rate and tidal volume to enhance CO_2 elimination**. **Simultaneously, the surgeon should decrease the insufflation pressure of CO_2 or, if necessary, desufflate the abdomen until the hypercarbia has resolved.**

Hemodynamic Effects Related to Patient Position and Type of Approach

Several animal and human studies have examined hemodynamic changes resulting from different surgical positions during laparoscopy (Joris et al., 1993; Kelman et al., 1972; Williams and Murr, 1993). In the supine position, cardiac output remains unchanged or decreases when intra-abdominal pressures are less than 15 mm Hg, whereas MAP and systemic vascular resistance increase (Pearle, 1996). If pneumoperitoneum pressures are increased beyond 20 mm Hg, cardiac output is reduced because of decreasing venous return and therefore MAP decreases. Alternatively, in the head-up position, heart rate increases, MAP decreases, systemic vascular resistance increases, and cardiac output decreases. In the head-down position, heart rate drops, MAP rises, systemic vascular resistance falls, and cardiac output increases (Pearle, 1996). These results have also been shown to hold true in steep Trendelenburg position used for laparoscopic and robotic radical prostatectomy (Falabella et al., 2007). The head-down position seems to be favorable for the laparoscopy patient because of higher cardiac output caused by increased venous return.

There is some evidence that the extraperitoneal approach may be beneficial with regard to hemodynamic effects compared with transperitoneal laparoscopy. Giebler et al. (1997) demonstrated that transperitoneal laparoscopy was associated with more pronounced changes in cardiac output, pulmonary artery pressure, central venous pressure, iliac venous pressure, and inferior vena caval pressure gradient as compared with retroperitoneal laparoscopy. With regard to pelvic laparoscopy, Meininger et al. (2004) compared the effects of prolonged intraperitoneal and extraperitoneal CO_2 insufflation on hemodynamics and gas exchange. With both insufflation methods, arterial CO_2 pressure increased rapidly, reaching higher levels with extraperitoneal insufflation. Therefore patients managed with extraperitoneal insufflation required significantly higher minute ventilation. Heart rate and central venous pressure increased in both groups, whereas mean arterial blood pressure and pH decreased in both groups.

Hormonal and Metabolic Effects During Laparoscopic Surgery

As in other surgical procedures, several hormones (e.g., β-endorphin, cortisol, prolactin, epinephrine, norepinephrine, dopamine) have been noted to increase during laparoscopic surgery as a response to tissue manipulation, intraoperative trauma, and postoperative pain (Cooper et al., 1982; Lefebvre et al., 1992; Lehtinen et al., 1987). The clinical significance of increased serum arginine vasopressin levels seen in open surgery and in response to intraperitoneal insufflation during laparoscopy remains unexplained (Cochrane et al., 1981; Melville et al., 1985; Solis Herruzo et al., 1989).

Several adverse metabolic changes observed during open cholecystectomy are less pronounced with laparoscopic cholecystectomy: (1) reduced postoperative plasma glucose elevation, (2) less decrease in insulin sensitivity, and (3) reduced hepatic stress response (Glerup et al., 1995; Jakeways et al., 1994; Thorell et al., 1993).

One important feature of the catabolic response is a complex intraorgan shift of nitrogen; this reaction has been best characterized in the liver (Glerup et al., 1995). The conversion of amino acids to urea by the liver is much higher after open cholecystectomy than it is after laparoscopic cholecystectomy. Therefore the catabolic reaction of the body is decreased with a laparoscopic versus an open approach (Fischer, 1995). Indeed, in the laparoscopic patient, the reduced postoperative hepatic catabolic stress associated with reduced tissue loss of amino-nitrogen may, in some way, be responsible for the more rapid convalescence that is the hallmark of laparoscopy in general. Last, catabolic responses in the form of released cytokines and opioids, resulting from augmented neurohumoral stimuli caused by incisional tissue trauma, may also be lessened with a laparoscopic approach (Fischer, 1995).

Immunologic Effects of Laparoscopic Surgery

A number of animal and clinical studies measuring a wide spectrum of inflammatory response mediators (e.g., C-reactive protein, interleukin-6) and other markers of cellular immune functions (pan–T cells [CD3], helper T cells [CD4], suppressor cells [CD8], and natural killer cells [CD16]; delayed-type hypersensitivity skin tests; serial phytohemagglutinin-induced T-cell proliferation) have suggested that laparoscopic procedures in general result in less immunosuppression than do their open counterparts (Bolla and Tuzzato, 2003; Cristaldi et al., 1997;; Karayiannakis et al., 1997; Kloosterman et al., 1994; Nguyen et al., 1999; Trokel et al., 1994). This may also play a role in hastening convalescence after laparoscopic procedures. However, in a study by Landman et al. (2004) there was no discernible difference in immunologic parameters between patients undergoing open or transperitoneal laparoscopic radical or total nephrectomy for renal cancer. Ultimately, whether a decrease in inflammatory response mediators and improved postlaparoscopic immune status will translate into a better long-term prognosis for patients with urologic cancers remains to be determined.

Key Points: Physiologic Considerations in the Adult

- Carbon dioxide is the most commonly used insufflant because it is noncombustible and rapidly absorbed in the blood.
- Helium is potentially useful for the patient with pulmonary disease in whom hypercarbia would be poorly tolerated.
- Intra-abdominal pressures during laparoscopy should not be allowed to exceed 20 mm Hg over extended periods, and a working pressure of 10 to 12 mm Hg is recommended.

Complications and Troubleshooting in Laparoscopic and Robotic Surgery

Historically, in large series the overall incidence of laparoscopic complications in urology has been in the range of 4% and **mortality has been distinctly unusual, with a rate of 0.03% to 0.08%** (Fahlenkamp et al., 1999; Mintz, 1977; Winfield et al., 1991). More contemporary series demonstrate a complication rate in the range of 13% to 22% (Table 14.2) (Parsons et al., 2004; Permpongkosol et al., 2007; Vallancien et al., 2002), likely representative of the introduction of new, more sophisticated laparoscopic procedures and more widespread use of laparoscopy. Vascular followed by adjacent organ injuries are the most common complications (Breda et al., 2009; Permpongkosol et al., 2007). The following section covers the myriad complications that can occur with any laparoscopic or robotic procedure. Recognition, resolution, and prevention of these various problems are discussed.

TABLE 14.2

Major Complications of Transperitoneal Abdominal Surgery

TOTAL PROCEDURES	894[a] (100% ABDOMINAL)	1311[b] (84% PELVIC)
Overall complications	13.2%	22.6%
Intraoperative/postoperative	5.7%/7.5%	3.6%/19%
Death	0.2%	0%
Vascular injury	2.8%	0.5%
Bowel injury	1.1%	1.2%
Adjacent organ injury	1.1%	0.8%
Conversion rate	1.7%	1.7%

[a] Data from Parsons JK, Varkarakis I, Rha KH, et al.: Complications of abdominal urologic laparoscopy: longitudinal five-year analysis. *Urology* 63:27–32, 2004.

[b] Data from Vallancien G, Cathelineau X, Baumert H, et al.: Complications of transperitoneal laparoscopic surgery in urology: review of 1311 procedures at a single center. *J Urol* 168:23–26, 2002.

Minimizing the Incidence of Complications During the Learning Curve

Early in a surgeon's experience with laparoscopic and robotic surgery, it is wise to start with low-risk surgical candidates of normal body habitus low-risk surgical candidates of normal body habitus. In addition, it is advisable and recommended by many laparoscopic organizations, as well as by hospital credentialing boards, that the neophyte minimally invasive surgeon seek training in three arenas: (1) in-depth instructional courses, including didactic, “live-case” transmissions and “hands-on” laboratory sessions; (2) preceptor training in which the surgeon-in-training views five or more procedures being done by an already skillful laparoscopic or robotic surgeon; and (3) a mentoring experience, during which a trained laparoscopic or robotic surgeon oversees the initial procedures performed by the surgeon-in-training (Society of American Gastrointestinal and Endoscopic Surgeons, 2010). Further training can be obtained through self-teaching using videos, a laparoscopic box trainer, and virtual reality (VR) simulators. A laparoscopic box trainer is extremely helpful for developing a sense of laparoscopic proprioception and for becoming facile with laparoscopic suturing and knot tying. Data have clearly shown benefits for individuals who have taken the time to practice their laparoscopic skills using a box trainer in all areas of laparoscopy (cutting, clipping, and suturing) compared with individuals who had no such training (Derossis et al., 1998). Other options include participation in a 1-week mini-residency, which has been found to increase the likelihood that participants would perform more complex laparoscopic procedures (81% of participants) (Corica et al., 2006). In addition, VR simulators have been shown to improve the operative performance of surgical trainees with limited laparoscopic experience when compared with no training or with box-trainer training (Nagendran et al., 2013).

Aside from training in the basic psychomotor skills, neophyte minimally invasive surgeons must be educated with regard to prevention, recognition, and appropriate treatment of complications.

General Procedural Complications

Malfunction of Equipment

A successful outcome of any laparoscopic or robotic procedure depends not only on the psychomotor technical skills of the surgeon but also on a proper working knowledge of all the equipment involved in performing these procedures. To ensure undisturbed functioning of all technology, the surgeon must be supported by well-trained staff who are capable of not only quickly recognizing any equipment malfunction but also providing an immediate, adequate response to correct problems. In this regard, the Society of American Gastrointestinal Endoscopic Surgeons has issued a troubleshooting guide for video and electronic failure. For integrated operating room systems offered by most major equipment manufacturers and the da Vinci Robotic System, the surgeon and operating room staff need to receive in-depth training on the system's operation, capabilities, and limitations. In this way, equipment failure will be minimized. In addition, the contact information for the equipment vendor's troubleshooting experts and any in-house support should be readily available.

With regard to the da Vinci Robotic System, equipment malfunction is rare. In a review of 11 institutions with a total of 8240 cases reviewed, the overall incidence of malfunction was 0.4%. Of the 34 cases with malfunction, 24 cases were canceled before the procedure, 2 cases were converted to laparoscopic procedures, and 8 were converted to open surgery (Lavery et al., 2008).

Complications Related to Obtaining the Pneumoperitoneum

Complications Associated With Closed Access (Veress Needle Placement)

Preperitoneal Placement.

Preperitoneal placement of the Veress needle may preclude successful trocar placement. If not recognized early, 1 to 2 L of CO_2 may be instilled. Once this much CO_2 has been insufflated into the preperitoneal space, many signs indicative of correct intraperitoneal insufflation may be present (e.g., distention, tympanic sound on percussion), thereby misleading the surgeon until the first trocar is placed. **The first sign of preperitoneal insufflation is that there may be a steep rise in pressure with only 500 mL of CO_2; plus, if more CO_2 is instilled, unequal distention of the abdomen occurs.** If this early sign is missed, then the laparoscope or robotic camera reveals only fat after trocar placement; the intraperitoneal viscera are not seen.

The next step is to evacuate the CO_2 through the sidearm of the trocar and proceed with an open insertion technique. The initial incision can be widened, and the peritoneal surface can be grasped with a pair of Allis clamps and incised. A Hasson cannula is placed and the peritoneal cavity is insufflated.

Several steps can be taken to avoid this complication. First, if the Veress needle is preperitoneal on initial insufflation, pressures are usually higher than the maximal initial allowable pressure of 10 mm. Second, if the Veress needle is preperitoneal, it cannot be easily advanced 1 cm deeper without resistance. If one has truly entered the peritoneal cavity properly, the Veress needle should be able to be moved 0.5 to 1 cm deeper without meeting any resistance.

Vascular Injuries.

During initial placement of the Veress needle at the umbilicus, minor or major intra-abdominal blood vessels may be punctured by the 14-gauge needle. The first sign of intravascular entry is blood appearing in the hub of the needle. Aspiration results in additional blood filling the syringe. As long as the needle has not been manipulated, it can usually be withdrawn without excessive bleeding. An alternative site for Veress needle placement or open cannula insertion should be used at this point. On proper entry into the peritoneal cavity and establishment of a pneumoperitoneum, **it is important that the path of the initial Veress needle passage be traced. The prior site of the Veress needle passage should be carefully inspected at a pressure of 5 mm Hg. Any site of bleeding can be expeditiously treated by applying gentle pressure and a surgical hemostatic agent as needed.**

To prevent this problem it is important when using an umbilical approach to direct the Veress needle toward the pelvis. One technique to help prevent this problem when using an umbilical access is to pass the Veress needle after making a 12-mm incision, bluntly spreading the subcutaneous fat, and grasping and stabilizing the anterior fascia with a pair of Allis clamps. These maneuvers become especially important in children, who have less space between intra-abdominal structures and the abdominal wall.

Surgeons should also be cognizant that any hemodynamic instability associated with loss of “working space” within the abdomen during the procedure may represent an expanding “unseen” retroperitoneal hematoma from unrecognized Veress needle injury.

Prevention of vascular complications can be further achieved by using a nonumbilical site for Veress needle passage (i.e., just superior and medial to the iliac crest or subcostal in the midclavicular line), where no major vessels are placed in danger.

Visceral Injuries.

During Veress needle placement, intra-abdominal organs may be punctured. The initial signs of this complication consist of aspiration of blood, urine, or bowel contents through the Veress needle or, in the case of a solid organ, high pressures on initial insufflation.

Management consists of simply removing the Veress needle. The Veress needle may then be reintroduced at a different site, or an open Hasson technique can be used through a separate incision site. On entry into the abdomen, any bleeding site on the liver or spleen can be treated with gentle pressure, an argon beam coagulator, or the application of a surgical hemostatic agent as needed. General surgical consultation should be sought in those cases in which there is difficulty achieving hemostasis.

Bowel or bladder entry by the Veress needle needs no further treatment other than needle withdrawal. Placing a nasogastric tube and a transurethral indwelling bladder catheter to decompress the stomach and bladder, respectively, before Veress needle passage can help to prevent these problems.

Complications During Open Access (Hasson Technique).

Potential problems associated with open access are similar to, albeit less frequent than, problems associated with a closed Veress needle access. The principal risk with the open access is injury to underlying viscera while traversing the peritoneum. In a densely scarred abdomen, the bowel may be adherent to the underside of the abdominal wall and therefore may still be injured. If a bowel injury is recognized early, it can often be repaired through the same incision that was made for insertion of the Hasson cannula. Although vascular injury with this approach is distinctly rare, the surgeon must realize that even with open access this devastating complication can occur (Hanney et al., 1999).

Complications Related to Insufflation and Pneumoperitoneum

Bowel Insufflation.

If entry into the bowel is not recognized at the time of irrigation and aspiration through the Veress needle, then the surgeon may well insufflate the small or large bowel. **The first sign of this problem is asymmetric abdominal distention followed by flatus and insufflation of only a small amount of CO_2 (<2 L) before high pressures are reached.**

If this complication is suspected, then the insufflation line should be disconnected; the outflow of gas will immediately confirm bowel entry. The needle can be withdrawn, and open access cannula placement should be done at a different abdominal site. Prevention of this problem is ensured if one properly performs the aspiration, irrigation, and aspiration tests recommended for safe Veress needle placement and if one avoids sites of prior surgery. Alternatively, initial use of open access technique should avoid this complication.

Gas Embolism.

CO_2 has favorable solubility in blood, as opposed to air, helium, or nitrous oxide; however, use of CO_2 may still result in a gas embolus. The most common cause of CO_2 embolism is puncture of a blood vessel or organ with the Veress needle, followed by insufflation; this can occur only when the surgeon has ignored the previously described tests for proper entry into the peritoneal cavity. The first sign of intravascular insufflation is acute cardiovascular collapse. Other signs include dysrhythmias, tachycardia, cyanosis, and pulmonary edema. **The diagnosis is usually made by the anesthesiologist based on an abrupt increase of end-tidal CO_2 accompanied by a sudden decline in oxygen saturation and then a marked decrease in end-tidal CO_2** (Loris, 1994). Sometimes, a “millwheel” precordial murmur can be auscultated (Keith et al., 1974). In addition, the anesthesiologist may notice foaming of a blood sample, if drawn, as a result of the presence of insufflated CO_2.

The treatment is immediate cessation of insufflation and prompt desufflation of the peritoneal cavity. The patient, if at all possible, is turned to a left lateral decubitus (i.e., right side up), head-down position in hopes of minimizing right ventricular outflow problems and forcing the air embolus to rise into the apex of the right ventricle. The patient is hyperventilated with 100% oxygen. Advancement of a central venous line into the right side of the heart with subsequent attempts to aspirate gas may rarely be helpful. The use of hyperbaric oxygen and cardiopulmonary bypass has also been reported (Abdel-Meguid and Gomella, 1996; Diakun, 1991; McGrath et al., 1989).

This devastating complication can be precluded by meticulous attention to Veress needle and initial trocar placement and performance of each of the recommended tests for intraperitoneal entry. Insufflation should never be initiated if the surgeon has even the slightest doubt about correct positioning of the Veress needle; instead, the surgeon should withdraw the Veress needle and pass it at an alternate site or should immediately proceed with open access.

Barotrauma.

Prolonged elevated pressures (>15 mm Hg) may result in barotrauma (Abdel-Meguid and Gomella, 1996; Diakun, 1991; McGrath et al., 1989). Prolonged high pressures may be caused by insufficient and infrequent monitoring of CO_2 pressure, malfunction of the insufflator, or additional pressures produced by auxiliary devices (e.g., argon beam coagulator, CO_2-cooled laser). Furthermore, barotrauma may be caused by ventilation techniques using positive end-expiratory pressure, resulting in rupture of a pulmonary bleb or bulla.

The initial sign of barotrauma may be hypotension caused by decreased cardiac output, secondary to an acute drop in venous return caused by compression of the vena cava. Also, a pneumothorax or pneumomediastinum may develop because of the high ventilation pressures. In addition, increased intra-abdominal pressures may exacerbate a hiatal hernia.

The anesthesiologist, who will notice an increase in ventilation pressures, usually alerts the surgeon to excessive intra-abdominal pressure. The surgeon should desufflate the abdomen and, once the hemodynamic changes have been reversed, reinitiate the pneumoperitoneum at 10 mm Hg. Any malfunctioning insufflator should be replaced. Also, if an argon beam coagulator or a CO_2-cooled laser device is used, the sidearm on one port should be left open to allow excess high-pressure gas to escape while the device is being activated.

Barotrauma secondary to insufflator malfunction can be avoided by routinely troubleshooting the insufflator before every case.

Subcutaneous Emphysema.

Subcutaneous emphysema develops as a result of improper placement of the Veress needle or, more commonly, to leakage of CO_2 around ports. The latter situation occurs when a secure seal around the Hasson cannula is not obtained, port site incisions are too large, the procedure is particularly lengthy, or high intra-abdominal pressures are used. The pathognomonic sign is crepitus over the abdomen and thorax; in male patients, a pneumoscrotum may also develop.

If the problem is caused by improper placement of the Veress needle, then withdrawal of the Veress needle and use of the open technique are recommended. If the problem develops intraoperatively, the surgeon should check for gas leakage around a port site, including the Hasson cannula if the open technique was used. If leakage is found, the surgeon can either place a purse-string suture around the port or, preferably, change the trocar to a larger size or switch to a balloon trocar, which creates a tight seal between the intra-abdominal balloon and outer cuff. Also, the surgeon should consider reducing the insufflation pressure. This complication is eminently avoidable if the surgeon adheres to all the diagnostic tests for proper Veress needle placement and ensures all port site incisions are carefully tapered to the size of the port to be placed. In this regard, it is important to place each port so that it is pointing toward the surgical field to avoid the continued forceful redirection of the port during the procedure that results in widening of the tissue tract around the port and subsequent escape of CO_2 into the surrounding subcutaneous tissues.

Several studies have demonstrated that the incidence of subcutaneous emphysema is higher during retroperitoneal laparoscopy than during transperitoneal laparoscopy, albeit without any clinically significant sequelae (Wolf et al., 1995; Zhao et al., 2008). In any event, the risk of surgical emphysema and other CO_2-related sequelae during retroperitoneoscopic and extraperitoneoscopic surgery can be effectively minimized by working at a lower pressure (i.e., 12 mm Hg vs. 15 mm Hg) (Rassweiler et al., 1998a) and using a balloon trocar to seal the initial entry site (Gill, 1998; Ng et al., 1999).

Pneumomediastinum, Pneumothorax, and Pneumopericardium.

Gas leaking along major blood vessels through congenital defects or secondary enlargement of openings in the diaphragm may lead to pneumomediastinum, pneumopericardium, or pneumothorax (Abreu et al., 2004; Kalhan et al., 1990; Pascual et al., 1990; See et al., 1993; Zhao et al., 2008). Although a pneumomediastinum is usually not associated with specific clinical symptoms, a pneumopericardium may result in impaired cardiac function. The incidence of the pneumopericardium is estimated to be 0.8% (Abreu et al., 2004). The diagnosis is usually made on a chest radiograph taken in the recovery room, except in rare instances when cardiac impairment occurs during the procedure. If there is sudden cardiac decompensation during a procedure, the same maneuvers should be undertaken as described for treatment of a suspected gas embolism, including interruption of the procedure and desufflation of the abdomen. If there is a strong suspicion of pericardial tamponade, pericardiocentesis is indicated.

A pneumothorax may be associated with pneumomediastinum, barotrauma, or direct puncture of the pleural space with a trocar (Doctor and Hussain, 1973; Kalhan et al., 1990; Pascual et al., 1990). The incidence of this complication has been found to be 1.6% to 4.0% (Abreu et al., 2004; Zhao et al., 2008). Like subcutaneous emphysema, the incidence of pneumothorax is more common in retroperitoneal procedures (Zhao et al., 2008). The earliest signs of this problem may be the development of subcutaneous emphysema, especially in the neck and chest area. More ominous signs, such as hypotension and decreased breath sounds with an increase in ventilatory pressure, are indicative of a *tension* pneumothorax. Although a chest radiograph will confirm the diagnosis, the development of pulmonary collapse with loss of breath sounds on one side mandates immediate decompression of the chest by passage of a 16-gauge needle into the second or third intercostal space in the midclavicular line followed by tube thoracostomy, if a tension pneumothorax is suspected (See et al., 1993).

Prevention of these problems is similar to the means to avoid subcutaneous emphysema: the surgeon must keep the intra-abdominal pressure preferably at 12 mm Hg, make sure all port site incisions are tight around the laparoscopic cannulae, and make sure all cannulae are well seated in the peritoneal cavity. In addition, all trocars must remain below the 12th rib. While dissecting in the upper quadrants of the abdomen, especially during laparoscopic ablative renal surgery, the surgeon should be aware of the anatomic relationships of the kidneys, adrenal glands, and great vessels to the diaphragm to avoid direct injury.

Complications Related to Initial “Blind” Placement of the First Trocar After Obtaining a Veress Needle Pneumoperitoneum

With the advent of nonbladed trocars (several of which also have clear tips for direct visualization of individual abdominal wall layers during port placement), the likelihood of catastrophic injuries to vital structures has been markedly reduced (Thomas et al., 2003).

Injury to Gastrointestinal Organs.

Perforation of the small or large intestine during passage of the primary port is the most common cause of trocar-induced injury of gastrointestinal organs. Other organs (e.g., stomach) are affected much less frequently. Given the lateral positioning of the spleen and liver, injury of these organs with the passage of the primary trocar is distinctly unusual. The first sign that surgical tools have entered the bowel depends on whether the injury is through one wall or both walls of the bowel. In the former instance, as soon as the laparoscope is introduced, the surgeon sees the mucosal folds of the interior of the bowel. However, with a through-and-through injury the diagnosis is not made until the first secondary trocar is passed; **at that time the surgeon should routinely pass the laparoscope through the secondary port to inspect the puncture site of the initial port.** The trocar will be seen passing completely through both walls of the bowel. If the surgeon fails to perform this maneuver routinely, this injury will not be noted until the end of the case when the trocars are being removed, thereby resulting in a broader injury and a prolonged time of intraperitoneal contamination. A missed bowel injury of this nature leads to peritonitis when diagnosed intraoperatively and possible death when discovered only in the postoperative period.

In the case of a one-wall injury of the bowel, the surgeon can elect to leave the trocar in place and pass a second trocar in another location using an open-access technique. On inspection of the abdomen, the site of injury to the bowel will be immediately apparent because the initial trocar will still be residing in the bowel. At this time, the surgeon may elect to open and repair the bowel or, if skilled in laparoscopy, may place two more ports and proceed to close the bowel using laparoscopic suturing or stapling techniques. An intraoperative consultation with a general surgeon should be obtained regardless of whether the urologist performs the repair because involvement of the general surgeon at the time of the acute event facilitates subsequent care should further complications arise while ensuring the best possible repair of the injury at the time of the acute event.

When the injury to the bowel is a through-and-through injury, it can be repaired similarly with an open or laparoscopic approach. In either case, the abdomen should be irrigated with 4 to 5 L of saline containing an antibiotic solution, and the patient must be placed on broad-spectrum antibiotic coverage.

Perforation of the stomach is distinctly rare, and the management of this complication is the same as for injury to the bowel, with primary closure and general surgery consultation. In addition, when the stomach is distended, a nasogastric or orogastric tube should be placed to decompress the stomach and facilitate further trocar insertion.

Injury to Intra-abdominal Vessels.

Major vascular injury is a rare but serious complication, occurring in 0.11% to 2% of cases (Geers and Holden, 1996; Hanney et al., 1995; Lin and Grow, 1999;

Parsons et al., 2004; Usal et al., 1998; Vallancien et al., 2002). It is far more common in procedures related to the retroperitoneum as opposed to pelvic laparoscopy. The aorta and common iliac arteries are most frequently involved. The inferior vena cava is less affected because of its lateral location in relation to the aorta; likewise, the common iliac vein is rarely involved, given its posterior position in relation to the common iliac artery. Rarely, in a patient with adhesions or prior surgery, intestinal mesenteric vessels servicing a “fixed” loop of bowel may be injured. In addition, the epigastric vessels are at risk for injury during trocar placement.

The first sign of a major vascular complication is the onset of sudden hypotension and associated tachycardia. If the trocar has not been moved, then, as the obturator is withdrawn, the diagnosis is made immediately based on whether there is pulsatile (arterial) or nonpulsatile (venous) profuse bleeding from the trocar sheath. If the trocar has been displaced from the injured vessel, then, depending on the vessel injured, when the laparoscope is introduced the surgeon will see blood rapidly accumulating in the abdominal cavity, a mesenteric hematoma, blood dripping from the trocar entry site, or, rarely, blood that preferentially accumulates retroperitoneally, in which case the space within the peritoneal cavity will appear to be markedly reduced and actively decreasing because of the expanding retroperitoneal hematoma.

The response to injury to a major arterial or venous structure must be rapid. A vascular or trauma surgeon should be called to the room. If blood is coming through the trocar, then the trocar should be closed and left in place. An emergency laparotomy is performed, and the trocar is followed to its point of entry into the vessel. The injured vessel should be controlled proximal and distal to the site of trocar injury with vessel loops or bulldog clamps, or alternatively a Satinsky clamp can be placed to isolate the area of injury so that as the trocar is withdrawn the wound can be controlled and repaired quickly. If the injury is discovered at the time of passage of the laparoscope (i.e., the trocar is no longer residing in the vessel), then swinging the sheath and laparoscope up to the underside of the abdominal wall and an immediate cutdown on top of the laparoscope and sheath provide for a rapid and safe laparotomy. Alternatively in this situation, the procedure can be converted to a hand-assist approach and the surgeon can then use the intra-abdominal hand to control the bleeding vessel.

The best way to handle this complication is to avoid it completely. In this regard, knowledge of the exact location and possible anatomic variations of major intra-abdominal blood vessels is mandatory. The preoperative computed tomography (CT) scan should be reviewed before operating to look for vena caval or other abnormalities of the great vessels. Because of limited intraperitoneal space, special care must be given to trocar placement in children and very thin adults. Several maneuvers can be used to help prevent vascular injury. These include ensuring that all the safety signs of passage of a Veress needle are present before proceeding with trocar passage, obtaining an adequate pneumoperitoneum before trocar passage (intra-abdominal pressure may be raised to 20 mm Hg temporarily for placement of the primary trocar), passing the initial trocar under direct endoscopic control (i.e., optical trocar), using blunt nonbladed trocars, and avoiding initial trocar passage through an abdominal scar.

Furthermore, it is helpful to consider having a "hemorrhage" tray available in the operating room at all times (Box 14.3). **This laparoscopic tray should contain a Satinsky clamp, a 10-mm suction tip for large clot evacuation, an Endo Stitch device with 4-0 Vicryl suture, a Lapra-Ty clip applier and a rack of Lapra-Ty clips (six clips per rack), two laparoscopic needle holders, and 4-0 vascular suture.** With this tray available, some injuries to major venous structures can be successfully resolved laparoscopically.

Box 14.3

Contents of Hemorrhage Tray for Laparoscopic Surgery

Laparoscopic Satinsky clamp
10-mm suction-irrigation tip
Endo Stitch device with 4-0 absorbable suture
Lapra-Ty clip applier and a packet of Lapra-Ty clips
6-inch length of 4-0 vascular suture on an SH needle with a Lapra-Ty clip preplaced on the end
Two laparoscopic needle drivers
Topical hemostatic agent of choice

SH, Small half.

Injury to the Urinary Tract.

Urinary tract injuries during laparoscopy are most commonly associated with trocar passage, specifically injury to the bladder at the time of initial trocar placement. The incidence varies widely in the gynecologic literature, ranging from 0.02% to 8.3% (Lin and Grow, 1999; Ostrzenski and Ostrzenska, 1998; Soong et al., 2007). Chances of this problem occurring have been greatly reduced by the introduction of blunt trocars.

The initial sign of this problem is pneumaturia or gross hematuria. The diagnosis can be confirmed by retrograde intravesical instillation of indigo carmine diluted with saline; this allows the surgeon to rapidly identify the cystotomy site. The injury can be repaired laparoscopically with laparoscopic suturing techniques; however, extensive defects may require open surgical repair (Ostrzenski and Ostrzenska, 1998). These injuries should always be closed and not left to heal on their own with prolonged Foley catheter drainage.

Prevention of this problem is simple. Preoperative placement of a urethral catheter to drain the bladder is recommended for all major laparoscopic urologic cases. Not only does it largely preclude bladder injury, but it also provides the necessary means for monitoring urine output during major laparoscopic procedures.

Complications Related to Placement of Secondary Trocars

Bleeding at the Sheath Site.

Blood dripping from the port entry site and onto the underlying abdominal viscera is the first sign of an injured abdominal wall vessel. The exact site of hemorrhage is determined by cantilevering the trocar into each of the four quadrants and noting which position of the trocar tamponades the bleeding.

Definitive therapy for this problem can be undertaken in one of three ways. The simplest method, albeit the most costly, is the insertion of curved electrosurgical scissors or forceps through another port, which can then be articulated up into the port site to coagulate the bleeding.

The least expensive method is to suture the area of hemorrhage. This can be accomplished by inserting a straight Keith needle with a 0-0 absorbable suture from the outside of the abdomen at one side of the affected quadrant and then grasping the needle with laparoscopic forceps and pushing it back out of the abdomen at the opposite side of the affected quadrant until it can be recovered on the surface of the abdomen (Fig. 14.29). This broad suture is then tied over a gauze 4- × 4-inch bolster on the abdominal surface; the port can be used throughout the procedure. Alternatively, various port closure devices, in particular the Carter-Thomason device, may be used to similarly pass a suture to control the bleeding (Ortega, 1996). Ultimately, at the end of the procedure a device of this type should be used to definitively close the port site and occlude the injured vessel, no matter which of the aforementioned techniques is used.

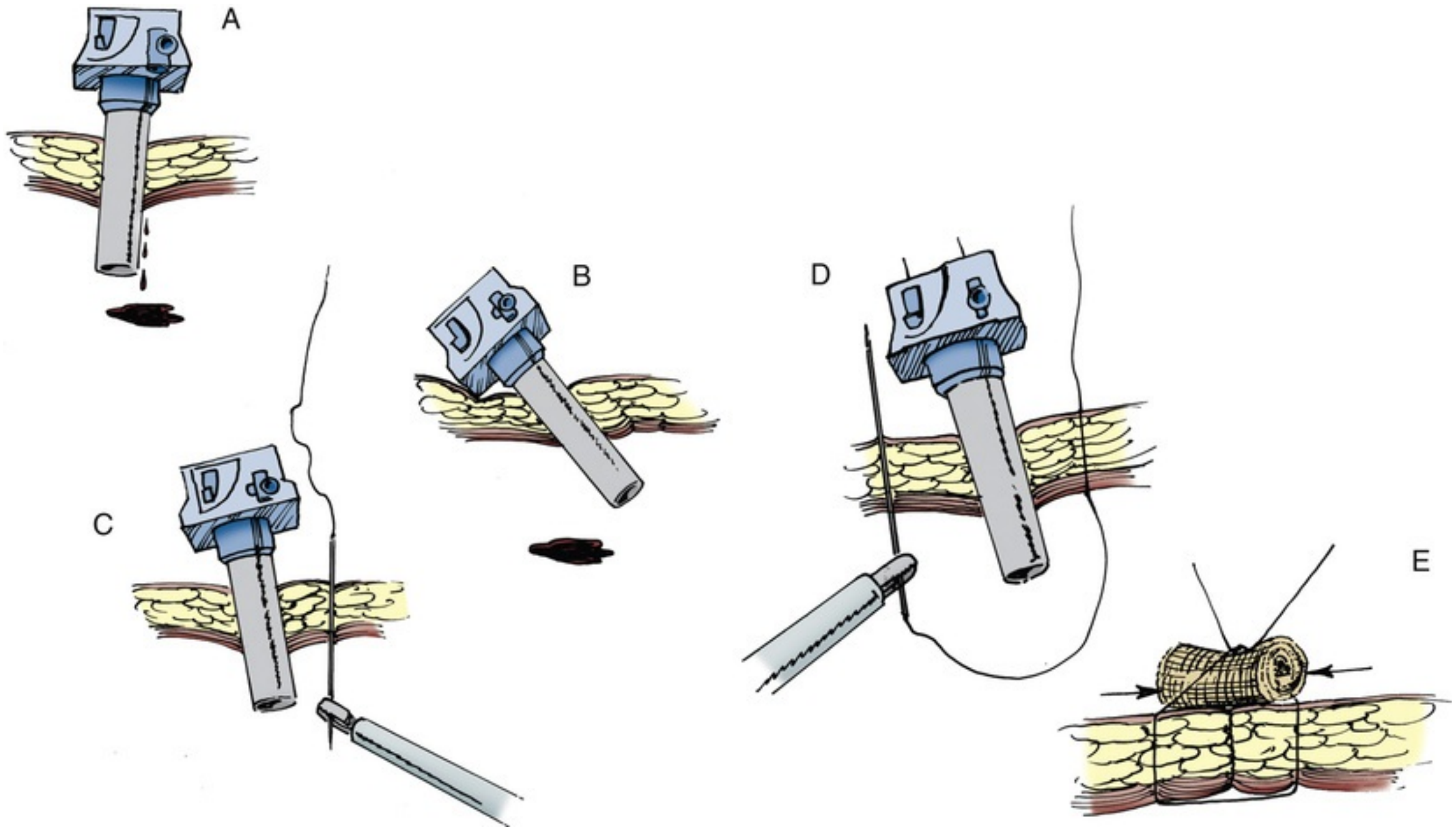

FIG. 14.29 (A) Bleeding at the cannula site. (B) Cannula can be cantilevered into each of the four different quadrants to identify the source of bleeding. (C and D) Straight Keith needle may be used to traverse the site of bleeding. (E) Suture is tied down over a gauze bolster. (From Clayman RV, McDougall EM, editors: *Laparoscopic urology,* St. Louis, 1993, Quality Medical Publishing.)

This problem can often be avoided by routinely transilluminating the abdominal wall, especially in the thin patient, before trocar placement so that large surface vessels and overlying peritoneal vessels can be avoided and to help identify the area of the inferior epigastric vessels. In addition, the routine spreading of the subcutaneous tissues at the proposed port site with a blunt clamp (e.g., Kelly clamp) may be helpful, and the use of only **blunt trocars has been shown to reduce the chance of vascular wall injury significantly** (Bhoyrul et al., 2000). In particular, a fivefold decrease in epigastric vessel injury has been demonstrated with blunt trocars (reduced incidence from 0.83% to 0.16%) (Hashizume and Sugimachi, 1997; Thomas et al., 2003). The incidence of any abdominal wall bleeding has also been shown to be dramatically reduced (3% vs. 9%) with blunt versus bladed trocars (Antoniou et al., 2013). Placing trocars either in the midline or at least 6 cm lateral to the midline has also been shown to reduce the risk of epigastric vessel injury (Hashizume and Sugimachi, 1997).

Trocar Position–Related Problems.

Three potential problems may occur when the secondary trocars are not properly positioned: "crossing swords," "striking handles," and "rollover." The problem of crossing swords is caused by the trocars being placed too close to one another; as a result, the intra-abdominal portions of two trocars cross each other so that the two trocars cannot be easily used to deliver instruments to the same surgical site. Similarly, the problem of striking handles is also caused by trocars being placed too close to one another. As a result, the upper portions of the trocars strike one another on the abdominal surface, again precluding delivery of instruments to a specific surgical site. Rollover is a variant of the crossing swords problem, but it occurs between the laparoscope and an instrument. Instead of running parallel to the surgical site, the primary cannula holding the laparoscope and one of the instrument-holding secondary ports are pointed toward each other. Consequently, as the instrument is advanced toward the surgical site, it strikes and is deflected by the larger laparoscope, thereby rolling over the laparoscope and therefore suddenly moving out of the field of view.

By definition, these problems are more likely to occur during LESS. Because the ports are purposely placed in close proximity to one another, the surgeon must use advanced techniques or special equipment to overcome these pitfalls. This special equipment may include articulating instrumentation, instruments with different shaft lengths, and a low-profile 5-mm laparoscope.

When the da Vinci Robotic System is used, the ports should be placed at least 8 to 10 cm away from one another to avoid robotic arm collision—the robotic equivalent of striking handles. This can sometimes be challenging in thin patients with limited abdominal wall space.

Usually these problems are a minor annoyance, and the surgeon and assistant need to experience the problem only once to adjust for it. To compensate for the problem of striking handles, if it should occur, the sheaths can be withdrawn a bit from the abdomen, thereby increasing the space between the handles of the instruments. The problems of crossing swords and rollover can be remedied by moving the handles of the crossing trocars closer to each other, thereby moving the tips of the trocars farther apart. When this is done to correct a rollover, the surgical site may be displaced into one corner of the monitor; however, the desired delivery of the instrument to the surgical site can then be accomplished. A 30-degree laparoscopic lens can usually allow the laparoscope to be placed parallel to the instrument it is rolling over and then rotated to maintain the operative site image and eliminate the rollover.

The best way to handle these situations is to properly place and direct each trocar at the beginning of the case, to avoid encountering these problems. For some procedures, such as pyeloplasty, this may be accomplished by placing all the trocars on the same line (i.e., midline) so that they are all working parallel to one another, whereas for procedures such as nephrectomy the goal is to place the trocars so that they surround the surgical site, forming a diamond pattern within which the kidney lies. Regardless, each trocar must be inserted so that it points to the pathology; this precludes the problem of having to redirect the trocar throughout the case, adding to surgeon fatigue and unnecessary trauma to the peritoneum and abdominal wall musculature. **Last, if trocar interactions become particularly vexing during a procedure, the surgeon should not hesitate to place an additional 5-mm trocar in a more conducive site to eliminate the problem.**

Complications Related to General Anesthesia Unique to Laparoscopy

Cardiac Arrhythmias and Cardiac Arrest.

Cardiac arrhythmias can be frequently seen during anesthesia in laparoscopic procedures; the most common is sinus tachycardia. Bradyarrhythmias (e.g., atrioventricular dissociation, nodal rhythm, sinus bradycardia) may develop independently or in combination with tachycardia during the same procedure (Myles, 1991). Conditions in laparoscopy leading to development of arrhythmias include CO_2 insufflation; hypercapnia; Trendelenburg position; anesthetic drugs (especially halothane in combination with spontaneous ventilation); and gas embolism (Harris et al., 1984; Myles, 1991). In rare cases, asystolic cardiac arrest and cardiovascular collapse may develop (Shifren et al., 1992).

The role of the anesthesiologist throughout the laparoscopic procedure is paramount. Continuous monitoring of cardiovascular parameters (electrocardiogram, arterial blood pressure) and pulmonary parameters (capnometry, in-line oxygen, airway pressures and tidal volume, frequent arterial blood gas analyses when indicated) is essential. Invasive cardiac monitoring should be instituted as appropriate in patients with heart disease or in high-risk patients (i.e., American Society of Anesthesiologists type 3 or 4) when prolonged and complicated laparoscopic procedures are expected.

Because hypercarbia is one of the most common underlying causes of cardiac arrhythmias, it is essential to monitor and control this problem. Overall, hypercapnia can be corrected rapidly by adjustment of ventilatory rate and tidal volume, use of positive end-expiratory pressure as needed, and reduction of intra-abdominal pressure to 10 mm Hg. The surgeon can also desufflate the abdomen for 5 to 10 minutes to allow the anesthesiologist to “catch up” and correct the hypercarbia; pneumoperitoneum can then be reinitiated at a lower pressure.

In rare cases, if the hypercarbia cannot be controlled by these maneuvers, helium should be substituted for CO_2 as the insufflant. For patients with preoperatively known severe pulmonary compromise, it is prudent to have a tank of helium and the proper helium yoke available in the operating room so that the insufflant can be easily switched. Alternatively, argon gas can be used in the acute situation because it is readily available in many operating rooms because of the argon beam coagulator (Badger et al., 2008).

In the event of cardiac arrest, the surgeon should immediately desufflate the abdomen and provide cardiac massage (compressions) while the anesthesiologist administers 100% oxygen and appropriate drug therapy. If a CO_2 embolus is suspected, additional maneuvers, such as immediately turning the patient to a left lateral decubitus, head-down position and possibly attempting to aspirate the embolus, may be performed.

Changes in Blood Pressure.

Hypertension may be caused by inadequate general anesthesia, elevated intra-abdominal pressures, or hypercarbia. Hypotension may be the result of hypoxia, pneumothorax, pneumomediastinum, gas embolus, or hemorrhage (Abdel-Meguid and Gomella, 1996).

In the event of a marked change in blood pressure, one of the aforementioned conditions must be ruled out. The initial response of the surgeon, provided that there is neither active bleeding nor evidence of retroperitoneal hemorrhage, should be to desufflate the abdomen. In addition, therapy specific to an underlying cause should be enacted.

Aspiration of Gastric Contents.

Aspiration of gastric contents may occur more frequently in patients with a hiatal hernia, significant obesity, diabetes with a history of gastroparesis, or any form of gastric outlet obstruction (Hanley, 1992). The combination of elevated intra-abdominal pressures from the pneumoperitoneum, morbid obesity, and use of the Trendelenburg position increases the likelihood of this complication (Abdel-Meguid and Gomella, 1996).

To prevent this problem in high-risk patients, oral or intravenous administration of 10 mg of metoclopramide is recommended. This medication may decrease the incidence of aspiration by increasing the tone of the lower esophageal sphincter. In addition, in patients with known gastroesophageal reflux, H_2 blockers reduce gastric acidity and attendant morbidity if aspiration of gastric contents should occur (Abdel-Meguid and Gomella, 1996; Hanley, 1992). Also, in patients with known gastroesophageal reflux or other predisposing factors for gastric aspiration, a cuffed endotracheal tube should always be placed. Last, among these high-risk patients, administration of atropine should be avoided because it decreases the tone of the lower esophageal sphincter (Duffey, 1979).

Hypothermia.

The patient's core temperature may drop during prolonged laparoscopic procedures, especially if there is leakage of insufflant around the port sites. The CO_2 that is used is typically neither warm nor humidified. The resulting decrease in temperature may be 0.3°C for each 50 L of CO_2 insufflated (Ott, 1991b). The ambient operating room temperature may exacerbate this effect.

The clinical effects of hypothermia are well described. Core body temperatures around 35°C may result in (1) increased bleeding tendency caused by impaired platelet function, reduced activity of coagulation factors, and enhanced fibrinolysis; (2) increased adrenergic response with vasoconstriction and increased arterial blood pressure; (3) prolonged recovery time as a result of increased blood gas solubility; (4) twofold to threefold increase in the incidence of early postoperative myocardial ischemia in high-risk patients; and (5) impaired wound healing and increased susceptibility to wound infections (Rosenberg and Frank, 1999).

In general there are no specific signs that can be appreciated intraoperatively except for cardiac arrhythmias. In particular, atrial fibrillation may occur in extreme cases of hypothermia (body core temperature of approximately 30°C).

In almost all cases, hypothermia can be avoided. Adjuncts to support the patient's body temperature include intravenous fluid warming, active warming by forced-air systems, circulating warm-water mattresses, and radiant heaters (Rosenberg and Frank, 1999). In addition, warming and humidifying CO_2 to physiologic levels, especially when a prolonged laparoscopic procedure is anticipated, is helpful (Ott, 1991a). However, warming the insufflant alone should be avoided because this causes a drying of the intraperitoneal tissues and has been associated with increased postoperative patient discomfort (Slim et al., 1999).

Complications Related to the Surgical Procedure

Bowel Injury: Electrosurgical.

Electrosurgically induced thermal injury may occur through of one of four mechanisms: inappropriate direct activation; coupling to another instrument; capacitive coupling; and insulation failure.

Active electrode trauma by unintended activation causes direct bowel or other organ injury and may occur when the electrosurgical instrument is left unobserved within the peritoneal cavity, when it is out of the camera's view, or when someone other than the primary surgeon carries out electrode activation. Furthermore, active electrode trauma may be seen when coagulation extends beyond the intended site (thermal spread) and reaches other adjacent structures (e.g., bowel, blood vessels, ureter). This is more commonly seen when high electrocoagulation settings (i.e., >30 watts) are used.

Direct coupling may occur when the active electrosurgical instrument touches another instrument that is in direct contact with other tissue (e.g., bowel). If this happens outside the field of view of the laparoscope or robotic camera, it may remain unnoticed by the surgical team.

Injury caused by capacitive coupling occurs when the surrounding charge, which is intrinsic to all activated monopolar electrodes, is not allowed to conduct back to and disperse through the abdominal wall (Munro, 1997; Zucker et al., 1995). This condition may develop when a metal cannula is anchored to the skin with a nonconductive plastic grip, which, as previously noted, should never be done (Fig. 14.30). As a result, the electrical field, which builds up around the activated electrosurgical instrument and is conducted to the metal trocar through which it has been placed, cannot then be conducted to the abdominal wall because the plastic retainer acts as an insulator. This may lead to a high power density along the portion of the metal cannula that is inside the abdomen. The electrical charge built up on the cannula can then travel to other tissues in contact with the cannula. Similarly, capacitive coupling may constitute a risk when electrosurgical probes are used through operating laparoscopes, which are, in turn, inserted through plastic sheaths. The metal shaft of the laparoscope then becomes a repository for electrical current and may discharge this energy to any tissue in contact with the laparoscope. The risk of this complication is also increased when older generators with high-voltage output and/or electrodes with thicker diameters are used, especially in coagulation rather than cutting mode (Munro, 1997).

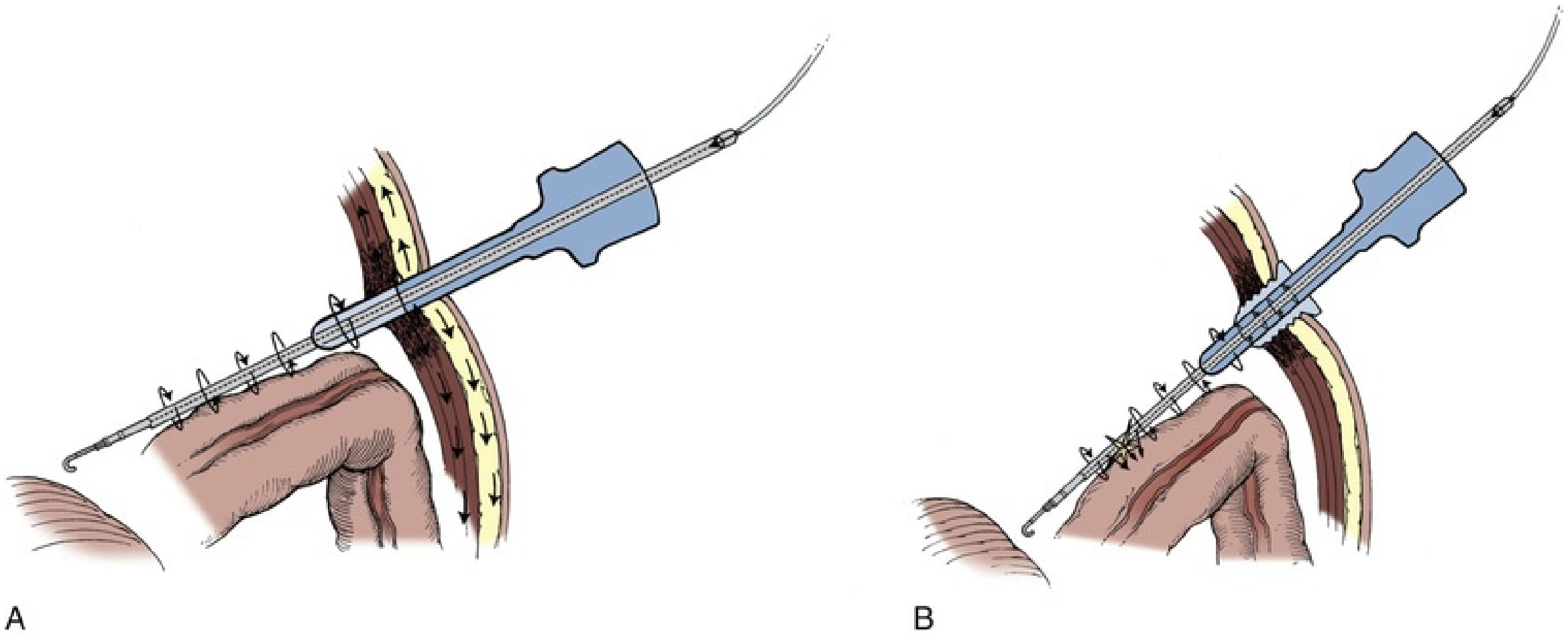

FIG. 14.30 Capacitive coupling. (A) Charge surrounding the activated monopolar electrode is conducted back to the all-metal cannula and dispersed by the abdominal wall. (B) The electrosurgical instrument is being used through a metal cannula that has been anchored to the skin with a nonconductive plastic grip; accordingly, the electrical field cannot be conducted to the abdominal wall because the plastic retainer acts as an insulator; a stronger electrical charge is thus conducted to any other tissue in contact with the cannula.

Last, insulation breakdown may allow current to escape along the shaft of the instrument, thereby harming tissues that are otherwise outside the field of view of the laparoscope. Insulation breakdown along the shaft of the instrument may be a result of repeated use, resterilization, or mechanical damage to the instrument during repeated insertion through a trocar. In this situation, the small break in insulation results in an area of very high power density that then discharges to the nearest soft tissue.

Intraoperatively, thermal injuries of the bowel may manifest as whitish spots on the serosal lining. In severe cases, the muscularis mucosae or the intestinal lumen may be seen. However, in many patients, thermal injury to the bowel is not recognized at the time of the procedure. **Postoperatively, the patient with unrecognized bowel trauma may not develop fever, nausea, or signs of peritonitis for many days because the full extent of bowel necrosis may take up to 18 days to fully develop** (Abdel-Meguid and Gomella, 1996). **Therefore the problem may not become evident until the patient has actually been discharged from hospital.**

Accordingly, bowel injury must be ruled out for any patient who develops a fever beyond postoperative day 1 or who complains of increasing abdominal discomfort. Although many patients may have the typical signs of fever, abdominal pain, ileus, and nausea and vomiting, this is not always the case. Instead many **patients may have low-grade temperature, leukopenia, and persistent and relatively extreme pain at the trocar site closest to the bowel injury** (Bishoff et al., 1999). Alternatively, laboratory values may be remarkable for leukocytosis with an associated left shift (i.e., increased percentage of neutrophils). In some patients, this occurs in the face of a normal or even low leukocyte count, making the left shift a more reliable sign than the absolute white cell count. Abdominal radiographs are notoriously inaccurate because the CO_2 from the laparoscopy may remain as free air for up to 9 days after the procedure; however, an ileus pattern is usually present. A more sensitive test is an abdominal CT scan with oral contrast accompanied by delayed films.

Minor postoperative thermal injuries of the bowel discovered late in the postoperative period (i.e., more than 5 to 7 days postoperatively) may be managed conservatively, aided by administration of antibiotics and an elemental diet. Indeed, a closed fistula may develop that will heal with this approach. However, if the patient does not respond rapidly or develops worsening peritonitis, open surgical exploration is mandatory. Thermal injury caused by monopolar cautery often results in tissue damage that extends beyond the visible area of necrosis. With this in mind, the surgeon should perform a bowel resection with a safety margin of 6 cm on either side before completing an end-to-end anastomosis (Abdel-Meguid and Gomella, 1996).

Thermal injury caused by bipolar electrosurgery is more confined to the visible area of damage. These injuries occur only as a result of direct firing of the instrument on the bowel. If the injury is small, it can be managed by simple excision of the defect and closure of the bowel wall. Bipolar injuries that involve more than half the circumference of the bowel should be treated by excision of the affected segment of the bowel followed by end-to-end anastomosis (Abdel-Meguid and Gomella, 1996).

The goal of every laparoscopic surgeon is to never experience a thermal complication. The surgeon can take several steps to lessen the risk. First, electrosurgical instruments must be carefully inspected before use for any “breaks” in the insulation; if these are found, the instrument must be sent for recoating. Second, electrosurgical instruments should never be left untended within the abdomen; when not in use they must be removed from the abdomen. Third, *only* the primary surgeon should control electrode activation. Fourth, isolation of the area to be cauterized from the surrounding tissues (vessels, nerves, ureter), as well as use of bipolar electrocautery, reduces the risk of thermal spread and injury to other tissues. Fifth, the electrosurgical device should never be activated unless the entire extent of the metal portion of the instrument is in view. This includes not only the active tip of the instrument but also any exposed, uncoated metal joints that may lie just behind the tip of the instrument. In this manner inadvertent direct injury to adjacent tissue and direct coupling to another instrument can be avoided. Sixth, problems of capacitive coupling can be precluded by not creating a situation in which a mixture of conducting and nonconducting elements is used by the surgeon (e.g., metal trocars combined with plastic retainers). In addition, use of modern generators and small-diameter electrodes can significantly decrease the risk of capacitive coupling (Munro, 1997), as can the use of blended or pure cutting current. The high voltages needed for pure coagulation current pose the greatest threat for electrosurgical injury, especially through the mechanism of capacitive coupling and insulation failure. Last, an active electrode monitoring system (Encision, Boulder, CO) is extremely helpful. With this system, any sudden break in the insulation of the electrosurgical instrument (e.g., with scissors or hook electrode) results in immediate shutdown of the electrosurgical current, thereby precluding an electrosurgical injury.

Bowel Injury: Mechanical.

Inadvertent mechanical damage can be caused by a wide variety of sharp and blunt instruments (e.g., laparoscopic graspers, scissors, retractors). This type of injury is more visible to the surgeon and is usually discovered intraoperatively or at the end of the procedure. Direct visual identification during the procedure allows the surgeon to repair the injury laparoscopically, even though the patient has not had a formal bowel preparation. Given its localized nature, bowel resection is rarely necessary. The abdomen should be irrigated copiously at the end of the procedure with 4 to 5 L of an antibiotic-containing solution.

If mechanical bowel injury is missed during the procedure, then postoperative symptoms typically develop much earlier than with an electrosurgical injury. Fever, nausea, ileus, and peritonitis develop in the very early postoperative period, and the diagnosis is confirmed by an abdominal CT scan with oral contrast. This type of injury should be managed with immediate return to the operating room to correct the problem by local excision or resection of bowel with subsequent end-to-end anastomosis and copious irrigation of the abdomen.

Delicate handling of tissue with laparoscopic instruments by the main surgeon and the assistants is essential to avoiding this complication. Atraumatic graspers should always be used when handling bowel. Likewise, it is important that all instruments be introduced under strict visual guidance into the peritoneal cavity. Instruments should never be left unattended and should be withdrawn from the abdominal cavity when not in use. Attentiveness, economy of motion, and deftness of touch are essential characteristics of the successful open and laparoscopic surgeon.

Vascular Injury.

Fortunately, direct major vascular injury during laparoscopic dissection is a rare event. The use of only blunt trocars, the small nature of the instrumentation, the limitations on surgical speed, and the magnification of the surgical field by the laparoscope minimize this potential problem.

During right renal dissection, in particular, the chance of a vena cava, renal vein, or gonadal vein injury is heightened. When this occurs, the surgeon can undertake several steps to resolve the bleeding. **First, the pneumoperitoneum pressure can be raised to 25 mm Hg, thereby slowing or stopping any venous bleeding.** With the use of the irrigator-aspirator, the blood can be cleared and the bleeding site identified. Next, through one of the 12-mm ports, a gauze sponge or pledget can be introduced into the abdomen and handled with a grasping forceps, thereby allowing the surgeon to identify and tamponade the area of bleeding. If the injury is small, then it may respond simply to direct pressure. Alternatively, surgical pharmaceuticals such as fibrin glue or gelatin matrix thrombin sealant (e.g., Floseal [Baxter, Deerfield, IL]) may be applied. If the injury is larger, then the surgeon must decide whether to convert to an open or hand-assist procedure or to attempt to secure and repair the injury laparoscopically. Depending on the severity of injury, a vascular surgery consultation may be appropriate. If a laparoscopic repair is attempted, intracorporeal suturing and possibly the use of a laparoscopic Satinsky clamp may be required. Throughout this period, it is essential for the anesthesiologist to administer sufficient fluids or blood replacement to preclude a hypovolemic state because the hypovolemic patient has a higher risk of possible air embolism at these higher intra-abdominal pressures (O'Sullivan et al., 1997).

If the surgeon is able to gain temporary control of the vessel with a grasper, then it is often helpful to place an extra 5-mm port that can be used by the assistant for suction and irrigation or to optimize the plan of approach to the injury, thereby facilitating laparoscopic suturing. Either way, the additional port allows the surgeon to repair the bleeding site using two hands and with excellent visualization of the surgical field.

Alternatively, the surgeon can convert from standard laparoscopy to a hand-assisted approach. The hand, in this case, is valuable because it can rapidly tamponade the bleeding site. In this regard it is recommended, if at all possible, to pinch the sidewalls of the vein (e.g., inferior vena cava) closed rather than just putting direct pressure on the top of the injury; the latter approach has a tendency to result in a gradual enlargement of the hole in the vein. Also, if the hole is pinched closed, a Satinsky clamp can be more easily passed beneath the surgeon's fingers to provide reliable control of the injury in preparation for a sutured repair.

Minor arterial injuries usually respond to tamponade. Larger aortic or renal artery injuries are much more difficult to resolve laparoscopically. Although the latter, if it occurs during a planned nephrectomy, can be handled by expeditiously taking the renal artery with a vascular stapler, the former may lead to immediate conversion and open repair. As mentioned earlier, addition of an additional 5-mm port can be very useful to help establish a clear field and allow the surgeon use of two hands to control the injury. If conversion to an open procedure is necessary, the area of injury should be tamponaded with laparoscopic forceps, and the surgeon can proceed to rapidly make a midline or subcostal incision by swinging one of the ports up to the underside of the abdominal wall and cutting down on the shaft of the port. The tamponading laparoscopic forceps are important to directing the surgeon immediately to the site of injury, which can then be properly repaired. Again, a vascular surgeon should be called into the room as necessary.

As mentioned previously in this chapter, because most bleeding episodes are unexpected, it is wise to have in the room a hemorrhage tray equipped

with all instruments necessary to control bleeding and for potential open conversion (see Box 14.3).

Nerve Injury.

Nerve injury is invariably a result of patient positioning in combination with the duration of the procedure. The exact incidence of this problem is not known. A survey of neuromuscular injuries associated with laparoscopic urologic surgery completed by 18 urologists from 15 institutions in the United States, published in 2000, found that in a total of 1651 procedures there were 46 neuromuscular injuries in 45 patients (2.8%) (Wolf et al., 2000).

If the patient is inadequately positioned and/or padded, nerve damage may result from abnormal nerve stretching or compression. Among position-related nerve injuries, the brachial plexus appears to be most at risk. Injury may be inflicted in several ways: (1) abduction of the arm beyond 90 degrees, (2) extreme outward rotation of the head of the humerus, and (3) compression damage when shoulder braces are used in the Trendelenburg position (Phong and Koh, 2007), which pushes the clavicle into the retroclavicular space. In particular, this has been reported as a problem with robotic radical prostatectomy when a steep Trendelenburg position is required and strapping the patient may be necessary to avoid slippage. Other nerves that can be affected by positioning include the femoral nerve, because of extreme lateral rotation and abduction of the hip joint, specifically in the lithotomy position, and the sciatic nerve, because of stretching along the superior leg when the patient is in the lateral decubitus position (Abdel-Meguid and Gomella, 1996; Hershlag et al., 1990; Liss et al., 2013). In addition, nerves may be injured during the surgery because of either direct mechanical injury or monopolar electrosurgical current.

Nerve palsy caused by positioning is recognized only postoperatively, often on the first postoperative day when the patient tries to ambulate. From a medical and a legal standpoint, a neurology consultation should be obtained as soon as the patient calls the surgeon's attention to a possible nerve injury. Neurologic examination with possible nerve conduction studies to document acute damage is important. Physical therapy may facilitate recovery. However, recovery in these cases, if it does not occur within the first few postoperative days, is often slow, requiring months.

Prevention is paramount. Table-mounted accessories for all major commercial operating room tables aid in safely and effectively positioning patients in the lateral decubitus position and in the prone position. If the arms are to be at the patient's sides, they should be pronated to protect the brachial plexus. If the patient is to be in a lateral decubitus position, all bony prominences should be padded with additional gel pads (i.e., hip, knee, and ankle on the downside leg), and a pillow is always placed between the legs. Padding should also be placed beneath Velcro straps and tape, which may be used on the upside hip and shoulder. If the patient is in the lithotomy position with steep Trendelenburg, as is often required during laparoscopic or robotic radical prostatectomy, shoulder braces should not be used because of the risk of brachial plexus injury. Instead, use of well-padded wide straps directly across the upper chest and use of the surgical beanbag (Carey and Leveillee, 2007) are excellent ways to secure the patient. Extreme abduction of the hip is also to be avoided; meticulous care to position the patient with attention to hip flexion should be taken when the patient is placed in lithotomy for a prolonged period. Padding must be checked each time the table position is changed, and the patient should be rechecked if he or she is suspected of sliding on the table.

Injury to the Urinary Tract, Spleen, or Pancreas.

Similar to open surgery, during laparoscopic or robotic surgical procedures the urinary tract, spleen, or pancreas may be injured.

Injury to the Urinary Tract

Bladder Injury.

Electrocautery and blunt, sharp, and laser dissection have been identified as intraoperative causes of bladder injury (Ostrzenski and Ostrzenska, 1998). Concomitant bladder or pelvic anomalies or pathologic conditions (prior pelvic or bladder surgery, endometriosis, malignant infiltration, bladder diverticula, amyloidosis, or previous radiation) are predisposing factors that increase the chances of this bladder injury (Ostrzenski and Ostrzenska, 1998).

When a bladder injury has occurred, the intraoperative signs may be subtle. One of the first signs is the presence of blood or gas in the Foley catheter bag. Also, the surgeon may notice clear fluid welling up in the pelvis, although this sign is often obscured if irrigation has been used during the procedure.

Postoperatively, if the bladder injury was missed, the patient may develop oliguria and urinary ascites; this may be accompanied by hyponatremia and, rarely, hyperkalemia with mild elevation of the serum creatinine concentration caused by the peritoneal absorption of urine. Patients who have been discharged from the hospital because of the minor nature of their laparoscopic procedure may contact their physician and complain of lower abdominal discomfort, abdominal swelling, fever, and, in the case of a gynecologic procedure, vaginal discharge.

An air-expanded urine collection bag initially may arouse intraoperative suspicion of a bladder injury; this presumptive diagnosis can be confirmed by the injection of saline mixed with indigo carmine through the Foley catheter. Postoperatively, the diagnosis can be made by conventional cystogram or CT cystogram.

The intraoperative diagnosis of a bladder injury can be followed by laparoscopic repair, either suturing with absorbable suture or, if the injury is small, using preformed suture loops to encircle and secure the cystotomy (Ostrzenski and Ostrzenska, 1998; Poffenberger, 1996). More extensive defects may require open repair.

When bladder injury is diagnosed postoperatively, the key factor is whether the drainage is extraperitoneal or intraperitoneal, which is largely dependent on the preceding laparoscopic access. Extraperitoneal extravasation without any complicating additional problems may be treated by simple placement of a transurethral indwelling Foley catheter. Intraperitoneal drainage is an indication for subsequent laparoscopic or open repair.

Prevention of bladder injury begins with preoperative placement of a Foley catheter. Avoidance of excessive coagulation near the bladder and dissection with exact knowledge of bladder anatomy (urachus, medial umbilical, and vesicocervical ligaments) are also key.

Ureteral Injury.

Ureteral injury is usually a result of thermal damage caused by dissection using monopolar electrocautery in the immediate vicinity of the ureter. Its incidence in laparoscopic hysterectomy is 1%; it may also occur during laparoscopic endometriosis ablation and tubal ligation and has been reported during pelvic lymphadenectomy and laparoscopic and robotic radical prostatectomy (Baumann et al., 1988; Grainger et al., 1990; Guillonneau et al., 2002; Jhaveri et al., 2014; Liu et al., 1997; Ostrzenski and Ostrzenska, 1998; Poffenberger, 1996; Yuh et al., 2014).

Typically, ureteral injuries remain unnoticed throughout the laparoscopic procedure. As opposed to a bladder injury, macroscopic hematuria or pneumaturia is distinctly unusual with this injury. The astute laparoscopist or robotic surgeon may make the diagnosis intraoperatively when urine is seen to be welling up in the wound. However, if irrigation has been used during the procedure, this sign is invariably obscured. Within 2 to 3 days after surgery, patients may have abdominal and/or flank pain, fever, signs of peritonitis, and leukocytosis (Grainger et al., 1990; Liu and McFadden, 2000).

The diagnosis of ureteral injury is most often made during the postoperative period when a contrast-enhanced abdominal or pelvic CT scan with delayed images is ordered because of the patient's complaint of flank pain, abdominal swelling, hematuria, urinary leakage from the wound, and/or the physical signs of urinary ascites. Depending on the function of the contralateral kidney and the amount of urine leakage, serum chemistries may reveal hyponatremia and, rarely, hyperkalemia with a mild elevation in the serum creatinine concentration.

If identified intraoperatively, the injury can be repaired laparoscopically or robotically, but conversion to an open procedure may be required. If the problem is detected in the postoperative period, the first step is to place an indwelling ureteral stent and a bladder catheter. If a stent cannot be placed, then a percutaneous nephrostomy should be placed and an antegrade attempt at stent placement can be made. Depending on the severity of injury, either early laparoscopic or open surgical intervention may be indicated rather than a conservative approach.

Prevention of this injury again highlights the importance of the surgeon's knowledge of anatomy and the course of the ureter with regard to its topographic relation to other anatomic structures (medial umbilical ligament, round ligament or vas deferens, and common iliac artery). During dissection, monopolar electrosurgical coagulation current should be used with great discretion around the ureter. Ideally, fine-tipped electrosurgical instruments should be used and the duration of discharge should be brief (i.e., multiple short bursts of current rather than a continuous multisecond discharge).

Pancreatic Injury.

Injury to the pancreas during left-sided laparoscopic adrenalectomy or radical nephrectomy is most commonly associated with mechanical retraction. The tail of the pancreas overlies the adrenal and may be injured during dissection of the medial aspect of the adrenal and division of the splenorenal ligament. The incidence of this complication is 2.1% for radical left nephrectomy and 8.6% for left adrenalectomy (Varkarakis et al., 2004). The diagnosis is rarely made intraoperatively, with 75% of pancreatic injuries diagnosed postoperatively.

The typical presentation is postoperatively with abdominal discomfort, elevated serum lipase and amylase levels, and leukocytosis. CT reveals a fluid collection that can often be drained percutaneously. A nasogastric tube is placed and oral intake is stopped. When drainage drops below 50 mL/24 h, the drain can be removed, followed by removal of the nasogastric tube and initiation of a low-fat diet.

Prevention of this complication requires the surgeon to widely dissect the line of Toldt and the splenophrenic attachments. The latter are freed to the level of the diaphragm. The colon is broadly reflected from the Gerota fascia, and the splenocolic and splenorenal ligaments are divided. With these maneuvers the spleen and colon rotate medially, carrying with them the tail of the pancreas, well away from the medial surface of the adrenal gland.

Splenic Injury.

The advent of laparoscopic surgery has been associated with a significant decrease in incidental splenectomy during left nephrectomy, with a fall from 4.3% to only 1.5% (Breda et al., 2009; Cooper et al., 1996). These injuries are invariably discovered intraoperatively and can effectively be treated with argon beam coagulation or with one of the newer hemostatic agents such as fibrin glue or thrombin-impregnated granules. **Avoidance of this complication is best achieved by wide mobilization of the spleen during left nephrectomy.** To this end the splenophrenic attachments, as well as the splenocolic and splenorenal ligaments, must be divided. Retraction in the area of the spleen should never be on the spleen but beneath the area of the splenocolic ligament so that the retractor is placed on these thicker tissues (Cooper et al., 1996; Simon et al., 2004).

Complications Related to Exiting the Abdomen

Bowel Entrapment.

During removal of laparoscopic ports and desufflation of the pneumoperitoneum, omentum or bowel may be entrapped at one of the port sites. If missed during the process of cannula removal, then in the early postoperative period, usually on the second or third postoperative day, the patient may develop an ileus and point tenderness at the port site incision.

The treatment is operative. The pneumoperitoneum is reestablished through one of the unaffected port sites, and three ports are replaced: one for the camera and two for grasping forceps. The entrapped bowel is visualized, and an atraumatic bowel clamp is placed on the bowel on either side of the area of herniation. Once this is done, the skin sutures of the affected port site are carefully cut and the wound is opened. The surgeon uses a fingertip to manually reduce the bowel into the abdominal cavity. The bowel can then be carefully inspected; if it appears viable, which is usually the case, it can be left in place and the port site closed. Rarely are formal bowel resection and reanastomosis required.

Bowel entrapment is the result of a technical error. Indeed, most laparoscopic ports have a hole drilled into the side of the port within a few millimeters of the end of the port's shaft. This hole equalizes the pressure in the port and the abdomen as the port is pulled out of the abdomen, thereby precluding any bowel being withdrawn with the port. Furthermore, if each port site is endoscopically inspected at the time of cannula removal, bowel or omentum that may have entered the port site can be readily identified and positioned back into the abdominal cavity. When the last endoscope-bearing port is removed, the assistant should pull up on the closure sutures or on a fascial clamp, and the surgeon should back the cannula out of the wound and up onto the shaft of the endoscope so that the endoscope is the last thing to leave the abdomen.

Bleeding at the Sheath Site.

Bleeding at the sheath site was previously discussed under Complications Related to Placement of Secondary Trocars. However, there are times when this problem does not become apparent until the end of the procedure as a result of tamponade from the trocar. Again, it is essential to inspect each trocar site at 5 mm Hg to rule out this problem.

Early Postoperative Complications

Pain.

Pain may be localized or diffuse. Early in the postoperative course, port site discomfort is to be expected. However, if postoperative pain is limited to a port site, it may also be secondary to herniation (immediate or late), bowel injury, or infection (late). Localized pain combined with a subcutaneous bulge may indicate a rectus sheath hematoma, bleeding and hematoma formation at a port site, or a port site hernia. Pain at a port site without swelling may be due to a particularly broad fascial suture or palpation of the knot of a port site fascial suture in a thin patient. Ultimately, if port site pain appears to be increasing on subsequent postoperative days, herniation should be suspected.

Immediate, severe, diffuse abdominal pain may be related to the release of noxious material during the procedure (e.g., cyst fluid in patients with autosomal-dominant polycystic kidney disease) or to a bowel injury. Immediate postoperative scapular discomfort may be a result of the CO_2 pneumoperitoneum causing some irritation of the diaphragm. Rarely, this discomfort may be sufficiently severe to mimic the symptoms of a pulmonary embolus. This pain is invariably along the area of the right posterior shoulder region. Delayed diffuse abdominal discomfort and development of peritoneal signs or simply ongoing abdominal discomfort accompanied by low-grade fever may be results of an unsuspected bowel injury.

Incisional Hernia.

In adults, the occurrence of an incisional hernia is usually confined to port sites larger than 10 mm. However, in the pediatric population, this complication can occur even with 5-mm ports. The patient usually reports localized discomfort accompanied by nausea and signs of ileus. Rarely, diffuse abdominal pain and/or signs of a complete bowel obstruction may be present. Examination reveals tenderness and, at times, swelling overlying the affected port site. A plain film of the abdomen may show an ileus pattern; however, the definitive study is abdominal CT, which can actually reveal the bowel protruding above the fascial level.

Laparoscopic repair with dissection of the hernia and subsequent intra-abdominal closure can be accomplished. The method for performing this procedure has already been described. In complicated cases in which a strangulated hernia is suspected or confirmed laparoscopically, general surgical consultation should be sought.

As discussed previously, **the risk of incisional hernia can be greatly reduced by using nonbladed as opposed to bladed trocars.** When bladed trocars are used, hernias can be avoided by performing a meticulous fascial suture closure of all trocar entry sites 10 mm or larger in all adults. In children, it is advisable to perform fascial closure of any “bladed” port site 5 mm or larger. The fascial layer is usually closed with an absorbable suture as previously described. **For patients in whom only nonbladed trocars have been used, fascial closure is indicated only of midline ports 10 mm or larger** (Kang et al., 2012) **or any port site that has been unduly stretched.** Indeed, some authors recommend no closure even of midline nonbladed trocar sites (Siqueira et al., 2004). Although there have been a few reports of a hernia developing after use of a nonbladed trocar (Kouba et al., 2007; Lowry et al., 2003; Zemet et al., 2012), this is distinctly rare. Indeed, the incidence of postoperative hernia formation fell from 1.8% with bladed trocars to only 0.19% for nonbladed trocars (Boike et al., 1995; Hashizume and Sugimachi, 1997; Thomas et al., 2003). With midline hand-assist approaches, a higher incidence of hernia formation has been identified than would otherwise be expected: 4.0% to 7.3% (Troxel and Das, 2005). Therefore some authors have recommended closure of this midline incision with interrupted nonabsorbable suture rather than a running closure (Troxel and Das, 2005).

In addition, transverse midline fascial incision has been shown to be superior to vertical midline fascial incision for reducing hernia risk (Brown and Goodfellow, 2005; Halm et al., 2009). Specifically, for robotic radical prostatectomy the change from vertical to horizontal incisions for the camera port and subsequent prostate removal port site has resulted in a reduction in incisional hernias of 5.4% to 0.4% (Liss et al., 2013).

Deep Venous Thrombosis and Pulmonary Embolism.

Although it seems reasonable to expect decreased venous return and therefore increased stasis with concomitant higher risk of deep venous thrombosis (DVT) and pulmonary embolism (PE) in patients undergoing laparoscopy, this is remarkably **not** the case. Indeed, there is no evidence that this complication occurs more often during laparoscopic or robotic procedures versus open surgery (Abdel-Meguid and Gomella, 1996; Secin et al., 2008).

Thus far there have been no randomized controlled trials addressing the issue of DVT prophylaxis in patients undergoing laparoscopic and robotic surgery. **The American Urological Association has released a Best Practice Policy Statement for the prevention of DVT in patients undergoing urologic surgery. Noting the lack of data available directly pertaining to laparoscopic and robotic surgery, the panel recommended the use of pneumatic compression stockings placed at the time of laparoscopic procedure for all patients. In addition, they acknowledged that certain high-risk groups may require the use of low-dose unfractionated heparin or low-molecular-weight heparin before, during, or after surgery.**

Pneumatic compression stockings should be placed preoperatively and continued for 48 to 72 hours postoperatively. In addition, in morbidly obese patients or in individuals at high risk for thrombosis (smoking, past history of DVT), the addition of unfractionated perioperative heparin (5000 units 2 hours preoperatively and then every 12 hours postoperatively) has also been recommended (Capan and Miller, 1999; Clagett et al., 1995; Secin et al., 2008). **With specific respect to upper retroperitoneal (renal, adrenal, ureter) laparoscopic procedures, at least one study** (Montgomery and Wolf, 2005) **indicated that sequential pneumatic compressive stockings provide equivalent DVT prophylaxis compared with subcutaneous fractionated heparin and that the use of subcutaneous heparin may increase the incidence of hemorrhagic complications.** However, it must be stressed that this was a nonrandomized study obtained from a prospective database augmented by retrospective chart review.

Wound Infections.

Overall, this is a rare complication with standard laparoscopy. However, with the hand-assist approach a higher incidence of wound infections has been noted. In one report the postoperative wound infection rate at the hand-assist site was 9% (Nelson and Wolf, 2002). Prevention of this complication is similar to open surgery and includes attention to antiseptic preparation and sterile draping of the abdominal wall, irrigation of each port site at the end of the procedure, and meticulous closure of the wound.

Rhabdomyolysis.

Rhabdomyolysis is a devastating complication after laparoscopic surgery. The exact incidence of this problem is not known, but one survey of neuromuscular injuries associated with laparoscopic urologic surgery found that of a total of 1651 procedures there were 6 cases (0.4%) of clinical rhabdomyolysis (Wolf et al., 2000). In another study, it was estimated that the occurrence of this problem among patients undergoing retroperitoneal laparoscopic procedures (e.g., renal, ureteral, adrenal) was higher, at 1% (Reisiger et al., 2005). Rhabdomyolysis is invariably associated with male patients undergoing longer laparoscopic renal procedures, especially if the kidney rest has been used for the entire case. Although extra padding applied to pressure areas can be useful in avoiding nerve compression and rhabdomyolysis, gel pads and foam egg crate padding have not been conclusively demonstrated to significantly reduce pressure on the patient's flank in the lateral position (Deane et al., 2008). As discussed previously, **male**

patients with a BMI of 25 or greater undergoing laparoscopic surgery in the lateral position with the kidney rest elevated and the table completely flexed are at highest risk of developing rhabdomyolysis as a result of flank pressure.

Rhabdomyolysis manifests immediately in the postanesthesia recovery room; the patient complains of severe pain in the downside hip area. Brown urine may also be noted. The serum creatine kinase value invariably exceeds 5000 units/dL.

Prevention of this problem is essential. This can, to some extent, be achieved by avoiding use of the kidney rest or using it for only the earliest part of the case (i.e., less than an hour) and avoiding prolonged periods of hypotension during the procedure (Cadeddu et al., 2001; Kuang et al., 2002; Parsons et al., 2004; Reisiger et al., 2005). Last, with increasing skill and experience, few procedures should proceed beyond 5 hours.

Late Postoperative Complications

Complications beyond the 3-week postoperative period are rare. These include primarily lymphatic complications and incisional hernia. The latter is addressed in the prior discussion because it can also appear as an early postoperative complication.

Lymphocele Formation.

Lymphocele formation is most commonly associated with pelvic procedures, such as pelvic lymph node dissection during radical prostatectomy (0.4% to 1.3% incidence) (Kavoussi et al., 1993; Liss et al., 2013) or with renal transplantation (0.6% to 18% incidence) (Bailey et al., 2003). The lymphocele may take weeks to develop and may occur despite a transperitoneal approach. Presentation may be by a mass effect, but the astute clinician should realize that it may also occur as a result of local compression causing lower extremity edema, and, in rare cases, venous thrombosis and PE. The lymphocele is diagnosed readily by CT. **Treatment is percutaneous drainage. Sclerosant therapy can be used to treat the lymphocele; however, if unsuccessful or if the lymphocele is not amenable to percutaneous drainage, then a transperitoneal laparoscopic marsupialization procedure is usually successful.** At the time of the procedure, a tag of omentum can be placed into the opening made in the lymphocele to try to prevent closure of the opening and recurrence.

Prevention of lymphocele formation requires meticulous attention to clipping suspected lymphatic structures. Monopolar electrocoagulation does not work well to seal lymphatics. Bipolar or harmonic devices have been shown to effectively seal lymphatic channels; however, the bipolar device created a seal that was 5- to 10-fold stronger than the harmonic device (Box et al., 2009).

Chylous Ascites.

After left-sided retroperitoneal surgery (i.e., left radical nephrectomy, donor nephrectomy), the patient may complain of a distended abdomen. Although this complaint is common in the initial few days after a laparoscopic procedure because of the pneumoperitoneum, irrigation fluid, and/or ileus, it is distinctly rare late in the patient's course. There is no associated fever, pain, or bowel dysfunction, and routine laboratory study findings are within normal limits. Usually the condition is self-limited and resolves without any intervention. If the presentation is not straightforward, then abdominal CT will reveal the underlying problem and allow diagnosis of the presence of ascites. If tapped, the fluid may reveal elevations in the level of lymphocytes, cholesterol, and triglycerides.

Treatment is usually dietary, with a low-fat, medium-chain triglyceride diet. One may also consider giving somatostatin or octreotide (Leibovitch et al., 2002; Negoro et al., 2006). In the rare situation in which the fluid does not resolve with these conservative measures or if the patient is symptomatic, the fluid can be tapped once or twice. If it continues to accumulate, then an open or laparoscopic exploration is undertaken. Once identified, the leaking lymphatic channel is dissected and secured with either suture or clips (Molina et al., 2003).

Prevention of this type of problem is extremely difficult because the lymphatics are not readily visible during the procedure. In particular with laparoscopic procedures, lymphatic leakage may be overlooked as result of tamponade by the pneumoperitoneum. To date, instances of postlaparoscopic chylous ascites have been cited only sparingly in the literature (He et al., 2011; Leibovitch et al., 2002; Molina et al., 2003; Negoro et al., 2006; Shafizadeh et al., 2002).

Training and Practicing Laparoscopic and Robotic Surgery

Surgeons learning how to perform laparoscopic procedures face several hurdles, including an altered 2D view of a 3D space, counterintuitive control of instruments, different ergonomic constraints, and an altered perspective of surgical anatomy (Piechaud and Pansadoro, 2006). Robotic surgical systems such as the da Vinci Robotic System overcome several of these issues by providing binocular, 3D vision, and intuitive instrument motion. However, the robotic system does have its own hurdles to overcome, such as complete lack of tactile feedback and a learning curve regarding the syncopation of the surgeon's console. In addition, much like life in general, the only thing constant about laparoscopic and robotic surgery is change. It is therefore necessary for minimally invasive surgeons, no matter how experienced, to master new skills and familiarize themselves with new technologies as they develop. With an ever-increasing emphasis on patient safety and operating room efficiency, new surgical skills and techniques should be developed and honed outside the operating room and then transferred into the operating room once proficiency has been developed. The tools and systems available for practicing and acquiring laparoscopic and robotic skills are detailed here.

Equipment for Practicing Laparoscopic and Robotic Surgery

A wide variety of practice models exist for laparoscopic and robotic surgery, ranging from inanimate laparoscopic training boxes to live animal and human cadaveric models. There has also been heightened interest in the development of computer-driven VR trainers that can be used to practice standard techniques and whole procedures. As a general premise, nonliving models should be used unless it is absolutely essential to have a live model.

Laparoscopic Training Boxes

The items necessary for a basic laparoscopic training box are a box with an opaque top that is suitable for placement of laparoscopic ports and a vision system consisting of a video monitor, a light source, and a camera or camera-lens combination (Fig. 14.31). Several commercially available training boxes are available, but the shortcomings are their high costs and limited access because they are often located in dedicated training facilities. However, with the widespread availability of mobile technology platforms and cost effectiveness of 3D printing, alternative options such as the iTrainer exist (Ruparel et al., 2014; Yoon et al., 2015). In general, the instruments and camera should be configured in a triangular fashion so that the camera lies between the right- and left-hand instruments. For optimal ergonomic positioning, the angle formed between the camera and the right- and left-hand instruments should be 25 to 45 degrees. In addition, the angle between the instruments and the horizontal plane should be less than 55 degrees (Frede et al., 1999). Some more formal training boxes have built-in camera holders so that one person can practice alone without the assistance of a "camera driver." When possible, however, a camera driver can adjust the lens and camera in, out, up, and down to match the motions of the surgeon. This is most helpful during more delicate maneuvers such as suturing in which panning the view from wide to close-up is essential. This gives the assistant the opportunity to practice "driving camera," which is also an essential skill for laparoscopy. Necessary instruments may include laparoscopic graspers, scissors, and dissectors or essentially any instrument necessary to meet the requirements of the training drill. Practice for basic suturing requires a pair of laparoscopic needle drivers and some suture. A 3-0 suture on an SH (small half) needle is best for general practice.



FIG. 14.31 Example of a standard laparoscopic training box with a monitor, camera-lens combination, and light source.

Whether simple or complex, inanimate training models can be placed within standard training boxes and act as the basis for general skill acquisition and progression. Training models for basic tasks such as touching areas of the box at different depths and heights within space, passing objects between instruments and through and around obstacles, and other helpful maneuvers such as cutting and tissue manipulation can be constructed from common materials such as paper, sponges, rubber gloves or tubing, and other commonly found materials. Alternatively, a variety of commercially available models are more realistic looking and may mimic actual operative scenarios more closely (eFig. 14.32).

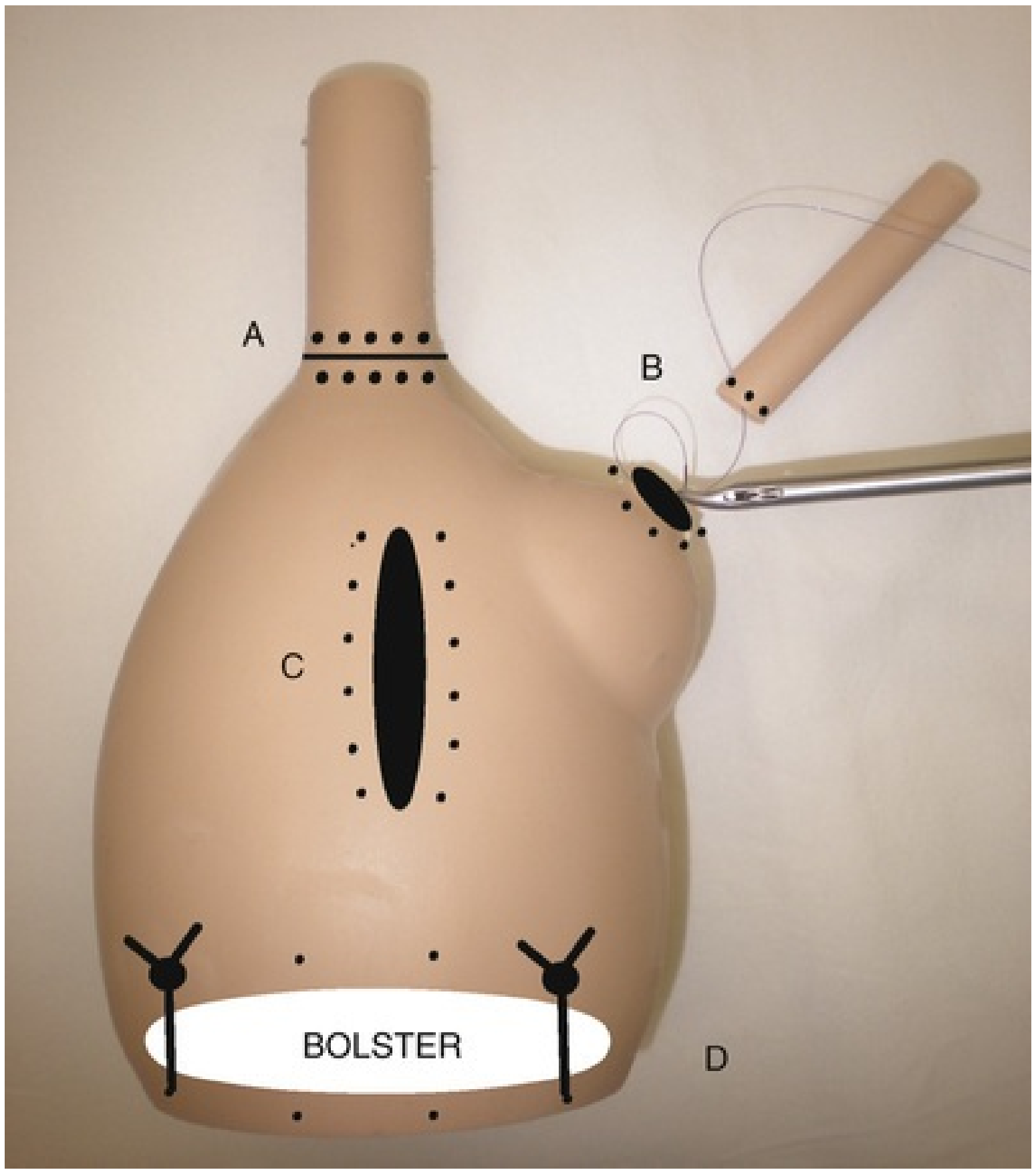

EFIG. 14.32 Example of a task-specific training model LapED (4-in-1) model. This model can be used to practice four different urology-specific tasks: *A,* vesicourethral anastomosis; *B,* dismembered pyeloplasty anastomosis; *C,* closure of cystotomy; and *D,* renorrhaphy. (From Abraham JB, Abdelshehid CS, Lee HJ, et al.: LapED 4-in-1 silicone training aid for practicing laparoscopic skills and tasks: a preliminary evaluation. *J Endourol* 22:1351–1357, 2008.)

Alternatively, nonliving animal tissue can be placed within the box trainer for skill acquisition exercises. The advantage of using real, but nonliving, animal tissue to construct training models is that it creates a more realistic environment providing closer-to-life tissue handling. Generally the tissues used are inexpensive and can be purchased at a butcher shop or market. The disadvantage is that it requires more intense cleanup after practice. Generally the field inside the training box is set up to mimic a specific surgical scenario and develop specific skills. For instance, the stomach and esophagus of a chicken can be divided and then sewn back together laparoscopically to practice the fashioning of a vesicourethral anastomosis or pyeloplasty (Laguna et al., 2006; Ramachandran et al., 2008).

Live Animal Models.

The obvious advantage of use of live animal models is the opportunity to train under more realistic conditions, including more accurate anatomic relationships of tissue and the necessity for hemostasis that does not exist with inanimate models. The disadvantages of use of live animal models are that it requires extensive resources such as a veterinary facility, personnel to care for and provide anesthesia for the animals, and, eventually, euthanasia of the animals. Obviously this can be quite costly. For these reasons, practicing surgical skills on live animals is not appropriate for daily practice. Instead, these opportunities are usually reserved for formal training courses or when the need for a realistic environment warrants the necessary resources. In general, the species of animal used for practice must have a sufficient peritoneal compartment to provide an adequate working space. For fine procedures, animals as small as rabbits can be used. Swine are the most common animals used for laparoscopic and robotic training because they are readily available, they have the appropriate size peritoneal compartment, and their anatomy mimics relatively well that of humans. However, the amount of bleeding that comes from a pig kidney (e.g., in partial nephrectomy) is not realistic compared with that of a human. In addition, the porcine bladder is almost completely intraperitoneal.

Cadaveric Models.

One of the first experiences most medical students have in their training is anatomy, and this entails cadaveric dissection. The reason is simple. Short of operating on real patients, there is no better or more realistic way to learn human anatomy. This holds true for surgical practice as well: however, because of the major resources necessary to have an anatomic gift program and the significantly high cost for a cadaver compared with alternative models, it is often not practical to use cadavers. If, however, facilities and funding are available and there is a need for practicing a procedure in the most realistic environment, there is no substitute for cadaveric models.

Virtual Reality Trainers

VR trainers are computer-based simulators that offer the opportunity to practice laparoscopic and robotic skills through specific tasks, as well as whole procedures. Typically, trainees view the computer-generated operative field or training drill on a computer monitor and perform tasks using laparoscopic manipulators. The instruments are depicted on the viewer and correspond with the trainee's movements. A major advantage of VR trainers is that they can collect information regarding trainee performance and track progress over time in terms of precision, economy of motion, and other parameters of interest. Because the trainers are computer based, it is possible to develop training programs and curricula including didactics, videos, and live practice sessions. The trainee can progress through the curriculum based on performance. VR trainers have been shown to improve the skills of trainees, helping to prepare them for better performance during live surgery (Lucas et al., 2008; Seymour et al., 2002). In addition, a systematic review demonstrated that VR training appears to decrease the operating time and improve the operative performance of surgical trainees with limited laparoscopic experience when compared with no training or with box-trainer training (Nagendran et al., 2013). Several commercially produced VR trainers for robotics, laparoscopy, and even single port surgery are available (eFig. 14.33 shows an example) but are costly as a result of the advanced technology and software development necessary. The VR robotic trainers have been shown to have face, content, and construct validity (Abboudi et al., 2013). A recent observational study analyzing the European Urology hands-on-training courses in VR simulation found that benchmark scores derived from expert performances offer relevant and challenging scores for trainees to achieve during VR simulation and can be a useful educational tactic in residency training programs (Raison et al., 2017).

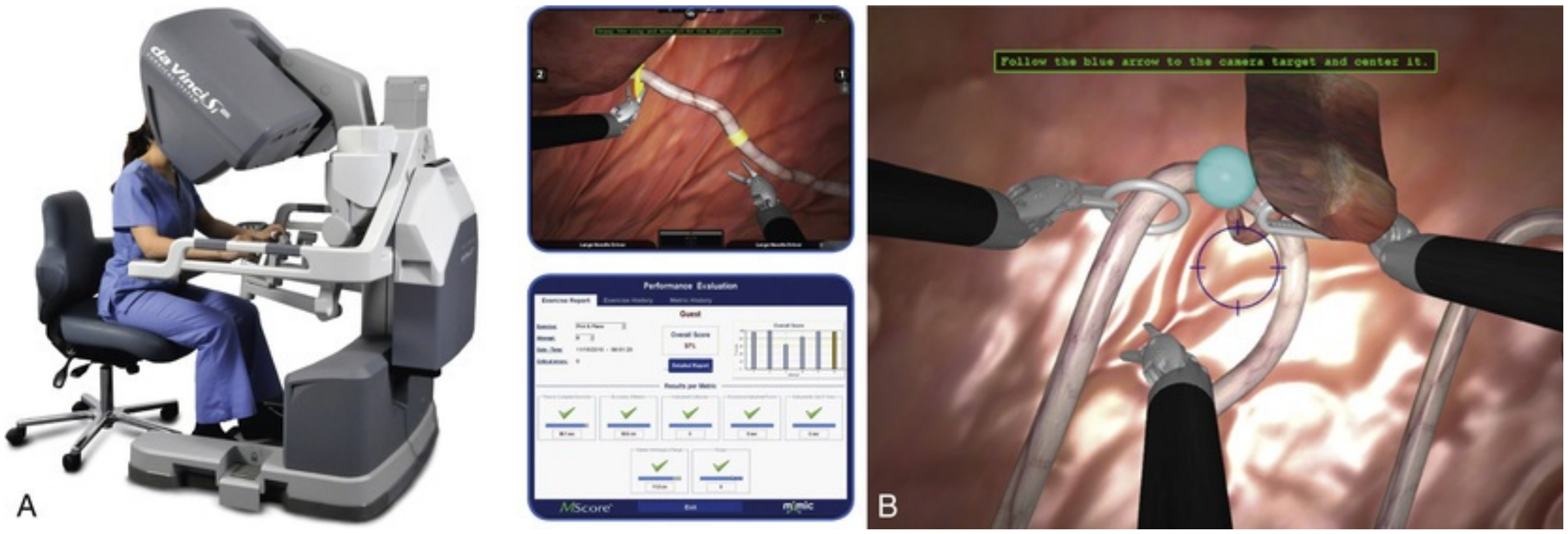

EFIG. 14.33 da Vinci Skills Simulator. (Copyright 2015 Intuitive Surgical, Inc. Used with permission.)

Formal Training Programs

Surgical competence is defined by technical and nontechnical skills (Hoznek et al., 2006). Traditionally these skills have been passed down from teacher to apprentice in the process of caring for and operating on real patients during residency training. The technical skills were taught during real operative procedures, and the nontechnical skills such as surgical judgment, problem anticipation and avoidance, and economy of motion, were gained by experience of the trainee with supervision from a more senior instructor. In this way, traditional residency programs have been more “learning” programs than “teaching” programs. With ever-increasing emphasis being placed on patient safety, operating room efficiency, and cost containment, there has been a great interest in evaluating the efficacy of formal training programs in laparoscopic and robotic surgery. Such programs offer the opportunity to receive formal instruction in a safe, stress-free environment with the intention of honing technical and nontechnical skills.

With this concept in mind, one method of concentrated instruction and skill acquisition is the “mini-residency” or “mini-fellowship.” In this training model, surgeons spend a period of several days (typically 5 days) receiving concentrated instruction on a given set of surgical skills or procedures, including didactic sessions, clinical case observation, and laboratory training using inanimate and animate models. Typically, the attendees also gain access to expert proctors during their initial learning curve for the new procedure. Mini-residency training has been shown to be effective in helping postgraduate urologists incorporate new laparoscopic and robotic procedures into their clinical practices. In one study of laparoscopic renal surgery mini-fellowship trainees at the University of California, Irvine, 73% of attendees were performing laparoscopic renal surgery 3 years later (Kolla et al., 2010). This was also found with robotic surgical training: of 47 urologists who took a 5-day training course for robotic radical prostatectomy, 90% were performing the procedure in their own practice at 3-year follow-up (Gamboa et al., 2009).

Key Points: Training and Practicing Laparoscopic and Robotic Surgery

- Laparoscopic VR trainers have been shown to improve the skills of trainees, helping to prepare them for better performance during live surgery.
- VR robotic trainers have been shown to have face, content, and construct

validity.

Conclusion

Laparoscopic procedures unthinkable in early 1990 are now performed routinely. Furthermore, the use of a robotic surgical platform to perform complex reconstructive procedures is improving the precision and often the outcomes of these operations and, more important, making it possible for a greater number of urologists to perform high-quality laparoscopic procedures. The widespread adoption of laparoscopy and robotic-assisted laparoscopy highlights the importance of having a detailed and robust understanding of the basics of minimally invasive surgery, including the physiologic effects of the pneumoperitoneum, obtaining access, and managing complications. The benefit will be more proficient laparoscopic and robotic surgeons who can handle any procedure and any complication without the massive incisions of years past and patients treated with a truly minimally invasive technique. Such should be the next step of our surgical path of discovery and evolution. At that point Osler's 20th century admonition, “Diseases that harm require treatments that harm less,” will be truly fulfilled. We are as yet still on the bridge to the future.

Acknowledgment

Special thanks to Dr. Michael Ordon for his previous contributions to this chapter.

Suggested Readings

Antoniou SA, Antoniou GA, et al. Blunt versus bladed trocars in laparoscopic surgery: a systematic review and meta-analysis of randomized trials. *Surg Endosc*. 2013;27(7):2312–2320.

Azhar RA, Bochner B, Catto J, et al. Enhanced recovery after urological surgery: a contemporary systematic review of outcomes, key elements, and research needs. *Eur Urol*. 2016;70(1):176–187.

Bai Y, Pu C, Yuan H, et al. Assessing the impact of barbed suture on vesicourethral anastomosis during minimally invasive radical prostatectomy: a systematic review and meta-analysis. *Urology*. 2015;85(6):1368–1375.

Bishoff JT, Allaf ME, et al. Laparoscopic bowel injury: incidence and clinical presentation. *J Urol*. 1999;161:887–890.

Breda A, Finelli A, et al. Complications of laparoscopic surgery for renal masses: prevention, management, and comparison with the open experience. *Eur Urol*. 2009;55(4):836–850.

Cadeddu JA, Wolfe JS Jr, et al. Complications of laparoscopic procedures after concentrated training in urological laparoscopy. *J Urol*. 2001;166(6):2109–2111.

Fahlenkamp D, Rassweiler J, et al. Complications of laparoscopic procedures in urology: experience with 2,407 procedures at 4 German centers. *J Urol*. 1999;162:765–770.

Frede T, Stock C, et al. Geometry of laparoscopic suturing and knotting techniques. *J Endourol*. 1999;13(3):191–198.

Ghani KR, Sukumar S, et al. Practice patterns and outcomes for open and minimally invasive partial nephrectomy since the introduction of robotic partial nephrectomy: results from the Nationwide Inpatient Sample. *J Urol*. 2014;191(4):907–912.

Landman J, Kerbl K, et al. Evaluation of a vessel sealing system, bipolar electrosurgery, harmonic scalpel, titanium clips, endoscopic gastrointestinal anastomosis vascular staples and sutures for arterial and venous ligation in a porcine model. *J Urol*. 2003;169(2):697–700.

Liu CD, McFadden DW. Laparoscopic port sites do not require fascial closure when nonbladed trocars are used. *Am Surg*. 2000;66(9):853–854.

Montgomery JS, Wolf JS Jr. Venous thrombosis prophylaxis for urological laparoscopy: fractionated heparin versus sequential compression devices. *J Urol*. 2005;173(5):1623–1626.

Orvieto MA, Chien GW, Laven B, et al. Eliminating knot tying during warm ischemia time for laparoscopic partial nephrectomy. *J Urol*. 2004;172(6 Pt 1):2292–2295.

Parsons JK, Varkarakis I, Rha KH, et al. Complications of abdominal urologic laparoscopy: longitudinal five-year analysis. *Urology*. 2004;63(1):27–32.

Patel VR, Palmer KJ, Coughlin G, et al. Robot-assisted laparoscopic radical prostatectomy: perioperative outcomes of 1500 cases. *J Endourol*. 2008;22(10):2299–2305.

Pearle M. *Physiologic effects of pneumoperitoneum*. Quality Medical Publishing: St. Louis; 1996.

Pempongkosol S, Link RE, et al. Complications of 2,775 urological laparoscopic procedures: 1993 to 2005. *J Urol*. 2007;177(2):580–585.

Ponsky L, Cherullo E, et al. The Hem-o-lok clip is safe for laparoscopic nephrectomy: a multi-institutional review. *Urology*. 2008;71(4):593–596.

Secin FP, Jiborn T, et al. Multi-institutional study of symptomatic deep venous thrombosis and pulmonary embolism in prostate cancer patients undergoing laparoscopic or robot-assisted laparoscopic radical prostatectomy. *Eur Urol*. 2008;53(1):134–145.

Vallancien G, Cathelineau X, et al. Complications of transperitoneal laparoscopic surgery in urology: review of 1,311 procedures at a single center. *J Urol*. 2002;168(1):23–26.

Wolf JS. Tips and tricks for hand-assisted laparoscopy. *AUA Update Ser*. 2005;24(2):10–15.

Wolf JS, Stoller M. The physiology of laparoscopy: basic principles, complications and other considerations. *J Urol*. 1994;152:294–302.

References

Abbou CC, Cicco D, et al. Retroperitoneal laparoscopic versus open radical nephrectomy. *J Urol*. 1999;161:1776–1780.

Abboudi H, Khan MS, et al. Current status of validation for robotic surgery simulators—a systematic review. *BJU Int*. 2013;111(2):194–205.

Abdel-Meguid T, Gomella L. *Prevention and management of complications*. Quality Medical Publishing: St. Louis; 1996.

Aboumarzouk OM, Stein RJ, et al. Laparoscopic partial nephrectomy in obese patients: a systematic review and meta-analysis. *BJU Int*. 2012;110(9):1244–1250.

Abreu SC, Sharp DS, et al. Thoracic complications during urological laparoscopy. *J Urol*. 2004;171(4):1451–1455.

Adams J, Moore R, et al. Laparoscopic genitourinary surgery utilizing 20 mm Hg intra-abdominal pressure. *J Laparoendosc Adv Surg Tech A*. 1999;9:131–134.

Adams JB, Micali S, et al. Complications of extraperitoneal balloon dilation. *J Endourol*. 1996;10(4):375–378.

Adams JB, Schulam PG, et al. New laparoscopic suturing device: initial clinical experience. *Urology*. 1995;46:242–245.

Ahlering TE, Eichel L, et al. Robotic radical prostatectomy: a technique to reduce pT2 positive margins. *Urology*. 2004;64(6):1224–1228.

Ahlering TE, Eichel L, et al. Impact of obesity on clinical outcomes in robotic prostatectomy. *Urology*. 2005;65(4):740–744.

Alexander G, Noe F, et al. Anesthesia for pelvic laparoscopy. *Anesth Analg*. 1969;48:14–18.

Amaral J, Chrotstek C. Experimental comparison of the ultrasonically-activated scalpel to electrosurgery and laser surgery for laparoscopic use. *Minim Invasive Ther Allied*

Technol. 1997;6:324–331.

Ames C, Perrone JM, et al. Holding strength of suture anchors for hepatic and renal parenchyma. *J Endourol*. 2005;19(10):1221–1225.

Anast JW, Stoller ML, et al. Differences in complications and outcomes for obese patients undergoing laparoscopic radical, partial or simple nephrectomy. *J Urol*. 2004;172(6 Pt 1):2287–2291.

Aneman A, Svensson M, et al. Intestinal perfusion during pneumoperitoneum with carbon dioxide, nitrogen, and nitric oxide during laparoscopic surgery. *Eur J Surg*. 2000;166(1):70–76.

Antoniou SA, Antoniou GA, et al. Blunt versus bladed trocars in laparoscopic surgery: a systematic review and meta-analysis of randomized trials. *Surg Endosc*. 2013;27(7):2312–2320.

Arthur H. Laparoscopy hazard. *BMJ*. 1970;4:492–493.

Azhar RA, Bochner B, Catto J, et al. Enhanced recovery after urological surgery: a contemporary systematic review of outcomes, key elements, and research needs. *Eur Urol*. 2016;70(1):176–187.

Badger WJ, Gallagher BL, et al. Hurdles to helium gas laparoscopy and a readily available alternative. *J Endourol*. 2008;22(11):2455–2459.

Bai Y, Pu C, Yuan H, et al. Assessing the impact of barbed suture on vesicourethral anastomosis during minimally invasive radical prostatectomy: a systematic review and meta-analysis. *Urology*. 2015;85(6):1368–1375.

Bailey SH, Mone MC, et al. Laparoscopic treatment of post renal transplant lymphoceles. *Surg Endosc*. 2003;17:1896–1899.

Baumann H, Jaeger P, et al. Ureteral injury after laparoscopic tubal sterilization by bipolar electrocoagulation. *Obstet*

Gynecol. 1988;71:483–485.

Bhoyrul S, Payne J, et al. A randomized prospective study of radially expanding trocars in laparoscopic surgery. *J Gastrointest Surg*. 2000;4(4):392–397.

Bishoff JT, Allaf ME, et al. Laparoscopic bowel injury: incidence and clinical presentation. *J Urol*. 1999;161:887–890.

Boike GM, Miller CE, et al. Incisional bowel herniations after operative laparoscopy: a series of nineteen cases and review of the literature. *Am J Obstet Gynecol*. 1995;172(6):1726–1731 [discussion 1731–3].

Bolla G, Tuzzato G. Immunologic postoperative competence after laparoscopy versus laparotomy. *Surg Endosc*. 2003;17(8):1247–1250.

Bongard F, Planim M, et al. Using helium for insufflation during laparoscopy. *JAMA*. 1991;266(3131).

Bonjer HJ, Hazebroek EJ, et al. Open versus closed establishment of pneumoperitoneum in laparoscopic surgery. *Br J Surg*. 1997;84(5):599–602.

Box GN, Lee HJ, et al. Comparative study of in vivo lymphatic sealing capability of the porcine thoracic duct using laparoscopic dissection devices. *J Urol*. 2009;181(1):387–391.

Brackman MR, Finelli FC, et al. Helium pneumoperitoneum ameliorates hypercarbia and acidosis associated with carbon dioxide insufflation during laparoscopic gastric bypass in pigs. *Obes Surg*. 2003;13(5):768–771.

Breda A, Finelli A, et al. Complications of laparoscopic surgery for renal masses: prevention, management, and comparison with the open experience. *Eur Urol*. 2009;55(4):836–850.

Brooks P. New laparoscopic retractors. *J Am Assoc Gynecol Laparosc*. 1993;1:60–61.

Brown JA, Chenven E, et al. Hand-assisted laparoscopic nephroureterectomy (HALNU): an assessment of the impact of obesity in 50 procedures. *J Laparoendosc Adv Surg Tech A*. 2008;18(1):61–68.

Brown SL, Woo EK. Surgical stapler-associated fatalities and adverse events reported to the Food and Drug Administration. *J Am Coll Surg*. 2004;199(3):374–381.

Brown SR, Goodfellow PB. Transverse versus midline incisions for abdominal surgery. *Cochrane Database Syst Rev*. 2005;(4) [CD005199].

Bucur P, Hofmann M, Menhadji A, et al. Comparison of pneumoperitoneum stability between a valveless trocar system and conventional insufflation: a prospective randomized trial. *Urology*. 2016;94:274–280.

Cadeddu J, Chan D, et al. Retroperitoneal access for transperitoneal laparoscopy in patients at high risk for intra-abdominal scarring. *J Endourol*. 1999;13:567–571.

Cadeddu JA, Wolfe JS Jr, et al. Complications of laparoscopic procedures after concentrated training in urological laparoscopy. *J Urol*. 2001;166(6):2109–2111.

Caldwell C, Ricotta J. Changes in visceral blood flow with elevated intra-abdominal pressure. *J Surg Res*. 1987;43:14–20.

Capan L, Miller S. Perioperative embolic complications. Benumof JL, Saidman LJ. *Anesthesia and perioperative complications*. ed 2. Mosby: St Louis; 1999:685–738.

Carbonell AM, Joels CS, et al. A comparison of laparoscopic bipolar vessel sealing devices in the hemostasis of small-, medium-, and large-sized arteries. *J Laparoendosc Adv Surg Tech A*. 2003;13(6):377–380.

Carey RI, Leveillee RJ. Patient positioning for robotic urologic procedures. Patel VR. *Robotic urologic surgery*. Springer: London; 2007:61–66.

Carter J. A new technique of fascial closure for laparoscopic incisions. *J Laparoendosc Surg*. 1994;4:143–148.

Chen RN, Moore RG, et al. Laparoscopic pyeloplasty. Indications, technique, and long-term outcome. *Urol Clin North Am*. 1998;25(2):323–330.

Chiu A, Azadzoi K, et al. Effects of intra-abdominal pressure on renal tissue perfusion during laparoscopy. *J Endourol*. 1994;8:99–103.

Chiu A, Chen K, et al. Direct needle insufflation for pneumoretroperitoneum: anatomic confirmation and clinical experience. *Urology*. 1995;46:432–437.

Chung HJ, Meng MV, et al. Upper quadrant access for urologic laparoscopy. *Urology*. 2003;62(6):1117–1119.

Clagett P, Anderson F, et al. Prevention of venous thromboembolism. *Chest*. 1995;108:312.

Cochrane J, Forsling M, et al. Arginine vasopressin release following surgical operations. *Br J Surg*. 1981;68:209–213.

Collins J. Inert gas exchange of subcutaneous and intraperitoneal gas pockets in piglets. *Respir Physiol*. 1981;46:391–404.

Colombo JR, Haber GP, et al. Laparoscopic partial nephrectomy in obese patients. *Urology*. 2007;69(1):44–48.

Cooper CS, Cohen MB, et al. Splenectomy complicating left nephrectomy. *J Urol*. 1996;155(1):30–36.

Cooper CS, Donovan JF, et al. Hip and knee replacement as a relative contraindication to laparoscopic pelvic lymph node dissection. *J Urol*. 1997;158(1):128–130.

Cooper G, Scoggins A, et al. Laparoscopy—a stressful procedure. *Anesthesia*. 1982;37:266–269.

Corica FA, Boker JR, et al. Short-term impact of a laparoscopic mini-residency experience on postgraduate urologists' practice patterns. *J Am Coll Surg*. 2006;203(5):692–698.

Crabtree J, Fishman A. Videoscopic surgery under local and regional anesthesia with helium abdominal insufflation. *Surg*

Endosc. 1999;13:1035–1039.

Cristaldi M, Rovati M, et al. Lymphocytic subpopulation changes after open and laparoscopic cholecystectomy: a prospective and comparative study on 38 patients. *Surg Laparosc Endosc*. 1997;3:255–261.

Dahn S, Schwalbach P, et al. Influence of different gases used for laparoscopy (helium, carbon dioxide, room air, and xenon) on tumor volume, histomorphology, and leukocyte-tumor-endothelium interaction in intravital microscopy. *Surg Endosc*. 2005;19(1):65–70.

Deane LA, Lee HJ, et al. Third place: flank position is associated with higher skin-to-surface interface pressures in men versus women: implications for laparoscopic renal surgery and the risk of rhabdomyolysis. *J Endourol*. 2008;22(6):1147–1151.

Derossis A, Bothwell J, et al. The effect of practice on performance in a laparoscopic simulator. *Surg Endosc*. 1998;12:1117–1120.

Diakun T. Carbon dioxide embolism: successful resuscitation with cardiopulmonary bypass. *Anesthesiology*. 1991;74:1151–1153.

Diamant M, Benumof J, et al. Hemodynamics of increased intra-abdominal pressure: interaction with hypovolemia and halothane anesthesia. *Anesthesiology*. 1978;48:23–27.

Doctor N, Hussain Z. Bilateral pneumothorax associated with laparoscopy. *Anesthesia*. 1973;28:75–81.

Doyle D, Mark P. Laparoscopy and vagal arrest. *Anesthesia*. 1989;44:448.

Duffey B. Regurgitation during pelvic laparoscopy. *Br J Anaesth*. 1979;51:1089–1090.

Dunn MD, Portis AJ, et al. Laparoscopic versus open radical nephrectomy: a 9-year experience. *J Urol*. 2000;164:1153–1159.

Eichel L, Abdelshehid C, et al. In vitro comparison of burst tension and puncture pressure in commonly used organ retrieval bags. *J Am Coll Surg*. 2004;199(1):166–169.

Ekman L, Abrahamsson J, et al. Hemodynamic changes during laparoscopy with positive end-expiratory pressure ventilation. *Acta Anaesth Scand*. 1988;32:447–453.

Elashry O, Wolf JJ, et al. Comparative clinical study of port closure techniques following laparoscopic surgery. *J Am Coll Surg*. 1996;183:335–344.

El-Minawi M, Wahbi O, et al. Physiologic changes during CO_2 and N_2O pneumoperitoneum in diagnostic laparoscopy. *J Reprod Med*. 1981;26:338–346.

Erdogru T, Teber D, et al. Comparison of transperitoneal and extraperitoneal laparoscopic radical prostatectomy using match-pair analysis. *Eur Urol*. 2004;46(3):312–319 [discussion 320].

Fahlenkamp D, Rassweiler J, et al. Complications of laparoscopic procedures in urology: experience with 2,407 procedures at 4 German centers. *J Urol*. 1999;162:765–770.

Falabella A, Moore-Jeffries E, et al. Cardiac function during steep Trendelenburg position and CO_2 pneumoperitoneum for robotic-assisted prostatectomy: a trans-oesophageal Doppler probe study. *Int J Med Robot*. 2007;3(4):312–315.

Fazeli-Matin S, Gill I, et al. Laparoscopic renal and adrenal surgery in obese patients: comparison to open surgery. *J Urol*. 1999;162:665–669.

Fearon KC, Ljungqvist O, Von Meyenfeldt M, et al. Enhanced recovery after surgery: a consensus review of clinical care for patients undergoing colonic resection. *Clin Nutr*. 2005;24(3):466–477.

Fentie DD, Barrett PH, et al. Metastatic renal cell cancer after laparoscopic radical nephrectomy: long-term follow-up. *J Endourol*. 2000;14(5):407–411.

Fischer CP, Bochicchio G, Shen J, et al. A prospective, randomized, controlled trial of the efficacy and safety of fibrin pad as an adjunct to control soft tissue bleeding during abdominal, retroperitoneal, pelvic, and thoracic surgery. *J Am Coll Surg*. 2013;217(3):385–393.

Fischer J. The metabolic response to laparoscopic cholecystectomy. *Ann Surg*. 1995;221:211–213.

Fitzgerald S, Andrus C, et al. Hypercarbia during carbon dioxide pneumoperitoneum. *Am J Surg*. 1992;163:186–190.

Frede T, Stock C, et al. Geometry of laparoscopic suturing and knotting techniques. *J Endourol*. 1999;13(3):191–198.

Friedman AL, Peters TG, et al. Fatal and nonfatal hemorrhagic complications of living kidney donation. *Ann Surg*. 2006;243(1):126–130.

Fugita OE, Chan DY, et al. Laparoscopic radical nephrectomy in obese patients: outcomes and technical considerations. *Urology*. 2004;63(2):247–252 [discussion 252].

Gamboa AJ, Santos RT, et al. Long-term impact of a robot assisted laparoscopic prostatectomy mini fellowship training program on postgraduate urological practice patterns. *J Urol*. 2009;181(2):778–782.

Garzotto M, Newman R, et al. Closure of laparoscopic trocar sites using a spring-loaded needle. *J Urol*. 1995;45:310–312.

Gaur D. Laparoscopic operative retroperitoneoscopy: use of a new device. *J Urol*. 1992;148:1137–1139.

Geers J, Holden C. Major vascular injury as a complication of laparoscopic surgery: a report of three cases and review of the literature. *Am Surg*. 1996;62:377–379.

Ghani KR, Sukumar S, et al. Practice patterns and outcomes for open and minimally invasive partial nephrectomy since the introduction of robotic partial nephrectomy: results from the Nationwide Inpatient Sample. *J Urol*. 2014;191:907–912.

Giebler R, Kabatnik M, et al. Retroperitoneal and intraperitoneal CO_2 insufflation have markedly different cardiovascular effects. *J Surg Res*. 1997;68:153–160.

Gill IS. Retroperitoneal laparoscopic nephrectomy. *Urol Clin North Am*. 1998;25:343–360.

Gill IS, Munch L, et al. Retroperitoneal laparoscopic nephroureterectomy: double-balloon technique. *Urology*. 1995;46:747–750.

Gill IS, Schweizer D, et al. Retroperitoneal laparoscopic radical nephrectomy: the Cleveland Clinic experience. *J Urol*. 2000;163:1665–1670.

Glascock J, Winfield H, et al. Carbon dioxide homeostasis during transperitoneal or extraperitoneal laparoscopic pelvic lymphadenopathy: a real-intraoperative comparison. *J Endourol*. 1996;10:319–323.

Glerup H, Heindorff H, et al. Elective laparoscopic cholecystectomy nearly abolishes the postoperative hepatic catabolic stress response. *Ann Surg*. 1995;221:214–219.

Gofrit ON, Mikahail AA, et al. Surgeons' perceptions and injuries during and after urologic laparoscopic surgery. *Urology*. 2008;71(3):404–407.

Goitein D, Papasavas P, et al. Microsphere intestinal blood flow analysis during pneumoperitoneum using carbon dioxide and helium. *Surg Endosc*. 2005;19(4):541–545.

Gossot D, Buess A, et al. Ultrasonic dissection for endoscopic surgery. *Surg Endosc*. 1999;13:412–417.

Grainger D, Soderstrom R, et al. Ureteral injuries at laparoscopy: insights into diagnosis, management, and prevention. *Obstet Gynecol*. 1990;75:839–843.

Guillonneau B, Rozet F, et al. Perioperative complications of laparoscopic radical prostatectomy: the Montsouris 3-year experience. *J Urol*. 2002;167(1):51–56.

Guillonneau B, Vallancien G. Laparoscopic radical prostatectomy: the Montsouris experience. *J Urol*.

2000;163(2):418–422.

Halevy A, Kais H, et al. Continuous esophageal pH monitoring during laparoscopic cholecystectomy. *Surg Endosc*. 1994;8:1294–1296.

Halm JA, Lip H, et al. Incisional hernia after upper abdominal surgery: a randomized controlled trial of midline versus transverse incision. *Hernia*. 2009;13:275–280.

Hanley E. Anesthesia for laparoscopic surgery. *Surg Clin North Am*. 1992;72:1013–1019.

Hanney R, Alle K, et al. Major vascular injury and laparoscopy. *Aust N Z J Surg*. 1995;65:533–535.

Hanney R, Carmalt H, et al. Use of the Hasson cannula producing major vascular injury at laparoscopy. *Surg Endosc*. 1999;13:1238–1240.

Harmann P, Kron I, et al. Elevated intra-abdominal pressure and renal function. *Ann Surg*. 1982;196:594–597.

Harris M, Plantevin O, et al. Cardiac arrhythmias during anesthesia for laparoscopy. *Br J Anaesth*. 1984;56:1213–1217.

Hashad MM, Atta M, et al. Safety of no bowel preparation before ileal urinary diversion. *BJU Int*. 2012;110(11 Pt C):E1109–E1113.

Hashikura Y, Kawasaki S, et al. Effects of peritoneal insufflation on hepatic and renal blood flow. *Surg Endosc*. 1994;8:759–761.

Hashizume M, Sugimachi K. Needle and trocar injury during laparoscopic surgery in Japan. *Surg Endosc*. 1997;11(12):1198–1201.

Hazebroek EJ, Haitsma JJ, et al. Mechanical ventilation with positive end-expiratory pressure preserves arterial oxygenation during prolonged pneumoperitoneum. *Surg Endosc*. 2002;16(4):685–689.

He B, Mitchell A, et al. Laparoscopic donor nephrectomy. *Aust*

N Z J Surg. 2011;81(3):159–163.

Hershlag A, Loy R, et al. Femoral neuropathy after laparoscopy. *J Reprod Med*. 1990;35:575–576.

Hoznek A, Salomon L, et al. Simulation training in video-assisted urologic surgery. *Curr Urol Rep*. 2006;7(2):107–113.

Isac WE, Autorino R, et al. The impact of body mass index on surgical outcomes of robotic partial nephrectomy. *BJU Int*. 2012;110(11 Pt C):E997–E1002.

Ishizaki Y, Bandai Y, et al. Safe intra-abdominal pressure of carbon dioxide pneumoperitoneum during laparoscopic surgery. *Surgery*. 1993;114:549–554.

Ivankovich A, Miletich D, et al. Cardiovascular effects of intraperitoneal insufflation with carbon dioxide and nitrous oxide in the dog. *Anesthesiology*. 1975;42:281–287.

Iwamura M, Tsumura H, et al. Port site recurrence of renal cell carcinoma following retroperitoneoscopic radical nephrectomy with manual extraction without using entrapment sac or wound protector. *J Urol*. 2004;171(3):1234–1235.

Jacobi C, Ordemann J, et al. Impact of laparoscopy with carbon dioxide versus helium on local and systemic inflammation in an animal model of peritonitis. *J Laparoendosc Adv Surg Tech*. 1999;3:305–312.

Jacobi C, Sabat R, et al. Pneumoperitoneum with CO_2 stimulates malignant colonic cells. *Surgery*. 1997;121:72–78.

Jakeways M, Mitchell V, et al. Metabolic and inflammatory responses after open or laparoscopic cholecystectomy. *Br J Surg*. 1994;81:127–131.

Jeschke K, Wakonig J, et al. Laparoscopic radical nephrectomy: a single-center experience of 51 cases. *Tech Urol*. 2000;6:9–11.

Jhaveri JK, Penna FJ, Diaz-Insua M, et al. Ureteral injuries sustained during robot-assisted radical prostatectomy. *J*

Endourol. 2014;28(3):318–324.

Johar RS, Hayn MH, Stegemann AP, et al. Complications after robot-assisted radical cystectomy: results from the International Robotic Cystectomy Consortium. *Eur Urol*. 2013;64(1):52–57.

Jorgensen J, Hanel K, et al. Thromboembolic complications of laparoscopic cholecystectomy. *BMJ*. 1993;306:518–519.

Joris J, Noirot D, et al. Hemodynamic changes during laparoscopic cholecystectomy. *Anesth Analg*. 1993;76:1067–1071.

Kalhan S, Reaney J, et al. Pneumomediastinum and subcutaneous emphysema during laparoscopy. *Cleve Clin J Med*. 1990;47:639–642.

Kang D, Woo SH, et al. Incidence of port-site hernias after robot-assisted radical prostatectomy with the fascial closure of only the midline 12-mm port site. *J Endourol*. 2012;26(7):848–851.

Kaouk JH, Goel RK, Haber GP, et al. Robotic single-port transumbilical surgery in humans: initial report. *BJU Int*. 2009;103(3):366–369.

Kaouk JH, Hafron J, et al. Is retroperitoneal approach feasible for robotic dismembered pyeloplasty: initial experience and long-term results. *J Endourol*. 2008;22(9):2153–2159.

Kapoor A, Nassir A, et al. Comparison of laparoscopic radical renal surgery in morbidly obese and non-obese patients. *J Endourol*. 2004;18(7):657–660.

Karayiannakis A, Makri G, et al. Systemic stress response after laparoscopic or open cholecystectomy: a randomized trial. *Br J Surg*. 1997;84:467–471.

Kashtan J, Green J, et al. Hemodynamic effects of increased abdominal pressure. *J Surg Res*. 1981;30:249–255.

Kavoussi L, Sosa E, et al. Complications of laparoscopic pelvic lymph node dissection. *J Urol*. 1993;149:322–325.

Keith L, Silver A, et al. Anesthesia for laparoscopy. *J Reprod Med*. 1974;12:227–233.

Kelman G, Swapp GH, et al. Cardiac output and arterial blood-gas tension during laparoscopy. *Br J Anaesth*. 1972;44:1155–1162.

Kemen M, Bein N, et al. Postoperative small intestinal motility after abdominal surgery. *Infusionstherapie*. 1991;18:233–235.

Kerbl K, Figenshau RS, et al. Retroperitoneal laparoscopic nephrectomy: laboratory and clinical experience. *J Endourol*. 1993;7(1):23–26.

Kim FJ, Chammas MF Jr, et al. Temperature safety profile of laparoscopic devices: Harmonic ACE (ACE), LigaSure V (LV), and Plasma Trisector (PT). *Surg Endosc*. 2008;22(6):1464–1469.

Kloosterman T, von Blomberg M, et al. Unimpaired immune function after laparoscopic cholecystectomy. *Surgery*. 1994;115:424–428.

Knos G, Sung Y, et al. Pneumopericardium associated with laparoscopy. *J Clin Anesth*. 1991;3:56–59.

Kolla SB, Gamboa AJ, et al. Impact of a laparoscopic renal surgery mini-fellowship program on postgraduate urologist practice patterns at 3-year followup. *J Urol*. 2010;184(5):2089–2093.

Kouba EJ, Hubbard JS, et al. Incisional hernia in a 12-mm non-bladed trocar site following laparoscopic nephrectomy. *Urol Int*. 2007;79(3):276–279.

Kuang W, Ng CS, et al. Rhabdomyolysis after laparoscopic donor nephrectomy. *Urology*. 2002;60(5):911.

Laguna MP, Arce-Alcazar A, et al. Construct validity of the chicken model in the simulation of laparoscopic radical prostatectomy suture. *J Endourol*. 2006;20(1):69–73.

Lamberton GR, Hsi RS, et al. Prospective comparison of four laparoscopic vessel ligation devices. *J Endourol*.

2008;22(10):2307–2312.

Landman J, Kerbl K, et al. Evaluation of a vessel sealing system, bipolar electrosurgery, harmonic scalpel, titanium clips, endoscopic gastrointestinal anastomosis vascular staples and sutures for arterial and venous ligation in a porcine model. *J Urol*. 2003;169(2):697–700.

Landman J, Olweny E, et al. Prospective comparison of the immunological and stress response following laparoscopic and open surgery for localized renal cell carcinoma. *J Urol*. 2004;171(4):1456–1460.

Landman J, Venkatesh R, et al. Modified renal morcellation for renal cell carcinoma: laboratory experience and early clinical application. *Urology*. 2003;62(4):632–634 [discussion 635].

Large MC, Kiriluk KJ, et al. The impact of mechanical bowel preparation on postoperative complications for patients undergoing cystectomy and urinary diversion. *J Urol*. 2012;188(5):1801–1805.

Lavery HJ, Thaly R, et al. Robotic equipment malfunction during robotic prostatectomy: a multi-institutional study. *J Endourol*. 2008;22(9):2165–2168.

Lee C. Acute hypotension during laparoscopy: a case report. *Anesth Analg*. 1975;54:142–143.

Lefebvre G, Thirion A, et al. Laparoscopic surgery versus laparotomy. Comparative analysis of stress markers. *J Gynecol Obstet Biol Reprod (Paris)*. 1992;21:507–511.

Lehtinen A, Laatikainen T, et al. Modifying effects of epidural analgesia or general anesthesia on the stress hormone response to laparoscopy for in vitro fertilization. *J In Vitro Fert Embryo Transf*. 1987;4:23–29.

Leibovitch I, Mor Y, et al. The diagnosis and management of postoperative chylous ascites. *J Urol*. 2002;167(2 Pt 1):449–457.

Leighton T, Liu S, et al. Comparative cardiopulmonary effects of carbon dioxide versus helium pneumoperitoneum. *Surgery*. 1993;113:527–531.

Lemanu DP, Singh PP, Stowers MD, et al. A systematic review to assess cost effectiveness of enhanced recovery after surgery programmes in colorectal surgery. *Colorectal Dis*. 2014;16(5):338–346.

Lewis D, Ryder W, et al. Laparoscopy—an investigation during spontaneous ventilation with halothane. *Br J Anaesth*. 1972;44:685–691.

Lin P, Grow D. Complications of laparoscopy. Strategies for prevention and cure. *Obstet Gynecol Clin North Am*. 1999;26:23–38.

Liss M, Skarecky D, et al. Preventing perioperative complications of robotic-assisted radical prostatectomy. *Urology*. 2013;81(2):319–323.

Liu C, Wang P, et al. Ureteral injury after laparoscopic surgery. *J Am Assoc Gynecol Laparosc*. 1997;4:503–506.

Liu CD, McFadden DW. Laparoscopic port sites do not require fascial closure when nonbladed trocars are used. *Am Surg*. 2000;66(9):853–854.

Ljungqvist O, Scott M, Fearon KC. Enhanced recovery after surgery: a review. *JAMA Surg*. 2017;152(3):292–298.

Loffer FD, Pent D. Laparoscopy in the obese patient. *Am J Obstet Gynecol*. 1976;125(1):104–107.

Loris J. *Anesthetic management of laparoscopy*. Churchill Livingstone: New York; 1994.

Lowry PS, Moon TD, et al. Symptomatic port-site hernia associated with a non-bladed trocar after laparoscopic live-donor nephrectomy. *J Endourol*. 2003;17(7):493–494.

Lucas SM, Zeltser IS, et al. Training on a virtual reality laparoscopic simulator improves performance of an unfamiliar live laparoscopic procedure. *J Urol*. 2008;180(6):2588–2591 [discussion 2591].

Madi R, Daignault S, et al. Extraperitoneal v intraperitoneal robotic prostatectomy: analysis of operative outcomes. *J Endourol*. 2007;21(12):1553–1557.

Makarov DV, Kainth D, et al. Physiologic changes during helium insufflation in high-risk patients during laparoscopic renal procedures. *Urology*. 2007;70(1):35–37.

Marshall R, Jebson P, et al. Circulatory effects of carbon dioxide insufflation of the peritoneal cavity for laparoscopy. *Br J Anaesth*. 1972;44:680–684.

McDougall E, Figenshau R, et al. Laparoscopic pneumoperitoneum: impact of body habitus. *J Laparoendosc Surg*. 1994;4:385–391.

McDougall E, Monk T, et al. The effect of prolonged pneumoperitoneum on renal function in an animal model. *J Am Coll Surg*. 1996;182:317–328.

McGrath R, Zimmerman J, et al. Carbon dioxide embolism treated with hyperbaric oxygen. *Can J Anaesth*. 1989;36:586–589.

McKernan J. Extraperitoneal prosthetic inguinal hernia repair using an endoscopic approach. *Int Surg*. 1995;80:26–28.

Meininger D, Byhahn C, et al. Prolonged intraperitoneal versus extraperitoneal insufflation of carbon dioxide in patients undergoing totally endoscopic robot-assisted radical prostatectomy. *Surg Endosc*. 2004;18(5):829–833.

Melville R, Frizis H, et al. The stimulus for vasopressin release during laparoscopy. *Surg Gynecol Obstet*. 1985;161:253–256.

Mendoza D, Newman RC, et al. Laparoscopic complications in markedly obese urologic patients (a multi-institutional review). *Urology*. 1996;48(4):562–567.

Meng MV, Freise CE, et al. Techniques to optimize vascular control during laparoscopic donor nephrectomy. *Urology*. 2003;61(1):93–97 [discussion 97–8].

Meraney A, Gill I. Extraperitoneoscopic pelvic surgery. *AUA*

Update Ser. 2001;20(38):298–303.

Merseburger AS, Herrmann TR, et al. EAU guidelines on robotic and single-site surgery in urology. *Eur Urol*. 2013;64:277–291.

Mertens zur Borg IR, Lim A, et al. Effect of intraabdominal pressure elevation and positioning on hemodynamic responses during carbon dioxide pneumoperitoneum for laparoscopic donor nephrectomy: a prospective controlled clinical study. *Surg Endosc*. 2004;18(6):919–923.

Micali S, Celia A, et al. Tumor seeding in urological laparoscopy: an international survey. *J Urol*. 2004;171(6 Pt 1):2151–2154.

Milsom J, Trencheva K, et al. Evaluation of the safety, efficacy, and versatility of a new surgical energy device (Thunderbeat) in comparison with Harmonic ACE, LigaSure V, and EnSeal devices in a porcine model. *J Laparoendosc Adv Surg Tech A*. 2012;22(4):378–386.

Milsom JW, Trencheva K, Sonoda T, et al. A prospective trial evaluating the clinical performance of a novel surgical energy device in laparoscopic colon surgery. *Surg Endosc*. 2015;29(5):1161–1166.

Minoli G, Terruzi V, et al. The influence of carbon dioxide and nitrous oxide on pain during laparoscopy: a double-blind, controlled trial. *Gastrointest Endosc*. 1982;28:173–175.

Mintz M. Risks and prophylaxis in laparoscopy: a survey of 100,000 cases. *J Reprod Med*. 1977;18:269–272.

Molina WR, Desai MM, et al. Laparoscopic management of chylous ascites after donor nephrectomy. *J Urol*. 2003;170(5):1938.

Monga M, Premoli J, et al. Forearm compression by laparoscopic hand-assist devices. *J Endourol*. 2004;18(7):654–656.

Monk B, Gordon N, et al. Closure of fascial incision made at the time of laparoscopy: development of a device. *J Laparoendosc Surg*. 1994;4:257–259.

Montgomery JS, Wolf JS Jr. Venous thrombosis prophylaxis for urological laparoscopy: fractionated heparin versus sequential compression devices. *J Urol*. 2005;173(5):1623–1626.

Motew M, Ivankovich A, et al. Cardiovascular effects and acid-base and blood gas changes during laparoscopy. *Am J Obstet Gynecol*. 1973;115:1002–1012.

Munro M. Complications of laparoscopic electrosurgery. Ponsky JL. *Complications of endoscopic and laparoscopic surgery*. Lippincott Williams & Wilkins: Philadelphia; 1997:265–284.

Myles P. Bradyarrhythmias and laparoscopy: a prospective study of heart rate changes with laparoscopy. *Aust N Z J Obstet Gynaecol*. 1991;31:171–173.

Nagendran M, Gurusamy KS, et al. Virtual reality training for surgical trainees in laparoscopic surgery. *Cochrane Database Syst Rev*. 2013;(8) [CD006575].

Negoro H, Oka H, et al. Two cases of chyloretroperitoneum following retroperitoneoscopic nephroureterectomy. *Int J Urol*. 2006;13:487–489.

Nelson CP, Wolf JS Jr. Comparison of hand assisted versus standard laparoscopic radical nephrectomy for suspected renal cell carcinoma. *J Urol*. 2002;167(5):1989–1994.

Nelson RJ, Chavali JSS, Yerram N, et al. Current status of robotic single-port surgery. *Urol Ann*. 2017;9(3):217–222.

Neuberger T, Andrus C, et al. Prospective comparison of helium versus carbon dioxide pneumoperitoneum. *Gastrointest Endosc*. 1994;40:30.

Nezhat F, Tazuke S, et al. Laparoscopy during pregnancy: a literature review. *JSLS*. 1997;1:17–27.

Ng C, Gill I, et al. Retroperitoneoscopic surgery is not associated with increased carbon dioxide absorption. *J Urol*.

1999;162:1268–1272.

Nguyen N, Luketich J, et al. Effect of open and laparoscopic surgery on cellular immunity in a swine model. *Surg Laparosc Endosc*. 1999;3:176–180.

O'Connor JP, Biyani CS, et al. Laparoscopic nephrectomy for renal-cell carcinoma during pregnancy. *J Endourol*. 2004;18(9):871–874.

Okhunov Z, Yoon R, et al. *Evaluation and comparison of contemporary energy-based surgical vessel sealing devices*. 2018.

Ono Y, Kinukawa T, et al. Laparoscopic radical nephrectomy for renal cell carcinoma: a five-year experience. *Urology*. 1999;53:280–286.

Ortega I. The Carter-Thomason needle suture passer to correct cannula induced defects and vascular injuries in the abdominal wall during laparoscopy. *J Am Assoc Gynecol Laparosc*. 1996;3(4 Suppl):S37.

Orvieto MA, Chien GW, et al. Eliminating knot tying during warm ischemia time for laparoscopic partial nephrectomy. *J Urol*. 2004;172(6 Pt 1):2292–2295.

Ostrzenski A, Ostrzenska K. Bladder injury during laparoscopic surgery. *Obstet Gynecol Surv*. 1998;53:175–180.

O'Sullivan D, Micali S, et al. Risk of carbon dioxide embolism from laparoscopic venous injuries. *J Urol*. 1997;157:401.

Ott D. Correction of laparoscopic insufflation hypothermia. *J Laparoendosc Surg*. 1991;1:183–186.

Ott D. Laparoscopic hypothermia. *J Laparoendosc Surg*. 1991;127–131.

Palmer R. Safety in laparoscopy. *J Reprod Med*. 1974;13:1–5.

Parker AS, Lewis R, et al. Evaluation of the impact of body mass index on outcome among renal mass patients treated with hand-assisted laparoscopic radical nephrectomy. *J Endourol*. 2008;22(2):301–306.

Parsons JK, Varkarakis I, et al. Complications of abdominal urologic laparoscopy: longitudinal five-year analysis. *Urology*. 2004;63(1):27–32.

Pascual J, Baranda M, et al. Subcutaneous emphysema, pneumomediastinum, bilateral pneumothorax, and pneumopericardium after laparoscopy. *Endoscopy*. 1990;22:59.

Pearle M. *Physiologic effects of pneumoperitoneum*. Quality Medical Publishing: St. Louis; 1996.

Perez J, Taura P, et al. Role of dopamine in renal dysfunction during laparoscopic surgery. *Surg Endosc*. 2002;16(9):1297–1301.

Permpongkosol S, Link RE, et al. Complications of 2,775 urological laparoscopic procedures: 1993 to 2005. *J Urol*. 2007;177(2):580–585.

Phillips JM, Narula N, et al. Histological evaluation of cold versus hot cutting: clinical impact on margin status for laparoscopic partial nephrectomy. *J Urol*. 2008;180(6):2348–2352.

Phong S, Koh L. Anaesthesia for robotic radical prostatectomy: considerations for laparoscopy in Trendelenburg position. *Anaesth Intensive Care*. 2007;35:281–285.

Piechaud PT, Pansadoro A. Transfer of skills from the experimental model to the patients. *Curr Urol Rep*. 2006;7(2):96–99.

Poffenberger R. Laparoscopic repair of intraperitoneal bladder injury: a simple new technique. *Urology*. 1996;47:248–249.

Ponsky L, Cherullo E, et al. The Hem-o-lok clip is safe for laparoscopic nephrectomy: a multi-institutional review. *Urology*. 2008;71(4):593–596.

Prentice J, Martin J. The Trendelenburg position: anesthesiologic considerations. Martin J. *Positioning in anesthesia and surgery*. ed 2. Saunders: Philadelphia;

1987:127–145.

Puri G, Singh H. Ventilatory effects of laparoscopy under general anaesthesia. *Br J Anaesth*. 1992;68:211–213.

Quinlan D, Naslund M, et al. Application of argon beam coagulation in urological surgery. *J Urol*. 1992;147:410–412.

Rademaker B, Bannenberg J, et al. Effects of pneumoperitoneum with helium on hemodynamics and oxygen transport: a comparison with carbon dioxide. *J Laparoendosc Surg*. 1995;1:15–20.

Raison N, Ahmed K, Fossati N, et al. Competency based training in robotic surgery: benchmark scores for virtual reality robotic simulation. *BJU Int*. 2017;119(5):804–811.

Ramachandran A, Kurien A, et al. A novel training model for laparoscopic pyeloplasty using chicken crop. *J Endourol*. 2008;22(4):725–728.

Raman JD, Bagrodia A, et al. Single-incision, umbilical laparoscopic versus conventional laparoscopic nephrectomy: a comparison of perioperative outcomes and short-term measures of convalescence. *Eur Urol*. 2008;55(5):1198–1204.

Raman JD, Bensalah K, Bagrodia A, et al. Laboratory and clinical development of single keyhole umbilical nephrectomy. *Urology*. 2007;70(6):1039–1042.

Ramirez D, Maurice MJ, Kaouk JH. Robotic perineal radical prostatectomy and pelvic lymph node dissection using a purpose-built single-port robotic platform. *BJU Int*. 2016;118(5):829–833.

Rane A, Rao P. Single-port-access nephrectomy and other laparoscopic urologic procedures using a novel laparoscopic port (R-port). *Urology*. 2008;72(2):260–263 [discussion 263–4].

Rassweiler J, Frede T. Robotics, telesurgery and telementoring—their position in modern urological laparoscopy. *Arch Esp*

Urol. 2002;55(6):610–628.

Rassweiler J, Seemann O, et al. Retroperitoneoscopy: experience with 200 cases. *J Urol*. 1998;160:1265–1269.

Rassweiler J, Stock C, et al. Organ retrieval system for endoscopic nephrectomy: a comparative study. *J Endourol*. 1998;12:325–333.

Rassweiler JJ, Autorino R, Klein J, et al. Future of robotic surgery in urology. *BJU Int*. 2017;120(6):822–841.

Raynor MC, Lavien G, et al. Elimination of preoperative mechanical bowel preparation in patients undergoing cystectomy and urinary diversion. *Urol Oncol*. 2013;31(1):32–35.

Reisiger K, Landman J, et al. Laparoscopic renal surgery and the risk of rhabdomyolysis: diagnosis and treatment. *Urology*. 2005;66(5 Suppl):29–35.

Richards W, Scovill W, et al. Acute renal failure associated with increased intra-abdominal pressure. *Ann Surg*. 1983;197:183–187.

Romero FR, Rais-Bahrami S, et al. Laparoscopic partial nephrectomy in obese and non-obese patients: comparison with open surgery. *Urology*. 2008;71(5):806–809.

Rosenberg H, Frank S. Causes and consequences of hypothermia and hyperthermia. Benumof JL, Saidman LJ. *Anesthesia and perioperative complications*. ed 2. Mosby: St Louis; 1999:338–356.

Roy S, Yoo A, Yadalam S, et al. Comparison of economic and clinical outcomes between patients undergoing laparoscopic bariatric surgery with powered versus manual endoscopic surgical staplers. *J Med Econ*. 2017;20(4):423–433.

Ruiz L, Salomon L, et al. Comparison of early oncologic results of laparoscopic radical prostatectomy by extraperitoneal versus transperitoneal approach. *Eur Urol*. 2004;46(1):50–54 [discussion 54–6].

Ruparel RK, Brahmbhatt RD, et al. “iTrainers”—novel and inexpensive alternatives to traditional laparoscopic box trainers. *Urology*. 2014;83(1):116–120.

Sainsbury DC, Dorkin TJ, et al. Laparoscopic radical nephrectomy in first-trimester pregnancy. *Urology*. 2004;64(6):1231.

Sarli L, Costi R, et al. Prospective randomized trial of low-pressure pneumoperitoneum for reduction of shoulder-tip pain following laparoscopy. *Br J Surg*. 2000;87(9):1161–1165.

Schippers E, Ottinger A, et al. Intestinal motility after laparoscopic vs conventional cholecystectomy. An animal experiment study and clinical observation. *Langenbecks Arch Chir*. 1992;377:14–18.

Schorr R. Regarding laparoscopy-associated mesenteric vascular events: description of an evolving clinical syndrome. *J Laparoendosc Adv Surg Tech*. 1998;8:249–250.

Scott D, Julian D. Observations on cardiac arrhythmias during laparoscopy. *BMJ*. 1972;1:411–413.

Sebesta MJ, Bishoff JT. Octylcyanoacrylate skin closure in laparoscopy. *JSLS*. 2004;8(1):9–14.

Secin FP, Jiborn T, et al. Multi-institutional study of symptomatic deep venous thrombosis and pulmonary embolism in prostate cancer patients undergoing laparoscopic or robot-assisted laparoscopic radical prostatectomy. *Eur Urol*. 2008;53(1):134–145.

See W, Monk T, et al. Complications of laparoscopy. *Laparosc Urol*. 1993;183–206.

Seed R, Shakespeare T, et al. Carbon dioxide homeostasis during anesthesia for laparoscopy. *Anesthesia*. 1970;25:223–231.

Seehofer D, Mogl M, et al. Safety and efficacy of new integrated bipolar and ultrasonic scissors compared to conventional laparoscopic 5-mm sealing and cutting instruments. *Surg Endosc*. 2012;26(9):2541–2549.

Seymour NE, Gallagher AG, et al. Virtual reality training improves operating room performance: results of a randomized, double-blinded study. *Ann Surg*. 2002;236(4):458–463 [discussion 463–4].

Sezeur A, Benoit J, et al. Elective cholecystectomy by celioscopy versus subcostal approach cholecystectomy. Comparative study of postoperative pain and discomfort. *Gastroenterol Clin Biol*. 1993;17:833–838.

Shafizadeh SF, Daily PP, et al. Chylous ascites secondary to laparoscopic donor nephrectomy. *Urology*. 2002;60:345.

Shalhav AL, Dunn MD, et al. Laparoscopic nephroureterectomy for upper tract transitional cell cancer: the Washington University experience. *J Urol*. 2000;163:1100–1104.

Sharp J, Pierson W, et al. Comparison of CO_2- and N_2O-induced discomfort during peritoneoscopy under local anesthesia. *Gastroenterology*. 1982;82:453–456.

Shifren J, Adlestein L, et al. Asystolic cardiac arrest: a rare complication of laparoscopy. *Obstet Gynecol*. 1992;79:840–841.

Shuford MD, McDougall EM, et al. Complications of contemporary radical nephrectomy: comparison of open vs. laparoscopic approach. *Urol Oncol*. 2004;22(2):121–126.

Shulman B, Aronson H. Capnography in the early diagnosis of carbon dioxide embolus during laparoscopy. *Can Anaesth Soc J*. 1984;31:455–459.

Simon SD, Castle EP, et al. Complications of laparoscopic nephrectomy: the Mayo Clinic experience. *J Urol*. 2004;171(4):1447–1450.

Siqueira TM Jr, Paterson RF, et al. The use of blunt-tipped 12-mm trocars without fascial closure in laparoscopic live donor nephrectomy. *JSLS*. 2004;8(1):47–50.

Slim K, Bousquet J, et al. Effect of CO(2) gas warming on pain after laparoscopic surgery: a randomized double-blind controlled trial. *Surg Endosc*. 1999;13(11):1110–1114.

Society of American Gastrointestinal and Endoscopic Surgeons. *Framework for post-residency surgical education and training*. https://www.sages.org/publications/guidelines/framework-for-post-residency-surgical-education-training/2003/; 2010.

Solis Herruzo J, Castellano G, et al. Plasma arginine vasopressin concentration during laparoscopy. *Hepatogastroenterology*. 1989;36:499–503.

Soong YK, Yu HT, et al. Urinary tract injury in laparoscopic-assisted vaginal hysterectomy. *J Minim Invasive Gynecol*. 2007;14(5):600–605.

Sorokin I, Canvasser NE, Irwin B, et al. The decline of laparoendoscopic single-site surgery: a survey of the Endourological Society to identify shortcomings and guidance for future directions. *J Endourol*. 2017;31(10):1049–1055.

Strate T, Bloechle C, et al. Hemostasis with the ultrasonically activated scalpel. *Surg Endosc*. 1999;13(727).

Sugihara T, Yasunaga H, et al. Does mechanical bowel preparation improve quality of laparoscopic nephrectomy? Propensity score-matched analysis in Japanese series. *Urology*. 2013;81(1):74–79.

Sugihara T, Yasunaga H, et al. Is mechanical bowel preparation in laparoscopic radical prostatectomy beneficial? An analysis of a Japanese national database. *BJU Int*. 2013;112(2):E76–E81.

Sukhotnik I, Bejar J, et al. Adverse effects of increased intra-abdominal pressure on small bowel structure and bacterial translocation in the rat. *J Laparoendosc Adv Surg Tech A*. 2006;16(4):404–410.

Sung GT, Gill IS. Laparoscopic adrenalectomy. *Semin Laparosc Surg*. 2000;7(3):211–222.

Suzuki K, Fujita K, et al. Efficacy of an ultrasonic surgical system for laparoscopic adrenalectomy. *J Urol*. 1995;154:484–486.

Swanstrom LL, Khajanchee Y, et al. Natural orifice transluminal endoscopic surgery: the future of gastrointestinal surgery. *Perm J*. 2008;12(2):42–47.

Swanstrom LL, Whiteford M, et al. Developing essential tools to enable transgastric surgery. *Surg Endosc*. 2008;22(3):600–604.

Takeda M, Go H, et al. Retroperitoneal laparoscopic adrenalectomy for functioning adrenal tumors: comparison with conventional transperitoneal adrenalectomy. *J Urol*. 1997;157:19–23.

Thomas MA, Rha KH, et al. Optical access trocar injuries in urological laparoscopic surgery. *J Urol*. 2003;170(1):61–63.

Thorell A, Nygren J, et al. The metabolic response to cholecystectomy: open versus laparoscopic surgery. *Clin Nutr*. 1993;12:1–2.

Thorington J, Schmidt C. A study of urinary output and blood-pressure changes resulting in experimental ascites. *Am J Med Sci*. 1923;165:880–890.

Tolksdorf W, Strang C, et al. The effects of the carbon dioxide pneumoperitoneum in laparoscopic cholecystectomy on postoperative spontaneous respiration. *Anesthetist*. 1992;41:199–203.

Tredree R, Debrix BW, et al. Evaluating the differences between fibrin sealants: recommendations from an international advisory panel of hospital pharmacists. *Eur J Hosp Pharm Sci*. 2006;12(1):3–9.

Trokel M, Bessler M, et al. Preservation of immune response after laparoscopy. *Surg Endosc*. 1994;8:1385–1388.

Troxel SA, Das S. Incisional hernia following hand-assisted laparoscopic surgery for renal cell cancer. *JSLS*. 2005;9(2):196–198.

Truong H, Gamboa LM, et al. In vivo comparative study of vessel and ureteral seal strengths and pathologic examination of tissue margins between the LigaSure V and the Harmonic Ace in the acute porcine model. *J Endourol*. 2008;22(Suppl) [Abstract 1584].

Urban D, Kerbl K, et al. Organ entrapment and renal morcellation: permeability studies. *J Urol*. 1993;150:1792–1794.

Usal H, Sayad P, et al. Major vascular injuries during laparoscopic cholecystectomy: an institutional review of experience with 2589 procedures and literature review. *Surg Endosc*. 1998;12:960–962.

Vallancien G, Cathelineau X, et al. Complications of transperitoneal laparoscopic surgery in urology: review of 1,311 procedures at a single center. *J Urol*. 2002;168(1):23–26.

Varkarakis J, Bartsch G, et al. Long-term morbidity and mortality of transurethral prostatectomy: a 10-year follow-up. *Prostate*. 2004;58(3):248–251.

Vilos GA, Ternamian A, et al. Laparoscopic entry: a review of techniques, technologies, and complications. *J Obstet Gynaecol Can*. 2007;29(5):433–465.

Webb D, Redgrave N, et al. Extraperitoneal laparoscopy: early experience and evaluation. *Aust N Z J Surg*. 1993;63:554–557.

Weld KJ, Arzola J, et al. Lapra-Ty holding strength and slippage with various suture types and sizes. *Urology*. 2008;71(1):32–35.

Williams M, Murr P. Laparoscopic insufflation of the abdomen depresses cardiopulmonary function. *Surg Endosc*.

1993;7:12–16.

Winfield H, Donovan J, et al. Urological laparoscopic surgery. *J Urol*. 1991;146:941–948.

Wolf JS. Tips and tricks for hand-assisted laparoscopy. *AUA Update Ser*. 2005;24(2):10–15.

Wolf JS, Marcovich R, et al. Survey of neuromuscular injuries to the patient and surgeon during urologic laparoscopic surgery. *Urology*. 2000;55(6):831–836.

Wolf JS, Monk TG, et al. The extraperitoneal approach and subcutaneous emphysema are associated with greater absorption of carbon dioxide during laparoscopic renal surgery. *J Urol*. 1995;154(3):959–963.

Wolf JS, Stoller M. The physiology of laparoscopy: basic principles, complications and other considerations. *J Urol*. 1994;152:294–302.

Yoon R, Del Junco M, Kaplan A, et al. Development of a novel iPad-based laparoscopic trainer and comparison with a standard laparoscopic trainer for basic laparoscopic skills testing. *J Surg Educ*. 2015;72(1):41–46.

Yuh B, Ruel N, et al. Complications and outcomes of robot-assisted salvage radical prostatectomy—a single institution experience. *BJU Int*. 2014;113(5):769–776.

Zemet R, Mazeh H, et al. Incarcerated hernia in 11-mm nonbladed trocar site following laparoscopic appendectomy. *JSLS*. 2012;16(1):178–181.

Zhao LC, Han JS, et al. Thoracic complications of urologic laparoscopy: correlation between radiographic findings and clinical manifestations. *J Endourol*. 2008;22(4):607–614.

Zorn KC, Gofrit ON, et al. da Vinci robot error and failure rates: single institution experience on a single three-arm robot unit of more than 700 consecutive robot-assisted laparoscopic radical prostatectomies. *J Endourol*. 2007;21(11):1341–1344.

Zorn KC, Widmer H, Lattouf JB, et al. Novel method of knotless vesicourethral anastomosis during robot-assisted radical prostatectomy: feasibility study and early outcomes in 30 patients using the interlocked barbed unidirectional V-LOC180 suture. *Can Urol Assoc J*. 2011;5(3):188–194.

Zucker K, Martin D, et al. Complications of instrumentation and equipment. Bailey RW. *Complications of laparoscopic surgery*. Quality Medical Publishing: St. Louis; 1995:58–74.

15

Basic Energy Modalities in Urologic Surgery

Michael W. Sourial MD, FRCSC, Shubha K. De MD, FRCSC, Manoj Monga MD, FACS, Bodo Egon Knudsen MD, FRCSC

Tissue Dissection and Cauterization

Electrosurgery

Electrosurgery is the application of electrical current to tissue to achieve the effects of cutting, coagulation, desiccation, or fulguration. Monopolar and bipolar electrosurgery techniques are used in urology in numerous applications. An understanding of the basic scientific principles and tissue effects is necessary for the surgeon to use the technology in a safe and efficient manner. Although the technology can be of great assistance to the surgeon, improper settings or poor application can result in patient injury (Massarweh et al., 2006).

Electrosurgical technology was first developed in the late 1800s. The technology originated from spark gap transmitters that were used to generate radio waves at that time. The waveform produced was of a steady frequency but varied in amplitude. Using a combination of inductors and capacitors, the waveform could be smoothed out, although this resulted in some power loss. French scientists in the 1890s experimented with the technology and determined that the raw output from the spark gap transmitter could coagulate tissue, and the smoothed-out current could cut tissue. Around the turn of the 20th century, the technology began to be used in clinical surgical cases in Europe (Massarweh et al., 2006; Van Way, 2000).

In the 1920s Bovie, an electrical engineer at the Massachusetts Institute of Technology, studied the work of his predecessors and developed a cutting loop that delivered electrical energy that could be used for cutting, coagulation, and desiccation. On October 1, 1926, at the Peter Bent Brigham Hospital in Boston, Cushing used the device to remove a highly vascular myeloma from the head of a patient that previously had been deemed inoperable because of the vascularity of the mass (Massarweh et al., 2006; Van Way, 2000).

Monopolar Electrosurgery

Basic Physics.

Electrosurgery uses radiofrequency current in the range of 400,000 to 600,000 hertz (Hz) to pass through tissue and create the desired effects. The generators deliver more than 100 watts (W) of power to the tissue at voltages ranging from 100 to 5000 volts (V). As the current is delivered to the tissue, the tissue is heated, and the effect occurs. **In contrast, with electrocautery, the instrument is heated and then applied to the tissue. Ohm's law, current (I) = voltage (V)/resistance (R), applies and states that the current is determined by the applied voltage and the tissue's resistance.** The higher the resistance of the tissue, the greater the voltage needed to drive the current through the tissue. Current is calculated as the flow of electrons during a specific period of time. Voltage is used to drive the current through the resistance, which in surgery is the tissue. When alternating current is used, resistance is termed *impedance*. As the resistance increases, the amount of voltage to drive the same amount of current also increases. As tissues become cauterized, their impedance increases, and a higher voltage is needed for the current to penetrate the tissue beneath (Jones et al., 2006; Massarweh et al., 2006; Van Way, 2000; Van Way and Hinrichs, 2000).

Cutting and coagulation currents can be applied and use similar frequencies. **For coagulation to occur, the current is interrupted approximately 30,000 times per second. This interruption results in short bursts of radiofrequency energy. For cutting current, the radiofrequency current is delivered continuously** (Fig. 15.1). With continuous energy delivery, the cells heat up rapidly to the point of boiling and then rupture, which results in the cutting effect. With coagulation, because the energy is interrupted, the cells are allowed to cool as the energy is cycled off, and the cells dry out instead of rupturing (Jones et al., 2006; Massarweh et al., 2006; Van Way, 2000).

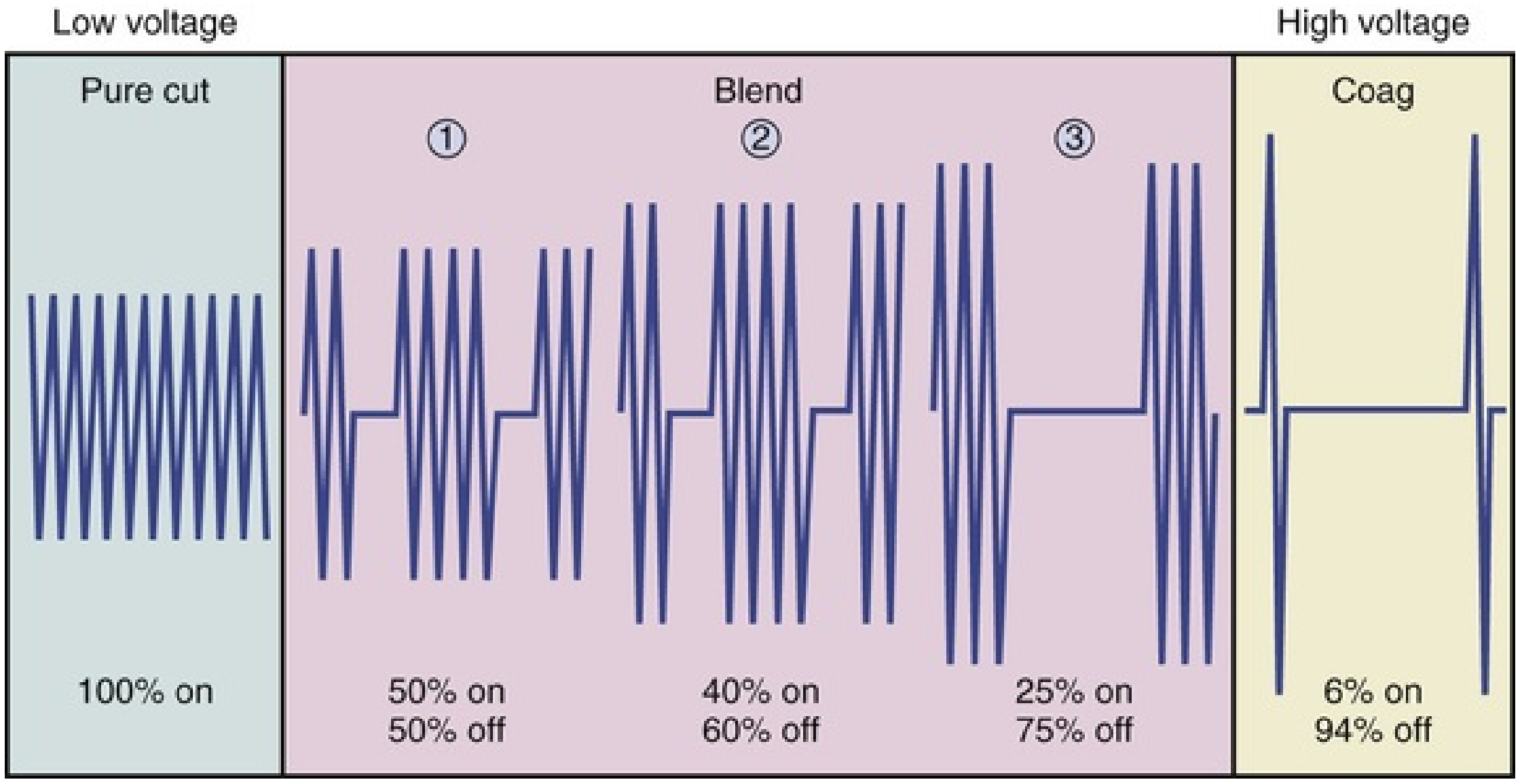

FIG. 15.1 Instrument settings relating voltage and current. Pure cut uses

continuous delivery, whereas coagulation uses interrupted delivery.
Blended modes modify the degree of interruption to desired effect.

Most generators also offer blended cutting, which adds some coagulation properties to the cutting current. This blended cutting is produced when the cutting current is interrupted similar to coagulation current. In contrast to coagulation current, where the generator output is concentrated into two or three cycles, blended cutting delivers more cycles to the tissue. The number of cycles delivered determines the degree of cutting versus coagulation. For example, a blend 1 setting may allow 50% of the current through, whereas a blend 3 setting may allow only 10% of the energy through, resulting in a greater coagulation effect (Jones et al., 2006; Massarweh et al., 2006; Van Way, 2000; Vilos and Rajakumar, 2013).

Modern electrosurgical generators are capable of high voltage and high wattage. This capability allows for either type of current to cut or coagulate. However, differences remain, and the coagulation current results in much more widespread tissue damage and charring but deeper hemostasis because of the higher voltages used compared with a lower voltage cutting current. **Cutting current employs voltages 10 to 20 times less than coagulation but is still greater than 100 V. Alternatively, coagulation current is delivered in short bursts at much higher voltage but with less current flow at the same amount of power.** The desiccation of the tissue results in increased impedance and lower current flow compared with cutting. Desiccation results in drying of the tissue and coagulation of blood vessels. The tissue is typically pale and dry with an eschar developing next to the electrode (Goddard et al., 1972; Jones et al., 2006; Massarweh et al., 2006; Van Way, 2000; Van Way and Hinrichs, 2000; Vilos and Rajakumar, 2013).

Fulguration results when the electrode is placed about 2 to 5 mm from the tissue. Electrical energy in the form of a spark arcs from the electrode to the tissue. A coagulation current setting on the generator usually is used, producing a darker char on the tissue with a superficial eschar. Fulguration can be effective at achieving hemostasis, but care must be taken to ensure the eschar is not too superficial, allowing for bleeding deeper in the tissue below the coagulum (Jones et al., 2006; Van Way, 2000).

Argon Beam Coagulator.

Traditional monopolar devices do not work well in a liquid environment, such as when there is significant blood in the targeted field. The fluid results in dispersion of the current, rendering it ineffective. To address this shortcoming, the argon beam coagulator was developed. **It works by adding a column of argon gas that passes over the electrode, and then electrosurgical energy ionizes the argon gas and helps to displace the blood in the surgical field. Because it is a noble gas, the current from the electrode is effectively transmitted to the underlying tissue.** The current follows the beam of gas and allows for diffuse superficial coagulation; this is ideal for obtaining hemostasis over a broad surface, such as during a partial nephrectomy. Typically, the argon beam coagulator is held slightly farther from the tissue at about 5 to 10 mm. It uses a standard generator and grounding pad but is operated at a higher power setting compared with traditional monopolar cautery in coagulation mode to desiccate the target tissues (Massarweh et al., 2006).

Generator Settings.

When adjusting the generator settings, it is important to set the generator at a high enough power setting to achieve effective cutting and coagulation. Setting the generator too low results in an inability of the electrode to cut the tissue and poor or limited effect of the coagulation. For coagulation to occur, approximately 30 to 50 W is needed. For cutting, setting the generator at 60 W is a reasonable starting point, subsequently adjusting the power as needed. Typically, fatty tissue is less conductive than muscle and may require higher settings of approximately 80 W. This information is intended as a rough guideline only; experience with individual generators varies (Massarweh et al., 2006; Van Way, 2000; Vilos and Rajakumar, 2013).

Although coagulation current may be used to “cut” tissue using lower power settings, it results in greater collateral damage compared with using a cutting setting. Although it may be reasonable to use coagulation when dividing muscle, it is better practice to use pure cut or cut on a blend setting to produce less charring and less ancillary tissue damage (Massarweh et al., 2006).

Safety

The incidence of electrosurgical injuries is estimated to be 2 to 5 per 1000 (Hulka et al., 1997; Loffer and Pent, 1975; Nduka et al., 1994). Understanding the principles of the electrosurgical devices and operating them within their safety parameters can help to decrease the risk of unintentional injuries.

During monopolar electrosurgery, the patient is part of a complete electrical circuit. Current is initially produced in the generator and is conducted over wires to the electrosurgical electrode. The electrode is used to deliver the current to the surgical site where it is focused. The current is distributed through the patient's body to the dispersive electrode (grounding pad), where it leaves the patient's body and travels over wires back to the generator to complete the circuit. **This system is designed to concentrate the energy at the tip of the electrode and then disperse it widely while traveling through the patient's body. If the current is allowed to concentrate in other locations, potential morbidity could ensue.**

Most electrosurgical injuries occur at the grounding pad site. Historically, the grounding pad was a metal plate that had contact gel applied to it before placing it in contact with the patient. Modern grounding pads are called dispersive electrodes and function in a similar but safer manner. The old-style metal grounding pads that were used with conductive gel could dry out during a case. Rather than have the current travel through a large contact patch, the dried-out pad could result in a very small contact patch that focused the current and resulted in electrical burns on the skin and underlying structures. Modern dispersive electrodes do not dry out and produce a safer, stable contact patch with the patient. Modern generators have a built-in self-test system that monitors the status of the dispersive electrode. If the generator becomes dislodged or loses contact in some way, the system shuts itself down and the ground fault warning is activated (Alkatout et al., 2012; Hutchisson et al., 1998; Nduka et al., 1994).

Injuries can ensue from inadvertent activation of the electrosurgical electrode. Injury can occur if a foot pedal is accidentally depressed and the electrode burns the drape or burns the patient at a site not intended. Handheld electrodes with a finger actuator are less likely to cause such an injury, although it is still possible. Other injuries can occur if electrosurgical energy is applied to unintended structures during surgery; this can occur when blood vessels and nerves are running close together. For example, the parasympathetic nerves that run near the prostate and are responsible for erections may be inadvertently injured when hemostasis is obtained with coagulation. During laparoscopic nephrectomy, the heel of a monopolar hook electrode may be inadvertently brought into contact with the bowel while activated, resulting in a bowel injury. Keeping the instruments in view, being aware of the surrounding structures, using low but effective power settings, and maintaining a general awareness of the instruments may help reduce such injuries.

The tissues of the body vary in their impedance (ability to conduct electrical energy). Structures such as blood vessels have lower impedance and preferentially conduct and concentrate current, whereas fat has high impedance. Tissue impedance is an important consideration when operating on structures such as the bowel, where current could get concentrated in the thin vascular pedicle that supports the structure. Current concentrated in the pedicle could damage the vascular supply to the tissue.

In patients with pacemakers or implantable cardioversion devices, the manufacturer should be consulted before surgery involving monopolar cautery to ensure that interference with the devices does not occur during surgery. The devices may have to be temporarily deactivated during the procedure (Madigan et al., 1999).

Prosthetic joints can also affect current conduction but are not an absolute contraindication to use of monopolar cautery. Ideally, the direct path of the electrical circuit should be directed away from the prosthetic joint. For example, if the patient has a right hip prosthesis, the dispersion electrode pad should be placed on the contralateral hip (Massarweh et al., 2006).

Insulation failures can occur if there is a breakdown in the insulating material that surrounds the electrosurgical electrode. Usually only the tip of the electrode is left without surrounding insulation, but if defects occur in other locations, the current may arc out in these spots leading to unintended injuries. Such an occurrence is more likely when higher-voltage coagulation modes are used. Reused instruments may be associated with such failures because the defects in the insulation may occur during the reprocessing, although disposable devices could also have defects (Massarweh et al., 2006). Several clinical reports of insulation failures during robotic-assisted laparoscopic surgery have been published (Cormier et al., 2012; Mues et al., 2011). A 33% failure rate of the first-generation robotic monopolar scissors tip cover accessory after one clinical use has been described (Engebretsen et al., 2013).

The surgeon is also at risk for electrosurgical burns. Surgical gloves do not provide much insulation from electrical current. Current can penetrate gloves when they become wet, through capacitance conducting, or when mechanical breakdown of the glove occurs (Tucker and Ferguson, 1991).

Capacitive Coupling.

Capacitive coupling is the transfer of energy within an electrical network by means of the capacitance between circuit nodes. Capacitive coupling occurs when two conductive elements are spaced apart by an insulator and energy is stored, creating an electrostatic field. When the net charge exceeds the

insulator's capacity, current is transmitted from the first conductor to the second. This occurrence is rare but can lead to complications during laparoscopic procedures using electrosurgery. When an active electrode that is surrounded by insulation is passed down a metal trocar, capacitive coupling can occur. However, it can also occur with plastic trocars. The injuries typically occur out of the surgeon's field of vision. An active electrode monitoring system and limiting the amount of time that high-voltage settings are used can decrease the risk of capacitive coupling (Jones et al., 2006; Tucker and Voyles, 1995; Vilos et al., 2001; Wang and Advincula, 2007).

General Safety Tips.

Using the lowest possible energy setting that achieves the desired surgical effect is the simplest of the basic principles for the safe use of electrosurgical instruments. Rather than starting at a high setting, the surgeon should slowly ramp up the energy setting until the desired effect is reached. With higher settings, the potential for arcing and capacitive coupling increases. The settings should not exceed settings recommended by the manufacturer.

During surgical use, the electrode tip can become coated with eschar, which causes an increase in impedance and can lead to arcing, spark generation, and ignition of the eschar. A scratch pad can be used to clean the eschar, but this can cause grooves to form on the electrode, which can promote further eschar buildup. Alternatively, a sponge can be used to clean the electrode tip. A sponge effectively clears the eschar and does not cause scratches to the electrode (Massarweh et al., 2006).

A common technique during open surgical procedures is for the surgeon to grasp a bleeding vessel with a forceps or hemostat and then have the assistant touch the instrument with the activated electrode of the Bovie; this delivers current through the instrument to the bleeding vessel. During these maneuvers, the surgeon must be careful not to touch the patient with his or her free hand. Doing so would create an alternative circuit that could allow the current to travel to a different part of the patient's body. Keeping a firm grasp on the forceps can also help to reduce the possibility of current traveling in an alternate path (Alkatout et al., 2012; Hutchisson et al., 1998; Jones et al., 2006).

Basic principles that should be observed include keeping the operating field neatly organized and not tangling cords when multiple corded instruments are used. Care should be taken not to wrap cords around metal instruments because insulation defects could lead to burns. The handheld electrodes should be secured in an insulated holster when not being used rather than resting them on the patient; this reduces the possibility of burns or injury through inadvertent activation (Massarweh et al., 2006).

Types of Electrosurgical Instruments

Monopolar Devices.

Electrosurgical instruments can be divided into two categories of delivery devices: monopolar and bipolar. For monopolar devices, the Bovie is the most widely used example and has broad applications in many surgical specialties, including urology. The size and shape of the electrode affect its interaction with the tissue. A smaller contact area results in higher current concentration, whereas a larger contact area results in the current being more dispersed. Greater power settings would be needed with the larger electrode to achieve a similar tissue effect. Many systems allow the surgeon to select the tip appropriate to the given procedure, and the tips can be changed if needed during the procedure to fit the application (Massarweh et al., 2006; Vilos and Rajakumar, 2013).

Bipolar Devices.

In contrast to monopolar systems in which a circuit is created by delivering the energy via an electrode and then removed from the patient using a dispersive electrode (grounding pad), **bipolar delivery does not require a dispersive electrode. Rather, the active and return electrodes are integrated in the delivery hand piece.** The tissue contained between the electrodes is the target tissue.

Bipolar “vessel sealing” devices have been developed that use computing technology built into the electrosurgical generators. These closed-looped feedback systems allow for vascular structures up to 7 mm in diameter to be fused and can help obviate the need for sutures, clips, or surgical staples. Several studies have confirmed the effectiveness of such devices demonstrating clinically equivalent burst pressures when compared with surgical staples, sutures, and titanium clips. Compared with the Harmonic scalpel, burst pressures were higher for vessels 4 to 7 mm in diameter (Harold et al., 2003; Kennedy et al., 1998; Landman et al., 2003; Takada et al., 2005). The LigaSure vessel sealing system (Covidien, Dublin, Ireland) has been used successfully for radical prostatectomy and cystectomy with a benefit in operating time and blood loss demonstrated compared with conventional vessel ligation. However, long-term damage to neurovascular structures was not addressed in these studies (Daskalopoulos et al., 2004; Sengupta and Webb, 2001).

Ultrasonic Instrumentation (High-Frequency Vibratory Device)

Ultrasonic devices offer an alternative to electrosurgical instruments. **These devices have elements that vibrate at ultrasonic frequencies of approximately 55,000 Hz. Mechanical energy and heat are generated, and these cause the denaturation of proteins and the formation of a coagulum that can seal small vessels. Depending on the instrument, vessels 2 to 3 mm in diameter can be sealed, and vessels up to 5 mm in diameter can be sealed with some newer instruments.** Newer instruments also produce less heat and charring to the surrounding tissue, limiting thermal injury. The heat generated is usually less than 80°C. The device is best applied to the tissue in a tension-free manner; this allows the instrument to divide the tissue effectively while coagulating at the same time, limiting blood loss. Aerosolized fatty droplets may develop as the tissue is divided, and this can negatively affect visualization through the laparoscope. Examples of such devices are the Ultra Shears (Covidien), Harmonic Scalpel (Ethicon Endo-Surgery, Johnson & Johnson, New Brunswick, NJ), and Thunderbeat (Olympus, Tokyo, Japan). Devices for open and laparoscopic surgery have been developed. The Harmonic scalpel has been shown to allow for effective tissue dissection and bleeding control during laparoscopic partial nephrectomy (Harris, 1978; Helal et al., 1997; Tremp et al., 2011).

Comparing Various Energy-Sealing Devices

There is a relative paucity of data comparing the safety and efficacy of the various energy-based sealing devices. Outcomes measured in studies include vessel sealing time, coagulation, transection of tissue, and ergonomics of the device. Potential disadvantages include collateral damage, variable burst pressures, the generation of potentially toxic vapors, and the high disposable costs.

In a study comparing the use of the LigaSure device with a Harmonic scalpel during laparoscopic radical prostatectomy, a benefit in functional outcomes including return to continence and erectile function was demonstrated in favor of the LigaSure device (Pastore et al., 2013). A study comparing the vessel sealing times and thermal spread of two bipolar vessel sealing systems (LigaSure and PK [Gyrus ACMI, Southborough, MA]) and an ultrasonic device (Harmonic scalpel) was performed. This study demonstrated that the two bipolar systems had faster vessel-sealing times with higher burst pressures compared with the ultrasonic device. However, the ultrasonic device had less thermal spread and smoke production (Lamberton et al., 2008). In a study comparing the histologic appearance of 40 renal tumor margins excised with cold scissors, LigaSure, and the Harmonic scalpel, despite some degree of cellular damage, the ability to determine whether cells at the margin were benign or malignant was not affected by using an energy-based bipolar or ultrasonic device (Phillips et al., 2008). The smoke plume produced by ultrasonic devices may also be less toxic compared with electrosurgically generated smoke (Fitzgerald et al., 2012).

Laser Instrumentation: Soft-Tissue Applications

A laser is a device that emits light through the process of optical amplification by the stimulated emission of electromagnetic radiation. The word *laser* is an acronym for "*l*ight *a*mplification by *s*timulated *e*mission of electromagnetic *r*adiation." In the 1980s lasers first became of interest to researchers and clinicians in urology, and at the present time a wide range of lasers are employed to treat various soft-tissue and stone conditions. Although the holmium:yttrium-aluminum-garnet (Ho:YAG) laser has become the accepted gold standard for the treatment of urinary calculi at this time, various wavelengths of lasers are employed to treat soft-tissue conditions such as stricture disease, benign prostatic hyperplasia (BPH), urothelial cell cancer, and genital skin lesions (Heinrich et al., 2010; Marks and Teichman, 2007; Zarrabi and Gross, 2011).

Lasers are a source of electromagnetic radiation that emit a beam of energy that may include nonoptical wavelengths and visible light. The properties of this light create the therapeutic effects used during surgical procedures. General components exist with all lasers, including an energy source, an active medium, and a resonant cavity. Light is generated with the active medium, which can be a solid, liquid, or gas. For the laser action to occur, most of the atoms or molecules within the active medium must be brought simultaneously to a higher energy state by an energy source; this is also referred to as pumping. The energy source energizes the atoms in the active medium and produces a population inversion, which is an excited state in which the atoms or molecules are primed for stimulated emission (Siegman, 1986; Troup, 1963).

Numerous types of energy sources drive lasers. Broadly, either electrical current or a different wavelength of light is used. The pump light can be generated by a flash lamp or a different wavelength laser. The specific energy source used depends on the type of laser; however, all are designed to produce laser light in a collimated beam (Siegman, 1986; Teichmann et al., 2007).

Light exists as electromagnetic waves representing spatial concentrations of energy. Each wave exists as a bundle of energy or as a particle called a *photon*. Photons are emitted and stimulate surrounding atoms and cause additional photons to be released. These have the same energy and travel in phase with the initial stimulating wave. The result is that the entire light is the same wavelength and travels in the same direction. The highly ordered, in-phase light arrangement is termed *coherence*. A long tube or cylinder is ideal for this process but not practical. A resonant cavity is created using mirrors to reflect light, allowing it to have many passes through the medium. A small portion of the amplified light escapes out of the resonant cavity and forms the beam of laser light (Stein, 1986; Stein and Kendall, 1984a; Welch et al., 1989).

Laser light has specific properties. It is monochromatic and of a single wavelength. The light is coherent with a uniform spatial relationship between all portions of the electromagnetic wave. It has directionality with minimal divergence, which allows it to maintain brightness over long distances. It is the high concentration of the bright laser light when focused on a small spot that gives it the properties to be a useful surgical tool but also a potential hazard (Stein and Kendall, 1984a; Welch et al., 1989).

The wavelength of laser light can vary and may be in the ultraviolet, the visible, or the infrared portions of the optical spectrum. Most lasers emit one or a couple of wavelengths; examples include the argon (488 nm—blue; 514 nm—green), the neodymium:YAG (Nd:YAG; 1064 nm and 1318 nm), and the Ho:YAG (2100 nm) lasers (Stein and Kendall, 1984a; Teichmann et al., 2007).

Pulsed and Continuous Wave Lasers

Depending on how the excitation energy is applied and how the laser cavity is configured, the output beam of laser light is either pulsed wave or continuous wave. The duration and energy of individual pulses can vary and depend on the type of laser. Pulses may be delivered individually, in groups, or continuously over a wide range of frequencies. A laser is considered continuous wave if the output emission is greater than 0.25 second. Clinically, a continuous wave laser delivers output that is continuous and of a constant amplitude; this allows for a stable, easy-to-control instrument. In contrast, a pulsed wave laser delivers bursts of energy, which works well for stone fragmentation but may be more difficult to control during soft-tissue interactions (Teichmann et al., 2007; Zarrabi and Gross, 2011).

The power of the laser is equal to the energy over time (P = energy/time or W = Joules per second [J/sec]), and a high degree of power can be reached with even a small amount of energy if very short pulses are used. Several techniques exist that can compress or shorten the pulse. Examples include Q-switching and mode locking. Q-switching involves interrupting the light beam in a controlled fashion so that the laser action is delayed until maximal population inversion has occurred in the active medium. It generates lower pulse repetition rates, higher pulse energy, and longer pulse duration compared with mode locking, another technique used to shorten the pulse. Mode locking, which can be combined with Q-switching, can create ultrashort pulses by fixing the way photons bounce back and forth in the resonant cavity. It can create very high power pulses because of their ultrashort duration (Stein and Kendall, 1984a; Teichmann et al., 2007; Zarrabi and Gross, 2011).

Delivery Systems

All medical lasers have a delivery system that allows for the laser energy to be directed to the intended target site. Delivery systems may be fixed rigid systems, such as articulating arms, or flexible systems, such as fiberoptic glass fibers. Fiberoptic systems are generally inexpensive and versatile; however, fiberoptic materials are unable to transmit all laser wavelengths. For example, the carbon dioxide (CO_2) laser, with a wavelength of 10.6 μm, does not pass through quartz or glass fiber optics, and instead a more rigid system composed of an articulating arm with a series of mirrors is employed. The final tissue interface usually contains a focusing device to optimize the laser energy delivery (Marks and Teichman, 2007; Stein and Kendall, 1984a, 1984b; Teichmann et al., 2007; Zarrabi and Gross, 2011).

Light-Tissue Interaction

Laser light is absorbed by tissue in a wavelength-dependent fashion. However, some of the light, independent of the wavelength, may be reflected by the boundary layer of the tissue. This light is lost for the surgical purpose and may cause heating and collateral damage in the surrounding tissue. The optical properties of the tissue and the surrounding irrigant can affect the degree of reflection. Because this process is not dependent on the wavelength, reflection is often not considered when selecting a wavelength for surgical lasers (Teichmann et al., 2007).

Some scattering of the laser energy may also occur. By scattering, some of the intended laser energy is taken out of the surgical field. The degree of scattering varies with the wavelength of the laser. Typically, lasers with shorter wavelengths have a much greater amount of scatter compared with lasers of longer wavelengths. This is an important consideration in selecting an appropriate laser for surgical applications (Teichmann et al., 2007).

The most important light-tissue interaction is absorption. When the laser beam enters into a medium in which it is absorbed, the intensity of the laser energy decreases in an exponential fashion that is consistent with Beer-Lambert law. This law states that a logarithmic dependence exists between the transmission of light through a substance, the product of the absorption coefficient of the substance, and the distance the light travels through the material. Absorbed laser energy is converted to heat and increases the temperature of the target tissue. If enough heat is generated, coagulation and subsequently vaporization can occur. A chromophore is required for absorption to occur. In the body, melanin, hemoglobin, and water are available chromophores; hemoglobin and water are most important for urologic applications (Teichmann et al., 2007; Zarrabi and Gross, 2011; Fig. 15.2).

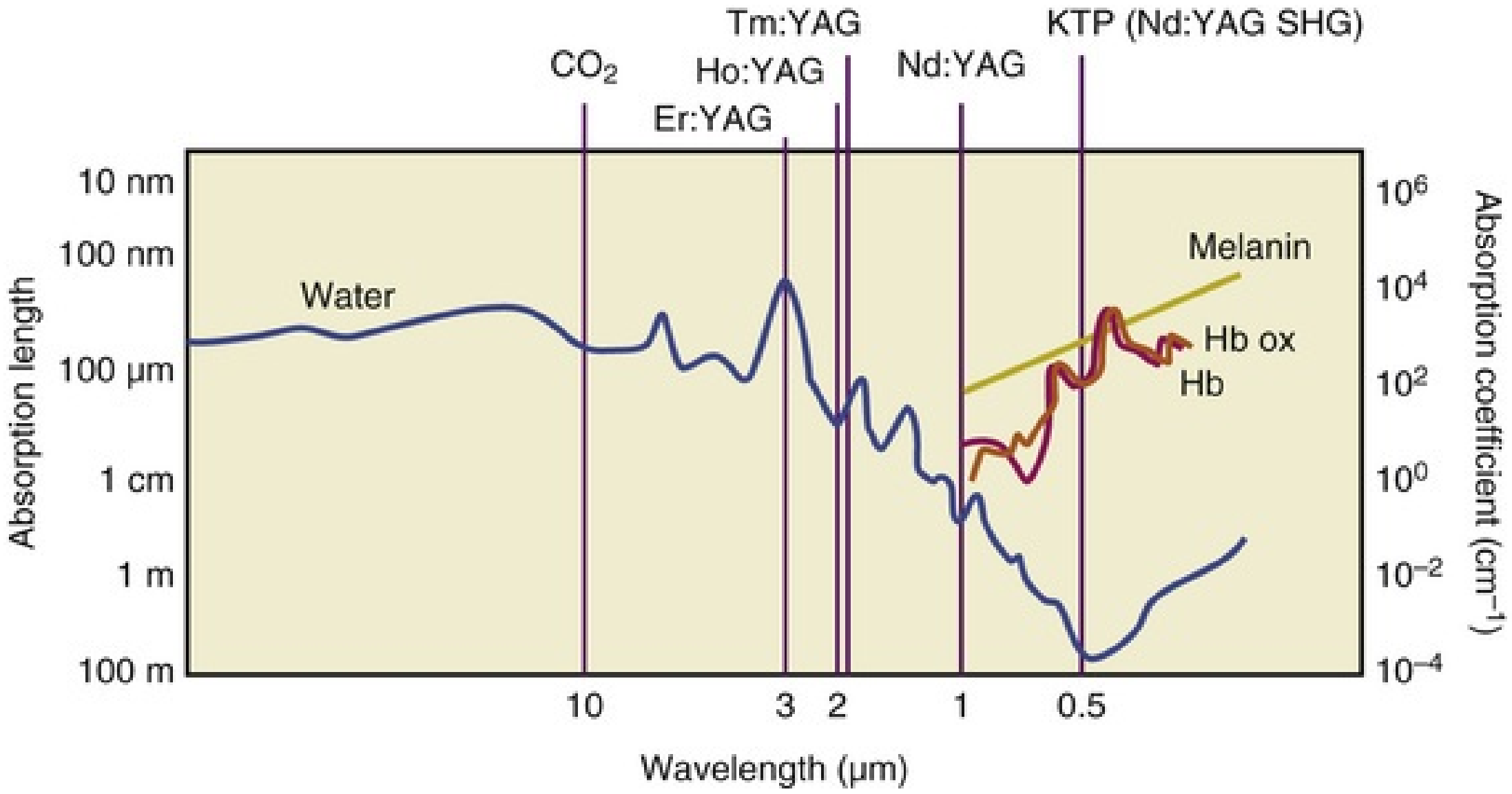

FIG. 15.2 Comparison of various laser wavelengths and absorptions in various media. *CO_2,* Carbon dioxide; *Er:YAG,* erbium:YAG; *Hb,* hemoglobin; *HbO_2,* oxyhemoglobin; *Ho:YAG,* holmium:YAG; *KTP,* potassium titanyl phosphate; *Nd:YAG,* neodymium:YAG; *SHG,* second Harmonic generation; *Tm:YAG,* thulium:YAG.

Types of Lasers

Neodymium:Yttrium-Aluminum-Garnet.

The Nd:YAG laser has a wavelength of 1064 nm and has a tissue depth of penetration of about 1 cm. It has hemostatic and coagulative tissue properties. Historically it has been used in urology for the treatment of BPH with visual laser ablation of the prostate (VLAP) and interstitial laser coagulation of the prostate. During VLAP, a side-firing laser fiber is used to direct the laser beam at 60- to 90-degree angles. The fiber is held off the prostatic tissue, and an area of heat-induced coagulative necrosis is produced as the tissue is targeted. The coagulated tissue is not entirely cleared at the time of surgery, but rather a sloughing process occurs in the weeks after surgery with associated edema. Prolonged postoperative catheterization may be needed in 30% of individuals (Cowles et al., 1995; Muschter, 2003; Norris et al., 1993).

Interstitial laser coagulation of the prostate involves placing laser-diffusing fibers directly into the adenoma of the prostate and can be performed either transurethrally or via a perineal approach. Similar to VLAP, the tissue undergoes coagulative necrosis and subsequently atrophies. The procedure can be safely performed in anticoagulated patients, but significant postoperative tissue edema can occur. Prolonged periods of catheterization after surgery—often 7 to 21 days—are required because of the high risk of urinary retention. Published retreatment rates of up to 20% at 2 years and 50% at 54 months suggest poor long-term durability (Daehlin and Frugard, 2007; Perlmutter and Muschter, 1998). With the advent of newer laser technology and techniques, the use of the Nd:YAG laser for BPH has largely been abandoned.

Potassium Titanyl Phosphate.

The potassium titanyl phosphate (KTP) laser, commonly referred to as the "green light" laser, is a frequency-doubled Nd:YAG laser. The Nd:YAG laser beam is passed through a KTP crystal, which results in doubling of the frequency and halves the wavelength to 532 nm, resulting in a visibly green laser beam. This wavelength is strongly absorbed by hemoglobin and in well-vascularized tissue has only 1 to 2 mm of tissue penetration compared with 10 mm for the standard Nd:YAG laser. The KTP laser is widely used for photoselective vaporization of the prostate (PVP) in which the well-vascularized prostate tissue is treated in a noncontact fashion with a side-firing laser fiber. The targeted tissue quickly increases in temperature above the boiling point and is vaporized leaving behind a rim of coagulated tissue that provides a layer of hemostasis. In contrast to VLAP, the limited depth of tissue penetration results in less tissue edema, and prolonged catheterization is usually not required (Barber and Muir, 2004; McAllister and Gilling, 2004; Teichmann et al., 2007; Zarrabi and Gross, 2011).

The early KTP laser systems were low-powered 34-W systems and were used in conjunction with a standard Nd:YAG laser. A hybrid surgical technique evolved in which the surgeon first performed a VLAP with the Nd:YAG laser and then used the KTP laser to perform bladder neck incisions. The goal was to try to reduce the prolonged catheterization and bothersome postoperative lower urinary tract symptoms after standard VLAP (Barber and Muir, 2004). Subsequently, a higher-powered 60-W KTP laser was developed. This KTP laser was a pulsed wave system but allowed for rapid delivery of the pulses that simulated the effect of a continuous wave laser. This laser permitted the photoselective vaporization of the prostate procedure to be performed independently of the standard Nd:YAG laser. Further refinement resulted in the development of an 80-W and a 120-W KTP laser, which demonstrated favorable outcomes and complications comparable with traditional transurethral resection of the prostate (TURP) (Kuromatsu et al., 2006; Ruszat et al., 2008; Thangasamy et al., 2012; Zang et al., 2016). More recently, a 180-W GreenLight XPS laser has been shown to be more favorable compared with the 120-W laser with regard to reduced operative time, fiber use, and PSA-reduction, suggesting more cost-effective and efficient tissue removal (Ben-Zvi et al., 2013).

Lithium Triborate.

The 120-W lithium triborate (LBO) laser was developed to increase the efficiency of the tissue vaporization compared with the 80-W KTP laser, especially for men with large prostates in whom procedures remained time consuming (Wosnitzer and Rutman, 2009). The LBO remains a 532-nm wavelength laser. The higher power allows the distance between the fiber tip and the target prostate tissue to be increased to 3.0 mm versus 0.5 mm for the KTP laser. The greater distance may help preserve the laser fiber and make it technically easier to use. However, hemostasis with the higher-powered system appears to be less compared with the 80-W system (Heinrich et al., 2010). Most recently, a 180-W LBO laser that works in conjunction with a liquid-cooled fiber delivery system (GreenLight XPS, AMS, Minnetonka, MN) was developed to increase efficiency further. The European GOLIATH study confirmed efficacy similar to TURP, and a North American multicenter trial demonstrated shorter lasering and operating times for the 180-W system compared with 120-W systems (Bachmann et al., 2014; Hueber et al., 2013). However, a steeper learning curve has been reported with the 180-W systems, with up to 120 procedures needed to work through the process and handle the higher power of the system safely and effectively (Misrai et al., 2014). In one study, there was little change in clinical outcomes including total operating time, lasering time, energy utilization, and complications between the 180-W and the 120-W LBO laser in an experienced PVP surgeon (Campbell et al., 2013).

Diode.

Diode lasers with wavelengths of 808 to 980 nm are absorbed well in water and behave similarly to Nd:YAG lasers (Orihuela et al., 1996). However, the laser is much more efficient than the Nd:YAG and requires only a standard wall plug for operation; this allows for a smaller, more portable laser design with fewer cooling requirements. More recently, interest in the diode laser as a tool for the surgical management of BPH increased. The 980-nm diode laser was used when the higher-powered LBO lasers were found to be not as effective in terms of hemostasis compared with the older 80-W KTP lasers. The diode laser appears to provide better hemostasis compared with the LBO laser but has a higher complication rate; postoperative frequency and urgency and epididymitis have been associated with its use (Chiang et al., 2010). In a randomized controlled trial, PVP with a diode laser was considered as safe and effective as monopolar TURP at 3-month follow-up, with similar complication and functional results. PVP had the advantage of shorter hospitalization and catheter indwelling times and no need for discontinuation of anticoagulant therapy (Cetinkaya et al., 2015). Another study prospectively following 80 patients who underwent PVP with the diode laser demonstrated that improved symptom scores, maximum flow rate, and postvoid residual urine observed at 24 weeks remained virtually unchanged at 1 and 2 years (Miyazaki et al., 2017).

Holmium:YAG.

The Ho:YAG laser is a 2140-nm pulsed laser that is used for soft-tissue and lithotripsy applications in urology. **The 2140-nm wavelength is strongly absorbed in water, traveling only about 0.5 mm in the fluid medium, making it ideal for the urologic environment. In the prostate, the absorption depth is about 0.4 mm, resulting in a high-energy density that leads to the rapid vaporization of tissue.** Heat is also generated during this process and allows for coagulation of small blood vessels up to a depth of approximately 2 mm.

It is held that the onset of vaporization occurs in the irrigant that is adjacent to the tip of the laser fiber. With each pulse of the laser, a steam bubble of a few millimeters in diameter is created. The bubble is not visible because it is present for only about 500 µsec—about the same length of time as the laser pulse duration. During holmium laser enucleation of the prostate (HoLEP), the laser pulses create the steam bubbles, which lead to the separation of the prostatic adenoma from the capsule of the prostate. Tissue vaporization occurs and leads to the white fibrous appearance of the tissue. The heat generated during the process allows for hemostasis to occur in the adjacent tissue. For persistently bleeding vessels, the laser can be “defocused” by increasing the distance between the fiber tip and the target bleeding vessel; this results in only the coagulation effect occurring with limited or no vaporization.

Before the development of the HoLEP technique, the use of the Ho:YAG laser for the treatment of BPH went through a series of steps. Similar to the KTP laser, the Ho:YAG laser was initially combined with the Nd:YAG laser to perform hybrid techniques in which the Nd:YAG was used first to perform VLAP, and then the Ho:YAG was used to make bladder neck incisions that reduced the need for prolonged postoperative catheterization (Gilling and Fraundorfer, 1998). These hybrid techniques subsequently led to holmium laser ablation of the prostate in which the laser energy was used to vaporize the prostatic tissue. This was a relatively easy procedure to learn but did require a high-powered Ho:YAG laser (80 to 100 W) and a side-firing laser fiber. However, the rate of vaporization was slow, and long procedure times were needed to treat men with large prostates adequately. The side-firing fibers would also fail if held too closely to the tissue, likely because of thermal breakdown (Tan et al., 2003). The development of holmium laser resection of the prostate (HoLRP) followed. This technique involved cutting pieces of the prostate off as it was resected, similar to a TURP. The sizes of the pieces could be larger than typical TURP chips but had to be small enough to be able to irrigate them out of the bladder at the completion of the resection. This technique was more challenging than holmium laser ablation of the prostate and remained time-consuming in patients with large prostates (Cresswell et al., 1997).

The next development was HoLEP, in which the median and two lateral lobes are enucleated and pushed into the bladder in a manner mimicking an open prostatectomy. Before the introduction of an effective tissue morcellator, some surgeons employed a traditional transurethral resection loop to cut up the adenoma in the bladder after the enucleation was completed. However, the tissue morcellator streamlined this process, and although it still carries with it the risk of bladder injury, it would appear to be much safer and less cumbersome than using a transurethral resection loop. HoLEP is performed in an almost bloodless field as a result of the coagulation produced by the Ho:YAG wavelength but also as a result of the extensive blunt dissection from the tip of the endoscope, similar to the use of a surgeon's finger during an open retropubic prostatectomy (Elzayat and Elhilali, 2006). HoLEP has proven to be a highly effective procedure with durable long-term results in men undergoing surgical management of BPH. It is effective for a broad range of prostate sizes and can be performed in men on anticoagulation (Elzayat et al., 2005, 2006; Krambeck et al., 2010; Tyson and Lerner, 2009). However, adoption of HoLEP has been slowed by the steep learning curve and the availability of other techniques that are easier to learn (Bae et al., 2010).

More recently, higher-powered Ho:YAG lasers (100-W, 120-W) have also been used for stone lithotripsy. These can allow for higher-frequency settings at lower pulse energies. Newer lasers also allow for adjustments of pulse duration. In an in vitro dusting model, a longer laser pulse duration provided effective stone comminution with the advantage of reducing laser fiber tip degradation and stone retropulsion (Emiliani et al., 2017; Wollin et al., 2017). Lumenis (Yokneam, Israel) has developed a new technology for their Lumenis Pulse 120H laser dubbed the “Moses effect.” The laser pulse is modulated to first separate the water then deliver the remaining energy to the stone, thereby reducing energy loss and improving fragmentation while reducing stone retropulsion. The technology requires use of their special Moses laser fibers. In a preclinical study, the use of the Moses technology resulted in significantly reduced retropulsion (stone movement was reduced by 50 times) and more efficient laser lithotripsy. In vivo assessment also suggested less ureteral damage in a porcine model using the Moses mode compared with regular mode (Elhilali et al., 2017). Similar results were also demonstrated in a stone simulator model (Ibrahim et al., 2017).

Thulium:YAG.

The thulium:YAG (Thu:YAG) laser is a continuous wave laser operating at a wavelength of approximately 2000 nm. It differs from the Ho:YAG laser in that the thulium ions are excited by high-power laser diodes instead of flashlamp excitation as in the Ho:YAG. As a result, there is less heat generation and increased power efficiency by a factor of five with the Thu:YAG laser, and no special electrical installation is needed to operate the laser (Teichmann et al., 2007). The slightly shorter wavelength compared with the Ho:YAG laser results in slightly less depth of tissue penetration. The continuous wave output promotes more of a direct cutting action of the laser versus tissue tearing and splattering with the pulsed output of the Ho:YAG. As the tissue is cut with the Thu:YAG, a seam of coagulated tissue is created and produces hemostasis. The coagulated tissues retain some water for efficient absorption of the laser energy during subsequent tissue passes (Teichmann et al., 2007).

Similar to other lasers, the Thu:YAG has been used in a variety of ways to treat BPH. Early reports described a tangerine technique in which the prostate was cut into slices with the laser (Xia et al., 2005). Hybrid techniques involving vaporization and resection (vaporesection) were developed and shown to be effective (Bach et al., 2010). Thulium laser enucleation of the prostate followed and was demonstrated to have results similar to HoLEP (Lancono et al., 2012; Netsch et al., 2017; Zang et al., 2012).

In stone lithotripsy, there appears to be very little stone retropulsion with the Thu:YAG laser, even at higher energy settings (8 J) (Kamal et al., 2016).

Carbon Dioxide.

The CO_2 laser produces a beam of infrared light with a wavelength of 9.4 to 10.6 µm. It is strongly absorbed by water and used for numerous medical purposes including dermatologic applications. It is a continuous wave laser and highly efficient with a ratio of output power to pump power of 20%. The infrared beam is delivered with a rigid arm containing a series of mirrors (Malek, 1992; Stein and Kendall, 1984b). In urology, it is primarily used to treat skin lesions such as condyloma, but it is also used to treat penile carcinoma when an organ-preserving strategy is employed (Bandieramonte et al., 2008; Colecchia et al., 2009; Finkelstein, 1984).

Intracorporeal Lithotripters

Table 15.1 summarizes characteristics of commonly used intracorporeal lithotripters.

TABLE 15.1

Characteristics of Commonly Used Intracorporeal Lithotripters

MODALITY	BLADDER	URETER	KIDNEY	FLEXIBLE	CONTACT	MI OF
EHL	✓	✓	✓	✓	1 mm from stone	Ele pro bul sub cav bul sho tha sto
Ultrasonic	✓	✓	✓	✓	Direct contact	Ra vib tip fra wh sin asp ren
Pneumatic	✓	✓	✓		Direct contact	Ba rep stri sin jac

Ho:YAG laser	✓	✓	✓	✓	Direct contact	Ph en rap an dis sto pr fra
Combination ultrasonic/pneumatic	✓		✓		Direct contact	Si pn ult lit

EHL, Electrohydraulic lithotripsy; *Fr,* French; *Ho:YAG,* holmium:YAG.

Electrohydraulic Lithotripsy

Electrohydraulic lithotripsy (EHL) has been implemented in biliary, pancreatic, and renal calculi. Initially employed in 1950 for bladder stones using 9-Fr probes, renal applications through flexible ureteroscopy became possible with technologic advances. First described in 1988, at a time when laser fiber technology was unable to flex in the same way, EHL became an innovative strategy to treat lower pole kidney stones endoscopically. Since then, more contemporary modalities have improved efficiency while minimizing complication risks.

Physics and Mechanism of Action

Two electrodes are positioned at the tip of the probe, creating a spark when triggered. **Immersed in a liquid, the electrical spark creates an immediate transition from fluid to gas, creating a rapidly expanding plasma shockwave radiating from the spark outward 360 degrees. The collapse of this shockwave creates a cavitation bubble, which creates a secondary shockwave and high-pressure microjets** (Vorreuther et al., 1995).

By adjusting spark discharge, the electrical and subsequent acoustic fragmentation potential can be optimized. Vorreuther and Engelking (1992b) identified that higher-voltage shocks produce linearly increasing peak pressures and steeper shockwave fronts. Lower-capacity probes produced shorter currents and shorter sparks with more narrow pulse widths. Because fluid vaporization provides the force required for fragmentation, a small space between the probe and stone is recommended during fragmentation. Typically, 1 mm is required because increasing the probe-to-stone distance leads to exponential decreases in shockwave power.

Probes between 1.9 and 3.3 Fr are available. Thinner probes are considered more versatile because of their application in flexible and semirigid ureteroscopy. Reducing probe diameter does not clearly lessen fragmentation potential; however, durability is decreased (Elashry et al., 1996). Pressure generated by EHL probes is estimated using the following formula:

$$\begin{aligned}&\text{Maximum pressure}\\&\quad = \text{Energy}/(\text{Pulse duration} \times \text{Fiber cross-sectional diameter})\end{aligned}$$

Tissue Effect

Vorreuther et al. (1995) attempted to quantify tissue damage resulting from the use of a 3.3-Fr Wolf EHL probe. With use of freshly harvested human ureters, researchers measured histologic changes after direct contact with the EHL probe. At 100 mJ, only punctate mucosal injuries were noted, whereas increasing to 400 to 600 mJ caused superficial mechanical defects in the muscularis. Increasing the energy to 1000 mJ caused transmural perforations. Microscopically, no thermal injuries were noted, and defects appeared to be due to mechanical disruptions, although limited to the cross-sectional diameter of the probe. When constant energy levels were maintained, altering voltage and/or capacity did not affect the resulting histologic findings. No damage was encountered at a distance of 1 mm between the probe tip and mucosa, even at maximal energy and pulse rates (Vorreuther et al., 1995). In a porcine model, bladder exposure to varying energy and total pulse numbers was performed using a 3-Fr probe. Scanning electron microscopy identified that the depth of mechanical mucosal denudation correlated independently with the energy setting and number of delivered pulses (Wu et al., 1994).

When tested in an intact ureter, the probe tip was centered in the lumen, and no histologic damage was encountered at energy settings less than 500 mJ/pulse. When energy levels reached 1000 mJ, a single pulse could produce a 1-cm longitudinal ureteric perforation. Thought to be secondary to cavitation bubbles, which can reach 1.5 cm in diameter at greater than 1300 mJ, the rapid expansion effectively burst the ureter (Vorreuther et al., 1995). The safe use of this (and any other) lithotripter requires a working knowledge of the physics behind stone fragmentation and the collateral effects on surrounding fluid and tissues (Fig. 15.3).

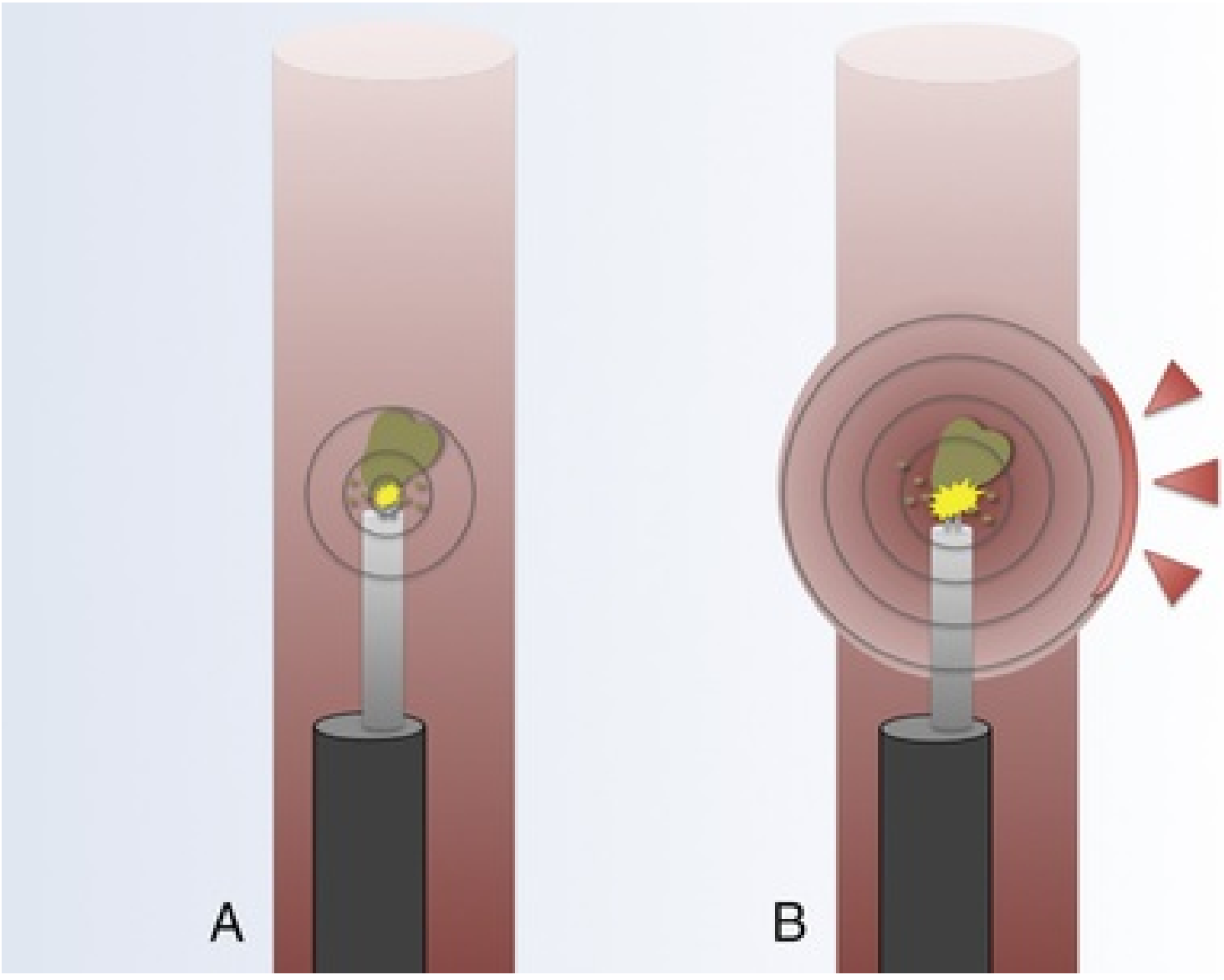

FIG. 15.3 (A) Electrohydraulic lithotripter probe spark producing a concentric shockwave within the ureter. (B) Higher energy settings create cavitation bubbles up to 1.5 cm, increasing the risk of ureteric injury and/or perforation.

Ureteroscopy

Initially, ureteral stone fragmentation with EHL was performed before the ability to visualize the upper urinary tract directly was available. When scope technology allowed adequate visualization with a sufficient working channel, EHL became a viable option for stone treatment (Goodfriend, 1984).

The collateral damage of EHL causing ureteral perforations during lithotripsy was reported in early studies using blind, fluoroscopically guided probe positioning and unreported energy settings (Goodfriend, 1984; Watson et al., 1987). In contrast, a series of 82 ureteroscopic cases using 2.4-Fr and 3.3-Fr probes through a 6.5-Fr semirigid ureteroscope reported no complications or perforations during lithotripter use and no strictures at 6 months (Vorreuther and Engelking, 1992a). **In 99% of cases, probe-to-stone contact was made, and using adjustable energy settings (265 to 1382 mJ/pulse), the average pulse energy was 450 mJ, resulting in 90% success rates.**

Elashry et al. (1996) performed a retrospective review of 45 patients failing extracorporeal shockwave lithotripsy (ESWL) who underwent EHL fragmentation. Performing 36 cases using flexible ureteroscopes (and a 1.9-Fr probe), 64% were interpolar and 17% were lower pole stones. Of the cases, 98% were considered successful (fragments <2 mm on direct visualization). Lower pole stones were effectively treated in 94% of patients, and at the time, laser fibers were not flexible enough to achieve active deflection into the lower pole. Another study of 114 patients undergoing flexible ureteroscopy confirmed the effective lower pole fragmentation by EHL; no statistical difference was noted between intrarenal stones based on location, and overall stone clearance rate was 80% (which decreased to 50% for stones >2 cm) (Dasgupta et al., 2004).

Larger stones have been successfully treated with flexible ureteroscopy and EHL when combined with Ho:YAG laser. Mariani (2007) reported on 15 patients with stones 2 to 4 cm (Kressel et al., 1992) and 17 patients with stones greater than 4 cm. With up to four outpatient treatment sessions, endoscopic management included laser lithotripsy to weaken large stones and EHL to debulk the fragments. The stone-free (fragments <4 mm) rate was 90%, and no reports of perforations or follow-up strictures were noted. Although not the current standard of care for stones of this size, with improvements in flexible scope and probe technology, larger stone burdens are commonly being attempted ureteroscopically.

Chemical stone composition has been shown to affect fragmentation efficiency during EHL ureteroscopy. A review of operating room times for 193 patients was compared with the chemical composition of ureteric stones. Uric acid stones required the most time, followed by calcium oxalate monohydrate, and in multivariate analysis, stone size was negatively associated with successful fragmentation (Song et al., 2012). This association may be due to the smooth outer surface and lamination of uric acid stones being more difficult for shockwave-generated fragmentation.

Bladder Stones

Cystolithotripsy was the initial application for EHL, and the reduced morbidity experienced with intracorporeal lithotripsy under direct vision was a major stepping-stone for endoscopy in urology. Although initial reports showed poor recurrence rates of bladder stones with EHL (50%) compared with vesicolithotomy (7.4%) (Short et al., 1984), very few complications were encountered. Since 1981, older patients were being treated, and cystolithotripsy was being combined with concurrent TURP (Bülow and Frohmüller, 1981). Because tip breakage and bladder perforations can still occur, it still must be used with caution (Bülow and Frohmüller, 1981; Pelander and Kaufman, 1980).

Key Points: Electrohydraulic Lithotripsy

- EHL probes create a spark, which produces a rapidly expanding plasma shockwave and cavitation bubble with high-pressure microjets.
- Increasing the distance from the target reduces its peak pressure exponentially.
- At less than 500 mJ, mucosal injuries are rare; at greater than 1000 mJ, the risk of tissue damage is increased.
- A 1.9-Fr probe can be used with flexible ureteroscopy and allows active deflection for acceptable rates of stone fragmentation in all calyces.
- Chemical stone composition and surface characteristics affect the efficiency of EHL fragmentation.

Pneumatic Lithotripsy

Pneumatic lithotripsy provides a versatile and dependable approach to urolithiasis throughout the genitourinary tract. Early clinical reports confirmed the efficacy of pneumatic lithotripsy, and success rates of 95% (Teh et al., 1998) have been reported. **With good fragmentation effect in hard stone compositions and attractive safety ratings, it continues to be popular globally in upper and lower tract stone disease.**

Basic Physics

Pneumatic lithotripsy uses ballistic forces to transfer kinetic energy from a handheld probe to the stone surface (Michel et al., 2008). Either compressed gas (medical air or CO_2 cartridges) or electromagnetic oscillations are used to drive a projectile forcefully against the probe tip, thrusting it forward like a piston. **Repetitive strikes (LithoClast [Boston Scientific, Marlborough, MA/Electro Medical Systems, Dallas, TX]), 12 Hz; electrokinetic lithotripter, 15 to 30 Hz) from the probe tip act as a jackhammer, fragmenting stones at the point of contact. When applied to compliant surfaces such as soft tissue, the impact energy is absorbed and dispersed, whereas rigid objects are not compliant, resulting in fracture.** Pneumatic lithotripters are safe for use in close proximity to the mucosa because soft-tissue injuries from probe contact are relatively mild (see following). Other advantages of pneumatic lithotripters are their durability, simplicity of use, and completely reusable components (Hofbauer et al., 1995). Adding to dependability are the successful fragmentation of all chemical stone composition (Teh et al., 1998) and the ability to use interchangeable probes to facilitate stone breakage anywhere in the genitourinary tract.

Probes are available in diameters of 0.8 mm (2.4 Fr), 1 mm (3 Fr), 1.6 mm (4.8 Fr), 2 mm (6 Fr), and 3.5 mm (10.5 Fr). In a head-to-head bench comparison of pneumatic (4.8-Fr probe, 2.5 bar), EHL (3-Fr probe, 80% power), laser (0.32-mm fiber, 100 mJ), and ultrasonic (4.5-Fr probe, power setting 3) lithotripters by Teh et al. (1998), fragmentation efficacy index (minutes per gram of fragmented stone) was compared. Pneumatic lithotripsy (5.00 ± 0.94 min/g) was the least efficient, whereas ultrasonic was the most efficient (8.49 ± 1.15 min/g), followed by laser (7.62 ± 0.78 min/g) and EHL lithotripters (6.60 ± 1.58

min/g). When probe sizes were increased at constant pressures (2 bar), incremental improvements in fragmentation were noted (3 Fr = 14 min/g, 6 Fr = 6 min/g). Pneumatic lithotripsy is effective in fragmenting harder stones and is less efficient in very soft stones; this is likely because the jackhammer effect produces numerous tiny fragments or because, in the case of extremely soft stones (i.e., matrix stones), the probe punches holes into stones without fragmentation.

Tissue Effects

A survival porcine model was used to test the short-term and long-term effects of 5- to 7-second bursts of LithoClast mucosal exposure to bladder and ureteric urothelium. A short duration was selected to simulate inadvertent contact experienced during stone fragmentation. Histologic changes in immediately sacrificed animals included focal areas of hemorrhage with mucosal erosions and transmural edema. At 3 and 6 weeks, the treated areas were unidentifiable, and histology failed to identify any significant changes. All animals experienced 24 to 48 hours of hematuria but failed to show any other systemic or diagnostic differences (Denstedt et al., 1995).

In a four-way comparison of intracorporeal lithotripters on iatrogenic urothelial trauma, Piergiovanni et al. (1994) **found perpendicular exposure to pneumatic probes to be the least traumatic (compared with laser, ultrasonic lithotripsy, and EHL).** Assessing perforation thresholds for each modality at 250 pulses, the 0.8-mm probe perforated ureteric walls, whereas larger probes (1- and 2-mm probes) were unable to perforate the ureter or bladder, regardless of total number of pulses.

Ureteroscopy

Thin pneumatic probes ranging from 0.8 to 1 mm are easily accommodated by ureteroscopes and are commonly used for semirigid ureteroscopy. Because of the high safety threshold, fragmentation efficacy, and cost effectiveness, it continues to be a popular modality. Comparing the shearing potential of four intracorporeal lithotripters on endoscopic baskets, **pneumatic devices are the only modality not to cut through wire** (Cordes et al., 2011). In ureteroscopy, where safety guidewires, trapped or hung baskets, and antiretropulsion devices may lie in close proximity to targeted stones, pneumatic lithotripters can provide an additional level of safety. Knowing that mucosal injury and wire damage are minimized with this technology may help provide confidence when aggressively treating difficult ureteric stones.

Probe size and pulse frequency settings can alter fracture efficiency. Even with the smallest diameter probes, hard stones can be fragmented through anterograde or retrograde ureteroscopy. An in vitro study using avian gut as a ureteric model examined the differing fragmentation rates of 5-mm phantom stones using different probes and settings. **Increasing probe diameter (0.8 to 1.6 mm) and pulse frequency (6 to 12 Hz) independently decreased the total number of required pulses to treat the stones completely** (Shadpour et al., 2009).

Stone migration is a significant disadvantage when treating ureteric stones because the ballistic effect of the probe can propel stones in capacious ureters into the kidney. Retropulsion has been reported in 10% of distal and 40% of proximal stones treated with pneumatic lithotripsy (Knispel et al., 1998). If flexible instruments are not readily available, stones washed into the kidney may require secondary procedures (i.e., ESWL). The risk of fragment migration is related to site, degree of impaction, size, lithotripsy modality, irrigation system, and degree of proximal ureteric dilation (Delvecchio et al., 2000; Hendlin et al., 2008; Lee et al., 2003). Antiretropulsion strategies such as stone pinning (between probe and urothelium), reverse Trendelenburg positioning, basket stabilization, and proximal placement of lidocaine gel may be used. Specific antiretropulsion products include the Stone Cone (Boston Scientific, Marlborough, MA), N Trap (Cook Urological, Spencer, IN), Passport Balloon (Boston Scientific), Parachute (Boston Scientific), Accordion (PercSys, Palo Alto, CA), and BackStop (Boston Scientific). Developed for markets where flexible instrumentation is not feasible, these products may help reduce the risk of stone migration (Bastawisy et al., 2011).

A randomized controlled trial of Ho:YAG laser (365 µm) and pneumatic lithotripsy (2.4-Fr probe) was performed in 79 patients undergoing semirigid ureteroscopy. Mean stone size was 12 mm, and most stones were located distally. Laser lithotripsy resulted in a superior stone-free rate at 1 month on radiographic and ultrasound follow-up (95% vs. 80.5%). Stone retropulsion was more common with pneumatic lithotripsy, and no significant complications were reported in either arm (Maghsoudi et al., 2008). A retrospective review of 500 patients treated from 1995 to 2002 showed that **stone-free rates are dramatically affected by stone position and size.** Stone-free rates for stones 10 mm or less were 97.1% for distal ureteric stones and 91% for proximal stones. For stones greater than 10 mm, distal stone-free rates were 89% for distal stones and 71.4% for proximal stones (Sözen et al., 2003). With a 6.4% overall complication rate, only 1.4% of patients developed mucosal injuries or perforations as a result of probe use.

Two series highlighted the safety of pneumatic lithotripsy in pregnant women with symptomatic ureteral stones (Abdel-Kader et al., 2013; Hoşcan et al., 2012). In both reports, the mean gestational age at presentation was 25 to 26 weeks, and most stones were located in the distal ureter. Using semirigid ureteroscopy, a stone-free rate of 85.3% to 100% was reported with no major anesthetic, surgical, or obstetric complications (Abdel-Kader et al., 2013). One patient developed premature contractions, which did not progress to early labor.

Ideally, a semirigid ureteroscope with a straight end on working channel should be used for pneumatic stone treatment because bending pneumatic probes reduce the transmitted energy from the generator to the stone (Grocela and Dretler, 1997). Although 2.4-Fr probes are flexible and can be accommodated by flexible ureteroscopes, an analysis by Zhu et al. (2000) quantified the energy loss secondary to probe bending. By measuring tip mechanics, impact momentum decreased 50% and energy by 76% when probe tips were deflected 33 degrees. With 48 degrees of deflection, only 30% of full fragmentation efficiency could be achieved.

Bladder Stones

Transurethral (Khosa et al., 2012; Rabani, 2012; Teh et al., 1998) **and percutaneous** (Agrawal et al., 1999; Wollin et al., 1999) **pneumatic lithotripsy have been found to be useful in large hard stones such as calcium oxalate monohydrate and cystine stones** (Denstedt et al., 1992). A retrospective series comparing ultrasonic, pneumatic, and mechanical lithotripsy for bladder stones showed equal efficacies for stones less than 3 cm (Razvi et al., 1996).

Khosa et al. (2012) reported a series of 100 children younger than 15 years old from Pakistan who underwent pneumatic cystolithotripsy using a 4-Fr “mini-scope” or a 7/8.5-Fr ureteroscope for bladder stones less than 3 cm. The average patient was 5 years old, and all surgeries were performed as outpatient procedures. Only 5% of patients developed hematuria, and one experienced postoperative urinary retention.

Cases of calcified foreign bodies such as encrusted ureteric stents (Grocela and Dretler, 1997) and eroded transobturator tapes (Osório et al., 2011) have been treated with pneumatic lithotripsy. An advantage of this modality with retained stents is that pneumatic lithotripters can be applied safely in transurethral or percutaneous cystolithotripsy, ureteroscopy, and percutaneous nephrolithotomy. Also, when stones abutted against the urothelium must be fragmented, pneumatic lithotripsy is safe to make contact with the urothelium for short periods.

Single setting TURP and percutaneous or transurethral pneumatic lithotripsy have been reported as treatments in patients in whom outlet obstruction is the precipitating cause of bladder stones (Aron et al., 2007; Sinik et al., 1998). Stone removal is performed initially, and if a percutaneous approach is used, the working sheath is maintained until after TURP to reduce the risk of extravasation. In a comparative analysis of patients undergoing either percutaneous or transurethral lithotripsy with simultaneous TURP, the percutaneous approach (using a 30-Fr sheath) decreased stone removal time by 45% and the need for secondary procedures (Tugcu et al., 2009). Patients who underwent purely transurethral procedures had their catheters removed earlier (2.2 days vs. 3.2 days) and had shorter admissions (1.2 days vs. 2.3 days); however, three patients (7.9%) developed subsequent urethral strictures.

Percutaneous Nephrolithotomy

Similar to treatment of bladder stones, percutaneous nephrolithotomy allows the use of larger scopes and larger probes. A Canadian trial comparing the StoneBreaker (Cook Urological, Spencer, IN) with the Swiss LithoClast showed improved fragmentation times, reduced setup time, and decreased user fatigue with the StoneBreaker. No differences in stone-free rates or complications were noted. The LithoClast uses medical air and requires a pedal for activation, whereas the lighter-weight StoneBreaker uses a CO_2 cartridge, is triggered by hand, and produces 10 times the impact pressure. Because pneumatic lithotripsy is valuable in large and hard stone compositions, it has been combined with ultrasonic lithotripters to improve on the advantageous characteristics of both modalities (see following). The Clinical Research Office of the Endourological Society reviewed 5800 percutaneous nephrolithotomy procedures (from 96 centers) to assess success rates based on mean Hounsfield units and various surgical characteristics. On regression analysis, pneumatic lithotripsy showed the highest probability of stone-free status (90%) even when compared with combination ultrasonic/pneumatic modalities (82%) (Anastasiadis et al., 2013).

Key Points: Pneumatic Lithotripsy

- Pneumatic lithotripsy uses compressed air to drive a projectile forcefully against the probe tip, transmitting repetitive ballistic forces to the stone surface similar to a jackhammer.
- Causing limited mucosal erosions and transmural edema, pneumatic lithotrites cause the least amount of trauma compared with other intracorporeal lithotripters.
- The efficiency of stone fragmentation is improved by increasing probe diameter and pulse frequency independently.
- Stone migration is a significant disadvantage when treating ureteric stones with pneumatic lithotripsy.

Ultrasonic Lithotripsy

Ultrasonic lithotripsy affords a straightforward method of stone fragmentation, while simplifying extraction. **Instead of manually extracting fragments after treatment, a central channel for suction provides simultaneous stone debris aspiration during lithotripsy.** The most common applications currently are percutaneous nephrolithotomy and cystolithotripsy, although applications in ureteroscopy exist.

Basic Physics

Ultrasonic lithotrites pass electrical current through piezoceramic crystals, producing directional sound waves of 23,000 to 27,000 Hz. The hand piece houses the piezoelectric interface, and waves propagate as mechanical vibrational energy longitudinally down a solid or metal probe to where contact is made with the stone (Segura and LeRoy, 1984). **As the metal probe vibrates, when contact is made with the stone, this reverberation transmitted to the stone causes fracturing** (Teh et al., 1998) **along with the mechanical trauma of the oscillating metal tip against the surface** (LeRoy and Segura, 1984). Solid metal probes disintegrate stones by transmitting mechanical energy in a transverse plane, rather than longitudinally as with hollow probes. Local fracture can produce fine debris, which is aspirated by the probe; or if the probe is applied to fault lines, regional breakage can be created, leading to larger fragments.

Tissue Effects

Using an amplitude of 50 μm, no perforations could be created in rabbit bladders. Edema and submucosal hemorrhages were caused when only suction was applied, and irrigation (20 mL/min) kept frictional heating to a minimum. Metal splinters were observed embedding into the bladder wall, but after 9 weeks, minimal inflammation was noted on histology (Stackl and Marberger, 1985).

Piergiovanni et al. (1994) compared the Olympus ultrasonic lithotripter with EHL, pneumatic, and Ho:YAG laser lithotripters to assess tissue effects on a porcine bladder. **Ureteral and bladder perforations were impossible with**

perpendicular application of the ultrasonic and pneumatic probes. Histologic analysis immediately after application displayed denuded epithelial layers and edema.

When applied to immediately removed human renal pelvis samples (postnephrectomy), perpendicular application of suction alone caused 50% to 80% mucosal denudation, whereas the ultrasonic probe (21,000 Hz) caused 100% mucosal stripping with no evidence of muscularis injury, regardless of application time (Khemees et al., 2013a). A case report from 1988 described symptomatic hyponatremia during cystolithotripsy using an ultrasonic lithotrite and distilled water with a resulting intraperitoneal perforation. Although this treatment is not common today, it highlights that clinical conditions may not always reflect animal or in vitro models, and caution should still be exercised (Batra et al., 1988).

Ureteroscopy

The first clinical series reporting the use of ultrasonic lithotripsy comprised 412 patients treated for bladder stones in 1984. Probe diameters range from solid 2.5-Fr probes (for semirigid ureteroscopy) to 6.0-Fr used for cystoscopy and nephroscopy. Several bladder stone series corroborate the low complication rates and high success rates for stones of varying sizes using transurethral and suprapubic approaches (Cetin et al., 1988; El Khader et al., 1995; Razvi et al., 1996). A review of 176 patients **undergoing** bladder stone surgery during 1976 to 1994 noted an 88% success rate for ultrasonic lithotripsy, failing with “very hard stones” (Razvi et al., 1996).

Ureteroscopic fragmentation using ultrasonic probes was slower to gain popularity because of the required advancement in ureteroscopic technology and reduced probe sizes (2.5–4.5 Fr) required. With 2.5-Fr “solid wire” probes, a central lumen for aspiration is impossible. Some flexibility can be achieved for applications requiring active deflection during flexible ureteroscopy. Because EHL, pneumatic lithotripsy, and laser lithotripsy gained popularity around the same time as solid wire probes were developed, ureteroscopic applications of this technology never reached the same popularity as use of the technology in upper and lower tract indications (Gur et al., 2004). Preliminary reports documented flexible ultrasonic probes used through fiberoptic flexible scopes, resulting in an 87.5% success rate in 16 patients (Higashihara and Aso, 1989).

Pedro and Netto (2008) compared ESWL with ultrasonic lithotripsy in 235 consecutive patients with proximal ureteric stones with near-equal efficacy (85.6% ultrasonic lithotripsy vs. 90% ESWL success rates) and no differences in complication rates and mean procedure times. A review of all semirigid ureteroscopic ultrasonic series by Gur et al. (2004) identified 9 studies from 1983 to 1999 ranging from 7 to 311 patients. Pooled analyses of 863 patients identified an overall fragmentation rate of 89%, perforation rate of 2.5%, and “other complications” rate of 3.8% (including strictures, avulsions, sepsis, and false passage formation).

Percutaneous Surgery

Applications in percutaneous surgery closely followed cystolithotripsy, and by the mid 1980s, ultrasonic lithotripsy was being applied to percutaneous renal surgery (Segura and LeRoy, 1984). Used in pediatrics, horseshoe kidneys (Holman et al., 1986), and total staghorn calculi (Rodrigues Netto et al., 1988), ultrasonic lithotripsy has been a versatile tool in percutaneous surgery. In approaches ranging from anatrophic nephrolithotomy to percutaneous surgery, ultrasonic fragmentation was found to reduce operating times (from 210 minutes to 120 minutes), admission times (from 7 days to 5 days), and secondary interventions (from 50% to 20%), with a much earlier return to normal physical activity (43 days vs. 9 days) (Rodrigues Netto et al., 1988).

Newer combined technologies have improved on the fragmentation capabilities of ultrasonic lithotripsy by combining it with pneumatic lithotrites (see following). Dual-modality fragmentation with combined ultrasonic lithotripsy and pneumatic lithotripsy showed improved stone-free rates (92% vs. 85% ultrasonography alone), fewer secondary procedures, and decreased operative times without an increase in complication rates (Cho et al., 2010). With regard to harder stones, a prospective randomized trial assessing 30 patients with cystine, calcium oxalate monohydrate, or calcium phosphate stones showed a clear advantage for combined fragmentation, whereas softer stones had more favorable results with the ultrasonic lithotripter alone (Lehman et al., 2008).

Because contact must be made between the probe and stone, drilling or painting motions are used to trap the stone between urothelium and the probe. Smaller stones may be brought to the probe and held in place with suction alone. Continuous irrigation helps improve visualization, decrease heat buildup, and wash stone debris through the probe. When soft stones (e.g., struvite) are encountered, complete fragmentation and suction removal of the stone may be facilitated with ultrasonic lithotripsy. For harder stones, a drilling technique can be used to fracture the stone into manually extractable stones.

Larger pieces can be fragmented further or extracted manually. **Using continuous irrigation and suction keeps the probe tip cool while continuously removing particles** (Hofmann et al., 2002). As the fluid is evacuated through the hand piece, it cools the piezoceramic crystals, which can rapidly increase in temperature if proper suction is not maintained. Without adequate suction, in addition to a noticeably hot hand piece, visualization and stone clearance are impeded. It is important to tailor suctioning to the irrigation rate during probe activation; otherwise air can be introduced when aspiration outpaces irrigation inflow, obscuring the field with bubbles. This situation can be avoided by reducing the suction pressure, increasing irrigation height (or pressure), or intermittently clamping the suction tubing to allow enough fluid to remain in the renal pelvis/bladder for distention and visualization.

Key Points: Ultrasonic Lithotripsy

- Piezoceramic crystals produce directional sound waves of 23,000 to 27,000 Hz. Vibrational energy is transmitted from the probe tip to the stone surface, and fragment debris are aspirated through the central lumen of the tip.
- In vitro testing shows that direct contact with the urothelium causes mucosal stripping, although deeper perforations are difficult to achieve.
- Ultrasonic lithotripsy is useful in large soft stones; however, for harder stones, ultrasonic lithotripsy is most efficacious when paired with pneumatic lithotripsy in dual-modality lithotrites.

Holmium:YAG and Erbium:YAG Laser Lithotripsy

Holmium:YAG lasers have revolutionized kidney stone management and flexible ureteroscopy. In conjunction with improved optical systems in actively deflecting ureteroscopes, all areas of the genitourinary tract are now safely accessible for endoscopic lithotripsy using these lasers. Preliminary testing of the Er:YAG laser showed improved fragmentation efficiency of kidney stones compared with the Ho:YAG laser. Producing larger fragments with a smaller soft tissue penetration depth, this technology holds promise for future application in endourology.

Basic Physics

Laser physics for tissue-based applications are discussed in detail in Laser Instrumentation: Soft Tissue Applications.

Early on, questions surrounded the mechanism of lithotripsy of holmium lasers. Preceding technologies, such as the ruby and Nd:YAG lasers, used photoacoustic or photomechanical processes, in which light energy created shockwaves that fragmented stones. In contrast, photothermal stone breakage during holmium laser use was hypothesized based on early observations of “glowing hot stones.” Photothermal processes involve direct light energy absorption (“photo”) by stone surfaces causing rapid temperature (“thermal”) increases, before significant heat diffusion can occur.

Using a combination of techniques, Chan et al. (1999) **identified the predominant mode of Ho:YAG lithotripsy to be photothermal.** Mass loss experiments showed less fragmentation when stones −80°C were treated. As expected with a thermal mechanism, more energy was required to increase temperatures to ejection thresholds when starting below physiologic temperatures. After treatment, chemical analysis of all stone types showed thermal breakdown components. Finally, synchronized photography failed to identify fragmentation during bubble expansion or collapse, and measured pressures were too low (2 to 20 bar) to induce fracture.

Ablation crater volumes are associated with the irradiated surface photon density (fluence) and pulse energy. A “Moses effect” occurs by the rapid vaporization of fluid creating a vapor channel between the fiber tip and stone surface, allowing for more direct energy transfer. Although photoacoustic forces are not thought to contribute to fracture, interstitial water vaporization is likely involved with fragment ejection. Tensile and compressive forces, which dictate Nd:YAG lithotripsy, ESWL, and EHL, are not important (Chan et al., 1999).

Ho:YAG lasers produce fine fragments in large part because of photothermal energy absorption by urolithiasis; this results in the breakdown and disintegration of the heated area, causing craters and fragmentation (Qiu et al., 2010). As a result of the relatively long pulse rate (250 to 350 µsec), the Ho:YAG laser is considerably less efficient than other shorter pulse lasers. Because erbium (Er):YAG lasers have a shorter pulse duration and longer wavelength (2940 µm), they can still produce small fragments, but with improved efficiency over Ho:YAG lithotripsy.

The Er:YAG laser uses optical energy, and similar to Ho:YAG, irradiation of the stone's surface leads to increasing temperatures. Er:YAG lasers produce a 2940-nm wavelength, which has a fivefold increase in photothermal absorption by urolithiasis. Although shockwave production is insufficient for stone breakage in Ho:YAG lasers, Er:YAG lasers also show improved photoacoustic vapor bubble force transmission. With higher acoustic transients, the Er:YAG laser forms a torpedo-shaped vapor bubble in the interfacing fluid between probe and stone. The vapor bubble of the Ho:YAG laser is pear shaped, leading to increased energy loss laterally, producing weak shockwaves with minimal effect on stone fracture.

The radiant threshold for Er:YAG to initiate lithotripsy is 0.47 J/cm^2 at 2940 nm for calcium oxalate monohydrate compared with a Ho:YAG threshold of 7.36 J/cm^2. Deeper craters and larger ablation volumes are produced at this wavelength (Lee et al., 2006). **The combination of effective photothermal and photoacoustic lithotripsy of Er:YAG leads to faster fragmentation, with larger subsequent pieces.** In vitro studies showed larger fragments are created by Er:YAG; however, calcium oxalate monohydrate and cystine stone lithotripsy resulted in fragments less than 1 mm for both lasers, which clinically would be considered equivalent. Soft tissue depth of penetration is 0.79 µm, which is a significant improvement in safety compared with Ho:YAG (0.5 to 1 mm).

A problem with Er:YAG laser technology is that the hydroxy silica quartz fibers used in Ho:YAG machines are not compatible. Although sapphire fibers used with Er:YAG are too brittle and thick to be used in routine endourologic procedures, salivary stones were treated in wet-field applications using semirigid instrumentation (Raif et al., 2006). ZBLAN fluoride glass fibers have favorable properties in regard to reflection losses and light attenuation. However, because of a much lower melting point, durability is inadequate for clinical use. Before this technology can be applied to kidney stones, improved mechanical, thermal, and chemical fiber reliability is required. Hybrid fibers using fluoride cores with sapphire protection tips and circumferential cladding may help provide the transmission and flexibility required for endourology (Qiu et al., 2010).

Ureteroscopy

By reducing the diameter of ureteroscopes, slender intracorporeal lithotripters must pass easily through a working channel smaller than 4 Fr while allowing room for irrigation. These instruments also must be durable enough to be advanced and retracted repeatedly through a scope without breaking, even when deflected 270 degrees. Ho:YAG laser lithotripsy fulfills these requirements because hydroxy silica fibers are thin, flexible, and durable and possess transmission efficiencies, allowing for effective photothermal stone fragmentation.

Flexible ureteroscopy typically uses 200-µm laser fibers, which have a minimal impact on scope deflection. For semirigid ureteroscopy, 365-µm fibers are more suitable, although they can be used with flexible nephroscopy if minimal deflection is required (i.e., upper pole stones). Smaller semirigid ureteroscopes such as the 4.5-Fr needle (Richard Wolf, Vernan Hills, IL) have smaller working channels, and smaller laser fibers (<300 µm fibers) are preferred to allow for adequate irrigant flow. These are considered workhorse fibers because they have been shown to display maximal efficiency and durability while being typically cheaper (than 200-µm fibers) (Kuo et al., 1998).

Laser fiber tips should be advanced until clearly visualized by the operator (about one-fourth of the screen) (Talso et al., 2016). During flexible ureteroscopy, this may become problematic for lower pole stones because fiber advancement can damage the scope liner or optics or fracture the fiber itself. If a fractured fiber is used while in a scope, catastrophic damage and costly repairs can result. Fiber advancement should be performed with the scope tip in neutral position and then actively deflected to the area of interest. Newer fibers (i.e., Flexiva TracTip [Boston Scientific, Marlborough, MA]) have been created with a carved bulbous tip, theoretically allowing the fiber to pass through an already deflected scope without damage. The cladding helps permit high energy transfer even when bent, and using a 240-µm core, it is rated to handle settings up to 50 W. In an analysis of 96 clinically used fibers, none were broken. Bench testing revealed only a loss of 5 degrees of ureteroscopic active deflection (U-500 flexible ureteroscope [Stryker Endoscopy, San Jose, CA]; from 275 degrees to 270 degrees) (Khemees et al., 2013b). Alternatively, for stone repositioning from difficult-to-reach areas to the upper pole, using endoscopic baskets may help reduce the need for prolonged extreme deflection.

Ureteroscopic laser fragmentation can be performed by several techniques. Dust-sized fragments are produced by painting the fiber across the surface of a stone. Avoiding the creation of large fragments that are difficult to pass makes basket extraction unnecessary. With the use of lower energy levels of 0.2 J and higher pulse rates (i.e., 40 Hz), small debris and minimal retropulsion are encountered while trading off a reduction in total fragmentation. Controlling for total energy, increasing pulse energy levels were found to result in larger fragments with faster fragmentation times. Alternatively, as laser fragmentation becomes more time consuming as fragments become smaller, the surgeon can create large pieces and remove them using an endoscopic basket (Sea et al., 2012).

A technique dubbed “popcorning” uses the photoacoustic and the photothermal mechanisms of laser lithotripsy. **Photoacoustic and photothermal properties of a laser are functions of pulse duration and energy. Longer pulse duration produces greater photothermal functionality.** Although most Ho:YAG lasers have fixed durations of 250 to 350 µm, adjustable units are becoming more common. Shorter pulses yield higher peak power in resulting shockwaves. **Longer pulse duration reduces stone retropulsion and fiber tip degradation, with similar stone fragmentation rates compared with shorter pulse duration** (Bader et al., 2015; Kang et al., 2006; Wollin et al., 2017). In a ureteric model, increasing pulse duration from 300 to 700 µm reduced stone retropulsion by 50% (Finley et al., 2005). Pulse duration is inversely related to power and can manipulate stone motion depending on the circumstance; this can be helpful in difficult-to-reach anatomy (i.e., lower pole stones) or when numerous fragments exist in a confined area (i.e., minor calyx). The fiber tip is placed several millimeters away from the stones (and mucosa), and shockwaves produced by vapor bubbles collapsing cause stones to bounce like popcorn. As stones are agitated, intermittent contact with the laser fiber causes photothermal disintegration. As time passes, the “popcorning” effect continues to produce smaller and smaller fragments, resulting in a fine stone dust, which is passed without consequence. An in vitro experiment identified settings of 1.0 J and 20 Hz as giving the most efficient fragmentation when using this technique (Chawla et al., 2008).

With improving endoscopic technology, ureteroscopy and intracorporeal lithotripsy have replaced ESWL for treatment of many ureteric stones. A review of 82 patients undergoing either ESWL or ureteroscopy for impacted proximal stones showed no difference in 3-month stone-free rates (80% vs. 68%) or complications, although patients undergoing ESWL required more secondary procedures (Khalil, 2013). Similar results were achieved in a prospective randomized trial comparing 180 patients undergoing ESWL or semirigid ureteroscopy and laser lithotripsy for stones less than 2 cm. No significant differences were found between the two modalities in terms of 3-month stone-free rates, although retreatment rates were higher for ESWL (6.1% vs. 1.1%, $P < 0.001$) (Kumar et al., 2013). In contrast, a multicenter randomized trial of distal and midureteric stones (n = 156) treated with ESWL or ureteroscopy and laser lithotripsy showed an advantage for ureteroscopy. The 3-month stone-free rate was 91% for ureteroscopy (vs. 51% for ESWL), and retreatment rates were significantly lower (9% vs. 45% in ESWL) (Hendrikx et al., 1999). Several authors found cost savings associated with ureteroscopy and laser use compared with ESWL because of higher success rates and lower retreatment rates (Cone et al., 2014; Parker et al., 2004). Laser lithotripsy had lower initial ($7575 vs. $9507) and total ($9378 vs. $15,583) charges.

Comparing other intracorporeal lithotripsy modalities, a retrospective review of 394 patients with proximal ureteral stones treated with laser or pneumatic lithotripsy via semirigid ureteroscopy was performed, showing 86% were treated successfully with pneumatic lithotripsy; 14% required secondary ESWL for residual fragments (identified on radiograph). Laser lithotripsy produced a 97% stone-free rate, and only 2% required secondary procedures. Ureteral perforations were uncommon and not significantly different between groups (Bapat et al., 2007). In larger distal and mid-ureteric stones (mean diameter 13 mm), a prospective randomized trial showed a delayed stone-free rate of 95% with laser lithotripsy versus 85% with pneumatic lithotripsy on noncontrast computed tomography. Laser use was associated with less stone migration, although complication rates were for both arms (Kassem et al., 2012).

Stone position plays a large part in the success rates of ureteroscopy and laser lithotripsy. In a retrospective study, 272 patients undergoing flexible ureteroscopy from 2002 to 2006 and laser lithotripsy for renal stones were found to have an overall stone-free rate of 94% on follow-up noncontrast computed tomography. Stone-free rates were best for upper pole stones (100%), followed by middle pole stones (95%) and lower pole stones (90%), although not significantly different ($P = 0.338$). Similarly for the ureter, stone-free rates decreased from distal ureteral (96.8%) to proximal ureteral (79.4) stone location. Complication and retreatment rates were significantly higher with proximal stone location (Seitz et al., 2007).

Effective fragmentation using laser lithotripsy can be accomplished for any chemical stone composition, although efficiency is decreased with harder stones. Maintaining consistent power settings, magnesium ammonium phosphate stones are the most readily fractured, followed by calcium hydrogen phosphate dehydrate, cystine, uric acid, and calcium oxalate monohydrate. Increasing energy improves fragmentation for all stone types (Teichman et al., 1998). The differences are partly related to the melting points of the various stones as well as the vapor-surface interface. However, after reviewing ureteroscopic procedures performed on 86 renal and 101 ureteral stones, Wiener et al. (2012) failed to show any differences in operating room time related to stone composition. Perhaps because of active fragment removal using endoscopic baskets, coarse fragmentation techniques may not be as sensitive to chemical composition. Instead, if disintegrated to stone dust, presumably harder stones would require more time.

Because of its relatively high safety profile, laser lithotripsy has been applied to children (Fraser et al., 1999; Yeow et al., 2009), patients with bilateral stones (Atis et al., 2013; Huang et al., 2012), and patients with anatomic abnormalities (i.e., horseshoe kidney, duplicated systems, transplant grafts) (Hyams et al., 2012; Molimard et al., 2010). Ureteroscopy and laser use have been found to be safe in a retrospective review of 25 anticoagulated patients. Semirigid (6.9-Fr probe) and flexible (7.5-Fr probe) ureteroscopy was performed, and basket extraction was avoided by dusting all stones. Distal ureteral dilation (8/10-Fr coaxial dilator, balloon dilator, 14-Fr ureteric access sheath) was performed in 11 patients, and stents were placed in all patients after the procedure. Stone-free rates were 96% (100% distal ureter and mid-ureter, 89% proximal and intrarenal locations). For lower pole stones, upper pole repositioning was performed. No cases of significant bleeding or early termination secondary to bleeding were reported with laser use. Similar findings were reported in children with von Willebrand disease (Christman et al., 2012; eFig. 15.4).

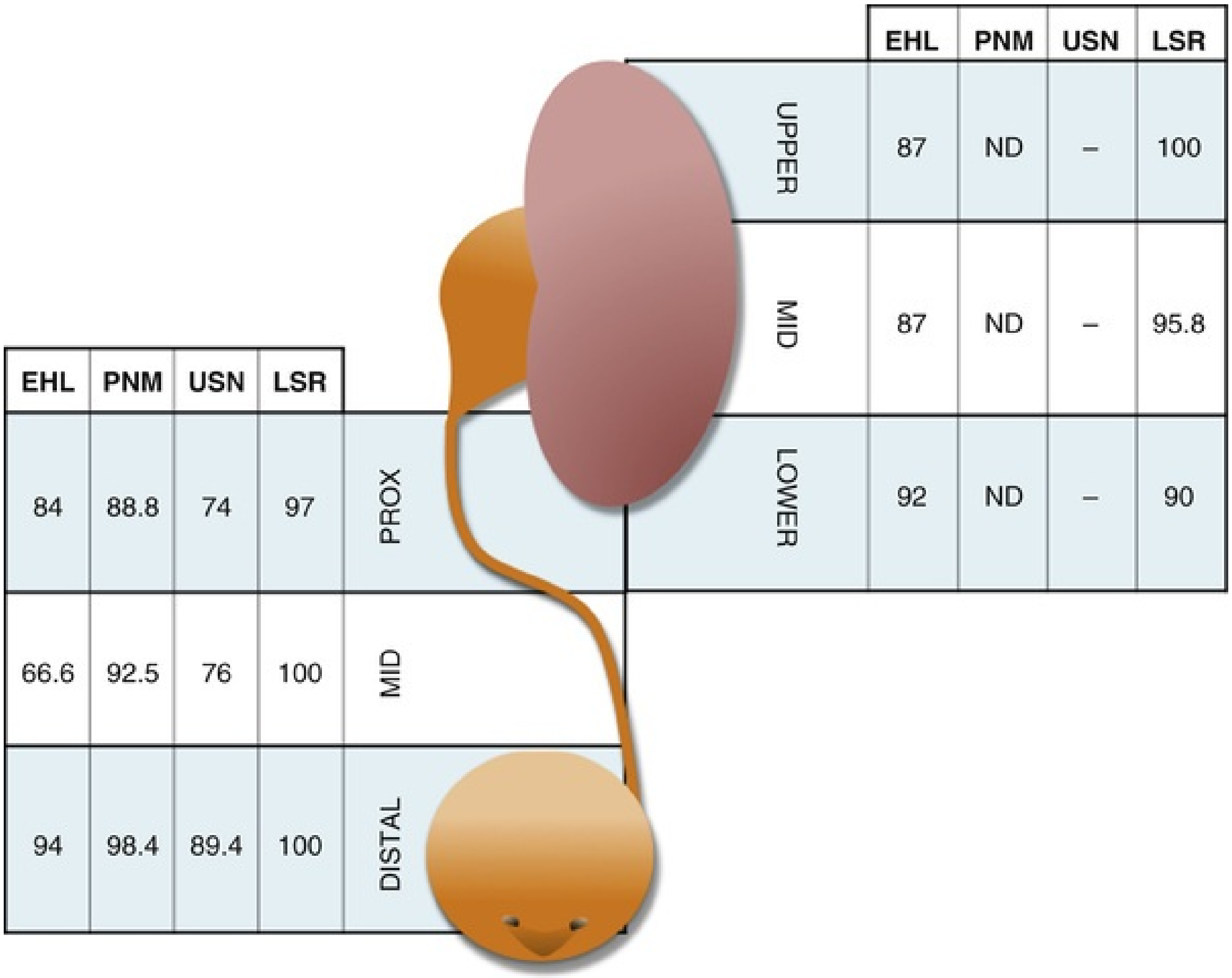

	EHL	PNM	USN	LSR
UPPER	87	ND	–	100
MID	87	ND	–	95.8
LOWER	92	ND	–	90

EHL	PNM	USN	LSR	
84	88.8	74	97	PROX
66.6	92.5	76	100	MID
94	98.4	89.4	100	DISTAL

EFIG. 15.4 Stone-free rates (percentage) for intracorporeal lithotripters used in ureteroscopy by anatomic region. *EHL,* Electrohydraulic lithotripsy; *LSR,* laser; *ND,* no data; *PNM,* pneumatic; *PROX,* proximal; *USN,* ultrasonic.

Up-front and disposable costs for laser lithotripters may be an issue for some hospitals. Because of the versatility of the Ho:YAG laser, it can be used not only in all parts of the genitourinary tract but also for interventions not involving stones. Reusable laser fibers allow a significant cost savings; one study from two hospitals showed a savings of more than $64,000 by using 37 fibers (varying manufacturers and sizes) for 540 semirigid and flexible ureteroscopy cases (Knudsen et al., 2011).

Percutaneous Nephrolithotomy

Although laser lithotripsy is not the favored modality for use in large renal stone burdens treated percutaneously, it plays an important role in flexible instrumentation. Anterograde nephroscopy using flexible scopes can access calyces that rigid nephroscopes cannot reach, reducing the need for multiple accesses. For patients with large impacted ureteric stones, reimplanted ureters, and reconstructed bladders, antegrade flexible ureteroscopy and laser lithotripsy can allow straightforward access to the stone. Coarse fragmentation and basket extraction simplify the procedure because the ureteric portion proximal to the obstruction is often dilated, allowing for active retrieval of larger stones.

Laser fragmentation is central to percutaneous nephrolithotomy performed with reduced-diameter sheaths (i.e., minipercutaneous, ultra-minipercutaneous, micropercutaneous). Developed initially for pediatrics, the procedure is now used in adults with sheath diameters ranging from 24 Fr (8 mm) to 16 gauge (1.3 mm). With use of extremely narrow sheaths, techniques require special miniaturized imaging technologies and laser lithotripsy. Because stone extraction is impossible with extremely narrow sheaths, 200-µm core sized laser fibers are used to dust stones, and debris is cleared by pressurized irrigation or passive urine flow. Indications have yet to be clearly defined; however, studies comparing efficacy with flexible ureteroscopy, standard percutaneous nephrolithotomy, and ESWL have been performed. A randomized study comparing flexible ureteroscopy and micropercutaneous nephrolithotomy (16-gauge "all-seeing needle" and 272-µm laser fiber) was performed in 70 patients for stones less than 1.5 cm. Equivalent stone-free rates, complication rates, and length of stay were identified. Increased pain scores (1.9 vs. 1.6, $P = 0.046$), analgesic requirements, and hemoglobin loss (0.96 g/dL vs. 0.56 g/dL, $P < 0.001$) were observed in the minipercutaneous nephrolithotomy arm. All patients had ureteric access sheaths placed, although 40% fewer patients required stent placement in the minipercutaneous nephrolithotomy arm (20% vs. 60%) (Sabnis et al., 2013).

Bladder Stones

In 1978 Fair reported the benefits of using a ruby laser to produce "stress pulses," which were able to fracture stones of any color, shape, size, hardness, and composition (Fair, 1978). Since then, Ho:YAG has become a useful option in transurethral and percutaneous approaches. In larger stone burdens, laser may not be the first choice; however, many still prefer laser cystolithotripsy because of its safety and ease of use.

With larger stones, the degree of fragmentation and stone dust produced by laser lithotripsy can reduce efficiency and visualization and increase operating room time. Combining lithotripter modalities and approaches in patients with stones greater than 4 cm may help reduce operative time and improve visualization and stone clearance (Sofer et al., 2004). The combination of laser and ultrasonic lithotripsy allows for fragmentation of hard stones, while suctioning fragments and improving visualization. A combined percutaneous and transurethral approach can also improve flow and allow larger fragment removal and stone manipulation by two surgeons simultaneously without increasing complication rates (Sofer et al., 2004). Use of a 24-Fr scope through a 30-Fr Amplatz sheath (Cook Urological, Spencer, IN) placed through the urethra (with or without urethral dilation) has been reported to improve irrigation drainage, visualization, and stone localization during laser lithotripsy in female (Kawahara et al., 2012a; Ramanathan, 1999) and male (Okeke et al., 2004) patients.

Total stone burden (volume and area on noncontrast computed tomography) was the only variable found to correlate with total procedural time required for laser cystolithotripsy. Using 550-µm laser fibers (100-W laser, set between 1.5 and 3.5 J, 5 Hz), cystolithotripsy was performed through a 26-Fr resectoscope. Stone hardness (measured by Hounsfield units and chemical stone composition) did not appear to affect operating room time significantly. Male gender added procedural time, although lithotripsy time was not significantly different between sexes (Kawahara et al., 2012b).

An advantage of laser cystolithotripsy is its use in flexible cystoscopy, allowing for treatment in reconstructed bladders and challenging genitourinary anatomy that precludes use of rigid instruments. Flexible laser lithotripsy has been used under local anesthetic in healthy men with stones greater than 3 cm, with minimal pain and improvements in lower urinary tract symptoms, without significant complications (Kara et al., 2009).

In pediatric urolithiasis, instrument diameter plays a key role in management options. Bladder stones have been successfully treated using 8-Fr ureteroscopes with 550-µm laser fibers for stones less than 4 cm (Ramakrishnan et al., 2005). No laser-related complications were encountered perioperatively, and no children showed recurrences or urethral stricture formation in long-term follow-up (mean 48 months). In children with complicated genitourinary reconstructions, augmentations, and continence procedures, percutaneous laser cystolithotripsy through a previous suprapubic catheter site allowed for maximal stone fragmentation while minimizing the risk to intraperitoneal structures and/or vascular supply to bowel segments used for augmentation (Cain et al.,

2002).

When indicated, concomitant treatment of bladder stones and BPH has been reported using several modalities of prostatic resection, including green light laser (De la Torre et al., 2012), HoLEP (Shah et al., 2007), and TURP (Philippou et al., 2011), without significantly increasing the rate of complications. Bladder calculi are treated first to avoid injuring the resection bed after prostatic surgery or risk leaving stones behind should the procedure be terminated early. Rare cases of prostatic stones causing lower urinary tract symptoms and bladder outlet obstruction can also be treated with laser lithotripsy. Using a 550-µm laser fiber (1 to 1.5 J, 15 to 20 Hz) through a rigid cystoscope, Goyal et al. (2013) reported complete stone removal resulting in improved International Prostate Scoring System scores and improved peak flow rates at 3 months. Concurrent laser urethrotomy can be performed if necessary.

Key Points: Holmium:YAG Laser Lithotripsy

- Laser lithotripsy has brought versatility to intracorporeal lithotripsy by allowing safe fragmentation in virtually all areas of the genitourinary tract.
- Ho:YAG laser fragmentation is predominantly because of photothermal decomposition and possibly photoacoustic propulsion of fragments.
- Laser output can be adjusted based on rate (Hz), energy (J), pulse duration (µsec), and fiber size (µm).
- Maximal deflection is achieved with 200-µm core-sized fibers during flexible ureteroscopy; however, maximal efficiency is seen with 365-µm core-sized fibers.
- Proper laser fiber handling can help reduce scope damage and prolong the life of reusable fibers.
- Techniques used during stone fragmentation include painting and “popcorning,” which create fine stone dust (precluding removal), or crude fragmentation for basket extraction.
- Laser lithotripsy can produce the smallest fragments and is efficacious in all stone compositions.
- Smaller stone fragments can be obtained with lower pulse energies and higher frequencies (“dusting”), whereas larger fragments can be obtained with higher pulse energies and lower frequencies. Longer pulse duration

reduces stone retropulsion.

Dual-Modality Lithotripters

Newer modalities have been developed by combining ultrasonic and pneumatic lithotripters into a single hand piece. The Swiss LithoClast Ultra and CyberWand (Olympus, Southborough, MA) use different strategies to capitalize on the advantages of each modality. Pneumatic lithotripsy is effective at fragmenting harder stones, whereas ultrasonic action produces smaller fragments, while simultaneously removing them from the field. These hybrid systems are available only as rigid probes and can be used only in transurethral or percutaneous procedures (Fig. 15.5).

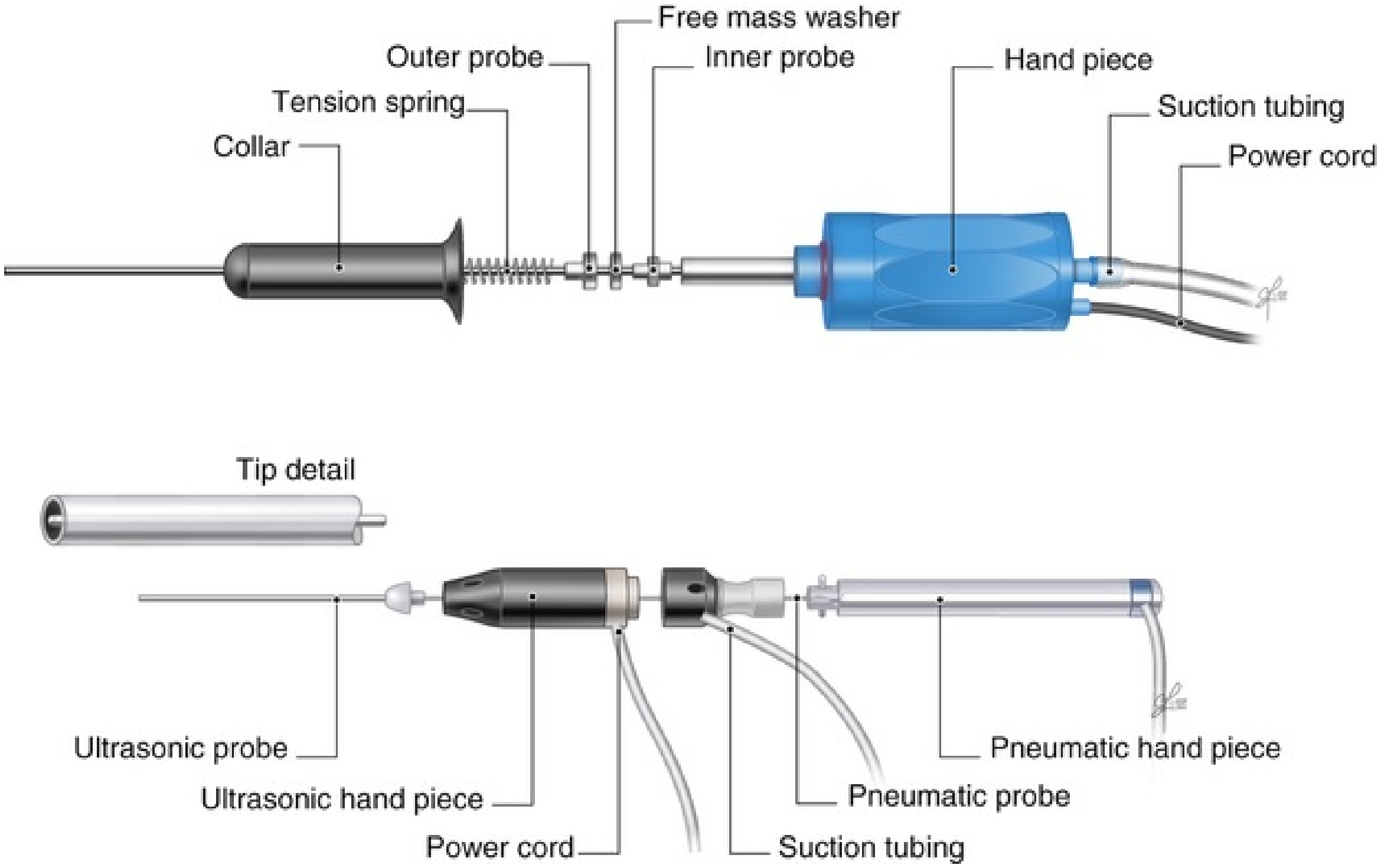
Free mass washer
Outer probe
Inner probe
Hand piece
Tension spring
Suction tubing
Collar
Power cord
Tip detail
Ultrasonic probe
Pneumatic hand piece
Ultrasonic hand piece
Pneumatic probe
Power cord
Suction tubing

FIG. 15.5 Dual-modality lithotripter configurations.

LithoClast Ultra

The LithoClast Ultra was the first dual-modality lithotripter, combining two independently functioning hand pieces that are fixed together. **The front piece houses the ultrasonic lithotripter, with a central channel allowing**

throughway for the slender pneumatic probe. The 1-mm solid pneumatic probe sits within the suction channel of the 3.3-mm hollow ultrasonic probe. Fine-tuning of positioning of the pneumatic probe tip (relative to the ultrasonic tip) can be achieved using the depth wheel built into the hand piece. Pneumatic activity can be triggered as needed or continuously from 2 to 12 cycles per second. The ultrasonic probe can be adjusted based on power and duty cycle. A composite pedal allows selective or combined use of each modality. Three cords attach to the hand piece for medical air, ultrasonic power, and suction. In-line suction allows continuous fragment removal and collection (using a stone trap) and hand piece cooling.

For maximal control, the tip of the pneumatic probe should be slightly recessed from the outer ultrasonic probe. In this way, the ultrasonic probe can make maximal contact with the stone surface, and pneumatic retropulsion is limited. When activated, the pneumatic tip advances and strikes the stone beyond the ultrasonic probe tip. If large immobile stones are being treated (i.e., staghorn calculi), better fragmentation can be achieved by adjusting the pneumatic probe 2.5 mm past the ultrasonic sheath; however, simultaneous treatment of smaller fragments may become more challenging (VonDerHaar et al., 2010).

CyberWand

The CyberWand uses an ultrasonic hand piece producing vibrational energy by means of a piezoceramic crystal. Disposable probes are made of an inner 2.77-mm and outer 3.75-mm cylindric metal tube. The inner probe screws onto the handset, extending 1 mm past the tip of the outer sheath. The fixed inner probe vibrates at a frequency of 21,000 Hz. Because of a free mass washer and dampening spring, the free-floating outer probe vibrates at approximately 1000 Hz, oscillating longitudinally 1 mm. Selecting “large stone” on the foot pedal couples both sheaths. **Ultrasonic energy from the inner sheath is transmitted to the outer sheath, which moves in a ballistic manner, similar to pneumatic lithotripters** (Auge et al., 2002). The “small stone” pedal allows for finer control and activates only the ultrasonic action of the inner probe. The hollow lumen of the inner sheath of the probe incorporates irrigation suction, which simultaneously clears stone debris during fragmentation while cooling the hand piece.

Noise levels related to CyberWand fragmentation (93 dB) were determined to be the loudest (at ear level) compared with the Storz Ultrasonic lithotrite (Storz, El Segundo, CA; 77 dB), Olympus LUS-2 single modality ultrasonic lithotripter (Olympus, Southborough, MA; 68 dB), and Ho:YAG laser (60 dB). If used for more than 90 minutes per day, only the CyberWand is above the threshold set by the US Department of Labor and Occupational Health and Safety Administration for risk of noise-related occupational hearing loss (Soucy et al., 2008).

ShockPulse-SE

The ShockPulse-SE (Olympus, Center Valley, PA) is a dual-action, single-probe lithotripter using either ultrasonic alone or ultrasonic along with intermittent ballistic shockwave energy to achieve rapid stone fragmentation. A large-probe lumen allows for simultaneous aspiration of stone fragments. The ShockPulse-SE is the first on the market with surgeon-controlled hand activation and an integrated suction control hand piece for improved ergonomics, obviating the need for an additional foot pedal on the floor. Probes of varying sizes (0.97 mm–3.76 mm) are available for various applications, including standard percutaneous nephrolithotomy (PCNL), mini-PCNL, semirigid ureteroscopy, and treatment of bladder stones.

Tissue Effects

Using fresh human urothelium from nephrectomy specimens, perpendicular application of the CyberWand and LithoClast was done for 2 to 8 seconds. Tissue effects were compared with untreated areas and control specimens (suction-only probe contact). Suction alone showed 50% to 80% denudation of urothelium, with no changes identified in the subepithelial or muscular layer. The CyberWand “small stone” setting showed 100% urothelial denudation, with separation of the subepithelial connective tissue layer and no muscular damage. During use with the “large stone” setting, a greater amount of subepithelial edema and muscular rupture was noted with increasing contact time to the mucosa.

For ultrasonography-only settings, the Swiss LithoClast Ultra and CyberWand (“small stone” setting) showed 100% urothelial denudation, with separation of the subepithelial connective tissue layer and no muscular damage. With 2 seconds of exposure, minimal tissue damage was noted. **Increasing contact time led to increased mucosal denudation and submucosal vacuolation.**

Muscle rupture worsened with increasing exposure times except for the single modality "small stone" setting on the CyberWand, which was unable to cause muscle rupture. Based on these findings, the authors concluded that both modalities were safe, although contact time when using dual-modality settings should be minimized when possible (Khemees et al., 2013a).

Clinical Use

Several studies showed that the combination of pneumatic and ultrasonic lithotripters is more efficient compared with pneumatic or ultrasonic lithotripsy alone. Each modality separately cleared phantom stones 3.8 times (pneumatic) and 1.7 times (ultrasonic) slower than combination lithotripsy with the Swiss LithoClast Ultra (Soucy et al., 2008). An in vitro experiment using gypsum stones was performed to compare penetration times of the CyberWand and Swiss LithoClast Ultra. Penetration times were 41% shorter with the CyberWand with no significant differences in overheating, blockages, or malfunctioning (Kim et al., 2007).

Clinical use was assessed by randomly assigning 20 patients to either ultrasonic or combined modality lithotripsy during percutaneous nephrolithotomy. Combination lithotripsy reduced fragmentation time from 43.7 minutes to 21.1 minutes ($P = 0.036$), with slightly improved complication and stone-free rates (Pietrow et al., 2003). To compare the clinical efficacy between dual-modality lithotrites, 138 patients with staghorn calculi were randomly assigned to either CyberWand or Swiss LithoClast Master fragmentation. Although shorter operative times were encountered with CyberWand allocation (77.1 minutes vs. 84.3 minutes, $P = 0.049$), no differences in stone clearance or complication rates were noted (Li et al., 2013).

Surgical technique during treatment can affect efficiency of stone fracture. Applying force to a hand piece against a stone can improve or reduce fragmentation efficacy. The rate of stone mass removal was measured in an in vitro analysis using 400 g, 1000 g, and 2000 g of in-line force on a CyberWand and Swiss LithoClast Ultra hand piece. For the CyberWand dual-modality settings, 400 g and 1000 g were significantly more efficient than 2000 g, whereas with ultrasonography alone (on the Swiss LithoClast), efficiency increased with pressure and rotation of the probe by 90 degrees. This study also corroborates the improved fragmentation of the CyberWand against all settings of the Swiss LithoClast (Goldman et al., 2009). Too much pressure on the

CyberWand may impede the movement of the outer low-frequency probe, leaving fragmentation to occur only with the ultrasonic action of the inner probe. However, the LithoClast Ultra functions better at higher pressures and with rotation. Because the pneumatic and the ultrasonic components are actively driven by separate mechanisms, applying pressure does not prevent movement as in the CyberWand (Goldman et al., 2009).

Key Points: Dual-Modality Lithotripters

- Dual-modality lithotripters combine ultrasonic and pneumatic lithotripsy to take advantage of the benefits of each.
- Swiss LithoClast uses two independently driven lithotrites combined in one hand piece.
- The CyberWand uses a double-layered probe with a central ultrasonic probe and a passively coupled low-frequency outer probe, which provides ballistic stone fragmentation.
- The ShockPulse-SE uses a single probe with ultrasonic and intermittent ballistic shockwave energy to achieve rapid stone fragmentation along with a surgeon-controlled hand piece allowing for device activation and suction control.
- When friable tissues are present or visualization is suboptimal secondary to bleeding or challenging anatomy, single-modality lithotripsy should be used. Reducing lithotripsy to ultrasonic-only activity and minimizing urothelial contact time lessen the potential for mucosal complications (i.e., bleeding, perforation, future stricture formation).

Suggested Readings

Anastasiadis A, Onal B, Modi P, et al. Impact of stone density on outcomes in percutaneous nephrolithotomy (PCNL): an analysis of the Clinical Research Office of the Endourological Society (CROES) PCNL global study database. *Scand J Urol*. 2013;47:509–514.

Bachmann A, Tubaro A, Barber N, et al. 180-W XPS GreenLight laser vaporisation versus transurethral resection of the prostate for the treatment of benign prostatic obstruction: 6-month safety and efficacy results of a European multicentre randomised trial—the GOLIATH study. *Eur Urol*. 2014;65:931–942.

Chawla SN, Chang MF, Chang A, et al. Effectiveness of high-frequency holmium:YAG laser stone fragmentation: the “popcorn effect. *J Endourol*. 2008;22:645–650.

Cone EB, Eisner BH, Ursiny M, et al. Cost effectiveness comparison of renal calculi treated with ureteroscopic laser lithotripsy versus shock wave lithotripsy. *J Endourol*. 2014;28:639–643.

Finley DS, Petersen J, Abdelshehid C, et al. Effect of holmium:YAG laser pulse width on lithotripsy retropulsion in vitro. *J Endourol*. 2005;19:1041–1044.

Hendlin K, Weiland D, Monga M. Impact of irrigation systems on stone migration. *J Endourol*. 2008;22:453–458.

Hofbauer J, Höbarth K, Marberger M. Electrohydraulic versus pneumatic disintegration in the treatment of ureteral stones: a randomized, prospective trial. *J Urol*. 1995;153(3):623–625.

Khemees TA, Kenneson MA, Zynger DL, et al. Histologic impact of dual-modality intracorporeal lithotripters to the renal pelvis. *Urology*. 2013;82:27–32.

Lamberton GR, Hsi RS, Jin DH, et al. Prospective comparison of four laparoscopic vessel ligation devices. *J Endourol*. 2008;22:2307–2312.

Landman J, Kerbl K, Rehman J, et al. Evaluation of a vessel sealing system, bipolar electrosurgery, harmonic scalpel, titanium clips, endoscopic gastrointestinal anastomosis vascular staples and sutures for arterial and venous ligation in a porcine model. *J Urol*. 2003;169:697–700.

Lee H, Ryan RT, Teichman JM, et al. Stone retropulsion during holmium:YAG lithotripsy. *J Urol*. 2003;169:881–885.

Marks AJ, Teichman JM. Lasers in clinical urology: state of the art and new horizons. *World J Urol*. 2007;25:227–233.

Nduka CC, Super PA, Monson JR, et al. Cause and prevention of electrosurgical injuries in laparoscopy. *J Am Coll Surg*. 1994;179:161–170.

Pastore AL, Palleschi G, Silvestri L, et al. Prospective randomized study of radiofrequency versus ultrasound scalpels on functional outcomes of laparoscopic radical prostatectomy. *J Endourol*. 2013;27:989–993.

Piergiovanni M, Desgrandchamps F, Cochand-Priollet B, et al. Ureteral and bladder lesions after ballistic, ultrasonic, electrohydraulic, or laser lithotripsy. *J Endourol*. 1994;8:293–299.

Ruszat R, Seitz M, Wyler SF, et al. GreenLight laser vaporization of the prostate: single-center experience and long-term results after 500 procedures. *Eur Urol*. 2008;54:893–901.

Seitz C, Tanovic E, Kikic Z, et al. Impact of stone size, location, composition, impaction, and hydronephrosis on the efficacy of holmium:YAG-laser ureterolithotripsy. *Eur Urol*. 2007;52:1751–1757.

Teichman JM, Vassar GJ, Glickman RD. Holmium:yttrium-aluminum-garnet lithotripsy efficiency varies with stone composition. *Urology*. 1998;52:392–397.

Van Way CW, Hinrichs CS. Electrosurgery 201: basic electrical principles. *Curr Surg*. 2000;57:261–264.

VonDerHaar JN, McAteer JA, Williams JC Jr, et al. In vitro evaluation of the Lithoclast Ultra Vario combination lithotrite. *Urol Res*. 2010;38:485–489.

Vorreuther R, Corleis R, Klotz T, et al. Impact of shock wave pattern and cavitation bubble size on tissue damage during ureteroscopic electrohydraulic lithotripsy. *J Urol*. 1995;153(3):849–853.

References

Abdel-Kader MS, Tamam A-A, Elderwy AA, et al. Management of symptomatic ureteral calculi during pregnancy: experience of 23 cases. *Urol Ann*. 2013;5:241–244.

Agrawal MS, Aron M, Goyal J, et al. Percutaneous suprapubic cystolithotripsy for vesical calculi in children. *J Endourol*. 1999;13:173–175.

Alkatout I, Schollmeyer T, Hawaldar NA, et al. Principles and safety measures of electrosurgery in laparoscopy. *JSLS*. 2012;16:130–139.

Anastasiadis A, Onal B, Modi P, et al. Impact of stone density on outcomes in percutaneous nephrolithotomy (PCNL): an analysis of the Clinical Research Office of the Endourological Society (CROES) PCNL global study database. *Scand J Urol*. 2013;47:509–514.

Aron M, Goel R, Gautam G, et al. Percutaneous versus transurethral cystolithotripsy and TURP for large prostates and large vesical calculi: refinement of technique and updated data. *Int Urol Nephrol*. 2007;39:173–177.

Atis G, Koyuncu H, Gurbuz C, et al. Bilateral single-session retrograde intrarenal surgery for the treatment of bilateral renal stones. *Int Braz J Urol*. 2013;39:387–392.

Auge BK, Lallas CD, Pietrow PK, et al. In vitro comparison of standard ultrasound and pneumatic lithotrites with a new combination intracorporeal lithotripsy device. *Urology*. 2002;60:28–32.

Bach T, Netsch C, Haecker A, et al. YAG laser enucleation (VapoEnucleation) of the prostate: safety and durability during intermediate-term follow-up. *World J Urol*. 2010;28:39–43.

Bachmann A, Tubaro A, Barber N, et al. 180-W XPS GreenLight laser vaporisation versus transurethral resection of the prostate for the treatment of benign prostatic obstruction: 6-month safety and efficacy results of a European multicentre randomised trial—the GOLIATH study. *Eur Urol*. 2014;65:931–942.

Bader MJ, Pongratz T, Khoder W, et al. Impact of pulse duration on Ho:YAG laser lithotripsy: fragmentation and dusting performance. *World J Urol*. 2015;33(4):471–477.

Bae J, Oh SJ, Paick JS. The learning curve for holmium laser enucleation of the prostate: a single-center experience. *Korean J Urol*. 2010;51:688–693.

Bandieramonte G, Colecchia M, Mariani L, et al. Peniscopically controlled CO2 laser excision for conservative treatment of in situ and T1 penile carcinoma: report on 224 patients. *Eur Urol*. 2008;54:875–882.

Bapat SS, Pai KV, Purnapatre SS, et al. Comparison of holmium laser and pneumatic lithotripsy in managing upper-ureteral stones. *J Endourol*. 2007;21:1425–1427.

Barber NJ, Muir GH. High-power KTP laser prostatectomy: the new challenge to transurethral resection of the prostate. *Curr Opin Urol*. 2004;14:21–25.

Bastawisy M, Gameel T, Radwan M, et al. A comparison of Stone Cone versus lidocaine jelly in the prevention of ureteral stone migration during ureteroscopic lithotripsy. *Ther Adv Urol*. 2011;3:203–210.

Batra YK, Kapoor R, Hemal AK, et al. Hyponatraemia and mental symptoms following vesical ultrasonic lithotripsy. *Anaesthesia*. 1988;43:675–676.

Ben-Zvi T, Hueber PA, Liberman D, et al. GreenLight XPS 180W vs HPS 120W laser therapy for benign prostate hyperplasia: a prospective comparative analysis after 200 cases in a single-center study. *Urology*. 2013;81(4):853–858.

Bülow H, Frohmüller HG. Electrohydraulic lithotripsy with aspiration of the fragments under vision—304 consecutive cases. *J Urol*. 1981;126:454–456.

Cain MP, Casale AJ, Kaefer M, et al. Percutaneous cystolithotomy in the pediatric augmented bladder. *J Urol*. 2002;168(4):1881–1882.

Campbell NA, Chung AS, Yoon PD, et al. Early experience photoselective vaporisation of the prostate using the 180W lithium triborate and comparison with the 120W lithium triborate laser. *Prostate Int*. 2013;1(1):42–45.

Cetin S, Ozgür S, Yazicioğlu A, et al. Ultrasonic lithotripsy of bladder stones. *Int Urol Nephrol*. 1988;20:361–365.

Cetinkaya M, Onem K, Rifaioglu MM, et al. 980-Nm diode laser vaporization versus transurethral resection of the prostate for benign prostatic hyperplasia: randomized controlled study. *Urol J*. 2015;12(5):2355–2361.

Chan KF, Vassar GJ, Pfefer TJ, et al. Holmium:YAG laser lithotripsy: a dominant photothermal ablative mechanism with chemical decomposition of urinary calculi. *Lasers Surg Med*. 1999;25:22–37.

Chawla SN, Chang MF, Chang A, et al. Effectiveness of high-frequency holmium:YAG laser stone fragmentation: the “popcorn effect. *J Endourol*. 2008;22:645–650.

Chiang PH, Chen CH, Kang CH, et al. GreenLight HPS laser 120-W versus diode laser 200-W vaporization of the prostate: comparative clinical experience. *Lasers Surg Med*. 2010;42:624–629.

Cho CO, Yu JH, Sung LH, et al. Comparison of percutaneous nephrolithotomy using pneumatic lithotripsy (Lithoclast) alone or in combination with ultrasonic lithotripsy. *Korean J Urol*. 2010;51:783–787.

Christman MS, Ziemba J, Casale P. Flexible ureteroscopy in children with von Willebrand disease. *J Endourol*.

2012;26:783–786.

Colecchia M, Nicolai N, Secchi P, et al. pT1 penile squamous cell carcinoma: a clinicopathologic study of 56 cases treated by CO_2 laser therapy. *Anal Quant Cytol Histol*. 2009;31:153–160.

Cone EB, Eisner BH, Ursiny M, et al. Cost effectiveness comparison of renal calculi treated with ureteroscopic laser lithotripsy versus shock wave lithotripsy. *J Endourol*. 2014;28:639–643.

Cordes J, Lange B, Jocham D, et al. Destruction of stone extraction basket during an in vitro lithotripsy—a comparison of four lithotripters. *J Endourol*. 2011;25:1359–1362.

Cormier B, Nezhat F, Sternchos J, et al. Electrocautery-associated vascular injury during robotic-assisted surgery. *Obstet Gynecol*. 2012;120(2):491–493.

Cowles RS 3rd, Kabalin JN, Childs S, et al. A prospective randomized comparison of transurethral resection to visual laser ablation of the prostate for the treatment of benign prostatic hyperplasia. *Urology*. 1995;46:155–160.

Cresswell MD, Cass CB, Fraundorfer MR, et al. Holmium: YAG laser resection of the prostate: preliminary experience with the first 400 cases. *N Z Med J*. 1997;110:76–78.

Daehlin L, Frugard J. Interstitial laser coagulation in the management of lower urinary tract symptoms suggestive of bladder outlet obstruction from benign prostatic hyperplasia: long-term follow-up. *BJU Int*. 2007;100:89–93.

Dasgupta P, Cynk MS, Bultitude MF, et al. Flexible ureterorenoscopy: prospective analysis of the Guy's experience. *Ann R Coll Surg Engl*. 2004;86:367–370.

Daskalopoulos G, Karyotis I, Heretis I, et al. Electrothermal bipolar coagulation for radical prostatectomies and cystectomies: a preliminary case-controlled study. *Int Urol Nephrol*. 2004;36:181–185.

De la Torre G, Barusso G, Chernobilsky V, et al. Outpatient simultaneous treatment of benign prostatic hyperplasia and bladder lithiasis with GreenLight and holmium laser. *J Endourol*. 2012;26:164–167.

Delvecchio FC, Kuo RL, Preminger GM. Clinical efficacy of combined Lithoclast and Lithovac stone removal during ureteroscopy. *J Urol*. 2000;164:40–42.

Denstedt JD, Eberwein PM, Singh RR. The Swiss Lithoclast: a new device for intracorporeal lithotripsy. *J Urol*. 1992;148(3):1088–1090.

Denstedt JD, Razvi HA, Rowe E, et al. Investigation of the tissue effects of a new device for intracorporeal lithotripsy—the Swiss Lithoclast. *J Urol*. 1995;153:535–537.

El Khader K, Ibn Attya A, Mamoun M, et al. Role of ultrasound lithotripsy in the treatment of lithiasis of the lower urinary tract. Apropos of 38 cases. *J Urol (Paris)*. 1995;101:165–168 [in French].

Elashry OM, DiMeglio RB, Nakada SY, et al. Intracorporeal electrohydraulic lithotripsy of ureteral and renal calculi using small caliber (1.9F) electrohydraulic lithotripsy probes. *J Urol*. 1996;156:1581–1585.

Elhilali MM, Badaan S, Ibrahim A, et al. Use of the Moses technology to improve holmium laser lithotripsy outcomes: a preclinical study. *J Endourol*. 2017;31(6):598–604.

Elzayat E, Habib E, Elhilali M. Holmium laser enucleation of the prostate in patients on anticoagulant therapy or with bleeding disorders. *J Urol*. 2006;175:1428–1432.

Elzayat EA, Elhilali MM. Holmium laser enucleation of the prostate (HoLEP): the endourologic alternative to open prostatectomy. *Eur Urol*. 2006;49:87–91.

Elzayat EA, Habib EI, Elhilali MM. Holmium laser enucleation of the prostate: a size-independent new “gold standard”. *Urology*. 2005;66(5 Suppl):108–113.

Emiliani E, Talso M, Cho SY, et al. Optimal settings for the noncontact Holmium:YAG stone fragmentation popcorn technique. *J Urol*. 2017;198(3):702–706.

Engebretsen SR, Huang GO, Wallner CL, et al. A prospective analysis of robotic tip cover accessory failure. *J Endourol*. 2013;27:914–917.

Fair HD Jr. In vitro destruction of urinary calculi by laser-induced stress waves. *Med Instrum*. 1978;12:100–105.

Finkelstein LH. CO2 laser surgery in urology. *Surg Clin North Am*. 1984;64:913–930.

Finley DS, Petersen J, Abdelshehid C, et al. Effect of holmium:YAG laser pulse width on lithotripsy retropulsion in vitro. *J Endourol*. 2005;19:1041–1044.

Fitzgerald JE, Malik M, Ahmed I. A single-blind controlled study of electrocautery and ultrasonic scalpel smoke plumes in laparoscopic surgery. *Surg Endosc*. 2012;26:337–342.

Fraser M, Joyce AD, Thomas DF, et al. Minimally invasive treatment of urinary tract calculi in children. *BJU Int*. 1999;84:339–342.

Gilling PJ, Fraundorfer MR. Holmium laser prostatectomy: a technique in evolution. *Curr Opin Urol*. 1998;8:11–15.

Goddard DW, Jones WR, Wescott JW. Electrosurgical units: particular attention to tube, spark gap and solid state generated currents; their differences and their similarities. *J Urol*. 1972;107:1051–1053.

Goldman DM, Pedro RN, Kossett A, et al. Maximizing stone fragmentation efficiency with ultrasonic probes: impact of probe pressure and rotation. *J Urol*. 2009;181:1429–1433.

Goodfriend R. Ultrasonic and electrohydraulic lithotripsy of ureteral calculi. *Urology*. 1984;23:5–8.

Goyal NK, Goel A, Sankhwar S. Transurethral holmium-YAG laser lithotripsy for large symptomatic prostatic calculi: initial experience. *Urolithiasis*. 2013;41:355–359.

Grocela JA, Dretler SP. Intracorporeal lithotripsy. Instrumentation and development. *Urol Clin North Am*. 1997;24:13–23.

Gur U, Lifshitz DA, Lask D, et al. Ureteral ultrasonic lithotripsy revisited: a neglected tool? *J Endourol*. 2004;18:137–140.

Harold KL, Pollinger H, Matthews BD, et al. Comparison of ultrasonic energy, bipolar thermal energy, and vascular clips for the hemostasis of small-, medium-, and large-sized arteries. *Surg Endosc*. 2003;17:1228–1230.

Harris FW. Electrosurgery in laparoscopy. *J Reprod Med*. 1978;21:48–52.

Heinrich E, Wendt-Nordahl G, Honeck P, et al. 120 W lithium triborate laser for photoselective vaporization of the prostate: comparison with 80 W potassium-titanyl-phosphate laser in an ex-vivo model. *J Endourol*. 2010;24:75–79.

Helal M, Albertini J, Lockhart J, et al. Laparoscopic nephrectomy using the harmonic scalpel. *J Endourol*. 1997;11:267–268.

Hendlin K, Weiland D, Monga M. Impact of irrigation systems on stone migration. *J Endourol*. 2008;22:453–458.

Hendrikx AJ, Strijbos WE, de Knijff DW, et al. Treatment for extended-mid and distal ureteral stones: SWL or ureteroscopy? Results of a multicenter study. *J Endourol*. 1999;13:727–733.

Higashihara E, Aso Y. Flexible ultrasonic lithotriptor and fiberoptic ureterorenoscope: a new approach to ureteral calculi. *J Urol*. 1989;142:40–42.

Hofbauer J, Höbarth K, Marberger M. Electrohydraulic versus pneumatic disintegration in the treatment of ureteral stones: a randomized, prospective trial. *J Urol*. 1995;153(3):623–625.

Hofmann R, Olbert P, Weber J, et al. Clinical experience with a new ultrasonic and LithoClast combination for percutaneous litholapaxy. *BJU Int*. 2002;90:16–19.

Holman E, Hódi I, Tóth C. Percutaneous nephrolithotomy and ultrasonic lithotripsy in patients with horseshoe kidney (analysis of 4 cases). *Orv Hetil*. 1986;127:2989–2991 [in Hungarian].

Hoşcan MB, Ekinci M, Tunçkıran A, et al. Management of symptomatic ureteral calculi complicating pregnancy. *Urology*. 2012;80:1011–1014.

Huang Z, Fu F, Zhong Z, et al. Flexible ureteroscopy and laser lithotripsy for bilateral multiple intrarenal stones: is this a valuable choice? *Urology*. 2012;80:800–804.

Hueber PA, Liberman D, Ben-Zvi T, et al. 180 W vs 120 W lithium triborate photoselective vaporization of the prostate for benign prostatic hyperplasia: a global, multicenter comparative analysis of perioperative treatment parameters. *Urology*. 2013;82:1108–1113.

Hulka JF, Levy BS, Parker WH, et al. Laparoscopic-assisted vaginal hysterectomy: American Association of Gynecologic Laparoscopists' 1995 membership survey. *J Am Assoc Gynecol Laparosc*. 1997;4:167–171.

Hutchisson B, Baird MG, Wagner S. Electrosurgical safety. *AORN J*. 1998;68:830–837 [quiz 838–40, 843–4].

Hyams E, Marien T, Bruhn A, et al. Ureteroscopy for transplant lithiasis. *J Endourol*. 2012;26:819–822.

Ibrahim A, Badaan S, Elhilali MM, et al. Moses technology in a stone simulator. *Can Urol Assoc J*. 2017 [Epub ahead of print].

Jones CM, Pierre KB, Nicoud IB, et al. Electrosurgery. *Curr Surg*. 2006;63:458–463.

Kamal W, Kallidonis P, Koukiou G, et al. Stone retropulsion with Ho:YAG and Tm:YAG lasers: a clinical practice-oriented experimental study. *J Endourol*. 2016;30(11):1145–1149.

Kang HW, Lee H, Teichman JM, et al. Dependence of calculus retropulsion on pulse duration during Ho:YAG laser lithotripsy. *Lasers Surg Med*. 2006;38(8):762–772.

Kara C, Resorlu B, Cicekbilek I, et al. Transurethral cystolithotripsy with holmium laser under local anesthesia in selected patients. *Urology*. 2009;74:1000–1003.

Kassem A, Elfayoumy H, Elsaied W, et al. Laser and pneumatic lithotripsy in the endoscopic management of large ureteric stones: a comparative study. *Urol Int*. 2012;88:311–315.

Kawahara T, Ito H, Terao H, et al. Amplatz sheath for cystolithotripsy using Ho:YAG laser in female patients. *Urology*. 2012;80:1154–1155.

Kawahara T, Ito H, Terao H, et al. Stone area and volume are correlated with operative time for cystolithotripsy for bladder calculi using a holmium:yttrium garnet laser. *Scand J Urol Nephrol*. 2012;46:298–303.

Kennedy JS, Stranahan PL, Taylor KD, et al. High-burst-strength, feedback-controlled bipolar vessel sealing. *Surg Endosc*. 1998;12:876–878.

Khalil M. Management of impacted proximal ureteral stone: extracorporeal shock wave lithotripsy versus ureteroscopy with holmium:YAG laser lithotripsy. *Urol Ann*. 2013;5:88–92.

Khemees TA, Kenneson MA, Zynger DL, et al. Histologic impact of dual-modality intracorporeal lithotripters to the renal pelvis. *Urology*. 2013;82:27–32.

Khemees TA, Shore DM, Antiporda M, et al. Evaluation of a new 240-μm single-use holmium:YAG optical fiber for flexible ureteroscopy. *J Endourol*. 2013;27:475–479.

Khosa AS, Hussain M, Hussain M. Safety and efficacy of transurethral pneumatic lithotripsy for bladder calculi in children. *J Pak Med Assoc*. 2012;62:1297–1300.

Kim SC, Matlaga BR, Tinmouth WW, et al. In vitro assessment of a novel dual probe ultrasonic intracorporeal lithotriptor. *J*

Urol. 2007;177:1363–1365.

Knispel HH, Klän R, Heicappell R, et al. Pneumatic lithotripsy applied through deflected working channel of miniureteroscope: results in 143 patients. *J Endourol*. 1998;12:513–515.

Knudsen BE, Pedro R, Hinck B, et al. Durability of reusable holmium:YAG laser fibers: a multicenter study. *J Urol*. 2011;185:160–163.

Krambeck AE, Handa SE, Lingeman JE. Holmium laser enucleation of the prostate for prostates larger than 175 grams. *J Endourol*. 2010;24:433–437.

Kressel K, Hoffmann H, Butz M. Long-term experience with transurethral rigid ureteroscopy as a complementary method to extracorporeal shockwave lithotripsy. *Urol Int*. 1992;48:76–80.

Kumar A, Nanda B, Kumar N, et al. A prospective randomized comparison between shockwave lithotripsy and semirigid ureteroscopy for upper ureteral stones <2 cm: a single center experience. *J Endourol*. 2013 [Epub ahead of print].

Kuo RL, Aslan P, Zhong P, et al. Impact of holmium laser settings and fiber diameter on stone fragmentation and endoscope deflection. *J Endourol*. 1998;12:523–527.

Kuromatsu I, Imamura T, Sugimura Y. Photoselective vaporization of the prostate (PVP) using 80 watt high power potassium-titanyl-phosphate (KTP) laser for benign prostatic hyperplasia: the first fifty-seven patients in Japan. *Nihon Hinyokika Gakkai Zasshi*. 2006;97:815–822 [in Japanese].

Lamberton GR, Hsi RS, Jin DH, et al. Prospective comparison of four laparoscopic vessel ligation devices. *J Endourol*. 2008;22:2307–2312.

Lancono F, Prezioso D, DiLauro G, et al. Efficacy and safety profile of a novel technique, ThuLEP (Thulium laser enucleation of the prostate) for the treatment of benign prostate hypertrophy. Our experience on 148 patients. *BMC Surg*. 2012;12(Suppl 1):S21.

Landman J, Kerbl K, Rehman J, et al. Evaluation of a vessel sealing system, bipolar electrosurgery, harmonic scalpel, titanium clips, endoscopic gastrointestinal anastomosis vascular staples and sutures for arterial and venous ligation in a porcine model. *J Urol*. 2003;169:697–700.

Lee H, Kang HW, Teichman JMH, et al. Urinary calculus fragmentation during Ho:YAG and Er:YAG lithotripsy. *Lasers Surg Med*. 2006;38:39–51.

Lee H, Ryan RT, Teichman JMH, et al. Stone retropulsion during holmium:YAG lithotripsy. *J Urol*. 2003;169:881–885.

Lehman DS, Hruby GW, Phillips C, et al. Prospective randomized comparison of a combined ultrasonic and pneumatic Lithotrite with a standard ultrasonic Lithotrite for percutaneous nephrolithotomy. *J Endourol*. 2008;22:285–289.

LeRoy AJ, Segura JW. Percutaneous ultrasonic lithotripsy. *Urol Radiol*. 1984;6:88–94.

Li Y, Zeng F, Yang Z, et al. Comparison of CyberWand dual probe lithotriptor and Swiss LithoClast master in ultrasonically guided percutaneous nephrolithotomy for renal staghorn calculi. *Zhong Nan Da Xue Xue Bao Yi Xue Ban*. 2013;38:853–856.

Loffer FD, Pent D. Indications, contraindications and complications of laparoscopy. *Obstet Gynecol Surv*. 1975;30:407–427.

Madigan JD, Choudhri AF, Chen J, et al. Surgical management of the patient with an implanted cardiac device. *Ann Surg*. 1999;230(5):639.

Maghsoudi R, Amjadi M, Norizadeh D, et al. Treatment of ureteral stones: a prospective randomized controlled trial on comparison of Ho:YAG laser and pneumatic lithotripsy.

Indian J Urol. 2008;24:352.

Malek RS. Laser treatment of premalignant and malignant squamous cell lesions of the penis. *Lasers Surg Med*. 1992;12:246–253.

Mariani AJ. Combined electrohydraulic and holmium:YAG laser ureteroscopic nephrolithotripsy of large (greater than 4 cm) renal calculi. *J Urol*. 2007;177:168–173 [discussion 173].

Marks AJ, Teichman JM. Lasers in clinical urology: state of the art and new horizons. *World J Urol*. 2007;25:227–233.

Massarweh NN, Cosgriff N, Slakey DP. Electrosurgery: history, principles, and current and future uses. *J Am Coll Surg*. 2006;202:520–530.

McAllister WJ, Gilling PJ. Vaporization of the prostate. *Curr Opin Urol*. 2004;14:31–34.

Michel MS, Honeck P, Alken P. New endourologic technology for simultaneous holmium:YAG laser lithotripsy and fragment evacuation for PCNL: ex-vivo comparison to standard ultrasonic lithotripsy. *J Endourol*. 2008;22:1537–1539.

Misrai V, Faron M, Guillotreau J, et al. Assessment of the learning curves for photoselective vaporization of the prostate using GreenLight 180-Watt-XPS laser therapy: defining the intra-operative parameters within a prospective cohort. *World J Urol*. 2014;32:539–544.

Miyazaki H, Hirano Y, Kato S, et al. Early experiences of contact laser vaporization of the prostate using the 980 nm high power diode laser for benign prostatic hyperplasia. *Low Urin Tract Symptoms*. 2017.

Molimard B, Al-Qahtani S, Lakmichi A, et al. Flexible ureterorenoscopy with holmium laser in horseshoe kidneys. *Urology*. 2010;76:1334–1337.

Mues AC, Box GN, Abaza R. Robotic instrument insulation failure: initial report of a potential source of patient injury. *Urology*. 2011;77:104–107.

Muschter R. Free-beam and contact laser coagulation. *J Endourol*. 2003;17:579–585.

Nduka CC, Super PA, Monson JR, et al. Cause and prevention of electrosurgical injuries in laparoscopy. *J Am Coll Surg*. 1994;179:161–170.

Netsch C, Becker B, Tiburtius C, et al. A prospective, randomized trial comparing thulium vapoenucleation with holmium laser enucleation of the prostate for the treatment of symptomatic benign prostatic obstruction: perioperative safety and efficacy. *World J Urol*. 2017;35(12):1913–1921.

Norris JP, Norris DM, Lee RD, et al. Visual laser ablation of the prostate: clinical experience in 108 patients. *J Urol*. 1993;150(5):1612–1614.

Okeke Z, Shabsigh A, Gupta M. Use of Amplatz sheath in male urethra during cystolitholapaxy of large bladder calculi. *Urology*. 2004;64:1026–1027.

Orihuela E, Pow-Sang M, Motamedi M, et al. Mechanism of healing of the human prostatic urethra following thermal injury. *Urology*. 1996;48:600–608.

Osório L, Carvalho FL, Branco F, et al. Endoscopic removal of an intravesical calcified sling using pneumatic lithotripsy and cystoscopic resection. *Urol Int*. 2011;87:489–491.

Parker BD, Frederick RW, Reilly TP, et al. Efficiency and cost of treating proximal ureteral stones: shock wave lithotripsy versus ureteroscopy plus holmium:yttrium-aluminum-garnet laser. *Urology*. 2004;64:1102–1106 [discussion 1106].

Pastore AL, Palleschi G, Silvestri L, et al. Prospective randomized study of radiofrequency versus ultrasound scalpels on functional outcomes of laparoscopic radical prostatectomy. *J Endourol*. 2013;27:989–993.

Pedro RN, Netto NR Jr. Proximal ureteral calculi: shock wave or ureterolithotripsy? *Urol Int*. 2008;81:198–201.

Pelander WM, Kaufman JM. Complications of electrohydraulic lithotresis. *Urology*. 1980;16:155–157.

Perlmutter AP, Muschter R. Interstitial laser prostatectomy. *Mayo Clin Proc*. 1998;73:903–907.

Philippou P, Volanis D, Kariotis I, et al. Prospective comparative study of endoscopic management of bladder lithiasis: is prostate surgery a necessary adjunct? *Urology*. 2011;78:43–47.

Phillips JM, Narula N, Deane LA, et al. Histological evaluation of cold versus hot cutting: clinical impact on margin status for laparoscopic partial nephrectomy. *J Urol*. 2008;180(6):2348–2352.

Piergiovanni M, Desgrandchamps F, Cochand-Priollet B, et al. Ureteral and bladder lesions after ballistic, ultrasonic, electrohydraulic, or laser lithotripsy. *J Endourol*. 1994;8:293–299.

Pietrow PK, Auge BK, Zhong P, et al. Clinical efficacy of a combination pneumatic and ultrasonic lithotrite. *J Urol*. 2003;169:1247–1249.

Qiu J, Teichman J, Wang T, et al. Comparison of fluoride and sapphire optical fibers for Er:YAG laser lithotripsy. *J Biophotonics*. 2010;3:277–283.

Rabani SM. Combined percutaneous and transurethral lithotripsy for forgotten ureteral stents with giant encrustation. *Nephrourol Mon*. 2012;4:633–635.

Raif J, Vardi M, Nahlieli O, et al. An Er:YAG laser endoscopic fiber delivery system for lithotripsy of salivary stones. *Lasers Surg Med*. 2006;38:580–587.

Ramakrishnan PA, Medhat M, Al-Bulushi YH, et al. Holmium laser cystolithotripsy in children: initial experience. *Can J Urol*. 2005;12:2880–2886.

Ramanathan R. The Amplatz sheath in the female urethra: a safe and effective approach for cystolitholapaxy. *BJU Int*. 1999;84:187–188.

Razvi HA, Song TY, Denstedt JD. Management of vesical calculi: comparison of lithotripsy devices. *J Endourol*. 1996;10:559–563.

Rodrigues Netto N Jr, Lemos GC, Palma PC, et al. Staghorn calculi: percutaneous versus anatrophic nephrolithotomy. *Eur Urol*. 1988;15:9–12.

Ruszat R, Seitz M, Wyler SF, et al. GreenLight laser vaporization of the prostate: single-center experience and long-term results after 500 procedures. *Eur Urol*. 2008;54:893–901.

Sabnis RB, Ganesamoni R, Doshi A, et al. Micropercutaneous nephrolithotomy (microperc) vs retrograde intrarenal surgery for the management of small renal calculi: a randomized controlled trial. *BJU Int*. 2013;112:355–361.

Sea J, Jonat LM, Chew BH, et al. Optimal power settings for Holmium:YAG lithotripsy. *J Urol*. 2012;187(3):914–919.

Segura JW, LeRoy AJ. Percutaneous ultrasonic lithotripsy. *Urology*. 1984;23(5):7–10.

Seitz C, Tanovic E, Kikic Z, et al. Impact of stone size, location, composition, impaction, and hydronephrosis on the efficacy of holmium:YAG-laser ureterolithotripsy. *Eur Urol*. 2007;52:1751–1757.

Sengupta S, Webb DR. Use of a computer-controlled bipolar diathermy system in radical prostatectomies and other open urological surgery. *ANZ J Surg*. 2001;71:538–540.

Shadpour P, Etemadian M, Saeidi A, et al. Evidence-based choice of pneumatic lithotripsy probe diameter using an improvised in vitro biomodel. *J Endourol*. 2009;23:317–321.

Shah HN, Hegde SS, Shah JN, et al. Simultaneous transurethral cystolithotripsy with holmium laser enucleation of the prostate: a prospective feasibility study and review of literature. *BJU Int*. 2007;99:595–600.

Short KL, Amin M, Harty JI, et al. Comparison of recurrence rates of calculi of the bladder in patients with indwelling catheters following vesicolithotomy, litholapaxy and electrohydraulic lithotripsy. *Surg Gynecol Obstet*. 1984;159:247–248.

Siegman AE. *Lasers*. University Science Books: Mill Valley, CA; 1986.

Sinik Z, Isen K, Biri H, et al. Combination of pneumatic lithotripsy and transurethral prostatectomy in bladder stones with benign prostatic hyperplasia. *J Endourol*. 1998;12:381–384.

Sofer M, Kaver I, Greenstein A, et al. Refinements in treatment of large bladder calculi: simultaneous percutaneous suprapubic and transurethral cystolithotripsy. *Urology*. 2004;64:651–654.

Song HC, Jung HB, Lee YS, et al. Influence of ureteral stone components on the outcomes of electrohydraulic lithotripsy. *Korean J Urol*. 2012;53:848–852.

Soucy F, Ko R, Denstedt JD, et al. Occupational noise exposure during endourologic procedures. *J Endourol*. 2008;22:1609–1611.

Sözen S, Küpeli B, Tunc L, et al. Management of ureteral stones with pneumatic lithotripsy: report of 500 patients. *J Endourol*. 2003;17:721–724.

Stackl W, Marberger M. Tissue damage during percutaneous ultrasonic lithotripsy. *Z Urol Nephrol*. 1985;78:655–658 [in German].

Stein BS. Laser physics and tissue interaction. *Urol Clin North Am*. 1986;13:365–380.

Stein BS, Kendall AR. Lasers in urology. I. Laser physics and safety. *Urology*. 1984;23:405–410.

Stein BS, Kendall AR. Lasers in urology. II. Laser therapy.

Urology. 1984;23:411–416.

Takada M, Ichihara T, Kuroda Y. Comparative study of electrothermal bipolar vessel sealer and ultrasonic coagulating shears in laparoscopic colectomy. *Surg Endosc*. 2005;19:226–228.

Talso M, Emiliani E, Haddad M, et al. Laser fiber and flexible ureterorenoscopy: the safety distance concept. *J Endourol*. 2016;30(12):1269–1274.

Tan AH, Gilling PJ, Kennett KM, et al. Long-term results of high-power holmium laser vaporization (ablation) of the prostate. *BJU Int*. 2003;92:707–709.

Teh CL, Zhong P, Preminger GM. Laboratory and clinical assessment of pneumatically driven intracorporeal lithotripsy. *J Endourol*. 1998;12:163–169.

Teichman JM, Vassar GJ, Glickman RD. Holmium:yttrium-aluminum-garnet lithotripsy efficiency varies with stone composition. *Urology*. 1998;52:392–397.

Teichmann HO, Herrmann TR, Bach T. Technical aspects of lasers in urology. *World J Urol*. 2007;25:221–225.

Thangasamy IA, Chalasani V, Bachmann A. Photoselective vaporisation of the prostate using 80-W and 120-W laser versus transurethral resection of the prostate for benign prostatic hyperplasia: a systematic review with meta-analysis from 2002 to 2012. *Eur Urol*. 2012;62(2):315–323.

Tremp M, Hefermehl L, Largo R, et al. Electrosurgery in urology: recent advances. *Expert Rev Med Devices*. 2011;8:597–605.

Troup GJ. *Masers and lasers; molecular amplification and oscillation by stimulated emission*. 2nd ed. Methuen: London; 1963.

Tucker RD, Ferguson S. Do surgical gloves protect staff during electrosurgical procedures? *Surgery*. 1991;110:892–895.

Tucker RD, Voyles CR. Laparoscopic electrosurgical complications and their prevention. *AORN J*. 1995;62:51–53 [55, 58–9 passim; quiz 74–7].

Tugcu V, Polat H, Ozbay B, et al. Percutaneous versus transurethral cystolithotripsy. *J Endourol*. 2009;23:237–241.

Tyson MD, Lerner LB. Safety of holmium laser enucleation of the prostate in anticoagulated patients. *J Endourol*. 2009;23:1343–1346.

Van Way CW, Hinrichs CS. Electrosurgery 201: basic electrical principles. *Curr Surg*. 2000;57:261–264.

Van Way CW 3rd. Electrosurgery 101. *Curr Surg*. 2000;57:172–177.

Vilos G, Latendresse K, Gan BS. Electrophysical properties of electrosurgery and capacitive induced current. *Am J Surg*. 2001;182:222–225.

Vilos GA, Rajakumar C. Electrosurgical generators and monopolar and bipolar electrosurgery. *J Minim Invasive Gynecol*. 2013;20:279–287.

VonDerHaar JN, McAteer JA, Williams JC Jr, et al. In vitro evaluation of the Lithoclast Ultra Vario combination lithotrite. *Urol Res*. 2010;38:485–489.

Vorreuther R, Corleis R, Klotz T, et al. Impact of shock wave pattern and cavitation bubble size on tissue damage during ureteroscopic electrohydraulic lithotripsy. *J Urol*. 1995;153(3):849–853.

Vorreuther R, Engelking R. Adjustable electrohydraulic lithotripsy for minimally invasive ureteroscopic stone treatment. *Urologe A*. 1992;31:76–80 [in German].

Vorreuther R, Engelking R. Impact of voltage and capacity on the electrical and acoustic output of intracorporeal electrohydraulic lithotripsy. *Urol Res*. 1992;20:355–359.

Wang K, Advincula AP. “Current thoughts” in electrosurgery. *Int J Gynaecol Obstet*. 2007;97:245–250.

Watson G, Murray S, Dretler SP, et al. An assessment of the pulsed dye laser for fragmenting calculi in the pig ureter. *J Urol*. 1987;138:199–202.

Welch AJ, Torres JH, Cheong WF. Laser physics and laser-tissue interaction. *Tex Heart Inst J*. 1989;16:141–149.

Wiener SV, Deters LA, Pais VM Jr. Effect of stone composition on operative time during ureteroscopic holmium:yttrium-aluminum-garnet laser lithotripsy with active fragment retrieval. *Urology*. 2012;80:790–794.

Wollin DA, Ackerman A, Yang C, et al. Variable pulse duration from a new Holmium:YAG laser: the effect on stone comminution, fiber tip degradation, and retropulsion in a dusting model. *Urology*. 2017;103:47–51.

Wollin TA, Singal RK, Whelan T, et al. Percutaneous suprapubic cystolithotripsy for treatment of large bladder calculi. *J Endourol*. 1999;13:739–744.

Wosnitzer MS, Rutman MP. KTP/LBO laser vaporization of the prostate. *Urol Clin North Am*. 2009;36:471–483 [vi].

Wu TT, Hsu TH, Li AF, et al. Morphological change in the urothelium after electrohydraulic versus pulsed dye laser lithotripsy. *Br J Urol*. 1994;74:685–689.

Xia SJ, Zhang YN, Lu J, et al. Thulium laser resection of prostate-tangerine technique in treatment of benign prostate hyperplasia. *Zhonghua Yi Xue Za Zhi*. 2005;85:3225–3228 [in Chinese].

Yeow W-C, Pemberton R, Barker A. Flexible ureterorenoscopy and laser lithotripsy in children. *J Indian Assoc Pediatr Surg*. 2009;14:63–65.

Zang F, Shao Q, Herrmann TR, et al. Thulium laser versus holmium laser transurethral enucleation of the prostate: 18 month follow-up data of a single center. *Urology*. 2012;79:869–874.

Zang YC, Deng XX, Yang DR, et al. Photoselective vaporization of the prostate with GreenLight 120-W laser versus transurethral resection of the prostate for benign prostatic hyperplasia: a systematic review with meta-analysis of randomized controlled trials. *Lasers Med Sci*. 2016;31(2):235–240.

Zarrabi A, Gross AJ. The evolution of lasers in urology. *Ther Adv Urol*. 2011;3:81–89.

Zhu S, Kourambas J, Munver R, et al. Quantification of the tip movement of lithotripsy flexible pneumatic probes. *J Urol*. 2000;164:1735–1739.

16

Evaluation and Management of Hematuria

Stephen A. Boorjian MD, Jay D. Raman MD, FACS, Daniel A. Barocas MD, MPH, FACS

Hematuria has been recognized as a sign of medical illness since antiquity (Armstrong, 2006; Ellis, 1979; Shokeir and Hussein, 1999). Yet it is only in the modern era that we have developed the technology to detect microscopic blood, the means to identify the source of hematuria, and the understanding of anatomy, physiology, and disease processes underlying this important sign. Today, hematuria is one of the most common indications for urologic evaluation (Mariani et al., 1989) and is recognized as a sign of potentially important illness. Therefore knowledge of the differential diagnosis, principles of evaluation, and strategies for management of hematuria is critical.

Classification and Timing of Hematuria

Hematuria may be classified according to its visibility and timing during the urinary stream. That is, gross hematuria (GH), sometimes referred to as *frank hematuria*, *macrohematuria*, or *visible hematuria*, is hematuria that can be seen with the naked eye. GH may be further characterized as initial, terminal, or total, depending on the phase of the urinary stream in which it is visible. This characterization may give some indication of the source of hematuria, with initial hematuria most commonly emanating from a urethral source; terminal hematuria from the bladder trigone, bladder neck, or prostate; and total hematuria from the bladder or above (Sokolosky, 2001).

GH must be distinguished from pigmenturia, which may be due to endogenous sources (e.g., bilirubin, myoglobin, porphyrins), foods ingested (e.g., beets and rhubarb), drugs taken (e.g., phenazopyridine), and simple dehydration. This distinction can be made easily by urinalysis with microscopy. Notably, myoglobinuria and other factors can cause false-positive chemical tests (e.g., urine dipstick) for hemoglobin, so urine microscopy is required to confirm the diagnosis of hematuria. **GH also must be distinguished from vaginal bleeding in women,** which usually can be achieved by obtaining a careful menstrual history, collecting the specimen when the patient is not having menstrual or gynecologic bleeding, or, if necessary, obtaining a catheterized specimen. GH may also be detected by the presence of blood spotting on the undergarments of incontinent patients. After ruling out vaginal bleeding and mimics of hematuria, a urologic source must be suspected.

Microscopic Hematuria

In contrast to GH, microscopic hematuria, or microhematuria (MH), is a sign rather than a symptom; a laboratory diagnosis defined as the presence of red blood cells (RBCs) on microscopic examination of the urine not evident on visual inspection of the urine. **The prevalence of MH among healthy participants in screening studies is approximately 6.5% (95% confidence interval [CI] 3.4 to 12.2),** with higher rates noted in studies with a predominance of males, older patients, and smokers (Davis et al., 2012). MH may be categorized by the presence or absence of associated symptoms and may be quantified according to number of RBCs per high-power field (HPF). The proper collection of a urine specimen and the details of urine dipstick testing and urinalysis are covered in Chapter 1.

Criteria for the Diagnosis of Microhematuria

A small number of RBCs may pass into the urine even under normal conditions, and normal processes (e.g., sexual activity, exercise) can result in minor amounts of MH (Kohanpour et al., 2012). At the same time, it has been shown that **MH caused by significant medical conditions, such as urinary tract malignancy, can be intermittent** (Davis et al., 2012). In fact, a meta-analysis reported that the rate of malignancy detected among patients evaluated for a single positive urinalysis was 3.6% (Davis et al., 2012). As such, **the American Urological Association (AUA) guideline panel defined MH as three or more RBCs/HPF,** concluding that higher thresholds would lead to missed opportunities to diagnose treatable urologic conditions (Davis et al., 2012; Nielsen and Qaseem, 2016). Moreover, the AUA guideline panel determined that **a single positive urinalysis is sufficient to prompt evaluation** (Davis et al., 2012). Other national and organizational guidelines vary with respect to criteria for MH diagnosis (Linder et al., 2017; Schmitz-Dräger et al., 2016; Table 16.1). Such differences in thresholds for initiating an evaluation reflect efforts to balance the benefits, harms, and costs associated with MH evaluation. Importantly, none have been robustly validated.

TABLE 16.1

Selected Guidelines for Evaluation of Asymptomatic

Microhematuria

GUIDELINE BODY	REFERENCE, YEAR	AGE/SEX	CRITERIA FOR EVALUATION	CYSTOSCOPY	IMA
American Urological Association	Davis et al., 2012	Adults	3 or more RBCs/HPF on a single UA	≥35 years old or with risk factors	CT urog pref
Canadian Consensus Document	Kassouf et al., 2016	Adults	3 or more RBCs/HPF on 2 out of 3 UAs	≥35 years old	Prov disc
Kaiser Permanente	Loo et al., 2009	Adults	More than 3 RBCs/HPF on 2 out of 3 UAs	Urologist discretion	CT urog IVP
American College of Obstetricians and Gynecologists and American Urogynecologic Society	Committee Opinion, 2017	Adults Women	Not stated	Avoid in never-smoking women age 35–50; only evaluate if >25 RBCs/HPF	Avo neve smo won 35– only eval >25 RBC
Japanese	Horie et al., 2014	Adults ≥40 years	5 or more RBCs/HPF on a single UA	≥40 years old, with risk factors	US
Dutch	van der Molen and Hovius, 2012	Adults ≥50 years	3 or more RBCs/HPF on 2 out of 3 UAs	>50 years; provider discretion in younger patients	US i year prov disc in yo patie
American College of Physicians	Nielsen and Qaseem, 2016	Adults	3 or more RBCs/HPF on a single UA	Not stated	Not
UK National Institute for Health and Care Excellence (NICE)	NICE, 2016 Anderson et al., 2008	Patients over age 60	1+ blood or more on urine dip stick test PLUS Dysuria or	Not stated	Not

			elevated leukocytosis		

CT, Computed tomography; *HPF,* high-power field; *IVP,* intravenous pyelogram; *RBC,* red blood cell; *RUS,* renal ultrasound; *UA,* urinalysis; *US,* ultrasound.

Requirement for Microscopic Evaluation

The results of urine dipstick tests must be confirmed on urinalysis with microscopy and alone are considered insufficient to prompt an evaluation according to most authorities (Davis et al., 2012; Jeffries et al., 2016; Nielsen and Qaseem, 2016). Indeed, chemical tests for hematuria detect the peroxidase activity of hemoglobin using benzidine, and therefore conditions such as myoglobinuria can falsely activate the test (Mariani et al., 1984). Thus a positive dipstick test merits microscopic examination of the urinary sediment but does not warrant full evaluation unless microscopy confirms the presence of three or more RBCs/HPF. If the urinalysis with microscopy is not confirmatory, but the clinician remains suspicious, repeat microscopic testing is reasonable with the frequency individualized based on provider judgment.

Specimens collected immediately after prolonged recumbency (first void in morning) or after vigorous physical or sexual activity may be falsely positive for hematuria (Addis, 1926; Kincaid-Smith, 1982). In addition, dilute urine (osmolality <308 mOsm) may result in false-negative microscopic examination as a result of RBC lysis (Vaughan and Wyker, 1971).

Causes of Microhematuria

In most studies, **one-third to two-thirds of patients evaluated for MH have been found to have a demonstrable cause** (Mohr et al., 1986; Murakami et al., 1990), including calculus (6.0%), benign prostatic enlargement (12.9%), urethral stricture (1.4%), and various other conditions (Table 16.2; Davis et al., 2012). Notably, **the evaluation of patients with MH has been found to yield a diagnosis of malignancy in 0.68% to 4.3% of cases,** depending on the characteristics of the population evaluated, the threshold for evaluation, and the completeness of the evaluation (Davis et al., 2012; Jung et al., 2011; Price et al., 2014). **The likelihood of identifying a malignancy has been found to be greater among patients with higher levels of microscopic hematuria (>25 RBCs/HPH), GH, or risk factors for malignancy** (Lippmann et al., 2017; Loo et al., 2013; Shephard et al., 2012; Sultana et al., 1996; Box 16.1).

TABLE 16.2

Differential Diagnosis of Asymptomatic Microhematuria[a]

CATEGORY	EXAMPLES	COMMON CLINICAL PRESENTATION AND RISK FACTORS
Neoplasm	Any	See Box 16.1
	Bladder cancer	Older age, male predominance, tobacco use, occupational exposures, irritative voiding symptoms
	Ureteral or renal pelvis cancer	Family history of early colon cancers or upper tract tumors, flank pain
	Renal cortical tumor	Family history of early kidney tumors, flank pain, flank mass
	Prostate cancer	Older age, family history, African-American
	Urethral cancer	Obstructive symptoms, pain, bloody discharge
Infection/inflammation	Any	History of infection
	Cystitis	Female predominance, dysuria
	Pyelonephritis	Fever, flank pain, diabetes, female predominance
	Urethritis	Exposure to sexually transmitted infections, urethral discharge, dysuria
	Tuberculosis	Travel to endemic areas
	Schistosomiasis	Travel to endemic areas
	Hemorrhagic cystitis	See Box 16.2
Calculus	Any	
	Nephroureterolithiasis	Flank pain, family history, prior stone
	Bladder stones	Bladder outlet obstruction
Benign prostatic enlargement		Male, older age, obstructive symptoms
Medical renal disease[b]	Any	Hypertension, azotemia, dysmorphic erythrocytes, cellular casts, proteinuria
	Nephritis	
	IgA nephropathy	
Congenital or acquired anatomic abnormality	Polycystic kidney disease	Family history of renal cystic disease

	Ureteropelvic junction obstruction Ureteral stricture Urethral diverticulum Fistula	History of UTI, stone, flank pain History of surgery or radiation, flank pain, hydronephrosis; stranguria, spraying urine Discharge, dribbling, dyspareunia, history of UTI, female predominance Pneumaturia, fecaluria, abdominal pain, recurrent UTI, history of diverticulitis or colon cancer
Other	Exercise-induced hematuria[c]	Recent vigorous exercise
	Endometriosis	Cyclic hematuria in a menstruating woman
	Hematologic or thrombotic disease	Family history or personal history of bleeding or thrombosis
	Papillary necrosis	African-American, sickle cell disease, diabetes, analgesic abuse
	Arteriovenous malformation	
	Renal vein thrombosis	
	Interstitial cystitis	Voiding symptoms
	Trauma	History
	Recent genitourinary surgery or instrumentation	History

[a] Differential diagnosis, having ruled out obvious benign causes, such as menstruation, recent instrumentation, uncomplicated cystitis, etc.

[b] Presence of hematologic illness, medical renal illness or use of anticoagulants or antiplatelet agents does not preclude the need for a hematuria evaluation.

[c] Exercise-induced hematuria is a diagnosis of exclusion. Absence of hematuria after abstinence from exercise must be confirmed.

IgA, Immunoglobulin A; *UTI,* urinary tract infection.

Box 16.1

Common Risk Factors for Urinary Tract Malignancy in Patients With Microscopic Hematuria

Male gender
Age older than 35 years
Past or current smoking history
Occupational or other exposure to chemicals or dyes (benzenes or aromatic amines)
Analgesic abuse
History of gross hematuria
History of urologic disorder or disease
History of irritative voiding symptoms
History of pelvic irradiation
History of chronic urinary tract infection
Exposure to known carcinogenic agents or chemotherapy such as alkylating agents
History of chronic indwelling foreign body

Modified from 2012 American Urological Association guidelines.

Selecting Patients for Evaluation of Microhematuria

The AUA guidelines recommend evaluating all adults with asymptomatic microscopic hematuria, with few exceptions, whereas other organizations have put forth narrower criteria for evaluation (Linder et al., 2017; Schmitz-Dräger et al., 2016; see Table 16.1). Specifically, the AUA and American College of Physicians High-Value Care Task Force recommend evaluating patients with MH “in the absence of an obvious benign cause” such as infection and menstruation (Davis et al., 2012; Nielsen and Qaseem, 2016). As such, **patients who are found to have MH in the setting of a suspected benign cause must have that benign cause substantiated by clinical evidence and be further evaluated once the suspected benign cause is resolved.** Unfortunately, uniform agreement does not exist on how to identify benign causes of hematuria. Perhaps as a result, substantial delays in diagnosis and inferior bladder cancer outcomes have occurred related to repeated empirical treatment of urinary tract infection (UTI) and voiding symptoms, particularly among women (Henning et al., 2013; Lyratzopoulos et al., 2013; Tracey et al., 2014). Thus it may be recommended that the **presence of infection be confirmed with a urine culture and the urinalysis should be repeated after treatment of the UTI to document**

resolution of the hematuria. If hematuria persists, further evaluation is warranted.

In addition, recent vigorous exercise may be associated with MH, but this entity should be considered a diagnosis of exclusion (Kincaid-Smith, 1982; Kohanpour et al., 2012; McInnis et al., 1998). Thus it is necessary to confirm the absence of MH after a period of abstinence from exercise. In addition, **patients who develop hematuria (microscopic or gross) who are taking anticoagulation or antiplatelet medications (e.g., warfarin, enoxaparin, heparin, aspirin, clopidogrel, nonsteroidal anti-inflammatory agents) should undergo a complete evaluation in the same manner as patients not taking such medications** because the prevalence of hematuria, as well as the likelihood of finding genitourinary cancers, among patients with hematuria on anticoagulation has been reported to be no different from patients not taking such medications (Culclasure et al., 1994; Davis et al., 2012; Jeong et al., 2013; Khadra et al., 2000; Nielsen and Qaseem, 2016). In fact, it has been noted that these medications may unmask genitourinary lesions at an earlier stage (Antolak and Mellinger, 1969; Kraus et al., 1984; Mariani, 1989; Schuster and Lewis, 1987). In one series, 82% of anticoagulated male patients evaluated for GH were found to have significant urologic lesions (Antolak and Mellinger, 1969), and 13.9% of such lesions in another series were found to be malignant (Schuster and Lewis, 1987). More recently, a population-based study in Ontario, Canada, showed that patients taking antithrombotic agents were more than twice as likely to be diagnosed with bladder cancer within 6 months after an episode of hematuria (Wallis et al., 2017). MH in the setting of trauma is detailed in Chapters 52 and 90.

At the same time, recognizing that one-third to two-thirds of patients with MH will have a negative hematuria evaluation, considered together with the health system financial burden and patient risks associated with MH evaluation, efforts have been put forth to develop a more individualized approach to the selection of patients for MH evaluation (Loo et al., 2013; Mohr et al., 1986; van der Molen and Hovius, 2012). For example, data from Kaiser Permanente demonstrated that, among patients undergoing a complete evaluation for hematuria, those with risk factors for malignancy (age >50 years, history of GH, tobacco use, male gender, or >25 RBCs/HPF) had higher rates of malignancy diagnosed at evaluation (10.7% to 11.6%) than patients classified as being at intermediate (1.1% to 2.5%) or low (0% to 0.3%) risk (Loo et al., 2013). Similarly, the American College of Obstetricians Gynecologists and American Urogynecologic

Society issued a joint statement in 2017 on asymptomatic microscopic hematuria in women, recommending withholding evaluation in never-smoking women aged 35 to 50 who have fewer than 25 RBCs/HPF because the risk of urinary tract malignancy in such patients has been demonstrated to be less than or equal to 0.5% (Committee for Gynecologic Practice, 2017). Nevertheless, it is important to recognize that, despite the potential benefits of such risk-based approaches, analyses of contemporary practice patterns have noted that **fewer than 25% of patients found to have hematuria are even referred for evaluation, and fewer than 10% undergo a complete evaluation with cystoscopy and imaging,** including among patients at high risk for malignancy (Ark et al., 2017; Bassett et al., 2015; Buteau et al., 2012; Elias et al., 2010; Friedlander et al., 2014). Thus, although ample room remains for improvement in the selection of patients for MH evaluation, currently there exists a huge variation in care delivery with a large proportion of at-risk patients not being evaluated in a proper and timely fashion. Therefore continued research and education are necessary and may in fact be facilitated by the implementation of such systems as decision support tools in the electronic medical record, telemedicine consultation, and one-stop hematuria clinics (Liedberg et al., 2016; Ooi et al., 2011).

The Question of Screening for Hematuria and Bladder Cancer

Bladder cancer is the sixth most commonly diagnosed cancer in the United States, and although no large-scale screening trials have been performed, **most believe that the harms and costs of mass screening for bladder cancer would prove to outweigh the potential benefits** (Chou and Dana, 2010; National Cancer Institute, 2018). Nonetheless, many primary care providers perform urinalysis as part of routine health examinations, creating numerous opportunistic screening events (Prochazka et al., 2005).

Key Points: Microscopic Hematuria

- MH is defined by the AUA guidelines as three or more RBCs/HPF, identified on one or more occasions on urine microscopy. Urine dipstick testing is insufficient for the diagnosis of MH.

- MH is common, with a prevalence of approximately 6.5% of adults, varying according to the characteristics of the population.
- Malignancy has been detected in approximately 3.5% of patients evaluated for asymptomatic MH. The risk of malignancy diagnosis is greater in patients with higher degrees of hematuria, male gender, and/or risk factors for malignancy and lower in absence of these risk factors.

Guideline-Based Evaluation of Patients With Microhematuria

See Fig. 16.1 for the evaluation algorithm of MH from the most recent AUA guidelines (Davis et al., 2012; https://www.auanet.org/guidelines/asymptomatic-microhematuria-(2012-reviewed-for-currency-2016)) and Table 16.1 for other organizational recommendations. Importantly, the AUA guidelines recommend that **patients meeting criteria for evaluation undergo a complete evaluation, even if one phase of the evaluation shows a suspected cause for the MH.** For example, a patient found to have a kidney tumor or stone disease during initial workup of MH should still undergo cystoscopy for clearance of bladder and urethral pathological processes.

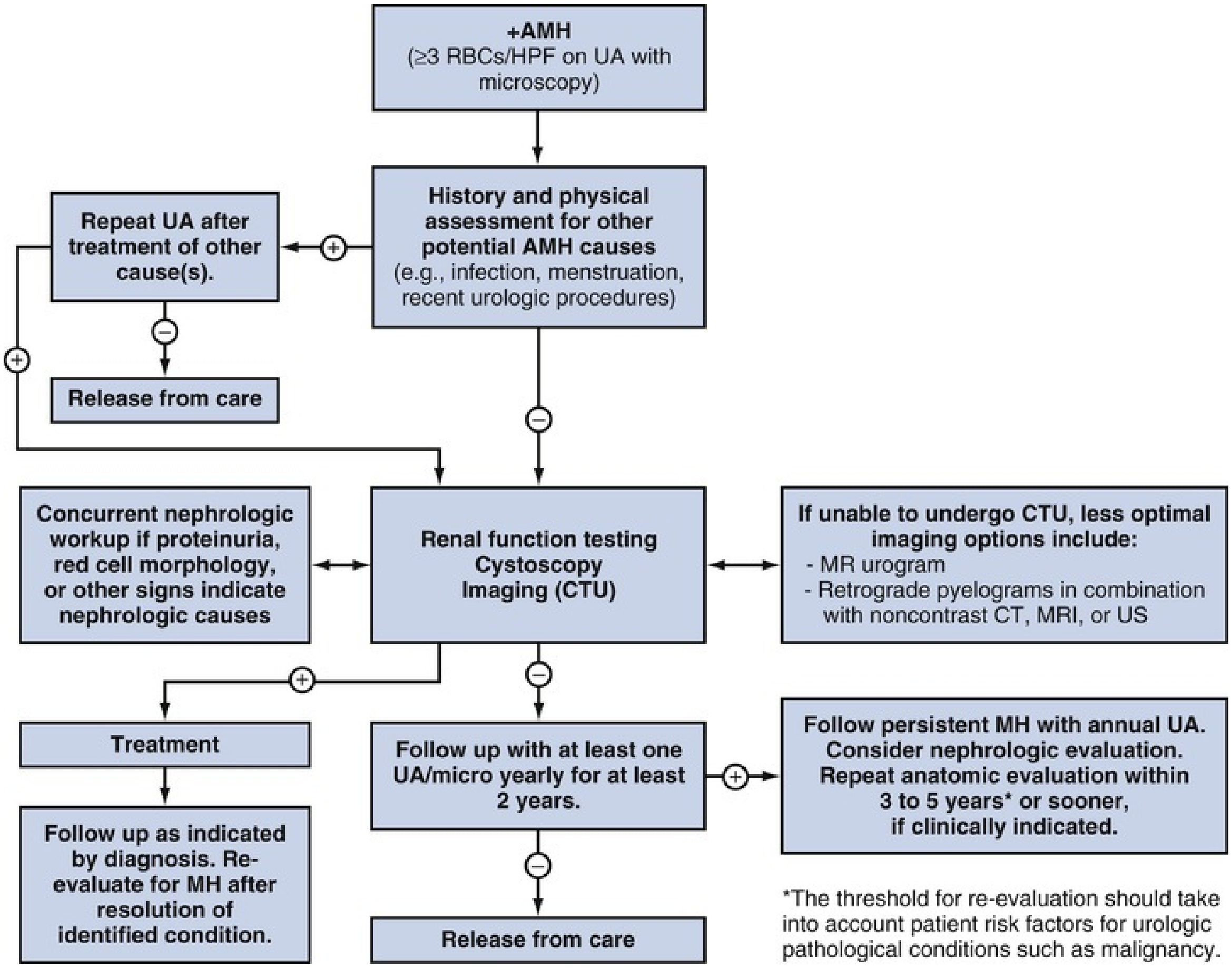
+AMH
(≥3 RBCs/HPF on UA with microscopy)
History and physical assessment for other potential AMH causes
(e.g., infection, menstruation, recent urologic procedures)
+
Repeat UA after treatment of other cause(s).
−
Release from care
+
−
Concurrent nephrologic workup if proteinuria, red cell morphology, or other signs indicate nephrologic causes
Renal function testing
Cystoscopy
Imaging (CTU)
If unable to undergo CTU, less optimal imaging options include:
- MR urogram
- Retrograde pyelograms in combination with noncontrast CT, MRI, or US
+
Treatment
−
Follow up with at least one UA/micro yearly for at least 2 years.
+
Follow persistent MH with annual UA. Consider nephrologic evaluation. Repeat anatomic evaluation within 3 to 5 years* or sooner, if clinically indicated.
Follow up as indicated by diagnosis. Re-evaluate for MH after resolution of identified condition.
−
Release from care
*The threshold for re-evaluation should take into account patient risk factors for urologic pathological conditions such as malignancy.

FIG. 16.1 American Urological Association guideline algorithm for evaluation of adult patients with asymptomatic microhematuria. *AMH,*

Asymptomatic microhematuria; *CT,* computed tomography; *CTU,* computed tomography urogram; *HPF,* high-power field; *MH,* microhematuria; *MR,* magnetic resonance; *MRI,* magnetic resonance imaging; *RBC,* red blood cell; *UA,* urinalysis; *US,* ultrasound. (From the American Urological Association.)

The evaluation of an appropriately selected patient with MH begins with a thorough history and physical examination. Specifically, the goal should be to identify causes that would warrant variation from the standard evaluation, such as infection, menstruation, recent vigorous exercise, known medical renal disease, acute viral illness, trauma, and the presence of foreign bodies in the urinary tract or recent urologic instrumentation. The history also should include an assessment of associated symptoms, such as GH, voiding symptoms, or flank pain. Patients' risk factors for known causes of hematuria also should be queried. It is important to know the patient's urologic history, particularly any surgeries or febrile UTIs. It is also critical to ask about the patient's general medical history to identify potentially contributory diagnoses, such as hypertension, renal insufficiency, bleeding disorders, or sickle cell disease. Current medication use, including anticoagulants and antiplatelet therapies, should be elicited, along with recent coagulation values and any concomitant medications that would potentiate the effects of blood thinners. Family history of nephritis, polycystic kidneys, and rare familial tumor syndromes of the kidney (e.g., von Hippel-Lindau syndrome) or urothelium (e.g., Lynch syndrome) also may be informative. In addition, the possibility of finding a tobacco-related illness, such as bladder cancer, makes this a potential "teachable moment" for tobacco users (Bassett et al., 2012; Fiore and Baker, 2013). Thus smoking cessation counseling should be a standard component of the hematuria evaluation discussion for current smokers.

Physical examination should focus on the genitourinary system (e.g., flank tenderness; masses in the flank, abdomen, suprapubic area, or urethra; and enlarged, nodular, tender, or fluctuant prostate.) Physical examination also may identify signs of coagulopathy (bruising), infection (fever), or renal disease (hypertension, edema). If urethral stricture or benign prostatic hyperplasia (BPH) is suspected, a urine flow rate and postvoid residual measurement may be helpful as well.

Laboratory testing includes urinalysis (if not performed previously) to confirm the presence of hematuria and check for dysmorphic red cells, cellular casts, or proteinuria; urine culture if the urinalysis or clinical presentation suggests infection; renal function testing (serum creatinine) to determine whether concomitant nephrologic evaluation is indicated and to guide the selection of appropriate upper tract imaging; and prostate-specific antigen in the appropriate setting.

If a benign cause of hematuria is discovered during the initial history and physical examination (e.g., UTI), that cause should be verified and treated and then the urine should be retested to ensure that the hematuria has resolved in the absence of the presumed benign cause. Moreover, **if a medical renal cause of hematuria is suspected based on the presence of renal insufficiency, hypertension, or abnormalities on urinalysis, nephrology evaluation is recommended, but the patient should still undergo urologic evaluation.**

Cystoscopy in the Diagnostic Evaluation of Hematuria

Cystoscopy is a key component of the hematuria evaluation because it is the most reliable way to evaluate the bladder for the presence of bladder cancer and provides the opportunity to evaluate the urethra. The AUA guidelines indicate that **cystoscopy should be performed in all adults who meet criteria for hematuria evaluation who are 35 years of age or older and/or have risk factors for malignancy.** Bladder cancer is rare (<1 per 100,000) among persons 35 years old or younger (National Cancer Institute, 2018; van der Molen and Hovius, 2012). Among 3762 individuals with asymptomatic MH from 17 screening studies, 98 (2.6%) were diagnosed with a urinary tract malignancy, of whom 95 (97%) were older than 35 years of age. For these reasons, the AUA guidelines state that **cystoscopy may be omitted in persons younger than age 35 years without risk factors or clinical suspicion for bladder cancer** or urethral pathology (see Box 16.1). Again, other organizational guidelines differ slightly in criteria for cystoscopy (see Table 16.1). Potential risks of the procedure include discomfort, injury to the urethra, infection, and the need for additional procedures such as biopsy.

Blue-light cystoscopy using 5-aminolevulinic acid (ALA) or hexyl-aminolevulinate (HAL) instillation is approved by the US Food and Drug Administration (FDA) for evaluation of patients with suspicion of papillary bladder cancer, but the studies supporting its use have been conducted in patients with known bladder cancer, thereby limiting generalizability to MH patients (Davis et al., 2012; Malmstrom et al., 2012). In light of the small incremental risk associated with ALA or HAL and blue-light cystoscopy (rare anaphylactoid shock, hypersensitivity, pain, cystitis, dysuria, hematuria) and the risk for unnecessary biopsies compared with conventional white light cystoscopy, the **AUA guideline recommends against using blue-light cystoscopy for evaluation of MH** (Davis et al., 2012).

Upper Tract Imaging in the Diagnostic Evaluation of Hematuria

Multiphasic computed tomography (CT) urogram (i.e., CT with precontrast, nephrographic, and excretory series) is the imaging study recommended by the AUA guidelines for the evaluation of asymptomatic MH (Davis et al., 2012). CT urography offers complete imaging of the urinary tract and has the highest sensitivity and specificity for detecting lesions of the renal parenchyma and the upper tracts (Vikram et al., 2009). Nonetheless, CT urography does carry risks and may not be appropriate for all patients (e.g., pregnancy, iodinated contrast allergy, renal insufficiency). Furthermore, CT urography uses a relatively high radiation dose (20–30 mSv, with considerable variability across centers), which may be associated with a risk of carcinogenesis (Board on Radiation Effects Research, 2006; Mettler et al., 2008; Tsili et al., 2007; Vrtiska et al., 2009). In the setting of a contraindication to CT urogram, magnetic resonance (MR) urogram may be used as the upper tract study. Moreover, for patients with a contraindication to MR imaging (e.g., pacemaker), as well as in the setting of significant renal function compromise (i.e., estimated glomerular filtration rate <30 and when the administration of gadolinium risks nephrogenic systemic fibrosis), renal parenchymal imaging with noncontrast CT or ultrasound, in conjunction with retrograde pyelography to evaluate the calyces, renal pelvis, and ureters, may be most appropriate.

Not surprisingly, given the overall low diagnostic yield of evaluating asymptomatic microscopic hematuria, together with the potential radiation exposure and health system costs of CT urogram, there remain discrepancies among organizational hematuria guidelines regarding imaging recommendations (Lisanti et al., 2014; Rhéaume-Lanoie et al., 2014; see Table 16.1). Interestingly, a recent modeling study evaluated the potential implications of replacing CT urogram with ultrasound and demonstrated that US plus cystoscopy would be more cost effective than other options with nearly the same diagnostic yield as CT urogram plus cystoscopy (Halpern et al., 2017). Nevertheless, such an approach is not risk stratified and importantly has not been prospectively tested.

Urine Cytology and Urinary Biomarkers in the Diagnostic Evaluation of Hematuria

Urine cytologic examination is highly sensitive and specific for the detection of high-grade urothelial carcinoma, but sensitivity decreases significantly for low-grade urothelial carcinoma, resulting in an overall sensitivity of 15.8% to 54.5%, and specificity of 95.0% to 100% for bladder cancer detection (Chahal et al., 2001; Grossman et al., 2005; Miyanaga et al., 1999; Steiner et al., 2008; Zippe et al., 1999). Indeed, in a large study of patients with hematuria, the sensitivity and specificity of positive/suspicious/atypical cytology were 45.4% and 89.5%, respectively (Mishriki et al., 2013).

Meanwhile, although several urine biomarkers have been approved or cleared by the FDA for detection and surveillance of bladder cancer, few studies have been conducted to evaluate these markers in patients with MH who do not have a history of bladder cancer. Available assays include nuclear matrix protein-22 (NMP-22), bladder tumor antigen, fluorescence in situ hybridization (FISH) for abnormalities of chromosomes 3, 7, 17, and 9p21 (UroVysion [Abbott Molecular, Abbott Park, IL]) and immunocytology for carcinoembryonic antigen and mucin glycoproteins (ImmunoCyt [Scimedx, Denville, NJ] and CertNDx [PCLS, Rock Hill, SC]).

NMP-22 offers a potential advantage in management of patients with MH: it is available as a point-of-care test. However, only two studies have focused on the asymptomatic patient with MH, with one finding a high sensitivity (90.9%) and the other in a screening population demonstrating very low sensitivity (6.0%). Specificity was moderate or high in both studies (76.3% and 82.5%, respectively) (Miyanaga et al., 1999; Steiner et al., 2008). Meanwhile, one study assessed FISH testing in patients with asymptomatic MH with a negative cytology and found that sensitivity and specificity may be high for upper tract tumors in this setting (Huang et al., 2012). A separate FISH study in asymptomatic MH patients (albeit without prior negative cytologic findings) showed sensitivity and specificity of 61% and 93%, respectively, for bladder tumors (Steiner et al., 2008). Immunocytology has been tested in the asymptomatic MH setting in one study of 189 patients (Schmitz-Drager et al., 2007). Here, eight bladder tumors were identified, of which seven were identified by the ImmunoCyt test, for a sensitivity of 87%. However, studies in the urothelial carcinoma follow-up setting have found a far more modest sensitivity (68.1%) (Comploj et al., 2013). The multianalyte urine test CertNDx assesses several markers (mutant *FGFR3*, quantified matrix metalloproteinase-2 [MMP-2], and hypermethylation of *TWIST1* and *NID2*). In a population of patients with hematuria (gross and microscopic) 50 years of age or older without diagnosis of bladder cancer, the sensitivity and specificity of this test were noted to be 87.9% and 56.3%, respectively (Karnes et al., 2012). A similar test, looking for methylation of *TWIST1*, *ONECUT2*, and *OTX1*, along with mutation of *FGFR3*, *TERT*, and *HRAS*, shows promising accuracy for detection of bladder cancer, with sensitivity of 93% and specificity of 86% when combined with age in a cohort of patients undergoing cystoscopy for evaluation of hematuria (van Kessel et al., 2017).

Together, because current evidence indicates that none of the available urinary biomarkers, including cytology, appear to be sufficiently sensitive or sufficiently validated to replace cystoscopy or imaging, **these studies are not recommended by most organizations in the initial evaluation of patients with asymptomatic MH** (Davis et al., 2012; Nielsen and Qaseem, 2016; see Table 16.1). However, **cytologic examination may be considered in patients with a negative initial workup in whom urothelial carcinoma is still suspected, as well as in patients with symptomatic MH**.

Natural History of Microhematuria in Patients With a Negative Initial Evaluation

One of the most vexing questions in the management of MH is how to proceed in patients for whom the initial evaluation is negative. MH has been reported to resolve in approximately one-third of these patients over a period of 3 months to several years (Jaffe et al., 2001; McGregor et al., 1998; Yamagata et al., 1996). Nevertheless, these studies contained large proportions of younger patients, many of whom did not undergo a complete workup at any time, raising the possibility of persistent occult urologic disease. In a set of studies in which patients underwent further evaluation for MH after an initial negative evaluation, 41 malignancies were identified among 1475 patients (2.8%). However, the initial evaluations in these series were often incomplete, the follow-up evaluations were variable, and most of the malignancies were found in a study using CT urography in patients who were not evaluated by CT in the first evaluation (Davis et al., 2012).

In the absence of high-quality evidence, the AUA has issued three guidelines statements, based on expert opinion, pertaining to the follow-up of patients with an initial negative workup (Davis et al., 2012). The first two can be summarized as recommending **following up annual urinalysis for 2 years after a complete negative hematuria workup and releasing the patient from care if the urinalyses confirm resolution of hematuria.** The third statement recommends **repeating the hematuria evaluation within 3 to 5 years in cases of persistent or recurrent asymptomatic MH or for development of symptoms or GH**. We would add that **patients with persistent or recurrent MH in the setting of an incomplete initial evaluation should have the evaluation completed or repeated.**

Key Points: Evaluation of Patients With Microhematuria

- Evaluation of adults with microscopic hematuria includes a history and physical examination, renal function testing, and upper tract imaging for all patients.
- White light cystoscopy is recommended in the evaluation of asymptomatic MH for patients 35 years of age or older and/or those with risk factors for malignancy.
- CT urogram is the preferred imaging modality for the evaluation of hematuria.
- Urine cytologic examination and biomarkers are not indicated in the initial evaluation of asymptomatic MH.
- Patients with a negative complete evaluation can be released from care if subsequent urinalyses confirm resolution of MH. Re-evaluation should be considered in patients with persistent/recurrent MH and in those with an incomplete initial evaluation.

Symptomatic Microscopic Hematuria

The differential diagnosis for symptomatic MH is equivalent to that for patients with asymptomatic MH. However, the risk for malignancy may be significantly higher than in asymptomatic MH (10.5% vs. 5.0% or less) (Shephard et al., 2012; Sultana et al., 1996). In the setting of a symptomatic, culture-documented urinary infection presenting with hematuria, with documentation of hematuria resolution after treatment, a complete workup can be avoided. Because the presence of symptomatic hematuria has been linked to an increased risk for malignancy, current AUA guidelines include several slight modifications to the recommendations for evaluation. Specifically, **cystoscopy is recommended in such patients regardless of age** (Davis et al., 2012). Moreover, although routine cytology is not recommended as part of the routine evaluation for the asymptomatic patient with microscopic hematuria, **cytologic examination is considered an option in the setting of irritative voiding symptoms,** although cystoscopy should not be omitted even if the cytologic findings are negative (Davis et al., 2012).

Gross Hematuria

The differential diagnosis for GH remains the same as outlined earlier for MH. However, **as the degree of hematuria increases, so does the likelihood of finding clinically significant lesions during evaluation** (Mariani, 1989). Specifically, among patients with GH, 50% have been found to have a demonstrable cause, and 20% to 25% have been found to have a urologic malignancy, most commonly bladder cancer and kidney cancer (Alishahi et al., 2002; Edwards et al., 2006; Khadra et al., 2000; Lee and Davis, 1953).

Given the increased frequency with which clinically significant findings are associated with GH, the recommended evaluation in this setting is relatively uniform. That is, **patients presenting with GH in the absence of antecedent trauma or culture-documented UTI should be evaluated with a urine cytologic examination, cystoscopy, and upper tract imaging, preferably CT urogram.** Meanwhile, patients with GH in the setting of a culture-documented UTI should have the infection treated and then a follow-up urinalysis obtained to ensure clearance of the hematuria. The initial assessment for patients presenting with GH should include the history, physical examination, and laboratory studies recommended for patients with MH. Further, patients with GH must be assessed for hemodynamic stability with careful attention to vital signs, anemia with a complete blood count, and, for patients on anticoagulation, coagulation parameters to ensure that levels are within the therapeutic range. After initial stabilization, diagnostic evaluation should then proceed, with cause-specific management as outlined below.

Although clear recommendations are lacking for the follow-up of patients with GH who are found to have a nondiagnostic initial evaluation, the follow-up schedule as outlined for patients with asymptomatic MH may be used as a reference, with consideration given for a full repeat evaluation if episodes of GH recur.

Hemorrhagic Cystitis

Intractable hematuria localizing to the bladder, or hemorrhagic cystitis, may range in severity from a transient condition that quickly resolves after conservative management to a life-threatening condition requiring urgent intervention. Unfortunately, patients in this situation are often elderly and infirm, with medical comorbidities that complicate plans for care.

Hemorrhagic cystitis is characterized by diffuse inflammation and bleeding from the bladder mucosa (Rastinehad et al., 2007). Numerous causes for this condition have been described (Box 16.2), a few of which merit particular mention here. Bacterial infections, for example, are a common cause of GH, with symptomatic resolution typically noted after appropriate treatment. Meanwhile, viral-induced hemorrhagic cystitis may affect children and immunosuppressed adults particularly (e.g., after renal or bone marrow transplantation). **BK virus, a member of the polyomavirus family, is the most common virus associated with hemorrhagic cystitis** (Gorczynska et al., 2005), and adenovirus, particularly types 11 and 35, has been correlated with hemorrhagic cystitis in children and renal transplant patients (Hofland et al., 2004; Lee et al., 1996). Treatment for viral hemorrhagic cystitis is primarily supportive, with hydration, diuresis, and bladder irrigation, although case reports of success with antiviral therapy exist (Rastinehad et al., 2007).

Box 16.2

Differential Diagnosis for Hemorrhagic Cystitis[a]

- Infectious
    - Bacterial
    - Viral (especially BK virus, adenovirus)
    - Fungal
    - Parasitic
- Trauma
    - External
    - Postsurgical (e.g., transurethral resection of the bladder)
- Malignancy

    - Bladder primary
    - Bladder invasion from local/distant primary
- Vascular malformation
- Chemical exposure
    - Cyclophosphamide
    - Ifosfamide
    - Busulfan
    - Thiotepa
    - Temozolomide
    - Aniline dye
    - Ether
    - Nonoxynol-9 (accidental urethral insertion of vaginal contraceptive)
- Radiation therapy history (e.g., prostate cancer, cervical cancer)
- Medication induced
    - Penicillin and derivatives (via immune reaction)
    - Bleomycin
    - Danazol
    - Allopurinol
    - Methenamine mandelate
    - Acetic acid
- Manifestation of systemic disease
    - Amyloidosis
    - Rheumatoid arthritis
- Crohn disease

---

[a] Bleeding localized to bladder after diagnostic workup for gross hematuria with cystoscopy, urine cytology, and upper tract imaging is without clear cause of alternative bleeding source.

Hemorrhagic cystitis also may result from exposure to the oxazaphosphorine class of chemotherapeutic agents, specifically cyclophosphamide and ifosfamide. Indeed, hemorrhagic cystitis has been reported to occur in 2% to 40% of patients treated with cyclophosphamide (Rastinehad et al., 2007) and is dose dependent. **Bladder toxicity results from renal excretion of the metabolite acrolein, which is produced by the liver and stimulates bladder mucosal sloughing and subsequent tissue**

edema/fibrosis (O'Reilly et al., 2002). The onset of hematuria is typically within 48 hours of treatment (Cox, 1979; Stillwell and Benson, 1988). **2-Mercaptoethane sulfonate (mesna), which binds to acrolein and renders it inert, has been suggested for prophylaxis against cyclophosphamide-induced hemorrhagic cystitis** (O'Reilly et al., 2002). Nevertheless, 10% to 40% of patients will develop the condition despite preventive treatment (Shepherd et al., 1991). Debate continues as to whether mesna is more effective at preventing hemorrhagic cystitis than hyperhydration with forced diuresis and/or continuous bladder irrigation (Shepherd et al., 1991; Vose et al., 1993).

Meanwhile, **radiation therapy for pelvic malignancy represents another predisposing factor to hemorrhagic cystitis.** Indeed, moderate to severe hematuria has been reported in approximately 5% of patients after pelvic radiotherapy, depending in part on factors such as the radiation dosage and mode of delivery, with onset between 6 months and 10 years after treatment (Corman et al., 2003; Smit and Heyns, 2010). Mechanistically, radiation damages the vascular endothelium, thereby inducing subsequent inflammation, fibrosis, and ischemia, with tissue necrosis and mucosal sloughing occurring through progressive obliterative endarteritis (Bevers et al., 1995; Chong et al., 2005; Hader et al., 1993). In the setting of such local vascular compromise, moreover, secondary infection frequently ensues, further compromising tissue healing (Del Pizzo et al., 1998). Importantly, receipt of both cyclophosphamide chemotherapy and pelvic radiation (Wallis et al., 2016) represents risk factors for bladder cancer, and as such, patients presenting with hematuria who have a history of such treatment should be evaluated for bladder cancer before the diagnosis of hemorrhagic cystitis is assigned.

Management of Hemorrhagic Cystitis

The management of hemorrhagic cystitis may occasionally be guided by the particular cause for the condition (e.g., treatment of infection). However, in most cases no cause-directed therapy can be offered, and instead, a sequential approach, depending on the severity of the condition, should be undertaken (Fig. 16.2). Supportive management in the form of increasing urine output via hydration/diuresis, catheter placement with continuous bladder irrigation, and transfusion as needed represent the mainstay of first-line therapy and typically suffice for mild cases. If hematuria continues and/or clotting of the urine cannot be controlled with bladder irrigation, cystoscopy under anesthesia with clot evacuation and fulguration of discrete bleeding sites, as well as biopsy of any areas suspicious for malignancy, is then recommended.

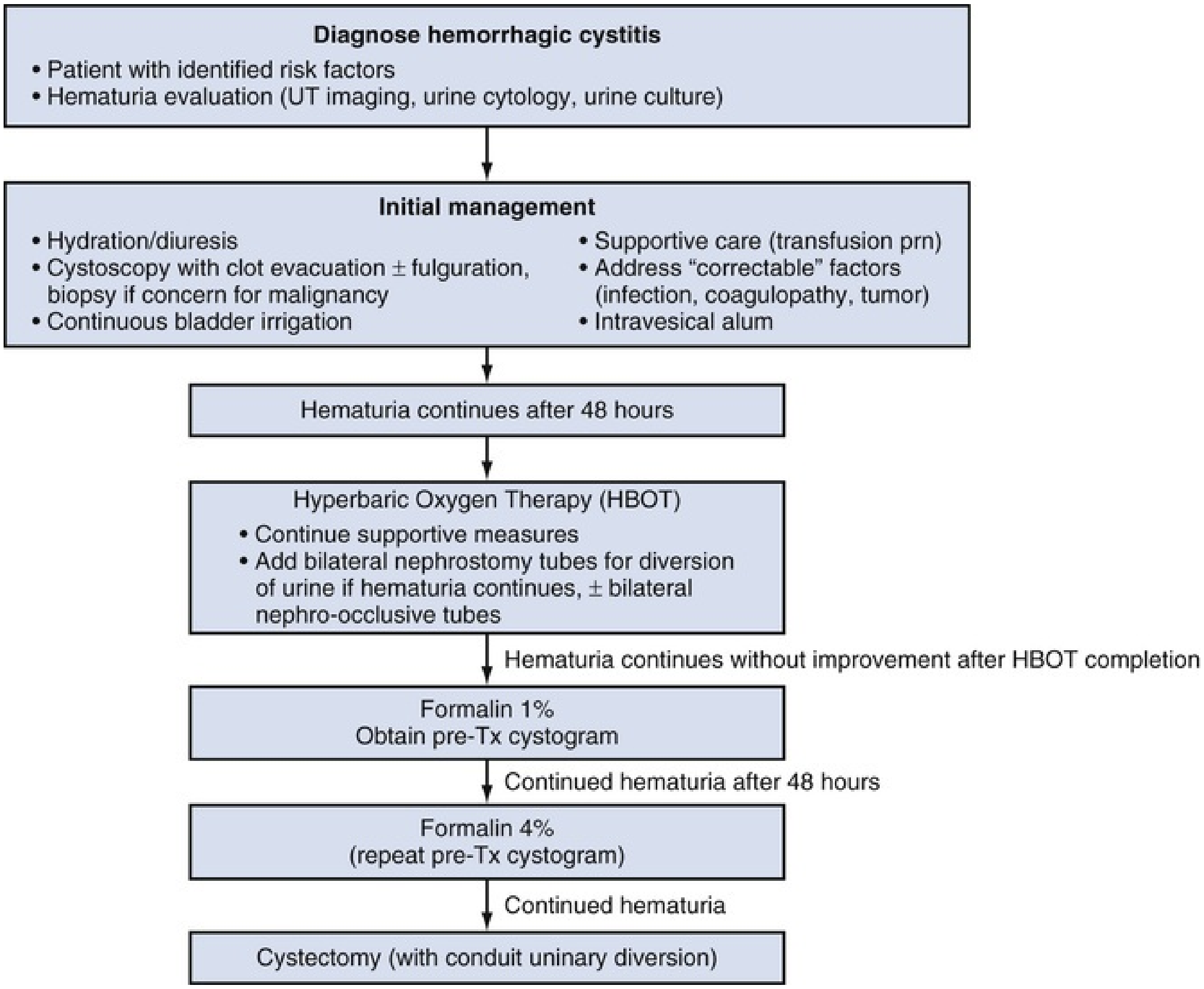
Diagnose hemorrhagic cystitis
• Patient with identified risk factors
• Hematuria evaluation (UT imaging, urine cytology, urine culture)
Initial management
• Hydration/diuresis
• Cystoscopy with clot evacuation ± fulguration, biopsy if concern for malignancy
• Continuous bladder irrigation
• Supportive care (transfusion prn)
• Address "correctable" factors (infection, coagulopathy, tumor)
• Intravesical alum
Hematuria continues after 48 hours
Hyperbaric Oxygen Therapy (HBOT)
• Continue supportive measures
• Add bilateral nephrostomy tubes for diversion of urine if hematuria continues, ± bilateral nephro-occlusive tubes
Hematuria continues without improvement after HBOT completion
Formalin 1%
Obtain pre-Tx cystogram
Continued hematuria after 48 hours
Formalin 4%
(repeat pre-Tx cystogram)
Continued hematuria
Cystectomy (with conduit uninary diversion)

FIG. 16.2 Management algorithm for patients with hemorrhagic cystitis. *prn,* As needed; *Tx,* treatment; *UT,* upper tract.

For hematuria that persists despite such conservative measures, various agents have been investigated for bleeding control. Importantly, there is a lack of large, prospective trials reporting comparative treatment efficacy and safety. Nevertheless, an overview of these measures is warranted to facilitate a systematic approach to management. For one, alum (aluminum ammonium sulfate or aluminum potassium sulfate) may be dissolved in sterile water (50 g alum in a 5-L bag of sterile water [1% alum solution]) and then used to irrigate the bladder at a rate of 200 to 300 mL/h. Through its action as an astringent at sites of bleeding, **alum may cause protein precipitation on the urothelial lining** (Ostroff and Chenault, 1982) **and thereby stimulate vasoconstriction**

and a decrease in capillary permeability (Choong et al., 2000)**. In small series, widely variable success rates (e.g., 45% to 100%), with limited durability of hematuria control, have been reported after alum instillation** (Abt et al., 2013; Choong et al., 2000; Westerman et al., 2016). Although cell penetration and therefore overall toxicity of this agent are low (consisting mainly of suprapubic discomfort and bladder spasms), **systemic absorption may nevertheless occur and may result in aluminum toxicity, with consequent mental status changes, particularly among patients with renal insufficiency.** However, alum may be instilled without anesthesia and has overall relatively favorable efficacy and safety profiles. Thus **this agent may be considered for first-line intravesical therapy among patients with hemorrhagic cystitis failing initial supportive measures, particularly among those without renal insufficiency.**

Although several alternatives exist for initial intravesical instillation therapy options, the collective data to support use are limited by small sample sizes, short-term follow-up, and varied definitions of treatment success. For example, prostaglandins (e.g., carboprost tromethamine [prostaglandin F2-α, PGF2-α]) (Abt et al., 2013) have been used intravesically for hemorrhagic cystitis, and although the precise mechanism of activity remains unclear, these agents are thought to cause vasoconstriction, platelet aggregation, and cytoprotection via mucous barrier regulation (Choong et al., 2000; Abt et al., 2013). Response rates of 50% to 60% have been noted (Choong et al., 2000; Abt et al., 2013), and in fact in a small (19 patients) prospective randomized study, no significant difference in efficacy was noted between PGF2 and alum (Praveen et al., 1992). Notably, however, difficulties with PGF2 access, storage, and high costs have limited generalized utility (Abt et al., 2013). As a defect in the bladder's glycosaminoglycan layer has been thought to contribute to the pathogenesis of hemorrhagic cystitis (Bassi et al., 2011; Payne et al., 2013), intravesical sodium hyaluronate has been used in this setting with noted symptomatic improvement (Payne et al., 2013; Shao et al., 2012). Alternatively, silver nitrate may be instilled into the bladder, resulting in chemical coagulation at bleeding sites. A 0.5% to 1% solution is instilled for 10 to 20 minutes (Rastinehad et al., 2007). The potential for precipitation and upper tract obstruction with this agent led to the recommendation for a cystogram to rule out reflux before administration (Rastinehad et al., 2007).

Aminocaproic acid represents another intravesical treatment alternative. A lysine analogue, aminocaproic acid is a competitive inhibitor of activators of plasminogen, including urokinase, and thus interrupts fibrinolysis and the cascade that perpetuates hemorrhage (Abt et al., 2013; Garber and Wein, 1989; Stefanini et al., 1990). **Continuous bladder irrigation with 200 mg aminocaproic acid/L of 0.9% normal saline has been described, with irrigation continued for 24 hours after hematuria resolves.** Symptom resolution has been reported in up to 92% of patients (Singh and Laungani, 1992). The risk for thromboembolic events may be increased with this treatment, and, importantly, aminocaproic acid must be given only after the bladder has been rendered clot free, because the agent will otherwise lead to the formation of hard clots difficult to eradicate from the bladder (Rastinehad et al., 2007).

Management for patients in whom hematuria remains refractory to the aforementioned measures is particularly challenging and is often guided by the patients' clinical status. That is, for clinically stable patients, **particularly with hemorrhagic cystitis resulting from radiation therapy or cyclophosphamide treatment** (Bratsas et al., 2004)**, hyperbaric oxygen therapy (HBOT) represents an option for the next step in management.** HBOT is carried out in a specially designed chamber and involves administration of 100% oxygen at a pressure of 2 to 3 atmospheres for approximately 90 minutes in 30 to 40 sessions (Bevers et al., 1995; Del Pizzo et al., 1998; O'Reilly et al., 2002). With this, local tissue oxygen tension increases and thus oxygen extraction by tissues increases, thereby diminishing edema and promoting neovascularization, all of which are critical steps in the wound healing process (Hader et al., 1993). Response rates to HBOT of 80% to 90% have been reported (Bevers et al., 1995; Corman et al., 2003; Chong et al., 2005; Mougin et al., 2016; O'Reilly et al., 2002) and have been maintained up to 2½ years after treatment (Weiss et al., 1994). However, with longer follow-up, most patients become symptomatic again, such that the 5-year complete response rate has been noted to be only 27% (Del Pizzo et al., 1998). Reported complications include claustrophobia (20%), otalgia (17%), and, rarely, seizures (O'Reilly et al., 2002). For patients with continued bleeding during therapy, consideration may be given as well to performing bilateral nephrostomy tube insertion, with or without occlusion of the ureters (Gonzalez et al., 2001), to decrease exposure of the hemorrhagic bladder to urokinase and thereby theoretically facilitate hemostasis (Rastinehad et al., 2007), particularly during the relatively prolonged time course of HBOT.

When hematuria persists despite the aforementioned measures, treatment escalation is warranted. In these cases, intravesical **formalin, a solution of formaldehyde that induces cellular protein precipitation and capillary**

occlusion (Choong et al., 2000)**, may be used**. Control of bleeding has been reported in 80% to 90% of cases with formalin (Choong et al., 2000; Ziegelmann et al., 2017), which are relatively higher rates than what has been noted with other intravesical treatments. However, because formalin instillation may induce significant pain, administration under general or spinal anesthesia is recommended. Moreover, intravesical **formalin therapy is associated with significant complications, including bladder fibrosis with associated decreased bladder capacity and ureteral stricturing with proximal hydronephrosis/renal injury** (Abt et al., 2013; Choong et al., 2000). Thus **pretreatment cystogram is recommended to exclude the presence of vesicoureteral reflux and/or bladder perforation** (Donahue and Frank, 1989), and patients must be counseled regarding the potential impact on subsequent bladder function. If reflux is documented, placement of occlusive ureteral catheters is recommended to limit upper tract exposure to the medication. Regardless, moreover, low concentrations of formalin (1% to 4%) should be used, because complication rates (albeit efficacy rates as well) have been linked to dosage (Donahue and Frank, 1989). Instillation (with volumes up to 300 mL or to bladder capacity) (Choong et al., 2000) should be done under gravity, with the catheter no more than 15 cm above the pubic symphysis. Instillation should be limited to 10 to 15 minutes and should be performed with the catheter on light traction to prevent urethral exposure, with care taken to protect all external areas of skin from exposure. Given the potential toxicities of formalin, together with the requirement for administration under anesthesia, this agent should be reserved for second-line therapy.

For clinically unstable patients, as well as for patients with continued intractable bleeding, **internal iliac artery angioembolization represents a potential next step** in management. As reported in 1974 (Hald and Mygind, 1974), angioembolization may be performed unilaterally or bilaterally, even in debilitated patients, with relatively limited risk (Ward et al., 2003). Selective embolization of the anterior branch of the internal iliac artery bilaterally is typically required to achieve hemostasis and may use any of a variety of embolic materials, including gelatin microspheres, polyvinyl alcohol particles, or coils (Loffroy et al., 2014). Care should be taken to avoid embolization of the posterior branch of the internal iliac artery, which, because of subsequent occlusion of the superior gluteal artery, may result in significant gluteal pain. Although initial hemorrhage control after selective angioembolization has been reported in 90% of patients from reported series, the durability of response has not been well established (Delgal et al., 2010). Importantly, moreover, the majority of studies have involved limited numbers of patients and have included heterogeneous clinical situations, including patients with pelvic tumors (Loffroy et al., 2014). As such, the reliability of this approach for patients with hemorrhagic cystitis, particularly, for example, after radiation therapy in which mucosal ischemia underlies the pathophysiology, remains uncertain.

In the setting of failed angioembolization and other conservative approaches, **cystectomy with urinary diversion may be necessary to control bleeding.** Although supravesical urinary diversion alone (e.g., ileal conduit) without cystectomy has been described, complications have been reported in up to 80% of patients with a retained bladder, specifically infection (pyocystis), with rehospitalization in 43% (Eigner and Freiha, 1990; Fazili et al., 2006), suggesting that cystectomy should be performed at the time of urinary diversion if feasible. Unfortunately, such patients are typically elderly, infirm, often significantly deconditioned from the prolonged sequence of bleeding and various therapies, and therefore in poor condition for surgery. As a result, perioperative complication rates have been noted to be significantly higher than what has been reported after cystectomy for bladder cancer (Linder et al., 2014). Therefore, as the clinical course for these patients unfolds, it remains critical for practitioners to carefully balance the risks and benefits of treatment alternatives with the potential for contributing to further deconditioning by extending the course of care.

Key Points: Hemorrhagic Cystitis

- Oxazaphosphorine chemotherapeutic agents have been linked to the development of hemorrhagic cystitis through exposure of the metabolite acrolein to the urothelium.
- Alum may be used as a first-line intravesical therapy for hemorrhagic cystitis in patients without renal dysfunction.
- Formalin is a highly effective form of intravesical therapy for hemorrhagic cystitis. A cystogram should be obtained before therapy to ensure no vesicoureteral reflux.
- HBOT has been associated with response rates of 80% to 100% for patients with hemorrhagic cystitis.

Hematuria From Prostatic Origin

As with hemorrhagic cystitis, hematuria from prostatic origin is a diagnosis made after a complete GH evaluation (including cytology, upper tract imaging, and cystoscopy) to confirm that no other source of hematuria exists. Varied causes exist for prostate-related hematuria, and the severity of such bleeding likewise may range from transient self-limiting episodes to continuous bleeding resulting in the obstruction of urinary flow and in transfusion dependence. Most commonly, prostate-related bleeding is due to BPH, prostate-related infection (prostatitis), or prostate cancer (Fig. 16.3).

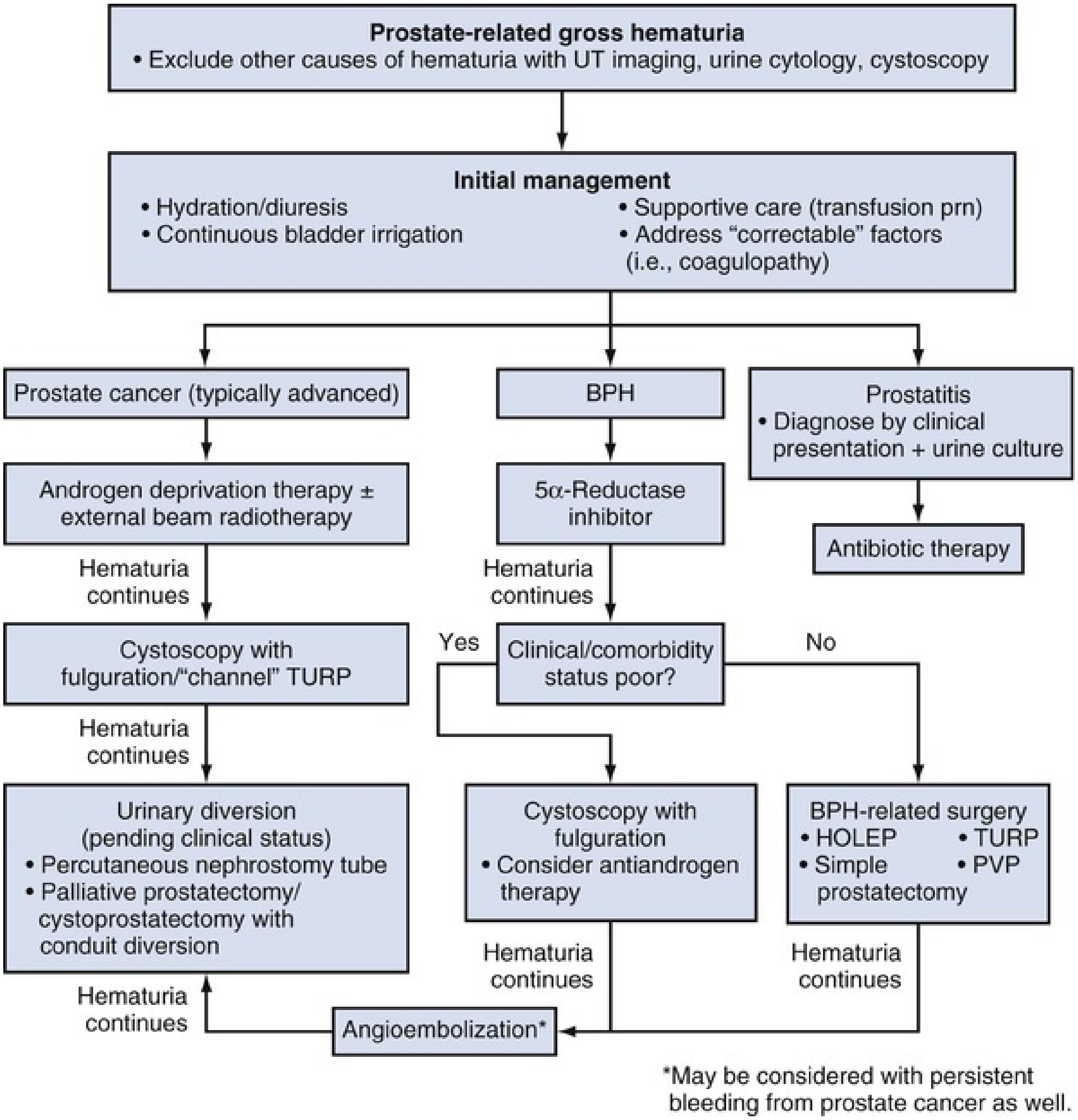
Prostate-related gross hematuria
• Exclude other causes of hematuria with UT imaging, urine cytology, cystoscopy
Initial management
• Hydration/diuresis
• Continuous bladder irrigation
• Supportive care (transfusion prn)
• Address "correctable" factors (i.e., coagulopathy)
Prostate cancer (typically advanced)
BPH
Prostatitis
• Diagnose by clinical presentation + urine culture
Androgen deprivation therapy ± external beam radiotherapy
5α-Reductase inhibitor
Antibiotic therapy
Hematuria continues
Hematuria continues
Cystoscopy with fulguration/"channel" TURP
Yes
Clinical/comorbidity status poor?
No
Hematuria continues
Urinary diversion (pending clinical status)
• Percutaneous nephrostomy tube
• Palliative prostatectomy/ cystoprostatectomy with conduit diversion
Cystoscopy with fulguration
• Consider antiandrogen therapy
BPH-related surgery
• HOLEP
• TURP
• Simple prostatectomy
• PVP
Hematuria continues
Hematuria continues
Hematuria continues
Angioembolization*
*May be considered with persistent bleeding from prostate cancer as well.

FIG. 16.3 Management algorithm for patients with persistent hematuria of prostate origin. *BPH,* Benign prostatic hyperplasia; *HOLEP,* holmium laser enucleation of the prostate; *prn,* as needed; *PVP,* photovaporization of the prostate; *TURP,* transurethral resection of the prostate; *UT,* upper tract.

BPH represents the most common cause of prostate-related bleeding and has been cited as the most common cause of GH in men older than 60 (Borth and Nickel, 2006). In fact, BPH has been reported to be the only pathological condition identified in approximately 20% of cases from hematuria studies (Hasan et al., 1994; Lynch et al., 1994). **The cause for BPH-related hematuria has been thought to be increased prostatic vascularity resulting from higher microvessel density in hyperplastic prostate tissue** (Borth and Nickel, 2006;

Deering et al., 1995; Foley et al., 2000; Pareek et al., 2003). This **noted increase in microvessel density has in turn been linked to higher levels of vascular endothelial growth factor (VEGF)** (Borth and Nickel, 2006; Pareek et al., 2003; Walsh et al., 2002).

Frequently, BPH-related hematuria episodes are mild and self-limiting, so once the diagnosis has been established, expectant management with encouraged hydration can be undertaken. Interestingly, although GH has historically been considered an indication for surgery in the setting of BPH, increased understanding of the molecular pathway contributing to the pathophysiologic process (i.e., increased VEGF) has translated into the incorporation of what may be considered targeted medical therapy in the management of patients with BPH-related hematuria.

Specifically, because the pathophysiology of BPH-related bleeding has been postulated as increased cell proliferation stimulating increased vascularity, efforts to suppress prostate growth via androgen ablation have been explored (Foley et al., 2000; Marshall and Narayan, 1993). Estrogens and antiandrogens have, in small case reports, been associated with decreased prostate bleeding, presumably through the repression of androgen-stimulated angiogenesis and the induction of programmed cell death within the prostate (Marshall and Narayan, 1993; Rittmaster et al., 1996). In particular, finasteride, a 5α-reductase inhibitor that blocks conversion of testosterone to dihydrotestosterone and is a treatment for prostate-related outlet obstructive symptoms, has been investigated extensively for BPH-related bleeding. **Treatment with finasteride is associated with decreased VEGF expression** (Pareek et al., 2003)**, prostate microvessel density** (Pareek et al., 2003)**, and prostatic blood flow** (Frauscher et al., 2003)**.**

Clinically, **multiple series have demonstrated efficacy of finasteride for BPH-related hematuria, including in patients being treated with anticoagulation. Symptom improvement or resolution has been consistently noted in approximately 90% of patients** (Carlin et al., 1997; Kearney et al., 2002; Miller and Puchner, 1998; Puchner and Miller, 1995; Sieber et al., 1998). A prospective randomized trial of finasteride versus expectant management in 57 patients with BPH-induced hematuria found that the rate of recurrent hematuria was significantly higher among patients in the control arm (63%) versus finasteride (14%) ($P < 0.05$). Furthermore, 26% of patients in the control arm required surgery for bleeding versus none of the finasteride-treated patients (Foley et al., 2000). The onset of action for finasteride is variable, with improvement in bleeding noted from as short as 2 weeks to up to 9 months after initiating therapy. In addition, a randomized trial of finasteride versus cyproterone acetate versus watchful waiting demonstrated a significant decrease in recurrent hematuria in the finasteride and in the cyproterone acetate cohorts, with no noted difference in efficacy between finasteride and cyproterone acetate in patients treated with this agent (Perimenis et al., 2002). Importantly, similar microvessel density changes and likely BPH-bleeding related sequelae are noted with dutasteride (type I and II 5α-reductase inhibition) (Sugie et al., 2014). Thus, although various forms of hormonal therapy remain options for BPH-related bleeding, the best data to date exist for 5α-reductase inhibition, which likely entails the least side-effect profile. Finally, contemporary studies highlight that, for those patients who eventually require BPH surgery, concurrent therapy with 5α-reductase inhibitors can decrease perioperative bleeding complications and morbidity (Bansal and Arora, 2017; Zhu et al., 2015).

In cases of BPH bleeding in which patients have difficulty with bladder emptying and/or presence of obstructing clot, large-bore catheter placement with irrigation to evacuate all clot material from the bladder should ensue, followed by continuous bladder irrigation until the urine has cleared. If such measures are not sufficient to control bleeding, patients should be taken for endoscopic management under anesthesia, with clot evacuation and electric or laser cauterization. Although the variety of nonspecific intravesical therapies as are used in hemorrhagic cystitis (e.g., aminocaproic acid) have been suggested for use in this setting as well (Borth and Nickel, 2006), limited evidence supports the efficacy of these agents for BPH-related bleeding. Thus **patients with persistent bleeding from BPH despite conservative therapies and/or endoscopic fulguration have traditionally been managed with transurethral resection of the prostate (TURP),** particularly when additional indications for BPH surgery coexist. Although alternative forms of such endoscopic prostate tissue removal/destruction are available (e.g., photoselective vaporization of the prostate, holmium laser enucleation of the prostate) and even suprapubic/retropubic prostatectomy may be undertaken, the principle with all such interventions is to remove the hyperplastic and friable transition-zone prostate tissue. In cases with persistent bleeding despite TURP, selective prostatic artery embolization (PAE), which has been increasingly explored as a treatment for BPH (Feng et al., 2017), is an option for management (Michel et al., 2002). Typically bilateral embolization is performed, here preferably with a superselective approach specifically addressing the prostatic arteries with gelatin microparticles, although selective embolization of the anterior branch of the internal iliac artery has been used as well (Pereira et al., 2016). Initial clinical success has been noted in 90% of patients from angioembolization series, albeit in very small patient numbers and with recurrence in 15% to 28% (Pereira et al., 2016). Although radical prostatectomy or cystoprostatectomy must be considered as well, as with hemorrhagic cystitis, often such patients are poor surgical candidates because of comorbidity status.

Prostatitis, traditionally secondary to bacterial infection, also may result in GH. Indeed, a prior study reported hematuria as the manifesting symptom in 2.5% of men with prostatitis (Rizzo et al., 2003). The mechanism of hematuria in prostatitis is unclear and may be related to inflammation (Borth and Nickel, 2006). Management in this setting should consist of antibiotics when culture-documented bacterial prostatitis is present. Significant recurrent hematuria in the setting of nonbacterial prostatitis is relatively uncommon, and it has been suggested that such cases should be treated with antibiotics in addition to standard supportive measures (Borth and Nickel, 2006).

Meanwhile, **hematuria from prostate cancer typically results in cases of significantly locally advanced tumors,** often with bladder base/trigonal invasion. Indeed, hematuria has been noted to be the most common local symptom among patients with advanced symptomatic prostate cancers (Din et al., 2009). Importantly, the hematuria in these patients, particularly in those who have previously received radiation therapy in the management of their prostate cancer, should be confirmed with endoscopic evaluation to be from a prostate source and not, for example, as a result of hemorrhagic cystitis or secondary bladder malignancy. Unfortunately, these tumors are typically invasive of the bladder and/or pelvic sidewall (T4), and the patients are often elderly and unwell. Thus treatment is primarily with palliative intent. Initial conservative measures, including catheter drainage with or without continuous bladder irrigation, suffice for most cases of mild prostatic bleeding. For patients in whom hematuria is not acutely life threatening, palliative external beam radiotherapy in patients who are radiation naïve with or without androgen deprivation therapy may be administered. Indeed, one series reported that hematuria from advanced prostate cancer responded to palliative radiation in 81% of patients at 6 weeks after treatment; however, durable symptom control was limited: the response rate 7 months after treatment in these patients was only 29% (Din et al., 2009). **Among patients who are not candidates for local therapy, as well as among patients in whom disease has recurred after previous local therapy, androgen deprivation therapy may resolve the hematuria** (Marshall and

Narayan, 1993) **by decreasing prostate vascularity** (Kaya et al., 2005).

In the situation of persistent hematuria with prostate cancer and, in particular, in the setting of bladder outlet obstruction, cystoscopy under anesthesia with fulguration and/or limited, or channel, transurethral resection of prostatic tissue should be undertaken. Moreover, selective angioembolization, as has been reported for severe post-TURP bleeding (Barbieri et al., 2002; Loffroy et al., 2014; Michel et al., 2002; Pereira et al., 2016), may be considered, although data on this approach in the setting of prostatic malignancy are scant and have demonstrated limited durability of bleeding control (Chen et al., 2017). Ultimately, if bleeding persists or escalates, consideration should be given to urinary diversion, which initially may be attempted with percutaneous nephrostomy tube insertion. **With continued prostate hemorrhage, palliative extirpative surgery, which may be in the form of radical prostatectomy but more typically requires cystoprostatectomy and conduit diversion, should be considered, pending patients' clinical and comorbidity status.**

Key Points: Hematuria From Prostatic Origin

- BPH represents the most common cause of GH in men older than 60 years.
- 5α-Reductase inhibitors may be used for BPH-related GH, with potential improvement having been noted within weeks after instituting therapy.
- Androgen deprivation may be effective for patients with locally advanced prostate cancer with GH.
- Angioembolization and/or urinary diversion represent salvage options for management of patients with refractory hematuria pending clinical status.

Urethral Bleeding

Urethral bleeding (urethrorrhagia) is defined as bleeding emanating from the urethra at a point distal to the bladder neck, occurring separate from micturition (Gontero, 2013). A careful history and physical examination may help elucidate whether the source of bleeding is truly from the urethra as opposed to other sites within the lower urinary tract. For example, **blood at the urethral meatus in the absence of volitional micturition, initial hematuria, or blood at the start of urination frequently implies pathological processes distal to the external urinary sphincter.** In women, differentiating urethral bleeding from that of gynecologic origin based on history alone may be challenging, and pelvic examination is typically necessary to clarify the site of origin (Sandhu et al., 2009). Importantly, retrograde urethrogram and cystourethroscopy remain the mainstays for diagnosis in patients with suspected urethral bleeding because direct visualization permits identification of pathological processes in the urethra and biopsy and fulguration allow for histologic characterization and cessation of bleeding.

Causes of urethral bleeding are best classified by gender (Box 16.3). **In men, trauma to the urethral epithelium represents the most common cause of urethral bleeding.** For example, blunt trauma via straddle injury, kick to the perineum, or pelvic fracture often manifests with bleeding and concurrent urinary retention (Mundy and Andrich, 2011). Perineal or penile bruising, accompanied by a hematoma, often is a clear indication of injury related to trauma. **Retrograde urethrography is essential in instances of trauma when a urethral injury is suspected** (Avery and Scheinfeld, 2012; Morey et al., 2014). Meanwhile, a history of foreign body insertion in patients with hematuria may necessitate imaging and/or cystoscopy to ensure no residual foreign elements remain that could perpetuate bleeding or result in subsequent calculus formation (Rahman et al., 2004). **Particular mention should be made to the evaluation of bloody urethral discharge and/or hematuria occurring in patients with a penile fracture. In this setting, prompt evaluation via retrograde urethrography or cystoscopy should be undertaken to evaluate for a urethral injury and to identify the nature and location of the injury before surgical exploration** (Avery and Scheinfeld, 2012; Morey et al., 2014). Evaluation of urethral trauma is covered in Chapter 133.

Box 16.3

Differential Diagnosis for Urethral Bleeding

Male

- Trauma
  - Blunt (straddle injury, kick to perineum)
  - Penetrating (foreign body insertion, failed urethral catheterization, ballistics)
  - Intercourse related (penile fracture, masturbation)
- Urethritis
  - Bacterial (gonococcal, nongonococcal)
  - Viral
  - Chemical (amiodarone induced)
  - Autoimmune (reactive arthritis)
- Malignancy
  - Urothelial carcinoma
  - Squamous cell carcinoma (meatus/glans)
- Condyloma
- Calculus disease

Female

- Trauma
  - Blunt (pelvic fracture)
  - Penetrating (foreign body)
- Urethral diverticulum
- Urethral caruncle
- Urethritis
- Malignancy
- Calculus disease

Urethritis refers to infection or inflammation of the epithelial lining of the urethra and has been reported secondary to bacterial or viral infection, chemical irritants (i.e., spermicidal jelly), medication-related (i.e. amiodarone), and, rarely, autoimmune systemic conditions (human leukocyte antigen B27 [HLA-B27] reactive arthritis) (Brill, 2010). Urethral discharge on palpation may be noted with urethritis in men. Urine microscopy and cultures, as well as urethral swabs for causative organisms, represent essential components of the evaluation.

Urethral tumors are rare, although blood per meatus may be a manifesting sign in patients with urothelial carcinoma, specifically in men who have undergone a radical cystectomy with urethra still in situ (White and Malkowicz, 2010). At the same time, urethral caruncles are benign urethral lesions typically originating from the posterior lip of the urethra, most commonly found in postmenopausal women (Conces et al., 2012). These lesions are thought to arise from prolapse of distal urethra as a consequence of estrogen deficiency. In addition to the classic presentation of dysuria, dyspareunia, and dribbling, women with a urethral diverticulum also may report intermittent episodes of bleeding, and urethral discharge may be noted on examination (Greenwell and Spilotros, 2015).

Hematuria Originating From the Upper Urinary Tract

Hematuria emanating from the upper urinary tract is frequently asymptomatic, although macroscopic bleeding with clots can result in subsequent ureteral obstruction, with patients experiencing “clot colic,” as well as anemia, and even rarely hemodynamic instability (Lano et al., 1979). Most often, hematuria from the upper tract manifests as total hematuria or bleeding throughout the duration of the urinary stream (Mazhari and Kimmel, 2002) and may be characterized by wormlike clots passed via the urethra. A variety of causes can result in bleeding from the upper tract (Box 16.4), with the most common causes of hematuria from the upper urinary tract including stones, trauma, and malignancy. The evaluation and management of these entities is described elsewhere. Here we highlight several particularly salient, albeit less frequent, causes of upper tract hematuria.

Box 16.4

Differential Diagnosis for Upper Urinary Tract Bleeding

- Renal glomerular diseases
  - IgA nephropathy (Berger disease)
  - Thin basement membrane disease
  - Acute glomerulonephritis (e.g., poststreptococcal)
  - Lupus nephritis
  - Hereditary nephritis (e.g., Alport syndrome)
- Renal tubulointerstitial diseases
  - Papillary necrosis
    - Sickle cell nephropathy
    - Analgesic nephropathy
  - Polycystic kidney disease
  - Medullary sponge kidney
- Vasculitis

- Henoch-Schönlein purpura
  - Wegener granulomatosis
- Infection
  - Pyelonephritis
  - Xanthogranulomatous pyelonephritis
  - Renal tuberculosis
  - Fungal infection
- Obstruction
  - Ureteropelvic junction obstruction
  - Ureteral stricture
- Nephrolithiasis
- Malignancy
  - Renal cortical tumors (renal cell carcinoma, benign tumors)
  - Upper tract urothelial carcinoma
- Fibroepithelial polyp
- Vascular diseases
  - Renal arteriovenous malformations (congenital, acquired)
  - Iliac arterioureteral fistula
  - Renal artery aneurysm (especially ruptured)
  - Renal artery pseudoaneurysm
  - Renal artery and/or vein thrombosis
  - Hemangioma
  - Atheroembolic disease (including infarction)
  - Nutcracker syndrome
  - Loin-pain hematuria syndrome
- Trauma
  - Blunt
  - Penetrating
- Lateralizing essential hematuria

Medical Renal Disease

Glomerular diseases are a constellation of acquired or inherited conditions in which the glomeruli are damaged. Consequences include loss of RBCs and protein in the urine, with the clinical sequelae of hematuria, hypoproteinemia with associated edema, and reduced glomerular filtration rate. **Urinary findings suggestive of a glomerular cause include the presence of RBC casts in the**

urinary sediment, dysmorphic RBCs, and proteinuria (Yun et al., 2004).

Meanwhile, tubulointerstitial diseases broadly refer to kidney diseases affecting structures in the kidney outside the glomerulus. For example, **sickle cell nephropathy is associated with sickle cell disease, whereby sickled erythrocytes decrease medullary blood flow, causing local ischemia, microinfarction, and papillary necrosis** (Pham et al., 2000). Analgesic nephropathy can likewise cause renal papillary necrosis and subsequently chronic interstitial nephritis. Percutaneous renal biopsy may be a valuable diagnostic modality in case of a suspicion for glomerular or tubulointerstitial causes of hematuria. Importantly, current guidelines advocate completion of the hematuria evaluation even when medical renal causes are suspected (Davis et al., 2012).

Vascular Conditions Affecting the Urinary Tract

A variety of vascular conditions can cause hematuria. For example, ureteroiliac artery fistula is an uncommon but potentially life-threatening cause of hematuria. **Predisposing factors include pelvic or vascular surgery, pelvic irradiation, extensive ureteral mobilization, and chronic ureteral stenting** (Muraoka et al., 2008). With regard to management, high mortality rates have been reported with surgical repair of ureteroiliac fistulas, and as such **angiographic localization with vascular stenting has become the current preferred management approach** (Keller et al., 1990; Vandersteen et al., 1997). Renal arteriovenous malformations (AVMs), meanwhile, are abnormal communications between intrarenal arterial and venous systems, with congenital and acquired (iatrogenic) causes. **Acquired AVMs account for 75% of such cases and have been associated with renal biopsy, renal surgery (partial nephrectomy, nephrolithotomy), and trauma** (Muraoka et al., 2008). **Arteriography with selective angioembolization is considered the primary diagnostic and therapeutic option for suspected renal AVMs,** affording symptom resolution with maximal preservation of functional renal parenchyma. Thus **expeditious angiography should be considered for patients with a recent history of a renal procedure presenting with GH.** The goal of AVM embolization is occlusion of the site where abnormal arterial and venous communication exists. Renal artery aneurysms, moreover, may be related to connective tissue disorders and are generally asymptomatic. Hypertension may be present in up to 90% of affected persons, and dissecting aneurysms may cause flank pain with GH (Coleman and Stanley, 2015). Renal artery aneurysms and pseudoaneurysms are generally managed initially with blood pressure control and subsequently via endovascular approaches in the refractory albeit hemodynamically stable patient, whereas surgical intervention is typically necessary in the unstable patient (Klausner et al., 2015; Mohan and Stephen, 2013).

"Nutcracker syndrome" (i.e., renal vein entrapment syndrome) is defined as the compression of the left renal vein between the abdominal aorta posteriorly and the superior mesenteric artery anteriorly. Hematuria has been postulated to occur as a result of increase in left renal vein pressure causing small-volume rupture of thin-walled capillaries into the collecting system (Wolfish et al., 1986). Left renal vein transposition, superior mesenteric artery transposition, and nephrectomy have been described as surgical approaches for management of this condition (Hohenfellner et al., 2002). More recently, endovascular stenting to maintain a patent renal vein has been reported as well.

Lateralizing Essential Hematuria and the Evaluation of Upper Urinary Tract Bleeding

Lateralizing essential hematuria, also termed *benign essential hematuria* or *chronic unilateral essential hematuria*, is defined as macroscopic hematuria cystoscopically localized to one side of the urinary system without a clear identifiable cause (Nakada, 2003). As such, patients have typically had normal prior radiographic studies. Although rare, manifestations of lateralizing essential hematuria may range from minimally symptomatic GH to clot retention and anemia (Nakada, 2003). The differential diagnosis for this entity is as noted earlier for upper tract bleeding (see Box 16.4), although in many such cases no identifiable cause can be determined.

Cystoscopy at the time of bleeding may allow lateralization of the source of hematuria. Subsequently, in the absence of a clear cause for bleeding localized to the upper tract in a patient with lateralizing essential hematuria, direct endoscopic inspection with ureteropyeloscopy is recommended as a diagnostic and potentially therapeutic modality (Nakada, 2003). **Critical components of diagnostic ureteropyeloscopy include the judicious use of guidewires (to avoid inadvertent urothelial injury), low-pressure irrigation, and systematic evaluation of all calices from a superior-to-inferior approach** (Ankem and Nakada, 2006). Biopsy samples can be obtained for lesions suspicious for malignancy, and fulguration of such tumors or other noted sources of bleeding (i.e., hemangioma) can be accomplished as well.

Key Points: Urethral Bleeding and Hematuria Originating From the Upper Urinary Tract

- Urethral bleeding should be suspected with blood at the meatus and/or initial hematuria.
- A concern for traumatic urethral injury should prompt retrograde urethrogram.
- Urinary findings suggestive of a glomerular or tubulointerstitial medical renal disease include the presence of RBC casts in the urinary sediment, dysmorphic RBCs, and proteinuria.
- In patients with GH after a recent renal procedure, expeditious angiography should be considered to allow for the diagnosis and management of renal AVM.

Suggested Readings

Bevers RFM, Bakker DJ, Kurth KH. Hyperbaric oxygen treatment for haemorrhagic radiation cystitis. *Lancet*. 1995;346:803–805.

Davis R, Jones JS, Barocas DA, et al. Diagnosis, evaluation and follow-up of asymptomatic microhematuria (AMH) in adults: AUA guideline. *J Urol*. 2012;188:2473–2481.

Foley SJ, Soloman LZ, Wedderburn AW, et al. A prospective study of the natural history of hematuria associated with benign prostatic hyperplasia and the effect of finasteride. *J Urol*. 2000;163:496–498.

Loo RK, Lieberman SF, Slezak JM, et al. Stratifying risk of urinary tract malignant tumors in patients with asymptomatic microscopic hematuria. *Mayo Clin Proc*. 2013;88:129–138.

Muraoka N, Sakai T, Kimura H, et al. Rare causes of hematuria associated with various vascular diseases involving the upper urinary tract. *Radiographics*. 2008;28:855–867.

References

Abt D, Bywater M, Engeler DS, et al. Therapeutic options for intractable hematuria in advanced bladder cancer. *Int J Urol*. 2013;20:651–660.

Addis T. The number of formed elements in the urinary sediment of normal individuals. *J Clin Invest*. 1926;2:409–415.

Alishahi S, Byrne D, Goodman CM, et al. Haematuria investigation based on a standard protocol: emphasis on the diagnosis of urologic malignancy. *J R Coll Surg Edinb*. 2002;47:422–427.

Anderson JFD, Feehally J, Goldberg L, et al. *Joint consensus statement on the initial assessment of haematuria. Prepared on behalf of the Renal Association and British Association of Urological Surgeons*. [(website)] http://www.renal.org/docs/default-source/guidelines-resources/joint-guidelines/joint-guidelines-archieve/Haematuria_-_RABAUS_consensus_guideline_2008.pdf; 2008.

Ankem MK, Nakada SY. Lateralizing essential hematuria. Nakada SY, Pearle MS. *Advanced endourology: the complete clinical guide*. Humana Press: Totowa, NJ; 2006:61–70.

Antolak SJ, Mellinger GT. Urologic evaluation of hematuria occurring during anticoagulant therapy. *J Urol*. 1969;101:111–113.

Ark JT, Alvarez JR, Koyama T, et al. Variation in the diagnostic evaluation among persons with hematuria: influence of gender, race and risk factors for bladder cancer. *J Urol*. 2017;198(5):1033–1038.

Armstrong JA. Urinalysis in Western culture: a brief history. *Kidney Int*. 2006;71:384–387.

Avery LL, Scheinfeld MH. Imaging of male pelvic trauma. *Radiol Clin North Am*. 2012;50:1201–1217.

Bansal A, Arora A. Transurethral resection of prostate and bleeding: a prospective, randomized, double-blind placebo-controlled trial to see the efficacy of short-term use of finasteride and dutasteride on operative blood loss and prostatic microvessel density. *J Endourol*. 2017;31:910–917.

Barbieri A, Simonazzi M, Marcato C, et al. Massive hematuria after transurethral resection of the prostate: management by intra-arterial embolisation. *Urol Int*. 2002;69:318–320.

Bassett JC, Alvarez J, Koyama T, et al. Gender, race, and variation in the evaluation of microscopic hematuria among Medicare beneficiaries. *J Gen Intern Med*. 2015;30(4):440–447.

Bassett JC, Gore JL, Chi AC, et al. Impact of a bladder cancer diagnosis on smoking behavior. *J Clin Oncol*. 2012;30:1871–1878.

Bassi PF, Costantini E, Foley S, et al. Glycosaminoglycan therapy for bladder diseases: emerging new treatments. *Eur Urol Suppl*. 2011;10:451–459.

Bevers RFM, Bakker DJ, Kurth KH. Hyperbaric oxygen treatment for haemorrhagic radiation cystitis. *Lancet*. 1995;346:803–805.

Board on Radiation Effects Research, Division on Earth and Life Studies. *Health risks from exposure to low levels of ionizing radiation: BEIR VII Phase 2*. National Academies Press: Washington, DC; 2006.

Borth CS, Nickel JC. Management of spontaneous prostate related bleeding. *AUA Update Series*. 2006.

Bratsas KS, Stephanides AA, Spyropoulos E, et al. Hyperbaric oxygen therapy for cyclophosphamide induced refractory hemorrhagic cystitis in a child. *J Urol*. 2004;172:679.

Brill JR. Diagnosis and treatment of urethritis in men. *Am Fam*

Physician. 2010;81:873–878.

Buteau A, Seideman CA, Svatek RS, et al. What is evaluation of hematuria by primary care physicians: use of electronic medical records to assess practice patterns with intermediate follow-up. *Urol Oncol*. 2012 [epub ahead of print November 17, 2012].

Carlin BI, Bodner DR, Spirnak JP, et al. Role of finasteride in the treatment of recurrent hematuria secondary to benign prostatic hyperplasia. *Prostate*. 1997;31:180–182.

Chahal R, Gogoi N, Sundaram S. Is it necessary to perform urine cytology in screening patients with haematuria? *Eur Urol*. 2001;39:283–286.

Chen JW, Shin JH, Tsao TF, et al. Prostatic arterial embolization for control of hematuria in patients with advanced prostate cancer. *J Vasc Interv Radiol*. 2017;28:295–301.

Chong KT, Hampson NB, Corman JM. Early hyperbaric oxygen therapy improves outcome for radiation-induced hemorrhagic cystitis. *Urology*. 2005;65:649–653.

Choong SKS, Walkden M, Kirby R. The management of intractable haematuria. *BJU Int*. 2000;86:951–959.

Chou R, Dana T. Screening adults for bladder cancer: a review of the evidence for the U.S. Preventive Services Task Force. *Ann Intern Med*. 2010;153:461–468.

Coleman DM, Stanley JC. Renal artery aneurysms. *J Vasc Surg*. 2015;62:779–785.

Committee on Gynecologic Practice, American College of Obstetricians and Gynecologists and the American Urogynecologic Society. Committee opinion no.703: asymptomatic microscopic hematuria in women. *Obstet Gynecol*. 2017;129(6):e168–e172.

Comploj E, Mian C, Ambrosini-Spaltro A, et al. uCyt+/ImmunoCyt and cytology in the detection of urothelial carcinoma: an update on 7422 analyses. *Cancer Cytopathol*.

2013;121:392–397.

Conces MR, Williamson SR, Montironi R, et al. Urethral caruncle: clinicopathologic features of 41 cases. *Hum Pathol*. 2012;43:1400–1404.

Corman JM, McClure D, Pritchett R, et al. Treatment of radiation induced hemorrhagic cystitis with hyperbaric oxygen. *J Urol*. 2003;169:2200–2202.

Cox PJ. Cyclophosphamide cystitis: identification of acrolein as the causative agent. *Biochem Pharmacol*. 1979;28:2045–2049.

Culclasure TF, Bray VJ, Hasbargen JA. The significance of hematuria in the anticoagulated patient. *Arch Int Med*. 1994;154:649–652.

Davis R, Jones JS, Barocas DA, et al. Diagnosis, evaluation and follow-up of asymptomatic microhematuria (AMH) in adults: AUA guideline. *J Urol*. 2012;188:2473–2481.

Deering RE, Bigler SA, Brown M, et al. Microvascularity in benign prostatic hyperplasia. *Prostate*. 1995;26:111–115.

Del Pizzo JJ, Chew BH, Jacobs SC, et al. Treatment of radiation induced hemorrhagic cystitis with hyperbaric oxygen: long-term followup. *J Urol*. 1998;160:731–733.

Delgal A, Cercueil JP, Koutlidis N, et al. Outcome of transcatheter arterial embolization for bladder and prostate hemorrhage. *J Urol*. 2010;183:1947–1953.

Din OS, Thanvi N, Ferguson CJ, et al. Palliative prostate radiotherapy for symptomatic advanced prostate cancer. *Radiother Oncol*. 2009;93:192–196.

Donahue LA, Frank IN. Intravesical formalin for hemorrhagic cystitis: analysis of therapy. *J Urol*. 1989;141:809–812.

Edwards TJ, Dickinson AJ, Natale S, et al. A prospective analysis of the diagnostic yield resulting from the attendance of 4020 patients at a protocol-driven haematuria clinic. *BJU Int*. 2006;97:301–305.

Eigner EB, Freiha FS. The fate of the remaining bladder following supravesical diversion. *J Urol*. 1990;144:31–33.

Elias K, Svatek RS, Gupta S, et al. High-risk patients with hematuria are not evaluated according to guideline recommendations. *Cancer*. 2010;116:2954–2959.

Ellis H. A history of bladder stone. *J R Soc Med*. 1979;72:248–251.

Fazili T, Bhat TR, Masood S, et al. Fate of the leftover bladder after supravesical urinary diversion for benign disease. *J Urol*. 2006;176:620–621.

Feng S, Tian Y, Liu W, et al. Prostatic arterial embolization treating moderate-to-severe lower urinary tract symptoms related to benign prostate hyperplasia: a meta-analysis. *Cardiovasc Intervent Radiol*. 2017;40:22–32.

Fiore MC, Baker TB. Should clinicians encourage smoking cessation for every patient who smokes? *J Am Med Assoc*. 2013;309:1032–1033.

Foley SJ, Soloman LZ, Wedderburn AW, et al. A prospective study of the natural history of hematuria associated with benign prostatic hyperplasia and the effect of finasteride. *J Urol*. 2000;163:496–498.

Frauscher F, Klausser A, Furhtmueller B, et al. Effects of finasteride on prostatic blood flow in patients with benign prostatic hyperplasia. *J Urol*. 2003;169:476 [abstract 1784].

Friedlander DF, Resnick MJ, You C, et al. Variation in the intensity of hematuria evaluation: a target for primary care quality improvement. *Am J Med*. 2014;127(7):633–640.e11.

Garber BB, Wein AJ. Common urologic bleeding problems. II. *AUA Update Series*. 1989.

Gontero P. Urethral bleeding. Gontero P, Kirby RS, Carson CC. *Problem based urology*. Springer-Verlag: London; 2013:75–81.

Gonzalez CM, Case JR, Nadler RB. Gluteraldehyde cross-linked collagen occlusion of the ureteral orifices with percutaneous nephrostomy: a minimally invasive option for treatment of refractory hemorrhagic cystitis. *J Urol*. 2001;166:977–978.

Gorczynska E, Turkiewicz D, Rybka K, et al. Incidence, clinical outcome, and management of virus-induced hemorrhagic cystitis in children and adolescents after allogeneic hematopoietic cell transplantation. *Biol Blood Marrow Transplant*. 2005;11:797–804.

Greenwell TJ, Spilotros M. Urethral diverticula in women. *Nat Rev Urol*. 2015;12:671–680.

Grossman HB, Messing E, Soloway M, et al. Detection of bladder cancer using a point-of-care proteomic assay. *J Am Med Assoc*. 2005;7293:810–816.

Hader JE, Marzella L, Myers RAM, et al. Hyperbaric oxygen treatment for experimental cyclophosphamide-induced hemorrhagic cystitis. *J Urol*. 1993;149:1617–1621.

Hald T, Mygind T. Control of life-threatening vesical hemorrhage by unilateral hypogastric artery muscle embolization. *J Urol*. 1974;112:60–63.

Halpern JA, Chughtai B, Ghomrawi H. Cost-effectiveness of common diagnostic approaches for evaluation of asymptomatic microscopic hematuria. *JAMA Intern Med*. 2017;177(6):800–807.

Hasan ST, German K, Derry CD. Same day diagnostic service for new cases of haematuria: a distinct general hospital experience. *Br J Urol*. 1994;73:152–154.

Henning A, Wehrberger M, Madersbacher S, et al. Do differences in clinical symptoms and referral patterns contribute to the gender gap in bladder cancer? *BJU Int*. 2013;112:68–73.

Hofland CA, Eron LJ, Washecka RM. Hemorrhagic adenovirus cystitis after renal transplantation. *Transplant Proc*.

2004;36:3025–3027.

Hohenfellner M, D'Elia G, Hampel C, et al. Transposition of the left renal vein for treatment of the nutcracker phenomenon: long-term follow-up. *Urology*. 2002;59:354–357.

Horie S, Ito S, Okada H, et al. Japanese guidelines of the management of hematuria 2013. *Clin Exp Nephrol*. 2014;18(5):679–689.

Huang WT, Li LY, Pang J, et al. Fluorescence in situ hybridization assay detects upper urinary tract transitional cell carcinoma in patients with asymptomatic hematuria and negative urine cytology. *Neoplasma*. 2012;59:355–360.

Jaffe JS, Ginsberg PC, Gill R, et al. A new diagnostic algorithm for the evaluation of microscopic hematuria. *Urology*. 2001;57:889–894.

Jeffries ER, Brewster SF, BAUS Section on Oncology. Urological recommendations from the National Institute for Health and Care Excellence (NICE) Guideline, June 2015: suspected cancer: recognition and referral. *BJU Int*. 2016;117(6):857–860.

Jeong CW, Lee S, Byun S-S, et al. No increase in risk of microscopic hematuria with aspirin use by asymptomatic healthy people. *JAMA Int Med*. 2013;173:1145–1146.

Jung H, Gleason JM, Loo RK, et al. Association of hematuria on microscopic urinalysis and risk of urinary tract cancer. *J Urol*. 2011;185(5):1698–1703.

Karnes RJ, Fernandez CA, Shuber AP. A noninvasive multianalyte urine-based diagnostic assay for urothelial cancer of the bladder in the evaluation of hematuria. *Mayo Clin Proc*. 2012;87:835–842.

Kassouf W, et al. Recommendations for the improvement of bladder cancer quality of care in Canada: a consensus document reviewed and endorsed by Bladder Cancer Canada (BCC), Canadian Urologic Oncology Group (CUOG), and

Canadian Urological Associate (CUA), December 2015. *Can Urol Assoc J*. 2016;10:E46–E80.

Kaya C, Ozyurek M, Turkeri LN. Comparison of microvessel densities in rat prostate tissues treated with finasteride, bicalutamide and surgical castration: a preliminary study. *Int J Urol*. 2005;12:194–198.

Kearney MC, Bingham JB, Bergland R, et al. Clinical predictors in the use of finasteride for control of gross hematuria due to benign prostatic hyperplasia. *J Urol*. 2002;167:2489–2491.

Keller FS, Barton RE, Routh WD, et al. Gross hematuria in two patients with ureteral-ileal conduits and double-J stents. *J Vasc Interv Radiol*. 1990;1:69–77.

Khadra MH, Pickard RS, Charlton M, et al. A prospective analysis of 1,930 patients with hematuria to evaluate current diagnostic practice. *J Urol*. 2000;163:524–527.

Kincaid-Smith P. Haematuria and exercise-related haematuria. *Br Med J (Clin Res Ed)*. 1982;4:1595–1597.

Klausner JQ, Lawrence PF, Harlander-Locke MP, et al. The contemporary management of renal artery aneurysms. *J Vasc Surg*. 2015;61:978–984.

Kohanpour MA, Sanavi S, Peeri M, et al. Effect of submaximal aerobic exercise in hypoxic conditions on proteinuria and hematuria in physically trained young men. *Iran J Kidney Dis*. 2012;6:192–197.

Kraus SE, Siroky MB, Babayan RK, et al. Hematuria and the use of nonsteroidal anti-inflammatory drugs. *J Urol*. 1984;132:288–290.

Lano MD, Wagoner RD, Leary FJ. Unilateral essential hematuria. *Mayo Clin Proc*. 1979;54:88–90.

Lee HJ, Pyo JW, Choi EH, et al. Isolation of adenovirus type 7 from the urine of children with acute hemorrhagic cystitis. *Pediatr Infect Dis J*. 1996;15:633–634.

Lee LW, Davis E Jr. Gross urinary hemorrhage: a symptom, not a disease. *JAMA*. 1953;153:782–784.

Liedberg F, Gerdtham U, Gralén K, et al. Fast-track access to urologic care for patients with macroscopic haematuria is efficient and cost-effective: results from a prospective intervention study. *Br J Cancer*. 2016;115(7):770–775.

Linder BJ, Tarrell RF, Boorjian SA. Cystectomy for refractory hemorrhagic cystitis: contemporary etiology, presentation and outcomes. *J Urol*. 2014;192:1687–1692.

Linder BJ, Bass EJ, Mostafid H, et al. Guideline of guidelines: asymptomatic microscopic haematuria. *BJU Int*. 2017 [Epub ahead of print].

Lippmann QK, Slezak JM, Menefee SA, et al. Evaluation of microscopic hematuria and risk of urologic cancer in female patients. *Am J Obstet Gynecol*. 2017;216(2):146.e1–146.e7.

Lisanti CJ, Toffoli TJ, Stringer MT, et al. CT evaluation of the upper urinary tract in adults younger than 50 years with asymptomatic microscopic hematuria: is IV contrast enhancement needed? *Am J Roentgenol*. 2014;203(3):615–619.

Loffroy R, Pottecher P, Cherblanc V, et al. Current role of transcatheter arterial embolization for bladder and prostate hemorrhage. *Diagn Interv Imaging*. 2014;95:1027–1034.

Loo R, Whittaker J, Rabrenivich V. National practice recommendations for hematuria: how to evaluate in the absence of strong evidence? *Perm J*. 2009;13(1):37–46.

Loo RK, Lieberman SF, Slezak JM, et al. Stratifying risk of urinary tract malignant tumors in patients with asymptomatic microscopic hematuria. *Mayo Clin Proc*. 2013;88:129–138.

Lynch TH, Waymont B, Dunn JA, et al. Rapid diagnostic service for patients with haematuria. *Br J Urol*. 1994;73:147–151.

Lyratzopoulos G, Abel GA, McPhail S, et al. Gender inequalities in the promptness of diagnosis of bladder and renal cancer after symptomatic presentation: evidence from secondary analysis of an English primary care audit survey. *BMJ Open*. 2013;3:e002861.

Malmstrom PU, Grabe M, Haug ES, et al. Role of hexaminolevulinate-guided fluorescence cystoscopy in bladder cancer: critical analysis of the latest data and European guidance. *Scand J Urol Nephrol*. 2012;46:108–116.

Mariani AJ. The evaluation of adult hematuria. *AUA Update Series*. 1989.

Mariani AJ, Luangphinith S, Loo S, et al. Dipstick chemical urinalysis: an accurate cost-effective screening test. *J Urol*. 1984;132:64–66.

Mariani AJ, Mariani AC, Macchioni C, et al. The significance of adult hematuria: 1,000 hematuria evaluations including a risk-benefit and cost-effectiveness analysis. *J Urol*. 1989;141:350–355.

Marshall S, Narayan P. Treatment of prostatic bleeding: suppression of angiogenesis by androgen deprivation. *J Urol*. 1993;149:1553–1554.

Mazhari R, Kimmel PL. Hematuria: an algorithmic approach to finding the cause. *Cleve Clin J Med*. 2002;69:870–876.

McGregor DO, Lynn KL, Bailey RR, et al. Clinical audit of the use of renal biopsy in the management of isolated microscopic hematuria. *Clin Nephrol*. 1998;49:345–348.

McInnis MD, Newhouse IJ, von Duvillard SP, et al. The effect of exercise intensity on hematuria in healthy male runners. *Eur J Appl Physiol Occup Physiol*. 1998;79:99–105.

Mettler FA Jr, Huda W, Yoshizumi TT, et al. Effective doses in radiology and diagnostic nuclear medicine: a catalog. *Radiology*. 2008;248:254–263.

Michel F, Dubruille T, Cercueil JP, et al. Arterial embolization for massive hematuria following transurethral prostatectomy.

J Urol. 2002;168:2550–2551.

Miller MI, Puchner PJ. Effects of finasteride on hematuria associated with benign prostatic hyperplasia: long-term follow-up. *Urology*. 1998;51:237–240.

Mishriki SF, Aboumarzouk O, Vint R, et al. Routine urine cytology has no role in hematuria investigations. *J Urol*. 2013;189:1255–1259.

Miyanaga N, Akaza H, Tsukamoto T, et al. Urinary nuclear matrix protein 22 as a new marker for the screening of urothelial cancer in patients with microscopic hematuria. *Int J Urol*. 1999;6:173–177.

Mohan IV, Stephen MS. Peripheral arterial aneurysms: open or endovascular surgery? *Prog Cardiovasc Dis*. 2013;56:36–56.

Mohr DN, Offord KP, Owen RA, et al. Asymptomatic microhematuria and urologic disease: a population-based study. *JAMA*. 1986;256:224–229.

Morey AF, Brandes S, Dugi DD 3rd, et al. Urotrauma: AUA guideline. *J Urol*. 2014;192:327–335.

Mougin J, Souday V, Martin F, et al. Evaluation of hyperbaric oxygen therapy in the treatment of radiation-induced hemorrhagic cystitis. *Urology*. 2016;94:42–46.

Mundy AR, Andrich DE. Urethral trauma. I. Introduction, history, anatomy, pathology, assessment and emergency management. *BJU Int*. 2011;108:310–327.

Murakami S, Igarashi T, Hara S, et al. Strategies for asymptomatic microscopic hematuria: a prospective study of 1,034 patients. *J Urol*. 1990;144:99–101.

Muraoka N, Sakai T, Kimura H, et al. Rare causes of hematuria associated with various vascular diseases involving the upper urinary tract. *Radiographics*. 2008;28:855–867.

Nakada SY. The diagnosis and management of lateralizing essential hematuria. *AUA Update Series*. 2003.

National Cancer Institute. *Cancer stat facts: bladder cancer*.

[(website)] http://seer.cancer.gov/statfacts/html/urinb.html; 2018.

National Institute for Health and Care Excellence (NICE) Guideline. [(website)] https://www.nice.org.uk/guidance/NG12/chapter/1-Recommendations-organised-by-site-of-cancer#urological-cancers; 2006.

Nielsen M, Qaseem A for the High-Value Care Task Force of the American College of Physicians. Hematuria as a marker of occult urinary tract cancer: advice for high-value care from the American College of Physicians. *Ann Intern Med*. 2016;164(7):488–497.

Ooi WL, Lee F, Wallace DM, et al. ‘One stop’ haematuria clinic in Fremantle Hospital, Western Australia: a report of the first 500 patients. *BJU Int*. 2011;108(Suppl 2):62–66.

O'Reilly KJ, Hampson NB, Corman JM. Hyperbaric oxygen in urology. *AUA Update Series*. 2002.

Ostroff EB, Chenault OW. Alum irrigation for the control of massive bladder hemorrhage. *J Urol*. 1982;128:929–930.

Pareek G, Shevchuk M, Armenakas N, et al. The effect of finasteride on the expression of vascular endothelial growth factor and microvessel density: a possible mechanism for decreased prostatic bleeding in treated patients. *J Urol*. 2003;169:20–23.

Payne H, Adamson A, Bahl A, et al. Chemical- and radiation-induced haemorrhagic cystitis: current treatments and challenges. *BJU Int*. 2013;112:885–897.

Pereira K, Halpern JA, McClure TD, et al. Role of prostate artery embolization in the management of refractory haematuria of prostatic origin. *BJU Int*. 2016;118:359–365.

Perimenis P, Gyftopoulos K, Markou S, et al. Effects of finasteride and cyproterone acetate on hematuria associated with benign prostatic hyperplasia: a prospective, randomized, controlled study. *Urology*. 2002;59:373–377.

Pham PT, Pham PC, Wilkinson AH, et al. Renal abnormalities in sickle cell disease. *Kidney Int*. 2000;57:1–8.

Praveen BV, Sankaranarayanan A, Vaidyanathan S. A comparative study of intravesical instillation of 15(s) 15 Me alpha and alum in the management of persistent hematuria of vesical origin. *Int J Clin Pharmacol Ther Toxicol*. 1992;30:7–12.

Price SJ, Shephard EA, Stapley SA, et al. Non-visible versus visible haematuria and bladder cancer risk: a study of electronic records in primary care. *Br J Gen Pract*. 2014;64(626):e584–e589.

Prochazka AV, Lundahl K, Pearson W, et al. Support of evidence-based guidelines for the annual physical examination: a survey of primary care providers. *Arch Intern Med*. 2005;165:1347–1352.

Puchner PJ, Miller MI. The effects of finasteride on hematuria associated with benign prostatic hyperplasia: a preliminary report. *J Urol*. 1995;154:1779–1782.

Rahman NU, Elliott SP, McAninch JW. Self-inflicted male urethral foreign body insertion: endoscopic management and complications. *BJU Int*. 2004;94:1051–1053.

Rastinehad AR, Kavoussi LR, Noble MJ. Hemorrhagic cystitis. *AUA Update Series*. 2007.

Rhéaume-Lanoie J, Lepanto L, Fradet V, et al. Diagnostic performance of ultrasound for macroscopic hematuria in the era of multidetector computed tomography urography. *Can Assoc Radiol J*. 2014;65(3):253–259.

Rittmaster RS, Norman RW, Thomas LN, et al. Evidence for atrophy and apoptosis in the prostates of men given finasteride. *J Clin Endocrinol Metab*. 1996;81:814–819.

Rizzo M, Marchetti F, Travaglini A, et al. Prevalence, diagnosis and treatment of prostatitis in Italy: a prospective urology outpatient practice study. *BJU Int*. 2003;92:955–959.

Sandhu KS, LaCombe JA, Fleischmann N, et al. Gross and microscopic hematuria: guidelines for obstetricians and gynecologists. *Obstet Gynecol Surv*. 2009;64:39–49.

Schmitz-Drager BJ, Beiche B, Tirsar LA, et al. Immunocytology in the assessment of patients with asymptomatic microhaematuria. *Eur Urol*. 2007;51:1582–1588.

Schmitz-Dräger BJ, Kuckuck EC, Zuiverloon TC, et al. Microhematuria assessment an IBCN consensus-based upon a critical review of current guidelines. *Urol Oncol*. 2016;34(10):437–451.

Schuster GA, Lewis GA. Clinical significance of hematuria in patients on anticoagulant therapy. *J Urol*. 1987;137:923–925.

Shao Y, Lu GL, Shen ZJ. Comparison of intravesical hyaluronic acid instillation and hyperbaric oxygen in the treatment of radiation-induced hemorrhagic cystitis. *BJU Int*. 2012;109:691–694.

Shephard EA, Stapley S, Neal RD, et al. Clinical features of bladder cancer in primary care. *Br J Gen Pract*. 2012;62:598–604.

Shepherd JD, Pringle LE, Barnett MJ, et al. Mesna versus hyperhydration for prevention of cyclophosphamide-induced hemorrhagic cystitis in bone marrow transplantation. *J Clin Oncol*. 1991;9:2016–2019.

Shokeir AA, Hussein MI. The urology of Pharaonic Egypt. *BJU Int*. 1999;84:755–761.

Sieber PR, Rommel FM, Huffnagle HW, et al. The treatment of gross hematuria secondary to prostatic bleeding with finasteride. *J Urol*. 1998;159:1232–1233.

Singh I, Laungani GB. Intravesical epsilon aminocaproic acid in the management of intractable bladder hemorrhage. *Urology*. 1992;40:227–229.

Smit SG, Heyns CF. Management of radiation cystitis. *Nat Rev Urol*. 2010;7:206–214.

Sokolosky MC. Hematuria. *Emerg Med Clin North Am*. 2001;19:621–632.

Stefanini M, English HA, Taylor AE. Safe and effective, prolonged administration of epsilon aminocaproic acid in bleeding from the urinary tract. *J Urol*. 1990;143:559–561.

Steiner H, Bergmeister M, Verdorfer I, et al. Early results of bladder-cancer screening in a high-risk population of heavy smokers. *BJU Int*. 2008;102:291–296.

Stillwell TJ, Benson RC Jr. Cyclophosphamide-induced hemorrhagic cystitis: a review of 100 patients. *Cancer*. 1988;61:451–457.

Sugie S, Mukai S, Tsukino H, et al. Effect of dutasteride on microvessel density in benign prostatic hyperplasia. *In Vivo*. 2014;28:355–359.

Sultana SR, Goodman CM, Byrne DJ, et al. Microscopic haematuria: urological investigation using a standard protocol. *Br J Urol*. 1996;78:691–696.

Tracey E, Watt H, Currow D, et al. Investigation of poorer bladder cancer survival in women than men in NSW Australia: a data linkage study. *BJU Int*. 2014;113:437–448.

Tsili AC, Efremidis SC, Kalef-Ezra J, et al. Multi-detector row CT urography on a 16-row CT scanner in the evaluation of urothelial tumors. *Eur Radiol*. 2007;17:1046–1054.

van der Molen AJ, Hovius MC. Hematuria: a problem-based imaging algorithm illustrating the recent Dutch guidelines on hematuria. *Am J Roentgenol*. 2012;198:1256–1265.

Vandersteen DR, Saxon RR, Fuchs E, et al. Diagnosis and management of ureteroiliac artery fistula: value of provocative arteriography followed by common iliac artery embolization and extraanatomic arterial bypass grafting. *J Urol*. 1997;158:754–758.

van Kessel KE, Beukers W, Lurkin I, et al. Validation of a DNA methylation-mutation urine assay to select patients with hematuria for cystoscopy. *J Urol*. 2017;197:590–595.

Vaughan ED Jr, Wyker AW Jr. Effect of osmolality on the evaluation of microscopic hematuria. *J Urol*. 1971;105:709–711.

Vikram R, Sandler CM, Ng CS. Imaging and staging of transitional cell carcinoma. II. Upper urinary tract. *Am J Roentgenol*. 2009;192:1488–1493.

Vose JM, Reed EC, Pippert GC, et al. Mesna compared with continuous bladder irrigation as uroprotection during high-dose chemotherapy and transplantation: a randomized trial. *J Clin Oncol*. 1993;11:1306–1310.

Vrtiska TJ, Hartman RP, Kofler JM, et al. Spatial resolution and radiation dose of a 64-MDCT scanner compared with published CT urography protocols. *Am J Roentgenol*. 2009;192:941–948.

Wallis CJD, Juvet T, Lee Y, et al. Association between use of antithrombotic medication and hematuria-related complications. *J Am Med Assoc*. 2017;318(13):1260–1271.

Wallis CJD, Mahar AL, Choo R, et al. Second malignancies after radiotherapy for prostate cancer: systematic review and meta-analysis. *BMJ*. 2016;352:i851.

Walsh K, Sriprasad S, Hopster D, et al. Distribution of vascular endothelial growth factor (VEGF) in prostate disease. *Prostate Cancer Prostatic Dis*. 2002;5:119–122.

Ward JF, Amling CL, McKusick MA. The use of percutaneous transcatheter embolization in urology. *AUA Update Series*. 2003.

Weiss JP, Mattei DM, Neville EC, et al. Primary treatment of radiation-induced hemorrhagic cystitis with hyperbaric oxygen: 10-year experience. *J Urol*. 1994;151:1514–1517.

Westerman ME, Boorjian SA, Linder BJ. Safety and efficacy of intravesical alum for intractable hemorrhagic cystitis: a contemporary evaluation. *Int Braz J Urol*. 2016;42(6):1144–1149.

White SE, Malkowicz SB. Management of the male urethra after cystectomy. *Urol Clin North Am*. 2010;37:475–479.

Wolfish NM, McLaine PN, Martin D. Renal vein entrapment syndrome: frequency and diagnosis: a lesson in conservatism. *Clin Nephrol*. 1986;26:96–100.

Yamagata K, Yamagata Y, Kobayashi M, et al. A long-term follow-up study of asymptomatic hematuria and/or proteinuria in adults. *Clin Nephrol*. 1996;45:281–288.

Yun EJ, Meng MV, Carroll PR. Evaluation of the patient with hematuria. *Med Clin North Am*. 2004;88:329–343.

Zhu YP, Dai B, Zhang HL, et al. Impact of preoperative 5a-reductase inhibitors on perioperative blood loss in patients with benign prostatic hyperplasia: a meta-analysis of randomized controlled trials. *BMC Urol*. 2015;15:47.

Ziegelmann MJ, Boorjian SA, Joyce DD, et al. Intravesical formalin for hemorrhagic cystitis: a contemporary cohort. *Can Urol Assoc J*. 2017;11:E79–E82.

Zippe C, Pandrangi L, Potts JM, et al. NMP22: a sensitive, cost-effective test in patients at risk for bladder cancer. *Anticancer Res*. 1999;19:2621–2623.

17

Complications of Urologic Surgery

Reza Ghavamian MD, Charbel Chalouhy MD

Like all surgical disciplines, urologic surgery can be associated with a variety of diverse complications. Although the advent of endourology and minimally invasive surgery has played an unprecedented role in minimizing morbidity, it has also introduced newly described and reported periprocedural complicating events. Training in urology has also witnessed another paradigm shift, from the era of classic surgical mentoring to the current use of simulators and virtual reality surgery. Learning curves of complex surgical procedures such as open radical prostatectomy once estimated to be around 100 to 1000 cases have dropped to 40 cases with robotic-assisted surgery. Surprisingly, complication rates have not followed the same trend, and some authors associate this with the increased number of young surgeons progressing through their learning curves. There has been a dramatic increase in the use of minimally invasive procedures in the surgical management of urologic disease. These include the wide range of modern endoscopic and endourologic procedures and the use of laparoscopic and robotic surgical techniques. As such, surgical training has also evolved with a dramatic decrease in the exposure to major open surgery in the average urologic training program. Today, major index and common urologic oncologic and reconstructive procedures are performed in a minimally invasive fashion. Although the new generation of surgeons are better trained in minimally invasive techniques, the principles for the treatment of major complications remains the same. Colombo et al. reported on the single-institution analysis of 1867 laparoscopic procedures. **Of these, the incidence of intraoperative and postoperative complications were 3.5% and 8.9%, respectively, with an associated mortality rate of 0.4%. Increased incidence of complications was associated with several factors, such as procedure complexity (laparoscopic partial nephrectomy and cystectomy), length of surgery greater than 4 hours, and serum creatinine greater than 1.5 mg/dL. Complications decreased with increasing surgeon experience** (Colombo et al., 2007). Several studies have shown that complications increase up to ninefold with procedure complexity and decrease fourfold with surgeon experience. In a study of 2407 procedures, Fahlenkamp et al. reported that as more experience is gained in urologic laparoscopy, the number of complications actually increases as more complex cases are tackled. The complication rate depended on the difficulty of the procedure and averaged 1.0%, 3.9%, and 9.2%, respectively, for easy, difficult, and very difficult operations. In this series, the overall complication rates increased from 4.4% to 16%, conversion rates increased from 0.8% to 5%, and mortality rates were 0.9% (Fahlenkamp et al., 1999). Laparoscopy has the same set of complications as open surgery. However, there is a unique set of complications related to pneumoperitoneum and access, for example. A high index of suspicion is necessary intraoperatively and postoperatively to detect and treat these complications in an expeditious and safe manner. Although technology has changed the actual performance of operations, it has also led to the development of minimally invasive means to treat surgical complications. These include interventional radiologic techniques and, in many instances, minimally invasive laparoscopic and/or robotic approaches to treat complications. Many recently graduated surgeons come to face challenging situations and complications that were not encountered during their training with an obvious lack of specific management guidelines. Robotic simulators of operative complications or animal models might come into play once again to bridge this gap in training.

As expected, there is a wide array of physiologic, medical, and surgical complications associated with different urologic procedures. Complications are even more specific to laparoscopic and minimally invasive surgery, which is being increasingly utilized in urologic practice. Physiologic complications such as arrhythmias, more specifically bradycardia resulting from gas extension of the peritoneum, can occur. Hypercarbia and acidosis caused by CO_2 and ventilatory problems with resultant decrease in respiratory reserve and increase in airway pressure can result. These physiologic effects are discussed elsewhere in this book in the chapters on laparoscopy.

Positioning, access, vascular, urologic, bowel, and visceral complications can occur. As such, procedure-specific complications, especially those associated with endourologic procedures, are not covered here and are addressed elsewhere in this book in the chapters that specifically address each particular procedure. Hence, this chapter will focus on various general complications of common major urologic procedures. It will also attempt to propose strategies to deal with and more importantly to avoid different complex scenarios.

Classification of Complications

The Clavien-Dindo Scale

The Clavien-Dindo grading system is the recommended uniform approach for describing and reporting complications after surgery. The stratification of this system depends on the severity of the complication and the invasiveness of the intervention required to manage it. The utilization of the Clavien-Dindo grading scale has increased over the past several years in urologic practice from 21% in 2010 to 50% in 2012 (Mitrapoulos, 2017, Yoon et al., 2013). This system was not designed for urologic surgery, but its use has been validated, and it has proven to be simple, reproducible, and applicable to our specialty (Rassweiler et al., 2012).

The Clavien-Dindo system is classically based on management of a complication rather than its severity or morbidity. It also does not differentiate between early and late postoperative complications or address intraoperative complication reporting, and it may not be suitable for pediatric urology. Despite this, it is the most commonly used tool and allows for objective reporting of postoperative complications. In fact, the interobserver agreement rate was reported to be as high as 89%, even in nebulous clinical scenarios when it was evaluated a few years after its early use (Clavien et al., 2009; Dindo et al., 2004).

In urology, this grading system has been the subject of procedure-specific assessments. De la Rosette et al. reported on the applicability of the Clavien-Dindo scale to percutaneous nephrolithotomy (PCNL). Specific complications were assigned to the different grade categories in an attempt to standardize this scoring system when reporting adverse outcomes related to PCNL. This study on 4230 patients from the PCNL global study database showed significant concordance among urologists when reporting the more severe complications in higher Clavien-Dindo grades than in lower grades (3 or less), when low interurologist reliability was identified (De la Rosette et al., 2012). This weakness is dependent on the mismatch perception of care providers to the potential risks patients are exposed to versus the actual management and treatments required for a specific complication after PCNL. Many groups have since evaluated the utility of the Clavien-Dindo grading system in different urologic procedures such as laparoscopic or open radical nephrectomy and robotic prostatectomy.

The Clavien classification serves its purpose in evaluating outcomes in academic and teaching centers. Utilizing this scheme, as an instrument in outcomes, there is an 80% observed concordance in surgical outcomes among postgraduate trainees and attending urologists (Elkoushy et al., 2013) (Table 17.1).

TABLE 17.1

The Clavien Dindo Classification[a]

GRADES	DEFINITION
Grade I	Any deviation from the normal postoperative course without the need for pharmacologic treatment or surgical, endoscopic, and radiologic interventions Allowed therapeutic regimens are: drugs as antiemetics, antipyretics, analgesics, diuretics, and electrolytes and physiotherapy. This grade also includes wound infections opened at the bedside.
Grade II	Requiring pharmacologic treatment with drugs other than such allowed for grade I complications. Blood transfusions and total parenteral nutrition are also included.
Grade III	Requiring surgical, endoscopic, or radiologic intervention
Grade IIIa	Intervention not under general anesthesia
Grade IIb	Intervention under general anesthesia
Grade IV	Life-threatening complication (including CNS complications)[b] requiring IC/ICU management
Grade IVa	Single-organ dysfunction (including dialysis)
Grade IVb	Multiorgan dysfunction
Grade V	Death of a patient
Suffix “d”	If the patients suffers from a complication at the time of discharge, the suffix “d” (for “disability”) is added to the respective grade of complication. This label indicates the need for a follow-up to fully evaluate the complication.

[a] The treatment modality used to correct a certain complication remains the cornerstone of this classification. There are seven grades, and some subdivisions of some grades allow pooling of the rare and severe complications.

[b] Brain hemorrhage, ischemic stroke, subarrachnoidal bleeding, but excluding transient ischemic attack (TIA).

CNS, Central nervous system; *IC,* intermediate care; *ICU,* intensive care unit.

Standardization is the cornerstone for reducing errors and avoidable morbidity. In the future, similar to different treatment guidelines, surgeons may have to define procedural guidelines. This will include optimal operational performance including a standardization of all surgical steps and adverse occurrences that can be considered as surgical errors. This would encourage analysis of the individual performance of a surgeon according to intraobserver and interobserver perceived errors. It is evident that grading systems such as the Clavien system are only one correct and necessary step in this direction.

Physiologic Complications

The surgeon should be familiar with physiologic complications such as arrhythmias, more specifically bradycardia resulting from gas extension of the peritoneum, hypercarbia, and acidosis caused by CO_2 and ventilatory problems, with resultant decrease in respiratory reserve and increase in airway pressure.

Positional and Neuromuscular Complications

Neuromuscular complications occur as a result of direct surgical trauma or improper positioning and pressure (Chuang et al., 2011). Positioning for urologic procedures is variable. A variety of positions are employed by the surgeon for adequate access to the target organ. This ranges from the classic supine position to full or modified lateral decubitus positions (flank positions) for renal surgery and modified and full lithotomy positions. Direct compression of specific nerves against the patient's own body, or the operation table is often the mechanism of injury. Obese patients are at increased risk as the weight of the patient's body can be excessive pressure on affected and vulnerable pressure points. These patients are also at risk for extended operating times because of their body habitus (Mendoza et al., 1996). Recently with the advent of robotic surgery, the patient is also positioned in exaggerated and steep Trendelenburg position. The upper and lower extremities are at risk for these “compromised” positions. Colombo et al. reported on a series of 1867 patients who underwent laparoscopic operations for urologic cancer and reported neuromuscular complications at 1% (Colombo et al., 2007). Others have reported an incidence of less than 3% in urologic procedures, although higher rates in the order of 6% have been reported in robotic series (Wolf et al., 2000; Mills et al., 2013). Permanent neurologic impairment is very rare, as spontaneous recovery often results with minor positional trauma. For the sake of discussion, we describe common positional nerve injuries and intraoperative nerve injuries.

Positional Nerve Injury

Positioning injuries are usually the result of compression injury during prolonged operative times with or without adequate padding and support. Insufficient padding and cushioning of pressure points contribute greatly to neuromuscular injuries, especially in obese patients. The clinical presentation is in the immediate postoperative period affecting the area of sensory and motor supply of the damaged nerve. Sensory loss, paresthesias, or motor deficit results depending on the affected nerve territory.

In the lithotomy and modified lithotomy positions, the posterior tibial nerve can be injured as a result of compression of the posterior knee against the stirrups, resulting in weak plantarflexion. This can be associated with sensory loss in the sole and lateral aspect of the foot and posterior calf paresthesia. The peroneal nerve can also can be compressed against the stirrups as it courses laterally around the fibular neck with resultant foot drop and foot eversion weakness. Excess traction of the legs and compression against stirrups are also associated with injuries to the pudendal nerve resulting in variable perineal sensory loss and rarely incontinence. The peroneal nerve is also at risk in the lateral position, as excess pressure on the dependent leg without adequate padding can be the mechanism of injury. Excessive pressure on the leg against the operative table results in ipsilateral foot drop. Although the obturator nerve is most at risk during pelvic surgery, positional injury to this nerve has been described with hyperflexion of the thigh at the hip joint in exaggerated lithotomy positions causing motor weakness in thigh adduction.

Injuries can also occur with supine positioning. **Inadequate cushioning and padding is very often the reason for sciatic nerve injury. Lateral calf and foot numbness usually ensues.** In the upper extremities, surgeons should carefully check for excessive abduction of the arm greater than 90 degrees on the arm board and secure it before prepping and draping the patient as this can be easily missed once patient is covered. Patients can wake up with shoulder pain and arm weakness of variable severity. Early physical therapy may be necessary. **Radial nerve injury can result in wrist drop. It usually occurs when the arm is dislodged off the armrest in supination and not secured properly. When the arm is dislodged in pronation, the median nerve is affected resulting in a weak hand grip and decreased palmar sensation. Ulnar nerve injuries occur with excessive hyperextension of the forearm and pronation, or when the elbow is flexed at 90 degrees with arms folded across the chest. Postoperatively, a weakened grip ensues or a claw hand consisting of extended metacarpophalangeal and flexed interphalangeal joints usually of the fourth and fifth fingers.** Recently with the advent of robotic prostatectomy, the arms are tucked in and affixed to the side of the patient's abdomen. Care must be taken to adequately pad the patient's hands to keep the wrist protected and straight. Also, compression of the ulnar nerve against the patient's torso or the table can result in the same consequences as described earlier. Sciatic nerve injuries can occur from inadequate padding and result in lateral calf and foot numbness.

The brachial plexus can also be at risk in the lateral position when the dependent shoulder or arm is under the rib cage. Symptoms include shoulder pain and arm weakness of variable degrees. **The majority of brachial plexus injuries result from excessive arm abduction (greater than 90 degrees) and external rotation and posterior shoulder displacement.** This can occur in the supine or lateral position. An axillary roll should be placed to protect the brachial plexus during flank positioning.

The lower extremities are the mostly affected in the prone position. Anterior tibial nerve compression can cause foot drop when the affected foot is left in plantarflexion for extended periods. The same mechanism of injury can be seen in the reverse Trendelenburg position because the patient's body weight exerted on the feet induces plantarflexion when adequate support and padding to the sole of the foot is not provided. Another nerve prone to injury in the prone position is the lateral femoral cutaneous nerve. Excessive pressure on the lateral thigh results in numbness in the lateral and anterior thigh.

Operative Nerve Injury

The most encountered nerves during urologic surgeries are the genitofemoral nerve, ilioinguinal, and obturator nerves. During ureteral reimplantation and psoas hitch procedures, postoperative neuropathy resulting from injuries to the genitofemoral, femoral, and lateral cutaneous nerve has been reported in close to 5% of patients (Pini and Leoni, 2011). **The anchoring suture on the psoas tendon can cause genitofemoral nerve entrapment affecting loss of sensation to the scrotum and medial thigh.** Symptoms range from paresthesia to severe pain in the nerve territory, a constellation of symptoms often referred to as *psoas syndrome*. The femoral nerve is also at risk for injury during psoas hitch operations. The thickness of the psoas tendon is variable in patients, and in some the tendon as a discrete entity is quite subtle. Care should be taken as in extremely thin patients the femoral nerve could be mistaken for the psoas tendon. As a matter of principle, longitudinally oriented sutures along the direction of the tendon are less inclined to entrap neural structures than horizontally oriented sutures along the width of the tendon.

The ilioinguinal nerve is at risk during inguinal orchiectomy, and hernia operations are responsible for the majority of ilioinguinal nerve injuries. **The ilioinguinal nerve courses across the anterior abdominal wall and along the inguinal canal to innervate the inguinal region and lateral hemiscrotum.** Symptoms of pain and paresthesia in this territory can result.

Intraoperative obturator nerve injury is a risk factor associated with pelvic lymph node dissection. The obturator nerve is also an important landmark in the lateral dissection during robotic radical cystectomy and must be identified and fully differentiated. With medial displacement of the external iliac vessels and of the nodal packets in the triangle of Marcille, the obturator nerve is exposed along its full length. **The obturator nerve holds important sensory function to the inner thigh and motor supply to the adductor muscles of the inner thigh** (Loeb et al., 2010). Indiscriminate application of clips in this area is ill advised. All clips must be applied with full visualization of the obturator nerve. If clips are applied to the nerve, they must be removed. In case of transection, repair is warranted by approximating the severed ends with 7-0 nonabsorbable sutures. This can be performed in an open fashion or using robotic technique if the ends can be approximated in a tension-free manner. Intensive postoperative physical therapy is initiated as soon as possible. Lower rates of obturator nerve injury have been reported in recent series compared with early experience with minimally invasive surgery (0.1% vs. 5.1%). The proximal portion of the nerve is at the highest risk as it emerges close to the internal iliac vein representing 77.8% of reported cases (Gözen et al., 2015).

Gluteal Compartment Syndrome

Gluteal compartment syndrome is a very rare condition usually associated with trauma and medical conditions, but cases in the literature associated with positioning are reported in obese patients and after prolonged operative times. Early signs include gluteal tenderness and decrease in vibratory sensation on neurologic examination. The thighs and gluteal regions can be swollen and engorged with severe pain on passive stretch (Heyn et al., 2006). Orthopedic consult is warranted whenever the diagnosis is suspected. Compartment pressure measurement and monitoring will dictate the next step in management. Usually, early fasciotomy will prevent severe rhabdomyolysis and spiking increases in creatine kinase as well as concurrent kidney injury. To decrease this risk, surgeons should be mindful of lengthy operative times and should ensure optimal positioning and padding for adequate cushioning, especially in obese patients (Keene et al., 2010).

Lower Extremity Compartment Syndrome

Lower extremity compartment syndrome has been encountered in patients in the lithotomy position, especially in early experience with minimally invasive surgery. Long operative times were associated with more complex cases performed laparoscopically or robotically. Compartment syndrome is attributable to impaired perfusion and decreased lower limb perfusion pressure leading to tissue ischemia and increase in compartmental pressure. The overall incidence of lower extremity compartment syndrome is 1 in 3500 cases, although higher incidences are seen in urology series (Mumtaz et al., 2002). In fact, compartment syndrome has been reported in as high as 1 in 500 cases of radical cystectomies because of prolonged operative times.

Prevention is key, especially in patients who are at risk, such as those with obesity or peripheral vascular disease or those undergoing procedures associated with marked perioperative blood loss. Other risk factors include muscular calves and intraoperative hypotension. Preventive measures include avoiding excessive elevation of the legs in the lithotomy position. Whenever this is needed in long procedures, lowering the limbs every 2 hours is advised. Dorsiflexion of the ankle should be avoided when positioning is completed at the start of the case, and care should be taken to effectively protect pressure points with enough cushioning. Fasciotomy and surgical decompression is warranted when compartment pressure is greater than 30 mmHg in symptomatic patients. When compartment pressure is greater than 50 mmHg for more than 3 to 4 hours, irreversible muscular damage ensues (Simms and Terry, 2005) (Fig. 17.1).

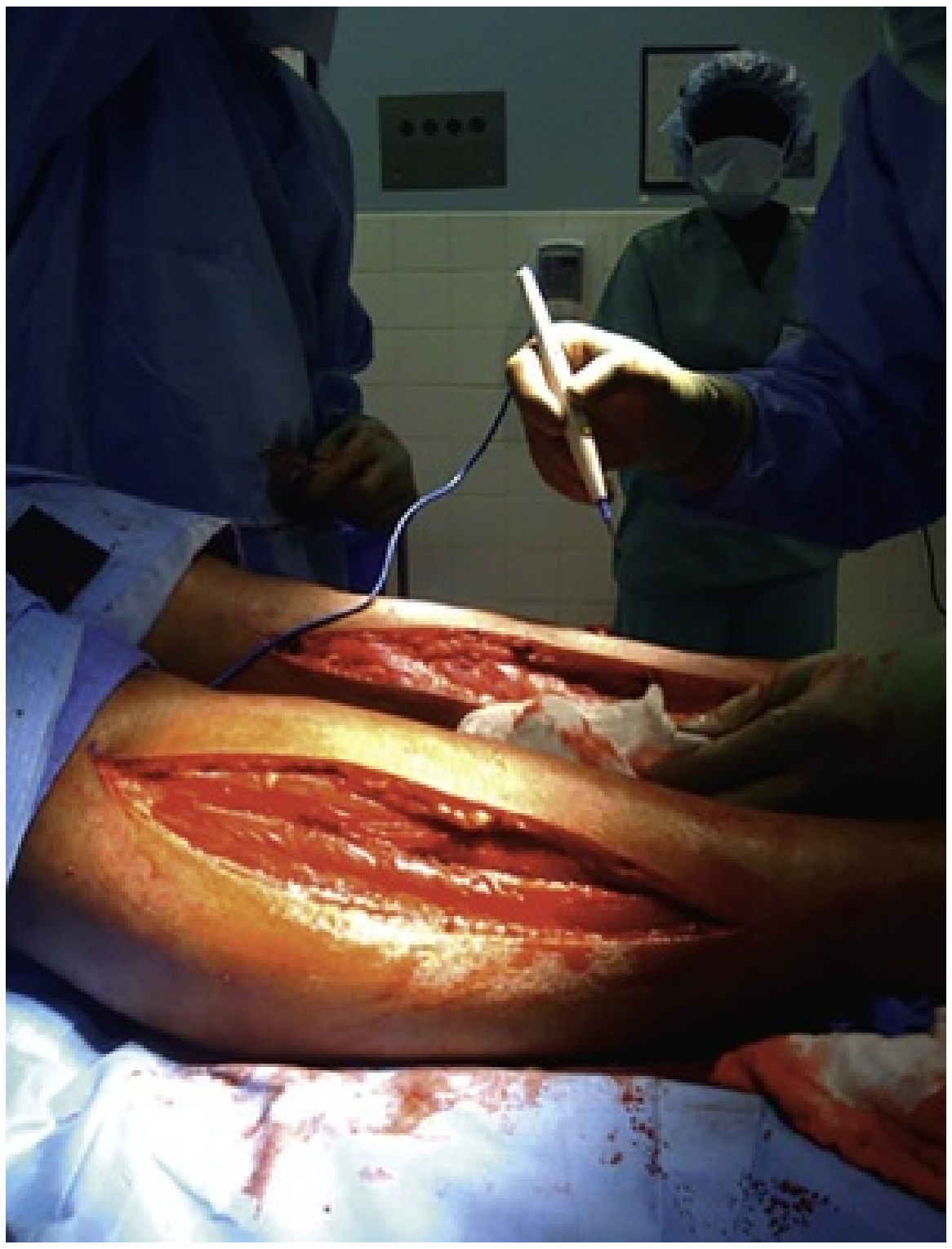

FIG. 17.1 Extended fasciotomies in a patient with bilateral lower extremity compartment syndrome.

Delays in diagnosis can have disastrous consequences. Extreme pain in the lower extremities should raise suspicion as to the presence of lower extremity compartment syndrome. One confounding differential diagnosis is deep venous thrombosis (DVT), but this can be reliably excluded by a lower extremity duplex scan. All staff should be aware of these risk factors to contribute to prevention in lengthy operations or help establish early postoperative diagnosis (Raza et al., 2004).

Urinary Complications

Urine leaks are common complications of urologic surgery. These injuries can happen in both upper tract and lower tract surgery and are specific to the particular operation performed. These include urinary complications in extirpative and reconstructive procedures. Overall, they can lead to significant morbidity and increase in hospital stay. Most common urinary complications occur with both minimally invasive and open techniques, and at times their management is similar. Detection is key, as intraoperative repair and reconstruction can lead to less morbidity and obviate subsequent secondary procedures. Unfortunately not all are detected intraopereatively, and many manifest several days or weeks postoperatively. We will describe common urinary complications as they pertain to upper tract and lower tract urologic procedures.

Urine Leaks After Upper Tract Urologic Surgery

Urine leaks can occur after extirpative and reconstructive upper tract surgery such as partial nephrectomy and pyeloplasty. The ureter can also be injured during various abdominal urologic, gynecologic, and general surgical retroperitoneal operations. For the most part, the principles of diagnosis and management are similar. In this section, we focus on common index urologic procedures and scenarios.

Urine Leaks After Partial Nephrectomy

With increasing experience with robotic partial nephrectomy, there has been a decrease in the reported incidence of urine leaks after partial nephrectomy. The reported incidence of urinary fistulas in series of open partial nephrectomy varies ranging from 0.5% to 21% (Campbell et al., 1994). With the introduction of laparoscopic partial nephrectomy, the specific rate of this complication decreased to 2.4%. This was attributed to a more conservative case selection for the laparoscopic approach, while bigger masses and more endophytic or hilar tumors were being addressed with the open approach and were associated with increased entries in the collecting system (Cacciamani et al., 2018). Currently, robotic partial nephrectomy has matured into a widespread technique, with remarkable precision for reconstruction compared with the open procedure regarding blood loss and associated complications. Some have reported a benefit in the robotic approach compared with the laparoscopic approach regarding ischemia time, positive margins, and renal functional recovery time, (Cacciamani et al., 2018). Although many reviews of the literature attempt to compare the rate of urinoma and other complications among different techniques, none have succeeded in demonstrating a statistical difference (Choi et al., 2015; Xia et al., 2017). In summary, the historical incidence of urine leak ranges from 1.0% to 17.4% for open partial nephrectomy and 1.6% to 16.5% for laparoscopic partial nephrectomy, and the most recent published series of robotic partial nephrectomy experts report rates as low as 0.78%.

Risk Factors and Diagnosis

Urine leaks are the most common complication of partial nephrectomy after hemorrhagic complications. As more complex tumors are tackled, especially with minimally invasive techniques, the rate of urinary complications can increase. Factors predisposing to urine leaks are well known. The most implicated factors are tumor size, endophytic nature, warm ischemia time, operative time, and hilar location of tumor.

Most minimally invasive techniques employ a transperitoneal approach. Symptoms can include ileus, fever, and abdominal pain. It is not clear whether leaving a drain would prevent these symptoms and lead to an earlier diagnosis. Regardless, many surgeons omit leaving a drain after minimally invasive partial nephrectomy given the very low incidence of urinomas. Urine leaks after open partial nephrectomy are contained in the retroperitoneum, however, resultant ileus, although rare, can also occur. On average, the mean postoperative day for presentation is 13 days (3 to 32 days) (Potretzke et al., 2016). Nearly 60% of patients will need to be readmitted for appropriate management. **Computed tomography with a urogram phase with contrast and delayed images to visualize the renal pelvis and ureter remains the mainstay for diagnosis as it can estimate the extent of urinoma or location of the leak accurately (Fig. 17.2).** The measurement of creatinine in the drain greater than 48 hours after surgery can help diagnose a urinary fistula but does not identify its location or severity.

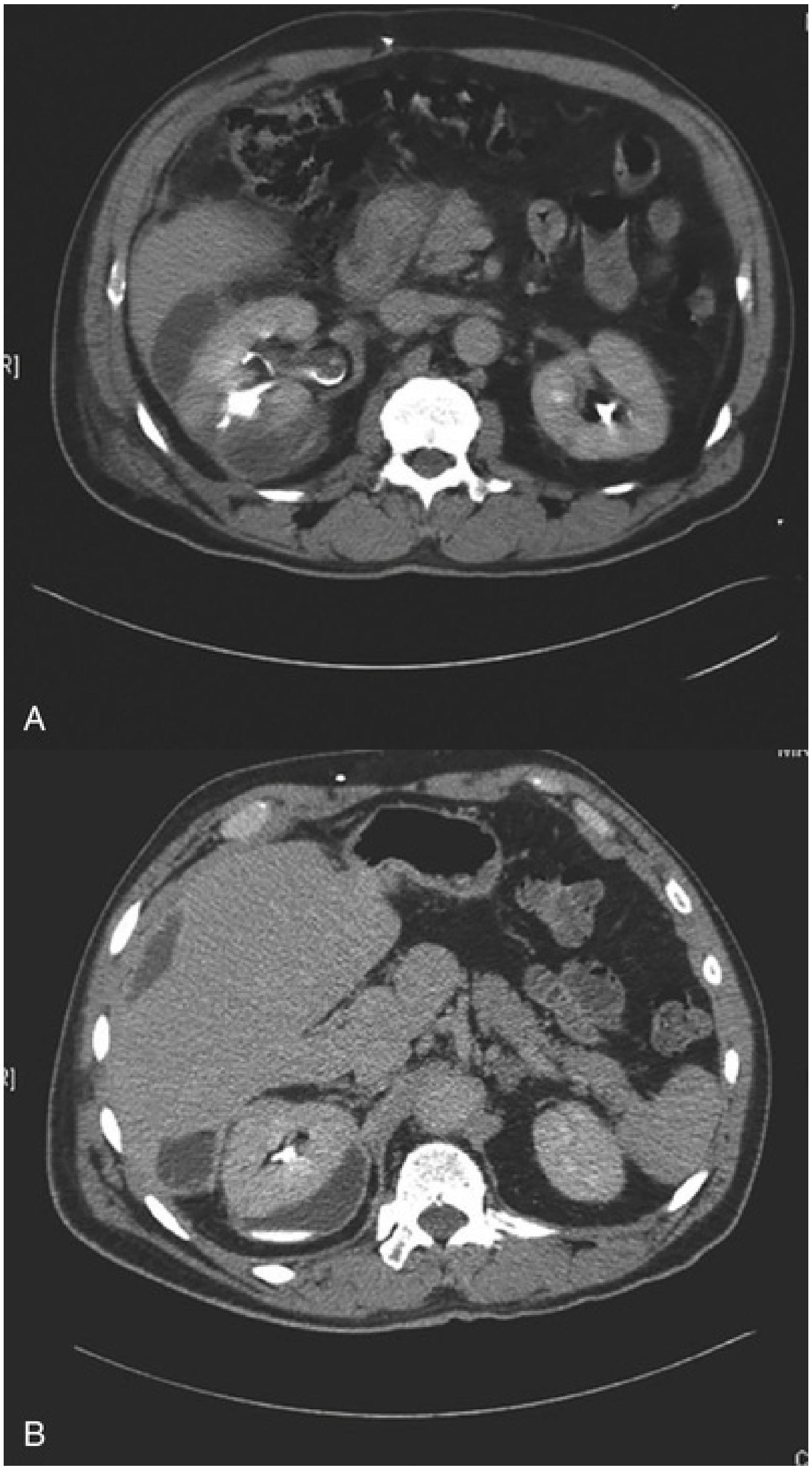

FIG. 17.2 (A) Delayed-phase computed tomography image revealing urinary leak after right laparoscopic partial nephrectomy. (B) Layering of contrast in retroperitoneum. (From Hakimi AA, Ghavamian R. Urinary and urologic complications of laparoscopic and robotic urologic surgeries. In: Ghavamian R, ed. *Complications of laparoscopic and robotic urologic surgery.* 1st ed. New York, NY: Springer; 2010:59–71.)

The recent adoption of robotic techniques has helped not only in the resection of the renal mass but also in the more facile reconstruction of the collecting system. Urine leaks can be avoided by proper identification and repair of collecting system entries during robotic partial nephrectomy. The visualization allows for optimal identification of calyceal entry. When suspected, retrograde infusion of methylene blue diluted in saline through a previously placed ureteral catheter helps identify the collecting system entry for repair. Collecting system entries are best repaired with absorbable sutures in a watertight fashion before parenchymal reconstruction.

Management

The management of renal leaks after open partial nephrectomy is the same as in robotic or laparoscopic partial nephrectomy. The pillar of management is a conservative approach as much as possible because the majority of these leaks will heal spontaneously as long as there is adequate drainage and no superimposed infection. To ensure adequate urine drainage, some patients require the surgical drain to be kept for a prolonged period.

The diagnosis is confirmed by sending the drain fluid for creatinine measurement. If the creatinine level is high, a urine leak is suspected. It should be noted that especially in robotic or laparoscopic procedures, initial increased drainage from the drain does not always indicate a urine leak. Because these are intraperitoneal operations, much of the increased drain output in the initial period could represent intraoperative blood and irrigation fluid that was in the peritoneal cavity and away from the surgical field while the patient was in the flank position but now drains as the patient lies in the supine position or becomes more mobile. Renal pelvic anatomy, although an uncommon variant, and patient age at time of surgery is shown to correlate with prolonged urine leaks defined as greater than 30 days (Meeks et al., 2008; Tomaszewski et al., 2014). **When a urine leak is suspected and demonstrated, the Foley catheter needs to be left in or reinserted. Increasing bladder pressures can theoretically increase upper tract pressures, exacerbating the leak. If the leak persists, ureteral stent insertion with a retrograde pyelogram will help reassess the severity of the leak and permit optimal drainage.** In one recent study, the need for secondary intervention was estimated between 4% and 38% depending on baseline patient and tumor characteristics (Tomaszewski et al., 2014). **If the urine leak persists despite the stent, the drain can be taken off suction because the latter can act as a siphon, keeping the fistula open, especially when positioned close to the location of the leak (Fig. 17.3). When**

this is suspected, the drain can be pulled out incrementally. Often urine leaks around the drain puncture site at the skin level and soaks the patient's dressings and skin around the drain site. To decrease the chance of skin excoriation and breakdown, a urostomy appliance can be positioned around the drain. The patient is instructed to keep a log of the outputs so that the clinician has an objective means to assess the resolution of the leakage.

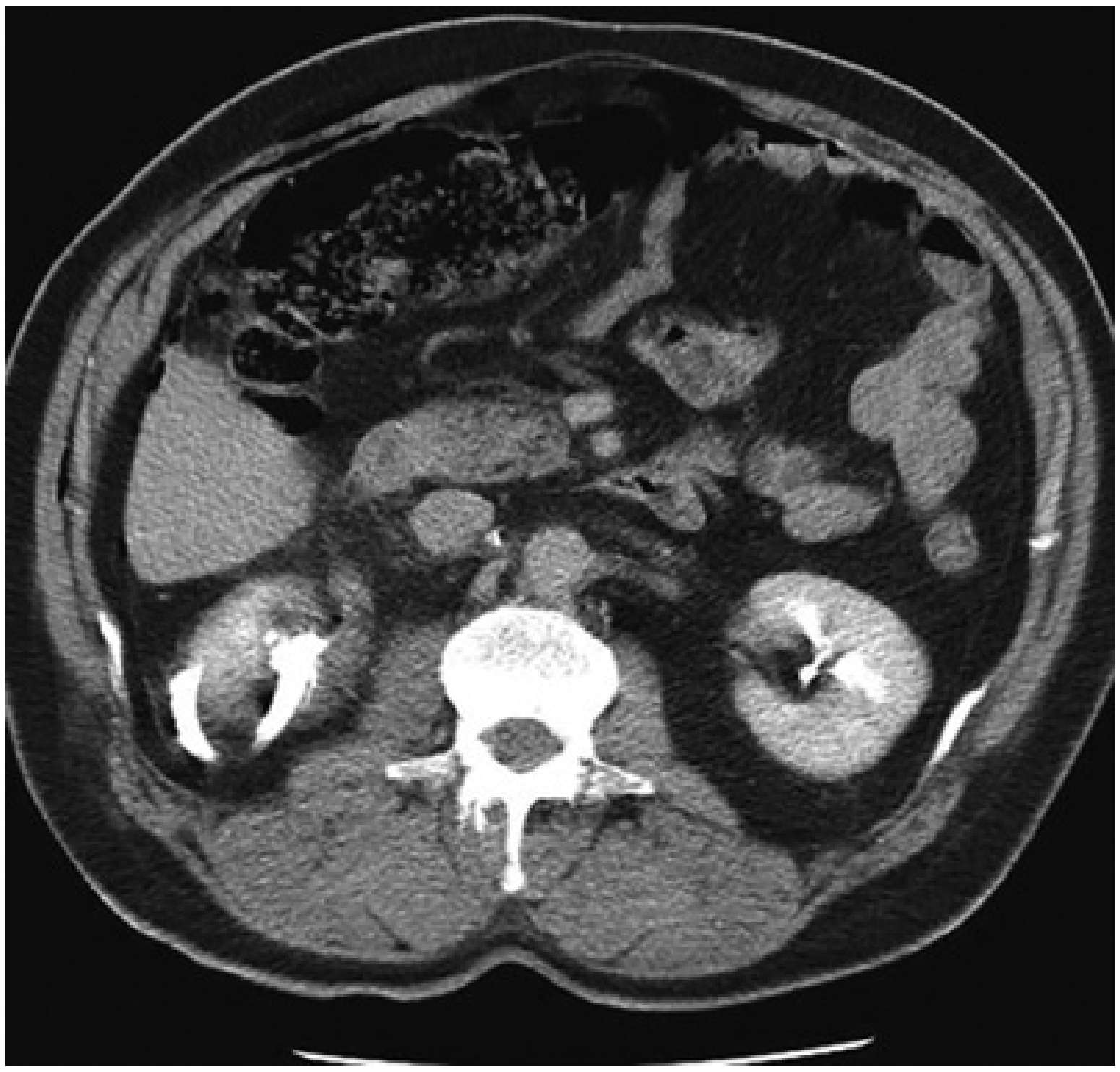

FIG. 17.3 Distal end of drain abutting the leak point, keeping the leak open and acting as a siphon. (From Hakimi AA, Ghavamian R. Urinary and urologic complications of laparoscopic and robotic urologic surgeries. In: Ghavamian R, ed. *Complications of laparoscopic and robotic urologic surgery.* 1st ed. New York, NY: Springer; 2010:59–71.)

Other described management strategies involve insertion of a second ureteral stent or percutaneous nephrostomy. Recently, ureteroscopy was reported to control urine leaks by a combination of caliceal fulguration and fibrin sealant application. Many small series report considerable success rates of novel techniques, but the mainstay of treatment remains proper drainage and management of the drains and catheters (Chu et al., 2015; Girard et al., 2014; Pardalidis et al., 2017). At any time during the management of these patients, surgeons should look for undrained collections or increasing amount of leaks, as these should prompt for better drainage usually achieved by interventional radiologic techniques (Fig. 17.4). Usually urine leaks will heal over time, and this can be seen as late as 80 days or more after surgery. Isolated reports of desmopressin are described but rarely employed. Unresolved refractory leaks leading to subsequent infection and prolonged morbidity for the patient can be managed by nephrectomy as a very last resort.

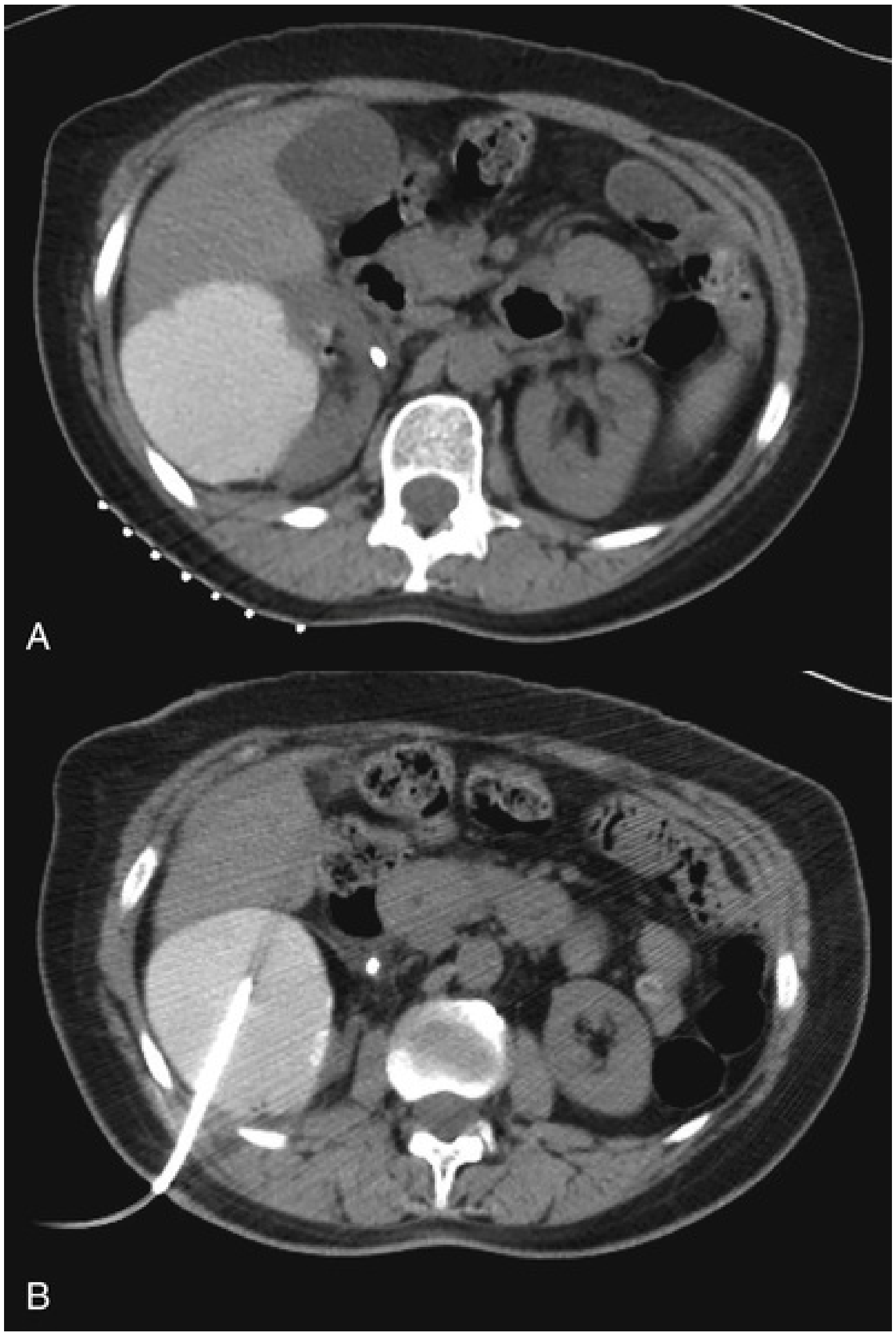

FIG. 17.4 (A) Delayed presentation of a large urinoma in right retroperitoneum after partial nephrectomy. (B) Percutaneous placement of a drain by interventional radiology.

Ureteral Injuries

Incidence and Anatomic Landmarks

Ureteral injuries could be the single most common surgical complication the urologist is challenged to manage, especially intraoperatively as consulted by other specialties. Despite the popular use of sophisticated sealing devices with most gynecologic surgeries, Blackwell et al. reported a 0.78% rate of ureteral injury during hysterectomy, with nearly 62% of those being unrecognized during surgery. Delayed recognition can lead to development of urinoma, ileus, sepsis, and shock with the need for nephrostomy tube diversion (Blackwell et al., 2018). Early recognition can have a great impact on morbidity, and the need for nephrostomy in early versus delayed recognition of ureteral injury was 2.3% and 23.4%, respectively.

Similar numbers can be identified in colorectal surgery, with rates of close to 1% during laparoscopic procedures. Risk factors include prior pelvic radiation, malignancy, prior abdominal surgery, adhesions, and extensive retroperitoneal lymph node dissection (Marcelissen et al., 2016). Some advocate the use of ureteral catheters before major pelvic operations, but there is no robust evidence for prophylactic placement of ureteral catheters to prevent injury. Some propose that routine ureteral stenting leads to ureteral edema and is associated with postoperative obstruction and acute kidney injury (Coakley et al., 2018).

During gynecologic procedures, the course of the ureter along the ovarian vessels and its close relation to the uterine artery and uterosacral ligament make it very vulnerable during ligation of these structures around the pelvic inlet and the infundibulopelvic ligament (Stany and Farley, 2008). A recent review of all laparoscopic hysterectomies found a 0.3% incidence of ureteral injuries, with all being in close proximity to the uterine artery and uterosacral ligament (Kiran et al., 2016).

Mechanisms of Ureteral Injury

Mechanisms of ureteral injury are very diverse ranging from pinpoint thermal injury that can be asymptomatic in the vast majority, to complete ligation and transluminal or partial transection. Partial or complete transections are the most commonly identified problems and are managed intraoperatively. Ligation and thermal injury have a more delayed presentation. Devascularization of the ureter can lead to delayed stricture formation or necrosis. The situation is distinctively different during urologic procedures. Permpongkosol et al. only identified six ureteral injuries (one intraoperative and five postoperative) in a study population of 2775 procedures. The best way to avoid ureteral injuries is to identify the ureter as early as possible, certainly before ligation of critical pedicles (Permpongkosol et al., 2007).

In summary, it is crucial to keep in mind important landmarks for the ureter during an ongoing surgery. The ureter can be injured proximally as it is in close proximity to the gonadal vessels. Later along its course, other common areas of injury are as it courses over the iliac vessels at the level of the pelvic brim. In the deep pelvis, the ureter can be damaged as it courses below the uterine vessels in the female patient. With the advent of robotic prostatectomy another potential area of injury is during the initial dissection of the seminal vesicles using a posterior approach initially during robotic prostatectomy. These anatomic sites can be of particular help during dissections, especially in tough situations such as retroperitoneal fibrosis or complex partial nephrectomy (Nies, 1998).

Intraoperative Management

A high index of suspicion is necessary to detect ureteral injuries. Depending on the operation performed, the surgeon must be cognizant of the locations at which ureteral injuries can happen. Certain anatomic landmarks can be used to help identify the ureter. In the upper abdomen, the ureter is in close proximity to the gonadal vessels and the lower pole of the kidney. In the lower abdomen, the pelvic brim is an excellent landmark. The ureter crosses over the common iliac artery, and one can dissect and isolate it and trace it from this location. If a ureter is injured with a needle that pierced transmurally, the suture must be removed and a ureteral stent placed endoscopically at the end of the procedure. The same principles can be applied for limited inadvertent thermal injuries to the ureter with monopolar devices and bipolar sealing devices.

Transection of the ureter requires more expertise, especially when one is willing to repair it laparoscopically. Partial tears with very reduced tissue loss and deterioration and no need for debridement can be closed primarily with 4.0 or 5.0 absorbable sutures after placing a stent through the ureterostomy. The stent will be left 4 to 8 weeks to allow enough time for healing (Figs. 17.5 and 17.6). When complete transection of the ureter occurs, the location of the injury mandates the repair strategy. For proximal transections in the upper two-thirds of the ureter, ultimately above the pelvic inlet, an open, laparoscopic, or robotic ureteroureterostomy can be performed after trimming both edges and performing adequate spatulated anastomosis. A stent should be left for optimal drainage.

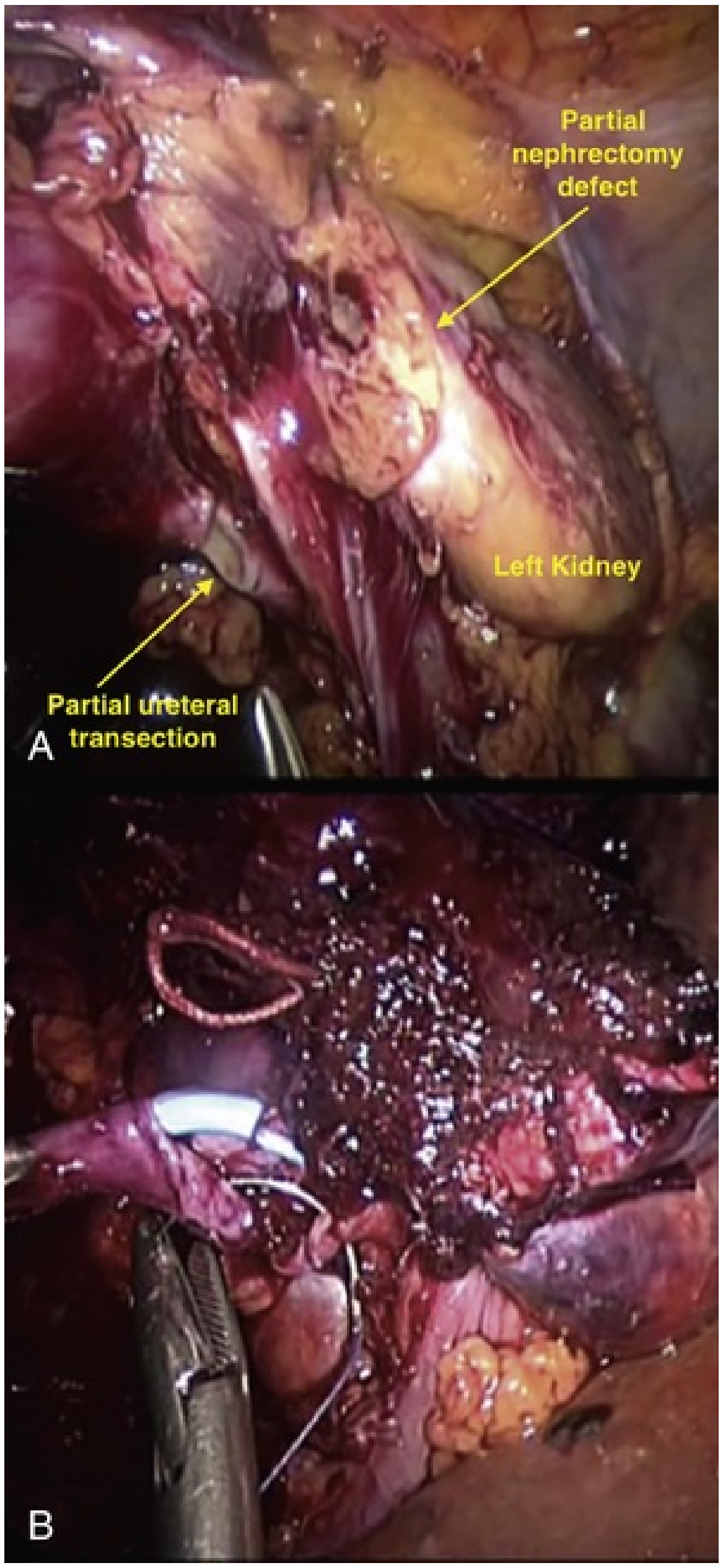
Partial nephrectomy defect
Left Kidney
Partial ureteral transection
A
B

FIG. 17.5 (A) Partial transection of proximal left ureter during laparoscopic partial nephrectomy. (B) Antegrade stent placement through the defect and laparoscopic repair after parenchymal repair is completed.

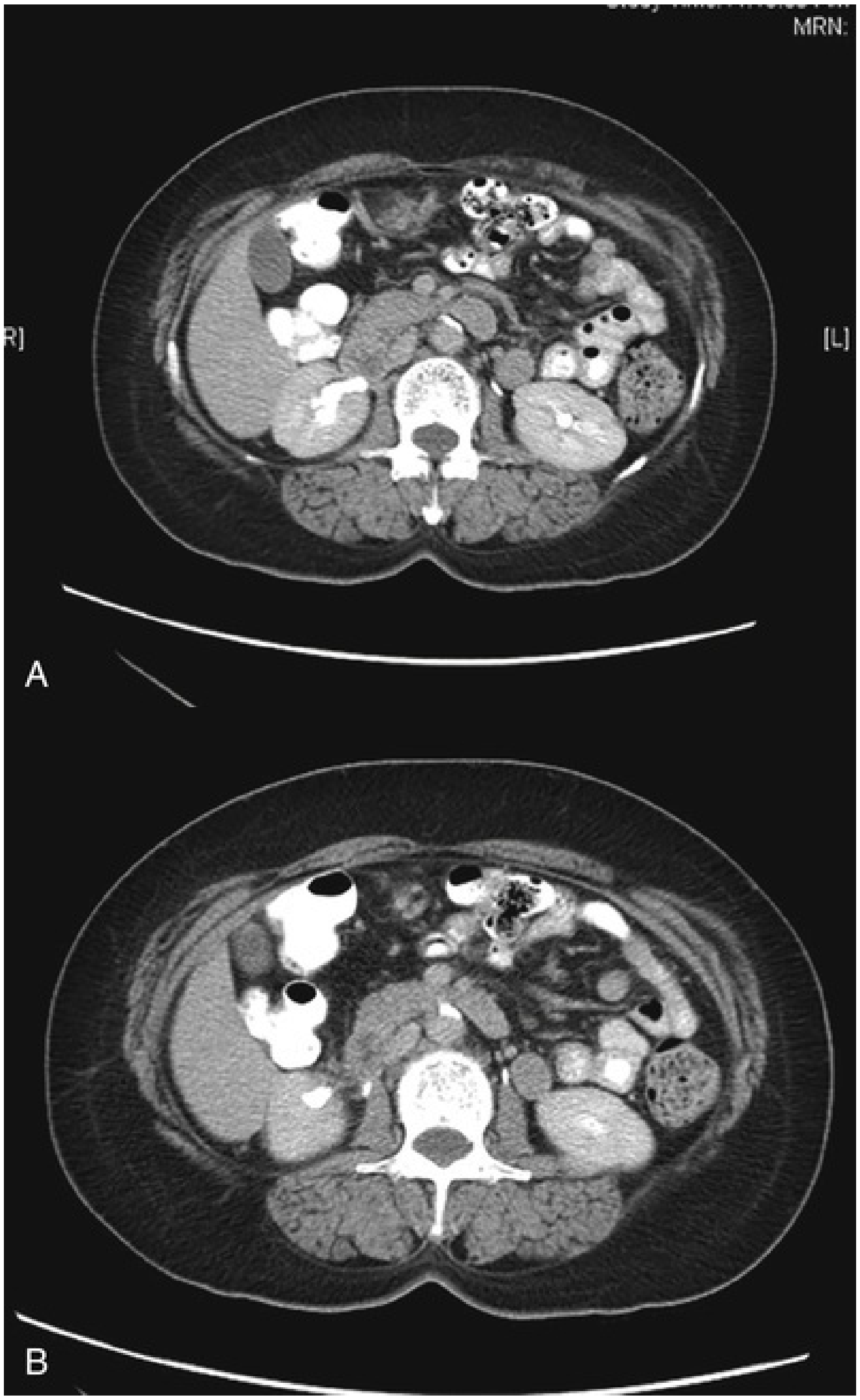

FIG. 17.6 (A) Delayed images of the patient in Fig. 17.5 taken 6 months after repair. (B) Contrast is seen in the lower pole collecting system and the ureter revealing excellent function and drainage.

A proficient minimally invasive surgeon could perform an ureteroneocystostomy with a psoas hitch without the need for open conversion. In the latter, a modified Gibson incision is usually enough in finalizing the new anastomosis. In rare circumstances, when tissue loss is extensive, a Boari flap is needed to compensate for extensive ureteral loss.

In all approaches, for all lesions recognized intraoperatively, the same principles apply. This is a tension-free anastomosis with a stent well-placed across the anastomosis and kept for at least 4 to 8 weeks in addition to a drain left in place to allow for adequate drainage of potential leaks or collections (Hoffman and Finan, 2013).

Presentation of Unrecognized Ureteral Injuries

Delayed recognition of ureteral injuries can be associated with significant morbidity as urine leaks lead to infection and urinary ascites, and sepsis could ensue. When the patient has a surgical drain, increased output through it should raise doubt for a ureteral injury. In gynecologic surgery, fistulous tract formation can occur between the ureter and vagina, representing 30% of indications for surgical repair in this scenario. In this same category of patients, ureteroneocystostomy was performed in the majority of the patients (70%) as the procedure of choice to manage the ureteral injury (Papanikolaou et al., 2013).

The preferred imaging modality to show the leak and delineate the extent of injury is computed tomography of the abdomen and pelvis with intravenous contrast and delayed images to visualize the full length of the ureter. Once the defect has been localized, it remains unclear when the exact and best time is for open or robotic ureteral repair and reconstruction when it is mandatory. Although many series have successfully compared early to delayed repair, it is agreed that every attempt should be made to manage the injury endoscopically with a primary ureteral stent or, alternatively, percutaneously with a nephrostomy tube and a stent placed in an antegrade fashion to bridge the gap in partial transections and small leaks (Li et al., 2012). Once all measures and attempts at endoscopic treatment and drainage have failed, it is agreed that waiting 6 weeks for surgical repair is safer as the inflammation has subsided by that time. In the early postoperative period, as long as the injury has been discovered in the first 7 days postoperatively and endoscopic management is considered inadequate, an early surgical repair could be attempted, as the inflammation is not extensive. Beyond this time, stent placement, percutaneous nephrostomy, or nephro-ureteral stent placement are all measures that aid in definite endoscopic management or temporarily until surgical repair is planned after 6 weeks. Stents should be left 4 to 8 weeks on average to allow time for the healing process, coinciding with the period in which inflammation decreases. All urinomas or collections must be drained, even when the leak has ceased, and interventional radiology can be of great help placing drains. In special situations in which severe infection is not controlled with antibiotics and collections ineffectively drain and persist, immediate surgical repair is the only means to manage these challenging cases regardless of the timing from surgery. Typically, these surgeries require expertise to address such injuries and surrounding tissue inflammation to achieve an optimal repair.

Ureterovaginal Fistula

The diagnosis of ureterovaginal fistula can be challenging, as this is often a delayed presentation. Usually the patient complains of ongoing incontinence. When the diagnosis is suspected, giving the patient intravenous methylene blue and clamping the Foley should stain a vaginal pad blue in the presence of a fistula. Sometimes a ureterovaginal fistula coexists with a vesicovaginal fistula. **In these circumstances, the presence of a vesicovaginal fistula must be ruled out and differentiated from a ureterovaginal fistula.** The double-dye pad test consists of giving the patient a load of oral pyridium while filling the bladder with methylene blue followed by clamping of the Foley catheter. A pad is placed in the vagina. An orange stain indicates a ureteral fistula, whereas blue staining is in favor of a vesicovaginal fistula. The presence of a blue stain distally and an orange stain proximally in the pad signifies concomitant presence of both fistulas.

Strictures

Despite adequate repair, stricture formation at the site of injury or fistula can occur. With the current advantages of laser and balloon dilators, endoscopic attempts to manage such complications are reasonable as an initial technique, especially for short and nonextensive strictures. **Definitive surgical repair may be necessary when the initial endoscopic attempt fails or the ureteral stricture is extensive and long (>2 cm).** It is often a challenging procedure because of ensuing fibrotic changes in the retroperitoneum that result from the previous urinary leak or ureteral injury. The principles of repair remain the same as discussed previously. **For upper ureteral injuries, where the ends can be mobilized and approximated, a ureteroureterostomy can be attempted for small segmental defects.** Recently, advanced reconstructive techniques with the use a robotic platform have been described to bridge extensive gaps with buccal mucosa grafts. The appendix is also described as a reasonable conduit to bridge ureteral defects on the right side. The advent of robotics has aided in the management of such injuries (Musch et al., 2013). One can assess the adequacy of vascular perfusion in the transected and "trimmed" ureteral ends with the Fire Fly technology of the robot. Intravenous infusion of indocyanine green fluorescence (ICG) can provide an objective assessment of ureteral health and vascularity before definitive repair (Bates et al., 2016). A ureteral repair is then attempted robotically. **Classic techniques of ureteral reimplantation with a psoas hitch for lower ureteral defects and a Boari flap for mid-ureteral injuries can be attempted robotically.** Upper ureteral strictures that are extensive are at times best managed with an ileal ureter interposition graft. Of course, open techniques for reconstruction should always be considered when significant intraabdominal challenges exist, such as multiple prior surgeries and adhesions that would render a robotic or laparoscopic repair not only difficult and lengthy but also at times impossible.

Prevention of ureteral injuries is key. Many strategies have been adopted to avoid such complications. This ranges from preoperative stenting of the ureters to lighted stents to aid more in localization when haptic feedback is limited, especially in the case of minimally invasive surgery.

Lower Tract Urinary Complications

Bladder Injuries

Bladder injuries are rare during robotic and laparoscopic urologic injuries. However, bladder injuries are more common during gynecologic and at times colorectal procedures. The bladder is at risk for injury during a hysterectomy during the creation of a bladder flap when the bladder dome is dissected from the lower uterine segment. Intraoperative recognition is key, and repair can be performed in two layers with absorbable sutures. A urethral catheter should be left for 7 to 10 days to ensure adequate healing and decrease the risk for subsequent vesicovaginal fistulas. Postoperative presentation can mimic ureteral injuries with abdominal distension, ileus, fever, chills, leukocytosis, and increased drainage from pelvic drains.

Diagnosis is established with a computed tomography cystogram. Intraperitoneal leaks are managed with robotic or open repair in two layers with absorbable sutures. On occasion, when a small, contained extraperitoneal leak is evident, management can be conservative with urethral catheter drainage. Often after hysterectomy, definitive repair of extensive bladder injury is the best option as the patient would be at risk for vesicovaginal fistula formation.

The most common complication at the bladder level at the time of urologic surgery is during robotic radical prostatectomy, when at times a “buttonhole” defect is created at the posterior bladder lip during dissection of the posterior aspect of the vesicoprostatic junction. Care must be taken to identify the correct plane for dissection without denuding the posterior bladder neck extensively. It is crucial to always identify the ureteral orifices when difficulty exists in dissection at this location resulting from previous endoscopic surgery of the prostate (e.g., transurethral resection), microwave therapy, or large prostates with the presence of an extensive median lobe. Temporary placement of 5-Fr pediatric feeding tubes or preoperative stenting may be necessary. Both maneuvers are helpful for the less experienced surgeon and rarely are necessary for the experienced robotic surgeon.

Another scenario is leakage from the site of a bladder cuff resection at the time of an open, robotic, or laparoscopic distal ureterectomy and reimplant or after an open, robotic, or laparoscopic nephroureterectomy. Management remains as outlined earlier, and resolution of the leak will occur as long as the leak and bladder are adequately drained for 7 to 10 days.

Urine Leaks After Radical Prostatectomy

Overview

Urinary leakage at the urethrovesical anastomotic junction is one of the most common complications in the early postoperative period (days 7 to 10) reaching an incidence of 0.3% to 15.4%(8). **Although no exact definition of urine leakage after radical prostatectomy exists, it consists of an increase in drainage from the surgical drain along with a proportional decrease of drainage from the urethral catheter.** It is confirmed by contrast extravasation from the anastomosis on cystography. The contrast extravasation is usually posterior along the possible weakest point of the anastomosis, although other areas of the anastomosis can leak also.

Early catheter removal on postoperative day 2 has been assessed in a comparative study for techniques of urethrovesical anastomosis including posterior reconstruction. Although this did not show an increased risk for urine leaks, early catheter removal remains an uncommon practice, with most surgeons recommending a 7- to 10-day catheterization requirement (Gratzke et al., 2016).

Classification of urine leak severity will have to follow the Clavien-Dindo grading system in an effort to standardize reporting. It is evident though that attempts for grading urine leaks depended mainly on the need for intervention for proper management. **Clinically significant urinary leaks consist of collections extraperitoneally in open radical prostatectomy or intraperitoneally after robotic prostatectomy.** These can result in ileus, requiring extended hospital stay and intravenous fluids. When associated with fever and signs of sepsis, antibiotic therapy or percutaneous drainage is warranted (Mochtar et al., 2007; Tan et al., 2010). The incidence of re-intervention for vesicourethral anastomotic leakage ranges from 0.5% for open procedures to 2.5% for some early series of robotic-assisted or laparoscopic radical prostatectomies. With increasing experience with robotic prostatectomy and the utilization of a watertight running anastomotic technique, the incidence of urinary extravasation has decreased. Then long-term sequelae can be a bladder neck contracture and a resultant fibrotic bladder neck. This can potentially contribute to a decrease in continence if the scar involves the external sphincter mechanism by decreasing sphincteric coaptation and function.

Contributing Factors

Postoperative blood loss is a predictor for the development of urinary extravasation. A postoperative hematocrit drop of more than 6 points identifies a group of patients at increased risk for urine extravasation. Other contributing factors are obesity, length of the operation, size of the bladder neck, and utilization or lack thereof of bladder neck reconstructive techniques (Fenig et al., 2006; Gnanapragasam et al., 2005). Some surgeons utilize a double-armed barbed suture rather than monofilament sutures to allow for sequential tightening of the running anastomosis in an effort to better attain a watertight anastomosis. However, the use of monofilament or barbed suture does not seem to affect rates of urine leakage after prostatectomy (Sammon et al., 2011).

Challenging radical prostatectomies such as salvage prostatectomies are associated with considerable complication rates. This is caused by a suboptimal urethrovesical anastomosis resulting from compromised quality of surrounding tissue from previous therapies or radiation (Ogaya-Pinies et al., 2018). Recently, attempts to decrease the associated morbidity of such operations were successful in decreasing urine leaks from 35% to 6% using tissue biografts scaffolding. However, every attempt at reconstruction using a watertight anastomosis can help in reducing the incidence of leaks.

In a large cohort, Tewari et al. showed that the incidence of urine leaks was also less after robotic radical prostatectomy when the vesicourethral anastomosis was achieved along with anterior reconstruction (1%) or total reconstruction (0.3%) compared with conventional apposition (2.3%) (Tan et al., 2010; Tewari et al., 2012).

Diagnosis

In case of a large leak, the diagnosis is rather straightforward. There is an increase in drainage from the surgical drain with an often (but not necessary) proportional decrease in urethral catheter output. **When suspected, the drain fluid can be sent for creatinine content, which will be high when a definite leak exists.** To help establish the diagnosis, retrograde cystography can be considered a valuable and contributive tool (Han et al., 2011). **Other imaging modalities such as computed tomography cystography can be utilized and are useful adjuncts in cases of concomitant fever and leukocytosis to rule out a concomitant collection (Figs. 17.7 and 17.8).** It is crucial to ensure that the urethral catheter is in place and draining optimally. Traction should never be employed as it can further disrupt the anastomosis and risk contracture formation.

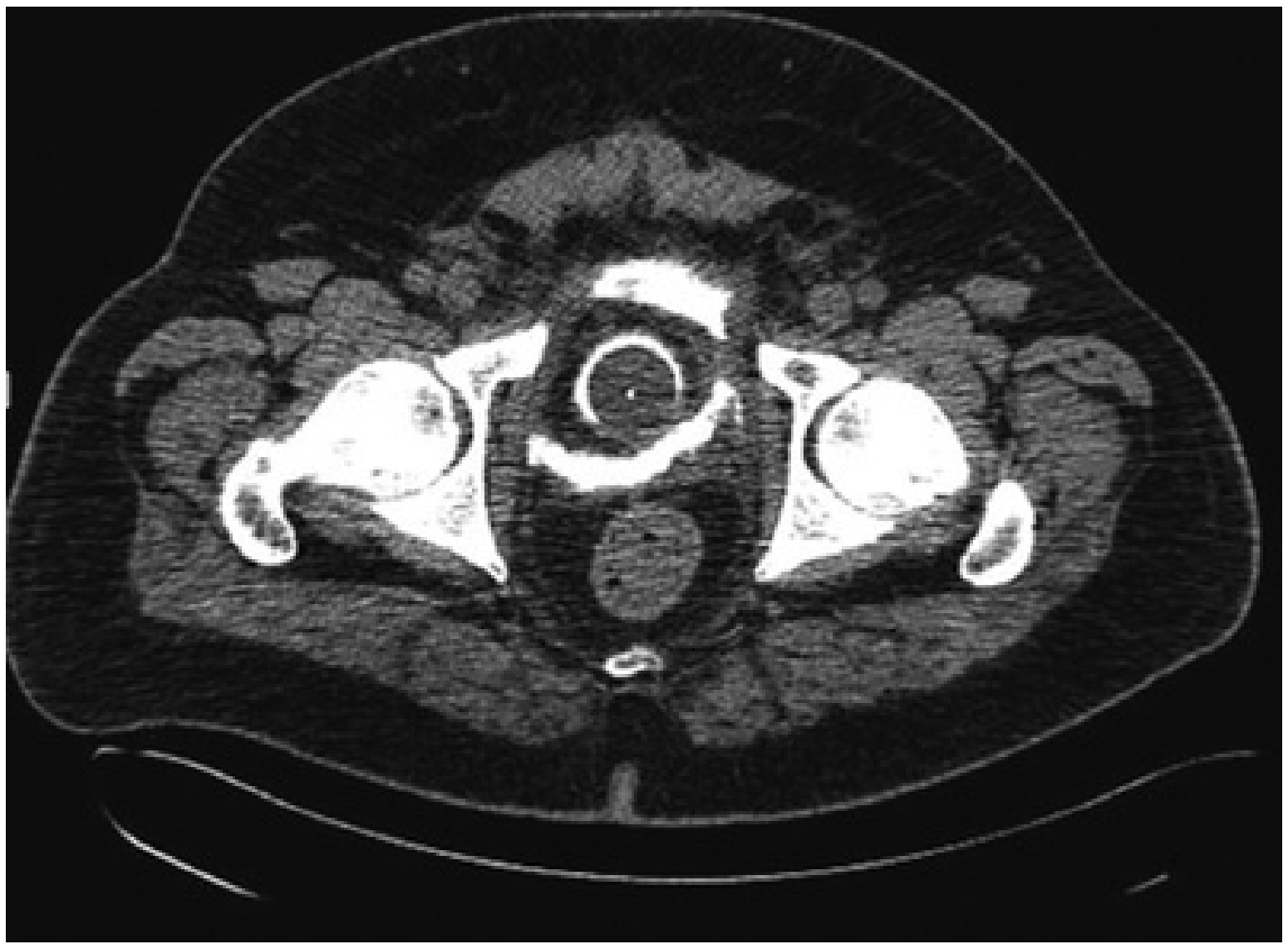

FIG. 17.7 Computed tomography cystogram demonstrating posterior leakage from the vesicourethral anastomosis after robotic radical prostatectomy tracking anteriorly. (From Hakimi AA, Ghavamian R. Urinary and urologic complications of laparoscopic and robotic urologic surgeries. In: Ghavamian R, ed. *Complications of laparoscopic and robotic urologic surgery.* 1st ed. New York, NY: Springer; 2010:59–71.)

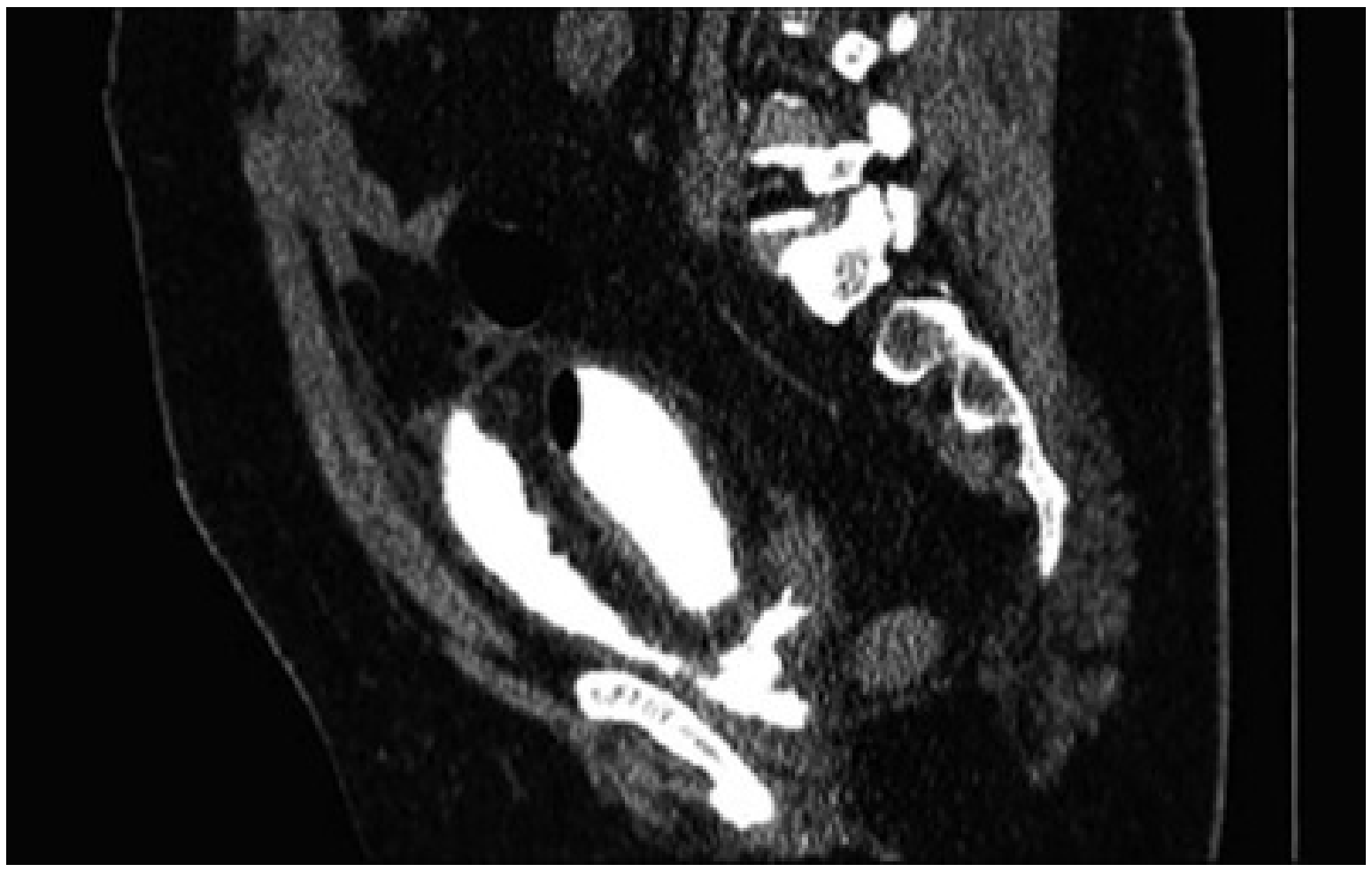

FIG. 17.8 Sagittal view of the patient in Fig. 17.7. (From Hakimi AA, Ghavamian R. Urinary and urologic complications of laparoscopic and robotic urologic surgeries. In: Ghavamian R, ed*. Complications of laparoscopic and robotic urologic surgery.* 1st ed. New York, NY: Springer;

2010:59–71.)

Management

The healing of a vesicourethral urine leakage is time-dependent. Leakage when detected in patients on postoperative day 8 was subsequently found in 20% of patients on postoperative day 14 and in 8% of patients in 3 weeks (Hakimi et al., 2012). All measures to manage leakage allow more time for the healing process in the absence of intraperitoneal leak, ileus, or sepsis.

Most urinary leaks are small, can be managed conservatively, and will spontaneously resolve with prolonged urethral catheter drainage. The initial step after fluid creatinine measurement is to ensure patency of the urethral catheter as the most important part of management is ensuring adequate bladder drainage. Side-fenestrated catheters have been known for better urine drainage and should be replaced if other types of catheters have been used (Moinzadeh et al., 2004). This can be achieved safely under radiologic guidance in some instances. If on computed tomography the drain is too close or overlying the anastomosis, it can be advanced and readjusted. In these instances, the drain can act as a siphon, encouraging the patency and persistence of the leak. The drain can also be taken off of bulb suction to allow for a more passive drainage mechanism. Large collections, especially when the drain has already been removed, should be managed by percutaneous drainage by interventional radiology to prevent abscess formation (Figs. 17.9 and 17.10).

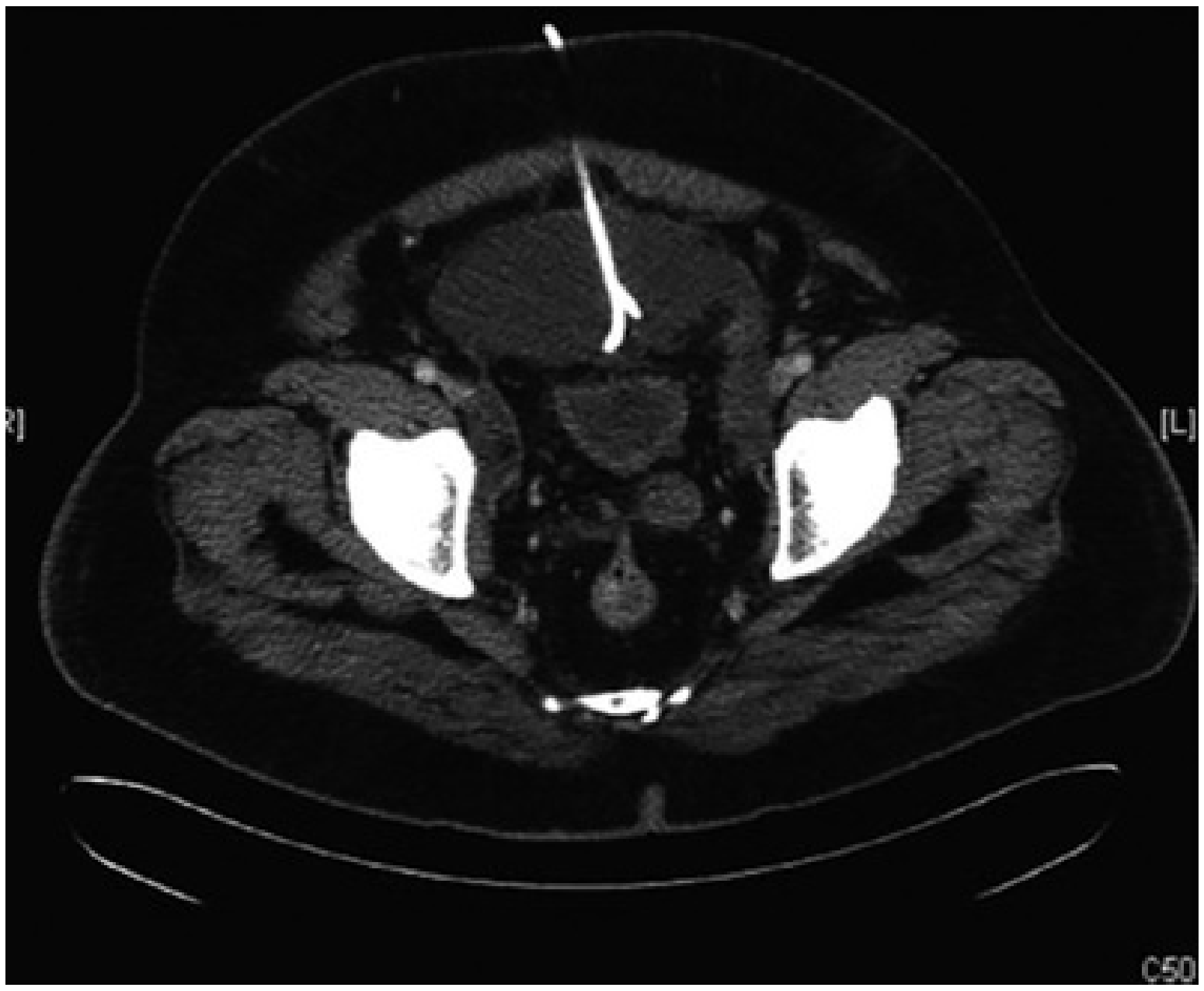

FIG. 17.9 Percutaneous drain placement in the anterior collection. (From Hakimi AA, Ghavamian R. Urinary and urologic complications of laparoscopic and robotic urologic surgeries. In: Ghavamian R, ed. *Complications of laparoscopic and robotic urologic surgery.* 1st ed. New York, NY: Springer; 2010:59–71.)

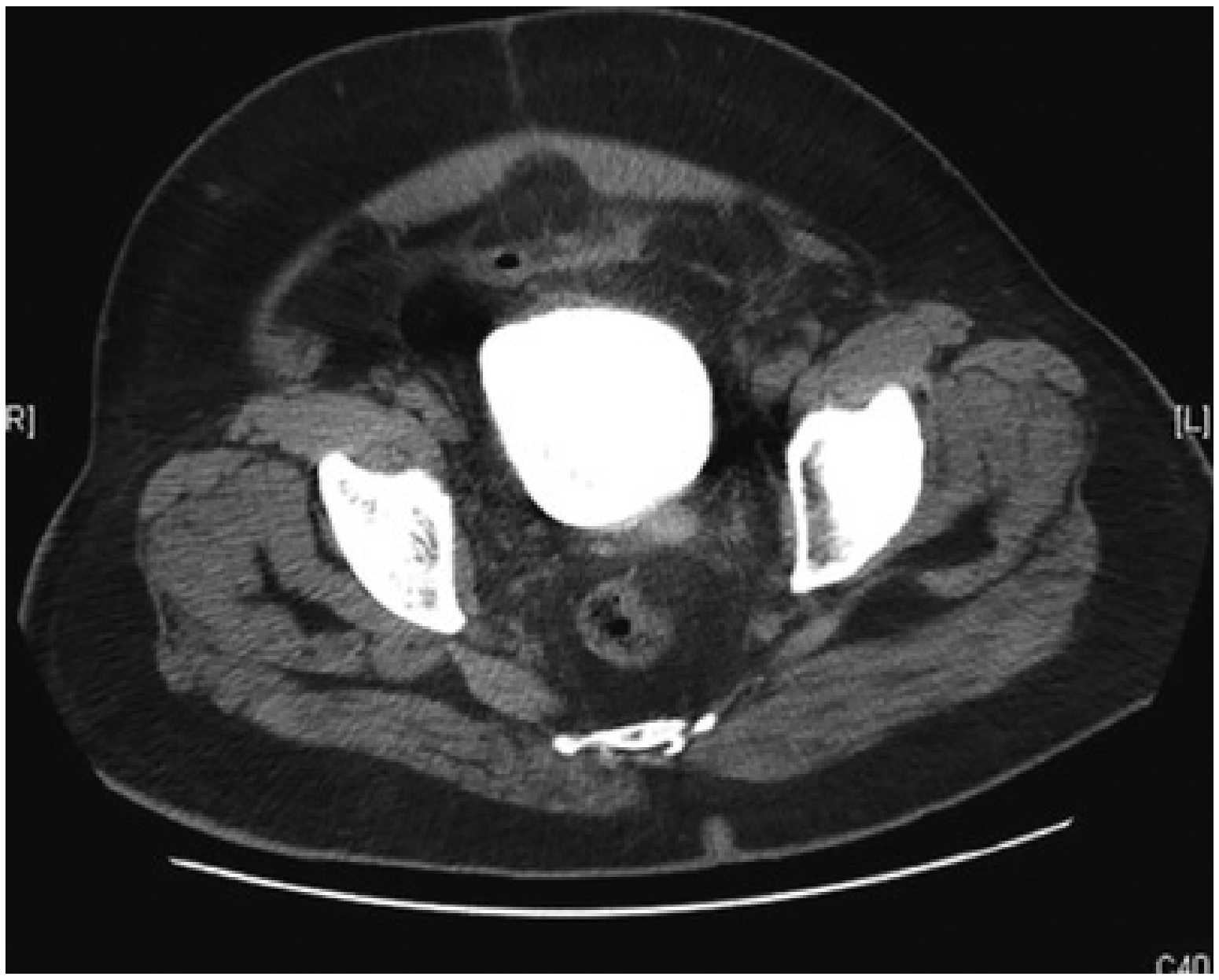

FIG. 17.10 Follow-up computed tomography cystogram of the patient in Fig. 17.7 revealing resolution of leakage.

If these measures fail to control the urine leak, then other conservative maneuvers can be attempted. These involve connecting the Foley catheter to suction to ensure maximal urine drainage across the anastomotic defect. Using a vented 18-gauge angiocatheter needle and connecting the Foley catheter to low intermittent wall suction tubing, or coupling an underwater pleural suction system (Pleur-evac) to the urinary catheter are the most reported and studied techniques (Shah et al., 2009). Continuous wall suction is counterproductive because of obstruction of the catheter holes with bladder mucosa.

Nephroureteral stents connected to a special suction drainage mechanism have been employed to minimize and ultimately stop a persistent leak (Fenig et al., 2006). Initial laparoscopic series reported that 1.6% to 2.2% of patients treated with laparoscopic radical prostatectomy required nephrostomy placement to control the leak (Mochtar et al., 2007). This effectively diverts urine output away from the new vesicourethral anastomosis, but it does not ensure its patency. These measures are extreme and rarely utilized or needed. A useful maneuver for total urinary diversion would be attempted cystoscopy with placement of open-ended ureteral catheters. This can be attempted gently under anesthesia. The ureteral orifices are identified, and open-ended catheters are passed under fluoroscopic guidance. The distal ends of the catheters are then exteriorized to the urethral catheter, essentially rendering the anastomosis dry. This maneuver should only be attempted when partial disruption exists and the orifices can be identified easily as cystoscopy in this setting risks total anastomotic disruption.

When all attempts at repair fail and substantial or total anastomotic disruption is suspected, repair is usually undertaken with a formal reconstruction. In the case of robotic radical prostatectomy, this can be attempted robotically. When major disruption is suspected in the early postoperative period, a formal early repair decreases the chance for ileus, infection, prolonged hospital stay, and long-term potential sequelae such as incontinence and bladder neck contracture. Delayed repair after postoperative day 7 is rarely embarked on as the tissues are friable and do not lend themselves for easy reconstruction. Here a computed tomography cystogram is mandatory, and placement of a percutaneous drain is essential, especially when the original operative drain has already been removed. Administration of parenteral antibiotics is essential when fever or leukocytosis is present. In this scenario, conservative measures with maximal drainage of the bladder and urinoma are essential, and resolution and recovery, albeit prolonged, will result.

Vascular Complications

Overview

Vascular injuries are the most dreaded complications during urologic surgery. Their significance is even more pronounced in the era of minimally invasive surgery. **They are among the most common major complications of laparoscopic and robotic surgeries and constitute the most common type of intraoperative complications.** One would expect the rates of major vascular injuries to decrease over the years as surgeons gain more experience. A thorough audit report indicates similar findings, except for the decrease of serious and major complications from 10% to 4% over the years (Davenport et al., 2006). However, more recent reports do not support this notion. This might be in part caused by the introduction of new surgeons and their advancement through their learning curve and the adoption of minimally invasive options for more complex urologic procedures. These injuries can occur at any time during the procedure. For minimally invasive procedures, they can occur while gaining access, during tissue dissection, or when isolating and dissecting major or minor vessels.

Vascular injuries can present intraoperatively or postoperatively. They can be largely avoided by careful attention to surgical technique and anatomy. Although exceptions exist, most major vascular injuries occur intraoperatively, and most postoperative bleeding is the result of unrecognized bleeding from smaller vessels. The consequences can be devastating when massive bleeding and hemodynamic instability occur and can result in major blood loss, major hemodynamic instability, shock, multiple organ failure, and death.

The key to management is early and prompt recognition and a calm response, especially when encountered intraoperatively. The challenge in managing these complications during minimally invasive surgery compared with open surgery is lack of manual compression for control of major vessels, selective use of instruments through available ports such as suction or vascular clamps, and difficulty in introduction of lap pads and sponges in the field to tamponade the bleeding and improve exposure. **In the event of major vessel injury, immediate conversion to an open operation, and prompt manual compression and control is key to a more favorable outcome.** It is prudent to obtain an intraoperative emergent vascular consult.

In this section, we discuss the incidence, diagnosis, and management of intraoperative and postoperative vascular complications including some common vascular complications of upper tract and lower tract urologic procedures.

Intraoperative Vascular Complications

The rate of vascular injuries during minimally invasive surgery is reported to be between 2% and 3% in urologic series (Breda et al., 2009). As a means for comparison, in nonurologic procedures, vascular injury rates are around 0.5% for minor procedures and can be as high as 20% for major procedures like hepatic resections (Kenney and Tuerk, 2008; Laurence et al., 2007; Siqueira et al., 2002). The proximity of the dissection to major blood vessels in upper tract procedures and the exceptional abundance of large- and medium- size vessels encountered during partial nephrectomies make these procedures prone to inadvertent vascular injuries. Surgical procedures of the lower urinary tract share many similarities with regard to complications when involving extended lymph node dissection along the iliac vessels, but complications remain relatively uncommon. Most urologic vascular injuries are related to dissection of major vessels. This is especially true for the kidney, a parenchymous organ with a rich blood supply. In nephrectomy and partial nephrectomy, dissection of major renal vessels off of the aorta and vena cava is needed.

Colombo et al. (2007) reviewed 1867 laparoscopic cases. The most common intraoperative complication was hemorrhage occurring in 2.3% of the cases. The incidence of postoperative hemorrhage was 2.7%. Hemorrhage accounted for 40% of all perioperative complications. In a review of 2775 laparoscopic urologic procedures, Permpongkosol et al. (2007) found that the two most common complications were intraoperative vascular injury (1.98%) and bleeding requiring transfusion (1.76%). Bleeding was more common in procedures around major vessels such as retroperitoneal lymph node dissection. Postoperative bleeding and drop in hematocrit occurs postoperatively evidenced by a hematocrit drop in 2.7% of patients. Similar numbers were reported by earlier and more recent series analyzing the outcomes of laparoscopic urologic procedures (Breda et al., 2009; Colombo et al., 2007; Permpongkosol et al., 2007; Simon et al., 2004).

Vascular surgery is the most common reason for conversion to open surgery. The rate for open conversion depends on the type of laparoscopic surgery being performed and on different series. Parsons et al. (2004) reported a 2.6% vascular injury rate in a series of 894 cases. In this series, vascular injuries accounted for 12 of the 13 open conversions. Laparoscopic live-donor nephrectomy keeps a higher incidence of emergent open conversion (Siqueira et al., 2002). In large academic centers, rates of open conversions were once reported to be near 1.5% and death near 0.2%, with the latter remaining very rare (Parsons et al., 2004). **Patient factors responsible for vascular complications and conversion to open surgery are previous abdominal surgery, concomitant abdominal pathology, obesity, and aberrant vascular anatomy.** The rates of vascular complications have also been shown to be expectedly and directly related to surgeon experience. It is for this reason that judicious case selection in one's initial surgical career and experience is key to avoiding major injury.

Management

The cognitive reaction of the surgeon to bleeding is considered the very first step in managing a vascular injury during laparoscopic or robotic urologic surgery. Control of the bleeding can be difficult and time-consuming, with compromised vision through the laparoscope. A study looking at improving these delays reported that reaction time is usually within 22 seconds, the time to control is within less than 1 minute, and the amount of time spent to repair is within 3 minutes. This accounts for 170 seconds on average, although lengthier repair periods are seen when the bleeding structure is temporarily controlled.

Algorithms have been designed to minimize blood loss and decrease the delay in management and further complications when an acute bleed occurs. A consensus summary proposed by Passerotti et al. is as follows (Passerotti et al., 2016). Increasing the pneumoperitoneum and intra-abdominal pressure to decrease venous bleeding should be done with caution as this puts the patient at risk for air embolus, especially when major venous injury has occurred. Aspiration and better exposure of the problematic site is key. Adequate and working suction devices and introduction of laparoscopic sponges for local control and better evacuation of blood are necessary. The decision to add laparoscopic ports should be made expeditiously but wisely to accommodate infield suction devices or vascular clamps while staying away from the work area of other trocars. Once all injuries are identified, especially in complex cases in which associated injuries need to be ruled out, repair is undertaken. Application of surgical clips should be judicious and not random (Figs. 17.11 and 17.12). When clips fail, they can complicate attempts at suture repair and subsequent application of stapling devices and additional attempts at suture repair, which remains the most reliable rescue measure for any damaged vessel. When the exposure is adequate and the bleeding is identified, select major vascular repair can be performed by the experienced minimally invasive surgeon who is adept at intracorporeal suturing (Figs. 17.13 and 17.14). In robotic surgery, the bedside assistant is key to maintaining exposure and providing pressure using the tip of the suction device with selective suctioning as needed. Vascular clamps can be applied selectively, allowing for a controlled repair. There should be a low threshold for conversion to open surgery and obtaining a vascular surgery consult.

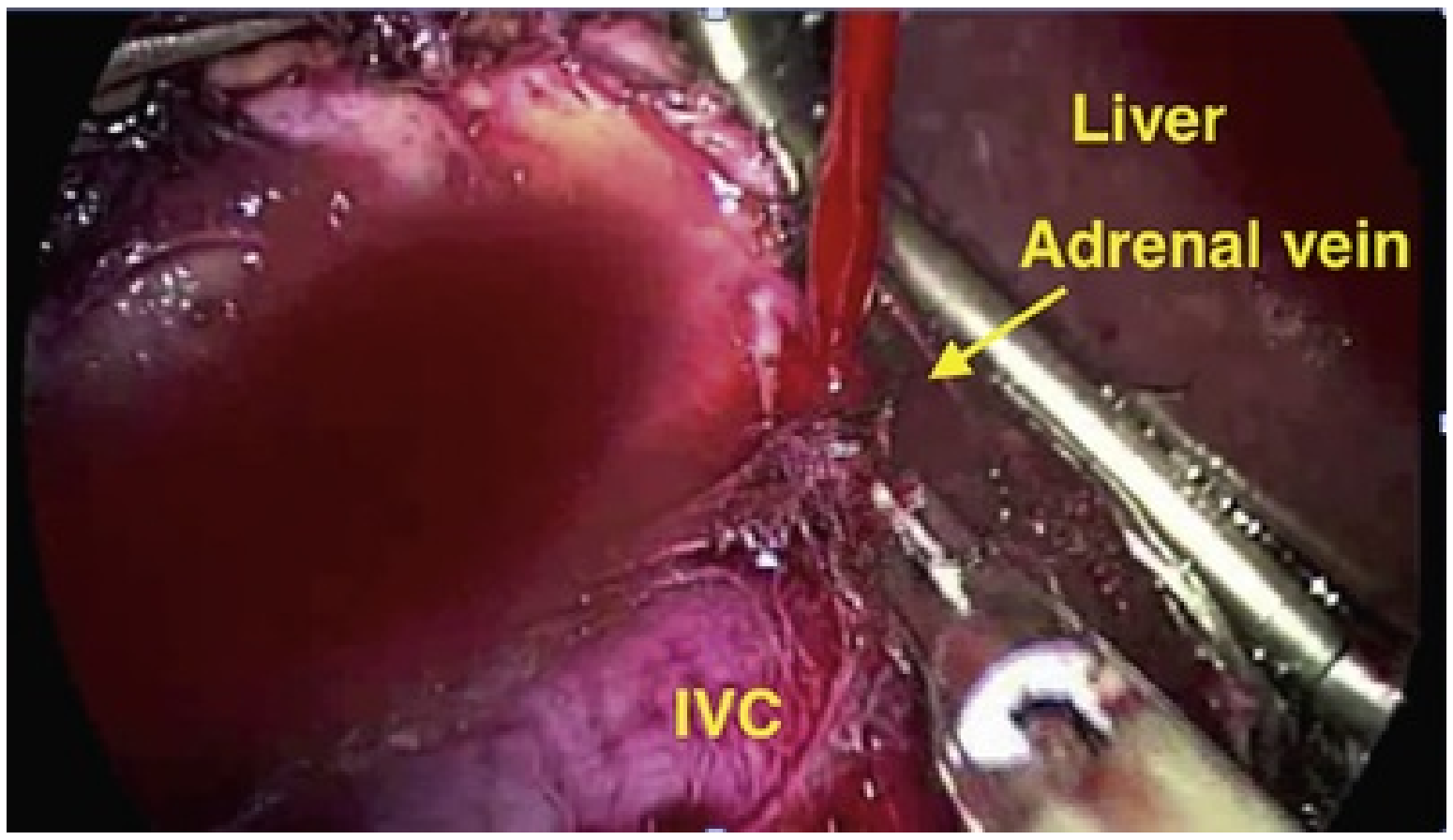

FIG. 17.11 Acute avulsion of the origin of the right adrenal vein during laparoscopic partial nephrectomy. *IVC,* Inferior vena cava.

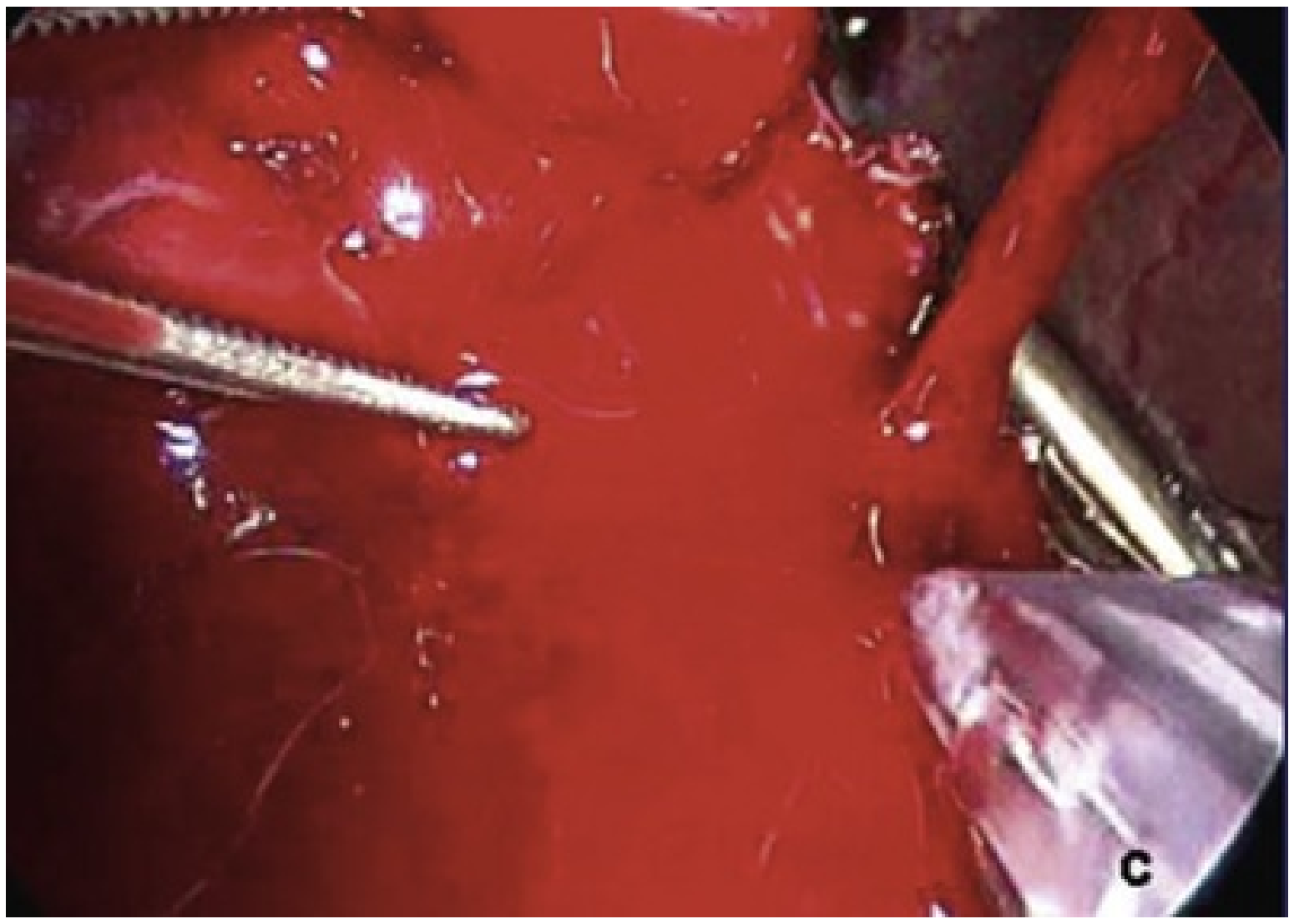

FIG. 17.12 Futile attempts in control with titanium surgical clips.

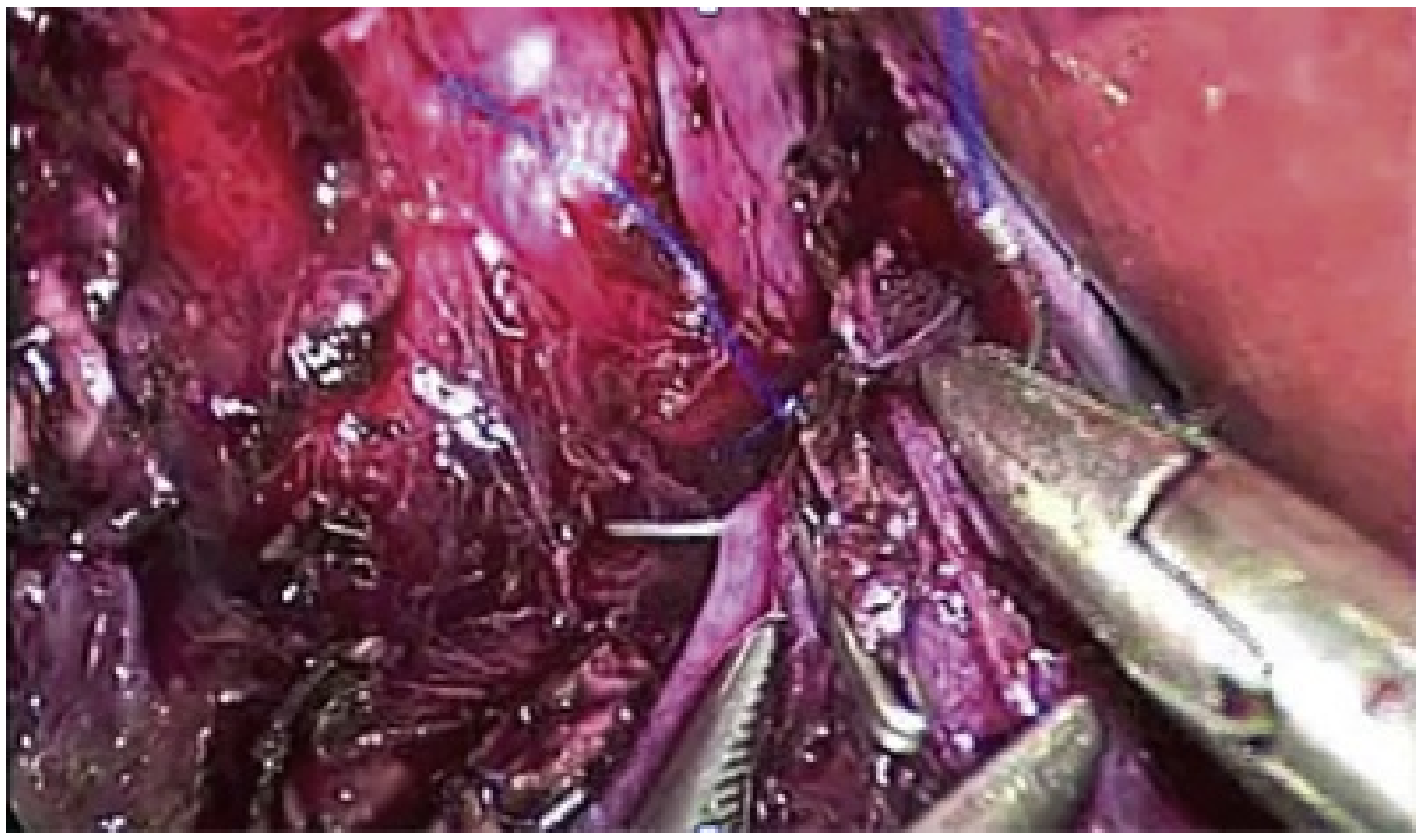

FIG. 17.13 Free-hand laparoscopic suture placement with 5.0 Prolene sutures allows a secure repair after adequate exposure.

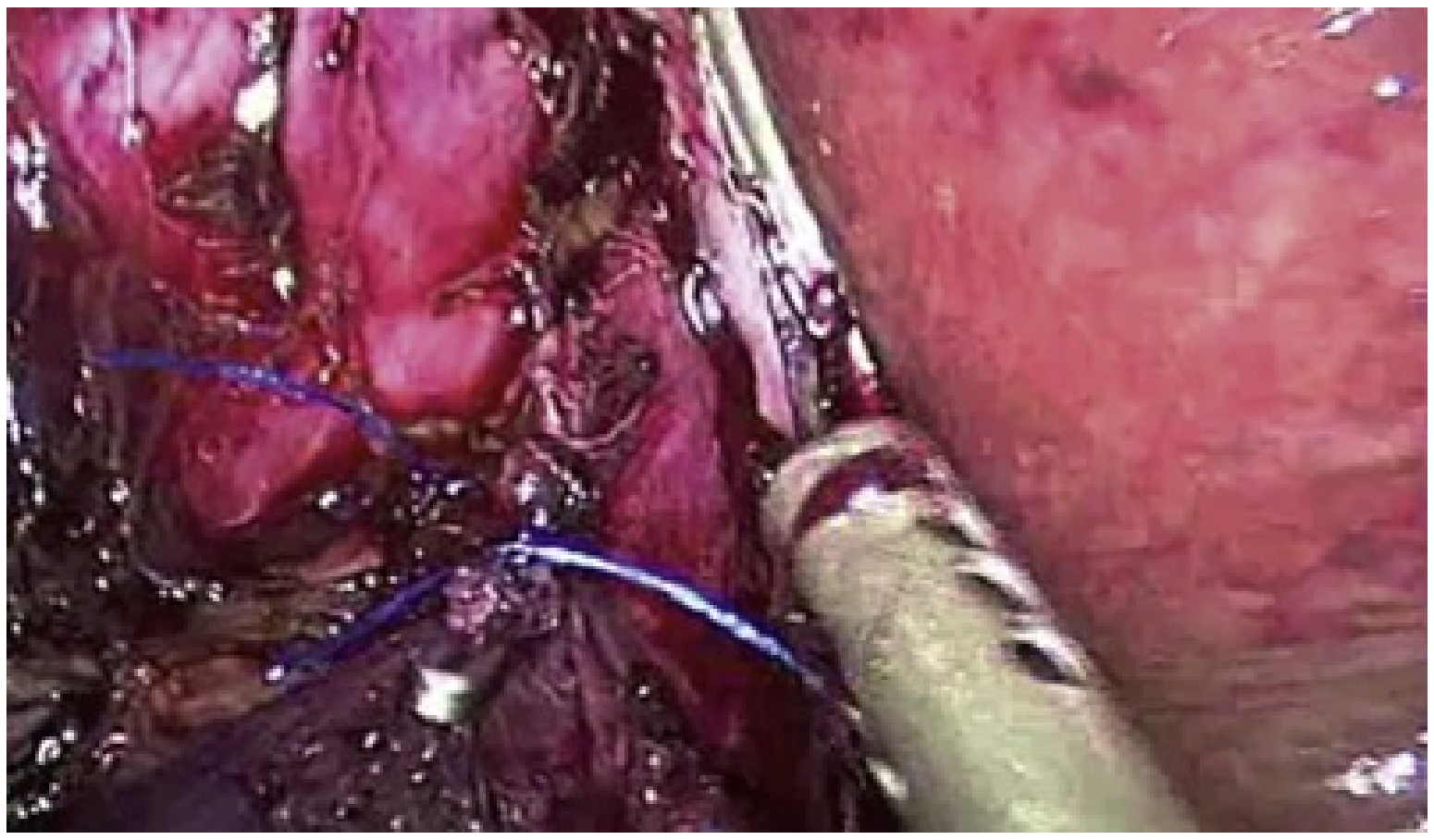

FIG. 17.14 Completed repair with interrupted sutures.

Vascular Injury During Abdominal Access

Access-related injuries to vascular structures have become very rare, with a reported incidence of 0.1%, but they can present a major challenge. A recent meta-analysis revealed a mean vascular injury rate of 0.044% while attempting blind insufflation and access to the abdominal cavity (Larobina and Nottle, 2005). Access-related injuries can result from Veress needle or trocar-related injuries. Aspiration of frank blood through the Veress needle when trying to obtain access is a red flag. Insufflation should be discontinued as this can cause CO_2 embolization with devastating consequences if a major vein is entered. **The signs of gas embolism can vary from a subtle change in hemodynamics: which include sudden hypoxia, hypercarbia, hypotension, arrhythmia, or cyanosis during insufflation. There could be a characteristic "mill wheel murmur."** The gas bubble can travel to the right heart or pulmonary artery. This results in obstruction of venous return and a reduction in cardiac output, leading to reduced pulmonary blood flow, pulmonary hypertension, and right heart failure. Asymptomatic air emboli are worrisome as they carry a high risk for death when systemic changes such as drop in mean arterial pressure or heart rate occur. Elevated right heart pressures and cyanosis of the head and upper extremities can occur. There is a reduction in end-tidal $CO_{2.}$ Transesophageal echocardiography can detect a gas bubble as small as 0.02 cc. **Treatment is immediate desufflation, administration of 100% FiO_2, and placement of the patient in the Trendelenburg and left lateral decubitus position to trap the air bubble in the right atrium. Then a central line is inserted in an attempt**

to aspirate the air bubble.

Whether needle- or trocar-associated injuries are suspected, once inside they should not be removed and should be kept in place without additional manipulation. When alternate access is established, this can help identify the site of injury and sometimes tamponade the bleeding in the case of trocar injury. Management depends on the extent of injury. A point puncture of a major vessel such as the aorta and vena cava with a Veress needle can be self-limiting as long as there is no expanding hematoma. Direct exposure and assessment is key. Trocar injuries are usually more extensive and almost always require repair and conversion to open surgery as devastating consequences can ensue. Through-and-through injuries in the front and back wall of the major vessels have been reported, and this can only be repaired reliably in an open fashion. Management of such injuries, once precisely delineated, is multidisciplinary, involving aggressive resuscitation by the anesthesia team, vascular surgery consultation, and open conversion if necessary. Many times depending on the experience of the surgeon, the injury can be repaired laparoscopically or robotically.

In most scenarios, full insufflation to 15 to 18 mmHg is needed to provide a taut abdomen for insertion of the trocars. Once all trocars are in, the pressure can be lowered to 12 to 15 mmHg for the remainder of the operation. A common insufflation device for robotic surgery is the AirSeal system. This system provides a valve-less trocar that can be used to maintain pneumoperitoneum while providing constant smoke evacuation. The constant insufflation and the trocar's special design prevent air leakage, providing a stable pneumoperitoneum. Although one advantage is maintaining pneumoperitoneum, it also provides lower tensile pressure on the abdominal wall and diaphragm, which can be beneficial in ventilating patients, especially in compromised surgical positions such as the steep Trendelenburg or flank position. The abdominal wall is therefore more lax, and it is crucial to insert all trocars with standard insufflation before switching on the AirSeal mode.

Mechanisms of Injury

Particular care is necessary at the level of the umbilicus given the proximity of the common iliac vessels and the aortic bifurcation. The relationship of the umbilicus to the iliac bifurcation varies widely from 5 cm cephalad to 3 cm caudally in both supine and Trendelenburg positions, and it is not always considered a reliable anatomic landmark for safer access.

The angle of entry of the Veress needle was implicated to play a role. In general, the Veress needle must be inserted at an angle between 45 degrees for patients with a normal BMI and 90 degrees for obese patients at the level of the umbilicus. This depends on the body habitus of the patient as the umbilical base moves caudally in relation to the aortic bifurcation as BMI increases. **In most situations, with the aortic and vena caval bifurcation near the umbilicus in general, the most likely vessel injured directly with an umbilical Veress needle or trocar is the left common iliac vein.** In thin patients, extra attention is needed as the distance between the abdominal wall and retroperitoneal structures can be as little as 2 cm. This distance is around 6 cm in the average patient, although it can markedly decrease in the Trendelenburg position, which brings the aortic bifurcation hazardously closer to the skin, especially in thinner patients. Some studies evaluated the utility of the anterior superior iliac spine (ASIS) as a more reliable anatomic landmark. The surgeon must be aware of abnormal or pathologic anatomic considerations. Many patients have concomitant vascular disease and an atherosclerotic aorta such as an abdominal aortic aneurysm (AAA) and aberrant or tortuous aorta, or common iliac arteries. In these patients, even a small puncture with the Veress needle could be more devastating and cause a “mini-fracture” of the aortic wall, as there will be a lack of elasticity and ability for spontaneous tamponade. This scenario is especially alarming in patients with an AAA in the vicinity or just above the iliac bifurcation. In these patients, the Veress needle has even a shorter distance to travel to the retroperitoneum to potentially cause a devastating injury. In this scenario the aneurysmal wall is diseased, and spontaneous tamponade may not occur. Furthermore, atherosclerotic plaques can embolize to lower extremities with devastating ischemic consequences. If the presence of an AAA is known or suspected before the operation, an alternative site for Veress needle entry such as the left upper quadrant can be used. It is also helpful to review preoperative cross-sectional imaging if available. If not, it is wise to obtain imaging for planning purposes.

Apart from the umbilicus, when the patient is in the lateral flank position for kidney procedures, the Veress needle can be safely used for entry. Classically, the left upper quadrant and the right upper quadrant provide a safe area for Veress needle insufflation. On the right side, deep entry by the Veress needle can puncture the liver as it drapes over the upper pole of the kidney. On the left side, splenic injuries are uncommon with the Veress needle unless a patient has splenomegaly. Despite the fact that these locations are classically reported as safe, the Veress needle can be applied safely in most locations in the abdomen. In robotic kidney surgery, the initial Veress needle can be placed where the camera trocar would eventually be placed; this is usually two fingerbreadths above the umbilicus in the lateral rectus line. The Veress needle must be pointed perpendicular to the posterior peritoneum to avoid injury to the bowel, which may be displaced more medially with the lateral position. Again, for cases in which there is a history of extensive abdominal surgery, open Hasson trocar or visual optical trocar as the initial entry mechanism can be employed as discussed later.

Comparison of Different Access Techniques

The inadequacy of reporting major and minor injuries during laparoscopy or robotic surgery underlies the difficulty in assessing the safety of respective techniques. For instance, a report by the US Food and Drug Administration (FDA) showed that 81% of deaths from trocar incidents were caused by major vessel injuries. The most commonly affected are the aorta, inferior vena cava, and iliac vessels, with the latter rarely resulting in a fatal outcome (Pereira et al., 2010).

Many techniques including the open Hasson technique and special bladeless trocars have been developed to prevent access injuries (Minervini et al., 2008). There is no consensus as to which technique is safer to use or preferred for less experienced surgeons. **The Hasson technique has classically been advocated to be the safest approach for inexperienced surgeons and in patients with previous abdominal surgery when extensive adhesions are suspected.** Regardless, Veress needles continue to be most commonly and widely used for access, although some old reports state a slightly higher risk for vascular complications (Molloy et al., 2002). This did not seem true in a recent Cochrane-based review indicating only higher access failure rates with Veress needles (Ahmad et al., 2015).

Currently, the optical bladeless trocar has been commonly used, and it provides extra security with visual feedback while going through the consecutive layers of the abdominal wall. Thomas et al. reported the rate of injuries as less than 0.31% in a large series of more than 1000 urologic procedures. Most of these were not major vascular injuries, with reported injuries to mesenteric or epigastric vessels (Thomas et al., 2003). When compared with the Hasson technique, optical bladeless trocars required markedly less time for placement and establishment of pneumoperitoneum (125 vs. 440 seconds) (Minnervini et al., 2008). Other safe devices that need to be mentioned are those that control axial force for penetrating the abdominal and fascial layers, as injuries mainly occur when excessive forward force is employed. The most common method involves introducing first an expandable sheath through which a cone-shaped port placement is achieved. While guiding trocar entry, it will help push away blood vessels and reduce the forceful hand movement by countertraction on the elastic outer sheath and simultaneous added control by the surgeon's nondominant hand. The rotational movement in trocar introduction in general is key. The trocar should also be introduced with two hands, the dominant hand controlling the top of the trocar and exerting the entry force while the nondominant hand is at the shaft of the trocar at the skin level to avoid sudden uncontrolled entry. It is crucial for the skin incision to be large enough to accommodate the shaft of the trocar. Otherwise, the trocar shaft will indent the skin, and the peritoneum and more excess force will be needed to push the trocar, resulting in sudden, uncontrolled entry and injury of deeper anatomic structures regardless of location.

Management of Vascular Incidents

Vessel injuries and their extent are assessed by suction, irrigation, and direct visualization with pressure and control above and below the area of bleeding in major open surgery. In case of major vessel injury, an extra suction device is advisable. A vascular surgery consult should be obtained if additional help is needed. Specific steps are necessary for prompt and efficacious control of laparoscopic intraoperative vascular injuries. A transient increase in abdominal pressure to 20 to 25 mmHg while maintaining the peritoneum is advised. In the case of major vessel injury, this step must be taken with caution as the risk for air embolism is increased. However, pneumoperitoneum can aid in delineation and temporization of even medium to large venous defects (Fig. 17.15). Direct pressure can be applied with gauze or a rolled Surgicel with the suction device by the bedside assistant. If the bleeding is under control, accessory trocars can be placed, and the operation can be continued laparoscopically if control and repair can be achieved. Open conversion is advisable if the extent of the injury cannot be delineated and control and repair cannot be achieved. There should be a low threshold for open conversion, and transfusion must be started as necessary before major volume depletion and hemodynamic instability occur.

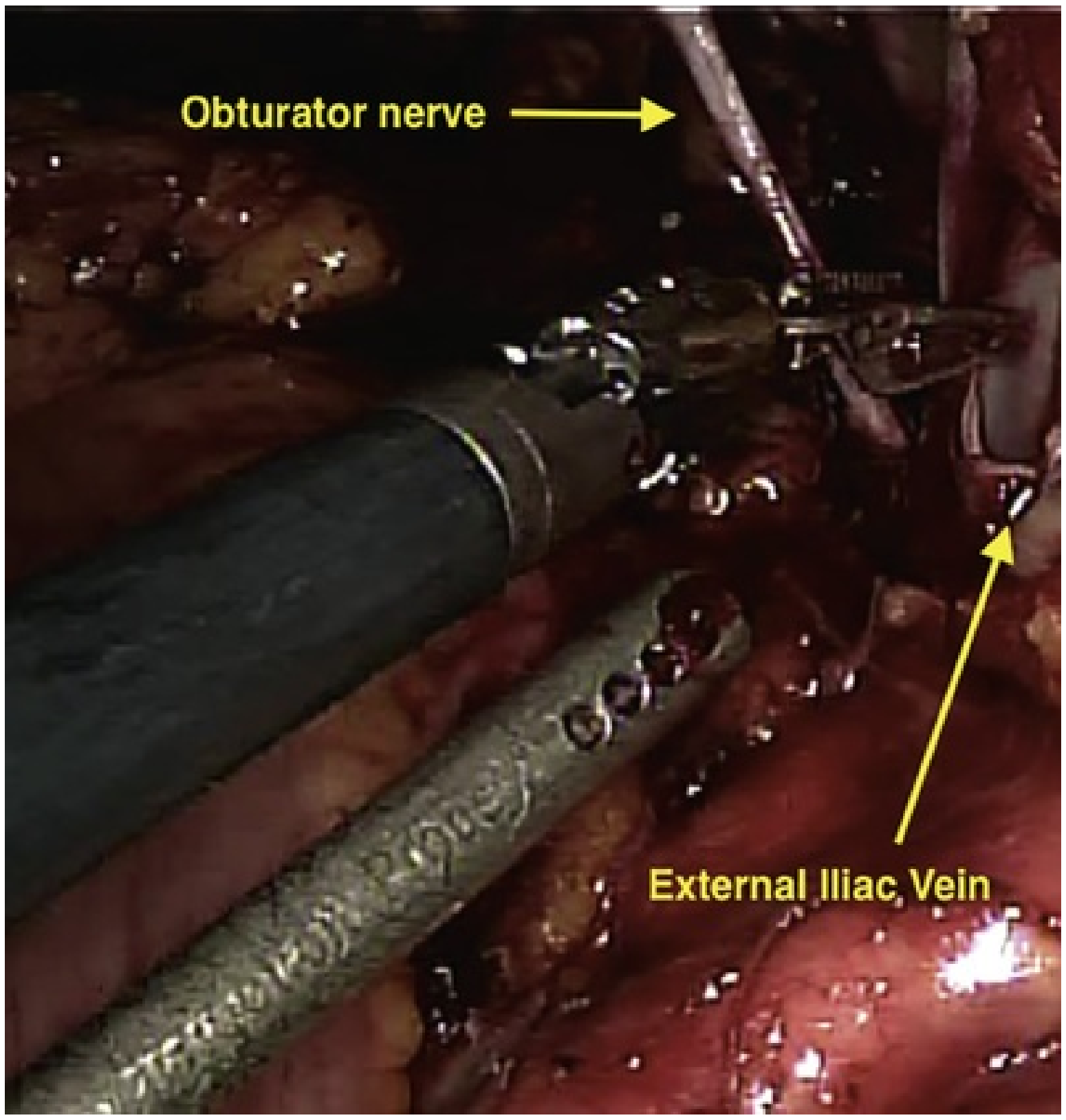

FIG. 17.15 During right robotic pelvic node dissection, the external iliac vein is partially transected. The endothelium of the vein can be easily appreciated. (From Tare D, Maria P, Ghavamian R. Vascular complications in laparoscopic and robotic urologic surgery. In: Ghavamian R, ed. *Complications of laparoscopic and robotic urologic surgery.* 1st ed. New York, NY: Springer; 2010:45–58.)

Injury to Epigastric Vessels

Epigastric vessel injuries occur in 0.2% to 2% of cases and constitute a special situation in which delayed presentation is common because trocars can tamponade the damaged vessels throughout the surgery (Joy et al., 2016). The epigastric vessels course in the lateral aspect of the rectus sheath. Most trocars are placed lateral to these vessels along the pararectal sheath. When trocars are displaced medially after entry to the skin, epigastric vessels can be injured. Although many studies have assessed the average distance of the epigastric vessels from landmarks like the ASIS or midline, an easy preventive measure is to ensure adequate transillumination of the abdominal wall before gaining access with additional ports. Lateral ports should be at least 5.5 to 6 cm lateral to the midline to avoid the epigastric vessels. Careful inspection of these sites once trocars are removed is essential (Pickett et al., 2010). Many techniques have been evaluated for repairing epigastric vessels. A Foley catheter placed across the port site with the balloon inflated and pulled up against the abdominal wall can help temporize excessive bleeding while a cut-down or laparoscopic suturing of the vessels is completed. This is rarely necessary for the laparoscopically adept surgeon. The easiest and most efficient endoscopic means is the fascial closure device or the Carter-Thomason CloseSure System. A figure-of-eight suture is passed under vision, and control of the injured vessels is performed. Visual confirmation is perfomed in a reliable fashion without the need for extending the port incisions. This technique is superior to attempts at placement of fascial sutures in these small trocar incisions.

Injury to Major Vessels

Major vessel injuries are the most feared complications, and training centers have developed a simulation-based system for trainees to expose them to such stressful situations and potential management options (Veneziano et al., 2016). Avoiding major vessel injury is the mainstay of reducing the accentuated morbidity associated with these incidents. Most of the time, these vessels cannot be ligated because of a lack of collateral circulation, and repair is mandated commonly through an open conversion. Some major vessel injuries can occur at the time of initial trocar insertion. Here care must be taken to ensure that the skin incision for the trocar is wide enough to avoid forceful entry. To adequately visualize when major bleeding is suspected, it is important to leave the trocar or Veress needle in place and to place accessory ports if the patient is stable. In many occasions, conversion to open surgery through a midline incision when possible is appropriate. The offending trocar should be left in place until open conversion as it may be contributing to partial occlusion and tamponade of the bleeding. During robotic surgery, if the bleeding is successfully and instantly temporized with the robotic Prograsp forceps, the other two robotic arms can aid in investigating the extent of injuries along with bedside suctioning. Repair can be attempted, or a rescue polyglactin suture on a computed tomography-1 needle with a Hem-o-lok polymer locking ligation system at the other end can be used to aid in fixing the injury. The suture is pulled up, and the Hem-o-lok will tent the vessel wall up and temporize the bleeding until the subsequent throw of the suture is accomplished. A computed tomography needle is used as it allows for a bigger target to identify the needle in a puddle of blood, which can often result after major bleeding laparoscopically.

If the vessel in question is the internal iliac or inferior mesenteric vessel, ligation may be possible given the presence of a good collateral circulation. Superior mesenteric artery injuries warrant repair universally as the flow through this axis cannot be compensated through other vessels, and devastating complications like bowel necrosis and death ensues. Immediate conversion to open and vascular consultation is mandatory. Retroperitoneal hematomas are a special situation when major vessel injuries are suspected. In such occurrences, if the patient is hemodynamically stable and the hematoma is not expanding, observation and conservative management is a reasonable choice, and the decision to continue or abort the procedure should be made based on its urgency. The surgeon should not carry dissection of the retroperitoneal space in cases of a confined hemorrhage. In other situations of hemodynamic instability or a rapidly expanding hematoma, open conversion is mandated to repair aortic, vena caval, or external iliac artery injuries. Pneumoperitoneum can substantially help in repair of venous tears by increasing the intra-abdominal insufflation to 20 mmHg. This usually decreases venous bleeding while suturing is carried out quickly to avoid gas embolism at such pressures before dropping the pressure to 12 to 15 mmHg as soon as possible. In a similar fashion, external iliac vein tear suturing can be safely achieved by increasing pneumoperitoneum and turning off the sequential compression devices. This allows for decompression of the iliac vein empty, thus permitting controlled repair of the injury. In addition, during robotic surgery efficient use of the fourth arm for clamping and holding tension and pressure affords more control than conventional laparoscopy during challenging vascular suturing (Fig. 17.16). The use of novel sealing devices such as vessel-sealing devices, ultrasonic shears, or bipolar robotic coagulation cannot be emphasized enough when carrying delicate dissections around major structures.

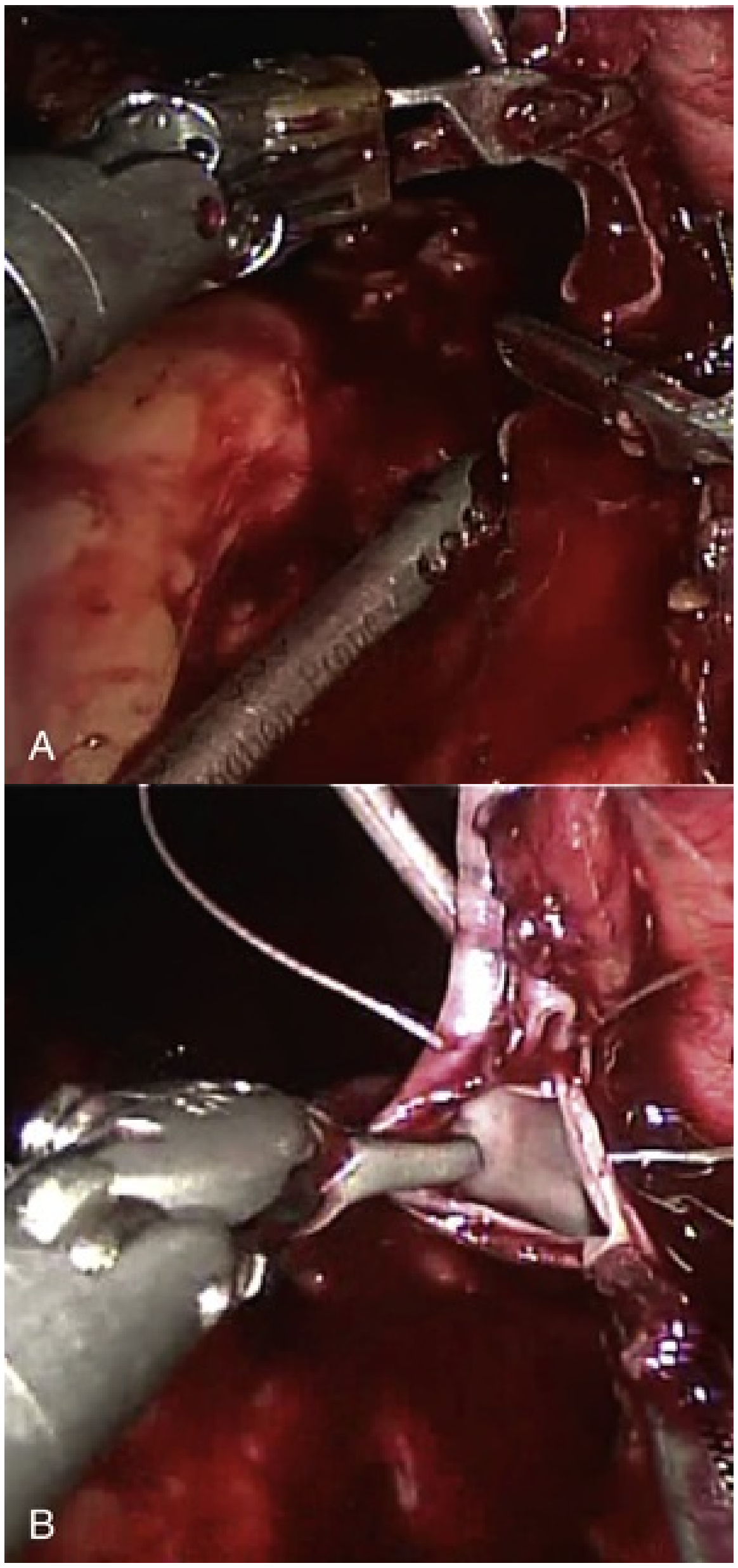
A
B

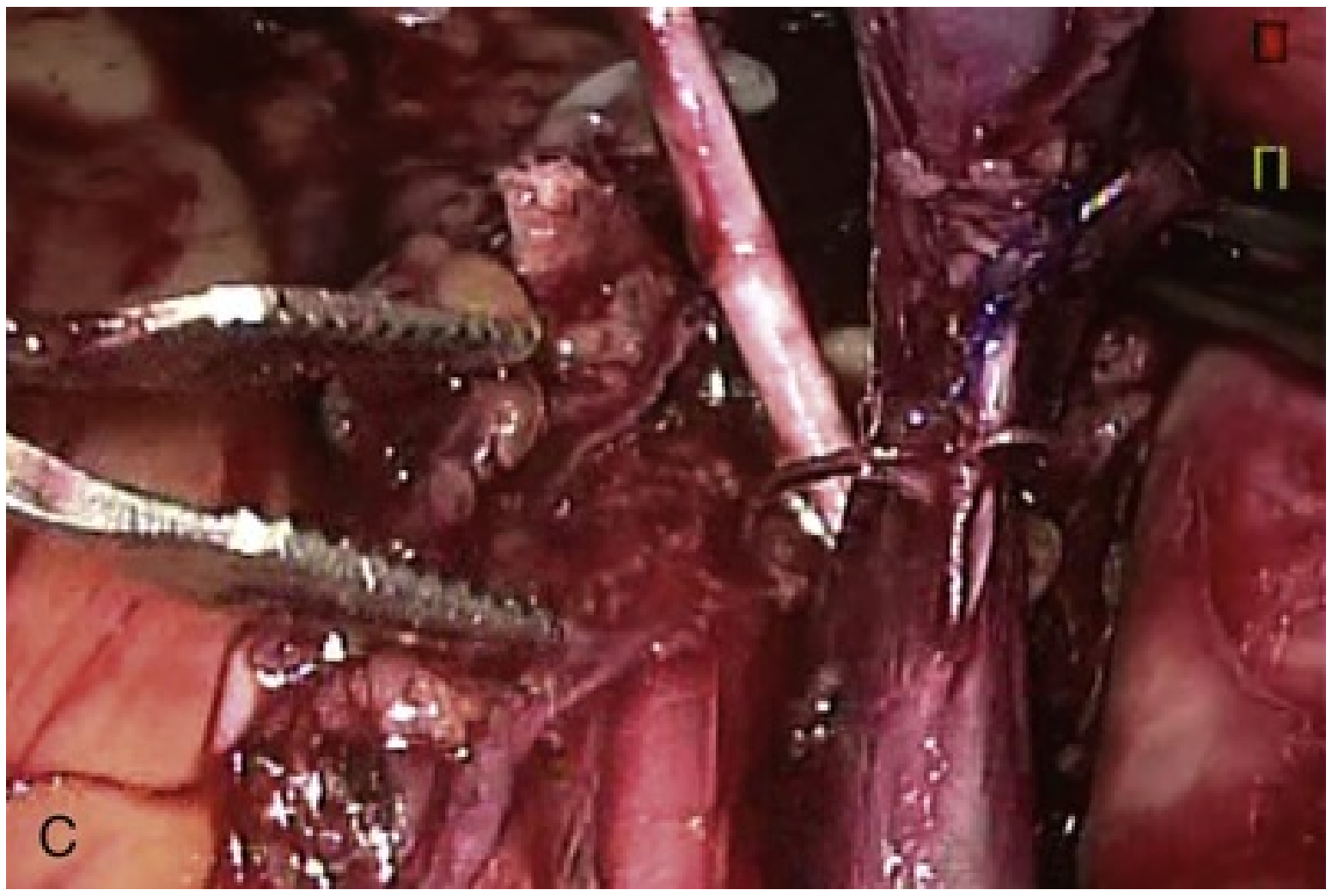

FIG. 17.16 (A) The fourth arm of the robot is utilized to gain temporary partial control. (B) The defect is repaired with a 5.0 running suture with excellent visualization and control. (C) Final repair with some luminal narrowing but proximal and distal filling of the vein with the sequential pneumatic device confirming flow. (From Tare D, Maria P, Ghavamian R. Vascular complications in laparoscopic and robotic urologic surgery. In: Ghavamian R, ed. *Complications of laparoscopic and robotic urologic surgery.* 1st ed. New York, NY: Springer; 2010:45–58.)

Stapler Malfunction

With the wide use of staplers across United States that coincides with the increased use of minimally invasive surgery, reports of staple malfunction have increased. A reported rate of malfunction around 1% has become universally accepted. In an early FDA report on stapler use over approximately 10 years, 112 related deaths were reviewed that were mostly related to staplers firing improperly or staple lines rupturing or forming inadequately (Brown and Woo, 2004). Recalls on stapling devices are more common mostly for broken components or sterility issues. Overall, there appears to be underreporting of stapler incidents as evidenced by the results of a recent survey sent to program directors revealing that most have experienced laparoscopic linear stapler malfunction at some point. In this report, 25% of the time there was a drastic change in the course of the operation to staple-related issue (Kwazneski et al., 2013). In urologic surgery, the most common use of staplers is on vascular pedicles of different organs, especially on the renal hilum. Prevention is key in this setting. This involves careful inspection of the stapler while unpacking, precise loading of the cartridges, and judicious application of the stapler on vascular structures. The most common cause of staple malfunction is when the structure to be stapled is too thick for proper application. The surgeon should adequately dissect the vessels for staple application. When applying the staple, the full length of the jaw and the end point of the stapler jaw must be completely visualized before firing. When applying it to the renal hilum and when there is no evidence of tumor thrombus in standard laparoscopic radical nephrectomy, the stapler must be applied closer to the kidney, allowing a portion of the renal vasculature below the stapler to still be exposed for a second "rescue" stapler to be applied below, in case of a jammed stapler (Fig. 17.17).

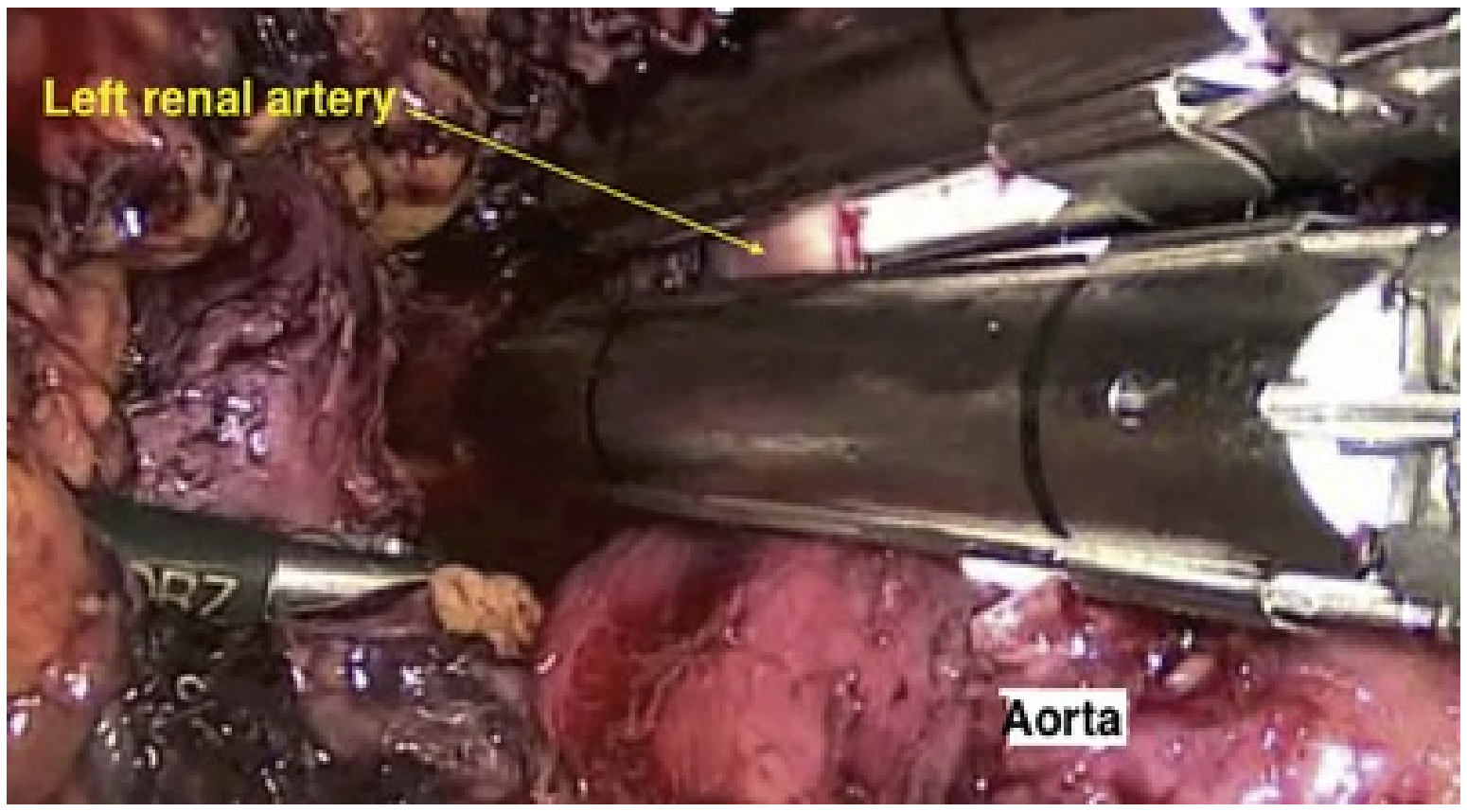

FIG. 17.17 The upper stapler is jammed during a laparoscopic left radical nephrectomy for a large renal mass. A second "rescue" stapler is manipulated under the jammed stapler for control of the artery.

Although some utilize Hem-o-lok clips for control of renal vasculature, most surgeons employ stapling devices as they ensure a more reliable means of control without the fear of dislodgement. Hem-o-lok or standard titanium clips can interfere with staple application if trapped in the stapler jaws, impeding the stapler and "jamming" the staple mechanism. One additional recommendation is the avoidance of excessive pressure and force on the handle, as this would overcome the safety lockout mechanism increasing the risk for malfunction.

Additional reviews of the FDA database do not conclude to the safety of one device over another for hilar control during nephrectomy, and incidents have been reported while using titanium clips, locking clips, and staplers. In locking clips, dislodgement has been reported as the leading cause of failure in 44% of cases. In titanium clips, difficulty closing or cutting and problems with jamming and the clip deployment device in automatic clip appliers were responsible for 26% and 27% of accidents, respectively. Although stapler lockup can be observed in 29% of associated incidents and staple line malformation in 44% of failures, rescue techniques can be quickly achieved with applying extra clips overlying the staple line or under the transection line (Hsi et al., 2007).

Postoperative Vascular Complications

Postoperative vascular complications can occur most frequently as a result of unrecognized bleeding at the time of surgery. This can be caused by complete or partial transection of an artery or vein. Arterial injuries usually are associated with a more rapid decrease in postoperative hematocrit and hemodynamic instability. On the contrary, venous bleeding is usually associated with a smaller bleeding vessel, is more self-limiting, and can present on a later postoperative day. Inadvertent ligation of major arteries leads to infarction of the target organ and hence delayed presentation of the injury. **Vascular complications account for the majority of early postoperative complications, especially in laparoscopic surgery** (Yaycioglu, 2005). In laparoscopic and robotic surgery, the presence of pneumoperitoneum temporarily tamponades small venous bleeding, leading to a delayed hemorrhagic presentation. Delayed presentation of vascular injuries in laparoscopy is especially concerning given the limited view of the laparoscope at any given moment. Injuries can occur anywhere along the shaft of the instruments or on entry and exit of the laparoscopic instruments and suction devices.

Some postoperative vascular complications are specifically worth mentioning as they pertain partial nephrectomy. Most hemorrhagic complications after partial nephrectomy occur after the patient has been discharged (Ramani et al., 2005). Iatrogenic vascular lesions after minimally invasive partial nephrectomy are rare occurrences generally seen 2 to 3 weeks postsurgery. The incidence is reported to be 2.0% to 2.7% (Hyams et al., 2011). These consist of arteriovenous (AV) fistulae and pseudoaneurysms, with the latter being more frequent. A recent systematic review and comparative analysis of 5229 patients who underwent open and minimally invasive partial nephrectomy was conducted. The incidence of pseudoaneurysm after open versus minimally invasive partial nephrectomy was 1.0% and 1.96%, respectively (Jain et al., 2013). AV fistulae and pseudoaneurysms form when segmental arteries and veins that are in close proximity in the tumor resection bed are injured on resection or suture repair. The deeper the tumor and the resection, the higher the chance is for these complications. Therefore patients with a higher nephrometry score can potentially be at higher risk for these complications (Chen et al., 2018). The risk for iatrogenic vascular lesions may be achieved by early unclamping as described in some robotic series related to a shorter ischemia time, especially if no arterial bleeding is present (Kondo et al., 2015). AV fistulae and pseudoaneurysms can exist alone or coexist. Several technical considerations can be undertaken to decrease the chance for AV fistulae or pseudoaneurysms. Careful inspection of the resection bed and suture ligation of larger segmental branches is advised. Often, a running absorbable suture through the tumor crater with careful needle passes, selectively suturing obvious vessels can aid in prevention. Sutures in the parenchymal repair should not be placed too deeply to avoid segmental branch injury (Tare et al., 2010).

Diagnosis and Management

The diagnosis is usually made in the immediate postoperative period with a precipitous decline in hematocrit. The presence of hematuria is a further alarming finding that would prompt radiologic evaluation. Renal pseudoaneurysms can be asymptomatic in up to 10% of cases, and these will be discovered on follow-up imaging studies. Some have suggested the use of selective enhanced computed tomography after partial nephrectomy in the early postoperative period to detect asymptomatic pseudoaneurysms. In a study of 117 patients who underwent computed tomography routinely on postoperative day 4, Takagi et al. reported a 15% detection rate. Only one patient had a hemorrhagic complication in the early postoperative period and was symptomatic. Patients with pseudoaneurysms less than 2 to 4 mm had spontaneous resolution (Takagi et al., 2014). Reports of presentation as enhancing lesions mimicking local recurrence or an avidly enhancing lesion in the arterial phase of a computed tomography scan have also been made (Campbell et al., 2016; Lonergan et al., 2016). When computed tomography appearance is equivocal, renal angiography will ultimately aid in the definitive diagnosis (Schommer et al., 2017). Most patients will present with fever, gross hematuria, flank pain, hypotension, bloody discharge from the drain site, dizziness, and syncope. A minority will have an acute major bleed and will require emergent embolization. This is especially true in case of multiple pseudoaneurysms in the same kidney, a scenario that can occur (Gupta et al., 2017). **When patients present with these symptoms, especially with a history of a recent partial nephrectomy, a high index of suspicion for a pseudoaneurysm should be present. In this case, many**

advocate a direct evaluation with arterial angiography, bypassing the computed tomography. This is to avoid an additional contrast load to the patient who might be anemic and intravascularly depleted, and also has mild renal compromise. It also is a more expeditious approach when the index of suspicion is high.

If pseudoaneurysms are incidentally detected on imaging obtained for other reasons, conservative management is an acceptable approach in the absence of gross hematuria, decreased hematocrit, and hemodynamic instability (Darbyshire et al., 2014). Serial monitoring of the hematocrit and hemodynamics is sufficient. When suspected with a documented decline in hematocrit, especially when the patient presents in a delayed fashion after discharge, computed tomography is indicated (Fig. 17.18). This reveals a characteristic blush in the arterial phase. After initial diagnosis using computed tomography with intravenous contrast and if hemodynamic instability exists and there is a precipitous decline in hematocrit, angiography and selective embolization of the bleeding vessel is indicated. This is the treatment of choice for pseudoaneurysms and AV fistulae (Fig. 17.19). If unsuccessful, the next step is surgical intervention. In a recent study with long-term follow-up of up to 10 years, technical success rates nearing 100% were frequently reported in the literature using super selective branching microcoil embolization (Strobl et al., 2016). Although parenchymal volume loss up to 25.2% was observed, the impact of embolization on renal function and estimated glomerular filtration rate (eGFR) did not appear to be detrimental.

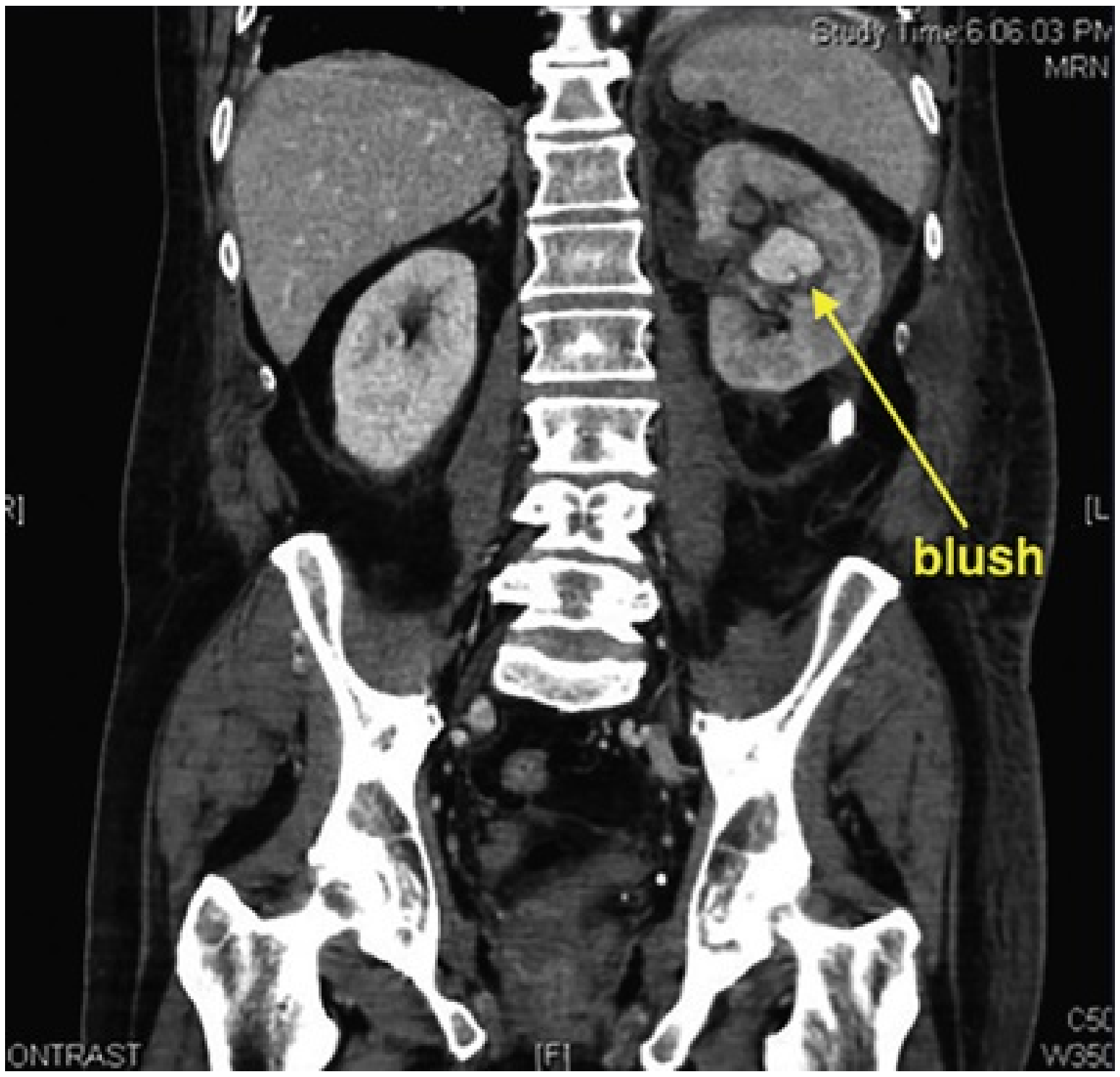
Study Time:6:06:03 PM
MRN
R]
[L
blush
ONTRAST
[F]
C50
W350

FIG. 17.18 Segmental renal arterial pseudoaneurysm. Arterial phase of a contrast computed tomography image revealing an arterial blush in a patient 2 days after a left laparoscopic partial nephrectomy. (From Tare D, Maria P, Ghavamian R. Vascular complications in laparoscopic and robotic urologic surgery. In: Ghavamian R, ed. *Complications of laparoscopic and robotic urologic surgery.* 1st ed. New York, NY: Springer; 2010:45–58.)

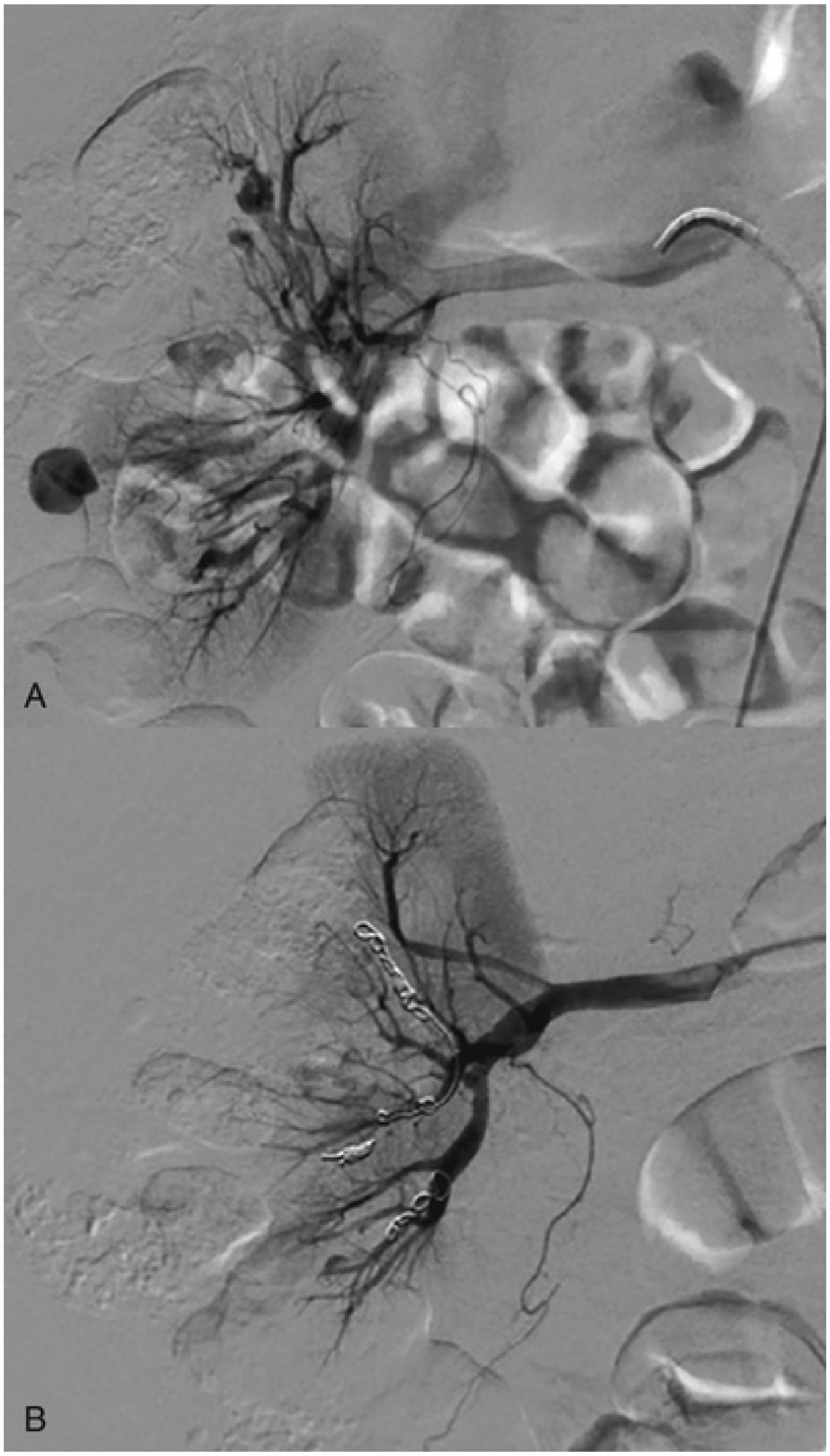

FIG. 17.19 (A) Renal arteriography revealing at least three pseudoaneurysms 2 days after a right robotic partial nephrectomy for a 6-cm midpole renal mass. (B) Selective coil embolization revealing resolution of the bleeding pseudoaneurysms.

Bowel Injuries

Incidence and Presentation

Bowel injuries can occur during major and minor open urologic procedures, and early recognition and repair is of paramount importance. The exact incidence of bowel injuries is difficult to ascertain. There is an underreporting of bowel injuries, as some are minor lacerations or serosal tears that do not interfere with the course and outcome of the operation. Intraoperative injuries that are missed can present with ileus, abdominal pain, leukocytosis, and sepsis, with major associated morbidity and mortality risk. Minimally invasive procedures present their own unique set of challenges in both the diagnosis and management of bowel injuries. With the increased utilization of minimally invasive laparoscopic and robotic procedures in urology, familiarity with presentation and management of these complications are of paramount importance. The mechanism of injury is also unique. Injuries that are detected intraoperatively can be managed accordingly. The reported incidence is established to be well below 1%, at approximately 0.2% What is unique about laparoscopic surgery is that delayed presentation of bowel injuries during laparoscopy or robotic surgery can carry devastating consequences including fever, abdominal pain at trocar site, generalized peritonitis, sepsis, and death (Van der Voort et al., 2004). Up to 69% of bowel injuries were not recognized intraoperatively and were found to occur any time from access and entry of the abdominal cavity to exit. In a classic manuscript on laparoscopic bowel injury, Bishoff et al. described their incidence and clinical presentation (Bishoff et al., 1999). **Delayed and unrecognized bowel injury has an atypical presentation after laparoscopic surgery. Classically, patients can present with absence of peritonitis, acute abdomen, or leukocytosis. Symptoms typically occur within 24 to 48 hours after surgery. Symptoms include single trocar site pain disproportional to the examination with no purulence, abdominal distension, ileus, and diarrhea. Complete blood count usually reveals leukopenia rather than leukocytosis** (Bishoff et al., 1999). When suspected, computed tomography of the abdomen and pelvis is warranted (Fig. 17.20). This is best obtained with oral and intravenous contrast with delayed images. If a rectal injury is suspected, rectal contrast is also preferred. **A complicating factor after laparoscopy is the presence of intra-abdominal gas, which can be expected up to 7 days**

postoperatively. Although some patients can still present with frank peritonitis, acute abdomen, and classic symptoms, a high index of suspicion for atypical presentation should exist after laparoscopy. Tackling more complicated cases with minimally invasive surgery accounts for the increased incidence of bowel injuries to 0.75% reported by Schwartz et al. from 0.65% in the previous decade. The rate of unrecognized injuries peroperatively decreased dramatically from 70.4% to 36.9% despite extensive adoption of laparoscopic surgery (Schwartz et al., 2010). Whether this reflects better awareness of surgical complications associated with laparoscopy or enhanced minimally invasive technologies such as sealing devices is yet to be determined, as multiple factors can effectively play a role.

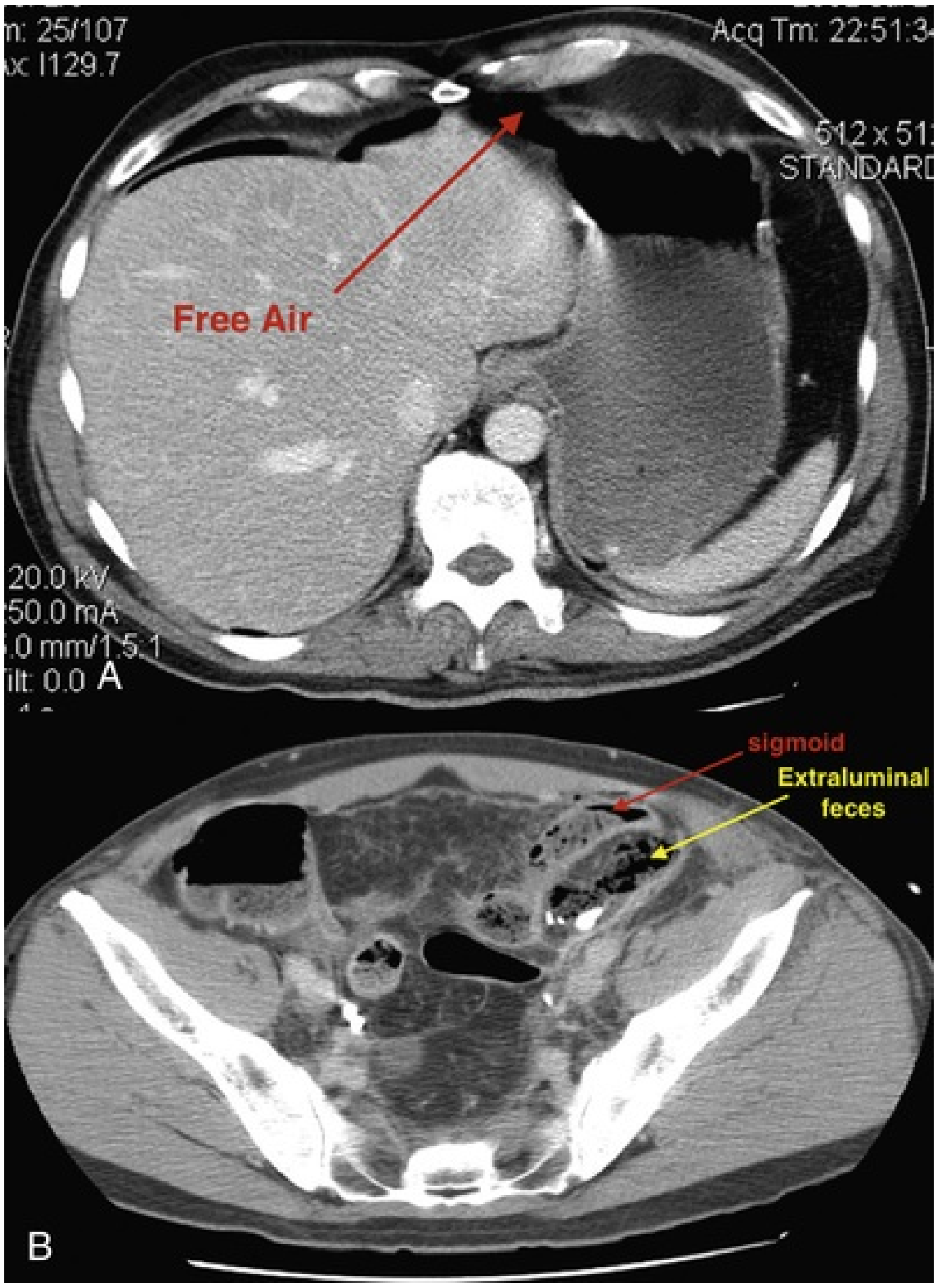
n: 25/107
xc I129.7
Acq Tm: 22:51:3
512 x 51
STANDARD
Free Air
20.0 kV
50.0 mA
.0 mm/1.5:1
ilt: 0.0
A
sigmoid
Extraluminal
feces
B

FIG. 17.20 (A) Computed tomography image revealing free air in a patient with leukopenia and left lower abdominal pain 3 days after a laparoscopic radical prostatectomy. (B) Pelvic axial images revealing extraluminal feces with air pockets.

Mechanisms of Injury

The mechanisms of bowel injury could be caused by poor technique in trocar insertion, Veress needle injuries, mechanical injuries resulting from exaggerated retraction, and tissue handling and electrocautery injuries. Trocar-associated injuries share similarities with instrument insertion–associated injuries. In fact, 21% of trocar access–related injuries were shown to be bowel injuries based on an FDA report, with some resulting in patient death. Extreme caution must be exercised when deciding which location to gain initial abdominal access for insufflation. **If a patient has a midline scar and previous abdominal operation, the position of the initial Veress needle should be in an alternative location in the abdomen away from that scar.** In many instances, bowel adhesions to the anterior abdominal wall can exist in sites well away from the abdominal incision. Here, the use of optical trocars and the open Hasson technique can decrease the chance for bowel injury. Most bowel injuries that occur as a result of Veress needle injuries are small bowel injuries**. The saline drop test examination is helpful to ascertain proper positioning of the Veress needle. After initial partial insufflation, the Veress needle must be able to be advanced 1 to 2 cm with no resistance.** This usually (but not always) denotes correct intraperitoneal position of the Veress. Once the Veress needle is in and the original camera trocar is inserted, it is imperative to check the peritoneal cavity for adhesions. The location of the anticipated following trocars must be devoid of bowel adhesions to the anterior abdominal wall. Complete insufflation is necessary to avoid tenting of the peritoneal lining and forceful uncontrollable insertion of the trocars. **The surgeon should consider a bowel prep for difficult cases or for patients with a history of extensive prior abdominal surgery. Lysis of adhesions can be carried out with cold laparoscopic scissors with no electrocautery to avoid thermal spread and delayed thermal injuries.** If bowel manipulation is necessary and lysis of adhesions is performed, careful attention to counter traction on the bowel prevents mechanical shear and denudation injuries. This is also true in robotic surgery, when careful manipulation of the bowel is even more paramount because of the absence of haptic feedback and the strong constant grasping force of the robotic prograsp instrument. Extensive lysis of adhesions is ill-advised away from the surgical field. As such, enough is required to allow the surgical field in focus to be accessed safely. Extensive “sweeping” maneuvers are also discouraged laparoscopically and robotically as these can lead to partial thickness and full-thickness denudations and bowel injuries. Mechanical bowel injuries occur when instruments are inserted blindly outside their safe range of motion. The injuries can involve abrasion, compression, and sharp wounds. Investigating the extent of injury is key. Often multiple bowel injuries can coexist, and this will guide the subsequent primary repair of bowel resection. It is of utmost importance at the start of the case and upon access of the abdomen to maximize the range of motion of instruments by lysis of adhesions and dissecting out the operative space wide enough to allow maximum safety (Venkatesh and Landman, 2006). **On occasion, extensive adhesions exist that may be prohibitive to safe intraperitoneal laparoscopic and robotic surgery. In these circumstances, open conversion may be the most prudent maneuver to prevent complications.**

Bowel injuries can be divided into early intraoperative injuries detected at the time of surgery and delayed injuries detected after the operation is completed. Most intraoperatively detected injuries can be managed intraoperatively, mostly with direct suture repair. Most injuries to the small bowel are direct perforations or serosal injuries. Both can be reliably repaired intraoperatively. Limited colonic injuries in the absence of major fecal spillage can also be repaired intraoperatively, open, laparoscopically, or robotically. Major bowel injuries that involve extensive lacerations or mesenteric injuries that leave a questionably viable bowel segment can be managed with bowel resection. A general surgical consultation is usually advisable. For an extensively diseased bowel, an end ileostomy and subsequent reconstitution of the intestinal tract may be advisable. Most extensive bowel injuries are managed with resection and primary stapled anastomosis. In the case of an extensive colonic injury with obvious fecal soilage, a colostomy may be required. Copious irrigation is necessary, and broad-spectrum antibiotics should be administered.

Most delayed presentations of bowel injury are caused by thermal injuries secondary to excessive and incorrect use of electrocautery. Monopolar electrocautery could be a dangerous energy modality in laparoscopic and robotic surgery. In one study, critical heat spreads of greater than 20 mm were found with monopolar devices used for 2 seconds at 60 watts. The use of bipolar energy significantly reduces thermal spread and should be the cautery modality of choice. Mean thermal spreads of 3.5 mm, 2.2 mm, 1.3 mm, and 2.8 mm were demonstrated for robotic hot shears, bipolar instruments, harmonic devices, and Ligasure devices, respectively (Hefermehl et al., 2013). **Stray electrosurgical current can be caused by poor technique or an insulation defect in the instrument resulting in direct or capacitative coupling with metal trocars.**

Maneuvers should be employed to prevent electrosurgical injuries. Judicious use of monopolar electrocautery should be employed. Most laparoscopic procedures should be performed with controlled sealing and shearing instruments such as harmonic scalpel or vessel-sealing devices. In robotic surgery, monopolar cautery is an important energy source that is still continuously employed on the dissecting scissors. As such, judicious application is mandatory. The surgeon should ensure that all bowel structures are away from the tip of the instrument for minimizing thermal spread. Instruments with thermal energy at the tip should be always in the field of vision. In laparoscopic surgery, the shaft of all instruments should be inspected before surgery so that no thermal injuries can occur along the shaft of the instrument out of the surgical field. The surgeon should inspect the surgical field on laparoscopic and robotic exit.

In robotic surgery, the console surgeon should be aware and directly visualize instrument introductions initially aiding the bedside assistant. The bedside assistant should exercise caution in gradual and slow instrument applications under direct vision before instrument memory on the robotic arm is achieved. The bedside assistant will have to be alert to any increased resistance when inserting a robotic instrument and needs to communicate with the console if resistance is encountered (Sotelo et al., 2016).

Conservative management of intraoperative thermal injury is ill advised. Most superficial bowel burns detected intraoperatively can be repaired with serosal Lambert sutures creating an extra serosal layer over the affected area of the bowel (Mert, 2015). When extensive burns are encountered, debridement and repair are mandatory with primary closure. Caution should be exercised as thermal spread could be beyond the level of the obvious serosal discoloration, and at times, a bowel resection and anastomosis with a formal open conversion may be necessary. Help from general surgery is advised when the initial repair does not seem to be optimal or a bowel diversion is sought.

Duodenal and Pancreatic Injuries During Nephrectomy

The duodenum is at risk for injury during right open, laparoscopic, and robotic renal procedures as kocherization of the duodenum is necessary for exposure of the renal hilum. Direct shearing or puncture injuries are encountered. Very minor trauma to any part of the duodenum leads to perforation, even when they are less than 5 mm with delayed presentation of fever, abdominal pain, and possible sepsis. Duodenal wall hematomas are another feared complication that could occur by compression. These hematomas can lead to prolonged obstructive ileus, demanding extended bowel rest, total parenteral nutrition, and lengthy hospital stay (Joshi and Sundaram, 2013). During left nephrectomy, similar attention should be paid to the tail of the pancreas, which is in close proximity to the upper pole of the left kidney and also the adrenal gland (Fig. 17.21). **Pancreatic injury is often associated with multiple complications related to uncontrolled pancreatic exocrine secretion, including pancreatic fistula, pseudocyst, and intra-abdominal abscess. Somatostatin analogues such as octreotide have been shown to decrease pancreas-related morbidity after major pancreatic resection in patients with pancreatic neoplasms and acute severe pancreatitis.** In one study, empirical use of octreotide for patients with pancreatic injury was questioned as patients treated with octreotide had a higher rate of fistula formation (48% vs. 40%), longer duration of fistula drainage, and longer hospital stay compared with untreated patients (Nwariaku et al., 1995). When obvious injury is encountered, distal pancreatectomy is employed intraoperatively. **Delayed presentation of pancreatic injury can occur postoperatively. Increased clear fluid drainage from the drain site and increased amylase in the drain fluid can be diagnostic.** Computed tomography is necessary to ensure that there are no large undrained collections. Additional drains can be placed as needed. In patients with no drains in whom the pancreatic injury was not detected intraoperatively, postoperative management includes percutaneous drain placement and somatostatin. The patient will need to be on bowel rest, nasogastric suction, and nutritional support (Debi et al., 2013). When drainage does not subside, distal pancreatectomy may be necessary.

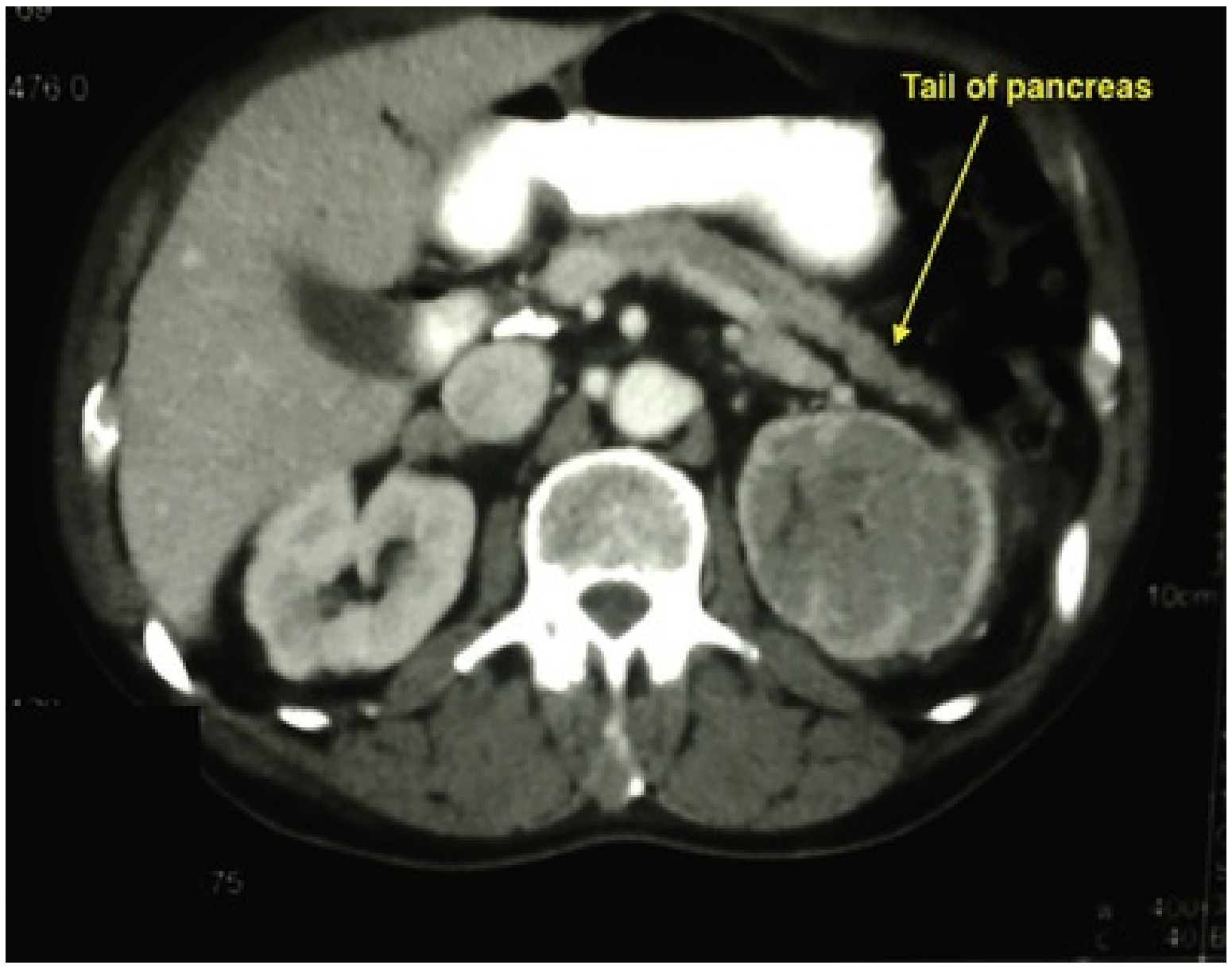

FIG, 17.21 Axial computed tomography image revealing the proximity of the tail of the pancreas to the upper pole of the kidney with a large upper pole mass.

Rectal Injury

Rectal injuries are a feared complication of difficult prostatectomies. With the advent of robotic prostatectomy, they remain a complication that is a concern during the learning curve of the operation. It is the most common bowel complication in radical prostatectomy. Significantly higher rectal injury rates have been reported for laparoscopic radical prostatectomy (1.0%) versus robotic radical prostatectomy (0.3%) and open radical prostatectomy (0.5%) (Tewari et al., 2012). **The incidence of rectal injury is the same for open and robotic prostatectomy, but the risk is higher in salvage prostatectomy.** In a recent review of 24,178 patients, the incidence of rectal injury was 0.47% for patients who underwent open or robotic prostatectomy and 6.86% for patients undergoing salvage prostatectomy. Besides salvage prostatectomy, local tumor stage, Gleason grade, lymph node status, and surgical experience, but not surgical approach (robotic vs. open), could be identified as risk factors for rectal injury in univariate and multivariate analyses (Mandel et al., 2018).

A higher level of experience and expertise is needed for salvage radical prostatectomy as rectal injury in this subgroup is reported to be around 6.8% in some series (Yuh et al., 2014, Mandel et al., 2018). In these complex cases, the risk for fistula formation is real. The overall incidence of rectoanastomosis fistula after radical prostatectomy in general is less than 0.1%. The extent of rectal laceration, prior radiation, and intraoperative signs of rectal infiltration are associated with development of a subsequent recto-anastomosis fistula (Mandel et al., 2018).

Surgery after transurethral resection of the prostate gland, microwave thermotherapy, or recurrent prostatitis is among other scenarios after which radical prostatectomy could be challenging. The intense fibrosis and changes in periprostatic tissues account for most of the difficulties encountered during surgery. The most common site of rectal injury in robotic prostatectomy is near the apex during a posterior dissection. Care should be taken to avoid electrocautery while dissecting on the anterior rectal wall as the posterior aspect of the prostate is dissected off the rectum. In cases in which intense fibrosis or difficulty in dissection is encountered, as in salvage prostatectomy, placement of a rectal EEA dilator may help in identification of the rectum. In salvage prostatectomies, consideration should be given to a modified bowel preparation in case a rectal perforation is encountered.

Management

Management consists of primary repair versus delayed repair and colostomy. **In the absence of gross fecal spillage, primary closure might be possible. This can be achieved with multilayer nonoverlapping sutures.** The rectal mucosa and serosa are closed with absorbable sutures. The perirectal tissues for bolstering the repair are closed with nonabsorbable sutures. The edges being sutured should be well-debrided and well-vascularized and approached tension-free. Usually, a two-layer repair can be performed approximating the lateral edges over the sutured repair (Yuh et al., 2014).

The integrity of the repair is assessed with a bubble test, which involves injecting air in the rectum through a Toomey syringe or a rectal tube while observing for air bubbles in the surgical field. Consideration is given to an omental or fat interposition if necessary and possible. A postoperative drain is mandatory. **Although minor rectal lacerations in a preoperatively prepped rectum can be repaired primarily, most moderate to extensive rectal injuries after salvage prostatectomy after radiation therapy are best managed with a diverting colostomy.** Postoperatively, a low-residue diet and broad-spectrum antibiotics are advised for 3 to 7 days.

Unrecognized rectal injuries can present in the immediate postoperative period. Depending on whether the procedure was open or robotic, leukopenia or leukocytosis can be present. Other symptoms include nausea, vomiting, ileus, focal pelvic pain lateralizing to one side, or frank peritonitis with an acute abdomen. Prompt evaluation with computed tomography of the abdomen and pelvis with rectal contrast or gastrograffin enema is usually enough to assess the injury and guide therapy. Surgical exploration with copious irrigation and diverting colostomy is usually the surgical procedure of choice to decrease the chance for sepsis and subsequent rectourethral fistula formation, because of the proximity of the urethrovesical anastomosis.

Port Site Hernia

The incidence of port site hernia in recent reviews ranges from 0.3% to 5.4%. Other factors identified in affecting port site hernia development include but are not limited to older age, previous hernia, operative time, and trocar size (Hussain et al., 2009). It presents usually as a painless bulge in mostly extraumbilical ports. The diagnosis can be confirmed by computed tomography (Fig. 17.22). The mean time to presentation is 9.6 days (1 to 54 days). It is more common in 12-mm trocars compared with 10-mm trocars (3.1% vs. 0.23%, respectively) (Kadar et al., 1993). Judicious use of trocars and the use of 5-mm trocars when sufficient can decrease the incidence of port site hernias. Recently, bladeless trocars are more commonly used. The fascial defect for a bladeless trocar is significantly smaller than for a bladed trocar of the same size (Pereira et al., 2016). Despite this, hernias associated with the use of 12-mm bladeless trocars have been reported in the literature (Park et al., 2012). A robotic 8-mm port off the midline would benefit from additional inspection as larger than expected fascial incisions can ensue secondary to excessive arm movements or extreme rotational maneuvers of the associated robotic arm. Although potentially offering greater patient cosmetic satisfaction, single-incision laparoscopic surgery (SILS) and laparoendoscopic single-site surgery (LESS) were associated with an increased incidence of incisional hernias (Buckley et al., 2016). In fact, larger incisions are required to accommodate multiple trocars through the access site, and many reviews suggest a higher incidence of umbilical hernia after single platform surgery at this anatomic site (Agaba et al., 2014).

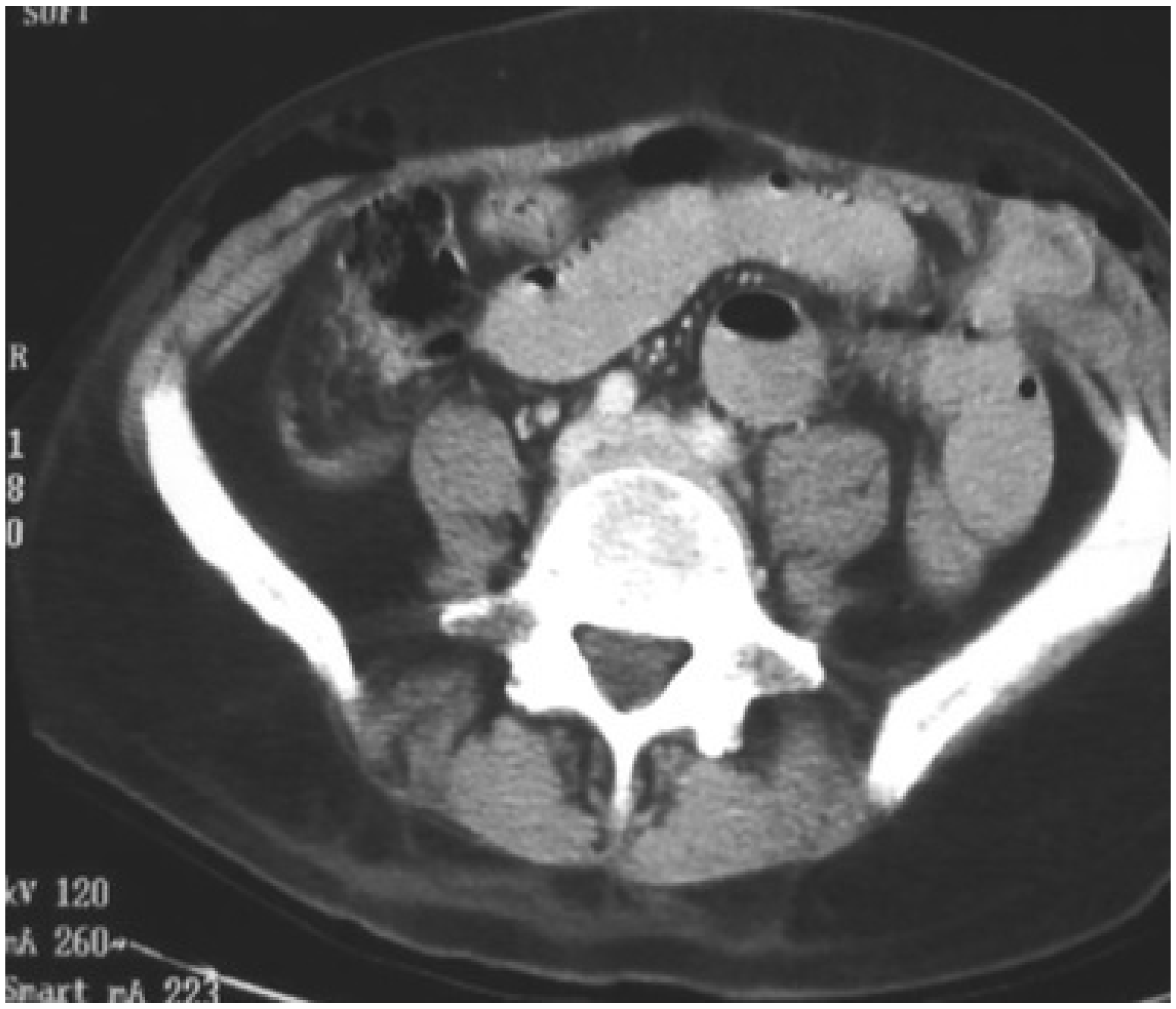

FIG. 17.22 Computed tomography image revealing a right lower quadrant port site hernia.

Closure of large fascial defects on the trocar sites with a single figure-of-eight absorbable suture with a fascial closure device will often suffice. In case of delayed presentation of a symptomatic or cosmetically unappealing port site hernia, most can be repaired laparoscopically or robotically with mesh interposition with excellent outcomes (Fig. 17.23).

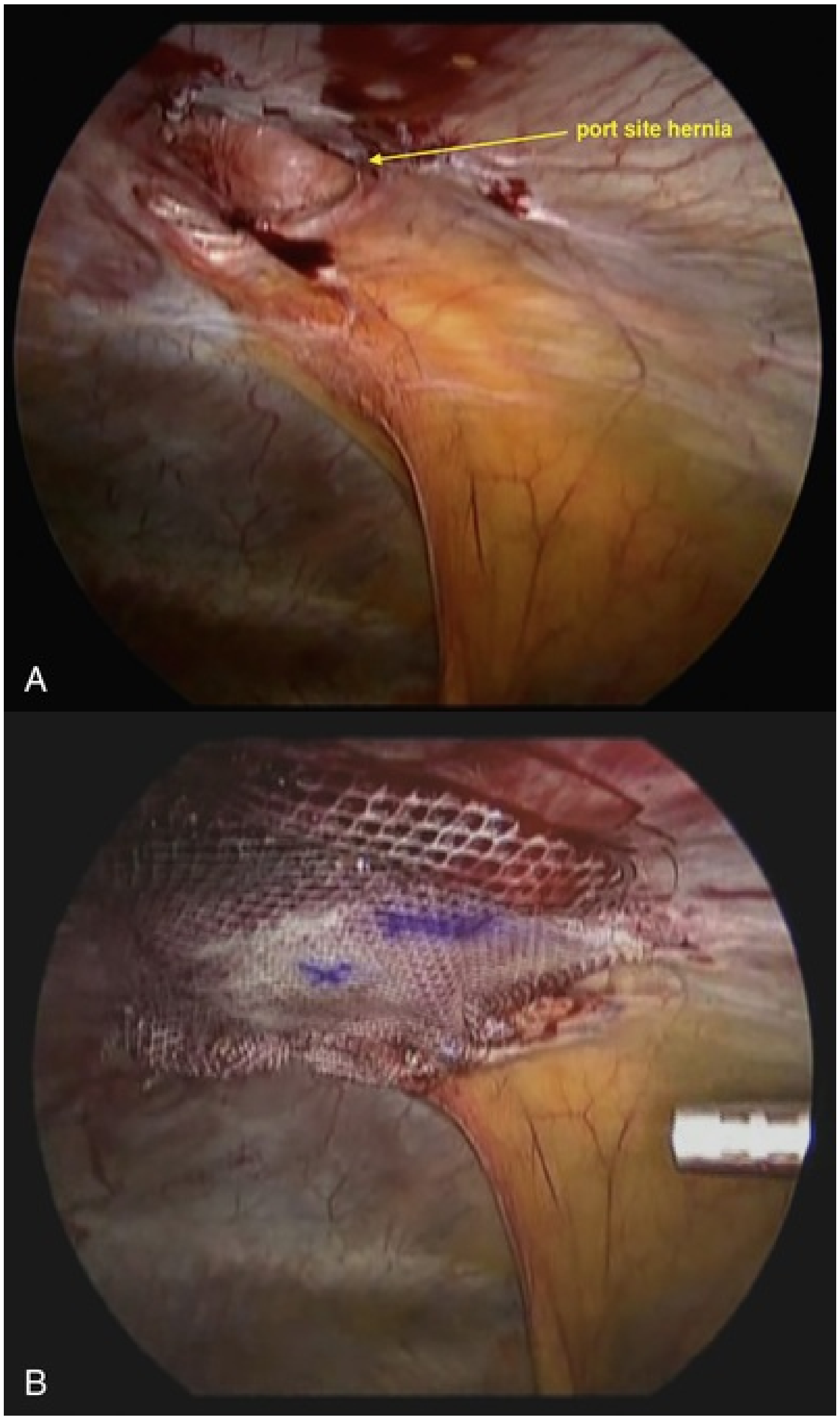

FIG. 17.23 (A) Laparoscopic view of a port site hernia. (B) Laparoscopic repair with mesh.

Venous Thromboembolism

The risk for venous thromboembolism (VTE) is increased with pelvic surgery, malignancy, obesity, and increased surgical times. Laparoscopic and robotic operations are on average longer than their open counterparts, especially during the initial learning curve of the surgeon. One might expect that the reverse Trendelenburg position and pneumoperitoneum (increased return from the legs) can create venous stasis and possibly increase the risk for DVT). Some have suggested that there is no evidence of increased incidence of DVT after laparoscopic surgery (Abdel-Meguid and Gomella, 1996). The true incidence of DVT and pulmonary embolism (PE) is not well known after laparoscopic urologic surgery. Secin et al. reported on a multi-institutional study of symptomatic DVT and PE after laparoscopic and robotic radical prostatectomy. Of the 5951 patients, 31 (0.5%) developed symptomatic VTE, 22 (71%) had DVT only, 4 had a PE without an identified DVT, and 5 had both a PE and DVT. Two patients died of PE. Smoking, large prostate size, patient re-exploration, longer operative times, and longer hospital stays were associated with VTE (Secin et al., 2008). A recent study addressed VTE after major urologic oncologic surgery with a focus on the incidence and timing of VTEs after 27,455 operations (Alberts et al., 2014). This was an American College of Surgeons National Surgical Quality Improvement Program (ACS NSQIP) study from 2005 to 2012. The risk for VTE for radical nephrectomy, partial nephrectomy, and radical nephroureterectomy was 1.1%. The risk for VTE in minimally invasive radical and partial nephrectomy was 0.7%. The risk for VTE after radical prostatectomy and radical cystectomy was 1.1% and 5.5%, respectively. The majority of VTEs occurred after discharge (82.6% after radical prostatectomy) (Alberts et al., 2014).

There are no consensus guidelines for VTE prophylaxis, and its utilization is variable. One recent population-based study of nationwide practices of 94,709 men who underwent radical prostatectomy was published. In this study, 52.2% used mechanical VTE prophylaxis only, 7.2% used pharmacologic prophylaxis, 10.6% used a combination of the two, and surprisingly 30% used no VTE prophylaxis (Weinberg et al., 2014). Patient- and procedure-specific risk factors also must be taken into account. It is important to adhere to local hospital policies on VTE prevention and prophylaxis. Data regarding thromboprophylaxis remains sparse to date, and current therapies employed depend mostly on local hospital policies to help assess the patient's risk factors and predisposition for DVT development. In an AUA best practice statement for the prevention of DVT released in 2009, patient risk stratification was introduced based on clinical characteristics of the patient and procedure being performed (Forrest et al., 2009). This helped identify patients at high risk for DVT development (e.g., age older than 60 years, prior thromboembolic events, cancer, hypercoagulable state) in whom pharmacologic prophylaxis is mandatory.

Older age, previous VTE or family history of VTE, presence of malignancy or obesity, and inherited or acquired coagulable states are risk factors. It is important to risk-stratify patients for their individual risk. There are no universally accepted method of VTE risk assessment. **The most widely used method for risk stratification is the Caprini score, modified by The American College of Chest Physicians** (Caprini, 2010; Gould et al., 2012). The system assigns an appointed value to each risk factor according to the relative risk for VTE based on the literature. The points are then totaled for a score (Table 17.2). **Patients are classified as very low risk (score 0), low risk (score 1 to 2), moderate risk (score 3 to 4) and high risk (score ≥5)** (Table 17.3). This model is validated and can be applied to patients undergoing urologic surgery.

TABLE 17.2

The Caprini Risk Assessment Model

1 POINT	2 POINTS	3 POINTS	5 POINTS
Age 41–60 y	Age 61–74 y	Age ≥75 y	Stroke (<1 mo)
Minor surgery	Arthroscopic surgery	History of VTE	Elective arthroplasty
BMI >25 kg/m^2	Major open surgery (>45 min)	Family history of VTE	Hip, pelvis, or leg fracture
Swollen legs	Laparoscopic surgery (>45 min)	Factor V Leiden	Acute spinal cord injury (<1 mo)
Varicose veins	Malignancy	Prothrombin 20210A	
Pregnancy or postpartum	Confined to bed (>72 h)	Lupus anticoagulant	
History of unexplained or recurrent spontaneous abortion	Immobilizing plaster cast	Anticardiolipin antibodies	
Oral contraceptives or hormone replacement	Central venous access	Elevated serum homocysteine	
Sepsis (<1 mo)		Heparin-induced thrombocytopenia	
Serious lung disease,		Other congenital or	

including pneumonia (<1 mo)		acquired thrombophilia	
Abnormal pulmonary function			
Acute myocardial infarction			
Congestive heart failure			
History of inflammatory bowel disease			
Medical patient at bed rest			

BMI, Body mass index; *min,* minutes; *mo,* month; *VTE,* venous thromboembolism; *y,* year.

From Gould MK, Garcia DA, Wren SM, et al.; American College of Chest Physicians: Prevention of VTE in nonorthopedic surgical patients: Antithombotic therapy and prevention of thrombosis, 9th ed: American College of Chest Physician Evidence-Based Clinical Practice Guidelines. *Chest* 141(2 suppl):e227S–e277S, 2012.

TABLE 17.3

Recommendations for Thromboprophylaxis in Various Risk Groups

RISK AND CONSEQUENCES OF MAJOR BLEEDING		
RISK FOR SYMPTOMATIC VTE	**AVERAGE RISK (~1%)**	**HIGH RISK (~2%) OR SEVERE CONSEQUENCES**
Very low (<0.5%)	No specific prophylaxis	No specific prophylaxis
Low (~1.5%)	IPC	IPC
Moderate (~3.0%)	LDUH, LMWH, *or* IPC	IPC
High (~6.0%)	LDUH or LMWH *plus* IPC	IPC until risk for bleeding diminishes and pharmacologic prophylaxis can be added
High-risk cancer surgery	LDUH or LMWH *plus* IPC and extended duration prophylaxis with LMWH postdischarge	IPC until risk for bleeding diminishes and pharmacologic prophylaxis can be added
High risk, LDUH an LMWH contraindicated or not available	Fondaparinux *or* low-dose aspirin (160 mg); IPC; or both	IPC until risk for bleeding diminishes and pharmacologic prophylaxis can be added

LDUH, Low-dose unfractionated heparin; *LMWH,* low–molecular-weight heparin; *IPC*, intermittent pneumatic compression; *VTE,* venous thromboembolism.

From Gould MK, Garcia DA, Wren SM, et al.; American College of Chest Physicians: Prevention of VTE in nonorthopedic surgical patients: Antithombotic therapy and prevention of thrombosis, 9th ed: American College of Chest Physician Evidence-Based Clinical Practice Guidelines. *Chest* 141(2 suppl):e227S–e277S, 2012.

In the majority of patients, DVT prophylaxis comprises mechanical prevention (i.e., early patient ambulation, intermittent pneumatic compression) and pharmacologic prevention (i.e., low–molecular-weight heparin or, less commonly, other agents such as unfractionated heparin).

Procedure-specific criteria for thromboprophylaxis are important considerations. General recommendations are tabulated in Table 17.3. **Very low-risk procedures require early and frequent ambulation.** This includes most transurethral and anti-incontinence procedures in which graduated compression stockings can be used as a safety measure. **In low-risk settings, mechanical prophylaxis with intermittent pneumatic compression or graduated compression stockings is sufficient. In patients with moderate risk, pharmacologic prophylaxis, preferably with low molecular weight heparin, is recommended, although low-dose unfractionated heparin or fondaparinux is acceptable. High-risk and very high-risk patients can be managed with low-molecular-weight heparin, low-dose unfractionated heparin, or fondaparinux. In these patients with multiple VTE risk factors, a pharmacologic method may be combined with mechanical methods.** As opposed to minimally invasive surgery, in major open surgery a more aggressive regimen combining sequential compression devices and efficient pharmacologic prophylaxis is recommended for prevention of DVT.

The optimal timing of DVT prophylaxis is not well known. **It is generally agreed that mechanical methods should commence just before surgery and that pharmacologic agents should ideally be started 2 to 12 hours preoperatively.** Fondaprarinux can be administered 6 to 8 hours after surgery. In practice, for high-risk patients, pharmacologic prophylaxis with subcutaneous heparin can be started just before or during most urologic procedures with no major risk for bleeding. Initiation of pharmacologic prophylaxis within 48 hours of surgery was not associated with an increased risk for intraoperative bleeding (Murphy et al., 2016). The length of treatment is another important aspect to consider because risk for DVT persists for an extended period postoperatively (Jordan et al., 2017). **In most cases, VTE prophylaxis should continue until the patient is fully ambulatory.** There is tremendous disparity in the definition of fully ambulatory patients. Despite early ambulation and mobilization, patients are still at increased risk for VTE as the risk persists for weeks after full mobilization (Amin et al., 2010). For most patients, prophylaxis beyond discharge is not currently recommended. However, data exist that there is an associated benefit with extended prophylaxis in major abdominal/pelvic surgery for patients with cancer. A recent meta-analysis of four randomized trials of patients undergoing major abdominal or pelvic surgery compared extended VTE prophylaxis with low-molecular-weight heparin for at least 1 month postoperatively versus VTE prophylaxis administered only during the in-hospital period. Extended VTE prophylaxis reduced the rate of VTE from 14% to 6% and the rate of symptomatic VTE from 2% to 0.2% without increasing the risk for bleeding (Rasmussen et al., 2009). Finally, in patients with a contraindication to anticoagulants or those with a high risk for intraoperative bleeding, mechanical methods should be employed preoperatively, and pharmacologic agents can be started or added postoperatively when adequate hemostasis is achieved and considered safe.

Lymphoceles

Lymphoceles are the most common complication caused by disruption of lymphatic drainage after pelvic lymph node dissection. They are lymph fluid-filled collections without an epithelial wall lining along major vessels, commonly the iliac vasculature. Lymphoceles were first described almost 50 years ago by Basinger and Gittes (Lebeis et al., 2015). It remains unclear whether the introduction of robotic and minimally invasive surgery is associated with suboptimal lymphostasis. However, the transperitoneal approach to robotic prostatectomy has been thought to be associated with a lower rate of lymphoceles because of theoretical peritoneal reabsorption of lymphatic fluid. **However, lymphoceles can still occur after transperitoneal operations in the deep pelvis, especially after pelvic lymphadenectomy, as loculations and retroperitonealization can occur as early as 48 to 72 hours postoperatively.** Reported incidence rates differ because of the variability of lymph node dissection templates and because most lymphoceles are asymptomatic. Lymphocele rates can range from 4.6% when limited lymphadenectomy is performed compared with as high as 10% when an extended nodal dissection is performed by the same group (Briganti et al., 2006). Lymphocele rates after major urologic oncologic series are summarized in Table 17.3. The techniques of lymphostasis using clips or bipolar devices have also been analyzed when applied on the femoral lymphatic channels. There is no robust data to suggest the best approach, although some results support the use of clips (Stolzenburg et al., 2017). Recently, the robotic vessel sealer has been advocated as an excellent instrument for nodal dissection allowing for the sealing of lymphatic channels as they are encountered. The lymphatic channels are effectively sealed obviating the need for indiscriminate application of Hem-o-Lok clips or titanium clips.

Most patients with lymphoceles are asymptomatic, and an incidental diagnosis is made on routine imaging or imaging performed for other reasons. Generally, asymptomatic lymphoceles smaller than 5 cm should be managed conservatively. When very large symptomatic lymphoceles develop with subsequent compressive symptoms on the iliac vasculature resulting in lymphostasis and lower extremity edema, pressure on the bladder, urinary frequency, and urgency, percutaneous drainage is warranted. Patients with delayed presentation are diagnosed with cross-sectional imaging (Fig. 17.24). **If the lymphocele is thick-walled and especially when a lymphocele reaccumulates after prior percutaneous drainage, laparoscopic drainage and marsupialization with a peritoneal window is warranted.** Aspiration is not advised as re-accumulation inevitably occurs and there is a risk for introduction of bacteria and infection. Sclerotherapy with agents like povidone-iodine or doxycycline have been attempted but could make surgical laparoscopic marsupialization into a peritoneal window more complex if subsequently necessary. Lymphocele infection is a feared complication, and urine leaks should always be part of the differential diagnosis. Patients can present with fever, chills, and signs of sepsis when superinfection of a large lymphocele is suspected. Treatment includes intravenous fluids and broad-spectrum antibiotics with percutaneous drainage.

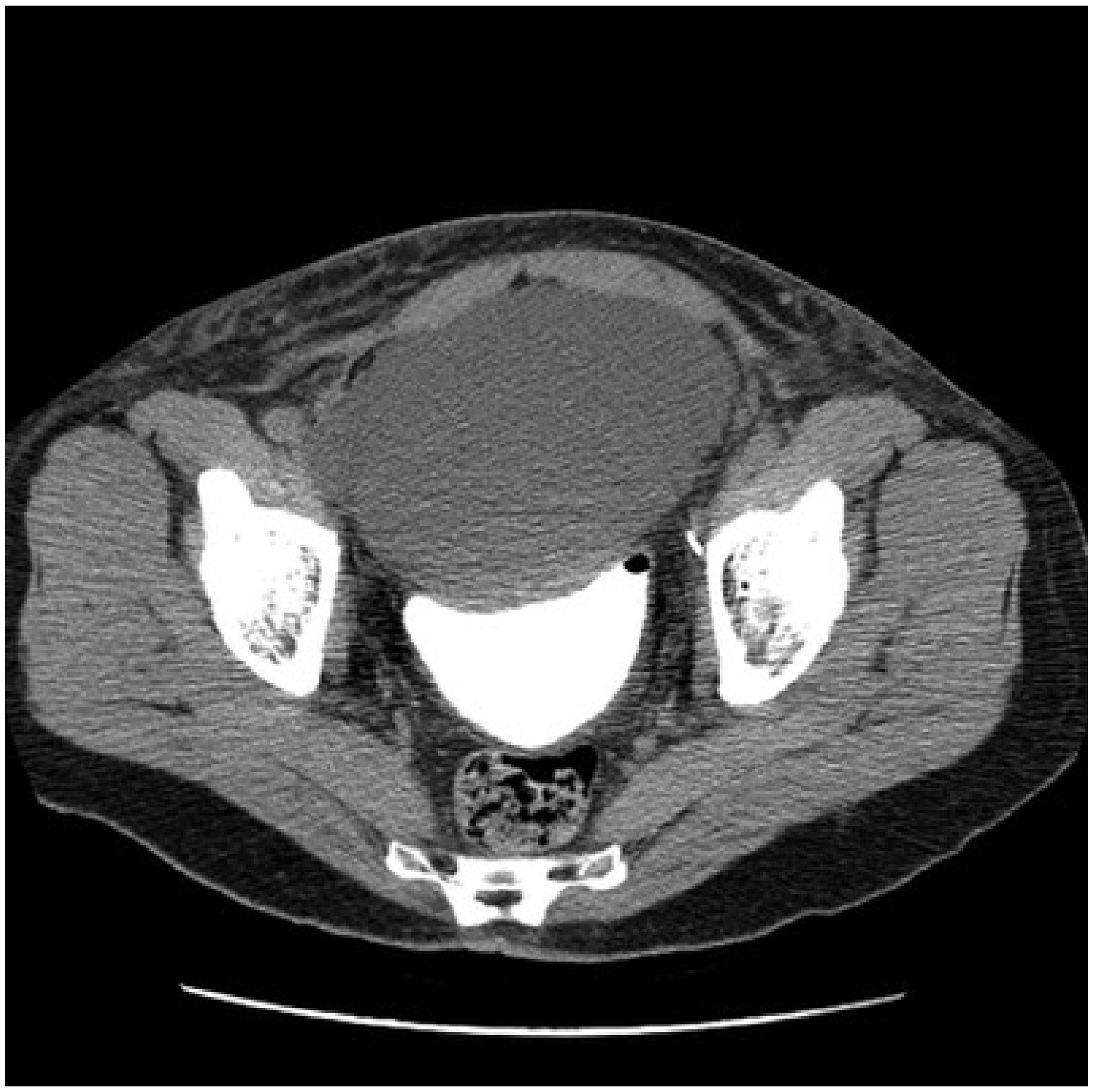

FIG. 17.24 Large lymphocele after robotic radical prostatectomy anterior to the bladder.

Inspection of the surgical field after pelvic lymph node dissection and radical upper tract surgery with or without lymphadenectomy is mandatory. Control of any apparent lymphatic vessels with clips and the use of bipolar sealing devices are crucial. Recently, use of adjunctive hemostatic agents such as fibrin sealants are advocated as an additional means for lymphostasis. Although designed for hemostasis, sealants can form a protective layer on lymphatic channels that run alongside smaller or large vessels, especially in the presence of minimal blood (Buelens et al., 2018). Preventive surgical techniques have been described to minimize the risk for lymphocele formation. Meticulous attention to detail during dissection is key. Lebeis et al. performed an interposition and fixation of the ipsilateral peritoneal flap on the bladder itself (Lebeis et al., 2015). Placement of a drain is advisable for most cases of major lymph node dissection, especially in the deep pelvis. The extraperitoneal or transperitoneal approach for radical prostatectomy does not seem to have any impact on the rate of symptomatic lymphocele formation in the current era of robotic surgery (Horovitz et al., 2017).

Conclusion

There is a wide array of complications that can occur in urologic surgery. The recent wide adoption of minimally invasive surgery, especially laparoscopic and robotic surgery, has introduced a new set of potential complications. With this, a new set of operative, diagnostic, and therapeutic skills are necessary to prevent, identify, and treat these complications. Although some complications are managed conservatively, many require medical and some require invasive intervention. Diagnostic and interventional radiology plays a crucial role in urologic complication detection and management. At times, minor or major operative intervention is needed. Although a high index of suspicion is key to the detection and diagnosis of a potential problem, prevention of complications remains the key to a more favorable surgical outcome. Judicious attention to patient selection, positioning, preoperative planning, and meticulous surgical technique is the hallmark of complication prevention.

Key Points

- A wide array of physiologic, urinary, vascular, bowel, and visceral complications can occur with all forms of urologic operations.
- With the wide adoption of laparoscopic and robotic surgery in urology, a unique set of complications is encountered.
- As more complex operations are performed in a minimally invasive fashion, the rate of complications can increase.
- Some complications after laparoscopic and robotic procedures can present in an atypical and delayed fashion.
- A high index of suspicion is necessary for prompt and timely intraoperative and postoperative diagnosis and management.
- The most important aspect of complication management is complication prevention with adequate planning, attention to detail, and meticulous surgical technique.

References

Abdel-Meguid TA, Gomella LG. Prevention and management of complications. Smith AD, Badlani GH, Bagley DH. *Smith's textbook of endourology*. Quality Medical: St. Louis, MO; 1996:851–869.

Agaba EA, Rainville H, Ikedilo O, et al. Incidence of port-site incisional hernia after single-incision laparoscopic surgery. *JSLS*. 2014;18(2):204–210.

Ahmad G, Gent D, Henderson D, et al. Laparoscopic entry techniques. *Cochrane Database Syst Rev*. 2015;(8) [CD006583].

Alberts BD, Woldu SL, Weinberg AC, et al. Venous thromboembolism after major urologic oncology surgery: a focus on the incidence and timing of thromboembolic events after 27,455 operations. *Urology*. 2014;84(4):799–806.

Amin AN, Girard F, Samama MM. Does ambulation modify thromboembolism risk in acutely ill medical patients? *Thrombo Haemost*. 2010;104(5):955.

Bates AS, Patel VR. Applications of indocyanine green in robotic urology. *J Robot Surg*. 2016;10(4):357–359.

Bishoff JT, Allaf ME, Kirkels W, et al. Laparoscopic bowel injury: incidence and clinical presentation. *J Urol*. 1999;161:887–890.

Blackwell RH, Kirshenbaum EJ, Shah AS, et al. Complications of recognized and unrecognized iatrogenic ureteral injury at time of hysterectomy: a population based analysis. *J Urol*. 2018;199(6):1540–1545.

Breda A, Finelli A, Janetschek G, et al. Complications of laparoscopic surgery for renal masses: prevention, management, and comparison with the open experience. *Eur Urol*. 2009;55(4):836–850.

Briganti A, Chun FK, Salonia A, et al. Complications and other surgical outcomes associated with extended pelvic lymphadenectomy in men with localized prostate cancer. *Eur Urol*. 2006;50:1006–1013.

Brown SL, Woo EK. Surgical stapler-associated fatalities and adverse events reported to the Food and Drug Administration. *J Am Coll Surg*. 2004;199(3):374–381.

Buckley FP 3rd, Vassaur HE, Jupiter DC, et al. Influencing factors for port-site hernias after single-incision laparoscopy. *Hernia*. 2016;20(5):729–733.

Buelens S, Van Praet C, Poelaert F, et al. Prospective randomized controlled trial exploring the effect of TachoSil on lymphocele formation after extended pelvic lymph node dissection in prostate cancer. *Urology*. 2018;118:134–140.

Cacciamani GE, Medina LG, Gill T, et al. Impact of surgical factors on robotic partial nephrectomy outcomes: comprehensive systematic review and meta-analysis. *J Urol*. 2018;200(2):258–274.

Campbell SC, Novick AC, Streem SB, et al. Complications of nephron sparing surgery for renal tumors. *J Urol*. 1994;151(5):1177–1180.

Campbell SP, Rowe SP, Gorin MA, et al. Renal pseudoaneurysm mimicking local cancer recurrence after partial nephrectomy. *Urol Case Rep*. 2016;11:1–3.

Caprini JA. Risk assessment as a guide for the prevention of the many faces of venous thromboembolism. *Am J Surg*. 2010;199(1 Suppl):S3–S10.

Chen J, Yang M, Wu P, et al. Renal arterial pseudoaneurysm and renal arteriovenous fistula following partial nephrectomy. *Urol Int*. 2018;100(3):368–374.

Choi JE, You JH, Kim DK, et al. Comparison of perioperative outcomes between robotic and laparoscopic partial nephrectomy: a systematic review and meta-analysis. *Eur*

Urol. 2015;67(5):891–901.

Chu W, Chien GW, Finley DS. Novel ureteroscopic technique for treatment of prolonged caliceal leak after partial nephrectomy. *J Endourol*. 2015;29(4):397–400.

Clavien PA, Barkun J, de Oliveira ML, et al. The Clavien-Dindo classification of surgical complications: five-year experience. *Ann Surg*. 2009;250(2):187–196.

Coakley KM, Kasten KR, Sims SM, et al. Prophylactic ureteral catheters for colectomy: a national surgical quality improvement program-based analysis. *Dis Colon Rectum*. 2018;61(1):84–88.

Colombo JR, Haber GP, Jelovsek JE, et al. Complications of laparoscopic surgery for urological cancer: a single institution analysis. *J Urol*. 2007;178(3 Pt 1):786–791.

Dindo D, Demartines N, Clavien PA. Classification of surgical complications: a new proposal with evaluation in a cohort of 6336 patients and results of a survey. *Ann Surg*. 2004;240(2):205–213.

Darbyshire D, Dukic I, Ali Z, et al. Conservative management of renal artery pseudoaneurysm following partial nephrectomy. *Ann R Coll Surg Engl*. 2014;96(2):e17–e18.

Davenport K, Timoney AG, Keeley FX, Members of the Baus Section of Endourology, et al. A 3-year review of The British Association of Urological Surgeons Section of Endourology Laparoscopic Nephrectomy Audit. *BJU Int*. 2006;97(2):333–337.

De la Rosette JJ, Opondo D, Daels FP, CROES PCNL Study Group, et al. Categorisation of complications and validation of the Clavien score for percutaneous nephrolithotomy. *Eur Urol*. 2012;62(2):246–255.

Debi U, Kaur R, Prasad KK, et al. Pancreatic trauma. *World J Gastroenterol*. 2013;19(47):9003–9011.

Elkoushy MA, Luz MA, Benidir T, et al. Clavien classification in urology: is there concordance among post-graduate trainees and attending urologists? *Can Urol Assoc J*. 2013;7(5–6):179–184.

Fahlenkamp D, Rassweiler J, Fornara P, et al. Complications of laparoscopic procedures in urology: experience with 2407 procedures at 4 German centers. *J Urol*. 1999;162(3 Pt 1):765–770.

Fenig DM, Slova D, Lepor H. Postoperative blood loss predicts the development of urinary extravasation on cystogram following radical retropubic prostatectomy. *J Urol*. 2006;175(1):146–150.

Forrest JB, Clemens JQ, Finamore P, American Urological Association, et al. AUA Best Practice Statement for the prevention of deep vein thrombosis in patients undergoing urologic surgery. *J Urol*. 2009;181(3):1170–1177.

Girard F, Thanigasalam R, Theveniaud PE, et al. Prolonged urinary leakage after partial nephrectomy: a novel management pathway. *Urology*. 2014;83(2):485–488.

Gnanapragasam V, Baker P, Naisby GP, et al. Identification and validation of risk factors for vesicourethral leaks following radical retropubic prostatectomy. *Int J Urol*. 2005;12(11):948–952.

Gould MK, Garcia DA, Wren SM, American College of Chest Physicians, et al. Prevention of VTE in nonorthopedic surgical patients: antithombotic therapy and prevention of thrombosis, 9th ed: American College of Chest Physician Evidence-Based Clinical Practice Guidelines. *Chest*. 2012;141(2 Suppl):e227S–e277S.

Gözen AS, Aktoz T, Akin Y, et al. Is it possible to draw a risk map for obturator nerve injury during pelvic lymph node dissection? The Heilbronn experience and a review of the literature. *J Laparoendosc Adv Surg Tech A*. 2015;25(10):826–832.

Gratzke C, Dovey Z, Novara G, et al. Early catheter removal after robot-assisted radical prostatectomy: surgical technique and outcomes for the Aalst technique (ECaRemA Study). *Eur Urol*. 2016;69(5):917–923.

Gupta N, Patel A, Ensor J, et al. Multiple renal artery pseudoaneurysms in patients undergoing renal artery embolization following partial nephrectomy: correlation with RENAL nephrometry scores. *Cardiovasc Intervent Radiol*. 2017;40(2):202–209.

Hakimi AA, Faleck DM, Sobey S, et al. Assessment of complication and functional outcome reporting in the minimally invasive prostatectomy literature from 2006 to the present. *BJU Int*. 2012;109:26.

Hakimi AA, Ghavamian R. Urinary and urologic complications of laparoscopic and robotic urologic surgeries. Ghavamian R. *Complications of laparoscopic and robotic urologic surgery*. 1st ed. Springer: New York, NY; 2010:59–71.

Han KS, Choi HJ, Jung DC, et al. A prospective evaluation of conventional cystography for detection of urine leakage at the vesicourethral anastomosis site after radical prostatectomy based on computed tomography. *Clin Radiol*. 2011;66:251.

Hefermehl LJ, Largo RA, Hermanns T, et al. Lateral temperature spread of monopolar, bipolar and ultrasonic instruments for robot assisted lapaprsocopic surgery. *BJU Int*. 2013;114(2):245–252.

Heyn J, Ladurner R, Ozimek A, et al. Gluteal compartment syndrome after prostatectomy caused by incorrect positioning. *Eur J Med Res*. 2006;11(4):170–173.

Hoffman MS, Finan M. Ureteral transection repaired during robot-assisted surgery. *J Robot Surg*. 2013;7(1):81–82.

Horovitz D, Lu X, Feng C, et al. Rate of symptomatic lymphocele formation after extraperitoneal vs transperitoneal robot-assisted radical prostatectomy and bilateral pelvic lymphadenectomy. *J Endourol*. 2017;31(10):1037–1043.

Hsi RS, Saint-Elie DT, Zimmerman GJ, et al. Mechanisms of hemostatic failure during laparoscopic nephrectomy: review of Food and Drug Administration database. *Urology*. 2007;70(5):888–892.

Hussain A, Mahmood H, Singhal T, et al. Long-term study of port-site incisional hernia after laparoscopic procedures. *JSLS*. 2009;13(3):346–349.

Hyams ES, Pierorazio P, Proteek O, et al. Iatrogenic vascular lesions after minimally invasive partial nephrectomy: a multi-institutional study of clinical and renal functional outcomes. *Urology*. 2011;78(4):820–826.

Jain S, Nyirenda T, Yates J, et al. Incidence of renal artery pseudoaneurysm following open and minimally invasive partial nephrectomy: a systematic review and comparative analysis. *J Urol*. 2013;189(5):1643–1648.

Jordan BJ, Matulewicz RS, Trihn B, et al. Venous thromboembolism after nephrectomy: incidence, timing and associated risk factors from a national multi-institutional database. *World J Urol*. 2017;35(11):1713–1719.

Joshi SS, Sundaram CP. Small bowel injury during laparoendoscopic single-site surgery for simple nephrectomy. *JSLS*. 2013;17(1):167–169.

Joy P, Simon B, Prithishkumar IJ, et al. Topography of inferior epigastric artery relevant to laparoscopy: a CT angiographic study. *Surg Radiol Anat*. 2016;38(3):279–283.

Kadar N, Reich H, Liu CY, et al. Incisional hernias after major laparoscopic gynecologic procedures. *Am J Obstet Gynecol*. 1993;168(5):1493–1495.

Kai Wen Chuang, Wayn Zaretz, Susan Gordon. Complications of surgical positioning AUA Update Series. 2011 [Vol 30, Lesson 17].

Keene R, Froelich JM, Milbrandt JC, et al. Bilateral gluteal compartment syndrome following robotic-assisted prostatectomy. *Orthopedics*. 2010;33(11):852.

Kenney PA, Tuerk IA. Complications of laparoscopic retroperitoneal lymph node dissection in testicular cancer. *World J Urol*. 2008;26:561–569.

Kiran A, Hilton P, Cromwell DA. The risk of ureteric injury associated with hysterectomy: a 10-year retrospective cohort study. *BJOG*. 2016;123(7):1184–1191.

Kondo T, Takagi T, Morita S, et al. Early unclamping might reduce the risk of renal artery pseudoaneurysm after robot-assisted laparoscopic partial nephrectomy. *Int J Urol*. 2015;22(12):1096–1102.

Kwazneski D 2nd, Six C, Stahlfeld K. The unacknowledged incidence of laparoscopic stapler malfunction. *Surg Endosc*. 2013;27(1):86–89.

Larobina M, Nottle P. Complete evidence regarding major vascular injuries during laparoscopic access. *Surg Laparosc Endosc Percutan Tech*. 2005;15(3):119–123.

Laurence JM, Lam VW, Langcake ME, et al. Laparoscopic hepatectomy, a systematic review. *ANZ J Surg*. 2007;77:948–953.

Lebeis C, Canes D, Sorcini A, et al. Novel technique prevents lymphoceles after transperitoneal robotic-assisted pelvic lymph node dissection: peritoneal flap interposition. *Urology*. 2015;85:1505–1509.

Li J, Chen Z, Zhu Q, et al. Early repair of pelvic and abdominal nonurological surgery-induced iatrogenic ureteral injuries in three distinct waiting-for-repair time periods. *Am Surg*. 2012;78(11):1270–1275.

Loeb S, Partin AW, Schaeffer EM. Complications of pelvic lymphadenectomy: do the risks outweigh the benefits? *Rev Urol*. 2010;12(1):20–24.

Lonergan PE, Farrelly C, Geoghegan T, et al. Asymptomatic renal pseudoaneurysm following laparoscopic partial nephrectomy. *Urology*. 2016;94:e5–e6.

Mandel P, Linnemannstons A, Chun F, et al. Incidence, risk factors, management and complications of rectal injuries during radical prostatectomy. *Eur Urol Focus*. 2018;4(4):554–557.

Marcelissen TA, Den Hollander PP, Tuytten TR, et al. Incidence of iatrogenic ureteral injury during open and laparoscopic colorectal surgery: a single center experience and review of the literature. *Surg Laparosc Endosc Percutan Tech*. 2016;26(6):513–515.

Meeks JJ, Zhao LC, Navai N, et al. Risk factors and management of urine leaks after partial nephrectomy. *J Urol*. 2008;180(6):2375–2378.

Mendoza D, Newman RC, Albala D, et al. Laparoscopic complications in markedly obese urologic patients (a multi-institutional review). *Urology*. 1996;48(4):562–567.

Mert AK, Kursat C, et al. Gastrointestinal complications of laparoscopic/robot-assisted urologic surgery and a review of the literature. *J Clin Med Res*. 2015;7(4):203–210.

Mills JT, Burris MB, Warburton DJ, et al. Positioning injuries associated with robotic assisted urological surgery. *J Urol*. 2013;190(2):580–584.

Minervini A, Davenport K, Pefanis G, et al. Prospective study comparing the bladeless optical access trocar versus Hasson open trocar for the establishment of pneumoperitoneum in laparoscopic renal procedures. *Arch Ital Urol Androl*. 2008;80(3):95–98.

Mitropoulos D, Artibani W, Biyani CS, et al. Validation of the Clavien-Dindo Grading System in Urology by the European Association of Urology Guidelines Ad Hoc panel. *Eur Urol Focus*. 2018;4(4):608–613.

Mochtar CA, Kauer PC, Laguna MP, et al. Urinary leakage after laparoscopic radical prostatectomy: a systematic review. *J Endourol*. 2007;21:1371.

Moinzadeh A, Abouassaly R, Gill IS, et al. Continuous needle vented Foley catheter suction for urinary leak after radical prostatectomy. *J Urol*. 2004;171:2366.

Molloy D, Kaloo PD, Cooper M, et al. Laparoscopic entry : a literature review and analysis of techniques and complications of primary port entry. *Aust N Z J Obstet Gyneceaol*. 2002;42:246–254.

Mumtaz FH, Chew H, Gelister JS. Lower limb compartment syndrome associated with the lithotomy position: concepts and perspectives for the urologist. *BJU Int*. 2002;90(8):792–799.

Murphy PB, Sothilingam N, Charyk Stewart T, et al. Very early initiation of chemical thromboembolism prophylaxis after blunt solid organ injury is safe. *Can J Surg*. 2016;59(2):118–122.

Musch M, Hohenhorst L, Pailliart A, et al. Robot-assisted reconstructive surgery of the distal ureter: single institution experience in 16 patients. *BJU Int*. 2013;111(5):773–783.

Nies C. Anatomy of the retroperitoneum from the viewpoint of minimally invasive surgery. *Chirurg*. 1998;69(6):597–603.

Nwariaku FE, Terracina A, Mileski WJ, et al. Is Octreotide beneficial following pancreatic injury? *Am J Surg*. 1995;170:582–585.

Ogaya-Pinies G, Kadakia Y, Palayapalayam-Ganapathi H, et al. Use of scaffolding tissue biografts to bolster vesicourethral anastomosis during salvage robot-assisted prostatectomy reduces leak rates and catheter times. *Eur Urol*. 2018;74(1):92–98.

Papanikolaou A, Tsolakidis D, Theodoulidis V, et al. Surgery for ureteral repair after gynaecological procedures: a single tertiary centre experience. *Arch Gynecol Obstet*.

2013;287(5):947–950.

Pardalidis P, Andriopoulos N, Kosmaoglou E, et al. Massive dilation of the ureter: an endoscopic management of persistent urinary leak after partial nephrectomy. *J Endourol Case Rep*. 2017;3(1):186–188.

Park MG, Kang J, Kim JY, et al. Trocar site hernia after the use of 12-mm bladeless trocar in robotic colorectal surgery. *Surg Laparosc Endosc Percutan Tech*. 2012;22(1):e34–e36.

Parsons JK, Varkarakis I, Rha KH, et al. Complications of abdominal urologic laparoscopy: longitudinal five-year analysis. *Urology*. 2004;63(1):27–32.

Passerotti CC, Cruz JA, Reis ST, et al. The effectiveness of a systematic algorithm for the management of vascular injuries during the laparoscopic surgery. *Curr Urol*. 2016;9(3):138–142.

Pereira Arias JG, Gamarra Quintanilla M, Leibar Tamayo A, et al. Complications and incidences in our first 250 robotic radical prostatectomies. *Actas Urol Esp*. 2010;34(5):428–439.

Pereira N, Hutchinson AP, Irani M, et al. 5-millimeter Trocar-site hernias after laparoscopy requiring surgical repair. *J Minim Invasive Gynecol*. 2016;23(4):505–511.

Permpongkosol S, Link RE, Su LM, et al. Complications of 2,775 urological laparoscopic procedures: 1993 to 2005. *J Urol*. 2007;177(2):580–585.

Pickett SD, Rodewald KJ, Billow MR, et al. Avoiding major vessel injury during laparoscopic instrument insertion. *Obstet Gynecol Clin North Am*. 2010;37(3):387–397.

Pini G, Leoni S. Sacral hitch vesical pexy: a new ancillary technique for ureteroneocystostomy. *Urologia*. 2011;78(4):274–282.

Potretzke AM, Knight BA, Zargar H, et al. Urinary fistula after robot-assisted partial nephrectomy: a multicentre analysis of 1 791 patients. *BJU Int*. 2016;117(1):131–137.

Ramani A, Desai M, Steinberg A, et al. Complications of laparoscopic partial nephrectomy in 200 cases. *J Urol*. 2005;173:42–47.

Rasmussen MS, Jorgensen LN, Wille-Jorgensen P. Prolonged thromboprophylaxis with low molecular weight heparin for abdominal or pelvic surgery. *Cochrane Database Syst Rev*. 2009;(1) [CD004318].

Rassweiler JJ, Rassweiler MC, Michel MS. Classification of complications: is the Clavien-Dindo classification the gold standard? *Eur Urol*. 2012;62(2):256–258.

Raza A, Byrne D, Townell N. Lower limb (well leg) compartment syndrome after urological pelvic surgery. *J Urol*. 2004;171(1):5–11.

Sammon J, Kim TK, Trinh QD, et al. Anastomosis during robot-assisted radical prostatectomy: randomized controlled trial comparing barbed and standard monofilament suture. *Urology*. 2011;78(3):572–579.

Schommer E, Gundian J, Thiel DD. “Pseudo” pseudoaneurysm following robotic assisted partial nephrectomy. *Can J Urol*. 2017;24(2):8773–8775.

Schwartz MJ, Faiena I, Cinman N, et al. Laparoscopic bowel injury in retroperitoneal surgery: current incidence and outcomes. *J Urol*. 2010;184(2):589–594.

Secin FP, Jiborn T, Bjartell AS, et al. Multi-institutional study of symptomatic deep venous thrombosis and pulmonary embolism in prostate cancer patients undergoing laparoscopic or robot-assisted laparoscopic radical prostatectomy. *Eur Urol*. 2008;53(1):134–145.

Shah G, Vogel F, Moinzadeh A. Nephroureteral stent on suction for urethrovesical anastomotic leak after robot-assisted laparoscopic radical prostatectomy. *Urology*. 2009;73(6):1375–1376.

Simms MS, Terry TR. Well leg compartment syndrome after pelvic and perineal surgery in the lithotomy position. *Postgrad Med J*. 2005;81(958):534–536.

Simon SD, Castle EP, Ferrigni RG, et al. Complications of laparoscopic nephrectomy: the Mayo clinic experience. *J Urol*. 2004;171(4):1447–1450.

Siqueira TM Jr, Kuo RL, Gardner TA, et al. Major complications in 213 laparoscopic nephrectomy cases: the Indianapolis experience. *J Urol*. 2002;168(4 Pt 1):1361–1365.

Sotelo RJ, Haese A, Machuca V, et al. Safer surgery by learning from complications: a focus on robotic prostate surgery. *Eur Urol*. 2016;69(2):334–344.

Stany MP, Farley JH. Complications of gynecologic surgery. *Surg Clin North Am*. 2008;88(2):343–359 [vii].

Stolzenburg JU, Kyriazis I, Liatsikos E. Postoperative lymphocele formation after pelvic lymph node dissection at the time of radical prostatectomy should not be considered an inevitable consequence of the approach. *Eur Urol*. 2017;71:159–160.

Strobl FF, D'Anastasi M, Hinzpeter R, et al. Renal pseudoaneurysms and arteriovenous fistulas as a complication of nephron-sparing partial nephrectomy: technical and functional outcomes of patients treated with selective microcoil embolization during a ten-year period. *Rofo*. 2016;188(2):188–194.

Takagi T, Kondo T, Tajima T, et al. Enhanced computed tomography after partial nephrectomy in early postoperative period to detect asymptomatic renal artery pseudoaneurysms. *Int J Urol*. 2014;21(9):880–888.

Tan G, Srivastava A, Grover S, et al. Optimizing vesicourethral anastomosis healing after robot-assisted laparoscopic radical prostatectomy: lessons learned from three techniques in 1900 patients. *J Endourol*. 2010;24:1975–1983.

Tare D, Maria P, Ghavamian R. Vascular complications in laparoscopic and robotic urologic surgery. Ghavamian R. *Complications of laparoscopic and robotic urologic surgery*. 1st ed. Springer: New York, NY; 2010:45–58.

Tewari A, Sooriakumaran P, Bloch DA, et al. Positive surgical margin and perioperative complication rates of primary surgical treatments for prostate cancer: a systematic review and meta-analysis comparing retropubic, laparoscopic, and robotic prostatectomy. *Eur Urol*. 2012;62:1–15.

Thomas MA, Rha KH, Ong AM, et al. Optical access trocar injuries in urological laparoscopic surgery. *J Urol*. 2003;170(1):61–63.

Tomaszewski JJ, Cung B, Smaldone MC, et al. Renal pelvic anatomy is associated with incidence, grade, and need for intervention for urine leak following partial nephrectomy. *Eur Urol*. 2014;66(5):949–955.

Van der Voort M, Heijnsdijk EA, Gouma DJ. Bowel injury as a complication of laparoscopy. *Br J Surg*. 2004;91(10):1253–1258.

Veneziano D, Poniatowski LH, Reihsen TE, et al. Preliminary evaluation of the SimPORTAL major vessel injury (MVI) repair model. *Surg Endosc*. 2016;30(4):1405–1412.

Venkatesh R, Landman J. Laparoscopic complications: gastrointestinal. Gill IS. *Textbook of laparoscopic urology*. Informa Healthcare USA: New York, NY; 2006:911–922.

Weinberg A, Wright J, Deibert C, et al. Nationwide practice patterns for the use of venous thromboembolism prophylaxis among men undergoing radical prostatectomy. *World J Urol*. 2014;32(5):1313–1321.

Wolf JS Jr, Marcovich R, Gill IS, et al. Survey of neuromuscular injuries to the patient and surgeon during urologic laparoscopic surgery. *Urology*. 2000;55(6):831–836.

Xia L, Wang X, Xu T, et al. Systematic review and meta-analysis of comparative studies reporting perioperative outcomes of robot-assisted partial nephrectomy versus open partial nephrectomy. *J Endourol*. 2017;31(9):893–909.

Yaycioglu O. Delayed complications. Ramakimar S, Jarrett T. *Complications of urologic laparoscopic surgery*. Taylor & Francis: Boca Raton, FL; 2005:149.

Yoon PD, Chalasani V, Woo HH. Use of Clavien-Dindo classification in reporting and grading complications after urological surgical procedures: analysis of 2010 to 2012. *J Urol*. 2013;190(4):1271–1274.

Yuh B, Ruel N, Muldrew S, et al. Complications and outcomes of salvage robot-assisted radical prostatectomy: a single-institution experience. *BJU Int*. 2014;113:769–776.

18

Urologic Considerations in Pregnancy

Melissa R. Kaufman MD, PhD

Physiologic Changes During Pregnancy

Pregnancy demands extensive adaptation to maternal anatomy, physiology, and metabolism. Such adaptations involve most organ systems, and basic understanding of these parameters will assist the urologist in determining the presence of pathology. This section outlines considerations that may affect treatment strategies for pregnant patients requiring urologic interventions.

Cardiovascular

Profound alterations in the cardiovascular system manifest during pregnancy to accommodate increased oxygen and nutrient demand from both the mother and fetus. Decreases in systemic vascular resistance caused by presence of the low-resistance placenta and vasodilation produced by progesterone and prostacyclin-mediated smooth muscle relaxation are evident even before uteroplacental circulation and represent the primary driver of subsequent cardiovascular alterations (Chapman et al., 1998). Resultant to such vascular resistance changes is a concomitant decrease in mean arterial pressure to an average of 10 mm Hg below baseline by the second trimester (Thadhani et al., 2001). Increases in sympathetic activity result in up to a 30% increase in maternal heart rate, which reaches a maximum at 20 weeks' gestation (Desai et al., 2004). Cardiac output (CO) is the product of stroke volume and heart rate, both of which increase as described earlier, thus pregnancy is accompanied by a massive CO increase beginning in early pregnancy and peaking on average at 30% to 50% above baseline preconception values (van Oppen et al., 1996). **In addition to the renal concerns outlined in the following section, it is critical for the urologic surgeon to consider the impact of positioning during surgical procedures with regard to maternal cardiac physiology.** CO in pregnancy is dependent on maternal position, and standard techniques for urology may pose unintended consequences. In the supine position, CO in the pregnant patient decreases by up to 30% at term compared with the lateral recumbent position (Clark et al., 1991). When supine, decreased blood return decreases stroke volume with a resultant drop in CO, which may occur abruptly. The gravid uterus may lessen venous return by compression of the inferior vena cava and less often, the aorta. Such aortocaval compression in the supine position is referred to as *supine hypotensive syndrome* and becomes more prominent as pregnancy progresses

(Toledano, 2014). Indeed, by late pregnancy, venous return from the lower extremities when a patient is supine may depend entirely on collateral circulation. General and regional anesthesia may impair sympathetic response to aortocaval compression with an inability to increase systemic vascular resistance, thus further reducing CO and hypotension. Aggressive management of maternal hypotension is critical to optimize uteroplacental perfusion during surgical procedure (Reitman and Flood, 2011). **Prevention of potential acute drops in venous return and CO may require avoidance of supine and lithotomy positions when feasible with right-side elevation to displace the uterus to the left.** Placement of a wedge may be logistically challenging, but achieving a 15- to 20-degree left tilt should reduce uterine compression of the inferior vena cava. Of note, venous compression by the expanding uterus additionally contributes to the clinical sequela of lower-extremity edema, varicosities, hemorrhoids, and critically, increased risk for deep venous thrombosis (DVT) (Antony et al., 2017; Pettker, 2017).

Respiratory

Intricate sequences of anatomic, hormonal, and metabolic alterations contribute to substantial changes in respiratory function during pregnancy. The configuration of the thoracic cage is altered during pregnancy secondary to relaxation of ligamentous attachments, with increased chest circumference by up to 7 cm (Antony et al., 2017). Diaphragmatic excursion is not impeded as gestation progresses because progesterone-mediated increases in diaphragmatic effort result in unchanged muscle function (Izci et al., 2003). Primary cranial displacement of the diaphragm up to 4 cm secondary to the expanding uterus in combination with pregnancy-related weight gain can mechanically constrict respiration. Diaphragmatic elevation, which can be up to 4 cm, decreases lung volume despite the chest wall expansion. This mechanical restriction manifests as a substantial reduction of parameters such as total lung capacity, expiratory reserve volume, and residual volume. Resultant decreases in functional residual capacity (FRC) may reach 80% of baseline values by term (Cruickshank et al., 1996). However, increased progesterone drives chronic hyperventilation, with up to a 50% increase in tidal volume by 8 weeks' gestation. This increased tidal volume drives up minute ventilation to increase alveolar oxygen and decrease alveolar carbon dioxide. Such decreased maternal serum carbon dioxide helps facilitate carbon dioxide transfer from the fetus and results in a chronic maternal respiratory acidosis. Compensation of this acidosis occurs partially from renal bicarbonate excretion.

Clinical implications for the urologist resulting from respiratory alterations in pregnancy are predominantly considerations of anesthesia and surgical positioning. Increased demand of the placenta, fetus, and maternal organs may increase oxygen consumption by up to 40% of nonpregnant levels, which lowers maternal oxygen reserves. In combination with decreased FRC, such compromise of maternal oxygen reserves creates an environment of higher susceptibility to events such as decreased oxygen saturation during intubation (Toledano, 2014). Upper airway alterations including edema of the oropharyngeal tissue, decrease in the glottic aperture, and mucosal friability complicate endotracheal tube placement and increase airway classification. Comorbidities such as obesity and preeclampsia further amplify induction issues. Supine positioning may additionally contribute to diminished FRC during general anesthesia.

Hematologic

Cardiovascular alterations in pregnancy are partially attributed to concomitant hematologic changes. Beginning at around 6 weeks' gestation, maternal blood volume progressively expands by an average of 40% to 50%. Such dramatic represents a combination of increases of both plasma volume and erythrocyte mass. However, plasma volume expansion exceeds red blood cell (RBC) mass, so maternal hematocrit decreases. Such physiologic anemia of pregnancy caused by dilutional effect reaches a nadir at 30 to 34 weeks and may be partially ameliorated by iron supplementation (Antony et al., 2017; Scott, 1972).

Additional expectations regarding hematologic issues include mild gestational thrombocytopenia (Burrows and Kelton, 1988). Platelet counts of less than 116,000 are exceedingly rare, and this threshold would mandate further evaluation, particularly in the perioperative period (Boehlen et al., 2000). However, although absolute counts decrease, there is no evidence of disruption of platelet function with intact ability to achieve hemostasis (Vincelot et al., 2001).

Indeed, for the consultant surgeon, an area of prominent importance is the state of hypercoagulability during gestation. Such hemostatic adaptation is necessary to avoid potential hemorrhage from the high-volume and low-resistance uteroplacental circulation. **Women manifest a 10-fold increased risk**

for thromboembolic disease during pregnancy as a result of a combination of venous stasis from inferior vena cava (IVC) compression and vascular trauma along with physiologic changes contributing to increases in plasma concentration of several procoagulants (Pettker, 2017). In addition to this Virchow triad of classic antecedents to venous thromboembolism (VTE), increased risk factors independent of pregnancy include age greater than 35 years, obesity, trauma, immobility, infection, smoking, nephrotic syndrome, coagulopathies, cancer, orthopedic surgery, and a history of venous thromboembolic disease. Although relatively uncommon, VTE remains a leading cause of maternal mortality and contributed to 9% of pregnancy-related deaths (Creanga et al., 2015). VTE includes DVT, primarily of the lower extremities, and pulmonary embolism, which predominantly arises from DVT.

Of concern for the consulting urologist is the independent risk for hospitalization associated with VTE, which was seventeen-fold higher than in a nonhospitalized cohort (Abdul Sultan et al., 2013). Surgical interventions during this high-risk period increase the potential complications of arrhythmia, hypoxia, pulmonary hypertension, and heart failure. Although most data in this population is regarding thromboprophylaxis for cesarean delivery, data may be extrapolated to pertain to urologic interventions. Periprocedural options to decrease VTE risk include nonpharmacologic interventions including graduated compression stockings and pneumatic compression, both of which have exceptionally favorable risk-benefit ratios (Zaccoletti and Zardini, 1992). In select high-risk circumstances with collaborative involvement of obstetrics and anesthesiology, low-dose unfractionated heparin may be appropriate therapy. Use of such therapeutic anticoagulation is contraindicated with most regional anesthesia, although unfractionated heparin may be reversed with administration of intravenous protamine sulfate. Additionally, when feasible, the left lateral decubitus position may reduce IVC compression and reduce the risk for postoperative DVT.

Of exceptional note for the urologist managing issues during pregnancy is the progressive rise in peripheral white blood cell (WBC) count during gestation. During the second and third trimesters, the mean WBC count is 8500/mm^3 (range 5600 to 12,200/mm^3) (Pitkin and Witte, 1979). This leukocytosis peaks during labor at levels up to 30,000/mm^3, complicating the use of WBC count during this period to assess for presence of infection.

Renal and Urinary Tracts

Remarkable demands on maternal resources facilitate adaptation of renal physiology during pregnancy, primarily secondary to hormonal coordination of volume expansion and vasodilation. Glomerular filtration rate (GFR) increases by 40% to 65% secondary to increased renal blood flow (Dunlop, 1981). **Increased GFR results in a decrease in serum levels of creatinine, urea, and uric acid. Of note, when determining the presence of potential renal impairment, average serum creatine during pregnancy decreases to 0.8 mg/dL** (Antony et al., 2017). Accompanying the decreased serum creatinine is a decrease in blood urea nitrogen (BUN) from an average of 13 mg/dL in nonpregnant women to 8 to 10 mg/dL during pregnancy. Renal tubular solute reabsorption compensates for renal losses because of increased GFR, balancing serum sodium. However, the threshold for stimulation of antidiuretic hormone release and thirst is decreased, resulting in a mild hyponatremia with serum sodium falling to 4 to 5 mmol/L below baseline.

Certainly, one of the most relevant parameters of interest to the urologist managing the pregnant patient is the physiologic alteration of renal function and structural changes to the upper and lower urinary tracts that occur. In addition to the metabolic changes, anatomic alterations are critical for understanding such that the urologist may discern typical findings from pathology.

Expectations during pregnancy include enlargement of the kidneys up to 1 cm. Increased size and weight is partially accounted for by dilation of the entire collecting system. **Historically on average, by term pelvicalyceal dilation is 15 mm on the right and 5 mm on the left and may be present in up to 90% of pregnancies** (Fried et al., 1983). More contemporary analysis encompassing 509 patients designed to provide sonographic reference data reported only rare dilations of the renal pelvis greater than 10 mm (Wadasinghe et al., 2016). Such dilation may begin very early in pregnancy, indicating that factors outside of mechanical compression play a role. Smooth muscle relaxation caused by higher circulating concentrations of progesterone, relaxin, and endothelin may contribute to dilation and increases in urinary dead space (Danielson et al., 1999; Gilson et al., 1992; Rasmussen and Nielsen, 1988). In fact, dilation may occur in patients with ectopic renal moieties, such as renal transplant in the pelvis. **Although smooth muscle relaxation may be a factor, mechanical compression by the gravid uterus exerts direct compression of the ureters, most predominantly on the right.** Such dilation begins by the second month and peaks during the second trimester, with ureteral diameter increasing by up to 2 cm. Discerning pathologic obstruction becomes increasingly complex, especially when combined with considerations for selective use of imaging studies to determine etiology (see Physiologic Hydronephrosis of Pregnancy later in this chapter). The clinical consequences of such collecting system distention may include increased incidence of pyelonephritis in patients with preexisting bacteriuria (see Management of Urinary Tract Infections in Pregnancy later in this chapter). Aside from rare cases with concomitant intra-abdominal pathology, expectations in the postpartum period are for complete resolution of hydroureteronephrosis.

Urine Chemistries During Pregnancy

Marked changes in renal tubular function during pregnancy result in a variety of alterations in urine chemistries that the urologist may encounter. Indeed, glycosuria during pregnancy is exceedingly common, with a 10- to 100-fold increase in urinary glucose excretion described (Antony et al., 2017). However, despite this well-documented glycosuria, the normal pattern during pregnancy is intermittent, and patients with repetitive findings should be screened by their obstetrician for diabetes.

Proteinuria and albuminuria additionally manifest during pregnancy and may increase as gestation advances. Secondary to hyperfiltration and potential reduction in tubular resorption, proteinuria during pregnancy is set at limits that exceed those of typical definitions in nonpregnant patients. In 24-hour collections, upper limits of 300 mg of proteinuria and 30 mg of albuminuria are expected, and increase from baseline occurs most dramatically in the first and second trimesters (Klein et al., 2014). Most urologists will encounter proteinuria on dipstick assessment, which is notoriously inaccurate in that renal concentration of urine is not accounted for with this method (Conrad et al., 2014). Patients with persistent proteinuria may benefit from further evaluation to rule out diabetes, preeclampsia, underlying renal disease, or urinary tract infection (UTI).

Due to fetal calcium requirements, maternal total calcium levels decline during pregnancy as reduced serum albumin results in fall of the albumin-bound fraction (Kovacs and Kronenberg, 1997). Consequently, calcinuria doubles during pregnancy. However, a physiologic parameter of importance, serum ionized calcium levels, are unchanged in the mother throughout the pregnancy.

Implications of this calcinuria on the development of urolithiasis are detailed in Urolithiasis in Pregnancy later in this chapter.

Hematuria in the Pregnant Patient

Anatomic changes during pregnancy caused by external compression from the gravid uterus may manifest in the bladder with an elevation of the trigone and increased vascularity. **Thus, microscopic hematuria is common with up to 20% of gravidas demonstrating idiopathic hematuria on dipstick urinalysis** (Antony et al., 2017; Stehman-Breen et al., 2002). Although benign in most instances, the presence of microscopic hematuria may suggest underlying pathology of exceptional impact. The most common etiologies for hematuria in pregnant patients include infection, urolithiasis, underlying renal disease, medications, trauma, obstruction, and tumors. Pregnancy-exclusive causes for hematuria include preeclampsia and placenta percreta. Further detail regarding placental abnormalities, infection, and malignancy are contained in subsequent sections of this chapter.

With regard to preeclampsia, microscopic hematuria may be found at a level of 2 to 8 times normal in these women. Preeclampsia is a systemic syndrome of pregnancy characterized by new-onset hypertension and proteinuria after 20 weeks' gestation (Maynard et al., 2016). Preeclampsia represents a critical diagnosis secondary to the risk for maternal mortality and compromised fetal outcomes. Determination of the correlation between early maternal microscopic hematuria and major adverse outcomes of pregnancy has been challenging to correlate, although most literature supports an association between idiopathic hematuria and the development of preeclampsia (Stehman-Breen et al., 2000; Stehman-Breen et al., 2002). In contradictory data, analysis of 700 pregnant women determined that 12.86% demonstrated asymptomatic idiopathic microscopic hematuria during early pregnancy, and of this population, no significant difference was revealed regarding incident pregnancy complications (Shahraki et al., 2016). A similar lack of correlation between early microscopic hematuria and preeclampsia, gestational hypertension, or small-for-gestational age infants was described in a cohort of over 900 pregnant women, thus the true implications of hematuria screening remains unclear (Brown et al., 2005).

Physiologic Hydronephrosis of Pregnancy

Critical for the consulting urologist is consideration of options for management of maternal hydronephrosis. A frequent concern from the consulting service is differentiation of physiologic versus pathologic findings, particularly in the presence of symptoms or history suspicious for anatomic obstruction. As surgeons are intimately aware, structure and function do not always correlate, and pathologic hydronephrosis is generally considered a rare entity. Of 30,552 women delivering at a single institution over a 3.5-year period, only 56 (0.2%) were admitted for symptomatic hydronephrosis (Fainaru et al., 2002). Indeed, a study of 81 gravid patients assessed longitudinally each trimester found poor correlation between symptoms of flank pain and hydronephrosis on ultrasound ($p = 0.39$) (Watson and Brost, 2006). In a prospective analysis of 51 consecutive patients at a mean gestational age of 27.5 weeks presenting with acute flank pain, maternal ultrasound and pain questionnaires discerned no correlation between the grade of hydronephrosis and pain intensity ($P = 0.466$) (Farr et al., 2017). These patients delivered at term with expected birth weights. Supporting studies stratifying 88 patients indicate that the degree of hydronephrosis does not impact ultimate outcomes of pregnancy with regard to birthweight ($P > 0.05$), although the maximal calyceal diameter was correlated to fetal weight at the time of diagnosis ($P = 0.02$) (Coban et al., 2015).

On exceptionally rare occasions, severe complications of physiologic hydronephrosis may arise, most notably the potential for calyceal rupture. First described in 1947, more than 30 case reports of this sporadic entity exist, with most of unknown etiology except for pregnancy (Boekhorst et al., 2015).

Management of symptomatic physiologic hydronephrosis in the absence of other pathologies such as calculi remains a dilemma for the urologist. A prospective randomized analysis between ureteral stenting and conservative measures demonstrated superiority for stenting with regard to symptomatic relief for moderate to severe hydronephrosis, which was offset by stent discomfort issues (Tsai et al., 2007). However, only 20% of the randomized patients were crossed over to the stent arm, implying that in most cases, conservative treatment should be favored. Conservative measures outlined in this study included analgesia, position, and intravenous fluids, and failure included signs of evolving infection or deteriorating renal function.

Supportive data for conservative therapies emerges from a case-controlled study of 53 women with symptomatic gestational hydronephrosis who were offered ureteral stenting (Cecen and Ulker, 2014). More than one-half (55%) elected conservative therapy, which again was composed of hydration, analgesia, and positioning maneuvers. Rates of complications, postpartum pain scores, or persistent hydronephrosis did not differ between groups ($P > 0.05$). The authors conclude that ureteral stent insertion in symptomatic gestational hydronephrosis does not generally add benefit over conservative treatment and should be reserved for complicated cases or additional pathologic obstructions. Analysis of 103 consecutive women with physiologic hydronephrosis revealed a 6% rate of intervention reserved for individuals manifesting overt symptoms of pyelonephritis (Puskar et al., 2001). Parameters that may increase the likelihood of surgical treatment with ureteral stenting for symptomatic hydronephrosis include maximal anterior-posterior renal pelvis diameter, parity, C-reactive protein level, WBC count, and pain on a visual analog scale (Ercil et al., 2017).

A variety of single-institution retrospective series exist supporting successful utilization of ureteral stenting for renal colic during pregnancy, although the studies are frequently contaminated by indications for obstructive pathologies such as nephrolithiasis (Choi et al., 2016; Sadan et al., 1994; Zwergel et al., 1996). Risks associated with stent insertion, in addition to known sequela of flank discomfort and irritative bladder symptoms, include rapid encrustation caused by hypercalciuria and hyperuricosuria (Goldfarb et al., 1989). However, data supporting rapid encrustation is sparse, and individualized assessment to timing of exchange is a more reasonable clinical approach. Certainly, for patients with enhanced risk resulting from the comorbidities of urinary lithiasis, frequent exchanges every 4 to 8 weeks may be optimal (Altamar and Miller, 2009).

Additional modalities of urinary drainage for refractory symptomatic hydronephrosis include percutaneous nephrostomy (PCN) drainage, which in the absence of noted obstructive pathologic condition, should be very selectively utilized because of duration of use, potential encrustation, and general discomfort with this approach.

General Considerations for Imaging of the Pregnant Patient

Important considerations for any consulting urologist, particularly with regard to management of acute situations such as urolithiasis or malignancy in pregnancy, are understanding of the recommendations for diagnostic imaging (see Chapters 3 and 4). Potential effects of irradiation on the fetus include teratogenesis, carcinogenesis, and mutagenesis. Ultimate risk depends on the gestational age and the amount of radiation delivered (Biyani and Joyce, 2002). During the first trimester, the period of early organogenesis and rapid cell division, the embryo is highly sensitive to the effects of radiation (Swartz and Reichling, 1978). Although the fetus has diminished sensitivity to the teratogenic effects of radiation in the second and third trimesters, such exposure may increase the risk for development of childhood malignant neoplasia (Harvey et al., 1985).

The American College of Obstetricians and Gynecologists (ACOG) has outlined clinical guidelines to drive management decisions and determine the diagnostic imaging modality that provides the optimal risk/benefit ratio in many situations (Committee on Obstetric Practice, 2017b). In general, each of these recommendations must be individualized to the clinical scenario, and in most cases, radiation doses for commonly employed urologic imaging are below threshold exposures with concern for fetal harm. Coordinated planning with the radiologist when feasible can often be of assistance to modify techniques to decrease total radiation dose or even acoustic output levels.

Practice recommendations from ACOG for diagnostic imaging include the following:

- Ultrasonography and magnetic resonance imaging (MRI) are not associated with risk and are the imaging techniques of choice for the pregnant patient, but they should be used prudently and only when use is expected to answer a relevant clinical question or otherwise provide medical benefit to the patient.
- **With few exceptions, radiation exposure through radiography, computed tomography (CT) scan, or nuclear medicine imaging techniques is at a dose much lower than the**

exposure associated with fetal harm. If these techniques are necessary in addition to ultrasonography or MRI or are more readily available for the diagnosis in question, they should not be withheld from a pregnant patient.

- The use of gadolinium contrast with MRI should be limited; it may be used as a contrast agent in the pregnant patient only if it significantly improves diagnostic performance and is expected to improve fetal or maternal outcomes.
- Nuclear medicine studies such as renogram to determine physiologic organ function or dysfunction may be selectively utilized during pregnancy depending on the physical and biochemical properties of the radioisotope. 99mTc (Technetium)-mercaptoacetyltriglycine (MAG3) is the most widely used renal radiopharmaceutical for urologic indications. The tracer is not filtered but is extracted by the tubules, and MAG3 renal scintigraphy is frequently employed to determine differential renal function and evaluate renal drainage parameters. In general, procedures utilizing Technetium 99m result in fetal exposure of less than 5 mGy, which is considered a safe dose in pregnancy (Committee on Obstetric Practice, 2017b). Technetium 99m has a half-life of 6 hours and is a pure gamma ray emitter, which minimizes radiation dose without image compromise, further supporting the safety of use of this agent during pregnancy.

Considerations for intraoperative fluoroscopy are always a concern for urologic surgery patients during pregnancy. Limiting radiation exposure may be accomplished by shielding of the fetus and utilizing collimation and low-dose spot films at the lowest exposure feasible for confirmation of radiographic findings during retrograde pyelogram or location for indwelling ureteral stent placement.

General Concepts for Surgical Management of the Pregnant Patient

Recommendations from the ACOG provide the urologist guidance regarding considerations for nonobstetric surgery during pregnancy (Committee on Obstetric Practice, 2017a). Overall, consultation with an obstetrician should be obtained to ensure that pertinent aspects of maternal physiology are considered along with the potential need for fetal monitoring.

Current practice recommendations from the ACOG for nonobstetric surgery include the following:

- No currently used anesthetic agents have been shown to have teratogenic effects in humans when using standard concentrations at any gestational age.
- Fetal heart rate monitoring may assist in maternal positioning and cardiorespiratory management and may influence a decision to deliver the fetus.
- **A pregnant patient should never be denied indicated surgery, regardless of trimester.**
- Elective surgery should be postponed until after delivery.
- **If possible, nonurgent surgery should be performed in the second trimester when preterm contractions and spontaneous abortion are least likely.**
- Surgery should be done at an institution with neonatal and pediatric services.
- An obstetric care provider with cesarean delivery privileges should be readily available.
- A qualified individual should be readily available to interpret the fetal heart rate patterns when applicable.

In combination with the unique physiologic challenges outlined previously that demand attention, during pregnancy there exist a variety of ethical considerations during perioperative decision-making for the urologist (Pais and

Reinstatler, 2018). Naturally there are critical diagnostic and therapeutic decisions that may directly affect not only the patient, but also the fetus. Although always a prudent maneuver to involve all stakeholders to facilitate discussion, ACOG has issued a committee opinion on maternal decision making indicating that **first and foremost, the patient's autonomy in decision making should be respected** (ACOG Committee on Ethics, 2005). Pregnant patients must be carefully counseled regarding the risks and benefits to both the patient and her child, recognizing the limitation of our medical knowledge. Overall, women should not be penalized or denied procedures just because they are pregnant.

As described previously, because of the tendency for the gravid uterus to compress the IVC, optimizing venous return often requires placing the patient in a left lateral decubitus position when feasible. This left lateral position should be modified and considered during open, laparoscopic, and endoscopic procedures.

Choice of surgical approach is predicated on surgeon experience and the exposure requirements. No randomized trials exist to compare open and laparoscopic procedures in the pregnant patient, but much available data suggest equal outcomes (Cunningham et al., 2013a). In general, laparoscopic procedures compare to laparotomy with regard to infant survival or fetal malformation, although earlier delivery and lower birth weight have been associated with laparoscopy in this setting (Reedy et al., 1997). In addition to careful consideration for port site placement under direct visualization based on fundal height, the Society of American Gastrointestinal Endoscopic Surgeons (SAGES) has created specific recommendations for laparoscopy during all trimesters of pregnancy, which may be extrapolated for a variety of urologic interventions (Pearl et al., 2011). They conclude that insufflation between 10 and 15 mm Hg may be safely employed during pregnancy. Higher insufflation pressures resulted in maternal cardiovascular and respiratory changes after 20 minutes, which should be avoided. Additionally suggested by the SAGES guidelines is utilization of intraoperative maternal end-tidal capnographic monitoring.

In most cases, excessive perinatal mortality has been attributed to the disease process itself rather than the morbidity of undergoing a surgical procedure (Mazze and Kallen, 1989). An association of preterm labor has been identified with general surgical procedures performed during the third trimester (Visser et al., 2001). Although no fetal loss was noted, preterm delivery occurred in 16% of pregnant patients requiring third-trimester interventions. Critical to the urologist for counseling, and further discussed later, is the 10% incidence of preterm labor demonstrated with ureteroscopic procedures during the third trimester (Johnson et al., 2012). This data reiterates the ACOG recommendations to perform nonurgent surgery during the second trimester, when preterm contractions and spontaneous abortion are least likely.

General Concepts of Urologic Medication Administration During Pregnancy

Prescription medication use during pregnancy is almost universal, with 97.1% in a cohort of over 9000 women reporting taking at least one medication during their pregnancy (Haas et al., 2018).

In 2015, the US Food and Drug Administration (FDA) substantially redesigned its regulations regarding the content of labeling for human prescription drugs and biologic products with regard to providing information for pregnancy (FDA, 2014). For decades, alphabetical categories were employed to convey risk based on known preclinical or clinical information. The modified rule requires removal of the pregnancy categories A, B, C, D, and X from all human prescription drug and biologic product labeling. The FDA guidance additionally requires that the labeling include a summary of the risks of using a drug during pregnancy and lactation, a discussion of the data supporting that summary, and relevant information to help health care providers make prescribing decisions and counsel women about the use of drugs during pregnancy and lactation. The promise is that the new labeling will create a consistent format for providing information about the risks and benefits of prescription drug and/or biologic product use during pregnancy. The challenge for the practitioner with infrequent need to access this information for the pregnant patient will be careful translation of the available evidence as opposed to a familiar system of general classification (Pernia and DeMaagd, 2016). Medications will require an individualized review without such previously standardized schema as the category system.

To provide the reader with the most contemporary information regarding safety of the wide variety of pharmaceuticals employed by the urologist, the practitioner is directed to the most current data available on the FDA website (FDA, 2018). Naturally, in addition to evaluation by the prescribing provider, consultation with the patient's obstetrician is prudent to ensure safety and continuity of care for both the mother and fetus. Exceptionally specific information regarding the teratogenic potential of a variety of commonly employed medications is outside the scope of this chapter but is elegantly detailed elsewhere for urologists desiring more extensive knowledge (Niebyl et al., 2017).

Of special mention are highly specific biologic agents in widespread use in urology. OnabotulinumtoxinA (BoNT-A) is one such agent in which application has revolutionized the treatment algorithms associated with idiopathic and neurogenic lower urinary tract symptoms. Dominant to this increased utilization is the relative ease of administration and low complication profile. With regard to use during pregnancy, prescribing information from the manufacturer indicates, based on animal data, BoNT-A may cause fetal harm (Allergan, 2018). In animal models, intramuscular injection resulted in reductions in fetal body weight and skeletal ossification. During the critical phases of organogenesis in rats and rabbits at doses that extrapolate to the maximum recommended human dose of 400 Units, daily injections revealed significant maternal toxicity, abortions, early deliveries, and even maternal death. However, a single dose at three different periods resulted in no adverse effect on fetal development. Overall, it is recommended to only employ BoNT-A during pregnancy if the benefit significantly outweighs the risk. Likewise, it remains unknown if BoNT-A is secreted in breast milk, so caution should be exercised when administering it to nursing mothers. Review of a global safety database of 232 pregnancies with maternal BoNT-A exposure revealed a prevalence of fetal defects comparable to rates in the general population (Brin et al., 2016). Limitations of extrapolation of the data in this report include that only 6 patients underwent injection for urologic indications.

Urolithiasis in Pregnancy

Urolithiasis remains one of the most frequent and often complex urologic consultations during pregnancy. With a reported incidence between 1 : 200 to 1 : 1500 pregnancies, renal colic secondary to kidney stones is the leading nonobstetric cause for hospitalization in the pregnant patient (Gorton and Whitfield, 1997; Riley et al., 2014; Rodriguez and Klein, 1988). Substantial morbidity to both mother and fetus are imposed by the pain of renal colic, urinary infection, and urinary tract obstruction, which associate urolithiasis with increased risk for preterm delivery, preeclampsia, placenta previa, and preterm premature rupture of membranes (Banhidy et al., 2007; Hendricks et al., 1991; Lewis et al., 2003; Maikranz et al., 1987; Rosenberg et al., 2011; Swartz et al., 2007). Despite the increased risk for pregnancy complications, no statistically significant impact on birth outcomes as measured by low birth weight, decreased Apgar scores, or perinatal mortality have been associated with symptomatic urolithiasis (Rosenberg et al., 2011).

Although there is a recognized increase in the incidence of urolithiasis in the general population over the past several decades, particularly in women, a concomitant increase in pregnant women above age-matched nonpregnant women has not been documented (Coe et al., 1978; Hendricks et al., 1991; Riley et al., 2014; Scales et al., 2007, 2012). Multiparous women have been reported to be acutely affected more often than primiparous women, in some cases by a ratio of approximately 3 : 1 (Horowitz and Schmidt, 1985; Rodriguez and Klein, 1988). However, when adjusted for age, the incidence for multiparous women is no greater than that for primiparous women (Swanson et al., 1995). Contemporary data utilizing a large, nationally representative population-based survey reveals a strong relationship between prior pregnancy and subsequent episodes of nephrolithiasis (Reinstatler et al., 2017).

Despite the predominance of right-sided hydronephrosis, there is a similar incidence of left and right symptomatic calculi (Parulkar et al., 1998; Rosenberg et al., 2011; Stothers and Lee, 1992). Most patients with symptomatic calculi present during the second or third trimester (Denstedt and Razvi, 1992; Stothers and Lee, 1992; Swanson et al., 1995).

Etiology

As extensively outlined earlier, pregnancy induces significant physiologic alterations including dramatic changes of both anatomy and physiology of the upper urinary tract (see Physiologic Changes During Pregnancy). To briefly recap, the most remarkable anatomic change is the dilation of the renal calyces, pelvis, and ureters, usually evident by 6 to 10 weeks' gestation. Physiologic hydronephrosis is the most common cause of dilation of the urinary tract in pregnancy and may produce pain that mimics renal colic from urolithiasis. Upper-tract dilation with a right-sided predominance is reported in up to 90% of pregnant women by the third trimester and may persist up to 12 weeks postpartum (Boridy et al., 1996; Schulman and Herlinger, 1975). Rarely, spontaneous rupture of the calyx may occur, again with a right-side predominance (Loughlin, 1994; MacNeily et al., 1991).

Both humoral and mechanical factors have been implicated in the cause of hydronephrosis in pregnant women. Increases of circulating progesterone during pregnancy results in relaxation of ureteral smooth muscle, potentially reducing peristalsis (Paller and Ferris, 1996). Recent evidence suggests that mechanical factors such as compression of the gravid uterus on the ureters is likely to be primary in the pathogenesis of hydronephrosis of pregnancy because of right predominance and rare dilation below the pelvic brim (Rasmussen and Nielsen, 1988; Schulman and Herlinger, 1975). Mixed data exist regarding women with altered urinary anatomy and hydronephrosis, but in general mechanical compression as a mechanism predominates (Dafnis and Sabatini, 1992; Rasmussen and Nielsen, 1988; Swanson et al., 1995).

When considering urolithiasis, other important physiologic changes in pregnancy outlined earlier (see Physiologic Changes During Pregnancy) include a 30% to 50% increase in GFR, modifying the interpretation of serum creatinine and BUN (Paller and Ferris, 1996). Critical for consideration with urolithiasis, **elevation in renal plasma flow and GFR also increases the filtered loads of sodium, calcium, and uric acid, resulting in a state of hypercalciuria and hyperuricosuria** (Boyle et al., 1966; Gertner et al., 1986; Howarth et al., 1977). Hypercalciuria is further exacerbated by the suppression of parathyroid hormone and the increase in circulating 1,25-dihydroxycholecalciferol production by the placenta, increasing intestinal absorption of calcium. Twenty-four–hour urine chemistries in pregnant patients demonstrated that urinary pH is elevated during pregnancy, most dramatically during the second trimester (Resim et al., 2006). However, these potentially lithogenic physiologic changes are offset by an increase in the excretion of urinary inhibitors, such as citrate and magnesium, as well as an increase in urine output (Biyani and Joyce, 2002). It has been postulated that metabolic alterations in the urine may contribute to the accelerated encrustation of ureteral stents during pregnancy (Denstedt and Razvi, 1992; Loughlin, 1994). Stones that occur during pregnancy are most commonly calcium phosphate in composition, a finding that may be explained by the relatively elevated urinary pH and hypercalciuria that occur in the pregnant state (Ross et al., 2008).

Evaluation

Although renal colic is the most common nonobstetric cause of abdominal pain in hospitalized pregnant patients, the diagnosis of urolithiasis in the pregnant patient remains challenging as many of the usual manifesting signs and symptoms may be masked by the patient's gravid status. As gestation progresses, the perception and localization of pain may be altered, and it has been reported that 28% of pregnant patients ultimately diagnosed with an obstructing stone were initially incorrectly diagnosed with appendicitis, diverticulitis, or placental abruption (Stothers and Lee, 1992). **The most common presenting symptom in pregnant patients remains flank pain, usually accompanied by either macroscopic or microscopic hematuria and, in some cases, UTI.** As outlined earlier, hematuria without discomfort is unusual in patients with obstructing stone disease (Swanson et al., 1995). Of importance in the pregnant patient is obtaining a urine culture as pyuria may be present at baseline, which diminishes the sensitivity of this parameter for detecting UTI (Hendricks et al., 1991; Houshiar and Ercole, 1996; Parulkar et al., 1998). A diagnosis of urinary calculi should be considered in evaluation of a pregnant patient who suffers from persistent infection with a urea-splitting organism. Vigilance in evaluation is mandated as many of the other nonspecific symptoms of urolithiasis including irritative voiding symptoms, chills, nausea, and emesis may occur with other intra-abdominal conditions.

The American Urological Association (AUA) has developed guidelines for surgical management of stones that specifically evaluate and address issues with management of the pregnant patient (Assimos et al., 2016a, 2016b). The panel acknowledges the challenges of diagnosis and treatment of stone disease during pregnancy because of the undue risks imposed to the developing fetus and inaccurate clinical presentation. **A multidisciplinary approach is strongly recommended with involvement of the obstetrician or maternal-fetal**

medicine physician, anesthesiologist, pharmacist, and urologist in collaboration to develop a safe and effective plan for the patient.

Imaging studies are the mainstay of diagnostics for urolithiasis in the pregnant patient when presenting symptoms and physical examination may be insufficient. Critical to determination of the optimal strategy for imaging, as discussed earlier (see General Considerations for Imaging of the Pregnant Patient), the ACOG has issued guidelines that may apply to urolithiasis designed to optimize safety for the developing fetus (Committee on Obstetric Practice, 2017b).

Practice recommendations from the ACOG for diagnostic imaging include primary use of ultrasonography and MRI as they are not associated with fetal risk, but still they should be used prudently and only when use is expected to answer a relevant clinical question or otherwise provide medical benefit to the patient. Indeed, ultrasonography has become the standard initial study in evaluation of the pregnant patient with suspected renal colic. Unfortunately, ultrasound is operator-dependent, and it can be exceptionally difficult to adequately visualize the ureter or distinguish physiologic hydronephrosis of pregnancy from ureteral obstruction because of calculus. In the pregnant patient, renal ultrasonography for the detection of calculi had a reported sensitivity of only 34% with a specificity of 86% (Stothers and Lee, 1992). Similar data suggest ultrasonography resulted in definitive diagnosis in only 60% of pregnant patients (Butler et al., 2000).

Several techniques have been suggested to improve the diagnostic capability of ultrasonography. Color Doppler imaging has been proposed to elucidate ureteral jets as this is a highly sensitive tool for obstruction (Deyoe et al., 1995). However, in the pregnant patient, ureteral jets may be unpredictable, and use of this technique for assessment of obstruction should be employed with caution (Burke and Washowich, 1998; Masselli et al., 2013).

Doppler ultrasound can additionally be utilized to calculate renal vascular resistance, which increases in the presence of acute obstruction (Ulrich et al., 1995). In a prospective analysis of 117 nonpregnant patients with ultrasonography, resistive index (RI) measurements had a 77% sensitivity and an 83% specificity in diagnosis of ureteral calculi, and a change in RI had an 88% sensitivity and a 98% specificity (Shokeir and Abdulmaaboud, 1999). Critical to understanding is that renal RI remains unchanged from the nonpregnant state throughout the course of pregnancy and is also unaffected by the physiologic hydronephrosis of pregnancy, which suggests that this imaging modality may be useful in detecting acute obstruction in this population (Horrigan et al., 1996). Operational use of RI in pregnant women found it had a 45% sensitivity and a 91% specificity in detecting an obstructing ureteral calculus, and a change in RI had a 95% sensitivity and a 100% specificity (Shokeir et al., 2000). Transvaginal ultrasound may also be utilized to provide imaging of the distal ureter. Overall, studies indicate that 14% of women undergoing intervention for a radiographically detected stone ultimately were found to harbor no such stone (White et al., 2013).

An additional recommended imaging modality in the pregnant patient is MRI. MRI does not rely on ionizing radiation or contrast medium, making it a potentially attractive tool for pregnant patients, however there are significant limitations for evaluation of urolithiasis. Because MRI does not visualize calcium, stones are visualized as filling defects overlying the high signal intensity of urine. Elucidation of smaller stones with this technique is difficult (Hattery and King, 1995; Roy et al., 1995). In symptomatic patients, MRI has been reported to accurately differentiate physiologic hydronephrosis of pregnancy from hydronephrosis resulting from an obstructing ureteral calculus (Spencer et al., 2004). Other techniques described include a half-Fourier acquisition single-shot turbo spin-echo (HASTE) MRI protocol to increase the utility of MRI in the evaluation of pregnant patients (Mullins et al., 2012).

Other imaging techniques for evaluation of urolithiasis in pregnancy including intravenous pyelogram and nuclear renography are fraught with limitations and should be infrequently employed in contemporary urologic practice (Biyani and Joyce, 2002; Stothers and Lee, 1992).

In the nonpregnant patient, noncontrast CT remains the gold standard for diagnosis of urolithiasis with almost 99% sensitivity and specificity. CT has been historically avoided in pregnancy because of the previously outlined risks of ionizing radiation to the fetus. However, as reported by ACOG, with few exceptions, radiation exposure via CT scan is at a dose much lower than the exposure associated with fetal harm. If these techniques are necessary in addition to ultrasonography or MRI or are more readily available for the diagnosis in question, they should not be withheld from the pregnant patient.

Utilization of low-dose radiation exposure CT has emerged as a technique of high utility and low risk for the pregnant patient and fetus (White et al., 2007). Although generally not employed as first-line diagnostics, low-dose CT in pregnancy reports a positive predictive value of 95% for urolithiasis and is additionally useful for potential nonurologic pathologies (White et al., 2013).

Protocols for ultra–low-dose CT may provide even greater utility for the pregnant population (Rob et al., 2017). Current **AUA guidelines suggest if ionizing radiation is necessary for diagnostic or treatment purposes, the radiologist along with the obstetrician can estimate radiation exposure so the total pregnancy exposure does not exceed the ACOG recommended maximum of 50 mGy.**

Following carefully metered use of diagnostic imaging, many considerations regarding optimal management must be devised for the pregnant patient. According to AUA guidelines, spontaneous passage rates for pregnant patients with ureteral stones have not been demonstrated to be different than those of nonpregnant patients. Therefore, in a patient whose symptoms are controlled, a period of observation should be the initial therapy. **Of pregnant patients with symptomatic calculi, 50% to 80% will pass their stones spontaneously when treated conservatively with hydration and analgesia** (Denstedt and Razvi, 1992; Gorton and Whitfield, 1997; Parulkar et al., 1998; Stothers and Lee, 1992). However, a stone event in pregnancy carries with it an increased risk for maternal and fetal morbidity, so patients should be followed closely for recurrent or persistent symptoms (Rosenberg et al., 2011; Swartz et al., 2007).

Pain management in the pregnant population is an actively evolving field with the traditional analgesic routine being frequent, small-dose administration of morphine (Valovska and Pais, 2018). Note that nonsteroidal anti-inflammatory agents such as ketorolac are contraindicated in pregnancy secondary to risk for fetal pulmonary hypertension and premature closure of the ductus arteriosus if administered in the third trimester.

In general, coordination with obstetrics should be performed to individualize pain management strategies for the patient's clinical situation and fetal risk. In the nonpregnant population, medical expulsive therapy (MET) with alpha-blockers or calcium channel blockers is frequently considered to facilitate stone passage by promoting relaxation of ureteric smooth muscle (McClinton et al., 2014). AUA guidelines for the nonpregnant patient endorse the use of MET for uncomplicated small distal stones with alpha-blockers (Assimos et al., 2016a, 2016b). The panel additionally reports that should MET be considered for the pregnant patient, the patient should be counseled that MET has not been adequately investigated in the pregnant population, and the pharmacologic agents are being used for an “off-label” purpose (Bailey et al., 2016).

Should a trial of observation fail, pregnant patients should be offered interventions. Intervention is required in approximately one-third of patients, usually for pain uncontrolled by analgesia or signs of persistent obstruction and infection. Generally, management options include temporizing measures such as ureteral stent placement or PCN drainage and definitive management via a variety of techniques. Overall, if surgical intervention is warranted, creation of a multidisciplinary team as described earlier (see General Concepts for Surgical Management of the Pregnant Patient) is imperative to optimize outcomes and limit risks.

When treatment is selected, it should be recognized that there remains controversy regarding the most appropriate method of intervention. Some authors have maintained that ureteral stents are the optimal treatment for such patients. Although ureteral stents effectively drain an obstructed collecting system, they are by no means the perfect solution to this problem. The changes in urinary chemistry that occur during pregnancy, hypercalciuria and hyperuricosuria, have been implicated in the accelerated encrustation of ureteral stents. Because of this phenomenon, multiple studies have recommended ureteral stent exchange in pregnant patients every 4 to 6 weeks (Valovska and Pais, 2018). For a woman in an early gestational stage, this fates her to multiple stent changes over the course of the pregnancy. An indwelling stent places these patients at an increased risk for bacteriuria, UTI, and stent migration, all of which are serious morbidities that may have an adverse effect on the pregnancy. Ureteral stents themselves are associated with pain, which can have a negative effect on a patient's quality of life.

Percutaneous nephrostomy drains are an alternative treatment option for pregnant patients with obstructing renal calculi. Just as with ureteral stents, nephrostomy tubes will effectively drain an obstructed collecting system. However, many of the same limitations that apply to ureteral stents also apply to nephrostomy drains including encrustation, colonization, pain, dislodgement, and the need for multiple interventions. In an analysis of 29 pregnant women managed with nephrostomy drainage, over one-half required tube exchanges, replacements, or flushing because of either dislodgement or obstruction (Khoo et al., 2004). Indeed, the majority of pregnant patients managed with nephrostomy drainage required exchange of the tube because of occlusion from debris (Kavoussi et al., 1992). One-third of the patients in this series ultimately required nephrostomy removal because of recurrent drain obstruction, fever, or pain.

Ultimately with either temporizing ureteral stent placement or nephrostomy drain placement, in most instances the patient will require a definitive procedure in the postpartum period for stone removal. As such, a trend toward offering definitive therapy with ureteroscopy (URS) in pregnant patients in the second trimester has recently evolved. Overall, complications in pregnant patients undergoing URS are uncommon. **Systematic review of over 100 pregnant patients who underwent URS reported an overall complication rate of 8.3%, with no significant difference in rates of urinary tract complications compared with the nonpregnant population** (Semins et al., 2009). With regard to obstetric outcomes, a multicenter trial that examined URS in pregnant women reported a complication rate of 4% (Johnson et al., 2012).

Critical to performing URS is consideration for fetal ionizing radiation exposure intraoperatively resulting from use of fluoroscopy. **Strategies to reduce or eliminate radiation exposure include use of low-dose or pulsed fluoroscopy with collimation to minimize scatter combined with lead shielding of the pelvis placed below the patient, direct visualization without fluoroscopy, or employment of intraoperative ultrasound guidance** (Deters et al., 2013).

Other treatment modalities frequently effective in the nonpregnant patient are not appropriate for this population. Although there have been reports of the inadvertent treatment of pregnant patients with shock wave lithotripsy, with no adverse sequelae to the fetus, pregnancy remains a contraindication to this treatment modality (Chaussy and Fuchs, 1989; Frankenschmidt and Sommerkamp, 1998). Likewise, highly invasive therapies such as percutaneous nephrolithotomy should be deferred until after delivery because this procedure often requires prolonged anesthesia and radiation exposure.

Key Points

- Ultrasonography is the standard initial imaging study in evaluation of the pregnant patient.
- A trend toward offering definitive therapy with URS in pregnant patients in the second trimester has evolved with acceptable complication rates.
- **It is important to minimize ionizing radiation exposure to the pregnant patient during URS by use of a below-table x-ray source and to shield the fetus with a lead apron placed below the patient.**

Pregnancy in Women With Congenital Urologic Conditions

Myelomeningocele

Individuals with myelomeningocele (MMC) present unique challenges for the urologist at baseline that escalate with the addition of pregnancy. Considerations include patient age, underlying comorbid disease, genetic implications for the offspring, pelvic bony and muscular anatomy, obesity, urinary diversion status, prior abdominal surgery, renal function, and presentation of the fetus. Appreciation of these physiologic, anatomic, and social considerations should guide the physician to optimize organization of multidisciplinary care for these patients.

Fertility

In general, female patients with MMC are considered to have normal fertility, with up to 70% of those who conceive having successful pregnancies (Jackson and Mott, 2007). However, as discussed in detail later in this chapter, the gravid uterus may impact already tenuous balance and ambulation issues, ventriculoperitoneal (VP) shunt drainage, bowel and bladder function, urinary diversion function, skin integrity, pulmonary function, cardiac function, and foremost, urinary infection risk. For patients who have previously undergone extensive pelvic surgery, experienced authors have suggested that visceral adhesions may negatively affect fertility because of uterine retroflexion and concomitant issues with conception and implantation (Hautmann and Volkmer, 2007; Thomas and Adams, 2009).

Urologists are intimately familiar with the risks of latex allergies in the congenitalism population, estimated to affect up to 60% of patients (Ricci et al., 1999; Sparta et al., 2004). Although most surgeons are accustomed with and prepared for the intraoperative consequences of a latex allergic reaction, special considerations may necessary when counseling patients regarding sexuality and birth control. Primarily, patients must be cognizant to utilize latex-free condoms, sexual aids, and intrauterine devices.

Preconception counseling is strongly encouraged when the opportunity exists and the pregnancy is planned. Involvement of a multidisciplinary team with high-risk obstetrics, urology, anesthesiology, orthopedics, and neurosurgery should be considered for consensus decision-making for the MMC patient desiring pregnancy. Provision for social work counseling may furthermore be exceptionally valuable. Genetic components of neural tube defects must be clearly delineated for MMC patients desiring conception. Risk for transmission to offspring if one parent is afflicted with MMC is variably quoted at 1% to 8% (Cameron and Moran, 2009; Laurence and Beresford, 1975; Mitchell et al., 2004). The threat is identical if the affected parent is male or female; however, the incidence in female offspring is 1 in 13 and diminishes to 1 in 50 for male children. However, if both parents are affected, the neural tube defect transmission rate increases dramatically to 15%.

Pregnancy

Pregnancies for MMC patients most often follow urinary tract surgery by many years with the initial goals of reconstruction likely aimed at protection of renal function and social continence with few considerations for eventual pregnancy. Although each patient presents a unique challenge, some concepts may be broadly applied for the MMC patient. Foremost is recognition that **the greatest risk factor for worsening renal function in pregnant patients with or without urinary reconstruction is preexisting renal insufficiency** (Thomas and Adams, 2009). Significant pregnancy-related loss of maternal renal function along with development of new-onset hypertension has been demonstrated, increasing the complication rates of preterm delivery and growth restriction (Chu et al., 1996; Hou, 1985). Superimposed on the issues of renal function is the recognition that some MMC patients may have a solitary kidney because of congenital absence or loss from dysfunction (Hautmann and Volkmer, 2007). It is critical to initiate assessment with a measurement of GFR as opposed to a singular creatinine value to accommodate for the altered body habitus and muscle mass when making decisions regarding treatment.

Combined with the increased risk for development of urolithiasis demonstrated for patients with urinary diversion, the complexities of the physiologic and anatomic changes that accompany pregnancy may be amplified in the congenitalism population. Risk for both upper and lower urinary tract calculi in patients with bladder augmentation have been variably estimated from 9% to as high as 50% (Welk and Herschorn, 2012). Although some hazard may be attributed to anatomic parameters such as incomplete emptying of continent reservoirs, contributing factors include chronic bacteriuria, intravesical foreign bodies, mucus secretion, metabolic acidosis, enteric hyperoxaluria, and dietary culprits (Hamid et al., 2008; Robertson and Woodhouse, 2006). Physiologic and anatomic changes of pregnancy may exacerbate the complexities of the MMC predisposition for calculi. Notably, extrinsic obstruction of the ureter by the gravid uterus against the pelvic brim may worsen preexisting hydronephrosis and urinary stasis, potentially predisposing to impairment of renal function or promotion of urinary infection. **Hydronephrosis of pregnancy after lower urinary tract reconstruction tends to worsen during weeks 20 to 28 of gestation, requiring increased vigilance of monitoring during this period** (Greenwell et al., 2003).

Fortunately, as addressed in the previous section, because of the protective effects of increased secretion of several inhibitors of urinary stone formation such as citrate, magnesium, and glycosoaminoglycans, even patients with a known history of stone disease do not experience an increased rate of urolithiasis during pregnancy (Altamar and Miller, 2009). However, in the MMC patient with altered body habitus and potential urinary diversion status, high levels of vigilance are mandated to detect manifestation of clinically significant stones during pregnancy. Of concern in this population is the altered sensory capacity to recognize upper tract obstruction, which may delay care until devastating systemic symptoms are present.

There is little guidance with regard to the retained bladder for patients with diversion without concomitant cystectomy. Some authors suggest that concerns involving a retained nonfunctional bladder, such as pyocystis, may unfortunately only become overt during pregnancy (Hautmann and Volkmer, 2007).

In addition to hydronephrosis, notable matters that may occur during the MMC pregnancy include **compromise of vascular perfusion of the diversion bowel segment, intestinal obstruction, stenosis or prolapse of a urostomy, compression of catheterizable channels, and metabolic complications** (Hautmann and Volkmer, 2007). Of special concern in patients with ureterosigmoidostomy is the possibility of mechanical deformation of the sigmoid or ureteral anatomoses, potentially resulting in disruption of the ureteral implants or incomplete emptying. Notably, rectal sphincter function necessary for appropriate function of the ureterosigmoidostomy may be compromised by vaginal delivery, leading to de novo urinary and potentially fecal incontinence. See later in this chapter for a discussion of the complexities of urinary diversion during pregnancy.

Mode of Delivery

Mode of delivery of the infant remains a controversial topic with a myriad of considerations. Before accurate counseling and planning for delivery, priority must be given to obtaining comprehensive records on prior surgical interventions and urinary tract evaluations including urodynamics and upper-tract studies. Although often the complete operative record will rarely be available for review, obtaining as much primary source information regarding specific procedures cannot be underscored. Individual practice patterns for pediatric reconstruction, in addition to often multiple operative revisions, make understanding the patient's anatomy a top priority.

Factors influencing the choice of delivery mode beyond the standard obstetric concerns include the type of diversion or prior surgical interventions, anatomic issues related to the underlying disease process, and fetal presentation (Hautmann and Volkmer, 2007). Continence may be impacted during the post–vaginal delivery period for patients with native urethras or ureterosigmoidostomy; this information should influence patient counseling. Vaginal delivery is not contraindicated in patients with augmentation cystoplasty in the setting of a native bladder neck and urethral continence mechanism. However, **for individuals with bladder neck reconstruction, vaginal delivery potentially carries a risk for injury to the pelvic support and continence mechanisms.** Although no consensus regarding expectations in this setting exist, data from a widely circulated survey regarding delivery mode for MMC with bladder neck reconstruction or artificial urinary sphincter indicated most practitioners would recommend cesarean section for these individuals (Hill et al., 1990). Few reports of pregnancy in the setting of an AUS exist, but available data suggest that a functioning AUS does not impact the complication profile during pregnancy and delivery (Fishman and Scott, 1993). Caveats are readily noted in these studies, such as the avoidance of high forceps delivery, and clearly no consensus of recommendation exists as most of these observations are anecdotal because few women face these dilemmas.

Previous incontinence procedures, most notably the prior placement of a pubovaginal sling, may also drive decisions regarding type of delivery. Some series have suggested that prior bladder neck sling does not preclude vaginal delivery because of the risk for incontinence (Tan et al., 2010). Literature reviews of the small patient numbers reported with pregnancy after synthetic mid-urethral sling suggest only a moderate decrease in continence after either vaginal or cesarean delivery (Huser et al., 2012). Overall urinary continence rates of 91.7% were noted during pregnancy and 80.6% during the postpartum. The majority of women in these studies (58.3%) proceeded with vaginal delivery. Certainly, for patients with any prior incontinence procedure, risks for functional injury and loss of continence with vaginal delivery should be discussed as they approach 19% in the overall population (Pollard et al., 2012). Although impossible to generalize this data to the MMC population because of the variation in risk factors, clearly some threat of continence disruption exists.

Discussion of long-term risk to continence and recommendation for the mode of delivery must be individualized. If vaginal delivery is primarily chosen, careful consideration must be given to avoidance of prolonged labor to reduce pelvic floor trauma. If cesarean section is chosen, emergent or elective, it is critical to involve a urologist familiar with the anatomy to reduce incidence of injury to the bladder or vascular pedicle. Patient proximity to appropriate levels of high-risk obstetric care may additionally drive decisions once labor has initiated as such patients may elect cesarean section in lieu of prolonged labor at a primary facility with the potential need for emergent cesarean section without appropriate adjunct expertise.

Patients with MMC frequently display elements of pelvic organ prolapse (POP) at baseline, which may be exacerbated by pregnancy and both vaginal delivery and even cesarean section. If the prolapse is significant enough to warrant operative repair before pregnancy, it may be prudent to avoid vaginal delivery as worsening of the prolapse may be inevitable in that setting. Another prominent anatomic consideration includes bony and muscular anatomy and capacity to abduct the hips, which may in some instance preclude the capacity for vaginal delivery.

An additional challenge with vaginal delivery that may depend on the level of the spinal dysraphism is difficulty generating sufficient Valsalva effort required to progress through the later stages of labor (Natarajan et al., 2002). Of course, the gravid uterus may exacerbate background restrictive airway disease by compressing the diaphragm and resulting in a potential for respiratory compromise.

As elegantly outlined by Hautmann and Volkmer (2007), pragmatic concerns that dictate options for mode of delivery are outlined as follows:

Vaginal delivery should be considered contraindicated in the following MMC patients:

- Patients with a narrow bony pelvis

- Patients with artificial sphincters or bladder neck reconstructions
- Patients with contracted hips

Vaginal delivery should be performed with caution in the following patients:

- Patients with ureterosigmoidostomy
- Fetal malpresentation
- Patients with uterine prolapse

Likewise, the authors endorse the following concerns should be noted for patients regarding proceeding with cesarean section:

- Patients with intraperitoneal VP shunts
- Patients with diversion pouches, enterocystoplasty, or neobladder

Technical considerations with cesarean section include performing the procedure via a high midline incision to avoid damage to the reservoir (Hensle et al., 2004; Hill et al., 1990). Catheterization of channels in the immediate preoperative period may assist with either avoidance or recognition of injury induced by the dissection.

An item of concern when contemplating pregnancy and cesarean section in the MMC population is the presence of a VP shunt. VP shunts are common in the patient with MMC, and hydrocephalus and malfunction during pregnancy may be associated with headache, nausea and emesis, and even potentially impaired consciousness (Hautmann and Volkmer, 2007). Functional obstruction caused by the gravid uterus increasing intra-abdominal pressure or mechanical obstruction may additionally cause neurologic sequela (Cusimano et al., 1990; Wisoff et al., 1991). Of significant concern is the potential for shunt infection during intra-abdominal surgery, particularly emergent cesarean section. This infection risk may be increased in the presence of prior urinary tract reconstruction with the possibility of spillage of contaminated urine into the peritoneal cavity containing the VP shunt.

Also dependent on the specific lesion level in MMC patients is the capability to detect the onset of labor (Daw, 1973). Curiously, although paraplegia does not appear to affect the contractile properties of the uterus, as mentioned earlier, the final stages of labor may be compromised because of deficits in the coordinated muscular effort necessary for the final stages of labor (Robertson, 1972; Stanton, 1974).

Prevention of Neural Tube Defects

Because polymorphisms in the folic acid metabolism pathway are considered primary deficits in the development of neural tube defects, promotion of folic acid supplementation for women desiring pregnancy is of critical importance (Wilson et al., 2003). By the early 1990s, a substantial public health effort was initiated in the United States through the collaboration of the Centers for Disease Control and Prevention, Health Services Administration, FDA, and the National Institutes of Health (1993). This program involved a three-stage approach for the prevention of neural tube defects: (1) dietary supplementation of 0.4 mg of folic acid for low-risk women and 4 mg of folic acid for high-risk women of childbearing age; (2) improvements in dietary habits; and (3) fortification of the US food supply. Notably, compared with routine supplementation of women without MMC of 0.4 mg folic acid per day, **doses of 4 to 5 mg per day have been advocated for the MMC patient desirous of fertility** (de Vylder et al., 2004). Prophylaxis is currently recommended with folic acid supplementation for 3 months before pregnancy and continuing through week 12 after delivery. Despite this regimen, there remains a risk for development of MMC caused by inborn errors of metabolism or discrepancies in the absorption of folic acid products (Leung et al., 2013). Additional genetic, dietary, and epigenetic alterations responsible for these continued hazards for development of neural tube defects are topics of vigorous current research initiatives in the postfolate supplementation era.

Monitoring and counseling of progeny for neural tube defects should be employed and tailored to the individual desires of the parents (Trudell and Odibo, 2014). Prenatal diagnosis of neural tube defects has been incorporated into routine prenatal care via screening through maternal serum alpha-fetal protein combined with ultrasound. Fetal MRI may also serve as an adjunct imaging modality with ultrasound to improve prognostic prediction.

Classic Bladder Exstrophy

Bladder exstrophy (BE) is an exceptionally complex and rare anomaly occurring in approximately 1 in 30,000 live births, with a generally accepted male predominance (Ebert et al., 2009). Treatment of the urologic and gynecologic consequences of classic BE in female children is an exceedingly intricate endeavor. Remarkable technical progress in the past several decades, spearheaded by comprehensive urologic care protecting renal function, has resulted in many BE patients once destined for death surviving to adulthood. Yet very few mechanisms exist to ensure a continuity of care for this unique population, particularly with regard to pelvic floor disorders, sexual function, fertility, and pregnancy (Eswara et al., 2016).

Genital Anatomy

Classic BE is a congenital malformation presenting with a spectrum of anatomic challenges arguably unparalleled in urology. Female BE patients display varying degrees of characteristic pubic diastasis accompanied by anterior displacement of the labia majora, vagina, and anus; a bifid clitoris; and a notable protrusion of the bladder through the abdominal wall defect (Gearhart and Mathews, 2016). The collection of insults to the female pelvic floor predisposes to a myriad of conditions as the BE patient ages (Miles-Thomas et al., 2006). Overall, the combination of bony pelvis and pelvic floor muscular defects contribute to severe compromise of the levator ani anterior support of the genitourinary and gynecologic pelvic organs (Stec, 2011). In general, women with BE display a reduction in vaginal depth with retained caliber. Also, the introitus is often narrow, stenotic, and anteriorly displaced with a horizontal vaginal lie (Woodhouse and Hinsch, 1997). Due to the pubic diastasis, which is predisposed to widen with growth, the labia, mons pubis, and clitoris are divergent. Deficiencies in the cardinal ligaments result in poor apical uterine support (Woodhouse, 1999). With abnormal displacement along the horizontal axis of the vagina, the uterus is predisposed to prolapse with the cervix near the introitus on the anterior wall. Current data indicate that pelvic osteotomy at the time of primary closure does not contribute to uterine prolapse with the primary influence being the width of the adult diastasis (Anusionwu et al., 2012, 2013). Indeed, a substantial issue that contributes to fertility and presents significant issues during pregnancy is POP in the BE female patient. Several single-institution series provide insight into the fate of the BE patient with regard to POP presentation with a commonly accepted incidence of 18% to 30% (Anusionwu et al., 2012; Mathews et al., 2003). The defining difference in the BE population is the accelerated pace of POP development, often independent of parity. In a series of 56 women with classic BE, 10 patients developed vaginal and uterine prolapse during the study period with a mean age of 16 years. An additional retrospective series of 52 BE female patients revealed that 52% developed POP, with 85% ultimately requiring surgical intervention (Nakhal et al., 2012). Supporting data regarding higher rates were identified in a series of BE women with continent urinary diversion, where the incidence of POP requiring surgical repair reached 38% (Rubenwolf et al., 2016).

Fertility

In general, women with BE are considered to have normal to only mildly impaired fertility, with approximately 68% of those who conceive having successful pregnancies (Giron et al., 2011). However, for patients who have previously undergone extensive pelvic surgery, experienced authors have suggested that visceral adhesions may negatively affect fertility because of uterine retroflexion and concomitant issues with conception and implantation (Hautmann and Volkmer, 2007). Of additional concern for the BE patient is the location of the cervix on the anterior vaginal wall, which may prohibit adequate semen delivery and delay fertility (Deans et al., 2012).

Pregnancy

Preconception counseling is strongly encouraged when the pregnancy is planned. Involvement of a multidisciplinary team with high-risk obstetrics, urology, and anesthesiology should be considered for consensus decision-making for the BE female desiring pregnancy. Each patient with BE presents a unique challenge for the practitioner. The myriad considerations include patient age, underlying comorbid disease, genetic implications for the offspring, pelvic bony and muscular anatomy, urinary diversion status, prior abdominal surgeries, continence, renal function, and presentation of the fetus. Appreciation of these physiologic, anatomic, and social considerations should guide the physician to optimize organization of care for these women.

Although contemporary data are lacking, the heritability of BE is estimated to effect 1 in 70 offspring (Shapiro et al., 1984). Even with sparse literature, advisement regarding the potential genetic component of BE should be provided if feasible in preconception counseling.

Tactics for management of POP during pregnancy are generally conservative, with bed rest and pessary insertion preferred and surgical management deferred until completion of childbearing (Nakhal et al., 2012). Notably, previously repaired POP in the BE female is likely to recur during pregnancy (Stein et al., 1995). Indeed, acute postpartum POP may affect nearly one-half of women with BE (Deans et al., 2012). Difficulties with intermittent catheterization via the native urethra may arise secondary to exacerbation of POP during pregnancy. Curiously, unlike expectations from the general population, the limited studies available for the BE female patient have yet to detect an association with parity and risk for persistent POP (Anusionwu et al., 2012; Ebert et al., 2009).

Additional hazards in the BE female patient include elevated risk for spontaneous abortion, which in some series reached 35% of pregnancies (Clemetson, 1958; Deans et al., 2012). In the 19 patients presented, there were 57 pregnancies (three sets of twins), which resulted in 56% live births, 35% spontaneous abortions, 2% terminations, and 7% stillbirths or neonatal deaths. Other contemporary populations of 20 BE patients reported 15% spontaneous abortion rates, similar to the general population (Dy et al., 2015). **An added concern of high acuity is the development of preeclampsia, which was demonstrated in 32% of patients in one series, predominantly occurring in women with baseline renal insufficiency** (Deans et al., 2012). Vigilance and appropriate preconception counseling are critical to inform the patient regarding the realistic details involving the relatively high rates of antenatal and postnatal complications, along with risks for fetal morbidity and mortality.

Mode of Delivery

Historically, of course some BE patients did undergo vaginal delivery, however anatomic constraints and postpartum prolapse remained a significant concern (Hautmann and Volkmer, 2007). Currently, **it is generally accepted that BE patients undergo planned caesarean delivery** with engagement of a multidisciplinary team (Dap et al., 2017; Dy et al., 2015; Stein et al., 1996; Wilby and Wood, 2015).

Before accurate counseling and planning for delivery, priority must be given to obtaining comprehensive records on prior surgical interventions and urinary tract evaluations including upper-tract studies. Although often the complete operative record will not be available for review, securing as much primary source information regarding specific procedures cannot be underscored. Individual practice patterns for pediatric reconstruction in addition to often multiple operative revisions make understanding the anatomy a priority for the urologist assuming care.

As noted earlier, for any bladder augmentation, it is preferable to perform the cesarean procedure via a high-midline or paramedian incision to avoid damage to the reservoir and augment mesentery (Hensle et al., 2004; Hill et al., 1990). Catheterization of channels in the immediate preoperative period may assist with either avoidance or recognition of injury induced by the dissection. An excellent overview of the cesarean section technique, along with discussion of one institution's best practices for pregnancy management in the BE population, is detailed in the University of Washington experience (Dy et al., 2015). Included in this compilation is the counseling that it is imperative for planning of the delivery that BE patients be counseled regarding such fetal risks and the incidence of preterm delivery with a mean gestation anticipated at 36 weeks. Of substantial concern is that an abnormal fetal presentation may be present in over one-half of BE women and requires extensive predelivery planning (Greenwell et al., 2003).

Profound risks exist for emergency cesarean section versus elective procedures, supporting the necessity for BE patient proximity to appropriate levels of high-risk obstetric care and urologic expertise to optimize outcomes for both the mother and infant (Deans et al., 2012).

Key Points

- Most patients with congenital conditions affecting the lower urinary tract have normal fertility and should have prenatal counseling.
- Complexities of pregnancy in the population with prior urinary diversion require an individualized approach.
- Mode of delivery is dependent on prior urinary reconstructions and patient preference, although in most of cases cesarean delivery is preferred for the BE patient.

Functional and Anatomic Urologic Concerns During Pregnancy

Intermittent Catheterization

Due to the expanding size of the gravid uterus coupled with frequently compromised body habitus and mobility, issues with intermittent catheterization may manifest as pregnancy progresses. These difficulties are not exclusive to compression of a continent catheterizable channel but may also present in patients utilizing their native urethra for catheterization. In one recent series of women with urinary diversions, 4 of 25 patients required an indwelling catheter during the pregnancy because of difficulties with intermittent catheterization (Huck et al., 2017).

Urinary Diversion

Due to the heterogeneous nature of the patient population, global principles of management are not feasible during pregnancy. However, series have demonstrated excellent outcomes with regard to management of the diversion patient during pregnancy.

Several manuscripts exist regarding the effect of the expanding uterus on mesenteric blood supply to an intestinal segment previously utilized for bladder augmentation or urinary diversion. Reports have noted that the pedicle supplying an ileal conduit is displaced cephalad and lateral to the expanding uterus, whereas the pedicle usually remains anterior to the uterus after augmentation cystoplasty (Gitlin et al., 2002; Schilling et al., 1996). Fortunately, it has been described in most patients that pregnancy slowly increases tension on the mesentery, leaving ample time for adaptation (Hautmann and Volkmer, 2007). Although it should always remain a consideration for delivery planning, it appears that adherence of the mesentery to the uterus is also rare (Gitlin et al., 2002; Hensle et al., 2004).

Contemporary series suggest high rates of UTI and tendency to premature delivery in the diversion patient (Huck et al., 2017). Patients without bladder neck closure may experience de novo incontinence secondary to pressure from the expanding uterus, which in most instances is expected to resolve after delivery (Hill et al., 1990). One specific caution regards the diagnosis of pregnancy in the augmented bladder. Due to false-positive readings resulting from urinary changes after interaction with the bowel mucosa, urine-based pregnancy tests are not recommended, and the use of serum human chorionic gonadotropin is preferable (Nethercliffe et al., 2001).

Continent Catheterizable Stoma

Women with continent channels may experience de novo stomal difficulties during pregnancy (Greenwell et al., 2003; Hensle et al., 2004). Such problems may be secondary to changes in body habitus, particularly if the channel is in the right lower quadrant. Enlargement of the uterus may compress and stretch the channel, making catheterization increasingly difficult during progression of the pregnancy. Such channel changes are typically expected to resolve after delivery. Alternative catheterization techniques, such as use of a coude-tip catheter, may occasionally be necessary. If the patient remains with a patent urethra and the procedure is technically feasible, use of native urethral catheterization may be indicated. Occasionally, the increased intra-abdominal pressure of the uterus can result in stomal prolapse or parastomal herniation, which again the patient may anticipate resolution after delivery.

Urinary Tract Infection and Urinary Diversion

Perhaps the most prevalent concern for patients with urinary diversion during pregnancy is the management of UTI. In the general population there is no difference in the incidence of asymptomatic bacteriuria (ASB) between pregnant and nonpregnant women. However, most patients with a continent diversion or augmentation cystoplasty can expect chronic, or at the very least intermittent, bacteriuria related to clean intermittent catheterization. ASB is often not treated, particularly in patients with bladder augmentation or performing intermittent catheterization. However, in pregnancy ASB requires intervention due to fetal risk. It is well recognized that the rate of pyelonephritis during pregnancy increases to 16% to 18% in women who previously underwent urinary diversion, and such infections can lead to preterm labor, fetal wastage, and infants small for gestational age (Hautmann and Volkmer, 2007; Vordermark et al, 1990). A similar risk profile appears to be present after augmentation cystoplasty, with several small series reporting up to 60% rates of UTI and pyelonephritis (Gitlin et al., 2002; Greenwell et al., 2003; Hill et al., 1990). Because of the potential catastrophic consequences of early pyelonephritis to the fetus, many physicians recommend use of daily antibiotics for these complex diversion patients (Thomas and Adams, 2009). Of course, the potential teratogenic effects of the antibiotic compounds must be considered with such decisions. One reasonable approach would be reserving daily antibiotic use to those patients in the highest risk categories such as those with baseline or new-onset hydronephrosis, multiple symptomatic infections, or a history of pyelonephritis before pregnancy. Other authors advocate culture surveillance and treatment only in the context of symptomatology, much as they would treat these patients outside pregnancy. This debate remains active and no consensus exists, leaving each decision to be at the physician's discretion and driven by individual patient parameters and desires.

Urologic Malignancy During Pregnancy

Although seemingly a relatively rare situation, malignancy during pregnancy occurs with an incidence of 1 in 1000 gestations (Cunningham et al., 2013b; Martin and Rowland, 2007). The most common malignancy discovered during pregnancy (1 in 5000) is breast malignancy. Management poses significant challenges of both diagnostics and interventions with regard to fetal and maternal concerns. Balancing the risks of continuation of the pregnancy, long-term maternal health, and delaying treatment requires an individualized approach that is reflected in the literature for urologic malignancy. Herein we review some potential diagnoses and proposed evolving strategies for treatment for the most common urologic malignancies during pregnancy. We encourage a multidisciplinary approach with obstetrics, medical oncology, and anesthesiology to optimize outcomes for the patient and fetus.

Many urologic issues present in an asymptomatic fashion during pregnancy because of the intense testing and screening that may uncover incidental or occult conditions. Indeed, some symptoms of more common urologic disorders, such as hematuria, flank pain, or hypertension may be attributed to more common conditions of pregnancy (Hendry, 1997).

Evaluation of malignancy is often predicated on focal or systemic imaging. As discussed in the previous section, radiation risks to the fetus must be balanced with the risk to maternal health. Mechanisms to decrease exposure and increase sensitivity for diagnosis must always be employed in these delicate situations.

One fascinating implication of malignancy and pregnancy is the status of the immune system during these seemingly disparate conditions. Indeed, pregnancy and malignancy are select and unique conditions in which highly antigenic agents are tolerated by the immune system (Beaman et al., 2016). It is believed that **in most cases, pregnancy does not change the biologic properties or progression of tumors,** but data is lacking. There is sparse information regarding pregnancy and urologic malignancy risk in the immunocompromised patient to guide counseling.

Renal Tumors

The most common urologic tumor described during pregnancy is renal cell carcinoma. Analogous to the situation encountered with nonpregnant patients, the primary symptoms at presentation include pain, hematuria, hypertension, and/or a palpable mass (Gladman et al., 2002). However, in the pregnant patient, identification of renal tumors may be delayed because of the low index of suspicion for renal malignancy combined with myriad additional indications for presentation with this symptom complex.

Outside of known risk factors such as tobacco use and genetic syndromes such as Von Hippel-Lindau disease, which may increase a patient's overall risk for development of renal cell carcinoma, **the specific physiologic stresses of pregnancy have not been determined in a causal relationship to development of renal cell carcinoma.** Disparate evidence regarding parity, hormonal status, and subtype of renal cell carcinoma has been presented without consensus (Khaled et al., 2016). Evaluation should minimize risk to the fetus, but accurate staging for determination of treatment is mandated. In conjunction with the American College of Radiology and the American Institute of Ultrasound in Medicine, the American College of Obstetricians and Gynecologists issued a committee opinion regarding optimal utilization of diagnostic imaging during pregnancy (Committee on Obstetric Practice, 2017b). Although ultrasonography and MRI are not associated with fetal risk and remain the techniques of choice in the pregnant patient, CT scan can be performed at a radiation dose range lower than the exposure associated with fetal harm. Either CT or MRI contrast-enhanced abdominal imaging is recommended by AUA guidelines for characterization of the renal mass, renal morphology, and evaluation of other abdominal organs and visceral metastases (Campbell et al., 2017).

Iodinated intravenous contrast agents administered for soft tissue enhancement during CT can cross the placenta and enter fetal circulation, although animal studies have not demonstrated teratogenic or mutagenic effects from administration (Webb et al., 2005). However, use of gadolinium-based agents for enhancement with MRI during pregnancy remains controversial, with administration limited to situations in which the benefits clearly outweigh the possible fetal risks (Ray et al., 2016). Therefore, when possible, use of CT imaging in the pregnant patient is likely preferred when contrast enhancement is required in the setting of staging urologic malignancy.

As the diagnosis in pregnant patients remains rare, a potential role for renal mass biopsy is present if there is a suspicion the radiologic finding may be hematologic, metastatic, inflammatory, or infectious (Campbell et al., 2017). In the setting of renal malignancy in the predominantly young pregnant patient, AUA guidelines suggest recommending genetic counseling to determine the presence of a familial renal neoplastic syndrome.

Case reports of tumor characteristics, clinical staging, and ultimate management strategies dominate the literature for renal cell carcinoma during pregnancy (Khaled et al., 2016). Engagement of a multidisciplinary team is mandated to direct appropriate therapy and define the expected risks to the fetus and provide guidance when termination of the pregnancy may be advisable. Management is like that for the nonpregnant patient, with the mainstay of treatment being nephron-sparing or radical nephrectomy, with timing to proceed ultimately dependent on the clinical status of the patient and the trimester of pregnancy. The approach must be tailored to the specific tumor and the comfort of the surgical team, with attention to the general considerations in the pregnant patient outlined earlier in this chapter.

A new paradigm for systemic therapy for metastatic renal cell carcinoma has emerged with the advent of multikinase inhibitors, mTOR inhibitors, antiangiogenic agents, and immunotherapies. In general, the safety of these agents during pregnancy is poorly characterized, with most agents avoided during pregnancy because of direct evidence of human fetal risk.

Angiomyolipoma

Benign renal tumors such as angiomyolipoma (AML), one-half of which are not associated with tuberous sclerosis complex, are the second most common renal tumor and primarily asymptomatic. However, in situations of spontaneous rupture, patients may present with hematuria, flank pain, and life-threatening retroperitoneal hemorrhage (Myoen et al., 2015). Although rare, the hormonal environment, vascular volume, and increased abdominal pressure may predispose to rupture in the pregnant patient. In review of 45 cases of ruptured AML during pregnancy, average tumor size was determined to be 9.6 cm. Approximately one-half of the cases presented as hemodynamically stable, with 91% of these women completing pregnancy with a term delivery. However, in unstable patients, fetal death occurred in 30%. With the substantial risk, benefits of imaging, especially serial imaging for women choosing observation, outweigh fetal risks. Outside of urgent surgical interventions, treatment of choice includes transarterial embolization, even with the associated risk for premature labor secondary to postembolization syndrome (Martin and Rowland, 2007).

Bladder Tumors

Fortunately, bladder cancer is exceedingly rare in pregnant patients, although case reports exist of transitional cell carcinoma, adenocarcinoma, squamous cell carcinoma, and benign leiomyoma (Mizuno et al., 2003; Spahn et al., 2005). **Typically, patients present with hematuria, which is estimated to be misdiagnosed as vaginal bleeding in 22% of pregnant women**. Obtaining a catheterized urine specimen is preferable in these situations to assist with source determination. Lower urinary tract symptoms such as urgency, frequency, and nocturia are common during pregnancy and may not raise concern for bladder malignancy in the otherwise young and low-risk population of pregnant women (Cardozo and Cutner, 1997).

Most case reports in the literature of bladder malignancy during pregnancy reflect general expectations of predominantly urothelial carcinoma, and most display nonmuscle invasive pathology (Spahn et al., 2005). Squamous cell carcinoma, traditionally associated with schistosomiasis, has been reported in three cases during pregnancy marked by aggressive disease and poor prognosis despite radical cystectomy (Alleemudder et al., 2016; Church and Dieh, 2013; Spahn et al., 2005).

Diagnosis and management of bladder cancer during pregnancy requires complex orchestration of disciplines and delicate balance of maternal and fetal risks. In general, adherence to AUA guidelines for management of non–muscle-invasive bladder cancer (NMIBC) and muscle-invasive bladder cancer are not always completely feasible during pregnancy depending on the stage of the patient and considering fate of the fetus (Chang et al., 2016, 2017). As mentioned earlier, the presence of hematuria during pregnancy should be evaluated per standard of care with cystoscopic evaluation combined with appropriate upper-tract imaging (Davis et al., 2012; Sandhu et al., 2009). Imaging requirements are predicated on diagnostic modalities appropriate for evaluation of urologic malignancy, which is primarily with CT scanning. Indeed, modalities such as ultrasound, which are generally accepted as safe imaging techniques in pregnancy, may only provide diagnosis in 52% of cases to date (Spahn et al., 2005).

Transurethral resection may be safely performed at any time during gestation to obtain a pathologic specimen to guide further treatment (Pais and Reinstatler, 2018). Further imaging for staging and metastatic evaluation will often be mandated. For most NMIBC, further treatments after endoscopic resection may be deferred until after delivery. One study documents utilization of bacille Calmette-Guérin immunotherapy during pregnancy without known adverse outcomes to the fetus; however this adjuvant therapy should be generally avoided because of the potential for systemic side effects and both maternal and fetal harm (Wax et al., 2002). Likewise, for intravesical mitomycin C, balancing this risk to the fetus with the potential benefit of adjuvant therapy must be carefully assessed for the pregnant bladder cancer patient, and in most instances, administration can be delayed until after delivery.

Muscle-invasive bladder tumors in pregnancy reported to date in the literature suggest overall poor prognosis (Spahn et al., 2005). No standard treatment strategy exists for this vulnerable population, and there is scare data supporting any specific treatment. Certainly, depending on the trimester at diagnosis, extent of disease, and individual desires of the additional stakeholders, definitive therapies with neoadjuvant chemotherapy and radical cystectomy may be timed to the nuances of the situation.

Management of Urinary Tract Infections in Pregnancy

A critically important aspect of urologic management of the pregnant patient includes understanding of the pathophysiology and potential complications of ASB recommendations with detailed analysis available elsewhere in this volume (see Chapter 55).

ASB is generally discovered in 2% to 7% of women during pregnancy (Nicolle et al., 2005; Patterson and Andriole, 1987). Historical data and contemporary systematic review confirm with moderate quality evidence that antibiotic treatment of ASB during pregnancy likely reduces the risk for progression of infection to pyelonephritis (Smaill and Vazquez, 2015). As described earlier (see Physiologic Changes During Pregnancy), a myriad number of anatomic and physiologic alterations progress during pregnancy that may affect the natural history of bacteriuria and subsequent progression to pyelonephritis (Davidson and Talner, 1978; Patterson and Andriole, 1987; Waltzer, 1981).

Indeed, in pregnant patients with untreated ASB, pyelonephritis may occur at an incidence of 15% to 45% (Pedler and Bint, 1987; Wright et al., 1993). Most women experience episodes of pyelonephritis when hydronephrosis and urinary stasis are most prominent in the third trimester (Cunningham et al., 1973). Approximately one-third of pregnant women who develop pyelonephritis have a documented prior history of pyelonephritis (Gilstrap et al., 1981).

Pyelonephritis during pregnancy, in addition to the potential sequela to the mother, places the fetus at risk, with suggestion that ascending urinary infections may contribute to up to 50% of premature deliveries, particularly before 30 weeks' gestation (Cunnington et al., 2013). **Because pregnant patients with ASB remain at higher risk for development of symptomatic lower or upper UTIs, which may precipitate adverse fetal outcomes such as decreased birth weight and premature labor, consensus opinions indicate that pregnant patients should be screened for ASB and positive cultures should be treated** (Nicolle et al., 2005; Nicolle LE 2018; US Preventive Services Task Force, 2008).

The increased likelihood that ASB may progress to acute pyelonephritis during pregnancy alters the morbidity of bacteriuria for this group. Treatment of

ASB in pregnancy likely decreases the incidence of acute pyelonephritis during pregnancy to 1% to 4% and reduces the potential for preterm birth and low birth weight (Smaill and Vazquez, 2015).

Therefore, contemporary recommendations include routine screening of all pregnant women for bacteriuria. **It is suggested that screening by urine culture be obtained at 12 to 16 weeks' gestation** (Nicolle et al., 2005; Nicolle LE, 2018; US Preventive Services Task Force, 2008). Currently, insufficient evidence exists regarding recommendations for repeat screening in women with initial negative cultures or those who underwent treatment for ASB.

As mentioned earlier, the guidelines are reflective of data suggesting that treatment of ASB can reduce morbidity and complications in pregnant patients. However, selection of an appropriate antimicrobial agent must be made in multidisciplinary collaboration to ensure optimization of safety and strategy for the mother and fetus (see General Concepts of Urologic Medication Administration during Pregnancy earlier in this chapter). In general, bacterial composition during pregnancy appears similar to that seen in nonpregnant patients (MacDonald et al., 1983). In general, beta-lactam antimicrobials such as ampicillin or cephalexin are considered safe and generally effective throughout pregnancy. In patients with penicillin allergy, nitrofurantoin is a reasonable alternative. If nitrofurantoin is used, however, it is discontinued at 35 weeks' gestation because of an increased risk for hemolytic anemia in the neonate.

With regard to duration of therapy for ASB, a recent systematic review included 1622 women and compared single-dose to short-course (4 to 7 days) antimicrobials (Smaill and Vazquez, 2015; Widmer et al., 2015). In this analysis, there was a trend toward diminished bacteriuria clearance in the single-dose regimen, however the optimal duration of therapy will ultimately be antimicrobial specific.

Pregnant patients with acute pyelonephritis should be hospitalized and treated with parenteral antimicrobial agents until clinical improvement occurs. More than 95% of these patients respond within 24 hours after administration of ampicillin and an aminoglycoside (Cunningham et al., 1973) or cephalosporins (Sanchez-Ramos et al., 1995). Parenteral treatment should be tailored on the basis of culture sensitivities before transitioning to oral antibiotics. If index of suspicion is elevated for obstructive pathology or clinical improvement is not rapid, further investigations with imaging are prudent. For outpatient therapy, culture-specific oral agents should then be given for at least 14 days (Faro et al., 1984). After completion of the treatment course, low-dose prophylaxis may be considered in select cases for prevention of reinfection (Sandberg and Brorson, 1991; Van Dorsten et al., 1987).

Urologic Management of Placental Abnormalities

One of the most ominous consultations for urology remains assistance with acute management of placental invasion involving the urinary tract. **Disorders of invasive placentation is the umbrella term to encompass the three levels of morbid placental attachment to or beyond the uterine wall secondary to invasion of the trophoblast into the myometrium** (Jauniaux et al., 2017). The three commonly referred terms used to describe the extent of invasion include *placenta accreta, increta,* and *percreta,* although *placenta accreta* is classically utilized in reference to the entire spectrum of placental invasion disorders. Failure of the placenta to separate normally from the uterine wall or invasion into adjacent organs is typically accompanied by the risk for exceptional, life-threatening hemorrhage and coagulopathy, with an average blood loss between 3000 and 5000 mL at delivery in women with placenta accreta (Hudon et al., 1998). Maternal mortality with placenta accreta has been reported as high as 7% and may occur despite optimal planning and transfusion management (Committee on Obstetric Practice, 2012; O'Brien et al., 1996). Prior caesarean delivery appears to be the predominant risk factor in contemporary series resulting from abnormal implantation in the myometrial scar with compromised vascularity (Jauniaux and Jurkovic, 2012). Advanced maternal age is additionally contributory, with women over 35 years of age accounting for 57% of placental adhesive disorders (Fitzpatrick et al., 2012). Current epidemiologic studies report an overall incidence of placenta accreta in the United States of 1 in 533 deliveries (Wu et al., 2005). Used as a singular term, a *placenta accreta* occurs when the placenta attaches to, but does not invade into, myometrium. When chorionic villi invade the myometrium, the condition is termed *placenta increta*. Most commonly **encountered by urology is the most severe form, *placenta percreta,* in which the chorionic villi have perforated the full thickness of the myometrium and breached the uterine serosa with possible adherence to surrounding organs such as the bladder, ureters, and rectum** (Wortman and Alexander, 2013).

Diagnosis and presentation of placental attachment disorders is highly heterogeneous, but the value of accurate predelivery assessment for multidisciplinary planning is immeasurable. With regard to urology-specific concerns during gestation, it is estimated that approximately 25% of women with placenta percreta will display hematuria (Konijeti et al., 2009). With knowledge of the potential risk factors for abnormal placentation, the clinician may choose to proceed with cystoscopic evaluation of such patients to evaluate the posterior bladder wall and significant invasion (Ibrahim et al., 2015; Liu et al., 2018; Takai et al., 2005). Biopsy of the hypervascular tissue visualized in the bladder is discouraged. Standard diagnostic modalities employed for evaluation of placental disorders with regard to imaging include grayscale ultrasonography, which displays sufficient sensitivity and specificity to establish an appropriate anatomic view of the abnormal placentation (Comstock et al., 2004). Adjunct utilization of MRI may be considered when ultrasound findings are inconclusive or invasion into regional vasculature or adjacent organs, such as the ureter, requires further delineation (Committee on Obstetric Practice, 2012).

Once placenta percreta is recognized, which ideally will occur at a significant time before delivery, assembly of a multidisciplinary team is the currently recommended standard of care to reduce maternal and fetal morbidity and mortality. Suggested involvement includes an appropriate anesthesiologist, obstetrician, experienced pelvic surgeon such as a gynecologic oncologist, intensivist, maternal-fetal medicine specialist, interventional radiologist, and as required, additional surgical subspecialties such as urology and general surgery (Eller et al., 2011). These initiatives are optimally accommodated at specialized tertiary centers where support personnel and intensive care is available and criteria for centers of excellence for management of placenta accreta have been outlined (Silver et al., 2015).

Recommended management generally involves planned preterm caesarean hysterectomy, which implies caesarean delivery with the placenta left in situ combined with hysterectomy. Optimal maternal and neonatal outcome in stable patients has been demonstrated with a planned delivery at 34 weeks’ gestation, often accompanied by carefully orchestrated administration of antenatal corticosteroids to facilitate fetal lung maturation (Committee on Obstetric Practice, 2012). However, delivery timing is individualized depending on patient preferences and clinical circumstances. Planned delivery to diminish blood loss and complications is the goal, but contingency plans for emergency should be outlined. Substantial morbidity is associated with unsuspected placental abnormalities at the time of delivery with the surgeon attempting removal of the adherent villous tissues (Warshak et al., 2010). Conservative management options have been explored for women with a strong desire for future fertility that entail leaving the placenta in situ after delivery to reduce operative blood loss and potentially preserve the uterus, although delayed hysterectomy is the most common outcome (Jauniaux et al., 2017; Skinner et al., 2012). Even with adjuvant therapies such as uterine artery embolization, methotrexate therapy, hemostatic sutures, pelvic devascularization, and balloon tamponade, there may be substantial delayed bleeding and infection, and the role of such management remains uncertain.

Preoperative planning by the urologist should include appropriate counseling of the patient with regard to placement of ureteral catheters or stents and potential manifestations of substantial injury or need for extirpative surgery for urologic organs and urinary diversion. Exceptionally distorted anatomy and abnormal vasculature places genitourinary organs at significant risk for inadvertent injury during caesarean delivery and/or hysterectomy, with overall rates estimated at 29% (Tam et al., 2012). Retrograde cystoscopic placement of ureteral catheters will facilitate ureteral identification and/or intraoperative injury (Jauniaux et al., 2017; Matsubara et al., 2013). If plans entail delayed hysterectomy because of intraoperative findings during caesarean delivery, conversion to indwelling double-J stents may be preferred if feasible based on the clinical situation. Additionally, up to one-third of women who undergo peripartum hysterectomy may require reexploration, and indwelling stents may be useful during these procedures to control of bleeding or genitourinary tract injury.

Many placenta percreta cases involve invasion of the detrusor muscle, but even with substantial uterine bleeding, bladder preservation should be attempted. For known invasion, planned cystotomy and partial cystectomy may reduce intraoperative complications as attempts to develop a plane to separate the placenta from the bladder may result in substantial hemorrhage (Konijeti et al., 2009). Patients should additionally be counseled regarding potential long-term sequela of damage to the urinary tract including fistula, incontinence, and neurogenic dysfunction.

Key Points for Management of Placental Abnormalities

- Ultrasound imaging is superior to MRI for routine screening of placenta accreta in at-risk patients, but the degree of invasion to adjacent pelvic tissues and organs may be better ascertained with MRI.

- Optimum timing for planned delivery for a patient with suspected placenta percreta is approximately 34 weeks.
- Patients who are diagnosed antenatally with placenta percreta should be referred to a tertiary care center and managed by a multidisciplinary team that includes urologists, general surgeons, obstetric anesthesiologists, interventional radiologists, and intensivists.
- Urologists should carefully counsel patients regarding complexities of management and outcomes for urinary tract injury and should consider retrograde catheter placement to prevent or identify ureteral injury.

Acknowledgments

For the exceptional expertise of Camille Ivey, Liaison Librarian for Health Sciences at Vanderbilt's Eskind Biomedical Library, for outstanding methodologic assistance with literature search and evaluation.

References

Abdul Sultan A, West J, Tata LJ, et al. Risk of first venous thromboembolism in pregnant women in hospital: population based cohort study from England. *BMJ*. 2013;347:f6099.

ACOG Committee on Ethics. ACOG Committee Opinion #321: maternal decision making, ethics, and the law. *Obstet Gynecol*. 2005;106(5 Pt 1):1127–1137.

Alleemudder DI, Alleemudder AI, Harry D, et al. Bladder squamous cell carcinoma in pregnancy. *J Obstet Gynaecol*. 2016;36(3):388–389.

Allergan. *BOTOX prescribing information*. http://www.allergan.com/assets/pdf/botox_pi.pdf; 2018.

Altamar H, Miller N. Management of kidney stones in pregnancy. *AUA Update Series*. 2009;28 [Lesson 35].

Antony K, Racusin DA, Aagaard K, et al. Maternal physiology. Gabbe SG, Simpson JL, Landon MH, et al. *Obstetrics: normal and problem pregnancies*. ed 7. Elsevier: Philadelphia, PA; 2017:39–60.

Anusionwu I, Baradaran N, Trock BJ, et al. Is pelvic osteotomy associated with lower risk of pelvic organ prolapse in postpubertal females with classic bladder exstrophy? *J Urol*. 2012;188(6):2343–2346.

Anusionwu I, Tekes A, Stec AA, et al. Comparison of musculoskeletal anatomic relationships, determined by magnetic resonance imaging, in postpubertal female patients with and without classic bladder exstrophy. *BJU Int*. 2013;112(2):E195–E200.

Assimos D, Krambeck A, Miller NL, et al. Surgical management of stones: American Urological Association/Endourological Society Guideline, PART I. *J Urol*. 2016;196(4):1153–1160.

Assimos D, Krambeck A, Miller NL, et al. Surgical management of stones: American Urological Association/Endourological Society Guideline, PART II. *J Urol*. 2016;196(4):1161–1169.

Bailey G, Vaughan L, Rose C, et al. Perinatal outcomes with tamsulosin therapy for symptomatic urolithiasis. *J Urol*. 2016;195(1):99–103.

Banhidy F, Acs N, Puho EH, et al. Maternal kidney stones during pregnancy and adverse birth outcomes, particularly congenital abnormalities in the offspring. *Arch Gynecol Obstet*. 2007;275(6):481–487.

Beaman KD, Jaiswal MK, Katara GK, et al. Pregnancy is a model for tumors, not transplantation. *Am J Reprod Immunol*. 2016;76(1):3–7.

Biyani CS, Joyce AD. Urolithiasis in pregnancy. I: pathophysiology, fetal considerations and diagnosis. *BJU Int*. 2002;89(8):811–818 [quiz i-ii].

Boehlen F, Hohlfeld P, Extermann P, et al. Platelet count at term pregnancy: a reappraisal of the threshold. *Obstet Gynecol*. 2000;95(1):29–33.

Boekhorst F, Bogers H, Martens J. Renal pelvis rupture during pregnancy: diagnosing a confusing source of despair. *BMJ Case Rep*. 2015;2015.

Boridy IC, Maklad N, Sandler CM. Suspected urolithiasis in pregnant women: imaging algorithm and literature review. *Am J Roentgenol*. 1996;167(4):869–875.

Boyle JA, Campbell S, Duncan AM, et al. Serum uric acid levels in normal pregnancy with observations on the renal excretion of urate in pregnancy. *J Clin Pathol*. 1966;19(5):501–503.

Brin MF, Kirby RS, Slavotinek A, et al. Pregnancy outcomes following exposure to onabotulinumtoxinA. *Pharmacoepidemiol Drug Saf*. 2016;25(2):179–187.

Brown MA, Holt JL, Mangos GJ, et al. Microscopic hematuria in pregnancy: relevance to pregnancy outcome. *Am J Kidney Dis*. 2005;45(4):667–673.

Burke BJ, Washowich TL. Ureteral jets in normal second- and third-trimester pregnancy. *J Clin Ultrasound*. 1998;26(9):423–426.

Burrows RF, Kelton JG. Incidentally detected thrombocytopenia in healthy mothers and their infants. *N Engl J Med*. 1988;319(3):142–145.

Butler EL, Cox SM, Eberts EG, et al. Symptomatic nephrolithiasis complicating pregnancy. *Obstet Gynecol*. 2000;96(5 Pt 1):753–756.

Cameron M, Moran P. Prenatal screening and diagnosis of neural tube defects. *Prenat Diagn*. 2009;29(4):402–411.

Campbell S, Uzzo RG, Allaf ME, et al. Renal mass and localized renal cancer: AUA guideline. *J Urol*. 2017;198(3):520–529.

Cardozo L, Cutner A. Lower urinary tract symptoms in pregnancy. *Br J Urol*. 1997;80(Suppl 1):14–23.

Cecen K, Ulker K. The comparison of double J stent insertion and conservative treatment alone in severe pure gestational hydronephrosis: a case controlled clinical study. *ScientificWorldJournal*. 2014;2014:989173.

Centers for Disease Control and Prevention. Recommendations for use of folic acid to reduce number of spina bifida cases and other neural tube defects. *JAMA*. 1993;269(10):1233 [6–8].

Chang SS, Bochner BH, Chou R, et al. Treatment of nonmetastatic muscle-invasive bladder cancer: American Urological Association/American Society of Clinical Oncology/American Society for Radiation Oncology/Society of Urologic Oncology clinical practice guideline summary. *J Oncol Pract*. 2017;13(9):621–625.

Chang SS, Boorjian SA, Chou R, et al. Diagnosis and treatment of Non-Muscle Invasive bladder cancer: AUA/SUO guideline. *J Urol*. 2016;196(4):1021–1029.

Chapman AB, Abraham WT, Zamudio S, et al. Temporal relationships between hormonal and hemodynamic changes in early human pregnancy. *Kidney Int*. 1998;54(6):2056–2063.

Chaussy CG, Fuchs GJ. Current state and future developments of noninvasive treatment of human urinary stones with extracorporeal shock wave lithotripsy. *J Urol*. 1989;141(3 Pt 2):782–789.

Choi CI, Yu YD, Park DS. Ureteral stent insertion in the management of renal colic during pregnancy. *Chonnam Med J*. 2016;52(2):123–127.

Chu SY, Hanson DL, Jones JL. Pregnancy rates among women infected with human immunodeficiency virus. Adult/Adolescent HIV Spectrum of Disease Project Group. *Obstet Gynecol*. 1996;87(2):195–198.

Church E, Dieh A. A rare case of aggressive squamous cell carcinoma of the bladder in pregnancy. *Obstet Med*. 2013;6(4):182–183.

Clark SL, Cotton DB, Pivarnik JM, et al. Position change and central hemodynamic profile during normal third-trimester pregnancy and post partum. *Am J Obstet Gynecol*. 1991;164(3):883–887.

Clemetson CA. Ectopia vesicae and split pelvis; an account of pregnancy in a woman with treated ectopia vesicae and split pelvis, including a review of the literature. *J Obstet Gynaecol Br Emp*. 1958;65(6):973–981.

Coban S, Biyik I, Ustunyurt E, et al. Is there a relationship between the grade of maternal hydronephrosis and birth weight of the babies? *J Matern Fetal Neonatal Med*. 2015;28(9):1053–1056.

Coe FL, Parks JH, Lindheimer MD. Nephrolithiasis during pregnancy. *N Engl J Med*. 1978;298(6):324–326.

Committee on Obstetric Practice. Committee Opinion No. 529: placenta accreta. *Obstet Gynecol*. 2012;120(1):207–211.

Committee on Obstetric Practice. Committee Opinion No. 696: nonobstetric surgery during pregnancy. *Obstet Gynecol*. 2017;129(4):777–778.

Committee on Obstetric Practice. Committee Opinion No. 723: guidelines for diagnostic imaging during pregnancy and lactation. *Obstet Gynecol*. 2017;130(4):e210–e216.

Comstock CH, Love JJ Jr, Bronsteen RA, et al. Sonographic detection of placenta accreta in the second and third trimesters of pregnancy. *Am J Obstet Gynecol*. 2004;190(4):1135–1140.

Conrad KP, Stillman IE, Lindheimer MD. The kidney in normal pregnancy and preeclampsia. Taylor R, Roberts J, Cunningham F, et al. *Chesley's hypertensive disorders in pregnancy*. ed 4. Academic Press: Amsterdam; 2014.

Creanga AA, Berg CJ, Syverson C, et al. Pregnancy-related mortality in the United States, 2006-2010. *Obstet Gynecol*. 2015;125(1):5–12.

Cruickshank DP, Wigton TR, Hays PM. Maternal physiology in pregnancy. Gabbe SG, Niebyl J, Simpson JL, et al. *Obstetrics: normal and problem pregnancies*. ed 3. Churchill Livingstone: New York; 1996.

Cunningham FG, Leveno KJ, Bloom SL, et al. General considerations and maternal evaluation. Cunningham FG, Leveno KJ, Bloom SL, et al. *Williams obstetrics*. ed 24. McGraw-Hill Education: New York, NY; 2013.

Cunningham FG, Leveno KJ, Bloom SL, et al. Neoplastic disorders. Cunningham FG, Leveno KJ, Bloom SL, et al. *Williams obstetrics*. ed 24. McGraw-Hill Education: New York, NY; 2013.

Cunningham FG, Morris GB, Mickal A. Acute pyelonephritis of pregnancy: a clinical review. *Obstet Gynecol*. 1973;42(1):112–117.

Cunnington M, Kortsalioudaki C, Heath P. Genitourinary pathogens and preterm birth. *Curr Opin Infect Dis*. 2013;26(3):219–230.

Cusimano MD, Meffe FM, Gentili F, et al. Ventriculoperitoneal shunt malfunction during pregnancy. *Neurosurgery*. 1990;27(6):969–971.

Dafnis E, Sabatini S. The effect of pregnancy on renal function: physiology and pathophysiology. *Am J Med Sci*. 1992;303(3):184–205.

Danielson LA, Sherwood OD, Conrad KP. Relaxin is a potent renal vasodilator in conscious rats. *J Clin Invest*. 1999;103(4):525–533.

Dap M, Larmure O, Morel O, et al. Pregnancy outcomes among patients with prior bladder exstrophy. *Int J Gynaecol Obstet*. 2017;139(3):368–369.

Davidson AJ, Talner LB. Late sequelae of adult-onset acute bacterial nephritis. *Radiology*. 1978;127(2):367–371.

Davis R, Jones JS, Barocas DA, et al. Diagnosis, evaluation and follow-up of asymptomatic microhematuria (AMH) in adults: AUA guideline. *J Urol*. 2012;188(6 Suppl):2473–2481.

Daw E. Pregnancy problems in a paraplegic patient with an ileal conduit bladder. *Practitioner*. 1973;211(266):781–784.

de Vylder A, van Driel MF, Staal AL, et al. Myelomeningocele and female sexuality: an issue? *Eur Urol*. 2004;46(4):421–426 [discussion 6-7].

Deans R, Banks F, Liao LM, et al. Reproductive outcomes in women with classic bladder exstrophy: an observational cross-sectional study. *Am J Obstet Gynecol*. 2012;206(6):496 e1–496 e6.

Denstedt JD, Razvi H. Management of urinary calculi during pregnancy. *J Urol*. 1992;148(3 Pt 2):1072–1074 [discussion 4-5].

Desai DK, Moodley J, Naidoo DP. Echocardiographic assessment of cardiovascular hemodynamics in normal pregnancy. *Obstet Gynecol*. 2004;104(1):20–29.

Deters LA, Belanger G, Shah O, et al. Ultrasound guided ureteroscopy in pregnancy. *Clin Nephrol*. 2013;79(2):118–123.

Deyoe LA, Cronan JJ, Breslaw BH, et al. New techniques of ultrasound and color Doppler in the prospective evaluation of acute renal obstruction. Do they replace the intravenous urogram? *Abdom Imaging*. 1995;20(1):58–63.

Dunlop W. Serial changes in renal haemodynamics during normal human pregnancy. *Br J Obstet Gynaecol*. 1981;88(1):1–9.

Dy GW, Willihnganz-Lawson KH, Shnorhavorian M, et al. Successful pregnancy in patients with exstrophy-epispadias complex: a University of Washington experience. *J Pediatr Urol*. 2015;11(4):213 e1–213 e6.

Ebert AK, Reutter H, Ludwig M, et al. The exstrophy-epispadias complex. *Orphanet J Rare Dis*. 2009;4:23.

Eller AG, Bennett MA, Sharshiner M, et al. Maternal morbidity in cases of placenta accreta managed by a multidisciplinary care team compared with standard obstetric care. *Obstet Gynecol*. 2011;117(2 Pt 1):331–337.

Ercil H, Arslan B, Ortoglu F, et al. Conservative/surgical treatment predictors of maternal hydronephrosis: results of a single-center retrospective non-randomized non-controlled observational study. *Int Urol Nephrol*. 2017;49(8):1347–1352.

Eswara JR, Kielb S, Koyle MA, et al. The recommendations of the 2015 American Urological Association working group on genitourinary congenitalism. *Urology*. 2016;88:1–7.

Fainaru O, Almog B, Gamzu R, et al. The management of symptomatic hydronephrosis in pregnancy. *BJOG*. 2002;109(12):1385–1387.

Faro S, Pastorek JG 2nd, Plauche WC, et al. Short-course parenteral antibiotic therapy for pyelonephritis in pregnancy. *South Med J*. 1984;77(4):455–457.

Farr A, Ott J, Kueronya V, et al. The association between maternal hydronephrosis and acute flank pain during pregnancy: a prospective pilot-study. *J Matern Fetal Neonatal Med*. 2017;30(20):2417–2421.

Fishman IJ, Scott FB. Pregnancy in patients with the artificial urinary sphincter. *J Urol*. 1993;150(2 Pt 1):340–341.

Fitzpatrick KE, Sellers S, Spark P, et al. Incidence and risk factors for placenta accreta/increta/percreta in the UK: a national case-control study. *PLoS ONE*. 2012;7(12):e52893.

Frankenschmidt A, Sommerkamp H. Shock wave lithotripsy during pregnancy: a successful clinical experiment. *J Urol*. 1998;159(2):501–502.

Fried AM, Woodring JH, Thompson DJ. Hydronephrosis of pregnancy: a prospective sequential study of the course of dilatation. *J Ultrasound Med*. 1983;2(6):255–259.

Gearhart JP, Mathews R. Exstrophy-epispadias complex. Wein AJ, Kavoussi LR, Partin AW, et al. *Campbell-Walsh urology*. ed 11. Elsevier: Philadelphia, PA; 2016:3182–3233.

Gertner JM, Coustan DR, Kliger AS, et al. Pregnancy as state of physiologic absorptive hypercalciuria. *Am J Med*. 1986;81(3):451–456.

Gilson GJ, Mosher MD, Conrad KP. Systemic hemodynamics and oxygen transport during pregnancy in chronically instrumented, conscious rats. *Am J Physiol*. 1992;263(6 Pt 2):H1911–H1918.

Gilstrap LC, Leveno KJ, Cunningham FG, et al. Renal infection and pregnancy outcome. *Am J Obstet Gynecol*.

1981;141(6):709–716.

Giron AM, Passerotti CC, Nguyen H, et al. Bladder exstrophy: reconstructed female patients achieving normal pregnancy and delivering normal babies. *Int Braz J Urol*. 2011;37(5):605–610.

Gitlin J, Rink RC, King S, et al. Conception, pregnancy and delivery in patients with augmented bladders. *J Urol*. 2002;167(256):1005.

Gladman MA, MacDonald D, Webster JJ, et al. Renal cell carcinoma in pregnancy. *J R Soc Med*. 2002;95(4):199–201.

Goldfarb RA, Neerhut GJ, Lederer E. Management of acute hydronephrosis of pregnancy by ureteral stenting: risk of stone formation. *J Urol*. 1989;141(4):921–922.

Gorton E, Whitfield HN. Renal calculi in pregnancy. *Br J Urol*. 1997;80(Suppl 1):4–9.

Greenwell TJ, Venn SN, Creighton S, et al. Pregnancy after lower urinary tract reconstruction for congenital abnormalities. *BJU Int*. 2003;92(7):773–777.

Haas DM, Marsh DJ, Dang DT, et al. Prescription and other medication use in pregnancy. *Obstet Gynecol*. 2018;131(5):789–798.

Hamid R, Robertson WG, Woodhouse CR. Comparison of biochemistry and diet in patients with enterocystoplasty who do and do not form stones. *BJU Int*. 2008;101(11):1427–1432.

Harvey EB, Boice JD Jr, Honeyman M, et al. Prenatal x-ray exposure and childhood cancer in twins. *N Engl J Med*. 1985;312(9):541–545.

Hattery RR, King BF. Technique and application of MR urography. *Radiology*. 1995;194(1):25–27.

Hautmann RE, Volkmer BG. Pregnancy and urinary diversion. *Urol Clin North Am*. 2007;34(1):71–88.

Hendricks SK, Ross SO, Krieger JN. An algorithm for diagnosis and therapy of management and complications of urolithiasis during pregnancy. *Surg Gynecol Obstet*. 1991;172(1):49–54.

Hendry WF. Management of urological tumours in pregnancy. *Br J Urol*. 1997;80(Suppl 1):24–28.

Hensle TW, Bingham JB, Reiley EA, et al. The urological care and outcome of pregnancy after urinary tract reconstruction. *BJU Int*. 2004;93(4):588–590.

Hill DE, Chantigian PM, Kramer SA. Pregnancy after augmentation cystoplasty. *Surg Gynecol Obstet*. 1990;170(6):485–487.

Horowitz E, Schmidt JD. Renal calculi in pregnancy. *Clin Obstet Gynecol*. 1985;28(2):324–338.

Horrigan TJ, Reese CS, Parres JA, et al. A study of resistive indices in the arcuate arteries of the kidney over the course of gestation. *J Perinatol*. 1996;16(6):467–469.

Hou S. Pregnancy in women with chronic renal disease. *N Engl J Med*. 1985;312(13):836–839.

Houshiar AM, Ercole CJ. Urinary calculi during pregnancy. When are they cause for concern? *Postgrad Med*. 1996;100(4):131–138.

Howarth AT, Morgan DB, Payne RB. Urinary excretion of calcium in late pregnancy and its relation to creatinine clearance. *Am J Obstet Gynecol*. 1977;129(5):499–502.

Huck N, Schweizerhof S, Honeck P, et al. Pregnancy after urinary diversion at young ages-risks and outcome. *Urology*. 2017;104:220–224.

Hudon L, Belfort MA, Broome DR. Diagnosis and management of placenta percreta: a review. *Obstet Gynecol Surv*. 1998;53(8):509–517.

Huser M, Belkov IA, Janku P, et al. Pregnancy and delivery following midurethral sling surgery for stress urinary incontinence. *Int J Gynaecol Obstet*. 2012;119(2):117–120.

Ibrahim MA, Liu A, Dalpiaz A, et al. Urological manifestations of placenta percreta. *Curr Urol*. 2015;8(2):57–65.

Izci B, Riha RL, Martin SE, et al. The upper airway in pregnancy and pre-eclampsia. *Am J Respir Crit Care Med*. 2003;167(2):137–140.

Jackson AB, Mott PK. Reproductive health care for women with spina bifida. *ScientificWorldJournal*. 2007;7:1875–1883.

Jauniaux E, Bhide A, Wright JD. Placenta accreta. Gabbe SG, Simpson JL, Landon MH, et al. *Obstetrics: normal and problem pregnancies*. ed 7. Elsevier: Philadelphia, PA; 2017:456–466.

Jauniaux E, Jurkovic D. Placenta accreta: pathogenesis of a 20th century iatrogenic uterine disease. *Placenta*. 2012;33(4):244–251.

Johnson EB, Krambeck AE, White WM, et al. Obstetric complications of ureteroscopy during pregnancy. *J Urol*. 2012;188(1):151–154.

Kavoussi LR, Albala DM, Basler JW, et al. Percutaneous management of urolithiasis during pregnancy. *J Urol*. 1992;148(3 Pt 2):1069–1071.

Khaled H, Lahloubi NA, Rashad N. Review on renal cell carcinoma and pregnancy: a challenging situation. *J Adv Res*. 2016;7(4):575–580.

Khoo L, Anson K, Patel U. Success and short-term complication rates of percutaneous nephrostomy during pregnancy. *J Vasc Interv Radiol*. 2004;15(12):1469–1473.

Klein P, Polidori D, Twito O, et al. Impaired decline in renal threshold for glucose during pregnancy—a possible novel mechanism for gestational diabetes mellitus. *Diabetes Metab Res Rev*. 2014;30(2):140–145.

Konijeti R, Rajfer J, Askari A. Placenta percreta and the urologist. *Rev Urol*. 2009;11(3):173–176.

Kovacs CS, Kronenberg HM. Maternal-fetal calcium and bone metabolism during pregnancy, puerperium, and lactation. *Endocr Rev*. 1997;18(6):832–872.

Laurence KM, Beresford A. Continence, friends, marriage and children in 51 adults with spina bifida. *Dev Med Child Neurol Suppl*. 1975;35:123–128.

Leung KY, De Castro SC, Savery D, et al. Nucleotide precursors prevent folic acid-resistant neural tube defects in the mouse. *Brain*. 2013;136(Pt 9):2836–2841.

Lewis DF, Robichaux AG 3rd, Jaekle RK, et al. Urolithiasis in pregnancy. Diagnosis, management and pregnancy outcome. *J Reprod Med*. 2003;48(1):28–32.

Liu Y, Fan D, Fu Y, et al. Diagnostic accuracy of cystoscopy and ultrasonography in the prenatal diagnosis of abnormally invasive placenta. *Medicine (Baltimore)*. 2018;97(15):e0438.

Loughlin KR. Management of urologic problems during pregnancy. *Urology*. 1994;44(2):159–169.

MacDonald P, Alexander D, Catz C, et al. Summary of a workshop on maternal genitourinary infections and the outcome of pregnancy. *J Infect Dis*. 1983;147(3):596–605.

MacNeily AE, Goldenberg SL, Allen GJ, et al. Sonographic visualization of the ureter in pregnancy. *J Urol*. 1991;146(2):298–301.

Maikranz P, Coe FL, Parks J, et al. Nephrolithiasis in pregnancy. *Am J Kidney Dis*. 1987;9(4):354–358.

Martin FM, Rowland RG. Urologic malignancies in pregnancy. *Urol Clin North Am*. 2007;34(1):53–59.

Masselli G, Derme M, Laghi F, et al. Imaging of stone disease in pregnancy. *Abdom Imaging*. 2013;38(6):1409–1414.

Mathews RI, Gan M, Gearhart JP. Urogynaecological and obstetric issues in women with the exstrophy-epispadias complex. *BJU Int*. 2003;91(9):845–849.

Matsubara S, Kuwata T, Usui R, et al. Important surgical measures and techniques at cesarean hysterectomy for placenta previa accreta. *Acta Obstet Gynecol Scand*. 2013;92(4):372–377.

Maynard SE, Karumanchi SA, Thadhani R. Hypertension and kidney disease in pregnancy. Skorecki K, Chertow GM, Marsden PA, et al. *Brenner and Rector's the kidney*. ed 10. Elsevier: Philadelphia, PA; 2016:1610–1639.

Mazze RI, Kallen B. Reproductive outcome after anesthesia and operation during pregnancy: a registry study of 5405 cases. *Am J Obstet Gynecol*. 1989;161(5):1178–1185.

McClinton S, Starr K, Thomas R, et al. Use of drug therapy in the management of symptomatic ureteric stones in hospitalized adults (SUSPEND), a multicentre, placebo-controlled, randomized trial of a calcium-channel blocker (nifedipine) and an alpha-blocker (tamsulosin): study protocol for a randomized controlled trial. *Trials*. 2014;15:238.

Miles-Thomas J, Gearhart JP, Gearhart SL. An initial evaluation of pelvic floor function and quality of life of bladder exstrophy patients after ureterosigmoidostomy. *J Gastrointest Surg*. 2006;10(4):473–477.

Mitchell LE, Adzick NS, Melchionne J, et al. Spina bifida. *Lancet*. 2004;364(9448):1885–1895.

Mizuno K, Sasaki S, Tozawa K, et al. Leiomyoma of the urinary bladder during pregnancy. *Int J Urol*. 2003;10(7):407–409.

Mullins JK, Semins MJ, Hyams ES, et al. Half Fourier single-shot turbo spin-echo magnetic resonance urography for the evaluation of suspected renal colic in pregnancy. *Urology*. 2012;79(6):1252–1255.

Myoen S, Mitsuzuka K, Saito H, et al. Spontaneous rupture of a renal angiomyolipoma at 25 weeks of pregnancy treated with transarterial embolization: a case report and review of the literature. *Int J Urol*. 2015;22(7):710–712.

Nakhal RS, Deans R, Creighton SM, et al. Genital prolapse in adult women with classical bladder exstrophy. *Int Urogynecol J*. 2012;23(9):1201–1205.

Natarajan V, Kapur D, Sharma S, et al. Pregnancy in patients with spina bifida and urinary diversion. *Int Urogynecol J Pelvic Floor Dysfunct*. 2002;13(6):383–385.

Nethercliffe J, Trewick A, Samuell C, et al. False-positive pregnancy tests in patients with enterocystoplasties. *BJU Int*. 2001;87(9):780–782.

Nicolle LE, Bradley S, Colgan R, et al. Infectious Diseases Society of America guidelines for the diagnosis and treatment of asymptomatic bacteriuria in adults. *Clin Infect Dis*. 2005;40(5):643–654.

Nicolle LE, et al. *Clinical practice guideline for the management of asymptomatic bacteriuria: 2018 update by the Infectious Diseases Society of America*. [In:] 2018.

Niebyl J, Weber RJ, Briggs GG. Drugs and environmental agents in pregnancy and lactation: teratology, epidemiology. Gabbe SG, Simpson JL, Landon MH, et al. *Obstetrics: normal and problem pregnancies*. ed 7. Elsevier: Philadelphia, PA; 2017:136–159.

O'Brien JM, Barton JR, Donaldson ES. The management of placenta percreta: conservative and operative strategies. *Am J Obstet Gynecol*. 1996;175(6):1632–1638.

Pais VM Jr, Reinstatler L. Urologic surgery in the pregnant patient. Taneja SS, Shah O. *Taneja's complications of urologic surgery: diagnosis, prevention, and management*. ed 5. Elsevier: New York, NY; 2018:183–194.

Paller MS, Ferris TF. The kidney and hypertension in pregnancy. Brenner BM. *Brenner and Rector's the kidney*. ed 5. Saunders: Philadelphia; 1996:1731–1763.

Parulkar BG, Hopkins TB, Wollin MR, et al. Renal colic during pregnancy: a case for conservative treatment. *J Urol*. 1998;159(2):365–368.

Patterson TF, Andriole VT. Bacteriuria in pregnancy. *Infect Dis Clin North Am*. 1987;1(4):807–822.

Pearl J, Price R, Richardson W, et al. Guidelines for diagnosis, treatment, and use of laparoscopy for surgical problems during pregnancy. *Surg Endosc*. 2011;25(11):3479–3492.

Pedler SJ, Bint AJ. Management of bacteriuria in pregnancy. *Drugs*. 1987;33(4):413–421.

Pernia S, DeMaagd G. The new pregnancy and lactation labeling rule. *P T*. 2016;41(11):713–715.

Pettker CaCL. Thromboembolic disorders in pregnancy. Gabbe SG, Simpson JL, Landon MH, et al. *Obstetrics: normal and problem pregnancies*. ed 7. Elsevier: Philadelphia, PA; 2017.

Pitkin RM, Witte DL. Platelet and leukocyte counts in pregnancy. *JAMA*. 1979;242(24):2696–2698.

Pollard ME, Morrisroe S, Anger JT. Outcomes of pregnancy following surgery for stress urinary incontinence: a systematic review. *J Urol*. 2012;187(6):1966–1970.

Puskar D, Balagovic I, Filipovic A, et al. Symptomatic physiologic hydronephrosis in pregnancy: incidence, complications and treatment. *Eur Urol*. 2001;39(3):260–263.

Rasmussen PE, Nielsen FR. Hydronephrosis during pregnancy: a literature survey. *Eur J Obstet Gynecol Reprod Biol*. 1988;27(3):249–259.

Ray JG, Vermeulen MJ, Bharatha A, et al. Association between MRI exposure during pregnancy and fetal and childhood outcomes. *JAMA*. 2016;316(9):952–961.

Reedy MB, Kallen B, Kuehl TJ. Laparoscopy during pregnancy: a study of five fetal outcome parameters with use of the Swedish Health Registry. *Am J Obstet Gynecol*. 1997;177(3):673–679.

Reinstatler L, Khaleel S, Pais VM Jr. Association of pregnancy with stone formation among women in the United States: a NHANES analysis 2007 to 2012. *J Urol*. 2017;198(2):389–

393.

Reitman E, Flood P. Anaesthetic considerations for non-obstetric surgery during pregnancy. *Br J Anaesth*. 2011;107(Suppl 1):i72–i78.

Resim S, Ekerbicer HC, Kiran G, et al. Are changes in urinary parameters during pregnancy clinically significant? *Urol Res*. 2006;34(4):244–248.

Ricci G, Gentili A, Di Lorenzo F, et al. Latex allergy in subjects who had undergone multiple surgical procedures for bladder exstrophy: relationship with clinical intervention and atopic diseases. *BJU Int*. 1999;84(9):1058–1062.

Riley JM, Dudley AG, Semins MJ. Nephrolithiasis and pregnancy: has the incidence been rising? *J Endourol*. 2014;28(3):383–386.

Rob S, Bryant T, Wilson I, et al. Ultra-low-dose, low-dose, and standard-dose CT of the kidney, ureters, and bladder: is there a difference? Results from a systematic review of the literature. *Clin Radiol*. 2017;72(1):11–15.

Robertson DN. Pregnancy and labour in the paraplegic. *Paraplegia*. 1972;10(3):209–212.

Robertson WG, Woodhouse CR. Metabolic factors in the causation of urinary tract stones in patients with enterocystoplasties. *Urol Res*. 2006;34(4):231–238.

Rodriguez PN, Klein AS. Management of urolithiasis during pregnancy. *Surg Gynecol Obstet*. 1988;166(2):103–106.

Rosenberg E, Sergienko R, Abu-Ghanem S, et al. Nephrolithiasis during pregnancy: characteristics, complications, and pregnancy outcome. *World J Urol*. 2011;29(6):743–747.

Ross AE, Handa S, Lingeman JE, et al. Kidney stones during pregnancy: an investigation into stone composition. *Urol Res*. 2008;36(2):99–102.

Roy C, Saussine C, Jahn C, et al. Fast imaging MR assessment of ureterohydronephrosis during pregnancy. *Magn Reson Imaging*. 1995;13(6):767–772.

Rubenwolf P, Thomas C, Thuroff JW, et al. Sexual function and fertility of women with classic bladder exstrophy and continent urinary diversion. *J Urol*. 2016;196(1):140–145.

Sadan O, Berar M, Sagiv R, et al. Ureteric stent in severe hydronephrosis of pregnancy. *Eur J Obstet Gynecol Reprod Biol*. 1994;56(2):79–81.

Sanchez-Ramos L, McAlpine KJ, Adair CD, et al. Pyelonephritis in pregnancy: once-a-day ceftriaxone versus multiple doses of cefazolin. A randomized, double-blind trial. *Am J Obstet Gynecol*. 1995;172(1 Pt 1):129–133.

Sandberg T, Brorson JE. Efficacy of long-term antimicrobial prophylaxis after acute pyelonephritis in pregnancy. *Scand J Infect Dis*. 1991;23(2):221–223.

Sandhu KS, LaCombe JA, Fleischmann N, et al. Gross and microscopic hematuria: guidelines for obstetricians and gynecologists. *Obstet Gynecol Surv*. 2009;64(1):39–49.

Scales CD Jr, Curtis LH, Norris RD, et al. Changing gender prevalence of stone disease. *J Urol*. 2007;177(3):979–982.

Scales CD Jr, Smith AC, Hanley JM, et al. Prevalence of kidney stones in the United States. *Eur Urol*. 2012;62(1):160–165.

Schilling A, Krawczak G, Friesen A, et al. Pregnancy in a patient with an ileal substitute bladder followed by severe destabilization of the pelvic support. *J Urol*. 1996;155(4):1389–1390.

Schulman A, Herlinger H. Urinary tract dilatation in pregnancy. *Br J Radiol*. 1975;48(572):638–645.

Scott DE. Anemia in pregnancy. *Obstet Gynecol Annu*. 1972;1:219–244.

Semins MJ, Trock BJ, Matlaga BR. The safety of ureteroscopy during pregnancy: a systematic review and meta-analysis. *J Urol*. 2009;181(1):139–143.

Shahraki AD, Bardeh ME, Najarzadegan MR. Investigation of the relationship between idiopathic microscopic hematuria (in the first and second trimesters) and major adverse outcomes of pregnancy. *Adv Biomed Res*. 2016;5:186.

Shapiro E, Lepor H, Jeffs RD. The inheritance of the exstrophy-epispadias complex. *J Urol*. 1984;132(2):308–310.

Shokeir AA, Abdulmaaboud M. Resistive index in renal colic: a prospective study. *BJU Int*. 1999;83(4):378–382.

Shokeir AA, Mahran MR, Abdulmaaboud M. Renal colic in pregnant women: role of renal resistive index. *Urology*. 2000;55(3):344–347.

Silver RM, Fox KA, Barton JR, et al. Center of excellence for placenta accreta. *Am J Obstet Gynecol*. 2015;212(5):561–568.

Skinner BD, Golichowski AM, Raff GJ. Laparoscopic-assisted vaginal hysterectomy in a patient with placenta percreta. *JSLS*. 2012;16(1):143–147.

Smaill FM, Vazquez JC. Antibiotics for asymptomatic bacteriuria in pregnancy. *Cochrane Database Syst Rev*. 2015;(8) [CD000490].

Spahn M, Bader P, Westermann D, et al. Bladder carcinoma during pregnancy. *Urol Int*. 2005;74(2):153–159.

Sparta G, Kemper MJ, Gerber AC, et al. Latex allergy in children with urological malformation and chronic renal failure. *J Urol*. 2004;171(4):1647–1649.

Spencer JA, Chahal R, Kelly A, et al. Evaluation of painful hydronephrosis in pregnancy: magnetic resonance urographic patterns in physiological dilatation versus calculous obstruction. *J Urol*. 2004;171(1):256–260.

Stanton S. Gynecologic complications of epispadias and bladder exstrophy. *Am J Obstet Gynecol*. 1974;119:749–754.

Stec AA. Embryology and bony and pelvic floor anatomy in the bladder exstrophy-epispadias complex. *Semin Pediatr Surg*.

2011;20(2):66–70.

Stehman-Breen C, Miller L, Fink J, et al. Pre-eclampsia and premature labour among pregnant women with haematuria. *Paediatr Perinat Epidemiol*. 2000;14(2):136–140.

Stehman-Breen CO, Levine RJ, Qian C, et al. Increased risk of preeclampsia among nulliparous pregnant women with idiopathic hematuria. *Am J Obstet Gynecol*. 2002;187(3):703–708.

Stein R, Fisch M, Bauer H, et al. Operative reconstruction of the external and internal genitalia in female patients with bladder exstrophy or incontinent epispadias. *J Urol*. 1995;154(3):1002–1007.

Stein R, Hohenfellner K, Fisch M, et al. Social integration, sexual behavior and fertility in patients with bladder exstrophy—a long-term follow up. *Eur J Pediatr*. 1996;155(8):678–683.

Stothers L, Lee LM. Renal colic in pregnancy. *J Urol*. 1992;148(5):1383–1387.

Swanson SK, Heilman RL, Eversman WG. Urinary tract stones in pregnancy. *Surg Clin North Am*. 1995;75(1):123–142.

Swartz HM, Reichling BA. Hazards of radiation exposure for pregnant women. *JAMA*. 1978;239(18):1907–1908.

Swartz MA, Lydon-Rochelle MT, Simon D, et al. Admission for nephrolithiasis in pregnancy and risk of adverse birth outcomes. *Obstet Gynecol*. 2007;109(5):1099–1104.

Takai N, Eto M, Sato F, et al. Placenta percreta invading the urinary bladder. *Arch Gynecol Obstet*. 2005;271(3):274–275.

Tam KB, Dozier J, Martin JN Jr. Approaches to reduce urinary tract injury during management of placenta accreta, increta, and percreta: a systematic review. *J Matern Fetal Neonatal Med*. 2012;25(4):329–334.

Tan HJ, Siu W, Faerber GJ, et al. Long-term durability of pubovaginal fascial slings in women who then become pregnant and deliver. *Int Urogynecol J*. 2010;21(6):631–635.

Thadhani R, Ecker JL, Kettyle E, et al. Pulse pressure and risk of preeclampsia: a prospective study. *Obstet Gynecol*. 2001;97(4):515–520.

Thomas JC, Adams MC. Female sexual function and pregnancy after genitourinary reconstruction. *J Urol*. 2009;182(6):2578–2584.

Toledano RD. Urologic emergencies and nonobstetric surgery during pregnancy. Gainsburg DM, Bryson EO, Frost EAM. *Anesthesia for urologic surgery*. Springer: New York; 2014:215–242.

Trudell AS, Odibo AO. Diagnosis of spina bifida on ultrasound: always termination? *Best Pract Res Clin Obstet Gynaecol*. 2014;28(3):367–377.

Tsai YL, Seow KM, Yieh CH, et al. Comparative study of conservative and surgical management for symptomatic moderate and severe hydronephrosis in pregnancy: a prospective randomized study. *Acta Obstet Gynecol Scand*. 2007;86(9):1047–1050.

Ulrich JC, York JP, Koff SA. The renal vascular response to acutely elevated intrapelvic pressure: resistive index measurements in experimental urinary obstruction. *J Urol*. 1995;154(3):1202–1204.

US Food and Drug Administration. Content and format of labeling for human prescription drug and biological products; requirements for pregnancy and lactation labeling. Final rule. *Fed Regist*. 2014;79(233):72063–72103.

US Food and Drug Administration. *Drugs@FDA*. https://www.accessdata.fda.gov/scripts/cder/daf/; 2018.

US Preventive Services Task Force. *Final Update Summary: Asymptomatic Becteriuria in Adults*. https://www.uspreventiveservicestaskforce.org/Page/Docume bacteriuria-in-adults-screening; 2008.

Valovska MI, Pais VM Jr. Contemporary best practice urolithiasis in pregnancy. *Ther Adv Urol*. 2018;10(4):127–138.

Van Dorsten JP, Lenke RR, Schifrin BS. Pyelonephritis in pregnancy. The role of in-hospital management and nitrofurantoin suppression. *J Reprod Med*. 1987;32(12):895–900.

van Oppen AC, Stigter RH, Bruinse HW. Cardiac output in normal pregnancy: a critical review. *Obstet Gynecol*. 1996;87(2):310–318.

Vincelot A, Nathan N, Collet D, et al. Platelet function during pregnancy: an evaluation using the PFA-100 analyser. *Br J Anaesth*. 2001;87(6):890–893.

Visser BC, Glasgow RE, Mulvihill KK, et al. Safety and timing of nonobstetric abdominal surgery in pregnancy. *Dig Surg*. 2001;18(5):409–417.

Vordermark JS, Deshon GE, Agee RE. Management of pregnancy after major urinary reconstruction. *Obstet Gynecol*. 1990;75(3 Pt 2):564–567.

Wadasinghe SU, Metcalf L, Metcalf P, et al. Maternal physiologic renal pelvis dilatation in pregnancy: sonographic reference data. *J Ultrasound Med*. 2016;35(12):2659–2664.

Waltzer WC. The urinary tract in pregnancy. *J Urol*. 1981;125(3):271–276.

Warshak CR, Ramos GA, Eskander R, et al. Effect of predelivery diagnosis in 99 consecutive cases of placenta accreta. *Obstet Gynecol*. 2010;115(1):65–69.

Watson WJ, Brost BC. Maternal hydronephrosis in pregnancy: poor association with symptoms of flank pain. *Am J Perinatol*. 2006;23(8):463–466.

Wax JR, Ross J, Marotto L, et al. Nonbilharzial bladder carcinoma complicating pregnancy—treatment with bacille Calmette-Guerin. *Am J Obstet Gynecol*. 2002;187(1):239–

240.

Webb JA, Thomsen HS, Morcos SK, et al. The use of iodinated and gadolinium contrast media during pregnancy and lactation. *Eur Radiol*. 2005;15(6):1234–1240.

Welk BK, Herschorn S. Augmentation cystoplasty. *AUA Update Series*. 2012;31 [Lesson 20].

White WM, Johnson EB, Zite NB, et al. Predictive value of current imaging modalities for the detection of urolithiasis during pregnancy: a multicenter, longitudinal study. *J Urol*. 2013;189(3):931–934.

White WM, Zite NB, Gash J, et al. Low-dose computed tomography for the evaluation of flank pain in the pregnant population. *J Endourol*. 2007;21(11):1255–1260.

Widmer M, Lopez I, Gulmezoglu AM, et al. Duration of treatment for asymptomatic bacteriuria during pregnancy. *Cochrane Database Syst Rev*. 2015;(11) [CD000491].

Wilby D, Wood D. Revision genitoplasty, sexual function, fertility, and pelvic organ prolapse in exstrophy and the management of prolapse. Wood HM, Wood D. *Transition and lifelong care in congenital urology*. Springer: Switzerland; 2015:55–64.

Wilson RD, Davies G, Desilets V, et al. The use of folic acid for the prevention of neural tube defects and other congenital anomalies. *J Obstet Gynaecol Can*. 2003;25(11):959–973.

Wisoff JH, Kratzert KJ, Handwerker SM, et al. Pregnancy in patients with cerebrospinal fluid shunts: report of a series and review of the literature. *Neurosurgery*. 1991;29(6):827–831.

Woodhouse CR. The gynaecology of exstrophy. *BJU Int*. 1999;83(Suppl 3):34–38.

Woodhouse CR, Hinsch R. The anatomy and reconstruction of the adult female genitalia in classical exstrophy. *Br J Urol*. 1997;79(4):618–622.

Wortman AC, Alexander JM. Placenta accreta, increta, and percreta. *Obstet Gynecol Clin North Am*. 2013;40(1):137–154.

Wright A, Walker R, Barrett D. The fluoroquinolones and their appropriate use in treatment of genitourinary tract infections. Ball T, Novicki E. *AUA update series*. American Urologic Association: Houston; 1993.

Wu S, Kocherginsky M, Hibbard JU. Abnormal placentation: twenty-year analysis. *Am J Obstet Gynecol*. 2005;192(5):1458–1461.

Zaccoletti R, Zardini E. [Efficacy of elastic compression stockings and administration of calcium heparin in the prevention of puerperal thromboembolic complications]. *Minerva Ginecol*. 1992;44(5):263–266.

Zwergel T, Lindenmeir T, Wullich B. Management of acute hydronephrosis in pregnancy by ureteral stenting. *Eur Urol*. 1996;29(3):292–297.

19

Intraoperative Consultation

Michael J. Schwartz MD, FACS, Jessica E. Kreshover MD, MS

Surgery can be unpredictable. Although there are certainly known preoperative factors that influence the degree of difficulty of a given surgery, unanticipated intraoperative findings, technical errors, and complications can occur regardless of the level of preparation of the surgical team. Intraoperative challenges present themselves in all surgical disciplines, requiring urgent intraoperative involvement of colleagues with expertise that the primary surgeon may not have. Intraoperative consultations fill this need.

Intraoperative consultations in urology span a wide range of disease processes, iatrogenic injuries to the genitourinary system, and trauma. As noniatrogenic genitourinary trauma management is covered extensively elsewhere in this text, this chapter focuses on intraoperative consultations outside of the trauma setting.

This is the first edition of this text to include a section on the topic of intraoperative consultations. Although not commonly covered in a formal didactic setting, precepts used in managing intraoperative consultations are familiar to most urologists. These principles are, at their core, the same that urologists strive to apply in day-to-day practice, albeit in circumstances that may be unique or unforeseen. Herein lies the challenge. As with any surgery, the intraoperative consultation requires the urologist to draw from accumulated experience gained through training and practice and apply judgment. **Applying good judgment and adherence to ethical tenets in unanticipated or inconvenient situations distinguishes a well-managed intraoperative consultation.** Here, we formally summarize management of intraoperative consultations in urology.

Intraoperative consultations occur daily and are defined as a call from the primary surgeon to a colleague for help, either within the same discipline or from another medical field. Consultations may occur because of iatrogenic injuries, unexpected findings, or the need for additional unanticipated surgery. Although a general discussion of unexpected findings may have taken place, the specifics of most unanticipated findings or change in surgical plan will not likely have been explicitly discussed with the patient as these occurrences are, by definition, unexpected. The role of the consulting urologist may also be highly variable. For example, the consulting urologist may entirely take over the remainder of a surgery if his or her skill set is most appropriate to manage the remainder of the procedure. However for some consultations, simply providing advice or guidance may be all that is necessary if the primary surgeon has all of the necessary skills to continue but needs a second opinion about how to proceed. One of the most routine examples of intraoperative consultation in surgery (which is often anticipated) is for help from our pathology colleagues. Intraoperative examination of tissue can be critical in determining the best surgical management of many malignancies or to determine if abnormal-appearing tissue is malignant in cases of unexpected operative findings. This chapter will focus on the urologist as the consultant and the wide range of reasons that we may receive the “call for help.”

Each intraoperative consultation is unique in both its scope and challenges. In most instances, the consulting urologist will not have any prior relationship with the patient. This limits the ability to gather a history that may be critical in decision making that may have permanent impact on a patient's medical condition or quality of life. At the time of the consult, the patient is most vulnerable—unconscious and unable to participate in discussions of how to address the situation. Some intraoperative consultations may be very straightforward, and others have a baseline level of complexity well above the majority of surgical cases.

Injuries to the genitourinary tract recognized in the postoperative setting are often associated with severe morbidity, and their management is far more complex than those recognized immediately at the time of surgery. For this reason, although it may be inconvenient at times, being called into the operating room to address a recognized injury during surgery is a blessing for all involved including the primary and consulting surgeons, but most importantly the patient. A recognized injury may be interpreted by some as a careless mistake and, at times, that may be true. However, identification of injury to the genitourinary tract at surgery may also represent vigilance and maintenance of a high degree of suspicion for such injury on the part of the primary surgeon. Calling for help is often a sign of integrity and is an act with the interest of the patient at its core (Langerman et al., 2014). When being called to the operating room for consultation, it should also be remembered that injuries are at times unavoidable or even intentional when it serves the interest of the patient (such as with a goal of oncologic cure). It should be regarded as an honor to be asked to help.

Ethical Considerations

The Patient-Physician (and Family-Physician) Relationship

Upon acceptance of an intraoperative consultation, the consulting urologist enters the patient-physician relationship (Langerman et al., 2014). Some of the most critical portions of the intraoperative consultation are not necessarily the procedure involved, but how the decision is made about what to do when there is a life-impacting choice at hand. Information gathering after receiving the call and discussions with family members during, and with the patient after, surgery are critical (Aubrey et al., 2014). If decisions are to be made during surgery, **full disclosure regarding the reason for the intraoperative consultation is imperative for the family or other surrogate to be able to make informed choices concerning the next course of action**. If the patient is stable, it may be best to have family discussions with both the primary surgeon and the consulting urologist present. Anecdotal evidence suggests that these discussions help to shape the new patient-physician relationship and build trust with the patient, even though the patient does not become aware of the intraoperative events or discussions until after the fact (Langerman, et al., 2014; Wu et al., 1997). The process of bringing as many stakeholders as possible to the table for discussion during surgery and before decisions are made minimizes the element of surprise that may otherwise accompany unexpected findings at surgery. These discussions contribute to the family's or surrogate's sense of transparency from the surgeon and consultant. Early and consistent communication helps the patient and family understand the condition being addressed and, of vital importance, helps set expectations surrounding recovery from surgery and any impact on day-to-day functions and quality of life. As the consulting urologist may also become either a secondary or primary physician for follow-up care, establishing trust early with the patient and family members is a standard that all should strive to achieve.

Decision Making

Intraoperative decision making, for the majority of consults, tends to be relatively straightforward. However, occasions will arise with extreme complexity of circumstance that leave no clear plan that is without significant risk or consequence for the patient. Regardless, the urologic consultant will inevitably fill the role of making an assessment and plan. Altering (or not altering) the surgical plan, aborting the procedure, or incorporating additional procedures are all options for consideration. Once an initial intraoperative assessment has been made, it is the role of the consulting urologist to discuss options for proceeding with the primary surgeon, anesthesiologist, and family members or other surrogate (Fig. 19.1). The simple act of discussing alternatives with these stakeholders can often bring forward a clear choice and make an otherwise difficult decision much more comfortable if all are in agreement. Calling colleagues for advice in such situations can also be tremendously helpful in confirming that all potential options are considered. The most important stakeholder—the patient—is unable to participate in decision making, a fact critical to recognize and respect as the consultant. Decisions made during an intraoperative consultation may be of no major consequence to the patient, or potentially may be life-altering and irreversible. As the consulting surgeon will most likely not have a prior relationship with the patient, the downstream consequences of acting intraoperatively or deferring definitive action to a later date must be carefully considered.

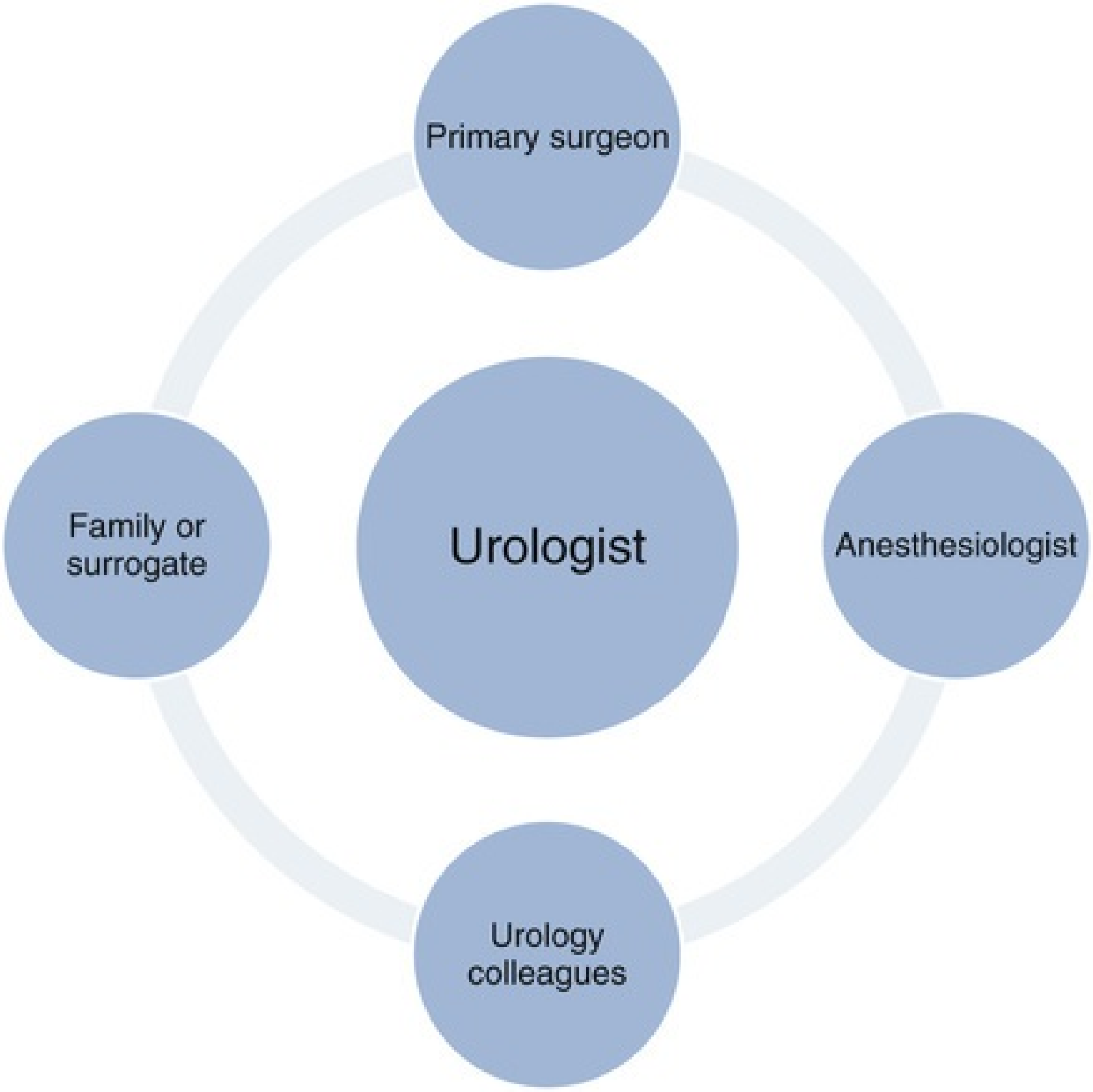

FIG. 19.1 Intraoperative decision-making stakeholders.

Similar to many challenges in medicine, the repercussions and complexity of our choices exist on a spectrum. For example, placing a stent to address a low-grade ureteral injury has low morbidity, would be unlikely to have long-term consequences, and is a reversible intervention. Most reasonable urologists would proceed when called on without the need to hold intraoperative discussions with the patient's family or awaken the patient to allow the patient to be made aware of and consent to the additional procedure. Disclosure of such intervention to the patient and family members nonetheless remains a critical component of the intraoperative consultation and postoperative care. Performing a more major reconstruction to address a complex proximal high-grade ureteral injury, not amenable to ureteroureterostomy, requires consideration of procedures that are either irreversible, hold much higher potential morbidity, or both. The innate characteristics and complexity of these reparative options warrant patient participation. However, the patient's right to decide must also be weighed against the possible harm of a delayed repair, second anesthesia, increased difficulty associated with reoperation, and compounding effect on recuperation time. In selected cases, complex repair during intraoperative consultation should be considered if the harm of deferring outweighs the benefits. **When considering whether or not to temporize or attempt definitive action at intraoperative consultation, current patient condition, procedure morbidity, long-term consequences, and reversibility should all be thoroughly considered. In general, options for any complex reconstruction may drastically differ in how they may or may not affect quality of life, and, with selected exceptions, are best deferred with temporizing measures until such time that the patient is able to participate in shared decision making.**

Surrogate decision makers may not always be present or reachable at the time of an intraoperative consultation when a choice must take place. It must also be remembered that the family member or other individual accompanying the patient at the hospital may or may not be an appropriate person to act on the patient's behalf if a complex intraoperative decision is to be made. Most hospitals will ask surgical patients to designate an individual as a surrogate before a planned operation. This practice can minimize guesswork and help gather additional information regarding patient preferences that can inform intraoperative decisions. However, it must be considered that surrogates may make decisions contrary to patient wishes, which can have consequences for the relationship between the patient and his or her surrogate, but also for the physician and the patient, especially if the recovery is fraught with complications (Langerman et al., 2016). Also, emergencies or other circumstances may arise when a surrogate has not been designated and it falls to the physician to act in a manner representing the patient's best interest.

Disagreements may arise between the primary and consulting surgeon about how to proceed during a given consultation. These situations may increase the tension already present during an intraoperative consultation when unexpected findings or iatrogenic injury increase the complexity of the surgery at hand. When such conflicts arise, the consulting surgeon should defer to the primary surgeon's judgment in most situations, as the primary surgeon holds a preexisting relationship with the patient (Langerman et al., 2014). However, when called for help, the expertise and skill set of the urologist are fundamentally unique from the primary surgeon's in most circumstances, and the consulting urologist should proceed in the best interest of the patient if deferring to the primary surgeon is deemed potentially harmful to the patient. Fortunately, the primary surgeon will defer to the consultant's expertise in most scenarios, but if disagreement persists, escalating the dispute to the department chairs or hospital medical director may be appropriate.

Ultimately, the decision maker at intraoperative consultation is the consultant. Gathering information from the medical record, imaging, and from all interested parties including the primary surgeon, patient surrogates, anesthesiologist, and colleagues, can inform intraoperative decisions. However, no other party among those in the group has the expertise and skill set to address a urologic issue other than the urologist. Acting in a manner as consistent as possible with what is perceived to be the patient's best interest while balancing the risks and benefits of the intervention will provide optimal chances of a favorable outcome.

Documentation

There may be temptation to editorialize when it comes to documenting the events of an intraoperative consultation. This may stem from an innate desire as physicians to explain why an event may have occurred—in other words, to make a diagnosis regarding the cause of the event. This is not to say that documenting a diagnosis as to the cause of an intraoperative consultation is not appropriate. For example, noting a urethral stricture as a cause for a difficult catheter passage is appropriate; there are directly observable findings that are fact-based and are appropriate to record. In addition, documenting communication regarding cause of an intraoperative injury from the primary surgeon may also be appropriate if it is fact-based and important to the management of the patient. For example, if the primary surgeon noted that the ureter was injured with cautery versus cold shears, this may change the management plan and if directly observed, should be documented. However, guessing at the cause of iatrogenic injury or laying blame at the feet of a colleague serves no medical purpose and does not rely on fact. Describing an injury as “careless” or “avoidable” in an operative dictation is in and of itself careless and avoidable—there is no room for conjecture or assignment of blame if an injury occurred.

When documenting an intraoperative consultation, it is critical that the consulting surgeon make as complete an assessment as possible. This includes scrubbing in to the surgery and creating a note summarizing the intraoperative findings. Relying on the primary surgeon to assess and document either his or her own assessment or the assessment of the consulting urologist is irresponsible and incomplete. Even if no injury is seen or no intervention is needed on the part of the consultant, **the primary observations of the consultant are critical to the medical record, and lack of documentation leaves the consultant vulnerable to legal action** (Morris et al., 2003).

Key Points

- The intraoperative consultation enters the physician into a new patient-physician relationship, and full disclosure regarding the reason for consultation is critical.

- When possible, all relevant stakeholders should be included when difficult intraoperative decisions are to be made.
- When considering whether or not to temporize or attempt definitive action at intraoperative consultation, current patient condition, procedure morbidity, long-term consequences, and reversibility should all be thoroughly considered.
- Complex reconstructions, with selected exceptions, are best deferred with temporizing measures until such time that the patient is able to participate in shared decision making.
- Documentation of intraoperative consultations should be fact-based and include the consultant's primary observations and assessment.

Surgical Time Out

In many countries around the world, a preoperative checklist—widely referred to as the “surgical time out”—is used as part of a universally applied protocol meant to increase patient safety and reduce medical errors. The role of a surgical time out for an intraoperative consultation is not clearly defined as is the case for the primary surgery taking place. It is also the case that the consulting urologist may not necessarily be able to ascertain what procedure is to be undertaken, if any, as part of the intraoperative consultation or what supplies are to be needed without gathering critical information that may not be possible without exploring the existing surgical field. Therefore, a traditional time out is typically not feasible before the urologist becomes involved with the procedure. However, once the urologist is satisfied with the information at hand and any necessary discussions with family members have taken place, there is opportunity to review the plan with everyone in the operating room similar to the traditional time out (Table 19.1). One critical piece of information that should be discussed and that is not part of the standard “time out” is the patient condition. As the condition of the patient may be highly variable at the time of the consultation, this should be reviewed, along with the patient's ability to tolerate the additional procedure. Although the patient condition would have likely been considered by the consulting urologist before deciding on the next course of action, inclusion in the time-out procedure ensures its review by the entire team and reaffirms the plan.

TABLE 19.1

Suggested Time-Out Procedure for Intraoperative Consultation

- Introduction of all staff in the operating room
- Patient identification (name, medical record number, date of birth)
- Current condition of the patient as per anesthesiologist and primary surgeon
- Name of the procedure to be performed
- Review and confirmed availability of necessary instrumentation with operating room staff
- Fluids for the operative field
- Estimate of blood loss and expected additional operative time
- Concerns not already addressed
- Verbal agreement and acknowledgement of plan by all staff in the room

Urethral Injury

Catheterization-related injuries to the urethra in the operating room are common in men. Urethral catheterization is performed across all medical disciplines by individuals with highly variable levels of experience with this procedure. Urethral stricture disease, prior surgery or pelvic radiation therapy, benign prostatic hyperplasia, and operator experience are all common contributors to failed catheter placement or urethral injury. Fortunately, the majority of these cases are handled fairly quickly and without significant consequences for the patient. Occasionally, however, urethral injury related to attempted catheter insertion may have substantial consequences including deferment of the planned primary surgery, voiding dysfunction, prolonged gross hematuria, acute renal failure, urethral stricture, or prolonged catheterization. Although relatively mundane, iatrogenic catheter-related injury to the urethra can add significantly to the cost of a patient's hospitalization and length of stay (Davis et al., 2016). As the period involving catheterization is extremely relevant to development of bacteriuria and catheter-associated urinary tract infection, iatrogenic injury is of particular concern for hospitals as reimbursements may be directly affected by such events. Much less common, urethral injuries from catheter placements may require other surgical intervention if the injury is more severe.

Difficult catheter consults plainly illustrate the importance of ascertaining the patient medical history as part of the intraoperative consultation. History of prior cystoscopic or abdominal surgery, prostate cancer, prostatectomy, radiation therapy, requirement for anticoagulation, and knowing the planned surgery are all relevant and guide management. Choice of catheter, need for cystoscopic placement, and risk associated with possible suprapubic catheterization, if necessary, are all influenced by this history.

Urethral injury may also occur during female pelvic reconstructive surgeries and may occur with concomitant bladder or ureteral injury, markedly raising the complexity of the repair required.

Incidence

The incidence of catheter-related iatrogenic urethral injuries in the operating room setting is unknown. However, reports evaluating the incidence of catheter-related injury in hospitalized patients show it to be between 3.2 and 6.7 injuries per 1000 male patients catheterized. (Davis et al., 2016; Kashefi et al., 2008). In addition, complications of Clavien-Dindo grade 2 or higher occur in up to 81% of men suffering iatrogenic urethral injury (Davis et al., 2016). Although not every iatrogenic urethral injury occurs in the operating room, in a busy hospital where tens of thousands of surgical cases are performed each year, consultations for catheter-related urethral injury are commonplace.

Mechanisms

Iatrogenic injuries to the male urethra most commonly occur as a result of tortuous urethral anatomy or benign prostatic enlargement in combination with inexperience of the individual attempting catheter insertion. Injuries are related to inadvertent inflation of the catheter balloon within the urethra or creation of a false passage with the catheter tip by trying to force the catheter into the bladder (Thomas et al., 2009). Female urethral injuries are far less common as the urethra is much shorter and does not have a tortuous course, and there is little risk for encountering stricture disease. Iatrogenic injury of the female urethra may occur in female pelvic reconstructive surgeries such as sling placement or prolapse repair.

Diagnosis

The diagnosis of urethral injury related to catheter placement is often straightforward with a history of failed catheter insertion with or without blood per urethra or within the catheter at the time of attempted placement. Cystoscopy may be performed to assist in diagnosis and to gauge the extent of injury. Intraoperative retrograde urethrography could also be used in assessment although would generally be more valuable in the trauma patient as the mechanism of injury may be more likely to cause disruption and require urethroplasty in that setting.

Iatrogenic injury to the female urethra during reconstruction will most often be recognized by cystoscopy, which is often performed precisely with the purpose of identifying injury to the bladder or the urethra. Visualization of a trocar passed for mesh placement or mesh itself within the urethra are obvious signs of injury. More subtle findings may include tethering of the urethra or bladder neck, which may indicate trocar or mesh placement through the walls of the lower urinary tract without penetration into the lumen. Other findings indicating injury during reconstructive surgery include visualization of a urethral catheter through an inadvertent urethrotomy created while dissecting between the anterior vagina and the posterior urethra.

Management

Male urethral injuries related to urethral instrumentation typically require either a specific choice of catheter or cystoscopy-guided catheter insertion to allow for successful placement. Similar to the trauma setting, a single attempt may be made to blindly place the catheter by the urologist, but if this fails, use of cystoscopy to visualize the urethral lumen and introduce a guidewire into the bladder is recommended. If the extent of stricture disease or urethral injury is too significant to allow for safe catheter insertion, percutaneous or open insertion of suprapubic catheters should be considered. The duration of catheterization after injury depends on the extent of injury, need for concomitant urethral dilatation at the time of catheter placement, and patient condition in the postoperative setting.

Urethral injuries unrelated to catheterization are rare. Unlike the bladder and ureters, which are in the operative field for many abdominal and pelvic operations, the urethra is not. For this reason, surgeries with likelihood of urethral injury are limited mainly to pelvic reconstructive surgery with a transvaginal or transperineal approach.

With a vaginal approach used in many operations for pelvic reconstruction, risk for fistula formation is an important concern when approaching repair of urethral or bladder injury in the female patient. Interposition of peritoneum, omentum, or labial fat between the anterior vaginal wall and the bladder or urethra should be considered in cases with a high anticipated risk for fistula formation.

Bladder Injury

There is significant overlap between the background, evaluation, and management of bladder injuries in the intraoperative setting and in the trauma setting. It is prudent for readers to also review Chapter 133 to familiarize themselves with bladder trauma. This section will focus on iatrogenic injury and its management. Some of this will overlap with what is delineated in Chapter 133.

Incidence

The bladder is the most commonly injured organ during pelvic surgery (Gomez et al., 2004). The pelvis, unlike the abdomen, is a fixed space—a factor that can increase the risk for bladder injury during pelvic surgery because of challenges of exposure, retractor placement, and small working space. Anatomic distortion from tumor mass effect, prior surgery or radiation therapy, or any combination of these features raises case complexity and the likelihood of bladder injury. Pelvic organ prolapse can also cause significant anatomic distortion, and bladder injury may also occur in the setting of pelvic reconstructive surgery when a vaginal approach is utilized. Table 19.2 summarizes incidences of bladder injury with various common pelvic surgeries.

TABLE 19.2

Incidence of Bladder Injury in Common Pelvic Surgeries

SURGERY	INCIDENCE OF BLADDER INJURY	AUTHORS
Cesarean section	0.28%–0.47%	Phipps et al., 2005 Rahman et al., 2009 Salman et al., 2017
Laparoscopic total hysterectomy	0.75%	Wong et al., 2018
Laparoscopic supracervical hysterectomy	0.29%	Wong et al., 2018
Laparoscopic-assisted vaginal		Wong et al., 2018

hysterectomy		
Vaginal hysterectomy	0.51%	Teeluckdharry et al., 2015
Abdominal hysterectomy	0.58%	Teeluckdharry et al., 2015
Transvaginal tape placement	3%–9%	Sharp and Adelman, 2016
Transobturator tape placement	0.5%	Sharp and Adelman, 2016
Hernia repair (inguinal surgery)	0.08%–0.3%	Summerton et al., 2012
Laparoscopic hernia repair	1.6%	Gomez et al., 2004

Mechanisms

Laceration is the most common mechanism of intraoperative injury to the bladder, leading to the majority of intraoperative bladder-related urology consultations. More rarely, devascularization injury can occur. Table 19.3 shows bladder injury severity classification.

TABLE 19.3

Grading System for Classifying Bladder Injury

GRADE	INJURY	DESCRIPTION
1	Hematoma	Contusion, intramural hematoma
1	Laceration	Partial thickness
2	Laceration	Extraperitoneal bladder wall laceration <2 cm
3	Laceration	Extraperitoneal (>2 cm) or intraperitoneal (<2 cm) bladder wall laceration
4	Laceration	Intraperitoneal (>2 cm) bladder wall laceration
5	Laceration	Laceration extending into trigone (bladder neck or ureteral orifice)
6		Not salvegable

Data from Moore EE, Cogbill TH, Jurkovich GJ, et al. Organ injury scaling. III: Chest wall, abdominal vascular, ureter, bladder, and urethra. *J Trauma*. 1992;33(3):337–339.

It makes intuitive sense that risk for bladder injury is highest when operating within the bladder. Endoscopic surgeries, most commonly transurethral resection of bladder tumor, are the most common and also underreported. Transurethral resection of a bladder tumor or bladder biopsy are by definition intentional injuries to the bladder wall that generally heal without consequence, with or without bladder decompression with a catheter as indicated. However, extraperitoneal or intraperitoneal bladder injuries may occur that require additional intervention, either with prolonged bladder decompression in the case of most extraperitoneal injury or open repair in the case of most intraperitoneal injury. The extent of hematuria, patient requirement for postoperative anticoagulation, significance of the perforation, anticipated requirement of postoperative continuous bladder irrigation, and development of abdominal distension during endoscopy are all factors that may determine management. With the majority of these procedures performed by urologists, their management is generally within the purview of the primary surgeon rather than an intraoperative consultation, depending on the skill set of the primary surgeon.

Diagnosis/Recognition

A high index of clinical suspicion is necessary to allow recognition and prompt treatment of bladder injury. Clinical indicators include a visible laceration to the bladder, visualization of the Foley catheter, extravasation of fluid (urine) into the surgical field, and blood (and/or gas during laparoscopy) into the catheter drainage bag (Gomez et al., 2004).

If there is clinical concern for injury without an obvious defect seen, fluid (with or without dye, e.g., methylene blue) may be instilled into the bladder via the catheter to help locate the injury. When fluoroscopy is available, contrast can be injected into the bladder for evaluation. Cystoscopy can also be used to visually assess the bladder. This has become the standard of care for urethral sling surgeries and hysterectomy to ensure the absence of bladder injury.

When bladder injury is found, it is important to ensure there is no concomitant injury to the ureters and/or ureteral orifices (Summerton et al., 2012). Means of assessing the ureters for injury are described in the Ureteral Injury section later in this chapter.

Management

Bladder lacerations should be repaired in one or more layers using absorbable suture. Devascularized urothelium or bladder wall should be debrided as needed. The closure should be tested by filling the bladder intraoperatively, serving both the purpose of allowing additional suture placement as needed and to reconfirm that no other previously unrecognized injuries are present. A catheter draining the bladder should remain in place postoperatively, and an intra-abdominal drain should be left. Most series recommend 7 to 14 days of bladder drainage. As the vast majority of postoperative cystograms are negative, their use should be considered but reserved for those cases with particular concern for the integrity of repair, complex repairs, or when the concern level is elevated for fistula formation.

When an injury is suspected but not visualized, a cystotomy may be performed to facilitate identification of the area of injury (Esparaz et al., 2015). Injuries involving the trigone may be more complex to repair. Ureteral integrity must be established, and the anterior vaginal wall may be involved, increasing the likelihood of postoperative fistula formation. When in question, the ureter should be reimplanted as the downstream consequences of leaving an injured ureter unrepaired are significant (Blackwell et al., 2018). Postoperative cystography carries a role in complex repairs to ensure that there is no leak before catheter removal and that no fistula has occurred (Sharp and Adelman, 2016).

Ureteral Injury

Incidence

Iatrogenic injury is the most common cause of ureteral injury comprising 75% to 80% of all cases (Dobrowolski et al., 2002; Elliott and McAninch, 2006). Injury can occur in abdominal or pelvic surgeries and with all modalities—open, laparoscopic, robotic, and endoscopic). Ureteral injuries have also been rarely reported after spinal surgery but are not typically recognized intraoperatively (Bjurlin et al., 2009; Pillai et al., 2013). Similar in contributing factors to those for bladder injuries, the fixed space of the pelvis, complex anatomy, prior procedures, or radiation therapy can all increase risk by altering the normal anatomic position of the ureter and by making it more difficult to identify. More than 90% of ureteral injuries are to the distal one-third of the ureter (Selzman and Spirnak, 1996). In modern series, the incidence of mid- and proximal ureteral injuries has risen likely as a result of increased endoscopic procedures by urologists, and distal injuries compose about three-fourths of cases (proximal and mid-ureteral injuries each composing about 13%) (Dobrowolski et al., 2002).

Most series report gynecologic surgeries as the source for a majority (>50%) of ureteral injuries (Blackwell et al., 2018; Brandes et al., 2004; Burks and Santucci, 2014). With changing technologies and an increasing number of endoscopic urologic procedures, there are series that report endoscopy as the source of a majority of ureteral injuries (Al-Awadi et al., 2005; Romero et al., 2011). Regardless, high-grade injuries (such as avulsion) during endoscopic procedures are rare. Changing technologies with increased shift toward minimally invasive (laparoscopic and robotic) surgeries have also been thought to increase iatrogenic injury. Gynecologic surgeries remain the predominant cause with colorectal, vascular, and urologic surgeries also contributing. Table 19.4 shows a summary of incidence of ureteral injury based on surgery type.

TABLE 19.4

Incidence of Ureteral Injury by Type of Surgery

SURGERY	INCIDENCE	AUTHOR
Transvaginal hysterectomy	0%–0.04%	Carley et al., 2002; Sharp and Adelman,

		2016
Transabdominal hysterectomy	0.35%–30%	Carley et al., 2002; Esparaz et al., 2015
Colorectal surgery	0.44%–5%	Anderson P, 2015; Burks and Santucci, 2014
Ureteroscopy	0.3%–4.1%	Esparaz et al., 2015

Mechanisms

The mechanisms for injury to the ureter are highly variable and can affect the options for management. Mechanisms include laceration (partial or complete), ligation (partial or complete) with kinking or occlusion, resection, crush injury, thermal injury, abrasion, avulsion, or devascularization. The mechanism of injury generally affects the grade of injury and the management. Table 19.5 summarizes grading of ureteral injury.

TABLE 19.5

Grading System for Classifying Ureteral Injury

GRADE	INJURY	DESCRIPTION
1	Hematoma	Contusion or hematoma without devascularization
2	Laceration	<50% transection
3	Laceration	>50% transection
4	Laceration	Complete transection with ≤2 cm devascularization
5	Laceration	Complete transection with >2 cm devascularization
6		Not salvageable

From Best CD, Petrone P, Buscarini M, et al. Traumatic ureteral injuries: a single institution experience validating the American Association for the Surgery of Trauma-Organ Injury Scale grading scale. *J Urol*. 2005;173(4):1202–1205.

Diagnosis/Recognition

A majority of iatrogenic ureteral injury goes unnoticed. Only 36% of ureteral injuries are recognized at the time of initial surgery during open surgical cases (Selzman and Spirnak, 1996). Even fewer injuries (12.5%) are recognized during laparoscopic surgery (Esparaz et al., 2015). **Early recognition of ureteral injury is important as failure to do so carries significant morbidity (pain, infection, azotemia, fistula formation, and reoperation).** Data also suggest that immediate recognition and repair portends more favorable outcomes in addition to fewer additional complications (Al-Awadi et al., 2005; Blackwell et al., 2018).

A very high index of suspicion is needed to identify these injuries, particularly during laparoscopy. Some indications of injury include extravasation of fluid (urine) into the surgical field, hydroureteronephrosis, or visualization of ureteral catheters (if placed preoperatively). Although hematuria should raise the level of clinical concern for ureteral injury, the absence of hematuria does not rule out clinically significant injury (Brandes et al., 2004).

There are multiple ways to assess the ureter when there is concern for ureteral injury in the intraoperative setting. Cystoscopy with retrograde urography can be used to assess the ureter. This has been shown to be the most accurate means in diagnosing the location and degree of injury and is considered the gold standard (Brandes et al., 2004). Retrograde studies can reliably identify or rule out ureteral injury and can often obviate the need for additional surgical dissection and direct visual assessment of the ureter if the study is normal. Retrograde urography is a particularly useful means of assessment during endoscopic procedures. **For cystoscopy alone, efflux can still be seen in the setting of partial transection or ligation and so retrograde pyelography is important when clinical suspicion for injury is high** (Teeluckdharry et al., 2015). Direct endoscopic inspection with ureteroscopy or ureteral stenting/catheterization may also be used. Unobstructed passage of ureteral catheters into the renal pelvis without resistance suggests that no significant ligation or lacerations are present. However, with many open, laparoscopic, or robotic surgeries, the patient may not be positioned appropriately, prepped, or on a surgical table in which retrograde urography, stenting, or direct inspection with ureteroscopy is possible.

Intraoperative excretory urography (e.g., intravenous pyelography) can be used in such cases. An abnormal or nondiagnostic finding warrants exploration (Brandes et al., 2004). Excretory dye (e.g., indigo carmine or methylene blue) may be used as well. Direct visualization of dye within the surgical field is indicative of higher-grade injury, and further exploration and direct visualization is needed. Excretory dye can be administered not only intravenously in these settings, but may also be injected directly into the urinary tract for more prompt assessment via ureteral catheter placement and injection or direct small-bore needle injection into the renal pelvis or ureter.

Meticulous dissection and direct inspection are critical to evaluating the ureter intraoperatively when injury is suspected and retrograde urography is not available. Adequate visualization is required, and further dissection should take place as needed to ensure the integrity of the ureter. Although inspection should allow for identification of a laceration or ligation, care should be taken to inspect for signs of ureteral contusion including bruising or hematoma and signs of devascularization injury including dusky appearance and/or lack of bleeding (Brandes et al., 2004). Although an open approach has been the gold standard for direct visualization, laparoscopic and robotic evaluation and repair in these settings may be feasible depending on the skill set of the consulting urologist (Han et al., 2012; Tracey et al., 2018). The ultimate deciding factors should be the urologist's preference, comfort, and proficiency that determine the modality of direct inspection.

Management

Management of ureteral injury is dependent not only on the location and mechanism of injury, but also importantly on patient characteristics and the expertise of the consulting urologist. The goals of management should be preservation of renal function and minimizing morbidity for the patient.

AUA guidelines recommend repair of traumatic ureteral injuries at the time of exploration in stable patients (grade C), and these recommendations may be extrapolated to acute iatrogenic injuries as many of the same principles apply (Morey, 2014). As the consulting surgeon, care should be taken to avoid pitfalls. In a stable patient, time should be taken to gather as much as information as possible that may influence the next course of action. The planned operation by the primary surgeon, indication for surgery, prior medical and surgical history, and reasons for suspecting ureteral injury or mechanism of injury, if known, should all be explored. If imaging is available, it should be reviewed to assist in risk stratification and surgical planning.

For unstable patients, temporary diversion can be employed and definitive management delayed until such time that the patient is able to tolerate a definitive repair (Morey, 2014). Diversion can take place with ligation of the ureter and percutaneous nephrostomy tube placement or with ureterostomy (Brandes et al., 2004). Temporary diversion can also be employed if the consulting surgeon lacks the skill set or expertise to complete the necessary interventions. Effort should be made to elicit additional help as necessary to prevent multiple procedures for the patient. But the primary rule of medicine remains—first do no harm.

Principles of Repair

The principles of ureteral repair remain the same regardless of the location of injury. It is important to debride devascularized tissue as needed. The lumen of the ureter should be maintained by creating a spatulated and tension-free mucosa-to-mucosa anastomosis with absorbable sutures. The closure should be watertight, and an indwelling ureteral stent should be placed to maintain ureteral patency and encourage urine flow across and not out through the area of reanastamosis. An external drain should be left in place postoperatively (Serafetinides et al., 2015). As possible, interposing omentum or peritonealization can aid in anastomosis healing and prevent fistualization.

Grade 1 and 2 Injuries

Low-grade injuries can occur via ligation, cold laceration, crush injuries, or minor thermal injuries. With ligation, the offending clip or suture should first be removed. Ligation injuries are the most common ureteral injury encountered in gynecologic surgery (Brandes et al., 2004). Grade 1 and 2 injuries should be managed with placement of a ureteral stent or nephrostomy tube (Summerton et al., 2012). Ureteral stenting is preferred over placement of a nephrostomy tube because there is a decreased risk for ureteral stricture formation (Brandes et al., 2004). This includes stenting in cases of ureteral contusion or small lacerations when clinically indicated.

Generally stents are left in place for 2 to 6 weeks (Gild et al., 2018). Evidence is lacking as to how these patients should be followed or reevaluated after their injury. It is prudent to obtain upper tract imaging (ultrasonography or CT) after stent removal to ensure the lack of stricture formation or obstruction. Renal scan may also be indicated to further evaluate for obstruction if other imaging is indeterminate.

Grade 3 to 5 Distal Ureteral Injuries

High-grade distal ureteral injuries should be managed with ureteroneocystotomy as the vascularity of a ureter-ureter anastomosis in this location is often compromised by the original injury and jeopardizes the chances for successful primary repair (Serafetinides et al., 2015). Although either nonrefluxing or refluxing reimplantation may be used, there is no clear advantage to a nonrefluxing anastomosis in an adult patient. The refluxing approach is generally preferred in the acute setting of intraoperative consultation because of its efficiency and lower risk for obstruction at the anastomosis (Baston et al., 2014; Burks and Santucci, 2014).

When direct reimplantation is not viable because of insufficient ureteral length, a psoas hitch can be used. The ipsilateral superior portion of the bladder's detrusor muscle is sutured to the ipsilateral psoas tendon to gain length and decrease tension on the anastomosis. Developing the space of Retzius and ligation of the contralateral bladder pedicle can allow for further mobilization of the bladder. When either of these maneuvers are insufficient, a tubularized bladder flap (Boari flap) or bladder advancement flap can be used to gain additional length. The technical aspects of these surgical procedures are reviewed in Chapters 42 and 53.

After reimplantation, a urinary catheter is left in the bladder for decompression while the bladder and anastomosis heal. A perivesical drain is left adjacent to the anastomosis, and most series report catheter use for 1 to 2 weeks. Cystography, as with repair of bladder injury, should be used selectively based on the complexity and concern regarding the integrity of the repair. The internal indwelling stent remains in place after the catheter is removed, usually for a total of 4 to 6 weeks postoperatively. As outlined earlier, the ureter should be assessed with imaging after all drains have been removed to confirm the absence of stricture (Sharp and Adelman, 2016).

Grade 3 to 5 Mid- and Proximal Ureteral Injuries

For higher-grade injuries above the level of the iliacs, primary repair over a ureteral stent should take place as possible (grade C) (Morey, 2014). Ureteroureterostomies are best for small ligation injuries and crush injuries when ureteral stenting alone is not possible (Brandes et al., 2004).

Grade 5 Injury

When complex repairs are needed, there should be strong consideration to temporize the patient and defer repair. Complex proximal ureteral injury repairs requiring reconstruction, such as ureterocalicostomy, transureterostotomy, ileal ureter interposition, or autotransplantation, may have significant risks and long-term effects to a patient's health and quality of life. Newer data on the use of appendiceal on lay grafts or buccal mucosal grafts to repair ureteral stricture disease provide additional options to consider with potentially less morbidity (Duty et al., 2015; Zhao et al., 2017). However, their use in the setting of an intraoperative consultation for ureteral injury has not been explored. Not only do these procedures require significant surgical expertise, but decisions to utilize any one of these approaches should enlist shared decision making between the patient and surgeon. It is challenging, and arguably impossible, to hold discussions with family members such that an informed decision can be made in the setting of unanticipated ureteral injury requiring potentially life-impacting, complex repair. Temporizing measures are strongly preferred here as best management practice.

Ureteroscopic Avulsion Injury

Serious ureteroscopic injury with avulsion is rare, with incidence reported as 0.06% to 0.45% (D'Addessi and Bassi, 2011). The proximal to mid-ureter is the region most prone to avulsion, which most commonly occurs with application of excessive force to a basketed stone at a site of impaction or ureteral narrowing. The primary goal in immediate management of avulsion injuries is to reestablish continuity. This can be accomplished in the same manner as other grade 4 laceration injuries. Immediate repair with ureteroureterostomy should be performed (assuming mid- or proximal ureteral location) (Brandes et al., 2004). Other management options include reimplantation (for distal avulsion) and ureterocalycostomy (for proximal injuries).

Ureteral Catheters

Depending on the culture at a particular hospital or institution, intraoperative consultations for ureteral catheterization before other colorectal or gynecologic surgery may be common or relatively rare. Ureteral catheters are requested most commonly in cases with anticipated anatomic distortion, making ureteral identification more challenging. Acute diverticulitis requiring surgery, large pelvic masses, prior radiation history, or prior surgery can all prompt consultation for ureteral catheter placement. Although there is perceived benefit by some that catheters help surgeons to locate the ureters, it has been demonstrated that prophylactic catheters do not decrease the risk for ureteral injury (Chou et al., 2009). However, catheters may help in the identification of ureteral injury when present. Ureteral catheters also carry risk that should not be underestimated or ignored. Iatrogenic injury may occur related to ureteral catheterization (Bothwell et al., 1994). Ureteral catheters also independently increase both the cost of hospitalization and the risk for acute kidney injury (AKI) in the postoperative setting, with 32.6% of catheterized patients versus 10.5% of noncatheterized patients developing AKI (Hassinger et al., 2018). In the same study, bilateral catheters also produced a higher incidence of AKI relative to unilateral catheter placement, suggesting catheter-related ureteral edema may be a likely etiology of AKI.

Because catheter placement is almost always an anticipated request, it is recommended that patients be counseled in advance regarding the risks and benefits of such a procedure by a urologist. In addition, the primary surgeon should regard it as their ethical responsibility to the patient both to reserve intraoperative consultations for unanticipated findings and to allow patients to be counseled as appropriate.

Renal Injury

Incidence

A majority of renal injury is traumatic, not iatrogenic, and thus intraoperative consultation for renal injury is far less common than that for other genitourinary organs. Although iatrogenic renal injury is rare, it can carry significant morbidity.

Mechanisms

Because a majority of renal injury is caused by trauma, the primary mechanisms for injury are blunt and penetrating. For iatrogenic injuries, hemorrhage is the most common issue resulting from renal vascular or parenchymal injuries. These can occur with many urologic procedures (e.g., percutaneous nephrolithotomy [PCNL], renal biopsy, enopyelotomy) but also with open abdominal or endovascular surgery (Esparaz et al., 2015). PCNL has become the most common cause of renovascular injury occurring in 0.9% to 3% of cases (Esparaz et al., 2015).

Diagnosis/Recognition

With a majority of iatrogenic cases occurring during PCNL, bleeding is most often recognized postoperatively as a result of gross hematuria, acute blood loss anemia, flank pain/flank hematoma, and hemodynamic stability. Most of these cases can be managed either conservatively or with interventional radiology and selective embolization. For acute renal bleeding, it is rare that urologic consultation is sought because of the acuity. Please refer to the subsection on renal trauma in Chapter 133 for details about this surgical approach.

Management

Management of renal trauma has trended more and more toward conservative approaches, even for high-grade injuries. Current AUA guidelines recommend immediate intervention (surgery or angioembolization) only in hemodynamically unstable patients or patients only transiently responsive to resuscitation [grade

B] (American Urological Association, 2017). For iatrogenic injury, most are minor and require supportive care and a conservative approach (Esparaz et al., 2015). In cases of significant bleeding during PCNL, this is usually venous in nature. Conservative measurements with catheter tamponade, clamping of the nephrostomy tube, mannitol administration, and placement of a larger nephrostomy tube are generally effective, and patients do not require exploration. Even for arterial bleeding, open exploration is generally not indicated, and interventional radiology selective angioembolization can be used to control hemorrhage. Angioembolization has been shown to decrease renal parenchymal loss and patient morbidity when compared with open exploration (involving partial or total nephrectomy) (Esparaz et al., 2015).

Key Points

- When bladder injury is found, it is important to ensure that there is no concomitant injury to the ureters or ureteral orifices.
- When a bladder injury is suspected but not visualized, a cystotomy may be performed to facilitate identification of the area of injury.
- Early recognition of ureteral injury is important as failure to do so carries significant morbidity.
- If ureteral injury is suspected but not visualized, imaging and/or endoscopic assessments should be performed to confirm the presence or absence of injury.
- Consultation for ureteral catheter placement should be reserved for the preoperative setting and for appropriately selected cases.

Placental Cases

Placental abnormalities carry a unique risk for obstetric surgeries. Abnormalities of placental attachment to the uterine wall are subclassified based on their depth of attachment. Placenta accreta, increta, and percreta classifications are made, respectively, with increasing invasiveness and complexity, though the term *placenta accreta* is often used to encompass the entire spectrum of disease (Silver and Barbour, 2015). These abnormalities carry significant risk for hemorrhage and morbidity. The incidence of accreta cases is climbing, likely related to increase in cesarean delivery, a known risk factor for development. Most cases of placenta accreta occur in patients with placenta previa (where the placenta is positioned low within the uterus and partially or completely covers the cervix). As such, accreta should be suspected in cases of placenta previa and should be evaluated accordingly.

Antenatal diagnosis of placenta accreta is important to management, allowing for appropriate operative planning. The most common means of assessment of the placenta is via ultrasonography. A high clinical suspicion is needed as data on sensitivity of ultrasonography to diagnose accreta is conflicting (Silver and Barbour, 2015). Magnetic resonance imaging (MRI) is often employed to try and aid in antenatal diagnosis, and there are mixed data as to whether it improves the accuracy of ultrasonography alone. Most studies on the sensitivity of imaging in diagnosing accreta are subject to bias (e.g., centers of excellence, known high-risk patients). At this point, it does not appear that MRI clearly changes management or improves outcomes overall, but MRI may have advantages specifically for placenta percreta in assessing the degree of invasion, which is important for presurgical planning (Jauniaux and Bhide, 2017; Silver and Barbour, 2015; Thiravit et al., 2017).

Placenta accreta cases are often managed with early cesarean delivery (34 to 35 weeks) to prevent emergency surgery at the time of labor. Often, hysterectomy is performed at the time to prevent dissection of the placenta. Controlled cesarean hysterectomy is associated with decreased morbidity as compared with cases in which removal of the placenta is attempted with the uterus left in place (Eller et al., 2009). Other management options include internal iliac artery embolization and postoperative use of methotrexate to shrink residual placental tissue. Suggested criteria for management of these complicated patients include involvement of a multidisciplinary team that involves urology. The reason for this is that placenta percreta cases can extend so deeply as to involve local organs such as the bladder and ureter. The most common site of placental invasion is the posterior aspect of the bladder (Silver and Barbour, 2015).

The urologist may have multiple roles in caring for these patients, both preoperatively and intraoperatively. Antenatally, patients may be evaluated for suspected percreta involving the bladder wall. Retrospective review of placenta percreta cases involving the bladder has shown bleeding to be the most common presenting complaint, with vaginal bleeding initially occurring in almost one-half of patients (Washecka and Behling, 2002). Only an approximate one-third of patients in this series had hematuria (gross or microscopic) (Washecka and Behling, 2002). Cystoscopy does not appear to be sensitive for determining all cases of bladder wall involvement as mucosa may not be involved or altered, even with extensive muscularis involvement. However, cystoscopy remains warranted for evaluation and preoperative planning (Konijeti et al., 2009; Washecka and Behling, 2002). If percreta is suspected and there are cystoscopic abnormalities, it is important to forego biopsy in these cases as it carries a risk for gross exsanguinating hematuria (Washecka and Behling, 2002).

Intraoperatively, urologic consultation may be called for in cases in which placenta accreta was unknown or in cases in which the patient did not seek prenatal care. Cystotomies may occur intentionally or incidentally during dissection of the uterus. Bladder repair should take place as usual, with complete resection of placental tissue and closure in two layers. Omental interposition should be considered to avoid development of a fistula as indicated. The bladder is left to dependent drainage with a urethral catheter, and a pelvic drain may be left in place to evaluate for urine leak postoperatively. Cystography may be considered postoperatively before catheter removal, depending on the quality of the cystorrhaphy and surgeon preference.

There are cases in which subtotal hysterectomy is performed with invasive uterine tissue left in place as removal would result in significant anatomic and functional impact to the patient. Examples include defunctionalized bladder capacity from resection or requirement for ileal ureter creation in cases of significant ureteral involvement. Postoperatively, methotrexate has been employed to shrink residual placental tissue and prevent additional surgeries and additional blood loss (Karras et al., 2015). However, significant hemorrhagic shock has occurred in patients with retained placenta, and the standard of care remains as removal of all placental products (Washecka and Behling, 2002).

Ureteral injury and involvement can occur in these cases up to 7% of the time (Eller et al., 2009). There are some data to suggest that placement of ureteral catheters may decrease the risk for ureteral injury and early morbidity in cases of placental abnormality (Eller et al., 2009). This holds true for both nonemergent and emergent cases. If ureteral injury occurs or is suspected, just as outlined earlier in this chapter, it is the responsibility of the consulting urologist to do what he or she feels is best for the patient *and* within his or her skill set.

Consults From Urology Colleagues

Just as with any intraoperative consultation, the call for help from colleagues within the same discipline may occur. The surgical skill sets of the primary urologist and consulting urologist may have significant overlap, and generally this implies a higher degree of case complexity or challenging decisions to be made necessitating the call. It may also be the case that the urologist on call does not have the surgical skill set necessary to address an intraoperative consult from a primary surgeon within another discipline. Sometimes the call is made by the primary urologist simply to reaffirm the decision being considered before proceeding with the surgery. Whatever the reason, intraoperative consults from colleagues within urology should be considered as a particularly high honor and a sign of respect.

References

Ethical Considerations

Aubrey L, Jordan AL, Rojnica M, et al. Surgeon-family perioperative communication: surgeons' self-reported approaches to the "surgeon-family relationship.". *J Am Coll Surg*. 2014;219(5):958–967.

Langerman A, Angelos P, Siegler M. The "call for help": intraoperative consultation and the surgeon-patient relationship. *J Am Coll Surg*. 2014;219(6):1181–1186.

Wu AW, et al. Ethical and practical issues in disclosing medical mistakes to patients. *J Gen Intern Med*. 1997;12:770–775.

Decision Making

Langerman A, Siegler M, Angelos P. Intraoperative decision making: the decision to perform additional, unplanned procedures on anesthetized patients. *J Am Coll Surg*. 2016;222(5):956–960.

White DB, Jonsen A, Lo B. Ethical challenge: when clinicians act as surrogates for unrepresented patients. *Am J Crit Care*. 2012;21:202–207.

Documentation

Morris JA Jr, Carrillo Y, Jenkins JM, et al. Surgical adverse events, risk management, and malpractice outcome: morbidity and mortality review is not enough. *Ann Surg*. 2003;237(6):844–851.

Urethral Injury

Davis NF, Quinlan MR, Bhatt NR, et al. Incidence, cost, complications and clinical outcomes of iatrogenic urethral catheterization injuries: a prospective multi-institutional study. *J Urol*. 2016;196(5):1473–1477.

Kashefi C, Messer K, Barden R, et al. Incidence and prevention of iatrogenic urethral injuries. *J Urol*. 2008;179(6):2254–2257.

Thomas AZ, Giri SK, Meagher D, et al. Avoidable iatrogenic complications of urethral catheterization and inadequate intern training in a tertiary-care teaching hospital. *BJU Int*. 2009;104(8):1109–1112.

Bladder Injury

Esparaz AM, Pearl JA, Herts BR, et al. Iatrogenic urinary tract injuries: etiology, diagnosis, and management. *Semin Intervent Radiol*. 2015;32(2):195–208.

Gomez RG, Ceballos L, Coburn M, et al. Consensus statement on bladder injuries. *BJU Int*. 2004;94(1):27–32.

Moore EE, Cogbill TH, Jurkovich GJ, et al. Organ injury scaling. III: chest wall, abdominal vascular, ureter, bladder, and urethra. *J Trauma*. 1992;33(3):337–339.

Phipps MG, Watabe B, Clemons JL, et al. Risk factors for bladder injury during cesarean delivery. *Obstet Gynecol*. 2005;105(1):156–160.

Rahman MS, Gasem T, Al Suleiman SA, et al. Bladder injuries during cesarean section in a University Hospital: a 25-year review. *Arch Gynecol Obstet*. 2009;279(3):349–352.

Salman L, Aharony S, Shmueli A, et al. Urinary bladder injury during cesarean delivery: maternal outcome from a contemporary large case series. *Eur J Obstet Gynecol Reprod Biol*. 2017;213:26–30.

Sharp HT, Adelman MR. Prevention, recognition, and management of urologic injuries during gynecologic surgery.

Obstet Gynecol. 2016;127(6):1085–1096.

Summerton DJ, Kitrey ND, Lumen N, et al. EAU guidelines on iatrogenic trauma. *Eur Urol*. 2012;62(4):628–639.

Wong JMK, Bortoletto P, Tolentino J, et al. Urinary tract injury in gynecologic laparoscopy for benign indication: a systematic review. *Obstet Gynecol*. 2018;131(1):100–108.

Ureteral Injury

Al-Awadi K, Kehinde EO, Al-Hunayan A, et al. Iatrogenic ureteric injuries: incidence, aetiological factors and the effect of early management on subsequent outcome. *Int Urol Nephrol*. 2005;37(2):235–241.

Andersen P, Andersen LM, Iversen LH. Iatrogenic ureteral injury in colorectal cancer surgery: a nationwide study comparing laparoscopic and open approaches. *Surg Endosc*. 2015;29(6):1406–1412; 10.1007/s00464-014-3814-1 [Epub 2014 Aug 26].

Baston C, Harza M, Preda A, et al. Comparative urologic complications of ureteroneocystostomy in kidney transplantation: transvesical Leadbetter-Politano versus extravesical Lich-Gregoir technique. *Transplant Proc*. 2014;46(1):176–179.

Best CD, Petrone P, Buscarini M, et al. Traumatic ureteral injuries: a single institution experience validating the American Association for the Surgery of Trauma-Organ Injury Scale grading scale. *J Urol*. 2005;173(4):1202–1205.

Blackwell RH, Kirshenbaum EJ, Shah AS, et al. Complications of recognized and unrecognized iatrogenic ureteral injury at time of hysterectomy: a population based analysis. *J Urol*. 2018;199(6):1540–1545.

Bothwell WN, Bleicher RJ, Dent TL. Prophylactic ureteral catheterization in colon surgery. A five-year review. *Dis*

Colon Rectum. 1994;37(4):330–334.

Bjurlin MA, Rousseau LA, Vidal PP, et al. Iatrogenic ureteral injury secondary to a thoracolumbar lateral revision instrumentation and fusion. *Spine J*. 2009;9(6):e13–e15.

Brandes S, Coburn M, Armenakas N, et al. Diagnosis and management of ureteric injury: an evidence-based analysis. *BJU Int*. 2004;94(3):277–289.

Burks FN, Santucci RA. Management of iatrogenic ureteral injury. *Ther Adv Urol*. 2014;6(3):115–124.

Carley ME, McIntire D, Carley JM, et al. Incidence, risk factors and morbidity of unintended bladder or ureter injury during hysterectomy. *Int Urogynecol J Pelvic Floor Dysfunct*. 2002;13(1):18–21.

Chou MT, Wang CJ, Lien RC. Prophylactic ureteral catheterization in gynecologic surgery: a 12-year randomized trial in a community hospital. *Int Urogynecol J Pelvic Floor Dysfunct*. 2009;20(6):689–693.

D'Addessi A, Bassi P. Ureterorenoscopy: avoiding and managing the complications. *Urol Int*. 2011;87:251–259.

de la Rosette JJMCH, Skrekas T, Segura JW. Handling and prevention of complications in stone basketing. *Eur Urol*. 2006;50:991–999.

Delacroix SE, Winters JC. Urinary tract injures: recognition and management. *Clin Colon Rectal Surg*. 2010;23:104–112.

Dobrowolski Z, Kusionowicz J, Drewniak T, et al. Renal and ureteric trauma: diagnosis and management in Poland. *BJU Int*. 2002;89(7):748–751.

Duty BD, Kreshover JE, Richstone L, et al. Review of appendiceal onlay flap in the management of complex ureteric strictures in six patients. *BJU Int*. 2015;115(2):282–287.

Elliott SP, McAninch JW. Ureteral injuries: external and iatrogenic. *Urol Clin North Am*. 2006;33:55–66.

Han CM, Tan HH, Kay N, et al. Outcome of laparoscopic repair of ureteral injury: follow-up of twelve cases. *J Minim Invasive Gynecol*. 2012;19(1):68–75.

Hassinger TE, Mehaffey JH, Mullen MG, et al. Ureteral stents increase risk of postoperative acute kidney injury following colorectal surgery. *Surg Endosc*. 2018;32(7):3342–3348.

Gild P, Kluth LA, Vetterlein MW, et al. Adult iatrogenic ureteral injury and stricture–incidence and treatment strategies. *Asian J Urol*. 2018;5(2):101–106.

Menderes G, Clark LE, Azodi M. Incidental ureteral injury and repair during robotic-assisted total laparoscopic hysterectomy. *J Minim Invasive Gynecol*. 2015;22(3):320.

Morey AF, Brandes S, Dugi DD 3rd, et al. Urotrauma: AUA guideline. *J Urol*. 2014;192(2):327–335.

Parpala-Sparman T, Paananen I, Santala M, et al. Increasing numbers of ureteric injuries after the introduction of laparoscopic surgery. *Scand J Urol Nephrol*. 2008;42:422–427.

Pillai SB, Hegde P, Venkatesh G. Ureteral injury after posterior lumbar discectomy with interbody screw fixation. *BMJ Case Rep*. 2013;2013.

Romero V, Akpinar H, Smith JJ 3rd, et al. Changing patterns in iatrogenic ureteral injuries. *Rev Urol*. 2011;13(4):e179–e183.

Selzman AA, Spirnak JP. Iatrogenic ureteral injuries: a 20-year experience in treating 165 injuries. *J Urol*. 1996;155(3):878–881.

Serafetinides E, Kitrey ND, Djakovic N, et al. Review of the current management of upper urinary tract injuries by the EAU Trauma Guidelines Panel. *Eur Urol*. 2015;67(5):930–936.

Summerton DJ, Kitrey ND, Lumen N, et al. EAU guidelines on iatrogenic trauma. *Eur Urol*. 2012;62(4):628–639.

Teeluckdharry B, Gilmour D, Flowerdew G. Urinary tract injury at benign gynecologic surgery and the role of cystoscopy: a systematic review and meta-analysis. *Obstet Gynecol*. 2015;126(6):1161–1169.

Tracey AT, Eun DD, Stifelman MD, et al. Robotic-assisted laparoscopic repair of ureteral injury: an evidence-based review of techniques and outcomes. *Minerva Urol Nefrol*. 2018;70(3):231–241.

Zhao LC, Weinberg AC, Lee Z, et al. Robotic ureteral reconstruction using buccal mucosa grafts: a multi-institutional experience. *Eur Urol*. 2017 [pii: S0302-2838(17)31000-X].

Renal Injury

Esparaz AM, Pearl JA, Herts BR, et al. Iatrogenic urinary tract injuries: etiology, diagnosis, and management. *Semin Intervent Radiol*. 2015;32(2):195–208.

Placental Cases

Eller AG, Porter TF, Soisson P. Optimal management strategies for placenta accreta. *BJOG*. 2009;116(5):648–654.

Jauniaux E, Bhide A. Prenatal ultrasound diagnosis and outcome of placenta previa accreta after cesarean delivery: a systematic review and meta-analysis. *Am J Obstet Gynecol*. 2017;217(1):27–36.

Karras G, Antonakopoulos N, Agrapidis D, et al. Diagnosis and management of placenta percreta with bladder involvement. *J Obstet Gynaecol*. 2015;35(3):308–310.

Konijeti R, Rajfer J, Askari A. Placenta percreta and the urologist. *Rev Urol*. 2009;11(3):173–176.

Silver RM, Barbour KD. Placenta accreta spectrum: accreta, increta, and percreta. *Obstet Gynecol Clin North Am*. 2015;42(2):381–402.

Thiravit S, Lapatikarn S, Muangsomboon K, et al. MRI of placenta percreta: differentiation from other entities of placental adhesive disorder. *Radiol Med*. 2017;122(1):61–68.

Washecka R, Behling A. Urologic complications of placenta percreta invading the urinary bladder: a case report and review of the literature. *Hawaii Med J*. 2002;61(4):66–69.

PART III

Pediatric Urology

OUTLINE

Section A Development and Prenatal Urology

Section B Basic Principles

Section C Lower Urinary Tract Conditions

Section D Upper Urinary Tract Conditions

Section E Genitalia

Section F Reconstruction and Trauma

Section G Oncology

SECTION A

Development and Prenatal Urology

OUTLINE

20 Embryology of the Genitourinary Tract
21 Urologic Aspects of Pediatric Nephrology
22 Perinatal Urology

Embryology of the Genitourinary Tract

Laurence S. Baskin MD, Gerald Cunha PhD

The human urogenital system can be divided into the urinary and reproductive systems. These systems are closely interrelated, especially early in development, which begins in the first trimester and is mostly complete by the end of the second trimester. The Carnegie collection of embryos depicts human development from the time of fertilization to the indifferent stage at approximately 8 to 9 weeks' gestation (Fig. 20.1; Mall and Meyer, 1921; Smith, 2016). **Subsequently, under the influence of androgens, differentiation of the male and female urogenital structures becomes apparent** (Blaschko et al., 2012; Fig. 20.2). In this chapter, we review the development of the human urogenital tract by organ system: external genitalia, prostate, gonads, uterus, vagina, bladder, ureters, and kidneys. Understanding normal development is essential for understanding abnormal development or urologic congenital anomalies and is the first step in planning treatment and surgical reconstruction if indicated.

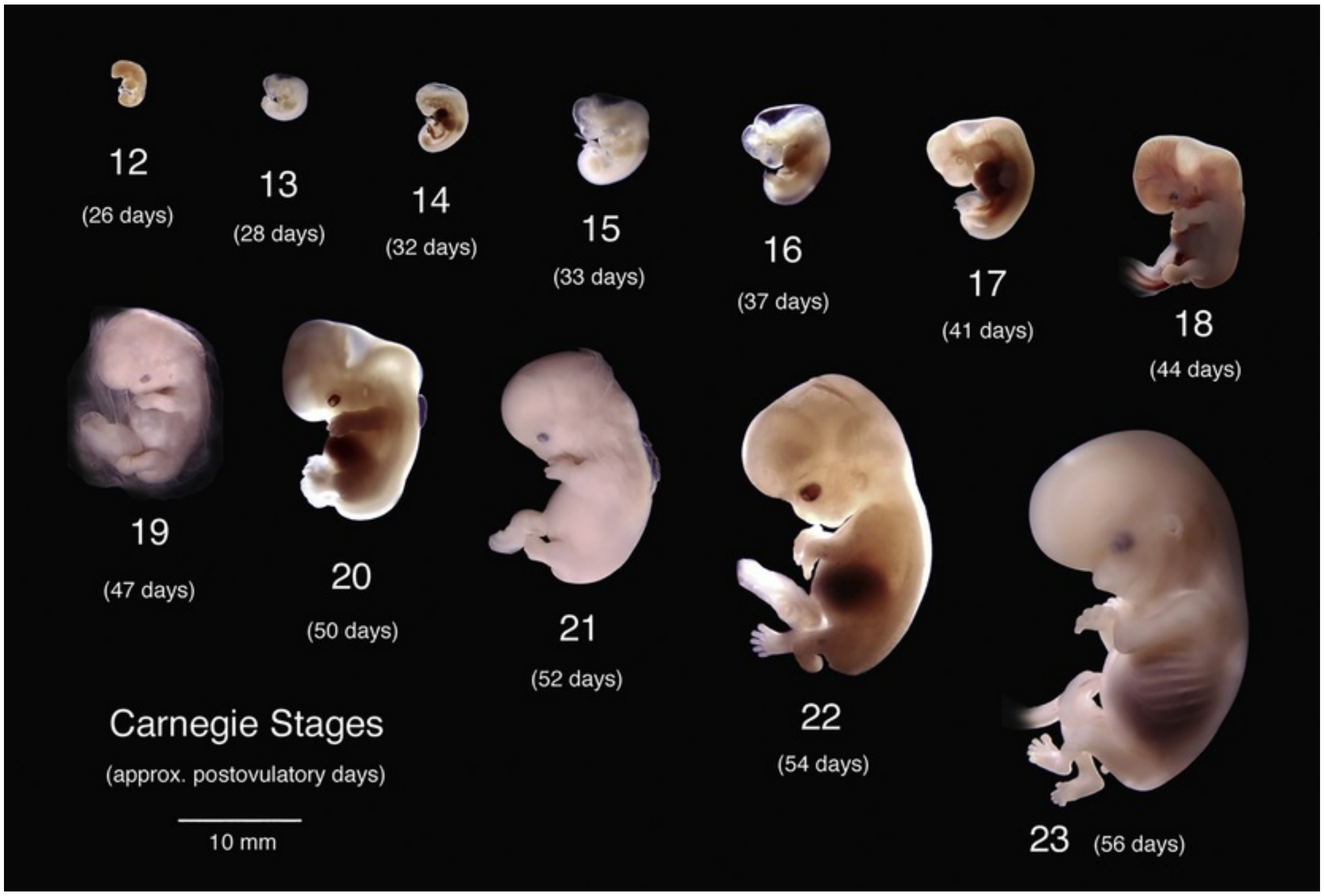
12
(26 days)
13
(28 days)
14
(32 days)
15
(33 days)
16
(37 days)
17
(41 days)
18
(44 days)
19
(47 days)
20
(50 days)
21
(52 days)
22
(54 days)
23 (56 days)
Carnegie Stages
(approx. postovulatory days)
10 mm

FIG. 20.1 Whole-mount photographs of developing human embryos from the Carnegie collection. Note the increasing size and morphologic complexity with developmental stage. (Image courtesy of Dr. Brad Smith, University of Michigan, from http://embryo.soad.umich.edu/carnStages/carnStages.html; NIH award N01-HD-6-3257 P/G F003637.)

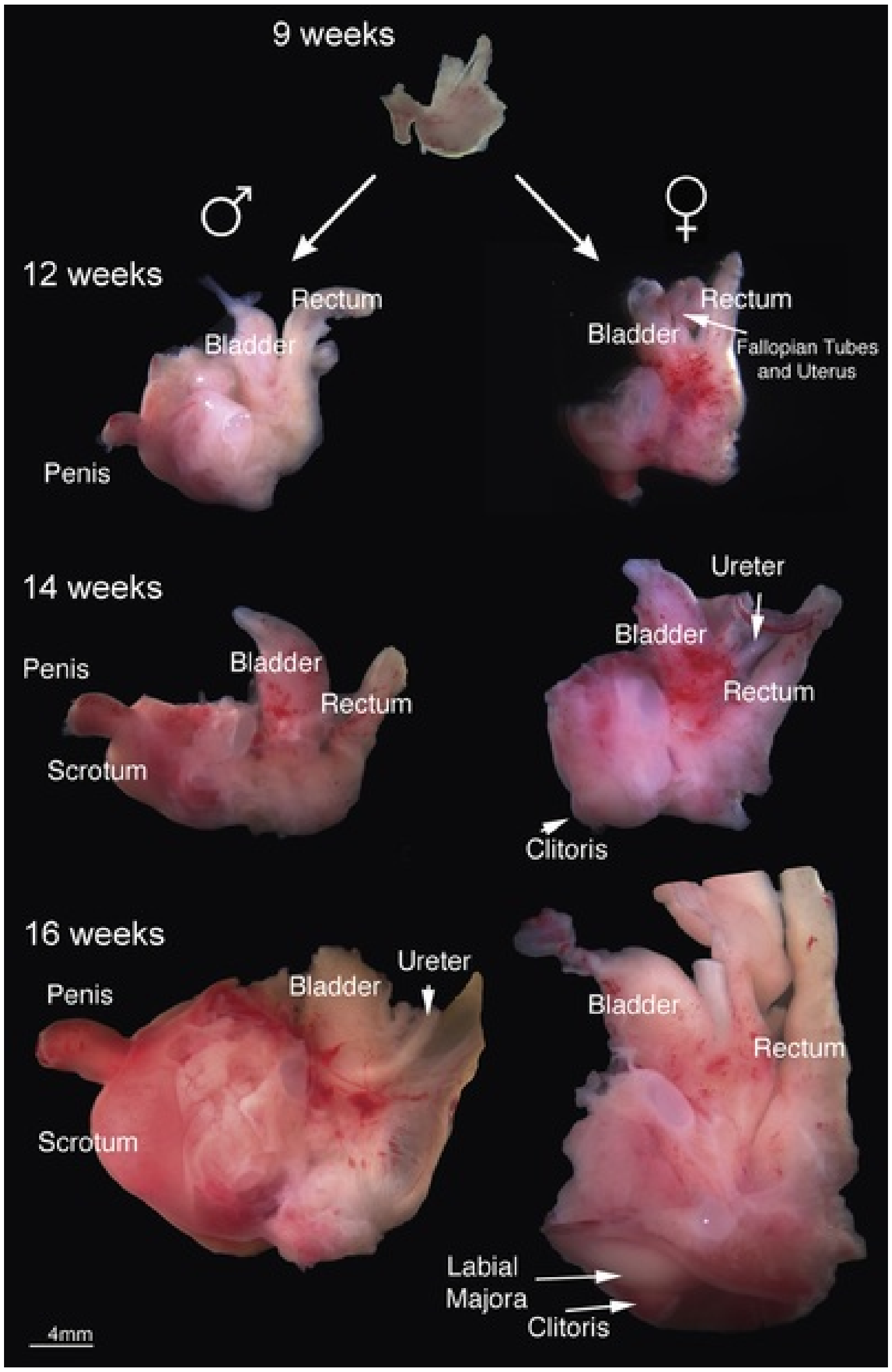
9 weeks
♂
♀
12 weeks
Rectum
Bladder
Penis
Rectum
Bladder
Fallopian Tubes
and Uterus
14 weeks
Penis
Bladder
Rectum
Scrotum
Ureter
Bladder
Rectum
Clitoris
16 weeks
Penis
Bladder
Ureter
Scrotum
Bladder
Rectum
Labial
Majora
Clitoris
4mm

FIG. 20.2 Gross ontogeny of the human fetal pelvis from 9 weeks' gestation (end of indifferent stage) to 16 weeks' gestation. Note the divergent development after 9 weeks' gestation, especially with respect to orientation of the external genitalia with the penis clearly visible at an approximately 90-degree angle from the body and the clitoris recessed close to the body wall.

Development of the External Genitalia

At 8 to 9 weeks' gestation, the external genitalia consist of an indifferent genital tubercle (Fig. 20.3). Sexual differentiation of the external genitalia is dependent on prior differentiation of the gonads. **The process of normal gonadal sexual differentiation is determined by the SRY region on the short arm of the Y chromosome** (Larney et al., 2014; Ohnesorg et al., 2014). The gene products of the SRY genetic cascade direct testicular development (Windley and Wilhelm, 2015). Additional genetic information required for development of male and female accessory sexual structures is located on the X chromosome and on the autosomes (Blaschko et al., 2012).

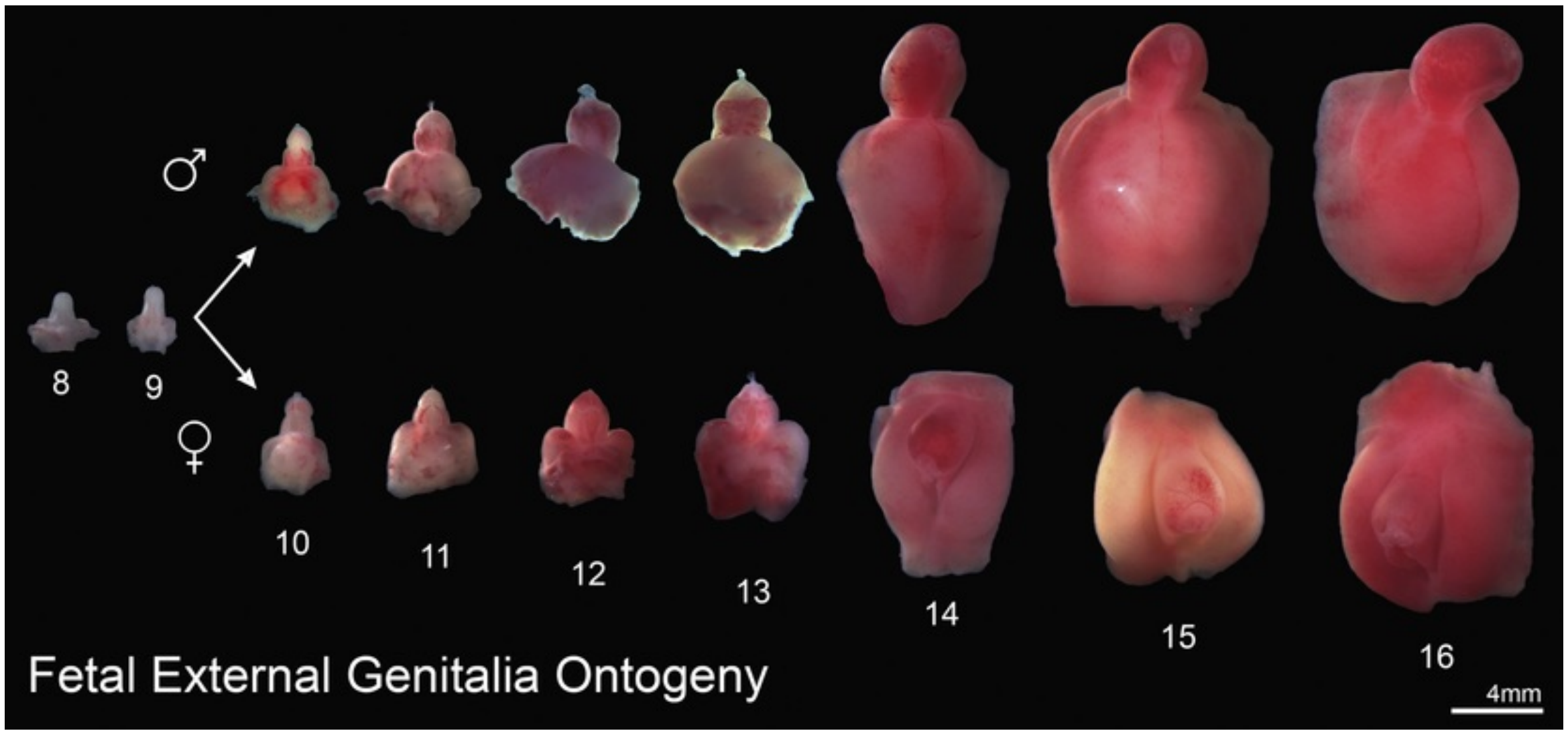

FIG. 20.3 Representative examples of human male *(top row)* and female *(bottom row)* external genitalia (8 to 16 weeks' gestation). Note the morphologic differences between the male and female genitalia after the indifferent stage (8 to 9 weeks' gestation), with lack of urethral fusion in the female specimens.

At approximately 9 weeks' gestation, the Leydig cells appear in the testis and begin to secrete testosterone (Blaschko et al., 2012; Dufau, 1988). Testosterone or the more potent androgen, dihydrotestosterone (DHT), masculinize the genital tubercle, **Wolffian duct (WD), and urogenital sinus (UGS).** Metabolic conversion of testosterone to DHT is mediated by type 2 5α-reductase, is expressed within the UGS and the genital tubercle, and is required for normal penile and prostatic development (Blaschko et al., 2012; Wilson et al., 1993; Wilson, 2001).

Masculinization of the external genitalia takes place under the influence of androgens. One of the first signs of masculinization is an increase in the distance between the anus and the genital structures (known as *anogenital distance*), followed by elongation of the genital tubercle and formation of a urethral plate (Fig. 20.4). The male genital tubercle, future penis, and clitoris contain tissue derived from all three germ layers. Ectoderm gives rise to the skin of the phallus. Mesoderm gives rise to the corporal bodies/erectile tissue. Endoderm gives rise to the urethra (see Fig. 20.4) and vestibular plate. The urethral plate (derived from endoderm) extends from the “pelvic urethra” into the future glans penis, terminating just before the distal tip of the future glans (Fig. 20.5). The urethral plate canalizes from proximal to distal to form a wide, diamond-shaped urethral groove within the penile shaft (opening zipper; Figs. 20.6 and 20.7). The canalization process is seen in the histologic sections in Fig. 20.5. Cellular proliferation (documented by the expression of Ki67) is abundant in the canalizing urethral plate (see Fig. 20.5), and apoptosis was not detected (based on the lack of expression of caspase 3; see Fig. 20.5C). The penile urethra forms as a result of complex fusion of the medial edges of the urethral folds (see Figs. 20.6 and 20.7). As development progresses, the epithelial edges of the urethral groove begin to fuse to form the midline penile raphe (closing zipper). By 11 to 12 weeks’ gestation, the coronal sulcus is evident separating the penile glans from the shaft. By 16 weeks, the urethral folds have completely fused in the ventral midline of the penile shaft (see Fig. 20.3). The normal ventral penile curvature, or chordee, that occurs during development resolves by the 20th week.

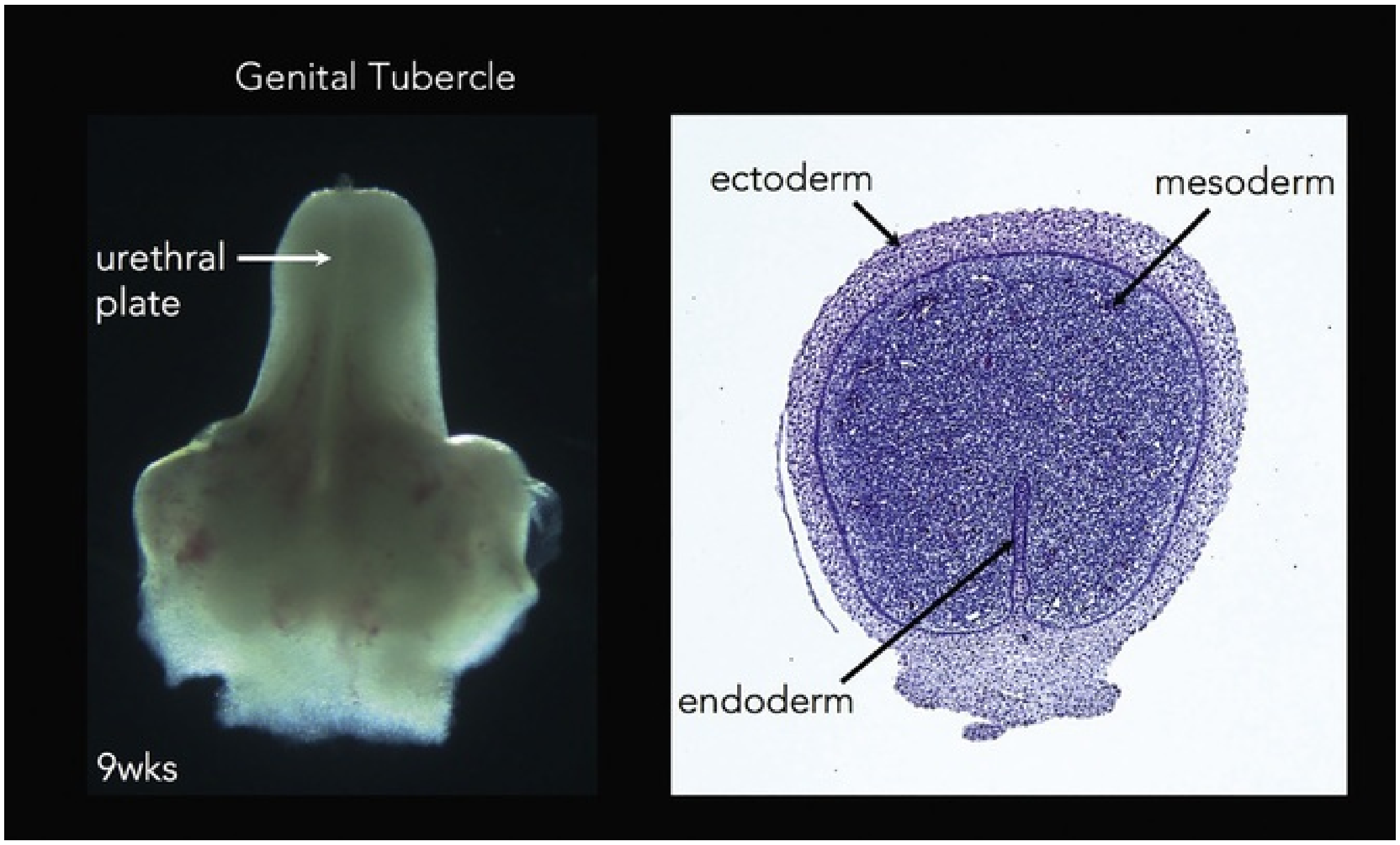
Genital Tubercle
urethral plate
9wks
ectoderm
mesoderm
endoderm

FIG. 20.4 A 9-week human male genital tubercle/future human penis. Note the urethral plate in the gross specimen. In the corresponding histologic cross-section, the three embryonic layers of external genitalia development are labeled: ectoderm (future skin and prepuce), mesoderm (erectile tissue) and endoderm (urethral plate and future urethra).

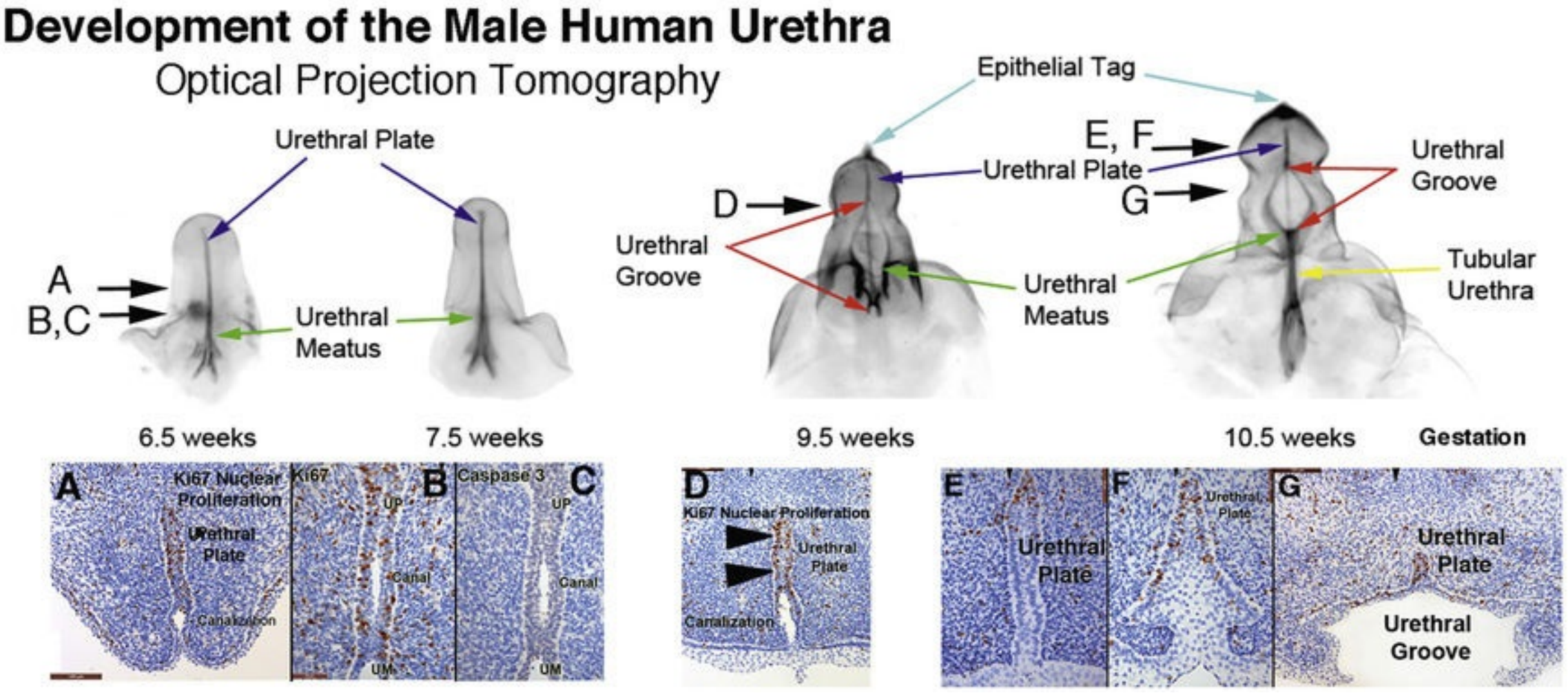
Development of the Male Human Urethra
Optical Projection Tomography
Urethral Plate
A
B,C
Urethral Meatus
Epithelial Tag
E, F
D
Urethral Plate
G
Urethral Groove
Urethral Groove
Urethral Meatus
Tubular Urethra
6.5 weeks
7.5 weeks
9.5 weeks
10.5 weeks
Gestation
A
Ki67 Nuclear Proliferation
Urethral Plate
Canalization
Ki67
B
UP
Canal
UM
Caspase 3
C
UP
Canal
UM
D
Ki67 Nuclear Proliferation
Urethral Plate
Canalization
E
Urethral Plate
F
Urethral Plate
G
Urethral Plate
Urethral Groove

FIG. 20.5 Optical projection tomography (OPT) of male urethral development from 6.5 to 10.5 weeks' fetal age. Note the urethral plate *(blue arrows)* that ends within the glans. Note the progression of the urethral meatus *(green arrows)* from the level of the scrotal folds at 6.5 weeks to the proximal penile shaft at 10.5 weeks. The wide open urethral groove

(red arrows) is best seen from 9.5 to 10.5 weeks, with clear progression of proximal to distal fusion of the edges of the urethral groove to form the tubular urethra *(yellow arrows).* The epithelial tag, which is of unknown significance, is marked by the *light blue arrow.* Corresponding serial immunohistochemical sections localizing the proliferation marker Ki67 are labeled with arrows in the OPT specimens A to G, with the exception of C, which illustrates no staining for the apoptotic marker Caspase 3. (From Li Y, Sinclair A, Cao M, et al. Canalization of the urethral plate precedes fusion of the urethral folds during male penile urethral development: the double zipper hypothesis. *J Urol.* 193(4);2015:1353–1359.)

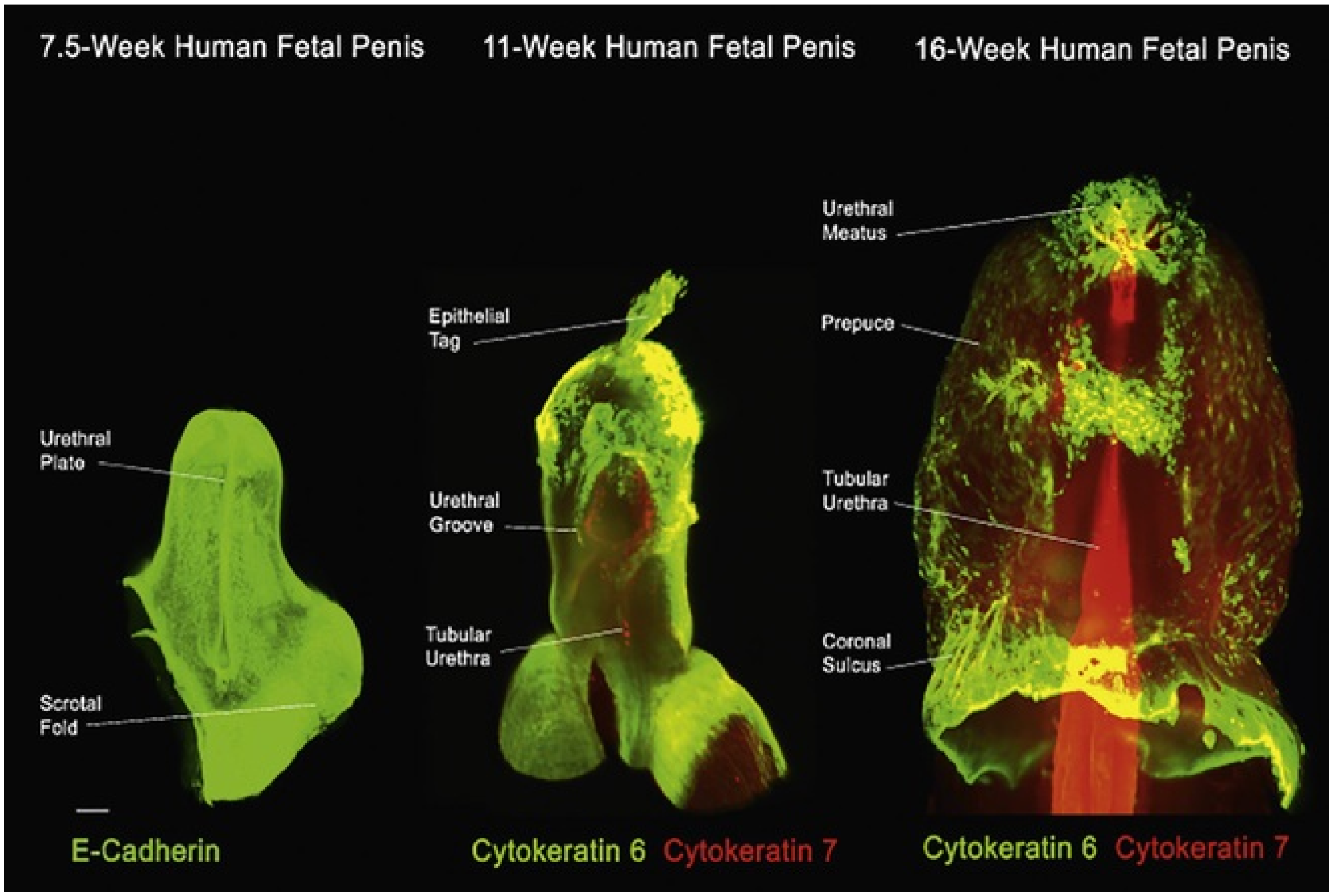
7.5-Week Human Fetal Penis
11-Week Human Fetal Penis
16-Week Human Fetal Penis
Urethral Meatus
Epithelial Tag
Prepuce
Urethral Plate
Urethral Groove
Tubular Urethra
Tubular Urethra
Coronal Sulcus
Scrotal Fold
E-Cadherin
Cytokeratin 6 Cytokeratin 7
Cytokeratin 6 Cytokeratin 7

FIG. 20.6 Lightsheet fluorescence microscopy images demonstrating development of the penile urethra at the ambisexual stage (*left,* 7.5 weeks), during active urethral canalization and fusion to form the urethra in the penile shaft (*middle,* 11 weeks), and during canalization to form the mature urethra in the glans penis (*right,* 16 weeks). E-cadherin is expressed at epithelial surfaces in development, Cytokeratin 6 is expressed in the urethral plate and epidermis, and Cytokeratin 7 is expressed in urothelium.

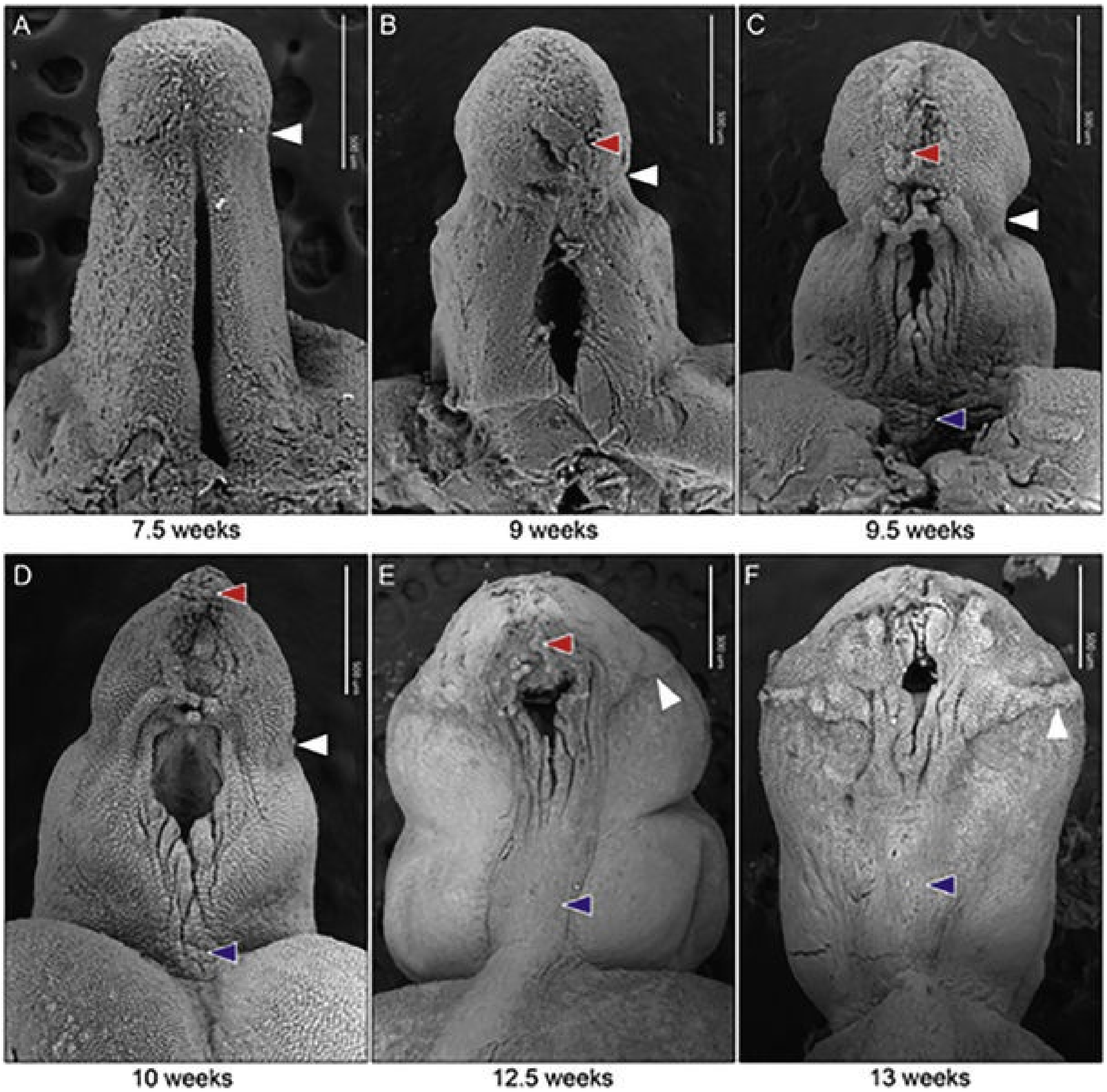

FIG. 20.7 (A to F) Scanning electron microscopy ontogeny of the developing human fetal penis from 7.5 to 13 weeks' gestation in ventral view. *White arrowheads* indicate the junction of the penile shaft to glans, *red arrowheads* indicate the distal epithelial tag, and *blue arrowheads* indicate the median penile raphe. (From Shen J, Overland M, Sinclair A, et al. Complex epithelial remodeling underlie the fusion event in early fetal development of the human penile urethra. *Differentiation*. 92(4);2016:169–182.)

The glanular urethra forms via a mechanism entirely different from urethral fold fusion, which occurs within the penile shaft (Liu et al., 2018). **Current evidence supports the view that the glanular urethra forms from UGS epithelium** (Kurzrock et al., 1999). The glanular urethra forms as a result of direct canalization of the urethra plate with epithelial remodeling within the glans (Baskin et al., 2018; Liu et al., 2018). By 18 weeks' gestation, penile and urethral development is essentially complete (Fig. 20.8).

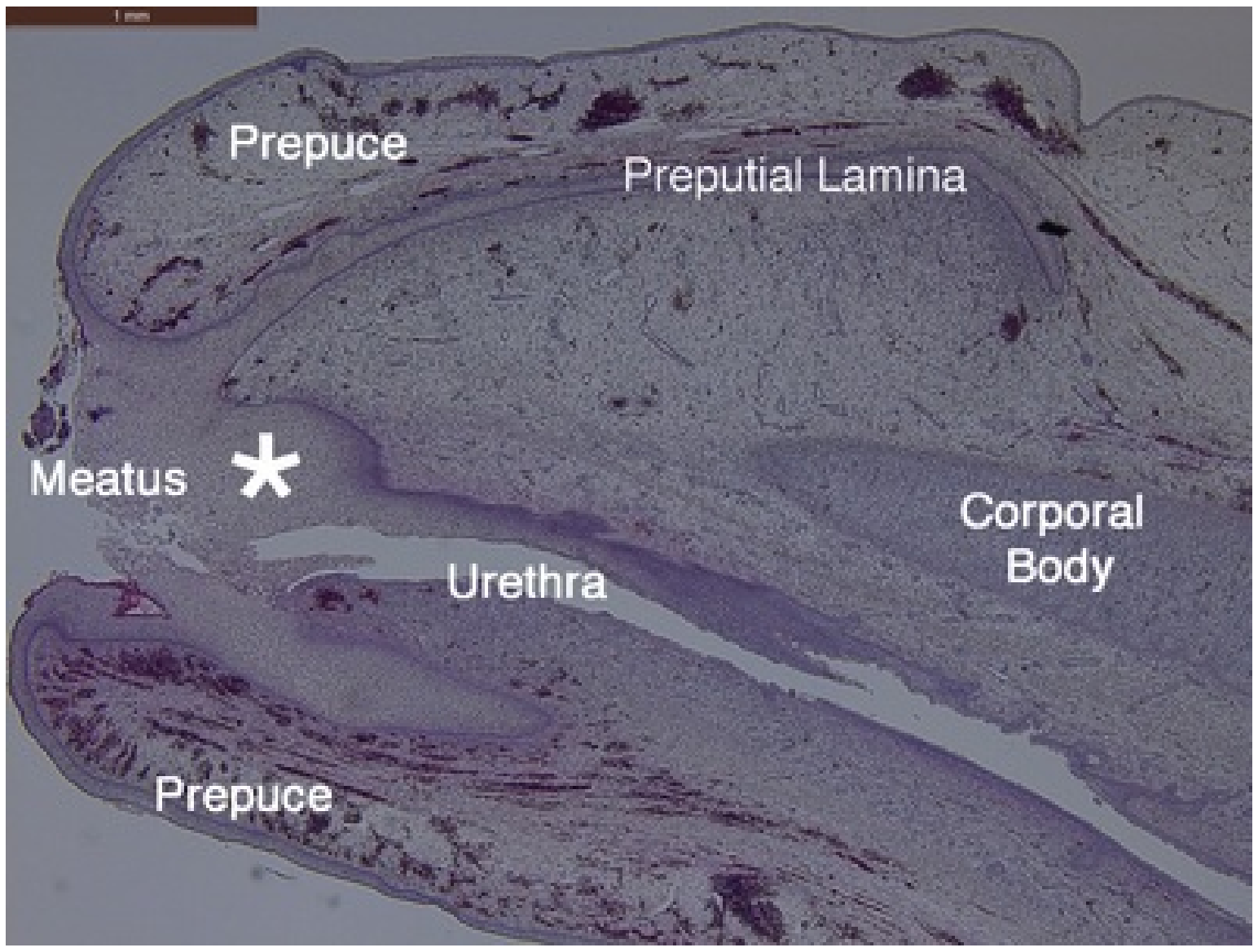

FIG. 20.8 Sagittal section of an 18-week human fetal penis. Note the remodeling of the distal aspect of the urethra. The glans, prepuce, corporal cavernosa, urethra, and meatus are labeled.

Anatomic and immunohistochemical studies suggest that epithelium of the entire urethra is derived from endoderm of the UGS (Kurzrock et al., 1999). The entire male urethra, including the majority of the glanular urethra, is formed from the endodermal urethral plate within the genital tubercle as a result of urethral fold fusion within the shaft and direct canalization of the urethral plate within the glans. This is in contrast with the outdated ectodermal extrusion theory of Glenister, which hypothesized that the glanular urethra formed by skin (ectodermal intrusion) growing into the glans and meeting the endodermally derived urethra (Glenister, 1954).

The future prepuce forms at the same time as the glanular urethra and is dependent on normal urethral development as described earlier. At about 8 weeks' gestation, low preputial folds appear on both sides of the penile shaft, which join dorsally to form a flat preputial ridge at the proximal edge of the corona. The preputial ridge initially does not entirely encircle the glans because it is blocked ventrally by incomplete development of the glanular urethra. With further development, the bilateral preputial folds (ventrolateral edges of the preputial ridge) extend distally to eventually cover most of the glans. At the same time, the bilateral preputial folds (foreskin) grow ventrally and fuse together in the ventral midline. During this process of distal and ventral growth of the prepuce, the epithelial preputial lamina is laid down, which separates the mesenchymal core of the glans from the mesenchyme of the prepuce, whose outer surface is covered with epidermis (see Fig. 20.3). Postnatally, the preputial lamina delaminates creating the preputial space, thus allowing retraction of the prepuce. **Clearly the development of the prepuce is linked to development of the urethra, because in hypospadias, preputial tissue is absent ventrally and excessive dorsally** (classic dorsal hooded foreskin; Baskin, 2017).

The origin of the nerve supply of the penis may be traced to week 5 of gestation, when neural crest cells differentiate into the peripheral and autonomic nervous systems. The somatic innervation of the penis comes principally from spinal nerves S2 to S4 by way of the pudendal nerve (Lue et al., 1984). After passing under the sacrospinous ligament and over the sacrotuberous ligament and through Alcock's canal (pudendal canal), the pudendal nerve passes through the transverse perineal muscle to course onto the dorsum of the penis as the dorsal nerve of the penis (Fig. 20.9; Breza et al., 1989). The autonomic innervation of the penis arises from the vesical and prostatic plexi, which are composed of sympathetic nerves from L1 and L2, and parasympathetic nerves from S2 to S4. The bilateral cavernous nerves leaves the pelvis between the transverse perineal muscles and the membranous urethra before passing beneath the arch of the pubis to supply each corpus cavernosum (Paick et al., 1993).

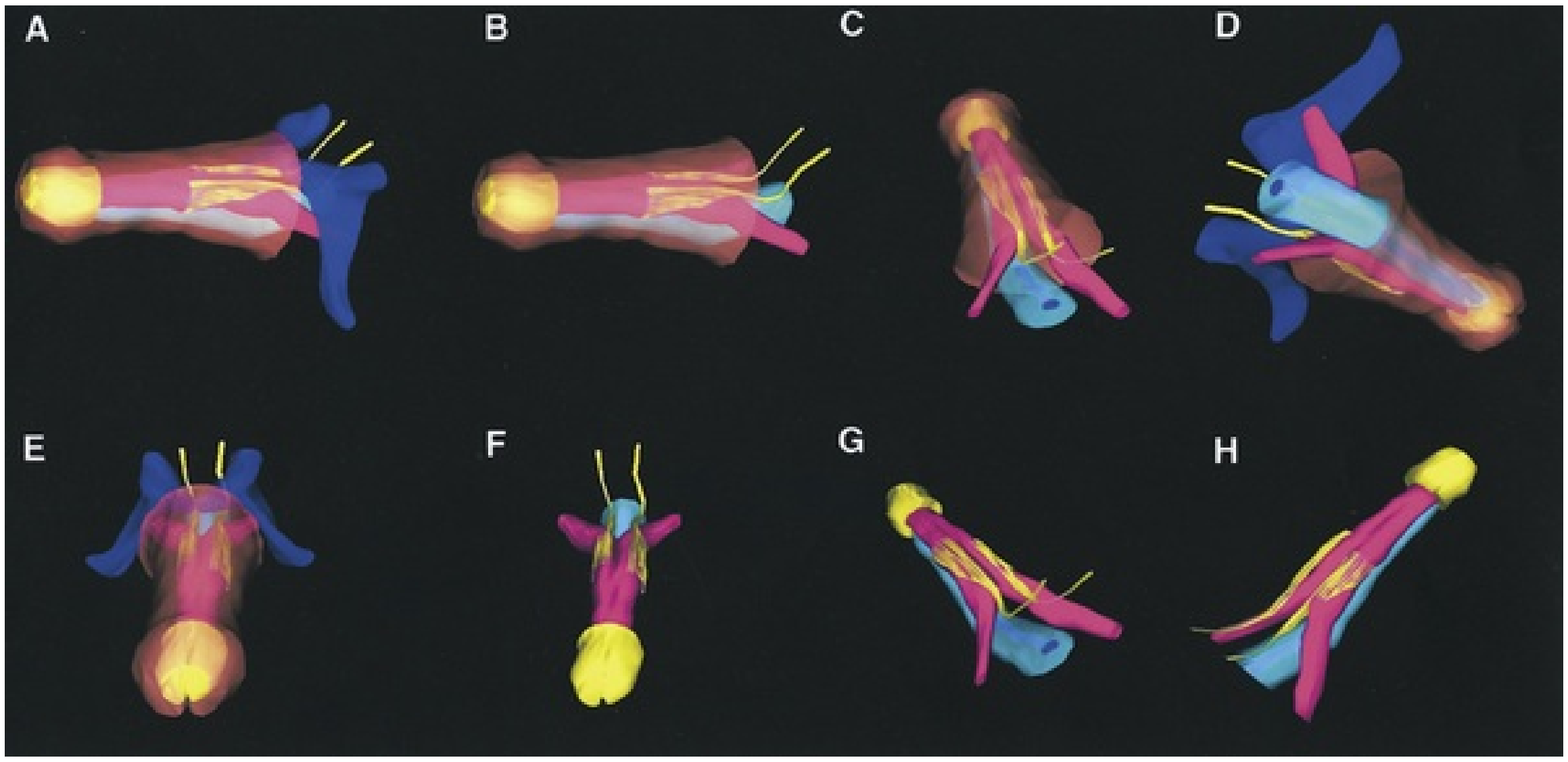

FIG. 20.9 (A to H) Multiple views of three-dimensional reconstruction of

human fetal penis dorsal nerve neuroanatomy at 17.5 weeks' gestation with respective layers removed for selective visualization. *Blue areas* represent pubic arch. *Yellow areas* represent nerves and glans. *Light blue areas* represent urethra. *Pink areas* represent corporeal bodies. *Brown areas* represent penile skin.

The dorsal penile nerve bundles exist not only in the 11 and 1 o'clock positions, but extend around the tunica to the junction of the corpus spongiosum and corpora cavernosa. Note the nerve-free zone at the 12 o'clock position (see Fig. 20.9; Baskin et al., 1998).

Clinical Correlation: Hypospadias

Hypospadias occurs in approximately 1 : 250 newborn males (Baskin, 2017). Hypospadias can be defined as (1) ectopic location of the urethral meatus, (2) incomplete development of the prepuce (dorsal hooded foreskin), and (3) ventral skin deficiency/penile curvature. **The most common location of the ectopic urethral meatus is at the junction of the penile shaft and glans penis (Baskin, 2017). This is consistent with the different mechanisms of urethral formation between the shaft of the penis and the glans (urethral fold fusion in the shaft and direct canalization of the urethral plate with the glans).** Fig. 20.10 shows two human fetal specimens, one with glanular hypospadias with the classic ectopic meatus and dorsal hooded foreskin and the other with persistent penile curvature secondary to penile scrotal webbing. The anatomy of the hypospadiac penis is exactly like a normal penis except for abnormalities in the development of the urethra and overlying skin and a ventrally deficient prepuce (Baskin et al., 1998). The abortive elements of the urethra and urethral spongiosum such as epithelium, connective tissue, smooth muscle, and blood vessels can be found in the adjacent tissue consistent with the hypospadias being an arrest in development and not a deformation anomaly (Baskin et al., 1998).

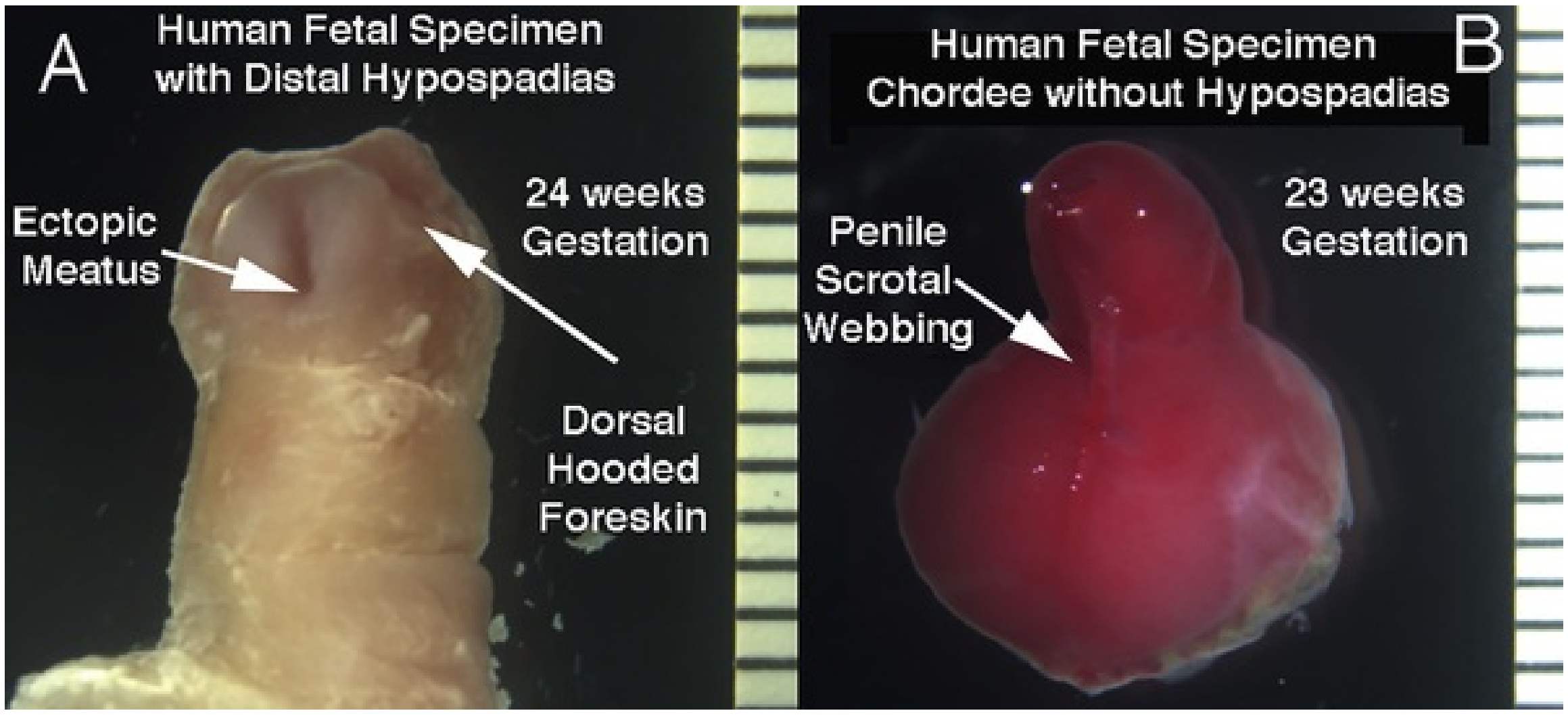
A
Human Fetal Specimen
with Distal Hypospadias
Ectopic
Meatus
24 weeks
Gestation
Dorsal
Hooded
Foreskin
Human Fetal Specimen
Chordee without Hypospadias
B
Penile
Scrotal
Webbing
23 weeks
Gestation

FIG. 20.10 A 24-week human fetal penis with classic distal hypospadias (A) and a 23-week human fetal specimen with chordee without hypospadias and penile webbing (B).

In the overwhelming majority of cases, the etiology of hypospadias remains unknown. A reasonable hypothesis is that hypospadias is caused by genetic susceptibility and maternal exposure to endocrine disruptors (Baskin et al., 2001). Rarely, a known genetic defect is present to explain the hypospadias. For example, a defect in the enzyme 5α-reductase type 2 (which converts testosterone to DHT) leads to severe hypospadias. 5α-reductase type 2 is expressed at the site of urethral fold fusion along the penile shaft and appears necessary for normal urethral development (Kim et al., 2002). Severe hypospadias is a consistent finding in patients without the 5α-reductase enzyme who lack the ability to properly fuse the edges of the urethral groove (see Fig. 20.13).

Clinical Correlation: Correction of Penile Curvature

Anatomic studies of penile innervation have allowed for strategic design of penile straightening procedures for ventral curvature associated with hypospadias and congenital penile curvature without hypospadias (Baskin et al., 1996, 1998, 2000). Along the penile shaft, the nerves course along the tunica albuginea and extend ventrally to completely surround the cavernous bodies up to the ventral junction with the spongiosum. From the glans to the crural bodies, where the bilateral corporal bodies (crura) separate to attach to the ventral pubic rami, the nerves are grouped into tight bundles at the 11 and 1 o'clock positions. **The 12 o'clock position is a nerve-free zone amendable to placement of**

dorsal plication sutures in mild to moderate degrees of curvature (Fig. 20.11). Also, the 12 o'clock position is where the tunica albuginea is thickest, facilitating anchoring of the plication suture (Baskin et al., 1998).

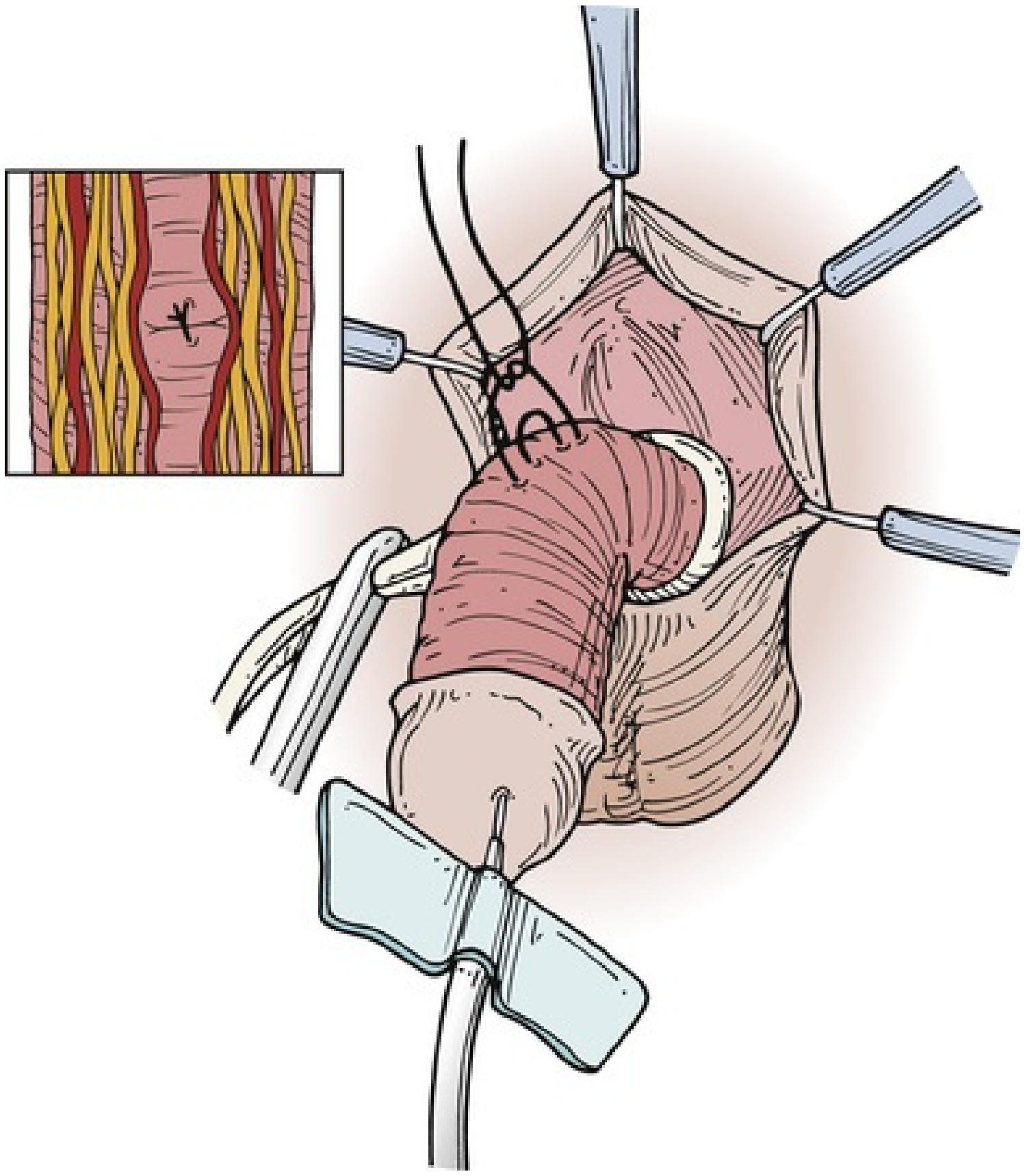

FIG. 20.11 Schematic of penile straightening technique using plication sutures at the 12 o'clock position, where there is a paucity of nerves, thereby avoiding nerve injury.

Clinical Correlation: Duplicated Urethra

Duplication anomalies of the urethra are extremely rare with both hypospadiac and epispadiac variations (Coleman et al., 2010). These are best explained embryologically by splitting of the urethral plate at the bladder to form complete duplication or splitting along the shaft of the genital tubercle to form a Y duplication. Sonic hedgehog appears to be an important genetic pathway controlling this process (Seifert et al., 2009).

Development of the Female External Genitalia

The clitoris forms in an analogous fashion to the penis except for lack of formation of the urethra (Overland et al., 2016; see Figs. 20.3 and 20.12). As in males, a urethral plate (properly called the *vestibular plate* in females) undergoes canalization to form a wide diamond-shaped vestibular groove (opening zipper, homologous to the urethral groove of males). Because formation of the vestibular groove and its subsequent canalization occurs in females (and in males), this process is androgen independent (Shen et al., 2016). **In contrast with penile formation, fusion of the urethral groove (closing zipper) does not take place, resulting in an open vestibular groove** (Overland et al., 2016; Figs. 20.12 and 20.13). Similar to the glans penis, the glans clitoris forms a cap on top of the distal end of the narrowed bilateral corporal (clitoral) bodies. Fusion of these clitoral bodies is manifest as a midline septum starting on the ventral aspect and extending about halfway into the glans. Large bundles of nerves course along the clitoral bodies with the highest density dorsally (Fig. 20.14) in a fashion analogous to the penis (Baskin et al., 1999). No nerves are noted at the 12 o'clock position, but nerves extend ventrolaterally completely around the tunica similar to that seen in the fetal penis. Like in the male, innervation of the glans clitoris occurs via multiple perforating branches that enter at the dorsal junction of the corporal body and the glans. **The lowest density of nerves in the glans is on the ventral aspect in juxtaposition to the glans septum** (Baskin et al., 1999).

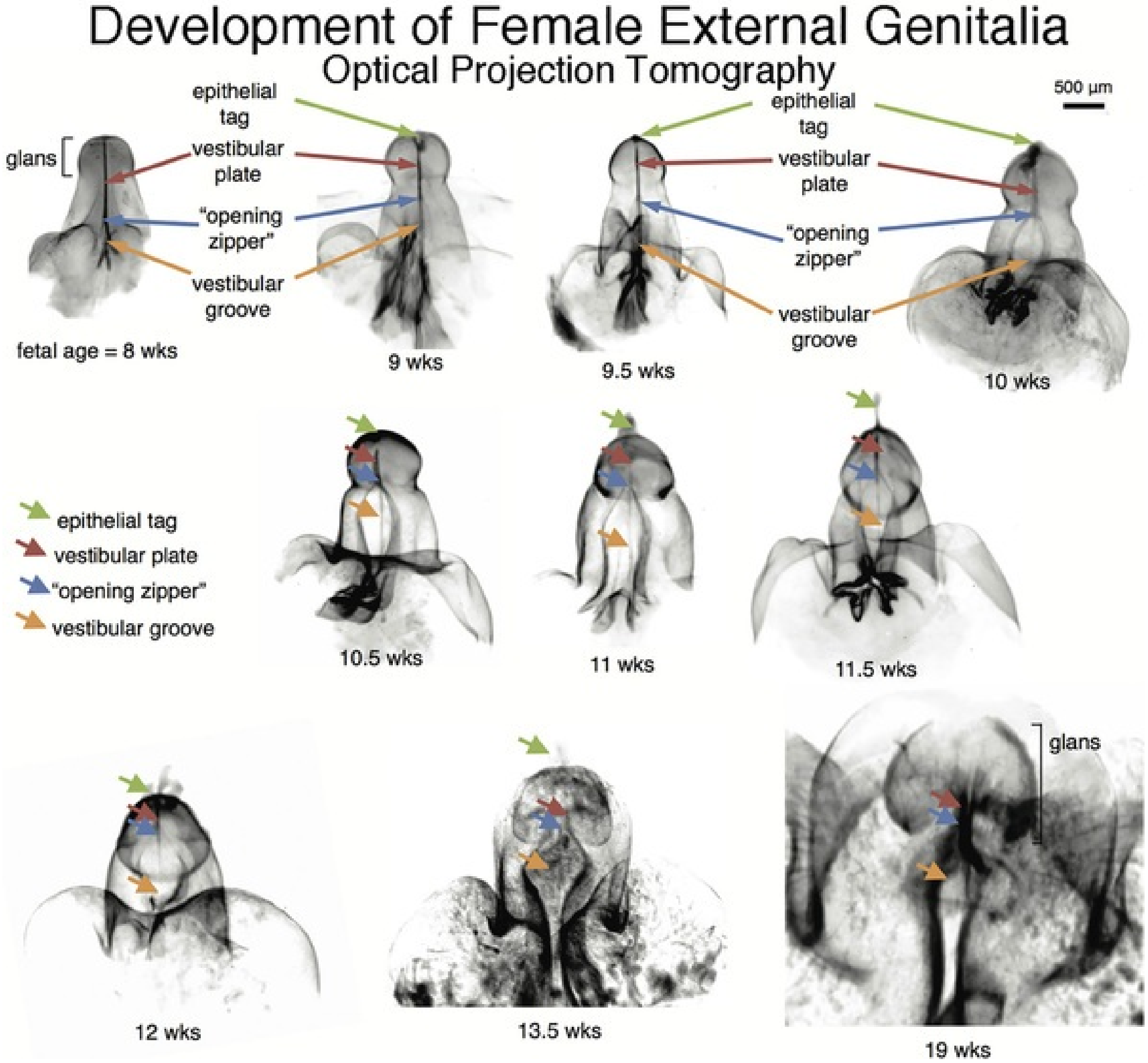
Development of Female External Genitalia
Optical Projection Tomography
500 µm
glans
epithelial tag
vestibular plate
"opening zipper"
vestibular groove
fetal age = 8 wks
9 wks
9.5 wks
epithelial tag
vestibular plate
"opening zipper"
vestibular groove
10 wks
epithelial tag
vestibular plate
"opening zipper"
vestibular groove
10.5 wks
11 wks
11.5 wks
12 wks
13.5 wks
glans
19 wks

FIG. 20.12 Optical projection tomography showing fetal ontogeny of human clitoris from 8 to 19 weeks' gestation. Note the opening zipper, which facilitates vestibular plate opening to form the vestibular groove, and lack of a closing zipper with the vestibular groove remaining open.

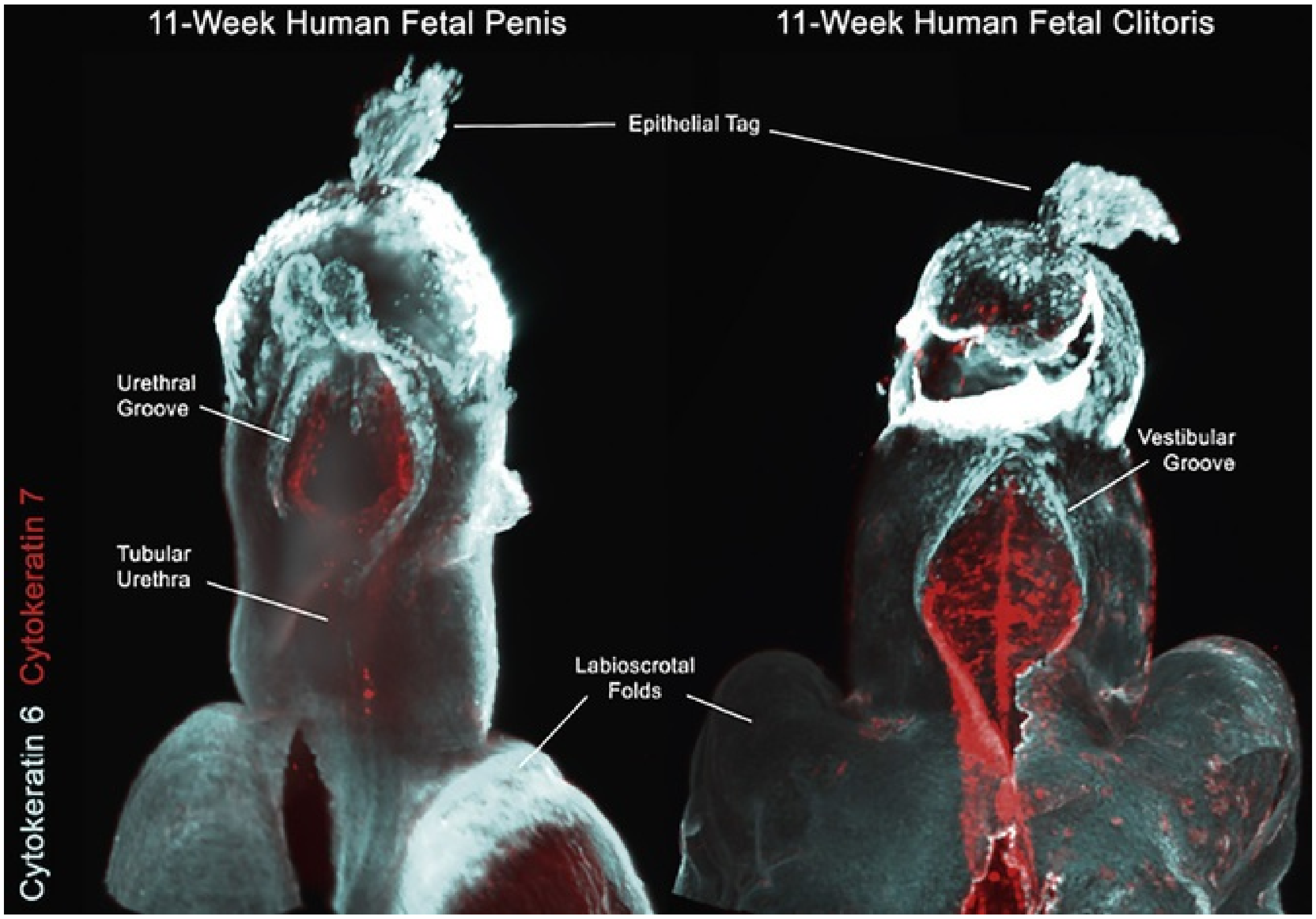
11-Week Human Fetal Penis
11-Week Human Fetal Clitoris
Epithelial Tag
Urethral Groove
Vestibular Groove
Tubular Urethra
Labioscrotal Folds
Cytokeratin 6 Cytokeratin 7

FIG. 20.13 Lightsheet fluorescence microscopy images of an 11-week human fetal penis *(left)* and clitoris *(right).* Cytokeratin 6 *(blue)* is expressed in the urethral plate and epidermis, and Cytokeratin 7 *(red)* is expressed in urothelium and the dorsal aspect of the vestibular groove. Proximal to distal canalization of the male urethral plate and the female vestibular plate has produced an open urethral groove in the penis and an open vestibular groove in the clitoris *(opening zipper).* Proximal to distal fusion of the urethral folds has produced the tubular urethral in the shaft of the male specimen only *(closing zipper).* In the clitoris, fusion does not occur, resulting in the mature open vestibular groove. Note the epithelial tag on both specimens.

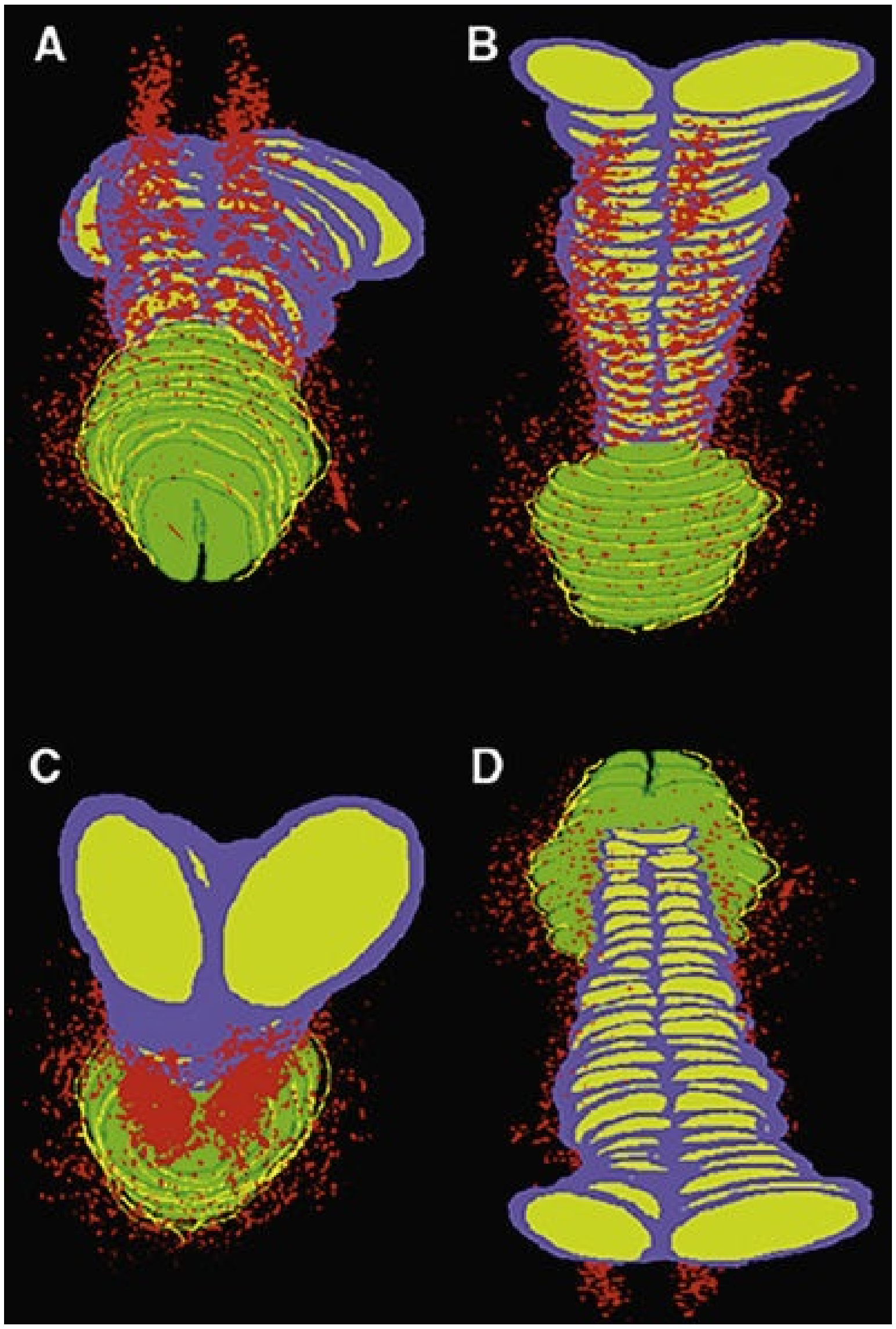

FIG. 20.14 Computer-generated three-dimensional reconstruction of normal human fetal clitoris at 24 weeks' gestation. *Red areas* represent nerve pathway with a paucity of nerves at the bottom and top midline of the clitoris. *Purple areas* represent a tunica of corporeal bodies. *Yellow areas* represent the interior of corporeal bodies. *Green areas* represent the glans clitoris. *Dark green and yellow areas* represent the clitoral hood. (A) Dorsal front view. (B) Dorsal back view. (C) Back ventral view. (D) Ventral view. (From Baskin LS, Erol A, Li YW, et al. Anatomical studies of the human clitoris. *J Urol.* 162(3 Pt 2);1999:1015–1020.)

Clinical Correlation: Congenital Adrenal Hyperplasia

Patients with congenital adrenal hyperplasia, an autosomal recessive disorder characterized by impaired cortisol synthesis, undergo varying degrees of virilization leading to genital atypia at birth (Auchus et al., 2010). These patients can be confused with patients with hypospadias (albeit with bilateral nonpalpable testis). Unlike normal female development, the vestibular groove undergoes varying degrees of closure forming a clitoral shaft urethra that is anatomically indistinguishable from a normal male urethra (Baskin, 2017). In the most severe cases, the clitoris looks exactly like a penis with a normal terminal urethral meatus, glans, and foreskin (Baskin, 2017). The only feature that distinguishes the male from the female is lack of palpable gonads (testes) and excess pigmentation.

Key Points: External Genitalia

- Androgens differentiate the ambisexual human genital tubercle at 7 to 8 weeks' gestation into the penis.
- The penile urethra is formed by an opening zipper (canalization of the urethral plate) followed by fusion of the urethral folds (closing zipper).
- The epithelium of the entire male urethra is of urogenital sinus origin.
- The clitoris forms in an analogous fashion to the penis except for lack of formation of the urethra within the clitoris.
- Anatomy of the hypospadiac penis is exactly like a normal penis except for abnormalities in development of the urethra, surrounding spongiosum, overlying skin, and a ventrally deficient prepuce.
- A nerve-free zone is present at the 12 o'clock position on the penile and clitoral tunica that is amendable to placement of dorsal plication sutures in mild to moderate degrees of curvature and other surgical procedures.

Development of the Human Prostate

The human prostate and seminal vesicles develop at the base of the bladder at 10 to 12 weeks' gestation (Fig. 20.15). Information on development of the human prostate is based on sparse literature on human fetal prostate coupled with extensive literature on prostatic development in laboratory animals in which detailed endocrinologic and mechanistic studies are possible. For example, the importance of androgens in prostatic development was originally determined through animal studies carried out by Alfred Jost (Jost, 1953) and Dorothy Price (Price and Ortiz, 1965) and then subsequently confirmed in humans (Wilson et al., 1981). Accordingly, in this review the contribution of animal studies to our understanding of human prostatic development will be noted.

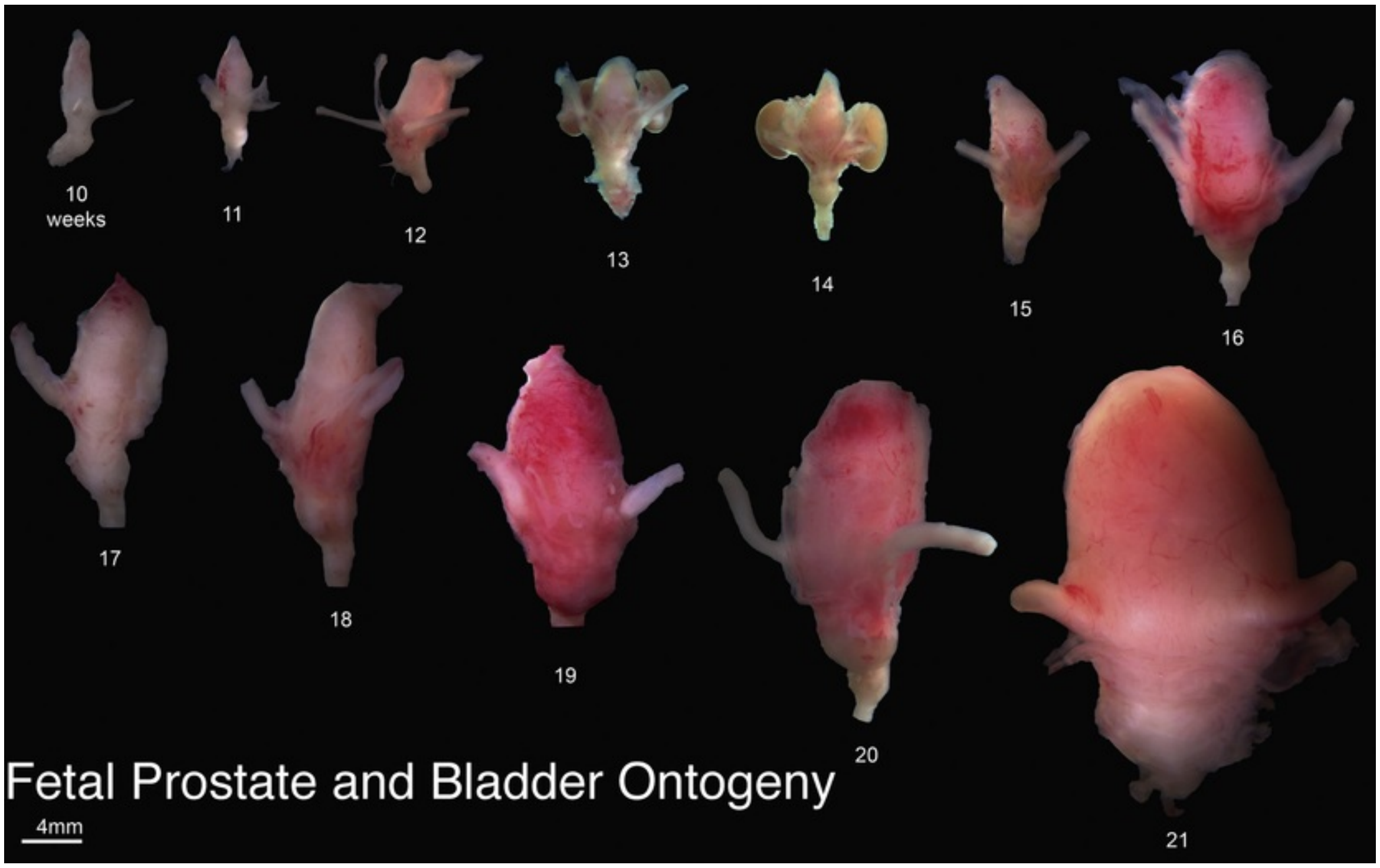

FIG. 20.15 Whole-mount photographs of human fetal bladder and prostate (10 to 21 weeks' gestation). Note the presence of the vas deferens medial to the ureters on the posterior aspect of the majority of specimens. The fetal testes and epididymis can be seen in the 13- and 14-week specimens. The fetal prostate is seen as a bulge of tissue just below the insertion of ureters and increases in size over time.

Human and mouse prostatic development can be subdivided into the following stages: (1) prebud UGS, (2) emergence of solid epithelial buds from urogenital sinus epithelium (UGE), (3) bud elongation and branching, (4) canalization of the solid epithelial “ducts,” (5) differentiation of luminal and basal epithelial cells, and (6) secretory cytodifferentiation. The human and mouse prostate develop below the urinary bladder (Fig. 20.16) from FOXA1-positive UGE. FOXA1 is a marker of the endodermal lineage (Besnard et al., 2004; Diez-Roux et al., 2011; Robboy et al., 2017). A unique feature of human prostatic development is formation of the verumontanum, a hillock elongated craniocaudally on the dorsal wall of the UGS (Fig. 20.17). The mesonephric (Wolffian) ducts and the fused Müllerian ducts (MDs; prostatic utricle) join the UGE on the apex of the verumontanum. **Thus, the verumontanum represents an interface between the mesodermal epithelia of the WDs and the prostatic utricle with endodermal UGE** (see Fig. 20.17).

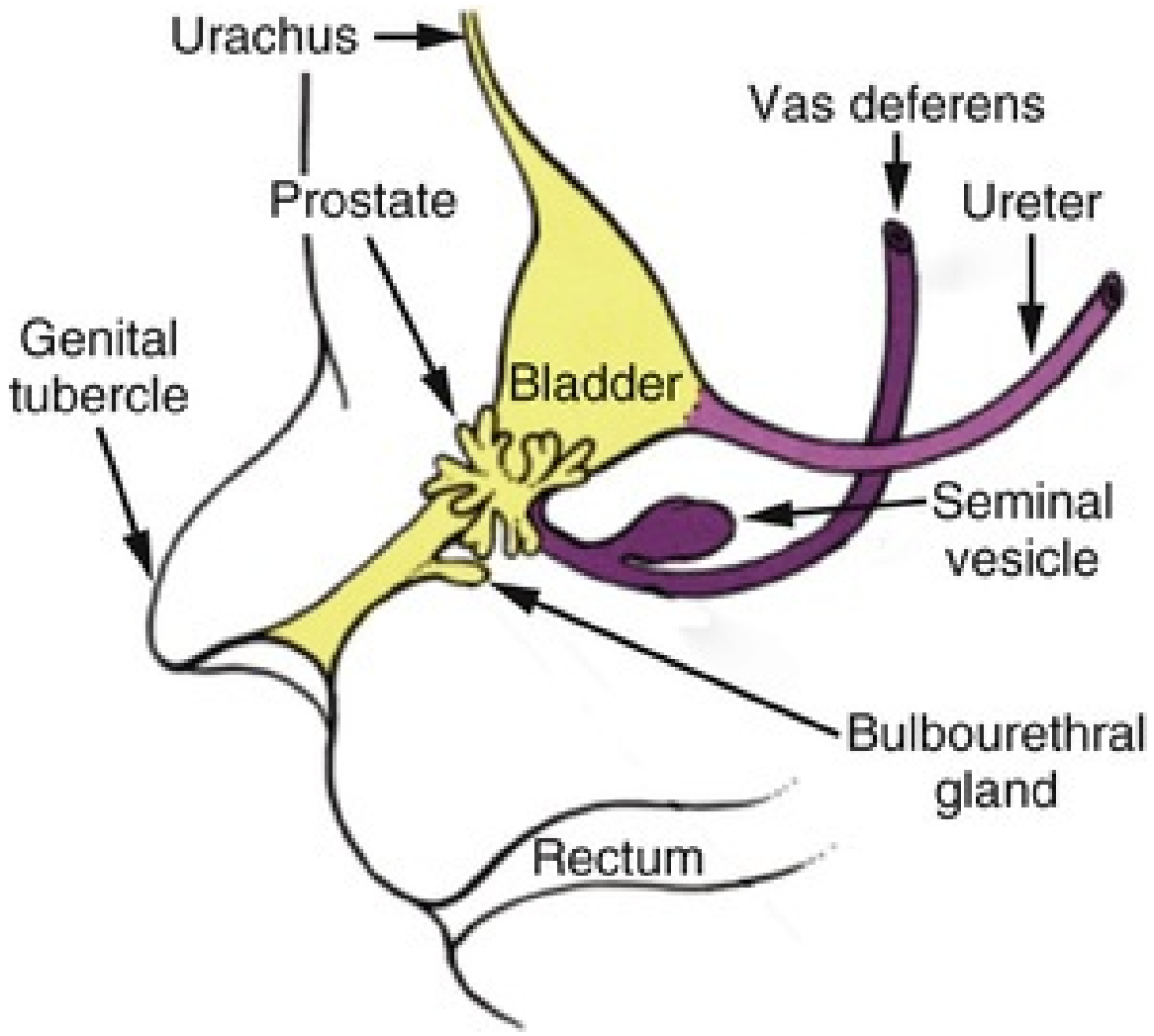

FIG. 20.16 Diagram of developing male urogenital organs. The bladder, urachus, prostate, urethra, and bulbourethral glands are derived from endodermal urogenital sinus epithelium *(yellow).* The ureter, vas deferens, and seminal vesicle are derived from the mesodermal mesonephric (Wolffian) ducts *(purple).* (Modified from Shen J, Cunha G, Sinclair A, et al. (2018). Macroscopic whole-mounts of the developing human fetal urogenital-genital tract: indifferent stage to male and female differentiation. *Differentiation*. pii: S0301-4681(18)30098-7. [Epub ahead of print].)

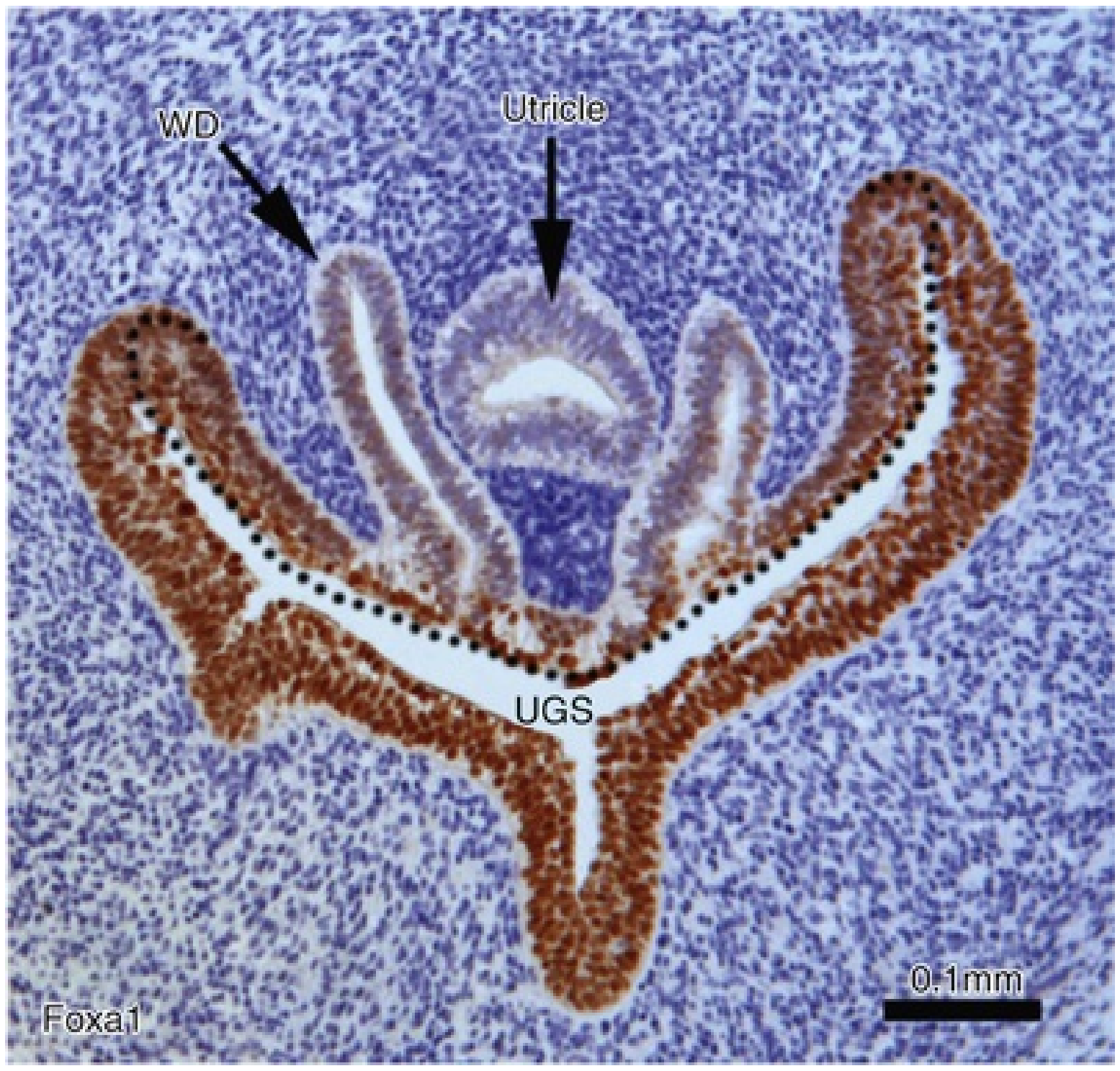

FIG. 20.17 Section of a prebud 9-week human fetal urogenital sinus *(UGS)* in the region of the verumontanum, a dorsal hillock projecting into the UGS *(dotted line).* The Wolffian ducts *(WDs)* flank the Müllerian-derived prostatic utricle, and both open into the UGS at/near the apex of the verumontanum. The section is immunostained for FOXA1, an endodermal marker.

The initial event in prostatic development is outgrowth of solid epithelial buds from the UGE into the surrounding mesenchyme during weeks 9 to 10. Because of the inherent difficulty of estimating specimen age, various investigators have reported initiation of human prostatic bud formation over a range of ages: 9.5 weeks (Dauge et al., 1986) to 10 weeks (Kellokumpu-Lehtonen et al., 1980; Zondek and Zondek, 1979). Most of the prostatic buds emerge from the UGE in the gutters, lateral to the verumontanum (Fig. 20.18). The craniocaudal extent of the verumontanum and the location of emergent prostatic buds are best appreciated through examination of the adult prostate gland (Fig. 20.19).

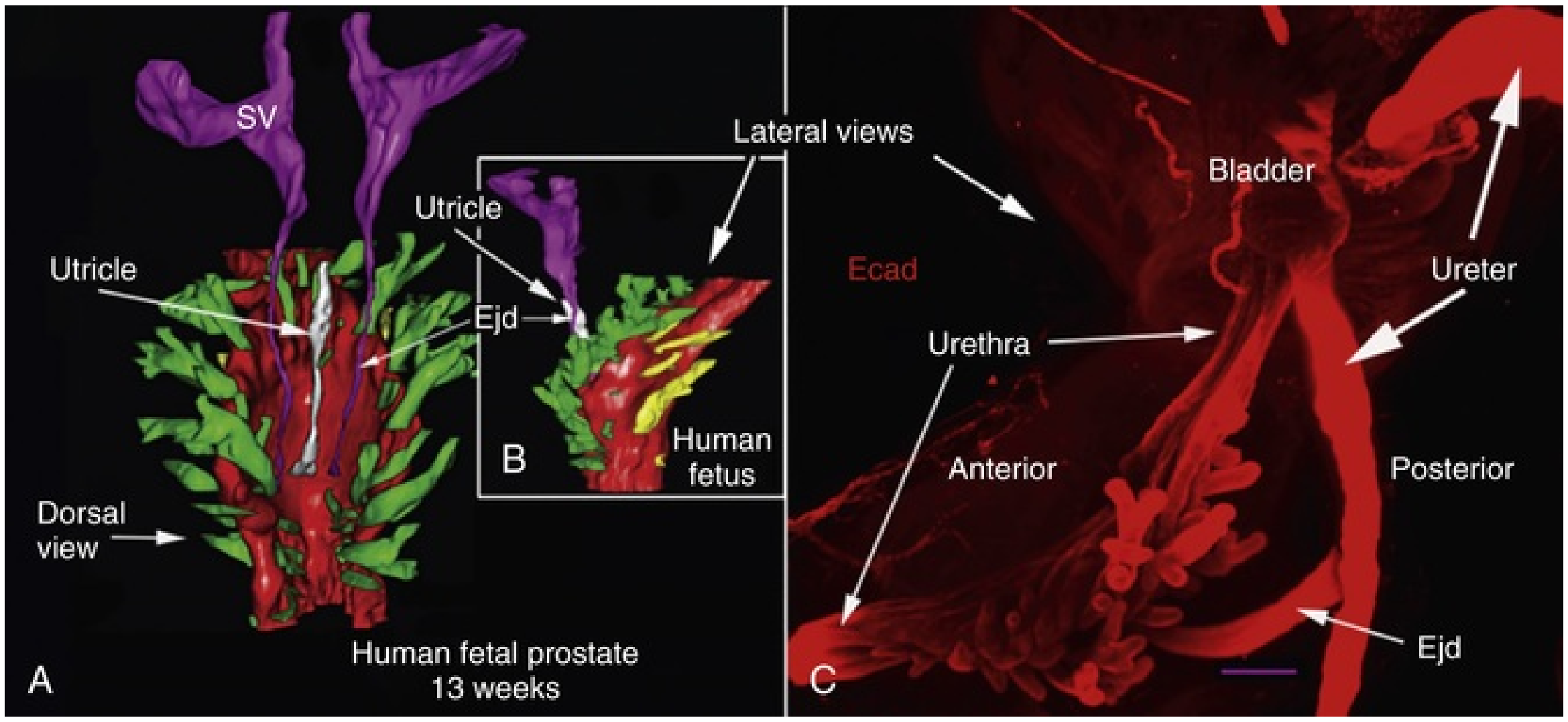
SV
Utricle
Utricle
Ejd
Lateral views
B
Human fetus
Dorsal view
A
Human fetal prostate 13 weeks
Ecad
Bladder
Ureter
Urethra
Anterior
Posterior
Ejd
C

FIG. 20.18 (A) Dorsal view of a 13-week male human fetal prostate showing the prostatic utricle *(white)* in the dorsal midline and prostatic ductal outgrowths *(green)* emerging from the lateral aspects of the verumontanum. (B) Lateral view of specimen (A). (C) Light sheetthree-dimensional reconstruction of a 12-week human fetal prostate in lateral view immunostained for E-cadherin *(red)* to display epithelium. Note that prostatic ducts have emerged from the posterior-lateral aspects of the urethra. *Ejd,* Ejaculatory duct. (A and B modified from Timms, 2008 and Timms and Hofkamp, 2011. From Cunha GR, Vezina CM, Isaacson D, et al. New insights in the development of the human prostate. *Differentiation*. 103:24–45, 2018.)

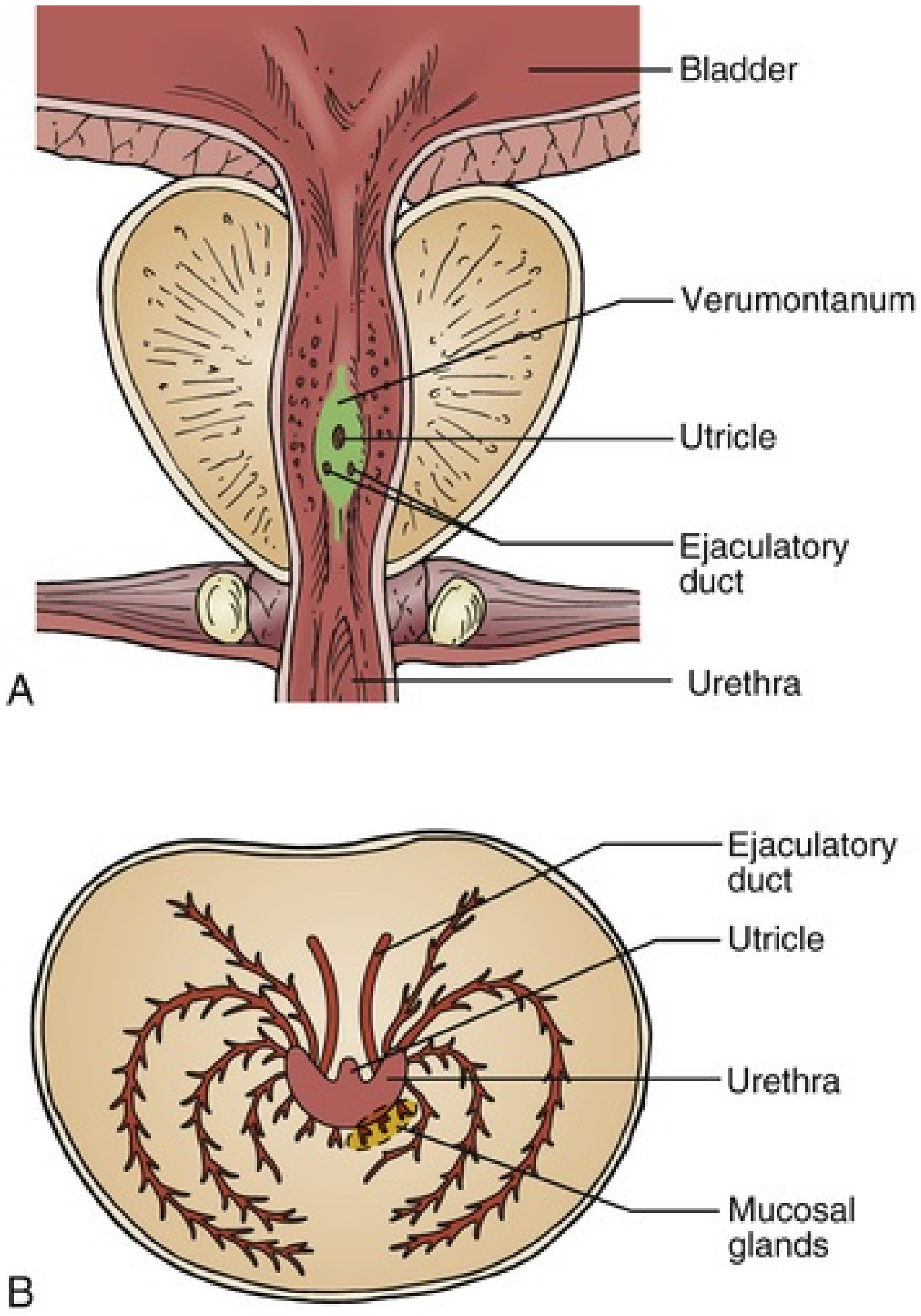

FIG. 20.19 Drawings of adult human prostate. (A) Anterior wall of the urethra has been removed to visualize the verumontanum *(green)* and the posterior and lateral walls of the prostatic urethra. Note the distribution of openings of the prostatic ducts in the "gutters" lateral to the verumontanum as described previously (Timms, 1997). (B) Drawing of a transverse section through the verumontanum of an adult human prostate showing the prostatic utricle and ejaculatory ducts joining the prostatic urethra. The prostatic ducts emerge from the urethra in the gutters lateral to the verumontanum. Mucosal glands emerge from the ventral aspect of the urethra. (From Cunha GR, Vezina CM, Isaacson D, et al. New insights in the development of the human prostate. *Differentiation* 103:24–45, 2018.)

Based on studies in mice, prostatic bud initiation is stochastic with cords of UGE cells emerging into the mesenchyme and receding throughout the budding process. This appears to also apply to human prostatic development as ventral prostatic buds reported in the human fetal prostate (Lowsley, 1912) are not represented in the adult prostate (McNeal, 1981). Prostatic bud growth and subsequent branching morphogenesis occur from approximately 11 weeks onward in a specific spatial pattern that eventually establishes the zonal subdivisions of the mature mouse, rat, and human prostate (Hayashi et al., 1991; Sugimura et al., 1986a; Timms, 2008; Timms and Hofkamp, 2011). The mouse and rat prostate are organized into anterior, lateral, dorsal, and ventral lobes, and ductal branching patterns differ greatly among lobes (Hayashi et al., 1991, Sugimura et al., 1986a). One manifestation of differences in ductal branching patterns is the distance from the prostatic urethra to the first ductal branch point. In the rat and mouse prostate, this distance is short for the ventral prostate and many-fold longer for the dorsal and lateral prostates (Hayashi et al., 1991; Sugimura et al., 1986a). We suspect that this is also true for the human prostate. Measurements from serial sections of the distance from the human fetal prostatic urethra to the first branch point is short in some areas (~250 µm; see Fig. 21.19A). Thick (0.5-mm) coronal sections of human fetal prostate reveal ducts with an initial branch point approximately 1000 µm from their origin from the urethra (see Fig. 21.19B; Cunha et al., 2018a). This approximately fourfold difference in ductal length to the first branch point is consistent with the idea that ductal branching patterns in the human prostate may be lobe specific, as is the case for mice and rats.

The solid prostatic "ducts" subsequently canalize from their proximal urethral connections, distally toward the ductal tips. "Ductal" canalization is associated with the differentiation of luminal and basal cells each expressing its unique profile of differentiation markers (Table 20.1) (Wang et al., 2001). The prebud UGE and "solid prostatic ducts" (before canalization) coexpress markers characteristic of both luminal and basal epithelial cells (see Table 20.1). Accordingly, it appears that epithelial cells destined to become luminal cells maintain luminal cell markers while losing basal cell markers, and epithelial cells destined to become basal cells preserve basal cell markers while losing luminal cell markers (Wang et al., 2001; see Table 20.1).

TABLE 20.1

Marker Expression Profiles in Urogenital Sinus Epithelium, Solid "Ducts," and Adult Human Prostate

MARKERS	PREBUD UGE	SOLID "DUCTS"	ADULT LUMINAL CELLS	ADULT BASAL CELLS
TP63	+	+	–	+
KRT5	+	+	–	+
KRT8	+	+	+	–
KRT14	+	+	–	+

KRT18	+	+	+	–
KRT19	+	+	–	+
GSTpi	+	+	–	+

UGE, Urogenital sinus epithelium.

Modified from Wang Y, Hayward S, Cao M, et al. Cell differentiation lineage in the prostate. *Differentiation.* 2001;68(4–5):270–279.

While prostatic ducts are elongating and undergoing branching, prostatic mesenchyme (UGM) differentiates into smooth muscle, and eventually adult prostatic stroma is mostly composed of smooth muscle (McNeal, 1983). Differentiation of UGM into smooth muscle occurs initially in ventral UGM, with smooth muscle differentiation subsequently spreading into lateral and dorsal areas (Fig. 20.20). It is perhaps worth noting that at 19 weeks ductal branching is most intense near the prostatic capsule, where smooth muscle is particularly abundant (Fig. 20.21; Cunha, et al., 2018b). Does this mean that prostatic smooth muscle plays a role in ductal branching morphogenesis?

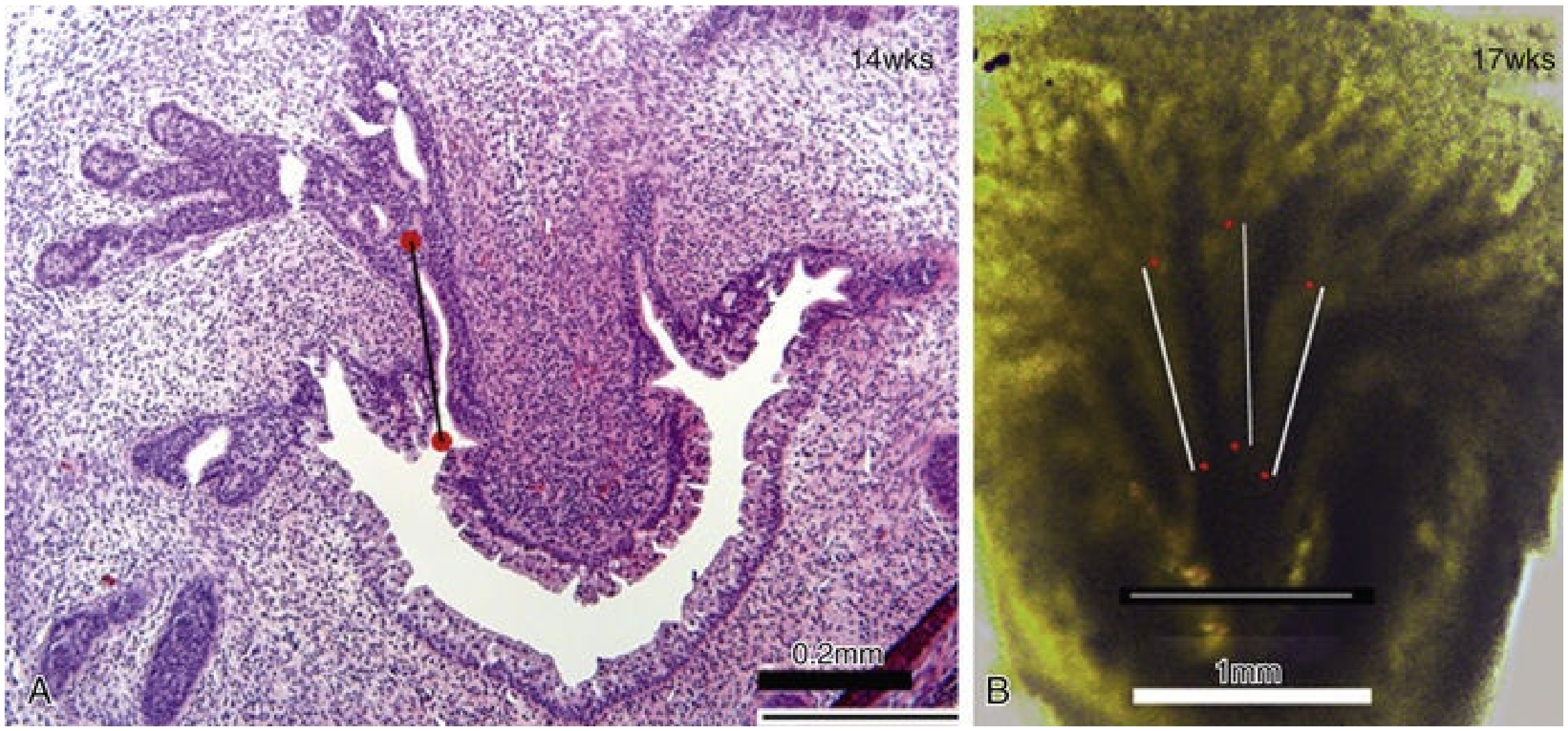

FIG. 20.20 (A) Section of human fetal prostate at 14 weeks' gestation. The *red dots* indicate the proximal origin of a prostatic duct from the urethra and the first branch point, respectively. The distance between these two points is approximately 250 µm. (B) Thick (0.5 mm) coronal section of a 17-week human fetal prostate photographed with transmitted light. *Red dots* are placed on three prostatic ducts depicting ductal length to the first branch point. In all three cases, the distance is approximately 1000 µm. The *thin white line* in (B) representing one of the three white lines above is approximately 1000 µm. (From Cunha GR, Vezina CM, Isaacson D, et al. New insights in the development of the human prostate. *Differentiation* 103:24–45, 2018.)

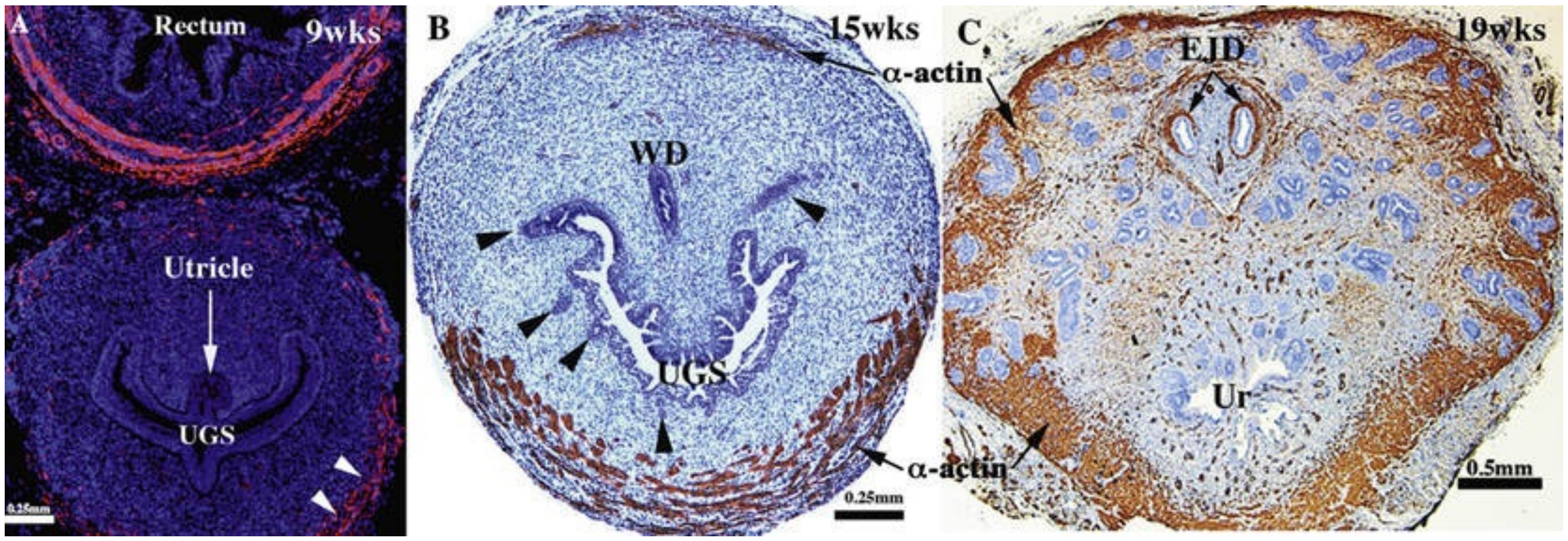

FIG. 20.21 Transverse sections of developing human prostate immunostained for smooth muscle α-actin. (A) Section through the verumontanum of a 9-week prebud UGS in which sparse α-actin–positive cells *(white arrowheads)* are seen in ventrolateral UGM. In contrast, α-actin–positive cells are abundant in the wall of the rectum. (B) Section of a human fetal prostate exhibiting smooth muscle bundles in ventral UGM at 15 weeks' gestation, with minimal α-actin positivity in the dorsal position. (C) Section of a human fetal prostate at 19 weeks' gestation showing α-actin–positive smooth muscle around the periphery, where solid "ducts" are branching. *EJD,* Ejaculatory ducts; *UGS,* urogenital sinus; *Ur,* urethra; *WD,* Wolffian duct.

The endocrinology of prostatic development emerged initially from animal studies (Jost, 1953; Price and Ortiz, 1965). **Androgens produced by fetal testes play a critical role in development of the prostate.** Morphogenetic/differentiation responses to androgens are mediated by nuclear androgen receptors (ARs) that are activated by either testosterone or DHT. The requirement of androgens in prostatic development comes primarily from the absence of prostate in mice and humans lacking functional ARs (Wilson et al., 1983) and from the development of the prostate in the female UGS exposed to androgens (Cunha, 1975). Although testosterone can activate ARs in the UGS by directly binding to the AR, the more potent androgen, DHT, plays a critical role in prostatic development. DHT is produced within the developing UGS by 5α-reductase 2 (5αR2; Russell et al., 1993; Russell and Wilson, 1994). DHT has a 10-fold greater affinity for the AR than testosterone (Deslypere et al., 1992). 5αR2 plays an important role in prostate and male external genitalia development (Andersson et al., 1991; Russell and Wilson, 1994) insofar as prostates of patients with 5αR2 deficiency are rudimentary (Imperato-McGinley and Zhu, 2002; Radmayr et al., 2008). Likewise, transgenic mice lacking steroid

5αR1 and 5αR2 have smaller prostates and seminal vesicles than controls (Mahendroo et al., 2001). 5αR2 is predominantly expressed in prostatic mesenchyme (Radmayr et al., 2008). The function of 5αR1 in urogenital development remains unclear as cloning and genetic studies demonstrate that the *5αR1* gene is normal in patients with 5αR2 deficiency (Andersson et al., 1991).

Mesenchymal-epithelial interactions play a fundamental role in development of the prostate, even though the overall developmental process is elicited by androgens via the AR. Under the influence of androgens, UGM induces and specifies prostatic development in the epithelium. Indeed, UGM can instructively induce prostatic development in embryonic and adult bladder epithelium of rodent and human origin (Aboseif et al., 1999; Cunha et al., 1980, 1983). Mesenchymal-epithelial interactions in the developing prostate are reciprocal. The presence of prostate epithelium plays a critical role in the differentiation of UGS mesenchyme into the periductal prostatic smooth muscle cells (Cunha et al., 1992; Hayward et al., 1998).

The role of mesenchymal versus epithelial AR in prostatic development was determined through use of tissue recombinants prepared with epithelium and mesenchyme from wild-type and AR-negative testicular feminization (Tfm) mice (wt-UGM+Tfm-UGE; Cunha and Lung, 1978). Analysis of chimeric prostates composed of AR-positive wild-type mesenchyme plus Tfm epithelium has demonstrated that AR-deficient Tfm epithelium (UGE or bladder epithelium) can undergo androgen-dependent ductal morphogenesis, epithelial proliferation, and columnar cytodifferentiation (Cunha and Lung, 1978; Shannon and Cunha, 1984; Sugimura et al., 1986b). The fact that mesenchymal (but not epithelial) ARs are required for prostatic ductal growth, branching, and columnar cytodifferentiation suggests that paracrine signals from UGM mediate the action of androgens on the epithelium. However, it is notable that in wt-UGM+Tfm bladder epithelium tissue recombinants, the AR-negative Tfm epithelium failed to express prostatic secretory proteins (Donjacour and Cunha, 1993). Therefore, ductal growth and branching morphogenesis is dependent on paracrine signals from AR-positive mesenchyme, and expression of secretory proteins requires epithelial AR.

Prostate development/differentiation is adversely affected by estrogenic compounds (Prins et al., 2006; Risbridger et al., 2001a; Timms et al., 2005; vom Saal et al., 1997). One acute effect of exogenous estrogen on prostatic development is squamous metaplasia, which is elicited by diethylstilbestrol (DES) in wild-type mice and estrogen receptor beta (ESR2) knockout mice, but not in estrogen receptor alpha (ESR1) null mice (Risbridger et al., 2001b), suggesting that prostatic squamous metaplasia is elicited via ESR1. The roles of epithelial (E) versus stromal (S) ESR1 in DES-induced prostatic squamous metaplasia were assessed as indicated in Table 20.2. Prostatic epithelial squamous metaplasia only occurred in wt-S+wt-E tissue recombinants. Thus, prostatic squamous metaplasia requires ESR1 simultaneously in both the epithelium and stroma.

TABLE 20.2

Squamous Metaplasia in Tissue Recombinants Composed of Wild-Type (Wt) and ESR1-Null Prostatic Epithelium and Mesenchyme

MESENCHYME	EPITHELIUM	SQUAMOUS METAPLASIA
Wt	Wt	+
Wt	ESR1 null	–
ESR1 null	Wt	–
ESR1 null	ESR1 null	–

Several candidate genes have been implicated in prostatic development. Stimulation of prostatic ductal growth and branching has been attributed to a variety of growth factors and growth factor regulators. Fibroblast growth factor-7 (FGF7 and FGF10, both of which play an important role in prostatic development, are produced by UGM and signal through receptors in developing prostatic epithelium (FGFR2-IIIb) to stimulate growth and branching of prostatic ducts (Donjacour et al., 2003; Finch et al., 1995, Sugimura et al., 1996; Thomson and Cunha, 1999). Activin-A and its antagonist, follistatin, also play a role in regulating prostate epithelial development (Cancilla et al., 2001; Risbridger and Cancilla, 2000). In vitro studies showed that activin-A inhibits prostatic ductal branching and growth, and follistatin increases ductal branching (Cancilla et al., 2001). Thus, prostatic ductal growth and branching may result from a balanced interplay between activin-A and its antagonist follistatin. Other TGFβ family members, bone morphogenetic proteins 4 and 7 (BMP4 and BMP7), restrict ductal branching in developing prostate (Grishina et al., 2005; Lamm et al., 2001). Another growth factor implicated in prostatic development is insulin-like growth factor-1 (Ruan and Kleinberg, 1999; Ruan et al., 1999).

The homeobox gene, *Nkx3.1*, is one of the earliest markers of developing and adult prostatic epithelium in mice (Bhatia-Gaur et al., 1999; Tanaka et al., 2000) and in adult human prostate (Ornstein et al., 2001). Hox homeobox genes are also involved in differentiation of male accessory sex glands (Podlasek et al., 1997, 1999). Hoxa-13 and Hoxd-13 are expressed in the embryonic UGS, and loss of function of these genes in mice results in bulbourethral gland agenesis and defective prostate and seminal vesicle development (Podlasek et al., 1997, 1999). p63 is a marker expressed in embryonic UGE and later in prostatic basal cells and is required for normal prostatic development and postnatal response to androgen deprivation and androgen replacement (Kurita et al., 2004; Signoretti et al., 2000). Fucosyltransferase-1 has also been implicated in prostatic development. A fucosyltransferase-1–binding monoclonal antibody defines a unique expression pattern in the developing prostate and inhibits growth and ductal branching in explants of neonate rat prostate (Marker et al., 2001). In the prebud stage in mice, androgens stimulate bands of *Edar, Nkx3-1,* and *Wnt10b* mRNAs to appear in anterior, ventral, and dorsolateral prostatic budding zones. These mRNAs are later focally restricted during bud initiation and elongation to nascent prostatic bud tips (Bieberich et al., 1996; Keil et al., 2014a; Sciavolino et al., 1997). In response to androgens, selected buds are stabilized as a result of activating WNT beta-catenin, which subsequently permits elongation of buds within prostatic budding zones while inhibiting buds elsewhere (Allgeier et al., 2010; Mehta et al., 2013). DNA methylation status of E-cadherin plays an important role in prostatic bud elongation. DNA methylation of the E-cadherin promoter during the prebud stage and continuing through bud initiation reduces E-cadherin transcription and increases bud epithelial cell motility (Keil et al., 2014b).

Development of the Human Seminal Vesicle

Development of the human seminal vesicle is so sparsely represented in the literature that a PubMed search on “seminal vesicle, human and development” reveals only two papers. Aumuller and Riva (1992) is the most informative literature. Human seminal vesicle appears as a diverticulum of the WD at about the 10th to the 12th week of gestation. The diverticulum elongates and folds back on itself, thus forming a “hooklike duct” with extensive “side ducts forming during months 4 to 5 of pregnancy” (Aumuller and Riva, 1992). Autonomic innervation of the human fetal seminal vesicles was initially detected by immunohistochemistry in the muscle coat of fetal seminal vesicles at 13 weeks’ gestation (Jen et al., 1995). Malformation and malignancy of human seminal vesicles are extremely rare and include rare cases of seminal vesicle cyst.

Key Points: Prostate Development

- Androgens produced by fetal testes play a critical role in development of the prostate.
- Mesenchymal-epithelial interactions play a fundamental role in development of the prostate, even though the overall developmental process is elicited by androgens via the AR.

Development of the Gonads

The gonads differentiate into testes or ovaries and ultimately produce sperm or oocytes, respectively. They develop in a bilateral pair of longitudinal ridges (gonadal ridges) composed of coelomic epithelium and underlying condensed mesenchyme. During the third week of gestation, primordial germ cells arise in the yolk sac and migrate from along the dorsal mesentery to populate the gonadal ridges located in the lower thoracic and upper lumbar levels (Fig. 20.22). **If primordial germ cells fail to reach the gonadal ridges, the gonads fail to develop.** During the sixth week of gestation, the surface epithelial cells of the genital ridge invade the mesenchyme of the gonadal ridges to form the primitive sex cords. The elongated indifferent gonads within the genital ridge at 7 to 8 weeks are macroscopically indistinguishable in males and females (Fig. 20.23). In the course of development, the testes will become more spherical in shape, and the ovaries will remain oblong. Morphometrics analysis shows that the length of the developing ovary is greater than that of the testis (Shen et al., 2018a).

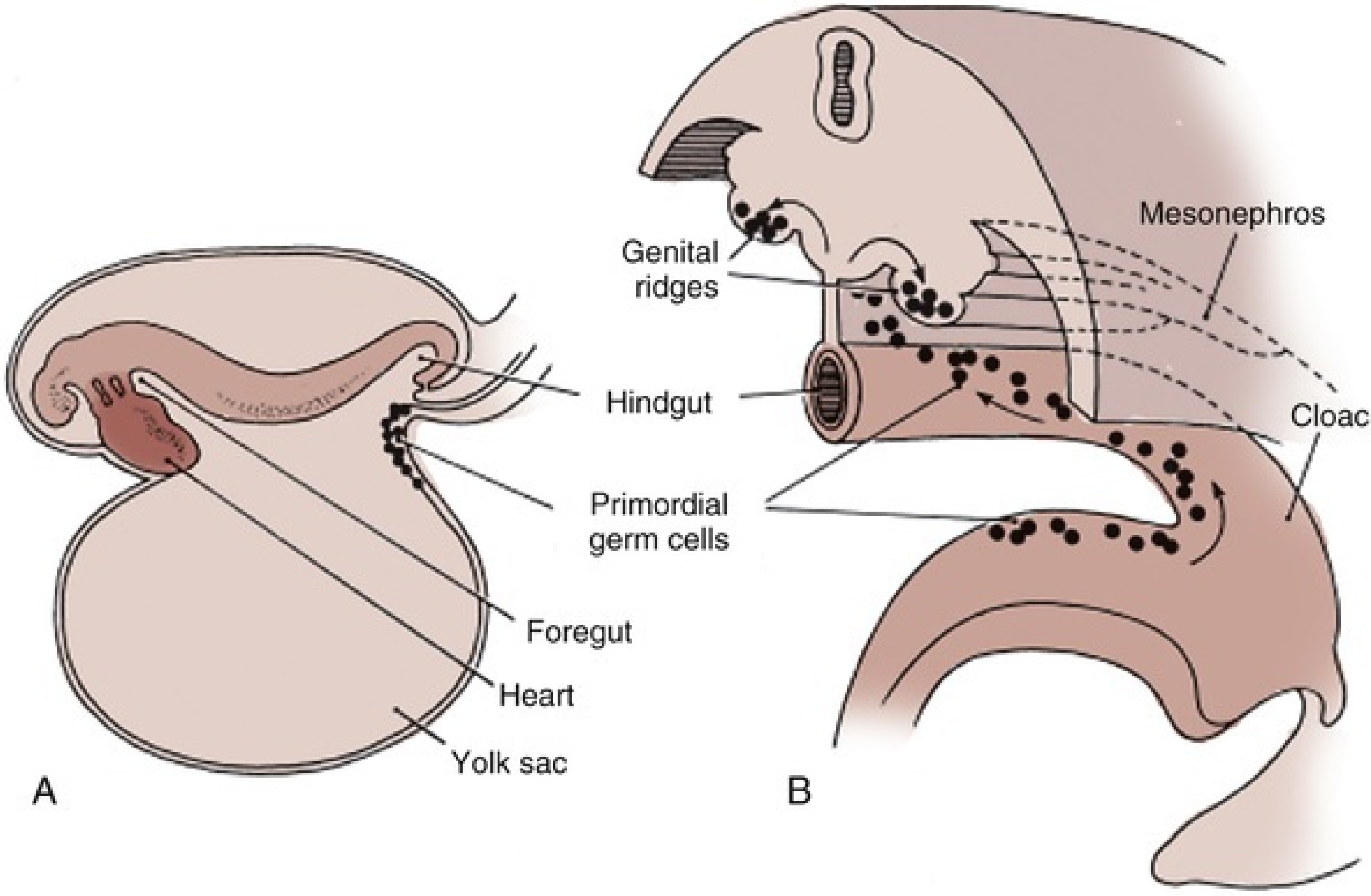

FIG. 20.22 (A) Site of the primordial germ cell origin in the wall of the yolk

sac in a 3-week-old embryo. (B) Migratory path of the primordial germ cells along the wall of the yolk sac and dorsal mesentery into the developing genital ridges. (Modified from Sadler TW. *Langman's medical embryology.* Baltimore, MD: Williams & Wilkins; 1985.)

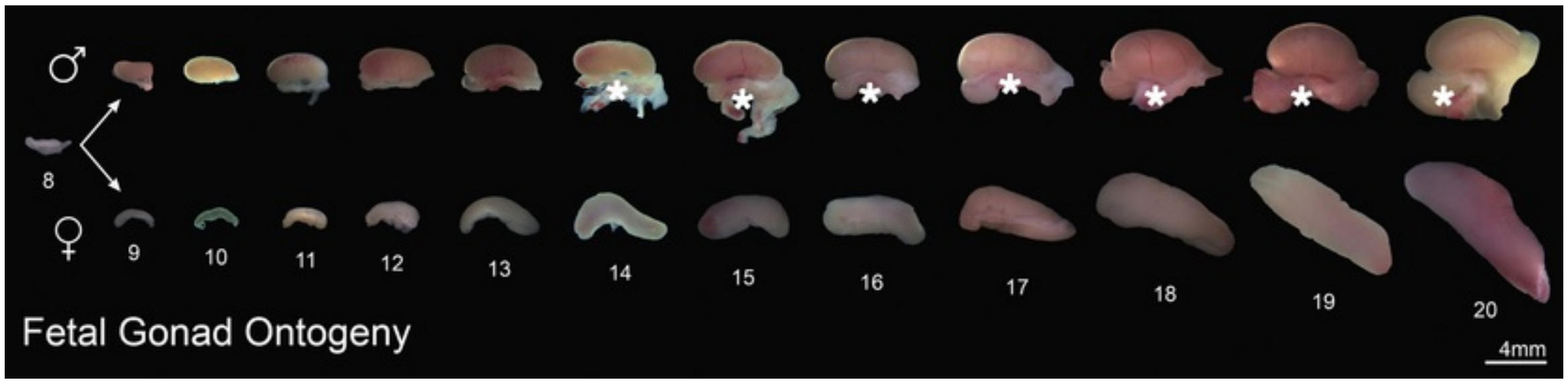

FIG. 20.23 Whole-mount photographs of human fetal gonadal ontogeny. Testis ontogeny *(top row)* and ovarian ontogeny *(bottom row)* are shown. The testis have a more spherical shape in contrast with the oblong shape of the ovaries. Note the epididymal attachments in many testis specimens.

Testicular Formation

Under the influence of SRY gene products, cells in the medullary region will form testicular epithelial cords in which Sertoli cells differentiate in association with primordial germ cells that migrate into these cords (Fig. 20.24; Larney et al., 2014). Sertoli cell differentiation only occurs if SRY protein is present; otherwise the sex cords will form ovarian follicles. These primitive testicular cords containing germ cells eventually will canalize and differentiate into seminiferous tubules in which sperm production will occur. Direct cell-to-cell contact between developing Sertoli cells and primordial germ cells is thought to play a key role in the proper development of male gametes. This interaction occurs shortly after the arrival of the primordial germ cells in the presumptive genital ridge. The testicular cords distal to the presumptive seminiferous tubules also develop lumen and differentiate into a set of thin-walled ducts called the *rete testis*. Just medial to the developing gonad, the tubules of rete testis connect with 5 to 12 residual mesonephric tubules that will form the efferent ductules that will convey sperm to the head of the epididymis. The epididymis and the vas deferens develop from the Wolffian (mesonephric) duct. During the course of development, the shape of the testis changes from oblong to relatively round, reducing its area of contact with the surrounding mesonephros (see Fig. 20.23).

As the testis continues to develop, the *tunica albuginea,* a thick connective tissue capsule subadjacent to its mesothelial surface, lines the testis.

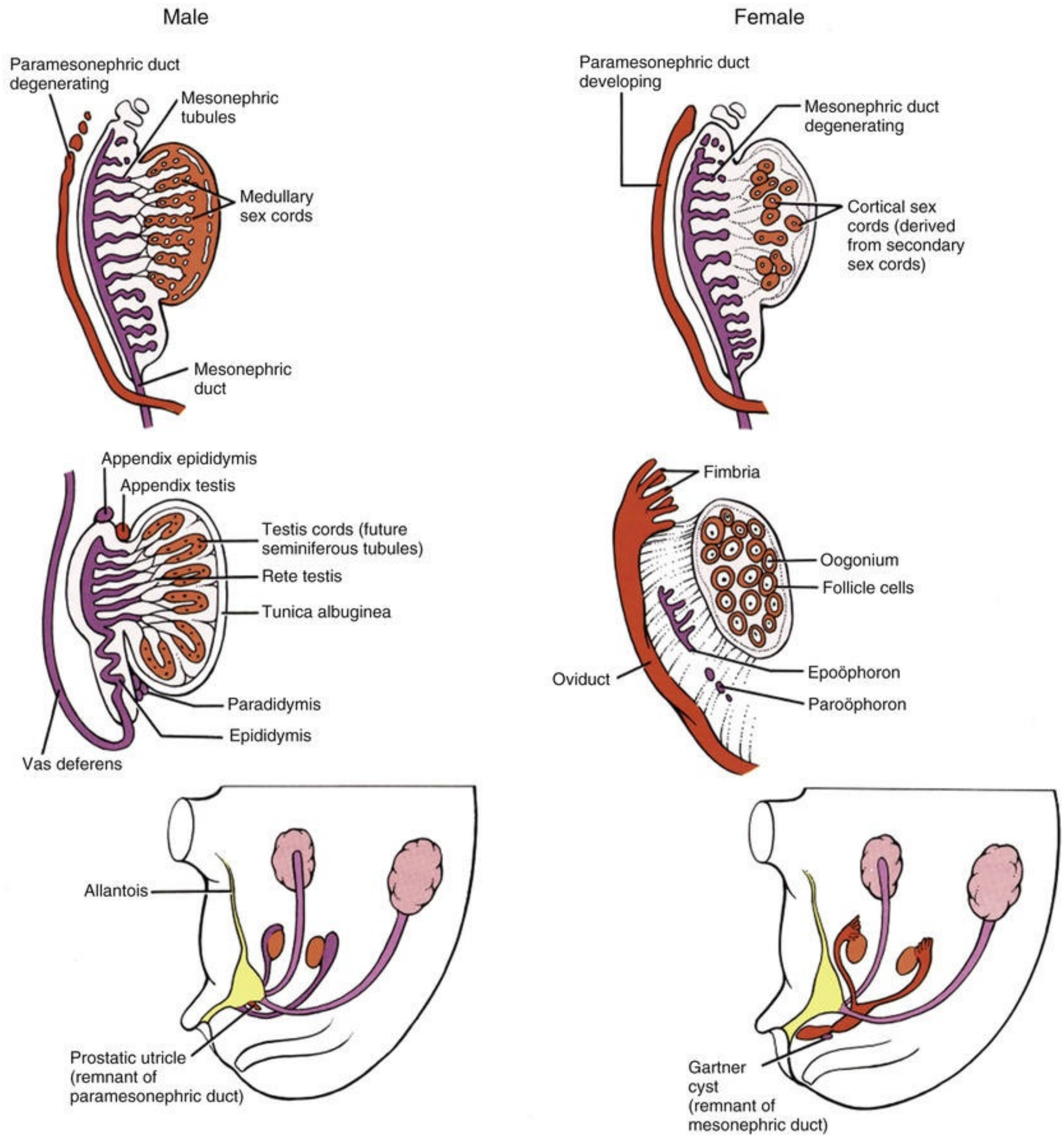
Male
Paramesonephric duct degenerating
Mesonephric tubules
Medullary sex cords
Mesonephric duct
Female
Paramesonephric duct developing
Mesonephric duct degenerating
Cortical sex cords (derived from secondary sex cords)
Appendix epididymis
Appendix testis
Testis cords (future seminiferous tubules)
Rete testis
Tunica albuginea
Paradidymis
Epididymis
Vas deferens
Fimbria
Oogonium
Follicle cells
Oviduct
Epoöphoron
Paroöphoron
Allantois
Prostatic utricle (remnant of paramesonephric duct)
Gartner cyst (remnant of mesonephric duct)

FIG. 20.24 Male and female gonad and genital development. The male and female genital structures are virtually identical through the seventh week. In males, SRY protein produced by the Sertoli cells causes the medullary sex cords to become presumptive seminiferous tubules and causes the cortical sex cords to regress. Müllerian-inhibiting substance (MIS), a glycoprotein hormone produced by the Sertoli cells, then causes the paramesonephric ducts to regress, leaving behind appendix testis and prostatic utricle as remnants. Appendix epididymis and paradidymis arise

from the mesonephric ducts. In females, cortical sex cords invest the primordial germ cells and become the ovarian follicles. In the absence of MIS, the mesonephric ducts degenerate and the paramesonephric ducts give rise to the fallopian tubes, uterus, and upper vagina. The remnants of the mesonephric ducts are found in the ovarian mesentery as the epoöphoron and paroöphoron, and in the anterolateral vaginal wall as the Gartner duct cysts. (Modified from Larsen WJ. *Human embryology.* New York, NY: Churchill Livingstone; 1997.)

As the developing Sertoli cells begin their differentiation in response to the SRY protein, they also begin to secrete a glycoprotein hormone called *Müllerian-inhibiting substance* (MIS; Behringer et al., 1994). **MIS causes the paramesonephric (Müllerian) ducts to regress rapidly between the 8th and 10th weeks of gestation.** Small MD remnants can be detected in males as a small epithelial cysts at the superior pole of the testis, called the *appendix testis.* The prostatic utricle is a small pouching opening on the apex of the verumontanum in the prostatic urethra and is also an MD remnant. In female embryos, MIS is absent; therefore the MDs do not regress and instead form most of the female internal genitalia. **Table 20.3 summarizes the embryologic origin of urogenital structures.**

TABLE 20.3

Embryologic Origin of Urogenital Structures

MALE	EMBRYONIC STRUCTURE	FEMALE
Testis Seminiferous tubules Rete testis (an anastomosing network of delicate tubules located in the hilum of the testicle [mediastinum testis])	Indifferent gonad Cortex Medulla	Ovary Ovarian follicles Rete ovarii (Hilus in which nerves and blood vessels enter the ovary (analogous to rete testis)
Gubernaculum testis (testicular descent into scrotum)	Gubernaculum	Ovarian ligament (descend and support ovary) Round ligament of uterus (support uterus in pelvis)
Efferent ductules of testis	Mesonephric tubules	Epoöphroon

Paradidymis (a small group of vestigial tubules located above the epididymis)	(mesonephros [second kidney])	Paroöphoron (both nonfunctional structures located between the ovary and fallopian tube)
Appendix of epididymis Ductus deferens Ejaculatory duct and seminal vesicle Ureter, pelvis, calices, and collecting tubules	Wolffian duct (mesonephric duct) Stalk of ureteric bud (Wolffian)	Gartner duct (anterior superior vaginal wall) Ureter, pelvis, calices, and collecting tubules
Kidney (metanephros) Nephrons (consists of the glomerulus, proximal tubule, loop of Henle, and distal tubule)	Intermediate mesoderm (metanephric blastema/mesenchyme)	Kidney (metanephros) Nephrons (consists of the glomerulus, proximal tubule, loop of Henle, and distal tubule)
Appendix of testis	Müllerian duct (paramesonephric duct)	Paratubal cyst (benign paraovarion cyst) Uterine tube (fallopian tube) Uterus Cervix
Bladder and trigone Urethra Prostate Verumontanum (seminal colliculus) Prostatic utricle Urethral (Peri) glands (Littre glands) Bulbourethral glands (Cowper's glands)	Urogenital sinus	Bladder and trigone Urethra Vagina, hymen Urethral glands (Skene's glands [lesser vestibular glands]) Urethral glands Greater vestibular glands (Bartholin glands)
Penis Glans penis Corpora cavernosa of penis Corpus spongiosum of penis	Genital tubercle	Clitoris Glans clitoris Corpora cavernosa of clitoris Bulb of vestibule (clitoral bulbs)
Ventral aspect of penis	Urethral folds/vestibular folds	Labia minora
Scrotum	Labia scrotal swellings	Labia majora

During the 9th and 10th weeks, Leydig cells differentiate from mesenchymal cells of the genital ridge in response to the SRY protein (Turner et al., 1995).

These endocrine cells produce testosterone. At an early stage of development, testosterone secretion is regulated by placental chorionic gonadotropin, but eventually fetal pituitary gonadotropins assume control of androgen production. **Between the 8th and 12th weeks, testosterone secretion by Leydig cells stimulates the mesonephric (Wolffian) ducts to transform into the paired epididymis, vas deferens, and seminal vesicle.** The cranial portions of the mesonephric ducts degenerate, leaving a small cystic remnant called the *appendix epididymis.* During the ninth week, five to twelve mesonephric tubules in the region of the epididymis make contact with the developing rete testis. It is not until the third month, however, that communication is established among the developing seminiferous tubules, rete testis, efferent ductules, and the epididymis. Meanwhile, mesonephric tubules near the inferior pole of the developing testis degenerate, sometimes leaving epithelial remnants, called the *paradidymis* (see Table 20.3).

Ovarian Formation

Female embryos lacking a Y chromosome do not elaborate SRY protein and therefore do not differentiate cords containing Sertoli cells. In the absence of Sertoli cells and SRY protein, MIS synthesis, Leydig cell differentiation, and androgen production do not occur. Consequently, masculinization of the genital ducts and accessory glands is not stimulated, and instead female development ensues. In females, the primitive sex cords break up into irregular cluster into which the germ cells migrate to form ovarian follicles. The germ cells differentiate into oogonia and enter the first meiotic division as primary oocytes during fetal life. The follicle cells then arrest further germ cell development until puberty, at which point individual oocytes resume gametogenesis in response to a monthly surge of gonadotropins.

Gonadal Descent

Morphologically, the human urogenital ridge is identical in both sexes at 7 to 8 weeks' gestation. **Before gonadal differentiation, the testis lies near the developing kidney in the upper lumbar region, loosely held in place by two ligamentous structures.** The cranial ligament is referred to as the *cranial suspensory ligament (CSL),* whereas the caudal ligament later develops into the gubernaculum (Fig. 20.25). Between 10 and 15 weeks, the testis has descended to the future inguinal region during the enlargement of the abdominal cavity, and the ovary only descends into the pelvis. The testis is anchored near the inguinal region by enlargement of the gubernaculum and regression of the CSL. As early as the 1700s, enlargement of the gubernaculum in males was observed to tether the testis near the groin while the kidney migrated cranially (Wyndham, 1943; van der Schoot, 1993). In females, the CSL continues to develop, keeping the ovary close to the kidney while the gubernaculum remains rudimentary. In males, androgen induces resorption of the CSL, and the gubernaculum enlarges to become a plump ligamentous body, "holding" the testis in the inguinal region. Starting in the seventh month, the gubernaculum begins to bulge beyond the external inguinal ring and extends into the scrotal location, and simultaneously it is hollowed out by the evaginating peritoneal diverticulum called the *processus vaginalis* (Heyns, 1987). The processus vaginalis allows the intra-abdominal testis to exit the abdominal cavity. The bulky distal end of the gubernaculum (known as the *bulb*) is resorbed in humans after completion of inguinoscrotal migration.

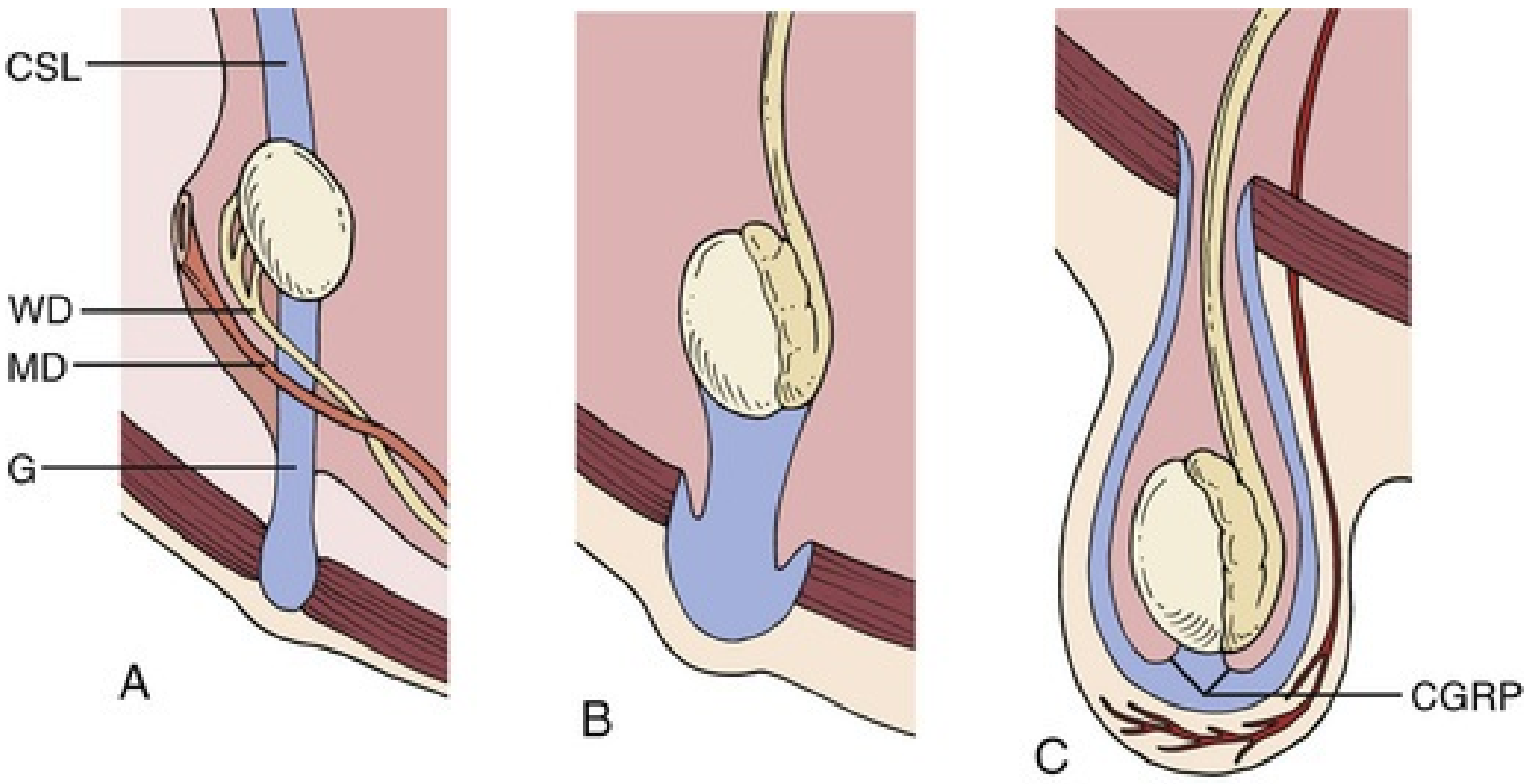

FIG. 20.25 The two stages of testicular descent. (A) Before descent, the developing testis is held in the urogenital ridge by the cranial suspensory ligament *(CSL)* cranially and the gubernaculum *(G)* caudally. The adjacent Wolffian duct *(WD)* forms the epididymis and vas deferens in the male, and the Müllerian duct *(MD)* forms the uterus and tubes in the female. (B) At the end of the transabdominal phase (*15 weeks), the testis is held near the future inguinal ring by the swelling reaction in the gubernaculum. The skin just beyond the gubernaculum is over the future external inguinal ring, as the scrotum is remote in the perineum of humans. (C) The inguinoscrotal phase requires the gubernaculum to elongate to the scrotum, under control

of androgens and calcitonin gene–related peptide *(CGRP)* released from the genitofemoral nerve (GFN). After migration is complete, the peritoneum of the processus vaginalis (PV) closes and then completely involutes and disappears. (Modified from Hutson JM, Li R, Southwell BR, et al. Regulation of testicular descent. *Pediatr Surg Int.* 2015;31[4]:317–325).

Caudal enlargement of the gubernaculum during the early relative transabdominal movement of the testis is known as the *swelling reaction* or *gubernacular outgrowth* (see Fig. 20.25). The gubernacular cord appears to shorten during this process as it becomes incorporated into the enlarging bulb (Wensing, 1986). Shortening of the cord may be an important mechanism to position the testis over the inguinal ring to permit abdominal pressure to push the testis out of the abdomen (Attah and Hutson, 1993; Husmann and Levy, 1995; Quinlan et al., 1988). Transection of the gubernacular cord can lead to either accidental testicular descent into the contralateral inguinal canal or an aberrant intra-abdominal location (Attah and Hutson, 1993; Beasley and Hutson, 1988; Frey and Rajfer, 1984).

The role of intra-abdominal pressure is controversial during the initial transabdominal descent but is thought to be important during transit through the inguinal canal and the subsequent scrotal migration (see Fig. 20.25). Androgens act mostly indirectly via the genitofemoral nerve, which produces calcitonin gene–related peptide (CGRP) to control the direction of migration of the testis (Hutson and Donahoe, 1986).

Inguinoscrotal descent requires migration of the gubernaculum over a considerable distance, along with an increase in length of the processus vaginalis. The force for movement may come from the intra-abdominal pressure, transmitted directly and indirectly to the testis via the lumen of the processus vaginalis and the gubernacular cord, respectively.

Although patients with defective androgen production or androgen metabolism show varied manifestations of cryptorchidism, the exact role of androgen in testicular descent still remains unclear. During intra-abdominal testicular descent, androgen appears to play a role in the regression of the CSL (van der Schoot, 1992). Gubernacular enlargement, in contrast, seems to occur independent of androgen activity, based on the fact that it occurs in androgen-resistant mice and humans (Hutson and Donahoe, 1986). The second migratory step—the inguinoscrotal phase—is thought to be androgen dependent. Migration of the gubernaculum beyond the inguinal region is absent in gonadotropin-deficient mice (Grocock et al., 1988) and those with complete androgen resistance (Hutson, 1986). Regression of the gubernacular bulb after the completion of scrotal descent also appears to be androgen dependent because the gubernaculum remains enlarged in humans with androgen resistance (Hutson and Donahoe, 1986).

INSL3 was identified as a novel gene product of the Leydig cells in 1993 (Adham et al., 1993). INSL3 is similar in structure to the peptide hormones relaxin or insulin and is expressed in both fetal and adult Leydig cells in a differentiation-dependent manner (Balvers et al., 1998) Mice lacking a functional *Insl3* gene demonstrate intra-abdominal cryptorchidism but otherwise no obvious defects in other male reproductive organs. Of more importance, early surgical correction of the cryptorchidism in these mice can restore normal fertility potential (Nef and Parada, 1999; Zimmermann et al., 1999). These are important findings because they reflect the phenotype most commonly observed in classic cryptorchidism in humans.

The ovaries also descend and become suspended within the broad ligament of the uterus. As in males, the female embryos develop a gubernaculum-like structure extending initially from the inferior pole of the ovary into the subcutaneous fascia of the presumptive labioscrotal folds. This “female gubernaculum” later penetrates the abdominal wall as part of a fully formed inguinal canal and becomes the round ligament of the uterus. **In females, although the gubernaculum does not shorten like that in males, it still causes the ovaries to descend during the third gestational month (by anchoring the ovaries in the pelvis) and places them attached to the peritoneal fold (the broad ligament of the uterus).** This translocation of ovaries appears to occur during the seventh week, when the gubernaculum becomes attached to the developing paramesonephric (Müllerian) ducts. As the paramesonephric ducts fuse to form the midline uterovaginal canal, the female gubernaculum becomes tethered to the developing uterus. In this fashion, the female gubernaculum becomes divided into two parts: (1) the segment that extends from the ovary to the uterus called the *ligament of the ovary* and (2) the segment that extends from the uterus through the inguinal canal and into the labia majora called the *round ligament of the uterus.* As in males, the processes vaginalis within the inguinal canal is normally obliterated, but occasionally it remains patent to become an indirect inguinal hernia (Fig. 20.26).

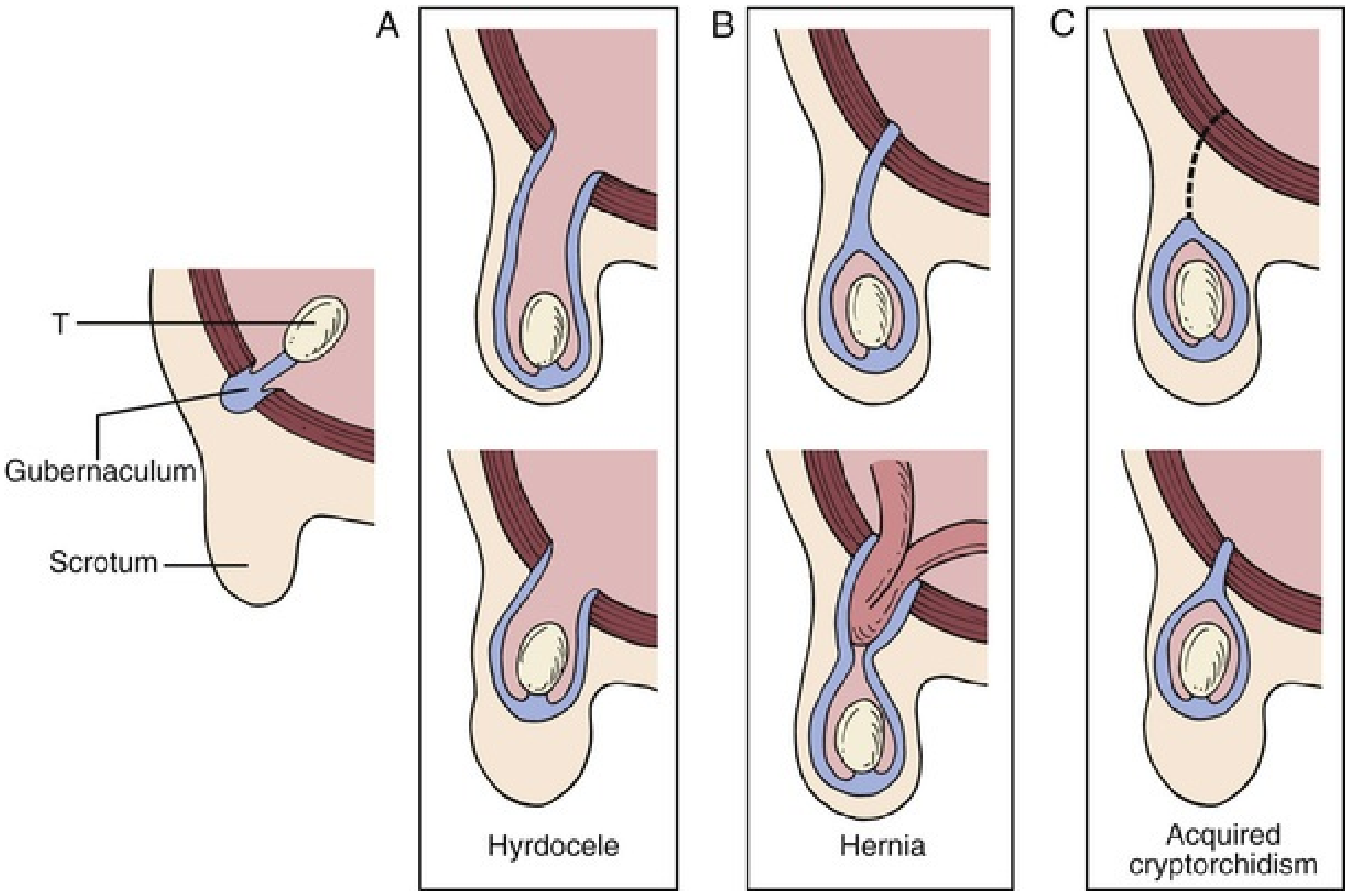

FIG. 20.26 Schematic depicting inguinoscrotal testicular descent and embryology explanation for congenital cryptorchidism, hydrocele, hernia, and acquired cryptorchidism (ascending testis [*T*]). At the end of the transabdominal phase, the enlarged gubernaculum occupies the future inguinal canal, and must migrate 3 to 5 cm to the scrotum (A, step 1), taking the testis inside the processus vaginalis, which elongates inside the gubernaculum. Failure of this first step causes congenital cryptorchidism. After migration is complete, the processus vaginalis closes (B, step 2), and failure of this causes inguinal hernia or hydrocele. The final process (C, step 3) is complete involution of the processus vaginalis remnant, allowing the spermatic cord to elongate after birth. Failure of this step is the likely cause of acquired cryptorchidism, as the fibrous remnant of the processus vaginalis prevents the spermatic cord growing normally. (Modified from Hutson JM, Li R, Southwell BR, et al. Regulation of testicular descent. *Pediatr Surg Int.* 2015;31[4]:317–325).

Clinical Correlation: Cryptorchidism

Cryptorchidism occurs in approximately 3% of newborn males (Fig. 20.27AB; Gurney et al., 2017). Hydroceles and hernia are even more common (Chan et al., 2016). An understanding of the mechanism of testicular descent affected or regulated via the CSL, gubernaculum, and processes vaginalis can explain the embryology of undescended testis, hydrocele, hernia, and acquired cryptorchidism (see Fig. 20.26). In the case of abnormal retention of the cranial suspensory ligament, the undescended testis is likely to be found in the abdomen (see Fig. 20.27AB). Abnormalities in the gubernacular attachment are likely to result in undescended testis located in the inguinal canal area or externally if the gubernacular attachment is ectopic in the perineum, femoral area, or near the penis. **Abnormalities in closure of the processes vaginalis can result in hydrocele or hernia, and lack of complete involution of the processus vaginalis can result in acquired cryptorchidism** (see Fig. 20.26C; Hutson and Donahoe, 1986).

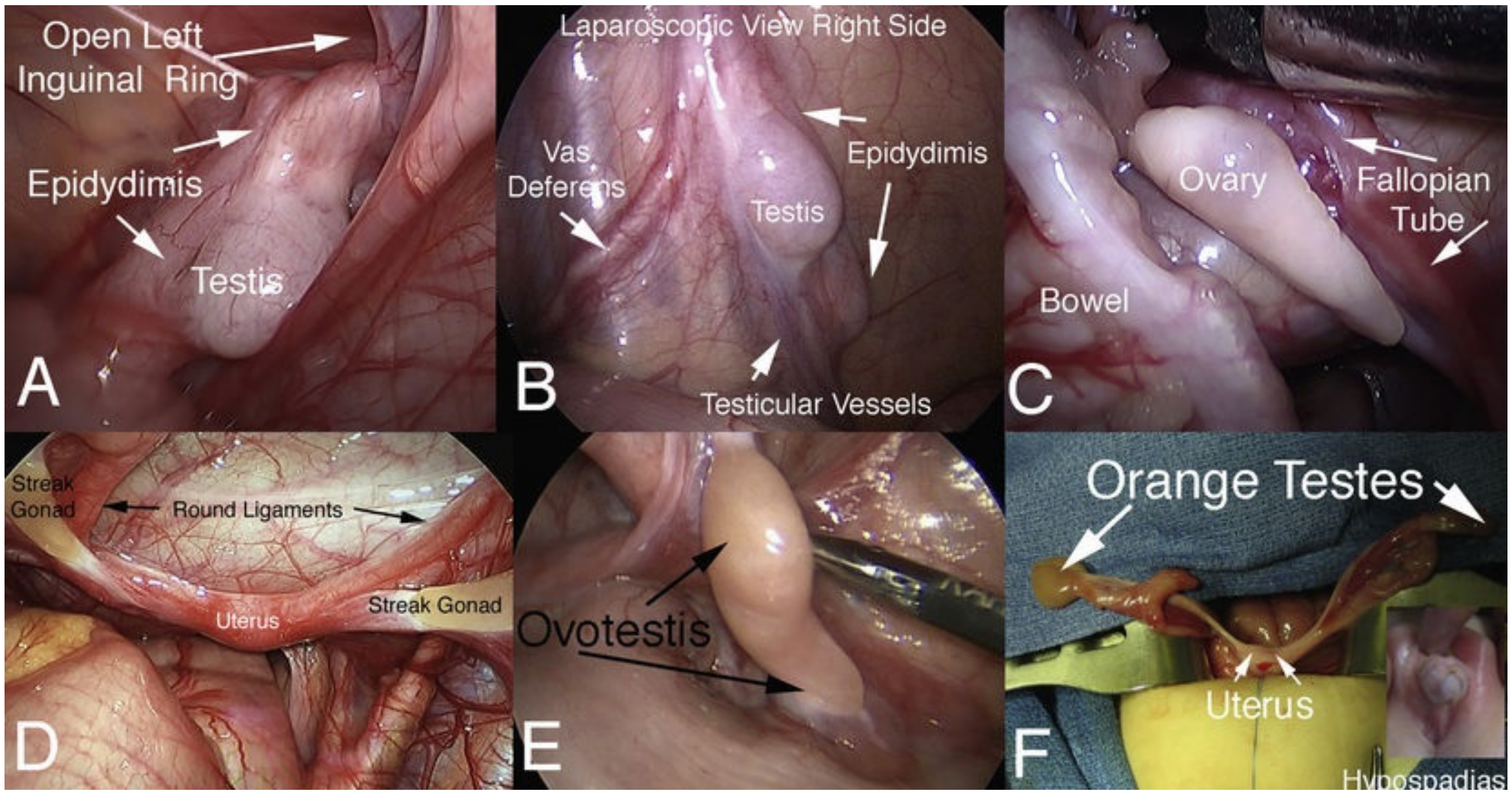
Open Left Inguinal Ring
Epidydimis
Testis
A
Laparoscopic View Right Side
Vas Deferens
Epidydimis
Testis
Testicular Vessels
B
Ovary
Fallopian Tube
Bowel
C
Streak Gonad
Round Ligaments
Uterus
Streak Gonad
D
Ovotestis
E
Orange Testes
Uterus
F
Hypospadias

FIG. 20.27 Human intraoperative photographs (A) Intraabdominal testis at internal ring. (B) High intraabdominal testis. (C) Normal ovary. (D) Streak gonads in a patient with XY gonadal dysgenesis. (E) Ovotestis in ovotesticular syndrome. (F), Retained Müllerian structures in gonadal dysgenesis (orange testis syndrome).

Clinical Correlation: Streak Gonad

Streak gonads typically occur with three genotypes (see Fig. 20.27D): (1) 45,XO (Turners syndrome; Hook and Warburton, 2014); (2) 46,XX (gonadal dysgenesis; Lee, Nordenstrom et al., 2016; Mouriquand et al., 2016); or (3) 46,XY (gonadal dysgenesis; Massanyi et al., 2013). The condition results if there is an absence of both MIS and testosterone. The absence of testosterone results in regression of WD, and hence normal male internal reproductive tracts will not develop. The absence of MIS allows the MDs to differentiate into the fallopian tubes, uterus, cervix, and upper vagina (see Fig. 20.27E). These patients have female-like internal and external genitalia and will require hormonal replacement for the nonfunctional streak gonad for development of secondary sex characteristics. **Patients with 46, XY genotype are at risk for gonadoblastoma and subsequent malignancy and therefore typically have the streak gonads removed** (Cools, 2014).

Clinical Correlation: Ovotesticular Syndrome

The presence of both ovaries and testis (Ovotestis) in humans is an extremely rare condition in which the gonad differentiates into both testicular and ovarian tissue (see Fig. 20.27E; Lee et al., 2016; Mouriquand et al., 2016). During fetal development and postnatally, both the testicular and ovarian tissue can function hormonally, although in contrast with potential female fertility with normal oocytes, functioning spermatogenesis in adulthood has not been reported. During fetal development, internal duct development usually corresponds to that of the adjacent gonad. MD structures typically develop on the gonad side(s) not containing testicular tissue. WD structures tend to be observed on the gonadal side(s) containing functioning testicular tissue. Patients born with ovotesticular syndrome often have atypical genitalia.

Clinical Correlation: Persistent Müllerian Duct Syndrome

Rarely, genetic males (XY) may have persistent MD structures (uterus and fallopian tubes), a condition known as *hernia uteri inguinale* (see Fig. 20.27F; Salehi et al., 2012). This typically results from abnormalities in the MIS receptor, thus eliminating MIS action and retained female internal genitalia in the setting of a relatively normal male phenotype. Clinically this can be found in patients undergoing exploration for bilateral abdominal testis. **Retained Müllerian structures can also result from immature development of the testis in which the timing of MIS production is out of phase with sensitivity of fetal Müllerian structures to MIS, which normally acts between 9 and 13 weeks' gestation.**

Key Points: Gonadal Development

- Under the influence of the *SRY* gene, the indifferent gonads of the ambisexual embryo differentiate into a testis.

- Androgens from the Leydig cell of the fetal testis drive male genital differentiation including prostatic development.
- MIS from Sertoli cells of the testis causes degeneration of female Müllerian ductal structures (uterus and fallopian tube).
- Both gonads descend to pelvic location by the third month of gestation, but the testis descends into the scrotum with the aid of the gubernaculum at about the seventh month.

Müllerian Structures (Female Internal Genitalia)

The Müllerian structures are not present in normal males secondary to the secretion of MIS from the testis (Behringer et al., 1994). In females, who lack testosterone, WDs resorb (Blaschko et al., 2012) and MDs are retained and develop into the uterine body, uterine cervix, and fallopian (uterine) tubes (Fig. 20.28). Note that in the whole-mount specimens it is impossible to differentiate the uterine body from the cervix and vagina. As expected, the size of the uterine body increases over time (see Fig. 20.28).

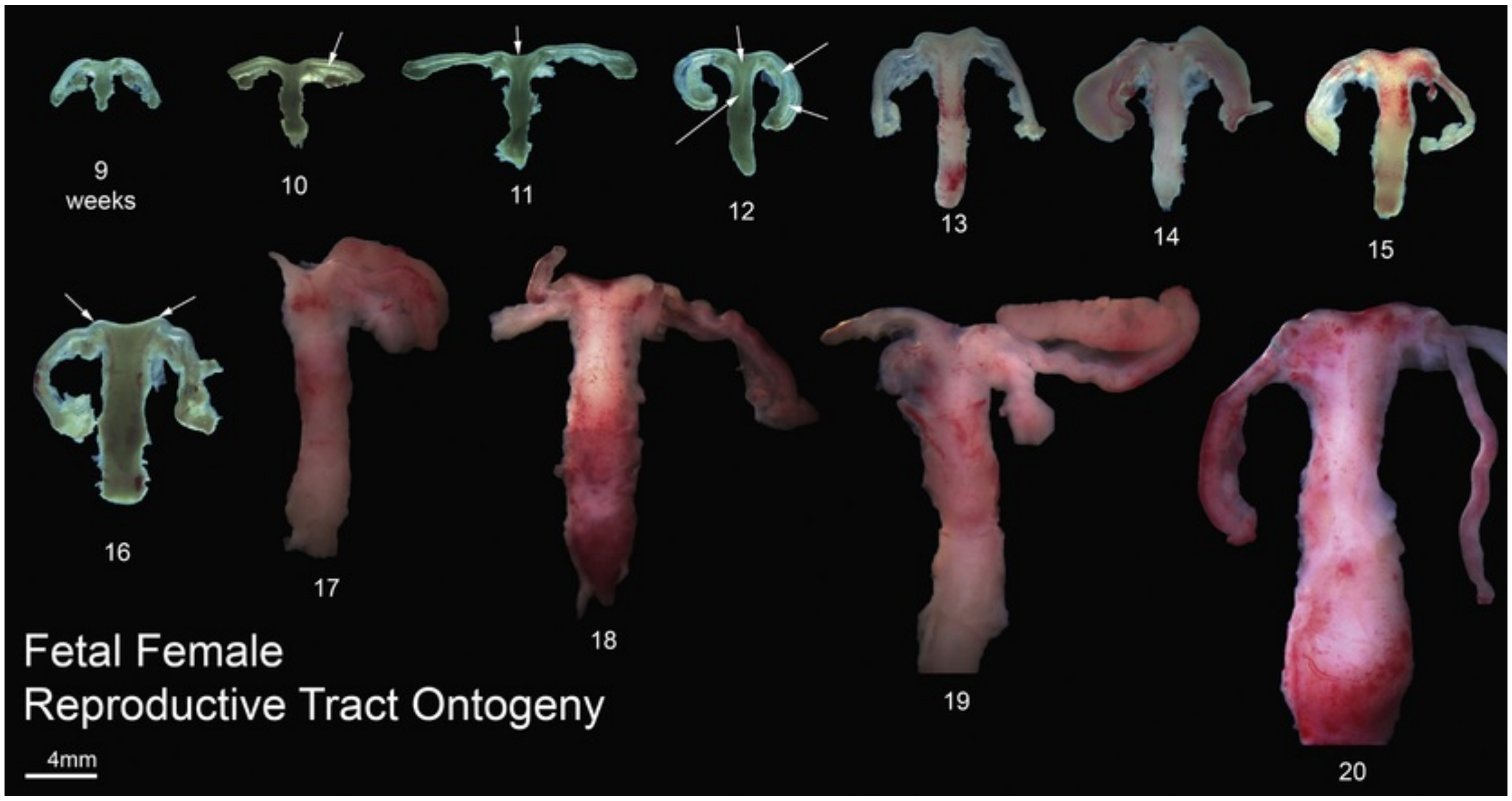

FIG. 20.28 Whole-mount photographs of developing human fetal female internal genitalia at 9 to 20 weeks' gestation. Note the increase in size and morphologic complexity with time, and that landmarks distinguishing the uterine corpus, cervix, and vagina are nonexistent. Specimens photographed with transmitted light (11, 12, and 16 weeks) permit visualization of internal (epithelial) organization in regions not too thick (note the epithelium defining the lumen of the uterine tube and the epithelium lining the uterus).

Development of the Human Female

Reproductive Tract

At the start of week 5 in human female and male embryos, the coelomic epithelium invaginates on the lateral surface of the paired urogenital ridges to initiate MD development (Fig. 20.29; O'Rahilly, 1973). The infoldings later become the tubal ostia of the Müllerian (paramesonephric) ducts. The paired MDs grow caudally within the urogenital ridges using the WDs as “guidewires.” Indeed, the WD is requisite for caudal MD migration to the UGS (Gruenwald, 1941; Kobayashi et al., 2005). Subsequently, the WDs of female fetuses degenerate, leaving vestigial remnants (epoöphoron and paroöphoron) usually found within the broad ligament of the uterus and Gartner's duct within the fibromuscular wall of the vagina (Moore and Persaud, 2003; see Table 20.3). During MD migration, the mesenchyme initially separates the MDs and the WDs (Fig. 20.30). More caudally, the conjoined basement membranes of the MDs and WDs are in contact without intervening mesenchyme. Even more caudally, the tip of the MD is in direct contact with WD (see Fig. 20.30), which led to the idea that the WD may contribute cells to the MD or vice versa (Frutiger, 1969). However, recent cell-lineage tracing experiments in mice do not support this contention (Kurita, 2010).

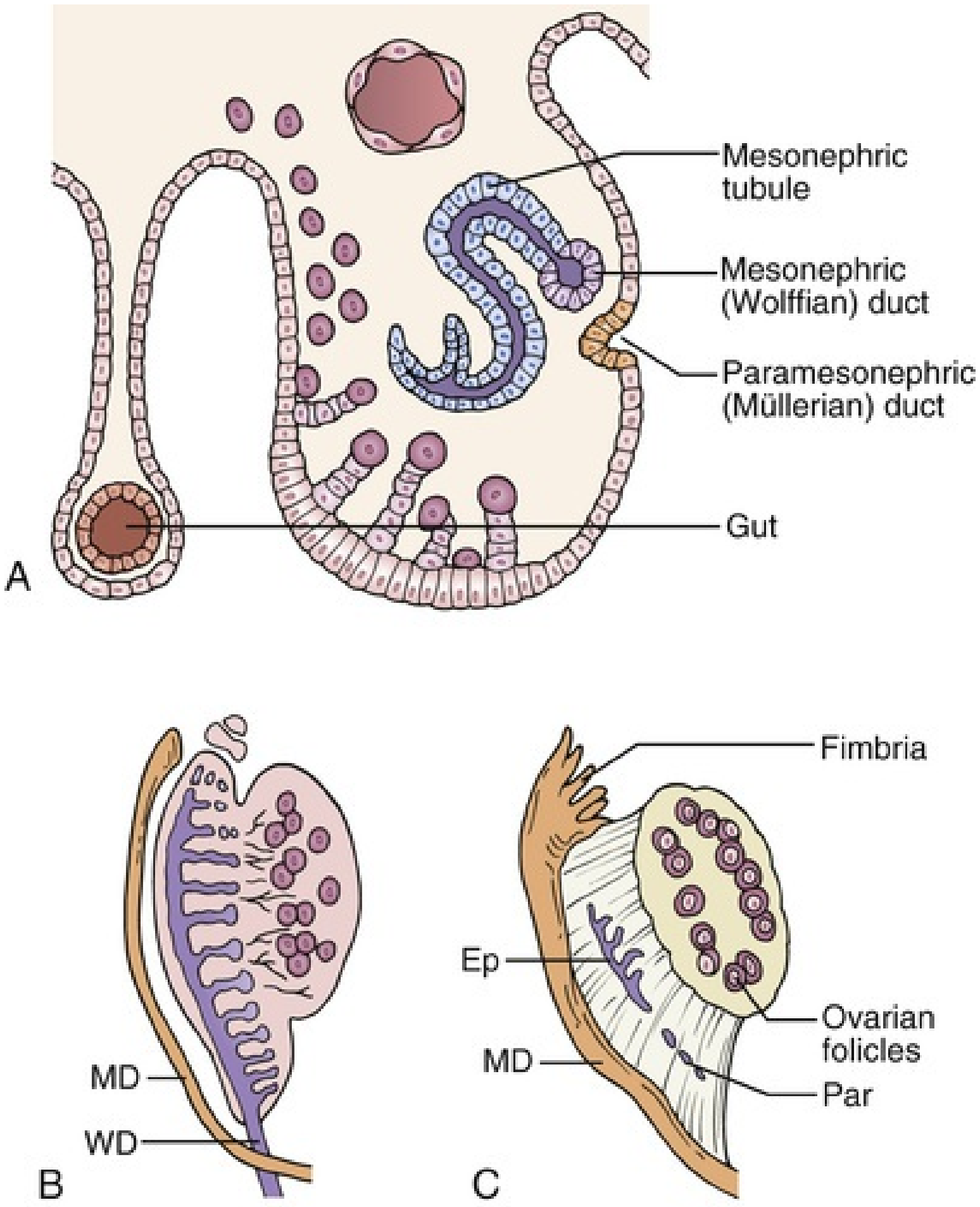
Mesonephric
tubule
Mesonephric
(Wolffian) duct
Paramesonephric
(Müllerian) duct
Gut
A
Fimbria
Ep
Ovarian
folicles
MD
Par
MD
WD
B
C

FIG. 20.29 Drawings depicting the formation and development of the Müllerian duct *(MD)*. (A) Drawing of the urogenital ridge containing a mesonephric tubule *(green),* the mesonephric (Wolffian) duct *(purple),* and the coelomic invagination *(orange)* forming the MD. Note also migrating primordial germ cells *(red).* (B) The MD *(orange)* is located lateral to the mesonephros and Wolffian duct *(WD, purple).* (C) Later stage showing fimbria and degenerated mesonephric structures *(purple)* (epoöphoron [Ep] and paroöphoron [Par]).

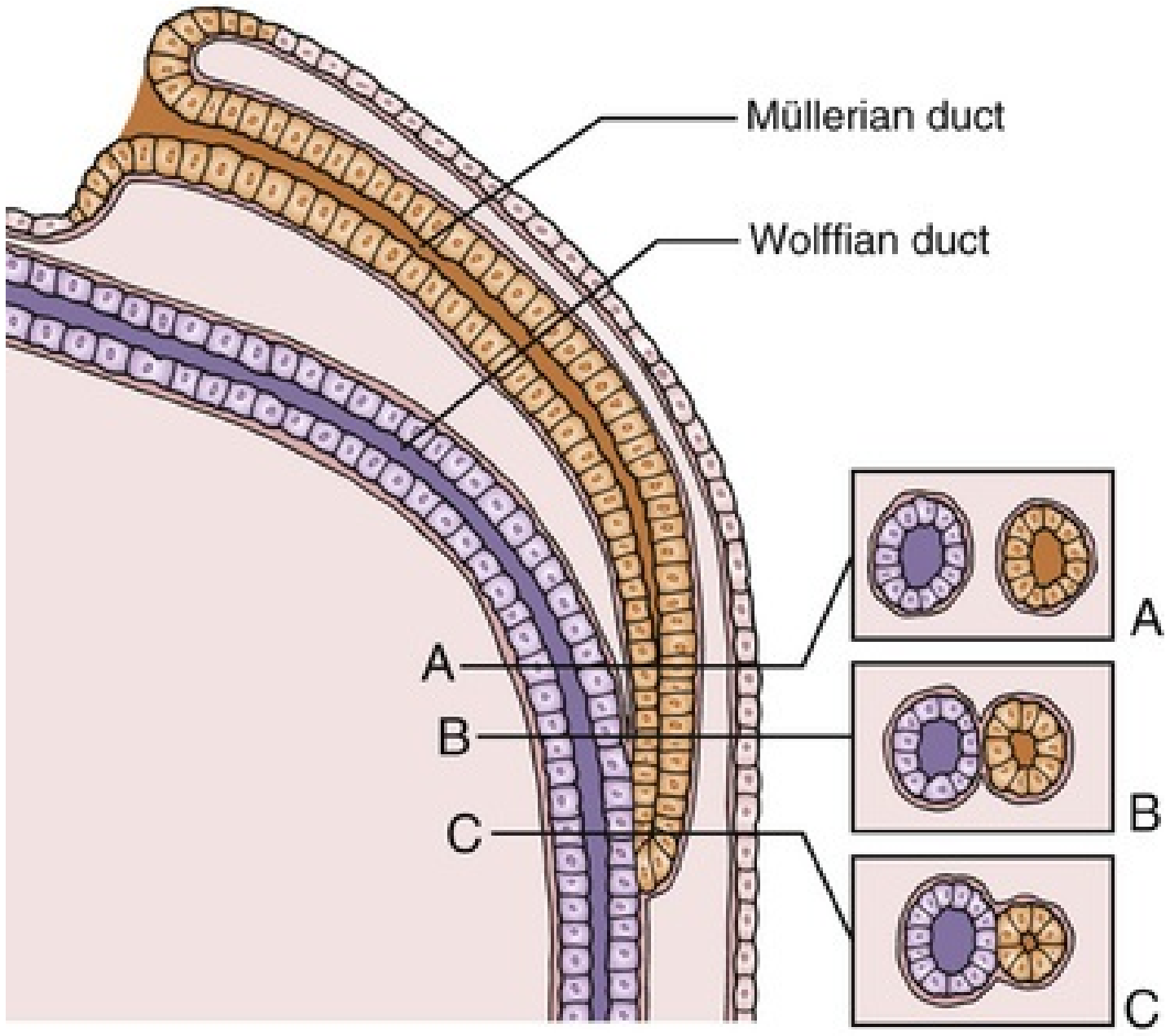

FIG. 20.30 Diagrammatic representation of the caudal migration of the Müllerian duct using the Wolffian duct as a “guidewire.” Note (A), the mesenchyme intervening between the Müllerian and Wolffian ducts, (B) contact of the basement membranes of the Müllerian and Wolffian ducts, and (C) direct contact of the epithelia of the Müllerian and Wolffian ducts. (From Robboy SJ, Kurita T, Baskin L, Cunha GR. New insights into human female reproductive tract development. *Differentiation.* 2017;97:9–22.)

The WDs and MDs exhibit two gentle curves in route to the UGS that define horizontal and vertical portions, as seen in frontal view (Fig. 20.31). The point of contact of the MDs with the UGS is called the *Müllerian tubercle,* which is poorly described and minimally illustrated in the literature and thus is a term of limited value. During the seventh to eighth weeks, the right and left MDs lie between the two WDs as these ducts approach and join the UGS. In the eighth week, the paired MDs fuse in the midline to form the uterovaginal canal (Fig. 20.32). During fusion, the paired MDs become separated by a midline epithelial septum, which disappears in the ninth week (Hunter, 1930; Koff, 1933; see Fig. 20.32, *inset*).

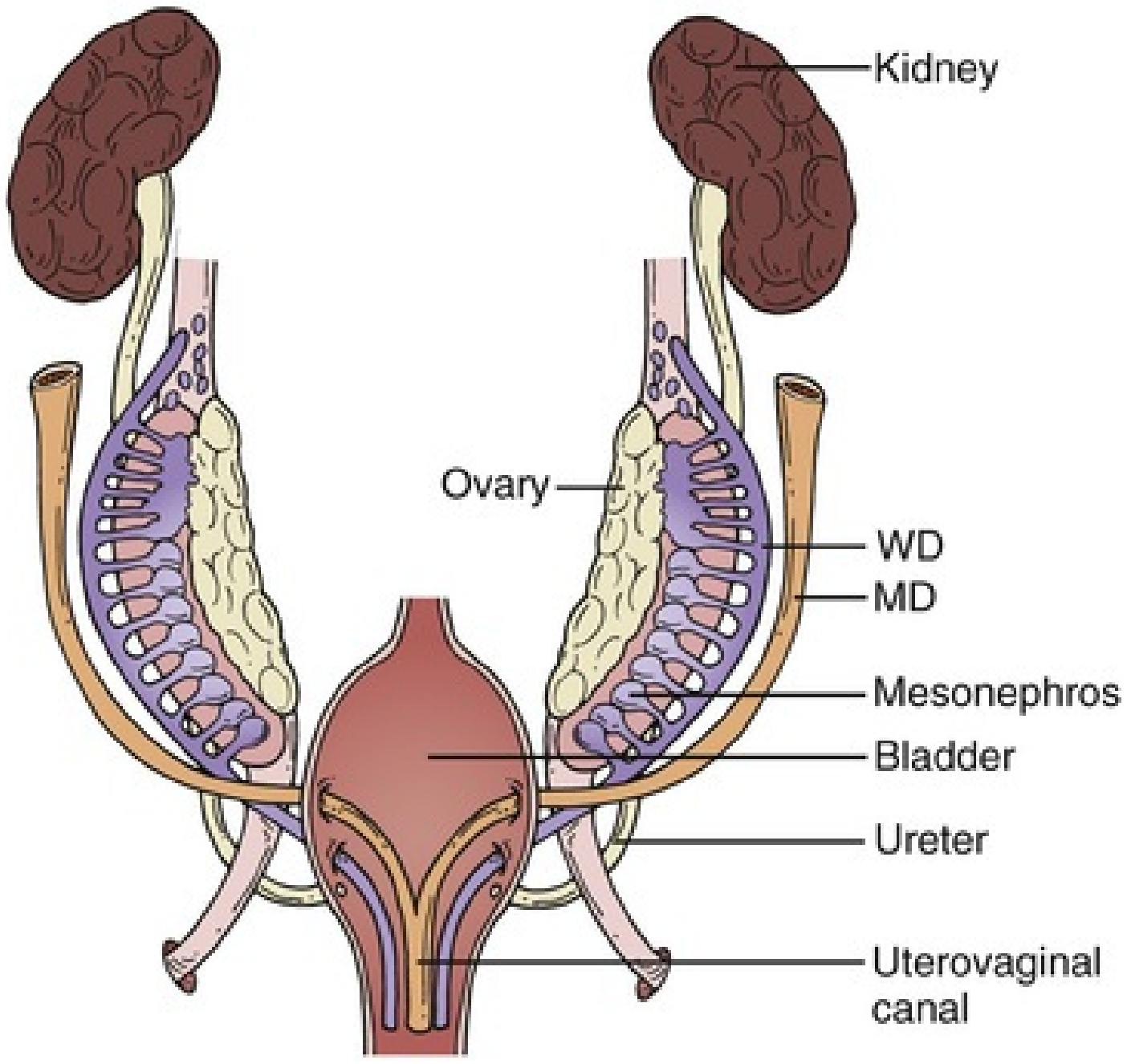
Kidney
Ovary
WD
MD
Mesonephros
Bladder
Ureter
Uterovaginal canal

FIG. 20.31 Diagram of rudiments of human female internal genitalia in the indifferent, bisexual stage (approximately 54 days' gestation, Carnegie stage 22). Müllerian derivatives are *orange,* and Wolffian derivatives are *purple.* Note the changing anatomic relationships between the Müllerian ducts *(MD)* and Wolffian ducts (WD). Note the mesonephros (second primitive kidney) that is dissolving in cranial to caudal fashion lateral to the WD. (Modified from Robboy SJ, Kurita T, Baskin L, Cunha GR. New insights into human female reproductive tract development. *Differentiation.* 2017.97:9–22.)

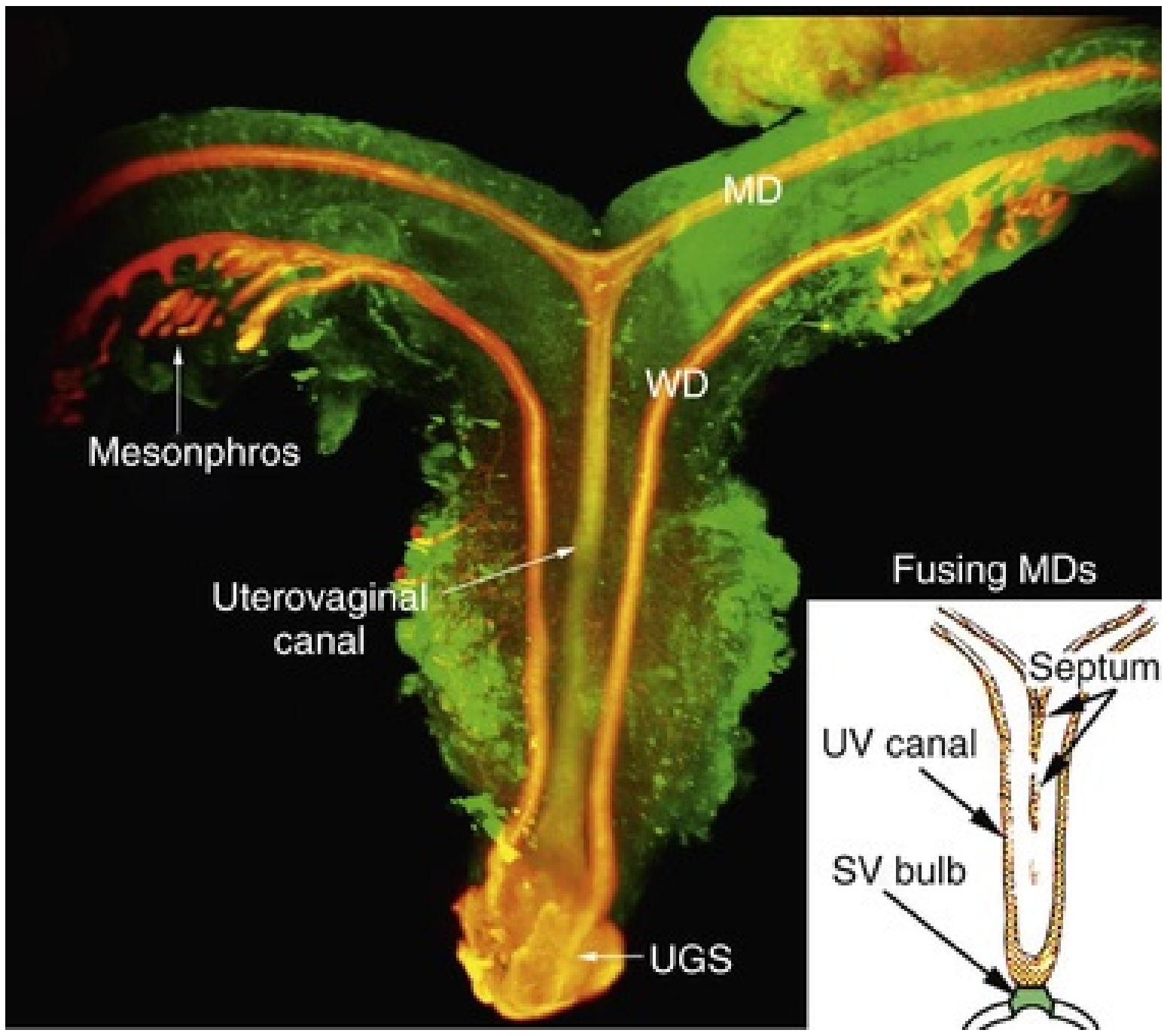

FIG. 20.32 Light sheet microscopy of a human female reproductive tract at 9.5 weeks (indifferent stage) stained with an antibody to E-cadherin that allows visualization of epithelium. The mesonephros and Wolffian ducts *(WD)* are present at this stage. Cranially, the unfused Müllerian ducts *(MD)* are destined to form the uterine tubes. Midline fusion of the MDs has created the uterovaginal canal that terminates caudally by joining the urogenital sinus *(UGS).* Inset depicts MD fusion to form the uterovaginal canal *(UV canal)* and the septum. Note the sinovaginal bulb *(SV bulb, green),* which is a UGS derivative. (From Cunha GR, Vezina CM, Isaacson D, et al. New insights in the development of the human prostate. *Differentiation.* 2018. pii: S0301-4681(18)30099-9. [Epub ahead of print].)

Uterine Tube

The uterine tubes, originally called the fallopian tubes, develop from the paired cranial portions of the MDs retained after the caudal segments fuse to form the midline uterovaginal canal (see Fig. 20.32). Fimbria develop from the irregular ostia of the MDs (see Fig. 20.29). At 8 weeks, the uterine tubes are narrow, and the epithelium defines a circular tubular profile. In the ensuing months, two noticeable changes occur: (1) The mucosa becomes highly folded, most prominently in the infundibulum and ampulla, and (2) the loose mesenchyme surrounding the epithelial tube differentiates into an inner stromal layer associated with the epithelium and outer layer of smooth muscle (Fig. 20.33).

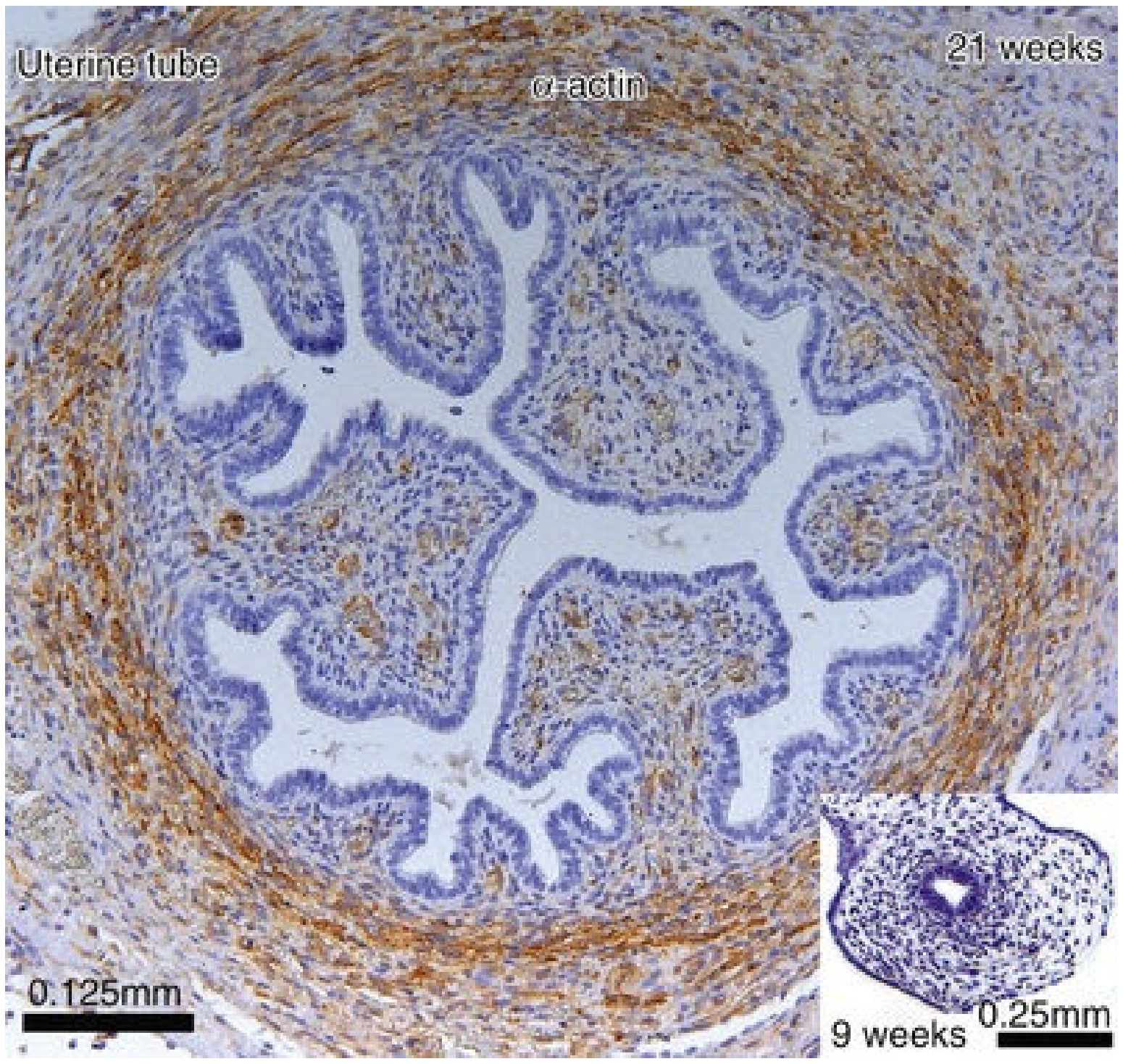

FIG. 20.33 Section of the ampulla of the human uterine tube at 21 weeks stained with an antibody to α-actin. Note the highly folded epithelium. *Inset* is the uterine tube at 9 weeks' gestation.

Uterus Corpus and Cervix

The uterine corpus develops from the cranial portion of the midline uterovaginal canal, which formed as a result of fusion of the MDs (see Fig. 20.32). **Initially a midline epithelial septum represents the zone of fusion of paired MDs that is subsequently eliminated. Failure of regression of the septum can lead to a variety of malformations (see later).** The cranial aspect of the uterovaginal canal forms the uterine corpus and uterine cervix (Fig. 20.34), and the caudal portion of uterovaginal canal is involved in vaginal development. The Müllerian epithelium lining of the cranial aspect of the uterovaginal canal remains simple columnar and eventually forms uterine and cervical glands that penetrate into the endometrial stroma. Cervical epithelium remains simple columnar and glandular cranially in the endocervix, but near the external os of the cervix the Müllerian epithelium differentiates into a stratified squamous epithelium that also covers the exocervix projecting into the vagina. The mesenchymal wall of the uterovaginal canal differentiates into endometrial stroma containing uterine and cervical glands. The endometrial stroma is in turn surrounded by a thick smooth muscle layer, the myometrium, which also differentiates from mesenchyme of the uterovaginal canal.

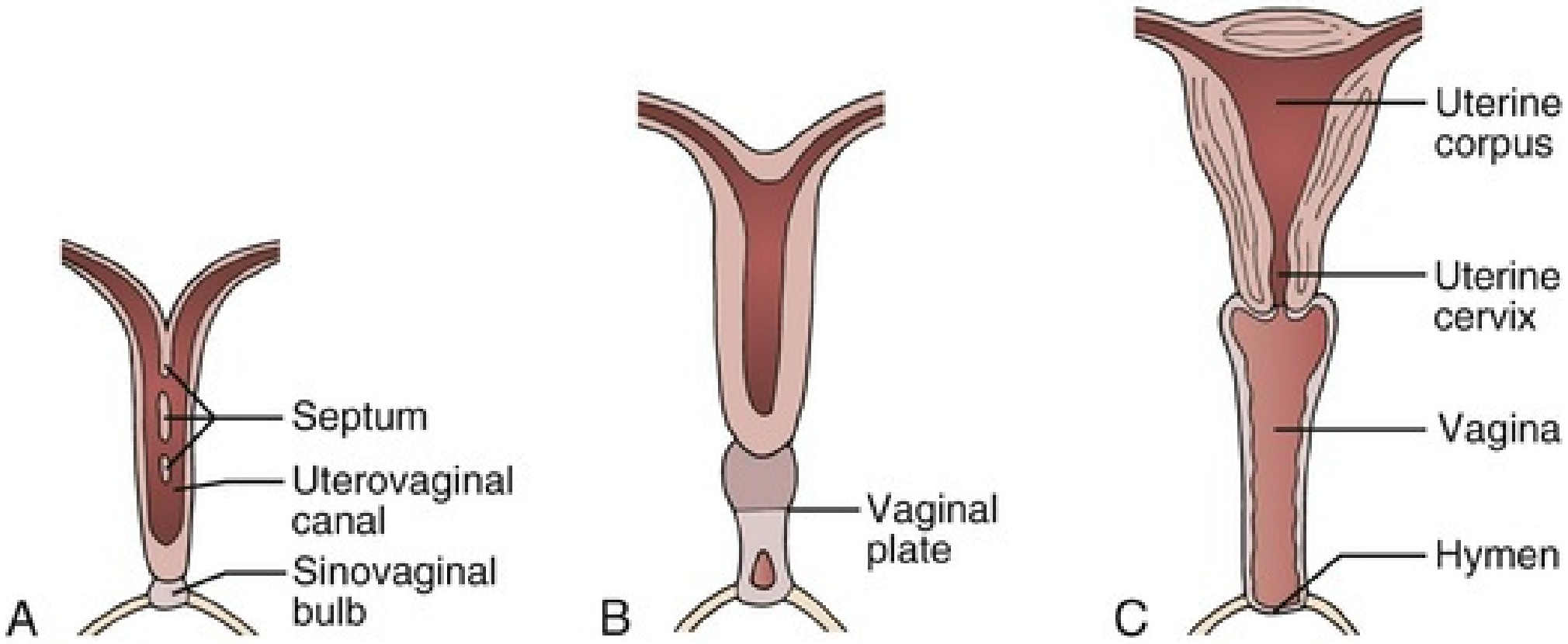

FIG. 20.34 Drawings depicting (A) fusion of the Müllerian ducts to form the uterovaginal canal and contact of the Müllerian epithelium of the uterovaginal canal with the sinovaginal bulb derived from urogenital sinus epithelium (UGE). In (B) the solid vaginal plate has formed from both UGE and Müllerian epithelium. In (C), the UGE has replaced the Müllerian epithelium up to the level of the exocervix.

Vagina

The origin of human vaginal epithelium has been debated for decades. Various investigators have proposed that vaginal epithelium receives contributions from epithelia of the UGS, MDs or WDs alone, or in combination (Koff, 1933; Bulmer, 1957; O'Rahilly, 1977; Forsberg, 1978). The two most popular views on derivation of human vaginal epithelium were advanced by Koff in 1933 and Bulmer in 1957 (Koff, 1933; Bulmer, 1957). Koff proposed that human vaginal epithelium derives from both Müllerian and endodermal epithelium of the UGS that forms the so-called *sinovaginal bulbs* (Koff, 1933). Koff maintained that Müllerian epithelium predominated in human vaginal epithelial development. In contrast, Bulmer proposed that UGS epithelial upgrowth “forms the whole of (the vaginal) epithelial lining.” The conclusions from both studies are based solely on hematoxylin and eosin (H&E)-stained sections.

We have utilized immunohistochemistry to explore the question of the relative contribution of Müllerian versus UGE to human vaginal epithelium. PAX2 is a protein expressed in Müllerian epithelium (Cunha et al., 2018; Kurita, 2010), and FOXA1 is a protein expressed in endodermal UGE and its derivatives

(Besnard et al., 2004; Diez-Roux et al., 2011; Robboy et al., 2017). PAX2 immunostaining was observed in the 8- to 9-week MD and in the uterovaginal canal (Fig. 20.35).

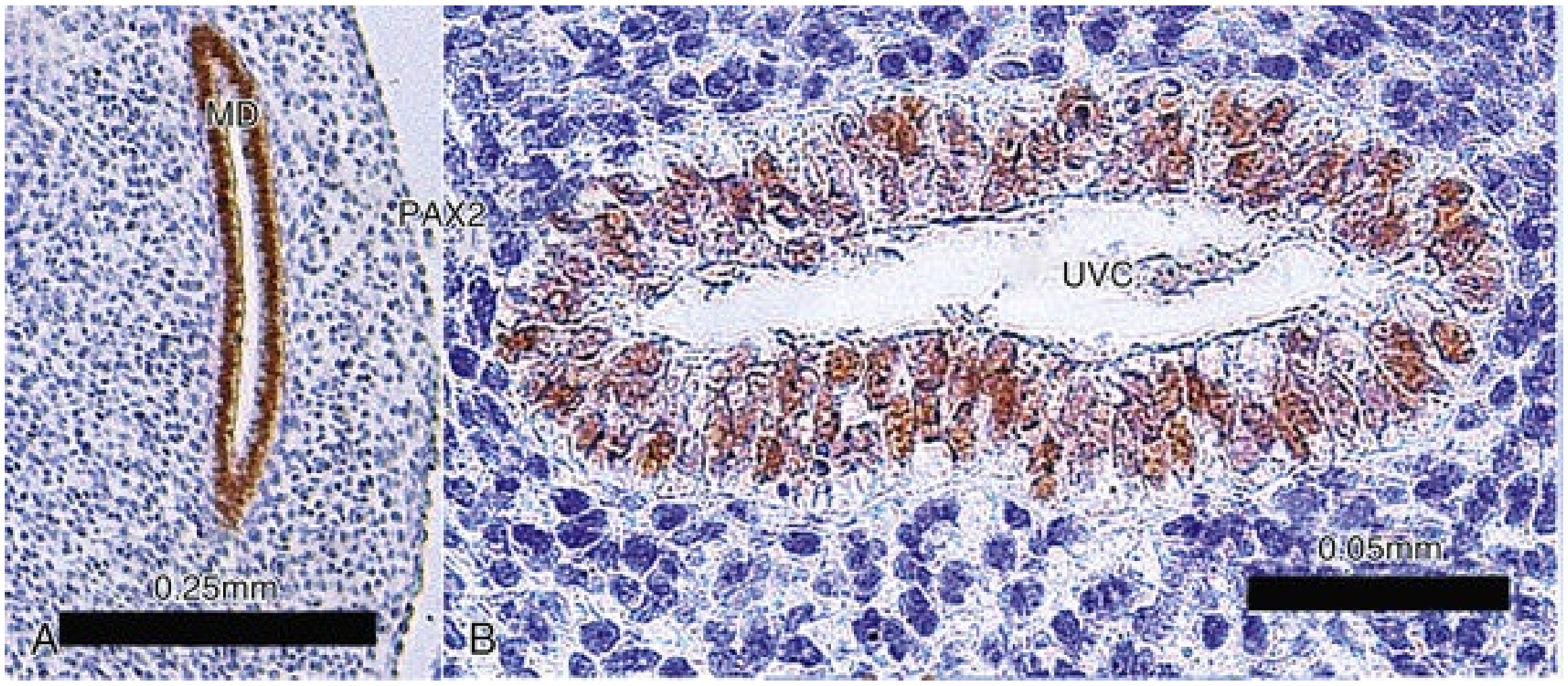

FIG. 20.35 PAX2 immunostaining of the (A) Müllerian duct *(MD)* and (B) uterovaginal canal *(UVC)* at 9 weeks.

The uterovaginal canal initially has a lumen throughout its entire length, but caudally the epithelium of the uterovaginal canal proliferates to form the solid vaginal plate that caudally abuts the endodermal UGS-derived epithelium of the sinovaginal bulbs (see Fig. 20.34). This is illustrated particularly well at 12 weeks, when the cranial (uterine) end of the uterovaginal canal is in continuity with the solid vaginal plate (Fig. 20.36). Both the solid vaginal plate and the uterovaginal canal are PAX2-reactive (see Fig. 20.36AB). In contrast, the caudal portion of the vaginal plate (sinovaginal bulb) is FOXA1-reactive as is the epithelium of the urethra and bladder (see Fig. 20.36CD). During the next several weeks (14 to 21 weeks), the solid vaginal plate increases in extent, and the areas of PAX2 and FOLXA1 reactivity change dramatically consistent with substantial replacement of PAX2-positive Müllerian epithelium by FOXA1-UGE.

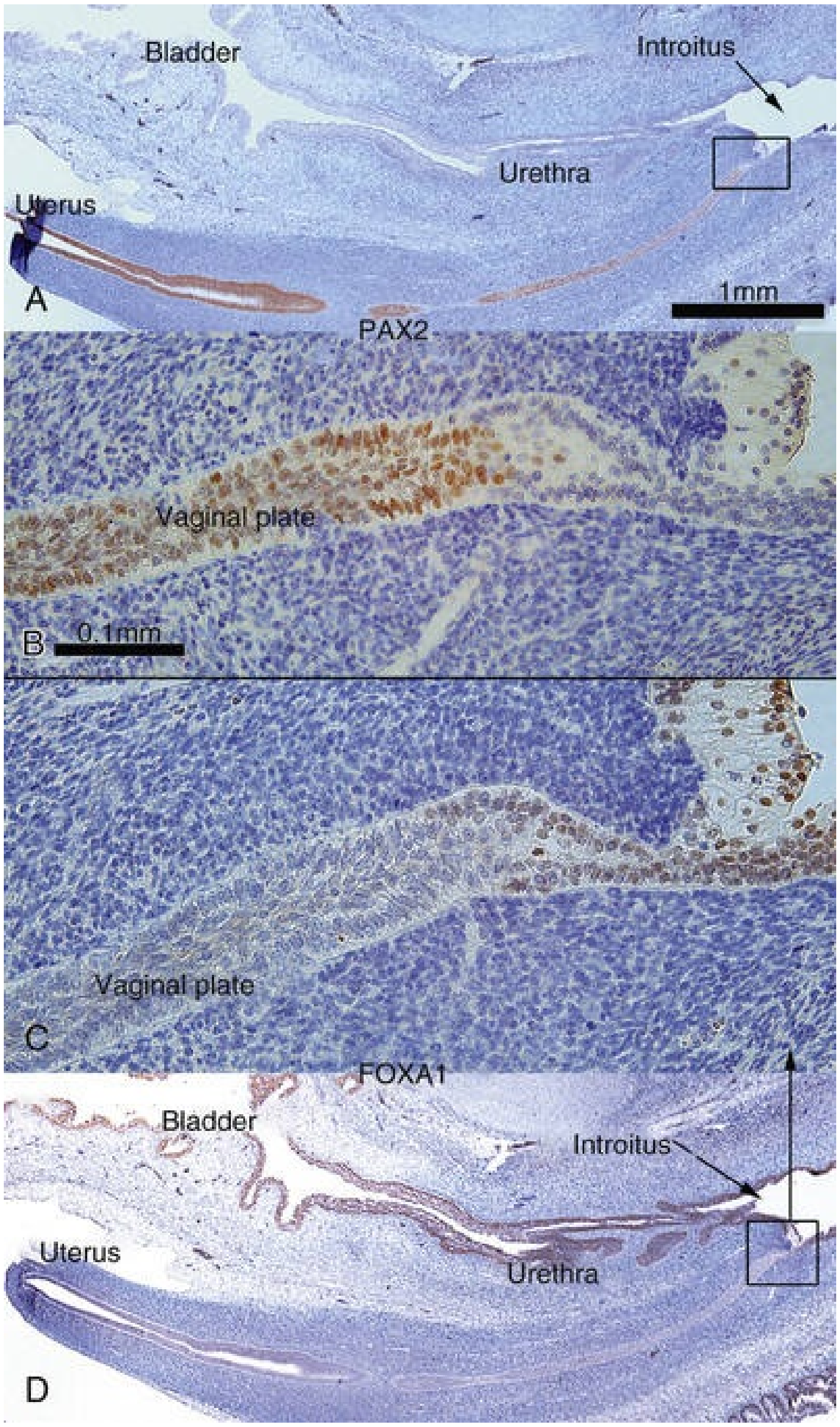
Bladder
Introitus
Urethra
Uterus
A
1mm
PAX2
Vaginal plate
B
0.1mm
Vaginal plate
C
FOXA1
Bladder
Introitus
Uterus
Urethra
D

FIG. 20.36 Sagittal sections of a 12-week human female fetal reproductive tract immunostained with PAX2 (A and B) and FOXA1 (C and D). PAX2-reactive epithelial cells extend to near the junction with the introitus/urethra (A and B). FOXA1-reactive epithelial cells extend only a short distance into the solid vaginal plate (C and D). Scale bar in (A) also refers to (D). Scale bar in (D) also refers to (C).

Canalization of the solid vaginal plate is initiated in approximately the 15th week and is mostly complete by 18 to 19 weeks (Koff, 1933), when vaginal fornices are well defined with the exocervix projecting into the vaginal vault. At this stage, PAX2 reactivity was seen continuously from the uterine tube to the upper vagina, and FOXA1-positive epithelium had extended cranially to the mid-vagina. At 21 weeks, the vaginal epithelium was many cell layers thick and glycogenated (likely caused by endogenous estrogen; Fig. 20.37AB). Epithelial PAX2 immunostaining was observed in epithelium of the uterine tube, the uterus (see Fig. 20.37D), and the cervix (see Fig. 20.37C). Epithelial FOXA1 staining was observed from the vaginal introitus to the cervix. The abrupt change in FOXA1/PAX2 staining occurred at the same point at the vaginal/cervical junction (see Fig. 20.37EF). **These immunohistochemical data support Bulmer's proposal that the entire human vaginal epithelium is derived from UGE, which is depicted in Fig. 20.34.** The most caudal segment of the vagina at the introitus is FOXA1 positive, and thus the presumption is that the epithelium of the hymen is derived from UGE.

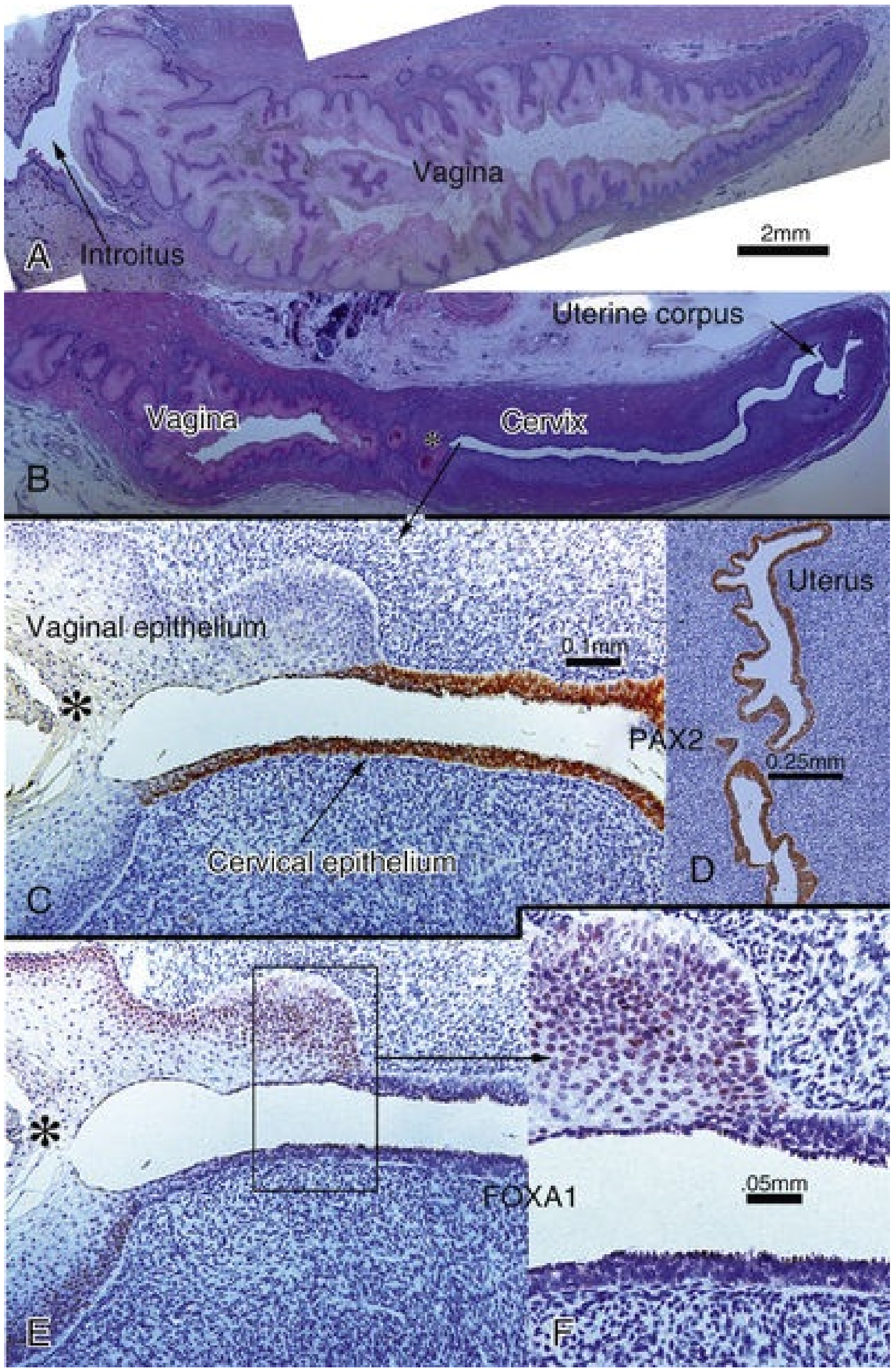
Vagina
A
Introitus
2mm
Uterine corpus
Vagina
Cervix
*
B
Vaginal epithelium
0.1mm
*
Cervical epithelium
C
Uterus
PAX2
0.25mm
D
*
FOXA1
.05mm
E
F

FIG. 20.37 Sagittal sections of a 21-week human female reproductive tract. Because of section orientation, (A) depicts the lower portion of the specimen (the introitus to the upper vagina), and (B) depicts the upper portion of the specimen (vagina, cervix, and uterus) (H&E stain). The vaginal epithelium is many layers thick as a result of estrogenic stimulation (A and B). In (B), note the abrupt transition in epithelial differentiation at the vaginal/cervical border (*). PAX2 staining of the vaginal/cervical border (C) shows prominent PAX2 immunostaining (indicative of Müllerian duct origin) of stratified but relatively thin cervical epithelium and PAX2-negative vaginal epithelium (C). Epithelium of the uterine corpus (D) is strongly PAX2-reactive. FOXA1 immunostaining was seen uniformly throughout the entire vagina, and FOXA1 immunostaining abruptly stopped at the vaginal/cervical border (E and F) in mirror image to PAX2 immunostaining (C). (*) denotes the interface between vaginal and cervical epithelium in (B), (C), and (E).

It is important to recognize that derivation of vaginal epithelium in the mouse is entirely different from that in the human as is the terminology. In the newborn mouse, the upper (cranial) portion of the vagina (called the *Müllerian vagina*) is lined by PAX2-positive Müllerian epithelium that abuts on the solid endodermal “sinus vagina.” Elegant lineage tracing experiments have shown that postnatally the Müllerian vaginal epithelium completely replaces the endodermal sinus vaginal epithelium (Kurita, 2010).

Clinical Correlation: Vaginal Agenesis and Imperforate Hymen

Failure of canalization of the vaginal canal results in atresia or blockage of the vagina. This occurs in approximately 1 : 80,000 women and is called a *transverse vaginal septum*. The septum is typically located at the junction of the middle and superior third of the vagina. **Failure of the inferior end of the vaginal canal to open may be caused by imperforate hymen, which is the most common cause of vaginal obstruction** (Fig. 20.38).

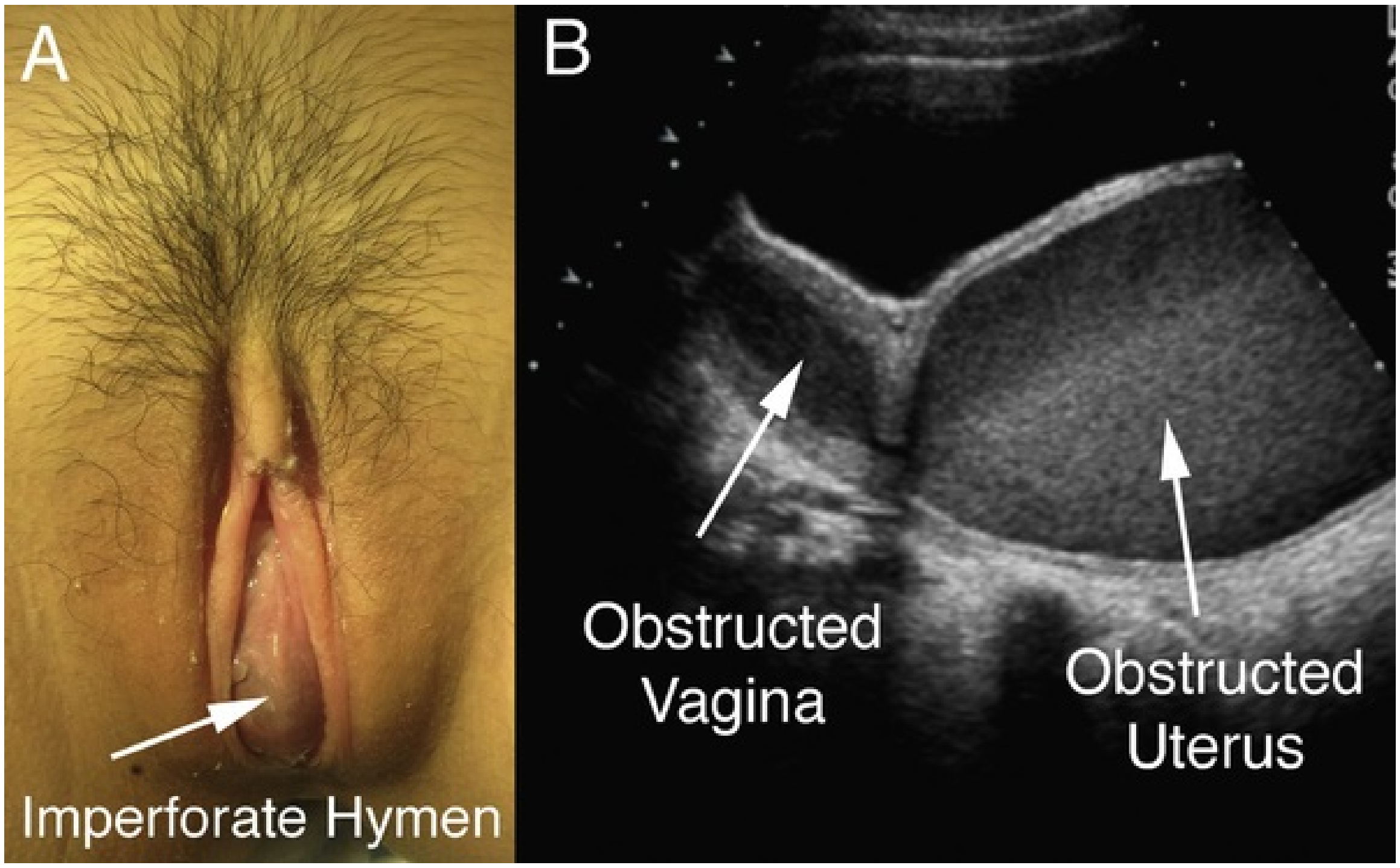

FIG. 20.38 (A) Gross photograph of bulging imperforate hymen in an 11-year-old female patient with cyclic abdominal pain. (B) Sonographic images of the same patient with dilated vagina and uterus.

Clinical Correlation: Uterus Didelphys

Uterus didelphys results from failure of the fusion of the caudal aspects of the Müllerian (paramesonephric) ducts. **A unicornuate uterus develops when one of the MDs fails to develop.**

Clinical Correlation: Obstructed Hemivagina and Unilateral Renal Anomalies

Obstructed hemivagina and ipsilateral renal agenesis (OHVIRA) syndrome is a rare congenital anomaly that involves Müllerian and urinary tract anomalies. OHVIRA syndrome usually presents after menarche with symptoms such as cyclic abdominal pain and vaginal discharge but can present more dramatically with an acute abdomen and tubo-ovarian abscess. More recently, there have been reports of OHVIRA syndrome with ipsilateral dysplastic kidneys or ectopic ureters (Schlomer et al., 2015). OHVIRA syndrome is thought to be caused by abnormal development of the MDs and the WDs (Capito et al., 2008). True renal agenesis can occur because of an absence in WD formation, ureteric bud formation, or metanephric blastemal formation. Findings in females with true renal agenesis also include an absent ipsilateral bladder hemitrigone. Prior studies suggest the reason the ipsilateral kidney is not visualized on imaging in OHVIRA syndrome is not because of true renal agenesis from an absence of WD formation but secondary to renal dysplasia and atrophy caused by abnormal WD formation associated with abnormal ipsilateral MD formation (Kiechl-Kohlendorfer et al., 2011). Usually the distinction between true agenesis versus dysplasia and atrophy does not have clinical implications. However, in cases of OHVIRA syndrome in which the ipsilateral dysplastic and atrophic kidney can lead to persistent vaginal leakage after resection of vaginal septum, we believe that it is important not to assume that renal agenesis is present in OHVIRA syndrome. **Hence, we accept the new terminology that OHVIRA syndrome should stand for obstructed hemivagina and ipsilateral renal anomalies** (Fig. 20.39; Schlomer et al., 2015).

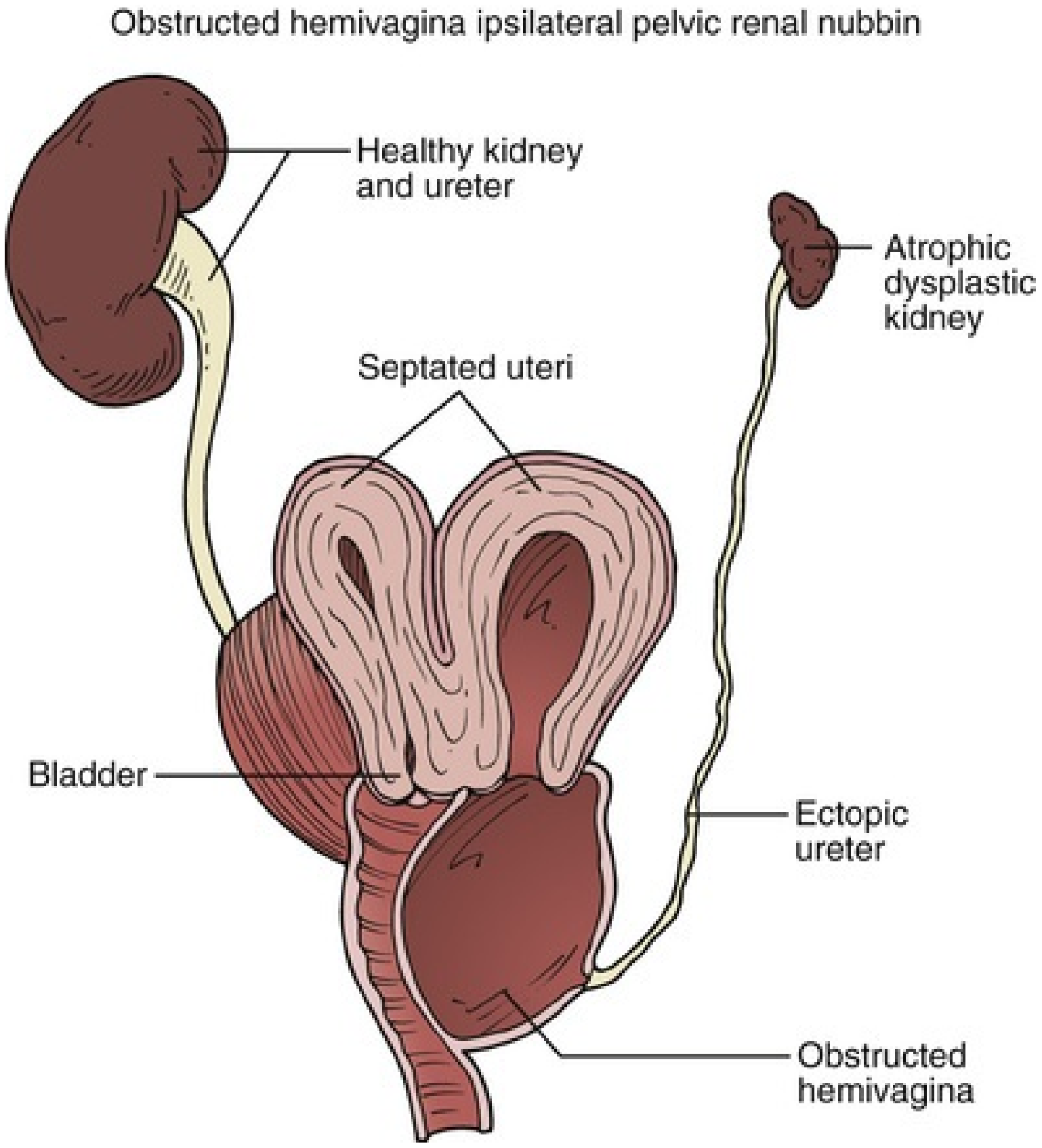
Obstructed hemivagina ipsilateral pelvic renal nubbin
Healthy kidney and ureter
Atrophic dysplastic kidney
Septated uteri
Bladder
Ectopic ureter
Obstructed hemivagina

FIG. 20.39 Schematic of obstructed hemivagina and unilateral renal anomaly. In this case, the ectopic ureter from a left pelvic dysplastic renal nubbin inserts into the left obstructed hemivagina.

Key Points: Müllerian Development

- Immunohistochemical data support Bulmer's proposal that the entire human vaginal epithelium is derived from UGE (without Müllerian or Wolffian cell origin).
- A midline epithelial septum represents the zone of fusion of paired MDs that is subsequently eliminated. Failure of regression of the septum can lead to uterine obstruction/duplication.
- Failure of the inferior end of the vaginal canal to open can be caused by imperforate hymen, which is the most common cause of vaginal obstruction.

Bladder: Ureteral Development

Both the bladder and ureters consist of a urothelial-lined lumen, a lamina propria consisting of extracellular matrix with unorganized smooth muscle, an outer layer of thick bundles of smooth muscle, and a serosal surface. The ureters and bladders of human males and females develop in similar fashion without differences in size. In contrast, in males the prostate develops below the insertion of the ureters into the trigone (see Fig. 20.15). Thus, in males the prostatic urethra is clearly larger in size than the homologous region in females (Fig. 20.40). The ureterovesical junction inserts into the bladder trigone in exactly the same fashion in both the male and female fetuses (see Figs. 20.15 and 20.40).

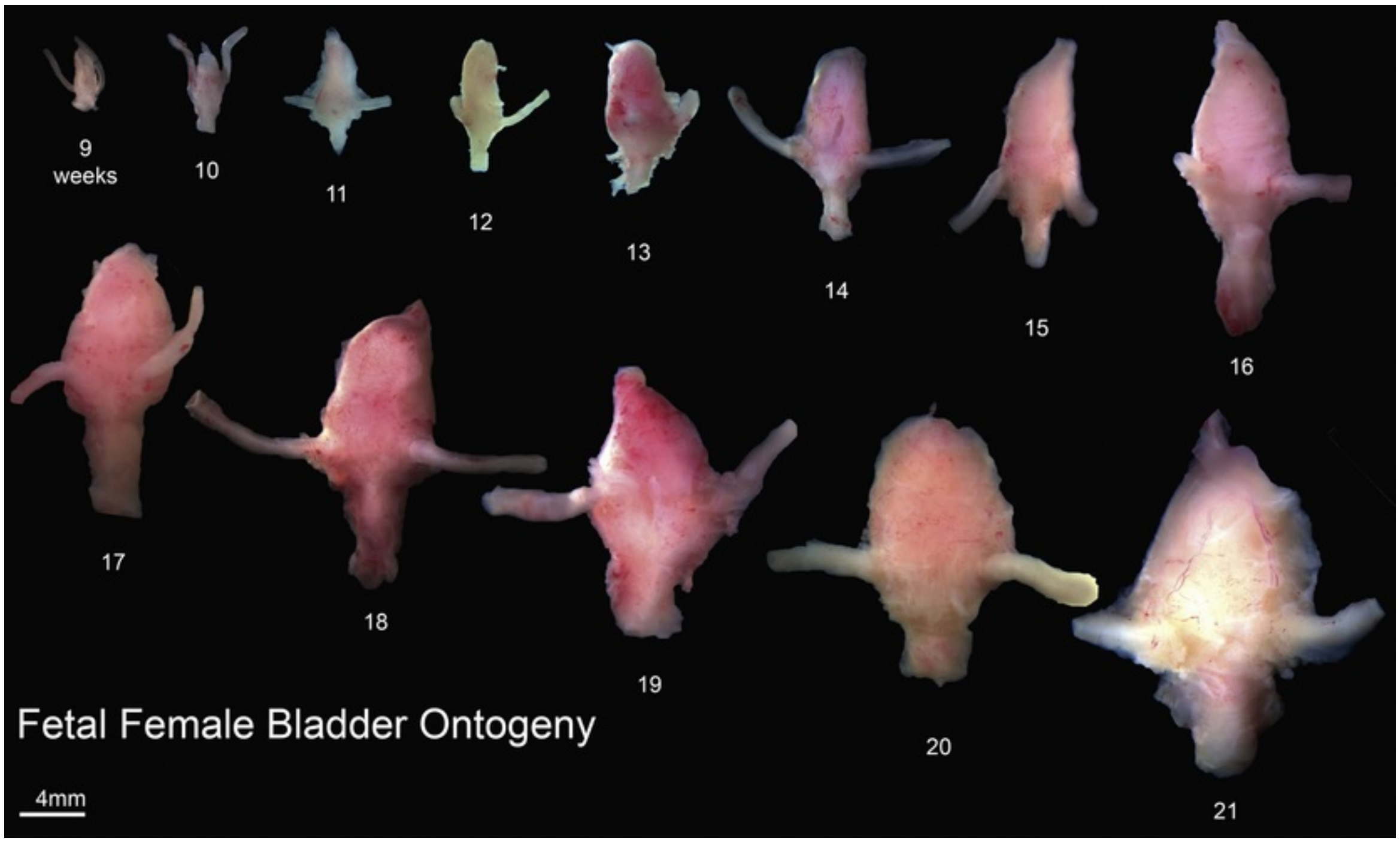

FIG. 20.40 Whole-mount photographs of human female fetal bladders (9 to 21 weeks' gestation). Compare to the male ontogeny (see Fig. 20.15), and note the lack of prostate tissue and vas deferens. Note that the male and female bladder sizes are similar at each gestational age.

Formation of Urogenital Sinus

At the fifth to sixth week of gestation, the urorectal septum separates the cloacal into the dorsal anorectal canal and ventral UGS (Fig. 20.41) based on the historic observations of Rathke and Tourneux (Rathke, 1832; Tourneux, 1888). Abnormalities in the cloacal membrane (and not the urorectal septum) are thought to lead to anorectal malformations (Fig. 20.42; Nievelstein et al., 1998). Ultimately, the UGS and its diverticulum, the allantois, form the bladder and urethra with the allantois being the embryologic precursor of the urachal remnant.

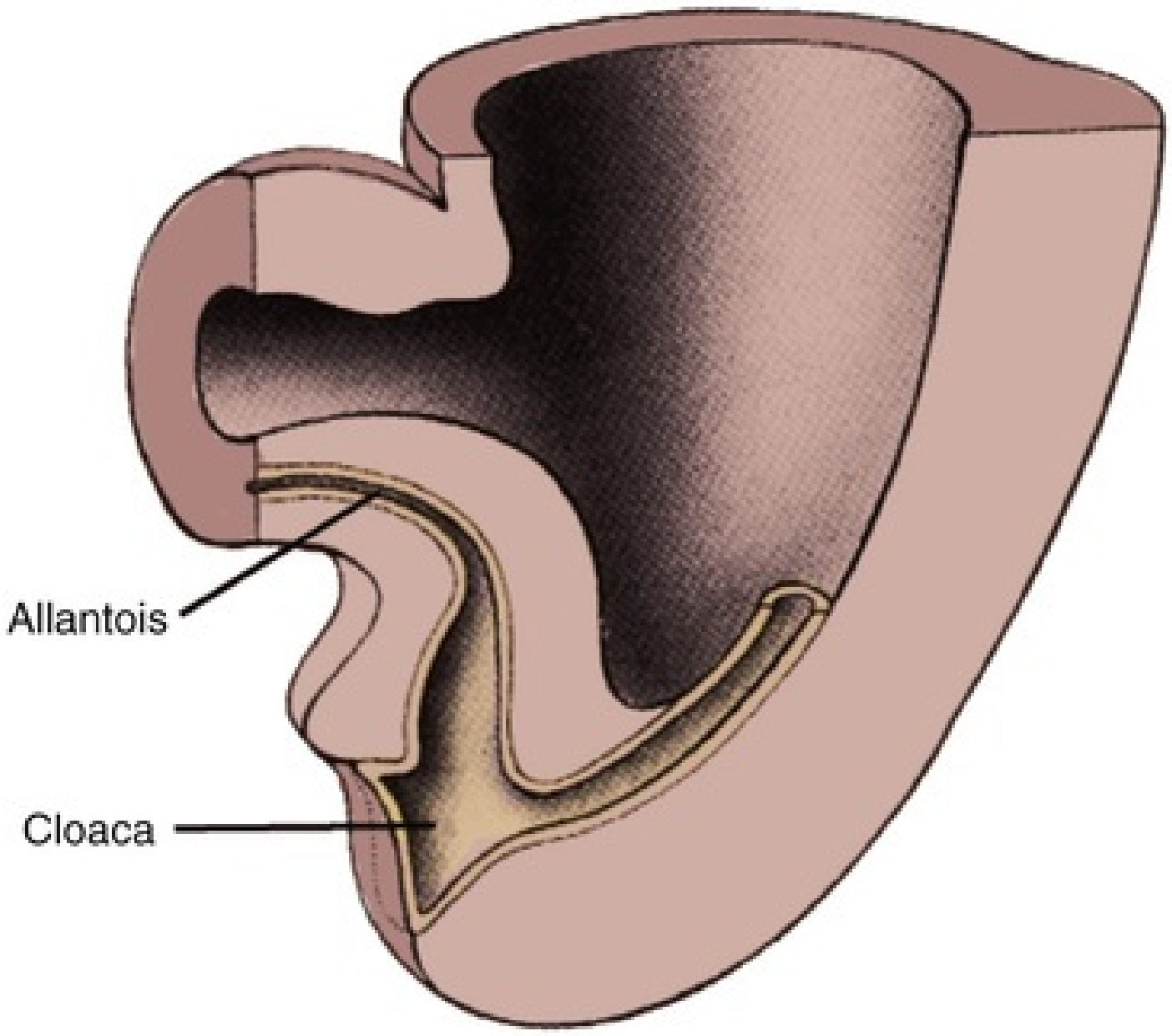
Allantois
Cloaca

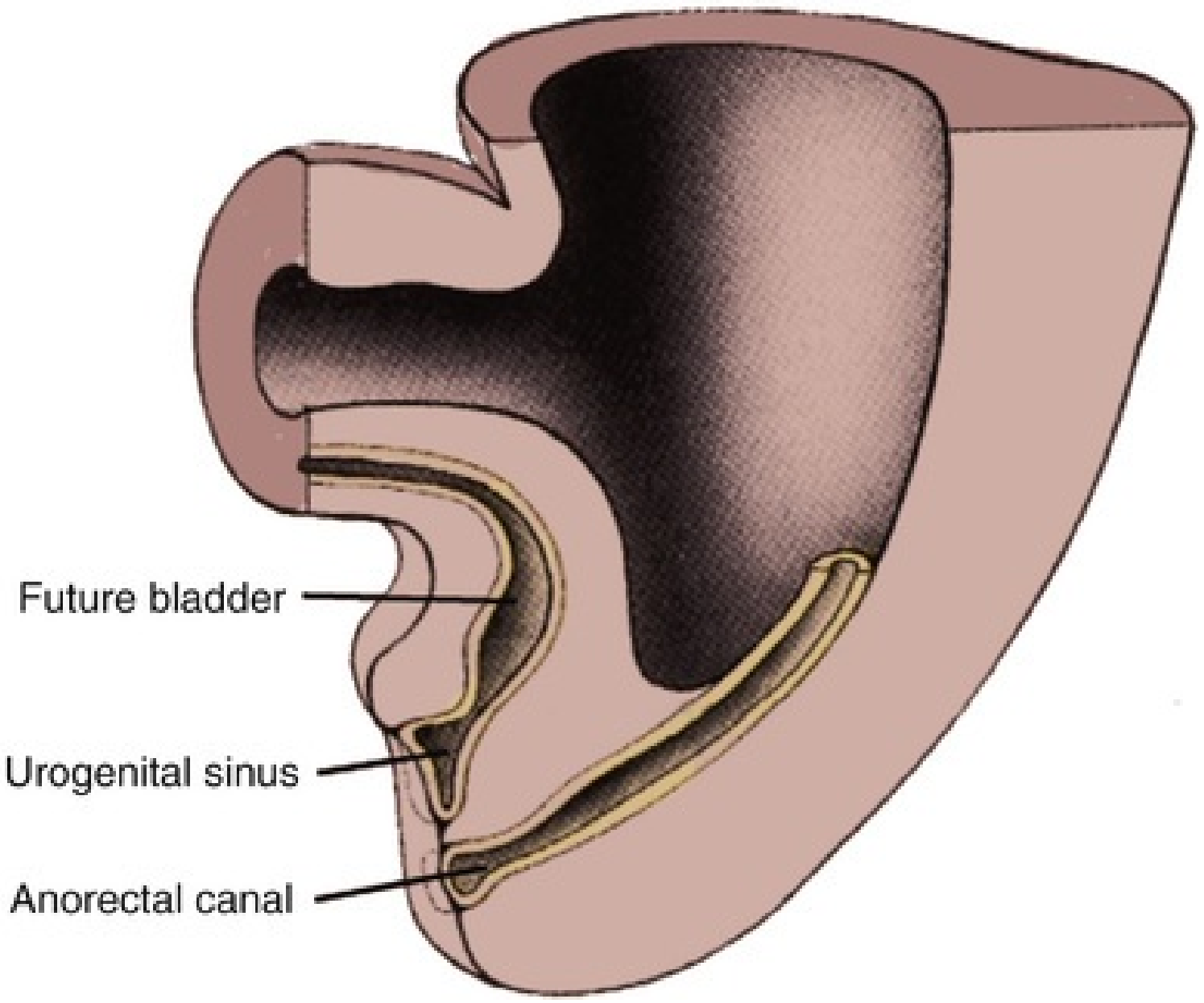
Future bladder
Urogenital sinus
Anorectal canal

FIG. 20.41 Development of the urogenital sinus. Between the fourth and sixth weeks, the cloaca is divided into an anterior urogenital sinus and a posterior anorectal canal. The superior part of the urogenital sinus, continuous with the allantois, forms the bladder. The constricted narrowing at the base of the urogenital sinus forms the pelvic urethra. The distal expansion of the urogenital sinus forms the vestibule of the vagina in females and the penile urethra in males. (Modified from Larsen WJ. *Human embryology.* New York NY: Churchill Livingstone; 1997.)

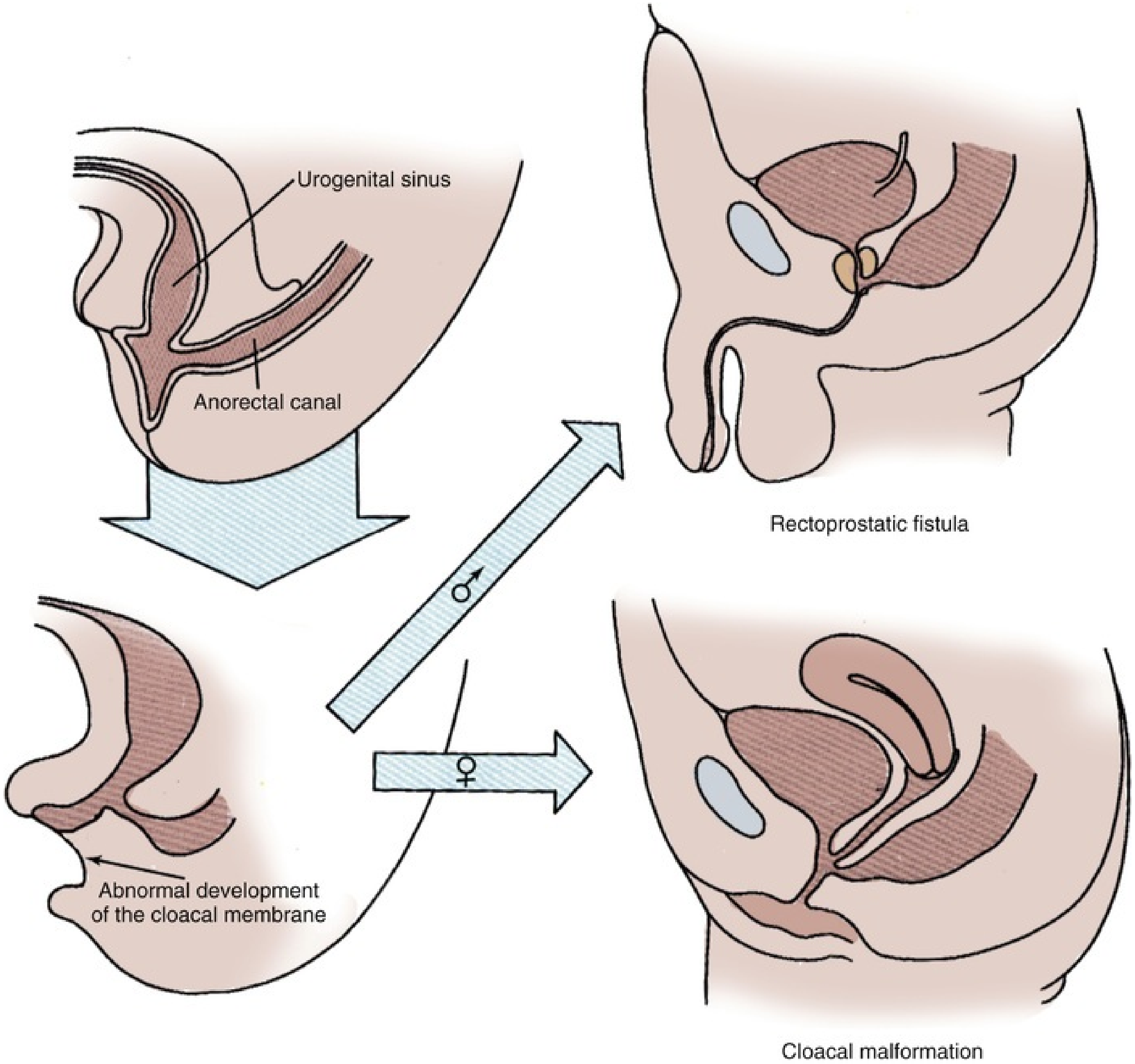
Urogenital sinus
Anorectal canal
Rectoprostatic fistula
♂
♀
Abnormal development of the cloacal membrane
Cloacal malformation

FIG. 20.42 Abnormal development of the cloacal membrane results in characteristic anomalies of the urogenital and lower gastrointestinal tract. (Modified from Larsen WJ. *Human embryology.* New York, NY: Churchill Livingstone; 1997.)

The Wolffian (mesonephric) ducts fuse with the cloaca just before its subdivision by the urorectal septum (Moore et al., 2016; see Table 20.3). The entrance of the mesonephric ducts into the primitive UGS serves as a landmark distinguishing the cephalad vesicourethral canal from the caudal UGS. The vesicourethral canal gives rise to the bladder and pelvic urethra. Early in development, the bladder is continuous with the allantois. The caudal portion of the UGS forms the phallic urethra in males and urethra and vaginal vestibule in females (Moore et al., 2016).

Formation of Trigone

Also, at approximately the fifth or sixth week of gestation, the *common excretory ducts* (the portion of mesonephric ducts distal to the origin of ureteric buds) dilate and connect to the UGS. The formation of these final connections involves apoptosis, which enables the ureters to disconnect from the mesonephric ducts and fuse to the bladder (Batourina et al., 2005). With use of cell-lineage studies (in mice), the fibromuscular wall of the trigone was found to form mostly from bladder smooth muscle cells with only a minor contribution from mesenchymal cells associated with the ureters (Viana et al., 2007). This is in contrast with the classic hypothesis in which the trigone is formed from an extension of the ureteral development into the trigone of the bladder (Weiss, 1988). The ureteral orifices incorporate into the bladder and migrate in a cranial and lateral direction within the base of the bladder.

The embryonic pattern of ureteral orifice incorporation into the developing bladder is inferred primarily from clinical observations of duplex kidneys with two ureters joining the bladder on the same side. The upper-pole ureteral orifice rotates dorsally relative to the lower-pole orifice and assumes a more caudal and medial position. **Weigert and Meyer recognized the regularity of this relationship between upper- and lower-pole ureteral orifices, which has come to be known as the Weigert-Meyer rule (Weigert, 1877; Meyer, 1907). According to this concept, an abnormally laterally placed lower-pole ureteral orifice may result from a ureteric bud arising too low on the mesonephric duct, therefore resulting in premature incorporation and migration within the developing bladder.** In such an abnormal ureteral orifice, vesicoureteral reflux is more likely to occur because of an inadequate intramural tunnel. In contrast, the abnormally caudal upper-pole ureteral orifice may result from a ureteric bud arising too high on the mesonephric duct. It may drain at the bladder neck and verumontanum or remain connected to mesonephric (Wolffian) duct derivatives such as the vas deferens in males (Mackie and Stephens, 1977; Schwarz and Stephens, 1978). **In females, the ectopic upper-pole ureter may insert into the remnants of the mesonephric ducts (e.g., Gartner duct cyst) or the vaginal vestibule** (Fig. 20.43; Glassberg et al., 1984).

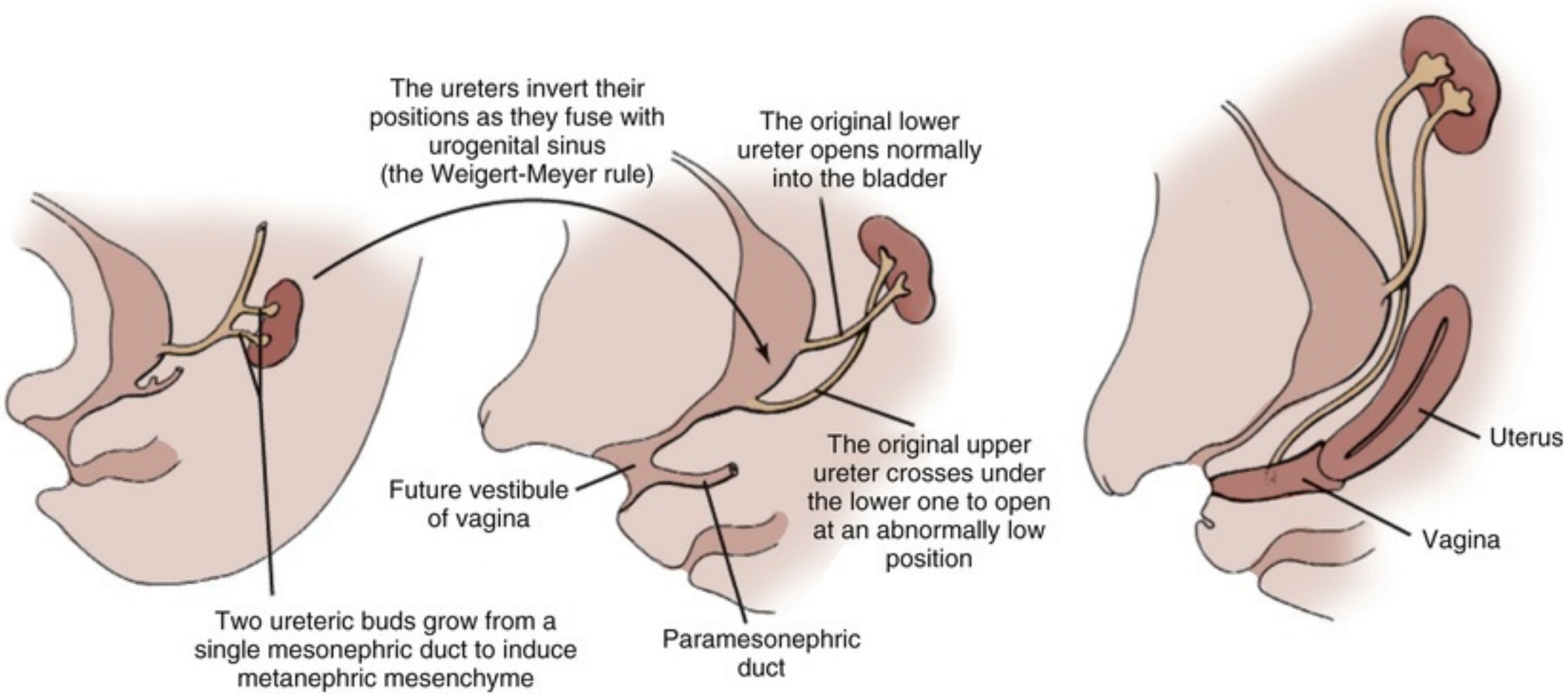
The ureters invert their positions as they fuse with urogenital sinus (the Weigert-Meyer rule)
The original lower ureter opens normally into the bladder
The original upper ureter crosses under the lower one to open at an abnormally low position
Future vestibule of vagina
Two ureteric buds grow from a single mesonephric duct to induce metanephric mesenchyme
Paramesonephric duct
Uterus
Vagina

FIG. 20.43 Embryologic schematic of the Weigert-Meyer rule, in which two ureteric buds grow from a single mesonephric duct to induce the metanephric mesenchyme. The ureters invert their positions as they fuse with the urogenital sinus. The upper-pole ureter crosses under the lower ureter and when ectopic can open into an abnormally low position such as draining into the vagina as illustrated. (Modified from Larsen WJ. *Human embryology.* New York, NY: Churchill Livingstone; 1997.)

Anomalous development of the WD may lead to an ectopic vas deferens. In certain clinical situations, the vas deferens is connected to the ureter rather than the verumontanum so that both the ureter and vas deferens drain into the prostatic urethra via a common duct. This situation may occur when the ureteric bud arises too high on the mesonephric duct and the subsequent common excretory duct becomes too long, resulting in incomplete absorption into the developing bladder (Schwarz and Stephens, 1978). This anomaly, although extremely rare, should be kept in mind when evaluating males with recurrent epididymitis and ipsilateral hydroureteronephrosis.

Development of the Ureter

At approximately 5 weeks' gestation, the stalk of the ureteric bud elongates to become the ureter. Morphologically, the ureter begins as a simple epithelial tube lined with cuboidal cells and surrounded by loose mesenchyme. The epithelium attains transitional differentiation by 14 weeks, whereas urine production has already started at approximately 12 weeks' gestation. The first signs of ureteral muscularization and development of elastic fibers are seen at 12 weeks' gestation. Smooth muscle differentiation is first detected in the subserosal region of the bladder dome and extends toward the bladder base and urethra, whereas smooth muscle differentiation in the ureter occurs later within the subepithelial region of the ureterovesical junction, ascending toward the intrarenal collecting system (Baker and Gomez, 1998). During embryonic ureteral and bladder development, epithelial-mesenchymal interactions are necessary for the induction of smooth muscle (Baskin et al., 1996a; Fig. 20.44). The sonic hedgehog (Shh) pathway is thought to be the key molecular pathway with the Shh expressing urothelium necessary for induction of bladder smooth muscle (Cao et al., 2010). Interestingly, smooth muscle differentiation occurs in subserosal bladder mesenchyme, implying a concentration gradient with higher levels of Shh inhibiting smooth muscle differentiation near the epithelium and lower levels inducing smooth muscle differentiation in more distant positions.

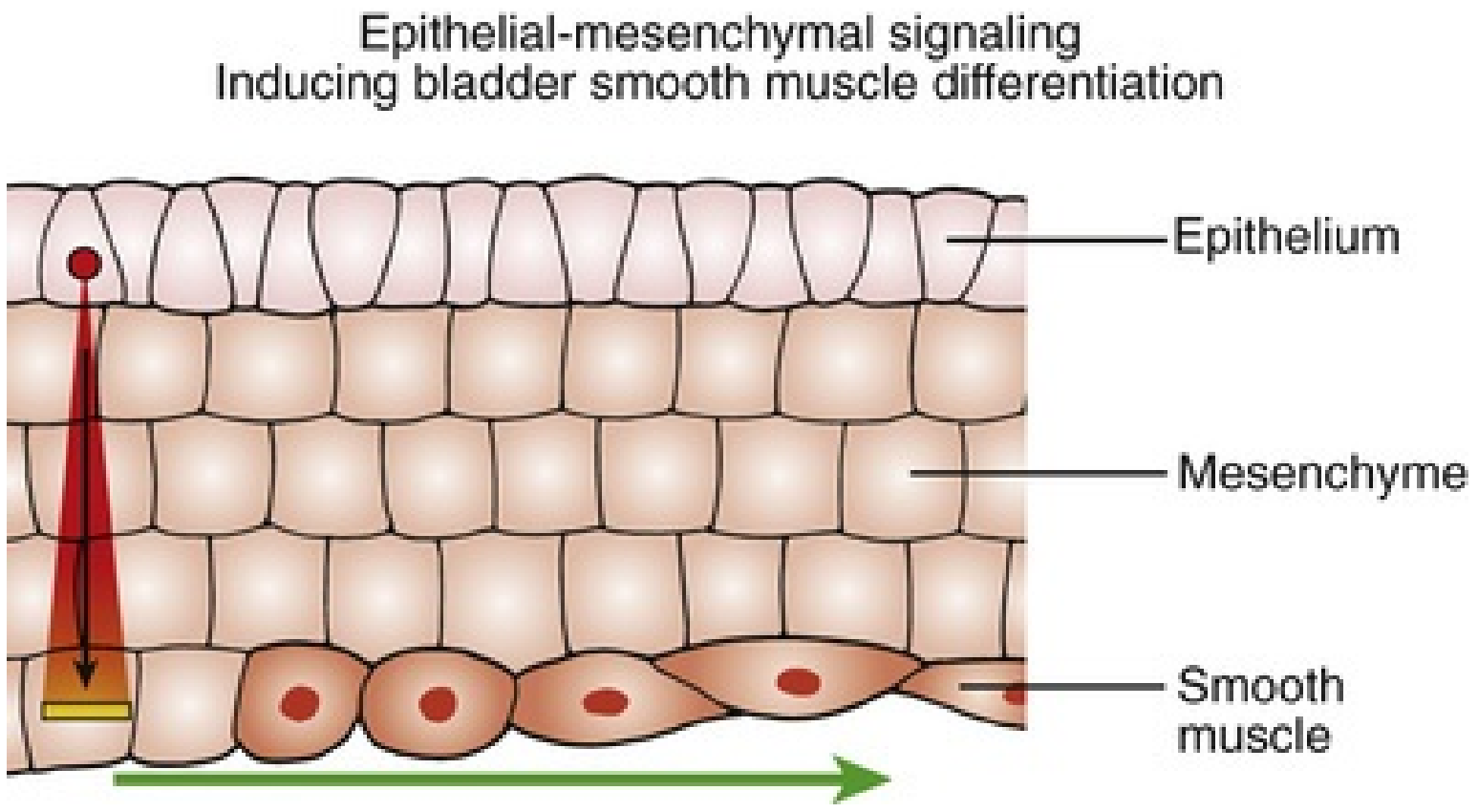
Epithelial-mesenchymal signaling
Inducing bladder smooth muscle differentiation
Epithelium
Mesenchyme
Smooth muscle

FIG. 20.44 Bladder smooth muscle differentiation is dependent on signaling from the urothelium to the bladder mesenchyme through the Sonic Hedgehog pathway. (Modified from Baskin LS, Hayward SW, Young P, Cunha GR. Role of mesenchymal-epithelial interactions in normal bladder development. *J Urol.* 1996;156(5):1820–1827.)

A number of genes have been implicated in congenital ureteral anomalies (Table 20.4). A mutation of the *PAX2* gene has been identified in a human family carrying renal coloboma syndrome, a rare autosomal dominant syndrome characterized by optic nerve coloboma, renal anomalies, and vesicoureteral reflux (Sanyanusin et al., 1996). *EYA1* is mutated in patients with the dominantly inherited disorder, branchio-oto-renal syndrome, which includes a duplex collecting system, renal hypoplasia and dysplasia, and renal agenesis (Abdelhak et al., 1997a). Pax2 is required for the growth and elongation of the mesonephric ducts before ureteric bud formation, whereas Eya1 appears to regulate the GDNF expression, which is a prerequisite for ureteric bud outgrowth. Bmp4 and FoxC1 appear to play a suppressive role in the ureteric bud outgrowth. Evidence suggests that BMPs control formation of smooth muscle in the proximal ureter and pelvis (Haraguchi et al., 2012). BMP4, expressed in the caudal mesenchyme cells, induces ureteral morphogenesis including smooth muscle and urothelial differentiation (Brenner-Anantharam et al., 2007). Consistent with such a role, *Bmp4*- and *Bmp5*-mutant mice display hydronephrosis and hydroureter (Miyazaki et al., 2003).

TABLE 20.4

Clinical Correlation: Selected Gene Mutations Associated With CAKUT Syndromes

SYNDROME	GENE	INHERITANCE	RENAL PHENOTYPES
Alagille	*JAG1* (Notch signaling pathway)	Autosomal Dominant	Agenesis, hypoplasia, cystic dysplasia, UPJ obstruction, VUR
Aniridia-Wilms tumor (WAGR)	*WT1*	Autosomal Dominant	Tumor, nephromegaly
ATR-X	*ATRX*	X-linked	Hypoplasia, agenesis, VUR, hydronephrosis
Branchio-oto-renal	*EYA1*, *SIX1*	Autosomal Dominant	Hypoplasia, VUR
Caudal regression	*VANGL1*	Autosomal Dominant Autosomal Recessive	Agenesis, ectopic kidney, hypoplasia, hydronephrosis, VUR
CHARGE	*CHD7*	Autosomal	Agenesis, hypodysplasia,

		Dominant	hydronephrosis, hydroureter
Cornelia de Lange	*NIPBL*	Autosomal Dominant	Hypoplasia, VUR, pelvic dilation, renal ectopia
Fraser	*FRAS1*, *FREM2*	Autosomal Recessive	Renal agenesis, cystic dysplasia, hypoplasia, hydronephrosis, bladder agenesis
Hypoparathyroidism-deafness-renal	*GATA3*	Autosomal Dominant	Agenesis, hypodysplasia, VUR
Kallmann	*KAL1*, *KAL2*	X-linked or Autosomal Dominant	Unilateral renal agenesis, VUR, cystic dysplasia
Maturity-onset diabetes of the young type V	*HNF1*	Autosomal Dominant	Cystic dysplasia, hypoplasia, glomerulocystic disease, agenesis, oligomeganephronia
Meckel-Gruber	*MKS1–4*	Autosomal Recessive	Cystic dysplasia, hypoplasia
Noonan	*NS1*	Autosomal Dominant	Cystic dysplasia, duplication, hydronephrosis
Okihiro (aero-renal-ocular)	*SALL4*	Autosomal Dominant	Pelvic or horseshoe kidney, hypoplasia, VUR
Pallister-Hall	*GL/3* (Sonic hedgehog signaling pathway)	Autosomal Dominant	Agenesis, hydronephrosis, hydroureter, renal ectopia, horseshoe kidney
Renal coloboma	*PAX2*	Autosomal Dominant	Hypoplasia, VUR, UPJ obstruction
Renal-hepatic-pancreatic dysplasia	*EVC, EVC2*	Autosomal Recessive	Cystic dysplasia
Rubinstein-Taybi	*CBP EP300*	Autosomal Dominant	Unilateral agenesis, cystic hypodysplasia, urethral defects
Roberts	*ESC02*	Autosomal Recessive	Agenesis, hypodysplasia, hydronephrosis
Silverman (dyssegmental dwarfism)	*HSPG2*	Uncertain	Hydronephrosis
Simpson-Golabi-Behmel	*GPC-3*	X-linked	Medullary cystic dysplasia
Smith-Lemli-Opitz	*DHCR7*	Autosomal	UPJ obstruction,

		Recessive	hydronephrosis, VUR, cystic dysplasia
Townes-Brocks	*SALL1*	Autosomal Dominant	Agenesis, hypoplasia, PUV, VUR, meatal stenosis
Zellweger	*PEX*	Autosomal Recessive	Cystic dysplasia, hydronephrosis

CAKUT, Congenital anomalies of the kidney and urinary tract; *PUV*, posterior urethral valves; *UPJ,* ureteropelvic junction; *VUR,* vesicoureteric reflux.

Data from Uy N, Reidy K. Developmental genetics and congenital anomalies of the kidney and urinary tract. *J Pediatr Genet.* 2016;5(1):51–60.

Development of the Bladder and Continence Mechanism

By the 10th week of gestation, the human bladder is a cylindrical tube lined by a single layer of cuboidal cells surrounded by loose mesenchymal tissue. The allantois becomes the urachus that connects the fetal bladder to the yolk sac, which is rudimentary in humans and probably nonfunctional. The apex of the bladder ultimately tapers as the urachus, and by the 12th week the urachus involutes to become a fibrous cord, the *median umbilical ligament.* The bladder epithelium consists of bilayered cuboidal cells between the 7th and 12th weeks and acquires mature urothelial characteristics between weeks 13 and 17. By the 21st week, bladder epithelium becomes four to five cell layers thick and demonstrates ultrastructural features similar to fully differentiated urothelium. Between the 7th and 12th weeks, the surrounding connective tissues condense, and smooth muscle fibers begin to appear, first at the region of the bladder dome and later proceeding toward the bladder base. Collagen fibers first appear in the lamina propria and then later extend into the deeper fibromuscular wall between the muscle fibers (Newman and Antonakopoulos, 1989).

Bladder compliance is thought to change during development. When studied in whole-organ preparations of fetal sheep bladders, bladder compliance is very low during early gestation and increases gradually thereafter (Coplen et al., 1994). The mechanism of these changes in bladder compliance may involve alterations in both smooth muscle tone and connective tissue composition. This phenomenon is also observed in developing human bladders (Kim et al., 1991). During gestation, bladder wall musculature increases in thickness and relative collagen content decreases. The ratio of thick-to-thin collagen fibers also decreases, whereas the amount of elastic fibers increases. These changes in compliance seem to coincide with the time of fetal urine production at approximately 10 weeks' gestation, suggesting a possible role for mechanical distention (Baskin et al., 1994). In organ cultures of fetal mouse bladders, distention promoted a more orderly development of collagen fiber bundles within the lamina propria in comparison with decompressed bladder explants, suggesting that mechanical factors from accumulating urine may play a role during bladder development (Beauboeuf et al., 1998).

No functional study has been done to assess human fetal continence mechanisms. Only a handful of ontogenic descriptions are available using human fetal specimens, providing a basis for speculative theories (Tanagho and Meyers, 1969; Yucel and Baskin, 2004). A mesenchymal condensation forms around the caudal end of the UGS after division of the cloaca and rupture of the cloacal membrane. Striated muscle fibers can be seen clearly by the 15th week. At this time, the smooth muscle layer becomes thicker at the level of bladder neck and forms the inner part of the urethral sphincter, which is composed of smooth muscle fibers centrally and striated muscle fibers peripherally (Bourdelat et al., 1992). Subsequently, sexual dimorphism comes into play with the formation of the prostate gland in males and the vagina in females (Tichy, 1989). The urethral sphincter muscle fibers extend posteriorly, projecting to the lateral wall of the prostate or to the lateral wall of the vagina.

Clinical Correlation: Vesico-ureteral Reflux

Vesicoureteral reflux occurs in 1 : 500 to 1 : 1000 births. The majority of vesicoureteral reflux is of no clinical consequence. More severe reflux in the setting of urinary tract infection is a risk factor for pyelonephritis (RIVUR Trial Investigators et al., 2014). The mechanism of reflux is a relatively short intramural ureteral tunnel that lacks sufficient muscle to facilitate the normal unidirectional passage of urine from the kidneys into the bladder. During normal bladder growth, ureteral valves often gain additional musculature, hence the high rate of spontaneous resolution of moderate and low grades of vesicoureteral reflux (Tanagho and Hutch, 1965). **In higher grades of reflux, the abnormal ureteral bud inappropriately signals the metanephric mesenchyme leading to renal dysplasia with reflux most likely an associated but noncausal phenomenon** (Mackie and Stephens, 1977).

Clinical Correlation: Bladder Exstrophy

Bladder exstrophy occurs in approximately 1 : 30.000 live births, with cloacal exstrophy being even less common at approximately 1 : 300,000 newborns (1987). Exstrophy of the bladder is characterized by a lower abdominal wall defect and separation of the pubic symphysis in which the anterior aspect of the bladder is open to the environment along with an open prostatic urethra and dorsal aspect of the penis (epispadias; Beaudoin et al., 1997). The trigone of the bladder and verumontanum in the prostate are visible on physical examination and the hemicorporal bodies. Embryologically, exstrophy of the bladder is caused by incomplete closure of the inferior aspect of the anterior abdominal wall and anterior bladder wall. Exstrophy of the bladder is thought to be secondary to failure of mesechymal cells to migrate between the ectoderm of the abdomen and endoderm of the cloaca during the fourth week of gestation. This results in absence of the inferior parts of the rectus abdominis muscle, external and internal oblique muscles, and transverse abdominis muscles. The thin epidermis and anterior wall of the bladder rupture, causing an open anterior bladder wall defect (Ambrose and O'Brien, 1974).

Clinical Correlation: Urachal Anomalies

In the adult, the urachus becomes a thick fibrous cord called the *median umbilical ligament*. If any remnant of the urachal lumen persists, anomalies of the urachus can occur such as a cyst (which often presents with infection), sinus (patency with the bladder), or fistula (complete patency with urine draining from the umbilicus). Treatment consists of excising retained patent structures (Mesrobian et al., 1997). Prophylactic excision of an incidentally found urachal anomaly does not appear warranted because the risk for malignancy later in life is remote and a large number of urachal anomalies would need to be removed to prevent a single case of urachal adenocarcinoma (Gleason et al., 2015).

Clinical Correlation: Duplication Anomalies

The ureter arises during the fourth week of embryonic development from the mesonephric, or Wolffian, duct. In ureteral duplication, the ureteric bud divides into two ureters resulting in two separate collecting systems for the kidney (Tanagho, 1976). This occurs in approximately 1% of the population, and most of the time the ureteral duplication is of no clinical consequence with both ureters either entering the bladder in their normal position in the trigone or connecting outside the bladder, the so-called *Y duplication*. **Ureteral**

duplication can be an issue when the upper-pole ureter does not insert into the bladder but instead into an ectopic site (see later) or the upper-pole ureter is blocked by a diverticulum within the bladder, a so-called *ureterocele* (see later).

Clinical Correlation: Ectopic Ureter

An ectopic ureter is defined as opening anywhere except into the trigone of the urinary bladder. In males, an ectopic ureter usually inserts into bladder neck or prostatic urethra but may also may insert into the vas deferens or seminal vesicle. In females, an ectopic ureter may insert into the bladder neck, the urethra, or the Gartner's duct and vaginal vestibule. In the latter two cases, these girls may present with persistent incontinence (Williams, 1954). Embryologically, an ectopic ureter results from the ureter not being incorporated into the posterior part of the urinary bladder. Instead it is carried caudally with the mesonephric duct and is incorporated into the caudal portion of the UGS. The caudal portion of the UGS becomes the prostatic urethra in males and the vagina in females, hence the explanation for the typical location of ectopic ureters.

Clinical Correlation: Ureterocele

Ureteroceles are saclike structures or diverticula of the distal ureter that can obstruct the flow of urine from the kidney to the bladder (Tanagho, 1972; Coplen and Duckett, 1995). They are most common in duplex systems affecting the upper-pole ureter but can also occur in single systems. It is possible that ureteroceles are a continuum with ectopic ureters, with pseudo-ureterocele being in between. The embryologic explanation of a ureterocele is controversial but thought to be secondary to a transient obstruction (Tanagho, 1972).

Key Points: Bladder/Ureteral Development

- The bladder and urethra develop from the endodermal urogenital sinus, which derives from the ventral portion of the cloaca after it becomes subdivided by the urorectal septum.
- Cell lineage studies have shown that the fibromusculature wall of the trigone is formed from bladder smooth muscle cells with only a minor

contribution from ureteric smooth muscle.

- According to the Weigert and Meyer rule, the upper-pole ureteral orifice rotates dorsally relative to the lower-pole orifice and assumes a more caudal and medial position with less chance of reflux.
- Ureteral duplication can be an issue when the upper-pole ureter does not insert into the bladder but instead in an ectopic site, or the upper-pole ureter is blocked by a diverticulum within the bladder, a so-called *ureterocele*.
- In females, ectopic ureters may insert into the bladder neck, urethra, or vaginal vestibule. In the latter two cases, these girls may present with persistent incontinence.

Kidneys

The kidneys develop in identical fashion regardless of sex (Fig. 20.45). Fetal lobulations are prominent as development progresses (Fig. 20.46). Note the increase in length and width of the fetal kidneys over time. The kidney shows a bifid ureter at 14 weeks' gestation, a variation of normal development in which the upper and lower poles have separate ureters that connect into a single ureter, in this case at the lower pole of the kidney (Moore et al., 2016). In humans, multiple normal variations of normal ureteral development have been described with bifid ureters as seen in Fig. 20.45 and complete ureteral duplication.

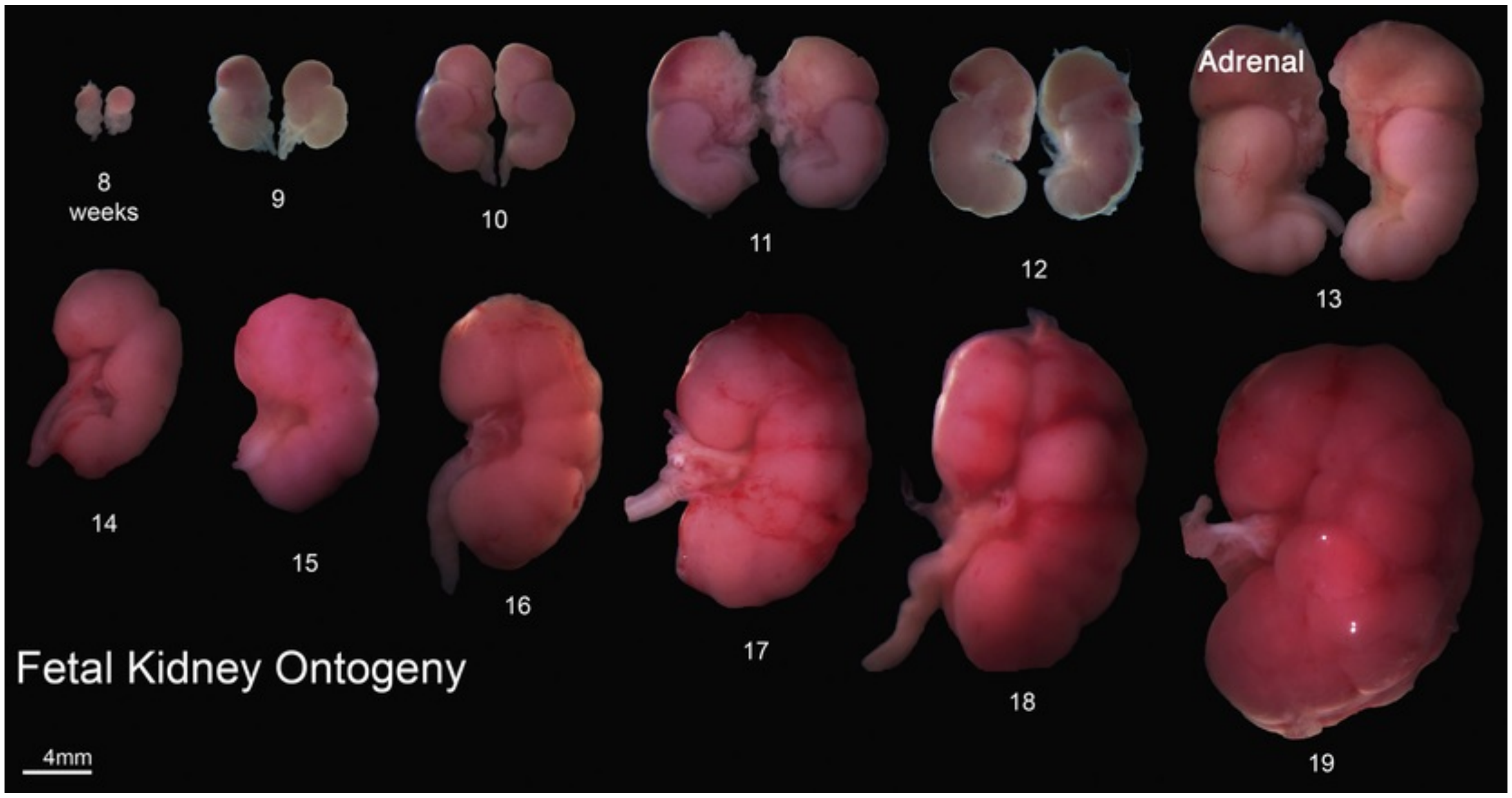

FIG. 20.45 Whole-mount photographs of human fetal kidneys (8 to 19 weeks' gestation). Note the progressive increase in renal size over time and well-visualized fetal lobulations (starting at 12 weeks' gestation). The adrenal gland can be seen capping the upper pole of the fetal kidney in the 8- to 13-week specimens. Relative sizes of specimens are not exact, but increase with age.

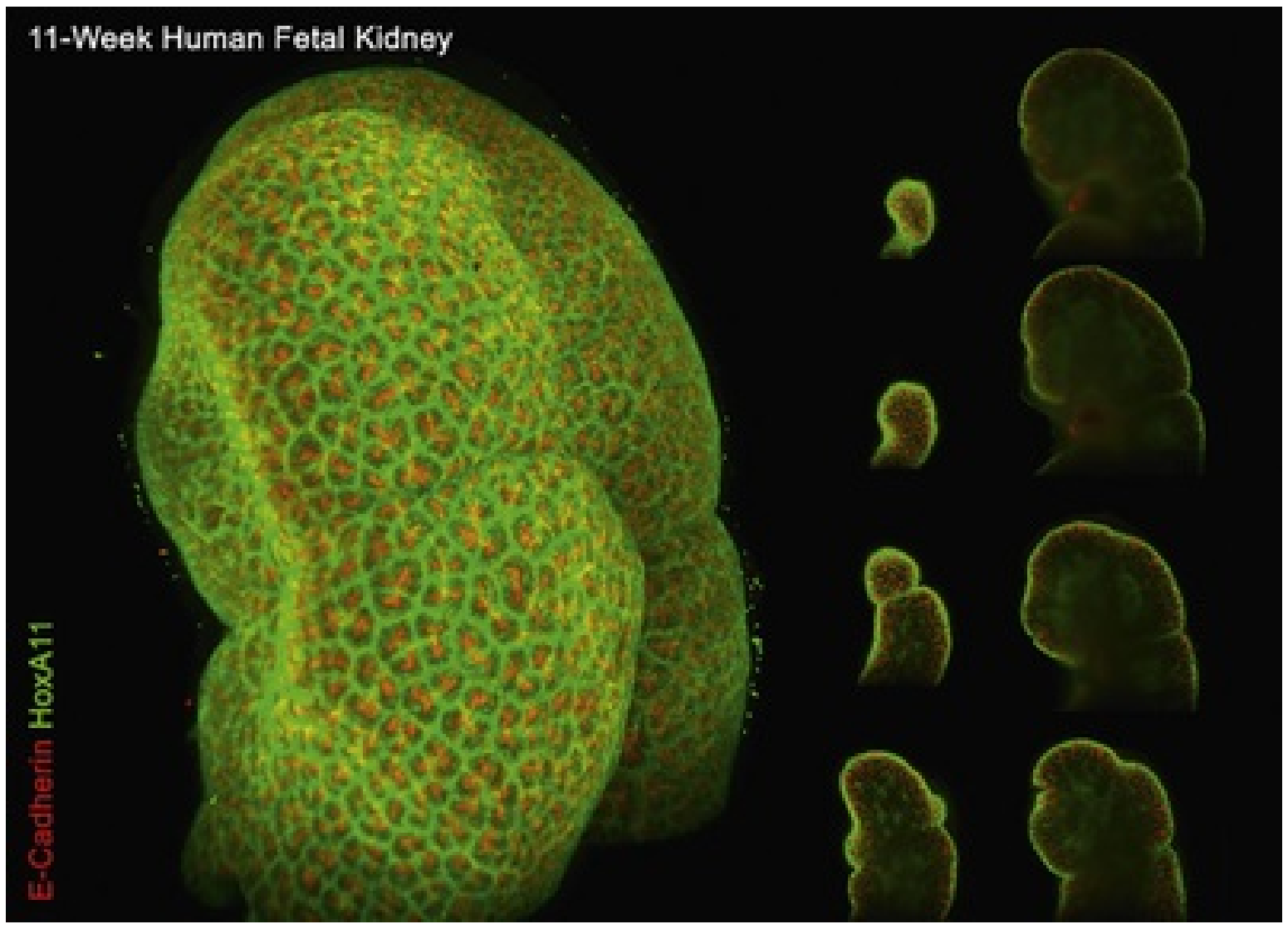

FIG. 20.46 An 11-week human fetal kidney stained for metanephric mesenchyme-expressed HoxA11 *(green)* and E-cadherin *(red)* imaged using lightsheet fluorescence microscopy. Individual optical sections *(left)* are reconstructed into full three-dimensional volume *(right).*

Early Events in Kidney Development

Mammals develop three sets of kidneys in the course of intrauterine life (Fanos et al., 2015; Moore et al., 2016; Pietila and Vainio, 2014; Ryan et al., 2018). **The embryonic kidneys are, in order of their appearance, the *pronephros*, the *mesonephros*, and the *metanephros*.** The first two kidneys regress completely (pronephros) or partially (mesonephros) in utero, and the third becomes the permanent kidney. **Embryologically, all three kidneys develop from the intermediate mesoderm.** As the notochord and neural tube develop, the mesoderm located on either side of the midline segregates into three subdivisions: *paraxial (somites)*, *intermediate*, and *lateral plate mesoderm*. As the embryo undergoes transverse folding, the intermediate mesoderm separates from the paraxial mesoderm and migrates ventrally to the dorsal wall of the intraembryonic coelom (the future abdominal cavity). At this time, there is a progressive craniocaudal development of the bilateral longitudinal mesodermal masses, called *nephrogenic* cords. Each cord bulges from the posterior wall of the coelomic cavity, producing the paired urogenital ridges. The gonadal ridge, discussed earlier, is located on the medial aspect of the urogenital ridge.

Pronephros and Mesonephros

The mammalian *pronephros* is a transitory, nonfunctional kidney analogous to that of primitive fish. In humans, the first evidence of the pronephros is seen late in the third week, and it completely degenerates by the start of the fifth week. Development of the pronephric tubules/vesicles starts at the cranial end of the nephrogenic cord in the thoracic region and progresses caudally. This craniocaudal wave of pronephric tubule/vesicle formation is followed immediately by craniocaudal degeneration of the pronephric tubules (Fig. 20.47A). Formation of pronephric tubule/vesicle formation involves a mesenchymal-to-epithelial conversion. The significance of the pronephros is the generation of the pronephric duct that grows caudally within the urogenital ridge. As the pronephric tubules degenerate, the retained pronephric duct becomes the mesonephric duct as it grows caudally into the domain of mesonephric tubule development. This simply involves a name change.

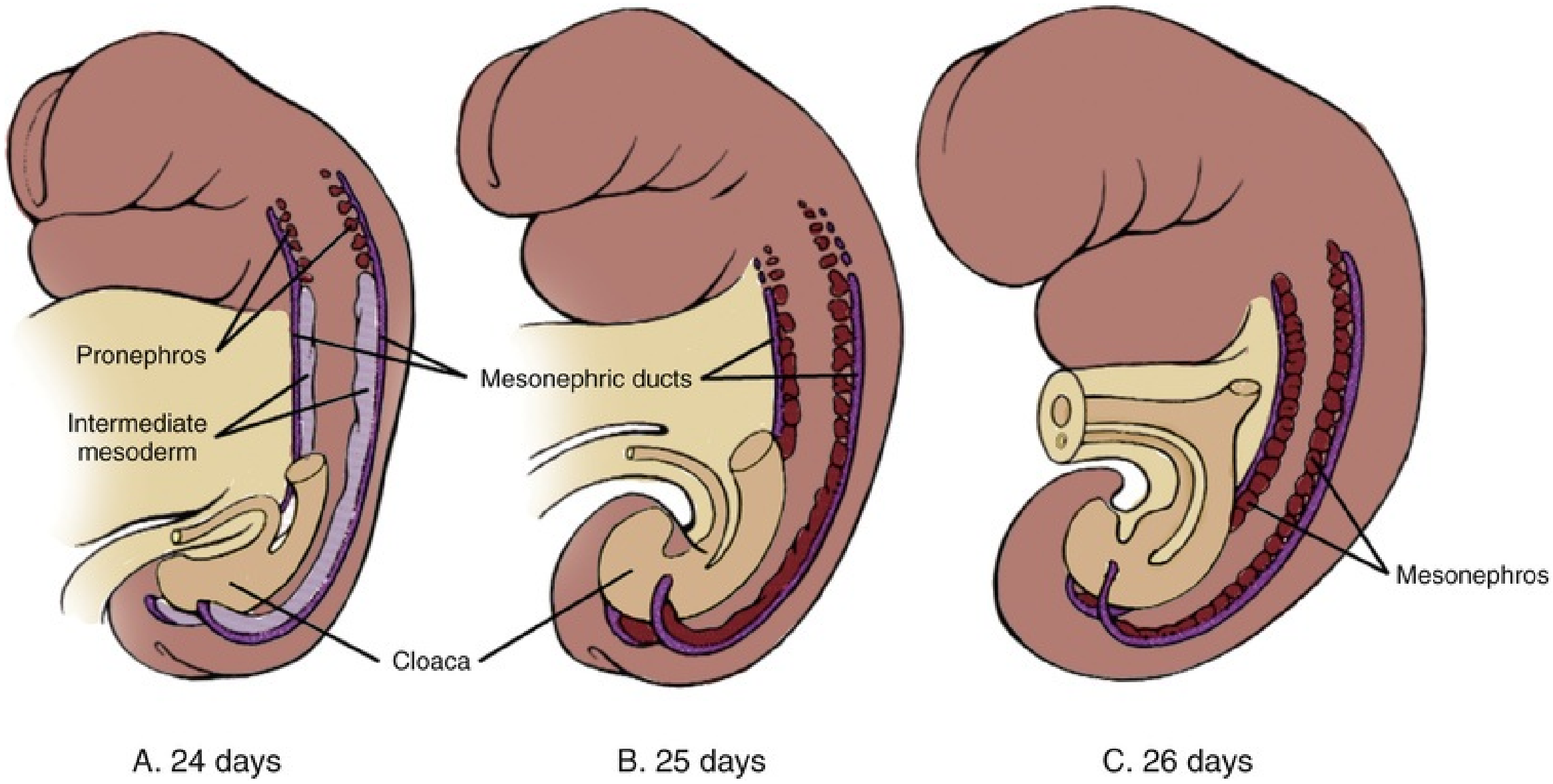

FIG. 20.47 Development of pronephros and mesonephros. (A) Pronephros develops in each of five to seven cervical segments, but this primitive renal structure degenerates quickly during the fourth week. The mesonephric ducts first appear on day 24. (B and C) Mesonephric vesicles and tubules form in a craniocaudal direction throughout the thoracic and lumbar regions. The cranial pairs degenerate as caudal pairs develop, and the definitive mesonephros contains about 20 pairs confined to the first three lumbar segments. (Modified from Larsen WJ. *Human embryology.* New York, NY: Churchill Livingstone; 1997.)

The second kidney, the *metanephros,* is also transient, but in higher vertebrates the metanephros serves as an excretory organ for the embryo while the definitive kidney, the *metanephros*, begins its development (see Fig. 20.47BC). As the bilateral *mesonephric ducts* (also called *Wolffian ducts*) extend caudally into the mesonephric mesenchyme within the urogenital ridge, mesonephric tubules are induced that join the paired mesonephric ducts. In total, approximately 40 mesonephric tubules form (see Fig. 20.31). The mesonephric (Wolffian) ducts extend caudally and eventually terminate by joining with the epithelium of the cloaca.

Formation of mesonephric tubules begins in the fourth week and involves the condensation of mesenchyme to form dense aggregates that in turn convert into epithelial vesicles. These vesicles subsequently elongate to form tortuous (initially *S*-shaped) tubules that join the mesonephric ducts. The formation of mesonephric tubules progresses from cranial to caudal and results in the formation of approximately 40 pairs of mesonephric tubules. Only a maximum of approximately 30 pairs of mesonephric tubules are seen at any one time as cranially tubules start to degenerate starting at about the fifth week before the most caudal tubules form (see Fig. 20.31). By the fourth month, the human mesonephros has degenerated, except for a few elements that persist into maturity as part of the male reproductive tract. In males, some of the cranially located mesonephric tubules become the efferent ducts of the testes. The paradidymis consists of retained mesonephric tubules near the head of the epididymis. In females, remnants of cranial and caudal mesonephric tubules form small, nonfunctional epithelial cysts residing within the broad ligament of the uterus, termed the *epoöphoron* and *paroöphoron* (see Table 20.3). As discussed earlier, residual segments of the mesonephric (Wolffian) duct are frequently found within the fibromuscular wall of the vagina.

Metanephros

The definitive kidney, or the *metanephros*, initially forms in the sacral region as *ureteric buds* sprout from the caudal portion of the mesonephric duct and come in contact with condensing *(metanephric mesenchyme)* at about the 4 weeks' gestation (Fig. 20.48). The ureteric bud elongates cranially into the metanephric mesenchyme and begins to branch dichotomously. The tip of the branching ureteric bud, called the *ampulla,* induces the metanephric mesenchyme to condense and to convert into epithelial vesicles. As the ureteric bud divides and branches, each new ampulla acquires a caplike condensation of metanephric mesenchyme that undergoes a mesenchymal-to-epithelial transition (see Fig.

20.45).

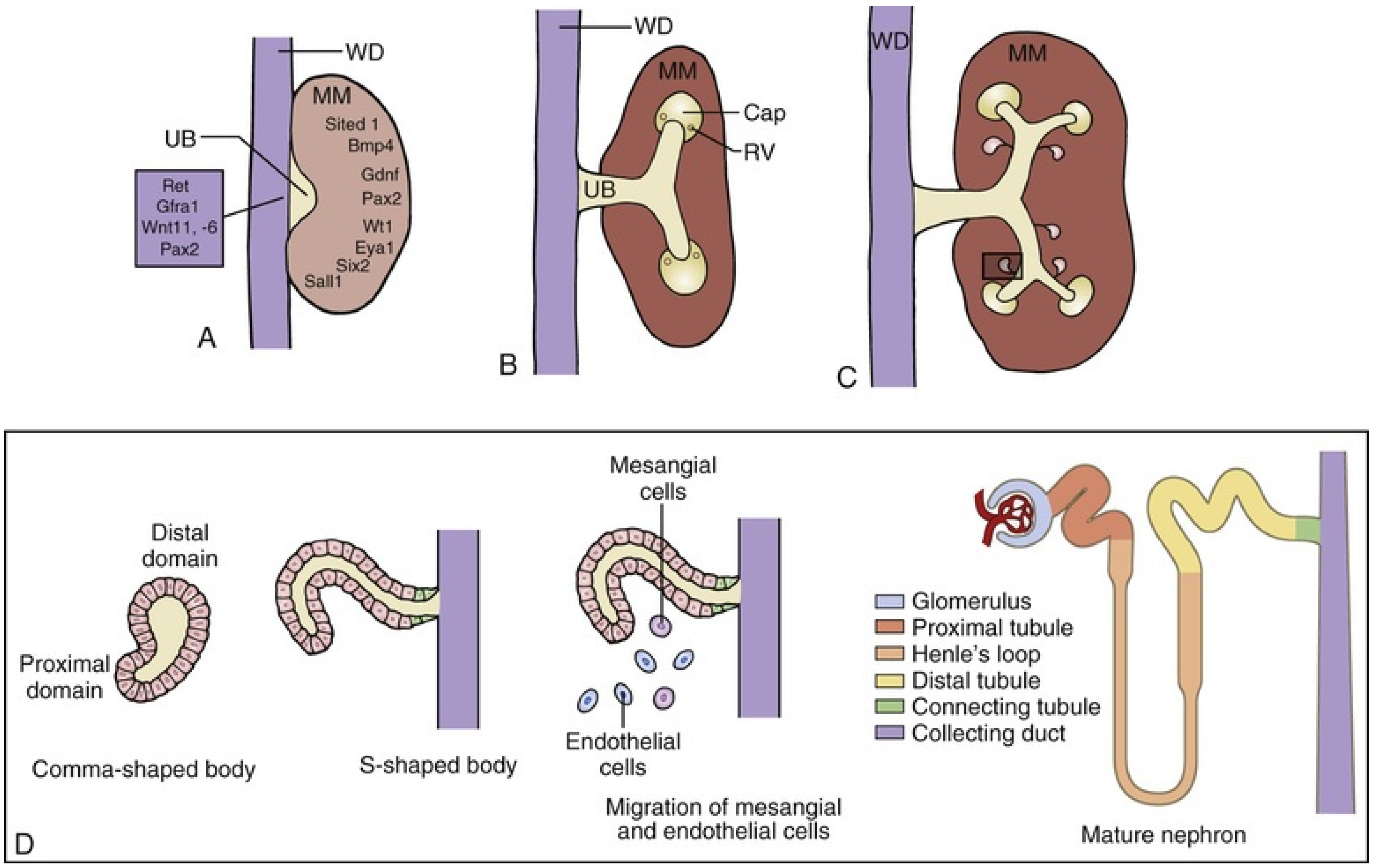
WD
UB
MM
Sited 1
Bmp4
Gdnf
Pax2
Wt1
Eya1
Six2
Sall1
Ret
Gfra1
Wnt11, -6
Pax2
A
WD
MM
Cap
RV
UB
B
WD
MM
C
Distal
domain
Proximal
domain
Comma-shaped body
S-shaped body
Mesangial
cells
Endothelial
cells
Migration of mesangial
and endothelial cells
Glomerulus
Proximal tubule
Henle's loop
Distal tubule
Connecting tubule
Collecting duct
Mature nephron
D

FIG. 20.48 Development of the metanephros (kidney). (A) Key factors in kidney development involve interplay between secreted signals and transcription factors both in the ureteral bud *(UB)* that is derived from the Wolffian duct *(WD)* and the kidney metanephric mesenchyme *(MM).* (B) The ureteral bud enters the kidney mesenchyme and makes the first *t*-type branch. At the same time, the ureteral bud induces the condensation of metanephric mesenchyme cells to form a cap of mesenchyme. Cap metanephric mesenchyme cells contain the progenitors/stem cells of the nephrons. (C) The sequential and reciprocal tissue interactions between the ureteral bud and the metanephric mesenchyme advance kidney morphogenesis–inducing nephrons. (D) The nephron becomes segmented into the glomerulus, proximal tubules, loop of Henle, distal tubule, connecting tubule, and collecting duct. The collecting duct drains the concentrated urine to the renal pelvis and from there via the ureter to the bladder. (Modified from Pietila I, Vainio SJ. Kidney development: an overview. *Nephron Exp Nephrol.* 2014;126[2]:40.)

The ureteric bud and metanephric mesenchyme exert reciprocal inductive effects on each other, and proper differentiation of these primordial structures depends on these reciprocal inductive signals (Fanos et al., 2015; McMahon, 2016; Pietila and Vainio, 2014; Reidy and Rosenblum, 2009; Uy and Reidy, 2016). **The metanephric mesenchyme induces the ureteric bud to elongate**

and branch (Cebrian et al., 2004), **and in turn the ureteric bud induces the metanephric mesenchyme to condense and undergo mesenchymal-epithelial conversion to form metaphoric tubules that will differentiate into nephrons.** The initially induced epithelial vesicles elongate and in turn form *S*-shaped structures, and further growth and elongation generates the complex elements of the nephron (the glomerulus, proximal convoluted tubule, loop of Henle, and distal convoluted tubule), all of which are derived from the metanephric mesenchyme. The urine collecting system, consisting of collecting ducts, calyces, pelvis, and ureter, is formed from the ureteric bud (see Fig. 20.48). Urine production by the metanephric kidney begins in the 10th week of gestation.

All metanephric nephrons are formed in the same way, and the overall process involves fairly well-defined developmental stages (Larson et al., 1983; Saxen and Sariola, 1987). The metanephric mesenchyme first condenses to form a four- to five-cell layered dense mesenchymal condensate around the ampulla of the advancing ureteric bud. Near the interface of the ampulla and its adjacent ureteric branch, a cluster of cells separates from a mesenchymal condensate and forms an oval mass called a *pretubular aggregate that undergoes mesenchymal-to-epithelial conversion.* An internal cavity forms within the epithelializing pretubular aggregate, at which point the structure is called the epithelial *renal vesicle* (stage I). Cells of the stage I renal vesicles are tall columnar and are stabilized by attachment to a newly formed basement membrane. The *renal vesicles* elongate to form a comma-shaped body that is in turn converted to an *S*-shaped body, one end of which establishes connection with the distal tip of a ureteric branch. Multipotential precursors residing within renal vesicles ultimately give rise to all epithelial cell types of the nephron (Herzlinger et al., 1992). Nephron segmentation into glomerular and tubular domains is initiated by the sequential formation of two clefts within the renal vesicle (stage II; upper and lower clefts). Creation of a lower cleft, termed the *vascular cleft*, precedes formation of a comma-shaped body. Generation of an upper cleft in the comma-shaped body precedes formation of an *S*-shaped body. At this stage, the cup-shaped glomerular capsule is recognized in the lowest limb of the *S*-shaped tubule. Epithelial cells lining the inner wall of this cup will compose the visceral glomerular epithelium, or podocyte layer. Cells lining the outer wall of the cup will form parietal glomerular epithelium, which lines the Bowman capsule. The glomerular capillary tuft is formed via recruitment and proliferation of endothelial and mesangial cell precursors. The rest of the *S*-shaped tubule develops into the proximal convoluted tubule, the loop of Henle, and the distal convoluted tubule. When the cup-shaped glomerular capsule matures into an oval structure, the nephron has now passed into stage III of development. Now the nephron can be divided into identifiable proximal and distal convoluted tubules. The stage IV nephron is characterized by a round glomerulus that closely resembles the mature renal corpuscle. The morphology of the proximal convoluted tubule resembles that of a mature nephron, whereas the distal segments are still primitive. In humans, all nephrons at birth are in varying steps of stage IV. Mesenchymal cells that do not become tubular epithelium give rise to interstitial stromal cells, which differentiate into a diverse population including fibroblasts, lymphocyte-like cells, and pericytes. Overall, these events are reiterated throughout the growing kidney so that older, more differentiated nephrons are located in the inner part of the kidney near the juxtamedullary region and newer, less differentiated nephrons are found at the cortex. In humans, although renal maturation continues to take place postnatally, nephrogenesis is essentially complete before birth at around 32 to 34 weeks' gestation (Pietila and Vainio, 2014; McMahon, 2016).

Collecting System

The dichotomous branching of the ureteric bud determines the eventual pelvicalyceal patterns and their corresponding renal lobules (Cebrian et al., 2004; see Fig. 20.48). In humans, the first nine branch generations are formed by approximately 15 weeks' gestation. By 20 to 22 weeks, ureteric bud branching is completed. Thereafter, collecting duct development occurs by extension of peripheral branch segments. Between 22 and 24 weeks' fetal gestation in humans, the peripheral (cortical) and central (medullary) domains of the developing kidney are established. The renal cortex, which represents 70% of total kidney volume at birth, becomes organized as a relatively compact, circumferential rim of tissue on the periphery of the kidney. The renal medulla, which represents 30% of total kidney volume at birth, has a modified cone shape with a broad base contiguous with cortical tissue. The apex of the cone is formed by convergence of collecting ducts in the inner medulla to form the *renal pyramids and papilla that project into the minor calyces.* Two to three minor calyces converge to form three to four major calyces that in turn empty into the renal pelvis. Distinct morphologic differences emerge between collecting ducts located in the medulla compared with those located in the renal cortex.

Medullary collecting ducts are organized into elongated linear arrays that converge centrally in a region devoid of glomeruli. In contrast, collecting ducts located in the renal cortex continue to branch and induce metanephric mesenchyme. The most central segments of the collecting system, formed from the first five generations of ureteric bud branching, undergo remodeling by increased growth and dilation of these tubules to form the calyces and renal pelvis.

Molecular Mechanisms of Kidney Development

The details of inductive interactions among metanephric mesenchyme, the branching ureteric bud, and more recently the stroma are becoming clearer and provide insight into the complex regulatory mechanisms underlying renal development (Bekheirnia et al., 2017; Capone et al., 2017; Uy and Reidy, 2016). Formation of renal tubules and the collecting system occurs sequentially and requires dynamic interactions among epithelial, mesenchymal, and stromal cells. Many of the early events in embryonic kidney development were first elucidated by manipulating lower vertebrate embryos and by using an in vitro organ culture system. Grobstein's pioneering work in the 1950s led to an organ culture technique (Grobstein, 1956) whereby the metanephric mesenchyme is separated from the ureteric bud during the early part of kidney development and grown in vitro on a filter. An inducer tissue, such as ureter or spinal cord, cultured on the opposite side of the filter provided the inductive signal. This ingenious experimental approach has established the kidney as a model system for studying the role of epithelial-mesenchymal interaction in organogenesis. **The development of many other organs, including lung, salivary glands, mammary glands, gonads, prostate, and bladder, also require epithelial-mesenchymal interactions for the controlled differentiation and proliferation of tissues** (Baskin et al., 1996a; Cunha, 1985).

Formation of Nephric Ducts

The first recognizable event in renal development is formation of pronephric ducts within the intermediate mesoderm. The early intermediate mesoderm destined to become nephric ducts is distinguished by expression of the transcription factors LIM1, PAX2, and SIM1, but only LIM1 appears to be absolutely essential for nephric duct formation (Shawlot and Behringer, 1995).

PAX2 may be important for maintaining other marker gene expression in the nephric ducts (Torres et al., 1995). Available data suggest a model in which few opposing secreted factors from the surrounding tissues cumulatively restrict LIM1 expression to the intermediate mesoderm. LIM1 then activates PAX2 expression to further orchestrate the formation of nephric ducts.

Ureteric Bud Outgrowth Into Metanephric Mesenchyme

The outgrowth of the ureteric bud from the mesonephric duct and its invasion into the condensing blastema of metanephric mesenchyme is a crucial initiating event in the development of the adult kidney *(metanephros)*. Many candidate genes have been identified to play a critical role in this process (Brunskill et al., 2008; McMahon, 2016; Pietila and Vainio, 2014). In particular, several lines of evidence have revealed a crucial role of the RET-GDNF-GFRα1 pathway in the ureteric bud outgrowth. Glial cell line–derived neurotrophic factor (GDNF) is a secreted peptide expressed in the metanephric mesenchyme that activates the RET receptor, which is expressed in the mesonephric duct. GDNF activation of RET requires the glycosylphosphatidylinositol (GPI)-linked protein GFRα1, which is expressed in both metanephric mesenchyme and the mesonephric duct (see Fig. 20.48). Gene knockout mutations in *Ret, GDNF* (Moore et al., 1996; Pichel et al., 1996; Pietila and Vainio, 2014), and *GFRα1* (Cacalano et al., 1998) inhibit ureteric bud outgrowth. In organ culture systems, recombinant GDNF is sufficient to induce ectopic ureteric bud outgrowth (Sainio et al., 1997). However, the competence of the mesonephric duct to respond to GDNF is restricted along its anteroposterior axis. This anteroposterior restriction might be mediated by suppressors of RET signaling within the surrounding tissue, such as bone morphogenetic protein-4 (BMP4). In organ culture, BMP4 can suppress the activity of GDNF to induce ectopic ureteric bud formation (Brophy et al., 2001). Proper location of ureteric bud formation is also controlled by the localized expression of GDNF within the metanephric mesenchyme. Both positive and negative regulators have been described for GDNF localization. Homozygous mutation of transcription factor Eya1 causes failure of ureteric bud outgrowth and a resultant lack of GDNF expression in metanephric mesenchyme, suggesting that Eya1 regulates GDNF expression (Xu et al., 1999). In humans, haploinsufficiency of Eya1 results in a dominantly inherited disorder called *branchio-oto-renal syndrome,* which involves kidney and urinary tract anomalies

(Abdelhak et al., 1997b; Brophy et al., 2001). Expression of PAX2 in the metanephric mesenchyme is also required for GDNF activation (Brophy et al., 2001). GDNF expression is also suppressed at the anterior boundary of the metanephric mesenchyme through the concerted action of the FoxC1 and FoxC2 transcription factors (Kume et al., 2000). Mutations in either *Fox* gene result in an expansion of GDNF expression and the formation of ectopic ureteric buds. Most *FoxC1* homozygous mutants have duplex kidneys, in which the upper ureter is dilated and connects aberrantly to mesonephric duct derivatives in males such as seminal vesicles and vas deferens. In the developing kidneys, *Slit2* is primarily expressed in the mesonephric duct, whereas *Robo2* is expressed in the metanephric mesenchyme (Piper et al., 2000). Mice deficient in *Slit2* or *Robo2* exhibit ectopic ureteric bud formation, multiple ureters and hydroureter, and anterior expansion of GDNF expression (Grieshammer et al., 2004). SPRY1 negatively regulates GDNF-RET signaling. Loss of *Spry1* function in mice results in renal malformations, including multiple ureters, duplex kidneys and hydroureter, and increased expression of GDNF in the metanephric mesenchyme (Basson et al., 2006). The data therefore suggest that multiple factors regulate, both positively and negatively, the precise timing and localization of GDNF, which then functions as a guidance cue to activate RET, which is required for proper development and patterning of the metanephric kidney.

In humans (and mice), congenital anomalies of the kidney and urinary tract (CAKUT) are associated with mutations in these transcription factors and signaling pathways that are required for normal nephron differentiation (Takasato and Little, 2015; Uy and Reidy, 2016; Marciano, 2017). For example, multiple transcription factors (including Hox11, Eya1, Pax2, Six1, Six2, Osr1, and Sall1) regulate the balance between differentiation and maintenance of the nephron progenitors. Wnt signaling is also required for differentiation into the renal vesicle. HNF1B and Notch signaling contribute to the specification of the proximal tubules and terminal nephron differentiation (Fig. 20.49).

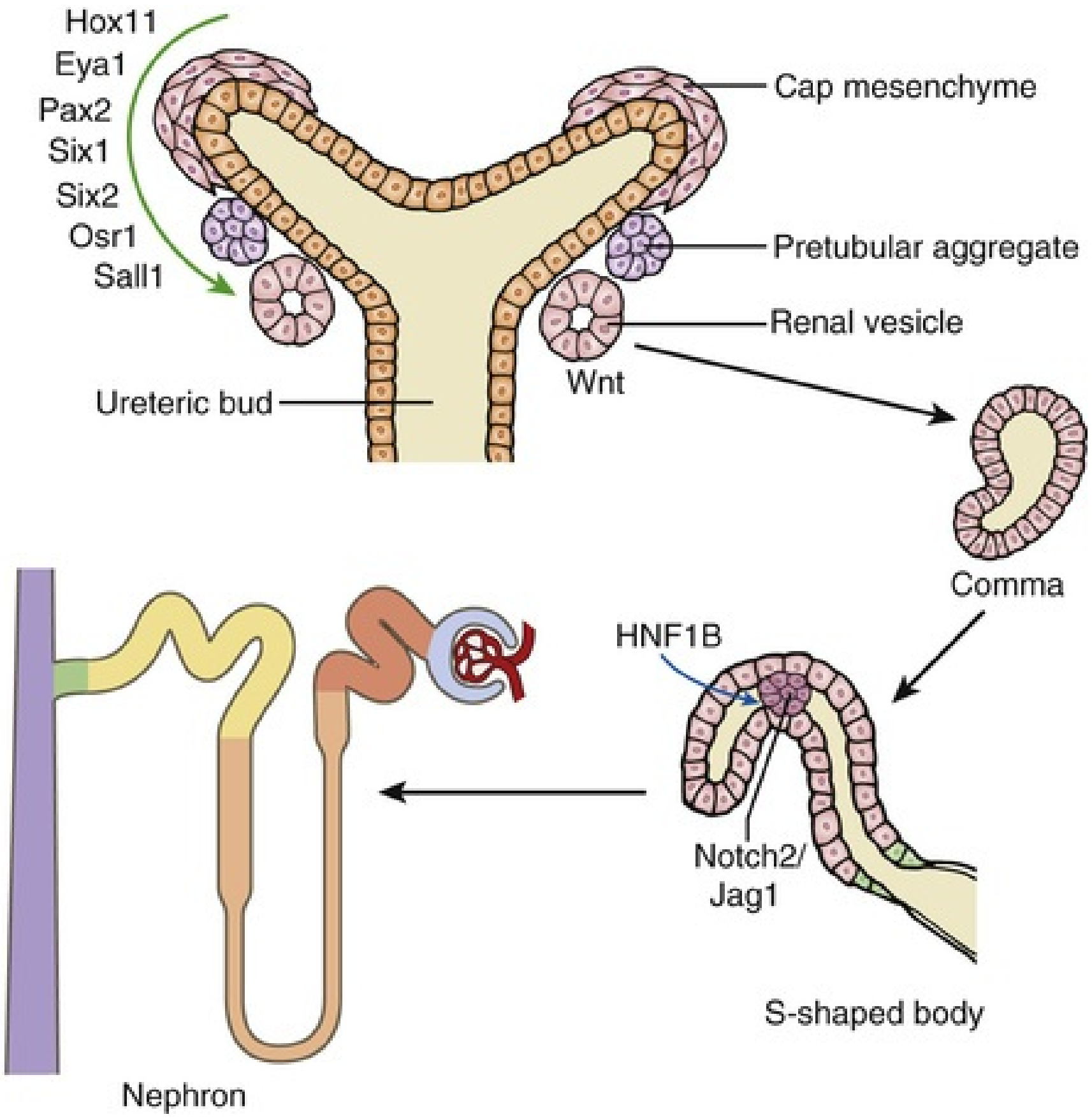
Hox11
Eya1
Pax2
Six1
Six2
Osr1
Sall1
Cap mesenchyme
Pretubular aggregate
Renal vesicle
Wnt
Ureteric bud
Comma
HNF1B
Notch2/
Jag1
S-shaped body
Nephron

FIG. 20.49 Congenital abnormalities of the kidney and urinary tract (CAKUT) are associated with mutations in transcription factors (including Hox11, Eya1, Pax2, Six1, Six2, Osr1, and Sall1) that regulate the balance between differentiation and maintenance of the nephron progenitors. Multiple gene pathways such as Wnt signaling are also required for differentiation into the renal vesicle. HNF1B and Notch signaling contribute to the specification of the proximal tubules and terminal nephron differentiation. (Modified from Uy N, Reidy K. Developmental genetics and congenital anomalies of the kidney and urinary tract. *J Pediatr Genet.* 2016;5[1]:51–60.)

Ureteric Bud Branching

Once the ureteric bud has contacted the metanephric mesenchyme, it undergoes a dichotomous branching morphogenesis (Cebrian et al., 2004; Costantini and Kopan, 2010). Many of the same factors that regulate the initial outgrowth of the ureteric bud also appear to be essential for the subsequent branching of the ureteric bud. Ureteric bud branching is positively regulated by genetic and nutritional factors. PAX2, a paired-box–type transcription factor that is mutated in humans with renal coloboma syndrome, is a positive regulator of ureteric bud branching. During renal development, *Pax2* is expressed in the mesonephric duct, ureteric bud, and metanephric mesenchymal aggregates induced by ureteric bud branch tips (see Fig. 20.48). Mice with a *Pax2* mutation exhibit decreased ureteric bud branching and renal hypoplasia (Porteous et al., 2000). Ureteric bud branching is also positively regulated by vitamin A and its retinoic acid receptor signaling, which promote Ret expression. Rarα and Rarβ2 are expressed in stromal cells surrounding Ret-expressing ureteric bud branch tips. Mice deficient in these receptors exhibit a decreased number of ureteric bud branches and diminished expression of Ret (Batourina et al., 2001). Certain markers such as Wnt11 might already be compartmentalized to opposing poles of the dilated ureteric bud tips, even before a morphologic branch point is evident (Pepicelli et al., 1997). In mice deficient for the homeobox gene *Emx2* (Miyamoto et al., 1997), ureteric bud outgrowth into the metanephric mesenchyme appears normal, but the leading edge of the ureteric bud never dilates and branching is suppressed. Thus, ureteric development is arrested before the first branching event, and the resulting metanephric mesenchyme does not express markers indicative of induction. Similarly, mice with mutation of *Sall1* exhibit developmental arrest just after ureteric bud outgrowth and before dilation of the leading edge of the ureteric bud (Nishinakamura et al., 2001). In normal murine embryos, *Sall1* is expressed in metanephric mesenchyme. Thus, *Sall1* might control mesenchyme-derived signals that are necessary for ureteric bud dilation and branch point determination. Clearly, the pattern of ureteric bud branching and the expression of ureteric bud–specific genes are influenced by the metanephric mesenchyme. Indeed, heterologous mesenchyme derived from lung primordia cannot change the pattern of ureteric bud branching to that of lung epithelia or induce the ureteric bud to express lung-specific genes (Lin et al., 2001). Studies have demonstrated that BMP/activin-like kinase-3 (ALK3) signaling negatively regulates early ureteric bud branching in vivo (Hartwig et al., 2008). The cell surface receptor ALK3 binds BMP2 and BMP4 with high affinity and is expressed in the mesonephric duct. Inactivation of ALK3 changes the pattern of primary ureteric bud branching from bifid to trifid and increases the number of first- and second-generation branches. These defects are associated with decreased formation of subsequent branch generations, resulting in a decreased complement of collecting ducts. These observations suggest that the pattern of early ureteric bud branching is a critical determinant of subsequent branching morphogenesis. **Thus, ureteric bud epithelial branching morphogenesis is controlled by both intrinsic and extrinsic factors working**

in concert to generate a kidney-specific branching pattern (see Table 20.4).

Tubulogenesis

Classic tissue recombination experiments focused almost exclusively on the relationship between metanephric mesenchymal cells and ureteric bud epithelial cells. It is now clear that at least three cell types are involved in the control of renal development: the ureteric bud tip cells, the condensed metanephrogenic mesenchymal cells, and the stromal or interstitial mesenchymal cells. Once induced by the ureteric bud, the metanephric mesenchyme patterns itself into at least two different cell populations, a tubular one and a stromal one. The tubular cell population is thought to derive from mesenchymal cells in direct contact with the ureteric bud ampulla (Stark et al., 1994; Torres et al., 1995; Vainio et al., 1989), whereas the stromal cell population surrounds the tubular cells (Hatini et al., 1996). Once the mesenchyme has been patterned, these cells in the tubular zone undergo morphogenesis to become renal tubular epithelial cells. There is evidence that this process is dependent not only on signals from the ureteric bud but also on signals from the mesenchyme itself. One of these autocrine signals may be Wnt4, whose expression is induced in cells of the tubular zone after interaction with the ureteric bud. In *Wnt4* gene knockout mice, the ureteric bud forms and invades the metanephric mesenchyme, but subsequent development of epithelial tubules is abolished (Stark et al., 1994). This suggests that two signals are essential for renal tubule formation—initial ureteric bud–derived signals activating Wnt4 expression in the metanephric mesenchyme and Wnt4 itself as a mesenchymal autocrine signal. Signals from the stromal cell population also contribute to tubule formation, because tubulogenesis is perturbed in *Bf2* gene knockout mice (Hatini et al., 1996). The discovery that Wnt4 acts as a downstream signal during the induction cascade leading to renal tubulogenesis leads to the question regarding the nature of the initial ureteric bud–derived signals. In vitro data suggest a role for FGF2 and other uncharacterized factors secreted by the ureteric bud (Karavanova et al., 1996). Candidate molecules that may cooperate with FGF2 are Wnt11 and BMP7 (Kispert et al., 1996; Vukicevic et al., 1996). Localization of RET protein to the ureteric bud tips is reinforced by both GDNF (Pepicelli et al., 1997) and signals emanating from surrounding stromal cells. For example, retinoic acid receptors are expressed in the stromal cells and are required for stromal cell–mediated signaling to maintain high levels of RET expression in the bud tips (Batourina et al., 2001; Mendelsohn et al., 1999). Consistent with the role of retinoic acid receptors in maintaining RET expression in the dividing ureteric bud, rats with vitamin A deficiency have smaller kidneys and fewer nephrons (Merlet-Benichou et al., 1999). The cellular cross-talk among stromal, mesenchymal, and ureteric bud cells is further highlighted by gain- and loss-of-function experiments involving FGFs and BMPs. *Fgf7*-null mutant mice have fewer branch points and correspondingly fewer nephrons, whereas ectopic FGF7 in organ culture can stimulate branching (Qiao et al., 1999a, 1999b). FGF1 and FGF10 affect elongation of the ureteric bud stalk before the branch-point decision is made (Qiao et al., 1999a). Null mutations in *Bmp7* are associated with even more severe phenotypic anomalies, exhibiting limited ureteric bud branching morphogenesis and complete renal developmental arrest. Yet it is difficult to assess how FGFs and BMPs exert their collective effects on branching given the interplay among all the cell types present in the early kidney (Dudley et al., 1999). In addition to the proteins just mentioned, a growing list of growth factors, secreted peptides, and their receptors have been implicated in the control of branching morphogenesis, most by using a variety of in vitro model systems (Pohl et al., 2000). For many of these factors, however, genetic studies have not proved conclusive in assigning specific functional roles during ureteric bud branching in vivo, either because of potential redundancies or embryonic lethalities before the onset of kidney development. Nevertheless, the role of these factors in renal development must be considered.

Mesenchymal-Epithelial Conversion

The inductive signals emanating from the ureteric bud promote condensation of the metanephric mesenchymal cells around the ureteric bud tips and subsequent tubulogenesis (Uy and Reidy, 2016). Mice with null mutations of *Pax2* or *Wt1* fail to exhibit ureteric bud outgrowth, and in both cases the metanephric mesenchyme does not respond to induction even when recombined with strong inducers in vitro (Brophy et al., 2001; Kreidberg et al., 1993). The establishment of glomerular versus tubular cell fates is dependent on negative feedback between *Wt1* and *Pax2* (Ryan et al., 1995). During early kidney development, the expression domain of *Pax2* is complementary to that of *Wt1* in *S*-shaped bodies. *Wt1* expression is restricted to glomerular epithelial precursors (Buckler et al., 1991), whereas *Pax2* expression is restricted to the portion that gives rise to tubular epithelial precursors of the proximal and distal nephron segments and later repressed in differentiated tubular epithelium (Dressler and Douglass, 1992). Evidence in support of Wnt proteins as mesenchyme inducers has been gained from in vitro induction assays using Wnt-expressing cell lines (Herzlinger et al., 1994; Kispert et al., 1998). Of the *Wnt* mutants examined to date, only *Wnt4*, which is expressed in the mesenchyme and not the ureteric bud, is crucial for propagation of the inductive signals. Although *Wnt4* mutant mesenchyme is able to aggregate in response to ureteric bud contact, these mutant aggregates do not form polarized epithelia. Rat ureteric bud cells secrete tubulogenic factors, such as leukocyte-inhibitory factor, which, together with FGF2, appears to stimulate growth and tubulogenesis in vitro (Plisov et al., 2001). Once induced to form aggregates, metanephric mesenchyme becomes polarized into an early renal vesicle. This vesicle is closely associated with the branching ureteric bud and will eventually connect to the ureteric bud epithelium to form a continuous tubule. Profound changes take place in the expression of cell adhesion molecules such as cadherins. Shortly after induction, metanephric mesenchyme expresses R-cadherin, cadherin-6, and E-cadherin, along with suppression of the mesenchyme-specific cadherin-11. Both R-cadherin and cadherin-6 mutants show defects in the rate of mesenchymal condensation and polarization (Dahl et al., 2002; Mah et al., 2000). Some renal vesicles in cadherin-6 mutants also fail to fuse to the ureteric bud epithelia, resulting in “dead-end” tubules and a subsequent loss of nephrons.

Renal Vascular Development

The origin of intrarenal vasculature is not completely understood. Until recently, it was thought that renal vasculature derived exclusively from branches off the aorta and other preexisting extrarenal vessels (“angiogenic” hypothesis). There is evidence, however, that the renal vessels may originate in situ, within the embryonic metanephric mesenchyme from vascular progenitor cells (“vasculogenic” hypothesis; Loughna et al., 1996; Tufro et al., 1999). Using antibodies to Flk-1, a vascular endothelial growth factor (VEGF) receptor present in angioblasts and mature endothelial cells, it was demonstrated that endothelial cell precursors were already present in the prevascular rodent metanephric mesenchyme before any vessels were discernible from a morphologic standpoint. When embryonic kidneys are cultured at the usual atmospheric oxygen concentration, vessels do not develop. However, if the explants are cultured in a hypoxic atmosphere containing 5% oxygen, capillary sprouts develop within and outside the glomeruli, an effect that is inhibited by anti-VEGF antibodies (Tufro-McReddie et al., 1997). Depending on the developmental potential of the cells involved, both angiogenesis and vasculogenesis may play a role in the development of renal vasculature (Abrahamson et al., 1998).

Clinical Correlation: Vascular Anomalies

As the kidneys migrate from their origin in the pelvis cranially into the upper lumbar region, they are vascularized by a succession of transient aortic sprouts that arise at progressively higher levels. These arteries do not elongate to follow the ascending kidneys but instead degenerate and are replaced by successive new arteries. The final pair of arteries forms in the upper lumbar region and becomes the definitive renal arteries. Occasionally, a more inferior pair of arteries persists as accessory lower-pole arteries. **These lower-pole arteries cross ventral to the ureter and can cause intermittent ureteropelvic junction obstruction requiring repositioning of the ureter behind the accessory lower-pole renal artery.** The common variation in blood supply to the kidney is a reflection of the continually changing embryonic renal vasculature. This is reflected in that 25% of adult kidneys have two or more renal arteries (Moore et al., 2016).

Clinical Correlation: Ascent Anomalies

Between the sixth and ninth weeks, the kidneys ascend to the upper lumbar region just below the adrenal glands (Fig. 20.50). The precise mechanism responsible for renal ascent is not known, but it is speculated that differential growth of the lumbar and sacral regions of the embryo plays a major role. When the kidney fails to ascend properly, its location becomes ectopic. If its ascent fails completely, it remains as a pelvic kidney. **The inferior poles of the kidneys may also fuse, forming a horseshoe kidney (incidence ~1 : 500) that crosses ventral to the aorta. During ascent, the fused lower pole is arrested by the inferior mesenteric artery and thus does not reach its normal site.** Typically, the horseshoe kidney produces no symptoms but can be associated with a slight increase in ureteropelvic-junction obstruction and renal calculi. Rarely, the kidney fuses to the contralateral one and ascends to the opposite side, resulting in a cross-fused ectopy.

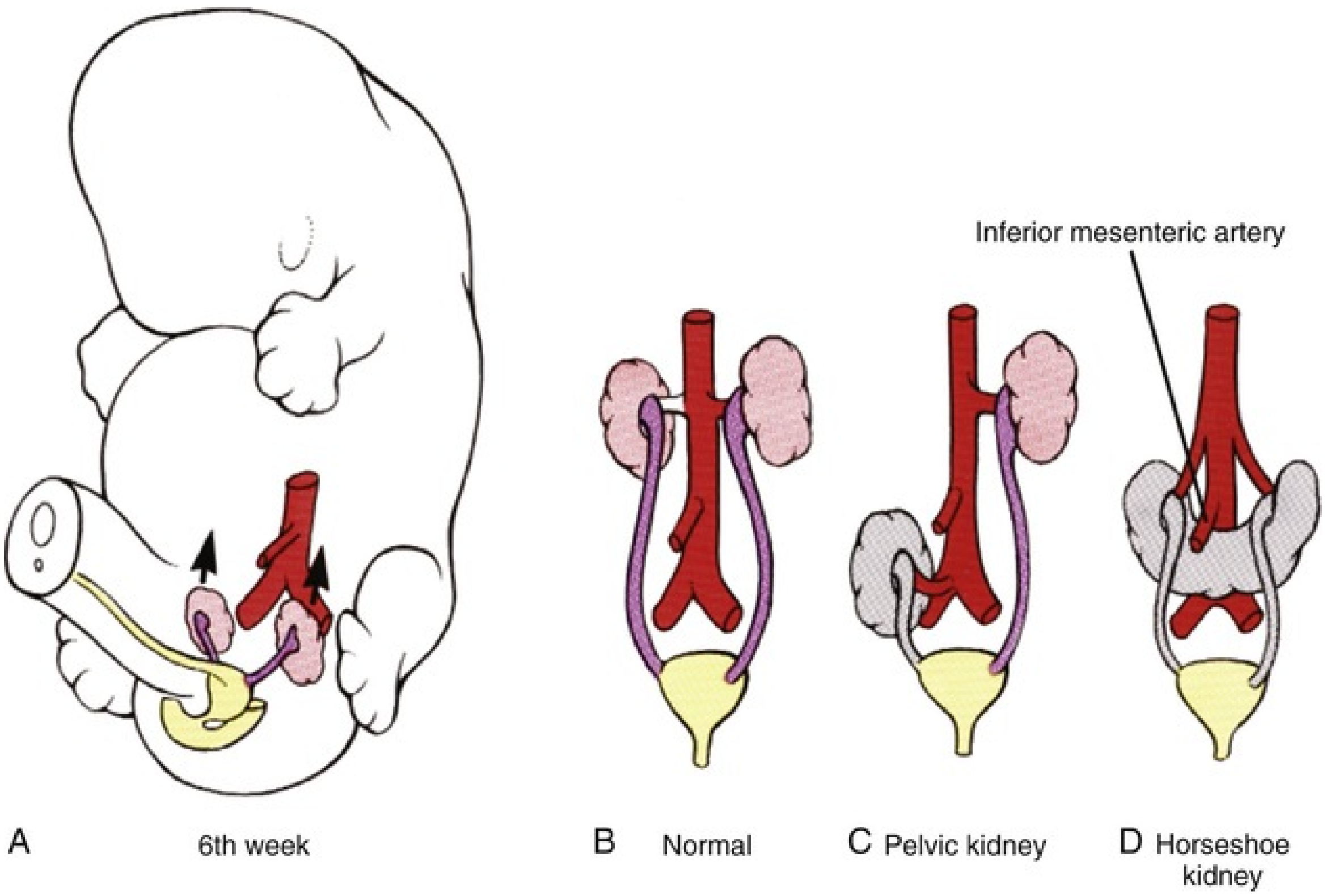

FIG. 20.50 Normal and abnormal ascent of the kidneys. (A and B) The metanephros normally ascends from the sacral region to its definitive lumbar location between the sixth and ninth weeks. (C) Rarely, a kidney may fail to ascend, resulting in a pelvic kidney. (D) If the inferior poles of the kidneys fuse before ascent, the resulting horseshoe kidney does not ascend to a normal position because of entrapment by the inferior mesenteric artery. (Modified from Larsen WJ. *Human embryology.* New York: Churchill Livingstone; 1997.)

Clinical Correlation: Cystic Renal Disease

Autosomal recessive polycystic kidney disease occurs in approximately 1 : 20,000 live births. Most cases have a mutation in the *PKHD1* gene that results in microscopic cystic kidney disease and congenital hepatic fibrosis (Guay-Woodford et al., 2014). The severe renal disease often results in pulmonary hypoplasia causing neonatal death. In patients with nonlethal pulmonary status, early renal replacement by peritoneal dialysis and subsequent renal/liver transplantation has allowed survival (Chandar et al., 2015).

Clinical Correlation: Multicystic Dysplastic Kidneys

Multicystic dysplastic kidneys occur in approximately 1 : 2400 to 1 : 4800 newborns. In the majority of cases, this is a unilateral process with the nonaffected kidney exhibiting compensatory hypertrophy (Gaither et al., 2018). Multicystic dysplastic kidneys are characterized by nonfunctional renal tissue without recognizable glomeruli. The malformed tissue consists of noncommunicating cysts of various sizes with dysplastic tubular epithelium (Rojas et al., 2011). The etiology is not known but is thought to be related to abnormal signaling between the ureteral bud and the metanephric blastema. Treatment consist of documenting that the contralateral kidney remains healthy and compensates for the lack of function of the multicystic dysplastic kidney. The multicystic dysplastic kidney will typically involute over time and is not at risk for cancer or hypertension (Gaither et al., 2018). **Renal agenesis may be a nonrecognizable form of multicystic dysplastic kidney in which the involution occurs early in gestation before the abnormal renal development can be detected by prenatal sonogram.**

Key Points: Kidney Development

- The urinary system begins its development before genital system development becomes evident. With the formation of mesonephric ducts, embryonic kidneys develop sequentially in the order of pronephros (completely reabsorbed), mesonephros (partially reabsorbed), and metanephros (permanent kidney).
- The metanephros develops as a result of inductive interactions involving the ureteric bud (an outgrowth of mesonephric duct), condensing blastema of metanephric mesenchyme, and stromal cells.
- Renal tubulogenesis occurs via mesenchymal-epithelial conversion, whereas dichotomous branching of the ureteric bud leads to the formation of the collecting system.
- Selected gene mutations are associated with congenital anomalies of the kidney and urinary tract.
- As the kidneys migrate from the pelvis, they are vascularized by a succession of transient aortic sprouts that arise at progressively higher levels. The final pair of arteries forms in the upper lumbar region and becomes the definitive renal arteries.

Acknowledgment

The authors would like to acknowledge the work of Dr. John Park, author of this chapter in the previous edition.

Suggested Readings

Baskin L, Shen J, Sinclair A, et al. Development of the human penis and clitoris. *Differentiation*. 2018;103:74–85.

Blaschko SD, Cunha GR, Baskin LS. Molecular mechanisms of external genitalia development. *Differentiation*. 2012;84(3):261–268.

Cunha G, Robboy SJ, Kurita T, et al. Development of the human female reproductive tract. *Differentiation*. 2018;103:45–65.

Cunha GR, Kurita T, Cao M, et al. Molecular mechanisms of development of the human fetal female reproductive tract. *Differentiation*. 2017;97:54–72.

Cunha GR, Vezina C, Isaacson D, et al. Development of the human prostate. *Differentiation*. 2018;103:24–45.

Isaacson D, Shen J, Overland M, et al. Three-dimensional imaging of the developing human fetal lower urogenital-genital tract: indifferent stage to male and female differentiation. *Differentiation*. 2018;103:14–23.

McMahon AP. Development of the mammalian kidney. *Curr Top Dev Biol*. 2016;117:31–64.

Pietila I, Vainio SJ. Kidney development: an overview. *Nephron Exp Nephrol*. 2014;126(2):40.

Shen J, Cunha GR, Sinclair A, et al. Macroscopic whole-mounts of the developing human fetal urogenital-genital tract: Indifferent stage to male and female differentiation. *Differentiation*. 2018;103:5–13.

Viana R, Batourina E, Huang H, et al. The development of the bladder trigone, the center of the anti-reflux mechanism. *Development*. 2007;134(20):3763–3769.

References

Abdelhak S, Kalatzis V, Heilig R, et al. Clustering of mutations responsible for branchio-oto-renal (BOR) syndrome in the eyes absent homologous region (eyaHR) of EYA1. *Hum Mol Genet*. 1997;6(13):2247–2255.

Abdelhak S, Kalatzis V, Heilig R, et al. A human homologue of the Drosophila eyes absent gene underlies branchio-oto-renal (BOR) syndrome and identifies a novel gene family. *Nat Genet*. 1997;15(2):157–164.

Aboseif S, El-Sakka A, Young P, et al. Mesenchymal reprogramming of adult human epithelial differentiation. *Differentiation*. 1999;65(2):113–118.

Abrahamson DR, Robert B, Hyink DP, et al. Origins and formation of microvasculature in the developing kidney. *Kidney Int Suppl*. 1998;67:S7–S11.

Adham N, Kao HT, Schecter LE, et al. Cloning of another human serotonin receptor (5-HT1F): a fifth 5-HT1 receptor subtype coupled to the inhibition of adenylate cyclase. *Proc Natl Acad Sci USA*. 1993;90(2):408–412.

Allgeier SH, Lin TM, Moore RW, et al. Androgenic regulation of ventral epithelial bud number and pattern in mouse urogenital sinus. *Dev Dyn*. 2010;239(2):373–385.

Ambrose SS, O'Brien DP 3rd. Surgical embryology of the exstrophy-epispadias complex. *Surg Clin North Am*. 1974;54(6):1379–1390.

Andersson S, Berman DM, Jenkins EP, et al. Deletion of steroid 5 alpha-reductase 2 gene in male pseudohermaphroditism. *Nature*. 1991;354(6349):159–161.

Attah AA, Hutson JM. The role of intra-abdominal pressure in cryptorchidism. *J Urol*. 1993;150(3):994–996.

Auchus RJ, Witchel SF, Leight KR, et al. Guidelines for the development of comprehensive care centers for congenital adrenal hyperplasia: guidance from the CARES Foundation initiative. *Int J Pediatr Endocrinol*. 2010;2010:275213.

Aumuller G, Riva A. Morphology and functions of the human seminal vesicle. *Andrologia*. 1992;24(4):183–196.

Baker LA, Gomez RA. Embryonic development of the ureter and bladder: acquisition of smooth muscle. *J Urol*. 1998;160(2):545–550.

Balvers M, Spiess AN, Domagalski R, et al. Relaxin-like factor expression as a marker of differentiation in the mouse testis and ovary. *Endocrinology*. 1998;139(6):2960–2970.

Baskin L. What is hypospadias? *Clin Pediatr (Phila)*. 2017;56(5):409–418.

Baskin L, Duckett J, Lue T. Penile curvature. *Urology*. 1996;48(3):347–356.

Baskin L, Meaney D, Landsman A, et al. Bovine bladder compliance increases with normal fetal development. *J Urol*. 1994;152(2 Pt 2):692–695 [discussion 696–697].

Baskin L, Shen J, Sinclair A, et al. Development of the human penis and clitoris. *Differentiation*. 2018;103:74–85.

Baskin LS. Restoring normal anatomy in female patients with atypical genitalia. *Semin Perinatol*. 2017;41(4):227–231.

Baskin LS, Erol A, Li YW, et al. Anatomical studies of hypospadias. *J Urol*. 1998;160(3 Pt 2):1108–1115 [discussion 1137].

Baskin LS, Erol A, Li YW, et al. Anatomy of the neurovascular bundle: is safe mobilization possible? *J Urol*. 2000;164(3 Pt 2):977–980.

Baskin LS, Erol A, Li YW, et al. Anatomical studies of the human clitoris. *J Urol*. 1999;162(3 Pt 2):1015–1020.

Baskin LS, Hayward SW, Young P, et al. Role of mesenchymal-epithelial interactions in normal bladder development. *J Urol*. 1996;156(5):1820–1827.

Baskin LS, Himes K, Colborn T. Hypospadias and endocrine disruption: is there a connection? *Environ Health Perspect*. 2001;109(11):1175–1183.

Basson MA, Watson-Johnson J, Shakya R, et al. Branching morphogenesis of the ureteric epithelium during kidney development is coordinated by the opposing functions of GDNF and Sprouty1. *Dev Biol*. 2006;299(2):466–477.

Batourina E, Gim S, Bello N, et al. Vitamin A controls epithelial/mesenchymal interactions through Ret expression. *Nat Genet*. 2001;27(1):74–78.

Batourina E, Tsai S, Lambert S, et al. Apoptosis induced by vitamin A signaling is crucial for connecting the ureters to the bladder. *Nat Genet*. 2005;37(10):1082–1089.

Beasley SW, Hutson JM. The role of the gubernaculum in testicular descent. *J Urol*. 1988;140(5 Pt 2):1191–1193.

Beauboeuf A, Ordille S, Erickson DR, et al. In vitro ligation of ureters and urethra modulates fetal mouse bladder explants development. *Tissue Cell*. 1998;30(5):531–536.

Beaudoin S, Simon L, Bargy F. Anatomical basis of a common embryological origin for epispadias and bladder or cloacal exstrophies. *Surg Radiol Anat*. 1997;19(1):11–16.

Behringer RR, Finegold MJ, Cate RL. Mullerian-inhibiting substance function during mammalian sexual development. *Cell*. 1994;79(3):415–425.

Bekheirnia MR, Bekheirnia N, Bainbridge MN, et al. Whole-exome sequencing in the molecular diagnosis of individuals with congenital anomalies of the kidney and urinary tract and identification of a new causative gene. *Genet Med*. 2017;19(4):412–420.

Besnard V, Wert SE, Hull WM, et al. Immunohistochemical localization of Foxa1 and Foxa2 in mouse embryos and adult tissues. *Gene Expr Patterns*. 2004;5(2):193–208.

Bhatia-Gaur R, Donjacour AA, Sciavolino PJ, et al. Roles for

Nkx3.1 in prostate development and cancer. *Genes Dev*. 1999;13(8):966–977.

Bieberich CJ, Fujita K, He WW, et al. Prostate-specific and androgen-dependent expression of a novel homeobox gene. *J Biol Chem*. 1996;271(50):31779–31782.

Blaschko SD, Cunha GR, Baskin LS. Molecular mechanisms of external genitalia development. *Differentiation*. 2012;84(3):261–268.

Bourdelat D, Barbet JP, Butler-Browne GS. Fetal development of the urethral sphincter. *Eur J Pediatr Surg*. 1992;2(1):35–38.

Brenner-Anantharam A, Cebrian C, Guillaume R, et al. Tailbud-derived mesenchyme promotes urinary tract segmentation via BMP4 signaling. *Development*. 2007;134(10):1967–1975.

Breza J, Aboseif SR, Orvis BR, et al. Detailed anatomy of penile neurovascular structures: surgical significance. *J Urol*. 1989;141(2):437–443.

Brophy PD, Ostrom L, Lang KM, et al. Regulation of ureteric bud outgrowth by Pax2-dependent activation of the glial derived neurotrophic factor gene. *Development*. 2001;128(23):4747–4756.

Brunskill EW, Aronow BJ, Georgas K, et al. Atlas of gene expression in the developing kidney at microanatomic resolution. *Dev Cell*. 2008;15(5):781–791.

Buckler AJ, Pelletier J, Haber DA, et al. Isolation, characterization, and expression of the murine Wilms' tumor gene (WT1) during kidney development. *Mol Cell Biol*. 1991;11(3):1707–1712.

Bulmer D. The development of the human vagina. *J Anat*. 1957;91:490–509.

Cacalano G, Farinas I, Wang LC, et al. GFRalpha1 is an essential receptor component for GDNF in the developing nervous system and kidney. *Neuron*. 1998;21(1):53–62.

Cancilla B, Jarred RA, Wang H, et al. Regulation of prostate branching morphogenesis by activin A and follistatin. *Dev Biol*. 2001;237(1):145–158.

Cao M, Tasian G, Wang MH, et al. Urothelium-derived Sonic hedgehog promotes mesenchymal proliferation and induces bladder smooth muscle differentiation. *Differentiation*. 2010;79(4–5):244–250.

Capito C, Echaieb A, Lortat-Jacob S, et al. Pitfalls in the diagnosis and management of obstructive uterovaginal duplication: a series of 32 cases. *Pediatrics*. 2008;122(4):e891–e897.

Capone VP, Morello W, Taroni F, et al. Genetics of congenital anomalies of the kidney and urinary tract: the current state of play. *Int J Mol Sci*. 2017;18(4).

Cebrian C, Borodo K, Charles N, et al. Morphometric index of the developing murine kidney. *Dev Dyn*. 2004;231(3):601–608.

Chan YY, Durbin-Johnson B, Kurzrock EA. Pediatric inguinal and scrotal surgery—practice patterns in US academic centers. *J Pediatr Surg*. 2016;51(11):1786–1790.

Chandar J, Garcia J, Jorge L, et al. Transplantation in autosomal recessive polycystic kidney disease: liver and/or kidney? *Pediatr Nephrol*. 2015;30(8):1233–1242.

Coleman RA, Winkle DC, Borzi PA. Urethral duplication: cases of ventral and dorsal complete duplication and review of the literature. *J Pediatr Urol*. 2010;6(2):188–191.

Cools M. Germ cell cancer risk in DSD patients. *Ann Endocrinol (Paris)*. 2014;75(2):67–71.

Coplen DE, Duckett JW. The modern approach to ureteroceles. *J Urol*. 1995;153(1):166–171.

Coplen DE, Macarak EJ, Levin RM. Developmental changes in normal fetal bovine whole bladder physiology. *J Urol*. 1994;151(5):1391–1395.

Costantini F, Kopan R. Patterning a complex organ: branching morphogenesis and nephron segmentation in kidney development. *Dev Cell*. 2010;18(5):698–712.

Cunha GR. Age-dependent loss of sensitivity of female urogenital sinus to androgenic conditions as a function of the epithelial-stromal interaction. *Endocrinology*. 1975;95:665–673.

Cunha GR. Mesenchymal-epithelial interactions during androgen-induced development of the prostate. *Prog Clin Biol Res*. 1985;171:15–24.

Cunha GR, Baskin L. Development of human male and female urogenital tracts. *Differentiation*. 2018;103:1–4.

Cunha GR, Battle E, Young P, et al. Role of epithelial-mesenchymal interactions in the differentiation and spatial organization of visceral smooth muscle. *Epithelial Cell Biol*. 1992;1:76–83.

Cunha GR, Lung B. The possible influences of temporal factors in androgenic responsiveness of urogenital tissue recombinants from wild-type and androgen-insensitive (Tfm) mice. *J Exp Zool*. 1978;205:181–194.

Cunha GR, Lung B, Reese B. Glandular epithelial induction by embryonic mesenchyme in adult bladder epithelium of Balb/c mice. *Invest Urol*. 1980;17:302–304.

Cunha GR, Robboy SJ, Kurita T, et al. Development of the human female reproductive tract. *Differentiation*. 2018;103:45–65.

Cunha GR, Sekkingstad M, Meloy BA. Heterospecific induction of prostatic development in tissue recombinants prepared with mouse, rat, rabbit, and human tissues. *Differentiation*. 1983;24:174–180.

Cunha GR, Vezina C, Isaacson D, et al. Development of the human prostate. *Differentiation*. 2018;103:24–45.

Cunha GR, Vezina CM, Isaacson D, et al. New insights in the development of the human prostate. *Differentiation*. 2018 [(in press)].

Dahl U, Sjodin A, Larue L, et al. Genetic dissection of cadherin function during nephrogenesis. *Mol Cell Biol*. 2002;22(5):1474–1487.

Dauge MC, Delmas V, Mandarim de Lacerda CA. Development of the human prostate during the first stages of fetal life. Morphometric study. *Bull Assoc Anat (Nancy)*. 1986;70(211):5–11.

Deslypere JP, Young M, Wilson JD, et al. Testosterone and 5 alpha-dihydrotestosterone interact differently with the androgen receptor to enhance transcription of the MMTV-CAT reporter gene. *Mol Cell Endocrinol*. 1992;88(1–3):15–22.

Diez-Roux G, Banfi S, Sultan M, et al. A high-resolution anatomical atlas of the transcriptome in the mouse embryo. *PLoS Biol*. 2011;9(1):e1000582.

Donjacour AA, Cunha GR. Assessment of prostatic protein secretion in tissue recombinants made of urogenital sinus mesenchyme and urothelium from normal or androgen-insensitive mice. *Endocrinology*. 1993;131:2342–2350.

Donjacour AA, Thomson AA, Cunha GR. FGF-10 plays an essential role in the growth of the fetal prostate. *Dev Biol*. 2003;261(1):39–54.

Dressler GR, Douglass EC. Pax-2 is a DNA-binding protein expressed in embryonic kidney and Wilms tumor. *Proc Natl Acad Sci USA*. 1992;89(4):1179–1183.

Dudley AT, Godin RE, Robertson EJ. Interaction between FGF and BMP signaling pathways regulates development of metanephric mesenchyme. *Genes Dev*. 1999;13(12):1601–1613.

Dufau ML. Endocrine regulation and communicating functions of the Leydig cell. *Annu Rev Physiol*. 1988;50:483–508.

Fanos V, Loddo C, Puddu M, et al. From ureteric bud to the first glomeruli: genes, mediators, kidney alterations. *Int Urol Nephrol*. 2015;47(1):109–116.

Finch PW, Cunha GR, Rubin JS, et al. Pattern of KGF and KGFR expression during mouse fetal development suggests a role in mediating morphogenetic mesenchymal-epithelial interactions. *Dev Dyn*. 1995;203:223–240.

Forsberg JG. Development of the human vaginal epithelium. Elsevier/North-Holland Biomedical: Amsterdam; 1978:3–20. Hafez ESE, Evans TN. *The human vagina*. vol 1.

Frey HL, Rajfer J. Role of the gubernaculum and intraabdominal pressure in the process of testicular descent. *J Urol*. 1984;131(3):574–579.

Frutiger P. Zur Fruhentwicklung der Ductus paramesonephrici und des Mullerschen Hugels beim Menschen. *Acta Anat (Basel)*. 1969;72(j):233–245.

Gaither TW, Patel A, Patel C, et al. Natural history of contralateral hypertrophy in patients with multicystic dysplastic kidneys. *J Urol*. 2018;199(1):280–286.

Glassberg KI, Braren V, Duckett JW, et al. Suggested terminology for duplex systems, ectopic ureters and ureteroceles. *J Urol*. 1984;132(6):1153–1154.

Gleason JM, Bowlin PR, Bagli DJ, et al. A comprehensive review of pediatric urachal anomalies and predictive analysis for adult urachal adenocarcinoma. *J Urol*. 2015;193(2):632–636.

Glenister T. The origin and fate of the urethral plate in man. *J Anat*. 1954;288:413–418.

Grieshammer U, Le M, Plump AS, et al. SLIT2-mediated ROBO2 signaling restricts kidney induction to a single site. *Dev Cell*. 2004;6(5):709–717.

Grishina IB, Kim SY, Ferrara C, et al. BMP7 inhibits branching morphogenesis in the prostate gland and interferes with

Notch signaling. *Dev Biol*. 2005;288(2):334–347.

Grobstein C. Trans-filter induction of tubules in mouse metanephrogenic mesenchyme. *Exp Cell Res*. 1956;10(2):424–440.

Grocock CA, Charlton HM, Pike MC. Role of the fetal pituitary in cryptorchidism induced by exogenous maternal oestrogen during pregnancy in mice. *J Reprod Fertil*. 1988;83(1):295–300.

Gruenwald P. The relation of the growing Mullerian duct to the Wolffian duct and its importance for the genesis of malformations. *Anat Rec*. 1941;81:1–19.

Guay-Woodford LM, Bissler JJ, Braun MC, et al. Consensus expert recommendations for the diagnosis and management of autosomal recessive polycystic kidney disease: report of an international conference. *J Pediatr*. 2014;165(3):611–617.

Gurney JK, McGlynn KA, Stanley J, et al. Risk factors for cryptorchidism. *Nat Rev Urol*. 2017;14(9):534–548.

Haraguchi R, Matsumaru D, Nakagata N, et al. The hedgehog signal induced modulation of bone morphogenetic protein signaling: an essential signaling relay for urinary tract morphogenesis. *PLoS ONE*. 2012;7(7):e42245.

Hartwig S, Bridgewater D, Di Giovanni V, et al. BMP receptor ALK3 controls collecting system development. *J Am Soc Nephrol*. 2008;19(1):117–124.

Hatini V, Huh SO, Herzlinger D, et al. Essential role of stromal mesenchyme in kidney morphogenesis revealed by targeted disruption of Winged Helix transcription factor BF-2. *Genes Dev*. 1996;10(12):1467–1478.

Hayashi N, Sugimura Y, Kawamura J, et al. Morphological and functional heterogeneity in the rat prostatic gland. *Biol Reprod*. 1991;45:308–321.

Hayward SW, Haughney PC, Rosen MA, et al. Interactions between adult human prostatic epithelium and rat urogenital sinus mesenchyme in a tissue recombination model. *Differentiation*. 1998;63(3):131–140.

Herzlinger D, Koseki C, Mikawa T, et al. Metanephric mesenchyme contains multipotent stem cells whose fate is restricted after induction. *Development*. 1992;114(3):565–572.

Herzlinger D, Qiao J, Cohen D, et al. Induction of kidney epithelial morphogenesis by cells expressing Wnt-1. *Dev Biol*. 1994;166(2):815–818.

Heyns CF. The gubernaculum during testicular descent in the human fetus. *J Anat*. 1987;153:93–112.

Hook EB, Warburton D. Turner syndrome revisited: review of new data supports the hypothesis that all viable 45,X cases are cryptic mosaics with a rescue cell line, implying an origin by mitotic loss. *Hum Genet*. 2014;133(4):417–424.

Hunter RH. Observations on the development of the human female genital tract. *Contr Embryol Carneg Inst*. 1930;22:91–108.

Husmann DA, Levy JB. Current concepts in the pathophysiology of testicular undescent. *Urology*. 1995;46(2):267–276.

Hutson JM, Donahoe PK. The hormonal control of testicular descent. *Endocr Rev*. 1986;7(3):270–283.

Imperato-McGinley J, Zhu YS. Androgens and male physiology the syndrome of 5alpha-reductase-2 deficiency. *Mol Cell Endocrinol*. 2002;198(1–2):51–59.

Isaacson D, Shen J, Overland M, et al. Three-dimensional imaging of the developing human fetal urogenital-genital tract: Indifferent stage to male and female differentiation. *Differentiation*. 2018;103:14–23.

Jen PY, Dixon JS, Gosling JA. Development of peptide-containing nerves in the human fetal vas deferens and seminal vesicle. *Br J Urol*. 1995;75(3):378–385.

Jost A. Problems of fetal endocrinology: the gonadal and hypophyseal hormones. *Rec Prog Horm Res*. 1953;8:379–418.

Karavanova ID, Dove LF, Resau JH, et al. Conditioned medium from a rat ureteric bud cell line in combination with bFGF induces complete differentiation of isolated metanephric mesenchyme. *Development*. 1996;122(12):4159–4167.

Keil KP, Abler LL, Laporta J, et al. Androgen receptor DNA methylation regulates the timing and androgen sensitivity of mouse prostate ductal development. *Dev Biol*. 2014;396(2):237–245.

Keil KP, Abler LL, Mehta V, et al. DNA methylation of E-cadherin is a priming mechanism for prostate development. *Dev Biol*. 2014;387(2):142–153.

Kellokumpu-Lehtonen P, Santti R, Pelliniemi LJ. Correlation of early cytodifferentiation of the human fetal prostate and Leydig cells. *Anat Rec*. 1980;196(j):263–273.

Kiechl-Kohlendorfer U, Geley T, Maurer K, et al. Uterus didelphys with unilateral vaginal atresia: multicystic dysplastic kidney is the precursor of renal agenesis and the key to early diagnosis of this genital anomaly. *Pediatr Radiol*. 2011;41(9):1112–1116.

Kim KM, Kogan BA, Massad CA, et al. Collagen and elastin in the normal fetal bladder. *J Urol*. 1991;146(2 Pt 2):524–527.

Kim KS, Liu W, Cunha GR, et al. Expression of the androgen receptor and 5 alpha-reductase type 2 in the developing human fetal penis and urethra. *Cell Tissue Res*. 2002;307(2):145–153.

Kispert A, Vainio S, McMahon AP. Wnt-4 is a mesenchymal signal for epithelial transformation of metanephric mesenchyme in the developing kidney. *Development*. 1998;125(21):4225–4234.

Kispert A, Vainio S, Shen L, et al. Proteoglycans are required for maintenance of Wnt-11 expression in the ureter tips. *Development*. 1996;122(11):3627–3637.

Kobayashi A, Kwan KM, Carroll TJ, et al. Distinct and sequential tissue-specific activities of the LIM-class homeobox gene Lim1 for tubular morphogenesis during kidney development. *Development*. 2005;132(12):2809–2823.

Koff AK. Development of the vagina in the human fetus. *Contrib Embryol Carnegie Inst Wash*. 1933;24:59–90.

Kreidberg JA, Sariola H, Loring JM, et al. WT-1 is required for early kidney development. *Cell*. 1993;74(4):679–691.

Kume T, Deng K, Hogan BL. Murine forkhead/winged helix genes Foxc1 (Mf1) and Foxc2 (Mfh1) are required for the early organogenesis of the kidney and urinary tract. *Development*. 2000;127(7):1387–1395.

Kurita T. Developmental origin of vaginal epithelium. *Differentiation*. 2010;80(2–3):99–105.

Kurita T, Medina RT, Mills AA, et al. Role of p63 and basal cells in the prostate. *Development*. 2004;131(20):4955–4964.

Kurzrock EA, Baskin LS, Cunha GR. Ontogeny of the male urethra: theory of endodermal differentiation. *Differentiation*. 1999;64(2):115–122.

Lamm ML, Podlasek CA, Barnett DH, et al. Mesenchymal factor bone morphogenetic protein 4 restricts ductal budding and branching morphogenesis in the developing prostate. *Dev Biol*. 2001;232(2):301–314.

Larney C, Bailey TL, Koopman P. Switching on sex: transcriptional regulation of the testis-determining gene Sry. *Development*. 2014;141(11):2195–2205.

Larson M, Hermansson K, Wolgast M. Hydraulic permeability of the peritubular and glomerular capillary membranes in the rat kidney. *Acta Physiol Scand*. 1983;117(2):251–261.

Lee PA, Nordenstrom A, Houk CP, et al. Global disorders of sex development update since 2006: perceptions, approach and care. *Horm Res Paediatr*. 2016;85(3):158–180.

Liaw A, Cunha GR, Shen J, et al. Development of the human bladder and ureterovesical junction. *Differentiation*. 2018;103:66–73.

Lin Y, Liu A, Zhang S, et al. Induction of ureter branching as a response to Wnt-2b signaling during early kidney organogenesis. *Dev Dyn*. 2001;222(1):26–39.

Liu X, Liu G, Shen J, et al. Human glans and preputial development. *Differentiation*. 2018;103:86–99.

Loughna S, Landels E, Woolf AS. Growth factor control of developing kidney endothelial cells. *Exp Nephrol*. 1996;4(2):112–118.

Lowsley OS. The development of the human prostate gland with reference to the development of other structures at the neck of the urinary bladder. *Am J Anat*. 1912;13(j):299–349.

Lue TF, Zeineh SJ, Schmidt RA, et al. Neuroanatomy of penile erection: its relevance to iatrogenic impotence. *J Urol*. 1984;131(2):273–280.

Mackie GG, Stephens FD. Duplex kidneys: a correlation of renal dysplasia with position of the ureteric orifice. *Birth Defects Orig Artic Ser*. 1977;13(5):313–321.

Mah SP, Saueressig H, Goulding M, et al. Kidney development in cadherin-6 mutants: delayed mesenchyme-to-epithelial conversion and loss of nephrons. *Dev Biol*. 2000;223(1):38–53.

Mahendroo MS, Cala KM, Hess DL, et al. Unexpected virilization in male mice lacking steroid 5 alpha-reductase enzymes. *Endocrinology*. 2001;142(11):4652–4662.

Mall F, Meyer A. Studies on abortuses: a survey of pathologic ova in the Carnegie Embryological Collection. Carnegie Institute of Washington publication No. 275. *Contrib Embryol*. 1921;12:1–364.

Marciano DK. A holey pursuit: lumen formation in the developing kidney. *Pediatr Nephrol*. 2017;32(1):7–20.

Marker PC, Stephan JP, Lee J, et al. fucosyltransferase1 and H-type complex carbohydrates modulate epithelial cell proliferation during prostatic branching morphogenesis. *Dev Biol*. 2001;233(1):95–108.

Massanyi EZ, Dicarlo HN, Migeon CJ, et al. Review and management of 46,XY disorders of sex development. *J Pediatr Urol*. 2013;9(3):368–379.

McMahon AP. Development of the mammalian kidney. *Curr Top Dev Biol*. 2016;117:31–64.

McNeal JE. The zonal anatomy of the prostate. *Prostate*. 1981;2(1):35–49.

McNeal JE. The prostate gland: morphology and pathobiology. *Monogr Urol*. 1983;4:3–37.

Mehta V, Schmitz CT, Keil KP, et al. Beta-catenin (CTNNB1) induces bmp expression in urogenital sinus epithelium and participates in prostatic bud initiation and patterning. *Dev Biol*. 2013;376(2):125–135.

Mendelsohn C, Batourina E, Fung S, et al. Stromal cells mediate retinoid-dependent functions essential for renal development. *Development*. 1999;126(6):1139–1148.

Merlet-Benichou C, Vilar J, Lelievre-Pegorier M, et al. Role of retinoids in renal development: pathophysiological implication. *Curr Opin Nephrol Hypertens*. 1999;8(1):39–43.

Mesrobian HG, Zacharias A, Balcom AH, et al. Ten years of experience with isolated urachal anomalies in children. *J Urol*. 1997;158(3 Pt 2):1316–1318.

Meyer R. Zur anatomie und entwicklungsgeschichte der ureterverdoppelung. Virchows Archiv für pathologische Anatomie und Physiologie und für klinische Medizin. *Berlin*. 1907;87:408.

Miyamoto N, Yoshida M, Kuratani S, et al. Defects of urogenital development in mice lacking Emx2. *Development*. 1997;124(9):1653–1664.

Miyazaki Y, Oshima K, Fogo A, et al. Evidence that bone morphogenetic protein 4 has multiple biological functions during kidney and urinary tract development. *Kidney Int*. 2003;63(3):835–844.

Moore K, Persaud T, Torchia M. *The urogenital system. The developing human. Clinically oriented embryology*. ed 10. Saunders: St Louis; 2016:241–282.

Moore KL, Persaud TVN. *The developing human*. ed 7. Saunders: Philadelphia; 2003.

Moore MW, Klein RD, Farinas I, et al. Renal and neuronal abnormalities in mice lacking GDNF. *Nature*. 1996;382(6586):76–79.

Mouriquand PD, Gorduza DB, Gay CL, et al. Surgery in disorders of sex development (DSD) with a gender issue: if (why), when, and how? *J Pediatr Urol*. 2016;12(3):139–149.

Nef S, Parada LF. Cryptorchidism in mice mutant for Insl3. *Nat Genet*. 1999;22(3):295–299.

Newman J, Antonakopoulos GN. The fine structure of the human fetal urinary bladder. Development and maturation. A light, transmission and scanning electron microscopic study. *J Anat*. 1989;166:135–150.

Nievelstein RA, van der Werff JF, Verbeek FJ, et al. Normal and abnormal embryonic development of the anorectum in human embryos. *Teratology*. 1998;57(2):70–78.

Nishinakamura R, Matsumoto Y, Nakao K, et al. Murine homolog of SALL1 is essential for ureteric bud invasion in kidney development. *Development*. 2001;128(16):3105–3115.

Ohnesorg T, Vilain E, Sinclair AH. The genetics of disorders of sex development in humans. *Sex Dev*. 2014;8(5):262–272.

O'Rahilly R. The embryology and anatomy of the uterus. Norris

HJ, Hertig AT, Abell MR. *The uterus*. Williams and Wilkins: Baltimore; 1973:17–39.

O'Rahilly R. Prenatal human development. Wynn RM. *Biology of the uterus*. Plenum Press: New York; 1977:35–57.

Ornstein DK, Cinquanta M, Weiler S, et al. Expression studies and mutational analysis of the androgen regulated homeobox gene NKX3.1 in benign and malignant prostate epithelium. *J Urol*. 2001;165(4):1329–1334.

Overland M, Li Y, Cao M, et al. Canalization of the vestibular plate in the absence of urethral fusion characterizes development of the human clitoris: the single zipper hypothesis. *J Urol*. 2016;195(4 Pt 2):1275–1283.

Paick J, Donatucci C, Lue T. Anatomy of cavernous nerves distal to prostate: microdissection study in adult male cadavers. *Urology*. 1993;42:145–149.

Pepicelli CV, Kispert A, Rowitch DH, et al. GDNF induces branching and increased cell proliferation in the ureter of the mouse. *Dev Biol*. 1997;192(1):193–198.

Pichel JG, Shen L, Sheng HZ, et al. Defects in enteric innervation and kidney development in mice lacking GDNF. *Nature*. 1996;382(6586):73–76.

Pietila I, Vainio SJ. Kidney development: an overview. *Nephron Exp Nephrol*. 2014;126(2):40.

Piper M, Georgas K, Yamada T, et al. Expression of the vertebrate Slit gene family and their putative receptors, the Robo genes, in the developing murine kidney. *Mech Dev*. 2000;94(1–2):213–217.

Plisov SY, Yoshino K, Dove LF, et al. TGF beta 2, LIF and FGF2 cooperate to induce nephrogenesis. *Development*. 2001;128(7):1045–1057.

Podlasek CA, Duboule D, Bushman W. Male accessory sex organ morphogenesis is altered by loss of function of Hoxd-13. *Dev Dyn*. 1997;208(4):454–465.

Podlasek CA, Seo RM, Clemens JQ, et al. Hoxa-10 deficient male mice exhibit abnormal development of the accessory sex organs. *Dev Dyn*. 1999;214(1):1–12.

Pohl M, Stuart RO, Sakurai H, et al. Branching morphogenesis during kidney development. *Annu Rev Physiol*. 2000;62:595–620.

Porteous S, Torban E, Cho NP, et al. Primary renal hypoplasia in humans and mice with PAX2 mutations: evidence of increased apoptosis in fetal kidneys of Pax2(1Neu) +/– mutant mice. *Hum Mol Genet*. 2000;9(1):1–11.

Price D, Ortiz E. The role of fetal androgens in sex differentiation in mammals. Ursprung RL, DeHaan H. *Organogenesis*. Holt, Rinehart and Winston: New York; 1965:629–652.

Prins GS, Huang L, Birch L, et al. The role of estrogens in normal and abnormal development of the prostate gland. *Ann N Y Acad Sci*. 2006;1089:1–13.

Qiao J, Sakurai H, Nigam SK. Branching morphogenesis independent of mesenchymal-epithelial contact in the developing kidney. *Proc Natl Acad Sci USA*. 1999;96(13):7330–7335.

Qiao J, Uzzo R, Obara-Ishihara T, et al. FGF-7 modulates ureteric bud growth and nephron number in the developing kidney. *Development*. 1999;126(3):547–554.

Quinlan DM, Gearhart JP, Jeffs RD. Abdominal wall defects and cryptorchidism: an animal model. *J Urol*. 1988;140(5 Pt 2):1141–1144.

Radmayr C, Lunacek A, Schwentner C, et al. 5-alpha-reductase and the development of the human prostate. *Indian J Urol*. 2008;24(3):309–312.

Rathke H. Abhandlungen zur Bildungs- und Entwicklungsgeschichte der Tiere. *Leipzig*. 1832.

Reidy KJ, Rosenblum ND. Cell and molecular biology of kidney development. *Semin Nephrol*. 2009;29(4):321–337.

Risbridger G, Wang H, Frydenberg M, et al. The metaplastic effects of estrogen on prostate epithelium: proliferation of cells with basal cell phenotype. *Endocrinology*. 2001;142:2443–2450.

Risbridger G, Wang H, Young P, et al. Evidence that epithelial and mesenchymal estrogen receptor-alpha mediates effects of estrogen on prostatic epithelium. *Dev Biol*. 2001;229(2):432–442.

Risbridger GP, Cancilla B. Role of activins in the male reproductive tract. *Rev Reprod*. 2000;5(2):99–104.

RIVUR Trial Investigators, Hoberman A, Greenfield SP, et al. Antimicrobial prophylaxis for children with vesicoureteral reflux. *N Engl J Med*. 2014;370(25):2367–2376.

Robboy SJ, Kurita T, Baskin L, et al. New insights into human female reproductive tract development. *Differentiation*. 2017;97:9–22.

Rojas CP, Urbiztondo AK, Bruce JH, et al. Comparative immunohistochemical study of multicystic dysplastic kidneys with and without obstruction. *Fetal Pediatr Pathol*. 2011;30(4):209–219.

Ruan W, Kleinberg DL. Insulin-like growth factor I is essential for terminal end bud formation and ductal morphogenesis during mammary development. *Endocrinology*. 1999;140(11):5075–5081.

Ruan W, Powell-Braxton L, Kopchick JJ, et al. Evidence that insulin-like growth factor I and growth hormone are required for prostate gland development. *Endocrinology*. 1999;140(5):1984–1989.

Russell DW, Wilson JD. Steroid 5 alpha-reductase: two genes/two enzymes. *Annu Rev Biochem*. 1994;63:25–61.

Russell WE, Dempsey PJ, Sitaric S, et al. Transforming growth factor-a (TGFa) concentrations increase in regenerating rat liver: evidence for a delayed accumulation of mature TGFa. *Encocrinology*. 1993;133:1731–1738.

Ryan D, Sutherland MR, Flores TJ, et al. Development of the human fetal kidney from mid to late gestation in male and female infants. *EBioMedicine*. 2018;27:275–283.

Ryan G, Steele-Perkins V, Morris JF, et al. Repression of Pax-2 by WT1 during normal kidney development. *Development*. 1995;121(3):867–875.

Sainio K, Suvanto P, Davies J, et al. Glial-cell-line-derived neurotrophic factor is required for bud initiation from ureteric epithelium. *Development*. 1997;124(20):4077–4087.

Salehi P, Koh CJ, Pitukcheewanont P, et al. Persistent mullerian duct syndrome: 8 new cases in Southern California and a review of the literature. *Pediatr Endocrinol Rev*. 2012;10(2):227–233.

Sanyanusin P, Schimmenti LA, McNoe TA, et al. Mutation of the gene in a family with optic nerve colobomas, renal anomalies and vesicoureteral reflux. *Nat Genet*. 1996;13(1):129.

Saxen L, Sariola H. Early organogenesis of the kidney. *Pediatr Nephrol*. 1987;1(3):385–392.

Schlomer B, Rodriguez E, Baskin L. Obstructed hemivagina and ipsilateral renal agenesis (OHVIRA) syndrome should be redefined as ipsilateral renal anomalies: cases of symptomatic atrophic and dysplastic kidney with ectopic ureter to obstructed hemivagina. *J Pediatr Urol*. 2015;11(2):77.e71–77.e76.

Schwarz R, Stephens FD. The persisting mesonephric duct: high junction of vas deferens and ureter. *J Urol*. 1978;120(5):592–596.

Sciavolino PJ, Abrams EW, Yang L, et al. Tissue-specific expression of murine Nkx3.1 in the male urogenital system. *Dev Dyn*. 1997;209(1):127–138.

Seifert AW, Bouldin CM, Choi KS, et al. Multiphasic and tissue-specific roles of sonic hedgehog in cloacal septation and external genitalia development. *Development*. 2009;136(23):3949–3957.

Shannon JM, Cunha GR. Characterization of androgen binding and deoxyribonucleic acid synthesis in prostate-like structures induced in testicular feminized (Tfm/Y) mice. *Biol Reprod*. 1984;31(j):175–183.

Shawlot W, Behringer RR. Requirement for Lim1 in head-organizer function. *Nature*. 1995;374(6521):425–430.

Shen J, Cunha GR, Sinclair A, et al. Macroscopic whole-mounts of the developing human fetal urogenital-genital tract: Indifferent stage to male and female differentiation. *Differentiation*. 2018;103:5–13.

Shen J, Isaacson D, Cao M, et al. Immunohistochemical expression analysis of the human fetal lower urogenital tract. *Differentiation*. 2018;103:100–119.

Shen J, Overland M, Sinclair A, et al. Complex epithelial remodeling underlie the fusion event in early fetal development of the human penile urethra. *Differentiation*. 2016;92(4):169–182.

Signoretti S, Waltregny D, Dilks J, et al. p63 is a prostate basal cell marker and is required for prostate development. *Am J Pathol*. 2000;157(6):1769–1775.

Smith B. *The Multi-dimensional human embryo*. University of Michigan: Ann Arbor, MI; 2016 [Available at] http://embryo.soad.umich.edu/.

Stark K, Vainio S, Vassileva G, et al. Epithelial transformation of metanephric mesenchyme in the developing kidney regulated by Wnt-4. *Nature*. 1994;372(6507):679–683.

Sugimura Y, Foster BA, Hom YK, et al. Keratinocyte growth factor (KGF) can replace testosterone in the ductal branching morphogenesis of the rat ventral prostate. *Int J Dev Biol*.

1996;40(5):941–951.

Sugimura Y, Cunha GR, Donjacour AA. Morphogenesis of ductal networks in the mouse prostate. *Biol Reprod*. 1986;34:961–971.

Sugimura Y, Cunha GR, Bigsby RM. Androgenic induction of deoxyribonucleic acid synthesis in prostatic glands induced in the urothelium of testicular feminized (Tfm/y) mice. *Prostate*. 1986;9:217–225.

Takasato M, Little MH. The origin of the mammalian kidney: implications for recreating the kidney in vitro. *Development*. 2015;142(11):1937–1947.

Tanagho EA. Anatomy and management of ureteroceles. *J Urol*. 1972;107(5):729–736.

Tanagho EA. Embryologic basis for lower ureteral anomalies: a hypothesis. *Urology*. 1976;7(5):451–464.

Tanagho EA, Hutch JA. Primary reflux. *J Urol*. 1965;93:158–164.

Tanagho EA, Meyers FH. The internal sphincter: is it under sympathetic control? *Invest Urol*. 1969;7(1):79–89.

Tanaka M, Komuro I, Inagaki H, et al. Nkx3.1, a murine homolog of Drosophila bagpipe, regulates epithelial ductal branching and proliferation of the prostate and palatine glands. *Dev Dyn*. 2000;219(2):248–260.

Thomson AA, Cunha GR. Prostatic growth and development are regulated by FGF10. *Development*. 1999;126(16):3693–3701.

Tichy M. The morphogenesis of human sphincter urethrae muscle. *Anat Embryol (Berl)*. 1989;180(6):577–582.

Timms BG. Anatomical perspectives of prostate development. N'az RK. *Prostate: basic and clinical aspects*. CRC Press: New York, NY; 1997:39–51.

Timms BG. Prostate development: a historical perspective. *Differentiation*. 2008;76(6):565–577.

Timms BG, Hofkamp LE. Prostate development and growth in benign prostatic hyperplasia. *Differentiation*. 2011;82(4–5):173–183.

Timms BG, Howdeshell KL, Barton L, et al. Estrogenic chemicals in plastic and oral contraceptives disrupt development of the fetal mouse prostate and urethra. *Proc Natl Acad Sci USA*. 2005;102(19):7014–7019.

Torres M, Gomez-Pardo E, Dressler GR, et al. Pax-2 controls multiple steps of urogenital development. *Development*. 1995;121(12):4057–4065.

Tourneux F. Sur les premiers développements du cloaques du tubercule génital et de l'anus chez l'embryon de mouton. *J Anat*. 1888;24:503–517.

Tufro A, Norwood VF, Carey RM, et al. Vascular endothelial growth factor induces nephrogenesis and vasculogenesis. *J Am Soc Nephrol*. 1999;10(10):2125–2134.

Tufro-McReddie A, Norwood VF, Aylor KW, et al. Oxygen regulates vascular endothelial growth factor-mediated vasculogenesis and tubulogenesis. *Dev Biol*. 1997;183(2):139–149.

Turner B, Fechner PY, Fuqua JS, et al. Combined Leydig cell and Sertoli cell dysfunction in 46,XX males lacking the sex determining region Y gene. *Am J Med Genet*. 1995;57(3):440–443.

Uy N, Reidy K. Developmental genetics and congenital anomalies of the kidney and urinary tract. *J Pediatr Genet*. 2016;5(1):51–60.

Vainio S, Lehtonen E, Jalkanen M, et al. Epithelial-mesenchymal interactions regulate the stage-specific expression of a cell surface proteoglycan, syndecan, in the developing kidney. *Dev Biol*. 1989;134(2):382–391.

van der Schoot P. Androgens in relation to prenatal development and postnatal inversion of the gubernacula in rats. *J Reprod*

Fertil. 1992;95(1):145–158.

van der Schoot P. Foetal testes control the prenatal growth and differentiation of the gubernacular cones in rabbits—a tribute to the late Professor Alfred Jost. *Development*. 1993;118(4):1327–1334.

Viana R, Batourina E, Huang H, et al. The development of the bladder trigone, the center of the anti-reflux mechanism. *Development*. 2007;134(20):3763–3769.

vom Saal FS, Timms BG, Montano MM, et al. Prostate enlargement in mice due to fetal exposure to low doses of estradiol or diethylstilbestrol and opposite effects at high doses. *Proc Natl Acad Sci USA*. 1997;94(5):2056–2061.

Vukicevic S, Kopp JB, Luyten FP, et al. Induction of nephrogenic mesenchyme by osteogenic protein 1 (bone morphogenetic protein 7). *Proc Natl Acad Sci USA*. 1996;93(17):9021–9026.

Wang Y, Hayward S, Cao M, et al. Cell differentiation lineage in the prostate. *Differentiation*. 2001;68(4–5):270–279.

Weigert C. Über einige bildungsfehler der ureteren. [Virchows] Archiv für pathologische Anatomie und Physiologie und für klinische Medizin. *Berlin*. 1877;70:490.

Weiss JP. Embryogenesis of ureteral anomalies: a unifying theory. *Aust N Z J Surg*. 1988;58(8):631–638.

Wensing CJ. Testicular descent in the rat and a comparison of this process in the rat with that in the pig. *Anat Rec*. 1986;214(2):154–160.

Williams DI. The ectopic ureter: diagnostic problems. *Br J Urol*. 1954;26(3):253–260.

Wilson JD. The role of 5alpha-reduction in steroid hormone physiology. *Reprod Fertil Dev*. 2001;13(7–8):673–678.

Wilson J, George F, Griffin J. The hormonal control of sexual development. *Science*. 1981;211:1278–1284.

Wilson JD, Griffin JE, George FW, et al. The endocrine control of male phenotypic development. *Aust J Biol Sci*. 1983;36(2):101–128.

Wilson JD, Griffin JE, Russell DW. Steroid 5 alpha-reductase 2 deficiency. *Endocr Rev*. 1993;14(5):577–593.

Windley SP, Wilhelm D. Signaling pathways involved in mammalian sex determination and gonad development. *Sex Dev*. 2015;9(6):297–315.

Wyndham NR. A morphological study of testicular descent. *J Anat*. 1943;77(Pt 2):179–188 [173].

Xu PX, Adams J, Peters H, et al. Eya1-deficient mice lack ears and kidneys and show abnormal apoptosis of organ primordia. *Nat Genet*. 1999;23(1):113–117.

Yucel S, Baskin LS. An anatomical description of the male and female urethral sphincter complex. *J Urol*. 2004;171(5):1890–1897.

Zimmermann S, Steding G, Emmen JM, et al. Targeted disruption of the Insl3 gene causes bilateral cryptorchidism. *Mol Endocrinol*. 1999;13(5):681–691.

Zondek LH, Zondek T. Effect of hormones on the human fetal prostate. *Contrib Gynecol Obstet*. 1979;5:145–158.

21

Urologic Aspects of Pediatric Nephrology

Michael C. Braun MD, Chester J. Koh MD

Introduction

Although many parents and patients consider them to be the same specialty, pediatric urologists and pediatric nephrologists train through very different pathways and often provide different viewpoints on urinary tract abnormalities. This is especially with regard to surgical and medical management, respectively, of the kidneys and the urinary tract, where the two specialties are tightly partnered in the treatment of the anatomic and functional effects of urinary tract malformations and acquired diseases. This chapter is designed to highlight topics and viewpoints in pediatric nephrology of which pediatric urologists should be aware, where the collaborative expertise of pediatric nephrologists and pediatric urologists is usually needed for optimal acute and chronic patient care.

Renal Function, Fluid, and Electrolyte Homeostasis

Renal Development

Renal morphogenesis is a complex, temporally and spatially regulated process by which precursor cells develop into a structurally and functionally normal kidney. Abnormal or dysregulated renal development results in a wide range of renal abnormalities collectively known as **congenital anomalies of the kidney and urinary tract (CAKUT) and that compose the most common cause of end-stage renal disease (ESRD) in children**. In humans, kidney and urinary tract development begins at approximately 3 weeks' gestation with the formation of the initial urinary excretory precursor, the pronephros, which undergoes complete involution (Combes et al., 2015; Little et al., 2012; Short and Smyth, 2016). At roughly 4 weeks' gestation, the mesonephros forms, followed at 5 weeks by the metanephros. Unlike the pronephros, the mesonephros is both functional and integral to the mature urinary tract. In males, residual segments of the mesonephric duct form the vas deferens, prostate, the seminal vesicles, as well as part of the epididymis; segments of the mesonephric tubules form the testicular efferent ductules. In females, the mesonephric ducts persist as the epoophoron and paroophoron. The metanephros, arising from metanephric mesenchyme, forms the mature nephron segments. In contrast, the ureteric bud gives rise to the renal collecting duct, the renal pelvis, and the ureters. By 34 to 36 weeks' gestation, nephrogenesis is complete, and the structural and functional relationship of each nephron segment is fully developed. On average, 1 million (range 0.2 to 2.7 million) individual nephrons in each kidney arise from embryonic precursor cells.

Concurrent with the morphogenesis of the kidney, functional development of the fetal kidney also progresses with increasing gestational age. Prenatally, the placenta controls fluid and electrolyte homeostasis, and the primary function of the fetal kidney is the production of urine to maintain amniotic fluid volume. In the later stages of gestation, urine output, tubular function, and glomerular filtration increase with gestational age.

After birth, the neonatal kidney undergoes physiologic changes to adapt to the extrauterine environment; rapid changes occur over the first several weeks and continue until reaching adult levels at 1 to 2 years of life.

Glomerular Filtration Rate

Glomerular filtration rate (GFR) refers to the volume of filtrate formed by the movement of plasma across the glomerular filtration barrier per unit of time. GFR is influenced by a number of factors, one of which is renal blood flow. This relationship between renal blood flow and GFR is evident as changes in both occur during fetal and postnatal development (Schell et al., 2014). Prenatally, the percentage of cardiac output received by the placenta is significantly greater than the fetal kidney. Postnatally, renal blood flow increases from 3% to 4% of total cardiac output to between 12% to 16% in the first year of life (Quigley, 2012). The increase in neonatal renal blood flow is caused by a combination of increased cardiac output and a marked decrease in renal vascular resistance relative to the increase in cardiac output. Several factors mediate the decrease in renal vascular resistance. These include a redistribution of intrarenal blood flow distribution, with an increase in intrarenal blood flow from the juxtamedullary glomeruli located in deeper regions of the renal cortex to glomeruli in the outer renal cortex. Furthermore, the renin-angiotensin system (RAS) plays an important role regarding changes in renal blood flow. Increasing levels of angiotensin II increase mean arterial pressure and vasoconstriction of the renal efferent arteriole, which in turn increases GFR by increasing glomerular capillary pressure. **Plasma renin, angiotensin II, and angiotensin-converting enzyme (ACE) levels increase in late gestation and postnatally are higher in the first 2 weeks of life than in adulthood.** Additionally, prostaglandins and nitric oxide exert vasodilatory effects, lower renal vascular resistance, and counterbalance the vasoconstrictive effects of the RAS activation (Gleason, 1987).

Prenatal and neonatal GFR is significantly lower than adult GFR levels (Schwartz et al., 2009). Because of placental effects, plasma creatinine concentrations in the first 48 hours after delivery reflects maternal rather than neonatal renal function. Under normal circumstances, by 7 days of life, creatinine levels fully reflect neonatal renal function and are normally less than 0.5 mg/dL in term infants. Subsequently, GFR doubles in term infants over the first 2 weeks of life and increases steadily until reaching adult levels by 2 years of age.

Tubular Function

Glomerular filtration is only the first step in the homeostatic processes required of the kidney. Concurrent with the maturation of GFR, there are morphologic and physiologic changes, particularly with respect to the renal tubules, that lead to maturation of the ability to maintain fluid and electrolyte homeostasis.

Both term and preterm neonates possess a higher total body water than older children and adults that is as much as 70% to 90% of total body weight (Gattineni and Baum, 2015). Although neonates have the ability to dilute urine to as low as 50 mOsm/L, their urinary concentrating ability is limited, thus promoting negative free water balance. Normal free water loss is as much as 1% to 2% loss of total body weight per day over the first 5 days of life in term neonates and even higher in preterm neonates. There are a number of factors that reduce the ability of the neonatal kidney to generate a concentrated urine including decreased responsiveness to antidiuretic hormone (ADH) and immaturity of the renal tubules. The immaturity of the tubules is both structural and functional. Structurally, the renal tubules increase in length with age, particularly the thick ascending limb of the loop of Henle. At birth, the activity of the sodium-potassium ATPase (Na^+,K^+-ATPase) exchanger, which drives sodium transport, is low but increases in the immediate neonatal period, with a peak increase at around 2 to 3 weeks of life. Finally, there is an increase in the concentration of urea in the medullary interstitium, which is required for the generation and maintenance of the countercurrent multiplier that is essential for the formation of concentrated urine.

Developmental Changes in Glomerular Filtration Rate and Tubular Function

The maintenance of the balance of sodium is an important function of the neonatal kidney. The ability of a neonate to conserve sodium in the first week of life is limited with an ensuing initial negative sodium balance during the first week of life, which shifts to a positive sodium balance by 2 to 3 weeks of age. The natriuresis seen during the first week of life is mediated primarily by increased levels of atrial natriuretic peptide. The maturational responses to achieve sodium homeostasis include elongation of the tubular segments, which creates a larger surface area for reabsorption and upregulation of the number or activity of transporters in renal tubular cell membranes. Additionally, endocrine and paracrine mechanisms including the renin-angiotensin-aldosterone system (RAAS), catecholamines, cortisol, and thyroid hormone drive sodium homeostasis. Elevated levels of renin and aldosterone stimulate sodium reabsorption in the proximal tubule, the thick ascending limb of the loop of Henle, and cortical collecting ducts. Similarly, increased levels of catecholamines directly or indirectly through the RAAS pathway stimulate sodium reabsorption. Furthermore, increases in both cortisol and thyroid hormone stimulate tubular sodium transporters.

The newborn kidney has a limited capacity to excrete potassium and tends to have higher serum potassium values than older children. The limited renal capacity of the neonatal kidney to excrete potassium is thought to be caused by the reduced number and responsiveness of the Na^+,K^+-ATPase exchanger and the potassium transporters in the distal tubule and cortical collecting ducts. Normally, 65% to 75% of filtered potassium is passively reabsorbed by the proximal tubule (Palmer, 2015; Zhou et al., 2004). The remainder of potassium reabsorption occurs in the thick ascending limb of the loop of Henle via NKCC2, and much smaller amounts are reabsorbed in the distal tubule and cortical collecting ducts via the Na^+,K^+-ATPase exchanger. Urinary potassium excretion however is predominantly mediated via the apical renal outer medullary potassium (ROMK) channel of the cortical collecting ducts. Although the levels of circulating aldosterone are noted to be higher in neonates, the neonatal kidney has a decreased responsiveness to aldosterone activation. The postnatal increase in potassium secretory capacity is largely related to increased activity of the Na^+,K^+-ATPase exchanger and an increase in the number of ROMK channels in the cortical collecting ducts, which in turn increases tubular responsiveness to aldosterone.

In the neonate, the mechanisms of urinary acidification and bicarbonate reabsorption are immature, and neonatal serum bicarbonate levels are lower than that seen in adults. As renal acidification and bicarbonate reclamation improve over the first 3 to 4 weeks of life, there is a steady rise in net acid excretion and plasma bicarbonate reabsorption (Quigley et al., 2004). The primary site of bicarbonate reabsorption is the proximal tubule, where 80% of filtered bicarbonate is reabsorbed. The sodium-hydrogen exchanger 3 (NHE3) and H^+-ATPase, which both secrete H^+ into the proximal tubular lumen, drive HCO_3 reabsorption in the proximal tubule. Carbonic anhydrase IV (CA), which catalyzes the conversion of secreted H^+ and filtered bicarbonate (HCO_3) into carbon dioxide (CO_2) and water, are less active in the newborn, limiting the ability to absorb HCO_3 and secrete an acid load. With maturation, the activity of these mechanisms increases, resulting in a concurrent increase in serum HCO_3 concentration. The final step in urinary acidification occurs through the secretion of H^+ via the apical H^+-ATPase in the cortical collecting ducts. Maturational increases in the activity of this transporter is essential to acid-base homeostasis. A critical factor affecting this process is the postnatal increase in glucocorticoid production, which has been shown to promote an increase in the number of NH_3 antiporters, which are essential for ammonia generation.

At birth, neonatal serum levels of calcium are higher than those seen in adults (Schell-Feith et al., 2010). There is a fall in serum calcium levels in the first day of life. The maturation of renal tubular calcium regulation is not fully understood. Although there is a rise in serum parathyroid hormone (PTH) levels associated with the falling calcium levels, neonates are typically in negative calcium balance marked by relative hypercalciuria. It is likely that neonates have a blunted response to the effects of PTH either directly or indirectly, which limits proximal tubule calcium reabsorption through both paracellular and transcellular pathways and calcium reabsorption in the distal tubule by the TRPV6 channel. Neonates have a much higher renal reabsorption of phosphate compared with adults. Renal tubular reabsorption of phosphate can be as high as 99% immediately after birth and remain greater than 90% during the neonatal period (Kaskal et al., 1988). The reabsorption of phosphorus is mediated largely via the tubular transporters, such as the 2Na-Pi IIc antiporter, which are more active in the immature kidney. As circulating levels and tubular responses to PTH increase after birth, the level of phosphorus reabsorption falls as the kidney matures.

Key Points

- CAKUT is the most common cause of ESRD in children.
- Prenatal and neonatal GFR is significantly lower than adult GFR levels.
- The maintenance of the balance of sodium is an important function of the neonatal kidney.
- The newborn kidney has a limited capacity to excrete potassium and tends to have higher serum potassium values than in older children.

Hematuria (Microscopic and Gross)

Hematuria is one of the most common reasons for referral to pediatric nephrologists and urologists. Hematuria can present as either gross hematuria with red or “tea-colored” urine, or microscopic hematuria with yellow urine with a positive dipstick for blood. Microscopic hematuria is defined as clear yellow urine with a positive urine dipstick for blood with greater than five red blood cells per high-power field in a freshly spun urine sample. **Isolated microscopic hematuria is reported to occur in approximately 1% of school-age children** (Dodge et al., 1976; Vehaskari et al., 1979). Less than 25% of these children will have hematuria on repeated testing, and **most will have spontaneous resolution of hematuria within 1 year of presentation.** The incidence of gross hematuria is difficult to ascertain, however, it is estimated to account for slightly more than 0.1% of pediatric emergency room visits. Although isolated microscopic hematuria is most commonly a benign condition, the differential diagnosis is quite broad, and a definitive diagnosis is determined in less than 30% of patients. Gross hematuria typically prompts more urgent referral and evaluation, and in the majority of cases, an underlying diagnosis can be made.

A detailed history should be obtained to determine if the hematuria is painless, intermittent or persistent, and microscopic or gross. Associated symptoms should be sought including a history of trauma, abdominal pain, fever, dysuria, voiding dysfunction, rash, joint pain, weight gain, swelling, exercise, headaches, or visual changes. A detailed family history should also be obtained with a focus on hematuria, bleeding disorders, hearing loss, urolithiasis, sickle cell disease, and renal disease. Vital signs including blood pressure should be carefully measured. A thorough physical examination should be performed, with particular attention to blood pressure, rashes, joint abnormalities, edema, abdominal or flank pain, abdominal masses, and perineal abnormalities.

The critical step in the evaluation of hematuria is the examination of a freshly voided urine sample that includes microscopic assessment. Grossly bloody or red urine is indicative of nonglomerular bleeding, and brown or “tea-colored” urine is suggestive of a glomerular origin of the hematuria. In all patients with gross hematuria, urine microscopy is essential to confirm the presence of red blood cells (RBCs). **The absence of RBCs in grossly bloody urine with a positive urine dipstick for heme is strongly suggestive of hemoglobinuria or myoglobinuria.** The urine sediment should be examined closely for the presence of crystals, which are suggestive of urolithiasis, and the presence of white blood cells or bacteria are suggestive of urinary tract infection. A semiquantitative assessment of RBC number should be done, including RBC morphology, as uniformly normal RBC morphology is suggestive of lower urinary tract bleeding, and dysmorphic or “crenallated” RBCs are suggestive of glomerular disease. Urine sediment should be carefully examined for the presence of RBC casts, which define glomerular nephritis. In patients with suspected glomerular disease, a quantitative assessment of proteinuria should be performed. Based on the history, physical findings, and complete assessment of the urine, a logical and structured evaluation can be performed.

Patients with findings suggestive of glomerular disease, proteinuria, hypertension, edema, or evidence of systemic disease should have a baseline evaluation of their renal function, serum electrolytes, complete blood counts, serum albumin, complement C3 and C4 levels, and ASO or anti-DNase B titers. Referral to a pediatric nephrologist is often warranted. Renal cysts, most commonly in polycystic kidney disease, can also present with gross hematuria. Patients with fever, abdominal pain, dysuria, or frequency should have urine cultures done as urinary tract infections are the most common cause of gross hematuria in children. A history of trauma, abdominal or flank pain associated with gross hematuria often accompanied with frank clots should prompt urologic evaluation, and imaging by computed tomography (CT) is often warranted. In patients with a family history of urolithiasis, gross hematuria, abdominal or flank pain, and a history of passing gravel, imaging such as renal ultrasonography or CT should be done and also may include a comprehensive evaluation for renal stones. Other rare causes include urinary obstruction, tumors, coagulopathies, and vascular malformations.

The causes of hematuria in children are numerous (Box 21.1), and the assessment of children with microscopic hematuria is based on associated history and physical features combined with urinary findings. In patients with an unremarkable history including family history and who are asymptomatic and have only isolated microscopic hematuria without proteinuria, the evaluation can be limited to testing the parents for hematuria and measurement of urinary calcium excretion. The value of urinary tract imaging in children with microscopic hematuria is controversial. The yield of routine ultrasonography is low, and reported findings are frequently of little clinical significance. When microscopic hematuria persists for several months, decisions on the need for urinary tract imaging should be based on associated clinical findings. Voiding cystourethrograms and cystoscopy are rarely helpful and are not indicated for the routine evaluation of children with isolated microscopic hematuria. In patients with a positive family history, personal history, abnormal physical findings, or urinary findings in addition to hematuria, a more comprehensive evaluation is recommended. Typically this would include a complete blood count, serum electrolytes, creatinine, albumin, C3, C4, ASO titer, antinuclear antibody (ANA) testing, and a quantitative measurement of urinary protein excretion. Additional testing such as hearing screening, hemoglobin electrophoresis, imaging, and genetic testing should be individualized.

Box 21.1

Causes of Hematuria in Children

Macroscopic

- Transient
- Hypercalciuria/nephrolithiasis
- Glomerulonephritis (all types)
- Cystitis
- Exercise
- Congenital anomalies of the urinary tract
- Benign urethrorrhagia
- Wilms tumor or bladder tumor
- Bleeding dyscrasia
- Renal vein thrombosis
- Papillary necrosis
- Nutcracker syndrome

Microscopic

- Transient
- Hypercalciuria/nephrolithiasis
- Glomerulonephritis (all types)
- Cystitis/pyelonephritis
- Exercise
- Congenital anomalies of the urinary tract

Thin basement membrane disease
Drugs
Interstitial nephritis
Sickle cell disease/trait

Key Points

- Isolated microscopic hematuria is reported to occur in approximately 1% of school-age children.
- Most children with microscopic hematuria will have spontaneous resolution within 1 year of presentation.
- Gross hematuria and a urinalysis with no RBCs and a positive heme dipstick is strongly suggestive of hemoglobinuria or myoglobinuria.

Proteinuria

Proteinuria is another common finding that prompts referral to a pediatric subspecialist. **It is important to recognize that urine contains protein under physiologic conditions and that children excrete urine free of protein frequently when evaluated by the semiquantitative dipstick method.** Urinary protein excretion varies by body mass and renal maturity. A normal urine protein-to-creatinine ratio in a newborn is less than 0.7 mg/mg, and less than 0.2 mg/mg in older children. If a timed collection is obtained, physiologic urinary protein excretion is typically less than 4 $mg/m^2/h$. Healthy adolescents and adults excrete less than 150 mg of protein in a 24-hour period. Urinary protein consists of both filtered plasma proteins and secreted tubular proteins. Although most filtered proteins are of low molecular weight, albumin accounts for nearly 30% of the total protein found in “normal” urine.

Proteinuria is categorized as either transient, orthostatic, or fixed (Box 21.2) (Hogg et al., 2000; Vehaskari and Rapola, 1982). **Transient proteinuria is characterized by disappearance of proteinuria after a positive test and accounts for more than 75% of patients with isolated proteinuria. Typically, transient proteinuria occurs in association with fever or exercise.** In an otherwise healthy child, transient proteinuria is a benign condition. Orthostatic proteinuria commonly occurs in adolescents and is defined as proteinuria only when the patient is in an upright position. Patients are otherwise healthy and do not have other evidence of renal disease. A diagnosis of orthostatic proteinuria is made by the measurement of urinary protein in the first-void urine and in a second sample after the patient has been upright for several hours (Abitbol et al., 1990). In orthostatic proteinuria, the initial first-void urine sample has normal protein values (protein-to-creatinine ratio <0.2 mg/mg), and the upright urine has increased levels of urine protein. Orthostatic proteinuria is usually transient and benign in nature; however patients should be closely evaluated to confirm that they are otherwise asymptomatic and have normal renal function and blood pressure. It is recommended that patients with orthostatic proteinuria be followed annually to ensure that there is no progression in their clinical findings. Fixed proteinuria is persistent and not dependent on postural changes. Protein excretion should be quantified either by a timed collection if possible or by first-void urine protein-to-creatinine ratio. Fixed proteinuria requires a more thorough evaluation.

Box 21.2

Causes of Proteinuria

- Transient
  - Exercise
  - Fever
  - Stress/illness
- Orthostatic
- Fixed
  - Drugs (chemotherapy, aminoglycosides, heavy metal intoxication)
  - Tubular disease (acute tubular necrosis, interstitial nephritis, cystic kidney diseases, Fanconi syndrome, graft-versus-host disease)
  - Reflux nephropathy
  - Glomerulonephritis: acute and chronic, all forms, including minimal change nephrotic syndrome
  - Other chronic renal disease (obstructive uropathy, congenital renal dysplasia, permanent residual dysfunction from acute disease [e.g., cortical necrosis, hemolytic uremic syndrome, glomerulonephritis])
  - Diabetes mellitus
  - Protein overload syndromes (hemolysis, rhabdomyolysis, hypergammaglobulinemia)

The differential diagnosis of proteinuria is quite broad, and the evaluation of patients with persistent proteinuria should be focused on identifying the underlying etiology of the proteinuria. It is essential to obtain a complete and thorough history and physical examination including a comprehensive family history with attention to family members with autoimmune disease, renal disease, diabetes, and ESRD. Associated symptoms should be sought including a history of fever, gross hematuria, excessive urinary foaming, growth failure, rash, joint pain, weight gain, swelling, headaches, or visual changes. Vital signs including blood pressure should be carefully measured. A thorough physical examination should be performed with particular attention to blood pressure, rashes, joint abnormalities, and edema. Laboratory investigation should be tailored to findings on the history and physical examination, but often include measurement of serum creatinine, albumin, electrolytes, complete blood count, cholesterol, and triglycerides. **If the patient has evidence of systemic disease or glomerular nephritis, testing should include C3, C4, and ANA screening.** Further diagnostic testing will be dependent on the results of these screening tests. If the screening studies are normal and the patient has persistent proteinuria, renal biopsy may be warranted to determine the underlying diagnosis.

Key Points

- It is important to recognize that urine contains protein under physiologic conditions and especially with fever and exercise.
- Transient proteinuria accounts for more than 75% of patients with isolated proteinuria.
- If a patient with proteinuria has evidence of systemic disease or glomerular nephritis, testing should include C3, C4, and ANA screening.

Glomerular Disease

Glomerular diseases in children have several etiologies, and they commonly present in specific age ranges (Box 21.3).

Box 21.3

Common Age Ranges for Presentation of Glomerular Diseases

Younger Than 1 Year of Age

- Congenital infections
- Diffuse mesangial sclerosis
- Genetic diseases:
  - Congenital nephrotic syndrome (CNS) and infantile nephrotic syndrome
  - Denys-Drash and Frasier syndromes

1 to 10 Years of Age

- Acute poststreptococcal glomerulonephritis (GN)
- Minimal change nephrotic syndrome (MCNS)
- Focal segmental glomerulosclerosis (FSGS)
- Henoch-Schönlein purpura (HSP)
- Hemolytic uremic syndrome (HUS)

7 Years of Age and Older

- Systemic lupus erythematosus (SLE)
- Systemic vasculitis
- Idiopathic crescentic GN
- Membranoproliferative GN (MPGN)
- Immunoglobulin A nephropathy
- Idiopathic and secondary FSGS

Membranous nephropathy (MN)
Alport syndrome
Nail-patella syndrome
Pulmonary-renal syndromes (Goodpasture syndrome [antiglomerular basement memebrane disease])

Nephrotic Syndrome

Nephrotic syndrome is a constellation of clinical findings common to a number of glomerular diseases. These features include proteinuria greater than 40 $mg/m^2/h$ or a urinary protein-to-creatinine ratio greater than 2.0 mg/mg, hypoalbuminemia, and hyperlipidemia. The reason for the increased hepatic production of lipoproteins during the nephrotic state is not entirely understood, but it appears to be associated with low plasma oncotic pressure and alterations in lipoprotein metabolism. **Although nephrotic syndrome may present as a feature of glomerular nephritis, it presents more commonly in children in isolation**.

Nephrotic syndrome of childhood has been divided into three broad groups: congenital/infantile, primary (inherited or idiopathic), and secondary. Approximately 10% of children have an identifiable secondary cause of nephrotic syndrome. The histologic lesions that are associated with secondary causes of nephrotic syndrome are frequently indistinguishable from the idiopathic lesions, but the treatment is targeted to the primary underlying cause in these cases. Over the past two decades, mutations in nearly 30 genes have been identified in either inherited or sporadic primary nephrotic syndrome.

Primary nephrotic syndrome is the occurrence of the constellation of clinical findings that define NS in the absence of an identifiable causative agent or disease. Primary NS is classified into four categories based on histologic findings: minimal change nephrotic syndrome (MCNS), mesangial proliferation (MES), focal segmental glomerulosclerosis (FSGS), and membranous nephropathy (MN). Nephrotic syndrome is classified by responsiveness to steroid therapy and histopathologic features if a biopsy is performed.

Steroid-sensitive nephrotic syndrome (SSNS) typically presents with dependent edema with variable swelling of the eyelids, scrotum, and labia. Hypertension is not typical. Microscopic hematuria is seen in approximately 20% of patients. Macroscopic hematuria is unusual.

Corticosteroids will induce a remission in the vast majority of children

with nephrotic syndrome. Therefore, for those with a typical clinical presentation, a kidney biopsy is not indicated before initiating steroid therapy. Atypical features that may require a kidney biopsy before treatment include age younger than 1 year at presentation, macroscopic hematuria, hypertension, hypocomplementemia, and extrarenal symptoms such as a rash or arthritis.

Edema is mild in most patients and can be managed with dietary restriction (Teoh et al., 2015). The current standard of care is to treat these children with corticosteroids. Most children receive initial treatment with prednisone (60 mg/m^2/day or 2 mg/kg/day). The current definition of steroid responsiveness is a resolution of proteinuria within 8 weeks of starting steroid therapy. Once the urine become negative for protein, the prednisone is switched to alternate days and tapered over 6 weeks or longer. Almost 50% of children with SSNS will experience multiple relapses (Teeninga et al., 2012).

Frequently-relapsing nephrotic syndrome (FRNS) is defined as two or more relapses within 6 months of initial response to steroid therapy or four or more relapses within any 12-month period. In this setting, the potential adverse effects of the cumulative steroid doses required to achieve sustained remission begin to exceed the benefits of maintaining nephrotic syndrome remission. Steroid-sparing strategies have also been developed to treat FRNS including alkylating agents such as oral cyclophosphamide, mycophenolate mofetil (MMF), B-cell depletion with rituximab, and calcineurin inhibitors (CNIs).

Steroid-dependent nephrotic syndrome (SDNS) is defined when a child with NS develops two consecutive relapses during steroid therapy or when the ability to achieve and/or remain in remission from nephrotic syndrome requires continuous administration of corticosteroids. Steroid-sparing strategies in this population include low-dose alternative-day corticosteroids, MMF, B-cell depletion with rituximab, and CNIs. Children with SDNS tend not to respond as well to alkylating agents as the FRNS subgroup.

Steroid-resistant nephrotic syndrome (SRNS) is seen in 15% to 20% of children with idiopathic NS and in a small subset of patients who were initially steroid responsive. It is defined as a failure to achieve remission after 6 to 8 weeks of full-dose daily prednisone. A biopsy is often recommended for steroid-resistant patients before initiating alternative therapies as there is a much higher prevalence of FSGS in this subset of patients (Lovric et al., 2015). A wide range of therapies has been utilized in patients with SRNS, with varying degrees of efficacy including intravenous pulse steroids, combined treatment with high-dose corticosteroids and alkylating agents, and cyclosporine or tacrolimus

(Büscher et al., 2016). Patients who achieve remission with CNIs are reported to have a high frequency of relapse when these agents are discontinued. Patients who are refractory to steroids and CNIs rarely respond to other therapies.

Congenital nephrotic syndrome (CNS) is defined as nephrotic syndrome presenting within 3 months after birth. CNS can be caused by either genetic defects or perinatal infections. Proteinuria often begins in utero and can be detectable in the first urine sample after birth. In cases of CNS, immunosuppressive therapy is not recommended as patients have been shown to be nonresponsive to these agents. Conservative management of edema consists of sodium and fluid restriction and intermittent intravenous albumin and loop diuretics. The management of these patients also includes a hypercaloric diet, thyroid hormone replacement, monitoring for thrombotic episodes, and aggressive management of infectious complications.

Minimal change nephrotic syndrome (MCNS) is the most common cause of nephrotic syndrome in childhood, accounting for 90% of patients presenting before 10 years of age and 70% to 80% of all pediatric patients with nephrotic syndrome. MCNS is characterized by response to corticosteroids and often a chronic relapsing course. Most patients have an excellent long-term prognosis. The peak incidence is in preschool children, with a median age of 2.5 years. MCNS is usually idiopathic in childhood, although there is a wide range of secondary causes of MCNS and an increasing number of genetic mutations linked to MCNS. The cornerstone of therapy for MCNS is corticosteroids, which will induce remission in nearly 90% of children. Up to 85% of patients achieve long-lasting remission. However, a subset of patients will continue to experience relapses into adulthood.

Focal segmental glomerulosclerosis (FSGS) is seen in the majority of children with SRNS. FSGS may be primary or secondary. As opposed to MCNS, less than 25% of patients with FSGS respond to steroid therapy. In children, primary FSGS typically presents between 2 and 7 years of age, with a higher incidence among African-Americans, Hispanics, and Asians. Genetic etiologies of steroid-resistant FSGS have been identified with increasing frequency. The vast majority of children with idiopathic FSGS present with nephrotic syndrome that is indistinguishable from SSNS. Definitive diagnosis requires kidney biopsy. Current guidelines recommend initial treatment of primary FSGS with high-dose prednisone for durations of 4 to 16 weeks or until complete remission. CNIs are often recommended for patients who are resistant or intolerant to corticosteroids. **FSGS can recur after kidney transplantation.** Treatment with plasmapheresis, B-cell depletion, and CNIs has been reported to be effective in some patients. However, many will lose their graft and return to dialysis.

Membranous nephropathy (MN) is a rare cause of nephrotic syndrome in childhood. The majority of childhood cases of MN are secondary to an underlying disorder; autoantibodies to phospholipase A_2 receptor (aPLA_2R) are frequently seen in children and adolescents with primary MN (Cossey et al., 2013). Hepatitis serology, serum complement levels, and ANA testing should be obtained. A kidney biopsy is required to establish a diagnosis. On biopsy, MN is characterized by the presence of subepithelial immune deposits. There are no universally accepted treatment guidelines for children with MN. The use of ACE inhibitor or angiotensin receptor blocker (ARB) therapy and a low-sodium diet are recommended. Corticosteroids alone can decrease proteinuria, but rarely leads to long-term remission when used in isolation. For this reason, corticosteroids are often used combined with an alkylating agent. CNIs are also commonly used. Recent data suggest that MMF and rituximab may be efficacious in MN secondary to PLA_2R-AB. MN is typically a slowly progressive disease, with 5% of children developing ESRD 5 years after diagnosis.

Persistence of nephrotic syndrome is associated with significant morbidity and even mortality. Because nephrotic syndrome frequently follows a chronic relapsing course, children are at risk for several recognized long-term complications. Spontaneous bacterial peritonitis occurs in 2% to 6% of these children and is typically caused by *Streptococcus pneumoniae* or gram-negative organisms. **Thromboembolism is one of the most serious complications of nephrotic syndrome.** Virtually all nephrotic patients are in a hypercoagulable state, and as many as 20% experience thrombotic events. Mortality, although rare, is most frequently caused by infectious complications and less commonly by thromboembolic events.

Glomerulonephritis

As opposed to isolated nephrotic syndrome, **glomerulonephritis classically presents with hematuria (gross or microscopic), proteinuria, hypertension, and acute kidney injury.** Inflammation leads to decreased renal function and retention of salt and water with ensuing hypertension and edema. Urinary features typically include “tea-colored” or “cola-colored” urine, with a urine sediment characterized by dysmorphic erythrocytes and red blood cell casts

(Kidney Disease Improving Global Outcomes [KDIGO], 2012). Although glomerular diseases can occur in almost any age group, most have a characteristic age range for disease onset. A number of systemic diseases may have their initial presentation with glomerulonephritis, so a careful examination for signs and symptoms of multisystem disease should be sought. It is essential to recognize that many patients with chronic glomerulonephritis may be asymptomatic in the early stages of disease progression. Therefore it is essential to determine if there is evidence of chronic kidney disease (CKD) at the time of initial evaluation. Features of CKD include anemia, growth failure, and the hallmarks of chronic kidney disease/mineral bone disease (CKD/MBD): hyperparathyroidism, hypocalcemia, and hyperphosphatemia. Initial laboratory evaluation of children with glomerulonephritis is focused on defining the severity of acute kidney injury, any metabolic derangements associated with decreased renal function, and whether the child has evidence of hypocomplementemia which, if present, significantly narrows the differential diagnosis. Hypocomplementemia, defined by a low C3 level when combined with normal C4 levels, is strongly supportive of a diagnosis of acute postinfectious glomerulonephritis or C3 glomerulopathy, and a low C3 level and a low C4 level focuses the diagnosis on either lupus nephritis or membranoproliferative glomerulonephritis. Normocomplementemia is a feature of the other common forms of glomerulonephritis that are seen in the pediatric population.

Acute poststreptococcal glomerulonephritis is the most common form of post-infectious glomerulonephritis (PIGN) in childhood. However, many other bacterial, viral, and parasitic pathogens are also associated with PIGN. Typically the child has a history of pharyngitis or pyoderma that precedes the presentation of glomerulonephritis by several weeks. Acute poststreptococcal glomerulonephritis is primarily a disease of school-age children. It is rare before 3 years of age and may occur as a sporadic or epidemic disease.

Clinical symptoms begin abruptly, with most patients presenting with edema and gross hematuria. Proteinuria is typically mild; however some patients can present with features of nephrotic syndrome. Mild to moderate hypertension is common, although some patients with severe disease present with hypertensive urgency or emergency. Acute kidney injury is typically mild, although in severe cases, rapidly progressive glomerulonephritis (RPGN) can occur, necessitating renal replacement therapy (RRT). Laboratory testing supportive of a diagnosis of PIGN includes a serum C3 level usually below 50% of normal levels, and an elevated ASO or DNase B titer. In the vast majority of cases, with conservative management, spontaneous improvement typically begins within 1 week, with resolution of the edema occurring in 5 to 10 days, and resolution of the hypertension occurring in 2 to 3 weeks. In the majority of patients, the clinical presentation and laboratory testing that includes complement levels is usually sufficient to make the diagnosis of PIGN, and there is no indication to perform a kidney biopsy to confirm the diagnosis. C3 levels typically return to normal within 8 to 12 weeks after presentation. However, if a child has persistently low C3 levels or has an atypical clinical course, a kidney biopsy may be indicated. Residual proteinuria may be present of up to 6 months after the acute injury, and microscopic hematuria may persist for more than 1 year.

Two other forms of hypocomplementemic nephritis, although rare, can present in childhood: **Membranoproliferative glomerulonephritis (MPGN)** and **C3 glomerulopathy (C3G),** which is further subdivided into dense deposit disease and C3-dominant glomerulonephritis (C3GN). These diseases typically present in late childhood and are rare before 5 years of age. The presentation of MPGN/C3G is varied and includes asymptomatic hematuria or proteinuria, nephrotic syndrome, and features that initially mimic PIGN, including low serum C3 levels in the remainder (Pickering et al., 2013). The presence of nephrotic syndrome and a depressed serum C4 level are early clues that differentiate MPGN from PIGN. Persistent hypocomplementemia in a patient with suspected PIGN is highly unusual and is suggestive of either G3G or MPGN. Although many MPGN patients have evidence of activation of the classical complement cascade with low serum C3 levels and low C4 levels, and patients with C3G patients commonly have signs of alternative pathway activation with persistently low C3 and normal C4 levels, these distinctions are not absolute and a kidney biopsy is required to establish the diagnosis of MPGN/C3G.

The final form of hypocomplementemic nephritis that presents in childhood is **systemic lupus erythematosus (SLE) and should be considered a likely diagnosis in any child with evidence of systemic disease, glomerulonephritis, and low C3 and C4 levels** (Hiraki et al., 2012). The clinical presentation of SLE ranges from asymptomatic microscopic hematuria or proteinuria to rapidly progressive glomerulonephritis. Usually other systemic manifestations of SLE are apparent. The presence of 4 out of 11 American College of Rheumatology classification criteria for SLE confers a 96% sensitivity and specificity for the diagnosis of SLE. Almost all patients have hypocomplementemia, positive antinuclear antibodies, and anti–double-stranded DNA titers. No combination of serologic markers effectively predicts the histologic type or severity of kidney involvement. The treatment of patients with mild renal disease (classes I and II) should be determined by the extrarenal manifestations and typically have a favorable renal prognosis. However, children with more extensive renal involvement (class III and IV) can have more progressive renal dysfunction if left untreated. Consensus treatment recommendations developed for children with SLE include the use of corticosteroids combined with immunosuppressive drugs in this patient population (Mina et al., 2012). However, only 80% of patients with class IV achieve sustained remission, and up to 50% of patients will experience at least one relapse.

Normocomplementemic Glomerulonephritis

Immunoglobulin A (IgA) nephropathy is the most common primary cause of glomerulonephritis throughout the world including in the pediatric population. Patients with this condition commonly present in the second and third decades of life, and it is rare in the first decade of life. The true incidence of IgA nephropathy is uncertain, as there are no reliable serologic markers, and a renal biopsy is the only way to definitively make the diagnosis. IgA nephropathy is defined by the presence of dominant IgA deposits in the glomerulus. These deposits are polymeric IgA1 with aberrant glycosylation patterns in the hinge region of the antibody (Kiryluk et al., 2011).

Most commonly, these patients present with recurrent episodes of painless macroscopic hematuria. The onset of gross hematuria is often concurrent with or immediately proceeded by an upper respiratory tract infection. The latency period between the onset of infectious symptoms and gross hematuria is considerably shorter in IgA nephropathy than that seen in patients with PIGN. The gross hematuria episodes typically resolve within a few days, but microscopic hematuria and variable degrees of proteinuria may persist. Occasionally there are complaints of flank or loin pain associated with the gross hematuria. Many patients will also present with incidental findings of microscopic hematuria and mild proteinuria. Less commonly, patients will present with isolated nephrotic syndrome. Most of the acute episodes resolve without specific therapy, and the long-term prognosis remains relatively good. There are currently no diagnostic markers for IgA nephropathy. A renal biopsy for suspected IgA nephropathy may be considered in patients who have impaired kidney function, hypertension, or significant proteinuria, as these individuals are at increased risk for developing ESRD. IgA nephropathy is a disease with a highly variable outcome. For patients with self-limited episodes of recurrent gross hematuria who do not develop significant proteinuria, the long-term outcome is quite good. Risk factors for progressive disease include persistent and significant degrees of proteinuria, hypertension, and an elevated serum creatinine. In the high-risk patient population, kidney function slowly deteriorates. Current data suggest that up to 20% to 30% of this population will develop ESRD and another 20% have progressive CKD.

Henoch-Schönlein purpura (HSP) is a self-limited systemic vasculitis syndrome of childhood characterized by symptoms that may occur asynchronously over a period of several days to weeks. These features include a purpuric rash, arthralgia, abdominal pain, and glomerulonephritis. Nephritis rarely, if ever, precedes the onset of purpura. Histologically, the glomerulonephritis in HSP is indistinguishable from idiopathic IgA nephropathy. Whereas IgA nephropathy is exclusively a renal disorder, HSP is characterized by its extrarenal manifestations. The pathophysiology is similar in its involvement of glomerular deposition of polymeric IgA1 immune complexes (Kiryluk et al., 2011). Most patients with HSP nephritis present with asymptomatic hematuria and mild proteinuria, although up to one-fourth of these patients develop gross hematuria. A small subset of patients will present with an acute nephritis and/or nephrotic syndrome, and presentation with RPGN is rare. HSP remains a clinical diagnosis as there are no specific diagnostic markers for this condition. Kidney biopsy is not necessary for diagnosis but can be helpful in making treatment decisions when patients develop nephrotic syndrome or RPGN. HSP usually spontaneously resolves within 1 to 2 weeks, but recurrent episodes occur fairly commonly for the first 4 months. Ultimately the vast majority of patients achieve full clinical remission (Dudley et al., 2013). Persistent urinary abnormalities, low-grade proteinuria, and microscopic hematuria is commonly seen for up to 3 months after presentation and for up to 2 years in 10% to 20% of children. A rapidly progressive clinical course with ensuing ESRD can be seen in a small percentage of patients. Patients with persistent heavy proteinuria may see progression over a period of several years. In a long-term follow-up study of patients with HSP, 44% of patients with nephrotic syndrome or acute nephritis at presentation developed hypertension or progressive CKD, compared with normal renal function in 82% of patients who presented with isolated hematuria.

Alport syndrome is a genetic disorder of the collagen type IV α3, α4, or α5 chains that form the mature glomerular basement membrane. The primary presenting clinical finding in all forms of Alport syndrome is persistent microscopic hematuria. Intermittent gross hematuria is also commonly seen. **Sensorineural deafness is a common feature that distinguishes Alport syndrome from other forms of glomerular disease.** Hearing deficits typically occur in late childhood, are bilateral, and initially involves high-frequency hearing loss that gradually worsens over time. A family history of kidney failure or deafness in a child with hematuria is highly suggestive of Alport syndrome. Ocular anomalies may develop later in childhood, including macular disease and anterior lenticonus. Other rare associations include leiomyomata of the esophagus, trachea, and the external genitalia in females. Alport syndrome has X-linked, autosomal dominant, and recessive forms of inheritance (Savige et al., 2016). The majority of patients have X-linked mutations in *COL4A5*, the gene encoding the α5 chain of collagen type IV. Autosomal disease is caused by mutations in *COL4A3* or *COL4A4*. Heterozygous mutations in *COL4A3* or *COL4A4* are inherited in a dominant fashion, and patients with mutations in both alleles present in a recessive manner. Kidney function is usually well preserved during the first decade of life in males with X-linked Alport syndrome. Frank proteinuria frequently appears during late childhood or early adolescence and is followed by development of hypertension and renal insufficiency (Savige et al., 2013). About 50% of males with X-linked disease reach ESRD by 25 years of age. Patients with autosomal recessive disease follow a course similar to males with X-linked Alport syndrome. There are no disease-specific treatments for Alport syndrome, and therapy is focused on reducing the rate of progression with RAAS inhibition to reduce proteinuric renal injury and to control hypertension (Kashtan et al., 2013).

Antineutrophilic cytoplasmic antibody (ANCA)-associated glomerulonephritis is a rare disease in childhood. Two target ANCA antigens have been identified: proteinase-3, or cANCA, and myeloperoxidase, or pANCA. ANCA-associated glomerulonephritis in childhood is divided into two small-vessel vasculitic syndromes: microscopic polyangiitis (MPA) and granulomatosis with polyangiitis (GPA) (Cabral et al., 2016). Eosinophilic granulomatosis with polyangiitis (Churg-Strauss syndrome) is extremely rare in childhood. Although ANCA-associated glomerulonephritis occurs primarily in adults, it can present in adolescence and occasionally during childhood. Nephritis is seen in 70% to 80% of children with either GPA or MPA. The features of GPA and MPA overlap where both typically present with a flulike prodrome and systemic symptoms such as fever, anorexia, malaise, weight loss, myalgias, arthritis and/or arthralgias, and skin lesions (purpura or urticaria). Lung disease occurs in both syndromes and can include life-threatening pulmonary hemorrhage. Granulomatous involvement of the upper airway, sinuses, nasal passages, and ears is present in many patients with GPA but not in MPA. A small subset of patients present with renal-limited vasculitis. Histologically, the principal finding is pauci-immune focal necrotizing glomerulonephritis, which is similar in both GPA and MPA and is often severe. All patients with nephritis have hematuria, most have proteinuria, and more than 70% have decreased renal function at diagnosis. Some patients present with RPGN. ANCA are detected in 85% to 95% of patients with active GPA (PR3-cANCA) and 70% with MPA (MPO-pANCA). ANCA-associated systemic vasculitis is an aggressive disease. Without treatment, mortality rates are 90% within 2 years. Patient and kidney survival have improved dramatically with intensive immunosuppressive therapy, however relapses are common. CKD persists in as many as one-half of patients, with nearly one-fourth of patients eventually developing ESRD.

Antiglomerular basement membrane (Anti-GBM) disease is an aggressive form of glomerulonephritis that is rarely seen in childhood. It is mediated by antibodies to the glomerular basement membrane. **Known as Goodpasture syndrome when associated with pulmonary hemorrhage,** it is rare in the first decade of life but has been reported in children as young as 2 years of age. Anti-GBM nephritis may occur as a rare complication after extracorporeal shock wave lithotripsy (ESWL), membranous nephropathy, or minimal-change disease. Anti-GBM nephritis may also occur in a small subset of patients with Alport syndrome after kidney transplantation. The Goodpasture target antigen is the carboxy-terminal region (NC1 domain) of the α3 chain of collagen type IV, the structural component of glomerular and pulmonary basement membranes. Patients present with acute nephritis or less commonly with symptoms of CKD. Pulmonary hemorrhage presenting as hemoptysis often precedes or accompanies the onset of nephritis; these episodes of hemoptysis may be life-threatening. More than 90% of patients have anti-GBM antibodies at the time of clinical presentation. Progression to irreversible kidney injury can occur within weeks. **The mainstay of therapy is plasmapheresis to remove the circulating antibody combined with immunosuppressive therapy to reduce new antibody production.** The kidney disease is unlikely to be reversible unless treatment is started early. Patients who recover from the acute disease generally do well, and disease relapses are extremely rare.

RPGN is a rare disorder in childhood that is traditionally divided into three groups; anti-GBM nephritis, immune complex nephritis, and pauci-immune disease associated with ANCA. Less commonly, other forms of proliferative glomerulonephritis may present as severe crescentic disease. This clinical syndrome is characterized by sudden onset and rapid decline in kidney function. It typically presents with gross hematuria, edema, anemia, and hypertension. Isolated nephrotic syndrome is uncommon. Pulmonary hemorrhage suggests a diagnosis of anti-GBM nephritis or ANCA vasculitis and may be fatal if treatment is delayed. Serologic studies including a C3, C4, ANA, ANCA, and anti-GBM antibodies should be obtained; however, a biopsy confirmation is essential and establishes the diagnosis in most patients. The renal biopsy commonly shows extensive crescent formation. Therapy is directed to the specific disease entity. Spontaneous resolution of RPGN is extremely unlikely. The prognosis is poor unless aggressive therapy is started early in the course of the disease.

Hemolytic uremic syndrome (HUS) is a common cause of severe acute kidney injury in a previously healthy young child. **The majority of children with HUS have an antecedent diarrheal illness caused by Shiga toxin–producing *Escherichia coli* (STEC).** Approximately 10% of HUS cases are not associated with STEC infections and are referred to as atypical HUS (aHUS). HUS, aHUS, and thrombotic thrombocytopenic purpura (TTP) are classified as forms of thrombotic microangiopathy (TMA), however the triggers, primary target organs, response to treatment, and clinical outcomes are distinct. HUS occurs in both sporadic and epidemic patterns. More than 70% of children in the United States with STEC-positive HUS have been infected with *E. coli* 0157:H7. The primary reservoir for *E. coli* 0157:H7 is farm animals, although contamination of fruits, juices, and vegetables is also common. HUS is initiated by damage to the endothelium with microthrombi formation, leading to the diagnostic triad of microangiopathic hemolytic anemia, thrombocytopenia, and acute kidney injury. In patients with aHUS, defects in regulation of the alternative complement pathway are commonly found (Loirat et al., 2015). These include mutations in complement factor H, factor I, membrane cofactor protein, C3, complement factor B, and autoantibodies against complement factor H and factor I. In young children, aHUS can occur as a complication of *S. pneumoniae* infection. Unlike other patients with HUS, these patients have a positive Coombs anemia. Of note, the use of fresh-frozen plasma is contraindicated in patients with pneumococcal-associated HUS.

After ingestion of *E. coli*–contaminated food, most affected children develop abdominal pain and bloody diarrhea. The colitis is usually self-limited, but complications may occur, including rectal prolapse, toxic megacolon, bowel wall necrosis, and bowel perforation. The onset of HUS is usually abrupt, occurring within 1 week after the onset of the diarrhea. The presenting symptoms are often caused by acute kidney injury. The severity of the acute kidney injury is highly variable, but one-half will develop oligoanuria and require dialysis. Hypertension is variable but may be severe. The mean duration of the acute kidney injury is 2 weeks. In aHUS, the antecedent illness is more nonspecific, often associated with fever, upper respiratory symptoms, and vomiting. Sometimes a prodromal illness is not apparent. Neurologic involvement is common and can mimic TTP. Most patients are very irritable and somnolent, and seizures and coma can occur in 10% of children. Virtually any organ can become damaged by the microvascular thrombi. Anemia is characterized by the presence of schistocytes, negative Coombs test, elevated reticulocytosis and lactose dehydrogenase levels, and a low serum haptoglobin. The prothrombin and partial thromboplastin time are usually normal. Serum C3 level and CH50 may be depressed in both STEC-positive HUS and aHUS but is more common in those with aHUS; an abnormal serum C3 level does not rule out the possibility of a genetic complement deficiency. In patients with clinical features suggestive of STEC-positive HUS, confirmation of a Shiga toxin–producing *E. coli* either by culture or the presence of the Shiga toxin is recommended. When aHUS is a consideration, it is important to measure ADAMT13 activity and inhibitor testing to rule out TTP and to evaluate the complement system by protein and genetic testing. For STEC-positive HUS, supportive medical care is by far the most important aspect of treatment. Meticulous attention must be paid to fluid and electrolyte management. **Severe acute kidney injury requiring dialysis still develops in nearly one-half of patients.** Packed red blood cell transfusions should be reserved for patients with clinical indications of severe anemia. Platelet transfusions should be avoided unless the patient is actively bleeding or the platelets are needed in preparation for an invasive procedure. During the prodromal phase of colitis, antimotility drugs are contraindicated, and antibiotics should be avoided as they have been reported to increase the probability of developing HUS. For patients with aHUS, Eculizumab, a monoclonal antibody to the complement component C5, is the therapy of choice. It has been shown to be highly effective in patients with complement dysregulation. Acute mortality in STEC-positive HUS is related to severe complications such as neurologic disease, cardiac failure, and multiorgan involvement. Kidney function typically improves spontaneously, and almost all patients are able to discontinue dialysis. However, long-term follow-up studies suggest that 5% to 25% of patients will develop CKD. aHUS generally follows a more severe clinical course and is more likely to relapse in the absence of chronic complement inhibition. Recurrent disease in either native kidneys or after kidney transplant is extremely rare in STEC-positive HUS but is quite common in aHUS. Eculizumab treatment is also recommended for aHUS patients undergoing kidney transplantation.

Key Points

- Corticosteroids will induce a remission in the vast majority of children with nephrotic syndrome.
- Focal segmental glomerulosclerosis is seen in the majority of children with steroid-resistant nephrotic syndrome.
- Minimal change nephrotic syndrome is the most common cause of nephrotic syndrome in childhood.
- IgA nephropathy is the most common primary cause of glomerulonephritis throughout the world.
- Hemolytic uremic syndrome is a common cause of severe acute kidney injury in a previously healthy young child.

Tubulopathies

Renal tubular disorders frequently present during routine laboratory investigation of children with failure to thrive. Tubular diseases can be isolated defects as in the case of distal renal tubular acidosis (RTA), or generalized defects as seen in Fanconi syndrome, and are primary or secondary in nature (Batlle and Haque, 2012). Tubulopathies such as renal glycosuria can result in solute wasting, and others such as Gordon syndrome result in excess solute reabsorption (O'Shaughnessy, 2015). Evaluation of patients with suspected tubular dysfunction begins with a careful history and physical examination focusing on a family history of renal or metabolic disease, and signs of failure to thrive, poor feeding, recurrent vomiting, dehydration, irritability, tetany, seizures, or icterus. The initial evaluation of patients with suspected tubular disease should include a complete blood count; a comprehensive metabolic panel including electrolytes, renal function, calcium, magnesium, and phosphorus; a venous or arterial blood gas; and urine for quantitative assessment of urine potassium, sodium, calcium, phosphorus, and magnesium excretion. In patients with suspected RTA, a metered urine pH should be obtained and urine sodium, potassium, and chloride concentrations to measure the urine anion gap. Additional testing including genetic testing should be based on the history and physical examination in combination with underlying metabolic disturbances. RTA is defined as an inappropriately elevated urine pH in the setting of metabolic acidosis. The **hallmark of RTA is hyperchloremic metabolic acidosis (normal anion gap acidosis);** the presence of metabolic acidosis must be confirmed by measurement of venous or arterial pH. In the setting of normal anion gap metabolic acidosis, a urine pH greater than 5.5 and an elevated urine anion gap are highly supportive of RTA (Carlisle et al., 1991).

Proximal RTA is defined by a decrease in the proximal tubule bicarbonate reabsorptive capacity, resulting in a low bicarbonate threshold with ensuing bicarbonate loss. Patients present with failure to thrive and hyperchloremic metabolic acidosis. However, patients with proximal RTA can reabsorb filtered bicarbonate below the lower resorption threshold. Thus patients with proximal RTA can maintain their serum bicarbonate level, although at a lower level than normal (typically 14 to 17 mEq/L). Because the distal tubule is intact, when the serum bicarbonate level is at or below the absorptive threshold of the proximal tubule, patients with proximal RTA can excrete urine with a pH less than 5.5. Isolated proximal RTA is rare and is more commonly seen in conjunction with Fanconi syndrome. Isolated proximal RTA can be caused by autosomal recessive mutations in the sodium bicarbonate cotransporter. Patients with this disorder usually have ocular defects, short stature, and intellectual impairment. Treatment of proximal RTA is challenging when exogenous alkali is not absorbed by the proximal tubule. Therefore, patients commonly require 10 to 15 mEq/kg/day of alkali with only modest improvement in serum bicarbonate levels.

Fanconi syndrome is a generalized disorder of the proximal tubule. **Patients with Fanconi syndrome typically present with failure to thrive, hyperchloremic metabolic acidosis with hypophosphatemia, and hypokalemia** (Moe et al., 2009). Typical urinary findings include glucosuria, aminoaciduria, and phosphaturia. Cystinosis is a common cause of Fanconi syndrome in children. It is an autosomal recessive disorder resulting in accumulation of free cysteine in intracellular lysosomes (Nesterova and Gahl, 2013). Presenting clinical features typically include polydipsia, polyuria, constipation, and failure to thrive. Many patients have evidence of rickets caused by renal phosphate wasting. Treatment of Fanconi syndrome is twofold; initially, the treatment of the underlying primary disease, if possible, and secondly, the replacement of urinary solute losses and the correction of acidosis.

Children with distal RTA present with short stature and failure to thrive, and they often have rickets. Classically, they have hyperchloremic metabolic acidosis, hypokalemia, hypercalciuria, and nephrocalcinosis. If the hypokalemia is severe, they may present with muscle weakness, cramps, and paralysis. The chronic metabolic acidosis results in bone demineralization. Patients with distal RTA are unable to excrete urine with a pH less than 5.5. Distal RTA may be either a primary or a secondary disorder. Primary distal RTA has been linked to autosomal dominant or autosomal recessive mutations in the basolateral Cl^-/HCO_3^- exchanger and autosomal recessive mutations in H^+-ATPase that are also associated with hearing loss. Secondary causes of distal RTA include medications and rheumatologic disorders. Distal RTA is treated by providing alkali equivalent to the amount of H^+ ion normally secreted by the distal nephron. Typically 3 to 5 mEq/kg/day of alkali is sufficient in most children to normalize the serum bicarbonate levels and correct the associated metabolic disturbances.

RTA associated with hyperkalemia is also known as type 4 RTA. It is associated with a number of disorders of either mineralocorticoid deficiency

or mineralocorticoid resistance. Decreased mineralocorticoid production is seen most commonly with 21-hydroxylase deficiency because Addison disease is rare in children. Angiotensin-converting enzyme inhibitor use can also result in functional hypoaldosteronism. Hyporeninemic hyperaldosteronism in children can be the result of drugs such as calcineurin inhibitors, nonsteroidal anti-inflammatory drugs (NSAIDs), and tubulointerstitial disease. Other common causes of type 4 RTA in children include obstructive uropathy and interstitial renal disease. In these disorders, aldosterone secretion is normal, but damage to the cortical collecting tubule results in functional resistance to aldosterone. Typically the degree of hyperkalemia is out of proportion to the severity of the renal insufficiency. Evaluation and management of type 4 RTA should be focused on defining the underlying etiology and treating the primary disease. Patients with glucocorticoid and mineralocorticoid deficiency should receive replacement therapy. Most cases of type 4 RTA caused by obstructive uropathy need urologic evaluation and surgery.

Dent disease is an X-linked recessive disorder characterized by low-molecular-weight proteinuria, nephrocalcinosis, recurrent urolithiasis, and progressive renal insufficiency. Dent disease results from a defect in the renal proximal tubule Cl^-/H^+ exchanger designated as CLC-5 (Devuyst et al., 2010). Patients with Dent disease have low–molecular weight proteinuria, not glomerular proteinuria (i.e., albumin). Treatment is directed at preventing renal calculi. Patients should have adequate fluid intake and eat a low-sodium diet. A thiazide diuretic may be helpful to decrease renal calcium excretion. ESRD usually occurs between the third and fifth decade of life.

Bartter syndrome is an autosomal recessive disorder, which usually presents in the first year of life with failure to thrive. Typically, patients have a prenatal history of polyhydramnios and prematurity, and polydipsia and polyuria as infants and young children. A history of constipation, salt craving, and muscle cramps are also quite common. **Hypokalemic metabolic alkalosis is the defining feature of Bartter syndrome** (Seyberth and Schlingmann, 2011). Blood pressure is typically normal, but plasma renin and aldosterone levels are elevated as a result of volume depletion. Bartter syndrome is commonly caused by mutations in the Na/K/2Cl cotransporter or in Barttin, which is associated with sensory neural deafness. Treatment of patients with Bartter syndrome is centered on replacement of urinary solute loss and management of polyuria.

Gitelman syndrome is an autosomal recessive disorder that also presents with hypokalemic alkalosis and can be confused with Bartter syndrome

(Seyberth and Schlingmann, 2011). Patients with Gitelman syndrome typically do not have failure to thrive, and there is no antenatal history of polyhydramnios. Hypomagnesemia is nearly universal in Gitelman syndrome, and urinary calcium excretion is low in Gitelman syndrome as opposed to Bartter syndrome, in which urinary calcium excretion is elevated. Many patients with Gitelman syndrome have a history of tetany and muscle cramps secondary to hypomagnesemia, which is an uncommon feature of Bartter syndrome. Gitelman syndrome is caused by mutations in the thiazide-sensitive NaCl cotransporter (NCC) found in the distal convoluted tubule. The keystone of treatment for Gitelman syndrome is magnesium and potassium supplementation to replace urinary loss.

Key Points

- The hallmark of RTA is hyperchloremic metabolic acidosis (normal anion gap acidosis).
- Children with distal RTA classically have hyperchloremic metabolic acidosis, hypokalemia, hypercalciuria, and nephrocalcinosis.
- Hypokalemic metabolic alkalosis is the defining feature of Bartter syndrome.
- RTA associated with hyperkalemia is also known as type 4 RTA.

Cystic Renal Disease

Cystic renal diseases are a common cause of both CKD and eventually ESRD in the pediatric population. Clinical presentation of these heterogeneous disorders is varied. Many patients are diagnosed prenatally or during the evaluation of hypertension, gross or microscopic hematuria, abnormal renal function, polyuria, or incidentally as part of an evaluation of abdominal pain or constipation. Often a specific diagnosis can be determined by imaging alone or by family history. However, genetic testing to achieve a definitive diagnosis is preferred. Currently there are no disease-specific treatment options that can alter disease progression or correct the underlying disorders. Therefore, therapy is conservative in nature and focused on management of complications that might accelerate CKD progression.

Multicystic dysplastic kidney (MCDK) disease appears on ultrasonography as a large reniform mass with noncommunicating cysts. The MCDK is nonfunctional and is usually unilateral; although rare, if MCDK is bilateral, neonatal mortality is nearly universal. Urologic anomalies are seen in up to 25% of patients with MCDK, including renal hypoplasia/dysplasia, vesicoureteral reflux, and ureteropelvic junction obstruction. Typically there is gradual reduction in the size of an MCDK with eventual involution over a period of months to years. The contralateral kidney typically shows compensatory hypertrophy. Because of the association of MCDK with VUR, voiding cystourethrography (VCUG) is recommended, particularly in patients with hydronephrosis and/or hydroureter. Serial monitoring of renal function, blood pressure, and renal ultrasonography is generally recommended at an interval of 3 months for the first year of life and then every 6 months up to involution, or at least up to 5 years. There is emerging data that patients with unilateral MCDK are at risk for development of early-onset hypertension and possible CKD. As a result, there is growing consensus that these patients should be monitored annually until well into adulthood.

Autosomal recessive polycystic kidney disease (ARPKD) is caused by a mutation in the *PKHD1* gene and occurs in approximately 1 : 40,000 live births (Bergmann et al., 2004). The kidneys are bilaterally enlarged as a result of fusiform cysts arising from the collecting ducts. The principal extrarenal manifestation of ARPKD is congenital hepatic fibrosis; over time, cystic dilation of the biliary tree develops with ensuing portal hypertension and liver failure. In addition to complications related to CKD, patients with ARPKD are at risk for ascending cholangitis, recurrent urinary tract infections, hypertension, nephrolithiasis, and bleeding from esophageal varices. Neonatal presentation with oligohydramnios/anhydramnios has a reported mortality rate of 25% to 50%. Over 75% of patients with ARPKD progress to ESRD by 5 years of age.

Autosomal dominant polycystic kidney disease (ADPKD) is caused by mutations in the polycystin-1 *(PKD-1)* or polycystin-2 *(PKD2)* gene, and it has a prevalence of roughly 1 : 1000 (Igarashi and Somlo, 2002; Torres et al., 2007). ADPKD usually presents in adulthood but can lead to clinical symptoms in older children and young adults. ARPKD is often identified in childhood either because of a positive family history, as an incidental finding on imaging for abdominal complaints (pain or constipation), or as part of an evaluation for hypertension or urinary tract infections. Similar to ARPKD, there is no disease-specific therapy approved in children. However, hypertension and urinary tract infections should be treated aggressively to limit disease progression. In patients with a family history of cerebral aneurysm, routine screening is currently not recommended in the pediatric population unless there are clinical signs or symptoms that warrant imaging.

Nephronophthisis in distinction to ARPKD or ADPKD is characterized by cyst formation at the corticomedullary junction, but the kidney size is typically normal. Most patients with nephronophthisis have a history of polyuria, polydipsia, anemia, and growth retardation, and eventually reach ESRD by early adolescence. Many forms of recessive nephronophthisis are syndromic in nature, and extrarenal manifestations are common; these include retinitis pigmentosa in Senior-Løken syndrome; cerebellar vermis aplasia and colobomas in Joubert syndrome; obesity, diabetes mellitus, and polydactyly in Bardet-Biedl syndrome; and skeletal dysplasias in Juene and Ellis-van Creveld syndromes. In patients with suspected recessive nephronophthisis, comprehensive genetic analysis is warranted as this can help to predict both complications and disease progression, and importantly can help with caregiver education. Currently there are more than 100 distinct genes that have been associated with nephronophthisis.

Other types of cystic kidney disease include **medullary cystic kidney disease,** which is an autosomal dominant disorder associated with hyperuricemia, gout, and ESRD in adults. Mutations in the gene encoding uromodulin/Tamm-Horsfall protein have been linked with one of the two types of medullary cystic kidney disease (type 2). In addition, glomerulocystic kidney disease is characterized by multiple small cortical cysts that result from cystic dilation of the Bowman space; the lack of tubular involvement distinguishes it from other forms of cystic disease. And medullary sponge kidney is a rare congenital cystic disorder in which there is ectasia of cortical ducts within the inner medulla of the kidney, resulting in a spongelike appearance on radiograph and is associated with nephrolithiasis and urinary tract infection.

Key Points

- Urologic anomalies are seen in up to 25% of patients with MCDK, including renal hypoplasia/dysplasia, VUR, and ureteropelvic junction obstruction.
- Autosomal recessive polycystic kidney disease (ARPKD) is caused by a mutation in the *PKHD1* gene.
- ADPKD is caused by a mutation in the polycystin-1 *(PKD-1)* or polycystin-2 *(PKD2)* gene.

Urolithiasis: Medical Management

Accurate data on the incidence and prevalence of urolithiasis in the pediatric population in the United States are not readily available. Although not as common as in the adult population, it is estimated that nephrolithiasis accounts for between 1 in 600 and 1 in 800 pediatric hospital admissions in the United States. Recent data suggest that the incidence of urolithiasis in the adolescent population has increased significantly over the past 10 years from roughly 20 per 100,000 in the late 1980s to more than 50 per 100,000 in 2014; this number is likely to be an underestimate as **urolithiasis remains under-diagnosed because many children are asymptomatic at the time of diagnosis** (Braun et al., 2016; Sas, 2011). Concurrent with the increase in the frequency of stone disease has been a shift in the types of stones seen at presentation. There has been a marked drop in the incidence of infectious stones from more than 60% before the 1980s to now less than 20%; there are similar reported reductions in the frequency of uric acid and ammonium acid urate stones. **The calcium stones are now the most prevalent.** The reasons behind these shifts are not clear, however in the United States, it has been proposed that changes in dietary practices, changes in types of fluids used for hydration, and the obesity epidemic underlie the rise in pediatric stone disease. Reported rates for stone recurrence in the pediatric population are variable, ranging from 15% to 20%, but may be as high as 30% in individuals with underlying metabolic disorders.

The clinical presentation of nephrolithiasis in children is varied and includes microscopic or gross hematuria, urgency, dysuria, frequency, hesitancy, and nonspecific abdominal or flank pain. Although increasingly less common in the United States, stones may be identified as part of the evaluation of urinary tract infections. It is not unusual for nephrolithiasis to be noted incidentally as part of a diagnostic evaluation for nonspecific complaints such as recurrent abdominal pain or failure to thrive. Children rarely present with the typical “renal colic” described in adults. In the United States, the majority of stones are found in the kidney, and presentation with bladder stones is more common in those with underlying urologic abnormalities.

Hypercalciuria is the most common risk factor identified in children with urolithiasis, and **the vast majority have idiopathic hypercalciuria.** Systemic hypercalcemia is less common and is associated with hyperparathyroidism, immobilization hypercalcemia, thyroid disease, idiopathic hypervitaminosis D, corticosteroid use, Williams syndrome, and rarely, mutation of the calcium-sensing receptor. Children with hypercalciuria are much more commonly normocalcemic, and with the exception of those on loop diuretics, most will have idiopathic hypercalciuria. There is, however, an increasing understanding of the genetic underpinnings of tubular dysfunction as a cause of hypercalciuria. Examples of this include mutations in *CLCN5* or *ORCL1* seen in Dent disease; mutations in *SLC12A1*, *KCNJ1*, *CLCNKB*, *BSND*, or *CASR* seen in Bartter syndrome; and mutations in *CLDN16* or *CLDN19* with familial hypomagnesemia with hypercalciuria and nephrocalcinosis.

Hyperoxaluria is a less common cause of urolithiasis and can be either primary or secondary. Secondary causes include enteric hyperoxaluria, excess vitamin C intake, and oxalate-rich diets. **Primary hyperoxaluria (PH)** is rare autosomal recessive disorder of oxalate metabolism of which there are three subtypes (Nazzal et al., 2016). PH type 1, which is the most common and most severe, is caused by aniline/glyoxylate aminotransferase (AGT) deficiency leading to increased systemic levels and excretion of glycolate and oxalate. PH type 2 is less common and is caused by mutations of glyoxylate reductase, leading to increased excretion of L-glycerate and oxalate. The clinical course of PH type 2 is usually less severe than in PH type 1. PH type 3 is the rarest and least severe form and is caused by mutations in *HOGA1*. Uric acid stones caused by hyperuricosuria can be either a primary disorder seen with inborn errors of purine metabolism (Lesch-Nyhan syndrome) or, more commonly, a secondary process associated with hematologic malignancies, gout, high purine intake, tubular disorders, or diabetes mellitus.

Other rare causes of pediatric urolithiasis include cystinuria and adenine phosphoribosyltransferase (APRT) deficiency. **Cystinuria** is a rare autosomal recessive disorder caused by mutations in either *SCL3A1* or *SLC7A9*, which result in decreased tubular reabsorption of cystine and other dibasic amino acids (ornithine, arginine, and lysine), leading to excessive excretion of cystine and stone formation. **APRT deficiency** is a rare autosomal recessive inborn error of adenine metabolism that results in the generation and urinary excretion of large amounts of poorly soluble 2,8-dihydroxyadenine with ensuing stone formation.

The evaluation of nephrolithiasis should begin with a history focused on symptoms associated with stones and predisposing factors including recurrent urinary tract infection, familial history of nephrolithiasis, gout, and conditions that increase enteric oxalate absorption: inflammatory bowel disease, short gut syndrome, or cystic fibrosis (Edvardsson et al., 2013). A through dietary history should be taken including sodium, calcium, fluid intake, and vitamin supplementation. Initial screening studies should focus on identifying a metabolic etiology for the kidney stones and should include serum electrolytes, blood urea nitrogen (BUN), creatinine, calcium, phosphorus, uric acid, and a venous blood gas (for evaluation of possible RTA). In the presence of hypercalciuria, hypercalcemia, or hypophosphatemia, serum parathyroid hormone and vitamin D levels should be obtained. Urine microscopy can be quite useful, particularly in the diagnosis of cystinuria or ARPT deficiency as the urinary crystals seen in these conditions are disease-specific. If the stone is available, it should be sent for analysis by infrared spectroscopy or radiographic diffraction. A urine culture should be done to rule out the presence of infection. Timed urine collections for calcium, oxalate, urate, citrate, and sodium should be performed for any child with stones if possible. For children in whom 24-hour urine collections are not feasible, spot ratios of urine solute to urine creatinine can be substituted. It is important to remember that normative data for urinary solute excretion vary with age. For example, a normal urine calcium-to-creatinine ratio for a 2-month-old child is in the 0.4 to 0.5 mg/mg range, and a ratio of 0.2 mg/mg is the upper limit of normal for a 5-year-old child. One of the primary goals of the initial evaluation is to identify patients with underlying metabolic disease for whom specific therapies will be beneficial and to determine which individuals are at risk for recurrent disease. In terms of imaging, to limit radiation exposure, ultrasonography is commonly employed in children for initial screening (Smith-Bindman et al., 2014). In patients with a nondiagnostic ultrasound examination, nonenhanced helical CT is highly sensitive and specific for the diagnosis of nephrolithiasis. Standard abdominal radiographs remain useful to determine stone burden and for longitudinal assessment of response to therapy. **Genetic testing is an increasingly important part of the evaluation of pediatric stone disease, as monogenic disorders may underlie urolithiasis or nephrocalcinosis in 20% of children.**

Medical therapy should be directed toward the underlying metabolic cause, if one has been identified, to prevent recurrence and growth of existing stones (Hernandez et al., 2015). **Increasing fluid intake with a minimum of 2 L/1.73 m^2/day** should be encouraged to decrease the chance of crystallization and growth of calculi.

With hypercalciuria, **salt restriction** will reduce urinary calcium losses by promoting reabsorption of sodium and calcium. Avoiding excessive protein intake to reduce the acid load is also recommended in recurrent stone formers. A thiazide diuretic can be used in the normocalcemic hypercalciuric patient to increase distal tubular reabsorption of calcium.

For primary hyperoxaluria, the goal of therapy is to decrease oxalate production, increase urine calcium oxalate solubility, and decrease crystal deposition in the kidney. Potassium citrate, orthophosphate, or magnesium citrate formulations are used to decrease urinary calcium oxalate supersaturation. A trial of pyridoxine should be given in PH type 1. About 20% of patients with PH type 1 will respond to pyridoxine treatment with normalization of urine oxalate concentration, and about 30% will have a partial response. However, pyridoxine is not effective in PH types 2 and 3 (Ben-Shalom and Frishberg, 2015). **Therefore, only successful liver transplantation can offer a potential cure for PH type 1.**

In individuals with hypocitraturia, a diet rich in fruits and vegetables, and/or supplemental potassium citrate is recommended. Sodium citrate should be avoided because the excess salt may increase hypercalciuria. In cystinuria, alkalization of the urine to a pH greater than 7.5 with potassium citrate will decrease cystine supersaturation. If stone formation continues despite high fluid intake and alkalinization of the urine, D-penicillamine or tiopronin can also be used. However, these medications are not always well tolerated. In hyperuricosuria, allopurinol, alkalinization of urine, and avoidance of protein excess are recommended. Struvite calculi often require surgical removal and prolonged treatment with antibiotics.

For children who present with acute renal colic, analgesia and adequate hydration with appropriate monitoring of fluid and electrolyte status are the mainstays of therapy. Radiologic evaluation should be performed, and in the setting of urinary obstruction, infection, acute kidney injury, or incontrollable pain, urologic intervention may be needed. For small ureteral stones (< 10 mm), management with observation with or without medical expulsive therapy is recommended. Urologic interventions such as ESWL, percutaneous nephrolithotripsy, ureteroscopy, and open surgery have all been successful therapies in children with urolithiasis. The choice of intervention is typically guided by stone size, composition, and location. Complete removal is important in children as residual small fragments are associated with regrowth and adverse outcomes. Medical expulsive therapy with an α-blocker has been successful in the management of small ureteral stones. ESWL is often employed for intermediate-size stones (10 to 20 mm) within the ureter or collecting system. Percutaneous nephrolithotomy is the recommended treatment for large renal pelvic or caliceal stones (>20 mm). Ureteroscopy is increasingly becoming a first-line procedure of choice, especially for distal ureteral stones greater than 10 mm. Open surgery is usually reserved for very young children with complex stones, children with orthopedic issues that limit positioning, or those who have failed primary therapy.

Urolithiasis has a high rate of recurrence, especially if an underlying metabolic disorder exists. Prevention with appropriate medical therapy and high fluid intake should be encouraged to limit morbidity. Long-term follow up is advisable as some children may develop CKD and progress to ESRD.

Key Points

- Urolithiasis remains underdiagnosed because many children are asymptomatic at the time of diagnosis.
- Calcium stones are now the most prevalent stones in children.
- Cystinuria results in decreased tubular reabsorption of cystine, ornithine, arginine, and lysine.

Hypertension

Hypertension in the pediatric population is defined as blood pressure on repeat measurements greater than the 95th percentile for age, gender, and height in comparison to normative population-based data. **The estimated prevalence of hypertension in children is much lower than the prevalence seen in the adult population; however, data suggests the increase in the prevalence in hypertension seen in the pediatric population in recent years is closely linked to increasing obesity rates in children** (Din-Dzietham et al., 2007, Falkner, 2010; Muntner, 2004). Weight-related disorders such as hypertension are now increasingly common in pediatric patients and are likely to account for the rise in the prevalence of hypertension from 2.7% noted in the early 1990s to 3.7% seen in the 2000s, with elevated blood pressures (previously known as prehypertension) observed in approximately 10% of children and adolescents.

An accurate measurement of blood pressure is essential to the diagnosis of hypertension (National High Blood Pressure Education Program, 2004). Accurate blood pressure measurement requires a cuff that is appropriate to the size of the child's upper arm; the bladder width should be at least 40% of the mid-arm circumference with a cuff length that covers at least two-thirds of the upper arm. Systolic blood pressure is defined by the first Korotkoff sound, with the disappearance of the Korotkoff sounds defining diastolic blood pressure. As accurate auscultatory measurement of blood pressure is often difficult in infants and young children, the use of automated (oscillometric) blood pressure measurement devices is now widespread; however it should be noted that pediatric normative blood pressure data is based on auscultatory and not oscillometric standards.

A recent clinical practice guidelines for management of hypertension in children and adolescents (Flynn et al., 2017) that was published by the American Academy of Pediatrics (AAP) update and refine reference data from the 4th Report of the National Institutes of Health Working Group for the management of blood pressure in children (2004). A major focus of this report was improving the recognition of hypertension by simplifying the initial screening blood pressure table. Furthermore, normative data by age, gender, and height have been revised, including only those children with a normal BMI. The blood pressure classification scheme has also been revised to align the classification system for adolescents with the absolute blood pressure values used in adult blood pressures guidelines (Redwine et al., 2012). **Current AAP guidelines now distinguish between children 1 to 13 years of age and adolescents older than 13 years of age, with normal blood pressure defined as less than the 90th percentile for children and less than 120/80 mmHg for adolescents** (Flynn et al., 2017). The term *prehypertension* has been abandoned and replaced with *elevated blood pressures* to be consistent with the adult guidelines.

Staging of hypertension is useful in determining which children require more immediate attention for diagnostic evaluation and management. In addition, staging can also predict the presence of end-organ damage from hypertension. Two other clinically relevant designations for severity of hypertension are important: (1) **hypertensive emergency**, when a patient has end-organ injury such as encephalopathy, pulmonary edema, or cerebral hemorrhage or clinical symptoms like blurred vision, headache, or nausea, which can be associated with severely elevated blood pressure; and (2) **hypertensive urgency**, when blood pressure is severely elevated without clear evidence of end-organ involvement or overt symptoms.

It also should be recognized that not every child with elevated blood pressure readings in the office setting has true hypertension. **Up to one-fourth of such patients have normal blood pressures outside of the office setting and are classified as having “white coat” hypertension.** The recent AAP care guidelines promote the **use of 24-hour ambulatory blood pressure monitoring (ABPM) in the evaluation of children and adolescents with suspected hypertension.** ABPM is not only useful in identifying patients with “white-coat” hypertension, but also it can identify individuals with so called “masked” hypertension: those with normal blood pressure readings in the office setting, but who are truly hypertensive. Furthermore, ABPM data is extremely useful in accessing effectiveness of antihypertensive regimens. Unfortunately, access to 24-hour ABPM is often limited and may require referral to pediatric subspecialists.

The causes of hypertension are classified as either **primary (essential)** or **secondary when a specific etiology is identified.** Historically, secondary causes of hypertension have been thought to predominate in the pediatric population (Vehaskari, 2009). However, with the rising rates of childhood obesity, the AAP guidelines have recognized that **primary (essential) hypertension is now the most common cause of hypertension in obese children older than 6 years of age with a positive family history of hypertension.**

Secondary causes of hypertension vary with age. In infants younger than 1 year of age, the majority of cases are caused by either coarctation of the aorta or renovascular disease. Renovascular disease may also present later in childhood. In school-age children, the dominant secondary causes of hypertension are renal parenchymal diseases including reflux nephropathy. Malignancy-associated hypertension, primarily with Wilms tumor and nephroblastoma, typically presents in infancy and early childhood, and pheochromocytoma is seen more frequently in the adolescent population. Secondary causes of hypertension should still be sought in adolescents, however, this population, much like adults, is far more likely to have primary (essential) hypertension.

Although hypertension is becoming more common in children, the differential diagnosis of childhood hypertension is quite broad. Features from the history, the physical, the age of the patient, and even the blood pressure values themselves can narrow the diagnostic focus. A secondary cause for hypertension should always be sought in infants younger than 1 year of age, and secondary causes should also be investigated thoroughly in preadolescent children as renal disease is the most common secondary cause of hypertension in this age group. The new AAP guidelines recognize that the **impact of obesity extends even into the early school-age population** as the previous guidelines recommended only a limited investigation into secondary causes of hypertension in patients older than 6 years of age with obesity, a strong family history of essential hypertension, and an unrevealing history and physical examination. Review of the patient's history should be focused on two areas; firstly, the presence of symptoms suggestive of hypertensive injury such as headaches, dizziness, diplopia, or vomiting; and secondly, information that provides insight into underlying causes of hypertension including neonatal history, urinary tract infections or unexplained fevers, signs and symptoms of renal or cardiac disease, chronic illness, medications, and family history of hypertension, kidney disease, early-onset cardiovascular disease, and diabetes.

The patient's weight, height, and growth percentiles should be defined. Ideally blood pressure measurements should be obtained in both upper extremities and in at least one lower extremity. The physical examination should focus on identifying signs of underlying disorders that are associated with hypertension.

Recommended initial diagnostic testing in all patients with confirmed hypertension includes a urinalysis, electrolytes, BUN, creatinine, and a lipid profile. Although commonly utilized, the current AAP guidelines do not recommend screening renal ultrasonography for patients older than 6 years of age unless there is an abnormal urinalysis or abnormal renal function. Additional testing such as renin and aldosterone levels; catecholamines; cortisol levels; genetic testing for forms of monogenic hypertension; or advanced imaging studies including VCUG, dimercaptosuccinic acid (DMSA) renal scans, CT angiography, magnetic resonance angiography (MRA), or angiography are often required based on an individual patient's clinical findings, initial screening studies, and the severity of the hypertension. Echocardiograms are no longer recommended as part of the initial screening of patients with confirmed hypertension. However, baseline echocardiography is now recommended at the initiation of pharmacologic therapy for all patients regardless of the etiology of their hypertension.

For patients with stage 1 hypertension or those with primary (essential) hypertension without end-organ damage, therapeutic lifestyle changes are the initial intervention of choice (Lurbe et al., 2009). There is clear data that support dietary modification (DASH diet), weight loss, and exercise in reducing blood pressure in children and adolescents. However, like all behavioral interventions, the long-term success of therapeutic lifestyle changes requires engagement not only of the patient, but of family members as well.

Pharmacologic therapy should be considered in patients with primary (essential) hypertension who do not have improvement in their blood pressure after a trial of therapeutic lifestyle changes, or in patients with stage 2 hypertension, evidence of end-organ damage, symptomatic hypertension, or secondary hypertension (Flynn and Daniels, 2006). Unlike adult hypertension guidelines, there are no data or evidence-based guidelines regarding which drug to select when initiating pharmacologic therapy. Acceptable first-line agents include diuretics, β-blockers, ACE inhibitors, ARBs, and calcium channel blockers. Rather than standardized approaches to pharmacologic therapy, most practitioners individualize therapy with the underlying renal, cardiac, or endocrine conditions guiding the choice of the initial agent. This would include the use of RAAS blockage for those with glomerulonephritis and other forms of CKD because of the additional benefit in terms of preventing CKD progression. Along similar lines is the use of RAAS inhibition in patients with type 1 or type 2 diabetes mellitus as these agents may slow or prevent the development of diabetic nephropathy. Conversely, the use of β-blockers in patients with asthma is not recommended. Adverse effects of each agent and available formulations need to be considered, because many standard adult hypertensive medications are not available in liquid formulations or are in fixed ratios that are not suitable for the pediatric population. Patients and families should be counseled about the potential side effects of the medications before initiation of therapy; this is especially important for adolescents who are engaged in organized sports and may be at risk for dehydration and acute kidney injury while on RAAS or diuretic therapy, and for sexually active adolescents on RAAS therapy regarding the potential for ACE fetopathy. Once therapy is initiated, blood pressure should be monitored closely, including laboratory monitoring, both for efficacy of the antihypertensive medication and for potential side effects. The goals of therapy for patients without diabetes or CKD have also been revised in the current AAP guidelines. Based on data suggesting that end-organ damage is present in patients with blood pressures greater than the 90th percentile but less than the 95th percentile, the current guidelines recommend **a target blood pressure goal of less than 90%, or less than 130/80 for adolescents.** Lower target goals are recommended for patients with CKD or diabetes mellitus (<50th percentile).

Key Points

- The increase in prevalence of pediatric hypertension in recent years is closely linked to increasing obesity rates in children.
- Up to one-fourth of patients have normal blood pressures outside of the office setting (“white coat” hypertension).
- Therapeutic lifestyle changes are the initial intervention of choice for patients with primary hypertension without end-organ damage.

Acute Kidney Injury

Acute kidney injury (AKI) is currently defined as an abrupt reduction in kidney function characterized by an absolute increase in serum creatinine of more than 0.3 mg/dL, a relative increase in serum creatinine of 50% from baseline, or 6 hours or more of oliguria (< 0.5 mL/kg/h of urine output). This precise definition is a result of a large body of work that recognized that AKI is a continuum renal injury wherein reductions in renal function are linked to adverse outcomes (Table 21.1 and Box 21.4) and shifts the focus to earlier detection and treatment of AKI before the development of significant morbidity, as noted in KDIGO staging table (Devarajan, 2013; Mehta et al., 2016; Selewski et al., 2014). Recent data suggest that the incidence of AKI is roughly 4 cases per 1000 pediatric hospital admissions, where as AKI is seen in up to one-third of all children admitted to intensive care units and one-half of pediatric patients with shock (Lameire et al., 2017). **Patients with AKI have been reported to have a nearly 15-fold increased mortality risk compared with patients without AKI (15% vs. 0.6%)** (Fitzgerald et al., 2016; Kaddourah et al., 2017). The estimated incidence of AKI requiring dialysis ranges from 1% to 2% in critically ill children (Slater et al., 2016; Sutherland et al., 2013). AKI can result from ischemic, toxic, or inflammatory mechanisms and can be further classified as caused by renal hypoperfusion (prerenal), structural injury to the kidneys (intrinsic), or urinary tract obstruction (postrenal). Primary renal disease is no longer the predominate cause of intrinsic AKI and has been supplanted by a heterogeneous mix of pathologic conditions including multiple organ failure, renal ischemia, nephrotoxic injury, congenital heart disease, bone marrow transplantation, and sepsis.

TABLE 21.1

KDIGO Criteria for Acute Kidney Injury

STAGE	SERUM CREATININE CHANGES	URINE OUTPUT CHANGES
I	SCr increase ≥0.3 mg/dL in 48 h or 1.5–1.9 times baseline	<0.5 mL/kg/h for 6–12 h
II	SCr increase 2.0–2.9 times baseline	<0.5 mL/kg/h for 12 h
III	SCr ≥3.0 increase or	< 0.5 mL/kg/h for 24 h

	SCr >4.0 mg/dL or If <18 years of age, estimated creatinine clearance <35 mL/min/1.73 m^2	or <0.3 mL/kg/h for 12 h

h, Hour; *KDIGO,* Kidney Disease Improvng Global Outcomes; *SCr,* serum creatinine.

Modified from Kellum JA, Lameire N; KDIGO AKI Guideline Work Group. Diagnosis, evaluation, and management of acute kidney injury: a KDIGO summary (Part 1). *Crit Care* 17(1):204, 2013.

Box 21.4

Causes of Acute Kidney Injury

Decreased true intravascular volume
  - Third-space losses: sepsis, trauma, burns, nephrotic syndrome
  - Gastrointestinal losses
  - Salt wasting: renal or adrenal
  - Diabetes insipidus: central or renal

Decreased apparent intravascular volume: congestive heart failure

Acute tubular necrosis/cortical necrosis
  - Hypoxic-ischemic insults
  - Medications: aminoglycosides, intravenous contrast agents, nonsteroidal anti-inflammatory drugs, chemotherapeutics
  - Exogenous toxins: ethylene glycol, methanol
  - Endogenous toxins: hemoglobin, myoglobin

Tumor lysis syndrome and uric acid nephropathy

Interstitial nephritis
  - Medication induced: anticonvulsants, antibiotics
  - Idiopathic

Glomerulonephritis: all causes

Vascular disorders
  - Hemolytic uremic syndrome
  - Renal artery or vein thrombosis

Infection
  - Pyelonephritis
  - Sepsis

Obstructive lesions
  - Obstructed single kidney
  - Bilateral ureteral obstruction

- Urethral obstruction

The diagnosis of AKI is dependent on increases in serum creatinine compared with baseline levels. As opposed to the adult population, normal serum creatinine levels vary in the pediatric population based on age, muscle mass, and body size; therefore there is no absolute creatinine level that defines pediatric AKI. Typically renal function needs to decrease by 50% before a change in serum creatinine can be measured, and changes in creatinine commonly lag behind the reduction in renal function (GFR) by 24 to 72 hours. This lack of sensitivity and delayed response has presented challenges to early identification of patients with AKI. A number of biomarkers to identify early AKI have been developed; these include neutrophil gelatinase-associated lipocalin (NGAL), kidney injury molecule-1 (KIM-1), and interleukin-18. Although there is substantial data in the adult population regarding the sensitivity and specificity of these biomarkers, and although there are emerging pediatric data, these biomarkers have not yet entered widespread clinical use, and the application of the data from adult studies is challenging in the pediatric population.

Differentiating between functional and intrinsic AKI is essential. **Functional AKI** is a sodium-avid state with maximal reabsorption of solutes and water by the intact proximal tubule; on the other hand, the tubular damage typical of **intrinsic AKI** results in impaired reabsorptive capacity of the proximal tubule. Functional AKI is typically characterized by fractional excretion of sodium (FE_{Na}) less than 1%, and greater than 3% is characteristic of intrinsic AKI. However, the use of FE_{Na} in patients on diuretic therapy is unreliable. In this setting, the fractional excretion of urea (FE_{Urea}) is very useful, with FE_{Urea} less than 35% being indicative of prerenal AKI.

AKI results in the disruption of normal electrolyte and fluid homeostasis. Common complications include **hyponatremia** caused by excessive free water retention, **hypernatremia** from sodium administration, **hyperkalemia** caused by reduction in glomerular filtration and tubular potassium secretion, **anion gap metabolic acidosis** secondary to impaired renal hydrogen ion excretion and concurrent impairment of bicarbonate reabsorption and regeneration, **hyperphosphatemia** caused by reduced renal excretion, and **hypocalcemia** secondary to increased serum phosphate and impaired vitamin D metabolism. Fluid overload in patients with AKI is challenging as adequate fluid resuscitation is essential for tissue perfusion in patients with prerenal AKI. However, there is a clear association between excessive fluid accumulation and adverse outcomes in the pediatric population.

Prerenal AKI requires prompt and vigorous fluid resuscitation with isotonic fluids. The use of potassium-containing fluids should be avoided until urine output is established and the severity of AKI is defined. If oliguria is present, conservative fluid management should be instituted. Fluid intake should therefore be limited to match output including insensible fluid loss with replacement of output. If patients are fluid overloaded, then urine output should not be replaced, and diuretics are likely indicated. If adequate urine output cannot be achieved with diuretic therapy, RRT may be required. In addition, aggressive nutritional support is essential for all patients with AKI (Kyle et al., 2013). Adequate calories should be provided that meet maintenance requirements and to limit or prevent excessive catabolism. Protein intake should not be restricted. If adequate nutrition cannot be achieved because of fluid restriction, early institution of RRT should be considered. Nephrotoxic agents should be avoided in AKI, as they may worsen the injury or delay recovery of function. Medications should be adjusted based on residual renal function. Importantly, patients in the early phase of AKI should be assumed to have a GFR of less than 15 mL/min/1.73 m^2, regardless of the absolute value of the serum creatinine.

Indications for initiating RRT in AKI typically include fluid overload that is unresponsive to diuretics, the need to deliver adequate nutrition, or to address hyperkalemia or metabolic disturbances that are refractory to medical therapy, and symptomatic uremia. RRT options include hemodialysis, peritoneal dialysis, and continuous renal replacement therapy (CRRT). The choice of dialysis modality depends on the patient's clinical status, the available clinical expertise, and the availability of appropriate resources. Hemodialysis provides the most efficient and rapid correction of fluid and electrolyte disturbances; however hemodialysis can be poorly tolerated in patients with hemodynamic instability. Therefore, **CRRT via hemodialysis has become the standard of care as it delivers slow continuous correction of fluid overload and electrolyte imbalances.** Peritoneal dialysis is also a CRRT modality and has been preferred in neonates and small infants when central venous access can prove challenging. The advantages of peritoneal dialysis include ease of performance and avoiding the requirement for specialized equipment, personnel, or anticoagulation. In critically ill children with respiratory failure, dwell volumes in the peritoneal cavity may be poorly tolerated, and previous abdominal surgery with compromise of the peritoneum, intra-abdominal infection, and ostomy placement can limit the application of peritoneal dialysis.

Data suggest that **children who have recovered from an episode of AKI are at significant risk for CKD,** as more than one-third have been reported to have either reduced kidney function or were dialysis-dependent on hospital discharge. Furthermore, nearly two-thirds of the patients with long-term follow-up had evidence of CKD. These data suggest that long-term follow-up is warranted for children who survive an AKI episode.

Key Points

- Hospitalized pediatric patients with AKI have a nearly 15-fold increased mortality risk compared with patients without AKI.
- Prerenal AKI requires prompt and vigorous fluid resuscitation with isotonic fluids.
- CRRT via hemodialysis has become the standard of care as it delivers slow continuous correction of fluid overload and electrolyte imbalances.

Chronic Kidney Disease

CKD is defined by the persistence of structural or functional abnormalities of the kidney for more than 3 months. The primary marker of kidney damage using the Kidney Disease Outcomes Quality Initiative (KDOQI) staging system is a decrease in GFR. This staging system was developed to stratify the severity of CKD and to guide clinical management, as the complications of CKD commonly develop at specific GFR levels irrespective of the etiology of CKD. There are a number of caveats with respect to applying this system to pediatrics. First, the staging of CKD excludes patients younger than 2 years of age. A normal term infant has a GFR of approximately 40 mL/min/1.73 m^2, and, as part of normal renal developmental processes, GFR does not reach final adult levels until nearly 2 years of age, thus GFR increases during the first 2 years of life can make definitive CKD staging in patients younger than 2 years of age problematic. Secondly, the requirement for renal abnormalities to persist for more than 3 months to meet the criterion for CKD makes this staging system inapplicable to newborns and infants younger than 3 months of age.

Causes of CKD in children are very different from those in adults and vary by age group within the pediatric population. In younger children, the most common causes are CAKUT: renal hypoplasia/dysplasia and obstructive lesions such as posterior urethral valves and prune belly syndrome. Renal cystic diseases, including multicystic kidneys, cystic renal dysplasia, juvenile nephronophthisis, and autosomal recessive polycystic kidney disease, are also common causes of CKD during childhood. Glomerular diseases such as nephrotic syndrome, focal segmental glomerulosclerosis, hemolytic uremic syndrome, membranoproliferative glomerulonephritis, membranous nephropathy, and lupus nephritis are uncommon causes of CKD in early childhood, but by late childhood and early adolescence, they become the predominant causes of CKD. Although the prevalence of ESRD, including renal transplantation and chronic dialysis, is well-defined, no incidence or prevalence data for pediatric CKD are available from North American registries.

The frequency and severity of the complications of CKD increase as CKD progresses. The classification of CKD is based on five stages (Table 21.2), and stage-based care guidelines for the management of these complications are detailed in consensus recommendation by the KDOQI and KDIGO initiatives (Inker et al., 2014; KDIGO, 2009; KDOQI, 2009).

TABLE 21.2

Classification of Chronic Kidney Disease for Children Older Than 2 Years of Age

STAGE	DEFINITION	GFR (mL/min/1.73 m^2)
I	Normal or ↓ GFR (with kidney damage)	≥90
II	Mild ↓ GFR (with kidney damage)	60–89
III	Moderate ↓ GFR	30–59
IV	Severe ↓ GFR	15–29
V	Kidney failure	<15 or dialysis

GFR, Glomerular filtration rate.

Protein malnutrition is seen in up to 20% of pediatric patients with any stage of CKD and is more common in advanced CKD and in infants and younger children. In younger children, the key factor contributing to malnutrition is inadequate intake. Although the underlying cause of malnutrition in children with CKD is often multifactorial, it is extremely important that this be recognized and treated promptly and aggressively, as malnutrition has been strongly associated with mortality. Children with CKD often have an impaired appetite, and this can be further complicated by nausea and vomiting. They may also require the restriction of specific dietary components, especially potassium and phosphate. Specialized formulas and diets designed for children with CKD are often required. A pediatric dietitian with experience in CKD/ESRD is essential to optimize caloric intake, which is the overriding treatment goal for malnutrition in children with CKD.

Growth impairment is a common complication in children with CKD and can have a major psychological impact on a child while negatively affecting their quality of life (QoL). Children with CKD are approximately 1.5 standard deviations below normal for height, and this height deficit is greatest in the youngest children. With aggressive treatment of nutritional deficiencies and renal osteodystrophy, a normal growth pattern is usually reestablished until the child reaches ESRD (CKD stage V). The causes of growth delay in children with CKD include malnutrition/protein-energy wasting, chronic acidosis, severe renal osteodystrophy, sodium depletion, and growth hormone resistance. Where possible, treatment should be directed to correction of these metabolic disturbances before the introduction of growth hormone (Haffner et al., 2000). Children with CKD are not growth hormone deficient, but rather have abnormalities along the growth hormone activation pathway including reduced production of insulin-like growth factor-1 (IGF-1), increased circulating levels of IGF-binding proteins that reduce IGF-1 activity, and resistance of bone to growth hormone activity. Despite the consensus recommendations for children with growth impairment and CKD, only about 1 in 4 children are prescribed recombinant growth hormone.

CKD/mineral bone disease, a term now employed to replace *renal osteodystrophy,* is a systemic disorder characterized by alterations in mineral metabolism, bone deformities, and calcific cardiovascular abnormalities in CKD. Insufficiency of $1,25(OH)_2$ vitamin D in CKD can be a result of deficient activation of cholecalciferol to the active form of 1,25-dihydrocholecalciferol in the kidney or a result of low cholecalciferol levels as a result of dietary insufficiency. In the later stages of CKD, retention of phosphate worsens as renal function declines. Both the elevation of phosphate levels in plasma and a fall in plasma calcium values stimulate parathyroid hormone secretion; the parathyroid hormone then increases phosphate excretion by the suppression of tubular phosphate reabsorption, thereby returning phosphate values to normal but at the expense of persistently elevated parathyroid hormone values. It has been shown that skeletal mineralization defects start in pediatric patients as early as CKD stage II, even before defects of bone turnover or any biochemical abnormality, except for an increase in circulating FGF-23 levels. The effects of metabolic bone disease on the epiphysis are unique to children with CKD and include growth failure, slipped epiphysis, and rickets.

There are a number of therapeutic approaches to prevent and treat renal bone disease in patients with CKD. Initially, if plasma levels of 25-OH vitamin D are low, then vitamin D_3 (cholecalciferol) supplements should be prescribed. Calcitriol (Rocaltrol), active 1,25 vitamin D, is typically prescribed if the parathyroid hormone levels exceeds the recommended limits and the calcium level is not elevated. In the presence of elevated plasma phosphate values, if dietary phosphate restriction is ineffective, phosphate binders such as calcium carbonate, calcium acetate, or sevelamer should be prescribed. Calcium-containing compounds are available in liquid formulations and, therefore, are most easily used in young children. However, excessive total calcium ingestion may lead to hypercalcemia, which has been associated with vascular calcification, even in children.

Multiple studies have evaluated QoL and social behavior in children with CKD and have **shown lower health-related QoL scores when compared with healthy controls and other children with chronic medical conditions;** in fact, patients with CKD/ESRD have lower QoL scores than children with cancer. Children with CKD are also at risk for neurocognitive impairment. Developmental problems have been reported in as many as 25% of infants with renal disease and correlates with the severity of renal dysfunction. Cognitive deficits are also noted in older children, and the overall IQ of school-age children with CKD is lower than the normal population.

Anemia is nearly universal in advanced CKD. **The most common cause of anemia with CKD is a deficiency of erythropoietin.** However, erythropoietin deficiency in CKD is often confounded by other causes of anemia including iron deficiency, blood loss associated with surgical procedures, and frequent phlebotomy. Erythropoietin-stimulating agents are essential for the management of the anemia in all CKD patients and especially in pediatric CKD patients (Kliger et al., 2013). Either epogen or darbepoetin can be used to successfully treat anemia in the vast majority of children with CKD. Iron therapy is also required for nearly all children with CKD, however iron therapy is affected by gastrointestinal side effects, and there is decreased absorption with concomitant use of phosphate-binding agents or proton pump inhibitors.

Children with CKD are in the highest risk category for cardiovascular disease, and registry data indicates that cardiovascular disease accounts for nearly one-half of all deaths of children on dialysis. Contributing risk factors include chronic hypertension, dyslipidemia, and abnormal mineral metabolism. Hypertension has been reported in more than one-half of children with CKD, and, even with antihypertensive medications, less than 50% were well controlled (ESCAPE Trial Group et al., 2009; Mitsnefes, 2012; Taler et al., 2013). Left ventricular hypertrophy is common in children with CKD, with nearly 60% to 80% of children who are initiating dialysis having left ventricular hypertrophy as well. Dyslipidemia is also seen in approximately 39% to 65% of children with CKD. The most common abnormality is hypertriglyceridemia, followed by elevated non-HDL cholesterol and lower HDL cholesterol levels. It is estimated that one-fourth of children have more than one lipid abnormality. Initial treatment options usually involve nutrition and dietary modification (Sarnak et al., 2015).

Electrolyte abnormalities in children with CKD are very common and include metabolic acidosis from renal tubular dysfunction and/or progressive uremia with ensuing retention of phosphate or sulfate anions. Treatment consists of correction of the acidosis with supplemental bicarbonate or citrate solutions and is particularly important for growth and bone health.

Hyponatremia may also occur as a result of urinary sodium wasting and is commonly seen in the setting of CKD associated with CAKUT. Hyperkalemia is frequently seen as a result of impaired renal potassium excretion and can be aggravated by concurrent metabolic acidosis; potassium control is often focused on dietary restriction and modification.

The natural course of CKD is gradual deterioration of kidney function. **This decline does not occur in a linear fashion as the later stages of CKD are associated with a more rapid progression.** Although there are no clear therapeutic interventions to prevent or reverse progression of CKD, several factors have been identified that may slow progression. In adults, intake of a reduced protein diet may reduce proteinuria and slow the decline of kidney function. However pediatric trials have shown that lower protein intake does not provide any benefit as measured by the rate of decline in creatinine clearance over a 2-year period. Therefore, it is not recommended to restrict protein intake in pediatric patients with CKD unless evaluation of an individual's diet or laboratory values suggests that their protein intake is clearly excessive. Strict blood pressure control is the only intervention that has been shown to decrease progression of CKD in children. Based on this, KDIGO guidelines recommend that the target blood pressure for children should be the 50th percentile for age, gender, and height, and particularly if children have proteinuria. Children with obstructive uropathies, particularly those with inadequate bladder emptying including those who require intermittent catheterization, as well as increasing hydronephrosis, which may indicate partial lower tract obstruction, should be dealt with promptly by a pediatric urologist. Similarly, for those with repeated urinary tract infections, efforts should be focused on prevention either by assuring appropriate bladder drainage or by using prophylactic daily antibiotics.

Key Points

- Causes of CKD in children are very different from those in adults and vary by age group within the pediatric population.
- The most common cause of anemia with CKD is a deficiency of erythropoietin.
- With CKD, kidney function declines in a nonlinear fashion as the later stages are associated with a more rapid progression.

End-Stage Renal Disease: Dialysis and Renal Transplantation

ESRD is defined by the need for either chronic dialysis or kidney transplantation to sustain life. There is no absolute creatinine or BUN level that mandates the initiation of chronic dialysis. **Typically initiation of dialysis is considered in children who have reached CKD stage V (GFR <15 mL/min/1.73 m^2) or when CKD is complicated by uncontrolled hypertension, volume overload, metabolic derangements, poor growth, or complications of uremia** (Greenbaum and Shaefer, 2012). There are two chronic dialytic modalities available for infants, children, and adolescents: **peritoneal dialysis** and **hemodialysis** (Chand et al., 2017; Fischbach et al., 2005). Selection of hemodialysis or peritoneal dialysis is dependent on a number of factors including the needs of the patient and family, patient size, age, lifestyle choices, and psychosocial risk.

Peritoneal dialysis is the most common initial modality for children younger than 9 years of age and less than 20 kg, as the treatment is provided at home and does not require central venous access. For older children, it offers the advantage of greater flexibility in the timing of treatments and better social integration. PD can be successfully performed in many patients with prior urologic surgeries including vesicostomies, however the presence of omphalocele, gastroschisis, diaphragmatic hernia, or bladder exstrophy are contraindications to peritoneal dialysis.

Peritoneal dialysis is performed via a process of repeated instillation and drainage of dialysis solution both into and out of the peritoneal space via a surgically implanted peritoneal dialysis catheter. The dialysate solutions contain electrolyte additives in physiologic concentrations, with the exception of potassium and phosphorus, to facilitate correction of electrolyte abnormalities and acid-base abnormalities. The glucose concentration in the dialysis solution creates an osmotic gradient that mediates the net movement of water into the peritoneal cavity, which is referred to as *ultrafiltration*. In peritoneal dialysis, solute clearance occurs via a process of diffusion whereby solutes move from a compartment of higher concentration to a compartment of lower concentration across the peritoneal membrane and by convection whereby solutes move via solvent drag with the movement of fluid between the blood and dialysate compartments. Peritoneal dialysis is typically performed overnight for 8 to 12 hours and thus achieves more steady metabolic and blood pressure control than hemodialysis. Peritoneal dialysis can be prescribed either manually (continuous ambulatory peritoneal dialysis) or using an automated machine (continuous cycling peritoneal dialysis). Continuous cycling peritoneal dialysis is prescribed for the majority of pediatric patients in the United States. The peritoneal dialysis prescription, including volumes, dwell times, and dextrose concentration, is tailored to each child's specific needs.

Infections, such as peritonitis and tunnel infections, are the most common complications of peritoneal dialysis (Warady et al., 2012). Peritonitis typically occurs more frequently in younger children. Peritonitis typically presents with acute onset of abdominal pain and cloudy dialysis fluid, and fluid with a white blood cell count greater than $100/mm^3$ and at least 50% neutrophils meet the presumptive criteria for peritonitis. Gram-positive organisms are the most common cause of peritonitis in the pediatric population, followed by culture-negative, and then gram-negative organisms. Fungal peritonitis, although rare, can require discontinuation of peritoneal dialysis, and transition to hemodialysis. Peritonitis can lead to the development of intra-abdominal adhesions, and ultimately peritoneal membrane failure. Peritoneal dialysis catheter exit site and tunnel infections are also important risk factors for peritonitis and can require catheter removal if persistent or recurrent. Noninfectious complications of peritoneal dialysis include the development of dialysate leak, abdominal hernias, hydrothorax, or hemoperitoneum.

In children older than 10 years of age, hemodialysis is the predominant chronic dialysis modality in the United States. As opposed to peritoneal dialysis, hemodialysis requires chronic central venous access. The ability to maintain hemodialysis access in infants and smaller children presents a major challenge for pediatric ESRD care. Options for hemodialysis access include arteriovenous fistula; arteriovenous graft, which uses a synthetic material to create a conduit between an artery and a vein; and central venous hemodialysis catheters. Arteriovenous fistulas have better survival rates and lower rates of infection compared with arteriovenous grafts or hemodialysis catheters and are recommended for children greater than 20 kg for whom renal transplantation is not eminent (Ma et al., 2013). However arteriovenous fistulas are not always technically possible, particularly in younger children for whom a central hemodialysis catheter may be necessary. Hemodialysis catheters are preferentially placed in the internal jugular veins; the subclavian veins should be avoided because of the risk for subclavian stenosis.

Hemodialysis removes metabolic waste products, solutes, and excess fluid via diffusion, convection, and ultrafiltration. Diffusion characterizes the solute movement across the semipermeable dialysis membrane against a concentration gradient. Convection is the movement of solutes with plasma water; it is determined by the amount of ultrafiltration and characteristics of the dialysis membrane. Ultrafiltration is the movement of water across the dialysis membrane by convective flow caused by a pressure or osmotic gradient. Hemodialysis fluid removal is determined by the transmembrane pressure gradient across the dialysis membrane and the permeability of a given dialysis membrane to water, and the dialysate solution contains electrolytes in physiologic concentrations to normalize electrolytes and correct acid-base abnormalities. Typically, pediatric patients receive in-center hemodialysis 3 to 4 times per week for 4 hours at a time to achieve adequate metabolic control and fluid balance. Home hemodialysis is also an option for select patients and caregivers; similar to peritoneal dialysis, home hemodialysis is provided daily at night to provide more consistent metabolic control and fluid balance than achieved with the thrice-weekly in-center hemodialysis treatments (Hothi et al., 2016).

For the vast majority of pediatric patients with ESRD, the ultimate treatment goal is renal transplantation, not long-term dialysis. Pediatric patients younger than 18 years of age account for less than 5% of all kidney transplantations performed in the United States (Dharnidharka et al., 2014; Lau et al., 2012; United States Renal Data System [USRDS], 2016). Of the approximately 900 annual pediatric kidney transplants, about two-thirds are from deceased donors and one-third are from living donors (primarily parents). For patients with an identified living related donor, a preemptive transplant before the need for dialysis is often recommended. The transplant community has recognized the **unique benefits that renal transplantation has for pediatric ESRD patients, including improved growth, neurocognitive development, and QoL.** Therefore, children on the transplant waiting list for deceased-donor organs before 18 years of age receive priority compared with the average adult deceased-donor transplantation candidate. Furthermore, children are also preferentially allotted kidneys from younger donors in an attempt to optimize the life of the allograft. Overall outcomes for pediatric kidney transplants are excellent, with 50% of deceased-donor transplants functioning 12.5 years post-transplant and 50% of living-donor kidneys functioning 20 years post-transplant.

Almost all children with ESRD should be considered for kidney transplantation; absolute contraindications are few but include active malignancy or uncontrolled infections. Cognitive impairment or intellectual disability should not automatically exclude a patient from consideration of kidney transplantation (Goldberg et al., 2015).

There are a number of unique considerations relating to renal transplantation in the pediatric population. In infants, because of technical issues and the increased risk for graft thrombosis, **many centers wait until the child is at least 10 kg and 65 cm in length before proceeding with transplantation.** As CAKUT is a common cause of ESRD in the pediatric population, urinary tract repair or reconstruction of anomalies needs to be addressed before transplantation to optimize outcomes. Compared with adults, immune-mediated glomerular disease and focal segmental glomerulosclerosis are common causes of ESRD in children, thus the risk for disease recurrence in the allograft must be considered both in terms of pretransplant evaluation and postoperative care. This is particularly of concern for primary focal segmental glomerulosclerosis, membranoproliferative glomerulonephritis, C3 glomerulopathy, and atypical hemolytic uremic syndrome. Adequate immunization before renal transplant is also a necessity. Surgical removal of native kidneys is often considered in the peritransplant period; indications for nephrectomy include chronic or recurrent pyelonephritis, hypertension refractory to medical therapy, and uncontrolled nephrotic syndrome.

For most children less than 20 kg, the allograft is placed intra-abdominally and anastomosed to the aorta and the inferior vena cava. For children more than 20 kg, a retroperitoneal approach is used with the allograft placed in the iliac fossa and vascular anastomoses to the common or external iliac vessels. An antirefluxing anastomosis for the donor ureter into the recipient bladder is common as this will reduce the risk for vesicoureteral reflux into the allograft. The use of ureteral stents at the time of transplantation to reduce the risk for ureteral obstruction appears to be largely center-specific.

In the immediate post-transplant period, primary graft dysfunction is reported to occur in less than 3% of pediatric kidney allografts, with delayed graft function requiring dialysis being reported in 5% of pediatric related living-donor allografts and 15% of pediatric deceased-donor allografts.

Immunosuppression, both in terms of induction at the time of transplantation and chronic maintenance therapy, are needed for long-term function of the allograft. Most pediatric transplant centers now use antibody-based agents such as thymoglobulin or basiliximab at the time of transplantation for induction therapy. Thereafter, children are typically maintained on long-term immunosuppression with a calcineurin inhibitor (tacrolimus or cyclosporine) and an antiproliferative agent such as mycophenolate mofetil. In the past decade, there has been a reduction in the use of steroids as part of maintenance therapy, with many centers adopting steroid-free maintenance immunosuppression for children thought to be at lower immunologic risk for rejection.

Infectious complications are a concern in all transplant recipients, particularly in younger children who may not yet have acquired native immunity to cytomegalovirus (CMV), Epstein-Barr virus, or the BK virus. Transplant centers commonly use valganciclovir as prophylaxis to reduce the risk for CMV disease. Trimethoprim-sulfamethoxazole is often used for prophylaxis against *Pneumocystis carinii* pneumonia early in the post-transplant period. However, chronic immunosuppression also increases the risk for renal cell carcinoma, thyroid carcinoma, and cutaneous malignancies by nearly sevenfold in transplant recipients compared with the general pediatric population.

In the pediatric renal transplant population, the risk for acute cellular rejection in the first year post-transplant is less than 10% in living-donor transplants and approximately 15% in deceased-donor transplants. Generally the rates of acute rejection decrease over the life of a renal allograft. Although most rejection episodes are reversible, rejection episodes negatively affect long-term graft function. Antibody-mediated rejection is increasingly being recognized as a cause of allograft dysfunction. The impact on antibody-mediated rejection on long-term allograft function and the treatment strategies for antibody-mediated rejection are areas of ongoing investigation; many centers are now using a combination of therapies for antibody-mediated rejection including intravenous immunoglobulin, rituximab, and/or apheresis. Over time, all transplants will lose substantial function as a result of a process-labeled chronic allograft nephropathy for which there is no current therapeutic intervention. With this progressive decline in allograft function, nearly all pediatric renal transplant recipients will eventually require either retransplantation or a return to dialysis.

Key Points

- Peritoneal dialysis is the most common initial modality for dialysis in children younger than 9 years of age and less than 20 kg.
- The unique benefits of renal transplantation include improved growth, neurocognitive development, and QoL.
- The risk for acute cellular rejection in the first year after pediatric renal transplantation is less than 10% in living-donor transplants.
- The risk for acute cellular rejection in the first year post-transplant is approximately 15% in deceased-donor transplants.

Summary

Effective partnership between pediatric urologists and pediatric nephrologists is needed for the optimal care of pediatric patients with kidney and urinary tract abnormalities. Although differences in opinion regarding best approaches may exist, a careful appreciation of the expertise of both specialties is needed, as both have expert teams of health care providers that can provide the full spectrum of care for these complex issues. As a result of these specialties working closely together, the management of these disorders has clearly improved to provide future generations of children with improved health and less burden from their kidney and urinary tract diseases.

Suggested Readings

Batlle D, Haque SK. Genetic causes and mechanisms of distal renal tubular acidosis. *Nephrol Dial Transplant*. 2012;27(10):3691–3704.

Ben-Shalom E, Frishberg Y. Primary hyperoxalurias: diagnosis and treatment. *Pediatr Nephrol*. 2015;30(10):1781–1791.

Chand D, Swartz S, Tuchman S, et al. Dialysis in children and adolescents: the pediatric nephrology perspective. *Am J Kidney Dis*. 2017;69(2):278–286.

Dharnidharka VR, Fiorina P, Harmon WE. Kidney transplantation in children. *N Engl J Med*. 2014;371(6):549–558.

Dodge WF, West EF, Smith EH, et al. Proteinuria and hematuria in schoolchildren: epidemiology and early natural history. *J Pediatr*. 1976;88(2):327–347.

Edvardsson VO, Goldfarb DS, Lieske JC, et al. Hereditary causes of kidney stones and chronic kidney disease. *Pediatr Nephrol*. 2013;28(10):1923–1942.

ESCAPE Trial Group, Wühl E, Trivelli A, et al. Strict blood-pressure control and progression of renal failure in children. *N Engl J Med*. 2009;361(17):1639–1650.

Falkner B. Hypertension in children and adolescents: epidemiology and natural history. *Pediatr Nephrol*. 2010;25(7):1219–1224.

Flynn JT, Kaelber DC, Baker-Smith CM, et al. Clinical practice guideline for screening and management of high blood pressure in children and adolescents. *Pediatrics*. 2017;140(3):e20171904.

Hernandez JD, Ellison JS, Lendvay TS. Current trends, evaluation, and management of pediatric nephrolithiasis. *JAMA Pediatr*. 2015;169(10):964–970.

Inker LA, Astor BC, Fox CH, et al. KDOQI US commentary on the 2012 KDIGO clinical practice guideline for the evaluation and management of CKD. *Am J Kidney Dis*. 2014;63(5):713–735.

Kaddourah A, Basu RK, Bagshaw SM, et al. Epidemiology of acute kidney injury in critically ill children and young adults. *N Engl J Med*. 2017;376(1):11–20.

Little MH, McMahon AP. Mammalian kidney development: principles, progress, and projections. *Cold Spring Harb Perspect Biol*. 2012;4(5):a008300.

Savige J, Gregory M, Gross O, et al. Expert guidelines for the management of Alport syndrome and thin basement membrane nephropathy. *J Am Soc Nephrol*. 2013;24(3):364–375.

Torres VE, Harris PC, Pirson Y. Autosomal dominant polycystic kidney disease. *Lancet*. 2007;369(9569):1287–1301.

References

Abitbol C, Zilleruelo G, Freundlich M, et al. Quantitation of proteinuria with urinary protein/creatinine ratios and random testing with dipsticks in nephrotic children. *J Pediatr*. 1990;116(2):243–247.

Batlle D, Haque SK. Genetic causes and mechanisms of distal renal tubular acidosis. *Nephrol Dial Transplant*. 2012;27(10):3691–3704.

Ben-Shalom E, Frishberg Y. Primary hyperoxalurias: diagnosis and treatment. *Pediatr Nephrol*. 2015;30(10):1781–1791.

Bergmann C, Senderek J, Schneider F, et al. PKHD1 mutations in autosomal recessive polycystic kidney disease (ARPKD). *Hum Mutat*. 2004;23(5):453–463.

Braun DA, Lawson JA, Gee HY, et al. Prevalence of monogenic causes in pediatric patients with nephrolithiasis or nephrocalcinosis. *Clin J Am Soc Nephrol*. 2016;11(4):664–672.

Büscher AK, Beck BB, Melk A, et al. Rapid response to cyclosporin A and favorable renal outcome in nongenetic versus genetic steroid-resistant nephrotic syndrome. *Clin J Am Soc Nephrol*. 2016;11(2):245–253.

Cabral DA, Canter DL, Muscal E, et al. Comparing presenting clinical features of 48 children with microscopic polyangiitis against 183 having granulomatosis with polyangiitis. An ARChiVe cohort study. *Arthritis Rheumatol*. 2016;68(10):2514–2526.

Carlisle EJF, Donnelly SM, Halprin ML. Renal tubular acidosis (RTA): recognize the ammonium defect and pHorget the urine pH. *Pediatr Nephrol*. 1991;5(2):242–248.

Chand D, Swartz S, Tuchman S, et al. Dialysis in children and adolescents: the pediatric nephrology perspective. *Am J*

Kidney Dis. 2017;69(2):278–286.

Combes AN, Davies JA, Little MH. Cell-cell interactions driving kidney morphogenesis. *Curr Top Dev Biol*. 2015;112:467–508.

Cossey LN, Walker PD, Larsen CP. Phospholipase A2 receptor staining in pediatric idiopathic membranous glomerulopathy. *Pediatr Nephrol*. 2013;28(12):2307–2311.

Devarajan P. Pediatric acute kidney injury: different from acute renal failure but how and why? *Curr Pediatr Rep*. 2013;1(1):34–40.

Devuyst O, Thakker RV. Dent's disease. *Orphanet J Rare Dis*. 2010;5:28.

Dharnidharka VR, Fiorina P, Harmon WE. Kidney transplantation in children. *N Engl J Med*. 2014;371(6):549–558.

Din-Dzietham R, Liu Y, Bielo MV, et al. High blood pressure trends in children and adolescents in national surveys, 1963 to 2002. *Circulation*. 2007;116(13):1488–1496.

Dodge WF, West EF, Smith EH, et al. Proteinuria and hematuria in schoolchildren: epidemiology and early natural history. *J Pediatr*. 1976;88(2):327–347.

Dudley J, Smith G, Llewelyn-Edwards A, et al. Randomized, double-blind, placebo-controlled trial to determine whether steroids reduce the incidence and severity of nephropathy in Henoch-Schönlein purpura. *Arch Dis Child*. 2013;98(10):756–763.

Edvardsson VO, Goldfarb DS, Lieske JC, et al. Hereditary causes of kidney stones and chronic kidney disease. *Pediatr Nephrol*. 2013;28(10):1923–1942.

ESCAPE Trial Group, Wühl E, Trivelli A, et al. Strict blood-pressure control and progression of renal failure in children. *N Engl J Med*. 2009;361(17):1639–1650.

Falkner B. Hypertension in children and adolescents:

epidemiology and natural history. *Pediatr Nephrol*. 2010;25(7):1219–1224.

Fischbach M, Edefonti A, Schröder C, et al. European Pediatric Dialysis Working Group. Hemodialysis in children: general practical guidelines. *Pediatr Nephrol*. 2005;20(8):1054–1066.

Fitzgerald JC, Basu RK, Akcan-Arikan A, et al. Acute kidney injury in pediatric severe sepsis: an independent risk factor for death and new disability. *Crit Care Med*. 2016;44(12):2241–2250.

Flynn JT, Daniels SR. Pharmacologic treatment of hypertension in children and adolescents. *J Pediatr*. 2006;149(6):746–754.

Flynn JT, Kaelber DC, Baker-Smith CM, et al. Clinical practice guideline for screening and management of high blood pressure in children and adolescents. *Pediatrics*. 2017;140(3):e20171904.

Gattineni J, Baum M. Developmental changes in renal tubular transport - an overview. *Pediatr Nephrol*. 2015;30(12):2085–2098.

Gleason CA. Prostaglandins and the developing kidney. *Semin Perinatol*. 1987;11(1):12–21.

Goldberg AM, Amaral S, Moudgil A. Developing a framework for evaluating kidney transplantation candidacy in children with multiple comorbidities. *Pediatr Nephrol*. 2015;30(1):5–13.

Greenbaum LA, Shaefer F. The decision to initiate dialysis in a pediatric patient. Warady BA, Schaefer F, Alexander SR. *Pediatric dialysis*. Springer: New York, NY; 2012:85–100.

Haffner D, Schaefer F, Nissel R, et al. Effect of growth hormone treatment on the adult height of children with chronic renal failure. German Study Group for Growth Hormone Treatment in Chronic Renal Failure. *N Engl J Med*. 2000;343(13):923–930.

Hernandez JD, Ellison JS, Lendvay TS. Current trends, evaluation, and management of pediatric nephrolithiasis. *JAMA Pediatr*. 2015;169(10):964–970.

Hiraki LT, Feldman CH, Liu J, et al. Prevalence, incidence, and demo- graphics of systemic lupus erythematosus and lupus nephritis from 2000 to 2004 among children in the US Medicaid beneficiary population. *Arthritis Rheum*. 2012;64(8):2669–2676.

Hogg RJ, Portman RJ, Milliner D, et al. Evaluation and management of proteinuria and nephritic syndrome in children: recommendation from a pediatric nephrology panel established at the National Kidney Foundation Conference on proteinuria, albuminuria, risk assessment, detection, and elimination (Parade). *Pediatrics*. 2000;105(6):1242–1249.

Hothi DK, Stronach L, Sinnott K. Home hemodialysis in children. *Hemodial Int*. 2016;20(3):349–357.

Igarashi P, Somlo S. Genetics and pathogenesis of polycystic kidney disease. *J Am Soc Nephrol*. 2002;13(9):2384–2398.

Inker LA, Astor BC, Fox CH, et al. KDOQI US commentary on the 2012 KDIGO clinical practice guideline for the evaluation and management of CKD. *Am J Kidney Dis*. 2014;63(5):713–735.

Kaddourah A, Basu RK, Bagshaw SM, et al. Epidemiology of acute kidney injury in critically ill children and young adults. *N Engl J Med*. 2017;376(1):11–20.

Kashtan CE, Ding J, Gregory M, et al. Clinical practice recommendations for the treatment of Alport syndrome. *Pediatr Nephrol*. 2013;28(1):5–11.

Kaskal FJ, Kumar FM, Feld LG, et al. Renal reabsorption of phosphate during development: tubular events. *Pediatr Nephrol*. 1988;2(1):129–134.

Kidney Disease: Improving Global Outcomes (KDIGO) CKD-MBD Work Group. KDIGO clinical practice guideline for the diagnosis, evaluation, prevention, and treatment of chronic kidney disease–mineral and bone disorder (CKD-MBD). *Kidney Int Suppl*. 2009;113:S1–S130.

Kidney Disease: Improving Global Outcomes (KDIGO). Glomerulonephritis Work Group. KDIGO clinical practice guideline for glomerulonephritis. *Kidney Int Suppl*. 2012;2(2):139–274.

Kidney Disease Outcomes Quality Initiative (KDOQI) clinical practice guideline for nutrition in children with CKD: 2008 update. Executive summary. *Am J Kidney Dis*. 2009;53(3 Suppl 2):S11–S104.

Kiryluk K, Moldoveanu Z, Sanders JT, et al. Aberrant glycosylation of IgA1 is inherited in both pediatric IgA nephropathy and Henoch-Schönlein purpura nephritis. *Kidney Int*. 2011;80(1):79–87.

Kliger AS, Foley RN, Goldfarb DS, et al. KDOQI US commentary on the 2012 KDIGO Clinical Practice Guideline for Anemia in CKD. *Am J Kidney Dis*. 2013;62(5):849–859.

Kyle UG, Akcan-Arikan A, Orellana RA, et al. Nutrition support among critically ill children with AKI. *Clin J Am Soc Nephrol*. 2013;8(4):568–574.

Lameire N, Van Biesen W, Vanholder R. Epidemiology of acute kidney injury in children worldwide, including developing countries. *Pediatr Nephrol*. 2017;32(8):1301–1314.

Lau KK, Giglia L, Chan H, et al. Management of children after renal transplantation: highlights for general pediatricians. *Transl Pediatr*. 2012;1(1):35–46.

Little MH, McMahon AP. Mammalian kidney development: principles, progress, and projections. *Cold Spring Harb Perspect Biol*. 2012;4(5):a008300.

Loirat C, Fakhouri F, Ariceta G, et al. An international consensus approach to the management of atypical hemolytic uremic syndrome in children. *Pediatr Nephrol*. 2015;31(1):15–39.

Lovric S, Ashraf S, Tan W, et al. Genetic testing in steroid-resistant nephrotic syndrome: when and how? *Nephrol Dial Transpl*. 2015;31(11):1802–1813.

Lurbe E, Cifkova R, Cruickshank JK, et al. Management of high blood pressure in children and adolescents: recommendations of the European Society of Hypertension. *J Hypertens*. 2009;27(9):1719–1742.

Ma A, Schroff R, Hothi D, et al. A comparison of arteriovenous fistulas and central venous lines for long term chronic hemodialysis. *Pediatr Nephrol*. 2013;28(2):321–326.

Mehta RL, Burdmann EA, Cerdá J, et al. Recognition and management of acute kidney injury in the International Society of Nephrology 0by25 Global Snapshot: a multinational cross-sectional study. *Lancet*. 2016;387(10032):2017–2025.

Mina R, von Scheven E, Ardoin SP, et al. Consensus treatment plans for induction therapy of newly diagnosed proliferative lupus nephritis in juvenile systemic lupus erythematosus. *Arthritis Care Res (Hoboken)*. 2012;64(3):375–383.

Mitsnefes MM. Cardiovascular disease in children with chronic kidney disease. *J Am Soc Nephrol*. 2012;23(4):578–585.

Moe OW, Seldin DW, Baum M. The Fanconi syndrome. Lifton R, Somlo S, Seldin DW, et al. *Genetic diseases of the kidney*. Elsevier: New York, NY; 2009:171–198.

Muntner P. Trends in blood pressure among children and adolescents. *JAMA*. 2004;291(17):2107.

National High Blood Pressure Education Program Working Group on High Blood Pressure in Children and Adolescents. The fourth report on the diagnosis, evaluation, and treatment of high blood pressure in children and adolescents. *Pediatrics*. 2004;114(2 Suppl 4th Report):555–576.

Nazzal L, Puri S, Goldfarb DS. Enteric hyperoxaluria: an important cause of end-stage kidney disease. *Nephrol Dial*

Transplant. 2016;31(3):375–382.

Nesterova G, Gahl WA. Cystinosis: the evolution of a treatable disease. *Pediatr Nephrol*. 2013;28(1):51–59.

O'Shaughnessy KM. Gordon syndrome: a continuing story. *Pediatr Nephrol*. 2015;30(11):1903–1908.

Palmer BF. Regulation of potassium homeostasis. *Clin J Am Soc Nephrol*. 2015;10(6):1050–1060.

Pickering MC, D'Agati VD, Nester CM, et al. C3 glomerulopathy: consensus report. *Kidney Int*. 2013;84(6):1079–1089.

Quigley R, Baum M. Neonatal acid base balance and disturbances. *Semin Perinatol*. 2004;28(2):97–102.

Quigley R. Developmental changes in renal function. *Curr Opin Pediatr*. 2012;24(2):184–190.

Redwine KM, Acosta AA, Poffenbarger T, et al. Development of hypertension in adolescents with pre-hypertension. *J Pediatr*. 2012;160(1):98–103.

Sarnak MJ, Bloom R, Muntner P, et al. KDOQI US commentary on the 2013 KDIGO clinical practice guideline for lipid management in CKD. *Am J Kidney Dis*. 2015;65(3):354–366.

Sas DJ. An update on the changing epidemiology and metabolic risk factors in pediatric kidney stone disease. *Clin J Am Soc Nephrol*. 2011;6(8):2062–2068.

Savige J, Gregory M, Gross O, et al. Expert guidelines for the management of Alport syndrome and thin basement membrane nephropathy. *J Am Soc Nephrol*. 2013;24(3):364–375.

Savige J, Colville D, Rheault M, et al. Alport syndrome in women and girls. *Clin J Am Soc Nephrol*. 2016;11(9):1713–1720.

Schell C, Wanner N, Huber TB. Glomerular development–shaping the multi-cellular filtration unit. *Semin Cell Dev Biol*. 2014;36:39–49.

Schell-Feith EA, Kist-van Holthe JE, van der Heijden AJ. Nephrocalcinosis in preterm neonates. *Pediatr Nephrol*. 2010;25(2):221–230.

Schwartz GJ, Muñoz A, Schneider MF, et al. New equations to estimate GFR in children with CKD. *J Am Soc Nephrol*. 2009;20(3):629–637.

Selewski DT, Cornell TT, Heung M, et al. Validation of the KDIGO acute kidney injury criteria in a pediatric critical care population. *Intensive Care Med*. 2014;40(10):1481–1488.

Seyberth HW, Schlingmann KP. Bartter- and Gitelman-like syndromes: salt-losing tubulopathies with loop or DCT defects. *Pediatr Nephrol*. 2011;26(10):1789–1802.

Short KM, Smyth IM. The contribution of branching morphogenesis to kidney development and disease. *Nat Rev Nephrol*. 2016;12(12):754–767.

Slater MB, Gruneir A, Rochon PA, et al. Risk factors of acute kidney injury in critically ill children. *Pediatr Crit Care Med*. 2016;17(9):e391–e398.

Smith-Bindman R, Aubin C, Bailitz J, et al. Ultrasonography versus computed tomography for suspected nephrolithiasis. *N Engl J Med*. 2014;371(12):1100–1110.

Sutherland SM, Ji J, Sheikhi FH, et al. AKI in hospitalized children: epidemiology and clinical associations in a national cohort. *Clin J Am Soc Nephrol*. 2013;8(10):1661–1669.

Taler SJ, Agarwal R, Bakris GL, et al. KDOQI US commentary on the 2012 KDIGO clinical practice guideline for management of blood pressure in CKD. *Am J Kidney Dis*. 2013;62(2):201–213.

Teeninga N, Kist-van Holthe JE, van Rijswijk N, et al. Extending prednisolone treatment does not reduce relapses in childhood nephrotic syndrome. *J Am Soc Nephrol*. 2012;24(1):149–159.

Teoh CW, Robinson LA, Noone D. Perspective on edema in childhood nephrotic syndrome. *Am J Physiol Renal Physiol*. 2015;309(7):F575–F582.

Torres VE, Harris PC, Pirson Y. Autosomal dominant polycystic kidney disease. *Lancet*. 2007;369(9569):1287–1301.

United States Renal Data System (USRDS). *2016 USRDS annual data report: Epidemiology of kidney disease in the United States*. [Bethesda, MD: National Institutes of Health, National Institute of Diabetes and Digestive and Kidney Diseases] 2016.

Vehaskari VM. Heritable forms of hypertension. *Pediatr Nephrol*. 2009;24(10):1929–1937.

Vehaskari VM, Rapola J. Isolated proteinuria: analysis of a school age population. *J Pediatr*. 1982;101(5):661–668.

Vehaskari VM, Rapola J, Koskimies O, et al. Microscopic hematuria in school children: epidemiology and clinicopathologic evaluation. *J Pediatr*. 1979;95(5 Pt 1):676–684.

Warady BA, Bakkaloglu S, Newland J, et al. ISPD guidelines/recommendations: consensus guideline for the prevention and treatment of catheter-related infections and peritonitis in pediatric patients receiving peritoneal dialysis. *Perit Dial Int*. 2012;32(Suppl 2):S32–S86.

Zhou H, Satlin LM. Renal potassium handling in healthy and sick newborns. *Semin Perinatol*. 2004;28(2):103–111.

22

Perinatal Urology

C.D. Anthony Herndon MD, FAAP, FACS, Rebecca S. Zee MD, PhD

Urinary tract dilation (UTD) represents the second most common anomaly detected during prenatal screening following cardiac defects and occurs with a frequency of 1% to 3%. (Nguyen et al., 2010). A majority of UTD cases are detected in the second trimester, which affords the opportunity for parental counseling in a setting that occurs well before delivery (Pathak and Lees, 2009). Discussions may include recommendations for postnatal evaluation and management or referral to centers of excellence when uncommon conditions such as lower urinary tract obstruction (LUTO) or bladder exstrophy are suspected. Although a majority of conditions such as transient dilation, ureteropelvic junction obstruction (UPJO) pattern of dilation, and vesicoureteral reflux (VUR) will not lead to surgical intervention, a subset of patients are at increased risk for urologic disease; thus clinical thresholds for the recommendation for prophylactic antibiotics (PA), lower urinary tract imaging, and more invasive upper tract imaging should be appreciated (Lee et al., 2006). The aim of this chapter is to provide a comprehensive overview of care for the patient with perinatal UTD inclusive of: grading systems utilized by providers, prenatal consultations for specific conditions and role for intervention, imaging modalities and indications, differential diagnosis with expected outcomes, a risk stratification system used for recommendation of postnatal evaluation and management, and urologic perinatal emergencies.

▶Videos 22.1, ▶22.2, and ▶22.3 demonstrate prenatal urinary tract dilation of the fetal kidney, fetal measurement of amniotic fluid index, and fetal ultrasonography documenting multicystic dysplastic kidney (MCDK).

Prenatal Imaging

Maternal-Fetal Ultrasound

Although fetal metanephric kidney begins at the 28th day of gestation, urine production begins in earnest at 14 weeks' gestation and can be detected on prenatal ultrasonography (Park, 2016). The American College of Obstetricians and Gynecologists (ACOG) recommends that the initial screening ultrasonography be performed between 18 and 20 weeks' gestation (ACOG, 2009). **In the United States, the initial fetal screening ultrasonography is performed around 20 weeks' gestational age, with an average of two scans for low-risk pregnancies and four scans for high-risk pregnancies** (Siddique et al., 2009)**. Ultimately, the exact timing is left to the discretion of the physician.** There are no set criteria for referral to a maternal-fetal medicine specialist, but increasing degrees of urinary tract dilation and/or an abnormal amniotic fluid index (AFI) should prompt referral. **The AFI is an assessment of amniotic fluid that should include the cumulative measurement of 4 pockets of fluid** (Fig. 22.1)**. Normal AFI is 8 to 18, oligohydramnios is less than 5 or 6, and polyhydramnios is 20 to 24.**

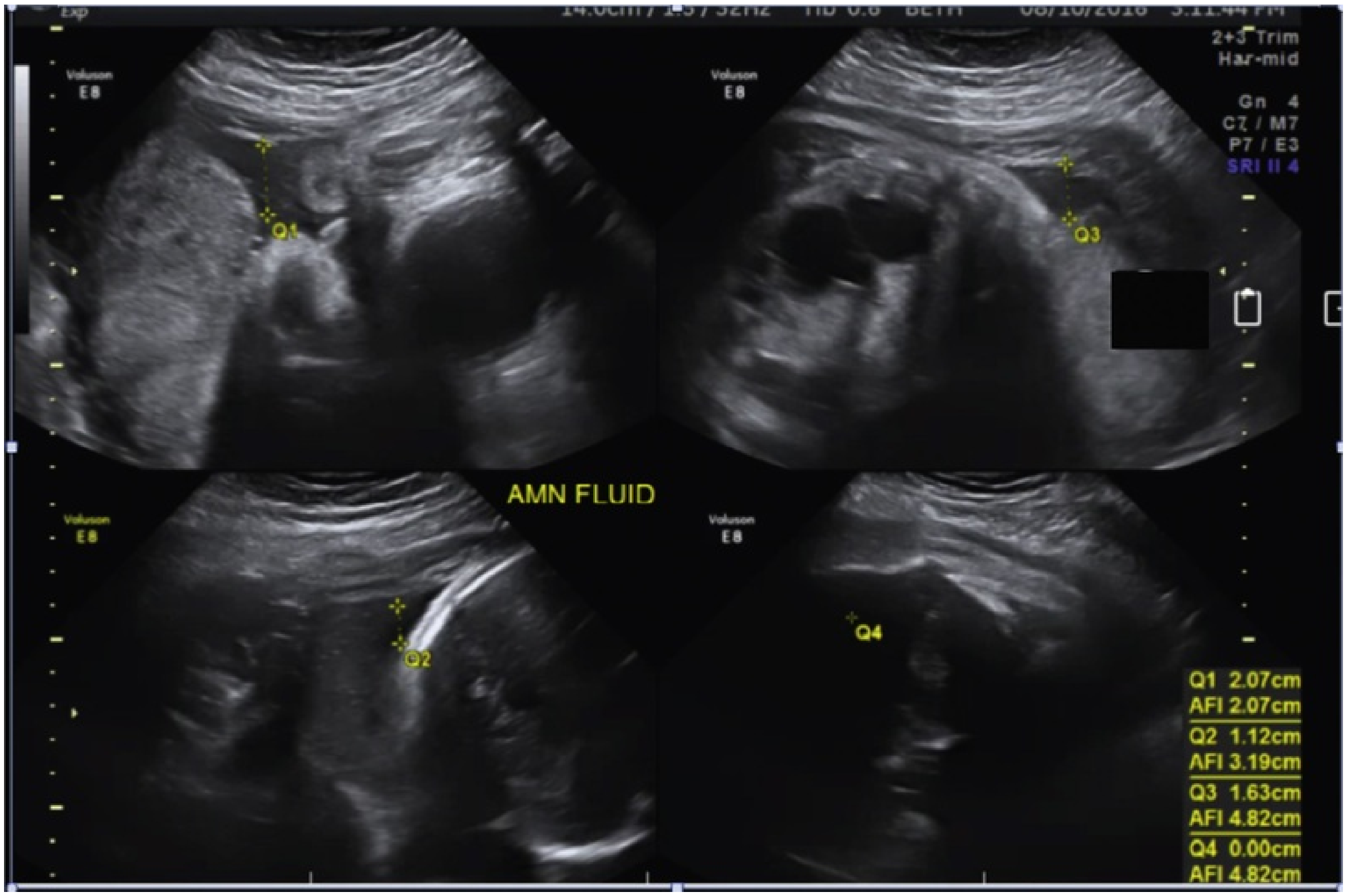

FIG. 22.1 The amniotic fluid index *(AFI)* is calculated by measurement of the four largest pockets of amniotic fluid.

The dilated urinary tract appears to be ideal for detection by ultrasonography, and several large studies have reported sensitivities of up to 89% (Grandjean et al., 1999; Stefos et al., 1999). Equally, over the past decade there has been a steady increase in the number of fetal ultrasound scans performed despite the lack of medical literature to support that prenatal identification of fetal anomalies improves outcome (Hsieh et al., 2009). Furthermore, this increased utilization of prenatal ultrasonography will lead to increased health care costs in the United States, with an estimate for 1 million mothers screened up to $270 million (Vintzileos et al., 2000).

The ability for prenatal ultrasonography to accurately determine the postnatal diagnosis varies. For example, Lee et al. (2006) **demonstrated a linear relationship between increasing severity of prenatal UTD and UPJO that does not exist with other common conditions such as VUR or duplex anomalies.** For rare conditions, a high index of suspicion affords the opportunity to make the correct diagnosis, but this varies as well. Conditions such as bladder/cloacal exstrophy and neural tube defects can be correctly diagnosed in a majority of patients, and diseases that affect genital ambiguity are not as consistently diagnosed (Boyd et al., 2008; Cheikhelard et al., 2000; Julian-

Reynier et al., 1994; Wiesel et al., 2005).

The main benefit of prenatal detection of urologic anomalies is to allow for the opportunity for open dialogue concerning the pathologic finding as it relates to the differential diagnosis, role for prenatal intervention, role of postnatal imaging, and natural history of the suspected disease (Clayton and Brock, 2011, 2018).

Fetal Magnetic Resonance Imaging

The use of fetal magnetic resonance imaging (MRI) is limited for the evaluation of prenatal UTD. The main indication for this modality is the need for specific anatomic detail. Many of these situations are rare, such as cloacal anomaly, urogenital sinus, cloacal/bladder exstrophy, and duplication anomalies that may result in bladder outlet obstruction (BOO) (Fig. 22.2).

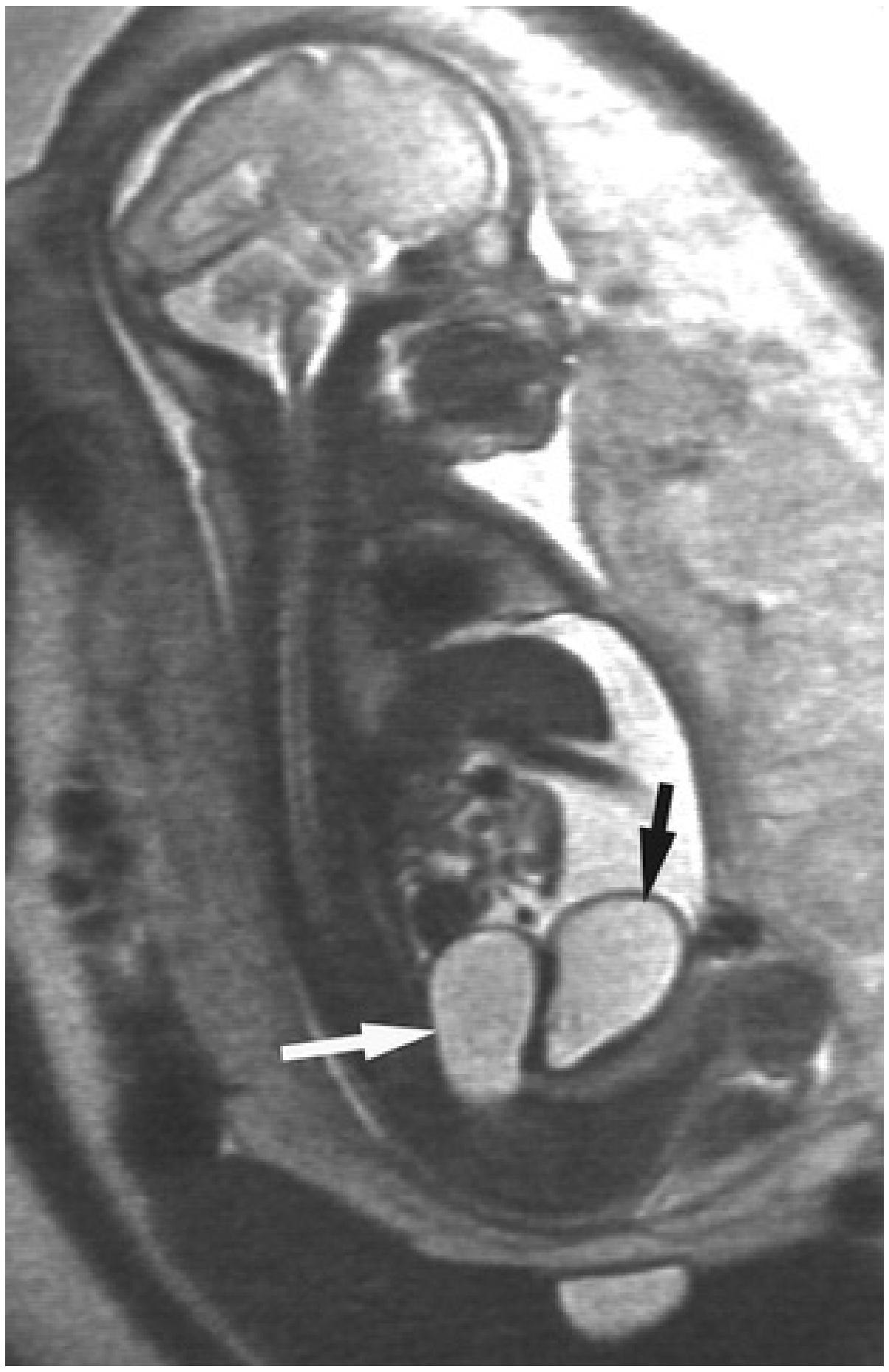

FIG. 22.2 Fetal magnetic resonance image demonstrating cloacal anomaly *(arrows)*.

Fetal MRI offers superiority over ultrasound imaging in regard to specific anatomic detail that may not be obtained with fetal ultrasonography, which has inherent factors such as amniotic fluid volume, maternal body habitus, fetal position, or pelvic bony structures (Hayashi et al., 2005).

Key Points

- The initial screening maternal ultrasound scan is performed around 20 weeks' gestation. Low-risk pregnancies average two scans, and high-risk pregnancies average four scans throughout pregnancy.
- Urinary tract dilation represents the second most common condition detected prenatally and occurs in 1% to 3% of pregnancies.
- Ultrasonography cannot reliably predict the severity of disease for all urologic conditions. It tends to correlate best with obstructive lesions such as UPJO or posterior urethral valve (PUV) and less with VUR.
- Prenatal detection of urologic disease affords the opportunity for the family to meet with a specialist before delivery to become informed about the anticipated course and natural history of the suspected diagnosis.

Grading Systems

Although a common condition, there is a lack of consensus in regard to the most useful grading system for the description of perinatal UTD. Zanetta et al. identified this discrepancy in a multispecialty survey that queried obstetricians, pediatricians, pediatric urologists, and pediatric radiologists. The authors demonstrated that a majority of providers use the anterior-posterior diameter (APD) system prenatally in comparison to postnatally, when the Society for Fetal Urology (SFU) or subjective (mild, moderate, severe) systems were more commonly employed (Zanetta et al., 2012).

Classification systems used to grade perinatal UTD rely on either objective or subjective findings and with some, a combination of the two. The three most common systems used that will be discussed include the anterior-posterior renal pelvic diameter (APRPD), SFU, and Urinary Tract Dilation (UTD) classification systems.

Anterior-Posterior Renal Pelvic Diameter

The most common system used prenatally by maternal-fetal specialists is the anterior-posterior renal pelvic diameter/anterior-posterior diameter (APRPD/APD) system. This strictly objective system is simple and defines the measurement by obtaining the diameter while measuring the kidney in the transverse plane at the mid-level of the kidney. The renal hilum can be used as an indicator of the optimal location of this measurement. The main drawback to this system is that it is operator dependent, which may lead to inaccurate measurements. For example, a common error occurs when the measurement of APD is taken with the kidney in the sagittal as opposed to the transverse plane.

Normative values are described for APD indexed with gestational age. An APD of less than 4 mm before 28 weeks and less than 7 mm after 28 weeks are considered physiologic. **A three-tier subjective grading system has been described that inversely correlates the incidence with the severity of urinary tract dilation** (Table 22.1). Several centers have demonstrated positive correlation between gestational age and APD. The physiologic increase in urine production that occurs in the third trimester may be a factor that accounts for this correlation (Chitty and Altman, 2003; Odibo et al., 2003).

TABLE 22.1

Fetal Urine Biochemistry Profile

Sodium	<100 mg/dL
Calcium	<8 mg/dL
Osmolarity	<200 mOsM/L
Total protein	<20 mg/dL
β_2-Microglobulin	<4 mg/L

From Johnson MP, Bukowski TP, Reitleman C, et al. In utero surgical treatment of fetal obstructive uropathy: a new comprehensive approach to identify appropriate candidates for vesicoamniotic shunt therapy. *Am J Obstet Gynecol* 170(6):1772 (Table 1), 1994.

Lee et al. (2006) **demonstrated that the severity of prenatal dilation demonstrates a linear relationship with obstructive lesions such as UPJO and posterior urethral valve (PUV) while demonstrating an inconsistent relationship with VUR** (Table 22.2).

TABLE 22.2

Definition of Antenatal Hydronephrosis by Anteroposterior Diameter and Estimated Severity Percentage Range

DEGREE	ANTEROPOSTERIOR DIAMETER		SEVERITY
	SECOND TRIMESTER	THIRD TRIMESTER	
Mild	4 to <7 mm	4 to <9 mm	56.7%–88.0%
Moderate	7 to ≤10 mm	9 to ≤15 mm	10.2%–29.8%
Severe	>10 mm	>15 mm	1.5%–13.4%

Data from Feldman et al., 2001; Ahmad and Green, 2005; Wollenberg et al., 2005; Lee RS, Cendron M, Kinnamon DD, Nguyen HT. Antenatal hydronephrosis as a predictor of postnatal outcome: a meta-analysis. *Pediatrics* 118(2):586–593, 2006; Coelho GM, Bouzada MCF, Pereira AK, et al. Outcome of isolated antenatal hydronephrosis: a prospective cohort study. *Pediatr Nephrol* 22(10):1727–1734, 2007. Coelho et al, 2008.

Several centers have demonstrated an APD threshold that may be predictive of the need for urologic surgery, most of which is repair of UPJO (Burgu et al., 2012; Coplen et al., 2006; Dhillon, 1998; Shamshirsaz et al., 2012).

The initial report performed at Great Ormond Street involved a randomized surgical intervention trial for patients with third-trimester prenatal APD greater than or equal to 15 mm and greater than 40% differential renal function. A total of 75 patients were prospectively randomized to surgical intervention of observation. In the surgery arm, 38 of 39 patients maintained renal function and demonstrated a decrease in dilation. For the observation arm, 17 of 36 patients improved, 12 remained stable, and 7 required intervention because of decreased function, and the APD ranged from 20 to 40 mm (Dhillon, 1998). Unfortunately, longitudinal data are lacking in this cohort, and thus the only conclusions represent short-term observations.

In general, it is difficult to set an exact limit on an APD threshold. Setting a low APD cutoff will increase the sensitivity of detection of UPJ but may result in significant overtesting. Likewise, raising the cutoff will result in increased specificity but will carry the risk for underdiagnosing urologic disease.

Society for Fetal Urology Grading System

The SFU is a subjective 5-point grading system that relies on a combination of renal pelvis/calyceal dilation and the integrity of the renal parenchyma (Fernbach et al., 1993) (Fig. 22.3). The system is simple but does demonstrate variability with intrarater and interrater variability with certain grades, which is to be expected with a completely subjective system (Vemulakonda et al., 2015). Interestingly, computer-enhanced visual learning appears to be an effective means of teaching the grading system to health care providers (Liu et al., 2015; Marks et al., 2011). The Chicago group demonstrated effectively through pretesting and post-testing that interactive computer module learning improved reliability of grading kidney dilation with the SFU system (Liu et al., 2015; Marks et al., 2011).

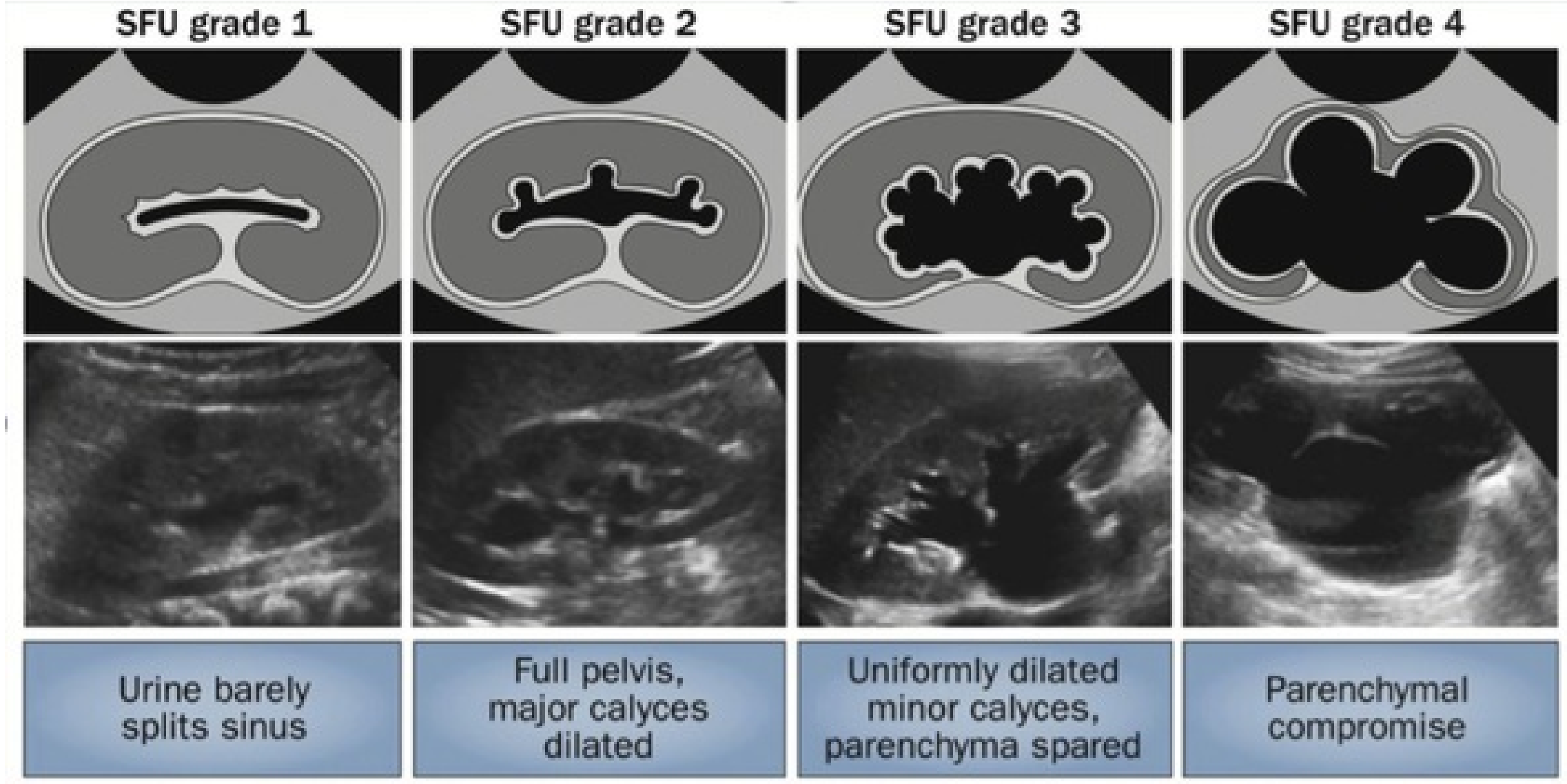
SFU grade 1
SFU grade 2
SFU grade 3
SFU grade 4
Urine barely splits sinus
Full pelvis, major calyces dilated
Uniformly dilated minor calyces, parenchyma spared
Parenchymal compromise

FIG. 22.3 Figures and ultrasound images demonstrating the Society for Fetal Urology (SFU) grading system. (Modified from Timberlake MD, Herndon CD. Mild to moderate postnatal hydronephrosis—grading systems and management. *Nat Rev Urol* 10[11]:652 [Figure 2], 2013).

The SFU system has been demonstrated to be predictive of both renal function and the need for surgical intervention in patients with prenatal urinary tract dilation. In 2007, Erickson et al. reported an inverse correlation between SFU grade and preserved differential renal function (>40%). A total of 33 of 33 (100%) patients with SFU grade 3 demonstrated retained function in comparison to only 27 of 38 (71%) with SFU grade 4 (Erickson et al., 2007). Some have used this as a basis for limiting the use of renal scintigraphy for the evaluation of postnatal urinary tract dilation (Herndon, 2012). In a retrospective review of 125 patients with prenatal UTD, Ross et al. found the SFU system to be predictive of the timing and need for surgical intervention. Three groups consisting of early surgical intervention, delayed surgical intervention, and continued observation were analyzed with respect to distribution of SFU grade. For early surgical intervention, most (89%) patients demonstrated SFU grade 4. For continued observation, most (78%) patients demonstrated SFU grade 3. For those that had delayed surgical intervention, SFU grade correlated less, with 62% demonstrating SFU grade 4 (Ross et al., 2011).

The SFU system is a simple system that can be easily learned and demonstrates the ability to predict renal function and the need for surgical intervention (Erickson et al., 2007; Kilby and Morris 2014; Liu et al., 2015; Marks et al., 2011; Ross et al., 2011). However, the subjective nature does limit its applicability, and other specialties do not appear to be using this system. Furthermore, it does not take into account the entire collecting system including the urinary bladder and ureter, which may affect postnatal decision making and are incorporated into other grading systems (Nguyen et al., 2014).

Urinary Tract Dilation Grading System

To address the lack of uniformity, the UTD grading system was developed by a multidisciplinary team that published a Consensus Statement in 2014. To address the lack of consistency in nomenclature, the group elected to use the term *urinary tract dilation (UTD).* Terms such as *hydronephrosis, caliectasis, pelviectasis,* and *pelvicaliectasis* were discouraged.

Great effort was made to develop a standardized technique for ultrasound imaging and principles for data reporting. The group felt that developing a standard process for the technique used for ultrasound imaging was crucial. Prenatally, it was felt that the measurement of the APD should be obtained with the spine of the fetus in the 6 o'clock or 12 o'clock position.

Postnatally, the APD should be obtained at the midpoint of the kidney in the transverse plane, which corresponds to the area of the hilar vessels. The maximal diameter of the renal pelvis should be obtained within the confines of the renal cortex. Finally, comparative studies should be in the same orientation of lie for the baby (supine versus prone). **The grading system consists of a 6-point template that combines two of the most common systems employed (APD and SFU) and includes both objective and subjective evaluation** (Fig. 22.4). The purpose of a standardized reporting template is to allow for a consistent evaluation that transcends the prenatal and postnatal periods (Nguyen et al., 2014).

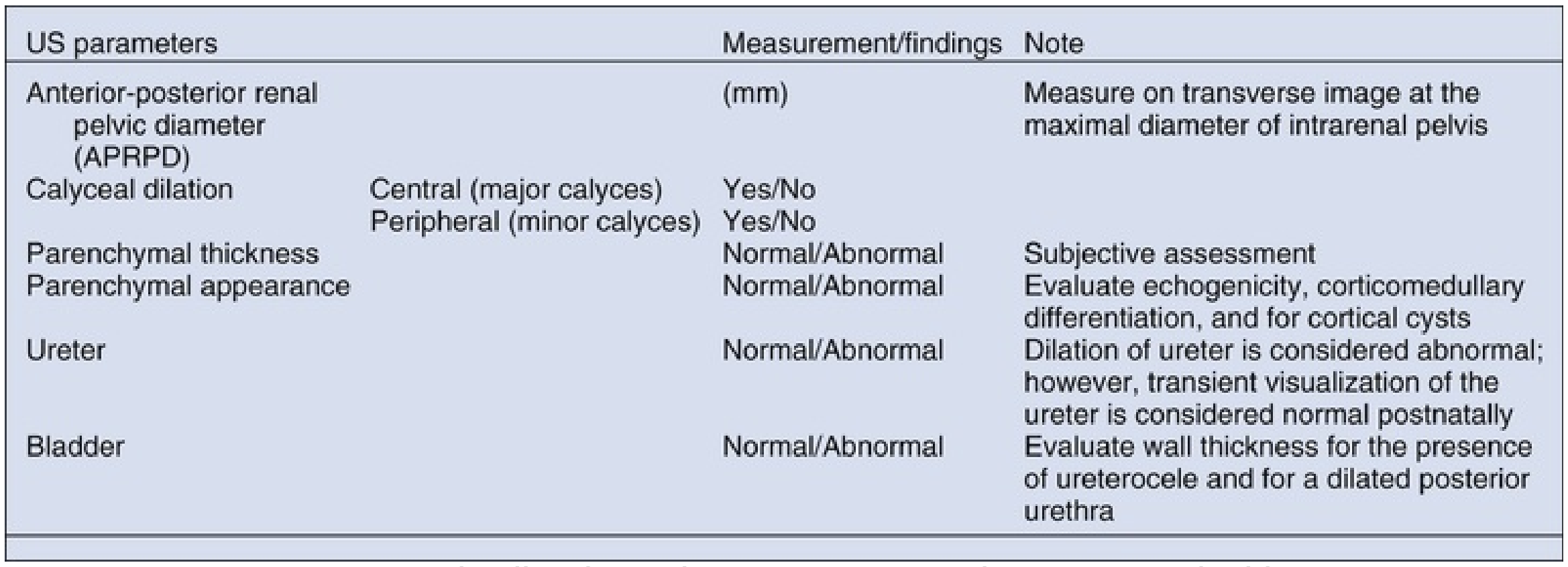

US parameters		Measurement/findings	Note
Anterior-posterior renal pelvic diameter (APRPD)		(mm)	Measure on transverse image at the maximal diameter of intrarenal pelvis
Calyceal dilation	Central (major calyces)	Yes/No	
	Peripheral (minor calyces)	Yes/No	
Parenchymal thickness		Normal/Abnormal	Subjective assessment
Parenchymal appearance		Normal/Abnormal	Evaluate echogenicity, corticomedullary differentiation, and for cortical cysts
Ureter		Normal/Abnormal	Dilation of ureter is considered abnormal; however, transient visualization of the ureter is considered normal postnatally
Bladder		Normal/Abnormal	Evaluate wall thickness for the presence of ureterocele and for a dilated posterior urethra

FIG. 22.4 Standardized 6-point parameters to be measured with ultrasonography using the urinary tract dilation classification system. (Modified from Nguyen HT, Benson CB, Bromley B, et al. Multidisciplinary consensus on the classification of prenatal and postnatal urinary tract dilation [UTD classification system]. *J Pediatr Urol* 10[6]:998 [Table 2], 2014).

In effort to mitigate postnatal overtesting, the UTD working group established a normative value for postnatal APD, which paralleled those observed for the prenatal period. An APD cutoff of less than 10 mm was selected in the absence of calyceal or ureteral dilation and felt to represent nonpathologic renal pelvis dilation. When combined with the accepted normative values for the prenatal period, a stepwise progression of nonpathologic renal pelvic dilation can be seen (Fig. 22.5).

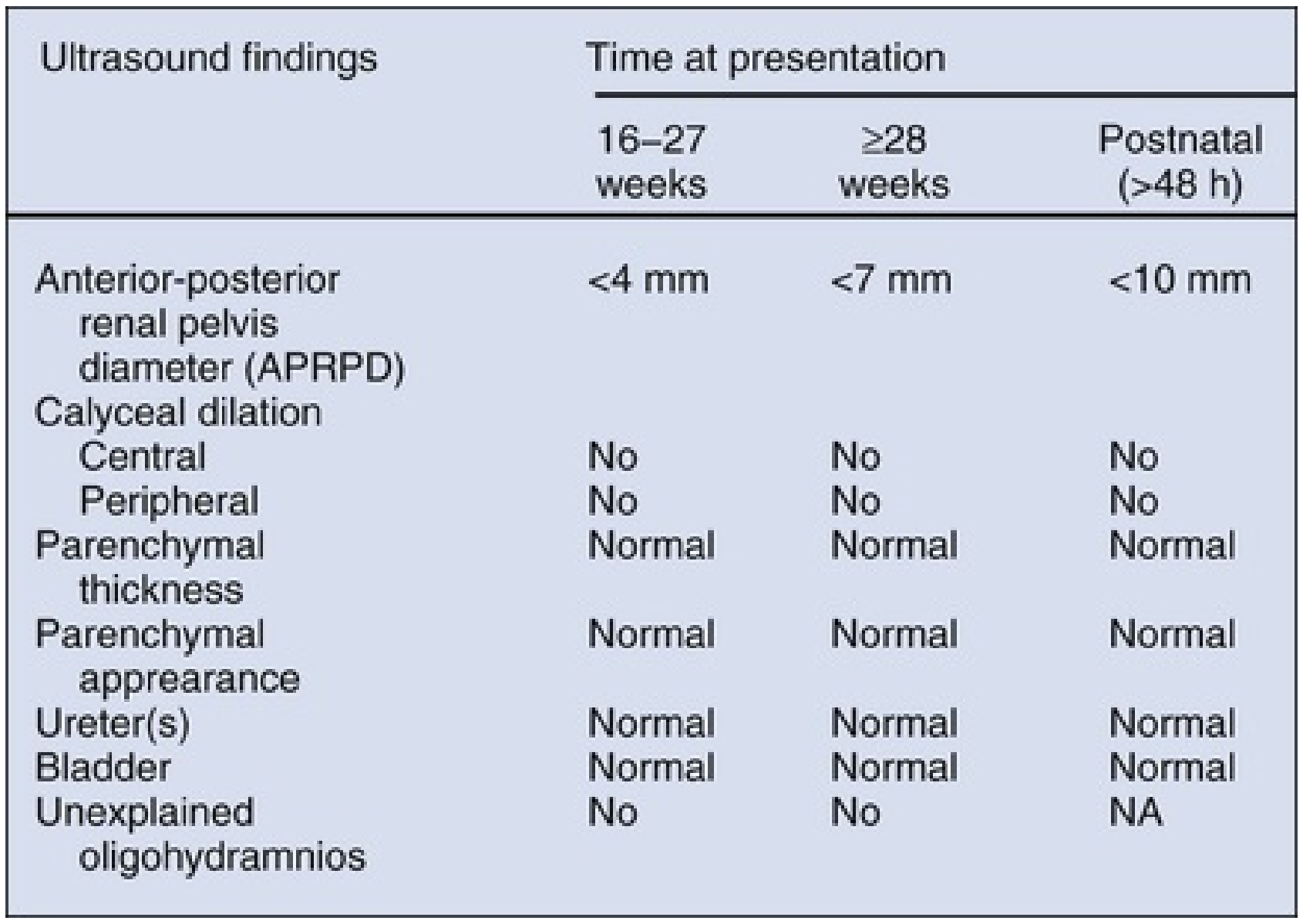

Ultrasound findings	Time at presentation		
	16–27 weeks	≥28 weeks	Postnatal (>48 h)
Anterior-posterior renal pelvis diameter (APRPD)	<4 mm	<7 mm	<10 mm
Calyceal dilation			
Central	No	No	No
Peripheral	No	No	No
Parenchymal thickness	Normal	Normal	Normal
Parenchymal apprearance	Normal	Normal	Normal
Ureter(s)	Normal	Normal	Normal
Bladder	Normal	Normal	Normal
Unexplained oligohydramnios	No	No	NA

FIG. 22.5 Normative thresholds for prenatal and postnatal anterior-

posterior diameter. (Modified from Nguyen HT, Benson CB, Bromley B, et al. Multidisciplinary consensus on the classification of prenatal and postnatal urinary tract dilation [UTD classification system]. *J Pediatr Urol* 10[6]:989 [Table 3], 2014.)

The intent of this reclassification was to create a more pragmatic approach to the postnatal evaluation of UTD. Parents should be advised that prenatal UTD represents a spectrum of disease, and significant pathologic conditions such as VUR may exist in the absence of pathologic renal pelvis dilation (Herndon et al., 1999b). Nonetheless, a paradigm shift has occurred in regard to the recommendation of invasive testing such as a voiding cystourethrogram (VCUG) that is no longer based solely on the probability of diagnosing VUR. A comprehensive risk stratification that includes urinary tract infection (UTI) should drive this recommendation, which is discussed later in this chapter (Zee et al., 2016).

Key Points

- An inverse relationship exists between the severity of UTD and the incidence of urologic disease.
- APD demonstrates a linear relationship for obstructive lesions such as UPJO and PUV.
- An APD of 15 in the third trimester demonstrates reasonable positive predictive value for the need for surgery for UPJO.
- The SFU system consists of a 5-point grading system that is based on calyceal dilation and integrity of the parenchyma.
- The UTD system consists of a combination of APD and SFU systems with the additional inclusion of the lower urinary tract and employs a standardized reporting system and risk stratification.

Prenatal Multidisciplinary Consultations

One of the main benefits of prenatal detection of urologic anomalies is the opportunity for discussion with the family and physician. Certain urologic conditions that may require immediate or urgent intervention postnatally are best served by multidisciplinary prenatal consultation. All stakeholders involved in the care of the mother and child should ideally develop a plan of care with agreed-upon responsibilities. These conditions include cloacal/bladder exstrophy, cloacal/urogenital sinus malformation, autosomal recessive polycystic kidney disease, BOO (PUV, prune belly syndrome, or urethral atresia), and myelomeningocele/neural tube defect spectrum of disease.

Parental Counseling for Fetal Intervention

Prenatal counseling for LUTO should include the maternal-fetal obstetrician, pediatric urologist, pediatric nephrologist, and neonatologist. A candid discussion should include a clear picture that captures our current state of understanding of the role of intervention. Although we have some unanswered questions related to those who may benefit, several statements can be reliably conveyed to the family. **First, fetal intervention will improve perinatal survival when indicated but carries significant risk with a collective reported complication rate to the mother and fetus of over 40%** (Elder et al., 1987; Morris et al., 2013)**. Second, selective treatment that affords perinatal survival has not been demonstrated to provide a reliable long-term impact on the need for renal replacement. This burden may be significant and lifelong. Third, every patient should be individualized in regard to a risk/benefit analysis that must allow for shared decision making in a multidisciplinary setting.**

Parental Counseling for Prenatal Surgery for Myelomingocele Closure

A multidisciplinary consultation should include the maternal/fetal obstetrician, pediatric neurosurgeon, pediatric urologist, and neonatologist. A complete fetal survey including echocardiogram should be completed along with a karyotype to aid in discussion with the family. Parents should be aware of the experimental nature of fetal myelomeningocele closure, and the procedure should only be performed at specialized centers that can be found at the North American Fetal Therapy Network (NAFTNet) website (https://www.naftnet.org/). Although it appears to have a positive role for decreasing the need for ventriculoperitoneal (VP) shunting and improving cognitive/motor function, the impact on overall bladder function does not appear to be meaningful (Adzick et al., 2011; Clayton et al., 2011; Danzer et al., 2009, 2016; Diwakar et al., 2013; Tulipan et al., 2015). Because of its experimental nature, the American College of Obstetricians and Gynecologists and the Society for Maternal-Fetal Medicine made recent recommendations that include the following:

> - Open maternal-fetal surgery for myelomeningocele repair has been demonstrated to improve a number of important pediatric outcomes at the expense of procedure-associated maternal and fetal risks.
> - Women with pregnancies complicated by fetal myelomeningocele who meet established criteria for in utero repair should be counseled in nondirective fashion regarding all management options, including the possibility of open maternal-fetal surgery.
> - Interested candidates for fetal myelomeningocele repair should be referred for further assessment and consultation to a fetal therapy center that offers this intervention and possesses the expertise, multidisciplinary team, services, and facilities to provide detailed information regarding maternal-fetal surgery and the intensive care required for patients who choose to undergo open maternal-fetal surgery (Committee on Obstetric Practice, Society for Maternal-Fetal Medicine, 2017).

Key Points

- Prenatal intervention for LUTO appears to improve perinatal survival but does not reliably affect long-term renal function.
- Parental consultation for fetal myelomeningocele closure should take place

at a center with expertise in fetal surgery that offers a multidisciplinary approach.

- Fetal surgery for myelomeningocele appears to improve motor/cognitive skills and decrease the need for VP shunting but offers no definitive benefit to bladder function.

Urinary Tract Dilation

Risk Stratification and Management for Prenatal Urinary Tract Dilation

The 6-point evaluation described with the UTD system is used to assign two levels of risk prenatally (A1 is low risk, and A2/A3 is increased risk). The allowable APD threshold transitions at 27 weeks' gestational age to allow for an increase in fetal growth and the physiologic urine production that occurs in the third trimester. **A1 (low risk) was defined as 4 to 7 mm APD or 7 to 10 mm APD from 16 to 27 weeks and after 28 weeks, respectively. Aside from central calyceal dilation (or dilation of the major calyx/infundibula), all other parameters measured were normal. A2/A3 (increased risk) was defined as APD greater than 7 mm at 16 to 27 weeks or greater than 10 mm after 28 weeks, respectively, and/or positive values for one of the other five parameters** (Fig. 22.6). Recommendations based on the risk assessment dictate subsequent follow-up within the prenatal period.

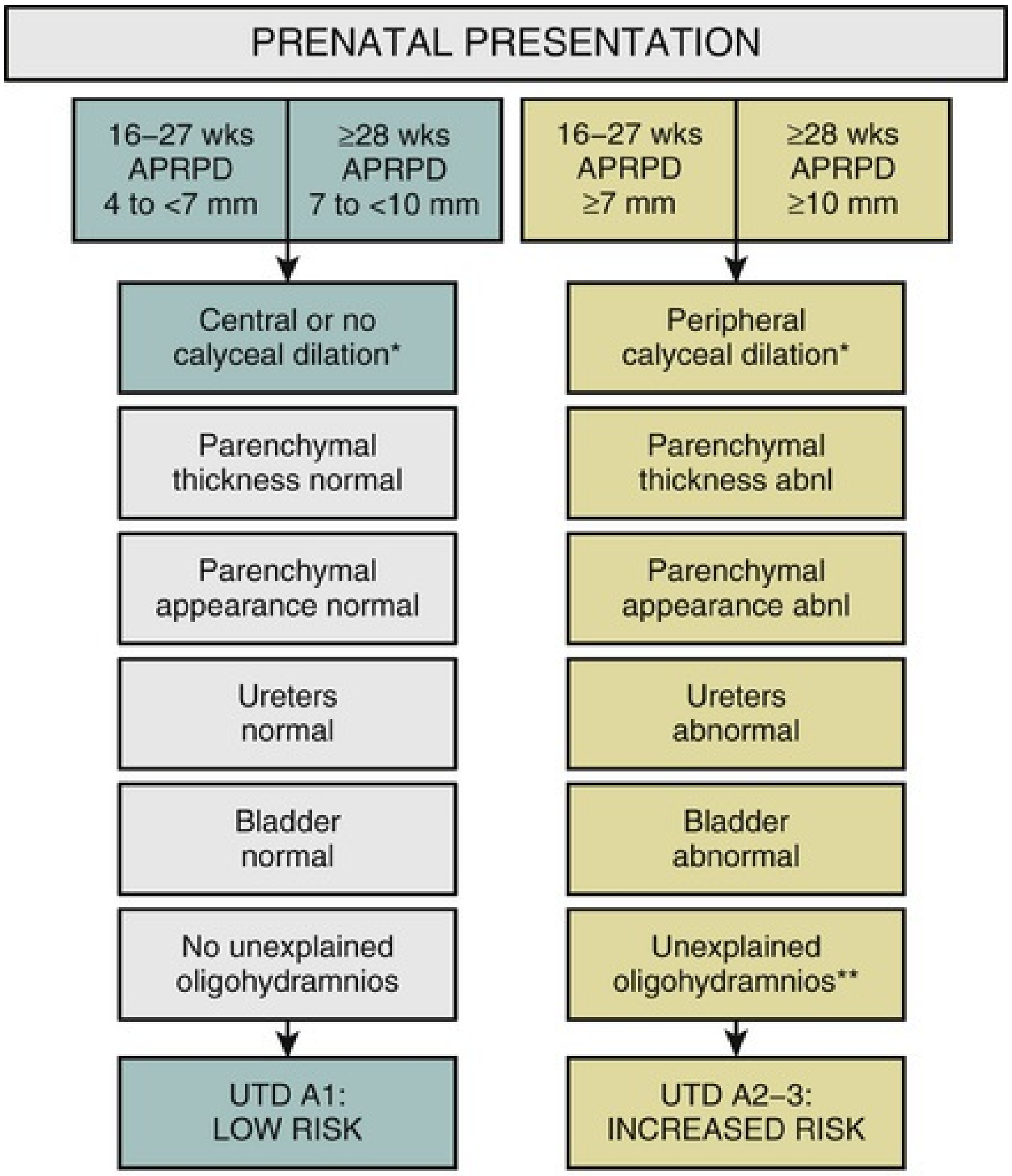
PRENATAL PRESENTATION
16–27 wks APRPD 4 to <7 mm
≥28 wks APRPD 7 to <10 mm
16–27 wks APRPD ≥7 mm
≥28 wks APRPD ≥10 mm
Central or no calyceal dilation*
Peripheral calyceal dilation*
Parenchymal thickness normal
Parenchymal thickness abnl
Parenchymal appearance normal
Parenchymal appearance abnl
Ureters normal
Ureters abnormal
Bladder normal
Bladder abnormal
No unexplained oligohydramnios
Unexplained oligohydramnios**
UTD A1: LOW RISK
UTD A2–3: INCREASED RISK

*Central and peripheral calyceal dilation may be difficult to evaluate early in gestation

**Oligohydramnios is suspected to result from a GU cause

FIG. 22.6 Risk stratification for prenatal urinary tract dilation (UTD) A1 prenatal ultrasound scan and A2/3 prenatal ultrasound scan. (Modified from Nguyen HT, Benson CB, Bromley B, et al. Multidisciplinary consensus on the classification of prenatal and postnatal urinary tract dilation [UTD classification system]. *J Pediatr Urol* 10(6):990 [Figure 3], 2014.)

For A1 UTD detected before 28 weeks, a second ultrasound should be performed after 32 weeks' gestation. For A2/A3, the recommendation was to obtain an ultrasound every 4 months until delivery. The rationale was twofold. First, the anatomic defect may progress significantly, which may alter the plan and location for delivery. Second, the likelihood of detecting a second fetal anomaly was increased with this degree of UDT. An ultrasound scan after 48 hours of birth is recommended in both cohorts. (Fig. 22.7) (Nguyen et al., 2014).

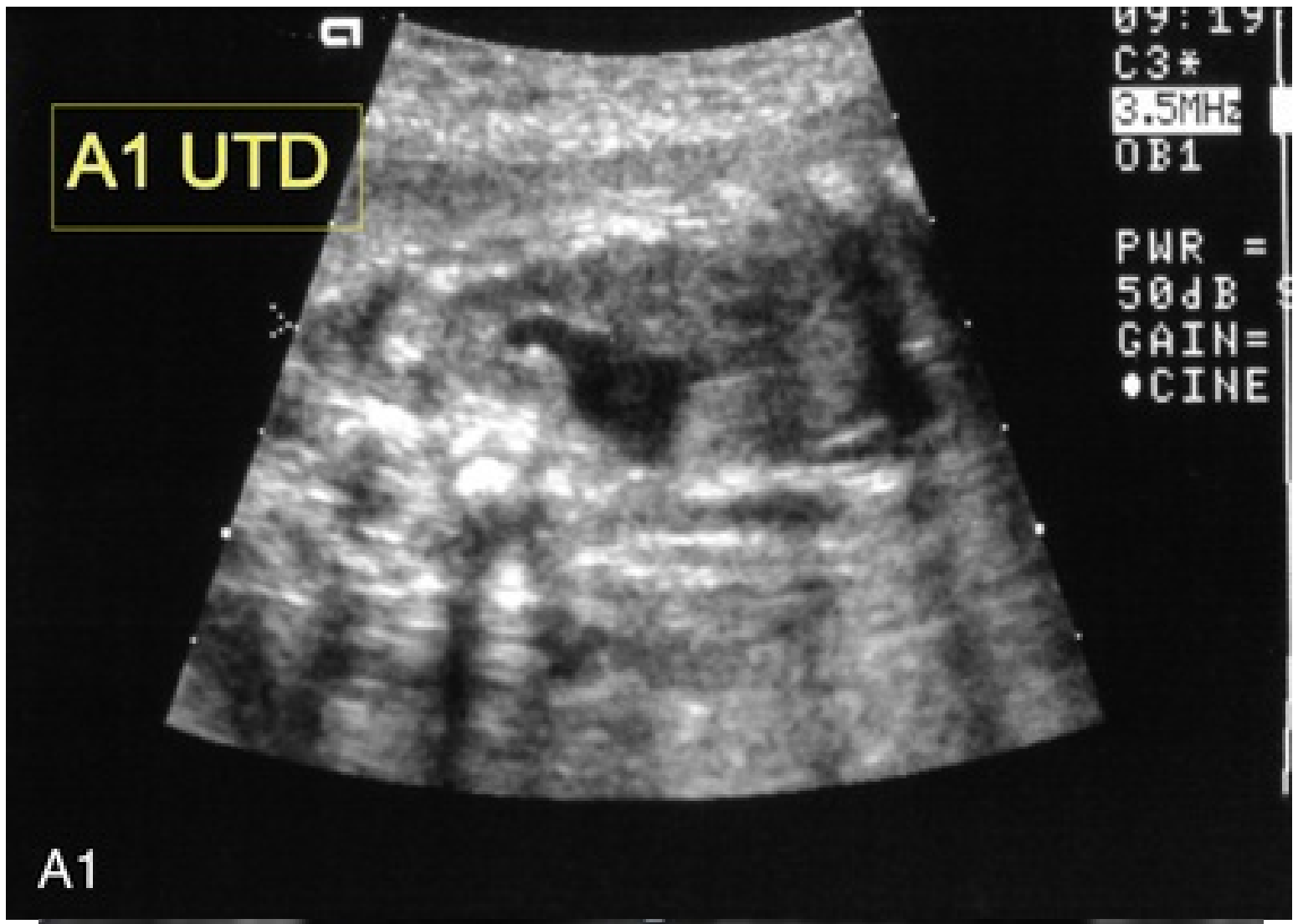
A1 UTD
09:19
C3*
3.5MHz
OB1
PWR =
50dB
GAIN=
●CINE
A1

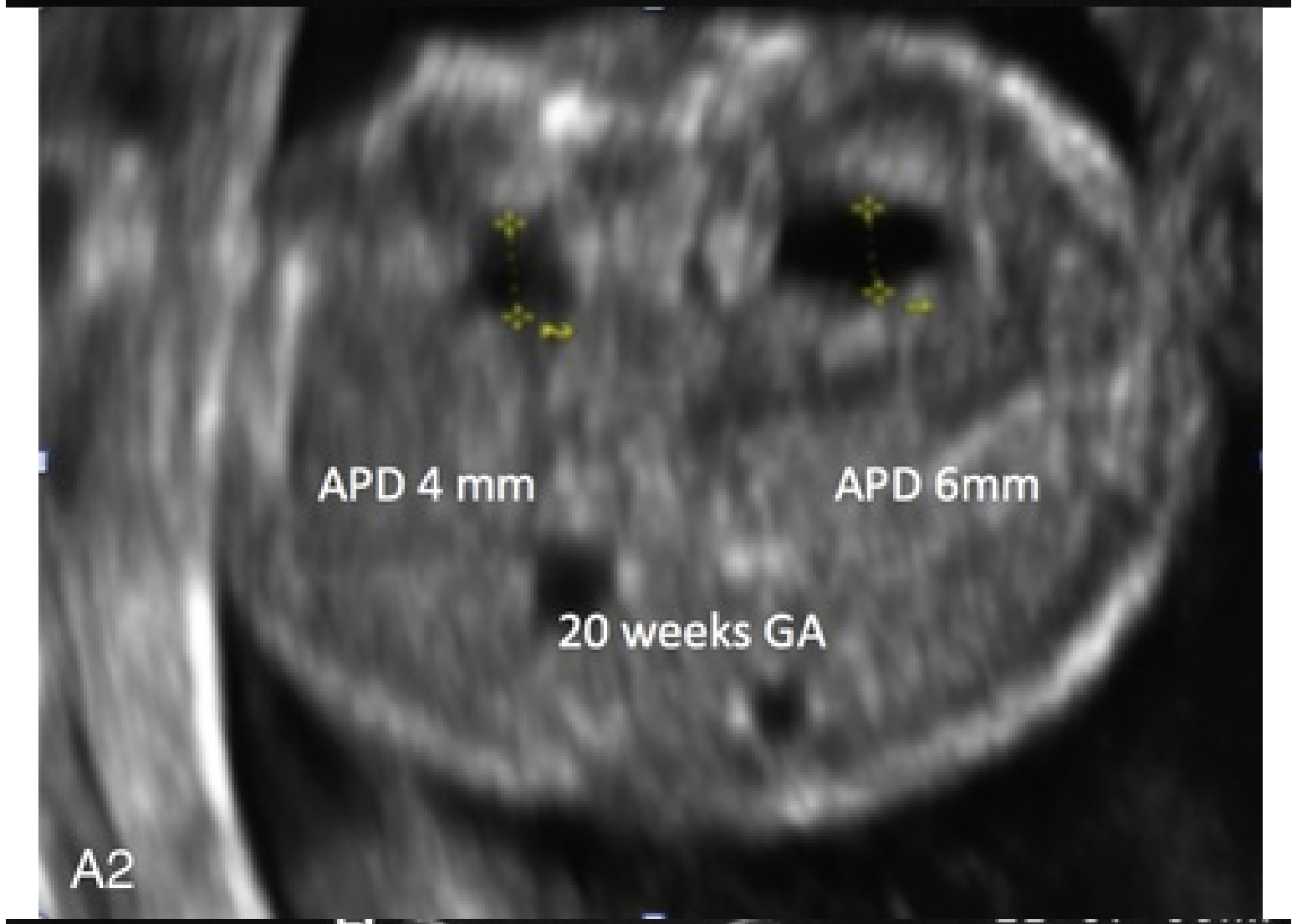
APD 4 mm
APD 6mm
20 weeks GA
A2

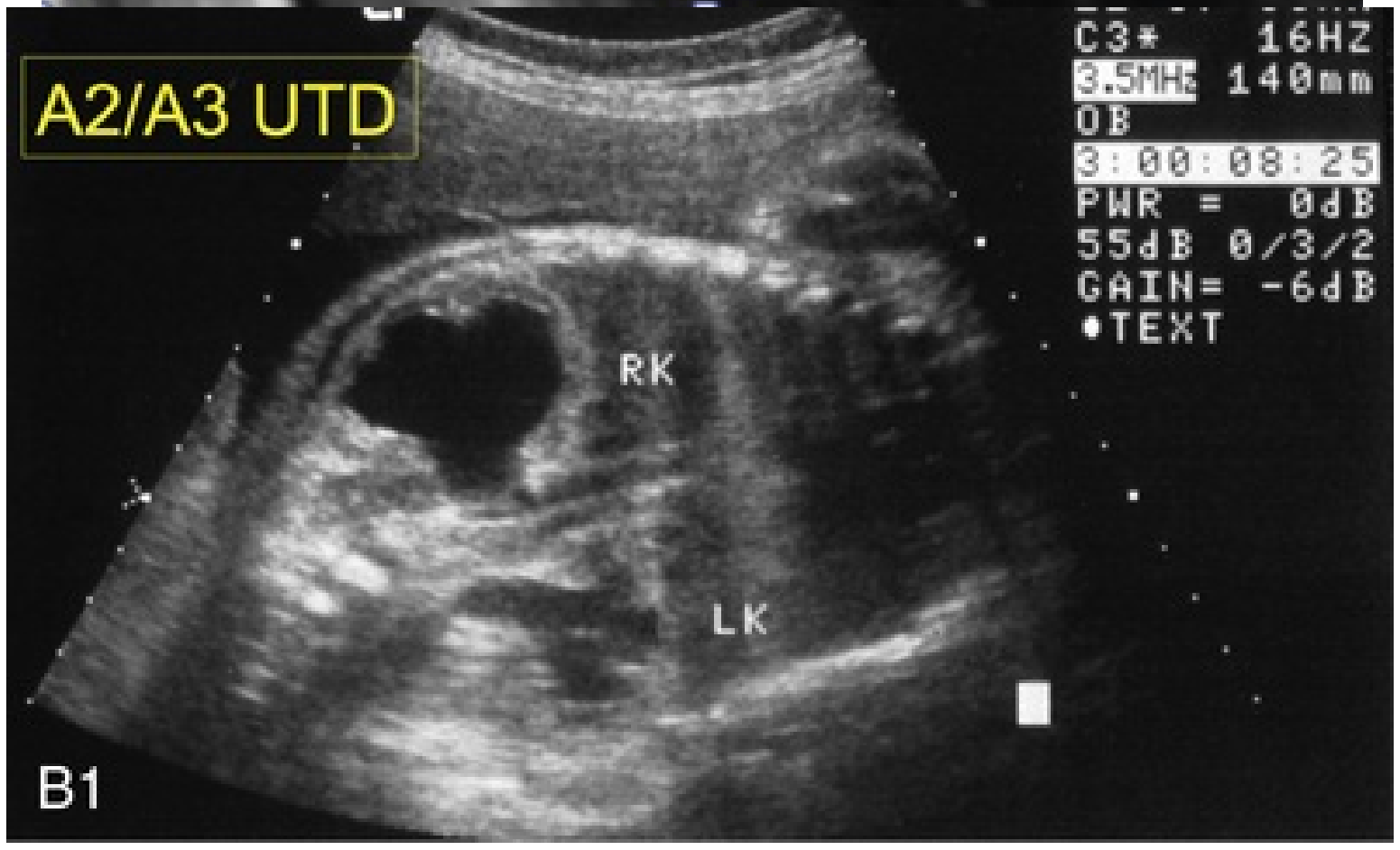
A2/A3 UTD
C3* 16HZ
3.5MHz 140mm
OB
3:00:08:25
PWR = 0dB
55dB 0/3/2
GAIN= -6dB
●TEXT
RK
LK
B1

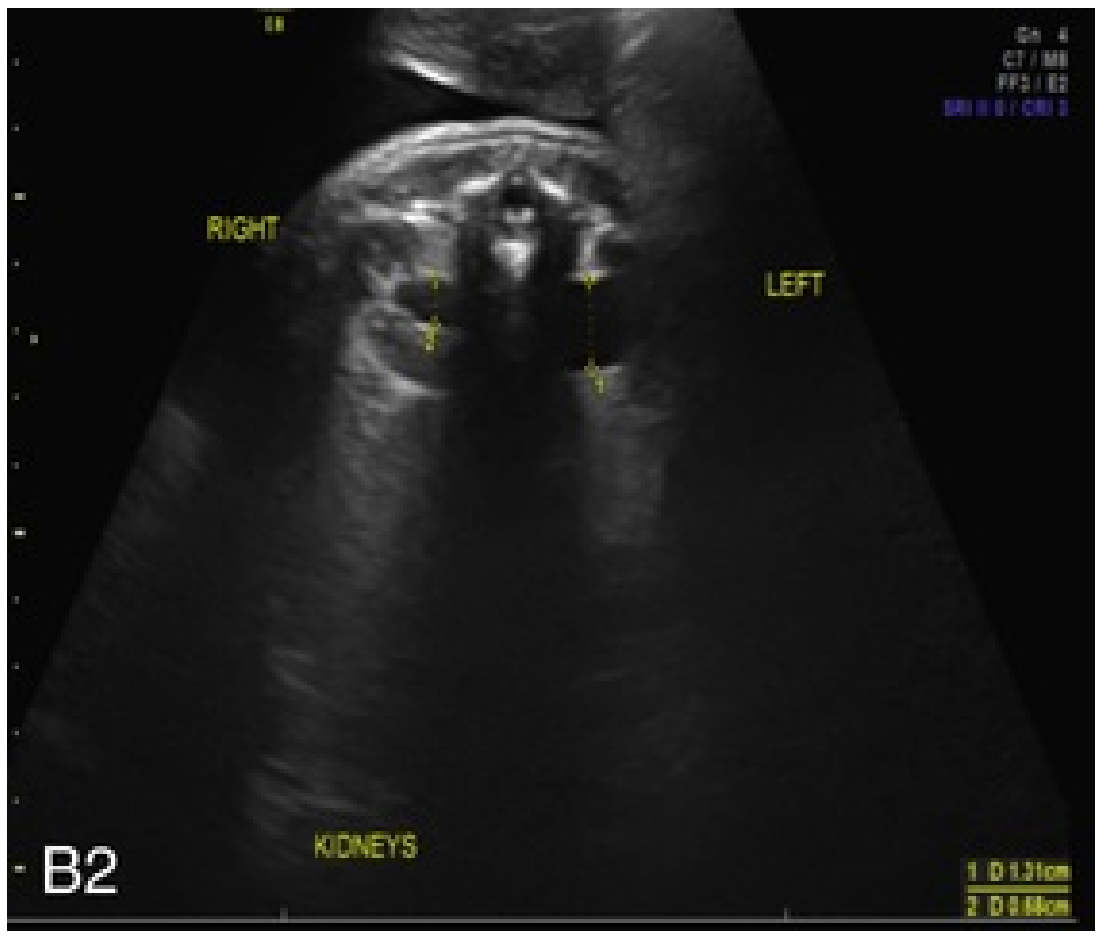

FIG. 22.7 Evaluation and management of prenatal Urinary tract dilation (UTD) 7. (A1) A1 UTD: Sagittal view of kidney. (A2) A1 UTD: Transverse mid-kidney demonstrating anterior-posterior diameter (APD) less than 10 mm with 20 weeks' gestational age. (B1) A2/3 UTD: Sagittal view of kidney with dilation of peripheral calyces and thinning of parenchyma. (B2) A 2/3 UTD: Transverse view of mid-kidney with APD greater than 10 mm.

Prenatal Management

Prenatal Intervention for Lower Urinary Tract Obstruction

The male fetus that presents with severe bilateral urinary tract dilation that includes the bladder, ureters, and kidneys with decreased amniotic fluid should be felt to have LUTO. This condition is a spectrum of disease, and thus each case, when identified, should be individualized as should the discussion with the families (Moslehi et al., 2001). The discussion with the family should be framed around the potential benefit of fetal intervention compared with implicit risks to both the fetus and the mother.

The constituents of amniotic fluid shift from the placenta to fetal urine during the 16th week of gestation (Pathak and Lees, 2009). Ideally, restoration of amniotic fluid will facilitate pulmonary development and potentially facilitate renal development as well. Mandell et al. determined through an observational cohort study that oligohydramnios that presents after 27 weeks appeared to lend a favorable outcome regarding pulmonary development (Mandell et al., 1992). Thus fetal intervention should be reserved for those that develop this condition very early in the second trimester. The overall need for intervention is rare and estimated to be about 1 : 60,000 (Herndon et al., 2000). **Several large systematic reviews have concluded that although feasible, there does not**

appear to be sufficient evidence to endorse its use to reliably affect long-term renal function. However, it is clear that postnatal survival is improved in part because those that do not have amniotic fluid restored will suffer fetal and/or neonatal demise (Biard et al., 2005; Clayton and Brock 2012, 2018; Coplen, 1997; Crombleholme et al., 1990; Freedman et al., 1999; McLorie et al., 2001; Morris et al., 2010; Nassr et al., 2017; Smith-Harrison et al., 2015).

Fetal intervention consists of early delivery, fetal shunting, or fetal surgery (Biard et al., 2005; Clayton and Brock 2012, 2018; Coplen 1997; Crombleholme et al., 1990; Freedman et al., 1999; Morris et al., 2010, 2011; Smith-Harrison et al., 2015). Interestingly, practice pattern variation exists between non-ultrasound and ultrasound physicians who would recommend early delivery in situations of early third-trimester identification of BOO, confirmed lung maturity and decreasing amniotic fluid (Herndon et al., 2000). When invasive fetal intervention is considered in the form of vesicoamniotic shunt (VAS) placement or fetal cystoscopy, a serial assessment of fetal urine should be performed to serve as a basis for renal function.

Fetal intervention carries significant risk to the pregnancy, and thus all procedures are performed in the controlled environment of the operating room with epidural anesthesia. The fetal anesthesia consists of injection of narcotics and/or paralytics into the umbilical vein with the aid of ultrasonography. Percutaneous assess is obtained with both VAS placement or fetal cystoscopy. **The clear advantage of fetal cystoscopy is the ability to directly visualize the posterior urethra and establish the diagnosis allowing for directed intervention.**

Fetal urine biochemistry that should be assessed includes urinary sodium, calcium, osmolarity, total protein, and β_2-microglobulin (Table 22.3). Serial bladder aspirations have proven more effective at determining renal function. In 1995, a total of 29 fetuses were managed with a minimum of three aspirations and demonstrated that the final urine collection was the strongest correlate with poor renal function (Johnson et al., 1995). In 2007, a systematic review of 23 studies revealed that urinary calcium and sodium were the strongest predictors of poor renal function, and β_2-microglobulin was less predictive (Morris et al., 2007). However, in 2015, a retrospective review of 72 cases in which fetal urine was obtained before 23 weeks revealed that sodium and β_2-microglobulin were significant predictors along with calcium (Abdennadher et al., 2015). Clinical predictors of poor renal function include oligohydramnios, renal parenchymal cysts, or increased echogenicity (Morris et al., 2007). However, fetal ultrasound urinary tract findings do not correlate with fetal urine biomarkers in their ability to predict renal function.

TABLE 22.3

Risk for Pathology by Degree of Antenatal Hydronephrosis

POSTNATAL PATHOLOGY	**DEGREE OF ANTENATAL HYDRONEPHROSIS (% [95% CI][A])**					**TRE P VAL**
	MILD (*N* = 587)	**MILD-MODERATE (*N* = 213)**	**MODERATE (*N* = 235)**	**MODERATE-SEVERE (*N* = 179)**	**SEVERE (*N* = 94)**	
Any pathology	11.9 (4.5, 28.0)	39.0 (32.6, 45.7)	45.1 (25.3, 66.6)	72.1 (47.6, 88.0)	88.3 (53.7, 98.0)	<.00
Ureteropelvic junction obstruction	4.9 (2.0, 11.9)	13.6 (9.6, 18.9)	17.0 (7.6, 33.9)	36.9 (17.9, 61.0)	54.3 (21.7, 83.6)	<.00
Vesicourethral reflux	4.4 (1.5, 12.1)	10.8 (7.3, 15.7)	14.0 (7.1, 25.9)	12.3 (8.4, 17.7)	8.5 (4.7, 15.0)	.10
Posterior urethral valves	0.2 (0.0, 1.4)	0.9 (0.2, 3.7)	0.9 (0.2, 2.9)	6.7 (2.5, 16.6)	5.3 (1.2, 21.0)	<.00
Ureteral obstruction	1.2 (0.2, 8.0)	11.7 (8.1, 16.8)	9.8 (6.3, 14.9)	10.6 (7.4, 15.0)	5.3 (1.4, 18.2)	.025
Other[c]	1.2 (0.3, 4.0)	1.9 (0.7, 4.9)	3.4 (0.5, 19.4)	5.6 (3.0, 10.2)	14.9 (3.6, 44.9)	.002

[a] Pointwise 95% confidence intervals were estimated by logistic regression with robust standard errors based on generalized estimating equations with a working independence correlation structure to adjust for clustering by study for all degrees of antenatal hydronephrosis except mild-moderate. Because only one study had subjects with mild-moderate antenatal hydronephrosis, the pointwise 95% CIs had to be estimated using logistic regression with unadjusted standard errors.

[b] Testing for trend in risks with increasing degree of antenatal hydronephrosis using logistic regression with robust standard errors based on generalized estimating equations with a working independence correlation structure.

[c] Includes prune-belly syndrome, VATER (vertebral, anal, tracheo-esophageal and renal anomalies) syndrome, solitary kidney, renal mass, and unclassified causes.

CI, Confidence interval.

Modified from Lee RS, Cendron M, Kinnamon DD, Nguyen HT. Antenatal hydronephrosis as a predictor of postnatal outcome: a meta-analysis. *Pediatrics* 118(2):590, 2006.

In 1982, the initial clinical experience was described for fetal intervention for BOO. Two patients had obstruction relieved in utero with fetal surgery, and both died in the early neonatal period as a result of renal failure. Seven patients were found to have equivocal renal function, and three underwent percutaneous shunt placement. Two survived and were felt to do well (Harrison et al., 1982).

With this early success, specialized centers began to pursue this endeavor in the early 1980s. One of the practical challenges was re-creating amniotic space to allow for placement of the shunt, which was alleviated with amnioinfusion (Pathak and Lees, 2009). With rapid expansion of this procedure, a number of complications began to surface, which challenged physicians to re-evaluate the benefit of intervention. Elder described a 44% complication rate for the first 57 reported patients who received fetal intervention. Specific complications included incomplete drainage (19%), premature labor (12%), urinary ascites (7%), and chorioamnionitis (5%) (Elder et al., 1987). Various case reports such as bowel herniation and direct injury to the fetus have equally been reported (Robichaux et al., 1991) (Fig. 22.8). The most common technique employed is percutaneous placement, and current models of shunt, such as the Rodeck, are designed to mitigate migration by lying flush against the abdominal wall in contrast with the original Harrison shunt (Farrugia 2016; Johnson et al., 1994) (Fig. 22.9).

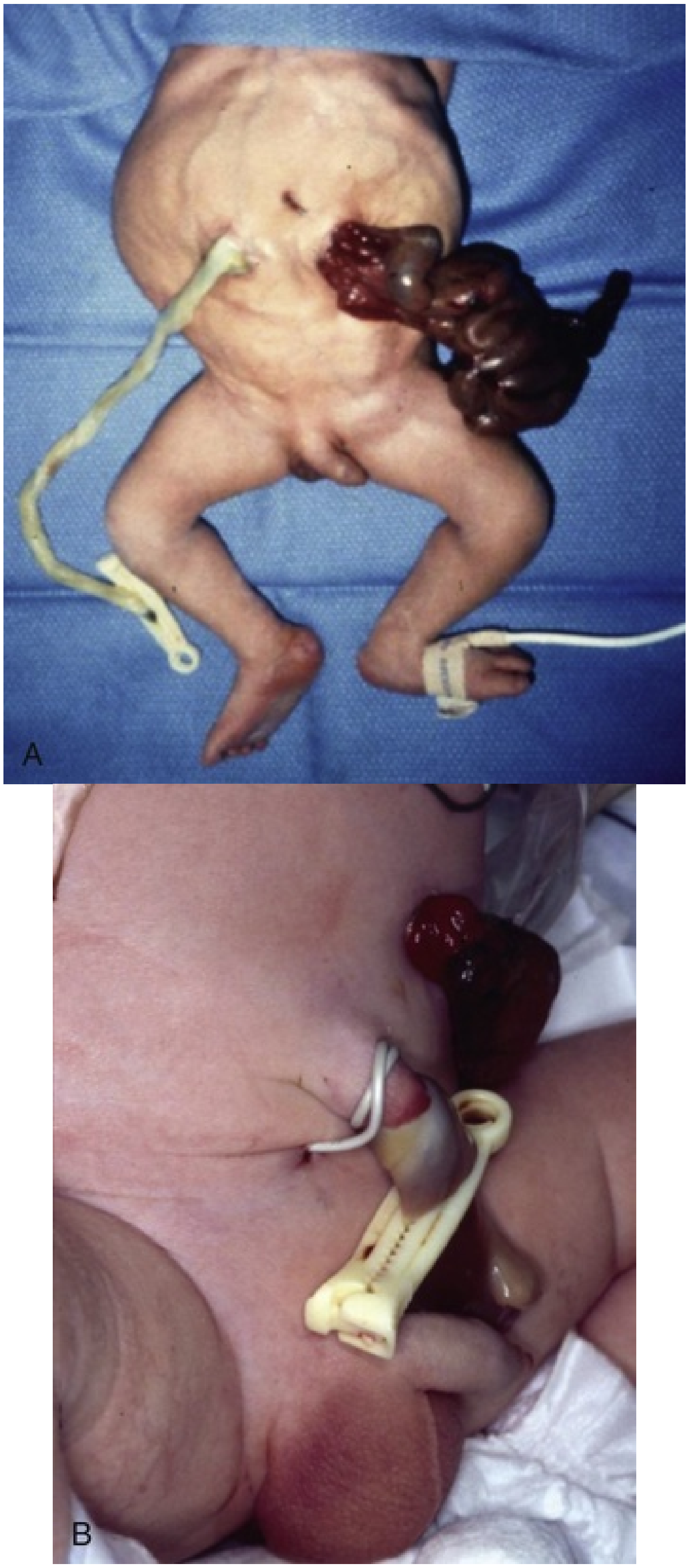

FIG. 22.8 Photo of neonates with previous insertion of vesicoamniotic shunt with herniation of bowel (A) and strangulation of umbilicus (B).

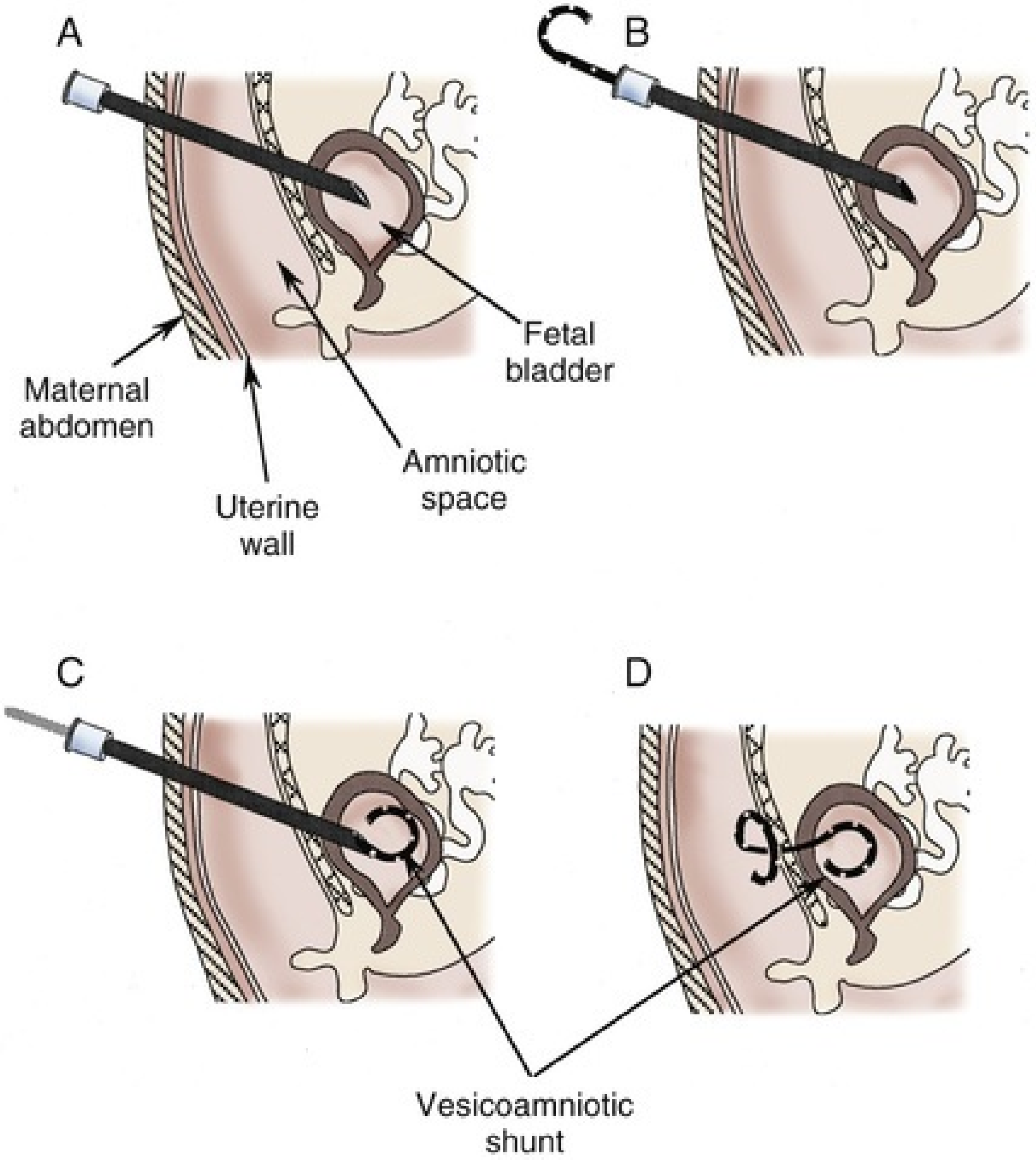

FIG. 22.9 Diagram showing technique of fetal vesicoamniotic shunt placement. The fetal bladder is initially reached with a needle, and a large-bore introducing sheath is passed into the bladder (A). Within this sheath, the shunt is passed (B and C). It is a double-pigtail shunt with holes at each end allowing free drainage between the bladder and amniotic space (D). (From Peters CA. Surgical management of fetal uropathies. In: Marshall FF, ed. *Textbook of operative urology.* Philadelphia, PA: Saunders; 1996:1063.)

The Philadelphia group reported long-term clinical outcome following VAS placement in 20 patients with a mean follow up of 5.8 years. The protocol included fetal ultrasound findings consistent with BOO from 18 to 22 weeks' gestational age with an assessment of renal function with three separate aspirations of the fetal bladder. Fetal urine profile was a predictor of early neonatal survival with 13 good, 2 borderline, and 3 poor. The diagnoses varied with PUV in 7, urethral atresia in 4, and prune belly syndrome in 7. Renal insufficiency was present in 10 of 18 patients, with 6 requiring renal replacement therapy. Bladder symptoms were felt to be adequate, with 6 patients requiring CIC. Of note, formal urodynamic studies were not reported, although 10 patients spontaneously voided with 1 other patient diverted with vesicostomy. Interestingly, quality of life was similar to the normal population and greater than other patients with chronic disease (Biard et al., 2005).

The Percutaneous Shunting in Lower Urinary Tract Obstruction (PLUTO) trial was a multicenter prospective randomized trial designed to assess the efficacy of fetal intervention. The eligible population included those with evidence of BOO in which the benefit of intervention was unclear. The study was prematurely terminated because of poor enrollment. A total of 31 patients were randomized, with 16 undergoing successful VAS placement and 15 observed. Perinatal death as expected was higher in the observed cohort (33% versus 66%). Equally, no meaningful impact on renal function was demonstrated, although two patients demonstrated normal renal function. Complications occurred in 7 of 16 (44%), with 3 premature rupture of membranes and 4 nonfunctional shunts (Morris et al., 2013a) (Fig. 22.10).

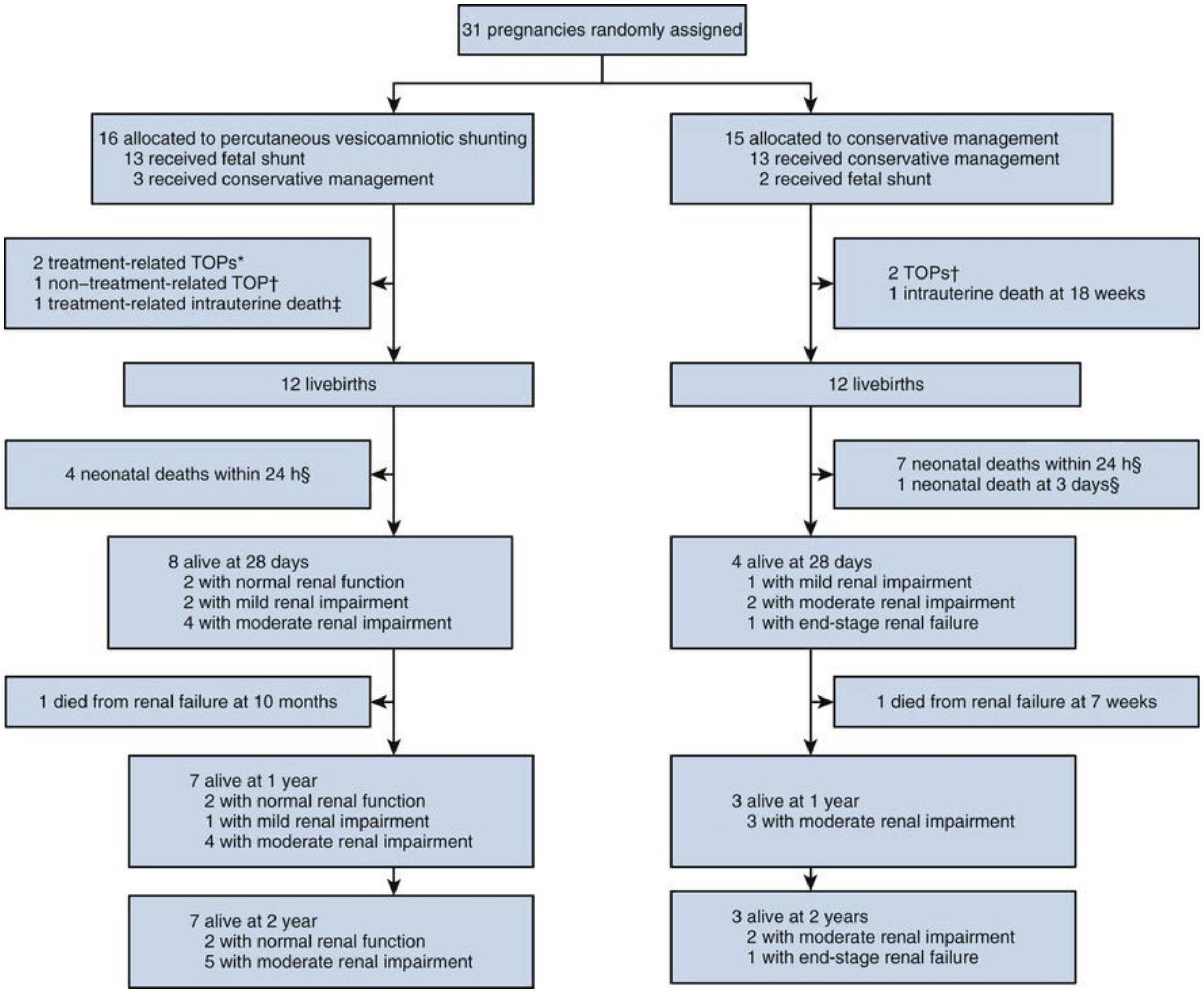
31 pregnancies randomly assigned
16 allocated to percutaneous vesicoamniotic shunting
13 received fetal shunt
3 received conservative management
15 allocated to conservative management
13 received conservative management
2 received fetal shunt
2 treatment-related TOPs*
1 non–treatment-related TOP†
1 treatment-related intrauterine death‡
2 TOPs†
1 intrauterine death at 18 weeks
12 livebirths
12 livebirths
4 neonatal deaths within 24 h§
7 neonatal deaths within 24 h§
1 neonatal death at 3 days§
8 alive at 28 days
2 with normal renal function
2 with mild renal impairment
4 with moderate renal impairment
4 alive at 28 days
1 with mild renal impairment
2 with moderate renal impairment
1 with end-stage renal failure
1 died from renal failure at 10 months
1 died from renal failure at 7 weeks
7 alive at 1 year
2 with normal renal function
1 with mild renal impairment
4 with moderate renal impairment
3 alive at 1 year
3 with moderate renal impairment
7 alive at 2 year
2 with normal renal function
5 with moderate renal impairment
3 alive at 2 years
2 with moderate renal impairment
1 with end-stage renal failure

FIG. 22.10 Outcomes of 31 patients enrolled in the Percutaneous Shunting in Lower Urinary Tract Obstruction (PLUTO) trial. (Modified from Morris RK, Malin GL, Quinlan-Jones E, et al., for the Percutaneous vesicoamniotic shunting in Lower Urinary Tract Obstruction [PLUTO] Collaborative Group. Percutaneous vesicoamniotic shunting versus conservative management for fetal lower urinary tract obstruction [PLUTO]: a randomised trial. *Lancet* 382[9903]:1497 [Figure 1], 2013a.)

Fetal Cystoscopy

In theory, fetal cystoscopy offers several distinct advantages over VAS placement with the similar benefit of decompression of the obstructed urinary system with return of amniotic fluid to promote pulmonary development and the potential to improve renal function. Direct visualization of the cause for LUTO has improved the ability to obtain a fetal diagnosis and affords the opportunity for directed intervention that will allow bladder cycling without the dependence on a functional device throughout pregnancy (Morris et al., 2011; Quintero et al., 2000; Ruano et al., 2010, 2015; Sananes et al., 2016). Associated complications are similar to VAS placement with the addition of urethrocutaneous and rectourethral fistula formation, which has been reported in up to 10% (Sananes et al., 2016). This in part is caused by the anatomic disadvantage associated with antegrade access and use of LASER energy to ablate the valve.

The first report of fetal cystoscopic ablation (FCA) of PUV was presented by Quintero's team as a case report at the Society for Fetal Urology annual meeting in 1999. Suprapubic access allowed the use of a neodymium-doped yttrium aluminum garnet (Nd:Yag) LASER to ablate the valve in an antegrade manner. After this successful attempt, several specialized centers employed this technique, and the results of published series have been mixed. In 2011, a systematic review of the literature identified four studies including 63 patients and revealed that fetal cystoscopy demonstrated a significant perinatal survival advantage over observation but was equivocal when compared with VAS placement (Morris et al., 2011). In 2016, short-term outcomes for 50 fetal cystoscopies revealed accuracy of diagnosis of LUTO in 91% of patients with 62% having PUV, 28% urethral atresia, and 10% urethral stenosis. Success was best achieved in the PUV group with 17 of 30 (57%) surviving and 13 of 17 (78%) having normal renal function at 1 year and 15 of 28 (54%) surviving and 11 of 15 (73%) having normal renal function at 2 years (Sananes et al., 2016).

Vesicoamniotic Shunt Placement Versus Fetal Cystoscopy

To assess the efficacy of VAS placement and fetal cystoscopy, a multicenter retrospective review of 111 consecutive patients with LUTO was performed. The strict inclusion criteria included were: diagnosis between 16 and 26 weeks, severe LUTO on fetal ultrasonography, absence of other anatomic abnormalities including cardiac echocardiogram, favorable urine electrolytes, and normal male karyotype. A total of 50 patients underwent fetal intervention (34 cystoscopy with laser ablation, 16 VAS) compared with 61 patients treated expectantly. The study did include previously published case studies.

Both VAS placement and FCA demonstrated a clear survival advantage when compared with observation alone for all cases of LUTO, with an adjusted relative risk (ARR) of 1.86 (95% confidence interval [CI], 1.01 to 3.42; P = 0.048) and 1.73 (95% CI, 1.01 to 3.08; P = 0.04), respectively. **Interestingly, for those diagnosed postnatally with PUV, FCA demonstrated an improvement in both 6-month survival (ARR 4.10; 95% CI, 1.75 to 9.62; $P < 0.01$) and renal function (ARR 2.66; 95% CI, 1.25 to 5.70; $P = 0.01$), and VAS only demonstrated an improvement in 6-month survival (ARR 3.76; 95% CI, 1.42 to 9.97; $P < 0.01$) and had no effect on renal function** (Ruano et al., 2015).

Recently, a report from the SFU endorsed a severity of disease classification system developed by Ruano that was indexed to perinatal and renal outcome (Ruano et al., 2016). The purpose was an attempt to better identify patients that may benefit from fetal intervention. Specifically, a combination of subjective and objective fetal parameters that include amniotic fluid volume, echogenicity of fetal kidney, renal cortical cysts, renal dysplasia, favorable urinary biomarkers, and presence of fetal intervention were use to stage patients (Fig. 22.11). **The rate of fetal intervention (either fetal cystoscopy or VAS), death within 24 hours, overall mortality, and need for renal replacement all were more prevalent in Stage III (worse) patients** (Braga et al., 2014).

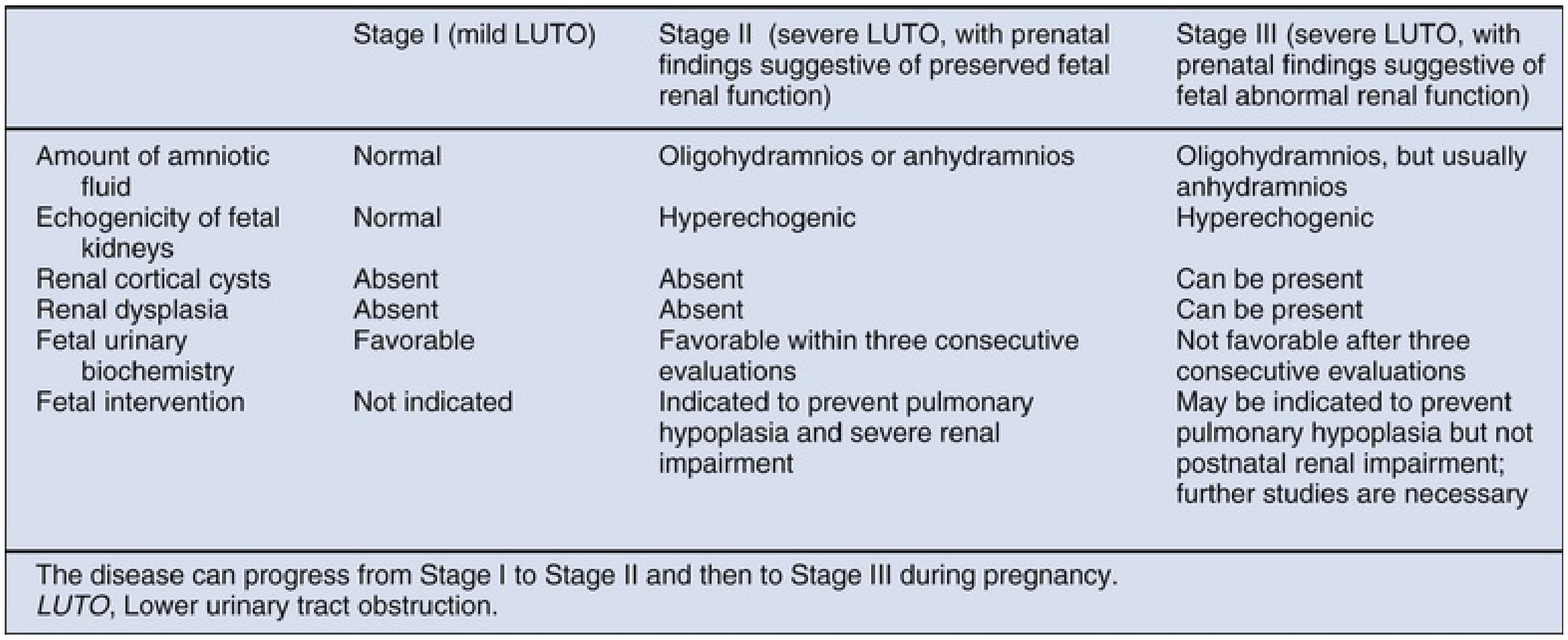

	Stage I (mild LUTO)	Stage II (severe LUTO, with prenatal findings suggestive of preserved fetal renal function)	Stage III (severe LUTO, with prenatal findings suggestive of fetal abnormal renal function)
Amount of amniotic fluid	Normal	Oligohydramnios or anhydramnios	Oligohydramnios, but usually anhydramnios
Echogenicity of fetal kidneys	Normal	Hyperechogenic	Hyperechogenic
Renal cortical cysts	Absent	Absent	Can be present
Renal dysplasia	Absent	Absent	Can be present
Fetal urinary biochemistry	Favorable	Favorable within three consecutive evaluations	Not favorable after three consecutive evaluations
Fetal intervention	Not indicated	Indicated to prevent pulmonary hypoplasia and severe renal impairment	May be indicated to prevent pulmonary hypoplasia but not postnatal renal impairment; further studies are necessary

The disease can progress from Stage I to Stage II and then to Stage III during pregnancy.
LUTO, Lower urinary tract obstruction.

FIG. 22.11 Classification system proposed by Ruano for prenatal lower urinary tract obstruction. (Modified from Farrugia MK, Braun MC, Peters CA, et al. Report on The Society for Fetal Urology panel discussion on the selection criteria and intervention for fetal bladder outlet obstruction. *J Pediatr Urol* 13[4]:345–351, 2017.)

Key Points

- Clinical predictors of poor outcome are oligohydramnios before 27 weeks, renal cortical cysts, and increased echogenicity.
- Prenatal intervention for LUTO appears to improve perinatal survival but does not reliably affect long-term renal function.
- Fetal cystoscopy affords the opportunity to establish a diagnosis and provide treatment for LUTO.
- Fetal cystoscopy may offer a short-term advantage for overall renal function when compared with VAS placement, but long-term renal data do not exist.

Postnatal Evaluation and Management

Over the past decade, the evaluation and management recommendations for postnatal UTD have become more evidence based (Braga et al., 2015, 2018; Capolicchio et al., 2018; Zee et al., 2016, 2017). A paradigm shift has occurred with recommendations for postnatal imaging and use of PA tailored to a risk assessment, which includes the likelihood of developing a UTI, renal deterioration, or need for surgical intervention. Previously, the evaluation was based on the probability of detecting diseases such as VUR, which occur in up to 24% of patients (Herndon et al., 1999a, 1999b; McLorie et al., 2001).

Imaging

Renal Ultrasound/Resolution of Urinary Tract Dilation

The initial postnatal ultrasound scan, as mentioned earlier, should not be obtained before 48 hours to account for intravascular volume depletion that occurs after delivery. It is important to note that this represents a form of third spacing that is mobilized over the first 24 to 48 hours of life (Maclaurin, 1966). Adherence to the standardization of technique and reporting outlined in the Consensus Statement is recommended (Nguyen et al., 2014). Some have advocated for delaying this initial ultrasound scan for up to 2 weeks postnatally without untoward event. Three levels of risk (P1, P2, and P3) were developed based on the degree of APD and positive values for the remaining five data points: P1 UTD (low risk) includes APD 10 mm to less than 15 mm and central calyceal dilation. P2 UTD (intermediate risk) includes APD greater than or equal to 15 mm and peripheral calyceal or ureteral dilation that may be in isolation. P3 UTD (high risk) includes APD greater than or equal to 15 mm and/or positive values for other data points such as parenchymal cysts or thinning (Fig. 22.12).

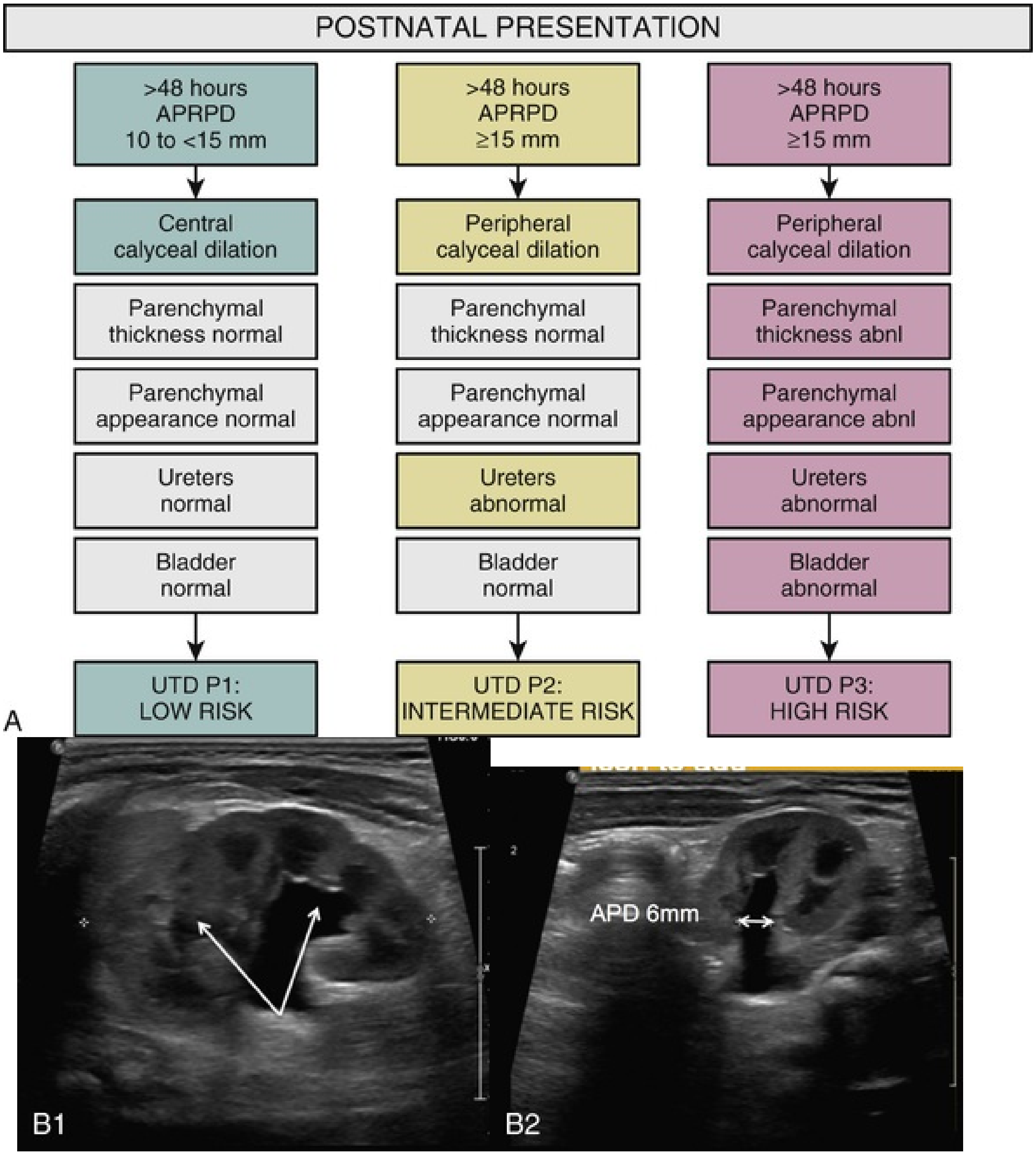
POSTNATAL PRESENTATION
>48 hours APRPD 10 to <15 mm
Central calyceal dilation
Parenchymal thickness normal
Parenchymal appearance normal
Ureters normal
Bladder normal
UTD P1: LOW RISK
>48 hours APRPD ≥15 mm
Peripheral calyceal dilation
Parenchymal thickness normal
Parenchymal appearance normal
Ureters abnormal
Bladder normal
UTD P2: INTERMEDIATE RISK
>48 hours APRPD ≥15 mm
Peripheral calyceal dilation
Parenchymal thickness abnl
Parenchymal appearance abnl
Ureters abnormal
Bladder abnormal
UTD P3: HIGH RISK
A
APD 6mm
B1
B2

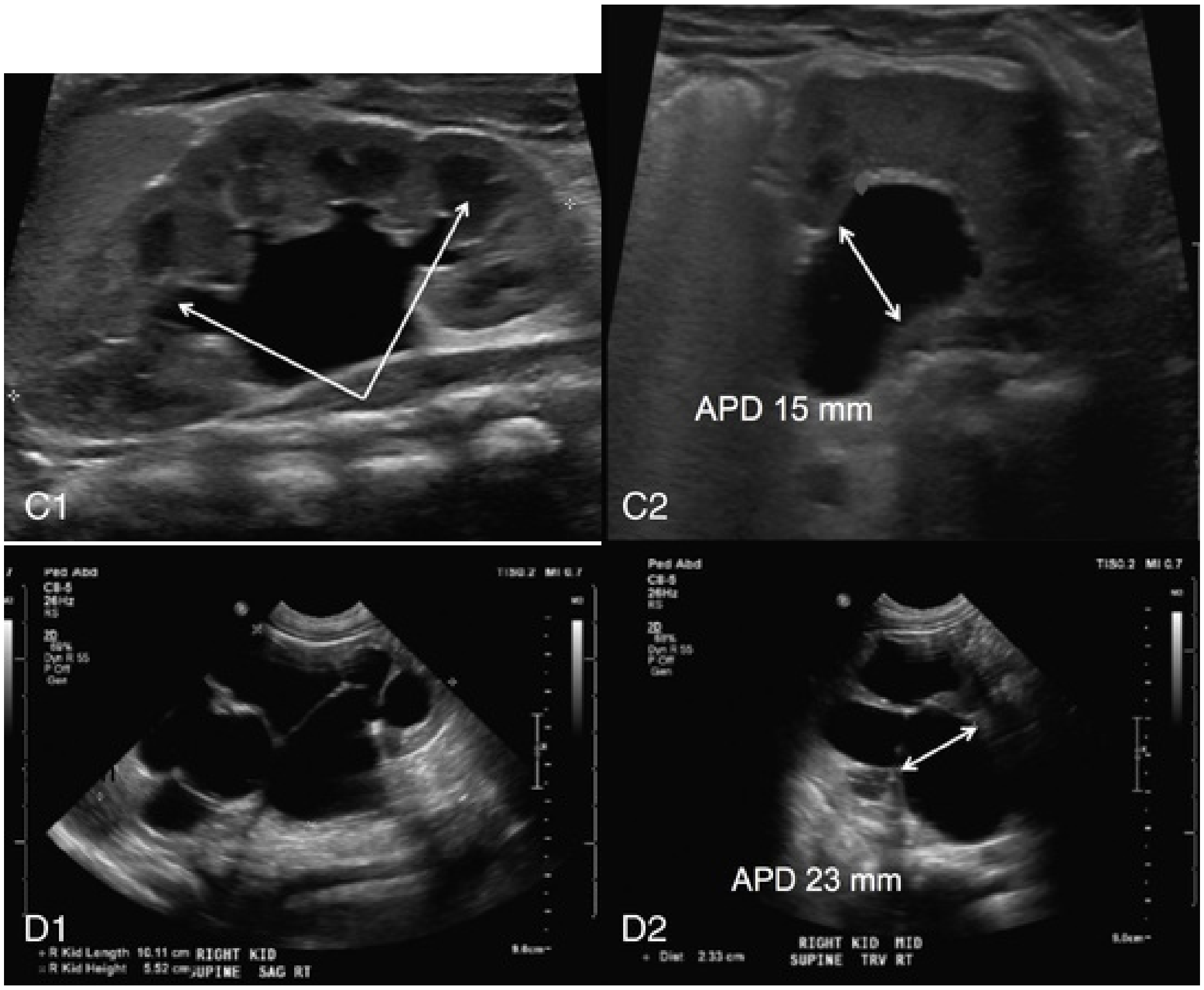

FIG. 22.12 (A) Risk stratification for postnatal urinary tract dilation *(UTD)*. (B1) P1 UTD Sagittal view of kidney with dilation of central calyx *(arrows)*. (B2) P1 UTD Traverse mid-kidney with anterior-posterior diameter (APD) of 6 mm *(arrows)*. (C1) P2 UTD Sagittal view of kidney with dilation of central and peripheral calyces *(arrows)*. (C2) P2 UTD Traverse mid-kidney with APD 15 mm *(arrows)*. (D1) P3 UTD Sagittal view of kidney with dilation of central and peripheral calyces with thinning of parenchyma. (D2) P3 UTD Traverse mid-kidney with APD 23 mm *(arrows)*. (A, Modified from Nguyen HT, Benson CB, Bromley B, et al. Multidisciplinary consensus on the classification of prenatal and postnatal urinary tract dilation [UTD classification system]. *J Pediatr Urol* 10[6]:993 [Figure 6], 2014.)

Resource utilization for the postnatal ultrasound imaging should be indexed to the probability of an untoward event that may affect clinical outcome. A couple of recent prospective studies have assessed the need for continued upper tract monitoring through survival curve analysis and impact of grade on resolution of urinary tract dilation. Zee et al. reported longitudinal follow-up on a multicenter analysis from the SFU registry and demonstrated that 100% of SFU grade 1 and 90% of SFU grade 2 (P1 UTD) will resolve within 30 and 48 months, respectfully (Zee et al., 2017). Similarly, Braga et al. demonstrated similar efficacy for SFU grade and UTD grade to predict resolution of urinary tract dilation that was similar to the outcomes reported with the SFU registry (Braga et al., 2018).

Voiding Cystourethrogram

The use of lower urinary tract imaging for the evaluation of UTD should be evidence based. Similar to using PA, the basis for lower urinary tract imaging has recently changed from the probably of identifying VUR to the risk for developing UTI (Zee et al., 2016). **A systematic review by Lee et al. demonstrated that the degree of upper tract dilation poorly correlates with the grade of VUR, which will be present in up to 31% of patients** (Adra et al., 1995; Lee et al., 2006; Nguyen et al., 2010)**. Furthermore, up to 25% of patients with VUR detected with prenatal UTD will have a normal initial postnatal ultrasound scan** (Herndon et al., 1999b).

Recently, the American Academy of Pediatrics endorsed a standardized approach for performing the VCUG (Frimberger et al., 2016). In general, an attempt should be made to minimize radiation by following the ALARA (as low as reasonably achievable) principal. The policy encourages use of a nonballoon catheter and cycling of the study that should increase reliability of the study. Images that are obtained should include a kidney, ureter, and bladder (KUB) radiograph, bladder filling, and voiding phases.

The recommendation for lower urinary tract imaging should be directed at those most at risk for UTI, which includes females, uncircumcised males, patients with high-grade kidney dilation, and patients with ureteral dilation. The decision is left to the discretion of the urologist after an informed discussion with the family about the risk factors mentioned earlier. Aside from concerns for BOO, which may include a thick-walled bladder (≥0.5 cm), distended urinary bladder, and bilateral hydroureteronephrosis, this study can be obtained as an outpatient. The historical benefit of identifying asymptomatic VUR remains unclear, but several observational studies have demonstrated active surveillance to be a safe and appropriate option for stable patients with known VUR (Kitchens et al., 2010).

Renal Scintigraphy

The role of renal scintigraphy in the evaluation of infants with prenatal UTD varies based on the clinical scenario and question to be answered. Various radionuclides can be used to determine differential renal function, presence of cortical parenchymal defects, and drainage of the collecting system. The main drawback of these studies is the lack of anatomic detail offered with other imaging modalities.

For the evaluation of obstruction in the neonate (or impaired renal function), mercaptoacetyltriglycine (MAG3) is preferred over diethylenetriaminepentaacetic acid (DTPA) because of its superior extraction qualities. Although both have the radionuclide technetium-99m (^{99m}Tc) chelated to them, MAG3 is the agent of choice. For MAG3, the proximal tubule extracts about 50% of the radiotracer with each cycle through the kidney, which then is secreted into the lumen of the collecting system. Additionally, a linear relationship to renal blood flow exists, and this property allows for measurement of renal function.

The standardized “well-tempered” renogram, as described by Conway and Maizels, assures consistency in regard to patient hydration status and bladder decompression, technique utilized in regard to pharmaceutical dose, diuretic dose and timing, and data acquisition and interpretation (Conway and Maizels, 1992). Generally, the patient is exposed to minimal radiation, although a linear relation exists between the degree of obstruction and exposure to radiation (Stratton et al., 2010). **In the asymptomatic infant, findings on MAG3 imaging that may represent a consideration for surgical intervention may include decreased differential function (<40%), T½ greater than 20 minutes, and significant retention on delayed upright imaging** (Sussman et al., 2017) (Fig. 22.13). **More specific detail in regard to indications for surgical intervention for UPJO are covered in Chapter 42.**

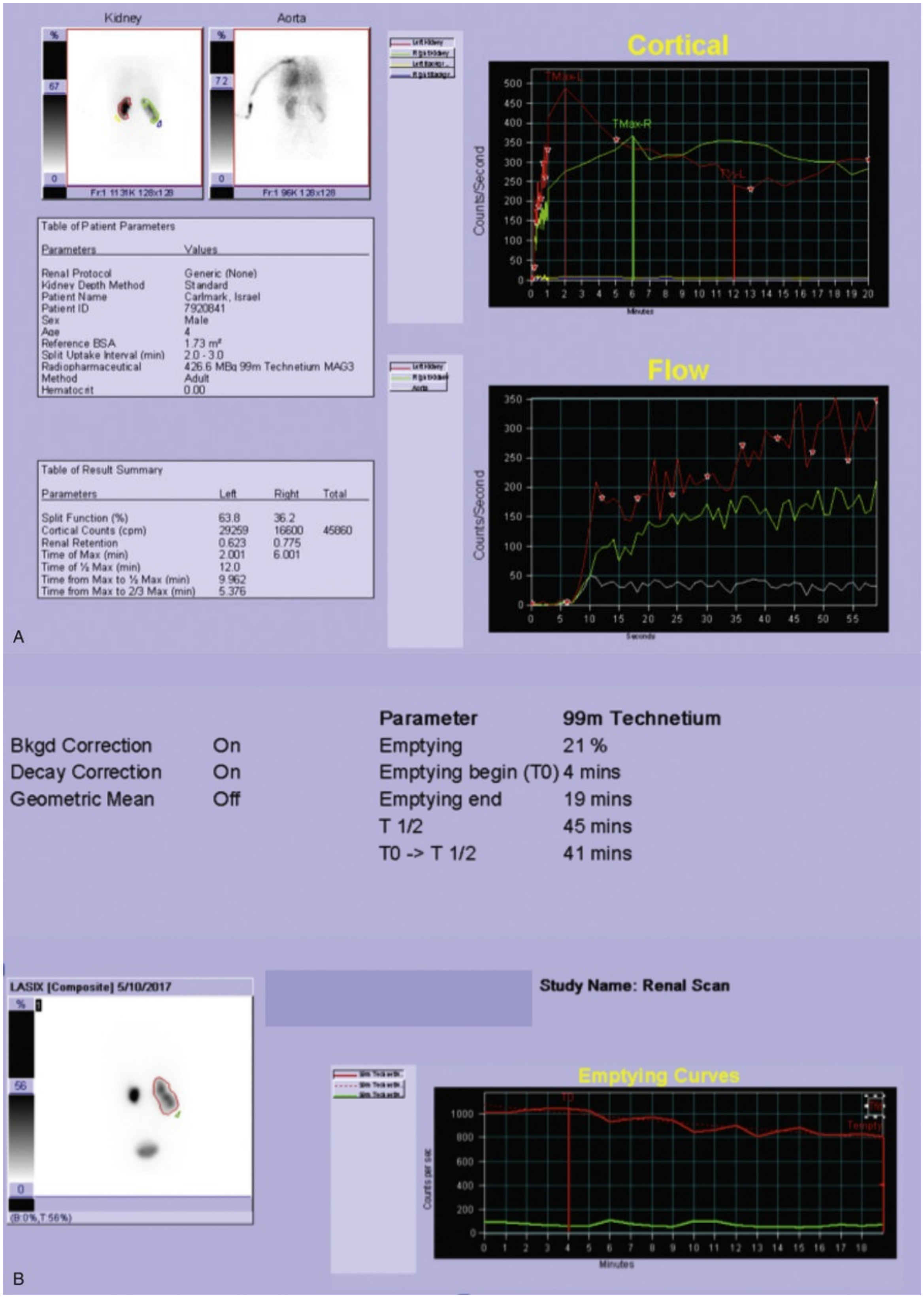
Kidney
Aorta
%
67
0
Fr:1 1131K 128x128
%
72
0
Fr:1 96K 128x128
Cortical
TMax-L
TMax-R
T½-L
Counts/Second
Minutes
Flow
Counts/Second
Seconds
A
LASIX [Composite] 5/10/2017
%
56
0
(B:0%,T:56%)
Emptying Curves
T0
Tempty
Counts per sec
Minutes
B

Table of Patient Parameters

Parameters	Values
Renal Protocol	Generic (None)
Kidney Depth Method	Standard
Patient Name	Carlmark, Israel
Patient ID	7920841
Sex	Male
Age	4
Reference BSA	1.73 m²
Split Uptake Interval (min)	2.0 - 3.0
Radiopharmaceutical	426.6 MBq 99m Technetium MAG3
Method	Adult
Hematocrit	0.00

Table of Result Summary

Parameters	Left	Right	Total
Split Function (%)	63.8	36.2	
Cortical Counts (cpm)	29259	16600	45860
Renal Retention	0.623	0.775	
Time of Max (min)	2.001	6.001	
Time of ½ Max (min)	12.0		
Time from Max to ½ Max (min)	9.962		
Time from Max to 2/3 Max (min)	5.376		

Bkgd Correction	On
Decay Correction	On
Geometric Mean	Off

Parameter	99m Technetium
Emptying	21 %
Emptying begin (T0)	4 mins
Emptying end	19 mins
T 1/2	45 mins
T0 -> T 1/2	41 mins

Study Name: Renal Scan

FIG. 22.13 (A) Cortical phase of mercaptoacetyltriglycine renal scan. (B) Drainage phase of mercaptoacetyltriglycine renal scan.

Although MAG3 renography appears to be ideal for identifying significant obstruction, a number of pitfalls have been identified. The most significant is an inherent false-positive scan that may occur with the dehydrated patient or when furosemide is given too early in the presence of a capacious system associated with severe dilation of the kidney and/or ureter (Nguyen et al., 2014). Ideally, the diuretic should be administered at the height of uptake, which will vary among patients (Ulman et al., 2000). To mitigate this phenomena, Sussman et al. described a formal upright protocol that appears to address this issue. Secondly, the study is invasive (with both an intravenous and urethral catheter), which negatively affects the patient experience. Finally, the region of interest requires attention to detail, which may affect the drainage curve, specifically when evaluating a severely dilated system that includes both the kidney and ureter.

The exact role of renal scintigraphy in the evaluation of postnatal UTD is not clearly defined. In part because of the aforementioned pitfalls, invasive nature of the study, and reliability for ultrasonography to predict renal preservation (differential function >40%) some have advocated for a selective approach while relying on serial renal ultrasonography in the early postnatal period (Burgu et al., 2012; Erickson et al., 2007; Herndon, 2012).

The role of the dimercaptosuccinic acid (DMSA) scan in evaluation of prenatal UTD is limited. The agent is bound to the proximal tubule with minimal secretion. Its main use is the detection of cortical defects, representative of dysplasia in the absence of infection, in patients diagnosed with VUR; confirmation of the absence of function in patients with suspected MCDK; or to ascertain polar function in patients with duplex collecting systems (British Nuclear Medicine Society, n.d.).

Magnetic Resonance Urography

The role of magnetic resonance urography (MRU) in the evaluation of prenatal UTD is not clearly defined. The main advantages are the lack of radiation while providing superior anatomic detail in addition to the ability to assess differential function, glomerular filtration rate, and drainage (Jones et al., 2004; McMann et al., 2006). The main drawbacks are cost, need for sedation and/or anesthesia, and lack of availability at all centers. One specific barrier for neonates is the need for prone positioning, which may create access issues if emergent airway problems were to develop.

The clinical application is reserved for situations that dictate information

in regard to specific anatomic detail and/or renal function to aid in operative planning such as ectopic ureter, megaureter, or anatomic vascular variants such as lower pole vessels resulting in UPJO (Weiss et al., 2015).

Key Points

- The initial postnatal ultrasound scan should be obtained at 48 hours to account for intravascular depletion that occurs in the initial postnatal period secondary to third spacing, which later becomes mobilized to the intravascular space.
- UTD classification assigns three levels of risk: P1 UTD (SFU 2; low risk) includes APD 10 mm to less than 15 mm and central calyceal dilation; P2 UTD (SFU 3; intermediate risk) includes APD greater than or equal to 15 mm and peripheral calyceal or ureteral dilation that may be in isolation; P3 (SFU 4; high risk) includes APD greater than or equal to 15 mm and/or positive values for other data points such as parenchymal cysts or thinning.
- The degree of APD dilation correlates poorly with the presence and degree of VUR in patients with prenatal UTD.
- Recommendations for VCUG for prenatal UTD should be based on risk for UTI in the absence of concerns for LUTO.

Management Recommendations for Postnatal Urinary Tract Dilation

P1 Urinary Tract Dilation (Low Risk)

Most patients evaluated in the postnatal period will have P1 UTD, and this will represent a transient condition. There has been recent evidence from two large patient registries in regard to risk for UTI, utility of PA, and expected resolution rates for urinary tract dilation (Braga et al., 2015, 2018; Capolicchio et al., 2018; Zee et al., 2016, 2017). Postnatal surveillance of the upper urinary tract should be indexed to the probability of disease progression. **For P1 or SFU 1/2, complete resolution has been demonstrated to occur in most patients between 24 and 48 months** (Braga et al., 2015, 2018; Capolicchio et al., 2018; Zee et al., 2016, 2017)**. Based on this data, it is reasonable to obtain the second postnatal ultrasonography between 3 and 6 months of age.**

Although there is slight discrepancy in associated risk factors for UTI between the SFU Hydronephrosis and McMaster registries, there is uniformity in not recommending PA or VCUG for those at "P1 UTD (SFU 1/2) or low risk" as defined by the 2014 Consensus Statement (Capolicchio et al., 2018; Nguyen et al., 2014; Zee et al., 2016).

P2 Urinary Tract Dilation (Intermediate Risk)

The evaluation and management of patients with P2 UTD is less defined. A recent survey of members of the Society for Pediatric Urology indicated that 24% to 46% of respondents would recommend the use of PA, which varied based on gender and circumcision status. Surprisingly, most participants (78%) would obtain a VCUG and a majority (58%) chose a renal scan to assess differential function and drainage (Jackson et al., 2017). **In the absence of more robust evidence, the recommendation for PA and VCUG is left to the discretion of the treating physician.** In most patients, the VCUG can be performed as an outpatient and combined with renal ultrasonography obtained at the first postnatal visit. **As mentioned earlier, an informed conversation with the family should include the expected rate of UTI, probability of detecting VUR, treatment of VUR, and natural history of disease.**

P3 Urinary Tract Dilation (High Risk)

The evaluation and management of this high-risk group is more defined. Several prospective studies have identified this group to be at most risk for UTI, deterioration of renal function, and need for surgical intervention (Braga et al., 2015, 2018; Capolicchio et al., 2018; Zee et al., 2016, 2017)**. The use of PA, lower urinary tract imaging, and renal scintigraphy are recommended for P3 UTD.** Practice pattern data indicate that most respondents to the Society for Pediatric Urology survey would support this approach (Capolicchio et al., 2018; Jackson et al., 2017; Nguyen et al., 2010, 2014). The second ultrasound scan should be obtained at 1 month and can be combined with a VCUG. On occasion, the consideration for LUTO may dictate other imaging for less severe upper tract dilation such as bilateral ureteral dilation and less severe renal distention. If P3 UTD persists, then a MAG3 renal scan should be obtained and can be combined with VCUG if not obtained previously. In regard to duration of PA in the absence of VUR, it is reasonable to continue until surgical intervention for UPJ or 1 year of age. This age cutoff recommendation is derived from prospective data that indicates most UTIs will occur within the first year of life (Zee et al., 2016).

Considerations for Severe Bilateral Urinary Tract Dilation

The recommendations mentioned in the previous section for timing for the evaluation and management of UTD are specific to isolated cases of unilateral disease. The presence of severe bilateral dilation of the kidney, ureters, and bladder with decreased amniotic fluid are strongly suggestive of BOO. In males, this may be a result of PUV, urethral stenosis, or prune belly syndrome. In females, this may secondary to a ureterocele, which should be associated with other findings such as a cystic bladder lesion. Other conditions such as megacystis or bilateral VUR may demonstrate upper and lower urinary tract dilation but will not be associated with oligohydramnios.

After delivery, it is important to promptly decompress the urinary bladder and begin antibiotic prophylaxis and proceed with prompt evaluation of the urinary tract to determine the etiology.

Key Points

- Complete resolution of P1 UTD should occur in most patients by 4 years of age.
- For P1 UTD (SFU 2), PA and VCUG are not recommended.
- For P2 UTD (SFU 3), the use of PA and VCUG are left to the discretion of the physician.
- For P3 UTD (SFU 4), PA and VCUG are recommended as well as a MAG3 renal scan.

Urinary Tract Infection

UTI will occur in 8% to 22% of patients with prenatal UTD. Recently, associated risk factors for UTI have been described by several retrospective single-center studies and two prospective registries and (Alconcher and Tombesi, 2004; Braga et al., 2013, 2015; Brophy et al., 2002; Coelho et al., 2007; Easterbrook et al., 2017; Estrada et al., 2009; Herndon et al., 1999b; Lee et al., 2006, 2008; Song et al., 2007; Tombesi and Alconcher, 2012; Zareba et al., 2014; Zee et al., 2016). **The degree of kidney dilation is predictive of risk for UTI in patients with prenatal UTD.** In a meta-analysis, Lee et al. demonstrated a linear relationship between the degree of kidney dilation and UTI with a reported incidence of 4%, 14%, 33%, and 40%, respectively for grades 1 to 4 (Lee et al., 2006). In 2007, Coelho reported similar findings in 192 patients that demonstrated a UTI rate of 11%, 18%, and 39% for mild, moderate, and severe hydronephrosis, respectively (Coelho et al., 2007). In 2012, Symanski reviewed 206 patients and showed high-grade kidney dilation significantly predicted UTI with a rate of 13.8% versus 4.1%. In a retrospective review, Herz et al. reported an overall incidence of 22% with high-grade VUR, ureterovesical junction obstruction (UVJO), and ureteral dilation over 11 mm to be predictive of UTI (Herz et al., 2014). Zee et al. reported from the multicenter prospective SFU registry, which prospectively followed 213 patients with prenatal UTD, and demonstrated an overall incidence of 8% of which 89% occurred within the first year of life (Zee et al., 2016) (Fig. 22.14). Multivariant regression analysis revealed female gender, high-grade kidney dilation, and intact foreskin. Braga reported from the McMaster registry, which demonstrated an overall UTI rate of 19% in 334 patients and identified female gender, intact foreskin, high-grade kidney dilation, ureteral dilation, VUR, and lack of prophylaxis to be predictors of UTI (Braga et al., 2015).

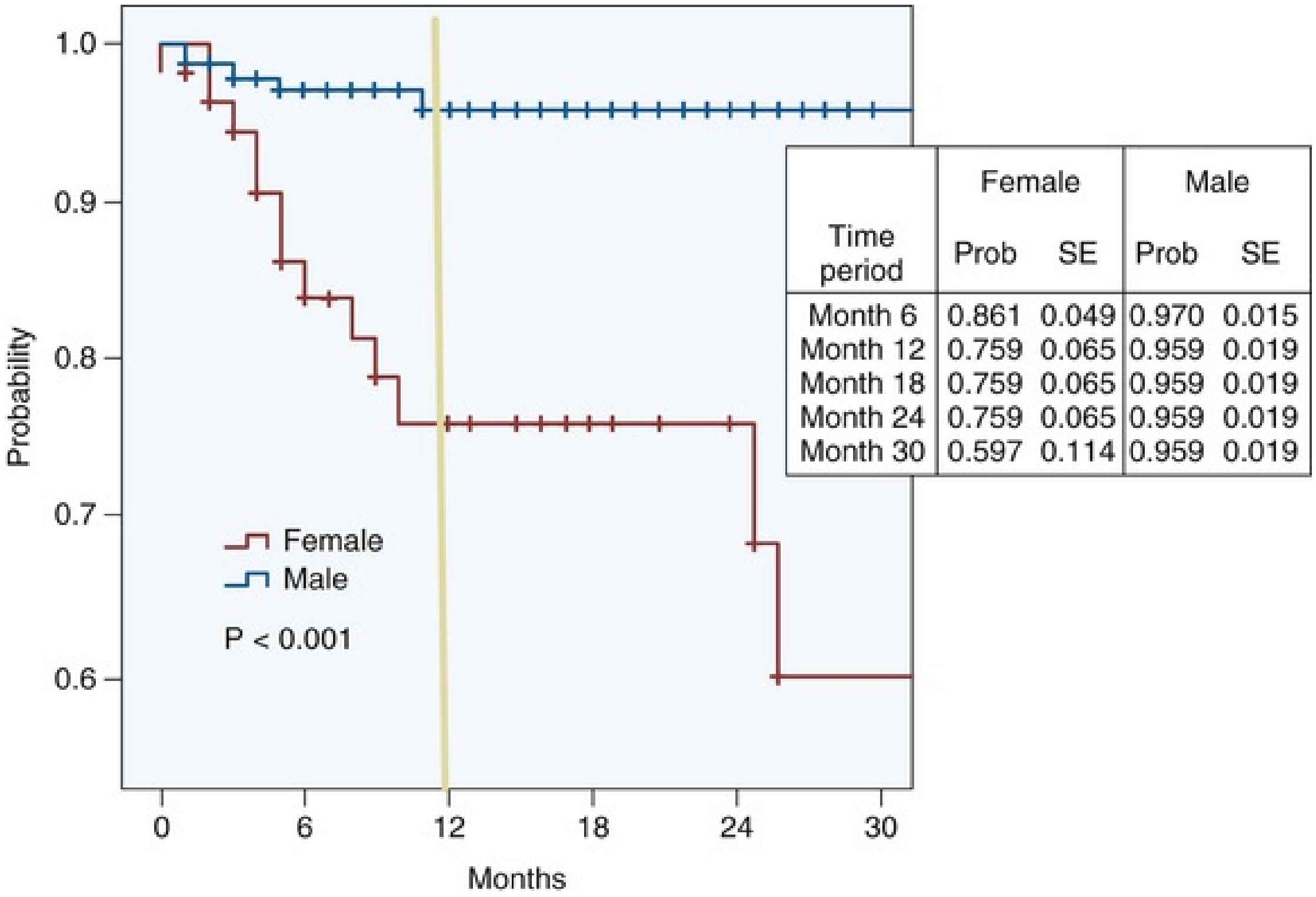

Time period	Female		Male	
	Prob	SE	Prob	SE
Month 6	0.861	0.049	0.970	0.015
Month 12	0.759	0.065	0.959	0.019
Month 18	0.759	0.065	0.959	0.019
Month 24	0.759	0.065	0.959	0.019
Month 30	0.597	0.114	0.959	0.019

FIG. 22.14 30-Month event-free survival by gender from date of birth to first urinary tract infection. (Modified from Zee RS, Herbst KW, Kim C, et al. Urinary tract infections in children with prenatal hydronephrosis: A risk assessment from the Society for Fetal Urology Hydronephrosis Registry. *J Pediatr Urol* 12[4]:261.e3 [Figure 2], 2016).

Uniformity exists in identifying female gender, high-grade kidney dilation (P3, SFU 4), and uncircumcised status as factors associated with increased risk for UTI (Braga et al., 2015; Zee et al., 2016)**. Potential factors that deserve further evaluation include ureteral dilation, VUR, and the use of PA** (Braga et al., 2015, 2016; Coelho et al., 2007; Herz et al., 2014). One potential confounder in analysis of these studies is the lack of uniform screening for VUR and severity of illness populated within the various studies.

Prophylactic Antibiotics

The role of PA for the prevention of UTI in patients with prenatal urinary tract dilation is not clearly defined (Alconcher and Tombesi, 2004; Braga et al., 2013, 2015; Brophy et al., 2002; Coelho et al., 2007; Easterbrook et al., 2017; Estrada et al., 2009; Herndon et al., 1999b; Herz et al., 2014; Lee et al., 2006, 2008; Merguerian et al., 2010. Song et al., 2007; Tombesi and Alconcher 2012; Zareba et al., 2014; Zee et al., 2016). Historically, the recommendation for

PA was not evidence based, and thus most patients who were identified with upper urinary tract dilation were placed on PA and evaluated with a VCUG. In part, this approach was based on the known association of VUR with prenatal dilation of the kidney, which could be present in up to 25%, even in those with resolved postnatal dilation (Herndon et al., 1999b; Upadhyay et al., 2003). A systematic review by Braga revealed a significant benefit for PA to reduce UTI for high-grade UTD versus low-grade UTD (28.9% vs. 14.6%, $P = 0.02$) (Braga et al., 2013). The Herz retrospective study reported a similar finding with a 7.9% versus 18.7% rate in those with PA and without PA, respectfully. Although these findings did not meet statistical significance, a fivefold reduction in UTI was demonstrated in a subset of patients with ureteral dilation who were managed with PA (Herz et al., 2014). The two prospective registries have reported divergent findings. The report from the SFU registry failed to demonstrate a reduction in UTI in patients managed with prophylaxis, and the McMaster registry revealed a significant risk reduction (Braga et al., 2015; Zee and Herndon, 2016; Zee et al., 2016). A recent systematic review of 11 studies that included over 3900 patients failed to demonstrate the efficacy of PA to prevent UTI. Pooled UTI rates from the nonrandomized trials ($n = 10$) failed to demonstrate a risk reduction with the use of PA: 7.5% (95% CI, 6.4% to 8.6%) no prophylaxis versus 9.9% (95% CI, 8.4% to 11.4%) prophylaxis (Easterbrook et al., 2017).

A paradigm shift has occurred in regard to the indiscriminate use of PA despite its excellent safety profile (Zee et al., 2016). A meaningful risk reduction for the development of UTI should exist in those in whom PA is recommended. Currently, several barriers exist that inhibit the ability to completely evaluate this impact. Primarily, the low incidence of UTI (8% to 19%) creates a limited number of events that hinders the ability to statistically discriminate PA's impact on risk for UTI. Second, as mentioned earlier, the populations evaluated in these studies are not clearly identified because of the varied use of screening for VUR and administration of PA in patients with prenatal UTD.

Current recommendations restrict the use of PA to those at increased risk for UTI. An evidence-based approach would support those with higher grades of UTD, boys with intact foreskin, females, and selectively those with VUR and/or ureteral dilation. Patient age and hepatic maturity should be factors used to select the appropriate antibiotic, which includes: amoxicillin (newborn and up), first-generation cephalosporins (newborn and up), nitrofurantoin (8 weeks of age and up), and trimethoprim (8 weeks of age and up) derivatives. Recent evidence indicates that a majority of pediatric urologists are supportive of this approach (Jackson et al., 2017).

Key Points

- The degree of dilation is predictive of risk for UTI in patients with prenatal UTD.
- Risk factors for UTI for prenatal UTD include female gender, intact foreskin, high-grade kidney dilation, ureteral dilation, and VUR.
- Prophylactic antibiotics are recommended for those at risk for UTI including P2 UTD (SFU 3) and P3 UT (SFU 4).

Key Conditions

Etiology of Prenatal Urinary Tract Dilation

Prenatal UTD represents a wide spectrum of disease, and a brief overview of common diagnoses will be discussed in the following sections as it pertains to prenatal UTD. (Table 22.4) A more in-depth review can be found in the accompanied respective chapters.

TABLE 22.4

Etiology and Incidence for Antenatal Hydronephrosis

ETIOLOGY	INCIDENCE
Transient urinary tract dilation	50%–70%
Ureteropelvic junction pattern dilation	10%–30%
Vesicoureteral reflux	10%–40%
Ureterovesical junction pattern dilation	5%–15%
Multicystic dysplastic kidney	2%–5%
Duplex system, ureterocele, ectopic ureter	5%–7%
Lower urinary tract obstruction (PUV, PBS)	0.1%%–0.5%

PBS, Prune belly syndrome; *PUV,* posterior urethral valve.

Modified from Nguyen HT, Herndon CDA, Cooper C, et al. The Society for Fetal Urology Consensus Statement on the evaluation and management of antenatal hydronephrosis. *J Pediatr Urol* 6(3):217, Table 5, 2010.

Transient Urinary Tract Dilation

The reported resolution rate for UTD varies throughout the literature ranging from 41% to 88% (Nguyen et al., 2010). As mentioned earlier, the ability to reliably interpret the literature is confounded by multiple factors, mainly inconsistency with use of nomenclature for grading and the lack of uniform screening for VUR. This condition is felt to represent physiologic nonpathologic dilation that demonstrates prenatal resolution rates between 21% and 56% (Adra et al., 1995; Corteville et al., 1991; Mandell et al., 1984). Several studies have demonstrated similar findings and documented postnatal resolution rates of 90% to 98% for patients with “mild” dilation, which likely would be re-classified as normal with the UTD system that accounts for physiologic dilation

(Barbosa et al., 2012; Maayan-Metzger et al., 2011; Zee et al., 2016).

Recently, resolution rates from prospective registries have further defined this population and have given insight to the timing of this event based on longitudinal follow-up. **Braga demonstrated greater than 90% resolution for SFU grade 1 and 2 patients at 12 and 18 months, respectively. Using data from the SFU Hydronephrosis Registry, similar findings were reported by Zee et al. (2017) for SFU grade 1 and 2 patients, which resolved in 100% at 26 months and 95% at 48 months, respectively.** (Fig. 22.15)

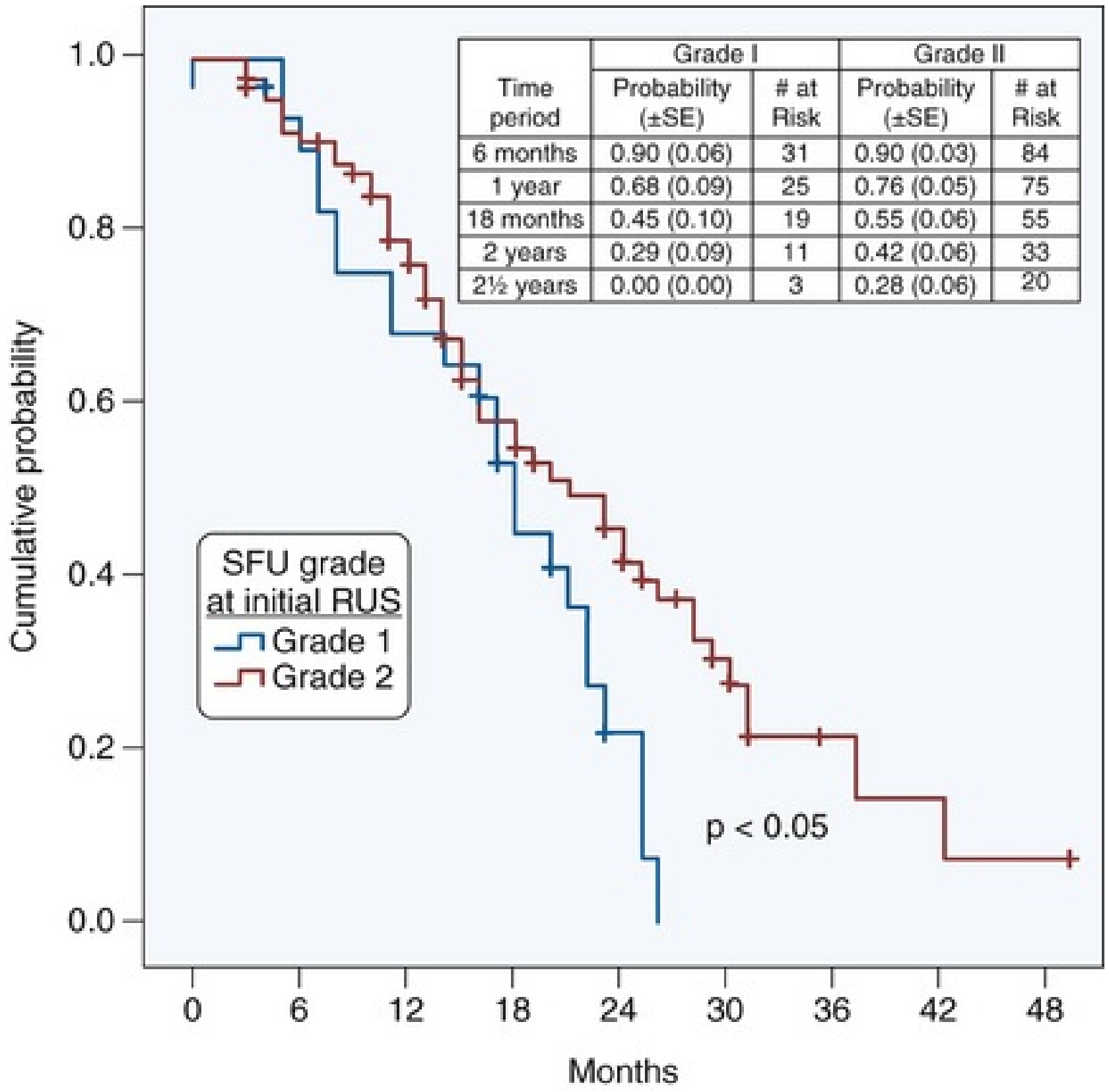

Time period	Grade I		Grade II	
	Probability (±SE)	# at Risk	Probability (±SE)	# at Risk
6 months	0.90 (0.06)	31	0.90 (0.03)	84
1 year	0.68 (0.09)	25	0.76 (0.05)	75
18 months	0.45 (0.10)	19	0.55 (0.06)	55
2 years	0.29 (0.09)	11	0.42 (0.06)	33
2½ years	0.00 (0.00)	3	0.28 (0.06)	20

FIG. 22.15 Resolution decay curve for patients presenting with the Society for Fetal Urology grade 1 *(gray)* or grade 2 *(black)* urinary tract dilation. At 2.5 years, the probability of resolution is 100% for grade 1 and 72% for grade 2, and at 4 years it is 95% for grade 2. (Modified from Zee RS, Herndon CDA, Cooper CS, et al. Time to resolution: a prospective evaluation from the Society for Fetal Urology Hydronephrosis registry. *J Pediatr Urol* 13(3):316.e1–316.e5, 2017.

The UTD classification system accounts for physiologic dilation of the renal pelvis, which should reduce the frequency of postnatal testing for UTD. It is well established that most patients with P1 UTD will resolve within 4 years (Zee et al., 2017). **One caveat is that some of these patients will have undiagnosed VUR, and both the parents and practitioner should be aware of this possibility, which can be seen in up to 31% of patients** (Adra et al., 1995; Herndon et al., 1999b; Upadhyay et al., 2003).

Ureteropelvic Junction Obstruction Pattern of Dilation

UPJO represents the most common surgical entity associated with prenatal UTD. The degree of prenatal UTD demonstrates a linear relationship with the development of the UPJO pattern of dilation (Lee et al., 2006). This represents a spectrum of disease with the more severe form undergoing more intensive imaging, which may clarify those patients who should be considered for surgical intervention. For the purposes of this chapter, we will restrict the discussion to those patients who demonstrate P2/P3 disease, which equates to SFU 3/SFU 4 or moderate/severe disease.

Several reports have demonstrated a prenatal APD threshold that is predictive of patients in whom surgery is performed for the UPJO pattern of dilation. The allowable degree of APD affects the sensitivity of detecting UPJO. As the limit is lowered, more nonobstructive conditions will be folded into this category. Several studies have identified a prenatal or postnatal APD that is predictive of UPJO (Alexander et al., 2015; Coplen, 1997; Dhillon, 1998; Shamshirsaz et al., 2012).

Following the work of Dhillon at Great Ormond Street, **Coplen demonstrated that a 15-mm APD threshold provided an acceptable sensitivity of 73% and a specificity of 82% for predicting those patients in whom surgical intervention was performed.** In evaluation of 257 neonates, 195 (76%) were observed with nonobstructive dilation with a mean APD of 11.8 mm. A total of 62 of 257 (24%) patients required surgical intervention, and the mean APD was statistically greater at 22.3 mm. The receiver operating characteristic curve for predicting surgical intervention was 15 mm, which identified obstruction in 80% of patients (Coplen, 1997). Finally, using data from the SFU registry, Shamshirsaz reviewed 53 patients with prenatal UTD identified in the second trimester (Shamshirsaz et al., 2012). This group identified separate APD thresholds for both the second and third trimesters. An APD of 9.5 mm for the second trimester and an APD of 15 mm for the third trimester were both predictive of those patients in whom surgical intervention was performed. In looking at postnatal APD, Burgu et al. reported a 20-mm threshold to be predictive of preservation of renal function in early neonatal UTD (Burgu et al., 2012).

A more recent meta-analysis consisted of five studies comprising 1159 patients and evaluated the threshold of 15-mm APD as a predictor for those in whom surgical intervention was deemed necessary. Pooled analyses with a 95% CI revealed a sensitivity of 0.81, specificity of 0.78, 3.73 positive likelihood ratios, and 0.24 negative likelihood ratios. The odds ratio for 15-mm APD to predict surgical intervention was 13.33. The postnatal APD was a significantly better predictor of surgical intervention when compared with prenatal APD (Zhang et al., 2018).

Although APD measurement is objective, it is dependent on factors such as patient position, hydration status, and degree of bladder fullness. Sharma et al. reported that position change (prone vs. supine) may be predictive of identifying patients who need surgical intervention for UPJ. When the measurement of APD decreased when measured in the prone versus supine position, 7 of 16 (43%) with APD of 30 to 40 mm and 11 of 15 (73%) with APD of 15 to 30 mm were observed without the need for surgery (Sharma et al., 2012).

The clinician should be aware that severe UTD does not equate to surgery in all patients. Ulman et al. (2000) reported outcome on 104 patients with severe UTD in whom surgery was performed in 23 (22%). Resolution occurred in 72 of 104 (69%) patients who were followed nonoperatively at a mean of 2.5 years.

The SFU grading system is equally successful in predicting differential renal function and identifying those patients who undergo surgical intervention for UPJO. Erickson demonstrated that 33 of 33 patients with SFU grade 3 UTD demonstrated preserved function on renal scintigraphy used to evaluate UPJO (Erickson et al., 2007). Ross et al. used this system to group patients into those who require early neonatal intervention. A retrospective review identified 125 patients with SFU grade 3 and 4 UTD. Early intervention was performed in 27 of 125 patients of whom 89% had SFU grade 4. Observation continued in 77 of 125 patients of whom 78% demonstrated SFU grade 3 (Ross et al., 2011).

Therapeutic intervention for UPJO is highly successful and is discussed in detail in Chapter 42. In brief, both open and minimally invasive surgical intervention demonstrated a success rate of 97% to 100% (Cain et al., 2001; Herndon et al., 2013; Minnillo et al., 2011; O'Brien and Shukla, 2012; Paradise et al., 2017; Sweeney et al., 2011). Practice pattern data suggest a threshold of 2 years of age when a majority of pediatric urologists would consider a minimally invasive approach toward the correction of UPJO (Jackson et al., 2017). However, efficacy has been demonstrated in infants younger than 6 months of age (Paradise et al., 2017).

Recommendations for Ureteropelvic Junction Obstruction Pattern of Dilation

A majority of patients will be followed without the need for surgical intervention postnatally. A postnatal ultrasound scan should be performed in the early neonatal period in those with P2 or P3 UTD. Prophylactic antibiotics may be considered with more severe forms of dilation (P3/SFU 4) because of the increased risk for UTI. Lower urinary tract imaging is recommended as well to exclude VUR and assure normalcy of the posterior urethra in males. The use of renal scintigraphy is left to the discretion of the physician and should be used for persistent P3 UTD because of its high correlation for the need of early surgical intervention. The timing of this study remains debated. A “well-tempered” baseline study can be performed at 1 month for severe disease. However, a practical approach has been recommended with consideration of serial ultrasonography to determine the fate of the obstruction. If P2 UTD and/or APD measures less than 20 mm, then normal differential function should exist, thus obviating the need for surgery. Neither approach is evidence based, and the practitioner should employ the practice with which he or she is most comfortable. **Recommendations for the consideration for surgery for UPJO include increased APD and urinary tract dilation on serial ultrasonography; decreased differential function (<40%) and/or a delayed drainage curve; or increased retention of radiotracer on delayed upright imaging on MAG3 renal scan.**

Vesicoureteral Reflux

VUR has been reported in up to 31% of patients screened with prenatal UTD (Adra et al., 1995; Herndon et al., 1999b; Lee et al., 2006; Nguyen et al., 2010; Upadhyay et al., 2003**). A systematic review of the literature by Lee et al. (2006) demonstrated that the grade of prenatal UTD correlates poorly with the severity of VUR.** Historically, screening for VUR was pursued because of the relatively high probability of detecting reflux. However, a change in the concept of VUR has become apparent with two phenotypes presenting clinically.

A majority of VUR cases present in girls with febrile UTI (fUTI) and are less associated with renal scarring and high-grade disease in comparison with VUR that is detected through screening of prenatal UTD, which is more common in boys and represents high-grade disease, with up to 40% of patients demonstrating renal dysplasia in the absence of UTI (Herndon et al., 1999b, 2001) (Fig. 22.16). Fortunately, this latter group demonstrates a low rate of UTI when circumcised and enjoys much higher resolution rates compared with published rates of resolution, perhaps related to delayed maturation of the bladder neck that resolves after 1 year of age. This clinical difference has lead to recommendations for less aggressive screening in the absence of UTI (Yeung et al., 1998). In 1999, prospective outcome data from three medical centers reviewed 71 patients (56 male) confirmed with postnatal VUR. Increase in kidney dilation with voiding was seen in 4 patients, and ureteral dilation was only seen in 15 patients (26 ureters). The initial postnatal ultrasound scan was normal in 25% of patients. VUR was bilateral in 36 of 56 males and 9 of 15 females. A UTI developed in 10 of 19 (53%) boys with intact foreskin. Surprisingly, 15 of 74 high-grade refluxing units resolved at an average age of 0.9 and 2.1 years for boys and girls, respectively. Other centers subsequently published similar results (Upadhyay et al., 2003). Of note, pooled resolution outcomes data from the 2010 AUA VUR guidelines failed to demonstrate a significant increased rate of resolution for prenatally identified VUR despite an overall resolution rate of 50% (Peters et al., 2010).

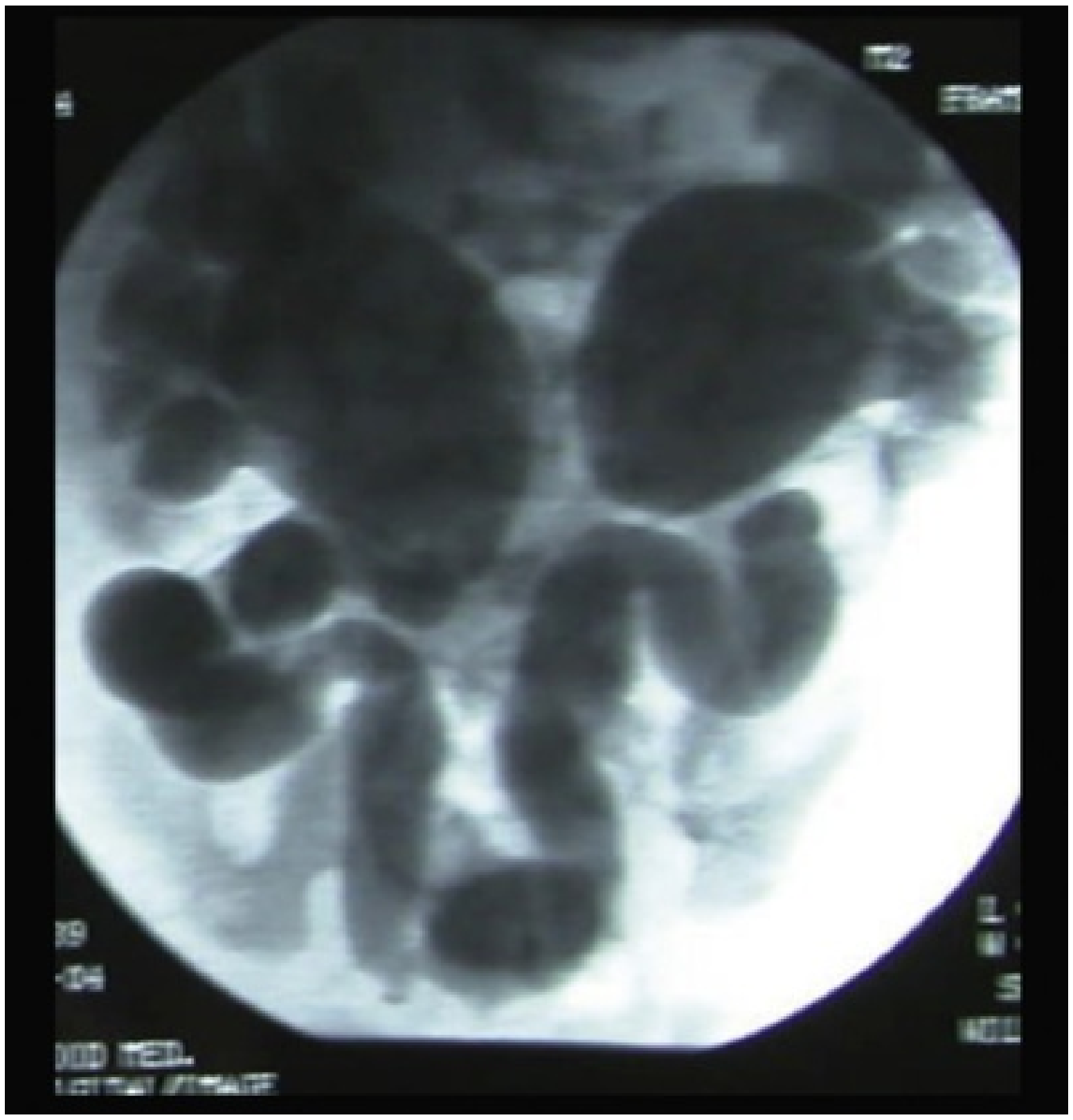

FIG. 22.16 Bilateral grade V vesicoureteral reflux in a patient with P1 urinary tract dilation (Society for Fetal Urology 2).

Whether prenatally detected VUR is a risk factor for UTI is debatable. Two large prospective registries have come to divergent opinions in this regard. The McMaster group demonstrated VUR to carry a significantly increased risk for fUTI. Males represented 78% of 334 patients enrolled overall. High-grade UTD was seen in 57% of the group. The overall rate of UTI was 19%. VUR was identified in 57 of 238 screened patients (43 of 57 [75%] high grade) of whom two-thirds were maintained on prophylaxis. Zee et al. demonstrated a dichotomous finding using multicenter data from the SFU Hydronephrosis registry. In review of 213 patients with prenatal UTD (154 of 213 [72% male]), high-grade UTD was present in only 26%. VUR was identified in 25 of 133 (19%) of 133 of 213 (62%) screened. The overall rate of UTI was 8%, and neither VUR nor ureteral dilation were associated with UTI. A critical review of these two registries demonstrates different rates of high-grade UTD, screening rates for VUR, and treatment with prophylaxis. This may be a result of regional referral practice pattern variation and implicit bias at each medical center in regard to the benefit of screening and prophylaxis. Nonetheless, the differing rates of UTI for VUR may in part be a result of comparison of different cohorts.

Practice pattern data for pediatric urologists suggest that gender, foreskin status, and grade of UTD affect recommendations for PA and VCUG that ranged from 26% to 57% and 85% to 88% for moderate- and high-grade UTD, respectively (SFU 3/4, P2/3) (Fig. 22.17).

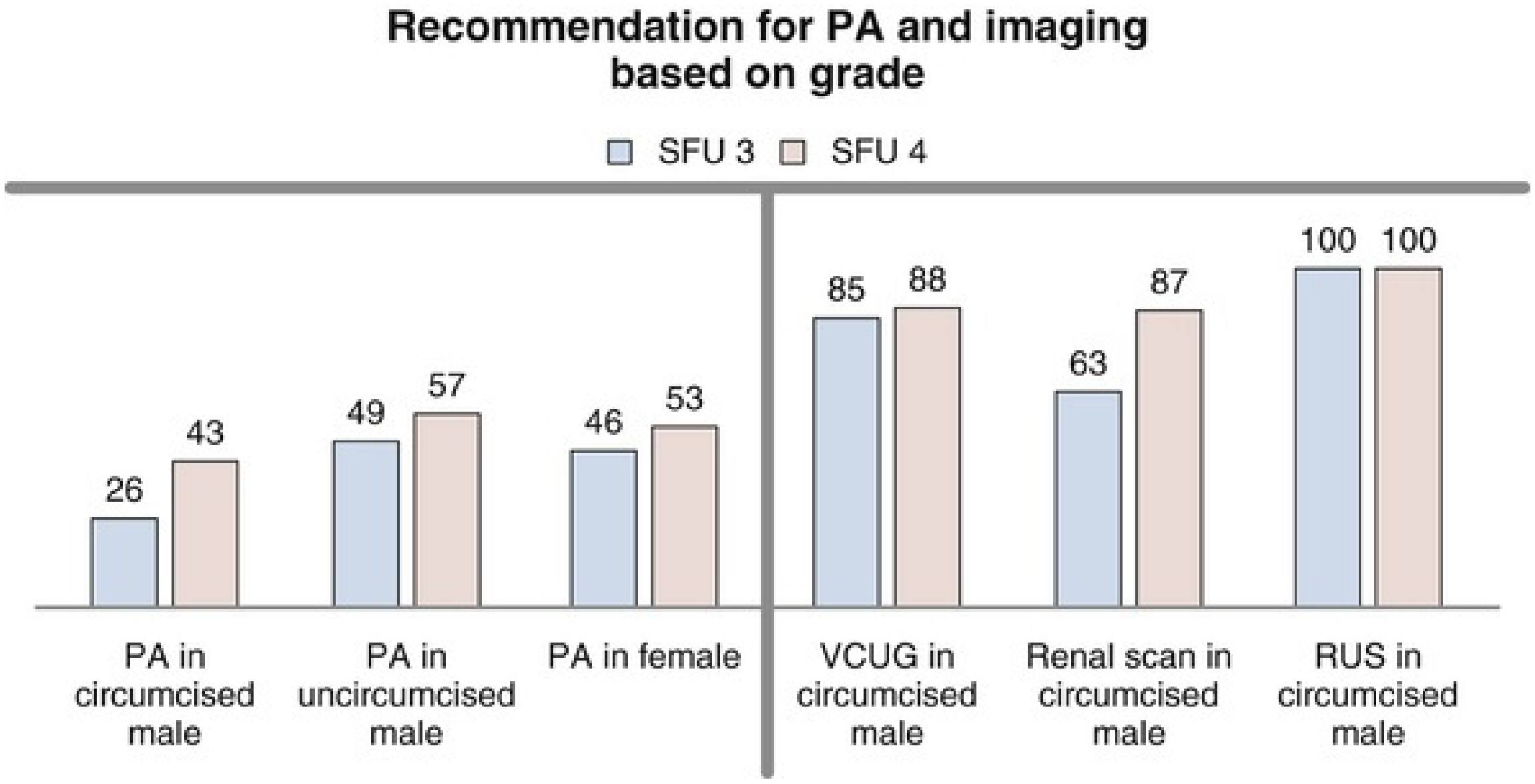

FIG. 22.17 Practice pattern recommendations for antibiotics, voiding cystourethrogram, and renal scintigraphy for members of Society for Pediatric Urology for a 1-month-old patient with Society for Fetal Urology (SFU) 3 or SFU 4 urinary tract dilation. (Modified from Jackson JN, Zee RS, Martin AN, et al. A practice pattern assessment of members of the Society of Pediatric Urology for evaluation and treatment of urinary tract dilation. *J Pediatr Urol* 13(6):604 [Figure 1], 2017).

Recommendations for Vesicoureteral Reflux

VUR is common in patients with a history of prenatal UTD. A reasonable approach would account for the risk for UTI to be the basis for screening. For example, females with high grade UTD or males with intact foreskin are at high risk for UTI and should be screened as opposed to circumcised males with low-grade UTD. An informed discussion concerning the natural history of VUR and costs/benefits of prophylaxis should occur between patients and providers.

Megaureter/Ureterovesical Junction Obstruction

Primary congenital megaureter is a less common cause for prenatal UTD and has been classified as obstructed, nonobstructed, refluxing, and refluxing/obstructed. Postnatally, it can be differentiated from a single-system ectopic ureter, which is usually associated with renal dysplasia and ureteral insertion distal to the bladder neck or vagina.

Several reviews have confirmed that a majority of patients can be followed without the need for surgical intervention. Shukla et al. reviewed the Children's Hospital of Philadelphia experience of 40 patients (Shukla et al., 2005). With a mean of 7 years, 50% of patients resolved urinary tract dilation. A secondary cohort of 10 patients were followed for a mean of 13.4 years. In this group, 4 patients demonstrated resolution, and 1 patient unfortunately experienced renal deterioration requiring nephrectomy. McLellan et al. reviewed the Boston Children's hospital experience in 54 patients with a mean follow-up of 2 years. Resolution was demonstrated in most patients (72%) and identified those with a ureteral diameter of 1.32 cm at increased risk for the need for surgical intervention (McLellan et al., 2002). Chertin et al. reported similar findings with surgical intervention in 31% at a mean follow up of 14.3 months with renal function of less than 30% and ureteral diameter of less than 1.33 cm as predictors of the need for surgery (Chertin et al., 2008). More recently using prospective data, Braga et al. reviewed 80 patients and demonstrated that ureteral diameter appeared to predict the need for surgery in 19 (24%) patients with a mean ureteral dilation of 17 mm versus 12 mm in the nonoperative group ($P = 0.04$). Overall, 76% of patients resolved at a mean follow-up of 19 months (Braga et al., 2016).

Recommendations for Megaureter

Postnatal renal/bladder ultrasonography and institution of PA should be performed shortly after birth. A VCUG should also be obtained to better classify the megaureter. Recently, the British Association of Pediatric Urologists published the following appropriate guidelines in a Consensus Statement:

1. Evaluation: Ureteral diameter of greater than 7 mm after 30 weeks as threshold for postnatal renal ultrasonography, initiation of PA, VCUG in all patients with special consideration for timing in those suspected to potentially have PUV, and consideration of renal scintigraphy to assess function and obstruction at the level of the ureterovesical junction (UVJ).
2. Surgical Intervention: Required in a minority and reserved for decreased

renal function (<40%), fUTI, or pain. Temporizing procedures such as cutaneous ureterostomy, cutaneous pyelostomy, or refluxing ureteral reimplantation should be performed for patients younger than 1 year of age. Ideally, the procedure should be deferred until 1 year of age and allow for a definitive ureteral reimplantation.

3. Follow-up: The British Association of Pediatric Urologists recommends long-term follow-up into adulthood because of the risk for late asymptomatic deterioration (Farrugia et al., 2014).

Lower Urinary Tract Obstruction (Posterior Urethral Valve, Prune Belly Syndrome, Urethral Stenosis/Atresia)

The prenatal detection of LUTO can be made with the constellation of oligohydramnios, bladder distention, and the lack of cycling on prenatal ultrasonography and varying degrees of ureteral and kidney dilation that may be severe and associated with cystic changes (Fig. 22.18). It is difficult to establish the exact diagnosis based on imaging alone in that PUV, urethral stenosis/atresia, and prune belly syndrome may present with a similar clinical picture. **Significant compression of the thoracic region from bladder distention coupled with decreased amniotic fluid may lead to immediate need for pulmonary resuscitation. Patients at highest risk are those in whom oligohydramnios was detected before 27 weeks' gestational age** (Mandell et al., 1984). Various prenatal features may favor a system under tension and present with "pop-offs" such as urinary ascites (secondary patent urachus), perirenal urinoma (Fig. 22.19), and VUR. These findings and the "keyhole" sign may favor the diagnosis of PUV or urethral atresia (Fig. 22.20). However, the only reliable method to determine the etiology is through direct visualization with fetal cystoscopy (Morris et al., 2011; Quintero et al., 1995; Ruano et al., 2010, 2011, 2015; Sananes et al., 2016). **As mentioned earlier in this chapter, with prenatal counseling, a narrow window between 18 and 24 weeks is the ideal time to consider intervention, which should be preceded by extensive counseling in regard to the expected benefits in relation to the relatively high complication rate** (Elder et al., 1987; Farrugia, 2016; Morris et al., 2013b). After delivery, the urologic team should be immediately on hand to aid in bladder decompression. The diagnosis of PUV can be distinguished from prune belly syndrome because of the lack of abdominal musculature and bilateral nonpalpable testes, which will be apparent on physical examination in the latter. A 5-Fr feeding tube should be placed into the urinary bladder and confirmed with a KUB scan, as some patients with a dilated posterior urethra may initially drain urine. Digital rectal pressure may be needed to direct the drainage catheter over the high riding bladder neck in some patients. **The neonatal team should be advised to avoid using a balloon catheter as it may drop down into the**

posterior urethra and obstruct or damage the urethra and impair drainage of the ureteral orifices (Jordan and Hoover, 1985). If one cannot pass a catheter into the urethra, then a percutaneous suprapubic catheter can be placed with ultrasound confirmation at the bedside using local anesthesia and an angiocatheter using the Seldinger technique.

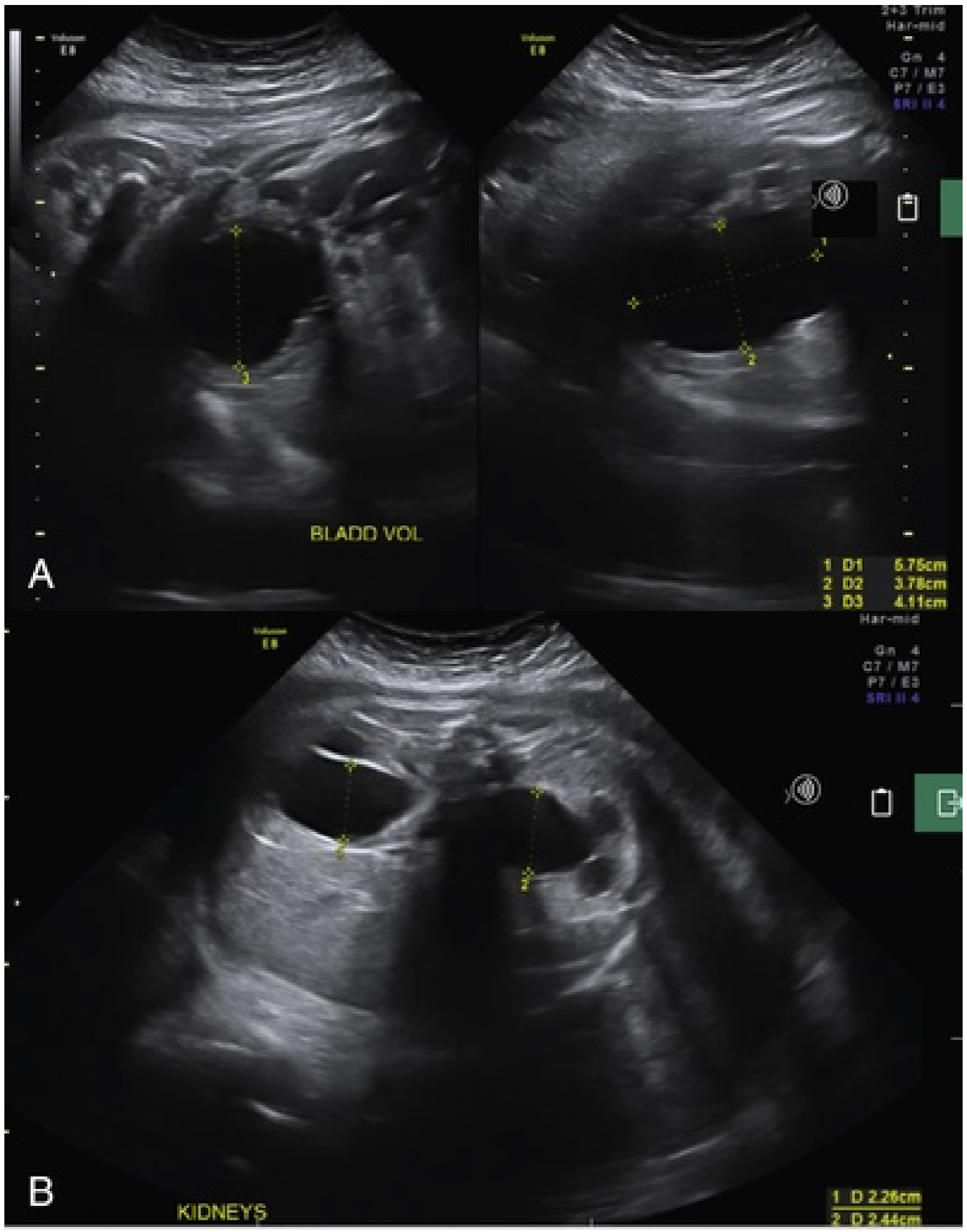
A
BLADD VOL
1 D1 5.75cm
2 D2 3.78cm
3 D3 4.11cm
B
KIDNEYS
1 D 2.26cm
2 D 2.44cm

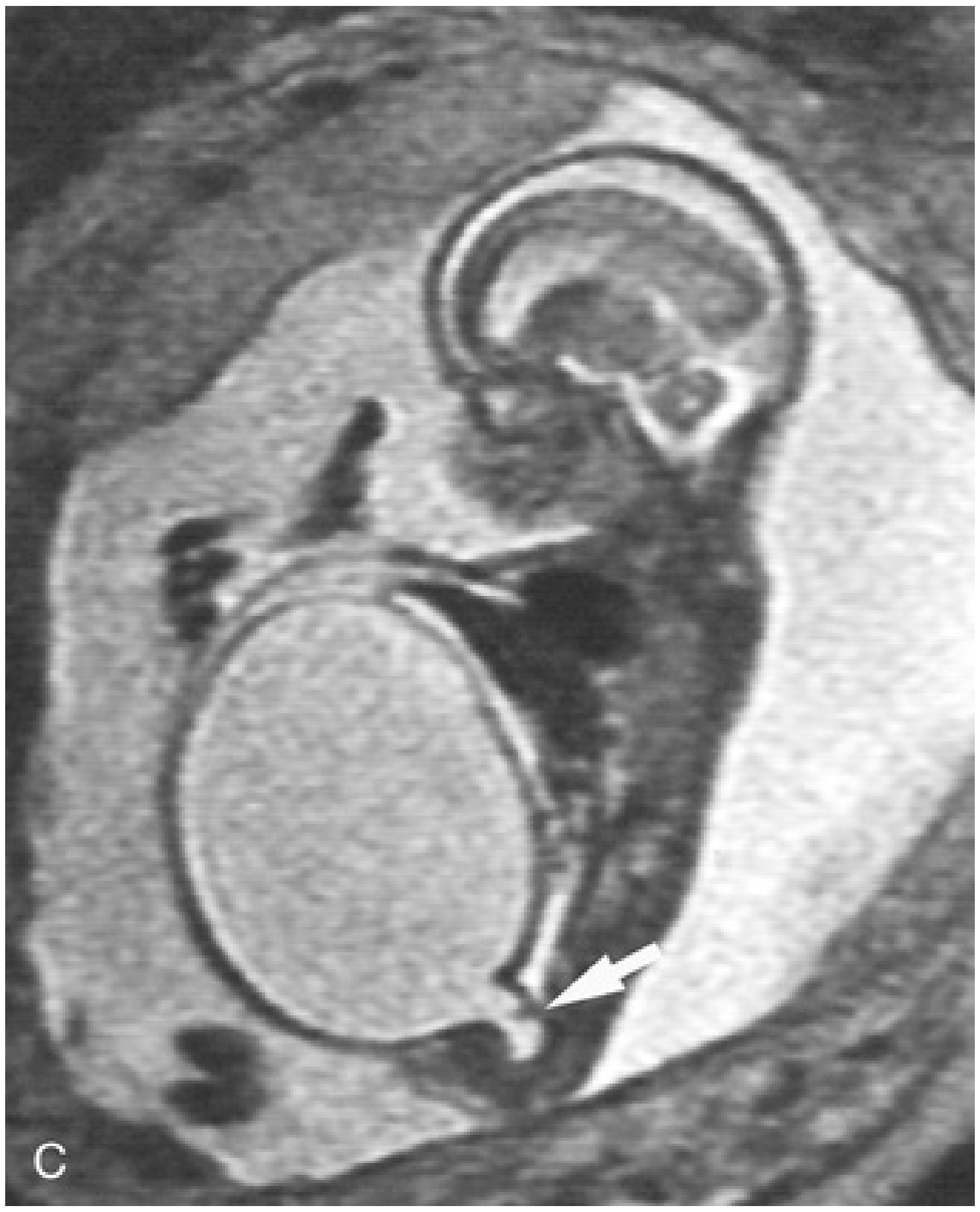

FIG. 22.18 (A) Prenatal imaging demonstrating megacystis with dilated upper urinary tract. (B) Transverse imaging demonstrating severe anterior-posterior diameter dilation of bilateral renal pelves. (C) Prenatal magnetic resonance imaging demonstrated a distended urinary bladder and dilated posterior urethra consistent with diagnosis of posterior urethral valves.

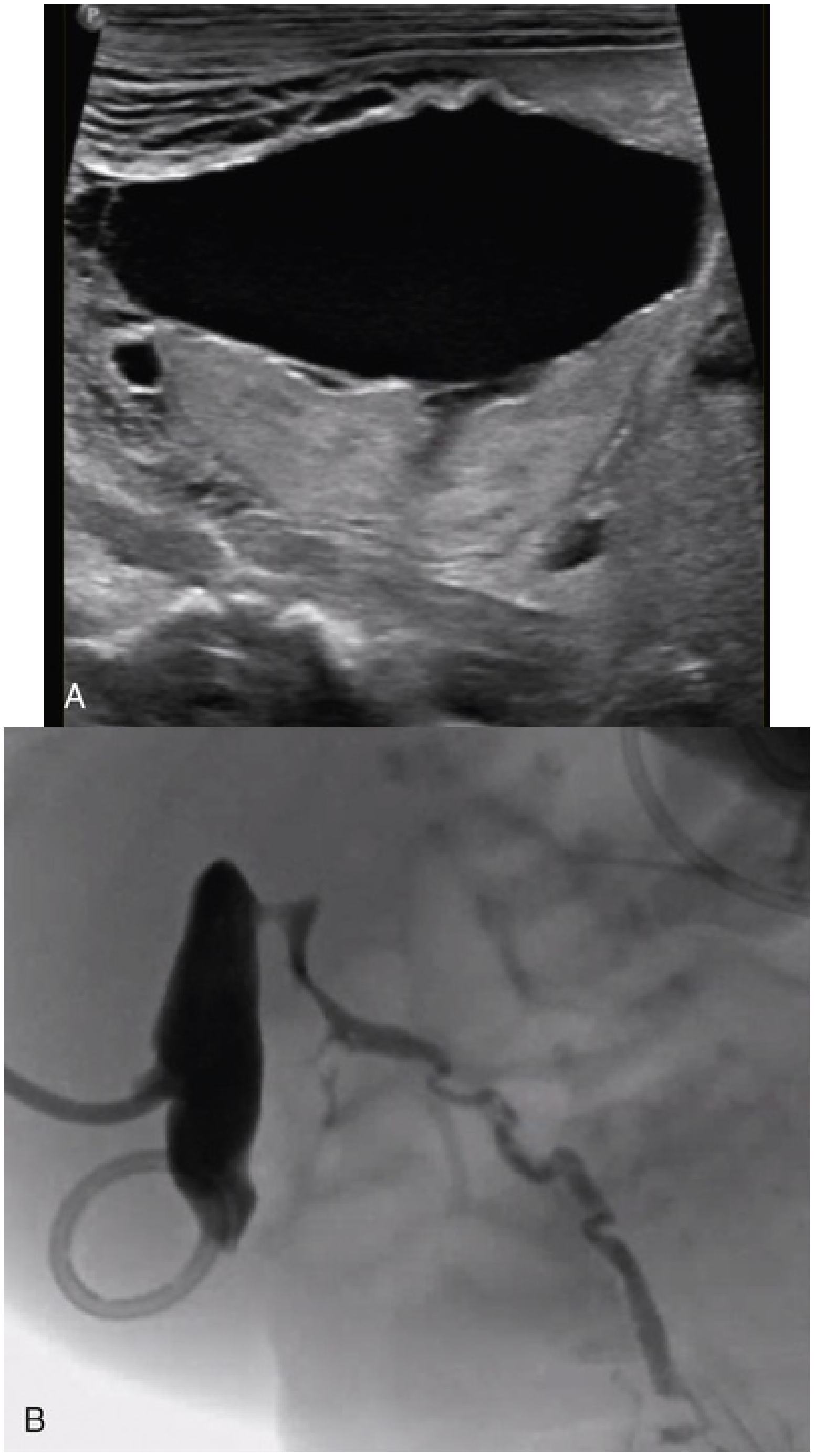

FIG. 22.19 (A) Perirenal urinoma. (B) Associated calyceal rupture depicted on antegrade nephrostogram.

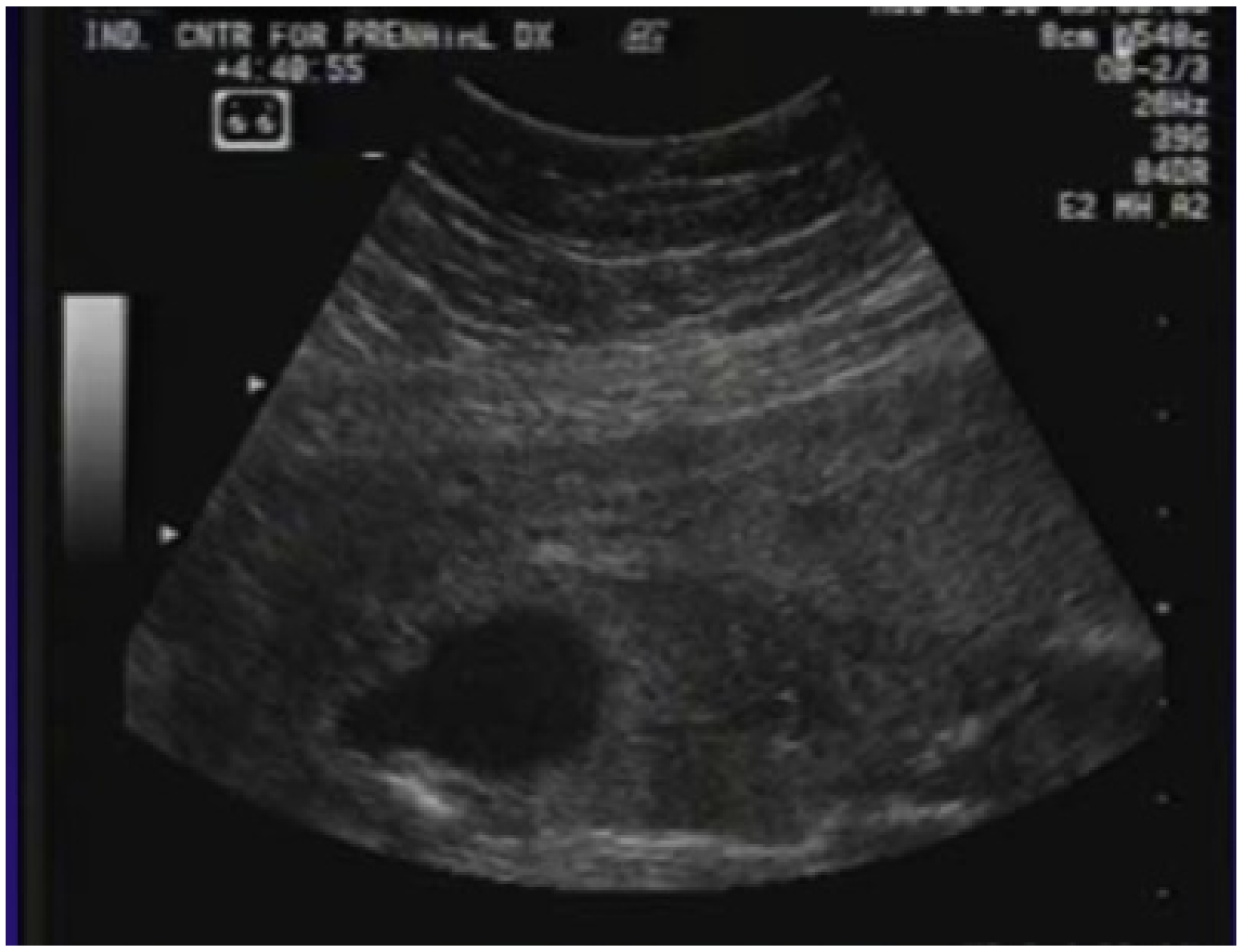

FIG. 22.20 Prenatal ultrasound scan demonstrating “keyhole” sign indicative of lower urinary tract obstruction.

Posterior Urethral Valves

PUV represents the most common form of LUTO and afflicts between 1.4 and 2.2 per 10,000 births (Anumba et al., 2005; Malin et al., 2012). This condition appears to be more common in minority ethnic groups. The diagnosis can be made by physical examination and lower urinary tract imaging (Fig. 22.21). **Unfortunately, the ability to identify this condition prenatally does affect the natural history of this condition with about one-third developing the need for long-term renal replacement. Chapter 33** discusses the evaluation and management of PUV in more detail.

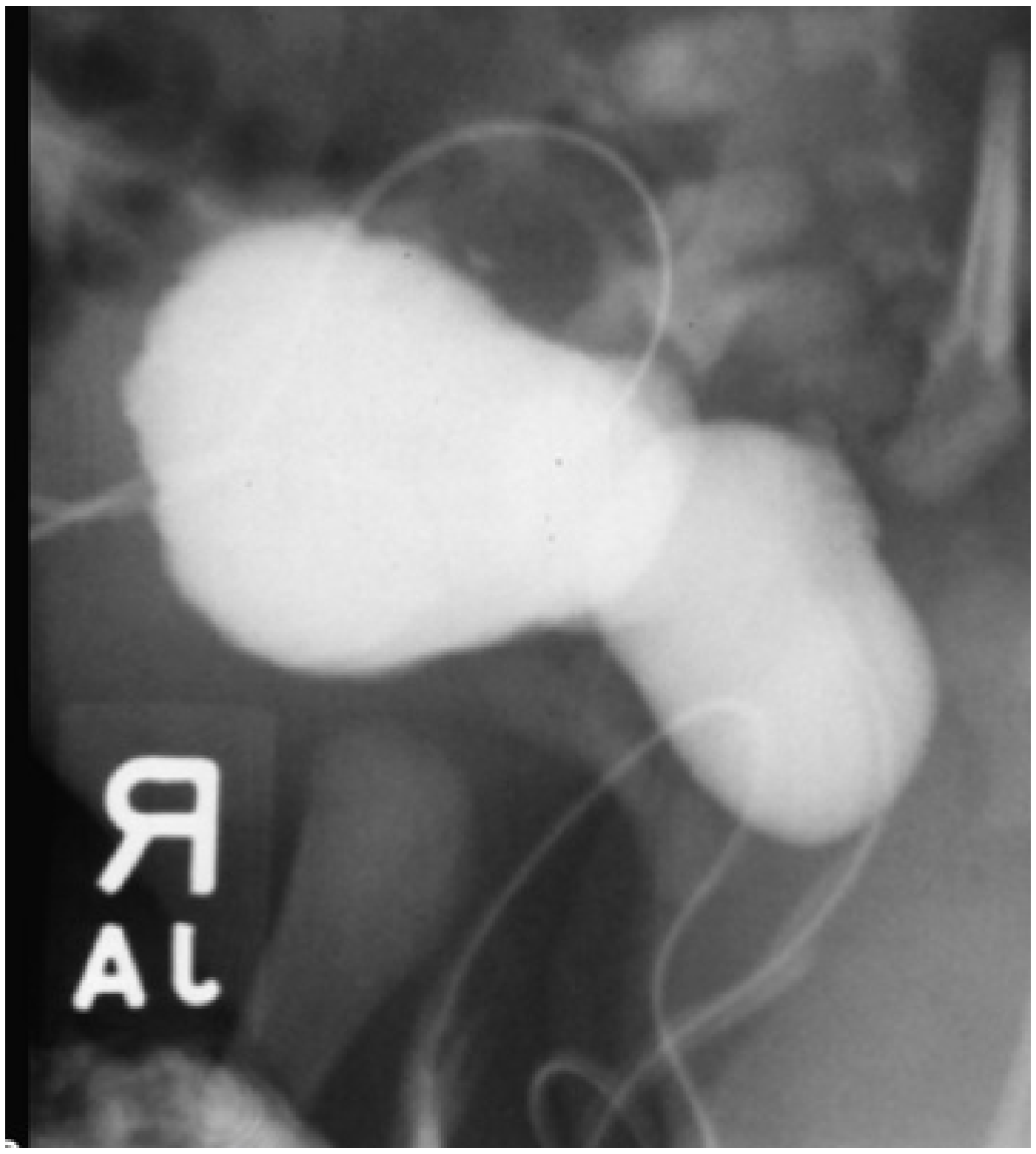

FIG. 22.21 Voiding cystourethrogram demonstrating a dilated posterior urethra consistent with the diagnosis of posterior urethral valves.

Prune Belly Syndrome/Megalourethra

The constellation of massive dilation of the bladder (megacystis) and upper urinary tract combined with the physical examination findings of absent/decreased rectus abdominal wall musculature with bilateral nonpalpable testes confers the diagnosis of prune belly syndrome (see Chapter 32 for a more detailed description). This condition may be associated with urethral atresia in which there may be associated oligohydramnios and clinical outcome similar to PUV. Additionally, congenital megalourethra may occur with this condition as well.

Urethral Stenosis/Atresia

Urethral stenosis and/or atresia more commonly resides with the constellation of signs that include oligohydramnios, severe bilateral urinary tract dilation, and bladder distention. Postnatally, a catheter will not pass into the bladder, and a narrowed penile urethra with a membrane at the level of the membranous/prostatic urethra can be seen on cystoscopy. Urinary diversion with a vesicostomy will be required initially but can be used to facilitate the PADUA (progressive augmentation by dilating the urethra anterior) procedure (Stalberg and González, 2012).

Congenital Megacystis

Two forms of congenital megacystis have been described. Massive reflux results from laterally displaced ureteral orifices that leads to cycling of refluxed urine and a resultant dilated urinary bladder that is often very thin. Surgical correction of the reflux will restore bladder dynamics (Burbige et al., 1984). The more lethal form occurs in association with microcolon-intestinal hypoperistalsis syndrome. Most children will require urinary diversion with vesicostomy or intermittent catheterization. Rarely do patients live past 1 year of age (Bloom and Kolon, 2002).

Recommendations for Lower Urinary Tract Obstruction

A baseline renal/bladder ultrasound scan should be performed and used as a guide after an interval of decompression. The neonatal team should be advised against performing an immediate VCUG in patients with renal insufficiency who require bladder decompression as it may be difficult to replace the catheter. The period of recommended bladder decompression will vary depending on the timing of the serum creatinine nadir. Some children may experience an initial increase in serum creatinine resulting from intravascular volume depletion and under-resuscitation. Equally, the neonatal team should be advised of the likely concentrating defect inherent with these disease processes that may be exacerbated with a postobstructive diuresis. The clinician should be aware that some patients may experience oliguria or even anuria after initial bladder decompression as the hypertrophied bladder wall creates resistance that initially is difficult to overcome with a tortuous dilated upper urinary tract (Fig. 22.22). This can be mitigated with antimuscarinics. A repeat ultrasound scan should be obtained to serve as a baseline for maximal decompression following intervention. A VCUG can be obtained at this point to guide in surgical management, which is discussed in more detail in Chapter 33.

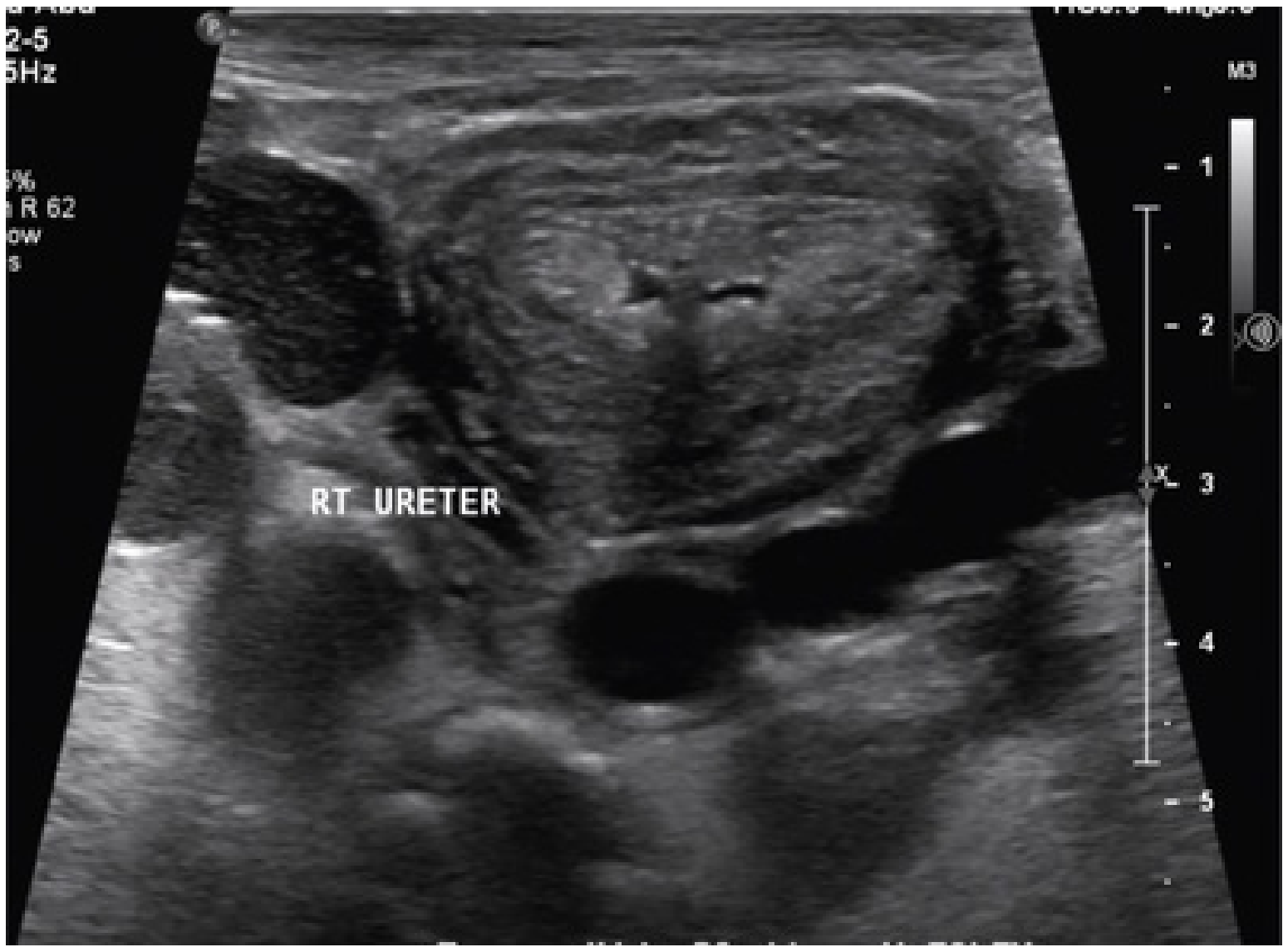

FIG. 22.22 Transverse ultrasound image of the bladder demonstrating marked thickening of the urinary bladder after decompression and associated bilateral distal ureteral dilation.

Kidney Anomalies

Multicystic Dysplastic Kidney

The majority of cystic disease that presents prenatally will not require surgical intervention or affect overall renal function. The clinical implications of MCDK are presented briefly in this chapter with a more in-depth review of the pathophysiology and other cystic diseases found in Chapter 38.

Prenatally, MCDK may be confused for P3 UTD, and thus a critical review of postnatal imaging is warranted. Debate exists as to whether this disease represents a severe obstruction that occurs on the continuum very early prenatally. Although classically multiple cysts in varying sizes are seen in the absence of a large central cyst, other more reniform phenotypes have been described (Fig. 22.23AB). Associated findings that occur in conjunction with MCDK include VUR, which may occur in 20%, and contralateral UPJ (Al-Khaldi et al., 1994; Atiyeh et al., 1992; Heikkinen et al., 1980).

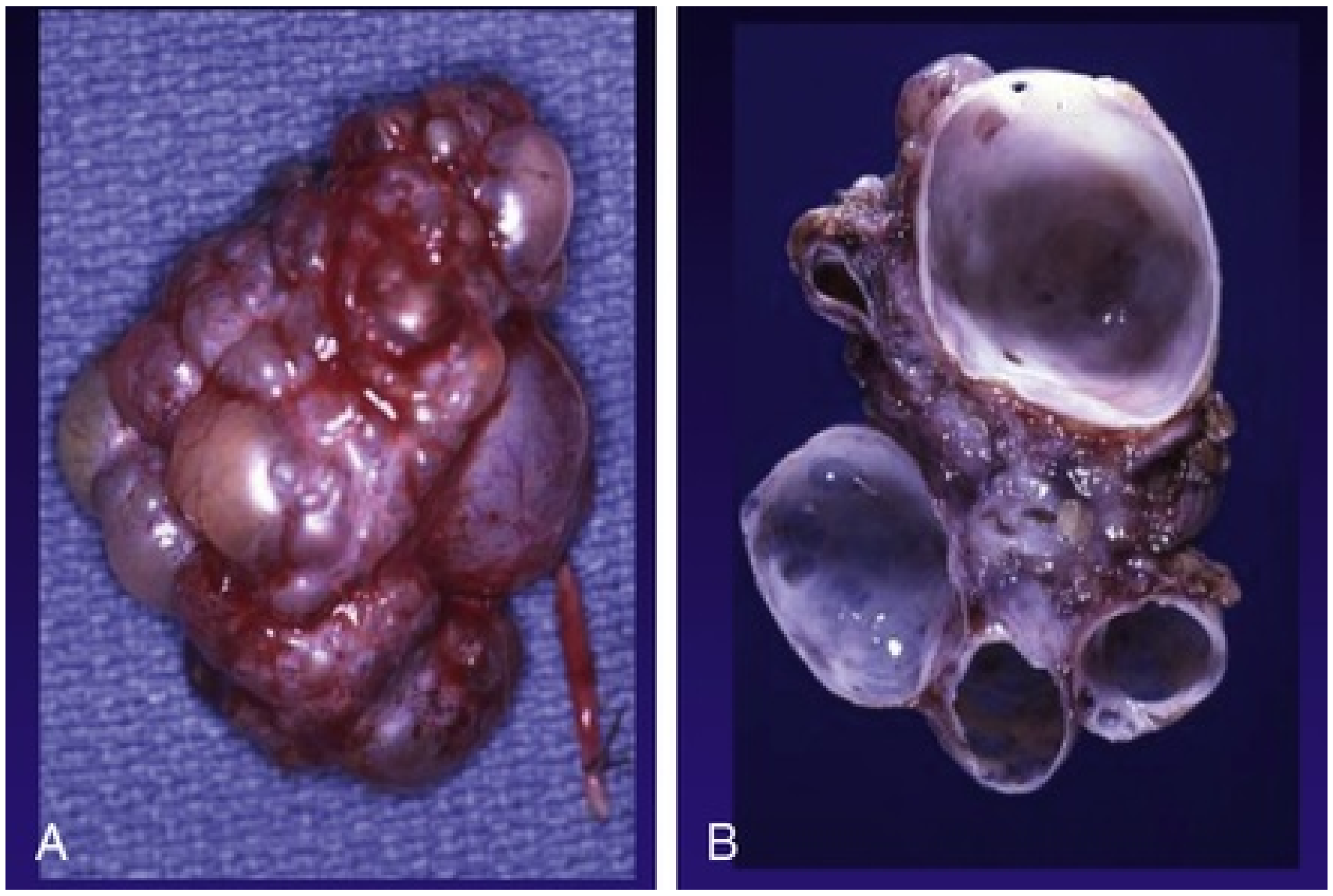

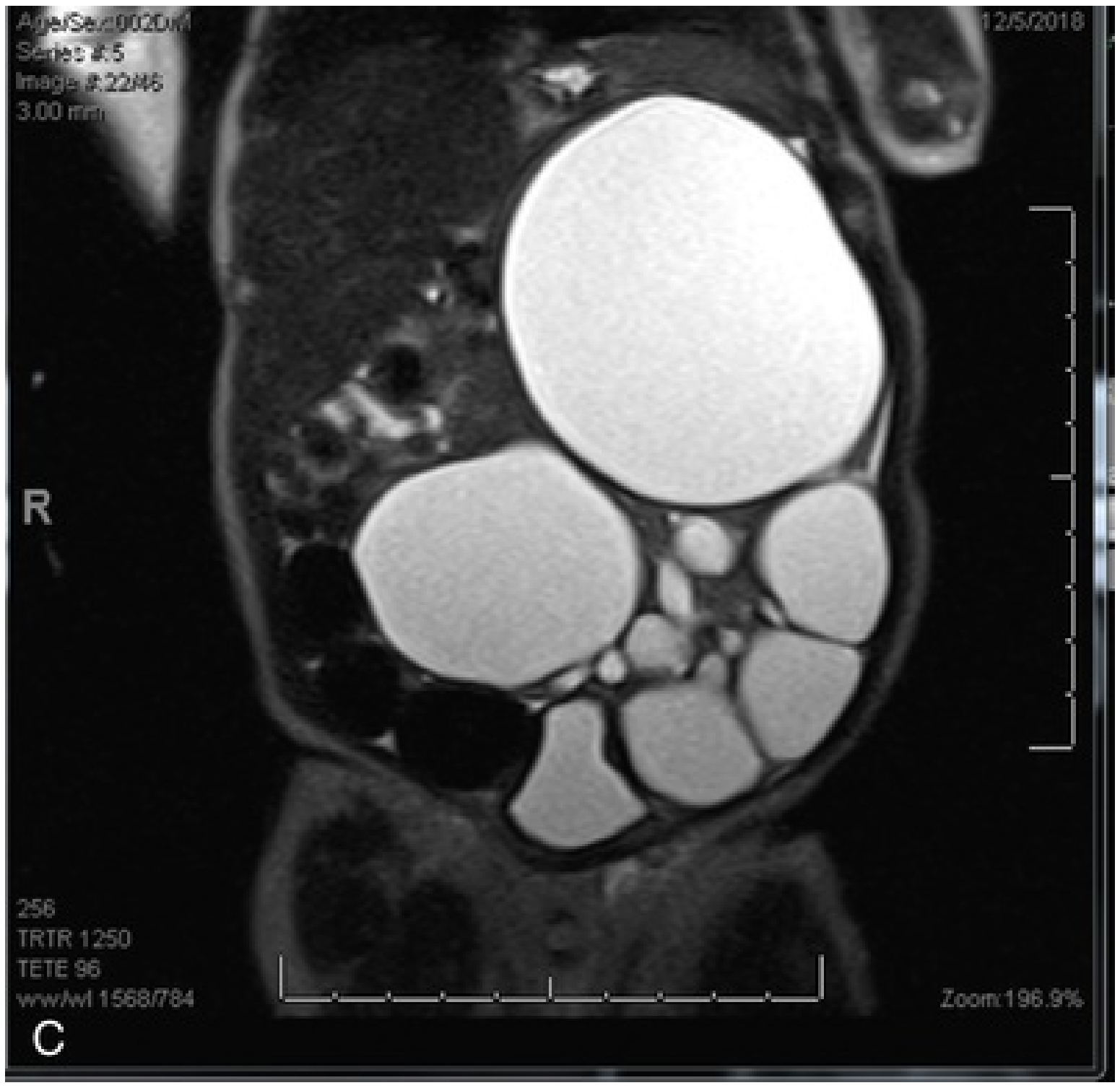

FIG. 22.23 (A and B) Image of non-functional cystic kidney that is reniform shape. (C) Magnetic resonance imaging demonstrating large multicystic dysplastic left kidney with multiple varied sized noncommunicating cysts.

The postnatal evaluation should include renal ultrasonography to substantiate the prenatal findings that were consistent with MCDK. Historically, lower urinary tract imaging to screen for VUR and DMSA renal scintigraphy to confirm the absence of function in the affected kidney were recommended. However, recently the utility of this approach has been challenged, although long-term outcome data are not available. Calaway retrospectively reviewed 133 patients with MCDK who were screened with a VCUG and found VUR present in 23 (17%). Of this group only 4 required surgical intervention. None of the patients with VUR followed without prophylactic antibiotics developed an fUTI (Calaway et al., 2014). From the same center, the ultrasound diagnosis of MCDK demonstrated a 100% correlation with this finding on renal scintigraphy in 84 patients with a normal bladder on ultrasonography (Whittam et al., 2014).

Historically, simple nephrectomy was recommended and based in part on the suspected risk for tumor development in a cystic kidney. However, Narchi conducted a systematic review of the literature that included 26 articles representing 1041 children with MCDK and failed to demonstrate a correlation between MCDK and Wilms tumor (Narchi, 2005). Serial ultrasonography is used to follow involution of cyst and assure normalcy and expected compensatory hypertrophy in the contralateral kidney. Of note, in a health cost analysis, Perez et al. demonstrated that early nephrectomy would be the most efficient therapy in treating these patients. However, this presumption in part assumed long-term follow-up with serial imaging (Pérez et al., 1998).

Recommendations for Multicystic Dysplastic Kidney

A postnatal renal/bladder ultrasound scan should be performed in the early postnatal period to confirm the prenatal findings. Currently, PA are not recommended because of the low risk for UTI. The decision to pursue a VCUG and DMSA is recommended with the caveat that this is not evidence based and the decision to refrain from these studies is acceptable practice. Future long-term prospective outcome studies are needed.

In the setting of a functional solitary kidney, blood pressure measurement, assessment of proteinuria, and the consideration of yearly ultrasonography should be pursued through puberty to monitor for hyperfiltration injury that may occur with compensatory hypertrophy. Of note, the consideration for serial imaging is not evidence based but in part designed to ensure consistent follow-up for this population that may be at increased risk for renal disease in adulthood. Complete involution of the affected cystic kidney should occur over this interval, and persistent cystic kidneys with a solid component may be considered for surgical removal.

Duplication Anomalies/Ureterocele/Ectopic Ureter

The prenatal identification of duplication anomalies typically occurs as a result of the obstruction of the upper pole moiety that follow the Meyer-Weigert rule. Dilation of the upper pole ureter can be seen and differentiated from the lower pole. A duplication anomaly should also be suspected in the setting of ureteral dilation that is greater than associated renal pelvis dilation. (Fig. 22.24). Cystic changes to the dysplastic upper pole may also be present. On occasion, prenatal ultrasonography may detect a cystic mass within the bladder that is more easily identified on postnatal bladder ultrasonography, which differentiates a ureterocele from an ectopic ureter. This may be difficult at times when the ureterocele opening is ectopic within the bladder neck (Chertin et al., 2003;

Godinho et al., 2013; Quintero et al., 2001). In a female, this may lead to LUTO with associated findings of oligohydramnios seen prenatally (Fig. 22.25). Ureterocele disproportion is a rare condition in which a large ureterocele is identified on bladder ultrasonography with minimal upper urinary tract dilation (Share and Lebowitz, 1989). **VUR is a common finding and equally follows the Meyer-Weigert law in which the upper pole moiety will insert more distally in the bladder with the lower pole moiety inserting more cephalad and lateral, which favors VUR** (Fig. 22.26). Most duplication anomalies will occur in females and are bilateral.

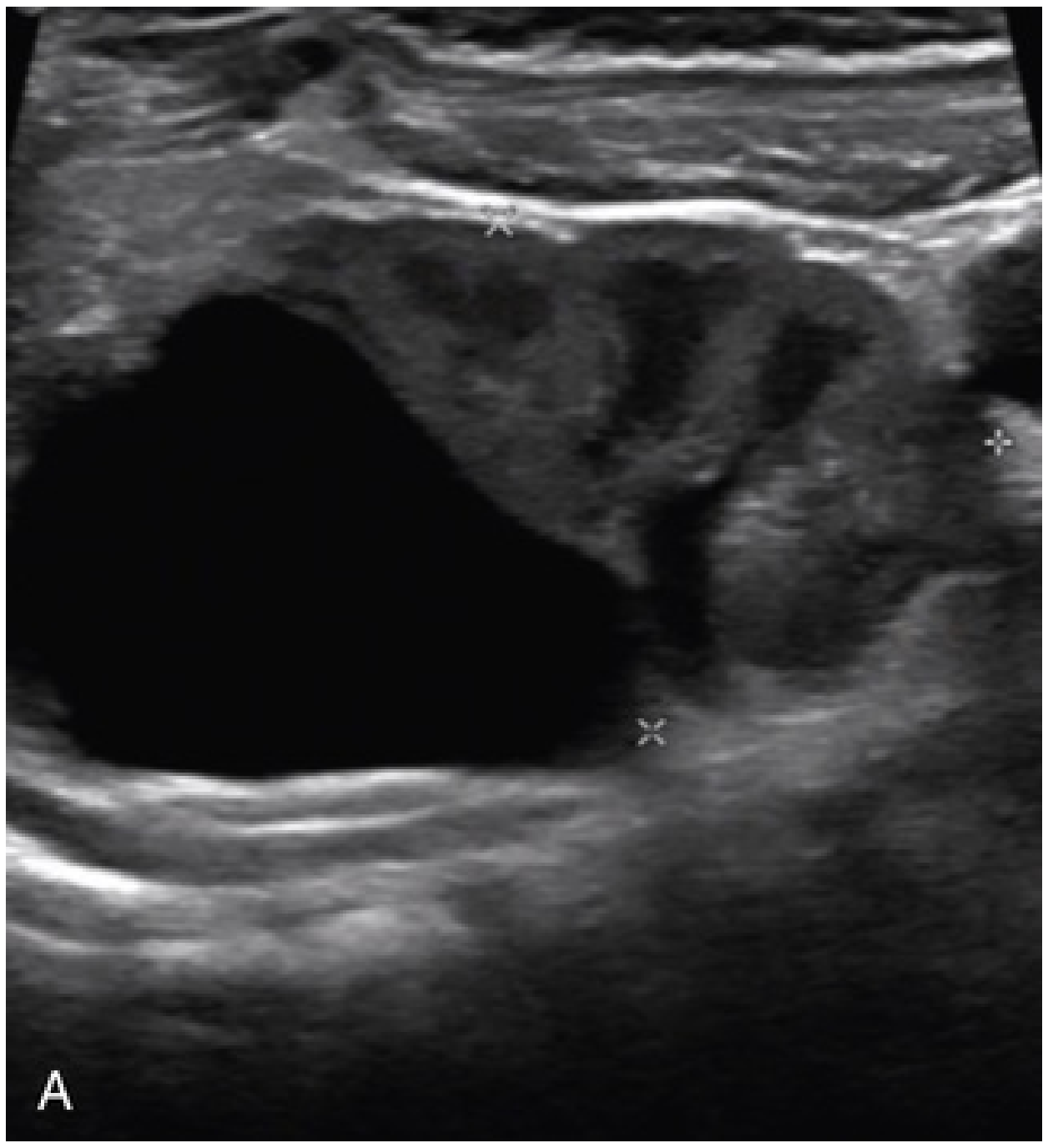

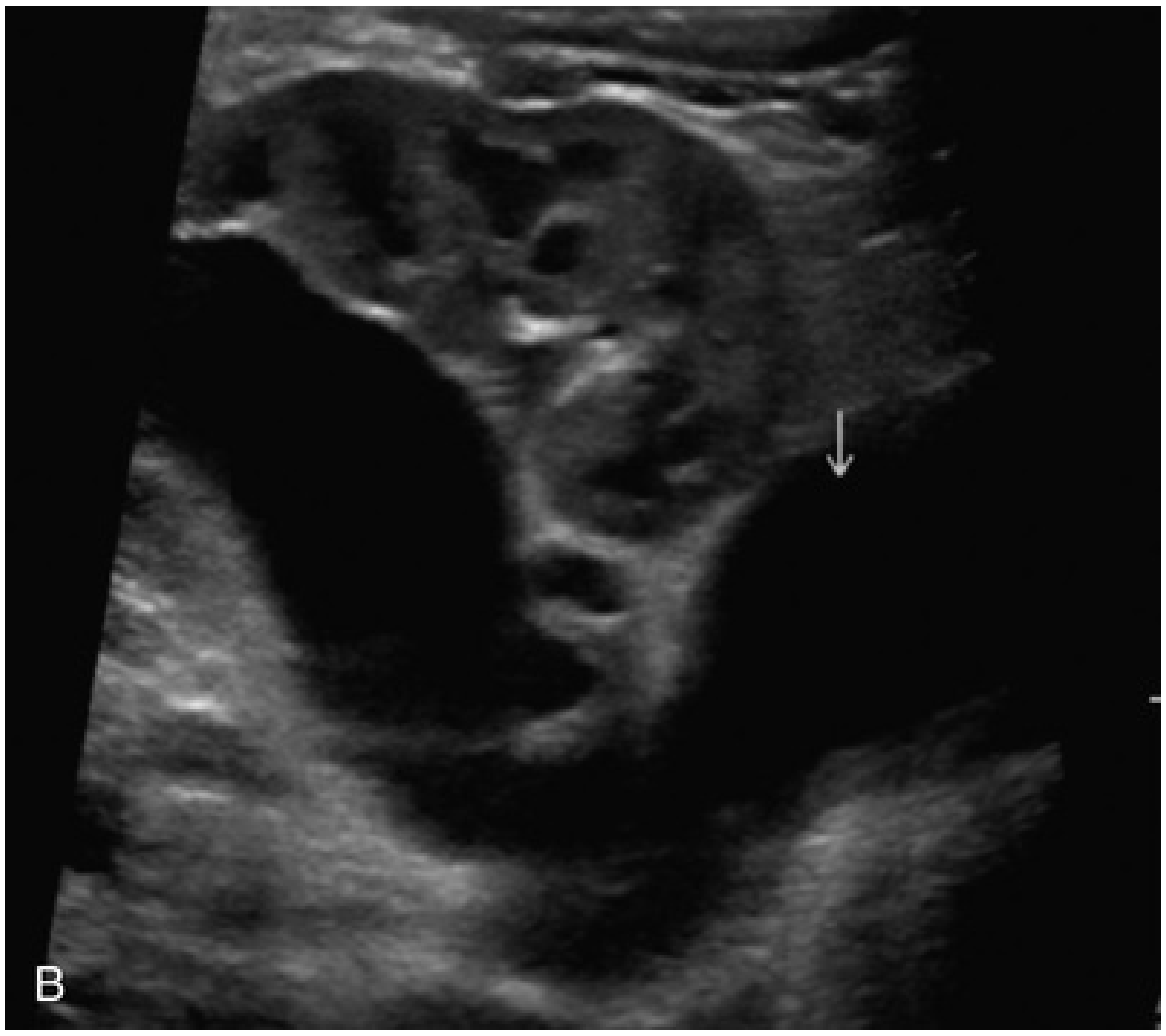

FIG. 22.24 (A and B) Upper pole ureteral dilation *(arrow)* that is more profound than renal pelvis suggestive of duplex system.

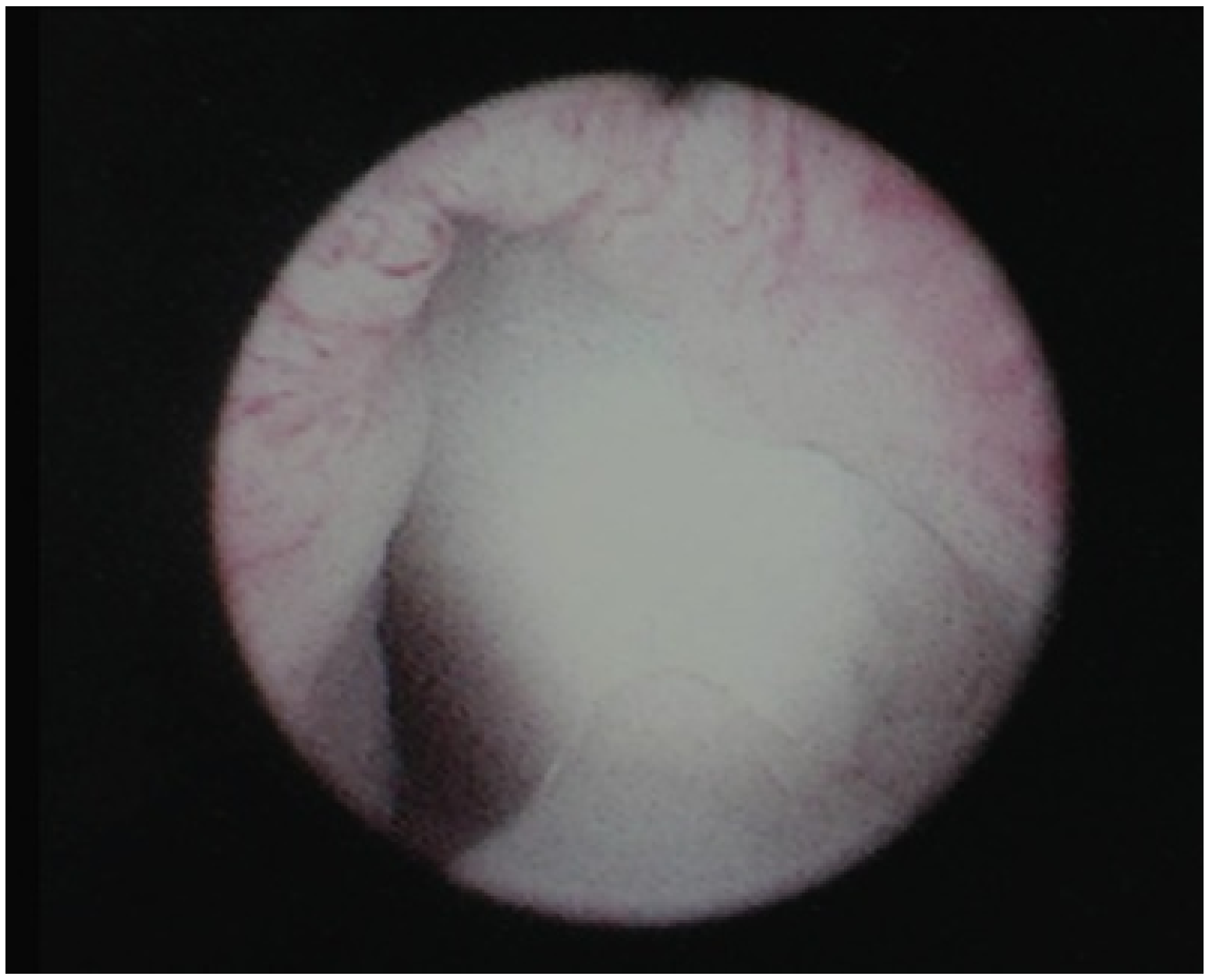

FIG. 22.25 Cystoscopic appearance of bladder outlet obstruction caused by ball-valving ureterocele.

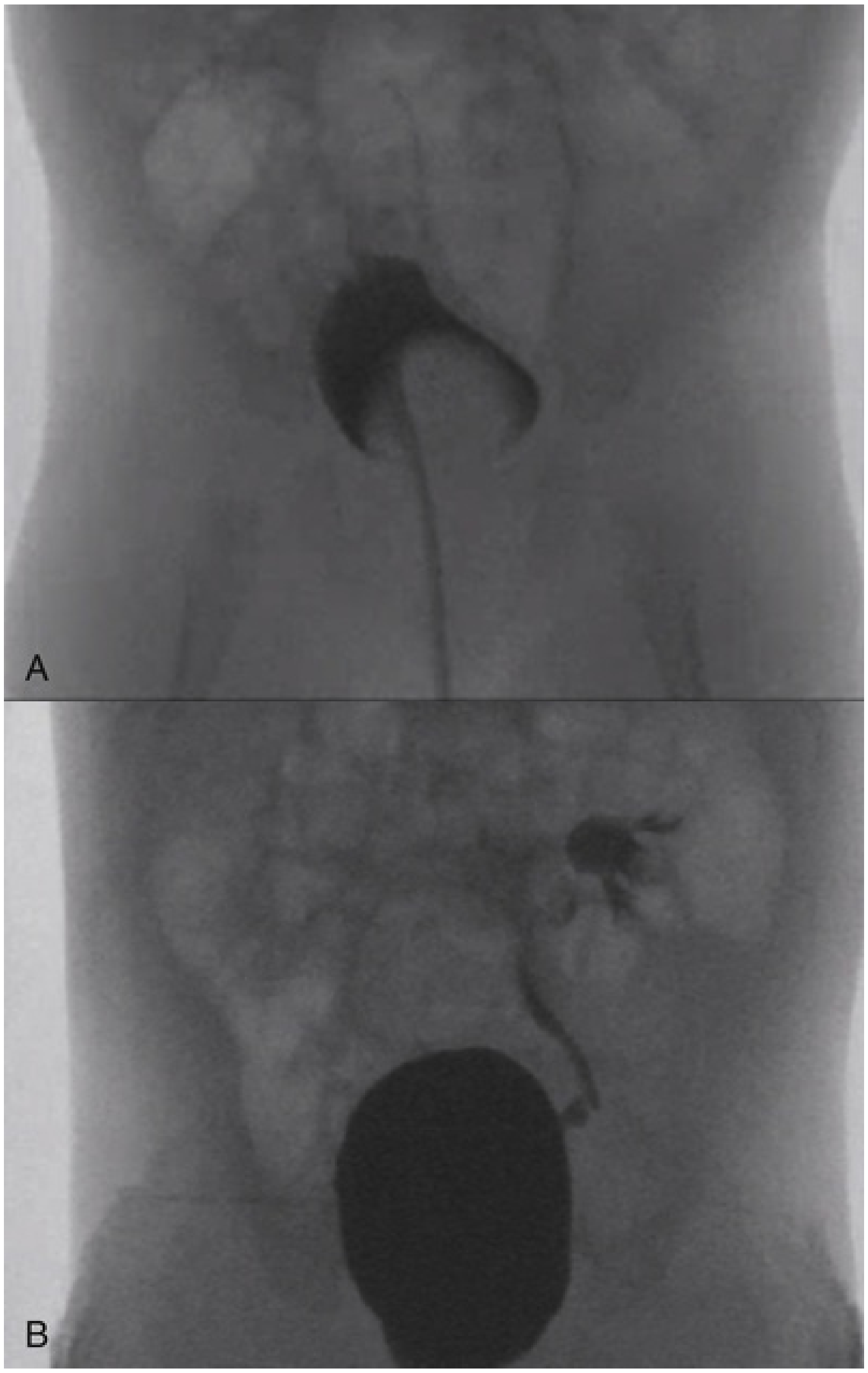

FIG. 22.26 (A) Filling defect on voiding cystourethrogram consistent with ureterocele. (B) “Drooping lily” consistent with lower pole vesicourethral reflex associated with a duplex system.

Postnatal ultrasonography should guide the clinician toward the correct diagnosis in most cases. **A ureterocele can be differentiated from an ectopic ureter based on the thickness of the cystic wall within the bladder. An ectopic ureter that infringes on the bladder may distort the bladder, but the wall of both the bladder and ureter will create two distinct structures** (Fig. 22.27).

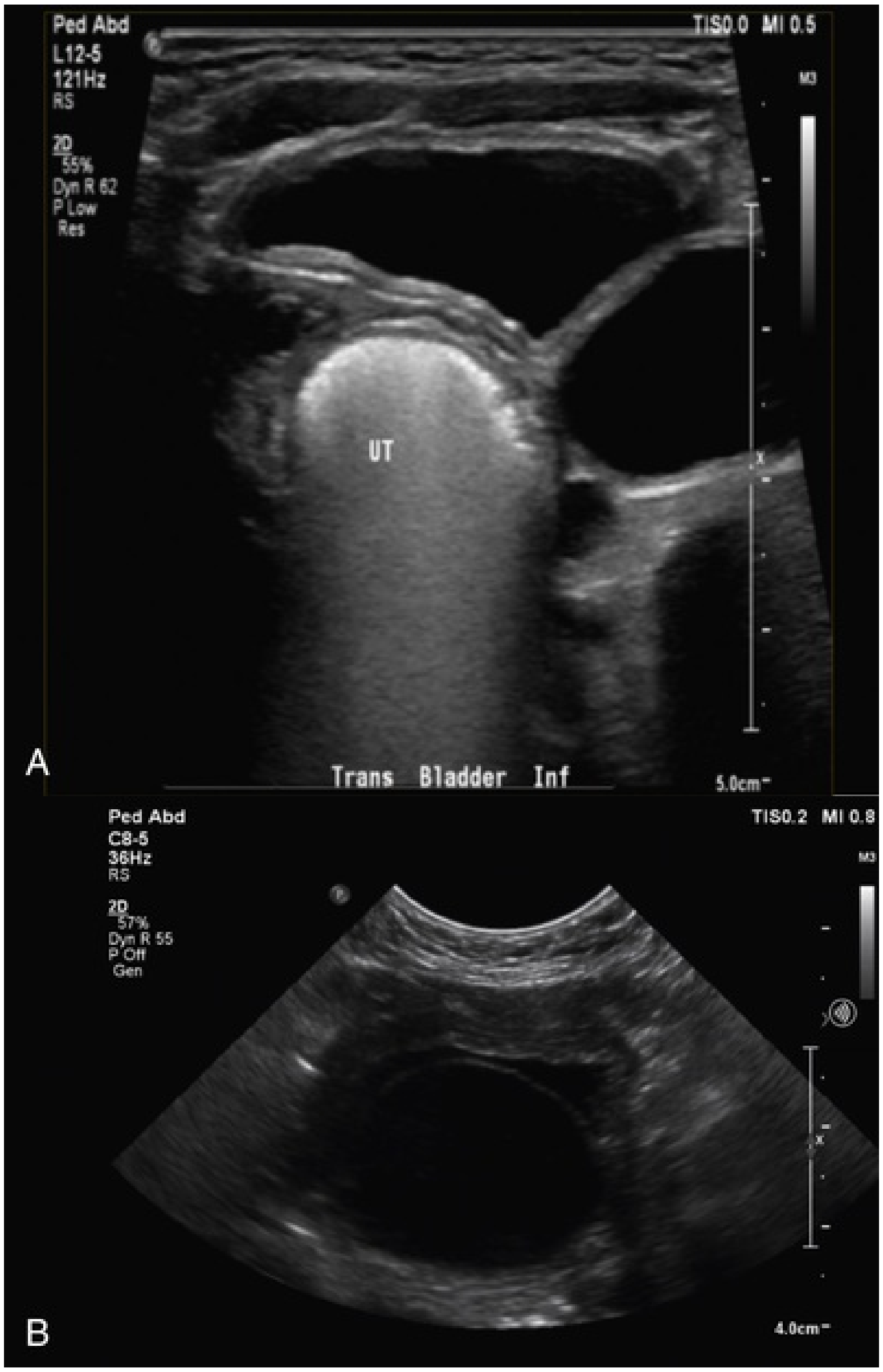
Ped Abd
L12-5
121Hz
RS
2D
55%
Dyn R 62
P Low
Res
TIS0.0 MI 0.5
M3
UT
A
Trans Bladder Inf
5.0cm
Ped Abd
C8-5
36Hz
RS
2D
57%
Dyn R 55
P Off
Gen
TIS0.2 MI 0.8
M3
B
4.0cm

FIG. 22.27 (A) Bladder level ultrasound image demonstrating ectopic ureter with clear bladder muscle tissue plane between the ureter. (B) Bladder level ultrasound image with cystic dilation within the bladder consistent with ureterocele.

Initial management may involve puncture of the ureterocele, but this approach is not absolute. Prenatal puncture to address BOO has been successfully described, but the need for this experimental treatment is rare (Quintero et al., 2001). Traditionally, decompression of the ureterocele is reserved for BOO or sepsis. However, recent practice patterns appear to support an elective role as first-line therapy despite the creation of reflux (Chertin et al., 2003, 2007; Jesus et al., 2011). Furthermore, some centers have supported a “watchful waiting” approach (Direnna and Leonard, 2006).

The primary objective for treatment of duplex systems with ureterocele or ectopic ureter should be directed at preservation of the lower pole moiety. This may involve an upper or lower urinary tract approach. In brief, the upper pole approach may involve nephron sparing or ablative methods, both of which have recently gained popularity with a minimally invasive approach (Mason et al., 2014; McLeod et al., 2014; Storm et al., 2011). The decision with regard to preservation of the upper pole is left to the discretion of the physician, as neither practice is evidence based. Long-term data confirm that most patients with an ectopic ureter can be managed with upper tract surgery alone (De Caluwe et al., 2002). The lower pole approach involves a common sheath ureteral reimplantation (both upper and lower moieties for duplex systems) and is reserved for those at most risk for UTI or high-grade VUR to the lower pole. Hussmann reported long-term follow-up and demonstrated the degree and presence of VUR predicted the need for surgery. In the Mayo experience, the absence of VUR afforded an entirely upper pole approach in all patients without VUR, low-grade VUR resulted in surgery in 40% as the result of UTI, and ureterocele excision was required in 96% of patients with high-grade VUR (Husmann et al., 1995).

Recommendations for Duplex Anomalies

In patients suspected of a ureterocele, an examination of the introitus should ensure the absence of a cystic mass that would correspond to a prolapsed ureterocele (Fig. 22.28). **A postnatal ultrasound scan should be performed shortly after birth with specific attention toward evaluation of the urinary bladder. PAs should begin at birth, as well as the characterization of VUR, size of the ureterocele, and an assessment for BOO. Renal scintigraphy may play a role in evaluating the degree of upper pole function, which may aid in surgical decision-making.** Generally speaking, the degree of VUR and upper moiety function will dictate treatment. For example, in a female patient with a ureterocele who is found to have high-grade VUR to the lower pole and preserved upper pole function, an initial incision would be appropriate given the high likelihood and need for lower urinary tract surgery based on the risk for UTI. For a male patient with no evidence of VUR and dysplastic changes to the upper pole, an upper pole approach may be appropriate with either renal preservation or ablation.

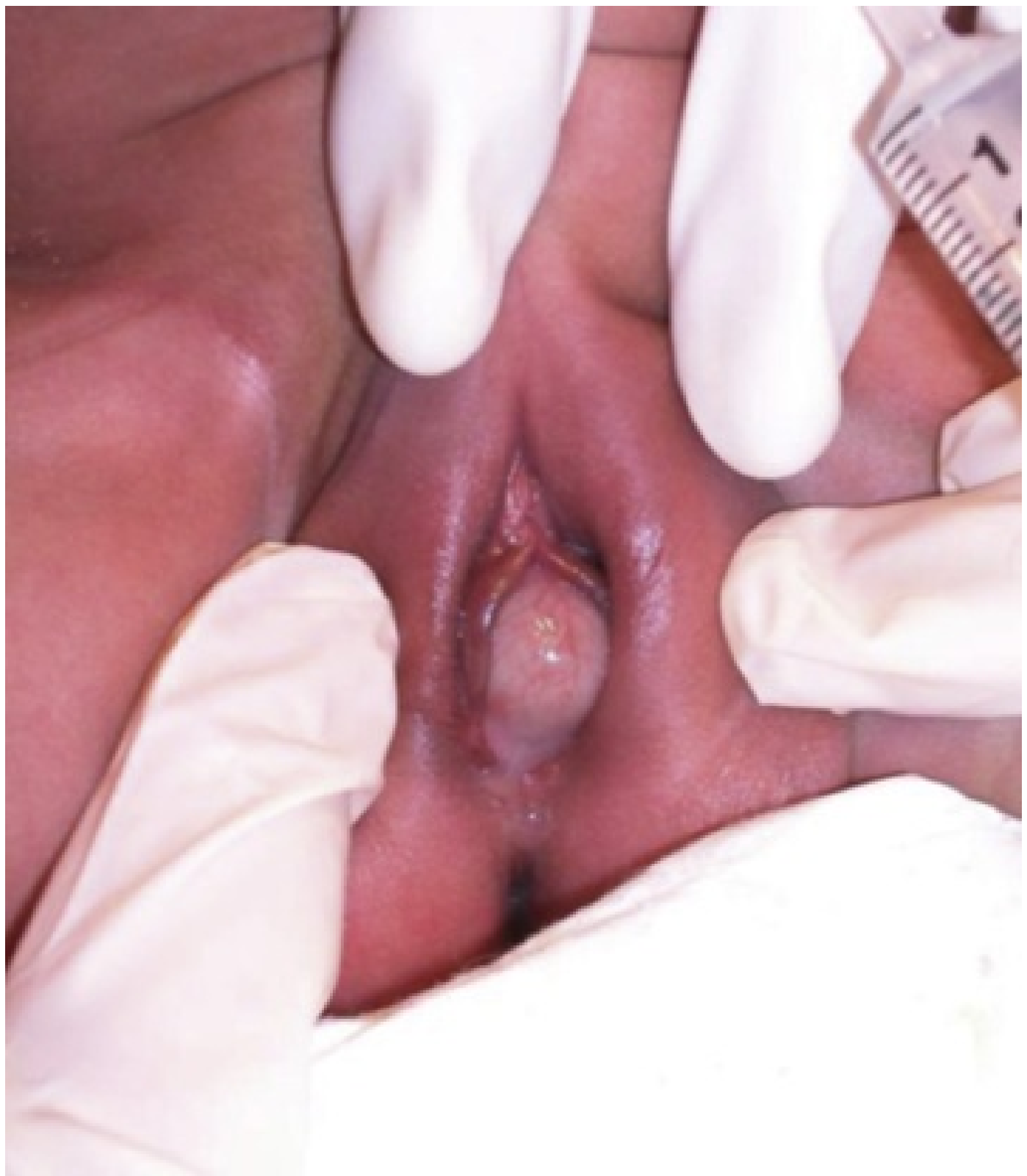

FIG. 22.28 Perineal examination reveals prolapsed ureterocele.

Exstrophy (Bladder/Cloacal)

The diagnosis of bladder/cloacal exstrophy in the prenatal period rarely gives rise for the need to therapeutically intervene. However, this does allow for appropriate identification to aid in prenatal counseling and more importantly afford the opportunity for patients to seek a center of excellence to discuss the anticipated postnatal course. The distinction between bladder and cloacal exstrophy has a profound impact on the natural history of the disease shared by caregivers and providers.

Bladder Exstrophy

Prenatally, bladder exstrophy is hallmarked by a nonvisualized bladder, abnormal genitalia, protruding mass (exstrophic bladder) inferior to a low-lying umbilicus, and widened pubic diastasis and has been reported to be detected in 50% of patients with the diagnosis (Wiesel et al., 2005) (Fig. 22.29AC). As opposed to cloacal exstrophy, the vertebral spine, kidneys, and the remainder of fetal survey is expected to be normal (Gearhart et al., 1995). Bladder exstrophy represents a midline anterior wall defect that affects the bladder and genitalia but should allow for otherwise development free from major organ system dysfunction, as seen with cloacal exstrophy. Some have reported that prenatal MRI may allow for a more complete evaluation of all organ systems to allow the condition to be definitively clarified to represent bladder exstrophy complex (Goldman et al., 2013).

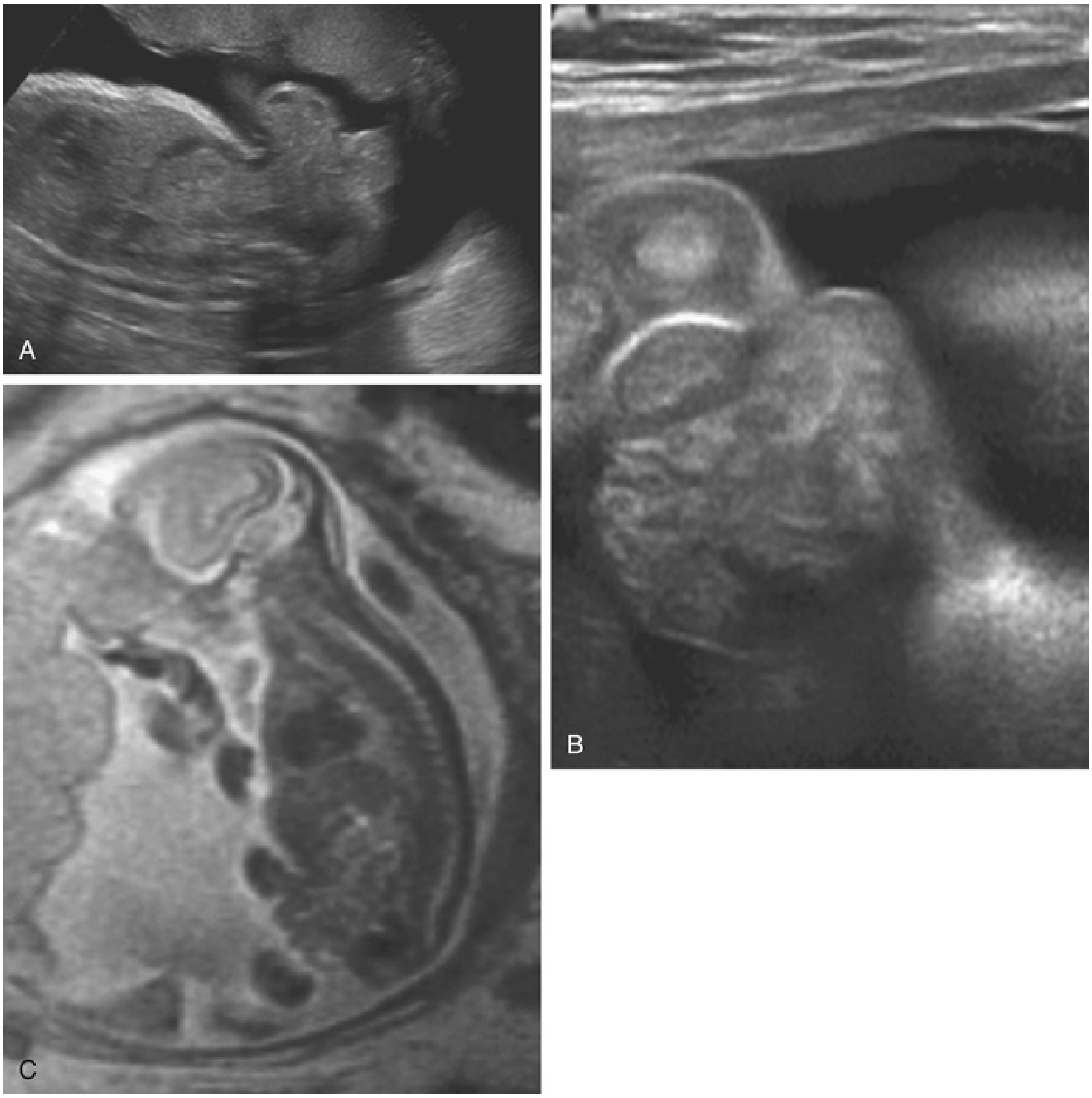

FIG. 22.29 Imaging of a male fetus with bladder exstrophy. (A) Ultrasound image in sagittal plane at 31 weeks' gestational age showing a wisp of umbilical cord, followed in caudal direction *(toward right of image)* by lower abdominal wall mass (exstrophied bladder), urethral plate, and penis. (B) Coronal view showing exstrophied bladder, penis, scrotum, and testes. (C) Sagittal magnetic resonance image showing the same fetus at 21 weeks' gestational age. Note lower abdominal wall, bladder, and penis.

Recommendations for Bladder Exstrophy

Postnatally, bladder exstrophy does not represent an emergent condition. However, the clinician should perform a thorough examination as variants of this condition such as bladder duplication may dramatically affect the expected course of this condition. Imaging should include renal ultrasonography.

Cloacal Exstrophy

The spectrum of omphalocele, exstrophy, imperforate anus, and spinal defects (OEIS) syndrome or cloacal exstrophy varies, and fortunately this condition is extremely rare. In addition to the aforementioned prenatal findings for bladder exstrophy complex, the addition of omphalocele and/or renal, vertebral, or limb anomalies may be encountered (Robin et al., 2007). **Austin et al.** (1998) **reviewed prenatal criteria for the diagnosis with a 9-patient experience that was combined with 13 historical cases in the literature. They found a persistent cloacal membrane in 3 of 22 patients and developed major and minor criteria for classifying the findings** (Table 22.5). Similar to bladder exstrophy, the early identification of cloacal exstrophy allows for prenatal counseling to occur at a center of excellence.

TABLE 22.5

Major and Minor Ultrasound Criteria for Cloacal Exstrophy

MAJOR
Nonvisualization of the urinary bladder Large midline infraumbilical anterior wall or cystic anterior wall structure (persistent cloacal membrane) Omphalocele Lumbosacral anomalies
MINOR
Lower extremity defects Renal anomalies Ascites Widened pubic arches Narrow thorax Hydrocephalus Solitary umbilical artery

Recommendations for Cloacal Bladder Exstrophy

After delivery, imaging of the patient with OEIS complex should include KUB and renal/spine ultrasonography with consideration of MRI. Decisions for surgical intervention will be dictated by the extent of organ system involvement.

Cloacal Malformation/Urogenital Sinus/Congenital Adrenal Hyperplasia

The prenatal detection of combined bladder and vaginal distention should raise the suspicion of BOO secondary to vaginal trapping of urine. The differential diagnosis should include cloacal malformation, urogenital sinus, and/or congenital adrenal hyperplasia (CAH). The latter invariably has a family history with autosomal inheritance, and the former should be associated with distal colonic obstruction, which should be seen prenatally. Prenatal counseling is a fundamental component with these conditions.

Cloacal Malformation

Cloacal malformation or persistent cloaca is rare and occurs 1 in 50,000 births. This condition only occurs in females and is a result of the arrest in development of the urorectal membrane and urogenital sinus that creates direct communication among the rectum, vagina, and urinary tract. **This condition may be associated with oligohydramnios, bilateral urinary tract dilation, and urinary ascites as seen with LUTO in males, as well as a large cystic mass arising out of the pelvis and the presence of calcified meconium caused by rectal obstruction on MRI** (Cilento et al., 1994; Hayashi et al., 2005; Shono et al., 2007; Winkler et al., 2012). One may also see a dilated vagina or uterus, and on occasion this may have a bifid character caused by a uterus didelphys. The proposed mechanism of urinary ascites is retrograde flow of urine through the uterus and fallopian tubes into the peritoneum, which may lead to oligohydramnios, but this will vary depending on the degree of gastrointestinal obstruction. Equally, an association with tracheo-esophageal fistula may be seen and should be considered in the presence of polyhydramnios. The delivery of patients with the potential diagnosis of cloacal malformation should be elective and inclusive of all necessary neonatal, pediatric surgical, and pediatric urologic care providers. The accuracy of prenatal imaging to diagnose this condition varies because of its rarity such that the clinician should have a heightened level of suspicion when the fetal ultrasound scan is suggestive of a persistent cloaca. In review of 6 patients with cloaca, Warne et al. (2002) described the Great Ormond Street experience that required fetoscopy in one patient and use of fetal MRI to diagnose the condition in two patients.

Urogenital Sinus/Congenital Adrenal Hyperplasia

CAH represents a rare autosomal recessive condition that results in a spectrum of genital ambiguity when it occurs in females. The most common variant involves 21-OH deficiency, which involves a defect in the gene that encodes 21-hydroxylase and is located on the short arm of chromosome 6. It is divided into classical, which is subdivided into salt-wasting (75%) and simple virilizing (25%) variants, and nonclassical, which has more benign course of disease. The disease afflicts 1 in 15,000 live births. The condition will clinically affect 1 of 8 in those potentially affected because males will not demonstrate ambiguity (Nimkarn et al., 2009; Winkler et al., 2012). The degree of urogenital sinus formation and genital virilization varies in severity and may be confused with other conditions such as cloacal malformation or urogenital sinus malformation.

Urogenital sinus malformation may also present with vaginal trapping of urine that leads to LUTO, similar to cloacal malformation in the absence of gastrointestinal obstruction (Fig. 22.30A–D). Urogenital sinus malformation typically has normal external genitalia, the finding of which favors the diagnosis of urogenital sinus rather than CAH.

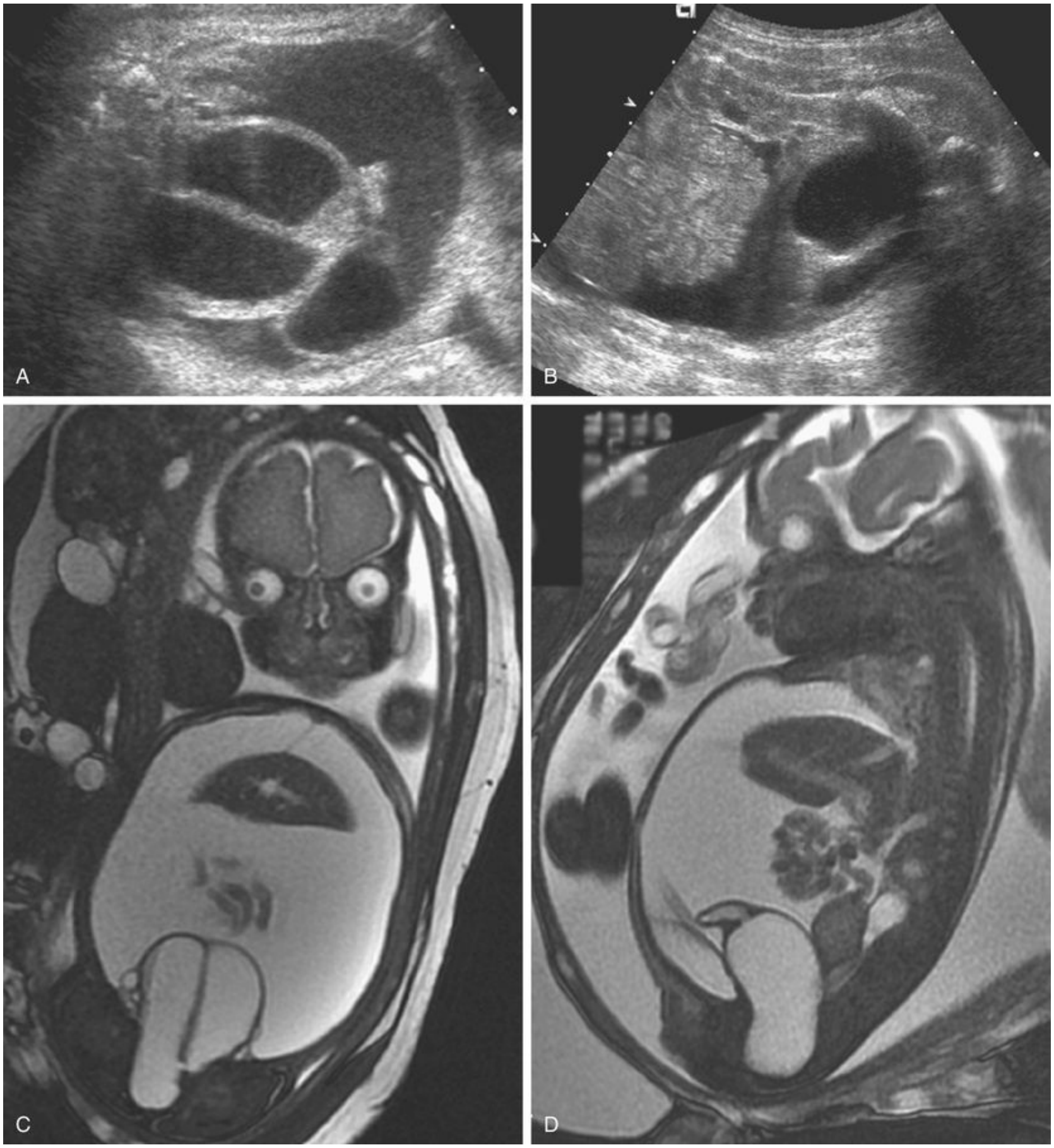

FIG. 22.30 Imaging of a female fetus at 30 weeks' gestational age with cloaca. (A) Transverse ultrasound view of abdomen showing dilated duplicate vagina, urinary bladder, and urinary ascites consistent with cloaca. (B) Sagittal ultrasound image showing bladder, markedly distended vagina, kidney with mild hydronephrosis, and urinary ascites outlining bowel and liver. (C) Coronal magnetic resonance image (MRI) showing duplicate vagina and urinary ascites. (D) Sagittal MRI of bladder, distended vagina, cervix, uterus, and intra-abdominal organs outlined by urinary ascites.

Prenatal Treatment of Congenital Adrenal Hyperplasia

Controversy exists around the prenatal identification and treatment of CAH. The condition is autosomal recessive, and with 50% of pregnancies resulting in a female birth, the overall clinical impact is 1 in 8. The partner (potential parent) with a first-degree relative or sibling with who is considering a pregnancy with a confirmed adult CAH patient should be offered genetic testing to characterize the offspring risk for disease. Fundamentally, prenatal treatment with dexamethasone administered by the 9th week of gestation is effective at reducing virilization in classical CAH in females (New et al., 2001; Nimkarn et al., 2009). This timing precedes the ability to determine fetal sex and thus exposes all children to treatment. Although prenatal treatment appears safe for the mother and fetus, the long-term impact has not been well defined and the needless exposure to 7 of 8 patients may not be justified.

Postnatal Treatment of Congenital Adrenal Hyperplasia

Postnatally, the immediate concern for electrolyte imbalance should be raised. In parallel to electrolyte stabilization, a concerted effort should be made to obtain a final diagnosis, which includes measurement of serum 17-hydroxyprogesterone and genetic testing. **Bladder decompression is a priority in those that present with LUTO secondary to vaginal retention of urine. In some cases, urinary and/or vaginal diversion will be required.** Medical and surgical care of this condition is discussed in Chapters 48 and 49.

Outcomes for Fetal Myelomeningocele Closure

The prenatal measurement of AFP combined with key ultrasound findings affords the opportunity to diagnosis neural tube defects prenatally with a high degree of accuracy **(**D'Addario et al., 2008; Boyd et al., 2008). Another biomarker that may be useful include amniotic fluid glial fibrillary acidic protein (AF-GFAP) (Lopez et al., 2013). As mentioned earlier, early prenatal diagnosis allows the ability for caregivers to consider pursuing consultation at centers of excellence that provide fetal surgical intervention.

To assess the benefit of prenatal closure of myelomeningocele, a multicenter randomized trial comparing prenatal closure versus postnatal closure was published in 2011. Prenatal closure was performed before 26 weeks' gestational age and was found to significantly decrease the need for VP shunting and appeared to improve cognitive ability and motor function as well. The most significant complications included preterm labor and uterine dehiscence (Adzick et al., 2011; Tulipan et al., 2015). **Specific to urology outcomes, prenatal closure did not improve urodynamic parameters or decrease the need for clean intermittent catheterization or urinary reconstruction** (Clayton and Brock, 2018).

Key Points

- Most patients with prenatal UTD will have transient dilation with reported resolution rates between 41% and 88%.
- Prenatal APD dilation of 15 mm in the third trimester is predictive of the need for surgery.
- VUR is reported in up to 31% of patients with prenatal UTD and occurs most commonly in males that have bilateral high-grade disease.
- MCDK does not pose an increased risk for Wilms tumor and can be safely observed in most patients.
- Duplication anomalies may be associated with VUR to the lower pole moiety, which may influence decisions for intervention to the obstructed upper pole moiety.
- Megaureter will resolve spontaneously in a majority of patients. However, surgical intervention is indicated for recurrent UTI, decreased function, or increasing UTD. Temporizing diverting procedures are recommended for patients who are younger than 1 year of age.
- Fetal closure of myelomeningocele appears to increase motor/cognitive skills and decrease the need for a VP shunt, but it does not improve urologic symptoms or urodynamic parameters or decrease the need for urinary reconstruction.

Perinatal Urgencies/Emergencies

Neonatal Urologic Emergencies

Neonatal urologic emergencies can be caused by a variety of genitourinary anomalies, birth trauma, or vascular etiologies. The urologist will often be consulted on an emergent basis for a urologic condition at birth based on clinical signs, symptoms, or physical examination. Thorough evaluation of the newborn should be pursued.

Abdominal Distension

Abdominal distension can be caused by a cystic lesion, solid mass, or urinary ascites as a consequence of obstruction or extravasation. Adjacent organs must be closely examined for concomitant involvement. A thorough examination of the entire abdomen should be performed.

Upper Urinary Tract Obstruction

Abdominal distension caused by urine collection is commonly a result of urinary tract obstruction, which is usually anticipated after detection on routine prenatal ultrasonography. The most common site of urinary tract obstruction is the UPJ. In addition to the upper tracts, urinary tract obstruction may occur at the UVJ, or the insertion site of an ectopic ureter. Percutaneous drainage may be required in select scenarios to address respiratory compromise or feeding intolerance (Fig. 22.31).

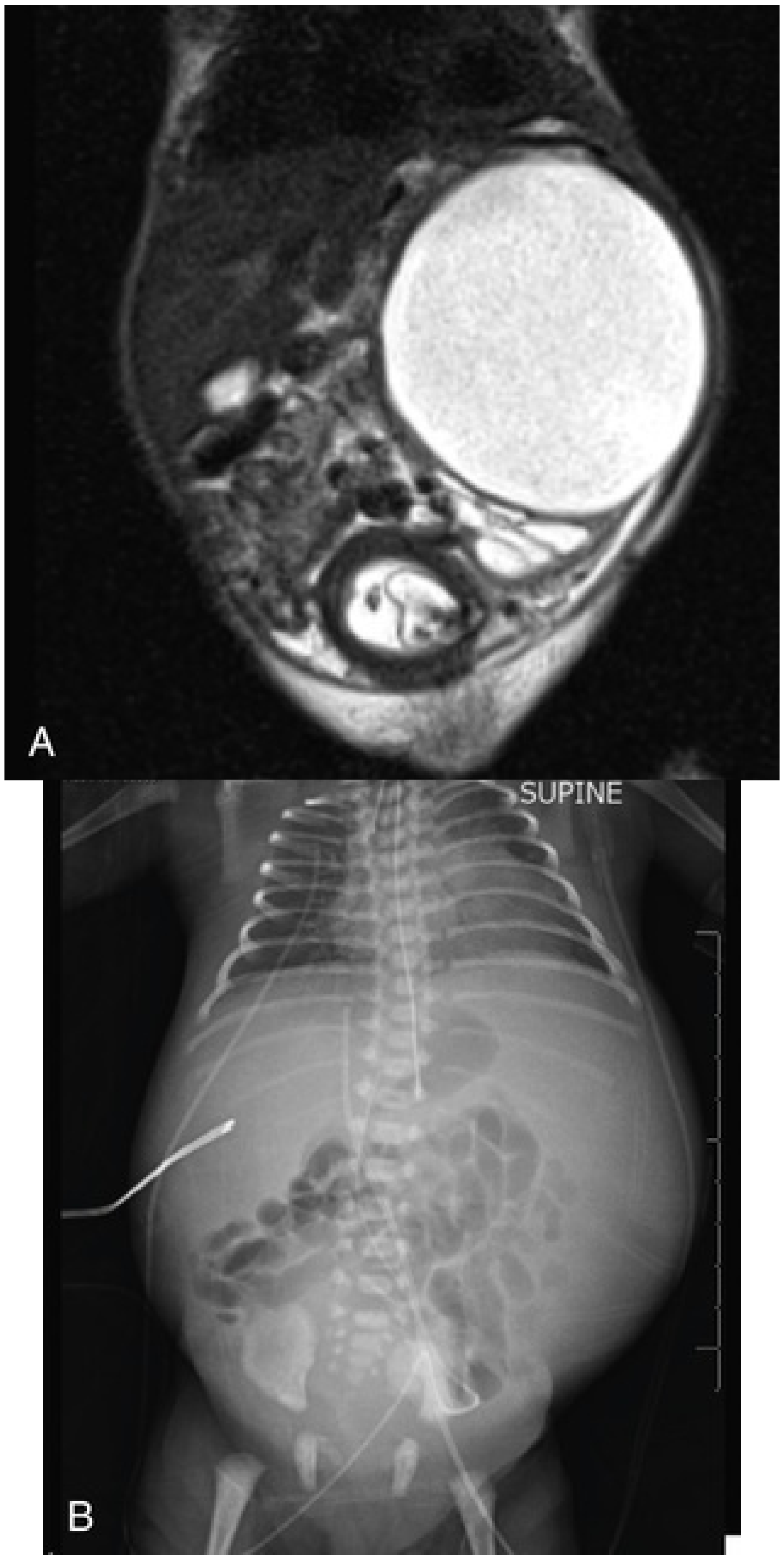
A
SUPINE
B

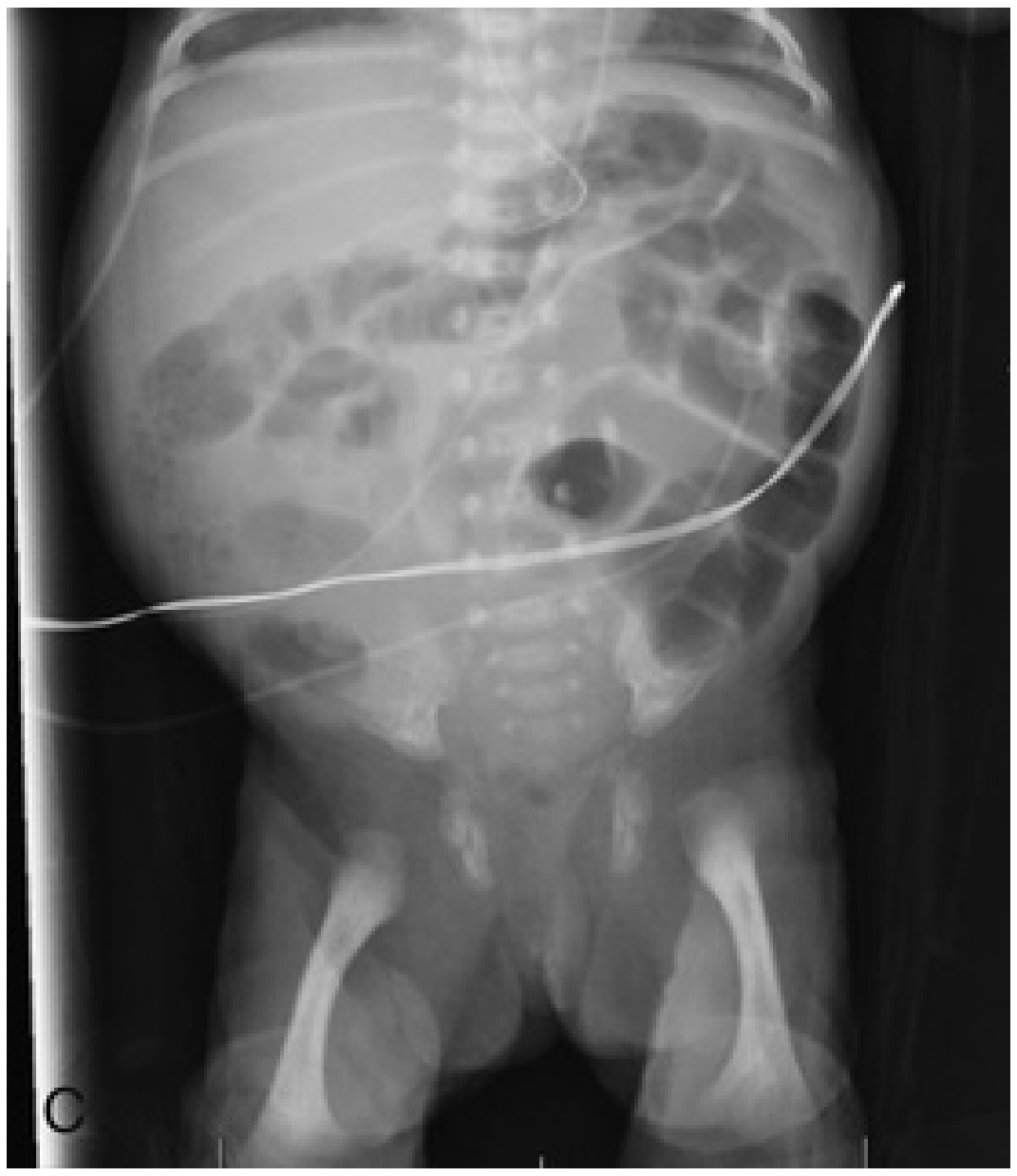

FIG. 22.31 (A) Neonatal magnetic resonance image demonstrating massive upper pole obstruction on left with ureterocele in bladder. (B) Left upper quadrant mass effect from upper pole obstruction. (C) Normalization of left upper quadrant after decompression of ureterocele.

Lower Urinary Tract Obstruction

Urinary Ascites

Urine accounts for neonatal ascites in up to 30% of cases (MacDonald et al., 1999). Neonates may display respiratory distress, oliguria/anuria, hyponatremia, hyperkalemia, and elevated serum creatinine (Oei et al., 2001). **PUV is the most common cause of urinary ascites** (Redman et al., 1979)**. Other causes of urinary ascites includes bladder rupture, cloacal malformation, persistent urogenital sinus, and urethral atresia** (Ravitz et al., 1973).

When bladder perforation is suspected, a catheter should be placed. Urine output and serum electrolytes should be followed closely. Bladder rupture can be confirmed with biochemical analysis of peritoneal fluid accompanied by a VCUG (Vasdev et al., 2009). The etiology of bladder rupture is often unexplained in the absence of obvious outlet obstruction (Vasdev et al., 2009). Most cases of spontaneous perforation heal with conservative therapy (Morrell et al., 1985). Although trauma is a rare cause of bladder perforation, there are reports of iatrogenic bladder rupture during placement of umbilical catheters that resolved with prompt recognition and surgical repair (Diamond and Ford, 1989; Dmochowski et al., 1986; Mata et al., 1987).

In a patient with persistent urogenital sinus or cloaca, urine pools in the vagina and can travel retrograde into the uterine cavity. Urinary ascites forms by urine extravasation directly into the peritoneal cavity through the fallopian tubes (Hahn-Pedersen et al., 1984). This can be diagnosed on VCUG.

Percutaneous drainage of urine may be required in select scenarios to relieve abdominal distention that affects pulmonary function.

Urinary Retention (>24 Hours After Birth)

BOO most commonly occurs in males presenting with LUTO, which may be caused by PUV, urethral atresia, or in rare occasions ureterocele. The condition will occur less commonly in females, and a high index of suspicion for urogenital sinus anomaly with vaginal distention should be considered. Equally, ureterocele may result in urinary retention as well. In addition to the aforementioned evaluation for each diagnosis, therapeutic intervention to relieve the obstruction should be pursued.

A catheter should be placed in the bladder. This may be difficult in select scenarios. For males, with PUV, a high bladder neck may impair advancement. The clinician should try placing a finger in the rectum to deflect the catheter above the bladder neck. For females, a catheter should be directed toward the bladder. However, drainage of the vagina is adequate as well and may allow for voiding.

In both scenarios, if attempts to decompress the bladder are unsuccessful, then percutaneous drainage should be pursued. **The Seldinger technique using a 16-gauge angiocatheter will allow passage of a 3.5-Fr feeding tube, or using a 14-gauge angiocatheter will allow passage of a 5-Fr feeding tube.**

In select scenarios with the urogenital sinus anomaly, intermittent drainage of the vagina will not allow bladder drainages, and a vesicostomy and/or vaginostomy may be required until definitive management can be performed (Fig. 22.32).

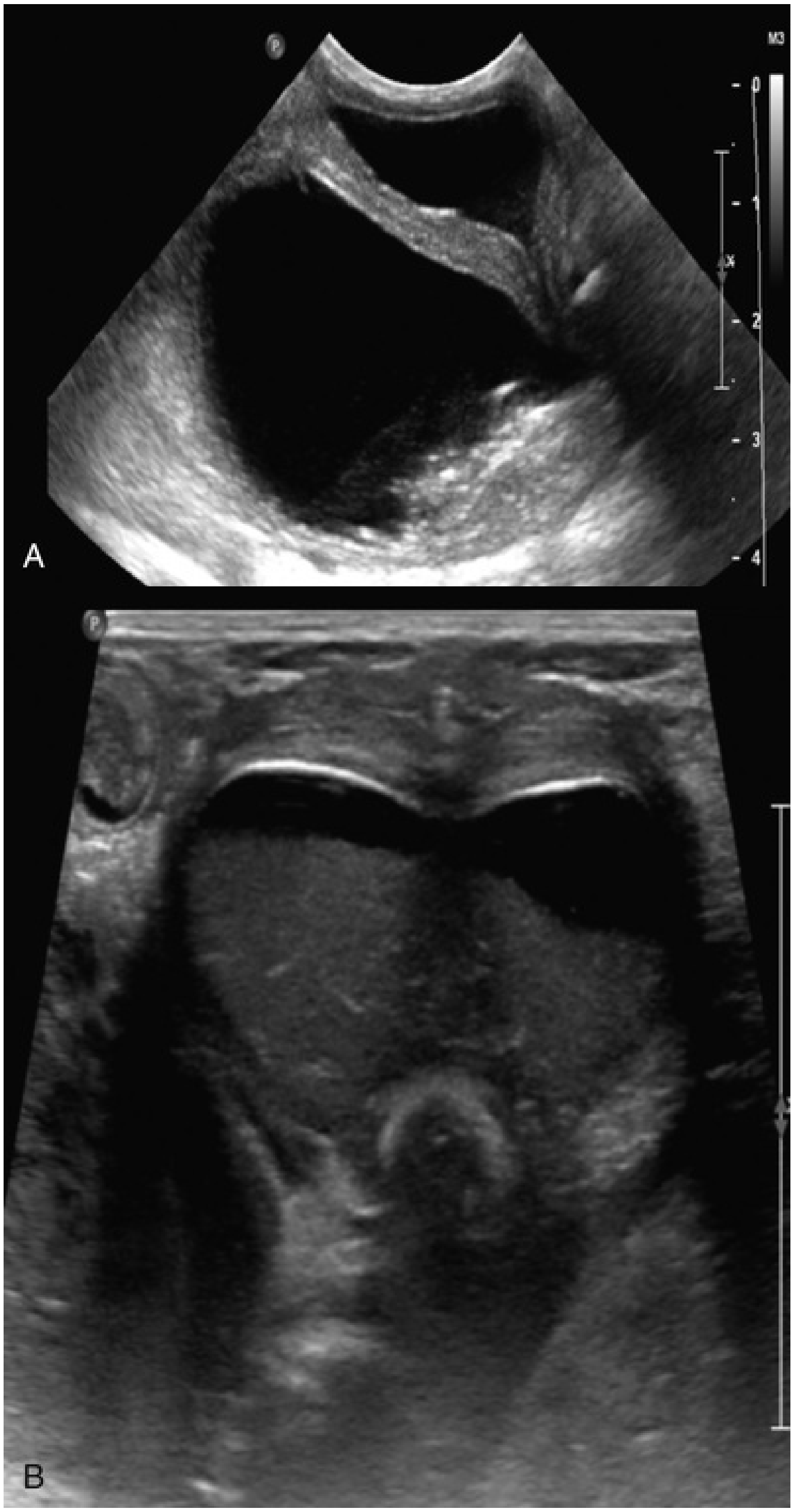
P
M3
0
1
2
3
4
A
P
B

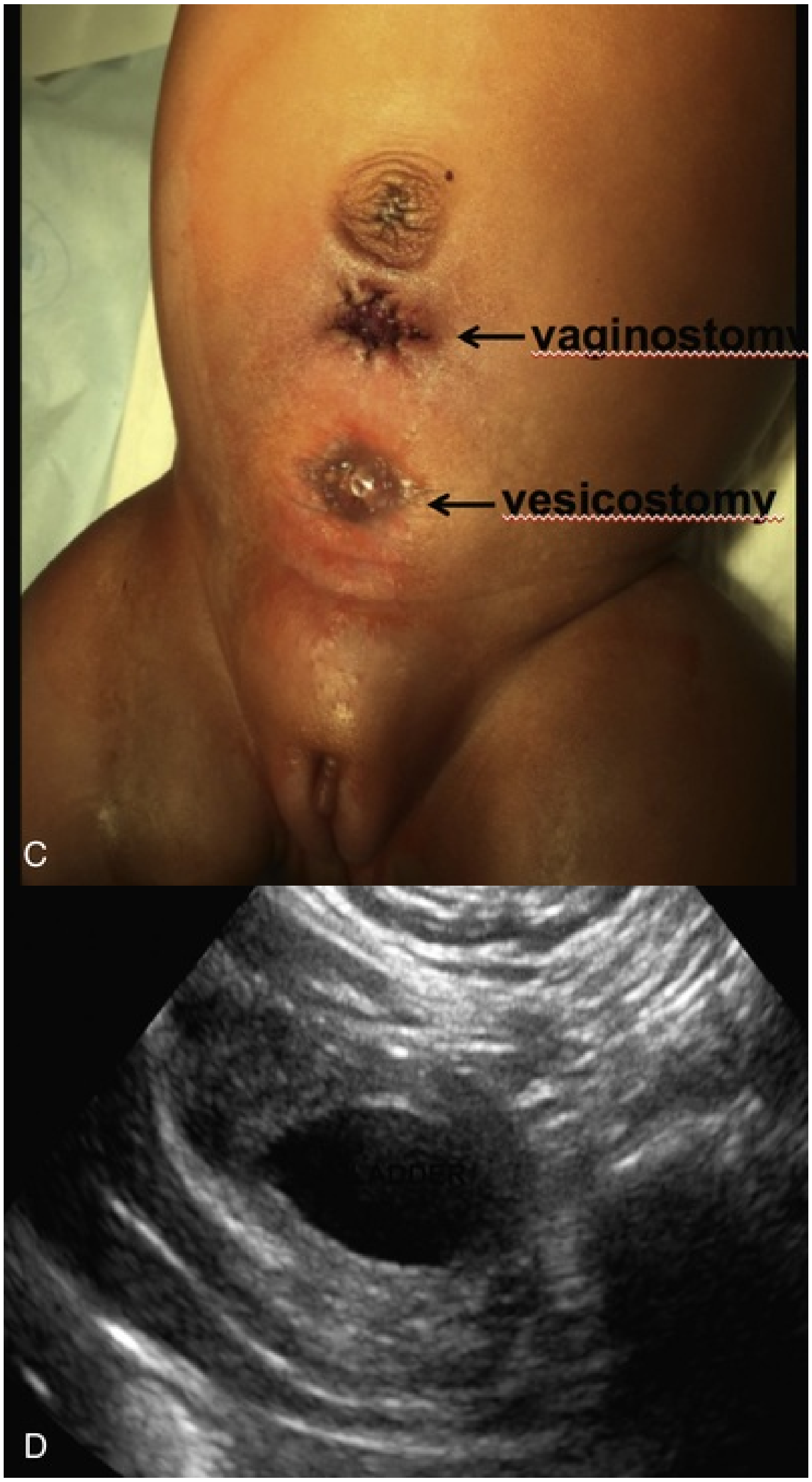

FIG. 22.32 (A and B) Sagittal and transverse ultrasound image of bladder and vagina demonstrating dilation despite intermittent catheter drainage of the bladder. (C) Vaginostomy and vesicostomy. (D) Status post vaginoplasty with complete decompression of vagina with normal cycling of the bladder.

Solid or Cystic Renal Masses

Abdominal masses may be organized into four broad categories: renal cystic lesions, pelvic cystic lesions, solid lesions, and nongenitourinary lesions. Renal cystic lesions include MCDK, autosomal recessive polycystic kidney disease, autosomal dominant polycystic kidney disease, and cystic nephroma. MCDK will appear as a multiloculated mass with little to no renal parenchyma on postnatal ultrasonography. Bilateral evaluation is warranted as the presence of contralateral anomaly such as VUR or UPJO is common (Al-Khaldi et al., 1994; Glassberg et al., 1987).

Renal solid lesions are uncommon in newborns. The most common solid renal tumor is congenital mesoblastic nephroma (Lamb et al., 2017; Glick et al., 2004). Although most patients are diagnosed between 1 and 5 years of age, Wilms tumor can be present at birth (Homsey et al., 1997). Other causes of solid renal lesions include ossifying renal tumor, rhabdoid tumor, clear cell sarcoma, and neuroblastoma. Patients commonly present with an abdominal mass and hematuria. Paraneoplastic syndromes such as hypertension and hypercalcemia have been reported (Glick et al., 2004). **Cystic and solid lesions can be distinguished on postnatal ultrasonography along with a careful family history to detect autosomal dominant or autosomal recessive polycystic kidney disease.** Further workup is determined based on sonographic findings.

Adrenal hemorrhage may be detected on renal ultrasonography prompting urologic consultation. Adrenal hemorrhage is more common on the right side with 10% to 15% of cases presenting bilaterally (Felc, 1995; Mittelstaedt et al., 1979). Suspected causes of adrenal hemorrhage include birth trauma, hypoxia, sepsis, or coagulopathy (Velaphi and Perlman, 2001). An adrenal hemorrhage commonly appears as an echogenic mass within the adrenal gland with absence of flow on Doppler signal (Singh, 2013). **An adrenal hemorrhage can range from a small incidental finding without clinical significance to a life-threatening hemorrhage. Clinical manifestations include anemia, jaundice, hypotension, and abdominal mass** (Khuri et al., 1980)**. Scrotal hemorrhage may be present in patients with a patent processus vaginalis prompting evaluation for an acute scrotum** (Avolio et al., 2002; Duman et al., 2004). The major alternative diagnosis is neuroblastoma, which may require further evaluation with MRI. Serial **ultrasonography should be performed every 1 to 2 weeks to demonstrate decreasing size of an adrenal hemorrhage.** Over time, a resolving adrenal hemorrhage will display peripheral eggshell calcifications as opposed to the stippled appearance of neonatal neuroblastoma.

Pelvic cystic lesions can be attributable to a distended bladder or urinary ascites as discussed earlier. Another potential cause in a female patient could be hydrometrocolpos, a condition in which the vagina is distended with cervical secretions caused by vaginal atresia, transverse vaginal septum, or imperforate hymen (Hahn-Pedersen et al., 1984). Alternatively, a urogenital sinus or cloaca may result in distension of the vagina with urine (Hahn-Pedersen et al., 1984). **It is important to carefully review the imaging as hydrometrocolpos can be mistaken for a distended bladder.** Ovarian cysts are common, occurring in up to 30% of female neonates (Bryant and Laufer, 2004). The characteristic ultrasound appearance is an anechoic, unilocular mass in the fetal pelvis (Meizner et al., 1991). Most ovarian cysts resolve spontaneously in the first 6 months of life (Bagolan et al., 2002).

Anorectal Malformation

The urologist should suspect genitourinary and spinal anomalies in any patient who presents with anorectal malformation as the incidence can approach 75% (McLorie et al., 1987). The most common anomalies include VUR, renal dysplasia, renal agenesis, and cryptorchidism (McLorie et al., 1987). The initial workup should include a thorough inspection of the perineum and back, and ultrasonography. The neonate should undergo spinal ultrasonography in the newborn period to rule out a tethered cord. **Assessment for VUR can be combined with videourodynamics and performed at 6 weeks of age. The patient should be maintained on urinary prophylaxis until this is performed.**

Ambiguous Genitalia

The urologist may be consulted emergently to examine a neonate born with ambiguous genitalia. This type of consultation can cause severe parental anxiety, and care should be taken to address parental concerns with sensitivity. **It is important to involve a multidisciplinary team of clinicians who are well-versed in disorders of sexual differentiation such as an endocrinologist, psychiatrist, and geneticist. The medical team should focus on correct diagnosis of the condition and gender assignment and should counsel the family appropriately on relevant management** (Lambert et al., 2010).

The most common cause of ambiguous genitalia at birth is CAH, which can affect up to 1 in 16,000 births (Speiser and White, 2003). Of babies born with ambiguous genitalia, 46,XX disorder of sex development (DSD) is the most common and results from exposure to androgens in fetal life caused by enzyme deficiency in the testosterone pathway or maternal exposure to androgens. Physical examination will not demonstrate palpable gonads. Ultrasonography will reveal a uterus and ovaries.

Initial evaluation should focus on the identification of classical salt-wasting CAH in which aldosterone synthesis is disrupted. An elevated serum potassium and low serum sodium level can lead to dehydration and cardiac arrhythmias. Laboratory testing should include karyotyping and serum studies including electrolytes, 17-hydroxyprogesterone, testosterone, and dihydrotestosterone levels. Other less common diagnoses that may account for ambiguous genitalia at birth include 46,XY DSD, 46,XX testicular DSD, sex chromosome DSD, and ovotesticular DSD. Accurate diagnosis of these conditions may require gonadal biopsy (discussed in detail in Chapter 48).

Intralabial Masses in a Female Patient

A clinician who is consulted to examine a newborn female with an interlabial mass should consider four main diagnoses: **imperforate hymen, prolapsed urethra, prolapsed ureterocele, and paraurethral cyst.** The diagnosis is often confirmed on physical examination. Gentle probing of the mass with a cotton-tipped applicator will assist in elucidating perineal anatomy. **An imperforate hymen or prolapsed urethra will appear in the midline. Hydrometrocolpos caused by imperforate hymen will appear as a white, bulging membrane at the introitus with or without associated UTD** (Turner and Leonard, 1997). Sonography will demonstrate fluid collection behind the bladder. Treatment involves incision of the hymen to allow the milky white secretions to drain from the vagina. **Urethral prolapse is uncommon in the newborn period. It appears as a circumferential collar of edematous and ecchymotic tissue at the urethral meatus and is more common in African-American females** (Lowe et al., 1986). Symptomatic treatment with warm compresses, topical moisturizers, and prevention of straining and coughing is advised.

Interlabial masses that typically do not appear in the midline include prolapsed ureterocele and paraurethral cyst. In both cases, an intact hymenal ring will be identified posterior to the lesion. A prolapsed ureterocele appears as a cystic structure emanating from the urethral meatus. Confirmation is achieved with ultrasonography and VCUG. A parameatal cyst is an opalescent, ovoid structure that will sometimes displace the urethral meatus and may interfere with urinary stream. Most parameatal cysts resolve without intervention (Herek et al., 2000).

Oliguria/Anuria

Most healthy neonates will void within the first 24 hours of life (Vuohelainen et al., 2008)**. Delay beyond the first day of life is generally benign but may result in parental anxiety. On examination, gentle palpation of the suprapubic region may prompt the neonate to void.** Ultrasound examination may be performed to visualize a distended bladder. Healthy males will void in a predictable pattern following circumcision. Seventy-five percent of breastfed males and 100% of formula-fed infants will void within 8 hours following circumcision (Narchi and Kulaylat, 1998).

Gross Hematuria

The urologic consultation for neonatal gross hematuria has a wide differential diagnosis (Table 22.6**). Urinalysis with microscopy should be performed to confirm that the blood is urinary in origin.** In female neonates, blood on the diaper is caused by withdrawal from maternal estrogens and will resolve spontaneously without intervention. Furthermore, blood on the diaper from dermatitis after a circumcision or red staining of urate crystals may be falsely attributed to hematuria.

TABLE 22.6

Causes of Neonatal Gross Hematuria

VASCULAR
• Renal vein thrombosis • Renal artery thrombosis • Bleeding disorder (vitamin K deficiency, thrombocytopenia)
URINARY TRACT OBSTRUCTION
• UPJO • PUV
ANATOMIC

• Autosomal recessive PKD • Autosomal dominant PKD • Medullary sponge kidney • Arteriovenous malformation
TRAUMA
• Suprapubic aspiration/traumatic catheterization
TUMORS
• Wilms tumor • Mesoblastic nephroma
RENAL
• Renal cortical/papillary necrosis • Glomerulonephritis

PKD, Polycystic kidney disease; *PUV,* posterior urethral valve; *UPJO,* ureteropelvic junction obstruction.

Initial workup should include abdominal ultrasonography with Doppler to evaluate the vasculature. The presence of hypertension in a neonate with gross hematuria suggests greater severity of disease. The clinician should suspect a thrombotic event, polycystic kidney disease, or renal cortical necrosis. **The most common thrombotic event is renal vein thrombosis (RVT), which accounts for up to 20% of cases of gross hematuria. RVT may present with the classic triad of gross hematuria, flank mass, and thrombocytopenia. Risk factors include maternal diabetes, prematurity, umbilical venous catheterization, and polycythemia.** Up to 50% of neonates with RVT have a prothrombotic disorder and should undergo hematologic evaluation (Kuhle et al., 2004). **Treatment consists of aggressive hydration and expectant management. Anticoagulation should be considered, and consultation with pediatric nephrology should be obtained.**

Renal artery thrombosis (RAT) is chiefly caused by umbilical artery catheter placement. The clinical presentation includes hypertension and congestive heart failure. A renal scan may reveal lack of perfusion to areas of the cortex. The umbilical artery catheter should be removed and thrombolytic therapy may be initiated (Schmidt and Andrew, 1995).

Renal cortical necrosis can result from any condition in which perfusion to the kidneys is decreased. Risk factors include hypotension, anoxia, severe hemorrhage, necrotizing enterocolitis, sepsis, placental abruption, or twin-twin transfusion syndrome (Jernigan, 2014). Renal ultrasonography will demonstrate loss of corticomedullary differentiation with a hypoechoic rim at the edge of the renal cortex (Sefczek et al., 1984). Treatment is supportive. Neonates who experience renal cortical necrosis carry a lifetime risk for renal failure.

Scrotal Mass in the Neonate

The assessment of a newborn scrotal mass should discern the acuity of the condition. A thorough discussion with the nursing staff and delivery team combined with palpation should allow for this assessment. The differential diagnosis is listed in Table 22.7.

TABLE 22.7

Causes of Scrotal Masses in the Neonate

Extravaginal torsion
Appendage torsion
Incarcerated hernia
Hydrocele
Epididymal cyst
Meconium
Testis tumors
Trauma
Hematoma from adrenal hemorrhage
Tumor seeding (renal or adrenal tumors)

Testicular Torsion

Testicular torsion in the newborn may be time-sensitive depending on the acuity of the presentation. Typically, torsion in the newborn period is extravaginal, which involves twisting of the tunica vaginalis and the spermatic cord contained within. Extravaginal torsion may be categorized into two separate phenomena, prenatal torsion (in utero) and postnatal torsion (acute) (during the first 30 days of life). This distinction is important because the salvage rate of a prenatally torsed testis is nearly nonexistent, whereas a postnatal extravaginal torsion carries a salvage rate of up to 44% (Brandt et al., 1992; Sorensen et al., 2003). Indeed, a survey of pediatric urologists found that 43% of respondents would treat a prenatal torsion as a surgical emergency, whereas 93% would immediately explore a neonate with postnatal torsion (Broderick et al., 2013).

A neonate with prenatal testicular torsion will present with an enlarged discolored scrotum accompanied by a nontender, solid testis that is fixed to the scrotal wall. In contrast, postnatal torsion will present with a postnatal change in scrotal examination (erythema and/or swelling), and the testis will be tender. In prenatal torsion, the testis will likely appear hyperechoic and avascular. In both prenatal and postnatal torsion, the testis can appear heterogeneous in echotexture. Bilateral or unilateral hydrocele may be present. Doppler studies will demonstrate absence of flow in the affected testis (Arena et al., 2006).

In the case of a nonsalvageable prenatal torsion, a contralateral orchidopexy may be performed on an urgent basis to avoid the devastating consequence of asynchronous contralateral torsion. There is no uniform agreement among pediatric urologists in regard to the urgency or ultimate need to explore these children. Generally, the risk for extravaginal torsion is thought to be present for only the first few weeks of life, and intervention should be pursued before this window closes.

For postnatal testicular torsion, management should be similar to what is recommended for acute testicular torsion that appears later in life, recognizing that the timing of presentation varies. The decision to proceed with immediate surgical exploration should be measured in which the parents are aware of the low salvage rate for the affected testis (Brandt et al., 1992; Sorenson et al., 2003). The main rationale behind intervention for postnatal torsion is the prevention of asynchronous contralateral torsion. A spinal anesthetic can be employed to avoid neonatal exposure to inhalation anesthetic.

To identify a scrotal mass, a thorough physical examination should be undertaken. Transillumination can assist in identifying a hydrocele. Gentle palpation of the mass may unveil a reducible inguinal hernia or a communicating hydrocele. An abdominal radiograph may reveal bowel gas in the scrotum if herniated bowel is present. The presence of stippled calcifications suggests a history of meconium peritonitis (Kenney et al., 1985). Wilms tumor or neuroblastoma may seed the testis through a patent processus. Scrotal hematoma has been reported to masquerade as neonatal torsion (Diamond, 2003). Testis tumors in this age group are rare and include yolk sac tumors, teratomas, juvenile granulosa cell tumors, and gonadal stromal tumors (Levy et al., 1994). Although rare, it is important to include possible malignancy in the differential diagnosis of a scrotal mass and perform an abdominal ultrasonography when suspected.

Key Points

- A urologic source for abdominal distention in the newborn includes urinary ascites, urinary obstruction (upper and lower tract), renal mass (cystic and solid), and rarely a retroperitoneal mass (adrenal).
- Urinary retention may occur with LUTO and may occur in males with PUV or females with urogenital sinus or cloacal anomaly.
- Renal tumors are uncommon in the newborn period, and the most common is mesoblastic nephroma.
- The newborn with ambiguous genitalia should prompt an evaluation for electrolyte disturbance caused by classical salt-wasting CAH. Gender assignment should be deferred.
- Gross hematuria in the neonate is not common and should be evaluated with urine analysis and Doppler abdominal ultrasonography.
- The acuity of neonatal testicular torsion will dictate the need for emergent exploration.

References

Abdennadher W, Chalouhi G, Dreux S, et al. Fetal urine biochemistry at 13–23 weeks of gestation in lower urinary tract obstruction: criteria for in-utero treatment. *Ultrasound Obstet Gynecol*. 2015;46(3):306–311.

Adra AM, Mejides AA, Dennaoui MS, et al. Fetal pyelectasis: is it always physiologic? *Am J Obstet Gynecol*. 1995;173(4):1263–1266.

Adzick NS, Thom EA, Spong CY, et al. A randomized trial of prenatal versus postnatal repair of myelomeningocele. *N Engl J Med*. 2011;364(11):993–1004.

Ahmad G, Green P. Outcome of fetal pyelectasis diagnosed antenatally. *J Obstet Gynaecol*. 2005;25(2):119–122.

Alconcher L, Tombesi M. Mild antenatal hydronephrosis: management controversies. *Pediatr Nephrol*. 2004;19(7):819–820.

Alexander SE, Arlen AM, Storm DW, et al. Bladder volume at onset of vesicoureteral reflux is an independent risk factor for breakthrough febrile urinary tract infection. *J Urol*. 2015;193(4):1342–1346.

Al-Khaldi N, Watson AR, Zuccollo J, et al. Outcome of antenatally detected cystic dysplastic kidney disease. *Arch Dis Child*. 1994;70(6):520–522.

American College of Obstetricians and Gynecologists. Practice Bulletin No. 101. Ultrasonography in pregnancy. *Obstet Gynecol*. 2009;113(2 Pt 1):451–461.

Anumba DO, Scott JE, Plant ND, et al. Diagnosis and outcome of fetal lower urinary tract obstruction in the northern region of England. *Prenat Diagn*. 2005;25(1):7–13.

Arena F, Nicòtina PA, Romeo C, et al. Prenatal testicular torsion: ultrasonographic features, management and histopathological findings. *Int J Urol*. 2006;13(2):135–141.

Atiyeh B, Husmann D, Baum M. Contralateral renal abnormalities in multicystic-dysplastic kidney disease. *J Pediatr*. 1992;121(1):65–67.

Austin PF, Homsy YL, Gearhart JP, et al. The prenatal diagnosis of cloacal exstrophy. *J Urol*. 1998;160(3 Pt 2):1179–1181.

Avolio L, Fusillo M, Ferrari G, et al. Neonatal adrenal hemorrhage manifesting as acute scrotum: timely diagnosis prevents unnecessary surgery. *Urology*. 2002;59(4):601.

Bagolan P, Giorlandino C, Nahom A, et al. The management of fetal ovarian cysts. *J Pediatr Surg*. 2002;37(1):25–30.

Barbosa JA, Chow JS, Benson CB, et al. Postnatal longitudinal evaluation of children diagnosed with prenatal hydronephrosis: insights in natural history and referral pattern. *Prenat Diagn*. 2012;32(13):1242–1249.

Biard JM, Johnson MP, Carr MC, et al. Long-term outcomes in children treated by prenatal vesicoamniotic shunting for lower urinary tract obstruction. *Obstet Gynecol*. 2005;106(3):503–508.

Bloom TL, Kolon TF. Severe megacystis and bilateral hydronephrosis in a female fetus. *Urology*. 2002;60(4):697.

Boyd PA, Devigan C, Khoshnood B, et al. Survey of prenatal screening policies in Europe for structural malformations and chromosome anomalies, and their impact on detection and termination rates for neural tube defects and Down's syndrome. *BJOG*. 2008;115(6):689–696.

Braga LH, Mijovic H, Farrokhyar F, et al. Antibiotic prophylaxis for urinary tract infections in antenatal hydronephrosis. *Pediatrics*. 2013;131(1):e251–e261.

Braga LHP, Ruzhynsky V, Pemberton J, et al. Evaluating practice patterns in postnatal management of antenatal hydronephrosis: a national survey of Canadian pediatric urologists and nephrologists. *Urology*. 2014;83(4):909–914.

Braga LH, Farrokhyar F, D'Cruz J, et al. Risk factors for febrile urinary tract infection in children with prenatal hydronephrosis: a prospective study. *J Urol*. 2015;193(5):1766–1771.

Braga LH, D'Cruz J, Rickard M, et al. The fate of primary nonrefluxing megaureter: a prospective outcome analysis of the rate of urinary tract infections, surgical indications and time to resolution. *J Urol*. 2016;195(4):1300–1305.

Braga LH, McGrath M, Farrokhyar F, et al. Society for Fetal Urology Classification vs Urinary Tract Dilation grading system for prognostication in prenatal hydronephrosis: a time to resolution analysis. *J Urol*. 2018;199(6):1615–1621.

Brandt MT, Sheldon CA, Wacksman J, et al. Prenatal testicular torsion: principles of management. *J Urol*. 1992;147(3):670–672.

British Nuclear Medicine Society. *Renal cortical scintigraphy (DMSA) clinical guidelines*. [updated February 2011; Available at] https://www.bnms.org.uk/procedures-guidelines/bnms-clinical-guidelines/renal-cortical-scintigraphy-dmsa.html.

Broderick KM, Martin BG, Herndon CD, et al. The current state of surgical practice for neonatal torsion: a survey of pediatric urologists. *J Pediatr Urol*. 2013;9(5):542–545.

Brophy MM, Austin PF, Yan Y, et al. Vesicoureteral reflux and clinical outcomes in infants with prenatally detected hydronephrosis. *J Urol*. 2002;168(4 Pt 2):1716–1719 [discussion 1719].

Bryant AE, Laufer MR. Fetal ovarian cysts: incidence, diagnosis and management. *J Reprod Med*. 2004;49(5):329–337.

Burbige KA, Lebowitz RL, Colodny AH, et al. The megacystis-megaureter syndrome. *J Urol*. 1984;131(6):1133–1136.

Burgu B, Aydogdu O, Soygur T, et al. When is it necessary to perform nuclear renogram in patients with a unilateral neonatal hydronephrosis? *World J Urol*. 2012;30(3):347–352.

Cain MP, Rink RC, Thomas AC, et al. Symptomatic ureteropelvic junction obstruction in children in the era of prenatal sonography—is there a higher incidence of crossing vessels? *Urology*. 2001;57(2):338–341.

Calaway AC, Whittam B, Szymanski KM, et al. Multicystic dysplastic kidney: is an initial voiding cystourethrogram necessary? *Can J Urol*. 2014;21(5):7510–7514.

Capolicchio JP, Braga LH, Szymanski KM. Canadian Urological Association/Pediatric Urologists of Canada guideline on the investigation and management of antenatally detected hydronephrosis. *Can Urol Assoc J*. 2018;12(4):85–92.

Cheikhelard A, Luton D, Philippe-Chomette P, et al. How accurate is the prenatal diagnosis of abnormal genitalia? *J Urol*. 2000;164(3 Pt 2):984–987.

Chertin B, de Caluwé D, Puri P. Is primary endoscopic puncture of ureterocele a long-term effective procedure? *J Pediatr Surg*. 2003;38(1):116–119.

Chertin B, Mohanan N, Farkas A, et al. Endoscopic treatment of vesicoureteral reflux associated with ureterocele. *J Urol*. 2007;178(4):1594–1597.

Chertin B, Pollack A, Koulikov D, et al. Long-term follow up of antenatally diagnosed megaureters. *J Pediatr Urol*. 2008;4(3):188–191.

Chitty LS, Altman DG. Charts of fetal size: kidney and renal pelvis measurements. *Prenat Diagn*. 2003;23(11):891–897.

Cilento BG, Benacerraf BR, Mandell J. Prenatal diagnosis of cloacal malformation. *Urology*. 1994;43(3):386–388.

Clayton DB, Brock JW. Prenatal ultrasonography: implications for pediatric urology. *J Pediatr Urol*. 2011;7(2):118–125.

Clayton DB, Brock JW. In utero intervention for urologic diseases. *Nat Rev Urol*. 2012;9(4):207–217.

Clayton DB, Brock JW. Current state of fetal intervention for lower urinary tract obstruction. *Curr Urol Rep*. 2018;19(1):12.

Clayton DB, Tanaka ST, Trusler L, et al. Long-term urological impact of fetal myelomeningocele closure. *J Urol*. 2011;186(4):1581–1585.

Coelho GM, Bouzada MC, Pereira AK, et al. Outcome of isolated antenatal hydronephrosis: a prospective cohort study. *Pediatr Nephrol*. 2007;22(10):1727–1734.

Coelho GM, Bouzada MC, et al. Risk factors for urinary tract infection in children with prenatal renal pelvic dilatation. *J Urol*. 2008;179(1):284–289.

Committee on Obstetric Practice, Society for Maternal-Fetal Medicine. Committee Opinion No. 720. Maternal-fetal surgery for myelomeningocele. *Obstet Gynecol*. 2017;130(3):e164–e167.

Conway JJ, Maizels M. The well tempered diuretic renogram: a standard method to examine the asymptomatic neonate with hydronephrosis or hydroureteronephrosis. A report from combined meetings of The Society for Fetal Urology and members of The Pediatric Nuclear Medicine Council—The Society of Nuclear Medicine. *J Nucl Med*. 1992;33(11):2047–2051.

Coplen DE. Prenatal intervention for hydronephrosis. *J Urol*. 1997;157(6):2270–2277.

Coplen DE, Austin PF, Yan Y, et al. The magnitude of fetal renal pelvic dilatation can identify obstructive postnatal hydronephrosis, and direct postnatal evaluation and management. *J Urol*. 2006;176(2):724–727.

Corteville JE, Gray DL, Crane JP. Congenital hydronephrosis: correlation of fetal ultrasonographic findings with infant outcome. *Am J Obstet Gynecol*. 1991;165(2):384–388.

Crombleholme TM, Harrison MR, Golbus MS, et al. Fetal intervention in obstructive uropathy: prognostic indicators and efficacy of intervention. *Am J Obstet Gynecol*. 1990;162(5):1239–1244.

D'Addario V, Rossi AC, Pinto V, et al. Comparison of six sonographic signs in the prenatal diagnosis of spina bifida. *J Perinat Med*. 2008;36(4):330–334.

Danzer E, Gerdes M, Bebbington MW, et al. Lower extremity neuromotor function and short-term ambulatory potential following in utero myelomeningocele surgery. *Fetal Diagn Ther*. 2009;25(1):47–53.

Danzer E, Thomas NH, Thomas A, et al. Long-term neurofunctional outcome, executive functioning, and behavioral adaptive skills following fetal myelomeningocele surgery. *Am J Obstet Gynecol*. 2016;214(2):269.e1–269.e8.

De Caluwe D, Chertin B, Puri P. Fate of the retained ureteral stump after upper pole heminephrectomy in duplex kidneys. *J Urol*. 2002;168(2):679–680.

Dhillon HK. Prenatally diagnosed hydronephrosis: the Great Ormond Street experience. *BJU Int*. 1998;81(S2):39–44.

Diamond DA, Ford C. Neonatal bladder rupture: a complication of umbilical artery catheterization. *J Urol*. 1989;142(6):1543–1544.

Diamond DA. Neonatal scrotal hematoma: mimicker of neonatal testicular torsion. *BJU Int*. 2003;91(7):675–677.

Direnna T, Leonard MP. Watchful waiting for prenatally detected ureteroceles. *J Urol*. 2006;175(4):1493–1495 [discussion 1495].

Diwakar L, Morris RK, Barton P, et al. Evaluation of the cost effectiveness of vesico-amniotic shunting in the management of congenital lower urinary tract obstruction (based on data from the PLUTO trial). *PLoS ONE*. 2013;8(12):e82564.

Dmochowski RR, Crandell SS, Corriere JN Jr. Bladder injury and uroascites from umbilical artery catheterization. *Pediatrics*. 1986;77(3):421–422.

Duman N, Oren H, Gülcan H, et al. Scrotal hematoma due to neonatal adrenal hemorrhage. *Pediatr Int*. 2004;46(3):360–362.

Easterbrook B, Capolicchio JP, Braga LH. Antibiotic prophylaxis for prevention of urinary tract infections in prenatal hydronephrosis: an updated systematic review. *Can Urol Assoc J*. 2017;11(1–2 Suppl 1):S3–S11.

Elder JS, Duckett JW Jr, Snyder HM. Intervention for fetal obstructive uropathy: has it been effective? *Lancet*. 1987;2(8566):1007–1010.

Erickson BA, Maizels M, Shore RM, et al. Newborn Society of Fetal Urology grade 3 hydronephrosis is equivalent to preserved percentage differential function. *J Pediatr Urol*. 2007;3(5):382–386.

Estrada CR, Peters CA, Retik AB, et al. Vesicoureteral reflux and urinary tract infection in children with a history of prenatal hydronephrosis—Should voiding cystourethrography be performed in cases of postnatally persistent grade ii hydronephrosis? *J Urol*. 2009;181(2):801–807.

Farrugia MK. Fetal bladder outlet obstruction: embryopathology, in utero intervention and outcome. *J Pediatr Urol*. 2016;12(5):296–303.

Farrugia MK, Hitchcock R, Radford A, et al. British Association of Paediatric Urologists consensus statement on the management of the primary obstructive megaureter. *J Pediatr Urol*. 2014;10(1):26–33.

Felc Z. Ultrasound in screening for neonatal adrenal hemorrhage. *Am J Perinatol*. 1995;12(5):363–366.

Feldman DM, DeCambre M, et al. Evaluation and follow-up of fetal hydro- nephrosis. *J Ultrasound Med*. 2001;20(10):1065–1069.

Fernbach SK, Maizels M, Conway JJ. Ultrasound grading of hydronephrosis: introduction to the system used by the Society for Fetal Urology. *Pediatr Radiol*. 1993;23(6):478–480.

Freedman AL, Johnson MP, Smith CA, et al. Long-term outcome in children after antenatal intervention for obstructive uropathies. *Lancet*. 1999;354(9176):374–377.

Frimberger D, Mercado-Deane MG. Section on Urology; Section on Radiology. Establishing a standard protocol for the voiding cystourethrography. *Pediatrics*. 2016;138(5).

Gearhart J, Benchaim J, Jeffs R, et al. Criteria for the prenatal diagnosis of classic bladder exstrophy. *Obstet Gynecol*. 1995;85(6):961–964.

Glassberg KI, Stephens FD, Lebowitz RL, et al. Renal dysgenesis and cystic disease of the kidney: a report of the Committee on Terminology, Nomenclature and Classification, Section on Urology, American Academy of Pediatrics. *J Urol*. 1987;138(4 Pt 2):1085–1092.

Glick RD, Hicks MJ, Nuchtern JG, et al. Renal tumors in infants less than 6 months of age. *J Pediatr Surg*. 2004;39(4):522–525.

Godinho AB, Nunes C, Janeiro M, et al. Ureterocele: antenatal diagnosis and management. *Fetal Diagn Ther*. 2013;34(3):188–191.

Goldman S, Szejnfeld PO, Rondon A, et al. Prenatal diagnosis of bladder exstrophy by fetal MRI. *J Pediatr Urol*. 2013;9(1):3–6.

Grandjean H, Larroque D, Levi S. The performance of routine ultrasonographic screening of pregnancies in the Eurofetus Study. *Am J Obstet Gynecol*. 1999;181(2):446–454.

Hahn-Pedersen J, Kvist N, Nielsen OH. Hydrometrocolpos: current views on pathogenesis and management. *J Urol*. 1984;132(3):537–540.

Harrison MR, Golbus MS, Filly RA, et al. Management of the fetus with congenital hydronephrosis. *J Pediatr Surg*. 1982;17(6):728–742.

Hayashi S, Sago H, Kashima K, et al. Prenatal diagnosis of fetal hydrometrocolpos secondary to a cloacal anomaly by magnetic resonance imaging. *Ultrasound Obstet Gynecol*. 2005;26(5):577–579.

Heikkinen ES, Herva R, Lanning P. Multicystic kidney. A clinical and histological study of 13 patients. *Ann Chir Gynaecol*. 1980;69(1):15–22.

Herek Ö, Ergin H, Karaduman D, et al. Paraurethral cysts in newborn: a case report and review of literature. *Eur J Pediatr Surg*. 2000;10(1):65–67.

Herndon CD. The role of ultrasound in predicting surgical intervention for prenatal hydronephrosis. *J Urol*. 2012;187(5):1535–1536.

Herndon CD, Ferrer FA, McKenna PH. A complex urologic problem demonstrates how far pediatric urology has progressed. *Conn Med*. 1999;63(12):707–711.

Herndon CD, McKenna PH, Kolon TF, et al. A multicenter outcomes analysis of patients with neonatal reflux presenting with prenatal hydronephrosis. *J Urol*. 1999;162(3 Pt 2):1203–1208.

Herndon CD, Ferrer FA, Freedman A, et al. Consensus on the prenatal management of antenatally detected urological abnormalities. *J Urol*. 2000;164(3 Pt 2):1052–1056.

Herndon CD, DeCambre M, McKenna PH. Changing concepts concerning the management of vesicoureteral reflux. *J Urol*. 2001;166(4):1439–1443.

Herndon CD, Herbst K, Smith C. The transition from open to laparoscopic pediatric pyeloplasty: a single-surgeon experience. *J Pediatr Urol*. 2013;9(4):409–414.

Herz D, Merguerian P, McQuiston L. Continuous antibiotic prophylaxis reduces the risk of febrile UTI in children with asymptomatic antenatal hydronephrosis with either ureteral dilation, high-grade vesicoureteral reflux, or ureterovesical junction obstruction. *J Pediatr Urol*. 2014;10(4):650–654.

Homsey YL, Anderson JH, Oudjhane K, et al. Wilms tumor and multicystic dysplastic kidney disease. *J Urol*. 1997;158(6):2256–2259.

Hsieh MH, Lai J, Saigal CS, Urologic Diseases in America Project. Trends in prenatal sonography use and subsequent urologic diagnoses and abortions in the United States. *J Pediatr Urol*. 2009;5(6):490–494.

Husmann DA, Ewalt DH, Glenski WJ, et al. Ureterocele associated with ureteral duplication and a nonfunctioning upper pole segment: management by partial nephroureterectomy alone. *J Urol*. 1995;154(2 Pt 2):723–726.

Jackson JN, Zee RS, Martin AN, et al. A practice pattern assessment of members of the Society of Pediatric Urology for evaluation and treatment of urinary tract dilation. *J Pediatr Urol*. 2017;13(6):602–607.

Jernigan SM. Hematuria in the newborn. *Clin Perinatol*. 2014;41(3):591–603.

Jesus LE, Farhat WA, Amarante AC, et al. Clinical evolution of vesicoureteral reflux following endoscopic puncture in children with duplex system ureteroceles. *J Urol*. 2011;186(4):1455–1458.

Johnson MP, Bukowski TP, Reitleman C, et al. In utero surgical treatment of fetal obstructive uropathy: a new comprehensive approach to identify appropriate candidates for vesicoamniotic shunt therapy. *Am J Obstet Gynecol*. 1994;170(6):1770–1776 [discussion 1776–1779].

Johnson MP, Corsi P, Bradfield W, et al. Sequential urinalysis improves evaluation of fetal renal function in obstructive uropathy. *Am J Obstet Gynecol*. 1995;173(1):59–65.

Jones RA, Perez-Brayfield MR, Kirsch AJ, et al. Renal transit time with MR urography in children. *Radiology*. 2004;233(1):41–50.

Jordan GH, Hoover DL. Inadequate decompression of the upper tracts using a Foley catheter in the valve bladder. *J Urol*. 1985;134(1):137–138.

Julian-Reynier C, Philip N, Scheiner C, et al. Impact of prenatal diagnosis by ultrasound on the prevalence of congenital anomalies at birth in southern France. *J Epidemiol Community Health*. 1994;48(3):290–296.

Kenney PJ, Spirt BA, Ellis DA, et al. Scrotal masses caused by meconium peritonitis: prenatal sonographic diagnosis. *Radiology*. 1985;154(2):362.

Khuri FJ, Alton DJ, Hardy BE, et al. Adrenal hemorrhage in neonates: report of 5 cases and review of the literature. *J Urol*. 1980;124(5):684–687.

Kilby MD, Morris RK. Fetal therapy for the treatment of congenital bladder neck obstruction. *Nat Rev Urol*. 2014;11(7):412–419.

Kitchens DM, Herndon A, Joseph DB. Outcome after discontinuing prophylactic antibiotics in children with persistent vesicoureteral reflux. *J Urol*. 2010;184(4):1594–1597.

Kuhle S, Massicotte P, Chan A, et al. A case series of 72 neonates with renal vein thrombosis. Data from the 1-800-NO-CLOTS registry. *Thromb Haemost*. 2004;92(4):729–733.

Lamb MG, Aldrink JH, O'Brien SH, et al. Renal tumors in children younger than 12 months of age. *J Pediatr Hematol Oncol*. 2017;39(2):103–107.

Lambert SM, Vilain EJ, Kolon TF. A practical approach to ambiguous genitalia in the newborn period. *Urol Clin North Am*. 2010;37(2):195–205.

Lee RS, Cendron M, Kinnamon DD, et al. Antenatal hydronephrosis as a predictor of postnatal outcome: a meta-analysis. *Pediatrics*. 2006;118(2):586–593.

Lee JH, Choi HS, Kim JK, et al. Nonrefluxing neonatal hydronephrosis and the risk of urinary tract infection. *J Urol*. 2008;179(4):1524–1528.

Levy DA, Kay R, Elder JS. Neonatal testis tumors: a review of the prepubertal testis tumor registry. *J Urol*. 1994;151(3):715–717.

Liu DB, Palmer B, Herndon CD, et al. Teaching of the Society for Fetal Urology grading system for pediatric hydronephrosis is improved by e-Learning using Computer Enhanced Visual Learning (CEVL): a multi-institutional trial. *J Pediatr Urol*. 2015;11(4):184.e1–184.e8.

Lopez J, Mikaelian I, Gonzalo P. Amniotic fluid glial fibrillary acidic protein (AF-GFAP), a biomarker of open neural tube defects. *Prenat Diagn*. 2013;33(10):990–995.

Lowe FC, Hill GS, Jeffs RD, et al. Urethral prolapse in children: insights into etiology and management. *J Urol*. 1986;135(1):100–103.

Maayan-Metzger A, Lotan D, Jacobson J, et al. The yield of early postnatal ultrasound scan in neonates with documented antenatal hydronephrosis. *Am J Perinatol*. 2011;28(8):613–618.

MacDonald MG, Mullett MD, Seshia MMK. *Avery's neonatology: pathophysiology and management of the newborn*. ed 5. Lippincott: Philadelphia, PA; 1999.

Maclaurin JC. Changes in body water distribution during the first two weeks of life. *Arch Dis Child*. 1966;41(217):286–291.

Malin G, Tonks AM, Morris RK, et al. Congenital lower urinary tract obstruction: a population-based epidemiological study. *BJOG*. 2012;119(12):1455–1464.

Mandell J, Kinard HW, Mittelstaedt CA, et al. Prenatal diagnosis of unilateral hydronephrosis with early postnatal reconstruction. *J Urol*. 1984;132(2):303–307.

Mandell J, Peters CA, Estroff JA, et al. Late onset severe oligohydramnios associated with genitourinary abnormalities. *J Urol*. 1992;148(2 Pt 2):515–518.

Marks A, Maizels M, Mickelson J, et al. Effectiveness of the computer enhanced visual learning method in teaching the society for fetal urology hydronephrosis grading system for urology trainees. *J Pediatr Urol*. 2011;7(2):113–117.

Mason MD, Anthony Herndon CD, Smith-Harrison LI, et al. Robotic-assisted partial nephrectomy in duplicated collecting systems in the pediatric population: techniques and outcomes. *J Pediatr Urol*. 2014;10(2):374–379.

Mata JA, Livne PM, Gibbons MD. Urinary ascites: complication of umbilical artery catheterization. *Urology*. 1987;30(4):375–377.

McLellan DL, Retik AB, Bauer SB, et al. Rate and predictors of spontaneous resolution of prenatally diagnosed primary nonrefluxing megaureter. *J Urol*. 2002;168(5):2177–2180 [discussion 2180].

McLeod DJ, Alpert SA, Ural Z, et al. Ureteroureterostomy irrespective of ureteral size or upper pole function: a single center experience. *J Pediatr Urol*. 2014;10(4):616–619.

McLorie GA, Sheldon CA, Fleisher M, et al. The genitourinary system in patients with imperforate anus. *J Pediatr Surg*. 1987;22(12):1100–1104.

McLorie G, Farhat W, Khoury A, et al. Outcome analysis of vesicoamniotic shunting in a comprehensive population. *J Urol*. 2001;166(3):1036–1040.

McMann LP, Kirsch AJ, Scherz HC, et al. Magnetic resonance urography in the evaluation of prenatally diagnosed hydronephrosis and renal dysgenesis. *J Urol*. 2006;176(4 Pt 2):1786–1792.

Meizner I, Levy A, Katz M, et al. Fetal ovarian cysts: prenatal ultrasonographic detection and postnatal evaluation and treatment. *Am J Obstet Gynecol*. 1991;164(3):874–878.

Merguerian PA, Herz D, McQuiston L, et al. Variation among pediatric urologists and across 2 continents in antibiotic prophylaxis and evaluation for prenatally detected hydronephrosis: a survey of American and European pediatric urologists. *J Urol*. 2010;184(4 Suppl):1710–1715.

Minnillo BJ, Cruz JA, Sayao RH, et al. Long-term experience and outcomes of robotic assisted laparoscopic pyeloplasty in children and young adults. *J Urol*. 2011;185(4):1455–1460.

Mittelstaedt CA, Volberg FM, Merten DF, et al. The sonographic diagnosis of neonatal adrenal hemorrhage. *Radiology*. 1979;131(2):453–457.

Morrell P, Coulthard MG, Hey EN. Neonatal urinary ascites. *Arch Dis Child*. 1985;60(7):676–678.

Morris RK, Quinlan-Jones E, Kilby MD, et al. Systematic review of accuracy of fetal urine analysis to predict poor postnatal renal function in cases of congenital urinary tract obstruction. *Prenat Diagn*. 2007;27(10):900–911.

Morris RK, Malin GL, Khan KS, et al. Systematic review of the effectiveness of antenatal intervention for the treatment of congenital lower urinary tract obstruction. *BJOG*. 2010;117(4):382–390.

Morris RK, Ruano R, Kilby MD. Effectiveness of fetal cystoscopy as a diagnostic and therapeutic intervention for lower urinary tract obstruction: a systematic review. *Ultrasound Obstet Gynecol*. 2011;37(6):629–637.

Morris RK, Malin GL, Quinlan-Jones E, et al. Percutaneous vesicoamniotic shunting versus conservative management for fetal lower urinary tract obstruction (PLUTO): a randomised trial. [for the; Percutaneous vesicoamniotic shunting in Lower Urinary Tract Obstruction (PLUTO) Collaborative Group]

Lancet. 2013;382(9903):1496–1506.

Morris R, Malin G, Quinlan-Jones E, et al. The Percutaneous shunting in Lower Urinary Tract Obstruction (PLUTO) study and randomised controlled trial: evaluation of the effectiveness, cost-effectiveness and acceptability of percutaneous vesicoamniotic shunting for lower urinary tract obstruction. *Health Technol Assess*. 2013;17(59):1–232.

Moslehi J, Herndon CD, McKenna PH. Posterior urethral valves presented at birth despite normal prenatal ultrasound scans. *Urology*. 2001;57(6):1178.

Narchi H, Kulaylat N. Neonatal circumcision: when can infants reliably be expected to void? *Pediatrics*. 1998;102(1 Pt 1):150–152.

Narchi H. Risk of Wilms' tumour with multicystic kidney disease: a systematic review. *Arch Dis Child*. 2005;90(2):147–149.

Nassr AA, Shazly SAM, Abdelmagied AM, et al. Effectiveness of vesicoamniotic shunt in fetuses with congenital lower urinary tract obstruction: an updated systematic review and meta-analysis. *Ultrasound Obstet Gynecol*. 2017;49(6):696–703.

New MI, Carlson A, Obeid J, et al. Prenatal diagnosis for congenital adrenal hyperplasia in 532 pregnancies. *J Clin Endocrinol Metab*. 2001;86(12):5651–5657.

Nguyen HT, Herndon CD, Cooper C, et al. The Society for Fetal Urology Consensus Statement on the evaluation and management of antenatal hydronephrosis. *J Pediatr Urol*. 2010;6(3):212–231.

Nguyen HT, Benson CB, Bromley B, et al. Multidisciplinary consensus on the classification of prenatal and postnatal urinary tract dilation (UTD classification system). *J Pediatr Urol*. 2014;10(6):992–998.

Nimkarn S, Lin-Su K. New MI. Steroid 21 hydroxylase deficiency congenital adrenal hyperplasia. *Endocrinol Metab Clin North Am*. 2009;38(4):699–718.

O'Brien ST, Shukla AR. Transition from open to robotic-assisted pediatric pyeloplasty: a feasibility and outcome study. *J Pediatr Urol*. 2012;8(3):276–281.

Odibo AO, Marchiano D, Quinones JN, et al. Mild pyelectasis: evaluating the relationship between gestational age and renal pelvic anterior-posterior diameter. *Prenat Diagn*. 2003;23(10):824–827.

Oei J, Garvey P, Rosenberg A. The diagnosis and management of neonatal urinary ascites. *J Paediatr Child Health*. 2001;37(5):513–515.

Paradise HJ, Huang GO, Elizondo Sáenz RA, et al. Robot-assisted laparoscopic pyeloplasty in infants using 5-mm instruments. *J Pediatr Urol*. 2017;13(2):221–222.

Park JM. Embryology of the genitourinary tract. Wein AJ, Kavoussi LR, Partin AW, et al. *Campbell-Walsh urology*. Elsevier: Philadelphia, PA; 2016:2823–2848.

Pathak S, Lees C. Ultrasound structural fetal anomaly screening: an update. *Arch Dis Child Fetal Neonatal Ed*. 2009;94(5):F384–F390.

Pérez LM, Naidu SI, Joseph DB. Outcome and cost analysis of operative versus nonoperative management of neonatal multicystic dysplastic kidneys. *J Urol*. 1998;160(3 Pt 2):1207–1211 [discussion 1216].

Peters C, Skoog S, Arant B Jr, et al. *Managment and screening of primary vesicoureteral reflux in children*. [Available at] https://www.auanet.org/guidelines/vesicoureteral-reflux-(2010-amended-2017; 2010.

Quintero RA, Johnson MP, Romero R, et al. In-utero percutaneous cystoscopy in the management of fetal lower obstructive uropathy. *Lancet*. 1995;346(8974):537–540.

Quintero RA, Shukla AR, Homsy YL, et al. Successful in utero endoscopic ablation of posterior urethral valves: a new dimension in fetal urology. *Urology*. 2000;55(5):774.

Quintero RA, Homsy Y, Bornick PW, et al. In-utero treatment of fetal bladder outlet obstruction by a ureterocele. *Lancet*. 2001;357(9272):1947–1948.

Ravitz GA, Kandzari SJ, Milam DF. Neonatal urinary ascites. *J Urol*. 1973;110(1):141–143.

Redman JF, Seibert JJ, Arnold W. Urinary ascites in children owing to extravasation of urine from the bladder. *J Urol*. 1979;122(3):409–411.

Robichaux AG 3rd, Mandell J, Greene MF, et al. Fetal abdominal wall defect: a new complication of vesicoamniotic shunting. *Fetal Diagn Ther*. 1991;6(1–2):11–13.

Robin NH, Sathienkijkanchai A, Herndon CD. A genetic model for cloacal exstrophy, the extreme cloacal malformation. *J Pediatr Urol*. 2007;3(3):214–217.

Ross SS, Kardos S, Krill A, et al. Observation of infants with SFU Grades 3–4 hydronephrosis: worsening drainage with serial diuresis renography indicates surgical intervention and helps prevent loss of renal function. *J Pediatr Urol*. 2011;7(3):266–271.

Ruano R, Duarte S, Bunduki V, et al. Fetal cystoscopy for severe lower urinary tract obstruction—initial experience of a single center. *Prenat Diagn*. 2010;30(1):30–39.

Ruano R, Yoshisaki CT, Salustiano EM, et al. Early fetal cystoscopy for first-trimester severe megacystis. *Ultrasound Obstet Gynecol*. 2011;37(6):696–701.

Ruano R, Sananes N, Sangi-Haghpeykar H, et al. Fetal intervention for severe lower urinary tract obstruction: a multicenter case-control study comparing fetal cystoscopy with vesicoamniotic shunting. *Ultrasound Obstet Gynecol*. 2015;45(4):452–458.

Ruano R, Sananes N, Wilson C, et al. Fetal lower urinary tract obstruction: proposal for standardized multidisciplinary prenatal management based on disease severity. *Ultrasound Obstet Gynecol*. 2016;48(4):476–482.

Sananes N, Cruz-Martinez R, Favre R, et al. Two-year outcomes after diagnostic and therapeutic fetal cystoscopy for lower urinary tract obstruction. *Prenat Diagn*. 2016;36(4):297–303.

Schmidt B, Andrew M. Neonatal thrombosis: report of a prospective Canadian and international registry. *Pediatrics*. 1995;96(5 Pt 1):939–943.

Sefczek RJ, Beckman I, Lupetin AR, et al. *Sonography of acute renal cortical necrosis*. 1984.

Shamshirsaz AA, Ravangard SF, Egan JF, et al. Fetal hydronephrosis as a predictor of neonatal urologic outcomes. *J Ultrasound Med*. 2012;31(6):947–954.

Share J, Lebowitz R. Ectopic ureterocele without ureteral and calyceal dilatation (ureterocele disproportion): findings on urography and sonography. *AJR Am J Roentgenol*. 1989;152(3):567–571.

Sharma G, Sharma A, Maheshwari P. Predictive value of decreased renal pelvis anteroposterior diameter in prone position for prenatally detected hydronephrosis. *J Urol*. 2012;187(5):1839–1843.

Shono T, Taguchi T, Suita S, et al. Prenatal ultrasonographic and magnetic resonance imaging findings of congenital cloacal anomalies associated with meconium peritonitis. *J Pediatr Surg*. 2007;42(4):681–684.

Shukla A, Cooper J, Patel R, et al. Prenatally detected primary megaureter: a role for extended followup. *J Urol*. 2005;173(4):1353–1356.

Siddique J, Lauderdale DS, VanderWeele TJ, et al. Trends in prenatal ultrasound use in the United States. *Med Care*. 2009;47(11):1129–1135.

Singh SP. Neonatal adrenal hemorrhage. Reid JR, Paladin A, Davros W, et al. *Pediatric radiology*. ed 1. Oxford University Press: Oxford, UK; 2013:228–230.

Smith-Harrison LI, Hougen HY, Timberlake MD, et al. Current applications of in utero intervention for lower urinary tract obstruction. *J Pediatr Urol*. 2015;11(6):341–347.

Song SH, Lee SB, Park YS, et al. Is antibiotic prophylaxis necessary in infants with obstructive hydronephrosis? *J Urol*. 2007;177(3):1098–1101 [discussion 1101].

Sorensen MD, Galansky SH, Striegl AM, et al. Perinatal extravaginal torsion of the testis in the first month of life is a salvageable event. *Urology*. 2003;62(1):132–134.

Speiser PW, White PC. Congenital adrenal hyperplasia. *N Engl J Med*. 2003;349(8):776–788.

Stalberg K, González R. Urethral atresia and anhydramnios at 18 weeks of gestation can result in normal development. *J Pediatr Urol*. 2012;8(3):e33–e35.

Stefos T, Plachouras N, Sotiriadis A, et al. Routine obstetrical ultrasound at 18–22 weeks: our experience on 7,236 fetuses. *J Matern Fetal Med*. 1999;8(2):64–69.

Storm DW, Modi A, Jayanthi VR. Laparoscopic ipsilateral ureteroureterostomy in the management of ureteral ectopia in infants and children. *J Pediatr Urol*. 2011;7(5):529–533.

Stratton KL, Pope JC, Adams MC, et al. Implications of ionizing radiation in the pediatric urology patient. *J Urol*. 2010;183(6):2137–2142.

Sussman RD, Blum ES, Sprague BM, et al. Prediction of clinical outcomes in prenatal hydronephrosis: importance of gravity assisted drainage. *J Urol*. 2017;197(3):838–844.

Sweeney DD, Ost MC, Schneck FX, et al. Laparoscopic pyeloplasty for ureteropelvic junction obstruction in children. *J Laparoendosc Adv Surg Tech A*. 2011;21(3):261–265.

Szymanski KM, Al-Said AN, Pippi Salle JL, et al. Do infants with mild prenatal hydronephrosis benefit from screening for vesicoureteral reflux? *J Urol*. 2012;88:576–581.

Tombesi MM, Alconcher LF. Short-term outcome of mild isolated antenatal hydronephrosis conservatively managed. *J Pediatr Urol*. 2012;8(2):129–133.

Tulipan N, Wellons JC, Thom EA, et al. Prenatal surgery for myelomeningocele and the need for cerebrospinal fluid shunt placement. *J Neurosurg Pediatr*. 2015;16(6):613–620.

Turner JH, Leonard JC. Renal scintigraphic findings in a patient with hydrometrocolpos. *Clin Nucl Med*. 1997;22(6):394–396.

Ulman I, Jayanthi VR, Koff SA. The long-term followup of newborns with severe unilateral hydronephrosis initially treated nonoperatively. *J Urol*. 2000;164(3 Pt 2):1101–1105.

Upadhyay J, McLorie G, Bolduc S, et al. Natural history of neonatal reflux associated with prenatal hydronephrosis: long-term results of a prospective study. *J Urol*. 2003;169(5):1837–1841.

Vasdev N, Coulthard MG, De la hunt MN, et al. Neonatal urinary ascites secondary to urinary bladder rupture. *J Pediatr Urol*. 2009;5(2):100–104.

Velaphi SC, Perlman JM. Neonatal adrenal hemorrhage: clinical and abdominal sonographic findings. *Clin Pediatr (Phila)*. 2001;40:545–548.

Vemulakonda VM, Wilcox DT, Torok MR, et al. Inter-rater reliability of postnatal ultrasound interpretation in infants with congenital hydronephrosis. *Int Urol Nephrol*. 2015;47(9):1457–1461.

Vintzileos AM, Ananth CV, Smulian JC, et al. Routine second-trimester ultrasonography in the United States: a cost-benefit analysis. *Am J Obstet Gynecol*. 2000;182(3):655–660.

Vuohelainen T, Ojala R, Virtanen A, et al. Predictors of delayed first voiding in newborn. *Acta Paediatr*. 2008;97(7):904–908.

Warne S, Chitty LS, Wilcox DT. Prenatal diagnosis of cloacal anomalies. *BJU Int*. 2002;89(1):78–81.

Weiss DA, Kadakia S, Kurzweil R, et al. Detection of crossing vessels in pediatric ureteropelvic junction obstruction: clinical patterns and imaging findings. *J Pediatr Urol*. 2015;11(4):173.e1–173.e5.

Whittam BM, Calaway A, Szymanski KM, et al. Ultrasound diagnosis of multicystic dysplastic kidney: is a confirmatory nuclear medicine scan necessary? *J Pediatr Urol*. 2014;10(6):1059–1062.

Wiesel A, Queisser-Luft A, Clementi M, EUROSCAN Study Group, et al. Prenatal detection of congenital renal malformations by fetal ultrasonographic examination: an analysis of 709,030 births in 12 European countries. *Eur J Med Genet*. 2005;48(2):131–144.

Winkler NS, Kennedy AM, Woodward PJ. Cloacal malformation: embryology, anatomy, and prenatal imaging features. *J Ultrasound Med*. 2012;31(11):1843–1855.

Wollenberg A, Neuhaus TJ, et al. Outcome of fetal renal pelvic dilatation diagnosed during the third trimester. *Ultrasound Obstet Gynecol*. 2005;25(5):483–488.

Yeung CK, Godley ML, Dhillon HK, et al. Urodynamic patterns in infants with normal lower urinary tracts or primary vesico-ureteric reflux. *Br J Urol*. 1998;81(3):461–467.

Zanetta VC, Rosman BM, Bromley B, et al. Variations in management of mild prenatal hydronephrosis among maternal-fetal medicine obstetricians, and pediatric urologists and radiologists. *J Urol*. 2012;188(5):1935–1939.

Zareba P, Lorenzo AJ, Braga LH. Risk factors for febrile urinary tract infection in infants with prenatal hydronephrosis: comprehensive single center analysis. *J Urol*. 2014;191(5 Suppl):1614–1618.

Zee RS, Herndon CDA. Prenatal diagnosis of congenital anomalies of the kidney and urinary tract. Barakat AJ, Rushton HG. *Congenital anomalies of the kidney and urinary tract. Cham*. Springer International Publishing: Switzerland; 2016:265–286.

Zee RS, Herbst KW, Kim C, et al. Urinary tract infections in children with prenatal hydronephrosis: a risk assessment from the Society for Fetal Urology Hydronephrosis Registry. *J Pediatr Urol*. 2016;12(4):261.e1–261.e7.

Zee RS, Herndon CDA, Cooper CS, et al. Time to resolution: a prospective evaluation from the Society for Fetal Urology Hydronephrosis registry. *J Pediatr Urol*. 2017;13(3):316.e1–316.e5.

Zhang L, Li Y, Liu C, et al. Diagnostic value of anteroposterior diameter of renal pelvis for predicting postnatal surgery: a systematic review and meta-analysis. *J Urol*. 2018;200(6):1346–1353.

SECTION B

Basic Principles

OUTLINE

23 Urologic Evaluation of the Child

24 Pediatric Urogenital Imaging

25 Infection and Inflammation of the Pediatric Genitourinary Tract

26 Core Principles of Perioperative Management in Children

27 Principles of Laparoscopic and Robotic Surgery in Children

23

Urologic Evaluation of the Child

Rachel Selekman MD, MAS, Hillary L. Copp MD, MS

Overview of Pediatric Urology

Pediatric urologists provide complete urologic care for children, performing not only the initial evaluation and diagnosis but also the medical and surgical therapy for diseases of the genitourinary system. Pediatric urology encompasses a spectrum of congenital and acquired disorders ranging from complex congenital anomalies such as bladder exstrophy to more routine, but nevertheless important, problems such as daytime wetting in a school-aged child. The basic approach to the pediatric patient requires taking a complete history, executing a thorough physical examination, and obtaining appropriate imaging as indicated.

In most cases, the pediatric urologist's initial contact with the patient is through an outpatient referral from a primary care physician or obstetrician seeking prenatal evaluation. However, some patients are seen in the emergency room or urgent care, and immediate consultation is requested. The pediatric urologist must efficiently assess patients and triage those requiring urgent evaluation versus those who are best cared for nonacutely by referral to the office setting (Table 23.1).

TABLE 23.1

Triage of Common Urologic Consults

Emergent	Acute postoperative problem
	Acute scrotum
	Newborn with ambiguous genitalia, bladder or cloacal exstrophy, posterior urethral valves, prune-belly syndrome, spina bifida
	Paraphimosis
	Priapism
	Trauma
Urgent (within 24 hours)	Newborn with bilateral hydronephrosis or solitary kidney with hydronephrosis
	Renal tumor
	Testicular mass
Semi-urgent (within 1–3 weeks)	Afebrile nephrolithiasis
	Amenorrhea in an adolescent female
	Consultation after treatment of a febrile urinary tract infection
	Gross hematuria in the absence of infection
	Interlabial mass

	Postnatal evaluation of prenatal unilateral hydronephrosis
Routine (at the family's convenience)	Asymptomatic hernia or hydrocele
	Circumcision evaluation
	Enuresis
	Hypospadias
	Labial adhesions
	Microscopic hematuria
	Undescended testicle
	Varicocele

This chapter introduces the pediatric urologic evaluation, focusing on the history and physical examination with emphasis on common clinical entities, examination techniques, and adjunct investigations such as radiographic imaging and select laboratory testing that are relevant to pediatric patients. The management of a pediatric patient with a urologic problem is often complex. The reader may find further details about specific conditions in other chapters.

Imaging

Radiologic evaluation of the pediatric patient initially consisted of abdominal plain films, then intravenous urography and voiding cystourethrography were introduced (Riccabona et al., 2002). Over the past decades, these modalities have undergone many developments and refinements. Then ultrasound was introduced to diagnostic imaging followed by nuclear medicine investigations. The need to reduce radiation exposure to the at-risk pediatric population and the increasing demand to combine morphologic and functional studies have driven innovations in these modalities as well as in computed tomography (CT) and magnetic resonance urography (MRU) (Darge et al., 2010). The following discussion focuses on the most common imaging modalities in modern pediatric urology with an overview of state-of-the-art techniques.

Ultrasonography

Ultrasonography is fundamental to pediatric urology. It is a relatively inexpensive imaging modality providing real-time evaluation of urologic structures without the need for sedation, ionizing radiation, or contrast agent injection. It is generally used as the primary imaging tool allowing for screening, providing orienting information to direct further imaging strategy, and allows for repeated follow-up investigations for monitoring the course of a urologic condition.

Renal Bladder Ultrasound

A pediatric renal bladder ultrasound requires an ultrasound device technically suited to neonatal, infant, or child with a variety of transducers with adaptable frequencies (3–10 MHz) (Riccabona et al., 2002). The patient must be hydrated with a full urinary bladder. A thorough ultrasound of the urogenital tract consists of evaluation of the bladder in longitudinal and transverse as well as oblique sections with visualization of the bladder wall, the ostial area, the distal ureters, the bladder neck, and the proximal urethra (partially using a transperineal approach), in the initially full bladder. Bladder capacity is measured. Kidneys are evaluated from ventral, lateral, and dorsal approaches, using prone and supine positioning, in multiple longitudinal and transverse sections covering the entire organ, also using high-resolution linear transducers for evaluation of renal parenchyma (including for corticomedullary differentiation, degree of echogenicity, and presence of cysts) noting renal volume measurements. Assessment of the renal collecting system is achieved with standardized axial measurement of any calyceal or pelvic distention, in prone and supine positions. Measurement of the ureters, if visible, should be performed. Last, the clinician should perform a postvoid evaluation, noting any residual urine in the bladder as well as reevaluating the distal ureters and the renal collecting system.

Advanced ultrasound techniques have significantly improved the potential of ultrasonography, particularly in evaluation of vesicoureteral reflux (VUR) and renal perfusion disturbances such as segmental pyelonephritis. New applications with particular importance in pediatric sonography are summarized here (Riccabona, 2009).

1. M-mode enables semi-quantitative assessment of ureteric peristalsis.
2. Harmonic imaging improves border delineation, particularly in liquid-filled structures such as the dilated collecting system, reduces artifacts, and improves depiction of ultrasound contrast media.
3. Sonographic contrast medium instilled into the bladder via a catheter enables a sonographic assessment of VUR and genitography without radiation exposure.
4. Doppler techniques allow a semiquantitative assessment of renal blood flow and perfusion. Color Doppler sonography gives a quick and comprehensive overview of vessel anatomy as well as flow velocity and direction in the renal vessels. The twinkling sign has improved potential for the assessment of urolithiasis, and color Doppler sonography improves assessment of the ureteric inflow jet.
5. Duplex Doppler sonography provides detailed information of flow profiles with a physiologically lower flow velocity, a higher resistive index, and relatively lower diastolic flow velocity evaluating indirect signs for perfusion disturbances (e.g., in renal vein thrombosis, renal artery stenosis, or renal failure).
6. Amplitude-coded color Doppler sonography demonstrates blood flow volume and allows depiction of peripheral renal vasculature and diagnosis of impaired perfusion.

However, ultrasonography has limitations not yet overcome by advanced techniques. Conventional ultrasonography is poor in detecting VUR and in anatomic evaluation of the urethra and the ureter. However, indirect signs such as thickening of the ureteric and pelvic wall, calyceal distention, renal parenchymal disease, dilated ureters, bladder wall thickening and trabeculation, or residual volume after voiding may indicate these pathologies. **Ultrasonography remains equipment and operator dependent and offers little functional information in the urinary bladder and insufficient anatomic evaluation of the ureters and urethra. Furthermore, it cannot distinguish obstructive from nonobstructive hydronephrosis. Therefore it is often used in conjunction with other imaging modalities.**

Prenatal Ultrasonography

The use of prenatal ultrasonography has increased globally, driven by enhancement of clinical care, improvement in technology access, changes in health care policy, financial interest, medicolegal fear, and necessity for parental reassurance (Clayton and Brock, 2011). Genitourinary anomalies are among the most commonly detected findings. In a large study of nearly 3700 fetuses with structural malformations, genitourinary anomalies composed approximately 20% of all structural malformations, with an increased sensitivity in the second trimester of 89% (Grandjean et al., 1999). Hydronephrosis is the most frequently identified fetal urologic abnormality, but the severity and clinical implications of prenatal hydronephrosis can vary greatly. The majority of fetuses with a urologic anomaly can be managed expectantly; those with suspected lower urinary tract obstruction may need urgent pediatric urology consultation (Clayton and Brock, 2012).

Scrotal Ultrasonography

Advances in ultrasound technology in recent years have made ultrasound the examination of choice for imaging scrotal pathology, whether acute or chronic (Munden and Trautwein, 2000). In addition, **Doppler technology has tremendously increased the radiologist's ability to assess flow within the prepubertal testicle if spermatic cord torsion is suspected**. Color Doppler sonography allows simultaneous real-time display of tissue morphology in gray-scale and color-encoded characteristics of blood flow**. It has a diagnostic accuracy of 95% in testicular torsion, similar to that obtained with radionuclide testicular scanning** (Pepe et al., 2006). Notably, ultrasonography should not be used in the evaluation of cryptorchidism. **It does not reliably localize nonpalpable testes nor rule out an intraabdominal testis; thus it does not assist in decision making** (Tasian and Copp, 2011).

Occult Spinal Dysraphism

The prevalence of occult spinal dysraphism is increased in children with urogenital anomalies (Koo et al., 2012). Spinal ultrasound has become more widely used for the evaluation of spinal lesions. It can be used in infants before 6 months of age when ossification of posterior elements prevents an acoustic window (Hughes et al., 2003). At this age, it has good agreement with magnetic resonance imaging (MRI), particularly for the detection of low-lying cord (90%). Because ossification timing is variable, it is recommended not to delay evaluation of concerning spinal lesions with spinal ultrasound.

Voiding Cystourethrogram

A voiding cystourethrogram is a classic, established examination in pediatric uroradiology. It may be performed either with fluoroscopy and iodinated contrast medium or with nuclear imaging agents (usually technetium-99m [^{99m}Tc] pertechnetate) using similar techniques.

Fluoroscopy

The examination begins with an initial plain film. This film should be inspected for bony abnormalities, the presence of stones, and the volume of stool. The bladder is catheterized, emptied, and low-pressure infusion of the radio-opaque contrast using physiologic filling pressures is begun (Riccabona, 2002). **During filling, oblique views of the ostial area should be obtained, particularly for demonstration of the anatomy of the vesicoureteral junction (e.g., ureteroceles or diverticula). Lateral views demonstrate low-degree VUR as well as the anatomy of the male urethra to assess for posterior urethral valves. In refluxing units, the kidney must be evaluated for the degree of calyceal distention, potential intrarenal reflux, and anatomic variations (e.g., duplex systems). The urethra and bladder must be visualized during voiding with attention to the bladder neck.** The presence of a widened proximal urethra, “spinning top urethra,” may be an important indicator of dysfunctional voiding (Saxton et al., 1988). Last, postvoid evaluation should include assessment of drainage of refluxed material from the upper collecting system, presence of any residual material in the bladder, and vaginal voiding in girls. Cyclic filling enables a higher vesicoureteral reflux detection rate (Hellstrom and Jacobsson, 1999; Polito et al., 2000).

Nuclear Cystography

The radionuclide voiding cystourethrogram may be more sensitive for reflux detection but offers poorer spatial resolution so that details of the urethra and collecting system and degree of reflux may not be seen (Darge and Riedmiller, 2004). The main advantage of radionuclide voiding cystourethrogram has been the lower radiation exposure compared with a fluoroscopic voiding cystourethrogram. However, modern imaging technology and a tailored examination has decreased the radiation exposure of the fluoroscopic voiding cystourethrogram (Haid et al., 2015).

Genitography

The anatomic evaluation of patients with complex congenital disorders may be useful to define anatomy for surgical reconstruction. This is commonly performed with a genitogram by placing catheters within sinuses and filling the entire bladder, urethra, vagina, and sinus(es) with contrast (al Jurayyan et al., 1995). It is important to identify a cervical impression at the vaginal dome, which suggests normal female internal organs. Notably, magnetic resonance imaging may also aid in defining the anatomy in pure urogenital sinus anomalies or patients with disorders of sex development.

Renal Scintigraphy

Radionuclide renal scintigraphy provides functional data to assist in the diagnosis and management of patients with a variety of suspected genitourinary tract problems, including obstruction (diuresis renography) and pyelonephritis and/or renal scar (renal cortical scintigraphy) (Taylor, 2014).

Diuretic Renography

Diuretic renography is based on a high endogenous rate of urine flow stimulated by the administration of furosemide; interpretation is based on washout of the radiopharmaceutical from the collecting system of the upper urinary tract (Taylor, 2014). The patient must be well hydrated and have an empty urinary bladder before the examination because a full bladder may affect upper-tract emptying and give false-positive results. The Paediatric Committee of the European Association of Nuclear Medicine has proposed guidelines for renograms in children and recommend tubular agents such as ^{99m}Tc-mercaptoacetyltriglycine for diuresis renography because tubular tracers are much more efficiently extracted by the kidney (Gordon et al., 2011).

Renography allows estimation of two aspects of renal function. First, renal clearance is the extraction of the tracer from the blood. This allows for the estimation of differential renal function by relative clearance and is undertaken 1 to 2 minutes after tracer injection. Second, renal excretion is the disappearance of the tracer from the kidney. This allows for evaluation of obstruction. Disappearance can be estimated by inspecting the renogram curve: an early peak followed by a rapidly descending phase is typical for normal excretion. A delay in excretion is characterized by a continuously ascending curve over 20 min or a curve that fails to fall and appears as a plateau.

Renal Cortical Scintigraphy

Renal cortical ^{99m}Tc-dimercaptosuccinic acid scintigraphy demonstrates a homogeneous concentration of the radiotracer throughout the kidney except for a lower concentration in the region of the collecting system (Taylor, 2014). They provide identification of functioning renal tissue in patients with congenital abnormalities or nonstandard anatomic location of the kidneys. These scans are also used to detect cortical abnormalities related to urinary tract infection (UTI) with a higher sensitivity in acute and chronic pyelonephritis compared with ultrasonography (Piepsz et al., 2001). Pyelonephritis and scarring are recognized by focal areas of decreased ^{99m}Tc-dimercaptosuccinic uptake in the renal parenchyma; however, a focal abnormality is not specific for pyelonephritis or a renal scar because any process that replaces, injures, or destroys normal cortical parenchyma will result in an abnormal scan. In addition, they measure relative function.

Urodynamic Testing

Urodynamic studies have become common practice in the evaluation of infants and children with neurogenic or nonneurogenic bladder given its

ability to provide an accurate assessment of lower urinary tract function for diagnosis and monitoring of response to treatment (Drzewiecki and Bauer, 2011)**. Urodynamic testing assesses bladder capacity, contractility, compliance, emptying ability, and degree of continence.** Urethral and rectal catheters are used to obtain intravesical and intra-abdominal pressure recordings. Detrusor pressure is calculated by continuous subtraction of the intra-abdominal from the intravesical pressure to correct for changes that may occur during laughing, coughing, movement, or talking during the study.

After the child voids or is catheterized (if maintained on clean intermittent catheterization), a multi-lumen urodynamic catheter is placed. The postvoid or postcatheter residual is measured. The child is made comfortable in the supine or sitting position. Electromyography of the external sphincter is performed by placing patch electromyography electrodes on the perineum. A rectal urodynamic catheter is placed to measure abdominal pressure. The bladder is then filled to expected bladder capacity at a rate 5% to 10% of the expected capacity per minute with warmed saline. Filling should continue until the child has a strong urge to void or is uncomfortable, micturition occurs, detrusor pressure exceeds 40 cm H_2O, infused fluid volume exceeds 150% of expected capacity, or the rate of leakage is greater than the rate of infusion. The filling cycle should be repeated to ensure accuracy. If available, the addition of fluoroscopic video imaging reveals the overall shape and contour of the bladder and bladder neck during filling and voiding and can identify intrinsic sphincter deficiency. Children are then encouraged to void, if able, with assessment of voiding pressure and electromyogram tracings.

Advanced Imaging

Magnetic Resonance Imaging

A comprehensive MR urography (MRU) protocol is a two-part imaging technique composed of precontrast sequences (static MRU) and postcontrast sequences (dynamic or excretory MRU) (Renjen et al., 2012). Magnetic resonance imaging (MRI) provides noninvasive cross-sectional imaging with excellent definition of normal anatomy, anomalous development, and pathological processes (Nguyen et al., 2006). Uniquely, MRI can also give functional information on the kidney (Hiorns, 2010). It can be used to evaluate congenital anomalies, mainly pelvicaliectasis and/or ureterectasis, and renal and bladder tumors. In addition, it provides additional anatomic detail when antenatal ultrasonography is inconclusive (Kajbafzadeh et al., 2008).

MRI is performed without exposure to ionizing radiation. However, the widespread use of MRI in pediatric uroradiology is limited by the requirement for sedation in young children, the lack of widely available MRI technology, and the high cost of MRI (Darge et al., 2013). Sedation can be avoided in infants, primarily those younger than 3 months of age, with the feed-and-wrap technique, which uses feeding and swaddling to induce natural sleep (Antonov et al., 2017).

Computed Tomography

Computed tomography (CT), with and without contrast enhancement, has become the mainstay of uroradiology in adults. It has been an attractive modality in children not because of diagnostic yield, but because of its availability, speed, lack of need for sedation, and cost efficacy (Hiorns, 2010). **However, its use in children is limited. There is a relatively high radiation dose required.** In addition, children have an increased sensitivity to radiation not only because of their long expected lifespan from the time of radiation exposure but also because of their growing status, as dividing cells are at increased risk for damage (Khong et al., 2013). In addition, infants have less fat (which changes the absorption of radiation serving as natural contrast), smaller structures, and different diseases (less malignancy and nephrolithiasis), further limiting the benefit of CT (Riccabona, 2009). **At present, CT should be used in pediatric urology in the context of severe blunt abdominal trauma and polytrauma, in stone disease, and for CT-angiography for evaluation of renal arteries** (Darge et al., 2013). Although ultrasonography should be used for initial diagnostic imaging in children with suspected nephrolithiasis, CT should be used for those with a nondiagnostic ultrasound in whom the clinical suspicion for stones remains high (Tasian and Copelovitch, 2014). Furthermore, radiation dose may be reduced by employing ultra-low-dose or low-dose protocols, which yield high sensitivity and specificity in evaluating renal colic, although may not be as effective in detecting stones smaller than 3 mm or in patients with a body mass index of more than 30 kg/m^2 (Rob et al., 2017).

If CT is indicated, dedicated age- and weight-adapted pediatric protocols for contrast medium and exposure parameters together with properly adjusted timing should be used. The scan area and range should be kept as small as possible and restricted to the clinically necessary size, and multiphasic scans should be avoided.

Key Points

- Ultrasonography is fundamental to pediatric urology. It is inexpensive and does not require sedation or radiation. It is used as the primary imaging tool.
- A voiding cystourethrogram is performed with fluoroscopy or nuclear imaging and evaluates for vesicoureteral reflux and posterior urethral valves.
- Radionuclide renal scintigraphy provides functional data for the diagnosis and management of obstruction, pyelonephritis, and renal scar.
- Urodynamic studies evaluate bladder function by assessing bladder capacity, contractility, compliance, emptying, and continence.
- MR urography provides anatomic detail and functional information without radiation, but its use is limited by availability, cost, and the need for sedation in some.

Presentations by Genitourinary Region

External Genitalia of the Male

Scrotal Conditions

Undescended Testicle.

Boys with an empty hemiscrotum at birth concerning for an undescended testis, also known as cryptorchidism, are among the most common referrals to the pediatric urologist. An empty hemiscrotum at birth represents either in utero torsion of the testicle or cryptorchidism. The incidence of congenital cryptorchidism in full-term boys is estimated to be 2% to 4% at birth and 1% at 1 year of age with increased incidence associated with prematurity and low birth weight (Barthold and Gonzalez, 2003; Weidner et al., 1999)**. In addition, older boys may develop acquired cryptorchidism because of ascending testes** (Gracia et al., 1997)**. Surgical correction is recommended for cryptorchidism, and the operative approach is based on the palpability and location of the testis; thus a careful physical exam is critical. Importantly, ultrasound does not reliably localize nonpalpable testicles nor does it rule out intraabdominal testicles and thus has no role in the routine evaluation of a child with an empty hemiscrotum** (Tasian and Copp, 2011).

There are multiple ways to examine a patient for cryptorchidism, and the examiner should use the method that is successful for him or her. As demonstrated in Video 23.1▶, we prefer to examine the patient in a warm room in supine position with legs spread apart, although frog-legged or standing positions are also common positions for successful examination. The inguinal canal should be visually inspected for signs of asymmetry or mass. An examiner stands on the side contralateral to the empty hemiscrotum and closes the internal inguinal ring with his or her nondominant hand to prevent a testicle from migrating into the abdomen. The examiner then slides his or her dominant hand from the anterior superior iliac spine down to the pubic tubercle to feel a testicle within the inguinal canal. To aid in lubrication, we recommend using a glove lubricated with soap and water. It is important to determine size, location, and texture of both gonads, with consideration of the anatomy of the testis, the epididymis, and the vas deferens, if palpable. The undescended testis may be found in the inguinal canal; in the superficial inguinal pouch; at the upper scrotum; or, rarely, in the femoral, perineal, or contralateral scrotal regions. If the testicle can be easily pulled into the scrotum and remains there upon release, it is a retractile testicle and needs no additional therapy. If the testicle is palpable but will not descend, it will require surgical correction. If doubt exists, a repeat examination 6 to 18 months later may be diagnostic as an ascended testicle becomes more difficult to manipulate into the scrotum as the boy ages. If the testicle is nonpalpable it may be intraabdominal or not present (from in utero testicular torsion). In this setting operative exploration is indicated. **Last, if gonads are nonpalpable bilaterally, a thorough examination for a disorder of sexual differentiation is indicated.**

Scrotal and Testicular Pain.

Acute scrotal pain is one of the most common urologic complaints seen in pediatric emergency departments. Boys with many types of inguinoscrotal pathology may have acute scrotal pain or swelling. **When findings are suspicious for spermatic cord torsion, emergent scrotal exploration is required with the goal of the patient getting to the operating room within 4 hours of onset of pain.** Thus obtaining a thorough history and physical exam is critically important to appropriately treat boys with spermatic cord torsion and to avoid unnecessary surgery in those who do not.

The differential diagnosis of acute scrotal pain includes spermatic cord torsion, torsion of the appendix testis or appendix epididymis, epididymitis/orchitis, hernia/hydrocele, trauma, sexual abuse, tumor, idiopathic scrotal edema, dermatitis, cellulitis, and vasculitis (Gatti and Patrick Murphy, 2007). Evaluation should begin with a history obtained from the caretaker and the patient. The examiner should inquire regarding the onset of pain because gradual onset of scrotal pain is more consistent with epididymitis, whereas sudden onset of scrotal pain suggests torsion of the spermatic cord or one of the appendices. Associated symptoms such as nausea and vomiting should be investigated because these are also more consistent with torsion of the spermatic cord or one of the appendices. Finally, a physical examination should be performed. Associated scrotal wall swelling, erythema, and superior displacement of the testis with an absent cremasteric reflex are very suggestive of spermatic cord torsion. However, the absence of any of these findings does not rule out torsion.

Testicular Torsion.

Two types of testicular torsion may occur: extravaginal torsion resulting from twisting of the spermatic cord proximal to the tunica vaginalis and intravaginal torsion resulting from the testicle and epididymis twisting within the tunica vaginalis. Extravaginal torsion occurs perinatally, whereas intravaginal torsion may occur at any time, with peak frequency during early adolescence (Skoglund et al., 1970; Zhao et al., 2011).

Management of perinatal extravaginal torsion remains controversial with varied opinions regarding the merit and role of "emergent" testicular exploration given the very low salvage rate as well as the role of contralateral orchidopexy of the healthy testis (Snyder and Diamond, 2010).

The classic presentation of intravaginal testicular torsion is the sudden onset of severe, unilateral pain that is often associated with nausea and emesis. The abdomen and inguinal area should be inspected for other causes of scrotal pain such as an inguinal hernia. Scrotal exam findings often include a higher riding testicle in the hemiscrotum, a transverse orientation, an anterior epididymis, absent cremasteric reflex, tenderness of the testicle and epididymis, and a firm testis. High-resolution ultrasound with color-flow Doppler can provide information about testicular blood flow. However, significant ischemic damage is believed to occur after 4 to 8 hours, and thus testicular torsion represents a true surgical emergency that should not be delayed awaiting confirmatory imaging (Bartsch et al., 1980).

Torsion of the Testicular or Epididymal Appendix.

The testicular appendix is a remnant of the müllerian duct, whereas the epididymal appendix is of wolffian duct origin (Gatti and Patrick Murphy, 2007). Torsion of an appendage occurs more commonly in the prepubertal age group, and presentation can mimic testicular torsion with a sudden onset of pain, nausea, and vomiting. Physical exam demonstrates localized tenderness at the superior pole of the testis or caput epididymis and is often associated with a reactive hydrocele. In boys with thin scrotal skin, the classic "blue dot" sign, reflective of a necrotic appendix, is seen (Fig. 23.1).

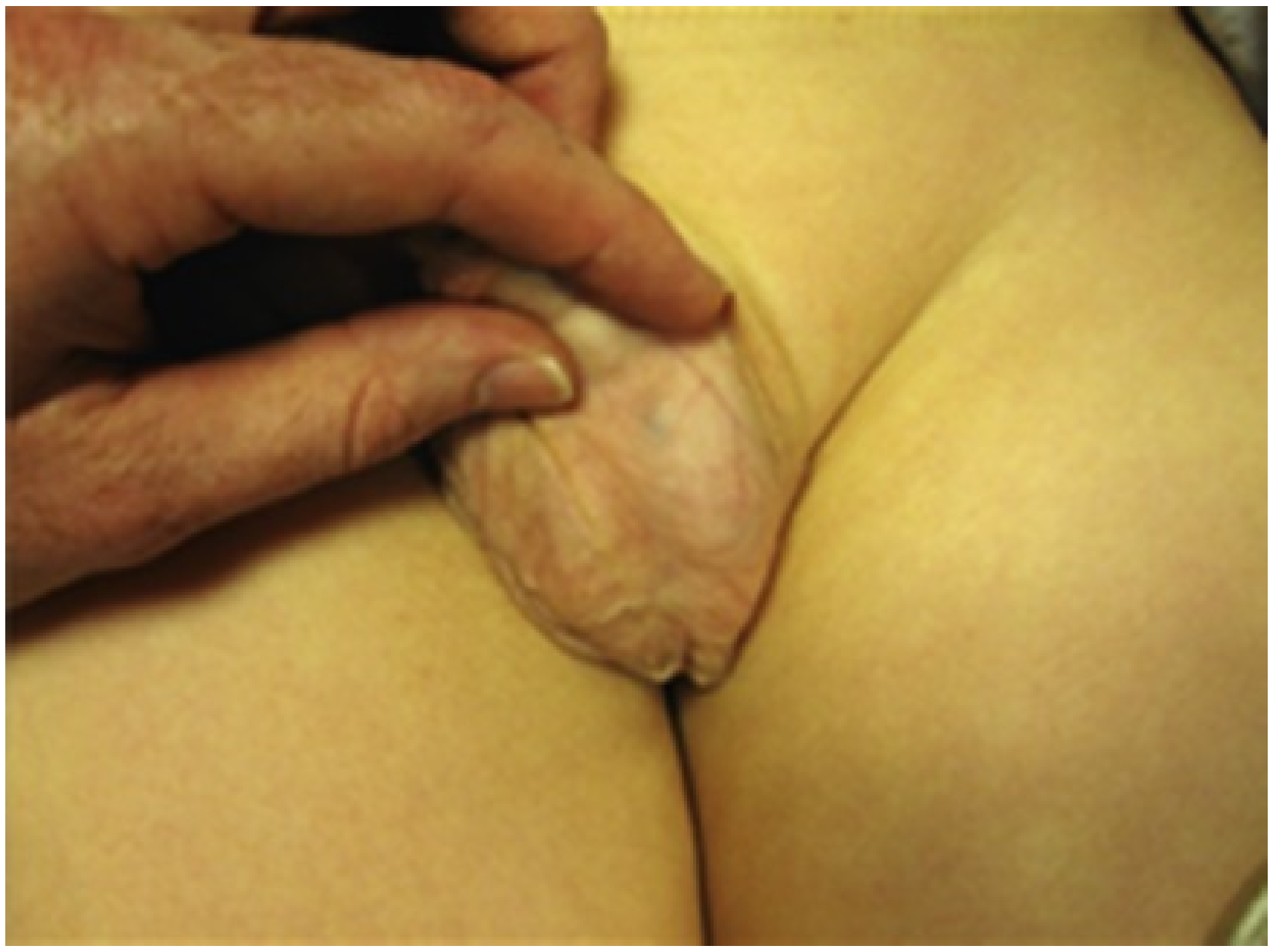

FIG. 23.1 Blue dot sign. Torsion of a testicular or epididymal appendage can mimic testicular torsion. Physical exam demonstrates localized tenderness at the superior pole of the testis or caput epididymis. In boys with thin scrotal skin, the classic "blue dot" sign is seen, reflective of a necrotic appendix.

Ultrasound showing the discrete appendage can be diagnostic, but a later study may only show increased blood flow to the adjacent epididymis and testis, resulting in the misdiagnosis of acute epididymitis or epididymo-orchitis (Rolnick et al., 1968). Pain is most responsive to nonsteroidal anti-inflammatory medications and resolves as the appendage infarcts and necroses. No further intervention is indicated.

Epididymo-orchitis.

Acute epididymitis accounts for up to 35% of pediatric cases of acute scrotal pain and is managed nonoperatively (Lewis et al., 1995). Epididymitis has a gradual onset of scrotal pain and swelling, usually without accompanying nausea. Color-flow Doppler sonography demonstrates increased testicular flow (Tarantino et al., 2001).

Urinalysis classically demonstrates pyuria and bacteriuria, and treatment of these cases is with antibiotics (Gatti and Patrick Murphy, 2007). **However, acute epididymitis associated with bacteriuria only accounts for approximately 15% of the cases of epididymitis, and antibiotics are not indicated for those without pyuria or positive urine culture** (Lau et al., 1997). These cases may be due to viral epididymitis or a postinfectious inflammatory phenomenon, which is usually diagnosed presumptively and is likely to be underreported (Gkentzis and Lee, 2014). In these patients, the condition is self-limiting and management is supportive. In contrast, the occurrence of epididymitis in infants suggests the presence of urinary infection and the likelihood of an associated structural genitourinary abnormality, such as an ectopic ureter, requiring complete urologic investigation (Williams et al., 1979).

Scrotal Mass

Hernia and Hydrocele.

Indirect inguinal herniorrhaphy is one of the most frequently performed surgical procedures in children, occurring up to 10 times more frequently in boys than in girls and also more commonly in premature infants (Brandt, 2008). Pediatric inguinal hernias commonly are seen as inguinal or inguinoscrotal swelling in infancy or new onset of scrotal swelling in older children. The swelling is observed with crying or straining or may be preceded by increasing abdominal pressure resulting from vomiting, constipation, or coughing. The examiner may see this in the office when babies cry or in older children by asking them to blow bubbles or blow up balloons; however, the surgeon may not see the bulge, and some will operate based on a classic description by caretakers or a referring physician, or a photograph obtained by the family. Hernias in children are repaired around the time they are diagnosed, even if they are asymptomatic. **Repair should take place in a timely manner to minimize the risk of incarceration, particularly in infants less than 12 months of age and in preterm infants who have the highest risk** (Brandt, 2008). It is our practice to surgically address hernias within a few weeks of presentation.

A hydrocele is a collection of fluid in the space surrounding the testicle between the layers of the tunica vaginalis, and in many cases they are associated with an indirect inguinal hernia (Kapur et al., 1998). Communicating hydroceles can be identified by a history of enlargement after activity or in the evening as compared with early morning (after being supine). **In the majority of infants, there is no indication for surgery within the first 24 months of age because they resolve spontaneously.** Those that do not develop until the child is several years old, and those associated with an inguinal hernia require surgical repair. The operation performed is high ligation of the patent processus vaginalis, the same procedure as that performed for inguinal hernia repair.

Varicocele.

Varicocele is an abnormal dilation and tortuosity of the internal spermatic veins within the pampiniform plexus of the spermatic cord. Varicocele have an incidence of 15% in adolescence with 90% being left-sided and 10% being right-sided (MacLellan and Diamond, 2006). **The optimal management of adolescent varicocele remains controversial given that 80% of adults with varicocele are fertile. The most commonly accepted indications for surgery in adolescents include hypotrophy of the involved testis, pain, bilateral disease, and varicocele in a solitary testis.**

The patient is examined in a warm room in the supine and standing positions. The scrotum is observed for visible swelling, and the spermatic cord is palpated at rest and during the Valsalva maneuver. They are graded as follows: grade 1, palpated with Valsalva; grade 2, palpated without Valsalva; grade 3, easily visible. Failure of a varicocele to decompress in the supine position, particularly on the right side, is a rare finding and warrants evaluation for a retroperitoneal tumor compressing the spermatic vein (Roy et al., 1989). To assess for testicular hypotrophy, serial testicular volume measurements should be undertaken given testicular asymmetry is common in adolescence (Vaganée et al., 2018). Prader and Rochester orchidometers are valuable in assessing testicular size, although ultrasonography is more accurate (Sakamoto et al., 2007).

Testicular Tumor.

A painless testicular mass is the most common presentation of a child with a testicular tumor. **Testicular tumors account for 1% of all pediatric solid tumors and may occur at any age with peak incidences before 3 years of age and again in the postpubertal period** (Ciftci et al., 2001). Accurate diagnosis of testicular tumors is critical in avoiding diagnostic delay, which results in distant metastases and poor prognosis. Therefore a solid scrotal mass in a child should be considered malignant until proved otherwise. Among malignant lesions, yolk sac tumors account for the majority of malignant tumors in prepubertal boys (Pohl et al., 2004). However, benign lesions, predominantly teratoma, represent nearly three-fourths of testicular tumors in prepubertal boys.

Diagnosing a testicular tumor requires exclusion of scrotal masses such as epididymitis, hernia, hydrocele, and spermatic cord torsion, which can be seen as a painless mass in the neonate. Although transillumination can differentiate if the primary component is fluid, such as a hydrocele, color Doppler ultrasonography is routinely performed to detect intratesticular neoplasms (Tallen et al., 2011). If an intratesticular mass is detected, a thorough examination of the lymph nodes should be performed to evaluate for lymphoma, leukemia, or metastatic disease. Physical examination should also evaluate for signs of precocious puberty, which may indicate the presence of a Leydig cell tumor. Finally, laboratory studies including α-fetoprotein and β-human chorionic gonadotropin should be obtained in any patient with a solid testicular tumor; those with concern for Leydig cell tumor should also be evaluated with serum testosterone and androstenediol levels.

Any suspicion of the malignant testicular tumor warrants radical orchiectomy via an inguinal approach to prevent scrotal violation by the tumor. Testis-sparing surgery may be performed for benign lesions such as teratoma, Leydig cell tumor, and epidermoid cyst based on imaging characteristics and potentially frozen biopsy findings (Woo and Ross, 2015).

Penile Conditions

When performing a penile exam, clinicians should appreciate that physiologic phimosis, or inability to retract the foreskin, is normal until at least 4 years of life and often extends into older age groups (Hayashi et al., 2011). In fact, 90% of foreskins are retractile by 3 years of age with less than 1% of males experiencing persistent phimosis by 17 years of age. These adhesions should not be manually separated if there is no bother (see conditions later) because the foreskin will become retractile over time with penile growth, erections, and smegma production. Notably, the position of the urethral meatus is almost never abnormal in the uncircumcised penis with a circumferential foreskin. Stretched penile length, measured from the pubic symphysis to the tip of the glans, and girth should be measured.

Foreskin

Phimosis and Paraphimosis.

Pathologic phimosis occurs when the prepuce cannot be retracted over the glans penis in older children, often because of inflammatory or traumatic injury resulting in an acquired inelastic scar that prevents retraction (Hayashi et al., 2011). This can cause balanoposthitis (inflammation of the glans and prepuce), dysuria, preputial ballooning during voiding because of urine entrapment, or retained smegma. **Topical corticosteroids are an effective treatment and is a safe, less invasive first-line treatment option before undertaking**

circumcision to correct phimosis (Moreno Corbalán et al., 2014).

Paraphimosis can occur when the foreskin is left retracted behind the glans penis for a period of time. This results in a tight constrictive band of tissue causing vascular engorgement and swelling of the glans, which prevents easy reduction of the foreskin to its anatomic position (Pohlman et al., 2013). **If left unattended, serious injury can occur and thus paraphimosis is a urologic emergency.** Reduction of the paraphimotic ring can be challenging because of severe edema of the tip of the foreskin and requires manual compression of the glans with compression of the edematous foreskin. This can be facilitated by placing a flexible self-adhering bandage around the penis, beginning from the tip and working toward the base, wrapping around the phallus approximately three times with each wrap. The wrap should be left in place for 15 to 20 minutes to reduce the edema. It can then be removed and manual reduction can be employed. In children, this procedure often requires some level of sedation. Subsequent re-wrapping for an additional 15 to 20 minutes may be employed after reducing the foreskin to its anatomic position to prevent recurrence of paraphimosis while the foreskin is inflamed.

Circumcision.

Male circumcision consists of the surgical removal of the foreskin from the penis. It is one of the most common procedures in the world. **Physicians counseling families about elective male circumcision should assist parents by explaining, in a nonbiased manner, the potential benefits and risks and by ensuring that they understand the elective nature of the procedure** (American Academy of Pediatrics Task Force on Circumcision, 2012).

Contraindications to newborn circumcision include significantly premature infants, those with blood dyscrasias, and individuals who have a family history of bleeding disorders. Before proceeding with a newborn circumcision, a thorough examination must be performed. Circumcision should not be performed if there is concern for congenital abnormalities such as hypospadias, suggested by deficient ventral foreskin, congenital penile curvature, deficient shaft skin such as penoscrotal fusion, or congenital buried penis. Occasionally, when the foreskin is retracted before a circumcision, the distal urethra and urethral meatus are enlarged (megameatus intact prepuce); in this case, the circumcision may be canceled in anticipation of formal operative repair. However, repair of this megameatus intact prepuce variant can be performed without an increased complication rate in those whose circumcision was completed (Chalmers et al., 2014; Duckett and Keating, 1989; Snodgrass and Khavari, 2006).

Newborn circumcisions are most commonly performed using the Gomco clamp, the Plastibell device, or the Mogen clamp. Significant acute complications of circumcision are rare, occurring in approximately 1 in 500 newborn male circumcisions (American Academy of Pediatrics Task Force on Circumcision, 2012). Acute complications are usually minor and most commonly involve bleeding, infection, or an imperfect amount of tissue removed. Late complications also occur, most commonly adhesions, skin bridges, and meatal stenosis.

The most common complication, bleeding, is generally minor and can be controlled by pressure on the wound (Lerman and Liao, 2001). Infection is the second most common complication and is also most commonly minor, treatable with local wound care and antibiotics if needed. Notably, the most common complication specifically associated with the Plastibell device is a retained or proximally migrated Plastibell, which occurs in approximately 3.5% of these circumcisions in a large series of 1129 patients. This can be managed by incising the device with a ring cutter, prying it open with hemostats, and removing it (Cilento et al., 1999). The skin should be treated with an ointment with each diaper change until epithelization has occurred.

Late complications can be treated electively as an outpatient surgical procedure as long as voiding remains normal during this period. The most common of these complications is urethral meatal stenosis, which may develop because the glans is no longer protected by the prepuce and the urethral meatus is in contact with ammonia produced by bacteria in urine-soaked diapers. If the stream has an upward deviation, this problem can be easily corrected with a meatotomy (Baskin et al., 1996).

Smegma Pearl or Smegmoma.

This common condition was noted in 5% of healthy children in one series although also is seen by the pediatric urologist as a “penile mass” (Fig. 23.2; Oster, 1976). **Smegma pearls, also referred to as smegmomas, are a benign collection of smegma in the subpreputial space of young uncircumcised boys.** This tends to occur before the ability to retract the foreskin in young boys or if the prepuce is not retracted regularly to clean the glans and coronal sulcus in older boys (Sonthalia and Singal, 2016). It is important to provide education and reassurance to the caretaker that this will resolve with proper hygiene as the prepuce becomes more retractile (Krueger and Osborn, 1986). It is particularly important to advise caretakers that this white or yellow thick material, with a texture and appearance like grits, will eventually emanate from between the foreskin and the glans. It is not infectious, and proper hygiene is the only necessary treatment.

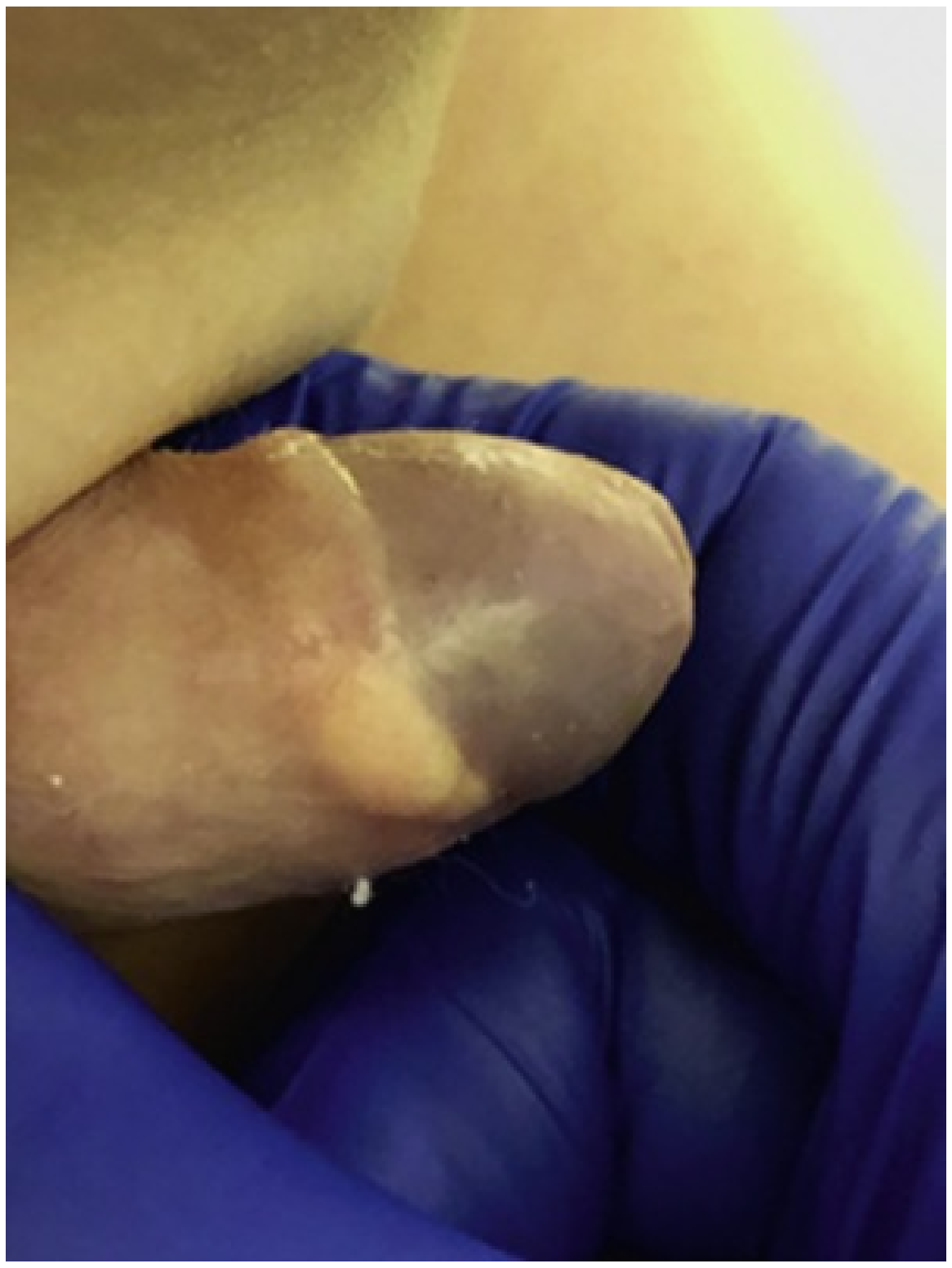

FIG. 23.2 Smegmoma. This common condition is a benign collection of smegma in the subpreputial space of young boys. This tends to occur before the ability to retract the foreskin in young boys or if the prepuce is not retracted regularly to clean the glans and coronal sulcus in older boys.

Inconspicuous Penis.

An inconspicuous penis refers to a penis that appears to be small with a normal stretched penile length measured from the pubic symphysis to the tip of the glans and normal diameter of the penile shaft. These conditions must be differentiated from micropenis, in which the stretched penile length is less than 2.5 standard deviations below the mean size for age (less than 1.9 cm in a full-term neonate) (Aaronson, 1994). If micropenis is diagnosed, evaluation should proceed with karyotype and assessment of the hypothalamic-pituitary-testicular axis.

The nomenclature for this type of penis has been variable in the literature. It is important to carefully examine and appropriately classify the type of inconspicuous penis to provide the appropriate treatment (Crawford 1977; Hadidi, 2014).

Buried Penis.

A buried penis is defined as an apparent absence of the penis characterized by an abnormally long inner prepuce sometimes accompanied by abnormal dartos fascia attachment, abnormal distal attachment of fundiform and suspensory ligaments, and excess suprapubic fat deposition (Hadidi, 2014). In many patients without voiding symptoms, this varied condition can simply be observed. Should treatment be desired, weight loss is first-line therapy and surgical reconstruction remains controversial. However, reconstruction is often indicated in those with congenital megaprepuce who have an abnormally long inner prepuce in conjunction with a phimotic ring causing progressive dilation of the inner foreskin from urine trapping. These patients experience intermittent ballooning and associated UTI and skin irritation.

Concealed Penis.

This acquired condition occurs after circumcision and is seen with a penis retracted behind the circumcision scar in the suprapubic fat pad. Treatment can be initiated with 0.05% betamethasone in conjunction with manual retraction (Palmer et al., 2005). Should this not be successful, surgical correction includes excision of the circumcision scar with possible need for penile skin flaps or Z-plasty for closure.

Webbed Penis.

A webbed penis involves only the inferior penoscrotal junction and the penis is not truly buried (Hadidi, 2014). Surgical correction is relatively straightforward and usually can be achieved by making a V-shaped midline incision that drops the scrotal skin away from the penis.

Abnormal Penile Orientation

Penile Torsion.

Penile torsion is a rotational deformity of the penile shaft, usually in the counterclockwise direction with normal orientation of the corporal bodies (Bauer and Kogan, 2009). This can be an isolated finding or it may be associated with other penile conditions such as hypospadias or curvature. Most forms of penile torsion are mild, primarily of cosmetic significance. Correction is typically indicated only if the rotation is at least 60 degrees and typically involves degloving the penile skin, rotating the glans in the direction opposite to the defect, and suturing the glans to the penile skin. In more severe cases, dorsal dartos flap rotation is an excellent option.

Penile Curvature.

Curvature of the penis may occur along the vertical or horizontal plane of the penis. Penile curvature is most commonly in the ventral direction, referred to as chordee, and is commonly associated with hypospadias. However, chordee may occur without hypospadias. There are three possible causes: (1) ventral skin tethering; (2) corporal disproportion; and (3) tethering by abnormal urethral plate development (Baskin et al., 1996). **Although there may be no cosmetic findings, the severe angulation with erection may interfere with sexual function** (Bennett and Gittes, 1980). Surgical correction is therefore indicated, although the technique will vary depending on the cause and severity of the curvature.

Parameatal Urethral Cyst.

The parameatal urethral cyst is rare anomaly and appears as a small vesicular lesion in proximity to the urethral meatus that does not usually interfere with urinary or sexual function (Fig. 23.3; Shiraki, 1975). To prevent recurrence and obtain an acceptable cosmetic outcome, complete excision can be performed. Care should be taken not to cause meatal stenosis.

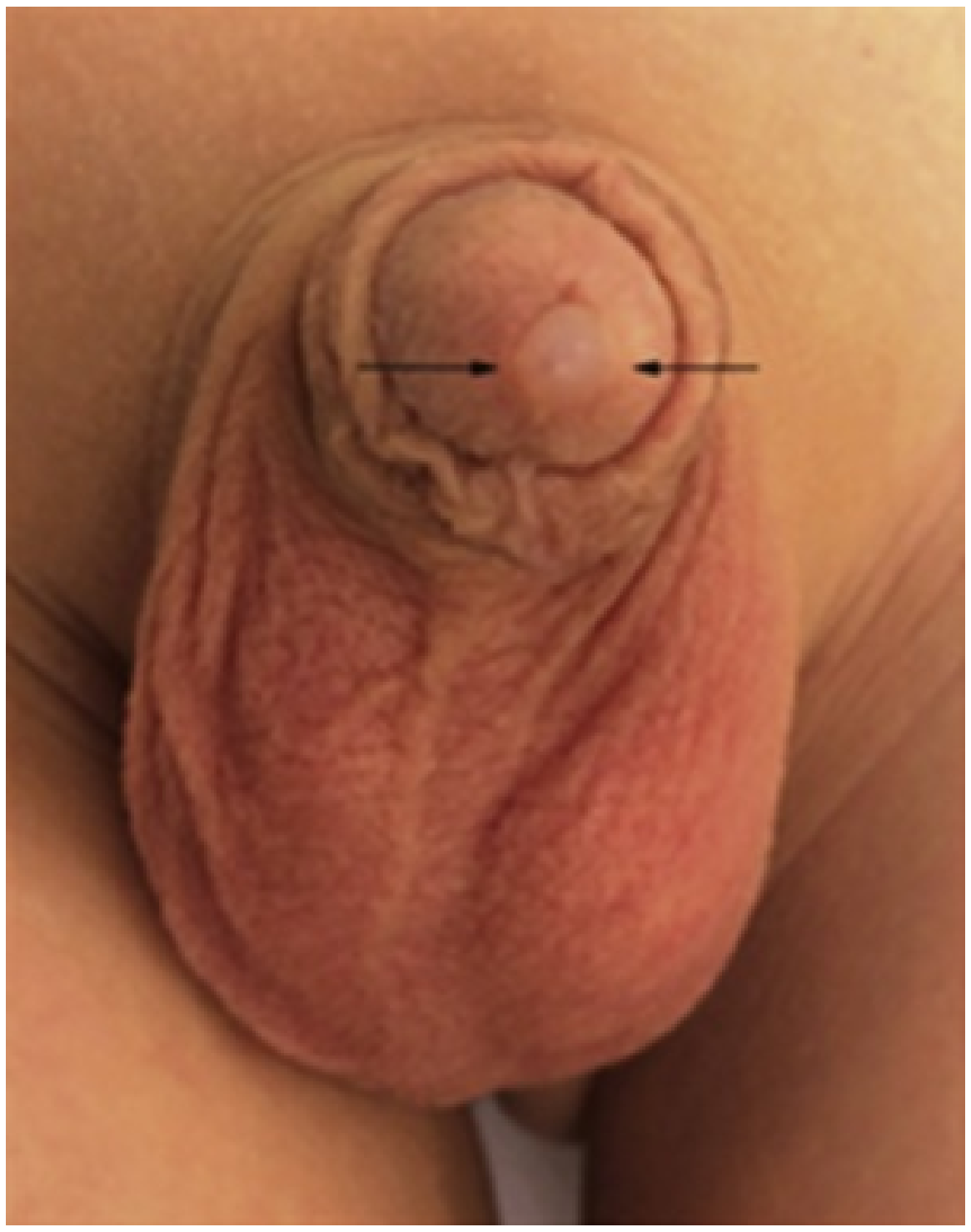

FIG. 23.3 Periurethral cyst. Periurethral cysts are usually asymptomatic, although sometimes are accompanied by dysuria, frequency, urinary stream distortion, or urinary retention.

Hypospadias.

Hypospadias is thought to be an arrest in normal penile development resulting from a combination of genetic and environmental causes with three resultant and related anomalies: a urethral defect with associated abortive corpus spongiosum, a preputial defect with ventral skin deficiency, and chordee (Cunha et al., 2015). It is the second most common congenital anomaly of the genitalia, although prevalence remains uncertain with a recent review noting prevalence ranging from 5 (in South America) to 34 (in North America) per 10,000 live births after reviewing literature screening more than 90,000,000 births (Springer et al., 2016).

If hypospadias is suspected on physical exam, a newborn circumcision should not be performed, and a referral to a pediatric urologist for further evaluation is warranted. The examination of the penis should evaluate the location of the meatus, presence of penile curvature, and assessment of the foreskin because these factors will inform the severity of the hypospadias and the course of treatment (Baskin, 2017)**. Importantly, a testicular exam is critical as the absence of both, or even one, palpable testicle may signal a**

disorder of sex development rather than isolated hypospadias. These patients should be evaluated with a karyotype and possible endocrinology assessment.

Priapism.

Priapism is a persistent penile erection, typically affecting only the corpora cavernosa, unrelated to sexual stimulation that is sustained for greater than 4 hours (Montague et al., 2003).

Priapism can be ischemic (veno-occlusive, low flow), nonischemic (arterial, high flow), and stuttering (intermittent). **All patients with priapism should evaluated immediately to intervene as soon as possible in those with ischemic priapism.** The most common cause in children is sickle cell disease (ischemic).

Evaluation should focus on differentiating ischemic from nonischemic priapism. Understanding the history of the episode is important with focus on degree of pain (only ischemic priapism is painful), history of similar episodes and inciting drugs, history of trauma, and history of hematologic disorders such as sickle cell. Physical exam should evaluate the genitalia because completely rigid corpora cavernosa suggests ischemic priapism; additional attention should focus on signs of trauma or malignancy. If uncertainty remains, laboratory evaluation for signs of blood dyscrasias (such as sickle cell anemia or leukemia), a cavernosal blood gas test assessing for hypoxia, and/or color duplex ultrasonography demonstrating absence of blood flow are diagnostic of ischemic priapism.

Treatment of priapism depends on its cause with sickle cell disease making up the majority of priapism in children, 65% (Donaldson et al., 2014). Treatment of low-flow priapism resulting from sickle cell disease includes concurrent treatment of the underlying disease with transfusion, alkalization, hydration, oxygen, and intracavernous treatment with aspiration (with or without irrigation) or intracavernous injection of sympathomimetics as indicated.

Key Points

- Cryptorchidism is among the most common referrals to pediatric urology, and diagnosis is based on physical exam alone.
- Acute scrotal pain has a wide differential, but testicular torsion must be ruled out because it represents a true surgical emergency.

- Topical corticosteroids use is a safe, less-invasive first-line treatment option before undertaking circumcision to correct phimosis if cicatrix is not present.
- If hypospadias is suspected, a newborn circumcision should not be performed and a referral to a pediatric urologist is warranted.
- Evaluation of children with priapism should focus on differentiating ischemic from nonischemic priapism as treatment depends on the cause.

External Genitalia of the Female

The patient should be examined in a warm room in supine position, frog-legged. Examination of the perineum in female infants and young girls should include examination of the urethral meatus, vaginal introitus, and anus. To aid in visualization, the labia majora can be gently grasped and pulled caudally and laterally to enable funneling of the introitus and vagina as demonstrated in Video 23.2 ▶ (Price, 2013). The clitoris is examined for evidence of hypertrophy, which may be suggestive of a disorder of sex differentiation.

Labial Adhesions

Labial adhesions are the most common interlabial anomaly identified in girls with an incidence of 1.8% with a peak incidence between 13 and 23 months (Leung et al., 1993). Fusion of the labia minora originates at the posterior fourchette and progresses for a variable distance toward the clitoris (Fig. 23.4). **Although labial adhesions are usually asymptomatic, urine pooling within the vagina may lead to postvoid dribbling and infection.** Asymptomatic patients should be managed conservatively given spontaneous resolution rates of 80% within 1 year (Bacon et al., 2015). In symptomatic patients, topical treatment with estrogen and/or steroid cream is often curative. Less often, manual separation using topical anesthesia with or without sedation is necessary. **Recurrence is common until a patient goes through puberty.**

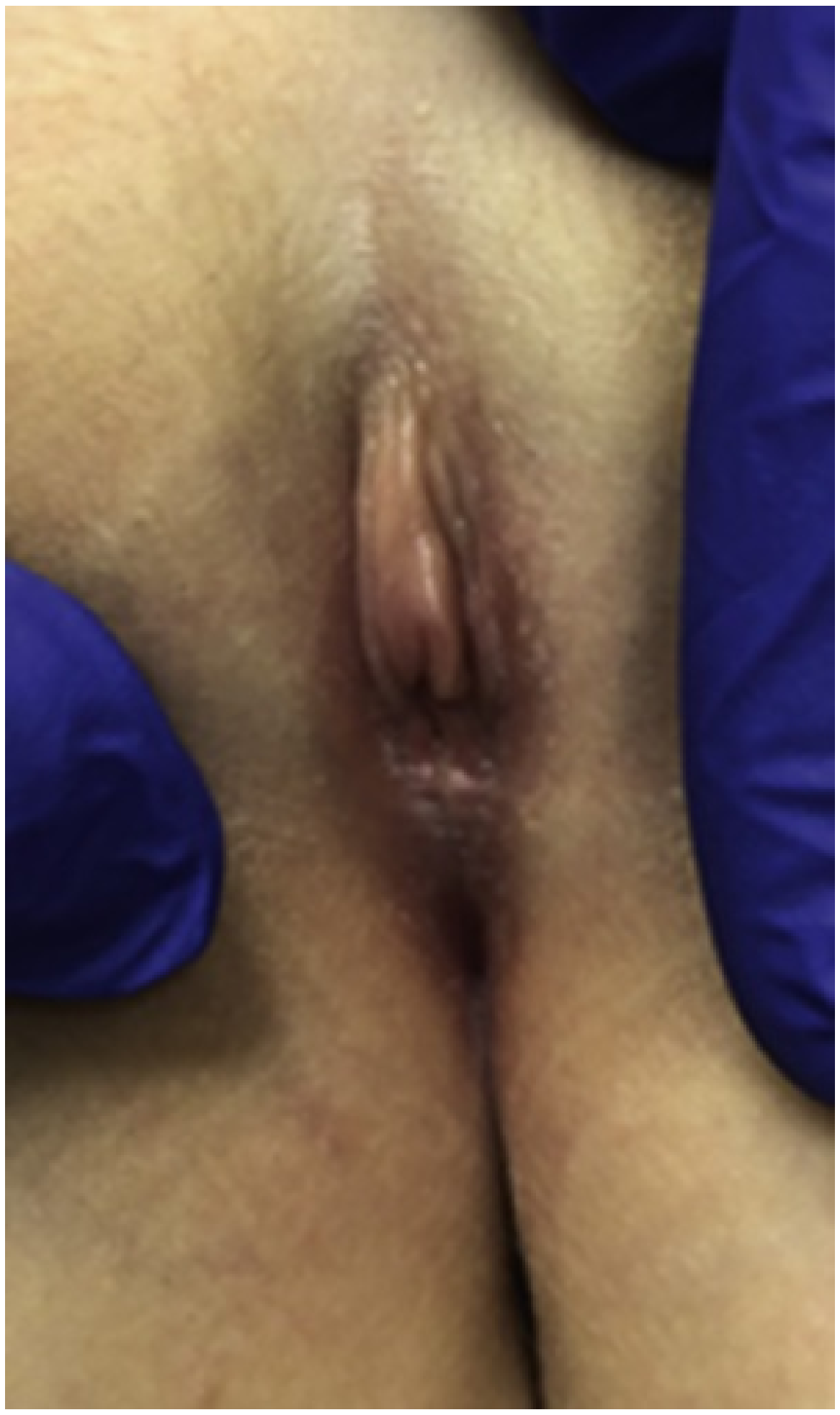

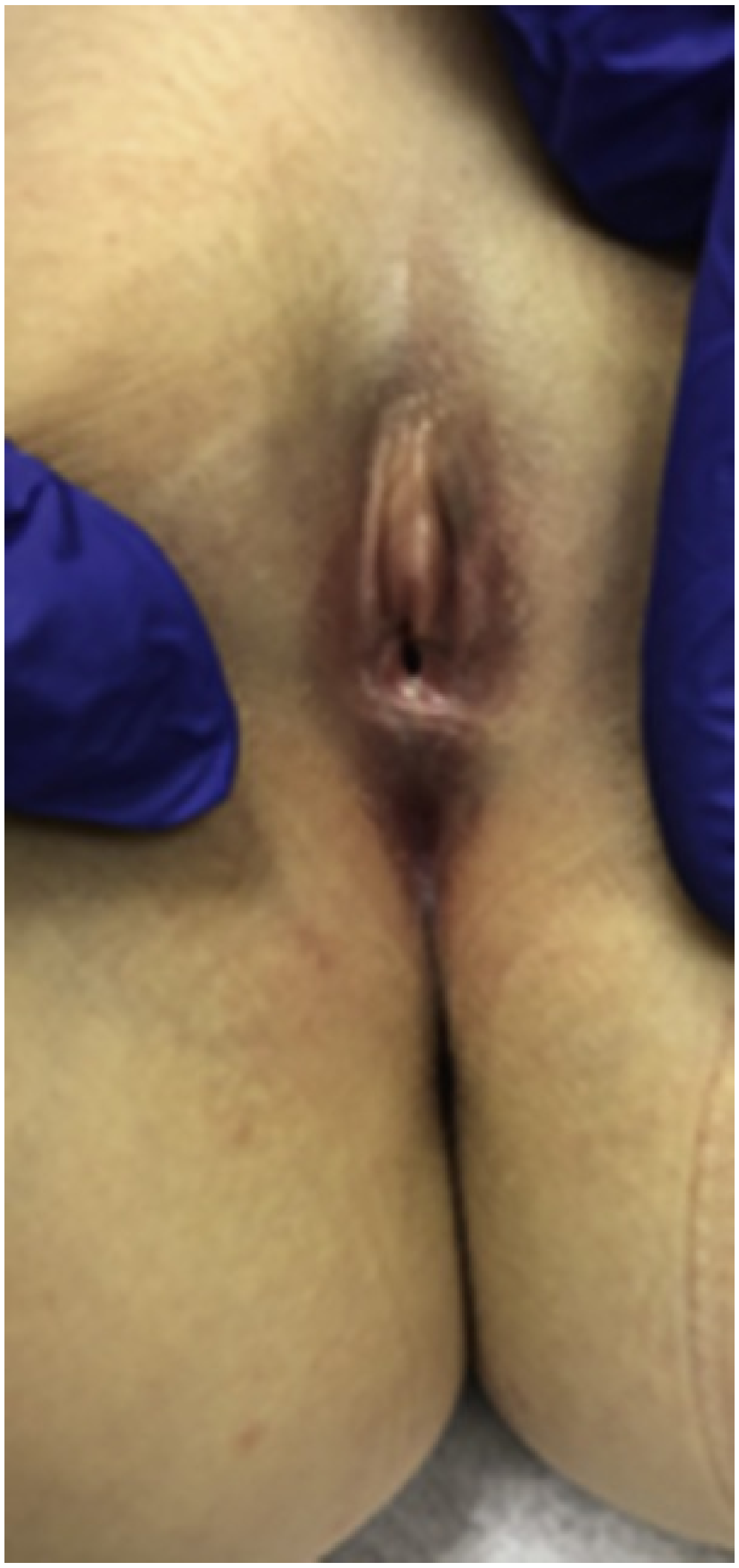

FIG. 23.4 Labial adhesions. Labial adhesions are the most common interlabial anomaly identified in girls. Fusion of the labia minora originates at the posterior fourchette and progresses for a variable distance toward the clitoris. Although labial adhesions are usually asymptomatic, urine pooling within the vagina may lead to postvoid dribbling and infection. Recurrence is common until the patient goes through puberty.

Interlabial Masses

Vaginal masses may be palpable or may protrude from the introitus. The differential diagnosis of interlabial masses is broad, including benign paraurethral cysts, hymen skin tags, urethral prolapse, imperforate hymen, prolapsed ureterocele, or, rarely, malignancies. Although age and racial background can help narrow the differential diagnosis, physical examination remains the most useful tool for determining the specific pathology. **An introital mass should be examined for site of origin, laterality, symmetry, and signs of infection or irritation.** The relationship of the mass to the vagina and urethra can be improved by gentle placement of a lubricated cotton applicator posteriorly or placement of a small feeding tube within the suspected urethral orifice, or both. A carefully performed examination and vaginoscopy under anesthesia may be necessary.

Hymenal Disorders

Imperforate Hymen.

Hymenal abnormalities are the most common outflow tract concern, with imperforate hymen occurring in 1 of 2000 girls (Fig. 23.5; Dietrich et al., 2014). **An imperforate hymen may result in hydrometrocolpos and a lower abdominal mass.** In infancy, examination demonstrates a midline bulging, pearly white membrane. In puberty, the inability to efflux menstrual blood leads to cyclic pelvic pain and primary amenorrhea. Inspection of the vulva reveals no hymenal opening and a bulging or bluish hymenal membrane. **Treatment involves incision of the imperforate hymen, which allows passage of the menstrual contents. No postoperative dilation is indicated because stenosis does not occur.**

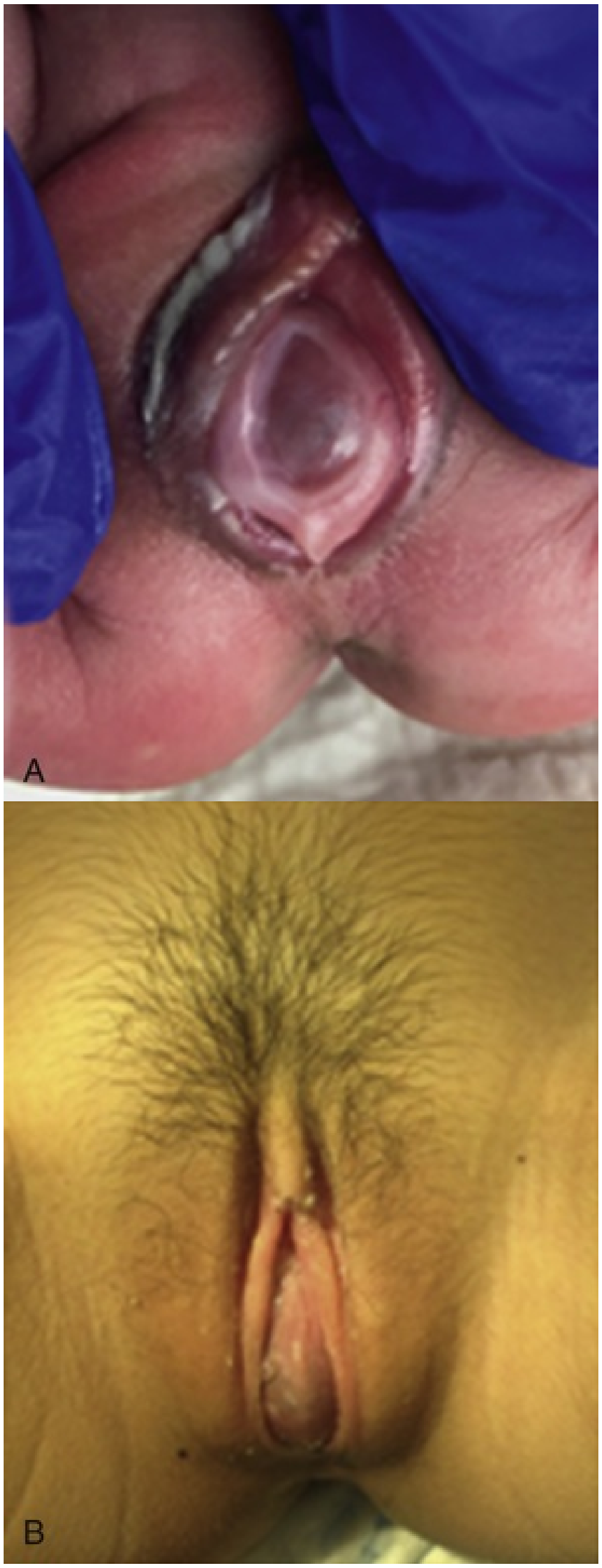

FIG. 23.5 Imperforate hymen. An imperforate hymen may result in hydrometrocolpos. (A) In infancy, examination demonstrates a midline bulging, pearly white membrane. (B) In puberty, the inability to efflux menstrual blood leads to cyclic pelvic pain and primary amenorrhea. Inspection of the vulva reveals no hymenal opening and a bulging or bluish hymenal membrane.

Hymenal Skin Tag.

Hymenal skin tags can cause confusion during examination because they can fall over the hymenal orifice, obscuring it (Price, 2013). It may be necessary to use a swab to delineate the tag and move it so that the rest of the hymen can be visualized. **These are considered a normal variant, are rarely symptomatic, and require no treatment.** When symptomatic, usually with bleeding, they should be excised to provide relief.

Paraurethral Cyst.

Interlabial cysts occur in between 1 : 1000 and 1 : 7000 newborn girls (Badalyan et al., 2012). **Paraurethral cysts, also called Skene cysts, are among the most common neonatal intralabial cysts** (Fig. 23.6). They are thin walled and golden or whitish and anterior to the vagina, rarely causing symptoms such as urinary stream deviation. When positively identified, no evaluation of upper urinary tract is required, and they are most often self-resolving. If persistent or symptomatic, paraurethral cyst incision may be performed. A careful, well-focused physical examination helps the clinician differentiate between this benign self-condition and other interlabial lesions.

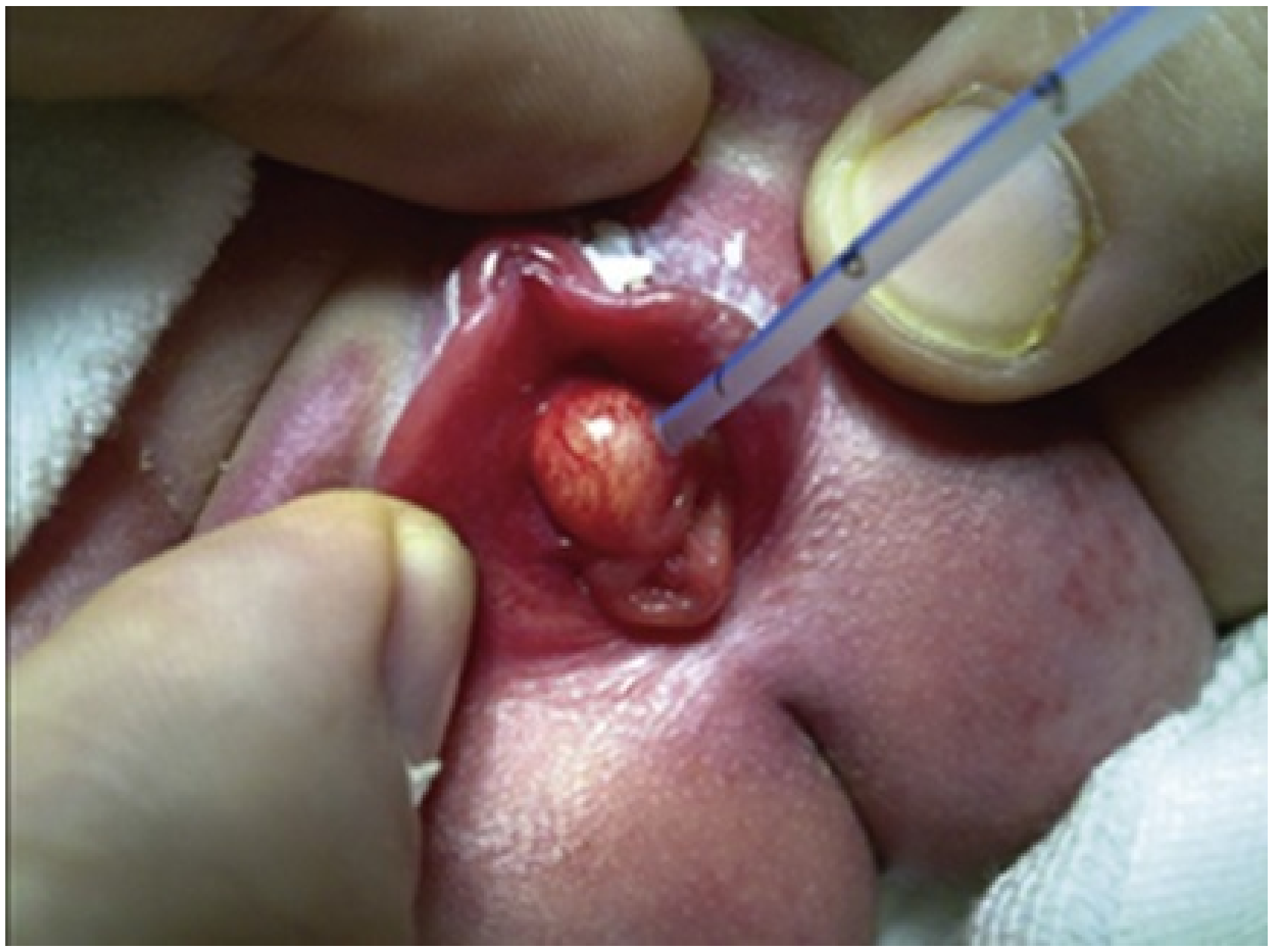

FIG. 23.6 Paraurethral cyst. Paraurethral cysts are among the most common neonatal intralabial cysts. They are thin walled and golden or

whitish and anterior to the vagina, rarely causing symptoms such as urinary stream deviation. A careful physical examination helps differentiate between this benign condition and other interlabial lesions.

Urethral Prolapse

Urethral prolapse is a circular eversion of mucosa protruding through the external meatus occurring most commonly in prepubertal black girls and in postmenopausal white women (Fig. 23.7; Richardson et al., 1982). Presentation in prepubertal girls usually results from vaginal bleeding resulting from contact of the friable, prolapsed mucosa with undergarments; voiding dysfunction is uncommon. Historically, treatment has comprised surgical manipulation (Fernandes et al., 1993; Redman, 1982). **Nonoperative treatment such as topical estrogen, corticosteroids, and sitz baths has resulted in reduction of the prolapse, although a high recurrence rate suggests that definitive surgical excision may still be required** (Jerkins et al., 1984). Although the cause of urethral prolapse is likely multifactorial, episodic increases in intra-abdominal pressure are likely contributory (Lowe et al., 1986). Therefore the authors recommend patients with urethral prolapse be screened and treated as necessary for underlying constipation.

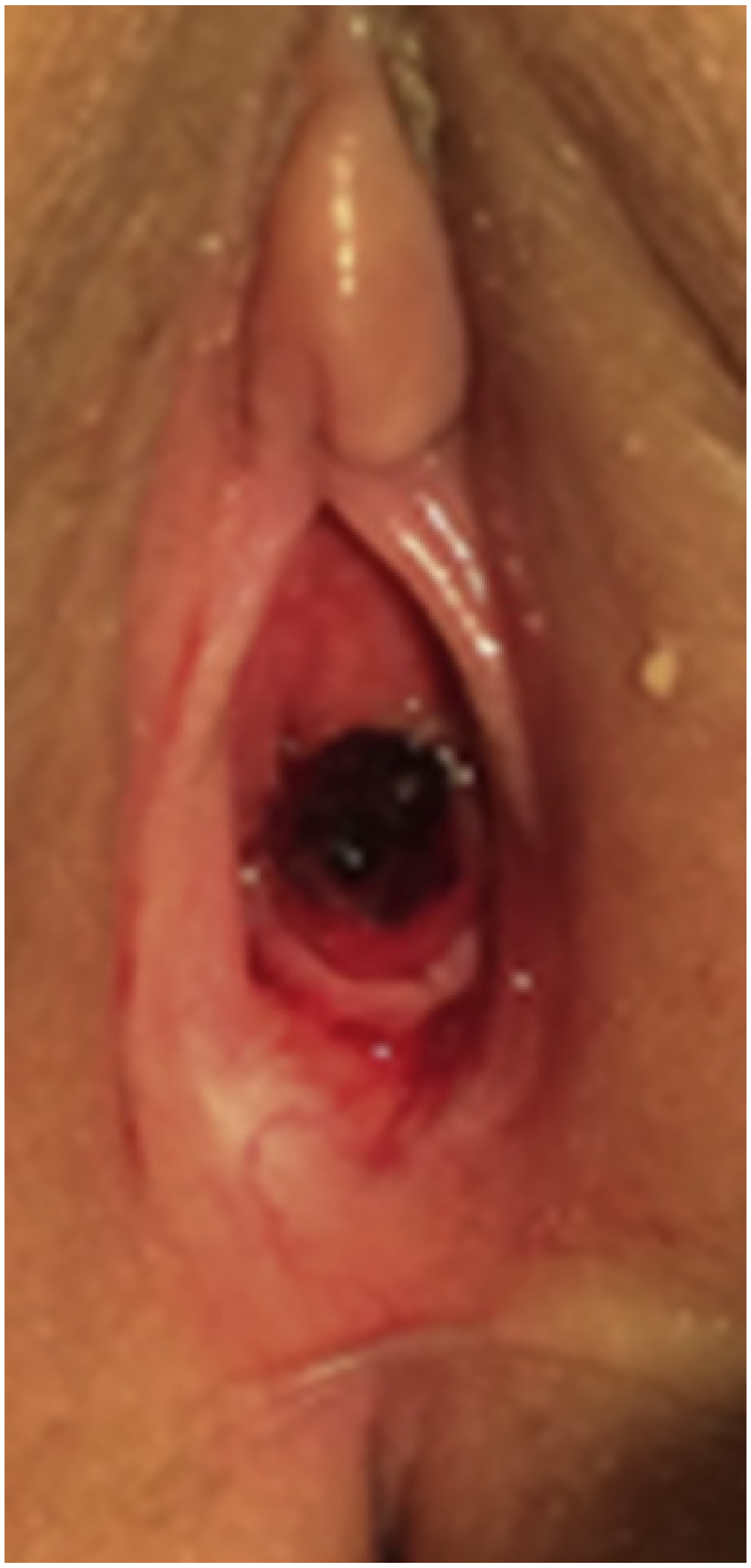

FIG. 23.7 Urethral prolapse. Urethral prolapse is a circular eversion of mucosa protruding through the external meatus occurring most commonly in prepubertal black girls and in postmenopausal white women. Presentation in prepubertal girls usually results from vaginal bleeding because of contact of the friable, prolapsed mucosa with undergarments.

Prolapsing Ureterocele

Ureteroceles represent a version of the ectopic ureter with a cystic dilation of the distal aspect of the ureter that is located either within the bladder or spanning the bladder neck and urethra. An important subgroup to recognize, referred to as ectopic or cecoureteroceles, are ureteroceles in which some portion of the ureterocele extends beyond the bladder neck into the urethra (Fig. 23.8; Glassberg et al., 1984). This may cause bladder outlet obstruction.

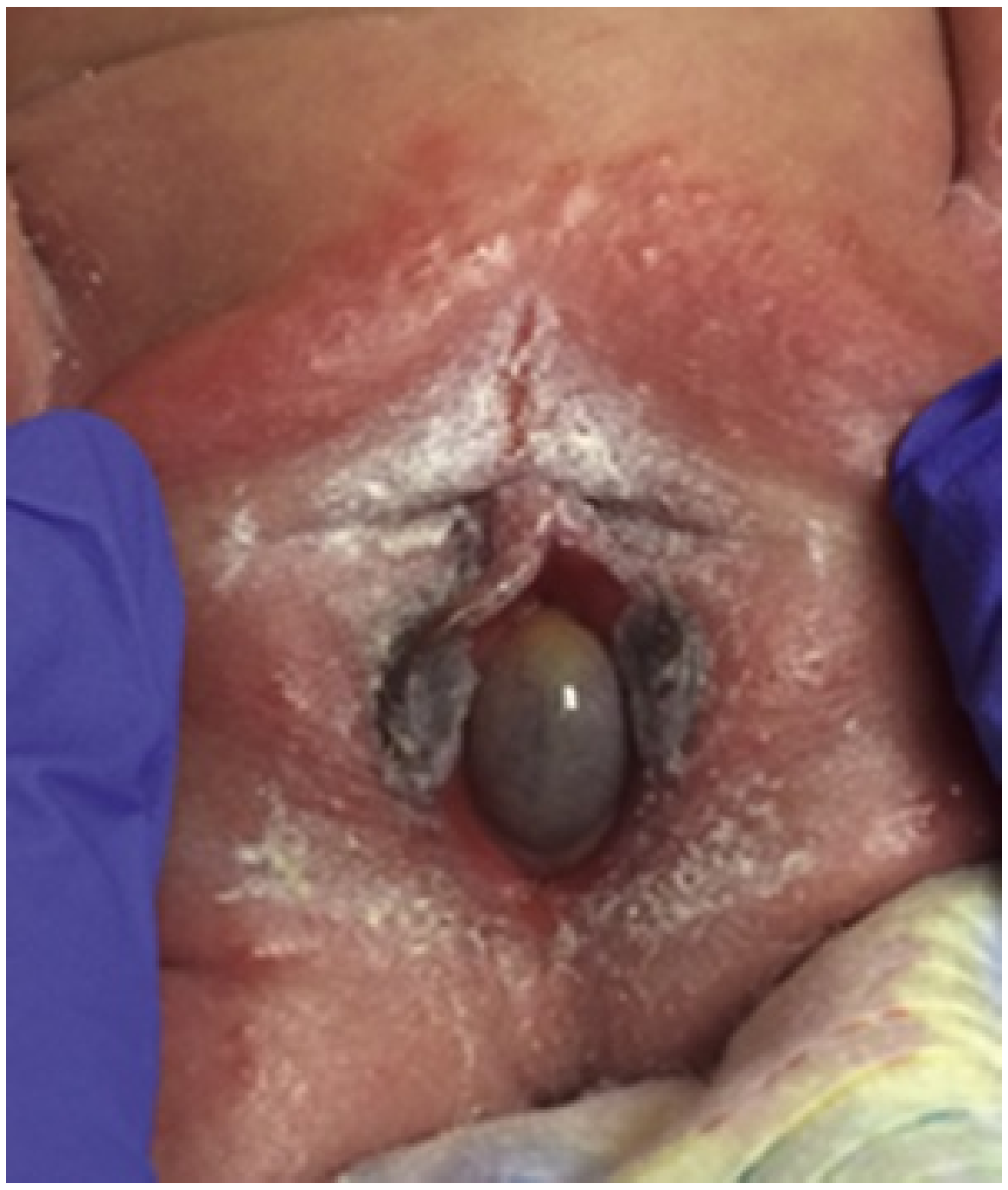

FIG. 23.8 Prolapsing ureterocele. Ureteroceles represent a version of the ectopic ureter with a cystic dilation of the distal aspect of the ureter that is located either within the bladder or spanning the bladder neck and urethra. An important subgroup to recognize are those in which some portion of the ureterocele extends beyond the bladder neck into the urethra, which may cause bladder outlet obstruction. Physical examination will demonstrate a smooth, congested, mucosa-covered interlabial mass protruding from the urethra that is distinct from the vagina.

History may reveal voiding difficulty resulting from urethral obstruction. Physical examination will demonstrate a smooth, congested, mucosa-covered interlabial mass protruding from the urethra that is distinct from the vagina. This can be differentiated from urethral prolapse because the ureterocele is not circumferential. **The diagnosis can be confirmed with a renal bladder ultrasound. Definitive surgical treatment differs depending on the patient's anatomy; however, initial treatment should begin with incision or endoscopic puncture of the ureterocele to relieve urethral obstruction** (Glassberg et al., 1984).

Vaginal Rhabdomyosarcoma

Primary vaginal tumors present at a mean age of less than 2 years (Hays et al., 1988). **The rhabdomyosarcoma botryoides subtype of rhabdomyosarcoma is most often described as a grapelike cluster of tissue emanating from the posterior aspect of the vestibule** (Aalia Sachedina et al., 2018). Diagnosis is confirmed with tissue biopsy and evaluation consists of staging imaging followed by chemotherapy and local excision in some circumstances.

Vaginal Discharge

Vaginal discharge is the most common gynecologic complaint in young girls. When treating young children with vaginal discharge, clinicians must understand the causes so that the condition can be adequately investigated and treated (McGreal and Wood, 2013).

Bladder and Bowel Dysfunction

Dysfunctional voiding is a common concern exhibited by approximately 40% of patients seen by the pediatric urologist (Farhat et al., 2000). Voiding dysfunction in children encompasses a variety of clinical entities typically occurring after toilet training; it may originate from behavioral issues that arise around this time in childhood development. The International Children's Continence Society developed standardized definitions to establish uniformity and clarity in the characterization of lower urinary tract function and dysfunction in children across multiple health care disciplines (Austin et al., 2014). Concomitant bladder and bowel disturbances have been labeled as bladder and bowel dysfunction (BBD). **Given its breadth of urinary symptoms, it is discussed later more completely in the urinary tract section.**

Patients with BBD may experience postmicturition dribbling, which can be confused with vaginal discharge. Elsewhere referred to as vesicovaginal reflux, postvoid dribbling, or vaginal voiding, this is observed in otherwise normal prepubertal girls after toilet training (Feldman and Bauer, 2006). During voiding, urine passes into the vagina, and this pooled urine dribbles out during standing, wetting the underwear. This occurs in patients who do not void with their legs wide enough apart to allow passage of urine, sometimes because of an obese or overweight habitus. This resolves with age and growth. In the interim, the child may be taught to empty her vagina by sitting faced backward on the toilet or manually spreading the labia during voiding.

Foreign Body

Recurrent or persistent vaginal discharge is distressing to the patient and her family. Foreign bodies, although an uncommon cause of vaginal discharge, must be considered. **Foreign bodies account for 4% of girls under 13 years of age with genitourinary complaints and 10% of the girls with a complaint of bloody discharge** (Smith et al., 2002). The most common foreign body is toilet paper. Ruling out a foreign body requires a careful genital examination in the clinic, and procedures such as a vaginal saline lavage (in cooperative patients) or an examination under anesthesia with vaginoscopy, which allows for a more thorough examination and for obtaining vaginal cultures and biopsies, if indicated.

Sexual Abuse

Sexual abuse is a prevalent reality in pediatric medicine and must be considered based on presentation with symptoms including vaginal, penile, or rectal pain, discharge, or bleeding, vulvovaginitis, and enuresis**. Given its impact beyond the female external genitalia, it will be discussed later in the urinary tract section.**

Other Vaginal Disorders

Patients with primary amenorrhea, the absence of menses at age 15 years, with normal growth and secondary sexual characteristics may have genitourinary anomalies. Evaluation should include a careful physical exam. The assessment should include breast development, as assessed by Tanner staging, growth (height, and weight), skin findings (hirsutism, acne, striae, increased pigmentation, vitiligo), and a careful genital examination for clitoral size, pubic hair development, intactness of the hymen, vaginal length, and presence of a cervix, uterus, and ovaries. If a normal vagina or uterus is not obviously present on physical examination, pelvic ultrasonography should be performed to evaluate for ovaries, uterus, and cervix.

Should the uterus be absent, evaluation may proceed with a karyotype and testosterone measurement to assess for vaginal atresia (müllerian agenesis, Mayer-Rokitansky-Küster-Hauser syndrome) versus disorders of sex development associated with 46, XY karyotype such as complete androgen insensitively syndrome or 5-alpha reductase deficiency. Management of each of these anomalies is complex and must balance the priorities of the patient as well as his or her parents considering psychological and anatomic ramifications of treatment options.

Should the uterus be present, outflow tract obstruction should be considered. As discussed earlier, one such obstructive pathology is imperforate hymen, which prevents efflux of menstrual blood, leading to cyclic pelvic pain and primary amenorrhea. This can be diagnosed on physical exam by inspection of the vulva revealing no hymenal opening, sometime with a bulging or bluish hymenal membrane. Treatment with surgical incision is definitive. Less commonly, a transverse vaginal septum may be present (Edmonds, 2003). Resulting from incomplete fusion between the müllerian duct component of the vagina and the urogenital sinus component, this incomplete vertical fusion leaves a transverse vaginal septum. Treatment involves surgical excision of the septal defect with a vaginal end-to-end anastomosis between the upper and lower portions of the vagina. Last, vaginal agenesis may be present, occurring in 1 in 5000 women (Kimberley et al., 2012). Although this may be an isolated müllerian anomaly, it may alternately be a consequence of failed induction of the müllerian duct secondary to anomalous wolffian duct formation. Therefore renal anomalies should be assessed with a renal bladder ultrasound.

Key Points

- The differential diagnosis of interlabial anomalies is broad and requires a careful physical examination for accurate diagnosis.
- Vaginal discharge is the most common gynecologic complaint in girls, and the examiner must consider foreign objects and sexual abuse as well as postmicturition dribbling.

Urinary Tract

Urinary Tract Infection and Pyelonephritis

Pediatric UTIs constitute a significant health burden on society, affecting an estimated 2.6% to 3.4% of children yearly and resulting in more than 1 million physician visits annually (Freedman and Urologic Diseases in America, 2005)**. Throughout childhood, the risk of UTI is 2% for boys and 8% for girls. Although female infants have a two- to fourfold higher prevalence of**

UTI than male infants, the prevalence of UTI is highest in boys younger than 1 year of age (Shaikh et al., 2008)**. Among boys, an uncircumcised boy has a tenfold higher risk of UTI compared with a circumcised boy.** In fact, circumcision is associated with decreased odds of UTI among boys with hydronephrosis (odds ratio 0.36, 95% confidence interval 0.29–0.44; Ellison et al., 2018). Given the association of UTI renal scarring that may lead to hypertension, proteinuria, and permanent renal damage, accurate diagnosis and treatment of UTI is important (Jakobsson et al., 1994).

Symptoms of UTI vary with patient age. Neither clinical symptoms nor laboratory tests will predict a UTI in febrile infants, and thus obtaining a urinary specimen is necessary (Crain and Gershel, 1990). Children younger than 2 years old often experience vague symptoms, including fever, irritability, poor feeding, vomiting, diarrhea, and ill appearance with increased likelihood of UTI in the setting of at least two of the following risk factors: (1) age less than 12 months, (2) white race, (3) absence of other fever source, (4) fever greater than 39°C, and (5) fever of 2 or more days (Subcommittee on Urinary Tract Infection, 2011). However, older children and adolescents may localize symptoms to the urinary tract, reporting dysuria, suprapubic pain, voiding dysfunction, incontinence, or flank and/or abdominal pain. There are no specific physical exam signs for UTI, although palpation in the suprapubic and flank areas may cause pain in the older child.

Pyelonephritis refers to an infection of the kidneys and is the most severe form of UTI in children. Clinically, this is associated with systemic features such as high fever, malaise, vomiting, abdominal and flank pain and tenderness, poor feeding, and irritability in infants (Strohmeier et al., 2014). Pyelonephritis is associated with significant short-term morbidity, including shock and septicemia, as well as acute kidney parenchymal injury. Permanent kidney damage may occur after acute pyelonephritis and is more frequent in children who have multiple episodes or who have vesicoureteral reflux.

Guidelines from the American Academy of Pediatrics and the National Institute for Health and Care Excellence recommend urine testing if treating a child for a suspected UTI (National Institute for Health and Clinical Excellence 2007, Subcommittee on Urinary Tract Infection, 2011). **Specifically, a noncontaminated urine sample should be collected, which requires catheterization or suprapubic aspiration in infants and young children who have not completed toilet training.** The diagnosis of UTI is generally confirmed by the pure growth of a bacteria of greater than 10^3 CFU/mL from a suprapubic aspirate or 10^4 CFU/mL from a bladder catheter specimen (Strohmeier et al., 2014). **In addition, adolescents should be evaluated for sexually transmitted infections.** Once a UTI is diagnosed, antimicrobial treatment should proceed based on local antibiograms. Importantly, even the most severe form of UTI in children, acute pyelonephritis, can be treated with oral antibiotics as long as the child can tolerate oral medication (Strohmeier et al., 2014).

Evaluation of children diagnosed with a UTI with imaging remains controversial. Imaging may detect renal damage from an acute infection as well as identify genitourinary anatomy that increases risk of future infection. Acute imaging with ultrasonography is recommended by the American Academy of Pediatrics and by the National Institute for Health and Clinical Excellence Guidelines (NICE); however, the NICE guidelines specifically recommend ultrasound only when the UTI is atypical (a child who is seriously ill, has poor urine flow, an abdominal or bladder mass, a raised creatinine, septicemia, fails to respond to suitable antibiotics within 48 hours, or is infected with non-*E. coli* organisms) (National Institute for Health and Clinical Excellence, 2007). Further imaging with a voiding cystourethrogram is recommended by the American Academy of Pediatrics in children 2 to 24 months only if the renal ultrasound reveals hydronephrosis, scarring, or other findings that would suggest either high-grade vesicoureteral reflux or obstructive uropathy (Subcommittee on Urinary Tract Infection, 2011). A voiding cystourethrogram is also recommended in other complex clinical circumstances such as a recurrent febrile UTI.

Vesicoureteral Reflux

Recurrent UTI occurs in up to 30% of children and occurs more commonly in those with VUR (Williams and Craig, 2011). VUR entails retrograde flow of urine from the bladder to the upper urinary tract and is graded from I to V based on the appearance of the ureter, renal pelvis, and calyces as seen on the radiographic contrast images generated by the voiding cystourethrogram (Duckett and Bellinger, 1982). Although spontaneous resolution of low-grade VUR is common, persistent VUR and UTI may detrimentally affect overall health and renal function. **Controversy exists regarding when to evaluate for VUR and the optimal management strategies including continuous antibiotic prophylaxis and/or surgical intervention.**

As discussed earlier, the American Academy of Pediatrics recommends obtaining a voiding cystourethrogram in children 2 to 24 months in the setting of recurrent febrile UTI or if a renal ultrasound reveals hydronephrosis, scarring, or other findings that would suggest high-grade VUR (Subcommittee on Urinary Tract Infection, 2011). The American Urological Association Guidelines regarding the Management and Screening of Primary VUR in Children further guide the screening of children for VUR (Peters et al., 2010a,b). Neonates with prenatal hydronephrosis have an approximately 16% incidence of VUR (female incidence is greater than male), and a voiding cystourethrogram is recommended for children with high-grade hydronephrosis (Society of Fetal Urology grade 3 and 4), hydroureter, or an abnormal bladder on ultrasound. Given a 27% prevalence of VUR in siblings of children with VUR, a voiding cystourethrogram or radionuclide cystogram is also recommended for these children if there is evidence of renal cortical abnormalities, renal size asymmetry on ultrasound, or if there is a history of UTI in the sibling who has not been tested.

The management of this pathology remains controversial, and these guidelines provide management strategies with aims of preventing recurrent febrile UTIs, preventing renal injury, and minimizing the morbidity of treatment and follow-up. In children older than 1 year of age, continuous antibiotic prophylaxis is recommended in the setting of BBD given the increased incidence of breakthrough UTI in these children. Continuous antibiotic prophylaxis is an option in (a) children less than 1 year of age with Grades I and II vesicoureteral reflux identified through screening or (b) those more than 1 year of age with any grade of VUR who do not have BBD, recurrent febrile UTI, or renal cortical abnormalities.

Bladder and Bowel Dysfunction

BBD is an umbrella term that includes lower urinary tract dysfunction and bowel dysfunction (Austin et al., 2014). **Patients with BBD experience a spectrum of symptoms and require a thorough history to guide therapy. The history should be obtained from the caretaker as well as the child because their perceptions may differ.**

Patients with BBD may have storage and voiding symptoms. Storage symptoms include urinary frequency, urgency, and nocturia as well as urinary incontinence. The examiner should further assess incontinence as continuous versus intermittent. Intermittent incontinence should be further categorized as daytime incontinence (occurring only while awake) and enuresis (occurring during sleeping periods). Voiding symptoms include hesitancy, straining, weak stream, intermittency, and dysuria. Other behaviors such as holding maneuvers, the sensation of incomplete emptying, and pain should be assessed. The examiner should also specifically inquire about the course of toilet training, whether there was an asymptomatic period, and whether there is any history of UTIs. The close relationship between bladder and bowel function requires screening of bowel dysfunction, preferably with a bowel diary using the Bristol Stool Form Scale (Nevéus et al., 2010). Finally, the examiner must differentiate patients whose symptoms are due to other underlying causes. For example, continuous leakage may suggest an ectopic ureter. Symptoms consistent with detrusor sphincter dyssynergia may be due to occult spinal dysraphism. Urinary retention may be caused by posterior urethral valves.

BBD plays a substantial role in development of recurrent UTI (Yang et al., 2017). Rectal distention can compress the adjacent bladder neck and trigonal region, leading to detrusor overactivity and possibly bladder outlet obstruction. The correlation between constipation and UTI may be due to increased uropathogenic organisms in the gastrointestinal tract leading to recurrent infection. Furthermore, improvement in BBD may prevent bacterial adherence, thereby preventing UTI. Moreover, children with BBD and any degree of VUR had the highest risk of recurrent UTI (Keren et al., 2015). BBD is also associated with a decrease in the spontaneous resolution rate of VUR in children receiving continuous antibiotic prophylaxis (Peters et al., 2010a,b).

A focused physical examination should evaluate the back for signs of occult spinal dysraphism as well as lower extremities for signs of weakness. The urologic exam should inspect the location and patency of the urethral meatus in boys and the introitus in girls. Depending on the history and physical exam findings, additional testing to evaluate suspected diagnoses may include a uroflow, postvoid residual, renal and bladder ultrasound, plain film for stool burden, voiding cystourethrogram, and urodynamic evaluation.

Methods of treating BBD must be tailored to the patient's symptoms. Importantly, basic management of BBD consists of behavioral modification therapy, also known as urotherapy, which includes improved hydration, timed voiding every 2 to 3 hours, and an adequate bowel regimen to properly manage constipation (Palmer, 2016). Successful treatment of urinary symptoms depends on thorough management of bowel issues. To minimize the impact of BBD on recurrent UTI, continuous antibiotic prophylaxis is recommended by the American Urologic Association for children with BBD and any grade of VUR.

Urinary Incontinence

Urinary incontinence is a very common problem in children. Development of bladder control begins when the child becomes aware of bladder filling, then develops the ability to suppress detrusor contractions voluntarily, and finally learns to coordinate sphincter and detrusor function (Jansson et al., 2005). Daytime urinary continence typically occurs by 4 years of age followed by night continence, generally achieved by 5 to 7 years of age. **Bladder capacity is based on the age and weight of the patient, equal (in millimeters) to**

$$\text{Weight (kilograms)} \times 8$$

in children less than 2 years of age, and

$$(\text{Age [years]} + 2) \times 30$$

in children greater than 2 years of age (Koff, 1983).

Urinary incontinence, particularly in those who never achieved continence, may be secondary to neurogenic causes, such as tethered cord, or other anatomic causes, such as an ectopic ureter. Alternately, urinary incontinence may be associated with other conditions including BBD and UTI, discussed in detail earlier. A child with urinary incontinence should be evaluated with a thorough history and physical considering this differential.

Sexual Abuse

Sexual abuse must be considered based on presentation with a range of symptoms including vaginal, penile, or rectal pain, discharge, or bleeding, vulvovaginitis, and enuresis. Sexual abuse of children is a prevalent reality in pediatric medicine; it is estimated to victimize 12% to 25% of girls and 8% to 10% of boys by the age of 18 (Anderson et al., 2014). Sexually transmitted diseases are often detectable in cases of sexual abuse. However, the diagnosis of sexual abuse is often made by the history and not by the physical examination because even girls who report repetitive penetrative penile-genital contact have no definitive evidence of penetration on examination of the hymen (Anderst et al., 2009a,b). Investigating sexual abuse requires detailed history taking and may be enhanced by consultation with a child abuse pediatrician specialist for a second opinion. If abuse is suspected, it must be reported to the police (Anderst et al., 2009a,b).

Flank Pain

Nephrolithiasis.

Pediatric nephrolithiasis is a growing public health burden with a 6% to 10% annual rise in incidence over the past 20 years with a mean annual incidence of 36 to 57 per 100,000 children in US population-based observational studies (Van Batavia and Tasian, 2016). Interestingly, the incidence of stones is increasing most drastically among adolescent girls and African-Americans, although the risk of stones is highest among boys in the first decade of life and girls in the second decade of life, returning to a male predominance in the third decade of life. **Notably, the majority of studies show no association between the body mass index and pediatric nephrolithiasis**. Other hypotheses explaining this increasing prevalence include a decrease in fluid intake, an increase in sugar-sweetened soft drinks, climate change, dietary sodium intake, incidental diagnosis, and comorbidities including hypertension and diabetes (Clayton and Pope, 2011).

Most children with nephrolithiasis experience abdominal or flank (renal colic) pain (Gearhart et al., 1991). Similar to adults with nephrolithiasis, the intensity of pain can vary and is often milder and less specific in younger children. Other symptoms may include gross hematuria, dysuria and urgency, and nausea/vomiting. Notably, 15% of pediatric patients with nephrolithiasis are diagnosed because of stone detection when abdominal imaging is performed for other purposes.

When nephrolithiasis is suspected, diagnostic evaluation begins with a thorough history focusing on patient or family history of nephrolithiasis, genitourinary tract structural abnormalities, metabolic conditions associated with stone formation such as malabsorption, medications associated with stone formation, and a history of recurrent UTI. Physical examination should attempt to localize pain and evaluate for fever. In addition, laboratory evaluation should evaluate for urine infection. Finally, the diagnosis of nephrolithiasis is confirmed by the detection of a stone. **When choosing the imaging modality, clinicians must consider that children are at increased risk from radiation exposure as well as recurrence with longer follow-up times given their longer life**

expectancies. Ultrasound imaging should be used for initial diagnostic imaging, reserving CT for those with a nondiagnostic ultrasound in whom the clinical suspicion for stones remains high (Tasian and Copelovitch, 2014). As with adults with nephrolithiasis, the initial step in acute management is determining the need for immediate urinary decompression, reserved for children with obstructed UTI or evidence of pyelonephritis, solitary kidney, or intractable pain, nausea, or emesis (Van Batavia and Tasian, 2016). Decompression can be performed with placement of a retrograde ureteral stent placement or a percutaneous nephrostomy tube. Nonacute management options include observation with pain control, medical expulsive therapy, and surgery. Alpha-blockers are recommended as first-line medical expulsion therapy in children, especially when stones are small and in a more distal ureteral location. **Surgical management is similar to that in adults**: extracorporeal shock wave lithotripsy and ureteroscopy for smaller stones and percutaneous nephrolithotomy reserved for larger renal stone burden. Last, **a metabolic evaluation is recommended, although the impact on mitigating the risk of recurrent stones in children is unknown, particularly in the context of the long-term compliance required** (Tasian and Copelovitch, 2014).

Pyelonephritis.

Pyelonephritis is a significant source of health care use and expenditure, with an inpatient hospitalization rate of 31 per 100,000 children in California in 2005, costing roughly $13.3 million (Copp et al., 2011). As discussed earlier, its presentation is dependent, in part, on the age of affected children and their ability to localize and articulate their symptoms. Older children and adolescents may report flank pain and should be evaluated with a clean-catch urine specimen to evaluate for underlying UTI and pyelonephritis. For further details of evaluation and treatment, see the section on UTI and pyelonephritis, earlier in the chapter.

Ureteropelvic Junction Obstruction

A ureteropelvic junction (UPJ) obstruction is a partial or complete restriction of the flow of urine from the renal pelvis to the ureter, which may be congenital or acquired (Koff et al., 1986). Congenital UPJ obstruction is usually caused by intrinsic stenosis of the proximal ureter at the UPJ, and less commonly by extrinsic compression, usually by an accessory renal artery, of the UPJ. Obstruction occurs more commonly in boys and more commonly in left renal units; bilateral involvement is 10% to 40% (Johnston et al., 1977).

Clinical presentation varies significantly by patient age. Most cases of UPJ obstruction are diagnosed during prenatal ultrasound; UPJ obstruction is the most common cause of prenatal hydronephrosis, occurring in up to 30% of patients found to have urinary tract dilation on prenatal ultrasound (Nguyen et al., 2014). In the absence of prenatal screening, newborns may have a palpable abdominal mass, UTI, hematuria, or failure to thrive. In contrast, older children experience intermittent flank or abdominal pain with nausea and vomiting, worse during brisk diuresis after, for example, caffeine or alcohol (Dietl's crisis) (González and Schimke, 2001). Other presenting signs may include hematuria, nephrolithiasis, or hypertension. For these children, ultrasonography should be performed during the acute painful episode to identify the presence of hydronephrosis. **Although UPJ obstruction is the most common anatomic cause of hydronephrosis, further imaging evaluation with diuretic renography characterizes the severity of UPJ obstruction**. Although UPJ obstruction is usually an isolated anatomic finding, approximately 10% of patients with UPJ obstruction have VUR. This is about a threefold increase compared with the general pediatric population. However, the VUR is often low grade and does not warrant routine screening in the absence of other risk factors such as hydroureter or recurrent UTI (Weitz and Schmidt, 2016).

Although not all patients with partial UPJ obstruction require intervention, severe UPJ obstruction will lead to progressive renal deterioration. Surgical pyeloplasty is indicated in asymptomatic patients with imaging signs of poor drainage (obstructive excretory curve on diuretic renography), renal deterioration (loss of renal function on renography), or progressive hydronephrosis on ultrasonography as well as for symptomatic children.

Gross Hematuria

Gross hematuria is defined by the presence of red blood cells in the urine that are visible to the naked eye, which can be confirmed with a urine dipstick for blood. Although this condition is uncommon, 0.13% of children seen in an emergency walk-in clinic, most children have an easily apparent cause (Diven and Travis, 2000). The most common diagnoses are UTI (26%), perineal irritation (11%), trauma (7%), meatal stenosis with ulceration (7%), coagulation abnormalities (3%), and nephrolithiasis (2%). Less common causes of gross hematuria include sickle cell disease/trait, glomerular disease, malignancies, and benign idiopathic urethrorrhagia. This differential diagnosis substantiates the importance of initiating evaluation of children with gross hematuria with a thorough history, physical examination, laboratory examinations including urinalysis and urine culture, and renal sonogram. Persistent gross hematuria without identifiable cause warrants cystoscopy with retrograde pyelograms. The role of newer imaging techniques such as MR urography as a replacement for cystoscopy and retrograde pyelography is being investigated in the adult setting (Gandrup et al., 2014; Lee et al., 2010). Generalizability to the pediatric setting, with a lower rate of urothelial carcinoma, is uncertain. If the cause of the gross hematuria is not apparent from these investigations, the child should be referred to a pediatric nephrologist, particularly in the setting of proteinuria.

Microhematuria

Microscopic hematuria is a common finding on urine dipstick examination and is confirmed as more than five red blood cells per high-power field on more than two occasions (Feld et al., 1998). Although the differential is wide, most cases are diagnosed as idiopathic or benign. Laboratory and radiographic evaluation, as well as the indications for a renal biopsy, are disputed. However, in the absence of urinary crystals, casts, or proteinuria or a family history of progressive renal disease, most patients may be observed and retested in 6 to 12 months.

Benign Idiopathic Urethrorrhagia.

Bloody spotting of the underwear in prepubertal and pubertal boys has been termed urethrorrhagia. Its cause remains elusive. Mean age at presentation is 10 years old with up to one-third of boys reporting concomitant dysuria (Walker et al., 2001). Evaluation with urine culture and ultrasonography is uniformly normal, and thus management with watchful waiting is recommended. **Complete resolution occurs in more than 90% of patients by 2 years. Thus further evaluation with retrograde urethrography or cystoscopy may be considered to evaluate for urethral stricture if symptoms persist beyond 2 years.** Notably, boys with urethrorrhagia appear to be at increased risk for urethral stricture, and instrumentation should be used judiciously in these patients.

Referral for Ultrasound Findings

Prenatal Hydronephrosis.

Dilation of the fetal renal collecting system, prenatal hydronephrosis, is one of the most common abnormalities detection on prenatal ultrasonography, occurring in up to 5% of all pregnancies. Several grading systems have been developed in attempt to correlate prenatal and postnatal ultrasound findings with the ultimate urologic diagnosis. There are several grading systems ranging from descriptive to semiquantitative to quantitative. Most recently, a multidisciplinary consensus panel developed the Urinary Tract Dilation Classification System based on anterior posterior renal pelvic diameter, calyceal dilation, parenchymal thickness, and appearance of the ureter and bladder (Nguyen et al., 2014). However, each system has its limitations and none is uniformly used at this time.

The diagnosis of prenatal hydronephrosis may cause significant parental anxiety and physician uncertainty with regard to prenatal and postnatal management. Variations in the definition and management of prenatal hydronephrosis make accurate counseling regarding the risk of postnatal pathology challenging (Lee et al., 2006). Fetal hydronephrosis may develop secondary to transient dilation of the collecting system or congenital anomalies of the kidney and urinary tract (CAKUT). **Based on postnatal imaging studies, up to two-thirds of antenatal hydronephrosis is due to transient hydronephrosis. Of the remaining patients identified with CAKUT, UPJ obstruction was the most common diagnosis followed by VUR.** Other less common causes of prenatal hydronephrosis resulting from CAKUT include urethral obstruction (posterior urethral valves or urethral atresia), ureteral obstruction (ureterocele, obstructing megaureter), multicystic dysplastic kidney, prune-belly syndrome, hydrometrocolpos, and bladder agenesis.

Prenatal counseling based on ultrasonography findings is complex. It depends on comorbidities, the severity of hydronephrosis, (bi)laterality, involvement of the bladder suggestive of obstruction, and amniotic fluid volume because oligohydramnios occurs with severe renal disease. With rare exception, all fetuses with unilateral prenatal hydronephrosis and most with bilateral prenatal hydronephrosis may be managed expectantly. However, it is recommended that repeat prenatal imaging be performed and special consideration be given to fetuses with bilateral disease associated with oligohydramnios and features of renal dysplasia (Liu et al., 2014).

Postnatal management of these patients continues to evolve with aims to balance invasiveness, radiation, and cost of testing against the benefits of UTI prevention and resultant renal preservation. The Society for Fetal Urology 2010 recommendations propose obtaining postnatal ultrasonography before discharge after delivery in those with bilateral hydronephrosis and hydronephrosis in solitary kidneys or in patients with suspected bladder outlet obstruction, whereas evaluation can be delayed in those with unilateral hydronephrosis and a normal contralateral kidney (Nguyen et al., 2010). **The ultrasound should not be performed before the second day of life because of relative dehydration at birth, which leads to an underestimation of the level of hydronephrosis.** Should hydronephrosis remain moderate to severe bilaterally, a voiding cystourethrogram generally should be performed before discharge. Voiding cystourethrogram should also be performed to rule out VUR as the cause of dilation if megaureter is visualized.

Renal Cysts

Renal cysts encompass a broad spectrum of conditions in children. Many renal cystic diseases originate from genetic mutations at the level of the primary cilia (Avni and Hall, 2010). Cystic diseases of the kidney that are genetic include autosomal recessive polycystic kidney disease, autosomal dominant polycystic kidney disease, glomerulocystic kidney disease and nephronophthisis/medullary sponge kidney complex, cystic dysplasia, and medullary cystic dysplasia associated with syndromes. Nongenetic diseases include obstructive dysplasia, cystic dysplasia, simple cysts, multilocular cysts, cystic tumors, and cysts associated with chronic dialysis. The differential diagnosis of renal cystic disease is a difficult challenge that can be solved by a step-by-step approach using ultrasound imaging as well as family history and attention to specific clinical features.

Sonographically, it is important to characterize the renal cortex, medulla, and corticomedullary differentiation as well as the size, location, and number of cysts. Subcapsular cysts are seen in glomerulocystic disease; medullary cysts are seen in medullary cystic dysplasia and autosomal recessive polycystic kidney disease; diffuse cortical cysts are present in autosomal dominant polycystic kidney disease; and macrocysts in autosomal dominant polycystic kidney disease, tuberous sclerosis complex, and the TCF-2-mutation. Ultrasound is helpful not only in diagnosis of renal cysts but also for evaluation of hepatic involvement as well as for monitoring of complications such as hemorrhage and nephrolithiasis.

Multicystic dysplastic kidney is the most common cause of cystic disease in children (Cardona-Grau and Kogan, 2015). It is characterized by multiple noncommunicating cysts of varying sizes with no identifiable normal renal parenchyma. Although associated anomalies in the contralateral kidney are present in up to half of patients, use of voiding cystourethrogram or renal scintigraphy should be limited to abnormalities on renal ultrasound or the development of UTI. Similarly, there is no indication for performing serial ultrasound examinations, although the examiner may perform one additional ultrasound at 1 year to adequately evaluate the contralateral solitary kidney with any further follow-up imaging guided by any abnormality of the contralateral kidney, abnormal blood pressure, or enlarging multicystic dysplastic kidney.

Isolated renal cysts may also be incidentally detected. Although not validated in children, a modified Bosniak classification may be used as a guideline to direct the need for surgical intervention because of an increased risk of malignancy (Wallis et al., 2008). This should be differentiated from a calyceal diverticulum, which is a cystic cavity within the kidney that communicates with a calyx or, less commonly, with the renal pelvis through a narrow isthmus (Ochoa Santiago et al., 2018). Although a calyceal diverticulum is often misdiagnosed as a renal cyst, diagnosis is confirmed by the excretory phase of CT or MR urography. Calyceal diverticuli are usually asymptomatic; treatment is indicated if associated with pain or infection, abscess formation, urosepsis, or symptomatic calculus formation (Estrada et al., 2009).

Renal Tumors

Renal malignancies represent 6% of cancer diagnoses among children younger than 15 years of age (incidence 7.9 per million) in the United States (Ries et al., 1999)**. Wilms' tumor is the most common form of renal cancer in children younger than 15 years of age, representing approximately 95% of diagnoses.** Much less common were renal cell carcinomas (2.6% of renal cancers), clear cell sarcoma of the kidney (1.6% of renal cancers), and rhabdoid tumors of the kidney (1% of renal cancers).

Wilms tumor occurred most commonly among children younger than 5 years of age with a peak incidence in the first 2 years of life, whereas rhabdoid tumor of the kidney was diagnosed primarily in infants and clear cell sarcoma of the kidney was diagnosed primarily during the first 4 years of life. Renal carcinomas, by contrast, occurred with highest incidence among 15- to 19-year-olds.

Wilms tumor is primarily a sporadic disease, although approximately 10% occur in the context of a syndrome, including WAGR syndrome, Denys-Drash syndrome, familial Wilms tumor, Perlman syndrome, Fanconi

anemia, Beckwith-Wiedemann syndrome, and Simpson-Golabi-Behmel syndrome. Wilms tumor also occurs more frequently in isolated hemihypertrophy and Li-Fraumeni syndrome but less commonly than in the aforementioned syndromes (Scott et al., 2006). Thus patients with these syndromes require surveillance for Wilms tumor, which includes periodic, scheduled renal bladder ultrasound. Children most often have an asymptomatic abdominal mass, which is firm, nontender, and smooth but rarely crosses the midline on physical exam (Geller and Kochan, 2011). Given the association of Wilms tumor with the syndromes noted earlier, the exam should evaluate for associated anomalies, such as aniridia, hemihypertrophy, and other genitourinary anomalies. Abdominal ultrasonography is typically the initial study performed for evaluation of an abdominal mass with further evaluation with contrast-enhanced CT or MRI to characterize and stage the renal mass. Ultimately, the diagnosis is confirmed histologically. Further staging and treatment should be performed in a multidisciplinary fashion with pediatric oncology.

Although other renal tumors are significantly less common than Wilms, it is important they remain in the differential diagnosis of a child with a renal mass. Congenital mesoblastic nephroma is the most common renal tumor on antenatal ultrasound and in infants, with a mean age at diagnosis of 3.5 months. Complete surgical resection usually provides excellent outcomes (van den Heuvel-Eibrink et al., 2008). Neuroblastoma appears distinct on imaging given its nonrenal tissue, and these children typically have larger masses and may appear clinically ill. Rhabdoid tumors of the kidney often are seen after metastasis and occur in children less than 2 years of age; presentation with fever or hematuria is common. Clear cell sarcoma commonly metastasizes to the bone, and some variants can be challenging to differentiate from Wilms tumors. Finally, renal medullary carcinoma is seen almost exclusively in patients with sickle cell disease/trait.

Incidental Urolithiasis

As discussed earlier, 15% of pediatric patients with nephrolithiasis are diagnosed incidentally. **In asymptomatic patients, management depends on the size of the stone.** Ureteral and obstructing renal stones should be treated as discussed earlier. An asymptomatic, nonobstructing renal stone may be observed, although these patients should be seen regularly with routine surveillance ultrasonography to monitor for increase in size or number of stones, or silent obstruction per guidelines by the American Urologic Association (Assimos et al., 2016). These guidelines also recommend metabolic evaluation including a 24-hour urine collection in toilet-trained children or a “spot” urine sample to screen for hypercalciuria and other metabolic causes.

Key Points

- UTIs affect 3% of children yearly with the highest prevalence in female infants and boys younger than 1 year. Recurrent UTI occurs in up to 30%, more commonly in those with VUR and BBD.
- Management of VUR remains controversial and aims to prevent recurrent febrile UTIs and renal injury and to minimize the morbidity of treatment and follow-up.
- BBD includes lower urinary tract dysfunction and bowel dysfunction. A thorough history from the caretaker and child is required to guide therapy.
- Pediatric nephrolithiasis is rising in incidence. Imaging must minimize radiation as children are at increased risk from exposure and have longer follow-up times given longer life expectancies.
- Prenatal hydronephrosis is due to transient collecting system dilation or CAKUT. Counseling depends on comorbidities, severity, (bi)laterality, bladder involvement, and amniotic fluid volume.

Acknowledgments

The authors gratefully acknowledge the work of Thomas F. Kolon, MD, MS, and Douglas A. Canning, MD, who authored this chapter in the previous edition.

References

Aalia Sachedina MD, Chan M F Kiri, MacGregor M F P Duncan, et al. More than grapes and bleeding: an updated look at pelvic rhabdomyosarcoma in young females. *J Pediatr Adolesc Gynecol*. 2018;1–17.

Aaronson IA. Micropenis: medical and surgical implications. *J Urol*. 1994;152(1):4–14.

al Jurayyan NA, Patel Pj Fau - al Herbish AS, al Herbish As Fau - Abdullah MA, et al. Ambiguous genitalia: comparative role of pelvic ultrasonography and genitography. *Ann Trop Paediatr*. 1995;15(3):203–207.

American Academy of Pediatrics Task Force on Circumcision. Male circumcision. *Pediatrics*. 2012;130:e756–e785.

Anderson B, Thimmesch I, Aardsma N, et al. The prevalence of abnormal genital findings, vulvovaginitis, enuresis and encopresis in children who present with allegations of sexual abuse. *J Pediatr Urol*. 2014;10(6):1216–1221.

Anderst J, Kellogg N, Jung I. Is the diagnosis of physical abuse changed when Child Protective Services consults a Child Abuse Pediatrics subspecialty group as a second opinion? *Child Abuse Negl*. 2009;33(8):481–489.

Anderst J, Kellogg N, Jung I. Reports of repetitive penile-genital penetration often have no definitive evidence of penetration. *Pediatrics*. 2009;124(3):e403–e409.

Antonov NK, Ruzal-Shapiro CB, Morel KD, et al. Feed and wrap MRI technique in infants. *Clin Pediatr*. 2017;56(12):1095–1103.

Assimos D, Krambeck A, Miller NL, et al. *Surgical management of stones: American Urological Association Endourological Society guideline*. [American Urological Association Education and Research, Inc] 2016.

Austin PF, Chase J, Franco I, et al. The standardization of terminology of lower urinary tract function in children and adolescents: update report from the Standardization Committee of the International Children's Continence Society. *J Urol*. 2014;191(6):1863–1865.e13.

Avni FE, Hall M. Renal cystic diseases in children: new concepts. *Pediatr Radiol*. 2010;40(6):939–946.

Bacon JL, Romano ME, Quint EH. Clinical recommendation: labial adhesions. *J Pediatr Adolesc Gynecol*. 2015;28(5):405–409.

Badalyan V, Burgula S, Schwartz RH. Congenital paraurethral cysts in two newborn girls: differential diagnosis, management strategies, and spontaneous resolution. *J Pediatr Adolesc Gynecol*. 2012;25(1):e1–e4.

Barthold JS, Gonzalez R. The epidemiology of congenital cryptorchidism, testicular ascent and orchiopexy. *J Urol*. 2003;170(6):2396–2401.

Bartsch G, Frank S, Marberger H, et al. Testicular torsion: late results with special regard to fertility and endocrine function. *J Urol*. 1980;124(3):375–378.

Baskin L. What is hypospadias? *Clin Pediatr*. 2017;56(5):409–418.

Baskin LS, Canning DA, Snyder HM, et al. Treating complications of circumcision. *Pediatr Emerg Care*. 1996;12(1):62–68.

Baskin LS, Duckett JW, Lue TF. Penile curvature. *Urology*. 1996;48(3):347–356.

Bauer R, Kogan BA. Modern technique for penile torsion repair. *J Urol*. 2009;182(1):286–291.

Bennett AH, Gittes RF. Congenital penile curvature without hypospadias. *Urology*. 1980;16(4):364–366.

Brandt ML. Pediatric hernias. *Surg Clin North Am*. 2008;88(1):27–43.

Cardona-Grau D, Kogan BA. Update on multicystic dysplastic kidney. *Curr Urol Rep*. 2015;16(10):67.

Chalmers D, Wiedel CA, Siparsky GL, et al. Discovery of hypospadias during newborn circumcision should not preclude completion of the procedure. *J Pediatr*. 2014;164(5):1171–1174.e71.

Ciftci AO, Bingöl-Koloğlu M, Şenocak ME, et al. Testicular tumors in children. *J Pediatr Surg*. 2001;36(12):1796–1801.

Cilento BG, Holmes NM, Canning DA. Plastibell complications revisited. *Clin Pediatr*. 1999;38(4):239–242.

Clayton DB, Brock JW III. Prenatal ultrasonography: implications for pediatric urology. *J Pediatr Urol*. 2011;7(2):118–125.

Clayton DB, Brock JW III. Prenatal ultrasound and urological anomalies. *Pediatr Clin North Am*. 2012;59(4):739–756.

Clayton DB, Pope JC. The increasing pediatric stone disease problem. *Ther Adv Urol*. 2011;3(1):3–12.

Copp HL, Halpern MS, Maldonado Y, et al. Trends in hospitalization for pediatric pyelonephritis: a population based study of california from 1985 to 2006. *J Urol*. 2011;186(3):1028–1034.

Crain EF, Gershel JC. Urinary tract infections in febrile infants younger than 8 weeks of age. *Pediatrics*. 1990;86(3):363–367.

Crawford BS. Buried penis. *Br J Plast Surg*. 1977;30(1):96–99.

Cunha GR, Sinclair A, Risbridger G, et al. Current understanding of hypospadias: relevance of animal models. *Nat Rev Urol*. 2015;12(5):271–280.

Darge K, Grattan-Smith JD, Riccabona M. Pediatric uroradiology: state of the art. *Pediatr Radiol*. 2010;41(1):82–91.

Darge K, Higgins M, Hwang TJ, et al. Magnetic resonance and computed tomography in pediatric urology. *Radiol Clin North*

Am. 2013;51(4):583–598.

Darge K, Riedmiller H. Current status of vesicoureteral reflux diagnosis. *World J Urol*. 2004;22(2):1–8.

Dietrich JE, Millar DM, Quint EH. Obstructive reproductive tract anomalies. *J Pediatr Adolesc Gynecol*. 2014;27(6):396–402.

Diven SC, Travis LB. A practical primary care approach to hematuria in children. *Pediatr Nephrol*. 2000;14(1):65–72.

Donaldson JF, Rees RW, Steinbrecher HA. Priapism in children: a comprehensive review and clinical guideline. *J Pediatr Urol*. 2014;10(1):11–24.

Drzewiecki BA, Bauer SB. Review articles urodynamic testing in children: indications, technique, interpretation and significance. *J Urol*. 2011;186(4):1190–1197.

Duckett JW, Bellinger MF. A plea for standardized grading of vesicoureteral reflux. *Eur Urol*. 1982;8(2):74–77.

Duckett JW, Keating MA. Technical challenge of the megameatus intact prepuce hypospadias variant: the pyramid procedure. *J Urol*. 1989;141(6):1407–1409.

Edmonds DK. Congenital malformations of the genital tract and their management. *Best Pract Res Clin Obstet Gynaecol*. 2003;17(1):19–40.

Ellison JS, Dy GW, Fu BC, et al. Neonatal circumcision and urinary tract infections in infants with hydronephrosis. *Pediatrics*. 2018 [e20173703-20173709].

Estrada CR, Datta S, Schneck FX, et al. Pediatric urology caliceal diverticula in children: natural history and management. *J Urol*. 2009;181(3):1306–1311.

Farhat W, Bägli DJ, Capolicchio G, et al. The dysfunctional voiding scoring system: quantitative standardization of dysfunctional voiding symptoms in children. *J Urol*. 2000;164(3 Pt 2):1011–1015.

Feld LG, Meyers KE, Kaplan BS, et al. Limited evaluation of microscopic hematuria in pediatrics. *Pediatrics*. 1998;102(4):E42.

Feldman AS, Bauer SB. Diagnosis and management of dysfunctional voiding. *Curr Opin Pediatr*. 2006;18(2):139–147.

Fernandes ET, Dekermacher S, Sabadin MA, et al. Urethral prolapse in children. *Urology*. 1993;41(3):240–242.

Freedman AL, P. Urologic Diseases in America. Urologic diseases in North America Project: trends in resource utilization for urinary tract infections in children. *J Urol*. 2005;173(3):949–954.

Gandrup KL, Løgager VB, Bretlau T, et al. Diagnosis of bladder tumours in patients with macroscopic haematuria: a prospective comparison of split-bolus computed tomography urography, magnetic resonance urography and flexible cystoscopy. *Scand J Urol*. 2014;49(3):224–229.

Gatti JM, Murphy J Patrick. Current management of the acute scrotum. *Semin Pediatr Surg*. 2007;16(1):58–63.

Gearhart JP, Herzberg GZ, Jeffs RD. Childhood urolithiasis: experiences and advances. *Pediatrics*. 1991;87(4):445–450.

Geller E, Kochan PS. Renal neoplasms of childhood. *Radiol Clin North Am*. 2011;49(4):689–709.

Gkentzis A, Lee L. The aetiology and current management of prepubertal epididymitis. *Ann R Coll Surg Engl*. 2014;96(3):181–183.

Glassberg KI, Braren V, Duckett JW, N. Report of the Committee on Terminology and P. Classification Section on Urology American Academy of, et al. Suggested terminology for duplex systems, ectopic ureters and ureteroceles. *J Urol*. 1984;132(6):1153–1154.

González R, Schimke CM. Ureteropelvic junction obstruction in infants and children. *Pediatr Clin North Am*. 2001;48(6):1505–1518.

Gordon I, Piepsz A, Sixt R. Guidelines for standard and diuretic renogram in children. *Eur J Nucl Med Mol Imaging*. 2011;38(6):1175–1188.

Gracia J, Navarro E, Guirado F, et al. Spontaneous ascent of the testis. *Br J Urol*. 1997;79(1):113–115.

Grandjean H, Larroque D, Levi S. The performance of routine ultrasonographic screening of pregnancies in the Eurofetus Study. *Am J Obstet Gynecol*. 1999;181(2):446–454.

Hadidi AT. Buried penis: classification surgical approach. *J Pediatr Surg*. 2014;49(2):374–379.

Haid B, Becker T, Koen M, et al. Lower radiation burden in state of the art fluoroscopic cystography compared to direct isotope cystography in children. *J Pediatr Urol*. 2015;11(1):35.e31–35.e36.

Hayashi Y, Kojima Y, Mizuno K, et al. Prepuce: phimosis, paraphimosis, and circumcision. *Sci World J*. 2011;11:289–301.

Hays DM, Shimada H, Raney RB, et al. Clinical staging and treatment results in rhabdomyosarcoma of the female genital tract among children and adolescents. *Cancer*. 1988;61(9):1893–1903.

Hellstrom M, Jacobsson B. Diagnosis of vesico-ureteric reflux. *Acta Paediatr Suppl*. 1999;88(431):3–12.

Hiorns MP. Imaging of the urinary tract: the role of CT and MRI. *Pediatr Nephrol*. 2010;26(1):59–68.

Hughes JA, De Bruyn R, Patel K, et al. Evaluation of spinal ultrasound in spinal dysraphism. *Clin Radiol*. 2003;58(3):227–233.

Jakobsson B, Berg U, Svensson L. Renal scarring after acute pyelonephritis. *Arch Dis Child*. 1994;70(2):111–115.

Jansson UB, Hanson M, Sillén U, et al. Voiding pattern and acquisition of bladder control from birth to age 6 years–a longitudinal study. *J Urol*. 2005;174(1):289–293.

Jerkins GR, Verheeck K, Noe HN. Treatment of girls with urethral prolapse. *J Urol*. 1984;132(4):732–733.

Johnston JH, Evans JP, Glassberg KI, et al. Pelvic hydronephrosis in children: a review of 219 personal cases. *J Urol*. 1977;117(1):97–101.

Kajbafzadeh A-M, Payabvash S, Sadeghi Z, et al. Comparison of magnetic resonance urography with ultrasound studies in detection of fetal urogenital anomalies. *J Pediatr Urol*. 2008;4(1):32–39.

Kapur P, Caty MG, Glick PL. Pediatric hernias and hydroceles. *Pediatr Clin North Am*. 1998;45(4):773–789.

Keren R, Shaikh N, Pohl H, et al. Risk factors for recurrent urinary tract infection and renal scarring. *Pediatrics*. 2015;136(1):e13–e21.

Khong PL, Ringertz H, Donoghue V, O. b. o. t. ICRP, C. H. Clement, M. Sasaki, P. L. Khong, H. Ringertz, V. Donoghue, D. Frush, M. Rehani, K. Appelgate and R. Sanchez, et al. Radiological protection in paediatric diagnostic and interventional radiology. *ICRP Publication 121*. 2013;42(2):1–63.

Kimberley N, Hutson JM, Southwell BR, et al. Original study vaginal agenesis, the hymen, and associated anomalies. *J Pediatr Adolesc Gynecol*. 2012;25(1):54–58.

Koff SA. Estimating bladder capacity in children. *Urology*. 1983;21(3):248.

Koff SA, Hayden LJ, Cirulli C, et al. Pathophysiology of ureteropelvic junction obstruction: experimental and clinical observations. *J Urol*. 1986;136(Pt 2):336–338.

Koo BN, Hong JY, Song HT, et al. Ultrasonography reveals a high prevalence of lower spinal dysraphism in children with urogenital anomalies. *Acta Anaesthesiol Scand*. 2012;56(5):624–628.

Krueger H, Osborn L. Effects of hygiene among the uncircumcised. *J Fam Pract*. 1986;22(4):353–355.

Lau P, Anderson PA, Giacomantonio JM, et al. Acute epididymitis in boys: are antibiotics indicated? *Br J Urol*. 1997;79(5):797–800.

Lee KS, Zeikus E, DeWolf WC, et al. MR urography versus retrograde pyelography/ ureteroscopy for the exclusion of upper urinary tract malignancy. *Clin Radiol*. 2010;65(3):185–192.

Lee RS, Cendron M, Kinnamon DD, et al. Antenatal hydronephrosis as a predictor of postnatal outcome: a meta-analysis. *Pediatrics*. 2006;118(2):586–593.

Lerman SE, Liao JC. Neonatal circumcision. *Pediatr Clin North Am*. 2001;48(6):1539–1557.

Leung AK, Robson WL, Tay-Uyboco J. The incidence of labial fusion in children. *J Paediatr Child Health*. 1993;29(3):235–236.

Lewis AG, Bukowski TP, Jarvis PD, et al. Evaluation of acute scrotum in the emergency department. *J Pediatr Surg*. 1995;30(2):277–281 [discussion 281-272].

Liu DB, Armstrong WRI, Maizels M. Hydronephrosis. *Clin Perinatol*. 2014;41(3):661–678.

Lowe FC, Hill GS, Jeffs RD, et al. Urethral prolapse in children: insights into etiology and management. *J Urol*. 1986;135(1):100–103.

MacLellan DL, Diamond DA. Recent advances in external genitalia. *Pediatr Clin North Am*. 2006;53(3):449–464.

McGreal S, Wood P. Mini-review recurrent vaginal discharge in children. *J Pediatr Adolesc Gynecol*. 2013;26(4):205–208.

Montague DK, Jarow J, Broderick GA, P. Members of the Erectile Dysfunction Guideline Update and A. Americal Urological, et al. American Urological Association guideline on the management of priapism. *J Urol*. 2003;170:1318–1324.

Moreno G, Corbalán J, Peñaloza B, et al. Topical corticosteroids for treating phimosis in boys. *Cochrane Database Syst Rev*. 2014;28(3):120–145.

Munden MM, Trautwein LM. Scrotal pathology in pediatrics with sonographic imaging. *Curr Probl Diagn Radiol*. 2000;29(6):185–205.

National Institute for Health and Clinical Excellence: *Urinary tract infection in children*, National Collaborating Centre for Women's and Children's Health. London, 2007.

Nevéus T, Eggert P, Evans J, et al. Evaluation of and treatment for monosymptomatic enuresis: a standardization document from the International Children's Continence Society. *J Urol*. 2010;183(2):441–447.

Nguyen HT, Benson CB, Bromley B, et al. Multidisciplinary consensus on the classification of prenatal and postnatal urinary tract dilation (UTD classification system). *J Pediatr Urol*. 2014;10(6):982–998.

Nguyen HT, Herndon CDA, Cooper C, et al. The Society for Fetal Urology consensus statement on the evaluation and management of antenatal hydronephrosis. *J Pediatr Urol*. 2010;6(3):212–231.

Nguyen MM, Katzberg RW, Wootton-Gorges SL, et al. Computed tomography and magnetic resonance imaging in paediatric urology. *BJU Int*. 2006;98(2):273–277.

Ochoa Santiago Y, Sangüesa Nebot C, Aliaga SP, et al. Calyceal diverticula in children: imaging findings and presentations. *Radiologia*. 2018;60(5):378–386.

Oster J. Clinical phenomena noted by a school physician dealing with healthy children. *Clin Pediatr*. 1976;15(8):748–751.

Palmer JS, Elder JS, Palmer LS. The use of betamethasone to manage the trapped penis following neonatal circumcision. *J Urol*. 2005;174(4 Pt 2):1577–1578.

Palmer LS. Evaluation and targeted therapy of voiding dysfunction in children. *Urology*. 2016;92(C):87–94.

Pepe P, Panella P, Pennisi M, et al. Does color Doppler sonography improve the clinical assessment of patients with acute scrotum? *Eur J Radiol*. 2006;60(1):120–124.

Peters CA, Skoog SJ, Arant BS, et al. *Management and screening of primary vesicoureteral reflux in children: AUA guideline*. 2010.

Peters CA, Skoog SJ, Billy J, et al. *Management and screening of primary vesicoureteral reflux in children: AUA guideline,* American Urological Association. 2010.

Piepsz A, Colarinha P, Gordon I, M. Paediatric Committee of the European Association of Nuclear, et al. Guidelines for 99mTc-DMSA scintigraphy in children. *Eur J Nucl Med*. 2001;28:BP37–BP41.

Pohl HG, Shukla AR, Metcalf PD, et al. Prepubertal testis tumors: actual prevalence rate of histological types. *J Urol*. 2004;172(6 Pt 1):2370–2372.

Pohlman GD, Phillips JM, Wilcox DT. Simple method of paraphimosis reduction revisited: point of technique and review of the literature. *J Pediatr Urol*. 2013;9(1):104–107.

Polito C, Moggio G, La Manna A, et al. Cyclic voiding cystourethrography in the diagnosis of occult vesicoureteric reflux. *Pediatr Nephrol*. 2000;14(1):39–41.

Price J. Injuries in prepubertal and pubertal girls. *Best Pract Res Clin Obstet Gynaecol*. 2013;27(1):131–139.

Redman JF. Conservative management of urethral prolapse in female children. *Urology*. 1982;19(5):505–506.

Renjen P, Bellah R, Hellinger JC, et al. Advances in uroradiologic imaging in children. *Radiol Clin North Am*. 2012;50(2):207–218.

Riccabona M. Cystography in infants and children: a critical appraisal of the many forms with special regard to voiding cystourethrography. *Eur Radiol*. 2002;12(12):2910–2918.

Riccabona M. Urinary tract imaging in infancy. *Pediatr Radiol*. 2009;39(S3):436–445.

Riccabona M, Lindbichler F, Sinzig M. Conventional imaging in paediatric uroradiology. *Eur J Radiol*. 2002;43(2):100–109.

Richardson DA, Hajj SN, Herbst AL. Medical treatment of urethral prolapse in children. *Obstet Gynecol*. 1982;59(1):69–74.

Ries LAG, Smith MA, Gurney JG, et al. *Cancer incidence and survival among children and adolescents: United States SEER Program 1975-1995*. National Cancer Institute, SEER Program: Bethesda, MD; 1999.

Rob S, Bryant T, Wilson I, et al. Ultra-low-dose, low-dose, and standard-dose CT of the kidney, ureters, and bladder: is there a difference? Results from a systematic review of the literature. *Clin Radiol*. 2017;72(1):11–15.

Rolnick D, Kawanoue S, Szanto P, et al. Anatomical incidence of testicular appendages. *J Urol*. 1968;100(6):755–756.

Roy CR, Wilson T, Raife M, et al. Varicocele as the presenting sign of an abdominal mass. *J Urol*. 1989;141(Pt 1):597–599.

Sakamoto H, Saito K, Oohta M, et al. Testicular volume measurement: comparison of ultrasonography, orchidometry, and water displacement. *Urology*. 2007;69(1):152–157.

Saxton HM, Borzyskowski M, Mundy AR, et al. Spinning top urethra: not a normal variant. *Radiology*. 1988;168(1):147–150.

Scott RH, Stiller CA, Walker L, et al. Syndromes and constitutional chromosomal abnormalities associated with Wilms tumour. *J Med Genet*. 2006;43(9):705–715.

Shaikh N, Morone NE, Bost JE, et al. Prevalence of urinary tract infection in childhood: a meta-analysis. *Pediatr Infect Dis J*. 2008;27(4):302–308.

Shiraki IW. Parameatal cysts of the glans penis: a report of 9 cases. *J Urol*. 1975;114(4):544–548.

Skoglund RW, McRoberts JW, Ragde H. Torsion of the spermatic cord: a review of the literature and an analysis of 70 new cases. *J Urol*. 1970;104(4):604–607.

Smith YR, Berman DR, Quint EH. Premenarchal vaginal discharge. *J Pediatr Adolesc Gynecol*. 2002;15(4):227–230.

Snodgrass WT, Khavari R. Prior circumcision does not complicate repair of hypospadias with an intact prepuce. *J Urol*. 2006;176(1):296–298.

Snyder HM, Diamond DA. Opposing views in utero/neonatal torsion: observation versus prompt exploration. *J Urol*. 2010;183(5):1675–1677.

Sonthalia S, Singal A. Smegma pearls in young uncircumcised boys. *Pediatr Dermatol*. 2016;33(3):e186–e189.

Springer A, van den Heijkant M, Baumann S. Worldwide prevalence of hypospadias. *J Pediatr Urol*. 2016;12(3):152.e1–152.e7.

Strohmeier Y, Hodson EM, Willis NS, et al. Antibiotics for acute pyelonephritis in children. *Cochrane Datab Syst Rev*. 2014;155(2) [135-120].

Subcommittee on Urinary Tract Infection. Urinary tract infection: clinical practice guideline for the diagnosis and management of the initial UTI in febrile infants and children 2 to 24 months. *Pediatrics*. 2011;128:595–610.

Tallen G, Hernáiz Driever P, Degenhardt P, et al. High reliability of scrotal ultrasonography in the management of childhood primary testicular neoplasms. *Klin Pädiatr*. 2011;223(03):131–137.

Tarantino L, Giorgio A, de Stefano G, et al. Echo color Doppler findings in postpubertal mumps epididymo-orchitis. *J Ultrasound Med*. 2001;20(11):1189–1195.

Tasian GE, Copelovitch L. Evaluation and medical management of kidney stones in children. *J Urol*. 2014;192(5):1329–1336.

Tasian GE, Copp HL. Diagnostic performance of ultrasound in nonpalpable cryptorchidism: a systematic review and meta-analysis. *Pediatrics*. 2011;127(1):119–128.

Taylor AT. Radionuclides in nephrourology, Part 2: pitfalls and diagnostic applications. *J Nucl Med*. 2014;55(5):786–798.

Vaganée D, Daems F, Aerts W, et al. Testicular asymmetry in healthy adolescent boys. *BJU Int*. 2018;122(4):654–666.

Van Batavia JP, Tasian GE. Clinical effectiveness in the diagnosis and acute management of pediatric nephrolithiasis. *Int J Surg*. 2016;36(Part D):698–704.

van den Heuvel-Eibrink MM, Grundy P, Graf N, et al. Characteristics and survival of 750 children diagnosed with a renal tumor in the first seven months of life: a collaborative study by the SIOP/GPOH/SFOP, NWTSG, and UKCCSG Wilms tumor study groups. *Pediatr Blood Cancer*. 2008;50(6):1130–1134.

Walker BR, Ellison ED, Snow BW, et al. The natural history of idiopathic urethrorrhagia in boys. *J Urol*. 2001;166(1):231–232.

Wallis MC, Lorenzo AJ, Farhat WA, et al. Risk assessment of incidentally detected complex renal cysts in children: potential role for a modification of the Bosniak Classification. *J Urol*. 2008;180(1):317–321.

Weidner IS, Møller H, Jensen TK, et al. Risk factors for cryptorchidism and hypospadias. *J Urol*. 1999;161(5):1606–1609.

Weitz M, Schmidt M. To screen or not to screen for vesicoureteral reflux in children with ureteropelvic junction obstruction: a systematic review. *Eur J Pediatr*. 2016;1–9.

Williams CB, Litvak AS, McRoberts JW. Epididymitis in infancy. *J Urol*. 1979;121(1):125–126.

Williams G, Craig JC. Long-term antibiotics for preventing recurrent urinary tract infection in children. *Cochrane Datab Syst Rev*. 2011;39 Suppl 1(3) [CD001534].

Woo LL, Ross JH. The role of testis-sparing surgery in children and adolescents with testicular tumors. *Urol Oncol*. 2015;34(2):76–83.

Yang S, Chua ME, Bauer S, et al. *Diagnosis and management of bladder bowel dysfunction in children with urinary tract infections: a position statement from the International Children's Continence Society*. 2017:1–13.

Zhao LC, Lautz TB, Meeks JJ, et al. Pediatric testicular torsion epidemiology using a national database: incidence, risk of orchiectomy and possible measures toward improving the quality of care. *J Urol*. 2011;186(5):2009–2013.

24

Pediatric Urogenital Imaging

Hans G. Pohl MD, FAAP

Imaging has long been a critical component in urologic investigation and diagnosis for both adults and children. However, studies that are routine and tolerable in adults may require anesthesia or specially trained technicians in children. Doses may need to be adjusted, and equipment may need to be available that is suitable for the smaller patient. The urologist treating children needs to be aware of these age-specific differences for the purposes of ordering and interpreting these tests.

Having decided that imaging of the urinary tract is appropriate, the clinician should weigh the doses of radiation given per study, whether interval follow-up would be necessary (thus presenting additional radiation exposure), the need for contrast agents, and the need for anesthesia/sedation to obtain adequate images against the anticipated clinical benefit. Although quantifying the radiation risk accurately for the individual patient is challenging, there is consensus that we should practice under the “as low as reasonably achievable” (ALARA) principle (Don et al., 2013; ICRP et al., 2013). As it is not currently possible to predict an individual's susceptibility to radiation effects, all patients should be treated as radiation sensitive (Kleinerman, 2009). The risks associated with radiation are touched on only briefly here, as this is discussed in more depth in Chapter 2.

Efforts to establish appropriate criteria for the selection of imaging modalities to evaluate the urinary tract in children have resulted in guidelines from a variety of professional organizations, such as the American Academy of Pediatrics (AAP), National Institute for Health and Care Excellence (NICE), Italian Society of Pediatric Nephrology, Canadian Pediatric Society (CPS), Polish Society of Pediatric Nephrology (PSPN), and European Association of Urology (EAU)/European Society for Pediatric Urology (ESPU) (Ammenti et al., 2012; Mori et al., 2007; Polish Society of Pediatric Nephrology, 2015; Roberts, et al., 2011; Robinson et al., 2014; Stein et al., 2015). Motivated by an interest in reducing unnecessary invasive testing, each guideline is based on the best available data at the time and expert opinion. Most recently, the American College of Radiology established a series of guidelines called the ACR Appropriateness Criteria, Hematuria-Child (2018) and Urinary Tract Infection-Child (2016), which seek to balance the relative radiation exposure from imaging against the diagnostic information yielded based on the prevalence of findings in specific clinical scenarios (Expert Panel on Pediatric Imaging, 2017).

This chapter describes the assets and liabilities of the imaging modalities employed in the evaluation of the pediatric urogenital system, organizing the discussion by nonionizing versus ionizing tests first and then describing what information can be gleaned by use of each modality at varying levels of the urinary tract as follows: (1) kidney and ureter, (2) bladder and urethra, and (3) scrotum, testes, and internal genitalia. At each level of the urinary tract, topics are organized by common reasons for evaluation as follows: (1) obstruction, (2) cysts and masses, (3) infection, (4) other congenital malformations not elsewhere covered, and (5) trauma.

Technique

Nonionizing

One form of nonionizing radiation, sonography is the archetype minimally invasive study that provides rationale for its widespread use. However, the same cannot be said about magnetic resonance imaging (MRI) because many children require sedation or anesthesia because of longer acquisition times (Arthurs et al., 2012). This risk associated with sedation or anesthesia is typically higher than the risk for nephrogenic systemic fibrosis (NSF) secondary to the use of gadolinium in a child with poor renal function or in the setting of immature renal function in a neonate, or even of iodinated-contrast nephropathy in children with poor renal function (Karcaaltincaba et al., 2009; Thomsen, 2007; Thomsen et al., 2007). Both contrast materials pose a higher risk for allergic reaction although still quite small (Arthurs and Bjørkum, 2013). The radiofrequency pulses creating the electromagnetic field can cause patient heating that must be monitored to prevent hyperthermia, which has been reported, though rarely (Kussman et al., 2004; Wang et al., 2007). The long-term safety of magnetic resonance (MR) exposure has been questioned based on revealed changes in gene expression related to magnetic field exposure (Bonassi et al., 2007; Kimura et al., 2008; Simi et al., 2008). Regardless, no human data have thus been produced, but there is recommendation to avoid fetal MR in the first trimester. Sonography has not shown to cause gene expression changes and is regarded as safe at all ages.

Key Point: Nonionizing Technique

- Contrast-enhanced sonography and machine learning–enhanced analysis of sonographic images should be considered as these tools become increasingly available, because they may obviate the need for more invasive testing.

Ionizing

Ionizing radiation is considered more harmful in children than in adults because of the greater radiosensitivity of developing tissues and potential for higher cumulative doses over the child's lifetime (Arthurs and Bjørkum, 2013). Thus, in children, the stochastic effects of repeated exposure (i.e., internal cell injury) can result in radiation-induced malignancies after a prolonged latent period. When evaluating the literature on ionizing radiation risk, care must be taken to determine if the risk reported is estimated, modeled, or measured from clinical practice. Variations in technique, patient age, size, and varied intervening studies during the long study intervals required can make measured studies difficult to interpret. Acknowledging these significant limitations in determining ionizing radiation risks in children, there appears to be reasonable evidence to suggest a dose-related risk in children and even in utero (Arthurs and Bjørkum, 2013). There is considerable work being done to reduce radiation doses of individual tests while still maintaining the necessary diagnostic accuracy to provide good care. Likewise, better medical decision making and offering nonionizing alternatives have gained momentum.

Key Point: Ionizing Technique

- The ALARA principle should be followed when considering imaging in children.

sonography

Fundamentals of Sonography in the Fetus and Child

A variety of urologic conditions can be diagnosed with near certainty prenatally using sonography to investigate the presence and quality of the renal cortex, the laterality of the abnormality, the position of the kidney(s) within the abdomen and association with other organs, and finally the presence of a normal amount of amniotic fluid and/or urine within the bladder (Dias et al., 2014).

Amniotic fluid is primarily a dialysate of fetal blood across the permeable fetal skin before 8 to 10 weeks. Early fetal urine production begins around 10 to 12 weeks, such that by 20 weeks, sonography can detect the majority of urologic abnormalities.

The features of a normal urinary tract include two kidneys, one on each side located in the renal fossa, with a renal cortex that is isoechoic or slightly hypoechoic to the liver, the presence of discrete interfaces between the cortex and the medulla, the absence of cortical cysts, and the absence of masses or dilation of the collecting system or bladder.

Because a bladder should be visualized in all fetuses by 10 to 12 weeks' gestation, bladder cycling might be observed if patience is exercised (Yiee and Wilcox, 2008). The normal bladder cycles regularly; however, the fetal bladder is never completely empty and always contains a small residual volume of urine. Lastly, attention should be placed on the placement of the umbilical cord and completeness of the anterior abdominal wall because these are highly associated with exstrophy and cloacal exstrophy.

It is important to recognize the subtle differences in the sonographic appearance of the newborn kidney in comparison to older children and adults. The distinct corticomedullary differentiation combined with a slightly hyperechoic renal parenchyma compared with a mature kidney can be mistaken for hydronephrosis in a newborn (Fig. 24.1) Also, the degree of hydronephrosis can be underestimated in an early postnatal sonogram (i.e., up to 2 days after birth) and/or in the setting of dehydration.

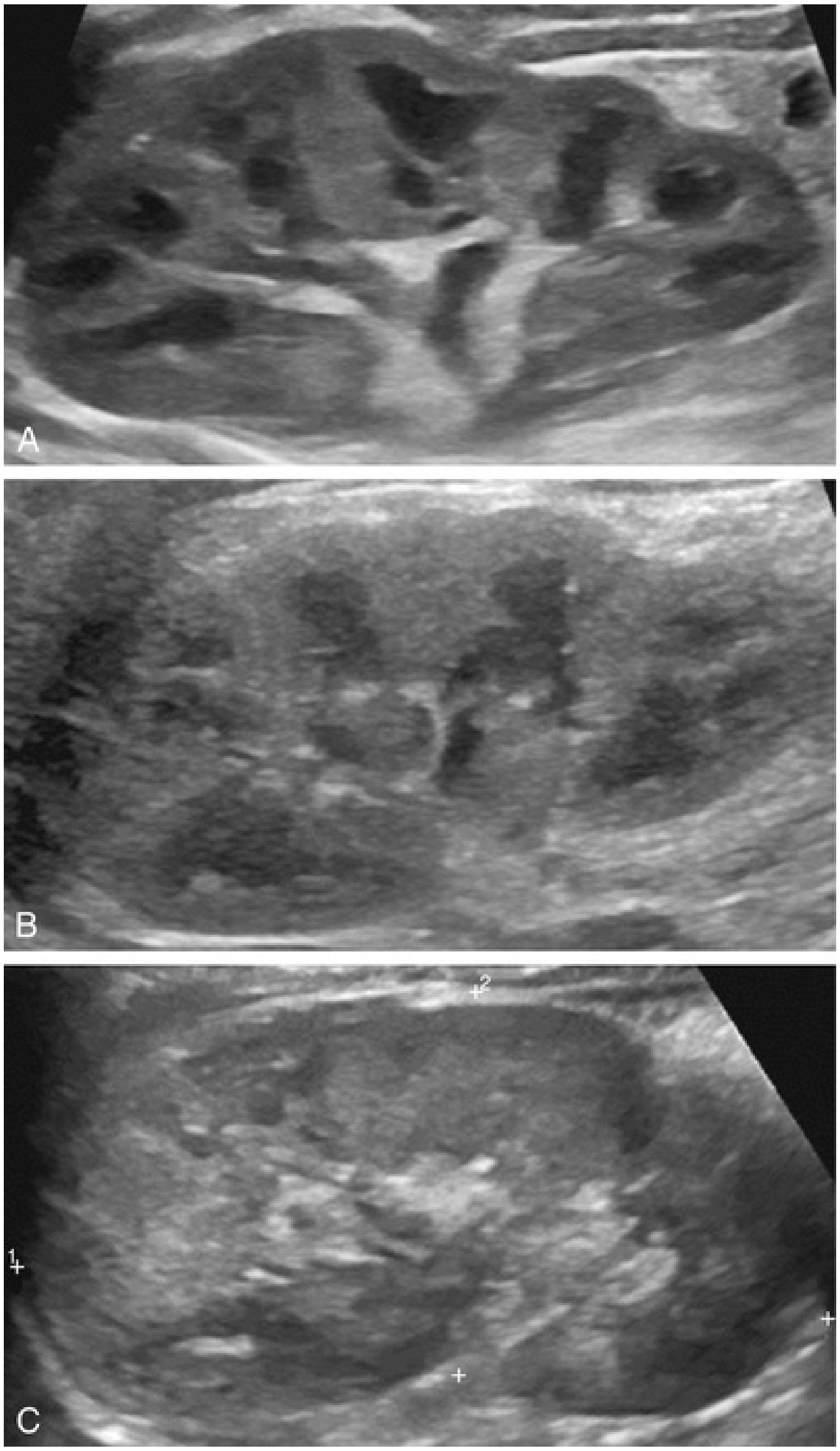

FIG. 24.1 (A and B) Postnatal sonograms demonstrating the high contrast cortico-medullary differentiation typical of the newborn kidney, which might be mistaken for dilated calyces. (C) For comparison, a renal sonogram in the older child.

Unfortunately, prenatal sonography does have a few limitations such as low amniotic fluid volume, maternal body habitus, maternal bowel gas, maternal pelvic bony structures, or fetal position. In these respects, MRI is a superior modality.

Kidney/Ureter

Obstruction

Hydronephrosis Versus Cystic Renal Diseases.

Dilation of the renal collecting system and parenchymal cysts are the most common findings on prenatal sonography (Blyth et al., 1993). A differential diagnosis list that considers most possibilities would include hydronephrosis (obstructive and nonobstructive), multicystic dysplastic kidney, polycystic kidney disease (autosomal recessive and autosomal dominant), and cystic nephroma.

Many parameters have been proposed for standardization of hydronephrosis reporting, but variation among specialties persists (Zanetta et al., 2012). The Society for Fetal Urology classification system is the most widely used by pediatric urologists and is based on the extent of calyceal dilation, involvement of minor calyces, and parenchymal thinning (Nguyen et al., 2010) (Fig. 24.2). Others use a measure of renal pelvic anteroposterior diameter or a combination of classification systems to aid in decision making and risk stratification (Timberlake and Herndon, 2013). These inconsistencies in hydronephrosis reporting make it paramount that the clinician review the actual images when making clinical decisions.

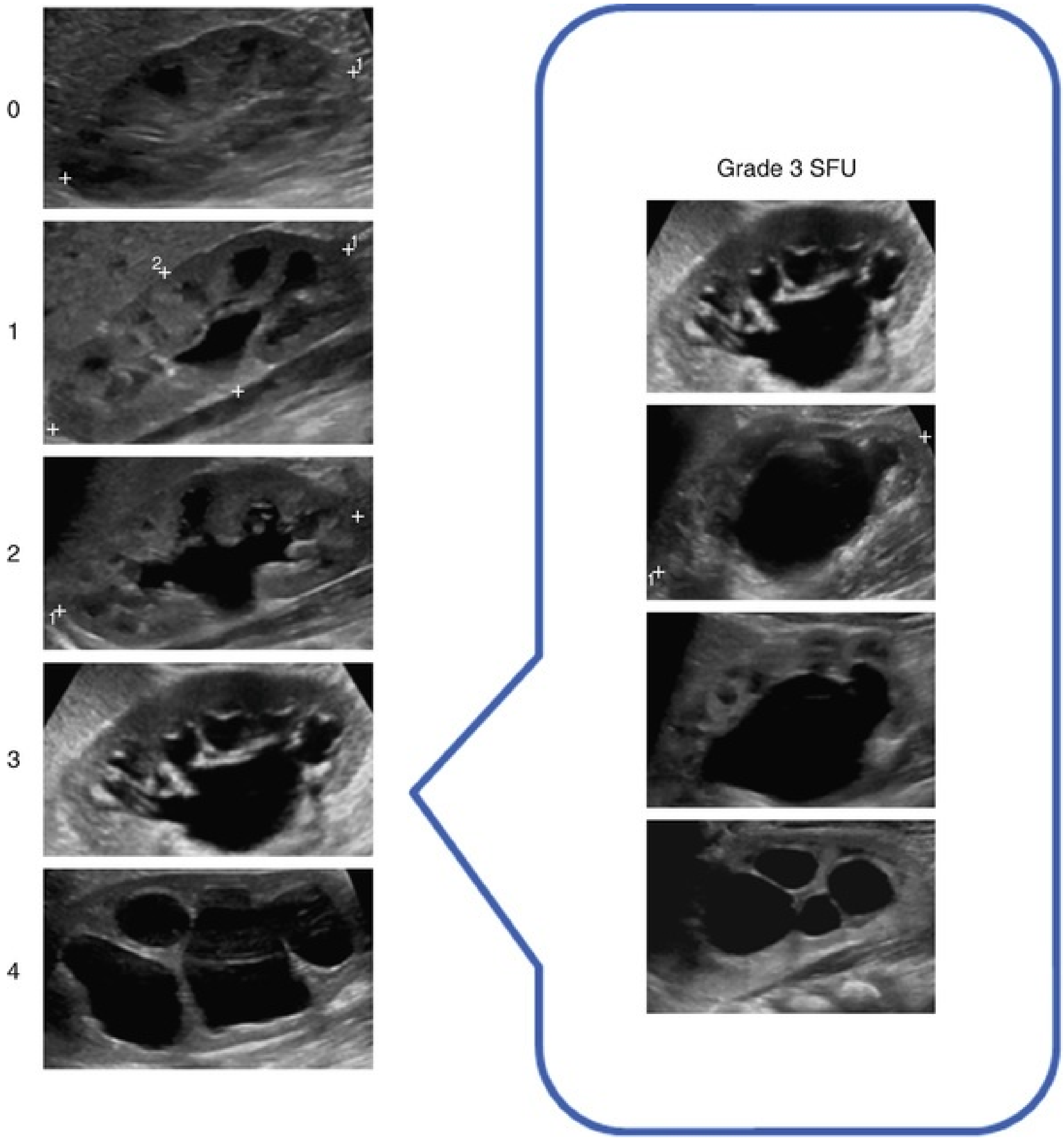

FIG. 24.2 The Society for Fetal Urology *(SFU)* criteria as demonstrated in postnatal sonograms. Grade 0 shows no central renal dilation. In grade 1, the renal pelvis only is visible; in grade 2, major calices can be identified; in grade 3, major and minor calices can be identified; and grade 4 has features of grade 3 but with parenchymal thinning as well. Within grade 3, there are many different degrees of collecting system dilation that conform to the criteria.

Although it has been debated that all cases of hydronephrosis represent obstruction in some form or another, the majority of hydronephrosis follows a benign natural history, such that improvement or resolution is seen. More profound developmental abnormalities present as moderate to severe hydronephrosis because of high-grade obstruction, and the transition between dilated and nondilated urinary tract localizes the site of obstruction to the ureteropelvic junction, ureterovesical junction, or urethra.

Dilated Ureters.

Generally considered a hallmark of obstruction, ureteral dilation may also occur in the absence of it, such as when it represents vesicoureteral reflux (VUR). Certain entities, such as megaureter and ureterocele, include both obstructive and nonobstructive variants that can be further evaluated using a functional test for urine drainage, typically diuresis renography or magnetic resonance urography (MRU).

Functional Interpretation of Sonography of the Kidney.

Although standard renal sonography is an anatomic study, inference of function has been proposed using a variety of techniques and measurements (Grenier et al., 2013; Inchingolo et al., 2013; Peters et al., 2013). The main clinical question in the setting of hydronephrosis is whether it is caused by obstruction, VUR, or neither as a normal variant. Hydronephrosis secondary to obstruction can be more fully evaluated using functional imaging. Hydronephrosis secondary to VUR is discussed later in this chapter. In the setting of bilateral hydroureteronephrosis, a thickened bladder, and poor emptying, voiding cystourethrography (VCUG) should be performed to rule out a posterior urethral valve (Fig. 24.3). Otherwise, diuretic renography is the gold standard. There are promising advancements using computer-aided shape analysis and ultrasound elastography to measure the dilated collecting system and renal parenchymal or pelvic tension as an indirect measure of obstruction (Cerrolaza et al., 2016; Grenier et al., 2013; Kang et al., 2013; Peters et al., 2013). If these sonographic techniques prove accurate in assessing function, then other ionizing techniques could be reduced dramatically or even avoided.

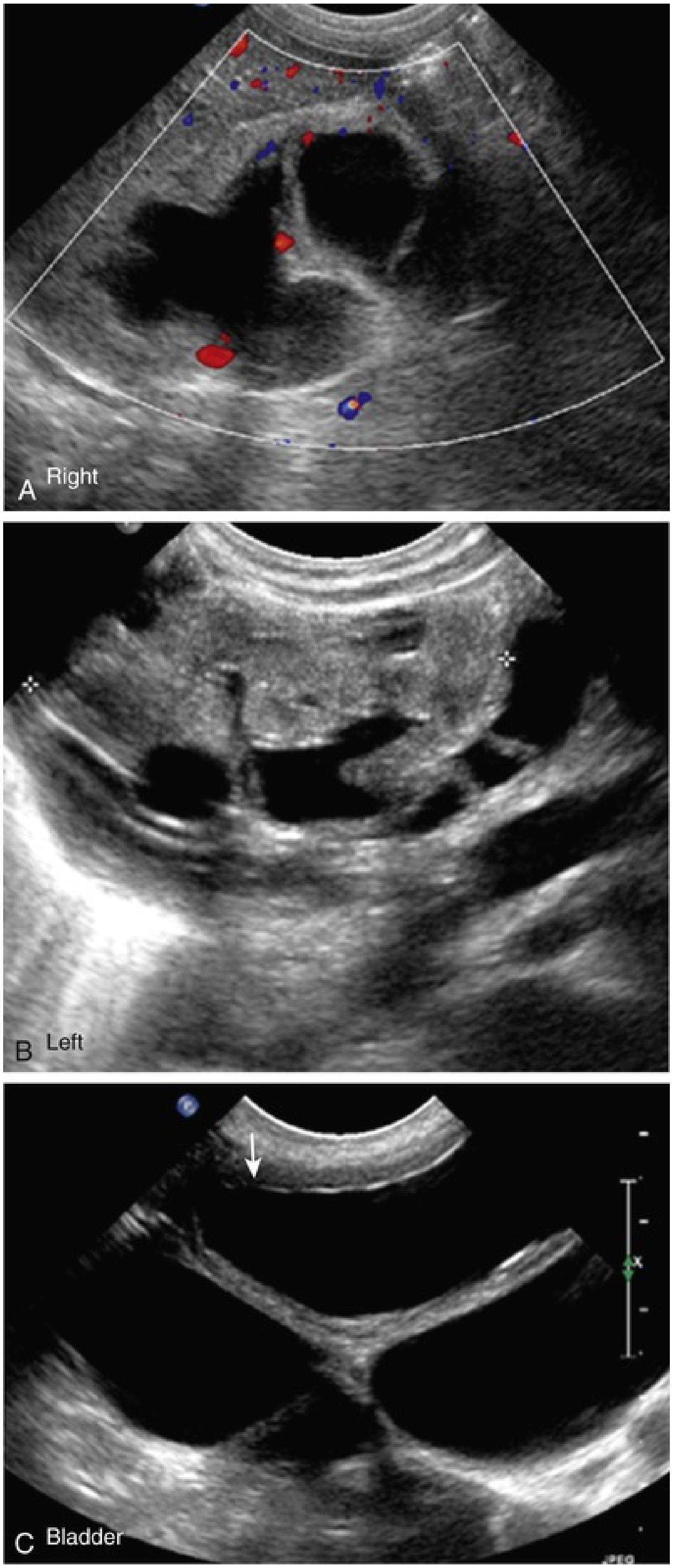
A Right
B Left
C Bladder
x
JPEG

FIG. 24.3 Sonographic example of an infant found to have posterior urethral valve. Images of the kidneys (A and B) demonstrate echogenic renal parenchyma, moderate to severe hydronephrosis, and renal cortical cyst (upper pole left kidney). The image of the bladder (C) demonstrates significant distal hydroureter bilaterally.

Key Points: Obstruction

- Sonography is the initial examination to perform for suspect obstruction, as well as being helpful for longitudinal follow-up.
- Based on the sonographic findings, ancillary imaging (e.g., VCUG and/or diuresis renography) might be considered.
- A normal infant renal sonogram can be confused with mature hydronephrosis because of hypoechoic renal pyramids with a distinct corticomedullary junction.
- Diagnosis of obstruction in children with diuresis renography requires a review of all parameters of the test because variations in technique can skew results considerably.

Cysts/Masses/Stones

Renal Cysts.

Cystic disease can mimic hydronephrosis on initial inspection but can be discriminated from it ultimately because cysts do not communicate with one another such as dilated calyces and pelvis do. In the case of multicystic dysplastic kidney (MCDK), the cysts are of varying sizes and randomly distributed throughout the renal parenchyma; in addition, they do not communicating with each other and are unilateral (Fig. 24.4A). By contrast, bilateral cystic lesions should raise concern for polycystic kidney disease of which two types are seen: autosomal recessive polycystic kidney disease (ARPKD) and autosomal dominant polycystic kidney disease (ADPKD). ARPKD is characterized by enlarged and homogeneously hyperechoic parenchyma that results from dilation of the collecting tubules (see Fig. 24.4B). ADPKD is identified by the presence of enlarged kidneys where the parenchyma is almost replaced by cysts. A multilocular cystic nephroma is a benign cystic renal tumor that shares features with MCDK and cystic Wilms tumor. It, too, presents as noncommunicating cysts of varying sizes, but generally has more parenchymal tissue than MCDK. Multilocular cystic nephroma is a tumor of infancy, whereas (cystic) Wilms tumor occurs in children at around 2 to 4 years of age.

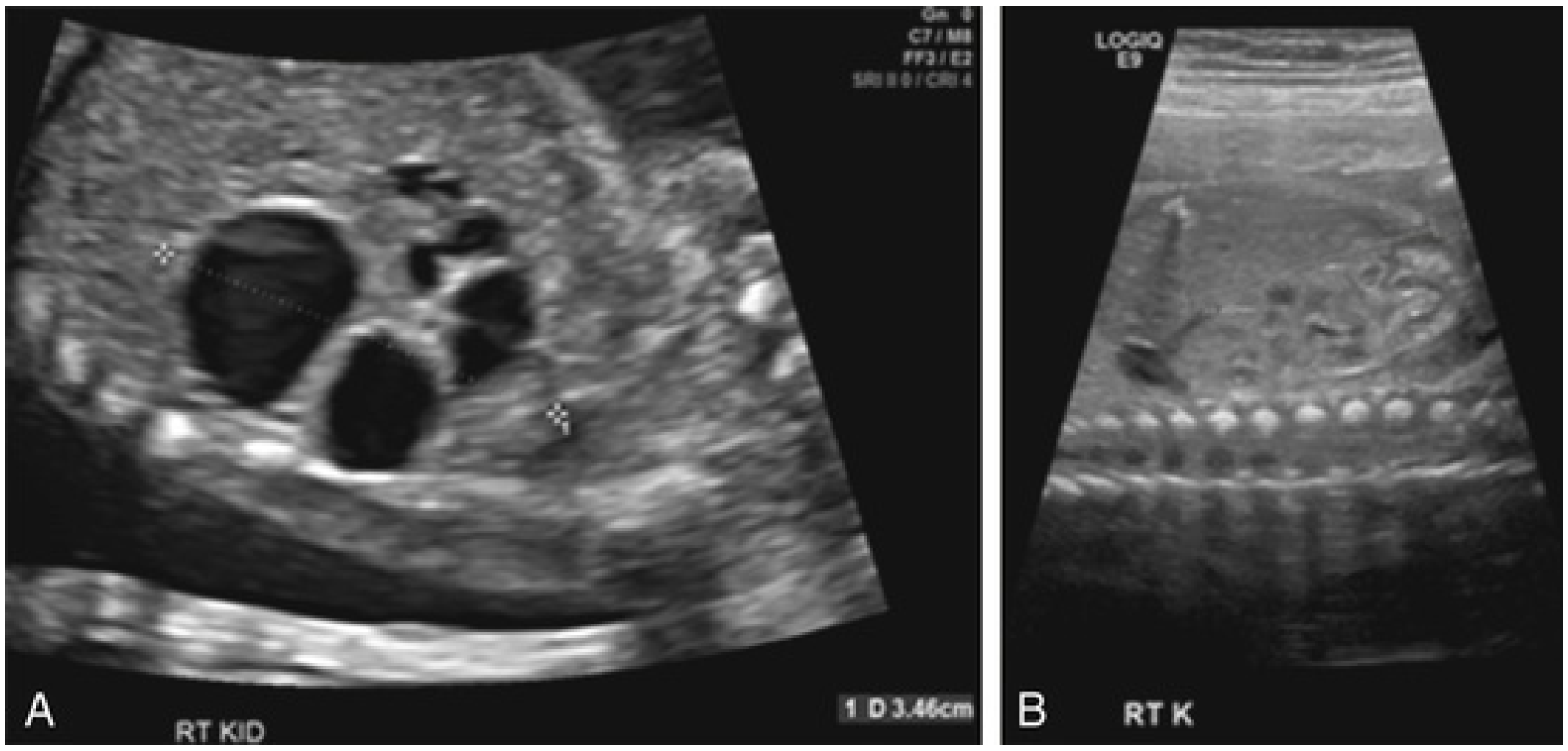

FIG. 24.4 (A) Prenatal sonogram demonstrating randomly distributed cortical cysts typically seen in multicystic dysplastic kidneys. (B) Prenatal sonogram demonstrating homogeneously hyperechogenic renal parenchyma of autosomal recessive polycystic kidney disease.

Renal/Abdominal Solid Masses.

A differential diagnosis list that considers most possibilities would include: neuroblastoma, congenital mesoblastic nephroma, Wilms tumor, renal vein thrombosis, renal artery thrombosis, adrenal hemorrhage, and rare renal solid tumors (rhabdoid, clear cell, angiomyolipoma) (Fig. 24.5). In most cases, hallmark features on sonography in the context of patient age and presenting symptoms and signs suggests the diagnosis; however, additional imaging with contrast-enhanced computed tomography (CT) is commonly performed.

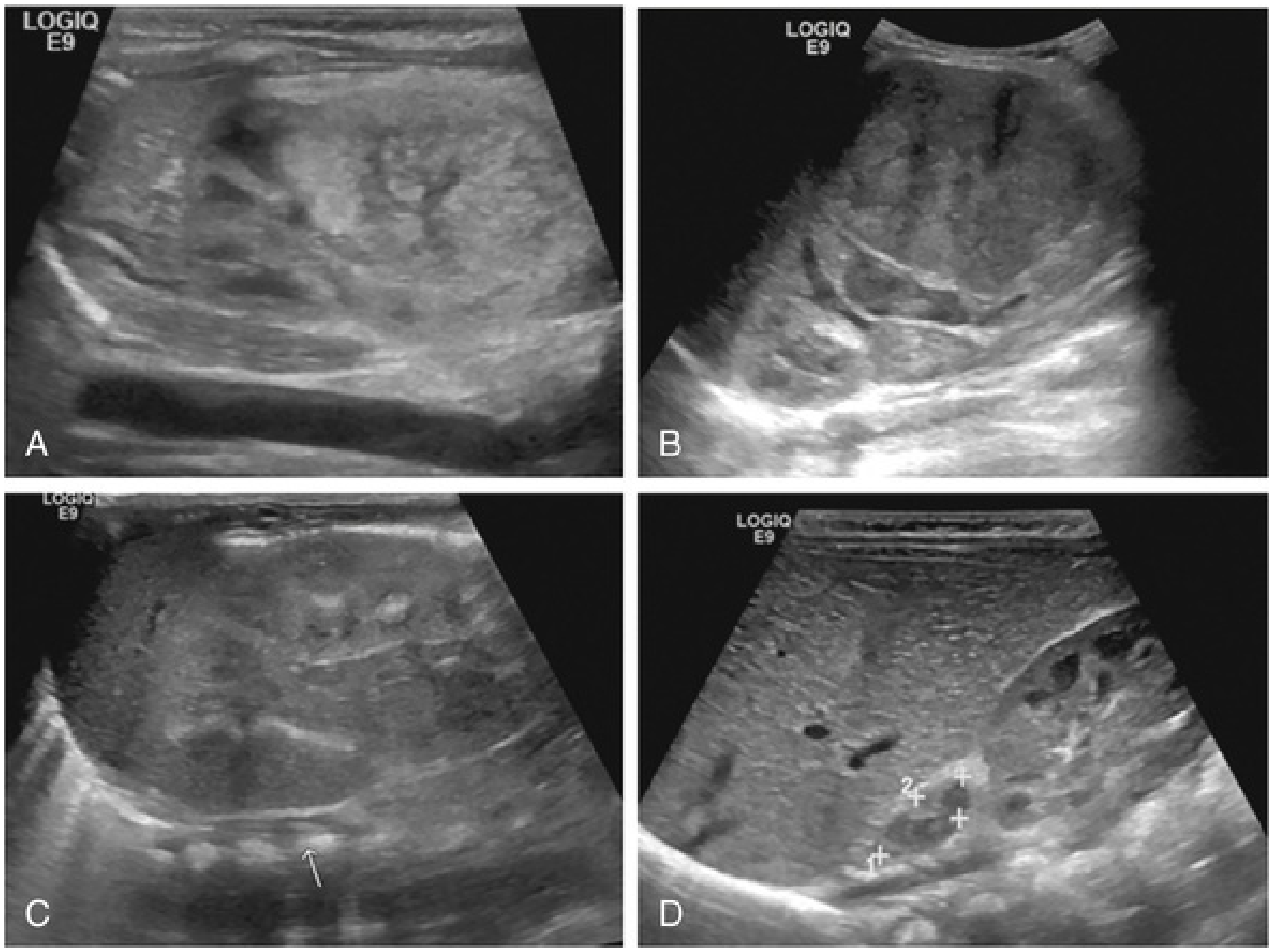

FIG. 24.5 Four sonographic examples of renal “enlargement” in which the diagnosis is suggested by the clinical presentation. (A) A 1-month-old male infant with a prenatally detected renal mass that was confirmed to be a congenital mesoblastic nephroma after nephrectomy. (B) A 17-month-old male patient with a right lower pole renal mass detected on physical examination and found to be Wilms tumor; (C) A 4-day-old female infant with acute kidney injury and hypertension with diffuse left renal enlargement diagnosed as renal vein thrombosis. (D) A 1-week-old female infant with prenatal diagnosis of a suprarenal mass consistent with adrenal hemorrhage.

Renal Stones.

Children with stone disease will likely have a lifetime of screening and point-of-care imaging, so an effort to minimize the amount of radiation is needed. The parent and older child should be well-informed of these intentions so as to play an active role in this plan, especially if visiting an unfamiliar emergency facility or physician. Sonography might be sufficient as an initial screening test or follow-up imaging in most children with acute renal colic from stones, as opposed to reflexively obtaining a CT scan or a kidney, ureter, and bladder (KUB) test. Sonography is ideal at detecting hydronephrosis and hydroureter, which can direct further imaging if the calculi cannot be definitively identified. It also can reliably detect intraparenchymal calculi and nephrocalcinosis (Fig. 24.6A). On sonography, calculi appear echogenic with shadowing, not to be confused with peripelvic fat, which is echogenic without shadowing. A "twinkling" artifact can also be seen when using color Doppler to distinguish calculi from other hyperechoic signals (Lee et al., 2001; Lu et al., 2013) (see Fig. 24.6B).

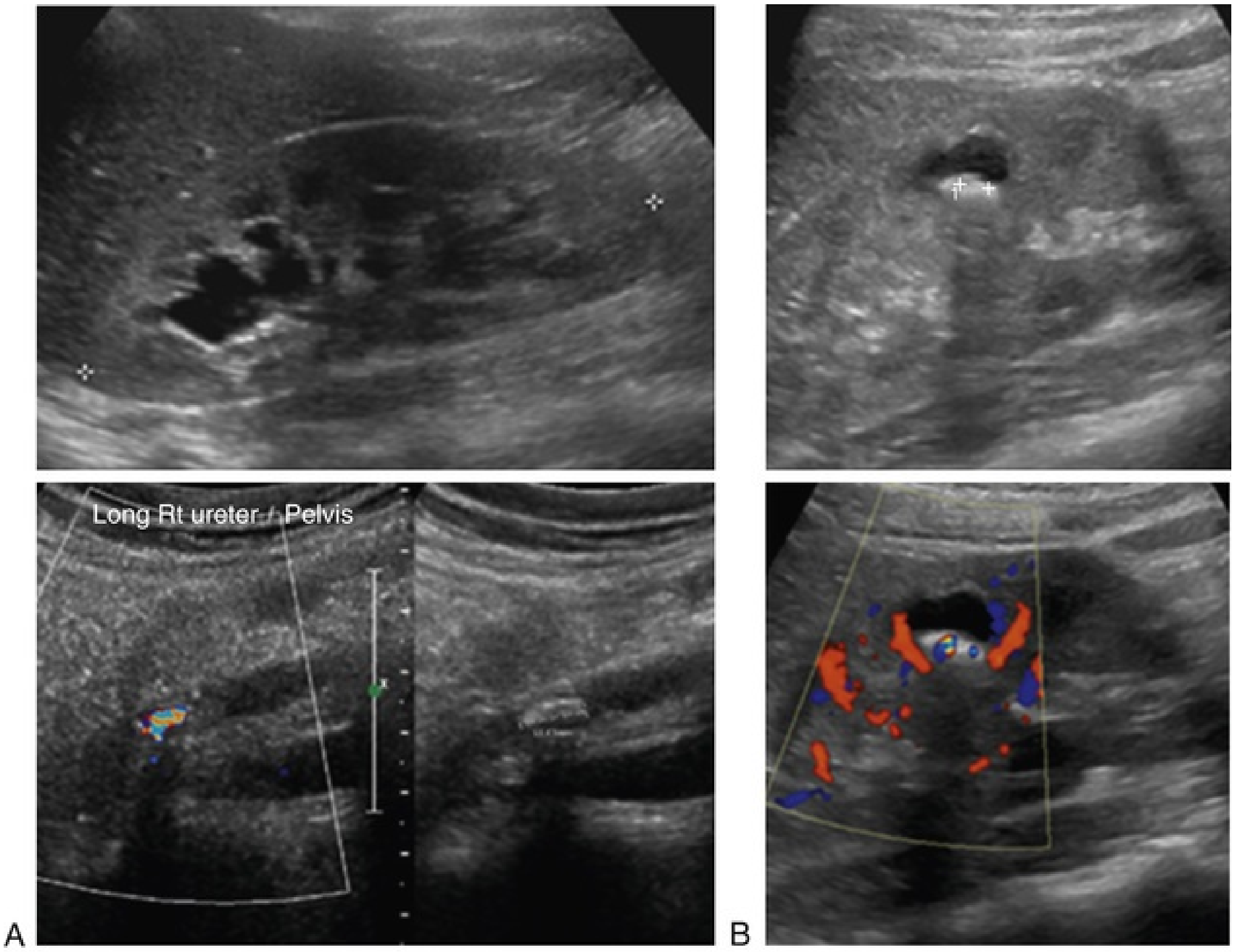

FIG. 24.6 (A) Renal sonogram demonstrating hydronephrosis and hydroureter associated with a mid-ureteral calculus. (B) "Twinkling" artifact seen by color Doppler application to a renal calculus.

Ureteral Stones.

Ureteral stones may present with or without dilated ureter above the stone, depending on the degree to which the stone obstructs urine flow. Unlike adults, ureteral stones in the distal/pelvic ureter are more easily imaged in children because of the shorter distance to the stone. The “twinkling” artifact is also seen in ureteral stones.

Key Points: Cysts/Masses/Stones

- Sonographically, MCDK is characterized by echolucent spaces (cysts) of varying sizes that are randomly distributed throughout the kidney with a paucity of renal parenchyma that is hyperechoic.
- ARPKD typically affects both kidneys and is characterized by enlarged and echogenic parenchyma.
- ADPKD typically affects both kidneys and is characterized by replacement of the renal parenchyma by cysts.
- Although patient age and hallmark sonographic features suggest the diagnosis of renal masses, contrast-enhanced CT of the abdomen should follow.

Infection

Sonography in the setting of UTI is typically used as an initial screening test to rule out obvious anatomic abnormalities that may warrant further investigation. Despite that it is not routinely employed during the onset of treatment for UTI, sonography should be employed when the patient fails to improve or worsens despite appropriate antibiotic treatment.

Sonography has been found to be very sensitive for the detection of *significant* renal abnormalities, but much less so for uncomplicated VUR, duplication anomalies, acute pyelonephritis, and focal renal scarring (Horgan et al., 1984; Jequier et al., 1985; Kangarloo et al., 1985; Leonidas et al., 1985). Alone it is rarely useful for most cases of nonfebrile and febrile UTI, so it is often used in complement with VCUG when there is suspicion for a urologic abnormality. Most imaging algorithms are applied after treatment and in the interest of identifying risk factors for recurrent UTIs, and anatomic abnormalities that increase the risk for complicated UTIs and associated renal injury. For patients requiring hospitalization, it is often advocated that screening sonography be obtained before discharge to exclude obstruction. Otherwise, imaging is delayed until after discharge.

In the absence of VUR, hydronephrosis revealed by sonography can be further evaluated by diuresis renography, which in combination, reliably localizes the site of obstruction in all cases (O'Hara, 2002; Shalaby-Rana et al., 1997). Despite its many advantages, standard gray-scale sonography is inferior in the detection of acute pyelonephritis or renal scarring in comparison to technetium-99m dimercaptosuccinic acid (^{99m}Tc-DMSA). A normal sonogram is not sufficient to risk-stratify a child with acute pyelonephritis or a good predictor of the presence of VUR (Nelson et al., 2014). Advances to improve sonographic accuracy in detection of acute pyelonephritis are promising (McArthur and Baxter, 2012).

Contrast-enhanced and noncontrast voiding sonography is proving its accuracy for detection of VUR, but the technique is still in its infancy and not yet widely performed (Darge, 2010; Fallah et al., 2012; Papadopoulou et al., 2009). It uses the detection of echogenic microbubbles tracked in real time during voiding and bladder cycling. A 5-point grading system has been developed similar to that used for VCUG (Darge and Troeger, 2002). It is associated with a higher cost because of time consumption, but certainly promising as a nonionizing detection and monitoring option for VUR (Piscitelli et al., 2008).

Key Points: Infection

- Numerous guidelines have been published on the radiographic evaluation after pediatric urinary tract infection and sonography is employed as an initial screening modality despite its low yield.
- A normal sonogram is insufficient to risk stratify a child with a febrile UTI and is not a good predictor for VUR.
- The “bottom-up” approach relies on VCUG—after sonography—to identify all cases of VUR that may result in overtreatment of low-grade VUR.
- The “top-down” approach replaces screening sonography with a DMSA renal scan to identify acute pyelonephritis and/or renal scarring. Proponents of this algorithm recommend VCUG only in response to abnormal DMSA scans as an indicator of high-risk patients.

Other Congenital Malformations

Sonography is the initial means to evaluate any congenital anomaly of the upper urinary tract for the various reasons already mentioned. In addition, sonography is the initial imaging evaluation for infants with suspected differences of sexual development to identify the presence and relationship between Müllerian structures and the urinary tract.

Trauma

Sonography has been shown to be useful to evaluate the pediatric trauma patient in the acute setting, where it compares favorably to contrast-enhanced CT for the initial evaluation of renal injuries (Amerstorfer et al., 2015). More recently, contrast-enhanced sonography has been demonstrated to be as sensitive as contrast-enhanced CT for the evaluation of pediatric blunt abdominal trauma (Miele et al., 2016).

Key Points: Trauma

- Abdominal sonography is useful as part of the acute trauma evaluation and compares favorably to contrast-enhanced CT. Sonography should be considered for the longitudinal evaluation of known renal injuries, particularly to assess resolution of perinephric hematomas or urinomas.
- Ionizing radiation is used to evaluate genitourinary trauma, frequently with the addition of intravenous or intraluminal iodinated contrast.
- Radiographic evaluation is deemed complete only when delayed views of the renal parenchyma and collecting system are obtained on CT, or when lateral projections of the bladdder, bladder neck, and urethra are obtained on cystourethrography.

Bladder/Urethra

Obstruction

Bladder sonography can be performed to assess both anatomy and basic function. From an anatomic standpoint, sonography can be used to detect ureteroceles, large diverticula, bladder calculi, bladder debris, or suspicious bladder masses (Fig. 24.7) Bladder wall thickness is a more difficult proposition because it changes significantly with bladder volume and age. Many have tried to standardize measurements of the bladder wall and index this to volume to predict pathology or define normality, but this has not gained widespread use because of its complexity and variability (Bright et al., 2010; Kaefer et al., 1997; Yeung et al., 2004). Regardless, a grossly thickened bladder on sonography should be viewed with suspicion if the clinical picture is consistent with voiding dysfunction (Yeung et al., 2007). Simple functional assessment of bladder emptying can be quantified by calculating prevoid and postvoid volumes. For example, a thickened bladder and dilated posterior urethra known as the “keyhole sign” is highly suggestive of a posterior urethral valve (Fig. 24.8).

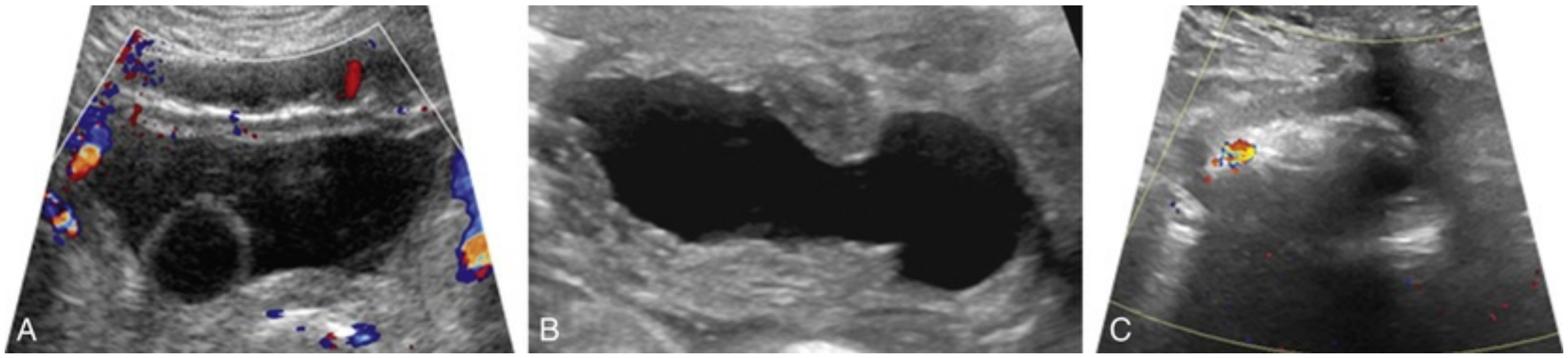

FIG. 24.7 Sonographic images of the bladder reveal ureterocele (A), diverticulum (B), and large calculi with “twinkling” artifact (C).

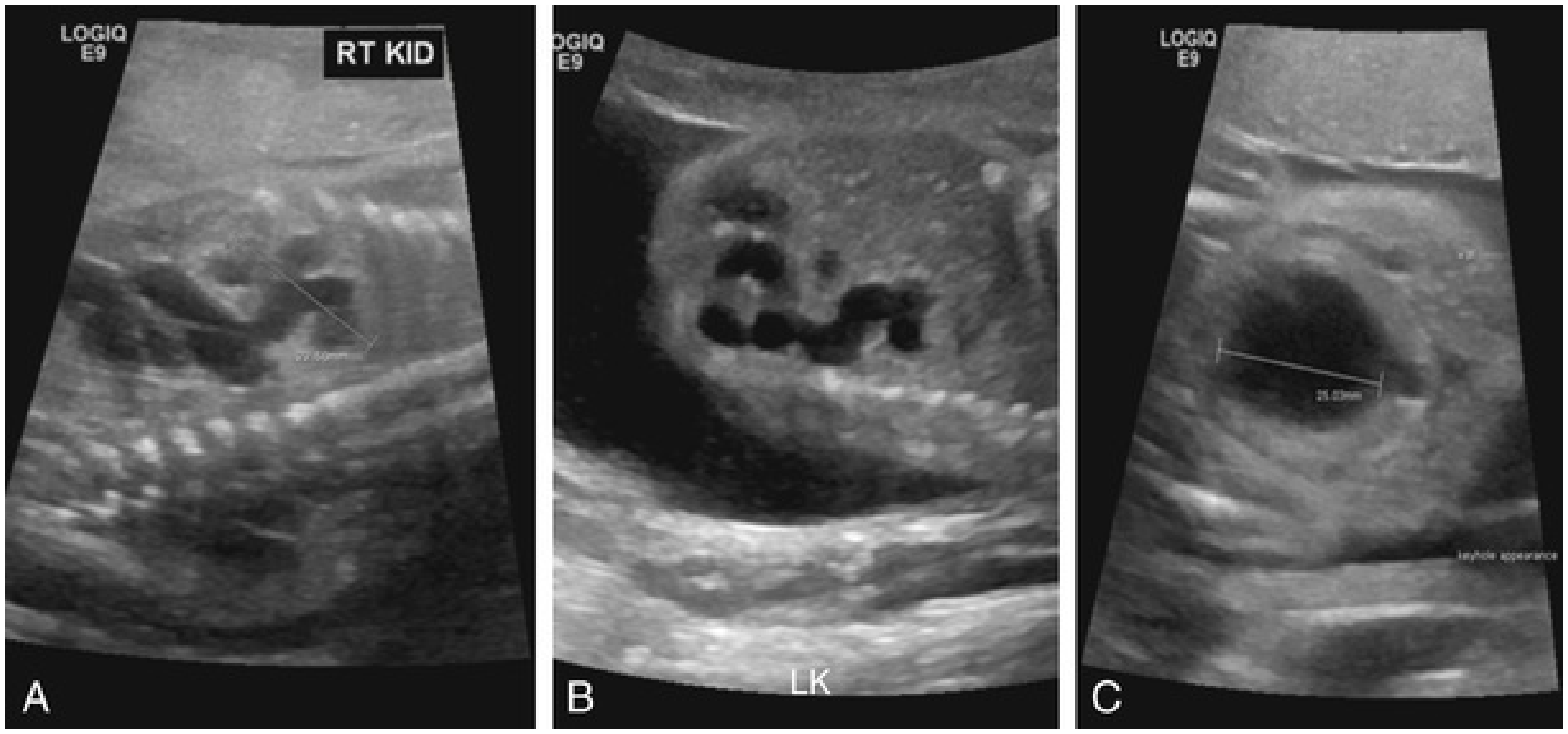

FIG. 24.8 Prenatal sonogram demonstrating bilateral hydronephrosis and hydroureter (A and B) and the thickened bladder and “keyhole” sign (C) typically associated with bladder outlet obstruction, in this case of posterior urethral valve.

Cysts/Masses

Midline Pelvic Cysts.

A differential diagnosis list that considers most possibilities would include: hydrometrocolpos (urogenital sinus anomalies), ovarian cyst, distended bladder, and urinary ascites. Hydrometrocolpos is distension of the uterus and vagina with mucus or blood, and results from vaginal obstruction secondary to imperforate hymen, vaginal atresia, transverse vaginal septum, or from retrograde flow of urine in urogenital sinus and cloacal malformations (Banerjee et al., 1992; Hill and Hirsch, 1985) (Fig. 24.9).

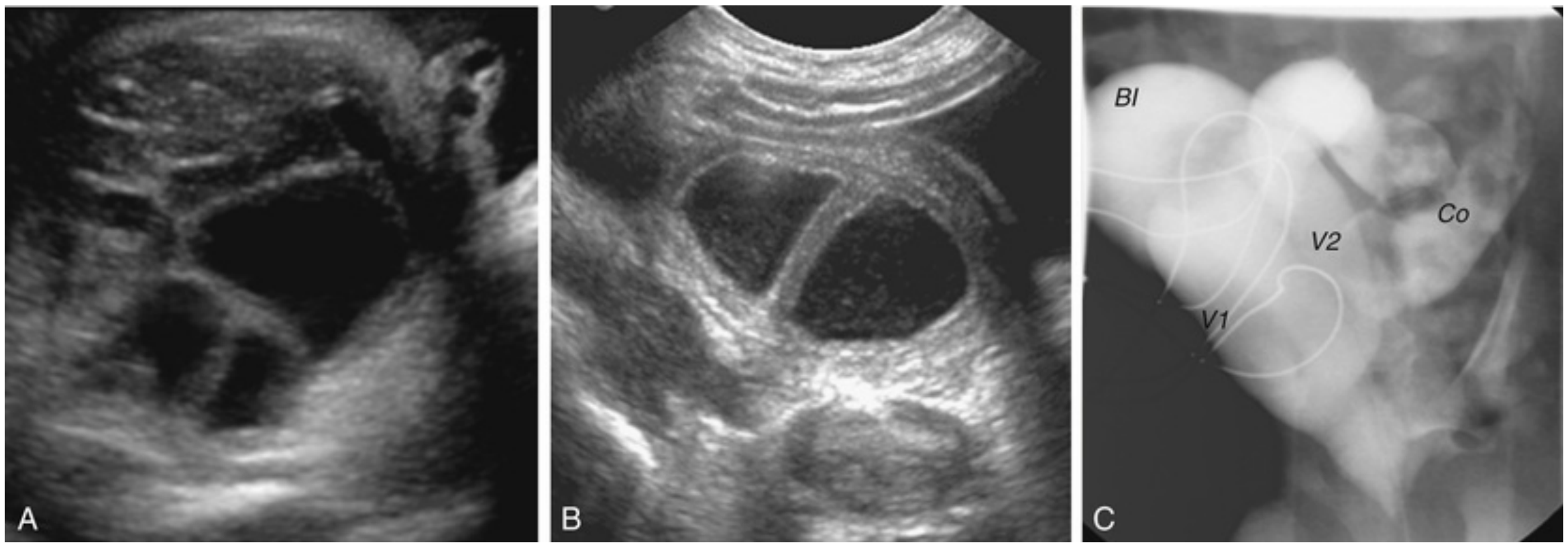

FIG. 24.9 (A) Prenatal sonogram performed for oligohydramnios in a 34-week female fetus demonstrating dual pelvic cystic structures below a dilated bladder. (B) Postnatal sonography confirms the pelvic structures to be hemivaginas. (C) Cystogram confirms the diagnosis of cloacal anomaly because the hemivaginas, dilated bladder, and distal colon are opacified with contrast medium injected into a single perineal opening. *Bl,* Bladder; *Co,* colon; *V1,* hemivagina; *V2,* hemivagina.

Bladder Tumors.

To properly assess the contents of the bladder and the bladder wall, it is important that the bladder be as full as possible, particularly if there is concern for a bladder mass. Bladder masses are well delineated by sonography and include: clot, benign and malignant tumors, foreign bodies, and pseudotumors. Children with gross hematuria might have intravesical clots easily distinguished from bladder tumors by imaging the patient supine and prone. A clot will be seen to move about the bladder, but a tumor will remain fixed. Tumors of the bladder wall can arise from the urothelium, mesenchyme, neuroendocrine cells, or in response to viral infection. Unfortunately sonography does not easily discriminate between histologic types, and further clinical assessment is indicated.

Infection

Aside from using sonography to evaluate urinary tract infections as a whole, viral cystitis can also be confirmed sonographically based on the presence of a thickened bladder wall, at times severe enough to be mistaken for a bladder mass. Typically, these patients present with a prodrome viral upper respiratory tract illness, gross total hematuria, and significant urgency and frequency of urination.

Other Congenital Malformations

Abdominal Wall Defects.

Though generally quite rare, bladder exstrophy and prune belly syndrome represent defects in formation of the abdominal wall with associated urogenital abnormalities. Classic bladder exstrophy can be identified prenatally when the bladder is not visualized, the lower abdominal wall is irregular, and the umbilicus is inferiorly placed. Prune belly syndrome is suggested by observing hydronephrosis/hydroureter, a distended bladder, and the absence of testes in the scrotum in a male fetus either prenatally or after birth (Fig. 24.10).

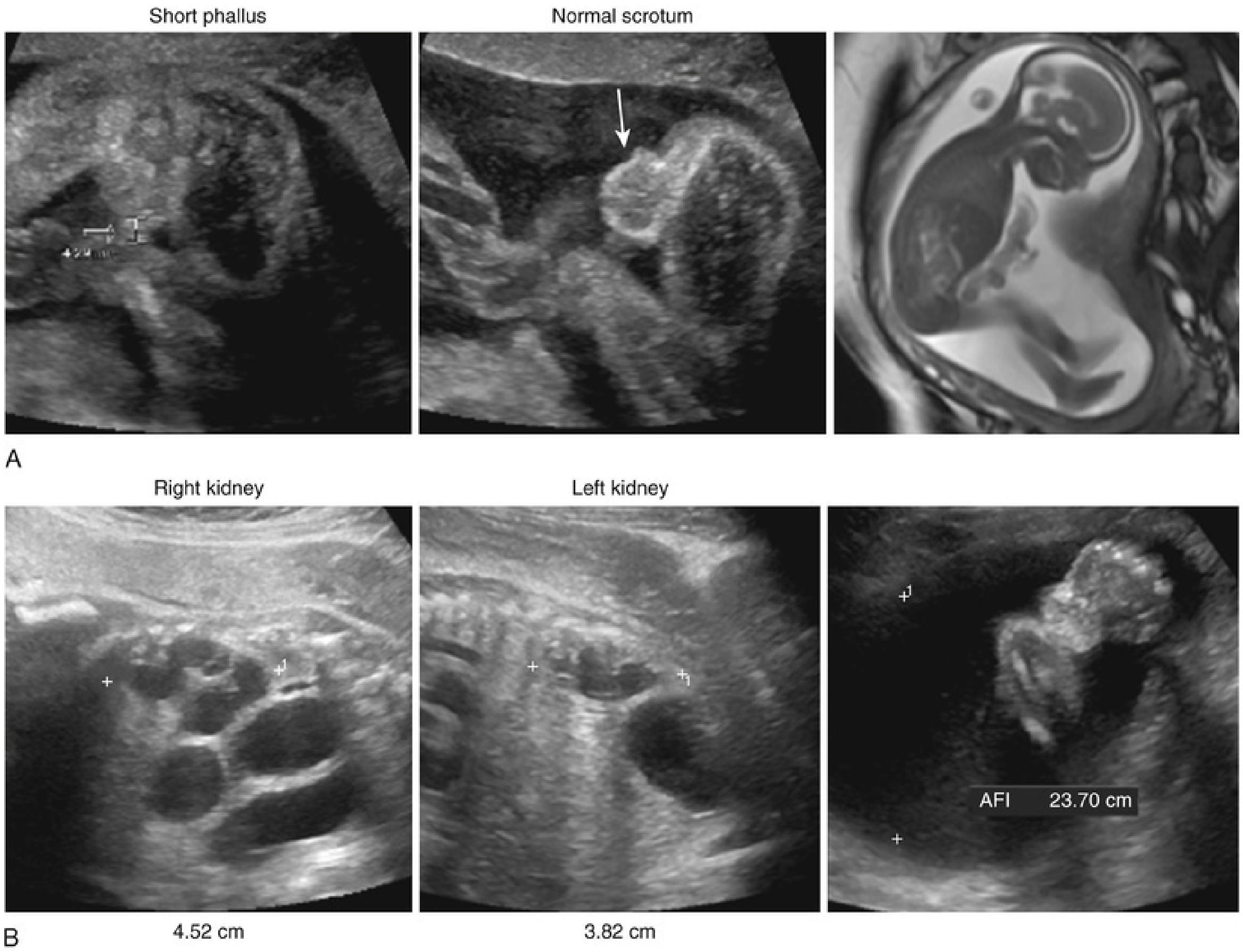

FIG. 24.10 (A) Prenatal sonogram and magnetic resonance image of a male fetus with classic bladder exstrophy. The kidneys were normal, and no hydroureter was seen, but the cord inserted low into the abdomen, the bladder was not visualized in pelvic views, and the phallus was short. (B) Prenatal sonogram of a male fetus with prune-belly syndrome demonstrating the presence of a high amniotic fluid index *(AFI).* Although prune-belly syndrome and posterior urethral valve share sonographic features, such as hydronephrosis and hydroureter, this case did not demonstrate a thickened bladder wall and distinct “keyhole” sign, which are typical of posterior urethral valve. Also, the testes were not seen in the scrotum, which is another prenatal clue that the diagnosis was prune-belly syndrome.

Trauma

Scrotum/Testes/Internal Genitalia

Acute Scrotum.

Genital imaging is limited to essentially four basic conditions: the acute or enlarged scrotum, testicular/paratesticular masses, cryptorchidism, and ambiguous genitalia. Sonography is always the initial and usually the only imaging modality needed. Overuse of sonography for scrotal concerns is widespread as most scrotal concerns can be diagnosed on the basis of history and physical examination rather than imaging. Likewise, overzealous interpretation of scrotal imaging especially in contradiction to the clinician's physical examination should be avoided.

In the acute scrotum, color Doppler sonography can be useful in differentiation of the child with an equivocal clinical examination for torsion (Baker et al., 2000; DaJusta et al., 2013). Surgical exploration should not be delayed if torsion is suspected and the delay to image will compromise salvageability. Because of reported false-negative results using color Doppler sonography, investigators have used high-resolution sonography to image torsion of the spermatic cord itself known as the “whirlpool sign.” (Fig. 24.11) (Vijayaraghavan, 2006). This was shown to increase sensitivity to 96% (from 76% using color Doppler sonography) and 99% specificity (Bandarkar and Blask, 2018; Kalfa et al., 2007). Salvageability of the testicle based on sonographic appearance is difficult to predict except in the setting of no arterial flow and parenchymal heterogeneity, in which case 100% were nonviable at exploration (Kaye et al., 2008).

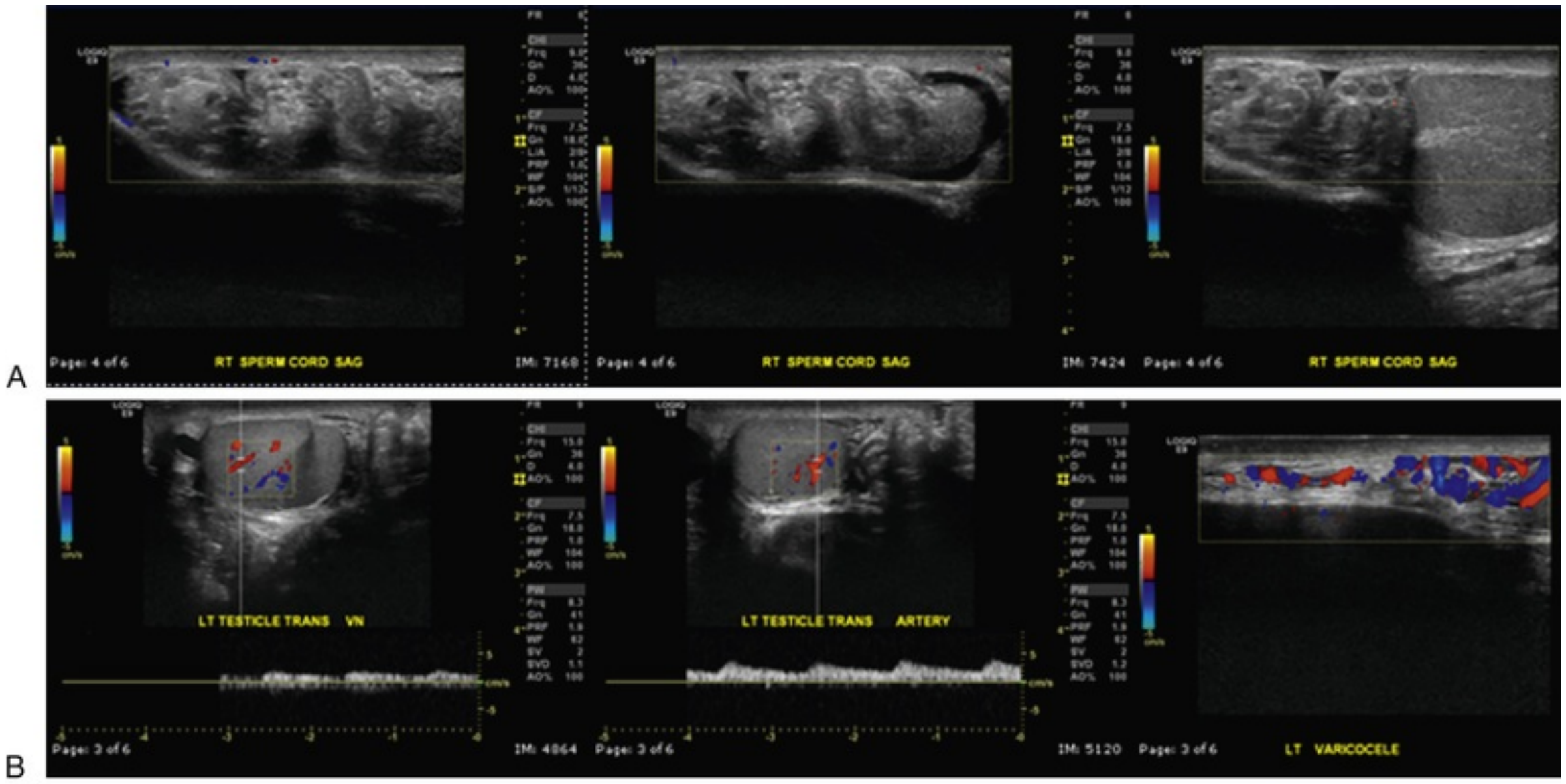
A
Page: 4 of 6
RT SPERM CORD SAG
IM: 7168
Page: 4 of 6
RT SPERM CORD SAG
IM: 7424
Page: 4 of 6
RT SPERM CORD SAG
B
LT TESTICLE TRANS VN
LT TESTICLE TRANS ARTERY
Page: 3 of 6
IM: 4864
Page: 3 of 6
IM: 5120
Page: 3 of 6
LT VARICOCELE

FIG. 24.11 Scrotal sonogram in a 19-year-old male patient with acute onset of right testis pain. Doppler sonography (A) shows the “whirlpool” sign, which has been associated with torsion of the spermatic cord. Doppler sonography did not identify flow, as compared with the left testis (B), which demonstrated ample flow in the nontorsed cord and testis. An

incidental left varicocele was noted as well.

Other nontorsion scrotal events can be seen with color Doppler sonography. Epididymo-orchitis can be visualized as hyperemia of the epididymis and/or testicle (Fig. 24.12). However, this must be correlated with the clinical presentation as this can also be seen in the setting of recent spontaneous detorsion. Torsion of a testicular or epididymal appendage can also be captured by a skilled technician as an upper pole/epididymal hypoechoic/avascular nodule with surrounding hyperemia. Acute idiopathic scrotal edema can be identified by the “fountain sign” or hyperemia of a thickened scrotal wall in the absence of any of the previously mentioned diagnoses (Geiger et al., 2010).

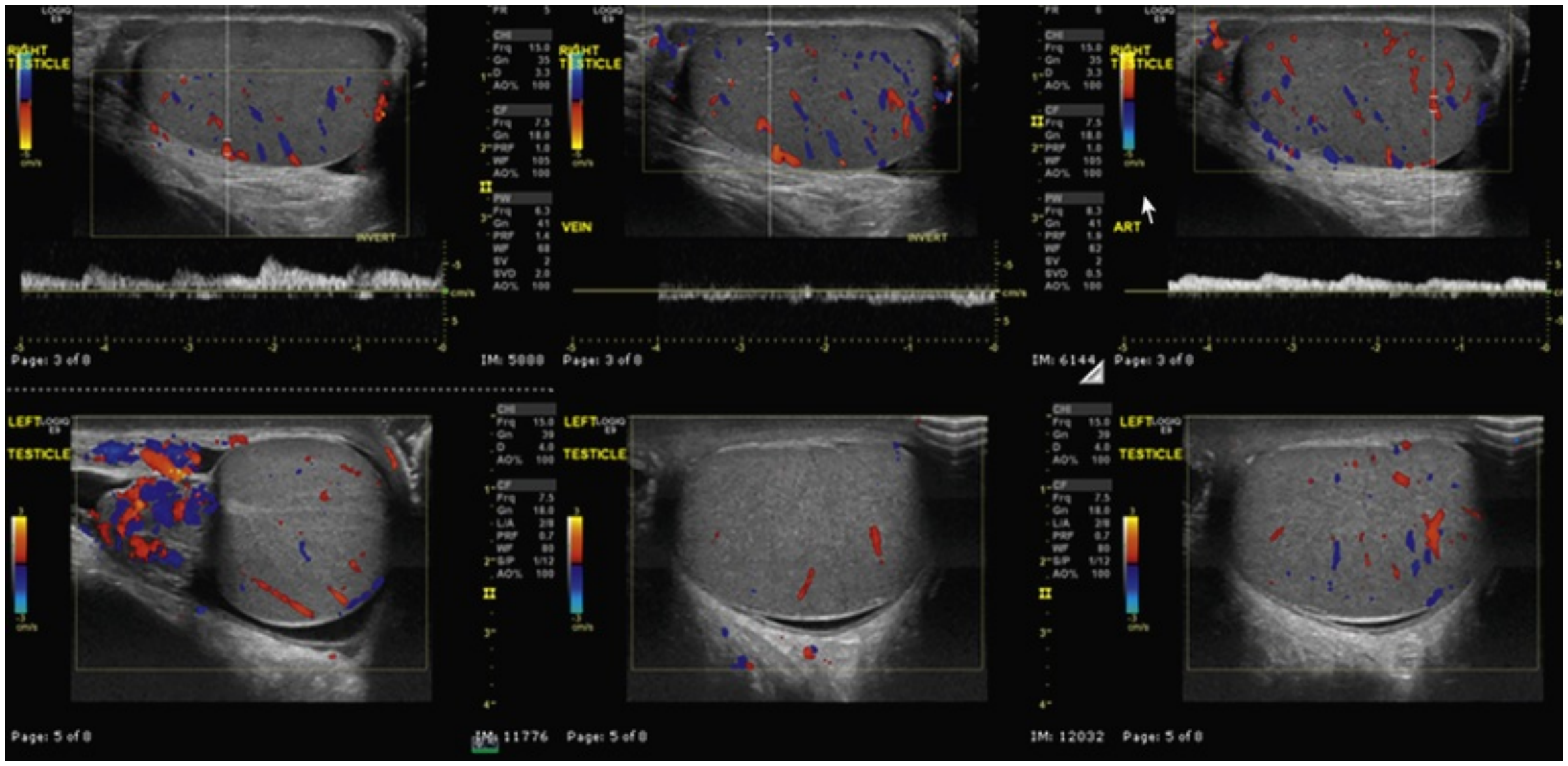

FIG. 24.12 Scrotal sonogram in a 13-year-old male patient with acute onset of left scrotal swelling showing hyperemia of the left epididymis consistent with epididymo-orchitis.

Key Points: Acute Scrotum

- In addition to careful history and physical examination, scrotal sonography provides much of the information needed to discriminate between inflammation, neoplasm, trauma, and testicular torsion.
- Nuclear scintigraphy may be used to evaluate testicular torsion but provides little additional information over what can be gleaned from sonography.

Cysts/Masses

Pediatric testicular and paratesticular masses must be viewed in conjunction with the patient's age and complete clinical picture but are generally well characterized by sonography (Delaney and Karmazyn, 2013). The most common prepubertal primary testicular tumor is benign teratoma characterized by a heterogeneous mass with areas of solid, cystic, and calcified components (Pohl et al., 2004). Yolk sac tumor is a homogenous well-vascularized mass. An epidermoid cyst has the unique appearance of hyperechoic and hypoechoic rings or “onion rings” with no internal blood flow (Delaney and Karmazyn, 2013) (Fig. 24.13). In the setting of congenital adrenal hyperplasia, bilateral hypoechoic, hyperemic, heterogenous adrenal rests can be seen in children who have improper steroid replacement or poor compliance. A full discussion of scrotal masses and their appearance is beyond the scope of this chapter but can be found in detail elsewhere in this book.

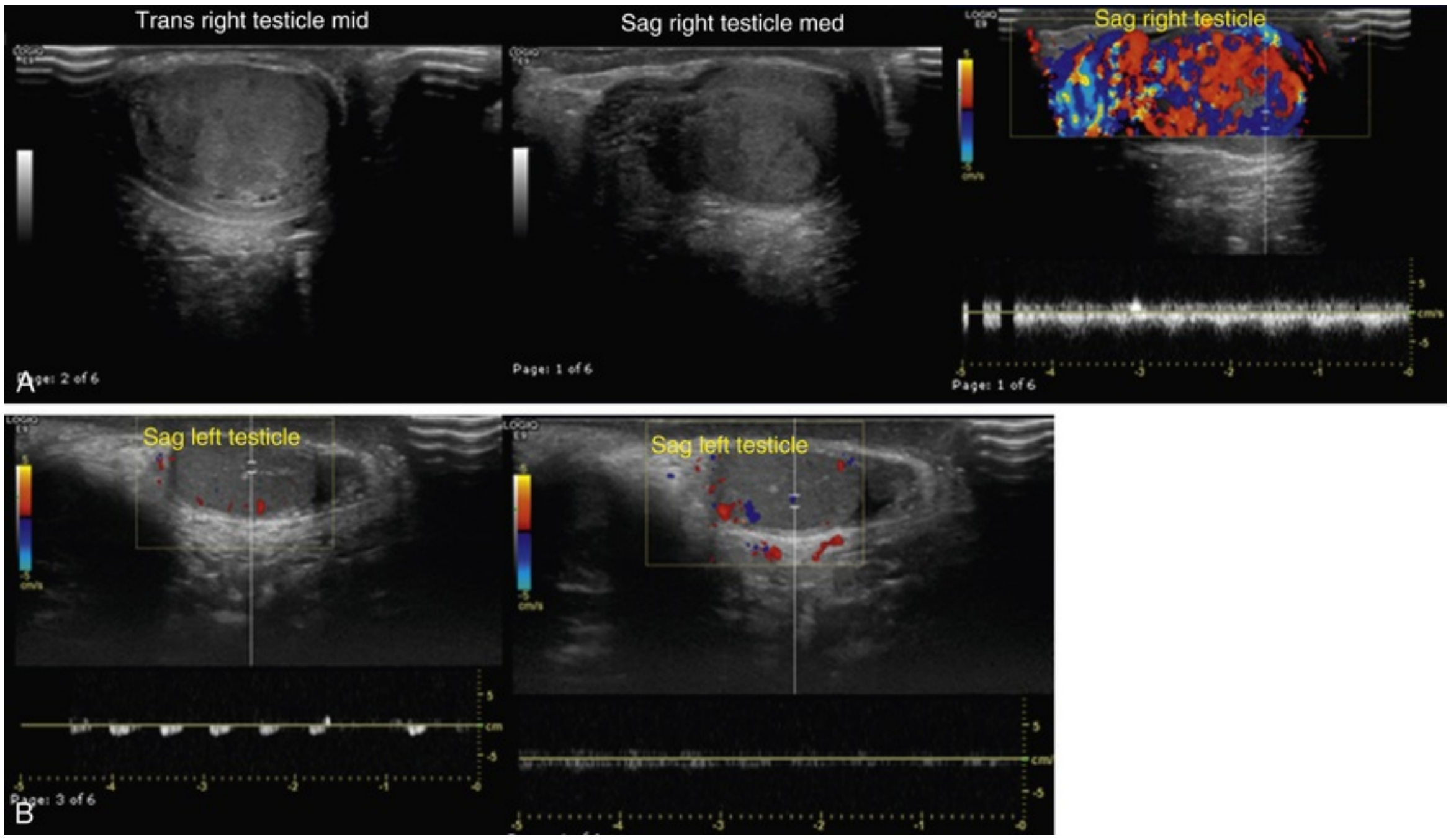
Trans right testicle mid
Sag right testicle med
Sag right testicle
Page: 2 of 6
Page: 1 of 6
Page: 1 of 6
A
Sag left testicle
Sag left testicle
Page: 3 of 6
B

FIG. 24.13 Scrotal sonogram in a 2-year-old male patient for an enlarged right testis (A), ultimately found to be a yolk sac tumor. For comparison, the normal left testis (B) is shown.

Undescended Testis

Sonography in the evaluation of routine cryptorchidism should not be pursued

(American Urological Association, n.d.). Multiple studies have confirmed its poor sensitivity of detecting and localizing the undescended testicle, and it does not alter the necessary treatment plan (Tasian and Copp, 2011). A reasonable exception would be cryptorchidism in a difficult-to-examine obese child where the presence of an inguinal testis on sonography would simplify the surgical approach. It is the primary imaging modality in the setting of ambiguous genitalia or severe hypospadias with nonpalpable gonads for detection of Müllerian structures, which can guide subsequent workup (Chavhan et al., 2008) (Fig. 24.14)

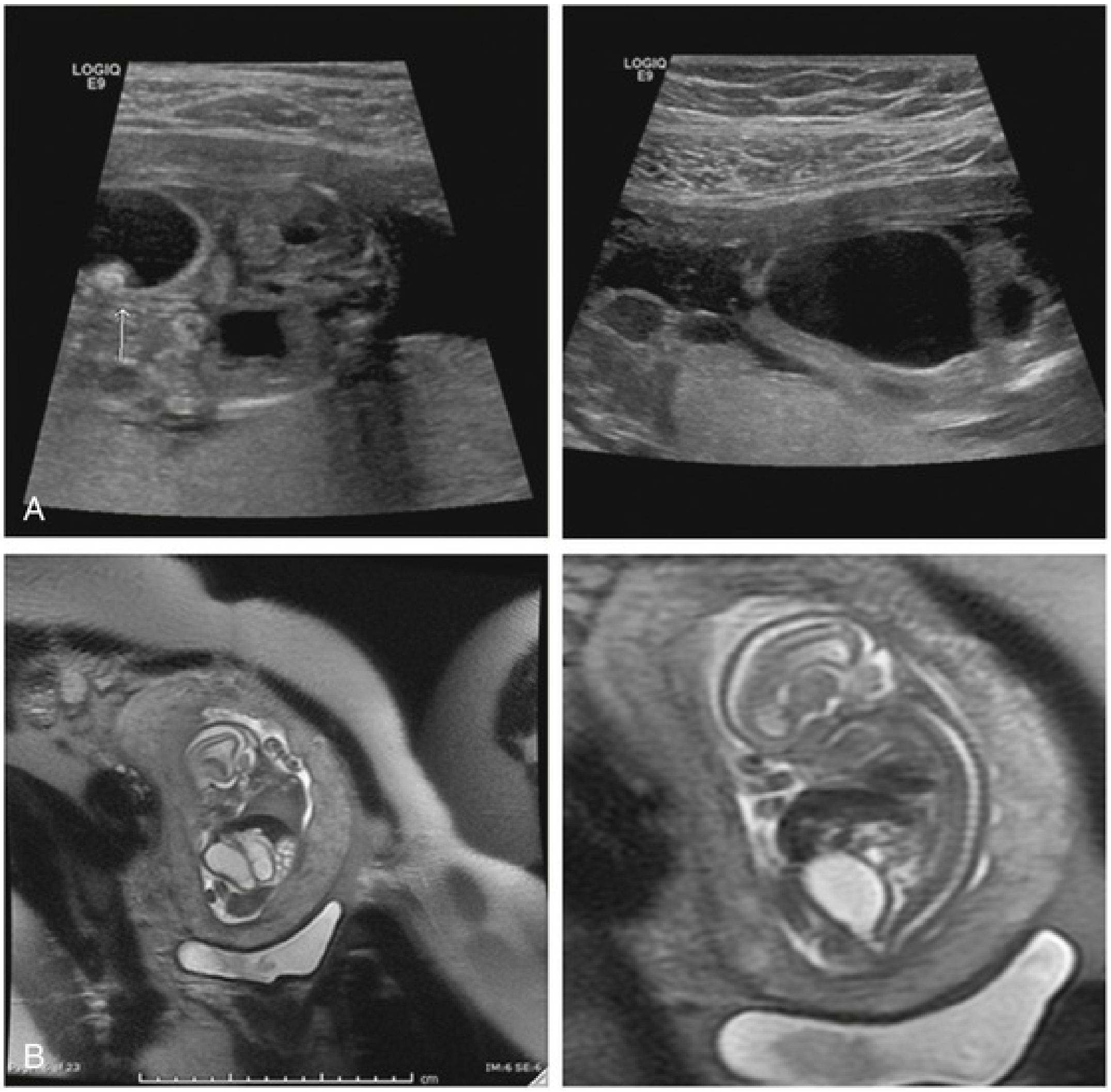

FIG. 24.14 Cryptorchidism in a difficult-to-examine obese child where the presence of an inguinal testis on sonography would simplify the surgical approach. It is the primary imaging modality in the setting of ambiguous genitalia or severe hypospadias with nonpalpable gonads for detection of

müllerian structures that can guide subsequent workup.

Key Points: Undescended Testis

- Sonography for the undescended testis is unreliable and should not be employed, perhaps with the exception of seeking the inguinal undescended testis in an overweight boy.

Differences of Sex Development

Although sonography plays little role in the initial evaluation of the routine undescended testis, it forms the basis for identification of internal genital structures in cases of differences in sex development, presenting as hypospadias with unilateral or bilateral nonpalpable testes, or genital anomalies in females (Guerra-Junior et al., 2018; Lambert et al., 2010).

Magnetic Resonance Imaging

Fundamentals of MRI in the Fetus and Child

MRI is generally used to characterize complex congenital anomalies when sonography is unable to provide sufficient detail. It is not as helpful in the setting of infection, stones, or trauma. Precontrast series may be sufficient to diagnose or confirm other congenital anomalies with great detail such as ectopic ureters, renal duplication anomalies, renal cysts, and calyceal diverticula. Certainly cost, accessibility, and need for sedation in young children limit its overall use.

Protocol

Magnetic resonance urography (MRU) is an excellent approach to providing anatomic and functional information for the urinary tract. Studies are typically performed after an intravenous hydration protocol using normal saline, with a Foley catheter in place. In addition, furosemide can be given either before or during the study. The combination of these two steps improves and hastens urinary tract distention and minimizes artifact during contrast-enhanced imaging. Before contrast administration, a variety of T2-weighted (fluid-sensitive) fast spin-echo (FSE) sequences are obtained, using a combination of rapid-acquisition (single-shot) sequences for quick anatomic assessment, and longer two-dimensional and three-dimensional FSE sequences with better resolution. Three-dimensional sequences can be reconstructed to optimize visualization of the urinary tract. After contrast, T1-weighted gradient-recalled echo images are initially acquired dynamically to provide assessment of renal vasculature, parenchymal enhancement, and excretory function. Dynamic acquisition can be used in functional assessment, most commonly performed via the Patlak method. Subsequently, delayed postcontrast images are obtained to improve delineation of the ureteral course.

MRI is performed in conjunction with a third-level obstetric ultrasound examination after approximately 20 weeks' gestational age.

Given the high sensitivity of MRI, any anatomic details that can be imaged with sonography are more easily appreciated by MRI.

Sedation in the Child

This standard protocol typically takes up to 1 hour to perform; a shortened format has been recently described that can be done in approximately 30 minutes, but larger studies need to be performed to compare efficacy. Given the length of the study, conscious sedation using Propofol, or in some cases general anesthesia, is often required for patients younger than 6 years of age. Imaging techniques to obviate the need for sedation include respiratory-triggered sequences in which scanning is only done when the child holds his or her breath. However, this increases the length of the study. Child life specialists can also help obviate the need for sedation by providing examination preparation and coping techniques.

Kidney/Ureter

Hydronephrosis/Obstruction

In the evaluation of hydronephrosis, MRU is a plausible alternative to the diuretic renogram with far superior anatomic resolution and no radiation exposure (Fig. 24.15). The detailed imaging can provide pinpoint localization of anatomic abnormalities, differential function, and assessment of drainage that can assist in surgical planning. Protocols and formulas have been developed to determine renal function and assess drainage (Jones et al., 2004). Many different protocols have been developed but are similar to those used in MAG3 diuretic renography. The contrast used is gadolinium-based. The child should be well hydrated and furosemide (1 mg/kg; max 20 mg) is given. Timing of the furosemide administration, bladder catheterization, and patient positioning varies by protocol (Darge et al., 2013; Vivier et al., 2010b). Precontrast T2 sequences are first obtained followed by three-dimensional T2 sequences with fat saturation and 1-mm slice thickness. The contrast is then slowly injected and a T1 fat-saturated dynamic scan is continued until contrast has filled the ureters (Darge et al., 2013). This method does require complex postprocessing by a clinician who is specialized in these techniques, which has thus far limited its widespread adoption. It is possible to use free programs such as “chop-fmru” (www.chop-fmru.com) or Image J (National Institutes of Health) to assist in generation of the functional analysis (Khrichenko and Darge, 2010; Vivier et al., 2010a). Its application in children is promising, but studies to confirm its equivalence to diuretic renography and widespread education on interpretation are still needed (Grattan-Smith and Jones, 2006; Perez-Brayfield et al., 2003).

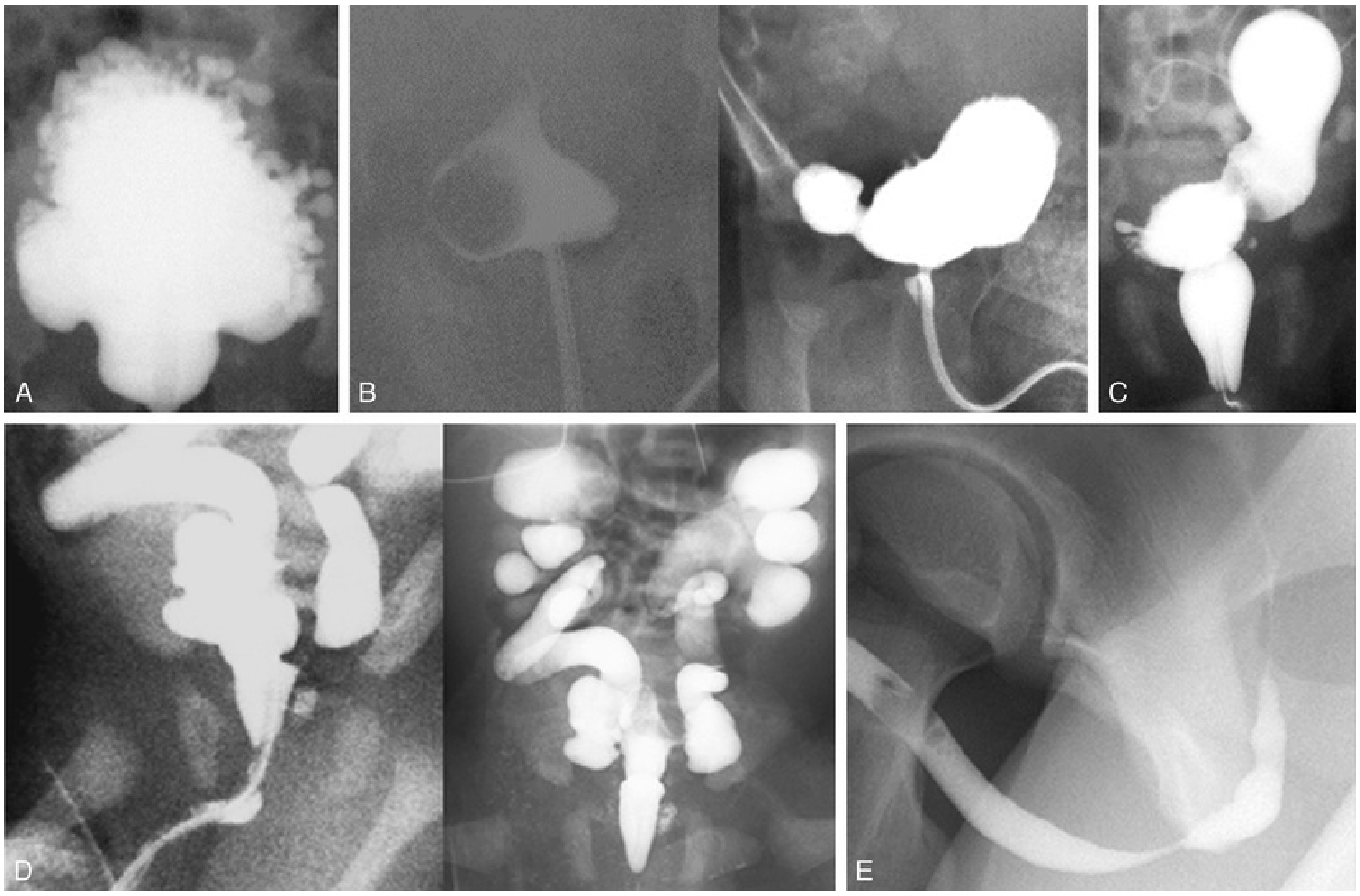

FIG. 24.15 Various findings on voiding cystourethrography scan. (A) A highly trabeculated bladder. (B) A ureterocele within the bladder *(left)* and then everting *(right).* (C) A large bladder diverticulum and elongated posterior urethra in a child with posterior urethral valve. (D) An elongated posterior urethra secondary to a posterior urethral valve and bilateral grade 5 vesicoureteral reflux. (E) A short distal bulbar urethral stricture.

Cysts/Masses/Stones

Much less helpful for the evaluation of stones, MRI is useful for the evaluation of renal complex renal cysts and renal masses. The sensitivity and specificity of MRI compares favorably to CT for detecting capsular penetration of renal masses (Sensitivity 62.9% vs. 68.6%, $P = 0.73$; Specificity 86.5% and 83.8% ($P = 1.0$). MRI was similarly accurate as CT for the detection of lymph node metastasis. However, MRI performs better than CT for the detection of synchronous contralateral lesions (Servaes et al., 2015).

Infection

Although gadolinium-enhanced MRI can image acute inflammatory lesions associated with pyelonephritis, its use is impractical because of the need for long sedation times required to acquire images and rarely is additional information obtained that is relevant to patient care. By comparison to other cross-sectional modalities, such as DMSA single photon emission CT (SPECT) and contrast-enhanced CT, gadolinium-enhanced MRI has similar accuracy for the detection of pyelonephritis (Majd et al., 2001).

Other Congenital Malformations

When confronted with complex anatomy, MRU provides anatomic details that can be helpful (Dickerson et al., 2015).

Bladder/Urethra

Although MRI can be used to evaluate the lower urinary tract, it is rarely more sensitive than a well-performed sonogram. However, MRI is extremely useful at further delineating masses felt to arise from the bladder, particularly rhabdomyosarcoma. Sequences might include a coronal wide–field-of-view short tau inversion-recovery sequence, diffusion-weighted imaging (b = 0, 100, or 600 sec/mm^2), nonenhanced and gadolinium-enhanced imaging of the pelvis, a three-dimensional volumetric T1-weighted sequence, and axial and sagittal T2-weighted fat-saturated sequences (pedsMRI app). Because urine masks hyperintense lesions on T2-weighted images, it is useful to employ nonenhanced T1-weighted imaging and to employ fast sequences to obtain images before gadolinium accumulates significantly within the tissues (Hoffer, 2005). On MRI, rhabdomyosarcoma demonstrates uniformly low signal intensity on T1-weighted images and heterogeneous high signal intensity on T2-weighted and contrast-enhanced T1-weighted fat-saturated images (Nigro and MacLennan, 2005). These differences in signal intensity have been ascribed to areas of tissue necrosis. Lastly, although MRI has proved useful in tumor staging, there are no features particular to the tumor itself that predict tumor subtype.

Scrotum/Testes/Internal Genitalia

Acute Scrotum

MRI plays no role in the evaluation of the acute scrotum.

Cysts/Masses

Although MRI plays no role in the evaluation of cysts and masses of the scrotum and testes, one might consider its use for tumor staging in patients with testicular cancer. Historically, CT of the abdomen with intravenous contrast has been used for tumor staging of the chest and abdomen, but the information obtained by MR sequences is predictably similar.

Undescended Testis

Sensitivity and specificity of MRI in comparison to sonography for identification of internal structures including gonadal detection is marginally better at best (Biswas et al., 2004; Gambino et al., 1992; Mansour et al., 2012).

Differences of Sex Development

In the setting of differences of sexual development, sonography and urogenitography are typically the only studies needed for both diagnosis and surgical planning. However, a few very complex cases have sometimes benefited from the additional anatomic information obtained on MRI. Overall, the expense and sedation requirement likely does not justify the routine use of MRI to understand this pelvic anatomy.

Conventional Radiography

Plain Abdominal Radiography

Plain abdominal radiography or KUB testing has been used not only for detection of radiopaque stones, but also for evaluation of constipation in children with voiding dysfunction. Unfortunately, there is little data to support its accuracy in detecting or evaluating treatment for constipation (Berger et al., 2012; Reuchlin-Vroklage et al., 2005). It can, however, provide impressive visual evidence for parents who are dubious of the diagnosis of constipation and therefore its treatment despite the child's clinical signs and symptoms.

Intravenous Pyelography

Intravenous pyelography has fallen out of favor with the advent of the previously mentioned modalities offering high-resolution anatomic studies and predictably reproducible functional studies. The IVP consists of multiple sequential radiographs throughout the excretion and drainage of contrast material and in different focal planes in attempts to obtain anatomic and functional information. Accurate localization of obstructive lesions and radiopaque stones can be seen on a well-performed study. Drainage time can also be assessed, although not as precisely as in diuretic renography.

Retrograde Pyelography

Retrograde pyelography involves injection of contrast into the ureteral orifice requiring anesthesia in a child. This is best used for intraoperative localization of an obstructive lesion identified preoperatively using other studies. However, free retrograde flow cannot be assumed to equate free, unobstructed antegrade flow and vice versa, especially after a prior surgical repair. For example, small postsurgical tissue flaps can cause obstructed antegrade flow but give an unobstructed appearance on retrograde pyelography.

Voiding Cystourethrography/Micturating Cystourethrogram

Fundamentals of Voiding Cystourethrography

Also known as VCUG and micturating cystourethrogram (MCUG), respectively, this test assesses the function of the lower urinary tract. Historically performed without sedation, clinicians have long recognized how invasive this study is on children, and protocols have been developed for mitigating pain and anxiety. When obtained to evaluate urinary tract infection, it is regarded as routine to defer VCUG at least until after the patient has received several days of antibiotics and is clinically improving.

After catheterization of the bladder, a brief fluoroscopic image ensures proper placement of the tip of the catheter in the bladder and that not too much catheter has been advanced. Failure to visualize the catheter in the midline suggests malposition, which might occur, for example, because of an abnormality of the utricle or posterior urethra in the male or into an ectopic ureter in the female. Additionally, too much catheter in the bladder can result in knotting of the catheter itself.

Kidney/Ureter

Obstruction

VCUG has been obtained routinely as part of the evaluation of children with hydronephrosis; however, the need to do so has been challenged (Kim et al., 2001; Yerkes et al., 1999). Instead, most algorithms reserve VCUG when hydronephrosis is seen along with dilated ureter(s).

Cysts/Masses

There is no renal cystic disease or mass that is specifically evaluated by VCUG.

Infection

VCUG has been delayed between 4 and 6 weeks after UTI, when it is indicated, on the premise that early MCUG/VCUG might demonstrate mild transient VUR created by inflammatory changes at the trigone. However, because it is rare for clinically significant VUR present during infection to disappear after treatment and because the identification of even transient VUR during UTI might be clinically meaningful, a prolonged waiting period is not necessary (Craig et al., 1997; Gross and Lebowitz, 1981). If VUR is detected on a MCUG performed early in the course of febrile UTI, it should be considered that ureteral dilation caused by endotoxin overestimates the degree of VUR (Hellström et al., 1987; Roberts, 1975).

Other Congenital Malformations

There are no congenital malformations of the kidney and ureter, other than ureterovesical junction anomalies, that benefit from VCUG evaluation.

Trauma

There is no renal or ureteral trauma that is specifically evaluated by VCUG.

Bladder/Urethra

Obstruction

VCUG is an excellent high-resolution anatomic study that is used to detect abnormalities such as those of the bladder wall (e.g., trabeculation, ureterocele, diverticula, bladder neck hypertrophy, tumors), those of the urethra (posterior urethral valve (Fig. 24.16), urethral stricture, diverticulum), bladder stones, bladder rupture, and foreign bodies. VCUG can be used to assess bladder emptying. The initial scout film can also identify many spinal abnormalities.

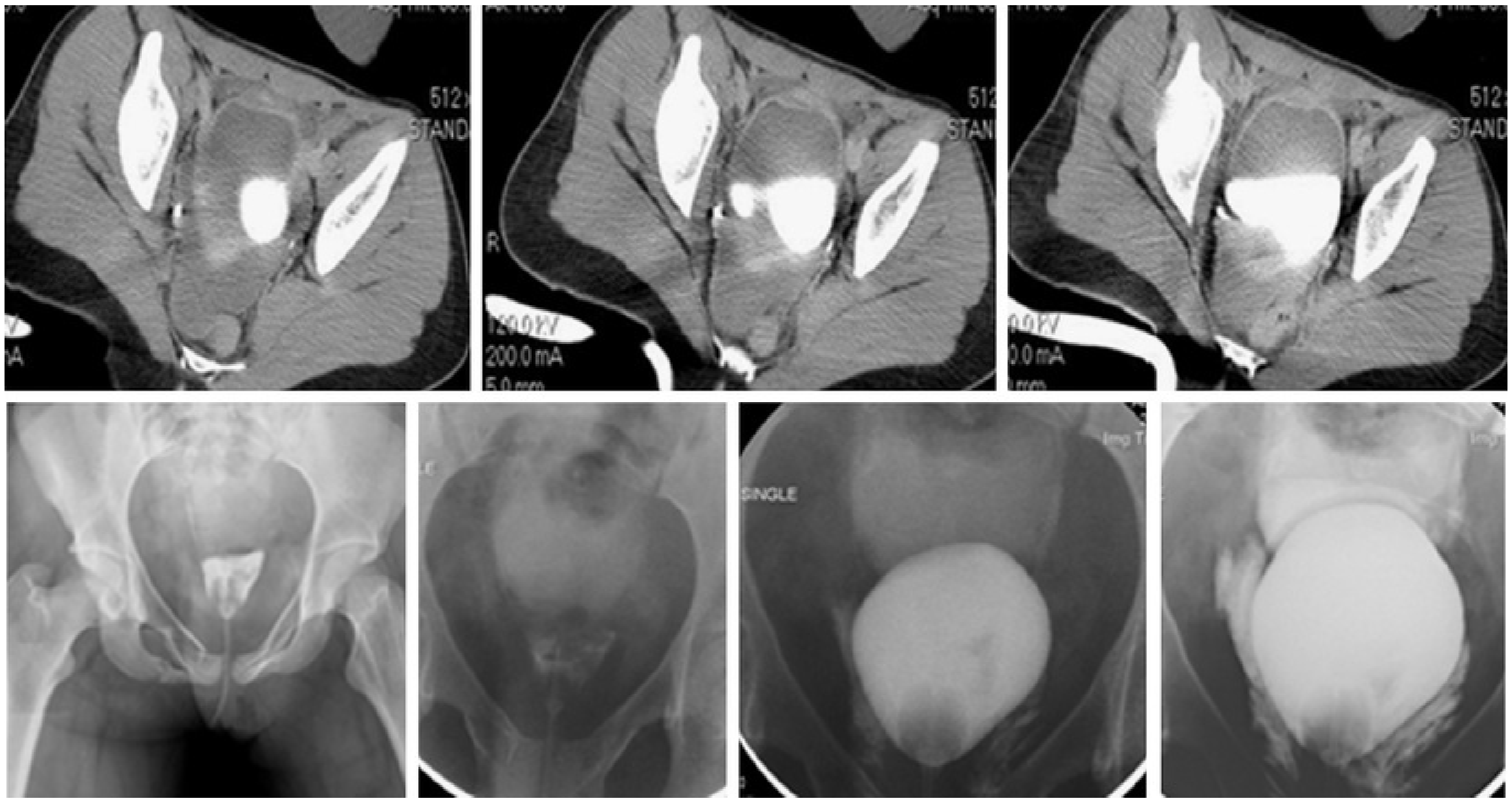

FIG. 24.16 A 15-year-old female patient with a pelvic fracture undergoes a screening computed tomography scan suggesting a bladder injury, which is confirmed by contrast cystography. Note the extreme elevation of the bladder neck (pie-in-the-sky) on the cystogram and clear demonstration of contrast collecting in the retroperitoneal space.

Cysts/Masses

Among the dilations and masses identified on VCUG, one finds urachal diverticula, bladder diverticula, dilated utricles, and fibroepithelial polyps.

Infection

VCUG likely provides little added information in the child with a single or few episodes of nonfebrile UTI (cystitis or urethritis); however, with increasing severity or frequency of recurrence, some would advocate for obtaining a VCUG to exclude anatomic risk factors for UTI. In circumcised males, particularly, the risk for UTI is exceedingly low such that any UTI in those patients might deserve evaluation.

Other Congenital Malformations

Positional instillation of contrast cystography is used sparingly with good effect for diagnosis of occult VUR in select children with a negative VCUG but persistent febrile UTIs despite treatment of all other potential etiologies (Hagerty et al., 2008b; Rubenstein et al., 2003). It is important, however, to perform the test properly with passive instillation of contrast at a height of 1 meter above the bladder as originally described to avoid creation of purely iatrogenic VUR (Hagerty et al., 2008a).

Trauma

Contrast imaging of the bladder and urethra is certainly indicated in circumstances of pelvic trauma, especially when blood is seen at the urethral meatus and/or the patient complains of difficulty voiding. Urethral injuries would be the most likely finding in these cases, and prompt intervention is mandatory (Fig. 24.17).

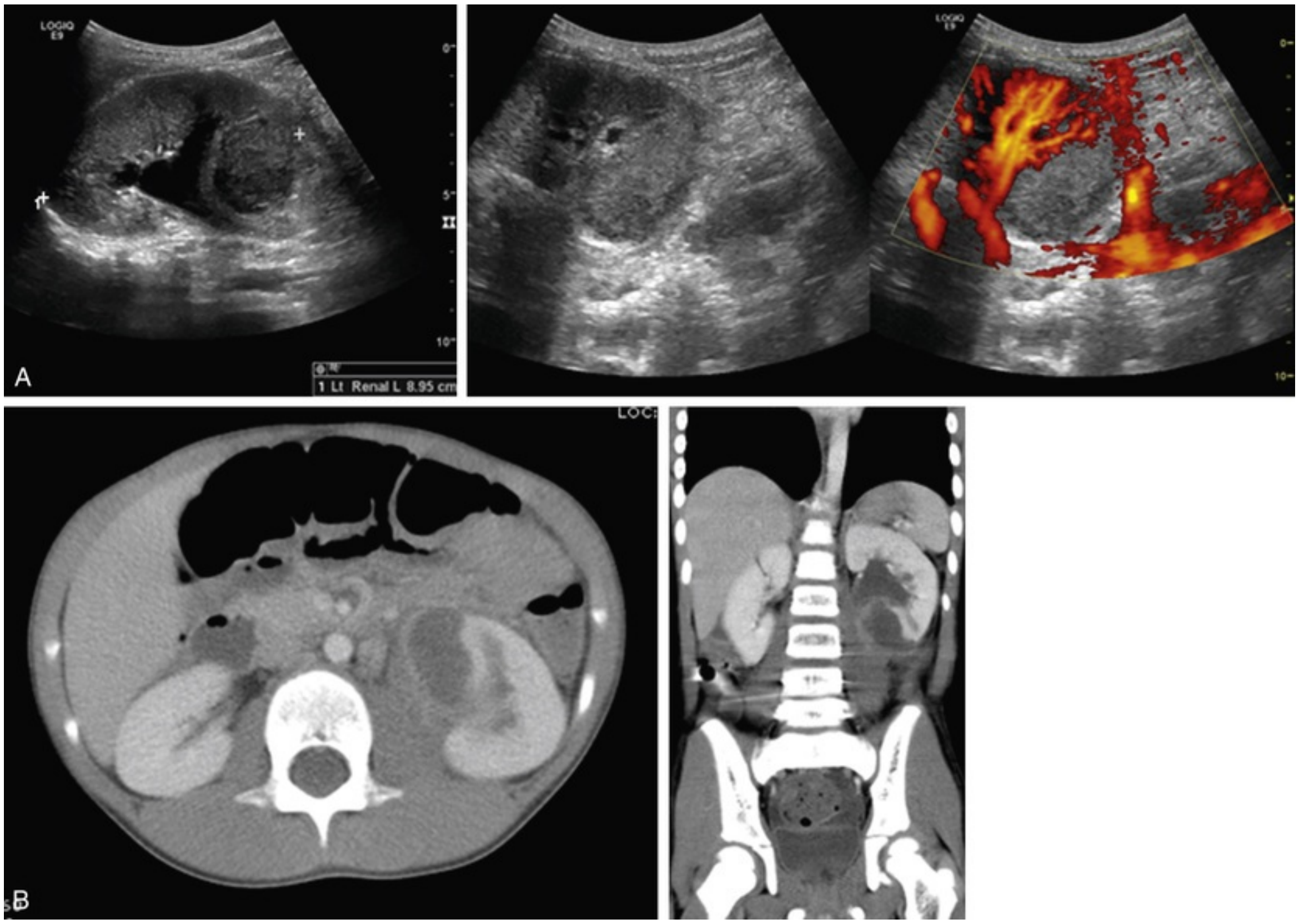

FIG. 24.17 A 6-year-old male patient presenting with abdominal pain, elevated erythrocyte sedimentation rate and C-reactive protein, and inability to stand erect. (A) A sonogram of the kidneys with Doppler views demonstrates a heterogeneous collection in the lower pole of the left kidney. (B) This region is confirmed on the computed tomography scan as a renal abscess.

Scrotum/Testes/Internal Genitalia

VCUG is not useful in the evaluation of genital anomalies with the exception of assessing urethral, bladder, and internal genital anatomy in cases of cloaca and urogenital sinus or differences in sex development.

Differences of Sex Development

Urogenitography can provide essential information for surgical planning and classification of patients with disorders of sexual differentiation. Typically a catheter is placed within the single perineal opening and contrast is injected under fluoroscopy to identify the confluence of urethral and vaginal structures as well as their orientation. Alternatively, a Foley catheter can be used with the balloon inflated and pressed up to the perineum with the tip in the perineal opening for retrograde filling (Chavhan et al., 2008). Results of the urogenitogram can be classified based on Shopfner's classification scheme (Shopfner, 1964) (Fig. 24.18).

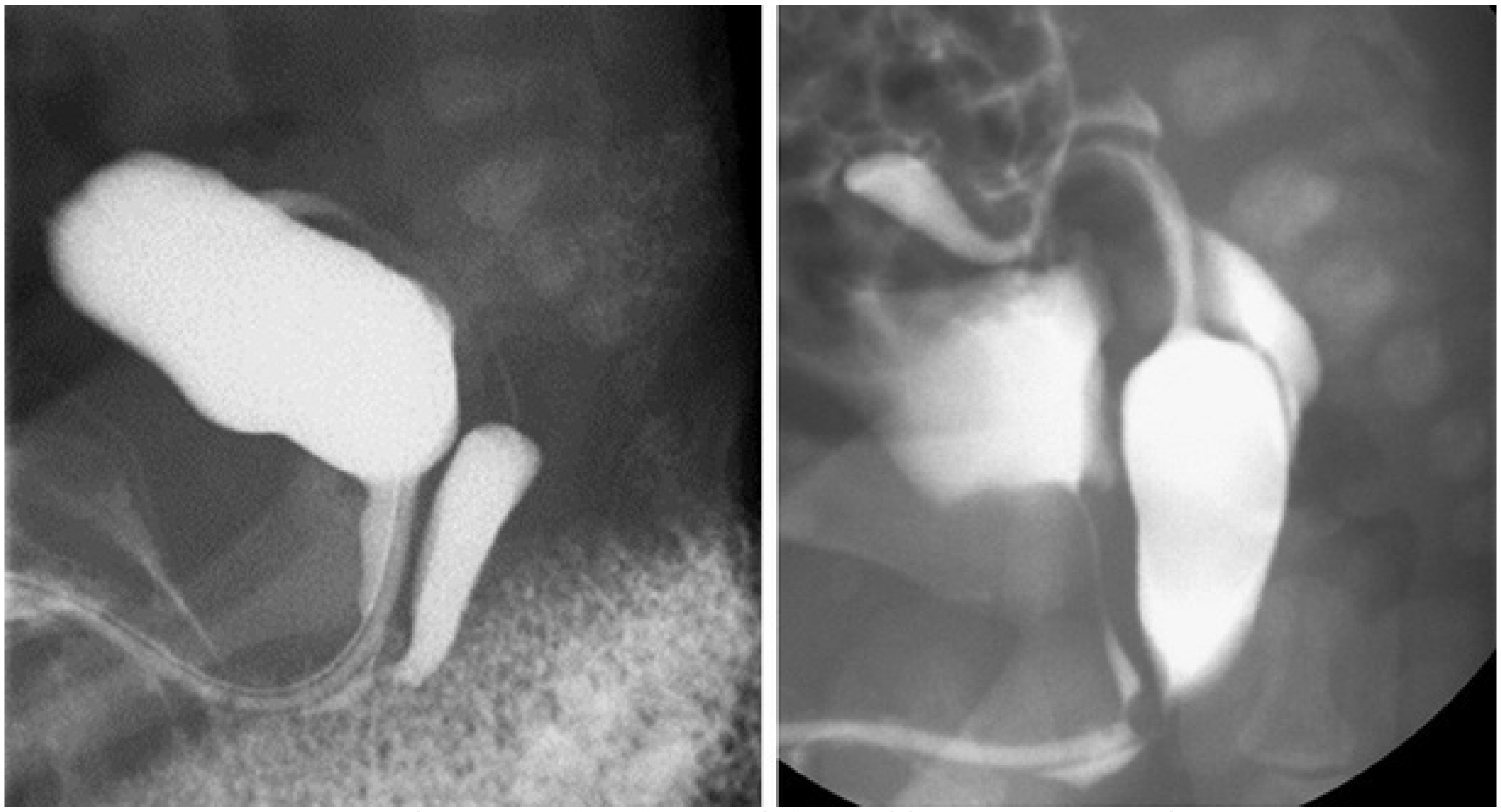

FIG. 24.18 Genitogram of an female infant with 46,XX ovotesticular disorder of sex development showing a low confluence of the urethra and vagina and reflux into the right fallopian tube. This is consistent with a Shopfner type III classification.

Computed Tomography

Fundamentals of CT Imaging in Children

The role of CT in children is less based on its diagnostic capabilities as it is on its availability and quick acquisition time. This advantage is best realized in cases of blunt abdominal trauma and polytrauma. However, with advances in sonography and MR, its need in pediatrics at the cost of potentially harmful radiation exposure is dwindling.

Kidney/Ureter

Obstruction

CT has little role in the evaluation of pediatric hydronephrosis as it offers little advantage over sonography with unwanted ionizing radiation. Like sonography, it is a detailed anatomic study but with the ability to imply function in noncalcareous hydronephrosis with the addition of intravenous contrast and delayed images. Although a delayed nephrogram and ureteral drainage compared with the contralateral side signals obstruction, this is difficult to quantitate. It can give detailed anatomic information in the setting of renal and ureteral anomalies in the more complex patient (e.g., those with ectopic kidney, ectopic ureter, megaureter, duplication anomalies, renovascular anomalies), which may be helpful in surgical planning when sonography or MRI are inconclusive or unavailable.

Cysts/Masses

The use of contrast-enhanced CT scans for evaluation of pediatric renal tumors is commonplace. A variety of solid renal masses commonly seen in children include congenital mesoblastic nephroma, neuroblastoma, Wilms Tumor, clear cell sarcoma, rhabdoid tumors, solitary multilocular cyst, metanephric adenoma, renal cell carcinoma, and angiomyolipoma. A full description of individual presentations of each renal tumor, of their natural history and management is found in Chapter 53.

Infection

CT has a limited role in the setting of childhood UTI and is best reserved for situations in which nonionizing modalities are inconclusive. Both MRI and CT imaging can be helpful in assessing infections related to renal abscess, extraurinary fistualization, and postoperative complications and secondary to urinary obstruction (Fig. 24.19).

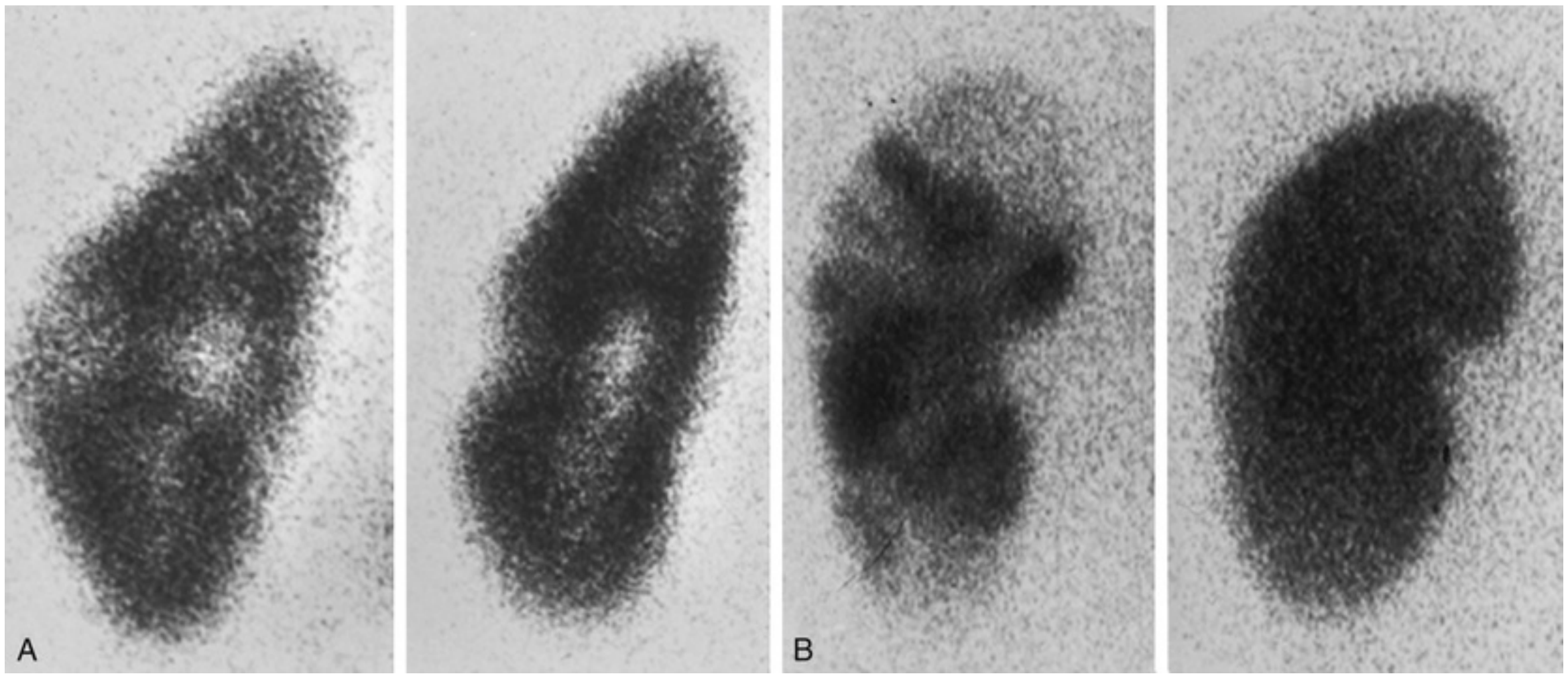

FIG. 24.19 Dimercaptosuccinic acid renal scans (A and B) demonstrating areas of photopenia with preservation of the renal contour consistent with acute pyelonephritis. The patient on the left (A) demonstrates formation of a renal scar, which can be differentiated from the acute lesion because of loss of the renal contour. The patient on the right (B) demonstrates complete resolution of all areas of APN after 6 months.

Calculus Disease

The most obvious advantage of CT is in the detection of urolithiasis. It is certainly better than sonography at detecting and quantifying stone burden, however, it has been shown that this increased accuracy is seldom clinically impactful (Passerotti et al., 2009). Care should be taken to follow the ALARA principle when choosing to use CT in all patients, but especially children with stone disease who will likely have a lifetime of frequent imaging episodes.

Trauma

CT with and without intravenous contrast is routinely used in the evaluation of pediatric abdominal trauma. When performed, it is imperative to obtain adequately timed images to thoroughly visualize the urinary tract. Frequently, in the rush to evaluate trauma patients, postintravenous enhanced images are obtained during the “arterial phase” when only the renal cortex is enhanced. Although this provides information regarding renal cortical contusion or laceration, injuries to the renal collecting system or ureter may not be seen.

Bladder/Urethra

CT plays little role in the evaluation of obstruction, infection, or congenital malformations of the lower genitourinary tract. Although it may be employed for the evaluation of bladder masses, MR may be preferred over CT because of its better resolution of soft tissues.

Trauma

CT of the lower tract and genitalia is typically reserved for detection of bladder or pelvic trauma. CT cystography can be performed either by antegrade/delayed filling or retrograde filling with a catheter to detect bladder/augment rupture. Although this could be performed with a conventional cystogram, CT can provide better anatomic resolution and immediate classification of such rupture as intraperitoneal or extraperitoneal, which would affect management options.

Scrotum/Testes/Internal Genitalia

CT has no role in the evaluation of the acute scrotum, cysts/masses of the external genitalia, or undescended testis, or for differences of sex development. CT scanning is part of the staging evaluation for testicular and paratesticular masses to assess for metastatic disease.

DMSA Renal Cortical Scintigraphy

Renal cortical scintigraphy using DMSA relies on uptake by proximal tubular cells, a process that is dependent on renal blood flow (Majd and Rushton, 1992). Focal renal blood flow is decreased in sites of acute pyelonephritis, which corresponds to areas of relative photon deficiency seen on DMSA scans (Rushton and Majd, 1992). Although AP lesions appear as areas of decreased peripheral uptake with preservation of the reniform contour, renal scars can be differentiated based on observation of volume loss that interrupts the normal reniform outline, thus resulting in concavity. These lesions can be focal, multifocal, or diffuse. Although it is possible for an experienced observer to distinguish between acute and chronic lesions, differentiation is frequently difficult in those kidneys with AP superimposed on preexisting renal scars. Using histopathologic criteria in a piglet autopsy study of induced AP, the sensitivity and specificity of DMSA for AP was 87% and 100%, respectively (Rushton et al., 1988). A similar experiment demonstrated slightly higher sensitivity with lower specificity but equivalent diagnostic accuracy when using single-photon emission computed tomography (SPECT) detection compared with planar (pinhole) detection (Majd et al., 1996).

The timing of DMSA scintigraphy is determined by whether one is seeking to document the acute inflammatory changes of pyelonephritis, or instead, irreversible renal cortical scarring. Because inflammation is a transient process, acute changes are reliably seen when the DMSA scan is obtained within days of the acute episode that gradually resolves over the next 5 months such that by 6 months any lesion demonstrated on scintigraphy is likely a fixed scar (Ghasemi et al., 2013; Stokland et al., 1996a, 1996b). Acute DMSA scan lesions persist in 36% to 52% of kidneys (Rushton and Majd, 1992) (see Fig. 24.19).

Diuretic Renal Scintigraphy

The gold standard for differentiation of obstructive and nonobstructive hydronephrosis/hydroureter is diuretic renography. This can be accomplished with either ^{99m}Tc-diethylenetriamine pentaacetic acid (DTPA) or more commonly, ^{99m}Tc-mercaptoacetyltriglycine. A strict protocol should be followed to ensure accurate and reproducible results (Conway and Maizels, 1992; Majd, 1989; Shulkin et al., 2008). There are four key elements to a successful diuretic renogram: (1) hydration, (2) selection of the appropriate region of interest (ROI) and background subtraction, (3) bladder drainage, and (4) timing of diuretic administration. An intravenous line is placed for hydration before the study in addition to encouragement of oral hydration before arrival because the dehydrated patient responds poorly to diuresis (Fig. 24.20). A catheter is helpful in eliminating any concerns of bladder filling affecting upper tract drainage, difficult interpretation secondary to VUR, or increased gonadal radiation exposure caused by radioactive urine. The ROI must be tightly drawn around either the renal cortex (for determination of differential renal function) or around the dilated collecting system (for measurement of drainage). The region of background subtraction should be similarly tightly drawn, being careful to include regions adjacent to the kidney and within the confines of the body. Inclusion of the wrong portion of the urinary tract in an ROI can result in spurious measurements (Fig. 24.21). Intravenous furosemide (1 mg/kg) is given when the dilated collecting system is determined to be maximally filled and not before. Differential renal function, washout curves, and washout half-times can then be computer-generated; however, additional features might be helpful in predicting natural history (Shalaby-Rana et al., 1997). For instance, we have observed that patients demonstrating a biphasic drainage curve, characterized by initial prompt drainage that ceases, or patients with poor gravity-assisted drainage, are more likely to progress to high-grade obstruction when followed over time (Fig. 24.22). Thus, management decisions should be made based on patient age, renal function, diuresis half-life, curve shape, and upright clearance. The clinician should be sure to review the actual drainage images, regions of interest used, and curves as any variation in technique can lead to misleading results. Unlike in adults, in children there are no established washout half-lives that define an obstructed or unobstructed state, and often repeat scans are required during longitudinal follow-up (Fig. 24.23). Diuresis renography can be helpful in the evaluation of intermittent obstruction. Reduction in renal blood flow as a result of increased intrapelvic pressure is suggested by the finding of cortical retention of tracer (akin to an obstructed nephrogram on an intravenous pyelogram). Cortical retention of tracer is seen up to 48 hours after the acute event, even when the hallmark features of Dietls crisis has resolved (nausea or vomiting and flank or abdominal pain) (Figs. 24.24 and 24.25). By comparison to renal sonography, diuresis renography provides a more reproducible and quantifiable evaluation of the urinary tract when properly performed (Fig. 24.26).

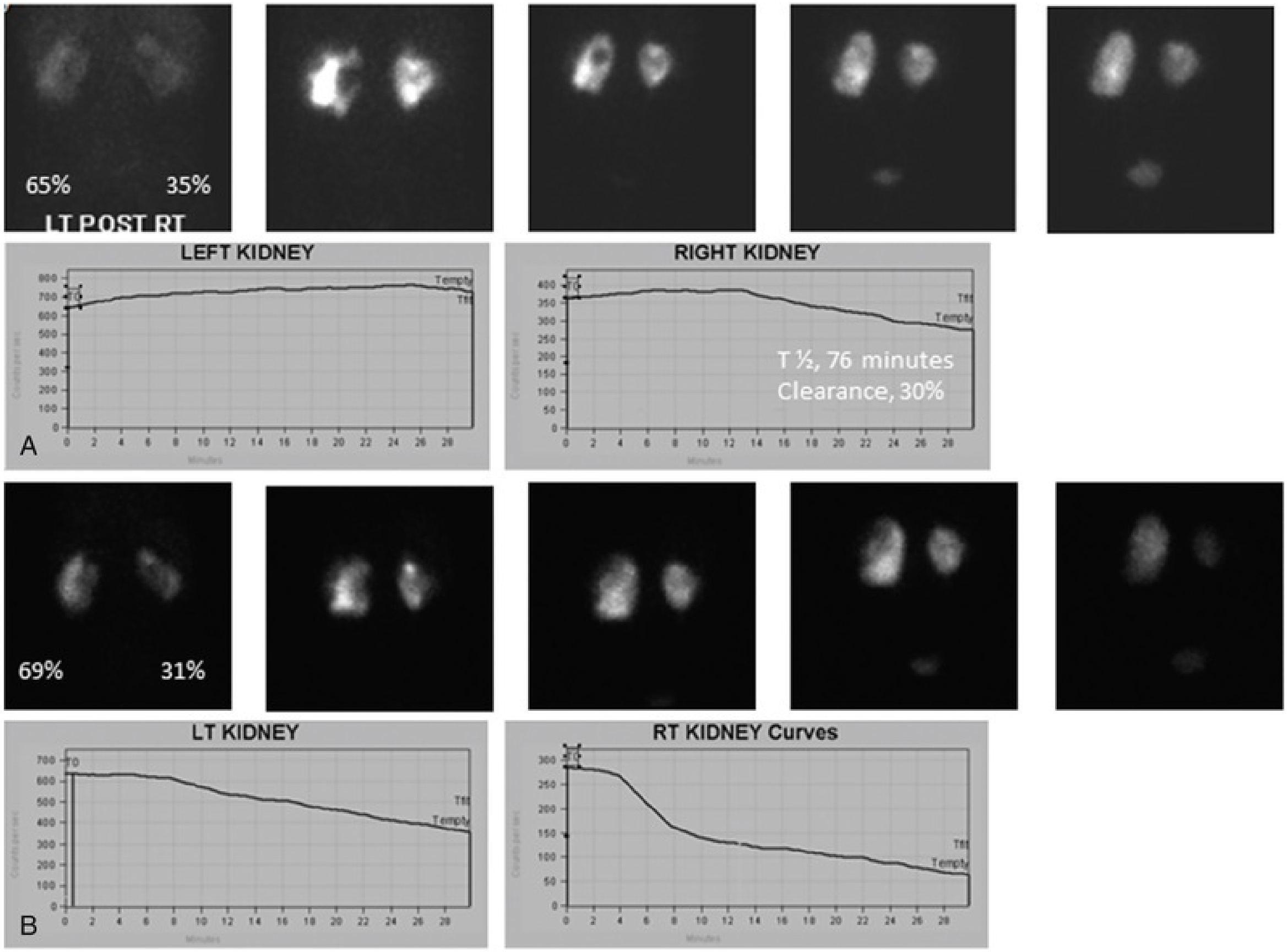

FIG. 24.20 The importance of controlling for patient hydration is apparent in this diuresis renogram being used to evaluate hydronephrosis in a young child after bilateral pyeloplasties. (A) The patient had been nothing by mouth (NPO) overnight for planned sedation during the diuresis renogram. Despite fluid resuscitation with 375 mL, only 30 mL of urine were drained through the urethral catheter. Cortical transit through both kidneys was observed to be poor, as well as drainage from both collecting systems. (B) The diuresis renogram was repeated 2 months later without NPO restrictions and with more aggressive hydration with 565 mL, which

resulted in diuresis of 425 mL of urine through the urethral catheter. Diuresis-induced drainage half-lives were improved for both kidneys, on the left side.

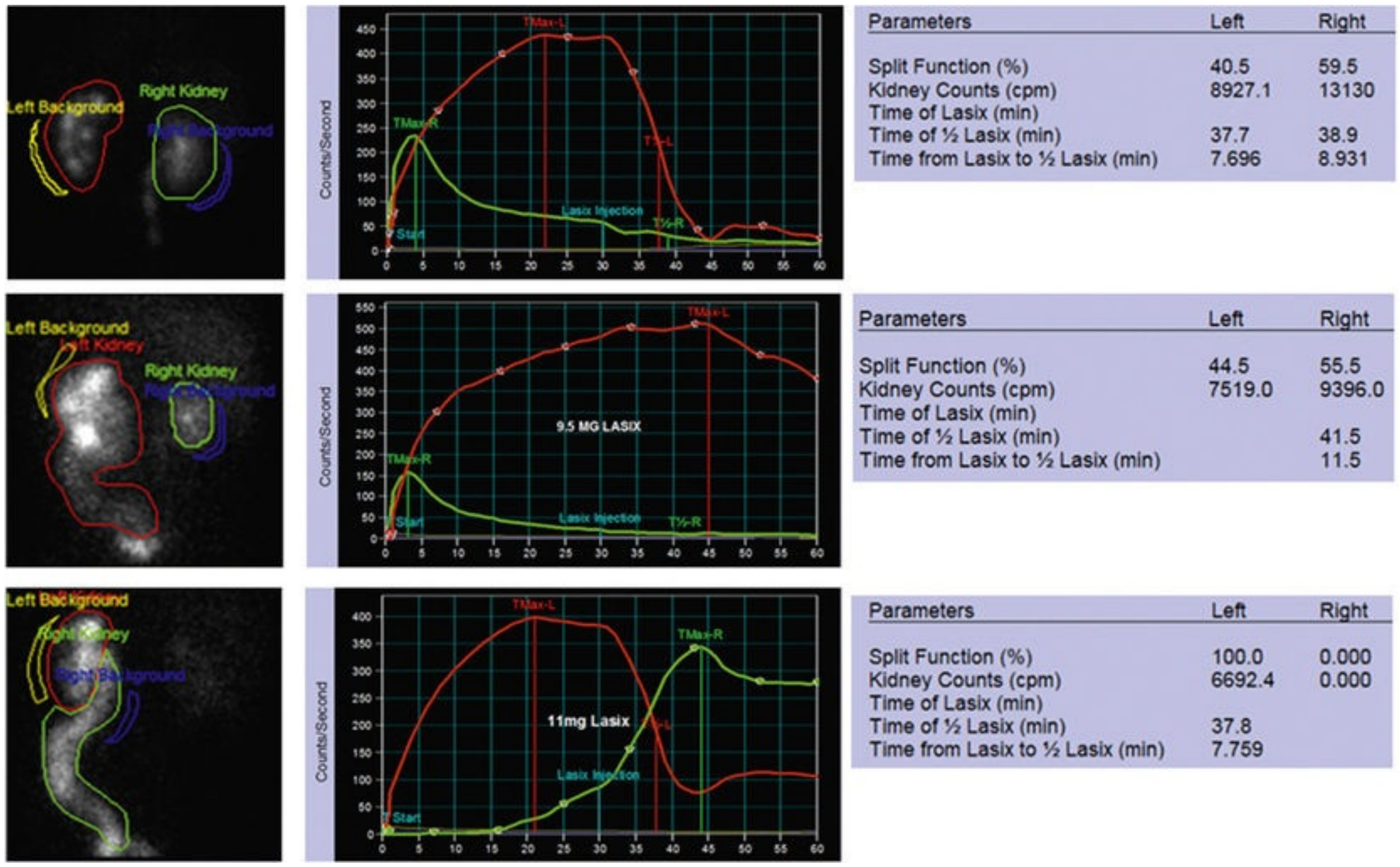

Parameters	Left	Right
Split Function (%)	40.5	59.5
Kidney Counts (cpm)	8927.1	13130
Time of Lasix (min)		
Time of ½ Lasix (min)	37.7	38.9
Time from Lasix to ½ Lasix (min)	7.696	8.931

Parameters	Left	Right
Split Function (%)	44.5	55.5
Kidney Counts (cpm)	7519.0	9396.0
Time of Lasix (min)		
Time of ½ Lasix (min)		41.5
Time from Lasix to ½ Lasix (min)		11.5

Parameters	Left	Right
Split Function (%)	100.0	0.000
Kidney Counts (cpm)	6692.4	0.000
Time of Lasix (min)		
Time of ½ Lasix (min)	37.8	
Time from Lasix to ½ Lasix (min)	7.759	

FIG. 24.21 The importance of selecting the correct region of interest *(ROI)* is apparent in this diuresis renogram being used to evaluate hydronephrosis and hydroureter in an infant. Furosemide is administered 30 minutes after administration of radiotracer with a diuresis half-life being calculated from the time when the tracer rather than when the furosemide is administered. When calculated in this fashion, the half-life ($T_{½}$) includes the time for tracer to pass through the cortex and to be secreted into and accumulate in the dilated collecting system. Instead, calculation of half-life should be made based on the time required for 50% of the tracer to drain from the dilated collecting system, annotated as TMax in this example. A to C, The effect of differing ROIs on the drainage curves for the left kidney confirms that obstruction does not exist at the level of the ureteropelvic junction but instead at the level of the ureterovesical junction.

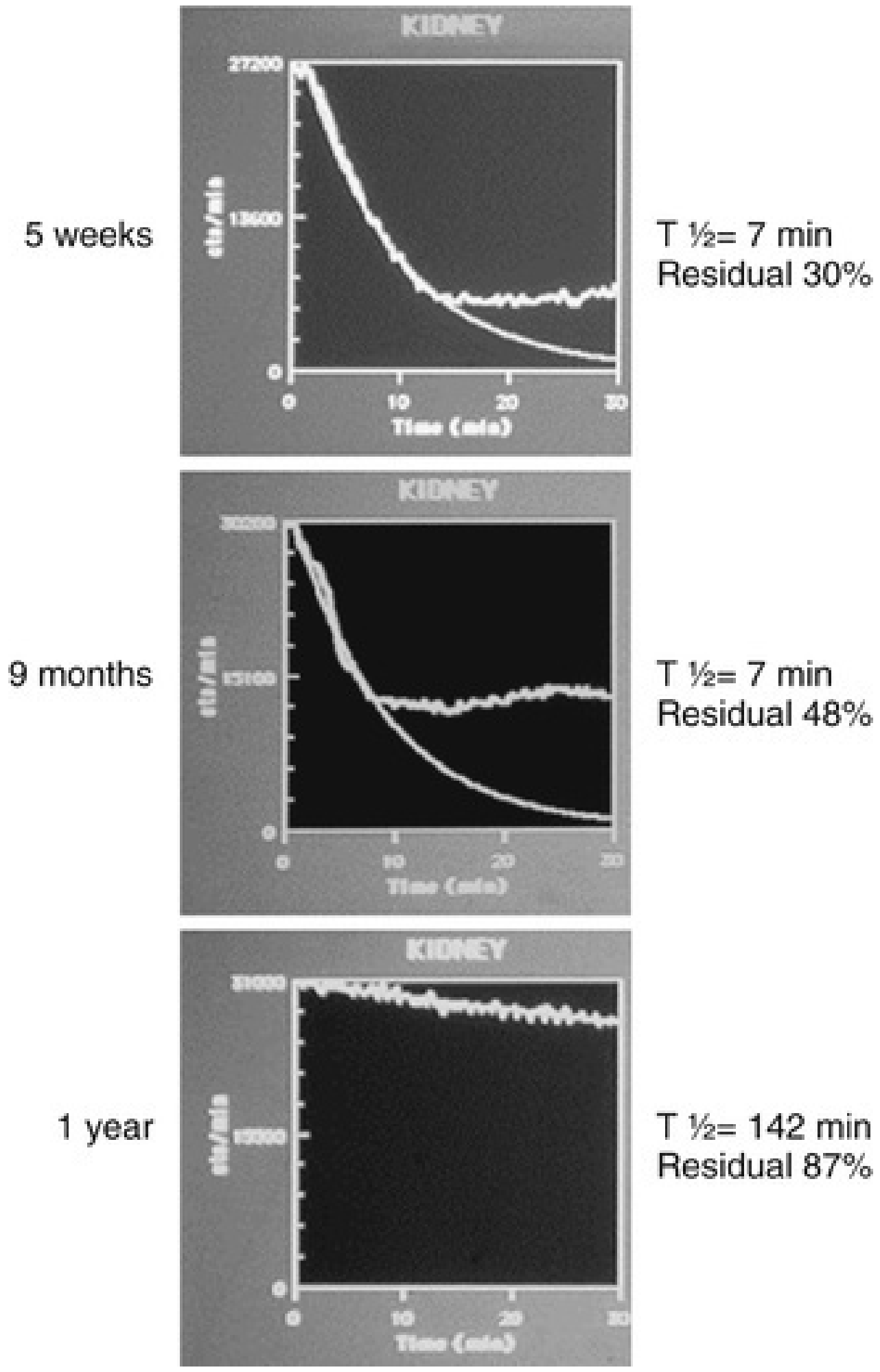

FIG. 24.22 A single diuresis renogram may not be sufficient to exclude obstruction. In this example, three consecutive MAG3 diuresis renograms on the same patient demonstrate progressively poor drainage (prolongation of the $T_{1/2}$ and retention of tracer).

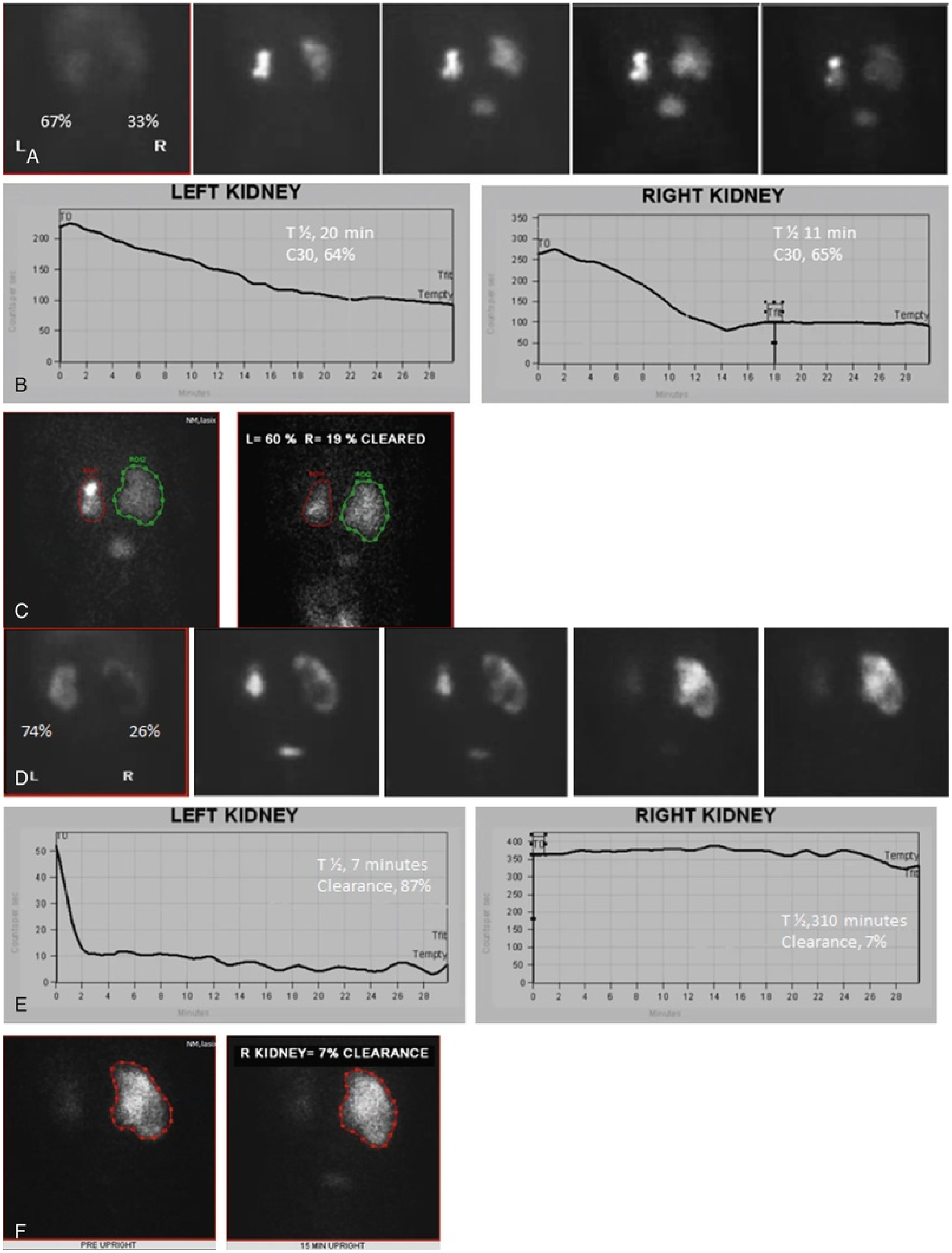
67%
33%
L
A
R
LEFT KIDNEY
T0
T ½, 20 min
C30, 64%
Tfit
Tempty
0
50
100
150
200
0 2 4 6 8 10 12 14 16 18 20 22 24 26 28
Minutes
B
RIGHT KIDNEY
T0
T ½ 11 min
C30, 65%
Tfit
Tempty
0
50
100
150
200
250
300
350
0 2 4 6 8 10 12 14 16 18 20 22 24 26 28
Minutes
NM,lasix
ROI1
ROI2
C
L= 60 % R= 19 % CLEARED
74%
26%
D
L
R
LEFT KIDNEY
T0
T ½, 7 minutes
Clearance, 87%
Tfit
Tempty
0
10
20
30
40
50
0 2 4 6 8 10 12 14 16 18 20 22 24 26 28
Minutes
E
RIGHT KIDNEY
T0
Tempty
Tfit
T ½,310 minutes
Clearance, 7%
0
50
100
150
200
250
300
350
400
0 2 4 6 8 10 12 14 16 18 20 22 24 26 28
Minutes
NM,lasix
F
PRE UPRIGHT
R KIDNEY= 7% CLEARANCE
15 MIN UPRIGHT

FIG. 24.23 Demonstration of the utility of gravity-assisted drainage (A) Initial MAG3 diuretic renogram at 42 days of age demonstrates asymmetric renal function with gradual accumulation of tracer within dilated collecting systems. (B) Diuresis results in indeterminate drainage from *both* collecting systems (right $T_{1/2}$ 20 minutes, left $T_{1/2}$ 11 minutes). After 30 minutes of

diuresis, equal amounts of tracer has cleared from both collecting systems: 65% *(right)* and 64% *(left)*. (C) After 15 minutes of upright positioning providing gravity-assisted drainage, there is additional clearance from both renal pelves, but more on the left than on the right. Follow-up MAG3 diuretic renogram at 8 months of age demonstrates worsening of renal function on the right side with delayed excretion of tracer into the right renal pelvis, and early spontaneous drainage of tracer from the left renal pelvis before administration of diuretic. (D) Diuresis results in accumulation of tracer in the right renal pelvis and further drainage from the left renal pelvis. (E) Diuresis curves demonstrate prompt drainage from the *left* renal pelvis; on the *right* drainage is negligible. (F) After 15 minutes of upright positioning, there is very little additional clearance from the right renal pelvis.

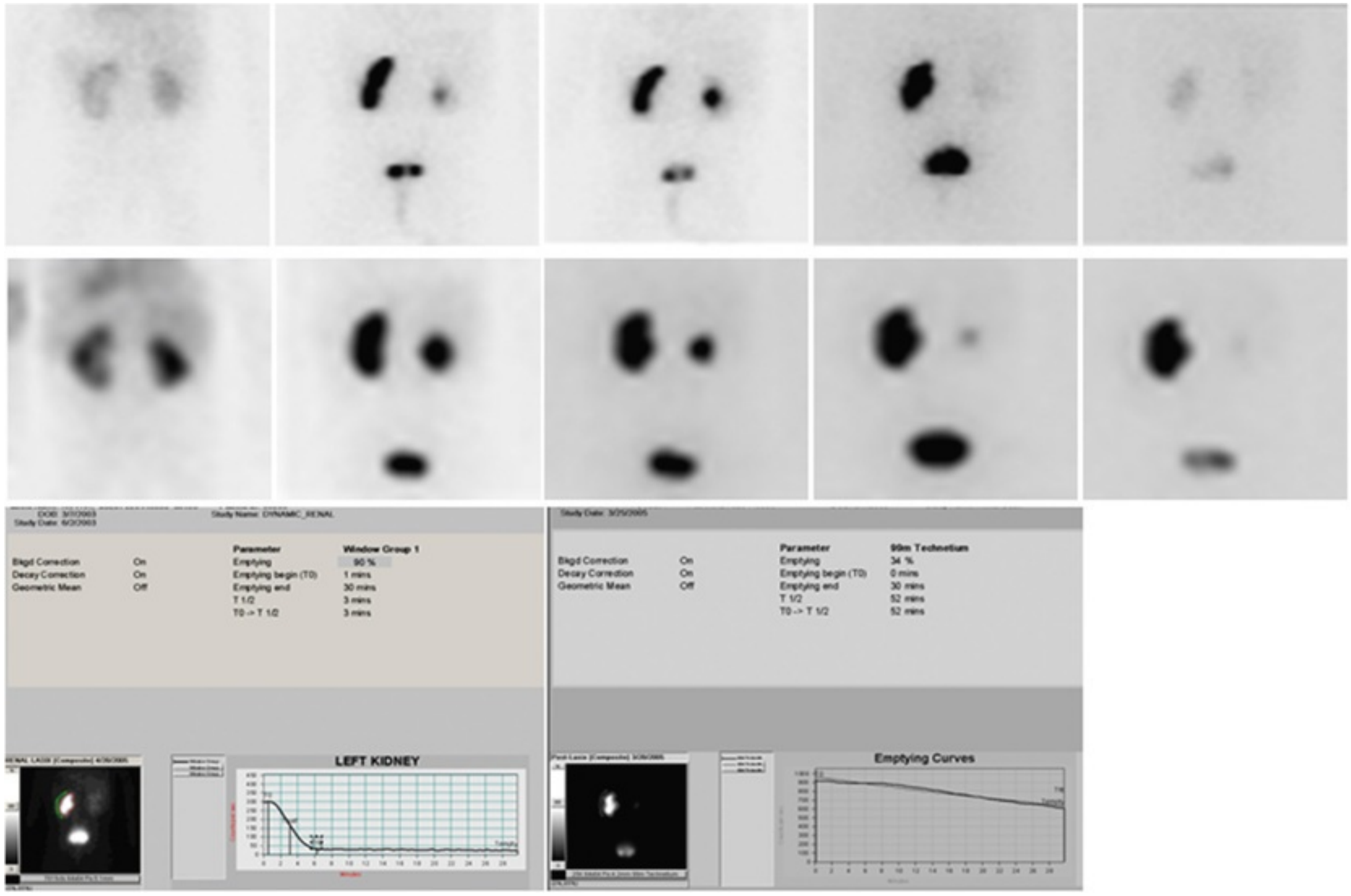

Study Name: DYNAMIC_RENAL

Bkgd Correction On
Decay Correction On
Geometric Mean Off

Parameter	Window Group 1
Emptying	90 %
Emptying begin (T0)	1 mins
Emptying end	30 mins
T 1/2	3 mins
T0 -> T 1/2	3 mins

Bkgd Correction On
Decay Correction On
Geometric Mean Off

Parameter	99m Technetium
Emptying	34 %
Emptying begin (T0)	0 mins
Emptying end	30 mins
T 1/2	52 mins
T0 -> T 1/2	52 mins

FIG. 24.24 (A) MAG3 diuresis renograms performed on a 3-month-old infant with prenatally detected hydronephrosis. The dilated right collecting system appears to drain well initially but demonstrates a prolonged half-life on repeat renography at 2 years of age (B). This child was managed with pyeloplasty based on these findings.

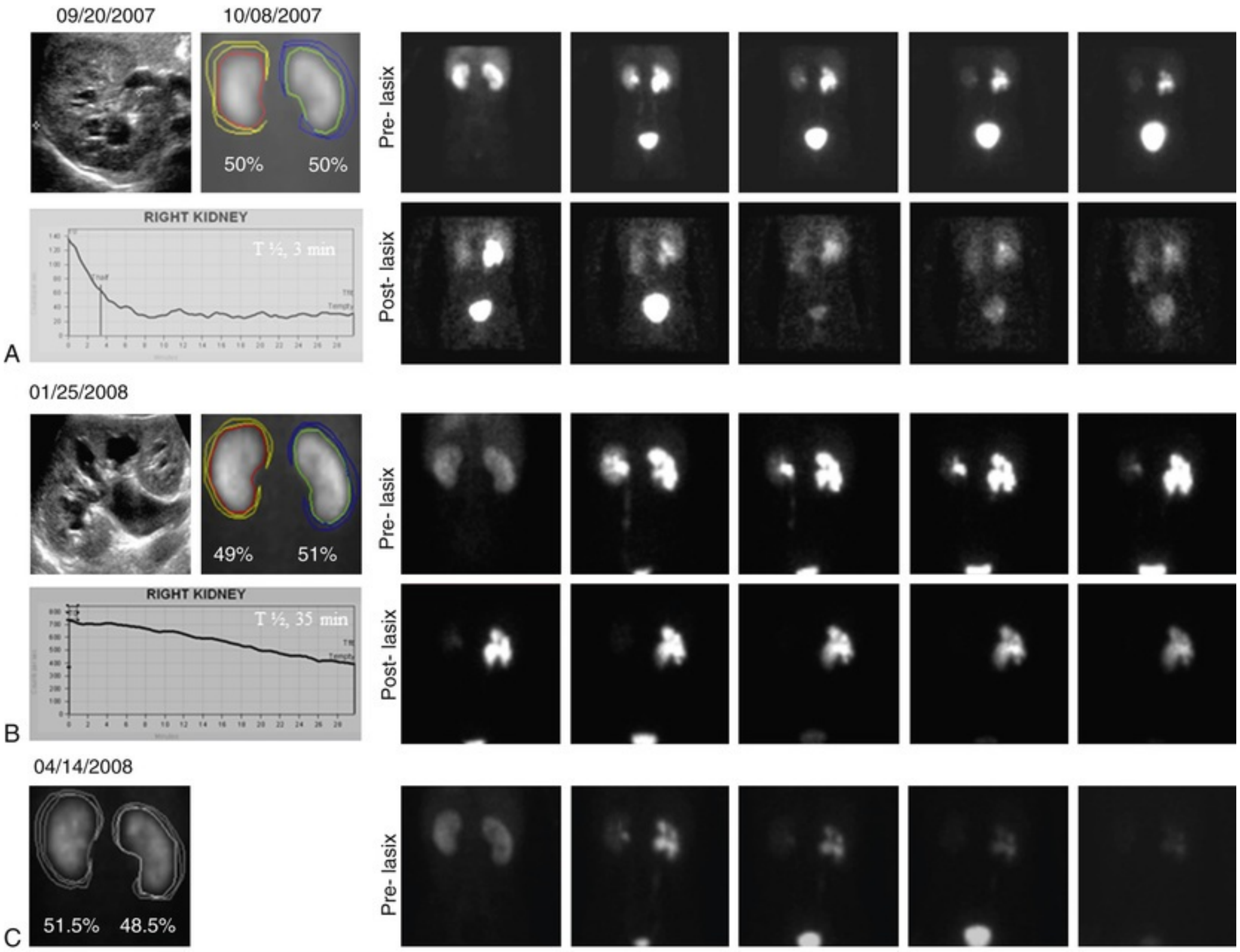
09/20/2007
10/08/2007
50%
50%
Pre- lasix
RIGHT KIDNEY
T ½, 3 min
Post- lasix
A
01/25/2008
49%
51%
Pre- lasix
RIGHT KIDNEY
T ½, 35 min
Post- lasix
B
04/14/2008
51.5%
48.5%
Pre- lasix
C

FIG. 24.25 Ultrasound scan shows mild right hydronephrosis in a 7-year-old male patient with right upper quadrant pain. (A) Diuresis renogram shows nonobstructive drainage. The patient presented a second time with pain. This time, the sonogram showed increased dilation of the right collecting system. (B) Diuresis renogram demonstrates worse drainage, and the patient reported pain after furosemide (Lasix) administration. (C) After pyeloplasty, renography shows prompt spontaneous drainage; furosemide was not administered. $T_{1/2}$, half-life.

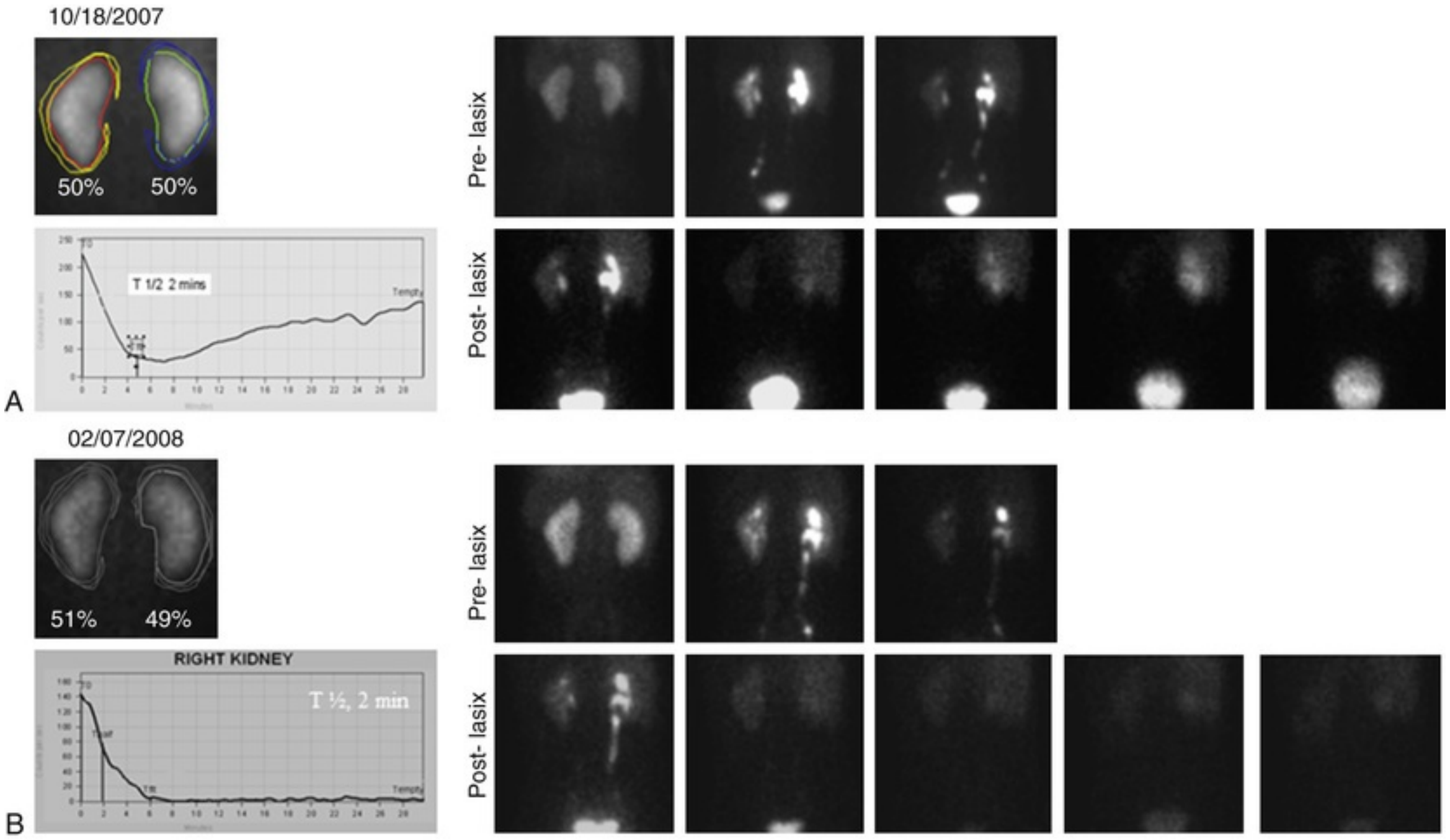
10/18/2007
50%
50%
T 1/2 2 mins
Tempty
Pre- lasix
Post- lasix
A
02/07/2008
51%
49%
RIGHT KIDNEY
T ½, 2 min
Tempty
Pre- lasix
Post- lasix
B

FIG. 24.26 (A) Initial diuresis renogram shows mild right hydronephrosis. After administration of furosemide (Lasix), there was rapid clearance of the tracer from the pelvicalyceal system with the washout half-life ($T_{1/2}$) of 2 minutes. A few minutes later, the patient developed right flank pain, and there was gradual accumulation of the tracer in the right kidney (rising second part of the curve) (A). (B) Postoperative differential renal function remained stable, and drainage improved significantly.

Radionuclide Cystography

Direct radionuclide cystography can be accurately used for detection of VUR with greater sensitivity and lower radiation exposure than standard VCUG (Brown et al., 2000; Sukan et al., 2003; Unver et al., 2006). However, it lacks the anatomic resolution of the collecting system and urethra, still requires urethral catheterization, and is still a nonphysiologic measurement. Exact grading comparisons to VCUG can be difficult but are certainly possible (Fretzayas et al., 1984; Polito et al., 2000; Unver et al., 2006; Zhang et al., 1987). Indirect radionuclide cystography can be performed without catheterization after radionuclide renography and provides a noninvasive, physiologic test, but it is not as sensitive as direct methods so is not routinely used for the purpose of VUR detection (Bower et al., 1985) (Figs. 24.27 and 24.28).

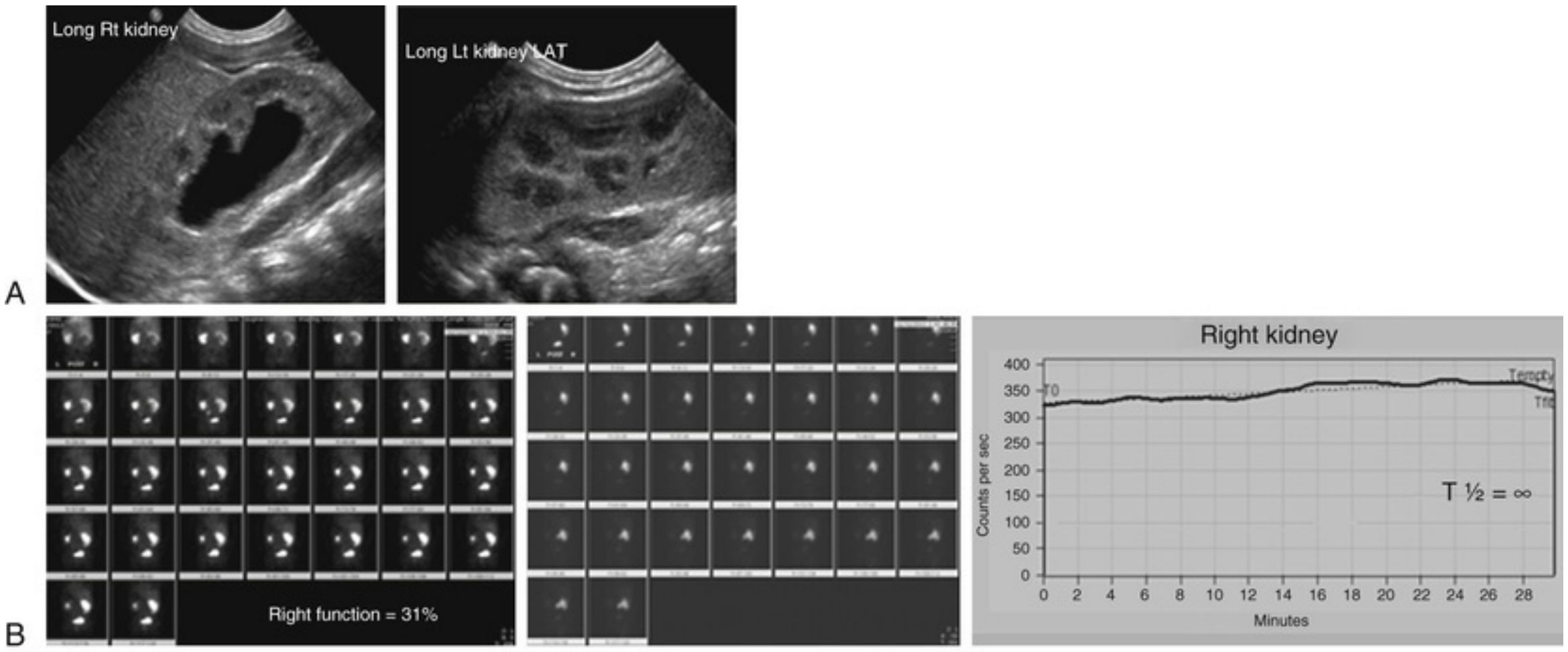
Long Rt kidney
Long Lt kidney LAT
A
B
Right function = 31%
Right kidney
400
350
300
250
200
150
100
50
0
Counts per sec
T0
Tempty
Tfd
T ½ = ∞
0 2 4 6 8 10 12 14 16 18 20 22 24 26 28
Minutes

FIG. 24.27 Sonography may not be sufficient to identify obstruction. (A) Renal sonogram demonstrating *moderate* (SFU grade 3) hydronephrosis (mostly intrarenal dilation) without hydroureter. The renal cortex is well preserved as cortico-medullary differentiation is present and there is no sonographic evidence of renal cortical cysts. The left kidney is normal. (B) ^{99m}Tc-MAG3 Lasix renal scan showing high-grade ureteropelvic junction obstruction with reduced renal function from the right kidney (31%). The diuresis curve demonstrates no drainage, and instead, reflects continuous accumulation of tracer in the right collecting system.



FIG. 24.28 Radionuclide cystography examples of mild (A), moderate (B), and severe (C) vesicoureteral reflux.

Radionuclide Testicular Scanning

Testicular scintigraphy has been around since the 1970s and is typically promoted to distinguish between testicular torsion and inflammatory conditions of the testicle (i.e., epididymitis, orchitis, testicular appendage torsion) (Holder et al., 1981). The test is performed by intravenous injection of ^{99m}Tc-pertechnetate followed by dynamic and static gamma images of the pelvis. Similar to renal scintigraphy, photon-deficient areas represent poor blood flow as in torsion, and photon-hyperdense areas can represent inflammation as in epididymitis. In experienced centers, this technique can be very sensitive and specific (up to 100%) and potentially perform better than sonography in the setting of the acute scrotum (Flores et al., 1996; Mendel et al., 1985; Wu et al., 2002). However, its lack of availability, invasiveness, and radiation exposure limit its widespread adoption over sonography. Perhaps the most appropriate use is in cases that are equivocal by examination and sonography, but only if potentially testicle-saving surgery is not unreasonably delayed (Kodali et al., 2013).

Suggested Readings

American Urological Association. *Choosing Wisely*. [Available at] http://www.choosingwisely.org/clinician-lists/american-urological-association-ct-to-screen-pediatric-patients-with-suspected-nephrolithiasis/.

Amerstorfer EE, Haberlik A, Riccabona M. Imaging assessment of renal injuries in children and adolescents: CT or ultrasound? *J Pediatr Surg*. 2015;50(3):448–455.

Bandarkar AN, Blask AR. Testicular torsion with preserved flow: key sonographic features and value-added approach to diagnosis. *Pediatr Radiol*. 2018;48(5):735–744.

Brown PH, Thomas RD, Silberberg PJ, et al. Optimization of a fluoroscope to reduce radiation exposure in pediatric imaging. *Pediatr Radiol*. 2000;30(4):229–235.

Cerrolaza JJ, Peters C, Martin A, et al. Quantitative ultrasound imaging of obstruction severity in pediatric hydronephrosis. *J Urol*. 2016;195(4 Pt 1):1093–1099.

Conway JJ, Maizels M. The “well tempered” diuretic renogram: a standard method to examine the asymptomatic neonate with hydronephrosis or hydroureteronephrosis. A report from combined meetings of The Society for Fetal Urology and members of The Pediatric Nuclear Medicine Council—The Society of Nuclear Medicine. *J Nucl Med*. 1992;33(11):2047–2051.

Expert Panel on Pediatric Imaging, Karmazyn BK, Alazraki AL, et al. ACR Appropriateness Criteria®. Urinary tract infection—child. *J Am Coll Radiol*. 2017;14(5S):S362–S371.

Majd M. Avoiding pitfalls in pediatric uroradiology: diuretic renography. *Dial Pediatr Urol*. 1989;12:6–8.

Mansour SM, Hamed ST, Adel L, et al. Does MRI add to ultrasound in the assessment of disorders of sex development? *Eur J Radiol*. 2012;81(9):2403–2410.

Mori R, Lakhanpaul M, Verrier-Jones K. Diagnosis and management of urinary tract infection in children: summary of NICE guidance. *BMJ*. 2007;335(7616):395–397.

Nguyen HT, Herndon CDA, Cooper C, et al. The Society for Fetal Urology consensus statement on the evaluation and management of antenatal hydronephrosis. *J Pediatr Urol*. 2010;6(3):212–231.

Pohl HG, Shukla AR, Metcalf PD, et al. Prepubertal testis tumors: actual prevalence rate of histological types. *J Urol*. 2004;172(6 Pt 1):2370–2372.

Rushton HG, Majd M, Chandra R, et al. Evaluation of 99mtechnetium-dimercapto-succinic acid renal scans in experimental acute pyelonephritis in piglets. *J Urol*. 1988;140(5 Pt 2):1169–1174.

Rushton HG, Majd M. Dimercaptosuccinic acid renal scintigraphy for the evaluation of pyelonephritis and scarring: a review of experimental and clinical studies. *J Urol*. 1992;148(5 Pt 2):1726–1732.

Stokland E, Hellström M, Jacobsson B, et al. Early 99mTc dimercaptosuccinic acid (DMSA) scintigraphy in symptomatic first-time urinary tract infection. *Acta Paediatr*. 1996;85(4):430–436.

Tasian GE, Copp HL. Diagnostic performance of ultrasound in nonpalpable cryptorchidism: a systematic review and meta-analysis. *Pediatrics*. 2011;127(1):119–128.

Yerkes EB, Adams MC, Pope JC 4th, et al. Does every patient with prenatal hydronephrosis need voiding cystourethrography? *J Urol*. 1999;162(3 Pt 2):1218–1220.

References

American Urological Association. *Choosing Wisely*. [Available at] http://www.choosingwisely.org/doctor-patient-lists/american-urological-association/.

Amerstorfer EE, Haberlik A, Riccabona M. Imaging assessment of renal injuries in children and adolescents: CT or ultrasound? *J Pediatr Surg*. 2015;50(3):448–455.

Ammenti A, Cataldi L, Chimenz R, et al. Italian Society of Pediatric Nephrology. Febrile urinary tract infections in young children: recommendations for the diagnosis, treatment and follow-up. *Acta Paediatr*. 2012;101(5):451–457.

Arthurs OJ, Bjørkum AA. Safety in pediatric imaging: an update. *Acta Radiol*. 2013;54(9):983–990.

Arthurs OJ, Edwards A, Austin T, et al. The challenges of neonatal magnetic resonance imaging. *Pediatr Radiol*. 2012;42(10):1183–1194.

Baker LA, Sigman D, Mathews RI, et al. An analysis of clinical outcomes using color doppler testicular ultrasound for testicular torsion. *Pediatrics*. 2000;105(3 Pt 1):604–607.

Bandarkar AN, Blask AR. Testicular torsion with preserved flow: key sonographic features and value-added approach to diagnosis. *Pediatr Radiol*. 2018;48(5):735–744.

Banerjee AK, Clarke O, MacDonald LM. Sonographic detection of neonatal hydrometrocolpos. *Br J Radiol*. 1992;65:268–271.

Berger MY, Tabbers MM, Kurver MJ, et al. Value of abdominal radiography, colonic transit time, and rectal ultrasound scanning in the diagnosis of idiopathic constipation in children: a systematic review. *J Pediatr*. 2012;161(1):44–50 [e1–e2].

Biswas K, Kapoor A, Karak AK, et al. Imaging in intersex disorders. *J Pediatr Endocrinol Metab*. 2004;17(6):841–845.

Blyth B, Snyder HM, Duckett JW. Antenatal diagnosis and subsequent management of hydronephrosis. *J Urol*. 1993;149(4):693–698.

Bonassi S, Znaor A, Ceppi M, et al. An increased micronucleus frequency in peripheral blood lymphocytes predicts the risk of cancer in humans. *Carcinogenesis*. 2007;28(3):625–631.

Bower G, Lovegrove FT, Geijsel H, et al. Comparison of "direct" and "indirect" radionuclide cystography. *J Nucl Med*. 1985;26(5):465–468.

Bright E, Oelke M, Tubaro A, et al. Ultrasound estimated bladder weight and measurement of bladder wall thickness—useful noninvasive methods for assessing the lower urinary tract? *J Urol*. 2010;184(5):1847–1854.

Brown PH, Thomas RD, Silberberg PJ, et al. Optimization of a fluoroscope to reduce radiation exposure in pediatric imaging. *Pediatr Radiol*. 2000;30(4):229–235.

Cerrolaza JJ, Peters C, Martin A, et al. Quantitative ultrasound imaging of obstruction severity in pediatric hydronephrosis. *J Urol*. 2016;195(4 Pt 1):1093–1099.

Chavhan GB, Parra DA, Oudjhane K, et al. Imaging of ambiguous genitalia: classification and diagnostic approach. *Radiographics*. 2008;28(7):1891–1904.

Craig JC, Knight JF, Sureshkumar P, et al. Vesicoureteric reflux and timing of micturating cystourethrography after urinary tract infection. *Arch Dis Child*. 1997;76(3):275–277.

Conway JJ, Maizels M. The "well tempered" diuretic renogram: a standard method to examine the asymptomatic neonate with hydronephrosis or hydroureteronephrosis. A report from combined meetings of The Society for Fetal Urology and members of The Pediatric Nuclear Medicine Council—The Society of Nuclear Medicine. *J Nucl Med*. 1992;33(11):2047–

2051.

DaJusta DG, Granberg CF, Villanueva C, et al. Contemporary review of testicular torsion: new concepts, emerging technologies and potential therapeutics. *J Pediatr Urol*. 2013;9(6):723–730.

Darge K. Voiding urosonography with US contrast agent for the diagnosis of vesicoureteric reflux in children: an update. *Pediatr Radiol*. 2010;40(6):956–962.

Darge K, Troeger J. Vesicoureteral reflux grading in contrast-enhanced voiding urosonography. *Eur J Radiol*. 2002;43(2):122–128.

Darge K, Higgins M, Hwang TJ, et al. Magnetic resonance and computed tomography in pediatric urology: an imaging overview for current and future daily practice. *Radiol Clin North Am*. 2013;51(4):583–598.

Delaney LR, Karmazyn B. Ultrasound of the pediatric scrotum. *Semin Ultrasound CT MR*. 2013;34(3):248–256.

Dias T, Sairam S, Kumarasiri S. Ultrasound diagnosis of fetal renal abnormalities. *Best Pract Res Clin Obstet Gynaecol*. 2014;28(3):403–415.

Dickerson EC, Dillman JR, Smith EA, et al. Pediatric MR urography: indications, techniques, and approach to review. *Radiographics*. 2015;35(4):1208–1230.

Don S, Macdougall R, Strauss K, et al. Image gently campaign back to basics initiative: ten steps to help manage radiation dose in pediatric digital radiography. *Am J Roentgenol*. 2013;200(5):W431–W436.

Fallah MM, Falahati M, Mohammadi A, et al. Comparative study of color Doppler voiding urosonography without contrast enhancement and direct radionuclide voiding cystography for diagnosis of vesicoureteric reflux in children. *J Ultrasound Med*. 2012;31(1):55–61.

Flores LG 2nd, Shiba T, Hoshi H, et al. Scintigraphic evaluation of testicular torsion and acute epididymitis. *Ann Nucl Med*. 1996;10(1):89–92.

Fretzayas A, Karpathios T, Dimitriou P, et al. Grading of vesicoureteral reflux by radionuclide cystography. *Pediatr Radiol*. 1984;14(3):148–150.

Gambino J, Caldwell B, Dietrich R, et al. Congenital disorders of sexual differentiation: MR findings. *Am J Roentgenol*. 1992;158(2):363–367.

Geiger J, Epelman M, Darge K. The fountain sign: a novel color doppler sonographic finding for the diagnosis of acute idiopathic scrotal edema. *J Ultrasound Med*. 2010;29(8):1233–1237.

Ghasemi K, Montazeri S, Pashazadeh AM, et al. Correlation of 99mTc-DMSA scan with radiological and laboratory examinations in childhood acute pyelonephritis: a time-series study. *Int Urol Nephrol*. 2013;45(4):925–932.

Grattan-Smith JD, Jones RA. MR urography in children. *Pediatr Radiol*. 2006;36(11):1119–1132 [quiz 1228–1229].

Grenier N, Gennisson J-L, Cornelis F, et al. Renal ultrasound elastography. *Diagn Interv Imaging*. 2013;94(5):545–550.

Gross GW, Lebowitz RL. Infection does not cause reflux. *Am J Roentgenol*. 1981;137(5):929–932.

Guerra-Junior G, Andrade KC, Barcelos IHK, et al. Imaging techniques in the diagnostic journey of disorders of sex development. *Sex Dev*. 2018;12(1–3):95–99.

Hagerty JA, Maizels M, Cheng EY. The PIC cystogram: its place in the treatment algorithm of recurrent febrile UTIs. *Adv Urol*. 2008;763620.

Hagerty JA, Maizels M, Kirsch A, et al. Treatment of occult reflux lowers the incidence rate of pediatric febrile urinary tract infection. *Urology*. 2008;72(1):72–76.

Hellström M, Jodal U, Mårild S, et al. Ureteral dilatation in children with febrile urinary tract infection or bacteriuria. *Am*

J Roentgenol. 1987;148(3):483–486.

Hill SJ, Hirsch JH. Sonographic detection of fetal hydrometrocolpos. *J Ultrasound Med*. 1985;4(6):323–325.

Hoffer FA. Magnetic resonance imaging of abdominal masses in the pediatric patient. *Semin Ultrasound CT MR*. 2005;26(4):212–223.

Holder LE, Melloul M, Chen D. Current status of radionuclide scrotal imaging. *Semin Nucl Med*. 1981;11(4):232–249.

Horgan JG, Rosenfield NS, Weiss RM, et al. Is renal ultrasound a reliable indicator of a nonobstructed duplication anomaly? *Pediatr Radiol*. 1984;14(6):388–391.

ICRP, Khong P-L, Ringertz H, et al. ICRP publication 121: radiological protection in paediatric diagnostic and interventional radiology. *Ann ICRP*. 2013;42(2):1–63.

Inchingolo R, Maresca G, Cacaci S, et al. Post-natal ultrasound morpho-dynamic evaluation of mild fetal hydronephrosis: a new management. *Eur Rev Med Pharmacol Sci*. 2013;17(16):2232–2239.

Jequier S, Forbes PA, Nogrady MB. The value of ultrasonography as a screening procedure in a first-documented urinary tract infection in children. *J Ultrasound Med*. 1985;4(8):393–400.

Jones RA, Perez-Brayfield MR, Kirsch AJ, et al. Renal transit time with MR urography in children. *Radiology*. 2004;233(1):41–50.

Kaefer M, Barnewolt C, Retik AB, et al. The sonographic diagnosis of infravesical obstruction in children: evaluation of bladder wall thickness indexed to bladder filling. *J Urol*. 1997;157(3):989–991.

Kalfa N, Veyrac C, Lopez M, et al. Multicenter assessment of ultrasound of the spermatic cord in children with acute scrotum. *J Urol*. 2007;177(1):297–301 [discussion 301].

Kang X, Safdar N, Myers E, et al. Automatic analysis of pediatric renal ultrasound using shape, anatomical and image acquisition priors. *Med Image Comput Assist Interv*. 2013;16(Pt 3):259–266.

Kangarloo H, Gold RH, Fine RN, et al. Urinary tract infection in infants and children evaluated by ultrasound. *Radiology*. 1985;154(2):367–373.

Karcaaltincaba M, Oguz B, Haliloglu M. Current status of contrast-induced nephropathy and nephrogenic systemic fibrosis in children. *Pediatr Radiol*. 2009;39(Suppl 3):382–384.

Kaye JD, Shapiro EY, Levitt SB, et al. Parenchymal echo texture predicts testicular salvage after torsion: potential impact on the need for emergent exploration. *J Urol*. 2008;180(4 Suppl):1733–1736.

Khrichenko D, Darge K. Functional analysis in MR urography—made simple. *Pediatr Radiol*. 2010;40(2):182–199.

Kim YS, Do SH, Hong CH, et al. Does every patient with ureteropelvic junction obstruction need voiding cystourethrography? *J Urol*. 2001;165(6 Pt 2):2305–2307.

Kimura T, Takahashi K, Suzuki Y, et al. The effect of high strength static magnetic fields and ionizing radiation on gene expression and DNA damage in Caenorhabditis elegans. *Bioelectromagnetics*. 2008;29(8):605–614.

Kleinerman RA. Radiation-sensitive genetically susceptible pediatric sub-populations. *Pediatr Radiol*. 2009;39(Suppl 1):S27–S31.

Kodali SK, Abdullah ZS, Sharma P, et al. Missed torsion in undescended testes detected by scintigraphy: testicular scintigraphy a decisive complementary tool. *Clin Nucl Med*. 2013;38(1):58–59.

Kussman BD, Mulkern RV, Holzman RS. Iatrogenic hyperthermia during cardiac magnetic resonance imaging. *Anesth Analg*. 2004;99(4):1053–1055 [table of contents].

Lambert SM, Vilain EJ, Kolon TF. A practical approach to ambiguous genitalia in the newborn period. *Urol Clin North Am*. 2010;37(2):195–205.

Lee JY, Kim SH, Cho JY, et al. Color and power Doppler twinkling artifacts from urinary stones: clinical observations and phantom studies. *Am J Roentgenol*. 2001;176(6):1441–1445.

Leonidas JC, McCauley RG, Klauber GC, et al. Sonography as a substitute for excretory urography in children with urinary tract infection. *Am J Roentgenol*. 1985;144(4):815–819.

Lu W, Sapozhnikov OA, Bailey MR, et al. Evidence for trapped surface bubbles as the cause for the twinkling artifact in ultrasound imaging. *Ultrasound Med Biol*. 2013;39(6):1026–1038.

Majd M. Avoiding pitfalls in pediatric uroradiology: diuretic renography. *Dial Pediatr Urol*. 1989;12:6–8.

Majd M, Nussbaum Blask AR, Markle BM, et al. Acute pyelonephritis: comparison of diagnosis with 99mTc-DMSA, SPECT, spiral CT, MR imaging, and power Doppler US in an experimental pig model. *Radiology*. 2001;218(1):101–108.

Majd M, Rushton HG, Chandra R, et al. Technetium-99m-DMSA renal cortical scintigraphy to detect experimental acute pyelonephritis in piglets: comparison of planar (pinhole) and SPECT imaging. *J Nucl Med*. 1996;37(10):1731–1734.

Majd M, Rushton HG. Renal cortical scintigraphy in the diagnosis of acute pyelonephritis. *Semin Nucl Med*. 1992;22(2):98–111.

Mansour SM, Hamed ST, Adel L, et al. Does MRI add to ultrasound in the assessment of disorders of sex development? *Eur J Radiol*. 2012;81(9):2403–2410.

McArthur C, Baxter GM. Current and potential renal applications of contrast-enhanced ultrasound. *Clin Radiol*.

2012;67(9):909–922.

Mendel JB, Taylor GA, Treves S, et al. Testicular torsion in children: scintigraphic assessment. *Pediatr Radiol*. 1985;15(2):110–115.

Miele V, Piccolo CL, Galluzzo M, et al. Contrast-enhanced ultrasound (CEUS) in blunt abdominal trauma. *Br J Radiol*. 2016;89(1061):20150823.

Mori R, Lakhanpaul M, Verrier-Jones K. Diagnosis and management of urinary tract infection in children: summary of NICE guidance. *BMJ*. 2007;335(7616):395–397.

Nelson CP, Johnson EK, Logvinenko T, et al. Ultrasound as a screening test for genitourinary anomalies in children with UTI. *Pediatrics*. 2014;133(3):e394–e403.

Nigro KG, MacLennan GT. Rhabdomyosarcoma of the bladder and prostate. *J Urol*. 2005;173(4):1365.

Nguyen HT, Herndon CDA, Cooper C, et al. The Society for Fetal Urology consensus statement on the evaluation and management of antenatal hydronephrosis. *J Pediatr Urol*. 2010;6(3):212–231.

O'Hara SM. Nuclear medicine. Belman AB, King LR, Kramer SA. *Guide to clinical pediatric urology*. Martin Dunitz Ltd.: London; 2002:107–140.

Papadopoulou F, Anthopoulou A, Siomou E, et al. Harmonic voiding urosonography with a second-generation contrast agent for the diagnosis of vesicoureteral reflux. *Pediatr Radiol*. 2009;39(3):239–244.

Passerotti C, Chow JS, Silva A, et al. Ultrasound versus computerized tomography for evaluating urolithiasis. *J Urol*. 2009;182(4 Suppl):1829–1834.

Perez-Brayfield MR, Kirsch AJ, Jones RA, et al. A prospective study comparing ultrasound, nuclear scintigraphy and dynamic contrast enhanced magnetic resonance imaging in the evaluation of hydronephrosis. *J Urol*. 2003;170(4 Pt

1):1330–1334.

Peters CA, Cerrolaza J, Safdar N, et al. *Quantitative imaging for ultrasound evaluation of pediatric hydronephrosis*. The Societies for Pediatric Urology. Pediatric Urology Fall Congress. 2013 [Available at] http://spuonline.org/fallcongress/abstracts/2013/P8.cgi [Las Vegas].

Piscitelli A, Galiano R, Serrao F, et al. Which cystography in the diagnosis and grading of vesicoureteral reflux? *Pediatr Nephrol*. 2008;23(1):107–110.

Pohl HG, Shukla AR, Metcalf PD, et al. Prepubertal testis tumors: actual prevalence rate of histological types. *J Urol*. 2004;172(6 Pt 1):2370–2372.

Polish Society of Pediatric Nephrology. *[Polish Society of Pediatric Nephrology recommendations for the management of children with urinary tract infection]*. [Available at] http://ptnfd.org/; 2015.

Polito C, Rambaldi PF, La Manna A, et al. Enhanced detection of vesicoureteric reflux with isotopic cystography. *Pediatr Nephrol*. 2000;14(8–9):827–830.

Reuchlin-Vroklage LM, Bierma-Zeinstra S, Benninga MA, et al. Diagnostic value of abdominal radiography in constipated children: a systematic review. *Arch Pediatr Adolesc Med*. 2005;159(7):671–678.

Roberts JA. Experimental pyelonephritis in the monkey. III. Pathophysiology of ureteral malfunction induced by bacteria. *Invest Urol*. 1975;13(2):117–120.

Roberts KB, Downs SM, Finnell SM, American Academy of Pediatrics Subcom- mittee on Urinary Tract Infection, Steering Committee on Quality Improvement and Management, et al. Urinary tract infection: clinical practice guideline for diagnosis and management of the initial UTI in febrile infants and children 2 to 24 months. *Pediatrics*.

2011;128(3):595–610.

Robinson JL, Finlay JC, Lang ME, Canadian Paediatric Society Infectious Diseases and Immunization Committee, Community Paediatrics Committee, et al. Urinary tract infections in infants and children: diagnosis and management. *Paediatr Child Health*. 2014;19(6):315–319.

Rubenstein JN, Maizels M, Kim SC, et al. The PIC cystogram: a novel approach to identify ‘occult’ vesicoureteral reflux in children with febrile urinary tract infections. *J Urol*. 2003;169(6):2339–2343.

Rushton HG, Majd M, Chandra R, et al. Evaluation of 99mtechnetium-dimercapto-succinic acid renal scans in experimental acute pyelonephritis in piglets. *J Urol*. 1988;140(5 Pt 2):1169–1174.

Rushton HG, Majd M. Dimercaptosuccinic acid renal scintigraphy for the evaluation of pyelonephritis and scarring: a review of experimental and clinical studies. *J Urol*. 1992;148(5 Pt 2):1726–1732.

Servaes S, Khanna G, Naranjo A, et al. Comparison of diagnostic performance of CT and MRI for abdominal staging of pediatric renal tumors: a report from the Children's Oncology Group. *Pediatr Radiol*. 2015;45(2):166–172.

Shalaby-Rana E, Lowe LH, Blask AN, et al. Imaging in pediatric urology. *Pediatr Clin North Am*. 1997;44(5):1065–1089.

Shopfner CE. Genitography in intersexual states. *Radiology*. 1964;82:664–674.

Shulkin BL, Mandell GA, Cooper JA, et al. Procedure guideline for diuretic renography in children 3.0. *J Nucl Med Technol*. 2008;36(3):162–168.

Simi S, Ballardin M, Casella M, et al. Is the genotoxic effect of magnetic resonance negligible? Low persistence of micronucleus frequency in lymphocytes of individuals after cardiac scan. *Mutat Res*. 2008;645(1–2):39–43.

Stein R, Dogan HS, Hoebeke P, European Association of Urology and European Society for Pediatric Urology, et al. Urinary tract infections in children: EAU/ESPU guidelines. *Eur Urol*. 2015;67(3):546–558.

Stokland E, Hellström M, Jacobsson B, et al. Early 99mTc dimercaptosuccinic acid (DMSA) scintigraphy in symptomatic first-time urinary tract infection. *Acta Paediatr*. 1996;85(4):430–436.

Stokland E, Hellström M, Jacobsson B, et al. Renal damage one year after first urinary tract infection: role of dimercaptosuccinic acid scintigraphy. *J Pediatr*. 1996;129(6):815–820.

Sukan A, Bayazit AK, Kibar M, et al. Comparison of direct radionuclide cystography and voiding direct cystography in the detection of vesicoureteral reflux. *Ann Nucl Med*. 2003;17(7):549–553.

Tasian GE, Copp HL. Diagnostic performance of ultrasound in nonpalpable cryptorchidism: a systematic review and meta-analysis. *Pediatrics*. 2011;127(1):119–128.

The Hospital for Sick Children. *pedsMRI app*. [Toronto, Ontario: The Hospital for Sick Children; Available at] https://itunes.apple.com/us/app/pedsmri/id934527233?mt=8.

Thomsen HS, Marckmann P, Logager VB. Nephrogenic systemic fibrosis (NSF): a late adverse reaction to some of the gadolinium based contrast agents. *Cancer Imaging*. 2007;7:130–137.

Thomsen HS. Current evidence on prevention and management of contrast-induced nephropathy. *Eur Radiol*. 2007;17(Suppl 6):F33–F37.

Timberlake MD, Herndon CDA. Mild to moderate postnatal hydronephrosis—grading systems and management. *Nat Rev Urol*. 2013;10(11):649–656.

Unver T, Alpay H, Biyikli NK, et al. Comparison of direct radionuclide cystography and voiding cystourethrography in detecting vesicoureteral reflux. *Pediatr Int*. 2006;48(3):287–291.

Vijayaraghavan SB. Sonographic differential diagnosis of acute scrotum: real-time whirlpool sign, a key sign of torsion. *J Ultrasound Med*. 2006;25(5):563–574.

Vivier PH, Dolores M, Taylor M, et al. MR urography in children. Part 2: how to use ImageJ MR urography processing software. *Pediatr Radiol*. 2010;40(5):739–746.

Vivier PH, Dolores M, Taylor M, et al. MR urography in children. Part 1: how we do the F0 technique. *Pediatr Radiol*. 2010;40(5):732–738.

Wang Z, Lin JC, Mao W, et al. SAR and temperature: simulations and comparison to regulatory limits for MRI. *J Magn Reson Imaging JMRI*. 2007;26(2):437–441.

Wu H, Sun SS, Kao A, et al. Comparison of radionuclide imaging and ultrasonography in the differentiation of acute testicular torsion and inflammatory testicular disease. *Clin Nucl Med*. 2002;27(7):490–493.

Yerkes EB, Adams MC, Pope JC 4th, et al. Does every patient with prenatal hydronephrosis need voiding cystourethrography? *J Urol*. 1999;162(3 Pt 2):1218–1220.

Yeung CK, Sreedhar B, Leung VT, et al. Ultrasound bladder measurements in patients with primary nocturnal enuresis: a urodynamic and treatment outcome correlation. *J Urol*. 2004;171(6 Pt 2):2589–2594.

Yeung CK, Sreedhar B, Leung YF, et al. Correlation between ultrasonographic bladder measurements and urodynamic findings in children with recurrent urinary tract infection. *BJU Int*. 2007;99(3):651–655.

Yiee J, Wilcox D. Abnormalities of the fetal bladder. *Semin Fetal Neonatal Med*. 2008;13(3):164–170.

Zanetta VC, Rosman BM, Bromley B, et al. Variations in management of mild prenatal hydronephrosis among maternal-fetal medicine obstetricians, and pediatric urologists and radiologists. *J Urol*. 2012;188(5):1935–1939.

Zhang G, Day DL, Loken M, et al. Grading of reflux by radionuclide cystography. *Clin Nucl Med*. 1987;12(2):106–109.

25

Infection and Inflammation of the Pediatric Genitourinary Tract

Christopher S. Cooper MD, FAAP, FACS, Douglas W. Storm MD, FAAP

Pediatric urinary tract infections (UTIs) constitute a significant burden to the American public: 2.4% to 2.8% of all American children are affected annually by a UTI, and UTIs account for 1.1 million medical visits per year (Freedman, 2005). Although UTIs are epidemic in children, not all UTIs are the same. Some children have a single, sentinel UTI, whereas others suffer recurrent infections in infancy and into childhood and beyond. Some UTIs are associated with fever, and others only cause lower urinary tract symptoms or malodorous urine. Some UTIs lead to renal scarring, hypertension, and/or end-stage renal disease, whereas others involve no long-term sequelae. Unfortunately, at this time, there is no definitive way to predict whether children will ever develop a UTI, to determine if they will suffer further UTIs, or to determine if they will be affected by long-term medical issues related to their infections. This chapter describes the pathogenesis, evaluation, and management of pediatric UTIs to facilitate the care provider's individualized management decisions for each child.

Evaluation and Management of a Child With a Fever

Infants and young children frequently visit health care providers with a history of fever of undetermined cause. Although an extensive discussion of the workup and management of febrile infants is beyond the scope of this chapter, it is important for all pediatric care providers to have a basic knowledge of the care and evaluation of these patients. For children, a clinically significant fever is generally defined as a rectal temperature of 100.4°F (38°C) or higher (Sur and Bukont, 2007). In a previously healthy child 3 to 36 months of age, a temperature of 39°C or higher warrants further evaluation (American College of Emergency Physicians Clinical Policies Committee, 2003; Baraff, 2000; Baraff et al., 1993). In the majority of these children, the source of their fever is a viral illness; however, 7% to 13% of these children, with no clear fever source, have occult bacteremia and serious bacterial infections (Baraff, 2000; Dagan et al., 1988; Kadish et al., 2000). Serious bacterial infections in these patients include bacteremia, bacterial gastroenteritis, cellulitis, meningitis, osteomyelitis, pneumonia, septic arthritis, and UTIs. These infections are more common in children younger than 90 days and especially in children younger than 29 days. In children younger than 90 days, 7.2% experience a serious bacterial infection, whereas 8.7% to 28% of children younger than 29 days have such a serious infection (Baker and Bell, 1999; Baraff et al., 1993; Ishimine, 2007).

The goal of evaluating the febrile child is to ensure that serious infections are not missed and that proper treatment is initiated quickly. A summary of the evaluation and treatment of a child with a rectal temperature higher than 38°C is provided in Fig. 25.1. In such an evaluation, the ability to detect a child appearing “toxic” is important because these patients show a higher rate of serious infections. Signs and symptoms of toxicity include cyanosis, decreased activity, hyper- and hypoventilation, inability to interact with parents, irritability, lethargy, poor tone, poor perfusion, tachycardia, and poor eye contact (Sur and Bukont, 2007). It is important to keep in mind that although toxic appearance, age younger than 30 days, and rectal temperature of 39.4°C or greater are highly predictive of bacteremia, not one of these features guarantees the identification of a child with a serious bacterial infection, and absence of these features also does not rule out a serious infection (Pantell et al., 2004). In fact, one study demonstrated that a “toxic”-appearing child was 92% likely to have a serious illness when compared with ill or well-appearing children (26% and 3%, respectively) (McCarthy et al., 1982; Teach and Fleisher, 1995).

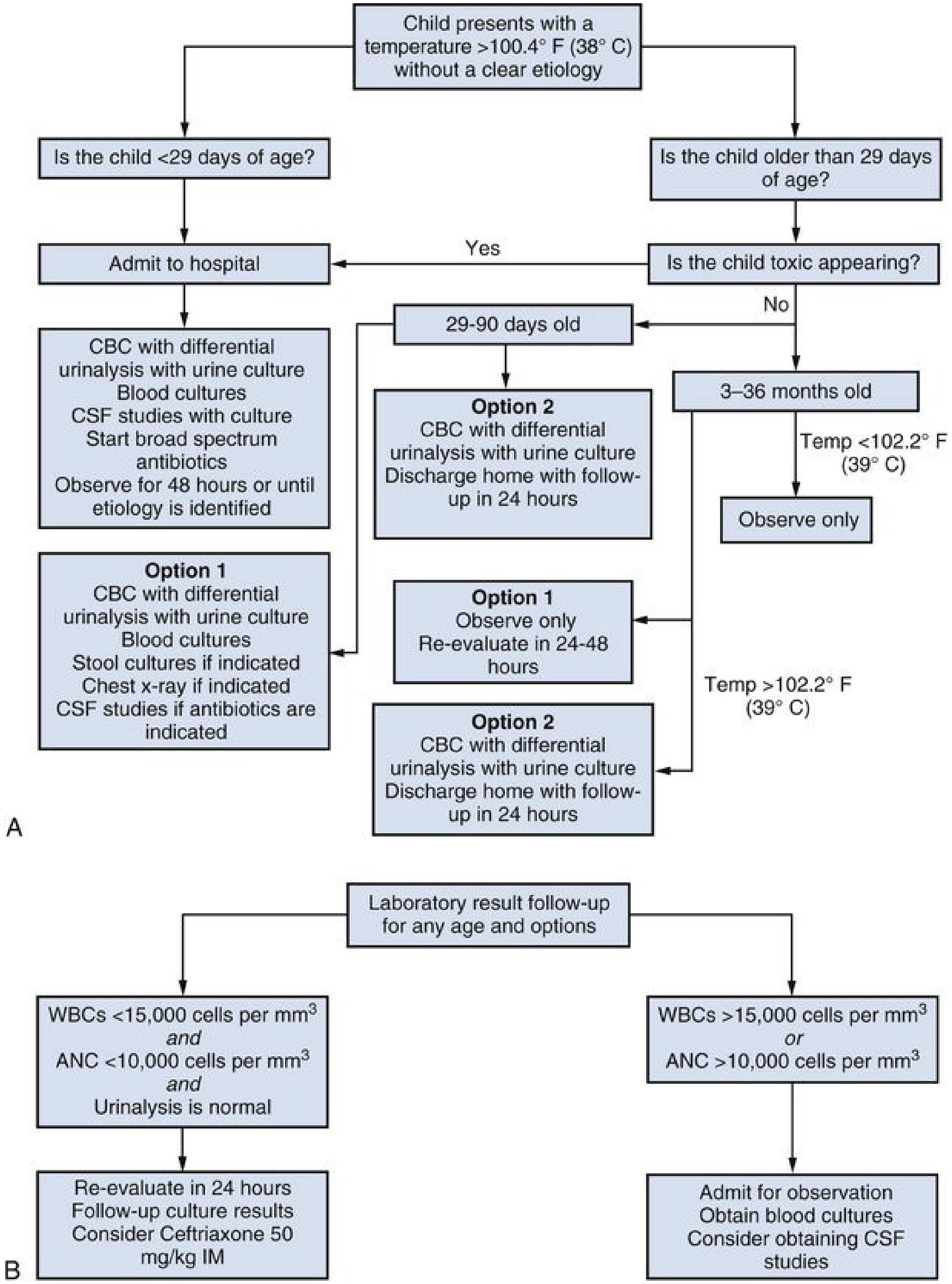
Child presents with a temperature >100.4° F (38° C) without a clear etiology
Is the child <29 days of age?
Is the child older than 29 days of age?
Admit to hospital
Yes
Is the child toxic appearing?
No
CBC with differential
urinalysis with urine culture
Blood cultures
CSF studies with culture
Start broad spectrum antibiotics
Observe for 48 hours or until etiology is identified
29-90 days old
Option 2
CBC with differential
urinalysis with urine culture
Discharge home with follow-up in 24 hours
3–36 months old
Temp <102.2° F (39° C)
Observe only
Option 1
CBC with differential
urinalysis with urine culture
Blood cultures
Stool cultures if indicated
Chest x-ray if indicated
CSF studies if antibiotics are indicated
Option 1
Observe only
Re-evaluate in 24-48 hours
Temp >102.2° F (39° C)
Option 2
CBC with differential
urinalysis with urine culture
Discharge home with follow-up in 24 hours
A
Laboratory result follow-up for any age and options
WBCs <15,000 cells per mm3
and
ANC <10,000 cells per mm3
and
Urinalysis is normal
WBCs >15,000 cells per mm3
or
ANC >10,000 cells per mm3
Re-evaluate in 24 hours
Follow-up culture results
Consider Ceftriaxone 50 mg/kg IM
Admit for observation
Obtain blood cultures
Consider obtaining CSF studies
B

FIG. 25.1 (A) Algorithm for the treatment of a child from birth to age 36 months with a fever higher than 100.4°F (38°C) with no cause for the fever. (B) Continued considerations for the treatment of a child aged 0 to 36 months with a fever higher than 100.4°F (38°C) with no cause for the fever.

ANC, Absolute neutrophil count; *CBC,* complete blood count; *CSF,* cerebrospinal fluid; *IM,* intramuscular; *WBCs,* white blood cells.

As is discussed in more detail later, the diagnosis of a UTI in children may be difficult because the symptoms can be nonspecific. In children from birth to age 24 months, the presence of a fever higher than 40°C, history of a previous UTI, suprapubic tenderness, and uncircumcised penis are the most useful signs and symptoms in predicting a UTI in a febrile child (Shaikh et al., 2007). Other factors such as vomiting, diarrhea, poor feeding, and irritability are not sensitive nor specific in screening for the presence of a UTI (Shaikh et al., 2007). In children older than 24 months, who are more verbal, the more classic symptoms of abdominal pain, back pain, dysuria, urinary frequency, and new-onset urinary incontinence are predictive of UTI (Shaikh et al., 2007). Successful diagnosis of an infection involves a high degree of suspicion and an understanding of the possible causes of fever, especially in very young children. **UTIs are the most common bacterial infection in children, accounting for 7% of febrile infections in infants and 7.8% of febrile infections in children older than 24 months** (Ishimine, 2007; Shaikh et al., 2008).

Key Points: Diagnosis of Urinary Tract Infection in a Child

- Signs and symptoms of a UTI in young children may be nonspecific.
- UTIs are the most common bacterial infection in a child presenting with a fever.
- Children who appear “toxic” on evaluation require close evaluation because they are likely to have a serious infection.

Definition of a Urinary Tract Infection

What constitutes a “significant” clinical UTI in a child is controversial. Urine has historically been considered sterile, so the presence of bacteria in a urine specimen begins to define whether a UTI is present. If a suprapubic aspiration was performed, then by some criteria recovery of any organisms defines a UTI. For catheterized specimens, recovery of at least 50,000 CFU/mL is required to define a UTI, and 100,000 CFU/mL are required if the specimen was collected via a clean-catch method (Hoberman et al., 1994). In addition, as discussed in the American Academy of Pediatrics (AAP) 2011 UTI clinical practice guideline for children 2 to 24 months, to establish the diagnosis of a UTI, a urinalysis (UA) should suggest infection (pyuria and/or bacteriuria) and identify at least 50,000 CFU/mL of a uropathogen cultured from a urine specimen obtained through urethral catheterization or suprapubic aspiration (Subcommittee on Urinary Tract Infection et al., 2011).

Pathogenesis of Urinary Tract Infection Development in Children

The factors that contribute to UTI development in children are not completely understood. Host features, bacterial characteristics, and immune status contribute to the development of pediatric UTIs. These influences are in a constant state of flux, particularly in children: for instance, immunity and gastrointestinal bacterial colonization are completely different in a newborn as compared with a 6-month-old child.

A typical UTI begins with periurethral contamination by a uropathogen that previously resided in the gastrointestinal tract. After moving to the periurethral environment, the bacteria colonize the urethra and migrate to the bladder. Once bacteria are within the bladder, the bacteria colonize and invade the bladder's superficial umbrella cells. Once within the umbrella cell, an immune response is elucidated. Some bacteria evade the immune response and multiply or form biofilms within the bladder cells. These bacteria may then survive and ascend to the kidneys. Kidney colonization results in bacterial toxin production and host tissue damage. If left untreated, bacteremia may occur (Fig. 25.2).

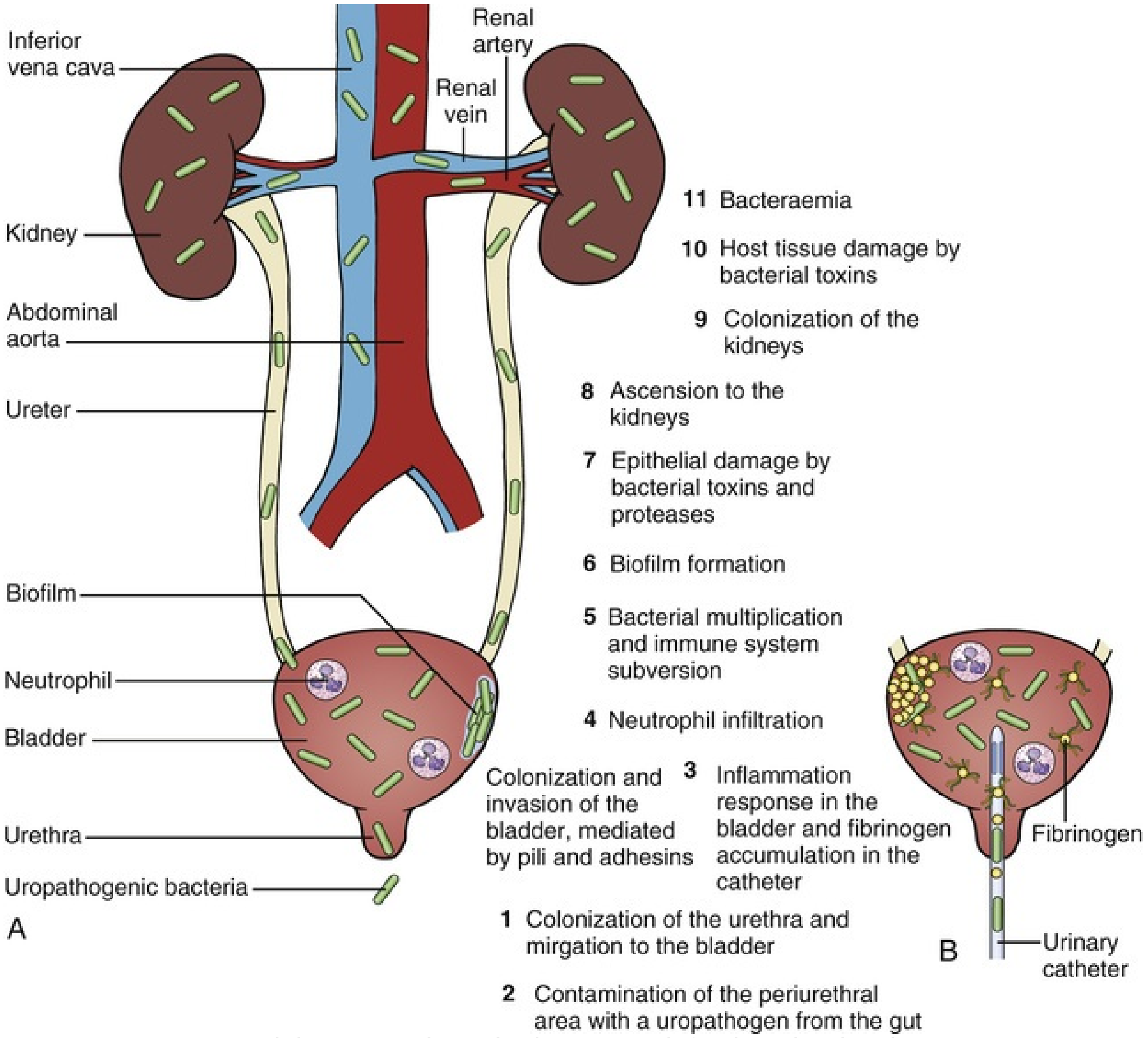
Inferior vena cava
Renal artery
Renal vein
Kidney
Abdominal aorta
Ureter
Biofilm
Neutrophil
Bladder
Urethra
Uropathogenic bacteria
A
11 Bacteraemia
10 Host tissue damage by bacterial toxins
9 Colonization of the kidneys
8 Ascension to the kidneys
7 Epithelial damage by bacterial toxins and proteases
6 Biofilm formation
5 Bacterial multiplication and immune system subversion
4 Neutrophil infiltration
Colonization and invasion of the bladder, mediated by pili and adhesins
3 Inflammation response in the bladder and fibrinogen accumulation in the catheter
1 Colonization of the urethra and mirgation to the bladder
2 Contamination of the periurethral area with a uropathogen from the gut
Fibrinogen
B
Urinary catheter

FIG. 25.2 (A) Uncomplicated urinary tract infections begin when uropathogens that normally reside in the gut colonize the urethra (Step 1). These bacteria then migrate to the bladder (Step 2), where they colonize and invade superficial umbrella cells within the urothelium (Step 3). Innate host inflammatory responses begin to clear bacteria (Step 4). Some bacteria, though, evade the immune system, and these bacteria may then multiply (Step 5) and form a biofilm (Step 6). These bacteria produce toxins and proteases that induce host cell damage (Step 7). They also release nutrients that promote bacterial survival and allow the bacteria to ascend to the kidneys (Step 8). Kidney colonization (Step 9) results in bacterial toxin production and host tissue damage (Step 10). UTIs can ultimately progress to bacteremia if the pathogen crosses the tubular epithelial barrier in the kidneys (Step 11). (B) Uropathogens that cause complicated UTIs follow the same initial steps as those described above, including periurethral colonization (Step 1) and migration to the bladder (Step 2). However, for the pathogens to cause infection, the bladder must be compromised. The most common cause of a compromised bladder is an indwelling urinary catheter. There is a robust immune response induced by catheterization (Step 3), resulting in fibrinogen accumulation along the catheter, providing an ideal environment for the attachment of uropathogens that express fibrinogen-binding proteins. This infection induces neutrophil infiltration (Step 4), but after their initial attachment to the fibrinogen-coated catheters, the bacteria multiply (Step 5), form biofilms (Step 6), promote epithelial damage (Step 7), and can seed infection of the kidneys (Steps 8 and 9), where toxin production induces tissue damage (Step 10). These uropathogens can also progress to bacteremia by crossing the tubular epithelial cell barrier (Step 11). (A, From Flores-Mireles AL, Walker JN, Caparon M, et al.: Urinary tract infections: epidemiology, mechanisms of infection and treatment options. *Nat Reviews. Microbiology* 13:269–284, 2015.)

Bacterial Factors Leading to Pediatric Urinary Tract Infections

Bacteria may be divided into commensal and virulent bacteria. The term *virulence* comes from the Latin word for poisonous, *veneficus*, and is defined as the ability of an organism to cause disease in a host. **Virulent bacteria that cause UTIs are otherwise known as uropathogenic bacteria. Virulent bacteria possess different adaptations and fitness factors that allow them to subvert or hijack host defenses and reside in an environment where they would not normally reside** (Johnson, 1991; Stapleton, 2014). These virulence mechanisms allow the bacteria to attach initially to urogenital mucosal surfaces and then to interact with these tissues by setting off cascades of signaling and other immunologic response events and subsequently invade the bladder (Stapleton, 2014). **Commensal bacteria may also cause UTIs, but commensals are defined by lacking the virulent traits that would allow bacteria to subvert a host's immune defenses.**

Escherichia coli is the most commonly studied UTI-causing organism because it is by far the most common bacterial UTI pathogen. Of the UTIs caused by *E. coli*, 80% are triggered by uropathogenic (virulent) *E. coli* (UPEC), whereas 20% of the *E. coli* causing UTIs are classified as commensal organisms (Bien et al., 2012; Krieger, 2002). This reflects the importance of virulence factors in UTI development. **Virulence factors include properties that improve bacterial adherence to uroepithelial cells, properties that allow bacterial nourishment in otherwise adverse environments, properties that protect bacteria from the host's immune response, and toxins that allow bacteria to invade host cells** (Fig. 25.3).

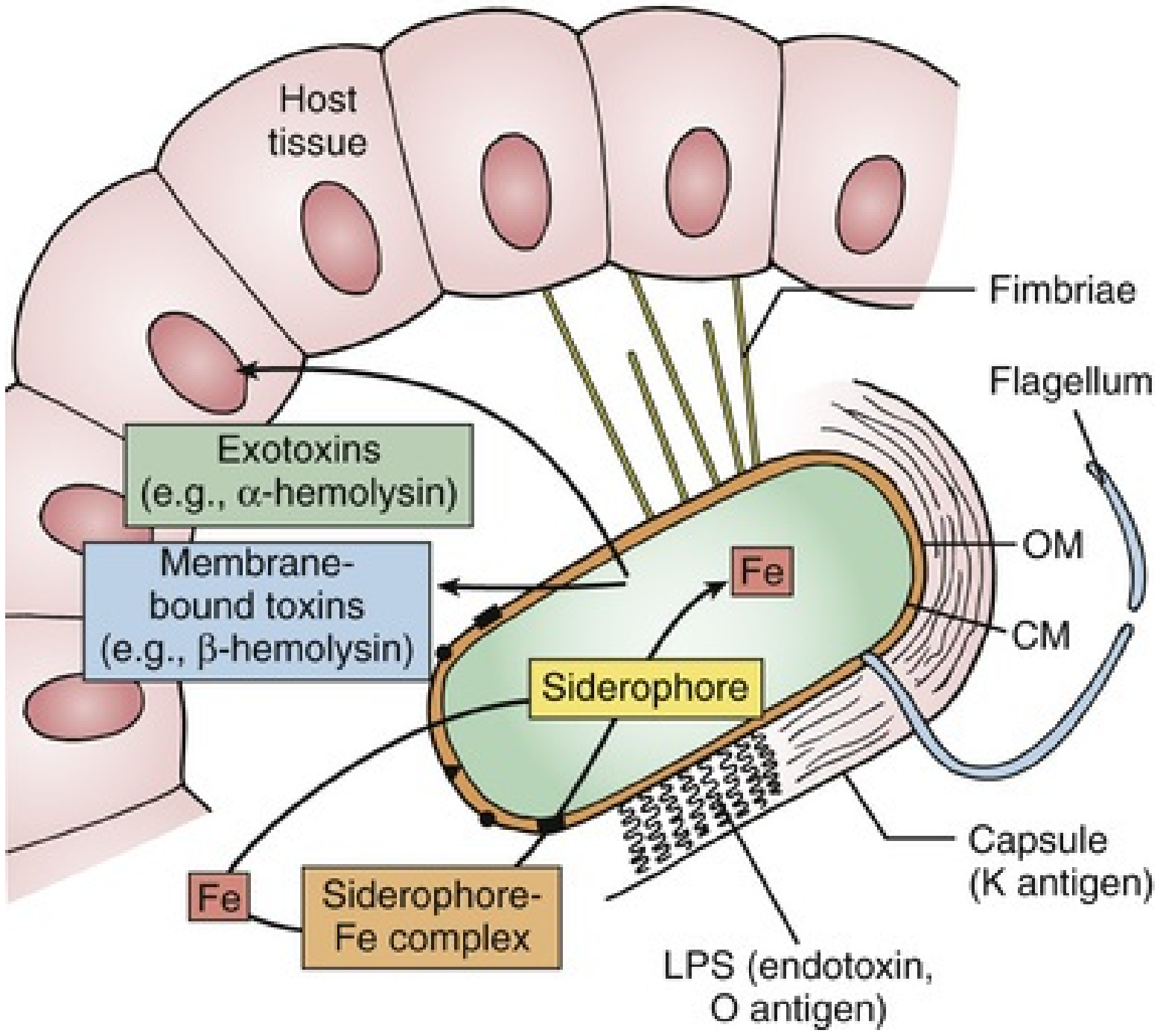
Host tissue
Fimbriae
Flagellum
Exotoxins (e.g., α-hemolysin)
Membrane-bound toxins (e.g., β-hemolysin)
Fe
OM
CM
Siderophore
Fe
Siderophore-Fe complex
Capsule (K antigen)
LPS (endotoxin, O antigen)

FIG. 25.3 Schematic representation of an *Escherichia coli* cell interacting with host tissue, highlighting features relevant to bacterial pathogenicity. *Solid black circles, triangles,* and *rectangles* indicate membrane proteins involved in transport, serum resistance, and so forth. *CM,* Cystoplasmic membrane; *LPS,* lipopolysaccharide; *OM,* outer membrane. (Modified from Johnson JR: Virulence factors in *Escherichia coli* urinary tract infection. *Clin Microbiol Rev* 4[1]:80–128, 1991. Copyright 1991, American Society for Microbiology.)

Bacterial Fimbriae

Bacterial adherence is perhaps the best understood and is one of the most studied virulence traits. Once the bacteria are within the bladder, the bacteria must adhere to the bladder epithelium to cause a UTI. **Adherence is considered the first step in UTI pathogenesis with special bacterial structures called *adhesins* mediating this process** (Guyer et al., 2001; Johnson and Stell, 2000; Johnson et al., 2001; Schilling et al., 2001; Wullt et al., 2001). These adhesins are also known as pili or F antigens, and they are filamentous appendages that project from the bacterial cells. Many gram-negative pathogenic bacteria, including *E. coli*, *Klebsiella*, *Proteus*, *Pseudomonas*, *Haemophilus*, *Salmonella*, and *Yersinia*, express a large family of adhesive fibers called chaperone-usher pathway (CUP) pili (Waksman and Hultgren, 2009; Wurpel et al., 2013). Thirty-eight distinct CUP pilus operons have been identified in *E. coli* genomes, and a single UPEC strain can encode more than 12 different CUP pili (Wurpel et al., 2013). Type 1 pili and pyelonephritis-associated (P) pili are the best characterized CUP pili. Type 1 pili are essential for colonization and invasion within the bladder uroepithelial cells (Hadjifrangiskou et al., 2012).

Pili can be classified into mannose sensitive, which is more common, or mannose resistant (Krieger, 2002). The most common mannose-sensitive adhesin is the type 1 pili. Adherence of this fimbriae is blocked by solutions of D-mannose and by concanavalin A (Johnson, 1991). Receptors for type 1 fimbriae are found in the muscular layers but not the epithelium of the human bladder, ureteral epithelium, and kidney cell lines (Fujita et al., 1989; Korhonen et al., 1981; Virkola et al., 1988). Strains of *E. coli*, expressing mannose-sensitive adhesins alone, with no mannose-resistant adhesins, are more commonly associated with patients with clinical symptoms of cystitis and/or asymptomatic bacteriuria (ASB) rather than pyelonephritis, suggesting that type 1 fimbriae play a more important role in the colonization and/or infection of the bladder versus contributing to clinical symptoms of pyelonephritis (Brooks et al., 1981; Gander et al., 1985; Latham and Stamm, 1984).

Another mannose-resistant adhesin is the P pili. These fimbriae were discovered to bind to and agglutinate erythrocytes of the P blood group (Kallenius et al., 1980a, 1980b). The binding site for this adhesin appears to be α-galactose-(1-4), a digalactoside in neutral glycosphingolipids found on epithelial cells and red blood cells. The different P blood group antigens and phenotypes that would bind these fimbriae are found in up to 75% of the population (Johnson, 1991). Binding sites have been identified in the human kidney and bladder, and **isolates expressing P fimbriae have been identified in up to 70% of strains causing clinical symptoms of pyelonephritis** (Johnson, 1991).

After bacterial adherence, a signal transduction cascade results in the uptake of bacteria by the bladder's superficial umbrella cells (Fig. 25.4; Kau et al., 2005; Martinez, 2000). These bacteria enter the bladder's epithelial cells, resulting in the formation of intracellular bacterial communities (IBCs) (Anderson et al., 2003). Typically, an innate defense expulsion defends the urothelium from bacterial invasion. This expulsion mechanism depends on Toll-like receptor 4 (TLR4). However, upon attachment to TLR4, UPEC, through the release of lipopolysaccharide (LPS), stimulates the release of adenylyl cyclase to produce cyclic antimicrobial peptides (AMPs), which induces exocytosis of UPEC into the apical plasma membrane of the bladder's umbrella cells (Song et al., 2009).

Invasion into the bladder urothelium allows UPEC to subvert certain host defenses and certain antibiotic treatments. During the formation of these IBCs, these normally fast-growing bacteria begin to grow at a slower rate until they eventually multiply to fill most of the umbrella cell's cytoplasm (Kau et al., 2005). Eventually the bacteria within the IBCs flux out of the host cell, which may allow bacteria to spread within the urinary tract. The bacteria may then re-enter the bladder epithelial cell and form a quiescent intracellular reservoir (QIR) within the underlying transitional cells. QIRs typically contain only 4 to 10 nonreplicating bacteria, which can remain viable for months, and when reactivated, they serve as seeds by releasing bacteria into the bladder lumen during uroepithelial turnover and result in reinitiation of another UTI (Justice et al., 2004).

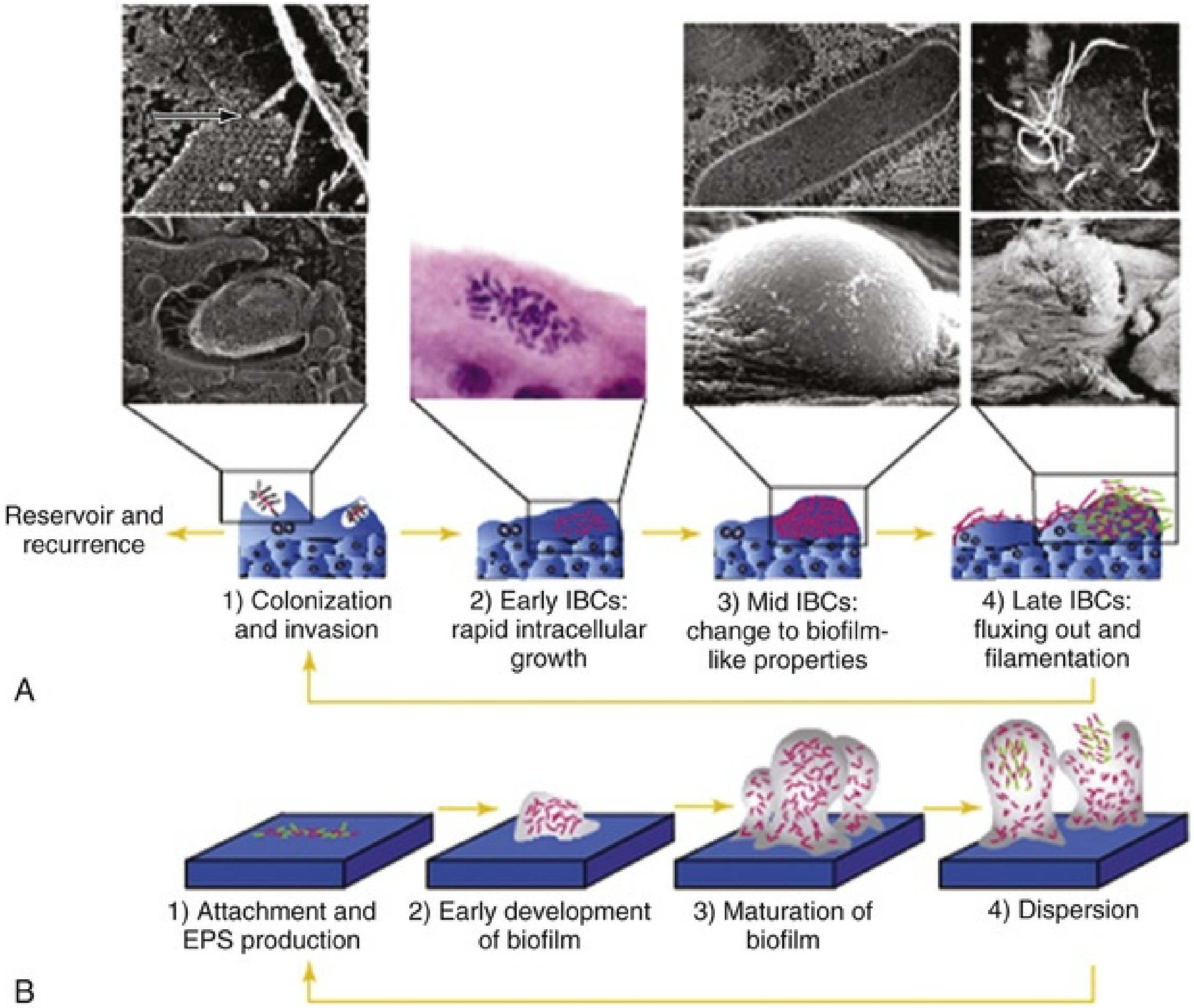
Reservoir and recurrence
1) Colonization and invasion
2) Early IBCs: rapid intracellular growth
3) Mid IBCs: change to biofilm-like properties
4) Late IBCs: fluxing out and filamentation
A
1) Attachment and EPS production
2) Early development of biofilm
3) Maturation of biofilm
4) Dispersion
B

FIG. 25.4 (A) Stages of bacterial invasion of uropathogenic *Escherichia coli* attaching to uroepithelial cell and subsequent formation of pod and dispersion. (B) The similar stages compared with previously known biofilm formation on inert surfaces such as urethral catheters. *EPS,* Extracellular polymeric substances; *IBCs,* intracellular bacterial communities. (From Kau A, Hunstad D, Hultgren SJ: Interaction of uropathogenic *Escherichia coli* with host uroepithelium. *Curr Opin Microbiol* 8:54, 2005.)

Aerobactin

All living cells, including bacteria, need iron. *E. coli* uses iron for oxygen storage and transport, DNA synthesis, electron transport, and metabolism of peroxides (Bagg and Neilands, 1987). As part of the host's response to infection, the amount of available iron is reduced to the invading pathogen by decreasing intestinal absorption, synthesizing additional iron-binding proteins, and shifting iron from the plasma pool into intracellular storage (Johnson, 1991). Therefore *E. coli* face a considerable challenge in acquiring and meeting their iron needs during an infection. The siderophore aerobactin extracts iron from host iron-binding proteins and then delivers the iron directly to bacterial iron centers (Carbonetti et al., 1986; de Lorenzo and Neilands, 1986; Williams and Carbonetti, 1986). Bacterial strains with the aerobactin system have a growth advantage in low iron conditions, including the serum and dilute urine.

Hemolysin

The cytolytic protein secreted by most hemolytic *E. coli* is known as alpha hemolysin (Cavalieri et al., 1984). Alpha hemolysin lyses erythrocytes of all mammals and is also toxic to a wide range of host cells contributing to inflammation, tissue injury, and impaired host defenses (Johnson, 1991). In human UTIs, hemolysin production is most common in bacterial strains from patients suffering pyelonephritis as compared with patients with cystitis symptoms.

Capsular Polysaccharide

Capsular polysaccharides, of which *E. coli* has more than 80 types, are linear polymers that coat the bacterial cell, interfering with antigen detection and protecting the cell from host defense detection (Jorgensen et al., 1976). **The capsules of most uropathic *E. coli* are composed of group II polysaccharides and are otherwise known as K antigens.** Encapsulated K bacterial strains are less well phagocytosed and also have anticomplementary activities, as compared with nonencapsulated strains, which leads to impaired bacterial clearance and complement activation (Harber et al., 1986; Howard and Glynn, 1971). The degree of host defense impairment tends to be proportional to the amount of polysaccharide (Howard and Glynn, 1971). These encapsulated strains are commonly associated with pyelonephritic UTIs rather than cystitis (Johnson, 1991).

Biofilm Formation

Uropathogens may also form biofilms to allow bacterial persistence and recurrent UTIs. Bacterial extracellular DNA, exopolysaccharides, pili, flagella, and other adhesions create a scaffold, which results in the formation of a biofilm. Biofilms create a multicellular bacterial community that is protected from immune responses and antimicrobial treatments. In addition, biofilms provide a physical barrier to antibiotic entry (Kostakioti et al., 2013). UPEC form biofilm-like IBCs within bladder urothelial cells, protecting the bacteria from neutrophils, antibiotics, and other stress (Anderson et al., 2003).

Key Points: Bacterial Factors

- UTI-causing bacteria may be subdivided into commensal and virulent types; although both cause UTI, virulent organisms cause the majority of UTIs.
- Virulent bacteria possess different adaptations and fitness factors that allow them to subvert or hijack host defenses and reside in an environment where they would not normally preside.
- Bacteria have a multitude of virulence factors, including properties that improve bacterial adherence to uroepithelial cells, properties that allow bacterial nourishment in otherwise adverse environments, properties that protect bacteria from the host's immune response, and toxins that allow bacteria to invade host cells.

Host Risk Factors Leading to Pediatric Urinary Tract Infections

Host factors that seem to affect the incidence of UTI development in children are associated with age, genetics, gender, and race and anatomic, functional, and behavioral features.

Gender and Age

The only time that UTIs are more prevalent in boys than in girls is at an age younger than 1 year. At all other ages, even among the elderly, UTIs are far more prevalent in females than in males (Shortliffe and McCue, 2002). About 2.7% of boys, compared with 0.7% of girls, experience a UTI during the first year of life (Winberg et al., 1975). After 1 year of life, the incidence of UTI development drops to 0.03% to 0.2% in males and increases to 1% to 3% in females (Foxman, 2002). **It has been estimated that 7% of girls and 2% of boys experience a UTI by the age of 6 years** (Marild, 1998).

UTIs are common in febrile children, with an incidence of 3% to 5%; however, the risk is greater in girls than in boys after 2 months of age. When evaluating children aged 2 months to 2 years, girls presenting with a fever have a 2.27 greater risk of being diagnosed with a UTI as compared to boys (American Academy of Pediatrics, 1999). In older children, especially in sexually active teenagers, there is also a female predominance of UTIs (Ma and Shortliffe, 2004).

Race

UTIs occur in all races, but they appear more commonly in Caucasian girls compared with girls of other races (Bachur and Harper, 2001; Keeton and Hillis, 1975; Shaw and Gorelick, 1999; Shaw et al., 1998). Several studies have shown that African-Americans have fewer UTIs, have lower rates of vesicoureteral reflux (VUR), and may be less likely to develop reflux nephropathy as compared with Caucasians and Hispanics (Hoberman and Wald, 1997; Kunin, 1968; Lohr et al., 1994; Pinto, 2004).

Genetics

Although certain individuals appear to be more prone to developing UTIs, no specific genes have been identified that are linked to developing these infections. Some observations on the occurrence of UTIs, however, lend evidence that there may be a genetic component to UTI development. Children with a history of VUR are still commonly susceptible to UTI development after their reflux resolves (Beetz et al., 2002; Mansfield et al., 1995). In addition, sisters of patients with recurrent UTIs have higher rates of significant bacteriuria compared with the general population (Stauffer et al., 2004). Moreover, the two greatest risk factors for women ages 18 to 30 years to develop recurrent UTIs include age at first infection and a mother with a history of UTIs (Scholes et al., 2000).

As previously discussed, P fimbriae are a common virulence factor identified on UPEC. At the time of this adhesin's discovery, glycolipids characterizing the P blood group antigens were found on host uroepithelial cells, acting as bacterial receptors. Because it was suspected that individuals with this P blood group phenotype would be more susceptible to UTI development, children with recurrent UTIs were tested for this phenotype. A study by Lomberg et al. (1983) identified that 97% of girls with recurrent pyelonephritis expressed the P1 blood group phenotype in comparison with 75% of controls without UTI.

Other blood group antigens expressed on the urothelial surface also appear to influence UTI susceptibility. These include the ABO, Lewis, and secretor phenotypes. Adult women with Le (a−b−) and Le (a+b+) blood phenotypes are three times as likely to have recurrent UTIs compared with women with the Le (a−b+) phenotype (Sheinfeld et al., 1989). In addition, Jantausch et al. (1994) identified that in children with a history of UTIs, the frequency of Le (a−b−) is also increased. In addition, the nonsecretor phenotype of ABH blood group antigens (ABH Ag) has been identified as associated with renal scars seen on ^{99m}Tc-dimercaptosuccinic acid (DMSA) scans in children with VUR and UTIs (Kanematsu et al., 2005).

Circumcision

Multiple studies demonstrate that circumcision reduces the rate of UTI development in the first 6 months of life by almost 10-fold (Roberts, 1986; Schoen et al., 2000; Wiswell et al., 1987;). This risk appears to correlate with a period during the first 6 months of life when there is an increased amount of uropathogenic bacteria colonizing the prepuce. This colonization appears to decrease and resolve by 5 years of age (Glennon et al., 1988; Wiswell et al., 1988). In a retrospective review, Wiswell and Roscelli (1986) examined the incidence of UTIs diagnosed by catheterization or suprapubic aspirate (SPA) in more than 200,000 males born in US Army hospitals between 1974 and 1983. They found the UTI incidence in circumcised males was 0.11%, whereas the incidence of infection in uncircumcised males was 1.12% compared with an incidence of 0.57% in female children during this study period.

These findings have led to controversy regarding the advantages and disadvantages of routine circumcision in boys. The American Academy of Pediatrics (AAP) Task Force on Circumcision (2012), after weighing the risks and benefits of circumcision in boys (including the prevention of UTIs in neonates), stated that the health benefits of newborn male circumcision outweigh the risks. Although the AAP could not justify routine circumcision in all males, it concluded that the benefits of circumcision are great enough to justify access to this procedure to families choosing it and to warrant third-party payment for the procedure. **However, the question of whether circumcision actually prevents infections later in life continues to be debated in the literature.** Using case-control methods, Singh-Grewal et al. (2005) identified that circumcision continues to decrease the rate of UTI development before and after 1 year of age. The degree of risk reduction, however, is dependent on the patient. In a meta-analysis, Singh-Grewal et al. (2005) identified that normal, healthy boys have a 0.5% to 1% risk of developing a UTI, and they calculated that approximately 111 healthy boys would need to be circumcised to prevent one UTI. Boys who have a history of recurrent UTIs and those who have high-grade VUR have a 10% and 30% risk of UTI recurrence, respectively (Singh-Grewal et al., 2005). Further, the number of boys who would need to undergo circumcision in these high-risk groups to prevent a UTI is 11 boys with a history of recurrent UTIs and 4 boys with a history of high-grade VUR (Singh-Grewal et al., 2005).

Fecal and Perineal Bacterial Colonization

The majority of bacteria causing UTIs enter the bladder via the fecal-perineal-urethral route, whereby bacteria that colonize the gut, perineum, and periurethral area ascend via a retrograde fashion into the lower urinary tract (Pfau and Sacks, 1981; Stamey and Sexton, 1975; Yamamoto et al., 1997). **In women who suffer recurrent UTIs, studies demonstrate that the majority of these reinfections are caused by the same strain of UPEC that persists in the fecal microbiota for 12 or more months and circulates through the fecal and vaginal reservoirs to cause recurrent infections** (Czaja et al., 2009; Hooton, 2001; Russo et al., 1995).

Studies also demonstrate that women who suffer recurrent UTIs have increased vaginal and periurethral colonization with enteric organisms with concomitant loss of normally predominant and protective vaginal lactobacilli (Gupta et al., 1998; Hooton et al., 1994). **Clinical studies show that women lacking vaginal lactobacilli are at increased risk for vaginal colonization with *E. coli*.** Exposure to antibiotics, especially trimethoprim-sulfamethoxazole (TMP-SMX), may eradicate these presumably protective lactobacilli (Stapleton, 2014). Whether a similar mechanism predisposes to UTI in children is unknown. However, Hansson et al. (1989) showed that treatment of schoolgirls for nonurologic infections, usually otitis media, resulted in colonization and bacteriuria with organisms likely to cause a symptomatic infection.

In addition, new data suggest that a microbiome exists with the urine. Until recently, urine within individuals not suffering a UTI has long been considered sterile. However, through the use of 16S RNA gene sequencing, urine within healthy individuals has been found to contain extensive numbers of bacteria that are not cultivated using standard routine microbiology laboratory testing (Lewis et al., 2013; Nelson et al., 2010; Siddiqui et al., 2011; Wolfe et al., 2012). Lewis et al. studied urine from asymptomatic adults 26 to 90 years of age, using clean catch urine samples. They found that samples from females had a more heterogeneous mix of bacteria genera as compared with samples obtained from adult males. Analysis of the specimens found that females generally had bacteria from the phyla Actinobacteria and Bacteroidetes. In addition, the bacteria identified appeared to fluctuate between the different age groups studied (Lewis et al., 2013).

The idea in identifying a urinary microbiome is that, like other environments within the human body such as the gut, resident microbiota maintains a symbiotic relationship resulting in normal urinary health, including metabolic and trophic functions as well as providing a protective barrier against urinary pathogens. Wolfe et al. (2012) examined the urinary microbiome in women suffering from urge urinary incontinence and compared that with the urine in asymptomatic adult women. Using 16S rRNA gene sequencing in urine collected from transurethral catheterization, they identified that the urinary microbiome differed between these two cohorts. These data suggest that the urinary microbiome may account for common urinary symptoms seen in adult women. Although studies have been performed in adults, it is reasonable that if a urinary microbiome exists, it begins to take shape in infancy and childhood. Within the gut, the intestinal microbiome undergoes dynamic changes during development, with the most dramatic changes in composition believed to occur throughout infancy and childhood (Palmer et al., 2007; Tiihonen et al., 2010). As in the gastrointestinal tract, a better understanding of any developing pediatric urinary microbiome may allow for a better understanding of urologic disease and symptoms in children and adults.

Anatomic Abnormalities

Clearly, anatomic abnormalities of a child's genitourinary system may lead to UTI development. Infections associated with urinary tract malformation usually appear before 5 years of age (Chang and Shortliffe, 2006). It is important to detect these abnormalities because many may be surgically correctible, and persistence of these abnormalities may lead to renal damage and/or recurrent infections. Possible anatomic abnormalities include hydronephrosis, ureteropelvic or ureterovesical junction obstruction, VUR, infection stones, infected nonfunctional renal segments, and infected necrotic papillae.

Given the role that anatomic abnormalities play in pediatric UTI development, the AAP continues to recommend that a renal and bladder ultrasound (RBUS) be performed on all children aged 2 to 24 months after they have experienced their first febrile UTI (Subcommittee on Urinary Tract Infection et al., 2011).

Vesicoureteral Reflux

The role that VUR plays in UTI development and the controversies surrounding it are discussed in greater detail later in this chapter and in Chapter 29. VUR has been identified in 1% to 2% of all newborns, but it is found in 25% to 40% of children after their first episode of UTI (Greenfield and Wan, 1996; Hellerstein, 1995). **Although VUR may be present in a child who has suffered a pyelonephritic infection, the majority of children who have suffered from pyelonephritis do not have VUR.** Rushton and Majd found that in children suffering DMSA-proven pyelonephritis, only 37% were shown to have VUR (Rushton et al., 1992). Kidneys associated with higher-grade VUR (grades III–IV), however, were twice as likely to exhibit pyelonephritic changes on DMSA scan (Rushton et al., 1992). The role that VUR plays in UTI development is complex and not completely understood. Variables such as reflux grade and early onset of reflux during bladder filling, patient age, gender of the child, and presence of bowel and bladder dysfunction most likely contribute to UTI development in the presence of VUR.

Sexual Activity

Previous studies have shown that sexual activity increases the risk of UTI development. Kunin (1968) demonstrated that sexually active females suffer more UTIs than sexually inactive females. This finding has prompted some to suggest that UTI may be used as a marker of teenage sexual activity (Nguyen and Weir, 2002). However, this relationship remains poorly defined.

Bladder and Bowel Dysfunction

Bladder and bowel dysfunction, also known as dysfunctional elimination syndrome, is known to contribute to pediatric UTI and VUR. Koff et al. (1998) originally coined the term *dysfunctional elimination syndrome,* which defined children who suffered from infrequent voiding, incomplete bladder emptying, constipation, and/or bladder overactivity. Generally, in addressing children with bladder dysfunction, there are two different entities: (1) overactive bladder and (2) dysfunctional voiding. Dysfunctional voiding terminology is used to describe children with no neurologic issues who exhibit increased activity of their pelvic floor during voiding (Sillen, 2008). Overactive bladder is defined as urinary urgency with or without urge incontinence, usually with frequency and nocturia (Wein and Rovner, 2002). Children suffering from dysfunctional elimination commonly are seen for evaluation of recurrent UTIs (with or without fever), daytime or nighttime urinary incontinence, urinary urgency, urinary frequency, constipation, and/or encopresis.

Children suffering from bladder dysfunction are relatively common. In a study of more than 3500 school-age children, Hellström et al. (1990) found that 6% of girls and 3.7% of boys had daytime urinary incontinence, and more than 8% of the girls showed a history of UTI. Another population-based study examined 1127 children aged 6 to 9 years and found that 29% reported at least one symptom suggestive of bladder dysfunction. Of these children, 9.4% of the girls and 2.8% of the boys had a reported history of a previous UTI (Hansen et al., 1997).

Treatment of a child's bladder and bowel issues reduces recurrent UTIs and improves VUR resolution. Treating children suffering from bladder overactivity with anticholinergics alone resulted in VUR resolution or improvement in 44% to 79% of children (Homsy et al., 1985; Koff and Murtagh, 1983; Scholtmeijer and Nijman, 1994). Treatment of children suffering from dysfunctional voiding with biofeedback resulted in VUR resolution in 55% to 63% of cases and improvement in VUR grade after 1 year of therapy (Kibar et al., 2007; Palmer et al., 2002). Treating bladder dysfunction improves a child's incontinence and reduces the risk of UTI development. Treatment of constipation also improves daytime and nighttime urinary incontinence and helps reduce the incidence of recurrent UTIs. In a study by Loening-Baucke (1997), 234 patients were treated for constipation. At baseline, 46% of these patients suffered from either daytime and/or nighttime urinary incontinence, whereas 11% had suffered at least one UTI. The UTIs were more common in constipated girls compared with constipated boys. Follow-up at least 12 months after starting constipation therapies showed that constipation was successfully relieved in 52% of the children. Relief of constipation resulted in the disappearance of daytime urinary incontinence in 89% and enuresis in 63%, and disappearance of all UTIs in all patients who were without any genitourinary tract anatomic abnormalities.

Neurogenic Bladder

Children with neurogenic bladders and elevated bladder storage pressures risk developing hydronephrosis and renal damage from the increased bladder pressure. In addition to this increased pressure, the physiologic effects of UTI have also been demonstrated to increase intrarenal pelvic pressures and to contribute to an even greater likelihood of renal damage in these individuals (Hansen et al., 2003). When left untreated, children with neurogenic bladders that fill or empty at abnormally high pressures appear to be at higher risk of developing UTIs and renal damage, possibly because of their inability to clear the bacteria spontaneously. Clean intermittent catheterizations facilitate the emptying of the bladders of patients with neurogenic bladder and lower chronic bladder distention and bladder pressure. **Multiple studies demonstrate that 40% to 80% of individuals who intermittently catheterize develop chronic bacteriuria and/or pyuria and most are asymptomatic. Importantly, this catheter-associated ASB appears to lack morbidity most of the time** (de la Hunt et al., 1989; Geraniotis et al., 1988; Gribble and Puterman, 1993; Johnson et al., 1994; Joseph et al., 1989; Schlager et al., 1995). **Ottolini et al.** (1995) **concluded that in the absence of VUR, ASB in patients managed with clean intermittent catheterization is not a significant risk factor for renal damage and does not require antibiotic therapy. Furthermore, stopping prophylactic antibiotic in children with spina bifida is associated with reduced bacterial resistance** (Zegers et al., 2017). In addition, even though most of these children have urine colonized with bacteria, most can undergo urodynamic studies without the need for prophylactic antibiotics (Shekarriz et al., 1999).

Some clinicians prescribe daily prophylactic antibiotics for children who perform chronic clean intermittent catheterization. This practice may delay or decrease bacteriuria in the short term, but in the long term, these prophylactic antibiotics have not been shown to be beneficial and instead may lead to the development of bacterial resistance (Clarke et al., 2005; Johnson et al., 1994). Studies have also been performed evaluating the use of different catheters and their effect on UTI development. **The use of sterile versus nonsterile, single versus multiuse, and lubricated versus nonlubricated catheters have shown no benefit in reducing the risk of UTI development** (Kiddo et al., 2015; Moore et al., 2007; Schlager et al., 1995). Bakke and Vollset (1993) identified that risk factors for UTI development in men and women treated with intermittent catheterization included high mean catheterization volume in women and low frequency of catheterization in men. In addition, they found that patients managed with prophylactic antibiotics were less prone to developing bacteriuria but were more prone to developing clinical UTIs. These findings point toward the role that timely, scheduled catheterizations play in preventing UTIs in those patients managed with clean intermittent catheterization.

Iatrogenic Factors

Catheter-associated UTI (CAUTI) is the most common nosocomial infection, accounting for more than 1 million cases each year in US hospitals and nursing homes (Tambyah and Maki, 2000). **The risk of UTI increases with the duration that the catheter is in place, and the overall incidence of bacteriuria is 8% and ranges from 3% to 10% per day** (Sedor and Mulholland, 1999). In children, nosocomial UTIs account for 6% to 18% of nosocomial infections on pediatric hospital services (Ford-Jones et al., 1989; Lohr et al., 1989). Nosocomial UTIs typically necessitate one extra hospital day per patient or nearly 1 million extra hospital days annually in the United States (Foxman, 2002).

CAUTI has been a prominent target for prevention and intervention. Over a 10-year period from 2001 to 2010, one study found that 3.8 million of 70.4 million catheterized adults developed a CAUTI (Daniels et al., 2014). Over this time, as the impetus to prevent CAUTIs has become realized, the CAUTI incidence rate has decreased from 9.4 cases per 100 catheterizations in 2001 to 5.3 cases per 100 catheterizations in 2010. Mortality from CAUTIs has also declined during this time from 5.4% in 2001 to 3.7% in 2010. Identified risk factors in children include duration of catheterization, a child with contact precautions, and a history of prior catheterization (Lee et al., 2016). **The best way to avoid the morbidity of CAUTI and its related cost is the judicious use of urinary catheters and the removal of urethral catheters in hospitalized patients as soon as they are no longer medically necessary.** In the most recent Healthcare Infection Control Practices Advisory Committee (HICPAC) guidelines, HICPAC notes that catheters should be placed in patients only as a necessity, rather than a convenience (Gould et al., 2009). In addition, HICPAC recommends the consideration of the use of alternatives to indwelling catheters when considered appropriate. These alternatives include the use of external catheters such as a condom-catheter and intermittent catheterization.

Immune Status

Generally, UTIs in young, healthy women are benign conditions with no long-term effects. In contrast, UTIs in young children and geriatric adults seem to be more complicated, with increased morbidity and long-term consequences (Shortliffe and McCue, 2002). Although this contrasting paradigm is incompletely understood, we know that the immune system is diminished at either end of the age spectrum, which may make younger and older individuals more susceptible to urinary infections. Clearly, the first few months of life appear to be the time of greatest risk for the development of UTI (Chang and Shortliffe, 2006). This increased susceptibility may in part be a result of an immature immune system. Serum IgG is lowest from age 1 to 3 months; serum IgA is also found in lower concentrations during the first several months of life and is known to be absent or almost absent along the urothelium during this time (Fliedner et al., 1986; Svanborg Eden et al., 1985; Yoder and Polin, 1986). A discussion of the role that one's immune system may play in UTI development should include the role that a strengthened immune system can play in UTI prevention. Based on these thoughts, there have been attempts to develop UTI vaccines. Since the mid-1990s, several vaccine approaches have been explored, including the use of heat-killed whole bacteria, bacterial cell extracts, and purified UPEC-associated virulence factors as antigens (Barber et al., 2013).

Because adherence is a key factor in UTI pathogenesis, one strategy for the development of vaccine therapy has been to target CUP pili. Vaccination with whole pili has not been effective in generating an antibody response that can protect against UTI development. However, adhesion-based vaccines have been shown to be effective at preventing host-pathogen interactions, thus preventing UTI establishment (Langermann et al., 2000; Mushtaq et al., 2013; Roberts et al., 2004; Savar et al., 2014). Most of these vaccines have been tested in animal models, but in January 2014 a Phase I clinical trial began to evaluate the efficacy of a FimC-FimH vaccine using a synthetic analogue of monophosphoryl lipid A as the adjuvant. Pathogenic UTI-causing bacteria rely on iron-chelating molecules and receptors that allow them to scavenge essential iron from the host (Wiles et al., 2008). The use of purified bacterial iron receptor proteins for vaccination has shown mixed results. Two iron receptors tested as vaccines in mice, IreA and LutA, provided protection against cystitis, whereas vaccination with another iron receptor, Hma, has demonstrated protection against pyelonephritis but not cystitis (Alteri et al., 2009).

These preliminary studies highlight how the focus on different virulence factors may serve as valuable vaccination candidates to prevent UTI from developing. However, similar to our current experience with anticancer chemotherapeutics, we must remember that the use of such factors in vaccine target development may result in inadvertent effects on members of the endogenous microfloras that naturally colonize our bodies that help prevent pathologic UTIs (Barber et al., 2013). Certain delivery methods and other adjuvants may be used in the future to prevent such side effects, and certainly such therapeutics may be useful for individuals susceptible to UTI development, whereas in others the costs and risks may not warrant vaccination.

Key Points: Host Risk Factors

- A multitude of host factors may make a child more susceptible to UTI development.
- The only time when UTIs are more prevalent in boys than in girls is at less than 1 year of age.
- Circumcision reduces the rate of UTI development in the first 6 months of life by almost 10-fold.
- Dysfunctional elimination syndrome is an important factor contributing to pediatric UTI development, and treatment of a child's bladder and bowel issues reduces recurrent UTIs and improves VUR resolution.
- In the absence of VUR, ASB in patients managed with clean intermittent catheterization is not a significant risk factor for renal damage and does not require antibiotic therapy.
- CAUTI is the most common nosocomial infection, and the majority of these infections may be prevented with the judicious use of indwelling catheters.

Classification of Pediatric Urinary Tract Infections

There are several ways to classify UTIs: complicated versus uncomplicated, upper (pyelonephritis) versus lower (cystitis), and first infection versus recurrent infections. A complicated UTI describes infections in individuals who have anatomic or functional abnormalities or the presence of foreign bodies such as ureteral stents or indwelling urethral catheters. This classification, however, may not be best applied to children because infections in neonates or infants are presumed to be complicated because of the common occurrence of urinary tract anatomic abnormalities and the high risk of morbidity in these young patients (Benador et al., 1997; Smellie et al., 1998).

UTIs are usually classified as involving the upper urinary tracts, based on the patient's clinical symptoms. Children are generally assumed to have pyelonephritis when they have a UTI associated with high fevers, nausea, vomiting, flank pain, or lethargy. On the other hand, cystitis is suspected when the child is afebrile and has only lower urinary tract symptoms, including urinary urgency, frequency or dysuria, malodorous urine, and/or suprapubic tenderness. However, using a child's presenting clinical symptoms to classify UTIs into lower and upper urinary tract involvement is not 100% accurate. DMSA scans are considered the gold standard for diagnosing a pyelonephritic infection. **Studies using DMSA scans have shown that, although the majority of patients with fever and systemic clinical findings consistent with acute pyelonephritis (APN) have positive renal scans, there is still a high false-positive rate when relying on symptoms alone to distinguish pyelonephritis from cystitis. Rushton and Majd** (1992) **and Tappin et al.** (1989) **demonstrated that in patients with fever and systemic symptoms, only 50% to 66% demonstrated acute inflammatory changes on DMSA scans. In addition, a small subset of patients who present with afebrile, seemingly lower UTIs may have a positive DMSA scan consistent with APN** (Verboven et al., 1990), but this was noted in only 1 of 9 patients. Differentiation of cystitis and pyelonephritis can also be difficult in children based on the nonspecific symptoms that children may exhibit at the time of their infection. This is especially true in infants younger than 90 days, who commonly experience symptoms that are difficult to interpret, such as failure to thrive, diarrhea, irritability, lethargy, malodorous urine, asymptomatic jaundice, oliguria, or polyuria (Chang and Shortliffe, 2006; Garcia and Nager, 2002).

Recurrent UTIs can be further subdivided into unresolved bacteriuria, bacterial persistence, and reinfection. Unresolved bacteriuria is most commonly caused by inadequate bacterial therapy, which could be secondary to noncompliance, antibiotic malabsorption, suboptimal drug metabolism, and resistant uropathogens that were unresponsive to the attempted therapy (Pewitt and Schaffer, 1997). In these instances, repeated directed treatment based on bacterial sensitivities determined by proper urine culture typically results in resolution of the infection.

Bacterial persistence and reinfection occur after sterile urine has been documented after previous UTI therapy. In cases of bacterial persistence, typically the nidus causing the infection has not been eradicated. Usually the same pathogen is documented on urine cultures during subsequent UTI episodes, despite negative cultures after previous antibiotic treatment. The uropathogen typically resides in a location shielded from antimicrobial therapy. Protected sites include anatomic abnormalities, urinary calculi, necrotic papillae, or foreign objects (i.e., urinary catheters, ureteral stents) (Abrahams and Stoller, 2003; Conrad et al., 1991; Kehinde et al., 2004; Richter et al., 2000; Schlager et al., 2001). Identification of the nidus is important, because typically the infection will persist until the source is removed.

Biofilms

Biofilms appear to play a role in bacterial persistence. Biofilms are structured communities of microorganisms encapsulated with a self-developed polymeric matrix and adherent to a living or inert surface (Tenke et al., 2012). **Antibiotics that are usually adept at microbial eradication often are unable to eradicate bacteria within a biofilm.** The failure of antimicrobial agents to treat biofilms has been associated with the following factors: (1) agents often fail to penetrate the full depth of a biofilm, (2) organisms within a biofilm often grow slowly and are resistant to the antibiotics that usually require active growth, (3) antimicrobial-binding proteins are poorly expressed in these biofilm bacteria, (4) bacteria within a biofilm activate many genes that alter the cell envelope, the molecular targets, and the susceptibility to antimicrobial agents, and (5) bacteria in a biofilm can survive in the presence of antimicrobial agents at a concentration 1000 to 1500 times higher than the concentration normally necessary to kill nonbiofilm-associated bacteria in the same species (Tenke et al., 2006).

Formation of biofilms may allow bacteria to exist at a bladder and at a kidney level. After bacteria reach the kidney, they have been shown to adhere to the urothelium and papillae. In animal models, these bacteria can adhere in thin biofilms to the urothelium before invading the renal tissue (Nickel et al., 1994). It has been further shown that antibacterial agents are less effective against bacteria within these renal biofilms (Nickel et al., 1994).

In addition, biofilms have been shown to form in foreign bodies within the genitourinary tract. These foreign bodies include urinary catheters, ureteral stents, and urinary calculi. Organisms have been shown to ascend through urethral catheters via extraluminal and intraluminal routes. Organisms colonizing the external surfaces of catheters seem to originate from either the gastrointestinal tract or the perineum, whereas intraluminal bacteria appear to come from exogenous sources (Tenke et al., 2012). In fact, it has been shown that 68% to 90% of ureteral stents become colonized with bacteria, whereas the rate of bacteriuria in the same patients is only 27% to 30% (Farsi et al., 1995; Reid et al., 1992).

Asymptomatic Bacteriuria

ASB is defined as the presence of two consecutive urine specimens yielding positive cultures ($>10^5$ CFU/mL) of the same uropathogen in a patient who is free of any infectious symptoms (Kass, 1956). It remains unclear why certain individuals with ASB do not develop symptoms, especially because the organisms recovered from their urine are commonly the same as those seen in patients suffering symptomatic UTIs. In fact, the most common organism obtained from these ASB individuals is *E. coli* (Raz, 2003). One possible mechanism is that the organisms infecting these asymptomatic individuals may be less virulent, resulting in colonization rather than infection.

Some have suggested that the term *asymptomatic bacteriuria* is misleading; some studies have shown that ASB is not always asymptomatic. Gaymans et al. (1976) noted that 30% of women in their study who were initially diagnosed with ASB later became symptomatic and required antibiotic therapy. Furthermore, Savage (1975) found that, although 1.6% of schoolgirls studied suffered from ASB, 60% to 70% of these children actually suffered from lower urinary tract symptoms and daytime and nighttime incontinence, which they admitted after careful questioning. Therefore these children with ASB may have actually been symptomatic.

ASB occurs in less than 1% of full-term infants and in 3% of premature infants (Edelmann et al., 1973). The identification of bacteriuria in these otherwise asymptomatic children is important because these young children may have few signs and symptoms in the face of an infection, and ASB may actually be a marker of underlying genitourinary disease. Given these issues, these infants should be treated with antimicrobial therapy and also should be imaged to evaluate for any congenital issues that could be leading to bacterial colonization (Whitworth, 1981). **ASB occurs in 0.8% of preschool girls and even fewer preschool boys** (Siegel et al., 1980). **Children in this age group who are without VUR and/or other genitourinary abnormalities do not require antibiotics to clear their bacteria because they do not appear to be at any risk for recurrent symptomatic infections, renal damage, or impaired renal growth** (Sidor and Resnick, 1983).

The annual incidence of ASB in school-age girls ranges from 1% to 2%, although about 5% of all school-age girls are estimated to have ASB by the age of 15 years (Kunin et al., 1964; Meadow et al., 1969; Savage et al., 1969). In these school-age girls, spontaneous resolution occurred in 50% in one study, although the 50% who cleared their infection were found to harbor ASB 1 year later (Raz, 2003). Of these patients were treated with antibiotics at the time of identifying the ASB, 20% had persistent cure, whereas 80% had recurrence, and some of these recurrent infections were symptomatic. Girls at this age who are found to have ASB are at very low risk for developing a decline in their renal function or for developing hypertension (Kunin, 1985; Lindberg et al., 1978). **Because antimicrobial therapy in these individuals is unlikely to prevent later asymptomatic or symptomatic bacteriuria, and untreated individuals appear to be at low risk of developing long-term sequelae related to the bacteriuria, routine antimicrobial therapy is not recommended.** Also, routine prophylactic antibiotics could certainly lead to alteration of their microbiota and increased antibiotic resistance in these individuals.

Screening children for ASB is not cost effective. Kemper and Avner (1992) showed that given the sensitivity and specificity of our screening methods and the prevalence of bacteriuria in asymptomatic children, routine screening would result in 20% false-positives. Because there is no evidence that detection and treatment of children with ASB prevent long-term consequences, they surmised that routine screening is neither cost effective nor warranted.

Bacterial Nephritis

Acute bacterial nephritis occurs as the inflammation from bacterial infection within the kidney begins to spread throughout the kidney in an increasingly suppurative process with heavier leukocytic infiltrate and focal areas of tissue necrosis (Davidson and Talner, 1973). **The advanced generalized form of acute nephritis has been termed *acute bacterial nephritis*, whereas the localized form has been called *acute focal bacterial nephritis* or *lobar nephronia*** (Lee et al., 1980). In these individuals, clinical signs and symptoms of septicemia are often present (Thornbury, 1991). Computed tomography (CT) findings include global renal enlargement, inflammatory changes in the perirenal fat, and thickening of Gerota fascia (Soulen et al., 1989). On contrast images, there may be ill-defined, nonhomogeneous decreased parenchymal enhancement that typically is wedge shaped (Fig. 25.5).

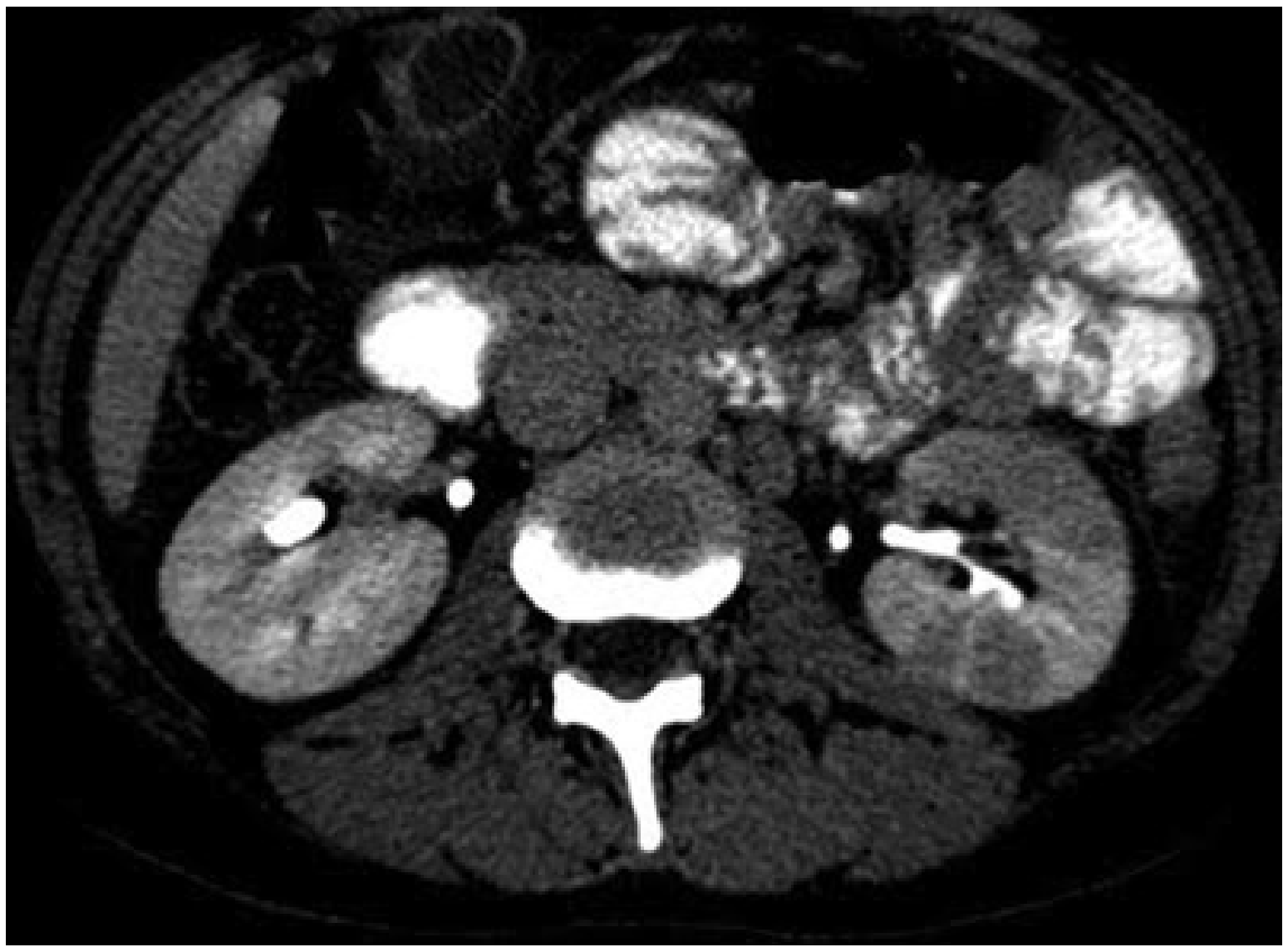

FIG. 25.5 Computed tomography scan demonstrating acute focal pyelonephritis (lobar nephronia).

Pyonephrosis

If purulent exudate from APN accumulates in a dilated renal collecting system, pyonephrosis may occur (Thornbury, 1991). This condition commonly occurs in a hydronephrotic kidney secondary to an obstructed urinary outflow. CT findings typically include an enlarged kidney with a grossly dilated collecting system containing higher-than-usual fluid attenuation.

Acute Renal Abscess

Individuals with a renal abscess often have symptoms similar to patients with pyelonephritis; however, in up to 20% of renal abscess cases, the urine culture may be negative (Thornbury, 1991). This diagnosis is usually based on radiographic findings. Ultrasound can detect an abscess as small as 1 cm and usually appears as a sonolucent area containing low-amplitude echoes (Soulen et al., 1989). CT appears to be the most sensitive and specific imaging modality to use in making the diagnosis of a renal abscess. Associated early CT findings include (1) a well-defined area of low attenuation or decreased enhancement or (2) a striated, wedge-shaped zone of increased or decreased enhancement. In later phases, these areas may coalesce to form a well-defined mass with homogeneous internal attenuation features indicating purulent fluid.

Key Points: Classification

- UTIs may be classified in a variety of ways.
- A UTI is commonly classified as pyelonephritis based on the patient's presenting symptoms, which commonly include fever, flank pain, nausea, and vomiting; however, based on DMSA studies, only 50% to 66% of patients with these symptoms demonstrate acute inflammatory changes on their DMSA scan.
- ASB occurs in 0.8% of preschool girls and even fewer preschool boys. Children in this age group who are without VUR and/or other genitourinary abnormalities do not require antibiotics to clear their bacteria, because they do not appear to be at any risk for recurrent symptomatic infections, renal damage, or impaired renal growth.

Diagnosis of Pediatric Urinary Tract Infection

Defining what constitutes a UTI is surprisingly difficult. Although multiple international guidelines delineate the diagnosis, evaluation, and management of pediatric UTIs, they differ significantly, and a consensus is lacking (Ammenti et al., 2012; Mori et al., 2007; Royal Children's Hospital Melbourne, 2011; Subcommittee on Urinary Tract Infection et al., 2011). At the most basic level, a UTI consists of the invasion of the urinary tract by organisms that result in pathologic changes. These pathologic changes may be caused directly by the infecting organism or by the host response to the infectious agent. In most cases, the individual also suffers symptoms from a UTI. To prove that a patient is experiencing a UTI requires a demonstration of the presence of the infecting organism in the urine and a confirmation that this organism is pathogenic. The presence of the infecting organism is routinely proven by urine culture. The presence of pathology within the urinary tract is frequently inferred by symptoms or by evidence of an immune response identified by urine or blood tests. As discussed in the following sections, controversy exists regarding the best method to obtain urine for analysis and culture as well as regarding the results that can be considered indicative of a true UTI.

Symptoms

The classic symptoms in an adult with a UTI, such as dysuria, frequency, urgency, or suprapubic or flank pain, become progressively more difficult to identify with decreasing age in the pediatric population. Symptoms in infants and young pediatric patients are typically nonspecific and include fever, irritability, poor feeding, jaundice, failure to thrive, vomiting, diarrhea, abdominal distention, or foul-smelling urine (Craig et al., 2010; Rudinsky et al., 2009; White, 2011).

Early after the neonatal period, fever is usually the primary symptom that leads to the diagnosis of a pediatric UTI. The overall prevalence of a UTI in febrile infants with no other identified source of fever is about 5% (Haddon et al., 1999; Hoberman et al., 1993). Fever lasting more than 2 days that is greater than or equal to 38°C without an identified source has been shown to have a positive likelihood ratio of 3.6 (confidence interval [CI] 1.4 to 8.8) of being an occult UTI (Shaikh et al., 2007). This likelihood increases with the duration and height of the fever. Although children with pyelonephritis tend to have fever, as noted previously, this is a nonspecific sign, and children with acute cystitis may also have fever. Older children may complain of more classic symptoms, such as dysuria, incontinence, changes in voiding habits, enuresis, or flank or abdominal pain (Shaikh et al., 2007). However, even when these symptoms are present, they are nonspecific and, in one series of children aged 2 to 19 years with such symptoms, the prevalence of a UTI was only 7.8% (Shaikh et al., 2008). Other causes of lower urinary tract symptoms are frequently seen in patients with bladder and bowel dysfunction or vulvovaginitis. **The lack of specific symptoms produced by a UTI frequently contributes to a lack of prompt diagnosis and treatment; however, the high prevalence of pediatric UTI dictates that it must remain a diagnostic consideration by clinicians caring for children.**

Because the specificity of UTI symptoms is lowest in neonates and young children, as is the difficulty in obtaining urine for analysis and culture in this age group, the AAP 2011 guidelines contained an action statement to assist physicians in determining which febrile children between 2 and 24 months of age should be tested for a UTI (Subcommittee on Urinary Tract Infection et al., 2011). This statement recommends that if the clinician believes a febrile infant with no apparent source of fever is not so ill as to require immediate antimicrobial therapy, then the likelihood of UTI should be assessed. If the likelihood of a UTI is low (<1%), then the infant could be followed without urine testing. If the likelihood is higher, urinary evaluation should be considered. The probability of a UTI in girls has been shown to be greater than or equal to 1%, and the probability is 2% if they had two or more, or three or more, of the following risk factors, respectively: white race, age less than 12 months, temperature greater than or equal to 39°C, fever lasting 2 days or more, or absence of another source of infection (Gorelick and Shaw, 2000). The probability of a UTI in an uncircumcised febrile boy between 2 and 24 months exceeds 1% without any other risk factors. In a circumcised febrile boy, the probability of a UTI has been found to be greater than or equal to 1%, and the probability is 2% if they had three or more of the following risk factors, respectively: nonblack race, temperature greater than or equal to 39°C, fever lasting 2 days or more, or absence of another source of infection (Shaikh et al., 2007).

In addition to the symptoms previously noted, risk factors for UTI should be elicited, such as a history of a previous UTI. Children younger than 6 years with a documented UTI have been noted to have a 12% risk of recurrence per year in a community-based study (Conway et al., 2007). Other risk factors that should be evaluated include the presence of genitourinary anomaly, history of abnormal prenatal or postnatal ultrasounds, family history, and previous genitourinary or gastrointestinal surgery. Such risk factors increase the probability of a UTI and the need for evaluation of a UTI in an unwell child. They may also point to predisposing conditions that require evaluation and treatment. **The possibility of sexually transmitted diseases in older children and adolescents with symptoms of urethritis must be considered. Urethritis can be caused by *Neisseria gonorrhoeae*, *Chlamydia trachomatis*, or *Ureaplasma urealyticum*, as well as routine uropathogens.**

A multicenter diagnostic and prospective observational study (Improving the Diagnosis and Treatment of UTI in Young Children in Primary Care [DUTY]) of 2740 children younger than 5 years of age in the United Kingdom was performed to identify clinical predictors, including signs, symptoms, and urine dipstick results that were most strongly associated with a UTI (Hay et al., 2016). Symptoms and signs that were useful in determining if a urine sample should be collected included pain/crying with passing urine, smelly urine, previous UTI, absence of severe cough, and impression of a severe illness being present. The same signs and symptoms, along with urine dipstick–positive leukocytes, nitrites, and/or blood, were useful in determining if antibiotic treatment was warranted. The authors of the study developed a point system based on these signs, symptoms, and dipstick results and demonstrated it was more accurate than clinical impression alone.

Physical Examination

Specific findings on physical examination in young children are rare and may consist of fever or lethargy. **Even if another source of fever and infection such as otitis, upper respiratory infection, or gastroenteritis has been identified, the clinician must keep in mind that a concurrent UTI has not been excluded.** It is not unusual for the pediatric urologist to see children with a history of recurrent episodes of otitis after their first diagnosed UTI and a subsequent DMSA scan showing renal scars suggesting that the children had multiple previous episodes of pyelonephritis misdiagnosed as otitis. The reduction in risk of a UTI when another infectious source has been identified may be smaller than anticipated, with several studies demonstrating a risk reduction of only about 50% (Bhat et al., 2011). In a study of 2411 febrile 1-year-old children, the prevalence of a UTI without an identified fever source was 5.9%, compared with 2.7% in those with a potential source (Shaw et al., 1998). In this study, the examining clinician incorrectly thought 64% of children with UTI had another source of fever. This highlights the need to **consider the possibility of a UTI in any febrile infant, even if another source has been identified.**

Boys and girls should have an abdominal examination to assess for a palpable abdominal mass that may indicate bladder distention or a flank mass consistent with hydronephrosis. Older children may experience suprapubic, abdominal, or flank tenderness. Costovertebral angle tenderness is suggestive of pyelonephritis. A careful examination of the external genitalia should be performed to rule out trauma, local irritation, urethral meatal stenosis or discharge, phimosis, foreign body, and anatomic abnormalities. Boys should be examined for testicular tenderness, which may be a sign of epididymo-orchitis. The introitus should be inspected in girls for discharge and signs of local irritation, ectopic ureter, or protruding urethral mass such as a prolapsing ureterocele. Examination of the back for signs of spina bifida occulta such as a prominent fat pad or asymmetric gluteal cleft or sacral dimple, along with a neurologic examination, may point to underlying neurologic causes of abnormal bladder function predisposing to UTIs.

Laboratories

Urine Collection Methods

Because of the nonspecific symptoms and signs, the diagnosis of a UTI requires the demonstration of an infectious agent or agents in the urine. In addition, the AAP guidelines also require evidence of pyuria for the diagnosis of a UTI to help distinguish a true infection from ASB or contamination. **Unfortunately, the chance of collecting a contaminated urine specimen increases with the decreasing degree of invasive collecting methods.** Different guidelines suggest different methods of collecting urine specimens. The least invasive method of obtaining a urine specimen consists of affixing a collection bag to the perineum. This method has the highest chance of contamination by perineal and rectal flora, as well as by white blood cells (WBCs) from outside the urinary tract, producing false-positive results. The urine from a collection bag only provides reliable information when the specimen is normal. A clean-catch midstream urine sample is also noninvasive but carries a higher chance of contamination from periurethral tissues than urine collected via more invasive methods including catheterization or SPA. The clean-catch urine is more reliable in an older girl or a circumcised boy or in an uncircumcised boy who will retract his foreskin compared with a younger girl or an uncircumcised boy who cannot retract the foreskin.

For young, non–toilet-trained children younger than 2 years of age, the AAP guidelines recommend either SPA or catheterization. The disadvantages of these methods include their invasiveness and the potential for trauma or infection and the fact that they may not be feasible as a routine procedure in primary care. The guidelines of the National Institute for Health and Care Excellence (NICE), Italian Society of Pediatric Nephrology (ISPN), and Royal Children's Hospital (RCH) Melbourne recommend a clean-catch urine specimen when possible. Compared with SPA, the clean-catch urine for culture has a sensitivity of 75% to 100% and a specificity of 57% to 100% (Bitsori and Galanakis, 2012; Whiting et al., 2006). Compared with SPA, the catheterized urine has a sensitivity of 95% and a specificity of 99% (Roberts, 2012).

Catheter insertion should be performed in a sterile fashion. The use of intraurethral and/or topical lidocaine has been demonstrated effective in reducing discomfort with bladder catheterization (Gerard et al., 2003; Mularoni et al., 2009; Vaughan et al., 2005). Successful catheterization in girls often requires a two-person technique. The labia majora should each be placed on gentle traction outward from the body and slightly lateral to help expose the vaginal and urethral opening to facilitate the correct location for catheter insertion. This method, as opposed to using a single hand and fingers spreading the labia laterally, more routinely exposes the normally recessed urethral opening and the surrounding anatomic landmarks. The exposure with this two-hand technique reduces the temptation to pull the labia too far laterally, which may occur with a single hand. Pulling the labia too far laterally can cause pain, making subsequent catheterization far more difficult and traumatic. After catheter insertion, the first several drops of urine obtained from a catheter should not be collected because they may contain urethral bacterial contamination.

The method of suprapubic aspiration involves prepping the skin and inserting a 22-gauge needle 1 to 2 cm above the pubic bone into the bladder and aspirating the urine into a sterile syringe. The reported success rates of obtaining urine by

SPA are variable and, although not routinely required, ultrasound confirmation of urine in the bladder, as well as guidance during the procedure, have demonstrated improved success rates (Buys et al., 1994; Gochman et al., 1991). Topical or local anesthetic may also be used, but data confirming a significant reduction in discomfort with their use are lacking.

Urinalysis

UA routinely consists of urinary dipstick testing and microscopic examination. A UA specimen should be performed on urine less than 1 hour after voiding if the specimen has been maintained at room temperature or less than 4 hours if refrigerated. Although a urine culture is the gold standard for diagnosis of a UTI, a culture requires at least 18 hours to demonstrate growth and 2 to 3 days to determine the final result and antibiotic susceptibilities. The UA provides rapid information that may be used to determine the likelihood of a UTI and the appropriateness of beginning antibiotic treatment for a presumed UTI. Although threshold values for positive and negative dipstick and microscopic examination results have not been adjusted for urinary specific gravity (i.e., dilution/concentration), it has been demonstrated that the positive and negative likelihood ratios of these results are affected by urine concentration (Chaudhari et al., 2017).

Urine Dipstick Tests

The most frequently used dipstick tests for evaluation of UTI include leukocyte esterase and nitrite. Leukocyte esterase is released from white cells that are broken down in the urine and serves as a marker for pyuria. **The sensitivity of leukocyte esterase for detecting UTI ranges from 47% to 95% in various studies with a summary estimate of 79% (95% CI 73%–84%)** (Hoberman et al., 1994; Williams et al., 2010). **The specificity ranges from 64%–92%, with false-positives resulting from other causes of inflammation or white cells in the urine** (Subcommittee on Urinary Tract Infection et al., 2011). **The summary estimate of leukocyte esterase specificity was 87% (95% CI 79%–91%) in a large meta-analysis by Williams et al.** (2010). The addition of other urinary biomarkers to the UA leukocyte esterase results, including AMPs, human a-defensin 5 (HD5) and human neutrophil peptides (HNP) 1–3, offer the possibility of improved UA specificity (Watson et al., 2016). Although some estimate that the leukocyte esterase test misses more than 20% of children with a

UTI, the AAP guidelines suggest the absence of leukocyte esterase in the urine helps distinguish individuals with ASB from those with a true UTI, because the absence of pyuria in children with a true UTI is rare (Bhat et al., 2011; Subcommittee on Urinary Tract Infection et al., 2011).

Urinary nitrite is reduced from dietary nitrates in the urine by gram-negative enteric bacteria. This conversion requires several hours to occur; thus a first-morning urine has the best sensitivity with this test. Frequent urination, as is often the case in infants and small children, may not permit enough time for the urine in the bladder to undergo significant conversion of nitrates to nitrites and therefore may result in a false-negative nitrite test more frequently than in older children (Mori et al., 2010). A dilute urine may also generate a false-negative test. Other reasons for false-negative tests include infection with gram-positive organisms that do not reduce nitrates. **Because of false-negatives, the sensitivity of the nitrite test is about 50%, with a reported range from 8% to 95%. The specificity, however, is very high, at 98%, with a range from 90% to 100%, meaning a positive nitrite test is very likely to reflect a true UTI.** In the large meta-analysis by Williams et al. (2010) the sensitivity and specificity for nitrites were 49% (95% CI 41%–57%) and 98% (95% CI 96%–99%), respectively.

If either leukocyte esterase or nitrite is positive, the sensitivity and specificity for UTI has been reported to be 88% (95% CI 82%–91%) and 79% (95% CI 69%–87%), respectively (Williams et al., 2010). If either of these tests is positive or the microscopic UA is positive (see following), the sensitivity increases to 99.8% with a specificity of 70% (Subcommittee on Urinary Tract Infection et al., 2011). If both tests are negative, the presence of a UTI is much less likely, with a negative likelihood ratio of 0.22; however, based on the severity of the clinical picture, including a consideration of the patient's age, in many cases the safest course of action may be to continue antibiotics until culture results are available (Perkins et al., 2012). Although not widely used, some have suggested that the addition of the dipstick results for blood and protein to leukocyte esterase and nitrite results improves sensitivity and specificity. Ramlakhan et al. (2011) demonstrated that if a sample was negative for all four of these parameters, the sensitivity for ruling out a UTI was 97.4% (95% CI 91%–99%) and a negative likelihood ratio of 0.10 (95% CI 0.02%–0.39%). They noted the best test for confirming a UTI was a combination of leukocyte esterase and nitrite and blood, with a specificity of 97.1% (95% CI 94%–99%) and positive likelihood ratio of 15.13 (6.99–32.76).

Urine Microscopic Examination

The traditional method of assessing pyuria by microscopy is on a centrifuged urine specimen with a threshold of 5 WBCs per high-power field (HPF); however, a threshold of 10 WBCs/HPF has been considered more reliable to predict UTI in children younger than 2 years old by the NICE, ISPN, and RCH Melbourne guidelines (Bitsori and Galanakis, 2012). Williams et al. (2010) reported the sensitivity and specificity of 5 microscopic WBCs/HPF for determining UTI as 74% (95% CI 67%–80%) and 86% (95% CI 82%–90%), respectively. The true positive rate for 5 WBCs/HPF and for 10 WBCs/HPF has been reported as 67% (range 55%–88%) and 77% (range 57%–92%), respectively. False-positive rates for 5 and 10 WBCs/HPF have been reported as 21% and 11%, respectively (Gorelick and Shaw, 1999). Given the sensitivity and specificity of microscopic pyuria, there does not appear to be an advantage of microscopy for WBCs alone over leukocyte esterase for the determination of UTI, and the additive value of microscopy to dipstick results is questionable (Cantey et al., 2015).

The most reliable rapid test for diagnosing a UTI consists of the microscopic identification of bacteria on unstained and Gram-stained uncentrifuged fresh urine specimens (Gorelick and Shaw, 1999; Williams et al., 2010). The sensitivity and specificity for microscopic bacteria are improved by Gram stain (Subcommittee on Urinary Tract Infection et al., 2011). The sensitivity of microscopic bacteria on Gram-stained samples to determine a UTI is 91% (95% CI 80%–96%) and on unstained samples it is 88% (95% CI 75%–94%). The specificity on stained and unstained samples is excellent at 96% and 92%, respectively; however, routine Gram stain does not appear to enhance the diagnosis of UTI in children undergoing UA (Cantey et al., 2015; Williams et al., 2010). Enhanced UA uses a WBC counting chamber on uncentrifuged urine and uses the microscopy of a Gram-stained urine smear for detection of bacteria. This improves predictive results but requires the availability of specialized equipment and personnel that are not routinely available in many clinical settings.

Urine Culture

A positive urine culture is essential for the diagnosis of a UTI. The definition of what constitutes a true positive urine culture based on the number of colony-forming units per milliliter of urine is debated. As with most tests,

the lower the threshold is set, the higher the likelihood of obtaining false-positive results and overtreating patients who do not have infection. Conversely, setting a higher threshold increases the chance of undertreating patients. Historically, the threshold used to diagnose a positive urine culture was greater than or equal to 10^5 CFU/mL of a uropathogen. However, this value was initially based on morning-voided urine samples in adult women, and this cutoff may not be as applicable in children (Kass, 1962).

Factors that may reduce the concentration of bacteria in the urine of a child with UTI include frequency of urination as well as urine output. At present, there is a lack of uniform agreement on what colony count should be used as the threshold values for the diagnosis of a pediatric UTI. The 2011 AAP guidelines suggest that, in children ages 2 to 24 months, the threshold value of greater than or equal to 10^5 CFU/mL be reduced. These new guidelines recommend that 50,000 CFU/mL, now including the requirement of a positive UA for pyuria from a urine sample obtained by catheterization or SPA, be used for the diagnosis of UTI. Alternatively, the European Association of Urology suggests that 10^4 CFU/mL is indicative of UTI with a midstream specimen if associated with symptoms, but 10^5 should be used if there are no symptoms (Downing et al., 2012).

Other guidelines have taken into consideration the risk of contamination by various methods of urine collection, and their threshold values have been adjusted accordingly. The RCH Melbourne guidelines suggest that any gram-negative bacteria by SPA and greater than 10^3 CFU/mL by catheterization is consistent with UTI. The ISPN guidelines use greater than 10^4 CFU/mL by catheterization for a catheterized specimen and more than 10^5 CFU/mL for a midstream/clean-catch specimen (Bitsori and Galanakis, 2012).

Contamination is more likely in cases with low colony counts. It is also more likely in cultures with heavy, mixed growth of bacteria. In such cultures, however, urologists must consider the possibility of the existence of a true UTI along with a contaminated specimen when making treatment decisions. Contamination is also more likely in cultures growing nonpathogenic organisms. Such organisms include *Lactobacillus*, coagulase-negative staphylococci, *Corynebacterium*, alpha-hemolytic streptococci, and *Candida* (Bhat et al., 2011).

Serum Tests

A variety of different serum and urine tests have been evaluated for their ability to differentiate kidney infection in a child with UTI. When bacteria invade the kidney, Toll-like receptor signaling initiates an immune response involving the production of cytokines and chemokines, and urinary levels of interleukin-6, interleukin-8, and transforming growth factor-β1 may be elevated (Krzemien et al., 2016; Montini et al., 2011). This local response may also be accompanied by a systemic response involving fever, elevated WBC, erythrocyte sedimentation rate (ESR), C-reactive protein (CRP), and procalcitonin. Fever, ESR, and peripheral WBC count have not been shown to differentiate reliably the upper from the lower UTI (Garin et al., 2007). CRP has reasonable sensitivity but low specificity for diagnosing kidney involvement, limiting its use (Bhat et al., 2011; Garin et al., 2007). Procalcitonin rises in response to bacterial endotoxins, although its exact role in the inflammatory response is unknown. **In a recent meta-analysis, procalcitonin was shown to be a more robust predictor compared with CRP or WBC for selectively identifying children who had APN during the early stages of UTI as well as those with late scarring as identified by DMSA scanning** (Leroy et al., 2013). **The sensitivity and specificity of a procalcitonin level greater than or equal to 0.5 ng/mL for detection of APN were 71% and 72%, respectively, and 70% sensitivity and 50% specificity for late renal scarring.** Although the sensitivity and specificity for procalcitonin appear limited, it is possible that combining this information with other clinical and laboratory data will improve identification of individuals with kidney infection and guide subsequent clinical management, including radiographic imaging (i.e., DMSA or voiding cystourethrogram [VCUG]). Investigation of urinary biomarkers, such as C-megalin, to identify children with renal scars after a febrile UTI is ongoing (Yamanouchi et al., 2017).

Key Points: Symptoms and Laboratory Analysis

- Symptoms of UTI in infants and young pediatric patients are typically nonspecific.
- Even if another source of fever and infection such as otitis, upper respiratory infection, or gastroenteritis has been identified, the clinician must keep in mind that a concurrent UTI has not been excluded.
- Urine from a collection bag only provides reliable information when the specimen is normal because of the high incidence of contamination.

- The guidelines for diagnostic criteria for a UTI vary.
- Leukocyte esterase has a high sensitivity but a lower specificity. Urinary nitrite has a high specificity but lower sensitivity.

Radiographic Imaging

Controversies With Imaging Strategies

As with many of the other aspects related to pediatric UTI, there is a lack of consensus regarding imaging after a first febrile UTI in children. Part of this controversy relates to a lack of evidence supporting the use of routine imaging in decreasing long-term sequelae of kidney infections, including renal scarring, hypertension, and renal insufficiency or failure (Moorthy et al., 2005; Wan et al., 2012; Wennerstrom et al., 2000). Previously, the standard evaluation consisted of an ultrasound and a VCUG. However, despite prevalence rates of VUR of more than 30% in many series of children with a febrile UTI, a lack of proven effectiveness of prophylactic antibiotics in preventing recurrent UTIs or renal scars in children with lower grades of VUR has led many to question the use of obtaining a VCUG in all children after their first UTI (Karmazyn et al., 2017). Recommendations vary significantly between guideline committees and various advocates (Table 25.1). The NICE guidelines recommend routinely obtaining an ultrasound in children less than 6 months old, but these guidelines limit it in those more than 6 months to children with either a recurrent UTI or an atypical UTI as defined by being seriously ill, by poor urine flow, by abdominal or bladder mass, by raised creatinine and septicemia, by failure to respond to treatment within 48 hours, or by infection with a non–*E. coli* organism (NICE, 2013). Conversely, the revised AAP guidelines recommended obtaining a renal ultrasound in all children less than 2 years of age with a febrile UTI, but these guidelines no longer recommend routinely performing a VCUG in these children if the ultrasound is normal (Subcommittee on Urinary Tract Infection et al., 2011). **In a rebuttal to the AAP guidelines, the Section of Urology of the AAP noted that the revised guideline was based on conclusions that were premature and represented a misinterpretation of data and did not agree that a VCUG should not be routinely performed** (Wan et al., 2012)**. Rather, they recommended that a VCUG remain as an accepted option. They noted that some children with VUR, most frequently those with higher-grade VUR, do benefit from early detection and treatment that prevents subsequent kidney infection, damage, and loss of function. Furthermore, the**

RIVUR study demonstrated a 50% reduction in febrile or symptomatic UTIs over 2 years in children with VUR on prophylaxis compared with placebo (Hoberman et al., 2014.)

TABLE 25.1

Summary of the Five Imaging Recommendations

GUIDELINES	ULTRASOUND	VOIDING CYSTOURETHROGRAM	LATE DMSA SCAN
RCH	Yes	If boys <6 mo and/or positive ultrasonography	No
NICE			
<6 mo	Yes	If positive ultrasonography and/or atypical UTI[a]	
≥6 mo	If atypical UTI	If children with risk factors[b]	If atypical UTI[a] If atypical UTI[a]
TDA	No	If positive acute DMSA	If positive acute DMSA
AAP	Yes	If positive ultrasonography	No
ISPN	Yes	If positive ultrasonography and/or children with risk factors[c]	If positive ultrasonography and/or VUR

[a] Seriously ill, poor urine flow, abdominal or bladder mass, raised creatinine, septicemia, failure to respond to correct antibiotic treatment within 48 h, or infection with non–*Escherichia coli* organisms.

[b] Dilation on ultrasonography, poor urine flow, non–*E. coli* infection, or family history of VUR.

[c] Abnormal prenatal ultrasonography of the urinary tract, family history of VUR, septicemia, renal failure, age <6 mo in a male infant, likely noncompliance of the family, abnormal bladder emptying, no clinical response to correct antibiotic treatment within 72 h, or non–*E. coli* infection.

AAP, Academy of Pediatrics; *DMSA,* ^{99m}Tc-dimercaptosuccinic acid; *ISPN,* Italian Society of Pediatric Nephrology; *NICE,* National Institute for Health and Care Excellence; *RCH,* Royal Children's Hospital (Melbourne); *TDA,* top-down approach; *UTI,* urinary tract infection; *VUR,* vesicoureteral reflux.

Data from La Scola C, De Mutiis C, Hewitt IK, et al.: Different guidelines for imaging after first UTI in febrile infants: yield, cost, and radiation. *Pediatrics* 131:e665–671, 2013.

Multiple studies have evaluated the potential sensitivity and specificity of various imaging guidelines after a first febrile UTI with respect to the identification of children with VUR, APN, or renal scars. One review demonstrated that the NICE and AAP protocols would miss 50% and 61% of children with grades III to V VUR and 62% and 100% of renal scars, respectively (La Scola et al., 2013). Another study demonstrated that the NICE protocol did not work as well in boys compared with girls with respect to negative predictive values (Wong et al., 2010). On the other hand, proponents of the NICE or AAP approaches note that significant numbers of children without high-grade VUR were spared the trauma, radiation exposure, and added expense by not undergoing a VCUG or a DMSA scan. In addition, proponents would note that those children possibly benefiting from the diagnosis of higher grades of VUR would be identified after a recurrent UTI and that prompt diagnosis and treatment of that recurrent UTI further minimizes the relatively low chance of renal damage and sequel in these children.

An alternative approach to imaging the febrile child with a UTI has been termed the *top-down approach* (TDA). Those advocating for a TDA recommend obtaining a DMSA scan in children after their first febrile UTI. By subsequently obtaining a VCUG in only those children with an abnormal DMSA scan, this approach may only miss 15% to 30% of children with dilating VUR; however, it does have a lower specificity than some of the other imaging guidelines (Hansson et al., 2004; La Scola et al., 2013; Preda et al., 2007; Tseng et al., 2007). The NICE guidelines recommend DMSA 4 to 6 months after acute infection for children younger than 3 years with atypical or recurrent UTI and for children older than 3 years with recurrent UTI. The AAP guidelines do not recommend routine DMSA.

Currently, it is fair to suppose that all imaging strategies fall short of the ultimate goal of being able to identify and test only those children that will benefit from the results of these tests. In addition, as with all testing, the clinician must ask if the results will alter the management of the child, and if the answer is *no*, then the test should not be ordered.

Ultrasound

Although the usefulness of obtaining an RBUS in all children with a UTI is questioned, the fact that it is noninvasive, free from radiation exposure, and widely available makes its routine use widely accepted for children with a history of UTI. The RBUS is frequently the initial imaging study, and it demonstrates abnormalities in about 15% of infants and young children after their first febrile UTI (Subcommittee on Urinary Tract Infection et al., 2011). It is estimated that 1% to 2% of these children will exhibit an abnormality that requires additional evaluation or treatment (Alon and Ganapathy, 1999;

Hoberman et al., 2003; Montini et al., 2008). In children older than several years, relative indications for obtaining RBUS include recurrent febrile UTIs, failure to respond as expected to antibiotic therapy, hypertension, and a family history of renal or urologic disease.

In addition to demonstrating the size, shape, and presence of both kidneys, ultrasound helps screen for previously undiagnosed congenital abnormalities, urinary tract obstruction, hydronephrosis, stones, pyonephrosis, and fluid collections such as renal or perirenal abscesses. If a child is unusually ill or not responding to treatment as expected, the clinician may want to obtain an ultrasound as soon as possible to rule out these conditions because these conditions would warrant additional urgent interventions. A limitation of obtaining an ultrasound during the acute phase of pyelonephritis is the potential for inflammatory changes and edema to cause false-positive results. The inflammatory changes during the acute phase may cause an overestimation of renal size that may not be reflective of the true baseline size of the kidney. If the infection and changes are localized, as in a case with an acute focal pyelonephritis (lobar nephronia), they may create the appearance of a mass or tumor. In addition, *E. coli* endotoxin may result in renal pelvis dilation that could be confused for hydronephrosis and lead to unnecessary testing (Subcommittee on Urinary Tract Infection et al., 2011).

Multiple studies demonstrate a strong correlation between the relative renal volume determined by ultrasound and the relative renal function determined by renal scintigraphy in children (Adibi et al., 2007; Sargent and Gupta, 1993; Troell et al., 1984, 1988; Weitz et al., 2013). However, the ultrasound has relatively poor sensitivity for identifying renal injury or scars compared with nuclear cortical renal scintigraphy, and it may miss more than 10% of renal scars (Christian et al., 2000; Massanyi et al., 2013; Moorthy et al., 2004). Despite this limitation, ultrasound may be useful in screening the children who would be most likely to benefit by further evaluation with a DMSA scan.

Some authors question the usefulness of obtaining an ultrasound in all children with a febrile UTI. The NICE guidelines do not recommend obtaining an ultrasound in children between 6 months and 3 years of age after the first febrile UTI unless it is atypical. Part of this questioning is related to the limitations of routine ultrasonography. High-resolution ultrasonography has improved the sensitivity of the ultrasound for detection of acute renal involvement (Morin et al., 1999). **It is also widely recognized that renal ultrasound includes a very low sensitivity for the detection of VUR, even**

with high grades of VUR (Juliano et al., 2013; Nepple et al., 2011; Supavekin et al., 2013; Suson and Mathews, 2014). In one large study of children less than 24 months of age after their first febrile UTI, the ultrasound failed to detect 73% of those patients considered to have urologic abnormalities that would require additional surgical or medical interventions (Wong et al., 2010). Others have demonstrated that a normal ultrasound was not associated with a decreased risk of recurrent pyelonephritis (Juliano et al., 2013).

Voiding Cystourethrogram

VCUG may be performed by the instillation of an iodinated contrast medium into the bladder and imaging with fluoroscopy or with the instillation of nuclear imaging agents such as ^{99m}Tc-pertechnetate. **When performed with contrast, the VCUG remains the gold standard imaging technique for the detection and grading of VUR.** Because of the improved anatomic resolution, many prefer to use a contrast VCUG as the initial method of evaluation and reserve the radionuclide cystogram for follow-up imaging. **The contrast VCUG provides additional information aside from grade that may be significant in evaluating and treating a child with a history of UTI. It provides anatomic information about the bladder such as size and shape and the presence of trabeculations or diverticula. The voiding images, which are an essential component of the standard VCUG, provide information about the function of the urinary sphincters as well as any evidence of urethral obstruction.** The images may also be evaluated for the stool pattern that could suggest constipation, which is frequently associated with UTIs and abnormal bladder function. In addition, the images may also demonstrate a spinal defect consistent with spina bifida occulta and may raise the possibility of a tethered spinal cord.

In evaluation of the child with UTI, VCUG may be performed as soon as the urine is sterile and the child is asymptomatic and demonstrating typical voiding (Hoberman and Wald, 1999). A negative VCUG does not completely eliminate the possibility of VUR. One study demonstrated that 30% of patients with a history of VUR and a single negative nuclear VCUG showed positive cystogram results 1 year later (Neel and Shillinger, 2000). A cyclic VCUG, in which the bladder is filled, the child voids, and the bladder is filled a second time and is followed by voiding, increases the sensitivity for VUR detection as well as the detection of an ectopic ureter. To minimize interinstitutional variables in the technical performance of a VCUG, the Sections of Urology and Radiology of the AAP established a standard protocol for the voiding cystourethrography

(Frimberger et al., 2016).

^{99m}Tc-Dimercaptosuccinic Acid

Cortical renal scan with DMSA combined with single-photon emission computed tomography (SPECT) is considered by many as the gold standard for identification of lesions in the renal parenchyma (Craig et al., 2000; De Palma and Manzoni, 2013). DMSA is injected intravenously and is taken up by the kidney, bound to the proximal renal tubular cells, and excreted very slowly in the urine, providing good and stable imaging of the renal cortex. The imaging is obtained 2 to 4 hours after injection. It has been shown with CT that DMSA may miss some lesions of APN; however, there are significant drawbacks to using CT in children with UTI (see following) (Lee et al., 2011). The radiation dose for DMSA scintigraphy has been estimated as 1 mSv (La Scola et al., 2013).

The maximum sensitivity of DMSA for detection of APN is within 1 week from the onset of symptoms (Zhang et al., 2014). **A DMSA within the first 10 days of APN shows abnormal results in 49% to 79% of patients, and this decreased to 30% by 1 month after a UTI** (Supavekin et al., 2013). **Therefore the timing of DMSA for detection of kidney involvement with a UTI significantly affects its sensitivity.** Acute DMSA studies usually demonstrate uptake defects in the cortex. In addition, the overall size of the kidney may appear enlarged because of inflammation and edema. **Assessment of irreversible renal damage and scar should not be performed earlier than 6 months after APN, and some suggest waiting up to 1 to 2 years for resolution of any reversible defects** (De Palma and Manzoni, 2013). Many acute cortical lesions are transient, but about 15% of children with these lesions develop evidence of renal scarring on repeated DMSA (Shaikh et al., 2010). Renal scars appear as regions of decreased uptake in the cortex, but they may be indistinguishable from regions of congenital renal dysplasia that are frequently associated with VUR.

Multiple studies demonstrate that the risk of an abnormal DMSA is increased in patients with dilating grades of VUR compared with those with nondilating or no VUR (Supavekin et al., 2013; Wong et al., 2010; Zhang et al., 2014). The degree of renal scarring has also been demonstrated to be worse with higher grades of VUR (Shaikh et al., 2010; Supavekin et al., 2013). In addition, abnormal DMSA scan has been demonstrated to decrease the likelihood of spontaneous VUR resolution independent of the grade of VUR (Nepple et al., 2008a, 2008b; Sjostrom et al., 2010). Most studies demonstrate that older children have a higher chance of renal cortical defects, which is a finding that is consistent with the cumulative nature of scars.

In addition to DMSA, other renal nuclear agents such as ^{99m}Tc-mercaptoacetyltriglycine (MAG3) may be used. Although it may not provide the level of detailed imaging of the renal cortex obtained with DMSA, it does have some advantages. This scan provides renal cortical imaging as well as imaging of the collecting system, which is useful in assessing obstruction of urinary flow. In a very hydronephrotic kidney, imaging of the collecting system may help reduce false-positive results that would be obtained with a DMSA. Because of its uptake and rapid excretion relative to DMSA, the duration of the study and the radiation dose to most organs, including the bladder and gonads, are reduced (Sfakianakis and Georgiou, 1997).

Computed Tomography

Although CT provides detailed anatomic imaging and excellent sensitivity for determination of kidney involvement with infection, the high degree of radiation, as well as potential problems with contrast media, severely limit any benefit of this imaging modality in a child with a UTI. The mean radiation dose for a pediatric abdominal/pelvic CT is 10 to 15 mSv (Miglioretti et al., 2013). One exception may be a noncontrast CT when there is a high index of suspicion for urolithiasis not identified by ultrasound. In addition, it may be useful for distinguishing inflammatory changes from the tumor at times when the acute ultrasound is suspicious for a renal mass. Typical findings associated with renal infection and inflammation include cortical regions of hypoattenuation, wedge-shaped defects, a loss of the corticomedullary differentiation, and striations. Although a renal abscess may show no function, a similar appearance can occur on the acute scans with an acute focal pyelonephritis, and delayed scans may be required to distinguish these entities.

Magnetic Resonance Imaging

Magnetic resonance imaging (MRI) provides excellent anatomic and functional renal imaging. However, the expense and potential need for sedation or anesthesia, as well as a limited availability of the procedure, restrict the use of routine MRI in the child with febrile UTI. In addition, there is a risk of nephrogenic systemic fibrosis in some patients with impaired renal function related to paramagnetic contrast media (De Palma and Manzoni, 2013).

Key Points: Radiographic Imaging

- Various conflicting guidelines have been developed for imaging the child with a UTI; however, all fall short of being able to identify and test only those children who will benefit from the results of these tests.
- Ultrasound is noninvasive and free of radiation and is readily available, but it is unreliable at detecting VUR and will also miss some renal scars.
- VCUG is the most reliable method of detecting and grading VUR as well as imaging the bladder and urethra.
- DMSA remains the gold standard for renal cortical imaging and provides relative renal function.

Management of Pediatric Urinary Tract Infection

Antibiotic Treatment

The goals of acute UTI management include eradicating the infectious agent, preventing renal scarring, and alleviating the child's symptoms. With successful antibiotic treatment, the urine usually becomes sterile after 24 hours (Beetz et al., 2002). **As may be expected, early antibiotic treatment of febrile UTI is a significant factor in limiting renal involvement and subsequent renal scarring** (Doganis et al., 2007; Hiraoka et al., 2003; Smellie et al., 1994; Winter et al., 1983). **One study of infants and young children with febrile UTI demonstrated that the incidence of acute scintigraphic renal lesions increased from 22% to 59% when the start of antibiotics went from 2 to 3 days from onset of symptoms** (Oh et al., 2012). **The rate of ultimate scar formation in this series also increased from 11% to 76.5% when the start of antibiotics went from 2 days to 6 days from the onset of symptoms, respectively.** The role of anti-inflammatory agents such as dexamethasone or methylprednisolone in reducing renal inflammation and ultimate scar formation has been demonstrated in several studies and is currently under investigation (Huang et al., 2011; Pohl et al., 1999; Sharifian et al., 2008).

Because a UTI frequently occurs in young children and neonates with nonspecific symptoms, and a definitive diagnosis based on urine culture may require a wait of 2 to 3 days, the clinician must maintain a high index of suspicion for UTI and must routinely begin antibiotics empirically. Surprisingly, although this empiric decision to begin antibiotics for a presumed UTI should be based on a UA and subsequently confirmed and adjusted based on urine culture results, a review of more than 40,000 outpatient pediatric UTIs suggests that a UA was obtained in only 75% of cases, and a urine culture was obtained only a little more than half the time (Copp et al., 2013). This practice may lead either to overtreatment with antibiotics in children who do not have UTIs or to undertreatment and therapeutic delay for those who do have UTIs but have a resistant bacteria requiring a different antibiotic. The indiscriminate use of broad-spectrum antibiotics also leads to increased side effects and bacterial resistance.

Inpatient Versus Outpatient Management

Management of suspected UTI should be based on a combination of factors including likely uropathogen, clinical status, and the reliability of the patient and the family to comply with medical recommendations. Fewer than 1% of patients evaluated for UTI in the outpatient setting require admission (Copp et al., 2011). Infants older than 2 months and nontoxic children with suspected pyelonephritis can be treated as outpatients as long as compliance with and tolerance to oral antibiotics is not an issue (American Academy of Pediatrics, 1999; Hoberman et al., 1999; Hodson et al., 2007; Montini et al., 2007). Most antibiotics result in extremely high urine antibiotic levels relative to serum, and several randomized comparative studies of oral and intravenous antibiotics have demonstrated no significant differences in the time elapsed to clinical improvement or to the prevention of renal scars (Bitsori and Galanakis, 2012; Hoberman et al., 1999; Hodson et al., 2007; Montini et al., 2007).

Hospitalization and parenteral antibiotics may be required based on patient age and clinical status. **A febrile UTI in newborns and young infants proceeds more frequently to urosepsis than it does in older children. Positive blood cultures are found in 20% of this age group, and this group is also more likely to develop electrolyte abnormalities including hyponatremia and hyperkalemia. For these reasons, newborns and young infants require hospitalization and parenteral antibiotics** (Beetz et al., 2002; Brady et al., 2010). Indications for hospitalization include infants younger than 1 month of age and, according to some, younger than 2 or even 6 months of age, toxic presentation or dehydration, intolerance to oral intake, and questionable compliance with antibiotics (Royal Children's Hospital Melbourne, 2011). Neonates require initial hospitalization and full septic evaluation along with parental antibiotics. After the diagnosis is confirmed by urine culture, the parenteral antibiotics may be changed to oral antibiotics depending on the clinical picture, which would include an improvement in symptoms. Significant clinical improvement, including defervescence, routinely takes at least 24 hours after beginning antibiotics (Hoberman et al., 1999). Within 48 hours of the start of therapy 90% of children have a normal body temperature, but if a child is not improving after 48 hours, an RBUS should be strongly considered. In addition, if urine culture results are not yet available, consideration should be given to broadening antimicrobial therapy (see Radiographic Imaging).

Antibiotic Duration

In children, antibiotic treatment lasting 7 to 14 days is recommended for febrile UTI because shorter courses have been proven inferior (American Academy of Pediatrics, 1999; Keren and Chan, 2002; Michael et al., 2003). With severe infections, such as focal pyelonephritis (previously termed acute lobar nephronia), a longer course of antibiotics of at least 3 weeks is sufficient in most cases (Beetz et al., 2002; Cheng et al., 2006). In many cases a renal abscess can also be treated with antibiotics; however, a lack of clinical response or resolution may require drainage. With less severe UTI, such as afebrile acute cystitis (lower UTI), a 2- to 4-day course has a reduced rate of recurrence compared with a single dose or a 1-day course and no significant difference compared with a 7- to 14-day course (Michael et al., 2003).

Antibiotic Selection

If a urine Gram stain was obtained, the results may help guide initial empiric antibiotic choice while awaiting urine culture results. *E. coli* remains the most common pediatric uropathogen (>80% of UTIs) (Edlin et al., 2013; Table 25.2). TMP-SMX and amoxicillin are used in approximately 50% of outpatient UTI visits, but these may be poor empirical choices because of high resistance rates of *E. coli*. Nitrofurantoin or a first-generation cephalosporin is an appropriate narrow-spectrum antibiotic choice for many children with a UTI; however, the age of the child and comorbid conditions should also be considered when selecting antibiotics (Copp et al., 2011; Edlin et al., 2013). Uropathogen prevalence and resistance rates also vary by gender and visit setting as well as by previous exposure to antibiotics, so these factors must be considered when choosing empiric antibiotic therapy. **Empirical treatment of acute UTI should be based on local/regional antibiograms that are revised and published on an annual basis because uropathogen prevalence and resistance patterns will vary regionally and will change with time** (Table 25.3). Table 25.3 lists common oral and parenteral antibiotics used for treatment of UTI along with common dosing and side effects.

TABLE 25.2

Uropathogen Prevalence by Gender and Clinical Setting[a]

ORGANISM	**MALE**		**FEMALE**	
	OUTPATIENT	**INPATIENT**	**OUTPATIENT**	**INPATIENT**
Escherichia coli	50% (48–52%)	37% (35–39%)	83% (83–84%)	64% (63–66%)
Enterobacter	5% (5–6%)	10% (8–11%)	1% (1–1%)	4% (4–5%)
Enterococcus	17% (16–18%)	27% (25–29%)	5% (5–5%)	13% (12–14%)
Klebsiella	10% (9–11%)	12% (10–13%)	4% (4–5%)	10% (9–11%)
Pseudomonas aeruginosa	7% (6–8%)	10% (8–11%)	2% (2–2%)	6% (5–7%)
Proteus mirabilis	11% (10–12%)	5% (4–6%)	4% (4–4%)	2% (2–3%)

[a] Based on national data from The Surveillance Network. Prevalence will vary based on region.

Data from Edlin RS, Shapiro DJ, Hersh AL, et al.: Antibiotic resistance patterns of outpatient pediatric urinary tract infections. *J Urol* 190(1):222–227, 2013.

TABLE 25.3

Details of Common Antibiotic Dosing

	DOSE	**COMMON SIDE EFFECTS**	**COMMENTS**
ORAL AGENTS			
Amoxicillin-clavulanate	20–40 mg/kg/day in 3 doses	Diarrhea, nausea/vomiting, rash	
TMP-SMX	6–12 mg/kg/day of TMP in 2 doses	Diarrhea, nausea/vomiting, photosensitivity, rash	Contraindicated <6 wk of age
Cefixime	8 mg/kg/day in 1 dose	Abdominal pain, diarrhea, flatulence, rash	
Cefpodoxime	10 mg/kg/day in 2 doses	Abdominal pain, diarrhea, nausea, rash	
Cefprozil	30 mg/kg/day in 2 doses	Abdominal pain, diarrhea, elevated LFTs, nausea	
Cephalexin	50–100 mg/kg/day in	Diarrhea, headache,	

	4 doses	nausea/vomiting, rash	
Nitrofurantoin	3–5 mg/kg in 2 doses	Nausea/vomiting, bad taste	Contraindicated <3 mo of age or when GFR is <50% or in children with G6PD deficiency
PARENTERAL AGENTS			
Ceftriaxone	75 mg/kg/day in 1 dose		Single daily dosing acceptable (Gauthier et al., 2004)
Cefotaxime	150 mg/kg/day divided q6-8h		
Ceftazidime	100–150 mg/kg/day divided q8h		
Gentamicin	7.5 mg/kg/day divided q8h		Single daily dosing acceptable alternative
Tobramycin	5 mg/kg/day divided q8h		
Piperacillin	300 mg/kg/day divided q6–8h		

G6PD, Glucose-6-phosphate dehydrogenase; *GFR,* glomerular filtration rate; *LFTs,* liver function tests; *TMP-SMX*, trimethoprim-sulfamethoxazole.

Data McCarthy PL, Sharpe MR, Spiesel SZ, et al.: Observation scales to identify serious illness in febrile children. *Pediatrics* 70:802–809, 1982.

In addition to *E. coli*, other common gram-negative bacterial uropathogens include *Klebsiella*, *Proteus*, *Enterobacter*, and *Citrobacter*. Gram-positive bacterial uropathogens include *Staphylococcus saprophyticus*, *Enterococcus*, and, rarely, *Staphylococcus aureus*. **Neonates and young infants should be covered for *Enterococcus* species when choosing empiric antibiotics because the incidence of infections with this uropathogen is higher in early infancy than at a later age** (Beetz and Westenfelder, 2011). ***Enterococcus* is frequently sensitive to ampicillin and first-generation cephalosporins.** A combination of ampicillin and a third-generation cephalosporin or aminoglycoside is considered a safe empiric choice for neonates and young infants receiving parenteral therapy. Aminoglycosides may be given in once-daily dosing and should be considered for patients at risk for *Pseudomonas* UTIs such as those with recent exposure to antibiotics or urinary tract abnormalities (Beetz and Westenfelder, 2011; Bitsori and Galanakis, 2012). Parenteral antibiotics may be converted to oral therapy in most children after several days based on culture results and the child's clinical response, including defervescence.

Most uropathogens are susceptible to narrow-spectrum antibiotic agents such as first-generation cephalosporins and nitrofurantoin. However, nitrofurantoin has poor tissue penetration and should not be used for febrile UTI/pyelonephritis. Nitrofurantoin has also been associated with increased risk of hemolytic anemia in infants less than 3 months of age and should not be used in this population. Similarly, TMP is contraindicated in premature infants and newborns less than 6 weeks of age (Beetz and Westenfelder, 2011). An empiric broad-spectrum antibiotic prescription is appropriate in children at risk for resistant UTI such as those with a history of previous UTI, recent antibiotic exposure, recent hospitalization, and presence of genitourinary anomaly (Allen et al., 1999; Cheng et al., 2008; Paschke et al., 2010). Broad-spectrum antibiotics include broad-spectrum penicillins (antipseudomonal penicillins and β-lactamase/β-lactam inhibitor combination penicillins), macrolides, fluoroquinolones, second-, third-, or fourth-generation cephalosporins, lincosamides, and carbapenems.

Although fluoroquinolones are highly effective against most uropathogens, bacterial resistance has increased as a result of widespread use. Fluoroquinolones should not be a first-line choice but should be reserved for those with suspected or proven resistant uropathogens such as *Pseudomonas aeruginosa*. In addition, the safety of quinolones in children has been questioned and is under investigation (Bradley et al., 2011).

Management After Urinary Tract Infection

After treatment of initial UTI, management is aimed at preventing subsequent UTIs. **Routinely repeating a urine culture in children treated with an antibiotic based on previous urine culture susceptibilities is not necessary** (Currie et al., 2003; Oreskovic and Sembrano, 2007). **Approximately 10% to 30% of children develop at least one recurrent UTI** (Nuutinen and Uhari, 2001; Peters et al., 2010; Shaikh et al., 2008; Winberg et al., 1975). **The recurrence rate is highest within the first 3 to 6 months after a UTI, and the more frequent and larger number of recurrent UTIs a child has had, the more likely he or she is to experience a subsequent UTI** (Kasanen et al., 1983; McCracken, 1984; Winberg et al., 1974). In boys younger than 1 year of age, 18% develop a recurrent infection, usually within the following year. If the initial infection is in a boy more than 1 year of age, his risk of a reinfection increases to 32%. A similar trend is noted in girls less than and greater than 1 year of age who have a recurrence risk of 26% and 40%, respectively (Winberg et al., 1974).

Parents should be counseled regarding the high risk of recurrent UTI and should be urged to seek prompt evaluation for subsequent febrile illnesses because prompt treatment from the time of onset of symptoms should help reduce renal damage. Renal scarring increases with an increasing number of febrile UTIs, with the risk going from 5% to 10%, 20%, 40%, and 60% after the first, second, third, fourth, and fifth pyelonephritic episodes, respectively (Jodal, 1987). Children who have had a febrile UTI should routinely have their height, weight, and blood pressure monitored by their primary care provider.

Identification of the risk factors predisposing a patient to UTIs helps direct individualized patient management by treating or eliminating these risk factors. UTIs, like infections in other sites of the body, are more likely to occur with increased inoculum and duration of exposure to the pathogen as well as in situations that compromise local and/or systemic immunity. Relative to UTIs, factors thought to increase the inoculum and duration of exposure include those that create urinary stasis as well as constipation. Surgical correction of obstructive uropathies should help reduce stasis. Infrequent voiding and urinary retention, or high pressures as may occur with dysfunctional voiding or obstructive uropathies, may compromise the local immunity of the bladder. As noted, a history of a recent UTI also predisposes the child to subsequent UTIs. In some patients, the risk factors responsible for recurrent UTIs may not be identifiable or modifiable, and these patients may benefit from nonspecific preventive therapies.

Prophylactic Antibiotics

The use of prophylactic antibiotics may be considered a nonspecific approach to the prevention of recurrent UTIs. The efficacy of prophylaxis has been questioned, even in children with VUR, by several relatively small randomized series including children with low grades of VUR (Garin et al., 2006; Montini et al., 2008; Pennesi et al., 2008; Roussey-Kesler et al., 2008). Neither the AAP guidelines nor the NICE guidelines recommend routinely prescribing prophylactic antibiotics to infants and children after their first UTI. **As may be expected, the benefit of prophylactic antibiotics is more easily demonstrated when used in specific populations known to be at high risk for recurrent UTI** (Brandström et al., 2010a). In populations known to be at higher risk for recurrent UTI, such as girls with dilating VUR (i.e., greater than or equal to grade III), prophylactic antibiotics have proven effective (Brandström et al., 2010a; Craig et al., 2009). **The following risk factors are associated with a low risk of recurrent UTI and therefore make it more difficult to demonstrate any benefit of prophylactic antibiotics: circumcised boys, no bowel or bladder dysfunction, no recent history of UTI, normal renal ultrasound or DMSA scan, a lack of anatomic abnormalities, and nondilating VUR** (Peters et al., 2010). The prospective randomized intervention for vesicoureteral reflux (RIVUR) trial compared TMP-SMX prophylaxis with placebo in 607 children with grade I-IV VUR after UTI; 554 of these patients were enrolled after their first UTI with a median age of 12 months. Importantly, the study also included children with bowel and bladder dysfunction (BBD), and of the 126 toilet-trained children, 56.3% had BBD. During the trial, 111 children had 171 recurrences of UTI, and 72.1% of these UTIs were febrile. The risk of febrile or symptomatic UTI recurrences was reduced by half in children receiving prophylaxis as compared with those receiving prophylaxis (25.5% vs. 37.4%; RR, 0.68; 95% CI 0.53–0.87), and this difference between the two treatment groups widened over time. However, further review of the data revealed that eight children would have to be treated with antibiotic prophylaxis for 2 years to prevent one case of febrile or symptomatic UTI. In addition, outcome renal scans (at the 2-year visit or 3–4 months after the child met treatment failure criteria) showed no significant difference between groups in the incidence of renal scarring (11.9% in the prophylaxis group and 10.2% in the placebo group; $P = 0.55$). The risk reduction for recurrent UTI was greatest in those children with bowel and bladder dysfunction at baseline, a history of febrile UTI, or higher grades of VUR (RIVUR Trial Investigators et al., 2014).

Antibiotic resistance is a concern regarding the use of prophylactic antibiotics. Multiple studies confirm that exposure to antibiotics increases the likelihood that any subsequent UTIs will be caused by bacteria resistant to the previously prescribed antibiotics (Allen et al., 1999; Brandström et al., 2010a; Conway et al., 2007; Craig et al., 2009; Paschke et al., 2010). This relates to the fact that the fecal flora frequently becomes resistant to the treatment antibiotic. In general, the risk of resistance appears to be about three times greater after treatment with antibiotics. Thus the prophylactic antibiotic chosen should be different than the therapeutic antibiotic used for the UTI.

The ideal antibiotic for prophylaxis would be effective against most uropathogens, be easily administered and tolerated without significant side effects, have high urinary concentrations and low serum concentrations, and make little impact on indigenous bacterial flora and bacterial resistance (Beetz and Westenfelder, 2011). The dosage is usually one-fourth the normal dose, and in toilet-trained children, it is routinely administered shortly before going to sleep in hopes of increasing the duration of antibiotic within the urinary bladder. Common choices for prophylactic antibiotics include TMP-SMX, TMP, nitrofurantoin, and first-generation cephalosporins. With increasing resistance of *E. coli* to TMP-SMX, its use in this manner is increasingly questionable. **Sulfonamides may compete for bilirubin binding sites on albumin and cause neonatal hyperbilirubinemia and kernicterus, so TMP-SMX is avoided during the first 6 weeks of life.**

Nitrofurantoin produces minimal effect on the fecal flora, and resistance rates have remained relatively low, making it an effective prophylactic antibiotic. Because serum levels with nitrofurantoin are low, it is not recommended for use with APN or urosepsis. In addition, it can cause hemolysis in children with glucose-6-phosphate dehydrogenase (G6PD) deficiencies by oxidizing hemoglobin to methemoglobin. This deficiency is found in about 10% of African-Americans, Sardinians, non-Ashkenazi Jews, Greeks, Eti Turks, and Thais. Long-term treatment has been associated with rare cases of pulmonary fibrosis.

Many unanswered questions exist regarding not only which patients benefit from prophylactic antibiotics but also the best therapeutic regimen. The ideal dosing and schedule, as well as the use of alternating antibiotics, remain to be defined. Patient noncompliance with a prescribed daily antibiotic is common (Daschner and Marget, 1975).

Cranberry juice has been suggested to reduce the incidence of UTIs. A meta-analysis that included adults and children demonstrated no UTI reduction for those using cranberry products as compared with placebo, water, or no treatment (Jebson and Craig, 2012). Several studies in children with neurogenic bladders also demonstrated no reduction on recurrent UTI (Foda et al., 1995; Schlager et al., 1999). However, several other studies in children did suggest a possible benefit of cranberry juice in reducing recurrent UTIs (Ferrara et al., 2009; Salo et al., 2012). At present, there does not appear to be enough evidence demonstrating conclusive benefit to warrant a recommendation for the routine use of cranberry juice or cranberry products in children for the prevention of UTIs.

Probiotics consist of live micro-organisms and have been reported to have possible beneficial effects in prevention of UTIs. A meta-analysis of 10 studies with 2865 children and adolescents showed that probiotics as monotherapy did not have a beneficial effect in reducing the incidence or recurrence of UTI. Moderate efficacy (RR = 0.92; 95% CI 0.85–0.99; $P = 0.02$) was demonstrated when a probiotic was used as adjuvant therapy to antibiotics (Hosseini et al., 2017).

Circumcision reduces the risk of UTIs in infants and toddlers (Wiswell et al., 1985). The risk reduction appears greatest in those with a history of recurrent UTIs and dilating VUR (Singh-Grewal et al., 2005). Some consider conditions that place boys at high risk for UTI as a relevant medical indication for circumcision. Such patients may have a history of recurrent febrile UTIs, obstructive uropathy, high-grade hydronephrosis, hydroureteronephrosis, or high-grade VUR (Zee et al., 2016). The benefit of prophylactic circumcision even in these patients is controversial.

Bladder and Bowel Dysfunction

Consideration and assessment of underlying bladder or bowel dysfunction as predisposing factors should occur with any pediatric UTI. **There exists a well-recognized association between bladder dysfunction and UTI, and bladder dysfunction predisposes children to recurrent UTI and renal injury**

(Hoebeke et al., 2001; Nijman, 2000). In particular, the risk of bladder colonization and UTI is increased in children with incomplete bladder emptying resulting from dysfunctional voiding or underactive bladder. In addition, there is an association between VUR and bladder dysfunction (Hoebeke et al., 2001; Koff et al., 1998; Schulman et al., 1999). It is thought that voiding against a closed sphincter can increase bladder pressure and may contribute to the development and to the persistence of VUR (Chandra and Maddix, 2000; Yeung et al., 1998, 2006). Treatment of bladder dysfunction, particularly overactive bladder, has been shown to improve the spontaneous VUR resolution rate, further suggesting an etiologic component for overactive bladder in the genesis of reflux (Homsy et al., 1985; Koff et al., 1998; Willemsen and Nijman, 2000).

Anorectal and lower urinary tract function are interrelated, and constipation is often associated with bladder dysfunction. Reported frequency of constipation associated with pediatric bladder dysfunction ranges from 30% to 88% (Burgers et al., 2013a, 2013b; O'Regan et al., 1986; Schulman et al., 1999). This relationship between abnormal bowel and bladder function is referred to as BBD or as the dysfunctional elimination syndrome (DES) (Bower et al., 2005; Burgers et al., 2013b; Feng and Churchill, 2001; Koff et al., 1998). **Children with VUR and bowel and/or bladder dysfunction are at particularly high risk for developing recurrent pyelonephritis** (Hellerstein and Nickell, 2002; Leslie et al., 2010; Sillen et al., 2010; Thompson et al., 2001)**. Recurrent UTI is estimated to occur in about 45% of these children as opposed to 15% without BBD** (Peters et al., 2010). **Treatment of constipation has been shown to reduce recurrent UTIs significantly and to improve bladder function** (Erickson et al., 2003; Loening-Baucke, 1997).

Detailed information regarding treatment of pediatric bladder and bowel dysfunction is reviewed in Chapters 30 and 36. In general, the initial conservative therapeutic measures for treating the child with bladder dysfunction include voiding behavior modification with timed voiding schedules and treatment of constipation, if present (Allen et al., 2007; Erickson et al., 2003). In patients who fail conservative treatment, directed therapy is focused toward improving the specific cause of bladder dysfunction. Targeted interventions may include pharmacologic therapy, biofeedback, electrical stimulation therapy, surgery, clean intermittent catheterization, or a combination of these therapies (Malm-Buatsi et al., 2007; Nelson et al., 2004; Van Arendonk et al., 2006a, 2006b). For children with a neurogenic bladder on intermittent catheterization, increasing the frequency of catheterization has been associated with decreased rates of recurrent UTI.

Management of Vesicoureteral Reflux

VUR remains a risk factor for recurrent pyelonephritis and renal scarring. The risk of both of these events increases with increasing grades of VUR and seems to become significant in most series with dilating VUR (i.e., grade III or higher) (Brandström et al., 2010a, 2010b; Conway et al., 2007; Hellerstein and Nickell, 2002; Holmdahl et al., 2010; Leslie et al., 2010; Montini et al., 2008; Oh et al., 2012; Roussey-Kesler et al., 2008; Shaikh et al., 2010). As previously noted, multiple studies have challenged the dogma that all children with a febrile UTI and reflux benefit from the diagnosis of VUR and subsequent treatment of this condition by either continuous antibiotic prophylaxis or surgical correction (Cooper et al., 2000; Garin et al., 2006; Hellerstein and Nickell, 2002; Leslie et al., 2010; Montini et al., 2008; Pennesi et al., 2008; Reddy et al., 1997; Roussey-Kesler et al., 2008; Subcommittee on Urinary Tract Infection et al., 2011; Thompson et al., 2001). Almost paradoxically, as more studies provide additional information regarding VUR, determining the ideal management of a patient with VUR has become increasingly complex and is discussed in detail in Chapter 29.

Sequelae of Pediatric Urinary Tract Infections

Renal Scarring

Pyelonephritic scarring occurs most commonly in the poles of the kidney and is associated with compound papillae (Hannerz et al., 1987). Children with pyelonephritis and VUR are at increased risk for renal scar development, and this risk increases with increasing grade of VUR (Lee et al., 2012; Oh et al., 2010; Shaikh et al., 2010). **After the acute inflammatory phase, the ultimate scar involves a loss of tissue that is reflected on radiographic imaging as thinning of the renal parenchyma over the calyces. The calyces themselves may become blunted and deformed.** It can be difficult or impossible to distinguish scar from regions of congenital dysplasia by radiographic imaging, although patients with a small kidney and diffusely decreased isotope uptake and decreased differential renal function are often considered to have renal dysplasia. Prompt antimicrobial treatment decreases the chance of permanent renal damage, as does the elimination of any subsequent episode of pyelonephritis (Oh et al., 2012). One review noted that for every hour antimicrobial therapy was delayed in treating a febrile UTI, the odds of new renal scarring increased by 0.8% (Shaikh et al., 2016). Others have shown that the odds of developing a renal scar double if antibiotics are begun after 72 hours from the start of a febrile UTI compared to children begun on antibiotics within 48 hours (Karavanaki, 2017). The use of anti-inflammatory agents to minimize renal injury and scar during the acute phase of pyelonephritis is under investigation (Huang et al., 2011; Pohl et al., 1999; Sharifian et al., 2008).

Xanthogranulomatous Pyelonephritis

Xanthogranulomatous pyelonephritis (XGP) is a specific form of chronic inflammatory kidney disease rarely seen in children that is usually associated with an element of obstruction and, most commonly, *Proteus* or *E. coli* (Rippentrop et al., 2002). Symptoms are often vague and nonspecific and may include fever, abdominal or flank pain or mass, and more nonspecific symptoms including weight loss and failure to thrive. Laboratory studies may demonstrate leukocytosis, anemia, and pyuria.

Imaging may demonstrate a masslike lesion with focal or diffuse renal involvement as well as perinephric extension (Cooper and Turner, 1997; Eastham et al., 1994; Malek and Elder, 1978). This may be mistaken for a malignancy and requires a high index of suspicion (Inouye et al., 2013; Nam et al., 2012). CT images may demonstrate areas of low attenuation that do not enhance as well as dilated calyces. Renal calculi are present in 38% to 70% of patients (Anhalt et al., 1971; Malek and Elder, 1978).

Nephrectomy is the treatment of choice for the diffuse form, whereas partial nephrectomy or conservative medical therapy may be indicated to manage focal XGP (Cooper and Turner, 1997; Nam et al., 2012). Technically, these operative cases can be extremely difficult because the process may extend beyond the kidney, distorting and destroying normal anatomy as it involves and encases surrounding structures, including the psoas muscle and, at times, even the great vessels (Loffroy et al., 2007; Malek and Elder, 1978).

Long-Term Sequelae

It is difficult to predict which children will develop long-term sequelae of pediatric UTI, including hypertension, preeclampsia, or chronic kidney disease (CKD) because of a lack of clear data establishing the long-term consequences after pediatric UTIs. A review of 23 papers including a total of 3573 children demonstrates that the majority of children with a history of febrile UTI develop no long-term sequelae (Toffolo et al., 2012). This seems to be true in particular if at birth the children had normal kidneys that were unaffected by significant renal dysplasia. **Toffolo et al. estimated that only 0.4% of children with normal renal function at the start of follow-up experienced a decrease in renal function.** This rate is consistent with that found in the prospective International Reflux Study in Children (Smellie et al., 1998) and in another series of 226 adults with a history of childhood UTI who were followed for 10 to 41 years, which noted that only two patients developed CKD that was attributed to UTIs (Jodal et al., 2006). Wennerstrom et al. (2000) demonstrated a decrease in mean GFR after 16 to 26 years of follow-up more frequently in children with bilateral renal scars but not unilateral scars compared with children without scars. This same group showed no significant difference in mean 24-hour ambulatory blood pressure between those with and without urographic renal scars. Two other studies with follow-up of 22 and 41 years demonstrated an increased prevalence of hypertension of 29% and 35%, respectively, in patients with scars, suggesting that scars are a risk factor for the development of hypertension (Bailey et al., 1992; Jacobson et al., 1989). The risk of hypertension appears to increase with the severity of renal scarring. It has also been demonstrated that during first pregnancies, hypertension was significantly more common in women with severe renal scarring (Martinell et al., 1996; Smellie et al., 1998).

Children with significant bilateral renal scars or reduction of renal function warrant long-term follow-up for assessment of hypertension, renal function, and proteinuria. Studies suggest that proteinuria may not only be a clinical feature of CKD but may hasten its progression. The use of renin-angiotensin antagonists may slow the progression of CKD in some of these patients (Wong et al., 2009). A historical cohort study demonstrated that with long-term follow-up 140 of 18,592 (0.75%) patients with a history of congenital anomalies of the kidney or urinary tract, pyelonephritis, or glomerular disease and no proteinuria or elevated creatinine during adolescence subsequently developed end stage renal disease (HR = 4.19, 95% CI 3.52–4.99 [Calderon-Margalit et al., 2018]).

Key Points: Management and Sequelae

- Delay in antibiotic treatment of a febrile UTI increases the incidence of renal parenchymal involvement and ultimate scar formation.
- Newborns and young infants should be hospitalized because of a higher incidence of urosepsis than older children.
- A total of 7 to 14 days of antibiotic treatment is recommended for children with febrile UTI; a 2- to 4-day course is acceptable for afebrile cystitis.
- Empiric antibiotic selection should be guided by local/regional antibiograms because of changing uropathogen prevalence and resistance patterns.
- Nitrofurantoin should not be used for febrile UTI/pyelonephritis.
- A total of 10% to 30% of children develop at least one recurrent UTI.
- Antibiotic prophylaxis has been demonstrated to decrease subsequent UTI in high-risk populations such as girls with dilating reflux.
- Bowel and bladder dysfunction increase the risk of recurrent UTI and should be evaluated and treated in any child with a UTI.

- Although the risk of long-term sequelae of pediatric UTIs is relatively low, children with significant bilateral renal scars or a reduction of renal function warrant long-term follow-up for the assessment of hypertension, renal function, and proteinuria.

Uncommon Pediatric Urinary Tract Infections

Viral Cystitis

Acute hemorrhagic cystitis in children has occasionally been related to UTIs caused by adenovirus-11. In a series from Mufson et al. (1973) that evaluated children suffering from hemorrhagic cystitis, adenovirus-11 was recovered from the urine in 14.5% of patients, adenovirus-21 was found in the urine of 9% of these children, and *E. coli* was present in 17.4% of the cohort. In the vast majority of the individuals, no infectious cause was identified.

Viral cystitis has commonly been identified in individuals after bone marrow transplantation and in other immunosuppressed individuals. Without successful treatment, severe viral cystitis and associated hemorrhagic cystitis is associated with a 50% to 80% mortality rate in these children (Gavin and Katz, 2002). BK virus, a DNA virus of the polyomavirus genus, has also been found in the urine of immunosuppressed and especially bone marrow transplant patients, causing symptomatic and asymptomatic infections (Apperley et al., 1987; Bedi et al., 1995).

Funguria

Fungal UTIs appear to be increasing in prevalence and are commonly associated with individuals who have recently received antibiotics or who have had indwelling urethral catheters. In one neonatal intensive care unit, funguria increased 10-fold throughout a 10-year period (Kossoff et al., 1998). Predisposing factors in children include antibiotic use, prematurity, intravenous and umbilical artery catheterization, parental nutrition, and an immunocompromised state (Keller et al., 1977). The urinary tract may serve as a portal of entry and as a site of disseminated fungal infection. In children with disseminated candidiasis, the kidney is the most commonly involved organ (Keller et al., 1977). *Candida* species are the most common cause of fungal UTI; C*andida albicans* is the most common species involved in these infections, followed by *Torulopsis glabrata*. It is important to recognize the infections caused by *Torulopsis glabrata* because these are commonly resistant to fluconazole (Kauffman et al., 2000).

Fungal bezoars may also form in the renal pelvis and potentially create urinary obstruction in these children (Bartone et al., 1988; Keller et al., 1977). For this reason, renal ultrasound may be beneficial in evaluating these patients, especially if the funguria is persistent. Urinary alkalization and oral antifungal therapy may occasionally dissolve some fungal balls, but if the child is suffering from renal obstruction, percutaneous or surgical removal of these fungus balls is necessary. Percutaneous drainage may also be needed so that local antifungal therapy can be administered. In these individuals, local and systemic amphotericin B and/or oral fluconazole may be useful for treatment. If the fungal balls are shown to persist, endoscopic or open surgical removal may be necessary.

The timing of treatment of asymptomatic funguria that are related to indwelling urethral catheters continues to be debated. In individuals with funguria secondary to these foreign bodies, progression to disseminated candidemia is rare (Kauffman et al., 2000). When repeated urine cultures grow greater than 10,000 to 15,000 CFU/mL, antifungal treatment is generally recommended. Stopping antibiotic therapy, changing or removing urethral catheters, and urinary alkalinization may be helpful in some cases, but these do not always clear the fungus from the urine. Prospective studies with intravesical amphotericin B bladder irrigation and oral fluconazole show that both may clear the funguria (Gubbins et al., 1994, 1999). Fluconazole has been used successfully in children, although its use is contraindicated in children less than 6 months of age.

Suggested Readings

Beetz R, Westenfelder M. Antimicrobial therapy of urinary tract infections in children. *Int J Antimicrob Agents*. 2011;38(Suppl):42–50.

Bitsori M, Galanakis E. Pediatric urinary tract infections: diagnosis and treatment. *Expert Rev Anti Infect Ther*. 2012;19:1153–1164.

Brandström P, Esbjörner E, Herthelius M, et al. The Swedish reflux trial in children: III. Urinary tract infection pattern. *J Urol*. 2010;184:286–291.

Copp HL, Yiee JH, Smith A, et al. Use of urine testing in outpatients treated for urinary tract infection. *Pediatrics*. 2013;132:437–444.

Craig JC, Williams GJ, Jones M, et al. The accuracy of clinical symptoms and signs for the diagnosis of serious bacterial infection in young febrile children: prospective cohort study of 15,781 febrile illnesses. *BMJ*. 2010;340:c1594.

Foxman B. Epidemiology of urinary tract infections: incidence, morbidity, and economic costs. *Am J Med*. 2002;113(Suppl 1A):5S–13S.

Garin EH, Olavarria F, Garcia Nieto V, et al. Clinical significance of primary vesicoureteral reflux and urinary antibiotic prophylaxis after acute pyelonephritis: a multicenter, randomized, controlled study. *Pediatrics*. 2006;117:626–632.

Hoberman A, Wald ER, Hickey RW, et al. Oral versus initial intravenous therapy for urinary tract infections in young febrile children. *Pediatrics*. 1999;104:79–86.

Hoberman A, Wald ER, Reynolds EA, et al. Pyuria and bacteriuria in urine specimens obtained by catheter from young children with fever. *J Pediatr*. 1994;124(4):513–519.

Jodal U. The natural history of bacteriuria in childhood. *Infect Dis Clin North Am*. 1987;1:713–729.

Justice SS, Hung C, Theriot JA, et al. Differentiation and development pathways of uropathogenic *E. coli* in urinary tract infections. *Proc Natl Acad Sci USA*. 2004;101(5):1333–1338.

Koff SA, Wagner TT, Jayanthi VR. The relationship among dysfunctional elimination syndromes, primary vesicoureteral reflux and urinary tract infections in children. *J Urol*. 1998;160(3 Pt 2):1019–1022.

La Scola C, De Mutiis C, Hewitt IK, et al. Different guidelines for imaging after first UTI in febrile infants: yield, cost, and radiation. *Pediatrics*. 2013;131:e665–e671.

Montini G, Kullus K, Hewitt I. Febrile urinary tract infections in children. *N Engl J Med*. 2011;365:239.

Peters CA, Skoog SJ, Arant BS Jr, et al. Summary of the AUA Guideline on Management of Primary Vesicoureteral Reflux in Children. *J Urol*. 2010;184:1134–1144.

Rushton HG, Majd M. Dimercaptosuccinic acid renal scintigraphy for the evaluation of pyelonephritis and scarring: a review of experimental and clinical studies. *J Urol*. 1992;148(5 Pt 2):1726–1732.

Shaikh N, Ewing AL, Bhatnagar S, et al. Risk of renal scarring in children with a first urinary tract infection: a systematic review. *Pediatrics*. 2010;126:1084–1091.

Shaikh N, Morone NE, Lopez J, et al. Does this child have a urinary tract infection? *JAMA*. 2007;298(24):2895–2904.

Subcommittee on Urinary Tract Infection, Steering Committee on Quality Improvement and Management, Roberts KB. Urinary tract infection: clinical practice guideline for the diagnosis and management of the initial UTI in febrile infants and children 2 to 24 months. *Pediatrics*. 2011;128(3):595–610.

Supavekin S, Surapaitoolkorn W, Pravisithikul N, et al. The role of DMSA renal scintigraphy in the first episode of urinary tract infection in childhood. *Ann Nucl Med*. 2013;27:170–176.

Wan J, Skoog SJ, Hulbert WC, et al. Section on urology response to new guidelines for the diagnosis and management of UTI. *Pediatrics*. 2012;129:e1051–e1053.

References

Abrahams HM, Stoller ML. Infection and urinary stones. *Curr Opin Urol*. 2003;13(1):63–67.

Adibi A, Adibi I, Khosravi P. Do kidney sizes in ultrasonography correlate to glomerular filtration rate in healthy children? *Australas Radiol*. 2007;51:555–559.

Allen HA, Austin JC, Boyt MA, et al. Initial trial of timed voiding is warranted for all children with daytime incontinence. *Urology*. 2007;69:962–965.

Allen UD, MacDonald N, Fuite L, et al. Risk factors for resistance to “first-line” antimicrobials among urinary tract isolates of *Escherichia coli* in children. *Can Med Assoc J*. 1999;160:1436–1440.

Alon US, Ganapathy S. Should renal ultrasonography be done routinely in children with first urinary tract infection? *Clin Pediatr (Phila)*. 1999;38:21–25.

Alteri CJ, Hagan EC, Sivick KE, et al. Mucosal immunization with iron receptor antigens protects against urinary tract infection. *PLoS Pathog*. 2009;5(9):e1000586.

American Academy of Pediatrics. Practice parameter: the diagnosis, treatment, and evaluation of the initial urinary tract infection in febrile infants and young children. Committee on Quality Improvement. Subcommittee on Urinary Tract Infection. *Pediatrics*. 1999;103(4 Pt 1):843–852.

American Academy of Pediatrics Task Force on Circumcision. Circumcision policy statement. *Pediatrics*. 2012;130(3):585–586.

American College of Emergency Physicians Clinical Policies Committee; American College of Emergency Physicians Clinical Policies Subcommittee on Pediatric Fever. Clinical policy for children younger than three years presenting to the emergency department with fever. *Ann Emerg Med*. 2003;42(4):530–545.

Ammenti A, Cataldi L, Chimenz R, et al. Febrile urinary tract infections in young children: recommendations for the diagnosis, treatment and follow-up. *Acta Paediatr*. 2012;101:451–457.

Anderson GG, Palermo JJ, Schilling JD, et al. Intracellular bacterial biofilm-like pods in urinary tract infections. *Science*. 2003;301:105–107.

Anhalt MA, Cawood CD, Scott R Jr. Xanthogranulomatous pyelonephritis: a comprehensive review with report of 4 additional cases. *J Urol*. 1971;105:10–17.

Apperley JF, Rice SJ, Bishop JA, et al. Late-onset hemorrhagic cystitis associated with urinary excretion of polyomaviruses after bone marrow transplantation. *Transplantation*. 1987;43(1):108–112.

Bachur R, Harper MB. Reliability of the urinalysis for predicting urinary tract infections in young febrile children. *Arch Pediatr Adolesc Med*. 2001;155(1):60–65.

Bagg A, Neilands JB. Molecular mechanism of regulation of siderophore-mediated iron assimilation. *Microbiol Rev*. 1987;51(4):509–518.

Bailey RR, Lynn KL, Smith AH. Long-term followup of infants with gross vesicoureteral reflux. *J Urol*. 1992;148:1709–1711.

Baker MD, Bell LM. Unpredictability of serious bacterial illness in febrile infants from birth to 1 month of age. *Arch Pediatr Adolesc Med*. 1999;153(5):508–511.

Bakke A, Vollset SE. Risk factors for bacteriuria and clinical urinary tract infection in patients treated with clean intermittent catheterization. *J Urol*. 1993;149:527–531.

Baraff LJ. Management of fever without source in infants and children. *Ann Emerg Med*. 2000;36(6):602–614.

Baraff LJ, Bass JW, Fleisher GR, et al. Practice guideline for the management of infants and children 0 to 36 months of age with fever without source. Agency for Health Care Policy and Research. *Ann Emerg Med*. 1993;22(7):1198–1210.

Barber AE, Norton JP, Spivak AM, et al. Urinary tract infections: current and emerging management strategies. *Clin Infect Dis*. 2013;57(5):719–724.

Bartone FF, Hurwitz RS, Rojas EL, et al. The role of percutaneous nephrostomy in the management of obstructing candidiasis of the urinary tract in infants. *J Urol*. 1988;140(2):338–341.

Bedi A, Miller CB, Hanson JL, et al. Association of BK virus with failure of prophylaxis against hemorrhagic cystitis following bone marrow transplantation. *J Clin Oncol*. 1995;13(5):1103–1109.

Beetz R, Mannhardt W, Fisch M, et al. Long-term followup of 158 young adults surgically treated for vesicoureteral reflux in childhood: the ongoing risk of urinary tract infections. *J Urol*. 2002;168(2):704–707.

Beetz R, Westenfelder M. Antimicrobial therapy of urinary tract infections in children. *Int J Antimicrob Agents*. 2011;38(Suppl):42–50.

Benador D, Benador N, Slosman D, et al. Are younger children at highest risk of renal sequelae after pyelonephritis? *Lancet*. 1997;349(9044):17–19.

Bhat RG, Katy TA, Place FC. Pediatric urinary tract infections. *Emerg Med Clin North Am*. 2011;29:637–653.

Bien J, Sokolova O, Bozko P. Role of uropathogenic *Escherichia coli* virulence factors in development of urinary tract infection and kidney damage. *Int J Nephrol*. 2012;2012:681473.

Bitsori M, Galanakis E. Pediatric urinary tract infections: diagnosis and treatment. *Expert Rev Anti Infect Ther*.

2012;19:1153–1164.

Bower WF, Yip SK, Yeung CK. Dysfunctional elimination symptoms in childhood and adulthood. *J Urol*. 2005;174:1623–1628.

Bradley JS, Jackson MA, Committee on Infectious Diseases, et al. The use of systemic and topical fluoroquinolones. *Pediatrics*. 2011;128:e1034–e1045.

Brady PW, Conway PH, Goudie A. Length of intravenous antibiotic therapy and treatment failure in infants with urinary tract infections. *Pediatrics*. 2010;126:196–203.

Brandström P, Esbjörner E, Herthelius M, et al. The Swedish reflux trial in children: III. Urinary tract infection pattern. *J Urol*. 2010;184:286–291.

Brandström P, Neveus T, Sixt R, et al. The Swedish reflux trial in children: IV. Renal damage. *J Urol*. 2010;184(1):292–297.

Brooks HJ, Benseman BA, Peck J, et al. Correlation between uropathogenic properties of *Escherichia coli* from urinary tract infections and the antibody-coated bacteria test and comparison with faecal strains. *J Hyg (Lond)*. 1981;87(1):53–61.

Burgers R, de Jong TP, Visser M, et al. Functional defecation disorders in children with lower urinary tract symptoms. *J Urol*. 2013;189:1886–1891.

Burgers RE, Mugie SM, Chase J, et al. Management of functional constipation in children with lower urinary tract symptoms: report from the Standardization Committee of the International Children's Continence Society. *J Urol*. 2013;190:29–36.

Buys H, Pead L, Hallett R, et al. Suprapubic aspiration under ultrasound guidance in children with fever of undiagnosed cause. *BMJ*. 1994;308:690–692.

Calderon-Margalit R, Golan E, Twig G, et al. History of childhood kidney disease and risk of adult end-stage renal disease. *N Engl J Med*. 2018;378:428–438.

Cantey JB, Gaviria-Agudelo C, McElvania TeKippe E, et al. Lack of clinical utility of urine gram stain for suspected urinary tract infection in pediatric patients. *J Clin Microbiol*. 2015;53:1282–1285.

Carbonetti NH, Boonchai S, Parry SH, et al. Aerobactin-mediated iron uptake by *Escherichia coli* isolates from human extraintestinal infections. *Infect Immun*. 1986;51(3):966–968.

Cavalieri SJ, Bohach GA, Snyder IS. *Escherichia coli* alpha-hemolysin: characteristics and probable role in pathogenicity. *Microbiol Rev*. 1984;48(4):326–343.

Chandra M, Maddix H. Urodynamic dysfunction in infants with vesicoureteral reflux. *J Pediatr*. 2000;136:754–759.

Chang SL, Shortliffe LD. Pediatric urinary tract infections. *Pediatr Clin North Am*. 2006;53(3):379–400.

Chaudhari PP, Monuteaux MC, Shah P, et al. The importance of urine concentration on the diagnostic performance of the urinalysis for pediatric urinary tract infection. *Ann Emerg Med*. 2017;70(1):63–71 [e8].

Cheng CH, Tsai MH, Huang YC, et al. Antibiotic resistance patterns of community-acquired urinary tract infections in children with vesicoureteral reflux receiving prophylactic antibiotic therapy. *Pediatrics*. 2008;122:1212–1217.

Cheng CH, Tsau YK, Lin TY. Effective duration of antimicrobial therapy for the treatment of acute lobar nephronia. *Pediatrics*. 2006;117:e84–e89.

Christian MT, McColl JH, MacKenzie JR, et al. Risk assessment of renal cortical scarring with urinary tract infection by clinical features and ultrasonography. *Arch Dis Child*. 2000;82:376–380.

Clarke SA, Samuel M, Boddy SA. Are prophylactic antibiotics necessary with clean intermittent catheterization? A randomized controlled trial. *J Pediatr Surg*. 2005;40(3):568–571.

Conrad S, Busch R, Huland H. Complicated urinary tract infections. *Eur Urol*. 1991;19(Suppl 1):16–22.

Conway PH, Cnaan A, Zaoutis T, et al. Recurrent urinary tract infections in children: risk factors and association with prophylactic antimicrobials. *J Am Med Assoc*. 2007;298:179–186.

Cooper CS, Chung BI, Kirsch AJ, et al. The outcome of stopping prophylactic antibiotics in older children with vesicoureteral reflux. *J Urol*. 2000;163(1):269–273.

Cooper CS, Turner JW. Focal xanthogranulomatous pyelonephritis in a 12-year-old Alaskan native. *J Urol*. 1997;157:632–633.

Copp HL, Shapiro DJ, Hersh AL. National ambulatory antibiotic prescribing patterns for pediatric urinary tract infection, 1998-2007. *Pediatrics*. 2011;127:1027–1033.

Copp HL, Yiee JH, Smith A, et al. Use of urine testing in outpatients treated for urinary tract infection. *Pediatrics*. 2013;132:437–444.

Craig JC, Simpson JM, Williams GJ, et al. Antibiotic prophylaxis and recurrent urinary tract infection in children. *N Engl J Med*. 2009;361:1748–1759.

Craig JC, Wheeler DM, Irwig L, et al. How accurate is dimercaptosuccinic acid scintigraphy for the diagnosis of acute pyelonephritis? A meta-analysis of experimental studies. *J Nucl Med*. 2000;41:986.

Craig JC, Williams GJ, Jones M, et al. The accuracy of clinical symptoms and signs for the diagnosis of serious bacterial infection in young febrile children: prospective cohort study of 15,781 febrile illnesses. *BMJ*. 2010;340:c1594.

Currie ML, Mitz L, Raasch CS, et al. Follow-up urine cultures and fever in children with urinary tract infection. *Arch*

Pediatr Adolesc Med. 2003;157:1237–1240.

Czaja CA, Stamm WE, Stapleton AE, et al. Prospective cohort study of microbial and inflammatory events immediately preceding *Escherichia coli* recurrent urinary tract infection in women. *J Infect Dis*. 2009;200(4):528–536.

Dagan R, Sofer S, Phillip M, et al. Ambulatory care of febrile infants younger than 2 months of age classified as being at low risk for having serious bacterial infections. *J Pediatr*. 1988;112(3):355–360.

Daniels KR, Lee GC, Frei CR. Trends in catheter-associated urinary tract infections among a national cohort of hospitalized adults, 2001-2010. *Am J Infect Control*. 2014;42:17–22.

Daschner F, Marget W. Treatment of recurrent urinary tract infection in children. II. Compliance of parents and children with antibiotic therapy regimen. *Acta Paediatr Scand*. 1975;64:105–108.

Davidson AJ, Talner LB. Urographic and angiographic abnormalities in adult-onset acute bacterial nephritis. *Radiology*. 1973;106(2):249–256.

de la Hunt MN, Deegan S, Scott JE. Intermittent catheterisation for neuropathic urinary incontinence. *Arch Dis Child*. 1989;64(6):821–824.

de Lorenzo V, Neilands JB. Characterization of iucA and iucC genes of the aerobactin system of plasmid ColV-K30 in *Escherichia coli*. *J Bacteriol*. 1986;167(1):350–355.

De Palma D, Manzoni G. Different imaging strategies in febrile urinary tract infection in childhood. What, when, why? *Pediatr Radiol*. 2013;43:436–443.

Doganis D, Siafas K, Mavrikou M, et al. Does early treatment of urinary tract infection prevent renal damage? *Pediatrics*. 2007;120:e922–e928.

Downing H, Thomas-Jones E, Gal M, et al. The diagnosis of urinary tract infections in young children (DUTY): protocol for a diagnostic and prospective observational study to derive and validate a clinical algorithm for the diagnosis of UTI in children presenting to primary care with an acute illness. *BMC Infect Dis*. 2012;12:158.

Eastham J, Ahlering T, Skinner E. Xanthogranulomatous pyelonephritis: clinical findings and surgical considerations. *Urology*. 1994;43:295–299.

Edelmann CM Jr, Ogwo JE, Fine BP, et al. The prevalence of bacteriuria in full-term and premature newborn infants. *J Pediatr*. 1973;82(1):125–132.

Edlin RS, Shapiro DJ, Hersh AL, et al. Antibiotic resistance patterns of outpatient pediatric urinary tract infections. *J Urol*. 2013;190(1):222–227.

Erickson BA, Austin JC, Cooper CS, et al. Polyethylene glycol 3350 for constipation in children with dysfunctional elimination. *J Urol*. 2003;170:1518–1520.

Farsi HM, Mosli HA, Al-Zemaity MF, et al. Bacteriuria and colonization of double-pigtail ureteral stents: long-term experience with 237 patients. *J Endourol*. 1995;9(6):469–472.

Feng WC, Churchill BM. Dysfunctional elimination syndrome in children without obvious spinal cord diseases. *Pediatr Clin North Am*. 2001;48:1489–1504.

Ferrara P, Romaniello L, Vitelli O, et al. Cranberry juice for the prevention of recurrent urinary tract infections: a randomized controlled trial in children. *Scand J Urol Nephrol*. 2009;43:369–372.

Fliedner M, Mehls O, Rauterberg EW, et al. Urinary sIgA in children with urinary tract infection. *J Pediatr*. 1986;109(3):416–421.

Foda MM, Middlebrook PF, Gatfield CT, et al. Efficacy of cranberry in prevention of urinary tract infection in a susceptible pediatric population. *Can J Urol*. 1995;2:98–102.

Ford-Jones EL, Mindorff CM, Langley JM, et al. Epidemiologic study of 4684 hospital-acquired infections in pediatric patients. *Pediatr Infect Dis J*. 1989;8(10):668–675.

Foxman B. Epidemiology of urinary tract infections: incidence, morbidity, and economic costs. *Am J Med*. 2002;113(Suppl 1A):5S–13S.

Freedman AL, Urologic Diseases in America Project. Urologic Diseases in North America Project: trends in resource utilization for urinary tract infections in children. *J Urol*. 2005;173(3):949–954.

Frimberger D, Bauer SB, Cain MP, et al. Establishing a standard protocol for the voiding cystourethrography. *J Pediatr Urol*. 2016;12:362–366.

Fujita K, Yamamoto T, Yokota T, et al. In vitro adherence of type 1-fimbriated uropathogenic *Escherichia coli* to human ureteral mucosa. *Infect Immun*. 1989;57(8):2574–2579.

Gander RM, Thomas VL, Forland M. Mannose-resistant hemagglutination and P receptor recognition of uropathogenic *Escherichia coli* isolated from adult patients. *J Infect Dis*. 1985;151(3):508–513.

Garcia FJ, Nager AL. Jaundice as an early diagnostic sign of urinary tract infection in infancy. *Pediatrics*. 2002;109(5):846–851.

Garin EH, Olavarria F, Araya C, et al. Diagnostic significance of clinical and laboratory findings to localize site of urinary infection. *Pediatr Nephrol*. 2007;22:1001–1006.

Garin EH, Olavarria F, Garcia Nieto V, et al. Clinical significance of primary vesicoureteral reflux and urinary antibiotic prophylaxis after acute pyelonephritis: a multicenter, randomized, controlled study. *Pediatrics*. 2006;117:626–632.

Gauthier M, Chevalier I, Sterescu A, et al. Treatment of urinary tract infections among febrile young children with daily intravenous antibiotic therapy at a day treatment center. *Pediatrics*. 2004;114:e469–e476.

Gavin PJ, Katz BZ. Intravenous ribavirin treatment for severe adenovirus disease in immunocompromised children. *Pediatrics*. 2002;110(1 Pt 1):e9.

Gaymans R, Haverkorn MJ, Valkenburg HA, et al. A prospective study of urinary-tract infections in a Dutch general practice. *Lancet*. 1976;2(7987):674–677.

Geraniotis E, Koff SA, Enrile B. The prophylactic use of clean intermittent catheterization in the treatment of infants and young children with myelomeningocele and neurogenic bladder dysfunction. *J Urol*. 1988;139(1):85–86.

Gerard LL, Cooper CS, Duethman KS, et al. Effectiveness of lidocaine lubricant for discomfort during pediatric urethral catheterization. *J Urol*. 2003;170:564–567.

Glennon J, Ryan PJ, Keane CT, et al. Circumcision and periurethral carriage of *Proteus mirabilis* in boys. *Arch Dis Child*. 1988;63(5):556–557.

Gochman RF, Karasic RB, Heller MB. Use of portable ultrasound to assist urine collection by suprapubic aspiration. *Ann Emerg Med*. 1991;20:631–635.

Gorelick MH, Shaw KN. Screening tests for urinary tract infection in children: a meta-analysis. *Pediatrics*. 1999;104:e54.

Gorelick MH, Shaw KN. Clinical decision rule to identify febrile young girls at risk for urinary tract infection. *Arch Pediatr Adolesc Med*. 2000;154:386–390.

Gould CV, Umscheid CA, Agarwal RK, et al. *Healthcare Infection Control Practices Advisory Committee (HICPAC): guideline for prevention of catheter-associated urinary tract infections*. https://www.cdc.gov/infectioncontrol/guidelines/cauti/index.

2009.

Greenfield SP, Wan J. Vesicoureteral reflux: practical aspects of evaluation and management. *Pediatr Nephrol*. 1996;10(6):789–794.

Gribble MJ, Puterman ML. Prophylaxis of urinary tract infection in persons with recent spinal cord injury: a prospective, randomized, double-blind, placebo-controlled study of trimethoprim-sulfamethoxazole. *Am J Med*. 1993;95(2):141–152.

Gubbins PO, McConnell SA, Penzak SR. Current management of funguria. *Am J Health Syst Pharm*. 1999;56(19):1929–1935 [quiz 1936].

Gubbins PO, Occhipinti DJ, Danziger LH. Surveillance of treated and untreated funguria in a university hospital. *Pharmacotherapy*. 1994;14(4):463–470.

Gupta K, Stapleton AE, Hooton TM, et al. Inverse association of H2O2-producing lactobacilli and vaginal *Escherichia coli* colonization in women with recurrent urinary tract infections. *J Infect Dis*. 1998;178(2):446–450.

Guyer DM, Gunther NW 4th, Mobley HL. Secreted proteins and other features specific to uropathogenic *Escherichia coli*. *J Infect Dis*. 2001;183(Suppl 1):S32–S35.

Haddon RA, Barnett PL, Grimwood K, et al. Bacteraemia in febrile children presenting to a paediatric emergency department. *Med J Aust*. 1999;170:475–478.

Hadjifrangiskou M, Gu AP, Pinkner JS, et al. Transposon mutagenesis identifies uropathogenic Escherichia coli biofilm factors. *J Bacteriol*. 2012;194:6195–6205.

Hannerz L, Wikstad I, Johansson L, et al. Distribution of renal scars and intrarenal reflux in children with a past history of urinary tract infection. *Acta Radiol*. 1987;28:443–446.

Hansen A, Hansen B, Dahm TL. Urinary tract infection, day wetting and other voiding symptoms in seven to eight year old Danish children. *Acta Paediatr*. 1997;86:1345–1349.

Hansen MH, Wang BY, Afzal N, et al. Effect of urinary tract infection on ureteropelvic junction obstruction in a rat model. *Urology*. 2003;61(4):858–863.

Hansson S, Dhamey M, Sigström O, et al. Dimercapto-succinic acid scintigraphy instead of voiding cystourethrography for infants with urinary tract infection. *J Urol*. 2004;172:1071–1073.

Hansson S, Jodal U, Lincoln K, et al. Untreated asymptomatic bacteriuria in girls: II—effect of phenoxymethylpenicillin and erythromycin given for intercurrent infections. *BMJ*. 1989;298(6677):856–859.

Harber MJ, Topley N, Asscher AW. Virulence factors of urinary pathogens. *Clin Sci*. 1986;70(6):531–538.

Hay AD, Sterne JA, Hood K, et al. Improving the diagnosis and treatment of urinary tract infection in young children in primary care: results from the DUTY Prospective Diagnostic Cohort Study. *Ann Fam Med*. 2016;14:325–336.

Hellerstein S. Urinary tract infections. Old and new concepts. *Pediatr Clin North Am*. 1995;42(6):1433–1457.

Hellerstein S, Nickell E. Prophylactic antibiotics in children at risk for urinary tract infection. *Pediatr Nephrol*. 2002;17(7):506–510.

Hellström AL, Hanson E, Hansson S, et al. Micturition habits and incontinence in 7-year-old Swedish school entrants. *Eur J Pediatr*. 1990;149(6):434–437.

Hiraoka M, Hashimoto G, Tsuchida S, et al. Early treatment of urinary infection prevents renal damage on cortical scintigraphy. *Pediatr Nephrol*. 2003;18:115–118.

Hoberman A, Chao HP, Keller DM, et al. Prevalence of urinary tract infection in febrile infants. *J Pediatr*. 1993;123:17–23.

Hoberman A, Charron M, Hickey RW, et al. Imaging studies after a first febrile urinary tract infection in young children. *N*

Engl J Med. 2003;348:195.

Hoberman A, Wald ER. Urinary tract infections in young febrile children. *Pediatr Infect Dis J*. 1997;16(1):11–17.

Hoberman A, Wald ER. Treatment of urinary tract infections. *Pediatr Infect Dis J*. 1999;18:1020–1021.

Hoberman A, Wald ER, Hickey RW, et al. Oral versus initial intravenous therapy for urinary tract infections in young febrile children. *Pediatrics*. 1999;104:79–86.

Hoberman A, Wald ER, Reynolds EA, et al. Pyuria and bacteriuria in urine specimens obtained by catheter from young children with fever. *J Pediatr*. 1994;124(4):513–519.

Hodson EM, Willis NS, Craig JC. Antibiotics for acute pyelonephritis in children. *Cochrane Database Syst Rev*. 2007;(4) [CD003772].

Hoebeke P, Van Laecke E, Van Camp C, et al. One thousand video-urodynamic studies in children with non-neurogenic bladder sphincter dysfunction. *BJU Int*. 2001;87:575–580.

Holmdahl G, Brandstrom P, Lackgren G, et al. The Swedish reflux trial in children: II. Vesicoureteral reflux outcome. *J Urol*. 2010;184:280–285.

Homsy YL, Nsouli I, Hamburger B, et al. Effects of oxybutynin on vesicoureteral reflux in children. *J Urol*. 1985;134(6):1168–1171.

Hooton TM. Recurrent urinary tract infection in women. *Int J Antimicrob Agents*. 2001;17(4):259–268.

Hooton TM, Roberts PL, Stamm WE. Effects of recent sexual activity and use of a diaphragm on the vaginal microflora. *Clin Infect Dis*. 1994;19(2):274–278.

Hosseini M, Yousefifard M, Ataei N, et al. The efficacy of probiotics in prevention of urinary tract infection in children: a systematic review and meta-analysis. *J Pediatr Urol*. 2017;13:581–591.

Howard CJ, Glynn AA. The virulence for mice of strains of

Escherichia coli related to the effects of K antigens on their resistance to phagocytosis and killing by complement. *Immunology*. 1971;20(5):767–777.

Huang YY, Chen M-J, Chiu N-T, et al. Adjunctive oral methylprednisolone in pediatric acute pyelonephritis alleviates renal scarring. *Pediatrics*. 2011;128:e496–e504.

Inouye BM, Chiang G, Newbury RO, et al. Adolescent xanthogranulomatous pyelonephritis mimicking renal cell carcinoma on urine cytology: an atypical presentation. *Urology*. 2013;81:885–887.

Ishimine P. The evolving approach to the young child who has fever and no obvious source. *Emerg Med Clin North Am*. 2007;25:1087–1115.

Jacobson SH, Eklöf O, Eriksson CD, et al. Development of hypertension and uraemia after pyelonephritis in childhood: 27 year follow up. *BMJ*. 1989;299:703–706.

Jantausch BA, Criss VR, O'Donnell R, et al. Association of Lewis blood group phenotypes with urinary tract infection in children. *J Pediatr*. 1994;124(6):863–868.

Jebson RG, Craig JC. Cranberries for preventing urinary tract infections. *Cochrane Database Syst Rev*. 2012;(10) [CD001321].

Jodal U. The natural history of bacteriuria in childhood. *Infect Dis Clin North Am*. 1987;1:713–729.

Jodal U, Smellie JM, Lax H, et al. Ten-year results of randomized treatment of children with severe vesicoureteral reflux: final report of the International Reflux Study in Children. *Pediatr Nephrol*. 2006;21:785–792.

Johnson HW, Anderson JD, Chambers GK, et al. A short-term study of nitrofurantoin prophylaxis in children managed with clean intermittent catheterization. *Pediatrics*. 1994;93(5):752–755.

Johnson JR. Virulence factors in *Escherichia coli* urinary tract infection. *Clin Microbiol Rev*. 1991;4(1):80–128.

Johnson JR, O'Bryan TT, Delavari P, et al. Clonal relationships and extended virulence genotypes among *Escherichia coli* isolates from women with a first or recurrent episode of cystitis. *J Infect Dis*. 2001;183(10):1508–1517.

Johnson JR, Stell AL. Extended virulence genotypes of *Escherichia coli* strains from patients with urosepsis in relation to phylogeny and host compromise. *J Infect Dis*. 2000;181(1):261–272.

Jorgensen SE, Short EC Jr, Kurtz HJ, et al. Studies on the origin of the alpha-haemolysin produced by *Escherichia coli*. *J Med Microbiol*. 1976;9(2):173–189.

Joseph DB, Bauer SB, Colodny AH, et al. Clean, intermittent catheterization of infants with neurogenic bladder. *Pediatrics*. 1989;84(1):78–82.

Juliano TM, Stephany HA, Clayton DB, et al. Incidence of abnormal imaging and recurrent pyelonephritis after first febrile urinary tract infection in children 2 to 24 months old. *J Urol*. 2013;190(4 Suppl):1505–1510.

Justice SS, Hung C, Theriot JA, et al. Differentiation and development pathways of uropathogenic *E. coli* in urinary tract infections. *Proc Natl Acad Sci USA*. 2004;101(5):1333–1338.

Kadish HA, Loveridge B, Tobey J, et al. Applying outpatient protocols in febrile infants 1-28 days of age: can the threshold be lowered? *Clin Pediatr (Phila)*. 2000;39(2):81–88.

Kallenius G, Mollby R, Svenson SB, et al. Identification of a carbohydrate receptor recognized by uropathogenic *Escherichia coli*. *Infection*. 1980;8(Suppl 3):288–293.

Kallenius G, Mollby R, Winberg J. In vitro adhesion of uropathogenic *Escherichia coli* to human periurethral cells. *Infect Immun*. 1980;28(3):972–980.

Kanematsu A, Yamamoto S, Yoshino K, et al. Renal scarring is associated with nonsecretion of blood type antigen in children with primary vesicoureteral reflux. *J Urol*. 2005;174(4 Pt 2):1594–1597.

Karavanaki KA, Soldatou A, Koufadaki AM, et al. Delayed treatment of the first febrile urinary tract infection in early childhood increased the risk of renal scarring. *Acta Paediatr*. 2017;106:149–154.

Karmazyn BK, Alazraki AL, Anupindi SA, et al. ACR Appropriateness Criteria® urinary tract infection-child. *J Am Coll Radiol*. 2017;14:S362–s371.

Kasanen A, Sundquist H, Elo J, et al. Secondary prevention of urinary tract infections: the role of trimethoprim alone. *Ann Clin Res*. 1983;15(Suppl 36):1–36.

Kass EH. Asymptomatic infections of the urinary tract. *Trans Assoc Am Physicians*. 1956;69:56–64.

Kass EH. Pyelonephritis and bacteriuria: a major problem in preventive medicine. *Ann Intern Med*. 1962;56:46–53.

Kau AL, Hunstad DA, Hultgren SJ. Interaction of uropathogenic *Escherichia coli* with host uroepithelium. *Curr Opin Microbiol*. 2005;8:54–59.

Kauffman CA, Vazquez JA, Sobel JD, et al. Prospective multicenter surveillance study of funguria in hospitalized patients. The National Institute for Allergy and Infectious Diseases (NIAID) Mycoses Study Group. *Clin Infect Dis*. 2000;30(1):14–18.

Keeton JE, Hillis RS. Urinary tract infections in black female children. *Urology*. 1975;6(1):39–42.

Kehinde EO, Rotimi VO, Al-Hunayan A, et al. Bacteriology of urinary tract infection associated with indwelling J ureteral stents. *J Endourol*. 2004;18(9):891–896.

Keller MA, Sellers BB Jr, Melish ME, et al. Systemic candidiasis in infants: a case presentation and literature review. *Am J Dis Child*. 1977;131(11):1260–1263.

Kemper KJ, Avner ED. The case against screening urinalyses for asymptomatic bacteriuria in children. *Am J Dis Child*. 1992;146(3):343–346.

Keren R, Chan E. A meta-analysis of randomized, controlled trials comparing short- and long-course antibiotic therapy for urinary tract infections in children. *Pediatrics*. 2002;109:E70.

Kibar Y, Ors O, Demir E, et al. Results of biofeedback treatment on reflux resolution rates in children with dysfunctional voiding and vesicoureteral reflux. *Urology*. 2007;70(3):563–566 [discussion 566–7].

Kiddoo D, Sawatzky B, Bascu CD, et al. Randomized crossover trial of single use hydrophilic coated vs multiple use polyvinylchloride catheters for intermittent catheterization to determine incidence of urinary infection. *J Urol*. 2015;194:174–179.

Koff SA, Murtagh DS. The uninhibited bladder in children: effect of treatment on recurrence of urinary infection and on vesicoureteral reflux resolution. *J Urol*. 1983;130(6):1138–1141.

Koff SA, Wagner TT, Jayanthi VR. The relationship among dysfunctional elimination syndromes, primary vesicoureteral reflux and urinary tract infections in children. *J Urol*. 1998;160(3 Pt 2):1019–1022.

Korhonen TK, Leffler H, Svanborg Eden C. Binding specificity of piliated strains of *Escherichia coli* and Salmonella typhimurium to epithelial cells, saccharomyces cerevisiae cells, and erythrocytes. *Infect Immun*. 1981;32(2):796–804.

Kossoff EH, Buescher ES, Karlowicz MG. Candidemia in a neonatal intensive care unit: trends during fifteen years and clinical features of 111 cases. *Pediatr Infect Dis J*. 1998;17(6):504–508.

Kostakioti M, Hadjifrangiskou M, Hultgren SJ. Bacterial biofilms: development, dispersal, and therapeutic strategies in the dawn of the postantibiotic era. *Cold Spring Harb Perspect Med*. 2013;3:a010306.

Krieger JN. Urinary tract infections: what's new? *J Urol*. 2002;168(6):2351–2358.

Krzemien G, Szmigielska A, Turczyn A, et al. Urine interleukin-6, interleukin-8 and transforming growth factor beta1 in infants with urinary tract infection and asymptomatic bacteriuria. *Cent Eur J Immunol*. 2016;41:260–267.

Kunin CM. Emergence of bacteriuria, proteinuria, and symptomatic urinary tract infections among a population of school girls followed for 7 years. *Pediatrics*. 1968;41(5):968–976.

Kunin CM. Does kidney infection cause renal failure? *Annu Rev Med*. 1985;36:165–176.

Kunin CM, Deutscher R, Paquin A Jr. Urinary tract infection in school children: an epidemiologic, clinical and laboratory study. *Medicine (Baltimore)*. 1964;43:91–130.

Langermann S, Möllby R, Burlein JE, et al. Vaccination with FimH adhesin protects cynomolgus monkeys from colonization and infection by uropathogenic *Escherichia coli*. *J Infect Dis*. 2000;181(2):774–778.

La Scola C, De Mutiis C, Hewitt IK, et al. Different guidelines for imaging after first UTI in febrile infants: yield, cost, and radiation. *Pediatrics*. 2013;131:e665–e671.

Latham RH, Stamm WE. Role of fimbriated *Escherichia coli* in urinary tract infections in adult women: correlation with localization studies. *J Infect Dis*. 1984;149(6):835–840.

Lee J, Kwon DG, Park SJ, et al. Discordant findings on dimercaptosuccinic acid scintigraphy in children with multi-detector row computed tomography-proven acute pyelonephritis. *Korean J Pediatr*. 2011;54:212–218.

Lee JK, McClennan BL, Melson GL, et al. Acute focal bacterial nephritis: emphasis on gray scale sonography and computed tomography. *AJR Am J Roentgenol*. 1980;135:87–92.

Lee NG, Marchalik D, Lipsky A, et al. Risk factors for catheter associated urinary tract infections in a pediatric institution. *J Urol*. 2016;195:1306–1311.

Lee YJ, Lee JH, Park YS. Risk factors for renal scar formation in infants with first episode of acute pyelonephritis: a prospective clinical study. *J Urol*. 2012;187:1032–1036.

Leroy S, Fernandez-Lopez A, Nikfar R, et al. Association of prolacitonin with acute pyelonephritis and renal scars in pediatric UTI. *Pediatrics*. 2013;131:870–879.

Leslie B, Moore K, Salle JL, et al. Outcome of antibiotic prophylaxis discontinuation in patients with persistent vesicoureteral reflux initially presenting with febrile urinary tract infection: time to event analysis. *J Urol*. 2010;184(3):1093–1098.

Lewis DA, Brown R, Williams J, et al. The human urinary microbiome; bacterial DNA in voided urine of asymptomatic adults. *Front Cell Infect Microbiol*. 2013;3:41.

Lindberg U, Claesson I, Hanson LA, et al. Asymptomatic bacteriuria in schoolgirls. VIII. Clinical course during a 3-year follow-up. *J Pediatr*. 1978;92(2):194–199.

Loening-Baucke V. Urinary incontinence and urinary tract infection and their resolution with treatment of chronic constipation of childhood. *Pediatrics*. 1997;100(2 Pt 1):228–232.

Loffroy R, Guiu B, Varbédian O, et al. Diffuse xanthogranulomatous pyelonephritis with psoas abscess in a pregnant woman. *Can J Urol*. 2007;14:3507–3509.

Lohr JA, Donowitz LG, Sadler JE 3rd. Hospital-acquired urinary tract infection. *Pediatrics*. 1989;83(2):193–199.

Lohr JA, Downs SM, Dudley S, et al. Hospital-acquired urinary tract infections in the pediatric patient: a prospective study. *Pediatr Infect Dis J*. 1994;13(1):8–12.

Lomberg H, Hanson LA, Jacobsson B, et al. Correlation of P blood group, vesicoureteral reflux, and bacterial attachment in patients with recurrent pyelonephritis. *N Engl J Med*. 1983;308(20):1189–1192.

Ma JF, Shortliffe LM. Urinary tract infection in children: etiology and epidemiology. *Urol Clin North Am*. 2004;31(3):517–526.

Malek RS, Elder JS. Xanthogranulomatous pyelonephritis: a critical analysis of 26 cases and of the literature. *J Urol*. 1978;119:589–593.

Malm-Buatsi E, Nepple KG, Boyt MA, et al. Efficacy of transcutaneous electrical nerve stimulation in children with overactive bladder refractory to pharmacotherapy. *Urology*. 2007;70:980–983.

Mansfield JT, Snow BW, Cartwright PC, et al. Complications of pregnancy in women after childhood reimplantation for vesicoureteral reflux: an update with 25 years of followup. *J Urol*. 1995;154(2 Pt 2):787–790.

Marild S. Incidence of first time symptomatic UTI in children under 6 years of age. *Acta Paediatr*. 1998;87:549–552.

Martinell J, Lidin-Janson G, Jagenburg R, et al. Girls prone to urinary infections followed into adulthood: indices of renal disease. *Pediatr Nephrol*. 1996;10:139–142.

Martinez JJ. Type 1 pilus-mediated bacterial invasion of the bladder epithelial cells. *EMBO J*. 2000;19:2803–2812.

Massanyi EZ, Preece J, Gupta A, et al. Utility of screening ultrasound after first febrile UTI among patients with clinically significant vesicoureteral reflux. *Urology*. 2013;82:905–909.

McCarthy PL, Sharpe MR, Spiesel SZ, et al. Observation scales to identify serious illness in febrile children. *Pediatrics*. 1982;70:802–809.

McCracken GH Jr. Recurrent urinary tract infections in children. *Pediatr Infect Dis*. 1984;3(3 Suppl):S28–S30.

Meadow SR, White RH, Johnston NM. Prevalence of symptomless urinary tract disease in Birmingham schoolchildren. I. Pyuria and bacteriuria. *BMJ*. 1969;3(5662):81–84.

Michael M, Hodson EM, Craig JC, et al. Short versus standard duration oral antibiotic therapy for acute urinary tract infection in children. *Cochrane Database Syst Rev*. 2003;(1) [CD003966].

Miglioretti DL, Johnson E, Williams A, et al. The use of computed tomography in pediatrics and the associated radiation exposure and estimated cancer risk. *JAMA Pediatr*. 2013;167:700–707.

Montini G, Kullus K, Hewitt I. Febrile urinary tract infections in children. *N Engl J Med*. 2011;365:239.

Montini G, Rigon L, Zucchetta P, et al. Prophylaxis after first febrile urinary tract infection in children? A multicenter, randomized, controlled, noninferiority trial. *Pediatrics*. 2008;122:1064–1071.

Montini G, Toffolo A, Zucchetta P, et al. Antibiotic treatment for pyelonephritis in children: multicentre randomised controlled non-inferiority trial. *BMJ*. 2007;335:386.

Moore KN, Fader M, Getliffe K. Long-term bladder management by intermittent catheterisation in adults and children. *Cochrane Database Syst Rev*. 2007;(4) [CD006008].

Moorthy I, Easty M, McHugh K, et al. The presence of vesicoureteric reflux does not identify a population at risk for renal scarring following a first urinary tract infection. *Arch Dis Child*. 2005;90:733–736.

Moorthy I, Wheat D, Gordon I. Ultrasonography in the evaluation of renal scarring using DMSA scan as the gold standard. *Pediatr Nephrol*. 2004;19:153–156.

Mori R, Lakhanpaul M, Verrier-Jones K. Diagnosis and management of urinary tract infection in children: summary of NICE guidance. *BMJ*. 2007;335:395–397.

Mori R, Yonemoto N, Fitzgerald A, et al. Diagnostic performance of urine dipstick testing in children with suspected UTI: a systematic review of relationship with age and comparison with microscopy. *Acta Paediatr*. 2010;99:581–584.

Morin D, Veyrac C, Kotzki PO, et al. Comparison of ultrasound and dimercaptosuccinic acid scintigraphy changes in acute pyelonephritis. *Pediatr Nephrol*. 1999;13:219–222.

Mufson MA, Belshe RB, Horrigan TJ, et al. Cause of acute hemorrhagic cystitis in children. *Am J Dis Child*. 1973;126(5):605–609.

Mularoni PP, Cohen LL, DeGuzman M, et al. A randomized clinical trial of lidocaine gel for reducing infant distress during urethral catheterization. *Pediatr Emerg Care*. 2009;25:439–443.

Mushtaq S, Woodford N, Hope R, et al. Activity of BAL30072 alone or combined with beta-lactamase inhibitors or with meropenem against carbapenem-resistant Enterobacteriaceae and non-fermenters. *J Antimicrob Chemother*. 2013;68:1601–1608.

Nam JK, Park SW, Lee SD, et al. Xanthogranulomatous pyelonephritis in Korean children. *Yonsei Med J*. 2012;53:1159–1164.

Neel KF, Shillinger JF. The prevalence of persistent vesicoureteral reflux after 1 negative nuclear medicine cystogram. *J Urol*. 2000;164:1067–1069.

Nelson DE, Van Der Pol B, Dong Q, et al. Characteristic male urine microbiomes associate with asymptomatic sexually transmitted infection. *PLoS ONE*. 2010;5:e14116.

Nelson JD, Cooper CS, Boyt MA, et al. Improved uroflow parameters and post-void residual following biofeedback therapy in pediatric patients with dysfunctional voiding does not correspond to outcome. *J Urol*. 2004;172:1653–1656.

Nepple KG, Arlen AM, Austin JC, et al. The prognostic impact of abnormal initial renal ultrasound on early reflux resolution. *J Pediatr Urol*. 2011;7:462–466.

Nepple KG, Knudson MJ, Austin JC, et al. Abnormal renal scans and decreased early resolution of low grade vesicoureteral reflux. *J Urol*. 2008;180:1643–1647.

Nepple KG, Knudson MJ, Austin JC, et al. Adding renal scan data improves the accuracy of a computational model to predict vesicoureteral reflux resolution. *J Urol*. 2008;180:1648–1652.

Nguyen H, Weir M. Urinary tract infection as a possible marker for teenage sex. *South Med J*. 2002;95(8):867–869.

NICE. *National Institute for Health and Care Excellence. Feverish illness in children. Assessment and initial management in children younger than 5 years*. [(website)] http://www.nice.org.uk/nicemedia/live/14171/63908/63908.p 2013.

Nickel JC, Costerton JW, McLean RJ, et al. Bacterial biofilms: influence on the pathogenesis, diagnosis and treatment of urinary tract infections. *J Antimicrob Chemother*. 1994;33(SupplA):31–41.

Nijman RJ. Classification and treatment of functional incontinence in children. *BJU Int*. 2000;85(Suppl 3):37.

Nuutinen M, Uhari M. Recurrence and follow-up after urinary tract infection under the age of 1 year. *Pediatr Nephrol*. 2001;16:69–72.

Oh MM, Cheon J, Kang SH, et al. Predictive factors for acute renal cortical scintigraphic lesion and ultimate scar formation in children with first febrile urinary tract infection. *J Urol*. 2010;183:1146–1150.

Oh MM, Kim JW, Park MG, et al. The impact of therapeutic delay time on acute scintigraphic lesion and ultimate scar formation in children with first febrile UTI. *Eur J Pediatr*. 2012;171:565–570.

O'Regan S, Yazbeck S, Hamberger B, et al. Constipation a commonly unrecognized cause of enuresis. *Am J Dis Child*. 1986;140:260–261.

Oreskovic NM, Sembrano EU. Repeat urine cultures in children who are admitted with urinary tract infections. *Pediatrics*. 2007;119:e325–e329.

Ottolini MC, Shaer CM, Rushton HG, et al. Relationship of asymptomatic bacteriuria and renal scarring in children with neuropathic bladders who are practicing clean intermittent catheterization. *J Pediatr*. 1995;127(3):368–372.

Palmer C, Bik EM, DiGiulio DB, et al. Development of the human infant intestinal microbiota. *PLoS Biol*. 2007;5:e177.

Palmer LS, Franco I, Rotario P, et al. Biofeedback therapy expedites the resolution of reflux in older children. *J Urol*. 2002;168(4 Pt 2):1699–1702 [discussion 1702–1693].

Pantell RH, Newman TB, Bernzweig J, et al. Management and outcomes of care of fever in early infancy. *J Am Med Assoc*. 2004;291(10):1203–1212.

Paschke AA, Zaoutis T, Conway PH, et al. Previous antimicrobial exposure is associated with drug-resistant urinary tract infections in children. *Pediatrics*. 2010;125:664–672.

Pennesi M, Travan L, Peratoner L, et al. Is antibiotic prophylaxis in children with vesicoureteral reflux effective in preventing pyelonephritis and renal scars? A randomized, controlled trial. *Pediatrics*. 2008;121:e1489–e1494.

Perkins J, Perkins K, Vilke GM, et al. Is culture-positive urinary tract infection in febrile children accurately identified by urine dipstick or microanalysis? *J Emerg Med*.

2012;43:1155–1159.

Peters CA, Skoog SJ, Arant BS Jr, et al. Summary of the AUA Guideline on Management of Primary Vesicoureteral Reflux in Children. *J Urol*. 2010;184:1134–1144.

Pewitt EB, Schaeffer AJ. Urinary tract infection in urology, including acute and chronic prostatitis. *Infect Dis Clin North Am*. 1997;11(3):623–646.

Pfau A, Sacks T. The bacterial flora of the vaginal vestibule, urethra and vagina in premenopausal women with recurrent urinary tract infections. *J Urol*. 1981;126(5):630–634.

Pinto KJ. Vesicoureteral reflux in the Hispanic child with urinary tract infection. *J Urol*. 2004;171(3):1266–1267.

Pohl HG, Rushton HG, Parl J-S, et al. Adjunctive oral corticosteroids reduce renal scarring: the piglet model of reflux and acute experimental pyelonephritis. *J Urol*. 1999;162:815–820.

Preda I, Jodal U, Sixt R, et al. Normal dimercaptosuccinic acid scintigraphy makes voiding cystourethrography unnecessary after urinary tract infection. *J Pediatr*. 2007;151:581–584.

Ramlakhan SL, Burke DP, Goldman RS. Dipstick urinalysis for the emergency department evaluation of urinary tract infections in infants aged less than 2 years. *Eur J Emerg Med*. 2011;18:221–224.

Raz R. Asymptomatic bacteriuria: clinical significance and management. *Int J Antimicrob Agents*. 2003;22(Suppl 2):45–47.

Reddy P, Evans M, Hughes P, et al. Antimicrobial prophylaxis in children with vesicoureteral reflux: a randomized prospective study of continuous therapy versus intermittent therapy versus surveillance. *Pediatrics*. 1997;100(Suppl 3):555–556.

Reid G, Denstedt JD, Kang YS, et al. Microbial adhesion and biofilm formation on ureteral stents in vitro and in vivo. *J*

Urol. 1992;148(5):1592–1594.

Richter S, Ringel A, Shalev M, et al. The indwelling ureteric stent: a “friendly” procedure with unfriendly high morbidity. *BJU Int*. 2000;85(4):408–411.

Rippentrop JM, Cooper CS, Hawtrey CE. Xanthogranulomatous pyelonephritis in a dysplastic kidney with reflux associated with posterior urethral valves. *J Urol*. 2002;167:1431–1432.

RIVUR Trial Investigators, Hoberman A, Greenfield SP, et al. Antimicrobial prophylaxis for children with vesicoureteral reflux. *N Engl J Med*. 2014;370(25):2367–2376.

Roberts JA. Does circumcision prevent urinary tract infection. *J Urol*. 1986;135(5):991–992.

Roberts JA, Kaack MB, Baskin G, et al. Antibody responses and protection from pyelonephritis following vaccination with purified Escherichia coli PapDG protein. *J Urol*. 2004;171:1682–1685.

Roberts KB. Revised AAP guideline on UTI in febrile infants and young children. *Am Fam Physician*. 2012;86:940–946.

Roussey-Kesler G, Gadjos V, Idres N, et al. Antibiotic prophylaxis for the prevention of recurrent urinary tract infection in children with low grade vesicoureteral reflux: results from a prospective randomized study. *J Urol*. 2008;179:674–679.

Royal Children's Hospital Melbourne. *Urinary tract infection guideline*. [(website)] http://www.rch.org.au/clinicalguide/guideline_index/Urinary_ 2011.

Rudinsky SL, Carstairs KL, Reardon JM, et al. Serious bacterial infections in febrile infants in the post-pneumococcal conjugate vaccine era. *Acad Emerg Med*. 2009;16:585–590.

Rushton HG, Majd M. Dimercaptosuccinic acid renal scintigraphy for the evaluation of pyelonephritis and scarring: a review of experimental and clinical studies. *J Urol*.

1992;148(5 Pt 2):1726–1732.

Rushton HG, Majd M, Jantausch B, et al. Renal scarring following reflux and nonreflux pyelonephritis in children: evaluation with 99m technetium-dimercaptosuccinic acid scintigraphy. *J Urol*. 1992;147(5):1327–1332.

Russo TA, Stapleton A, Wenderoth S, et al. Chromosomal restriction fragment length polymorphism analysis of *Escherichia coli* strains causing recurrent urinary tract infections in young women. *J Infect Dis*. 1995;172(2):440–445.

Salo J, Uhari M, Helminen M, et al. Cranberry juice for the prevention of recurrences of urinary tract infections in children: a randomized placebo-controlled trial. *Clin Infect Dis*. 2012;54:340–346.

Sargent MA, Gupta SC. Sonographic measurement of relative renal volume in children: comparison with scintigraphic determination of relative renal function. *AJR Am J Roentgenol*. 1993;161:157–160.

Savage DC. Natural history of covert bacteriuria in schoolgirls. *Kidney Int Suppl*. 1975;4:S90–S95.

Savage DC, Wilson MI, Ross EM, et al. Asymptomatic bacteriuria in girl entrants to Dundee primary schools. *BMJ*. 1969;3(5662):75–80.

Savar NS, Jahanian-Najafabadi A, Mahdavi M, et al. In silico and in vivo studies of truncated forms of flagellin (FliC) of enteroaggregative Escherichia coli fused to FimH from uropathogenic Escherichia coli as a vaccine candidate against urinary tract infections. *J Biotechnol*. 2014;175:31–37.

Schilling JD, Mulvey MA, Hultgren SJ. Structure and function of *Escherichia coli* type 1 pili: new insight into the pathogenesis of urinary tract infections. *J Infect Dis*. 2001;183(Suppl 1):S36–S40.

Schlager TA, Anderson S, Trudell J, et al. Effect of cranberry juice on bacteriuria in children with neurogenic bladder receiving intermittent catheterization. *J Pediatr*. 1999;135:698–702.

Schlager TA, Clark M, Anderson S. Effect of a single-use sterile catheter for each void on the frequency of bacteriuria in children with neurogenic bladder on intermittent catheterization for bladder emptying. *Pediatrics*. 2001;108(4):E71.

Schlager TA, Dilks S, Trudell J, et al. Bacteriuria in children with neurogenic bladder treated with intermittent catheterization: natural history. *J Pediatr*. 1995;126(3):490–496.

Schoen EJ, Colby CJ, Ray GT. Newborn circumcision decreases incidence and costs of urinary tract infections during the first year of life. *Pediatrics*. 2000;105(4 Pt 1):789–793.

Scholes D, Hooton TM, Roberts PL, et al. Risk factors for recurrent urinary tract infection in young women. *J Infect Dis*. 2000;182(4):1177–1182.

Scholtmeijer RJ, Nijman RJ. Vesicoureteric reflux and videourodynamic studies: results of a prospective study after three years of follow-up. *Urology*. 1994;43(5):714–718.

Schulman SL, Quinn CK, Plachter N, et al. Comprehensive management of dysfunctional voiding. *Pediatrics*. 1999;103(3):E31.

Sedor J, Mulholland SG. Hospital-acquired urinary tract infections associated with the indwelling catheter. *Urol Clin North Am*. 1999;26(4):821–828.

Sfakianakis GN, Georgiou MF. MAG3 SPECT: a rapid procedure to evaluate the renal parenchyma. *J Nucl Med*. 1997;38:478–483.

Shaikh N, Ewing AL, Bhatnagar S, et al. Risk of renal scarring in children with a first urinary tract infection: a systematic review. *Pediatrics*. 2010;126:1084–1091.

Shaikh N, Mattoo TK, Keren R, et al. Early antibiotic treatment for pediatric febrile urinary tract infection and renal scarring. *JAMA Pediatr*. 2016;170:848–854.

Shaikh N, Morone NE, Bost JE, et al. Prevalence of urinary tract infection in childhood: a meta-analysis. *Pediatr Infect Dis J*. 2008;27:302–308.

Shaikh N, Morone NE, Lopez J, et al. Does this child have a urinary tract infection? *J Am Med Assoc*. 2007;298(24):2895–2904.

Sharifian M, Anvaripour N, Karimi A, et al. The role of dexamethasone on decreasing urinary cytokines in children with acute pyelonephritis. *Pediatr Nephrol*. 2008;23:1511–1516.

Shaw KN, Gorelick M, McGowan KL, et al. Prevalence of urinary tract infection in febrile young children in the emergency department. *Pediatrics*. 1998;102(2):e16.

Shaw KN, Gorelick MH. Urinary tract infection in the pediatric patient. *Pediatr Clin North Am*. 1999;46(6):1111–1124 [vi].

Sheinfeld J, Schaeffer AJ, Cordon-Cardo C, et al. Association of the Lewis blood-group phenotype with recurrent urinary tract infections in women. *N Engl J Med*. 1989;320(12):773–777.

Shekarriz B, Upadhyay J, Freedman AL, et al. Lack of morbidity from urodynamic studies in children with asymptomatic bacteriuria. *Urology*. 1999;54(2):359–361 [discussion 362].

Shortliffe LM, McCue JD. Urinary tract infection at the age extremes: pediatrics and geriatrics. *Am J Med*. 2002;113(Suppl 1A):55S–66S.

Siddiqui H, Nederbragt AJ, Lagesen K, et al. Assessing diversity of the female urine microbiota by high throughput sequencing of 16S rDNA amplicons. *BMC Microbiol*. 2011;11:244.

Sidor TA, Resnick MI. Urinary tract infection in children. *Pediatr Clin North Am*. 1983;30(2):323–332.

Siegel SR, Siegel B, Sokoloff BZ, et al. Urinary infection in infants and preschool children. Five-year follow-up. *Am J Dis Child*. 1980;134(4):369–372.

Sillen U. Bladder dysfunction and vesicoureteral reflux. *Adv Urol*. 2008;815472.

Sillen U, Brandstrom P, Jodal U, et al. The Swedish reflux trial in children: V. Bladder dysfunction. *J Urol*. 2010;184(1):298–304.

Singh-Grewal D, Macdessi J, Craig J. Circumcision for the prevention of urinary tract infection in boys: a systematic review of randomised trials and observational studies. *Arch Dis Child*. 2005;90(8):853–858.

Sjostrom S, Sillen U, Jodal U, et al. Predictive factors for resolution of congenital high grade vesicoureteral reflux in infants: results of univariate and multivariate analyses. *J Urol*. 2010;183:1177–1184.

Smellie JM, Poulton A, Prescod NP. Retrospective study of children with renal scarring associated with reflux and urinary infection. *BMJ*. 1994;308:1193–1196.

Smellie JM, Prescod NP, Shaw PJ, et al. Childhood reflux and urinary infection: a follow-up of 10-41 years in 226 adults. *Pediatr Nephrol*. 1998;12(9):727–736.

Song J, Bishop BL, Li G, et al. TLR4-mediated expulsion of bacteria from infected bladder epithelial cells. *Proc Natl Acad Sci USA*. 2009;106:14966–14971.

Soulen MC, Fishman EK, Goldman SM, et al. Bacterial renal infection: role of CT. *Radiology*. 1989;171(3):703–707.

Stamey TA, Sexton CC. The role of vaginal colonization with enterobacteriaceae in recurrent urinary infections. *J Urol*. 1975;113(2):214–217.

Stapleton A. Urinary tract infection pathogenesis: host factors.

Infect Dis Clin North Am. 2014;28:149–159.

Stauffer CM, van der Weg B, Donadini R, et al. Family history and behavioral abnormalities in girls with recurrent urinary tract infections: a controlled study. *J Urol*. 2004;171(4):1663–1665.

Subcommittee on Urinary Tract Infection, Steering Committee on Quality Improvement and Management, Roberts KB. Urinary tract infection: clinical practice guideline for the diagnosis and management of the initial UTI in febrile infants and children 2 to 24 months. *Pediatrics*. 2011;128:595–610.

Supavekin S, Surapaitoolkorn W, Pravisithikul N, et al. The role of DMSA renal scintigraphy in the first episode of urinary tract infection in childhood. *Ann Nucl Med*. 2013;27:170–176.

Sur DK, Bukont EL. Evaluating fever of unidentifiable source in young children. *Am Fam Physician*. 2007;75(12):1805–1811.

Suson KD, Mathews R. Evaluation of children with urinary tract infection: impact of the 2011 AAP guidelines on the diagnosis of vesicoureteral reflux using a historical series. *J Pediatr Urol*. 2014;10(1):182–185.

Svanborg Eden C, Kulhavy R, Marild S, et al. Urinary immunoglobulins in healthy individuals and children with acute pyelonephritis. *Scand J Immunol*. 1985;21(4):305–313.

Tambyah PA, Maki DG. The relationship between pyuria and infection in patients with indwelling urinary catheters: a prospective study of 761 patients. *Arch Intern Med*. 2000;160(5):673–677.

Tappin DM, Murphy AV, Mocan H, et al. A prospective study of children with first acute symptomatic *E. coli* urinary tract infection: early 99m technetium dimercaptosuccinic acid scan appearances. *Acta Paediatr Scand*. 1989;78(6):923–929.

Teach SJ, Fleisher GR. Efficacy of an observation scale in detecting bacteremia in febrile children three to thirty-six months of age, treated as outpatients. Occult Bacteremia Study Group. *J Pediatr*. 1995;126(6):877–881.

Tenke P, Kovacs B, Jäckel M, et al. The role of biofilm infection in urology. *World J Urol*. 2006;24(1):13–20.

Tenke P, Köves B, Nagy K, et al. Update on biofilm infections in the urinary tract. *World J Urol*. 2012;30(1):51–57.

Thompson RH, Chen JJ, Pugach J, et al. Cessation of prophylactic antibiotics for managing persistent vesicoureteral reflux. *J Urol*. 2001;166(4):1465–1469.

Thornbury JR. Acute renal infections. *Urol Radiol*. 1991;12(4):209–213.

Tiihonen K, Ouwehand AC, Rautonen N. Human intestinal microbiota and healthy ageing. *Ageing Res Rev*. 2010;9:107–116.

Toffolo A, Ammenti A, Montini G. Long-term clinical consequences of urinary tract infections during childhood: a review. *Acta Paediatr*. 2012;101:1018–1031.

Troell S, Berg U, Johansson B, et al. Ultrasonographic renal parenchymal volume related to kidney function and renal parenchymal area in children with recurrent urinary tract infections and asymptomatic bacteriuria. *Acta Radiol Diagn (Stockh)*. 1984;25:411–416.

Troell S, Berg U, Johansson B, et al. Comparison between renal parenchymal sonographic volume, renal parenchymal urographic area, glomerular filtration rate and renal plasma flow in children. *Scand J Urol Nephrol*. 1988;22:207–214.

Tseng MH, Lin WJ, Lo WT, et al. Does a normal DMSA obviate the performance of voiding cystourethrography in evaluation of young children after their first urinary tract infection? *J Pediatr*. 2007;150:96–99.

Van Arendonk KJ, Austin JC, Boyt MA, et al. Frequency of wetting is predictive of response to anticholinergic treatment in children with overactive bladder. *Urology*. 2006;67:1049–1053.

Van Arendonk KJ, Knudson MJ, Austin JC, et al. Improved efficacy of extended release oxybutynin in children with persistent daytime urinary incontinence converted from regular oxybutynin. *Urology*. 2006;68:862–865.

Vaughan M, Paton EA, Bush A, et al. Does lidocaine gel alleviate the pain of bladder catheterization in young children? A randomized, controlled trial. *Pediatrics*. 2005;116:917–920.

Verboven M, Ingels M, Delree M, et al. 99mTc-DMSA scintigraphy in acute urinary tract infection in children. *Pediatr Radiol*. 1990;20(7):540–542.

Virkola R, Westerlund B, Holthofer H, et al. Binding characteristics of *Escherichia coli* adhesins in human urinary bladder. *Infect Immun*. 1988;56(10):2615–2622.

Waksman G, Hultgren SJ. Structural biology of the chaperone-usher pathway of pilus biogenesis. *Nat Rev Microbiol*. 2009;7:765–774.

Wan J, Skoog SJ, Hulbert WC, et al. Section on urology response to new guidelines for the diagnosis and management of UTI. *Pediatrics*. 2012;129:e1051–e1053.

Watson JR, Hains DS, Cohen DM, et al. Evaluation of novel urinary tract infection biomarkers in children. *Pediatr Res*. 2016;79:934–939.

Wein AJ, Rovner ES. Definition and epidemiology of overactive bladder. *Urology*. 2002;60(5 Suppl 1):7–12.

Weitz M, Licht C, Müller M, et al. Renal ultrasound volume in children with primary vesicoureteral reflux allows functional assessment. *J Pediatr Urol*. 2013;9:1077–1083.

Wennerstrom M, Hansson S, Jodal U, et al. Renal function 16 to 26 years after the first urinary tract infection in childhood. *Arch Pediatr Adolesc Med*. 2000;154:339–345.

White B. Diagnosis and treatment of urinary tract infections in children. *Am Fam Physician*. 2011;83:409–415.

Whiting P, Westwood M, Bojke L, et al. Clinical effectiveness and cost-effectiveness of tests for the diagnosis and investigation of urinary tract infection in children: a systematic review and economic model. *Health Technol Assess*. 2006;10:1–154.

Whitworth JA. Management of asymptomatic bacteriuria. *Aust N Z J Med*. 1981;11(3):321–328.

Wiles TJ, Kulesus RR, Mulvey MA. Origins and virulence mechanisms of uropathogenic *Escherichia coli*. *Exp Mol Pathol*. 2008;85(1):11–19.

Willemsen J, Nijman RJ. Vesicoureteral reflux and videourodynamic studies: results of a prospective study. *Urology*. 2000;55:939–943.

Williams GJ, Macaskill P, Chan SF, et al. Absolute and relative accuracy of rapid urine tests for urinary tract infection in children: a meta-analysis. *Lancet Infect Dis*. 2010;10:240–250.

Williams PH, Carbonetti NH. Iron, siderophores, and the pursuit of virulence: independence of the aerobactin and enterochelin iron uptake systems in *Escherichia coli*. *Infect Immun*. 1986;51(3):942–947.

Winberg J, Andersen HJ, Bergström T, et al. Epidemiology of symptomatic urinary tract infection in childhood. *Acta Paediatr Scand Suppl*. 1974;252:1–20.

Winberg J, Bergstrom T, Jacobsson B. Morbidity, age and sex distribution, recurrences and renal scarring in symptomatic urinary tract infection in childhood. *Kidney Int Suppl*. 1975;4:S101–S106.

Winter AL, Hardy BE, Alton DJ, et al. Acquired renal scars in children. *J Urol*. 1983;129:1190–1194.

Wiswell TE, Enzenauer RW, Holton ME, et al. Declining frequency of circumcision: implications for changes in the absolute incidence and male to female sex ratio of urinary tract infections in early infancy. *Pediatrics*. 1987;79(3):338–342.

Wiswell TE, Miller GM, Gelston HM Jr, et al. Effect of circumcision status on periurethral bacterial flora during the first year of life. *J Pediatr*. 1988;113(3):442–446.

Wiswell TE, Roscelli JD. Corroborative evidence for the decreased incidence of urinary tract infections in circumcised male infants. *Pediatrics*. 1986;78(1):96–99.

Wiswell TE, Smith FR, Bass JW. Decreased incidence of urinary tract infections in circumcised male infants. *Pediatrics*. 1985;75:901–903.

Wolfe AJ, Toh E, Shibata N, et al. Evidence of uncultivated bacteria in the adult female bladder. *J Clin Microbiol*. 2012;50:1376–1383.

Wong CS, Pierce CB, Cole SR, et al. Association of proteinuria with race, cause of chronic kidney disease, and glomerular filtration rate in the chronic kidney disease in children study. *Clin J Am Soc Nephrol*. 2009;4:812–819.

Wong SN, Tse NK, Lee KP, et al. Evaluating different imaging strategies in children after first febrile urinary tract infection. *Pediatr Nephrol*. 2010;25:2083–2091.

Wullt B, Bergsten G, Samuelsson M, et al. The role of P fimbriae for colonization and host response induction in the human urinary tract. *J Infect Dis*. 2001;183(Suppl 1):S43–S46.

Wurpel DJ, Beatson SA, Totsika M, et al. Chaperone-usher fimbriae of Escherichia coli. *PLoS ONE*. 2013;8:e52835.

Yamamoto S, Tsukamoto T, Terai A, et al. Genetic evidence supporting the fecal-perineal-urethral hypothesis in cystitis caused by *Escherichia coli*. *J Urol*. 1997;157(3):1127–1129.

Yamanouchi S, Kimata T, Kino J, et al. Urinary C-megalin for screening of renal scarring in children after febrile urinary tract infection. *Pediatr Res*. 2017 [Epub ahead of print].

Yeung CK, Godley ML, Dhillon HK, et al. Urodynamic patterns in infants with normal lower urinary tracts or primary vesico-ureteric reflux. *Br J Urol*. 1998;81:461.

Yeung CK, Sreedhar B, Sihoe JD, et al. Renal and bladder functional status at diagnosis as predictive factors for the outcome of primary vesicoureteral reflux in children. *J Urol*. 2006;176(3):1152–1156 [discussion 1156–7].

Yoder MC, Polin RA. Immunotherapy of neonatal septicemia. *Pediatr Clin North Am*. 1986;33(3):481–501.

Zee RS, Herbst KW, Kim C, et al. *J Pediatr Urol*. 2016;12:261 [e1–e7].

Zegers SH, Dieleman J, van der Bruggen T, et al. The influence of antibiotic prophylaxis on bacterial resistance in urinary tract infections in children with spina bifida. *BMC Infect Dis*. 2017;17:63.

Zhang X, Xu H, Zhou L, et al. Accuracy of early DMSA scan for VUR in young children with febrile UTI. *Pediatrics*. 2014;133:e30–e38.

26

Core Principles of Perioperative Management in Children

Sherry S. Ross MD, Janey R. Phelps MD

Pediatric Anesthesia

Perioperative Home

Over 20 years ago, the American Academy of Pediatrics defined the Patient/Family-Centered Medical Home in policy statements describing it as care that is accessible, patient- and family-centered, continuous, comprehensive, and culturally sensitive. This resulted in the development of the Perioperative Surgical Home (PSH) defined by the American Society of Anesthesiologists (ASA) as an innovative, patient-centered surgical continuity of care model that incorporates shared decision making with the goal to create methods for improving the patient/family perioperative experience while improving clinical outcomes and controlling costs. This concept was greatly influenced by the Patient Protection and Affordable Care Act (PPACA) of 2010 in its introduction of accountable care organizations (ACOs; Patient Protection and Affordable Care Act, 2010). ACOs are designed to hold multiple providers jointly accountable for achieving quality targets and reductions in cost (Kash et al., 2014, Vetter et al., 2013).

The perioperative experience is subdivided into groups that include preoperative, intraoperative, postoperative, and postdischarge. Multidisciplinary representatives work together in each group to create a set of standardized care pathways founded on evidence-based medicine. This includes development of Early Recovery After Surgery (ERAS) pathways to promote early mobilization after surgery; increase the use of multimodal analgesia and decrease opioid consumption; endorse early removal of surgical drains; encourage early advancement of diet; and decrease the length of hospital stay. The development of Pediatric PSHs, with a multidisciplinary approach led by both surgeons and anesthesiologists, with defined evidence-based guidelines and protocols will result in appropriate resource utilization and increase patient and provider satisfaction.

Anesthesia and Potential Neurocognitive Effects

On December 14, 2016, the United States Food and Drug Administration (FDA) made a safety statement regarding the possible neurocognitive effects of exposure to anesthesia in children and pregnant women. **The statement warns**

that repeated or lengthy use of general anesthetic and sedation drugs during surgeries or procedures in children younger than 3 years of age or in pregnant women during their third trimester may affect the development of children's brain (FDA Statement, 2016). This warning comes after a plethora of animal studies demonstrated neuropoptosis and cognitive deficits in animals after exposure to anesthesia (Rappaport et al., 2015). These studies extrapolate the period of neuronal vulnerability comparative with the fetal brain in the third trimester, newborns, and children up to 3 years of age. The FDA acknowledges that a number of surgeries in this age group cannot be delayed but stress that the risk and benefits of nonemergent surgeries should be carefully weighed, especially if the surgery will be longer than 3 hours or if multiple surgeries are required (FDA statement, 2016).

Although the FDA has released a safety statement, studies are still lacking that provide direct translation of the animal studies to humans. The FDA has partnered with the International Anesthesia Research Society to create Smart TOTs with the goal to design, implement, and conduct long-term studies in humans to answer this question. The General Anesthesia Compared to Spinal Anesthesia (GAS) study, sponsored by Smart TOTs, is an ongoing international, multicenter, randomized controlled trial comparing neurocognitive outcomes following randomization to either awake-regional anesthesia or to sevoflurane-based general anesthesia in children younger than 60 weeks of age but born at more than 26 weeks' gestation who require inguinal hernia repair. The initial 2-year follow-up results were published in January 2016, and authors reported no difference in cognitive development scores between the two study arms (Davidson et al., 2016). The Pediatric Anesthesia NeuroDevelopment Assessment (PANDA) project is another study sponsored by Smart TOTs and is a sibling-matched observational cohort study that examined whether a single anesthesia exposure in healthy children younger than 3 years of age is associated with an increased risk for impaired global cognitive function (IQ) as the primary outcome and abnormal domain-specific neurocognitive functions and behavior as secondary outcomes at 8 to 15 years of age. The study found that mean IQ scores were not significantly different between the exposed and unexposed siblings, with both groups scoring somewhat higher than average. This study was not able to evaluate the effects of prolonged or repeated exposures to anesthetics (Sun et al., 2016). Other studies have shown different outcomes including a study comparing 33,514 children exposed to anesthesia with 159,619 that were not exposed. The authors reported that anesthetic exposure before 4 years of age was associated with slightly lower school grades and IQ test scores (Glatz et al., 2017).

Research is ongoing in an attempt to determine the long-term effects of anesthesia and sedation on the developing brain of infants and children. In the meantime, the pediatric urologist must stay abreast on this topic. Many children's hospitals have crafted an institutional statement for families to address the FDA's statement and keep their patients informed. **In situations in which a surgery is not elective, it is important to acknowledge and discuss each parental concern with what is known, including the fact that initial human studies conclude a short exposure to a single anesthetic does not lead to decreased neurocognitive dysfunction and that patients deserve a high-quality anesthetic and appropriate pain control and the lack of such can lead to increased morbidity** (Soriano and Anand, 2005).

Key Points

- Families should be informed of current FDA recommendations including what is known and what studies are currently underway to allow thorough informed consent.

Preoperative Assessment and Preparation for Surgery

Anesthesia Risk

The administration of anesthesia is not without risk, and certain patient conditions, such as upper respiratory infections, asthma exacerbations, dehydration, uncontrolled diabetes, prematurity, and febrile illnesses, increase the risk for a complication. Comorbidities can also increase the risk associated with anesthesia administration. Strict adherence to the American Society of Anesthesiology nil per os (NPO) guidelines decreases the risk for potential aspiration. Additional risks include postoperative nausea and vomiting, bronchospasm, laryngospasm, stridor, emergence delirium, and postanesthesia maladaptive behaviors. Rare but more severe risks include allergic reactions to anesthetic medications, anaphylaxis, aspiration, malignant hyperthermia, and death. Although discussion of these risks is typically covered with the family by the anesthesia team, the pediatric urologist should be well versed in this area.

Preoperative Setting

Preoperative preparation is the foundation of ensuring a safe procedure, favorable outcomes, and satisfied families. Numerous studies have shown that pain is influenced by expectations about treatments and pain stimuli intensity (Atlas and Wager, 2012). It is important to ensure that children and parents have realistic postprocedure pain expectation that is delivered in an understandable and age-based language for a more positive emotional and physical outcome (Jaaniste et al., 2007; Jipson and Melamed, 2007; Noel et al., 2012). Certified child life specialists (CCLSs) are trained professionals who are experts in assisting children and families through various techniques to help overcome anxiety-filled experiences in the health care setting. When possible, a CCLS should be utilized in the preoperative setting to help with education and expectations and reduce both child and parental anxiety (Brewer et al., 2006; Grissom et al., 2016; Klosky et al., 2004). Information technology devices (personal computers, smartphones, handheld video games) are usually easily accessible, are cost-effective, can be used at any time or place in the preoperative or perioperative period, and have been shown to reduce distress in children (Faber et al., 2013; Manning et al., 2013; Muessig et al., 2013; Schoffman et al., 2013). Recent studies have found that use of virtual reality–guided operating room tours significantly reduces anxiety and improves compliance during the induction of anesthesia in children compared with conventional information (Ryu et al., 2017). Preoperative anxiety and behavioral stress is an important issue in pediatric surgery patients and may affect up to 50% of children who undergo surgical procedures (Kain et al., 1996). **Additionally, preoperative anxiety in children is predictive of postoperative pain levels and behaviors.** Studies have reported that children with high levels of preoperative anxiety have higher pain scores after surgery with a slower pain recovery after discharge. Higher anxiety is also predictive of emergence delirium, defined as agitation, crying, and/or thrashing during the recovery period (Kain et al., 2006). **New-onset maladaptive behaviors such as general anxiety, nighttime crying, enuresis, separation anxiety, and temper tantrums may occur in up to 50% of children who have undergone surgery, and although these behaviors appear to improve over time, some may persist past the postoperative period** (Kain et al., 1996, 2004). This highlights the importance of targeting ways to decrease both child and parental anxiety (Kain et al., 2004).

Special Preoperative Considerations

Jehovah's Witness

Jehovah's Witness is an evangelical religion with the belief that an individual's life is contained within blood and that accepting transfusion of blood and blood products is sinful. **Parents who are responsible for a child may want to refuse blood products on behalf of their children. However, the surgeon's legal and ethical obligation is with the child patient and not the parents.** The American Academy of Pediatrics recommends that health care providers recognize and respect the importance of religion and avoid unnecessary polarization when conflict over religious practices occur (American Academy of Pediatrics, 1997). However, it should be clear that surgeons and anesthesiologists will not allow a child to die for lack of blood products (Kiran et al., 2014). At our institution, parents are required to sign a separate consent explaining that medical personnel will override their refusal of blood products in life-threatening instances. If this occurs, an automatic court order is submitted to override parental refusal. **Pediatric urologists should be aware of laws in their state and policies at**

their institution.

Department of Social Services

Children in the custody of the Department of Social Services may undergo surgery and anesthesia with consent from a court-ordered legal guardian or designee. In these situations, it is important to either obtain surgical and anesthetic consents preoperatively or ensure that the designee is present or available for consent.

Pain Assessment Tools

The International Association for the Study of Pain defines pain as an unpleasant sensory and emotional experience associated with actual or potential tissue damage (Merskey and Bogduk, 1994). This definition illustrates the complexity of pain, which is magnified in pediatric patients when the ability to assess pain is limited because of cognitive ability and restricted communication skills. Self-assessment of pain is considered the gold standard, but the ability to use self-assessment measurements to rate pain is not present in children younger than 3 years of age.

The age-based self-assessment pain tools that have been validated in children are listed in Fig. 26.1 (von Baeyer, 2006). Commonly used pain scales in children are the Wong-Baker FACES pain rating scale and the numeric pain rating scale (Fig. 26.2). Objective pain scales are available for premature infants (e.g., the PIPP [Premature Infant Pain Profile]), neonates (e.g., the NIPS [Neonatal Infant Pain Scale], CRIES [assess crying, oxygenation, vital signs, facial expression and sleeplessness]) and nonverbal and cognitively impaired children (e.g., FLACC [Face, Legs, Activity, Cry, Consolability], CHEOPS [Children's Hospital of Eastern Ontario Pain Scale]). While the FLACC is a commonly used objective pain scale for nonverbal and cognitively impaired children, its interpretation in the immediate postoperative period can be confusing in the presence of emergency delirium (Manworren and Hynan, 2003; Merkel et al., 1997; Voepel-Lewis et al., 2002).

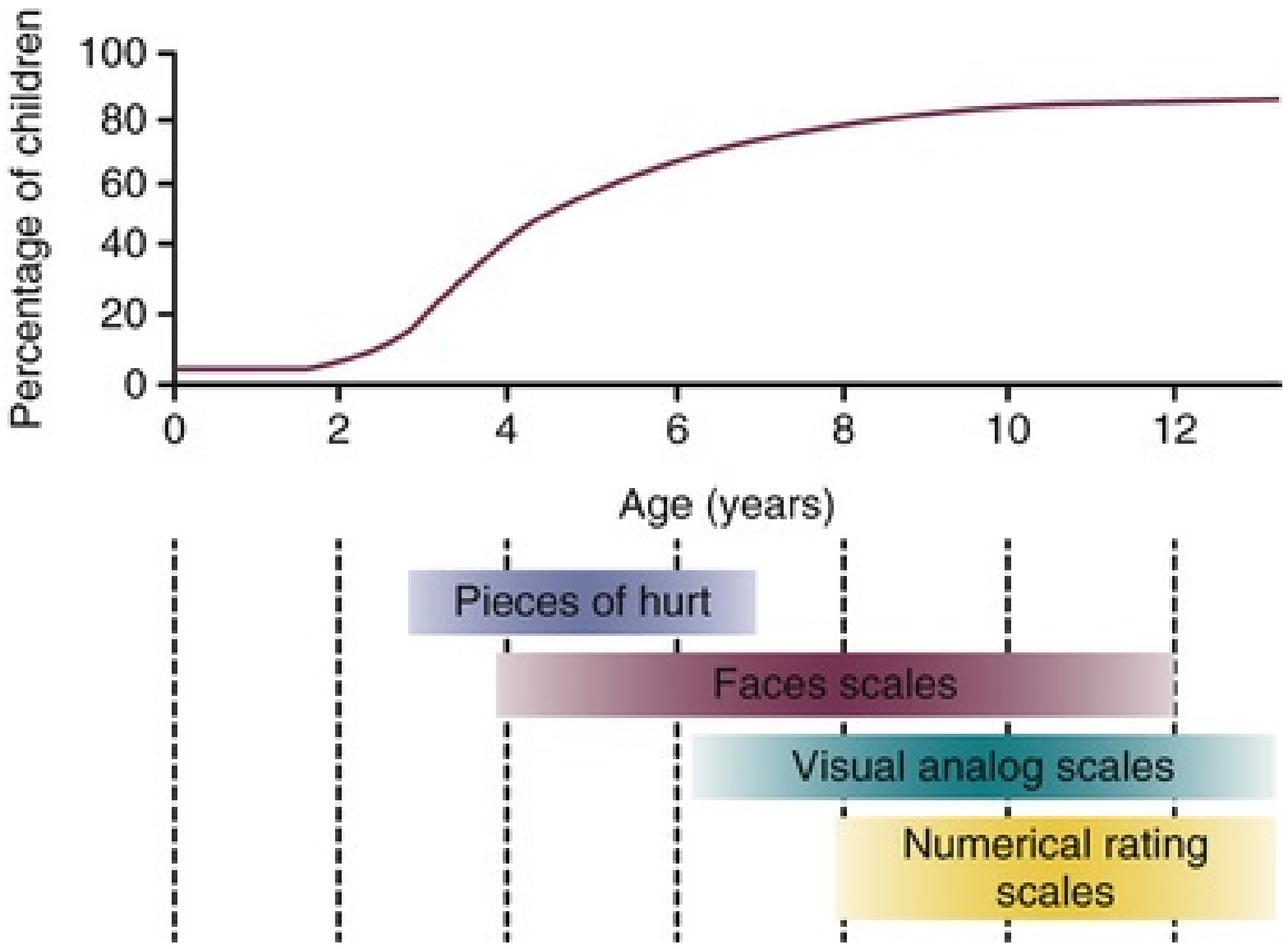

FIG. 26.1 Age-based self-assessment pain tools that have been validated in children. (Data from Cote C, Lerman J, eds. *A practice of anesthesia for infants and children.* 5th ed. Philadelphia, PA: Saunders; 2013 (Chapter 43, Figure 43.5.)

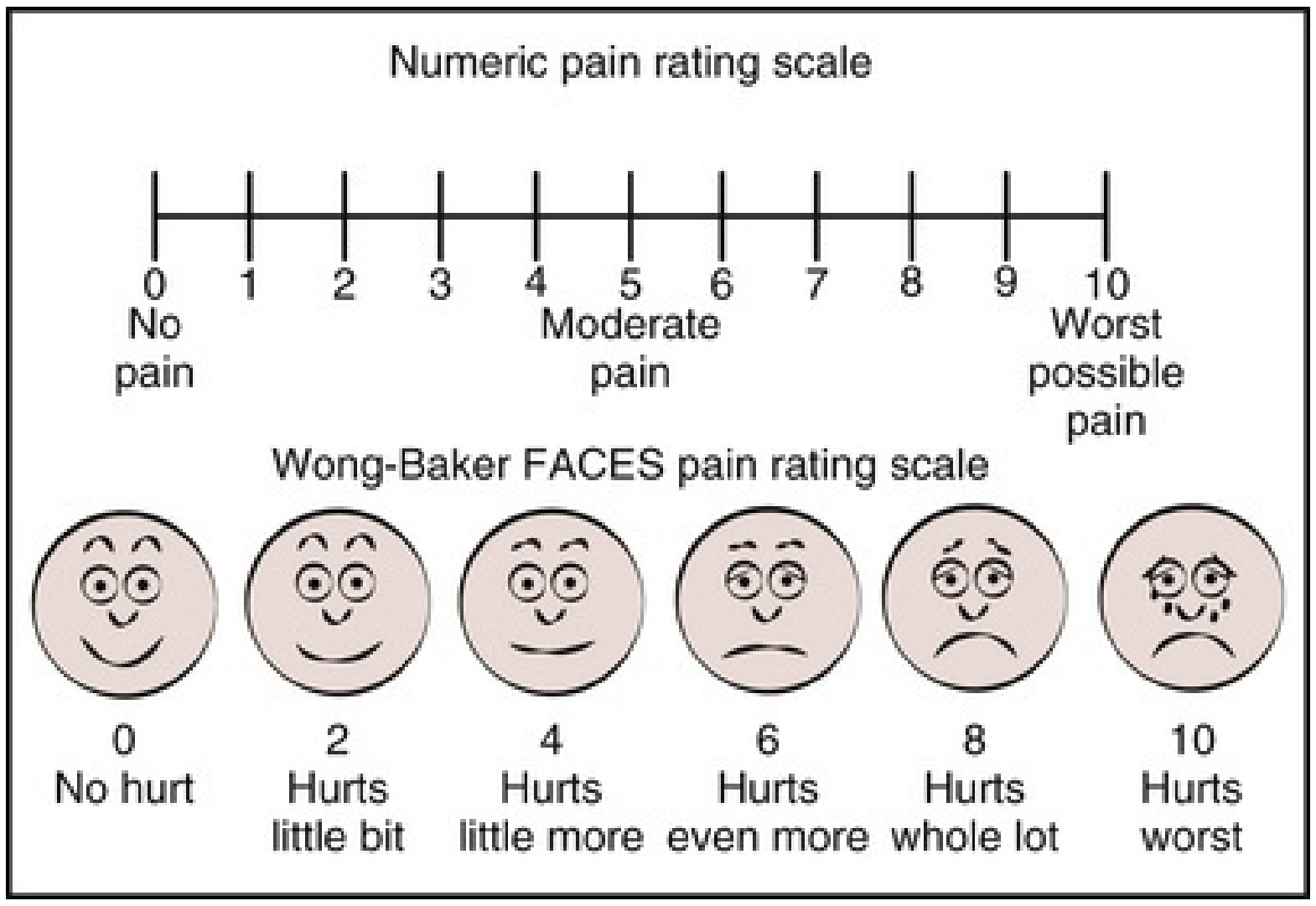
Numeric pain rating scale
0
1
2
3
4
5
6
7
8
9
10
No pain
Moderate pain
Worst possible pain
Wong-Baker FACES pain rating scale
0 No hurt
2 Hurts little bit
4 Hurts little more
6 Hurts even more
8 Hurts whole lot
10 Hurts worst

FIG. 26.2 Numeric scale for patients rating of intensity of pain. (From Wong-Baker FACES Foundation. Wong-Baker FACES® Pain Rating Scale. 2016; Accessed July 24, 2018 with permission from http://www.WongBakerFACES.org. Originally published in *Whaley & Wong's Nursing Care of Infants and Children.* © Elsevier Inc.)

Pain should not only be described in terms of intensity, but it is just as important to qualify the pain in terms of location and duration and to ask what makes it better or worse. The quality of the pain should be understood. Pain cannot be appropriately treated until the location of it is determined. Interestingly, pain is not always at the surgical site.

NPO Status

Fasting Times

Preoperative fasting times have been well established by the ASA (ASA, 2011), the Canadian Anesthesiologists' Society (Merchant et al., 2013), and the European Society of Anaesthesiology (Smith et al., 2011) for both adults and children. See Table 26.1 for the ASA NPO guidelines (Flick and Schears, 2002; Schmitz et al., 2011). Carbohydrate drinks may reduce thirst and hunger and assist with decreasing irritability in young children so should be allowed (Oyama et al., 2011; Hausel et al., 2001). **Prolonged fasting can lead to a variety of adverse effects such as hunger, thirst, hypoglycemia, and dehydration (Hung, 1992; Experts debate NPO, 1994).** Dehydration is especially important for the preoperative child because their potential for fluid loss is higher than for adults (Manworren, 2000). In light of the negative effects of prolonged dehydration and studies demonstrating that clear liquids are cleared faster than previously thought, some European pediatric societies have published a consensus statement endorsing clear liquids up to 1 hour before anesthesia. The consensus statement has been endorsed by the Association of Paediatric Anaesthetists of Great Britain and Ireland, the European Society for Paediatric Anaesthesiology, and L'Association Des Anesthesistes-Reanimateurs Pediatriques d'Expression Francaise (Thomas et al., 2018). In the inpatient setting, maintenance intravenous fluids during the preoperative fasting period may prevent dehydration (Ferrari et al., 1999). In the outpatient setting, when NPO guidelines are followed, fasting fluid deficit is typically minimal, but fasting recommendations are not always followed, so fluid deficits may be high. Effort should be made to schedule surgical cases appropriately and to proceed with younger children earlier in the day because they are more vulnerable to hypovolemia.

TABLE 26.1

American Society of Anesthesiologists NPO Guidelines

INGESTED MATERIAL	MINIMUM FASTING PERIOD (hours)

Clear liquids	2
Breast milk	4
Infant formula	6
Nonhuman milk	6
Light meal	6
Regular meal	8

In emergency situations, the need for surgery should be weighed against the risk for pulmonary aspiration if NPO status is unknown or if guidelines are not met.

Modified from Apfelbaum JL, Agarkar M, Connis RT; American Society of Anesthesiologists Committee. American Society of Anesthesiologists: Practice guidelines for preoperative fasting and the use of pharmacologic agents to reduce the risk of pulmonary aspiration: application to healthy patients undergoing elective procedures: an updated report by the American Society of Anesthesiologists Committee on Standards and Practice Parameters. *Anesthesiology.* 2011;114(3):495–511.

In emergency and urgent surgical cases in which delaying surgery can be detrimental to the patient, gastric content aspiration can result in subsequent development of pneumonitis (James et al., 1984; Raidoo et al., 1990). Rapid-sequence induction and intubation was introduced into anesthesia practice to protect the lungs from aspiration of gastric contents in patients with a full stomach (Neuhaus et al., 2013).

Special NPO Situations

Ketogenic Diet

Patients with epilepsy may be on a ketogenic diet, and it is generally recommended that they remain on their diet preoperatively with the same NPO instructions of a light meal 6 hours preinduction and clears 2 hours preinduction. **They should receive carbohydrate-clear fluids and avoid of drugs that can increase gluconeogenesis, such as dexamethasone** (Soysal et al., 2016; Sampath et al., 2007).

Enteral Tube Feeds

Enteral formulas should be discontinued 6 hours before induction of anesthesia, however pedialyte can be given up to 2 hours before induction (Nespoli et al., 2012). For patients with postpyloric feeding tubes, there is a decreased risk for gastroesophageal reflux and pneumonia, and some may advocate that feeds can continue for nonabdominal surgeries (Jiyong et al., 2013). However, at our institution the same NPO guidelines are used regardless of postpyloric feeds because exact positioning of the tube is not always known and the morbidity associated with aspiration can be high.

Diabetes and Metabolic Disorders

Patients with diabetes and other metabolic disorders deserve special considerations because volume depletion caused by preoperative fasting, coupled with discontinuation of outpatient diabetes medications may contribute to preoperative hyperglycemia (Hans et al., 2006). If possible, elective surgery for children with diabetes should be delayed until glycemic control is optimized. Recommendations include absence of ketonuria, normalized serum electrolytes, and HbA1c value near or within the recommended age-appropriate range (Rhodes et al., 2005). Although preoperative admission is not necessary, some studies have recommend admission for major surgical procedures to optimize metabolic control (Chadwick and Wilkinson, 2004). The patient should never undergo anesthesia without a blood glucose determination before the anesthetic is started. If the surgery has to be delayed for any reason, frequent blood glucose monitoring is mandatory. **It should be the goal that all diabetic patients are scheduled as first-case starts.**

Metformin should be discontinued 24 hours before the procedure because of a long half-life and the risk for lactic acidosis in the presence of dehydration, hypoxemia, or poor tissue perfusion (Mercker et al., 1997). Other oral drugs, such as sulfonylureas and thiazolidinediones, may be discontinued on the morning of the procedure. Insulin-dependent patients should receive their normal dosages of insulin on the day before surgery (Rhodes et al., 2005). At our institution, we recommend that one-half the amount of any long-acting insulin should be given the night before surgery.

The planned surgical procedure directs management of the diabetic child treated with an insulin pump. Specific recommendations should be discussed with the anesthesiologist and/or endocrinologist. In brief, for short minor procedures the patient should continue the insulin pump. For longer procedures, some protocols recommend intravenous insulin infusions or subcutaneous insulin glargine (Glister and Vigersky, 2003). Pediatric diabetic patients who require emergency surgery are typically managed with intravenous insulin infusion and frequent blood sugar checks (Rhodes et al., 2005).

A preoperative anesthesia consult should be considered in patients with metabolic and mitochondrial disorders. Patients with mitochondrial disorders can have an exacerbation of their disease with administration of propofol and lactated Ringer's solution, so these are traditionally avoided. There are numerous metabolic disorders, and it is beyond the scope of this chapter to address each one. However, in general, metabolic disorders such as glycogen storage disorder and urea cycle disorders result in impaired glucose metabolism. These patients cannot tolerate periods without a glucose source and therefore must have glucose-containing fluids while NPO. For these patients, preoperative discussions with the pediatric anesthesiologist are important, and preoperative hospitalization for glucose management should be considered.

Medication Administration

Fasting patients can take medications with a clear fluid 2 hours or more before surgery. **Medications that should be taken on the morning of surgery include antiseizure, gastrointestinal reflux, and asthma medications**. Medications that should not be taken include warfarin and aspirin (stop 7 to 10 days preoperatively), herbal medications, and angiotensin-converting enzyme inhibitors. Some herbal therapies such as Valeria and medications with rebound effects when stopped suddenly (e.g., Clonidine) should not be stopped without physician supervision (Lerman, 2013).

Preoperative Studies

Laboratory Tests

Although some institutions may order routine preoperative studies or laboratory tests, the use of routine preoperative blood testing has been thoroughly evaluated in the literature, and most studies report that in the absence of a clinical indication, routine laboratory evaluation has little use and is not cost-effective (Delahunt and Turnbull, 1980; Johnson and Mortimer, 2002; Kaplan, 1988; MacPherson et al., 2005). Preoperative laboratory tests should be obtained in a thoughtful manor and reserved for patients undergoing complex procedures with the potential for hemodynamic shifts and significant blood loss. Premature infants, patients with metabolic disorders, or patients with complex medical conditions may require preoperative laboratory tests. **The ASA recommends that pregnancy testing should be offered to female patients of childbearing age and to those in whom the result would alter the patient's management** (Apfelbaum et al., 2012). Our institutional policy is that girls of menstrual age receive a urin human chorionic gonadotropin (Hcg) test preoperatively.

Chest X-Ray and Electrocardiogram

Routine preoperative chest x-rays and electrocardiograms (ECGs) are not indicated in pediatric patients, and both tests should be reserved for patients with an indication for the study. It should be noted that a murmur alone is not an indication for an ECG, however pathologic murmurs or patients with cardiac symptoms should be evaluated by cardiology (Lerman, 2013). Last, the need for bacterial endocarditis prophylaxis should be clearly understood and appropriate antibiotic prophylaxis administered in the preoperative period (Nishimura et al., 2017; Wilson et al., 2008).

Pulmonary Function Testing

Pulmonary function test in certain patients, such as patients with poorly controlled asthma and severe scoliosis, may be indicated and the results can help with postoperative planning (Lao et al., 2013).

Urine Evaluation

Urologic procedures in which the urinary tract is opened electively, such as bladder reconstruction, or in cases of diagnostic or therapeutic endoscopy, there is an increased risk for postoperative infection (Cruse, 1992). In these cases, preoperative urine culture is important to identify urinary pathogens and select bacteria-sensitive antibiotics. **Positive urine cultures should be treated before surgical intervention** (Cai et al., 2016). Asymptomatic bacteriuria can be clinically significant and should be treated preoperatively in patients if a sterile urine sample can be obtained (Raz, 2003).

Comorbidities: Perioperative Planning and Postoperative Considerations

Premature Infants

Infants born before 37 weeks’ gestation are considered premature, and those born before 26 weeks or weighing less than 800 g are considered micro-preemies. **The risk associated with anesthesia is greater in preterm neonates because of their immature organ systems.** Respiratory function in the premature infant is challenging because of inadequate surfactant levels, especially in infants born before 34 weeks' gestation. Premature infants may also have higher oxygen consumption and low pulmonary functional residual capacity, as well as tracheomalacia (McCann and Soriano, 2014). **Premature infants have a high risk for postoperative apnea during the first 12 to 23 hours postanesthesia, which can result in death.** Therefore, 23-hour postoperative observation with cardiorespiratory monitoring is recommended in premature infants less than 50 to 60 weeks’ postgestational age (Cote et al., 1995; Davidson et al., 2015; McGregor et al., 2002). **Term infants also have an increased risk for postoperative apnea and should be observed for 23 hours if less than 44 weeks’ postgestational age.**

Premature infants, especially those born less than 28 weeks' gestational age, are at risk for retinopathy of prematurity and blindness, which can be exacerbated by hyperoxia, so the goal is to tolerate oxygen saturation in the low 90s (McGregor et al., 2002). Premature infants are at increase risk for hypothermia because they have immature skin, decreased brown fat, and a larger surface–to–body area ratio. Therefore a warm environment is mandatory (McCann and Soriano, 2014). Also, there is a higher potential for large fluid losses because of higher rates of evaporation from skin and surgical wound sights as well as decreased ability to concentrate urine (McCann and Soriano, 2014).

Asthma and Pulmonary Disease

Asthma control should be optimized before any elective procedure to decrease the risk for morbidity and mortality. Asthmatics and patients with any pulmonary pathology are at increase risk for intraoperative bronchospasm and laryngospasm (Gal, 1994). **The most dangerous times for an airway event is during induction and emergence from anesthesia because of mechanical stimulation, and vigilance is required for early recognition and treatment** (Olsson 1987; Bordet et al., 2002). **It is important not to examine or stimulate the patient at these times.**

For children with asthma, continuation of inhaled beta-2-agonist has been shown to improve lung function and decrease perioperative respiratory adverse events (Scalfaro et al., 2001; Silvanus et al., 2004). Perioperative corticosteroids are reportedly safe, but oral steroids should be utilized only in children with more severe lung disease to avoid the risk for postoperative wound infection and interference with surgical site healing (Kabalin et al., 1995; Vathenen et al., 1991).

Acute Upper Respiratory Tract Infection (URTI)

URTI increases the risk for adverse events, and a risk-benefit analysis should occur for all elective cases in the face of a URTI. Ideally, surgery should be delayed for 2 to 8 weeks, depending on severity, to allow resolution of inflammation and decrease the risk for perioperative respiratory adverse events (Von Ungern-Sternberg et al., 2010).

Cardiovascular Anomalies

Congenital heart disease is the most common form of congenital abnormality occurring in 1% of newborns (Marelli et al., 2007). **Children with a history of congenital heart disease have a higher reported rate of perioperative cardiac arrest with an increased risk for perioperative morbidity and mortality relative to their noncongenital heart disease peers** (Maxwell et al., 2013, 2014; Ramamoorthy et al., 2010). The Pediatric Perioperative Cardiac Arrest (POCA) Registry is the best source of information regarding risk stratification. Overall, infants with a functional single ventricle, patients with suprasystemic pulmonary hypertension, patients with left ventricular outflow tract obstruction, and those with dilated cardiomyopathy are considered high risk (Gottlieb and Andropoulos, 2013; Saettele et al., 2016).

Other risk factors include emergency procedures, severe congenital heart disease, single-ventricle physiology, previous surgery within 30 days, perioperative inotropic support, preoperative cardiopulmonary resuscitation, acute or chronic kidney injury, and mechanical ventilation, which have been shown to significantly increase postoperative mortality (Faranoni et al., 2016). Critical evaluation of surgical need is necessary in this complex population.

Renal Abnormalities

Renal disease is a rare but significant cause of morbidity and mortality in children and is an important consideration in children with urologic abnormalities who are in need of surgery. Infants and children younger than 6 years of age typically have kidney insufficiency caused by developmental abnormalities, such as obstructive uropathy, and older children typically have acquired conditions (Bennett and Bromley, 2007). Hematologic implications of chronic kidney disease (CKD) include the potential for anemia, which can alter respiratory function by decreasing oxygen availability, and with more invasive surgeries would require preoperative blood transfusion. Elevations in urea can result in platelet dysfunction, increasing the risk for intraoperative bleeding and resulting in poor nutrition and slow gastric emptying. Cardiac function may also be affected resulting in cardiomyopathy, congestive heart failure, and pulmonary edema (Guruswamy and Barbour, 2015).

Urine output may be normal, or children may have polyuria, oligouria, or anuria affecting total body fluid volumes. Electrolyte abnormalities can occur including hyponatremia, hyperkalemia, hypocalcemia, hyperphosphatemia, and metabolic acidosis. **In the perioperative period, abnormalities such as hyperkalemia can increase the risk for cardiac arrhythmias.**

Preoperatively, laboratory evaluation should include a complete blood count, serum chemistry panel, and coagulation screening. In patients with suspected cardiac or lung abnormalities, a chest x-ray or ECHO and an ECG should be performed (Guruswamy and Barbour, 2015). Antihypertensive and immunosuppressive medications should be continued unless otherwise advised by the nephrologist or the anesthesiologist. Preoperative dialysis is performed if indicated and surgery avoided for 4 to 6 hours after hemodialysis (Guruswamy and Barbour, 2015).

Patients with CKD stage 1 should be treated postoperatively with general pain medications, including nonsteroidal anti-inflammatory drugs (NSAIDs), opioids, and tramadol (Tawfic and Bellingham, 2015). Patients with CKD stage 2 have mild impairment of renal function but are able to excrete drugs and metabolites so do not require medication adjustments (Bailie et al., 2005; Khwaja and Throssell, 2009; Levey et al., 2003; National Kidney Foundation, 2002). They should be monitored for additional renal deterioration caused by perioperative events and the effect of NSAIDs on kidney function (Lee et al., 2007). Patients with stages 3 and 4 CKD have moderate to severe impairment of renal function. **NSAIDs can significantly worsen renal function in children with CKD stages 3 and 4 and should be avoided.** Attention should be given to adjusting analgesic drug dosages based on GFR, and patients should be monitored closely for any sedation effect (Murtagh, 2007; National Kidney Foundation, 2002; Sear, 2005).

Hematologic Disorders

Hemoglobinopathies are among the most common inherited diseases around the world, and there are two main groups that include the thalassemia syndromes, including α- and β-thalassemia and the structural hemoglobin variants HbE, HbC, and the most common HbS or sickle cell disease.

Sickle cell disease is a chronic illness characterized by hemolysis and vasoocclusion caused by irreversible sickling and clumping of the red blood cells. Patients with sickle cell disease have chronic anemia and are susceptible to pain crisis, acute chest syndrome, strokes, splenic sequestration, cardiomyopathy, congestive heart failure, and renal disease (Falk, 1982; Lopez et al., 1973; Marchant and Walker, 2003; Seeler 1972).

Acute chest syndrome, which is the main cause of death during the administration of general anesthesia, occurs postoperatively in approximately 10% of children with sickle cell disease (Delatte et al., 1999; Firth and Head, 2004; Howard et al., 2015; Vichinsky et al., 1995). Preoperative assessment of children with sickle cell disease should evaluate for end-organ damage, including respiratory insufficiency and cardiac problems. Preoperative testing is dependent on the patient but should include a baseline CBC at a minimum (Marchant and Walker, 2003). A preoperative exchange transfusion versus a simple transfusion may be indicated. Important intraoperative factors that should be incorporated into the anesthetic includes maintenance of normothermia, adequate hydration, pain control, and avoidance of hypoxia and acidosis, which all can lead to increased sickling of red blood cells. Tourniquets should be avoided in patients with sickle cell disease.

The most important factor in the perioperative management of children

with sickle cell disease is avoidance of dehydration, especially during the preoperative NPO status. Perioperative fluid management should include intravenous fluid hydration during preoperative fasting and postoperative intravenous fluid support until the patient is tolerating adequate oral intake (Reed and Vichinsky, 1998). Low oxygen levels, vascular stasis, hypothermia, acidosis, and infection should be avoided postoperatively. Adequate pain medication, hydration until oral intake has resumed, and early postoperative ambulation are important. Recommendations for preoperative transfusion should be discussed with the hematologist (Fu et al., 2005; Koshy et al., 1995; Alotaibi et al., 2014).

Oncologic Disorders

Chemotherapy and Perioperative Considerations

Chemotherapeutic drugs have systemic effects, and because most are antiproliferative agents targeting cells that rapidly divide, cardiac, pulmonary, renal, hepatic, gastrointestinal, bone marrow, and neurologic damage is common. Because patients may undergo elective or emergency procedures at any point during chemotherapy administrations, it is important to be aware of the preoperative evaluation needs and the potential side effects of these agents. A detailed drug history is important to understand the exact chemotherapy regime and the potential side effects. Preoperative testing is dependent on the chemotherapy regimen, patient's symptoms, and timing of chemotherapy treatments.

Specific chemotherapy agents have significant toxicity that can impact anesthesia administration. **Bleomycin can result in pulmonary toxicity in 6% to 10% of patients treated with this medication, and it can be fatal in severe cases** (Simpson et al., 1998), **with exposure to high-inspired oxygen levels during anesthesia resulting in pulmonary toxicity** (Donat, 1999). Cardiac toxicity caused by chemotherapy is common and can result in arrhythmias, blood pressure fluctuations, cardiomyopathy, congestive heart failure, and so on. Several chemotherapy drugs are nephrotoxic and may contribute to either acute or chronic renal failure. Similarly, the hematopoietic effects of chemotherapy medications including pancytopenia can result in a decreased oxygenation, increased risk for hemorrhage, and sepsis.

Pheochromocytoma

Pheochromocytomas are rare neuroendocrine tumors of the adrenal medulla that synthesize and store catecholamines, specifically norepinephrine and epinephrine, which can produce potentially fatal complications when stimulated by anesthesia induction or surgical manipulation. Preoperative and intraoperative management of hypertension is essential for a safe anesthetic. A detailed discussion of pheochromocytomas is covered in this text. **In brief, for children medications are given with a goal of blood pressure reduction of <50th percentile for age and height, and this is often achieved with an alpha-2 receptor antagonist before beta blockade to prevent the likelihood of severe hypertensive crisis from unopposed alpha-receptor stimulation** (Agrawal et al., 2014; Bravo and Tagle, 2003; Ludwig et al., 2007; Romero et al., 2015). Some protocols recommend that patients be placed on a high-sodium and high–fluid-intake diet. These investigators report this regimen helps prevent intraoperative and postoperative hypotension (Agrawal et al., 2014; Bravo and Tagle, 2003; Ludwig et al., 2007; Romero et al., 2015). Additionally, they recommend hospital admission 24 to 36 hours preoperatively for pharmacologic management and intravenous fluid hydration. **Postoperatively hypoglycemia can occur because of acute catecholamine reduction and resulting elevated serum insulin levels. Glucose levels should be monitored** (Hack, 2000).

Spina Bifida

Patients with spina bifida can have multiple challenges because of their underlying neurologic abnormalities, anatomic abnormalities, and the possible associated comorbidities. It is important to consider all aspects during surgical planning. Approximately 90% of infants born with spina bifida have hydrocephalus or will develop hydrocephalus over time. In some cases, a ventriculoperitoneal (VP) shunt may be required. A focused physical examination can identify papilledema or abnormal cognitive function (Whitney et al., 2016). In the perioperative period, adequate shunt function is necessary to avoid intraoperative complications (Whitney et al., 2016). If poor shunt function is suspected, elective operative cases should be rescheduled.

Recent studies report that 53% of patients with spina bifida have some degree of scoliosis (Mummareddy et al., 2017). Spinal defects can alter the thoracic capacity and affect lung function. Because pulmonary disorders may not be clinically evident, if patients are being considered for surgery, respiratory function testing may be helpful. In the operating room, it is important to understand the spinal abnormalities and to evaluate for possible pressure points to ensure that adequate padding is in place for pressure sore prevention. For patients with severe skeletal deformities, a postoperative air mattress may be helpful when extended hospitalizations are anticipated.

Patients with high-level neural tube defects with lesions between T5 and T8 are at an increased risk for autonomic dysreflexia, a potentially life-threatening syndrome caused by a dysregulated *sympathetic* discharge reflex. A sympathetic trigger such as noxious stimuli can lead to severe complication including uncontrolled hypertension, bradycardia, stroke, and potentially death. Spina bifida patients may have anaphylactic latex allergy. Symptoms include bronchoconstriction, vasodilation and subsequent hypotension, increased capillary permeability, coronary vasoconstriction, and myocardial depression. Without immediate recognition and treatment, severe cases can be fatal.

Pain control in patients with spina bifida can be challenging, particularity in patients with shunted hydrocephalus. Placement of epidural catheters in patients with spina bifida has been reported in the adult literature (Tidemarsh and May, 1998), and a recent abstract presented by Roth et al. reported safety of thoracic-level epidural catheter in select spina bifida patients (Roth et al., 2017). Although experience at our institution is smaller, five patients with spina bifida have undergone perioperative epidural catheter placement with good pain control and no long-term complications. More studies are needed to evaluate the safety of this pain-control option. Other pain options include regional blocks and incision infusion catheter placements (Chalmers et al., 2015) as well as standard pain control options such as patient-controlled analgesia (PCA) and intravenous medications.

Congenital Adrenal Hyperplasia

Congenital adrenal hyperplasia (CAH) compromises a group of autosomal recessive disorders of cortisol biosynthesis. The cause in 95% of cases is 21-hydroxylase deficiency. This enzyme defect results in cortisol deficiency, which may or may not be associated with aldosterone deficiency and excess androgens. The severity of CAH can vary from severe to mild and is most often subclassified as salt losing or non–salt losing. Deficiency of aldosterone in the salt-wasting form results in renal sodium losses, hypovolemia, and hyperkalemia. Cortisol deficiency results in poor cardiac contractility with decreases in vascular tone (Minette et al., 2013).

During times of stress, such as surgery, patients with classic CAH are unable to mount an appropriate cortisol response. In major physical stress, such as surgery, patients require a stress dose of steroids, preferably given intravenously with intravenous fluids (Claahsen-van der Grinten et al., 2011). Epinephrine and cortisol deficiency can result in hypoglycemia with fasting, so glucose-containing fluids should be administered, and children should be monitored for low glucose levels (Merke and Bornstein, 2005).

Key Points

- Anesthesia risks include postoperative nausea and vomiting, bronchospasam, laryngospasm, stridor, emergence delirium, and postanesthesia maladaptive behaviors.
- NPO violation significantly increases the risk for gastric aspiration and pneumonitis.
- Premature infants have a significantly increased risk for perioperative complications.
- Spina bifida patients have the potential for multiple comorbidies, which should be considered perioperatively.
- Autonomic dsyreflexia is life threatening. Pediatric urologists should know signs and symptoms of onset.

Acute Preoperative Events

Sepsis

Pediatric sepsis is a leading source of morbidity, mortality, and health care costs in infants and children (Centers for Disease Control and Prevention, 2017). The overall mortality rate is 0% to 5% in previously healthy children (Booy et al., 2001; Nhan et al., 2001) and 10% in chronically ill children with septic shock (Kutko et al., 2003). There are multiple etiologies for sepsis/systemic inflammatory response syndrome, but infections are a common cause. In cases of urologic sepsis, an infective etiology is the likely source. Broad-spectrum agents may be used initially to cover all pathogens while cultures are pending. If cultures cannot be obtained, antibiotics should not be withheld and should be started immediately.

The first 6 hours of resuscitation of septic patients, referred to as the "golden hours," are crucial and frequently coincide with the time for emergency surgery (Dellinger et al., 2008; LeDoux et al., 2000). Aggressive fluid administration with or without vasopressor support is necessary. **Supplemental oxygen therapy is valuable in severely septic patients, even if they do not have signs of respiratory distress** (Schuz-Stubner et al., 2008). If large intraoperative volume losses are anticipated during the surgical procedure, this should be discussed and preparations should be made, including blood type and cross-match, and appropriate intravascular volume resuscitation devices should be placed. Evaluation of serum chemistries, complete blood counts, and coagulation levels should be performed. Patients in septic shock will require the intensive care unit for postoperative management. For pain control, peripheral nerve blocks may be effective and avoid the systemic effects of opioids in a hemodynamically unstable patient. Spinal and epidural anesthesias are generally avoided in patients in shock because of hemodynamic effects and potential coagulopathies (Guay, 2006; Schuz-Stubner et al., 2008).

Trauma

Traumatic injuries continue to be a major cause of death in US children between 1 and 14 years of age (Heron et al., 2009). Often these children require surgical intervention, especially in high-impact traumas, when the risk for urologic injury is increased. In emergent cases, a focused history and physical examination should be performed.

Imaging evaluation may be needed but should not delay emergency life-saving intervention. Laboratory testing is useful, but blood can be obtained in the operating room setting to prevent delays and should include a complete blood count, electrolytes, type and cross-match, coagulation factors, and possible arterial blood gas, depending on the clinical scenario (Hymel et al., 1997; Linzer, 2010).

Pediatric trauma victims should always be considered as full-stomach patients, and rapid-sequence induction is the gold standard (Sagarin et al., 2002). The operating room must be kept as warm as possible during trauma cases to avoid complications related to hypothermia, such as coagulopathies, especially in infants and younger children (Bone et al., 1992). Postoperative pain control is important and may help reduce anxiety and fear in children (Schechter et al., 1997). Oral, rectal, and intravenous acetaminophen can be used. Ibuprofen is also effective (Clark et al., 2007). Opioids should not be withheld in general, unless there are concerns that preclude administration of these medications (Berde and Sethna, 2002).

Upper Respiratory Tract Infection

URTI is the most common nonpreventable cause of surgery cancellations (Bathla et al., 2010). Infection-induced inflammation of the upper respiratory mucosa will result in the airway developing a hyperreactive state with increased secretions and increased sensitivity to irritants, including those used for anesthesia. **This increase in hyperreactivity can persist for 6 to 8 weeks following infection and result in an increased risk for perioperative respiratory adverse events, including laryngospasm, stridor, bronchospasm, cough, breath-holding, desaturation, bradycardia, atelectasis, and pneumonia** (Tait and Malviya, 2005; Tait et al., 2001). If children have or have had a recent URTI, surgeons and anesthesiologists must evaluate the patient and determine whether to postpone surgery or proceed with caution. Studies have shown that a laryngeal mask results in less perioperative airway complications than an endotracheal tube in children with a URTI (Tait and Pandit, 1998).

Urinary Tract Infection (UTI)

The American Urological Association (AUA) guidelines state that, for urologic surgery where there is an existing infection such as bacteriuria at the time of endoscopic procedures, the infection should be eradicated before surgical manipulation with a therapeutic course of antibiotics in an attempt to sterilize the operative field (AUA, 2018).

In spite of these guidelines, there are very few studies that address the need for preoperative urine evaluation in pediatric urologic surgery or the need to delay surgery in the presence of UTIs. However, studies have clearly shown that preoperative UTI, particularly if recurrent, is recognized as a high-risk factor for postoperative infection (Grabe, 2010; Hamasuna et al., 2004; Matsumoto et al., 2007; Yamamoto et al., 2005). Based on these studies and on current recommendations, preoperative urine cultures should be obtained preoperatively if a sterilized field is required and can be obtained. If a UTI or bacteremia is present in surgical cases in which the lower or upper urinary tract will be surgically manipulated, antibiotics should be administered and the surgical procedure rescheduled until the urine is sterile.

In some cases, such as an indwelling catheter or infected stones, sterilization of the urine may not be possible. In these cases, perioperative urine culture may be beneficial to document microbial organisms and determine antibiotic sensitivity when a postoperative infection develops. Although there are no standardized recommendations for patients with neurogenic bladder, given the complexity of surgical reconstruction coupled with guidelines, common practice is to obtain a preoperative urine culture and therapeutically treat based on microbial sensitivities. More studies are needed to develop specific guidelines for preoperative evaluation of urine for pediatric urologic procedures.

Nonspecific Fever

The most common cause of perioperative fever involves an infectious etiology. In children, this is typically associated with URTI, which has a viral etiology in 95% of cases, and allergies and rhinitis can also play a role (Tait and Malviya, 2005). Patients undergoing blood transfusion can also have febrile events up to 1 week after transfusion (Gilliss et al., 2011). Allergic reactions to drugs and noninfective etiologies such as autoimmune disorders, malignancy, or other medical comorbidities can also contribute to perioperative nonspecific fevers (Adnet, 2000; Pile 2006). When children present in the perioperative setting with a nonspecific fever, the anesthesiologist and surgeon need to decide whether to cancel the case or continue with the surgery. The physical examination will play an important role in this decision.

Key Points

- Antibiotics are the mainstay of sepsis treatment and should be administered as soon as possible. Culture should be obtained if possible.
- Urine cultures should be obtained preoperatively when indicated, and positive cultures should be treated with antibiotics based on sensitivities.

ERAS Protocols

The goal of the ERAS pathway is to expedite patient recovery to baseline function by maintaining perioperative organ function and limiting postoperative stress (George et al., 2018). The ERAS pathway employs several components, which include avoiding prolonged fasting, early enteral nutrition and mobilization, preoperative oral carbohydrate loading, and enhanced efforts in patient education. Anesthesia strategies include standardization of anesthetic-related medications, antiemetics, and standardized intraoperative fluid management. These protocols have been found to decrease length of hospital stay, the number of complications, and hospital cost in the adult population (Adamina et al., 2011; Auyong et al., 2015; Geltzeiler et al., 2014; He et al., 2015; Kagedan et al., 2015; Miller et al., 2014; Stowers et al., 2015; Tang et al., 2013; Thiele et al., 2015).

Two evidence-based reviews of ERAS pathways in the pediatric population have highlighted the potential value of this approach. One review concluded that ERAS-like pathways applied to the appropriate pediatric patients may decrease opioid use and reduce length of hospital stay (Shinnick et al., 2016). Similarly, Pearson and Hall reviewed nine studies and the elements in the ERAS pathway including limited use of postoperative nasogastric tubes with postoperative feeding, limited use of urinary catheters, early mobilization, and nonopioid pain management. This group reported earlier return of bowel function with reduced time to oral feeds and reductions in length of hospitalization (Pearson and Hall, 2017). Recently, a prospective study comparing pediatric patients undergoing urologic reconstructive surgery with postoperative management following a specific ERAS protocol were compared with historical patients. Patients managed on the ERAS protocol had a decreased length of stay and a decrease in 90-day complications without increased readmissions, reoperations, or emergency department visits (Rove et al., 2018). Based on these reviews and this recent prospective study, it appears that ERAS protocols in children are beneficial and should be developed for the pediatric surgical population.

Intraoperative Considerations

Preoperative Antibiotics

Surgical site infections (SSIs) are a major cause of increased morbidity, mortality, readmissions, and extended length of hospitalization (de Lissovoy et al., 2009; Magill et al., 2014). The guiding principles for surgical antibiotic prophylaxis include administration of an antimicrobial agent intended to reduce the risk for postoperative local and systemic infection as determined by the ability of the patient to respond to bacterial invasions, the likelihood of bacterial invasions, and the potential morbidity related to the infection and benefit, which outweighs the risk associated with antibiotic administration (AUA, 2018).

Administration of antibiotics preoperatively in children is guided by recommendations in the adult literature. Recommendations by urologic procedure are available at http://www.auanet.org/guidelines. Commonly used antimicrobials, dosages, and redosing intervals used for surgical prophylaxis are shown in Table 26.2. Unfortunately, there is limited data on antimicrobial prophylaxis, specifically for pediatric patients undergoing urologic procedures, and, interestingly, common practices are undergoing evaluation and changes (Baillargeon et al., 2014; Chan et al., 2017; Rangel et al., 2011; Smith et al., 2017). Timing of antibiotics should allow for adequate serum and tissue concentrations before incision (Bratzler et al., 2004; Galandiuk et al., 1989). **Administration of the preoperative antibiotic dose should occur within 60 minutes of surgical incision** (Bratzler et al., 2004; Steinberg et al., 2009). Because of prolonged infusion time, vancomycin and fluoroquinolones should be administered within 120 minutes before incision (Bratzler et al., 2013).

TABLE 26.2

Common Antimicrobials Used for Surgical Prophylaxis

ANTIMICROBIAL	RECOMMENDED PEDIATRIC DOSAGE	INTRAOPERATIVE DOSING INTERVAL (hours)
Ampicillin-Sulbactam	50 mg/kg of ampicillin	2
Ampicillin	50 mg/kg	2
Aztreonam	30 mg/kg	4
Cefazolin	30 mg/kg	4
Cefuroxime	50 mg/kg	4
Cefotaxime	50 mg/kg	3
Cefoxitin	40 mg/kg	2
Cefotetan	40 mg/kg	6

Cetriaxone	50–75 mg/kg	NA
Ciprofloxacin	10 mg/kg	NA
Clindamycin	10 mg/kg	6
Ertapenem	15 mg/kg	NA
Fluconazole	6 mg/kg	NA
Gentamicin	2.5 mg/kg	NA
Levofloxacin	10 mg/kg	NA
Metronidazole	15 mg/kg Neonates <1200: 7.5 mg/kg	NA
Moxifloxacin	10 mg/kg	NA
Piperacillin-tazobactam	Infants 2–9 months: 80 mg/kg of piperacillin Children >9 months and <40 kg: 100 mg/kg piperacillin	2
Vancomycin	15 mg/kg	NA

Common side effects of antibiotics are allergic reaction, including anaphylaxis and gastrointestinal symptoms (nausea, vomiting, pain), *Clostridium difficile* infection, and antibiotic resistance.

The presence of comorbidities such as renal or liver insufficiency may affect recommended dosages, which may require dosage adjustment.

Modified from Bratzler DW, Houck PM; Surgical Infection Prevention Guideline Writers Workgroup. Antimicrobial prophylaxis for surgery: an advisory statement from the National Surgical Infection Prevention Project. *Am J Surg.* 2005:189:395.

Intraoperative and Perioperative Fluid Management

Both restrictive and liberal intraoperative fluid regiments have led to complications, so the pediatric anesthesiologist will aim to provide optimal fluid management based on the patient's fluid deficit, maintenance fluid requirements, and intraoperative fluid losses. Fluid deficit requirements will take into account length of NPO status and the presence of a bowel prep. Maintenance requirements can be calculated by the 4-2-1 rule, originally described in 1957 but still widely used today. The 4-2-1 rule is 4 mL/kg/h for the first 10 kg, 2 mL/kg/h for the second 10 kg, and 1 mL/kg/h for every kilogram greater than 20 kg. For example, a 22-kg patient's maintenance requirement will be 62 mL/h (Holliday and Segar, 1957). There are numerous studies looking at the best crystalloid and colloid replacement. However, overall there is no definitive evidence-based preference as long as optimal fluid management is achieved. Some investigators argue that lactated Ringer's solution with balanced electrolytes are superior to normal saline, which can lead to dilutional acidosis (Lobo and Awad, 2014). There are some caveats regarding fluid therapy, such as limiting dextrose-containing maintenance fluid in neonates less than 2 to 4 months of age because of their immature livers, avoiding lactated fluids in patents with mitochondrial diseases, and avoiding potassium-containing fluids in dialyzed patients, to name a few.

During the postsurgical period, patients should continue maintenance fluid therapy until they can tolerate adequate fluid and nutritional intake by mouth. Historically, hypotonic fluid, such as .45%, was recommended for postoperative fluid management. However, recent studies have found that although the incidence of hyponatremia (<135 mmol/L) in the pediatric postsurgical patient is relatively low (Au et al., 2008; Cladis et al., 2011; Eulmesekian et al., 2010), there is consistent consensus that postoperative patients are at an increased risk for low serum sodium levels. One reason for the development of hyponatremia is the surgically induced stress-related increased release of antidiuretic hormone (ADH). ADH is typically produced by the hypothalamus and subsequently released from the posterior pituitary gland. ADH works in the collecting duct to increase the presence of aquaporin-2 channels, which ultimately increases water permeability and water reabsorption. ADH is normally produced in response to osmolality changes. However, multiple perioperative events such as nausea, pain, and hypoxia can increase release as well (Bailey et al., 2010). Because there is an increased risk for postoperative hyponatremia and the sequel associated with it, current recommendations include the use of isotonic fluid, such as 0.9% NS or lactated Ringer's solution, with dextrose (D_5) for maintenance therapy in the healthy postsurgical child (McNab et al., 2014). If normal saline is selected, potassium should be added. Potassium should be added at 10 mEq/L if <10 kg and 20 mEq/L if >10 kg. Premature infants have immature kidneys, which are unable to handle large solute loads, and maintenance intravenous fluids should be guided to minimize impact on the kidneys.

Anaphylaxis

Perioperative anaphylaxis is a clinical condition that is more likely to occur during adulthood than during childhood and primarily occurs within minutes following anesthetic induction. Neuromuscular blocking agents and β-lactam antibiotics are the main triggers involved in cases of perioperative anaphylaxis.

Latex-induced allergy can occur but is now less common. Anaphylaxis results in cardiovascular collapse with tachycardia, hypotension, severe bronchospasm, and hives. **Management includes immediate cessation of the drug or suspected culprit, 100% oxygen, Trendelenburg positioning, aggressive fluid therapy, albuterol, and epinephrine.** Surgery should be postponed (Dewachter et al., 2015).

Malignant Hyperthermia

Malignant hyperthermia is a rare but potentially fatal hypermetabolic disorder that is triggered by succinylcholine and inhaled anesthetics, excluding nitrous oxide. **The initial signs of malignant hyperthermia include unexplained hypercarbia, sinus tachycardia, masseter muscle spasm, and hyperthermia. Later signs include severe metabolic acidosis, peaked T waves from hyperkalemia, generalized muscle rigidity, and rhabdomyolysis**.

If a patient is determined to be susceptible to malignant hyperthermia, the patient should be scheduled as a first-start case to avoid exposure to inhaled anesthetics leftover from the previous case. Activated charcoal filters decrease the length of time needed to “prepare” the machine from 20 to 104 minutes to 90 seconds (www.MHAUS.org).

If a malignant hyperthermic event is suspected, all triggering agents should be stopped, backup support should be requested, dantrolene should be obtained, and the patient should be disconnected from the anesthesia machine until it is replaced with a clean machine. An arterial line and Foley catheter should be placed. A team member can be instructed to call the 24-hour malignant hyperthermia hotline at 1-800-644-9737 to obtain expert help at any time during the event. Patients should be admitted for 24 to 48 hours for continued treatment, supportive care, and for the possibility of recrudescence. Hyperkalemia and cardiac arrest should be treated aggressively. A cognitive aid (https://www.ncbi.nlm.nih.gov/books/NBK1146/figure/mhs.F2/) is helpful in any emergency situation to ensure that all treatment and supportive options are being utilized. In spite of the much lower mortality rate of 5% in recent years, there is still significant morbidity related to malignant hyperthermia, so quick recognition and aggressive treatment is necessary. All incidences of malignant hyperthermia should be reported to the malignant hyperthermia registry (www.MHaus.org/registry), which can be accessed for data collection.

Laparoscopic Procedures

Minimally invasive surgery was introduced to pediatric urology more than 30 years ago with the description of diagnostic laparoscopy for nonpalpable testes (Cortesi et al., 1976). There are multiple benefits to laparoscopy and robotic-assisted laparoscopic surgery in children, so utilization has significantly increased. Even though laparoscopy is well tolerated in children, there are anatomic and physiologic challenges in the pediatric population that should be considered.

In children, chest wall compliance is increased and functional residual capacity is decreased. Decreased chest wall compliance in the presence of increased airway pressures caused by CO_2 insufflation can result in oxygen desaturation (Wedgewood and Doyle, 2001). Pneumoperitoneum also influences cardiovascular function, but the overall impact is minimal in children with normal cardiac function (Gentili et al., 2000). There have been concerns about renal and brain perfusion, but to date, there has been no evidence to conclude there are detrimental effects to these organs (Bellon et al., 2018; Gómez Dammeier et al., 2005; Maesani et al., 2016).

Proper positioning is important in laparoscopic cases to ensure adequate access to the organ of interest. All pressure points should be padded to prevent nerve injuries. **An axillary roll should be used to prevent brachial plexus compression when operating on a patient in the lateral decubitus position, and the neck should be maintained in a neutral position in alignment with the spine (Martin, 1987).** To avoid lower-extremity nerve injuries, the dependent leg is flexed and a cushion is placed between the knees to minimize pressure on these areas.

Multimodal analgesia has been shown to speed up postoperative progress with the use of both nonopioid analgesics (NSAIDs) and opioid agents (Brasher et al., 2014; Michelet et al., 2012, 2016). Regional analgesia may decrease the side effects of opioid agents.

One of the most important considerations in children undergoing laparoscopic procedure is the possibility of a CO_2 embolus. This event occurs during insufflation when a high volume of CO_2 enters the venous system resulting in obstruction to the outflow of the right ventricle and pulmonary circulation. This results in sudden oxygen desaturation and cardiovascular collapse. Decreasing end-title CO_2 coupled with a mill-wheel murmur are classic findings (Gutt et al., 2004). **Treatment includes placement of the patient in the left lateral decubitus (right side up) and Trendelenberg positions and aspiration of the air embolus through a central line if one is in place** (Gutt et al., 2004).

Intraoperative Pain Management

The choice of intraoperative pain management techniques are dependent on patient factors, surgical factors, and comfort level of the pediatric anesthesiologist. Epidural analgesia is a good choice for both intraoperative and postoperative pain management for open surgical procedures with large incisional sites. Epidurals can be safely placed in patients as small as 2 kg in the hands of experienced pediatric anesthesiologists (Long et al., 2016).

Neuraxial and regional anesthesia is safely performed in anesthetized versus awake pediatric patients, and this is the standard approach (Taenzer et al., 2014). The use of regional or neuraxial analgesia during the intraoperative period allows for avoidance or minimized use of opioids. Decreased use of opioids during the intraoperative period can also be achieved by the use of multimodal analgesia. Acetaminophen, a Cox-2 inhibitor, and gabapentin can be administered preoperatively in certain patient populations. Intravenous acetaminophen can also be administered during the intraoperative period. The current trend is to use intravenous as opposed to rectal acetaminophen during the intraoperative period because the absorption of rectal acetaminophen is so unpredictable (Anderson et al., 1995; Birmingham et al., 1997; Houck et al., 1995; Howell and Patel, 2003; Khalili et al., 2016).

Intravenous lidocaine has been shown to be beneficial as a multimodal analgesic approach intraoperatively, with some studies advocating for its use to continue for 24 hours during the immediate postoperative course (Kranke et al., 2015; McCarthy et al., 2010). Intravenous lidocaine is used in a majority of ERAS protocols. It is important to know if an intravenous lidocaine infusion is part of the intraoperative anesthesia plan to ensure that it is included in the total local anesthesia calculations to avoid toxicity.

Other adjuncts that are used for intraoperative pain management include intravenous ketamine and dexmedetomidine infusions. Both can decrease the overall narcotic need and improve postoperative analgesia. Dexmedetomidine is one of the few drugs used in anesthesia that has been shown in animal models to be protective against neurocognitive effects (Perez-Zoghbi et al., 2017). Intravenous ketorolac is an option for multimodal analgesia and has been safely used in neonates less than 6 months of age but is commonly reserved for infants 6 months and older with normal renal function.

It is important to discuss pain management with the anesthesiologist for intraoperative and postoperative pain management.

Key Points

- Antibiotics are the mainstay to prevent SSIs. Selection of antimicrobial should consider the site and potential source of infection.
- Interoperative complications can occur. Pediatric urologists should be knowledgeable in recognition and treatment.

Postoperative Management

Immediate Postoperative Management

During the immediate postsurgical period, attention is focused on respiratory and cardiovascular status because of the risk for adverse events. **Respiratory events include hypoxia, airway obstruction, laryngospasm, bronchospasm, postobstructive pulmonary edema, and aspiration**. The incidence of adverse events are increased in patients who are intubated, ASA 3-4, and age less than 1 year of age, children with a respiratory pathology, premature infants, and those with current or recent upper respiratory infection (Murat et al., 2004). Multiple intubation attempts can lead to airway edema and present as stridor. Laryngospasm can result in the need for reintubation if positive pressure ventilation and propofol-induced relaxation of the vocal cords are not successful. Bronchospasm can be treated with albuterol/atrovent nebulizers but if severe, treatment may require epinephrine, steroids, magnesium, and continuous albuterol treatments. Depending on the severity these patients may need to be admitted for continual treatment and airway support.

Children with congenital cardiac disease are at a higher risk for a cardiac adverse event (Saettele et al., 2016). Fortunately, the risk for postoperative pediatric cardiac arrest in the noncardiac population is rare with an incidence of less than 1 per 100,000 pediatric anesthetics. (Morray et al., 2000; Zgleszewski et al., 2016). When a cardiac arrest does occur in the postoperative setting, most are in children younger than 5 and most are deemed preventable (Christensen and Voepel-Lewis, 2017; Christensen et al., 2013, 2017). This highlights the necessity of continual vigilance and early recognition and treatment of adverse events in the pediatric postanesthesia care unit (PACU).

Children, especially between the ages of 2-8 years, can emerge from anesthesia with restlessness, agitation, delirium, combativeness, and an inability to be consoled. This phenomenon is referred to as emergence delirium and has a reported incidence of 10-80%, depending on the study (Voepel-Lewis et al., 2003). Typically this event occurs within the first 30 minutes and is self-limited. However, it is very disturbing to care providers and parents and can be dangerous to the child resulting in self-injury, removal of Foley catheters and intravenous catheters, and damage to the surgical site. It is important to rule out pain and normal behavior (e.g., temper tantrum) for the particular patient. There is a scoring system for emergence delirium, the Post Anesthesia Emergence Delirium (PAED) scale, that can be used to help differentiate emergence delirium from pain or other etiologies (Sikich and Lerman, 2004). The most distinguishing quality of emergence delirium is the inability to recognize the patient's surroundings or parents. Patients who are highly anxious preoperatively are at a higher risk for emergence delirium. Treatment may involve low-dose bolus of propofol by the anesthesiologist with immediate vigilance for airway compromise after administration. Dexmedetomidine, fentanyl, and clonidine may be used as well. It is important to discuss the possible risk for emergence delirium with the parents or care providers preoperatively. If patients are deemed high-risk, anesthesiologists may preemptively treat before the anesthetic effect has ended.

Postanesthesia Care Unit and Pain Management

Postoperative pain can be extremely distressful to the patient, care provider, and parents. The anesthesiologist should not leave the patient's beside in the PACU until there is a postoperative pain plan in place. Pain assessment and management has been discussed in an earlier section and the institutional pain scale should be used to evaluate pain with titration of both narcotic and non-narcotic pain medications. PCA and PCA by proxy can be initiated in the PACU for patients admitted for surgery when this is the plan for pain control. PCAs can be safely used in patients as young as 4 years old who are cognitively appropriate, and PCA by proxy (parent- or nurse-administered PCAs) are available in many children's hospitals. If a regional or neuraxial technique is used, then the anesthesiologist must ensure this is functioning well. Patients should not be discharged from the PACU until adequate pain control has been achieved.

Discharge from the PACU can be achieved once the patient returns to their baseline function with normal hemodynamics. The Aldrete score and Post-Anesthetic Discharge Scoring System (PADSS) is often utilized to determine readiness to leave the PACU. (Biedermann et al., 2014; Marley and Moline, 1996; Marshall and Chung, 1999). An anesthesiologist should provide a brief postanesthesia evaluation note that must include respiratory function, cardiovascular function, mental status, temperature, pain, nausea, vomiting, and postoperative hydration. Documentation is required by The Centers for Medicaid and Medicare, which must be completed within 48 hours of the anesthetic.

Inpatient and Outpatient Postoperative Pain Management

Studies show that approximately 80% of surgical patients have postoperative pain, which is most often described as moderate to severe (Apfelbaum et al., 2003). **Appropriate postoperative pain management in the pediatric patient is a major concern because studies show pain management in children is often inadequate because of challenges with pain assessment and concerns about opioid side effects** (Astuto et al., 2007; Lee and Jo, 2014; Morton, 2007; Segerdahl et al., 2008; Taylor et al., 2008). Poor pain management can increase the risk for complications, increase recovery time, and increase morbidity and mortality (Katz et al., 1996; Kehlet and Holte, 2001; Sharrock et al., 1995) in the adult population, which is extrapolated to the pediatric population, prompting attention to adequate pain management.

Expectations for pain including the expected quality and duration of postoperative pain should be discussed preoperatively with the patient and/or family. **For pain management, both inpatient and outpatient pain management should include a multimodal approach.** For surgical pain, a combination of acetaminophen and NSAIDs is the basis for the treatment. This combination has been shown to decrease opioid use by 30% to 40% (Michelet et al., 2012; Wong et al., 2013). Opioids can be used for breakthrough pain but are commonly associated with side effects such as nausea, pruritus, constipation, and respiratory depression. **Of note, regulatory authorities warn against using codeine in children with absolute contraindicated use following tonsillectomy for obstructive sleep apnea** (USDA, 2017). During the initial postoperative period, patients should be on a scheduled pain regimen to preemptively address pain. Treating pain as needed has been shown to be inadequate for quality postoperative pain control (Simons and Moseley, 2008; Sutters et al., 2010). Table 26.3 shows the most common narcotic and non-narcotic analgesics used in pediatrics.

TABLE 26.3

Pediatric Pain Medication Dosages and Intervals

NARCOTIC	ORAL DOSAGE PER kg	IV DOSAGE PER kg	FREQUENCY	PCA DOSAGE PER kg
Morphine	0.3 mg/kg	0.05–0.1 mg/kg	Every 3–4 hours	0.02 mg/kg every 10 minutes +/− basal 0.02 mg/kg/h
Hydromorphone	0.04 mg/kg	0.01 mg/kg	Every 3–4 hours	0.004 mg/kg every 10 minutes +/− basal 0.002–0.004 mg/kg/h
Fentanyl[a]	NA	0.5–1 mcg/kg	Every 30–60 minutes	0.5 mcg/kg every 6 minutes +/− basal 0.5 mcg/kg/h
Oxycodone	0.1 mg/kg	NA	Every 4 hours	NA
Codeine[b]	Not recommended	NA	NA	NA
Methadone[c]	0.1–0.2 mg/kg	0.1 mg/kg	Every 12–24 hours	NA
NON-NARCOTIC	**ORAL DOSAGE PER kg**	**IV DOSAGE PER kg**	**FREQUENCY**	**NOTES**
Acetaminophen	15 mg/kg	>2 years: 15 mg/kg	Every 6 hours	IV FDA-approved >2 years; <2 years lower dosages have been used. Consult Pediatric Anesthesia <2 years
Ibuprofen[d]	10 mg/kg	NA	Every 8 hours	
Ketorolac[d]	NA	0.5 mg/kg (max 30 mg)	Every 8 hours	0.1 mg/kg loading dose (max 30 mg) × 1. Use limited to 72–96 hours because of renal toxicity
Celecoxib[e]	2–4 mg/kg	NA	Every 12 hours	Max dose 200 mg twice a

				day
Naproxen[f]	5 mg/kg	NA	Every 12 hours	Max dose 500 mg twice a day
Tramadol	1 mg/kg	Not available in US	Every 6 hours	
Gabapentin	5 mg/kg/day titrated to max 35 mg/kg/day	NA	Every 8 hours	Indicated for neuropathic pain. Because of drowsiness, titrate every 2–3 days to maximize tolerated dose
Lyrica	5–10 mg/kg/day	NA	Every 12 hours	Neuropathic pain if gabapentin failure

[a] Fentanyl has a short half-life and is not ideal for sustained pain but can work well to help control acute pain of short duration such as procedural pain. Also can be given intranasally, 1–2 mcg/kg.

[b] Codeine has a black box warning for patients who cannot convert it to morphine (no analgesic benefit) and patients who are ultraconverters and convert a dangerous amount to morphine resulting in death.

[c] Long half-life, and can accumulate causing respiratory depression and death, and possible cardiovascular events in children with prolonged QT syndrome, so ECG required. Consider consultation with a pediatric pain expert before administration.

[d] Ibuprofen and ketorolac are not recommended <6 months of age.

[e] Celecoxib is only FDA-approved for juvenile idiopathic/rheumatoid arthritis >2 years and 10 kg.

[f] Naproxen is only for children >2 years of age.

Opioid Use in Children

Opiate overdose and abuse in children and adolescents frequently results from access to unused pain medications in the household. Currently there are no standard guidelines in pediatric urology for optimal opioid prescriptions, and recent studies have shown that without a standardized protocol, opioid over-prescription rates may be as high as 64% (Garren et al., 2019). Studies also show that decreasing prescribed opioid quantity by 50% can be done without impacting pain control in the postoperative pediatric urology patient (Cardona-Grau et al., 2019). Also concerning is a recent study from our institution that found that up to 62% of patients had leftover opioid medications, with 78% of families failing to dispose of excess opioids after resolution of post-surgical pain (Garren et al., 2019). Therefore it is important to prescribe an adequate number of opioids, ideally without excess, and parents and patients should be educated on the proper storage and disposal of unused narcotics. Our institution has implement educational handouts, which include pain scales and recommended treatment for each level, storage recommendations for opioids, and information about proper disposal. We have also implemented narcotic dropboxes, where patients can dispose of their unused medications. Additionally, we are trialing envelopes containing a substance that will make the narcotics unpalatable. Additional information on the proper disposal of opioids can be found at https://www.fda.gov.

A multimodal approach to pain management not only consists of various drugs but also consists of nonpharmacologic interventions such as distraction with music or art therapy, hypnosis, and/or acupuncture. These techniques can be incredibly valuable, especially in patients with chronic pain conditions.

In addition to pain management, it is imperative to utilize physical therapy to enhance early mobilization. Early postoperative fatigue has several etiologies including noise, medication, and the inflammatory response. Studies have shown that late fatigue results in loss of muscle mass, weight loss, and weakness (Kehlet and Rosenberg, 1997). Both at home and in the hospital setting, sleep hygiene is essential. For children, this includes a set bedtime, avoiding caffeine after 6 PM, and avoiding the use of electronics at bedtime. Melatonin and trazodone are both non–habit-forming and should be considered if sleep is an issue.

Key Points

- Perioperative complications most often occur in the immediate postoperative period.
- Team members should be aware of potential postoperative complications and monitor patients for these potential events after surgery.
- Postoperative pain control is important for optimal surgical outcomes. A multimodal drug approach is recommended.
- Proper administration and disposal of unused narcotics are necessary to prevent overdoses with these medications.

References

Adamina M, Kehlet H, Tomlinson GA, et al. Enhanced recovery pathways optimize health outcomes and resource utilization: a meta-analysis of randomized controlled trials in colorectal surgery. *Surgery*. 2011;149:830.

Adnet P, Levtavel P, Krivosic-Horber R. Neuroleptic malignant syndrome. *Br J Anaesth*. 2000;85:129–135.

Agrawal R, Mishra SK, Bhatia E, et al. Prospective study to compare peri-operative hemodynamic alterations following preparation for pheochromocytoma surgery by phenoxybenzamine or prazosin. *World J Surg*. 2014;38(3):716–723.

Alotaibi GS, Alsaieh K, Bolster L, et al. Preoperative transfusion in patients with sickle cell disease to prevent perioperative complications: a systemic review and meta-analysis. *Hematology*. 2014;9(8):463–471.

American Academy of Pediatrics Committee on Bioethics. Religious objections to medical care. *Pediatrics*. 1997;99:279–281.

American Society of Anesthesiologists Committee. Practice guidelines for preoperative fasting and the use of pharmacologic agents to reduce the risk of pulmonary aspiration: application to healthy patients undergoing elective procedures: an updated report by the American Society of Anesthesiologists Committee on standards and practice parameters. *Anesthesiology*. 2011;114(3):495.

American Urological Association. *AUA Guidelines*. http://www.auanet.org/guidelines.

Anderson BJ, Woolard GA, Holford NHG. Pharmacokinetics of rectal paracetamol after major surgery in children. *Paediatr Anaesth*. 1995;5:237–242.

Apfelbaum JL, Chen C, Mehta SS, et al. Postoperative pain experience: results from a national survey suggest postoperative pain continues to be undermanaged. *Anesth Analg*. 2003;97:534–540.

Apfelbaum JL, Connis RT, Nickinovich DG, Committee on Standards and Practice Parameters: American Society of Anesthesiologists Task Force on Preanesthesia Evaluation, et al. *Anesthesiology*. 2012;116(3):522–538.

Astuto M, Rosano G, Rizzo G, et al. Methodologies for the treatment of acute and chronic nononcologic pain in children. *Minerva Anestesiol*. 2007;73:459–465.

Atlas LY, Wager TD. How expectations shape pain. *Neurosci Lett*. 2012;520(2):140–148.

Au AK, Ray PE, McBryde KD, et al. Incidence of postoperative hyponatremia and complications in critically-ill children treated with hypotonic and normotonic solu- tions. *J Pediatr*. 2008;152:33–38.

Auyong DB, Allen CJ, Pahang JA, et al. Reduced length of hospitalization in primary total knee arthroplasty patients using an updated enhanced recovery after orthopedic surgery (ERAS) pathway. *J Arthroplasty*. 2015;30:1705.

Bailey AG, McNaull PP, Jooste E, et al. Perioperative crystalloid and colloid fluid management in children: where are we and how did we get here? *Anesth Analg*. 2010;110:375–390.

Bailie GR, Uhlig K, Levey AS. Cinical practice guideline in nephrology: evaluation, classification and stratification of chronic kidney disease. *Pharmacotherapy*. 2005;25:491–502.

Baillargeon E, Duan K, Brzezinski A, et al. The role of preoperative prophylactic antibiotics in hypospadias repair. *Can Urol Assoc J*. 2014;8:236–240.

Bathla S, Mohta A, Gupta A, et al. Cancellation of elective cases in pediatric surgery: an audit. *J Indian Assoc Pediatr*

Surg. 2010;15:90–210.

Bellon M, Skhiri A, Julien-Marsollier F, et al. Paediatric minimally invasive abdominal and urological surgeries: current trends and perioperative management. *Anaesth Crit Care Pain Med*. 2018;37:453–457.

Bennett J, Bromley P. Renal transplantation. Bingham R, Thomas AL, Sury M. *Hatch and Sumner's textbook of paediatric anaesthesia*. ed 3. CRC Press: London; 2007:630–634.

Berde CB, Sethna NF. Analgesics for the treatment of pain in children. *N Engl J Med*. 2002;347:1094–1103.

Biedermann S, Wodey E, De La Brière F, et al. Paediatric discharge score in ambulatory surgery. *Ann Fr Anesth Reanim*. 2014;33(5):330–334.

Birmingham PK, Toblin MJ, Henthorn TK, et al. Twenty-four hour pharmacokinetic of rectal acetaminophen in children: an old drug with new recommendations. *Anesthesiology*. 1997;87(2):244–252.

Bone RC, Balk RA, Cerra FB, et al. Definitions for sepsis and organ failure and guidelines for the use of innovative therapies in sepsis. The ACCP/SCCM Consensus Conference Committee. American College of Chest Physicians/Society of Critical Care Medicine. *Chest*. 1992;101:1644–1655.

Booy R, Habibi P, Nadel S, Meningococcal Research Group, et al. Reduction in case fatality rate from meningococcal disease associated with improved healthcare delivery. *Arch Dis Child*. 2001;85:386–390.

Bordet F, Allaouchiche B, Lansiaux S, et al. Risk factors for airway complications during general anaesthesia in paediatric patients. *Paediatr Anaesth*. 2002;12:762–769.

Brasher C, Gafsous B, Dugue S, et al. Postoperative pain management in children and infants: an update. *Paediatr Drugs*. 2014;16:129–140.

Bratzler DW, Dellinger EP, Olsen KM, American Society of Health-System Pharmacists; Infectious Disease Society of America; Surgical Infection Society; Society for Healthcare Epidemiology of America, et al. Clinical practice guidelines for antimicrobial prophylaxis in surgery. *Am J Health Syst Pharm*. 2013;70(3):195–283.

Bratzler DW, Houck PM. Antimicrobial prophylaxis for surgery: an advisory statement from the national surgical infection prevention project. [for; the Surgical Infection Prevention Guidelines Writers Workgroup] *Clin Infect Dis*. 2004;38:1706–1715.

Bravo EL, Tagle R. Pheochromocytoma: state-of-the-art and future prospects. *Endocr Rev*. 2003;24(4):539–553.

Brewer S, Gleditsch SL, Sybilk D, et al. Pedaitric anxiety: child life intervention in day surgery. *J Pediatr Nurs*. 2006;21(1):13–22.

Cai T, Mazzoli S, Lanzafame P, et al. Asymptomatic bacteriuria in clinical urological practice: preoperative control of bacteriuria and management of recurrent UTI. *Pathogens*. 2016;5(1).

Cardona-Grau D, Bush RA, Le HK, et al. Reducing opioid prescriptions in outpatient pediatric urological surgery. *J Urol*. 2019;201:1–5.

Centers for Disease Control and Prevention. *Preterm birth*. https://www.cdc.gov/mmwr/volumes/65/wr/mm6543a1.htm.

Chadwick V, Wilkinson KA. Diabetes mellitus and the pediatric anesthetist. *Paediatr Anaesth*. 2004;14:716–723.

Chalmers DJ, Bielsky A, Wild TT, et al. Continuous local anesthetic infusion for children with spina bifida undergoing major reconstruction of the lower urinary tract. *J Pediatr Urol*. 2015;11(2):72.

Chan KH, Whittam BM, Moser EAS, et al. Adverse events associated with surgical antibiotic prophylaxis for outpatient circumcision at US children's hospitals. *J Pediatr Urol*. 2017;13(2):205.

Christensen R, Voepel-Lewis T. When the worst happens: cardiac arrest in the pediatric PACU. *J Perianesth Nurs*. 2017;32(4):382–384.

Christensen R, Voepel-Lewis T, Lewis I, American Heart Association's Get with the Guidelines-Resuscitation, et al. Pediatric cardiopulmonary arrest in the post anesthesia care unit: analysis of data from the American Heart Association Get with the Guidelines-Resuscitation registry. *Paediatr Anaesth*. 2013;23:517–523.

Christensen RE, Haydar B, Voepel-Lewis TD. Pediatric cardiopulmonary arrest in the post anesthesia care unit, rare but preventable: analysis of data from wake up safe, the pediatric anesthesia quality improvement initiative. *Anesth Analg*. 2017;124:1231–1236.

Claahsen-van der Grinten HL, Stikkelbroech NM, Otten BJ, et al. Congenital adrenal hyperplasia—pharmacologic interventions from prenatal phase to adulthood. *Pharmacol Ther*. 2011;132(1):1–14.

Cladis FP, Bykowski M, Schmitt E, et al. Postoperative hyponatremia following calvarial vault remodeling in craniosynostosis. *Paediatr Anaesth*. 2011;21:1020–1025.

Clark E, Plint AC, Correll R, et al. A randomized, controlled trial of acetaminophen, ibuprofen, and codeine for acute pain relief in children with musculoskeletal trauma. *Pediatrics*. 2007;119:460–467.

Cortesi N, Ferrari P, Zambarda E, et al. Diagnosis of bilateral abdominal cryptorchidism by laparoscopy. *Endoscopy*. 1976;8:33–34.

Cote CJ, Zaslavsky A, Downes JJ, et al. Postoperative apnea in former preterm infants after inguinal herniorrhaphy. A combined analysis. *Anesthesiology*. 1995;82:809–822.

Cruse P. Surgical wound infection. Wonsiewicz M. *Infectious disease*. Saunders: Philadelphia, PA; 1992:758–764.

Davidson AJ, Disma N, de Graaff JC, et al. Neurodevelopmental outcome at 2 years of age after general anaesthesia and awake-regional anaesthesia in infancy (GAS): an international multicenter, randomized controlled trial. *Lancet*. 2016;387:239–250.

Davidson AJ, Morton NS, Arnup SJ, et al. Apnea after awake regional and general anesthesia compared to spinal anesthesia study-comparing apnea and neurodevelopmental outcomes, a randomized controlled trial. General Anesthesia compared to Spinal anesthesia (GAS) Consortium. *Anesthesiology*. 2015;123(1):38–54.

de Lissovoy G, Fraeman K, Hutchins V, et al. Surgical site infection: incidence and impact on hospital utilization and treatment costs. *Am J Infect Control*. 2009;37:387–397.

Delahunt B, Turnbull PR. How cost effective are routine preoperative investigations? *N Z Med J*. 1980;92:431–432.

Delatte SJ, Hebra A, Tagge EP, et al. Acute chest syndrome in the postoperative sickle cell patient. *J Pediatr Surg*. 1999;34:188–192.

Dellinger RP, Levy MM, Carlet JM, International Surviving Sepsis Campaign Guidelines Committee; American Association of Critical-Care Nurses; American College of Chest Physicians; American College of Emergency Physicians; Canadian Critical Care Society; European Society of Clinical Microbiology and Infectious Diseases; European Society of Intensive Care Medicine; European Respiratory Society; International Sepsis Forum; Japanese Association for Acute Medicine; Japanese Society of Intensive Care Medicine; Society of Critical Care Medicine; Society of Hospital Medicine; Surgical Infection Society; World Federation of Societies of Intensive and Critical Care

Medicine, et al. Surviving Sepsis Campaign: international guidelines for management of severe sepsis and septic shock: 2008. *Crit Care Med*. 2008;36(1):296–327.

Dewachter P, Mouton-Faivre C, Hepner DL. Perioperative anaphylaxis: what should be known? *Curr Allergy Asthma Rep*. 2015;15(5):21.

Donat SM. Peri-operative care in patients treated for testicular cancer. *Semin Surg Oncol*. 1999;17:282–288.

Eulmesekian PG, Perez A, Minces PG, et al. Hospital- acquired hyponatremia in postoperative pediatric patients: prospective observational study. *Pediatr Crit Care Med*. 2010;11:479–483.

Experts debate NPO. An absolute rule or a guideline? *Same Day Surg*. 1994;18:45–56.

Faber AW, Patterson DR, Bremer M. Repeated use of immersive virtual reality therapy to control pain during wound dressing changes in pediatric and adult burn patients. *J Burn Care Res*. 2013;34(5):563–568.

Falk RH, Hood WB Jr. The heart in sickle cell anemia. *Arch Intern Med*. 1982;143(9):1680–1684.

Faranoni D, Vo D, Nasr VG, et al. Development and validation of a risk stratification score for children with congenital heart disease undergoing noncardiac surgery. *Anesth Analg*. 2016;123(4):824–830.

Ferrari L, Rooney F, Rockof M. Preoperative fasting practices in pediatrics. *Anesthesiology*. 1999;90:978–980.

Firth PG, Head CA. Sickle cell disease and anesthesia. *Anesthesiology*. 2004;101:766–785.

Flick RP, Schears GJ, Warner MA. Aspiration in pediatric anesthesia: is there a higher incidence compared with adults? *Curr Opin Anaesthesiol*. 2002;15(3):323–327.

Fu T, Corrigan NJ, Quinn CT, et al. Minor elective surgical procedures using general anesthesia in children with sickle cell anemia without pre-operative blood transfusion. *Pediatr Blood Cancer*. 2005;45:43–47.

Gal TJ. Bronchial hyperresponsiveness and anesthesia: physiologic and therapeutic perspectives. *Anesth Analg*. 1994;78:559–573.

Galandiuk S, Polk HC Jr, Jagelman DG, et al. Re-emphasis of priorities in surgical antibiotic prophylaxis. *Surg Gynecol Obstet*. 1989;169:218–222.

Garren B, Lawrence M, McNaull PP, et al. Opioid prescribing patterns, storage, handling, and disposal in postoperative pediatric urology patients. *J Pediatr Urol*. 2019 [in press].

Geltzeiler CB, Rotramel A, Wilson C, et al. Prospective study of colorectal enhanced recovery after surgery in a community hospital. *JAMA Surg*. 2014;149:955.

Gentili A, Lannettone CM, Pigna A, et al. Cardiocirculatory changes during videolaparoscopy in children: an echocardiographic study. *Paediatr Anaesth*. 2000;10:399–406.

George JA, Koka R, Gan TJ, et al. Review on of the enhanced recovery pathway for children: perioperative anesthetic considerations. *Can J Anaesth*. 2018;65(5):569–577.

Gilliss BM, Looney MR, Gropper MA. Reducing noninfectious risks of blood transfusion. *Anesthesiology*. 2011;115:635–649.

Glatz P, Sandin RH, Pedersen NL, et al. Association of anesthesia and childhood with long-term academic performance. *JAMA Pediatr*. 2017;171(1):e163470.

Glister BC, Vigersky RA. Perioperative management of type 1 diabetes mellitus. *Endocrinol Metab Clin North Am*. 2003;32:411–436.

Gómez Dammeier BH, Karanik E, Glüer S, et al. Anuria during pneumoperitoneum in infants and children: a prospective study. *J Pediatr Surg*. 2005;40:1454–1458.

Gottlieb EA, Andropoulos DB. Anesthesia for the patient with congenital heart disease presenting for noncardiac surgery. *Curr Opin Anaesthesiol*. 2013;26(3):318–326.

Grabe M, Bartoletti R, Johansen B, et al. *Guidelines on urological infections*. https://uroweb.org/wp-content/uploads/19-Urological-infections_LR2.pdf; 2010.

Grissom S, Boles J, Bailey K, et al. Play-based procedural preparation and support intervention for cranial radiation. *Support Care Cancer*. 2016;24(6):2421–2427.

Guay J. Benefits of adding epidural analgesia to general anesthesia: a meta-analysis. *Br J Anaesth*. 2006;20:335–340.

Guruswamy V, Barbour R. Anaesthesia for children with renal disease. *BJA Educ*. 2015;15(6):294–298.

Gutt CN, Oniu T, Mehrabi A, et al. Circulatory and respiratory complications of carbon dioxide insufflation. *Dig Surg*. 2004;21:95–105.

Hack HA. The perioperative management of children with phaeochromocytoma. *Paediatr Anaesth*. 2000;10(5):463–476.

Hamasuna R, Betsunoh H, Sueyoshi T, et al. Bacteria of preoperative urinary tract infections contaminate the surgical fields and develop surgical site infections in urologic operations. *Int J Urol*. 2004;11:941–947.

Hans P, Vanthuyne A, Dewandre PY, et al. Blood glucose concentration profile after 10 mg dexamethasone in non-diabetic and type 2 diabetic patients undergoing abdominal surgery. *Br J Anaesth*. 2006;97:164–170.

Hausel J, Nygren J, Lagerkranser M, et al. A carbohydrate-rich drink reduces preoperative discomfort in elective surgery patients. *Anesth Analg*. 2001;93:1344–1350.

He F, Lin X, Xie F, et al. The effect of enhanced recovery program for patients undergoing partial laparoscopic hepatectomy of liver cancer. *Clin Transl Oncol*. 2015;17:694.

Heron M, Hoyert DL, Murphy SL, et al. Deaths: final data for

2006. *Natl Vital Stat Rep*. 2009;57:1–134.

Holliday MA, Segar WE. The maintenance need for water in parental fluid therapy. *Pediatrics*. 1957;19(5):823–832.

Houck CS, Sullivan LJ, Wilder RT, et al. Pharmacokinetics of a higher dose of rectal paracetamol in children. *Anesthesiology*. 1995;83:A1126.

Howard J, Hart N, Roberts-Harewood M, BCSH Committee, et al. Guidelines on the management of acute chest syndrome in sickle cell disease. *Br J Haematol*. 2015;169(4):492–505.

Howell TK, Patel D. Plasma paracetamol concentrations after different doses of rectal paracetamol in older children. A comparison of 1 g vs. 40 mg × kg(−1). *Anaesthesia*. 2003;58(1):69–73.

Hung P. Preoperative fasting. *Nurs Times*. 1992;88:57–60.

Hymel KP, Abshire TC, Luckey DW, et al. Coagulopathy in pediatric abusive head trauma. *Pediatrics*. 1997;99:371–375.

Jaaniste T, Hayes B, von Baeyer CL. Providing children with information about forthcoming medical procedures: a review and synthesis. *Clin Psychol*. 2007;14(2):124–143.

James CF, Modell JH, Gibbs CP, et al. Pulmonary aspiration: effects of volume and pH in the rat. *Anesth Analg*. 1984;63:665–668.

Jipson JL, Melamed BG. New approaches on the horizon: comments on Jaaniste, Hayes, and von Baeyer's “Providing children with information about forthcoming medical procedures: a review and synthesis”. *Clin Psychol*. 2007;14(2):149–156.

Jiyong J, Tiancha H, Huiqin W, et al. Effect of gastric versus post-pyloric feeding on the incidence of pneumonia in critically ill patients: observations from traditional and Bayesian random-effects meta-analysis. *Clin Nutr*. 2013;32:8.

Johnson RK, Mortimer AJ. Routine pre-operative blood testing: is it necessary? *Anaesthesia*. 2002;57:914–917.

Kabalin CS, Yarnold PR, Grammer LC. Low complication rate of corticosteroid-treated asthmatics undergoing surgical procedures. *Arch Intern Med*. 1995;155:1379–1384.

Kagedan DJ, Ahmed M, Devitt KS, et al. Enhanced recovery after pancreatic surgery: a systematic review of the evidence. *HPB (Oxford)*. 2015;17:11.

Kain ZN, Caldwell-Andrews AA, Maranets I, et al. Preoperative anxiety and emergence delirium and post operative maladaptive behaviors. *Anesth Analg*. 2004;99(6):1648–1654.

Kain ZN, Mayes LC, Caldwell-Andrews AA, et al. Preoperative anxiety, postoperative pain, and behavioral recovery in young children undergoing surgery. *Pediatrics*. 2006;118(2):651–658.

Kain ZN, Mayes LC, O'Connor TZ, et al. Preoperative anxiety in children. Predictors and outcomes. *Arch Pediatr Adolesc Med*. 1996;150:1238–1245.

Kaplan EB, Sheiner LB, Boeckmann AJ, et al. The usefulness of preoperative laboratory screening. *JAMA*. 1988;253:3576–3581.

Kash BA, Zhang Y, Cline KM, et al. The perioperative surgical home (PSH): a comprehensive review of US and non-US studies shows predominantly positive quality and cost outcomes. *Milbank Q*. 2014;92(4):796–821.

Katz J, Jackson M, Kavanagh BP, et al. Acute pain after thoracic surgery predicts long-term post-thoracotomy pain. *Clin J Pain*. 1996;12:50–55.

Kehlet H, Holte K. Effect of postoperative analgesia on surgical outcome. *Br J Anaesth*. 2001;87:62–72.

Kehlet H, Rosenberg J. Surgical stress: pain, sleep and convalescence. Kinney JM, Tucker HN. *Physiology, stress and malnutrition: functional correlates, nutritional intervention*. Lippincott-Raven: Philadelphia, PA; 1997:95–

112.

Khalili GR, Shafa A, Yousefi R. Comparison of the effects of preemptive intravenous and rectal acetaminophen on pain management after inguinal herniorrhaphy in children: a placebo-controlled study. *Middle East J Anaesthesiol*. 2016;23(5):543–548.

Khwaja A, Throssell D. A critique of the UK NICE guidance for the detection and management of individuals with chronic kidney disease. *Nephron Clin Pract*. 2009;113:c207–c213.

Kiran Chand N, Bala Subramanya H, Venkateswara Rao G. Management of patients who refuse blood transfusion. *Indian J Anaesth*. 2014;58(5):658–664.

Klosky JL, Tyc VL, Srivastava DK, et al. Brief report: evaluation of an interactive intervention designed to reduce pediatric distress during radiation therapy procedures. *J Pediatr Psychol*. 2004;29:621–626.

Koshy M, Weiner SJ, Miller ST, et al. Surgery and anesthesia in sickle cell disease. Cooperative Study of Sickle Cell Diseases. *Blood*. 1995;86:3676–3684.

Kranke P, Jokinen J, Pace NL, et al. Continuous intravenous perioperative lidocaine infusion for postoperative pain and recovery. *Cochrane Database Syst Rev*. 2015;(7) [CD009642].

Kutko MC, Calarco MP, Flaherty MB, et al. Mortality rates in pediatric septic shock with and without multiple organ system failure. *Pediatr Crit Care Med*. 2003;4:333–337.

Lao L, Weng X, Qui G, et al. The role of preoperative pulmonary function tests in the surgical treatment of extremely severe scoliosis. *J Orthop Surg Res*. 2013;8:32.

LeDoux D, Astiz ME, Carpati CM, et al. Effects of perfusion pressure on tissue perfusion in septic shock. *Crit Care Med*. 2000;28:2729–2732.

Lee A, Cooper MG, Craig JC, et al. Effects of nonsteroidal anti-inflammatory drugs on postoperative renal function in adults with normal renal function. *Cochrane Database Syst Rev*. 2007;(2) [CD002765].

Lee JY, Jo YY. Attention to postoperative pain control in children. *Korean J Anesthesiol*. 2014;66:183–188.

Lerman J. Preoperative assessment and premedication in paediatrics. *Eur J Anaesthesiol*. 2013;30(11):645–650.

Levey AS, Coresh J, Balk E, et al. National Kidney Foundation practice guidelines for chronic kidney disease: evaluation, classification, and stratification. *Ann Intern Med*. 2003;139:137–147.

Linzer J. Do routine laboratory tests add to the care of the pediatric trauma patient? *Clin Pediatr Emerg Med*. 2010;11:4.

Lobo DP, Awad S. Should chloride-rich crystalloids remain the mainstay of fluid resuscitation to prevent “pre-renal” acute kidney? *Kidney Int*. 2014;86:1096.

Long JB, Joselyn AS, Bhalla T, et al. PRAN investigators: the use of neuraxial catheters for postoperative analgesia in neonates: a multicenter safety analysis from the pediatric regional anesthesia network. *Anesth Analg*. 2016;122(6):1965–1970.

Lopez R, Shimizu N, Cooperman JM. Recurrent folic acid deficiency in sickle cell disease. *Am J Dis Child*. 1973;125(4):544–548.

Ludwig AD, Feig DI, Brandt ML, et al. Recent advances in the diagnosis and treatment of pheochromocytoma in children. *Am J Surg*. 2007;194(6):792–796 [discussion 796–797].

MacPherson RD, Reeve SA, Stewart TV, et al. Effective strategy to guide pathology test ordering in surgical patients. *ANZ J Surg*. 2005;75:138–143.

Maesani M, Pares F, Michelet D, et al. Hemodynamic and cerebral oxygenation during paediatric laparoscopy in fluid optimised patients. *Br J Anaesth*. 2016;116:564–566.

Magill SS, Edwards JR, Bamberg W, et al. Multistate point-prevalence survey of health care-associated infections. *N Engl J Med*. 2014;370:1198–1208.

Malignant Hyperthermia Association of the United States. www.MHAUS.org.

Manning ML, Davis J, Sparnon E, et al. iPads, droids, and bugs: infection prevention for mobile handheld devices at the point of care. *Am J Infect Control*. 2013;41(11):1073–1076.

Manworren RCB, Fledderman M. Preparation of the child and family for surgery. Wise B, McKenna C, Garvin G, et al. *Nursing care of the general pediatric surgical patient*. Aspen Publishers: Gaithersburg, MD; 2000:3–15.

Manworren RC, Hynan LS. Clinical validation of FLACC: pre-verbal patient pain scale. *Pediatr Nurs*. 2003;29(2):140–146.

Marchant WA, Walker I. Anaesthetic management of the child with sickle cell disease. *Paediatr Anaesth*. 2003;13(6):473–489.

Marelli AJ, Mackie AS, Ionescu-Ittu R, et al. Congenital heart disease in the general population: changing prevalence and age distribution. *Circulation*. 2007;115:163–172.

Marley RA, Moline BM. Patient discharge from the ambulatory setting. *J Post Anesth Nurs*. 1996;11(1):39–49.

Marshall SI, Chung F. Discharge criteria and complications after ambulatory surgery. *Anesth Analg*. 1999;88(3):508–517.

Martin JT. *Positioning in anesthesia and surgery*. ed 2. WB Saunders: Philadelphia, PA; 1987.

Matsumoto T, Kiyota H, Matsukawa M, et al. Japanese guidelines for prevention of perioperative infections in urological field. *Int J Urol*. 2007;14:890–909.

Maxwell BG, Wong JK, Kin C, et al. Perioperative outcomes of major noncardiac surgery in adults with congenital heart disease. *Anesthesiology*. 2013;119:762–769.

Maxwell BG, Wong JK, Lobato RL. Perioperative morbidity and mortality after noncardiac surgery in young adults with congenital or early acquired heart disease: a retrospective cohort analysis of the National Surgical Quality Improvement Program database. *Am Surg*. 2014;80:321–326.

McCann ME, Soriano SG. Progress in anesthesia and management of the newborn surgical patient. *Semin Pediatr Surg*. 2014;23(5):244–248.

McCarthy GC, Megalla SA, Habib AS. Impact of intravenous lidocaine infusion on postoperative analgesia and recovery from surgery: a systematic review of randomized controlled trials. *Drugs*. 2010;70:1149–1163.

McGregor ML, Bremer DL, Cole C, et al. Retinopathy of prematurity outcome in infants with prethreshold retinopathy of prematurity and oxygen saturation >94% in room air: the high oxygen percentage in retinopathy of prematurity study. *Pediatrics*. 2002;110:540–544.

McNab S, Ware RS, Neville KA, et al. Isotonic versus hypotonic solutions for maintenance intravenous fluid administration in children. *Cochrane Database Syst Rev*. 2014;(12) [CD009457].

Merchant R, Chartrand D, Dain S, et al. Guidelines to the practice of anesthesia revised edition 2013. *Can J Anaesth*. 2013;60(1):60–84.

Mercker SK, Maier C, Neumann G, et al. Lactic acidosis as a serious perioperative complication of antidiabetic biguanide medication with metformin. *Anesthesiology*. 1997;87:1003–1005.

Merke DP, Bornstein SR. Congenital adrenal hyperplasia. *Lancet*. 2005;365(9477):2125–2136.

Merkel SI, Voepel-Lewis T, Shayevitz JR, et al. The FLACC: a behavioral scale for scoring post-operative pain in young children. *Pediatr Nurs*. 1997;23(3):293–297.

Merskey H, Bogduk N. *Descriptions of chronic pain syndromes* *and definitions of pain terms. Classification of chronic pain*. ed 2. IASP Press: Seattle, Washington; 1994 [(Updated 2011)].

Michelet D, Andreu-Gallien J, Bensalah T, et al. A meta-analysis of the use of nonsteroidal anti-inflammatory drugs for pediatric postoperative pain. *Anesth Analg*. 2012;114:393–406.

Michelet D, Andreu-Gallien J, Skhiri A, et al. Factors affecting recovery of postoperative bowel function after pediatric laparoscopic surgery. *J Anaesthesiol Clin Pharmacol*. 2016;32:369–375.

Miller TE, Thacker JK, White WD, the Enhanced Recovery Study Group, et al. Reduced length of hospital stay in colorectal surgery after implementation of an enhanced recovery protocol. *Anesth Analg*. 2014;118:1052.

Minette MS, Hoyer AW, Pham PP, et al. Cardiac function in congenital adrenal hyperplasia: a pattern of reversible cardiomyopathy. *J Pediatr*. 2013;162(6):1193–1198.

Morray JP, Geiduschek JM, Ramamoorthy C, et al. Anesthesia-related cardiac arrest in children: initial findings of the Pediatric Perioperative Cardiac Arrest (POCA) Registry. *Anesthesiology*. 2000;93:6–14.

Morton NS. Management of postoperative pain in children. *Arch Dis Child Educ Pract Ed*. 2007;92:ep14–ep19.

Muessig KE, Pike EC, Legrand S, et al. Mobile phone applications for the care and prevention of HIV and other sexually transmitted diseases: a review. *J Med Internet Res*. 2013;15(1):e1.

Mummareddy N, Dewan MC, Mercier MR, et al. Scoliosis in myelomeningocele: epidemiology, management, and functional outcome. *J Neurosurg Pediatr*. 2017;20(1):99–108.

Murat I, Constant I, Maudhuy HL. Perioperative anaesthetic morbidity in children: a database of 24,165 anaesthetics over a 30-month period. *Paediatr Anaesth*. 2004;14(2):158–166.

Murtagh FE, Chai MO, Donohoe P, et al. The use of opioid analgesia in end-stage renal disease patients managed without dialysis: recommendations for practice. *J Pain Palliat Care Pharmacother*. 2007;21:5–16.

National Kidney Foundation. K/DOQI clinical practice guidelines for chronic kidney disease: evaluation, classification, and stratification. *Am J Kidney Dis*. 2002;39:S1–S266.

Nespoli L, Coppola S, Gianotti L. The role of the enteral route and the composition of feeds in the nutritional support of malnourished surgical patients. *Nutrients*. 2012;4:1230.

Neuhaus D, Schmitz A, Gerber A, et al. Controlled rapid sequence induction and intubation—an analysis of 1001 children. *Paediatr Anaesth*. 2013;23(8):734–740.

Nhan NT, Phuong CXT, Kneen R, et al. Acute management of dengue shock syndrome: a randomized double-blind comparison of 4 intravenous fluid regimens in the first hour. *Clin Infect Dis*. 2001;32:204–212.

Nishimura RA, Otto CM, Bonow RO, et al. 2017 AHA/ACC focused update of the 2014 AHA/ACC guidelines for the management of patients with valvular heart disease: a report of the American College of Cardiology/American Heart Association Task Force on Clinical Practice Guidelines. *J Am Coll Cardiol*. 2017;135(25):e1159–e1195.

Noel M, Chambers CT, McGrath RM, et al. The influence of children's pain memories on subsequent pain experience. *Pain*. 2012;153(8):1563–1572.

Olsson GL. Bronchospasm during anaesthesia. A computer-aided incidence study of 136,929 patients. *Acta Anaesthesiol Scand*. 1987;31:244–252.

Oyama Y, Hideo I, Keisuke S, et al. Effects of preoperative oral carbohydrates and trace elements on perioperaive nutritional status in elective surgery patients. *Middle East J Anaesthesiol*. 2011;21(3):375–383.

Patient Protection and Affordable Care Act (Public Law 111–148 [2010]). https://www.gpo.gov/fdsys/pkg/PLAW-111publ148/pdf/PLAW-111publ148.pdf.

Pearson KL, Hall NJ. What is the role of enhanced recovery after surgery in children? A scoping review. *Pediatr Surg Int*. 2017;33:43–51.

Perez-Zoghbi JF, Zhu W, Grafe MR, et al. Dexmedetomidine-mediated neuroprotection against sevoflurane-induced neurotoxicity extends to several brain regions in neonatal rats. *Br J Anaesth*. 2017;119(3):506–516.

Pile JC. Evaluating postoperative fever: a focused approach. *Cleve Clin J Med*. 2006;73(Suppl 1):S62–S66.

Raidoo DM, Rocke DA, Brock-Utne JG, et al. Critical volume for pulmonary acid aspiration: reappraisal in a primate model. *Br J Anaesth*. 1990;65:248–250.

Ramamoorthy C, Haberkern CM, Bhananker SM, et al. Anesthesia-related cardiac arrest in children with heart disease: data from the Pediatric Perioperative Cardiac Arrest (POCA) registry. *Anesth Analg*. 2010;110:1376–1382.

Rangel SJ, Fung M, Graham DA, et al. Recent trends in the use of antibiotic prophylaxis in pediatric surgery. *J Pediatr Surg*. 2011;46(2):366–371.

Rappaport BA, Suresh S, Hertz S, et al. Anesthetic neurotoxicity—clinical implications of animal models. *N Engl J Med*. 2015;372:796–797.

Raz R. Asymptomatic bacteriuria: clinical significance and management. *Int J Antimicrob Agents*. 2003;22:45–47.

Reed W, Vichinsky EP. New considerations in the treatment of sickle cell disease. *Annu Rev Med*. 1998;49:461–474.

Rhodes ET, Ferrair LR, Wolfsdorf JI. Perioperative management of pediatric surgical patients with diabetes mellitus. *Anesth Analg*. 2005;101(4):986–999.

Romero M, Kapur G, Baracco R, et al. Treatment of hypertension in children with catecholamine-secreting tumors: a systematic approach. *J Clin Hypertens*. 2015;7(9):720–725.

Roth JD, Misseri R, Cain MP, et al. *Epidural analgesia in low level spina bifida patients - a proof of concept*. [Abstract Society of Pediatric Fall Congress] 2017 [Sept 8].

Rove KO, Brockel MA, Saltzman AF, et al. Prospective study of enhanced recovery after surgery protocol in children undergoing reconstructive operations. *J Pediatr Urol*. 2018;14(3):252.

Ryu JH, Park SJ, Park JW, et al. Randomized clinical trial of immersive virtual reality tour of the operating theater in children before anaesthesia. *Br J Surg*. 2017;104(12):1628–1633.

Saettele AK, Christensen JL, Chilson KL, et al. Children with heart disease: risk stratification for non-cardiac surgery. *J Clin Anesth*. 2016;35:479–484.

Sagarin MJ, Chiang V, Sakles JC, et al. Rapid sequence intubation for pediatric emergency airway management. *Pediatr Emerg Care*. 2002;18:417–423.

Sampath A, Kossoff EH, Furth SL, et al. Kidney stones and the ketogenic diet: risk factors and prevention. *J Child Neurol*. 2007;22(4):375–378.

Scalfaro P, Sly PD, Sims C, et al. Salbutamol prevents the increase of respiratory resistance caused by tracheal intubation during sevoflurane anesthesia in asthmatic children. *Anesth Analg*. 2001;93:898–902.

Schechter NL, Blankson V, Pachter LM, et al. The ouchless place: no pain, children's gain. *Pediatrics*. 1997;99:890–894.

Schmitz CJ, Kellenberger CJ, Neuhaus D, et al. Fasting times and gastric contents volume in children undergoing deep propofol sedation—an assessment using magnetic resonance imaging. *Paediatr Anaesth*. 2011;21(6):685–690.

Schoffman DE, Turner-McGrievy G, Jones SJ, et al. Mobile apps for pediatric obesity prevention and treatment, healthy eating, and physical activity promotion: just fun and games? *Transl Behav Med*. 2013;3(3):320–325.

Schuz-Stubner S, Pottinger JM, Coffin SA, et al. Nosocomial infections and infection control in regional anaesthesia. *Acta Anaesthesiol Scand*. 2008;52:1144–1157.

Sear JW. Kidney dysfunction in the postoperative period. *Br J Anaesth*. 2005;95:20–32.

Seeler RA. Deaths in children with sickle cell anemia. *Clin Pediatr (Phila)*. 1972;11:634–637.

Segerdahl M, Warren-Stomberg M, Rawal N, et al. Children in day surgery: clinical practice and routines. The results from a nation-wide survey. *Acta Anaesthesiol Scand*. 2008;52:821–828.

Sharrock NE, Cazan MG, Hargett MJ, et al. Changes in mortality after total hip and knee arthroplasty over a ten-year period. *Anesth Analg*. 1995;80:242–248.

Shinnick JK, Short HL, Heiss KF, et al. Enhancing recovery in pediatric surgery: a review of the literature. *J Surg Res*. 2016;202:165–176.

Sikich N, Lerman J. Development and psychometric evaluation of the pediatric anesthesia emergence delirium scale. *Anesthesiology*. 2004;100:1138–1145.

Silvanus MT, Groeben H, Peters J. Corticosteroids and inhaled salbutamol in patients with reversible airway obstruction markedly decrease the incidence of bronchospasm after tracheal intubation. *Anesthesiology*. 2004;100:1052–1057.

Simons J, Moseley L. Post-operative pain: the impact of prescribing patterns on nurses’ administration of analgesia.

Paediatr Nurs. 2008;20(8):14–19.

Simpson AB, Paul J, Graham J, et al. Fatal bleomycin pulmonary toxicity in the west of Scotland 1991–95: a review of patients with germ cell tumours. *Br J Cancer*. 1998;78:1061–1066.

Smith I, Kranke P, Murat I, et al. Perioperative fasting in adults and children: guidelines from the European Society of Anaesthesiology. *Eur J Anaesthesiol*. 2011;28(8):556–569.

Smith J, Patel A, Zamilpa I, et al. Analysis of preoperative antibiotic prophylaxis in stented distal hypospadias repair. *Can J Urol*. 2017;24(2):8765–8769.

Soriano SG, Anand KJ. Anesthetics and brain toxicity. *Curr Opin Anesthesiol*. 2005;18(3):293–297.

Soysal E, Gries H, Wray C. Pediatric patients on ketogenic diet undergoing general anesthesia—a medical record review. *J Clin Anesth*. 2016;35:170–175.

Steinberg JP, Braun BI, Hellinger WC, et al. Timing of antimicrobial prophylaxis and the risk of surgical site infection: results from the Trial to Reduce Antimicrobial Prophylaxis Errors. *Ann Surg*. 2009;250:10–16.

Stowers MD, Lemanu DP, Hill AG. Health economics in enhanced recovery after surgery programs. *Can J Anaesth*. 2015;62:219.

Sun LS, Li G, Miller TL, et al. Association between a single general anesthesia exposure before age 36 months and neurocognitive outcomes in later childhood. *JAMA*. 2016;315:2312–2320.

Sutters KA, Miaskowski C, Holdridge-Zeuner D, et al. A randomized clinical trial of the efficacy of scheduled dosing of acetaminophen and hydrocodone for the management of postoperative pain in children after tonsillectomy. *Clin J Pain*. 2010;26(2):95–103.

Taenzer AH, Walker BJ, Bosenberg AT, et al. Asleep versus awake: does it matter? Pediatric regional block complications by patient state: a report from the Pediatric Regional Anesthesia Network. *Reg Anesth Pain Med*. 2014;39:279–283.

Tait AR, Malviya S. Anesthesia for the child with an upper respiratory tract infection: still a dilemma? *Anesth Analg*. 2005;100:59–65.

Tait AR, Malviya S, Voepel-Lewis T, et al. Risk factors for perioperative adverse respiratory events in children with upper respiratory tract infections. *Anesthesiology*. 2001;95:299–306.

Tait AR, Pandit UA, Voepel-ewis T, et al. Use of the laryngeal mask airway in children with upper respiratory tract infections: a comparison with endotracheal intubation. *Anesth Analg*. 1998;86(4):706–711.

Tang J, Humes DJ, Gemmil E, et al. Reduction in length of stay for patients undergoing oesophageal and gastric resections with implementation of enhanced recovery packages. *Ann R Coll Surg Engl*. 2013;95:323.

Tawfic QA, Bellingham G. Postoperative pain management in patients with chronic kidney disease. *J Anaesthesiol Clin Pharmacol*. 2015;31(1):6–13.

Taylor EM, Boyer K, Campbell FA. Pain in hospitalized children: a prospective cross-sectional survey of pain prevalence, intensity, assessment and management in a Canadian pediatric teaching hospital. *Pain Res Manage*. 2008;13:25–32.

Thiele RH, Rea KM, Turrentine FE, et al. Standardization of care: impact of an enhanced recovery protocol on length of stay, complications, and direct costs after colorectal surgery. *J Am Coll Surg*. 2015;220:430.

Thomas M, Morrison C, Newton R, et al. Consensus statement on clear fluids fasting for elective pediatric general anesthesia. *Paediatr Anaesth*. 2018;28(5):411–414.

Tidemarsh MD, May AE. Epidural anaesthesia and neural tube defects. *Int J Obstet Anesth*. 1998;7(2):111–114.

US Food and Drug Administration. *FDA statement. FDA review results in new warnings about using general anesthetics and sedation drugs in young children and pregnant women*. https://www.fda.gov/downloads/Drugs/DrugSafety/UCM533 [Animal Studies re neuropoptosis: 1–19].

US Food and Drug Administration. www.fda.gov/Drugs/DrugSafety/ucm549679.htm.

Vathenen AS, Knox AJ, Wisniewski A, et al. Time course of change in bronchial reactivity with an inhaled corticosteroid in asthma. *Am Rev Respir Dis*. 1991;143:1317–1321.

Vetter TR, Goeddel LA, Boudreaux AM, et al. The perioperative surgical home: how can it make the case so everyone wins? *BMC Anesthesiol*. 2013;13(1):6.

Vichinsky EP, Haberkern CM, Neumayr L, et al. A comparison of conservative and aggressive transfusion regimens in the perioperative management of sickle cell disease. The Preoperative Transfusion in Sickle Cell Disease Study Group. *N Engl J Med*. 1995;333:206–213.

Voepel-Lewis T, Malviya S, Tait AR. A prospective cohort study of emergence agitation in the pediatric postanesthesia care unit. *Anesth Analg*. 2003;96:1625–1630.

Voepel-Lewis T, Merkel S, Tait AR, et al. The reliability and validity of the face, legs, activity, cry, consolability observational tool as a measure of pain in children with cognitive impairment. *Anesth Analg*. 2002;95(5):1224–1229.

von Baeyer CL. Children's self-reports of pain intensity: scale selection, limitations and interpretation. *Pain Res Manag*. 2006;11:157–162.

Von Ungern-Sternberg BS, Boda K, Chambers NA, et al. Risk assessment for respiratory complications in paediatric anaesthesia: a prospective cohort study. *Lancet*. 2010;376:773–783.

Wedgewood J, Doyle E. Anaesthesia and laparoscopic surgery in children. *Paediatr Anaesth*. 2001;11:391–399.

Whitney PS, Chem M, Sturgess J. *BJA Education*. 2016;16(7):230–235.

Wilson W, Taubert KA, Gewitz M, et al. Prevention of infective endocarditis: guidelines from the American Heart Association: a guideline from the American Heart Association Rheumatic Fever, Endocarditis and Kawasaki Disease Committee, Council on Cardiovascular Disease in the Young, and the Council on Clinical Cardiology, Council on Cardiovascular Surgery and Anesthesia, and the Quality of Care and Outcomes Research Interdisciplinary Working Group. *J Am Dent Assoc*. 2008;139(Suppl):3S–24S.

Wong I, St John-Green C, Walker SM. Opioid-sparing effects of perioperative paracetamol and nonsteroidal anti-inflammatory drugs (NSAIDs) in children. *Paediatr Anaesth*. 2013;23:475–495.

Yamamoto S, Kanamaru S, Kunishima Y, et al. Perioperative antimicrobial prophylaxis in urology: a multicenter prospective study. *J Chemother*. 2005;17:189–197.

Zgleszewski SE, Graham DA, Hickey PR, et al. Anesthesiologist- and system-related risk factors for risk-adjusted pediatric anesthesia-related cardiac arrest. *Anesth Analg*. 2016;122:482–489.

27

Principles of Laparoscopic and Robotic Surgery in Children

Thomas Sean Lendvay MD, FACS, Jonathan Scott Ellison MD

Ever since the first report of laparoscopic nephrectomy in 1993 and robotic prostatectomy in 2002, urologists have been on the forefront of minimally invasive surgery (MIS). As technology has advanced, so too have the broadened indications for MIS. Perhaps in no other subspecialty of urology is this truer than for pediatric urology, where smaller working spaces and a focus on reconstructive rather than extirpative procedures demand specific technical considerations. Minimally invasive approaches have become standard practice for many commonly performed pediatric urologic procedures. The pediatric urologist must therefore be familiar with several aspects of MIS, including risk-benefit considerations, physiologic implications, unique complications, state-of-the-art technology, and patient selection criteria to optimize patient outcomes.

Because pediatric urology manages a wide variety of congenital anatomic abnormalities, the pediatric urologist applying MIS technologies needs to be nimble, creative, and resourceful. A number of innovations in MIS have spawned from pediatric urologists recognizing “better” ways to apply MIS in our pediatric patients. Our sutures are smaller and tissues are more delicate, thus we have pushed the envelope on the mechanical and technical limitations of MIS technologies. Furthermore, pediatric urologists have championed methods to simulate and evaluate pediatric surgery in an effort to drive improved patient outcomes. In this chapter, we discuss advantages and disadvantages of MIS in children; applications; physiologic considerations of the pneumoperitoneum in children; patient selection; various approaches and instrumentation; complications of MIS in children; and how pediatric MIS is being simulated, taught, and evaluated.

Advantages and Disadvantages of Minimally Invasive Surgery

When counseling families about proposed surgical recommendations, it is imperative that the pediatric urologist is comprehensive about the pros and cons of MIS (Table 27.1). Because most of the decades-old evidence supporting our reconstructive procedures has been established in open surgery, patients and families need to be aware of how MIS approaches can provide amazing outcome improvement opportunities and can also yield unique challenges not encountered in the original literature.

TABLE 27.1

Pros and Cons of Minimally Invasive Surgery in Children

PROS	CONS
Cosmesis Convalescence Pain control Less physiologic stress Ergonomics (robotics)	Cost Learning curve Ergonomics (laparoscopy) Specific complications (i.e., port site hernia, complications caused by pneumoperitoneum)

Advantages of Minimally Invasive Surgery

One commonly reported advantage of MIS is an improved cosmetic outcome as compared with an open approach. Laparoscopy and robotic-assisted surgery offer two distinct advantages in this regard. First, smaller laparoscopic port incisions contract over time, as compared with larger, open incisions (Finkelstein et al., 2016a, 2016b) (Fig. 27.1). Second, port placement can be adjusted to position insertion sites in less discrete locations, commonly referred to as *hidden incision endoscopic surgery* (HIdES) (Gargollo, 2011). Although many families with children undergoing urologic intervention have minimal concerns with postoperative scar appearances, scar bother can be a significant concern for patients, especially as scars grow with the patients (Garcia-Roig et al., 2017;

Wang et al., 2018). Survey data of families with children undergoing pyeloplasty, ureteral reimplantation, and bladder augmentation revealed that in all cases, laparoscopic incisions would be preferred. However, in the setting of decreased surgical efficacy, the propensity to choose laparoscopic incisions declined (Barbosa et al., 2013). Conversely, a crowd-sourced study, of which 62% of respondents had undergone previous surgery of any type, revealed a preference for dorsal lumbotomy and Pfannenstiel incisions for renal and pelvic surgeries, respectively, as compared with laparoscopic incisions. However, if told that laparoscopy would result in lower pain and improved convalescence, a significant proportion of respondents changed their preference in favor a laparoscopic approach. **Thus, it would seem that cosmesis is an important consideration for patients and families, but is prioritized lower than other surgical outcomes.**

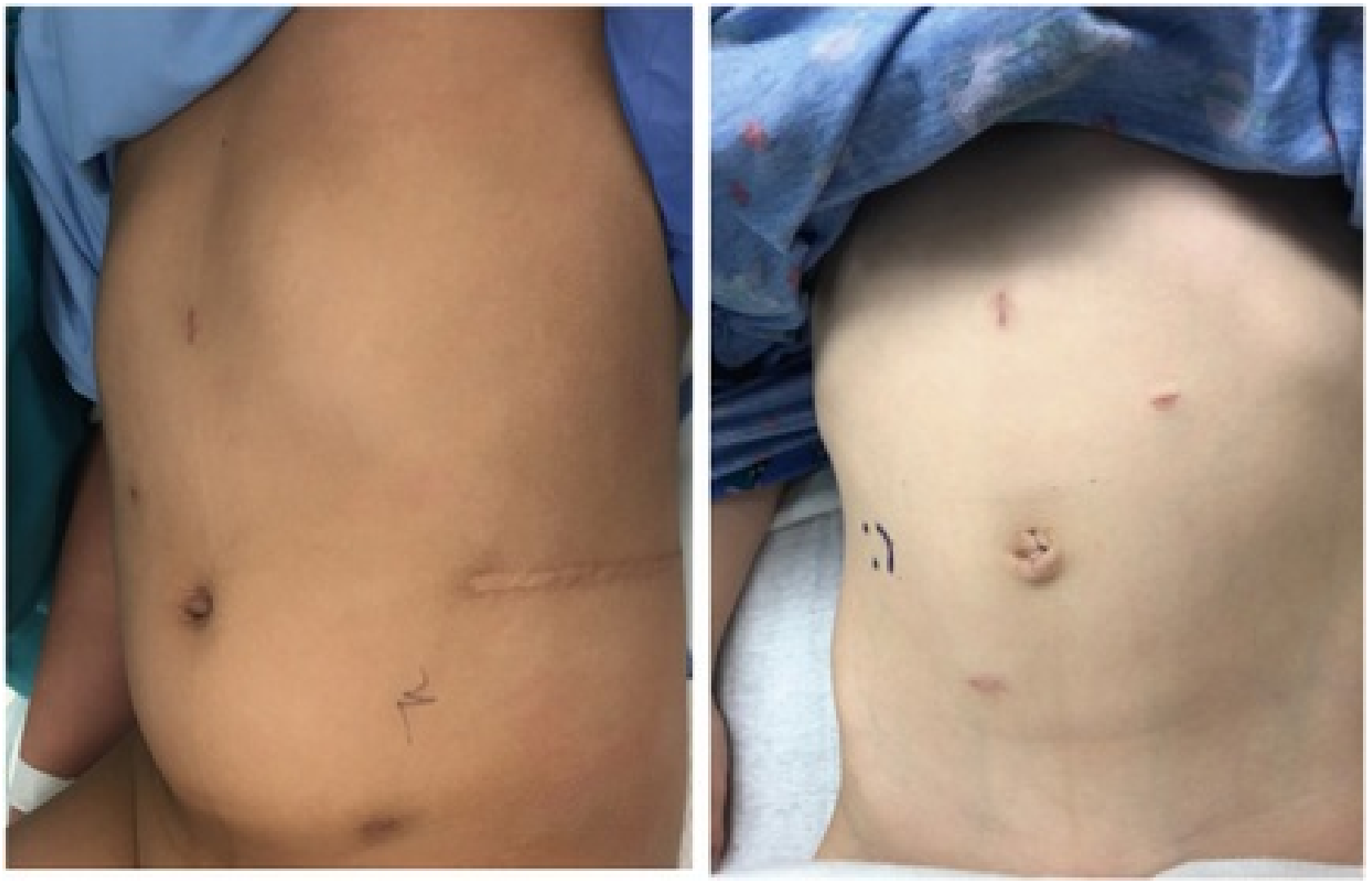

FIG. 27.1 Examples of open flank incision *(left)* and robotic port site incisions *(right)* after open and robotic-assisted pyeloplasty, respectively. The child on the left subsequently had a robotic-assisted revision pyeloplasty, and port sites are visible on the abdomen as well.

Many alterations to conventional laparoscopic or robotic port placements have been trialed to improve cosmesis. Single-port laparoscopy, or laparoendoscopic single-site surgery (LESS), has been developed primarily to reduce the need for additional incisions. The use of smaller instrumentation, allowing for correspondingly smaller incisions, has been reported in a number of urologic procedures. Mini-laparoscopy, utilizing 3- to 3.5-mm ports, has been utilized in pyeloplasty and ureteral reimplantation with equivalent success and improved cosmetic outcomes as compared with standard laparoscopic instrumentation (Fiori et al., 2013; Pini et al., 2012; Simforoosh et al., 2014). So called "needlescopic" instrumentation, utilizing endoscopic cameras and instruments 2 mm in diameter, has been reported for orchiopexy (Gill et al., 2000). Finally, micro-laparoscopic instrumentation, measuring less than 2 mm in diameter, also exists (Pini et al., 2012). Combinations of varying port sizes can further expand the efficiency of the procedure while optimizing cosmetic results.

As robotic instrumentation is not available smaller than 5 mm, additional strategies in port placement have been proposed. HIdES involves placement of the ports below the pants-line to make these incisions more discreet (Fig. 27.2). HIdES has been reported to have equivalent perioperative outcomes to standard robotic-assisted pyeloplasty (Hong et al., 2018). Typically, this involves one port within the umbilicus, and the remaining ports are placed more inferiorly. As opposed to traditional port placement, where the camera port is placed in the umbilicus, this port arrangement requires the camera to be placed in an inferior port for renal procedures, though more traditional approaches can be utilized for pelvic surgery. As such, robotic docking angles may also need to be altered to allow full functionality of all robotic arms. In a survey of families with children undergoing urologic procedures, families preferred HIdES incisions to open or standard laparoscopic or robotic incisions (Gargollo, 2011).

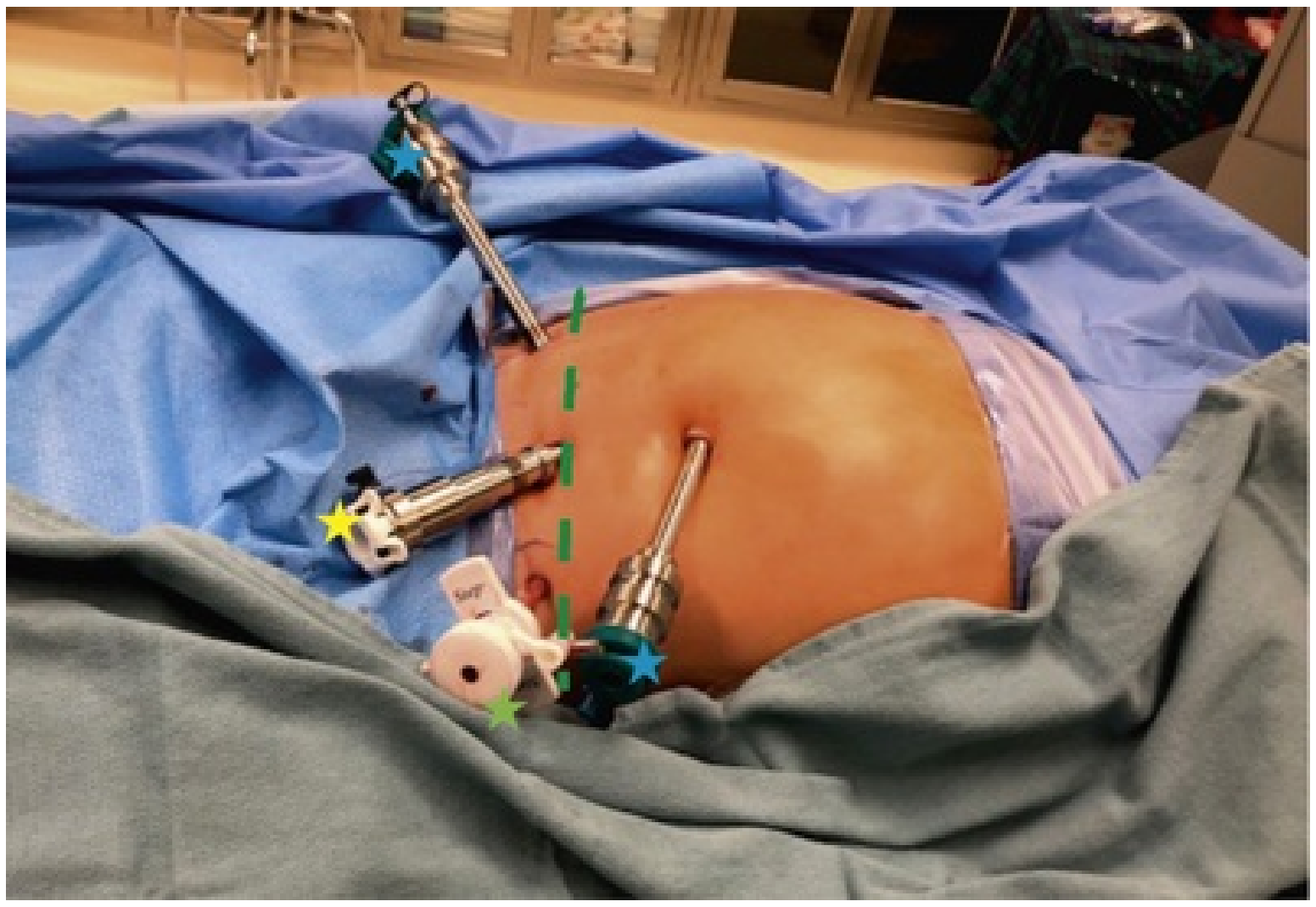

FIG. 27.2 Hidden incision port placement (HIdES) for a right robotic-assisted pyeloplasty. Placement of the robotic working port *(blue star)* in the umbilicus and the remaining robotic port *(blue star),* camera port *(yellow star),* and 5-mm assistant port *(green star)* below the pant line

(green dashed line) allow for inconspicuous incisional scars postoperatively.

Another frequently cited benefit to MIS is improved convalescence, which is a result of decreased abdominal wall stress and organ mobilization. Length of stay is frequently cited as a proxy outcome for convalescence, as little data exist regarding return to school or typical activities at home after pediatric laparoscopic or robotic interventions. In addition to reducing length of stay, another potential benefit of a minimally invasive approach would be the ability to transition traditional inpatient operations to an ambulatory setting.

Length of stay appears to be reduced in most of the common pediatric urologic interventions with either the laparoscopic or robotic approach. This has been shown to be the case in pyeloplasty on the strength of both a randomized trial and several meta-analyses of observational studies (Braga et al., 2009; Cundy et al., 2014; Gatti et al., 2017; Mei et al., 2011). Additionally, reduced length of stay is a benefit of robotic-assisted ureteral reimplant (Deng et al., 2018; Smith et al., 2011). In both procedures, the average reduction in length of stay is measured in hours, not days, as routine in-hospital care for such procedures is often relatively short. **The true benefit lies in minimizing prolonged length of stay. One recent analysis has shown an 86% decreased risk in length of stay greater than 2 days after robotic-assisted pyeloplasty** (Varda et al., 2018). In more complex operations in which a typical open operation might result in postoperative in-hospital stay of 1 week or more, the benefit of MIS appears to be even greater. In small case series for appendicovesicostomy in patients with prior abdominal operations and in augmentation enterocystoplasty, robotic-assisted approaches resulted in an average reduction in the length of stay of 2 to 2.5 days (Chua et al., 2018; Murthy et al., 2015) (Table 27.2).

TABLE 27.2

Overview of Reported Length-of-Stay Benefits for Selected Minimally Invasive Surgical Procedures in Children

OPERATION	MEAN LOS BENEFIT
Pyeloplasty (Braga et al., 2009; Mei et al., 2011)	No benefit—0.75 days
Ureteral reimplant (Smith et al., 2011)	0.75 days
Bladder augmentation/appendicovesicostomy (Murthy et al.,	2–2.5 days

2015)	

LOS, Length of stay.

Because of the cost of inpatient medicine, efforts have been made not only to reduce length of inpatient stay but to eliminate the need for overnight hospitalization altogether. Several authors have reported on the safety and feasibility of robotic-assisted upper urinary tract reconstruction as a day surgery. Although these are small, carefully selected case series, they demonstrate that these procedures, which traditionally would require at least an overnight admission, could be done in an ambulatory setting (Fichtenbaum et al., 2018; Finkelstein et al., 2016a, 2016b).

Advantages in postoperative pain control after laparoscopic or robotic-assisted procedures are challenging to measure in children, owing both to the quick recovery of most children and the challenges of comparing objective assessment tools across various age groups. Analgesic use is often measured as a proxy for postoperative pain. **Notably, intraoperative pain requirements may be higher in some pediatric urologic procedures when performed laparoscopically. The benefit of postoperative analgesia varies depending on the procedure. Procedures with minimal postoperative pain in general, such as hernia or hydrocele repair, may show limited benefit or even increased pain postoperatively with a minimally invasive approach.** This may be a result of the increased stress of the abdominal wall from pneumoperitoneum as compared with a small, less morbid inguinal incision (Koivusalo et al., 2009). However, other procedures, such as pyeloplasty and appendicovesicostomy, do show reduced postoperative analgesic requirements (Gundeti et al., 2011; Lee et al., 2006). Although some authors have reported a benefit toward reduced analgesic use after MIS approaches, improved standardization in reporting practices is needed to better quantify these outcomes.

Taken in concert, the previously mentioned data suggest that the benefit of MIS in terms of postoperative convalescence, hospital discharge, and postoperative pain experiences are likely dependent on the morbidity of the comparative open operation. For procedures in which the open approach results in minimal additional surgical stress, the benefit may not be realized and laparoscopic approaches may even be a hindrance to postoperative recovery. However, as the morbidity and complexity of the procedures increase, so too does the minimally invasive perioperative benefit to the child.

An additional benefit of a minimally invasive approach is improved visibility of vital structures. This benefit is in part a result of the optical magnification and illumination of the laparoscopic and robotic cameras (Peters et al., 2018). Direct visualization is especially useful in the deep pelvis. The benefits of improved visualization include decreased manipulation of the posterior bladder wall during robotic-assisted ureteral reimplantation (▶Video 27.1), improved visualization of the distal ureter during ureterectomy (▶Video 27.2), and improved visualization of the spermatic vessels tracking superiorly through the retroperitoneum during laparoscopic orchiopexy (Boysen et al., 2016; Ellison and Lendvay, 2017).

Drawbacks of Minimally Invasive Surgery

There exist three major detractors to MIS in pediatrics. **First, laparoscopic and robotic-assisted techniques are often complicated and technically demanding, necessitating a steep learning curve. Second, MIS may be ergonomically more stressful to the surgeon, especially with regard to pure laparoscopy. Third, the addition of the robotic platform may significantly increase procedural costs.**

Learning curves for laparoscopic and robotic procedures, specifically pyeloplasty and ureteral reimplantation, have been estimated to be between 20 and 40 cases to achieve equivalent outcomes to open procedures (Akhavan et al., 2014; Sorensen et al., 2011; Tasian et al., 2013). Although a full discussion of surgical training in MIS will be discussed later in this chapter, it should be noted that such studies were performed in the earlier era of robotic-assisted surgery. As surgeons become exposed earlier and more often to robotic-assisted procedures throughout surgical training, learning curves early in practice may actually decrease over time.

The ergonomic stress of laparoscopy cannot be understated. Surgeons demonstrate increased physical and mental strain while performing laparoscopic tasks, such as suturing, as compared with the same tasks in an open setting (Berguer et al., 2001). As in open surgery, high-volume laparoscopic surgeons may experience significant or even debilitating injuries from challenging ergonomic conditions during laparoscopy. Indeed, up to 87% of surgeons in one survey reported physical pain associated with laparoscopic experience (Park et al., 2010). The robotic platform may provide improved ergonomics and lower physical strain experienced by surgeons (Berguer and Smith, 2006). However, it is important to note that up to 56% of high-volume surgeons will experience evidence of ergonomic strain, even with the robotic platform (Lee et al., 2017).

Cost is perhaps the largest detractor for MIS, especially as it pertains to robotics, wherein the initial robotic setup costs typically run between $1 and $2 million, and maintenance costs are greater than those for standard laparoscopic equipment (Barbash and Glied, 2010). Thus, additional costs per case for robotic-assisted surgery typically runs between $1000 and $4000 as has been shown in several cost-comparison studies for common pediatric procedures such as pyeloplasty and ureteral reimplantation (Bennett et al., 2017; Kurtz et al., 2016; Varda et al., 2018). Because of a reduced length of stay for robotic procedures, direct costs per robotic procedure may actually be lower than the comparative open surgery (Rowe et al., 2012). However, because of overhead and potential increase in operating room (OR) time, these benefits may not translate into overall cost savings (Bennett et al., 2017; Varda et al., 2018). Thus, benefit in overall cost is likely volume dependent as a result of large equipment overhead costs, and may only be realized if a reduced length of stay creates a greater capacity for the hospital to improve patient throughput (Leddy et al., 2010).

In summary, the benefits of minimally invasive pediatric urology are real and measurable. Barring disruptive technology to place downward pricing pressure on the dominant robotic companies, cost-reduction in robotic surgery will likely be dependent on efficient use of operative time and minimizing postoperative costs. Relying on the value-equation in health care, where value is equal to quality divided by cost, one must demonstrate a *value* in MIS. Primary outcomes in terms of surgical success rates are not likely to be improved upon from an open approach, where success rates for ureteral reimplant and pyeloplasty already reach greater than 95%. Thus, it is incumbent on minimally invasive pediatric urologists to demonstrate consistently reproducible secondary benefits such as improved convalescence and decreased hospital stay and to further quantify the outpatient benefits in terms of quality of life and patient-reported outcomes for MIS while reducing the cost discrepancies to the open approach.

Key Points: Advantages and Disadvantages of Minimally Invasive Surgery

- Patient preferences for postsurgical incisions are influenced by location; innovative port placements optimize cosmesis without compromising outcomes.
- Mean length-of-stay reduction with MIS may be minimal, but benefits are

realized by limiting prolonged stays and enabling more ambulatory surgical procedures.

- Although robotics may offer ergonomic advantages over laparoscopy or open surgery, ergonomic fatigue is commonly reported with use of the robotic platform as well.

Physiology of the Pneumoperitoneum

Unlike open surgery where the abdominal cavity experiences ambient temperatures and atmospheric pressures, MIS approaches introduce unique physiologic changes, which can alter the normal expectations of perioperative and postoperative course. Familiarizing oneself with these considerations is critical to minimizing cardiovascular, pulmonary, intracranial, renal, and stress-response–related morbidity.

Cardiovascular Changes

Cardiovascular changes during laparoscopy may be seen because of the impact of the pneumoperitoneum on vascular resistance, the sympathetic and parasympathetic responses to peritoneal distension, or the response to systemic intravascular absorption of carbon dioxide (CO_2). Initial insufflation will stimulate the vagal nerve, which can rarely result in cardiovascular collapse but is more typically self-limited (Aghamohammadi et al., 2009; Myles, 1991). Tachyarrhythmias might arise from sympathetic responses to the distended peritoneum or hypercapnia from absorption of the insufflated CO_2. These tachyarrhythmias are typically limited in duration and do not appear to affect overall mean heart rates or arterial blood pressure (Bozkurt et al., 1999). In older children or with intra-abdominal pressures greater than 10 mmHg, a decrease in cardiac index may be observed (De Waal and Kalkman, 2003). This decrease in cardiac index may be the product of compression of the right atrium and subsequent decrease in venous return (Gueugniaud et al., 1998). **Even insufflation at less than 10 mmHg can result in significant changes to cardiac preload and afterload, as measured by transesophageal echocardiography. These changes do not correlate to measurable changes in cardiac performance, such as left ventricular ejection fraction, perhaps a result of increased workload on the myocardium** (Gentili et al., 2000). Conversely, operating at lower insufflation pressures of 5 mmHg results in an increase in cardiac index and may be of importance in children with congenital cardiac disease (De Waal and Kalkman, 2003).

Pulmonary Changes

Insufflation of the abdominal cavity results in substantial changes to intraoperative pulmonary function. These observed changes are thought to be the result of a number of factors, including upward displacement of the diaphragm, reduction in muscular tone of the chest wall, and decreased venous return and subsequent intrathoracic blood volume caused by increased abdominal pressures (Manner et al., 1998). These effects may be further compounded by steep Trendelenburg positioning required in pelvic surgery. Infants may be particularly affected by pulmonary stress because of their small size. **Younger children absorb more CO_2 during abdominal insufflation as a proportion of their body mass, which may lead to prolonged effects of CO_2 elimination in the immediate postoperative period** (McHoney et al., 2003)**. During laparoscopic procedures utilizing up to 15 mmHg of insufflation pressure, tidal volume and dynamic compliance decrease.** Proportionally, the most substantial changes are noted in the pulmonary dynamic compliance, which had been measured to decrease in infants by a mean of 48% from baseline. Trendelenburg positioning tends to increase peak inspiratory pressures while decreasing lung compliance during laparoscopy. To counteract these changes, ventilator adjustments are required to restore end-tidal CO_2 to baseline, including increases in peak inspiratory pressure or ventilator rate (Bannister et al., 2003; Taylor et al., 2006). Similar pulmonary effects are seen with both transperitoneal and retroperitoneal approaches, although retroperitoneal insufflation has not been studied as extensively (Halachmi et al., 2003). CO_2 absorption will result in rise in both the $PaCO_2$ and end-tidal CO_2. End-tidal measurements appear to rise more dramatically in some instances, such as in children with complex cardiac anatomy. Furthermore, CO_2 continues to be eliminated up to 10 minutes after desufflation of the abdomen. As such, in children most susceptible to changes in the pulmonary dynamics, direct measurement of $PaCO_2$ via arterial blood draw may be preferred (Wulkan and Vasudevan, 2001).

Intracranial Pressure

A significant rise in intracranial pressure has been noted during pediatric laparoscopy. This is of particular importance in children with ventriculoperitoneal (VP) shunts. Hypercapnia, which results in part from changes in pulmonary gas exchange and direct absorption of CO_2 from the peritoneum (Gargollo, 2011), will increase cerebral blood flow (Wedgewood and

Doyle, 2001). Interestingly, even when arterial CO_2 levels are kept constant, an increase in intracranial blood flow during pneumoperitoneum still occurs. The mechanism by which the intracranial blood flow increases in the absence of hypercapnia is unclear but is hypothesized to be either caused by direct redistribution of cardiac output or catecholamine-driven vasoconstriction (Huettemann et al., 2002). **Intracranial pressure increases substantially during laparoscopy in children with VP shunts, thought to be in part a result of increased venous congestion via a "Valsalva-like" mechanism and a direct obstruction to the distal shunt itself.** This rise in pressure has been successfully managed with ventricular drainage (Uzzo et al., 1997). However, the use of invasive monitoring for intracranial pressures in these children has been called into question. In spite of prolonged operative times and insufflation pressures of up to 20 mmHg, one series of children with VP shunts found no changes in clinically significant parameters, such as bradycardia or hypertension, associated with pneumoperitoneum. Furthermore, shunt revision rates were similar to that reported elsewhere in the literature, suggesting laparoscopic procedures can be safely performed in this patient population without invasive monitoring (Jackman et al., 2000).

Renal Physiology

Oliguria and anuria during laparoscopic surgery is a known phenomenon of particular note during urologic surgeries. This effect appears more profound in younger children, with up to 88% of infants younger than 1 year of age exhibiting short periods of intraoperative anuria. Although only 14% of children older than 1 year of age will exhibit anuria, up to one-third of those younger than 1 year of age will exhibit oliguria (Dammeier et al., 2005). These changes are thought to arise from decreased renal blood flow, which results from decreased cardiac output, impaired venous return, and direct compression of the pneumoperitoneum on the kidney. Interestingly, there does appear to be intrarenal shunting of blood flow, resulting in preferential increases in blood flow during pneumoperitoneum to the renal medulla (Razvi et al., 1996). Direct compression has been postulated to be the most important component of decreased renal blood flow, based on in vivo animal models, as changes in the venous return and cardiac output appear to have minimal impact on renal perfusion (Chiu et al., 1994; Razvi et al., 1996). However, declines in glomerular filtration rate and release of renal injury markers, such as *N*-methyl-ß-D-glucosaminidase, occur well after release of pneumoperitoneum, suggesting a role for renal regulatory mechanisms beyond just compression (Cisek et al., 1998). Notably, all of these changes do appear to be reversible, with clinical parameters normalizing within 24 hours and physiologically measured parameters normalizing within 1 week (Cisek et al., 1998; Dammeier et al., 2005). However, early in recovery, the physiologic impact on renal function remains abnormal within the first 60 to 90 minutes postoperatively (Cisek et al., 1998; Razvi et al., 1996). From a clinical standpoint, it is important to recognize oliguria as a potential outcome after laparoscopy unrelated to intravascular fluid status. As this effect will normalize spontaneously and in the absence of other markers of under-resuscitation, isolated postlaparoscopic oliguria should not be managed with bolus-hydration beyond typical postoperative management. However, because renal blood flow and function may be affected in the early postoperative period, caution should be used during this timeframe in administration of medications such as non-steroidal anti-inflammatory drugs and aminoglycoside medications that may further alter renal blood flow.

Acid-base physiology may be significantly altered by CO_2 absorption during insufflation. Hypercapnia is likely driven by two main effects. At insufflation pressures less than 10 mmHg, direct absorption of the gas by the peritoneal lining results in elevated $PaCO_2$. Once intra-abdominal pressures exceed 10 mmHg, increased respiratory dead space from ventilation-perfusion mismatch likely also contributes to a rise in $PaCO_2$ (Lister et al., 1994). Acidosis resulting from an increase in $PaCO_2$, however, returns to baseline after desufflation. This is in contrast with lactic acidosis noted after laparotomy, which persists for several hours postoperatively (Kwak et al., 2010). However, in vivo models to replicate pneumoperitoneum in infants suggest that smaller peritoneal spaces may be more susceptible to acid-base changes, resulting in more profound and persistent changes to base excess lasting several hours after surgery (Sümpelmann et al., 2006). Porcine studies suggest that maintenance of intravascular volume with colloid replacement during laparoscopy can mitigate hemodynamic changes and base-excess, though the implications of this approach in clinical practice remain undefined (Osthaus et al., 2008). In addition to systemic changes in CO_2 concentration, local increases in CO_2 within the peritoneal cavity result in a buildup of H^+ and HCO_3^-. This local acidosis is thought to contribute to postlaparoscopic pain (Hanly et al., 2005).

Stress Response to the Pneumoperitoneum

Increase in intra-abdominal pressure has been associated with several systemic stress responses, including catecholamine and cytokine release. Pneumoperitoneum results in release of epinephrine and norepinephrine within 5 minutes of insufflation, with a more profound response in the lateral decubitus position (Mikami et al., 1996). At 20 mmHg of intra-abdominal pressure, the release in catecholamines appears to be associated with and is likely driven by decreased cardiac output and increased systemic vascular resistance. Stimulation of the sympathetic nervous system was not noted at lower intra-abdominal pressures of 10 mmHg, suggesting a modifiable effect of pneumoperitoneum and potential benefit to maintaining lower insufflation pressures during laparoscopy if feasible (Mikami et al., 1998).

The stress response after laparotomy can be significant, but less so after laparoscopy because of the ability to minimize tissue damage and visceral manipulation. **Interleukin-6 and C-reactive protein levels remain significantly elevated after open surgery as compared with laparoscopic intervention for up to 48 hours. Pain and fatigue scores are correspondingly lower after laparoscopy** (Jakeways et al., 1994; Kristiansson et al., 1999). The benefits of laparoscopy on inflammatory responses appear to be realized both in local (i.e., peritoneal) inflammatory markers and systemic inflammatory assessment. Counts of polymorphonuclear cells and macrophages, as well as interleukin-6 release, were lower on peritoneal lavage after CO_2 laparoscopy than laparotomy. Interestingly, achieving pneumoperitoneum with room air, as opposed to CO_2, resulted in a similarly increased inflammatory response as laparotomy, suggesting that at least some of the benefit of the minimized laparoscopic stress response is a result of the characteristics of the insufflation gas (Ure et al., 2002). The dampened local immune response has been proposed to be the result of CO_2 conversion to H^+ and HCO_3^-, resulting in peritoneal acidosis (Hanly et al., 2005). This dampened response has been shown to blunt the inflammatory cascade associated with sepsis (Hanly et al., 2003; Hiki et al., 2006). Of note, pediatric-specific data has not shown such changes in the inflammatory response postlaparoscopy, suggesting that these changes may be age-dependent (Bozkurt et al., 2000; McHoney et al., 2005; Simon et al., 2009).

Key Points: Physiology of the Pneumoperitoneum

- Infants pose anatomic and physiologic challenges such as limited working space, a pliable abdominal wall, and cardiopulmonary changes with insufflation.
- Insufflation pressures even less than 10 mmHg may affect cardiac preload and afterload, with specific implications in children with complex cardiac anatomy.
- A diminished postoperative inflammatory response may result in postoperative complications such as visceral injury presenting without peritoneal signs.
- Intracranial pressure may increase with pneumoperitoneum, though the presence of ventriculopertioneal shunts is not a contraindication to laparoscopy.
- Oliguria after laparoscopy is common and should not be managed with reflex fluid resuscitation without further assessment of volume status.

Patient Selection for Mimimally Invasive Surgery

Although MIS is a highly technical approach to surgery, decision making and judgment determine significant outcomes in our patients. Understanding when to apply and not to apply MIS approaches is vital to optimizing surgical success. The most common pediatric procedures undertaken in a minimally invasive fashion are orchiopexy for intra-abdominal testicles, pyeloplasty, and ureteral reimplantation (▶Video 27.3). However, a number of successful MIS applications have been described, as listed in Table 27.3.

TABLE 27.3

Minimally Invasive Pediatric Urologic Procedures Reported in the Literature

UPPER URINARY TRACT
Radical nephrectomy (Hamilton et al., 2000; Yao and Poppas, 2000)
Partial nephrectomy (Yao and Poppas, 2000; Lee et al., 2005)
Nephroureterectomy (Figenshau et al., 1994; Yao and Poppas, 2000)
Heminephroureterectomy (Janetschek et al., 1997; Yao and Poppas, 2000)
Pyeloplasty (Lee et al., 2006; Minnillo et al., 2011)
Calyceal diverticulectomy (Casale et al., 2004a, 2004b, 2004c; Long et al., 2015)
Ureterocalicostomy (Casale et al., 2008a, 2008b, 2008c; Radford et al., 2011)
Pyelolithotomy (Casale et al., 2004a, 2004b, 2004c; Lee et al., 2007)
Nephropexy (Resnick et al., 2006; Matsui et al., 2004)
Renal cyst ablation (Okeke et al., 2003; Shiraishi et al., 2006)
Renal denervation (Resnick et al., 2006; Casale et al., 2008a, 2008b, 2008c)
Adrenalectomy (Miller et al., 2002; Skarsgard and Albanese, 2005)
LOWER URINARY TRACT
Bladder diverticulectomy (Kok et al., 2000; Meeks et al., 2009)
Partial cystectomy and removal of urachal remnant (Yamzon et al., 2008; Jeong et al., 2013)
Appendicovesicostomy (Casale et al., 2004a, 2004b, 2004c; Nguyen et al., 2009)
Auto-augmentation (Ehrlich and Gershman, 1993; Poppas et al., 1996)
Intravesical and extravesical ureteral reimplant (Kutikov et al., 2006b; Casale et al., 2008a, 2008b, 2008c)

Ureteroureterostomy (Leavitt et al., 2012; Ellison and Lendvay, 2017)
Augmentation enterocystoplasty (Gundeti et al., 2011; Murthy et al., 2015)
Utricle excision (Yeung et al., 2001; Lima et al., 2004)

GENITAL SURGERY

Varicocelectomy (Glassberg et al., 2008; Kaouk and Palmer, 2008)
Neovagina (Templeman et al., 2000; Kim et al., 2011)
Undescended testis (Jordan et al., 1992; Godbole and Najmaldin, 2001)
Sacrocolpopexy (Christopoulos et al., 2011; Henninger et al., 2015)
Retroperitoneal lymph node dissection (Tomaszewski et al., 2010; Cost et al., 2012)

OTHER

Antegrade continent enema (Van Savage and Yohannes, 2000; Karpman et al., 2002)

Although several patient factors make MIS more technically challenging, there are currently only two absolute contraindications to laparoscopic and robotic-assisted surgery in children: (1) inability of the patient to tolerate pneumoperitoneum and (2) inability of the surgeon to safely perform the procedure.

The ability of a child to tolerate pneumoperitoneum is dependent on adequate cardiac and pulmonary reserve in response to the increased intra-abdominal pressure. The degree of stress on the cardiopulmonary circulation is dependent on the level of pneumoperitoneum. Thus, children with more severe cardiopulmonary disease can be managed safely by operating at lower insufflation pressures of 5 mmHg, which results in a subsequent increase in cardiac index (De Waal and Kalkman, 2003). Even in severe cardiopulmonary disease, laparoscopy has been safely performed. **However, as children with congenital cardiac disease have higher 30-day morbidity and mortality, this unique patient population requires special considerations during laparoscopy** (Chu et al., 2017).

Although there are no specific age or size restrictions in laparoscopy or robotic-assisted surgery, several considerations must be made in preparing to operate on the youngest of children. Robotic-assisted surgery has been reported in children within the first week of life, as small as 2.2 kg (Mariano et al., 2004; Meehan, 2009; Meehan and Sandler, 2007). Several reports have demonstrated the safety of common pediatric urologic procedures (e.g., pyeloplasty) in children younger than 1 year of age, using both pure laparoscopic and robotic-assisted techniques (Kutikov et al., 2006a, 2006c). Furthermore, laparoscopic orchiopexy in infants with nonpalpable testes has arguably become a standard of care, considered equal to open exploration in experienced hands (Kolon et al., 2014). Even retroperitoneal surgery, with a smaller relative working space than transperitoneal access, has been successfully reported in infants (Leclair et al., 2009). **However, one must consider that the working space of the infant will be limited, often allowing only 1 L of insufflation volume as compared with 5 to 6 L of insufflation in the adult population** (Finkelstein et al., 2015)**. Smaller working spaces can pose technical challenges to the surgeon, making intra-corporeal suturing and multiquadrant surgery more difficult.** The degree to which this smaller working space affects perioperative outcomes or operative time has not been well quantified. However, when measuring the distance between the anterior superior iliac spines and also the puboxyphoid distance, distances less than 13 cm and 15 cm, respectively, appear to be associated with higher rates of arm collision during robotic surgery. Percutaneous introduction of 3-F graspers, 2-mm scissors, or antegrade ureteral stent introduction via a 14-gauge angiocatheter needle can eliminate the need for additional 3- or 5-mm assistant ports and thus allow for additional extracorporeal working space for the surgeon and assistant (Hotaling et al., 2009; Noh et al., 2011). Lastly, the relatively small size of an infant compared with the large footprint of the robotic-platform itself can limit nursing and anesthesia access to the child. Thus, proper perioperative planning is required to ensure safe and efficient patient positioning and access to pressure points, intravenous catheters, and the airway for the entire operative team (Mariano et al., 2004). In closing, although feasible, robotic and laparoscopic surgery in younger infants may pose additional technical challenges.

Operating on a hostile abdomen with higher risk for intra-abdominal adhesions because of prior abdominal surgeries or procedures such as VP shunts is often considered a relative contraindication to minimally invasive surgery. **Laparoscopy in children with prior abdominal surgeries is associated with a higher rate of open conversion and intraoperative events such as enterotomy** (Metzelder et al., 2006)**. However, successful completion of these procedures in a laparoscopic fashion is feasible, and when accomplished, may yield increasing returns in terms of convalescence and pain control** (Chua et al., 2018). Because not all reoperative abdomens are similar, predicting *a priori* children that may be at higher risk can be challenging. A “Hostile Abdomen Index” has been reported, with scores ranging from 1 to 4 given for both preoperative conditions and intraoperative findings. A preoperative score of

3 or 4 has been associated with a higher risk for significant hemorrhage and enterotomy and may be useful to help guide surgeons in preoperative counseling and perioperative planning (Goldfarb et al., 2014) (Table 27.4).

TABLE 27.4

Hostile Abdomen Index Scoring Table

1 No prior surgery No hernia No skin disease or infection	**2** One prior laparotomy or hernia
3 Two prior laparotomies Extremes in patient size (small or large) Coagulopathy Prior abdominal radiation (not at surgical site) History of inflammatory bowel disease Acute abdominal wall infection (not at surgical site)	**4** More than two laparotomies History of diffuse peritonitis or abdominal abscess Large abdominal mass Abdominal mesh Bowel obstruction with severe distension Prior failure of laparoscopy caused by adhesions Prior abdominal radiation (intended surgical site) Active inflammatory bowel disease Hemodynamic instability Severe chronic obstructive pulmonary disease Late pregnancy Acute abdominal wall infection (at port site)

Key Points: Patient Selection in Minimally Invasive Surgery

- The inability to safely achieve pneumopertioneum is the only patient factor that contraindicates MIS.
- Patient positioning for infants must take into account the ability of the anesthetic team to reach the patient's airway and intravenous access.

- Preoperative assessment of a hostile abdomen will suggest risk for conversion to open surgery, aid in surgical planning, and contribute to patient counseling.

Access

As in adult MIS approaches, access or introduction of the initial ports can be varied depending on surgeon preference, anatomic considerations, and equipment availability.

Veress Needle

The Veress needle operates on a principle of a covered needle, exposed during applications of pressure and retracting on release of this pressure. Insertion of the needle through the fascial planes will expose the needle at the point of pressure against the fascia and retract once the fascia has been perforated, thus covering the needle when it enters the abdomen. Because of the laxity and thin nature of the pediatric abdominal wall, **Veress insertion presents several challenges. First, it may be difficult to create enough tension to release the needle and perforate the fascia, even with excessive force (Fig. 27.3). Second, one must be wary of the depth of insertion, as the vasculature and viscera may reside shallower than anticipated in older patients.** Age younger than 2 years has previously been described as a relative contraindication to Veress needle access (Schulam et al., 1999).

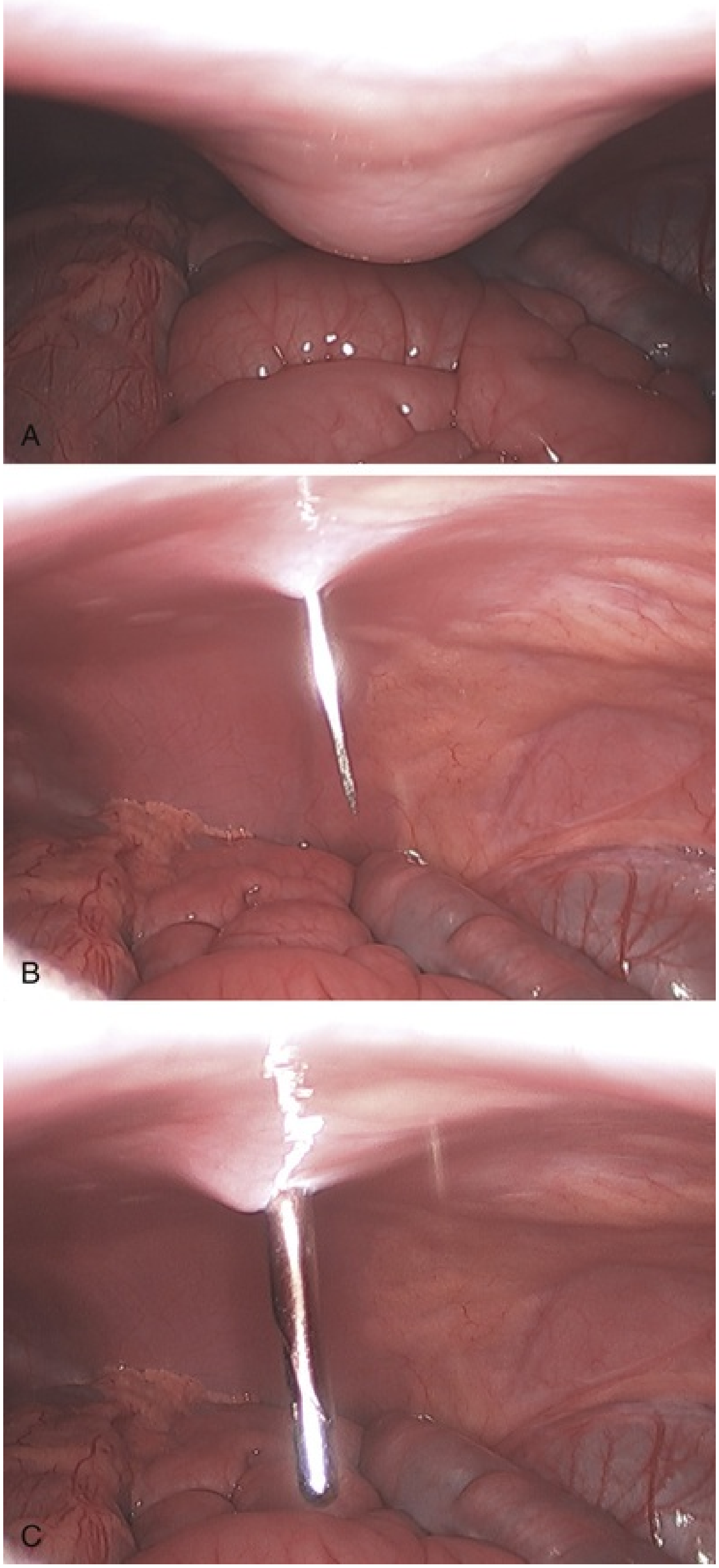
A
B
C

FIG. 27.3 Veress needle for laparoscopic access. (A) Percutaneous attempt at Veress placement in an infant, viewed intra-abdominally. Note the laxity of the abdominal wall, which is displaced and near the underlying small intestine; (B) incising the fascia and peritoneum in the same infant with an 11-blade scalpel to allow easier entry; (C) insertion of the Veress needle after incision of the fascia. In this approach, the sharp edge of the Veress needle is not exposed, but the Veress may still serve as a guide for insertion of a 5-mm radially dilating port.

Several facets of Veress access are commonly debated, such as point of entry and the need to lift the abdominal wall before insertion. Traditionally, midline insertion of the Veress needle at the umbilicus was preferred (Vilos et al., 2007). However, it should be noted that the umbilicus is a poor indicator for the location of the aortic and caval bifurcations, and thus any blind insertion techniques at the midline should be approached with caution (Sriprasad et al., 2006). Palmer's point, located within the left upper quadrant 3 cm inferior to the left subcostal border in the midclavicular line, is an alternative point of entry when there is a risk for periumbilical adhesions or unsuccessful umbilical access (Vilos et al., 2007). **Lifting the abdomen by hand or with towel clips does not appear to raise the peritoneal lining above the underlying viscera sufficiently enough to prevent injury** (Vilos et al., 2007)**. Furthermore, such an approach appears to have a higher risk for failed access and failing to prevent complications** (Ahmad et al., 2008).

Complications of Veress needle access include major vascular or visceral injury, failed access, extraperitoneal insufflation, or minor vascular injury. Overall, complication rates are low, with rates of only about 0.2% presented in the literature. Furthermore, rates of vascular and visceral injury compose a minority of these complications. However, the majority of visceral injuries are considered “major” (Azevedo et al., 2009). Interestingly, self-reported complications via a survey of members of the Society of Pediatric Urology revealed a higher reported rate of Veress needle injuries than open access injuries, although this was relatively early in the widespread use of laparoscopy. The overall rate of access complications was higher than found in other published literature, suggesting a potential for publication bias in assessing these rare injuries (Peters, 1996). Although the rates of complications are low, the consequences of Veress injury may be substantial. During passage of the Veress needle, several tests may be employed to test for adequate intra-abdominal placement. These include a double-click test, aspiration, hanging drop test, and measurement of initial insufflation pressures. The double-click test is based on the theory that one is perforating two fascial layers during insertion. Aspiration is performed with a small syringe to confirm no return of blood or visceral contents. The drop test involves instillation of saline via the needle, where prompt drainage of the saline could indicate peritoneal access. Although these three tests, particularly the aspiration test, may help to ensure no vascular or visceral injury exists, they have a low positive predictive value to suggest appropriate peritoneal placement. However, consistent measurements of initial insufflation pressures less than 10 mmHg are highly predictive of adequate peritoneal access (Teoh et al., 2005). The true benefit of many of these confirmatory tests may lie in the early recognition of major intra-abdominal injury, where proceeding with insufflation and dilation of the trocar could lead to catastrophic consequences.

Open Access

Open laparoscopy, or the Hasson technique, was first described in 1970 and relies on a small incision with access into the peritoneum to allow for direct insertion of a laparoscopic port. This technique is classically performed with an incision at the umbilicus with exposure and incision of the abdominal fascia. Visualization of the bowel or omentum is considered an essential step in confirming safe intra-abdominal access (Hasson et al., 2000). A modification of this technique involves direct entry through the umbilicus, where there is a natural absence of the transabdominal fascial planes (Fig. 27.4). The transumbilical approach has been shown to be safe and efficient, often taking less than 1 minute. This technique relies on a small incision, equal to or less than the port diameter, to prevent leakage of pneumoperitoneum from the opening (Esposito, 1997; Nakaoka et al., 2010). Even in obese patients, in whom the technique might be more challenging, efficiency is not lost in the majority of cases (Moberg et al., 2007). Consideration of the umbilical anatomy is important for this technique. Even in adults, up to 25% of the population may have a natural fascial opening at the umbilicus, based on cadaver studies (Fathi et al., 2012). However, the umbilicus is typically covered with thickened skin and a confluence of the medial and median umbilical ligaments with the ligamentum teres hepatis. Variations exist in the configuration and branching of these ligamentous structures, which could affect ease of umbilical access (Oh et al., 2008). **Of clinical relevance, it is important to note that confluence of these ligaments at the umbilicus may make access more challenging, potentially**

necessitating a more formal exposure and incision of the umbilical stalk (Tröbs et al., 2016)**. Because support of the umbilical opening varies as well, it is important to formally close the fascial edges to prevent port site hernia after the procedure** (Tröbs et al., 2016).

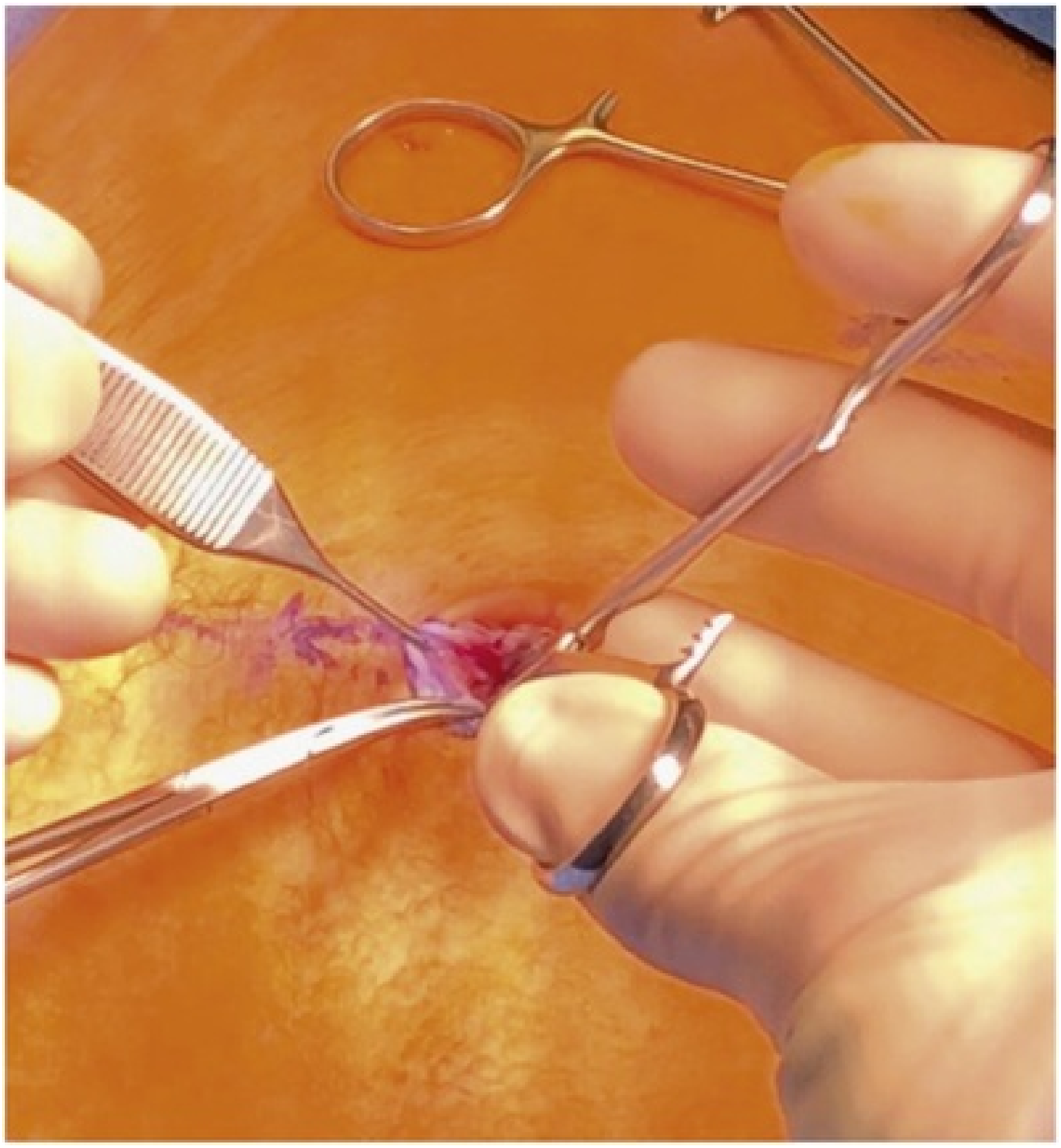

FIG. 27.4 Open umbilical access. The surgeon retracts the inferior umbilical edge with Adson forceps while the assistant retracts laterally. The hemostat is introduced gently inferiorly through the natural fascial opening into the peritoneum.

Visual Obturator Access

Optical access trocars allow direct visualization with the laparoscopic camera while the port is being placed into the abdomen. The surgeon can thus visualize the layers of the abdominal wall as they are entered. Successful uses of these devices have been described with and without prior insufflation via a Veress needle and may be more effective than the Veress needle in accomplishing successful access (Marcovich et al., 2000; Rabl et al., 2008). The optical access trocar does not eliminate risk for major vascular or visceral injury, although the rates of injury are quite low, similar to other access techniques (Sharp et al., 2002; String et al., 2001). Rates of injury may be higher in the desufflated abdomen and some surgeons prefer to gain Veress needle access with pneumoperitoneum before placement of the visual obturator (Brown et al., 2005). One limitation of the visual obturator in children is the size of most devices, ranging between 10 and 12 mm (Brown et al., 2005; McKernan and Finley, 2002).

Comparative Effectiveness of Access Techniques

Numerous studies have assessed comparative success and risks with various access techniques, though most of the comparisons are between direct access (i.e., Hasson) and Veress needle access. Commonly, outcomes are stratified by major complications such as visceral or major vascular injuries, minor complications such as omental injury or insufflation into an undesired space (i.e., pre-peritoneal), and failure of access. **There does not appear to be any significant difference in the incidence of visceral injury between open and Veress needle access techniques, though the incidence rates are so low that demonstrating statistical differences would require an enormous study population** (Jiang et al., 2012). Minor complications such as preperitoneal insufflation do appear to be higher with the Veress needle technique. Furthermore, failure of access appears to be lower with direct open entry (Ahmad et al., 2008; Merlin et al., 2003). One randomized trial evaluating direct open access to a visual obturator technique found a quicker time to entry with direct access at a cost of potential higher risk for access-related complications, including one case requiring open conversion. However, given the small number of patients enrolled, it is difficult to generate a final conclusion on overall complication rates (Minervini et al., 2008). It is important to note that none of these studies included pediatric patients, so direct prospective comparisons of any access technique in children are lacking.

Key Points: Access

- When placing a Veress needle in children, considering the laxity and thin nature of the abdominal wall helps minimize intra-abdominal vascular or visceral injury.

- Veress needle access has a higher rate of failed access but similar rates of major complications; however, studies specific to children are lacking.
- The umbilicus is a poor predictor of the location of the aortic bifurcation, which may exist superior to the umbilicus in a substantial proportion of patients.

Approach

Transperitoneal

The most common approach to laparoscopic procedure is via the peritoneum, which has the advantage of easy access to the abdomen, a large working space, and surgeon familiarity with anatomic orientations. Although the pediatric abdomen distends to a smaller absolute volume than the adult abdomen, the laxity of the pediatric abdominal wall likely allows for greater proportional volume expansion than in the adult patient. Transperitoneal approaches are preferred for intra-abdominal testes, which can be easily identified typically at the level of or just above the internal inguinal ring. Renal surgery can be approached via a transperitoneal approach with reflection of the colon or (on the left side) transmesenteric exposure. The posterior bladder is easily accessible via a transperitoneal approach and can be routinely mobilized to expose the prevesicular space if needed. Furthermore, the intestinal tract is easily accessible for any reconstruction that might require bowel.

Retroperitoneal

The retroperitoneal approach is favored by some surgeons, although it may be technically challenging, resulting in a smaller working space and anatomic orientation that may not be as intuitive to the early learner. However, this approach avoids the peritoneal cavity and its contents, thereby potentially reducing the risk for catastrophic complications such as visceral injury. Renal surgery is especially attractive via this approach, and all common pediatric renal operations including nephrectomy, heminephrectomy, and pyeloplasty have been described in a retroperitoneal manner (El-Ghoneimi et al., 2000, 2003; Wallis et al., 2006). Similar to a retroperitoneal approach, the space of Retzius can also be insufflated and accessed without entering the peritoneum. Although this technique is utilized in adult prostatectomy, applications in the pediatric population may be more limited, though the anterior bladder neck could be well visualized via this approach.

Vesicoscopic

In management of the lower urinary tract, specifically ureteroneocystotomy, minimally invasive approaches with access directly into the bladder have been described. Similar in the challenges to retroperitoneal surgery, this approach is limited by smaller working space. Complications may occur at a higher frequency in small bladders (Kutikov et al., 2006b). Furthermore, although the ports may be visualized with direct insertion into the bladder, any extravesical tracking is not visualized, which may place intra-peritoneal structures at risk during port placement. These procedures have been described using pure laparoscopy and robotic assistance (Peters and Woo, 2005). Although the learning curves have not been strictly studied in these populations, there appears to be higher rates of complications and failures in the early (i.e., 30 cases) surgical experience (Jayanthi, 2018; Kutikov et al., 2006b). In experienced hands, however, the success rate approaches that of open repair after reaching the learning curve (Jayanthi, 2018).

Key Point: Approach

- Retroperitoneal and vesicoscopic approaches minimize exposure to the peritoneal cavity but may pose challenges related to small working spaces.

Equipment and Instrumentation

Knowledge of all available instrumentation in one's armamentarium is vital to being a safe and efficient minimally invasive surgeon. This includes knowledge of standard and advanced laparoscopic and robotic instruments, options for hemostasis, and optimal imaging strategies.

Laparoscopic Ports

As mentioned earlier, laparoscopic surgery can be performed via a variety of access port sizes. Most commonly utilized are 5-mm ports, though occasionally larger instruments require 10- or 12-mm ports. Smaller port sizes and instrumentation are available, including mini-laparoscopic (3-mm), needlescopic (2-mm), and micro-laparoscopic (<2-mm) instrumentation. A number of procedures including orchiopexy, nephrectomy, and upper tract reconstruction have been reported with these techniques (Borer et al., 1999; Ferrer et al., 2000; Gill et al., 2000; Pini et al., 2012). **Proposed advantages to smaller instruments include: need for smaller incisions, which then translates to improved cosmetic outcomes and decreased postoperative pain; stiffer instruments with improved precision and control; and smaller instruments, which may result in less visceral trauma** (Pini et al., 2012). However, certain limitations exist with this smaller instrumentation. Surgeons have noted operating with smaller instruments to be more technically challenging, with a potentially increased learning curve (Gill et al., 2000). Furthermore, smaller instruments may be more fragile, and the scope of available instruments is more limited in smaller diameters. Thus, standard hemostatic devices, vascular clips, or staplers may not be available to the surgeon. Visualization has been raised as a concern, though advances in high-definition optics have mitigated this to some degree (Pini et al., 2012).

Single-Site Surgery

Laparoscopic single-site surgery, often referred to as laparoendoscopic single-site surgery (LESS), was introduced to urologic surgeons in 2007, when the first single-port nephrectomy was performed (Desai et al., 2008). Soon thereafter, the first nephroureterectomy performed via a single laparoscopic port was also described in children (Bayazit et al., 2009). Since that time, LESS has been described additionally in pediatric varicoceles, orchiectomy, and hernia repair (Kaouk and Palmer, 2008; Marietti et al., 2010). Although most experience in LESS is focused on the adult population, infants have safely undergone LESS for general surgical indications such as pyloromyotomy (Muensterer et al., 2010). The main benefits of LESS are in the cosmetic outcomes, as the single port system can be introduced via the umbilicus, thereby hiding the single scar and creating essentially “scar-less” laparoscopic surgery. The impact of improved cosmetic outcomes, however, may be limited to the early postoperative period. **In one prospective study of children undergoing single-site and standard laparoscopic appendectomy, the single-site approach was initially superior in parent perception of scarring. However, this benefit was negated in longer-term follow-up, and after 18 months there was no difference in scar perception between groups** (Gasior et al., 2014). Additional benefits related to limiting access to a single port include potential for decreased pain and complications, however, evidence to support these specific benefits in LESS is lacking (Tracy et al., 2008).

LESS is accomplished via a multitude of proprietary multitrocar devices that allow placement of multiple instruments through a single incision. These single-port devices vary in size and usability, which may affect their utility in the pediatric population. One specific challenge of LESS is the crowding of instruments, which can contribute to a learning curve for this technique, even for the experienced laparoscopic surgeon. Instrument crowding results in fewer degrees of freedom, clashing of instruments, and potential limited visibility (Hansen et al., 2011). Learning curves for LESS, though not specifically defined in the pediatric population, show sequential improvement in time over the first 25 to 75 cases (Fader et al., 2010; Hernandez et al., 2010). Techniques that surgeons have adapted to counter the concerns of limited working space include: (1) staggering the trocar depth to improve extracorporeal mobility; (2) inserting stay-sutures and/or instruments via fascial-stab incisions for increased assistance intra-abdominally; (3) using a 45-degree lens for improved extracorporeal visibility and mobility of the assistant; and (4) inverting instruments to minimize the surgeon's hands from clashing within a confined working space (Hansen et al., 2011). Additionally, LESS on the robotic platform has been introduced, which improves on some of the technical limitations of pure laparoscopic single-port approaches and has been used successfully across a number of surgical disciplines (Autorino et al., 2013). Notably, however, in the United States, the da

Vinci Single-Site system is only approved for indications of cholecystectomy, benign hysterectomy, and salpingo-oophorectomy (Intuitive Surgical, 2018).

Hemostatic Devices

Several categories of cautery devices exist, most of which are utilized across both the pediatric and adult populations. Monopolar electrocautery is the simplest and most readily available. However, this cautery may be less precise and requires conduction through the patient, who must be grounded. When applying monopolar electrocautery laparoscopically, it is important to note that the laparoscopic instrument is sheathed in an insulating layer, thus protecting the patient from inadvertent dispersion of electricity. However, any exposed metal may also transmit the cautery, and thus all exposed metal toward the working end of the instrument must be in view during cauterization and away from surrounding structures.

Bipolar electrocautery conducts electricity between two points within the patient, and thus is more controlled. However, substantial lateral spread may be seen, with the potential for inadvertent injury. Typically vessels greater than 5 mm should not be addressed with standard bipolar electrocautery. Advanced bipolar devices rely on an internal feedback mechanism to measure tissue seal and adjust current accordingly. This technology optimizes the efficacy of the device while minimizing collateral damage**. It should be noted, however, that all available devices create at least 2 mm of high thermal energy laterally, and thus a safe margin should be applied when utilizing these devices** (Lamberton et al., 2008). The available advanced bipolar instruments have varying functional specifics, such as time to seal, burst pressure of the sealed vessel, production of particulate matter, and impact on visibility. Comparisons of these variables have been performed using in vitro studies; in pediatrics, one should consider the potential impact of visibility from particulate matter in especially small working spaces. Furthermore, smaller-diameter vasculature may be more amenable to ligation with advanced bipolar electrocautery. Although not specifically reported for renal vasculature, the LigaSure device (Medtronic, Minneapolis, MN) has been utilized safely to control the splenic hilum during laparoscopic splenectomy in a pediatric population (Romano et al., 2003).

Similar in appearance to a bipolar electrocautery device is the Harmonic Scalpel (Ultracision Shears Harmonic Scalpel LCS; Ethicon SAS, Issy-les-Moulineaux, France), which converts electric current to high-frequency vibrations, allowing for division of moderate-sized vessels (Fig. 27.5). This device has been reported to be safe for vessels up to 5 mm as long as appropriate time for coagulation is applied (Msika et al., 2001). The Harmonic Scalpel has been reported for use in laparoscopic nephrectomy, though not for control of the hilum in those cases (Helal et al., 1997). Similar to bipolar electrocautery, this device has also been reported to be effective for control of the splenic hilum in children, raising potential uses for more major vasculature in the pediatric population (Schaarschmidt et al., 2002).

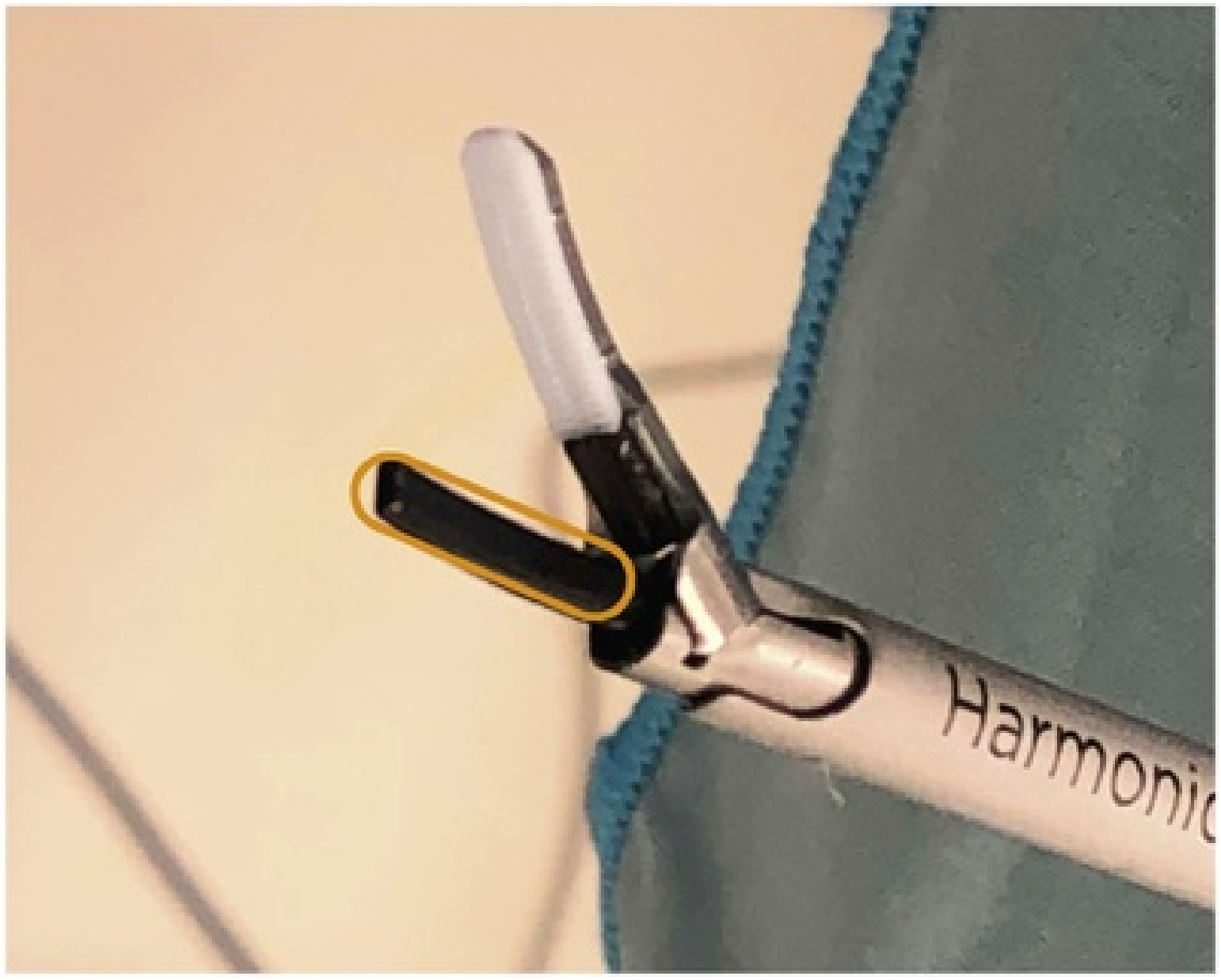

FIG. 27.5 Harmonic scalpel. Jaws *(orange oval)* vibrate at high frequencies to create tissue shearing and coagulation.

Staplers

Laparoscopic stapling devices are typically utilized for vascular control or transection of bowel during reconstructive urologic procedures. Staple characteristics include distance between staples, length and width of the staple load, and potential for articulating. Until recently, laparoscopic staplers required at least a 12-mm port for insertion, given the diameter of the entire device. However, several newer devices on the market currently exist that can be inserted via a 5-mm port. These staplers are shorter in length and smaller in diameter, making them attractive for use in the pediatric population, where working space is often limited (Kuthe et al., 2016).

Clips

Laparoscopic clips are typically applied with manual force, compressing the vessels. It should be noted that Hem-o-lock clips are contraindicated for live donor nephrectomy because of three reports of slippage from the renal artery, resulting in death. The U.S. Food and Drug Administration (FDA) specifically notes donor nephrectomy and does not comment, however, on the use in nephrectomy for benign or malignant disease (Friedman et al., 2012). Titanium clips measure between 5 and 10 mm and can be utilized for moderate-sized vasculature. Typically, the vessel is controlled with clips both proximally and distally to prevent back-bleeding, and an additional clip or series of clips is placed proximally to prevent slippage and hemorrhage.

Suture Assistance

Intracorporeal laparoscopic-assisted suturing can be technically challenging and physically demanding (Berguer et al., 2001). As such, several suturing-assistance devices exist to provide improved surgeon comfort and efficiency. These devices typically rely on either a pretied suture to serve as a lasso around the structure of interest or as a mechanically assisted needle device. Such devices have been shown to improve suturing efficiency (Bermas et al., 2004; Wolf et al., 1997). However, these devices may lack the precision needed for delicate tissue handling in the pediatric setting, and some require 12-mm port sizes.

Robotic-Assisted Surgery

The first pediatric robotic-assisted surgery was reported in 2001, a successful Nissen fundoplication (Meininger et al., 2001). Since that initial report, the popularity of robotic-assisted surgery in pediatrics has risen exponentially, with particular interest within pediatric urology, where complex reconstruction is often encountered. Pyeloplasty and ureteral reimplantation are the two most frequently reported indications in the pediatric population, though several additional indications ranging in complexity also exist (Cundy et al., 2018; Kurtz et al., 2017; Varda et al., 2018).

When positioning for robotic surgery, it is important to ensure that all pressure points are padded appropriately, especially because access to these pressure points intraoperatively may be obscured by the docked robot. Renal surgery is typically facilitated in a lateral decubitus position with “airplaning” of the operative table. Meanwhile, pelvic surgery is facilitated by Trendelenburg positioning. Thus, both require the patient to be secured firmly to the table to prevent patient shifting during repositioning intraoperatively. Notably, pelvic surgery was initially described in dorsal lithotomy positioning with docking between the legs. However, even with the first-generation robotic platforms, pelvic surgery can be accomplished via a modified supine position, obviating the need for dorsal lithotomy and inherent risks (Fig. 27.6).

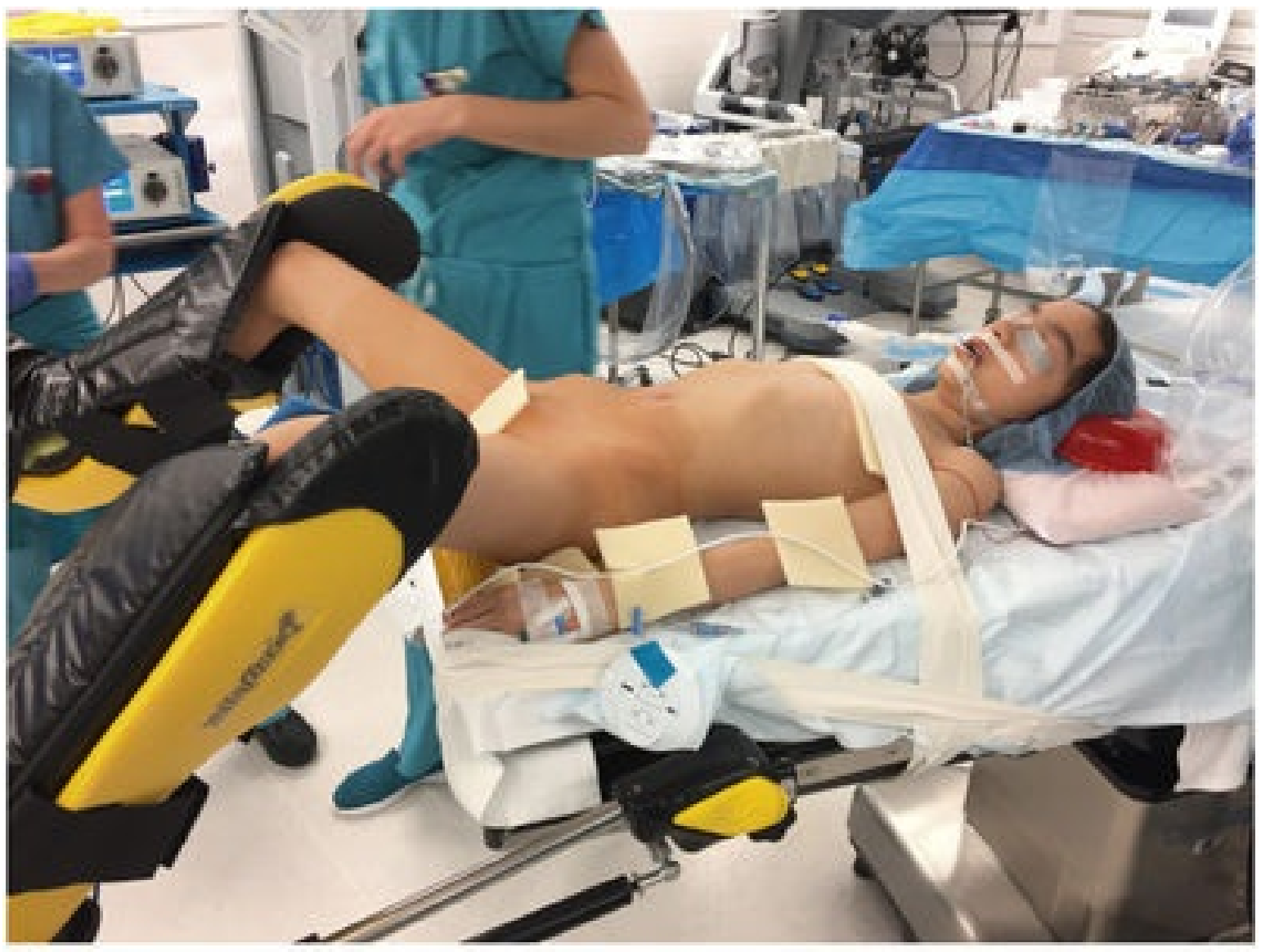

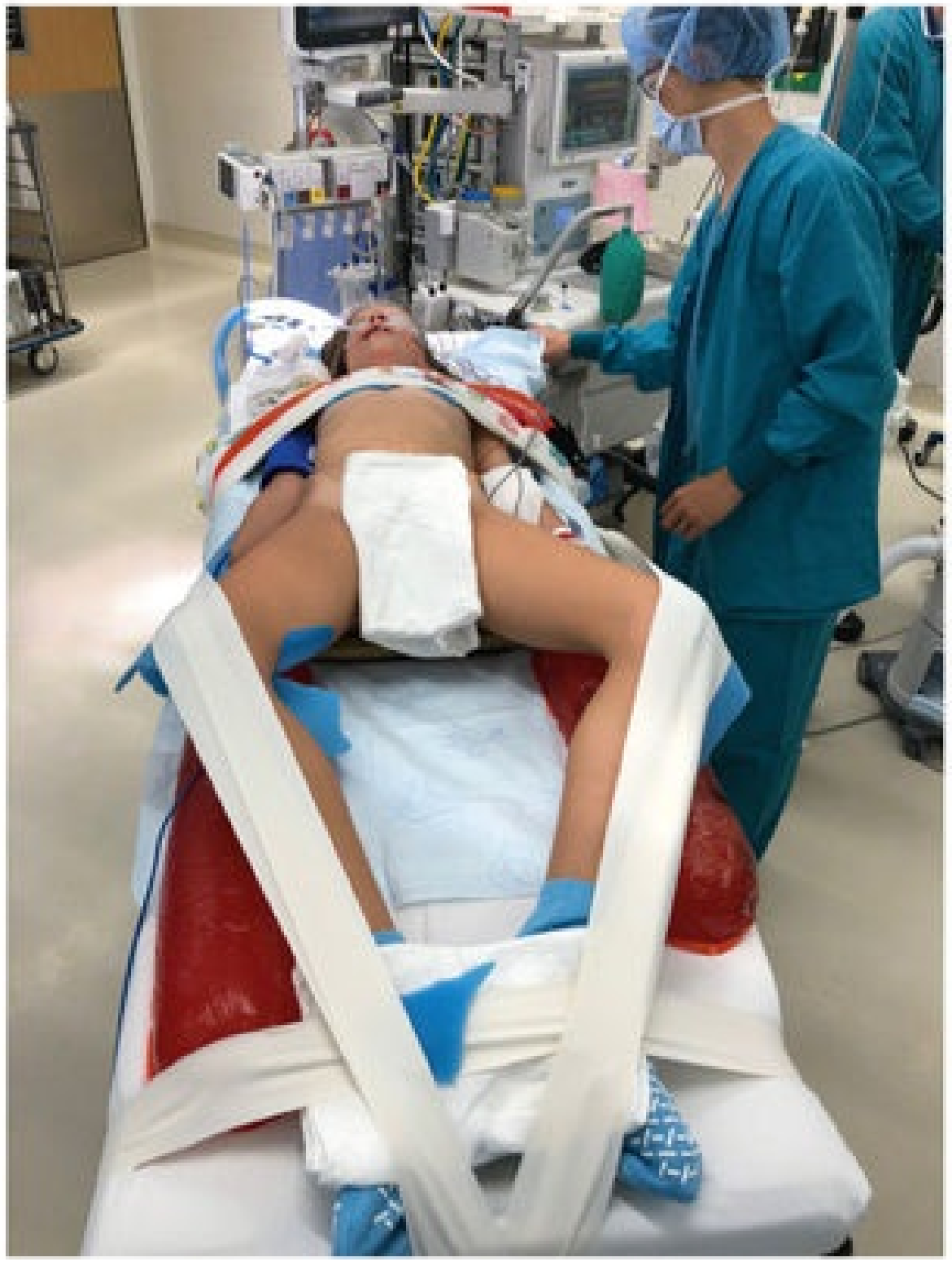

FIG. 27.6 Dorsal lithotomy *(top)* and modified supine *(bottom)* positioning options for robotic-assisted ureteral reimplantation. All pressure points are adequately padded. The child's sacrum is elevated in the modified supine position to facilitate robotic docking while minimizing extracorporeal interference between the robotic arms.

The da Vinci robotic platform (Intuitive Surgical Inc., Sunnyvale, CA) is currently one of only two FDA-approved platforms within the United States, and by far the most commonly utilized. Robotic instrumentation is available through 5- and 8-mm ports, though 5-mm instrumentation is more limited in scope and functionality. In fact, although attractive in pediatrics because of smaller size, the articulating wrists of the 5-mm instruments actually require a larger intracorporeal working space, resulting in lower surgeon efficiency for similar tasks (Ballouhey et al., 2018). **Commonly cited advantages of the robotic platform include improved visualization with three-dimensional optics and magnification, first-person camera control, wristed instrumentation, and a surgeon-controlled additional arm to provide retraction and assistance.** These benefits have allowed expansion of MIS to complex reconstructive procedures that previously may have been undertaken with an open approach (▶ Video 27.4). However, the current robotic platform is costly and lacks tactile feedback, and many iterations of the robot are restricted to single-quadrant surgery because of extracorporeal fixation of the robotic arms. Early in development, instrumentation was somewhat limited. However, most standard laparoscopic instruments such as cauterizing devices, staplers, and clip appliers are currently available within the robotic platform as well. The da Vinci Xi system is the newest robotic platform available, with proposed advantages of functioning within smaller working spaces, improved ability to perform multiquadrant surgery, and more efficient docking (Goonewardene et al., 2017; Raheem et al., 2017). Several of these advantages, such as the multiquadrant functionality and functionality in smaller spaces, are particularly attractive in the pediatric population.

Given the rise in popularity for robotic-assisted surgery, it is only natural that research and design efforts are dedicated to advancing this technology. Many patents associated with the da Vinci robotic system have expired within the past few years or are due to expire in coming years. Several patents exist for new platforms with additional features such as eye-tracking consoles, haptic feedback, and separate docking carts for individual robotic arms, as well as advances in 5-mm and single-port instrumentation (Rassweiler et al., 2017). Additional advances in robotic technology include improved telemonitoring programs, which may ultimately pave the way for telemedicine and remote surgery (Shin et al., 2015). Remote surgery may have a unique place in pediatric urology, where less common diseases may result in a need for regionalization of surgical care (Wang et al., 2015).

Key Points: Instrumentation

- Smaller instrumentation may offer cosmetic and convalescent benefits at a cost of decreased maneuverability or versatility of instrumentation available.
- Visualization of the entire uninsulated section of the instrument is vital to minimizing inadvertent cautery injury.
- All electrocautery devices create at least 2 mm of lateral thermal energy spread, and care must be taken based on these specifications during their use.
- Pelvic exposure may be achieved with side docking using a robotic platform, thereby avoiding exposure to lithotomy positioning–related complications.
- Robotic platforms represent specialized surgical instrumentation and should be applied only if optimizing surgical value and minimizing patient risk.

Complications of Minimally Invasive Surgery

Several complications exist specific to the minimally invasive approach. It is important that surgeons recognize these complications, their typical presentations, and recommended management algorithms when embarking on laparoscopic or robotic-assisted endeavors.

Visceral Injury

Visceral injuries during minimally invasive surgeries within pediatric urology are exceedingly rare. Mechanisms of visceral injury include injury during intra-abdominal access and trocar placement, thermal injury from electrical current deployed within the abdomen, or direct injury with laparoscopic or robotic instrumentation through instrument passage or visceral retraction. Access injuries with either the Veress needle or open direct visualization techniques are quite rare. Across several series of more than 1000 patients, no access injuries to either the viscera or the vasculature were reported using either access technique (Dangle et al., 2016; Yanke and Horowitz, 2007).

Thermal injury to viscera should be addressed if immediately recognized. However, because of the progression of the injury and subsequent cellular necrosis over time, these injuries often present in a delayed fashion, sometimes up to several days after surgery (Bishoff et al., 1999)**. Four mechanisms exist for transmission of monopolar thermal energy to the viscera: (1) Direct application of cautery to the tissue, typically in an inadvertent fashion; (2) direct coupling—or "arching"—when the noninsulated instrument is closely approximated to the tissue, resulting in an unintended current path; (3) capacitive coupling resulting from a direct current through the instrument in spite of insulation and spreading to tissue when the point of contact is small; (4) transition of current through pedicled structures and subsequent injury at the end of the pedicle—the so-called "pedicle effect"** (Humes et al., 2010). By directly visualizing the full exposed end of the instrument and minimizing monopolar cautery, one can minimize the risk for inadvertent thermal injury. However, bipolar cautery can also result in transmission of thermal energy of up to and in some cases greater than 2 mm beyond the intended target. Thus the surgeon must be aware of the adjacent anatomy when any mechanism of cautery is utilized laparoscopically (Harold et al., 2003).

Importantly, visceral injury typically presents in a delayed fashion with a distinct constellation of symptoms including single-site trocar pain, failure to thrive, abdominal distension, low-grade fever, and leukopenia, which unchecked may progress to sepsis. Many patients ultimately require exploratory laparotomy for management, though some reports exist of initial exploratory laparoscopy (Bishoff et al., 1999). Because of a dampened immune response after laparoscopy, these patients do not present with classic peritoneal signs (Hanly et al., 2003; Hiki et al., 2006). Management of a visceral injury requires a high index of suspicion and a low threshold for confirmatory imaging and surgical exploration. Immediate recognition of the injury can be managed by reinforcement of the serosal layer, which can often be accomplished without conversion to open intervention.

Vascular Injury

Similar to visceral injury, major injury to the great vessels is rarely reported, with a 0.7% rate in the adult literature and limits to case reports in the pediatric literature (Guloglu et al., 2004; Montero et al., 2001). Injury during passage of instruments or needles, such as introduction of robotic instruments into the abdomen, is likely a more common mechanism of major vascular injury, yet still rare (Dangle et al., 2016). However, these injuries underscore the importance of situational awareness, careful instrument handling, and clear communication between the bedside assistant and surgeon at the console.

Knowledge of vascular anatomy is essential for safe placement of trocars during laparoscopy and is of utmost importance at point of initial access and insufflation, which often is done via blind insertion of a Veress needle or open insertion of a trocar with limited intra-abdominal visualization. **The umbilicus is commonly thought to fall below the aortic bifurcation, although up to 40% of patients may have an umbilicus that lies above the bifurcation** (Hurd et al., 1992)**. Furthermore, placement of the patient in the Trendelenburg position may actually increase the likelihood of the umbilicus falling above the bifurcation** (Nezhat et al., 1998)**. The implications of this anatomic relationship are the dangers of proceeding with blind needle or trocar insertion at the umbilicus, which could result in injury to underlying major vasculature.** In almost all cases, the left iliac vein crosses midline at the umbilicus, exposing this vessel to the highest risk for vascular injury (Hurd et al., 1992). The plane between both anterior superior iliac spines more reliably falls below the bifurcation of both the aorta and vena cava and may represent a safer alternative for blind needle insertion at the midline (Sriprasad et al., 2006). Interestingly, aberrant anatomy of the distal aorta and iliac vasculature including the presence of intraperitoneal vessels has been reported in children with congenital genitourinary disease such as cloacal malformations and common urogenital sinus (Dykes et al., 1993). Thus, in theory, certain children with genitourinary malformations may be at increased risk for vascular injury during peritoneal access.

Even more common, but perhaps underappreciated, is the risk for injury to the abdominal wall vasculature. Inferior epigastric injury has been reported in children with an incidence of up to 2.5% (Philips and Amaral, 2001). Because of the somewhat predictable anatomy of the epigastric vasculature, port placement 5.5 cm lateral to midline (in adults) or greater than one-third the distance from midline to the anterior superior iliac spine has been proposed to minimize the risk for injury (Joy et al., 2017). In children, however, one can often visualize these vessels, either within the abdomen or via transillumination of the abdominal wall.

Major vascular injury is typically recognized promptly. Standard techniques with Veress needle entry call for aspiration of fluid through the needle to ensure no vascular backflow. If blood is recognized at this step, one should leave the Veress needle in place without manipulation, which could result in shearing or dislodgement of the needle (Montero et al., 2001). Intra-abdominal access is gained elsewhere. If the Veress needle becomes dislodged, one should inspect the posterior abdomen for a retroperitoneal hematoma (Fig. 27.7). Venous injuries can be managed with conservative approaches, including removal of the Veress needle under direct vision and tamponade with the pneumoperitoneum. Arterial or uncontrolled venous hemorrhage must be addressed promptly.

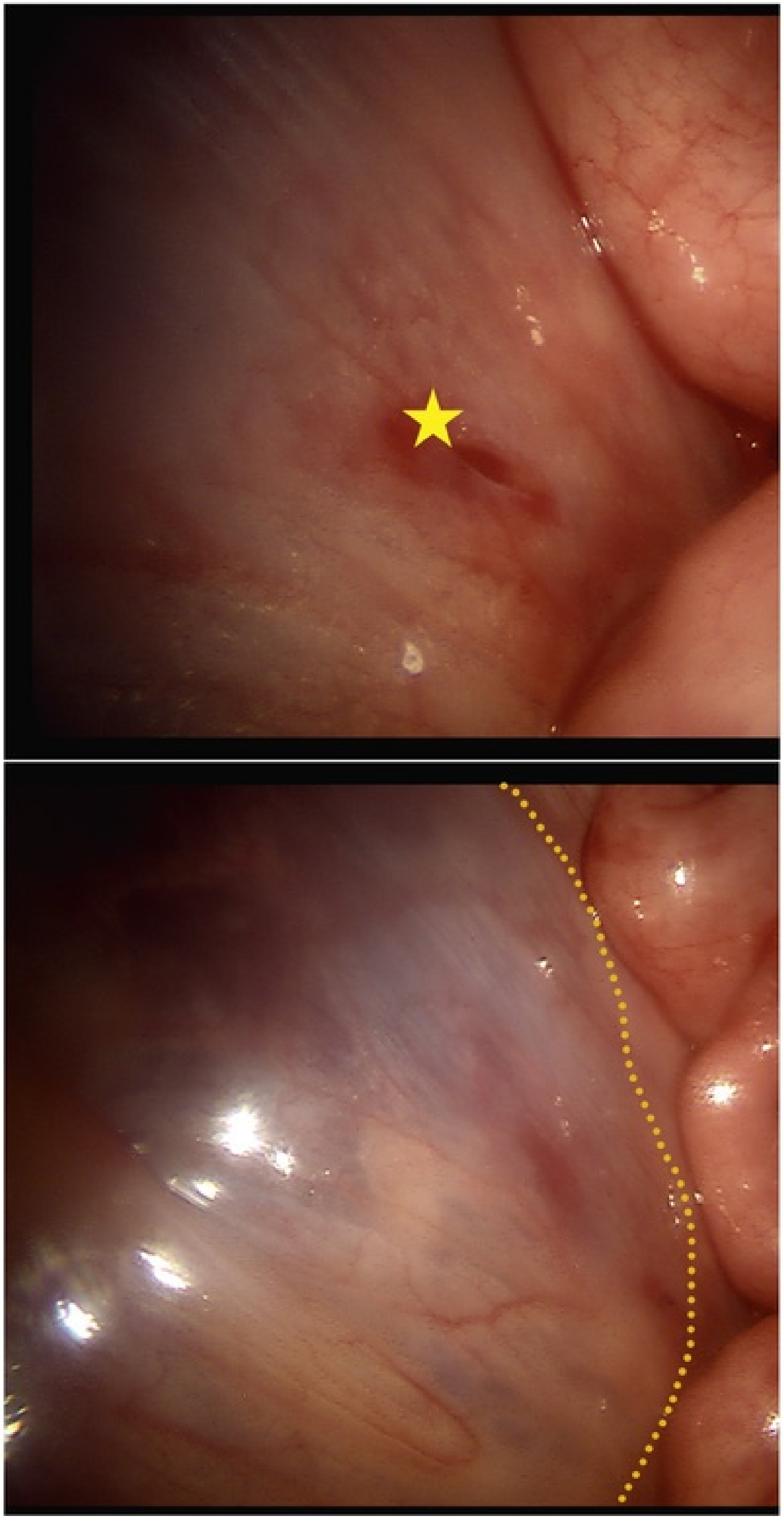

FIG. 27.7 Veress needle vascular injury. *Yellow star (top)* indicates site of Veress injury into the retroperitoneum. *Orange dashes (bottom)* indicate extent of retroperitoneal hematoma. This represents a common iliac vein puncture managed conservatively given adequate tamponade during pneumoperitoneum and absence of expansion of hematoma at the end of the case.

Incisional Hernia (Fig. 27.8)

Port-site hernias are reported in up to 3.2% of cases in the pediatric urology literature (Cost et al., 2010). Omental herniation is a common presentation, often coming to clinical attention within the first week postoperatively (Paya et al., 2008). **Because of the small body habitus and laxity of the abdominal wall, there is no "safe" area for access wherein port site hernias can be avoided. Port sites on the lateral abdominal wall constituted the majority of reported herniations in one series** (Paya et al., 2008)**. Furthermore, size of the port does not correlate to the risk for herniation in children. The 5-mm port sites are not "free," and omental herniation has even been reported in children through 3-mm port sites** (Yee and Duel, 2006). Younger children appear to be at higher risk for hernia formation compared with older children (Cost et al., 2010). Accordingly, it is the authors' practice to close all port sites, irrespective of size or location, in all prepubertal children.

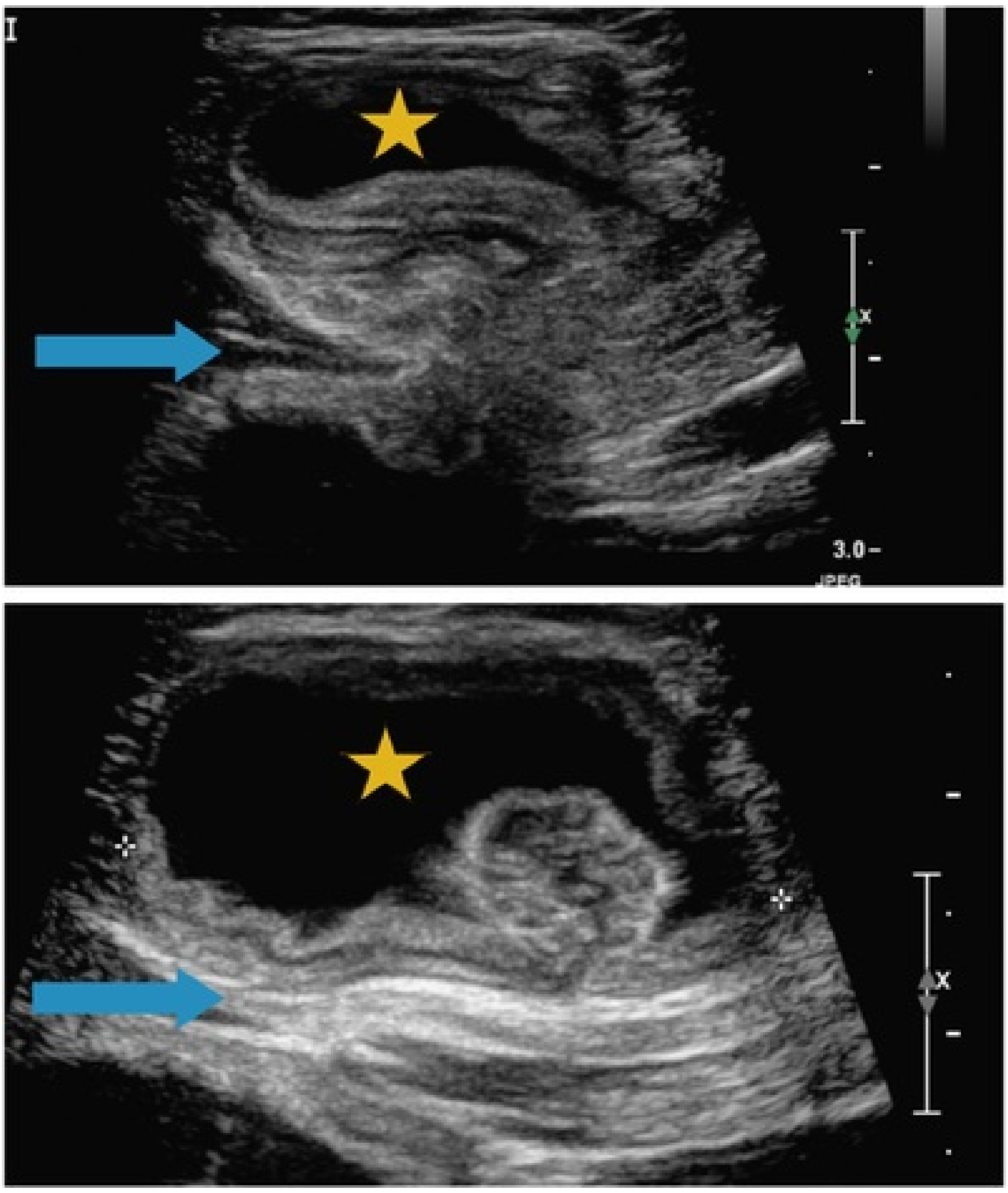

FIG. 27.8 Ultrasound scan showing small intestine *(orange star)* herniating through a fascial defect, superior to the abdominal wall fascia *(blue arrow)*.

Pulmonary Air Embolus

Air embolization from insufflated gas is an infrequent but catastrophic complication. Fortunately, this complication has been reported only rarely in the pediatric population. CO_2 is utilized for insufflation because of its rapid absorption and buffering within the circulation. As opposed to diffusion across the peritoneal membrane, it appears the highest risk for entry of CO_2 into the systemic circulation is caused by vascular injury. In children, umbilical vein injury has been postulated to be the source of entry for most reported cases (Taylor and Hoffman, 2010). One concern, especially in young children, is the potential for contaminant gases, such as oxygen or nitrogen, to be present within the abdomen during insufflation. **This becomes of even greater concern when the area for intra-abdominal expansion approximates the dead space within**

the anesthetic circulation, such as in neonates. In these situations, it has been estimated that up to 10% of insufflated gas may be contaminants of O_2 or N_2 as opposed to CO_2. For this reason, flushing of the insufflation tubing is recommended before inducing pneumoperitoneum (Taylor et al., 2015).

Key Points: Complications

- Injury to abdominal wall vasculature is underreported and can be minimized by visualization of the epigastric vessels before port placement.
- Because of the risk for herniation, closure of all port sites in the pediatric population after MIS is recommend.
- Unrecognized intestinal injury from cautery effect may present in a delayed fashion and should be approached with a high index of suspicion.
- Preflushing of insufflation tubing is recommended, especially in infants, as up to 10% of initial insufflated gas may be oxygen or nitrogen contaminant.

Simulation Training and Evaluation

The expansion of minimally invasive technologies has created an environment ideally suited for simulation and objective performance feedback. Through ubiquitous video-capture capabilities, surgeons can review their performances, others can watch and rate, video can be modeled into virtual reality (VR) environments, and surgeons can rehearse their cases or warm up within the same OR as the patient care arena. These opportunities have allowed for tracking and acceleration of learning curves. Ultimately, we will be able to provide lifelong learning feedback to practicing clinicians and provide objective feedback for learner-centered competency-based advancement through training programs.

Minimally Invasive Surgery Training

Currently, there are no standards for how MIS skills are taught and advanced. Escolino et al., calling on experiences in European pediatric MIS education, posited that there are eight stages to the acquisition of MIS skills (Escolino et al., 2016) (Table 27.5). A more recent review of the optimal paradigm of MIS training to reduce complications and accelerate learning curves suggested a similar pathway (Brunckhorst et al., 2016).

TABLE 27.5

Stages of Minimally Invasive Surgery Skills Acquisition

1. Attend theoretical classes to establish an understanding of pathophysiology, perioperative care, contraindications to surgery, and management of complications.
2. Complete 10 to 20 hours of dry skills lab for fundamental laparoscopic technical skills acquisition.
3. Complete 10 hours of in vivo wet lab practicing similar steps of procedures as would be performed in human surgery.
4. Attend a high volume center for 1 to 3 months.
5. Perform basic laparoscopic surgeries (e.g., orchiopexies, hernias, varicocelectomies) under supervision.
6. Perform complex laparoscopic procedures (e.g., nephrectomies, partial nephrectomies, pyeloplasties) under supervision.
7. Perform procedures independently with some form of expert review.
8. Practice with ongoing feedback, review, and credentialing.

Fortunately, this framework mirrors current training methods in the United States, however, there is significant variability among centers at each of these stages. Thus, much of the determination of advancement is left up to one or two mentors at each site without independent review of the trainee. The Escolino et al. group suggested using objective skills assessment tools, which have been validated across many procedures. Smith et al. conducted a survey of pediatric urology fellows and program directors in North America to understand the robotic-assisted laparoscopic experience fellows were receiving and how Accreditation Council for Graduate Medical Education (ACGME) Milestones scores improved over the course of the training year with regard to MIS skills (Smith et al., 2017). Of the 35 fellows and 30 program directors sent the survey, 16 (46%) and 14 (47%), respectively, responded. More than one-half of fellows stated they performed more than 20 robotic cases in their fellowship year. There was a mismatch, however, between the self-perceptions and the program directors' Milestones scores on graduation, where 75% of fellows and 57% of program directors felt the final MIS Milestones scores were 4 or better. In addition, the survey elucidated that a minority of fellows had any exposure to simulation training during their ACGME year.

Minimally Invasive Surgery Assessment

In 1997, Martin et al. introduced the first broadly applicable objective structured assessment of technical skills (OSATS) tool for dry lab open surgical performance (Martin et al., 1997). Having been now cited over 1600 times, this study laid the foundation to the era of quantifiable surgical technique. **In laparoscopy and robotic surgery, two such OSATS tools—the Global Objective Assessment of Laparoscopy (GOALS)** (Vassiliou et al., 2005) **and Global Evaluative Assessment of Robotic Skills (GEARS)** (Goh et al., 2012) **—have been the backbone to evidence-based demonstration of technical skills in MIS.** Trainees and faculty can now be assessed objectively through these tools, which focus on technical skills domains including depth perception, bimanual dexterity, efficiency, tool control, tissue handling, and autonomy. Through these domains, composite scores have been repeatedly validated to discriminate skill and expertise. The performance domains also correlate to clinical outcomes and generalize to a number of MIS surgeries. These tools are agnostic to the procedure and the reviewers (Reznick and MacRae, 2006). Groups have used live in-person evaluations, postperformance video review with content experts, and video review through crowdsourcing (Goh et al., 2012; Kishore et al., 2008; Lendvay et al., 2015; Vassiliou et al., 2005). Argun et al. (2015) validated a urologic-specific objective assessment tool for cystoscopy and ureteroscopy. In their validation study, 30 trainees from three different sites performed endoscopy tasks on high-fidelity reality-based training modules that simulated the upper and lower urinary tract. The assessment tools used could discriminate training level and cognitive/technical skills.

One significant barrier to obtaining expert evaluations has been the timeliness and consistency of the expert reviews. Thus, in 2014, Chen et al. tested the use of obtaining technical skills assessments through the use of crowdsourcing instead of from expert surgeons (Chen et al., 2014). Using laypeople, they were able to show that an accurate blinded video review of surgery performance using the validated GEARS tool correlated with assessments by expert surgeons. Further validation studies have been performed demonstrating the speed, accuracy, and versatility of using crowds to assess skill in simulation lab, animate lab, and human surgery settings (Aghdasi et al., 2015; Deal et al., 2016; Ghani et al., 2016; Holst et al., 2015; Kowalewski et al., 2016; Lendvay et al., 2015; Polin et al., 2016; Powers et al., 2016; White et al., 2015).

Minimally Invasive Surgery Simulation

MIS can be easily replicated in simulated environments. A number of home-grown and industry-developed physical and VR simulators (Satava, 1993) have been created to provide a learner-centered platform for technical skills practice. The most common reality-based conventional laparoscopic simulation devices have been the box trainers (Fig. 27.9). These frequently come with monitors to give the same two-dimensional visualization as seen in human laparoscopic surgery. Most training programs have these, and trainees can usually access these at all hours and even at home. VR simulators also exist for conventional laparoscopy and have been shown to provide benefit in accelerating learning curves, priming surgeons right before surgery, and allowing for patient-specific surgical rehearsal (Nataraja et al., 2018). Makiyama et al. (2012) demonstrated that a patient's radiographic imaging could be modeled into a VR simulator exercise allowing the surgeon to practice a laparoscopic nephrectomy before performing the procedure on the patient. The module included the patient-specific renal hilar vasculature as identified through computed tomography (CT) imaging so the surgeon could understand and practice how to approach the hilum for ligation. Three-dimensional printing technology has also enabled patient-specific modeling to provide surgeons with lifelike anatomic representations on which they can practice tumor resections, pyeloplasties, or even cloaca repairs before the surgery (Ahn et al., 2017; Bernhard et al., 2016; Cheung et al., 2014) (Fig. 27.10).



FIG. 27.9 Box trainers allow for simulation of a variety of laparoscopic tasks, ranging from basic to complex, and are a mainstay for dry lab training. Multiple tasks can be exchanged within a single trainer, allowing for cost-containment.

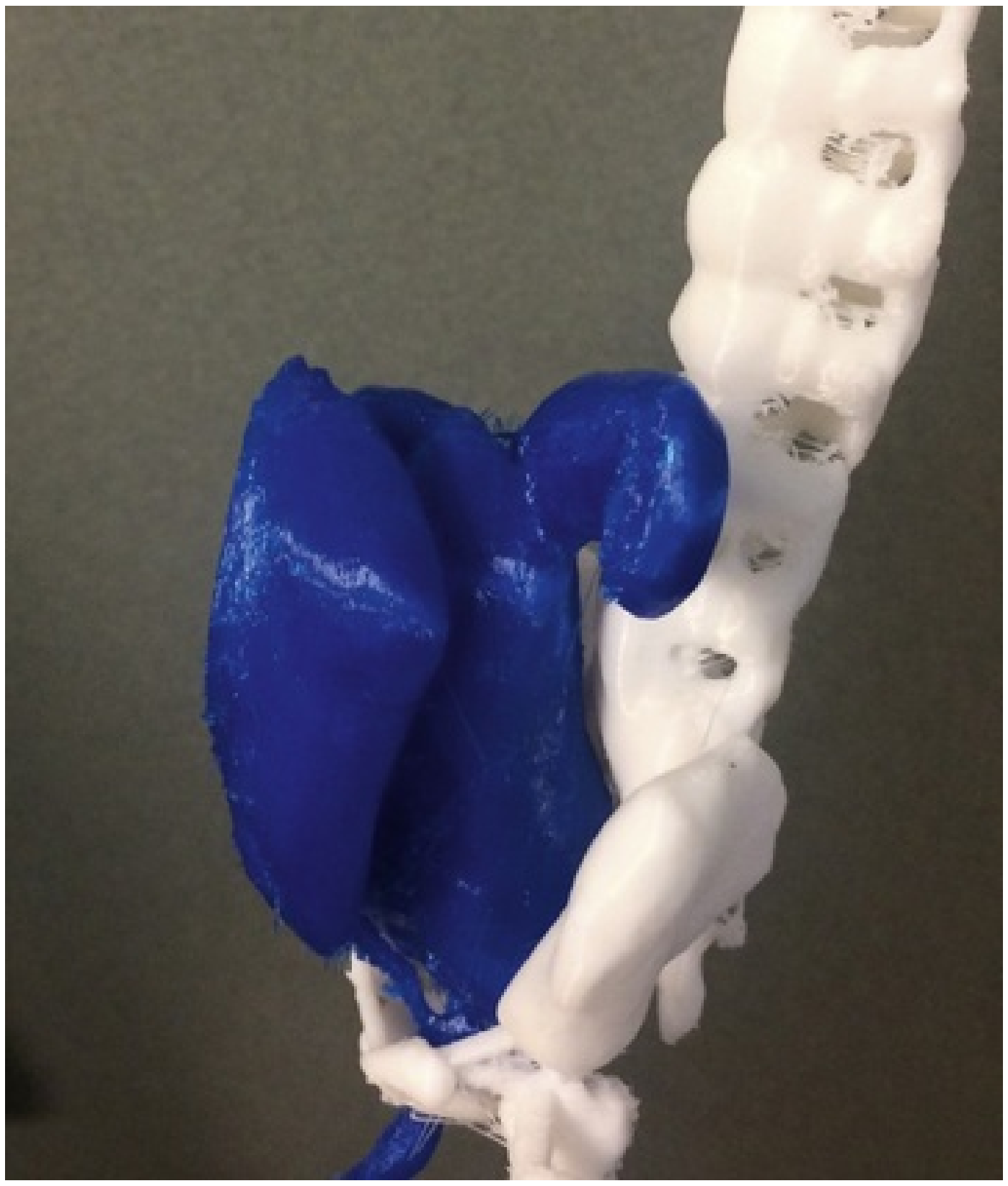

FIG. 27.10 Three-dimensional printing of complex surgical anatomy may aid in surgical simulation and preparation before the planned operation. Color and component materials can be altered for each key anatomic structure, here allowing for differentiation between the spinal cord and the common cloacal structures.

The Fundamentals of Laparoscopic Surgery (FLS) has been the mainstay of basic laparoscopic skills simulation training for over a decade (Okrainec et al., 2011). The American Board of Surgery has adopted this skills curriculum as the standard means to graduate a general surgery resident in laparoscopy. Steigerwald et al. showed that subjects who performed well on the overall and individual FLS modules performed well doing human laparoscopic cholecystectomies, confirming that simulation skills transfer to the OR (Steigerwald et al., 2015). The FLS scores also discriminated (construct validity) different training levels of the subjects. Brydges et al. (2010) validated that a pediatric version of FLS could discriminate experience in laparoscopy levels among a cohort of 18 pediatric urology fellows attending a laparoscopic course. Urology, specifically pediatric urology, does not have a mandated fundamental skills curriculum, however. In 2015, Sweet et al. introduced a variation of FLS called the Basic Laparoscopic Urologic Surgery (BLUS) curriculum, which includes four psychomotor tasks (intracorporeal suturing, peg transfer, pattern cutting, and clip applying) and a cognitive test conceived through validation by experts at 10 academic training sites around North America (Kowalewski et al., 2016; Sweet et al., 2012). This curriculum discriminated skill levels, and studies testing whether the BLUS skills translate to operative performance are ongoing. It remains to be seen if the American Board of Urology will mandate such a simulation curriculum for residency graduation.

The robotic surgery platform is the most optimal device for tracking and simulation modeling. Currently, the da Vinci surgical robot (Intuitive Surgical Inc., Sunnyvale, CA) is the most widely used clinical robot. The video from the console can be recorded in either two-dimensional or three-dimensional mode, and the movement data of the surgical arms can be tracked through software that extrapolates path lengths, velocities, and other tool motions that are all surrogates for expertise. Through the da Vinci Logger system, surgical educators interested in tracking the tool and hand motions of the trainees can capture data about trainee technical skill performance and progress (Hung et al., 2018). **Through machine learning algorithms, Hung et al. (2018) ingested multiple kinematic metrics of robotic surgeries and were able to, with 87% accuracy, predict whether a patient could be discharged 2 days or fewer or more than 2 days. This represents the beginnings of how movement signatures of the surgeon can potentially predict a patient's surgical outcome.**

Furthermore, the robotic platform is an information or data delivery interface. Real-time imaging data, biophysiology data, and pathology data can be delivered to the surgeon through the robotic cockpit or console (Simorov et al., 2012). In theory, a surgeon who has more information about where to dissect and how he or she is performing may yield improved patient outcomes. **In addition, the platform software can be tailored to avoid dangerous or margin-violating movements via no-go or no-fly zones** (Simorov et al., 2012)**. This represents a form of augmented reality (AR) which overlays the robotic experience with visual, haptic, auditory information to assist the surgeon in performing more exact surgery**. Chowriappa et al. (2015) tested the hypothesis that providing a surgeon subject with haptic (force) direction of the surgical instruments while doing a simulated robotic urethrovesical anastomosis would improve the surgeon's performance compared with a group of surgeons who were not exposed to the guiding instruments. Fifty-two subjects went through simulator proficiency training to familiarize each individual with the platforms. They were then randomized to perform surgery with AR or without. Multiple needle-driving and needle-holding metrics and the bimanual dexterity and force sensitivity metrics were statistically higher in the AR group. In addition, when testing for cognitive workload and demand using the National Aeronautics and Space Administration Task Load Index assessment test, the AR group had lower cognitive load. This was the first demonstration of urologic robotic surgery skills being enhanced through the use of augmented reality.

Minimally Invasive Surgery Warm-Up

Athletes, musicians, dancers, and other highly technical professionals warm up before doing their criterion performance. Yet surgeons, arguably the highest-stakes professionals, do not have a codified routine warm-up process. Evidence supports the benefits of doing a brief warm-up of some laparoscopic or robotic skills drills through reality-based or VR-based modules (Abdalla et al., 2015; Lendvay et al., 2008, 2013; Pike et al., 2017; Sethi et al., 2009). In Lendvay et al., surgical trainees and faculty were randomized to receive a robotic VR warm-up or not before doing some robotic suturing drills (Lendvay et al., 2013). Technical skills performance was assessed through tool motion metrics. The subjects who had performed a brief robotic VR warm-up showed statistically significantly better performance metrics when doing both similar and dissimilar reality-based tasks including intracorporeal suturing. In addition, expert robotic surgeons had more improvement than novices. They concluded that even expert robotic surgeons might derive performance enhancement through VR warm-up in clinical practice. Because the VR robotic simulator is attached to the clinical robotic console, it would be practical for the warm-up to proceed without hindering the normal flow of a clinical day. Systematic reviews of warm-up studies have looked at the value of technical skills warm-up for conventional laparoscopic surgery (Abdalla et al., 2015; Pike et al., 2017). **Abdalla et al. (2015) limited their review to prospective studies with residents and/or faculty only with clear hypotheses and objective outcomes. They found six studies meeting their inclusion criteria encompassing 196 cases from 87 participants; five of the six studies showed a statistically significant improvement in technical skills among the warmed-up groups relative to the controls.** They concluded that for laparoscopy, the data provide evidence that warm-up should be further explored and assessed with patient outcomes. Each of the studies reviewed benefited from using OSATS tools to quantify skill across a range of performers.

Warm-up does not have to be limited to psychomotor drills, however. Mental rehearsal has been shown to enhance the technical skills of surgeons (Arora et al., 2011; Pugh, 2012). Much like alpine skiers visualize the gates and turns of the downhill course before competition, Arora et al. demonstrated that surgeons performing mental visualizations of the steps of a laparoscopic cholecystectomy before doing a VR laparoscopic cholecystectomy had statistically significantly higher OSATS scores than their controls for all sessions (Arora et al., 2011). The group used mental imagery statements to immerse the subject in the case. For example, the subject was told to imagine the cautery smoke as they dissect the gallbladder from the liver and visualize the specific grasping instrument required for a particular step. The subjects were assessed by the quality that the imagery was assimilated through a Mental Imagery Questionnaire immediately after the exercise but before the technical skills test. It's possible that reviewing radiographic images and reading the patient's chart before doing surgery may also focus and enhance technical performance.

Minimally Invasive Surgery Learning Curves

As with any procedure, there is a learning curve to becoming proficient. In the era of increasing objective metrics of surgery and the desire to apply evidence to improving patient outcomes, clinicians have sought to establish learning curves for various MIS procedures. As the granularity of outcomes and performance metrics increases, multidimensional learning curve analyses are possible, which help guide trainers and credentialing bodies in determining minimum case volume thresholds and proficiency benchmarks for advancement and privileging.

When evaluating the learning curve for laparoscopic surgery in children, Ku et al. determined that for a single surgeon, operative time (mean 181 minutes down to 125 minutes, $P = 0.02$) and length of hospital stay (mean 5.4 days down to 2.5 days, $P = 0.009$) decreased after ten cases (Ku et al., 2005). Because the study period was over 5 years, the authors stated that the annual case volume does not need to be high to achieve reasonable learning curves. However, there was no mention in the study of the volume of other laparoscopic cases being performed by this surgeon over the study period, which might have influenced the general proficiency of the surgeon.

In 2013, Abboudi et al. performed a systematic review of learning curves for laparoscopic and robotic surgery across adult and pediatric studies (Abboudi et al., 2014). For robotic prostatectomies, studies supported that, after 100 cases, blood loss and operative times saw the biggest drops. For robotic cystectomies, statistically significant improvement was noted after 16 to 30 cases. Again, these studies did not isolate the robotic experience of the subject surgeons, meaning that the surgeons might have been performing other robotic surgeries during the study, thus affecting proficiency**. A few studies in their analysis covered pediatric robotic surgery. In one study, Sorensen et al.** (2011) **demonstrated statistically significant lower operative times after 15 to 20 cases for a surgeon at the beginning of his or her learning curve. And when looking at pediatric urology fellows, Tasian et al.** (2013) **observed that fellows approached expert-level operative time benchmarks after 37 pediatric robotic pyeloplasties.**

When comparing learning curves for novices performing conventional laparoscopic versus robotic-assisted laparoscopic pyeloplasty anastomoses in a porcine model, Passerotti et al. demonstrated that the learning curve is faster in the robotic-assisted group (Passerotti et al., 2009). The objective anastomotic quality score of each of the three surgeons increased over the five procedures they each did, with the robotic procedures consistently being scored higher than the laparoscopic procedures.

Key Points: Simulation Training and Evaluation

- Several standardized evaluation tools exist to assess trainee progress with minimally invasive techniques.
- High-fidelity simulation models contribute to early training for novice surgeons and case-specific training simulation for more experienced surgeons.
- Kinematic metrics and fluidity of motion are associated with surgical outcomes.
- Evolution of technology in the form of augmented reality and three-dimensional visualization may help improve surgical safety in the future.
- Warm-up exercises, both mental and physical, can help prepare the surgeon for the complex surgical tasks that are demanded intraoperatively.

Conclusion

Numerous studies have shown that MIS in pediatric urology patients is safe, effective, and superior in some circumstances to open approaches. However, along with the value proposition for families to have some procedures performed through MIS, laparoscopic providers need to be aware that there are physiologic, anatomic, and instrumentation-related considerations that can yield surgical effects dissimilar to those in adult patients and/or open approaches. The advancement of surgical technology in MIS has exploded, whereas open surgical technologies have remained relatively stagnant. This promises to allow surgeons to shape the future of MIS. Furthermore, never before have we been able to drill down to the skill of surgeons and provide the type of feedback we can today so that we can make sure that every provider is competent, proficient, and enlightened about best practices in MIS.

Suggested Readings

Bozkurt P, Kaya G, Yeker Y, et al. The cardiorespiratory effects of laparoscopic procedures in infants. *Anaesthesia*. 1999;54(9):831–834.

Cost NG, Lee J, Snodgrass WT, et al. Hernia after pediatric urological laparoscopy. *J Urol*. 2010;183(3):1163–1167.

Dammeier BG, Karanik E, Glüer S, et al. Anuria during pneumoperitoneum in infants and children: a prospective study. *J Pediatr Surg*. 2005;40(9):1454–1458.

Dangle P, Akhavan A, Odeleye M, et al. Ninety-day perioperative complications of pediatric robotic urological surgery: a multi-institutional study. *J Pediatr Urol*. 2016;12(2):102.e1–102.e6.

Escolino M, Turrà F, Settimi A, et al. Training for MIS in pediatric urology: proposition of a structured training curriculum. *Transl Pediatr*. 2016;5(4):315–323.

Gargollo PC. Hidden incision endoscopic surgery: description of technique, parental satisfaction and applications. *J Urol*. 2011;185(4):1425–1431.

Hanly EJ, Mendoza-Sagaon M, Murata K, et al. CO_2 pneumoperitoneum modifies the inflammatory response to sepsis. *Ann Surg*. 2003;237(3):343–350.

Jiang X, Anderson C, Schnatz PF. The safety of direct trocar versus Veress needle for laparoscopic entry: a meta-analysis of randomized clinical trials. *J Laparoendosc Adv Surg Tech A*. 2012;22(4):362–370.

Lamberton GR, Hsi RS, Jin DH, et al. Prospective comparison of four laparoscopic vessel ligation devices. *J Endourol*. 2008;22(10):2307–2312.

Lee G, Lee M, Green I, et al. Surgeons’ physical discomfort and symptoms during robotic surgery: a comprehensive ergonomic survey study. *Surg Endosc*. 2017;31(4):1697–1706.

Mariano ER, Furukawa L, Woo RK, et al. Anesthetic concerns for robot-assisted laparoscopy in an infant. *Anesth Analg*. 2004;99(6):1665–1667.

Pike T, Pathak S, Mushtaq F, et al. A systematic examination of preoperative surgery warm-up routines. *Surg Endosc*. 2017;31(5):2202–2214.

Rassweiler JJ, Autorino R, Klein J, et al. Future of robotic surgery in urology. *BJU Int*. 2017;120(6):822–841.

Sorensen MD, Delostrinos C, Johnson MH, et al. Comparison of the learning curve and outcomes of robotic assisted pediatric pyeloplasty. *J Urol*. 2011;185(6):2517–2522.

Steigerwald SN, Park J, Hardy KM, et al. Does laparoscopic simulation predict intraoperative performance? A comparison between the Fundamentals of Laparoscopic Surgery and LapVR evaluation metrics. *Am J Surg*. 2015;209(1):34–39.

References

Abboudi H, Khan MS, Guru KA, et al. Learning curves for urological procedures: a systematic review. *BJU Int*. 2014;114(4):617–629.

Abdalla G, Moran-Atkin E, Chen G, et al. The effect of warm-up on surgical performance: a systematic review. *Surg Endosc*. 2015;29(6):1259–1269.

Aghamohammadi H, Mehrabi S, Mohammad Ali Beigi F. Prevention of bradycardia by atropine sulfate during urological laparoscopic surgery a randomized controlled trial. *Urology J*. 2009;6(2):92–95.

Aghdasi N, Bly R, White LW, et al. Crowd-sourced assessment of surgical skills in cricothyrotomy procedure. *J Surg Res*. 2015;196(2):302–306.

Ahmad G, Duffy J, Phillips K, et al. Laparoscopic entry techniques. *Cochrane Database Syst Rev*. 2008;(2) [CD006583].

Ahn JJ, Shnorhavorian M, Oelschlager A-MEA, et al. Use of 3D reconstruction cloacagrams and 3D printing in cloacal malformations. *J Pediatr Urol*. 2017;13(4):395.e1–395.e6.

Akhavan A, Avery D, Lendvay TS. Robot-assisted extravesical ureteral reimplantation: outcomes and conclusions from 78 ureters. *J Pediatr Urol*. 2014;10(5):864–868.

Argun OB, Chrouser K, Chauhan S, et al. Multi-institutional validation of an OSATS for the assessment of cystoscopic and ureteroscopic skills. *J Urol*. 2015;194(4):1098–1106.

Arora S, Aggarwal R, Sirimanna P, et al. Mental practice enhances surgical technical skills: a randomized controlled study. *Ann Surg*. 2011;253(2):265–270.

Autorino R, Kaouk JH, Stolzenburg JU, et al. Current status and future directions of robotic single-site surgery: a systematic review. *Eur Urol*. 2013;63(2):266–280.

Azevedo JL, Azevedo OC, Miyahira SA, et al. Injuries caused by Veress needle insertion for creation of pneumoperitoneum: a systematic literature review. *Surg Endosc*. 2009;23(7):1428–1432.

Ballouhey Q, Clermidi P, Cros J, et al. Comparison of 8 and 5 mm robotic instruments in small cavities. *Surg Endosc*. 2018;32(2):1027–1034.

Bannister CF, Brosius KK, Wulkan M. The effect of insufflation pressure on pulmonary mechanics in infants during laparoscopic surgical procedures. *Paediatr Anesth*. 2003;13(9):785–789.

Barbash GI, Glied SA. New technology and health care costs—the case of robot-assisted surgery. *N Engl J Med*. 2010;363(8):701–704.

Barbosa JA, Barayan G, Gridley CM, et al. Parent and patient perceptions of robotic vs open urological surgery scars in children. *J Urol*. 2013;190(1):244–250.

Bayazit Y, Aridogan IA, Abat D, et al. Pediatric transumbilical laparoendoscopic single-site nephroureterectomy: initial report. *Urology*. 2009;74(5):1116–1119.

Bennett WE, Whittam BM, Szymanski KM, et al. Validated cost comparison of open vs. robotic pyeloplasty in American children's hospitals. *J Robot Surg*. 2017;11(2):201–206.

Berguer R, Smith W. An ergonomic comparison of robotic and laparoscopic technique: the influence of surgeon experience and task complexity. *J Surg Res*. 2006;134(1):87–92.

Berguer R, Smith W, Chung Y. Performing laparoscopic surgery is significantly more stressful for the surgeon than open surgery. *Surg Endosc*. 2001;15(10):1204–1207.

Bermas H, Fenoglio M, Haun W, et al. Laparoscopic suturing and knot tying: a comparison of standard techniques to a mechanical assist device. *JSLS*. 2004;8(2):187–189.

Bernhard JC, Isotani S, Matsugasumi T, et al. Personalized 3D printed model of kidney and tumor anatomy: a useful tool for patient education. *World J Urol*. 2016;34(3):337–345.

Bishoff JT, Allaf ME, Kirkels W, et al. Laparoscopic bowel injury: incidence and clinical presentation. *J Urol*. 1999;161(3):887–890.

Borer JG, Cisek LJ, Atala A, et al. Pediatric retroperitoneoscopic nephrectomy using 2 mm. instrumentation. *J Urol*. 1999;162(5):1725–1730.

Boysen W, Belleville L, Ahkavan A, et al. MP55-11 multi-institutional review of outcomes and complications of robotic-assisted laparoscopic extravesical ureteral reimplantation (RALUR-EV) for treatment of primary vesicoureteral reflux (VUR) in children. *J Urol*. 2016;195(4):e739–e740.

Bozkurt P, Kaya G, Altintas F, et al. Systemic stress response during operations for acute abdominal pain performed via laparoscopy or laparotomy in children. *Anaesthesia*. 2000;55(1):5–9.

Bozkurt P, Kaya G, Yeker Y, et al. The cardiorespiratory effects of laparoscopic procedures in infants. *Anaesthesia*. 1999;54(9):831–834.

Braga LH, Pace K, DeMaria J, et al. Systematic review and meta-analysis of robotic-assisted versus conventional laparoscopic pyeloplasty for patients with ureteropelvic junction obstruction: effect on operative time, length of hospital stay, postoperative complications, and success rate. *Eur Urol*. 2009;56(5):848–858.

Brown JA, Canal D, Sundaram CP. Optical-access visual obturator trocar entry into desufflated abdomen during laparoscopy: assessment after 96 cases. *J Endourol*. 2005;19(7):853–855.

Brunckhorst O, Volpe A, van der Poel H, et al. Training, simulation, the learning curve, and how to reduce complications in urology. *Eur Urol Focus*. 2016;2(1):10–18.

Brydges R, Farhat WA, El-Hout Y, et al. Pediatric urology training: performance-based assessment using the fundamentals of laparoscopic surgery. *J Surg Res*. 2010;161(2):240–245.

Casale P, Feng WC, Grady RW, et al. Intracorporeal laparoscopic appendicovesicostomy: a case report of a novel approach. *J Urol*. 2004;171(5):1899.

Casale P, Grady RW, Feng WC, et al. The pediatric caliceal diverticulum: diagnosis and laparoscopic management. *J Endourol*. 2004;18(7):668–671.

Casale P, Grady RW, Joyner BD, et al. Transperitoneal laparoscopic pyelolithotomy after failed percutaneous access in the pediatric patient. *J Urol*. 2004;172(2):680–683.

Casale P, Meyers K, Kaplan B. Follow-up for laparoscopic renal denervation and nephropexy for autosomal dominant polycystic kidney disease–related pain in Pediatrics. *J Endourol*. 2008;22(5):991–994.

Casale P, Mucksavage P, Resnick M, et al. Robotic ureterocalicostomy in the pediatric population. *J Urol*. 2008;180(6):2643–2648.

Casale P, Patel RP, Kolon TF. Nerve sparing robotic extravesical ureteral reimplantation. *J Urol*. 2008;179(5):1987–1989 [discussion 1990].

Chen C, White L, Kowalewski T, et al. Crowd-sourced assessment of technical skills: a novel method to evaluate surgical performance. *J Surg Res*. 2014;187(1):65–71.

Cheung CL, Looi T, Lendvay TS, et al. Use of 3-dimensional printing technology and silicone modeling in surgical simulation: development and face validation in pediatric laparoscopic pyeloplasty. *J Surg Educ*. 2014;71(5):762–767.

Chowriappa A, Raza SJ, Fazili A, et al. Augmented-reality-based skills training for robot-assisted urethrovesical anastomosis: a multi-institutional randomised controlled trial. *BJU Int*. 2015;115(2):336–345.

Christopoulos P, Cutner A, Vashisht A, et al. Laparoscopic sacrocolpopexy to treat prolapse of the neovagina created by vaginal dilation in Rokitansky syndrome. *J Pediatr Adolesc Gynecol*. 2011;24(2):e33–e34.

Chu DI, Tan JM, Mattei P, et al. Mortality and morbidity after laparoscopic surgery in children with and without congenital heart disease. *J Pediatr*. 2017;185:88 [e3–93.e3].

Chua ME, Ming JM, Kim JK, et al. Laparoscopic-assisted versus open appendicovesicostomy procedure in patients with prior abdominal surgeries: a comparative study. *Urology*. 2018;116:93–98.

Chiu AW, Azadzoi KM, Hatzichristou DG, et al. Effects of intra-abdominal pressure on renal tissue perfusion during laparoscopy. *J Endourol*. 1994;8(2):99–103.

Cisek LJ, Gobet RM, Peters CA. Pneumoperitoneum produces reversible renal dysfunction in animals with normal and chronically reduced renal function. *J Endourol*. 1998;12(2):95–100.

Cost NG, DaJusta DG, Granberg CF, et al. Robot-assisted laparoscopic retroperitoneal lymph node dissection in an adolescent population. *J Endourol*. 2012;26(6):635–640.

Cost NG, Lee J, Snodgrass WT, et al. Hernia after pediatric urological laparoscopy. *J Urol*. 2010;183(3):1163–1167.

Cundy TP, Harley SJ, Marcus HJ, et al. Global trends in paediatric robot-assisted urological surgery: a bibliometric and progressive scholarly acceptance analysis. *J Robot Surg*. 2018;12(1):109–115.

Cundy TP, Harling L, Hughes-Hallett A, et al. Meta-analysis of robot-assisted vs conventional laparoscopic and open pyeloplasty in children. *BJU Int*. 2014;114(4):582–594.

Dammeier BG, Karanik E, Glüer S, et al. Anuria during pneumoperitoneum in infants and children: a prospective study. *J Pediatr Surg*. 2005;40(9):1454–1458.

Dangle P, Akhavan A, Odeleye M, et al. Ninety-day perioperative complications of pediatric robotic urological surgery: a multi-institutional study. *J Pediatr Urol*. 2016;12(2):102.e1–102.e6.

De Waal E, Kalkman C. Haemodynamic changes during low-pressure carbon dioxide pneumoperitoneum in young children. *Paediatr Anesth*. 2003;13(1):18–25.

Deal SB, Lendvay TS, Haque MI, et al. Crowd-sourced assessment of technical skills: an opportunity for improvement in the assessment of laparoscopic surgical skills. *Am J Surg*. 2016;211(2):398–404.

Deng T, Liu B, Luo L, et al. Robot-assisted laparoscopic versus open ureteral reimplantation for pediatric vesicoureteral reflux: a systematic review and meta-analysis. *World J Urol*. 2018;36(5):819–828.

Desai MM, Rao PP, Aron M, et al. Scarless single port transumbilical nephrectomy and pyeloplasty: first clinical report. *BJU Int*. 2008;101(1):83–88.

Dykes EH, Oesch I, Ransley PG, et al. Abnormal aorta and iliac arteries in children with urogenital abnormalities. *J Pediatr Surg*. 1993;28(5):696–700.

Ehrlich RM, Gershman A. Laparoscopic seromyotomy (auto-augmentation) for non-neurogenic neurogenic bladder in a child: initial case report. *Urology*. 1993;42(2):175–178.

El-Ghoneimi A, Farhat W, Bolduc S, et al. Laparoscopic dismembered pyeloplasty by a retroperitoneal approach in children. *BJU Int*. 2003;92(1):104–108.

El-Ghoneimi A, Sauty L, Maintenant J, et al. Laparoscopic retroperitoneal nephrectomy in high risk children. *J Urol*. 2000;164(3 Pt 2):1076–1079.

Ellison JS, Lendvay TS. Robot-assisted ureteroureterostomy in pediatric patients: current perspectives. *Robotic Surg*. 2017;4:45–55.

Escolino M, Turrà F, Settimi A, et al. Training for MIS in pediatric urology: proposition of a structured training curriculum. *Transl Pediatr*. 2016;5(4):315–323.

Esposito C. Transumbilical open laparoscopy: a simple method of avoiding complications in pediatric surgery. *Pediatr Surg Int*. 1997;12(2–3):226–227.

Fader AN, Rojas-Espaillat L, Ibeanu O, et al. Laparoendoscopic single-site surgery (LESS) in gynecology: a multi-institutional evaluation. *Am J Obstet Gynecol*. 2010;203(5):501.e1–501.e6.

Fathi AH, Soltanian H, Saber AA. Surgical anatomy and morphologic variations of umbilical structures. *Am Surg*. 2012;78(5):540–544.

Ferrer FA, Cadeddu JA, Schulam P, et al. Orchiopexy using 2 mm. laparoscopic instruments: 2 techniques for delivering the testis into the scrotum. *J Urol*. 2000;164(1):160–161.

Fichtenbaum EJ, Strine AC, Concodora CW, et al. Tubeless outpatient robotic upper urinary tract reconstruction in the pediatric population: short-term assessment of safety. *J Robot Surg*. 2018;12(2):257–260.

Figenshau RS, Clayman RV, Kerbl K, et al. Laparoscopic nephroureterectomy in the child: initial case report. *J Urol*. 1994;151(3):740–741.

Finkelstein JB, Levy AC, Silva MV, et al. How to decide which infant can have robotic surgery? Just do the math. *J Pediatr Urol*. 2015;11(4):170.e1–170.e4.

Finkelstein JB, Small AC, Casale P. Small miracles: wound contracture in MIS. *Soc Pediatr Urol*. 2016.

Finkelstein JB, Van Batavia JP, Casale P. Is outpatient robotic pyeloplasty feasible? *J Robot Surg*. 2016;10(3):233–237.

Fiori C, Morra I, Bertolo R, et al. Standard vs mini-laparoscopic pyeloplasty: perioperative outcomes and cosmetic results. *BJU Int*. 2013;111(3 Pt B):E121–E126.

Friedman A, Peters T, Ratner L. Regulatory failure contributing to deaths of live kidney donors. *Am J Transplant*. 2012;12(4):829–834.

Garcia-Roig ML, Travers C, McCracken C, et al. Surgical scar location preference for pediatric kidney and pelvic surgery: a crowdsourced survey. *J Urol*. 2017;197(3):911–919.

Gargollo PC. Hidden incision endoscopic surgery: description of technique, parental satisfaction and applications. *J Urol*. 2011;185(4):1425–1431.

Gasior AC, Knott EM, Holcomb GW 3rd, et al. Patient and parental scar assessment after single incision versus standard 3-port laparoscopic appendectomy: long-term follow-up from a prospective randomized trial. *J Pediatr Surg*. 2014;49(1):120–122.

Gatti JM, Amstutz SP, Bowlin PR, et al. Laparoscopic vs open pyeloplasty in children: results of a randomized, prospective, controlled trial. *J Urol*. 2017;197(3):792–797.

Gentili A, Iannettone C, Pigna A, et al. Cardiocirculatory changes during videolaparoscopy in children: an echocardiographic study. *Paediatr Anesth*. 2000;10(4):399–406.

Ghani KR, Miller DC, Linsell S, et al. Measuring to improve: peer and crowd-sourced assessments of technical skill with robot-assisted radical prostatectomy. *Eur Urol*. 2016;69(4):547–550.

Gill IS, Ross JH, Sung GT, et al. Needlescopic surgery for cryptorchidism: the initial series. *J Pediatr Surg*. 2000;35(10):1426–1430.

Glassberg KI, Poon SA, Gjertson CK, et al. Laparoscopic lymphatic sparing varicocelectomy in adolescents. *J Urol*.

2008;180(1):326–331.

Godbole P, Najmaldin A. Laparoscopic orchidopexy in children. *J Endourol*. 2001;15(3):251–256.

Goh AC, Goldfarb DW, Sander JC, et al. Global evaluative assessment of robotic skills: validation of a clinical assessment tool to measure robotic surgical skills. *J Urol*. 2012;187(1):247–252.

Goldfarb MA, Protyniak B, Schultheis M. Hostile Abdomen Index Risk stratification and laparoscopic complications. *JSLS*. 2014;18(1):14–19.

Goonewardene S, Catterwell R, Brown M, et al. Robotic surgery with the Da Vinci Xi: simultaneous upper and lower tract surgery. *J Robot Surg*. 2017;11(3):373–374.

Gueugniaud PY, Abisseror M, Moussa M, et al. The hemodynamic effects of pneumoperitoneum during laparoscopic surgery in healthy infants: assessment by continuous esophageal aortic blood flow echo-Doppler. *Anesth Analg*. 1998;86(2):290–293.

Guloglu R, Dilege S, Aksoy M, et al. Major retroperitoneal vascular injuries during laparoscopic cholecystectomy and appendectomy. *J Laparoendosc Adv Surg Tech A*. 2004;14(2):73–76.

Gundeti MS, Acharya SS, Zagaja GP, et al. Paediatric robotic-assisted laparoscopic augmentation ileocystoplasty and Mitrofanoff appendicovesicostomy (RALIMA): feasibility of and initial experience with the University of Chicago technique. *BJU Int*. 2011;107(6):962–969.

Halachmi S, El Ghoneimi A, Bissonnette B, et al. Hemodynamic and respiratory effect of pediatric urological laparoscopic surgery: a retrospective study. *J Urol*. 2003;170(4):1651–1654.

Hamilton BD, Gatti JM, Cartwright PC, et al. Comparison of laparoscopic versus open nephrectomy in the pediatric population. *J Urol*. 2000;163(3):937–939.

Hanly EJ, Aurora AR, Fuentes JM, et al. Abdominal insufflation with CO_2 causes peritoneal acidosis independent of systemic pH. *J Gastrointest Surg*. 2005;9(9):1245–1252.

Hanly EJ, Mendoza-Sagaon M, Murata K, et al. CO_2 pneumoperitoneum modifies the inflammatory response to sepsis. *Ann Surg*. 2003;237(3):343–350.

Hansen EN, Muensterer OJ, Georgeson KE, et al. Single-incision pediatric endosurgery: lessons learned from our first 224 laparoendoscopic single-site procedures in children. *Pediatr Surg Int*. 2011;27(6):643–648.

Harold KL, Pollinger H, Matthews B, et al. Comparison of ultrasonic energy, bipolar thermal energy, and vascular clips for the hemostasis of small-, medium-, and large-sized arteries. *Surg Endosc*. 2003;17(8):1228–1230.

Hasson HM, Rotman C, Rana N, et al. Open laparoscopy: 29-year experience. *Obstet Gynecol*. 2000;96(5 Pt 1):763–766.

Henninger V, Reisenauer C, Brucker SY, et al. Laparoscopic nerve-preserving colposacropexy for surgical management of neovaginal prolapse. *J Pediatr Adolesc Gynecol*. 2015;28(5):e153–e155.

Hernandez J, Ross S, Morton C, et al. The learning curve of laparoendoscopic single-site (LESS) cholecystectomy: definable, short, and safe. *J Am Coll Surg*. 2010;211(5):652–657.

Helal M, Albertini J, Lockhart J, et al. Laparoscopic nephrectomy using the harmonic scalpel. *J Endourol*. 1997;11(4):267–268.

Hiki N, Shimizu N, Yamaguchi H, et al. Manipulation of the small intestine as a cause of the increased inflammatory response after open compared with laparoscopic surgery. *Br J Surg*. 2006;93(2):195–204.

Holst D, Kowalewski TM, White LW, et al. Crowd-sourced assessment of technical skills: an adjunct to urology resident surgical simulation training. *J Endourol*. 2015;29(5):604–609.

Hong YH, DeFoor WR, Reddy PP, et al. Hidden incision endoscopic surgery (HIdES) trocar placement for pediatric robotic pyeloplasty: comparison to traditional port placement. *J Robot Surg*. 2018;12(1):43–47.

Hotaling JM, Shear S, Lendvay TS. 14-gauge angiocatheter: the assist port. *J Laparoendosc Adv Surg Tech A*. 2009;19(5):699–701.

Huettemann E, Terborg C, Sakka SG, et al. Preserved CO_2 reactivity and increase in middle cerebral arterial blood flow velocity during laparoscopic surgery in children. *Anesth Analg*. 2002;94(2):255–258.

Humes DJ, Ahmed I, Lobo DN. The pedicle effect and direct coupling: delayed thermal injuries to the bile duct after laparoscopic cholecystectomy. *Arch Surg*. 2010;145(1):96–98.

Hung AJ, Chen J, Gill IS. Automated performance metrics and machine learning algorithms to measure surgeon performance and anticipate clinical outcomes in robotic surgery. *JAMA Surg*. 2018;153(8):770–771.

Hurd WW, Bude RO, DeLancey J, et al. The relationship of the umbilicus to the aortic bifurcation: implications for laparoscopic technique. *Obstet Gynecol*. 1992;80(1):48–51.

Intuitive Surgical. *Indications for Use, United States*. [Available at] https://www.intuitivesurgical.com/company/indications-for-use.php; 2018.

Jackman SV, Weingart JD, Kinsman SL, et al. Laparoscopic surgery in patients with ventriculoperitoneal shunts: safety and monitoring. *J Urol*. 2000;164(4):1352–1354.

Jakeways M, Mitchell V, Hashim I, et al. Metabolic and inflammatory responses after open or laparoscopic cholecystectomy. *Br J Surg*. 1994;81(1):127–131.

Janetschek G, Seibold J, Radmayr C, et al. Laparoscopic heminephroureterectomy in pediatric patients. *J Urol*. 1997;158(5):1928–1930.

Jayanthi V. Vesicoscopic cross-trigonal ureteral reimplantation: high success rate for elimination of primary reflux. *J Pediatr Urol*. 2018;14(4):324.e1–324.e5.

Jeong HJ, Han DY, Kwon W-A. Laparoscopic management of complicated urachal remnants. *Chonnam Med J*. 2013;49(1):43–47.

Jiang X, Anderson C, Schnatz PF. The safety of direct trocar versus Veress needle for laparoscopic entry: a meta-analysis of randomized clinical trials. *J Laparoendosc Adv Surg Tech A*. 2012;22(4):362–370.

Jordan GH, Robey EL, Winslow BH. Laparoendoscopic surgical management of the abdominal/transinguinal undescended testicle. *J Endourol*. 1992;6(2):159–163.

Joy P, Prithishkumar IJ, Isaac B. Clinical anatomy of the inferior epigastric artery with special relevance to invasive procedures of the anterior abdominal wall. *J Minim Access Surg*. 2017;13(1):18.

Kaouk JH, Palmer JS. Single-port laparoscopic surgery: initial experience in children for varicocelectomy. *BJU Int*. 2008;102(1):97–99.

Karpman E, Das S, Kurzrock EA. Laparoscopic antegrade continence enema (Malone) procedure: description and illustration of technique. *J Endourol*. 2002;16(6):325–328.

Kim SK, Jeong JO, Kwon YS, et al. Laparoscopic rectosigmoid flap vaginoplasty. *J Plast Surg Hand Surg*. 2011;45(4–5):226–231.

Kishore TA, Pedro RN, Monga M, et al. Assessment of validity of an OSATS for cystoscopic and ureteroscopic cognitive and psychomotor skills. *J Endourol*. 2008;22(12):2707–2712.

Koivusalo AI, Korpela R, Wirtavuori K, et al. A single-blinded, randomized comparison of laparoscopic versus open hernia repair in children. *Pediatrics*. 2009;123(1):332–337.

Kok K, Seneviratne H, Chua H, et al. Laparoscopic excision of congenital bladder diverticulum in a child. *Surg Endosc*. 2000;14(5):501.

Kolon TF, Herndon CA, Baker LA, et al. Evaluation and treatment of cryptorchidism: AUA guideline. *J Urol*. 2014;192(2):337–345.

Kowalewski TM, Sweet R, Lendvay TS, et al. Validation of the AUA BLUS tasks. *J Urol*. 2016;195(4):998–1005.

Kristiansson M, Saraste L, Soop M, et al. Diminished interleukin-6 and C-reactive protein responses to laparoscopic versus open cholecystectomy. *Acta Anaesthesiol Scand*. 1999;43(2):146–152.

Ku JH, Yeo WG, Kim HH, et al. Laparoscopic nephrectomy for renal diseases in children: is there a learning curve? *J Pediatr Surg*. 2005;40(7):1173–1176.

Kurtz MP, Leow JJ, Varda BK, et al. Robotic versus open pediatric ureteral reimplantation: costs and complications from a nationwide sample. *J Pediatr Urol*. 2016;12(6):408.e1–408.e6.

Kurtz MP, Leow JJ, Varda BK, et al. The decline of the open ureteral reimplant in the United States: national data from 2003 to 2013. *Urology*. 2017;100:193–197.

Kuthe A, Haemmerle A, Ludwig K, et al. Multicenter prospective evaluation of a new articulating 5-mm endoscopic linear stapler. *Surg Endosc*. 2016;30(5):1883–1893.

Kutikov A, Guzzo TJ, Canter DJ, et al. Initial experience with laparoscopic transvesical ureteral reimplantation at the Children's Hospital of Philadelphia. *J Urol*. 2006;176(5):2222–2226.

Kutikov A, Nguyen M, Guzzo T, et al. Robot assisted pyeloplasty in the infant—lessons learned. *J Urol*. 2006;176(5):2237–2240.

Kutikov A, Resnick M, Casale P. Laparoscopic pyeloplasty in the infant younger than 6 months—is it technically possible? *J Urol*. 2006;175(4):1477–1479.

Kwak H, Jo Y, Lee K, et al. Acid-base alterations during laparoscopic abdominal surgery: a comparison with laparotomy. *Br J Anaesth*. 2010;105(4):442–447.

Lamberton GR, Hsi RS, Jin DH, et al. Prospective comparison of four laparoscopic vessel ligation devices. *J Endourol*. 2008;22(10):2307–2312.

Leavitt DA, Rambachan A, Haberman K, et al. Robot-assisted laparoscopic ipsilateral ureteroureterostomy for ectopic ureters in children: description of technique. *J Endourol*. 2012;26(10):1279–1283.

Leclair MD, Vidal I, Suply E, et al. Retroperitoneal laparoscopic heminephrectomy in duplex kidney in infants and children: a 15-year experience. *Eur Urol*. 2009;56(2):385–391.

Leddy LS, Lendvay TS, Satava RM. Robotic surgery: applications and cost effectiveness. *Open Access Surg*. 2010;2010(3):99–107.

Lee G, Lee M, Green I, et al. Surgeons’ physical discomfort and symptoms during robotic surgery: a comprehensive ergonomic survey study. *Surg Endosc*. 2017;31(4):1697–1706.

Lee RS, Passerotti CC, Cendron M, et al. Early results of robot assisted laparoscopic lithotomy in adolescents. *J Urol*. 2007;177(6):2306–2310.

Lee RS, Retik AB, Borer JG, et al. Pediatric retroperitoneal laparoscopic partial nephrectomy: comparison with an age matched cohort of open surgery. *J Urol*. 2005;174(2):708–

712.

Lee RS, Retik AB, Borer JG, et al. Pediatric robot assisted laparoscopic dismembered pyeloplasty: comparison with a cohort of open surgery. *J Urol*. 2006;175(2):683–687.

Lendvay TS, Brand TC, White L, et al. Virtual reality robotic surgery warm-up improves task performance in a dry laboratory environment: a prospective randomized controlled study. *J Am Coll Surg*. 2013;216(6):1181–1192.

Lendvay TS, Casale P, Sweet R, et al. Initial validation of a virtual-reality robotic simulator. *J Robot Surg*. 2008;2(3):145–149.

Lendvay TS, White L, Kowalewski T. Crowdsourcing to assess surgical skill. *JAMA Surg*. 2015;150(11):1086–1087.

Lima M, Aquino A, Domini M, et al. Laparoscopic removal of müllerian duct remnants in boys. *J Urol*. 2004;171(1):364–368.

Lister DR, Rudston-Brown B, Warriner CB, et al. Carbon dioxide absorption is not linearly related to intraperitoneal carbon dioxide insufflation pressure in pigs. *Anesthesiology*. 1994;80(1):129–136.

Long C, Weiss D, Kolon T, et al. Pediatric calyceal diverticulum treatment: an experience with endoscopic and laparoscopic approaches. *J Pediatr Urol*. 2015;11(4):172.e1–172.e6.

Makiyama K, Nagasaka M, Inuiya T, et al. Development of a patient-specific simulator for laparoscopic renal surgery. *Int J Urol*. 2012;19(9):829–835.

Manner T, Aantaa R, Alanen M. Lung compliance during laparoscopic surgery in paediatric patients. *Paediatr Anesth*. 1998;8(1):25–29.

Marcovich R, Del Terzo MA, Wolf JS Jr. Comparison of transperitoneal laparoscopic access techniques: optiview visualizing trocar and Veress needle. *J Endourol*. 2000;14(2):175–179.

Mariano ER, Furukawa L, Woo RK, et al. Anesthetic concerns for robot-assisted laparoscopy in an infant. *Anesth Analg*. 2004;99(6):1665–1667.

Marietti S, DeCambre M, Fairbanks T, et al. Early experience with laparoendoscopic single-site surgery in the pediatric urology patient population. *J Endourol*. 2010;24(8):1321–1324.

Martin J, Regehr G, Reznick R, et al. Objective structured assessment of technical skill (OSATS) for surgical residents. *Br J Surg*. 1997;84(2):273–278.

Matsui Y, Matsuta Y, Okubo K, et al. Laparoscopic nephropexy: treatment outcome and quality of life. *Int J Urol*. 2004;11(1):1–6.

McHoney M, Corizia L, Eaton S, et al. Carbon dioxide elimination during laparoscopy in children is age dependent. *J Pediatr Surg*. 2003;38(1):105–110.

McHoney M, Eaton S, Wade A, et al. Inflammatory response in children after laparoscopic vs open Nissen fundoplication: randomized controlled trial. *J Pediatr Surg*. 2005;40(6):908–914.

McKernan JB, Finley CR. Experience with optical trocar in performing laparoscopic procedures. *Surg Laparosc Endosc Percutan Tech*. 2002;12(2):96–99.

Meehan JJ. Robotic surgery in small children: is there room for this? *J Laparoendosc Adv Surg Tech A*. 2009;19(5):707–712.

Meehan JJ, Sandler A. Robotic repair of a Bochdalek congenital diaphragmatic hernia in a small neonate: robotic advantages and limitations. *J Pediatr Surg*. 2007;42(10):1757–1760.

Meeks JJ, Hagerty JA, Lindgren BW. Pediatric robotic-assisted laparoscopic diverticulectomy. *Urology*. 2009;73(2):299–301.

Mei H, Pu J, Yang C, et al. Laparoscopic versus open pyeloplasty for ureteropelvic junction obstruction in children: a systematic review and meta-analysis. *J Endourol*.

2011;25(5):727–736.

Meininger DD, Byhahn C, Heller K, et al. Totally endoscopic Nissen fundoplication with a robotic system in a child. *Surg Endosc*. 2001;15(11):1360.

Merlin T, Hiller JE, Maddern GJ, et al. Systematic review of the safety and effectiveness of methods used to establish pneumoperitoneum in laparoscopic surgery. *Br J Surg*. 2003;90(6):668–679.

Metzelder M, Jesch N, Dick A, et al. Impact of prior surgery on the feasibility of laparoscopic surgery for children: a prospective study. *Surg Endosc*. 2006;20(11):1733–1737.

Mikami O, Fujise K, Matsumoto S, et al. High intra-abdominal pressure increases plasma catecholamine concentrations during pneumoperitoneum for laparoscopic procedures. *Arch Surg*. 1998;133(1):39–43.

Mikami O, Kawakita S, Fujise K, et al. Catecholamine release caused by carbon dioxide insufflation during laparoscopic surgery. *J Urol*. 1996;155(4):1368–1371.

Miller K, Albanese C, Harrison M, et al. Experience with laparoscopic adrenalectomy in pediatric patients. *J Pediatr Surg*. 2002;37(7):979–982.

Minervini A, Davenport K, Pefanis G, et al. Prospective study comparing the bladeless optical access trocar versus Hasson open trocar for the establishment of pneumoperitoneum in laparoscopic renal procedures. *Arch Ital Urol Androl*. 2008;80(3):95–98.

Minnillo BJ, Cruz JA, Sayao RH, et al. Long-term experience and outcomes of robotic assisted laparoscopic pyeloplasty in children and young adults. *J Urol*. 2011;185(4):1455–1460.

Moberg AC, Petersson U, Montgomery A. An open access technique to create pneumoperitoneum in laparoscopic surgery. *Scand J Surg*. 2007;96(4):297–300.

Montero M, Tellado M, Rios J, et al. Aortic injury during diagnostic pediatric laparoscopy. *Surg Endosc*. 2001;15(5):519.

Msika S, Deroide G, Kianmanesh R, et al. Harmonic scalpel™ in laparoscopic colorectal surgery. *Dis Colon Rectum*. 2001;44(3):432–436.

Muensterer OJ, Adibe OO, Harmon CM, et al. Single-incision laparoscopic pyloromyotomy: initial experience. *Surg Endosc*. 2010;24(7):1589–1593.

Murthy P, Cohn JA, Selig RB, et al. Robot-assisted laparoscopic augmentation ileocystoplasty and Mitrofanoff appendicovesicostomy in children: updated interim results. *Eur Urol*. 2015;68(6):1069–1075.

Myles PS. Bradyarrhythmias and laparoscopy: a prospective study of heart rate changes with laparoscopy. *Austr NZ J Obstet Gynaecol*. 1991;31(2):171–173.

Nakaoka T, Uemura S, Yoshida T, et al. Umbilical center insertion method for initial trocar placement in pediatric laparoscopic surgery. *Osaka City Med*. 2010;56(2):21–26.

Nataraja R, Webb N, Lopez P. Simulation in paediatric urology and surgery, part 2: an overview of simulation modalities and their applications. *J Pediatr Urol*. 2018;14(2):125–131.

Nezhat F, Brill AI, Nezhat CH, et al. Laparoscopic appraisal of the anatomic relationship of the umbilicus to the aortic bifurcation. *J Am Assoc Gynecol Laparosc*. 1998;5(2):135–140.

Nguyen HT, Passerotti CC, Penna FJ, et al. Robotic assisted laparoscopic Mitrofanoff appendicovesicostomy: preliminary experience in a pediatric population. *J Urol*. 2009;182(4):1528–1534.

Noh PH, DeFoor WR, Reddy PP. Percutaneous antegrade ureteral stent placement during pediatric robot-assisted laparoscopic pyeloplasty. *J Endourol*. 2011;25(12):1847–1851.

Oh CS, Won HS, Kwon CH, et al. Morphologic variations of the umbilical ring, umbilical ligaments and ligamentum teres hepatis. *Yonsei Med J*. 2008;49(6):1004–1007.

Okeke AA, Mitchelmore AE, Keeley FX, et al. A comparison of aspiration and sclerotherapy with laparoscopic de-roofing in the management of symptomatic simple renal cysts. *BJU Int*. 2003;92(6):610–613.

Okrainec A, Soper NJ, Swanstrom LL, et al. Trends and results of the first 5 years of Fundamentals of Laparoscopic Surgery (FLS) certification testing. *Surg Endosc*. 2011;25(4):1192–1198.

Osthaus WA, Huber D, Bäumker C, et al. Plasma volume replacement with HES 130/0.42 obviates negative side effects of pneumoperitoneum in piglets. *Paediatr Anesth*. 2008;18(10):922–928.

Park A, Lee G, Seagull FJ, et al. Patients benefit while surgeons suffer: an impending epidemic. *J Am Coll Surg*. 2010;210(3):306–313.

Passerotti CC, Passerotti AMA, Dall'Oglio MF, et al. Comparing the quality of the suture anastomosis and the learning curves associated with performing open, freehand, and robotic-assisted laparoscopic pyeloplasty in a swine animal model. *J Am Coll Surg*. 2009;208(4):576–586.

Paya K, Wurm J, Fakhari M, et al. Trocar-site hernia as a typical postoperative complication of minimally invasive surgery among preschool children. *Surg Endosc*. 2008;22(12):2724–2727.

Peters BS, Armijo PR, Krause C, et al. Review of emerging surgical robotic technology. *Surg Endosc*. 2018;32(4):1636–1655.

Peters CA. Complications in pediatric urological laparoscopy: results of a survey. *J Urol*. 1996;155(3):1070–1073.

Peters CA, Woo R. Intravesical robotically assisted bilateral ureteral reimplantation. *J Endourol*. 2005;19(6):618–622.

Philips PA, Amaral JF. Abdominal access complications in laparoscopic surgery1. *J Am Coll Surg*. 2001;192(4):525–536.

Pike T, Pathak S, Mushtaq F, et al. A systematic examination of preoperative surgery warm-up routines. *Surg Endosc*. 2017;31(5):2202–2214.

Pini G, Porpiglia F, Micali S, et al. Minilaparoscopy, needlescopy and microlaparoscopy: decreasing invasiveness, maintaining the standard laparoscopic approach. *Arch Esp Urol*. 2012;65(3):366–383.

Polin MR, Siddiqui NY, Comstock BA, et al. Crowdsourcing: a valid alternative to expert evaluation of robotic surgery skills. *Am J Obstet Gynecol*. 2016;215(5):644.e1–644.e7.

Poppas DP, Uzzo RG, Britanisky RG, et al. Laparoscopic laser assisted auto-augmentation of the pediatric neurogenic bladder: early experience with urodynamic followup. *J Urol*. 1996;155(3):1057–1060.

Powers MK, Boonjindasup A, Pinsky M, et al. Crowdsourcing assessment of surgeon dissection of renal artery and vein during robotic partial nephrectomy: a novel approach for quantitative assessment of surgical performance. *J Endourol*. 2016;30(4):447–452.

Pugh CM. Warm-ups, mental rehearsals and deliberate practice: adopting the strategies of elite professionals. *J Surg Res*. 2012;176(2):404–405.

Rabl C, Palazzo F, Aoki H, et al. Initial laparoscopic access using an optical trocar without pneumoperitoneum is safe and effective in the morbidly obese. *Surg Innov*. 2008;15(2):126–131.

Radford AR, Thomas DF, Subramaniam R. Ureterocalicostomy in children: 12 years experience in a single centre. *BJU Int*. 2011;108(3):434–438.

Raheem AA, Sheikh A, Kim DK, et al. Da Vinci Xi and Si platforms have equivalent perioperative outcomes during robot-assisted partial nephrectomy: preliminary experience. *J Robot Surg*. 2017;11(1):53–61.

Rassweiler JJ, Autorino R, Klein J, et al. Future of robotic surgery in urology. *BJU Int*. 2017;120(6):822–841.

Razvi HA, Fields D, Vargas JC, et al. Oliguria during laparoscopic surgery: evidence for direct renal parenchymal compression as an etiologic factor. *J Endourol*. 1996;10(1):1–4.

Resnick M, Chang AY, Casale P. Laparoscopic renal denervation and nephropexy for autosomal dominant polycystic kidney disease related pain in adolescents. *J Endourol*. 2006;175(6):2274–2276.

Reznick RK, MacRae H. Teaching surgical skills—changes in the wind. *N Engl J Med*. 2006;355(25):2664–2669.

Romano F, Caprotti R, Franciosi C, et al. The use of LigaSure during pediatric laparoscopic splenectomy: a preliminary report. *Pediatr Surg Int*. 2003;19(11):721–724.

Rowe CK, Pierce MW, Tecci KC, et al. A comparative direct cost analysis of pediatric urologic robot-assisted laparoscopic surgery versus open surgery: could robot-assisted surgery be less expensive? *J Endourol*. 2012;26(7):871–877.

Satava RM. Virtual reality surgical simulator. *Surg Endosc*. 1993;7(3):203–205.

Schaarschmidt K, Kolberg-Schwerdt A, Lempe M, et al. Ultrasonic shear coagulation of main hilar vessels: a 4-year experience of 23 pediatric laparoscopic splenectomies without staples. *J Pediatr Surg*. 2002;37(4):614–616.

Schulam PG, Hedican SP, Docimo SG. Radially dilating trocar system for open laparoscopic access. *Urology*. 1999;54(4):727–729.

Sethi AS, Peine WJ, Mohammadi Y, et al. Validation of a novel virtual reality robotic simulator. *J Endourol*. 2009;23(3):503–508.

Sharp HT, Dodson MK, Draper ML, et al. Complications associated with optical-access laparoscopic trocars. *Obstet Gynecol*. 2002;99(4):553–555.

Shin DH, Dalag L, Azhar RA, et al. A novel interface for the telementoring of robotic surgery. *BJU Int*. 2015;116(2):302–308.

Shiraishi K, Eguchi S, Mohri J, et al. Laparoscopic decortication of symptomatic simple renal cysts: 10-year experience from one institution. *BJU Int*. 2006;98(2):405–408.

Simforoosh N, Abedi A, Sharifi SH, et al. Comparison of surgical outcomes and cosmetic results between standard and mini laparoscopic pyeloplasty in children younger than 1 year of age. *J Pediatr Urol*. 2014;10(5):819–823.

Simon P, Burkhardt U, Sack U, et al. Inflammatory response is no different in children randomized to laparoscopic or open appendectomy. *J Laparoendosc Adv Surg Tech A*. 2009;19(S1):S71–S76.

Simorov A, Otte RS, Kopietz CM, et al. Review of surgical robotics user interface: what is the best way to control robotic surgery? *Surg Endosc*. 2012;26(8):2117–2125.

Skarsgard ED, Albanese CT. The safety and efficacy of laparoscopic adrenalectomy in children. *Arch Surg*. 2005;140(9):905–908 [discussion 909].

Smith PH 3rd, Carpenter M, Herbst KW, et al. Milestone assessment of minimally invasive surgery in Pediatric Urology fellowship programs. *J Pediatr Urol*. 2017;13(1):110.e1–110.e6.

Smith RP, Oliver JL, Peters CA. Pediatric robotic extravesical ureteral reimplantation: comparison with open surgery. *J Urol*. 2011;185(5):1876–1881.

Sorensen MD, Delostrinos C, Johnson MH, et al. Comparison of the learning curve and outcomes of robotic assisted pediatric pyeloplasty. *J Urol*. 2011;185(6):2517–2522.

Sriprasad S, Yu DF, Muir GH, et al. Positional anatomy of vessels that may be damaged at laparoscopy: new access criteria based on CT and ultrasonography to avoid vascular injury. *J Endourol*. 2006;20(7):498–503.

Steigerwald SN, Park J, Hardy KM, et al. Does laparoscopic simulation predict intraoperative performance? A comparison between the Fundamentals of Laparoscopic Surgery and LapVR evaluation metrics. *Am J Surg*. 2015;209(1):34–39.

String A, Berber E, Foroutani A, et al. Use of the optical access trocar for safe and rapid entry in various laparoscopic procedures. *Surg Endosc*. 2001;15(6):570–573.

Sümpelmann R, Schuerholz T, Marx G, et al. Haemodynamic, acid-base and blood volume changes during prolonged low pressure pneumoperitoneum in rabbits. *Br J Anaesth*. 2006;96(5):563–568.

Sweet RM, Beach R, Sainfort F, et al. Introduction and validation of the American Urological Association basic laparoscopic urologic surgery skills curriculum. *J Endourol*. 2012;26(2):190–196.

Tasian GE, Wiebe DJ, Casale P. Learning curve of robotic assisted pyeloplasty for pediatric urology fellows. *J Urol*. 2013;190(4):1622–1627.

Taylor KL, Holtby H, Macpherson B. Laparoscopic surgery in the pediatric patient post Fontan procedure. *Paediatr Anesth*. 2006;16(5):591–595.

Taylor SP, Hoffman GM. Gas embolus and cardiac arrest during laparoscopic pyloromyotomy in an infant. *Can J Anaesth*. 2010;57(8):774–778.

Taylor SP, Sato TT, Balcom AH, et al. Gas analysis using Raman spectroscopy demonstrates the presence of intraperitoneal air (nitrogen and oxygen) in a cohort of children undergoing pediatric laparoscopic surgery. *Anesth Analg*. 2015;120(2):349–354.

Templeman CL, Hertweck SP, Levine RL, et al. Use of laparoscopically mobilized peritoneum in the creation of a neovagina. *Fertil Steril*. 2000;74(3):589–592.

Teoh B, Sen R, Abbott J. An evaluation of four tests used to ascertain Veres needle placement at closed laparoscopy. *J Minim Invasive Gynecol*. 2005;12(2):153–158.

Tomaszewski JJ, Sweeney DD, Kavoussi LR, et al. Laparoscopic retroperitoneal lymph node dissection for high-risk pediatric patients with paratesticular rhabdomyosarcoma. *J Endourol*. 2010;24(1):31–34.

Tracy CR, Raman JD, Cadeddu JA, et al. Laparoendoscopic single-site surgery in urology: where have we been and where are we heading? *Nat Rev Urol*. 2008;5(10):561.

Tröbs RB, Vahdad MR, Cernaianu G. Transumbilical cord access (TUCA) for laparoscopy in infants and children: simple, safe and fast. *Surg Today*. 2016;46(2):235–240.

Ure B, Niewold T, Bax N, et al. Peritoneal, systemic, and distant organ inflammatory responses are reduced by a laparoscopic approach and carbon dioxide vs air. *Surg Endosc*. 2002;16(5):836–842.

Uzzo RG, Bilsky M, Mininberg DT, et al. Laparoscopic surgery in children with ventriculoperitoneal shunts: effect of pneumoperitoneum on intracranial pressure—preliminary experience. *Urology*. 1997;49(5):753–757.

Van Savage JG, Yohannes P. Laparoscopic antegrade continence enema in situ appendix procedure for refractory constipation and overflow fecal incontinence in children with spina bifida. *J Urol*. 2000;164(3):1084–1087.

Varda BK, Wang Y, Chung BI, et al. Has the robot caught up? National trends in utilization, perioperative outcomes, and cost for open, laparoscopic, and robotic pediatric pyeloplasty in the United States from 2003 to 2015. *J Pediatr Urol*. 2018;14(4):336.e1–336.e8.

Vassiliou MC, Feldman LS, Andrew CG, et al. A global assessment tool for evaluation of intraoperative laparoscopic skills. *Am J Surg*. 2005;190(1):107–113.

Vilos GA, Ternamian A, Dempster J, et al. Laparoscopic entry: a review of techniques, technologies, and complications. *J Obstet Gynaecol Can*. 2007;29(5):433–447.

Wallis MC, Khoury AE, Lorenzo AJ, et al. Outcome analysis of retroperitoneal laparoscopic heminephrectomy in children. *J Urol*. 2006;175(6):2277–2282.

Wang HH, Tejwani R, Zhang H, et al. Hospital surgical volume and associated postoperative complications of pediatric urological surgery in the United States. *J Urol*. 2015;194(2):506–511.

Wang MK, Li Y, Selekman RE, et al. Scar acceptance after pediatric urologic surgery. *J Pediatr Urol*. 2018;14(2):175.e1–175.e6.

Wedgewood J, Doyle E. Anaesthesia and laparoscopic surgery in children. *Paediatr Anesth*. 2001;11(4):391–399.

White LW, Kowalewski TM, Dockter RL, et al. Crowd-sourced assessment of technical skill: a valid method for discriminating basic robotic surgery skills. *J Endourol*. 2015;29(11):1295–1301.

Wolf SJ, Soble JJ, Nakada SY, et al. Comparison of fibrin glue, laser weld, and mechanical suturing device for the laparoscopic closure of ureterotomy in a porcine model. *J Urol*. 1997;157(4):1487–1492.

Wulkan ML, Vasudevan SA. Is end-tidal CO_2 an accurate measure of arterial CO_2 during laparoscopic procedures in children and neonates with cyanotic congenital heart disease? *J Pediatr Surg*. 2001;36(8):1234–1236.

Yamzon J, Kokorowski P, De Filippo RE, et al. Pediatric robot-assisted laparoscopic excision of urachal cyst and bladder cuff. *J Endourol*. 2008;22(10):2385–2388.

Yanke BV, Horowitz M. Safety of the Veress needle in pediatric laparoscopy. *J Endourol*. 2007;21(7):695–697.

Yao D, Poppas DP. A clinical series of laparoscopic nephrectomy, nephroureterectomy and heminephroureterectomy in the pediatric population. *J Urol*. 2000;163(5):1531–1535.

Yee DS, Duel BP. Omental herniation through a 3-mm umbilical trocar site. *J Endourol*. 2006;20(2):133–134.

Yeung CK, Sihoe JD, Tam YH, et al. Laparoscopic excision of prostatic utricles in children. *BJU Int*. 2001;87(6):505–508.

SECTION C

Lower Urinary Tract Conditions

OUTLINE

28 Clinical and Urodynamic Evaluation of Lower Urinary Tract Dysfunction in Children

29 Management Strategies for Vesicoureteral Reflux

30 Bladder Anomalies in Children

31 Exstrophy-Epispadias Complex

32 Prune-Belly Syndrome

33 Posterior Urethral Valves

34 Neuromuscular Dysfunction of the Lower Urinary Tract in Children

35 Functional Disorders of the Lower Urinary Tract in Children

36 Management of Defecation Disorders

37 Lower Urinary Tract Reconstruction in Children

28

Clinical and Urodynamic Evaluation of Lower Urinary Tract Dysfunction in Children

---

Duncan T. Wilcox MD, MBBS, Kyle O. Rove MD

Evaluation of the urinary tract should be tailored to the patient at hand, as no presentation is alike, and underlying etiologies and resulting phenotypes can vary dramatically. Similarly, age and timing of presentation may also influence testing needs. Increasingly, urologists can accurately diagnose lower urinary tract pathology with a thorough clinical history, physical examination, and noninvasive tests, thus avoiding invasive, complex, and often more expensive studies in many clinical scenarios. When testing is required, it may be performed as part of a diagnostic workup, screening, surveillance, or follow-up testing after a procedure. Initially we will review the approach to making a diagnosis, highlighting important aspects of the history, physical examination, and, where appropriate, investigations in patients with lower urinary tract dysfunction. We will then identify some common scenarios for comprehensive lower urinary tract evaluation. More in-depth discussion of clinical entities can be found elsewhere in this text but are discussed briefly here for context.

Clinical Evaluation

History

Complete workup of a patient with incontinence, voiding dysfunction, or known lower urinary tract pathology begins with a thorough patient history. We prefer to take the history directly from the child when possible. This should be tailored to the patient's age and maturational status in the context of voluntary bladder and bowel control. The approach to working up lower urinary tract symptoms includes first attempting to identify an anatomic or neurologic etiology for lower urinary tract symptoms. If these are ruled out, then it is appropriate to ascertain the type of underlying bladder (and/or bowel) dysfunction. **The important components of a complete history should include symptomatology, voiding frequency, bowel function, prior urinary tract infections, relevant family history, maternal prenatal history including screening ultrasonography, birth history, developmental milestones including toilet training, neuropsychiatric conditions, past medical and surgical history, social history, diet, and review of systems.**

Storage Symptoms

The urologist should ask about symptoms attributable to lower urinary tract storage dysfunction such as urgency, frequency, or incontinence. Incontinence timing should be determined (continuous versus intermittent, day versus night, how often). Signs of increased or decreased bladder capacity might also be inferred from the history, and a directed workup to confirm this may be helpful. Secondary enuresis (new incontinence after at least 6 months of being dry) may occur in response to changes in daily activities or new stressors at home or school. This should be explored.

Diet should also be reviewed with the patient, as known bladder irritants like caffeinated beverages (e.g., soda, tea, coffee, sports drinks, energy drinks) can directly contribute to symptoms of urinary urgency (Arya et al., 2000; Leclair and Héloury, 2010).

Voiding Symptoms

In boys, history of deviated or narrowed urinary stream, prolonged urination, inability to completely empty, straining, dysuria, and postvoid dribbling should be elicited. With girls who urinate spontaneously, posture on the toilet is relevant. Sitting with legs tightly together, slouching, or sitting on the edge of the toilet with feet barely touching the floor promotes pelvic floor musculature activation, which increases bladder outlet resistance. This may result in increased voiding pressures and contribute to dysuria or incomplete emptying, subsequently increasing the risk for bladder dysfunction or urinary tract infections. Proper posture on the toilet should be encouraged, and if needed, a footstool can be used (Fig. 28.1). Sometimes, the child might be encouraged to sit on the toilet "backwards" facing the tank, thus ensuring the legs are apart to minimize poor posture. Holding maneuverers—sometimes referred to by parents as "doing the potty dance," posturing, crossing the legs, grabbing the perineum, or squatting—are witnessed in pediatric patients trying to postpone bladder emptying in response to need to urinate (or detrusor overactivity [DO]) (Yerkes, 2009). Posturing maneuvers increase perineal pressure and inhibit bladder contractions through the sacral reflex arc, likely through increased afferent cosignaling (gate control theory of pain transmission, which states that increased large-fiber afferent signals will decrease signals transmitted by smaller fibers through the dorsal horn). The latter is felt to be one of the possible mechanisms of action for transcutaneous electrical nerve stimulation (TENS), posterior tibial nerve stimulation (PTNS), and sacral neuromodulation (Hoebeke et al., 2001; Malm-Buatsi et al., 2007; Roth et al., 2008; Schober et al., 2015).

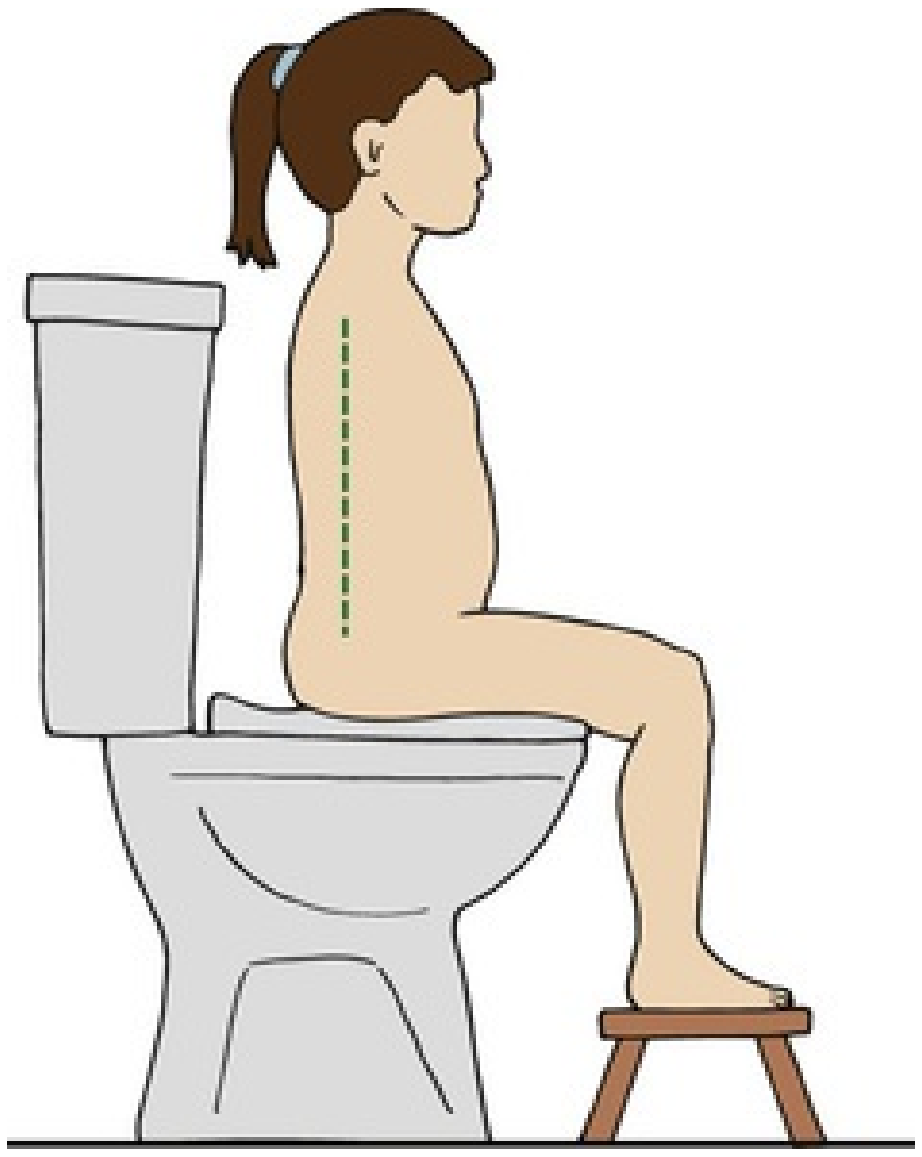

FIG. 28.1 Proper posture on toilet with support for feet if necessary. Avoid

dangling feet over edge as this likely increases pelvic floor muscle tone, inhibiting relaxation for voiding.

Bowel Function

Bowel dysfunction is often coincident with lower urinary tract dysfunction given similar innervation of the rectum through the sacral nerve roots (S2–S4) (Burgers et al., 2013). As such, obtaining bowel function history is extremely important, as there are cases in which predominant bowel dysfunction may be the only underlying cause of urinary symptoms. Specificity when obtaining a bowel function history is key because constipation as a concept confuses many parents and patients. Asking if a patient has constipation is usually insufficient, so we suggest providers delve more specifically into bowel movement frequency, fecal incontinence, abdominal pain, size of stool, and consistency of bowel movements according to the Bristol stool scale (Lewis and Heaton, 1997).

The Bristol stool scale is a useful guide designed to classify the form of human feces into seven distinct categories (Fig. 28.2). Sometimes referred to in the United Kingdom as the “Meyers scale,” it was developed at the University of Bristol in 1997 (Lewis and Heaton, 1997). The scale ranges from 1 to 7, with 1 corresponding to small, hard pellets and 7 corresponding to watery diarrhea. We use it as a clinical communication aid with our patients and their families in terms of what to strive for and to facilitate titration of supplemental fiber or laxatives.

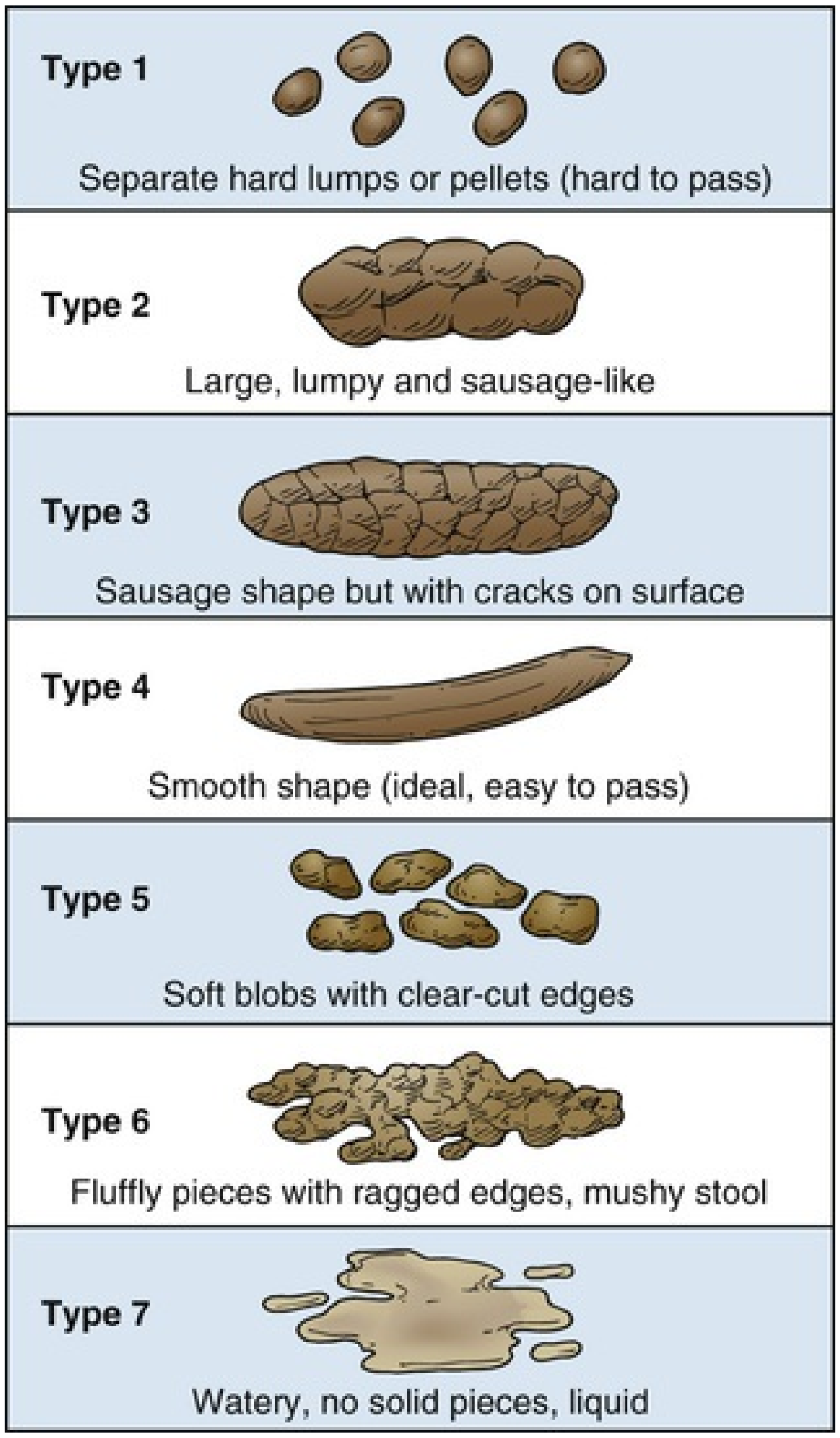
Type 1
Separate hard lumps or pellets (hard to pass)
Type 2
Large, lumpy and sausage-like
Type 3
Sausage shape but with cracks on surface
Type 4
Smooth shape (ideal, easy to pass)
Type 5
Soft blobs with clear-cut edges
Type 6
Fluffly pieces with ragged edges, mushy stool
Type 7
Watery, no solid pieces, liquid

FIG. 28.2 Bristol stool chart with visuals and descriptions of different stool types. This scale provides a helpful, objective reference for documenting stool consistency when talking to patients about bowel function. (Modified from Lewis SJ, Heaton KW. Stool form scale as a useful guide to intestinal transit time. *Scand J Gastroenterol*. 1997;32(9):920–924.)

We find it helpful to offer a healthy baseline of bowel function as a goal, specifically that patients should have a soft, smooth, daily bowel movement that is easy to expel without pain (Bristol 3 to 4). A consensus definition of functional constipation in children can be found in the Rome IV criteria published in 2016 and is shown in Table 28.1 (Drossman 2016; Rasquin et al., 2006). However, the definition of functional constipation and/or bowel dysfunction remains controversial (Austin et al., 2014; Drossman and Hasler, 2016). From a practical standpoint, we have found the questions mentioned earlier related to bowel function sufficient to identify patients with concomitant bowel-related problems and design appropriate.

TABLE 28.1

Rome IV Criteria for Functional Constipation in Children

FUNCTIONAL CONSTIPATION
Must include two or more of the following in a child with a developmental age of 4 years or older with insufficient criteria for a diagnosis of irritable bowel syndrome:
• Two or fewer defecations per week • One or more episodes of fecal incontinence per week • History of retentive posturing or excessive volitional stool retention • History of painful or hard bowel movements • Presence of a large fecal mass in the rectum • History of large-diameter stools that obstruct the toilet • Functional nonretentive fecal incontinence (FNRFI)
Must include all of the following in a child with a developmental age of at least 4 years:
• Defecation in places inappropriate to the social context at least once per month • No evidence of an inflammatory, anatomic, metabolic, or neoplastic process • No evidence of fecal retention

Modified from Rasquin A, Di Lorenzo C, Forbes D, et al. Childhood functional gastrointestinal disorders: child/adolescent. *Gastroenterology.* 2006;130(5):1527–1537; Drossman DA. Functional gastrointestinal disorders: history, pathophysiology, clinical features, and Rome IV. *Gastroenterology*. 2016;150(6):1262–1279.e2.

In 2013, the Standardization Committee of the International Children's Continence Society (ICCS) published a treatment algorithm for the management of functional constipation in patients with lower urinary tract symptoms (Fig. 28.3).

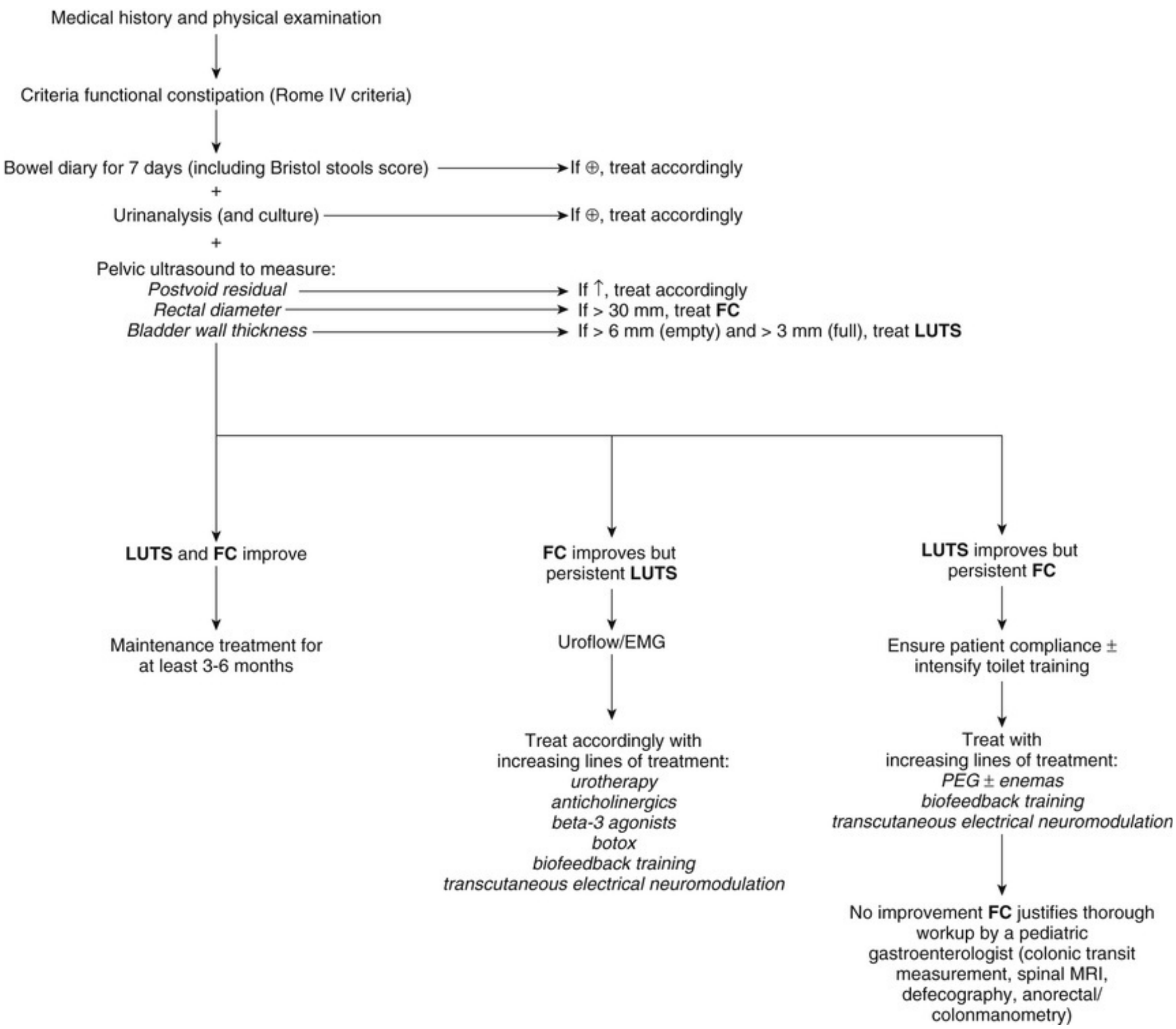
Medical history and physical examination
Criteria functional constipation (Rome IV criteria)
Bowel diary for 7 days (including Bristol stools score)
If ⊕, treat accordingly
+
Urinanalysis (and culture)
If ⊕, treat accordingly
+
Pelvic ultrasound to measure:
Postvoid residual
Rectal diameter
Bladder wall thickness
If ↑, treat accordingly
If > 30 mm, treat FC
If > 6 mm (empty) and > 3 mm (full), treat LUTS
LUTS and FC improve
Maintenance treatment for at least 3-6 months
FC improves but persistent LUTS
Uroflow/EMG
Treat accordingly with increasing lines of treatment:
urotherapy
anticholinergics
beta-3 agonists
botox
biofeedback training
transcutaneous electrical neuromodulation
LUTS improves but persistent FC
Ensure patient compliance ± intensify toilet training
Treat with increasing lines of treatment:
PEG ± enemas
biofeedback training
transcutaneous electrical neuromodulation
No improvement FC justifies thorough workup by a pediatric gastroenterologist (colonic transit measurement, spinal MRI, defecography, anorectal/ colonmanometry)

FIG. 28.3 Algorithm for the management of functional constipation *(FC)* and lower urinary tract symptoms *(LUTS). EMG,* Electromyogram, *MRI,* magnetic resonance imaging, *PEG,* polyethylene glycol. (Modified from Burgers RE, Mugie SM, Chase J, et al. Management of functional constipation in children with lower urinary tract symptoms: report from the Standardization Committee of the International Children's Continence Society. *J Urol.* 2013;190[1]:29–36.)

Clinical Aids

Patients diaries can be especially useful in determining elimination habits, and corresponding urinary symptoms. Although a number of diaries have been described, the most common are the 7-day bowel and bladder diary (Fig. 28.4A) and 48-hour frequency-volume chart (see Fig. 28.4B). The 7-day bowel and bladder diary involves the patient or parent tracking timing of voids, bowel movements, associated stool consistency, and presence of any incontinence of urine or stool in the day or night. This tool provides a very complete picture, eliminating problems with recall bias (Lane et al., 2011; Roth and Austin, 2014). Objective data regarding bowel function can aid with the diagnosis of functional constipation.

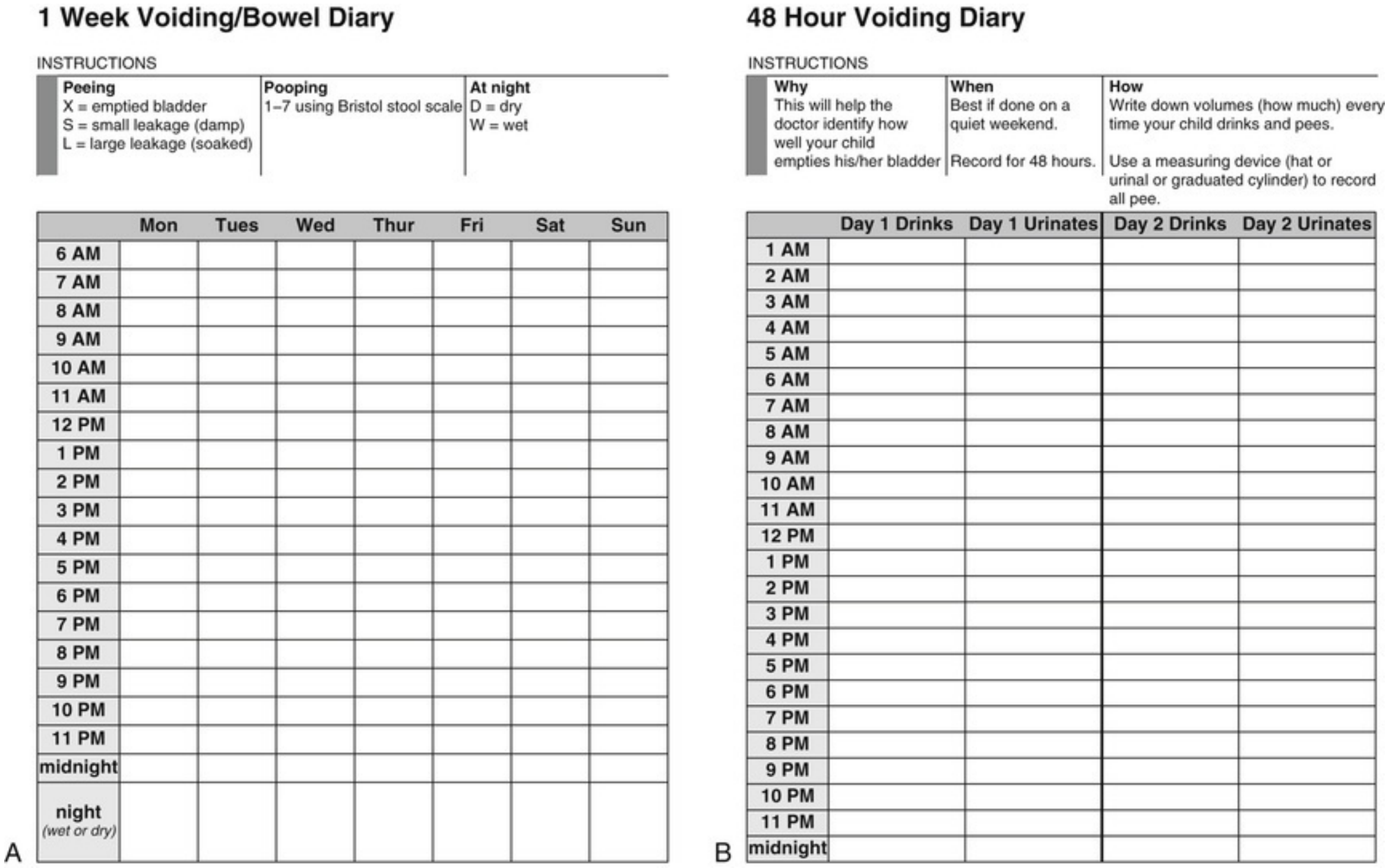

1 Week Voiding/Bowel Diary

INSTRUCTIONS

Peeing	Pooping	At night
X = emptied bladder S = small leakage (damp) L = large leakage (soaked)	1–7 using Bristol stool scale	D = dry W = wet

	Mon	Tues	Wed	Thur	Fri	Sat	Sun
6 AM							
7 AM							
8 AM							
9 AM							
10 AM							
11 AM							
12 PM							
1 PM							
2 PM							
3 PM							
4 PM							
5 PM							
6 PM							
7 PM							
8 PM							
9 PM							
10 PM							
11 PM							
midnight							
night *(wet or dry)*							

48 Hour Voiding Diary

INSTRUCTIONS

Why	When	How
This will help the doctor identify how well your child empties his/her bladder	Best if done on a quiet weekend. Record for 48 hours.	Write down volumes (how much) every time your child drinks and pees. Use a measuring device (hat or urinal or graduated cylinder) to record all pee.

	Day 1 Drinks	Day 1 Urinates	Day 2 Drinks	Day 2 Urinates
1 AM				
2 AM				
3 AM				
4 AM				
5 AM				
6 AM				
7 AM				
8 AM				
9 AM				
10 AM				
11 AM				
12 PM				
1 PM				
2 PM				
3 PM				
4 PM				
5 PM				
6 PM				
7 PM				
8 PM				
9 PM				
10 PM				
11 PM				
midnight				

FIG. 28.4 (A) Example of a 1-week voiding and bowel diary. Patients are separately provided pictographic Bristol Stool Scale for reference. (B) Example of 48-hour frequency and volume chart that provides greater detail about liquid intake and urinary output.

For patients with a primary complaint of voiding dysfunction, a 48-hour frequency-volume chart may be obtained (Hoebeke et al., 2010). A toilet seat "hat" with measurements or graduated cylinder should be provided to measure volumes. Weekends with normal planned activities are suggested to complete the task, which consists of recording volumes of fluid intake and output and taking note of any incontinence episodes. The diary does not necessarily have to be filled out on consecutive days, but each should cover a 24-hour period (Austin et al., 2014). This type of diary can help determine a number of different voiding parameters, including functional or maximum bladder capacity and presence of polyuria. Because liquid intake is recorded, its contribution (either through type of product or overall volume) can be determined (e.g., intake of caffeinated beverages or large intake of fluids before bedtime). **Completion of a frequency-volume chart is useful in pediatric patients with bowel and bladder dysfunction and should always be performed in spontaneous voiders resistant to first-line, conservative therapies.** Functional bladder capacity can be compared with estimated bladder capacity. Multiple studies have attempted to ascertain an accurate method of estimated bladder capacity for children. The most widely cited methods and those we use include estimated bladder capacity (in mL) in infants up to 1 year of age calculated as (weight in kilograms × 7) (Fairhurst et al., 1991), and estimated bladder capacity in older children calculated as (age in years + 2) × (30) (Koff, 1983; Berger et al., 1983).

In summary, parents and even patients may not be attuned to subtle but pathologic voiding habits, and diaries are an easy, low-cost method to clarify these clinical details.

Urinary Tract Infections

History of urinary tract infection should be elicited and in particular, whether the infections were associated with fever and/or symptoms. For reference, asymptomatic bacteruria is relatively uncommon, found in 1% of girls and 0.03% of boys (Kemper and Avner, 1992). Collection technique should also be ascertained as bagged specimens should not be considered reliable (unless negative). Symptoms of fever with a culture-documented urinary tract infection may indicate incomplete bladder emptying or urinary stasis. Care and finesse should be used to differentiate nonspecific lower urinary tract symptoms associated with voiding dysfunction and nondescript, undocumented “urinary tract infections,” particularly in the presence of negative urine cultures. Depending on the circumstances, redirection of patient and family expectations and education about signs and symptoms of infection in the context of underlying pathologies may be required.

Neurologic Function

Screening for neurologic symptoms should be performed as part of a complete medical history. Specifically, clinicians should inquire about changes in perineal numbness, gait, altered sensorium of the extremities, or new difficulties with balance or coordination. Positive findings here may indicate underlying occult neurologic disease requiring further workup. Such symptoms are particularly worrisome when they are newly onset in previously healthy patients who present with secondary enuresis or other lower urinary tract problems.

Validated Questionnaires

Validated questionnaires (also referred to by some as *patient-reported outcomes*) provide for an objective means to measure patient perspectives on symptoms, quality of life, and emotional impact of medical conditions. The best questionnaires are validated and tested extensively to ensure reproducibility and internal and external validity with respect to the condition(s) being tested and the population of interest, among others. Important validated questionnaires for pediatric patients with lower urinary tract pathology are discussed in the following sections.

Dysfunctional Voiding Symptom Score.

The Dysfunctional Voiding Symptom Score (DVSS) was designed for use in pediatric patients and was first reported in 2000. It is largely based on the American Urological Association Symptom Index, which assesses lower urinary tract symptoms that result from benign prostatic hyperplasia (Farhat et al., 2000). It consists of ten questions that assess a variety of symptomatic domains include storage and voiding symptoms, but also includes posturing and bowel habits. Each question is scored from 0 to 3, depending on how often each particular item occurred in the month prior for a maximum score of 30.

Dysfunctional Voiding and Incontinence Scoring System.

The Dysfunctional Voiding and Incontinence Scoring System (DVISS) is composed of 14 questions (13 assess symptoms, and 1 addresses quality of life). The maximum score is 35 + 3, and a cutoff value of 9 was determined for boys and girls to differentiate normal from abnormal voiders (Akbal et al., 2005). The majority of the questions are scored with yes or no answers.

Pediatric Urinary Incontinence Quality of Life Score.

The Pediatric Urinary Incontinence Quality of Life Score (PinQ) was developed and psychometrically validated by Bower et al. and measures quality of life as a function of urinary incontinence in a child (Bower et al., 2006). PinQ has been shown to have excellent internal validity, content validity, and test retest reliability. During development and validation, no correlation was shown between the questions, suggesting minimal content overlap (Bower et al., 2006). A proxy version that can be completed by parents or guardians showed good correlation with the child (intraclass correlation coefficient [measure of agreement between groups with 0 meaning no correlation and 1 perfect correlation] 0.681, 95% confidence interval [CI], 0.416 to 0.840). The PinQ has 20 questions, each graded from 0 to 4 (answers include no, hardly ever, sometimes, often, and all the time) with a maximum score of 80. Questions fall into one of two categories: intrinsic (internalizing) and extrinsic (externalizing) behaviors, and subscores can be calculated for each. These categories relate to how each patient processes and manages incontinence emotionally. Higher scores indicate worse dysfunction and lower quality of life. The PinQ does not appear to be influenced by other underlying comorbidities (Deshpande et al., 2011). It has been translated into multiple languages and shown to be reliable in multiple cultural contexts.

With regard to overlap, the DVSS and PinQ were shown to be complementary, providing a composite view of lower urinary tract symptomatology and subsequent effect on quality of life (Thibodeau et al. 2013). The DVSS showed increased ability to discriminate changes in response to ongoing treatment (Altan et al., 2017).

Incontinence Symptom Index-Pediatric.

The Incontinence Symptom Index-Pediatric (ISI-P) questionnaire was modified from the Incontinence Symptom Index (ISI) questionnaire for use in a pediatric population in 2007 and was designed to be filled out by patients between 11 and 17 years of age (rather than by caregivers) (Nelson et al., 2007). The ISI-P has 11 questions for a maximum score of 44. Like the DVISS, a cutoff value of 9 was determined for both sexes.

Psychological Screening.

Children with lower urinary tract pathology can commonly have coexisting behavioral and emotional disorders that can contribute to the presentation. In several representative studies, 20% to 30% of children with nocturnal enuresis, 20% to 40% with daytime incontinence, and 30% to 50% with fecal incontinence are affected by comorbid behavioral disorders (Gontard et al., 2011). Just as we recommend excluding organic causes of disease, psychological screening should be obtained to adequately diagnose and treat identified conditions.

Child Behavior Checklist.

The Child Behavior Checklist (CBCL) rates children on behavior and emotions and is filled out by parents or guardians (Achenbach and Ruffle, 2000). Widely used in child psychology, this questionnaire can be used in patients between 18 months and 18 years of age. There are two versions, one covering preschool-age children (18 months to 5 years) and older children (6 to 18 years). A Likert scale is used to answer the 100+ questions, which assess internalizing behaviors (i.e., anxiety or depression) and externalizing behaviors (i.e., acting out, aggression, hyperactivity).

Short Screening Instrument for Psychological Problems in Enuresis.

The Short Screening Instrument for Psychological Problems in Enuresis (SSIPPE) is a brief, derivative instrument of seven internalizing questions taken from the CBCL and six externalizing items from the Attention Deficit Hyperactivity Disorder scale of the Disruptive Behavior Disorders Rating instrument (Van Hoecke et al., 2007). Either the CBCL or SSIPPE can be used to assess behavior and emotions. As the SSIPPE is shorter, it can be used to screen for problems. If two or more issues in either the internalizing or externalizing section are positive, the full CBCL can be completed. Should that verify underlying behavioral or emotional disturbance, a full child psychology referral is recommended.

Selecting an Appropriate Patient-Reported Outcome Measure.

Atlan et al. performed a novel comparison of several questionnaires, including the Dysfunctional Voiding Symptom Score (DVSS), Incontinence Symptom Index–Pediatric (ISI-P), Dysfunctional Voiding and Incontinence Scoring System (DVISS), and Pediatric Urinary Incontinence Quality of Life (PinQ) (Altan et al. 2017). Forty-two patients with bowel and bladder dysfunction were compared with 42 healthy controls and asked to complete all four questionnaires before treatment; underwent standard treatments for 3 months including urotherapy, anticholinergics, or desmopressin; and then all patients repeated the questionnaires and assigned subjective recovery rates as a percentage to represent overall recovery or progress. The DVISS (designed by the authors' department) was reported to have better discrimination with respect to diagnosis, and the DVSS, DVISS, and ISI-P all correlated well with subjective recovery rates. The PinQ, which measures emotional impact of incontinence on quality of life, did not correlate well with therapy or subjective recovery. This could indicate that either the questionnaire does not assess domains that are readily affected by therapy, emotional states that result from underlying voiding dysfunction are less malleable, therapies affecting symptoms take longer to manifest as measurable emotional change, or emotional change does not result from symptom relief.

Physical Examination

Patients who present with complaints attributed to lower urinary tract function should undergo a physical examination. This examination should be comprehensive, with particular attention paid to vital signs and neurologic, abdominal, and genitourinary systems. The relevant findings in each of these areas are discussed in the following sections.

Vital Signs

Vital signs including height, weight, temperature, heart rate, and blood pressure should be obtained at all clinic visits. Height and weight can be used to calculate body mass index (BMI), which is equal to weight in kg divided by height in m^2. An underweight or overweight BMI has been correlated to risk for higher lower urinary tract symptom scores (Oliver et al., 2013). Although commonly used as a screening tool to counsel families, BMI was originally devised in the 19th century and validated for an adult population (Quetelet, 1869). Its values are felt to be inaccurate in children and adolescents, and to correct for this, BMI z-scores based on BMI percentile can be used to better classify children as overweight or obese (Cole, 1991). This approach, however, is cumbersome and does not lend itself to quick interpretation by clinicians. Recently, Peterson et al reported that triponderal mass index (TMI) classified 2285 patients 8 to 29 years of age as healthy or overweight better than BMI z-scores (Peterson et al., 2017). TMI is calculated by mass in kg divided by the height in m^3. The authors demonstrate that TMI misclassified patients less often as overweight than BMI z-scores (8.4% vs 19.4%). The TMI thresholds to diagnose overweight status were 16.0 kg/m^3 for boys and 16.8 kg/m^3 for girls and were 18.8 kg/m^3 for boys and 19.7 kg/m^3 for girls to diagnose obese status. These results underscore the difficulties in interpreting BMI data for pediatric and adolescent patient groups.

Elevated blood pressure (as determined by age, sex, and height-related nomogram) may be indicative of underlying renal disease. Abnormal values warrant repeating the blood pressure measurement to confirm, ideally at separate visits. As renal disease often occurs secondary to urinary tract pathology, abnormal blood pressure readings should be investigated further with imaging such as renal bladder ultrasonography and appropriate laboratory studies (urinalysis, serum creatinine, and/or cystatin C).

Neurologic Examination

Neurologic assessment of reflexes, strength, coordination, and sensation of all extremities should be performed. Although the findings of upper extremity function do not inform the function of the lower urinary tract, the presence or absence of upper extremity function (fine-motor control, sensation, handedness) can affect care decisions involving self-catheterization. Use of aids for mobility or ambulation should be documented (e.g., wheelchair, walker, crutches, ankle foot orthosis [AFO] devices), although context for use can vary considerably. The Centers for Disease Control and Prevention (CDC) National Spina Bifida Patient Registry uses a standardized approach to classifying patients' functional neurologic level and mobility status, which do not correlate (Thibadeau et al., 2013; Sawin et al., 2015). These objective definitions are shown in Table 28.2.

TABLE 28.2

Objective Classification of Lower Extremity Function in Terms of Functional Neurologic Level and Ambulation Phenotype[a]

FUNCTIONAL NEUROLOGIC LEVELS	
LEVEL OF LESION	**FUNCTIONAL ABILITY**
Thoracic	Flaccid lower extremities
High-lumbar	Hip flexion present
Mid-lumbar	Knee extension present
Low-lumbar	Foot dorsiflexion present
Sacral	Foot plantarflexion present
AMBULATORY PHENOTYPE OR MOBILITY STATUS	
PHENOTYPE	**DEFINITION**
Perfect ambulator	Walk, run, jump indoors and outdoors for all activities without assistance.
Community ambulators	Walk indoors and outdoors for most activities, may need crutches/braces/walker. May use wheelchair for long trips out in the community.

Household ambulators	Walk indoors only with crutches/braces/walker. Get in and out of chair with little assistance. Wheelchair for some indoor activities at home, school, and for all activities in the community.
Nonfunctional ambulators	Walking only in therapy sessions. Wheelchair at all other times.
Nonambulators	Wheelchair bound at all times. Able to transfer from chair to bed.

[a] 2 years of age and older.

Deep tendon reflexes, gait, perineal/anal sensation, and rectal tone should be assessed. The anocutaneous reflex (i.e., “anal wink”) is present when stroking the anus and causes involuntary contraction of the external anal sphincter (Sanders et al., 2002). The bulbocavernosus or Osinski reflex can be assessed by seeing contraction of the external anal sphincter in response to squeezing the glans penis or clitoris (Vodušek and Deletis, 2002). Absence of either of these reflexes indicates interruption of the sacral reflex arcs (S2–S4), which also control bowel and bladder function.

The spine should be visualized and palpated to rule out occult neurologic issues that might arise with bony vertebral or sacral abnormalities. In the vast majority of cases, this examination will reveal a normal spine with an unremarkable, symmetric gluteal cleft. Kriss et al. found that 4.8% of healthy neonates had midline skin stigmata that were referred for further workup, with 7.7% of these (or only 0.4% of the population) having an occult lesion of the spine (Kriss and Desai, 1998). No patient with a simple dimple overlying the sacrum was found to have spinal dysraphism in this study.

Deviations like those shown in Fig. 28.5 require further investigation. Importantly, various cutaneous findings have different predictive value of occult spinal dysraphism (Ben-Sira et al., 2009). Skin changes can range from a sacral dimple <2.5 cm from the anus (low risk) to an abnormal-appearing gluteal cleft or a dermal sinus tract to a vascular malformation (high-risk). **Presence of a lipoma, mass, or hair tuft overlying the spine or sacrum should also be investigated as these confer high risk for occult spinal dysraphism or tethered cord (Guggisberg et al. 2004).** Cases with multiple skin stigmata or findings consistent with VACTERL syndrome are also stratified as high risk. Ultrasonography has been advocated for improved cost and avoidance of general anesthesia sometimes required for MRI. Ultrasonography of the spine may be appropriate for patients up to 6 months of age (ossification of the spine occurs by 10 to 12 months of age) for low-risk lesions, understanding that ultrasonography has been reported to have decreased sensitivity (50% to 70%) (Scheible et al., 1983; Hughes et al., 2003; Drolet and Boudreau, 2004). High-risk lesions, however, should be evaluated with MRI of the lumbar and sacral spine (Ben-Sira et al., 2009).

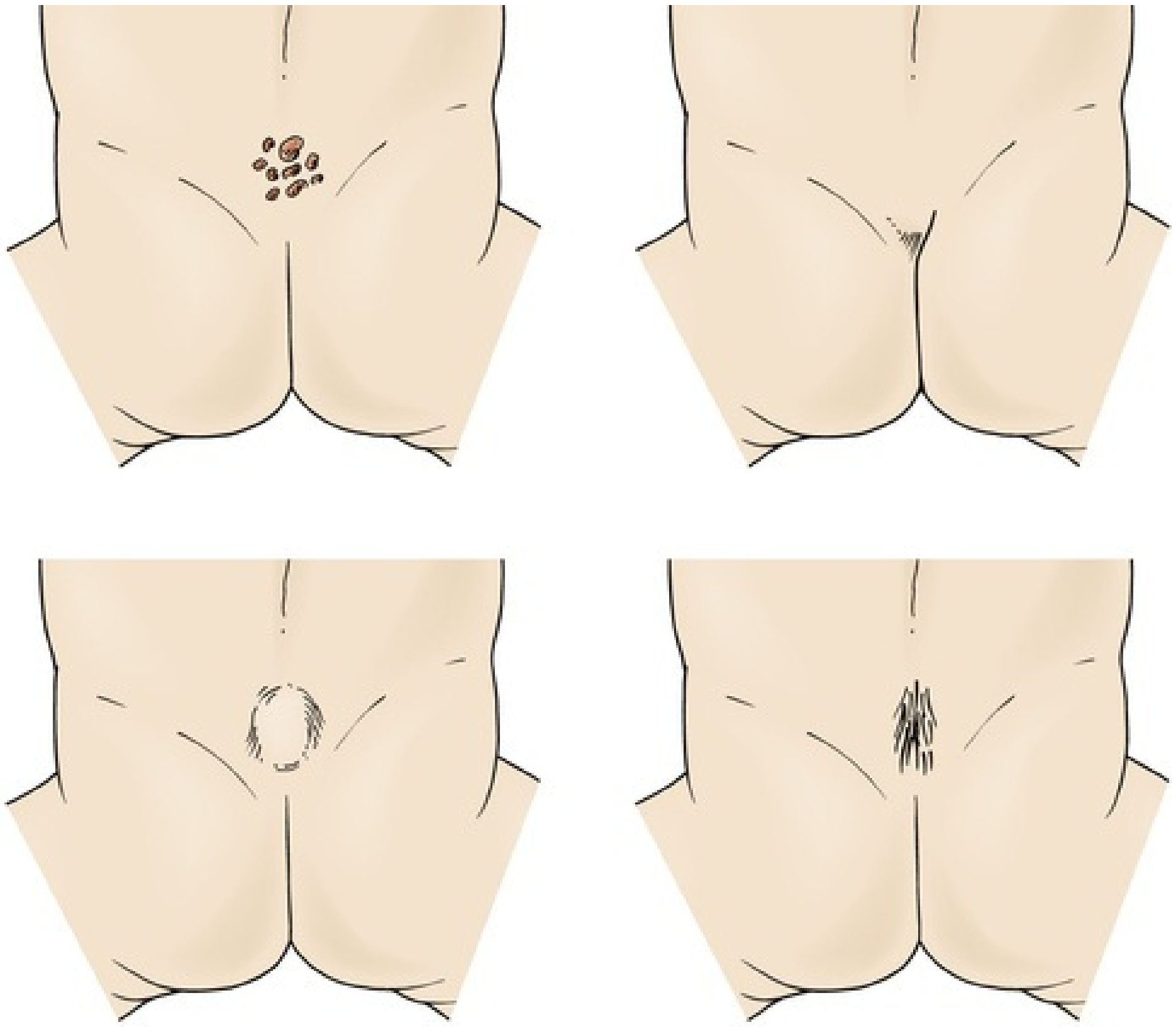

FIG. 28.5 Skin changes over the spine that are suspicious for spina bifida, including isolated macules, deviated cleft, protuberance or mass, or isolated tuft of hair.

Abdominal Examination

Abdominal exam should begin with visual inspection to note the presence of asymmetry or distention, which may indicate bowel gas, fecal retention, or underlying bowel dysfunction. Palpation of all four quadrants should be performed to uncover the presence of enlarged kidneys or bladder, abdominal masses, or palpable stool in the colon. Stool is typically only felt in patients with extreme cases of constipation and may be more appreciable in small children. Tenderness to palpation and/or fullness of the suprapubic area may indicate urinary retention or a full bladder.

Genital Examination

Genitourinary examination should include inspection of the genitalia, looking for evidence of damp underwear or external genital irritation, which can occur with incontinence.

In the male patient, the penis should be inspected and examined. The provider should note the patient's circumcision status. Any erythema, swelling, or tenderness of the prepuce should be documented as possible evidence of balanitis. If circumcised, meatal stenosis should be noted if present. Meatal stenosis only occurs in circumcised males, secondary to irritation of the exposed meatus that induces epithelialization to create a ventral web. **Meatal stenosis is felt to only be relevant if there is significant deviation or narrowing of the stream, and patients and caregivers should be counseled that concurrent symptoms may not necessarily be attributable to this finding or improve with surgical correction.** Inspection of the meatus may be sufficient along with clinical history, but our preference has been to observe the urinary stream directly during voiding to note stream caliber and direction.

In the female patient, the introitus should be examined for pooling of urine or ongoing signs of inflammation (erythema, swelling). Labial fusion is common, particularly in children younger than 2 years of age who are still in diapers (Farage and Maibach, 2005). It rarely causes bladder outlet obstruction and can be treated conservatively. It will usually resolve spontaneously with time by the time of puberty as increased circulating estrogens change the vaginal epithelium (Williams et al., 1986). In some cases, labial fusion can result in pooling of the urine, which may result in urinary stasis and bacterial colonization, thus increasing the probability of developing a urinary tract infection (Leung and Robson, 1993). In cases in which there is ongoing concern, topical estrogen can be used, but families should be counseled that about 10% of cases will recur. If there is concern for continuous incontinence, the vaginal introitus should be examined for an ectopic ureteral orifice. Deformities of the urethral meatus, typically a ventral meatal web, have previously been associated with lower urinary tract dysfunction. Hoebeke et al. described the findings of meatal anomalies in 88 of 288 girls referred for urodynamic study and noted that meatal anomalies were associated with increased likelihood of voiding dysfunction (Hoebeke et al. 1999). A second study by Klijn et al. found a similar association (Klijn et al., 2012). Although previously there was more enthusiasm within the pediatric urology community to surgically intervene in female patients with urethral anomalies, there is only minimal evidence to support such an intervention, underscored by the finding by Klijn that not all meatal anomalies are associated with urinary symptoms.

Key Points

- History and physical examination should be performed to ascertain whether the patient has primarily a storage or emptying disorder. Further workup and treatment is then tailored as needed.
- The important components of a complete history should include symptomatology, voiding frequency, bowel function, prior urinary tract infections, relevant family history, maternal prenatal history including screening ultrasonography, birth history, developmental milestones including toilet training, neuropsychiatric conditions, past medical and surgical history, social history, diet, and review of systems.
- Seven-day bowel and bladder diaries and 48-hour frequency volume charts are invaluable in diagnosing simple and complex lower urinary tract voiding dysfunction.
- Validated questionnaires can be used to assess symptoms (DVSS, DVISS, ISI-P), quality of life (PinQ), and behavioral changes in response to underlying urinary dysfunction (CBCL, SSIPPE).
- Particular attention should be paid to the lower back on physical examination with both visual inspection (examine for dimples, deviations of the gluteal cleft, hair tufts, dermal sinuses, and vascular malformations) and palpation (presence of sacrum, rule out mass).

Laboratory Testing

Urinalysis

Dipstick urinalysis is readily available in most outpatient urology practices. Importantly, urinalysis can aid in the detection of glucosuria, proteinuria, hematuria, leukocyturia, and bacteriuria. Glucosuria occurs in response to prolonged periods of elevated blood glucose in diabetes and may result in polyuria. Proteinuria might be found in isolation on urinalysis. For this reason, urinalysis testing should be repeated at a separate occasion, or 24-hour urine collection with quantification of urine protein may be performed if intrinsic renal disease is suspected. Presence of white blood cells (on dipstick analysis or by microscopy) indicates inflammation or possible infection. Microscopic hematuria is common in the setting of infection, but may also be found in isolation in patients with bowel and bladder dysfunction. Asymptomatic microscopic hematuria in children rarely requires further workup. **Urinalysis with or without urine culture should be performed if there are irritative voiding symptoms (dysuria, urgency, or frequency) to rule out untreated urinary tract infection.**

Markers on urinalysis for infection (leukocyte esterase, nitrite, white blood cells, and/or bacteria on microscopy) should be interpreted within the clinical context of patient symptoms. Urinalysis is a low-cost, easy-to-implement screening tool, and negative urinalysis in a patient who presents with lower urinary tract symptoms is reassuring. In cases with a suspicious urinalysis, confirmatory testing with urine culture and/or institution of empiric antibiotic therapy is indicated.

Urine Culture

We do not recommend testing all patients with disordered lower urinary tracts with urine culture, as this will lead to overtesting, false positives and overtreatment, particularly in patients who are colonized with bacteria. Patients who perform clean, intermittent self-catheterization are at high risk for bacterial colonization of the bladder, and urine culture should be reserved for those patients with a high pretest probability of symptomatic urinary tract infection (fever, abdominal or suprapubic pain, malaise, new-onset urinary incontinence or worsened incontinence, new or worsened bladder spasm). Malodorous urine often invites the question as to whether a child is silently harboring a urinary tract infection. In a study by Struthers et al., 110 patients underwent urinalysis and culture as part of admission for unwell or febrile children not specifically suspected of having a urinary tract infection, and there was no correlation between parental concerns of malodorous urine and positive urine culture (Struthers et al., 2003). Another study by Gauthier et al. similarly asked 331 parents in the emergency department with their child about smelly urine in the context of suspected urinary tract infection and found a small association between the two (adjusted odds ratio [AOR] 2.73, 95% CI, 1.46 to 5.08) (Gauthier et al., 2012). **By itself, the presence of malodorous urine does not have enough sensitivity or specificity to definitively rule in or rule out testing.**

These two results are not necessarily in conflict, as they were performed under conditions with different pretest probabilities for urinary tract infection. We recommend to parents and patients with isolated malodorous urine in the absence of other signs or symptoms of urinary tract infection to increase hydration so as to alter the specific gravity of the urine and dilute volatile compounds. This avoids further testing in most cases and subsequent overtreatment, which fosters antibiotic-resistant organisms. Overtreatment can compound the difficulty in treating patients who develop true symptomatic, recurrent urinary tract infections.

Additional Testing

Blood samples are rarely indicated in the typical workup of lower urinary tract dysfunction, unless the history, physical examination, or other testing reveals possible underlying kidney disease or risk factors for the development of kidney disease. For example, proteinuria on repeat urinalysis should prompt serum creatinine testing and/or 24-hour urine collection to quantitate total protein content of the urine.

Key Points

- Children presenting with lower urinary tract symptoms should have urinalysis testing, with important test details including specific gravity, protein, and glucose, and the presence of white blood cells, red blood cells, or bacteria.

- Isolated malodorous urine in the general population lacks sensitivity and specificity to detect positive urine culture in an otherwise asymptomatic patient.
- Blood testing is not recommended unless there are specific concerns for concomitant upper tract disease.

Urodynamic Evaluation

Urodynamic testing, whether through noninvasive tests like uroflowmetry, pelvic ultrasonography, or patch EMG or invasive tests like formal cystometry requires a common, standardized language from which accurate descriptors of test results can be drawn. In 2014, the ICCS published an update to the previous 2006 report on standardized terminology of lower urinary tract function (Nørgaard et al., 1998; Nevéus et al., 2006; Austin et al., 2014). This important document codifies language to describe results of tests in common terms, thus allowing researchers and clinicians to compare studies and results on a comparable basis, avoiding ambiguous older verbiage. **We highly recommend that all clinicians who treat patients with lower urinary tract dysfunction read this important paper.**

Noninvasive Testing

Uroflowmetry

Uroflow studies measure the flow of urine during urination. They are performed by having the child void into a special toilet or device that measures volume per time (Fig. 28.6A). This study is readily available in most urologists' offices and providers for a number of different objective measures, including voided volume, void pattern, and maximum (Qmax) and average (Qavg) urinary flow rates. **The most important variables obtained by the uroflow are voided volume, Qmax, and void pattern** (Van De Beek et al., 1997). Uroflowmetry may be performed concomitantly with electromyography (EMG) testing of the pelvic floor musculature and external urethral sphincter by affixing pads to the perineum.

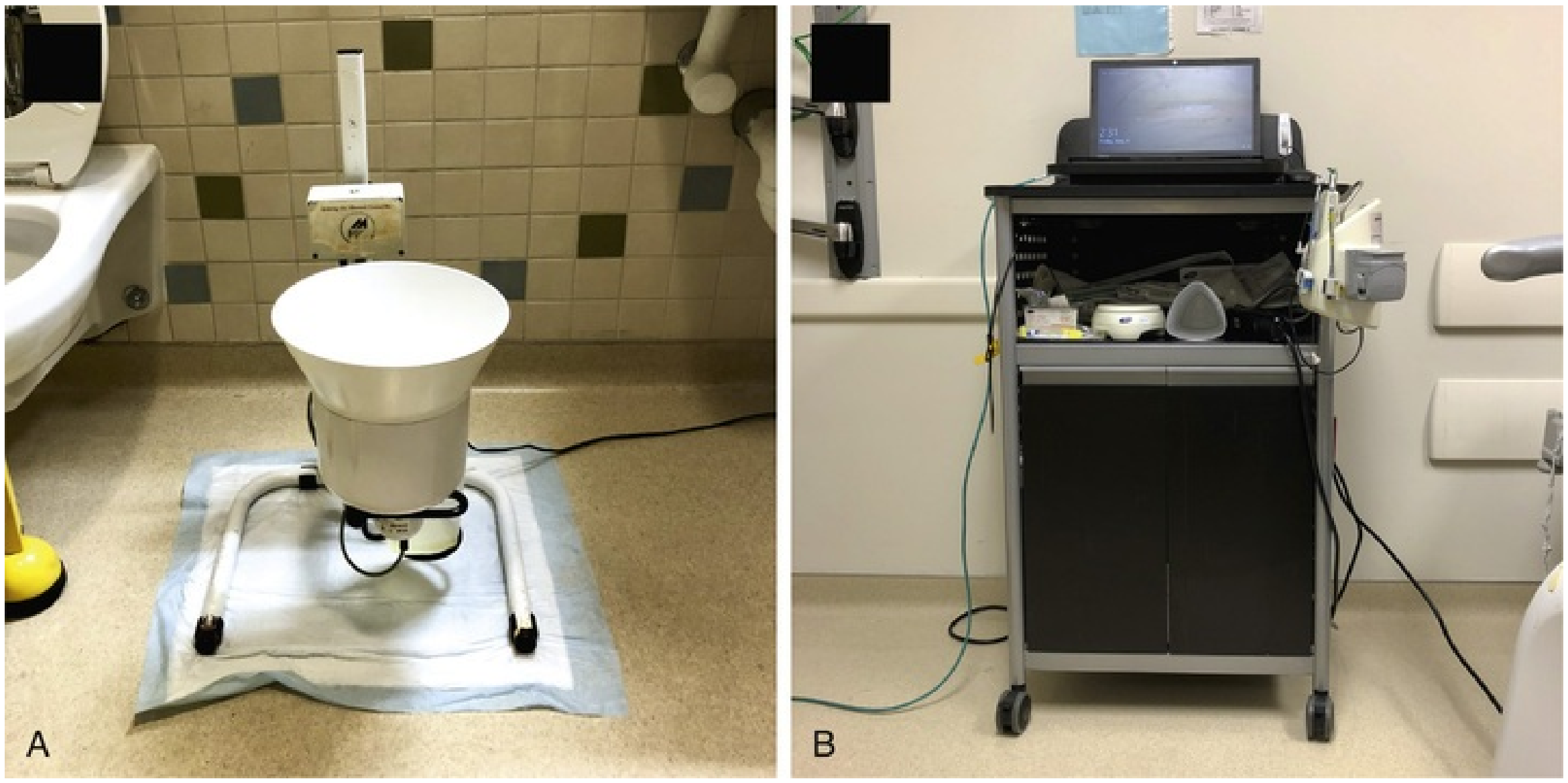

FIG. 28.6 (A) Uroflowmetry test equipment. (B) Urodynamic testing setup with computer and pressure transducer.

As noted earlier, the ICCS developed standardized terminology and definitions for uroflowmetry reporting, describing specific types of urine flow patterns (Fig. 28.7). These are not absolute, but they do provide a guide to possible underlying etiologies of lower urinary tract dysfunction.

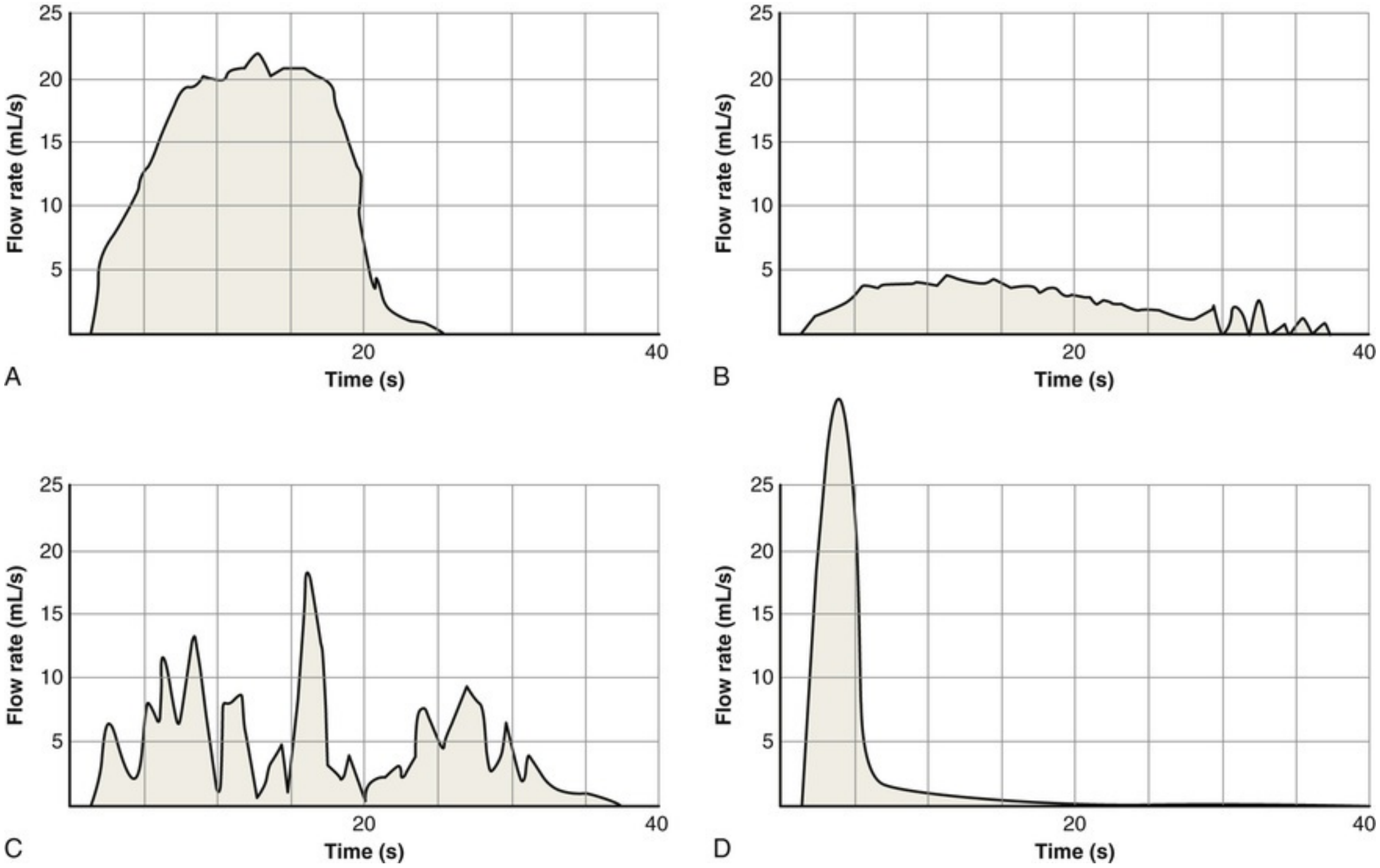

FIG. 28.7 (A) Example of uroflowmetry printout for a normal patient with a bell-shaped curve. Total volume is usually recorded, and a minimum of ~50 to 100 mL is needed to qualitatively assess urine flow pattern. (B) Obstructive flow pattern. (C) Overactivity pattern that resembles staccato or flow starting and stopping. (D) Peaked flow pattern with rapid emptying of the bladder, which may cause turbulence and possible symptoms during urination.

Bell-Shaped Curve.

A healthy child of any age, sex, race, or voided volume should result in a bell-shaped curve.

Tower-Shaped Curve.

A high-amplitude, peaked curve of short duration suggests an overactive bladder with sudden detrusor contraction. Not all children with overactive bladder, however, present with this voiding phenotype.

Staccato-Shaped Curve.

This flow pattern is irregular and fluctuates but does not reach zero flow during voiding. Intermittent sphincter overactivity is suggested to be the underlying cause and is felt to be associated with bowel and bladder dysfunction.

Interrupted-Shaped Curve.

Like the staccato curve, the interrupted shape uroflow result is also irregular, but there are segments of the curve that read zero flow, indicating cessation of urination and inadequate detrusor contraction (as in underactive bladder with Valsalva voiding). Between abdominal strains to void, the flow of urine ceases. Another possible explanation is detrusor-sphincter dyssynergia (DSD), in which the external sphincter does not relax appropriately with detrusor contraction. Uroflow testing with EMG can determine whether this is the case.

Plateau-Shaped Curve.

This uroflow result is a flat, low-amplitude prolonged flow curve that is suggestive of downstream obstruction (bladder outlet, posterior urethral valves, urethral stricture). This curve type may also be seen in patients with underactive bladder, whereby a continuous, low-amplitude pressure either from the detrusor or Valsalva generates force to expel urine.

Further Standardization.

Qmax is considered the most relevant variable of a uroflow measurement. Peaks may be artifactual, so Qmax should be only be registered when the peak lasts at least 2 seconds (Szabo and Fegyverneki, 1995). Multiple attempts have been made to find objective, quantifiable methods to normalize uroflow results to allow better comparisons between different patients (Chang and Yang, 2008; Kanematsu et al., 2010; Vijverberg et al., 2011; Gupta et al., 2013; Yang et al., 2014). Some of these efforts were suboptimal or based on populations that lacked generalizability. Recently, Franco et al reported on a method to overcome prior issues, including using a large healthy, asymptomatic patient group of varied ages to define normal and abnormal (Franco et al., 2016). His group also corrected for total bladder capacity (voided volume + PVR), understanding that flow rates naturally diminish with underdistention and overdistention of the bladder. Finally, the authors normalized actual flow results to an expected result, which provides for a single number or index by which to judge and classify the result. In this study, 1268 healthy children who were presumed normal voiders were used to create quadratic equations using nonlinear regression for each sex. A flow index was calculated for each patient, and ROC analysis was performed to predict flow pattern. Second voids for each patient were used to verify the resulting predicted flow patterns of either plateau, bell-shaped, or tower in configuration. Specificity to detect each of the predominant flow patterns was high (83% to 97% for males, 66% to 86% for females). Staccato and interrupted patterns (see later) were not classifiable because of irregular flow patterns, and the authors suggest that the ICCS update uroflow nomenclature to make *staccato, interrupted*, and *smooth* each a subtype of the three primary patterns. Table 28.3 provides the necessary equations to calculate the estimated Qmax, the Qmax flow index (FI), and finally the reference ranges to classify each curve as either plateau, bell-shaped, or tower. Voided volumes greater than 50 mL are required to have an interpretable result.

TABLE 28.3

Calculation of Estimated Qmax, Qmax Flow Index,[a] and Reference Ranges to Determine Flow Types

	QUADRATIC EQUATIONS	DERIVATION OF QMAX FI	QMAX FI RANGES FOR CLASSIFICATION		
	ESTIMATED QMAX		PLATEAU	BELL-	TOWER

				SHAPED	
Male	$11.26 + 0.0701(\text{TBC}) - 0.0000513(\text{TBC}^2)$	Actual Qmax/Estimated Qmax	≤0.70	0.71–1.25	>1.25
Female	$10.723 + 0.073(\text{TBC}) - 0.0000423(\text{TBC}^2)$		≤0.68	0.69–1.10	>1.10

[a] Flow index is actual Qmax divided by estimated Qmax.

FI, Flow index.

There are a few caveats that should be mentioned. (1) To obtain an interpretable uroflow, the child must be toilet trained; (2) uroflowmetry only provides information during the elimination phase, not the storage phase; and (3) when voided volume is less than 50% of expected bladder capacity (EBC) for age, the result may not be valid (Austin et al., 2014), although the flow index is valid down to 50 mL (Franco et al., 2016). Finally, it is critical to obtain more than one curve to improve the accuracy, reliability, and interpretation of the test.

Pelvic Ultrasonography

Ultrasonography in children has become a mainstay of diagnosis and workup of voiding dysfunction. It can be particularly useful either as a formal radiology-performed examination (renal and bladder ultrasonography) or in the clinic (prevoid and postvoid pelvic ultrasonography). In patients with non-neurogenic and neurogenic lower urinary tract dysfunction, ultrasonography can be a useful tool to determine which patients might benefit from invasive testing (formal urodynamics). By measuring bladder volumes and wall thicknesses in children with voiding dysfunction, nocturnal enuresis (Yeung et al., 2004), and recurrent urinary tract infections (Yeung et al., 2007), clinicians can predict which children are more likely to have pathology on urodynamics. In children with spina bifida, thickness of the bladder wall has been correlated with higher bladder pressures and decreased compliance on urodynamics, which puts the upper urinary tract at risk for deterioration (Tanaka et al., 2008).

Prevoid and postvoid ultrasonography of the pelvis is quick, painless, and can usually be done in the urology clinic if an adequate machine is available. This allows for a noninvasive and nonionizing method to visualize the bladder and rectum. Relevant measurements are discussed in the following sections.

Bladder Wall Thickness.

Pelvic ultrasonography may show thickened bladder wall (>**5 mm thick when**

empty or >3 mm thick when full) indicating increased detrusor workload during emptying (Fig. 28.8A) (Jequier and Rousseau, 1987). **Measurement can be performed with the bladder empty or full, and wall thickness inversely varies with fullness of the bladder.** Increased wall thickness has been associated with voiding dysfunction, DO, and increased activation of the pelvic floor musculature (Charalampous et al., 2013).

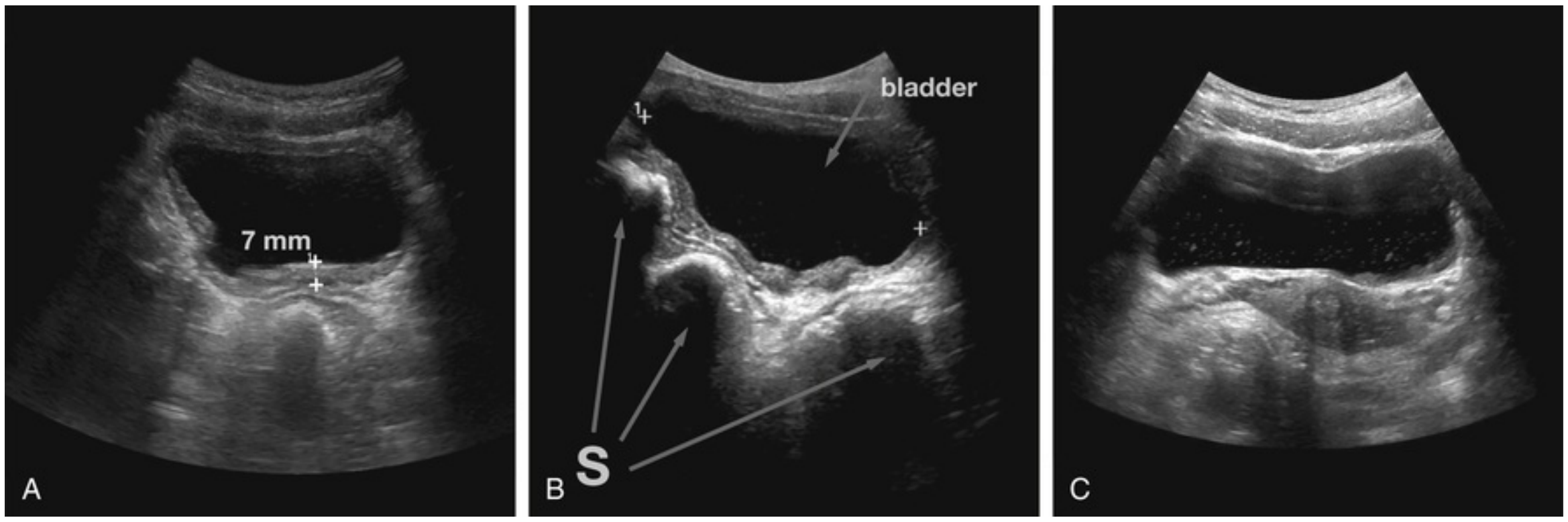

FIG. 28.8 (A) Thickened bladder wall. (B) Large stool balls posterior to the bladder denoted by *'S'* seen in rectum that are distorting the shape of the bladder. These are prominent and visible on pelvic ultrasound. (C) Mobile debris visible within the bladder on pelvic ultrasound.

Yeung et al. reported on bladder ultrasound findings and their correlation to urodynamic findings and treatment outcomes in 514 patients with nocturnal enuresis as compared with 339 healthy age-matched controls (Yeung et al., 2004). Specifically, they measured the bladder volume wall index (BVWI, ratio of bladder volume to wall, normalized to expected, expressed as a percentage) and found that normal BVWI was highly predictive of normal voiding function. Interestingly, the authors found that patients with nocturnal enuresis and normal BVWI had better response to desmopressin therapy than those with abnormal BVWI (<70% = thick-walled, small-capacity bladder or >130% = thin-walled, high-capacity bladder).

Postvoid Residual.

Postvoid residual (PVR) is any urine remaining in the bladder after voiding (or self-catheterization). It is typically calculated from measurements in neurologically intact children. Obtained values can be highly variable from measurement to measurement in the same individual and is adversely affected by bladder overdistention (Chang and Yang, 2008; Yang and Chang, 2008). Chang and Yang suggested that abnormal PVR urine volume should be defined as low as PVR greater than 20 mL on repeat micturitions without bladder overdistention (Chang et al., 2013). In a study of 1128 healthy Taiwanese children between 4 and 12 years of age with a bell-shaped uroflow pattern and a voided volume greater than 50 mL, age-specific cutoffs for normal PVRs were determined. For children 4 to 6 years of age, a single PVR greater than 30 mL or greater than 21% of functional bladder capacity (voided volume + PVR) as a percentage of EBC was deemed abnormal. For children 7 to 12 years of age, a single PVR greater than 20 mL or 15% of EBC was considered elevated.

To be considered a valid measurement of PVR, normative conditions must have been present: the bladder should not be underdistended (<50% EBC) nor overdistended (>115% EBC); PVR should be obtained immediately after voiding (<5 minutes).

Rectal Diameter.

As the rectum is situated behind the bladder, it is typically seen on pelvic ultrasonography. Patients with functional constipation may show a large stercoral bolus (stool ball, see **Fig. 28.8B**) in the rectum, which should be correlated with clinical findings. **Rectal diameter greater than 30 mm in a child without the urge to defecate is suggestive of bowel dysfunction, though rectal diameter alone may not be entirely predictive** (Joensson et al. 2008; M. Y. Berger et al., 2012).

Urinary Debris.

Debris on ultrasonography usually indicates urinary stasis, but it also raises the question as to its relation to possible underlying infection (see Fig. 28.8C). McQuaid et al. studied 3995 patients presenting for voiding cystourethrogram and renal bladder ultrasonography on the same day, for which urine culture was part of the preimaging protocol (McQuaid et al. 2017). In this study, 34 patients with debris were matched to 155 controls, and the authors found a significant correlation on conditional logistic regression between positive urine culture and presence of debris (odds ratio 7.88, 95% CI, 1.88 to 33.04, $P = 0.0048$). Primary limitation of this study is its generalizability given the screening nature of the urine culture in presumably asymptomatic patients. Stevenson et al examined their institutional database for a similar cohort of 445 patients with imaging and urine culture, noting that 20% of patients had a positive urine culture and 22% had debris on imaging (Stevenson et al., 2018). Although the rates differ slightly from the prior study, they found a similarly elevated risk for positive infection in the setting of debris on ultrasonography (relative risk 3.90, 95% CI, 2.73 to 5.55). The authors calculated the sensitivity and specificity for bladder debris to detect a positive urine culture was 52% and 86%, respectively.

Future.

Ultrasonography has the potential to also perform other measurements, such as to assess the viscoelastic properties of the detrusor wall and use this as a correlate to bladder compliance, which is typically measured invasively during formal urodynamics. Nenadic et al. showed proof of principle for this with an ex-vivo model and in-vivo vibrometry measurements in three healthy controls and two patients with neurogenic bladder undergoing simultaneous urodynamics (Nenadic et al., 2016). Compliance measures had high correlation with noninvasive ultrasound bladder vibrometry measurements.

Patch Electromyography

Electromyography (EMG) is typically performed in conjunction with uroflowmetry, but is not routinely used in all urology practices. **EMG, when positioned on the perineum or near the anal sphincter, provides electrical potentials of the pelvic floor musculature, which should become quiescent during voiding** (Fig. 28.9). Lag time is the time from the start of pelvic floor relaxation at the beginning of voiding effort to the start of urine flow. Lag times for children with a full bladder typically range from 2 to 6 seconds (Van Batavia et al., 2011). Shorter lag times less than 2 seconds are associated with DO and symptoms of urgency/frequency (Combs et al., 2013; Van Batavia et al., 2014). Prolonged lag times greater than 6 seconds are associated with primary bladder neck dysfunction (Combs et al., 2005). **The addition of EMG to the urologist's armamentarium allows for greater appreciation of coordination between pelvic floor musculature, sphincteric relaxation, and bladder emptying, thus providing for a noninvasive method to denote synergistic or dysynergic voiding patterns**.

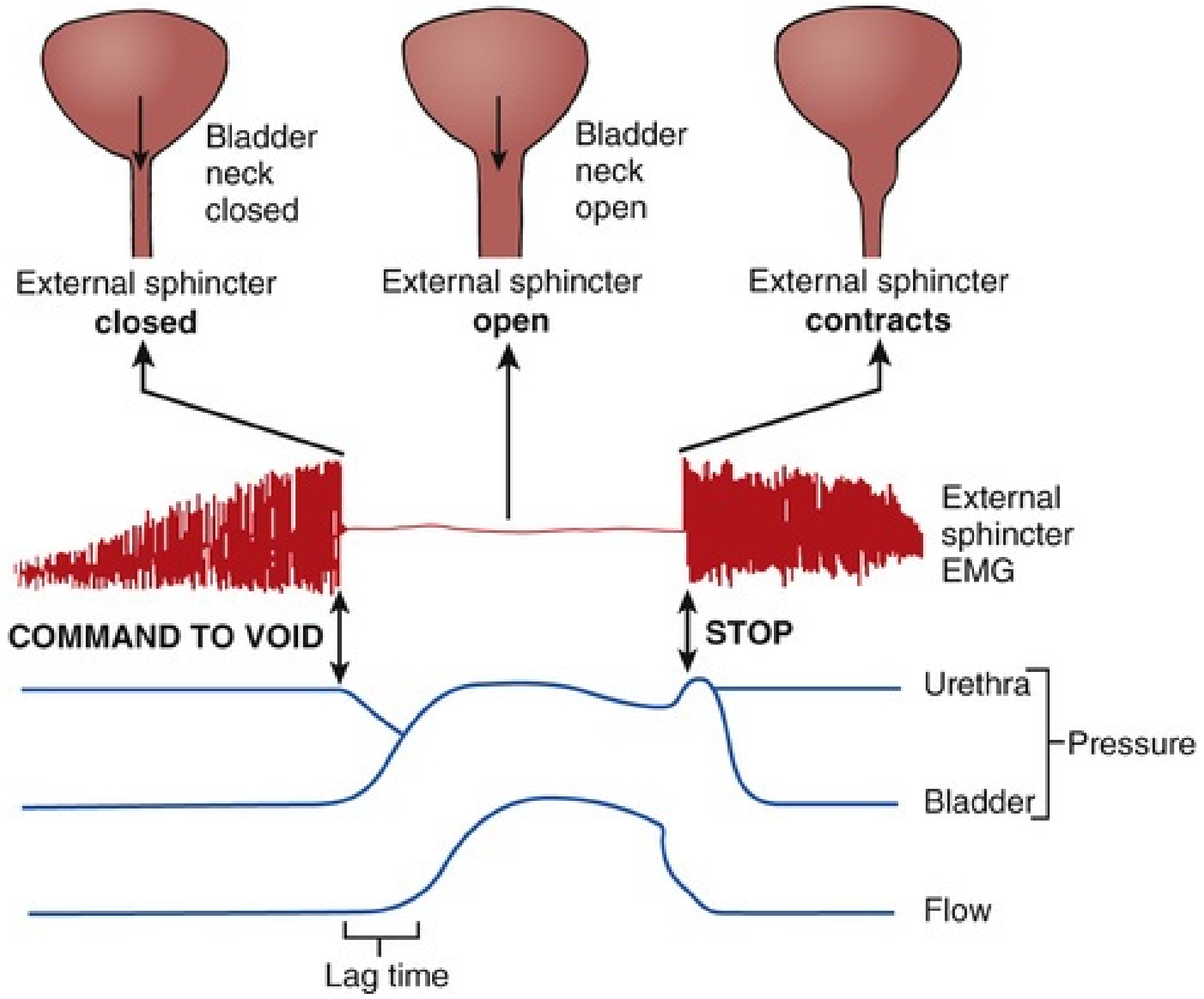
Bladder
neck
closed
External sphincter
closed
Bladder
neck
open
External sphincter
open
External sphincter
contracts
External
sphincter
EMG
COMMAND TO VOID
STOP
Urethra
Pressure
Bladder
Flow
Lag time

FIG. 28.9 Normal physiologic coordinated activity of the bladder and external sphincter (and pelvic floor musculature) during volitional voiding and the expected electromyographic potential. Lag time is also demonstrated. (Modified from Blaivas JG. Pathophysiology of lower urinary tract dysfunction. *Clin Obstet Gynecol*. 1985; 12: 295–309.)

Other Measures

Functional bladder capacity (sometimes referred to as total bladder capacity) is defined as the working, day-to-day capacity of the urinary bladder. It can be obtained a number of ways, including largest volume recorded on voiding diary or by taking voided volume on uroflowmetry plus PVR. Normal cutoffs vary, but typically 70% to 115% (or 130% in some studies) of EBC is considered the normal range (Rushton et al., 1996; Yang and Chang, 2008; Yeung et al., 2004).

Key Points

- Noninvasive urodynamics includes modalities like uroflowmetry, patch electromyography, and pelvic ultrasonography.
- Uroflowmetry provides useful information regarding flow characteristics

during urination, including shape or pattern. Qmax is the most relevant quantitative variable when assessing bladder outflow.

- Ultrasonography is another useful adjunct, noninvasive examination that can provide a number of different clinically important variables, including prevoid and postvoid bladder volumes to calculate PVR, bladder wall thickness, rectal diameter, and presence of debris.
- Electromyography provides for assessing coordination between the bladder and external sphincter to determine whether voiding is synergistic or dyssynergia and can also be used in conjunction with uroflowmetry to determine the lag time.

Formal Urodynamics

Urodynamics in children is not too dissimilar to adult patients, in that it allows for objective information regarding bladder-filling dynamics; bladder compliance; presence of vesicoureteral reflux; other congenital bladder, bladder neck, or urethral anomalies (when performed with fluoroscopy); bladder capacity; bladder pressures; detrusor-sphincter dyssynergia; DO; and PVR. There are no formal recommendations for when urodynamics are indicated in children, and practice patterns vary considerably in the application and routine use of urodynamics to screen, diagnose, and follow various pediatric patient populations. **In patients with known lower urinary tract dysfunction secondary to a congenital or acquired neurologic deficit or caused by severe obstructive uropathy, formal urodynamic studies establish bladder pressures. Similarly, patients with pathologies that might result in neurogenic bladder—particularly those with new-onset lower urinary tract symptoms—should also be thoroughly investigated so as to verify bladder function.**

Common pediatric conditions known to result in neurogenic bladder include spinal dysraphism, sacrococcygeal teratoma, sacral agenesis, transverse myelitis, and spinal cord injury. Lower urinary tract dysfunction also commonly results from severe obstructive processes, such as posterior urethral valves, urethral atresia, or large ectopic ureteroceles. **Studies of pediatric patients with lower urinary tract symptoms in the absence of neuropathy have examined the utility of routine invasive urodynamics and found that significant information was rarely obtained to justify testing** (Hoebeke et al., 2001, Soygur et al., 2004, Kaufman et al., 2006). Studies may be obtained for baseline or surveillance measurements in patients with known disease, may be repeated to reestablish baseline measures before medical or surgical therapies, or may be done to rule in or rule out neurogenic bladder. Many congenital conditions affecting lower urinary tract function result in altered function over time, potentially necessitating repeat urodynamic study (De Gennaro et al., 1998; De Gennaro et al., 2001; Koff et al., 2002). Similarly, providers may opt to repeat studies after implementation of a new medical or surgical therapy to reestablish filling pressures and determine other important urodynamic parameters. **Generally, formal urodynamic testing should be reserved for patients in whom a new or abnormal result will affect treatment options.** Here, we cover some unique considerations in pediatric patients.

Unique Considerations in Pediatric Patients

Knowledgeable and professional staff are critical to successful urodynamic testing in children, who require a “kind, understanding and relaxed atmosphere” (Hjälmås, 1988). Oftentimes, patients will have already had invasive studies or urodynamics testing and will arrive to their appointment with anxiety. Parents should be allowed in the room throughout the study. Television, video games, or interactive tablets can serve as a useful distraction (Drzewiecki and Bauer, 2011). Standardization of the technique is paramount for efficiency and adequate interpretation of results across studies, and Spinoit et al. recently published a short protocol with video explaining standard urodynamics setup and technique in pediatric patients (Spinoit et al., 2016). A typical machine is shown in Fig. 28.6B.

To this end, however, there are still some areas of controversy and variation in practice that are less well defined. One area includes the need for routine urinalysis, urine culture, and/or prophylactic antibiotics before ambulatory urodynamic testing. A large, retrospective review of a single institution in which urine cultures were routinely performed before urodynamic testing demonstrated that there was an increased likelihood of bacteruria in patients with known risk factors (e.g., patients who perform clean intermittent catheterization) (Snow-Lisy et al., 2017). Posturodynamics infection was diagnosed in only 1.4% of patients, although this was in the setting of 21% of patients having received either prophylactic or treatment antibiotics before the test. Risk factors for postprocedure infection included performing intermittent or overnight catheterization, recent clinically diagnosed urinary tract infection, immunosuppression, or symptoms on the day of the procedure. The authors called into question the need for routine urine cultures given the low clinical yield, even in spite of a high rate of bacteruria in that patient population undergoing urodynamics.

A similar study of patients undergoing voiding cystourethrogram showed that the risk for postcystogram infection was about 1% (Johnson et al., 2017). In this study, 50% of patients were taking antibiotics at the time of the test, but counterintuitively, of the 12 patients who developed infection, 11 were taking antibiotics before and up to the procedure. Given the rarity of infection, the study suggests a large proportion of patients were unnecessarily treated.

Finally, a quality improvement initiative was started at another center to selectively identify patients appropriate for screening urinalysis on the basis of symptoms before voiding cystogram (Mouton et al., 2017). Out of 266 urodynamic studies, only 3 met criteria for urinalysis, of which 2 were positive. One test was performed, and the other was rescheduled. **Taken together, routine screening or antibiotic prophylaxis for urinary tract infection before urodynamics in all patients likely constitutes overtreatment.** Select patients with risk factors might benefit from screening, prophylaxis, or empiric treatment, but the data here are also weak. New lower urinary tract symptoms on the day of or leading up to the procedure may prove to be the most rational approach to selective screening for infection before urodynamics, which is a fairly low-risk procedure for subsequent urinary tract infection.

Sedation either for catheter placement or the entire procedure may create concerns about the effects on urodynamic parameters (Sweeney et al., 2008). Urodynamics studies aim to simulate bladder function and compliance. Sedation may alter the bladder's function through altered neurologic pathways or direct pharmaceutical effect on the detrusor muscle. For these reasons, general anesthesia is not recommended, and sedation should be avoided (Wen et al., 2000). Several studies have demonstrated a reduction in detrusor contractions in animal models (Ha et al., 1993; Schaufele et al., 1995). When sedation is required, it may only be needed for insertion of the urodynamic catheters, which can be done in advance of the study. For sedation during cystometry, ketamine may provide some benefits over mizadolam in onset and recovery time and improved effect (Thevaraja et al., 2013). Safety may be improved with ketamine as well over other common sedatives (Bhatt et al., 2017). Bozkurt et al. performed the only study to examine urodynamic results in the same patients with and without sedation (Bozkurt et al., 1996). No significant changes were noted in any urodynamic parameters, although this remained a small sample size and has not been repeated.

The patient should empty the bladder before the study, or urine can be emptied with catheter placement for the bladder instillation. Sitting versus supine positions do not appear to affect measurements (Lorenzo et al., 2007). Lidocaine jelly is used to aid insertion of multichannel or microtranducer pressure catheters into the bladder and rectum, reducing pain and discomfort (Gerard et al., 2003). The smallest-size catheter should be used, typically 6 Fr dual-lumen disposable catheters (Schäfer et al., 2002). For patients with a vesicostomy, a Foley catheter with the balloon inflated can be put on small amount of tension to occlude the bladder. For patients with a catheterizable urinary channel without bladder neck closure, pressure catheters may be placed either through the channel or through the native urethra. Similarly, patients with a colostomy can have the catheter to measure abdominal pressures (P_{abd}) placed in the colostomy as opposed to the rectum (if present). In female patients, the abdominal catheter may be placed in the vagina for comparable results to measure P_{abd} (Schäfer et al, 2002). Patch electrodes are placed symmetrically on the perineum in the 3 and 9 o'clock positions left and right of the anus for electromyography. Patches should be secure to the skin to ensure adequate conductivity. This may be obtained by using alcohol preparation pads and fine abrasive paper before application. EMG was originally described with bipolar perianal muscle needle electrodes; however, these are no longer recommended in children as needle placement causes pain and anxiety, and surface electrodes have been shown to produce similar, accurate results (de Jong and Klijn, 2009; Maizels and Furlit, 1979). Urodynamic systems should be capable of sampling greater than 1000 Hz to allow for accurate clinical discrimination between movement artifact and true sphincter activity (de Jong and Klijn, 2009).

Ambulatory urodynamic monitoring or natural fill cystometry offers an alternative to traditional cystometry with the benefit of natural, physiologic diuresis to fill the bladder and a more natural environment with minimization of Hawthorne effect and physiologic stress but the potential downside of increased time, increased effort, and lack of standardized pediatric protocols and experience (De Gennaro et al., 2008). In one study, 29 infants and young children with a mean age of 3.9 years underwent natural-fill cystometry via a suprapubically placed 6-Fr dual-lumen catheter in the bladder and a 5-Fr vented balloon-tip catheter placed in the rectum 24 hours before testing (Yeung, 1998). In this study, 14 patients underwent conventional study for comparison and demonstrated significant differences in bladder capacity (69.5 vs. 91.6 mL, $P <$

0.02), change in Pdet during filling (8.4 vs. 12.7 cm H_2O, P <0.01), and maximum recorded pressure during micturition (112.8 vs. 89.3 cm H_2O, P <0.01). Another study of healthy children and adult patients demonstrated similar findings that ambulatory testing resulted in lower voided volumes, smaller changes in Pdet during filling, and higher voiding pressures as compared with conventional testing (Robertson et al., 1994).

Unlike adult patients, urodynamics in the pediatric setting must account for a wide variation in estimated bladder capacities, from newborns (30 to 50 mL) to young adults (400 to 500 mL). This is important because urodynamics parameters can be affected by the fill rate, particularly if it is too fast, thus producing artifactual results. Hjalmas noted that **a fill rate of 5% to 10% of EBC per minute appears ideal** (Hjälmås 1988). Saline or contrast medium should not be cold, and rather should be between room temperature and body temperature (Goodman et al., 2003). A randomized controlled trial of room temperature vs body temperature infusate was performed in 91 pediatric patients undergoing urodynamics (Chin-Peuckert et al., 2004). Each patient underwent two filling cycles with order of the infusate randomly selected. No differences were seen in leak point pressures, voiding pressures, or PVR. Room-temperature saline demonstrated higher bladder capacity, and higher pressure at maximum capacity than body-temperature saline, but these differences, although significant, were not felt to be clinically significant. Filling should be stopped when the patient expresses a strong urge to void, discomfort is present, micturition occurs, leakage is greater than the fill rate, detrusor pressures exceed 40 cm H_2O consistently, or the instilled volume has exceeded 150% of the expected capacity (Drzewiecki and Bauer, 2011). Repeat filling cycles in a single setting may be performed with the same or slower fill rate to confirm findings. Prior editions of the International Children's Continence Society guidelines for urodynamic terminology and testing made formal recommendations for two or more filling cycles, but the most recent guidelines (as of 2015) note this can be done at the discretion of the provider (Nørgaard et al., 1998; Bauer et al., 2015). In a study of 70 patients with DO and 42 patients with normal urodynamic parameters, maximum filling pressures and number of contractions varied significantly across three repeated filling cycles on formal urodynamics, with pressures decreasing between the first and third cycle and number of contractions decreasing in subsequent cycles compared with the first (Sözübir et al., 2005). Repeat cycles may prolong the test and lead to further anxiety. Providers should consider the marginal benefit of repeat filling cycles against the information obtained by the first run.

Adding fluoroscopic imaging capabilities to urodynamics is referred to as *video urodynamics*. It requires that a radiopaque contrast agent be used in place of saline for instillation into the bladder. If the capability exists, this technique can increase diagnostic specificity and add more useful information about bladder shape and trabeculations, presence of vesicoureteral reflux or bladder diverticula, and configuration of the bladder neck (open vs. closed) (Glazier et al. 1998). Timing of events like reflux or incontinence can be correlated with visual cues about bladder fullness.

Interpretation of Studies

Interpretation of urodynamics should be done by a trained pediatric urologist, advanced practice provider, or urodynamicist. Intrarater and interrater reliability of interpretation of individual, objective urodynamics parameters was found to be generally good to excellent (intraclass correlation coefficient ranging from 0.74 to 0.99) in an adult multicenter study (Zimmern et al., 2006). Although objective parameters may be largely measured similarly between practitioners, subjective interpretation of pediatric urodynamics shows much poorer agreement (Venhola et al., 2003). Attempts to improve the interpretation through a grading scheme or standardization have been made (MacNeily et al., 2007). Despite these efforts, interpretation of pediatric urodynamic studies remains fairly subjective, even among peers who trained together (Dudley et al. 2017).

Formal urodynamic testing encompasses the storage and voiding phases. During the storage phase, several important parameters are reported, including Pves, Pabd, and Pdet. Pves and Pabd are the reported pressures from the bladder and rectal catheters, respectively. These should be “zeroed” at the beginning of the examination with respect to atmospheric pressure and the height of the pubic symphysis. Pdet is determined by subtracting Pabd from Pves (Pdet = Pves – Pabd). Pdet corresponds to the inferred pressure generated by the detrusor muscle. During normal filling, P_{det} should remain flat without any changes during cough, laugh, or Valsalva. Peaks (rise and fall) in detrusor pressure during filling corresponds to DO. This can be further divided into neuropathic and idiopathic DO, depending on whether neuropathology is present or not. Providers interpreting urodynamics should verify that there was no provocative action that resulted in DO such as cough or Valsalva. These contractions may not be sensed by patients in many cases. In patients with normal sphincteric function, detrusor contractions during filling are usually accompanied by increased contraction of the pelvic floor and external sphincter to guard against leakage, and this can be noted on the EMG strip. Detrusor underactivity is not readily apparent from Pdet, but manifests as large bladder capacity, low filling pressure, and no contractions during filling in combination with absence of a sustained detrusor contraction during attempted voiding with inability to empty.

Bladder compliance is a measure the urodynamic provider should calculate for every patient. Compliance equals bladder volume (ΔV in mL) divided by change in pressure ($\Delta Pdet$ in cm H_2O). Compliance generally refers to the bladder's ability to accommodate an increase in volume with a negligible to small increase in pressure. Compliance cannot be inferred from Pdet measures alone, and providers should be aware that small or contracted bladders with low capacity may not exhibit absolute detrusor pressures that are considered dangerous (>30 to 40 cm H_2O), but when compliance is calculated, it may appear abnormal (<20 mL per cm H_2O) (McGuire et al., 1981; Ghobish, 2001). In this situation, the absolute pressure is likely more useful than compliance to demonstrate safe upper tracts despite small capacity. The shape of the Pdet tracing is also important to consider if it is elevated. If it rises early in the study, this suggests early loss of compliance and may portend unfavorable outcomes for the patient as he or she may spend a majority of the day at higher pressures. The provider should also take time to verify that bladder and abdominal leads were appropriately zeroed to avoid missing abnormal compliance or falsely low Pdet readings. Additionally, compliance may not be readily quantified in the setting of marked DO. To minimize variability, the ICCS recommends identifying the most linear portion of the volume-pressure relationship during the study and using this to calculate compliance (Bauer et al., 2015). Ideally, this measure spans the entire filling phase.

Leak point pressures should also be noted if there is incontinence during the filling phase of the cystometrogram. Leak point pressures come in two varieties and should be distinguished from one another: detrusor leak point pressure (DLPP) and abdominal leak point pressure (ALPP). DLPP is noted when there is incontinence in the absence of increased abdominal pressure and no detrusor contraction (Austin et al., 2014). This measure is more commonly used by pediatric urologists as it denotes the pressure at which “pop off” occurs. If this leakage occurs at low pressures (<40 cm H_2O), then the upper urinary tract is considered safe (McGuire et al., 1981; Landau et al., 1994; Tanaka et al., 1999). Patients with high DLPP (>40 cm H_2O) or no DLPP with high pressures (absence of incontinence during study) are at increased risk for damage to the upper tract because these pressures may be transmitted to the upper tracts. McGuire et al. demonstrated this in pediatric patients with myelodysplasia, in whom the authors demonstrated DLPP greater than 40 cm H_2O, resulted in hydronephrosis or secondary vesicoureteral reflux in 85% of patients (McGuire et al., 1981). **The exact “safe” cutoff has not been defined, but most experts agree that 40 cm H_2O should be considered the upper limit and that providers should strive for the lowest pressure that is reasonably achievable** (Rosier et al., 2013). ALPP is noted when there is incontinence secondary to a rise in abdominal pressure (e.g., cough, laugh, Valsalva) in the absence of a detrusor contraction, and it represents the ability of the bladder outlet to resist increases in Pabd (Austin et al., 2014; McGuire et al., 1993). The pressure is traditionally taken from Pves (as opposed to Pdet). Although most emphasis in pediatric urodynamics is on protecting the upper urinary tract, ALPP is purely a measure of outlet function. Normal ranges of ALPP in children are not available. The closest analog are normal ranges in adult females by McGuire et al. (McGuire et al., 1993). ALPP less than 60 cm H_2O reflects intrinsic sphincter deficiency, 60 to 90 cm H_2O denotes equivocal measure with some component of sphincter deficiency, and greater than 90 cm H_2O translates to no deficiency.

Although DLPP and ALPP are both referred to as leak point pressures, they refer to very different characters of lower urinary tract function. DLPP corresponds to an impaired bladder's response to increased detrusor pressure. Lower DLPP (<40 cm H_2O) is considered safe, and higher readings are concerning for increased likelihood of injury to the upper tract. Stated otherwise, an elevated DLPP refers to a bladder in which pressures are too high before the pop-off mechanism of urethral leakage occurs. ALPP measures outlet resistance (bladder neck and sphincter) to increases in abdominal pressure. Low ALPP signifies intrinsic sphincter deficiency.

Maximum bladder capacity should be noted for any study and corresponds to the volume instilled during the study. This measure may be confounded if there is profound incontinence during filling. This measure should be differentiated from estimated bladder capacity (see earlier) and functional bladder capacity. Functional bladder capacity refers to the volume the bladder typically sees during normal routines before emptying. This is best gained through the use of a voiding diary, also discussed earlier. Abnormal bladder capacity exists when either the maximum or functional bladder capacity is abnormally high (>130%

of estimated bladder capacity) or low (<66% of estimated bladder capacity). Unto itself, abnormal bladder capacity is not necessarily concerning, but will often be present with other urologic or urodynamic findings (e.g., large bladder capacity and infrequent emptying or low bladder capacity and increased Pdet and/or loss of compliance).

If the patient is able to void, several important parameters should be noted during the emptying phase. This portion of urodynamics is referred to as a pressure-flow study. It combines uroflowmetry (discussed earlier) with a pressure study, and just as with uroflowmetry, the results are only valid under normative conditions: patient is able to void, there is minimum voided volume of 50 to 100 mL, and voided volume not less than 50% of functional bladder capacity (de Jong and Klijn, 2009). Flow rate (either Qavg or Qmax measured in mL/s) and voiding pattern should be recorded. Pdet at maximum flow is also important to note. The pressure the detrusor generates to facilitate voiding and flow rate are related to urethral resistance. Elevated Pdet and low Qmax may indicate urethral or bladder outlet obstruction. This may be anatomic (e.g., urethral valves or urethral stricture) in which there is appropriate coordination between relaxation of the pelvic floor and urethral sphincter, or functional (detrusor-sphincter dyssynergia [DSD]) in which there is a detrusor contraction without relaxation of the pelvic floor and urethral sphincter. To differentiate between these two conditions, it is necessary to examine the flow curve, Pdet, and EMG leads together. In DSD, the flow is often intermittent or staccato, the Pdet is higher than expected, and EMG readings show increased activity reflecting nonrelaxation. Normal ranges for Pdet at Qmax in children are similar to adults. Average Pdet at Qmax is 66 cm H_2O in boys and 57 cm H_2O in girls (Schmidt et al., 2002, 2004; Defreitas et al., 2004). Healthy newborn and infant males normally have increased voiding pressures in the presence of a urethral catheter used during urodynamics, and Pdet during voiding may be as high as 118 cm H_2O and 75 cm H_2O for these groups, respectively (Sillén, 2004; Yeung et al., 1995). Finally, PVR should be noted.

To summarize, urodynamic findings that increase the level of concern for injury to the upper urinary tract include: (1) impaired compliance (<10 mL per cm H_2O considered severely impaired, 10 to 20 mL per cm H_2O is moderately impaired, >20 mL per cm H_2O is normal); (2) detrusor sphincter dyssynergia (DSD) coupled with poor emptying, inability to void, and/or elevated voiding pressures; (3) sustained, elevated Pdet during filling; (4) elevated DLPP (>40 cm

H_2O); and (5) elevated voiding pressures in the setting of poor flow.

Frequency of Testing

The CDC National Spina Bifida Patient Registry published a urology protocol in 2016 that discusses, at least from a research perspective, how often centers (21 total centers across the United States as of 2018) will perform various testing in spina bifida patients (Routh et al., 2016). These patients tend to be the most frequent patients who undergo regular urodynamics. The protocol specifies that a baseline study be obtained at around 3 months, and is repeated at 1, 2, and 3 years of age. If there is vesicoureteral reflux or a “hostile” bladder, urodynamics will be repeated yearly thereafter up to 5 years of age. The pediatric urology community hopes to learn more from this registry protocol about the ideal interval of testing in general (e.g., imaging, labs, renal and bladder ultrasonography).

With regard to clinical practice, there are primarily two schools of thought: (1) annual testing with or without imaging (video urodynamics) and (2) limited testing in response to changes in clinical status (e.g., new urinary tract infections, new-onset or worsening incontinence, new-onset or worsening hydronephrosis). One argument against the limited testing approach is that hydronephrosis is not a particularly sensitive indicator of changing bladder dynamics. Kaufman et al. demonstrated this in 1996, when they published on 214 spina bifida patients who had undergone regular renal and bladder ultrasonography and urodynamics (Kaufman et al., 1996). Upper tract hydronephrosis responded well to changing therapy (increased frequency of clean intermittent catheterization or overnight catheter drainage), but on follow-up urodynamics, patients with poor compliance did not show appreciable improvements in urodynamic parameters of the lower urinary tract. In this study, 34 children (16%) went on to have surgery. The counterargument to yearly surveillance urodynamics is the increased cost and the number of studies needed to detect a meaningful change in bladder pressure or compliance to require intervention. Most agree, at a minimum, that regular follow-up of patients with neurogenic bladder is important to ensure safe upper tracts, adequate emptying of the bladder, and minimization of risk for urinary tract infection. Should any of these clinical parameters change, then further investigation is warranted.

Key Points

- Urodynamics is the gold standard for evaluation and diagnosis of lower urinary tract dysfunction.
- Universal strategies of antibiotic prophylaxis or urine cultures before urodynamics do not appear to be effective at preventing postprocedure urinary tract infection, which occurs 1.4% of the time.
- Special considerations in pediatric urodynamics include use of sedation for catheter placement and/or the procedure itself and bladder fill rate, accounting for the varied expected bladder capacities across a wide range of patient ages and sizes.
- Concepts of bladder capacity, Pves, Pabd, Pdet, compliance, timing of loss of compliance, DLPP, ALPP, Pdet at maximum flow, detrusor-sphincter dyssynergia, and PVR are all key components that must be meticulously understood by providers interpreting pediatric urodynamics.
- DLPP and ALPP are different concepts, with DLPP more emphasized in pediatric urodynamic testing as it relates to preservation of or risk to the upper urinary tract.

Evaluation Strategies for Specific Clinical Entities

Lower urinary tract dysfunction encompasses a wide range of diagnoses, pathologies, and possible underlying etiologies. The more common scenarios the pediatric urologist might encounter in practice are discussed here to provide context for clinical evaluation and diagnostic workup.

Non-Neurogenic Lower Urinary Tract Dysfunction

This group includes patients with bowel and bladder dysfunction (overactive and underactive bladder, voiding postponement), nonmonosymptomatic enuresis (daytime urinary symptoms plus nocturnal enuresis), and primary monosymptomatic nocturnal enuresis. These patients may complain of urgency and frequency, and they may have incontinence during the day and/or at night. There is an increased risk for urinary tract infections in these patients, which sometimes confounds the diagnosis. These functional lower urinary tract symptoms may be predominantly storage- or emptying-related.

The large majority of these patients can be diagnosed with a thorough clinical history, physical examination, selective use of noninvasive testing (see later), institution of behavioral and diet changes, and use of appropriate medications targeting the lower urinary tract (e.g., anticholinergics, alpha blockers). Routine use of formal urodynamics in this patient population was found to be low yield, and study information rarely alters choice of therapy in most cases (Parekh et al., 2001). This was confirmed in a prospective manner by the European Bladder Dysfunction Study in 2008 in patients with urgency and voiding dysfunction, who showed no correlation between urodynamics and treatment outcomes (Bael et al., 2008).

There is, however, a small subset of patients who fail conservative, second-line, and even third-line therapies for non-neurogenic voiding dysfunction. Patients with persistent symptoms are at increased likelihood of positive, actionable findings on urodynamics (Kaufman et al., 2006).

Spinal Dysraphism

Many of these patients are referred to urology with a known diagnosis (myelomeningocele accounts for 90% of open spinal dysraphism). Most require ongoing diagnostic study, evaluation, and aggressive treatment to preserve the upper tracts and monitor lower urinary tract dynamics, which change with time (Satar et al., 1995; Kaefer et al., 1999). The more challenging patients are those with possible underlying occult spinal dysraphism (e.g., tethered cord) or other etiologies causing neurogenic bladder. These patients may have only subtle outward evidence of neurologic compromise, and some may only present with changes in the urinary tract. Regardless of the underlying cause, the goal of the urologist is to document and help achieve normal bladder volume, low storage pressures (normal bladder compliance), complete emptying, and adequate protection of the upper urinary tract. Urodynamics is especially useful to this end. Repeat study should be performed before surgical interventions, ensuring that the correct procedure(s) have been planned for the patient.

Sacral Agenesis

Sacral agenesis involves partial or complete absence of the sacrum and is associated with disordered nerve formation at those levels. Patient symptoms vary considerably, as there is no strict correspondence between radiographic and clinical presentation. Nearly one-third of patients remain undiagnosed until later in childhood and present with incontinence, inability to toilet train, or urinary tract infection prompting urologic workup. Examination findings include flattened buttocks, lacking upper portion of the gluteal cleft, and missing sacrum/coccyx on palpation. Diagnosis can be confirmed with a plain radiograph, and this diagnosis may be discovered incidentally in some cases. Urodynamic studies are indicated if voiding dysfunction is present and may show either areflexic bladder with little external sphincter function or DO and concomitant detrusor-sphincter dyssynergia (Guzman et al., 1983).

Anorectal Malformations

Anorectal malformations are commonly associated with abnormalities of the spinal cord like tethering. A tethered spinal cord involves fixation of the conus medularis within the spinal canal, often to L1 or L2. Normally, this structure is freely floating, and termination of the spinal cord rises as children experience axial growth. When fixed, however, the spinal cord is increasingly under traction, and patients may experience gait changes, disordered sensorium of the lower extremities and perineum, and lower urinary tract dysfunction. Although urinary tract symptoms may not be immediately present at birth when the diagnosis of anorectal malformation is made, most recommend a baseline urodynamics study (even in the absence of spinal cord abnormality), particularly after surgical repair (Taskinen et al., 2002; Mosiello et al., 2003). Patients should be monitored and counseled as to changes in urologic function, which should prompt repeat study.

Posterior Urethral Valves

Posterior urethral valves remain the most common underlying cause of lower urinary tract obstruction in boys, and about 15% will progress to have “valve bladder syndrome” (Podestá et al., 2000). In these patients, bladder dysfunction is associated with progressive hydronephrosis and chronic kidney disease (Mitchell, 1982). A large proportion of patients will experience DO and loss of compliance with progression to myogenic failure (Ghanem et al., 2004; Glassberg, 2001; Peters et al., 1990). Patients can also have a component of polyuria secondary to nephrogenic diabetes insipidus that can hamper efforts to maximize bladder emptying. As with other pathologic conditions affecting lower urinary tract function, bladder dynamics in posterior urethral valve patients can change with time. Regular follow-up with urology is important, as changes in clinical status should prompt escalation of care and additional study.

Pelvic Tumors Requiring Extirpation

Resection of pelvic tumors, like sacrococcygeal teratoma, a rare germ cell tumor in neonates, is well-recognized to cause lower urinary tract dysfunction in as many as 50% of patients postoperatively (Malone et al. 1990; Gabra et al., 2006). The proposed mechanism of injury is disruption of the sacral plexus of nerves to the bladder. Urinary symptoms may not be obvious in the newborn period, but ongoing monitoring and high-index of suspicion should be used in these patients to avoid underdiagnosis of bladder dysfunction. Urodynamic testing will often reveal a wide range of pathologies, including DO, detrusor-sphincter dyssynergia, and bladder areflexia (Boemers et al., 1994; Ozkan et al., 2006).

Cerebral Palsy

Voiding dysfunction commonly affects patients with cerebral palsy (up to one-third). The underlying neurologic injury is typically an upper motor neuron lesion, and many these patients present with irritative voiding symptoms (Decter et al., 1987). A standard stepwise approach to workup is warranted in these patients, beginning with a thorough clinical evaluation and implementation of conservative therapies. In select patients who respond poorly to therapy escalation and who desire an improved outcome, urodynamics may be warranted. Common findings at urodynamics include increased bladder capacity, incontinence, detrusor underactivity and overactivity, and rarely sphincter dyssynergia (Mayo, 1992; Richardson and Palmer, 2009).

Spinal Cord Injury

Spinal cord injury causing voiding dysfunction has both an acute and chronic/stabilizing phase. Initially in the acute period after a spinal cord injury, spinal shock results in urinary retention. Implementation of a bladder drainage program should be instituted. A large study of 42 pediatric spinal cord injury patients with at least 1 year of follow-up demonstrated a wide variety of voiding dysfunction phenotypes (Generao et al., 2004). Unsurprisingly, higher lesions (cervical and thoracic) were more associated with detrusor-sphincter dyssynergia than lower lesions (lumbar). In the United Kingdom, guidelines for spinal cord injury workup and management provide that video urodynamics be performed at baseline around 3 to 6 months after the injury, and surveillance urodynamics be performed at follow-up visits for new signs of deterioration, changing management objectives, or follow-up of previously “unsafe” findings (e.g., loss of bladder compliance) (Abrams et al., 2008).

Transverse Myelitis and Other Central Nervous System Disorders

Transverse myelitis is an inflammatory condition of the spinal cord and causes a presentation similar to that of spinal cord injury. There is an acute spinal shock phase followed by a chronic phase. One large series by Tanaka and Kurzrock found that at 7.1 years after onset of disease, 40% to 50% of patients have functional motor recovery, but 86% still had voiding dysfunction, and 77% had complaints of bowel dysfunction (Tanaka et al., 2006). Motor recovery and lower extremity spasticity did not correlate with bladder function. Common findings at initial urodynamics were DO (59%), loss of compliance (47%), sphincter dyssynergia (41%), and detrusor leak point pressure (DLPP) above 40 cm H_2O (12%). The authors recommend early evaluation with ultrasonography and urodynamics with institution of clean intermittent catheterization to preserve the upper tracts.

Acknowledgments

We would like to thank Drs. Paul Austin and Gino Vricella for their contributions to the previous edition of this chapter.

Suggested Readings

Austin PF, Bauer SB, Bower W, et al. The standardization of terminology of lower urinary tract function in children and adolescents: update report from the Standardization Committee of the International Children's Continence Society. *J Urol*. 2014;191(6):1863–1865.e13.

Burgers RE, Mugie SM, Chase J, et al. Management of functional constipation in children with lower urinary tract symptoms: report from the standardization committee of the international children's continence society. *J Urol*. 2013;190(1):29–36.

Chase J, Austin P, Hoebeke P, et al. The management of dysfunctional voiding in children: a report from the Standardisation Committee of the International Children's Continence Society. *J Urol*. 2010;183(4):1296–1302.

Franco I, von Gontard A, De Gennaro M, et al. Evaluation and treatment of nonmonosymptomatic nocturnal enuresis: a standardization document from the International Children's Continence Society. *J Pediatr Urol*. 2013;9(2):234–243.

Hoebeke P, Bower W, Combs A, et al. Diagnostic evaluation of children with daytime incontinence. *J Urol*. 2010;183(2):699–703.

Neveus T, Eggert P, Evans J, et al. Evaluation of and treatment for monosymptomatic enuresis: a standardization document from the International Children's Continence Society. *J Urol*. 2010;183(2):441–447.

von Gontard A, Baeyens D, Van Hoecke E, et al. Psychological and psychiatric issues in urinary and fecal incontinence. *J Urol*. 2011;185(4):1432–1436.

References

Abrams P, Agarwal M, Drake M, et al. A proposed guideline for the urological management of patients with spinal cord injury. *BJU Int*. 2008;101(8):989–994.

Achenbach TM, Ruffle TM. The child behavior checklist and related forms for assessing behavioral/emotional problems and competencies. *Pediatr Rev*. 2000;21(8):265–271.

Akbal C, Genc Y, Burgu B, et al. Dysfunctional voiding and incontinence scoring system: quantitative evaluation of incontinence symptoms in pediatric population. *J Urol*. 2005;173(3):969–973.

Altan M, Çitamak B, Bozaci AC, et al. Is there any difference between questionnaires on pediatric lower urinary tract dysfunction? *Urology*. 2017;103:204–208.

Arya LA, Myers DL, Jackson ND. Dietary caffeine intake and the risk for detrusor instability:a case-control study. *Obstet Gynecol*. 2000;96(1):85–89.

Austin PF, Bauer SB, Bower W, et al. The standardization of terminology of lower urinary tract function in children and adolescents: update report from the Standardization Committee of the International Children's Continence Society. *J Urol*. 2014;191(6):1863–1865.e13.

Bael A, Lax H, de Jong TP, et al. The relevance of urodynamic studies for urge syndrome and dysfunctional voiding:a multicenter controlled trial in children. *J Urol*. 2008;180(4):1486–1495.

Bauer SB, Nijman RJ, Drzewiecki BA, International Children's Continence Society Standardization Subcommittee, et al. International Children's Continence Society standardization report on urodynamic studies of the lower urinary tract in children. *Neurourol Urodyn*. 2015;34(7):640–647.

Ben-Sira L, Ponger P, Miller E, et al. Low-risk lumbar skin stigmata in infants: the role of ultrasound screening. *J Pediatr*. 2009;155(6):864–869.

Berger RM, Maizels M, Moran GC, et al. Bladder capacity (ounces) equals age (years) plus 2 predicts normal bladder capacity and aids in diagnosis of abnormal voiding patterns. *J Urol*. 1983;129(2):347–349.

Berger MY, Tabbers MM, Kurver MJ, et al. Value of abdominal radiography, colonic transit time, and rectal ultrasound scanning in the diagnosis of idiopathic constipation in children: a systematic review. *J Pediatr*. 2012;161(1) [44–50.e1–2].

Bhatt M, Johnson DW, Chan J, et al. Risk factors for adverse events in emergency department procedural sedation for children. *JAMA Pediatr*. 2017;171(10):957–964.

Boemers TM, van Gool JD, de Jong TP, et al. Lower urinary tract dysfunction in children with benign sacrococcygeal teratoma. *J Urol*. 1994;151(1):174–176.

Bower WF, Sit FKY, Bluyssen N, et al. PinQ: a valid, reliable and reproducible quality-of-life measure in children with bladder dysfunction. *J Pediatr Urol*. 2006;2(3):185–189.

Bower WF, Wong EMC, Yeung CK. Development of a validated quality of life tool specific to children with bladder dysfunction. *Neurourol Urodyn*. 2006;25(3):221–227.

Bozkurt P, Kilic N, Kaya G, et al. The effects of intranasal midazolam on urodynamic studies in children. *Br J Urol*. 1996;78(2):282–286.

Burgers RE, Mugie SM, Chase J, et al. Management of functional constipation in children with lower urinary tract symptoms: report from the Standardization Committee of the International Children's Continence Society. *J Urol*. 2013;190(1):29–36.

Chang SJ, Chiang IN, Hsieh CH, et al. Age- and gender-specific nomograms for single and dual post-void residual urine in healthy children. *Neurourol Urodyn*. 2013;32(7):1014–1018.

Chang SJ, Yang SS. Inter-observer and intra-observer agreement on interpretation of uroflowmetry curves of kindergarten children. *J Pediatr Urol*. 2008;4(6):422–427.

Charalampous S, Printza N, Hashim H, et al. Bladder wall thickness and urodynamic correlation in children with primary nocturnal enuresis. *J Pediatr Urol*. 2013;9(3):334–338.

Chin-Peuckert L, Rennick JE, Jednak R, et al. Should warm infusion solution be used for urodynamic studies in children? A prospective randomized study. *J Urol*. 2004;172(4 Pt 2):1657–1661 [discussion 1661].

Cole TJ. Weight-stature indices to measure underweight, overweight, and obesity. Anthropometric assessment of nutritional status. Himes JH. *Anthropometric assessment of nutritional status*. Alan R Liss: New York, NY; 1991:83–111.

Combs AJ, Grafstein N, Horowitz M, et al. Primary bladder neck dysfunction in children and adolescents I: pelvic floor electromyography lag time—a new noninvasive method to screen for and monitor therapeutic response. *J Urol*. 2005;173(1):207–210 [discussion 210–211].

Combs AJ, Van Batavia JP, Horowitz M, et al. Short pelvic floor electromyographic lag time: a novel noninvasive approach to document detrusor overactivity in children with lower urinary tract symptoms. *J Urol*. 2013;189(6):2282–2286.

De Gennaro M, Capitanucci ML, Capozza N, et al. Detrusor hypocontractility in children with posterior urethral valves arises before puberty. *Br J Urol*. 1998;81(Suppl 3):81–85.

De Gennaro M, Capitanucci ML, Silveri M, et al. Detrusor hypocontractility evolution in boys with posterior urethral valves detected by pressure flow analysis. *J Urol*. 2001;165:2248–2252.

De Gennaro M, Capitanucci ML, Silveri M, et al. Continuous (6 hour) urodynamic monitoring in children with neuropathic bladder. *Eur J Pediatr Surg*. 2008;6:21–24.

de Jong TP, Klijn AJ. Urodynamic studies in pediatric urology. *Nat Rev Urol*. 2009;6(11):585–594.

Decter RM, Bauer SB, Khoshbin S, et al. Urodynamic assessment of children with cerebral palsy. *J Urol*. 1987;138(4):1110–1112.

Defreitas GA, Zimmern PE, Lemack GE, et al. Refining diagnosis of anatomic female bladder outlet obstruction: comparison of pressure-flow study parameters in clinically obstructed women with those of normal controls. *Urology*. 2004;64(4):675–679 [discussion 679–681].

Deshpande AV, Craig JC, Smith GH, et al. Factors influencing quality of life in children with urinary incontinence. *J Urol*. 2011;186(3):1048–1052.

Drolet BA, Boudreau C. When good is not good enough: the predictive value of cutaneous lesions of the lumbosacral region for occult spinal dysraphism. *Arch Dermatol*. 2004;140(9):1153–1155.

Drossman DA. Functional gastrointestinal disorders: history, pathophysiology, clinical features, and Rome IV. *Gastroenterology*. 2016;150(6):1262–1279.e2.

Drossman DA, Hasler WL. Rome IV-functional gi disorders: disorders of gut-brain interaction. *Gastroenterology*. 2016;150(6):1257–1261.

Drzewiecki BA, Bauer SB. Urodynamic testing in children: indications, technique, interpretation and significance. *J Urol*. 2011;186(4):1190–1197.

Dudley AG, Casella DP, Lauderdale CJ, et al. Interrater reliability in pediatric urodynamic tracings: a pilot study. *J Urol*. 2017;197(3):865–870.

Fairhurst JJ, Rubin CM, Hyde I, et al. Bladder capacity in infants. *J Pediatr Surg*. 1991;26(1):55–57.

Farage M, Maibach H. Lifetime changes in the vulva and vagina. *Arch Gynecol Obstet*. 2005;273(4):195–202.

Farhat W, Bägli DJ, Capolicchio G, et al. The dysfunctional voiding scoring system: quantitative standardization of dysfunctional voiding symptoms in children. *J Urol*. 2000;164(3 Pt 2):1011–1115.

Franco I, Shei-Dei Yang S, Chang SJ, et al. A quantitative approach to the interpretation of uroflowmetry in children. *Neurourol Urodyn*. 2016;35(7):836–846.

Gabra HO, Jesudason EC, McDowell HP, et al. Sacrococcygeal teratoma—a 25-year experience in a UK regional center. *J Pediatr Surg*. 2006;41(9):1513–1516.

Gauthier M, Gouin S, Phan V, et al. Association of malodorous urine with urinary tract infection in children aged 1 to 36 months. *Pediatrics*. 2012;129(5):885–890.

Generao SE, Dall'Era JP, Stone AR, et al. Spinal cord injury in children: long-term urodynamic and urological outcomes. *J Urol*. 2004;172(3):1092–1094 [discussion 1094].

Gerard LL, Cooper CS, Duethman KS, et al. Effectiveness of lidocaine lubricant for discomfort during pediatric urethral catheterization. *J Urol*. 2003;170(2 Pt 1):564–567.

Ghanem MA, Wolffenbuttel KP, De Vylder A, et al. Long-term bladder dysfunction and renal function in boys with posterior urethral valves based on urodynamic findings. *J Urol*. 2004;171(6):2409–2412.

Ghobish AG. Storage detrusor pressure in bilateral hydroureteronephrosis. *Eur Urol*. 2001;39(5):571–574.

Glassberg KI. The valve bladder syndrome: 20 years later. *J Urol*. 2001;166(4):1406–1414.

Glazier DB, Murphy DP, Fleisher MH, et al. Evaluation of the utility of video-urodynamics in children with urinary tract infection and voiding dysfunction. *J Urol*. 1998;160(1):281–

282.
Goodman TR, Kilborn T, Pearce R. Warm or cold contrast medium in the micturating cystourethrogram (MCUG): which is best? *Clin Radiol*. 2003;58(7):551–554.
Guggisberg D, Hadj-Rabia S, Viney C, et al. Skin markers of occult spinal dysraphism in children:a review of 54 cases. *Arch Dermatol*. 2004;140(9):1109–1115.
Gupta D, Sankhwar SN, Goel A. Uroflowmetry nomograms for healthy children 5 to 15 years old. *J Urol*. 2013;190(3):1008–1014.
Guzman L, Khoshbin S, Bauer SB, et al. Evaluation and management of children with sacral agenesis. *Urology*. 1983;22(5):506–510.
Ha JH, Lee KY, Kim WJ. The action of diazepam in the isolated rat detrusor muscle. *J Urol*. 1993;150(1):229–234.
Hjälmås K. Urodynamics in normal infants and children. *Scand J Urol Nephrol Suppl*. 1988;114:20–27.
Hoebeke P, Bower W, Combs A, et al. Diagnostic evaluation of children with daytime incontinence. *J Urol*. 2010;183(2):699–703.
Hoebeke P, Van Laecke E, Everaert K, et al. Transcutaneous neuromodulation for the urge syndrome in children: a pilot study. *J Urol*. 2001;166(6):2416–2419.
Hoebeke P, Van Laecke E, Raes A, et al. Anomalies of the external urethral meatus in girls with non-neurogenic bladder sphincter dysfunction. *BJU Int*. 1999;83(3):294–298.
Hoebeke P, Van Laecke E, Van Camp C, et al. One thousand video-urodynamic studies in children with non-neurogenic bladder sphincter dysfunction. *BJU Int*. 2001;87(6):575–580.
Hughes JA, De Bruyn R, Patel K, et al. Evaluation of spinal ultrasound in spinal dysraphism. *Clin Radiol*. 2003;58(3):227–233.
Jequier S, Rousseau O. Sonographic measurements of the

normal bladder wall in children. *AJR Am J Roentgenol*. 1987;149(3):563–566.

Joensson IM, Siggaard C, Rittig S, et al. Transabdominal ultrasound of rectum as a diagnostic tool in childhood constipation. *J Urol*. 2008;179(5):1997–2002.

Johnson EK, Malhotra NR, Shannon R, et al. Urinary tract infection after voiding cystourethrogram. *J Pediatr Urol*. 2017;13(4):384.e1–384.e7.

Kaefer M, Pabby A, Kelly M, et al. Improved bladder function after prophylactic treatment of the high risk neurogenic bladder in newborns with myelomeningocele. *J Urol*. 1999;162(3):1068–1071.

Kanematsu A, Kazuyoshi J, Yoshimura K, et al. Objective patterning of uroflowmetry curves in children with daytime and nighttime wetting. *J Urol*. 2010;184(4 Suppl):1674–1679.

Kaufman MR, DeMarco RT, Pope JC 4th, et al. High yield of urodynamics performed for refractory nonneurogenic dysfunctional voiding in the pediatric population. *J Urol*. 2006;176(4):1835–1837.

Kaufman M, Ritchey ML, Roberts AC, et al. Decreased bladder compliance in patients with myelomeningocele treated with radiological observation. *J Urol*. 1996;156(6):2031–2033.

Kemper KJ, Avner ED. The case against screening urinalyses for asymptomatic bacteriuria in children. *Am J Dis Child*. 1992;146(3):343–346.

Klijn AJ, Bochove-Overgaauw D, Winkler-Seinstra PL, et al. Urethral meatus deformities in girls as a factor in dysfunctional voiding. *Neurourol Urodyn*. 2012;31(7):1161–1164.

Koff SA. Estimating bladder capacity in children. *Urology*. 1983;21(3):248.

Koff SA, Mutabagani KH, Jayanthi VR. The valve bladder syndrome: pathophysiology and treatment with nocturnal bladder emptying. *J Urol*. 2002;167(1):291–297.

Kriss VM, Desai NS. Occult spinal dysraphism in neonates:assessment of high-risk cutaneous stigmata on sonography. *AJR Am J Roentgenol*. 1998;171(6):1687–1692.

Landau EH, Churchill BM, Jayanthi VR, et al. The sensitivity of pressure specific bladder volume versus total bladder capacity as a measure of bladder storage dysfunction. *J Urol*. 1994;152(5 Pt 1):1578–1581.

Lane MM, Czyzewski DI, Chumpitazi BP, et al. Reliability and validity of a modified Bristol stool form scale for children. *J Pediatr*. 2011;159(3):437–441.e1.

Leclair MD, Héloury Y. Non-neurogenic elimination disorders in children. *J Pediatr Urol*. 2010;6(4):338–345.

Leung AKC, Robson WLM. Labial fusion and asymptomatic bacteriuria. *Eur J Pediatr*. 1993;152(3):250–251.

Lewis SJ, Heaton KW. Stool form scale as a useful guide to intestinal transit time. *Scand J Gastroenterol*. 1997;32(9):920–924.

Lorenzo AJ, Wallis MC, Anthony Cook A, et al. What is the variability in urodynamic parameters with position change in children? Analysis of a prospectively enrolled cohort. *J Urol*. 2007;178(6):2567–2570.

MacNeily AL, Leonard MP, Metcalfe PD, et al. Development of an objective score to quantify the pediatric cystometrogram. *J Urol*. 2007;178(4):1752–1757.

Maizels M, Firlit CF. Pediatric urodynamics: a clinical comparison of surface versus needle pelvic floor/external sphincter electromyography. *J Urol*. 1979;122(4):518–522.

Malm-Buatsi E, Nepple KG, Boyt MA, et al. Efficacy of transcutaneous electrical nerve stimulation in children with overactive bladder refractory to pharmacotherapy. *Urology*. 2007;70(5):980–983.

Malone PS, Spitz L, Kiely EM, et al. The functional sequelae of sacrococcygeal teratoma. *J Pediatr Surg*. 1990;25(6):679–680.

Mayo ME. Lower urinary tract dysfunction in cerebral palsy. *J Urol*. 1992;147(2):419–420.

McGuire EJ, Fitzpatrick CC, Wan J, et al. Clinical assessment of urethral sphincter function. *J Urol*. 1993;150(5 Pt 1):1452–1454.

McGuire EJ, Woodside JR, Borden TA, et al. Prognostic value of urodynamic testing in myelodysplastic patients. *J Urol*. 1981;126(2):205–209.

McQuaid JW, Kurtz MP, Logvinenko T, et al. Bladder debris on renal and bladder ultrasound: a significant predictor of positive urine culture. *J Pediatr Urol*. 2017;13(4):385.e1–385.e5.

Mitchell ME. Persistent ureteral dilatation following valve resection. *Dial Pediatr Urol*. 1982;5:8–11.

Mosiello G, Capitanucci ML, Gatti C, et al. How to investigate neurovesical dysfunction in children with anorectal malformations. *J Urol*. 2003;170(4 Pt 2):1610–1613.

Mouton D, Adeyiga AO, Cefaratti M. Should you skip the dip? A VCUG Performance Improvement Project. *J Radiol Nurs*. 2017;36(1):15–20.

Nelson CP, Park JM, Bloom DA, et al. Incontinence symptom index—pediatric: development and initial validation of a urinary incontinence instrument for the older pediatric population. *J Urol*. 2007;178(4):1763–1767.

Nenadic I, Mynderse L, Husmann D, et al. Noninvasive evaluation of bladder wall mechanical properties as a function of filling volume: potential application in bladder compliance assessment. *PLoS ONE*. 2016;11(6):e0157818.

Nevéus T, von Gontard A, Hoebeke P, et al. The standardization of terminology of lower urinary tract function in children and adolescents: report from the Standardisation Committee of the International Children's Continence Society. *J Urol*. 2006;176(1):314–324.

Nørgaard JP, van Gool JD, Hjälmås K, et al. Standardization and definitions in lower urinary tract dysfunction in children. *Br J Urol*. 1998;81(Suppl 3):1–16.

Oliver JL, Campigotto MJ, Coplen DE, et al. Psychosocial comorbidities and obesity are associated with lower urinary tract symptoms in children with voiding dysfunction. *J Urol*. 2013;190(4 Suppl):1511–1515.

Ozkan KU, Bauer SB, Khoshbin S, et al. Neurogenic bladder dysfunction after sacrococcygeal teratoma resection. *J Urol*. 2006;175(1):292–296.

Parekh DJ, Pope JC, Adams MC, et al. The use of radiography, urodynamic studies and cystoscopy in the evaluation of voiding dysfunction. *J Urol*. 2001;165(1):215–218.

Peters CA, Bolkier M, Bauer SB, et al. The urodynamic consequences of posterior urethral valves. *J Urol*. 1990;144(1):122–126.

Peterson CM, Su H, Thomas DM, et al. Tri-ponderal mass index vs body mass index in estimating body fat during adolescence. *JAMA Pediatr*. 2017;171(7):629–636.

Podestá ML, Ruarte A, Gargiulo C, et al. Urodynamic findings in boys with posterior urethral valves after treatment with primary valve ablation or vesicostomy and delayed ablation. *J Urol*. 2000;164(1):139–144.

Quetelet AD. *Physique Sociale Ou Essai Sur Le Développement Des Facultés De L'homme*. [Muquardt C. ed] 1869.

Rasquin A, Di Lorenzo C, Forbes D, et al. Childhood functional gastrointestinal disorders: child/adolescent. *Gastroenterology*. 2006;130(5):1527–1537.

Richardson I, Palmer LS. Clinical and urodynamic spectrum of bladder function in cerebral palsy. *J Urol*. 2009;182(4

Suppl):1945–1948.

Robertson AS, Griffiths CJ, Ramsden PD, et al. Bladder function in healthy volunteers: ambulatory monitoring and conventional urodynamic studies. *Br J Urol*. 1994;73:242–249.

Rosier PFWM, Kuo HC, De Gennaro M, et al. Urodynamic testing. Abrams P, Cardoza L, Khoury S, et al. *Incontinence: 5th international consultation on incontinence*. Health Publication: Plymouth, UK; 2013:429–506.

Roth EB, Austin PF. Evaluation and treatment of nonmonosymptomatic enuresis. *Pediatr Rev*. 2014;35(10):430–436 [quiz 437–438].

Roth TJ, Vandersteen DR, Hollatz P, et al. Sacral neuromodulation for the dysfunctional elimination syndrome: a single center experience with 20 children. *J Urol*. 2008;180(1):306–311.

Routh JC, Cheng EY, Austin JC, et al. Design and methodological considerations of the centers for disease control and prevention urologic and renal protocol for the newborn and young child with spina bifida. *J Urol*. 2016;196(6):1728–1734.

Rushton HG, Belman AB, Zaontz MR, et al. The influence of small functional bladder capacity and other predictors on the response to desmopressin in the management of monosymptomatic nocturnal enuresis. *J Urol*. 1996;156(2 Pt 2):651–655.

Sanders C, Driver CP, Rickwood AMK. The anocutaneous reflex and urinary continence in children with myelomeningocele. *BJU Int*. 2002;89(7):720–721.

Satar N, Bauer SB, Shefner J, et al. The effects of delayed diagnosis and treatment in patients with an occult spinal dysraphism. *J Urol*. 1995;154(2):754–758.

Sawin KJ, Liu T, Ward E, et al. The national spina bifida patient registry: profile of a large cohort of participants from the first 10 clinics. *J Pediatr*. 2015;166(2):444–450.e1.

Schäfer W, Abrams P, Liao L, et al. Good urodynamic practices: uroflowmetry, filling cystometry, and pressure-flow studies. *Neurourol Urodyn*. 2002;21(3):261–274.

Schaufele P, Schumacher E, Acevedo CG, et al. Diazepam, adenosine analogues and calcium channel antagonists inhibit the contractile activity of the mouse urinary bladder. *Arch Int Pharmacodyn Ther*. 1995;329(3):454–466.

Scheible W, James HE, Leopold GR, et al. Occult spinal dysraphism in infants: screening with high-resolution real-time ultrasound. *Radiology*. 1983;146(3):743–746.

Schmidt F, Jorgensen TM, Djurhuus JC. Twenty-four-hour ambulatory urodynamics in healthy young men. *Scand J Urol Nephrol*. 2004;215:75–83.

Schmidt F, Shin P, Jørgensen TM, et al. Urodynamic patterns of normal male micturition: influence of water consumption on urine production and detrusor function. *J Urol*. 2002;168(4 Pt 1):1458–1463.

Schober MS, Sulkowski JP, Lu PL, et al. Sacral nerve stimulation for pediatric lower urinary tract dysfunction: development of a standardized pathway with objective urodynamic outcomes. *J Urol*. 2015;194(6):1721–1727.

Sillén U. Bladder function in infants. *Scand J Urol Nephrol*. 2004;215:69–74.

Snow-Lisy DC, Halline C, Johnson EK, et al. Reassessing the utility of routine urine culture with urodynamics:uti incidence and risk factors. *J Pediatr Urol*. 2017;13(4):372.e1–372.e8.

Soygür T, Arikan N, Tokatli Z, et al. The role of video-urodynamic studies in managing nonneurogenic voiding dysfunction in children. *BJU Int*. 2004;93(6):841–843.

Sözübir S, Celik A, Emir N, et al. Consistency of urodynamic parameters in children with detrusor instability: how many times should the bladder be filled? *Urol Int*. 2005;75:129–132.

Spinoit AF, Decalf V, Ragolle I, et al. Urodynamic studies in children: standardized transurethral video-urodynamic evaluation. *J Pediatr Urol*. 2016;12(1):67–68.

Stevenson SM, Lau GA, Andolsek WC, et al. Bladder debris on ultrasound as a predictor for positive urine culture in a pediatric population. *J Pediatr Urol*. 2018;14(3):254.e1–254.e5.

Struthers S, Scanlon J, Parker K, et al. Parental reporting of smelly urine and urinary tract infection. *Arch Dis Child*. 2003;88(3):250–252.

Sweeney H, Rzepski B, Hochman H, et al. Identifying characteristics of children requiring sedation for urodynamics. *Urol Nurs*. 2008;28(4):269–272.

Szabo L, Fegyverneki S. Maximum and average urine flow rates in normal children—the Miskolc nomograms. *Br J Urol*. 1995;76(1):16–20.

Tanaka H, Kakizaki H, Kobayashi S, et al. The relevance of urethral resistance in children with myelodysplasia: its impact on upper urinary tract deterioration and the outcome of conservative management. *J Urol*. 1999;161(3):929–932.

Tanaka H, Matsuda M, Moriya K, et al. Ultrasonographic measurement of bladder wall thickness as a risk factor for upper urinary tract deterioration in children with myelodysplasia. *J Urol*. 2008;180(1):312–316.

Tanaka ST, Stone AR, Kurzrock EA. Transverse myelitis in children: long-term urological outcomes. *J Urol*. 2006;175(5):1865–1868.

Taskinen S, Valanne L, Rintala R. Effect of spinal cord abnormalities on the function of the lower urinary tract in patients with anorectal abnormalities. *J Urol*. 2002;168(3):1147–1149.

Thevaraja AK, Batra YK, Rakesh SV, et al. Comparison of low-dose ketamine to midazolam for sedation during pediatric urodynamic study. *Paediatr Anaesth*. 2013;23(5):415–421.

Thibadeau JK, Ward EA, Soe MM, et al. Testing the feasibility of a National Spina Bifida Patient Registry. *Birth Defects Res A Clin Mol Teratol*. 2013;97(1):36–41.

Thibodeau BA, Metcalfe P, Koop P, et al. Urinary incontinence and quality of life in children. *J Pediatr Urol*. 2013;9(1):78–83.

Van Batavia JP, Combs AJ, Glassberg KI. Short pelvic floor EMG lag time II: use in management and follow-up of children treated for detrusor overactivity. *J Pediatr Urol*. 2014;10(2):255–261.

Van Batavia JP, Combs AJ, Hyun G, et al. Simplifying the diagnosis of 4 common voiding conditions using uroflow/electromyography, electromyography lag time and voiding history. *J Urol*. 2011;186(4 Suppl):1721–1726.

Van De Beek C, Stoevelaar HJ, McDonnell J, et al. Interpretation of uroflowmetry curves by urologists. *J Urol*. 1997;157(1):164–168.

Van Hoecke E, Baeyens D, Vanden Bossche H, et al. Early detection of psychological problems in a population of children with enuresis: construction and validation of the short screening instrument for psychological problems in enuresis. *J Urol*. 2007;178(6):2611–2615.

Venhola M, Reunanen M, Taskinen S, et al. Interobserver and intra-observer agreement in interpreting urodynamic measurements in children. *J Urol*. 2003;169(6):2344–2346.

Vijverberg MA, Klijn AJ, Rabenort A, et al. A comparative analysis of pediatric uroflowmetry curves. *Neurourol Urodyn*. 2011;30(8):1576–1579.

Vodušek DB, Deletis V. Intraoperative neurophysiological monitoring of the sacral nervous system. *Neurophys*

Neurosurg. 2002;197–217.

von Gontard A, Baeyens D, Van Hoecke E, et al. Psychological and psychiatric issues in urinary and fecal incontinence. *J Urol*. 2011;185(4):1432–1436.

Wen JG, Yeung CK, Djurhuus JC. Cystometry techniques in female infants and children. *Int Urogynecol J*. 2000;11(2):103–112.

Williams TS, Callen JP, Owen LG. Vulvar disorders in the prepubertal female. *Pediatr Ann*. 1986;15(8):588–589 [592–601, 604–605].

Yang SS, Chang SJ. The effects of bladder over distention on voiding function in kindergarteners. *J Urol*. 2008;180(5):2177–2182 [discussion 2182].

Yang SS, Chiang IN, Hsieh CH, et al. The Tzu Chi nomograms for maximum urinary flow rate (Qmax) in children: comparison with Miskolc nomogram. *BJU Int*. 2014;113(3):492–497.

Yerkes EB. Urologic issues in the pediatric and adolescent gynecology patient. *Obstet Gynecol Clin North Am*. 2009;36(1):69–84.

Yeung CK. Continuous real-time ambulatory urodynamic monitoring in infants and young children using infrared telemetry. *Br J Urol*. 1998;81(Suppl 3):76–80.

Yeung CK, Godley ML, Ho CK, et al. Some new insights into bladder function in infancy. *Br J Urol*. 1995;76(2):235–240.

Yeung CK, Sreedhar B, Leung VT, et al. Ultrasound bladder measurements in patients with primary nocturnal enuresis: a urodynamic and treatment outcome correlation. *J Urol*. 2004;171(6 Pt 2):2589–2594.

Yeung CK, Sreedhar B, Leung YF, et al. Correlation between ultrasonographic bladder measurements and urodynamic findings in children with recurrent urinary tract infection. *Br J Urol*. 2007;99(3):651–655.

Zimmern P, Nager CW, Albo M, et al. Interrater reliability of filling cystometrogram interpretation in a multicenter study. *J Urol*. 2006;175(6):2174–2177.

29

Management Strategies for Vesicoureteral Reflux

Antoine E. Khoury MD, FRCSC, FAAP, Elias Wehbi MD, FRCSC

Vesicoureteral reflux (VUR) is the retrograde flow of urine from the bladder to the upper urinary tract. Despite VUR being a relatively common condition, there are many clinical challenges that arise. VUR has been associated with upper tract damage, such as the presence of scarring, and can be associated with congenital renal dysplasia. Historically, it has been treated in a relatively dichotomous fashion, however, more recently, there is emerging literature on the need to view VUR as a spectrum of disease and to treat those with the condition more on the basis of risk stratification. Despite multiple large randomized studies, which have attempted to address several key issues with the medical management of VUR, there remain many unresolved questions regarding the etiology, diagnosis, and medical management of VUR.

This chapter sheds light on these many issues, which have arisen and continue to evolve and offer a perspective to the modern medical management of VUR in children.

Historical Perspective

VUR has a unique distinction of having evolved from an anatomic curiosity around the first century AD into one of the most contentious and complex areas of urology today. Galen and da Vinci made the first references to VUR by Western medicine when they alluded to the ureterovesical junction (UVJ) as a mediator of unidirectional flow of urine from the kidneys to the bladder. Although VUR was first demonstrated to be a normal finding in dogs and rabbits by Semblinow in 1907, it was a gynecologic misadventure that revealed to Pozzi in 1893 that VUR in human adults may not be a normal state (A Treatise on Gynaecology: v. 3, 1893). In 1907, Sampson suggested that the oblique course of the ureter through the bladder wall created a locking mechanism at the UVJ and also was the first to imply that VUR might lead to renal infection. Although Young was able to uniformly demonstrate VUR in all people in cadaveric studies performed in the late 19th century, it was Gruber who was able to dissect the UVJ more clearly and realized the incidence of VUR varied with the length of the ureter in the bladder and the formation of the trigone (Gruber, 1929).

Pivotal discoveries occurred when Hutch reported on a relationship between VUR and chronic pyelonephritis in paraplegic patients, and Hodson observed that urinary tract infection (UTI) and renal scarring carried a high likelihood of VUR in children (Hutch, 1952, 2002; Hodson, 1959).

Two seminal bodies of work defined the modern era of VUR. First, Ransley and Risdon defined the pathophysiology of reflux nephropathy by demonstrating the relationship between infection, reflux, and pyelonephritic scarring (Ransley and Risdon, 1979). Second, these observations complemented the clinical studies of Smellie et al., who galvanized the related concepts inherent in clinical UTI, bacterial pyelonephritis, renal scarring, and VUR (Smellie et al., 1991). In 1985, a consensus system for the grading of reflux was published by Lebowitz et al. on the basis of the International Reflux Study Group's deliberations (Lebowitz, et al., 1985).

The virtues of medical therapy to avert infections and surgical therapy to correct reflux have been debated for more than 25 years. This debate has further evolved with the introduction of the biodegradable dextranomer and hyaluronic acid for use in endoscopic correction of reflux, and re-examination of the universal need for continuous antibiotic prophylaxis (CAP) and the importance of bowel and bladder dysfunction (BBD). Although the fundamental biologic importance of reflux disease is not in question, many facets of how reflux diagnosis and management are approached may take new shape in the coming decade.

Demographics

Prevalence

Assessing the prevalence rate of a condition that is known to at times be transient is difficult. The tendency for VUR to resolve spontaneously on one hand or persist beyond its natural resolution rate because of abnormal bladder dynamics or associated conditions makes it difficult to confidently generalize the true prevalence of reflux for a given population. In 1967, Köllermann and Ludwig attempted to identify the prevalence of VUR in children admitted to hospital for nonurologic conditions, and after preforming voiding cystourethrography (VCUG) on 103 children, they detected an overall incidence of 30% (29/103) with a higher relative rate in infants 0 to 12 months of age (*n* = 19) compared with children 1 to 5 years of age (*n* = 10) (Köllermann and Ludwig, 1967).

Another study attempted to answer this question with voiding ultrasonography in newborns, examining 2000 children. After a complete workup of children deemed to be at higher risk for VUR based on sonographic findings at time of birth, a rate of VUR of 0.8% was detected (Hiraoka et al., 1999). There is also historical literature evaluating children undergoing cystography for various indications beyond UTIs and estimated its prevalence. An important meta-analysis by Sargent revealed the prevalence of reflux was **estimated to be approximately 30% in children with UTIs and 17% in those who had imaging cystography for other reasons, such as hydronephrosis** (Sargent, 2000). In another study, 157 adults with incidental hypertension without any evidence of renal abnormality were investigated using suprapubic injection of Technetium-99m (^{99m}Tc) into a full bladder. The overall prevalence of VUR was estimated to be 19%, with high-grade reflux in more than one-half of the refluxing group (Barai et al., 2004).

In asymptomatic infants followed for antenatal hydronephrosis, the prevalence of reflux ranges from 15% in those with absent or mild hydronephrosis on postnatal ultrasonography (Phan et al., 2003) to 38% in a group with various postnatal upper tract sonographic anomalies, including hydronephrosis, renal cysts, or renal agenesis (Zerin and Leiser, 1998).

In more recent studies, the prevalence over time has been known to fluctuate and be closely related to the sex of the child and is discussed in the subsequent section.

Sex

There has long been an accepted difference in the rates of VUR in males and females, with conflicting results in the literature. Multiple studies have shown higher rates of VUR in males over females earlier in life, with prevalence rates shifting with age. These differences may suggest a gender dichotomy in the function of the lower urinary tract, bladder outlet, and urethra. A large study from Chand et al. showed that females were almost twice as likely to have reflux as males (Chand et al., 2003), and another more **recent study showed that the male:female prevalence of VUR can be as high as 3:1 at 0 to 6 months of age but shifts to approximately 1:1 by 21 to 24 months of age** (Capozza et al., 2017).

A confounding factor in understanding true sex differences in reflux between males and females is the sex-driven predisposition to UTI. The greater incidence of UTI results in more frequent evaluation and therefore detection of VUR. For example, several studies have shown that there is a 10- to 12-fold increased risk for UTI in uncircumcised infant males (1% compared with 0.12%), (Wiswell, 1992; Morris and Wiswell, 2012; Jagannath et al., 2012), explaining the higher rates of VUR detection in this group. In a related finding, only 10% of patients entered into the International Reflux Study in Children from the United States were boys compared with 24% entered from Europe. The circumcision rate in the latter group was only 5% compared with 62% in the US group ($P < .001$). In some studies, circumcision was more effective in decreasing the risk for breakthrough UTI (BUTI) than antibiotic prophylaxis or antireflux surgery (Kwak et al., 2004; Alsaywid et al., 2010). Similarly, females have a higher propensity for UTI after the first year of life and in childhood relative to males, resulting in higher rates of VUR detected in girls (Zorc et al., 2005).

Reflux in the Fetus

Prenatally detected hydronephrosis is common, estimated to occur between 1% to 5% of pregnancies (Braga et al., 2017). Traditionally, the recommendation was to screen these infants for VUR (Nguyen et al., 2010; St Aubin et al., 2013). **However current indications for obtaining a VCUG in the newborn period are limited to those with findings on renal bladder ultrasonography (RBUS)**

indicative of higher risk for significant VUR, such as higher grades of hydronephrosis (particularly bilateral hydronephrosis), renal cortical abnormalities, ureteral dilation, suspicion of anatomic anomalies such as ureteroceles or duplication of the collecting system, and bladder abnormalities.

In older studies in which infants were screened with VCUG, **VUR was found in 10% to 40%** (Lee et al., 2008; Peters and Rushton, 2010; Yeung et al., 2017), and up to 19% having bilateral VUR (Yeung et al., 2017; Zerin et al., 1993). There was a significantly higher incidence of bilateral dilating VUR, up to 80%, in children who initially presented with prenatal hydronephrosis (Evans et al., 2015).

VUR in these infants is likely of low clinical significance because the incidence of pyelonephritis is rather low, as demonstrated in the study by Zee et al., who evaluated a cohort of 213 infants with prenatal hydronephrosis, of which 133 had VCUG as part of their workup. In this group, only 19% (25/133) had VUR, and only two went on to develop a UTI (Zee et al., 2016).

Another important study by Estrada et al. showed a slightly different incidence of febrile UTIs in patients with hydronephrosis who were either initially screened with VCUG or followed with ultrasonography alone (Estrada et al., 2009b). In this study, the incidence of VUR was 28%. The rate of UTI in screened patients with and without VUR was 1.6% and 1.3%, respectively, although those with VUR were on prophylactic antibiotics. One interesting finding was that there was a significantly higher rate of UTI (4.4%) in a group of patients who did not undergo an initial VCUG but went on to have a febrile UTI. In this cohort, when a VCUG was performed, 75% (12/16) had VUR.

These studies further emphasize the importance of individualizing care, and extreme approaches for either obtaining or limiting routine VCUG in the evaluation of a child with hydronephrosis should be tempered.

Age

It is well accepted that reflux is significantly more common in younger children and may resolve spontaneously over time (Garcia-Roig et al., 2017). Resolution rates are multifactorial, and the prevalence of VUR for a given age is difficult to assess, however, one large study by Chand et al. provides a review of a large cohort and found that in children who present with UTIs, the incidence of VUR for patients ages less than 2, 2 to 6, 7 to 11, and 12 to 21 years was 38.6%, 26.9%, 19.7%, and 7.6%, respectively (Table 29.1).

TABLE 29.1

Incidence of Reflux in Patients With Urinary Tract Infections

AGE (YEARS)	INCIDENCE (%)
<2	38.6
2–6	26.6
7–11	19.7
12–21	7.6

From Chand DH, Rhoades T, Poe SA, et al., Incidence and severity of vesicoureteral reflux in children related to age, gender, race and diagnosis. *J Urol*. 2003;170(4):1548–1550.

Race

Significant racial differences exist, notably in the prevalence and impact of VUR. In older studies, **up to a 10-fold reduction in VUR in female children of African descent was observed** (Skoog and Belman, 1991)**. More recently, this difference appears to decrease to threefold** (Chand et al., 2003), possibly because of narrowing socioeconomic differences, an increase in prevalence of interracial families, and improved access to care. What was interesting in this study was the absence of grade IV and V VUR in the cohort of African-American children who were younger than 6 years, underscoring the significant racial differences in rates of VUR (Chand et al., 2003).

In the Randomized Intervention for Children with Vesicoureteral Reflux (RIVUR) study, 80% of patients enrolled were Caucasian (RIVUR Trial Investigators et al., 2014). In a series of non-Caucasian children with a 4:1 male-to-female ratio, 58% of whom were younger than 1 year of age presenting with UTI (72%), voiding difficulties (10%), or other malformations (14%), reflux was present in only 10% (West and Venugopal, 1993). Even in follow-up for antenatal hydronephrosis, reflux was found in 17.6% of 51 non-black versus 0% of 58 black infants (Horowitz et al., 1999). The stark contrast in rates of reflux disappear over time and likely with maturation of the antireflux mechanism in Caucasian children as the race-associated frequency of reflux becomes equal after 10 years of age (Melhem and Harpen, 1997).

Key Points: Demographics

- The younger the child with UTI, the greater is the likelihood of discovering reflux.
- Males may tend to have higher rates of UTI earlier in life, but this contrast is overshadowed by diagnosis of VUR in females who present with UTI.
- VUR is relatively rare in children of African descent.

Inheritance and Genetics

Sibling Reflux

There has been a clearly established body of literature evaluating the connection between VUR in siblings. The prevalence of VUR in siblings of affected children, who mostly present with UTIs, is roughly **30% but has been as high as 50%** in some studies (Nelson et al., 2016; Giannotti et al., 2011; Ataei et al., 2004; Cordell et al., 2010; Menezes and Puri, 2009; Puri et al., 2011; Hollowell and Greenfield, 2002).

This increased prevalence, however, may be more relevant for younger siblings. In one study by Menezes et al., VUR was present in almost 88% of siblings who were screened and who were younger than 3 years of age. In this study, a group of symptomatic siblings who had UTIs also had a high rate of high-grade VUR and a higher incidence of renal scarring (36%) (Menezes and Puri, 2009). The authors therefore concluded that siblings who are younger than 3 years of age of patients who present with VUR grade III to IV should be screened. One of the limitations of this study is that only index patients with VUR grade III to IV were included, and so recommendations can only be made for siblings younger than 3 years of age, whereas no recommendations can be made for siblings of patients with VUR grades I and II, who form the majority of patients with VUR (RIVUR Trial Investigators et al., 2014).

Another study found that the incidence of VUR in older siblings may be as low as 7% in keeping with known spontaneous resolution rates over time (Connolly et al., 1996). This differed from the results of a report by Ataei et al., which showed similar rates of VUR in siblings above and below a cutoff age of 6 years (Ataei et al., 2004).

Identical twins may be a unique subset of patients as these siblings may have a higher rate of sibling VUR. One study by Kaefer et al. showed a 100% concordance rate in identical twins (Kaefer et al., 2000).

In a study by Giannotti et al. of 251 families with at least two siblings with VUR, the incidence of VUR in twins was evaluated. There were 12 families with affected twins having an index sibling who presented with reflux and a twin diagnosed either through screening or having presented with infection herself. Only two siblings of index patients had infection (2/12, 17%), whereas the remaining 10 (83%) were diagnosed after screening (Giannotti et al., 2011).

Although the majority of twin siblings were female with higher grades of VUR, none of them showed evidence of renal scarring on diagnostic workup, compared with 3/12 (25%) of their twins, who were the index patients.

The high rate of VUR in twin sibling studies **supports the notion of some hereditary impact on VUR,** and although a heightened prevalence of reflux exists in siblings of refluxing index patients, given the known tendency for reflux to resolve spontaneously, one would also expect a lower incidence of VUR in older siblings (Connolly et al., 1996).

When considering the impact of VUR on siblings, the impact of screening is important to consider, especially in patients who may be asymptomatic. This needs to be balanced with the presence of clinically meaningful VUR, where diagnosis and some form of treatment may be beneficial. In one retrospective study of 123 screened siblings, 44 (36%) demonstrated VUR on VCUG (Houle et al., 2004). Of these patients, 37 underwent renal imaging. Ultrasonography was abnormal in 30% and renal scintigraphy, when used, was abnormal in 28%. However, in siblings older than 2 years of age, renal scintigraphic abnormalities were twice as common as in the entire group of siblings. The authors concluded that renal damage is therefore progressive in the older siblings and proposed earlier screening of siblings of refluxing index patients. However, this study fails to address the fact that renal damage may have occurred very early, and over time (beyond 2 years of age), renal growth may have exaggerated the appearance of such scintigraphic abnormalities. Finally, the reporting of scintigraphic results by many sibling reflux studies is confounded by failing to differentiate between congenital parenchymal changes often associated with higher grades of reflux and true scarring secondary to infection and inflammation. In the absence of such data and faced with the invasive nature of a VCUG, one is left with the following question: Is asymptomatic reflux in a sibling of clinical concern? If the propensity for UTI, with or without VUR, could be reliably determined to be genetically regulated, it would strengthen the case for screening siblings for reflux. Because risk for infection cannot be readily determined in either an index patient or his or her sibling, the likelihood of developing a UTI as a justification for screening siblings for reflux should be cautioned. **Because it is the likelihood of renal damage, higher in certain scenarios, that can be associated with reflux that is the issue, rather than reflux itself, siblings may be better served by noninvasively screening for cortical abnormalities first, and screening for reflux if history of compounding factors such as UTI or BBD are present.** The intensity of renal imaging, using ultrasonography for general screening or a nuclear scan for highest accuracy, could then be tempered by clinical factors, including family history, patient and family compliance with follow-up, blood pressure, a history of UTI and fever, and voiding dysfunction. The absence of renal imaging abnormalities would allow the clinician to conclude with some confidence that reflux, if present, has not resulted in significant renal damage. This approach to screening siblings, particularly the group of index patients who present with high-grade VUR, is especially appealing as further **workup can be individualized based on the perceived risk of the sibling** (Springer and Subramaniam, 2014).

Should screening depend on sibling age? Because the risk for new renal scarring after pyelonephritis is lower in older children (Menezes and Puri, 2009), older siblings would likely suffer fewer consequences from reflux-induced pyelonephritis and therefore stand to benefit less from confirming a diagnosis of reflux and instituting antibiotic prophylaxis over an infant or younger sibling.

Imaging the kidneys to assess the impact of VUR, if any, provides a rational initial approach to sibling screening. If consideration of age and renal integrity is combined, a possible graded approach to screening can be developed for older siblings with or without renal structural abnormalities. The urologic and voiding history must also play a deciding role in whether a sibling is ultimately screened by a VCUG for VUR. Thus, in older siblings with normal kidneys on ultrasound and without BBD, little would be gained from detecting reflux that could not be addressed by responding to a febrile UTI in the usual fashion as for the general pediatric population. In the younger siblings, especially those with BBD or who are not toilet trained, a normal ultrasound scan serves as part of the bases for clinical judgment regarding the likelihood for infection rather than an immediate need to diagnose reflux. In any sibling, if reflux is diagnosed, the indications for reflux correction remain the same as for the general refluxing pediatric population.

The American Urological Association (AUA) 2010 VUR guidelines recommend screening siblings of children with VUR with a VCUG if there is evidence of cortical abnormalities on ultrasound or a history of UTI. This is especially important in the presence of grade 3 to 4 hydronephrosis on ultrasonography (Skoog et al., 2010). It is also reasonable to take an observational approach to screening, especially for those with grade 1 to 2 hydronephrosis (Skoog et al., 2010).

Genes Involved

In addition to sibling reflux, a prospective screen of progeny of patients with reflux revealed a 66% rate of reflux in the offspring (Noe et al., 1992). Familial VUR most closely conforms to an autosomal-dominant inheritance pattern, but because of variable penetrance and expressivity, large multigenerational pedigrees traceable to linkage analyses have been difficult to ascertain (Sanna-Cherchi et al., 2005).

The substantially higher rate of reflux in siblings and progeny of index patients compared with the general population defines these patients as susceptible to reflux and potentially associated renal morbidity. Previous segregation and linkage analyses have implicated a number of loci in the pathogenesis of VUR, though no specific gene product or functional role for these loci in reflux has yet been identified (Darlow et al., 2017).

Moreover, formation of multiple ureteric buds may also lead to short duplex ureters, duplex kidneys, and ectopic and dysplastic kidneys (Nino et al., 2016; Batourina et al., 2005; Grieshammer et al., 2004; Basson et al., 2005; Hains et al., 2010).

This led to the theory that mutations of genes involved in early ureteric bud formation and positioning increases the risk for developing urinary obstruction, VUR, and possibly hydronephrosis during fetal life and after birth in both humans and mice (Hains et al., 2010; Wang et al., 2011; Uetani and Bouchard, 2009).

Several genes have been observed to regulate these developmental processes and, by extension, are believed to serve as potential regulators of UVJ integrity, though their specific connection to VUR is clinically unproved. Indeed, genetic misregulation of ureteric budding is believed to underlie many congenital anomalies of the kidney and urinary tract (CAKUT) (Miyazaki and Ichikawa, 2003).

The subsequent section will discuss current candidate genes or loci that have been implicated, however to date, **despite family-based association analyses of large parent-affected-child trios and case/control association analyses, compared with a large control population, there are no compelling associations between single gene or specific loci linked with nonsyndromic VUR** (Darlow et al., 2017)**.**

Pax2: Paired box gene 2 *(PAX2)* is a transcription factor regulating kidney, central nervous system, and ocular development in mice. It is necessary for ureteric budding in mice (Keller et al., 1994; Lee et al., 2017). *PAX2* is located on human chromosome 10q24, and mutations have been reported in human syndromes involving colobomas and renal anomalies, including hypoplasia, dysplasia, glomerulonephritis, and VUR (Sanyanusin et al., 1995; Lee et al., 2017). However, *PAX2* has not been shown to be a major determinant of primary VUR (Lee et al., 2017; Darlow et al., 2017; Choi et al., 1998; Cunliffe et al., 1998).

Gdnf/RET: Glial-derived neurotrophic factor (Gdnf) and its receptor RET show strong involvement in UVJ formation in mice (Yu et al., 2004; Lee et al., 2017). Overexpression of *RET* in mice leads to abnormal placement of the ureteric bud and is associated with a high incidence, 30% in some studies, of VUR at birth compared with 4% in wild-type mice. Nevertheless, the Gdnf-Ret signaling complex has been found to not mediate VUR in humans (Nino et al., 2016; Shefelbine et al., 1998; Lee et al., 2017). One reason for the conflicting studies in the literature on reflux genetics is that clusters of specific populations with their own inherent genetic backgrounds occasionally amplify a putative gene association for VUR that does not apply to all populations. This is partly why *RET* can show a very high-frequency *RET* polymorphism in patients with primary VUR from one ethnogeographic region but not in a similar cohort of patients with primary VUR in another (Darlow et al., 2009; Nino et al., 2016; Lee et al., 2017).

Uroplakin III: Another fascinating animal model of VUR is observed after deletion of the uroplakin III gene (Hu et al., 2000). However, no structural uroplakin III gene alterations have been noted in human cohorts with VUR (Giltay et al., 2004; Jiang et al., 2004). One explanation for this finding may be that major uroplakin mutations are developmentally lethal in humans.

Osr1: Odd-skipped related 1 *(Osr1)* is a transcriptional repressor that plays critical roles in maintaining the mesenchymal stem cell population within the developing kidney (Fillion et al., 2017). A study in newborn pups with a heterozygous loss-of-function mutation in *Osr1* exhibited a 21% incidence of VUR and had hydronephrosis and urinary tract duplications. Osr1 expression is important in the ureteral mesenchyme and within the developing bladder. Sequencing in 186 affected children revealed variable results, however it may be a candidate gene implicated in the pathogenesis of VUR and CAKUT, although more definitive studies are warranted (Fillion et al., 2017).

10q26 Region: In a large genome-wide linkage and association study, the 10q26 region was a major genetic contributor to primary nonsyndromic VUR. A family-based association analysis, which included 1098 parent-affected-child trios was evaluated. The study also included a case-control association analysis of 1147 affected cases and 3789 matched controls. The analysis did not reveal any significant associations per se, but subsequent parametric linkage analysis of 460 families with more than 1000 individuals identified a single region on 10q26 that showed strong linkage (HLOD = 4.90; ZLRLOD = 4.39) to VUR (Darlow et al., 2017). This region contains more than 65 genes that may serve as candidate genes for further study.

Notwithstanding an observed pattern of autosomal dominant inheritance in some families, the failure to identify any strong genetic mechanism in primary VUR in humans, despite the presence of convincing animal and human genetic models of reflux, argues for a more complex polygenetic mechanism of disease. Indeed, in the large whole-genome linkage and association scans for primary nonsyndromic reflux done to date, no clear overlap involving previously reported genes was found (Cordell et al., 2010; Darlow et al., 2017). Although several areas of the genetic code have been explored, there is still no dominant gene or major gene locus specifically linked to nonsyndromic VUR in any of the populations tested.

See Fig. 29.1 for list of common human genes implicated in CAKUT, including VUR.

Gene	Kidney developmental stage	Location	Signals	Gene product	Disease	Inheritance type	#Gene OMIM	Reference number
Ureteric budding								
RET	Ureteric budding	10p13	GDNF signaling	RTK	Bilateral renal hypodysplasia/agenesis VUR, ureteral obstruction, megaureter, duplex kidney, renal abnormalities, as well as Hirschsprung disease	AR	191830	23,82
PAX2	Ureteric budding	10q24.31	(–)	PAX (paired box domain)	Papillorenal syndrome that comprises renal defects (oligomeganephronia, hypodysplasia, VUR, and cysts) and ocular defects affecting the optic nerve and/or the retina	AD	120330	39,83
EYA1	Ureteric budding	8q13.3	RTK signaling pathway	Eyes absent homolog 1	BO syndrome	AD	602588	26,27
SALL1	Ureteric budding	16q12.1	(–)	Sal-like protein 1 (also known as spalt-like transcription factor 1)	Townes-Brocks syndrome, as well as BOR syndrome	AD	107480	28,29
SIX1	Ureteric budding	14q23.1	(–)	SIX homeobox 1, 2, and 5	BOR syndrome, BO syndrome	AD	608389	30
SIX2	Ureteric budding	2p21	WNT-pathway	SIX homeobox 2	Renal hypodysplasia	NA	604994	31
BMP4	Ureteric budding	17q22.2	BMP-BMPR signaling system	Bone morphogenetic protein 4	Syndromic microphthalmia, orofacial cleft	AD	112262	31
GATA3	Ureteric budding	10p14	(–)	(–)	Hypoparathyroidism, sensorineural deafness, renal dysplasia	AD	146255	84
Development of the metanephric kidney								
ROBO2	Development of the metanephric kidney	3p12.3	SLIT2-ROBO2 signaling pathway	Receptor for the Slit2 ligand	VUR	NA	610878	41
SLIT2	Development of the metanephric kidney	4p15.31	SLIT2-ROBO2 signaling pathway	Slit protein	Cystic dysplastic kidneys, unilateral renal agenesis, and duplicated collecting system	NA	603746	41,44
SRGAP1	Development of the metanephric kidney	12q14.2	SLIT2-ROBO2 signaling pathway	SRGAP1(small GTPase activating protein)	Cystic dysplastic kidneys, unilateral renal agenesis, duplicated collecting system	NA	606523	44
MET								
WNT4	MET	1p36.12	WNT pathway	Protein Wnt-4	Müllerian aplasia, hyperandrogenism	AD	158330	47
FGF20	MET	8p22	(–)	Fibroblast growth factor 20	Renal hypodysplasia/aplasia	AR	605558	50
RAS								
AGT	RAS	1q42.2	RAS pathway	Angiotensinogen	Renal tubular dysgenesis	AR	106150	53
REN	RAS	1q32.1	RAS pathway	Ren	Renal tubular dysgenesis	AR	179820	53
ACE	RAS	17q23.3	RAS pathway	Angiotensin converting enzyme	Renal tubular dysgenesis	AR	106180	53
AGTR1	RAS	3q24	RAS pathway	Angiotensin II receptor type 1	Renal tubular dysgenesis	AR	106165	52
Nephron patterning and elongation								
Uromodulin (UMOD)	Nephron patterning elongation	16p12.3	(–)	Tamm-Horsfall protein (uromodulin)	Medullary cystic kidney disease type 2, familial juvenile hyperuricemic nephropathy, and glomerulocystic kidney disease	NA	191845	54,55
Unknown								
TRAP1	Unknown (possibly antiapoptotic and endoplasmic reticulum-stress signaling in proximal tubules and in thick medullary ascending limbs of Henle's loop.)	16p13.3	(–)	TRAP1 heat shock protein 75 (also known as TNF receptor associated protein1-mitochondrial HSP90 protein)	CAKUT or CAKUT in VACTERL	NA	606219	61
HNF1B	Unknown (possibly wolffian duct from a very early developmental stage of the kidney)	17q12	(–)	HNF1B protein	Renal cysts and diabetes syndrome also referred to as MODY5, renal hypodysplasia, multicystic dysplastic kidney, cystic kidney diease, single kidney, oligomeganephronia	AD	189907	83
PKHD1	(–)	6p12.3-p12.2	(–)	Protein fibrocystin	Autosomal recessive polycystic kidney polycystic kidney, and hepatic disease	AR	606702	59
KAL1	(–)	Xp22.31	FGF signaling, that there is an interaction between anosmin-1 and FGFR1	Anosmin 1	VUR, hypogonadotropic hypogonadism 1 with or without anosmia (Kallmann syndrome)	XL	300836	64,65
HOXA13	(–)	7p15.2	(–)	Homeobox protein	VUR, hand-foot-genital syndrome, Guttmacher syndrome (preaxial deficiency, postaxial polydactyly, and hypospadias)	AD	142959	67
NIPBL	(–)	5p13.2	(–)	Delangin	VUR, cornelia de Lange syndrome	AD	608667	68

FIG. 29.1 Genes, signaling pathways, and defects linked to clinical phenotypes of congenital anomalies of the kidney and urinary tract (CAKUT). (–), Unknown; *AD,* autosomal dominant; *AR,* autosomal recessive; *BO,* branchio-otic; *BOR,* branchio-oto-renal; *FGF,* fibroblast growth factor; *FGFR1,* FGF receptor 1; *HSP,* heat shock protein; *GDNF,* glial cell-line–derived neurotrophic factor; *MET,* mesenchymal-to-epithelial transition; *MODY,* maturity-onset diabetes of the young; *NA,* not applicable; *OMIM,* Online-Mendelian inheritance in man; *RAS,* renin-angiotensin system; *RTK,* receptor tyrosine kinase; *TNF,* tumor necrosis factor; *VACTERL,* combination of at least three of the following congenital anomalies: vertebral defects (V), anorectal malformations (A), cardiac defects (C), tracheoesophageal fistula with or without esophageal atresia (TE), renal malformations (R), and limb defects (L); *VUR,* vesicoureteral reflux; *WNT,* wingless and integration site growth factor. (Data from Lee KH, Gee HY, Shin, JI. Genetics of vesicoureteral reflux and congenital anomalies of the kidney and urinary tract. *Investig Clin Urol.* 2017;58(Suppl 1):S4–S13.)

Key Points: Screening, Inheritance, and Genetics

- The prevalence of reflux is higher in siblings.
- Probably multiple genes are involved.
- It cannot be assumed that all cortical abnormalities in refluxing siblings are acquired.
- Mass screening of siblings is unnecessary, and clinicians should be selective based on sibling risk profile.

Embryology of the Ureterovesical Junction

A full discussion of the embryology of the trigone and ureteric orifice is found elsewhere in this text. In brief, two events proceed simultaneously to govern the ultimate position and integrity of the UVJ. At one point, the embryonic ureter buds from the mesonephric (or Wolffian) duct to form the metanephric duct or early fetal ureter. The Wolffian duct (early vas deferens) and early ureter can be thought of as forming the two upper arms of a *Y* with the distal mesonephric duct as the stem of the *Y*. Although budding is occurring, the distal mesonephric duct is being drawn and incorporated into the region of the urogenital sinus (UGS), which later becomes the bladder. Incorporation continues until the entire stem is absorbed, leaving the two arms of the Y to enter the bladder separately—one as the ureter and the other as the vas and ejaculatory duct in the male prostatic urethra (or the vestigial Gartner duct in the female vagina). Seminal embryologic work by Mackie and Stephens showed that the two arms of the Y also rotate relative to each other once they contact the UGS/bladder wall, resulting in the ureteric orifice being proximal to the ejaculatory duct orifice. If the ureteric bud reaches the UGS too soon (thought to be caused by early budding), overrotation draws it high and lateral in the bladder wall, leading to inadequate incorporation, insufficient intramural length in the bladder wall, and reflux (Mackie et al., 1975). If the ureteric bud reaches the UGS too late (because of late budding), insufficient rotation occurs, resulting in an ectopic ureter that is drawn distally and medially, often obstructing in the bladder neck region or elsewhere. Furthermore, early or late budding is also thought to affect the contact between bud epithelium and the metanephros, leading to renal malformations, dysplasia, hypoplasia, or even agenesis.

To further augment the work by Mackie and Stephens, Batourina showed that the nephric duct might not differentiate into the trigone but undergo apoptosis, a pivotal step for transposition of the ureter (Batourina et al., 2005). This step may be mediated by vitamin A–induced signals from the primitive bladder.

Functional Anatomy of the Antireflux Mechanism

The phenomenon of VUR represents a balance of several factors. Abnormality in any of these factors alone or in combination will allow or cause the retrograde flow of urine from the bladder up the ureter and ultimately to the kidney. These factors include the functional integrity of the ureter, the anatomic composition of the UVJ, and the functional dynamics of the bladder.

First, for purposes of reflux prevention, the ureter represents a dynamic conduit, which propels a bolus of urine antegrade by neuromuscular propagation of peristalsis. In so doing, reflux is actively opposed.

The second component is the anatomic design of the UVJ. At the heart of this unique mechanism lies an intramural portion of ureter that travels within the detrusor muscle as it traverses the bladder wall (Fig. 29.2) (Elbadawi, 1972). At the extravesical bladder hiatus, the three muscle layers of the ureter separate. The outer ureteral muscle merges with the outer detrusor muscle to form Waldeyer's sheath, which contributes to formation of the deep trigone. Interestingly, recent studies have shown that Waldeyer's sheath might not be unique to the UVJ. Rusu et al. used immunohistochemistry to stain proximal ureteric specimens, removed at time of nephrectomy, to show very elegantly that Waldeyer's sheath may not only be present near the UVJ, but that it may be a common anatomic characteristic of the ureter itself (Rusu et al., 2017).

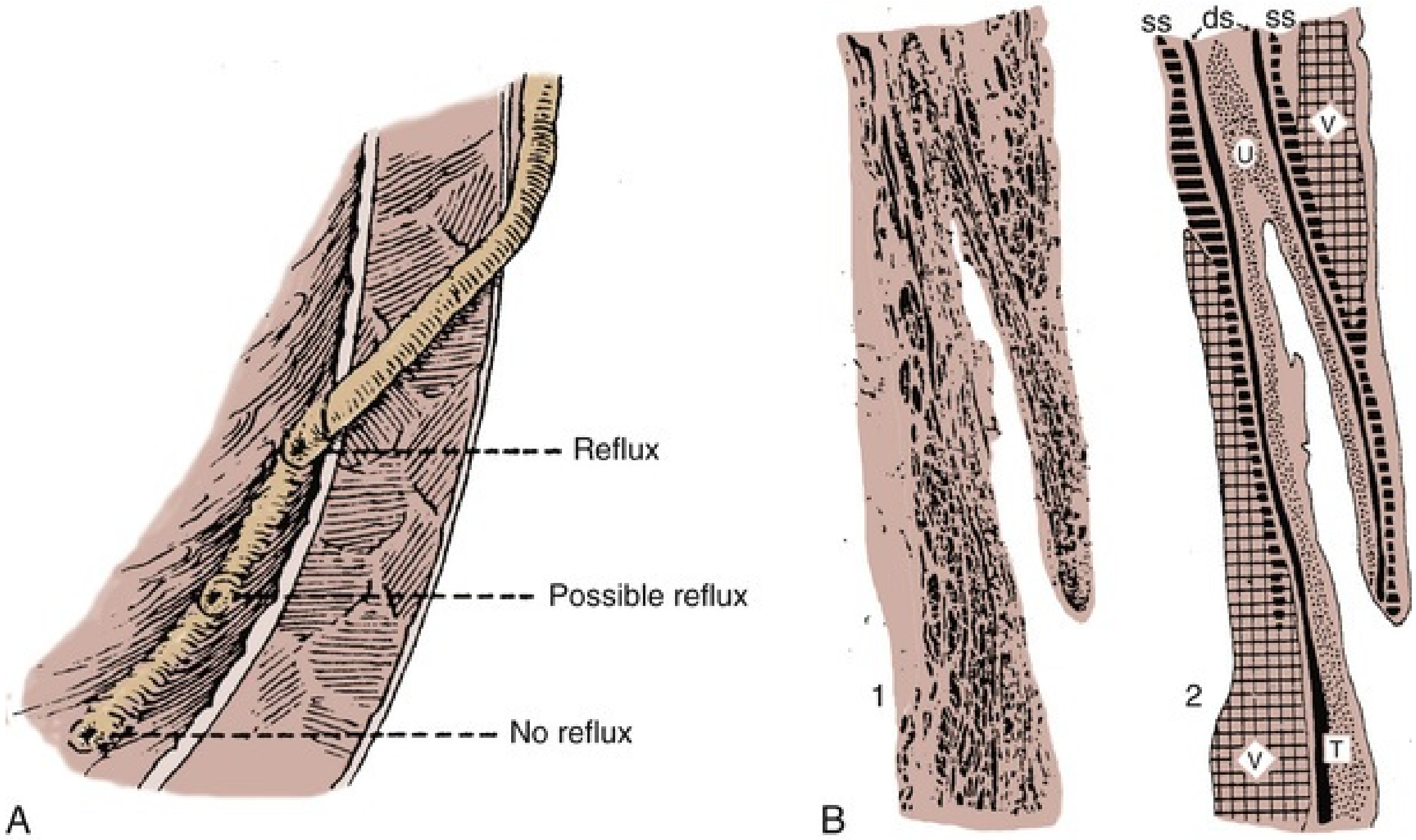

FIG. 29.2 (A) A refluxing ureterovesical junction has the same anatomic features as a nonrefluxing orifice, except for inadequate length of the intravesical submucosal ureter. Some orifices with marginal submucosal tunnels may reflux intermittently. (B) Ureterovesical junction in longitudinal section. *1,* Photomicrograph; *2,* diagrammatic representation. The ureteral muscularis *(U)* is surrounded by superficial *(ss)* and deep *(ds)* periureteral sheaths that extend in the roof of the submucosal segment and continue beyond the orifice into the trigonal muscle *(T)*. The relationship of the superficial sheath to the vesical muscularis *(V)* is clearly seen. Transverse fascicles in the superior lip of the ureteric orifice belong to the superficial and deep sheaths. No true space separates the ureter from the bladder. (A, From Glenn J. *Urologic surgery.* 2nd ed. New York, NY: Harper & Row; 1975; B, from Elbadawi A. Anatomy and function of the urethral sheath. *J Urol*. 1972;107[2]:224.)

The intramural ureter remains passively compressed by the bladder wall during bladder filling, preventing urine from entering the ureter. Adequate intramural length and fixation of the ureter between its extravesical and intravesical points are required to create this antirefluxing compression valve. Paquin's early dissections of the UVJ in children revealed an approximately 5:1 ratio of tunnel length to ureteral diameter in nonrefluxing junctions compared with a 1.4:1 ratio in refluxing UVJs (Paquin, 1959) (Table 29.2).

TABLE 29.2

Mean Ureteral Tunnel Length and Diameter in Normal Children

AGE (YEARS)	INTRAVESICAL URETERAL LENGTH (mm)	SUBMUCOSAL URETERAL LENGTH (mm)	URETERAL DIAMETER AT THE URETEROVESICAL JUNCTION (mm)
1–3	7	3	1.4
3–6	7	3	1.7
6–9	9	4	2.0
9–12	12	6	1.9

From Paquin AJ. Ureterovesical anastomosis: the description and evaluation of a technique. *J Urol*. 1959;82:573–583.

Later on, work by Lyon et al. challenged this theory in part by stating that not only is the length of the intramural tunnel important, but so is the configuration of the ureteric orifice (Lyon et al., 1969). **The importance of ureteric orifice configuration relative to ureteral tunnel length in determining UVJ competence was recently confirmed using computer modeling** (Villanueva et al., 2015). One thing that both these theories lack and what modern surgical techniques do not account for is the intrinsic qualities of the ureter itself in the tunnel and its role in ultimately allowing for ureteric collapse with bladder filling to prevent reflux.

One study that attempts to merge these various concepts uses complex statistical modeling to unify findings from existing studies and accepted dogma. Villanueva et al. modeled ureteral collapse pressure using several of the factors that are known to play a role in tube collapse, beyond the length of the tunnel itself, and found that not only is the pressure required to collapse the ureter inversely related to its diameter (a widely known fact), but that for a ureteral tunnel length greater than 1 cm, pressures required to collapse the ureter did not decrease by any significant amount. If the ureteral thickness or ureteral stiffness increased, an increase in pressure was required to collapse the ureter. This was only significant for ureteral thicknesses not commonly seen in practice (e.g., wall thickness of 2.5 mm in a 6.4-mm–diameter ureter) (Villanueva et al., 2015). Such studies are crucial for the broader understanding of reflux and further challenge long-standing dogma, which, although holds much truth, can oftentimes be too simplistic to explain the complete interconnectedness between the ureter and the bladder in the normal, nonreflux UVJ.

Intravesically, the inner muscle of the ureter merges with the detrusor muscle to contribute to the superficial trigone. Some of these inner ureteral fibers pass medially to contribute to the intraureteric ridge. The cellular and molecular details that characterize normal and refluxing UVJs are still unknown. However, it is likely that in addition to architectural deficiencies of tunnel length, abnormalities in uterovesical smooth muscle and extracellular matrix composition, neural function, configuration of the orifice may contribute to reflux (Oswald et al., 2004; Lyon et al., 1969; Villanueva et al., 2015).

Opening of the UVJ is achieved by active contraction of the longitudinal muscles within the tunnel. This draws the extravesical and intravesical points of the intramural ureter closer together, shortening and widening the tunnel, which allows passage of the urine bolus into the bladder. Indeed, when viewed cystoscopically, a lateral displacement of the ureteric orifice accompanies a jet of urine into the bladder. Although such lateral displacement is functionally normal and necessary to permit urine to pass, permanent lateral displacement by virtue of a short tunnel characterizes the cystoscopic position of the refluxing ureteric orifice. Closure of the UVJ results both from compression of the intramural ureter and a return to its full tunnel length as the ureteral muscle relaxes. Thus active and passive mechanisms dynamically reconfigure the tunnel as needed to allow antegrade passage of urine while preventing retrograde flow. Finally, the existence of local efferent and afferent neuromuscular coordination between the UVJ and the periureteral bladder wall is suggested by neurophysiologic studies that induce elevation or decrease in intraluminal UVJ pressure during bladder filling (Shafik, 1996).

Key Points: Functional Anatomy

- Integrity of the antireflux mechanism depends on balancing the anatomic and functional relationships between the ureter and the bladder.
- Reflux may be of an anatomic or functional origin in the UVJ, bladder, or bladder outlet.

Causes of Vesicoureteral Reflux

The occurrence of VUR represents a balance of several factors. The degree to which each contributes to the pathologic processes largely defines whether reflux is considered primary or secondary. Reflux likely represents an imbalance between dynamic storage and voiding characteristics of the bladder and the architectural competency of the UVJ to resist reflux. If looked at through this lens, one may consider that most reflux indeed may be secondary and in fact may be transient or reversible.

In general, **reflux is considered primary if it is caused by a fundamental deficiency in the function of the UVJ antireflux mechanism while the remaining factors (bladder and ureter) remain normal or relatively noncontributory. Secondary reflux, then, implies reflux caused by overwhelming the antireflux function of the UVJ, either resulting from sustained and repeated increases in intravesical pressures or anatomic anomalies, such as in the case of duplication anomalies and periureteral diverticulae. VUR is also closely tied to the presence of bladder dysfunction, either of a congenital, acquired, or behavioral nature and is often a major contributor to the presence of secondary reflux** (Santos et al., 2017; Shaikh et al., 2016a; Elder and Diaz, 2013). It is also accepted that reflux is often considered secondary if its absence was documented at some point before its detection.

Primary Reflux

As stated earlier, primary reflux represents a congenital defect in the structure and therefore function of the UVJ. Reflux occurs despite an adequately low-pressure urine storage profile in the bladder. The length-to-diameter ratio of the intramural ureteral tunnel is almost always less than that described by Paquin in 1959 (Paquin, 1959).

The interplay as to what ultimately causes reflux is complex and likely involves more than just a simple lack of tunnel length, as what has been historically taught. There are multiple factors that likely play a role beyond inadequate tunnel length and poor or weak detrusor muscle backing. These can include a significantly dilated ureter, intrinsic stiffness of a ureter, and abnormal bladder characteristics, to name a few. The dilated ureter often poses a challenge when a nonrefluxing ureteral reimplant is desired. This has traditionally prompted both long tunnels (>5 cm) or a reduction in ureteral diameter by tapering, plication, or both in an attempt to reconstruct a successful antireflux mechanism. On the other hand, construction of a new tunnel with a full 5:1 length-to-diameter ratio may not be absolutely required to correct reflux (Villanueva et al., 2015).

Secondary Reflux

Secondary VUR occurs in the presence of two distinct settings, either resulting from an **increase in intravesical pressure** or an anatomically **abnormal UVJ.** An increase in intravesical pressure can be broadly considered to arise from outlet obstruction, either mechanical blockage, for example in the presence of posterior urethral valves (PUVs), strictures, or masses, to name a few, or from a functional obstruction, such as in the presence of either neurogenic or non-neurogenic obstruction of the continence mechanisms, as in the presence of bladder sphincter dyssynergia or dysfunctional voiding, respectively. Conditions caused by innate **bladder detrusor pathology** are usually considered to be of either a neurogenic or non-neurogenic origin as well, as in the case of spinal pathology or again, dysfunctional voiding, respectively.

In contrast with anatomic obstruction, neurologic causes of elevated bladder pressures also predispose to VUR. In particular, neurogenic bladder associated with spina bifida is at risk for reflux (Bauer et al., 1982). VUR can be present in up to 30% of patients with neurogenic bladders resulting from spinal dysraphism. This fact must be borne in mind during the evaluation of the child with UTI or incontinence. Special attention to the potential for occult spinal dysraphism, including sacral dimple, hairy patch, gluteal cleft abnormality, diminished rectal tone, or significant and often refractory constipation or encopresis, should prompt consideration for investigation of coexistent spinal cord abnormalities. In those patients who are known to have spinal dysraphism and VUR, a more conservative approach to managing the lower urinary tract is generally advised. This often includes early initiation of clean intermittent catheterization (CIC), consideration for anticholinergic administration, and close follow-up with serial imaging. There should be a low threshold for further diagnostic studies with any evidence of progression, such as worsening hydronephrosis or VUR grade and bladder wall characteristics on VCUG. Urodynamic extremes that predispose to reflux in the absence of abnormal neurologic conditions may also exist. Some studies suggest that a secondary aspect to neonatal reflux is a peculiarity found in male infants. In a study by Yeung et al., 22 of 24 infants with reflux showing urodynamic evidence of overactivity, inadequate, or obstructive voiding patterns were males (Yeung et al., 1998). Normal or immature voiding patterns were observed in all infants in the nonrefluxing control group, of which 16 of 21 were male. In infants, higher voiding pressures are associated with reflux, particularly in boys (Chandra et al., 1996), and may contribute to the male preponderance of reflux in infancy. This would explain the higher gender inequalities within this age range and also the high resolution rates and gender shift, which were previously discussed.

Urodynamic evaluation suggests these elevated infant bladder pressures may be caused by inadequate sphincter relaxation during this stage of development (Chandra et al., 2000). However, detrusor activity in such infants is largely normal during filling, with slightly diminished bladder capacities in some (Podesta et al., 2004), though neurogenic detrusor overactivity during filling has been observed, again predominantly in male infants (Yeung et al., 1998). Considering that the high prevalence for reflux in infants coexists with urodynamic evidence of elevated voiding pressures, these observations suggest that infant voiding patterns may be a part of normal development. Thus, even though the UVJ likely matures with age, the interplay between the UVJ and infant voiding patterns may predispose children, and even more so males, to a form of secondary reflux that resolves as these infants grow older and voiding matures.

In older children, acquired abnormalities in bladder and bowel function, commonly known as *BBD*, have been associated with UTI and reflux.

The precise cause of bladder dysfunction is unclear, but may evolve from a persistence of the expected early attempts to suppress bladder contractions during the toilet-training months by volitional contraction of the external sphincter (Allen, 1985). If this behavior becomes prolonged or intensifies, often driven by the child's overwhelming desire for continence, bladder voiding pressures increase. Continence is gradually exchanged for incomplete emptying, resulting in a higher UTI risk. Although investigation of a UTI might diagnose some patients with persistent primary reflux, the elevated bladder pressures gradually distort bladder and UVJ architecture and may create secondary reflux (Koff et al., 1992). Structural failure of the UVJ is likely a critical determinant because high voiding pressures of approximately 100 cm H_2O are common in normal bladders and structurally intact nonrefluxing UVJ. Indeed, with structural failure of the UVJ, reflux occurs at low voiding pressures or during early filling, which is a poor prognostic factor for reflux resolution (Koff et al., 1992; McMillan et al., 2006).

Detrusor overactivity is the most common urodynamic abnormality associated with reflux in neurologically normal children and was found to be as high as 90% in one study of children with voiding dysfunction or idiopathic detrusor overactivity (Glassberg et al., 2010). With regard to VUR resolution in these patients, children with dysfunctional bladders were significantly more likely to exhibit resolution or improvement of reflux (by 2 grades or more) with targeted treatment for the underlying lower urinary tract pathology, with either timed voiding, biofeedback, anticholinergic administration, or alpha blockers (Fast et al., 2013). Overall, 42% of females and 80% of males had complete resolution of VUR with targeted treatments and antibiotic prophylaxis, although this was not statically significant because of underpowering of the study (Fast et al., 2013).

In one study of 37 girls with primary reflux, 75% had overactive detrusor contractions (Taylor et al., 1982). However, the observation that treatment of such patients with oxybutynin can eliminate reflux in up to 80% of involved ureters strongly argues that an overactive bladder frequently can be partly responsible for reflux by either causing secondary reflux or perpetuating primary reflux (Seruca, 1989; Koff et al., 1983; Homsy et al., 1985). One study in 30 children showed concomitant treatment of BBD and use of anticholinergic treatment resulted in complete VUR resolution or a decrease in grade in 70% of the children (Acar et al., 2009). **Thus it is apparent that primary and secondary reflux may not always be mutually exclusive or that what is perceived as primary reflux in some children may, in fact, be secondary to BBD.**

With regard to **abnormalities of the UVJ,** these can arise from either pathology of the ureteric orifice, such as in the case of ureteroceles or with duplication anomalies, or caused by adjacent bladder pathology, such as in the case of a paraureteral diverticulum. Iatrogenic injury to the UVJ can also lead to VUR. Several of these causes are discussed in detail elsewhere in this text.

Regardless of the cause of secondary VUR, in order for clinicians to be able to alter the disease trajectory, a clear understanding of the underlying condition must take place so that a tailored treatment approach to the patient's care can be instituted. See Fig. 29.3 for a simplified algorithm for causes of secondary VUR.

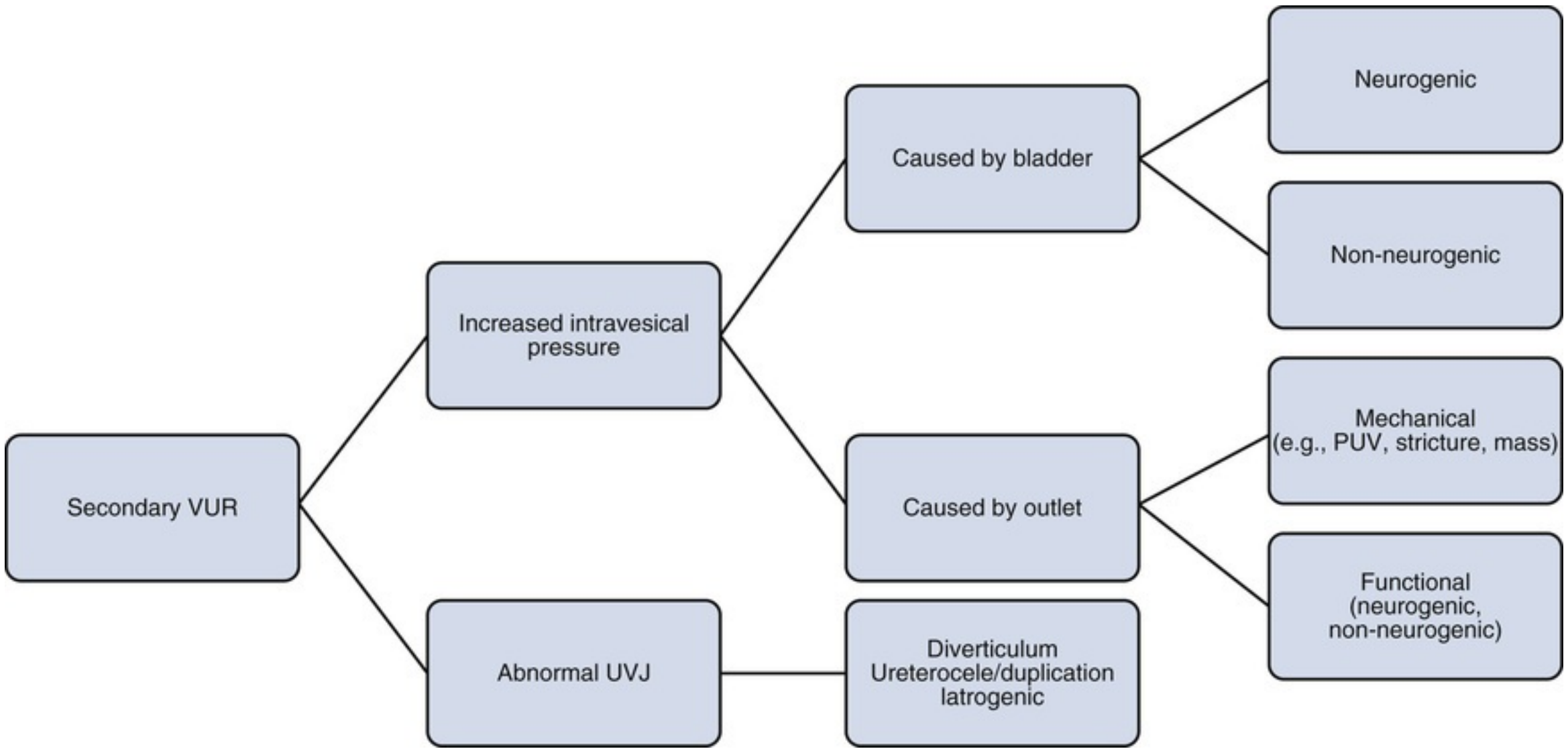
Secondary VUR
Increased intravesical pressure
Abnormal UVJ
Caused by bladder
Caused by outlet
Diverticulum
Ureterocele/duplication
Iatrogenic
Neurogenic
Non-neurogenic
Mechanical (e.g., PUV, stricture, mass)
Functional (neurogenic, non-neurogenic)

FIG. 29.3 Simplified algorithm for causes of secondary reflux.

Clinical Correlates

The previous discussion clearly suggests that multiple opportunities exist for modifying the course of reflux if secondary causes are appreciated, identified, and treated. If VUR is seen as a spectrum of disease with a primary component, which is the innate or biologic predisposition related to patient factors, and the added contribution from secondary elements, which if understood and then treated, the child's trajectory could be sufficiently modified such that once the effects of secondary factors are eliminated, only *true primary* VUR is in fact treated.

Van Gool et al. identified that 18% of children enrolled in the European arm of the International Reflux Study in Children harbored voiding dysfunction associated with more frequent UTIs and greater persistence of reflux compared with those without voiding dysfunction (van Gool et al., 1992).

Similar findings were reported from the Swedish Reflux Trial in which a cohort of children 1 to 2 years of age with grade 3 and 4 reflux were assessed and followed for 2 years for lower urinary tract dysfunction prevalence and type (Sillén et al., 2010). Twenty percent of children harbored some form of dysfunction at entry. The prevalence of bladder dysfunction increased to 34% at 2 years of follow-up. A negative correlation was found between dysfunction at follow-up and reflux improvement ($P = .002$). In addition, scintigraphic renal abnormalities at study entry and at follow-up were also associated with dysfunction (*P* = .001) (Brandström et al., 2010a). Failure to address bladder abnormalities can adversely affect the outcome of antireflux surgery (Koff et al., 1998).

The AUA guidelines (Published, 2010; Reviewed and Validity Confirmed, 2017) suggest that BBD is by far one of the most critical and modifiable variables that affect VUR resolution, overall management, and attendant UTIs (Peters et al., 2010). A meta-analysis now indicates that **BBD is associated with a higher incidence of UTIs while on antibiotic prophylaxis and after surgical correction of VUR, with less VUR resolution at 24 months from diagnosis and with reduced success of endoscopic surgery. In the studies selected by the panel that qualified as having acceptable levels of evidence, BBD did not appear to reduce the success of open surgical reflux correction** (Fig. 29.4).

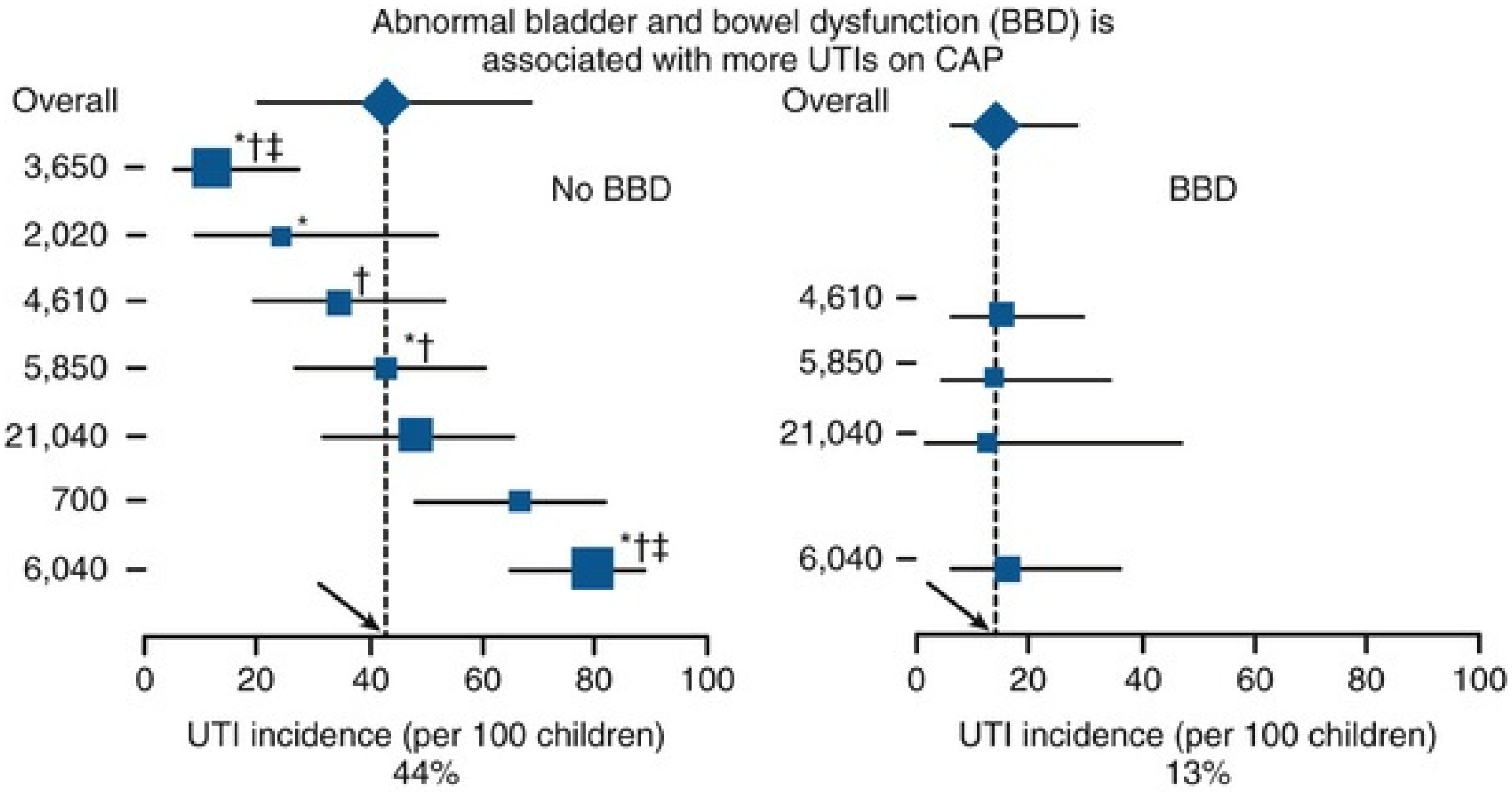

FIG. 29.4 Bladder and bowel dysfunction *(BBD)* and urinary tract infection *(UTI). CAP,* Continuous antibiotic prophylaxis. (From Peters CA, Skoog SJ, Arant BS, et al. Summary of the AUA guideline on management of primary vesicoureteral reflux in children. *J Urol*. 2010;184:1134–44.)

Thus, although BBD is discussed in detail elsewhere in this text, a thorough evaluation of the toilet-trained child with reflux must recognize dribbling, urgency, incontinence, or constipation as symptoms of coexisting BBD. The classic presentation for severe BBD is classic curtsying behavior in girls and squeezing the penis in boys, which acts to suppress bladder contractions. **Constipation often leads to sympathetic, concomitant contraction of both**

anal and urinary sphincters (Grundy and Brierley, 2018) resulting in frequent constipation and encopresis with reflux and UTI. **Constipation must be recognized and eliminated first to establish optimal conditions for successful spontaneous resolution of reflux.** There has been a significant shift in the paradigm for treating children with VUR, ensuring that aggressive treatment of any underlying BBD is addressed. Several studies have demonstrated this link and shown that correcting BBD reduces UTIs in children with VUR (Elder and Diaz, 2013; Santos et al., 2017). A recent study by Shaikh et al. combined data from the RIVUR study (discussed later in detail) and the Careful Urinary Tract Infection Evaluation (CUTIE) study, two large longitudinal studies, and demonstrated the dramatic impact of BBD on the rates of recurrent UTIs in this larger cohort (Shaikh et al., 2016a). The authors showed that in children off CAP, 51% of those with both BBD and VUR experienced recurrent UTIs compared with 20% of those with VUR alone and 35% with BBD alone. Thirty two percent of children with neither BBD nor VUR had UTIs (Shaikh et al., 2016a). Other authors have also shown the close link between BBD, especially constipation, VUR, and recurrent UTIs (Halachmi and Farhat, 2008; Santos et al., 2017; Snodgrass, 1991; Elder and Diaz, 2013; Leonardo et al., 2007; O'Regan and Yazbeck, 1985; O'Regan et al., 1986; Chase et al., 2004).

Urinary Tract Infection and Reflux

The relationships between UTI, VUR, and renal scarring have been historically poorly understood, and management of VUR had focused on surgical correction as the mainstay. Contemporary approaches have shifted from this traditional scheme to focusing initially on the medical management of VUR, surgically treating mostly high-risk patients or those who are refractory or have shown progression. **Reflux is not a general cause of UTI, but is perceived to be a clinical accelerant of upper tract bacteriuria by mechanically delivering infected urine to the renal pelvis** (Peters and Rushton, 2010; Ransley and Risdon, 1979). Infection-related cystitis is expected to incite bladder irritability and dysuria, upsetting the voiding pattern and lowering the threshold for reflux in a given UVJ. In primate studies, surgically created reflux followed by introduction of pathogenic bacteria into the bladder was associated with reflux persistence (Roberts et al., 1988).

In children with dilating reflux, hydroureter and hydronephrosis, in theory, can act as a reservoir for pathogenic organisms to the bladder, and sterilizing the urinary tract may prove more difficult (Blickman and Lebowitz, 1984). Colonized urine might then cyclically reflux retrograde to the upper tracts. Similarly, ureteral atony secondary to the effects of the presence of endotoxin could fail to expel infected urine from the upper tracts, but this does not appear to reduce the ultimate resolution of reflux (Roberts, 1992). Indeed, the dilated upper tracts seen in high-grade reflux explored in the randomized prospectively controlled Swedish Reflux Trial were associated with a 57% rate of recurrent febrile UTI in patients on surveillance without antibiotic prophylaxis (Holmdahl et al., 2010). Reflux correction or antibiotic prophylaxis reduced the recurrent infection rate to approximately 20% ($P = .0001$).

Key Points: Urinary Tract Infection and Reflux

- Reflux is not a general cause of UTI.
- Reflux facilitates pyelonephritis.

Grading of Reflux

Grading systems generally exist to help prognosticate the behavior of the disease they classify. In 1981, the International Reflux Study Committee proposed a grading system for VUR that remains in general use today (Duckett and Bellinger 1982; Lebowitz et al., 1985). **Five grades of reflux are used to depict the appearance of the ureter, renal pelvis, and calyces as seen on the radiographic contrast images generated by a VCUG** (Table 29.3; Fig. 29.5). Using such a system serves several purposes. Grading standardizes the description of the degree of reflux for clinical management of the individual patient and is used for grouping research subjects in the design of clinical studies and trials. Grading facilitates documenting the natural history of the reflux process in the individual patient. It also permits establishing quantitative associations between reflux and other clinical parameters to determine whether such associations hold clinical relevance. Most importantly, describing the initial grade in primary reflux is the most significant parameter associated with prediction of reflux resolution and further serves as an objective means to risk-stratify more appropriately.

TABLE 29.3

International Classification of Vesicoureteral Reflux

GRADE	DESCRIPTION
1	Into a nondilated ureter
2	Into the pelvis and calyces without dilation
3	Mild to moderate dilation of the ureter, renal pelvis, and calyces with minimal blunting of the fornices
4	Moderate ureteral tortuosity and dilation of the pelvis and calyces
5	Gross dilation of the ureter, pelvis, and calyces; loss of papillary impressions; and ureteral tortuosity

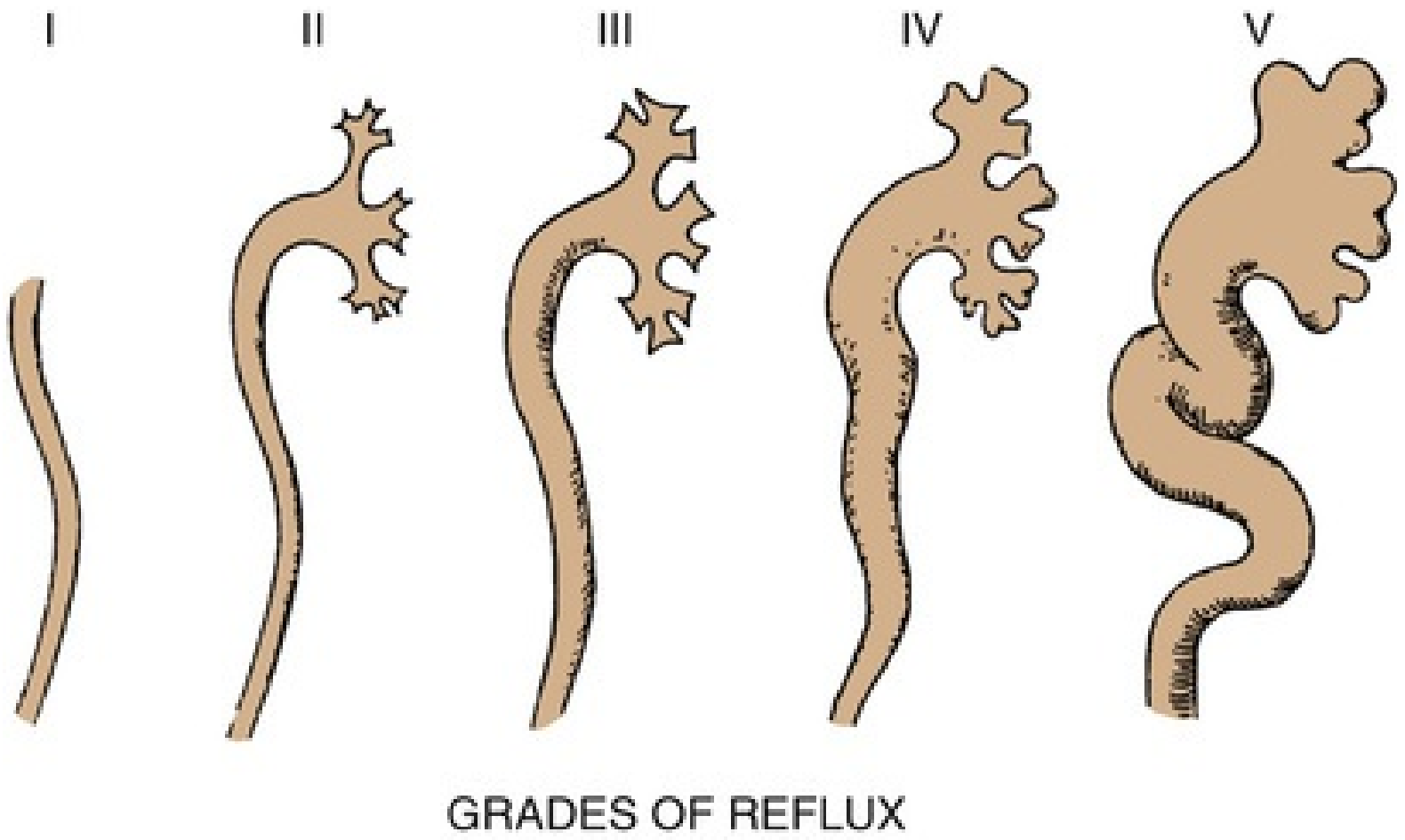

FIG. 29.5 International classification of vesicoureteral reflux.

Despite the widespread use of the five-point grading system, several shortcomings exist. For example, the expected concordance between ureteral and calyceal dilation does not always occur (Fig. 29.6). Either the ureter or the calyces may demonstrate dilation out of proportion to the calyces or ureter, respectively. Whether this reflects an anomaly in the biomechanical tissue properties or peristaltic activity of the excessively dilated ureter, as compared with the typical refluxing upper tract, is unknown. Nevertheless, such anatomy is difficult to grade using the current system.

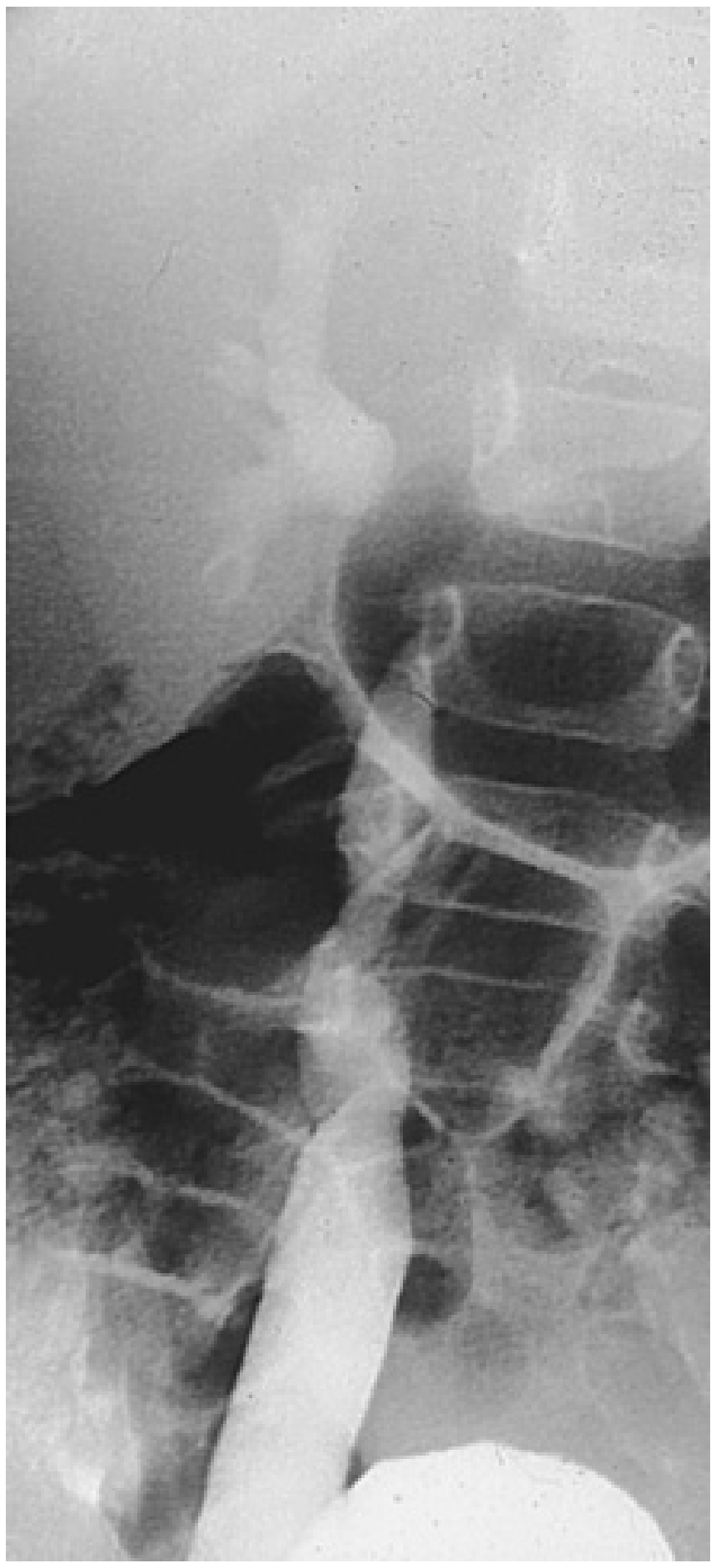

FIG. 29.6 A refluxing ureter with significant dilation of the lower segment but no distortion of the collecting system may be different from the typical system with grade II reflux.

Despite the wide acceptance of this grading system, there is often significant interobserver variability when images are read and grades are assigned. One study, which utilized data retrieved from the RIVUR trial, found that from the 560 left and 524 right ureters graded by a local radiologist and two blinded study reference radiologists, all three agreed on the grade of VUR in only 59% of ureters; two of three agreed on 39% of ureters; and all three disagreed on 2% of ureters. There were higher agreement rates for other VCUG findings such as bladder shape (Schaeffer et al., 2017). A similar finding was reported by O'Neil et al., especially for grades II to IV, although there was reasonable concordance at extremes of grading (O'Neil et al., 2014).

Attempts also have been made to grade reflux using radionuclide cystography (RNC). Because RNC does not provide discrete images of the ureteral and calyceal architecture required to assign reflux grade, classifying reflux by RNC is difficult. Alternative RNC grading has been proposed (Zhang et al., 1987). This provides reasonable concordance to the objectives of the classic grading system by collapsing grades 2 and 3, as well as grades 4 and 5, into low-grade and high-grade reflux, respectively (Fig. 29.7). The clinical impact of this may be noteworthy because, as previously stated, there may be some difficulty in obtaining high interobserver consensus for these grades, and perhaps collapsing the grading system into fewer groupings may be of benefit, although the impact of the reduction in grading detail from five grades (1 to 5) to two (low and high) on understanding reflux pathophysiology and on the design of clinical studies has yet to be determined.

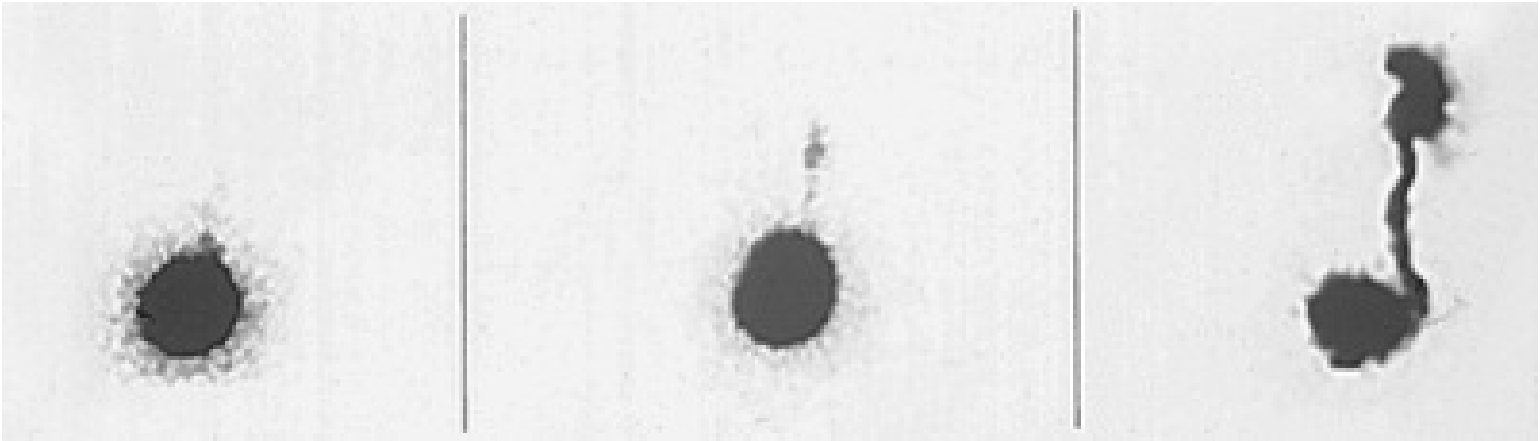

FIG. 29.7 Nuclear voiding cystography showing right-sided reflux. Radionuclide tracer can be quantitated (from left to right) as grade 1 (grade I of the international grading system), grade 2 (grades II to III of the international grading system), and grade 3 (grades IV to V of the international grading system).

Finally, more recent studies have shown the utility of voiding urosonography, which will be discussed in detail later, however no alternate grading system has been proposed. Similar to RNC, grading may likely be more simplified, as detection of the ultrasound contrast with the level of detail seen on traditional VCUG is not yet widespread (Darge, 2010; Kuzmanovska et al., 2017).

Although grading is purely a classification of the appearance of contrast in the upper tract, ascribing an absolute value to the grade has the potential to cast the reflux in unequivocal terms, to the exclusion of other factors that modulate reflux at the time the images are acquired. Inherent bladder dynamics, the bladder outlet, and even ipsilateral UVJ obstruction all influence the degree of reflux at any given assessment (Lebowitz, 1992). Grade, reflux detection, and reflux resolution are all interrelated and are influenced by the degree of bladder filling, the voiding cycle, the number of filling cycles during the contrast cystogram, and whether the reflux occurs during filling or only during voiding. None of these parameters is built into the grading system for reflux used currently. However, given that the principal role of a reflux grading system is to help prognosticate reflux resolution, future incorporation of other parameters may provide additional clinical acumen. Finally, it must be remembered that reflux grade is still presently determined by an imaging study that requires invasion of a sensitive anatomic region. For a given reflux grading result, the variables of bladder dynamics, filling, and voiding cannot necessarily be replicated with certainty in a given patient each time he or she is studied. It is reasonable to speculate that reflux grade could easily vary up or down by at least one grade if sequential studies were performed in a given patient. Thus the entire reflux literature, which historically reports results in terms of five separate grades, must be considered with some circumspection because the veracity of grade at the time of the contrast study may be, to some extent, arbitrary.

Cortical Defects

Congenital Defects Versus Acquired Scar

Previous interpretation of defects seen on renal imaging have been assumed to be scars and sequelae of some presumed condition usually associated with either obstruction or VUR. In a renal context, the term *scar* is most accurately used to describe the fibrous, contracted regions of the kidney that have been destroyed, usually by infection, and often appear as a photopenic area by scintigraphy or, when larger, as hyperechoic and shrunken areas on ultrasonography. The importance of renal scars lies in the realization that they are usually the preventable complication of pyelonephritis, being directly influenced by the presence of VUR in the context of a bladder infection, and when these inciting factors are left unchecked, they can lead to devastating consequences, especially in the pediatric kidney.

Studies have shown the link between VUR, particularly higher grades, and renal maldevelopment that often appears identical to postinfection pyelonephritic scars on ultrasound or renal scans (Murer et al., 2007; Peters and Rushton, 2010; Nordenström et al., 2017a; Yeung et al., 1997; Sjöström et al., 2004; Ylinen et al., 2003). Over time, both in the literature and in clinical practice, the terminology of scarring has become contaminated by the inclusion of reflux-associated congenital dysplasia. However, until such time that primary reflux can be averted prenatally (Gobet et al., 1998) or during the early postnatal phase of continued renal development, dysplasia or reflux nephropathy will remain a nonpreventable sequela of abnormal urinary tract development.

Reflux-Associated Renal Dysplasia

The association of renal maldevelopment with the highest grades of reflux is expected by the theory of Mackie and Stephens, which suggests that an abnormal origin of the ureteric bud will interact suboptimally with the metanephric blastema (Mackie and Stephens, 1975) (eFig. 29.8). This process is believed to be one of the causes of renal dysplasia associated with reflux. Several studies have confirmed the association of VUR and a smaller than normal ipsilateral kidney, an overall reduced relative renal function, and global (Najmaldin et al., 1990; Burge et al., 1992) or focal (Risdon 1993) areas of poor uptake by scintigraphy. These infants tend to be males, and the preponderance of refluxing renal units are grade 4 or 5 (Marra et al., 1994, 2004) (Table 29.4; Fig. 29.9). Indeed, boys tend to be spared an infectious cause of reflux-associated scarring because they have a lower incidence of recurrent UTIs (Capozza et al., 2017; Wennerström et al., 2000). Renal dysplasia is not unique to primary isolated VUR but also may occur in a variety of urologic settings. Duplex renal moieties (Mackie and Stephens, 1975), prune-belly syndrome (Manivel et al., 1989), and PUVs may exhibit reflux-associated renal dysplasia, particularly when the grade of reflux has been high.

TABLE 29.4

Congenital Renal Scarring

GRADE OF VESICOURETERAL REFLUX	NO. PATIENTS NORMAL (%)	SLIGHT DAMAGE (%)	SEVERE DAMAGE (%)
1–3	13 (100)	—	—
4	8 (53)	5 (34)	2 (13)
5	2 (15)	5 (38)	6 (46)

Modified from Marra G, Barbieri G, Dell'Agnola CA, et al. Congenital renal damage associated with primary vesicoureteral reflux detected prenatally in male infants. *J Pediatr*. 1994;124(5 Pt 1):726–730.

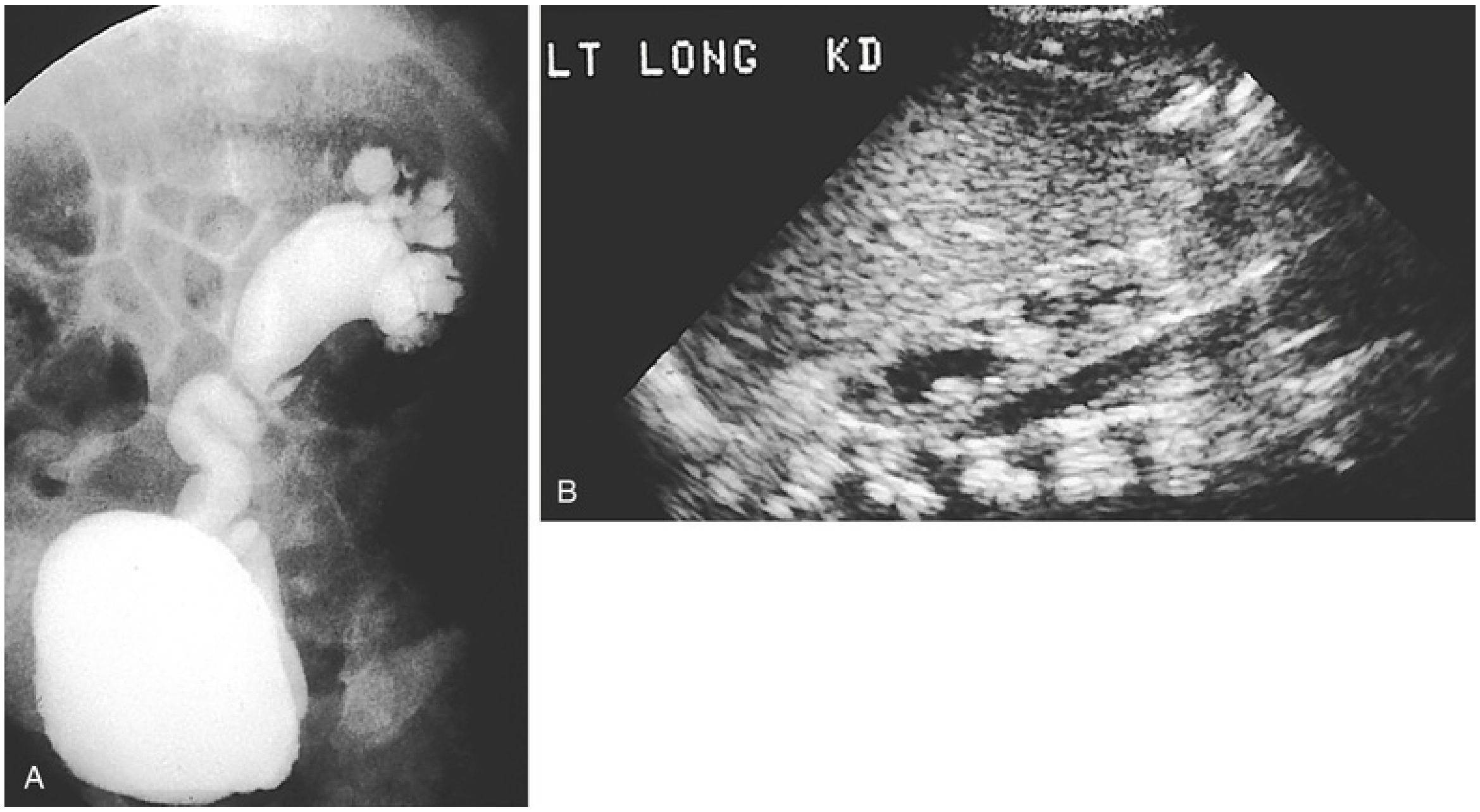

FIG. 29.9 (A) Massive reflux in a boy with antenatally diagnosed hydronephrosis. (B) Ultrasonography demonstrating a kidney with poor internal differentiation. No function was seen on scan.

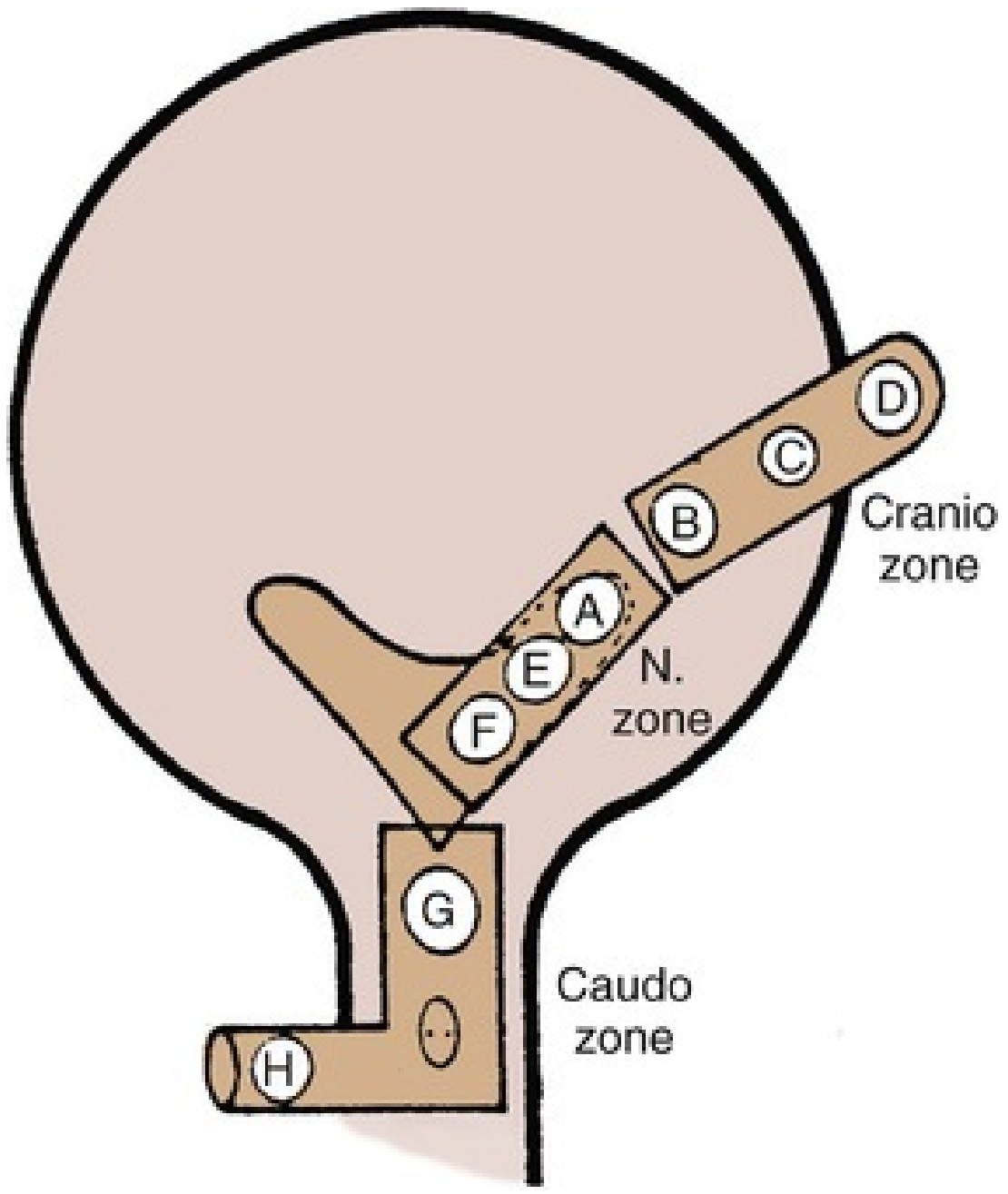

EFIG. 29.8 Classification of ureteric orifice position. Obstruction usually occurs in the caudo zone, and ureters positioned in the cranio zone are likely to result in reflux. Ureters positioned in the normal *(N.)* zone are associated with normal kidneys. Because of ureteric bud abnormality, renal dysplasia occurs with ureters projecting from both abnormal positions. (From Mackie GC, Stephens FD. Duplex kidneys: a correlation of renal dysplasia with position of the ureteral orifice. *J Urol.* 1975;114:274.)

Acquired Renal Scars

It is now firmly established that nephropathy from primary VUR requires the colonization of urine with pathogenic bacteria in the face of normal voiding dynamics. There are specific conditions with VUR and sterile urine that can lead to upper tract damage, however, these usually occur in secondary causes of the reflux, such as in PUVs (Taskinen et al., 2012; Lopez Pereira et al., 2013; Sarhan, 2017). Rare conditions such as congenital megacystis or megacystis-megaureter syndrome can also lead to upper tract damage in the face of sterile urine, but these are exceedingly rare and discussed elsewhere (Kawamura 1977; Burbige et al., 1984; Taghavi et al., 2017). Indeed, the basis of classic medical management of reflux is to maintain urine sterility while allowing reflux to resolve spontaneously. In the absence of infection and secondary causes of VUR producing high storage or emptying pressures, sterile urinary reflux is considered insufficient to cause renal damage. This concept has been most definitively demonstrated by the elegant series of experiments by Ransley and Risdon (Ransley and Risdon, 1981). Reflux was induced experimentally in a pig model by unroofing the intravesical ureteral tunnel. Only if the urine was subsequently infected could pyelonephritis and reflux nephropathy be induced. Without urine infection, no nephropathy could be created (Ransley and Risdon, 1981). Large clinical studies have reiterated these experimental findings, demonstrating new reflux-associated scarring only in children with recurrent UTIs (Smellie et al., 1975; Huland et al., 1984). Animal studies by Hodson et al. that induced reflux and bladder outflow obstruction led to atrophic pyelonephritis, similar to obstructive nephropathy, despite the absence of infection (Hodson et al., 1975). In this model, scarring was intensified by the presence of urinary microorganisms. Thus abnormal hydrodynamic bladder characteristics may modulate even sterile reflux, **but reflux is unlikely to be of any clinical significance in the absence of infection with relatively normal bladder function.** These earlier observations of Hodson, however, **underscore the importance of normalizing bladder and bowel function while awaiting reflux resolution.**

Pathophysiology of Acquired Scarring

Renal scarring is a sequel of infectious pyelonephritis, however, VUR exploits several conditions that predispose to scarring. Most importantly, **reflux provides a mechanical hydrodynamic mechanism that facilitates the ascension of microorganisms from the bladder to the kidneys. Thus reflux may be considered an accelerant for renal tissue infection after bacterial colonization of the bladder.** This principle has been confirmed by studies showing an increased incidence of pyelonephritis in high-grade reflux compared with low-grade reflux (Majd et al., 1991; Alsaywid et al., 2010; McLorie et al., 1990). Furthermore, the frequency of scarring itself appears to be directly proportional to the grade of reflux with which it is associated (Winter et al., 1983; Weiss et al., 1992b). This principle is also supported by observations after reflux correction. In one study of 74 patients in whom preoperative and postoperative scintigraphy studies were available, more than 90% of renal units corrected for reflux showed no new scars during a mean follow-up period of 19 months, despite asymptomatic bacteriuria in 47% of the patients during follow-up (Choi et al., 1999; Leung et al., 2017).

Age

The kidney's predilection for postpyelonephritic scarring is inversely proportional to age. This point is a guiding principle that must be considered in all decisions regarding reflux diagnosis and choice of therapy. The greatest risk for postinfectious renal scarring occurs within the first year of life (Winberg, 1992; Capozza et al., 2017). Similarly, patients younger than 4 years of age are more prone to developing scarring after a single UTI than older children (Garcia-Roig et al., 2018; Sargent, 2000; Smellie and Normand, 1985), though scarring may still occur beyond 5 years of age (Smellie and Normand, 1985; Benador et al., 1997; Sargent, 2000). Indeed, although younger patients are the most vulnerable to scarring, scarring in older children is often the result of late diagnosis, delayed or inadequate treatment of infection, and social factors that often interfere with patient management. Thus, in older children with reflux in whom relinquishing care from the urologist back to the family physician is being considered, it is vital that the child's BBD be completely corrected and the fundamental principles for suspecting and diagnosing UTI and its prompt management be reiterated before transfer (Coulthard et al., 2009; Coulthard, 2002).

The seminal studies of **Ransley and Risdon proposed a "big bang" theory for the origin of scars after infant pyelonephritis** (Ransley and Risdon, 1981)**. They observed that most of the scarring occurs after the initial bout of pyelonephritis and that further scarring in the absence of repeated pyelonephritic episodes is unlikely to occur.** Consequently, the assumption is that little change in the initial scarring pattern is to be expected in follow-up imaging. **However, the uncertainties introduced by such factors as (1) the weakly substantiated assumption that a relatively greater scarring propensity exists in younger kidneys, (2) the reports of new follow-up scarring in the landmark reflux studies (see later discussion), (3) the failure to differentiate between postpyelonephritic imaging defects versus intrinsic developmental dysplasia associated with reflux, (4) the changing appearance of such imaging defects with renal growth over time, and (5) the limited ability to compare different imaging modalities in the reflux literature (ultrasound vs. renal scan) together must challenge the notion that the**

greatest postinfection parenchymal loss occurs after the first infection.

Key Points: Cortical Defects

- Sterile reflux is unlikely to cause scarring.
- The youngest patients are at greatest risk for postpyelonephritic renal scarring.
- Most parenchymal abnormalities are detected after the first episode of pyelonephritis.

Papillary Anatomy

Another factor governing renal susceptibility to scarring is the configuration of the papillae as their ducts open to the calyces. Papillae with a concave architecture (compound papillae) present their ducts at right angles, whereas more convex papillae possess ducts that end obliquely, producing a valvular effect that guards against backflow of urine into the medullary collecting ducts (Fig. 29.10). The more polar calyces are composed preferentially of compound papillae compared with the middle calyces. The former are more commonly the site of intrarenal reflux (reflux into the ducts) and are the prime regions of susceptibility to scarring (Roberts, 1992). Furthermore, necropsy studies have determined that reflux into compound papillae occurs at lower pressures than into simple papillae (Funston et al., 1978). Intrarenal reflux can occur with as little as 2 mm Hg pressure in the neonate (Fig. 29.11). By 1 year of age, the pressure required is one order of magnitude greater (Funston et al., 1978) and helps explain the relative infrequency of intrarenal reflux in older children.

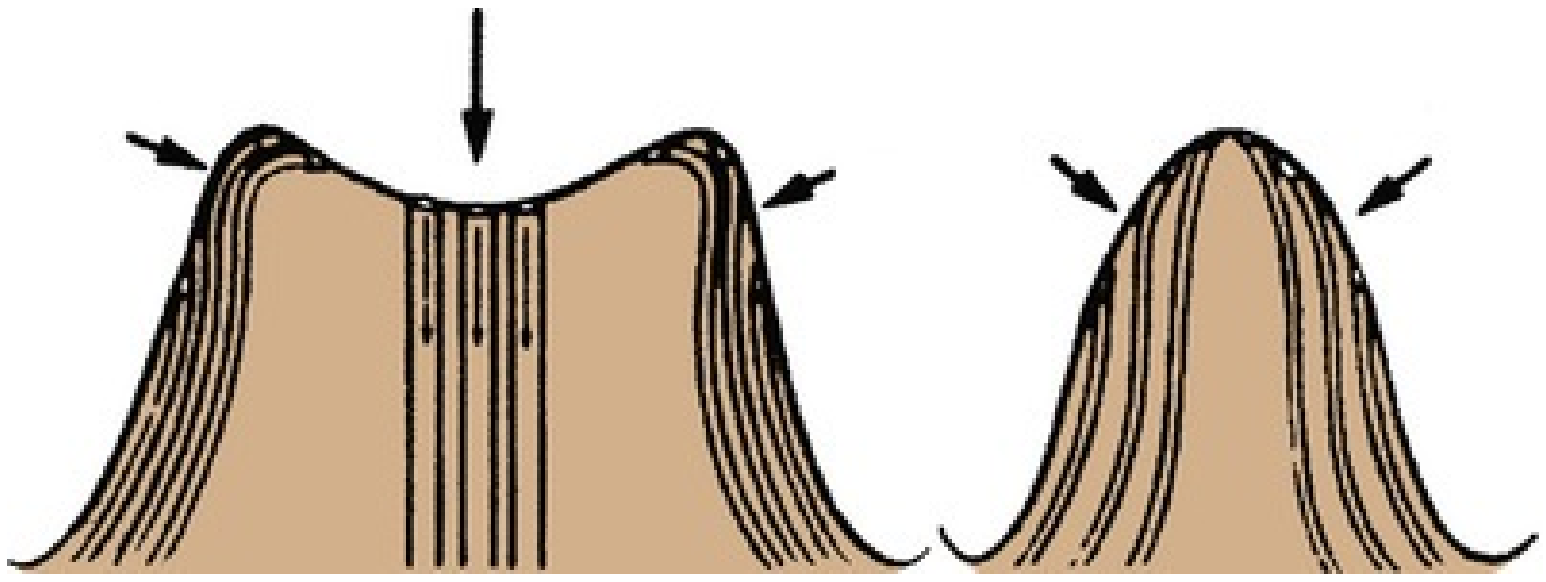

FIG. 29.10 Papillary configuration in intrarenal reflux. A convex papilla *(right)* does not reflux because the crescentic or slitlike openings of its collecting ducts open obliquely onto the papilla. In contrast, a concave *(left)*

or flat papilla refluxes because its collecting ducts open at right angles onto a flat papilla. (From Ransley PG, Risdon RA. Reflux and renal scarring. *Br J Radiol*. 1978;14[Suppl.]:1.)

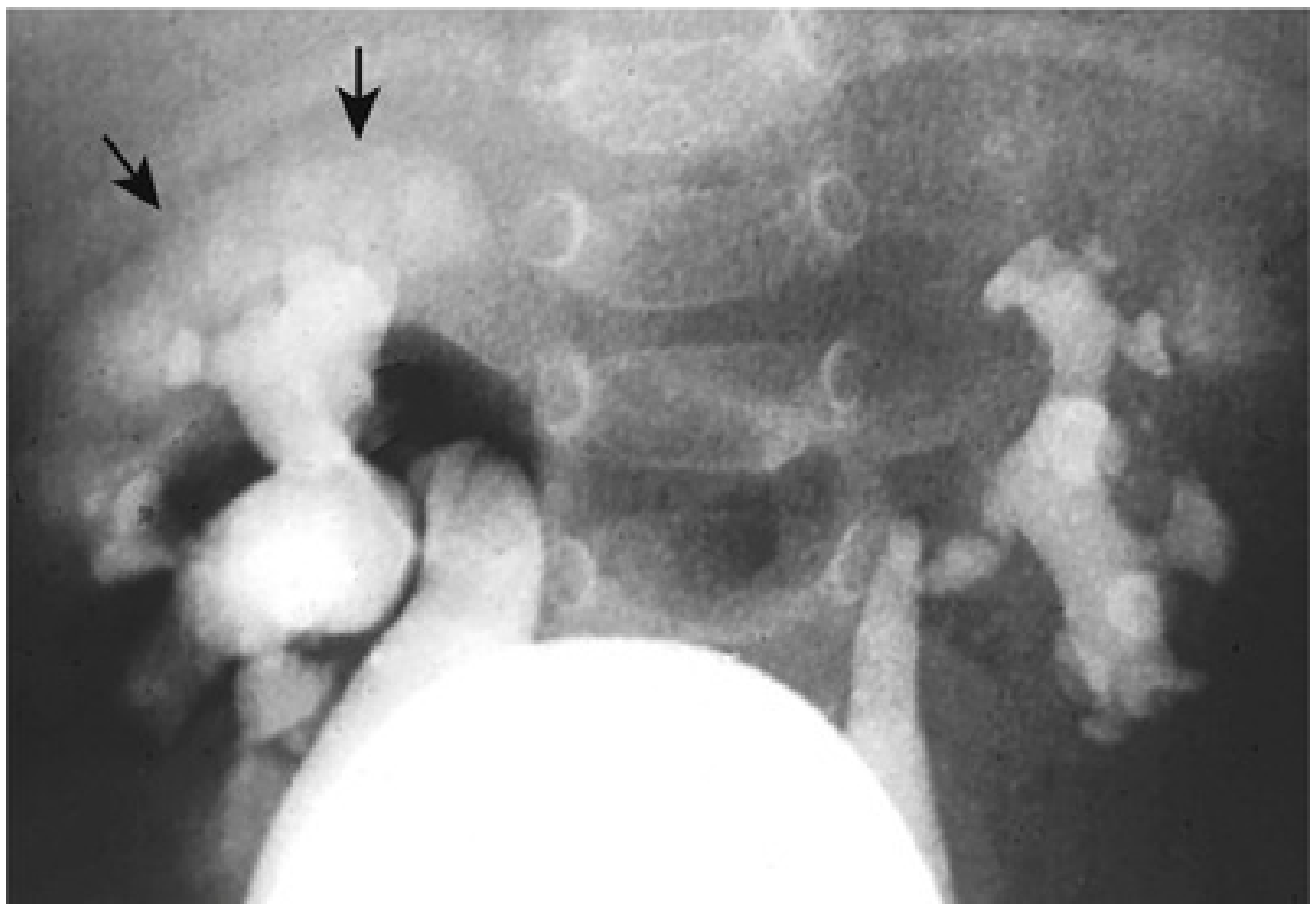

FIG. 29.11 Intrarenal reflux *(arrows)* shown on a voiding cystourethrogram.

Bacterial Virulence

Bacteria possess phenotypes that provide infective advantage when exposed to the lumen of the urinary tract. Chief among these is the ability to adhere to uroepithelium. Adherence is mediated by interaction between specific molecules or ligands located on bacterial fimbriae and specific receptors on host uroepithelial cells. A full discussion of the mechanism of action of uropathogenic bacteria is found elsewhere in this text. Once bacteria bind to host epithelium, specific biologic responses are activated in both the microorganism and host cell. Bacterial responses are designed to facilitate their survival and proliferation, as well as inhibit host defenses. These include release of endotoxin and reduction of ureteral peristalsis, which may lead to urinary stasis and reduced antegrade flow of urine. The host inflammatory response perpetuates the classic symptoms of UTI. Although a more systematic understanding of bacterial-host interactions in the propensity for reflux-associated renal scarring is not yet available, it appears that bacteria responsible for postpyelonephritic scars in the presence of reflux often express fewer than three virulence factors (Lomberg et al., 1984). Ironically, then, less virulent bacteria are most often sufficient to produce scarring in the presence of reflux.

Host Susceptibility and Response

Nonhematogenous bacterial access to the urinary tract rests essentially with periurethral organisms. Thus the type and number of vaginal and preputial organisms will determine individual propensity for bladder colonization. Local factors such as hygiene and bowel habits also will influence the bacterial load presented to the perineal surface from the intestinal tract, the latter being the principal repository for organisms that infect the urinary tract. The functional diversity of the host receptors for bacterial adherence also plays a role in the success or failure of bacteria to gain entry to the bladder. In one study, girls with recurrent UTI harbored far heavier periurethral colonization than a control group of girls who were infection free, suggesting a variation in the function of antibacterial defenses in susceptible females (Bollgren and Winberg, 1976). Furthermore, such factors may exhibit both gender- and age-related dimorphism (Bollgren and Winberg, 1976). The great majority of UTIs in both sexes younger than 6 months of age is confined to uncircumcised boys (Rushton and Majd, 1992) and is consistent with the observation that *Escherichia coli* colonization is dense in infant boys but sparse in girls (Bollgren and Winberg, 1976).

Perhaps the greatest tangible factor in promoting susceptibility to UTI is urinary dwell time. The postvoid urine volume is traditionally singled out as being suspect in providing sanctuary for ascending urethral organisms. Perhaps more important, however, is the overall dwell time between voids, which provides the greatest advantage to bacterial proliferation. **When the average doubling time for *E. coli* is measured in minutes, it is self-evident that a quantity of microorganisms sufficient for clinical infection can easily incubate exponentially in a bladder that is not emptied for several hours.**

Advances also have been made in understanding the renal epithelial response to pathogens. The classic components of the innate immune response to infection include activation of the complement system; recruitment of neutrophils and macrophages with scavenging ability; and production of a variety of cytokines, chemokines, and defensins (antimicrobial peptides). One family of receptors, the Toll-like receptors (TLRs), responds to highly constant antigens expressed in bacteria (Chowdhury et al., 2004). The best studied of these, TLR4, detects lipopolysaccharide (LPS). A breakthrough in understanding renal infection came with the demonstration that mutations encoding the *TLR4* gene were responsible for LPS hyporesponsiveness. Nevertheless, molecules accessory to TLR4 are important to its response to LPS. Similarly, molecules such as CXCR1 and CXCR2 are receptors for interleukin-8, the principal renal epithelial secreted chemokine responsible for neutrophil migration. Deficiencies of CXCR expression and function may underlie human susceptibility to pyelonephritis. Such advances placed into the context of VUR provide interesting and powerful opportunities to modify the natural history of the condition.

As well as orchestrating the assembly of the phagosome for bacterial clearance, **the fallout of these renal epithelial processes that is the inflammatory response leads to local tissue damage and scarring.** Hallmarks of the response include capillary congestion, ischemia, reperfusion injury, and free oxygen radical and inflammatory cytokine release (Roberts, 1992). Microabscess formation later coalesces into scar tissue typical of the histologic changes of chronic pyelonephritis (Roberts, 1992). Although limiting the inflammatory response to reduce scarring may appear logical, no specific pyelonephritis anti-inflammatory pharmacotherapy is yet available. Traditional nonspecific anti-inflammatory agents, both steroidal and nonsteroidal, are not currently indicated in the treatment of pyelonephritis; in their current formulations, the latter pose a threat to renal function. Nevertheless, the concept has been demonstrated experimentally in animals. A full understanding of the specific pathways involved in reflux-associated pyelonephritis could provide key strategies to limiting specific renal inflammatory fallout without limiting bacterial clearance. Until then, antimicrobial therapy instituted in a timely fashion, usually within 24 to 48 hours, is the single most effective pharmacologic strategy to date to limit the scarring consequences of pyelonephritis in both young and older children (Ransley and Risdon, 1981).

Hypertension

VUR has long been held as a primary cause of significant hypertension in children. Arterial derangements in the renin-angiotensin system and sodium-potassium adenosine triphosphatase activity (Goonasekera et al., 1998) may be involved, although the precise pathophysiologic process is not clear. Although methodologic flaws (Farnham et al., 2005) taint many studies of hypertension in the pediatric urology population, one study using continuous ambulatory blood pressure monitoring revealed some correlation between progression to hypertension and more severe reflux nephropathy in children (Lama et al., 2003). An adult review of 157 patients with hypertension, but no evidence of abnormal renal parameters, discovered latent VUR in 20% of the subjects on cystography, demonstrating that a significant association between reflux and hypertension exists in adulthood (Barai et al., 2004). The striking association between VUR diagnosed for the first time only in adulthood and arterial hypertension continues to underscore the importance of remaining vigilant about untreated infections in the reflux population (Kohler et al., 1997). Nevertheless, it remains unclear whether it is the nephropathy associated with postinfection scarring, congenital dysplasia associated with reflux, or some combination of both that predisposes to hypertension (Wolfish et al., 1993). This latter observation questions whether prevention of postinfection scarring per se in the management of VUR will specifically help offset future hypertensive risk in cases in which congenital renal dysplasia is already present. There is obvious potential for the cause of reflux-associated hypertension to rest with deranged renal microvascular mechanisms associated with parenchymal defects. This suggests that successful correction of reflux alone is unlikely to ameliorate blood pressure (Wallace et al., 1978). Indeed, removal of renal segments verified by selective renal vein sampling of arteriolar or segmental vessel renin levels has provided durable normalization of blood pressure in carefully selected patients (Tash et al., 2003) with up to 67% of patients becoming normotensive after nephrectomy (Schlomer et al., 2011). On occasion, complete removal of a small unilateral congenitally dysplastic or globally scarred and shrunken kidney also may correct renovascular hypertension (Dillon and Smellie, 1984; Schlomer et al., 2011) because such kidneys are clearly not amenable to partial nephrectomy for any discrete segment.

Renal Growth

Several studies have attempted to demonstrate that correction of reflux will restore retarded renal growth associated with reflux, particularly when the growth defect is in a unilaterally affected kidney. However, reflux correction is a poor predictor of catch-up growth in such kidneys (Hagberg et al., 1984; Shimada et al., 1988). A significant factor governing growth of an ipsilateral kidney is the function of its contralateral mate. Although forestalling infection in the presence of VUR will maintain the normal trajectory of renal growth in most cases (Edwards et al., 1981), it must be remembered that compensatory hypertrophy of the contralateral kidney will magnify the perceived impact of infection on renal growth because the contralateral developing kidney will generally assume the required renal function whenever the ipsilateral kidney is unable to contribute optimally to function. When reflux correction has been associated with improved renal growth, it is likely this is caused by removal of the propensity for ascending infection rather than the elimination of the reflux per se (Willscher et al., 1976a, 1976b; Beetz et al., 1991).

Renal Failure and Somatic Growth

Today, with modern management, renal failure resulting from primary VUR-associated infection should be nonexistent, yet it is still rarely seen. This is largely caused by the virtual paradigm shift in reflux management championed by Smellie et al. during their pivotal studies of reflux and infection in children during the 1970s and 1980s. Over the past 30 years, chronic pyelonephritis as a primary cause of end-stage renal disease has fallen from 25% to 15% (Advisory Committee to the Renal Transplant Registry, 1975) to less than 2% (Meiland et al., 2007; Geerlings 2016; NAPRTCS, 2004). Reflux nephropathy in all its forms, however, was the second most common primary diagnosis in non-black pediatric transplant recipients. In a registry of children on renal replacement therapy (RRT) in Australia and New Zealand, reflux nephropathy was the primary diagnosis for 13.6% of children (Craig et al., 2000) and the second leading cause for initiation of RRT after glomerulonephritis (Orr et al., 2009). The incidence has changed somewhat, but this may reflect a shift in diagnosis from nephropathy caused by VUR to congenital dysplasia (Orr et al., 2009).

The medical renal disease (Hinchliffe et al., 1994) that accompanies renal scarring can include hyperfiltration, concentrating defects, proteinuria, microalbuminuria (Lama et al., 1997), renal tubular acidosis (Guizar et al., 1996), and increased fractional excretion of sodium and magnesium. Although all of these parameters are likely the direct result of tubular and parenchymal damage or dysplasia, concentrating defects and increased concentrations of tubular enzymes (Carr et al., 1991) have been reported in the presence of sterile reflux, independent of any history of infection per se (Walker et al., 1973). The concentrating defect is proportional to reflux grade and improves after reflux cessation. These observations have suggested that a relative flow resistance may be created by retrograde nature of reflux and raises the possibility of a functionally obstructive parameter in reflux pathogenesis. However, the precise relationship between antegrade flow, retrograde flow, and bladder dynamics has not been more fully articulated.

One of the best global parameters of renal function in children is the somatic growth curve. Many children with VUR fall below the normal age-adjusted growth curve, particularly in patients with bilateral reflux and some degree of renal damage. Furthermore, successful suppression of pyelonephritis through either medical prevention of infection or surgical correction of reflux itself can result in catch-up growth, both for height and weight (Polito et al., 1997, 1996). Although a clear superiority has yet to be demonstrated between medical and surgical therapy to affect growth improvement or subsequent renal scarring after an initial pyelonephritic insult, surgical correction of reflux can benefit somatic growth when recurrent BUTI indicates failure of antibiotic prophylaxis (Sutton et al., 1989).

Diagnosis and Evaluation of Vesicoureteral Reflux

Confirmation of Urinary Tract Infection

Acquired reflux nephropathy can be a potentially catastrophic condition with significant, yet potentially preventable aspects. If certain risk factors are addressed and eliminated, damage to the upper urinary tract can be lessened and even prevented entirely. Upper tract scarring in the context of VUR is a combination of several factors, however, one of the most important is the presence of infected urine. When present in the lower urinary tract, bacteria can more easily ascend to involve infection of renal units. Because preventable reflux nephropathy is predicated on the combined effects of UTI and reflux, confirming and documenting true UTIs is paramount in the initial appropriate management of the patient with reflux. Many variables are responsible for the accurate assessment and interpretation of urine studies in the context of reflux. These include clinical history and presence of fever; age of the patient; method of urine specimen collection, storage, and delivery; circumcision status in males; and the results of urine dipstick and microscopic analyses. Confirming true pyuria by dipstick or microscopic analysis, in addition to the presence of bacteriuria, will help to differentiate infection from contamination.

The importance of obtaining an appropriately collected urine specimen cannot be overemphasized. In infants, oftentimes caused by parental and clinician discomfort, a urine specimen collection will often entail the placement of an adhesive urine bag over the genitalia. Unfortunately, routine practice is so variable that such guidelines are often difficult to follow or confirm, and **microbial contamination of bagged specimens is common. Conversely, this method is most useful for establishing the presence of pyuria or if the resulting urine culture is negative.** Although fevers are common in infants, UTI composes only 5% of children presenting with fever (Hoberman et al., 1997). Thus the ability to easily rule out a UTI in the febrile infant with reflux facilitates management. If there is a high clinical suspicion for UTI in an infant, the more accurate method is to obtain a catheterized specimen. Even this method may prove suspect in the uncircumcised infant whose preputial skin is not yet retractable to easily reveal the urethral meatus. In this and other instances in which the urethral route is difficult or compromised in patients of any age, some also advocate for suprapubic aspiration, which provides the most accurate method of obtaining a urine sample, in children who cannot provide a midstream urine specimen (Subcommittee on Urinary Tract Infection, Steering Committee on Quality Improvement and Management, and Roberts, 2011). Although this technique has limited risks, particularly if guided by ultrasonography, technical expertise and experience are required, and many parents and physicians perceive the procedure as unacceptably invasive. In males with severe phimosis and girls with significant labial adhesions, it may be the only reliable means to obtaining an uncontaminated urine specimen (Subcommittee on Urinary Tract Infection, Steering Committee on Quality Improvement and Management, and Roberts, 2011).

In the younger child, however, repeated catheterization for specimen acquisition and radiographic assessment should be considered carefully. This routine practice is coming under greater scrutiny as the long-term sequelae of repeated catheterizations has become appreciated (Stashinko and Goldberger, 1998) and could become a factor in patient compliance with follow-up.

In patients who can void spontaneously, a clean voided midstream-catch specimen is adequate (Subcommittee on Urinary Tract Infection, Steering Committee on Quality Improvement and Management, and Roberts, 2011). The initial urine is discarded because it can be rich in periurethral organisms.

Attention to these details cannot be overemphasized as major management decisions, including operative intervention to correct reflux, often rest solely on a diagnosis of UTI. Conversely, confirming microbial growth in a urine specimen is of little value if the mode of collection is highly suspect and likely to harbor contamination. Again, confirmation of UTI begins with collection of the urine specimen. If storage is necessary, specimens should be maintained at 4°C until transfer to the laboratory. Keeping in mind that in children who are not toilet trained, a bagged specimen is of little use, unless negative, as contamination rates can be quite high with associated high false-positive rates (Sørensen et al., 1988; Subcommittee on Urinary Tract Infection, Steering Committee on Quality Improvement and Management, and Roberts, 2011; Springer and Subramaniam, 2014; Selekman et al., 2016). Urine should be collected via midstream catch in children who are toilet trained and with a retracted foreskin in males who are uncircumcised. **Finally, it is important to reiterate that urine culture results cannot be accurately interpreted without reviewing the urine analysis and evaluating the overall clinical picture.**

Key Points: Diagnosis and Evaluation of Vesicoureteral Reflux

- The method of urine collection and the presence of pyuria are of utmost importance in the diagnosis of UTI to avoid false-positive culture results.
- The gold standard study for the diagnosis of reflux requires bladder catheterization.
- Nuclear cystograms, though more sensitive, provide much less anatomic detail than does a VCUG.
- Parental perceptions of reflux management must be considered when treating a child with reflux.
- Upper tract assessment is based on serial studies.
- The challenge in imaging is to differentiate congenital reflux–associated renal dysplasia from scarring acquired after infection.

Evaluating Urinary Tract Infection

Numerous factors may trigger the search for reflux in the patient after one or more UTIs. The probability of finding VUR in children with a UTI varies depending on the study of interest, but the rate centers around 30% (Sargent, 2000). Furthermore, in some patients, higher grades of reflux may be associated with various degrees of existing renal parenchymal maldevelopment, or dysplasia (Nakai et al., 2003; Farhat et al., 2000). In addition, because reflux tends to resolve over time, it is reasonable that UTI is more commonly associated with reflux in younger patients (Smellie et al., 1981; Capozza et al. 2017).

As the basic evaluation for children with a history of UTI and suspected VUR inevitably involves some form of invasive testing or subjects children to some form of radiation, there is tremendous push to limit the intrusive and often traumatic experience for both parents and children, when possible.

It is the position of the authors that a risk-stratified approach be taken to optimally evaluate and manage each patient in the diagnosis and evaluation of children with suspected VUR. This does not preclude a basic approach to the evaluation of children with UTIs, but reinforces the need to view VUR less as a dichotomous condition and more as a spectrum of disease greatly affected by both the degree of underlying severity, innate patient risk factors, risk for morbidity from repeat infection, and invasiveness of treatment.

Because of the higher incidence of renal scarring in patients with VUR and repeat UTIs (de Bessa et al., 2015; Wang et al., 2015; Nagler et al., 2011; Peters et al., 2010), most approaches for the evaluation of children with repeat UTIs prompt some form of workup to rule out VUR (Fig. 29.12). However, the current state of the VUR debate makes it difficult to predict which evaluated patients might harbor clinically significant reflux, given how common UTIs are in children, although some reassurance can be provided when a voiding study is negative for VUR.

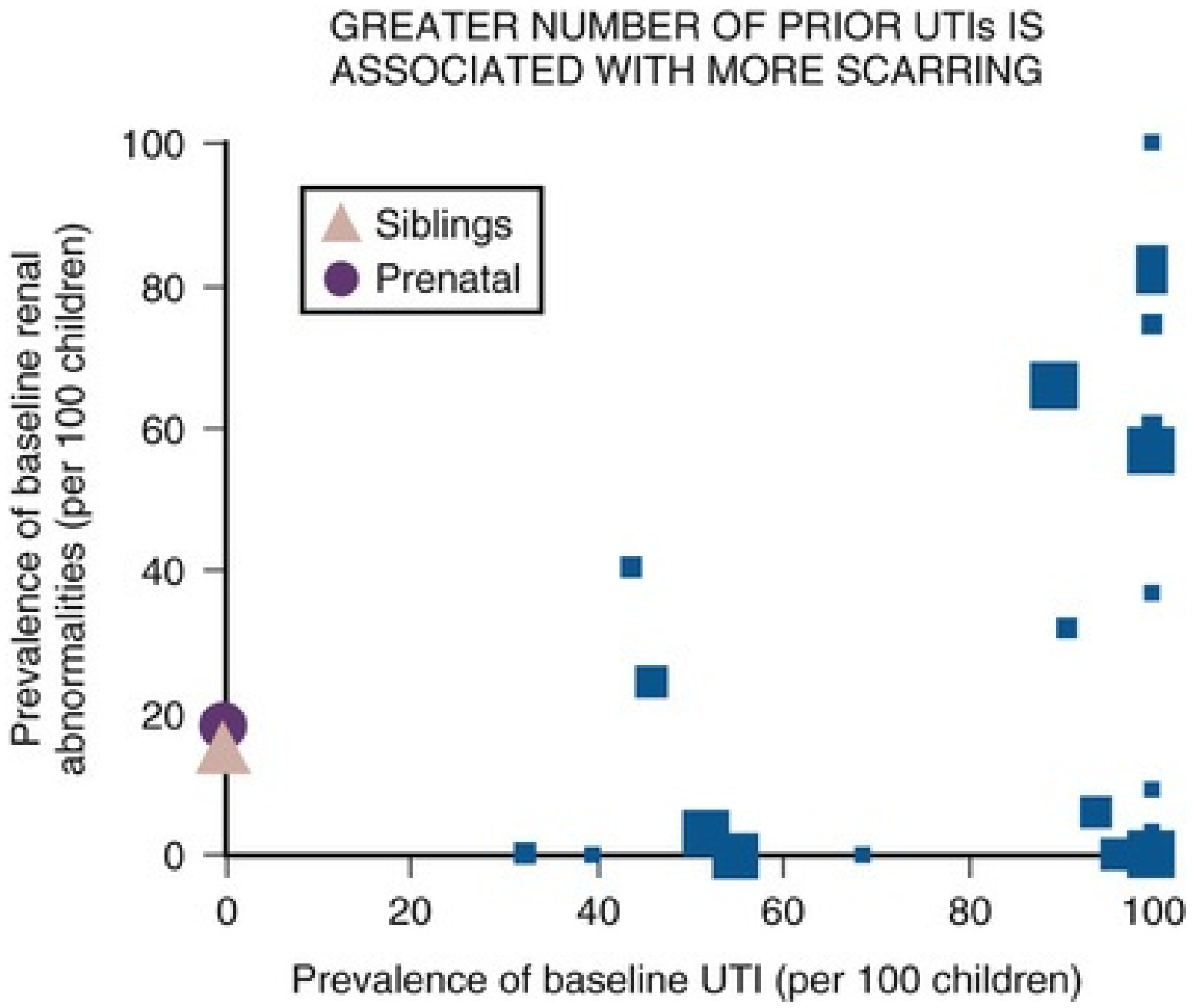

FIG. 29.12 Urinary tract infection *(UTI)* history. (From Peters CA, Skoog SJ, Arant BS Jr, et al. Summary of the AUA Guideline on Management of Primary Vesicoureteral Reflux in Children. *J Urol.* 2010;184(3):1134–1144.)

There is also parental concern over the invasiveness of VCUG and the need to include it as part of the initial diagnostic workup. This occasionally limits the initial diagnostic workup to ultrasonography only, which may help rule out any significant gross structural defects. This is also in keeping with guidelines released from the **American Academy of Pediatrics (AAP), which recommend ultrasonography in children younger than 2 years of age with a first febrile UTI as the initial diagnostic test, delaying a VCUG unless there are significant findings on ultrasonography** (Subcommittee on Urinary Tract

Infection, Steering Committee on Quality Improvement and Management, and Roberts, 2011). Thus, taking the appropriate voiding, fever, and family histories into account, ultrasonography of the bladder and kidneys can be considered a reasonable minimum in evaluating the infant or child after a UTI. Even the detection of reflux after treatment for UTI could be of questionable significance if the child is older and/or if no fever accompanies the UTI. On the other hand, the presence of structural renal anomalies or significant asymmetry in renal size, ureteral dilation, or bladder anomalies would support proceeding with a VCUG (Subcommittee on Urinary Tract Infection, Steering Committee on Quality Improvement and Management, and Roberts, 2011; The National Institute for Health and Care Excellence, 2018).

The advent of prenatal ultrasonography has likely augmented the detection of asymptomatic reflux in newborns as a result of surveillance for persistent postnatal hydronephrosis and the ensuing performance of cystography in these infants. It must be remembered that the sonographic finding of primary hydronephrosis is generally much more common than dilation caused by active reflux at the time of ultrasonography. Indeed, there is little correlation between the degree of antenatal hydronephrosis and the presence and grade of reflux (Phan et al., 2003; Farhat et al., 2000). A corollary study also demonstrated normal postnatal sonograms in 25% of patients with VUR and antenatal hydronephrosis (Lebowitz, 1993).

Assessment of the Lower Urinary Tract

Cystographic Imaging

The basis of reflux detection lies in demonstrating the retrograde passage of an imaging contrast material from the bladder to the ureter and renal pelvicalyceal system. The currently available methodologies require a source of contrast agent in the bladder. The two approaches, the indirect and direct cystograms, can be performed depending on whether the contrast enters the bladder indirectly after excretory urography or directly, usually by urethral catheterization. Indirect cystography, although avoiding the invasive nature of urethral catheterization, is prone to false-positive interpretation as a result of contrast that does not originate from the bladder remaining in the ureter or pelvis after filtration and antegrade passage and false-negative results in lower grades of reflux (Conway et al., 1975). However, it has been suggested that the value of indirect cystography may lie in ruling out the presence of VUR (Carlsen et al., 1986).

The VCUG is a fluoroscopic study that provides information on both the functional dynamics and structural anatomy of the urinary tract. The detailed technique of the VCUG is discussed more fully elsewhere in this text. Bladder contrast is instilled by gravity after urethral catheterization at a maximum height of 70 cm of water (Lebowitz et al., 1985). Bladder capacity is recorded when contrast influx ceases. Static images record bladder contour, presence of diverticula or ureteroceles, volume at which reflux occurs, grade of reflux, configuration and blunting of calyces, and intrarenal reflux, if present. Passive or active reflux is demonstrated dynamically during fluoroscopy while filling and voiding, respectively. In addition, bladder neck anatomy, funneling or dilation, and urethral patency are parameters derived from the VCUG. Delayed or postvoid films are crucial in documenting clearance of contrast from the upper tracts because retained contrast, particularly with dilated pelvicalyceal systems, could signify the presence of a concomitant UPJ obstruction (UPJO), either primarily or secondarily as a result of distortion of the UPJ by massive retrograde filling of the pelvis by the reflux (Hollowell et al., 1989). Care should also be exercised in the child with dilating reflux on a VCUG when there is significant contrast dilution in a dilated ureter. One should consider the presence of concomitant UVJ obstruction in the context of VUR when some or all of the following are seen: (1) dilated proximal ureter/not necessarily kidney, (2) transition area to distal, aperistaltic juxtavesical segment, (3) decrease in contrast caused by mixing with trapped, nonopaque urine, and (4) delay in drainage on postvoid film above aperistaltic distal ureteral segment (Blickman and Lebowitz, 1984).

These may suggest some form of delayed drainage at the UVJ, which could represent possible obstruction, and care should be exercised in these cases.

The VCUG and RNC are the two common forms of direct cystography and constitute the present-day gold standard approaches to reflux detection. More recently, to eliminate the need for ionizing radiation, some studies have demonstrated a growing interest in sonographic detection of reflux using either color Doppler imaging (Valentini et al., 2001; Galia et al., 2004; Castagnetti et al., 2006) or echo-enhancing contrast agents (Berrocal et al., 2001; Darge et al., 2001, 2002; McEwing et al., 2002; Valentini et al., 2004; Ntoulia et al., 2018; Piskunowicz et al., 2016). Modern transducers coupled with the use of echo-enhancing contrast agents can image reflux well in children with comparable results to traditional VCUG, especially when using new techniques and second-generation enhancing agents (Kuzmanovska et al., 2017; Piskunowicz et al., 2016; Valentini et al., 2001; Ntoulia et al., 2018; Castagnetti et al., 2006; Darge, 2008a, 2008b, 2010; Riccabona et al., 1993).

The RNC uses a radionuclide tracer labeled with ^{99m}Tc pertechnetate and scintigraphy to detect reflux. Indirect RNC is performed through passive filling of the bladder after intravenous injection and passage of tracer into the bladder is achieved (Gordon et al., 2001). This requires that children be toilet-trained. Children are instructed to void, and images are captured to detect reflux, if present. Direct RNC utilizes directed filling of the bladder with a catheter, similar to VCUG (Fettich et al., 2003). RNC has historically enjoyed a reputation for requiring approximately 1% the radiation exposure generated by the continuous fluoroscopy VCUG and 10% of that for pulsed fluoroscopy VCUG (Ward et al., 2008; Blaufox et al., 1971; Diamond et al., 1996), and for indirect RNC, the need for catheterization is avoided altogether. Presently, the reduced radiation exposure of modern digital techniques has significantly narrowed the difference between fluoroscopy and RNC, especially when certain refinements are employed. Although less anatomic detail is traditionally afforded by the RNC, newer techniques have been able to increase both its sensitivity and specificity. For indirect RNC, this includes data captured during failed voids, adding extra imaging sequences at intervals during bladder filling and by using simple mathematical criteria to determine if VUR was present when visual imaging results were equivocal (Keir et al., 2013). Sensitivity and specificity for indirect RNC has been noted in the literature to be 70% to 74% (Gordon et al., 1990; Keir et al., 1998) and 90% (Gordon et al., 1990), respectively. Direct RNC has shown good correlation with VCUG for VUR (Unver et al., 2006), and certain studies have shown techniques that track bladder volume during filling to further help define the grade of reflux, something that has been a major criticism of this imaging modality (Agrawal et al., 2009).

Although traditional grading of VUR with RNC has been difficult, it can be an ideal imaging study to both screen and monitor the natural history or surgical follow-up of reflux. In contrast with the VCUG, the instilled bladder contrast material itself is the radiation source. Reflux is detected on scintigraphic gamma camera images (Fig. 29.13). Lack of confounding imaging densities typical of fluoroscopy and the ability to obtain prolonged exposures allow for greater sensitivity of the RNC in grade 2 to 5 reflux. Ironically, grade I reflux into the distal ureter is often poorly detected because of the overlying exposure generated by contrast within the bladder. Bladder volume grading has been a useful technique to improve on this. This involves filling the bladder with small infusions of saline mixed with radionuclide tracer, usually at a rate of 10% of the estimated bladder capacity, and noting the volume when reflux is first seen on scintigraphy. Several images are captured, including a 30-second anterior prevoid static image, a voiding dynamic set, and an anterior postvoid static image (Agrawal et al., 2009). As the volume when reflux is first seen has been shown to be a useful measure in understanding overall reflux severity and may affect spontaneous resolution rates (Weiss et al., 1992a; Polito et al., 2000), the use of this technique may offer augmented prognostic measures for children with VUR. Thus RNC and VCUG imaging can be used complementarily, balancing radiation exposure with the need for dynamic information and anatomic detail. Notwithstanding the previous discussion, modern digital fluoroscopic equipment has further reduced the radiation exposure of conventional fluoroscopy, thereby narrowing the difference in radiation exposure between the two modalities (Fettich et al., 2003; Ward et al., 2008; Diamond et al., 1996; Blaufox et al., 1971; Jaju et al., 2015; Linke et al., 2016).

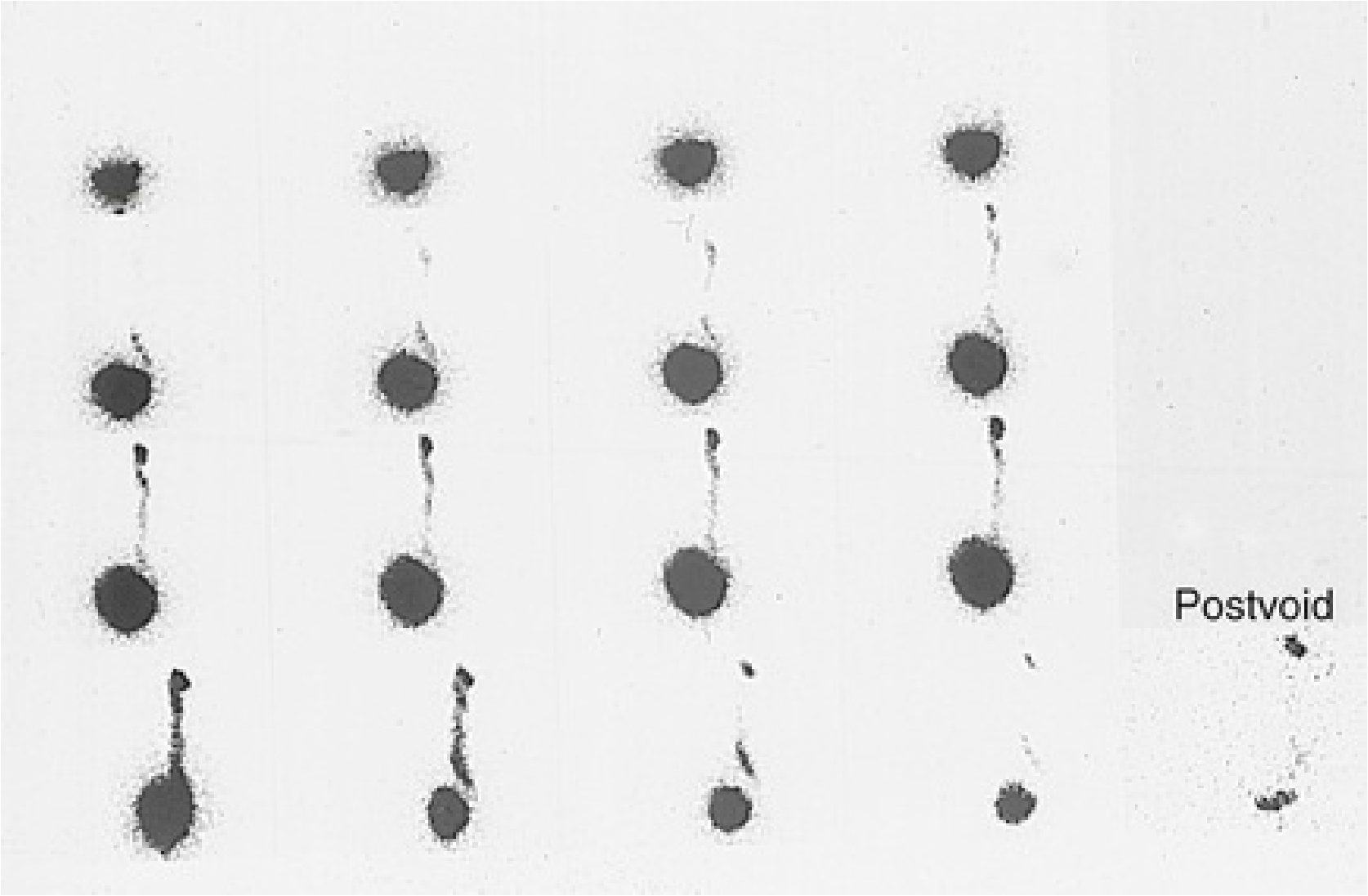

FIG. 29.13 Radionuclide cystogram showing right-sided reflux that worsens with bladder filling. The upper collecting system drains fully with voiding.

Direct imaging of reflux is affected by several parameters. These include bladder contraction during voiding, the volume instilled into the bladder, presence of infection, and therefore inflammation of the UVJ mucosa. Reflux may occur during filling or only during active bladder contraction associated with voiding. Consequently, if a patient is unable to void in the artificial setting of the radiography suite, false-negative results may ensue if reflux is present during the high pressure portion of the test associated with voiding. More importantly, even during voiding, reflux may not be demonstrated on a single filling-voiding cycle. Several studies have demonstrated a roughly 12% to 20% greater detection rate for VUR if a cyclic study is performed (Paltiel et al., 1992; Papadopoulou et al., 2002; Novljan et al., 2003). A cyclic VCUG involves a second or third cycle of bladder filling and emptying under fluoroscopic observation. To limit the overall exposure to ionizing radiation, there may be a role for cyclic VCUG without the real-time fluoroscopy, limiting the amount of images acquired and standardizing image capture at several time points during a three-cycle study without significantly compromising the overall information garnered during the study (Kadioglu et al., 2006). Cyclic RNC has also been employed as a diagnostic strategy (Fettich and Kenda, 1992).

Reflux may also be demonstrated during catheter filling of the bladder. Because filling assumes far lower intravesical pressures than that of voiding, unless there is active detrusor overactivity, reflux during filling and passive reflux along with grade are generally considered poor prognostic signs for future reflux resolution (Lee et al., 2016). Early reflux during filling can be a common finding in patients with acquired or neurogenic voiding dysfunction, wherein high-resistance voiding gradually remodels the bladder wall and UVJ, leading to complete failure of the latter's antireflux mechanism and reflux at low volumes of the filling phase (Koff, 1992). This is in contrast with reflux that occurs only during the higher pressure voiding phase of bladder emptying. Moreover, technical inconsistencies can lead to variations in rates of reflux detection: if the bladder is underfilled, reflux may be underdetected.

One difficult dilemma in the performance of voiding studies involves cystography during active infection. The primate work by Roberts showed that in the presence of bacterial infection, there is decreased peristalsis with subsequent ureteral dilation and decreased drainage, which can help explain this phenomenon (Roberts, 1992). On the other hand, evoking reflux during active cystitis, by definition, will transmit bacteria to the upper urinary tract and renal pelvis and risks iatrogenic pyelonephritis. Nevertheless, the general consensus has been to delay the voiding study for at least 1 week or longer to allow for adequate recovery from the acute infection episode (Craig et al., 1997), although there have been several studies that show little difference in delaying the diagnostic workup and note that ensuring the urine is sterile and that the child has clinically improved with treatment is necessary before a VCUG is obtained (Golmakani et al., 2016). If it is imperative to make the diagnosis of reflux in children with a history of recurrent pyelonephritis and repeatedly negative voiding studies in the intercurrent periods, cystography during UTI should be considered, particularly if family compliance with follow-up is uncertain.

Cystoscopy and the Positioning of the Instillation of Contrast Cystogram

Modern management of reflux does not include routine cystoscopy. It is rare for cystoscopy to add any information that will alter management of a patient with reflux, either at the time of initial diagnosis or during follow-up. Its use, especially in children with UTI or reflux, should be considered only exceptionally. Similarly, the appearance and configuration of the ureteric orifices and intramural tunnel length that are afforded by cystoscopy and once considered useful parameters have over time provided little correlation with either the diagnosis or grade of reflux (Duckett, 1983). Cystoscopy can provide useful information immediately before open surgery, such as evaluation of orifice position, duplication anomalies, and the proximity of diverticula to the orifice, and confirm the absence of mucosal inflammatory changes and urethral patency if indicated.

In a select group of patients who present with recurrent febrile UTIs and no evidence of VUR on VCUG, there is some evidence to suggest that the positional instillation of contrast (PIC) with fluoroscopy may have some benefit.

The technique of PIC cystography involves cystoscopy while the child is under anesthesia. With the bladder empty, the cystoscope beak is positioned close to and facing the ureteric orifice. Contrast is instilled at the ureteric orifice using the irrigation port of the cystoscope from a height of 1 meter above the bladder. Fluoroscopic spot imaging is done simultaneously with the instillation. PIC-VUR is confirmed if retrograde flow of contrast into the ureter/kidney pelvis is observed. The bladder is emptied before the procedure is repeated on the contralateral side.

Several studies have shown occult reflux using PIC cystography (Rubenstein et al., 2003; Hagerty et al., 2008; Cheng 2009; Tareen et al., 2006) and a reduction in recurrent UTI rates after successful medical or surgical management in these children (Cheng 2009; Palmer et al., 2011; Matsumoto et al., 2011).

It is conceivable that the antireflux mechanisms may be less robust in some patients with recurrent UTI. The unique, but unphysiologic, nature of the PIC technique may then reveal reflux in such cases. Furthermore, PIC cystography does not allow for age-adjusted instillation pressures; some pressures may be too high in younger patients and may be creating iatrogenic reflux rather than unmasking relevant, physiologically borderline reflux.

A multi-institutional study by the PIC Cystography Group (Hagerty et al., 2008) examined the clinical significance of reflux discovered by PIC in 118 children with a history of febrile UTIs and negative VCUGs. VUR diagnosed by PIC was treated by surgery (endoscopic injection in 104 patients, reimplantation in 3) or by antimicrobial prophylaxis (11 patients). In the 98 evaluable patients, VUR grade was 1 to 3 and was unilateral in 34 patients and bilateral in 64 patients. Treating occult VUR identified by PIC cystography, with either antibiotics or surgery, reduced the incidence rate of febrile UTI by 20-fold (from 0.161 per patient per month before PIC-VUR treatment to 0.008 per patient per month after treatment). In another study, there was also a statistically significant association between PIC-VUR grade and severity of renal scarring on ^{99m}Tc dimercaptosuccinic acid (DMSA) scans (Berger et al., 2013).

It is generally believed that VUR does not cause UTI; however, in this nonrandomized study (with the patients acting as their own controls), PIC cystography provides some evidence and rationale for antireflux therapy in a very limited subset of patients.

Although some data have shown that a role for PIC cystography may exist in the evaluation of the patient with multiple UTIs, it should not be used as a first-line diagnostic tool, because a general anesthetic is necessary. Rather, it should be reserved for a very select group of patients who pose rare, diagnostic dilemmas. **Until prospective studies randomizing patients with PIC-VUR to treatment or observation to confirm its clinical benefit are performed, its role remains very limited.**

Assessment of the Upper Urinary Tract

Rationale for Serial Assessment of Upper Tracts

The known effects of VUR on the upper tracts are largely what direct the need for reflux diagnosis and correction. Pyelonephritis propagated by reflux causes renal scarring, impedes attainment of full renal growth potential, and increases the risk for renovascular hypertension (Mattoo et al., 2016; Rushton et al., 1992; Willscher et al., 1976b; Schlomer et al., 2011). Therefore, imaging of the upper tracts is directed at assessing renal structure and function, with attention to the aforementioned parameters. A fundamental goal in upper tract imaging with VUR is to ascertain whether abnormalities are caused by ongoing or resolved reflux and differentiate them from congenital dysplasia, medical renal disease, or hydronephrosis. Almost always, particularly in the youngest patients in whom VUR has the greatest potential to cause renal injury, these goals are best achieved through serial imaging of the kidneys over a period of months to years.

Many observational studies raised concern for the sequelae of UTIs and highlighted the potential for successful intervention. Reflux status**, coupled with the age of the patient, sex, race, family history of reflux, and bladder and bowel functional status, serve as a guide to selective imaging, which attempts to balance intensity of imaging studies with propensity for renal damage.**

Renal Sonography

RBUS is noninvasive, is performed relatively quickly, and does not require intravenous access for contrast agents, which makes it ideal for initial evaluation. It is, therefore, the initial mainstay of renal imaging in VUR management. As a nonionizing, noninvasive imaging platform, coupled with its ability to assess renal vasculature, it is also ideal for serial follow-up of the kidneys.

Ultrasonography lends itself well to quantitative assessment of renal dimensions (Rodriguez et al., 2001; Chen et al., 2002), which then can be used to follow renal growth over time. Renal growth can be referenced to standard renal growth curves. In reflux diagnosed in the neonatal period, baseline renal dimensions are obtained, and appropriate renal growth can be monitored. The impact of any intercurrent febrile UTI can be gauged by observing the effects on renal growth, which is impacted significantly as the number of infections increases (Parvex et al., 2008). Similarly, if the UTI history between follow-up visits for reflux is unclear, serial assessment of renal size can help the urologist advise on the need for further assessment of renal function by scintigraphy or on the need for reflux correction. Indeed, in the presence of reflux, modern postnatal renal sonography provides excellent correlation between renal length and scintigraphic hypoplasia (Farhat et al., 2002a, 2002b).

Ultrasonography is also useful for evaluation of renal corticomedullary differentiation. Loss of corticomedullary differentiation, or an increase in overall echogenicity of the kidney, is associated with some degree of renal functional impairment (Chi et al., 2006; Stember et al., 2016). In neonates, in particular, these parameters can be useful in assessing the overall status of a renal unit in the context of higher grades of reflux, even before any history of UTI or pyelonephritis has occurred. Coupled with a relatively smaller ipsilateral kidney, loss of corticomedullary differentiation or increased echogenicity suggests a degree of intrinsic renal dysplasia that developmentally accompanies high-grade reflux (Chi et al., 2006). In the neonate with no infection history, such findings should not be confused with acquired renal scarring caused by pyelonephritis.

Notwithstanding the value of renal sonography, it must be remembered that the RBUS cannot diagnose VUR. Although it is tempting to speculate on the presence of reflux with postnatal hydronephrosis, particularly of higher grades, there is no significant correlation between a normal sonogram and the absence of reflux (Farhat et al., 2000; Zamir et al., 2004). Similarly, renal sonography is limited in its ability to visualize minor renal cortical abnormalities. Several studies have shown the superiority of renal scintigraphy over ultrasonography in detecting renal scars (Veenboer et al., 2015; Hitzel et al., 2002), however, ultrasonography remains a more feasible diagnostic test for regular surveillance imaging and may be suited to the noninvasive detection of larger cortical defects or renal size asymmetry (Merguerian et al., 1999).

Modern enhancements in ultrasound technology permit imaging of perfusion abnormalities in tissue. In reflux nephropathy using color Doppler ultrasonography, renal resistive index measurements derived from blood flow in interlobar and arcuate arteries are significantly increased in higher grades of reflux and correlate positively with scintigraphic findings from the same renal unit (Radmayr et al., 1999). Resistive indices are also higher in patients with pyelonephritis confirmed by nuclear scintigraphy compared with patients with lower UTI alone (Ozcelik et al., 2004). Animal studies have also demonstrated that contrast-enhanced harmonic ultrasonography can detect histologically confirmed regions of reflux-induced pyelonephritis with great sensitivity and more than 80% positive and negative predictive values (Farhat et al., 2002a, 2002b).

Renal Scintigraphy

The gold standard for functional imaging of renal parenchyma is scintigraphy using ^{99m}Tc-labeled DMSA. The radiotracer is taken up only by functioning proximal tubular tissue mass, where it binds for several hours. The uptake of DMSA provides a good proportional representation of glomerular filtration (Taylor, 1982). Renal scintigraphy should be standardized to capture function accurately and is useful clinically to dichotomize approaches when surgical intervention is considered, which rarely involve removal, from correction of VUR. Most institutions perform scans using a gamma camera positioned posteriorly, however, in cases with severe hydronephrosis, conjugate views may measure differential function more accurately (Pippi Salle et al., 2008; Wehbi et al., 2016). Because of the edema and inflammatory changes associated with pyelonephritis, tubular uptake of radiotracer is impaired, and these areas appear photopenic (Fig. 29.14). Although many such affected areas in the kidney resolve, especially with prompt medical treatment (Fernández-Menéndez et al., 2003), when they persist, irreversible renal damage or scarring is said to have occurred (Rushton and Majd, 1992). In a study of 79 children followed for 1 to 4 years, DMSA scanning provided 98% sensitivity and 92% specificity for scar detection (Merrick et al., 1980). Although Rushton's study suggested that subsequent scarring was independent of the presence or absence of VUR (Rushton and Majd, 1992), a meta-analysis found that reflux conferred an approximately threefold increased risk for detecting renal cortical abnormalities after infection (Faust et al., 2009; Pietrzak-Stelasiak et al., 2017; Nordenström, Holmdahl, et al., 2017a). Indeed, considering the overall incidence of pyelonephritis in children, VUR is present in 30% of such patients (Hoberman et al., 2003; Sargent, 2000). Nonetheless, the importance of VUR lies in the realization that it remains a spontaneously resolving or surgically treatable cause for this ascending group of renal infections (Rushton et al., 1991).

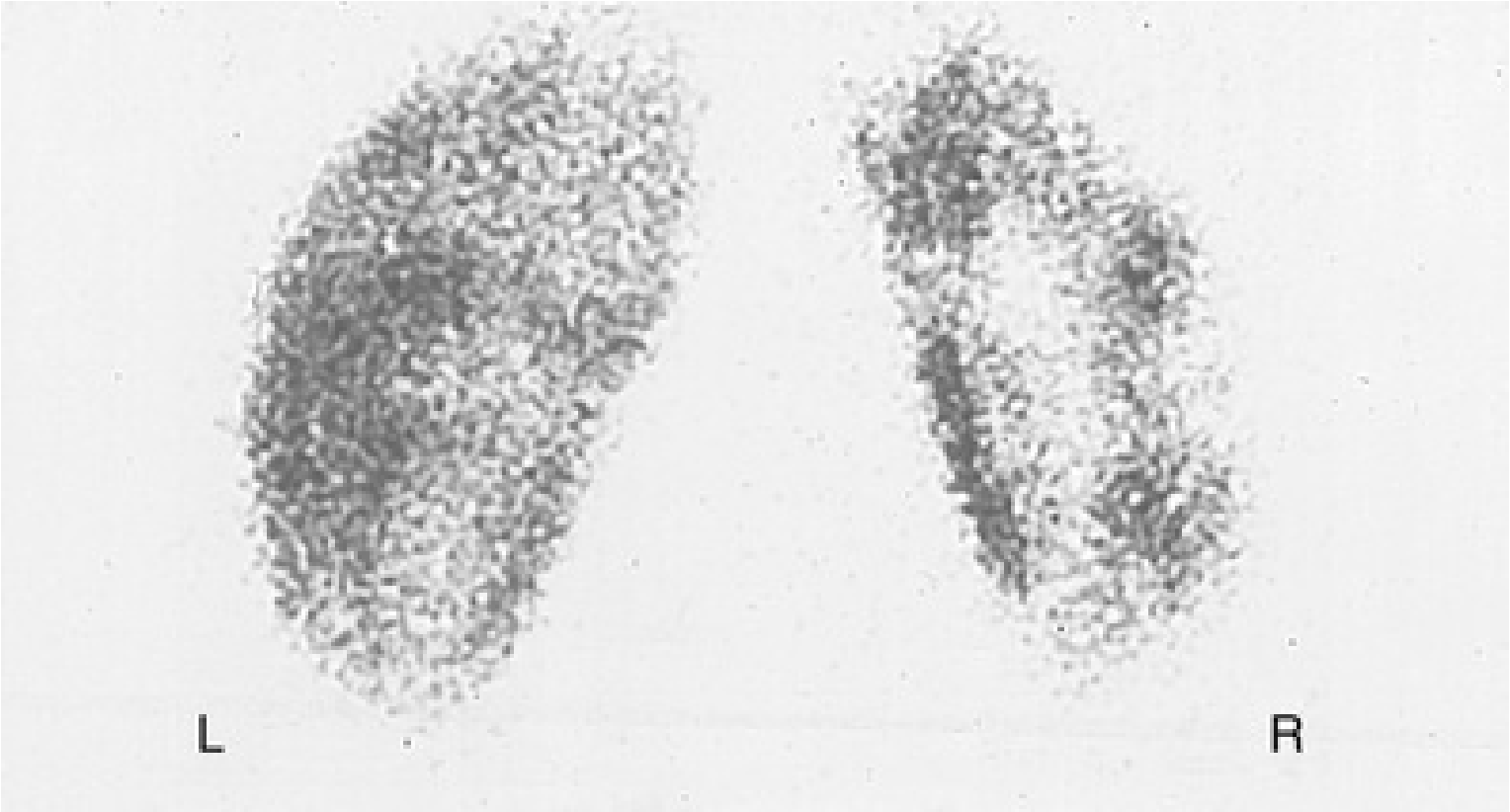

FIG. 29.14 Dimercaptosuccinic acid renal scintigraphy. Pinhole images show a normal left kidney and a right kidney with multiple cortical defects.

One advance in traditional nuclear scintigraphy of the kidneys is single-photon emission computed tomography (SPECT imaging). This approach reconstructs three-dimensional images of the renal cortical architecture, which can be viewed in any aspect in 360 degrees of rotation. Although SPECT images provide slightly higher sensitivity for detection of cortical defects, they do not add appreciably to standard pinhole DMSA images in the clinical management of reflux (Majd et al., 1996).

Despite the well-established guidelines for renal cortical scintigraphy from the Society of Nuclear Medicine (Mandell et al., 1997), investigators in the RIVUR study reported a significant degree of interinstitutional variability in how DMSA scans are performed, with 17% of RIVUR DMSA scans rejected because of poor quality (Ziessman et al., 2009).

Much has been written in the literature on the role of DMSA scanning in the management of VUR as an indirect investigation to the diagnosis of reflux itself, for the detection of reflux-associated renal damage and acute pyelonephritic changes, and for follow-up of reflux. DMSA and ultrasonography are often used complementarily, particularly when knowledge of relative renal function is desired (Riccabona et al., 1993). As a general rule, the utility of scintigraphy can best be appreciated in the context of the data it provides relevant to reflux: imaging cortical defects and relative renal function. The usefulness of this information will depend on what associated clinical and radiologic data are at hand. If reflux and infection history are unclear or unknown in a new patient referred for evaluation after UTI, scintigraphy can provide the gold standard for demonstration of cortical defects and help with counseling on additional studies. This serves the basis for the top-down approach (TDA), which is discussed later.

Confirmation of acute pyelonephritis can help ensure that adequate antimicrobial therapy is provided. If surgical intervention is planned and significant renal asymmetry exists on ultrasonography, quantification of relative function by scintigraphy can help in the decision between reflux correction and nephrectomy.

DMSA scanning also demonstrates congenital cortical maldevelopment, particularly in high-grade reflux, in the absence of any history of UTI or outlet obstruction (Wallin and Bajc, 1994; Nguyen et al., 2000). The distinction between congenital cortical defects and postinfection scarring is critical and may influence management decision making.

Controversies in Usage of Invasive Investigations

There are few conditions in pediatric urology more widely disputed with regard to diagnosis and management than VUR. A myriad of factors throughout essentially all aspects of the patient-parent-clinician interaction from diagnosis to surveillance to treatment exist.

The well-recognized distress of the family and patient associated with urethral catheterization, particularly in children, coupled with the advent of low-morbidity outpatient correction using endoscopic approaches has challenged conventional reflux management and therapy. Literature evaluating the utility of VCUG in the workup and diagnosis, as well as the role of medical management to prevent infection, is oftentimes conflicting.

All aspects of VUR have come under scrutiny, including incidence of renal scarring, association of VUR and renal failure, peak ages of susceptibility for renal scars, and indications for intervention, including the assumption that resolution or permanent correction of reflux is an absolute necessity. This has given rise to added pressures of avoiding bladder catheterization in view of the distress it creates in young patients (Stashinko and Goldberger, 1998; Elder, 2005).

Sedation (Stokland et al., 2003; Thacker et al., 2016; Blumberg, 2012), topical urethral anesthetic (Gerard et al., 2003), and hypnosis (Butler et al., 2005) have all been effective in mitigating the deleterious psychological effects of cystography.

Clinicians should resolve how each investigation, especially invasive ones, affects the overall clinical decision tree and how the results enable the safe management of each patient, either by intervention or conservative methods. All of this should be weighed against the degree of distress each test causes the child.

Renal Scintigraphy and the Top-Down Approach

The TDA is a concept based on the notion that only clinically relevant reflux with potential to cause renal injury is worthy of uncovering, with the critical assumption that VUR in the absence of scintigraphic renal abnormality is unlikely to cause future renal damage. As part of the initial workup, only a DMSA renal scan is obtained shortly after a febrile UTI, reserving a VCUG for patients with abnormal findings on renal scan. Essentially a DMSA scan is used to distinguish which children may benefit for workup to rule out VUR. In these cases, children with a negative DMSA scan undergo no further evaluation unless they develop recurrent UTI, in which case a VCUG should be obtained. If the significance or febrile nature of a potential pyelonephritis is unclear, particularly in a younger patient, a follow-up DMSA scan 4 to 6 months after UTI can rule out subsequent scarring, particularly if a normal scan exists from a prior evaluation. DMSA scanning can be particularly useful if the diagnosis of pyelonephritis is unclear during an acute infection.

Hansson et al. retrospectively reviewed 303 children younger than 2 years of age who had undergone evaluation by DMSA and VCUG within 3 months of their first UTI (Hansson et al., 2004). In this study, 82% of these infections were febrile, DMSA was abnormal in 51%, and VUR was found in 26% of the children (80/303), of whom 53 patients (66%) had abnormal DMSA scans; no abnormalities were detected in the remaining 27 patients. An approach based on identifying renal cortical abnormalities before obtaining a VCUG would have identified the 53 children with VUR presumably at risk for further scarring, and it would have excluded 120 children (40%) without VUR or renal abnormalities from an unnecessary VCUG.

Implementation of a TDA would obviously not have detected 34% (27/80) of the cases of VUR. However, in 74% of these patients VUR was low grade, and in the remaining 7 cases (grade 3 to 5 VUR, all of whom were on continuous prophylactic antibiotics) it either resolved or improved significantly during a 2-year follow-up period, with one patient developing a renal scar on repeat DMSA scintigraphy.

In a follow-up study from the same institution, Preda et al. prospectively confirmed these observations in 290 children younger than 1 year of age presenting with UTIs, of whom 79% were febrile (Preda et al., 2007). Positive scans were observed in 51%, including 85% (44 in 52) of the children found to have VUR. Of the 8 cases of VUR with normal DMSA scans, 7 were low grade, with one male patient having grade 3 VUR. There were no acquired renal scars on follow-up, despite one episode of BUTI.

Although several protocols advocate for an acute-phase and delayed-phase DMSA scan as part of the TDA, one study showed little clinical utility in the acute-phase scan as most irregularities of significance were seen on the delayed scan. They advised against an acute-phase DMSA scan during infection, as in this study, similar rates of febrile UTIs were found in patients with or without defects on the acute-phase DMSA scan (5%) (Kawai et al., 2017).

Although the TDA approach can decrease the number of VCUGs and detect more significant VUR, recent estimates based on robust data suggest test performance of DMSA to be less than historically presumed. One meta-analysis has shown that the TDA performs poorly at detecting high-grade VUR with a sensitivity and specificity of only 79% and 53%, respectively (Mantadakis et al., 2011). The most recent Cochrane review on the subject evaluating the summary sensitivity and specificity estimates of DMSA at detecting any VUR were 0.75 (95% CI, 0.67 to 0.81) and 0.48 (95% CI, 0.38 to 0.57), respectively, and 0.93 (95% CI, 0.77 to 0.98) and 0.44 (95% CI, 0.33 to 0.56) for high-grade VUR, respectively (Shaikh, et al., 2016b). In this meta-analysis, the authors concluded that DMSA scans lack the specificity to detect any VUR, even high-grade VUR. They also found that children with a normal DMSA scan have a less than 1% probability of having high-grade VUR (Shaikh et al., 2016b). However, the reverse is not true, because 70% of children with febrile UTIs would have positive findings on DMSA, therefore, inappropriately being labeled as high-risk.

A more recent report noted that because there have been access issues with acquiring DMSA scans in the acute setting, coupled with the higher radiation exposure, cost, and delay in treatment initiation, the TDA should be used on a risk-stratified basis, suggesting that efforts need to be directed to early and reliable identification of UTI, institution of effective treatment, and addressing BBD, as well as any other risk factors, as early as possible (Abdelhalim and Khoury, 2017).

In the TDA, DMSA scans are not intended to detect VUR per se, but merely aid in determining which patients with a history of UTI show enough evidence to support further evaluation with a VCUG.

Controversies in Usage of Invasive Investigations

National Institutes for Clinical Excellence Guidelines

In an attempt to streamline the investigations and treatment in infants and children presenting with UTI, the National Institutes for Clinical Excellence (NICE) in the United Kingdom proposed a set of guidelines aimed at reducing morbidity, antibiotic usage, and cost (The National Institute for Health and Care Excellence, 2018; Baumer and Jones, 2007). In infants younger than 6 months of age, investigations are limited to ultrasonography of the urinary tract, with cystography and DMSA reserved for those with “atypical” or recurrent UTIs. In patients older than 6 months but less than 3 years of age, a VCUG is recommended if the child has “atypical” or recurrent UTIs, which includes dilation on ultrasonography, poor urine flow, infection with non–*E. coli* bacteria, or family history of VUR. If a child in this age group responds well to treatment in 48 hours, no VCUG is indicated. Children older than 3 years of age should not have a routine VCUG ordered after a first UTI. The guidelines do not recommend early DMSA renal scan to confirm or exclude renal involvement and rely on RBUS in patients to determine the need for further investigation. The major criticism to this approach lies in the poor correlation between the appearance of the kidneys on ultrasonography and the presence of renal parenchymal changes or the presence and grade of VUR (Shaikh et al., 2016b; Hung et al., 2016). One study that used a historical cohort of 43 patients 2 to 24 months of age with ultrasonography, VCUG, and renal scans applied the NICE guidelines and found that they would have missed 63% of the children with VUR grade II and above, including a high proportion of grades IV and V, 44% of the children with renal scarring, and 20% of the children with decreased renal uptake, including some children with bilateral renal scarring and with decreased renal function (Narchi et al., 2015). In a similar study with 98 infants, had the NICE guidelines been applied, that is, only those with an abnormal RBUS would have been further investigated, 25 refluxing ureters and 22 scarred kidneys would have been left undiagnosed (Tse et al., 2009).

Taken together, an oversimplified approach that does not take into account the broader spectrum of patients with varying risks for future infections and the impact of VUR limits the applicability of these recommendations. They fail to address key differences, which exist between children in clinical practice at presentation. Moreover, the NICE committee did not provide any robust clinical outcomes to validate these guidelines or confirm the safety of this approach, and thus its use in general clinical practice should be with caution.

American Academy of Pediatrics Guidelines for Febrile Urinary Tract Infection Diagnosis and Management in Young Children

In 2011, the AAP released revised guidelines for the diagnosis and management of febrile UTI in children 2 to 24 months of age (Subcommittee on Urinary Tract Infection, Steering Committee on Quality Improvement and Management, and Roberts, 2011). The guidelines were developed after a rigorous review of the literature including six randomized controlled trials of CAP to prevent recurrent UTI. The guidelines are summarized in Table 29.5.

TABLE 29.5

American Academy of Pediatrics Clinical Practice Guideline on Febrile Urinary Tract Infection in Febrile Infants and Young Children: Key Updates

AREA OF MANAGEMENT	UPDATES FROM THE 1999 GUIDELINE
Diagnosis	Both an abnormal urinalysis result and a positive urine culture result are needed to confirm inflammation
	A positive culture result is defined as at least 50,000 colony-forming units per milliliter, rather than the previous criterion of at least 100,000 colony-forming units per milliliter
	Guidance is added for using clinical criteria to establish a threshold to decide whether to obtain a urine specimen
Treatment	Oral treatment is as effective as parenteral treatment
Imaging	Voiding cystourethrography is not recommended routinely after the first febrile urinary tract infection; ultrasonography should include the bladder and kidneys
Follow-up	Emphasis is on urine testing with subsequent febrile illnesses, rather than on regularly repeated urine cultures after treatment

Note: The guideline applies to infants and children 2 to 24 months of age with unexplained fever.

Data from Subcommittee on Urinary Tract Infection, Steering Committee on Quality Improvement and Management, Roberts KB. Urinary tract infection: clinical practice guideline for the diagnosis and management of the initial UTI in febrile infants and children 2 to 24 months. *Pediatrics*. 2011;128(3):595–610.

To establish the diagnosis, stricter criteria for the diagnosis of infection were suggested, including a lowered threshold for urine culture colony-forming units per milliliter (50,000 from 100,000) and the additional requirement of an abnormal urinalysis. Oral and parenteral antibiotic treatments are now considered equally effective. The use of RBUS retains its traditional and important role in structural assessment. **The inconclusive lack of efficacy of CAP in preventing UTI and renal injury led to the most significant deviation from past practice, the recommendation to forgo VCUG after the *first* febrile UTI unless indicated by any abnormal RBUS findings or after a subsequent febrile UTI.**

If hydronephrosis, findings suggestive of renal scarring/dysplasia, or obstructive uropathy are present, a VCUG should be obtained. Similarly, any complex or clinically atypical scenario supports obtaining a VCUG after the first febrile UTI. These recommendations attempt to balance the risk for missing clinically significant VUR after a first febrile UTI in infants, against the invasiveness, radiation exposure, and patient and family anxiety surrounding VCUG.

The Section on Urology of the AAP guidelines disagreed with some of these recommendations in view of the quality of the studies cited. Some of the critical issues were related to inclusion of data from underpowered studies, nonuniform urine-collection techniques, not accounting for either the role of bladder and bowel dysfunction or the link between VUR and renal scarring, and lastly, assuming the presenting infection was truly the first clinically significant infection (Wan et al., 2012).

Undoubtedly the AAP recommendations have resulted in a significant reduction in the number of children undergoing VCUG, however, the guidelines fail to address the need for an individualized, risk-based approach to treating children with suspected VUR.

Associated Anomalies and Conditions

Ureteropelvic Junction Obstruction

VUR and UPJO are two of the most common pathologic conditions in pediatric urology. Thus it is not unusual that these two conditions coexist. Whether the concomitant presence of these two conditions is a random event or is causally related remains unclear. It has been speculated that a developmental ureteric bud anomaly may be responsible for the imperfect formation of both the UVJ and the UPJ (Bomalaski et al., 1997).

The incidence of VUR associated with UPJO ranges from 0.6% in historical studies (Bomalaski et al., 1997) **to as high as 5.2% to 8.2% in more contemporary studies** (Weitz and Schmidt 2016; ElSheemy et al., 2017). When the two conditions were primarily present, most of the patients in these studies had reflux that was coincidentally discovered, was of low grade, and resolved spontaneously with time. A significant limitation to several published studies includes their retrospective nature. Such patients typically exhibited a significant discrepancy between the minimal degree of ureteral dilation and the significantly dilated renal pelvis. Thus the apparent grade of reflux may be overestimated, and management decisions based on the grade of reflux are inaccurate at best. Conversely, the incidence of UPJO in patients with reflux ranges from 0.75% to 3.6% (Lebowitz and Blickman, 1983; Bomalaski et al., 1997), with high-grade reflux being five times more likely to be associated with UPJO than lower grades of reflux (Lebowitz and Blickman 1983; Bomalaski et al., 1997). Indeed, in one study of children with reflux and hydronephrosis, 50% of high-grade sonographic hydronephrosis, commonly associated with the highest grades of reflux, showed an obstructive pattern on furosemide (Lasix) scintigraphy (Stauss et al., 2003).

Three radiologic signs might suggest the existence of UPJO in the setting of reflux. First, if the pelvis shows little or no filling while the ureter is dilated by contrast, this may indicate a point of kinking secondary to reflux or from a primary UPJO (Fig. 29.15). Second, contrast that enters the pelvis may be poorly visualized because of dilution in a large pelvic volume and exhibits markedly lower radiodensity compared with the ureter or bladder. Finally, a large pelvis that fails to drain promptly and retains contrast postvoid is also suggestive of UPJO.

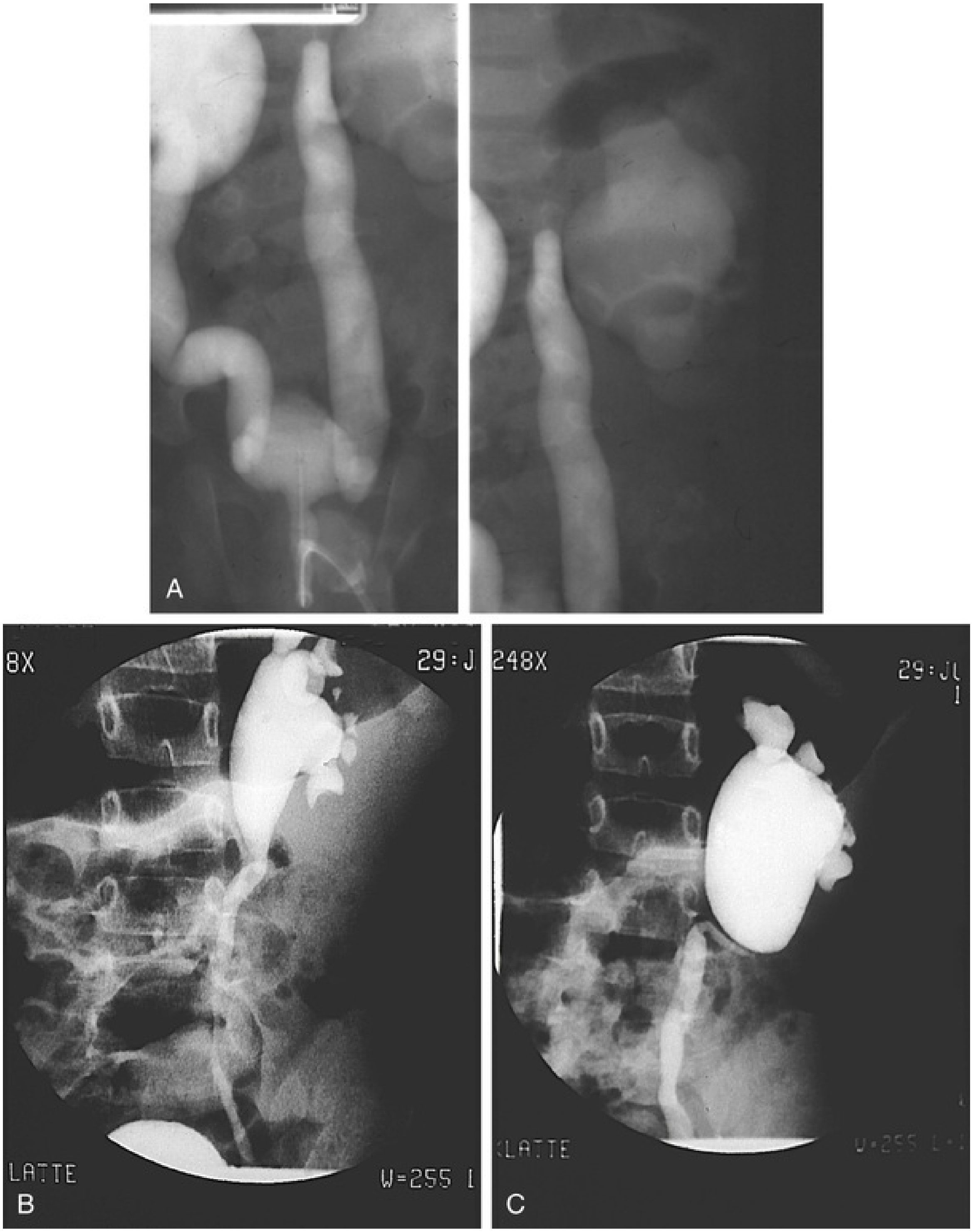
A
8X
29:J
LATTE
W=255 I
B
248X
29:JL
LATTE
C

FIG. 29.15 Reflux and ureteropelvic junction (UPJ) obstruction. (A) Significant reflux fills the left ureter to the level of the UPJ. Minimal filling of the pelvis can be a sign of obstruction at this level. (B) In a different patient, reflux is seen as the bladder fills. (C) Significant kinking of the UPJ occurs with voiding.

Radiographic studies of UPJO associated with VUR may indicate true anatomic obstruction or simply dilation caused by pelvi-ureteral dilation in higher grades of reflux. Hollowell et al. referred to three clinical categories of concomitant obstruction and reflux (Hollowell et al., 1989). Group 1 had primary UPJO and incidental low-grade reflux, and group 2 had secondary UPJO from high-grade reflux. These two groups represent true anatomic obstruction for which pyeloplasty is recommended. Group 3 represents only significant dilation of the upper tracts without obstruction, which is confirmed by documenting good drainage on postvoid images at cystography or by renal scintigraphy.

The cause of secondary UPJO is unclear. Several factors are thought to predispose or even aggravate a potential narrowing at the level of the UPJ. High-grade reflux may result in kinking of the upper ureter and adjacent pelvic junction. The chronic effects of high-grade reflux also may passively stretch the renal pelvis so that atonicity and an inability to propel urine through the UPJ may occur (Whitaker 1973). In the setting of UTI propagated to the upper tracts by reflux, inflammation and ureteritis can also contribute to transient or chronic obstruction at the UPJ.

The convergence of two ureteral anomalies in the same patient raises additional management questions in the situation in which treatment of one anomaly may affect the natural history of the other. **Nevertheless, the guiding therapeutic principle is the preservation of renal function. Sterile reflux can be safely observed, however, obstruction even in the absence of infection may jeopardize renal function. Therefore, in the presence of reflux, if scintigraphy with catheter drainage confirms UPJO, correction of obstruction takes precedence over surgical repair of VUR.** The secondary insult to the UPJ from reflux is an evolving process that cannot be efficiently or adequately corrected by surgical repair of the reflux itself. Furthermore, reflux correction alone risks amplifying upper tract dilation caused by postoperative edema in the lower ureter and risks introducing infection to the obstructed renal pelvis.

The simultaneous open correction of UPJO and reflux has always raised concern over surgical manipulation of both the upper and lower ureter at the same time and its potential negative impact on ureteral vascularity. However, endoscopic VUR correction at the time of pyeloplasty for secondary or primary UPJO is a reasonable option despite its lower success rate.

Ureteral Duplication

VUR is the most common abnormality associated with complete ureteral duplications. The embryologic origin of the duplicated ureter supports the observation that reflux occurs most commonly into the lower pole. This relationship is based on the studies of Weigert and Meyer, who documented the more lateral and proximal insertion of the lower moiety ureter associated with a shorter intramural ureter resulting in an incompetent UVJ (Weigert 1877; Meyer 1946) (eFig. 29.16).

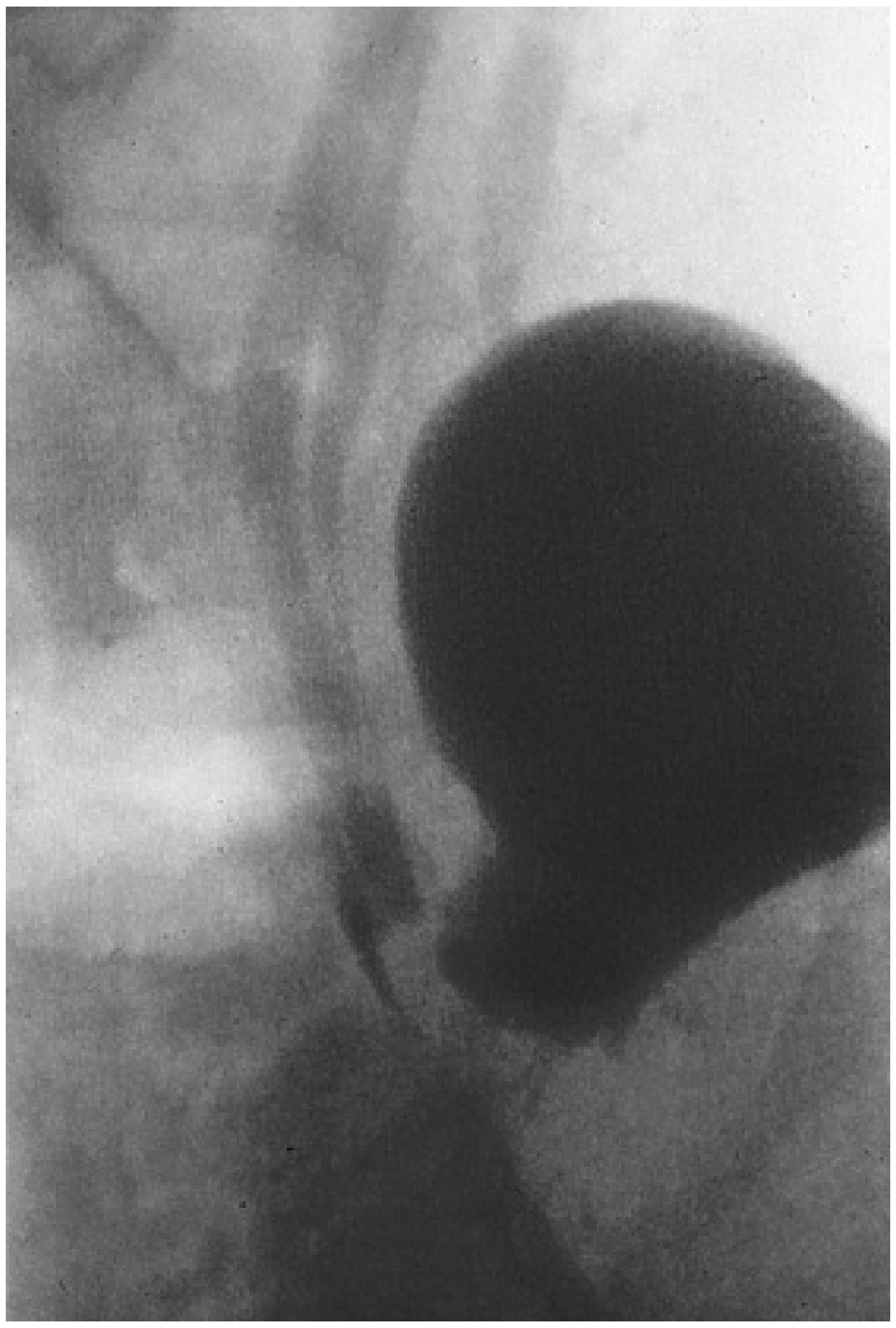

EFIG. 29.16 Reflux into both ureters of a complete duplication, as shown here, is less common than reflux into the lower pole ureter alone.

The incidence of reflux is increased in patients with complete ureteral duplication (Privett et al., 1976). Earlier studies provide a limited view of whether reflux in a duplex moiety carries increased patient risk because of the lack of control groups, arbitrary patient selection, and short follow-up. Traditionally, the tendency was to recommend VUR correction in patients with complete duplication and low-grade reflux as it may take longer to resolve compared with single-system VUR (Estrada et al., 2009a). However, the observation that duplication is not associated with risk for increasing grade, BUTI, or scarring (Husmann and Allen 1991) makes conservative management a more reasonable option (Lee et al., 1991; Peppas et al., 1991). In a series of 105 patients with complete duplication, 36% were managed nonoperatively with spontaneous rates of reflux resolution of 85% for grades I and II, and 36% for grade III (Lee et al., 1991). A more recent series supports this finding in low-grade reflux but notes that high-grade reflux into lower pole ureters in females is more prone to BUTI and scarring and therefore may warrant more aggressive management (Estrada et al., 2009a; Afshar et al., 2005b).

Bladder Diverticula

A full discussion of bladder diverticula is found elsewhere in this text. The outpouching of mucosa between detrusor muscle bundles, which lacks any true muscle backing itself, commonly defining a bladder diverticulum, has the theoretic potential to affect the natural history of VUR in two ways. Most commonly, if the UVJ is distorted by a paraureteral diverticulum, which shares an anatomic point of origin at or near the UVJ, it is possible that the diverticulum could compromise the antireflux configuration of the UVJ to cause reflux (eFig. 29.17). Neither cystoscopy nor imaging is predictive of whether paraureteral diverticula truly compromise the resolution of reflux, as has been commonly believed. Hutch was the first to recognize that bladder diverticula were congenital abnormalities that occurred primarily in smooth-walled normal bladders in children (Hutch, 1952). Several retrospective studies demonstrate the high rates of VUR in the presence of a paraureteral bladder diverticulum and in a series of 131 children with 202 refluxing ureters, 27% had a periureteral diverticulum (Im et al., 2015). In addition, the risk for recurrent UTIs increased in ureters with paraureteral diverticulum (odds ratio 3.1, $p = 0.020$) (Im et al., 2015).

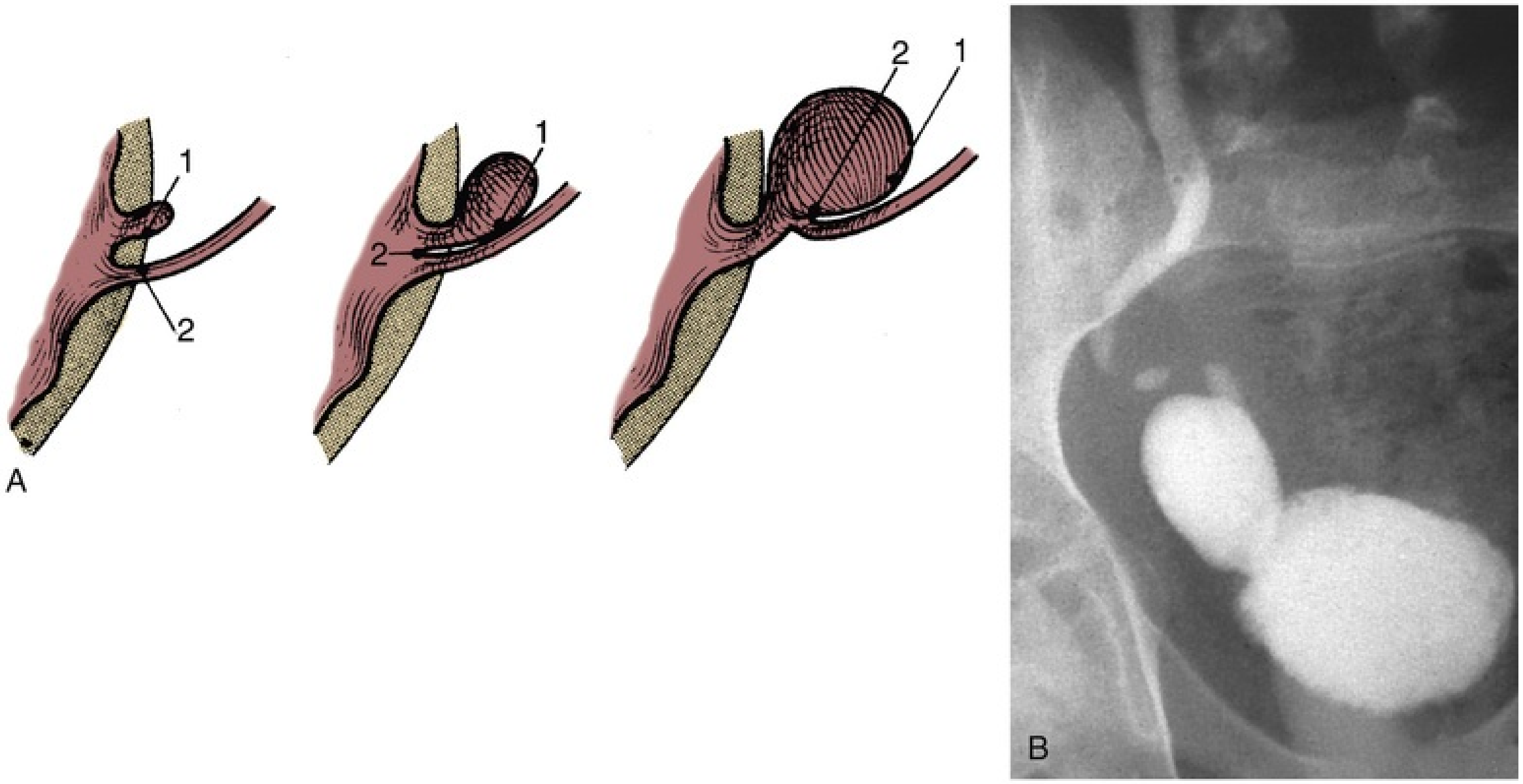

EFIG. 29.17 (A) Schematic representation of a bladder diverticulum *(2)*. A small amount of mucosa initially herniates through a congenital defect in the bladder musculature. The defect enlarges with voiding. Finally, the ureteric orifice *(1)* is incorporated into the diverticulum. (B) Reflux into a right-sided paraureteral diverticulum and ureter seen on voiding cystography. (A, From Hernanz-Schulman M, Lebowitz RL. The elusiveness and importance of bladder diverticula in children. *Pediatr Radiol*. 1995;15[6]:399–402.)

However, another retrospective cohort analysis of 84 patients with paraureteral diverticula and reflux showed no significant difference in spontaneous resolution rates (60%, 39%, and 22% for grades I to II, III, and IV to V reflux with paraureteral diverticulum vs. 52%, 28%, and 33% in a matched control group of 95 patients with reflux without diverticulum). Rates of UTI and scarring were similar in both groups. Multivariate analysis revealed reflux grade to be the only predictor of resolution in both groups (Afshar et al., 2005a). Thus **reflux associated with paraureteral diverticula resolves at rates similar to that of primary reflux and should be managed according to the prevailing indications for the reflux itself, irrespective of the diverticulum.** However, when a refluxing ureter enters a diverticulum, the latter is no longer paraureteral. With no muscular support to the UVJ, reflux is not expected to resolve. In a given patient, indications for repair require the combined consideration of the potential impact of unresolved reflux, if any, along with whether the diverticulum itself is of sufficient size or conformation to incite complications.

Renal Anomalies

By definition, primary reflux represents dysfunction of the UVJ. Because the development of both the UVJ and the kidney itself are linked to the origin and fate of the ureteral bud, it is reasonable to consider the existence of reflux whenever an anomaly of renal form or number is present. **Significant renal anomalies associated with reflux are multicystic dysplastic kidney (MCDK) and renal agenesis.** In the largest series to date, 75 patients with MCDK showed a prevalence of contralateral reflux of 26% (19 patients), and one-half of these were low grade (1 to 2) (Miller et al., 2004). Spontaneous resolution occurred in a mean of 4.4 years, regardless of grade. Only one patient had reflux corrected surgically. In a small series of ureteral ectopia, one patient with MCDK had the contralateral ureter enter into the ductus deferens (Wunsch et al., 2000), further underscoring the importance of documenting the contralateral kidney's ureteral conformation in patients with MCDK. Although contralateral renal growth often displays compensatory hypertrophy, one study observed somewhat less compensatory hypertrophy by 1 year of age (Zerin and Leiser, 1998) than may be expected if contralateral reflux is absent (5.1 vs. 6.2 cm median renal lengths, $P < .001$).

Renal agenesis is associated with an even higher prevalence of contralateral anomalies. Several studies have shown that in children with solitary renal agenesis, the rate of contralateral renal pathology varies from 32% to 46%. VUR was by far the most common contralateral defect ranging from 24% to 28%, with UVJ and UPJO seen in 11% and 6% to 7%, respectively (Cascio et al., 1999; Westland et al., 2013). In another study, 19 cases of contralateral reflux were observed in 51 patients with ipsilateral renal agenesis (Song et al., 1995). Reflux repair or persistence was documented in 9 and 7 patients, respectively, with spontaneous resolution observed in only 3 patients. Whether renal agenesis represents one extreme on a continuum that includes MCDK is unclear. Nevertheless, these data suggest that contralateral reflux associated with renal agenesis may show less tendency to spontaneous resolution than that associated with MCDK.

Megacystis-Megaureter Association

Massive bilateral VUR can cause a gradual remodeling of the entire upper urinary tract. The gross inefficiency of the bladder that expels urine to both the exterior and the upper tracts results in gradual bladder dilation as the refluxed urine returns to the bladder. This perpetuates marked ureteral dilation, leading to the radiographic appearance of massive hydroureter and a thin-walled enlarged bladder (Burbige et al., 1984). The phenomenon is referred to as the *megacystis-megaureter association* or syndrome. This configuration is even discernable in utero (Mandell et al., 1992). It is more frequent in males, and the differentiation from posterior valves is crucial (Kaefer et al., 1997). Although the latter is caused by an obstructive lesion, megacystis-megaureter is a nonobstructive condition akin to cardiac dilation by regurgitation from incompetent valves. Voiding studies will readily demonstrate an open posterior urethra and differentiate megacystis-megaureter from posterior valves or prune-belly syndrome. The persistent large residual urine volume is a significant risk factor for recurrent UTI. Vesicostomy can temporize by eliminating the residual urine volume and establishing safe drainage of the upper tracts until ureteral reimplantation can be performed. Given the propensity for reflux to exacerbate the effects of bacteriuria and the fact that UVJ dysfunction is the primary factor perpetuating the syndrome, surgical correction for the reflux is generally indicated. Treatments aimed at improving an already patent bladder outlet are contraindicated, risk infection, and fail to correct the primary cause. A period of bladder rehabilitation by strict attention to emptying in the postoperative period (Koefoot et al., 1981) usually will result in a return to normal bladder volume and contractile behavior. This suggests that potentially normal underlying bladder physiology can be realized if the propensity for reflux is corrected.

Other Anomalies

VUR also has been described in association with a number of congenital conditions and syndromes. No precise common genetic insult has been determined to explain such associations. A complete survey of the Online Mendelian Inheritance in Man Database developed by Johns Hopkins University, maintained by the National Center of Biotechnology Information, reveals more than 40 different syndromes in which VUR has been described (http://www.ncbi.nlm.nih.gov/Omim/getmap.cgi?l193000). These include the VACTERL association (*V*ertebral, *A*nal, *C*ardiac, *T*racheo*E*sophageal, *R*enal, and *L*imb anomalies), CHARGE syndrome (*C*oloboma, *H*eart disease, *A*tresia choanae, *R*etarded development, *G*enital hypoplasia, and *E*ar anomalies), and imperforate anus. In cases in which VUR is anticipated, a VCUG is the initial study of choice to disclose both dysfunction at the UVJ and overall bladder and bladder outlet anatomy.

Pregnancy and Reflux

The morphology of the urinary tract is altered with the onset of pregnancy and increases throughout gestation (Beydoun 1985). **Bladder tone decreases because of edema and hyperemia, changes that predispose the patient to bacteriuria. In addition, urine volume increases in the upper collecting system as the physiologic dilation of pregnancy evolves.** The slower drainage that results can enhance the growth of organisms and increase the propensity to develop pyelonephritis. It seems logical to assume that during pregnancy the presence of VUR in a system already prone to bacteriuria would lead to increased morbidity. A number of studies have been conducted to examine this relationship.

The presence of active reflux appears to present a risk factor for the affected mother. In 1958, Hutch described a higher incidence of pyelonephritis during pregnancy in 23 women with a history of reflux and recurrent bacteriuria (Hutch et al., 1963). Heidrick et al. evaluated 321 women with cystography either during the last trimester or within 30 hours after delivery (Heidrick et al., 1967). The incidence of pyelonephritis was 33% in women with reflux compared with less than 5% in women without reflux. Finally, cystograms performed 4 to 6 months postpartum in 100 women with a history of asymptomatic bacteriuria during pregnancy showed reflux in 21%. Bacteriuria was easier to clear in patients without reflux (67%) than in those with reflux (33%) (Williams et al., 1970).

Maternal history also becomes a factor if past reflux, renal scarring, or a tendency to UTIs is included. Martinell et al. compared the outcome of pregnancy in matched controls with that in 41 women with and without renal scarring after childhood UTIs (Martinell et al., 1990). They found that women with a history of prior infections had a high incidence of bacteriuria during pregnancy, whereas those with renal scarring and persistent reflux were more prone to develop acute pyelonephritis. In a similar study, the outcome of pregnancy was assessed in 88 women with previous bacteriuria. Women with known scars had a 3.3-fold increased incidence of hypertension, a 7.6-fold increased risk for preeclampsia, and a higher rate of obstetric interventions. Women with normal kidneys and reflux also had an increased risk for hypertension during the last trimester (McGladdery et al., 1992). Pregnant women with bilateral renal scars were also shown to have a higher incidence of preeclampsia than those with unilateral scarring (24% vs. 7%, respectively) (El-Khatib et al., 1994), and those with creatinine elevation are also at risk (Jungers et al., 1987). In a large study of 158 women with reflux nephropathy, pregnancy was uneventful in patients with normal blood pressure and renal function, whereas the risks for fetal demise and accelerated maternal renal disease were increased in women with impaired renal function (Jungers, 1996).

Another study evaluated pregnancies in women with a history of VUR and found that those with renal scars had an almost 2.5 times higher rate of hypertension during pregnancy and almost twice the rates of proteinuria (Roihuvuo-Leskinen et al., 2015).

Austenfeld and Snow studied the implications of reimplantation surgery and found an increased risk for UTI and fetal loss in 31 women who had undergone ureteral reimplantation as children, despite correction of the anomaly (Austenfeld and Snow, 1988). In a follow-up study comparing these patients with a new cohort of historical controls, women with UTIs and reflux who underwent reimplantation (suggesting an initially higher degree of reflux and increased renal scarring) were still at significant risk for UTI during pregnancy (Mansfield et al., 1995). However, they were not at a higher risk for miscarriage than the general population. In a larger study of 77 pregnancies in 41 women whose ureters had been reimplanted, Bukowski et al. reported that the incidence of pyelonephritis during pregnancy was slightly higher than in the general population but that the fetus and mother were at significant risk when renal scarring or hypertension was present (Bukowski et al., 1998). Although these studies may at first suggest a limited benefit to reimplantation during a subsequent pregnancy, several factors must be borne in mind. None of these studies document any associated BBD in these women, which may have existed in childhood and continued unrecognized into the fertility years. Also, bladder dynamics change during pregnancy as a result of increasing uterine size. Although it is assumed that reflux remains absent during pregnancy after correction in childhood, radiologic verification that the surgically corrected UVJ remains competent (reflux free) is not feasible, and such data are not available. Finally, it is not known whether formerly refluxing renal units in such adult patients carry a latent predisposition or heightened susceptibility to pyelonephritis during the pregnancy as a consequence of previous postinfection damage during childhood and/or any inherent reflux-associated dysplasia, both of which would persist despite surgery at the bladder level. Nevertheless, in keeping with the more recent emphasis on preexisting renal status when considering reflux management, at least one meta-analysis of the significance of a pregnancy and reflux association also suggests that the presence of renal scarring, and not the presence or absence of reflux, is the principal factor driving morbidity during pregnancy in such women (Hollowell, 2008). When combined with the known physiologic renal and bladder changes during pregnancy, it is reasonable to speculate that such kidneys may carry a heightened predisposition to pyelonephritis.

In summary, the majority of studies examining the effects of VUR on pregnancy suggest that women with a history of reflux have increased morbidity during pregnancy because of infection-related complications, whether the reflux has been corrected or not. Women with hypertension and moderate renal impairment are also at risk for preterm birth. In addition, 43% of their offspring who underwent a VCUG had VUR (North et al., 2000).

The morbidity during pregnancy of women with persistent reflux without renal scarring remains poorly defined, but the tendency to UTI seems to be increased. Because of the difficulty in predicting an outcome for this subset of patients, some clinicians recommend surgical correction for girls with reflux that persists beyond puberty, although there has been a trend toward discontinuation of prophylactic antibiotics in older girls with active reflux and close monitoring. Long-term follow-up studies of these patients through puberty are unavailable.

Key Points: Pregnancy and Reflux

- Physiologic changes in the ureter and bladder during pregnancy may influence the propensity for reflux-associated pyelonephritis in pregnant patients with reflux.
- In the absence of definitive studies to the contrary, correction of reflux may be considered before pregnancy.

Natural History and Management

Spontaneous Resolution

The one feature of VUR that provides the greatest relief to parents and at the same time creates confusion in reflux study design and literature interpretation is spontaneous resolution. Traditionally, the basis of medical therapy was predicated on an expected rate of spontaneous resolution. At birth, the probability of spontaneous resolution of primary reflux is roughly inversely proportional to the initial grade. If a patient is encountered at a later age, resolution from any point in time forward will depend on initial grade of reflux, if it is known, and age at presentation.

Reflux likely resolves spontaneously as a result of remodeling of the UVJ over time, with progressive elongation and consolidation of the intravesical ureter and antireflux mechanism and stabilization of bladder dynamics. Conversely, failure to achieve normal bladder and bowel function likely accounts for reflux persistence beyond the statistical norms in many patients.

Resolution by Grade

Most cases of low-grade reflux (grade I and II) will resolve. Several studies have documented this high rate of spontaneous resolution. However, the variance in several reported studies for resolution rates for grade 2 reflux was 63% (Duckett, 1983), 80% (Arant, 1992), and 85% (Edwards et al., 1977). This belies the fact that lower urinary tract dynamics may also play a role in mitigating spontaneous resolution.

Grade 3 reflux will resolve in approximately 50% of cases (Duckett 1983; McLorie et al., 1990). Very few cases of higher-grade reflux (grades 4 and 5, and bilateral grade 3) will resolve spontaneously. Analyses from several sources, including the International Reflux Study in Children, support a uniformly low likelihood of resolved high-grade reflux, with no more than 25% (Weisset al., 1992a) and as little as 9% (Skoog et al., 1987) of patients demonstrating spontaneous resolution. In another study of children younger than 1 year of age who were diagnosed with high-grade reflux 4 and 5, there was a slightly higher resolution rate of 35.7% (5 of 14 renal units) (Wildbrett et al., 2013).

In one of the largest retrospective series to date, Estrada et al. generated nomograms to predict spontaneous resolution rates based on several factors including grade. With almost 2 years of follow-up, resolution rates for grades 1, 2, 3, and 4/5 were 72%, 61%, 49%, and 32%, respectively (Estrada et al., 2009a). Clearly there are shortcomings to even large retrospective studies, especially with a significantly higher proportion of patients in the higher-risk groups having undergone surgery, which may bias the data. Considering the fact that any given reflux grade is assigned on the basis of a dynamic voiding study, the possibility for variations by at least one grade, especially in assigning higher grades of reflux, is quite real. Thus, attempting to discriminate true differences in resolution rates for grades 3 and higher reflux may not be particularly clinically relevant.

Kirsch et al. developed a novel prediction tool, the Vesicoureteral Reflux Index (VURI), a validated tool that incorporates timing of reflux, presence of associated anomalies, sex, and VUR grade to predict complete or partial resolution of reflux by at least two grades. It has been validated for children younger than and older than 24 months of age (Kirsch et al., 2014; Garcia-Roig et al., 2017). Cooper et al. also looked at the ratio of ureteric diameter, normalized to the L1–L3 vertebral body distance. They found that the ratio correlated with VUR grade and that the higher the ureteral diameter ratio the lower the likelihood of spontaneous resolution (Cooper et al., 2015; Arlen et al., 2017).

The volume at which VUR occurs on cystography was also found to be a useful predictor of reflux resolution. When reflux occurred at greater than 75% of predicted bladder capacity, it was significantly more likely to resolve spontaneously than if VUR occurred at lower volumes (McMillan et al., 2006).

These tools allow for counseling practitioners and families on more direct indications for both reflux intervention or relaxing follow-up, including a reconsideration of the ongoing need for prophylactic antibiotics. **Because the consequences of reflux pose the greatest threat, the ability to predict them rather than predict reflux persistence or resolution may be more clinically relevant.**

Resolution by Age

The age at which reflux begins or is first encountered will play a more important role in the management of the patient with reflux than the grade itself. It is self-evident that if reflux is a congenital disorder with an inherent tendency to resolve spontaneously over time, it will be most prevalent in neonates and young children and demonstrate the greatest tendency to resolve in this group. Conversely, in any analysis, if reflux is truly primary, is encountered in an older child, and has been present since birth, it already has demonstrated a propensity to persist and therefore is self-selected for reflux that is unlikely to resolve (Skoog et al., 1987). The initial 1997 AUA guidelines provided a synthesis of large numbers and reasonable statistical estimates of resolution rates segregated by age and grade (Elder et al., 1997) (Fig. 29.18). Subsequent revisions of the guidelines in 2010, which were again validated in 2017, provide a similar picture for resolution rates of VUR and refocus the importance of identifying patients that would benefit from screening based on several potential risk factors, beyond age.

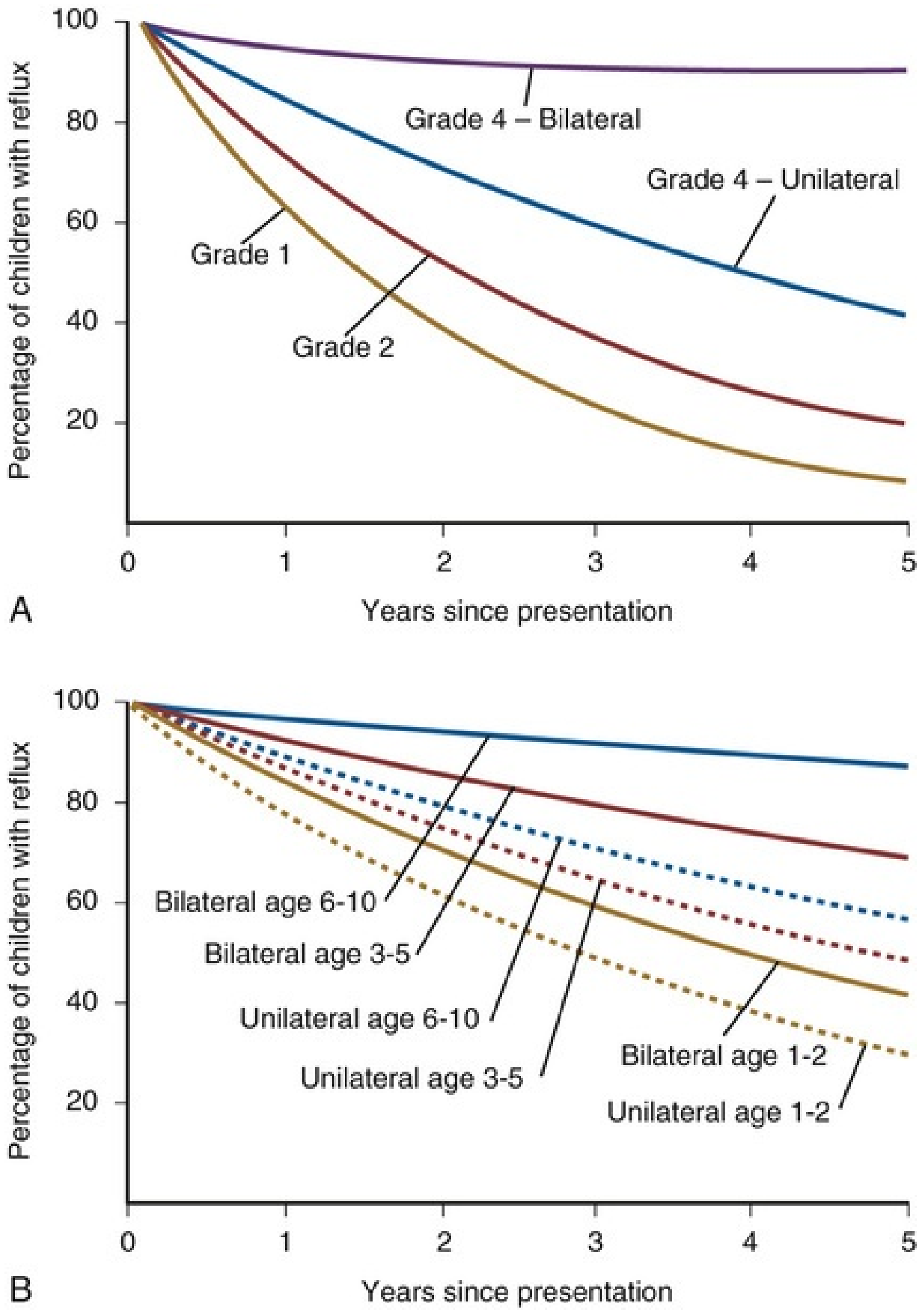

FIG. 29.18 (A) Percent chance of persistence of grades 1, 2, and 4 reflux for 1 to 5 years after initial evaluation. (B) Percent chance of persistence of grade 3 reflux by age for 1 to 5 years after initial evaluation. (Data from Elder JS, Peters CA, Arant BS Jr, et al. Pediatric Vesicoureteral Reflux Guidelines Panel summary report on the management of primary vesicoureteral reflux in children. *J Urol*. 1997;157[5]:1846–1851.)

Interpretation of other large studies suggest that diagnosis at 5 years of age and in infancy is associated with a similar resolution rate (20% per year), regardless of age (Connolly et al., 2001). However, as stated at the outset, it must be remembered that resolution 5 years after 5 years of age implies reflux has required 10 years to resolve versus resolution 5 years after birth. Moreover, the observation by McLorie et al. that high-grade reflux in patients presenting after birth showed no difference in resolution rates between subjects younger and older than 1 year of age may reflect the generally poor resolution rate of high-grade reflux to begin with (McLorie et al., 1990). The study by Skoog et al. observed that 30% to 35% of subjects resolved their reflux each year (Skoog et al., 1987). Reflux in younger patients (<12 months of age) resolved more quickly (1.44 vs. 1.85 years, $P < .02$), with grade 3 requiring slightly more time than grade 2 to resolve (1.56 vs. 1.97 years, $P < .04$).

This has been seen in other studies that have shown some benefit in watching children with even higher grades of reflux. In a retrospective study of 62 children reviewed after 10 years of follow-up, the overall resolution rate for infants older and younger than 1 year of age was 39% for renal units (Wildbrett et al., 2013). When dichotomizing the patients into low- and high-grade reflux per renal unit in children younger than 1 year of age, mild-moderate reflux grades I to III had a resolution rate of 40% (12/30 renal units) compared with 36% (5/14) with high-grade IV to V reflux. In children older than 1 year of age, resolution rates were different between the groups. The resolution rate was 39% (9/23) and 0% (0/2) for low-grade I to III and high-grade IV to V reflux, respectively. Although the number of patients in the high-grade group older than 1 year of age is small, this study showed that even for children with high-grade reflux, when diagnosed early on, there is spontaneous resolution in over one-third of patients, and this should at least warrant consideration for primary conservative therapy. This might not be the case for children diagnosed with high-grade reflux at an older age.

There was a similar finding in a prospective study of 115 infants with high-grade reflux defined as grade III to IV. A spontaneous resolution rate, to grades 0 to II, was seen in 29% of children in the first year (Sjöström et al., 2004). This decreased to 9% yearly thereafter (Sjöström et al., 2004). In another Swedish study, a spontaneous resolution rate, again defined as reflux grade 0 to II, in a prospectively followed cohort of 77 infants randomized to either endoscopic treatment or CAP showed a spontaneous resolution rate of 21% in the patients on CAP (Nordenström et al., 2017b).

The traditional period of observation for resolution is 5 years. In the study by McLorie et al., 92% of resolved grade III reflux occurred within 4 years (McLorie et al., 1990). A similar finding in another large retrospective cohort of 334 children reviewed over a 12-year period was seen with an annual spontaneous resolution rate for grades I, II, III, IV and V of 45%, 22.7%, 17%, 14.9%, and 9.3%, respectively (Cha and Lee, 2016). At the end of this study, the

Kaplan-Meier curves showed an unusually high rate of spontaneous resolution, with a cumulative resolution rate over a 5-year period for grades I, II, III, IV, and V of 92.9%, 94.9%, 85%, 74.4%, and 64.4%, respectively (Cha and Lee, 2016).

There are significant differences in spontaneous resolution rates across several studies with regard to time to resolution and overall resolution rates for respective grades, which highlights the difficulty and feasibility in capturing the impact of all measurable and nonmeasurable variables that alter the likelihood of reflux resolving over time without significant intervention. **Expectations for reflux resolution and impact of comorbidities depends on a multitude of variables, which define each child's dynamic risk that varies over time.**

Principles of Management

Regardless of era, throughout the history of VUR diagnosis and management, **one principle supplants all: that the preservation of renal function and prevention of UTI and renal scarring is paramount.**

In the face of the paradigm shift after the 2011 AAP recommendation to limit the initial investigation to RBUS (Subcommittee on Urinary Tract Infection, Steering Committee on Quality Improvement and Management and Roberts, 2011) and ultimate reduction in cystography and associated diagnosis of VUR (Lee et al., 2017), clinical practices have evolved to refocus management into a risk-based fashion. This upholds the notion that VUR cannot be distilled into a dichotomous process. Patients present with a wider spectrum of severity, which extends beyond the classic grading system, including a multitude of dynamic factors, which can alter a child's overall risk for infection or progression over time. For example the perceived impact of associated BBD on resolution of VUR and recurrent UTIs is significant (Peters et al., 2010; Elder and Diaz, 2013; Santos et al., 2017; Shaikh et al., 2016a). Taken together with the fact that the medical and surgical therapies for reflux have historically purported to offer similar benefit to patients, much debate between fundamental approaches to diagnosis, management, and follow-up strategies has existed for decades. The tension embedded in decision making for reflux management stems from the almost perfect results attainable by open surgical correction of reflux, now commonly successful in more than 98% (Baek and Kim, 2013) of cases and in the era of robotic-assisted laparoscopic surgery, likely less morbid (Baek and Koh, 2017).

Regardless, traditional practice in reflux management has held that the end does not justify the means; reflux correction is not indicated merely because it can be corrected easily and reliably. As stated earlier, almost as much as 90% of grade I to II and between 50% to 85% of grade III VUR will resolve (Cha and Lee, 2016; Wildbrett et al., 2013; Knudson et al., 2007; Estrada et al., 2009a; Peters et al., 2010). Even high-grade reflux may resolve spontaneously in certain situations (Alsaywid et al., 2010; Sjöström et al., 2004; Nordenström et al., 2017a, 2017b; Holmdahl et al., 2010; Wildbrett et al., 2013; Farhat et al., 2000).

The essential tenets of reflux management are as follows:

1. Spontaneous resolution of reflux is very common and facilitated by correction of BBD.
2. Higher grades of reflux are less likely to resolve spontaneously, especially when diagnosed in older children after UTI.
3. Sterile reflux is unlikely to cause significant renal damage.
4. Prevention of UTI is more important than VUR resolution.
5. The use of prophylactic antibiotics is safe and beneficial, particularly in high-risk patients.
6. There is a role for medical management for most forms of reflux.

Rather than providing strict guidelines for treatment, these principles provide ample room to individualize treatment on the basis of the particular preferences and tolerances of physicians, families, and patients for the various burdens each of these principles entails. **The classic approach has been to offer daily low-dose prophylactic antibiotic suppression of infections as the first line of treatment while awaiting spontaneous reflux resolution, regardless of grade.** Clearly, age at presentation and grade will factor into predicting when and if resolution is likely to occur. In addition, in patients diagnosed after one or more episodes of pyelonephritis, the presence of scarring on renal scans may temper a decision for extended prophylaxis and observation, particularly if scarring is extensive, the reflux is high grade, renal function is already globally depressed, or congenital dysplasia of one or both kidneys is present. In such cases, tolerance for another infection despite prophylaxis may be low, or simple uneasiness with the notion of ongoing reflux may invite strong consideration for reflux correction.

Some practitioners are withdrawing prophylaxis as the child progresses beyond the toilet-training years, or even after certain risk factors such as BBD have been eliminated. Most children with asymptomatic reflux will require little or no formal follow-up as long as lifelong attention to good bladder and bowel habits is reinforced and they are counseled to seek prompt medical attention and reassessment if pyelonephritis were to occur in the future. Nevertheless, controversy remains as to whether to correct asymptomatic bilateral high-grade reflux with normal RBUS in an older child, especially males. Girls have traditionally undergone surgical correction, even for asymptomatic reflux that fails to resolve after the toilet-training years on the premise that it will reduce maternal and fetal morbidity during a future pregnancy (Mansfield et al., 1995; Hollowell, 2008; Roihuvuo-Leskinen et al., 2015). Using the rationale of antibiotic withdrawal in the older child, several studies have attempted to identify a risk profile for patients that remained infection free off antibiotic prophylaxis and consequently, those that would be at higher risk for infection off antibiotic prophylaxis (Baquerizo and Peters, 2014; Drzewiecki et al., 2012; Cooper et al., 2000). Two studies showed that between 8% and 10% of patients will subsequently develop recurrent febrile UTIs (Drzewiecki et al., 2012; Cooper et al., 2000; Leslie et al., 2010), mandating re-evaluation and possible surgical correction of reflux (Cooper et al., 2000). In cases in which the cessation of antibiotics is desired, it is incumbent on the clinician to identify *prospectively* if the child demonstrates a sufficiently reduced risk (e.g., resolved BBD) to ensure that cessation of antibiotics does not lead to recurrent infection (Hidas et al., 2015).

Medical Management: Continuous Antibiotic Prophylaxis

Although some reports have suggested the existence of “waterhammer” renal damage from high-grade reflux of sterile urine against the renal papillae (Hodson et al., 1975), no such clinical entity has been predictably demonstrated. Because it is not reflux per se that is actually being managed, **the hallmark of observational therapy attempts to decrease certain risk factors to prevent infection and maintain urinary sterility through the judicious use of single daily low-dose CAP.** Often, antibiotics are given as oral suspensions once per day and preferably at night. **Nighttime dosing allows for antibiotic concentration in the bladder urine over the longest period of expected physiologic retention, when infection is most likely to develop.** For children younger than 2 months of age, the most commonly used medications are trimethoprim and amoxicillin. Antimicrobials in children over this age are numerous, and practice patterns vary from region to region. Clinicians should consult local susceptibility tables and initiate optimal antimicrobial therapy. See Table 29.6 for a list of commonly used prophylactic antibiotics and their doses.

TABLE 29.6

Commonly Used Prophylactic Antibiotics and Their Dosages

ANTIBACTERIAL AGENT	DOSAGE	CAUTION IN AGE GROUP	ADVERSE EFFECTS[a]
Amoxicillin	5 mg/kg/day	None	Diarrhea
Sulfisoxazole (sulfafurazole)	20–30 mg/kg/day	<2 months	Kernicterus
Trimethoprim	2 mg/kg/day	<3 months	Hyponatremia
Trimethoprim/sulfamethoxazole (cotrimoxazole)	Trimethoprim 1–2 mg/kg/day 1–2 mg/kg/day	<2 months	Kernicterus
Nitrofurantoin	2–3 mg/kg/day	<1 months	Hemolysis in G6PD deficiency
Cefalexin		None	

[a] The most important adverse effect for each treatment is listed.

G6PD, Glucose-6-phosphate dehydrogenase.

Data from Shah G, Upadhyay J. Controversies in the diagnosis and management of urinary tract infections in children. *Paediatr Drugs.* 2005;7(6):339–346.

Children younger than 2 months of age possess relative hepatic immaturity and are unable to clear sulfamethoxazole efficiently; the drug displaces fetal bilirubin and leads to jaundice. After 2 months of age, the antibiotic of choice becomes trimethoprim-sulfamethoxazole (TMP-SMX; Septra, Bactrim). Like virtually any drug, some mild side effects should be kept in mind and include gastrointestinal upset and allergy. Although transient leukopenia has been reported with TMP-SMX, it is rare, resolves with discontinuation of the drug, and is not believed to be significant enough to warrant regular monitoring of white blood cell counts in all children taking the drug. The other drug most commonly used is nitrofurantoin (Macrodantin). Nitrofurantoin may minimize the development of resistance to fecal organisms, the latter being the largest reservoir for urine infectivity. This drug can uncommonly produce interstitial lung disease (pulmonary fibrosis and interstitial pneumonitis). However, oral tolerance is less than with TMP-SMX because of taste, and gastrointestinal symptoms are subjectively worse. A comprehensive literature review of the use of these drugs by Karpman and Kurzrock in children revealed a low incidence of significant hepatic (five patients) or pulmonary (nine patients) involvement, almost always associated with full-dose rather than once-daily low-dose therapy (Karpman and Kurzrock, 2004). Finally, a growing literature on the use of probiotics (live microorganisms such as strains of *Lactobacillus*, which may displace and suppress the growth of uropathogenic bacteria) is addressing UTI prophylaxis in children (Bruce et al., 2003; Reid and Devillard. 2004; Salvini et al., 2004). The mechanisms that underlie the demonstrated benefit of probiotic use are now emerging (Reid and Bruce 2006; Storm et al., 2011). Further studies will be required to define the use of this attractive approach in the medical treatment of patients with reflux.

Breakthrough febrile UTIs or pyelonephritis while on antibiotic prophylaxis, despite appropriate bladder and bowel habits, are generally considered an indication for termination of medical management with CAP and correcting the reflux. This possibility underscores the importance of proper antibiotic selection and dosing, patient and parental acceptance and compliance with the chosen therapy, and meticulous attention to proper collection and handling of urine culture specimens. **Although the interaction between host defenses and bacterial virulence factors is what dictates BUTI, Smellie has provided useful interpretations surrounding practical causes of BUTI: (1) If the organism is sensitive to the prescribed prophylactic antibiotic, the child or parent has likely not been compliant or the dose is too low. (2) If the organism is resistant to the prescribed antibiotic, either the residual bladder volume is too high too often or the dose is too high** (Smellie, 1991). Indeed, many referrals for definitive reflux correction result from BUTI after full-dose antibiotic usage for extended periods. However, currently CAP is selectively discontinued in patients with low risk for UTI, demonstrating that persistent reflux per se may never be the cause of morbidity. Thus factors associated with reflux resolution should not be conflated with the more important factors that may be associated with its complications. Hidas et al. retrospectively developed a risk-based model from factors identified to be associated with BUTIs. Using these factors, they prospectively validated the model in another cohort of patients and confirmed that there was little difference between what the model predicted and actual 2-year BUTI rates, which were 19% and 21%, respectively. The patients were stratified into three risk groups based on parameters in the risk model and showed that the 2-year risk for BUTI for children on prophylactic antibiotics was 8.6%, 26.0%, and 62.5% for low, intermediate, and high risk-groups, respectively (Hidas et al., 2015).

Additionally, several risk calculators have been devised that incorporate current, known modifiers of risk profile (Baquerizo and Peters, 2014). Some of these factors include grade and laterality of reflux, age of child, presence of BBD, number of infections, presenting symptoms, bladder volume at time or reflux, associated anomalies, and presence of renal scarring (Baquerizo and Peters, 2014; Cooper, 2012).

Antibiotic Controversies and Potential New Approaches

Summarizing what has been learned from the retrospective and prospective studies discussed thus far helps achieve a broader appreciation for reflux management. Several key points are summarized as follows:

1. Antibiotic prophylaxis appears to provide little benefit for those with grade II or lower VUR, particularly in the absence of BBD (Wang et al., 2018; Garcia-Roig et al., 2018; Roussey-Kesler et al., 2008).
2. Conversely, antibiotic prophylaxis does appear to be beneficial for those with grade III or higher VUR, at least among girls (Holmdahl et al., 2010).
3. Approximately 15% of children with VUR will have a recurrent febrile UTI within 2 years, and about 15% of these children will develop a renal scar (Shaikh et al., 2010).
4. Bowel and/or bladder dysfunction is a major risk factor for recurrent UTIs on or off antibiotics, which will occur in about 45% of children with BBD, as opposed to 15% of those without BBD (Peters et al., 2010).
5. A higher grade of VUR is associated with an increased risk for both pyelonephritis and new renal damage (Alsaywid et al., 2010).
6. The effect of age on the risk for renal damage is not well defined, although many believe that younger children are more susceptible to renal damage from pyelonephritis.

With this in mind, the principal rationale for antibiotic use in the management of reflux is the prevention of UTI, principally febrile pyelonephritis, which may lead to permanent postinfection renal scarring. Driving this rationale in part is the belief that the *first* febrile UTI, in the presence of reflux, will create the greater proportion of clinically significant postinfection scarring, despite the fact that this concern is based on animal models of experimentally induced reflux with a priori **normal** renal development (Torres et al., 1985).

However, several prospective studies have brought into question the ability of chronic low-dose antibiotic prophylaxis to prevent UTI in children with and without reflux and even in children with significant high-grade VUR to prevent significant renal damage (Garin et al., 2006; Roussey-Kesler et al., 2008; Pennesi et al., 2008). For example, in children with grade II to IV VUR, after an initial UTI, randomization of 50 patients each to antibiotic prophylaxis versus no-treatment groups showed no difference in the rate of subsequent UTI or renal scarring (Pennesi et al., 2008). This was also seen in the multicenter French trial of 225 children with reflux 1 to 3 years of age, randomized to CAP versus no treatment. Although this found a difference in the rates of UTI between groups, no statistically significant reduction overall was seen, although a subset analysis did suggest some benefit in boys with grade III reflux (Roussey-Kesler et al., 2008). As a corollary, patients with ongoing reflux in whom prophylactic antibiotics have been withdrawn have not suffered any increased incidence of UTI when compared with age-matched refluxing control patients who remain on prophylaxis (Leslie et al., 2009; Baquerizo and Peters, 2014; Drzewiecki et al., 2012). Similarly, patients who have failed endoscopic reflux correction that remains uncorrected fail to show any increased incidence of UTI regardless of whether they remain on prophylaxis (Moore et al., 2009).

Initial studies were plagued with a host of important shortcomings, including small patient numbers, heterogeneous patient populations, high dropout rates, inaccurate urine-collection methods (i.e., bags), no placebo controls, routine screening rather than evaluation in response to clinically significant events, screening bagged sample collections in uncircumcised infants, and lack of distinction between febrile and nonfebrile UTIs. Several prospective studies have attempted to address many of these shortcomings.

Nevertheless, despite their limitations, these studies have succeeded in shedding light on an evolving approach to managing VUR in which it is no longer considered a dichotomous condition, but indeed a dynamic process. It is influenced by a host of environmental and innate patient variables, which if not accounted for, lead to a reduction in treatment success.

This was abundantly clear in the Swedish Reflux Trial in which even in high-grade VUR, unless one accounts for gender differences, associated BBD, and age of the patients, expectations for benefit of a particular therapy cannot be realistically achieved (Brandström et al., 2010c). It offered a plausible alternative to up-front correction with minimally invasive approaches for even high-grade disease.

When added to the underlying concern for the long-term use of antibiotics in general, studies that bring into question the efficacy of antibiotic prophylaxis are giving rise to reflux management alternatives. These include focusing more on modifiable factors such as BBD and using CAP as a tool to decrease a child's overall risk, until other modifiable factors, such as BBD, can be corrected.

Many studies have called into question, at least for low-grade VUR, mostly grades I and II and select grade III, that one alternative is close observation for UTI symptoms without CAP, coupled with early and precise treatment of culture-proven UTI. Two pediatric studies of children with UTIs suggest that early (within 24 hours) versus later (within 4 to 7 days) antibiotic treatment does not necessarily reduce the incidence of postpyelonephritic scarring if the kidneys become involved in the UTI, though early treatment may reduce initial renal involvement (Doganis et al., 2007; Hewitt et al., 2008). Moreover, in both studies, reflux was not found to be a significant variable affecting scarring incidence, and results should be interpreted with caution. Limitations such as precise knowledge of timing of UTI onset and the previously mentioned limitations of DMSA scanning in differentiating preexisting renal dysplasia from true postinfection renal scars remain.

Finally, given the uncertain incidence of incidental and clinically silent VUR in the normal population and the high propensity for reflux to resolve over time, primary treatments, such as endoscopic correction or open surgical repair, without knowing which patients will benefit physiologically and clinically, will likely result in both unnecessary correction of reflux destined to resolve naturally and/or correction of reflux with no clinical benefit. This brings home the notion that any treatment, either pharmacologic, surgical, or through close observation, requires the clinician to understand his or her patient beyond the mere presence of VUR and must include the concept of clinical risk stratification and individualized treatments.

The seminal message for diagnosing and treating children with VUR is becoming clearer, although not yet wholly understood. Approaches to identifying the child's current risk profile, including the host of social and behavioral elements that can affect his or her risk for recurrence of UTI and alter the trajectory to spontaneous resolution, are critical. Teaching and periodic review of perineal hygiene techniques, timely bladder-emptying habits, healthy dietary and bowel measures to prevent constipation, and carefully evaluating family compliance and access to prompt care should influence treatment plans. Patients identified as high risk benefit from initiation of CAP. Given that most VUR has a chance to resolve over time, trying to shift patients into a lower-risk category with CAP until the sum total of the momentum for recurrent infection is diminished is a worthwhile endeavor. This necessitates regular evaluation of patients for known risk variables and attacking each in turn. Movement from risk strata up or down should be considered at each visit based on a child's initial risk at diagnosis, and recommendations move fluidly to mirror that of the patient.

Careful discussion of the obligations and expectations should take place to assess whether watchful waiting is an optimal approach in each case, and careful discernment by the clinician is imperative to be able to predict who benefits from a less invasive approach to VUR therapy.

Landmark Studies

Several studies have attempted to shed light on the efficacy of medical management for VUR as a whole, and looking at patients with specific grades of reflux, namely low-grade VUR, usually defined as grades I to III and high-grade VUR, IV to V. Despite efforts to ultimately clarify the role of CAP in VUR, several well-constructed studies have failed to present a unifying construct that clearly fits the role for medical management. Initially, Edwards et al. led a series of studies that repeatedly demonstrated the ability of low-dose prophylactic antibiotics to prevent infection and renal scarring while reflux resolved in a significant majority of children (Edwards et al., 1977). Since then, several large-scale prospective studies validated this approach in part, however, several questions arose as a consequence. We hope to more fully rationalize the finding in the studies listed in the following sections and help to further define the role for medical management on the natural history of VUR.

International Reflux Study in Children

The International Reflux Study in Children was a North American (Weiss et al., 1992b) and European (Tamminen-Mobius et al., 1992) cooperative study that randomized children younger than 9 years of age with high-grade reflux to CAP or corrective open surgery. **Although surgery was complicated by temporary**

postoperative obstruction in some patients, it was more effective than prophylaxis in reducing, but not eliminating, the occurrence of pyelonephritis. Nevertheless, the incidence of UTI (38%) was the same in both arms. Furthermore, the modalities were equally effective in reducing, but not eliminating, new scar formation. Only the European arm stratified data for the effect of dysfunctional voiding behaviors (18%) (van Gool et al., 1992). **When untreated, voiding dysfunction was associated with more UTIs, more persistent cases of reflux, and greater grade variation during follow-up.**

Birmingham Reflux Study (Birmingham Reflux Study Group 1987)

Medical and surgical management was prospectively compared in a randomized cohort of 104 patients with high-grade reflux over a 5-year period (Birmingham Reflux Study Group, 1987). Again, the incidence of new scars was the same using either treatment modality. Although more than one-half of the patients continued to reflux at 5 years, all cases of new scarring occurred within the first 2 years, consistent with the “big bang” concept of postinfectious renal injury mentioned earlier.

Swedish Reflux Study

This large, prospective trial evaluated prophylaxis and endoscopic injection for children with dilating VUR compared with surveillance across 23 centers in Sweden. Several studies were published regarding UTI recurrence, VUR outcomes, new renal damage, and impact of BBD. There were 203 children (128 girls and 75 boys), 1 to 2 years of age, with VUR grade III or IV randomized to CAP (69), up-front corrective surgery with endoscopic injection (66), or surveillance (68) (Brandströmet al., 2010a). Patients underwent VCUG and renal scintigraphy at entry, and at the end of the 2-year study. Among patients, 67 febrile UTIs occurred in 42 girls, and 8 infections occurred in 7 boys. In girls, the recurrence rate was 19% with prophylaxis, 23% with endoscopic treatment, and 57% with surveillance ($p = 0.0002$). In boys, there was no difference between treatment groups (Holmdahl et al., 2010; Brandström et al., 2010b). When evaluating the presence of new damage, of the 13 girls with new scars, 8 had been on surveillance and 5 had endoscopic treatment, with none seen in the patients on CAP ($p = 0.016$) (Brandströmet al., 2010c). Among boys, two had new lesions. Finally, patients with BBD at follow-up had less resolution of VUR

(Sillén et al., 2010). These studies show that there is a role for up-front treatment with either endoscopic injections or CAP, predominantly in girls, with associated reductions in both recurrent UTIs and new renal scars. Reiterated in an editorial by Canning, gone are the days of treating all patients with VUR similarly, and the importance of identifying at-risk populations is vital (Canning, 2012). Even in high-grade VUR, in this study, we see significant gender differences that call into question traditional dogma.

Randomized Intervention for the Management of Vesicoureteral Reflux Study

The lack of appropriate (placebo) controls or observational arms in prior retrospective reflux studies has further called their conclusions into question. The RIVUR study was sponsored by the National Institute of Diabetes and Digestive and Kidney Diseases (NIDDK) and is a multicenter, double-blind, randomized, placebo-controlled trial designed to evaluate the effectiveness of antimicrobial prophylaxis in children found to have reflux after an initial UTI (RIVUR Trial Investigators et al., 2014). The 19 clinical sites and collaborating centers enrolled 607 children with grade I to IV reflux after an initial or second febrile or symptomatic UTI. Study participants were randomized to oral placebo versus oral TMP-SMX antibiotic prophylaxis. The primary outcome measure was the development of recurrent febrile or symptomatic UTI (Chesney et al., 2008; Greenfield et al., 2008; Keren et al., 2008; RIVUR Trial Investigators et al., 2014). Results suggested that antibiotic prophylaxis reduced recurrent UTI risk by 50%, from 23.6% (72/305) for subjects on placebo to 12.9% (39/302) for those in the prophylaxis arm. The effect was more robust in subjects with febrile UTI or bowel/bladder dysfunction at baseline. However, renal scarring appeared unaffected by prophylaxis (11.9%) versus placebo (10.2%). Despite the robust design of this study and its prospective nature, several limitations highlight the significant challenges in conducting such studies. The compliance figures showed that approximately 75% of antibiotic subjects took the drug only 75% of the time, almost one-third discontinued the drug and were withdrawn from analysis, and 2% in each group reported adverse drug reaction. Using more stringent criteria for treatment failure (e.g., multiple UTI recurrences, ± fever, ± symptoms), twice as many placebo subjects suffered treatment failure (9.5% vs. 5% of antibiotic subjects). However, the converse is that 90% treatment success was achieved with placebo alone. Finally, 484 (83%) of baseline nuclear scans in both groups were obtained 1 to 4 months after the index infection event.

However, the scan data cannot conclude whether positive baseline scan findings were a result of the index infection or were related to renal dysplasia coincident with the genesis of reflux itself.

Since the RIVUR data have been released, several reanalyses have attempted to further shed light on several aspects of this study that contradicted previous literature. As previously discussed, known VUR with frequent infections leads to more renal scarring. Several key studies have also shown benefit to CAP for reduction of UTI. With this in mind, how can one rationalize the findings that there was no difference in renal scarring in the groups, despite seeing the 50% relative risk reduction to CAP? To help provide clarity, Wang et al. reanalyzed the original RIVUR data set and stratified patients into low- and high-risk groups based on known modifiers (Wang et al., 2018). One interesting finding regarding patient population characteristics was that most of the patients were females (>90%) with low to intermediate grade VUR (I to III). Only 8.3% of the overall cohort had grade IV VUR. To reconcile previous findings where there was significant benefit with treating higher-risk patients (Alsaywid et al., 2010; McLorie et al., 1990; Nordenström, Holmdahl, et al., 2017a; Holmdahl et al., 2010), it may be quite plausible that the effects of CAP seen in the RIVUR trial may have been diluted in a predominantly low-risk cohort. There was a greater difference in the number of recurrent UTIs in the low- and high-risk patients, 31.5% versus 11.4%, respectively. The number needed to treat to prevent one infection for low- and high-risk patients was 18 and 5, respectively, providing a more favorable treatment profile. In keeping with previous studies in which there was no significant difference for patients with lower grades of VUR (Roussey-Kesler et al., 2008), Wang's reanalysis confirmed the benefit of CAP in high-risk patients and questioned its value in low-risk patients where the rate of UTI in CAP or placebo was 13.8% and 19.2%, respectively ($p = 0.151$). Although this was an exploratory analysis of a large data set with inherent limitations itself, it attempts to reconcile the findings of separate published work involving low- and high-risk patients (Holmdahl et al., 2010; Roussey-Kesler et al., 2008; Garin et al., 2006) and further reinforces the need for a risk-stratified approach to the management of VUR, with greater attention to patient selection to identify the specific subset of children who stand to benefit clinically from prophylaxis.

Additional Prospective Studies

Medical management alone was assessed in 59 patients (84 refluxing ureters, grades I to III) by the Southwest Pediatric Nephrology Group (Arant, 1992).

Resolution occurred in 67%, BUTI in 33%, and new scarring in 10% of the low-grade and 28% of the patients with grade III reflux. Scholtmeijer demonstrated resolution in 57% of 47 cases of grade III to IV reflux followed by watchful waiting and prophylaxis for 5 years (Scholtmeijer, 1993). Interestingly, 15 cases underwent surgical correction after BUTI, and 6 of these subsequently developed new scars, whereas 2 of the patients managed medically developed new scars.

In the Antibiotic Prophylaxis and Recurrent Urinary Tract Infection in Children (PRIVENT) study, 576 children with a history of UTI were randomized to CAP or placebo (Craig et al., 2009). The patient population was heterogeneous with regard to VUR status and type of follow-up imaging. There was a decrease in the number of UTIs when placed on a low-dose, long-term regime with an absolute risk reduction of 6% from 19% to 13%. The modest decrease was present across all subgroups analyzed. In a similar study by Garin et al., 218 patients with and without VUR were treated with CAP or observation (Garin et al., 2006). After 1 year, there was no statistically significant difference between patients on CAP or in the observations group. The overall incidence of UTI after pyelonephritis in the whole cohort was 20.1%. Among patients in the observation arm, the incidence of infection in patients with and without VUR was 22.4% and 23.3%, respectively ($p = 0.99$). Among patients on CAP, the recurrence rate of UTI after pyelonephritis for those with and without VUR was 23.5% and 8.8%, respectively ($P = 0.63$). This cohort of patients would most closely represent a low-risk group, with only 37 patients overall having at most grade III reflux out of the entire population. In the study by Roussey-Kesler, 225 patients with low-grade VUR I to III were randomized to CAP or no treatment. They found no significant difference in recurrent UTI rates between the two groups: 17% and 26% ($p = 0.2$) for patients on CAP and no treatment, respectively (Roussey-Kesler et al., 2008).

Key Points: Natural History and Management

- Reflux has a natural tendency to resolve spontaneously given enough time.
- The likelihood of resolution is inversely proportional to grade but is influenced by several factors.
- Maintaining urine sterility (through both prophylactic antibiotics and strict attention to bladder and bowel management) is the cornerstone of watchful

waiting medical management.

- CAP results in a reduction in UTIs but does not necessarily reduce renal scarring or chronic kidney disease.
- Prophylactic antibiotics are more likely to benefit patients with higher-grade VUR, baseline bladder dysfunction, febrile UTI, BBD, or those that present with a febrile UTI.

Individualizing Patient Care

Throughout this section, several overriding themes have been reinforced; namely the need for individualized care and the importance of reassessing ongoing management and tailoring it to the dynamic changes that either increase or decrease a child's risk for infection.

When a child initially presents to a clinician for care, it is imperative to **establish the severity of the condition and the child's risk for recurrent UTI and renal injury**, which should dictate management. The minimum initial approach necessitates an accurate history to document the number and severity of clinically significant UTIs and to review the upper tracts with a high-quality renal, bladder ultrasound scan to first gauge the extent of renal injury, if any. Once this basic information is obtained, the role for further workup with a VCUG can be considered. In patients with multiple, well-documented, clinically significant UTIs on history, especially with significant associated morbidity, such as need for hospital admission or upper tract findings on ultrasonography, ruling out VUR in the presence of these infections becomes imperative. This contrasts with the patient who presents with an equal number of nonfebrile "infections" with questionable urine studies and a normal ultrasound scan. A clinician may opt to offer a more conservative approach to the workup and management, with likely little adverse outcome.

Our group has developed a tool to help stratify patients at each encounter and assess the likelihood of BUTIs (Hidas et al., 2013) (Fig. 29.19). This same principle was used to retrospectively review 252 patients and identify the dominant candidate risk factors that increase the risk for UTI and then confirmed this risk model in 52 children followed prospectively for at least 2 years (Hidas et al., 2015). What was garnered from this study was that those children at greatest risk for BUTIs were those that presented initially with UTI, had high-grade VUR, were female, and had BBD. Patients were stratified into low-, intermediate-, and high-risk groups based on these variables, thus tailoring management for each child, while providing guidance to the individualized approach to each child's care. In this study, 68% of children with VUR were in the low-risk category and only had an 8.6% chance of BUTI, and 28% were intermediate risk and had a 27% chance of BUTI (Hidas et al., 2015). Only 6.3% were defined as high risk; however their rate of BUTI was 63%. This is consistent with high-quality data that confirms the predominance of low-risk type patients in large cohort studies, when all-comers with VUR are included in the analysis, as is the case in the RIVUR study (RIVUR Trial Investigators et al., 2014; Wang et al., 2018).

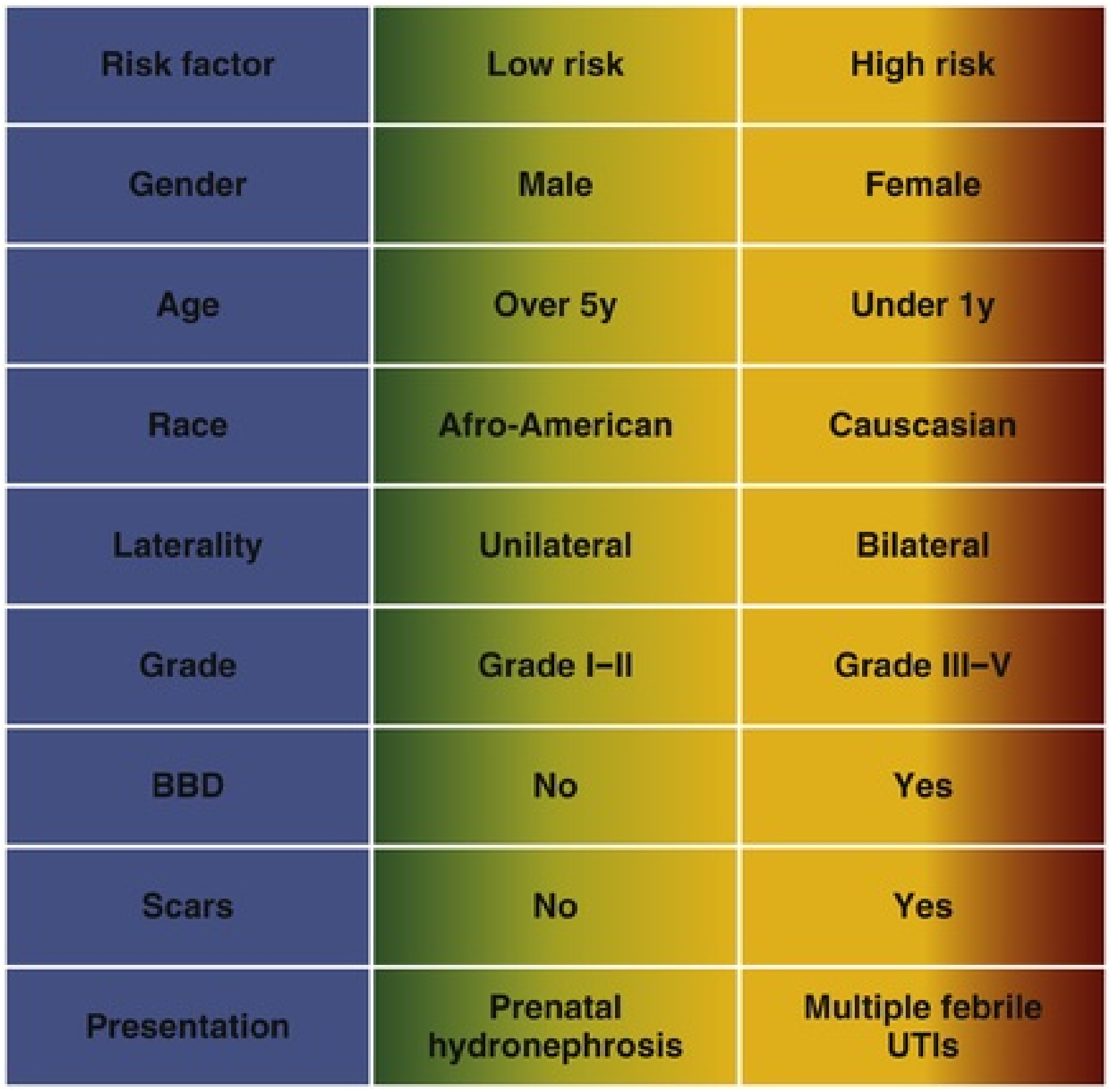

Risk factor	Low risk	High risk
Gender	Male	Female
Age	Over 5y	Under 1y
Race	Afro-American	Causcasian
Laterality	Unilateral	Bilateral
Grade	Grade I–II	Grade III–V
BBD	No	Yes
Scars	No	Yes
Presentation	Prenatal hydronephrosis	Multiple febrile UTIs

FIG. 29.19 Risk factors and risk groups for vesicoureteral reflux. (Modified from Hidas G, Nam A, Soltani T, et al. Primary vesico-ureteric reflux: The need for individualised risk stratification. *Arab J Urol.* 2013;11[1]:8–12.)

A clinician can use this risk characterization to better understand the specific child's risk for infection in the context of VUR and guide each patient's care, identifying which factors need to be modified to reduce each child's risk profile, not only to prevent infection, but also to decrease the intensity of treatment and follow-up when possible. As an example: An uncircumcised male child evaluated and found to have BBD and intermediate grade VUR puts him at intermediate risk for BUTI. The clinician may opt to continue or start CAP until the BBD and potential phimosis is confidently treated, at which point the child's risk might be considered to have been downgraded and the risk for BUTI is sufficiently lowered (from 28% to 8.6%) such that CAP can be safely discontinued. Conversely, if a child presents with high-grade VUR, BBD, and is a female, the clinician may consider a trial of CAP, but given that the risk for BUTI is high, discussion with the family regarding a more aggressive approach with up-front correction of VUR may not be entirely unreasonable.

The spectrum of VUR is continuous and dynamic, and seeing it through this lens is critical. The clinician's aim should be to prevent infection, which has been repeatedly shown to be a game changer. The goal should be to allow for the possibility of spontaneous resolution of VUR over time while preventing UTI-associated scarring in the process.

The modern management of VUR should be specific to each child and malleable enough to adapt to the ongoing changes in each child's particular risk profile.

References

Abdelhalim A, Khoury AE. Critical appraisal of the top-down approach for vesicoureteral reflux. *Investig Clin Urol*. 2017;58(Suppl 1):S14–S22.

Acar B, Arikan FI, Germiyanoğlu C, et al. Influence of high bladder pressure on vesicoureteral reflux and its resolution. *Urol Int*. 2009;82(1):77–80.

Advisory Committee to the Renal Transplant Registry. The 12th report of the human renal transplant registry. Prepared by the Advisory Committee to the Renal Transplant Registry. *JAMA*. 1975;233(7):787–796.

Afshar K, Malek R, Bakhshi M, et al. Should the presence of congenital para-ureteral diverticulum affect the management of vesicoureteral reflux? *J Urol*. 2005;174(4):1590–1593.

Afshar K, Papanikolaou F, Malek R, et al. Vesicoureteral reflux and complete ureteral duplication. Conservative or surgical management? *J Urol*. 2005;173(5):1725–1727.

Agrawal V, Rangarajan V, Kamath T, et al. Vesicoureteric reflux: evaluation by bladder volume graded direct radionuclide cystogram. *J Indian Assoc Pediatr Surg*. 2009;14(1):15–18.

Allen TD. Vesicoureteral reflux and the unstable bladder. *J Urol*. 1985;134(6):1180.

Alsaywid BS, Saleh H, Deshpande A, et al. High grade primary vesicoureteral reflux in boys: long-term results of a prospective cohort study. *J Urol*. 2010;184(4 Suppl):1598–1603.

Arant BS. Medical management of mild and moderate vesicoureteral reflux: followup studies of infants and young children. A preliminary report of the Southwest Pediatric Nephrology Study Group. *J Urol*. 1992;148(5 Pt 2):1683–

1687.

Arlen AM, Kirsch AJ, Leong T, et al. Validation of the ureteral diameter ratio for predicting early spontaneous resolution of primary vesicoureteral reflux. *J Pediatr Urol*. 2017;13(4):383.e1–383.e6.

Ataei N, Madani A, Esfahani ST, et al. Screening for vesicoureteral reflux and renal scars in siblings of children with known reflux. *Pediatr Nephrol*. 2004;19(10):1127–1131.

Austenfeld MS, Snow BW. Complications of pregnancy in women after reimplantation for vesicoureteral reflux. *J Urol*. 1988;140(5 Pt 2):1103–1106.

Baek M, Kim KD. Current surgical management of vesicoureteral reflux. *Korean J Urol*. 2013;54(11):732–737.

Baek M, Koh CJ. Lessons learned over a decade of pediatric robotic ureteral reimplantation. *Investig Clin Urol*. 2017;58(1):3–11.

Baquerizo BV, Peters CA. Antibiotic prophylaxis and reflux: critical review and assessment. *F1000Prime Rep*. 2014;6(104):104.

Barai S, Bandopadhayaya GP, Bhowmik D, et al. Prevalence of vesicoureteral reflux in patients with incidentally diagnosed adult hypertension. *Urology*. 2004;63(6):1045–1048 [discussion 1048–1049].

Basson MA, Akbulut S, Watson-Johnson J, et al. Sprouty1 is a critical regulator of GDNF/RET-mediated kidney induction. *Dev Cell*. 2005;8(2):229–239.

Batourina E, Tsai S, Lambert S, et al. Apoptosis induced by vitamin A signaling is crucial for connecting the ureters to the bladder. *Nat Genet*. 2005;37(10):1082–1089.

Bauer SB, Colodny AH, Retik AB. The management of vesicoureteral reflux in children with myelodysplasia. *J Urol*. 1982;128(1):102–105.

Baumer JH, Jones RWA. Urinary tract infection in children, National Institute for Health and Clinical Excellence. *Arch Dis Child Educ Pract Ed*. 2007;92(6):189–192.

Beetz R, Hohenfellner R, Schofer O, et al. Long-term follow-up of children with surgically treated vesicorenal reflux: renal growth. *Eur Urol*. 1991;19(1):39–44.

Benador D, Benador N, Slosman D, et al. Are younger children at highest risk of renal sequelae after pyelonephritis? *Lancet*. 1997;349(9044):17–19.

Berger C, Becker T, Koen M, et al. Positioning irrigation of contrast cystography for diagnosis of occult vesicoureteric reflux: association with technetium-99m dimercaptosuccinic acid scans. *J Pediatr Urol*. 2013;9(6 Pt A):846–850.

Berrocal T, Gayá F, Arjonilla A, et al. Vesicoureteral reflux: diagnosis and grading with echo-enhanced cystosonography versus voiding cystourethrography. *Radiology*. 2001;221(2):359–365.

Beydoun SN. Morphologic changes in the renal tract in pregnancy. *Clin Obstet Gynecol*. 1985;28(2):249–256.

Birmingham Reflux Study Group. Prospective trial of operative versus non-operative treatment of severe vesicoureteric reflux in children: five years' observation. Birmingham Reflux Study Group. *Br Med J (Clin Res Ed)*. 1987;295(6592):237–241.

Blaufox MD, Gruskin A, Sandler P, et al. Radionuclide scintigraphy for detection of vesicoureteral reflux in children. *J Pediatr*. 1971;79(2):239–246.

Blickman JG, Lebowitz RL. The coexistence of primary megaureter and reflux. *AJR Am J Roentgenol*. 1984;143(5):1053–1057.

Blumberg K. Sedation and the VCUG. *Pediatr Radiol*. 2012;42(3):290–292.

Bollgren I, Winberg J. The periurethral aerobic bacterial flora in healthy boys and girls. *Acta Paediatr Scand*. 1976;65(1):74–

80.

Bomalaski MD, Hirschl RB, Bloom DA. Vesicoureteral reflux and ureteropelvic junction obstruction: association, treatment options and outcome. *J Urol*. 1997;157(3):969–974.

Braga LH, McGrath M, Farrokhyar F, et al. Society for Fetal Urology Classification versus Urinary Tract Dilation Grading System for prognostication in prenatal hydronephrosis: a time to resolution analysis. *J Urol*. 2017;199(6):1615–1621.

Brandström P, Esbjörner E, Herthelius M, et al. The Swedish reflux trial in children: I Study design and study population characteristics. *J Urol*. 2010;184(1):274–279.

Brandström P, Esbjörner E, Herthelius M, et al. The Swedish reflux trial in children: III Urinary tract infection pattern. *J Urol*. 2010;184(1):286–291.

Brandström P, Nevéus T, Sixt R, et al. The Swedish reflux trial in children: IV. Renal damage. *J Urol*. 2010;184(1):292–297.

Bruce AW, Reid G. Probiotics and the urologist. *Can J Urol*. 2003;10(2):1785–1789.

Bukowski TP, Betrus GG, Aquilina JW, et al. Urinary tract infections and pregnancy in women who underwent antireflux surgery in childhood. *J Urol*. 1998;159(4):1286–1289.

Burbige KA, Lebowitz RL, Colodny AH, et al. The megacystis-megaureter syndrome. *J Urol*. 1984;131:1133–1136.

Burge DM, Griffiths MD, Malone PS, et al. Fetal vesicoureteral reflux: outcome following conservative postnatal management. *J Urol*. 1992;148(5 Pt 2):1743–1745.

Butler LD, Symons BK, Henderson SL, et al. Hypnosis reduces distress and duration of an invasive medical procedure for children. *Pediatrics*. 2005;115(1):e77–e85.

Canning DA. Re: the Swedish reflux trial: review of a randomized, controlled trial in children with dilating vesicoureteral reflux. *J Urol*. 2012;188(2):598–599.

Capozza N, Gulia C, Heidari Bateni Z, et al. Vesicoureteral reflux in infants: what do we know about the gender prevalence by age? *Eur Rev Med Pharmacol Sci*. 2017;21(23):5321–5329.

Carlsen O, Lukman B, Nathan E. Indirect radionuclide renocystography for determination of vesico-ureteral reflux in children. *Eur J Nucl Med*. 1986;12(4):205–210.

Carr MC, Peters CA, Retik AB, et al. Urinary levels of renal tubular enzyme N-acetyl-beta-D-glucosaminidase in relation to grade of Vesicoureteral reflux. *J Urol*. 1991;146(2 Pt 2):654–656.

Cascio S, Paran S, Puri P. Associated urological anomalies in children with unilateral renal agenesis. *J Urol*. 1999;162(3 Pt 2):1081–1083.

Castagnetti M, Cimador M, Tudisco V, et al. Discrepancy between power-Doppler voiding urosonography and voiding cystourethrography is not relevant for the management of primary vesicoureteric reflux. *J Pediatr Surg*. 2006;41(7):1285–1289.

Cha J, Lee SJ. High spontaneous resolution rates of severe primary vesicoureteral reflux and minimal development of new renal scars. *Child Kidney Dis*. 2016;20(1):18–22.

Chand DH, Rhoades T, Poe SA, et al. Incidence and severity of vesicoureteral reflux in children related to age, gender, race and diagnosis. *J Urol*. 2003;170(4):1548–1550.

Chandra M, Maddix H. Urodynamic dysfunction in infants with vesicoureteral reflux. *J Pediatr*. 2000;136(6):754–759.

Chandra M, Maddix H, McVicar M, et al. Transient urodynamic dysfunction of infancy: relationship to urinary tract infections and vesicoureteral reflux. *J Urol*. 1996;155(2):673–677.

Chase JW, Homsy Y, Siggaard C, et al. Functional constipation in children. *J Urol*. 2004;171(6 Pt 2):2641–2643.

Chen JJ, Pugach J, Patel M, et al. The renal length nomogram:

multivariable approach. *J Urol*. 2002;168(5):2149–2152.

Cheng EY. PIC cystography: an effective test for the diagnosis of clinically significant occult reflux. *J Urol*. 2009;182(4):1264–1265.

Chesney RW, Carpenter MA, Moxey-Mims M, et al. Randomized intervention for Children With Vesicoureteral Reflux (RIVUR): background commentary of RIVUR investigators. *Pediatrics*. 2008;122(Suppl 5):S233–S239.

Chi T, Feldstein VA, Nguyen HT. Increased echogenicity as a predictor of poor renal function in children with grade 3 to 4 hydronephrosis. *J Urol*. 2006;175(5):1898–1901.

Choi H, Oh SJ, So Y, et al. No further development of renal scarring after antireflux surgery in children with primary vesicoureteral reflux: review of the results of technetium-99m dimercapto-succinic acid renal scan. *J Urol*. 1999;162(3 Pt 2):1189–1192.

Choi KL, McNoe LA, French MC, et al. Absence of PAX2 gene mutations in patients with primary familial vesicoureteric reflux. *J Med Genet*. 1998;35(4):338–339.

Chowdhury P, Sacks SH, Sheerin NS. Minireview: functions of the renal tract epithelium in coordinating the innate immune response to infection. *Kidney Int*. 2004;66:1334–1344.

Connolly LP, Treves ST, Zurakowski D, et al. Natural history of vesicoureteral reflux in siblings. *J Urol*. 1996;156(5):1805–1807.

Connolly LP, Zurakowski D, Connolly SA, et al. Natural history of vesicoureteral reflux in girls after age 5 years. *J Urol*. 2001;166(6):2359–2363.

Conway JJ, Belman AB, King LR, et al. Direct and indirect radionuclide cystography. *J Urol*. 1975;113(5):689–693.

Cooper CS. Individualizing management of vesicoureteral reflux. *Nephrourol Mon*. 2012;4(3):530–534.

Cooper CS, Chung BI, Kirsch AJ, et al. The outcome of stopping prophylactic antibiotics in older children with vesicoureteral reflux. *J Urol*. 2000;163(1):269–272 [discussion 272–273].

Cooper CS, Alexander SE, Kieran K, et al. Utility of the distal ureteral diameter on VCUG for grading VUR. *J Pediatr Urol*. 2015;11(4):183.e1–183.e6.

Cordell HJ, Darlay R, Charoen P, et al. Whole-genome linkage and association scan in primary, nonsyndromic vesicoureteric reflux. *J Am Soc Nephrol*. 2010;21(1):113–123.

Coulthard MG. Do kidneys outgrow the risk of reflux nephropathy? *Pediatr Nephrol*. 2002;17(7):477–480.

Coulthard MG, Verber I, Jani JC, et al. Can prompt treatment of childhood UTI prevent kidney scarring? *Pediatr Nephrol*. 2009;24(10):2059–2063.

Craig JC, Knight JF, Sureshkumar P, et al. Vesicoureteric reflux and timing of micturating cystourethrography after urinary tract infection. *Arch Dis Child*. 1997;76(3):275–277.

Craig JC, Irwig LM, Knight JF, et al. Does treatment of vesicoureteric reflux in childhood prevent end-stage renal disease attributable to reflux nephropathy? *Pediatrics*. 2000;105(6):1236–1241.

Craig JC, Simpson JM, Williams GJ, et al. Antibiotic prophylaxis and recurrent urinary tract infection in children. *N Engl J Med*. 2009;361(18):1748–1759.

Cunliffe HE, McNoe LA, Ward TA, et al. The prevalence of PAX2 mutations in patients with isolated colobomas or colobomas associated with urogenital anomalies. *J Med Genet*. 1998;35(10):806–812.

Darge K. Voiding urosonography with ultrasound contrast agents for the diagnosis of vesicoureteric reflux in children. I. Procedure. *Pediatr Radiol*. 2008;38(1):40–53.

Darge K. Voiding urosonography with US contrast agents for the diagnosis of vesicoureteric reflux in children. II.

Comparison with radiological examinations. *Pediatr Radiol*. 2008;38(1):54–63 [quiz 126–127].

Darge K. Voiding urosonography with US contrast agent for the diagnosis of vesicoureteric reflux in children: an update. *Pediatr Radiol*. 2010;40(6):956–962.

Darge K, Troeger J. Vesicoureteral reflux grading in contrast-enhanced voiding urosonography. *Eur J Radiol*. 2002;43(2):122–128.

Darge K, Zieger B, Rohrschneider W, et al. Contrast-enhanced harmonic imaging for the diagnosis of vesicoureteral reflux in pediatric patients. *AJR Am J Roentgenol*. 2001;177(6):1411–1415.

Darlow JM, Molloy NH, Green AJ, et al. The increased incidence of the RET p.Gly691Ser variant in French-Canadian vesicoureteric reflux patients is not replicated by a larger study in Ireland. *Hum Mutat*. 2009;30(5):E612–E617.

Darlow JM, Darlay R, Dobson MG, et al. Genome-wide linkage and association study implicates the 10q26 region as a major genetic contributor to primary nonsyndromic vesicoureteric reflux. *Sci Rep*. 2017;7(1):14595.

de Bessa J Jr, de Carvalho Mrad FC, Mendes EF, et al. Antibiotic prophylaxis for prevention of febrile urinary tract infections in children with vesicoureteral reflux: a meta-analysis of randomized, controlled trials comparing dilated to nondilated vesicoureteral reflux. *J Urol*. 2015;193(5 Suppl):1772–1777.

Diamond DA, Kleinman PK, Spevak M, et al. The tailored low dose fluoroscopic voiding cystogram for familial reflux screening. *J Urol*. 1996;155(2):681–682.

Dillon MJ, Smellie JM. Peripheral plasma renin activity, hypertension and renal scarring in children. *Contrib Nephrol*. 1984;39:68–80.

Doganis D, Siafas K, Mavrikou M, et al. Does early treatment of urinary tract infection prevent renal damage? *Pediatrics*. 2007;120(4):e922–e928.

Drzewiecki BA, Thomas JC, Pope JC 4th, et al. Observation of patients with vesicoureteral reflux off antibiotic prophylaxis: physician bias on patient selection and risk factors for recurrent febrile urinary tract infection. *J Urol*. 2012;188(4 Suppl):1480–1484.

Duckett JW. Vesicoureteral reflux: a “conservative” analysis. *Am J Kidney Dis*. 1983;3(2):139–144.

Duckett JW, Bellinger MF. A plea for standardized grading of vesicoureteral reflux. *Eur Urol*. 1982;8:74–77.

Edwards D, Normand IC, Prescod N, et al. Disappearance of vesicoureteric reflux during long-term prophylaxis of urinary tract infection in children. *Br Med J*. 1977;2(6082):285–288.

Edwards D, Smellie JM, Normand IC, et al. Effect of vesicoureteric reflux on renal growth in children with urinary tract infection. *Arch Dis Child*. 1981;56(8):593–600.

Elbadawi A. Anatomy and function of the ureteral sheath. *J Urol*. 1972;107(2):224–229.

Elder JS. Imaging for vesicoureteral reflux—is there a better way? *J Urol*. 2005;174(1):7–8.

Elder JS, Diaz M. Vesicoureteral reflux—the role of bladder and bowel dysfunction. *Nat Rev Urol*. 2013;10(11):640–648.

Elder JS, Peters CA, Arant BS Jr, et al. Pediatric Vesicoureteral Reflux Guidelines Panel summary report on the management of primary vesicoureteral reflux in children. *J Urol*. 1997;157(5):1846–1851.

El-Khatib M, Packham DK, Becker GJ, et al. Pregnancy-related complications in women with reflux nephropathy. *Clin Nephrol*. 1994;41(1):50–55.

ElSheemy MS, Ghoneima W, Abdelwahhab M, et al. The role of voiding cystourethrography in asymptomatic unilateral isolated ureteropelvic junction obstruction: a retrospective study. *J Pediatr Urol*. 2017;13(2):206.e1–206.e7.

Estrada CR, Passerotti CC, Graham DA, et al. Nomograms for predicting annual resolution rate of primary vesicoureteral reflux: results from 2,462 children. *J Urol*. 2009;182(4):1535–1541.

Estrada CR, Peters CA, Retik AB, et al. Vesicoureteral reflux and urinary tract infection in children with a history of prenatal hydronephrosis—should voiding cystourethrography be performed in cases of postnatally persistent grade II hydronephrosis? *J Urol*. 2009;181(2):801–806 [discussion 806–807].

Evans K, Asimakadou M, Nwankwo O, et al. What is the risk of urinary tract infection in children with antenatally presenting dilating vesico-ureteric reflux? *J Pediatr Urol*. 2015;11(2):93.e1–93.e6.

Farhat W, McLorie G, Geary D, et al. The natural history of neonatal vesicoureteral reflux associated with antenatal hydronephrosis. *J Urol*. 2000;164(3 Pt 2):1057–1060.

Farhat W, McLorie G, Bagli D, et al. Greater reliability of neonatal ultrasonography in defining renal hypoplasia with antenatal hydronephrosis and vesicoureteral reflux. *Can J Urol*. 2002;9(1):1459–1463.

Farhat WG, Traubici J, Sherman C, et al. Reliability of contrast enhanced sonography with harmonic imaging for detecting early renal scarring in experimental pyelonephritis in a porcine model: preliminary results. *J Urol*. 2002;168(3):1114–1117.

Farnham SB, Adams MC, Brock JW 3rd, et al. Pediatric urological causes of hypertension. *J Urol*. 2005;173(3):697–704.

Fast AM, Nees SN, Van Batavia JP, et al. Outcomes of targeted treatment for vesicoureteral reflux in children with nonneurogenic lower urinary tract dysfunction. *J Urol*.

2013;190(3):1028–1032.

Faust WC, Diaz M, Pohl HG. Incidence of post-pyelonephritic renal scarring: a meta-analysis of the dimercapto-succinic acid literature. *J Urol*. 2009;181(1):290–297 [discussion 297–298].

Fernández-Menéndez JM, Málaga S, Matesanz JL, et al. Risk factors in the development of early technetium-99m dimercaptosuccinic acid renal scintigraphy lesions during first urinary tract infection in children. *Acta Paediatr*. 2003;92(1):21–26.

Fettich J, Colarinha P, Fischer S, et al. Guidelines for direct radionuclide cystography in children. *Eur J Nucl Med Mol Imaging*. 2003;30(5):B39–B44.

Fettich JJ, Kenda RB. Cyclic direct radionuclide voiding cystography: increasing reliability in detecting vesicoureteral reflux in children. *Pediatr Radiol*. 1992;22(5):337–338.

Fillion ML, El Andalousi J, Tokhmafshan F, et al. Heterozygous loss-of-function mutation in Odd-skipped related 1 (Osr1) is associated with vesicoureteric reflux, duplex systems, and hydronephrosis. *Am J Physiol Renal Physiol*. 2017;313(5):F1106–F1115.

Funston MR, Cremin BJ. Intrarenal reflux: papillary morphology and presure relationships in children's necropsy kidneys. *Br J Radiol*. 1978;51(609):665–670.

Galia M, Midiri M, Pennisi F, et al. Vesicoureteral reflux in young patients: comparison of voiding color Doppler US with echo enhancement versus voiding cystourethrography for diagnosis or exclusion. *Abdom Imaging*. 2004;29(3):303–308.

Garcia-Roig M, Ridley DE, McCracken C, et al. Vesicoureteral reflux index: predicting primary vesicoureteral reflux resolution in children diagnosed after age 24 months. *J Urol*. 2017;197(4):1150–1157.

Garcia-Roig M, Travers C, McCracken CE, et al. National trends in the management of primary vesicoureteral reflux in children. *J Urol*. 2018;199(1):287–293.

Garin EH, Olavarria F, Garcia Nieto V. Clinical significance of primary vesicoureteral reflux and urinary antibiotic prophylaxis after acute pyelonephritis: a multicenter, randomized, controlled study. *Pediatrics*. 2006;117(3):626–632.

Geerlings SE. Clinical presentations and epidemiology of urinary tract infections. *Microbiol Spectr*. 2016;4(5).

Gerard LL, Cooper CS, Duethman KS, et al. Effectiveness of lidocaine lubricant for discomfort during pediatric urethral catheterization. *J Urol*. 2003;170(2 Pt 1):564–567.

Giannotti G, Menezes M, Hunziker M, et al. Sibling vesicoureteral reflux in twins. *Pediatr Surg Int*. 2011;27(5):513–515.

Giltay JC, van de Meerakker J, van Amstel HK, et al. No pathogenic mutations in the uroplakin III gene of 25 patients with primary vesicoureteral reflux. *J Urol*. 2004;171(2 Pt 1):931–932.

Glassberg KI, Combs AJ, Horowitz M. Nonneurogenic voiding disorders in children and adolescents: clinical and videourodynamic findings in 4 specific conditions. *J Urol*. 2010;184(5):2123–2127.

Gobet R, Cisek LJ, Zotti P, et al. Experimental vesicoureteral reflux in the fetus depends on bladder function and causes renal fibrosis. *J Urol*. 1998;160(3 Pt 2):1058–1062 [discussion 1079].

Golmakani H, Sharbaf FG, Esmaeili M, et al. Comparison of the voiding cystourethrogram results one and three weeks after the first urinary tract infection in 1-month to 15-year-old children. *J Pediatr Nephrol*. 2016;4(3):97–101.

Goonasekera CD, Dillon MJ. Reflux nephropathy and hypertension. *J Hum Hypertens*. 1998;12(8):497–504.

Gordon I, Colarinha P, Fettich J, et al. Guidelines for indirect radionuclide cystography. *Eur J Nucl Med*. 2001;28(3):BP16–BP20.

Gordon I, Peters AM, Morony S. Indirect radionuclide cystography: a sensitive technique for the detection of vesico-ureteral reflux. *Pediatr Nephrol*. 1990;4(6):604–606.

Greenfield SP, Chesney RW, Carpenter M, et al. Vesicoureteral reflux: the RIVUR study and the way forward. *J Urol*. 2008;179(2):405–407.

Grieshammer U, Le Ma, Plump AS, et al. SLIT2-mediated ROBO2 signaling restricts kidney induction to a single site. *Dev Cell*. 2004;6(5):709–717.

Gruber CM. A comparative study of the intra-vesical ureters (uretero-vesical valves) in man and in experimental animals. *J Urol*. 1929;21(5):567–582.

Grundy L, Brierley SM. Cross-organ sensitization between the colon and bladder: to pee or not to pee? *Am J Physiol Gastrointest Liver Physiol*. 2018;314(3):G301–G308.

Guizar JM, Kornhauser C, Malacara JM, et al. Renal tubular acidosis in children with vesicoureteral reflux. *J Urol*. 1996;156(1):193–195.

Hagberg S, Hjälmås K, Jacobsson B, et al. Renal growth after antireflux surgery in infants. *Z Kinderchir*. 1984;39(1):52–54.

Hagerty JA, Maizels M, Cheng EY. The PIC cystogram: its place in the treatment algorithm of recurrent febrile UTIs. *Adv Urol*. 2008;763620.

Hains DS, Sims-Lucas S, Carpenter A, et al. High incidence of vesicoureteral reflux in mice with Fgfr2 deletion in kidney mesenchyma. *J Urol*. 2010;183(5):2077–2084.

Halachmi S, Farhat WA. Interactions of constipation, dysfunctional elimination syndrome, and vesicoureteral reflux. *Adv Urol*. 2008;828275.

Hansson S, Dhamey M, Sigström O, et al. Dimercapto-succinic acid scintig-raphy instead of voiding cystourethrography for infants with urinary tract infection. *J Urol*. 2004;172(3):1071–1073 [discussion 1073–1074].

Heidrick WP, Mattingly RF, Amberg JR. Vesicoureteral reflux in pregnancy. *Obstet Gynecol*. 1967;29(4):571–578.

Hewitt IK, Zucchetta P, Rigon L, et al. Early treatment of acute pyelonephritis in children fails to reduce renal scarring: data from the Italian Renal Infection Study Trials. *Pediatrics*. 2008;122(3):486–490.

Hidas G, Billimek J, Nam A, et al. Predicting the risk of breakthrough urinary tract infections: primary vesicoureteral reflux. *J Urol*. 2015;194(5):1396–1401.

Hidas G, Nam A, Soltani T, et al. Primary vesico-ureteric reflux: the need for individualised risk stratification. *Arab J Urol*. 2013;11(1):8–12.

Hinchliffe SA, Kreczy A, Ciftci AO, et al. Focal and segmental glomerulosclerosis in children with reflux nephropathy. *Pediatr Pathol*. 1994;14(2):327–338.

Hiraoka M, Hori C, Tsukahara H, et al. Vesicoureteral reflux in male and female neonates as detected by voiding ultrasonography. *Kidney Int*. 1999;55(4):1486–1490.

Hitzel A, Liard A, Véra P, et al. Color and power Doppler sonography versus DMSA scintigraphy in acute pyelonephritis and in prediction of renal scarring. *J Nucl Med*. 2002;43(1):27–32.

Hoberman A, Charron M, Hickey RW, et al. Imaging studies after a first febrile urinary tract infection in young children. *N Engl J Med*. 2003;348(3):195–202.

Hoberman A, Wald ER. Urinary tract infections in young febrile children. *Pediatr Infect Dis J*. 1997;16(1):11–17.

Hodson CJ. The radiological diagnosis of pyelonephritis. *Proc R Soc Med*. 1959;52:669–672.

Hodson CJ, Maling TM, McManamon PJ, et al. The pathogenesis of reflux nephropathy (chronic atrophic pyelonephritis). *Br J Radiol*. 1975;(Suppl 13):1–26.

Hollowell JG. Outcome of pregnancy in women with a history of vesico-ureteric reflux. *BJU Int*. 2008;102(7):780–784.

Hollowell JG, Greenfield SP. Screening siblings for vesicoureteral reflux. *J Urol*. 2002;168(5):2138–2141.

Hollowell JG, Altman HG, Snyder HM 3rd, et al. Coexisting ureteropelvic junction obstruction and vesicoureteral reflux: diagnostic and therapeutic implications. *J Urol*. 1989;142(2 Pt 2):490–493 [discussion 501].

Holmdahl G, Brandström P, Läckgren G, et al. The Swedish reflux trial in children: II. Vesicoureteral reflux outcome. *J Urol*. 2010;184(1):280–285.

Homsy YL, Nsouli I, Hamburger B, et al. Effects of oxybutynin on vesicoureteral reflux in children. *J Urol*. 1985;134(6):1168–1171.

Horowitz M, Gershbein AB, Glassberg KI. Vesicoureteral reflux in infants with prenatal hydronephrosis confirmed at birth: racial differences. *J Urol*. 1999;161(1):248–250.

Houle AM, Cheikhelard A, Barrieras D, et al. Impact of early screening for reflux in siblings on the detection of renal damage. *BJU Int*. 2004;94(1):123–125.

Hu P, Deng FM, Liang FX, et al. Ablation of uroplakin III gene results in small urothelial plaques, urothelial leakage, and vesicoureteral reflux. *J Cell Biol*. 2000;151(5):961–972.

Huland H, Busch R. Pyelonephritic scarring in 213 patients with upper and lower urinary tract infections: long-term followup. *J Urol*. 1984;132(5):936–939.

Hung TW, Tsai JD, Liao PF, et al. Role of renal ultrasonography in predicting vesicoureteral reflux and renal scarring in children hospitalized with a first febrile urinary tract infection. *Pediatr Neonatol*. 2016;57(2):113–119.

Husmann DA, Allen TD. Resolution of vesicoureteral reflux in completely duplicated systems: fact or fiction? *J Urol*. 1991;145(5):1022–1023.

Hutch JA. Vesico-ureteral reflux in the paraplegic: cause and correction. *J Urol*. 1952;68(2):457–469.

Hutch JA. Vesico-ureteral reflux in the paraplegic: cause and correction. *J Urol*. 2002;167(3):1410–1414 [discussion 1422].

Hutch JA, Ayres RD, Noll LE. Vesicoureteral reflux as cause of pyelonephritis of pregnancy. *Am J Obstet Gynecol*. 1963;87(4):478–485.

Im YJ, Lee YS, Kim SW, et al. Implications of paraureteral diverticulum for the management of vesicoureteral reflux. *Int J Urol*. 2015;22(9):850–853.

Jagannath VA, Fedorowicz Z, Sud V, et al. Routine neonatal circumcision for the prevention of urinary tract infections in infancy. *Cochrane Database Syst Rev*. 2012;(11) [CD009129].

Jaju A, Shaw HL, Don S, et al. ALARA: impact of practice quality improvement initiative on dose reduction in pediatric voiding cystourethrogram. *AJR Am J Roentgenol*. 2015;205(4):886–893.

Jiang S, Gitlin J, Deng FM, et al. Lack of major involvement of human uroplakin genes in vesicoureteral reflux: implications for disease heterogeneity. *Kidney Int*. 2004;66(1):10–19.

Jungers P, Houillier P, Chauveau D, et al. Pregnancy in women with reflux nephropathy. *Kidney Int*. 1996;50(2):593–599.

Jungers P, Houillier P, Forget D. Reflux nephropathy and pregnancy. *Baillieres Clin Obstet Gynaecol*. 1987;1(4):955–969.

Kadioglu A, Mihmanli I, Kantarci F, et al. Cyclic voiding cystouretrography without the use of fluoroscopic monitoring. *Eur J Radiol*. 2006;57(1):138–147.

Kaefer M, Peters CA, Retik AB, et al. Increased renal echogenicity: a sonographic sign for differentiating between obstructive and nonobstructive etiologies of in utero bladder distension. *J Urol*. 1997;158(3 Pt 2):1026–1029.

Kaefer M, Curran M, Treves ST, et al. Sibling vesicoureteral reflux in multiple gestation births. *Pediatrics*. 2000;105(4 Pt 1):800–804.

Karpman E, Kurzrock EA. Adverse reactions of nitrofurantoin, trimethoprim and sulfamethoxazole in children. *J Urol*. 2004;172(2):448–453.

Kawai S, Kanai T, Hyuga T, et al. Top-down approach is possible strategy for predicting breakthrough fUTIs and renal scars in infants. *Pediatr Int*. 2017;59(7):781–785.

Kawamura N. Megacystis-megaureter syndrome. *Nihon Rinsho*. 1977;35(Suppl 1):1188–1189.

Keir MJ, Coulthard MG, Lee REJ. Radionuclide cystography revisited. *Nucl Med Commun*. 1998;19(11):1106.

Keir MJ, Lambert HJ, Coulthard MG. Maximizing the sensitivity of the indirect radionuclide cystogram: a retrospective audit. *Pediatr Nephrol*. 2013;28(11):2137–2141.

Keller SA, Jones JM, Boyle A. Kidney and retinal defects (KRD), a transgene-induced mutation with a deletion of mouse chromosome 19 that includes the Pax2 locus. *Genomics*. 1994;23:309–320.

Keren R, Carpenter M, Greenfield S, et al. Is antibiotic prophylaxis in children with vesicoureteral reflux effective in preventing pyelonephritis and renal scars? A randomized, controlled trial. *Pediatrics*. 2008;122(6):1409–1410 [author reply 1410–1411].

Kirsch AJ, Arlen AM, Leong T, et al. Vesicoureteral reflux index (VURx): a novel tool to predict primary reflux improvement and resolution in children less than 2 years of age. *J Pediatr Urol*. 2014;10(6):1249–1254.

Knudson MJ, Austin JC, McMillan ZM, et al. Predictive factors of early spontaneous resolution in children with primary vesicoureteral reflux. *J Urol*. 2007;178(4 Pt 2):1684–1688.

Koefoot RB Jr, Webster GD, Anderson EE, et al. The primary megacystis syndrome. *J Urol*. 1981;125(2):232–234.

Koff SA. Relationship between dysfunctional voiding and reflux. *J Urol*. 1992;148(5 Pt 2):1703–1705.

Koff SA, Campbell K. Nonoperative management of unilateral neonatal hydronephrosis. *J Urol*. 1992;148(2 Pt 2):525–531.

Koff SA, Murtagh DS. The uninhibited bladder in children: effect of treatment on recurrence of urinary infection and on vesicoureteral reflux resolution. *J Urol*. 1983;130(6):1138–1141.

Koff SA, Wagner TT, Jayanthi VR, et al. The relationship among dysfunctional elimination syndromes, primary vesicoureteral reflux and urinary tract infections in children. *J Urol*. 1998;160(3 Pt 2):1019–1022.

Köhler J, Tencer J, Thysell H, et al. Vesicoureteral reflux diagnosed in adulthood: incidence of urinary tract infections, hypertension, proteinuria, back pain and renal calculi. *Nephrol Dial Transplant*. 1997;12(2):2580–2587.

Köllermann MW, Ludwig H. On vesico-ureteral reflux in normal infants and children. *Z Kinderheilkd*. 1967;100(3):185–191.

Kuzmanovska D, Risteski A, Kambovska M, et al. Voiding urosonography with second-generation ultrasound contrast agent for diagnosis of vesicoureteric reflux: first local pilot study. *Open Access Maced J Med Sci*. 2017;5(2):215–221.

Kwak C, Oh SJ, Lee A, et al. Effect of circumcision on urinary tract infection after successful antireflux surgery. *BJU Int*. 2004;94(4):627–629.

Lama G, Salsano ME, Pedulla M. Angiotensin converting enzyme inhibitors and reflux nephropathy: 2-year follow-up. *Pediatr Nephrol*. 1997;11(6):714–718.

Lama G, Tedesco MA, Graziano L. Reflux nephropathy and hypertension: correlation with the progression of renal damage. *Pediatr Nephrol*. 2003;18(3):241–245.

Lebowitz RL. The detection and characterization of vesicoureteral reflux in the child. *J Urol*. 1992;148(5 Pt 2):1640–1642.

Lebowitz RL. Neonatal vesicoureteral reflux: what do we know? *Radiology*. 1993;187(1):17.

Lebowitz RL, Blickman JG. The coexistence of ureteropelvic junction obstruction and reflux. *AJR Am J Roentgenol*. 1983;140(2):231–238.

Lebowitz RL, Olbing H, Parkkulainen KV, et al. International system of radiographic grading of vesicoureteric reflux. *Pediatr Radiol*. 1985;15(2):105–109.

Lee JH, Choi HS, Kim JK, et al. Nonrefluxing neonatal hydronephrosis and the risk of urinary tract infection. *J Urol*. 2008;179(4):1524–1528.

Lee JN, Lee SM, Ha YS, et al. VUR timing on VCUG as a predictive factor of VUR resolution after endoscopic therapy. *J Pediatr Urol*. 2016;12(4):255.e1–255.e6.

Lee KH, Gee HY, Shin JI. Genetics of vesicoureteral reflux and congenital anomalies of the kidney and urinary tract. *Investig Clin Urol*. 2017;58(Suppl 1):S4–S13.

Lee PH, Diamond DA, Duffy PG, et al. Duplex reflux: a study of 105 children. *J Urol*. 1991;146(2 Pt 2):657–659.

Lee T, Ellimoottil C, Marchetti KA, et al. Impact of clinical guidelines on voiding cystourethrogram use and vesicoureteral reflux incidence. *J Urol*. 2017;199(3):831–836.

Leonardo CR, Filgueiras MF, Vasconcelos MM, et al. Risk factors for renal scarring in children and adolescents with lower urinary tract dysfunction. *Pediatr Nephrol*. 2007;22(11):1891–1896.

Leslie B, Moore K, Salle JL, et al. Outcome of antibiotic prophylaxis cessation in patients with persistent vesicoureteral reflux who initially presented with a febrile urinary tract infection. *J Pediatr Urol*. 2009;5:S30.

Leslie B, Moore K, Salle JL, et al. Outcome of antibiotic prophylaxis discontinuation in patients with persistent vesicoureteral reflux initially presenting with febrile urinary tract infection: time to event analysis. *J Urol*. 2010;184(3):1093–1098.

Leung L, Chan IHY, Chung PHY, et al. Endoscopic injection for primary vesicoureteric reflux: predictors of resolution and long term efficacy. *J Pediatr Surg*. 2017;52(12):2066–2069.

Linke SY, Tsiflikas I, Herz K, et al. Ultra low-dose VCUG in children using a modern flat detector unit. *Eur Radiol*. 2016;26(6):1678–1685.

Lomberg H, Hellström M, Jodal U, et al. Virulence-associated traits in Escherichia coli causing first and recurrent episodes of urinary tract infection in children with or without vesicoureteral reflux. *J Infect Dis*. 1984;150(4):561–569.

Lopez Pereira P, Martinez Urrutia MJ, Espinosa L, et al. Long-term consequences of posterior urethral valves. *J Pediatr Urol*. 2013;9(5):590–596.

Lyon RP, Marshall S, Tanagho EA. The ureteral orifice: its configuration and competency. *J Urol*. 1969;102(4):504–509.

Mackie GG, Stephens FD. Duplex kidneys: a correlation of renal dysplasia with position of the ureteral orifice. *J Urol*. 1975;114(2):274–280.

Mackie GG, Awang H, Stephens FD. The ureteric orifice: the embryologic key to radiologic status of duplex kidneys. *J Pediatr Surg*. 1975;10(4):473–481.

Majd M, Rushton HG, Chandra R, et al. Technetium-99m-DMSA renal cortical scintigraphy to detect experimental acute pyelonephritis in piglets: comparison of planar (pinhole) and SPECT imaging. *J Nucl Med*.

1996;37(10):1731–1734.

Majd M, Rushton HG, Jantausch B, et al. Relationship among vesicoureteral reflux, P-fimbriated Escherichia coli, and acute pyelonephritis in children with febrile urinary tract infection. *J Pediatr*. 1991;119(4):578–585.

Mandell GA, Eggli DF, Gilday DL, et al. Procedure guideline for renal cortical scintigraphy in children. Society of Nuclear Medicine. *J Nucl Med*. 1997;38(10):1644–1666.

Mandell J, Lebowitz RL, Peters CA, et al. Prenatal diagnosis of the megacystis-megaureter association. *J Urol*. 1992;148(5):1487–1489.

Manivel JC, Pettinato G, Reinberg Y, et al. Prune belly syndrome: clinicopathologic study of 29 cases. *Pediatr Pathol*. 1989;9(6):691–711.

Mansfield JT, Snow BW, Cartwright PC, et al. Complications of pregnancy in women after childhood reimplantation for vesicoureteral reflux: an update with 25 years of followup. *J Urol*. 1995;154(2 Pt 2):787–790.

Mantadakis E, Vouloumanou EK, Georgantzi GG, et al. Acute Tc-99m DMSA scan for identifying dilating vesicoureteral reflux in children: a meta-analysis. *Pediatrics*. 2011;128(1):e169–e179.

Marra G, Barbieri G, Dell'Agnola CA, et al. Congenital renal damage associated with primary vesicoureteral reflux detected prenatally in male infants. *J Pediatr*. 1994;124(5 Pt 1):726–730.

Marra G, Oppezzo C, Ardissino G, et al. Severe vesicoureteral reflux and chronic renal failure: a condition peculiar to male gender? Data from the ItalKid Project. *J Pediatr*. 2004;144(5):677–681.

Martinell J, Jodal U, Lidin-Janson G. Pregnancies in women with and without renal scarring after urinary infections in childhood. *BMJ*. 1990;300(6728):840–844.

Matsumoto F, et al. Positioning the instillation of contrast at the ureteral orifice cystography can be useful to predict postoperative contralateral reflux in children with unilateral vesicoureteral reflux. *Int J Urol*. 2011;18(1):80–82.

Mattoo TK, Chesney RW, Greenfield SP, et al. Renal scarring in the Randomized Intervention for Children with Vesicoureteral Reflux (RIVUR) Trial. *Clin J Am Soc Nephrol*. 2016;11(1):54–61.

McEwing RL, Anderson NG, Hellewell S, et al. Comparison of echo-enhanced ultrasound with fluoroscopic MCU for the detection of vesicoureteral reflux in neonates. *Pediatr Radiol*. 2002;32(12):853–858.

McGladdery SL, Aparicio S, Verrier-Jones K, et al. Outcome of pregnancy in an Oxford-Cardiff cohort of women with previous bacteriuria. *Q J Med*. 1992;83(303):533–539.

McLorie GA, McKenna PH, Jumper BM, et al. High grade vesicoureteral reflux: analysis of observational therapy. *J Urol*. 1990;144(2 Pt 2):537–540 [discussion 545].

McMillan ZM, Austin JC, Knudson MJ, et al. Bladder volume at onset of reflux on initial cystogram predicts spontaneous resolution. *J Urol*. 2006;176(4 Pt 2):1838–1841.

Meiland R, Stolk RP, Geerlings SE, et al. Association between Escherichia coli bacteriuria and renal function in women: long-term follow-up. *Arch Intern Med*. 2007;167(3):253–257.

Melhem RE, Harpen MD. Ethnic factors in the variability of primary vesico-ureteral reflux with age. *Pediatr Radiol*. 1997;27(9):750–751.

Menezes M, Puri P. Familial vesicoureteral reflux—is screening beneficial? *J Urol*. 2009;182(4 Suppl):1673–1677.

Merguerian PA, Jamal MA, Agarwal SK. Utility of SPECT DMSA renal scanning in the evaluation of children with primary vesicoureteral reflux. *Urology*. 1999;53(5):1024–1028.

Merrick MV, Uttley WS, Wild SR. The detection of pyelonephritic scarring in children by radioisotope imaging. *Br J Radiol*. 1980;53(630):544–556.

Meyer R. Normal and abnormal development of the ureter in the human embryo: a mechanistic consideration. *Anat Rec*. 1946;96(4):355–371.

Miller DC, Rumohr JA, Dunn RL, et al. What is the fate of the refluxing contralateral kidney in children with multicystic dysplastic kidney? *J Urol*. 2004;172(4 Pt 2):1630–1634.

Miyazaki Y, Ichikawa I. Ontogeny of congenital anomalies of the kidney and urinary tract, CAKUT. *Pediatr Int*. 2003;45(5):598–604.

Moore K, Leslie B, Lorenzo AJ, et al. Is it reasonable to observe patient with persistent vesico-ureteral reflux after failed first endoscopic injection? *J Urol*. 2009;181(4s):221–222.

Morris BJ, Wiswell TE. Circumcision and lifetime risk of urinary tract infection: a systematic review and meta-analysis. *J Urol*. 2012;189(6):2118–2124.

Murer L, Benetti E, Artifoni L. Embryology and genetics of primary vesicoureteric reflux and associated renal dysplasia. *Pediatr Nephrol*. 2007;22(6):788–797.

Nagler EV, Williams G, Hodson EM, et al. Interventions for primary vesicoureteric reflux. *Cochrane Database Syst Rev*. 2011;(6) [CD001532].

Najmaldin A, Burge DM, Atwell JD. Reflux nephropathy secondary to intrauterine vesicoureteric reflux. *J Pediatr Surg*. 1990;25(4):387–390.

Nakai H, Kakizaki H, Konda R, et al. Clinical characteristics of primary vesicoureteral reflux in infants: multicenter retrospective study in Japan. *J Urol*. 2003;169(1):309–312.

Narchi H, Marah M, Khan AA, et al. Renal tract abnormalities missed in a historical cohort of young children with UTI if the NICE and AAP imaging guidelines were applied. *J*

Pediatr Urol. 2015;11(5):252.e1–252.e7.

The National Institute for Health and Care Excellence. *Urinary tract infection in under 16s: diagnosis and management*. [1–24; Available at] https://www.nice.org.uk/guidance/cg54; 2018.

Nelson CP, Finkelstein JA, Logvinenko T, et al. Incidence of urinary tract infection among siblings of children with vesicoureteral reflux. *Acad Pediatr*. 2016;16(5):489–495.

Nguyen HT, Bauer SB, Peters CA, et al. 99M Technetium dimercapto-succinic acid renal scintigraphy abnormalities in infants with sterile high grade vesicoureteral reflux. *J Urol*. 2000;164(5):1674–1678 [discussion 1678–1679].

Nguyen HT, Herndon CD, Cooper C, et al. The Society for Fetal Urology consensus statement on the evaluation and management of antenatal hydronephrosis. *J Pediatr Urol*. 2010;6(3):212–231.

Nino F, Ilaria M, Noviello C, et al. Genetics of vesicoureteral reflux. *Curr Genomics*. 2016;17(1):70–79.

Noe HN, Wyatt RJ, Peeden JN Jr, et al. The transmission of vesicoureteral reflux from parent to child. *J Urol*. 1992;148(6):1869–1871.

Nordenström J, Holmdahl G, Brandström P, et al. The Swedish infant high-grade reflux trial: study presentation and vesicoureteral reflux outcome. *J Pediatr Urol*. 2017;13(2):130–138.

Nordenström J, Sjöström S, Sillén U, et al. The Swedish infant high-grade reflux trial: UTI and renal damage. *J Pediatr Urol*. 2017;13(2):146–154.

North RA, Taylor RS, Gunn TR. Pregnancy outcome in women with reflux nephropathy and the inheritance of vesico-ureteric reflux. *Aust N Z J Obstet Gynaecol*. 2000;40(3):280–285.

North American Pediatric Renal Transplant Cooperative Study (NAPRTCS). *Annual report*. [Available at] https://web.emmes.com/study/ped/annlrept/annlrept2004.pdf; 2004.

Novljan G, Kenig A, Rus R, et al. Cyclic voiding urosonography in detecting vesicoureteral reflux in children. *Pediatr Radiol*. 2003;18(10):992–995.

Ntoulia A, Back SJ, Shellikeri S, et al. Contrast-enhanced voiding urosonography (ceVUS) with the intravesical administration of the ultrasound contrast agent Optison™ for vesicoureteral reflux detection in children: a prospective clinical trial. *Pediatr Radiol*. 2018;48(2):216–226.

O'Neil BB, Cartwright PC, Maves C, et al. Reliability of voiding cystourethrogram for the grading of vesicoureteral reflux. *J Pediatr Urol*. 2014;10(1):107–111.

O'Regan S, Schick E, Hamburger B, et al. Constipation associated with vesicoureteral reflux. *Urology*. 1986;28(5):394–396.

O'Regan S, Yazbeck S. Constipation: a cause of enuresis, urinary tract infection and vesico-ureteral reflux in children. *Med Hypotheses*. 1985;17(4):409–413.

Orr NI, McDonald SP, McTaggart S, et al. Frequency, etiology and treatment of childhood end-stage kidney disease in Australia and New Zealand. *Pediatr Nephrol*. 2009;24(9):1719–1726.

Oswald J, Schwentner C, Brenner E, et al. Extracellular matrix degradation and reduced nerve supply in refluxing ureteral endings. *J Urol*. 2004;172(3):1099–1102.

Ozçelik G, Polat TB, Aktas S, et al. Resistive index in febrile urinary tract infections: predictive value of renal outcome. *Pediatr Nephrol*. 2004;19(2):148–152.

Palmer BW, Hemphill M, Wettengel K, et al. The value of PIC cystography in detecting de novo and residual vesicoureteral reflux after dextranomer/hyaluronic acid copolymer injection. *Int J Nephrol*. 2011;2011:276308.

Paltiel HJ, Rupich RC, Kiruluta HG. Enhanced detection of vesicoureteral reflux in infants and children with use of cyclic voiding cystourethrography. *Radiology*. 1992;184(3):753–755.

Papadopoulou F, Efremidis SC, Oiconomou A, et al. Cyclic voiding cysto-urethrography: is vesicoureteral reflux missed with standard voiding cystourethrography? *Eur Radiol*. 2002;12(3):666–670.

Paquin AJ. Ureterovesical anastomosis: the description and evaluation of a technique. *J Urol*. 1959;82:573–583.

Parvex P, Willi JP, Kossovsky MP, et al. Longitudinal analyses of renal lesions due to acute pyelonephritis in children and their impact on renal growth. *J Urol*. 2008;180(6):2602–2606 [discussion 2606].

Pennesi M, Travan L, Peratoner L, et al. Is antibiotic prophylaxis in children with vesicoureteral reflux effective in preventing pyelonephritis and renal scars? A randomized, controlled trial. *Pediatrics*. 2008;121(6):e1489–e1494.

Peppas DS, Skoog SJ, Canning DA, et al. Nonsurgical management of primary vesicoureteral reflux in complete ureteral duplication: is it justified? *J Urol*. 1991;146(6):1594–1595.

Peters C, Rushton HG. Vesicoureteral reflux associated renal damage: congenital reflux nephropathy and acquired renal scarring. *J Urol*. 2010;184(1):265–273.

Peters CA, Skoog SJ, Arant BS Jr, et al. Summary of the AUA Guideline on Management of Primary Vesicoureteral Reflux in Children. *J Urol*. 2010;184(3):1134–1144.

Phan V, Traubici J, Hershenfield B, et al. Vesicoureteral reflux in infants with isolated antenatal hydronephrosis. *Pediatr Nephrol*. 2003;18(12):1224–1228.

Pietrzak-Stelasiak E, Bieńkiewicz M, Woźnicki W, et al. Usefulness of parametric renal clearance images in the assessment of basic risk factors for renalnal clearance images in the assessment of basic risk factors for renal scarring in children with recurrent urinary tract infections. *Nucl Med Rev Cent East Eur*. 2017;20(2):76–80.

Pippi Salle JL, Cook A, Papanikolaou F, et al. The importance of obtaining conjugate views on renographic evaluation of large hydronephrotic kidneys: an in vitro and ex vivo analysis. *J Urol*. 2008;180(4):1559–1565.

Piskunowicz M, Świętoń D, Rybczyńska D, et al. Comparison of voiding cystourethrography and urosonography with second-generation contrast agents in simultaneous prospective study. *J Ultrason*. 2016;16(67):339–347.

Podesta ML, Castera R, Ruarte AC. Videourodynamic findings in young infants with severe primary reflux. *J Urol*. 2004;171(2 Pt 1):829–833 [discussion 833].

Polito C, La Manna A, Capacchione A. Height and weight in children with vesicoureteric reflux and renal scarring. *Pediatr Nephrol*. 1996;10(5):564–567.

Polito C, Marte A, Zamparelli M, et al. Catch-up growth in children with vesico-ureteric reflux. *Pediatr Nephrol*. 1997;11(2):164–168.

Polito C, Moggio G, La Manna A, et al. Cyclic voiding cystourethrography in the diagnosis of occult vesicoureteric reflux. *Pediatr Nephrol*. 2000;14(1):39–41.

Preda I, Jodal U, Sixt R, et al. Normal dimercaptosuccinic acid scintigraphy makes voiding cystourethrography unnecessary after urinary tract infection. *J Pediatr*. 2007;151(6):581–584 [584.e1].

Privett JT, Jeans WD, Roylance J. The incidence and importance of renal duplication. *Clin Radiol*. 1976;27(4):521–530.

Puri P, Gosemann JH, Darlow J, et al. Genetics of vesicoureteral reflux. *Nat Rev Urol*. 2011;8(10):539–552.

Radmayr C, Klauser A, Maneschg C, et al. Importance of the renal resistive index in children suffering from vesicoureteral reflux. *Eur Urol*. 1999;36(1):75–79.

Ransley PG, Risdon RA. The pathogenesis of reflux nephropathy. *Contrib Nephrol*. 1979;16:90–97.

Ransley PG, Risdon RA. Reflux nephropathy: effects of antimicrobial therapy on the evolution of the early pyelonephritic scar. *Kidney Int*. 1981;20(6):733–742.

Reid G, Bruce AW. Probiotics to prevent urinary tract infections: the rationale and evidence. *World J Urol*. 2006;24(1):28–32.

Reid G, Devillard E. Probiotics for mother and child. *J Clin Gastroenterol*. 2004;38(Suppl 2):S94–S101.

Riccabona M, Ring E, Maurer U. Scintigraphy and sonography in reflux nephropathy: a comparison. *Nucl Med Commun*. 1993;14(4):339–342.

Risdon RA. The small scarred kidney in childhood. *Pediatr Nephrol*. 1993;7(4):361–364.

RIVUR Trial Investigators, Hoberman A, Greenfield SP, et al. Antimicrobial prophylaxis for children with vesicoureteral reflux. *N Engl J Med*. 2014;370(25):2367–2376.

Roberts JA. Vesicoureteral reflux and pyelonephritis in the monkey: a review. *J Urol*. 1992;148(5 Pt 2):1721–1725.

Roberts JA, Kaack MB, Morvant AB. Vesicoureteral reflux in the primate. IV. Infection as cause of prolonged highgrade reflux. *Pediatrics*. 1988;82(1):91–95.

Rodriguez LV, Lock J, Kennedy WA, et al. Evaluation of sonographic renal parenchymal area in the management of hydronephrosis. *J Urol*. 2001;165(2):548–551.

Roihuvuo-Leskinen HM, Vainio MI, Niskanen KM, et al. Pregnancies in women with childhood vesicoureteral reflux. *Acta Obstet Gynecol Scand*. 2015;94(8):847–851.

Roussey-Kesler G, Gadjos V, Idres N, et al. Antibiotic prophylaxis for the prevention of recurrent urinary tract infection in children with low grade vesicoureteral reflux: results from a prospective randomized study. *J Urol*. 2008;179(2):674–679 [discussion 679].

Rubenstein JN, Maizels M, Kim SC, et al. The PIC cystogram: a novel approach to identify “occult” vesicoureteral reflux in children with febrile urinary tract infections. *J Urol*. 2003;169(6):2339–2343.

Rushton HG, Majd M. Pyelonephritis in male infants: how important is the foreskin? *J Urol*. 1992;48(2 Pt 2):733–736 [discussion 737–738].

Rushton HG, Majd M, Jantausch B, et al. Renal scarring following reflux and nonreflux pyelonephritis in children: evaluation with 99m technetium-dimercaptosuccinic acid scintigraphy. *J Urol*. 1992;147(5):1327–1332.

Rushton HG, Rushton HG, Jantausch B, et al. Relationship among vesicoureteral reflux, P-fimbriated Escherichia coli, and acute pyelonephritis in children with febrile urinary tract infection. *J Pediatr*. 1991;119(4):578–585.

Rusu MC, Pop F, Petre N, et al. The sheath of Waldeyer is not a specific anatomical trait of the ureterovesical junction. *Morphologie*. 2017;102(336).

Salvini F, Granieri L, Gemmellaro L, et al. Probiotics, prebiotics and child health: where are we going? *J Int Med Res*. 2004;32(2):97–108.

Sanna-Cherchi S, Reese A, Hensle T, et al. Familial vesicoureteral reflux: testing replication of linkage in seven new multigenerational kindreds. *J Am Soc Nephrol*. 2005;16(6):1781–1787.

Santos JD, Lopes RI, Koyle MA. Bladder and bowel dysfunction in children: an update on the diagnosis and treatment of a common, but underdiagnosed pediatric problem. *Can Urol Assoc J*. 2017;11(1–2 Suppl 1):S64–S72.

Sanyanusin P, Schimmenti LA, McNoe LA. Mutation of the PAX2 gene in a family with optic nerve colobomas, renal anomalies and vesicoureteral reflux. *Nat Genet*. 1995;9(4):358–364 [Erratum in Nat Genet 1996].

Sargent MA. What is the normal prevalence of vesicoureteral reflux? *Pediatr Radiol*. 2000;30(9):587–593.

Sarhan OM. Posterior urethral valves: impact of low birth weight and preterm delivery on the final renal outcome. *Arab J Urol*. 2017;15(2):159–165.

Schaeffer AJ, Greenfield SP, Ivanova A, et al. Reliability of grading of vesicoureteral reflux and other findings on voiding cystourethrography. *J Pediatr Urol*. 2017;13(2):192–198.

Schlomer BJ, Smith PJ, Barber TD, et al. Nephrectomy for hypertension in pediatric patients with a unilateral poorly functioning kidney: a contemporary cohort. *J Pediatr Urol*. 2011;7(3):373–377.

Scholtmeijer RJ. Treatment of vesicoureteric reflux: results of a prospective study. *Br J Urol*. 1993;71(3):346–349.

Selekman RE, Allen IE, Copp HL. Determinants of practice patterns in pediatric UTI management. *J Pediatr Urol*. 2016;12(5):308.e1–308.e6.

Seruca H. Vesicoureteral reflux and voiding dysfunction: a prospective study. *J Urol*. 1989;142(2 Pt 2):494–498 [discussion 501].

Shafik A. Electroureterogram in the obstructed ureter and vesicoureteral reflux. *J Surg Res*. 1996;65(2):145–148.

Shaikh N, Ewing AL, Bhatnagar S, et al. Risk of renal scarring in children with a first urinary tract infection: a systematic review. *Pediatrics*. 2010;126(6):1084–1091.

Shaikh N, Hoberman A, Keren R, et al. Recurrent urinary tract infections in children with bladder and bowel dysfunction. *Pediatrics*. 2016;137(1).

Shaikh N, Spingarn RB, Hum SW. Dimercaptosuccinic acid scan or ultrasound in screening for vesicoureteral reflux among children with urinary tract infections. *Cochrane Database Syst Rev*. 2016;(7) [CD010657].

Shefelbine SE, Khorana S, Schultz PN, et al. Mutational analysis of the GDNF/RET-GDNFR alpha signaling complex in a kindred with vesicoureteral reflux. *Hum Genet*. 1998;102(4):474–478.

Shimada K, Matsui T, Arima M, et al. Clinical analysis of the small kidney associated with VUR. *Int Urol Nephrol*. 1988;20(3):231–238.

Sillén U, Brandström P, Jodal U, et al. The Swedish reflux trial in children: v. Bladder dysfunction. *J Urol*. 2010;184(1):298–304.

Sjöström S, Sillén U, Bachelard M, et al. Spontaneous resolution of high grade infantile vesicoureteral reflux. *J Urol*. 2004;172(2):694–698 [discussion 699].

Skoog SJ, Belman AB. Primary vesicoureteral reflux in the black child. *Pediatrics*. 1991;87(4):538–543.

Skoog SJ, Belman AB, Majd M. A nonsurgical approach to the management of primary vesicoureteral reflux. *J Urol*. 1987;138(4 Pt 2):941–946.

Skoog SJ, Peters CA, Arant BS Jr, et al. Pediatric Vesicoureteral Reflux Guidelines Panel summary report: clinical practice guidelines for screening siblings of children with vesicoureteral reflux and neonates/infants with prenatal hydronephrosis. *J Urol*. 2010;184(3):1145–1151.

Smellie J, Edwards D, Hunter N, et al. Vesico-ureteric reflux and renal scarring. *Kidney Int Suppl*. 1975;4:S65–S72.

Smellie JM. Reflections on 30 years of treating children with urinary tract infections. *J Urol*. 1991;146(2 Pt 2):665–668.

Smellie JM, Normand IC. Urinary infections in children. *Postgrad Med J*. 1985;61(720):895–905.

Smellie JM, Normand IC, Katz G. Children with urinary infection: a comparison of those with and those without vesicoureteric reflux. *Kidney Int*. 1981;20(6):717–722.

Snodgrass W. Relationship of voiding dysfunction to urinary tract infection and vesicoureteral reflux in children. *Urology*. 1991;38(4):341–344.

Song JT, Ritchey ML, Zerin JM, et al. Incidence of vesicoureteral reflux in children with unilateral renal agenesis. *J Urol*. 1995;153(4):1249–1251.

Sørensen K, Lose G, Nathan E. Urinary tract infections and diurnal incontinence in girls. *Eur J Pediatr*. 1988;148(2):146–147.

Springer A, Subramaniam R. Relevance of current guidelines in the management of VUR. *Eur J Pediatr*. 2014;173(7):835–843.

St Aubin M, Willihnganz-Lawson K, Varda BK, et al. Society for fetal urology recommendations for postnatal evaluation of prenatal hydronephrosis—will fewer voiding cystourethrograms lead to more urinary tract infections? *J Urol*. 2013;190(4 Suppl):1456–1461.

Stashinko EE, Goldberger J. Test or trauma? The voiding cystourethrogram experience of young children. *Issues Compr Pediatr Nurs*. 1998;21(2):85–96.

Stauss J, Connolly LP, Connolly SA, et al. Dynamic renal scintigraphy in children with vesicoureteral reflux and suspected coexisting ureteropelvic junction obstruction. *J Urol*. 2003;170(5):1966–1970.

Stember JN, Lynch D, Behr G, et al. Sonographic prediction of pediatric renal scarring with full parameter normalization. *J Ultrasound Med*. 2016;35(8):1639–1643.

Stokland E, Andréasson S, Jacobsson B. Sedation with midazolam for voiding cystourethrography in children: a randomised double-blind study. *Pediatr Radiol*. 2003;33(4):247–249.

Storm DW, Patel AS, Koff SA, et al. Novel management of urinary tract infections. *Curr Opin Urol*. 2011;21(4):328–333.

Subcommittee on Urinary Tract Infection, Steering Committee on Quality Improvement and Management, Roberts KB. Urinary tract infection: clinical practice guideline for the diagnosis and management of the initial UTI in febrile infants and children 2 to 24 months. *Pediatrics*. 2011;128(3):595–610.

Sutton R, Atwell JD. Physical growth velocity during conservative treatment and following subsequent surgical treatment for primary vesicoureteric reflux. *Br J Urol*. 1989;63(3):245–250.

Taghavi K, Sharpe C, Stringer MD. Fetal megacystis: a systematic review. *J Pediatr Urol*. 2017;13(1):7–15.

Tamminen-Möbius T, Brunier E, Ebel KD, et al. Cessation of vesicoureteral reflux for 5 years in infants and children allocated to medical treatment. The International Reflux Study in Children. *J Urol*. 1992;148(5 Pt 2):1662–1666.

Tareen BU, Bui D, McMahon DR, et al. Role of positional instillation of contrast cystography in the algorithm for evaluating children with confirmed pyelonephritis. *Urology*. 2006;67(5):1055–1057 [discussion 1058–1059].

Tash JA, Stock JA, Hanna MK. The role of partial nephrectomy in the treatment of pediatric renal hypertension. *J Urol*. 2003;169(2):625–628.

Taskinen S, Heikkilä J, Rintala R. Effects of posterior urethral valves on long-term bladder and sexual function. *Nat Rev Urol*. 2012;9(12):699–706.

Taylor A Jr. Quantitation of renal function with static imaging agents. *Semin Nucl Med*. 1982;12(4):330–344.

Taylor CM, Corkery JJ, White RH. Micturition symptoms and unstable bladder activity in girls with primary vesicoureteric reflux. *Br J Urol*. 1982;54(5):494–498.

Thacker PG, Collins HR, Hill J. Distress experienced during pediatric VCUGs - a granular, prospective assessment using the brief behavioral distress scale. *Pediatr Radiol*. 2016;46(5):660–665.

Torres VE, Kramer SA, Holley KE, et al. Interaction of multiple risk factors in the pathogenesis of experimental reflux nephropathy in the pig. *J Urol*. 1985;133(1):131–135.

Tse NK, Yuen SL, Chiu MC, et al. Imaging studies for first urinary tract infection in infants less than 6 months old: can they be more selective? *Pediatr Nephrol*. 2009;24(9):1699–1703.

Uetani N, Bouchard M. Plumbing in the embryo: developmental defects of the urinary tracts. *Clin Genet*. 2009;75(4):307–317.

Unver T, Alpay H, Biyikli NK, et al. Comparison of direct radionuclide cystography and voiding cystourethrography in detecting vesicoureteral reflux. *Pediatr Int*. 2006;48(3):287–291.

Valentini AL, De Gaetano AM, Minordi LM, et al. Contrast-enhanced voiding US for grading of reflux in adult patients prior to antireflux ureteral implantation. *Radiology*. 2004;233(1):35–39.

Valentini AL, Salvaggio E, Manzoni C, et al. Contrast-enhanced gray-scale and color Doppler voiding urosonography versus voiding cystourethrography in the diagnosis and grading of vesicoureteral reflux. *J Clin Ultrasound*. 2001;29(2):65–71.

van Gool JD, Hjälmås K, Tamminen-Möbius T, et al. Historical clues to the complex of dysfunctional voiding, urinary tract infection and vesicoureteral reflux. The International Reflux Study in Children. *J Urol*. 1992;148(5 Pt 2):1699–1702.

Veenboer PW, Hobbelink MG, Ruud Bosch JL, et al. Diagnostic accuracy of Tc-99m DMSA scintigraphy and renal ultrasonography for detecting renal scarring and relative function in patients with spinal dysraphism. *Neurourol*

Urodyn. 2015;34(6):513–518.

Villanueva CA, Nelson CA, Stolle C. Intravesical tunnel length to ureteral diameter ratio insufficiently explains ureterovesical junction competence: a parametric simulation study. *J Pediatr Urol*. 2015;11(3):144.e1–144.e5.

Walker D, Richard G, Dobson D, et al. Maximum urine concentration: early means of identifying patients with reflux who may require surgery. *Urology*. 1973;1(4):343–346.

Wallace DMA, Rothwell DL, Williams DI. The long-term follow-up of surgically treated vesicoureteric reflux. *BJU Int*. 1978;50(7):479–484.

Wallin L, Bajc M. The significance of vesicoureteric reflux on kidney development assessed by dimercaptosuccinate renal scintigraphy. *Br J Urol*. 1994;73(6):607–611.

Wan J, Skoog SJ, Hulbert WC, et al. Section on Urology response to new Guidelines for the diagnosis and management of UTI. *Pediatrics*. 2012;129(4):e1051–e1053.

Wang H, Li Q, Liu J, et al. Noninvasive assessment of antenatal hydronephrosis in mice reveals a critical role for Robo2 in maintaining anti-reflux mechanism. *PLoS ONE*. 2011;6(9):e24763.

Wang HH, Gbadegesin RA, Foreman JW, et al. Efficacy of antibiotic prophylaxis in children with vesicoureteral reflux: systematic review and meta-analysis. *J Urol*. 2015;193(3):963–969.

Wang ZT, Wehbi E, Alam Y, et al. A reanalysis of the RIVUR trial using a risk classification system. *J Urol*. 2018;199(6):1608–1614.

Ward VL, Strauss KJ, Barnewolt CE, et al. Pediatric radiation exposure and effective dose reduction during voiding cystourethrography. *Radiology*. 2008;249(3):1002–1009.

Wehbi E, Salle A, Kanaroglou N, et al. Measurement of differential renal function by scintigraphy in hydronephrotic kidneys: importance of conjugate views for accurate evaluation. *J Urol*. 2016;195(2):471–475.

Weigert C. Über einige Bildungsfehler der Ureteren. *Virchows Arch Pathol Anat Physiol Klin Med*. 1877;70:490–501.

Weiss R, Tamminen-Mobius T, Koskimies O, et al. Characteristics at entry of children with severe primary vesicoureteral reflux recruited for a multicenter, international therapeutic trial comparing medical and surgical management. The International Reflux Study in Children. *J Urol*. 1992;148(5 Pt 2):1644–1649.

Weiss R, Duckett J, Spitzer A. Results of a randomized clinical trial of medical versus surgical management of infants and children with grades III and IV primary vesicoureteral reflux (United States). The International Reflux Study in Children. *J Urol*. 1992;148(5 Pt 2):1667–1673.

Weitz M, Schmidt M. To screen or not to screen for vesicoureteral reflux in children with ureteropelvic junction obstruction: a systematic review. *Eur J Pediatr*. 2016;176(1):1–9.

Wennerström M, Hansson S, Jodal U, et al. Primary and acquired renal scarring in boys and girls with urinary tract infection. *J Pediatr*. 2000;136(1):30–34.

West W, Venugopal S. The low frequency of reflux in Jamaican children. *Pediatr Radiol*. 1993;23(8):591–593.

Westland R, Schreuder MF, Ket JC, et al. Unilateral renal agenesis: a systematic review on associated anomalies and renal injury. *Nephrol Dial Transplant*. 2013;28(7):1844–1855.

Whitaker RH. Methods of assessing obstruction in dilated ureters. *Br J Urol*. 1973;45(1):15–22.

Wildbrett P, Schwebs M, Abel JR, et al. Spontaneous vesicoureteral reflux resolution in children: a ten-year single-centre experience. *Afr J Paediatr Surg*. 2013;10(1):9–12.

Williams DI, Hulme-Moir I. Primary obstructive mega-ureter. *Br J Urol*. 1970;42(2):140–149.

Willscher MK, Bauer SB, Zammuto PJ, et al. Infection of the urinary tract after anti-reflux surgery. *J Pediatr*. 1976;89(5):743–747.

Willscher MK, Bauer SB, Zammuto PJ, et al. Renal growth and urinary infection following antireflux surgery in infants and children. *J Urol*. 1976;115(6):722–725.

Winberg J. Commentary: progressive renal damage from infection with or without reflux. *J Urol*. 1992;148(5 Pt 2):1733–1734.

Winter AL, Hardy BE, Alton DJ. Acquired renal scars in children. *J Urol*. 1983;129(6):1190–1194.

Wiswell TE, John K. Lattimer Lecture. Prepuce presence portends prevalence of potentially perilous periurethral pathogens. *J Urol*. 1992;148(2 Pt 2):739–742.

Wolfish NM, Delbrouck NF, Shanon A, et al. Prevalence of hypertension in children with primary vesicoureteral reflux. *J Pediatr*. 1993;123(4):559–563.

Wünsch L, Hübner U, Halsband H. Long-term results of treatment of single-system ectopic ureters. *Pediatr Surg Int*. 2000;16(7):493–497.

Yeung CK, Chowdhary SK, Sreedhar B. Minimally invasive management for vesicoureteral reflux in infants and young children. *Clin Perinatol*. 2017;44(4):835–849.

Yeung CK, Godley ML, Dhillon HK, et al. The characteristics of primary vesico-ureteric reflux in male and female infants with prenatal hydronephrosis. *Br J Urol*. 1997;80(2):319–327.

Yeung CK, Godley ML, Dhillon HK, et al. Urodynamic patterns in infants with normal lower urinary tracts or primary vesico-ureteric reflux. *Br J Urol*. 1998;81(3):461–467.

Ylinen E, Ala-Houhala M, Wikström S. Risk of renal scarring in vesicoureteral reflux detected either antenatally or during the neonatal period. *Urology*. 2003;61(6):1238–1242 [discussion 1242–1243].

Yu OH, Murawski IJ, Myburgh DB, et al. Overexpression of RET leads to vesicoureteric reflux in mice. *Am J Physiol Renal Physiol*. 2004;287(6):F1123–F1130.

Zamir G, Sakran W, Horowitz Y, et al. Urinary tract infection: is there a need for routine renal ultrasonography? *Arch Dis Child*. 2004;89(5):466–468.

Zee RS, Herbst KW, Kim C, et al. Urinary tract infections in children with prenatal hydronephrosis: a risk assessment from the Society for Fetal Urology Hydronephrosis Registry. *J Pediatr Urol*. 2016;12(4):261.e1–261.e7.

Zerin JM, Leiser J. The impact of vesicoureteral reflux on contralateral renal length in infants with multicystic dysplastic kidney. *Pediatr Radiol*. 1998;28(9):683–686.

Zerin JM, Ritchey ML, Chang AC. Incidental vesicoureteral reflux in neonates with antenatally detected hydronephrosis and other renal abnormalities. *Radiology*. 1993;187(1):157–160.

Zhang G, Day DL, Loken M, et al. Grading of reflux by radionuclide cystography. *Clin Nucl Med*. 1987;12(2):106–109.

Ziessman HA, Majd M. Importance of methodology on (99m)technetium dimercapto-succinic acid scintigraphic image quality: imaging pilot study for RIVUR (Randomized Intervention for Children with Vesicoureteral Reflux) multicenter investigation. *J Urol*. 2009;182(1):272–279.

Zorc JJ, Levine DA, Platt SL, Multicenter RSV-SBI Study Group of the Pediatric Emergency Medicine Collaborative Research Committee of the American Academy of Pediatrics, et al. Clinical and demographic factors associated with urinary tract infection in young febrile infants. *Pediatrics*.

2005;116(3):644–648.

30

Bladder Anomalies in Children

Aaron D. Martin MD, MPH, Christopher C. Roth MD

The *International Classification of Diseases* (ICD-10-CM) classifies birth defects as structural or functional anomalies, and the urinary bladder can be affected by entities across this spectrum. Structural anomalies include bladder exstrophy, bladder duplication, bladder agenesis, urachal anomalies, and diverticular disease. Functional bladder anomalies are often secondary to other conditions such as bladder outlet obstruction and neurogenic dysfunction. Some conditions, such as the bladder findings in prune-belly syndrome (PBS), may be structural and functional. Many of these conditions represent common clinical entities for the practicing pediatric urologist and are covered in detail elsewhere in this text. This chapter focuses on less commonly encountered congenital anomalies as well as some of the rare acquired conditions of the bladder that may arise in children. Because many of the congenital conditions are encountered prenatally, we review the relevant embryology as well as normal and abnormal prenatal bladder imaging. The current literature regarding the clinical management of these conditions also is discussed.

Congenital Bladder Anomalies

Embryology of the Urinary Bladder

A clinically relevant understanding of the embryologic development of the bladder and urachus is essential to correctly interpret the prenatal and postnatal findings and to counsel patients and/or their families toward optimal management. **Definitive nephrons within the embryologic kidneys begin urine production around the 10th week of gestation; it is at that time that the first signs of lower urinary tract anomalies may become evident** (Rosenblum et al., 2017). The key developmental milestones leading to the handling of fetal urine are important to review. Between the fourth and sixth weeks of gestation, the urorectal septum divides the endodermal cloaca into a ventral urogenital sinus and a dorsal rectum. The cranial part of the urogenital sinus is continuous with the allantois and develops into the bladder and pelvic urethra. The caudal portion gives rise to the phallic urethra in males and the distal vagina in females. Unlike in males, the entire female urethra is derived from the pelvic part of the urogenital sinus. The allantois develops as an extraembryonic cavity from the yolk sac and connects with the cranioventral portion of the cloaca, the future bladder. Around the fourth to fifth month of gestation, the allantoic duct and ventral cloaca involute as the bladder descends into the pelvis. **The descent causes the allantoic duct to elongate because it does not grow with the embryo. This epithelialized fibromuscular tube continues to become narrower until it obliterates into a thick fibrous cord, the urachus** (Moore et al., 2011). **The obliterated urachus becomes the median umbilical ligament and connects the apex of the bladder with the umbilicus** (Nix et al., 1958).

Normal and Abnormal Antenatal Sonographic Findings of the Bladder

Normal fetal bladder imaging by default is absence of abnormal bladder imaging with varying and broad criteria to suggest an abnormality is present. Normal physiologic variation and bladder cycling require careful attention before diagnosing an abnormality. The fetal bladder manifests as an elliptical structure filled with anechoic fluid within the pelvis. It is bordered laterally by the umbilical arteries. The pubic bones mark the anterior border and the rectosigmoid the posterior border. The bladder wall thickness should not exceed 3 mm, and the mucosa and musculature have an echogenicity similar to that of other structures in the pelvis (McHugo and Whittle, 2001). **The bladder can be visualized in approximately 50% of cases in the fetal pelvis at the 10th week of gestation, concurrent with the onset of urine production** (Green and Hobbins, 1988)**. The detection rate increases with fetal age to 78% at 11 weeks, 88% at 12 weeks, and almost 100% at 13 weeks** (Rosati and Guariglia, 1996)**. Compared with abdominal ultrasound, transvaginal ultrasound increases the quality of the obtained images as well as the detection rate with the bladder visualized in 94% of women at 12 weeks estimated gestational age** (Braithwaite et al., 1996)**. The fetal bladder empties every 15 to 20 minutes; therefore a second ultrasound in the same setting is mandatory in case of nonvisualization of the bladder. The bladder's diameter increases during the first trimester but should not be more than 6 to 8 mm.**

The fetal sex, the amount of amniotic fluid, and the appearance of the umbilical cord become increasingly important in the interpretation and differential diagnosis of abnormal bladder findings. Fetal sex is difficult to determine before week 14 and should not be based on the presence or absence of a phallus but on visualization of the testes (Efrat et al., 1999). The measurement of amniotic fluid as an indicator of fetal urine production is a critical portion of every antenatal ultrasound. Until 16 weeks of gestation, the amniotic fluid is mainly consistent with placental transudate, at which time it changes to predominantly fetal urine (Takeuchi et al., 1994). The umbilical cord should contain two arteries and one vein without evidence of a fluid-filled urachus (Bronshtein et al., 1990).

Nondilated or Absent Bladder

In addition to dilation the fetal bladder may also appear hypoplastic or absent on ultrasound. In cases of nonvisualization of the bladder, it is possible that the bladder is completely absent, malformed, or is not filling with urine. An otherwise normal bladder may not fill with urine secondary to renal dysfunction or ectopic drainage of urine. When the bladder is poorly visualized, specific notation of renal development and amniotic fluid level become important factors in determining the possible cause. **To truly diagnose an absent fetal bladder on ultrasound, the examination has to be repeated after 15 to 20 minutes to**

rule out that the fetus has not simply emptied the bladder.

Bladder Agenesis.

Embryologic development of bladder agenesis remains difficult to explain. The division of the cloaca into the urogenital sinus and the anorectum apparently is regular, because the hindgut is usually normal. Therefore the defect can be due to either atrophy of the cranial part of the urogenital sinus or failure to incorporate the mesonephric ducts and ureters into the trigone (Krull et al., 1988). The absence of the bladder is often associated with neurologic, orthopedic, or other urogenital anomalies, such as renal dysplasia or agenesis or absence of the prostate, seminal vesicles, penis, and vagina (Aragona et al., 1988). **The incidence is approximated at 1 : 600,000 with 65 cases in the literature including 26 live births, a significant majority are female** (Nazer et al., 2018)**. The defect is compatible with life only if the ureters drain ectopically into normally developed müllerian structures in females or in the rectum in males.** In surviving infants, the diagnosis can be confirmed by antegrade or retrograde contrast imaging. MRI and CT imaging can also be used to provide greater anatomic detail before surgical intervention (Indiran et al., 2013). Renal function can be preserved after creation of an ureterosigmoidostomy or external stoma (Berrocal et al., 2002; Glenn, 1959).

Bladder Hypoplasia.

The bladder can be hypoplastic as a result of inadequate filling or storing of urine during fetal life. Although the bladder is formed during fetal development and can be detected on antenatal ultrasound throughout pregnancy, it never reaches an adequate capacity. Conditions caused by inadequate bladder outlet resistance (e.g., severe epispadias), separation defects (e.g., urogenital sinus abnormalities), abnormalities of renal development (e.g., bilateral renal dysplasia or agenesis), or urine bypassing the bladder (e.g., ureteral ectopia) can lead to underdevelopment of the fetal bladder. Some of these bladders grow once the malformation is corrected; however, later bladder augmentation is often required to reach adequate capacity.

Cloacal and Bladder Exstrophy.

Bladder exstrophy conditions are characterized by the presence of a bladder template only. Therefore it can be suspected in the absence of regular bladder filling during fetal ultrasound. **Bladder exstrophy can be distinguished from**

bladder agenesis by the bladder template on the lower abdominal wall, which, along with the amniotic fluid level, remains normal throughout the pregnancy (Gearhart et al., 1995; Mirk et al., 1986). Covered cloacal exstrophy can have a unique presentation when an omphalocele, pelvic diastasis, and genital anomalies are present, although so too is a fluid-filled bladder (Mallmann et al., 2014). Despite a recognizable pattern on prenatal ultrasound, a majority of bladder exstrophy cases are not diagnosed prenatally. Fetal MRI has been used in cases of suspected exstrophy, and this modality has been shown to provide additional anatomic details that could enhance the completeness of prenatal counseling (Goldman et al., 2013).

Dilated Bladder and Congenital Megacystis

Megacystis.

Historically, congenital megacystis was thought to be caused by bladder neck obstruction, leading to massive bilateral vesicoureteral reflux (VUR) and a thin bladder wall (Paquin et al., 1960; Williams, 1957). Even the describing authors recognized that surgical interventions at the bladder neck level did not change the future outcome. Harrow (1967) revisited the subject and recognized that all patients had normal urethras and complete emptying of their bladders on voiding cystourethrography (VCUG). Therefore the observed reflux is not an after-effect of obstruction but rather the cause of the bladder dilation from continuous recycling of the urine between the upper tract and bladder (Harrow, 1967). **Although this scenario is relevant in a subset of children with VUR, the clinical term *megacystis* over time has evolved to not directly reference any one cause of bladder dilation, more so; in the modern literature it simply implies a prenatally dilated bladder.**

Megacystis, much like hydronephrosis, is not a diagnosis but a finding on prenatal ultrasound that requires careful attention to differentiate the physiologic from the pathological. Unlike the kidney, however, the bladder by design will at times be distended with urine, making this finding particularly difficult to qualify. As such, the criteria for diagnosing megacystis have been refined over time. A large retrospective evaluation of more than 24,000 fetuses identified megacystis without an objective definition in 15 (0.06%) fetuses. In the same report, 300 consecutive fetuses between 10 and 14 weeks’ gestation were assessed to evaluate bladder length as a ratio to crown-rump length. All the control study subjects were found to have a sagittal bladder length less than 10%

of crown-rump length, which equated to bladder length of 6 mm or less (Sebire et al., 1996).

With use of the same method of assessment, those previously diagnosed with megacystis were found to have a minimum bladder length to crown-rump length ratio of 13% and a minimum bladder diameter of 8 mm. **Thus at 10 to 14 weeks' gestation the longitudinal bladder length should be 6 mm or less and can be considered abnormal if at least 8 mm** (Sebire et al., 1996)**. Other researchers have used similar definitions of more than 6 mm** (Favre et al., 1999; Pellegrino et al., 2017) **and at least 7 mm** (Kagan et al., 2010; Liao et al., 2003; Robyr et al., 2005) **in their reports on megacystis in the first trimester** (Fig. 30.1).

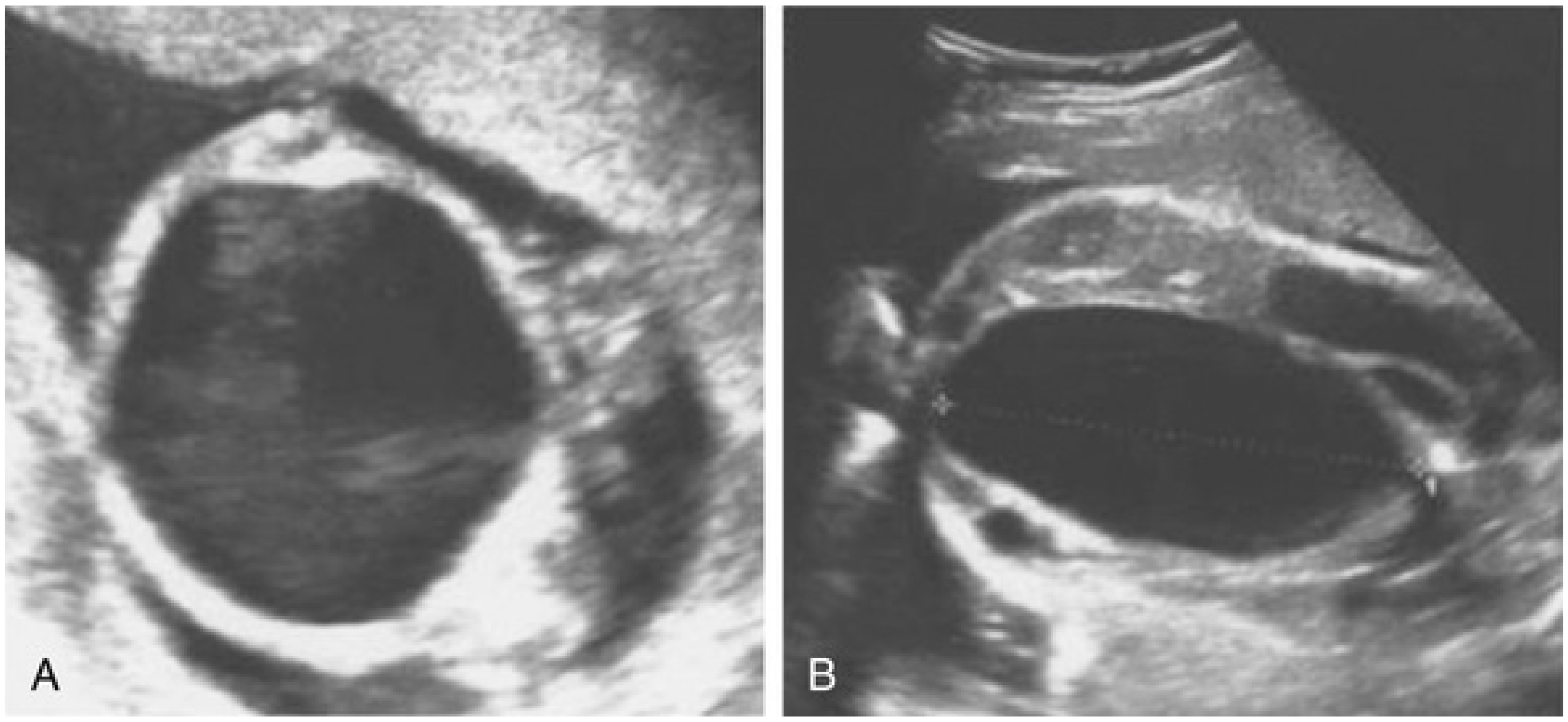

FIG. 30.1 Fetal megacystis at 18 weeks of gestation (A) and at 38 weeks of gestation (B). (From Pellegrino M, et al.: Prenatal detection of megacystis: not always an adverse prognostic factor. Experience in 25 consecutive cases in a tertiary referral center, with complete neonatal outcome and follow-up. *J Pediatr Urol* 13:486.e1–486.e10, 2017.)

Defining an abnormal bladder beyond the first trimester has been less precise, and most reports use a subjective definition. Studies focusing on later gestation tend to narrow in on a disease process such as posterior urethral valves (PUV) (Hutton et al., 1994) and PBS (Chen et al., 2010), in which bladder enlargement becomes a part of a series of findings and is therefore less importantly defined solely by size. Also important beyond the first trimester is the recognition of bladder cycling as a marker of normal function. **An "enlarged bladder" has been referenced in several studies as a bladder that does not empty during a**

45-minute period of sonographic observation. This definition of megacystis is often used beyond the first trimester (Bornes et al., 2013; Müller Brochut et al., 2014; Robyr et al., 2005).

Attempts have been made to objectively define megacystis in the second and third trimesters. Investigators have sought to develop a formula to use in predicting expected bladder sagittal length (SL). Using a series of 39 control fetuses, they observed a near linear relationship between bladder length and gestational age (GA) between 15 and 40 weeks' gestation. Using this data they developed a formula

$$\text{SL (mm)} = \text{GA (weeks)} - 5 \ (95\% \ \text{CI} +/- 7)$$

,which can be applied to fetuses in the referenced age range. A measurement above the 95% CI (i.e., GA + 2) would be considered an "enlarged bladder," although "megacystis" was defined as 10 mm greater than the 95% CI (i.e., GA + 12). The distinction between the two terms is reasoned to allow more specific prenatal counseling (Maizels et al., 2004).

The differential diagnosis for megacystis includes obstructive and nonobstructive processes that can be observed in the fetus and child. Obstructive processes can be grouped under the term lower urinary tract obstruction (LUTO), which can be caused by PUV, urethral atresia, and urethral stenosis/anterior urethral valves. Nonobstructing causes can include PBS, megacystis-microcolon-intestinal-hypoperistalsis syndrome (MMIHS), and cloacal anomalies with recognized crossover for some of these conditions. A meta-analysis of 26 publications reviewed more than 1000 subjects with megacystis and reported on the definitive diagnoses that were made in these reports. **In a majority of patients a diagnosis was made with PUV (57%) being the most common. Urethral atresia/stenosis (7%), PBS (4%), MMIHS (1%), and cloacal anomalies (0.7%) represented the other defined causes. No defined cause could be found in more than one-third of the fetuses (36.5%). Because the male-specific diagnosis of PUV is the leading cause of megacystis, this prenatal finding demonstrates an 8 : 1 male predominance** (Taghavi et al., 2017; Table 30.1).

TABLE 30.1

Definitive Diagnoses in Fetuses With Megacystis

STUDY YEAR, AUTHOR	***n***	**PUV**	**URETHRAL ATRESIA/STENOSIS**	**PBS**	**MMIHS**	**CLOACAL ABNORMA**
1985, Mahony et al.	40	28/40	3/40			
1997, Kaefer et al.	15	8/15		1/15		
1997, Wisser et al.	9		1/9			
1998, Abbott et al.	22	8/22	1/22			
1998, Montemarano et al.	21	10/21		4/21		
1999, Favre et al.	16			3/16		1/16
2003, Jouannic et al.	19	3/19				
2004, Maizels et al.	37	14/37		2/37	2/37	
2005, Robyr et al.	24	9/24	14/24			
2011, Ruano et al.	15	7/15	5/15		2/15	1/15
2011, Osborne et al.	20	10/20	1/20	8/20	1/20	
2011, Lee et al.	61	17/61	11/61	13/61	2/61	1/61
2012, Al-Hazmi et al.	561	369/561	27/561			
2013, Bornes et al.	84	25/84	10/84	1/84	4/84	3/84
2014, Fievet et al.	69	23/69[a]		7/69	1/69	
2014, Müller Brochut et al.	54	16/54	1/54	2/54		1/54
Total	**1067**	**568/998** (57%)	**74/998** (7%)	**41/1067** (4%)	**12/1067** (1%)	**7/1067** (0.7%

[a] Not included in totals for PUV and urethral atresia/stenosis because the diagnosis was not specified.

From Taghavi K, Sharpe C, Stringer MD: Fetal megacystis: a systematic review. *J Pediatr Urol* 13:7–15, 2017.

Megacystis can include a range of bladder measurements and can have an unpredictable outcome based on the data available during the first trimester. This observation has led several researchers to work toward better defining outcomes based on the degree of bladder dilation, gestational age at presentation, and genetic abnormalities. Chromosomal abnormalities in association with megacystis have been reasoned to result in poor outcomes. High rates of termination of pregnancy for fetuses with megacystis and aneuploidy limit an accurate assessment of general urologic outcomes in this population. **An abnormal karyotype has been observed in 30/145 (21%) fetuses with megacystis. The most common abnormalities were trisomy 13 and 18, which accounted for 80% of affected karyotypes. The observed rate of these patterns significantly exceeded the expected rate based on maternal age and fetal nuchal translucency.** Pregnancy termination was elected in 26/30 aneuploid fetuses and the remaining 4 fetuses did not survive to term (Liao et al., 2003).

The authors evaluated the remaining fetuses with normal karyotypes and follow-up data to determine the rate of spontaneous resolution for megacystis. **They compared fetuses with longitudinal bladder diameters of 7 to 15 mm with those with diameters of more than 15 mm. The spontaneous resolution rate in the former group, which included 79 fetuses, was 89.9% with the remainder being found to have obstructive uropathy. This contrasts sharply with the latter group, which had a 0% resolution rate with all 30 subjects having obstructive uropathy** (Liao et al., 2003).

One of the larger studies regarding resolution of megacystis comes from the collective database shared by the fetal medicine units across the Netherlands (Fontanella et al., 2017). From 2000 to 2014, 541 fetuses were evaluated for megacystis with 247 excluded from further evaluation secondary to termination, fetal intervention, or loss to follow-up. The prenatal assessment of genetic abnormalities was not included in the database, although the high rate of pregnancy termination (35% of the study population) results in a selective group available for evaluation. Early megacystis was defined as bladder enlargement detected before 18 weeks gestational age (WGA) and late megacystis as that detected after 18 WGA. Routine follow-up imaging was used to detect resolution of megacystis. Early presentation (before 18 WGA) and early resolution (before 23 WGA) were key determinants in the study. **The overall rate of resolution**

was 20% with those with early presentation demonstrating 38% resolution and those with late presentation demonstrating 12% resolution. In the subgroup of fetuses with early presentation, a maximal longitudinal bladder diameter of 12 mm or less was a sensitive predictor of resolution with 70% resolving during gestation. Of those presenting before 18 WGA and resolving before 23 WGA, none demonstrated urologic sequelae requiring surgery postnatally. Conversely, 84% of those presenting after 18 WGA and resolving at some point beyond 23 WGA required urologic intervention postnatally despite prenatal resolution of megacystis. This particular study highlights the relevance of prenatally detected bladder enlargement and its later clinical significance.

Megacystis Microcolon Intestinal Hypoperistalsis Syndrome.

MMIHS is a specific cause of a dilated fetal bladder and is a condition not covered elsewhere in this text. Although representing only a small percentage of cases with megacystis (approximately1%), this clinical entity remains important secondary to morbidity of the syndrome. **Prenatally megacystis is the most consistently recognized feature, and unlike cases of LUTO, most of these patients have normal to increased amniotic fluid levels. The gastrointestinal findings of MMIHS are often not evident prenatally on ultrasound, although amniotic fluid sampling for digestive enzymes, if done, will be abnormal in 80% of cases** (Muller et al., 2005). The pathological basis of the disease is smooth muscle dysfunction within the gastrointestinal and urinary systems. Actin smooth muscle filament function has been evaluated genetically with mutations in *ACTG2* identified in this population (Tuzovic et al., 2015).

There is a female predominance with roughly 70% of historic cases. **The overall survival rate based on reported cases is 20%; however, when considering cases from 2004 to 2011 the survival rate improved to 55%, suggesting improvement in understanding and management of this condition** (Gosemann and Puri, 2011). **The postnatal findings include abdominal distention, bilious vomiting, and failure to pass meconium. The clinical suspicion of bowel obstruction in the background of an enlarged bladder should be evaluated as MMIHS.** Differentiation from other causes of intestinal obstruction is based on clinical findings, although colon biopsy confirming the presence of ganglion cells can be done to rule out Hirschsprung disease. Contrast imaging of the intestinal tract often demonstrates hypomobility of the small intestine and a small colon. The enteric complications of this syndrome can be fatal, and these neonates are often managed with ileostomy, gastrostomy tube insertion, and TPN. Complications of TPN including blood-borne infections and liver dysfunction are leading causes of mortality in this population, and small intestinal transplantation has been successfully used with promising results.

The urologic morbidity is often secondary to enteric complications, although short-term management of the bladder with intermittent catheterization or vesicostomy is important for minimizing complications from urinary retention. VUR is uncommon in this syndrome and therefore early contrast imaging of the bladder is of limited utility. **Once these children are stable from an enteric standpoint, more thorough evaluation with urodynamics can be considered with an acontractile bladder the expected finding. Normal micturition in older patients has been reported, although most patients will require ongoing CIC. Like patients with a posterior urethral valve or neurogenic bladder, lifetime urologic care will be needed** (Wymer et al., 2016).

Bladder Duplication

Duplication of the bladder and urethra can be complete or incomplete with variable orientation. Abrahamson (1961) attempted to classify the various bladder duplication anomalies and found complete duplication in the sagittal plane the most common. **In incomplete duplications, the two bladder halves communicate and are usually drained by a single urethra. In complete duplications, the two bladders are fully separated entities with normal mucosa and a full-thickness musculature wall divided by a peritoneal fold** (Fig. 30.2)**. Although the size and quality of each entity can be different, they are usually supplied with their own ureter and are drained by an individual urethra and external meatus** (Esham and Holt, 1980). In rare cases, one bladder can lack a urethra. This leads to ipsilateral renal dysplasia via complete obstruction (Cheng and Maizels, 1996). Continence can vary.

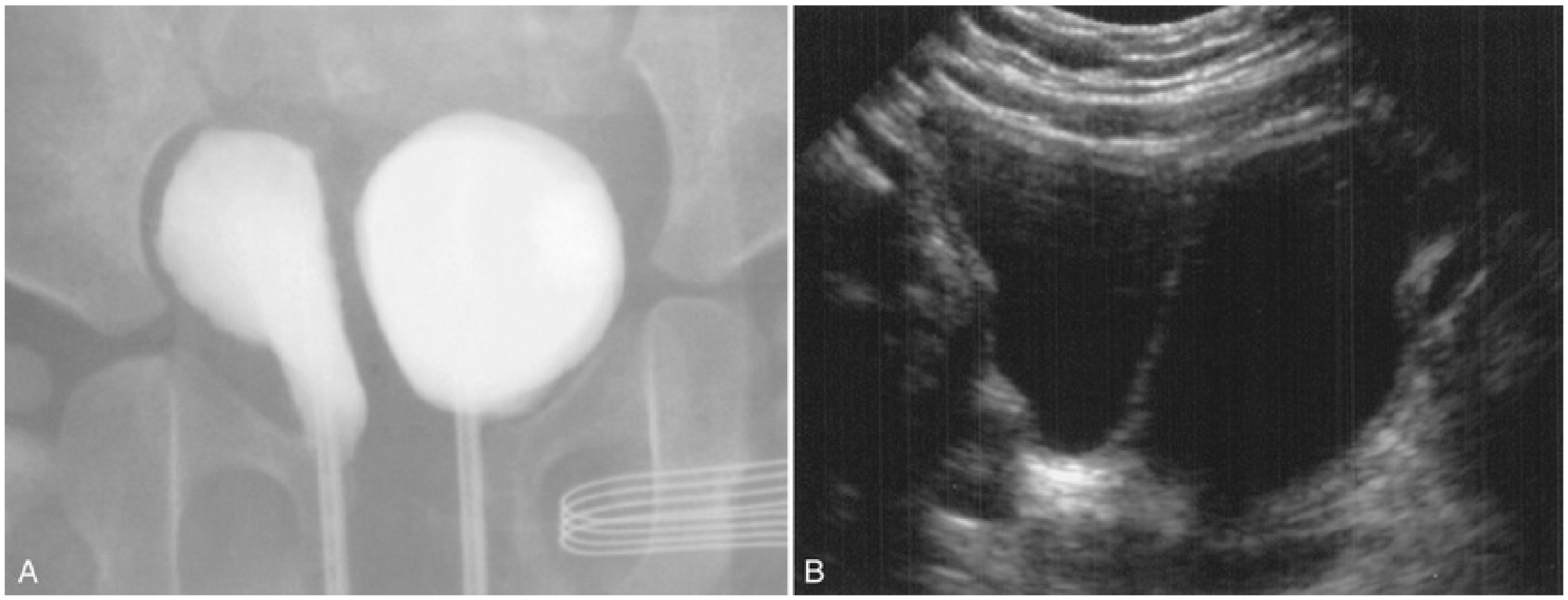

FIG. 30.2 Complete bladder duplication. (A) Vesicoureterogram image of complete bladder duplication with catheters inserted into each individual urethra. Note the size discrepancy. (B) Ultrasound image of the same patient.

Associated duplication anomalies of the external genitalia have been reported in up to 90% of cases; associated duplication anomalies of the lower GI tract have been reported in up to 42% of cases (Kossow and Morales, 1973). Duplicated vaginas can be connected to a separate unicornate uterus. Duplicated penises are supplied with an individual urethra. Additional urologic abnormalities such as VUR, renal ectopia, or dysplasia are commonly found. Association with other nonurologic congenital anomalies are more frequent in sagittal than coronal duplications. Multiple manifestations have been described, including GI malformations, duplications of the spine, spina bifida conditions, and various fistula formation between the urogenital and GI tract (Berrocal et al., 1999). In duplication variations of the classic cloacal-bladder exstrophy complex, patients have an exstrophic bladder and urethra in addition to a closed regular intra-abdominal bladder (Perren and Frey, 1998).

The diagnosis is often made in the newborn period because of associated malformations of the GI tract or external genital tract. However, many children are not diagnosed until recurrent infections or incontinence initiates a urologic workup. Although similarities exist, there are many variations necessitating individual management. Complete preoperative diagnostic evaluations with karyotype, ultrasound, videourodynamic studies, genitogram, and cross-sectional imaging are useful to understand the anatomic relationships. VCUG and nuclear renal scans can supply additional information regarding VUR and renal function. Often the final treatment plan has to be deferred until the time of endoscopic and surgical exploration of the malformation. Initial treatment is directed toward renal preservation and prevention of infections by relieving possibly obstructed genitourinary tracts. Long-term goals include achieving continence and reconstructing the internal and external genitalia. Incomplete duplications may not require surgical procedures if both bladder halves are sufficiently drained by a common urethra. In complete duplications, the two bladders can be combined into one. If both sphincter complexes are competent, the distal urethras are connected. If one is incompetent, the corresponding bladder neck can be closed and the connected urethra excised. Duplicated vaginas are combined in the midline, and a vulvoplasty is performed. The urogenital duplications also can be left uncorrected if the patient is asymptomatic; Gastol reported two successful pregnancies in a 26-year-old woman (Gastol et al., 2000). **Because of the rarity of the disease and the large variety of manifestations, the surgeries must be individualized and should be performed in centers experienced in complex urogenital reconstruction.**

Congenital Diverticula

Diverticula typically develop as herniation of bladder mucosa between defects of bladder smooth muscle fibers. The neck of the resulting diverticulum depends on the size of the muscular defect. The incidence is reported to be low, with 1.7% in a selected pediatric population of children undergoing radiographic evaluation for symptomatic disease (Blane et al., 1994). The true incidence is likely higher as symptomatic diverticula are rare and undiscovered.

Bladder diverticula can be detected on prenatal ultrasound (Gaudet et al., 1999) **but are mostly discovered during postnatal workup for infection, hematuria, incontinence, or obstruction. Large diverticula can be seen with sonography, but the gold standard remains VCUG, which will reveal possible accompanying VUR and likelihood of postvoid retention of urine.** Nuclear renal studies can be used to obtain information concerning anatomy, kidney function, and ureteral obstruction if hydroureteronephrosis is present. Congenital diverticula can be dynamic and may not be present on every study. Radiographic studies may have to be repeated in cases of continuous clinical suspicion.

Paraureteral Congenital Diverticula.

Paraureteral diverticula are by far the most common congenital diverticula and categorized as primary or secondary by Hutch in his landmark article (Hutch, 1961). **Primary paraureteral diverticula are seen in smooth-walled bladders,**

occur isolated with no other diverticula, can be intermittent on imaging, and happen in children with no infravesical obstruction. Secondary paraureteral diverticula are found in trabeculated bladders as one of many diverticula in the bladder, are always present on imaging, and are caused by infravesical obstruction. These are acquired and therefore are discussed later in this chapter.

Primary diverticula arise as a localized herniation of bladder mucosa through the ureteral hiatus between the intravesical ureter and the roof of the ureteral hiatus. These primary diverticula are most likely caused by a congenitally deficient bladder wall (Fig. 30.3). Some authors have implied an isolated defect in the Waldeyer sheet; however, congenital diverticula often occur on one side only and a unilateral defect seems unlikely (Stephens, 1963).

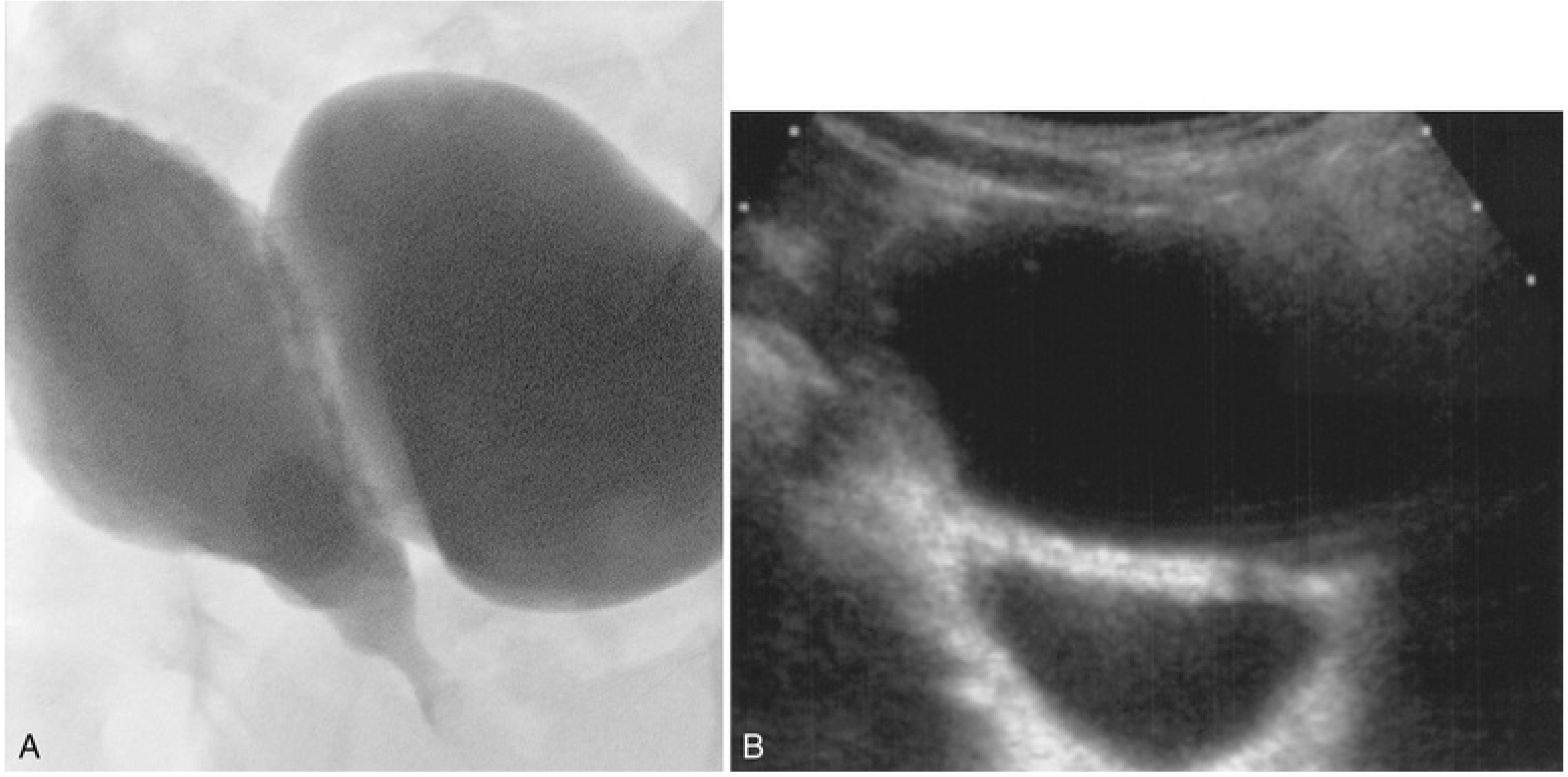

FIG. 30.3 Primary paraureteral diverticulum. (A) Vesicoureterogram image of large primary paraureteral diverticulum. (B) Ultrasound image of the same diverticulum.

Small, asymptomatic congenital diverticula detected during unrelated workups can be treated conservatively. Many surgeons tend to recommend excision of paraureteral diverticula if they are accompanied by VUR. Girls show spontaneous resolution of their diverticula in association with VUR more frequently than boys. In his review of 304 patients with VUR, Amar (1972) confirmed the lesser resolution rate in boys. He attributed it to higher voiding pressures even without the presence of infravesical obstruction. A primary paraureteral diverticulum does not preclude

endoscopic subureteral injection of dextranomer/hyaluronic acid (Deflux) for correction of VUR (Perez-Brayfield et al., 2003).

Posterolateral and Multiple Congenital Diverticula.

These diverticula are often found in children with generalized connective tissue diseases, such as Ehlers-Danlos, Williams, or Menkes syndrome, but are occasionally seen in the absence of a known genetic syndrome (Babbitt et al., 1979; Garat et al., 2007; Hebert and Martin, 2015; Levard et al., 1989)**. These diverticula can become massive and many times fill larger than the bladder itself** (Figs. 30.4 and 30.5)**. Interestingly, pathological analysis does not necessarily show the classic herniation of mucosa through a bladder muscle defect but instead an attenuated muscle wall, allowing laxity in the absence of obstruction** (Garat et al., 2007).

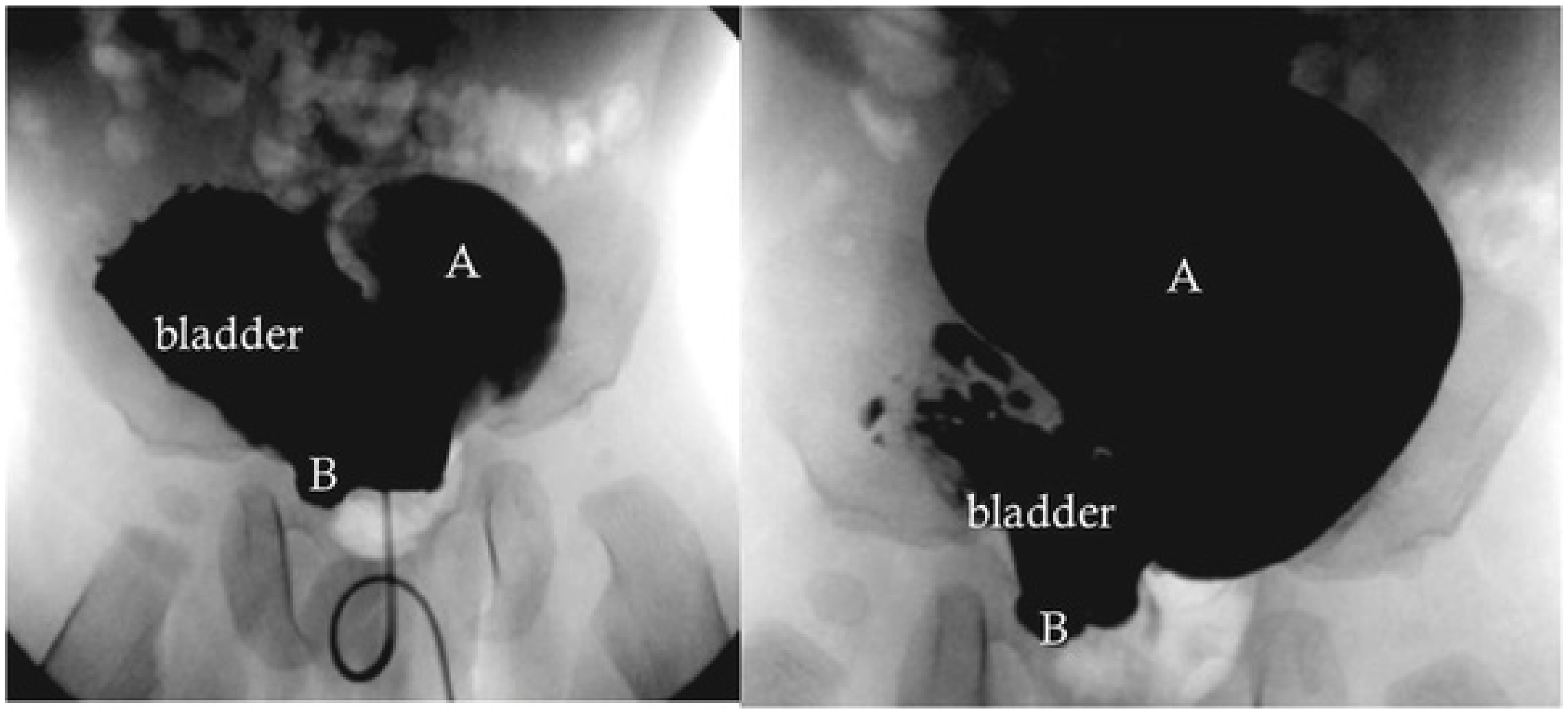

FIG. 30.4 In the left panel, the voiding cystourethrogram demonstrates the large superior diverticulum (A) and a smaller one posteriorly near the bladder neck (B). In right panel, postvoid film reveals the residual urine volume within the diverticulum.

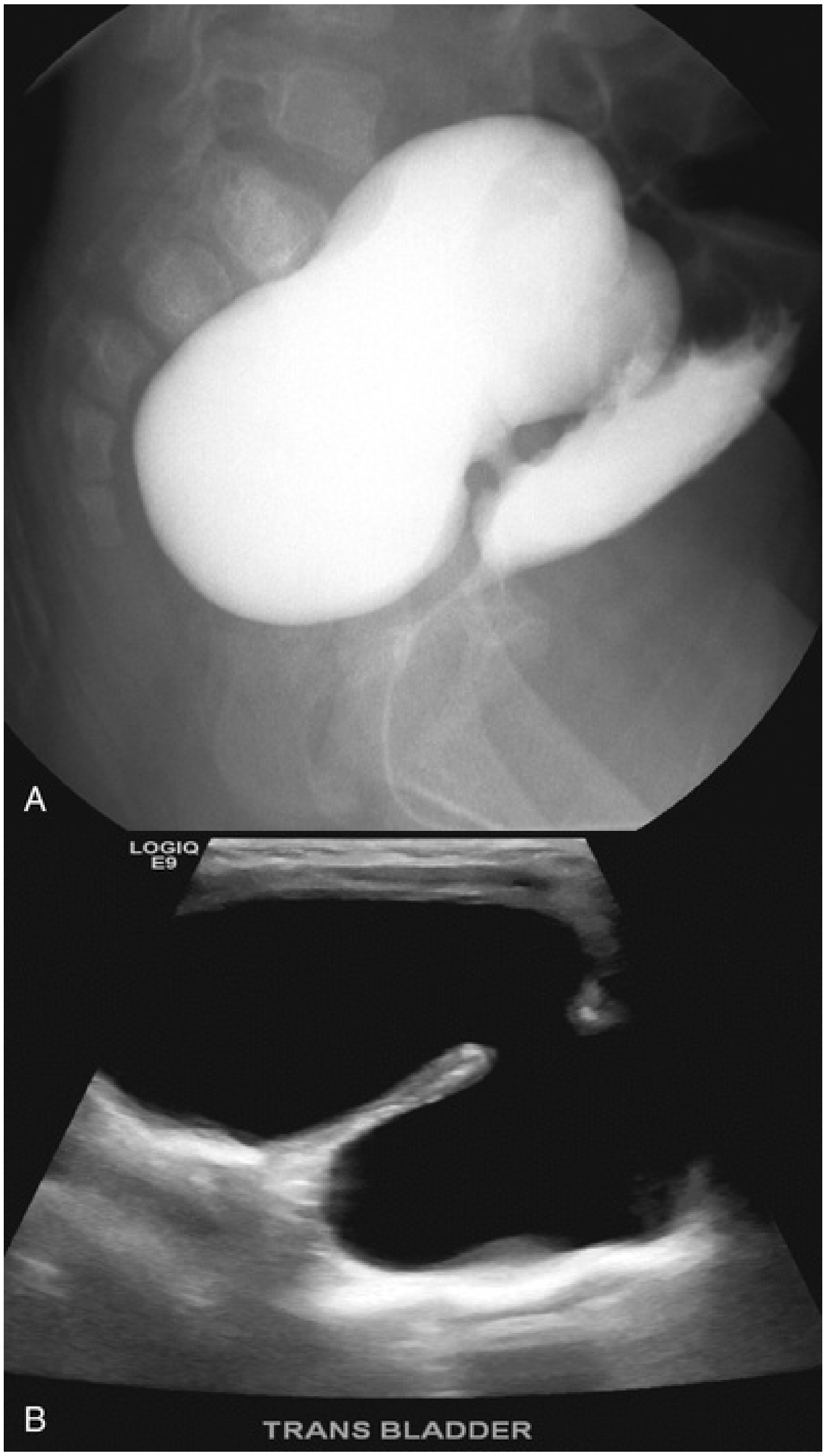

FIG. 30.5 Primary isolated posterolateral diverticulum in a newborn. (A) VCUG with diverticulum seen larger than the bladder. (B) Sonogram of the same diverticulum.

The most common presenting symptom is recurrent urinary tract infections (UTIs) resulting from poor emptying or urinary stasis in the diverticula. These can even lead to stone formation. If the child is asymptomatic, then close observation is recommended, especially in the setting of the earlier-mentioned connective tissue disorders. However, resection can be performed successfully using standard open or laparoscopic approaches in eliminating recurrent UTIs and many times improving spontaneous voiding. Unfortunately, recurrence or formation of new diverticula is common in syndromic patients, so surgical treatment must be carefully weighed with quality-of-life considerations. In some cases, urinary diversion with vesicotomy or suprapubic drainage may be preferred. Urodynamics should be pursued postoperatively to assess for any obstruction or high-pressure voiding that could expedite recurrence.

Key Points: Congenital Bladder Anomalies

- Persistent megacystis in the background of oligohydramnios is concerning for LUTO; megacystis that resolves before delivery may not have any postnatal sequela.
- Megacystis microcolon intestinal hypoperistalsis syndrome may have only megacystis noted prenatally.
- Nondilated anomalies are the most severe forms of congenital urologic malformations, such as bladder exstrophy. Usually normal amniotic fluid levels are found.
- Bladder agenesis is compatible with life only if the ureters drain ectopically.
- Children with connective tissue disorders can have multiple bladder diverticula that may require treatment because of stasis-related infections or stones.

Urachal Anomalies

The treatment of a symptomatic urachal remnant in a child typically requires complete surgical excision with a bladder cuff. This is a fairly simple operation performed either open or laparoscopically with low morbidity. It is the asymptomatic incidental urachal remnant that presents a clinical conundrum. Although urachal adenocarcinoma in a child is unreported, malignant transformation in an adult can be devastating with a high mortality and a much more complicated surgical excision. Ashley et al. (2007) have advocated for excision of all childhood urachal remnants when discovered regardless of symptoms to avoid potential adult progression; however, Gleason et al. (2015) were able to better quantify the risk of progression and recommend excision only in cases of symptomatic presentation (Fig. 30.6).

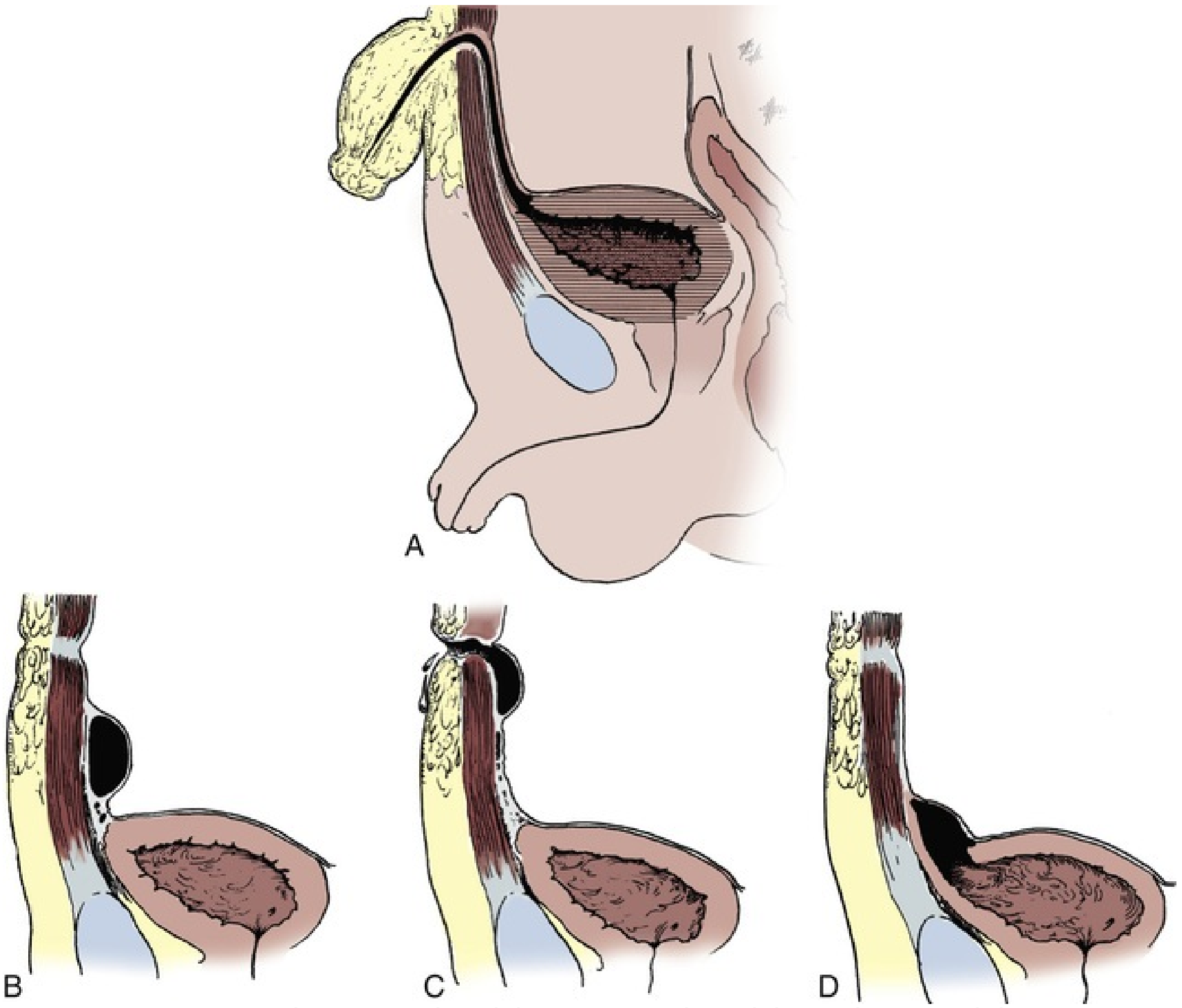

FIG. 30.6 Urachal anomalies. (A) Patent urachus. (B) Urachal cyst. (C) Umbilical-urachus sinus. (D) Vesicourachal diverticulum.

Patent Urachus.

Patent urachus is explained by nondescent of the bladder or, more commonly, failure of the epithelial-lined urachal canal to obliterate. Bladder obstruction during fetal development has been blamed for the urachus remaining tubular. The fact that urachal patency is often absent with severely obstructed bladders in utero, however, casts doubt on this theory. In addition, only up to 14% of patients with a patent urachus have postnatal confirmation of in utero bladder obstruction (Mesrobian et al., 1997; Schreck and Campbell, 1972). Obliteration of the urachus may be independent from the level of bladder distention. Therefore retubularization, rather than primary patency, may be the cause for urinary drainage from the umbilicus. This theory is supported by reports of umbilical urinary fistulas in acquired bladder obstructions later in life (Berman et al., 1988; Schubert et al., 1982).

A patent urachus is suspected in the neonatal period by continuous or intermittent drainage of fluid from the umbilicus. The most common organisms cultured from the umbilical drainage include *Staphylococcus aureus, Escherichia coli, Enterococcus, Citrobacter,* and, rarely, *Proteus* species (Mesrobian et al., 1997). Additional manifestations include an enlarged or edematous umbilicus and delayed healing of the cord stump (Razvi et al., 2001; Schiesser et al., 2003). The diagnosis is confirmed by demonstration of the fluid-filled canal on longitudinal ultrasound or contrast filling on retrograde fistulogram or VCUG (Fig. 30.7; Mesrobian et al., 1997). MRI can aid in the diagnosis but usually depends on the bladder's filling status. It is important to differentiate the condition from a patent omphalomesenteric duct. The presence of both anomalies in the same patient is rare (Mendoza et al., 1968).

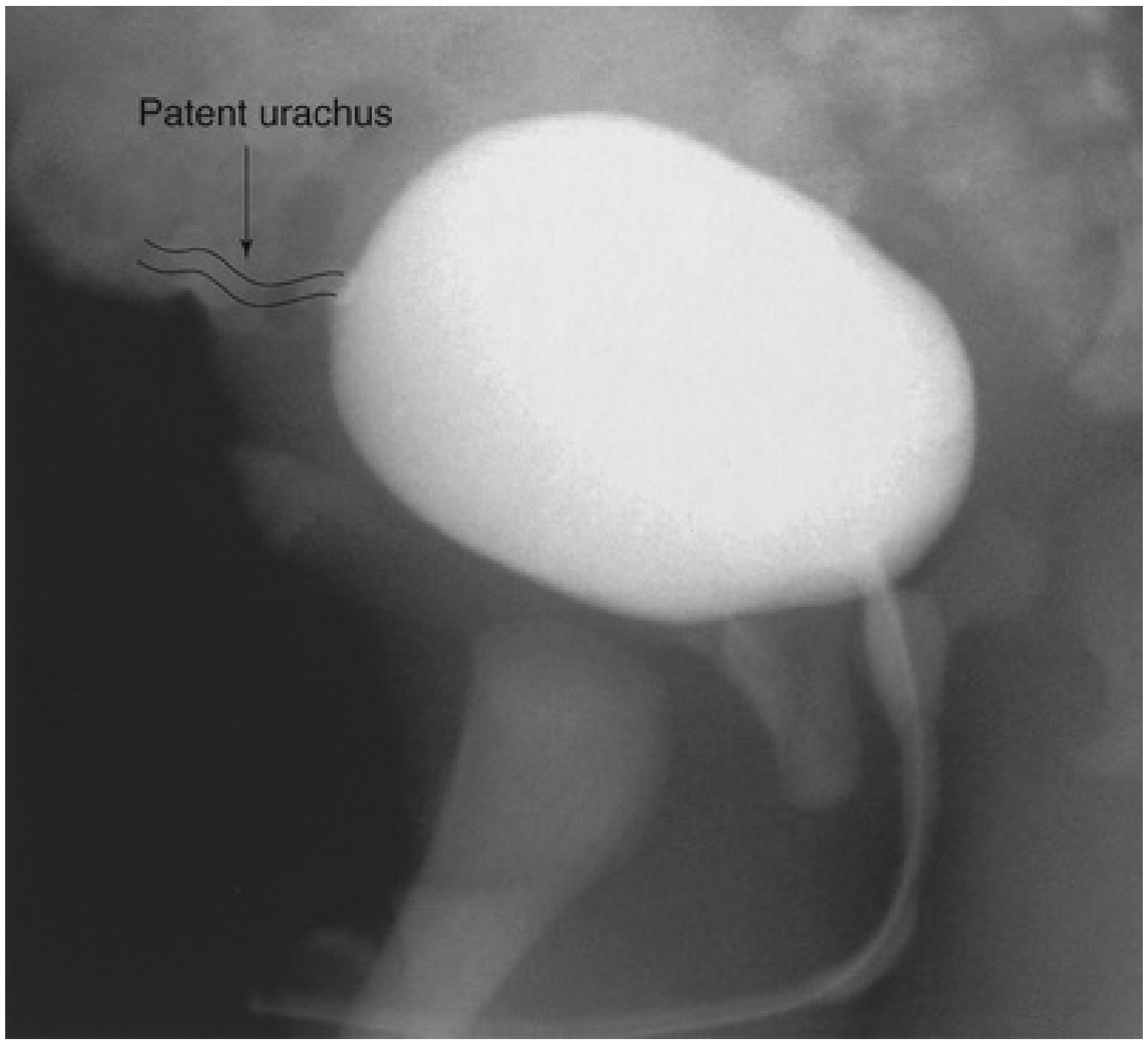

FIG. 30.7 Patent urachus. Vesicoureterogram image of patent urachus in a newborn. Retrograde contrast filling of patent canal with contrast pooling in umbilicus.

Management of an infected urachus with abscess formation includes

initial drainage under antibiotic coverage. Once the infection has subsided, complete excision of the patent urachus, including a bladder cuff, is required (Nix et al., 1958). It is important to remove all anomalous tissue. This avoids recurrences or stone formation and prevents the rare event of later transformation into a malignant adenocarcinoma (Ashley et al., 2007; Blichert-Toft and Nielsen, 1971; Goldman et al., 1988; Sheldon and Essig, 1994; Upadhyay and Kukkady, 2003).

Traditionally, the patent urachus is surgically excised using a transverse or midline infraumbilical incision. Before surgery, a balloon catheter is used to distend the bladder. In infants, a small transverse subumbilical incision is often possible because the bladder dome is still high. A feeding tube or small catheter is placed into the patent urachus for better intraoperative identification. The urachus can be incised circumscriptly, without removing the umbilicus for cosmetic reasons. The rectus fascia is incised in a longitudinal fashion, muscles spread apart, and the dome of the distended bladder identified. The urachus is identified and isolated, and a vessel loop is placed. The dissection continues extraperitoneally toward the umbilicus until the previously incised umbilical portion is free and can be pulled into the surgical field. It is then removed. A bladder cuff including the urachal insertion is marked and excised using electrocautery. The bladder is closed watertight in two layers. The catheter can be left in place overnight and removed the following morning.

Alternatively, urachal remnants can be removed laparoscopically. This can be done even in children younger than 6 months of age (Cadeddu et al., 2000; Fahlenkamp et al., 1995; Khurana and Borzi, 2002; Turial et al., 2007). Khurana and Borzi (2002) described their laparoscopic experience with 4 children between 5 months and 10 years and found the procedure to be safe in children of all ages. Technically, they suggested a three-port approach, with the camera port in the midline between the umbilicus and the xiphoid and two working ports on either side in the upper quadrant. Turial et al. (2007) reported on 27 children with a median age of 4.7 years. Early in their series they inserted the camera port at the umbilicus with working ports into the right and left upper abdomen. Later they preferred to place the camera into the left lower abdominal wall, with 2-mm working ports at the left lower and upper abdomen for better visualization of the urachus at the umbilicus. They reported no intraoperative or postoperative complications, no recurrences, and a median operating time of 35 minutes.

The advantage of the laparoscopic technique is the good visualization of the course of the urachus and the bladder dome. However, laparoscopic techniques require an intra-abdominal approach and pose the potential risk for spilling infected or malignant material into the abdominal cavity as well as intraperitoneal urinary extravasation. Robotic-assisted removal and single-port laparoscopy also have been suggested (Ahmed et al., 2017).

Urachal Sinus.

In the umbilical-urachus sinus, the urachus obliterates at the bladder level but remains open at the umbilical site, causing a continuously draining sinus. The manifestation is similar to that of the patent urachus. The diagnosis is made by sinugram. The caudal part of the urachus is filled with desquamated epithelial cells, and no connection to the bladder can be identified. **The presence of a persistent omphalomesenteric duct has to be considered. This would manifest as a Meckel diverticulum connected to the umbilicus. These structures can be very difficult to differentiate from an umbilical-urachus sinus because no connection to the bladder or bowel can be seen on sinugram. However, the surgical approach to both anomalies requires the complete excision of all tissue.** Unlike urachal structures, omphalomesenteric remnants can show gastric or small bowel mucosa on histologic examination.

Urachal Cyst.

There is no communication of the cyst with the bladder or umbilicus. However, the fluid-filled cyst can drain through the umbilicus or into the bladder intermittently. Urachal cysts are found more commonly in the distal part of the urachus and manifest more commonly in adults than in infants or children (Cilento et al., 1998). The cyst material consists of desquamated epithelial cells. These cells can become infected; *Staphylococcus aureus* has been identified as the most common organism (Mesrobian et al., 1997).

Once infected, urachal cysts can manifest as umbilical abscess formation or bladder infections. Additional symptoms include localized lower abdominal pain, voiding symptoms, or even a painful palpable mass. The diagnosis is confirmed by ultrasound, demonstrating the localized cyst between the anterior abdominal wall and the peritoneum. In a case of massive infection or difficult manifestation, a CT or MRI can clarify the anatomy and extent of disease (Berrocal et al., 2002). If unrecognized, the infected cyst can perforate into the bladder (Maruschke et al., 2003) or peritoneal cavity. This can cause peritonitis and formation of an enteric fistula (Ohgaki et al., 2003; Quek et al., 2003) Treatment consists of draining the infected cyst, followed by complete excision of the urachal remnant structures.

Urachal Diverticulum.

The urachus obliterates almost completely, except at the level of the bladder apex. Here it forms a diverticulum of varying size. These lesions are usually asymptomatic and found incidentally on nonrelated radiographic workups. Although the diverticula can enlarge in the case of urinary obstruction, this rarely causes problems because they tend to have a large opening and drain into the bladder well. Stone formation and urinary tract infections have been reported, especially in the case of a narrowed neck causing the need for intervention.

Key Points: Urachal Anomalies

- Urachal anomalies are usually detected postnatally because of umbilical drainage.
- Infected urachal remnants are treated with antibiotics followed by surgical excision.
- Urachal remnant can be confused for a persistent omphalomesenteric duct on preoperative workup.
- Asymptomatic, incidentally found urachal remnant excision should be discussed with the family because of the potential for malignant transformation as an adult.

Acquired Bladder Anomalies in Children

Noninflammatory Acquired Conditions

Acquired Diverticula

Acquired diverticula are the result of infravesical obstruction, which has to be addressed first. After bladder outlet resistance is normalized, diverticulectomy may become unnecessary because of natural remodeling of the bladder. If symptomatic, the diverticulum should be excised with ipsilateral ureteral reimplantation if it is near or included in the diverticulum. This can be successfully performed intravesically or extravesically and open or laparoscopically/robotically (Christman and Casale, 2012; Jayanthi et al., 1995; Yu, 2002).

Secondary paraureteral diverticula are acquired and develop as a result of existing infravesical obstruction or a neurogenic bladder as originally described by Hutch (1961)**. The resulting increased infravesical pressure forces the bladder mucosa to bulge between the muscle fibers. These diverticula are usually just one of many pop-off mechanisms that can occur throughout the bladder.** These diverticula also can be caused by weakening in the bladder muscle by infection (Barrett et al., 1976) or development of a muscular defect after bladder surgery (Sheu et al., 1998).

In both types of paraureteral diverticula, the Waldeyer's sheath eventually becomes damaged as the diverticulum expands in size. The increasing diverticulum pulls the intravesical ureter out of its anchored position, causing dysfunction of the ureterovesical junction. Eventually, the enlarged diverticulum can become responsible for ureteral obstruction. This even has been associated with renal dysplasia (Amar, 1972; Livne and Gonzales, 1985).

Paraureteral diverticula or posterolateral diverticula can become so large that they compress the bladder neck or posterior urethra. The resulting bladder outlet obstruction starts a vicious circle by continuously filling and expanding the diverticulum. This increases the obstruction and subsequently causes complete urinary retention (Sheldon and Essig, 1994; Zia-Ul-Miraj, 1999). This can be seen with the congenital diverticular syndromes discussed previously, leading to surgical intervention.

Bladder Hemangiomas

These benign vascular tumors are mostly seen in association with Klippel-Trenaunay or Sturge-Weber syndromes. They are typically solitary and less than 3 cm in diameter but can be multifocal. They are typically discovered because of gross hematuria with or without irritative voiding symptoms. Treatment can safely be performed with bladder biopsy with fulguration or neodymium:yttrium-aluminum-garnet (Nd:YAG) laser irradiation for small tumors, or partial cystectomy if large or concern for rapid blood loss (Cheng et al., 1999; Numanoğlu and Tatli, 2008).

Fibroepithelial Polyps

Although rare in the bladder, fibroepithelial polyps can be a cause of hematuria and irritative voiding symptoms. There have been case reports citing bladder outlet obstruction, ureteral obstruction, and bladder irritation. **A review of 21 years of bladder tumor specimens at Children's Hospital of Philadelphia revealed fibroepithelial polyps to be the second most frequent bladder tumor after rhabdomyosarcoma** (Huppmann and Pawel, 2011)**. Simple endoscopic resection is typically curative.**

Inflammatory Acquired Conditions

Nephrogenic Adenoma and Cystitis Cystica

Nephrogenic adenoma of the urinary bladder is a rare benign tumor mostly found in adults. Sporadic case reports in children describe the lesion as a reaction to infection, lithiasis, trauma, or surgery. Heidenreich et al. (1999) found a significant predominance of girls compared with boys (5 : 1), typically with hematuria or irritative bladder symptoms. The diagnosis is established after cystoscopy with biopsy. **Treatment consists of transurethral fulguration or resection of isolated nephrogenic adenomas. Although malignant transformation was not reported, tumor recurrence developed in 80% of the children, with a latency period of 4 years** (Heidenreich et al., 1999). Resection of nephrogenic adenoma followed by successful long-term resolution using ibuprofen and trimethoprim-sulfamethoxazole also has been described (Voss and Peppas, 2013).

Hungerhuber et al. (2008) reported a rare case of an adenocarcinoma in a 25-year-old patient who developed a neurogenic bladder after a car accident. He subsequently developed a nephrogenic adenoma, which was resected several times. Although the initial pathological finding was benign, a moderately differentiated adenocarcinoma was found after several resections. He underwent a radical cystectomy and remained tumor free (Hungerhuber et al., 2008).

Kao et al. (2013) reviewed 21 cases of nephrogenic adenomas from urinary bladder biopsies. Most patients had a history of bladder augmentation with recurrent stone formation and infections. The immunohistochemical profile suggested that nephrogenic adenomas are derived from distal tubular cells (Kao et al., 2013).

Cystitis cystica can present a similar picture of fluid-filled cystic masses in response to chronic inflammation. Cystitis cystica is best treated with long-term antibiotic prophylaxis. This disease process is almost exclusively in females. Cystitis glandularis is even rarer in children and occurs because of metaplasia of mucus-secreting epithelium. There has been concern of this being a premalignant lesion; however, few data are available to support this claim (Bastianpillai et al., 2018).

Eosinophilic Cystitis

Eosinophilic cystitis in children is sporadically described in case reports with a predominance in boys. **The cause remains unclear, and the histopathological examination includes inflammatory cells with numerous eosinophils throughout all layers of the bladder wall** (Tsakiri et al., 2004)**. Manifesting symptoms include dysuria, hematuria, suprapubic pain, and urinary retention. The diagnosis is made by cystoscopy with transurethral biopsy of the lesion, which has no “typical” appearance** (Fig. 30.8). Immunologic diseases and allergies have been suggested to be causative for the development of the lesions. In a large review of 135 cases, van den Ouden (2000) found transurethral resection combined with corticosteroids, antihistamines, or antibiotics to be most successful for all age groups. In neonates and young children, the disease can be self-limited and observation is justified (Al-Omar et al., 2005). In a case series of 4 patients between 5 days and 18 years, all were diagnosed by biopsy after clinical suspicion and were successfully treated with a combination of steroids, antihistamines, and antibiotics (Sparks et al., 2013).

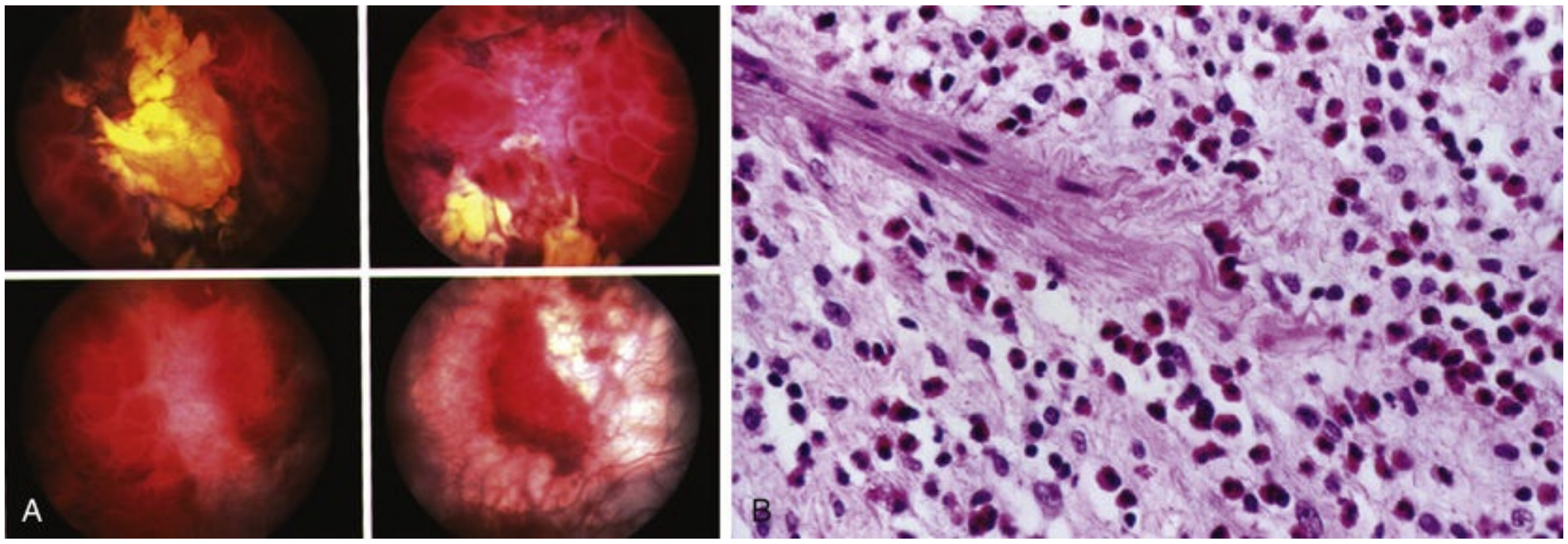

FIG. 30.8 Eosinophilic cystitis. (A) Cystoscopic views of lesion detected as mass on ultrasound in teenage male with severe dysuria and gross hematuria. (B) Biopsy of mucosal lesion demonstrating eosinophilic infiltrate and no evidence of malignancy.

Hemorrhagic Cystitis

Hemorrhagic cystitis in children is almost always in relation to treatment for childhood malignancies especially hematologic. Cyclophosphamide or ifosfamide treatment is the most common risk factor, but this is thought to be exacerbated by viral infections such as BK virus, cytomegalovirus, and adenovirus in the immunocompromised child. Pelvic radiation can also lead to significant hemorrhagic cystitis. Urothelial toxic agents such as cyclophosphamide are now given with mercaptoethane sulfonate sodium (mesna) to prevent significant bleeding. **Bladder irrigation can be difficult and traumatic in these children because of the limited catheter sizes that can be used. Duthie et al. (2012) have shown improved success with an early detection protocol, catheter avoidance, and addition of oral sodium pentosan polysulfate.** This shows great promise and a way to avoid further trauma in these children (Duthie et al., 2012).

Key Points: Acquired Bladder Anomalies in Children

- Acquired bladder diverticula can become large enough to cause urinary obstruction or create stasis leading to recurrent UTIs.
- After resection of nephrogenic adenomas, routine cystoscopy is necessary because of an 80% recurrence rate in children.

- Cystitis cystica can mimic a bladder tumor and is best treated with long-term antibiotic prophylaxis.
- Eosinophilic cystitis has no “typical” appearance and requires biopsy for diagnosis.
- Cyclophosphamide therapy can lead to hemorrhagic cystitis. For prevention, mesna is given simultaneously, and oral sodium pentosan polysulfate shows promise.

Acknowledgments

We would like to recognize and thank Dr. Dominic Frimberger and Dr. Bradley Kropp for their exceptional and thorough work on the prior editions of this chapter. Much of their writing has been included in this edition and updated where applicable.

References

Abrahamson J. Double bladder and related anomalies: clinical and embryological aspects and a case report. *Br J Urol*. 1961;33:195–214.

Ahmed H, Howe AS, Dyer LL, et al. Robot-assisted laparoscopic urachal excision in children. *Urology*. 2017;106:103–106.

Al-Omar O, Fisher MB, Sarle R, et al. Eosinophilic cystitis in a neonate. *J Urol*. 2005;173:576.

Amar AD. Vesicoureteral reflux associated with congenital bladder diverticulum in boys and young men. *J Urol*. 1972;107:966–968.

Aragona F, Glazel GP, Zaramella P, et al. Agenesis of the bladder: a case report and review of the literature. *Urol Radiol*. 1988;10:207–209.

Ashley RA, Inman BA, Routh JC, et al. Urachal anomalies: a longitudinal study of urachal remnants in children and adults. *J Urol*. 2007;178:1615–1618.

Babbitt DP, Dobbs J, Boedecker RA. Multiple bladder diverticula in Williams ‘Elfin-Facies’ syndrome. *Pediatr Radiol*. 1979;8:29–31.

Barrett DM, Malek RS, Kelalis PP. Observations on vesical diverticulum in childhood. *J Urol*. 1976;116:234–236.

Bastianpillai C, Warner R, Beltran L, et al. Cystitis cystica and glandularis producing large bladder masses in a 16-year-old boy. *JRSM Open*. 2018;9 [2054270417746060].

Berman SM, Tolia BM, Laor E, et al. Urachal remnants in adults. *Urology*. 1988;31:17–21.

Berrocal T, López-Pereira P, Arjonilla A, et al. Anomalies of the distal ureter, bladder, and urethra in children: embryologic, radiologic, and pathologic features. *Radiogr Rev Publ Radiol*

Soc N Am Inc. 2002;22:1139–1164.

Berrocal T, Novak S, Arjonilla A, et al. Complete duplication of bladder and urethra in the coronal plane in a girl: case report and review of the literature. *Pediatr Radiol*. 1999;29:171–173.

Blane CE, Zerin JM, Bloom DA. Bladder diverticula in children. *Radiology*. 1994;190:695–697.

Blichert-Toft M, Nielsen OV. Congenital patient urachus and acquired variants. Diagnosis and treatment. Review of the literature and report of five cases. *Acta Chir Scand*. 1971;137:807–814.

Bornes M, Spaggiari E, Schmitz T, et al. Outcome and etiologies of fetal megacystis according to the gestational age at diagnosis. *Prenat Diagn*. 2013;33:1162–1166.

Braithwaite JM, Armstrong MA, Economides DL. Assessment of fetal anatomy at 12 to 13 weeks of gestation by transabdominal and transvaginal sonography. *Br J Obstet Gynaecol*. 1996;103:82–85.

Bronshtein M, Yoffe N, Brandes JM, et al. First and early second-trimester diagnosis of fetal urinary tract anomalies using transvaginal sonography. *Prenat Diagn*. 1990;10:653–666.

Cadeddu JA, Boyle KE, Fabrizio MD, et al. Laparoscopic management of urachal cysts in adulthood. *J Urol*. 2000;164:1526–1528.

Chen L, Cai A, Wang X, et al. Two- and three-dimensional prenatal sonographic diagnosis of prune-belly syndrome. *J Clin Ultrasound JCU*. 2010;38:279–282.

Cheng EY, Maizels M. Complete duplication of the bladder and urethra in the coronal plane: case report. *J Urol*. 1996;155:1414–1415.

Cheng L, Nascimento AG, Neumann RM, et al. Hemangioma of the urinary bladder. *Cancer*. 1999;86:498–504.

Christman MS, Casale P. Robot-assisted bladder diverticulectomy in the pediatric population. *J Endourol*. 2012;26:1296–1300.

Cilento BG, Bauer SB, Retik AB, et al. Urachal anomalies: defining the best diagnostic modality. *Urology*. 1998;52:120–122.

Duthie G, Whyte L, Chandran H, et al. Introduction of sodium pentosan polysulfate and avoidance of urethral catheterisation: improved outcomes in children with haemorrhagic cystitis post stem cell transplant/chemotherapy. *J Pediatr Surg*. 2012;47:375–379.

Efrat Z, Akinfenwa OO, Nicolaides KH. First-trimester determination of fetal gender by ultrasound. *Ultrasound Obstet Gynecol Off J Int Soc Ultrasound Obstet Gynecol*. 1999;13:305–307.

Esham W, Holt HA. Complete duplication of bladder and urethra: a case report. *J Urol*. 1980;123:773–775.

Fahlenkamp D, Schönberger B, Lindeke A, et al. Laparoscopic excision of the sinusoidal remnants of the urachus in a 3-year-old boy. *Br J Urol*. 1995;76:135–137.

Favre R, Kohler M, Gasser B, et al. Early fetal megacystis between 11 and 15 weeks of gestation. *Ultrasound Obstet Gynecol*. 1999;14:402–406.

Fontanella F, Duin L, Adama van Scheltema PN, et al. Fetal megacystis: prediction of spontaneous resolution and outcome. *Ultrasound Obstet Gynecol*. 2017;50:458–463.

Garat JM, Angerri O, Caffaratti J, et al. Primary congenital bladder diverticula in children. *Urology*. 2007;70:984–988.

Gastol P, Baka-Jakubiak M, Skobejko-Wlodarska L, et al. Complete duplication of the bladder, urethra, vagina, and uterus in girls. *Urology*. 2000;55:578–581.

Gaudet R, Heim N, Merviel P, et al. Prenatal diagnosis of a congenital bladder diverticulum. Case report and benefits of prenatal diagnosis. *Fetal Diagn Ther*. 1999;14:301–305.

Gearhart JP, Ben-Chaim J, Jeffs RD, et al. Criteria for the prenatal diagnosis of classic bladder exstrophy. *Obstet Gynecol*. 1995;85:961–964.

Gleason JM, Bowlin PR, Bagli DJ, et al. A comprehensive review of pediatric urachal anomalies and predictive analysis for adult urachal adenocarcinoma. *J Urol*. 2015;193:632–636.

Glenn JF. Agenesis of the bladder. *J Am Med Assoc*. 1959;169:2016–2018.

Goldman IL, Caldamone AA, Gauderer M, et al. Infected urachal cysts: a review of 10 cases. *J Urol*. 1988;140:375–378.

Goldman S, Szejnfeld PO, Rondon A, et al. Prenatal diagnosis of bladder exstrophy by fetal MRI. *J Pediatr Urol*. 2013;9:3–6.

Gosemann J, Puri P. Megacystis microcolon intestinal hypoperistalsis syndrome: systematic review of outcome. *Pediatr Surg Int*. 2011;27:1041–1046.

Green JJ, Hobbins JC. Abdominal ultrasound examination of the first-trimester fetus. *Am J Obstet Gynecol*. 1988;159:165–175.

Harrow BR. The myth of the megacystis syndrome. *J Urol*. 1967;98:205.

Hebert KL, Martin AD. Management of bladder diverticula in menkes syndrome: a case report and review of the literature. *Urology*. 2015;86:162–164.

Heidenreich A, Zirbes TK, Wolter S, et al. Nephrogenic adenoma: a rare bladder tumor in children. *Eur Urol*. 1999;36:348–353.

Hungerhuber E, Bach E, Hartmann A, et al. Adenocarcinoma of the bladder following nephrogenic adenoma: a case report. *J Med Case Rep*. 2008;2:164.

Huppmann AR, Pawel BR. Polyps and masses of the pediatric urinary bladder: a 21-year pathology review. *Pediatr Dev Pathol Off J Soc Pediatr Pathol Paediatr Pathol Soc*. 2011;14:438–444.

Hutch JA. Saccule formation at the ureterovesical junction in smooth walled bladders. *J Urol*. 1961;86:390–399.

Hutton KA, Thomas DF, Arthur RJ, et al. Prenatally detected posterior urethral valves: is gestational age at detection a predictor of outcome? *J Urol*. 1994;152:698–701.

Indiran V, Chokkappan K, Gunaseelan E. Rare case of urinary bladder agenesis–multislice CT abdomen imaging. *J Radiol Case Rep*. 2013;7:44–49.

Jayanthi VR, McLorie GA, Khoury AE, et al. Extravesical detrusorrhaphy for refluxing ureters associated with paraureteral diverticula. *Urology*. 1995;45:664–666.

Kagan KO, Staboulidou I, Syngelaki A, et al. The 11-13-week scan: diagnosis and outcome of holoprosencephaly, exomphalos and megacystis. *Ultrasound Obstet Gynecol Off J Int Soc Ultrasound Obstet Gynecol*. 2010;36:10–14.

Kao C-S, Kum JB, Fan R, et al. Nephrogenic adenomas in pediatric patients: a morphologic and immunohistochemical study of 21 cases. *Pediatr Dev Pathol Off J Soc Pediatr Pathol Paediatr Pathol Soc*. 2013;16:80–85.

Khurana S, Borzi PA. Laparoscopic management of complicated urachal disease in children. *J Urol*. 2002;168:1526–1528.

Kossow JH, Morales PA. Duplication of bladder and urethra and associated anomalies. *Urology*. 1973;1:71–73.

Krull CL, Heyns CF, de Klerk DP. Agenesis of the bladder and urethra: a case report. *J Urol*. 1988;140:793–794.

Levard G, Aigrain Y, Ferkadji L, et al. Urinary bladder diverticula and the Ehlers-Danlos syndrome in children. *J Pediatr Surg*. 1989;24:1184–1186.

Liao AW, Sebire NJ, Geerts L, et al. Megacystis at 10-14 weeks of gestation: chromosomal defects and outcome according to bladder length. *Ultrasound Obstet Gynecol*. 2003;21:338–341.

Livne PM, Gonzales ET. Congenital bladder diverticula causing ureteral obstruction. *Urology*. 1985;25:273–276.

Maizels M, Alpert SA, Houston JTB, et al. Fetal bladder sagittal length: a simple monitor to assess normal and enlarged fetal bladder size, and forecast clinical outcome. *J Urol*. 2004;172:1995–1999.

Mallmann MR, Reutter H, Müller A, et al. Prenatal diagnosis of covered cloacal exstrophy. *Fetal Diagn Ther*. 2014;36:333–336.

Maruschke M, Kreutzer HJ, Seiter H. [Bladder rupture caused by spontaneous perforation of an infected urachal cyst]. *Urol Ausg A*. 2003;42:834–839.

McHugo J, Whittle M. Enlarged fetal bladders: aetiology, management and outcome. *Prenat Diagn*. 2001;21:958–963.

Mendoza CB, Cueto J, Payan H, et al. Complete urachal tract associated with Meckel's diverticulum. *Arch Surg Chic Ill 1960*. 1968;96:438–439.

Mesrobian HG, Zacharias A, Balcom AH, et al. Ten years of experience with isolated urachal anomalies in children. *J Urol*. 1997;158:1316–1318.

Mirk P, Calisti A, Fileni A. Prenatal sonographic diagnosis of bladder extrophy. *J Ultrasound Med*. 1986;5:291–293.

Moore KL, Persaud TVN, Torchia MG. Urogenital system. *The developing human*. Elsevier: Philadelphia, PA; 2011:255–297.

Müller Brochut A-C, Thomann D, Kluwe W, et al. Fetal megacystis: experience of a single tertiary center in Switzerland over 20 years. *Fetal Diagn Ther*. 2014;36:215–222.

Muller F, Dreux S, Vaast P, et al. Prenatal diagnosis of megacystis-microcolon-intestinal hypoperistalsis syndrome: contribution of amniotic fluid digestive enzyme assay and fetal urinalysis. *Prenat Diagn*. 2005;25:203–209.

Nazer II, Alhashmi G, Sharief SN, et al. A case of urinary bladder agenesis and bilateral ectopic ureters: a case report. *BMC Urol*. 2018;18:83.

Nix JT, Menville JG, Albert M, et al. Congenital patent urachus. *J Urol*. 1958;79:264–273.

Numanoğlu KV, Tatli D. A rare cause of hemorrhagic shock in children: bladder hemangioma. *J Pediatr Surg*. 2008;43:e1–e3.

Ohgaki M, Higuchi A, Chou H, et al. Acute peritonitis caused by intraperitoneal rupture of an infected urachal cyst: report of a case. *Surg Today*. 2003;33:75–77.

van den Ouden D. Diagnosis and management of eosinophilic cystitis: a pooled analysis of 135 cases. *Eur Urol*. 2000;37:386–394.

Paquin AJ, Marshall VF, McGOVERN JH. The megacystis syndrome. *J Urol*. 1960;83:634–646.

Pellegrino M, Visconti D, Catania VD, et al. Prenatal detection of megacystis: not always an adverse prognostic factor. Experience in 25 consecutive cases in a tertiary referral center, with complete neonatal outcome and follow-up. *J Pediatr Urol*. 2017;13:486.e1–486.e10.

Perez-Brayfield MR, Kirsch AJ, Jones RA, et al. A prospective study comparing ultrasound, nuclear scintigraphy and dynamic contrast enhanced magnetic resonance imaging in the evaluation of hydronephrosis. *J Urol*. 2003;170:1330–1334.

Perren F, Frey P. The exstrophy-epispadias complex in the duplicated lower urinary tract. *J Urol*. 1998;159:1681–1683.

Quek ML, Shpall AI, Daneshmand S. Colourachal fistula in an adult presenting with feculent umbilical drainage. *J Urol*.

2003;170:184.

Razvi S, Murphy R, Shlasko E, et al. Delayed separation of the umbilical cord attributable to urachal anomalies. *Pediatrics*. 2001;108:493–494.

Robyr R, Benachi A, Daikha-Dahmane F, et al. Correlation between ultrasound and anatomical findings in fetuses with lower urinary tract obstruction in the first half of pregnancy. *Ultrasound Obstet Gynecol*. 2005;25:478–482.

Rosati P, Guariglia L. Transvaginal sonographic assessment of the fetal urinary tract in early pregnancy. *Ultrasound Obstet Gynecol*. 1996;7:95–100.

Rosenblum S, Pal A, Reidy K. Renal development in the fetus and premature infant. *Semin Fetal Neonatal Med*. 2017;22:58–66.

Schiesser M, Lapaire O, Holzgreve W, et al. Umbilical cord edema associated with patent urachus. *Ultrasound Obstet Gynecol*. 2003;22:646–647.

Schreck WR, Campbell WA. The relation of bladder outlet obstruction to urinary-umbilical fistula. *J Urol*. 1972;108:641–643.

Schubert GE, Pavkovic MB, Bethke-Bedürftig BA. Tubular urachal remnants in adult bladders. *J Urol*. 1982;127:40–42.

Sebire NJ, Von Kaisenberg C, Rubio C, et al. Fetal megacystis at 10-14 weeks of gestation. *Ultrasound Obstet Gynecol*. 1996;8:387–390.

Sheldon CA, Essig K. Congenital bladder diverticulum causing bladder outlet obstruction: case report and review of the literature. *Pediatr Surg Int*. 1994;9:141–143.

Sheu JC, Huang YH, Chang PY, et al. Results of surgery for vesicoureteral reflux in children: 6 years’ experience in an Asian country. *Pediatr Surg Int*. 1998;13:138–140.

Sparks S, Kaplan A, DeCambre M, et al. Eosinophilic cystitis in the pediatric population: a case series and review of the literature. *J Pediatr Urol*. 2013;9:738–744.

Stephens F. *Congenital malformations of the rectum, anus and genito-urinary tracts*. Williams & Wilkins: Baltimore; 1963.

Taghavi K, Sharpe C, Stringer MD. Fetal megacystis: a systematic review. *J Pediatr Urol*. 2017;13:7–15.

Takeuchi H, Koyanagi T, Yoshizato T, et al. Fetal urine production at different gestational ages: correlation to various compromised fetuses in utero. *Early Hum Dev*. 1994;40:1–11.

Tsakiri A, Balslev I, Klarskov P. Eosinophilic cystitis induced by penicillin. *Int Urol Nephrol*. 2004;36:159–161.

Turial S, Hueckstaedt T, Schier F, et al. Laparoscopic treatment of urachal remnants in children. *J Urol*. 2007;177:1864–1866.

Tuzovic L, Tang S, Miller RS, et al. New insights into the genetics of fetal megacystis: ACTG2 mutations, encoding γ-2 smooth muscle actin in megacystis microcolon intestinal hypoperistalsis syndrome (Berdon Syndrome). *Fetal Diagn Ther*. 2015;38:296–306.

Upadhyay V, Kukkady A. Urachal remnants: an enigma. *Eur J Pediatr Surg Off J Austrian Assoc Pediatr Surg Al Z Kinderchir*. 2003;13:372–376.

Voss K, Peppas D. Recurrent nephrogenic adenoma: a case report of resolution after treatment with antibiotics and nonsteroidal anti-inflammatory medication. *Urology*. 2013;82:1156–1157.

Williams DI. Congenital bladder-neck obstruction and megaureter; clinical observations. *Br J Urol*. 1957;29:389–392.

Wymer KM, Anderson BB, Wilkens AA, et al. Megacystis microcolon intestinal hypoperistalsis syndrome: case series and updated review of the literature with an emphasis on urologic management. *J Pediatr Surg*. 2016;51:1565–1573.

Yu TJ. Extravesical diverticuloplasty for repair of a paraureteral diverticulum and the associated refluxing ureter. *J Urol*.

2002;168:1135–1137.

Zia-Ul-Miraj M. Congenital bladder diverticulum: a rare cause of bladder outlet obstruction in children. *J Urol*. 1999;162:2112–2113.

31

Exstrophy-Epispadias Complex

John P. Gearhart MD, Heather N. Di Carlo MD

The exstrophy-epispadias complex of genitourinary malformations can be as simple as a glanular epispadias or an overwhelming multisystem defect such as cloacal exstrophy (Fig. 31.1). This chapter provides a comprehensive overview of the entire bladder exstrophy–epispadias–cloacal exstrophy spectrum. In addition, all modern methods of exstrophy management and their complications and outcomes are discussed.

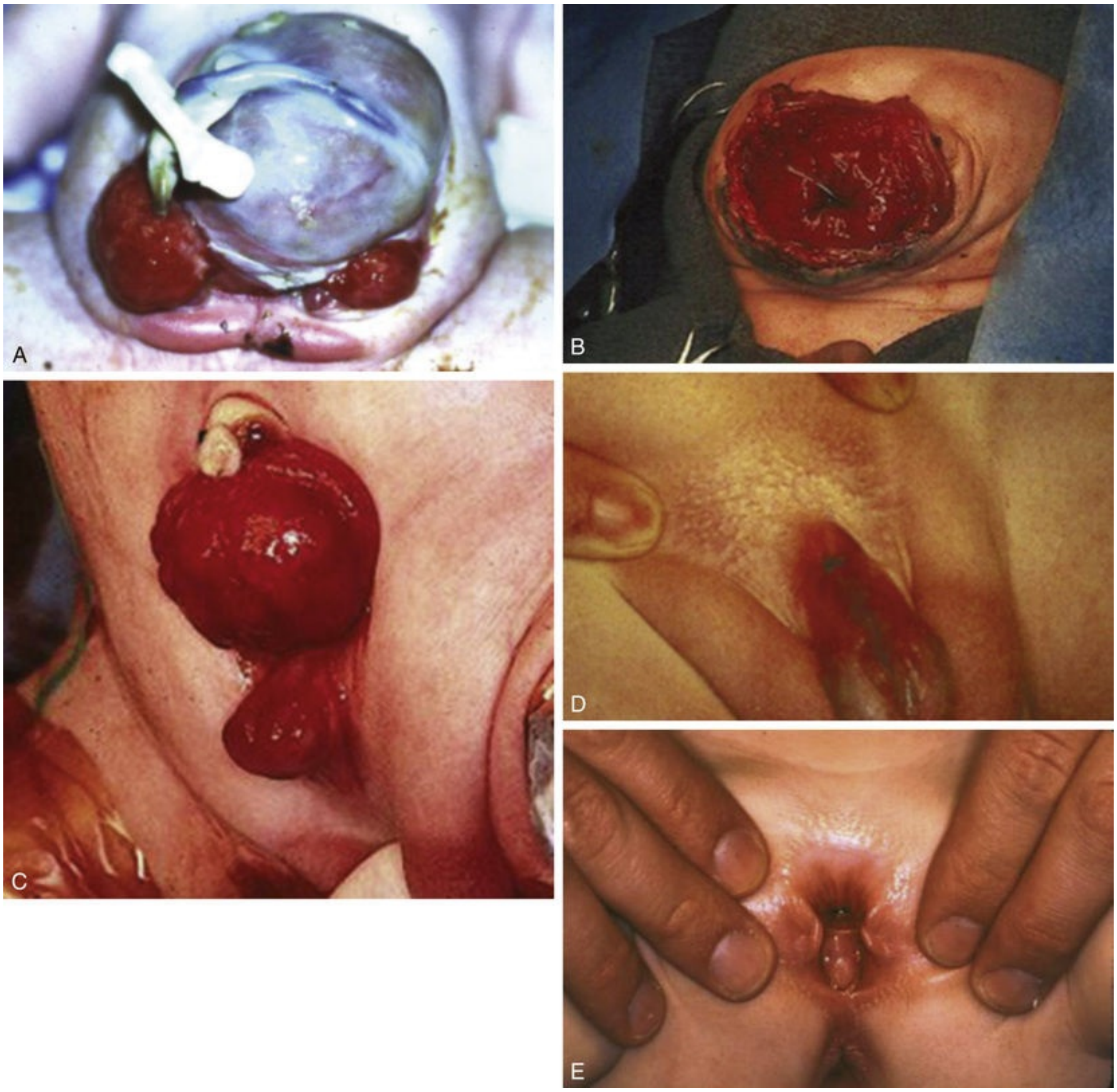

FIG. 31.1 Entities that constitute the exstrophy-epispadias complex. (A) Cloacal exstrophy. (B) Superior vesical fissure. (C) Classic bladder exstrophy. (D) Male epispadias. (E) Female epispadias.

Historical Aspects

In older texts, the first account of bladder exstrophy was ascribed to Assyrian-Babylonian sources dating from the first and second millennia BCE. At that time, birth anomalies in humans and animals were carefully recorded on tablets for their importance as omens, based on their interpretation by divination experts. Feneley and Gearhart (2000) examined Assyrian-Babylonian descriptions of congenital anomalies from cuneiform texts at the British Museum in London. Although references to anomalies involving the external genitalia were frequent (e.g., hermaphroditism, absence of external genitalia, unilateral and bilateral undescended testes), references to renal and bladder anomalies were few and difficult to interpret medically. Duplication and laterality of anomalies were described in detail because of their distinct significance, but malformations in combination were not recorded. On the basis of these studies performed with a prominent Assyriologist, a definitive description of bladder or cloacal exstrophy was not corroborated. **The first described case of epispadias is attributed to the Byzantine emperor Heraclius (CE 610–641), and the first description of cloacal exstrophy to Schenck in 1595** (Feneley and Gearhart, 2000).

Incidence and Inheritance

The incidence of bladder exstrophy is estimated to be 2.15 cases per 100,000 live births in the United States (Nelson et al., 2005a; Siffel et al., 2011). An internationally conducted prospective study places the incidence of bladder exstrophy at 1/46,000 live births (Cervellione et al., 2015). The male-to-female ratio of bladder exstrophy derived from multiple series is 2.3 : 1 (Shapiro et al., 1984). However, two series reported a 5 : 1 to 6 : 1 male-to-female ratio of exstrophy births (Ives et al., 1980; Lancaster, 1987).

The risk of recurrence of bladder exstrophy in a given family is approximately 1 in 100 (Ives et al., 1980). Shapiro et al. (1985) in a questionnaire identified the recurrence of exstrophy and epispadias in only 9 of approximately 2500 indexed cases. Lattimer and Smith (1966) cited a set of identical twins with bladder exstrophy and another set of twins in whom only one child had exstrophy. Shapiro's series identified five sets of male and female nonidentical twins in whom only one twin was affected with exstrophy; five sets of male identical twins in whom both twins were affected; one set of identical male twins in whom only one twin was affected; and three sets of female identical twins in whom only one twin had the exstrophy anomaly (Shapiro et al., 1984). Reutter et al. (2003) have demonstrated six families with two occurrences of the exstrophy-epispadias complex, one in which the proband was the product of a consanguineous union and four discordant twin pairs. Also, Boyadjiev et al. (2004a) found four multiplex families (2.7%) in a cohort of 151 families with the exstrophy-epispadias complex. There were three twin pairs, two of which were monozygotic, and concordance was present in only one of the twin pairs. Consanguinity was present in one family. Bladder exstrophy or epispadias was not reported until the 1980s in the offspring of parents with the exstrophy-epispadias complex. **Shapiro et al.** (1984) **determined that the risk of bladder exstrophy in the offspring of individuals with bladder exstrophy and epispadias is 1 in 70 live births, a 500-fold greater incidence than in the general population.** Boyadjiev et al. (2004a) studied sibling data from 200 families and found 259 unaffected children in addition to the probands with exstrophy. Twenty-six probands had first-, second-, or third-degree relatives with congenital anomalies unrelated to the exstrophy-epispadias complex, most of which were midline defects and oral clefts. Four probands had a total of seven biologic children who were unaffected. Data from Boyadjiev et al. (2004a) indicate that the average maternal age for exstrophy mothers was 34 years and the average paternal age was 32 years. In addition, 49% of probands were born from first pregnancies. This may represent societal changes indicating advancing maternal age for first pregnancies and increased risk of exstrophy when assisted reproductive techniques are used (Wood et al., 2003).

A (2011) multi-institutional study from North America and Europe involving an analysis of 441 families divided the study into mild epispadias (n = 43), intermediate-classic exstrophy (n = 366), and severe (cloacal) exstrophy (n = 31). Males were over-represented in all groups. Cleft lip and cleft palate were seen in a high prevalence. Maternal smoking during the first trimester was associated closely with cloacal exstrophy, and maternal preconception folic acid supplementation was associated with the mildest phenotype (epispadias) (Reutter et al., 2011).

Exploration of possible causes for the exstrophy-epispadias complex continues. A report from Israel indicated a 10-fold increase in exstrophy births to mothers who had received large doses of progesterone in the early part of the first trimester. Wood et al. (2003) reported on a sizable series of children with exstrophy conceived using assisted reproductive techniques. A 7.5-fold increase in incidence was noted when in vitro fertilization (IVF) was used. These two reports indicate a role for hormonal changes in the cause of the exstrophy-epispadias complex. In a large series of 214 females, no association with parental age, maternal reproductive history, or periconception maternal exposure to alcohol, drugs, radiation, or infections was found (Gambhir et al., 2008). However, periconception maternal exposure to smoking was significantly more common in patients with cloacal exstrophy than in the combined group of patients with classic exstrophy-epispadias.

Genetic studies to identify a genetic locus for the exstrophy-epispadias complex are underway. **Boyadjiev et al.** (2004b) **have reported finding a breakpoint disruption in the 5′ region of the *CASPR3* gene on chromosome 9. This observation is the first to suggest a possible genetic basis for development of the exstrophy-epispadias complex.** In another recent study by Ludwig et al. (2009), risk loci for the exstrophy spectrum were found in seven separate chromosomes, with susceptibility genes in several regions. *P63*, a member of the *p53* tumor suppressor gene, has been implicated in the potential association with bladder exstrophy. The N-terminal truncated isoform of p63, ΔNp63, promotes stem-cell proliferation while inhibiting apoptosis and may play a role in the development of abdominal and ventral bladder wall (Cheng et al., 2006). Compared with patients with normal control, bladder exstrophy patients have been shown to have decreased ΔNp63 expression in the bladder epithelium (Wilkins et al., 2012). Still, no genomic mutations of *p63* have yet been identified in bladder exstrophy patients (Ching et al., 2010).

Qi et al. (2011) used genome-wide expression profiling to identify 162 bladder exstrophy-epispadias complex candidate genes that had twofold or higher expression differences between exstrophic and normal bladder smooth muscles in mouse and human embryologic bladder tissues. They also found 16 candidate genes that are expressed in the infraumbilical endoderm and mesoderm. Most of these genes have functions related to cellular assembly, musculoskeletal system development, and connective tissue morphology. Specifically, 30% of these genes were related to the desmosomal structure and cytoskeleton assembly, of which 69% were underexpressed in exstrophic bladders. In this study, the two most downregulated genes in exstrophic bladders, desmin and desmuslin, encode muscle-specific proteins that interact with desmoplakin, the sixth most overexpressed gene in exstrophic bladders. New data from Ching et al. (2010) and Qi et al. (2013) have shown significant dysregulation of *p63* in tissue from newborns with bladder exstrophy. More recent developments in genome-wide association studies implicate other potential gene loci responsible for bladder exstrophy. For example, the *ISL 1* gene located on chromosome 5q11.1, which encodes a LIM zinc-binding/homeobox-domain transcription factor, has been shown to have association with bladder exstrophy. In murine models, this gene has shown a developmental role in the genital area, thus providing additional evidence for a susceptibility gene (Draaken et al., 2015). *ISL 1* was further implicated in association with classic bladder exstrophy (CBE) in a large genome-wide association case-control study of 268 CBE patients and 1354 matched controls. A meta-analysis of a small nucleotide polymorphism marker located at the *ISL 1* locus of chromosome 5q11.2 was significantly associated with CBE ($P < 0.001$) (Zhang et al., 2017). *ISL 1* has been shown to regulate factors associated with development of the genital tubercle, such as Bmp4, Fgf10, and Wnt5a (Ching et al., 2018). Continuing research in this cutting edge field will provide more clarity into the role of genetics in exstrophy.

Embryology

Bladder exstrophy, cloacal exstrophy, and epispadias are variants of the exstrophy-epispadias complex (see Fig. 31.1). The cause of this complex is thought to be the failure of the cloacal membrane to be reinforced by ingrowth of mesoderm (Muecke, 1964). The cloacal membrane is a bilaminar layer situated at the caudal end of the germinal disk that occupies the infraumbilical abdominal wall. Mesenchymal ingrowth between the ectodermal and endodermal layers of the cloacal membrane results in formation of the lower abdominal muscles and the pelvic bones. The cloacal membrane is subject to premature rupture, and, depending on the extent of the infraumbilical defect and the stage of development during which the rupture occurs, bladder exstrophy, cloacal exstrophy, or epispadias results (Ambrose and O'Brien, 1974).

After mesenchymal ingrowth occurs, the urorectal septum grows in a caudal direction and divides the cloaca into a bladder anteriorly and a rectum posteriorly (Fig. 31.2). Distally, the septum meets the posterior remnant of the bilaminar membrane, which eventually perforates and forms the urogenital and anal openings. The paired genital tubercles migrate medially and fuse in the midline, cephalad to the dorsal membrane before perforation.

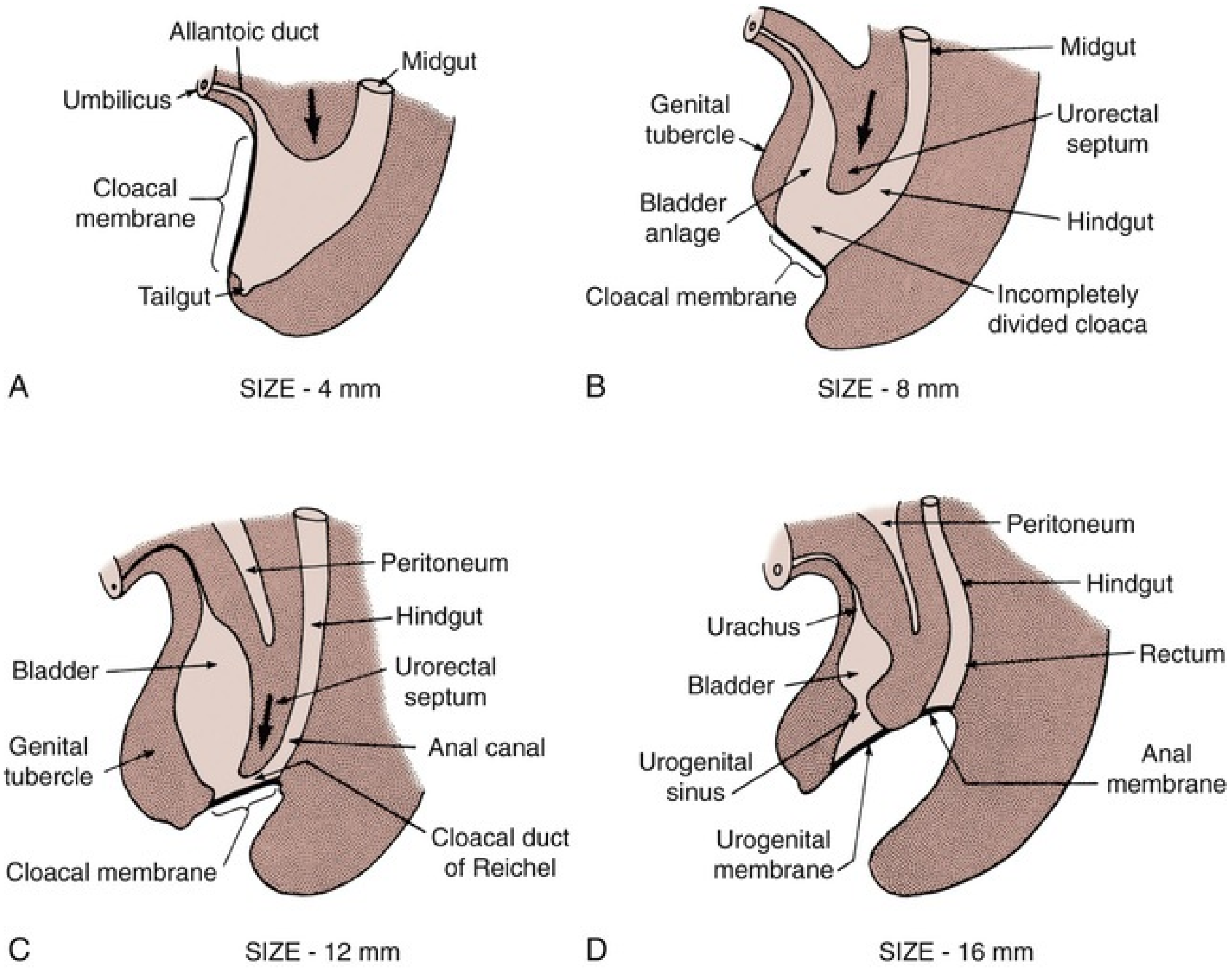
Allantoic duct
Umbilicus
Midgut
Cloacal membrane
Tailgut
A
SIZE - 4 mm
Genital tubercle
Midgut
Urorectal septum
Bladder anlage
Hindgut
Cloacal membrane
Incompletely divided cloaca
B
SIZE - 8 mm
Peritoneum
Hindgut
Bladder
Urorectal septum
Genital tubercle
Anal canal
Cloacal membrane
Cloacal duct of Reichel
C
SIZE - 12 mm
Peritoneum
Hindgut
Urachus
Rectum
Bladder
Urogenital sinus
Anal membrane
Urogenital membrane
D
SIZE - 16 mm

FIG. 31.2 Development of the cloaca and cloacal membrane in the 4- to 160-mm embryonic stages. Caudal growth of the urorectal septum leads to separation of the anterior urogenital sinus from the posterior rectum.

The theory of embryonic maldevelopment in exstrophy held by Marshall and Muecke (1968) **is that the basic defect is an abnormal overdevelopment of the cloacal membrane during the fourth week of gestation, which prevents medial migration of the mesenchymal tissue and proper lower abdominal wall development.** The timing of the rupture of this defective cloacal membrane determines the variant of the exstrophy-epispadias complex that results. Classic exstrophy accounts for more than 50% of the patients born with this complex (Marshall and Muecke, 1968; Muecke, 1964). Martinez-Frias et al. (2001), using epidemiologic factors of low birth weight, twinning, single umbilical artery, and associated defects, postulated that cloacal exstrophy and exstrophy of the bladder are two different expressions of a primary developmental field defect; cloacal exstrophy is an early defect. It has been postulated that one or both of the lateral body wall folds fail to move far enough ventrally to meet its counterpart in the midline (Sadler and Feldkamp, 2008).

Thus, if closure fails in the abdominal and pelvic region, cloacal exstrophy results, and if failure occurs in the pelvis alone, classic exstrophy occurs.

Other plausible theories concerning the cause of the exstrophy-epispadias complex exist. Abnormal development of the genital hillocks caudal to the normal position, with fusion in the midline below rather than above the cloacal membrane, has been embraced by other investigators (Ambrose and O'Brien, 1974; Patton and Barry, 1952). Another interesting hypothesis that remains controversial describes an abnormal caudal insertion of the body stalk, which results in a failure of interposition of the mesenchymal tissue in the midline (Mildenberger et al., 1988). As a consequence of this failure, translocation of the cloaca into the depths of the abdominal cavity does not occur. A cloacal membrane that remains in a superficial infraumbilical position represents an unstable embryonic state with a strong tendency to disintegrate (Johnston and Kogan, 1974), which has been supported by the laboratory work of Thomalla et al. (1985).

Another interesting theory is that maldevelopment of the bony pelvis rather is the inciting issue for the development of exstrophy. Beaudoin et al. (1997) have suggested that lack of “rotation” of the pelvic ring primordium prevents structures attached to the pelvic ring from joining in the midline, allowing herniation of the bladder to occur. The cause of this inadequate rotation remains elusive.

Key Points: The Exstrophy-Epispadias Complex

- The incidence of bladder exstrophy in the United States is estimated to be 2.15 cases per 100,000 live births.
- Bladder exstrophy, cloacal exstrophy, and epispadias are variants of the exstrophy-epispadias complex.
- In classic bladder exstrophy, most anomalies are related to defects of the abdominal wall, bladder, genitalia, pelvic bones, rectum, and anus.
- The male genital defect is severe and remains the most troublesome aspect of the surgical reconstruction.
- In females, the vagina is shorter than normal, hardly greater than 6 cm in depth, but of normal caliber. The vaginal orifice is frequently stenotic and displaced anteriorly, the clitoris is bifid, and the labia, mons pubis, and

clitoris are divergent.

Classic Bladder Exstrophy

Anatomic Considerations

Exstrophy of the bladder is part of a spectrum of anomalies involving the urinary tract, the genital tract, the musculoskeletal system, and sometimes the intestinal tract. In CBE, most anomalies are related to defects of the abdominal wall, bladder, genitalia, pelvic bones, rectum, and anus. Because of the involved nature of this defect, the deficits are described here as they affect each system.

Bony Pelvis and Spinal Defects

Formerly, CBE was thought to show only the characteristic widening of the pubic symphysis caused by malrotation of the innominate bones with an outward rotation or eversion of the pubic rami at their junction with the iliac bones. **However, modern imaging using three-dimensional (3D) computed tomography (CT) has demonstrated previously unknown rotational and dimensional abnormalities** (Sponseller et al., 1995). **Rotational anomalies include (1) external rotation of the posterior pelvis/iliac wings; (2) external rotation of the anterior pelvic segment; (3) coronal rotation of the sacroiliac joint; (4) acetabular retroversion; (5) convergence of iliac wings; and (6) femoral retroversion. Dimensional anomalies include (1) increased pubic diastasis; (2) shortened anterior pubic segment (30%); and (3) increased intertriradiate cartilage distance.**

Sponseller et al. (1995), using CT of the pelvis with 3D reconstruction, were the first to accurately characterize the exact bony defect associated with CBE and cloacal exstrophy. In reviewing a large group of patients with exstrophy of the bladder, using pelvic CT scans and age-matched controls, Sponseller et al. (1995) found that patients with CBE have a mean external rotation of the posterior pelvis of 12 degrees on each side, along with retroversion of the acetabulum, and a mean 18 degrees of external rotation of the anterior pelvis, along with 30% shortening of the pubic rami, in addition to the previously described diastasis of the symphysis pubis (Fig. 31.3). In long-term follow-up there was a foot progression angle of 20 to 30 degrees of external rotation beyond the normal limits seen in early childhood, which improves with age. Likewise, patients with cloacal exstrophy not only had pelvic deformities to a greater degree but also had asymmetry of the preceding parameters between the right and left sides of the pelvis, malformation of the sacroiliac joints, and occasional dislocations of the hip (Sponseller et al., 1995).

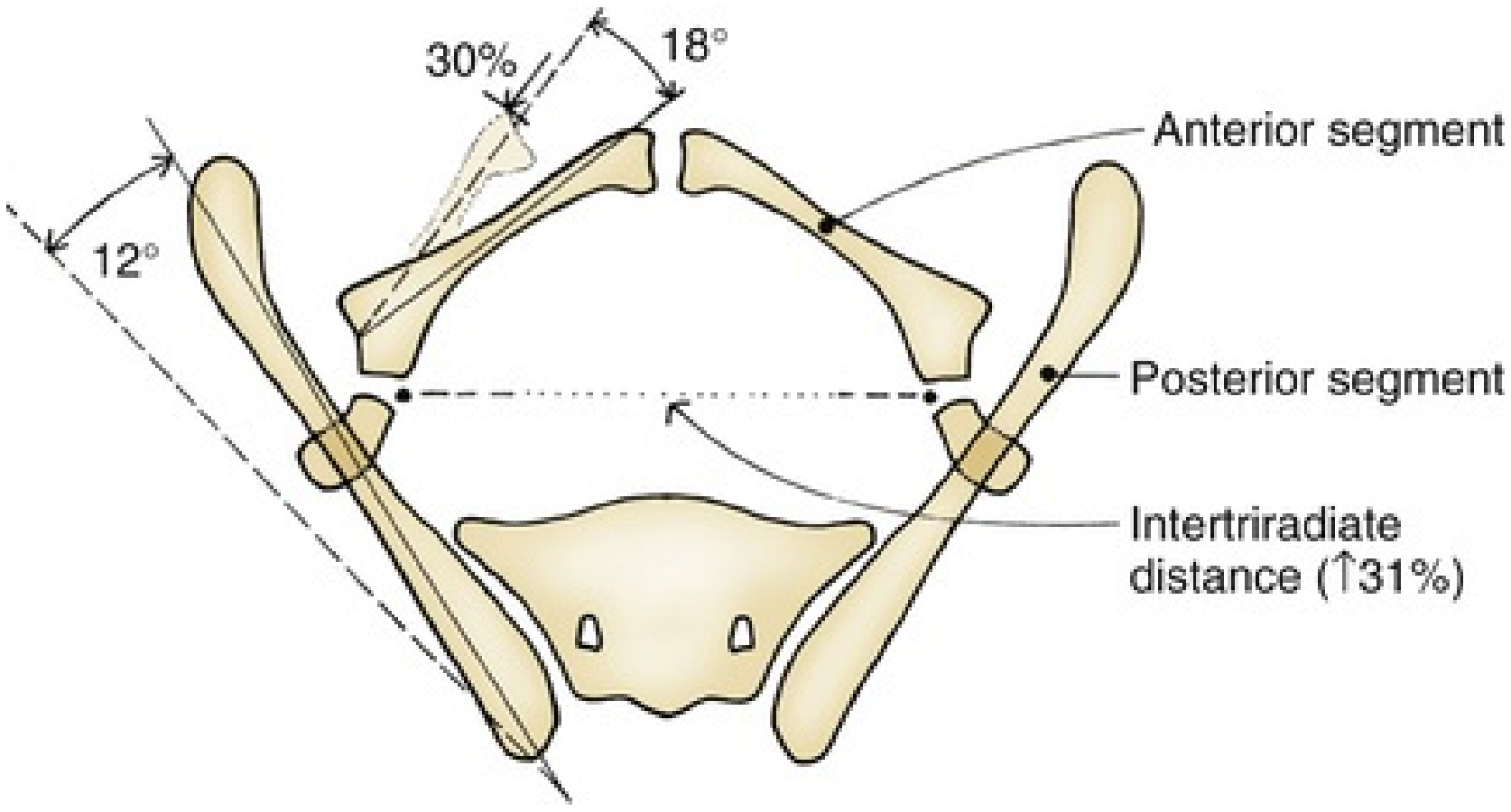

FIG. 31.3 Pelvic bone abnormalities noted in classic bladder exstrophy. The posterior bone segment is externally rotated (12 degrees mean on each side), but the length is unchanged. The anterior segment is externally rotated (18 degrees mean on each side) and shortened by 30%. The distance between the triradiate cartilage is increased by 31%.

Data from Stec et al. (2001a), who used 3D models from CT scans, found the sacroiliac joint angle (before closure) was 10 degrees larger than controls in the exstrophy pelvis, being 10 degrees more toward the coronal plane than sagittal (Fig. 31.4); the exstrophy pelvis had 14.7 degrees more inferior rotation than controls. In addition, the sacrum in exstrophy patients has a 42.6% larger volume and 23.5% more surface area than in controls.

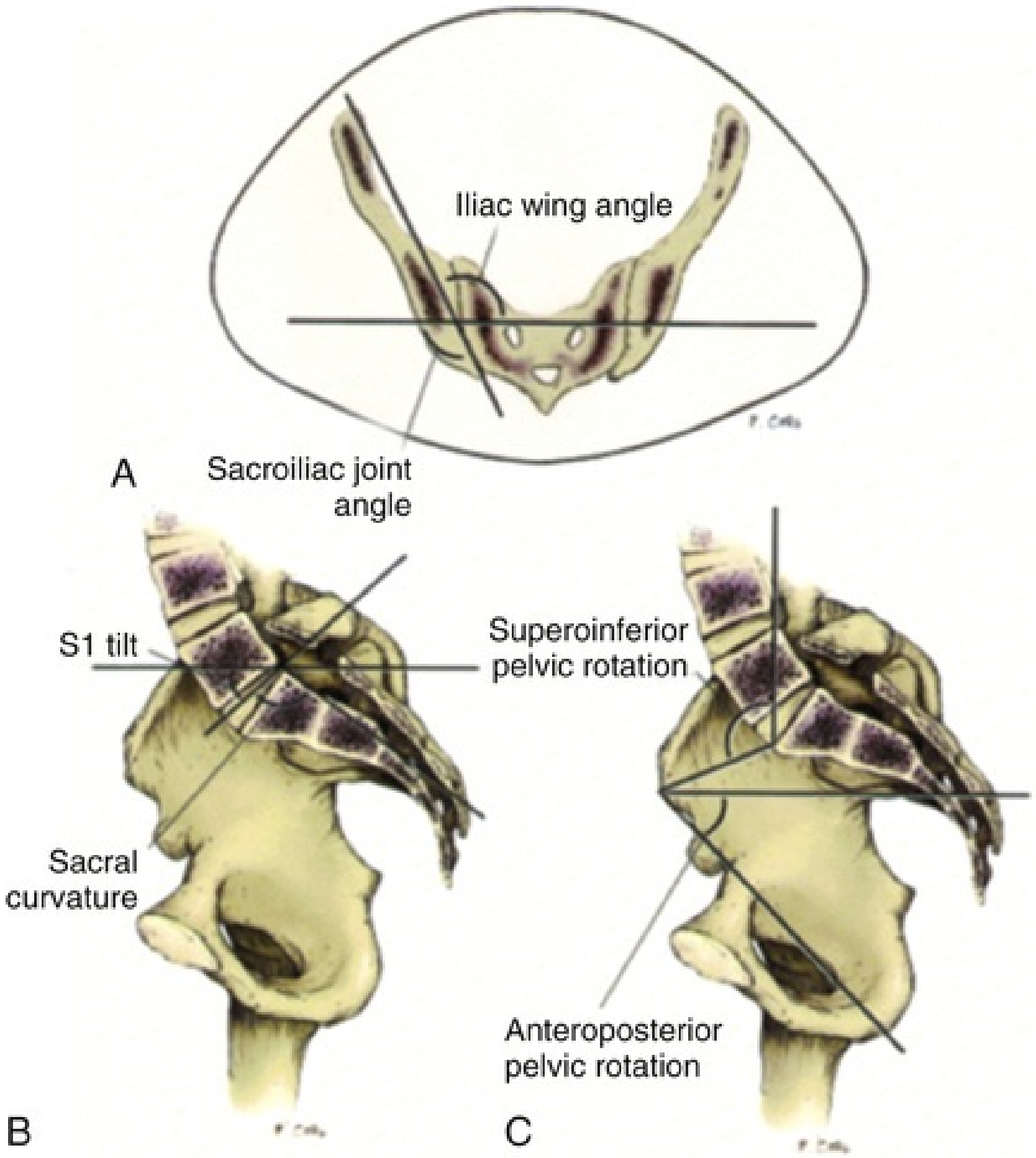

FIG. 31.4 Sacroiliac joint angles before closure in children with classic exstrophy 10 degrees larger than normal controls. The bony pelvis has 14.7 degrees inferior rotation compared with normal controls. (From Stec AA, Pannu HK, Tadros YE, et al: Evaluation of the bony pelvis in classic bladder exstrophy using 3D CT—further insights. *Urology.* 58:1030, 2001.)

These rotational deformities of the pelvic skeletal structures contribute to the short, pendular penis seen in bladder exstrophy. Outward rotation and lateral displacement of the innominate bones also accounts for the increased distance between the hips, waddling gait, and outward rotation of the lower limbs in these children, which causes little disability and usually corrects to some degree over time. The 30% shortage of bone in the exstrophy pelvis has largely gone unexplained. Studies by Stec and Gearhart (2003) about using sections from the entire bony pelvis in fetal exstrophy specimens and normal aborted fetuses reported that the ultrastructure, bone development, microscopic growth patterns, and endochondral ossification were absolutely the same. Thus restoration of the physiologic shape of the pelvis may lead to more normal bone growth, decreased shortage of bone, and a more appropriate distribution of the mechanical and developmental forces on a more closed, normally functioning pelvic ring.

The incidence of spinal anomalies in exstrophy had formerly not been well studied. A large study of 299 children with bladder exstrophy from a single center indicated spinal variations without clinical significance (spina bifida occulta, lumbarization or sacralization of vertebrae) in 11%, uncomplicated scoliosis in 2.7%, and spinal dysraphism in 4%, including myelomeningocele, lipomeningocele, scimitar sacrum, and hemivertebrae, but only 1 patient demonstrated any evidence of neurologic dysfunction (Cadeddu et al., 1997).

Pelvic Floor Defects

Stec et al. (2001b), using 3D models created from CT scans of children with CBE and normal age-matched controls, found that the puborectal slings were supporting two times more body cavity area than normal. The levator ani group is positioned more posteriorly in exstrophy patients, with 68% located posterior to the rectum and 32% anterior (vs. 52% posterior and 48% anterior in healthy controls) (Fig. 31.5). The levators are also rotated outward 15.5 degrees, and in the coronal aspect the levators are 31.7 degrees more flattened than normal. This deviation from normal makes the exstrophy puborectal sling more flattened than its normal conical shape. There was no significant difference in the length or thickness of these muscles between patients with exstrophy and controls.

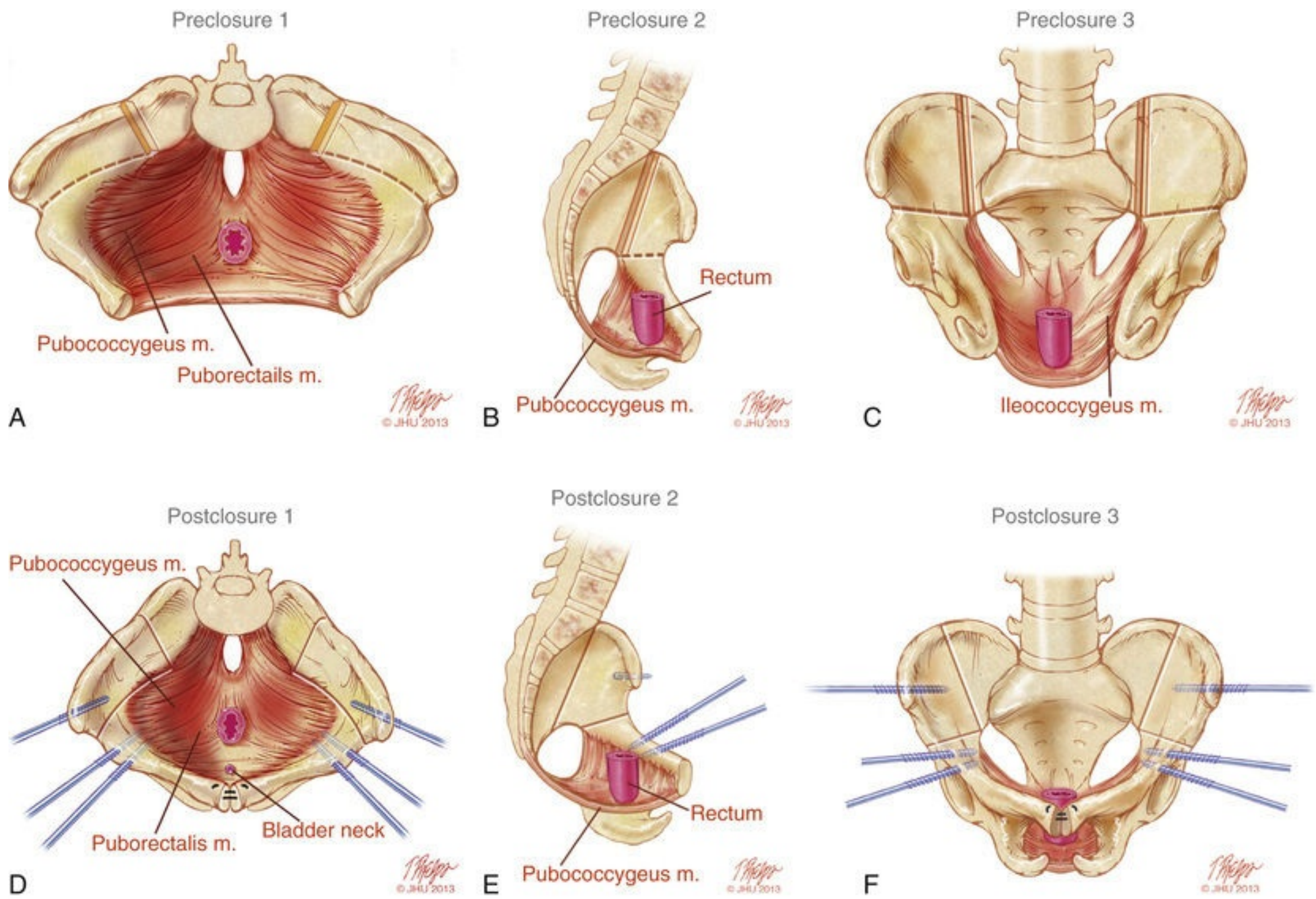
Preclosure 1
Preclosure 2
Preclosure 3
Rectum
Pubococcygeus m.
Puborectails m.
A
© JHU 2013
B
Pubococcygeus m.
© JHU 2013
C
Ileococcygeus m.
© JHU 2013
Postclosure 1
Postclosure 2
Postclosure 3
Pubococcygeus m.
Bladder neck
Puborectalis m.
Rectum
D
© JHU 2013
E
Pubococcygeus m.
© JHU 2013
F
© JHU 2013

FIG. 31.5 (A) Pelvic floor anatomy before closure of exstrophy. Osteotomy incisions marked. (B) Lateral view of pelvic floor anatomy showing postdisplacement of pelvic floor muscles behind rectum. (C) Head-on view of pelvic floor musculature showing paucity of anterior pelvic floor musculature. (D) Pelvic floor anatomy after pelvic bony closure with intrafragmentary pins placed and bony apposition. (E) Lateral view of pelvic floor anatomy after closure showing new anterior distribution of pelvic floor musculature and pin placement. (F) Head-on view of pelvic floor musculature showing new anterior distribution of muscle and bony apposition. (Used with permission of Brady Urological Institute.)

A comparison of 3D magnetic resonance imaging (MRI) in children with exstrophy before closure and normal controls indicated that the levator ani group was less dome shaped and more irregular in those with exstrophy (Williams et al., 2004). Also, there was no relationship between the amount of pubic diastasis and the extent of disproportionate curvature of the levator ani group. In addition, Halachmi et al. (2003) reported on the postoperative appearance of the pelvic floor with 3D MRI. In 2 patients who had some degree of continence, the intrasymphyseal distance was shortest, the angle of the levator ani divergence more normal, and the bladder neck most deeply positioned in the pelvis. Gargollo et al. (2005), reporting on a mixed group of patients, noted that the puborectalis angle in those with dry intervals was decreased compared with that before closure. These 2 studies correlate well with earlier findings of Gearhart et al. (1993c) showing that in the adult patients who were dry, the puborectalis angle was less than 65 degrees. **Stec et al.** (2012c), **used 3D MRI to evaluate the pelvis before and after primary closure. Of the 19 patients, 12 had closure as newborns without osteotomy and 7 had closure outside of the newborn period with an osteotomy. The preoperative and postoperative MRIs revealed that closure (1) reshapes the pelvis from a boxlike configuration to a more inwardly rotated hammock; (2) redistributes a significant portion of the levator group into the anterior compartment; and (3) facilitates a smooth uniform contouring of the pelvic floor.** Quantitatively, this was demonstrated by 10- to 11-degree increase in the ischial angle and 6.0- to 6.2-degree decrease in the obturator internus angle. These data reinforce the necessity for aggressive dissection and posterior placement of the posterior vesicourethral unit into the pelvis and the role of pelvic osteotomy and pelvic fixation.

Abdominal Wall Anomalies

The triangular defect caused by the premature rupture of the abnormal cloacal membrane is occupied by the exstrophied bladder and posterior urethra. The fascial defect is limited inferiorly by the intrasymphyseal band, which represents the divergent urogenital diaphragm. This band connects the posterior vesicourethral unit to the pubic ramus on anatomic study. The anterior sheath of the rectus muscle has a fanlike extension behind the urethra and bladder neck that inserts into the intrasymphyseal band. Investigations into the relationship of the rectus muscle and fascia to the urogenital diaphragm (Wakim and Barbet, 2002) have found no gross or histologic evidence of the presence of any striated sphincter. However, clear evidence of bladder musculature extending laterally to the pubis was found where it interdigitates with fibers from the rectus fascia, forming the fibrous urogenital diaphragm (Wakim and Barbet, 2002). Gearhart et al. (1991) have shown the importance of radical incision of these fibers lateral to the urethral plate down to the level of the inferior pubic ramus and levator hiatus, and data from failed exstrophy closures show these fibers to be intact in many patients at the time of reclosure.

At the upper end of the triangular fascial defect is the umbilicus. In bladder exstrophy, the distance between the umbilicus and the anus is foreshortened. Because the umbilicus is situated well below the horizontal line of the iliac crest, there is an unusual expanse of uninterrupted abdominal skin. If an umbilical hernia is present, it is usually of insignificant size. The umbilical hernia is repaired at the time of the initial exstrophy closure. Omphaloceles frequently seen in cloacal exstrophy are rare in exstrophy and are usually small and closed at the time of bladder closure.

The frequent occurrence of indirect inguinal hernias is attributed to a persistent processus vaginalis, large internal and external inguinal rings, and lack of obliquity of the inguinal canal. Connolly et al. (1995), in a review of 181 children with bladder exstrophy, reported inguinal hernias in 81.8% of boys and 10.5% of girls. At the time of closure of the bladder exstrophy, these hernias should be repaired by excision of the hernial sac and repair of the transversalis fascia and muscle defect to prevent recurrence or a direct inguinal hernia. The contralateral side should also be explored because the incidence of synchronous or asynchronous bilaterality is 81.8% (Connolly et al., 1995). Recent data by Lavien et al. (2014) in a large group of 136 exstrophy closures clearly demonstrated that if pelvic osteotomy is used for the closure, the incidence of development of a hernia is lower and the risk of recurrence after repair is significantly lower.

Anorectal Defects

The perineum is short and broad and the anus is situated directly behind the urogenital diaphragm; it is displaced anteriorly and corresponds to the posterior limit of the triangular fascial defect. Data from Stec et al. (2011) found in a series of 678 patients with classic exstrophy an incidence of colorectal anomalies of 1.8%. The most common anomaly was imperforate anus, second was rectal stenosis, and third was congenital rectal prolapse. Although the incidence is low, it is a 72-fold increase compared with the general population.

Isolated colorectal abnormalities occur in roughly 2% of exstrophy patients, considerably more frequent than the general population. This most commonly manifests as imperforate anus, followed by rectal stenosis and rectal prolapse (Stec et al., 2011). The divergent levator ani and puborectalis muscles and the distorted anatomy of the external sphincter contribute to varying degrees of anal incontinence and rectal prolapse. Anal continence is usually imperfect at an early age. Rectal prolapse frequently occurs in untreated exstrophy patients and is usually transient and easily reduced. Prolapse disappears after bladder closure and pubic apposition. The appearance of prolapse in an infant is an indication to proceed with definitive management of the exstrophied bladder. **If rectal prolapse occurs at any time after exstrophy closure, posterior urethral or**

bladder outlet obstruction should be suspected, and immediate evaluation of the outlet tract by cystoscopy should be performed (Baker and Gearhart, 1998).

Male Genital Defect

The male genital defect is severe and remains the most troublesome aspect of the surgical reconstruction (Fig. 31.6). Formerly, it was thought that the individual corpora cavernosa were of normal caliber but appeared shorter because of the wide separation of the crural attachments, the prominent dorsal chordee, and the shortened urethral groove. **However, Silver et al.** (1997b) **described the genital defect for the first time in exacting detail. MRI was used in adult men with bladder exstrophy and compared with results for age- and race-matched controls.** It was found that the anterior corporeal length of male patients with bladder exstrophy was almost 50% shorter than that of normal controls (Fig. 31.7). However, although the posterior length of the corporeal body was the same as in age-matched controls, the diameter of the anterior corporeal segment was 30% greater than normal. Also, on MRI, although the diastasis of the symphysis pubis increased the intrasymphyseal and intercorporeal distances, the angle between the corpora cavernosa was unchanged because the corporeal bodies were separated in a parallel fashion. Therefore the penis appears short not only because of the diastasis of the pubic symphysis but also because of marked congenital deficiency of anterior corporeal tissue (Silver et al., 1997b). In a recent surgical anatomic study by Perovic and Djinovic (2008), precise description of the penile defect included (1) corporeal bodies separated and triangular in shape; (2) a long convex ventral surface and a short wedge-shaped dorsal surface; and (3) neurovascular bundle length determined by its lie on the individual corporeal bodies.

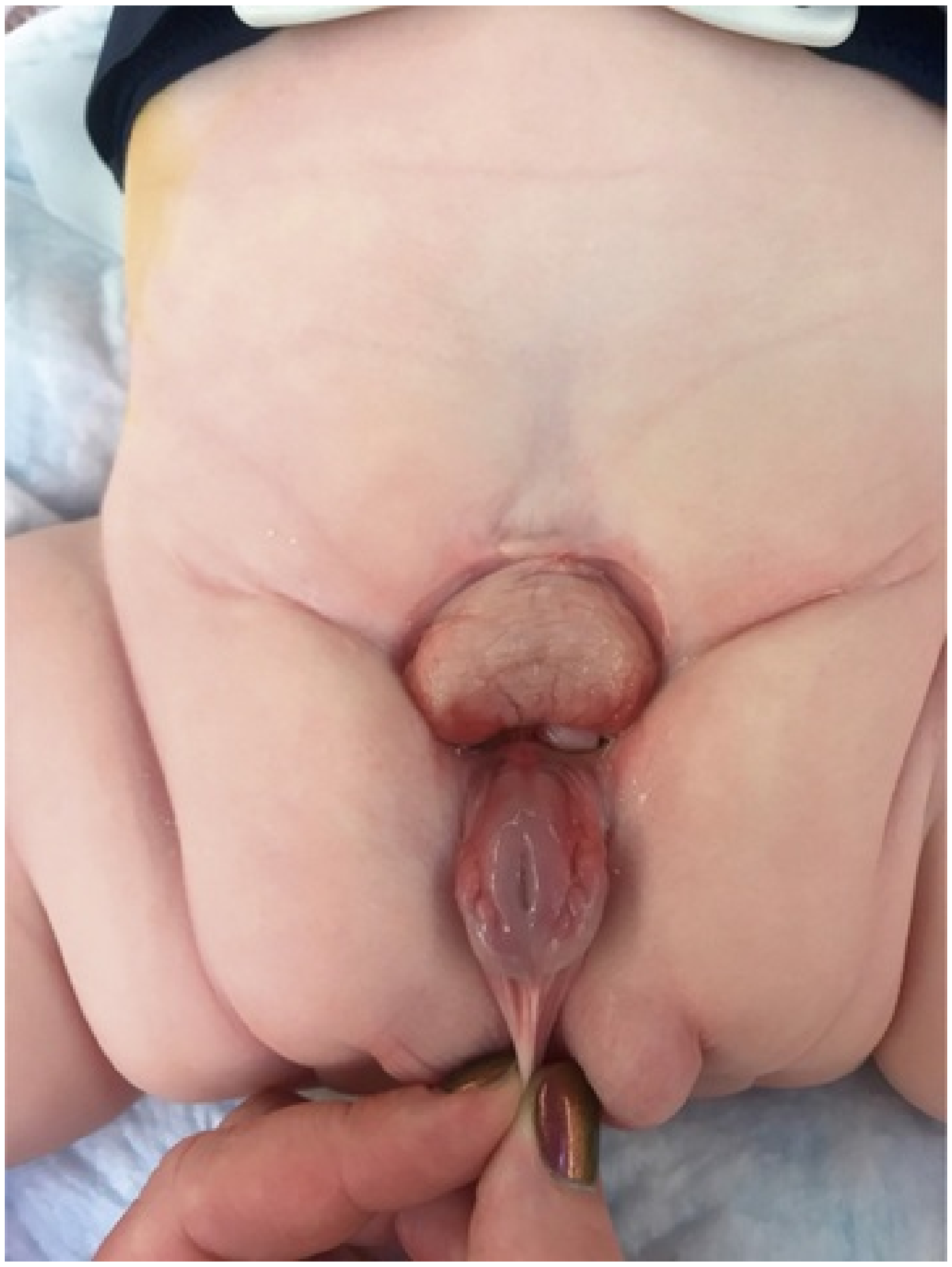

FIG. 31.6 Newborn male with classic bladder exstrophy. Note the dorsal chordee, short urethral plate, and flattening of the scrotum.

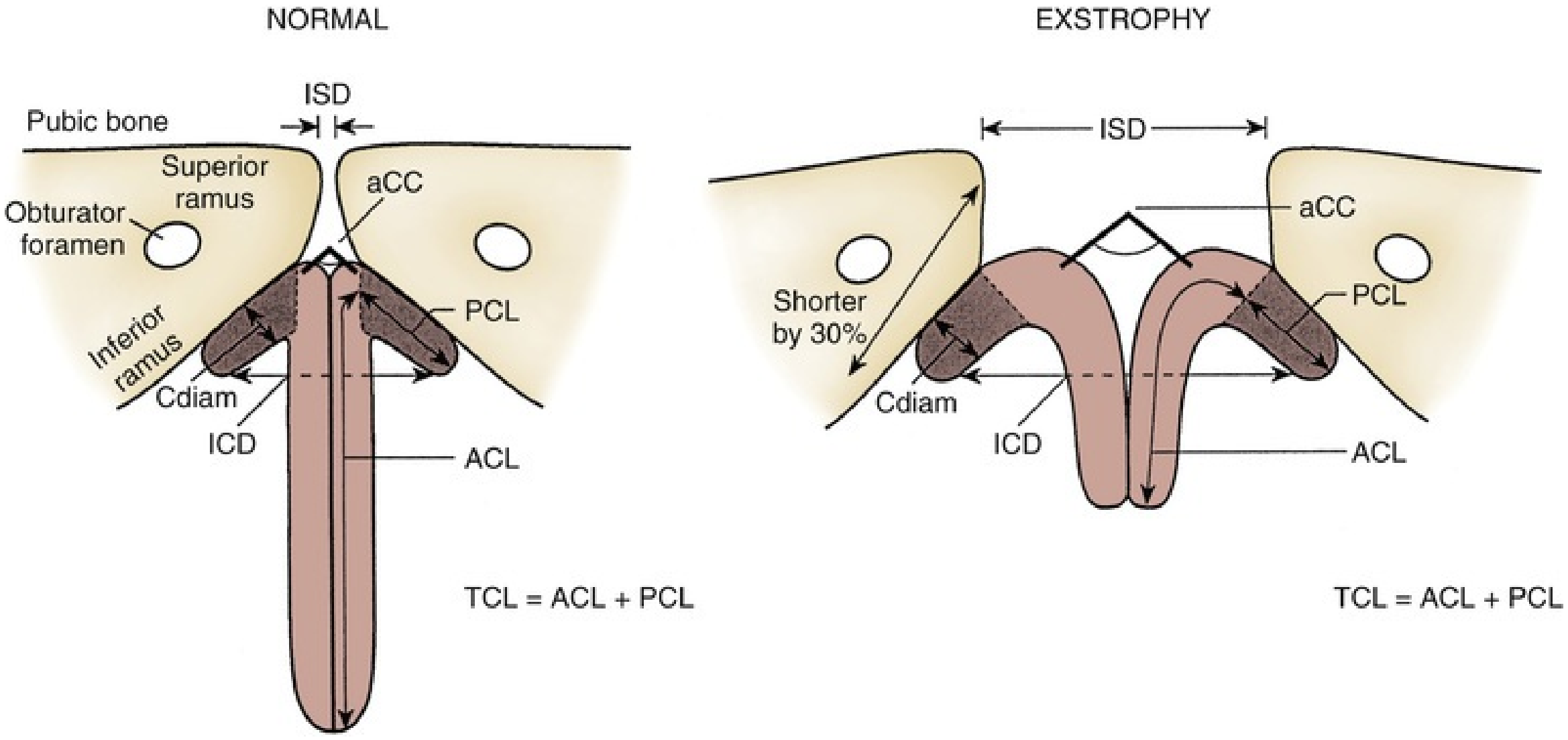
NORMAL
EXSTROPHY
ISD
Pubic bone
Superior ramus
Obturator foramen
aCC
PCL
Inferior ramus
Cdiam
ICD
ACL
TCL = ACL + PCL
ISD
aCC
Shorter by 30%
PCL
Cdiam
ICD
ACL
TCL = ACL + PCL

FIG. 31.7 Separation of the pubic bones in men with classic exstrophy

combined with the congenital deficiency of the anterior corporal tissue leads to the shorter appearance of the penis. *aCC,* Corpora cavernosa suspended angle; *ACL,* anterior corporal length; *Cdiam,* corpus cavernosum diameter; *ICD,* intercorporal distance; *ISD,* intersymphyseal distance; *PCL,* posterior corporal length; *TCL,* total corporal length.

In a study by Gearhart et al. (1993c), **13 adult men born with bladder exstrophy were evaluated with MRI of the pelvis to evaluate the size and configuration of the prostate and accessory sex organs. The volume, weight, and maximum cross-sectional area of the prostate appeared normal compared with published control values** (Fig. 31.8). In none did the prostate extend circumferentially around the urethra, and the urethra was anterior to the prostate in all patients. Silver et al. (1997a) reported free and total prostate-specific antigen (PSA) levels for a group of adult men with exstrophy. Although the levels were measurable, they were below the upper limits of established age-specific reference ranges for normal men. The vas deferens and ejaculatory ducts are normal in the exstrophy patient, and the mean seminal vesicle length in men is normal compared with published controls.

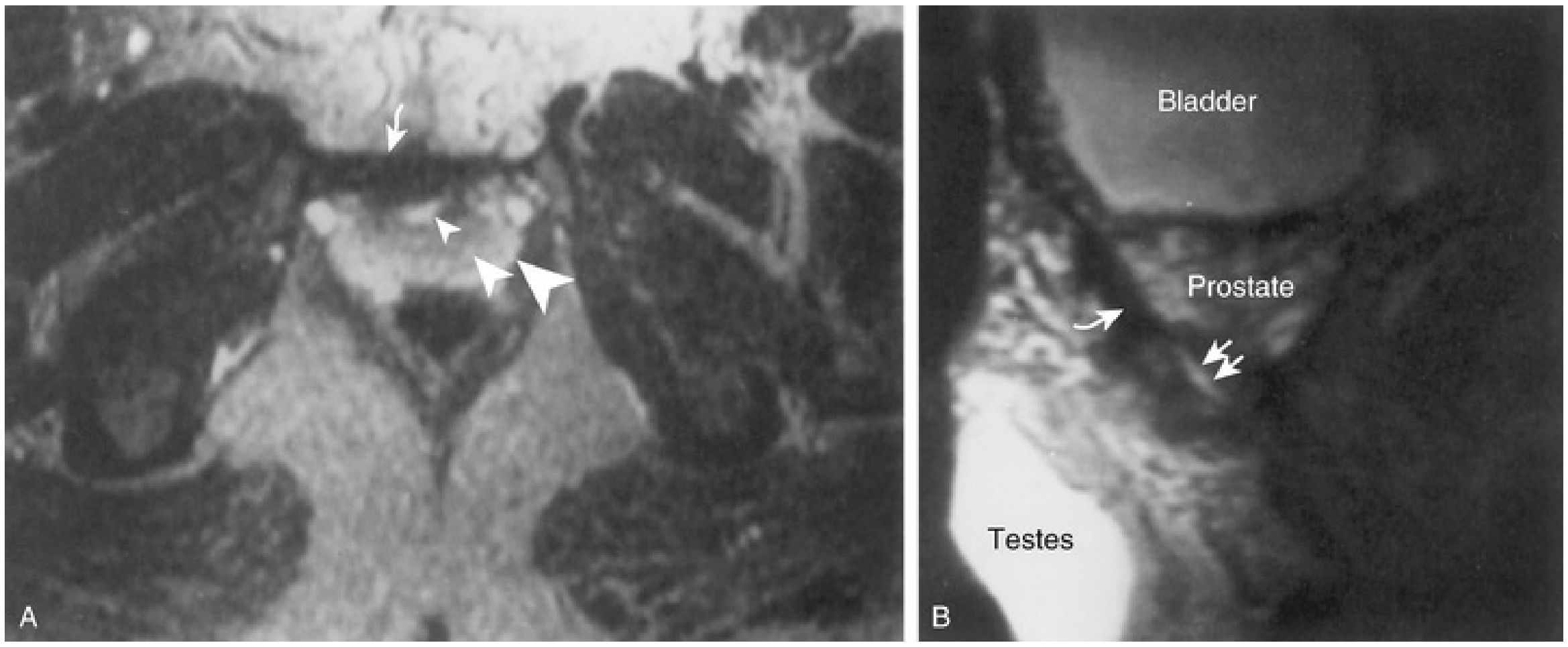

FIG. 31.8 (A) Axial T2-weighted image of the midprostate in a 20-year-old continent patient with bladder exstrophy. *Small arrowhead,* Lumen of the urethra; *medium arrowhead,* transitional zone; *large arrowhead,* peripheral zone. *Curved arrow,* Fibrous band of the intersymphyseal bar. (B) Sagittal T2-weighted image through the midprostate gland shows anterior urethra *(double arrows)* and posterior prostate gland. Intersymphyseal fibrous band *(curved arrow)* extends along the entire length of the prostate.

Autonomic innervation of the corpus cavernosum is provided by the cavernous nerves. These autonomic nerves are displaced laterally in

patients with exstrophy (Schlegel and Gearhart, 1989). These nerves are preserved in almost all exstrophy patients because potency is preserved after surgery. However, retrograde ejaculation may occur after bladder closure and/or bladder neck reconstruction.

Testis function has not been studied in a large group of postpubertal exstrophy patients, and it is generally believed that fertility is not impaired by testicular dysfunction. In 29 of the authors' adult exstrophy patients, all sperm harvested for in vitro fertilization had normal parameters. The testes frequently appear undescended in their course from the widened separated pubic tubercles to the flat, wide scrotum. Most testes are retractile and have an adequate length of spermatic cord to reach the scrotum without the need for orchiopexy.

Female Genital Defects

Reconstruction of the female genitalia presents a less complex problem than in the male (Fig. 31.9). **The vagina is shorter than normal, hardly greater than 6 cm in depth, but of normal caliber. The vaginal orifice is frequently stenotic and displaced anteriorly; the clitoris is bifid; and the labia, mons pubis, and clitoris are divergent. The cervix enters the vagina superiorly, so it lies in the anterior vaginal wall near the introitus. The fallopian tubes and ovaries are normal.** The clitoral halves should be joined and the two ends of the labia minora joined to make a fourchette at the time of primary closure. Vaginal dilation or episiotomy may be required to allow satisfactory intercourse in the mature female. Prior data by Stec et al. (2001b) and recent 3D ultrasound data by Ebert et al. (2009) show that although the levator hiatus has a normal anteroposterior length, it is almost two times wider than normal. This defective pelvic floor may predispose mature females to the development of uterine prolapse, making uterine suspension necessary. This usually occurs after childbirth but can occur even in the nulliparous patient. When studied in a large adult female population, 10 of 56 women developed uterine prolapse at a mean age of 16 years. Six patients had been managed with reconstruction that included a posterior iliac osteotomy (Mathews et al., 2003a). Mean age at the time of osteotomy was 2.1 years. Formerly, it was thought that osteotomy in the newborn or during early childhood would be protective against the development of uterine prolapse in adult life. However, new data from Anusionwu et al. (2013) in a large group of women with exstrophy showed that the width of the adult diastasis was the only factor on univariate analysis to predict adult prolapse.

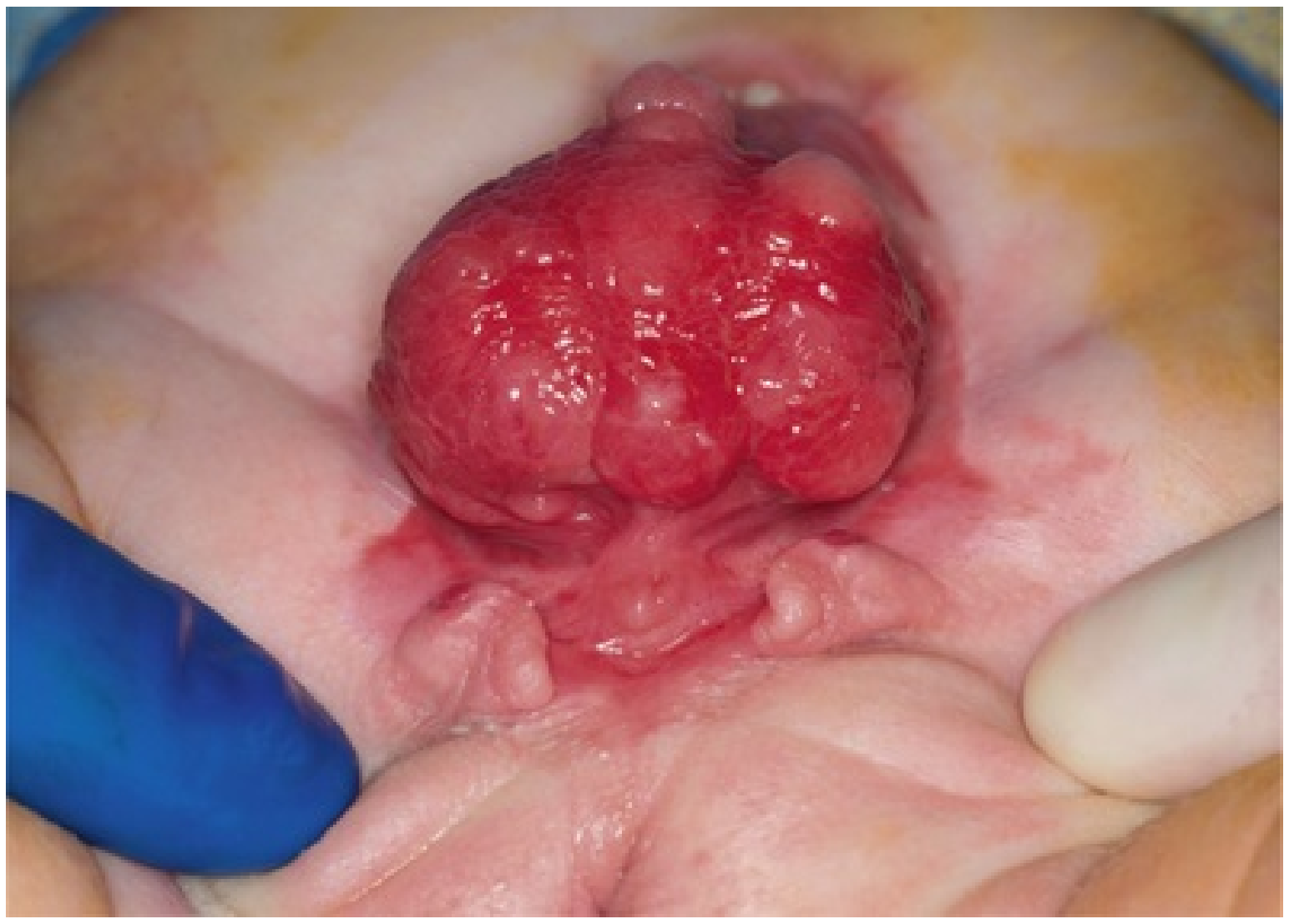

FIG. 31.9 Newborn girl with classic bladder exstrophy. Notice the open urethral plate, bifid clitoral halves, and anterior displacement of the vaginal orifice.

Benz et al. applied stereoscopic visualization techniques to 3D MRI reconstructions and made observations about genital and pelvic anatomy in females with CBE (Benz et al., 2018). By comparing the portion of the clitoral body attached to the pelvis to the portion in the anterior soft tissue, they found that the majority of the clitoral body is anterior to the pelvic attachment in female patients with CBE, contrary to the findings in normal patients and in males with CBE (Fig. 31.10).

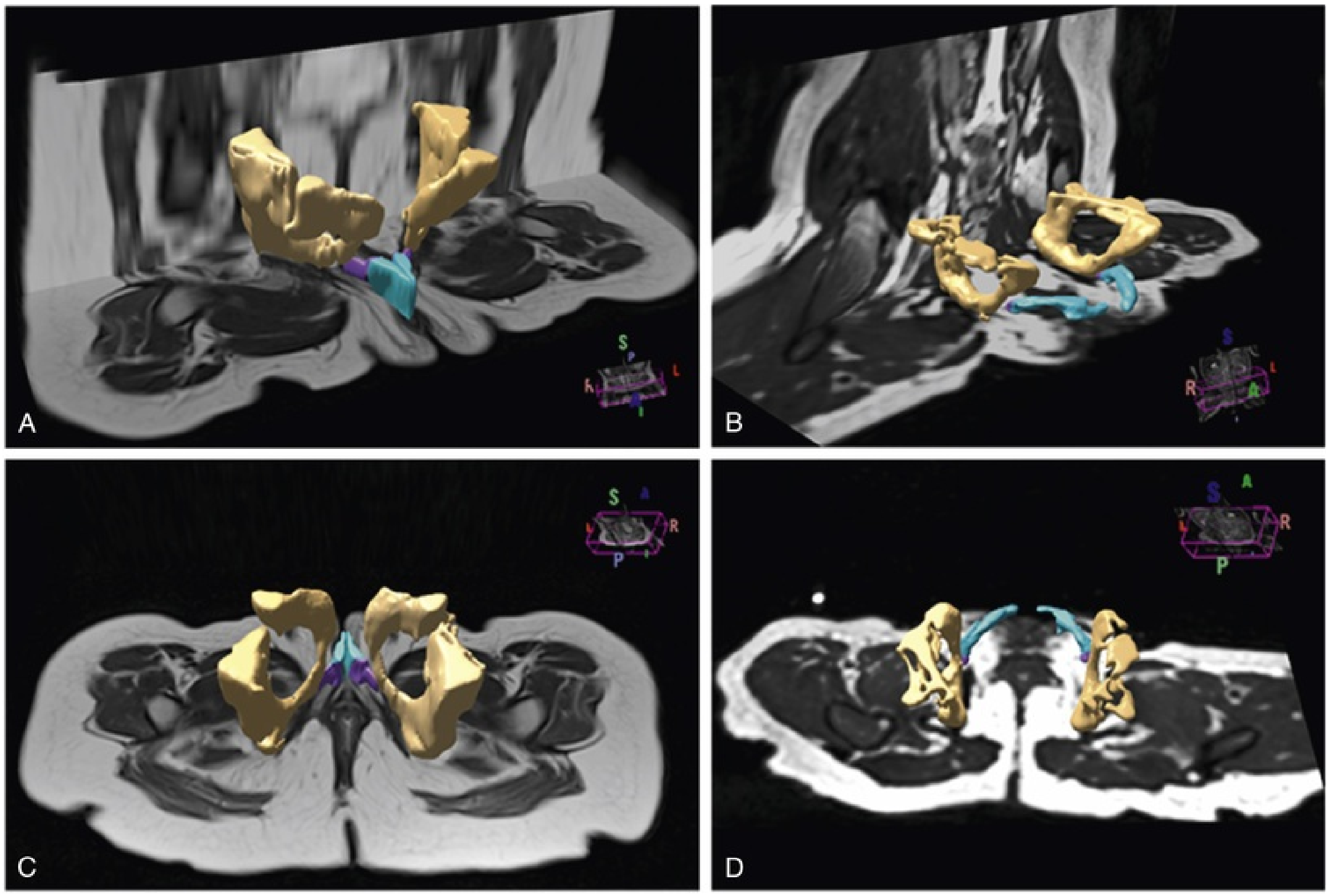

FIG. 31.10 Three-dimensional reconstruction of pelvic magnetic resonance imaging in normal female and bladder exstrophy patients. The coronal (A) and a superior-view axial (C) renderings show the pelvic and genital anatomy of 7-year-old female without exstrophy. The anterior and posterior (*blue* and *purple,* respectively) segments of the corpora cavernosa are shown. The coronal (B) and a superior-view axial (D) rendering of a female with bladder exstrophy patient before surgical repair is shown.

Urinary Defects

At birth, the bladder mucosa usually appears normal; but often hamartomatous polyps may be present on the bladder surface. The bladder mucosa should be frequently irrigated with saline and protected from trauma by some form of protective membrane before closure so that cystic or metaplastic changes in the mucosal surface do not occur.

The size, distensibility, and neuromuscular function of the exstrophied bladder, as well as the size of the triangular fascial defect to which the bladder muscles attach, affect the decision to attempt repair. In the past several years, multiple basic science studies have been published that further delineate the exact nature of the exstrophied bladder in the newborn. **One of the first papers to characterize the neuromuscular function of the bladder was published by**

Shapiro et al. (1985). **In their work, muscarinic cholinergic receptor density and binding affinity were measured in control subjects and in patients with CBE. The density of the muscarinic cholinergic receptors in the control and exstrophy groups were similar, as was the binding affinity of the muscarinic receptor.** Therefore the neurophysiologic composition of the exstrophied bladder is not grossly altered during its anomalous development. Studies have investigated the neural innervation of the newborn exstrophy bladder and its muscle and collagen content. Lee et al. (1996) looked at bladder biopsy specimens obtained from 12 newborns with bladder exstrophy, compared them with age-matched controls, and found an increase in the ratio of collagen to smooth muscle. Using anticollagen antibodies, they evaluated various types of collagen in these bladders and found there was no statistical difference in the amount of type I collagen in the bladders of newborns with exstrophy at initial closure, but there was a threefold increase in type III collagen. Peppas et al. (1999) found, in patients who gained adequate bladder capacities and were awaiting bladder neck reconstruction, that the ratio of collagen to smooth muscle decreased markedly after a successful closure and infection-free follow-up. Lais et al. (1996) reported similar findings and found that the ratio of smooth muscle to collagen increased after a successful closure.

In an extension of the studies just cited, Mathews et al. (1999b) **looked at the number of myelinated nerves per field in the bladders of normal newborn subjects and those with exstrophy. The average number of myelinated nerves per field was significantly reduced in the exstrophy bladders compared with controls. This reduction in nerve fibers appears to be the result of a lack of small fibers with preservation of larger nerve fibers. In light of the findings, it is believed that bladder exstrophy in a newborn represents an earlier stage of bladder development and differentiation.**

In a large study by Rosch et al. (1997), **multiple immunocytochemical and histochemical markers were examined in patients with epispadias or CBE. These studies involved indirect immunocytochemistry for vasoactive intestinal polypeptide (VIP), neuropeptide Y (NPY), substance P (SP), calcitonin gene–related peptide (CGRP), protein gene product (PGP) 9.5, and nicotinamide adenine dinucleotide phosphate diaphorase (NADPHd). No evidence of bladder muscle dysinnervation was found morphologically in any cases of CBE. Therefore, although a newborn with bladder exstrophy may have a maturational delay in bladder development, these bladders have**

the potential for normal development after a successful primary closure.

When the bladder is small, fibrosed, inelastic, and covered with polyps, functional repair may be impossible (Fig. 31.11). Novak et al. (2005) investigated the pathology and malignant potential of the polyps found in these small bladders. Two types of polyps were observed, with some overlap in findings: fibrotic and edematous. Both were associated with overlying squamous metaplasia in approximately 50% of cases. Varying degrees of von Brunn nests, cystitis cystica, and cystitis glandularis were noted. Cystitis glandularis was noted in a higher percentage of secondary closures. Because of the potential risk of adenocarcinoma associated with cystitis glandularis, future surveillance of these patients with urine cytology and cystoscopy as they enter adulthood is recommended. The more normal bladder may be invaginated or it may bulge through a small fascial defect, indicating the potential for satisfactory capacity after successful initial closure. Further investigation revealed that bladder polyps, particularly those that appear after a failure closure tend to impede bladder growth (Jayman et al., 2017). **Not until examination under anesthesia can the true defect be adequately evaluated because the depth of this bladder extension into the pelvis cannot be appreciated unless the patient is under anesthesia.**

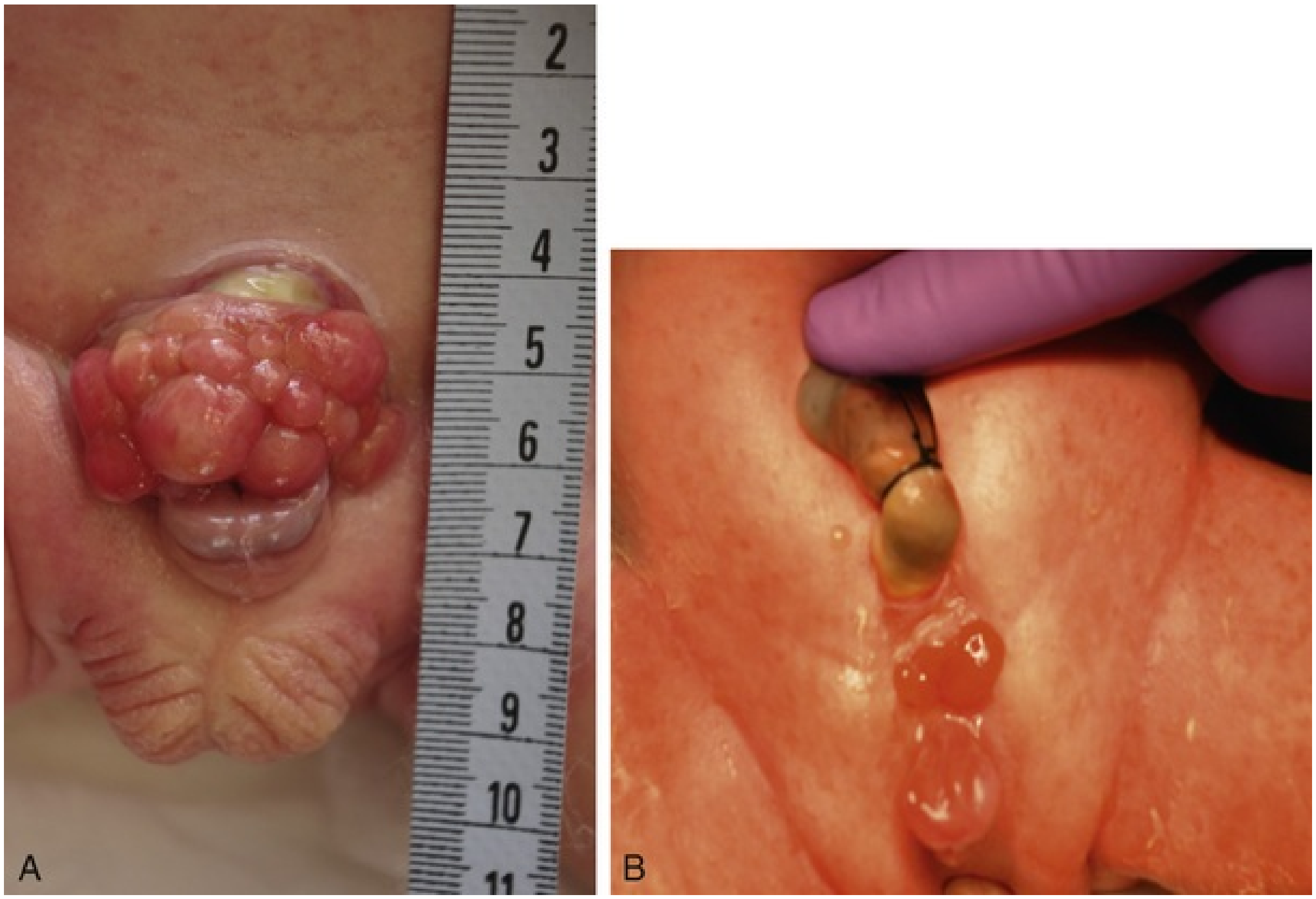

FIG. 31.11 (A) Small bladder template covered with polyps, unsuitable for closure. (B) Extremely small bladder template in newborn unsuitable for closure.

Bladder function was assessed in a group of continent exstrophy patients with normal reflexive bladders. Normal cystometrograms were obtained in 70% to 90% of patients (Toguri et al., 1987). Diamond et al. (1999), looking at 30 patients with bladder exstrophy at various stages of reconstruction, found that 80% of patients had compliant and stable bladders before bladder neck reconstruction. After bladder neck reconstruction, approximately half of the patients maintained normal bladder compliance and a lesser number maintained normal stability. The authors believed that compliance and stability were impaired after bladder neck reconstruction and that 25% of patients with exstrophy may maintain normal detrusor function after reconstruction. In an earlier paper by Hollowell et al. (1993), 13 of 21 children revealed involuntary contractions and only 4 revealed stable bladders before bladder neck reconstruction. Also, 7 of 21 had increased pressures (greater than 10 cm H_2O), suggesting decreased compliance. The difference in findings between these 2 urodynamic studies is difficult to explain from an experimental perspective. However, standardized methods of bladder neck repair do not exist, and these differences may be reflected in the different urodynamic findings after bladder neck repair in these 2 groups of patients.

Several interesting aspects of the microstructure of the bladder in children with bladder exstrophy were noted by Mathews et al. (2004), who used specimens obtained from children with bladder exstrophy at various stages of reconstruction (newborn bladder closure, bladder neck reconstruction, augmentation cystoplasty). At the cellular level, important differences were noted. Caveolae, which are important intracellular structures involved in cell-cell signaling, were found to be normal in the patients with a successful closure and improvement in bladder capacity and significantly lacking in the patients who required eventual augmentation cystoplasty (Fig. 31.12). In addition, the ultrastructure of cells in the patients in whom closure failed was noted to be abnormal. In a study by Suson et al. (2012a), an attempt was made to further identify similarities and differences between exstrophy smooth muscle and normal bladder muscle. More than 95% of exstrophy and control smooth muscle cells stained positive for actin and myosin. The intracellular calcium has been shown to be significantly lower in smooth muscle cells of exstrophic bladders compared with vesicoureteral reflux controls. More exstrophy cells migrated than control cells, although it is not known if this movement is organized or directional. There were no differences in cell proliferation between the two groups. In a second study, Suson et al. (2012b) showed that enhanced exstrophy smooth muscle cell migration was a result of excess transforming growth factor-β1 signaling but was independent of increases in intracellular calcium concentration.

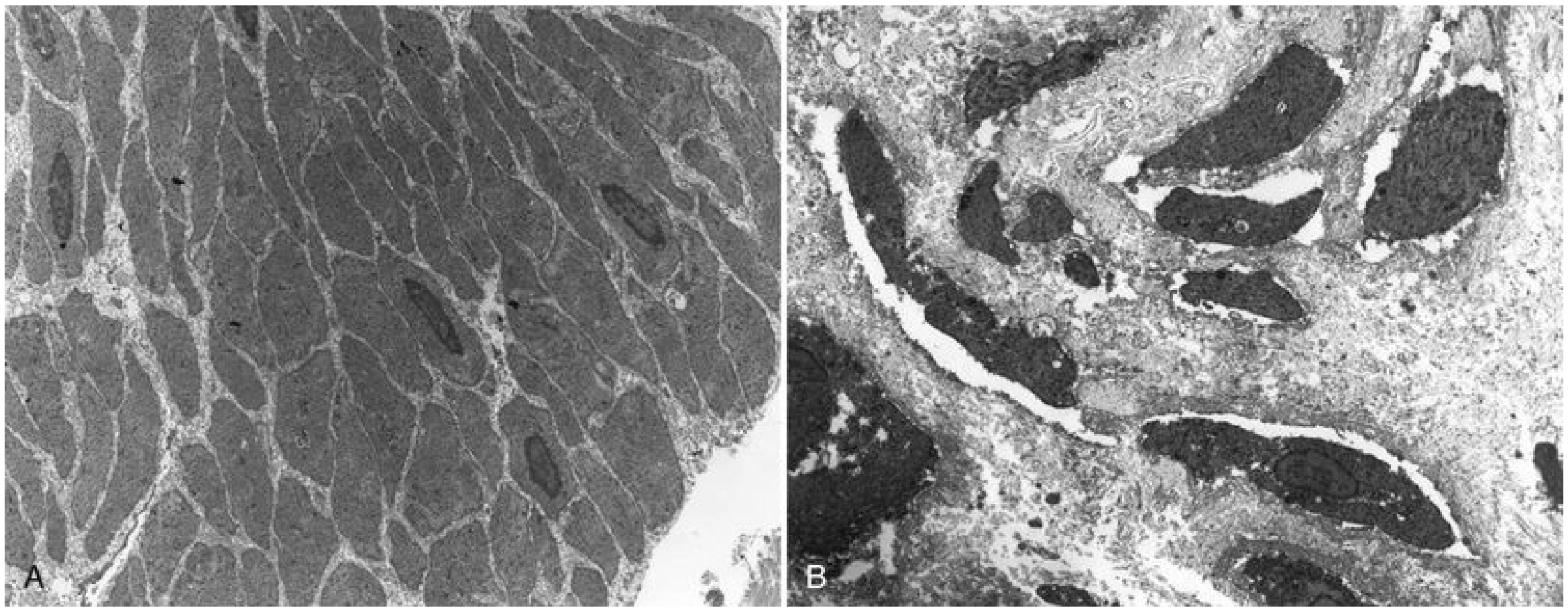

FIG. 31.12 Ultrastructural changes noted in the exstrophic bladder. (A) Normal muscle and nerve profiles in the newborn bladder. (B) After failure

of prior closure, significant deterioration is noted with increased intercellular collagen and degenerating muscle in an immunohistologic study. (From Mathews R, Gosling JA, Gearhart JP: Ultrastructure of the bladder in classic exstrophy: correlation with development of continence. *J Urol.* 172:1446–1449, 2004.)

The upper urinary tract is usually normal, but anomalous development does occur. In a recent report by Stec et al. (2012), 674 patients were reviewed; 462 were found to have had ultrasound examination. In this large review, 13 of 462 (2.8%) had a renal anomaly. The most common malformation was a duplicated collecting system (6); others included hypoplastic or absent kidney (3), pelvic kidney (2), ureteropelvic junction obstruction (1), and multicystic dysplastic kidney. This is a higher incidence than the 0.57% seen after 2 to 4 years of follow-up by antenatal screening (Rosendahl, 1990). The ureters have an abnormal course in their termination. The peritoneal pouch of Douglas between the bladder and the rectum is enlarged and unusually deep, forcing the ureter down laterally in its course across the true pelvis. The distal segment of the ureter approaches the bladder from a point inferior and lateral to the orifice, and it enters the bladder with little or no obliquity. **Therefore reflux in the closed exstrophy bladder occurs in 100% of patients, and reimplantation surgery is required at bladder neck reconstruction. If excessive outlet resistance is gained at the time of either initial closure or combined epispadias and bladder exstrophy closure, and recurrent infections may be a problem even with suppressive antibiotics. Ureteral reimplantation and/or revision of the outlet may be required before bladder neck reconstruction.** Ultimately, a successful staged reconstruction with bladder neck repair does not appear to adversely affect renal function (Schaeffer et al., 2013).

Exstrophy Complex and Variants

In addition to the three main presentations of the bladder exstrophy-epispadias complex—CBE, cloacal exstrophy, epispadias—many variations in anatomy and types of defects have been noted. Because there is probably a common embryologic origin for all of these defects, they all share many or some of the defects noted in the three major components of the complex—skeletal, urinary, and genital. The presence of a characteristic musculoskeletal defect of the exstrophy anomaly with no major defect in the urinary tract has been named *pseudoexstrophy* (Marshall and Muecke, 1968). Predominant characteristics include an elongated, low-set umbilicus and divergent rectus muscles that attach to the separated pubic bones. In this variant, the mesodermal migration has been interrupted in its superior aspect only, thus wedging apart the musculoskeletal elements of the infraumbilical abdominal wall.

In the superior vesical fissure variant of the exstrophy complex, the musculature and skeletal defects are exactly the same as those in classic exstrophy; however, the persistent cloacal membrane ruptures only at the uppermost portion, and a superior vesical fistula results that actually resembles a vesicostomy. Bladder extrusion is minimal and is present only over the normal umbilicus (see Fig. 31.1B).

In a large review of an exstrophy database of more than 815 patients, Lowentritt et al. (2005) **reported 25 exstrophy complex variants, of which six were cloacal exstrophy variants. Continence rates after bladder neck repair were compatible with classic exstrophy.** Three cases were reported by Arap and Giron (1986) in which the patients had classic musculoskeletal defects, and two of the three were continent. Of the two male patients, one had an associated complete epispadias and the other had a completely normal penis. Therefore the external genital manifestations in exstrophy variants can vary.

In addition to pseudoexstrophy, superior vesical fissure, and duplicated exstrophy, isolated occurrences of a fourth entity, covered exstrophy, have been reported (Cerniglia et al., 1989). This has also been referred to as *split symphysis variant.* A common factor in these patients is the presence of musculoskeletal defect associated with classic exstrophy but no significant defect of the urinary tract. Chandra et al. (1999) reported a covered exstrophy with incomplete duplication of the bladder. However, in cases of covered exstrophy (Cerniglia et al., 1989; Narasimharao et al., 1985), there has been an isolated ectopic bowel segment present on the inferior abdominal wall near the genital area, which can be either colon or ileum with no connection with the underlying gastrointestinal tract and only epispadias in the male. A patient seen at our institution had the standard appearance of most split symphysis variants, and the bladder could actually be seen through a thin membrane of lower abdominal skin (Fig. 31.13); all of the classic musculoskeletal defects of exstrophy were present. These patients should all undergo formal exstrophy closure at birth.

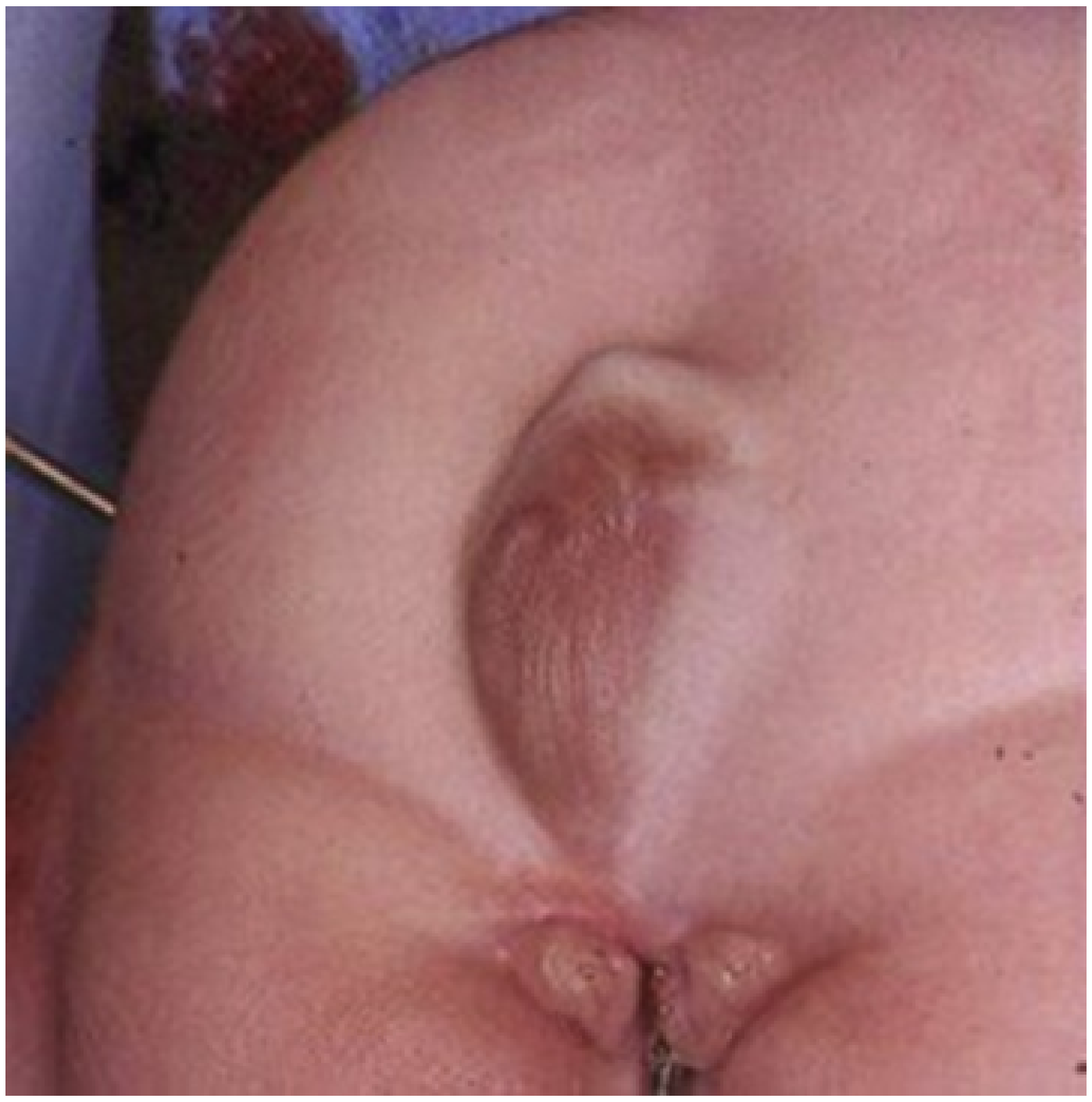

FIG. 31.13 Skin-covered exstrophy in a female patient. Note urethral sound in the bladder and the subcutaneous position below the skin of the abdominal wall. No bowel is sequestered on the abdominal wall, as has been reported in some patients with this variant.

There are two different forms of bladder duplication: anteroposterior duplication and side-by-side duplication. Anteroposterior duplication is considered a duplicate exstrophy with a patch of everted bladder mucosa on the anterior abdominal wall and a second bladder lying in the pelvis. The ureters attach to the closed bladder, rendering the superficial mucosa dry. The mainstay of treatment has been resection of the ectopic mucosa and closure of the abdominal wall defect. Side-by-side duplication involves patients who have two separately formed bladder halves in a left-right orientation with a midline septum between the bladders containing muscle. Each bladder has its own ureter and an intact sphincter. Often there is diastasis of the pubis and rectus muscle.

The bladder exstrophy–epispadias–cloacal exstrophy complex has a wide range of presentations. Variants are rare, but it is important to recognize the different appearances at birth, because the initial treatment will greatly influence the long-term outcome. Two patient groups had better outcomes than those with classic presentations—superior vesical fissure and skin-covered cloacal exstrophy. Because the sphincter is intact, patients with superior vesical fissure went through regular toilet training and became continent without the need for a later bladder neck procedure. Many reports of exstrophy variants include these patients, leading to the wrong belief that all patients with variants perform better than those with bladder exstrophy. Lowentritt et al. (2005) suggest that other than superior vesical fissure, all variants should be managed with formal exstrophy closure at birth and followed in the same manner as their classic presentations.

Prenatal Diagnosis

Even with modern ultrasound modalities, the prenatal diagnosis of bladder exstrophy is often difficult to delineate. Frequently, a diagnosis of omphalocele or gastroschisis is made and the exstrophy condition is overlooked. Ultrasound evaluation of the fetus by means of high-resolution real-time units allows a thorough survey of the fetal anatomy, even during routine obstetric ultrasound examinations (Gearhart et al., 1995a). Several groups have outlined important criteria for the diagnosis of CBE prenatally. In these reviews, the absence of a normal fluid-filled bladder on repeated examinations suggested the diagnosis, as did a mass of echogenic tissue on the lower abdominal wall (Mirk et al., 1986; Verco et al., 1986). An umbilical cord insertion-to-genital tubercle below the fifth percentile for gestational age also provides a quantitative measurement by which an exstrophy diagnosis can be assessed (Fishel-Bartal et al., 2017). **In a review of 25 prenatal ultrasound examinations with the subsequent birth of a newborn with CBE, Gearhart et al.** (1995a) **made several observations: (1) absence of bladder filling, (2) a low-set umbilicus, (3) widening pubis ramus, (4) diminutive genitalia, and (5) a lower abdominal mass that increased in size as the pregnancy progressed and as the intra-abdominal viscera increased in size** (Fig. 31.14).

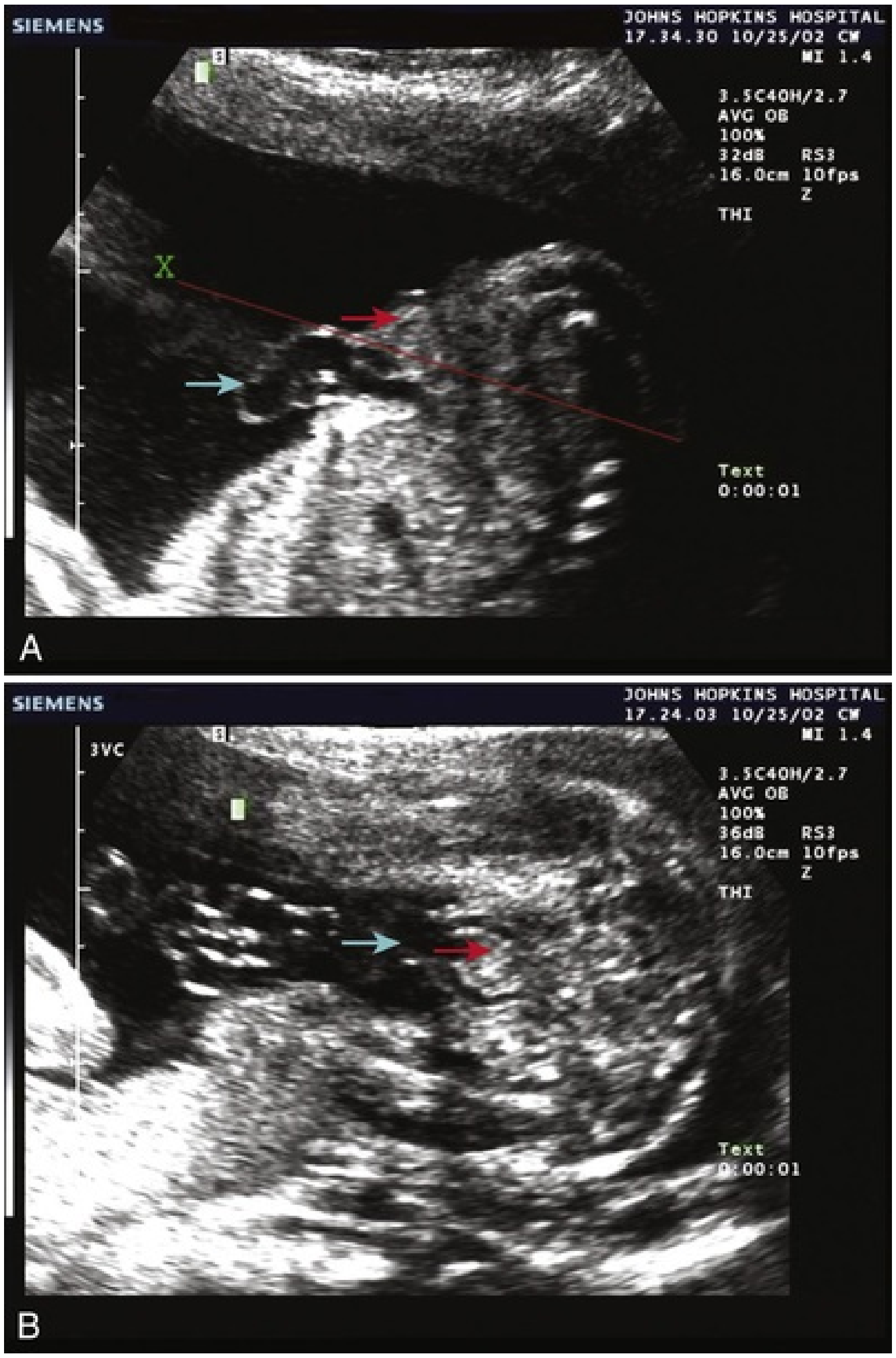
SIEMENS
JOHNS HOPKINS HOSPITAL
17.34.30 10/25/02 CW
MI 1.4
3.5C40H/2.7
AVG OB
100%
32dB RS3
16.0cm 10fps
Z
THI
X
Text
0:00:01
A
SIEMENS
JOHNS HOPKINS HOSPITAL
17.24.03 10/25/02 CW
MI 1.4
3VC
3.5C40H/2.7
AVG OB
100%
36dB RS3
16.0cm 10fps
Z
THI
Text
0:00:01
B

FIG. 31.14 Prenatal ultrasound scan demonstrating bladder exstrophy. (A) Longitudinal view showing the low-set umbilicus (*cyan arrow,* lack of intra-abdominal bladder, and lower abdominal mass *(red arrow)*. (B) Transverse view through the plane *(X)* in A shows presence of the umbilicus *(cyan arrow)* and the upper edge of the bladder plate that appears hyperechoic *(red arrow).*

The application of 3D ultrasonography and fetal MRI has only somewhat improved the antenatal diagnosis of bladder and cloacal exstrophy, because only 25% of cases of bladder exstrophy-epispadias complex are diagnosed prenatally (Goyal et al., 2012). In our practice, fetal MRI is reserved for patients in whom 3D ultrasonography is not sufficient to differentiate satisfactorily between classic and cloacal exstrophy, or when other severe anomalies are suspected. With the increased granularity of MRI, this imaging modality may be used to exclude cloacal exstrophy or associated spinal anomalies (Goldman et al., 2013). The main reason for the prenatal diagnosis of bladder exstrophy is so that the parents can be counseled regarding the risks and benefits and other aspects of the condition. After appropriate counseling, arrangements can be made for delivery of the baby in a specialized exstrophy center where immediate reconstruction of the exstrophy can occur. Delivery in a specialized exstrophy center allows the parents to be exposed to the expertise of multiple disciplines, including the all-important psychological support these parents need when a child with a birth defect of this magnitude is delivered.

Key Points: Prenatal Diagnosis

Diagnostic criteria for CBE on ultrasound include

- Absence of bladder filling
- Low-set umbilicus
- Widening pubic rami
- Diminutive genitalia
- Lower abdominal mass that increases in size as the pregnancy progresses

Surgical Reconstruction of Bladder Exstrophy

Sweetser et al. (1952) initially described a staged surgical approach for bladder exstrophy. From 4 to 6 days before bladder closure, bilateral iliac osteotomies were performed. Epispadias repair was performed as a separate procedure. The continence procedure was limited to freeing the fibers from the intrasymphyseal band and wrapping this band around the urethra at the time of closure to increase outlet resistance.

The initial staged approach to functional bladder closure included three separate stages: bladder and abdominal wall closure; bladder neck reconstruction and antireflux procedure; and later epispadias repair. This approach was recommended for most cases of exstrophy reconstruction beginning in the early 1970s (Cendron, 1971; Jeffs et al., 1972; Williams and Keaton, 1973). **Although this procedure was successful, it has been modernized in the last 15 years to include bladder closure, abdominal wall closure, and posterior urethral closure well onto the shaft of the penis in the newborn period with bilateral innominate and vertical iliac osteotomy, if indicated; epispadias repair at 6 months to 1 year of age; and bladder neck reconstruction along with antireflux procedure at age 5 to 7 years, when the child has achieved an adequate bladder capacity for bladder neck reconstruction and/or when the child is motivated to participate in a postoperative voiding program** (Gearhart and Jeffs, 1998).

Other methods of treatment of the newborn with bladder exstrophy have been offered. Grady and Mitchell (1999) proposed combining bladder exstrophy closure with penile repair in the newborn period. Kelly (1995) has recommended a staged repair in which no osteotomy is used and a second-stage “radical soft-tissue mobilization” is performed before later urethral repair. Schrott et al. (1984) recommended bladder closure, ureteral reimplantation, epispadias repair, and bladder neck reconstruction in the newborn period. Last, Stein et al. (1999) recommended ureterosigmoidostomy in the newborn period with abdominal wall and bladder closure.

Evaluation and Management at Birth

At birth, although the bladder mucosa is usually smooth, pink, and intact, it is also sensitive and easily denuded. In the delivery room the umbilical cord should be tied with 2-0 silk close to the abdominal wall so that the umbilical clamp does not traumatize the delicate mucosa and cause excoriation of the bladder surface. The bladder can then be covered with a nonadherent film of plastic wrap (e.g., Saran Wrap) (Fig. 31.15) to prevent sticking of the bladder mucosa to clothing or diapers. In addition, each time the diaper is changed the wrap should be removed, the entire bladder surface irrigated with sterile saline, and clean plastic wrap placed over the bladder surface area.

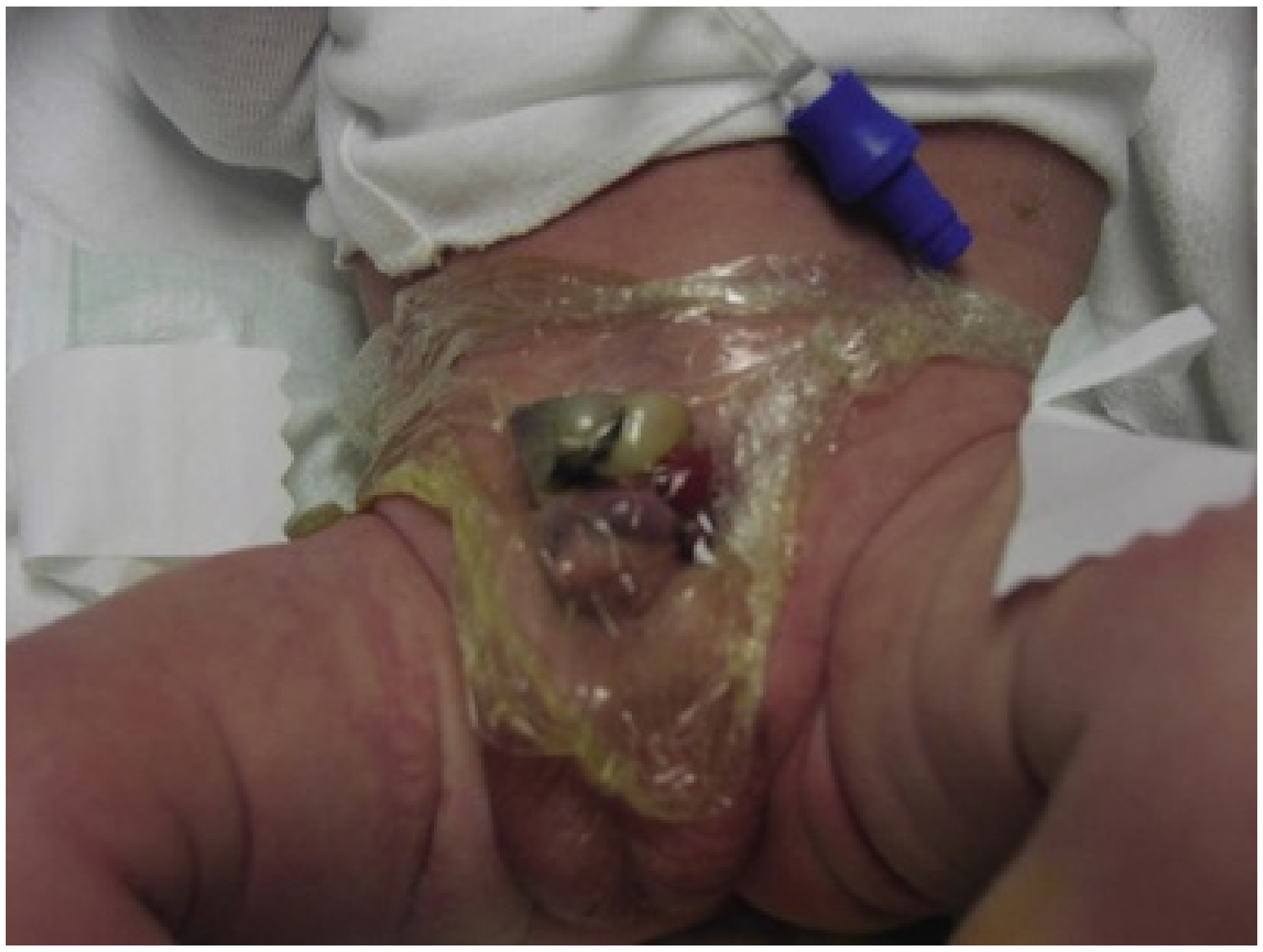

FIG. 31.15 Use of plastic wrap to keep bladder plate moist before closure.

The parents typically need reassurance at this stage. Counseling of the parents and decisions regarding eventual therapy should begin prenatally if the condition is diagnosed by prenatal ultrasonography. The parents should be educated by a surgeon with a special interest and experience in managing the exstrophy spectrum. An exstrophy support team should be available and should include a pediatric orthopedic surgeon, pediatric anesthesiologist, social workers, nurses with special interest in bladder exstrophy, and a child psychiatrist or psychologist with expertise and experience in genital anomalies. The Association for the Bladder Exstrophy Community is available and has a website for parents and family members to obtain further information about the bladder exstrophy condition.

Cardiopulmonary and general physical assessment measures can be carried out in the first few hours of life. Well-done ultrasound studies are usually sufficient to provide evidence of renal structure, function, and drainage, even in the first few hours of life before the patient undergoes closure of the exstrophy defect.

Circumstances may be less than ideal at birth. A thorough neonatal assessment may have to be deferred until transportation to a major children's medical center can be arranged. With modern transportation, no child is ever more than a few hours away from a neonatal center with full diagnostic and consultative services. During travel the bladder should be protected by a plastic membrane, as in the nursery, to prevent damage to the delicate newborn bladder mucosa.

Key Points: Bladder Exstrophy: Evaluation of the Newborn

- When evaluating a newborn with bladder exstrophy, a detailed exam must be performed:
    - Evaluate the size and quality (which includes polyp burden) of the bladder template. A suitable size for closure during the newborn period is 3 x 3cm.
    - Evaluate the extent of pubic diastasis radiographically and the malleability of the pelvis with an examination under anesthesia.
    - Determine the need for osteotomy.
    - Examine the length and width of the urethral plate.
    - Examine the penile length.
    - Evaluate the patient for associated anomalies.

Selection of Patients for Immediate Closure

Successful treatment of exstrophy with functional closure demands that the potential for success in each child be carefully considered at birth by an experienced exstrophy surgeon. The size and the functional capacity of the detrusor muscle are important considerations for the eventual success of functional closure. Correlation between apparent bladder size and the potential bladder capacity must not be confused. In minor grades of exstrophy that approach the condition of complete epispadias with incontinence, the bladder may be small yet may demonstrate acceptable capacity, either by bulging when the baby cries or by indenting easily when touched by a sterile gloved finger in the operating room with the child under anesthesia. **Sometimes a good bit of previously unappreciated bladder can be discovered behind the fascia on examination with anesthesia** (Gearhart and Jeffs, 1998). Once the bladder is relieved of surface irritation and repeated trauma, the small bladder can enlarge and increase in capacity with the absence of sphincter activity and with minimal outlet resistance. If the infant is robust and has a good bladder template and an experienced exstrophy team is present, then a newborn closure should be strongly considered. From new basic science studies, expression of the protein uroplakin II, found on surface urothelial cells, appears to be significantly higher in bladder specimens from non-exstrophy controls and newborn closures when compared with specimens from delayed exstrophy closures (Kasprenski et al., 2018b). As such, urothelial markers of bladder differentiation show that early closure may potentiate bladder growth.

Small Exstrophy Bladder Unsuitable for Newborn Closure

A small, fibrotic bladder patch that is stretched between the edges of the small triangular fascial defect without elasticity or contractility cannot be selected for the usual closure procedure (Gearhart and Jeffs, 1998) (see Fig. 31.11A). Examination with the patient under anesthesia is often required to assess the bladder adequately, particularly if considerable edema, excoriation, and polyp formation have developed between birth and the time of assessment. **Decisions regarding the suitability of bladder closure or the need for waiting should be made only by surgeons with a great deal of experience in the exstrophy condition** (Gearhart and Jeffs, 1998). Some conditions preclude primary closure, including penoscrotal duplication, ectopic bowel within the extruded bladder (a relative contraindication), a hypoplastic bladder, and significant bilateral hydronephrosis.

In a study of delayed primary closures by Baradaran et al. (2012a), the bladder growth of those delayed because of small bladder templates was compared with those whose closure was delayed secondary to late referral to the institution. Thirty-two (97%) of the 33 patients underwent pelvic osteotomy. Those delayed for small bladder templates tended to be older at the age of primary closure (305 days vs. 172 days). Overall, the mean bladder capacity of patients in the small bladder template group was 36 mL smaller than the bladder capacities of those undergoing neonatal closure (95% CI −65 to −10). In those whose primary closure was delayed because of late referral, the bladder capacities were 29 mL less than neonatal closures (95% CI −60 to 5). Although the measured bladder capacities were smaller in the patients with a delayed primary closure, notably, the annual growth is similar (Baradaran et al., 2012a).

Thus waiting for the bladder template to grow for 6 to 12 months in the child with a small bladder is not as risky as submitting a small bladder template to closure in an inappropriate setting, resulting in dehiscence and possible future incontinence. Ultimately, delaying the primary closure when indicated does not jeopardize the growth of the bladder (Baradaran et al., 2012a; Ferrara et al., 2014). If the bladder does not grow to sufficient size for closure after 6 to 12 months, other options include excision of the bladder and a nonrefluxing colon conduit or ureterosigmoidostomy.

Osteotomy

Children born with bladder exstrophy have not only an exposed bladder but also a wide diastasis of the pubic rami (average 4.8 cm), resulting in an open pelvic ring. In addition, the larger the bladder template, the wider the resultant diastasis and the greater the need for osteotomy. The musculoskeletal function of the hip and lower extremity appears to be normal throughout childhood; however, the gait is characterized by external foot rotation, which lessens with growth as lower extremity muscle function strengthens, even if osteotomy is not performed.

Several types of pelvic osteotomies have been developed to help to close the pelvic ring, decrease the stress on the abdominal wall during initial exstrophy closure, and improve the outcome of future genitourinary reconstruction. Pelvic osteotomies also provide the added benefit of decreased incidences of primary and recurrent inguinal hernias (Lavien et al., 2014). Shultz (1958) was the first, as far as we know, to describe bilateral posterior iliac osteotomy as part of a two-stage repair of bladder exstrophy. Bilateral posterior iliac osteotomy was performed, and 1 to 3 weeks later exstrophy closure was accomplished. This early osteotomy was shown to lower rates of wound dehiscence and to help achieve a more secure and better genitourinary reconstruction.

Patients may undergo pelvic osteotomy at any stage of exstrophy repair if the diastasis prevents attainment of these urologic goals. **In general, we do not routinely perform osteotomy on newborns unless the diastasis is over 4 cm or the malleability of the pelvis is poor as judged jointly by a senior pediatric urologist and pediatric orthopedic surgeon.** The rates of failed closures in newborn patients with osteotomy was found to be statistically similar to the rates of carefully selected newborns without osteotomy (6.5% vs. 10.5%, *P* = 0.466) (Inouye et al., 2016). The laxity of the sacroiliac ligaments usually allows closure of the defect without undue tension in the first 48 to 72 hours of age. We make this decision with the patient under anesthesia at the time of primary closure with our pediatric orthopedic colleagues.

Types of osteotomies that have been used include bilateral osteotomy of the superior pubic ramus, diagonal osteotomy of the iliac wing, and anterior innominate osteotomy with or without vertical iliac osteotomy. The more commonly used combined anterior innominate and vertical osteotomy was developed for several reasons: (1) the osteotomy is performed with the patient in the supine position as for the urologic repair, avoiding the need to turn the patient; (2) the anterior osteotomy also allows placement of an external fixator and intrafragmentary pins under direct vision; (3) a greenstick-type closing-wedge osteotomy of the ilium is also performed adjacent to the sacrum in most patients, creating two large bony fragments that are easily movable; (4) the cosmetic appearance of this osteotomy is superior to that of a posterior iliac osteotomy (Gearhart et al., 1996b); and (5) the superior pelvic bone malleability and ease of apposition of the pubic bone without tension.

After failure of initial closure in children with significant pubic diastasis, as seen in large bladder templates and cloacal exstrophy, osteotomy is always required. Pubic approximation may not be possible in a single step at the time of abdominal closure when the diastasis is extreme (>6 cm). The use of staged closure of the pelvis after osteotomy has been used successfully in this circumstance. This technique has been used for the treatment of children with extreme diastasis, even in younger patients, and the cloacal exstrophy condition.

Pelvic osteotomy performed at the time of initial closure confers several advantages, including (1) easy approximation of the symphysis with diminished tension on the abdominal wall closure and elimination of the need for fascial flaps; (2) placement of the posterior vesicourethral unit deep within the pelvic ring, enhancing bladder outlet resistance; and (3) bringing the large pelvic floor muscles near the midline, where they can support the bladder neck and aid in eventual urinary control (Fig. 31.16). After pubic approximation with osteotomy, some patients show the ability to stop and start the urinary stream, experience dry intervals, and in some cases become completely continent (Gearhart and Jeffs, 1991a). In a review of a large number of patients referred to our institution after failed exstrophy procedures, it was found that a majority of the patients who had partial or complete dehiscence of the bladder or major bladder prolapse had not undergone an osteotomy at the time of initial bladder closure (Gearhart et al., 1993b). We recommend performing bilateral transverse innominate and vertical iliac osteotomy when bladder closure is performed after 72 hours of age (Fig. 31.17). In addition, if the pelvis is not malleable or if the pubic bones are more than 4 cm apart at the time of initial examination under anesthesia, osteotomy should be performed, even if closure is done before 72 hours of age. A well-coordinated surgery and anesthesia team can perform osteotomy and proceed to bladder closure without undue loss of blood or risk of prolonged anesthesia in the child. However, osteotomy together with posterior urethral and bladder closure and abdominal wall closure is a 5- to 7-hour procedure in these infants.

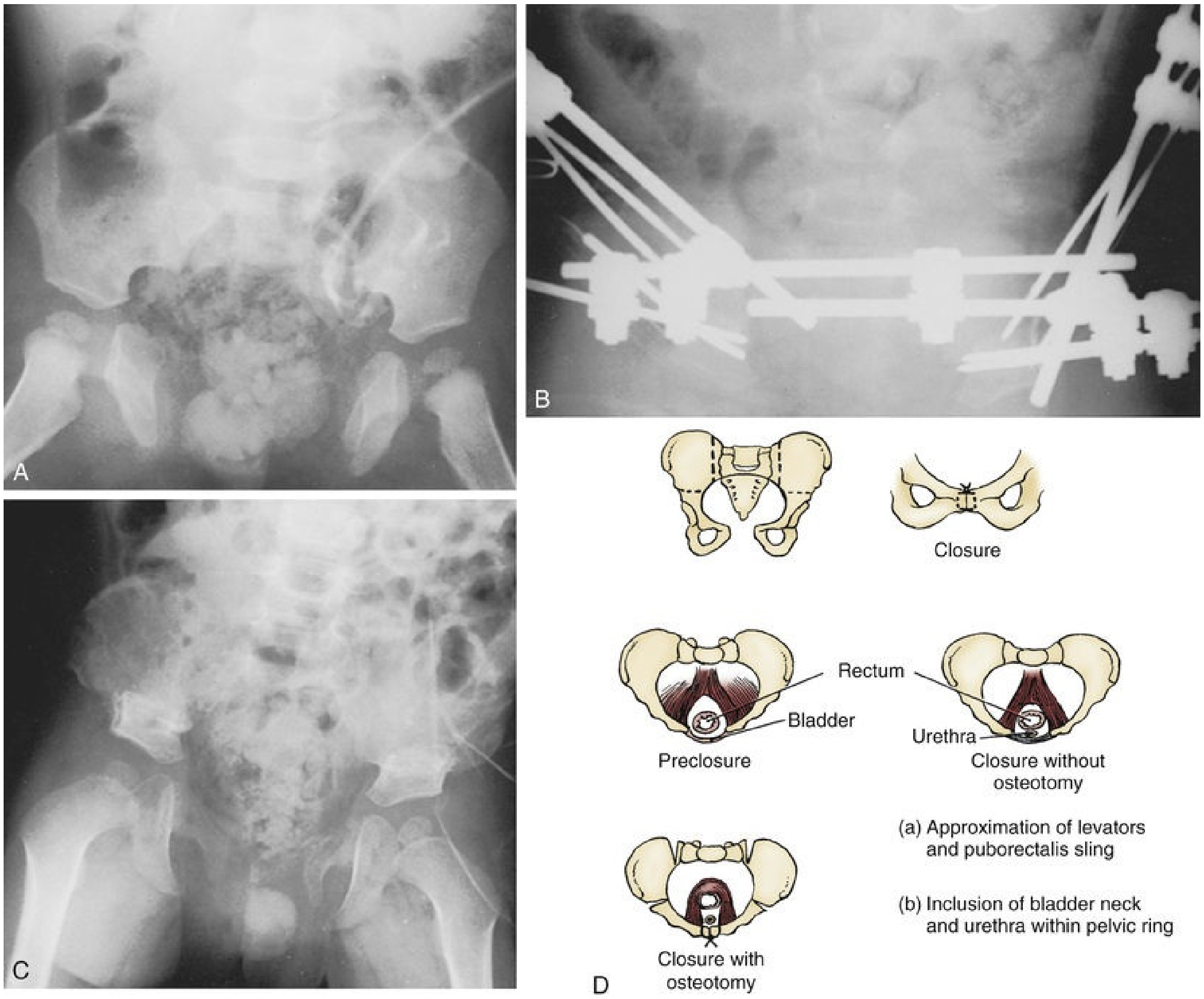
A
B
C
Closure
Rectum
Bladder
Preclosure
Urethra
Closure without osteotomy
(a) Approximation of levators and puborectalis sling
(b) Inclusion of bladder neck and urethra within pelvic ring
Closure with osteotomy
D

FIG. 31.16 (A) An 8-month-old patient with classic bladder exstrophy closed at birth without osteotomy with complete dehiscence. Patient was initially seen at 8 months of age. (B) Patient after having undergone anterior innominate and vertical iliac osteotomy and placement of intrafragmentary pins and external fixator. (C) The same patient 4 months after removal of external fixator and pins. Successful closure was achieved. (D) The technique of combined osteotomy showing incision sites.

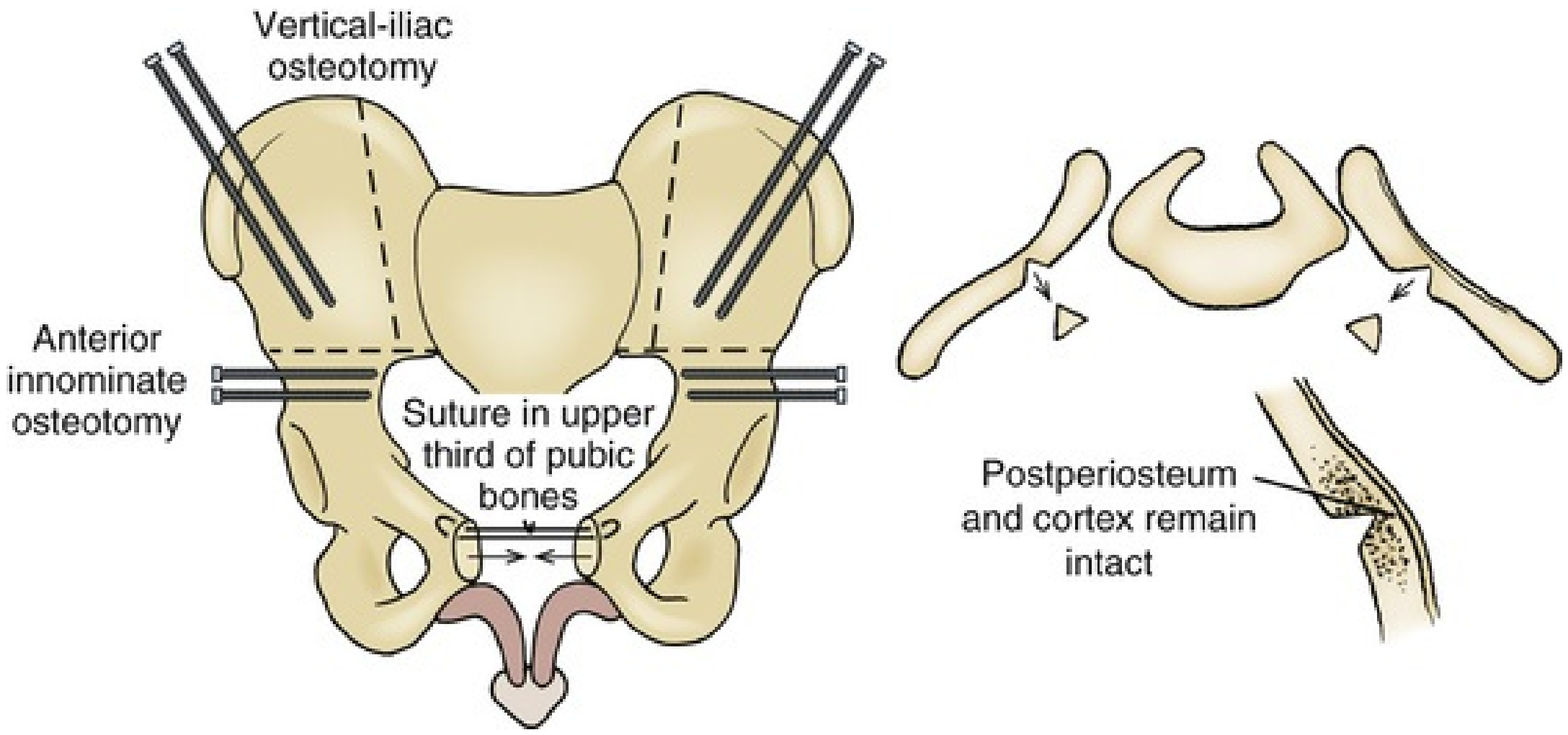
Vertical-iliac osteotomy
Anterior innominate osteotomy
Suture in upper third of pubic bones
Postperiosteum and cortex remain intact

FIG. 31.17 The technique of combined osteotomy showing bony incision sites and pin placement.

If the patient is younger than 72 hours old and examination under anesthesia reveals that the pubic bones are malleable and able to be brought together easily in the midline by medial rotation of the greater trochanters, the patient can undergo closure without osteotomy. No chances should be taken with a decision of this magnitude, and if any doubt exists, an osteotomy should be performed.

The most frequently used osteotomy today is the bilateral anterior innominate and vertical iliac osteotomy, popularized by Gearhart et al. in 1996 (Gearhart et al., 1996b). This approach improves the ease of symphyseal approximation in the patient with exstrophy compared with posterior approaches. In our experience, this osteotomy is superior to the pubic mobilization seen with simple bilateral transverse anterior innominate osteotomy or even pubic ramotomy. **With the ease of approximation obtained with this combined osteotomy, tension on the midline abdominal closure is lessened and the rates of bladder dehiscence and bladder prolapse are markedly decreased** (Gearhart and Jeffs, 1998). In addition, pelvic closure allows anterior movement of the levator ani to strengthen the puborectalis sling. This helps position the bladder neck and posterior urethra deep within the pelvic ring and improved continence rates. This also moves the pelvic floor muscles into a more anterior position, thus providing more support for the anterior pelvic organs.

Combined osteotomy is performed by placing the patient in the supine position, preparing and draping the lower body below the costal margins, and placing soft, absorbent gauze over the exposed bladder. The pelvis is exposed from the iliac wings inferiorly to the pectineal tubercle and posteriorly to the sacroiliac joints. The periosteum and sciatic notch are carefully elevated, and a Gigli saw is used to create a transverse innominate osteotomy exiting anteriorly at a point halfway between the anterior superior and anterior inferior spines (see Fig. 31.17). This osteotomy is created at a slightly more cranial level than that described for a Salter osteotomy to allow placement of external fixator pins in the distal segments. In addition to the transverse osteotomy, the posterior ileum may be incised from the anterior approach in an effort to correct the deformity more completely. For this part of the osteotomy, an osteotome is used to create a closing wedge osteotomy vertically and just lateral to the sacroiliac joints. The proximal posterior iliac cortex is left intact and used as a hinge (see Fig. 31.17). This combination osteotomy easily corrects the abnormalities in the anterior and posterior segments of the pelvis.

Two fixator pins are placed in the inferior osteotomized segment, and two are placed in the wing of the ileum superiorly. Radiographs are obtained to confirm pin placement, soft tissues are closed, and the urologic procedure is performed (see Fig. 31.16). At the end of the procedure, the pelvis is closed with a suture between the two pubic rami. The external fixators are then applied between the pins to hold the pelvis in a correct position. In a newborn with less than optimal amounts of cancellous bone, only one pin is placed inferiorly and superiorly in the wing of the ileum, instead of two as in older children.

Radiographs are taken 7 to 10 days after surgery to look for complete reduction of the symphyseal diastasis. If this diastasis has not been completely reduced, the right and left sides can be gradually approximated by means of the fixator bars over several days. Longitudinal skin traction is used to keep the legs still (Fig. 31.18). The patient remains supine in traction for approximately 4 weeks to prevent dislodgement of tubes and destabilization of the pelvis. The external fixator is kept on for 4 to 6 weeks, until adequate callus is seen at the site of the osteotomy (see Figs. 31.16B and 31.17). Postoperatively, in newborns who undergo closure without osteotomy in the first 48 to 72 hours of life, the baby is immobilized in modified Bryant traction in a position in which the hips have 90 degrees of flexion. When modified Bryant traction is used, the traction is used for 4 weeks. A horizontal mattress suture of No. 2 nylon is placed between the fibrous cartilage of the pubic rami and tied anteriorly to the pubic closure at the time of bladder closure. **Evidence obtained by Sussman et al.** (1997) **from biomechanical testing in an intact piglet pelvic model revealed that all methods of pubic approximation were weak compared with the intact symphysis. However, the best technique with the strongest load-to-failure ratio was a No. 2 nylon horizontal mattress suture**.

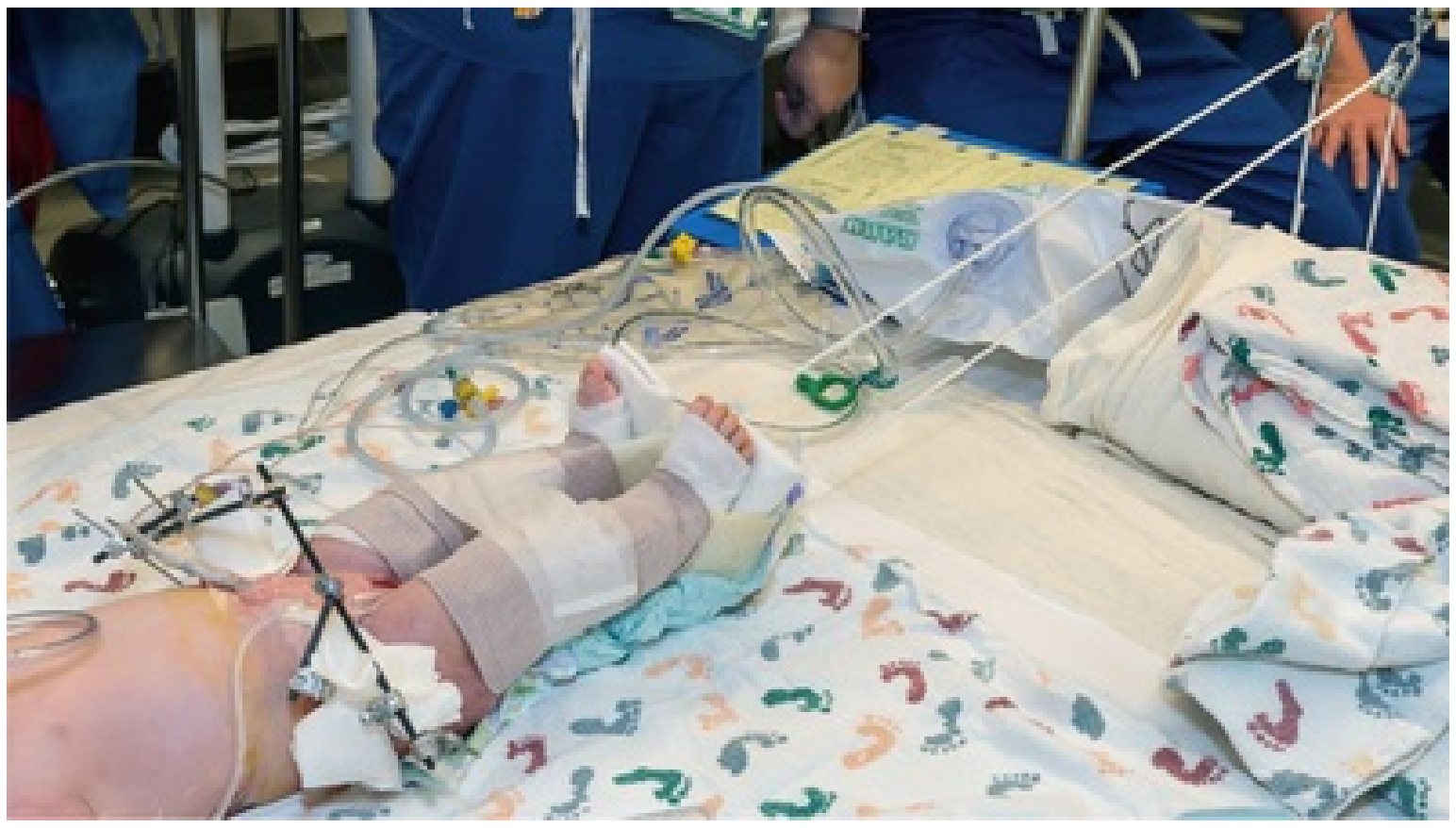

FIG. 31.18 Three-week-old patient after primary of bladder exstrophy with external fixator in place and modified Buck traction.

Complications of Osteotomy and Immobilization Techniques

Complications of inadequate immobilization can include failure of the closure, bladder prolapse, loss of suprapubic tubes, and ureteral stents. Closely related to inadequate immobilization is inadequate pain and movement control. With tunneled epidural catheters for 2 to 3 weeks, pain and movement are well controlled while the pelvic bone callus formation increases in the osteotomy wound and the wound stabilizes.

Some centers still prefer to use spica casts and mummy wraps. In a series from Seattle, the authors preferred spica casts with or without osteotomy over other techniques and felt this allowed earlier discharge from the hospital (Shnorhavorian et al., 2010). However, in a large series of 86 failed exstrophy closures, Meldrum et al. (2003) found that most had been immobilized with a mummy wrap or spica cast. Successful closure was noted in 97% of those immobilized with an external fixator and modified Buck traction. In our experience, we have seen a similar success rate in patients immobilized in such a manner during the primary closure. When patients with repeat closures were included, more than 92% of patients immobilized with longitudinal traction and external fixation were successfully closed. In contrast, however, we have seen that only 53% of patients immobilized with spica casts are successfully closed (Table 31.1). As such, we recommend longitudinal traction and external fixation, particularly in the setting of pelvic osteotomy, to ensure appropriate immobilization and stability of the pelvis (Baumgartner et al., 2017a). Recently, advocates of spica casts have begun to apply them for 8 weeks for better and safer immobilization.

TABLE 31.1

Pelvic Immobilization After the Closure of Classic Bladder Exstrophy

METHOD OF IMMOBILIZATION	TOTAL CLOSURES		CLOSURES WITH OSTEOTOMY		CLOSURES WITHOUT OSTEOTOMY	
	TOTAL NO. (N = 245)	NO. FAILED (%)	TOTAL NO. (N = 180)	NO. FAILED (%)	TOTAL NO. (N = 60)	NO. FAILED (%)
Spica cast	112	53 (47.3)	53	16 (30.2)	55	36 (65.5)
External fixation with traction	133	10 (7.5)	127	10 (7.9)	5	0
P-value		<0.005		<0.005		0.006

Modified from Baumgartner T, Jayman J, Friedlander D, et al.: The role of pelvic and lower limb immobilization in classic bladder exstrophy: an institutional study of three mainstay techniques. Pediatric Urology Fall Congress, Society for Pediatric Urology, Montreal, Canada, 2017.

Sponseller et al. (2001) reported on a total of 86 combined bilateral anterior innominate and vertical iliac osteotomies performed in 88 children. Of these, 10 children had cloacal exstrophy and 72 had bladder exstrophy with at least 2 years of clinical follow-up (mean 4.8 years). Complications included 7 cases of transient left femoral nerve palsy, which resolved fully by 12 weeks after surgery. There were no cases of right femoral nerve palsy, although the same surgeon performed the same technique on both sides. Patients with transient femoral nerve palsy were on bed rest for the first 6 to 8 weeks; a knee immobilizer was needed for the remaining 6 weeks until resolution. Other complications included 3 cases of delayed ileal union, 1 case of superficial infection of the ileal femoral incision that required irrigation and debridement, 1 case of transient right thigh abductor weakness, 1 infection of the ileum around a pin site requiring irrigation and debridement, and 1 case of transient right peroneal palsy. Almost all patients had skin inflammation around the pins, particularly those in the proximal (iliac crest) segments. This was always controlled with the use of oral antibiotics. In a paper by Satsuma et al. (2006), comparisons were made between patients who underwent posterior iliac or combined osteotomy. Pubic approximation was better and the mean recurrence far less in the combined transverse innominate and vertical iliac osteotomy. Thus the combined approach corrected and maintained the pelvic ring with fewer complications than a posterior pelvic osteotomy.

When good callus formation is seen on radiography, the fixating device and pins are removed at the bedside with the patient under light sedation. The age of the patient plays a role in the amount of correction of the diastasis that is maintained over time. On review of the previously described types of osteotomy, classic and cloacal exstrophy patients gained approximation, although the former group gained greater correction toward normal (Gearhart et al., 1996b). Greater preoperative diastasis as well as less optimal bone density in the newborn contributes to the greater difficulty in obtaining and maintaining closure of the pelvic bone deformity over time.

It is our impression that partial recurrence of diastasis occurs in classic exstrophy by two mechanisms, even after osteotomy. First, the pelvis may partially derotate because of early loosening of pins before the time of osteotomy healing; this is seen mostly in infants. In the older child, increased bone density allows more rigid external fixation and thus better maintenance of the corrected position. Second, there is long-term undergrowth of the ischiopubic segment, which has been shown to be 33% smaller than normal in the adult with exstrophy, as the pelvis grows. Pubic diastasis increases with growth in the patient with uncorrected exstrophy. Therefore, even with some loss of approximation, significant correction remains in comparison with the unoperated state. **We regard the main role of osteotomy to be relaxation of tension on the bladder, posterior urethra, and abdominal wall repair during healing.** Therefore we use osteotomy less in newborns and young infants because ligament laxity allows the pelvis to be closed without tension if the diastasis is reasonable and pubic bones are malleable. However, it becomes essential in the older child with a failed exstrophy repair, in the patient with cloacal exstrophy, and in a newborn with a wide diastasis and excellent bladder template. In patients undergoing combined exstrophy closure and epispadias repair, osteotomy allows the pubis to be joined, making it easier for the corpora to be brought over the closed proximal urethra (Gearhart et al., 1998). In a large series of failed exstrophy reclosures (mean age 23.2 months), 56 patients were found who underwent repeat pelvic osteotomy (Nelson et al., 2006). All of the reclosures were successful, and 95% of the patients had a normal gait after reoperative osteotomy. There were no femoral or sciatic nerve palsies, and only five local pin site infections, which were easily treated. Repeat pelvic osteotomy is safe with few complications in experienced hands.

Whichever type of osteotomy is used, pelvic ring closure not only allows midline approximation of the abdominal wall structures but also allows the levator ani and puborectalis muscles to lend potential support to the bladder outlet, thus increasing resistance to urinary outflow (see Fig. 31.16D) (Gearhart et al., 1993b, 1996b; McKenna et al., 1994; Schmidt et al., 1993; Sponseller et al., 1991). Furthermore, a continence procedure can be performed later on the bladder neck and urethra deep within the closed pelvic ring at a distance from the surface without independent movement of the two halves of the pubis. The urethra and bladder neck are set more deeply in the true pelvis, in a more normal relationship than when acutely angulated.

Although the use of osteotomy during initial closure has significantly increased success rates, failures can still occur even with the use of osteotomy. Sirisreetreerux et al. (2017) looked at a large group (n = 156) of exstrophy patients closed with an osteotomy, of which 30% failed their primary closure. Using multivariate analysis, the authors found that the use of Buck's traction and external fixation with an immobilization time greater than 4 weeks significantly lowered the risk of failure. Although osteotomy performed by general, not pediatric, orthopedic surgeons had significantly higher odds of failure. Interestingly, the type of osteotomy and the use of epidural anesthesia did not significantly impact failure rates. Thus osteotomy is a valuable adjunct to both primary and secondary exstrophy closure, but failures can still occur (Sirisreetreerux et al., 2017).

Immobilization Techniques

- Mummy wrap
- Spica casts

- Modified Bryant's traction (only when osteotomy is not performed)
- Modified Buck's traction (used in combination with external fixator device)
- External fixator device

Surgical Options in the Newborn With Classic Bladder Exstrophy

Regardless of which reconstructive method is used, the surgical correction of bladder exstrophy actually begins with preoperative anesthetic management. This frequently involves a combination of general and epidural anesthesia. Epidural catheters are advanced between 6 cm and 10 cm through the insertion needle to reach the T10-12 thoracic dermatome (Kost-Byerly et al., 2008). This is initially injected with a fractionated dose of 1 mL/kg of 0.25% (2.5 mg/mL) bupivacaine with 1 : 200,000 epinephrine (5 mcg/mL), using electrocardiography to monitor for intramuscular injection. Intraoperatively, the catheter is reinjected in 2-hour intervals with 0.6 mL/kg of 0.25% bupivacaine with 1 : 200,000 epinephrine or a 1 mL/kg 0.125% (1.25 mg/mL) solution of bupivacaine with 1 : 200,000 epinephrine for the duration of the procedure.

Although modern staged repair of exstrophy (MSRE) currently enjoys widespread popularity, other methods have been described for the primary reconstruction of exstrophy and are used in good centers. This section discusses the other types of repair and their use and application. The outcomes and complications are discussed in separate sections; many are similar and their correction the same.

Kelly Repair

The radical soft-tissue mobilization procedure was developed by Kelly in the late 1980s and early 1990s as a means to improve on the technique described by Ansell (1983) and to obviate pelvic osteotomies that were often required to obtain a tension-free closure (Ansell, 1983). It is a multistage repair that includes (1) closure of the bladder dome and hernia repair at birth, followed at age 3 to 6 months by (2) reconstruction of the proximal urethra with associated sphincteric tissue with penile lengthening and creation of a penoscrotal urethrostomy in boys, and (3) repair of the resulting penoscrotal hypospadias at around 3 years of age. The unique aspects relate to the second stage, in which a more radical mobilization of the pelvic floor muscles is performed (Kelly, 1995). Specifically, the dissection includes the periosteum of the ischium and pubis, where the attachment of the voluntary and involuntary sphincter muscles, as well as the pudendal nerves and vessels, are found. The muscles are then wrapped around the reconstructed proximal urethra in an attempt to provide a continence mechanism. The neourethra is constructed from the urethral plate on the dorsum of the penis after it is dissected from the corporeal bodies much as in the penile disassembly technique. However, unlike the penile disassembly technique, the meatus is always brought to the penoscrotal junction and later is brought distally.

Complete Repair: Complete Primary Repair of Exstrophy

Developed by Mitchell, the complete repair combines the standard bladder closure with the “penile disassembly” technique for epispadias repair in an effort to decrease the number of procedures required for reconstruction and to provide continence without the need for formal bladder neck reconstruction (Grady and Mitchell, 1999).

This technique of penile repair was developed by Mitchell and Bägli (1996). It has now been incorporated in the complete primary repair of exstrophy (CPRE) for primary closure in the newborn.

The penis is dissected into three components—the right and left corpora with their associated hemiglans and the urethral wedge (urethral plate with its associated spongiosa) (Fig. 31.19). The dissection as in the Cantwell-Ransley repair begins on the ventral aspect of the penis. The dissection moves medially just above the Buck fascia but is taken down to the tunica albuginea of the corpora. Care is taken to preserve the spongiosum with the urethral wedge, and this dissection is carried posteriorly to the area of the bladder neck. The penis was formerly separated into the three aforementioned components. However, recently because of soft tissue loss, proponents have begun leaving the plate attached to the glans, with the repair resembling a modified Cantwell-Ransley repair (Borer et al., 2017). In a recent study by Kasprenski et al., 22 patients who underwent CPRE with complete penile disassembly were found to have soft-tissue loss (Kasprenski et al., 2018a). If the surgeon feels the urethral plate should be detached from the glans, the urethra is brought between the corpora to a hypospadiac position. The corpora are then positioned in the midline with interrupted sutures. Skin closure is similar to that of standard hypospadias repair with fine absorbable sutures. If concomitant exstrophy closure is to be done, the dissection then moves proximally into the pelvis to be able to move the structures into the pelvis. Another part of the complete repair is bladder neck “tailoring” to provide some outlet resistance after closure in the newborn (see Fig. 31.19).

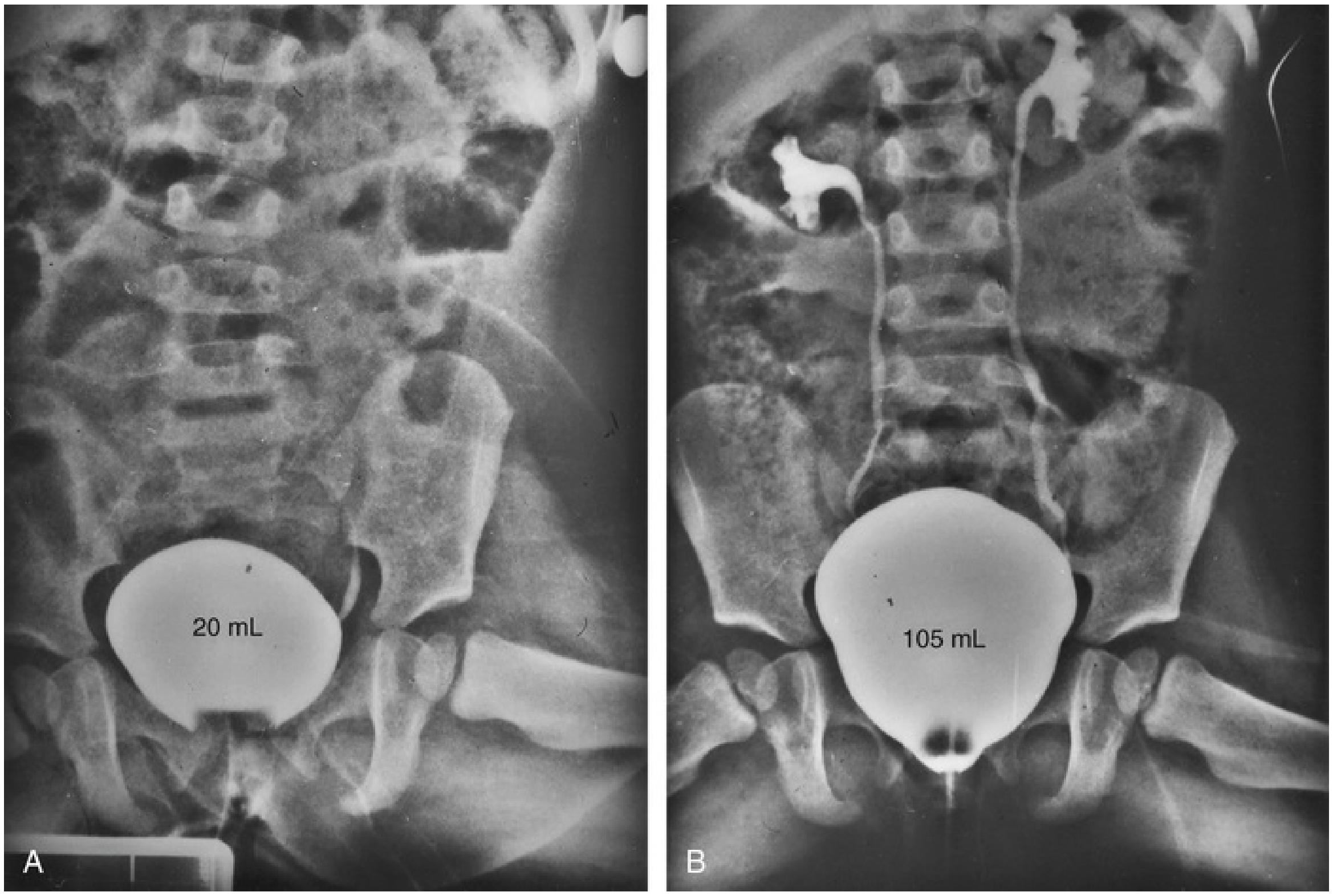

FIG. 31.19 (A) Initial cystogram under anesthesia showing small bladder capacity after bladder closure. (B) Improvement in bladder capacity noted after urethroplasty.

Mitchell emphasizes the importance of dissecting the perineal membrane from the pubis, allowing the bladder and posterior urethra to be set deep into the pelvis. This feature, however, is common to all properly performed exstrophy reconstructions and helps ensure success. The dissection of the urethral plate from the corpora leaves 60% to 75% of patients with hypospadias (Hafez and El-Sherbiny, 2005), and 50% of children require ureteral reimplantation in the first year of life (Grady and Mitchell, 1999).

Schrott-Erlangen Approach

The Erlangen approach is clearly the most evolved of any of the primary closure techniques. In the Erlangen approach, developed by Schrott and popularized by Rosch, if the bladder template is deemed of adequate size, the “total” repair is done at 8 weeks of age. If the template is too small at birth, the bladder only is closed with bilateral groin exploration, closure of the pubis, epispadias repair, and no osteotomy. In the classic Erlangen total repair, the bladder is closed along with bilateral reimplantations, bladder neck plasty, bilateral groin exploration, epispadias repair, pubic closure, no osteotomy, and an epidural catheter for 5 days. Osteotomy is only done in cloacal exstrophy and reoperative closures. Thus the Erlangen repair is truly a complete repair, encompassing all phases of exstrophy repair in one setting (Schrott et al., 1984). A long-term follow-up study of nearly 20 years found that 10 of 16 patients were objectively continent of urine and that most had normal renal function (Ebert et al., 2010).

Mainz Repair

Hohenfelner et al. first began using ureterosigmoidostomy for failed exstrophy patients and for patients with small bladder templates, which led to its use as a technique in primary exstrophy closures. Beginning in 1964, this was begun in all newborns with exstrophy, irrespective of bladder template size at birth. At the age of 2 years, the patient undergoes ureterosigmoidostomy. Some of the remnant bladder is made into a small seminal receptaculum, and the penis is reconstructed during the same procedure. In girls, the external genitalia are reconstructed and anterior fixation of the uterus is performed. In boys and girls, cosmetic correction is usually needed later. However, this usually means only one further operation. In 1996 Fisch et al. reported long-term results with the Mainz Sigma pouch (Fisch et al., 1996). This was designed to reduce intracolonic pressures and to maintain better fecal continence. Most of the patients are immediately started on oral alkalinization.

Regardless of the method of exstrophy reconstruction chosen for the newborn, certain surgical principles remain: (1) radical mobilization of the posterior vesicourethral unit from surrounding tissue; (2) combined closure with epispadias repair in only very carefully selected patients; (3) tension-free closure of the abdominal wall and pelvic bones with adjunctive osteotomy if needed; and (4) definition of strict criteria for selection of newborns to undergo closure.

Modern Staged Reconstruction of Bladder Exstrophy

The primary objective in functional closure is to convert the bladder exstrophy into a complete epispadias with the urethra well up onto the proximal shaft or midshaft of the penis with combined complete epispadias repair in only highly select patients. The resultant incontinence with balanced posterior outlet resistance not only preserves renal function but also stimulates bladder growth. Typically, epispadias repair is now performed at around 6 months of age, after testosterone stimulation. Bladder neck repair usually occurs when the child is 4 to 5 years of age, has an adequate bladder capacity, and, most important, is ready to participate in a postoperative voiding program. Many repairs such as the Erlangen, Kelly, and CPRE were purported to establish continence without the need for bladder neck repair, but recent reports have shown the need for an outlet procedure in almost all patients (Gargollo et al., 2011; Gearhart et al., 2005, 2007; Shoukry et al., 2009).

Bladder, Posterior Urethral, and Abdominal Wall Closure

Various steps in primary bladder closure are illustrated in Fig. 31.20A to H. A strip of mucosa 2 cm wide, extending from the distal trigone to well below the verumontanum up to the midshaft of the penis in the male and to the level of the vaginal orifice in the female, is outlined for prostatic and posterior urethral reconstruction in the male and adequate urethral closure in the female. The male urethral groove may be adequate, in which case no transverse incision of the urethral plate must be performed for urethral lengthening (see Fig. 31.20A). We tend not to incise a urethral plate unless the length of the urethral groove from the verumontanum to the urethral glans is so short that it interferes with eventual penile length and produces dorsal angulation. If so, the urethral groove is lengthened after the manner of Johnston (1974) or Duckett (1977). The drawings in Figs. 31.20B and C show marking of the incision just above the umbilicus, down the junction of the bladder and paraexstrophy skin, to the level of the urethral plate.

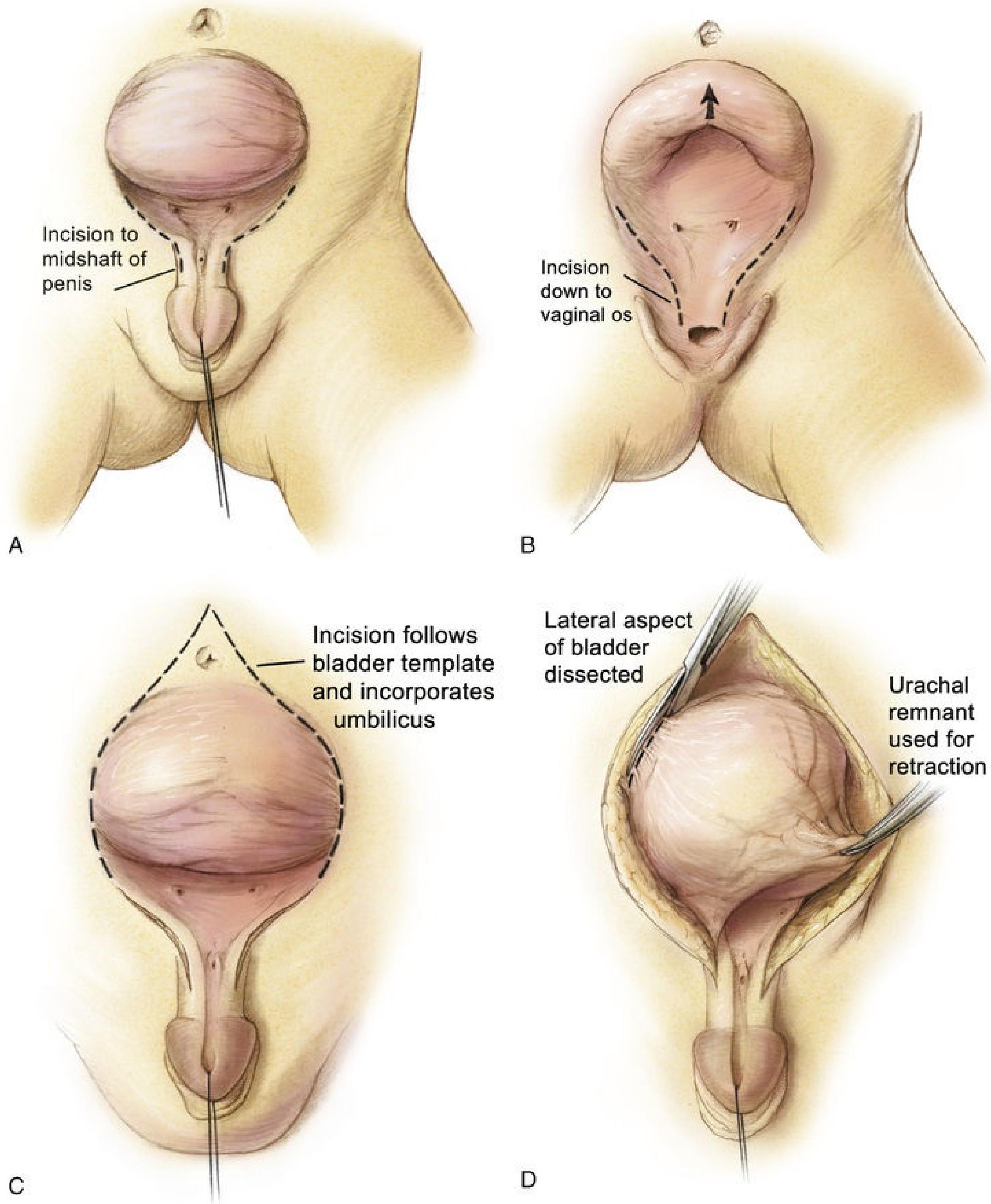
Incision to midshaft of penis
A
Incision down to vaginal os
B
Incision follows bladder template and incorporates umbilicus
C
Lateral aspect of bladder dissected
Urachal remnant used for retraction
D

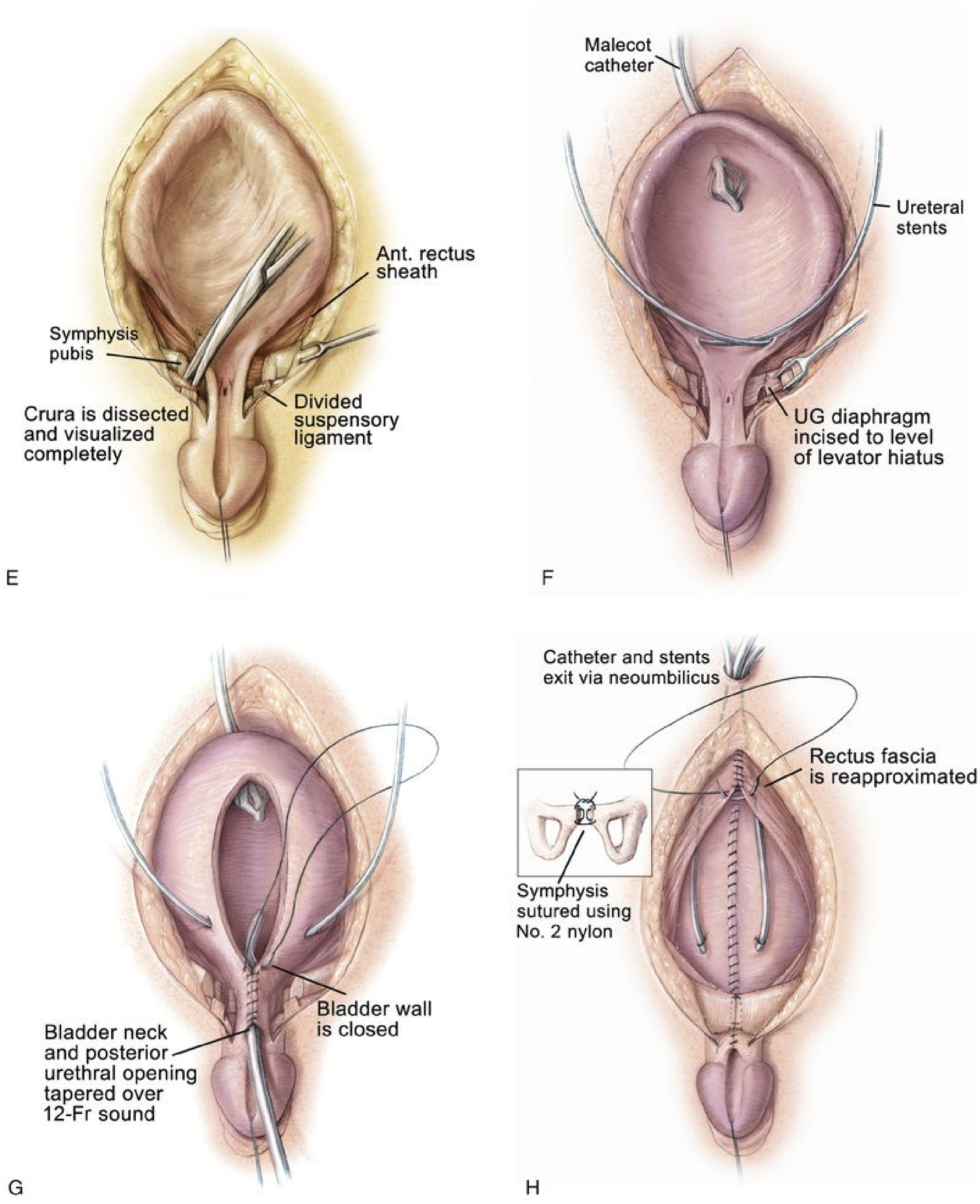
Ant. rectus sheath
Symphysis pubis
Crura is dissected and visualized completely
Divided suspensory ligament
E
Malecot catheter
Ureteral stents
UG diaphragm incised to level of levator hiatus
F
Bladder wall is closed
Bladder neck and posterior urethral opening tapered over 12-Fr sound
G
Catheter and stents exit via neoumbilicus
Rectus fascia is reapproximated
Symphysis sutured using No. 2 nylon
H

FIG. 31.20 Steps in the initial closure of the bladder and posterior urethra with or without osteotomy. The bladder plate is dissected off the anterior abdominal wall. (A) Initial incision around the bladder plate in the male. (B) Initial incision around the bladder plate in the female. (C) Incision follows the bladder template and includes the umbilicus. (D) Dissection of the lateral aspect of the bladder from the abdominal wall. (E) Dissection of the crura from the symphysis pubis. (F) Division of the urogenital (UG)

diaphragm fibers. Note stents and suprapubic tubes in place in the bladder. (G) Initial layer of the bladder closure. Urethral meatus is calibrated to 14-Fr size. Stents are brought out of the bladder. (H) Pubic approximation is performed with No. 2 nylon mattress suture *(see inset).* Abdominal wall closure is completed. Suprapubic tube and stents are brought out through the neoumbilicus. (Copyright Brady Urological Institute.)

An appropriate plane is entered just above the umbilicus, and a plane is established between the rectus fascia and the bladder (Fig. 31.20D). The umbilical vessels are doubly ligated and incised and allowed to fall into the pelvis. The peritoneum is taken off the dome of the bladder at this point so that the bladder can be placed deep into the pelvis at the time of closure. The plane is continued caudally down between the bladder and rectus fascia until the urogenital diaphragm fibers are encountered bilaterally. The pubis is encountered at this junction, and a double-pronged skin hook can be inserted into the bone at this time and pulled laterally to accentuate the urogenital diaphragm fibers and help the surgeon radically incise these fibers between the bladder neck, posterior urethra, and pubic bone (Fig. 31.20E). Gentle traction on the glans at this point shows the insertion of the corporeal body on the lateral inferior aspect of the pubis. These urogenital diaphragm fibers are taken down sharply with electrocautery down to the levator hiatus in the pelvic floor in their entirety (Fig. 31.20F). If this maneuver is not performed adequately, the posterior urethra and bladder will not be placed deeply into the pelvis, and when the pubic bones are brought together, the posterior vesicourethral unit will be brought anteriorly into an unsatisfactory position for later Cantwell-Ransley epispadias repair. Di Carlo et al. have recently shown the advantage of using 3D MRI–guided dissection of the pelvic diaphragm to enhance the accuracy and safety of this dissection (Fig. 31.21) (Di Carlo et al., 2017). If the urethral plate is left in continuity, it must be mobilized up to the level of the prostate to create as much additional urethral and penile length as possible. Further urethral lengthening can be performed at the time of epispadias repair.

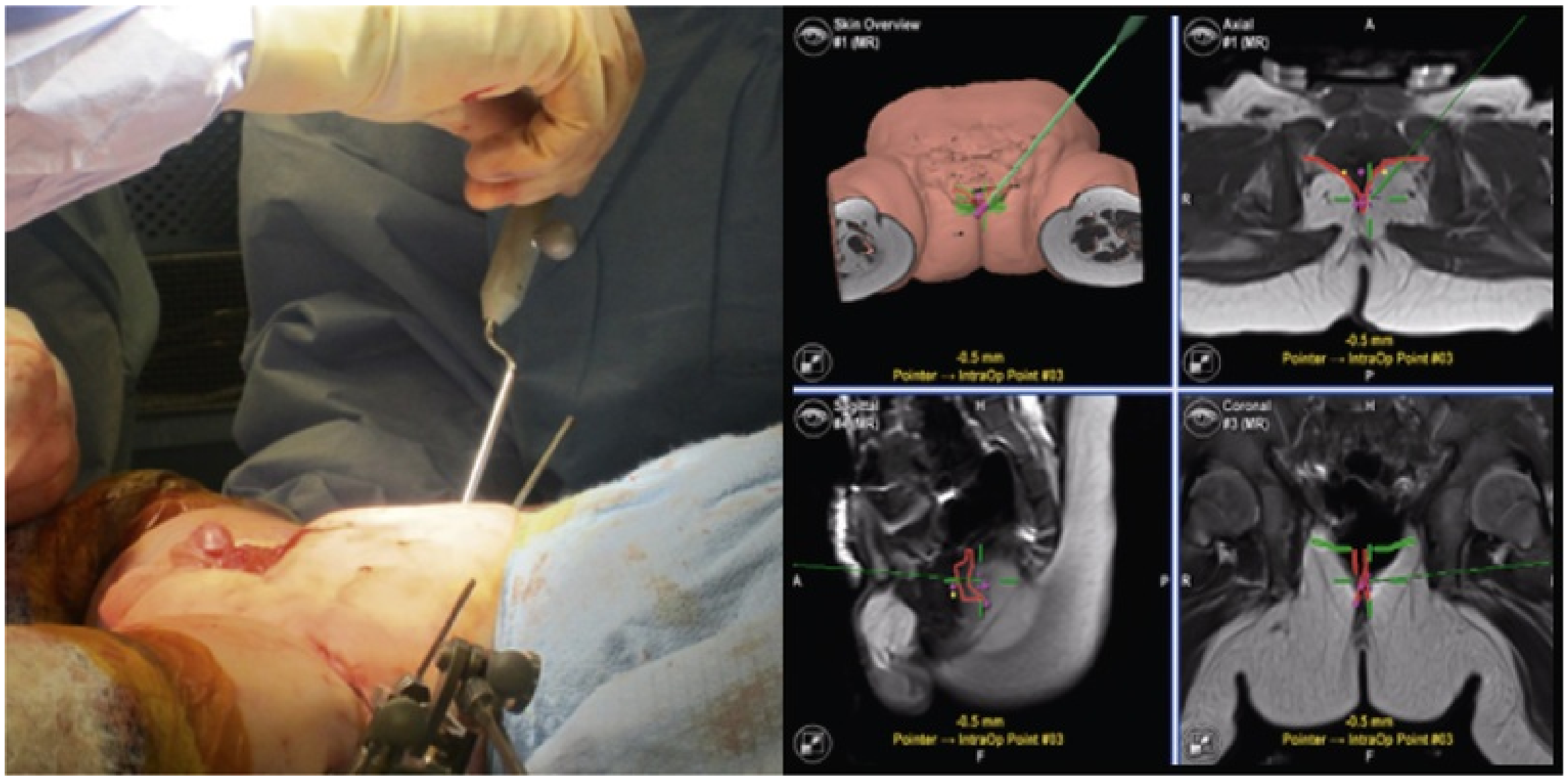
Skin Overview
#1 (MR)
-0.5 mm
Pointer → IntraOp Point #03
Axial
#1 (MR)
A
R
-0.5 mm
Pointer → IntraOp Point #03
P
H
A
-0.5 mm
Pointer → IntraOp Point #03
F
Coronal
#3 (MR)
H
P
R
-0.5 mm
Pointer → IntraOp Point #03
F

FIG. 31.21 Intraoperative image-guided exstrophy repair with preoperative magnetic resonance imaging (MRI) is performed with Brainlab. During the closure, the surgeon identifies the urogenital muscle fibers and the smooth and striated muscle fibers of the posterior urethra and bladder plate *(left).* These structures are verified with a three-dimensional reconstruction of a triplanar MRI *(right).*

Penile lengthening is achieved by exposing the corpora cavernosa bilaterally and freeing the corpora from their attachments to the suspensory ligaments on the anterior part of the inferior pubic rami. **However, because Silver et al.** (1997b) **showed that there is a 50% shortage of length of the corporeal bodies in exstrophy versus normal controls, any penile length that is obtained is through correction of chordee and change in angulation of the penis rather than true penile lengthening.** The wide band of fibers and muscular tissue representing the urogenital diaphragm is detached subperiosteally from the pubis bilaterally (Fig. 31.20E). Reluctance to free the bladder neck and urethra well from the inferior ramus of the pubis moves the neobladder opening cephalad should any separation of the pubis occur during healing, thus increasing the chance of bladder prolapse. The mucosa and muscle of the bladder, bladder neck, and urethra are then easily closed well onto the mid-shaft of the penis in the midline anteriorly (Fig. 31.20G). This posterior vesicourethral unit should be “tapered” over a 12-Fr sound. The purpose of this tapering is to slightly narrow and elongate this unit to allow it to be placed deeply into the pelvis. The size of the opening should allow enough resistance to aid in bladder adaptation and to prevent prolapse but not enough outlet resistance to cause upper tract changes. This area will be the site of future bladder neck reconstruction. The posterior urethra and bladder neck are buttressed with a second layer of local tissue if possible. The bladder is drained by a suprapubic nonlatex Malecot catheter for a period of 4 weeks. The urethra is not stented to avoid necrosis with accumulation of secretions in the neourethra. Stents provide drainage during the first 10 to 14 days after closure, because swelling caused by the pressure of closure of a small bladder can obstruct the ureters and give rise to obstruction and transient hypertension. If there are no problems with the stents during healing, we leave the stents in for as long as 2 to 3 weeks.

When the bladder and urethra have been closed and the drainage tubes placed, pressure over the greater trochanters bilaterally allows the pubic bones to be approximated easily in the midline. Horizontal mattress sutures are placed in the pubis and tied with a knot away from the neourethra (Fig. 31.20H). Often we are able to use another stitch of No. 2 nylon at the most caudal insertion of the rectus fascia onto the dorsal pubic bone. This maneuver adds to the security of the pubic closure. A V-shaped flap of abdominal skin at a point corresponding to the normal position of the umbilicus is tacked down to the abdominal fascia, and a drainage tube exits this orifice. The method described by Hanna (1986) is our most commonly performed procedure. Before and during the procedure, the patient is given broad-spectrum antibiotics in an attempt to convert a contaminated field into a clean surgical wound.

For the very short penis at birth, the urethral groove must be transected. As described by Duckett (1977), the groove is then cut distal to the verumontanum with continuity maintained between the thin, mucosal, paraexstrophy non–hair-bearing skin adjacent to the posterior urethra and bladder neck and the skin and mucosa of the penile skin and glans. Flaps in the area of the thin skin are subsequently moved distally and rotated to reconstruct the urethral groove, resurfacing the penis dorsally. The corporeal bodies are not brought together at this juncture because later Cantwell-Ransley repair is planned.

Combined Bladder Closure and Epispadias Repair

MSRE has yielded consistently good cosmetic and functional results, and the use of osteotomy has improved the potential for successful initial closure and later continence. **In an effort to decrease costs, decrease the morbidity associated with multiple operative procedures, and possibly affect continence, there has been interest in performing single-stage reconstruction or combining**

procedures in appropriately selected patients. This technique was first described by Lattimer and Smith (1966) but was abandoned in the 1970s because of high complication and failure rates. The technique was revisited by Gearhart and Jeffs (1991a) for failed exstrophy closures and more recently by Grady and Mitchell for newborn patients (1999). In the combined exstrophy and epispadias repair, bladder closure is combined with the modified Cantwell-Ransley epispadias repair (Baird et al., 2005c; Gearhart and Mathews, 2000). This technique can be applied to delayed primary closure and failed closures. This method does not require making the patient hypospadiac.

Results have now emerged in groups of boys undergoing single-stage reconstruction (bladder closure and epispadias repair) in infancy (Baird et al., 2005c; Gearhart et al., 1998). In our opinion, this technique should be limited to boys of older age (older than 6 months) because of evidence indicating that potential complication of these combined procedures is significant loss of penile and corporeal tissue that makes further reconstruction problematic (Cervellione et al., 2010). Patients should be carefully selected, and use of these extensive procedures by the occasional exstrophy surgeon is not recommended. **Selection should take into account phallic size and length, depth of the urethral groove, and size of the bladder template in those with delayed primary closures, as well as perivesical and urethral scarring in those who have undergone a prior failed closure** (Baird et al., 2005c; Gearhart et al., 1998; Gearhart and Jeffs, 1991a).

Management After Primary Closure

The initial step of the MSRE converts a patient with exstrophy into one with mid-penile shaft epispadias and incontinence. After the surgery, patients typically spend 3 days in the intensive care unit for optimizing pain control and weaning from ventilation. Adequate pain control may be achieved with a combination of tunneled epidural lidocaine administration and intravenous patient controlled analgesia (Stec et al., 2012b). **Before removal of the suprapubic tube, 4 weeks after surgery the bladder outlet is calibrated by a urethral catheter or a urethral sound to ensure free drainage. A complete ultrasound examination is performed to ascertain the status of the renal pelvises and ureters, and appropriate urinary antibiotics are administered because all patients have reflux after closure.** Residual urine is estimated by clamping the suprapubic tube, and specimens for culture are obtained before the patient leaves the hospital and at subsequent intervals to detect infection and ensure that the bladder is empty. If the initial ultrasound examination shows good drainage, upper tract imaging by ultrasonography is repeated 3 months after discharge from the hospital and at intervals of 6 months to 1 year during the next 2 to 3 years to detect any upper tract changes caused by reflux, infection, or obstruction. Prophylactic antibiotics should be continuous because all patients with bladder exstrophy, once it has been closed, have vesicoureteral reflux. If a useful continence interval has resulted from the initial closure, a further operation for incontinence may not be required; however, this situation is unusual. After the conversion from exstrophy to complete epispadias with incontinence, the bladder gradually increases in capacity as inflammatory changes in the mucosa resolve.

Cystoscopy and cystography at yearly intervals are used to evaluate the degree of reflux noted in almost 100% of patients and to provide an estimate of interval bladder growth (Gearhart and Jeffs, 1998). Even in a completely incontinent patient, bladder capacity gradually increases to a point at which the bladder can be distended at cystography to its true capacity. This must be done under anesthesia in young children because the values obtained differ markedly from those obtained when trying to fill the bladder of a crying, squirming infant on an x-ray table (Gearhart and Jeffs, 1998). If the bladder has not achieved a capacity of at least 30 mL by 1 to 2 years, concern must be voiced to the parents about the overall ability of the bladder to undergo a continence procedure. Currently, the best parameters available to predict overall success are the size of the bladder template at birth and a successful primary closure with absence of infections.

Should bladder outlet resistance be such that urine is retained within the bladder and reflux and ureteral dilation develop with infected urine, it may be necessary to dilate the urethra or to begin intermittent catheterization (Baker et al., 1999). Sometimes the posterior urethral obstruction can be such that it requires a transurethral incision of the stricture to maintain an adequate posterior urethral outlet. If bladder outlet resistance persists and infections continue, an antireflux procedure may be required as early as 6 months to 1 year after initial closure (Mathews and Gearhart, 2003). After primary CPRE repair, 50% of patients require ureteral reimplantation in the first year after closure. Because of this problem, some units are trying ureteral reimplantation at the time of bladder closure, but the numbers of patients treated in this fashion is small (Braga et al., 2010). If severe upper tract changes occur, surgical revision of the bladder outlet by advancing skin flaps into the orifice or even patching the stricture may be necessary to prevent scarring and further obstruction. As mentioned previously, transurethral incision of the urethral stricture to obtain a balanced outlet should be tried before surgical revision.

Judgment is required to know when to avoid attempts at functional closure and to know when to turn to urinary diversion as a means to preserve renal function. This change of plan is seldom necessary if an adequate outlet has been constructed at the initial closure and if careful attention has been paid to the details of follow-up of the bladder and posterior urethra. An important caveat is that if there are recurrent urinary tract infections (UTIs) and the bladder is distended on ultrasonography, cystoscopy should be performed. The posterior urethra should be carefully examined anteriorly for erosion of the intrapubic stitch, which may be the cause of the recurrent infections (Baker et al., 1999). If the intrapubic stitch is seen in the posterior urethra, a small suprapubic incision should be made and the stitch should be removed, or, if it can be grasped, it should be removed transurethrally. Husmann et al. (1990) have shown acceptable levels of upper tract function after primary closure if prophylactic antibiotics were used after initial closure and elevated urinary residuals were kept below 50 mL. In a recent study by Schaeffer et al. (2013), glomerular filtration rate (GFR) was measured before closure and 1 year after bladder neck reconstruction and was found to be no worse or higher than normal values.

Key Points: Management After Primary Closure

- Adequate bladder drainage
- Adequate ureteral drainage
- Adequate immobilization and movement control
- Adequate pain control

Selected Technical Aspects of Other Methods of Closure

Kelly Repair

The multiple-stage Kelly repair begins when the bladder is closed up to the level of the posterior urethra with no attempt to bring the pubic bones into apposition.

The second step of the Kelly repair, which differs from other types of repair, is the radical soft-tissue mobilization. This is accomplished by making an incision around the old bladder closure and by making parallel incisions on the urethral plate extending proximally to halfway between the ureteric orifices and the verumontanum. This maneuver helps expose the corpora laterally as they move over toward their insertion onto the pubis. The mucosa lateral to the urethra is excised, as is some of the mucosa of the bladder (Fig. 31.22A and B). The initial lateral extension of the incision exposes the dorsal nerves of the penis and the attachment of the corpora to the pubis (see Fig. 31.22B). The urethral plate is mobilized from the corporeal bodies and moved to below them to create a penoscrotal hypospadias.

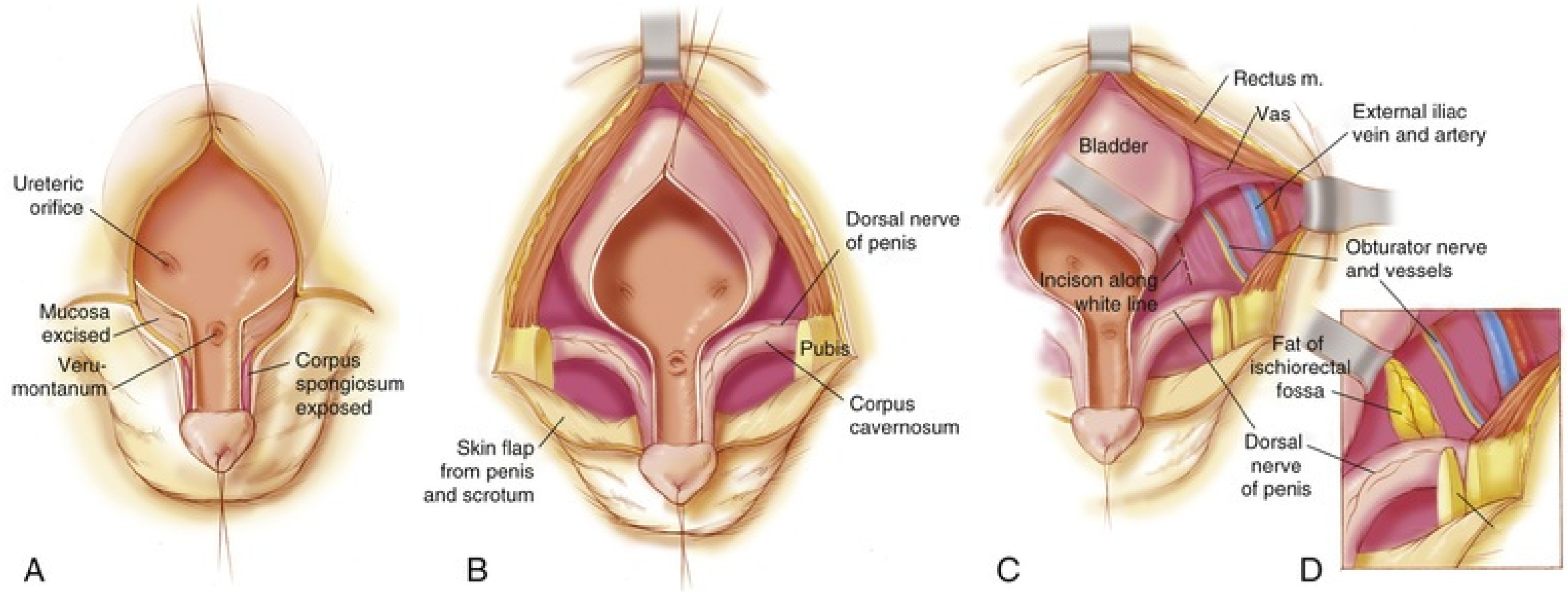
Ureteric orifice
Mucosa excised
Veru-montanum
Corpus spongiosum exposed
A
Dorsal nerve of penis
Pubis
Corpus cavernosum
Skin flap from penis and scrotum
B
Rectus m.
Vas
External iliac vein and artery
Bladder
Obturator nerve and vessels
Incison along white line
Fat of ischiorectal fossa
Dorsal nerve of penis
C
D

FIG. 31.22 Kelly repair. (A) The penis has been degloved and pulled down over the scrotum. The corpora are exposed with their attachments to the pubis. The dorsal nerves of the penis are identified emerging from the pelvis superior to the attachment of the corpus to the pubis. (B) The extraperitoneal plane behind the left rectus muscle has been opened. The vas is identified and retracted with peritoneum. The external iliac vessels and obturator vessels and nerves are identified. The initial incision is made into the pubis to create a flake of bone, taking care to go down only to the level of the emergence of the dorsal nerve of the penis. (C) The pelvic floor is opened, and the bladder and rectum retracted medially. An incision is made through the levator medial to the white line. This incision is taken out to the wall of the pelvis so that the attachment of the levator to the back of the pubis will be moved with the bone flake. (D) Deeper, the ischiorectal fossa is encountered where the pudendal vessels are identified and freed up. Once the vessels and bone flake are totally free, the tissues of the penis, bladder neck, and urethra are reconstructed. (A and B, Redrawn from Kelly with permission.)

Laterally, the extraperitoneal space behind the rectus is entered and the vas is retracted (Fig. 31.22C). An incision is made in the superior aspect of the pubis downward, creating a “flake” to which the corpora of the penis and remnants of the urogenital diaphragm are attached medially (Fig. 31.22D). The incision is then taken deeper to the superior aspect of the levator ani. The incision is carried through the levator muscles both deeply and anteriorly to where the levators insert on the back of the pubis. The pudendal vessels and nerves are freed from any attachments. When it appears the entire course has been determined, the flake of the pubis is incised totally and the urethral and bladder neck area and muscles are brought together without tension.

Mitchell Repair

The Mitchell repair is often done after a few months of age. The former difference was that the urethra is separated from its attachments to the underlying corporeal bodies and pelvic diaphragm during the first stage of the procedure. Mitchell purports that this allows better posterior positioning of the bladder neck and posterior urethra into the pelvis. This combined bladder closure with penile repair was originally thought to be sufficient for the patient to achieve urinary continence, but this has been found not to be the case in that most of these patients require bladder neck repair (Gargollo et al., 2011; Gearhart et al., 2005; Shoukry et al., 2009).

The closure is begun in the standard fashion, but the incision is carried out onto the urethral plate, taking care to preserve its blood supply and avoiding corporeal injury. The penis is then somewhat disassembled into three components—the right corpus, left corpus, and urethral wedge (Fig. 31.23)—because it is believed that each corpora has its own blood supply. However, the urethral plate draws blood from spongiosa so that there can be ischemia. Recently, because of soft tissue loss, the repair has changed to become more like the Cantwell-Ransley repair by leaving the urethral plate attached to the glans (Borer et al., 2017). The dissection moves cranially and the intersymphyseal band is incised. This is also accomplished as in the MSRE procedure by going medial to the inferior aspect of the pubis and cutting these fibers from their posterior urethral attachment all the way down to the levator hiatus (Gearhart et al., 2007). During standard closure of the bladder, the bladder neck is tailored and the urethra is closed in an attempt to move the urethra to the tip of the penis (see Fig. 31.23). If it does not reach the tip of the penis, the urethra is taken to the base of the penis in a hypospadiac position in a majority (70%) of patients (see Fig. 31.23).

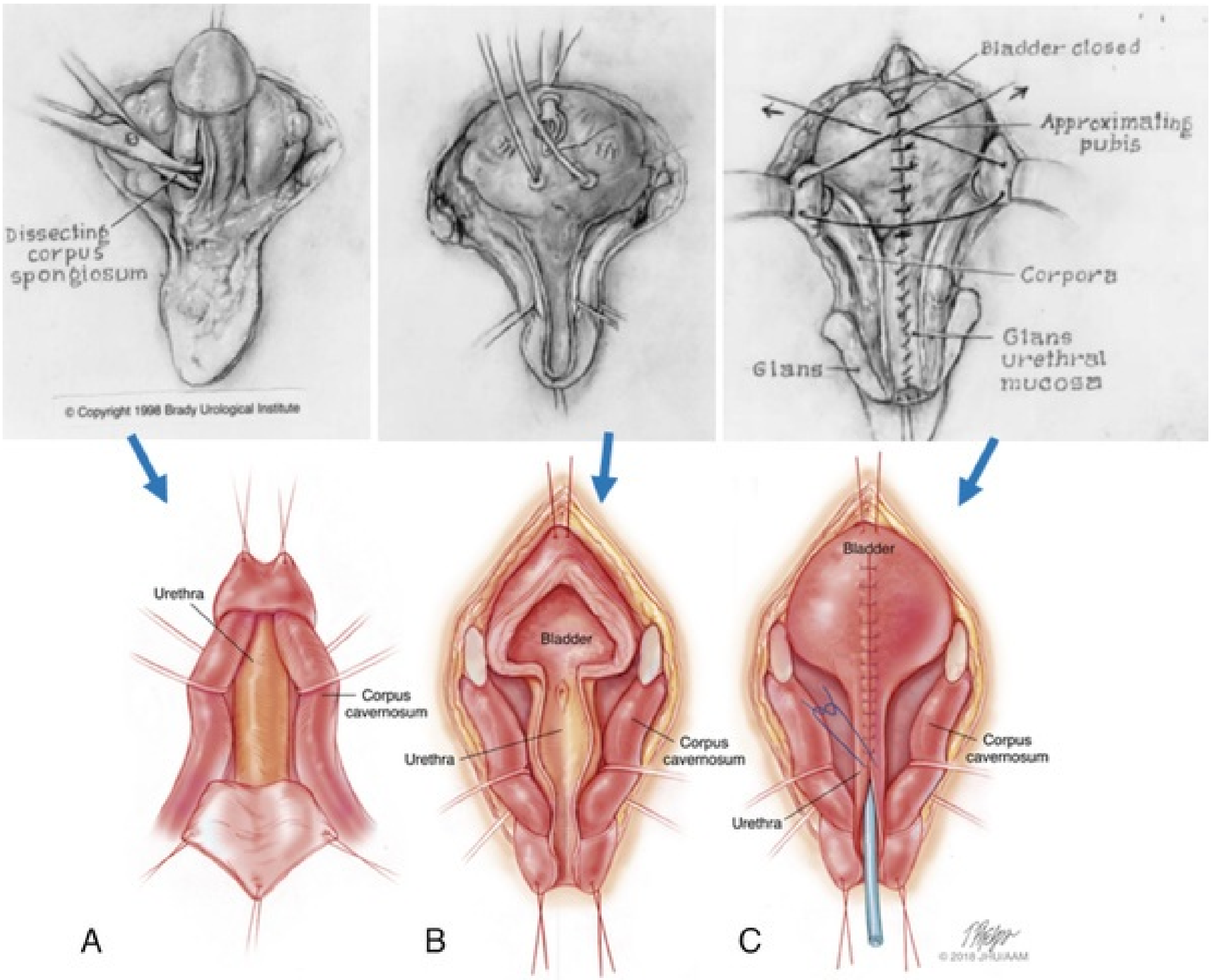
Dissecting corpus spongiosum
© Copyright 1998 Brady Urological Institute
Bladder closed
Approximating pubis
Corpora
Glans
Glans urethral mucosa
Urethra
Corpus cavernosum
A
Bladder
Urethra
Corpus cavernosum
B
Bladder
Corpus cavernosum
Urethra
C
© 2018 JHU/AAM

FIG. 31.23 Modified penile disassembly during complete primary repair of bladder exstrophy. (A) Dissection of the urethral plate in the ventral approach with the urethral plate attached distally to the corpora and glans. (B) Dorsal view shows dissection of the corpora from urethra until the distal centimeter for maintenance of vascular structure and symmetry, similar to the modified Cantwell-Ransley epispadias repair. (C) The bladder is closed and the urethra is tubulerized. (Modified from Gearhart JP, Mathews R: Penile reconstruction combined with bladder closure in the management of classic bladder exstrophy: illustration of technique. *Urology.* 55:764–770, 2000, *top.*)

The repair is very similar in the female patient, with care taken to mobilize the bladder neck, urethra, and vagina as a single unit. Unlike the Kelly repair but similar to MSRE, an osteotomy is used in both sexes if the child is older than 3 days old or the diastasis is judged to be excessive.

Penile and Urethral Closure in Exstrophy

Epispadias Repair

Historically, bladder neck reconstruction was performed before penile and urethral reconstruction. An increase in bladder capacity in patients with extremely small bladder capacities after epispadias repair prompted a change in the management program (Gearhart and Jeffs, 1989a) (see Fig. 31.19). In a group of patients with a small bladder capacity after initial closure, there was a mean increase of 55 mL in males only 22 months after epispadias repair. However, with MSRE, the epispadias repair is now performed at about 6 to 10 months of age in all patients. Recent data by Kufner et al. (2010) clearly demonstrated better eventual overall bladder capacity in patients in whom the epispadias repair was completed before 12 months of life. With this modification, possibly all patients can achieve an appropriate capacity by the time they are physically and mentally ready to undergo bladder neck reconstruction. Because most boys with exstrophy have a somewhat small penis and a shortage of available penile skin, all patients undergo testosterone stimulation before urethroplasty and penile reconstruction (Gearhart and Jeffs, 1987).

Many techniques have been described for reconstruction of the penis and urethra in patients with CBE. Current methods of epispadias repair in bladder exstrophy are the Cantwell-Ransley repair (1989), the modified Cantwell-Ransley repair (1995), and the penile disassembly technique described by Mitchell and Bägli (1996).

Regardless of the surgical technique chosen for reconstruction of the penis in bladder exstrophy, four key concerns must be addressed to ensure a functional and cosmetically pleasing penis. These concerns are (1) correction of dorsal chordee, (2) urethral reconstruction, (3) glanular reconstruction, and (4) penile skin closure.

Although it is possible to achieve some penile lengthening and release of chordee at the time of initial closure, it is always necessary to perform formal penile elongation with release of chordee at the time of urethroplasty in exstrophy patients. Data of Silver et al. (1997b) clearly showed that this is more of an apparent lengthening of the penis than a true lengthening because the anterior corporeal bodies in exstrophy patients have 50% less length than age-matched controls. All remnants of the suspensory ligaments and old scar tissue from the initial bladder closure must be excised. Further dissection of the corpora cavernosa from the inferior pubic ramus can be achieved. It is often surprising how little is accomplished in freeing the corporeal bodies from the pubis at the time of initial exstrophy closure (Gearhart, 1991).

Lengthening of the urethral groove is also essential. In the penile disassembly technique described by Mitchell and Bägli (1996), the urethral plate is dissected completely from the glans; in more than 70% of patients it is not long enough to reach the tip of the penis, and as a result hypospadias is present, with further reconstruction needed at another time (Hafez and El-Sherbiny, 2005).

Chordee

Besides lengthening of the urethral groove, dorsal chordee must be addressed. To release dorsal chordee, surgeons may lengthen the dorsomedial aspect of the corpora by incision and anastomosis of the corpora (Gearhart et al., 1992). Also, length can be gained by placement of a dermal graft to allow lengthening of the dorsal aspect of the corpora (Woodhouse, 1986). However, most of these techniques, especially grafting, are reserved for patients who are seen in adolescent and adult years for epispadias surgery with the need for some increased penile length and correction of residual chordee.

Urethral Reconstruction

Urethral reconstruction is an important aspect of external genital reconstruction in exstrophy. This can be accomplished by many previously reported methods, most of which have been abandoned: (1) tubularization of dorsal urethral groove; (2) free grafts of genital and extragenital skin; (3) ventral transverse island flaps; and (4) double-faced ventral island flaps. Most modern techniques of epispadias repair associated with bladder exstrophy use tubularization of the urethral plate, moving the urethral plate under the corporeal bodies after closure to lessen the incidence of urethrocutaneous fistula, to give the penis a more downward deflection, and to make a more easily catheterizable urethral channel (Surer et al., 2000). With the penile disassembly technique, interrupted sutures are often used to try and get the urethra to the tip of the penis again after it is completely detached, with resultant hypospadias in many. Although some authors have described the ease and success of hypospadias repair after penile disassembly (Shnorhavorian et al., 2008), a large European study (Berrettini et al., 2011) found the opposite with a 50% complication rate. Patients who did well underwent a two-stage repair and placement of a graft before urethroplasty.

Our preference for urethroplasty and penile reconstruction, if the urethral groove has adequate length, is the modified Cantwell-Ransley repair (Gearhart et al., 1992, 1995c, 2005) (Fig. 31.24). Currently, in the modern applications of the staged reconstruction of bladder exstrophy, epispadias repair is performed when the child is 6 to 10 months of age. At the time of primary closure the urethra is closed well up on the penile shaft.

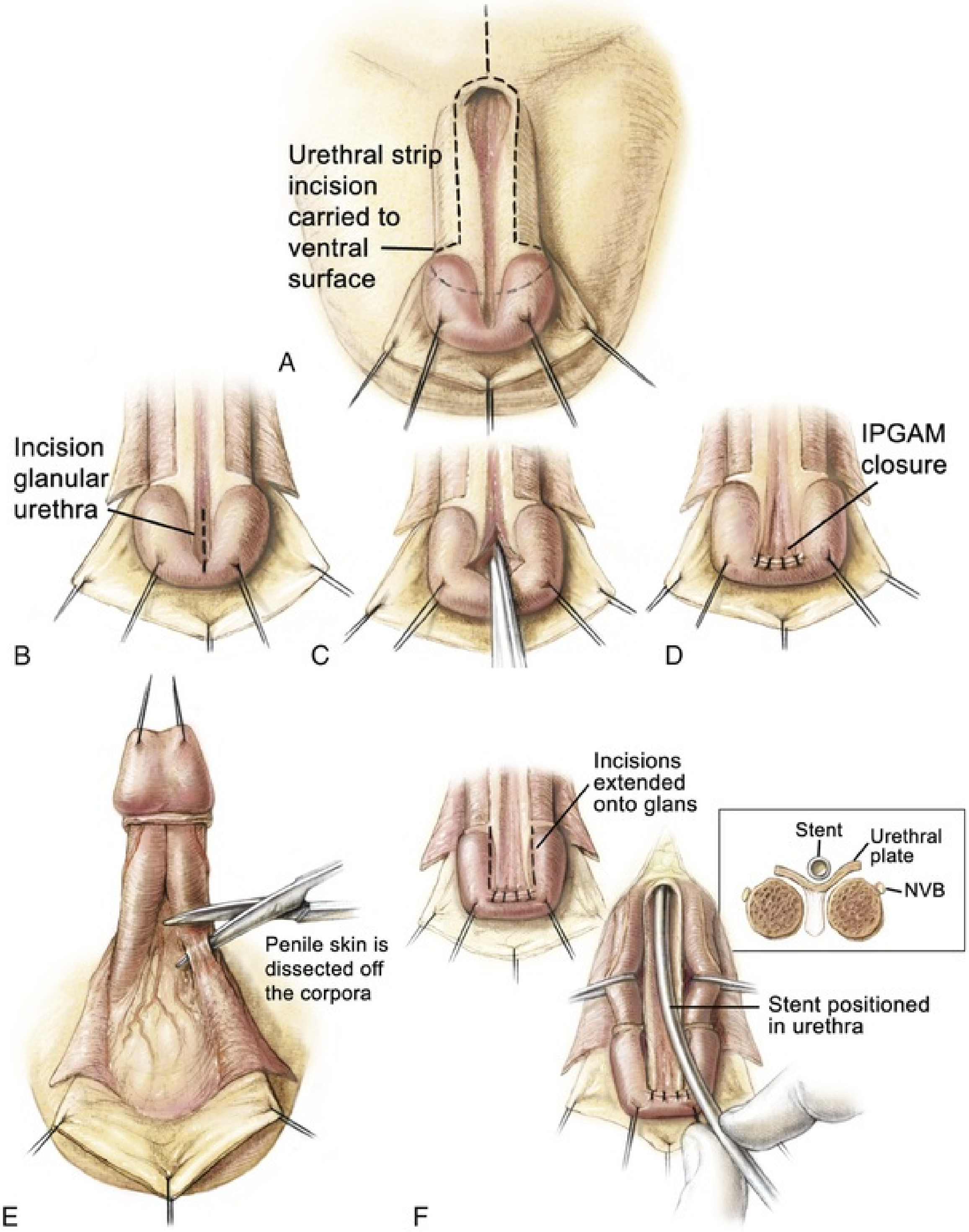
Urethral strip
incision
carried to
ventral
surface
A
Incision
glanular
urethra
B
C
IPGAM
closure
D
Penile skin is
dissected off
the corpora
E
Incisions
extended
onto glans
Stent
Urethral
plate
NVB
Stent positioned
in urethra
F

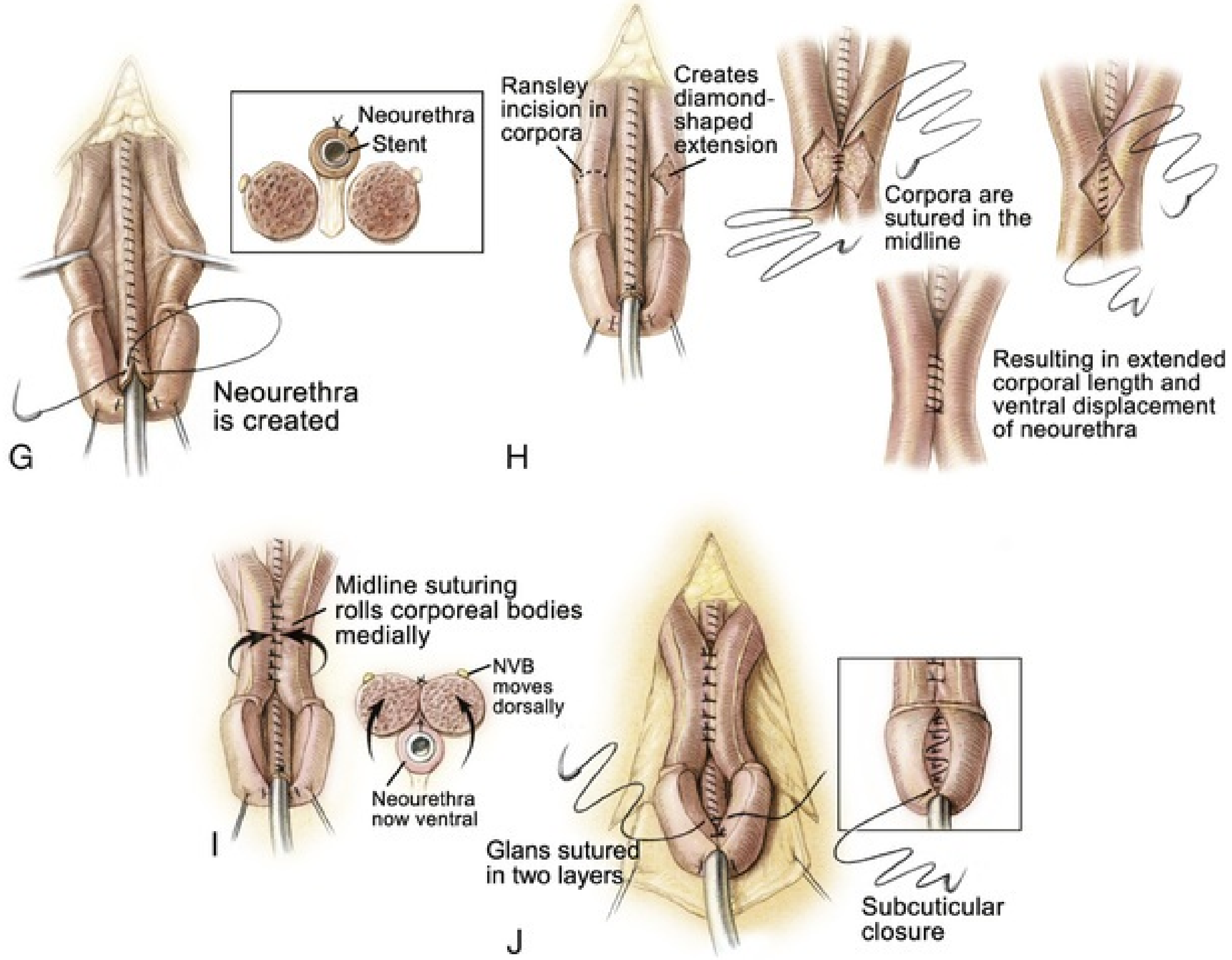
Neourethra
Stent
Neourethra
is created
G
Ransley
incision in
corpora
Creates
diamond-
shaped
extension
Corpora are
sutured in the
midline
Resulting in extended
corporal length and
ventral displacement
of neourethra
H
Midline suturing
rolls corporeal bodies
medially
NVB
moves
dorsally
Neourethra
now ventral
I
Glans sutured
in two layers
Subcuticular
closure
J

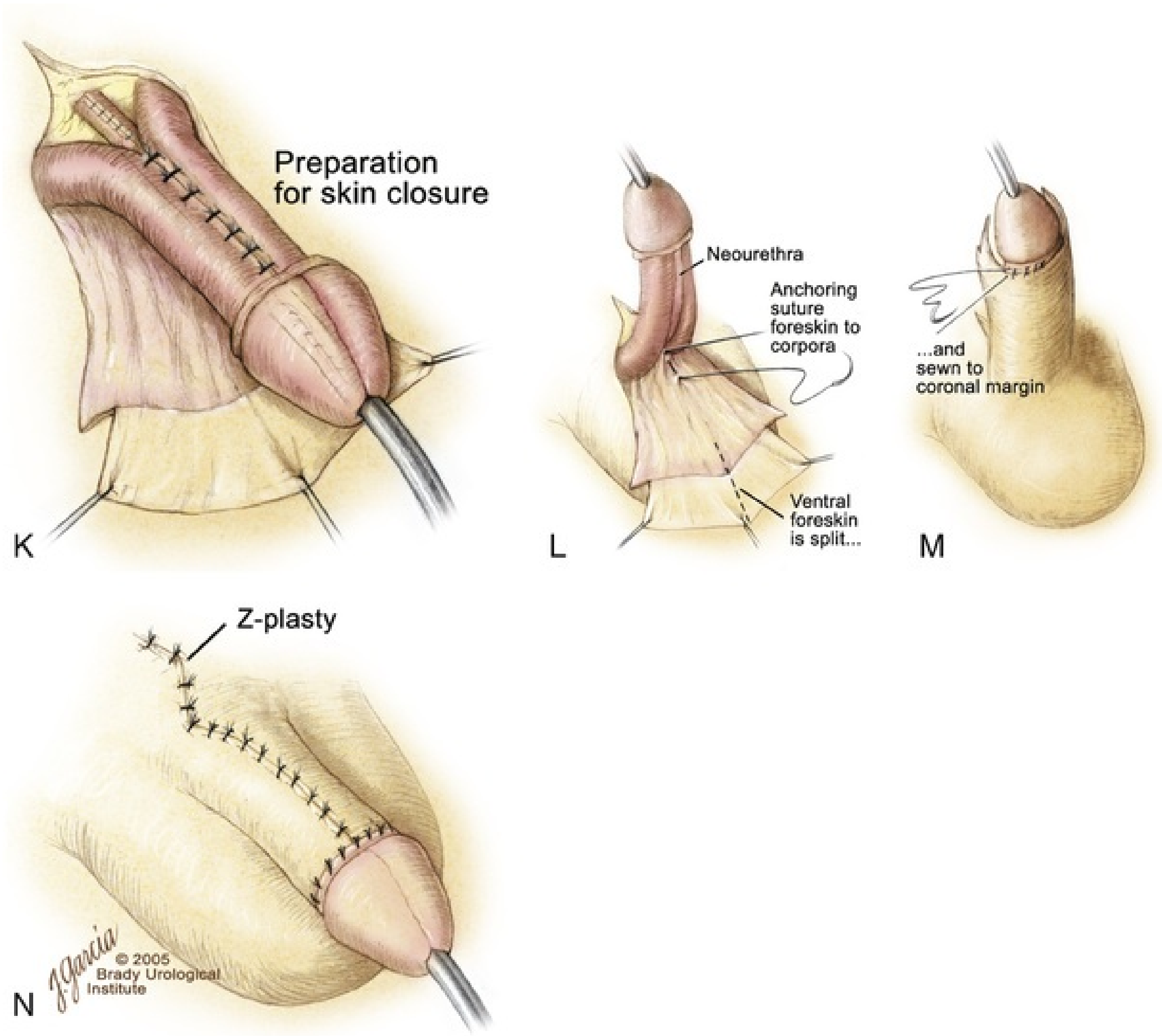
Preparation
for skin closure
K
Neourethra
Anchoring
suture
foreskin to
corpora
Ventral
foreskin
is split...
L
...and
sewn to
coronal margin
M
Z-plasty
N
J Garcia
© 2005
Brady Urological
Institute

FIG. 31.24 Modified Cantwell-Ransley epispadias repair. (A) Initial incision line extending around the urethral plate and the coronal sulcus. (B to D) Performance of the reversed meatal advancement and glanuloplasty procedure to bring the urethral meatus to the tip of the glans. (E) Dissection of the foreskin on the ventral aspect of the penis. (F) The corpora are dissected off the urethral plate, and parallel incisions are made into the glans to create glans wings. Note the lateral position of the neurovascular bundles (NVB) *(inset).* (G) The urethra is tabularized using a continuous running suture. (H) Approximation of the corpora using the incisions in the corpora if indicated. (I) Corpora approximated above the urethra to provide an anatomically ventral location of the urethra *(see inset).* (J) Glans is reconstructed in two layers. (K) Preparation for skin closure. (L) Suture is placed at the base of the penis to locate the foreskin on the shaft of the penis as well as to provide an area of distinction between the penis and the scrotum. (M) Foreskin is sewn to the coronal sulcus. (N) Completion of the repair with resurfacing of the penis and use of a proximal Z-plasty incision to provide downward penile deflection. (Copyright Brady Urological Institute.)

The modified Cantwell-Ransley procedure is begun by placing a transverse stitch through the glans as a traction stitch. Incisions are made over two parallel lines marked previously on the dorsum of the penis that outline an 18-mm–wide strip of urethral mucosa, extending from the prostatic urethral meatus to the tip of the penis (see Fig. 31.24A). For this procedure, a deep vertical incision is made in the urethral plate distally. The incision is then closed with 6-0 polyglycolic sutures in a transverse fashion (see Figs. 31.24B to D). This procedure flattens the distal urethral plate and advances the urethra to the tip of the phallus so that it will be in excellent glanular position when the glanular wings are closed over the reconstructed urethra. Glanular mucosal areas of the dorsal glans are excised adjacent to the urethral strip, and thick glanular flaps are constructed bilaterally (see Fig. 31.24F). Lateral skin flaps are mobilized and undermined. A Z incision of the suprapubic area permits wide exposure and division of the suspensory ligaments and old scar tissue from initial exstrophy closure (see Fig. 31.24F).

Ventral penile skin is taken down to the level of the scrotum (see Fig. 31.24E). Care is taken to preserve the mesentery to the urethral plate, which arises proximally and extends upward between the corporeal blood supply to the urethral plate. Dissection of the corpora is begun ventrally with dissection on the surface of Buck fascia covering the corporeal bodies. The plane is followed closely until one exits on the dorsum of the penis between the corpus spongiosum and the corporeal body, first on one side and then on the other (see Figs. 31.24F and G). Vessel loops are placed around the corporeal bodies, and the dissection is extended proximally on the corpora to dissect the urethral plate free from the corporeal bodies up to the level of the prostate. Although difficulties may be expected when dissecting proximally where the paraexstrophy skin flaps had been sutured to the urethral plate, this has not been encountered in our experience, and dissection is kept just on the corporeal bodies while proceeding proximally. The urethral plate is also dissected distally past the level of the junction of the glans with the corporeal bodies. In this manner, adequate mobilization is obtained, and it is not difficult to bring the corporeal bodies over the urethra at the level of the corona. This separates the penis into three components: the two corpora and the urethral plate (see Fig. 31.24F). Complete penile disassembly is not undertaken, because the most distal 1-cm attachment of the mucosa plate to the glans is left intact (Surer et al., 2000).

The neurovascular bundles, situated between Buck fascia and the corporeal wall, are typically left intact in young patients if rotation of the corporeal bodies over the urethra effectively straightens the penis. If not, the neurovascular bundles are dissected free from the corporeal bodies, with vessel loops being placed around these structures so that the neurovascular bundles will not be compromised when incisions are made in the corpora and the corpora are rotated medially over the neourethra (see Fig. 31.24H). After the corporeal bodies are incised or rotated over the urethra, the urethral strip is closed in a linear manner from the prostatic opening to the glans over an 8-Fr silicone stent with 6-0 polyglycolic acid sutures. After this is accomplished, incisions are made in the corporeal bodies at the point of maximum curvature, opening a diamond-shaped effect in the erectile tissue (see Fig. 31.24H). The corpora are then closed over the neourethra with two running sutures of 5-0 PDS, and the diamond-shaped defects in the adjacent area of the corpora are sutured to each other. This procedure effectively displaces the urethra ventrally in a normal position. This not only causes the downward deflection of the penis but also allows some additional length by dorsal rotation and approximation of the corporeal bodies over the neourethra. After the urethra has been transferred to the ventrum, further sutures of 4-0 polyglycolic acid are placed between the corporeal bodies to bury the urethra further, especially at the level of the junction of the glans and the corporeal bodies at the corona (see Fig. 31.24I).

The glans wings are then closed over the glanular urethra using subcuticular sutures of 5-0 polyglycolic acid, and the glans epithelium is closed with 6-0 polyglycolic acid sutures (see Fig. 31.24I). The ventral skin is then brought up and sutured to the ventral edge of the corona, and the flaps are fashioned to provide adequate coverage and lengthening of the dorsum of the penis. The skin is reapproximated with interrupted 5-0 or 6-0 polyglycolic acid sutures (see Figs. 31.24K to M). A Z-plasty at the base of the penis is closed with interrupted 5-0 or 6-0 polyglycolic acid sutures. A silicone stent is left indwelling in the neourethra to provide drainage for 10 to 12 days (see Fig. 31.24).

Penile Skin Closure

If skin closure continues to be a problem in genital reconstruction because of the paucity of skin associated with this condition, a Z-plasty incision and closure at the base of the penis prevents skin contraction and upward tethering of the penis. The ventral foreskin can be split in the midline and brought to the dorsum as lateral preputial flaps for coverage of the penile shaft. If the flaps are a bit asymmetrical, a staggered dorsal suture line results, with less upward tethering. Alternatively, a buttonhole can be created in the ventral foreskin and simply transposed to the dorsum for additional penile skin coverage. All patients in our series are given testosterone enanthate 2 mg/kg intramuscularly 5 weeks and 2 weeks before repair.

Postoperative Problems

Postoperative pain and bladder spasms after extensive external genital reconstructive surgery require a combined effort of the pediatric anesthesia pain service and the surgical service. Controlling bladder spasms is paramount because they are associated with urinary extravasation and fistula formation. All of our patients have a caudal epidural catheter placed at the time of surgery, and oxybutynin is started immediately after surgery to decrease the incidence of bladder spasms and enhance the patient's comfort. At the time of discharge, the plastic dressing on the penis is left intact and the child is discharged with narcotics, antispasmodics, and appropriate broad-spectrum antibiotic coverage.

Female Exstrophy

The principles of repair of female and male exstrophy are similar. However, in the female patient we recommend the following: (1) radical dissection of the bladder and urethra from surrounding structures while connection to the vagina is maintained; (2) dissection of the lateral aspects of the posterior vesicourethral and vaginal unit from their attachments to the urogenital diaphragm; (3) tension-free closure of the abdomen, bladder-urethra, and external genitalia; and (4) judicious use of osteotomy and proper immobilization of the pelvis and extremities.

As in the male patient, if the pelvic bones are separated over 4 cm or are not malleable under anesthesia, an osteotomy is then performed. The transverse innominate osteotomy along with vertical iliac osteotomy is commonly used in our practice. Interfragmentary pins are placed and the fixator is applied after the soft-tissue surgery has been completed. An interesting finding in more than 1287 exstrophies in our institutional-approved database is that even with a large bladder template the diastasis tends to be narrower in female than in male patients. Thus closure in female exstrophy patients is easier to perform, and female patients do not require an osteotomy as commonly as male patients.

The vagina is prepared with an iodine preparation so that if it is violated during the dissection it can simply be closed. In the closure, we start our dissection along the medial aspect of the clitoral or corporeal halves and move deeply into the pelvis. Pinpoint electrocautery at a low setting is used to limit bleeding and tissue injury. The dissection of the vagina proceeds laterally and posteriorly. The urethrovaginal septum is left intact to preserve its blood supply. As in the male patient, the dissection proceeds posterior and downward until the levator hiatus is reached, with the urogenital diaphragm fibers lateral and posterior to the vesicourethral plate and vaginal incision. This maneuver allows placement of the unit deeply into the pelvis and, more important, keeps it from being displaced anteriorly when the pelvic bones are brought together.

The bladder is closed with a single figure-of-eight layer of 3-0 polyglactin suture to maximize postclosure bladder volume. The urethra is closed with a single layer of 4-0 to 5-0 polyglactin depending on the thickness of the tissue. An indwelling suprapubic tube is brought out through the dome of the bladder along with two small feeding tubes that act as stents and are left in place for 4 full weeks. These exit the neoumbilicus as described by Hanna (1986). No tubes are brought out through the neourethra because this can be associated with wound infection and prolapse or dehiscence. A No. 2 nylon suture in a horizontal mattress fashion is used to bring the pubic bones into apposition. Once the pubic bones are brought together, a routine subcutaneous and skin closure are performed. A mons plasty is then performed, and the subcutaneous tissue of the clitorides are brought together with 5-0 polyglactin and the epithelium with 6-0 polyglactin sutures. If needed, a Y-V labioplasty is performed for better exteriorization of the vaginal introitus.

If an osteotomy has been performed, the external fixator is then placed and a pelvic x-ray study is obtained. If pin and fixator placement are optimal, then the infant is placed in modified Buck traction for 4 weeks. If an osteotomy was not performed, the infant is placed in Bryant traction for 4 weeks. Postoperative care is the same as in the male patient, with an indwelling epidural catheter and bladder spasms controlled by the epidural and oral oxybutynin.

Continence and Antireflux Procedure

Although some modern exstrophy repair methods are claimed to establish suitable continence without formal bladder neck repair, many patients are referred to our unit still incontinent after only prior newborn repair or after newborn repair and multiple injections of various substances into the bladder neck area. Likewise, other groups have reported their outcomes with newborn repair, and most have recommended some sort of outlet procedure. In our unit each child has a cystoscopy and gravity cystogram under anesthesia yearly after newborn closure to assess bladder growth. Prior data by Gearhart and Jeffs have shown that after newborn exstrophy closure there should be an average increase in bladder capacity of 54 mL in 24 months (Gearhart and Jeffs, 1989b). Chan et al. (2001) found that in selected exstrophy patients who underwent closure, epispadias repair, and bladder neck reconstruction at our institution, a median bladder capacity of 100 mL was more common in the group of patients who were completely dry after bladder neck reconstruction. Most of these children were 5 to 7 years of age and were ready emotionally, maturationally, and intellectually to participate in a postoperative voiding program. An intense pre–bladder neck repair program is conducted by a senior urology nurse practitioner, senior clinical nurses, and a child psychologist well versed in voiding issues. These sessions are begun for the child and parents at least 6 months before an outlet procedure. Successful completion of the program is required before surgery is scheduled.

Continence and antireflux procedures performed at our institution are illustrated in Fig. 31.25. Most patients with reflux are safely managed conservatively with prophylactic antibiotics until their bladder neck reconstruction is performed. However, a small population of patients may require ureteral reimplantation before a bladder neck procedure in the event of pyelonephritis, recurrent UTIs, worsening hydronephrosis, or decreasing renal function (Tourchi et al., 2015). The bladder is opened through a transverse incision at the bladder neck with a vertical extension. The later midline closure of this incision is the width of the bladder neck and enlarges the vertical dimension of the bladder, which in exstrophy is often short (see Fig. 31.25A). A Cohen transtrigonal ureteral reimplantation or a cephalotrigonal reimplantation is performed to move the ureter across the bladder, above the trigone, or to direct the ureter cephalad up onto the edge of the trigone (see Fig. 31.25B and C; Canning et al., 1992). If the ureters are low on the trigone and there is a need to move the ureteral hiatus higher, the hiatus is simply cut in a cephalad direction, and cross-trigonal reimplants are performed at the upper aspect of the trigone (see Fig. 31.23C).

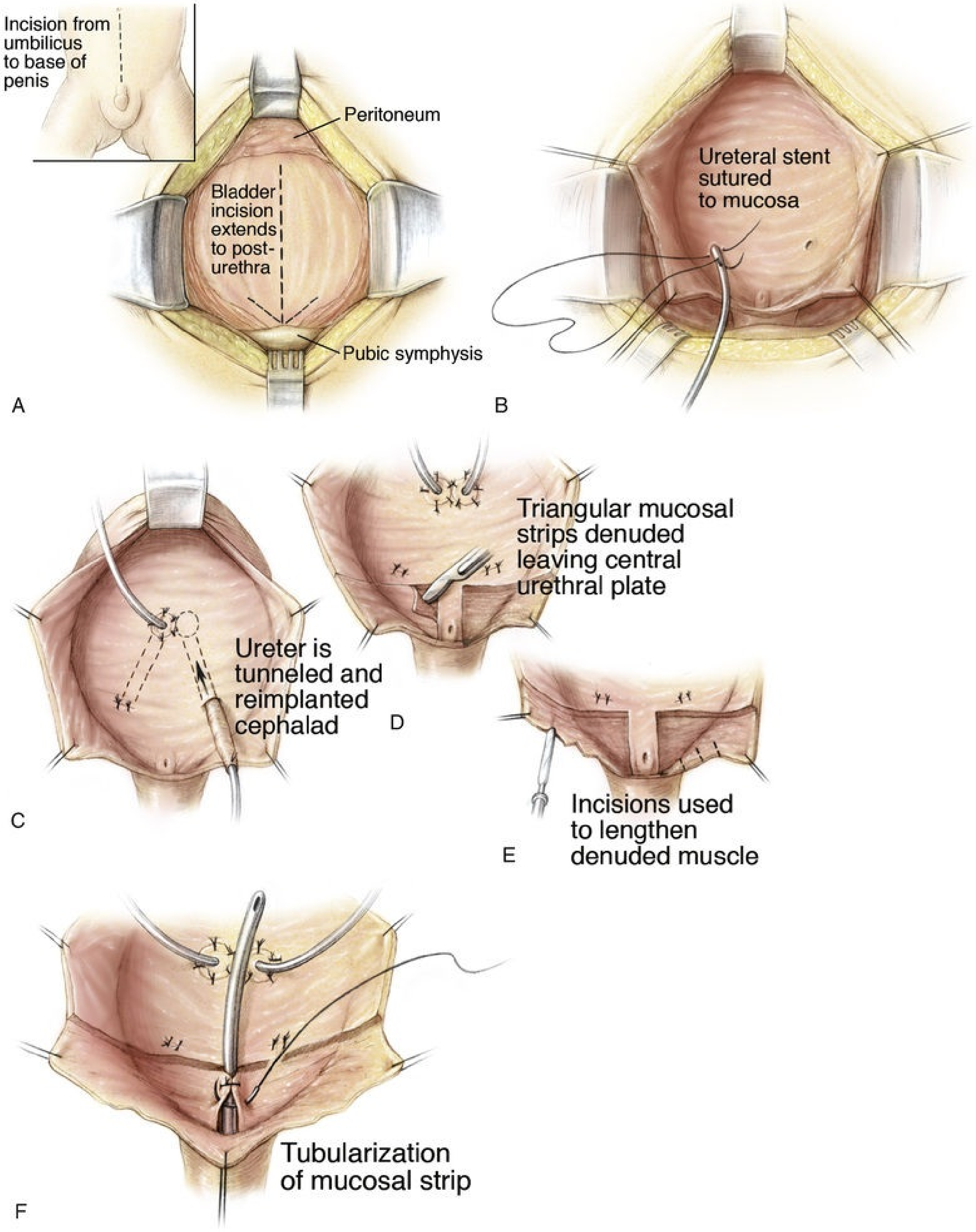
Incision from umbilicus to base of penis
Peritoneum
Bladder incision extends to post-urethra
Pubic symphysis
A
Ureteral stent sutured to mucosa
B
Ureter is tunneled and reimplanted cephalad
C
Triangular mucosal strips denuded leaving central urethral plate
D
Incisions used to lengthen denuded muscle
E
Tubularization of mucosal strip
F

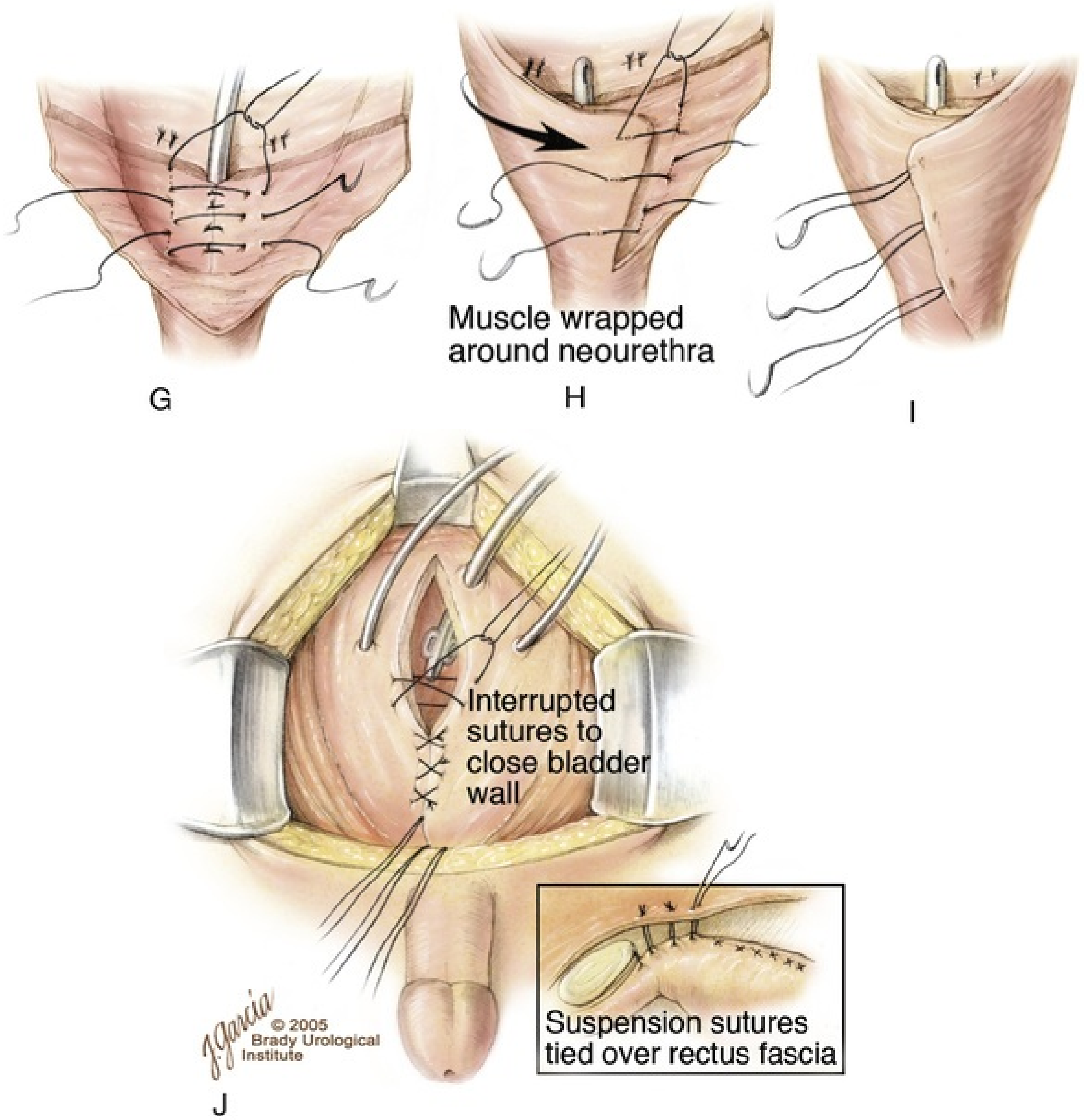
G
Muscle wrapped around neourethra
H
I
Interrupted sutures to close bladder wall
J Garcia
© 2005 Brady Urological Institute
Suspension sutures tied over rectus fascia
J

FIG. 31.25 Modified Young-Dees-Leadbetter bladder neck reconstruction. (A) Vertical bladder incision with distal transverse extension where the bladder and posterior urethra are under the pubic bar. (B and C) Ureters are identified, mobilized, and reimplanted in a cephalotrigonal position. (D and E) Segments of mucosa are excised from either side of a median strip (1.5 cm × 3 cm) that will form the neourethra. Short incisions in the muscle will permit extension of the bladder neck. (F) Urethra is tabularized using a continuous running suture. (G) Posterior urethra and bladder neck are reconstructed. (H and I) Bladder muscle is brought together in a double-breasted fashion over the neourethra. (J) Bladder closure is completed and the distal suspensory sutures are tied over the abdominal wall *(see inset).* Suprapubic tube and stents are left in place; however, the urethra is left unstented. (Copyright Brady Urological Institute.)

The continence procedure is begun by selecting a posterior strip of mucosa 15 mm wide and 30 mm long that extends distally from the mid-trigone to the prostate or posterior urethra (see Fig. 31.25D). Bladder muscle lateral to the mucosal strip is denuded from the mucosa. It is often helpful at this juncture to use one or two epinephrine-soaked sponges to aid in the control of bleeding and the visualization of the denuded area. Tailoring of the denuded lateral muscle triangles is aided by multiple small incisions on the free edge bilaterally that allow the area of the reconstruction to assume a more cephalad position (see Fig. 31.25E). **These muscle flaps not only are smaller but also are not incised transversely at their cephalad extent as described in the original Young-Dees procedure to prevent denervation and ischemia. The basic premise is to create a mucosa-lined tube inside a muscular funnel that narrows from its junction with the floor of the bladder that extends caudally.** The edges of the mucosa and underlying muscle are closed with interrupted sutures of 4-0 polyglycolic acid (see Fig. 31.25F). The adjacent denuded muscle flaps are overlapped and sutured firmly in place with a 3-0 PDS to provide reinforcement of the bladder neck and urethral reconstruction (see Figs. 31.25G to I). An 8-Fr urethral stent may be used as a guide during posterior urethral and bladder neck reconstruction but is removed after the repair is completed. After the bladder neck repair is completed, the repair is suspended to the rectus fascia (see Fig. 31.25J, *inset*).

Very radical dissection of the bladder, bladder neck, and posterior urethra is required, not only within the pelvis but also from the posterior aspect of the pubic bar to provide enough mobility for the bladder neck reconstruction. This maneuver allows adequate bladder neck narrowing and tightening of the bladder neck repair and subsequent anterior suspension of the newly created posterior urethra and bladder neck. In patients after CPRE repair in the newborn period who had a vesicocutaneous fistula after closure, great care must be taken anteriorly during mobilization of the bladder neck because the tissues are more adherent to the back of the intrasymphyseal bar. If visualization of the posterior urethra is problematic, the intrasymphyseal bar can be cut, thus providing a widened field of exposure. The intrasymphyseal bar is approximated with 2-0 sutures of PDS. If the intrasymphyseal bar is cut, abduction of the lower extremities should be restricted in the postoperative period to allow proper healing of the intrasymphyseal bar.

Postoperative Care

Ureteral stents are placed in the reimplanted ureters and brought out through the wall of the bladder, and the bladder is drained by suprapubic tube, which is left indwelling for a 3-week period. **At the end of 4 weeks the suprapubic tube is clamped and the patient is allowed to attempt to void. Initially, the tube should not be clamped for more than 1 hour. If voiding does not occur, the child is given an anesthetic and an 8-Fr Foley catheter is placed**. This is left in place for 5 days, then removed, and another voiding trial is begun. This part of the postoperative period is most demanding on the patient and family. Some children require several catheter placements before voiding is initiated. If the child can empty the bladder satisfactorily, the suprapubic tube is removed. Frequent bladder and renal ultrasound examinations are required in the first few months after bladder neck repair.

Modern Initial Repair of Bladder Exstrophy: Outcomes and Results

The use of functional reconstruction in bladder exstrophy has resulted in dramatic improvement in the success of reconstruction. Several series (Purves and Gearhart, 2008; Shnorhavorian et al., 2008) have demonstrated the success and applicability of early newborn closure with or without pelvic osteotomy. Important older series have shown acceptable continence rates with preservation of renal function in a majority of patients treated in early life.

Two of the most reliable predictors of eventual urinary continence are the size of the bladder template at birth and a successful primary closure. Regardless of the technique used, a complication-free newborn closure of the abdomen, pelvis, bladder, and proximal or complete urethra paves the way for an optimal long-term result. A very large series by Surer et al. (2001) demonstrated the importance of a successful primary closure in a large group of exstrophy patients who underwent early closure. At other centers 68 patients (57 male and 11 female patients) were referred for bladder neck reconstruction after primary closure; 20% had concomitant pelvic osteotomy at the time of closure. The majority of patients underwent closure within the first 72 hours of life. Mean capacity at the time of bladder neck repair was 121 mL. The results were that 83% were continent and voiding per the urethra. This application of early successful closure and follow-up reconstruction by a second surgeon shows convincingly that a successful primary closure is one of the most important determinants of eventual bladder capacity and continence regardless of who originally performed the repair.

Initial Closure

Long-term data on all modern types of exstrophy repair can be difficult to obtain. Nonetheless, this section addresses what has been gleaned from the recent literature. Most data come from the MSRE and CPRE groups. In a large series reported by Hernandez et al. (2008), clinical information from 189 patients who had undergone primary closure between 1988 and 2004 was extracted from our exstrophy database. The records of 131 patients (95 males) who underwent MSRE with a modified Cantwell-Ransley repair by a single surgeon in 1988 to 2004 were reviewed with a minimum 5-year follow-up. The importance of a successful initial closure is emphasized by Oesterling and Jeffs (1987) and Husmann et al. (1989a), who found that the onset of continence was quicker and the continence rate was higher in those who underwent a successful primary closure with or without osteotomy. In addition, Novak et al. (2010) reported on patients with bladder exstrophy who underwent more than one attempt at primary closure. If a patient underwent two closures, the chance of having an adequate bladder capacity for bladder neck repair was 60%, and the chance of voided continence was 17% overall. Patients who underwent three closures had only a 50% chance of an adequate capacity and less than a 16% chance of voided continence. In an evaluation of this select group, it was found that at the time of primary closure, 80% of patients had no form of pelvic osteotomy. Thus the chance of achieving an adequate bladder capacity and eventual continence after more than one exstrophy closure is markedly diminished. These very poor results underline the importance of a secure abdominal, bony pelvis and posterior vesicourethral unit in the newborn with exstrophy.

Also, compared with many of the other repairs, data are available from several units on their results with the CPRE repair. In a series by Shnorhavorian et al. (2008), 2 of 39 patients had dehiscence of the fascia and 9 of 39 developed a vesicocutaneous fistula. Complications seen in the CPRE repair are as much as those seen in MSRE. However, some are particular to this repair. A large series of vesicocutaneous fistulae was reported from a single institutional study; some patients had an osteotomy, and others did not (Shoukry et al., 2009). In addition, several series have reported the need for early ureteral reimplantation after closure and the occurrence of significant upper tract changes in many patients (Grady and Mitchell, 1999). This has prompted the call for ureteral reimplantation at the time of exstrophy closure by one group (Braga et al., 2008).

Although many earlier published series were small, the incidence of bladder prolapse and dehiscence is reported to be low. However, in a recent large series of primary CPRE repairs by Shoukry et al. (2009), the incidence of major prolapse and dehiscence was 15.8% even with the use of osteotomy. In this author's series we have seen a number of referred patients with complete dehiscence and major bladder prolapse after newborn CPRE repair. However, the other complicating factors we have seen, in addition to the aforementioned, have been significant losses of soft tissue including partial or complete loss of the penile glans in 9 patients and the loss of the urethrovaginal septum in 2. In a series by Hammouda (2003), 5 of 42 patients had ischemic loss of glans tissue after CPRE repair. Thus the complications of primary closure between CPRE and MSRE are similar, but much more serious if soft-tissue loss occurs.

In a report using the Erlangen repair by Rosch et al. of 100 closures, the complications in general were mild, with urethrocutaneous fistulae in 2%, minimal hydronephrosis in 20%, and severe hydronephrosis requiring further surgery in 3% (Rosch et al., 2001). There were no incidents of bladder prolapse or dehiscence. Osteotomy was not used in any patient, but a very sophisticated coaptation technique involving the obturator foramen was used in all patients.

Interest in the outcomes of exstrophy closure has expanded to interest in the economic outcomes of the treatment of this major birth defect and who should be doing these types of operations in the newborn. In a paper by Nelson et al. (2005b), high-volume hospitals (those closing more than five exstrophies per year) had lower overall costs per patient than low-volume hospitals (fewer than five exstrophies per year). In addition, Nelson et al. (2008) found that a successful newborn closure had overall markedly lower inflation-adjusted hospital charges than reclosures as a result of shorter operating times and shorter length of stay.

A corollary to these papers was one from Meldrum et al. (2005), who found that when exstrophy closures failed and the exstrophy had to be reclosed, the success rates and ultimate continence were better in patients of fellowship-trained pediatric urologists than those of other surgeons (general urologists, non–fellowship-trained pediatric urologists, and general pediatric surgeons).

In the evaluation of this group of selected exstrophy patients, it was found that at the time of initial closure, 19 of 23 patients had no osteotomy; 6 of the patients had obtained bladder capacity suitable for bladder neck reconstruction; 3 were dry, and 3 were incontinent. Bladder size was inadequate in 9 patients who had been monitored for bladder growth. The chance of achieving an adequate bladder capacity and eventual continence after more than one closure attempt is markedly diminished. Last, the importance of early initial closure was emphasized by Husmann et al. (1989a), who showed that only 10% of the patients who undergo bladder closure before 1 year of age, but 40% of those who undergo the procedure at a later age require eventual augmentation.

Epispadias Repair

Although urinary incontinence remains the most significant problem for patients with CBE and epispadias, anxiety about inadequate and unattractive genitalia still poses the greatest concern to male patients. We began using the modified Cantwell-Ransley repair in patients with classic exstrophy or epispadias in 1988 and have reported our early experience (Gearhart et al., 1992, 1995c).

Since 1988 the modified Cantwell-Ransley repair has been performed for 129 male patients with either CBE (97 patients) or epispadias (32 patients) (Baird et al., 2005b). At the time of surgery, the patients' ages ranged from 1 to 18 years with an average age of 19 months. Of the 97 patients with bladder exstrophy, 31 had a short urethral groove requiring paraexstrophy skin flaps for penile lengthening at the time of initial bladder exstrophy closure. Of the 32 epispadiac patients, 26 had penopubic and 6 had penile epispadias at presentation.

This technique was used for primary urethroplasty in 106 patients with bladder exstrophy and 32 with epispadias. The modified Cantwell-Ransley repair was used as a secondary procedure after failed urethroplasty in 15 patients with exstrophy and 8 with epispadias and was combined with reclosure of bladder exstrophy in 18 patients. Early epispadias repair was performed when the patients were 6 months to 1 year of age. However, because of concerns about getting the urethra deeper under the corpora at the glanular level, beginning in 1994 we further modified the Cantwell-Ransley repair by detaching the mucosal plate from the corona except for the distal 0.5 to 1 cm of the plate inside the glans.

While standing, 120 patients had a horizontal or downward-angled penis. The incidence of urethrocutaneous fistula in the immediate postoperative period was 16%, and at 3 months it was 12%. Nine patients developed a urethral stricture of the proximal anastomotic site, and 12 had minor skin separation of the dorsal skin closure. Cystoscopy with catheterization in 120 patients revealed an easily negotiable channel in all; 8 patients required further penile straightening surgery; 15 patients older than 16 years had engaged in satisfactory intercourse. All reported orgasms and ejaculation with a straight penis on erection. One patient reported that his penis was shorter after surgery.

Modern penile reconstructive techniques should create a straight and functional penis with a glanular meatus, an easily catheterizable neourethral channel (if needed), and an acceptable cosmetic appearance. Many adolescents considered their odd-appearing genitalia with a short, widened penis upwardly deviated to be a greater psychosocial problem than incontinence, and therefore every effort should be made to restore the penis to a normal condition. In 1989 Ransley et al. introduced a concept to release dorsal chordee by incision and anastomosis of the dorsomedial aspect of the corpora over the urethra and urethral meatotomy at the distal end of the glans, to move the meatus to a more normal position and secure good direction of the urinary stream (reverse MAGPI [meatal advancement and glansplasty incision]) (Ransley et al., 1989). Ransley's group has reported its long-term experience with 95 patients in whom the modified Cantwell-Ransley repair was used: fistula occurred in only 4% of patients, and a urethral stricture in only 5% (Kajbafzadeh et al., 1995).

Dissection of the urethral strip to inside the glans penis provides a ventral position of the urethra and the glans and submerges the urethra well below the corpora at the glans level. This approximation of raw surface of glanular tissues dorsally over the urethra is clearly why the incidence of fistula in the area of the corona is rare compared with the Young repair. Fistulae in our patients usually appear at the base of the penis, where the urethra comes up proximally between the corporeal bodies. In patients who have had a prior failed exstrophy closure, failed epispadias repair, or have recurrent urethrocutaneous fistulas leading to a limited reserve of tissue, a tunica vaginalis flap, harvested from one of testicles, may be used during the reconstruction of the urethra to minimize the rates of fistulization (Lue et al., 2015).

In modern exstrophy reconstructive techniques, most surgeons try to preserve the urethral plate at the time of exstrophy closure. Because the use of paraexstrophy skin flaps has been associated with the development of strictures, the use of these flaps is limited to selected patients in whom penile lengthening cannot be achieved with standard techniques.

Papers from several institutions have reported their results with the Mitchell-Bägli penile disassembly technique. Complications are similar to those of other methods of epispadias repair (i.e., fistula and urethral stricture) (Kibar et al., 2009a; Zaontz et al., 1998). Although not a complication, a high percentage are made hypospadiac as the completely dissected urethral plate fails to reach the tip of the glans. The rate of being made hypospadiac has been reported as 38% to 83% (El-Sherbiny and Hafez, 2005; Mitchell and Bägli, 1996).

As mentioned in the prior section on exstrophy closure, ischemic loss of the glans, urethral plate, and corpora have been reported by Hammouda (2003) and Husmann and Gearhart (2004) after penile disassembly. Cervellione et al. (2010) have reported the largest series of penile ischemic injury in the exstrophy-epispadias spectrum. Most occurred at the time of exstrophy closure, and 19 of 24 did not have a pelvic osteotomy. The suggested explanation by the authors was compression of the pudendal vessels as a result of tension after pelvic apposition and/or direct injury to the pudendal vessels. Stopping the closure and doing an immediate osteotomy while the vessels had time to regain flow was the recommended course of action.

Repair of the hypospadias in these patients has been reported by the Seattle group as not difficult or associated with major complications. However, data from Hafez and El-Sherbiny (2005) and Gearhart and Baird (2005) show that difficulties can be associated with these repairs. In an attempt to deal with the issues and prevent them, El-Sherbiny and Hafez (2005) and Perovic et al. (1999) have modified the Mitchell repair to resemble the modified Cantwell-Ransley repair (Gearhart and Baird, 2005) by keeping the urethral plate attached to the distal glans to obviate the need for making the child hypospadiac at the time of isolated epispadias repair or when associated with CPRE.

In our opinion, none of the current epispadias repairs offers any significant gain in penile length by removal of the entire urethral plate from the glans or even the use of a free graft. Data reported by Silver et al. (1997b) clearly showed that although anterior corporeal length is significantly less in patients with exstrophy, posterior corporeal length is normal. These findings suggest that penile lengthening procedures at the time of epispadias repair improve apparent penile length and straighten the penis but do not transfer additional tissue (i.e., length) to the corporeal bodies. We have observed that the modified Cantwell-Ransley repair effectively corrects corporeal chordee and adds some penile length, and it can be hoped that dorsal penile curvature, often seen at puberty, will be lessened. In our significant experience with adolescent exstrophy males with significant dorsal chordee, we agree with Perovic et al. (1999) that movement of the neurovascular bundles along with incision and grafting of the resultant defect gives better results long term than incision and corpora cavernostomy. Typically in our experience, incision and rotation are used only for older patients with marked chordee. In the patients in whom corporeal rotation is used without corporeal incision and anastomosis, the neurovascular bundle is left intact and not dissected from its bed. Although review of findings reveals that almost all penises are straight or deflected downward, many of these patients are still young children. The long-term assessment of penile and urethral reconstruction in exstrophy patients by the modified Cantwell-Ransley repair has shown that in patients with bladder exstrophy and epispadias there is some increase in penile length, and a relatively straight penis with an adequate urethral caliber, which is adequate to void and ejaculate through, can be achieved with minimal morbidity. Long-term reports with the penile disassembly technique have also demonstrated a reasonably straight penis (Grady, 2003).

Bladder Neck Repair

Bladder neck reconstruction results in the exstrophy population have been reported by several groups. Some extensive experiences have come from the European groups in Lyon and Paris. Mouriquand et al. (2003) reported on 80 children with bladder exstrophy and 25 with incontinent epispadias. Follow-up ranged from 1 to 11 years; 45% of the group with exstrophy and 52% of those with epispadias had a dry interval longer than 3 hours. Although the continence rate was low, many of the exstrophy patients did not undergo closure until 6 to 12 months of age. Many underwent epispadias repair after bladder neck reconstruction, a factor known to influence eventual capacity and continence. Lottmann et al. (1998) presented a long-term follow-up study of Cendron's exstrophy patients who underwent complete reconstruction. With the Young-Dees repair, Lottman et al. (1998) were able to achieve urinary continence in 71% of male patients and 53% of female patients. Overall continence was 65% with a mean follow-up of 12 years after bladder neck repair. Series from North America using mainly the classic Young-Dees-Leadbetter repair reported continence rates ranging from 60% to 82% (Chan et al., 2001; Cole et al., 2003; Franco et al., 1994; Husmann et al., 1989a; McMahon et al., 1996; Mergurian et al., 1991; Perlmutter et al., 1991; Table 31.2). **The most important long-term factor gleaned from a review of all these series is the fact that bladder capacity at the time of bladder neck reconstruction is the most important determinant of eventual success.**

TABLE 31.2

Urinary Continence After Functional Bladder Closure

	BAIRD AND GEARHART ET AL. (2007)	PURVES ET AL. (2008)	SCHAEFFER ET AL. (2011)
No. of closures evaluated	67[a]	41[b]	27[c]
Patients confirmed dry day >3 h; dry hours[d]	70%	74%	56%

[a] All male.

[b] All female.

[c] Young-Dees-Leadbetter procedure after complete primary repair of exstrophy as newborn.

[d] Patients reported that they were dry for more than 3 hours during the daytime.

Data from Baird AD, Nelson CP, Gearhart JP: Modern staged repair of bladder exstrophy: a contemporary series, *J Pediatr Urol* 3(4):311–315, 2007; Purves JT, Baird AD, Gearhart JP: The modern staged repair of bladder exstrophy in the female: a contemporary series, *J Pediatr Urol* 4:150, 2008; Schaeffer AJ, Stec AA, Purves JT, et al: Complete primary repair of bladder exstrophy: a single institution referral experience, *J Urol* 1886:1041, 2011.

Records of 95 patients who underwent all stages of MSRE by a single surgeon at our institution between 1988 and 2004 were reviewed by Baird et al. (2007); 67 patients with bladder neck reconstruction and minimum 5-year follow-up were available for analysis. The current voiding status of each patient was obtained from parental or patient interview or direct observation by the nursing and physician staff. The patients were categorized as spontaneous voiding not on intermittent catheterization and were assigned a status of (1) completely dry—day and night; (2) socially continent—dry at least 3 hours during the day with occasional wet nights; or (3) wet—dry for less than 3 hours during the day and wet at night (Table 31.3).

TABLE 31.3

Urinary Continence After 67 Initial Bladder Neck Reconstructions

RESULT	AVERAGE DRY INTERVAL	NO. OF PATIENTS	% OF PATIENTS
Continent	3 hours	47	70%
Social continence (dry daytime, occasional wet nights)	3 hours	7	10%
Wet	<3 hours	13	19%

Of the 67 male patients who underwent bladder neck repair, the mean age for primary closure was 4 months (range, 6 hours to 4 months). The mean age at bladder neck repair was 4.8 years (range, 40 to 60 months), and these patients had a mean bladder capacity before repair of 98 mL (range, 75 to 185 mL). Of the 67 patients, 47 (70%) are continent and voiding urethrally without the need for augmentation or intermittent catheterization. Seven patients (10%) had social continence with occasional wet nights. The renal units of all patients who underwent bladder neck repair were evaluated by intravenous pyelography or ultrasound postoperatively on multiple occasions to assess preservation of renal function after the outlet procedure. One patient had reflux and hydronephrosis after the outlet procedure and bilateral reimplantation and developed left pyelonephritis with resultant mild scarring. Dimercaptosuccinic acid (DMSA) scanning revealed nearly normal bilateral renal function. Conservative follow-up revealed resolution of the reflux with time. One patient developed ureteral obstruction and required reoperative reimplantation. Prolonged outlet obstruction required cystoscopy and placement of an 8-Fr catheter in 19 patients, and prolonged suprapubic drainage was required in 13 patients. Thirteen (19%) failed bladder neck repair completely; 6 have undergone continent diversion, and 7 await further surgery. The mean time to daytime continence was 14 months (range 4 to 23 months), and the mean time to nighttime dryness was 23 months (range 11 to 34 months). No correlation was found between age at bladder neck reconstruction and age at achievement of continence.

The findings in this series were that continence was more likely in patients who underwent primary exstrophy closure before 72 hours of age or after 72 hours of age with an osteotomy. These results coincide with those of Husmann et al. (1989a), who found that patients who underwent delayed closure without osteotomy showed a continence rate of only 10%. There was another revealing factor in this study. Bladder capacity at the time of bladder neck repair gave a strong indication of not only who would be dry but also who would be dry sooner. If the patients were divided into those with a preoperative bladder capacity greater than or less than 100 mL, results showed that the group with the larger capacity had a high rate of continence: 42 of 50 dry and voiding versus 5 of 17 in the lower-capacity group. In addition, the mean times to dryness in the higher- and lower-capacity groups were 10 months and 21 months, respectively (14 months in the group overall).

In a similar series by Purves et al. (2008), the results in females mirrored those of the male group, with a slightly higher continence rate of 74% (dry day and night) and social continence again in 10%. Again, patients with capacity greater than 100 mL had better outcomes. In a phenomenon not seen in the males, 6 patients (20%) became continent after bladder and pelvic closure alone.

A continence procedure should be delayed until the bladder reaches a capacity of 100 mL and the child is motivated to be dry and participate in a postoperative voiding program. The vast majority achieve daytime dryness within 12 months after bladder neck repair. A few patients gain a longer daytime dry interval during the second year after their outlet procedure. However, patients who are not dry within 2 years are considered incontinent, and the procedure is considered to have failed. The onset of nighttime continence varies from 2 to 3 years and takes longer than the time needed for daytime continence. Caione et al. (1999) showed that use of desmopressin acetate (DDAVP) can increase the onset and number of dry nights in these patients. In the series by Baird et al. (2007), 25% of patients required either DDAVP or oxybutynin to establish nighttime dryness.

Urodynamic evaluation by Dave et al. (2001) showed that patients with good continence after bladder neck repair had high cystometric bladder capacity and compliance compared with those who were incontinent. However, unstable contractions were seen in both groups. Also, higher end filling pressures were reported, and those patients had a high incidence of nonobstructive hydronephrosis. These findings, in addition to those of Bolduc et al. (2002), indicate that careful lifelong follow-up is essential in these patients after successful childhood reconstruction.

From diagnosis and primary closure to bladder neck repair for urinary continence, the management of bladder exstrophy courses over years with a number of diagnostic and therapeutic procedures. Fig. 31.26 displays a summary of the timeline for bladder exstrophy repair.

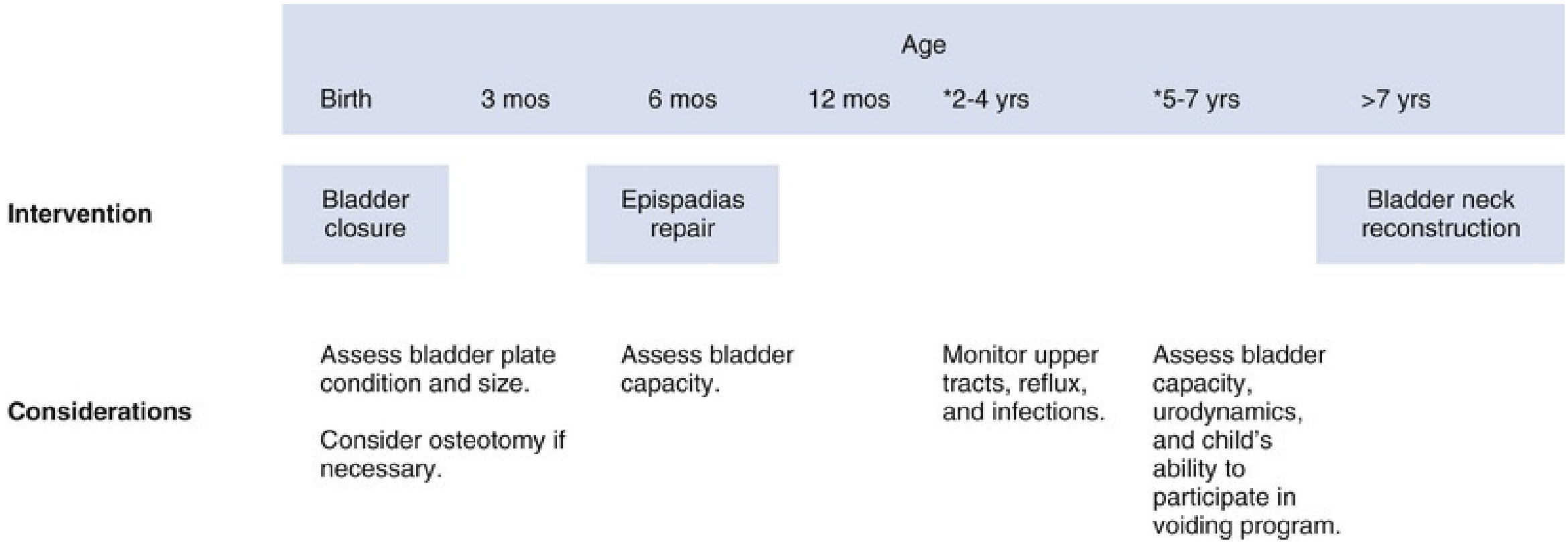
Age
Birth
3 mos
6 mos
12 mos
*2-4 yrs
*5-7 yrs
>7 yrs
Intervention
Bladder closure
Epispadias repair
Bladder neck reconstruction
Considerations
Assess bladder plate condition and size.
Consider osteotomy if necessary.
Assess bladder capacity.
Monitor upper tracts, reflux, and infections.
Assess bladder capacity, urodynamics, and child's ability to participate in voiding program.

FIG. 31.26 Timeline for exstrophy reconstruction. *The authors recommend yearly cystogram and cystoscopy to monitor bladder growth.

Key Points: Preparation for Continence Procedure in Bladder Exstrophy

- Bladder capacity of >100 mL (minimum)
- Stable urodynamics
- Child is motivated and ready to participate in a voiding improvement program.
- Exposure to voiding improvement program 6 months before bladder neck repair
- Evaluation by child psychologist with a background in pediatric urology

Other Modern Exstrophy Repairs: Continence Outcomes

Schrott-Erlangen Approach

Rosch et al. (2001) have reported on 100 patients, using this technique in newborns and failed closures: 91 children with exstrophy (69 boys and 22 girls) and 9 with complete epispadias (7 boys and 2 girls) have had this procedure performed. The complete single-stage repair was performed in 47 children and included pelvic closure without osteotomy, bladder neck reconstruction, an antireflux procedure, and epispadias repair using the Cantwell-Ransley technique. An additional 53 patients underwent primary reconstruction elsewhere and then had bladder neck reconstruction and epispadias repair performed. Continence was defined as dryness for more than 3 hours and no nocturnal enuresis. Partial continence was defined as dryness for 1 to 3 hours, or for longer than 3 hours with occasional stress incontinence or wet nights. Patients dry for less than 1 hour were considered incontinent. Among the patients undergoing single-stage repair, 34 of 39 are dry (72%) and voiding per urethra, 2 of 39 are on clean intermittent catheterization (CIC), and 3 of 39 are on CIC after augmentation; 4 patients are partially continent and 2 are dry on desmopressin. Four patients are incontinent and 3 have undergone continent diversion. Of 53 patients who underwent primary closure elsewhere, 55% are continent and 7 have been augmented; 14 are partially continent and 10 are incontinent, 4 of whom have undergone continent diversion.

Complete Repair

Various series have been published about outcomes, including the need for ureteral reimplantation in the first year of life, the number of patients requiring hypospadias repair after this procedure, and the complication rates of this procedure. However, little has been published about the long-term continence results or the need for bladder neck reconstruction in this group of patients. Borer et al. (2005) reported that ultimately almost 65% to 70% of patients undergoing CPRE in the newborn period require a bladder outlet procedure. In an updated series, Gargollo et al. (2011) found that 80% of patients with long-term follow-up required bladder neck repair. In a series by Hafez et al. (2005) with some patients who had delayed or failed primary closures, 84% of males and 50% of females required bladder neck repair to be dry. Some of these required concomitant bladder augmentation to be dry. In another large series by Shoukry et al. (2009), no patients were continent after CPRE alone and most required augmentation to be dry. More important, early dry intervals *did not* translate into later continence.

Shnorhavorian et al. (2008) reviewed their experience with 39 patients older than 19 years with CPRE. Daytime voided continence was achieved in 74% of males and females with 4 years of follow-up. However, only 20% and 43% of boys and girls, respectively, achieved continence without the need for bladder neck repair; 18% achieved dryness with bladder neck injection only. In a recent large series of CPRE patients referred for reclosure or after successful closure for bladder neck reconstruction, the results were interesting (Schaeffer et al., 2011). All patients were operated on by an experienced senior surgeon who does not do CPRE in newborns. None of the 14 referred patients who underwent successful CPRE in the newborn period was continent for any appreciable interval after closure. Of the 19 patients who underwent bladder neck reconstruction after complications with their newborn closure, only 25% were voiding from the urethra and continent. In the group with a successful primary closure (n = 14), 57% were dry day and night and 28% were dry during the day only (Schaeffer et al., 2011). Of major interest, all patients who were dry after bladder neck reconstruction had a successful primary closure with pelvic osteotomy and hypospadias repair before 1 year of age, and none required ureteral reimplantation before bladder neck repair. These data clearly show that in the majority of cases “complete repair” patients need to undergo bladder neck repair. However, as in all of the major repairs, a successful primary closure with fewer bladder violations and interval surgeries will increase the chance for bladder growth and voided continence. In a recent study, Di Carlo et al. (2018) reported an expanded series of bladder neck reconstructions in patients who underwent an outlet procedure after a successful primary closure without complications; 60% were dry during the day and night, 25% remained totally incontinent, and 11% were dry during the day only. All had an osteotomy at birth, early hypospadias repair, and no ureteral reimplantation during infancy. Long-term data seem to suggest that an older age may also favor continence outcomes (Ellison et al., 2016).

Other methods have combined epispadias repair with bladder exstrophy closure in the male patient. In a series of 38 boys with classic exstrophy, Baird et al. (2005c) evaluated patients with either failed or delayed primary closures. The complications were those seen with routine exstrophy repairs including urethrocutaneous fistula, urethral strictures, and so on. Three boys were dry with combined closure alone. Nineteen boys went on to modified Young-Dees-Leadbetter bladder neck repair; 12 (63%) of these 19 were totally dry day and night. These data as well as the data of Mitchell and Grady clearly show that epispadias repair and exstrophy closure can be combined with acceptable results. However, the complications are real and can portend the loss of any chance at volitional voiding, and the procedures should be performed only by experienced exstrophy surgeons and not the occasional surgeon. The combination of the epispadias repair may also pose the unique complication of ischemic penile loss in the form of total glandular and corporal loss, hemiglans loss, corporal atrophy, or hemiglans and corporal loss (Schaeffer et al., 2011).

Kelly Repair

There are few papers with long-term follow-up of the Kelly technique. However, a recent presentation by the Melbourne group gives the best and most current results that can be found with this repair (Jarzebowski et al., 2009). Data were collected in children older than 4 years. Complete continence was defined as dryness for longer than 3 hours day and night (with 2 or fewer wet nights per month). Partial continence was dryness for 2 or more hours during the day and 3 or more wet nights per month and/or stress incontinence. Of 31 patients on whom the Kelly technique was used, 24 void spontaneously and 17 of 31 void in an unaided fashion (without intermittent catheterization or augmentation); 3 of 17 (18%) were voiding in an unaided fashion and had complete continence, and 9 of the remaining 17 (53%) had partial continence. The 18% dry and voiding rate compares favorably with that recently reported for CPRE. Another study from Italy (Berrettini et al., 2009) showed that in 5 of 9 boys, continence was achieved with a Mainz pouch in 1, intermittent catheterization in 2, and by voiding in 2; 1 of 9 experienced glans loss (Berrettini et al., 2009).

Exstrophy Reconstruction Failures and Complications

Failed Closure

After any form of repair, failures can manifest as complete bladder dehiscence, bladder prolapse, neourethral stricture and obstruction, soft-tissue loss, and vesicocutaneous fistula (Fig. 31.27) (Massanyi et al., 2013). Meldrum et al. (2005) reported on a select group of children in whom exstrophy reconstruction had failed before referral to a tertiary care facility. In the cohort of 101 children, 51 had primary surgical management performed by a fellowship-trained pediatric urologist, 18 by a general urologist, 6 by a pediatric surgeon, and 9 by an unknown surgeon. After successful reclosure, 38 patients eventually developed adequate bladder capacity for bladder neck reconstruction, and only 26% (10) eventually achieved dryness. These data emphasize the need for initial successful reconstruction and suggest that individuals undertaking this reconstruction should be comfortable with the complexity of repair. It is prudent for the surgeon who may see only a few patients with this condition to consider referral of these complex management situations to a center staffed by professionals with special expertise and experience.

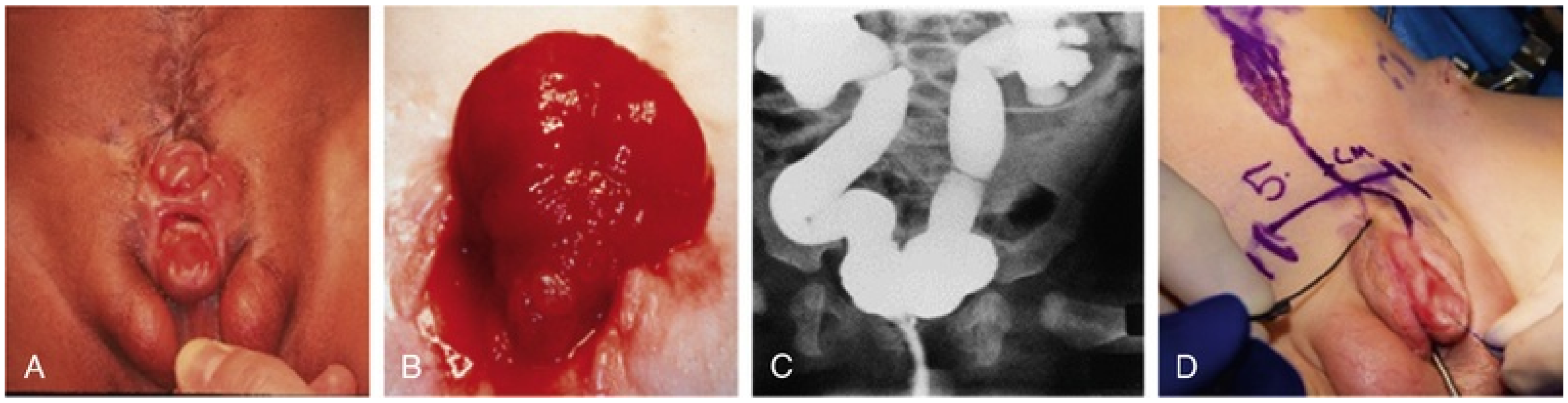

FIG. 31.27 Examples of failed bladder exstrophy closures. (A) Bladder prolapse; (B) bladder dehiscence; (C) outlet obstruction; (D) vesicocutaneous fistula. A combination of these, or any complication that necessitates a repeat closure, would also define a failed bladder closure.

In a large series by Schaeffer et al. (2008), 185 patients who underwent closure by 1 of 2 surgeons were reviewed for major and minor complications (Table 31.4). Sixty-three underwent osteotomy at the time of primary closure.

There were 14 major complications (11%) and 27 minor complications (14%). Major urologic complications included bladder prolapse or dehiscence in 6 male patients (3%), all of whom underwent successful reclosure. Major orthopedic complications, including nonunion in 2 patients, leg-length inequality in 1, and persistent joint pain in 1, developed in 4 of 63 patients (6%) who underwent osteotomy. Major neurologic complications included femoral nerve palsy in 4 of the 185 patients (2%). There were 21 minor urologic complications (11%), including posterior bladder outlet obstruction in 4 patients, urethrocutaneous fistula in 2, suprapubic tube removal in 2, intrapubic stitch erosion in 4, febrile urinary tract infection in 6, and surgical site infection in 3. Six patients (3%) had minor orthopedic complications, including pelvic osteomyelitis in 1, pin site infection in 3, and a pressure sore from immobilization in 1.

TABLE 31.4

Urologic, Orthopedic, and Neurologic Complications in 185 Primary Bladder Closures

UROLOGIC COMPLICATIONS	**NUMBER**
Bladder prolapse/dehiscence	6
Postoutlet obstruction	4
Suprapubic tube removal	2
Intrapubic stitch erosion	4
Febrile urinary tract infection	6
Wound infection	3
Bladder calculi	5
ORTHOPEDIC COMPLICATIONS	
Nonunion osteotomy	2
Leg length inequity	1
Persistent joint pain	1
Pelvic osteomyelitis	1
Pin site infection	3
Pressure sore	1
NEUROLOGIC COMPLICATIONS	
Femoral nerve palsy	4

Dehiscence, which may be precipitated by incomplete mobilization of the pelvic diaphragm and inadequate pelvic immobilization postoperatively, wound infection, abdominal distention, or urinary tube malfunction, necessitates a 4- to 6-month recovery period before a second attempt at

closure can be made (Gearhart and Jeffs, 1991a; Gearhart et al., 1993b) (Fig. 31.28A1). Dehiscence and prolapse after CPRE have also been reported and may be associated with glans, corporeal, urethral plate, and other major soft-tissue loss (Figs. 31.28B and C). Tension-free reclosure with osteotomy and immobilization are important factors in initial and subsequent closures. Unfortunately, the chance of obtaining adequate bladder capacity for bladder neck plasty and eventual continence after multiple closures is markedly diminished (Gearhart et al., 1996a; Novak et al., 2010). Similarly, bladder prolapse is considered a failure and requires bladder reclosure or revision. In a recent series from a single institution of 122 patients who underwent reclosure with a mean follow-up of 14 years, the voided continence rate was 16% (Novak et al., 2010). In a patient with significant bladder prolapse or dehiscence, at the time of secondary closure we combine epispadias repair with bladder, posterior urethral, and abdominal wall closure (Gearhart et al., 1998). The patient is given testosterone enanthate intramuscularly 5 weeks and 2 weeks before surgical repair and undergoes an osteotomy with concomitant bladder, urethral, and abdominal wall closure. Major soft-tissue loss that is seen after CPRE necessitates extensive preoperative planning; use of buccal mucosal or full-thickness grafts and tissue expansion may be required before definitive surgery (Gearhart and Baird, 2005).

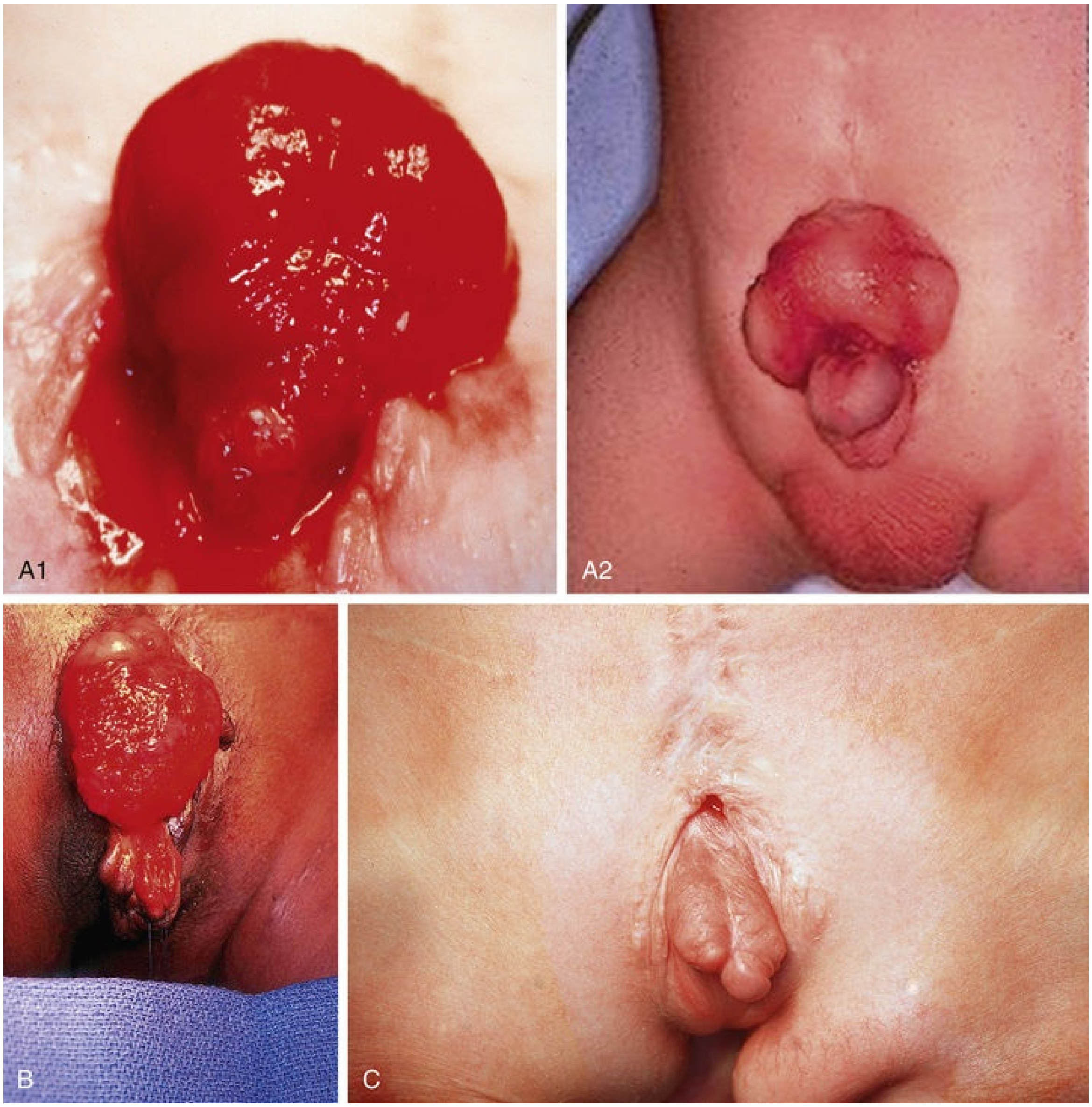

FIG. 31.28 (A1) Failed female newborn closure. (A2) Major bladder prolapse after CPRE without osteotomy. (B) Complete dehiscence and loss of right glans and partial loss of corpora after CPRE repair. (C) Loss of right glans and urethra after penile disassembly in newborn (under testosterone stimulation before placement of full thickness skin graft).

Baird et al. (2005c) reported on 38 boys undergoing combined exstrophy closure and epispadias repair along with osteotomy; in 30, prior reconstruction had failed. Complications in this group were limited to urethrocutaneous fistulae and urethral strictures. Although the results after reclosure are not as good as those obtained with a successful primary closure, they are respectable and may obviate the need for bladder augmentation.

Neourethral stricture is often associated with paraexstrophy skin flap use, pubic suture reaction, erosion, or the use of urethral stents. This may be somewhat subtle; however, warning signs consist of UTIs, detectable increased bladder volumes on ultrasonography, bladder stones, prolonged dry intervals, and unexplained rectal prolapse. In a review by Baker et al. (1999), posterior urethral obstruction was found in 41 patients. Most episodes occurred within 60 days after primary closure. If diversion was used for longer than 6 months, the ultimate fate of the bladder was augmentation. If diversion was used for less than 6 months, most reconstructions were ultimately bowel free. The authors have also seen outlet obstruction, including complete obliteration after the CPRE and Kelly repair (Hernandez et al., 2008). Whether this is a result of ischemic damage to the urethral plate or technical error is unclear. Regardless, because there is a paucity of long-term data from these two repairs, the outlet must be monitored carefully as with all exstrophy patients after primary closure. Ultimately, posterior urethral obstruction after exstrophy closure markedly decreases the success of any repair. This complication presents a significant risk to the upper urinary tract and should be detected early.

Although all closed exstrophy bladders have vesicoureteral reflux, upper tract deterioration is the ultimate fate of significant outlet obstruction. At this point the management includes urethral dilation (incision), open urethroplasty, or upper tract diversion. If renal function is compromised, the choice must achieve unquestionable free drainage to allow the upper tracts and kidneys to recover fully. Further bladder neck or urethral reconstruction should not be performed until the posterior urethral stricture is clearly repaired and free drainage has been achieved. After CPRE repair, up to 50% of patients require bilateral ureteral reimplantation during the first year after surgery because of UTIs and increasing hydronephrosis.

Massanyi et al. (2012) found that a large number of patients with a vesicocutaneous fistula after primary closure actually have a failed closure. On evaluation 13 of 18 patients referred because of vesicocutaneous fistulae were found to have a failed closure represented by (1) a fistulous tract in the lower abdominal midline; (2) a pubic diastasis increased from preclosure measurements; and (3) cystoscopic evidence of an anteriorly positioned bladder just beneath the abdominal skin.

Despite satisfactory closure, some bladders never achieve adequate capacity to act as functional bladders. Baradaran et al. (2011) presented a large series of patients including those with failed primary bladder closures (n = 62) who underwent successful secondary closure; these patients were evaluated and compared with another group of patients with successful primary closures (n = 48). Both groups were followed over 5 years. Bladders in patients who had had a successful primary closure had a significantly larger cystographic capacity than the group with failed closure. Bladders grew at a significantly slower rate in the group with failed procedures and had significantly lower bladder capacities over time. These data underscore the importance of a successful primary closure. It has become clear that multiple bladder closures, bladder prolapse, dehiscence, bladder calculi, recurrent infections, and vesicostomy have a negative impact on the potential of the exstrophy bladder (Silver et al., 1997b).

Unsuccessful primary closures regardless of the method of repair really calls into question the ability of the bladder to grow, undergo an eventual bladder neck reconstruction, and be continent of urine. Schaeffer et al. (2011) reported on a large series of patients with failed CPRE procedures who were referred for further treatment. Of the 23 male patients, only half obtained a capacity sufficient for a bladder neck procedure, and only 25% were voiding and continent. Novak et al. (2010) reported a very large series of 122 patients with a failed primary or secondary closure of whom 94 underwent a successful repeat closure. Only 38 were candidates for bladder neck repair and only 17 of the 94 (18%) were voiding and continent. Thus, regardless of the type of repair, a failed closure portends significant implications for long-term surgical outcomes.

We have used transurethral injection of collagen and dextranomer around the bladder neck to increase outlet resistance and stimulate the bladder to grow after successful reclosure. However, in our hands this has not been as successful as reported by Caione et al. (1993a, 1993b). If the bladder does not grow to a sufficient size for bladder neck reconstruction, bladder augmentation is recommended in this situation. If the bladder neck or urethra or both are problematic, a catheterizable continent stoma with or without bladder neck plasty or transection is performed, along with augmentation (Gearhart et al., 1995b).

Further ramifications include the financial burden outside the obvious costs of a repeat closure (Hesh et al., 2016). That is, a failed primary closure may cost the patient and their family an additional $19,677 in total hospital fees during a year of follow-up, with associated professional fees of more than $24,000.

Key Points: Evaluation of a Failed Closure

- Quality of the bladder template
- Perivesical and periurethral scarring
- Pelvic diastasis
- Prior pelvic osteotomy
- Minimum of 4 months delay since failure (Kasprenski et al., 2018)

Failed Bladder Neck Repair

Even with experienced exstrophy surgeons, missteps can occur, and there remains a subgroup of children with urinary incontinence after bladder neck reconstruction secondary to (1) inadequate outlet resistance; (2) a small bladder capacity (lack of growth after bladder neck reconstruction); (3) decreased compliance; or (4) a combination of these factors.

If urinary continence, defined as a 3-hour dry interval, is not achieved within 2 years after bladder neck reconstruction, failure to achieve dryness has resulted. Occasionally the dry interval is nearly acceptable for daytime dryness (i.e., longer than 2 hours). In these situations urethral bulking agents have been used in an attempt to avoid further major reconstructive procedures (Burki et al., 2006a). Formerly, collagen was the bulking agent of choice, but often multiple injections were required (Ben-Chaim et al., 1995a). In a large series from Paris, Lottmann et al. (2006) reported on the use of a dextranomer-based bulking agent in childhood with incontinence from multiple causes. Twenty-six patients had the exstrophy-epispadias syndrome. Of the 9 exstrophy patients, 4 achieved success; in the epispadias group the success rate was much higher (longer than 3 hours dry by intermittent catheterization or voiding).

In a recent large series of specifically exstrophy-epispadias patients (Shah et al., 2014b) with a median follow-up of 8 years, 41 underwent injection before bladder neck reconstruction and 25 after bladder neck reconstruction. Injection before bladder neck reconstruction did result in 50% developing an adequate capacity for bladder neck reconstruction, but only 9 (22%) became dry. Bladder capacity was the most predictive variable of a successful bladder neck reconstruction after bladder neck injection. In the group of 25 patients with prior bladder neck surgery of whom 16 were partially dry (1 to 3 hours), all were rendered socially continent (dry for longer than 3 hours) after bladder neck injection. Of the 9 dry for less than 1 hour, bladder neck injection was not helpful at all. **Thus outlet injection after a failed bladder surgery is more**

successful if a reasonable dry interval has been achieved with open bladder neck surgery. In recent data from Alova et al. (2012), bladder neck surgery after prior dextranomer bladder neck injection was not found to be more difficult and success rates were acceptable with long-term follow-up. However, repeated dextranomer injections after a prior failure did not result in success. Currently, a major NIH approved Phase 1 study using the patients' own harvested myoblasts grown in the lab and reinserted into the bladder neck to achieve dryness after failed bladder neck surgery is ongoing (ClinicalTrials.gov, NCT01011777).

Some successes have been seen with repeated Young-Dees-Leadbetter repair if the bladder neck is patulous, the bladder capacity is adequate, and urodynamic evaluation reveals a stable bladder (Gearhart et al., 1991a). In that series only 50% of patients with a failed prior bladder neck reconstruction were candidates for reoperative surgery. In this highly select group, continence rates were acceptable after reoperative bladder neck reconstruction. All of these patients had excellent bladder capacity (>100 mL) and were stable on urodynamics before the redo repair. A majority of bladder neck failures require eventual augmentation or continent diversion (Burki et al., 2006b). The artificial urinary sphincter has been used with some success in patients who have a good bladder capacity. However, in most of these failures the bladder capacity is small and augmentation is required. At the time of reoperative surgery, either the bladder neck is transected proximal to the prostate with a Mitrofanoff substitution or a continence procedure, such as creation of an artificial sphincter, is performed. In our extensive experience with failed bladder neck reconstructions, most of the patients have had several surgeries of the bladder neck area and are desperate to be dry. In a recent large series of 31 patients who had undergone prior bladder neck reconstruction, Novak et al. (2009) found that most patients had undergone multiple prior repairs to achieve continence. Bladder neck transection along with enterocystoplasty was performed with initial continence achieved in 86%. Seven patients underwent further bladder neck surgery, and 90% achieved dryness by intermittent catheterization. One renal unit was lost, nonobstructive hydronephrosis developed in 8, and bladder stones occurred in 30%.

Delayed urinary continence has been reported at the onset of puberty in some males, and this has been attributed to prostatic growth. On MRI, the prostate of exstrophy patients is cloverleaf shaped and absent anteriorly, and its mean weight and maximal cross section and volume are normal (Gearhart et al., 1992). Therefore it is doubtful that growth of this abnormally configured prostate can have much impact on urinary continence after failed bladder neck repair, and improved continence at puberty may be a result of changes in the pelvic floor with maturity.

Key Points: Evaluation of the Failed Bladder Neck Reconstruction

- Bladder capacity under anesthesia
- Stable urodynamics
- Re-evaluation by voiding improvement program
- Re-evaluation by child psychologist

Failed Genitourethral Reconstruction

Common complications of modern epispadias repair include urethrocutaneous fistula formation. This has been reported in as few as 4% and as many as 19% of cases (Kajbafzadeh et al., 1995; Surer et al., 2000). Urethral tortuosity with difficult catheterization or strictures are uncommon with modern epispadias repair. Since the application of the penile disassembly for epispadias reconstruction, newer, more significant complications have been noted (Hammouda, 2003). Gearhart and Baird (2005) have reported loss of the glans, corpora, or both in addition to loss of penile skin and the urethral plate (see Fig. 31.28C). Whether this is secondary to surgical misadventure, vagaries in the blood supply of the penis, or the intrinsic difficulties in the procedure remain a topic of debate. Reconstruction of these complications has required additional techniques, including tissue expansion, full-thickness skin grafting, buccal mucosal grafting, and other complex techniques. In some patients with significant losses, neophalloplasty may eventually provide the material for final cosmetic reconstruction. Recent data by Massanyi et al. (2012) show the applicability of radial forearm phalloplasty in patients who have lost glans, corpora, and other soft tissue as a consequence of epispadias repair or in cloacal exstrophies where penile tissue hardly exists. This alternative allows a sensate cosmetic neophallus for this special group of exstrophy failures.

At an older age, unsightly penile scars and a short phallus may prompt further surgical intervention. Scar excision can be closed in a plastic fashion if enough penile skin is available. Otherwise, flaps or full-thickness skin grafts can be used. In severe cases, tissue expanders can be placed under the penile skin and gradually inflated over 6 weeks to allow more penile skin and obviate the need for grafting. Freeing all scar tissues and suspensory ligament tissue can maximize available penile length. A dorsal dermal corporeal graft or ventral corporeal plication or rotation may also help lengthen as well as correct any chordee. However, it must be recognized that the exstrophy penis, when compared with age- and race-matched controls, is congenitally deficient in anterior corporeal tissue as assessed by MRI (Silver et al., 1997b). Therefore overly aggressive attempts at penile lengthening may result only in corporeal denervation and devascularization without additional lengthening.

Alternative Techniques of Reconstruction

Not all children with bladder exstrophy are candidates for primary repair at initial evaluation because of a small bladder plate or significant hydronephrosis. Additional reasons for seeking other methods of treatment include failure of initial closure with a small remaining bladder or failure of continence surgery, or both. Excluding the patients in whom initial treatment fails, this discussion deals with options available when modern repair is not chosen by the surgeon or for other reasons has not been suitable.

Ureterosigmoidostomy

Whichever urinary diversion is chosen, the upper tracts and renal function are initially normal. This allows the reimplantation of normal-sized ureters in a reliable, nonrefluxing manner into the colon or other suitable reservoir. Historically, ureterosigmoidostomy was the first form of diversion to be popularized for patients with exstrophy. Although the initial series was associated with multiple metabolic problems, results improved markedly with newer techniques of reimplantation (Koo et al., 1996; Zarbo and Kay, 1986). Ureterosigmoidostomy is favored by some because of the lack of an abdominal stoma. **However, this form of diversion should not be offered until anal continence is normal and after the family has been made aware of the potential serious complications, including pyelonephritis, hyperkalemic acidosis, rectal incontinence, ureteral obstruction, and delayed development of malignancy** (Duckett and Gazak, 1983; Spence et al., 1979). More recently, ureterosigmoidostomy has been proposed again as an initial treatment of bladder exstrophy with acceptable continence and renal preservation on follow-up of 10 years or longer. In a long-term Swiss study by Gobet et al. (2009) of 42 patients, 50% had their ureterosigmoidostomy in place and were fecally continent at 50 years of age. One had developed a colonic malignancy and 60% had normal renal function. Another study from Sweden by Pettersson et al. (2013) found a higher rate of colorectal cancer than the Swiss study and a higher rate of rediversion. The mean time from ureterosigmoidostomy was 38 years. Almost all of the malignancies were poorly differentiated adenocarcinoma. The difference in the results of these two European studies is unclear but underscores the need for lifelong vigilance for early detection of cancer (Honeck et al., 2017).

Stein et al. (1999) treated a group of 128 patients with bladder exstrophy-epispadias with the Mainz technique for ureterosigmoidostomy. The Mainz Sigma pouch is constructed and the ureters reimplanted in a nonrefluxing manner. The abdominal wall is reconstructed and the bladder is closed as a seminal receptacle above the prostate. The penis is then reconstructed at a later date. D'elia et al. (2004) reported on 26 patients with the exstrophy-epispadias complex who showed excellent continence rates with long-term upper tract preservation when compared with standard ureterosigmoidostomy. Continence was achieved in 95% of patients with a rectal reservoir. Their recommendation for treatment in a number of patients with severely impaired renal function was that a colonic conduit was the best method of choice for diversion. In the patients with a normal or slightly dilated upper tract and intact anal sphincters, a Mainz rectal reservoir was recommended. Although the group from Mainz reported no cancer in a long-term follow-up study of patients who underwent ureterosigmoidostomy, the risk for malignancy still exists. Patients who have had mixing of urine and feces at any time during reconstruction remain at high risk for the development of cancers (Smeulders and Woodhouse, 2001). Bladder exstrophy patients in whom an initial reconstruction has failed and who have polyposis at the time of repeated closure may also be at higher risk for the later development of malignancy (Novak et al., 2005). This is especially true in today's mobile society, in which careful long-term follow-up may be difficult to guarantee. All patients with a ureterosigmoidostomy should have a yearly renal ultrasound and colonoscopy in adult life.

Continent Urinary Diversion in the Exstrophy Patient

In modern pediatric urology there is usually little need for incontinent urinary diversion in the patient with bladder exstrophy. In a young child with a bladder that is too small to close, or in a failed closure where the bladder template is too small to reclose, we recommend a nonrefluxing colon conduit. This protects the kidneys from vesicoureteral reflux, and undiversion can be performed when clinically indicated at an older age.

Advances in the reconstruction of the lower urinary tract in the past several years have been applied to the patient with exstrophy (Cervellione et al., 2008). Most commonly, further reconstruction is required in the patient in whom bladder neck reconstruction has failed. If a patient does not meet the criteria for bladder neck reconstruction (i.e., inadequate bladder capacity or inability to conform to a voiding regimen), deferring surgery is advisable. Patients in whom bladder neck reconstruction fails are most often destined to augmentation cystoplasty and continent urinary diversion. Surer et al. (2003) reported on 91 patients with the exstrophy-epispadias complex who underwent continent urinary diversion. The majority had undergone prior failed bladder neck reconstruction (n = 62). Seventy-nine patients (87%) had exstrophy closure before referral, 53 also underwent bladder neck reconstruction, and 29 patients had never reached adequate capacity for bladder neck reconstruction. Ten of the 53 patients underwent one prior attempt, 35 underwent two prior attempts, and 8 underwent three prior attempts at bladder neck reconstruction. A combined augmentation cystoplasty, continent urinary diversion, and bladder neck closure was performed in 59 patients (65%), and reaugmentation and continent urinary diversion was performed in 18 children. Ileocystoplasty was used in 41 patients, and sigmoid cystoplasty was performed in 30 patients. The appendix was used as the continent channel in 67 patients. Continence using intermittent catheterization through the stoma was achieved in 93% of children with the most common complication reported being that of bladder stones, noted in 26%. Although infrequent, failures can occur with continent urinary diversion in exstrophy (Frimberger et al., 2003). The most common modes of failure were a deintussusception of a nipple valve, inadequate tunnel for an appendiceal channel, or continued bladder neck incompetence. The vast majority of these complications can be successfully repaired. Equally successful outcomes have been reported by Baird et al. (2005a) in adolescents who had undergone a mean of eight prior procedures before their definitive repair.

Occasionally, urinary diversion must be established at a very young age (5 years or younger). The need for early diversion in exstrophy is mainly driven by upper tract changes and social factors and can be safe in younger children with a favorable continence outcome. In a recent study by Baradaran et al. (2012b), 19 patients underwent early diversion (14 continent, 5 incontinent). Of the group who underwent early continent diversion, 7 had an early desire to be dry; 4 had persistent severe hydronephrosis; 1 had severe recurrent pyelonephritis; 1 underwent a repeat continent urinary diversion; 1 had inaccessible proper follow-up; and only 2 had a successful primary closure. Three patients had neobladder creation, 10 had augmentation with a continent stoma, and 2 had ureterosigmoidostomy. Currently, all patients with stomas are dry on intermittent catheterization. Continence can be achieved in most patients with exstrophy after failure of bladder neck reconstruction and is typically obtained through augmentation cystoplasty and closure of the bladder neck. If a patient is unlikely to develop adequate capacity for eventual bladder neck reconstruction, moving early to continent urinary diversion is preferable. One long-term concern has been the risk of malignancy in patients with continent urinary diversion. Recent data by Husmann and Rathbun (2008) revealed that the overall rate of malignancy is low unless associated with coexisting carcinogenic stimuli (prolonged tobacco, chronic immunosuppression) or the inherent risk associated with bladder exstrophy.

Key Points: Continent Urinary Diversion in the Exstrophy Patient

- Typically failed bladder closures that do not grow after reclosure
- Small newborns with bladders that do not grow after closure
- Bladders that do not achieve dryness or adequate capacity after bladder neck reconstruction
- Upper tract decomposition after bladder neck reconstruction or primary bladder closure

Transitional Exstrophy Patient: Adolescent and Adult Concerns

As children with exstrophy grow into adulthood, there is an increasing need to address long-term functional and psychological aspects of dealing with a multiorgan birth defect. Some aspects such as sexuality and continence are common to all forms of the exstrophy-epispadias complex; however, in cloacal exstrophy there are additional neurologic and orthopedic aspects that can lead to significant disability.

A mainstay of the functional reconstruction of the exstrophy-epispadias complex is the preservation of renal function. Functional reconstruction of the exstrophy-epispadias complex has been associated with good preservation of renal function (DeMaria et al., 1980; Schaeffer et al., 2013). Renal function, however, can be compromised after urinary diversion (Husmann et al., 1988). Although urinary diversion has been used successfully as a temporary modality for providing upper tract decompression (Baradaran et al., 2012b), most children eventually undergo undiversion to continent urinary pouches. Long-term urinary diversion is now infrequently used in the exstrophy-epispadias complex.

Continence

Early surgical management of patients with bladder exstrophy included initial cystectomy and replacement with an ileal conduit or ureterosigmoidostomy. The use of ureterosigmoidostomy has fallen into disfavor because of an increased identification of lethal colonic cancer (Gobet et al., 2009). Renal function, however, was preserved in the majority of patients with ureterosigmoidostomy. Some institutions have been using continent catheterizable pouches for bladder management (Nerli et al., 2008). More recently, however, use of augmentation cystoplasty with bladder neck reconstruction or closure has been used successfully to provide continence in the majority of patients (Kavanagh et al., 2012; Novak et al., 2009). Long-term concerns about augmentation cystoplasty continue to be raised. Fontaine et al. (2000) evaluated 53 patients who had undergone augmentation cystoplasty and had at least 10 years of follow-up. In 80% of patients, there was no reduction in GFR noted. Remediable causes were found to account for the reduction in GFR noted in the remaining 20% of patients, leading the researchers to conclude that augmentation cystoplasty was effective in providing urine storage without compromising long-term renal function. Because of the long-term potential for carcinogenesis in patients who had undergone ureterosigmoidostomy, concerns were raised regarding tumor formation in children with augmentation cystoplasty. **Husmann and Rathbun** (2008) **reviewed their experience with 153 patients who had undergone augmentation cystoplasty; 38 of these patients had bladder exstrophy, of whom 3 developed multifocal adenocarcinoma, which suggests that there may be an inherent risk for long-term carcinogenesis in patients with bladder exstrophy who undergo augmentation.** Exposure to cigarette smoking increased the potential for the development of cancers in patients with augmentation cystoplasty, as did the use of immunosuppression for post-transplant management. Endoscopic surveillance beginning 5 years after reconstruction has been suggested; however, identification of early lesions can be difficult in the augmented bladder. Fecal incontinence has recently been noted in patients with bladder exstrophy and appears to persist into adulthood (El-Hout et al., 2010). Although this has not been noted by other investigators, ongoing evaluation for this psychologically debilitating problem seems appropriate.

Male Concerns

Sexuality

The most often expressed male concerns relate to the length, appearance, and the axis deviation (chordee) of the penis noted with exstrophy. Functional penile length can be gained by degloving the penis and resecting all of the residual scar tissue and releasing any remnants of the suspensory ligaments. Skin coverage can be a significant problem after penile lengthening procedures. Use of tissue expansion permits local skin to be used for coverage; however, this will require preplanning. Placement of a tissue expander and subsequent expansion can take 4 to 6 weeks. If the penile skin is not ideal for expansion, full-thickness grafting is a suitable alternative (Hernandez et al., 2008). Residual dorsal chordee from childhood reconstruction is not uncommon. Grafts (dermal grafts, tunica vaginalis, human AlloDerm) can be used to lengthen the dorsal aspect of the penis. Our preference is human AlloDerm because it is readily available, durable, and easy to use. Because of its anatomy, the penis must be opened dorsally for one half of its circumference as described by Perovic and Djinovic (2008) to lengthen and straighten the penis. Early measurements and determinations from artificial erections must be adequate because after grafting, the artificial erections can leak saline through the suture lines and give misleading information about the adequacy of correction.

In the cloacal exstrophy patient, the corporeal structures can be very small, and the only option for a functional phallus would be reconstruction with flap phalloplasty (see previous). Retention of all of the present corporeal and glanular tissue permits a location for anchorage of the neophallus (Ballaro et al., 1999).

Sexual function and libido in exstrophy patients are normal (Woodhouse, 1998). The erectile mechanism in patients who have undergone epispadias repair appears to be intact: 87% of boys and young men in the Hopkins series experienced erections after repair of epispadias (Surer et al., 2000). Woodhouse (1998), Ben-Chaim et al. (1996), and Ebert et al. (2008) reported satisfactory orgasmic function in most patients. In the men who had participated in sexual intercourse, female partners also expressed sexual satisfaction. In the series by Ben-Chaim, the only patients who had no ejaculation were 2 patients who had undergone cystectomy. A report from Castagnetti et al. (2010) of 19 men with bladder exstrophy evaluated via the International Index of Erectile Function questionnaire and compared with normal men indicated a higher incidence of erectile dysfunction (58%) as compared with the normal controls (23%). Erectile function was worse in those who had undergone multiple surgeries for treatment of incontinence. Orgasmic function was also noted to be lower in men with exstrophy. No difference in sexual desire, sexual satisfaction, or overall satisfaction was indicated, leading the authors to conclude that men with bladder exstrophy seem to lead a sexual life that is as satisfactory as that of their peers. Overall, it seems from the reports of many investigators that most men with exstrophy are able to achieve normal erectile function and are sexually satisfied. In a recent survey study by Baumgartner et al. exploring the long-term sexual health outcomes in men with bladder exstrophy it was found that 85% of respondents reported being sexually active in their lifetime, with an average Sexual Health Inventory for Men score as 19.8 (Baumgartner et al., 2017b). Of the patients 31 who had undergone semen analysis, only 4 had reported azoospermia.

As men grow into adulthood, additional concerns are now becoming evident and require transition of care to adult urology specialists. Men with bladder exstrophy will increasingly be seeking evaluation for prostatic hyperplasia and prostate cancer (Berkowitz et al., 2008). Silver et al. (1997a) reported on the ability to identify PSA in men with exstrophy. PSA was noted to be below the upper age-specific limit of norms, indicating that PSA changes could be muted in men with exstrophy. Routine digital rectal examination and PSA screening should become part of the standard follow-up for men with bladder exstrophy as with age-related screenings for normal men.

Male Fertility

Reconstruction of the male genitalia and preservation of fertility were not primary objectives in early surgical management of bladder exstrophy. Sporadic instances of pregnancy or the initiation of pregnancy by males with bladder exstrophy have been reported. In two large exstrophy series, male fertility was documented. Only 3 of 68 men in one study (Bennett, 1973) and 4 of 72 in another (Woodhouse et al., 1983) had successfully fathered children. Milking the urethra in an antegrade fashion from proximal to distal has provided pregnancy in some cases (Woodhouse, 1999). **In a large series of 2500 patients with exstrophy and epispadias** (Shapiro et al., 1985), **there were 38 males who had fathered children.**

Hanna and Williams (1972) compared semen analyses in men who had undergone primary closure and ureterosigmoidostomy. A normal sperm count was found in only 1 of 8 men after functional closure and in 4 of 8 men with diversion. The difference in observed fertility potential is probably attributable to iatrogenic injury to the verumontanum during functional closure or bladder neck reconstruction. Retrograde ejaculation may also account for low sperm counts after functional bladder closure. In a long-term study from our institution, Ben-Chaim et al. (1996) found that 10 of 16 men reported they ejaculated a few cubic centimeters of volume, 3 ejaculated only a few drops, and 3 had no ejaculation. Semen analysis was obtained in 4 patients: 3 had azoospermia and 1 had oligospermia. The average ejaculated volume of the patients who had sperm counts was 0.4 mL. In another large series by Stein et al. (1994) from Germany, the authors found that none of the patients who had reconstruction of the external genitalia could ejaculate normally, nor had they fathered children. Five patients who did not undergo reconstruction had normal ejaculation, and 2 had fathered children. The conclusion was that male patients with genital reconstruction and closure of the urethra demonstrated high risk of infertility. In a large study of successful primary closure from a large exstrophy center by Ebert et al. (2008), sperm parameters were poor in 18 of 21 patients, and follicle-stimulating hormone was increased in 25% of patients (Ebert et al., 2009). Ebert et al. (2010) reported on 17 adult men with bladder exstrophy undergoing the Erlangen approach single-stage procedure. At a mean follow-up of 19 years, 15 had bladder preservation and 12 were voiding per urethra; 16 men had proven ejaculation and 3 had normal sperm counts, 7 had oligoasthenospermia, and 6 had azoospermia. The potential for normal sperm counts was greater in patients who underwent only a single bladder neck procedure.

Assisted reproductive techniques have been applied to the exstrophy population (D'Hauwers et al., 2008). Regardless of the method of reconstruction of the external genitalia and bladder neck, newer techniques such as gamete intrafallopian transfer (GIFT) or intracytoplasmic sperm injection (ICSI) can be used to assist these patients in their goal of achieving pregnancy. Use of GIFT or ICSI in 21 men with exstrophy led to successful pregnancy with no instances of exstrophy in any of the offspring.

Female Concerns

Sexuality

The three main female concerns are the appearance of the external genitalia, adequacy of the vaginal opening, and uterine prolapse. Although initial correction of the female external genitalia defect is performed at birth, sometimes “touch-up” surgery must be performed at puberty. The appearance of the external genitalia is compromised because of the recurrence of the pubic diastasis, which leads to widening of the inferior abdominal scar and separation of the pubic hair. In addition, separation of the clitoral halves may be noted. To repair this in adolescence, mons flaps are raised laterally and brought to the midline and sewn to the fascia and themselves easily. In extreme cases with an extremely scarred flat mons veneris, tissue expanders can be placed laterally and gradually inflated over 6 weeks. These flaps are moved medially and used to reconstruct the mons. The pseudocapsules are rolled together in the midline to give the mons a more elevated appearance. Mobilizing lateral mons veneris flaps brings the clitoral halves closer to the midline and makes them easier to reconstruct into a single entity. Topical estrogen cream is used three times daily for 2 weeks before any external genital surgery to soften scars, increase skin viability, and improve local vascularity. The vaginal orifice is more vertical and somewhat stenotic in exstrophy compared with normal females (Cervellione et al., 2010). Insertion of tampons and sexual intercourse can therefore be difficult. Rotating an inverted U-flap of perineal skin into the incised posterior vaginal wall permits widening of the vaginal os (Stein et al., 1995). Uterine prolapse may be noted more frequently in women who have had vaginal wall cutback (Mathews et al., 2003a). After vaginal reconstruction, if the patient is not sexually active a vaginal dilator is used once daily until sexual activity occurs.

Uterine prolapse has been noted more frequently and at younger ages in girls with exstrophy-epispadias complex (Mathews et al., 2003a). Woodhouse (1999) reported prolapse in a number of patients, and it is a considerable problem to correct. Seven patients had total prolapse, one of whom had never had intercourse or a pregnancy. Woodhouse believes that prolapse may occur in up to half of patients after pregnancy. In a report from Mathews et al. (2003a), vaginal and uterine prolapse was noted commonly and even early in life (mean age 16 years). Uterine suspension provided only modest success for the prevention of recurrent prolapse. Stein et al. (1995), in a large exstrophy series from Germany, found that uterine fixation was required to correct prolapse in 13 patients with long-term follow-up of more than 25 years. The anterior displacement of the vaginal os and the marked posterior displacement of the puborectalis sling with its deficient anterior component were postulated as reasons for prolapse. Use of osteotomy has not been shown to reduce the incidence of uterine prolapse; however, the degree of pubic diastasis has been shown to be significant (Anusionwu et al., 2012). **The degree of prolapse depends on the degree of pubic bone divergence and the diameter of the opening in the levator hiatus for the vagina and rectum** (Miles-Thomas et al., 2006). We suspend the uterus to the sacrum with human AlloDerm or Pelvicol pubovaginal sling. The suspensory substance is sewn to the uterus from the cervix and dome of the uterus so that it can be snugly suspended to the ligaments on the front of the uterus. Regardless of the method of repair, the uterus must be anchored in such a way that it is fixated in the pelvis and less susceptible to prolapse.

Prophylactic suspension of the uterus in adolescent girls with exstrophy undergoing urinary reconstruction should be considered to prevent prolapse (Stein et al., 1999). Woodhouse (1999) believed that although prophylactic surgery may be helpful, once prolapse occurs, anterior fixation is insufficient to correct uterine prolapse in the exstrophy patient. Woodhouse recommends fixing both sides of the uterus from the cervix to the top of the uterus bilaterally to the presacral ligaments.

Mathews et al. (2003a) reported on a large series of girls and women with the exstrophy complex. All girls older than 18 years indicated that they had normal sexual desire, and many were sexually active. Mean age for commencement of sexual activity was 19.9 years. Although a few patients complained of dyspareunia, most indicated normal orgasms. Some patients indicated that they restricted sexual activity because of the cosmetic appearance of their external genitalia. Mons plasty is therefore important to obtain a cosmetically pleasing appearance either in infancy or in adolescence because hair-bearing skin and fat should be used to cover the midline defect. As mentioned earlier, we perform this procedure at the time of initial closure. It certainly can be done in adolescence with the use of rhomboid flaps, as popularized by Kramer et al. (1986).

Female Fertility

Krisiloff et al. (1978) reported on 45 women with bladder exstrophy who successfully delivered 49 normal offspring. The main complication after pregnancy was cervical and uterine prolapse, which occurred frequently. Burbage et al. (1986) described 40 women ranging from 19 to 36 years of age who were treated in infancy for bladder exstrophy; 14 pregnancies in 11 of these women resulted in 9 normal deliveries, 3 spontaneous abortions, and 2 elective abortions. Uterine prolapse occurred in 7 of the 11 patients during pregnancy. All had undergone prior permanent urinary diversions. Spontaneous vaginal deliveries were performed in those women, and cesarean sections were performed in women with functional bladder closures to eliminate stress on the pelvic floor and to avoid traumatic injury to the urinary sphincter mechanism (Krisiloff et al., 1978). With modern reconstructive techniques, successful pregnancies have been reported in female patients who have undergone continent urinary diversion (Kennedy et al., 1993). Giron et al. (2011) reported on 14 women who had undergone successful reconstruction and had 22 pregnancies. Seventeen pregnancies resulted in healthy newborns, 1 premature delivery of an infant who did well, 4 spontaneous abortions caused by genital prolapse, and 1 postpartum demise. After delivery, 3 mothers had temporary urinary incontinence, 1 mother had a vesicocutaneous fistula, and 7 women (50%) had genital prolapse.

In a larger report on 52 women with bladder exstrophy, Deans et al. (2012) reported on reproductive outcomes. Of those who attempted conception, 66% were successful; 19 patients conceived and there were 3 sets of twins—a total of 57 pregnancies. There were 34 of 57 live births (56%), 21 of 57 miscarriages (35%), 1 termination, and 4 stillbirths. There were 4 major complications related to delivery including 1 ureteral transection, 1 fistula formation, and 2 postpartum hemorrhages. In a recent survey study of 29 female exstrophy patients with continent urinary diversion, 12 (41%) of 29 respondents reported becoming pregnant. This resulted in 16 healthy newborns by elective cesarean section and one spontaneous abortion (Rubenwolf, Thomas et al., 2016). Deans et al. (2012) stress that pregnancy in women with bladder exstrophy remains high risk for the mother and the fetus and stress the need for referral to a tertiary care center for successful outcomes. In the majority of cases, planned cesarean section appears to be the safest mode for delivery.

Quality of Life

Overall and health-related quality of life (QoL) have become increasingly important as reconstructive techniques have improved and survival has become universal. Most groups have limited their studies to those with CBE. The preliminary results of the QUALEX (Quality of Life of Bladder Exstrophy) study (Jochault-Ritz et al., 2010) suggest that after reconstruction patients had reduced QoL. Adolescents reported a superior QoL score as compared with adults and children. Another report from Wittmeyer et al. (2010) of 47 patients (9 women and 16 men) also showed that QoL scores were less than norms; however, these reductions were mainly based on health concepts including limitation of physical activity and general health perception. Dodson et al. (2010) reported that overall adolescent QoL was comparable with norms, but parents reported significantly impaired adolescent general health and family activity and increased parental emotional distress. **Schaeffer et al.** (2013) **confirmed that adolescents with bladder exstrophy appear to have good QoL scores when compared with norms; although incontinent patients had a tendency to have lower QoL scores, the sample size evaluated was inadequate to demonstrate statistical significance.**

Long-Term Adjustment Issues

Interest has increased in long-term adjustment issues in patients with bladder exstrophy. Children with exstrophy undergo multiple reconstructive surgeries and have potential problems with respect to urinary incontinence and sexual dysfunction. However, the ultimate outcome would be better measured by how these children adjust overall in society. The severe nature of the exstrophy disorder could predict that this birth defect could have substantial psychological implications. Parental reaction to the child's medical condition may change the way the parents interact with the child. Incontinence may have a negative impact on social function and self-esteem. Multiple hospitalizations may interfere with the ability to be like other children. Concerning the potential medical and psychological implications of this anomaly, children born with exstrophy may be at increased risk for difficulties.

Formerly, there was a limited amount of information in the literature concerning this condition and its treatment and whether or not it has a deleterious effect on children and their families. Montagnino et al. (1998) evaluated younger children who performed more poorly and had disturbed behavior, specifically in skills related to function in school. Children who achieved continence after the age of 5 years were more likely to have problems with acting-out behavior. There were no differences in adjustment based on male or female sex, bladder versus cloacal exstrophy, type of continence strategy, or gender reassignment versus no reassignment. The conclusions of this long-term study were that children with exstrophy do not have clinical psychopathology (Montagnino et al., 1998). There was acting-out behavior rather than depression or anxiety, suggesting that improved outcomes may be achieved through a focus on normal adaptation rather than potential psychological stress. In addition, earlier achievement of continence through reconstructive efforts is potentially of psychological benefit.

This work was further supported by Catti et al. (2006), who found that QoL in adults was better in those who were continent with a good body image. More recently a large survey study demonstrated that patients with bladder exstrophy tend to have normative emotional and behavioral functionality, and expectantly, impaired functioning, such as internalizing symptoms of depression, anxiety or somatization was found in older patients (Hankinson et al., 2014). Moreover, males were liable to have higher rates of impairment compared with their female counterparts. Reiner (1999) studied 42 children with exstrophy and presented preliminary results suggesting that these patients tend to have more severe behavioral and developmental problems than children with other anomalies, significant body distortion, and self-esteem problems. Reiner has recommended early intervention with the exstrophy patient and family and continuation with long-term psychiatric support into adult life.

In a study from Europe, Feitz et al. (1994) found a more positive picture when they evaluated 11 women and 11 men with exstrophy, of whom 9 women (82%) and 10 men (91%) did not manifest any clinical levels of psychological stress. The authors concluded that these adults had a positive attitude toward life. With the use of structured instruments and appropriate evaluation and interviews, Reiner and Gearhart (2006) indicated that all 20 patients evaluated met criteria for at least one anxiety disorder. Older patients experienced waning of anxiety associated with peer discovery of incontinence after successful surgical reconstruction, and all noted intensified sexual activity with age. Data from Reiner et al. (2008) from a large series of male patients revealed that 14% experienced suicidal ideation. As they became older, 31% experienced this phenomenon; a few attempted adolescent or early adulthood suicide, and 1 succeeded. These findings underline the importance of screening patients for psychopathology as they age.

In an important study by Lee et al. (2006), females were found to have more close friendships, fewer disadvantages in relation to healthy peers, and more partnerships than males. There were no gender differences in adjustment within educational and professional careers, which overall were very good. Ebert et al. (2005) reviewed by questionnaire a group of 100 exstrophy adolescents. Education and social integration were high. All patients were heterosexual and almost 50% were sexually active, but almost 60% expressed anxiety about sexual activity. The most important finding was that 94% of patients expressed an interest in psychological assistance, underlining the importance of early childhood intervention.

Being born with exstrophy per se does not result in childhood psychopathology. Children with exstrophy exhibit some tendency toward increased problems with acting out or lack of attainment of age-appropriate adaptive behavior (Montagnino et al., 1998; Reiner, 1999). **Therefore early counseling should be part of the standard management strategy for all children with the exstrophy-epispadias complex.** In addition, patients and families should be encouraged to continue with psychological support as the child grows into adulthood.

Key Points: Bladder Exstrophy—Priorities in Management

- Size and quality of bladder template
- Extent of pubic diastasis and malleability of the pelvis
- Need for osteotomy
- Length and width of urethral plate
- Penile size
- Associated anomalies

Epispadias

Epispadias varies from a mild glanular defect in a covered penis to the penopubic variety with complete incontinence in males or females. It is most commonly noted as a component of bladder and cloacal exstrophy.

Male Epispadias

Isolated male epispadias is a rare anomaly, with a reported incidence of 1 in 117,000 males. Most male epispadias patients (about 70%) have complete epispadias with associated incontinence (Gearhart and Jeffs, 1998). Epispadias consists of a defect in the dorsal wall of the urethra. The normal urethra is replaced by a broad, mucosal strip lining the dorsum of the penis extending toward the bladder, with potential incompetence of the sphincter mechanism. The displaced meatus is free of deformity, and occurrence of urinary incontinence is related to the location of the dorsally displaced urethral meatus (Gearhart and Jeffs, 1998). The displaced meatus may be found on the glans, on the penile shaft, or in the penopubic region. All types of epispadias are associated with varying degrees of dorsal chordee (Fig. 31.29). In penopubic or subsymphyseal epispadias, the entire penile urethra is opened and the bladder outlet may be large enough to admit the examining finger, indicating obvious gross incontinence (see Fig. 31.1D). To a lesser extent than in those with CBE, patients with epispadias have a characteristic widening of the symphysis pubis caused by outward rotation of the innominate bones. This separation of the pubis causes divergent penopubic attachments that contribute to the short, pendular penis with dorsal chordee. Therefore the penile deformity is virtually identical to that observed in bladder exstrophy. The reported male-to-female ratio of epispadias varies between 3 : 1 (Dees, 1949) and 5 : 1 (Kramer and Kelalis, 1982a).

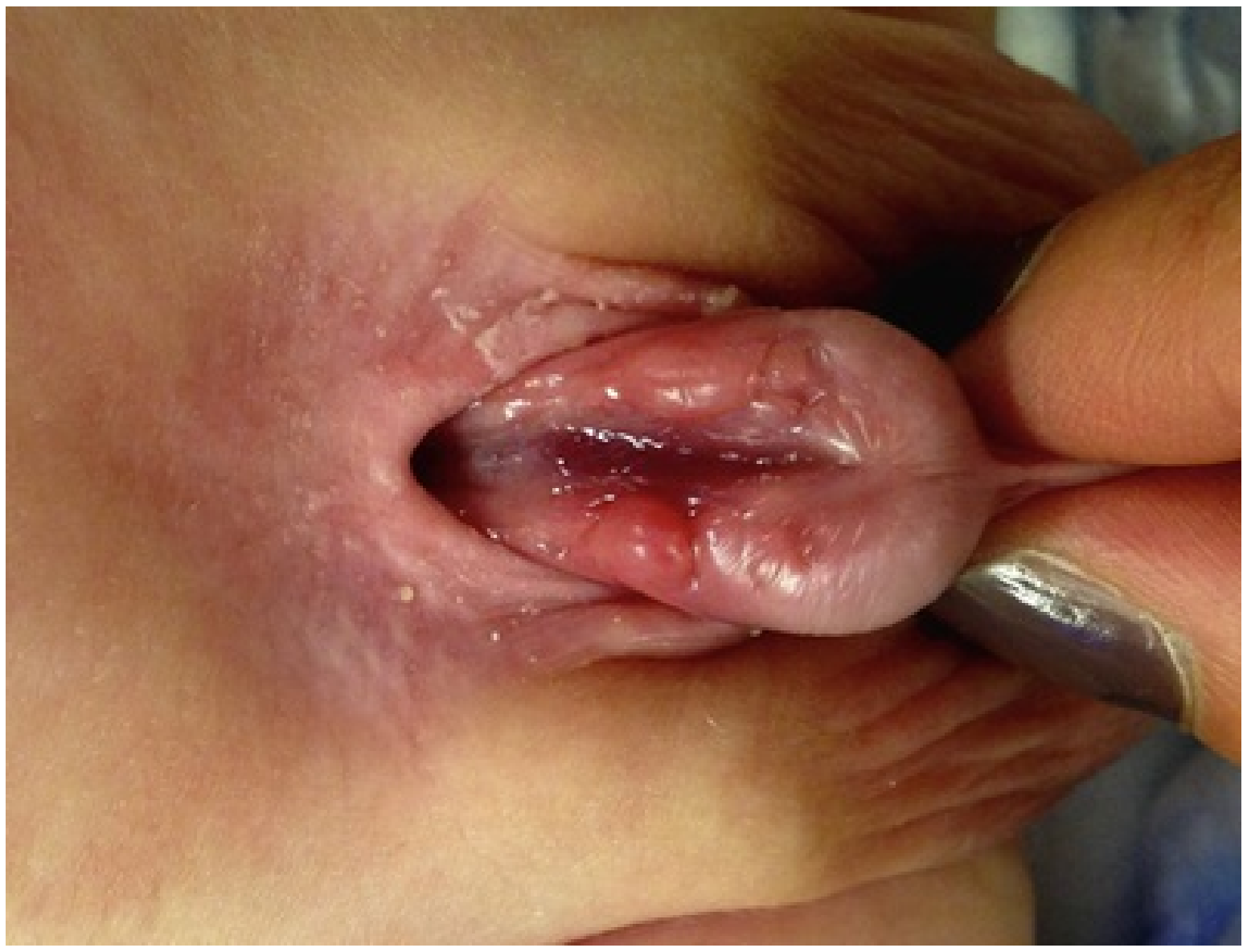

FIG. 31.29 Complete male epispadias.

Kramer and Kelalis (1982a) reviewed their experience with 82 male patients with epispadias. Penopubic epispadias occurred in 49 patients, penile epispadias in 21, and glanular epispadias in 12. Urinary incontinence was observed in 46 of 49 patients with penopubic epispadias, in 15 of 21 patients with penile epispadias, and in no patient with glanular epispadias. The goals of the treatment of complete male epispadias include creation of normal urinary control and establishment of a straight, cosmetically acceptable penis of adequate length that is functional for sexual intercourse.

Associated Anomalies

Anomalies associated with complete epispadias are usually confined to deformities of the external genitalia, diastasis of the pubic symphysis, and deficiency of the urinary continence mechanism. The only renal anomaly observed in 11 cases of epispadias was agenesis of the left kidney (Campbell, 1952). In a review by Arap et al. (1988), 1 case of renal agenesis and 1 case of ectopic kidney occurred among 38 patients.

The ureterovesical junction is inherently deficient in complete epispadias, and the incidence of reflux has been reported in a number of series to be between 30% and 40% (Arap et al., 1988; Kramer and Kelalis, 1982a). In a review by Ben-Chaim et al. (1995b) of a series of 15 patients with complete male epispadias treated at our institution, a lower rate of vesicoureteral reflux was noted compared with male patients with CBE (100% vs. 82%, respectively); the rate of inguinal hernias (33%) was also significantly lower. A possible explanation for the lower incidence of reflux in complete male epispadias is that the pouch of Douglas is not as enlarged and deep. Therefore the distal ureter enters the bladder in a more oblique fashion than in classic exstrophy (Gearhart and Jeffs, 1998).

Surgical Management

The objectives of repair of penopubic epispadias include achievement of urinary continence with preservation of the upper urinary tracts and the reconstruction of cosmetically acceptable genitalia. The surgical management of incontinence in penopubic epispadias is practically identical to that in closed bladder exstrophy.

Young (1922) reported the first cure of incontinence in a male patient with complete epispadias. Since this initial report, continence after surgical reconstruction has progressively improved (Arap et al., 1988; Burkholder and Williams, 1965; Kramer and Kelalis, 1982a; Mollard et al., 1998; Peters et al., 1988). In patients with complete epispadias and good bladder capacity, epispadias and bladder neck reconstruction can be performed in a single-stage operation. Urethroplasty formerly was performed after bladder neck reconstruction (Arap et al., 1988; Kramer and Kelalis, 1982a). However, improvements in bladder capacity in the small bladder associated with exstrophy (Gearhart and Jeffs, 1989a) and that associated with epispadias (Peters et al., 1988) have led us to perform urethroplasty and penile elongation before bladder neck reconstruction. A small, incontinent bladder with reflux is hardly an ideal situation for bladder neck reconstruction and ureteral reimplantation. Before bladder neck reconstruction there was an average increase in bladder capacity of 95 mL within 18 months after epispadias repair in the patients with an initial small bladder capacity and a continence rate of 87% after the continence procedure (Peters et al., 1988). In a series by Ben-Chaim et al. (1995b) composed exclusively of patients with complete male epispadias, bladder capacity increased by an average of 42 mL within 18 months after urethroplasty. Nine (82%) of 11 patients were dry day and night after an average of 9 months.

In epispadias, as in bladder exstrophy, bladder capacity is the predominant indicator of eventual continence (Ritchey et al., 1988). Arap et al. (1988) **reported higher continence rates in patients who had an adequate bladder capacity before bladder neck reconstruction than in those with inadequate capacity (71% vs. 20%, respectively).** In addition, in Arap's group of patients with complete epispadias, most obtained continence within 2 years, similar to results in patients with CBE.

A firm intrasymphyseal band typically bridges the divergent symphysis, and an osteotomy is not usually performed. The Young-Dees-Leadbetter bladder neck plasty, Marshall-Marchetti-Krantz suspension, and ureteral reimplantation are performed when the bladder capacity reaches approximately 100 mL, which usually occurs between 4 and 5 years of age when the child is ready to be dry. Genital reconstruction procedures in epispadias and exstrophy are similar. The following reconstructive maneuvers must take place: release of dorsal chordee and division of the suspensory ligaments; dissection of the corpora from their attachments to the inferior pubic ramus; lengthening of the urethral groove; and lengthening of the corpora, if needed, by incision and anastomosis or grafting or by medial rotation of the ventral corpora in a more downward direction.

Urethral reconstruction in complete epispadias has been performed in many ways. A transverse island flap was used by Monfort et al. (1987). The urethra, once reconstructed, can be positioned between and below the corpora (Cantwell, 1895; Gearhart et al., 1992, 1995c; Ransley et al., 1989). Mitchell and Bägli (1996) reported their experience with a complete penile disassembly technique, and a multicenter experience was reported in a total of 17 patients from four institutions (Zaontz et al., 1998). Chordee was reliably corrected, erectile function was preserved, the urethra was eventually situated in a cosmetic fashion, and satisfactory cosmesis was achieved. Caione and Capozza (2001) reported on their experience with the use of penile disassembly and reapproximation of the perineal muscle complex for the management of boys with epispadias, indicating the ability to achieve continence without the need for additional bladder neck reconstruction. A recent small series by Kibar et al. (2009b) of patients with complete epispadias showed that complications with use of the disassembly repair were in the acceptable range. Unlike the use of this in the exstrophy group, there was no ischemia of the glans or corpora. However, most patients required additional surgery because hypospadias was created in a number of patients. Repair of this hypospadias can be challenging and can have high complication rates (Berrettini et al., 2011). Cervellione et al. (2010) did report on 4 patients who underwent penile disassembly or radical soft-tissue mobilization (Kelly procedure) who had significant corporeal loss after surgery. Ransley and Surer et al. reported excellent results using the modified Cantwell-Ransley procedure, saving cavernocavernostomy for patients with very severe chordee and especially those in the older age group (Kajbafzadeh et al., 1995; Surer et al., 2000). For detailed description of the surgical reconstruction, see the previous discussion in the section on bladder exstrophy.

It was formerly thought that the effect of urethral lengthening and prostatic enlargement may be significant in complete epispadias by increasing outlet resistance if continence was not perfect as the child became older. Earlier in a series by Arap et al. (1988), the establishment of continence had no relation to puberty and usually occurred within 2 years, usually preceding puberty by several years. In the series reported by Ben-Chaim et al. (1995b), as stated previously, all patients obtained daytime continence at a mean of 9 months after bladder neck reconstruction, and 9 (82%) of 11 patients attained total day and night continence. All patients voided spontaneously. After a mean follow-up of 7 years, all patients maintained normal upper tracts and kidney function. All of them had cosmetically pleasing genitalia, as judged by parents, patients, and physicians, and experienced normal erections. A 36-year-old patient was married and had fathered three children. Many of the patients were younger than 16 years and had not yet become sexually active. Results of urethroplasty in epispadias have been reported in a number of publications (Kajbafzadeh et al., 1995; Mesrobian et al., 1986; Ransley et al., 1989; Zaontz et al., 1998). In a modern series of modified Cantwell-Ransley repairs reported by Surer et al. (2000), the incidence of postoperative fistula in the 3-month period after surgery was 19%, and the incidence of urethral stricture formation was less than 10%. Catheterization and cystoscopy could easily negotiate the neourethral channel in all patients who underwent a modified Cantwell-Ransley epispadias repair. In another modern series reported by Mollard et al. (1998), the continence rate was 84% and the fistula rate was less than 10%. In Mollard's series with long-term follow-up, patients had normal erections; the vast majority had regular sexual intercourse, and most had normal ejaculation or had fathered children. Most of Surer's patients were young, and assessment of genital reconstruction must be deferred until these patients are sexually mature and active (Surer et al., 2000). Hafez and Helmy (2011) reported on three patients with isolated penopubic epispadias who underwent postpubertal reconstruction using penile disassembly, indicating good cosmesis with a meatus at the tip.

Although many methods of epispadias repair exist, meticulous follow-up of the urethra, appropriate selection of patients, and surgical experience remain the milestones of success. Last, Ransley et al. (Kajbafzadeh et al., 1995) obtained very good results using a modified Cantwell-Ransley repair in a large number of patients with epispadias. The fistula rate was 4%, and the urethral stricture rate was 5.3%. Baird et al. (2005b) reported on 129 boys who underwent a modified

Cantwell-Ransley repair. Of this group, 32 had penopubic epispadias. Twenty-four procedures were primary repairs and eight were secondary repairs. Urethrocutaneous fistula occurred in 13% of primary and 25% of secondary repairs. A urethral stricture occurred in one patient.

Achievement of urinary continence in patients with isolated epispadias is summarized in Table 31.5. A majority of these patients underwent reconstruction by means of a modified Young-Dees-Leadbetter bladder neck plasty. Urinary continence was obtained in 82% of male patients (Ben-Chaim et al., 1995b). As in the exstrophy population, repair of the epispadiac deformity results in an increase of outlet resistance and possible increase in bladder capacity before bladder neck reconstruction. Although complete epispadias and bladder exstrophy patients achieve improvement in bladder capacity after epispadias repair, the mean increase in overall capacity is higher in those with complete epispadias. This increase in bladder capacity may account for increased continence in this group compared with the CBE population. Clinically, these bladders are more supple, easier to mobilize, and more amenable to bladder neck reconstruction. Ben-Chaim et al. (1995b) reported that the mean time to initial continence after bladder neck reconstruction was 90 days in patients with complete male epispadias compared with 110 days in those with bladder exstrophy. These results suggest that for patients with complete epispadias, bladder capacity before reconstruction and the rate of achieving continence afterward are better than in exstrophy. The reason may be that the bladder is not exposed in utero and does not have any scarring from prior closure; therefore its potential for expansion is higher.

TABLE 31.5

Urinary Continence After Bladder Neck Reconstruction (BNR) in Patients With Complete Epispadias

	BEN-CHAIM ET AL. (1995B)	GEARHART ET AL. (1993A)	KRAMER AND KELALIS (1982A)	ARAP Et AL. (1988)	BURKHOLDER AND WILLIAMS (1965)	BRAGA Et AL. (2008)
No. of patients	15	11	53	38	27	17
MALES						
Treated with BNR	11		32[a]	21	17	17

Surgically corrected incontinence	9		22	15	8	13
Percent with surgically corrected incontinence	82%		69%	71%	47%	76%
FEMALES						
Treated with BNR	0	9	12	9	10	
Surgically corrected incontinence	0	8	10	7	7	
Percent with surgically corrected incontinence	0	87%	83%	77%	70%	

[a] All complete female epispadias cases.

Data from Ben-Chaim J, Peppas DS, Jeffs RD, et al: Complete male epispadias: genital reconstruction achieving continence, *J Urol* 153:1665, 1995; Gearhart JP, Peppas DS, Jeffs RD: Complete genitourinary reconstruction of female epispadias, *J Urol* 149:1010, 1993; Kramer SA, Kelalis P: Assessment of urinary continence in epispadias: review of 94 patients, *J Urol* 128:290, 1982; Arap S, Nahas WC, Giron AM, et al: Continent epispadias: surgical treatment of 38 cases, *J Urol* 140:577, 1988; Burkholder GV, Williams DI: Epispadias and incontinence: surgical treatment in 27 children, *J Urol* 94:674 1965; Braga LH, Lorenzo AJ, Bägli DJ, et al: Outcome analysis of isolated male epispadias: single center experience with 33 cases, *J Urol* 179(3):1107–1112, 2008.

In a different approach to the treatment of incontinence associated with epispadias reported by Duffy and Ransley (1998), 12 boys aged 3 to 7 years underwent endoscopic submucosal injection of plastic microspheres. All patients had undergone a modified Cantwell-Ransley epispadias repair before injection. The procedure was performed 24 times, with a total volume of 83 mL of material injected into 59 sites in the posterior urethra. Mean follow-up was 10.8 months. Three patients (25%) were rendered completely dry, the degree of incontinence was improved in 6 patients, and there was no change in 3 patients. The authors offered this approach as an alternative to bladder neck reconstruction in patients with primary epispadias. Ben-Chaim et al. (1995a) reported that submucosal injection of collagen in the bladder neck area can have a role in improving stress incontinence when the patient with complete epispadias has incomplete urinary control or as an adjunct after bladder neck reconstruction. In a recent study by Kibar et al. (2009a) of complete epispadias, 1 patient out of 12 was continent after bladder neck injection.

Kramer et al. (1986) reported the success of genital reconstruction in epispadias, with good long-term follow-up ending with a straight penis angled downward in almost 70% of patients, with normal erectile function. Of this group, 80% had satisfactory sexual intercourse, and of 29 married patients, 19 had fathered children. These results were mirrored in the long-term follow-up study of Mollard et al. (1998).

A carefully constructed and well-planned approach to the management of urinary incontinence in genital deformities associated with complete epispadias should provide a satisfactory cosmetic appearance, normal genital function, and preservation of fertility potential in most patients.

Female Epispadias

Female epispadias is a rare congenital anomaly; it occurs in 1 of every 484,000 female patients (Gearhart and Jeffs, 1998; Fig. 31.30). **We use the classification of Davis** (1928), **which describes three degrees of epispadias in female patients** (Figs. 31.31A to D). **In the least severe degree of epispadias, the urethral orifice simply appears patulous. In intermediate epispadias, the urethra is dorsally split along most of the urethra. In the most severe degree of epispadias, the urethral cleft involves the entire length of the urethra and sphincteric mechanism and the patient is rendered incontinent** (Fig. 31.31). The genital defect is characterized by a bifid clitoris. The mons is depressed in shape and coated by a smooth, glabrous area of skin. Beneath this area, there may be a moderate amount of subcutaneous tissue and fat, or the skin may be closely applied to the anterior and inferior surface of the symphysis pubis. The labia minora are usually poorly developed and terminate anteriorly at the corresponding half of the bifid clitoris, where there may be a rudiment of a preputial fold. These external appearances are most characteristic: on minimal separation of the labia, one sees the urethra, which may vary considerably, as mentioned previously. The symphysis pubis is usually closed but may be represented by a narrow fibrous band. The vagina and internal genitalia are usually normal. Because the external appearance changes may be minimal, some children are identified only because of persistent incontinence (Shetty et al., 2011; Yeni et al., 2004).

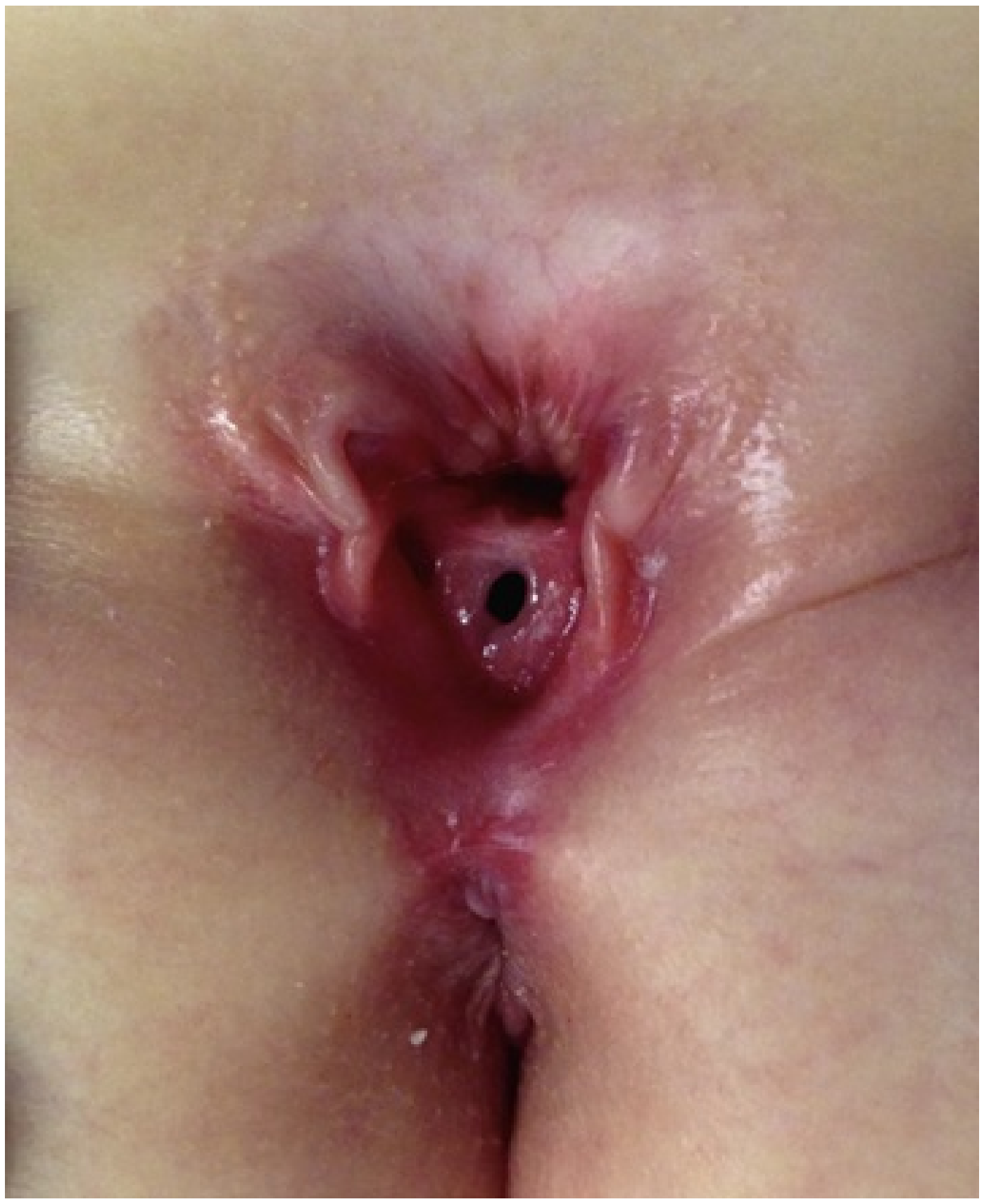

FIG. 31.30 Complete female epispadias.

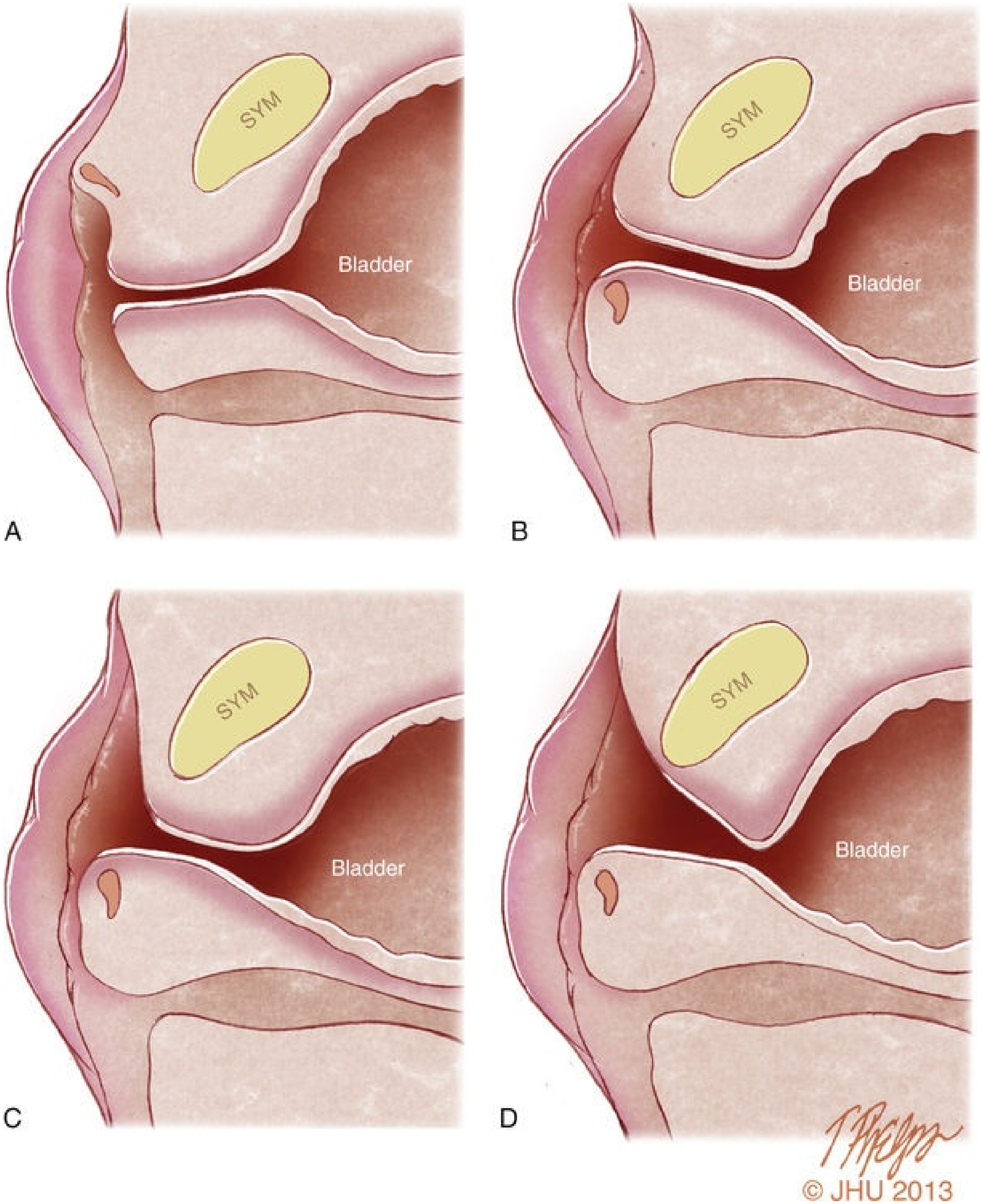
SYM
Bladder
A
SYM
Bladder
B
SYM
Bladder
C
SYM
Bladder
D
© JHU 2013

FIG. 31.31 (A) Normal female anatomy. (B) Vesicular epispadias—urethra mainly normal but relation to clitoris altered. (C) Subsymphyseal epispadias—defect in anterior wall of urethra for about one-half its length. (D) Retrosymphyseal epispadias—defect in anterior wall of entire urethra. Sphincter is usually involved. *SYM,* Symphysis. (Used with permission of Brady Urological Institute.)

Associated Anomalies

The ureterovesical junction is inherently deficient in patients with epispadias, and the ureters are often laterally placed in the bladder with a straight course so that reflux occurs. The incidence of reflux is reported to be 30% to 75% (Gearhart et al., 1993a; Kramer and Kelalis, 1982b). Because there is no outlet resistance, the bladder is small and the wall is thin. After initial reconstruction, the urethral resistance that is created allows the bladder to grow and develop to an acceptable capacity for bladder neck reconstruction.

Surgical Objectives

Objectives for repair of female epispadias parallel those devised for male patients: (1) achievement of urinary continence, (2) preservation of the upper urinary tracts, and (3) reconstruction of functional and cosmetically acceptable external genitalia.

Operative Techniques

With the patient in the lithotomy position, the defect of the female epispadias with incontinence is apparent (Fig. 31.32A). The two halves of the clitoris are widely separated, and the roof of the urethra is cleft between the 9 o'clock and 3 o'clock positions. The smooth mucosa of the urethra tends to blend cephalad with the thin, hairless skin over the mons. The urethral incision is begun at the cephalad extent of the vertical incision at the base of the mons and is brought inferiorly through the full thickness of the urethral wall at the 9 o'clock and 3 o'clock positions (Fig. 31.32B). Sutures can be placed in the urethra to permit downward traction on the urethra so that the roof of the urethra is excised to a level near the bladder neck (Fig. 31.32C). Often one finds the dissection proceeding under the symphysis. An inverting closure of the urethra is then performed over a 10-Fr Foley catheter. Suturing is begun near the bladder neck and progresses distally until closure of the neourethra is accomplished (Fig. 31.32D). Attention is then given to denuding the medial half of the bifid clitoris and the labia minora so that proper genital coaptation can be obtained.

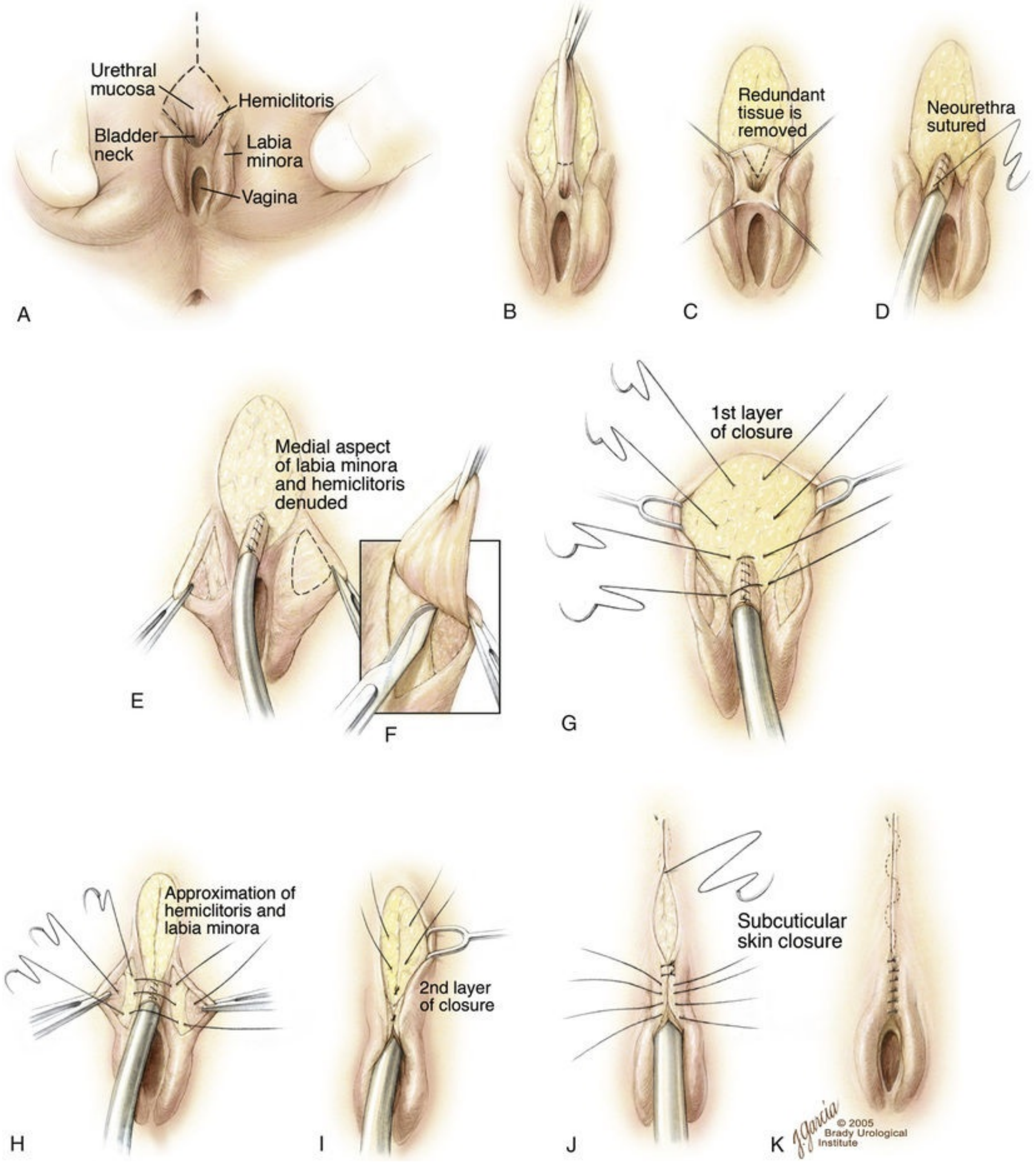
Urethral mucosa
Hemiclitoris
Bladder neck
Labia minora
Vagina
A
B
Redundant tissue is removed
C
Neourethra sutured
D
Medial aspect of labia minora and hemiclitoris denuded
E
F
1st layer of closure
G
Approximation of hemiclitoris and labia minora
H
2nd layer of closure
I
Subcuticular skin closure
J
K
J.Garcia
© 2005 Brady Urological Institute

FIG. 31.32 (A) Typical appearance of female epispadias with initial incisions outlined. (B) Excision of the glabrous skin of the mons. (C) Tapering of the urethra with a dorsal resection of a wedge of tissue. (D) Reconstruction of the urethra over a catheter with running suture. (E and F) Medial aspect of the labia minora and clitoris. (G) Initial layer of mons closure. (H) Approximation of the labia minora over the urethral reconstruction. (I) Second layer of mons closure. (J) Creation of clitoral hood. (K) Completion of mons closure. (Copyright Brady Urological Institute.)

After this is done, fat from the mons and subcutaneous tissue can be used to cover the suture line and obliterate the space in front of the pubic symphysis (Figs. 31.32E and F). The two halves of the clitoris and labia minora are brought together using interrupted sutures of 6-0 polyglycolic acid. The corpora may be partially detached from the anterior ramus of the pubis to aid in the urethral closure. Also, bringing these tissues together may contribute by adding resistance to the urethra. Mons closure is further aided by mobilizing subcutaneous tissue laterally and bringing it medially to fill any prior depression that remains (Fig. 31.32G). The subcutaneous layer is closed with 4-0 polyglactin suture in an interrupted fashion (Fig. 31.32H). The skin is closed with interrupted sutures of 6-0 polypropylene (Figs. 31.32I to K).

A 10-Fr catheter is left indwelling for 5 to 7 days. Should the patient undergo simultaneous bladder neck reconstruction, a Foley catheter is not left in the urethra and the patient is placed in the supine position for the abdominal part of the procedure.

Achievement of a satisfactory cosmetic appearance of the external genitalia and urinary continence in the female child with epispadias represents a surgical challenge. Many operations have been reported to control continence in the epispadias group, but the results are disappointing. These procedures include transvaginal plication of the urethra and bladder neck, muscle transplantations, urethra twisting, cauterization of the urethra, bladder flap, and Marshall-Marchetti vesicourethral suspension (Davis, 1928; Gross and Kresson, 1952; Marshall et al., 1949; Stiles, 1911). These procedures may increase urethral resistance, but they do not correct incontinence or the malformed anatomy of the urethra, bladder neck, and genitalia.

The challenge of the small bladder in the female epispadias patient is comparable with a situation seen in patients with a closed exstrophy. The small, incontinent bladder, with or without reflux, is hardly an ideal setting for a successful bladder neck reconstruction and ureteral reimplantation. A third of all incontinent epispadias patients have a bladder capacity of less than 60 mL, in our experience and that of Kramer and Kelalis (1982b). Bladder augmentation, injection of polytetrafluoroethylene (Teflon) in the bladder neck area, and simultaneous bladder neck reconstruction and bladder neck augmentation have been offered as a solution to this challenge. However, primary closure of the epispadiac urethra in children with closed exstrophy was found to increase bladder capacity without causing hydronephrosis, and this approach has been applied to male and female patients with epispadias (Ben-Chaim et al., 1995b;

Gearhart and Jeffs, 1989a; Peters et al., 1988). Although we typically perform urethral and genital reconstruction at 6 months to 1 year of age, we advocate delaying bladder neck reconstruction until the child is 4 to 5 years old. Not only does this delay allow the bladder to increase in capacity but also it allows the child to accept essential instructions for toilet training, which is critical to achieving satisfactory continence in the postoperative state.

Data from de Jong et al. (2000) combined a standard exterior genitoplasty plus urethroplasty with a percutaneous bladder neck suspension. The authors felt the suspension moved the bladder neck into an intra-abdominal position. In this small series, one patient was dry and voiding, two required bladder neck bulking agents, and one was on CIC. In another small series from India, Bhat et al. (2008) performed a urethroplasty and the perineal musculature was double-breasted over the urethral closure from the bladder neck distally. Bhat et al. reported impressive results with two totally continent, one partially continent, and one continent patient after bladder neck reconstruction.

Surgical Results

The continence rate of 87.5% in our female patients is comparable with that of Hanna and Williams (1972), who found a 67% continence rate in female patients with good bladder capacity, and those of Kramer and Kelalis (1982b), who reported an 83% continence rate in patients with adequate bladder capacity. All of our patients seen for primary treatment have achieved a capacity in excess of 80 mL (see Table 31.5).

Hendren (1981) and Kramer and Kelalis (1982b) showed that genitourethral reconstruction can be accomplished with satisfactory results. At our institution, patients who underwent prior urethral and genital reconstruction had a mean bladder capacity at bladder neck reconstruction of 121 mL, making the bladder suitable for the reconstruction and eventual continence without the use of augmentation cystoplasty or need for intermittent catheterization.

The time interval to achieve continence in our patients was a mean of 18 months for those who underwent genitourethral and bladder neck reconstruction in one procedure and 23 months for those who underwent preliminary urethroplasty and genital reconstruction after bladder neck reconstruction. In a series by Klauber and Williams (1974), the mean interval to acceptable continence was 2.25 years. Also, in a series by Kramer and Kelalis (1982b), some patients became continent within a short period, whereas complete continence was delayed for several years in others. The time delay for achieving continence may represent increased pelvic muscular development, as suggested by Kramer and Kelalis (1982b). In regard to the interval to continence, no advantage appears to be gained by preliminary urethroplasty. However, we believe that the advantage gained by increased bladder capacity at the time of bladder neck reconstruction outweighs any advantage gained by a combined approach. Suson et al. (2013) compared 22 girls with complete female epispadias with 23 girls with CBE. Although girls with female epispadias had reconstruction at a later age than those with CBE, bladder growth rate did not differ between the two groups (Suson et al., 2013). Neither group had any difference in number of surgical procedures, development of continence with or without the need for bladder neck reconstruction, or eventual need for continent urinary diversion.

Key Points: Male and Female Epispadias: Priorities in Management

- Degree of epispadias and continence
- Associated anomalies
- Bladder capacity
- Aesthetic and functional genitalia

Cloacal Exstrophy

Cloacal exstrophy includes a spectrum of abnormalities but is primarily an anterior abdominal wall defect. A reported incidence of 1 : 200,000 to 1 : 400,000 makes this one of the rarer urologic abnormalities (Hurwitz et al., 1987). Although prior reports have suggested a male-to-female ratio of 2 : 1 (Gearhart and Jeffs, 1998), a large study by Boyadjiev et al. (2004a) indicated that the sex ratio may be 1 : 1. Most cases are sporadic, and isolated incidences of unbalanced translocations have been reported to be potentially causative (Thauvin-Robinet et al., 2004); however, one report noted recurrence in siblings, perhaps indicating a more multifactorial cause. Recent reports have indicated a greater incidence of cloacal exstrophy associated with maternal exposure to cigarette smoke (Gambhir et al., 2008). Mothers of infants with cloacal exstrophy were more compliant with preconceptional folate use. Associated defects of the neurospinal axis, intestinal tract, and urogenital and skeletal systems are frequently noted. When neurospinal defects and omphalocele coexist with cloacal exstrophy, the term *OEIS complex* (omphalocele, exstrophy, imperforate anus, spinal defects) has been used (Keppler-Noreiul, 2001). Advances in the care of critically ill children has resulted in most infants with cloacal exstrophy surviving into adulthood. The focus of management has therefore shifted to improving QoL (Mathews et al., 1998).

Anatomic Considerations

The classic constellation of anomalies that are noted in children with cloacal exstrophy includes exstrophy of the bladder, complete phallic separation, wide pubic diastasis, exstrophy of the terminal ileum between the two halves of the bladder, a rudimentary hindgut, imperforate anus, and the presence of an omphalocele. Many children have associated spinal defects, and various lower extremity malformations may be noted (Jain and Weaver, 2004; Loder and Dayioglu, 1990). The urogenital anomalies in cloacal exstrophy are similar to those seen with CBE (see previous), although they are typically of greater severity.

Neurospinal Abnormalities

Abnormalities of the spinal cord or vertebral column or both have been noted in 85% to 100% of children with cloacal exstrophy (Appignani et al., 1994; McLaughlin et al., 1995). Although most patients have lumbar myelodysplasia (80%), thoracic defects may be noted in 10%, with the remaining having sacral defects. In a large series of 34 patients from a single center with cloacal exstrophy and associated spinal defects, Mathews et al. (1998) noted lipomeningocele in 17, myelomeningocele in 8, and spina bifida and isolated cord tethering in 7 and 2 patients, respectively. The nearly universal incidence of spinal abnormalities has led some authors to suggest MRI for all patients with a diagnosis of cloacal exstrophy (Cohen, 1991). Spinal ultrasound evaluation, which is easily performed, has been noted to be comparable with MRI for the diagnosis of spinal anomalies in infants with cloacal exstrophy (Dick et al., 2001). Karrer et al. (1988) noted that only 1 in 5 children with spinal dysraphism noted on ultrasonography had a sacral abnormality visible on the skin surface.

The embryologic basis for the neurospinal defects associated with cloacal exstrophy has been postulated to be secondary to disruption of the tissue of the dorsal mesenchyme rather than failure of neural tube closure (McLaughlin et al., 1995). Alternatively, it has been suggested that the defects that lead to the formation of cloacal exstrophy may lead to the developing spinal cord and vertebrae being pulled apart (Cohen, 1991). Functional deficits can range from patients who have almost normal sensation of the pelvis and lower extremity to patients who are wheelchair bound. The presence of a clinically significant neurologic anomaly was found to negatively affect the development of continence (Husmann et al., 1999). Only 1 of 13 neurologically impaired patients in this series developed voided continence.

The neuroanatomic dissections performed by Schlegel and Gearhart (1989) further indicate that the neuroanatomic landmarks in the infant with cloacal exstrophy are different from those in the normal newborn, with the autonomic bladder innervation being derived from a more medial location (Fig. 31.33). This potentially puts the nerve supply in jeopardy during initial bladder dissection and reconstruction and can potentially leave the bladder neuropathic after reconstruction (Husmann et al., 1999). Innervation to the duplicated corporeal bodies arises from the sacral plexus, travels in the midline, perforates the pelvic floor, and courses medially to the hemibladders (Schlegel and Gearhart, 1989). Innervation abnormalities were also noted at a histologic level in the studies by Rosch et al. (1997). When compared with those in patients with bladder exstrophy, the neural elements identified on immunohistochemical evaluation were found to show significant structural abnormalities.

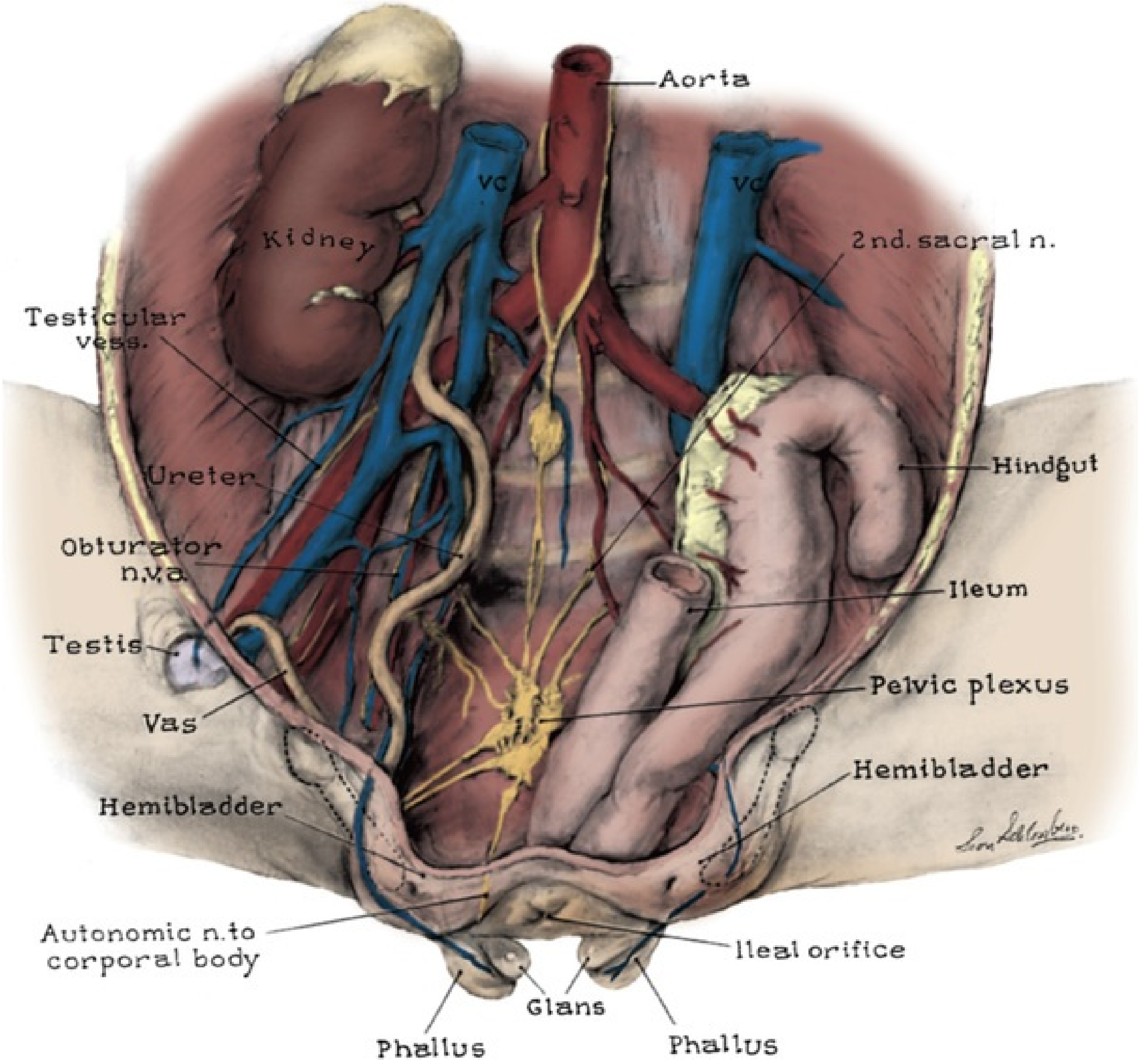
Aorta
VC
VC
Kidney
2nd. sacral n.
Testicular vess.
Hindgut
Ureter
Obturator n.v.a.
Ileum
Testis
Pelvic plexus
Vas
Hemibladder
Hemibladder
Autonomic n.to corporal body
Ileal orifice
Glans
Phallus
Phallus

FIG. 31.33 Internal view of a patient with cloacal exstrophy. Pudendal vessels, nerves, and other vessels and autonomic innervations of the corporal bodies are demonstrated. Internal structures of the pelvis along with duplication of the vena cava in this dissected specimen are also shown.

Skeletal System Abnormalities

Anomalies of the skeletal system are universally noted in children with cloacal exstrophy. The pubic diastasis noted in the exstrophy-epispadias complex are seen at their most extreme with cloacal exstrophy. Sponseller et al. (1995), studying patients with the exstrophy complex, noted that the posterior segment of the pelvis in children with cloacal exstrophy was angled farther posteriorly and there was a greater likelihood of asymmetry between the two sides. Similarly, the anterior segment of the pelvis had more severe degrees of external rotation. The actual length of the bone segments, however, was similar between those with cloacal and classic exstrophy. The interpubic distance (diastasis) in children with cloacal exstrophy was noted to be almost twice that in children with CBE. Malformation of the sacroiliac joints and side-to-side asymmetry were also noted. Most children with cloacal exstrophy therefore require osteotomy for successful reconstruction. **Stec et al.** (2003) **noted that microscopically the bones in children with cloacal exstrophy were similar to those in normal controls and were developing at a similar rate, indicating that the potential for growth was also similar.**

Vertebral anomalies not associated with myelodysplasia were noted in 8 of 37 children with cloacal exstrophy (Mathews et al., 1998). Loder and Dayioglu (1990) noted vertebral anomalies in 3 of 5 children with cloacal exstrophy. Absence or shortening of limbs was also noted, as were clubfoot malformations. Skeletal and limb anomalies were also reported by Diamond (1990) in 12% to 65% of patients. The vast majority were clubfoot deformities, although absence of feet, severe tibial or fibular deformities, and congenital hip dislocations were commonly noted in this group of patients. A similar high incidence of foot abnormalities and greater than normal abduction of the hips was noted in a study by Greene et al. (1991).

Intestinal Tract Abnormalities

Gastrointestinal tract anomalies occur in virtually all patients with cloacal exstrophy. In Diamond's series (1990), the incidence of omphalocele was 88%, and most other series report an incidence of 95% or greater. In the series reported by Mathews et al. (1998), 100% of patients had an omphalocele. Omphaloceles vary in size and usually contain small bowel or liver or both. Immediate closure of the omphalocele defect in the newborn period is advised to prevent subsequent rupture.

Hurwitz et al. (1987), in a large review of cloacal exstrophy patients, reported a 46% incidence of associated gastrointestinal tract anomalies, with malrotation, duplication anomalies, and anatomically short bowel occurring with equal frequency. A hindgut remnant of varying size is also noted in most patients. Hurwitz noted a 23% incidence of short gut syndrome, which is compatible with the 25% incidence reported by Diamond (Diamond, 1990; Hurwitz et al., 1987).

It now seems well accepted that short gut syndrome may occur in the presence of normal small bowel length, suggesting absorptive dysfunction and emphasizing the absolute need to preserve as much large bowel as possible. If not used for incorporation into the fecal stream, the hindgut remnant may be preserved for use in urogenital tract reconstruction (Mathews et al., 1998). Modern techniques have reduced the incidence of short gut syndrome in the majority of patients (Sawaya et al., 2010).

Genitourinary Abnormalities

Müllerian anomalies have been frequently noted in conjunction with cloacal exstrophy. The most commonly reported müllerian anomaly was uterine duplication, seen in 95% of patients (Diamond, 1990). The vast majority of these patients had partial uterine duplication, predominantly a bicornate uterus. Vaginal duplication occurred in 65% of patients, and vaginal agenesis was seen in 25% to 50% of patients. In a report by Hurwitz et al. (1987), cases of complete duplication of the uterus and fallopian tubes associated with both vaginal duplication and vaginal agenesis were noted. Gearhart and Jeffs (1991b) recommended preservation of all müllerian duplication anomalies for possible use in reconstructing the lower urinary tract.

Upper urinary tract anomalies occurred in 41% to 60% of patients in Diamond's review (1990). The most common anomalies were pelvic kidney and renal agenesis, both occurring in up to one-third of patients. Hydronephrosis and hydroureter were common, occurring in one-third of patients. Multicystic dysplastic kidneys and fusion anomalies were seen less frequently. Ectopic ureters draining to the vasa in the male and into the uterus, vagina, or fallopian tubes in the female were also reported (Diamond, 1990). A similar incidence of upper tract defects was noted by Mathews et al. (1998). Ureteral duplication, congenital stricture, and megaureter were also reported.

Genital anomalies in the male have typically included complete separation of the two phallic halves and accompanying separation of the scrotal halves. Asymmetry of these structures can also be seen and can provide additional challenges to successful reconstruction. Testes may be noted in the scrotum but are frequently noted to be undescended, and associated inguinal hernias are a common finding. Girls typically have widely divergent clitoral halves.

The lower urinary tract is typically composed of two exstrophied hemibladders flanking the exstrophied intestinal segment. Each bladder half usually drains the ipsilateral ureter and is closely related to the ipsilateral phallic segment. Variations of anatomy, however, are frequently seen, and every patient has unique anatomic features.

Additional System Anomalies

Life-threatening cardiovascular and pulmonary anomalies are rarely seen in cloacal exstrophy. Reported cases included two patients with cyanotic heart disease and one with aortic duplication. A bilobed lung was reported in two patients and an atretic right upper lung in one. Also, Schlegel and Gearhart (1989) reported caval duplication in their anatomic dissection of a patient with cloacal exstrophy.

Because of the complexity and the multisystem nature of cloacal exstrophy, Manzoni et al. (1987) have devised a grid for the clarification of anatomy in each patient and to permit planning for reconstruction (Fig. 31.34). This permits the standard form of cloacal exstrophy to be separated from variants and allows the soft-tissue components of the defect to be described systematically.

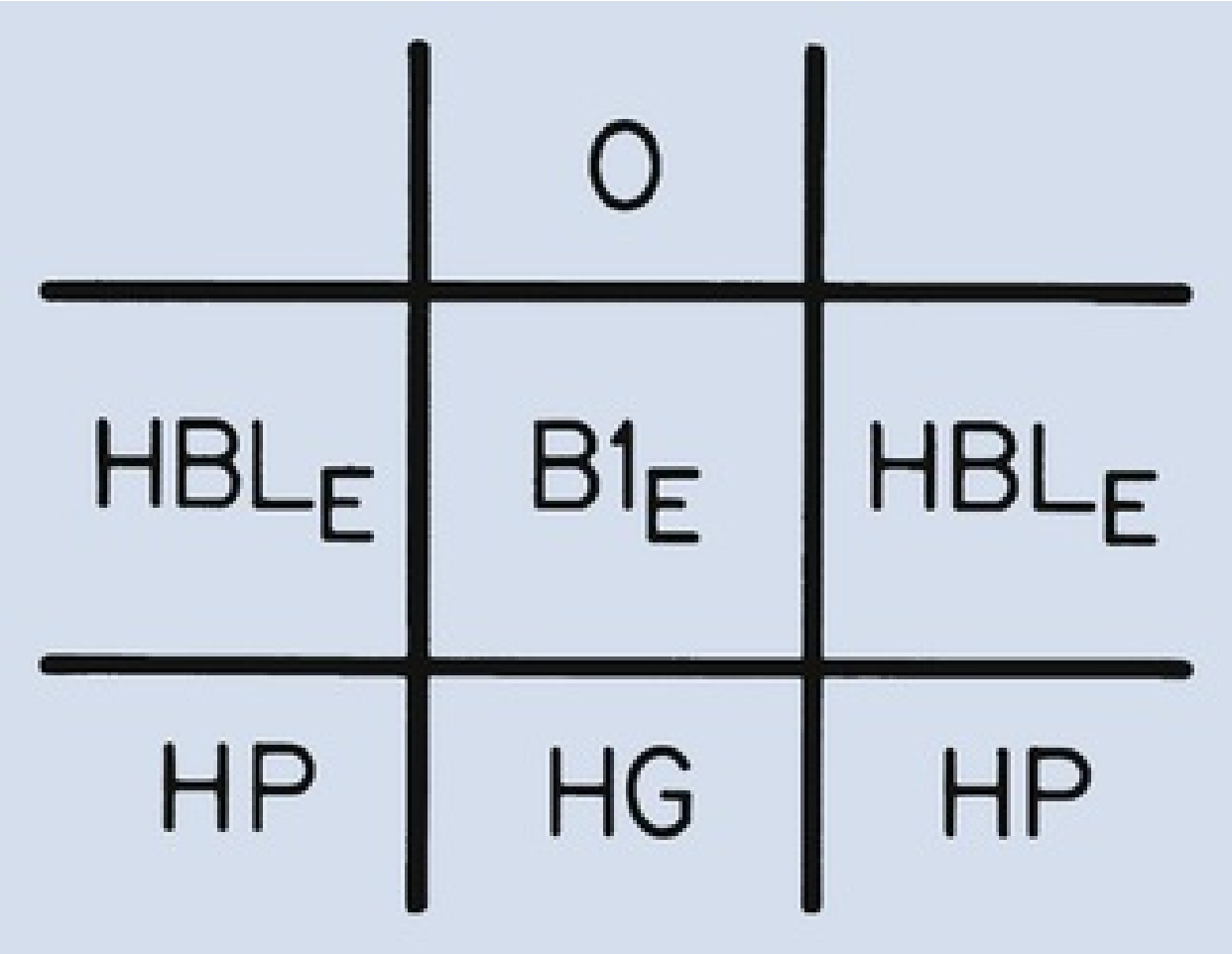

	O	
HBL_E	$B1_E$	HBL_E
HP	HG	HP

FIG. 31.34 Coding grid used to describe cloacal exstrophy and its variants. *$B1_E$,* Everted bowel; *HBL_E,* hemibladder; *HG,* hindgut; *HP,* hemiphallus; *O,* omphalocele. (From Manzoni GA, Ransley PG, Hurwitz RS: Cloacal exstrophy and cloacal exstrophy variants: a proposed system of classification, *J Urol* 138:1065. 1987.)

Cloacal Exstrophy Variants

Cloacal exstrophy usually includes an open and everted intestinal segment situated between two hemibladders, an omphalocele, and a blind-ending tailgut with an imperforate anus. The pubic symphysis and the rectus muscles are widely separated. The phallus is bifid, and the scrotum or labia are split and laterally displaced. In girls the vagina is bifid with two uteri. Given that cloacal exstrophy encompasses abnormalities of the genitourinary, gastrointestinal, and musculoskeletal systems, and often the neurologic system, it is not surprising that a wide range of variants from the classic presentation have been reported. The treatment of cloacal exstrophy has evolved from palliation of an almost universally fatal disorder into complex genitourinary and gastrointestinal reconstruction and a near-normal life span.

Of six cases reported by Lowentritt et al. (2005) with cloacal variants, five were skin covered and one involved duplication of the bowel and hemibladders. Cases of cloacal exstrophy are challenging in their surgical management, and the variations of the complex add to the difficulties of initial diagnosis and management. Only by using a combination of genitograms, retrograde ureterograms, and bowel continence studies was it possible to understand the complex anatomy of the patients in these groups. Three patients had no spinal abnormalities and one had spina bifida occulta. Three patients in this group had innervation of the pelvic floor, enabling successful Pena procedures in two, with the third patient awaiting the procedure. Cloacal variants have a lower incidence of spinal abnormalities and a higher rate of fecal continence compared with their classic presentations. Overall, these patients had a low incidence of severe comorbid conditions. Therefore appropriate treatment of these genitourinary malformations can significantly affect and improve QoL.

Prenatal Diagnosis

Since the initial description of cloacal exstrophy in the early 1980s, further refinements in its prenatal ultrasound diagnosis have occurred (Meizner and Bar-Ziv, 1985). These authors indicated that the three main criteria used to identify the diagnosis were a large midline infraumbilical anterior abdominal wall defect, lumbosacral myelomeningocele, and failure to visualize the urinary bladder. Chitrit et al. (1993) reported the diagnosis of monozygotic twins with cloacal exstrophy detected during antenatal ultrasound screening. Since these initial reports, there have been only occasional case reports of prenatal diagnosis of cloacal exstrophy, and only 15% of patients with this anomaly have been diagnosed by prenatal ultrasonography, according to the literature. With the marked improvements in survival of patients with cloacal exstrophy in the last

20 years and the common application of fetal ultrasonography, early diagnosis may permit appropriate prenatal counseling for parents and expedite postnatal care.

Austin et al. (1998) reviewed 20 patients with this abnormality, expanded on the diagnostic findings, and proposed major and minor criteria for the prenatal ultrasound diagnosis of cloacal exstrophy, based on the frequency of occurrence rather than the severity of individual findings. A criterion was considered major if it was present in more than 50% of cases. The gestational age at diagnosis of cloacal exstrophy ranged from 15 to 32 weeks (mean, 22 weeks). Major diagnostic criteria included nonvisualization of the bladder in 91%, a large midline infraumbilical anterior wall defect or a cystic anterior wall structure in 82%, an omphalocele in 77%, and a myelomeningocele in 68%. Minor criteria included lower extremity defects in 23%, renal anomalies in 23%, ascites in 41%, widened pubic arches in 18%, narrow thorax in 9%, hydrocephalus in 9%, and a single umbilical artery in 9%. Hamada et al. (1999) reported a single case in which ultrasonography revealed a wavy cordlike segment of soft tissue protruding from the anterior abdominal wall of the fetus below the umbilicus. This was found to be prolapsed terminal ileum, which resembled the trunk of an elephant. The authors suggested that this sonographic image be added to the criteria described by Austin et al. (1998) for making a prenatal diagnosis of cloacal exstrophy.

MRI has been used successfully for the prenatal evaluation of cloacal exstrophy (Chen et al., 2008). In conjunction with ultrasonography, excellent definition of anatomy can now be obtained. MRI was found to be superior to ultrasonography when a normal bladder is not identified (Calvo-Garcia et al., 2013). In addition, MRI was able to definitively identify the omphalocele, gender ambiguity, and spinal defect that were not easily defined with ultrasonography (Goto et al., 2012).

Antenatal diagnosis now permits parental counseling and postnatal management. Extensive parental counseling regarding the significant anatomic anomalies that constitute the complex is appropriate in conjunction with psychological support. Prenatal identification of cloacal exstrophy should permit planned maternal-fetal transfer to a center with subspecialty experience for perinatal management (Keppler-Noreuil et al., 2007).

Surgical Reconstruction of Cloacal Exstrophy

The initial successful reconstruction of cloacal exstrophy was reported by Rickham and Johnston (Rickham, 1960). Survival in the 1970s remained at about 50%; however, the institution of intensive postnatal care led to improvement in survival in the 1980s to almost 100%. Where access to subspecialty care is limited, survival can be severely compromised.

Evaluation and Management at Birth

Immediate management is directed to the medical stabilization of the infant. Complete physical examination and determination of the various anatomic defects present allow creation of short- and long-term management strategies (Box 31.1). This initial planning stage should include decisions about gender assignment. The bowel and bladder segments are kept moist with protective plastic dressings as with bladder exstrophy (Gearhart and Jeffs, 1998). Presence of neurospinal abnormalities requires immediate neurosurgical evaluation. Consultations from social work, pediatric orthopedic surgery, and other disciplines should be obtained. Evaluation of the genitalia and gender assignment should be made by a gender assignment team, including a pediatric urologist, pediatric surgeon, pediatrician, pediatric endocrinologist, and child psychologist or psychiatrist. Gender assignment decisions should be made in conjunction with appropriate parental counseling and involvement. In a large medical center with experience in dealing with complex malformations, these multiple consultations should be done in a short period of time. If there are medical concerns or the bladder segments are too small for closure, delayed closure after initial intestinal diversion is appropriate (Mathews et al., 1998).

Box 31.1

Modern Functional Reconstruction of Cloacal Exstrophy

Immediate Neonatal Assessment

Evaluate associated anomalies
Decide whether to proceed with reparative surgery

Functional Bladder Closure (Soon After Neonatal Assessment)

One-Stage Repair (Few Associated Anomalies)

Excision of omphalocele
Separation of cecal plate from bladder halves
Joining and closure of bladder halves and urethroplasty
Bilateral anterior innominate and vertical iliac osteotomy
Terminal ileostomy/colostomy
Genital revision if needed

Two-Stage Repair

- First stage (newborn period)
  - Excision of omphalocele
  - Separation of cecal plate from bladder halves
  - Joining of bladder halves
  - Gonadectomy in male with unreconstructible phallus
  - Terminal ileostomy/colostomy
- Second stage
  - Closure of joined bladder halves and urethroplasty
  - Bilateral anterior innominate and vertical iliac osteotomy
  - Genital revision if needed

Anti-incontinence/Reflux Procedure (Age 5–7 yr)

- Bladder capacity ≥100 mL (very small select group of patients)
  - Young-Dees-Leadbetter bladder neck reconstruction
  - Bilateral Cohen ureteral reimplantations
  - Bowel and/or stomach segment used to augment bladder
  - Continent diversion with abdominal/perineal stoma

Vaginal Reconstruction

Vagina constructed or augmented using colon, ileum, or full-thickness skin graft

Key Points: Evaluation of the Newborn With Cloacal Exstrophy

- Neurospinal anomalies
- Size of the omphalocele
- Size and quality of the bladder templates
- Width of pubic diastasis
- Other associated anomalies

Gender Assignment

Because of the significant separation of the corpora of the penis and scrotum and the reduction in corporeal size noted in boys with cloacal exstrophy, early reports recommended universal gender reassignment of boys (46,XY) with cloacal exstrophy to functional females (Tank and Lindenaur, 1970). To this end, bilateral orchiectomy was combined with phallic reconstruction as a functional clitoris and early or delayed vaginoplasty. Reiner and Gearhart (2004) have reported on 29 males with cloacal exstrophy who had gender reassignment to female. Psychosexual evaluation indicated that all of these patients had a marked male shift in psychosexual development despite having no pubertal hormonal surges. Mirheydar et al. (2009) reported a case of masculinization in a 46,XY gender-converted patient secondary to an ectopic testis. A comparison of patients with cloacal exstrophy and other cloacal anomalies at the Great Ormond Street Hospital for Sick Children, however, indicated no difference in social or behavioral competence or psychological problems. Gender assignment was not associated with childhood psychological, emotional, or behavioral problems (Baker Towell and Towell, 2003). Schober et al. (2002), reporting on 14 children who had undergone early gender reassignment, indicated that although patients had masculine childhood behavior, they had a feminine gender identity. Currently, however, most authors recommend assigning gender that is consistent with karyotypic makeup of the individual if at all possible (Fig. 31.35). A recent survey of pediatric urologists indicated that two-thirds of respondents favored gender-congruent assignment (Diamond et al., 2006). This policy can be supported by a report indicating that the histology of the testis at birth is normal (Mathews et al., 1999a). Furthermore, with evolution of techniques for phallic reconstruction, a functional and cosmetically acceptable phallus can now be constructed (Husmann et al., 1989b; Massanyi et al., 2012).

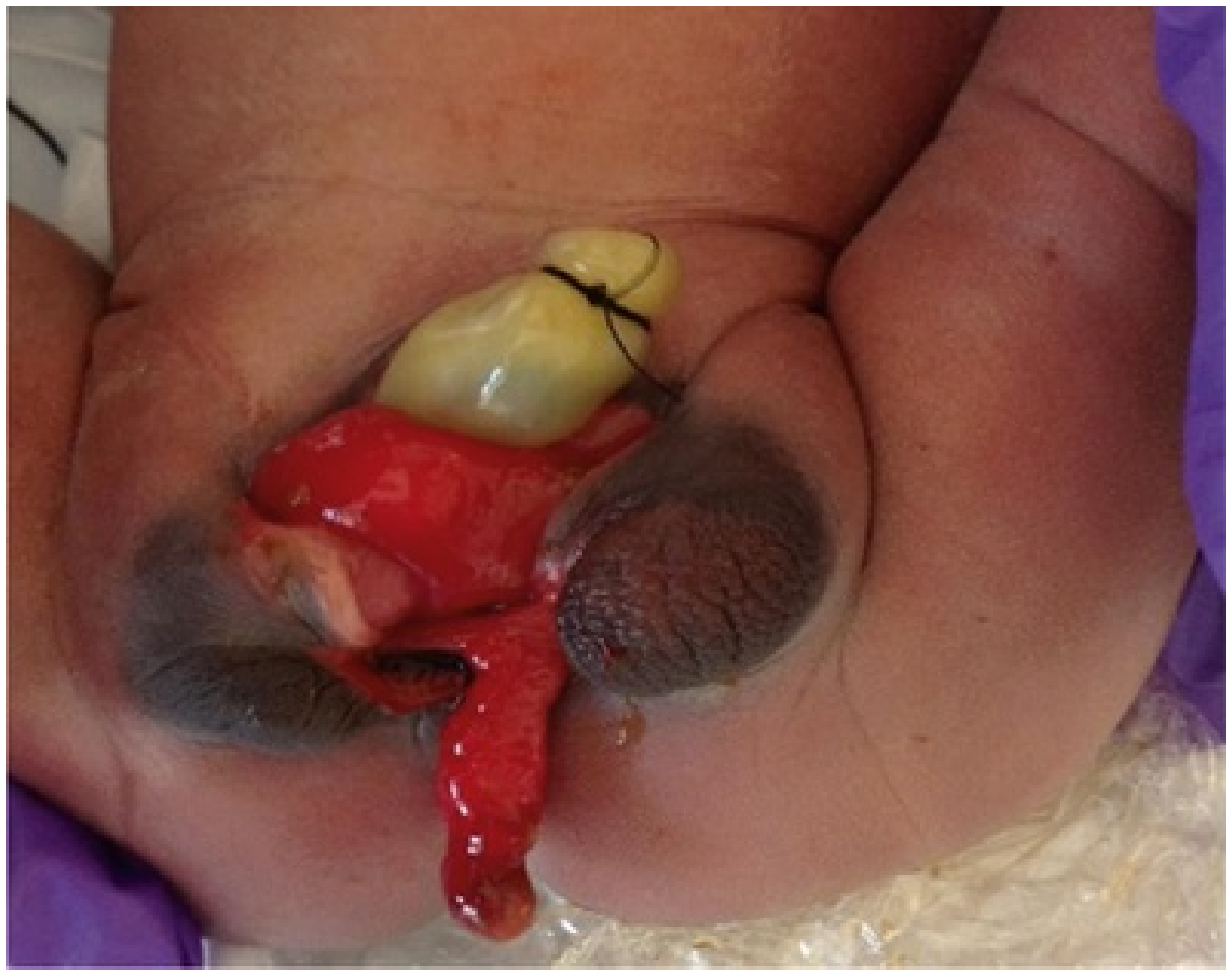

FIG. 31.35 A 46,XY child with cloacal exstrophy with a dominant right hemiphallus. This child was reconstructed and reared as male.

Immediate Surgical Reconstruction

Cloacal exstrophy patients should undergo carefully planned and individualized reconstructions (Lund and Hendren, 1993; Mathews et al., 1998; Ricketts et al., 1991). For infants with spinal dysraphism and myelocystocele, neurosurgical consultation should be obtained and closure undertaken as soon as the infant's condition is medically stable. After closure of the myelocystocele, long-term follow-up is mandatory to evaluate for subtle changes in the neurologic evaluation that could herald cord tethering. Symptomatic spinal cord tethering can be seen in up to 33% of children (McLaughlin et al., 1995). A more recent series evaluating neuro-orthopedic manifestations in cloacal exstrophy indicated that 57 of 68 children had spina bifida (Suson et al., 2010). Of 62 children who were of walking age, 37 were able to ambulate completely, 17 ambulated with devices, and 8 were wheelchair bound.

Neonatal omphalocele closure is recommended to prevent untimely rupture and is typically combined with intestinal diversion. Formerly, initial attempts focused on ileostomy with resection of the hindgut remnant. Since the recognition of the metabolic changes that occur in patients with ileostomy, an attempt is always made to use the hindgut remnant to provide additional length of bowel for fluid absorption (Husmann et al., 1989a; Mathews et al., 1998). Tubularization of the cecal plate with end colostomy has been shown to be beneficial in reducing the incidence of short gut syndrome (Sawaya et al., 2010). Enlargement of the hindgut remnant and increased water absorption have been noted in children who have had the hindgut remnant incorporated into construction of a fecal colostomy (Taghizadeh et al., 2009). The hindgut segment may be anastomosed in an isoperistaltic or retroperistaltic fashion to increase motility and generate formed stool. Children who have anal stenosis and not imperforate anus may have the capability for later continence and may be treated with a pull-through procedure (Ricketts et al., 1991). If the hindgut remnant is not used for bowel reconstruction, it should be left as a mucous fistula to be used for later bladder augmentation or vaginal reconstruction (Lund and Hendren, 1993; Mathews et al., 1998). If gastrointestinal reconstruction is combined with bladder closure, approximation of the pubis, usually with osteotomies, is beneficial in reconstruction of the pelvic ring and increases the potential for successful bladder and abdominal wall closure (Mathews et al., 1998). Some authors have suggested that gastrointestinal reconstruction after initial fecal diversion be delayed for 1 to 2 years of observation (Soffer et al., 2000). After this time, radiographic evaluation is performed to determine residual colonic length. If near-normal colonic length is noted, a pull-through procedure is performed. If there is short colon but the patient is able to make solid stool, the patient may still be a candidate for pull-through procedures. A number of patients who can make solid stool can now be managed with pull-through procedures in conjunction with bowel management strategies to help them stay clean (Levitt et al., 2008). Bowel-lengthening procedures have also been used to improve absorptive function and benefit nutritional outcomes (Figueroa-Colon et al., 1996). Children who are unable to make solid stool are typically managed with a permanent fecal stoma.

At the initial stage of omphalocele closure, if it is determined that bladder and abdominal wall closure may not be accomplished, the bladder halves are approximated in the midline without further dissection and the defect is converted to a bladder exstrophy (Mathews et al., 1998; Ricketts et al., 1991). This permits abdominal distention to allow enlargement of this bladder plate for later closure. If the hindgut segment is not used in the initial reconstruction of the bowel, it is left as a mucous fistula.

Urinary Reconstruction

Modern Staged Reconstruction

The staged management of the urinary tract follows that used for the management of bladder exstrophy (Gearhart and Jeffs, 1991b). Once the bladder halves have been approximated posteriorly, the lateral edges are separated from the abdominal wall and brought together in the midline. As in the patient with classic exstrophy, placement of the bladder and posterior urethra deep into the pelvis remains a key factor in the successful surgical reconstruction of the urinary tract. Use of an AlloDerm patch to reduce the incidence of erosion of the interpubic stitch and prevent penopubic fistulization has been shown to be beneficial (Henderson et al., 2011). Inguinal hernias that are noted should be repaired at the time of closure. In genetic females and in genotypic male subjects undergoing gender reassignment, reconstruction should be performed to improve the appearance of the genitalia. Recent reports by Thomas et al. (2007) in a series using a staged approach found successful results in a series of seven patients, all with tethered cords.

Reconstruction of the external genitalia in the immediate postnatal period is performed to make the infant's appearance more congruent with the gender assigned. The psychiatric studies of children who have had gender assignment have fueled interest in male gender assignment if adequate unilateral or bilateral corporeal tissue is present (Reiner, 2004). Histologic studies indicate normal histology in the testes of male subjects who have had gender reassignment despite the presence of cryptorchidism (Mathews et al., 1999a). Past results of phallic reconstruction in male patients with limited penile tissue have been disappointing. Penile replacement with phalloplasty has now permitted successful reconstruction to be performed and allows most if not all genotypic males to be raised with a congruent sex (Lumen et al., 2008). Multiple flaps have been used successfully for phallic reconstruction (Bluebond-Langner and Redett, 2011; Massanyi et al., 2012). If male-to-female reassignment is deemed necessary, initial female genital reconstruction should bring the phallic halves together in the midline as a clitoris.

However, in instances with adequate corporeal tissue, either unilaterally or bilaterally, epispadias repair can be performed at around age 1 using the standards identified for the staged reconstruction. Vaginal reconstruction can be performed early in the genetic female patient. In gender-converted male patients who require reconstruction of a neovagina, delayed reconstruction is appropriate. Reconstruction may be performed by using a preserved hindgut segment or expanded perineal skin (Belloli et al., 1997). Long-term dilation of the neovagina may be required.

Pubic approximation permits abdominal wall closure and usually requires osteotomy and fixation with postoperative traction. External fixation and traction are typically maintained for 6 to 8 weeks to permit healing. Much like in CBE, sufficient pelvic immobilization after the closure of cloacal exstrophy is crucial for success. As shown in Table 31.6, the failure rate of bladder closures immobilized with external fixation and modified Buck's traction has been shown to be significantly lower than those immobilized with spica casts (Benz et al., 2017).

TABLE 31.6

Pelvic Immobilization After the Closure of Cloacal Exstrophy

METHOD OF IMMOBILIZATION	TOTAL CLOSURES		CLOSURES WITH OSTEOTOMY		CLOSURES WITHOUT OSTEOTOMY	
	TOTAL NO. (N=88)	NO. FAILED	TOTAL NO. (N=60)	NO. FAILED	TOTAL NO. (N=28)	NO. FAILED
Spica cast	46	33 (71.7)	18	9 (50)	28	24 (85.7)
External fixation with traction	43	4 (9.3)	43	4 (9.3)	0	0
P-value		<0.001		0.002		

Benz: 2018.

Role of Osteotomy

Infants who are medically stable may be considered for urinary tract reconstruction in the immediate postnatal period. **Osteotomy is indicated in all children with cloacal exstrophy at the time of bladder closure because of the wide diastasis that is invariably present** (Mathews et al., 1998). Osteotomy allows the pelvic ring, bladder, and abdominal wall to be closed without undue tension on the closure. Reduction in dehiscence and postoperative ventral hernias has been noted in patients treated with osteotomy. In a large series reported by Ben-Chaim et al. (1995c), significant complications occurred in 89% of patients who underwent closure of the cloacal exstrophy without osteotomy but in only 17% of patients who underwent osteotomy at the time of initial cloacal exstrophy closure. The patients who underwent osteotomy and those who did not were similar in terms of size of the omphalocele, presence of myelomeningocele, and time of primary closure. However, it is not surprising that osteotomy had no effect on eventual continence of patients with cloacal exstrophy.

Currently, combined bilateral anterior innominate and vertical iliac osteotomies are routinely used at our institution and have been attributed to a significant increase in the odds of a successful closure (Shah et al., 2014a; Tourchi et al., 2017). In fact, pelvic osteotomy increases the odds of successful closure by nearly sixfold (OR 5.8, 95% CI 1.7–19.6; $P = 0.004$). This approach does not require the patient to be repositioned on the operating table before commencement of bladder and abdominal wall closure. In addition, this method obviates the use of a posterior approach and any complication of the procedure related to the spinal or back closure. In a series of five patients with extreme pubic diastasis greater than 10 cm, Silver et al. (1999) described initial pelvic osteotomy and gradual pelvic closure of the fixator for 1 to 2 weeks, followed by abdominal wall and bladder closure. Closure was successful in all patients without technical problems or complications. This technique of staged pelvic closure may provide reliable initial secondary repair in patients with cloacal exstrophy in whom one-stage pelvic closure is not feasible, even with pelvic osteotomy. When compared with combined pelvic osteotomy with bladder closure, the staged approach results in comparable closure outcomes and overall complication rate (Inouye et al., 2014). An interpubic titanium bar has been added to permit stabilization of the pubic approximation and maintain the reduction in diastasis (Fig. 31.36) (Mathews et al., 2006). Because of the possible asymmetry that can be noted in the pelvic bones, care must be used when performing osteotomies and fixation. In patients who have lower extremity abnormalities, providing postoperative traction can also be challenging.

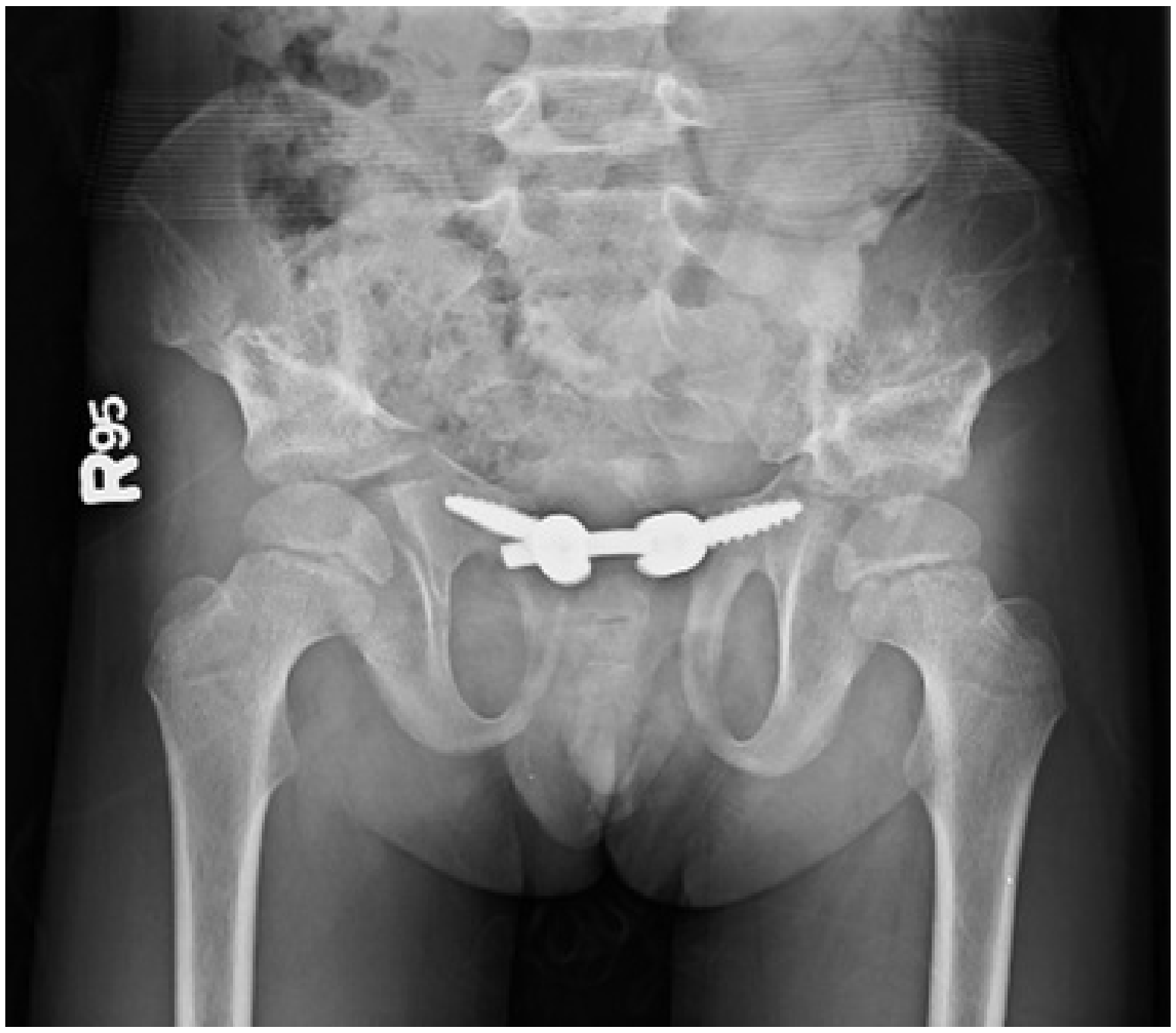

FIG. 31.36 Pubic apposition using titanium plate in cloacal exstrophy with extreme preoperative diastasis (8 cm) now with complete pelvic reduction.

Failure of urinary reconstruction in children with exstrophy can lead to lack of growth of the bladder and may require loss of the bladder template. Recently Shah et al. (2014a) identified potential causes for failure of the urinary reconstruction in a large series of children with cloacal exstrophy undergoing reconstruction at a tertiary medical center. They compared 26 patients (6,XY males, 8,XX females, and 12,XY gender-converted females) in whom prior urinary reconstruction had failed and who had been referred for reconstruction, with 34 patients (17,XY males, 12,XX females, and 5,XY gender-converted females) who underwent successful primary closure, to identify potential risk factors for failure.

In the first week of life 77% of patients with failed procedures had undergone closure, compared with 26% of those having undergone successful closure. In addition, only 31% of patients in whom closure had failed had osteotomy, compared with 82% of those who had undergone successful closure. In the patients with failed closure, 76% were immobilized with spica casts or mummy wraps. Among those in whom closure was successful, 56% were immobilized using modified Buck traction and external fixation, and an additional 20% were immobilized using Bryant traction with or without external fixation. Intersymphyseal plates to prevent separation of the pubis were used in 30% of patients with successful closure and in 50% of patients with successful reclosure;

92% of patients with successful reclosure had osteotomy. Use of a technique that staged the closure over a 2- to 3-week period after performance of the osteotomy by gradually cranking the fixator medially was also shown to be of benefit in providing a successful primary or secondary closure (Mathews et al., 2006).

Single-Stage Reconstruction

One stage reconstruction has been reported by Grady and Mitchell (1999), a procedure similar to that done for bladder exstrophy. If there is a large omphalocele or medical issues, they also recommend delay in attempting a single-stage reconstruction. In the authors’ experience with single-stage closures, we found a failure rate approaching 48%. This is a sharp contrast with the failure rate of a staged closure, 15%, which the authors recommend and routinely perform at their institution. In this situation, the conversion to a bladder exstrophy and subsequent reconstruction of the bladder and penis as a single step is performed. Lee et al. (2006) presented a limited experience in seven children with cloacal exstrophy who underwent reconstruction performed using a single-stage approach. There was one mortality before reconstruction. Six children who underwent reconstruction had dry intervals before toilet training. Some patients have required bladder neck injection to enhance continence. One child is voiding spontaneously and one child has undergone augmentation cystoplasty.

Failed Cloacal Exstrophy

The failure of the bladder closure associated with cloacal exstrophy is a tremendous setback in the reconstruction of this major birth defect. As such, ensuring successful primary bladder closure is paramount. In a large series examining the outcomes of bladder closure in cloacal exstrophy, it was found that a staged cloacal closure and the use of pelvic osteotomy were significant independent predictors of a successful closure outcome (Jayman et al., 2017). After the bladder closure, adequate immobilization secures the pelvis, contributing to the ultimate success of the closure. In our experience with closing cloacal exstrophy bladders, the use of external fixation, along with longitudinal traction for 6 weeks, is associated with high rates of success. On the other hand, immobilization with spica casts may not provide the pelvic stabilization necessary for a successful closure. Thus, the authors do not recommend such immobilization techniques in this difficult group of patients. Failed bladder closures also have financial ramifications to the patient and their families. The cost of cloacal exstrophy closure exceeds $136,000, and an additional $59,000 for attaining urinary continence. Patients who fail their primary closure accumulate significantly more total hospital charges than patients who experience successful closure (Goldstein et al., 2016). Fortunately, the complication rate of the secondary closure is thought to be similar to the complication rate of the primary closure (Friedlander et al., 2016).

Techniques to Create Urinary Continence

Urinary continence is possible in most children but usually requires bladder augmentation and the use of intermittent catheterization. Frequently, more than one procedure will be necessary over the lifetime of the patient. In a large series of cloacal exstrophy patients in which urinary continence was attempted, Maruf et al. found that a median of 2 (range 1–4) urinary continence procedures are typically performed to achieve a dry interval greater than 3 hours (Maruf et al., 2018). Revisions of the continent diversion were a frequent cause of requiring numerous procedures.

Multiple series by Gearhart and Jeffs (1991b), Mitchell et al. (1990), and Hendren (1992) have shown the applicability of modern techniques for lower tract reconstruction to help these patients achieve urinary continence. Enhancement of bladder capacity may be performed using a hindgut segment, if available; ileum; or stomach. Continence appears to be more difficult to achieve in male patients who undergo gender reassignment, and a continent stoma may be most applicable in this special group of patients (Mathews et al., 1998). In genetic female patients, successful continence has been achieved after Young-Dees-Leadbetter bladder neck reconstruction, but the majority of patients have required intermittent catheterization (Husmann et al., 1999). Similar findings were reported in a series by Mitchell et al. (1990). Husmann et al. (1999) reported that the success rate of Young-Dees-Leadbetter bladder neck reconstruction in the cloacal exstrophy population was closely related to the presence of coexisting neurologic abnormalities.

Urinary continence can be achieved in these individuals in many ways. An orthotopic urethra can be constructed from local tissue, vagina, ileum, stomach, or ureter. A catheterizable stoma can be constructed from ileum when enough bowel is present and fluid loss is not a problem. The bladder may be augmented with unused hindgut, ileum, or stomach. However, surgery to provide a continent urinary reservoir should be delayed until a method of evacuation can be taught and the child is old enough to participate in self-care. In our experience, the median age at which children are continent for urine is 11 years old (Maruf et al., 2018). The choice between a catheterizable urethra and an abdominal stoma depends on the adequacy of the urethra and bladder outlet, interest and dexterity of the child, and orthopedic status regarding the spine, hip joints, braces, and ambulation. A more recent evaluation of a large cohort of children with cloacal exstrophy (Suson et al., 2010) indicates that more than 50% of children (35 of 61) were able to achieve continence, 30 of 35 using intermittent catheterization through a continent stoma and the rest voiding or catheterizing via the urethra. An innovative approach is required to find a suitable solution for each individual patient according to the patient's bladder size and function and mental, neurologic, and orthopedic status.

Long-Term Issues in Cloacal Exstrophy

Because survival has become almost universal, the focus has changed in cloacal exstrophy to improving QoL. Improvement in functional outcomes has become the mainstay of improving the QoL. It must be stressed that although broad management strategies can be suggested, the management of patients with cloacal exstrophy must be individualized to maximize functional outcomes.

The factor most likely to lead to long-term disability is the level of the neurologic defect. Early aggressive evaluation and management of the neurologic issues with long-term close follow-up to evaluate for signs of cord tethering are critical to make sure that function can be preserved (McLaughlin et al., 1995).

Further management is most determined by the degree of neurologic deficit. When neurologic issues are minimal or absent, bowel pull-through and voided continence would be ideal. Ricketts et al. (1991) have presented a continence score that can be used in this group of children. Using a six-point scoring system to determine bowel and bladder continence (6 = best; 0 = worst), they evaluated 12 patients who had been managed over time. They had 7 patients with a continence score of 1 (colostomy and incontinent bladder) and only 1 patient who had a score of 5 (enema program and a continent bladder), attesting to the difficulties presented with surgical reconstruction.

Some children have required permanent ileostomy for management of their gut. Husmann et al. (1999) noted that patients undergoing permanent ileostomy, in comparison with terminal colostomy, had greater initial morbidity; however, bowel adaptation appeared to occur by age 3 years with resolution of the short gut syndrome in most. If patients with terminal ileostomy were aggressively managed with hyperalimentation, growth characteristics in the two groups were very similar. As noted earlier, bowel reconstructive techniques have permitted most children to avoid the long-term debility associated with short gut syndrome.

Attempts at phallic reconstruction in the past had minimal success because of the diminutive nature of the corpora in boys and the wide pubic separation. Modern reconstructive surgical techniques may allow some boys to have complete phallic reconstruction performed with forearm or other grafts. Fertility appears to be universally compromised in boys, but girls have normal fertility, and pregnancy has been reported. Girls have higher degrees of cervical prolapse when compared with their counterparts with bladder exstrophy.

Summary

Evolution in management of cloacal exstrophy has permitted near-universal survival with significant improvement in cosmetic and functional outcomes. Debate continues regarding the issue of gender reassignment, and long-term data are still accruing on the best strategy for management. Continence can be achieved with appropriate reconstruction and the use of intermittent catheterization. Despite the extensive malformations noted, many patients have lived fruitful lives.

Key Points: Cloacal Exstrophy—Priorities in Management

- Medical stabilization
- Evaluation of associated anomalies
- Colonic functionalization
- Separation of bladder from the gastrointestinal tract
- Functional genital reconstruction

Dedication

This chapter is dedicated to Dr. Richard Grady, respected colleague and friend, who left us too soon.

Acknowledgment

The authors gratefully acknowledge the role of Dr. Mahir Maruf in editing this chapter.

Suggested Readings

Baird AD, Frimberger D, Gearhart JP. Reconstructive lower urinary tract surgery in incontinent adolescents with exstrophy/epispadias complex. *Urology*. 2005;66(3):636–640.

Baird AD, Gearhart JP, Mathews RI. Applications of the modified Cantwell-Ransley epispadias repair in the exstrophy-epispadias complex. *J Pediatr Urol*. 2005;1(5):331–336.

Baird AD, Mathews RI, Gearhart JP. The use of combined bladder and epispadias repair in boys with classic bladder exstrophy: outcomes, complications and consequences. *J Urol*. 2005;174(4):1421–1424.

Borer JG, Gargollo PC, Hendren WH, et al. Early outcome following complete primary repair of bladder exstrophy in the newborn. *J Urol*. 2005;174:1674–1678.

Ebert A, Scheuering S, Schott G, et al. Psychosocial and psychosexual development in childhood and adolescence within the exstrophy-epispadias complex. *J Urol*. 2005;174(3):1094–1098.

Gearhart JP, Baird AD. The failed complete repair of bladder exstrophy: insights and outcomes. *J Urol*. 2005;174:1669–1672.

Gearhart JP, Ben-Chaim J, Jeffs RD, et al. Criteria for the prenatal diagnosis of classic bladder exstrophy. *Obstet Gynecol*. 1995;85:961.

Grady R, Mitchell ME. Complete repair of exstrophy. *J Urol*. 1999;162:1415.

Hernandez D, Purves JT, Gearhart JP. Complications of surgical reconstruction of the exstrophy-epispadias complex. *J Pediatr Urol*. 2008;4:460–466.

Mathews R, Gosling JA, Gearhart JP. Ultrastructure of the bladder in classic exstrophy—Correlation with development of continence. *J Urol*. 2004;172:1446.

Schaeffer AJ, Stec AA, Purves JT, et al. Complete primary repair of bladder exstrophy: a single institution referral experience. *J Urol*. 2011;186:1041–1046.

Sponseller PD, Bisson LJ, Gearhart JP, et al. The anatomy of the pelvis in the exstrophy complex. *J Bone Joint Surg Am*. 1995;77:177.

Stec AA, Tekes A, Erlan G, et al. Evaluation of pelvic floor muscular distribution after primary closure of classic bladder exstrophy by 3D MRI. *J Urol*. 2012;188:1535.

Wild AT, Sponseller PD, Stec AA, et al. The role of osteotomy in surgical repair of bladder exstrophy. *Semin Pediatr Surg*. 2011;20:71–78.

References

Alova I, Margaryan M, Verkarre V, et al. Outcome of continence procedures after failed endoscopic treatment with dextranomer-based implants (DEFLUX). *J Pediatr Urol*. 2012;8:40.

Ambrose SS, O'Brien DP. Surgical embryology of the exstrophy-epispadias complex. *Surg Clin North Am*. 1974;54:1379.

Ansell JE. Exstrophy and epispadias. Glenn JF. *Urologic surgery*. JB Lippincott: Philadelphia; 1983:647.

Anusionwu I, Baradaran N, Trock BJ, et al. Is pelvic osteotomy associated with lower risk of pelvic organ prolapse in postpubertal females with classic bladder exstrophy? *J Urol*. 2012;188:2343.

Anusionwu I, Tekes A, Stec AA, et al. Comparison of musculoskeletal anatomic relationships, determined by magnetic resonance imaging, in postpubertal female patients with an without classic bladder exstrophy. *BJU Int*. 2013;112:195.

Appignani BA, Jaramillo D, Barnes PD, et al. Dysraphic myelodysplasias associated with urogenital and anorectal anomalies: prevalence and types seen with MR imaging. *AJR Am J Roentgenol*. 1994;163(5):1199–1203.

Arap S, Giron AN. Duplicated exstrophy: report of three cases. *Eur Urol*. 1986;12:451.

Arap S, Nahas WC, Giron AM, et al. Continent epispadias: surgical treatment of 38 cases. *J Urol*. 1988;140:577.

Austin P, Holmsy YL, Gearhart JP, et al. Prenatal diagnosis of cloacal exstrophy. *J Urol*. 1998;160:1179.

Baird AD, Frimberger D, Gearhart JP. Reconstructive lower urinary tract surgery in incontinent adolescents with exstrophy/epispadias complex. *Urology*. 2005;66(3):636–640.

Baird AD, Gearhart JP, Mathews RI. Applications of the modified Cantwell-Ransley epispadias repair in the exstrophy-epispadias complex. *J Pediatr Urol*. 2005;1(5):331–336.

Baird AD, Mathews RI, Gearhart JP. The use of combined bladder and epispadias repair in boys with classic bladder exstrophy: outcomes, complications and consequences. *J Urol*. 2005;174(4):1421–1424.

Baird AD, Nelson CP, Gearhart JP. Modern staged repair of bladder exstrophy: a contemporary series. *J Pediatr Urol*. 2007;3(4):311–315.

Baker LA, Gearhart JP. Staged approach to bladder exstrophy and the role of osteotomy. *World J Urol*. 1998;16:205.

Baker LA, Jeffs RD, Gearhart JP. Urethral obstruction after primary exstrophy closure: what is the fate of the genitourinary tract? *J Urol*. 1999;161:618.

Baker Towell DM, Towell AD. A preliminary investigation into quality of life, psychological distress and social competence in children with cloacal exstrophy. *J Urol*. 2003;169:1850.

Ballaro A, Pryor J, Ralph D. Prosthesis implantation after radial free flap phalloplasty in patients with bladder exstrophy. *Int J Impot Res*. 1999;11:341–342.

Baradaran N, Cervellione RM, et al. Effect of failed initial closure on bladder growth in children with bladder exstrophy. *J Urol*. 2011;186:1450.

Baradaran N, Cervellione RM, Stec AA, et al. Delayed primary repair of bladder exstrophy: ultimate effect on growth. *J Urol*. 2012;188(6):2336–2341.

Baradaran N, Cervellione RM, Stec AA, et al. Delayed primary repair of bladder exstrophy: ultimate effect on growth. *J Urol*. 2012;188:2336.

Baradaran N, Stec A, Wang MH, et al. Urinary diversion in early childhood: indications and outcomes in the exstrophy patients. *Urology*. 2012;80:191.

Baumgartner T, Jayman J, Friedlander D, et al. The role of pelvic and lower limb immobilization in classic bladder exstrophy: an institutional study of three mainstay techniques. Pediatric Urology Fall Congress. S. f. P. *Urology*. 2017 [Montreal, Canada].

Baumgartner TS, Lue KM, Sirisreetreerux P, et al. Long-term sexual health outcomes in men with classic bladder exstrophy. *BJU Int*. 2017;120(3):422–427.

Beaudoin S, Simon L, Bargy F. Anatomical basis of the common embryological origin for epispadias and bladder or cloacal exstrophy. *Surg Radiol Anat*. 1997;19:11–16.

Ben-Chaim J, Jeffs RD, Peppas DS, et al. Submucosal bladder neck injections of glutaraldehyde cross linked bovine collagen for the treatment of urinary incontinence in patients with the exstrophy-epispadias complex. *J Urol*. 1995;154:862.

Ben-Chaim J, Jeffs RD, Reiner WG, et al. The outcome of patients with classic bladder exstrophy in adult life. *J Urol*. 1996;155:1251.

Ben-Chaim J, Peppas DS, Jeffs RD, et al. Complete male epispadias: genital reconstruction achieving continence. *J Urol*. 1995;153:1665.

Ben-Chaim J, Peppas DS, Sponseller PD, et al. Application of osteotomy in the cloacal exstrophy patient. *J Urol*. 1995;154:865.

Bennett AH. Exstrophy of the bladder treated by ureterosigmoidostomies. *Urology*. 1973;2:165.

Benz K, Dunn E, Solaiyappan M, et al. *Novel observations of female pelvic anatomy in classic bladder exstrophy using three-dimensional MRI reconstruction*. 2018 [American

Urological Association Annual Meeting. San Francisco, CA, American Urological Association].

Benz KS, Jayman J, Maruf M, et al. Pelvic and lower extremity immobilization for cloacal exstrophy bladder and abdominal closure in neonates and older children. *J Ped Surg*. 2018;53:2160–2163.

Berkowitz J, Carter HB, Gearhart JP. Prostate cancer in patients with the bladder exstrophy-epispadias complex: insights and outcomes. *Urology*. 2008;71(6):1064–1067.

Berrettini A, Castagnetti M, Rigamonti W. Resultant hypospadias after epispadias repair in bladder exstrophy in bladder exstrophy patients: a difficult surgical task with high complication rate. *J Pediatr Surg*. 2011;46(10):1965–1969.

Berrettini A, Castagnetti M, Rigamonti W, et al. Radical soft tissue mobilization and reconstruction (Kelly procedure) for bladder exstrophy (correction of exstrophy) repair in males: initial experience with nine cases. *Pediatr Surg Int*. 2009;25(5):427–431.

Bhat AL, et al. Single-stage perineal urethroplasty for for continence in female epispadias: a preliminary report. *Urology*. 2008;72(2):300–303.

Bluebond-Langner R, Redett RJ. Phalloplasty in complete aphallia and ambiguous genitalia. *Semin Plast Surg*. 2011;25:196–205.

Bolduc S, Capolicchio G, Upadhyay J, et al. The fate of the upper urinary tract in exstrophy. *J Urol*. 2002;168:2579.

Borer JG, Gargollo PC, Hendren WH, et al. Early outcome following complete primary repair of bladder exstrophy in the newborn. *J Urol*. 2005;174:1674–1678.

Borer JG, Vasquez E, Canning DA, et al. Short-term outcomes of the multi-institutional bladder exstrophy consortium: successes and complications in the first two years of collaboration. *J Pediatr Urol*. 2017;13(3):275.e271–

275.e276.

Boyadijiev S, South S, Radford C, et al. *Characterization of reciprocal translocation 46XY,t(8;9)(p11.2;13) in a patient with bladder exstrophy identifies CASPR3 as a candidate gene and shows duplication of the regions flanking the pericentric heterochromatin on chromosome 9 in normal population*. [Presented at American Society of Genetics, Oct 29] 2004 [Toronto, Canada].

Boyadijiev SA, Dodson JL, Radford CL, et al. Clinical and molecular characterization of the bladder exstrophy-epispadias complex: analysis of 232 families. *BJU Int*. 2004;94:1337.

Braga LH, Lorenzo AJ, Bägli DJ, et al. Outcome analysis of isolated male epispadias: single center experience with 33 cases. *J Urol*. 2008;179(3):1107–1112.

Braga LH, Lorenzo AJ, Bagli DJ, et al. Bilateral ureteral reimplantation at primary bladder exstrophy closure (CPRE-BUR) protect the upper tracts? *J Urol*. 2010;183:2337.

Burbage KA, Hensle TW, Chambers WJ, et al. Pregnancy and sexual function in bladder exstrophy. *Urology*. 1986;28:12.

Burkholder GV, Williams DI. Epispadias and incontinence: surgical treatment in 27 children. *J Urol*. 1965;94:674.

Burki T, Hamid R, Duffy P, et al. Long-term followup of patients after redo bladder neck reconstruction for bladder exstrophy complex. *J Urol*. 2006;176:1138–1141.

Burki T, Hamid R, Ransley PG, et al. Injectable polydimethylsiloxane for treating incontinence in children with the exstrophy-epispadias complex: long-term results. *BJU Int*. 2006;849–853.

Cadeddu JA, Benson JE, Silver RI, et al. Spinal abnormalities in classic bladder exstrophy. *Br J Urol*. 1997;79:975.

Caione P, Capozza N. Evolution of male epispadias repair: 16-year experience. *J Urol*. 2001;165(6 Pt 2):2410–2413.

Caione P, Kapoza N, Lais A, et al. Female genito-urethroplasty and submucosal periurethral collagen injections as adjunctive procedures for continence in the exstrophy-epispadias complex. *Br J Urol*. 1993;71:350.

Caione P, Lais A, Dejenaro N, et al. Glutaraldehyde cross linked bovine collagen in the exstrophy-epispadias complex. *J Urol*. 1993;150:631.

Caione P, Napo S, DeCastro R. Low dose desmopressin in the treatment of nocturnal urinary incontinence in exstrophy-epispadias complex. *BJU Int*. 1999;84:329.

Calvo-Garcia MA, Kline-Fath BM, et al. Fetal MRI of cloacal exstrophy. *Pediatr Radiol*. 2013;43:593.

Campbell M. Epispadias: a report of 15 cases. *J Urol*. 1952;67:988.

Canning DA, Gearhart JP, Peppas DS, et al. The cephalotrigonal reimplant in bladder neck reconstruction for patients with exstrophy or epispadias. *J Urol*. 1992;150:156.

Cantwell FV. Operative technique of epispadias by transplantation of the urethra. *Ann Surg*. 1895;22:689.

Castagnetti M, Tocco A, Capizzi A, et al. Sexual function in men born with classic bladder exstrophy: a norm related study. *J Urol*. 2010;183:1118–1122.

Catti M, Paccalin C, Rudigoz RC, et al. Quality of life for adult women born with bladder and cloacal exstrophy: a long-term follow up. *J Pediatr Urol*. 2006;2(1):16–22.

Cendron J. La réconstruction vésicale. *Ann Chir Infant*. 1971;12:371.

Cerniglia F, Roth DA, Gonzalez ET. Covered exstrophy and visceral sequestration in a male newborn. *J Urol*. 1989;141:903.

Cervellione RM, Bianchi A, Fishwick J, et al. Salvage procedures to achieve continence after failed bladder exstrophy repair. *J Urol*. 2008;176:304–306.

Cervellione RM, Husmann DA, Bivalacqua TJ, et al. Penile ischemic injury in the exstrophy/epispadias spectrum: new insights and possible mechanisms. *J Pediatr Urol*. 2010;6:450.

Cervellione RM, Mantovani A, Gearhart J, et al. Prospective study on the incidence of bladder/cloacal exstrophy and epispadias in Europe. *J Pediatr Urol*. 2015;11(6):337.e331–337.e336.

Chan DY, Jeffs RD, Gearhart JP. Determinates of continence in the bladder exstrophy population after bladder neck reconstruction. *Urology*. 2001;165:1656.

Chandra S, Sharma A, Bharga S. Covered exstrophy with incomplete duplication of the bladder. *Pediatr Surg Int*. 1999;15:422.

Chen CP, Chang TY, Liu YP, et al. Prenatal 3-dimensional sonographic and MRI findings in omphalocele-exstrophy-imperforate anus-spinal defects complex. *J Clin Ultrasound*. 2008;36:308–311.

Cheng W, Jacobs WB, Zhang JJ, et al. DeltaNp63 plays an anti-apoptotic role in ventral bladder development. *Development*. 2006;133(23):4783–4792.

Ching BJ, Wittler L, Proske J, et al. p63 (TP73L) a key player in embryonic urogenital development with significant dysregulation in human bladder exstrophy tissue. *Int J Mol Med*. 2010;26(6):861–867.

Ching ST, Infante CR, Du W, et al. Isl1 mediates mesenchymal expansion in the developing external genitalia via regulation of Bmp4, Fgf10 and Wnt5a. *Hum Mol Genet*. 2018;27(1):107–119.

Chitrit Y, Zorn B, Filidori M, et al. Cloacal exstrophy in monozygotic twins detected through antenatal ultrasound scanning. *J Clin Ultrasound*. 1993;21:339.

Cohen AR. The mermaid malformation: cloacal exstrophy and occult spinal dysraphism. *Neurosurgery*. 1991;28:834.

Cole EE, Adams MC, Brock JW, et al. Outcome of continence procedures in the pediatric patient: a single institutional experience. *J Urol*. 2003;170:560.

Connolly JA, Peppas DS, Jeffs RD, et al. Prevalence in repair of inguinal hernia in children with bladder exstrophy. *J Urol*. 1995;154:1900.

Dave S, Grover VP, Agarwala S, et al. Cystometric evaluation of reconstructed classical bladder exstrophy. *BJU Int*. 2001;88:403.

Davis DM. Epispadias in females and the surgical treatment. *Surg Gynecol Obstet*. 1928;47:600.

Deans R, Banks F, Liao LM, et al. Reproductive outcomes in women with classic bladder exstrophy: an observational cross-sectional study. *Am J Obstet Gynecol*. 2012;206:496.e1–496.e6.

de Jong TP, Dik P, Klijn AJ. Female epispadias repair: a new 1-stage technique. *J Urol*. 2000;164(2):492–494.

Dees JE. Congenital epispadias with incontinence. *J Urol*. 1949;62:513.

D'elia G, Pahernik S, Fisch M, et al. Mainz Pouch II technique: 10 years' experience. *BJU Int*. 2004;93:1037.

DeMaria JE, Alton DJ, Krueger RP, et al. Renal function in continent patients after surgical closure of bladder exstrophy. *J Urol*. 1980;124:85–88.

D'Hauwers KW, Feitz WF, Kremer JA. Bladder exstrophy and male fertility: pregnancies after ICSI with ejaculated or epididymal sperm. *Fertil Steril*. 2008;89(2):387–389.

Di Carlo H, Tekes A, Gearhart JP. V7-01 intraoperative MRI-guided navigation of the pelvic floor during exstrophy closure. *J Urol*. 2017;197(4):e823.

Di Carlo HN, Maruf M, Michaud J, et al. Continence after BNR in the complete repair of bladder exstrophy (CPRE): a single institution expanded experience. *J Urol*. 2018 [Submitted].

Diamond DA. Management of cloacal exstrophy. *Dial Pediatr Urol*. 1990;13:2.

Diamond DA, Bauer SB, Dinlenc C, et al. Normal urodynamics in patients with bladder exstrophy: are they achievable? *J Urol*. 1999;162:841.

Diamond DA, Burns JP, Mitchell C, et al. Sex assignment for newborns with ambiguous genitalia and exposure to fetal testosterone: attitudes and practices of pediatric urologists. *J Pediatr*. 2006;148(4):445–449.

Dick EA, de Bruyn R, Patel K, et al. Spinal ultrasound in cloacal exstrophy. *Clin Radiol*. 2001;56:289.

Dodson JL, Furth SL, Yenokyan G, et al. Parent perspectives of health related quality of life for adolescents with bladder exstrophy-epispadias as measured by the child health questionnaire-parent form 50. *J Urol*. 2010;184(4 Suppl):1656–1661.

Draaken M, Knapp M, Pennimpede T, et al. Genome-wide association study and meta-analysis identify ISL1 as genome-wide significant susceptibility gene for bladder exstrophy. *PLoS Genet*. 2015;11(3):e1005024.

Duckett JW. Use of paraexstrophy skin pedicle grafts for correction of exstrophy and epispadias repair. *Birth Defects Orig Artic Ser*. 1977;13:171.

Duckett JW, Gazak JM. Complications of ureterosigmoidostomy. *Urol Clin North Am*. 1983;10:473.

Duffy PG, Ransley PG. Endoscopic treatment of urinary incontinence in children with primary epispadias. *Br J Urol*. 1998;81:309–311.

Ebert A, Scheuering S, Schott G, et al. Psychosocial and psychosexual development in childhood and adolescence within the exstrophy-epispadias complex. *J Urol*. 2005;174(3):1094–1098.

Ebert AK, Bals-Pratsch M, Seifert B, et al. Genital and reproductive function in males after functional reconstruction of the exstrophy-epispadias complex–long-term results. *Urology*. 2008;72(3):566–569.

Ebert AK, Falkert A, Germer U, et al. Biometry of the pubovisceral muscle and levator hiatus assessed by three-dimensional ultrasound in females with bladder exstrophy epispadias complex after functional reconstruction. *Ultrasound Obstet Gynecol*. 2009;34:98.

Ebert AK, Schott G, Bals-Pratsch M, et al. Long-term follow-up of male patients after reconstruction of the bladder-exstrophy-epispadias complex: psychosocial status, continence, renal and genital function. *J Pediatr Urol*. 2010;6(1):6–10.

El-Hout Y, Salle JL, Al-Saad T, et al. Do patients with classic bladder exstrophy have fecal incontinence? A web-based study. *Urology*. 2010;75:1166–1168.

Ellison JS, Shnorhavorian M, Willihnganz-Lawson K, et al. A critical appraisal of continence in bladder exstrophy: long-term outcomes of the complete primary repair. *J Pediatr Urol*. 2016;12(4):205.e201–205.e207.

El-Sherbiny MT, Hafez AT. Complete repair of bladder exstrophy in boys: can hypospadias be avoided? *Eur Urol*. 2005;47(5):691–694.

Feitz WF, Vangrunsven VJ, Froeling FM. Outcome analysis of the psychosexual and socioeconomic development of adults born with bladder exstrophy. *J Urol*. 1994;152:1417.

Feneley M, Gearhart JP. *A history of bladder and cloacal exstrophy [abstract]*. [American Urological Association Annual Meeting, May 1] 2000 [Anaheim, California].

Ferrara F, Dickson AP, Fishwick J, et al. Delayed exstrophy repair (DER) does not compromise initial bladder development. *J Pediatr Urol*. 2014;10(3):506–510.

Figueroa-Colon R, Harris PR, Birdsong E, et al. Impact of intestinal lengthening on the nutritional outcome for children with short bowel syndrome. *J Pediatr Surg*. 1996;31:912–916.

Fisch M, Wammack R, Hohenfellner R. The sigma rectum pouch (Mainz pouch II). *World J Urol*. 1996;14:68–72.

Fishel-Bartal M, Perlman S, Messing B, et al. Early diagnosis of bladder exstrophy: quantitative assessment of a low-inserted umbilical cord. *J Ultrasound Med*. 2017.

Fontaine E, Leaver R, Woodhouse CR. The effect of intestinal urinary reservoirs on renal function: a 10-year follow-up. *BJU Int*. 2000;86:195–198.

Franco I, Culligan M, Reed EF, et al. The importance of catheter size in achievement of urinary continence in patients undergoing a Young-Dees-Leadbetter procedure. *J Urol*. 1994;152:710.

Friedlander DA, Di Carlo HN, Sponseller PD, et al. Complications of bladder closure in cloacal exstrophy: do osteotomy and reoperative closure factor in? *J Pediatr Surg*. 2016.

Frimberger D, Lakshmanan Y, Gearhart JP. Continent urinary diversions in the exstrophy complex: why do they fail? *J Urol*. 2003;170:1338–1342.

Gambhir L, Höller T, Müller M, et al. Epidemiological survey of 214 families with bladder exstrophy-epispadias complex. *J Urol*. 2008;179:1539–1543.

Gargollo P, Hendren WH, Diamond DA, et al. Bladder neck reconstruction is often necessary after complete primary repair of exstrophy. *J Urol*. 2011;185(6 Suppl):2563–2571.

Gargollo PC, Borer JG, Retik AB, et al. Magnetic resonance imaging of pelvic musculoskeletal and genitourinary anatomy in patients before and after complete primary repair of bladder exstrophy. *J Urol*. 2005;174(4 Pt 2):1559–1566.

Gearhart JP. Failed bladder exstrophy closure: evaluation and management. *Urol Clin North Am*. 1991;18:687.

Gearhart JP, Baird A, Nelson CP. Results of bladder neck reconstruction after newborn complete primary repair of exstrophy. *J Urol*. 2007;178:1619–1622.

Gearhart JP, Baird AD. The failed complete repair of bladder exstrophy: insights and outcomes. *J Urol*. 2005;174:1669.

Gearhart JP, Baird AD, Mathews RI. Applications of the modified Cantwell-Ransley repair in the exstrophy-epispadias complex. *J Pediatr Urol*. 2005;1:31.

Gearhart JP, Ben-Chaim J, Jeffs RD, et al. Criteria for the prenatal diagnosis of classic bladder exstrophy. *Obstet Gynecol*. 1995;85:961.

Gearhart JP, Ben-Chaim J, Scortino C. The multiple reoperative bladder exstrophy closure: what affects the potential of the bladder? *Urology*. 1996;47:240.

Gearhart JP, Canning DA, Jeffs RD. Failed bladder neck reconstruction: options for management. *J Urol*. 1991;146:1082.

Gearhart JP, Forschner DC, Jeffs RD, et al. A combined vertical and horizontal pelvic osteotomy approach for primary and secondary repair of bladder exstrophy. *J Urol*. 1996;155:689.

Gearhart JP, Jeffs RD. The use of parenteral testosterone therapy in genital reconstructive surgery. *J Urol*. 1987;138:1077.

Gearhart JP, Jeffs RD. Bladder exstrophy: increase in capacity following epispadias repair. *J Urol*. 1989;142:525.

Gearhart JP, Jeffs RD. State of the art reconstructive surgery for bladder exstrophy at the Johns Hopkins Hospital. *Am J Dis Child*. 1989;143:1475.

Gearhart JP, Jeffs RD. Management of the failed exstrophy closure. *J Urol*. 1991;146:610.

Gearhart JP, Jeffs RD. Techniques to create urinary continence in cloacal exstrophy patients. *J Urol*. 1991;146:616.

Gearhart JP, Jeffs RD. The bladder exstrophy-epispadias complex. Walsh PC, et al. *Campbell's urology*. ed 3. WB Saunders: Philadelphia; 1998:1939.

Gearhart JP, Leonard MP, Burgers JK. Cantwell-Ransley technique for repair of epispadias. *J Urol*. 1992;148:851.

Gearhart JP, Mathews R. Penile reconstruction combined with bladder closure in the management of classic bladder exstrophy: illustration of technique. *Urology*. 2000;55:764–770.

Gearhart JP, Mathews RI, Taylor S, et al. Combined bladder closure in epispadias repair and the reconstruction of bladder exstrophy. *J Urol*. 1998;160:1182.

Gearhart JP, Peppas DS, Jeffs RD. Complete genitourinary reconstruction of female epispadias. *J Urol*. 1993;149:1010.

Gearhart JP, Peppas DS, Jeffs RD. Failed exstrophy closure: strategy for management. *Br J Urol*. 1993;71:217.

Gearhart JP, Peppas DS, Jeffs RD. The application of continent urinary stomas to bladder augmentation replacement in the failed exstrophy reconstruction. *Br J Urol*. 1995;75:87.

Gearhart JP, Scortino C, Ben-Chaim J. The Cantwell-Ransley repair in exstrophy and epispadias: lessons learned. *Urology*. 1995;46:92.

Gearhart JP, Yang A, Leonard MP, et al. Prostate size and configuration in adult patients with bladder exstrophy. *J Urol*. 1993;149:308.

Giron AM, Passerotti CC, Nguyen H, et al. Bladder exstrophy: reconstructed female patients achieving normal pregnancy and delivering normal babies. *Int Braz J Urol*. 2011;37:605–610.

Gobet R, Weber D, Renzulli P, et al. Long-term follow up (37-69 years) of patients with bladder exstrophy treated with ureterosigmoidostomy: uro-nephrological outcome. *J Pediatr Urol*. 2009;5:190.

Goldman S, Szejnfeld PO, Rondon A, et al. Prenatal diagnosis of bladder exstrophy by fetal MRI. *J Pediatr Urol*. 2013;9(1):3–6.

Goldstein SD, Inouye BM, Reddy S, et al. Continence in the cloacal exstrophy patient: what does it cost? *J Pediatr Surg*. 2016;51:622–625.

Goto S, Suzumori N, Obayashi S, et al. Prenatal findings of omphalocele-exstrophy of the bladder-imperforate anus-spinal defects (OEIS) complex. *Congenit Anom (Kyoto)*. 2012;52:179.

Goyal A, Fishwick J, Hurrell R, et al. Antenatal diagnosis of bladder/cloacal exstrophy: challenges and possible solutions. *J Pediatr Urol*. 2012;8:140.

Grady RW. *Technique for repair of bladder exstrophy and epispadias: long-term follow up*. [American Academy of Pediatrics, New Orlanes. Nov 1] 2003.

Grady R, Mitchell ME. Complete repair of exstrophy. *J Urol*. 1999;162:1415.

Greene WB, Dias LS, Lindseth RE, et al. Musculoskeletal problems in association with cloacal exstrophy. *J Bone Joint Surg Am*. 1991;73(4):551–560.

Gross RE, Kresson SL. Exstrophy of the bladder: observations from 80 cases. *JAMA*. 1952;149:1640.

Hafez AT, El-Sherbiny MT. Complete repair of bladder exstrophy: management of resultant hypospadias. *J Urol*. 2005;173(3):958–961.

Hafez AT, El-Sherbiny MT, Shorrab AA, et al. Complete primary repair of bladder exstrophy in children presenting late and those with failed initial closure: single center experience. *J Urol*. 2005;174:1549–1552.

Hafez AT, Helmy T. Complete penile disassembly for epispadias repair in postpubertal patients. *Urology*. 2011;78:1407–1410.

Halachmi S, Farhat W, Konen O, et al. Pelvic floor magnetic resonance imaging after neonatal single stage reconstruction in male patients with classic bladder exstrophy. *J Urol*. 2003;170:1505.

Hamada H, Pakano K, Shinah H, et al. New ultrasonographic criterion for the prenatal diagnosis of cloacal exstrophy: elephant trunk-like image. *J Urol*. 1999;162:2123.

Hammouda HM. Results of complete penile disassembly for epispadias repair in 42 patients. *J Urol*. 2003;170(5):1963–1965.

Hankinson JC, Eldridge MA, Ostrander R, et al. Emotional and behavioral functioning in children with bladder exstrophy-epispadias complex: a developmental perspective. *J Pediatr Urol*. 2014;10(1):136–141.

Hanna MN. Reconstruction of the umbilicus during functional closure of bladder exstrophy. *Urology*. 1986;27:340.

Hanna MK, Williams DI. Genital function in males with exstrophy and epispadias. *Br J Urol*. 1972;44:1969.

Henderson CG, North AC, Gearhart JP. The use of AlloDerm as an adjunct in the closure of the bladder—cloacal exstrophy complex. *J Pediatr Urol*. 2011;7:44–47.

Hendren WH. Congenital female epispadias with incontinence. *J Urol*. 1981;125:58.

Hendren WH. Ileal nipple for continence in cloacal exstrophy. *J Urol*. 1992;148:372.

Hernandez D, Purves JT, Gearhart JP. Complications of surgical reconstruction of the exstrophy-epispadias complex. *J Pediatr Urol*. 2008;4:460–466.

Hesh CA, Young E, Intihar P, et al. The cost of failure: the economic impact of failed primary closure in classic bladder exstrophy. *J Pediatr Surg*. 2016;51(8):1312–1316.

Hollowell JG, Hill PD, Duffy PG, et al. Evaluation and treatment of incontinence after bladder neck reconstruction in exstrophy and epispadias. *Br J Urol*. 1993;140:743.

Honeck P, Kienle P, Huck N, et al. Adenocarcinoma in continent anal urinary diversion: is a sigma rectum pouch a surgical option after failed ureterosigmoidostomy? *Urology*. 2017;103:209–213.

Hurwitz RS, Manzoni GA, Ransley PG, et al. Cloacal exstrophy: a report of 34 cases. *J Urol*. 1987;138:1060.

Husmann DA, Gearhart JP. Loss of penile glans and/or corpora following primary repair of bladder exstrophy using the complete penile disassembly technique. *J Urol*. 2004;172:1696.

Husmann DA, McLorie GA, Churchill BM. Closure of the exstrophic bladder: an evaluation of the factors leading to its success and its importance on urinary continence. *J Urol*. 1989;142:522.

Husmann DA, McLorie GA, Churchill BM. Phallic reconstruction in cloacal exstrophy. *J Urol*. 1989;142(2 Pt 2):563–564.

Husmann DA, McLorie GA, Churchill BM. Factors predisposing to renal scarring: following staged reconstruction of classical bladder exstrophy. *J Pediatr Surg*. 1990;25:500–504.

Husmann DA, McLorie GA, Churchill BM. A comparison of renal function in the exstrophy patient treated with staged reconstruction versus urinary diversion. *J Urol*. 1998;140(5 Pt 2):1204–1206.

Husmann DA, Rathbun SR. Long-term follow up of enteric bladder augmentations: the risk for malignancy. *J Pediatr Urol*. 2008;4:381.

Husmann DA, Vanderstein VR, McLorie GA, et al. Urinary continence after staged bladder reconstruction in cloacal exstrophy: the affect of co-existing neurological abnormalities on urinary continence. *J Urol*. 1999;161:1598.

Inouye BM, Lue K, Abdelwahab M, et al. Newborn exstrophy closure without osteotomy: is there a role? *J Pediatr Urol*. 2016;12(1):51.e51–51.e54.

Inouye BM, Tourchi A, Di Carlo HN, et al. Safety and efficacy of staged pelvic osteotomies in the modern treatment of cloacal exstrophy. *J Pediatr Urol*. 2014;10(6):1244–1248.

Ives E, Coffey R, Carter CO. A family study of bladder exstrophy. *J Med Genet*. 1980;17(2):139–141.

Jain M, Weaver DD. Severe lower limb defects in exstrophy of the cloaca. *Am J Med Genet*. 2004;128A:320.

Jarzebowski AC, McMullin ND, Grover SR, et al. The Kelly technique of bladder exstrophy repair: continence, cosmesis and pelvic organ prolapse outcomes. *J Urol*. 2009;182(4 Suppl):1802–1806.

Jayman J, Tourchi A, Shabaninia M, et al. The surgical management of bladder polyps in the setting of exstrophy epispadias complex (EEC). *Urology*. 2017.

Jeffs RD, Charrios R, Mnay M, et al. Primary closure of the exstrophied bladder. Scott R. *Current controversies in urologic management*. WB Saunders: Philadelphia; 1972:235.

Jochault-Ritz S, Mercier M, Aubert D. Shoirt and long-term quality of life after reconstruction of bladder exstrophy in infancy: preliminary results of the QUALEX (QUAlity of Life of bladder Exstrophy) study. *J Pediatr Surg*. 2010;45:1693.

Johnston JH. Lengthening of the congenital or acquired short penis. *Br J Urol*. 1974;46:685.

Johnston JH, Kogan SJ. The exstrophic anomalies and their surgical reconstruction. *Curr Probl Surg*. 1974;46:1–39.

Kajbafzadeh AN, Duffy PG, Ransley PG. The evolution of penile reconstruction and epispadias repair: a report of 180 cases. *J Urol*. 1995;154:858.

Karrer FM, Flannery AM, Nelson MDJ, et al. Anorectal malformations: evaluation of associated spinal dysraphic syndromes. *J Pediatr Surg*. 1988;23:45.

Kasprenski M, Maruf M, Jayman J, et al. *Penile disassembly in exstrophy: time to reevaluate?*. 2018 [American Urological Association Annual Meeting. San Francisco, American Urological Association].

Kasprenski M, Yang Z, Maruf M, et al. *Terminal markers of urothelial differentiation: a comparison of newborn and delayed bladder exstrophy closures to controls*. 2018 [Society of Government Service Urologists Kimbrough Meeting. Scottsdale, Arizona, Society of Government Service Urologists].

Kavanagh A, Afshar K, Scott H, et al. Bladder neck closure in conjunction with enterocystoplasty and Mitrofanoff diversion for complex incontinence: closing the door for good. *J Urol*. 2012;188(4 Suppl):1561–1565.

Kelly JH. Vesical exstrophy: repair using radical mobilisation of soft tissues. *Pediatr Surg Int*. 1995;10(5):298–304.

Kennedy WA, Hensle TW, Riley EA. Pregnancy after orthotopic continent urinary diversion. *Surg Gynecol Obstet*. 1993;177:405.

Keppler-Noreuil K, Gorton S, Foo F, et al. Prenatal ascertainment of OEIS complex/cloacal exstrophy - 15 new cases and literature review. *Am J Med Genet A*. 2007;143A(18):2122–2128.

Keppler-Noreuil KM. OEIS complex (omphalocele-exstrophy-imperforate anus-spinal defects): a review of 14 cases. *Am J Med Genet*. 2001;99:271.

Kibar Y, Roth CC, Frimberger D, et al. Our initial experience with the technique of complete primary repair for bladder exstrophy. *J Pediatr Urol*. 2009;5:186–189.

Kibar Y, Roth C, Frimberger D, et al. Long-term results of penile disassembly technique for correction of epispadias.

Urology. 2009;73:510–514.

Klauber G, Williams DI. Epispadias with incontinence. *J Urol*. 1974;111:110.

Koo HP, Avolio L, Duckett JW Jr. Long-term results of ureterosigmoidostomy in children with bladder exstrophy. *J Urol*. 1996;156:2037.

Kost-Byerly S, Jackson EV, Yaster M, et al. Perioperative anesthetic and analgesic management of newborn bladder exstrophy repair. *J Pediatr Urol*. 2008;4(4):280–285.

Kramer SA, Jackson IT. Bilateral rhomboid flaps for reconstruction of the external genitalia in epispadias-exstrophy. *Plast Reconstr Surg*. 1986;77:621.

Kramer SA, Kelalis P. Assessment of urinary continence in epispadias: review of 94 patients. *J Urol*. 1982;128:290.

Kramer SA, Kelalis PP. Surgical correction of female epispadias. *Eur Urol*. 1982;8:321.

Krisiloff M, Puchner PJ, Tretter W, et al. Pregnancy in women with bladder exstrophy. *J Urol*. 1978;119:478.

Kufner M, Gearhart JP, Mathews RI. Impact of epispadias repair on bladder growth in boys with classic bladder exstrophy. *J Pediatr Urol*. 2010;6:578.

Lais A, Paolocci N, Ferro N, et al. Morphometric analysis of smooth muscle in the exstrophy-epispadias complex. *J Urol*. 1996;156:819.

Lancaster PA. Epidemiology of bladder exstrophy: a communication from the International Clearinghouse for Birth Defects Monitoring Systems. *Teratology*. 1987;36:221.

Lattimer JK, Smith MJK. Exstrophy closure: a follow up on 70 cases. *J Urol*. 1966;95:356.

Lavien G, Di Carlo HN, Shah BB, et al. Impact of pelvic osteotomy on the incidence of inguinal hernias in classic bladder exstrophy. *J Pediatr Surg*. 2014;49(10):1496–1499.

Lee BR, Perlman EJ, Partin AW, et al. Evaluation of smooth muscle and collagen subtypes in normal newborns and those with bladder exstrophy. *J Urol*. 1996;156:203.

Lee RS, Grady R, Joyner B, et al. Can a complete primary repair approach be applied to cloacal exstrophy? *J Urol*. 2006;176(6 Pt 1):2643–2648.

Levitt MA, Mak GZ, Falcone RA, et al. Cloacal exstrophy—pull-through or permanent stoma? A review of 53 patients. *J Pediatr Surg*. 2008;43:164.

Loder RT, Dayioglu MM. Association of congenital vertebral malformations with bladder and cloacal exstrophy. *J Pediatr Orthop*. 1990;10:389.

Lottmann H, Melin Y, Lombrail P, et al. Reconstruction of bladder exstrophy: retrospective study of 57 patients with evaluation of factors in favor of acquisition of continence. *Ann Urol*. 1998;32:233.

Lottmann HB, Margaryan M, Lortat-Jacob S, et al. Long-term effects of dextranomer endoscopic injections for the treatment of urinary incontinence: an update of a prospective study of 61 patients. *J Urol*. 2006;176:1762–1766.

Lowentritt BH, Vanzijl S, Frimberger D, et al. Variants of the exstrophy complex: a single institutional experience. *J Urol*. 2005;173:1732–1737.

Ludwig M, Rushendorf F, Saar K, et al. Genome-wide linkage scan for bladder exstrophy-epispadias complex. *Birth Defects Res A Clin Mol Teratol*. 2009;85(2):174–178.

Lue K, Gandhi NM, Young E, et al. The tunica vaginalis flap as an adjunct to epispadias repair: a preliminary report. *Urology*. 2015;86(5):1027–1031.

Lumen N, Monstrey S, Selvaggi G, et al. Phalloplasty: a valuable treatment for males with penile insufficiency. *Urology*. 2008;71(2):272–276 [discussion 276–277].

Lund DT, Hendren WH. Cloacal exstrophy: experience with 20 cases. *J Pediatr Surg*. 1993;28:1360.

Manzoni GA, Ransley PG, Hurwitz RS. Cloacal exstrophy and cloacal exstrophy variants: a proposed system of classification. *J Urol*. 1987;138:1065.

Marshall VF, Marchetti AA, Krantz KE. The correction of stress incontinence by simple vesicourethral suspension. *Surg Gynecol Obstet*. 1949;88:509.

Marshall VF, Muecke E. Congenital abnormalities of the bladder. *Handbuch der urologie*. Springer-Verlag: New York; 1968:165.

Martinez-Frias ML, Bermejo E, Rodriguez-Pinilla E, et al. Exstrophy of the cloaca and exstrophy of the bladder: two different expressions of a primary developmental field defect. *Am J Med Genet*. 2001;99:261.

Maruf M, Kasprenski M, Jayman J, et al. Achieving urinary continence in cloacal exstrophy: the surgical cost. *J Pediatr Surg*. 2018;53(10):1937–1941.

Massanyi EZ, Gupta A, et al. Radial forearm free flap phalloplasty for penile inadequacy in patients with exstrophy. *J Urol*. 2012;9:368.

Massanyi EZ, Shah B, Schaeffer AJ, et al. Persistent vesicocutaneous fistula after repair of classic bladder exstrophy: a sign of failure? *J Pediatr Urol*. 2013;9:867–871.

Mathews R, Gosling JA, Gearhart JP. Ultrastructure of the bladder in classic exstrophy—correlation with development of continence. *J Urol*. 2004;172:1446.

Mathews R, Jeffs RD, Reiner WG, et al. Cloacal exstrophy: improving the quality of life—The Johns Hopkins experience. *J Urol*. 1998;160:2552.

Mathews RI, Gan M, Gearhart JP. Urogynaecologic and obstetric issues in women with the exstrophy-epispadias complex. *BJU Int*. 2003;91:845.

Mathews RI, Gearhart JP. Ureteral reimplantation before bladder neck repair: indications and outcome. *Urology*.

2003;61:820.

Mathews R, Gearhart JP, Bhatnagar R, et al. Staged pelvic closure of extreme pubic diastasis in the exstrophy-epispadias complex. *J Urol*. 2006;176:2196–2198.

Mathews RI, Perlman E, Gearhart JP. Gonadal morphology in cloacal exstrophy: implications in gender assignment. *BJU Int*. 1999;83:484.

Mathews RI, Wills M, Perlman E, et al. Neural innervation of the newborn exstrophy bladder: an immunohistological study. *J Urol*. 1999;162:506.

McKenna PH, Khouri AE, McLorie GA, et al. Iliac osteotomy: a model to compare the options in bladder and cloacal exstrophy reconstruction. *J Urol*. 1994;151:182.

McLaughlin KT, Rink RC, Kalsbeck GE, et al. Cloacal exstrophy: the neurological implications. *J Urol*. 1995;154:782.

McMahon DR, Kane MP, Husmann DA, et al. Vesical neck reconstruction in patients with the exstrophy-epispadias complex. *J Urol*. 1996;155:1411.

Meizner I, Bar-Ziv J. In utero prenatal ultrasonic diagnosis of a rare case of cloacal exstrophy. *J Clin Ultrasound*. 1985;13:500.

Meldrum KK, Baird AD, Gearhart JP. Methods of pelvic and extremity immobilization following bladder exstrophy closure: associated complications and impact on surgical success. *Urology*. 2003;62:1109.

Meldrum KK, Mathews RI, Nelson CP, et al. Subspecialty training and surgical outcomes in children with failed bladder exstrophy closure. *J Pediatr Urol*. 2005;1(2):95–99.

Mergurian PA, McLorie GA, McMullin ND, et al. Continence in bladder exstrophy: determinates of success. *J Urol*. 1991;145:350.

Mesrobian H, Kelalis P, Kramer SA. Follow up of cosmetic appearance and genital function in boys with exstrophy: review of 53 patients. *J Urol*. 1986;136:256.

Mildenberger H, Lkuth D, Dziuba M. Embryology of bladder exstrophy. *J Pediatr Surg*. 1988;23:116.

Miles-Thomas J, Gearhart JP, Gearhart SL. Initial evaluation of pelvic floor function on the quality of life of bladder exstrophy patients with ureterosigmoidostomy. *J Gastrointest Surg*. 2006;10:473–477.

Mirheydar H, Evason K, Coakley F, et al. 46, XY female with cloacal exstrophy and masculinization at puberty. *J Pediatr Urol*. 2009;5:408–411.

Mirk M, Calisti A, Feleni A. Prenatal sonographic diagnosis of bladder exstrophy. *J Ultrasound Med*. 1986;5:291.

Mitchell ME, Brito CG, Rink RC. Cloacal exstrophy reconstruction for urinary continence. *J Urol*. 1990;144:554.

Mitchell MI, Bägli DJ. Complete penile disassembly for epispadias repair: the Mitchell technique. *J Urol*. 1996;155:300.

Mollard P, Bassett T, Mure PY. Male epispadias: experience with 45 cases. *J Urol*. 1998;160:55–59.

Monfort G, Morisson-Lacombe GM, Guys JM, et al. Transverse island flap and double flap procedure in the treatment of congenital epispadias in 32 patients. *J Urol*. 1987;138:1069.

Montagnino B, Czyzewski DI, Runyon RD, et al. Adjustment issues in patients with exstrophy. *J Urol*. 1998;160:1471.

Mouriquand PDE, Bubanj T, Feyaerts A. Long-term results of bladder neck reconstruction for incontinence in children with classical bladder exstrophy or incontinent epispadias. *BJU Int*. 2003;92:997.

Muecke EC. The role of the cloacal membrane in exstrophy: the first successful experimental study. *J Urol*. 1964;92:659.

Narasimharao KI, Chana RS, Mitra SR, et al. Covered exstrophy and visceral sequestration: a rare exstrophy variant.

J Urol. 1985;133:274.

Nelson CP, Dunn RL, Wei JT. Contemporary epidemiology of bladder exstrophy in the United States. *J Urol*. 2005;173(5):1728–1731.

Nelson CP, Dunn RL, Wei JT, et al. Surgical repair of bladder exstrophy in the modern era: contemporary practice patterns and the role of hospital case volume. *J Urol*. 2005;174(3):1099–1102.

Nelson CP, King J, Sponseller PD, et al. Repeat pelvic osteotomy in patients with failed closure of bladder exstrophy: applications and outcomes. *J Pediatr Surg*. 2006;41:1109–1112.

Nelson CP, North AC, Ward MK, et al. Economic impact of failed or delayed primary repair of bladder exstrophy: differences in cost of hospitalization. *J Urol*. 2008;179(2):680–683.

Nerli RB, Kamat GV, Alur SS, et al. Bladder exstrophy in adulthood. *Indian J Urol*. 2008;24:164–168.

Novak TE, Costello JP, Orosco R, et al. Failed exstrophy closure: management and outcome. *J Pediatr Urol*. 2010;6:381.

Novak TE, Lakshmanan Y, Frimberger D, et al. Polyps and the exstrophic bladder: cause for concern? *J Urol*. 2005;174:1522–1526.

Novak TE, Salmasi AH, Lakshmanan Y, et al. Bladder neck transection for intractable pediatric urinary incontinence. *J Urol*. 2009;181(1):310–314.

Oesterling JE, Jeffs RD. The importance of a successful initial bladder closure in the surgical management of classical bladder exstrophy: analysis of 144 patients treated at the Johns Hopkins Hospital between 1975 and 1985. *J Urol*. 1987;137:258.

Patton BR, Barry A. The genesis of exstrophy of the bladder and epispadias. *Am J Anat*. 1952;90:35.

Peppas DS, et al. A quantitative histology of the bladder in various stages of reconstruction utilizing color morphometry. Gearhart JP, Mathews RI. *Exstrophy-epispadias complex: research concepts and clinical applications*. Plenum: New York; 1999:41.

Perlmutter AD, Weinstein MD, Rademan C. Vesical neck reconstruction in patients with the exstrophy-epispadias complex. *J Urol*. 1991;146:613.

Perovic SV, Djinovic RP. New insight into surgical anatomy of epispadiac penis and its impact on repair. *J Urol*. 2008;179(2):689–695.

Perovic SV, Vukadinovic V, Djordjevic ML, et al. Penile disassembly technique for epispadias repair: variants of technique. *J Urol*. 1999;162(3 Pt 2):1181–1184.

Peters CA, Gearhart JP, Jeffs RD. Epispadias and incontinence: the child with a small bladder. *J Urol*. 1988;140:1199.

Pettersson L, Tranberg J, Abrahamsson K, et al. Half century of follow up after ureterosigmoidostomy performed in early childhood. *J Urol*. 2013;189:1870.

Purves JT, Baird AD, Gearhart JP. The modern staged repair of bladder exstrophy in the female: a contemporary series. *J Pediatr Urol*. 2008;4:150.

Purves JT, Gearhart JP. Complications of radical soft-tissue mobilization procedure as a primary closure of exstrophy. *J Pediatr Urol*. 2008;4:65–69.

Qi L, Chen K, Hur DJ, et al. Genome-wide expression profiling of urinary bladder implicates desmosomal and cytoskeletal dysregulation in the bladder exstrophy-epispadias complex. *Int J Mol Med*. 2011;27:755.

Qi L, Wang M, Yagnik G, et al. Candidate gene association study implicates p63 in the etiology of nonsyndromic bladder-exstrophy-epispadias complex. *Birth Defects Res A*

Clin Mol Teratol. 2013 [(in press)].

Ransley PG, Duffy PG, Wollin M. Bladder exstrophy closure and epispadias repair. *Operative surgery: paediatric surgery*. ed 4. Butterworths: Edinburgh; 1989:620.

Reiner WG. Psychosocial concerns in bladder and cloacal exstrophy patients. *Dial Pediatr Urol*. 1999;22:8.

Reiner WG. Psychosexual development in genetic males assigned female: the cloacal exstrophy experience. *Child Adolesc Psychiatr Clin N Am*. 2004;13:657.

Reiner WG, Gearhart JP. Discordant sexual identity in some genetic males with cloacal exstrophy assigned to female sex at birth. *N Engl J Med*. 2004;350:333–341.

Reiner WG, Gearhart JP. Anxiety disorders in children with epispadias-exstrophy. *Urology*. 2006;68(1):172–174.

Reiner WG, Gearhart JP, Kropp B. Suicide and suicidal ideation in classic exstrophy. *J Urol*. 2008;180:1661–1663.

Reutter H, Boyadjiev SA, Gambhir L, et al. Phenotype severity in the bladder exstrophy-epispadias complex: analysis of genetic and nongenetic contributing factors in 441 families from North America and Europe. *J Pediatr*. 2011;159:825.

Reutter H, Shapiro E, Gruen JR. Seven new cases of familial isolated bladder exstrophy and epispadias complex (BEEC) and review of the literature. *Am J Med Genet A*. 2003;120A:215–221.

Ricketts R, Woodard JR, Zwiren GT, et al. Modern treatment of cloacal exstrophy. *J Pediatr Surg*. 1991;26:444.

Rickham PP. Vesicointestinal fissure. *Arch Dis Child*. 1960;35:97.

Ritchey ML, Kramer SA, Kelalis PP. Vesical neck reconstruction in patients with epispadias and exstrophy. *J Urol*. 1988;139:1278.

Rosch W, Christl A, Strauss B, et al. Comparison of preoperative innervation pattern and post reconstructive urodynamics in the exstrophy-epispadias complex. *Urol Int*. 1997;59:6.

Rosch W, Schott G, Scheuring S, et al. Long-term outcome analysis of the first 100 complete repairs of bladder exstrophy with the Erlangen technique. *BJU Int*. 2001;87(Suppl):24.

Rosendahl H. Ultrasound screening for fetal urinary tract malformations: a prospective study in general population. *Eur J Obstet Gynecol Reprod Biol*. 1990;36(1–2):27–33.

Rubenwolf P, Thomas C, Thuroff JW, et al. Sexual function and fertility of women with classic bladder exstrophy and continent urinary diversion. *J Urol*. 2016;196(1):140–145.

Sadler TW, Feldkamp ML. The embryology of the body wall closure: relevance to gastrocschisis and other ventral body wall defects. *Am J Med Genet C Semin Med Genet*. 2008;148:181–185.

Satsuma S, Kobayshi D, Yoshiya S, et al. Comparison of posterior and anterior pelvic osteotomy for bladder exstrophy complex. *J Pediatr Orthop*. 2006;15:141–146.

Sawaya D, Goldstein S, Seetharamiah R, et al. Gastrointestinal ramifications of the cloacal exstrophy complex: a 44-year experience. *J Pediatr Surg*. 2010;45:171.

Schaeffer AJ, Purves JT, King JA, et al. Complications of primary closure of classic bladder exstrophy. *J Urol*. 2008;180(4 Suppl):1671–1674.

Schaeffer AJ, Stec AA, Baradaran N, et al. Preservation of renal function in the modern staged repair of classic bladder exstrophy. *J Pediatr Urol*. 2013;9(2):169–173.

Schaeffer AJ, Stec AA, Purves JT, et al. Complete primary repair of bladder exstrophy: a single institution referral experience. *J Urol*. 2011;186(3):1041–1046.

Schlegel PN, Gearhart JP. Neuroanatomy of the pelvis in an infant with cloacal exstrophy: a detailed microdissection with histology. *J Urol*. 1989;141:583.

Schmidt AH, Teenan TL, Tank ES. Pelvic osteotomy for bladder exstrophy. *J Pediatr Orthop*. 1993;13:214.

Schober JM, Carmichael PA, Hines M, et al. The ultimate challenge of cloacal exstrophy. *J Urol*. 2002;167:300.

Schrott KM, Siegel A, Schrott G. Fruhzeitige total reconstruktion der blasenexstrophie. Springer: Berlin; 1984:383–386. Rodeck R. *Deutschland urology*. vol 35.

Shah BB, Di Carlo H, Goldstein SD, et al. Initial bladder closure of the cloacal exstrophy complex: outcome related risk factors and keys to success. *J Pediatr Surg*. 2014;49(6):1036–1039 [discussion 1039–1040].

Shah BB, Massanyi EZ, Dicarlo H, et al. Role of urethral bulking agents in epispadias-exstrophy complex patients. *J Pediatr Urol*. 2014;10(1):176–180.

Shapiro E, Jeffs RD, Gearhart JP, et al. Muscarinic cholinergic receptors in bladder exstrophy: insights into surgical management. *J Urol*. 1985;134:309.

Shapiro E, Lepor H, Jeffs RD. The inheritance of the exstrophy-epispadias complex. *J Urol*. 1984;132:308–310.

Shetty MV, Bhaskaran A, Sen TK. Female epispadias. *Afr J Paediatr Surg*. 2011;8:215–217.

Shnorhavorian M, Grady RW, Andersen A, et al. Long-term followup of complete primary repair of exstrophy: the Seattle experience. *J Urol*. 2008;180:1615–1619.

Shnorhavorian M, Song K, Zamilpa I, et al. Spica casting compared to Bryant's traction after complete primary repair of exstrophy: safe and effective in a longitudinal cohort study. *J Urol*. 2010;184:669.

Shoukry A, Ziada A, Morsi H, et al. Outcome of complete primary bladder exstrophy repair: single-center experience. *J Pediatr Urol*. 2009;10:1–4.

Shultz WG. Plastic repair of exstrophy of bladder combined with bilateral osteotomy of ilia. *J Urol*. 1958;79(3):453–458.

Siffel C, Correa A, Amar E, et al. An epidemiologic study from the International Clearinghouse for Birth Defects Surveillance and Research, and an overview of the literature. *Am J Med Genet C Semin Med Genet*. 2011;157:321.

Silver RI, Partin AW, Epstein JI, et al. Prostate specific antigen in men born with bladder exstrophy. *Urology*. 1997;49:253.

Silver RI, Sponseller PG, Gearhart JP. Staged closure of the pelvis in cloacal exstrophy: first description of a new approach. *J Urol*. 1999;161:263.

Silver RI, Yang A, Ben-Chaim J, et al. Penile length in adulthood after exstrophy reconstruction. *J Urol*. 1997;158:999.

Sirisreetreerux P, Lue KM, Ingviya T, et al. Failed primary bladder exstrophy closure with osteotomy: multivariable analysis of a 25-year experience. *J Urol*. 2017;197(4):1138–1143.

Smeulders N, Woodhouse CR. Neoplasia in adult exstrophy patients. *BJU Int*. 2001;88:647.

Soffer SZ, Rosen NG, Hong AR, et al. Cloacal exstrophy: a unified management plan. *J Pediatr Surg*. 2000;35:932.

Spence HM, Hoffman WW, Fosmire PP. Tumors of the colon as a later complication of ureterosigmoidostomy of exstrophy of the bladder. *Br J Urol*. 1979;51:466.

Sponseller PD, Bisson L, Jani L, et al. Anterior innominate osteotomy in repair of bladder exstrophy. *J Bone Joint Surg Am*. 2001;83:184.

Sponseller PD, Bisson LJ, Gearhart JP, et al. The anatomy of the pelvis in the exstrophy complex. *J Bone Joint Surg Am*. 1995;77:177.

Sponseller PD, Gearhart JP, Jeffs RD. Anterior innominate osteotomies for failure or late closure bladder exstrophy. *J Urol*. 1991;146:137.

Stec AA, Baradaran N, Gearhart JP. Congenital renal anomalies in patients with classic bladder exstrophy. *Urology*. 2012;79:207.

Stec AA, Baradaran N, Tran C, et al. Colorectal anomalies in patients with classic bladder exstrophy. *J Pediatr Surg*. 2011;46(9):1790–1793.

Stec AA, Baradaran N, Schaeffer A, et al. The modern staged repair of classic bladder exstrophy: a detailed postoperative management strategy for primary bladder closure. *J Pediatr Urol*. 2012;8(5):549–555.

Stec AA, Pannu HK, Tadros YE, et al. Evaluation of the bony pelvis in classic bladder exstrophy using 3 D CT—further insights. *Urology*. 2001;58:1030.

Stec AA, Pannu HK, Tadros YE, et al. Pelvic floor evaluation in classic bladder exstrophy using 3-dimensional computerized tomography—Initial insights. *J Urol*. 2001;166:1444.

Stec AA, Tekes A, Ertan G, et al. Evaluation of pelvic floor muscular redistribution after primary closure of classic bladder exstrophy by 3-dimensional magnetic resonance imaging. *J Urol*. 2012;188:1535.

Stec AA, Wakim A, Barbet P, et al. Fetal bony pelvis in the bladder exstrophy complex: normal potential for growth? *Urology*. 2003;62:337.

Stein R, Fisch M, Bauer H, et al. Operative reconstruction in external and internal genitalia in female patients with bladder exstrophy and epispadias. *J Urol*. 1995;154:1002.

Stein R, Fisch M, Black P. Strategies for reconstruction after unsuccessful or unsatisfactory primary treatment of patients with bladder exstrophy and incontinent epispadias. *J Urol*. 1999;161:1934.

Stein R, Stuckel M, Fisch M, et al. Fate of the adult exstrophy patient. *J Urol*. 1994;152:1413.

Stiles HJ. Epispadias in the female: surgical treatment. *Surg Gynecol Obstet*. 1911;13:127.

Surer I, Baker LA, Jeffs RD, et al. The modified Cantwell-Ransley repair in exstrophy and epispadias: 10 year experience. *J Urol*. 2000;164:1040.

Surer I, Baker LA, Jeffs RD, et al. Modified Young-Dees-Leadbetter bladder neck reconstruction in patients with successful primary bladder closure elsewhere: a single institution experience. *J Urol*. 2001;165:2438.

Surer I, Ferrer FA, Baker LA, et al. Continent urinary diversion and the exstrophy epispadias complex. *J Urol*. 2003;169:1102.

Suson K, Novak T, Benson J, et al. The neuro-orthopedic manifestations of the omphalocele-exstrophy-imperforate anus-spinal defects (OEIS) Complex. *J Urol*. 2010;184:1651.

Suson KD, Preece J, Baradaran N, et al. The fate of the complete female epispadias and exstrophy bladder–is there a difference? *J Urol*. 2013;190(4 Suppl):1583–1588.

Suson KD, Stec AA, et al. Initial characterization of exstrophy bladder smooth muscle cells in culture. *J Urol*. 2012;188:1521.

Suson KD, Stec AA, Gearhart JP, et al. Transforming growth factor-β1 mediates migration in cultured human control and exstrophy bladder smooth muscle cells. *J Urol*. 2012;188:1528.

Sussman J, Sponseller PD, Gearhart JP, et al. A comparison of methods of repairing the symphysis pubis in bladder exstrophy by tensile testing. *BJU Int*. 1997;79:979.

Sweetser TH, Chisolm TC, Thompson WH. Exstrophy of the urinary bladder: discussion of anatomic principles applicable to repair with a preliminary report of a case. *Minn Med*. 1952;35:654.

Taghizadeh A, Qteishat A, Cuckow PM. Restoring hindgut continuity in cloacal exstrophy: a valuable method of optimizing bowel length. *Eur J Pediatr Surg*. 2009;19:141.

Tank ES, Lindenaur SM. Principles of management of exstrophy of the cloaca. *Am J Surg*. 1970;119:95.

Thauvin-Robinet C, Faivre L, Cusin V, et al. Cloacal exstrophy in an infant with 9q34.1-qter deletion resulting from a de novo unbalanced translocation between chromosome 9q and Yq. *Am Anal Med Genet A*. 2004;126:303.

Thomalla J, Rudolph RA, Rink RC, et al. Induction of cloacal exstrophy in the chick embryo with a CO2 laser. *J Urol*. 1985;134:991.

Thomas JC, DeMarco RT, Pope JC 4th, et al. First stage approximation of the exstrophic bladder in patients with cloacal exstrophy–should this be the initial surgical approach in all patients? *J Urol*. 2007;178(4 Pt 2):1632–1635.

Toguri AG, Churchill BM, Schillinger JF, et al. Continence in cases of bladder exstrophy. *J Urol*. 1987;119:538.

Tourchi A, Di Carlo HN, Inouye BM, et al. Ureteral reimplantation before bladder neck reconstruction in modern staged repair of exstrophy patients: indications and outcomes. *Urology*. 2015;85(4):905–908.

Tourchi A, Jayman J, Zhaoyong F, et al. *Multivariate analyses of the factors affecting success in cloacal exstrophy primary closure*. 2017 [Pediatric Urology Fall Congress. Montreal, Canada, Society for Pediatric Urology].

Verco PW, Khor BH, Barbary J, et al. Ectopic vesicae in utero. *Australas Radiol*. 1986;30:117.

Wakim A, Barbet JP. Connections of the bladder plate and bladder neck with the bony pelvis in a fetus with classic bladder exstrophy. *Urology*. 2002;60:142–146.

Wilkins S, Zhang KW, Mahfuz I, et al. Insertion/deletion polymorphisms in the DeltaNp63 promoter are a risk factor for bladder exstrophy epispadias complex. *PLoS Genet*. 2012;8(12):e1003070.

Williams AM, Solaiyappan M, Pannu HK, et al. 3-dimensional magnetic resonance imaging modeling of the pelvic floor musculature in classic bladder exstrophy before pelvic osteotomy. *J Urol*. 2004;172(4 Pt 2):1702–1705.

Williams DI, Keaton J. Vesical exstrophy: twenty years' experience. *Br J Surg*. 1973;60:203.

Wittmeyer V, Aubry E, Liard-Zmuda A, et al. Quality of life in adults with bladder exstrophy-epispadias complex. *J Urol*. 2010;184:2389.

Wood HP, Trock BP, Gearhart JP. In vitro fertilization and the cloacal-bladder exstrophy-epispadias complex: is there an association? *J Urol*. 2003;169:1512–1515.

Woodhouse CRJ. The management of erectile deformity in adults with exstrophy and epispadias. *J Urol*. 1986;135:932.

Woodhouse CRJ. Sexual function in boys with exstrophy, myelomeningocele, and micropenis. *Urology*. 1998;52:3.

Woodhouse CRJ. The gynecology of exstrophy. *BJU Int*. 1999;83:34.

Woodhouse CRJ, Ransley PC, Williams DI. The exstrophy patient in adult life. *Br J Urol*. 1983;55:632.

Yeni E, Unal D, Verit A, et al. An adult female epispadias without exstrophy was presented with urinary incontinence: a case report. *Int Urogynecol J Pelvic Floor Dysfunct*. 2004;15:212–213.

Young HH. An operation for the cure of incontinence associated with exstrophy. *J Urol*. 1922;7:1.

Zaontz M, Steckler RE, Shortliffe LM, et al. Multicenter experience with the Mitchell technique for epispadias repair. *J Urol*. 1998;160:1972.

Zarbo A, Kay R. Uterosigmoidostomy in bladder exstrophy: a long-term follow-up. *J Urol*. 1986;136:396.

Zhang R, Knapp M, Suzuki K, et al. ISL1 is a major susceptibility gene for classic bladder exstrophy and a regulator of urinary tract development. *Sci Rep*.

2017;7:42170.

32

Prune-Belly Syndrome

Francisco Tibor Dénes MD, PhD, Roberto Iglesias Lopes MD, PhD

Prune-belly syndrome (PBS) includes a constellation of anomalies with variable degrees of severity. The three major findings are deficiency of the abdominal musculature, bilateral intra-abdominal testes, and anomalous urinary tract. The urinary tract is characterized by variable degrees of hydronephrosis, renal dysplasia, dilated tortuous ureters, enlarged bladder, and dilated prostatic urethra. Additional associated anomalies involve the respiratory tract, gastrointestinal tract, cardiac system, and musculoskeletal system. There is a broad spectrum of severity of the syndrome: some children do not survive the newborn period and others are minimally affected. The most important determinant of long-term survival is usually the severity of the urinary tract anomaly, in particular, the degree of renal dysplasia.

The characteristic abdominal wall was first described by Frölich in 1839, and the full triad of anomalies by Parker in 1895. Osler's vivid description of the abdominal wall of an infant with the characteristic findings led to the term *prune-belly syndrome* (Osler, 1901). Other names that have been applied to this syndrome include *triad syndrome, Eagle-Barrett syndrome,* and *abdominal musculation syndrome* (Eagle and Barrett, 1950; Greskovich and Nyberg, 1988).

The incidence of PBS has been reported to be 1 in 29,000 to 1 in 40,000 live births, similar to that of bladder exstrophy (Williams and Burkholder, 1967); **95% occur in males** (Wheatley et al., 1996). Females with PBS have the abdominal wall deficiency and urinary tract dysmorphism without any gonadal anomaly (Rabinowitz and Schillinger, 1977; Reinberg et al., 1991b). A higher incidence is noted in twins, blacks, and children born to younger mothers. In developed countries, the incidence appears to be declining because of prenatal diagnosis and termination of pregnancy. In a review reported in 2010 by Routh et al. of the Kids' Inpatient Database (United States based) evaluating newborns with PBS during their initial hospitalization between 2000 and 2006, the weighted incidence estimate was 3.8 cases per 100,000 live births.

Genetics

The high male-to-female ratio, occasional occurrence in male siblings and cousins, and increased occurrence in twins suggest a genetic basis for PBS. Yet most cases are sporadic and have a normal karyotype. One in 23 children with PBS is the product of a twin pregnancy (Ives, 1974). However, the majority of reported twins have been discordant for PBS, evidence against a genetic cause. It has been suggested that the cause in twins may be due to an uneven distribution of mesenchymal tissue at a critical time of primitive streak development during the third week of embryogenesis (Coplen et al., 1996). There is a reported association with Turner syndrome, monosomy 16, trisomy 13, and trisomy 18 (Amacker et al., 1986; Hoagland and Hutchins, 1987). A variety of inheritance patterns have been proposed, including X-linked recessive (Frydman et al., 1993), a two-step autosomal dominant mutation (Riccardi and Grum, 1977), and polygenetic transmission (Adeyokunnu and Familusi, 1982; Garlinger and Ott, 1974; Lockhart et al., 1979). A report by Ramasamy et al. (2005) suggested a sex-influenced autosomal recessive mode of inheritance in familial PBS. The consensus, however, remains that an associated chromosomal abnormality is the exception rather than the rule because most have a normal karyotype. Other reports have noted an association between PBS and Beckwith-Wiedemann syndrome (Silengo et al., 2002; Sinico et al., 2004).

Embryology

Several theories about the embryogenesis of PBS have been proposed. However, because there is no experimental model that can be used to test these theories, the exact mechanism remains elusive. The four main theories are (1) an early in utero posterior urethral obstruction resulting in severe dilation of urinary tract and possible fetal ascites and oligohydramnios (Beasley et al., 1988; Pagon et al., 1979; Strumme, 1903; Wheatley et al., 1996); (2) a primary defect in the lateral plate mesoderm, which is the precursor of the ureters, bladder, prostate, urethra, and gubernaculum (Gonzalez et al., 1990; Ives, 1974); (3) an intrinsic defect of the urinary tract leading to ureteral dilation and fetal ascites (Cazorla et al., 1997; Monie and Monie, 1979; Nakayama et al., 1984; Smythe, 1981; Symonds and Driscoll, 1974); and (4) a yolk sac defect (Stephens, 1983; Stephens and Gupta, 1994). None of these theories has universal acceptance, and there is some overlap between them.

Clinical Features of Prune-Belly Syndrome

Genitourinary Anomalies

Kidneys

A spectrum of renal abnormalities extends from normal renal parenchyma to dysplasia (Figs. 32.1 and 32.2). The more severely dysplastic kidneys are generally associated with bladder outlet obstruction in which there has not been decompression through a patent urachus (Potter, 1972). **Dysplasia is present in 50% of cases; however, it may vary in degree and laterality (Rogers and Ostrow, 1973; Stephens, 1983). Renal dysplasia in PBS of the Potter type II and IV varieties is seen.** The Potter type II variety with few nephrons and parenchymal disorganization is more indicative of a renal mesenchymal defect, whereas the Potter type IV with cortical and tubular cysts is associated with outlet obstruction (Wigger and Blanc, 1977).

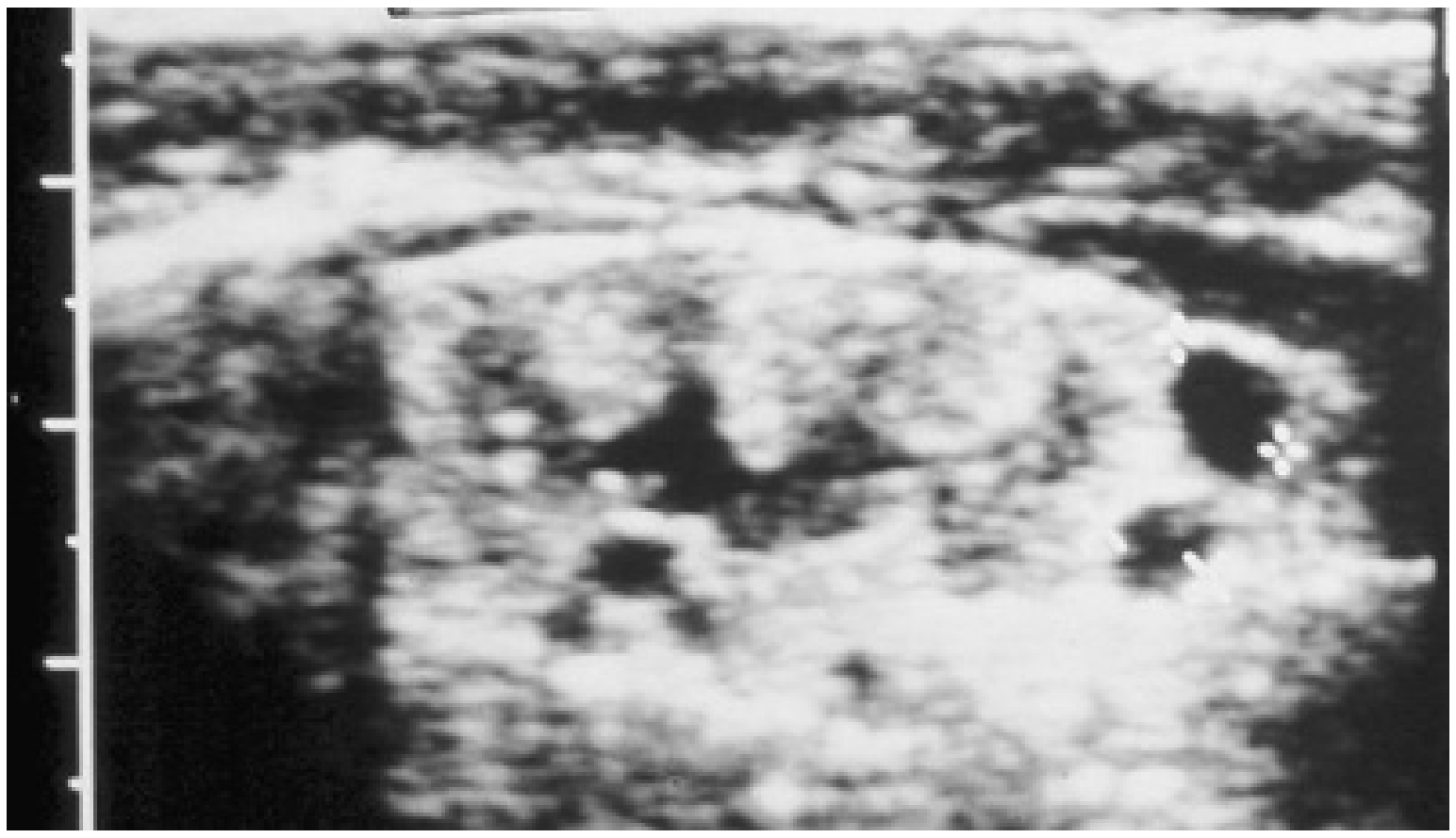

FIG. 32.1 Ultrasound scan of a kidney of a newborn with prune-belly syndrome demonstrating markedly echogenic renal parenchyma and cortical cysts indicative of renal dysplasia.

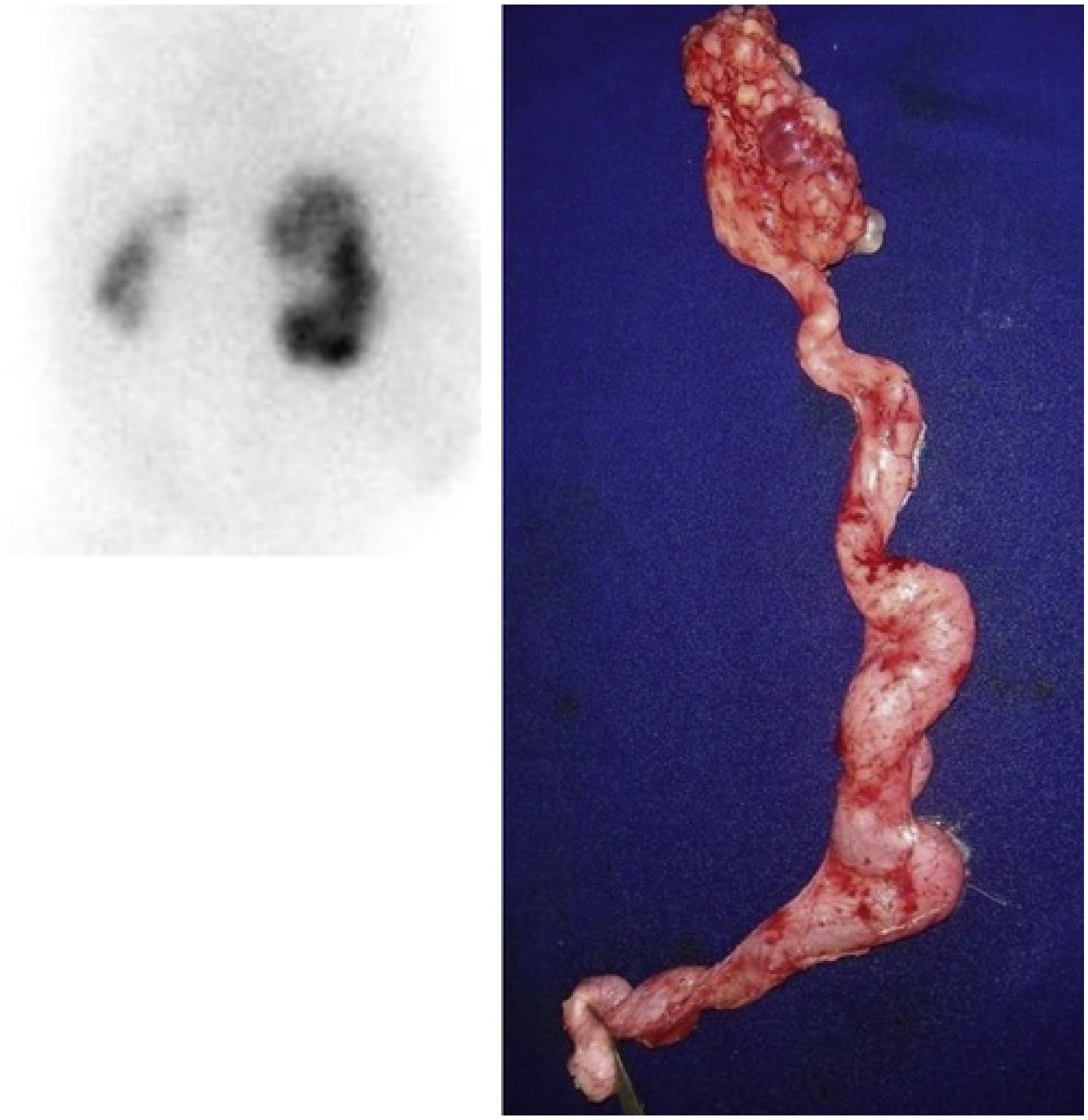

FIG. 32.2 Unilateral renal dysplasia with dilation and tortuosity of the ureter in a patient with prune-belly syndrome.

The renal collecting system is characteristically dilated, often to a severe degree. The degree of dilation, however, does not correlate with the degree of renal dysplasia. Calyceal morphology may be well preserved, even in the presence of massively dilated ureters and renal pelvis (Berdon et al., 1977). Some patients may have one severely dysplastic or dilated kidney, and the other kidney may have only mild abnormalities. Ureteropelvic junction obstruction can occur on a primary or secondary basis; however, nonobstructive hydronephrosis is the rule (Woodard and Parrott, 1978b). It is renal infection rather than obstruction that poses the greatest risk to renal function.

Ureters

The ureters are typically dilated, tortuous, and redundant. The proximal (upper) portions of the ureters are usually less abnormal than the distal

segments, although massive dilation and stenosis can occur at all levels (Fig. 32.3). In many patients the severity of the urinary tract abnormalities is not proportional to the degree of flaccidity of the abdominal wall. Histologic sectioning demonstrates lack of smooth muscle cells and increase in fibrous connective tissue. Generally, there are more normal-appearing smooth muscle cells in the proximal segments (Palmer and Tesluk, 1974; Stephens, 1983). This fact is critical when ureteral reconstruction is undertaken. The ratio of collagen to smooth muscle cells in prune-belly ureters has been noted to be elevated, especially in refluxing ureters (Gearhart et al., 1995). A decreased number of thick and thin myofibrils noted on ultrastructural examination is thought to contribute to the poor peristalsis (Berdon et al., 1977; Stephens, 1983).

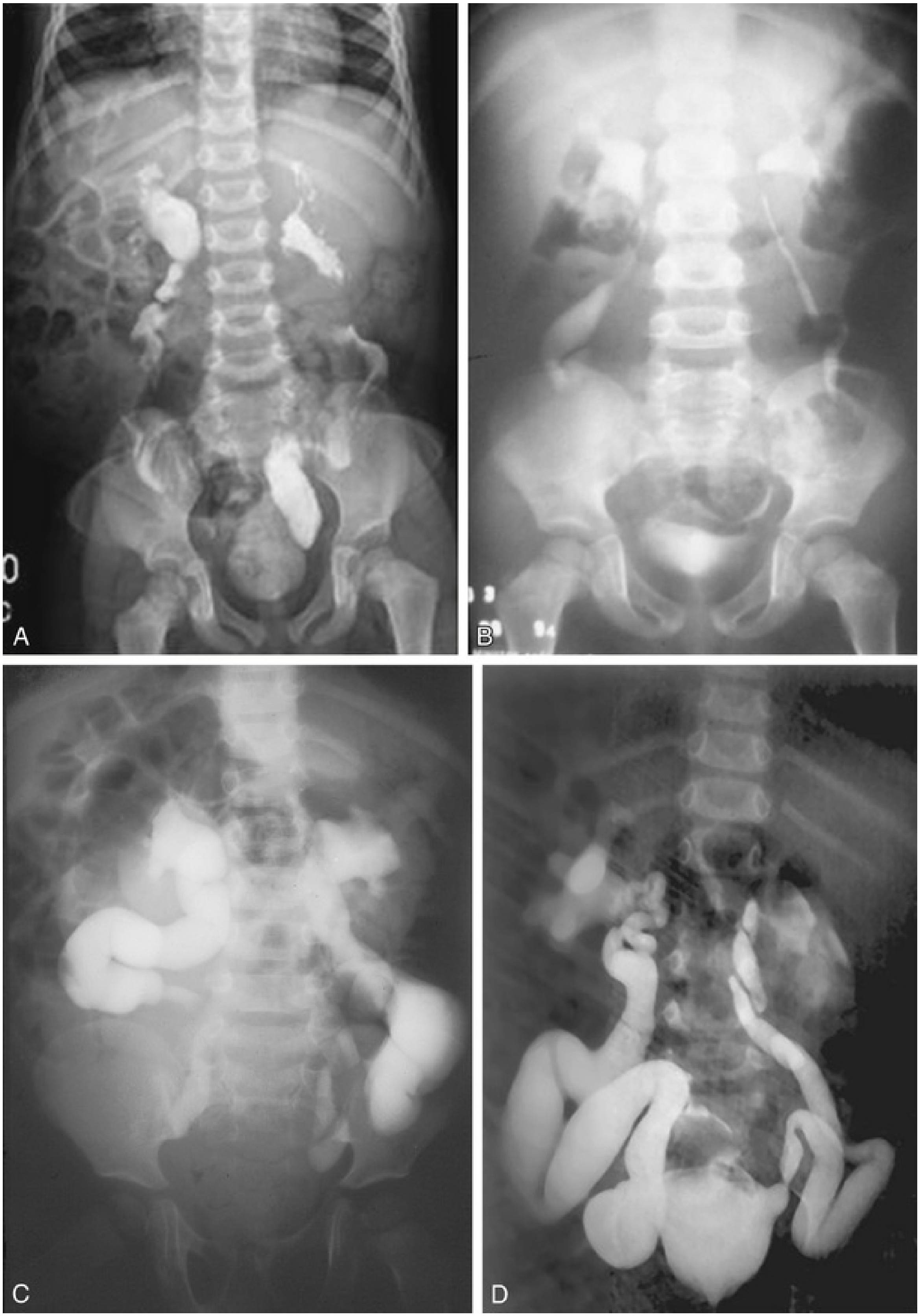

FIG. 32.3 Excretory urogram (A to C) demonstrating the variability in the

degree of hydroureteronephrosis in prune-belly syndrome. Note the preservation of calyceal architecture, despite severe ureteral dilation in C. (D) Dilated tortuous refluxing ureters as seen on a voiding cystourethrogram.

Vesicoureteral reflux is present in 75% of children with PBS (Berdon et al., 1977; Fallat et al., 1989) (Fig. 32.4). Obstruction is not common but has been reported at the ureteropelvic and ureterovesical junctions (Manivel et al., 1989; Moerman et al., 1982; Wigger and Blanc, 1977).

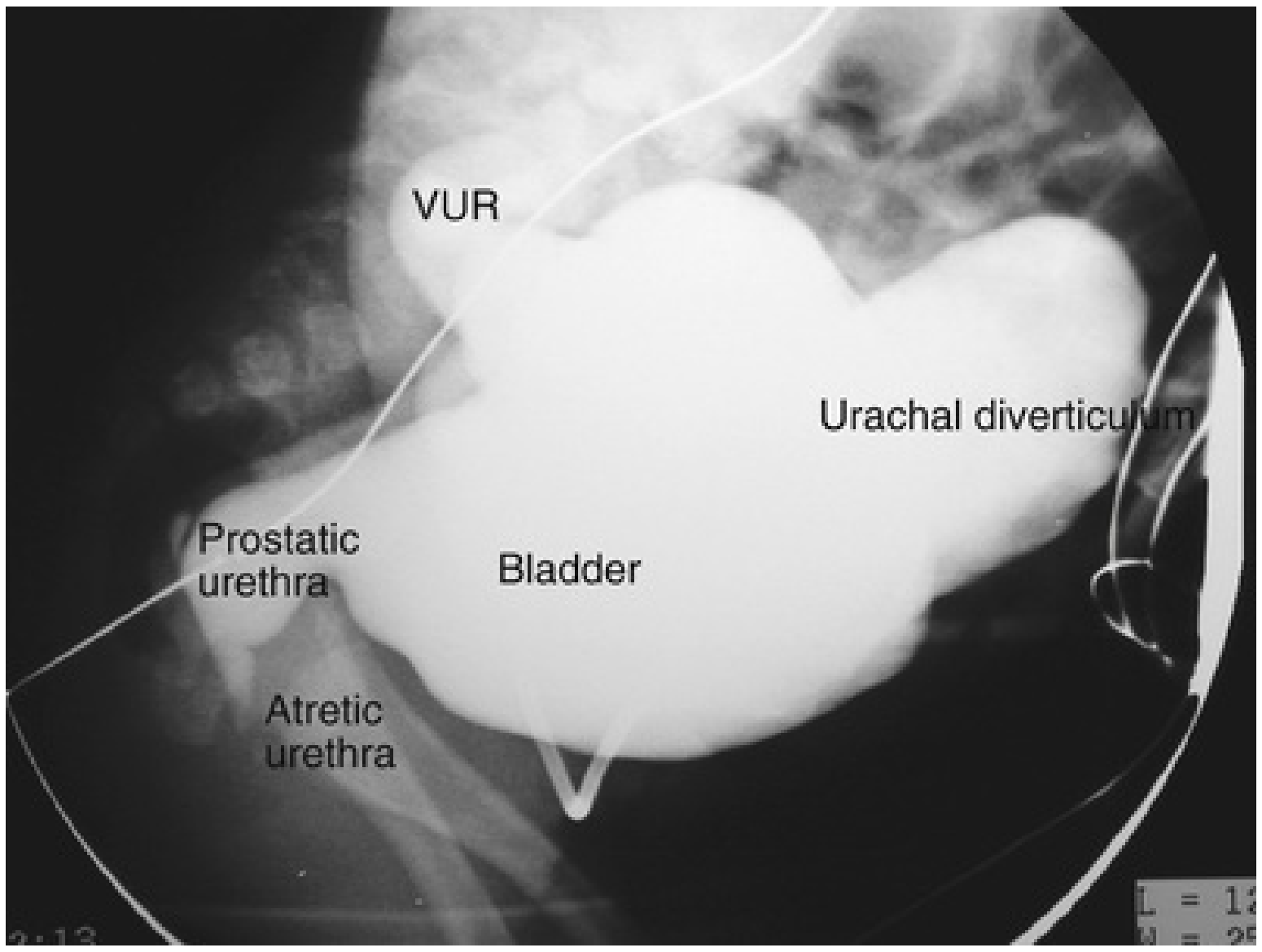

FIG. 32.4 Voiding cystourethrogram of a child with prune-belly syndrome demonstrating posterior urethral dilatation, urethral atresia, urachal diverticulum, and vesicoureteral reflux *(VUR)*.

These large ureters may have ineffective peristalsis because of poor ureteral wall coaptation. The ureteral conduction wave reaches a reduced smooth muscle cell population of poor contractile potential related to reduced myofibrils, often separated by patches of collagen, with the resulting bolus of urine reaching more dilated and nonpropulsive ureteral segments as it progresses toward the bladder (Woodard and Smith, 1998). This can be seen fluoroscopically as ineffective peristalsis, resulting in upper tract stasis, which may lead to infection (Nunn and Stephens, 1961; Williams and Burkholder, 1967).

Bladder

The bladder usually appears massively enlarged with a pseudodiverticulum at the urachus (Fig. 32.5). The urachus is patent at birth in 25% to 30% of children (Lattimer, 1958; Stephens and Gupta, 1994; Wigger and Blanc, 1977). Despite being very thick, the bladder wall is smooth, unlike that seen in obstructed bladders. Histologically, the bladder has an increased ratio of collagen to muscle fibers in the absence of obstruction (Workman and Kogan, 1990). However, smooth muscle hypertrophy can be seen in the obstructed prune bladder (Perlmutter, 1976). The pelvic distribution of ganglion cells has been shown to be normal (Burke et al., 1969; Nunn and Stephens, 1961); however, a decrease in α_{1a}-adrenoceptor immunostaining intensity has been documented (Schneider-Monteiro et al., 2010). A recent quantitative microscopic study showed that the bladder of PBS fetuses had lower concentrations of smooth muscle fibers, collagen type III and nerves, structural alterations that can be involved in the functional bladder abnormalities later in life (Julio Junior et al., 2017). The trigone is splayed with the ureteral orifices displaced laterally and superiorly, possibly contributing to the high incidence of vesicoureteral reflux (Williams and Burkholder, 1967).

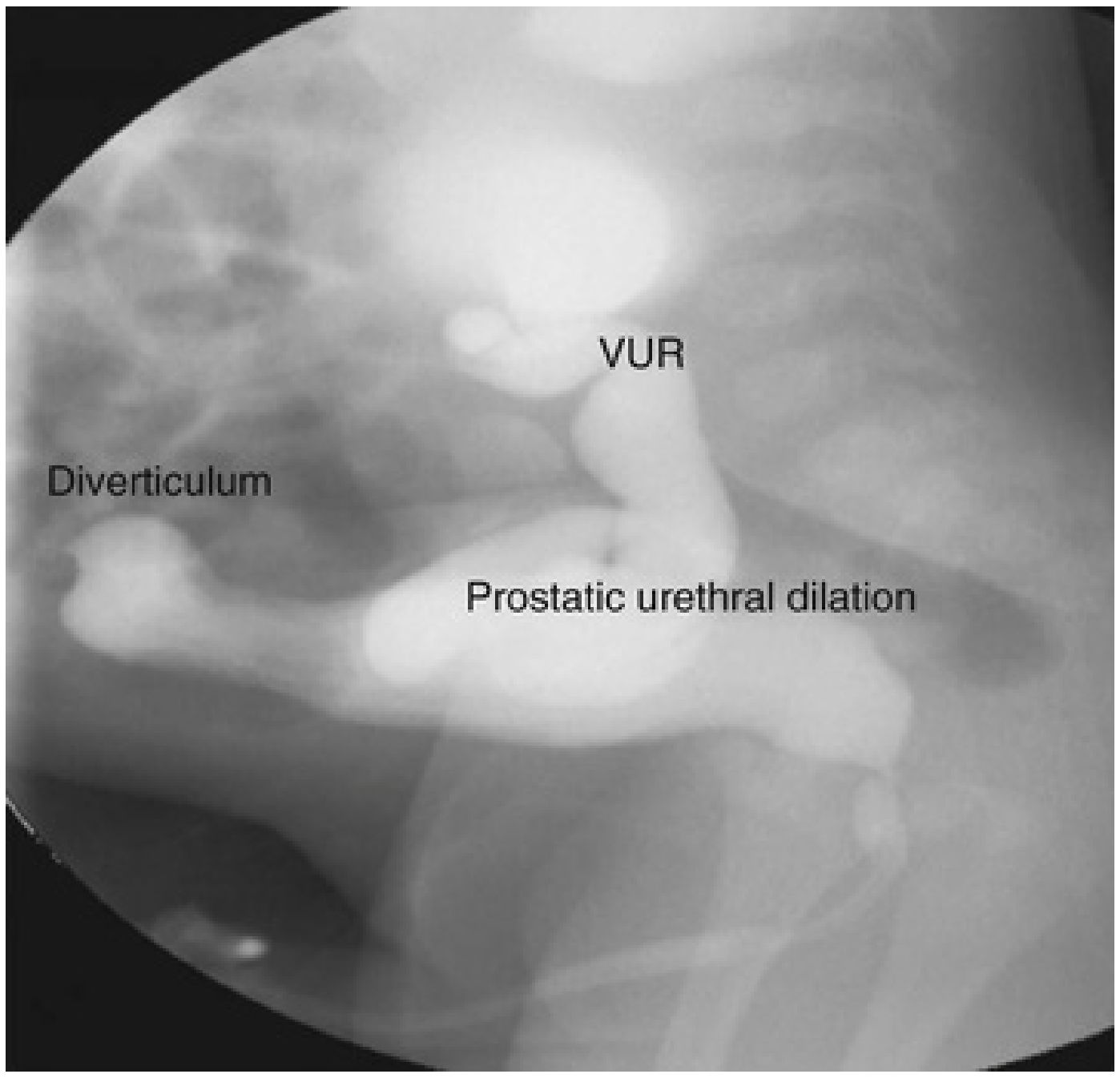

FIG. 32.5 Voiding cystourethrogram of a child with prune-belly syndrome demonstrating prostatic urethral enlargement related to a hypoplastic prostate and also demonstrating a urachal diverticulum and vesicoureteral reflux *(VUR)*.

On voiding, the bladder neck opens widely into a dilated prostatic urethra (see Fig. 32.5). Urodynamic assessment generally shows normal compliance; however, there is a delayed first sensation to void and a large capacity (Snyder et al., 1976). The ability to empty the bladder is variable, with some emptying well and others carrying a significant postvoid residual. This is thought to be due to a relative outlet obstruction and the inability of the bladder to generate sufficient pressure with a detrusor contraction. When the relative outflow resistance prevents effective bladder emptying, the term *unbalanced voiding* is used (Kinahan et al., 1992; Snyder et al., 1976). **Despite these limitations, about 50% of prune-belly patients void spontaneously with normal voiding pressures, normal flow rates, and low postvoid residuals** (Kinahan et al., 1992; Nunn and Stephens, 1961). However, as Kinahan et al. (1992) demonstrated, deterioration of balanced voiding can occur with growth, resulting in significant postvoid residuals, which emphasizes the need for periodic assessment.

Key Points: Clinical Features

- Kidney dysplasia occurs in half of the patients.
- Hydroureteronephrosis is often to a severe degree; however, the calyceal morphology may be well preserved.
- The proximal portion of the ureters has more normal muscle than the distal portions.
- Vesicoureteral reflux is present in most patients.
- The bladder is large with a pseudodiverticulum at the urachus and a wide bladder neck opening into a dilated prostatic urethra.

Prostate and Accessory Sex Organs

The dilation of the posterior urethra is due to prostatic hypoplasia, probably related to abnormal mesenchymal-epithelial development (Stephens and Gupta, 1994). Histologically, there are few prostatic cellular elements, with a reduction of epithelial and smooth muscle cells and an increase in connective tissue cells (Moerman et al., 1982; Popek et al., 1991; Stephens and Gupta, 1994). Various obstructive lesions of the distal posterior urethra have been described—urethral atresia, valves, urethral stenosis, urethral membrane, and urethral diverticulum—

and are thought to occur in 20% of cases (Hoagland and Hutchins, 1987). Stephens (1983) described an angulation of the urethra during voiding, referred to as *type IV valves*, which results from lack of prostatic parenchymal tissue. Prostatic hypoplasia, the cause of which is controversial, is thought to be a factor in the ejaculatory failure of patients with PBS (Volmar et al., 2001). The vas deferens and seminal vesicles are often atretic, although either may be dilated or thickened (Stephens and Gupta, 1994). Hypoplasia and agenesis of the prostate and seminal vesicle were frequent findings in a study made with magnetic resonance imaging in adult patients with PBS (Dénes et al., 2017). **The epididymis may be poorly attached to the testis, as is seen commonly in abdominal undescended testes. There may also be lack of continuity between the efferent ductules and the rete testis.** Ejaculation occurs usually in a retrograde fashion because of an incompetent bladder neck.

Anterior Urethra

Although the anterior urethra of the PBS child is usually normal, several anomalies of the urethral segment have been reported; the most common are urethral atresia or hypoplasia and megalourethra (Kroovand et al., 1982; Perrotin et al., 2001). **Unless it is associated with a patent urachus, urethral atresia is often lethal** (see Fig. 32.4). It has been postulated that urethral atresia or hypoplasia occur because the urethra is unused rather than malformed. Spontaneous bladder rupture with fistula formation has also been reported (Reinberg et al., 1993).

PBS is associated with two variations of megalourethra (Mortensen et al., 1985; Shrom et al., 1981). The fusiform type is a deficiency of the corpus cavernosum, as well as the spongiosum, and the scaphoid variety is a deficiency of the spongiosum only with preservation of the glans and corpora cavernosa (Fig. 32.6). With the scaphoid variety, the ventral urethra dilates with voiding, whereas with the fusiform variety the entire phallus dilates with voiding. The fusiform variety is thought to result from a mesenchymal deficiency of the urethral folds, whereas the scaphoid variety results from a mesenchymal deficiency of the urethral supportive tissues (Dorairajan, 1963). Megalourethra is more commonly seen in PBS than any other syndrome (Appel et al., 1986). Transient in utero obstruction of the junction between the glanular and penile urethra has been proposed to cause megalourethra.

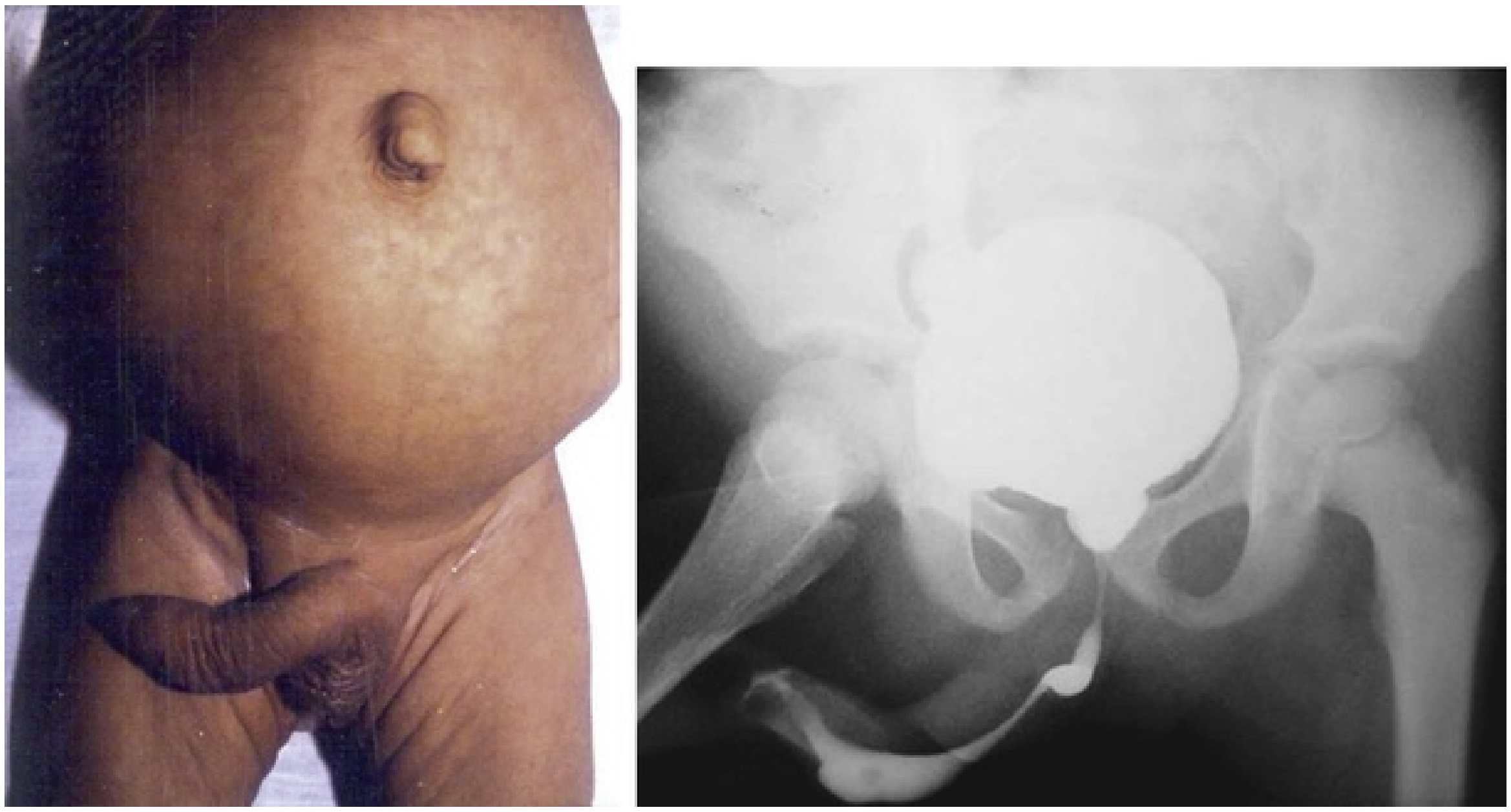

FIG. 32.6 Scaphoid megalourethra and posterior urethral dilation.

Testes

Bilateral intra-abdominal testes lying over the iliac vessels and adjacent to the dilated ureters are the most typical findings (Fig. 32.7). Although mechanical forces such as a distended bladder and intra-abdominal pressure have been implicated in maldescent of the testes (Hutson and Beasley, 1988; Kaplan et al., 1986), the fact that some patients with the typical urinary tract and abdominal musculature anomalies (because of incomplete presentation of the syndrome in the *pseudo prune* patients) may have descended testes raises some doubt about pure mechanical factors.

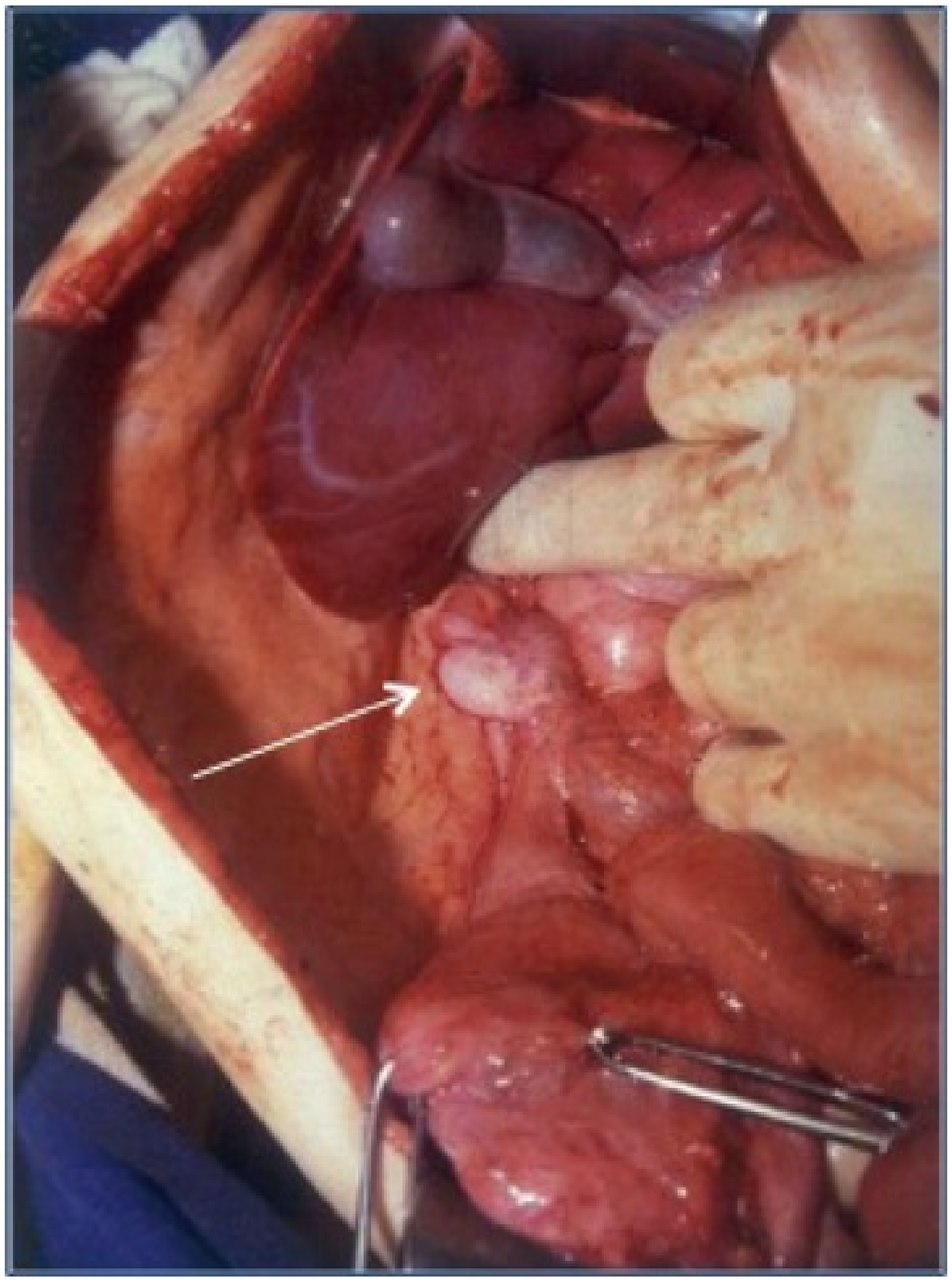

FIG. 32.7 Cryptorchid right testis lying high in the abdominal cavity *(arrow)*.

Pak et al. (1993) compared the histology of the testes in patients with PBS with that of non-prune-belly intra-abdominal testes and that of age-matched control subjects. **They found no difference in germ cell counts, Ad spermatogonia, and Leydig cells between PBS testes and non-PBS intra-abdominal testes. However, because germ cell counts in patients with PBS who are younger than 1 year are similar to those of age-matched controls, the implication is that the environmental state of the abdomen is a major factor in their later spermatogenic potential** (Coplen et al., 1996; Nunn and Stephens, 1961). This mirrors findings of Nunn and Stephens (1961) of normal germinal epithelium of fetal and newborn PBS testes. Alternatively, Orvis et al. (1988) noted decreased numbers of spermatogonia and Leydig cell hyperplasia in fetal PBS testes, implying an intrinsic testicular abnormality. Another study also showed a lower concentration of Leydig cells in the testes of PBS fetuses (Favorito et al., 2017).

Azoospermia is usually found in adult patients with PBS, and no patient with PBS has been reported to have spontaneously fathered a child (Woodhouse and Snyder, 1985). The infertility is thought to be due to a combination of testicular histologic abnormalities, structural defects of the ducts, and prostatic abnormalities also associated to retrograde ejaculation (Tayakkanonta, 1963). More recently, paternity with normal live births was documented in adult patients with classic PBS, achieved by sperm retrieval techniques and intracytoplasmic sperm injection (Fleming et al., 2013; Kolettis et al., 1999). Normal pregnancy with assisted vaginal delivery was also described in a female patient with the syndrome (Hillman et al., 2012).

Three cases of testis tumor have been reported (Parra et al., 1991; Sayre et al., 1986; Woodhouse and Ransley, 1983). Massad et al. (1991) described histologic testicular patterns similar to those in intratubular germ cell neoplasia in three infants. Although the risk of malignancy may be relatively low considering the lack of germinal epithelium (Uehling et al., 1984), it is clear that placement of the testis in the scrotum and long-term follow-up are necessary to reduce the risk of testicular malignancy and enhance detection.

Extragenitourinary Abnormalities

Of all children with PBS, 75% have non–urinary tract abnormalities (Geary et al., 1986). After the obvious abdominal wall defect, the most common issues are cardiac, pulmonary, and orthopedic (Table 32.1). In addition to these organ specific morbidities, nearly 50% of children with PBS are born premature, which significantly contributes to comorbidities.

TABLE 32.1

Nonurologic Associated Abnormalities in Children With Prune-Belly Syndrome

COMORBID CONDITION	PATIENTS WITH PBS (%)
Cardiovascular	25
Dermatologic	2
Gastrointestinal	24
Head, eyes, ears, nose, and throat	5
Hematologic	4
Immunologic/inflammatory	5
Metabolic/endocrine	22

Musculoskeletal	23
Neurologic	5
Other syndrome	6
Prematurity	43
Weight (g)	
• <2000	26
• 2000–2500	30
• >2500	42
Respiratory	58
Sepsis/infectious disease	14

PBS, Prune-belly syndrome.

Data from Routh JC, Huang L, Retik AB, Nelson CP: Contemporary epidemiology and characterization of newborn males with prune belly syndrome. *Urology.* 76:44–48, 2010.

Abdominal Wall Defect

The appearance of the abdominal wall gives newborns with PBS their most characteristic feature (Fig. 32.8). Although in some cases the musculature of the abdominal wall may be totally absent (Manivel et al., 1989), most commonly there is uneven involvement with the medial and inferior muscular segments typically most deficient (Mininberg et al., 1973; Randolph, 1977). The appearance at birth is that of wrinkled, redundant skin with an abdomen that bulges in the flanks. One may be able to discern intra-abdominal organs through the thinned abdominal wall. **The most severely affected areas may have skin, subcutaneous fat, and a single fibrous layer on the peritoneum** (Baird and Sadovnick, 1987; Mininberg et al., 1973). **Randolph conducted electromyographic mapping and demonstrated the inferior and medial segments to be most consistently affected** (Randolph et al., 1981a). Electron microscopy has demonstrated a nonspecific pattern of myofilament disarray, Z-line disorganization, and mitochondrial proliferation (Afifi et al., 1972; Randolph et al., 1981b; Woodard and Smith, 1998). The fact that normal spinal anterior horn cells have been shown rules out a neuropathic cause for the muscular deficiency (Nunn and Stephens, 1961). However, the muscular deficiency is typically inconsistent and patchy, and as mentioned earlier, may be disproportional to the abnormalities of the urinary tract.

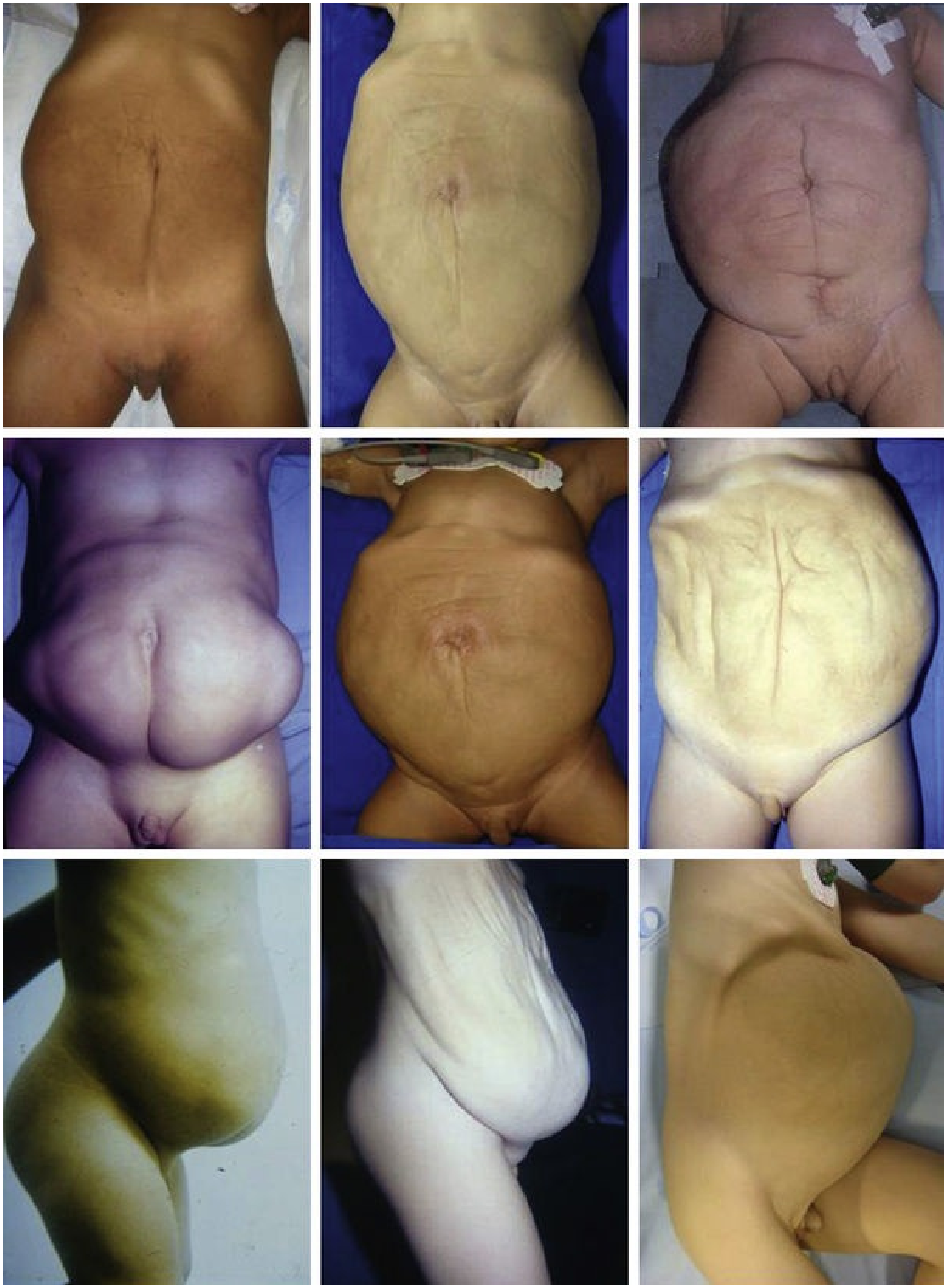

FIG. 32.8 The variability of the abdominal wall defect in patients with prune-belly syndrome.

As the patients grow, some of them show improved abdominal tonus and appearance with fewer wrinkles, whereas in others the abdomen takes on more of a pot-belly appearance (Fig. 32.9). Gait is usually not affected, although it may be delayed, and the children tend to roll to their side and use their arms to sit from a supine position. The poor support of the lower chest wall results in flaring of the costal margin (Woodard and Smith, 1998). These children are more vulnerable to respiratory illness because their cough effectiveness is compromised. In spite of these abdominal wall issues, Woodard and Smith (1998) reported good wound healing without a tendency toward infections or incisional hernias.

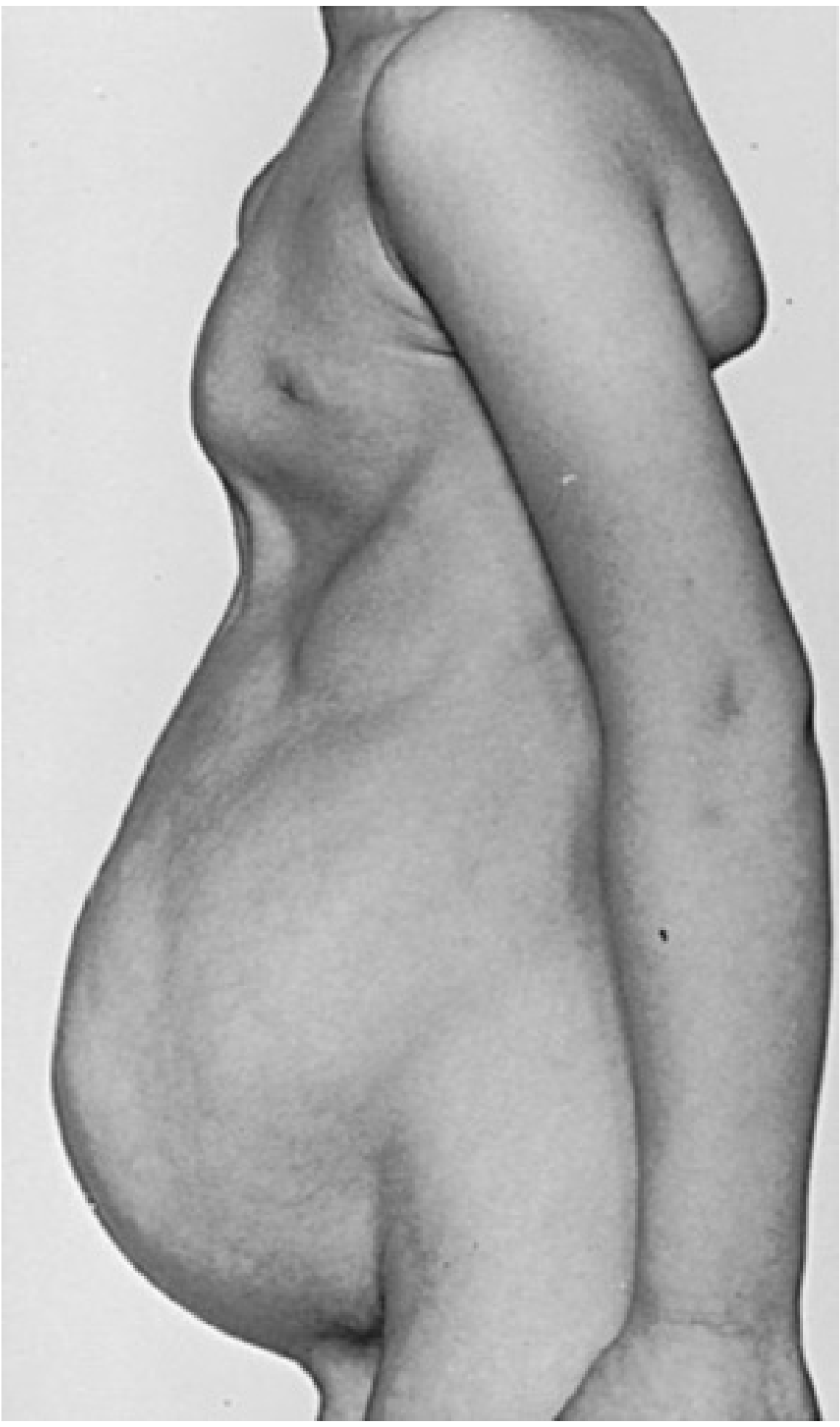

FIG. 32.9 Older child with prune-belly syndrome, showing the absence of wrinkling, the "pot-belly" appearance, and the consequent deformity of the lower ribs.

Cardiac Anomalies

Cardiac anomalies such as patent ductus arteriosus, atrial and ventricular septal defects, ventricular septal defect, and tetralogy of Fallot occur in 10% of children with PBS (Adebonojo, 1973). Cardiac abnormalities at birth may take precedence over urologic issues.

Pulmonary Abnormalities

Pulmonary difficulties can be observed at any age in patients with PBS. **Pulmonary hypoplasia can result from severe oligohydramnios related to renal dysplasia or severe bladder outlet obstruction and may result in newborn demise. In addition, pneumothorax and pneumomediastinum can be seen with or without pulmonary hypoplasia** (Skoog, 1992). **Significant pulmonary difficulties have been reported in 55% of PBS survivors** (Geary et al., 1986, Routh, 2010). In nearly half of newborns with PBS, intubation and mechanical ventilatory support will be required with its attendant morbidities (Routh et al., 2010).

The lack of ability to generate significant intra-abdominal pressure may contribute to pneumonia and lobar atelectasis (Alford et al., 1978; Ewig et al., 1996). Acute respiratory illnesses or anesthetic procedures can easily lead to respiratory infections and insufficiency in the patient with PBS, who may have underlying chronic bronchitis from repeated respiratory problems and impaired cough mechanism. Many patients demonstrate significant restrictive lung disease secondary to associated musculoskeletal abnormalities such as scoliosis and rib cage abnormalities, most commonly *pectus excavatum* (Coplen et al., 1996; Fig. 32.10).

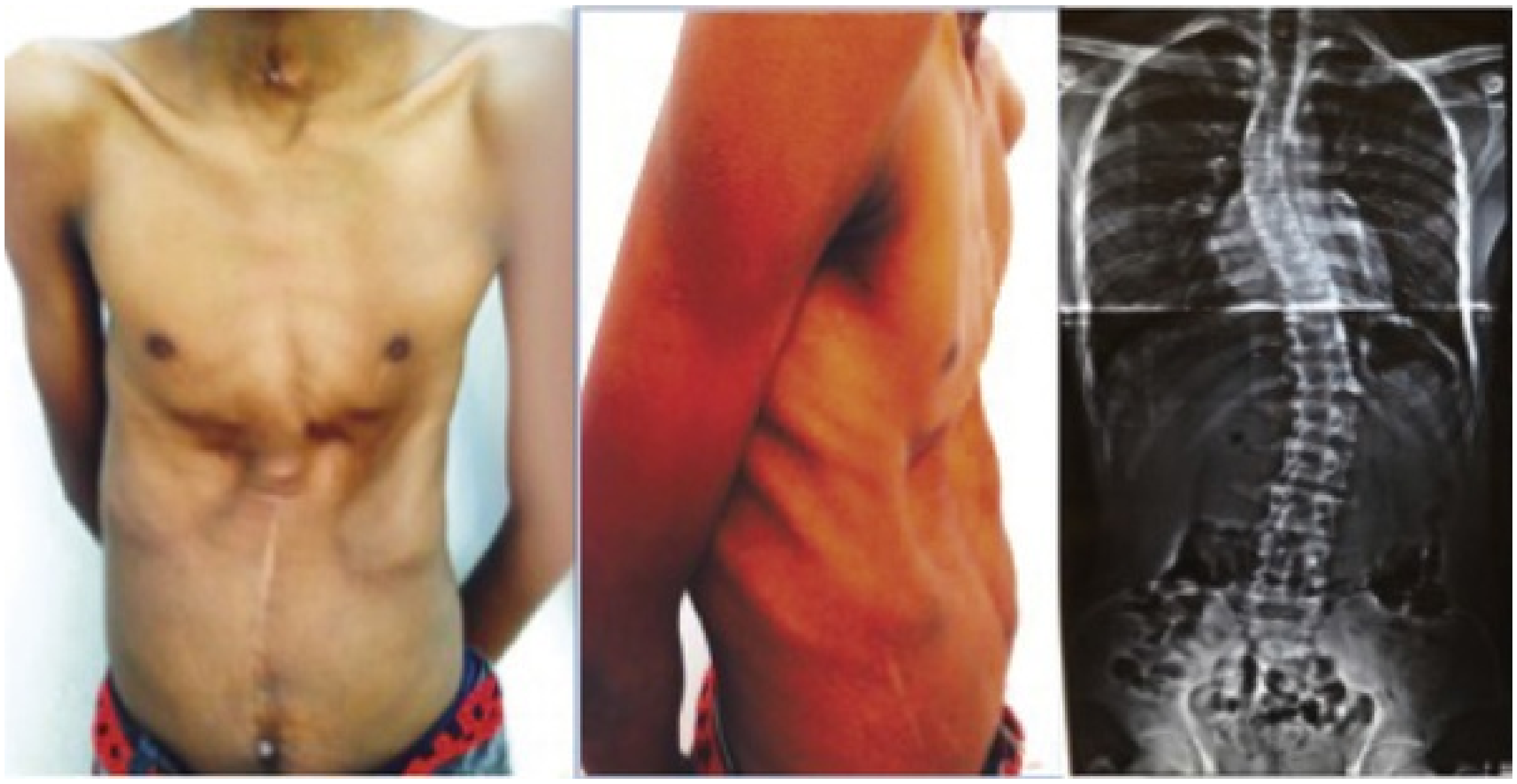

FIG. 32.10 Older child with *pectus scavatum* and scoliosis (note scars from previous tracheostomy and abdominoplasty, as well as a umbilical appendicovesicostomy).

Gastrointestinal Abnormalities

In at least 30% of cases, gastrointestinal anomalies are observed. The majority of the anomalies result from incomplete rotation of the midgut giving way to a wide mesentery, which results in increased bowel mobility with intestinal malrotation, volvulus, atresias, and stenosis (Silverman and Huang, 1950; Wright et al., 1986). Splenic torsion related to abnormal mesenteric fixation has also been reported (Heydenrych and Du Toit, 1978; Teramoto et al., 1981, Tran et al., 2013). Omphalocele, gastroschisis, situs inversus abdominis, VACTERL (vertebral defects, anal atresia, cardiac defects, tracheoesophageal fistula, renal anomalies, and limb abnormalities) and anorectal abnormalities have been reported (Awad and Lall, 2016; Morgan et al., 1978; Petersen et al., 1972; Ramagopal et al., 2016; Short et al., 1985; Walker et al., 1987; Wilbert et al., 1978; Fig. 32.11). With a limited ability to generate intra-abdominal pressure as a result of the abdominal muscular hypoplasia, constipation becomes a lifelong problem and may lead to acquired megacolon (Woodard and Smith, 1998).

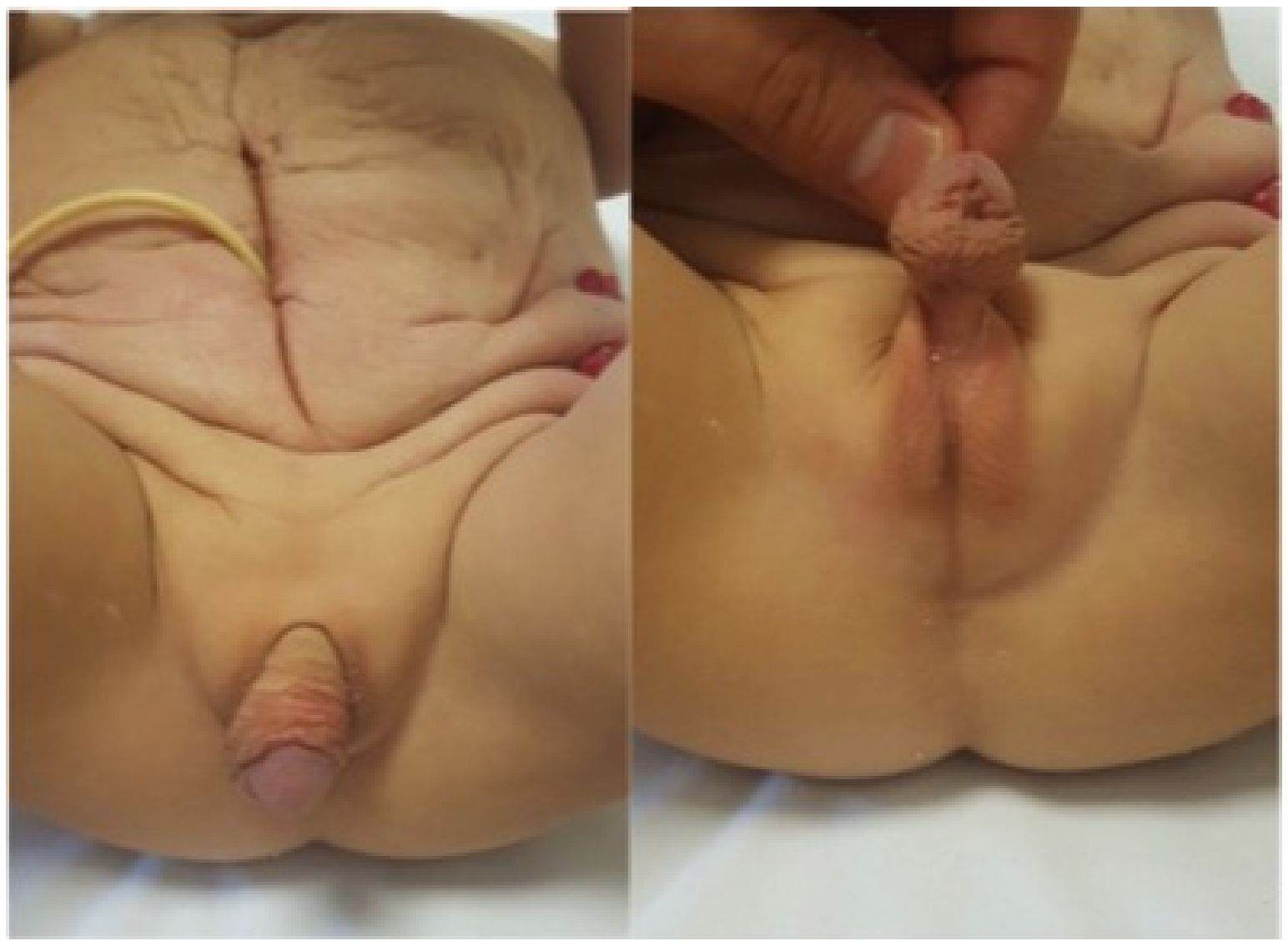

FIG. 32.11 Patient with prune-belly syndrome and associated anal imperforation.

Orthopedic Abnormalities

Orthopedic abnormalities, ranging in incidence up to 65% in contemporary series, are second in frequency to those of the genitourinary tract and abdominal wall (Grimsby et al., 2015). Some think the musculoskeletal defects result from the abnormal mesenchymal development at 6 weeks of gestation (Loder et al., 1992). Green et al. (1993), however, pointed out that because many of the deformities are unilateral, the most likely cause is the compressive effect of oligohydramnios. Oligohydramnios may also result in *talipes equinovarus* (26%), hip dysplasia (5%), and congenital scoliosis (4%) (Woodard and Smith, 1998). Dimpling of the lateral aspect of the knees is a common finding in oligohydramnios and is frequent in patients with PBS (Fig. 32.12). It has also been proposed that a distended bladder that impinges on the external iliac vessels may compromise the blood supply to the lower extremities and, in severely affected cases, result in lower extremity hypoplasia, absence, or amputation (Green et al., 1993; Smith, 1913) (Fig. 32.13). Some malformations tend to manifest or worsen with growth, such as renal osteodystrophy, dislocation of the hip, scoliosis, and pectus excavatum or carinatum (Green et al., 1993; Loder et al., 1992).

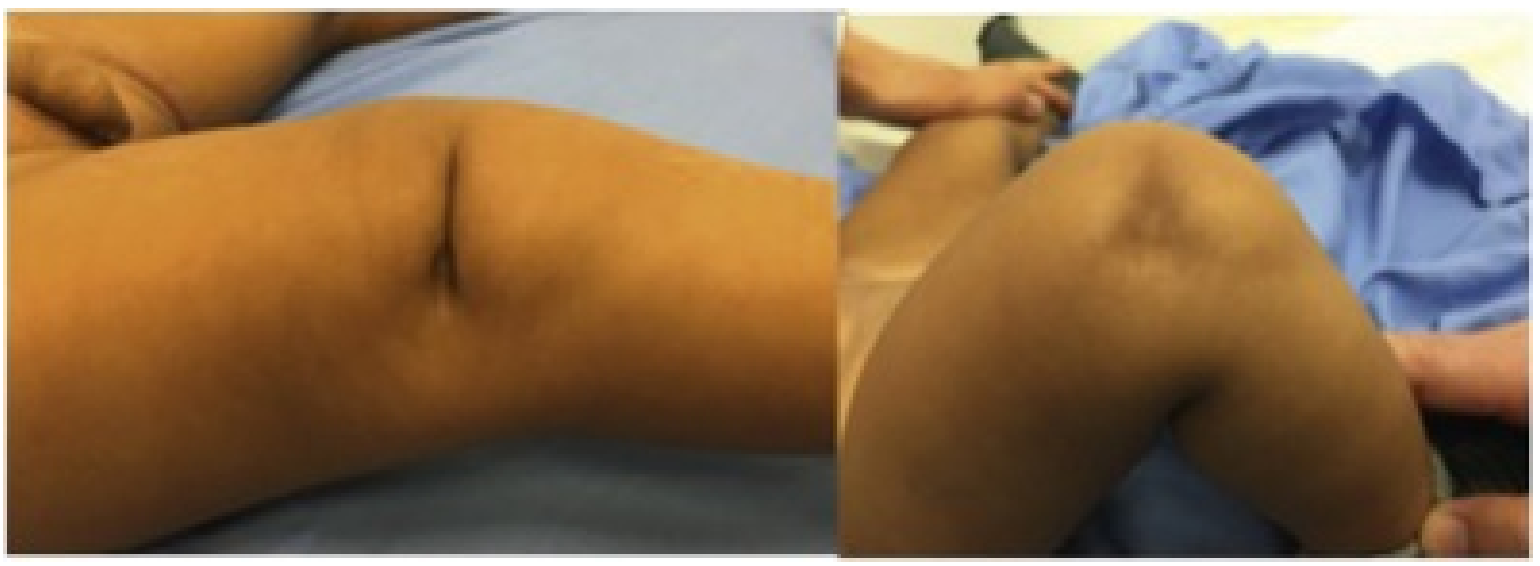

FIG. 32.12 Knee dimple (right leg), a characteristic finding in patients with the prune-belly syndrome.

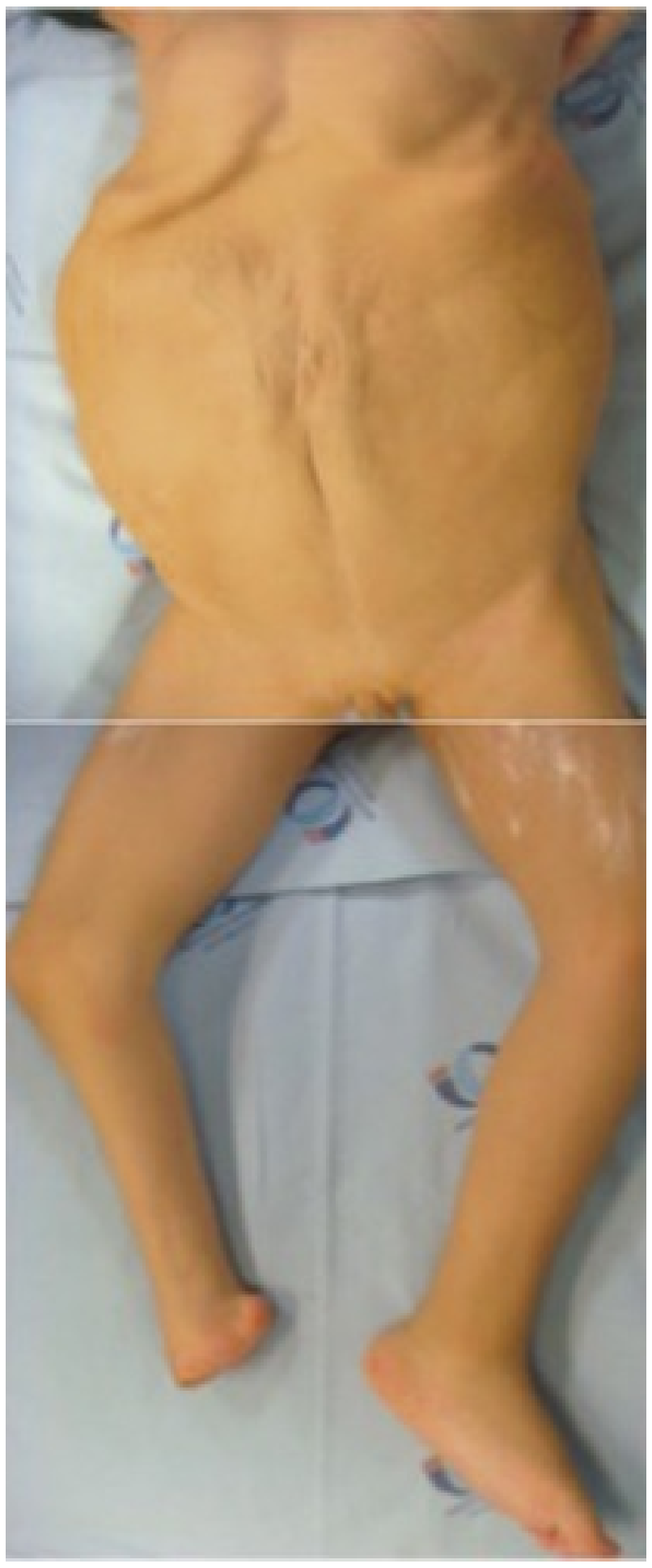

FIG. 32.13 Right foot amputation in a patient with the prune-belly syndrome.

Oral Abnormalities

There are reports on oral manifestations of the syndrome, including dental and bone abnormalities (Basso et al., 2012; Pessoa and Galvão, 2013).

Key Points: Associated Abnormalities

- Megalourethra is more commonly seen in PBS than any other syndrome. With the scaphoid variety, the ventral urethra dilates with voiding, whereas with the fusiform variety, the entire phallus dilates with voiding.
- Infertility is thought to be due to a combination of testicular histologic abnormalities, structural defects of the ducts, and prostatic abnormalities and retrograde ejaculation.
- Pulmonary hypoplasia can result from severe oligohydramnios related to renal dysplasia or severe bladder outlet obstruction and may result in newborn demise.
- Although one of the hallmarks of the syndrome, the abdominal flaccidity has no direct relationship with the intensity of the urologic abnormalities and does not impair the short and long-term survival of the patient. Together with the orthopedic abnormalities, if significant and left untreated, it may cause a decrease in the quality of life in the adolescent and adult patients.

Presentation

Prenatal Diagnosis and Management

Prenatal ultrasonography has played a major role in the identification of congenital genitourinary abnormalities. Fetal hydronephrosis can be diagnosed accurately in the second trimester and is present in approximately 1% of all pregnancies. However, the cause of the hydronephrosis cannot be accurately determined in all cases. Elder (1990) estimated that the accuracy of determining the cause of fetal hydronephrosis varies from 30% to 85%.

In particular, PBS occurs prenatally with findings similar to those of other causes of bladder outlet obstruction (Fig. 32.14), **as in posterior urethral valves or megacystis-megaureter syndrome** (Kramer, 1983). **Although an accurate diagnosis of PBS has been made as early as 11 to 14 weeks of gestation** (Shimizu et al., 1992; Yamamoto et al., 2001; Fig. 32.15), **the classic findings of hydroureteronephrosis, a distended bladder, and irregular abdominal circumference are not consistently seen at 30 weeks** (Bovicelli et al., 1980; Christopher et al., 1982; Okulski, 1977; Shih et al., 1982). Early fetal ascites has been suggested to correlate with PBS (Scarbrough et al., 1988). The majority of patients with PBS do not have demonstrable urinary obstruction, and the degree of hydroureteronephrosis does not correlate with the postnatal renal function (Gadziala et al., 1982).

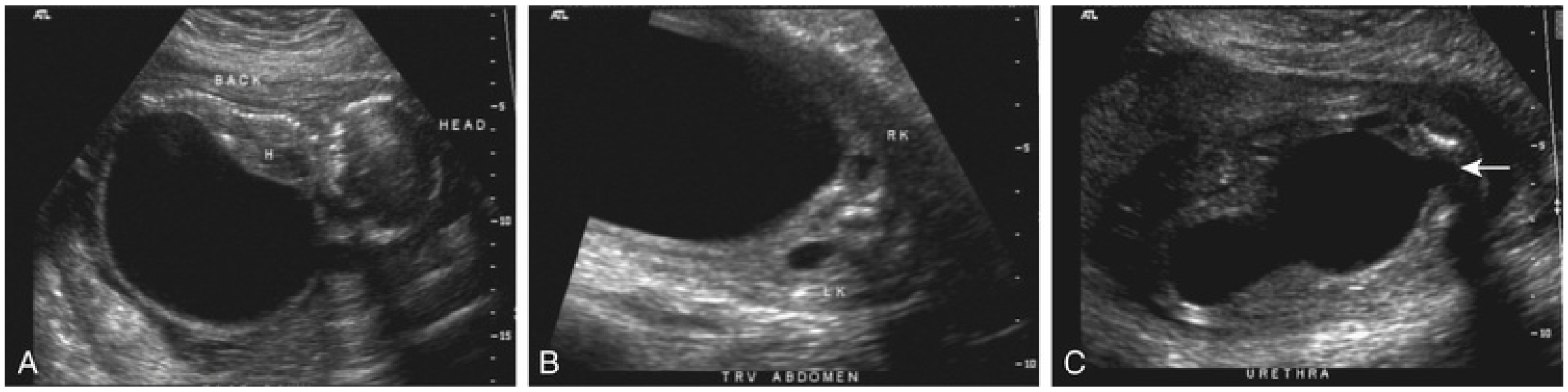

FIG. 32.14 Prenatal sonogram of a fetus with prune-belly syndrome. (A) Massively dilated bladder that fills most of the abdominal cavity. Note the lack of amniotic fluid. (B) The cephalic portion of the bladder reaching the level of both kidneys with hydronephrosis and renal parenchyma noted. (C) A dilated bladder with a urachal diverticulum *(arrow)* and an elongated and dilated posterior urethra. (Courtesy C. Peters.)

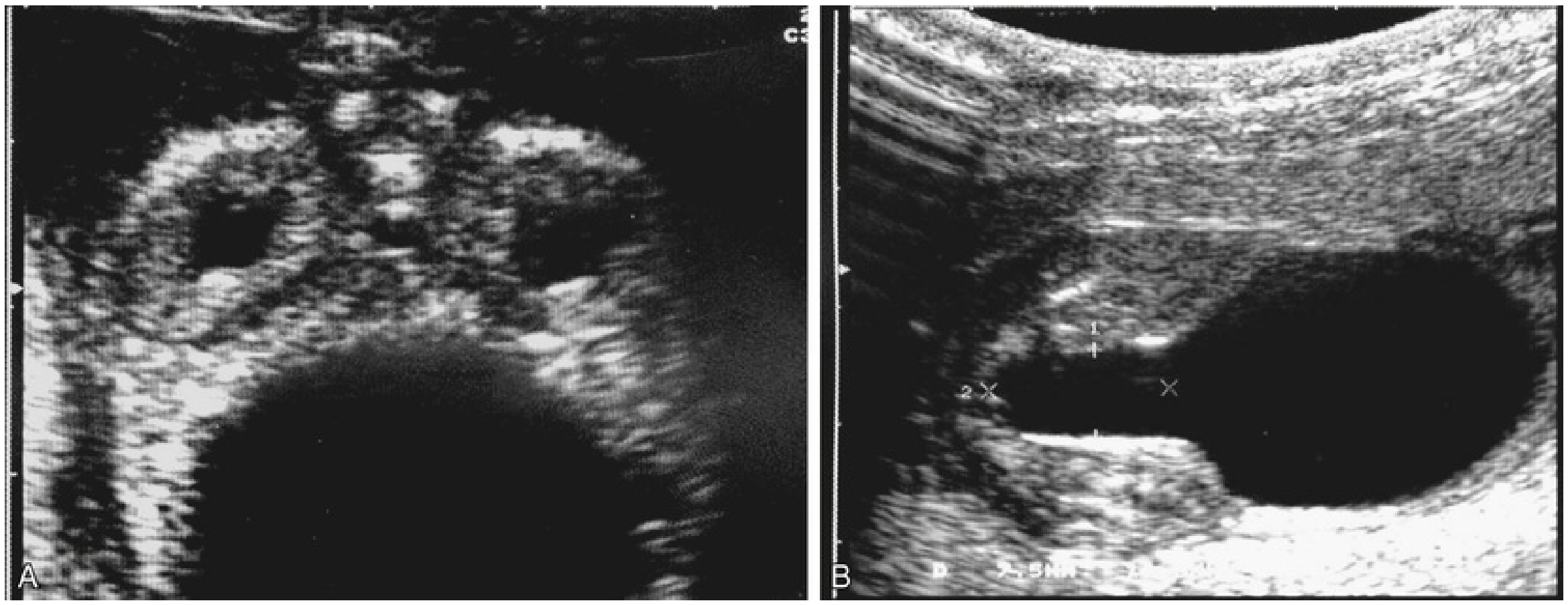

FIG. 32.15 (A) Fetus with prune-belly syndrome demonstrating distended bladder with hydronephrotic echogenic kidneys. (B) Distended bladder with dilated prostatic urethra indicative of outlet obstruction from urethral atresia. (Courtesy E. Ruiz.)

Whereas some have recommended in utero intervention for relief of urinary tract dilation and oligohydramnios (Estes and Harrison, 1993; Gadziala et al., 1982; Glazer et al., 1982; Leeners et al., 2000; Nakayama et al., 1984; Scarborough et al., 1988), others have recommended termination of pregnancy (Pescia et al., 1982). **Nevertheless, it is difficult to justify the advocacy of pregnancy termination in light of our inability to diagnose precisely the cause of prenatal hydronephrosis and inability to predict postnatal renal function on the basis of the degree of urinary tract dilation, except in rare cases of early and severe oligohydramnios.** Prenatal intervention has been applied to PBS with no proven benefit in terms of postnatal renal function (Biard et al., 2005; Blaicher et al., 2005; Elder et al., 1987; Freedman et al., 1999; Sholder et al., 1988). The only circumstances in which prenatal intervention may be justified are the rare situations of urethral atresia with progressive oligohydramnios (Perez-Brayfield et al., 2001; Reinberg et al., 1993; Steinhardt et al., 1990) or cases in which decompression of the urinary tract is necessary to prevent dystocia (Gadziala et al., 1982).

Neonatal Presentation

The appearance of the abdominal wall immediately suggests the diagnosis of PBS (see Fig. 32.7), whether or not the diagnosis was suspected prenatally. Other associated abnormalities such as cardiac or pulmonary should take precedence over the urinary tract because, in the absence of true bladder outlet obstruction, as seen with urethral atresia, the hydroureteronephrosis is not life threatening.

Spectrum of Disease

With the number of variable anomalies present in PBS, it is understandable that there is a wide spectrum of clinical presentations. The three major categories of presentation in the neonatal period were described by Woodard (1985; Table 32.2).

TABLE 32.2

Spectrum of Prune-Belly Syndrome

CATEGORY	CHARACTERISTICS
I	Renal dysplasia
	Oligohydramnios
	Pulmonary hypoplasia
	Potter features
	Urethral atresia
II	Full triad features
	Minimal or unilateral renal dysplasia
	No pulmonary hypoplasia
	May progress to renal failure
III	Incomplete or mild triad features
	Mild to moderate uropathy
	No renal dysplasia
	Stable renal function
	No pulmonary hypoplasia

Category I

Category I consists of neonates who have experienced marked oligohydramnios as a result of renal dysplasia or severe bladder outlet obstruction with resultant pulmonary hypoplasia and skeletal abnormalities. Most infants with urethral atresia fall in this category. The exceptions to this are patients with urethral atresia and a patent urachus (Rogers and Ostrow, 1973). Those in this category who are not stillborn commonly succumb within a few days of life to pulmonary hypoplasia or later to renal failure. Approximately 20% of newborns with PBS die in the perinatal period

(Burbige et al., 1987; Fallat et al., 1989; Woodard and Parrott, 1978b). It would be unusual for any urologic intervention in this category of patients to alter the course of events. Simple catheter drainage is all that is justifiable.

Category II

Category II patients demonstrate the full spectrum of the disorder with moderate or unilateral renal insufficiency and moderate to severe hydroureteronephrosis. Pulmonary hypoplasia is not a prominent feature of this group of patients. The clinical course is that of stabilization of renal function at or somewhat below normal or progressive azotemia. The presence of significant hydroureteronephrosis, vesicoureteral reflux, and postvoid residual, causing urinary tract infection, is associated with recurrent pyelonephritis, which further compromises renal function. It is in this group of patients that significant controversy over management exists (Randolph, 1977; Waldbaum and Marshall, 1970; Woodard and Parrott, 1978b).

Category III

Category III consists of patients with mild features of the triad or incomplete forms of PBS. This category comprises the majority of patients with PBS in whom hydroureteronephrosis is present to some degree but renal function is well maintained (Woodard, 1998; Woodhouse et al., 1982). **There is no evidence of pulmonary insufficiency.** There is little controversy that urologic intervention in the group is reserved for patients who demonstrate repeated urinary tract infections, probably related to urinary stasis or vesicoureteral reflux, or development of upper tract deterioration (Woodard and Smith, 1998). As previously noted, there is poor correlation between the extent of abdominal wall deficit and the degree of hydronephrosis or renal dysplasia, or both. This is also apparent in other variants of the syndrome. Some children have markedly dilated urinary tracts with minimal or no dysplasia and therefore normal renal function. Therefore the appearance of the abdominal wall or the degree of hydronephrosis may have little bearing on the long-term prognosis of children with PBS.

Incomplete Syndrome

Patients with incomplete syndrome are males who may not have all the features of the triad syndrome but share other features. Some of them, also called *pseudo* *prune* patients, have unilateral abdominal wall deficiency and unilateral undescended testis (Grover et al., 2017). **Most typically, these incomplete forms of the syndrome lack the typical abdominal wall features but have the common uropathy and cryptorchidism. Many of these patients may experience renal failure and therefore require close observation, monitoring, and selective intervention.** Bellah reported a relatively high (8/15) tendency to progressive renal failure in his population of pseudo prune patients. This may be partially attributed to a delay in diagnosis in the absence of the obvious abdominal musculature deficiency and therefore a tendency to experience recurring urinary tract infections (Bellah et al., 1996).

Adult Presentation

Patients with incomplete forms of PBS and specifically those who lack the abdominal wall features may seek medical assistance as late as adulthood with symptoms of renal failure and hypertension (Kerbl and Pauer, 1993; Lee, 1977). Although there have been isolated reports of adults with no history of urinary tract infections, most who present in adulthood eventually develop urinary tract infections from the chronic urinary stasis associated with the syndrome (Culp and Flocks, 1954).

Female Syndrome

Five percent of patients with PBS are female, most of whom have abdominal wall deficiency and an abnormal urinary tract (Reinberg et al., 1991b). Rabinowitz and Schillinger (1977) reported female patients with the typical abdominal wall deficit and a normal urinary tract. In the series of Reinberg et al. (1991b), bladder outlet obstruction was commonly seen along with a 40% occurrence of anorectal anomalies similar to the statistics for the male; 40% did not survive the newborn period.

Evaluation and Management

Initial Management

The initial evaluation of the newborn with PBS requires a team consisting of a neonatologist, a nephrologist, and a urologist. Other specialists, particularly a cardiologist, may be indicated. Early orthopedic evaluation is also warranted. The major initial concern is that of management of cardiac and respiratory issues. An immediate chest radiograph is necessary to exclude commonly associated pulmonary abnormalities such as pneumothorax, pneumomediastinum, and pulmonary hypoplasia, which is commonly a result of oligohydramnios (Perlman and Levin, 1974). Early urologic intervention is indicated only for neonates with evidence of bladder outlet obstruction, in whom a percutaneous suprapubic tube can be inserted in the neonatal intensive care unit.

Initial evaluation of renal function and the urinary tract status is important but must be tempered by transitional neonatal physiology. Although an initial creatinine level is important in establishing a baseline, it may be more reflective of the mother's renal function, and therefore the trend in creatinine levels over the course of the early postnatal days or weeks is much more predictive of long-term renal function.

Serum creatinine, blood urea nitrogen (BUN), and electrolytes are necessary to assess for the potential systemic acidosis and electrolyte imbalances that may be seen in renal insufficiency. It has been shown in multiple reports that a baseline creatinine level of less than 0.7 mg/dL is predictive of adequate renal function through childhood in the absence of repeated insults from pyelonephritis (Geary et al., 1986; Noh et al., 1999; Reinberg et al., 1991a).

Early renal and bladder ultrasonography, once the newborn is stabilized, is necessary to assess the renal parenchyma for its thickness, density, and presence or absence of cortical cysts and degree of urinary tract dilation (see Fig. 32.1).

Avoidance of urinary tract infection is essential because of urinary stasis and often compromised baseline renal function. Circumcision is advisable in the absence of a structural penile abnormality to reduce the risk of infant urinary tract infections. Similarly, prophylactic antibiotic therapy is recommended, especially before urinary tract instrumentation, including

the initial voiding cystourethrogram (VCUG). Although instrumentation without a defined purpose that may alter management should be avoided, a VCUG to assess the bladder outlet and bladder emptying ability, especially in the presence of renal insufficiency, is warranted (Woodard and Smith, 1998). The VCUG is necessary in neonates with renal insufficiency to rule out bladder outlet obstruction as the cause versus urinary stagnation. In up to 70% of children with PBS, vesicoureteral reflux is diagnosed (Berdon et al., 1977; Fallat et al., 1989). A recent study reported the usefulness of magnetic resonance urography (MRU) in revealing significant anatomic and functional findings that were not readily apparent when using standard imaging for children with PBS, such as calyceal diverticula, abnormal renal pelvic anatomy, and particularly renal dysplasia, which is poorly characterized in the PBS population outside of renal biopsy studies (Garcia-Roig et al., 2016). Therefore MRU may provide a more detailed assessment than isolated kidney and bladder ultrasonography, excretory urography, or renal nuclear scan techniques. Disadvantages of MRU are the need for gadolinium (with contrast-associated risks, including the rare occurrence of nephrogenic systemic fibrosis), its high cost and availability, and the need for sedation (Garcia-Roig et al., 2016).

Any instrumentation should be carried out with strict attention to sterile technique to reduce the risk of inoculation of a static urinary system. An early VCUG is not necessary in the presence of normal renal function and evidence of adequate bladder drainage per urethra or a patent urachus.

Key Points: Initial Management

- A team consisting of neonatology, nephrology, urology, and other specialties such as cardiology is necessary.
- A VCUG is indicated in the neonatal period if there is renal insufficiency or evidence of bladder outlet obstruction and only after antibiotic prophylaxis.
- A chest radiograph to evaluate for pneumothorax, pneumomediastinum, and pulmonary hypoplasia is necessary.
- Baseline assessment of renal function should include renal and bladder ultrasonography, BUN, creatinine, and electrolytes.
- Circumcision is advisable in the absence of a structural penile abnormality.
- Early intervention is indicated for evidence of bladder outlet obstruction and

preferably with a percutaneous suprapubic tube.

As noted, neonates can be categorized on the basis of their spectrum of disease (see Table 32.1). *Category I:* There is little disagreement on the management of category I patients with PBS because there is no evidence that anything beyond supportive care is justifiable. In particular, intervention in the urinary tract is not indicated beyond simple bladder drainage because the fate of these patients usually cannot be altered (Woodard and Smith, 1998).

Category III: At the other end of the spectrum, category III patients rarely require early urologic intervention for the urinary tract because they are in a balanced state of hydronephrosis with good, if not normal, renal function. Children in this category require regular monitoring of urinary tract dilation (ultrasonography) and renal function (serum creatinine), as well as urinary tract infection. However, their cryptorchidism requires correction during the first year of life. Some of these patients have persistent vesicoureteral reflux that may require surgical treatment on mid- to long-term follow-up, if symptomatic. Others will also benefit from abdominoplasty (▶Video 32.1) because they may have significant flaccidity that persists or worsens during childhood.

Category II: These patients require individualized evaluation and management on the basis of the fact that within this category there are variable degrees of severity of each facet of PBS. There is, however, much controversy over their management. Evaluation of renal function or renal drainage, or both, is required in those with renal insufficiency. Excretory urography, although providing dramatic images of the urinary tract (see Fig. 32.3), does not provide sufficient information on comparative function. Renal parenchymal function is best assessed by a technetium-99m (^{99m}Tc)-dimercaptosuccinic acid (DMSA) renal scan at 4 to 6 weeks of age to prevent difficulties in interpretation related to transitional neonatal physiology. Renal outflow obstruction is best assessed by ^{99m}Tc-mercaptoacetyltriglycine (MAG3), which also provides an assessment of comparative renal function with massive hydronephrosis and resultant stasis. In the presence of poor renal function, assessment of renal outflow obstruction by nuclear scan techniques may be limited; therefore selective use of the Whitaker antegrade perfusion test may be helpful.

Aggressive surgical intervention was initially derived from early observations of the unfavorable mid- and long-term prognosis for category II infants as a group. Compilation of the cases reported in the literature between 1950 and 1970 by Waldbaum and Marshall (1970) revealed that 86% of the 56 accurately traceable patients had died, with or without surgical intervention. The obvious implication was that a more aggressive approach was necessary to improve the fate of the infant with PBS. With the recognition that infection and progressive renal insufficiency are the factors that most often pose the greatest threat to quality of life and survival, surgical reconstruction to normalize the anatomy and function of the genitourinary tract was advocated. Early reconstruction of the urinary system to reduce stasis and eliminate reflux or obstruction has included ureteral shortening, infolding, and vesicoureteral reimplantation as well as reduction cystoplasty. Although rarely, eventual dysplastic or hydronephrotic kidneys with severely reduced function may require removal if symptomatic. Reconstruction is best delayed until the child is at least 3 months of age to allow for pulmonary maturation. This approach has been successful in achieving anatomic and functional improvement as evidenced by stable radiographic studies, stable creatinine values, and a reduced occurrence of infection (Jeffs et al., 1977; Randolph et al., 1981b; Waldbaum and Marshall, 1970; Woodard and Parrott, 1978b). Early urinary tract reconstruction can be done comprehensively with orchiopexy, abdominoplasty, and circumcision without increasing the morbidity of the procedure. In a report of comprehensive reconstructive experience, 35 patients who have undergone urinary tract reconstruction have maintained a normal creatinine level, whereas 5 demonstrated moderate to severe renal insufficiency, and 3 required renal transplantation in a follow-up ranging from 15 months to 26 years (Lopes et al., 2015).

An alternative approach of limited surgical intervention has also been applied. Proponents advocate close surveillance with medical management of bacteriuria and surgical intervention only in patients with proven obstruction or intractable infection. Opinions vary about the management of vesicoureteral reflux in the PBS population. There is no reason to believe that reflux in this population is any less important, and correction of high-grade reflux seems prudent. Success with minimal surgical intervention has been reported (Duckett et al., 1980; McMullin et al., 1988; Tank and McCoy, 1983; Woodhouse et al., 1979). On the other hand, Woodhouse et al. (1979) reviewed a series of patients with PBS managed conservatively. Of these 11 patients, who were monitored from infancy, 9 remained well except for a few urinary tract infections for periods of up to 24 years. They were said to have normal voiding patterns and normal renal function. Certainly, patients in category III are candidates for this type of management.

The paucity of long-term data for category II patients, the probable variation in assignment of disease severity in treatment groups, and the variable natural history of the disease make comparisons of these retrospective studies difficult. **Spontaneous improvement in ureteral appearance and function may occur with normal growth and elongation of the ureters** (Duckett et al., 1980). **Also, some patients with gross abnormalities of the urinary collecting system have survived decades without medical attention** (Asplund and Laska, 1975; Lee, 1977; Texter and Koontz, 1980). **Yet progressive uropathy is also well known to occur, and many patients with PBS ultimately require renal transplantation** (Reinberg et al., 1989). Controversy will persist over category II patients until accurate application of a medical or surgical approach is possible on the basis of distinct clinical features. Lopes et al. (2015) emphasize the individualization of care in their 27-year experience with 46 patients.

Surgical Management of the Patient With Prune-Belly Syndrome

Surgical management of children with PBS can be divided into three categories: urinary tract procedures, orchiopexy, and abdominal wall reconstruction.

Urinary Tract

Urinary tract reconstruction is generally reserved for children with progressive or severe hydroureteronephrosis, high-grade vesicoureteral reflux, recurrent upper tract infections, true obstructive uropathy, and progressive renal failure. Temporary urinary diversion also has a role in the very young or the very ill child.

Urinary Diversion

Supravesical Urinary Diversion.

In some patients the occurrence of repeated upper tract infections or deterioration of renal function dictates the need for temporary urinary diversion. Although cutaneous vesicostomy usually provides adequate upper tract drainage and decompression, in rare instances more proximal diversion is indicated because of ureteropelvic or ureterovesical junction obstruction. In these settings, a cutaneous pyelostomy or a distal ureterostomy, respectively, are advocated rather than a proximal ureterostomy because they avoid sacrificing a normal proximal ureter that may be useful in later reconstruction.

Cutaneous Vesicostomy.

Urinary diversion may be necessary as a temporary measure in children with acute renal failure, urinary sepsis, or bladder outlet obstruction from urethral atresia with limited patency of the urachus (Fig. 32.16) (Joseph, 1999; Teramoto et al., 1981). **When temporary urinary diversion is indicated, a cutaneous vesicostomy is the procedure of choice. This is best done by the Blocksom technique as described by Duckett (1974) and Duckett et al. (1980).** If there is a large urachal diverticulum, it can be excised at that time. It is advisable to create a larger-than-normal stoma in the patient with PBS because stenosis is common, probably because of the decreased intra-abdominal pressure (Snow and Duckett, 1987).

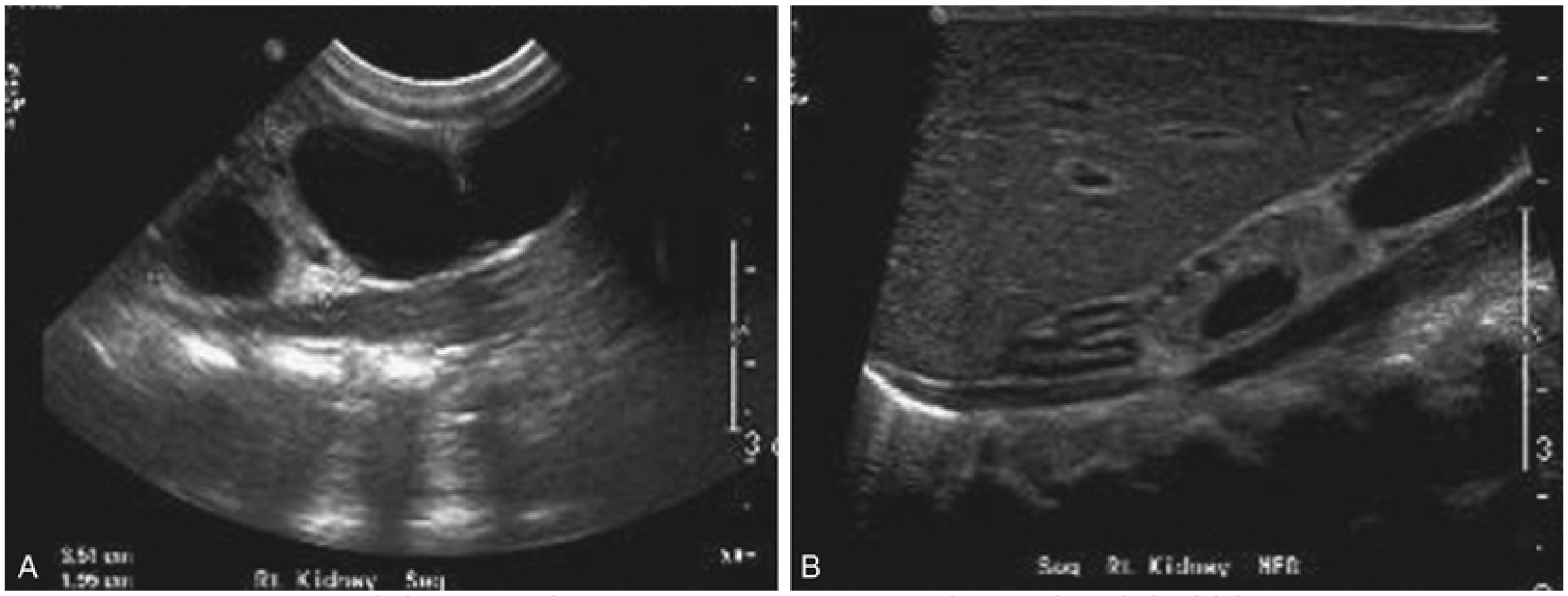

FIG. 32.16 (A) Prevesicostomy ultrasonography of the right kidney demonstrating massive hydronephrosis with echogenic parenchyma. (B) Postvesicostomy ultrasonography demonstrating a decompressed kidney with echogenic parenchyma and cortical cysts. (Courtesy C. Peters.)

Upper Urinary Tract Reconstruction

Ureteroplasty and Ureterocystoneostomy.

Ureteral remodeling remains controversial. It is best undertaken in children who demonstrated repeated nonsuppressible upper urinary tract infections or those with progressive anatomic or functional upper tract deterioration resulting from ureteral dilatation and tortuosity, frequently associated with vesicoureteral reflux (Fig. 32.17). **The goal of remodeling and reimplantation is to reduce urinary stasis and correct massive reflux.** The key to success relies on meticulous surgical technique and preservation of the upper few centimeters of proximal ureter, which are often less dilated, for reconstruction. Even then, tailoring or infolding of these segments may be necessary for adequate reimplantation into the abnormal bladder. This step can be difficult, in that the creation of a submucosal tunnel in the abnormal bladder for these ureters can be challenging (Woodard and Trulock, 1986).

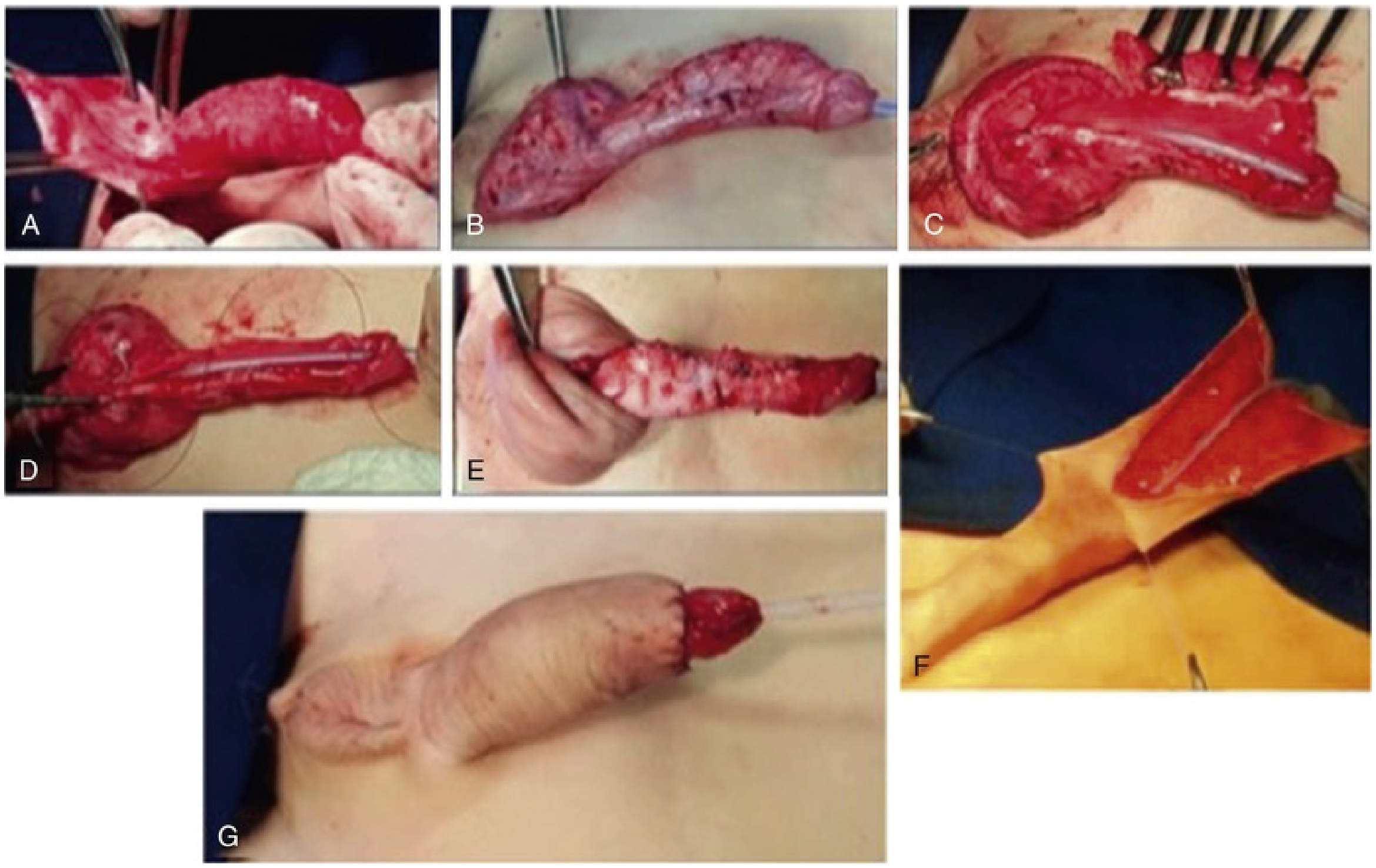

FIG. 32.17 Surgical correction of megalourethra in a patient with the prune-belly syndrome: (A) Penile deglovement. (B) Exposure of the scaphoid megalourethra. (C and D) Tailoring of the dilated urethral segment. (E) Completed urethroplasty. (F) Presentation of excessive preputial skin. (G) Completed procedure after urethroplasty and circumcision (note empty scrotum).

Pyeloplasty.

In cases with associated secondary ureteropelvic junction obstruction, proximal ureterolysis without compromising ureteral vascularization may decompress the renal pelvis. In those with true mechanical obstruction, a nondismembered ureteropyelostomy between the dilated pelvis and a normal upper ureteral segment may normalize urinary drainage.

Woodard et al. have demonstrated excellent success in this population when these procedures were performed in the neonatal period or in the older child

(Woodard and Parrott, 1978b; Woodard and Zucker, 1999). However, they no longer recommend such extensive reconstructive surgery before the age of 3 to 6 months. Fallat et al. (1989) as well as Lopes et al. (2015) have reported excellent results of extensive comprehensive surgery, including the reconstruction of the upper and lower urinary tracts, abdominoplasty, and orchiopexy in large groups of patients, with experiences ranging from 17 to 27 years that showed functional stabilization of the urinary tract in up to 90% of the children.

Lower Urinary Tract Reconstruction

Reduction Cystoplasty.

In many patients with PBS, poor bladder contractibility leads to incomplete and infrequent vesical emptying, further increasing urinary stasis or vesicoureteral reflux. This leads to the concept of reducing the size of the bladder and remodeling it into a more spheric shape to better direct the contractible forces (Perlmutter, 1976). A variety of approaches have been proposed, from simple excision of the urachal diverticulum to the excision of redundant mucosa with the creation of overlapping between flaps to improve contractibility (Williams and Parker, 1974; Woodard and Trulock, 1986). Over time, however, high bladder capacity and residual volumes seem to recur (Bukowski and Perlmutter, 1994). It seems therefore that reduction cystoplasty would be justified only to remove the larger urachal diverticulum or as part of a more extensive urinary tract reconstruction. In some patients, intermittent catheterization through the urethra or through an appendicovesicostomy channel is likely to afford better long-term bladder emptying with reduction of residual urinary volumes until the patient is able to achieve better voiding pressures with age or as a result of abdominoplasty (Joseph, 1999).

Internal Urethrotomy.

The normal resistance of the urinary sphincter has been implicated in “unbalanced” urethrovesical function, contributing to large postvoid residuals. Snyder and Cukier proposed lowering urethral resistance by internal urethrotomy to improve bladder emptying (Cukier, 1977; Snyder et al., 1976). In patients studied by urodynamic flow rate profilometry, improved flow rates with reduced residual urine and improvement in the radiographic appearance of the upper tracts were found (Snyder et al., 1976; Woodhouse et al., 1979). Internal urethrotomy has been considered in PBS children with high postvoid residuals, increasing hydroureteronephrosis, or vesicoureteral reflux with recurrent upper tract infections but sustained long-term success has not been demonstrated. Williams (1979) advocated using an Otis urethrotome achieving a No. 24- to 30-Fr caliber with one or two incisions made anteriorly or anterolaterally, whereas Smith and Woodard (2002) recommended direct visual urethrotomy at the distal end of the prostatic urethra. Interestingly, internal urethrotomy did not result in incontinence in this population. Despite these early reports, no further experience with urethrotomy has been described. It is difficult to imagine this procedure being performed in infants and small children currently.

Anterior Urethral Dilation or Reconstruction.

Urethral maldevelopment may be present as urethral atresia or hypoplasia (see Fig. 32.4). Patients with this abnormality may survive without any intervention but frequently require some form of treatment to improve bladder emptying. Passerini-Glazel et al. (1988) reported on progressive gentle urethral dilation with good success. This technique may be used in situ or through and through in cases in which a vesicostomy has been performed (Fig. 32.18). As reported by Reinberg et al. (1993), however, urethral dilation is not uniformly successful. More recently, Kajbafzadeh et al. (2010) reported significant improvement of the urethral caliber after one to three sessions of hydrodistention in patients with urethral hypoplasia. Although a reasonable alternative in difficult cases, there are no reports of formal urethroplasties with skin or mucosal grafts in patients with PBS.

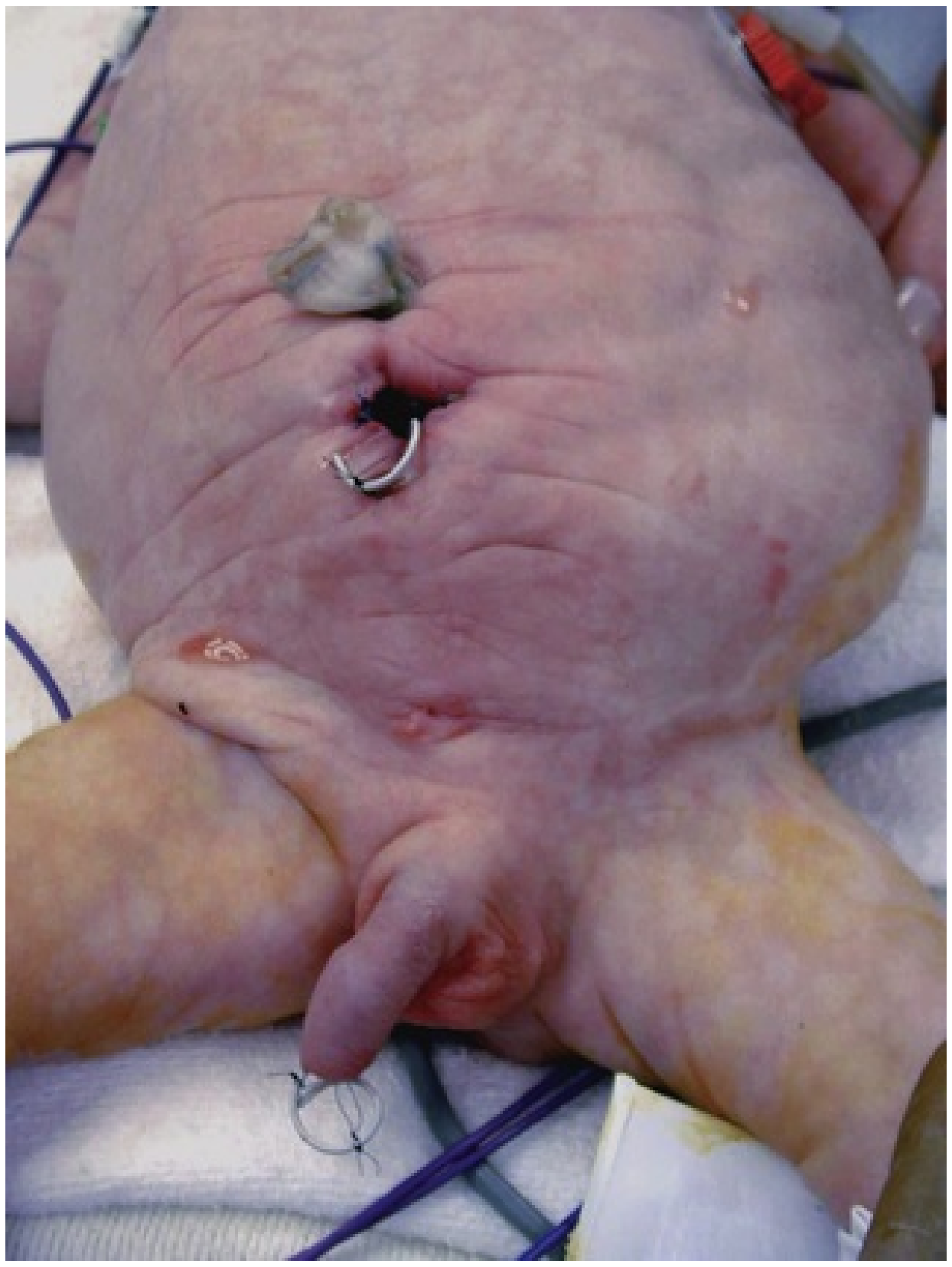

FIG. 32.18 Prune-belly syndrome patient with urethral atresia. Note vesicostomy and double-J stent through the urethra for progressive urethral dilation.

As noted previously, megalourethra in PBS is common, either in the fusiform or scaphoid types (Appel et al., 1986). This is best approached with a circumferential subcoronal incision and penile degloving (Fig. 32.19). The redundant urethra can be excised or infolded to provide support and reconstructed over an appropriately sized catheter. Alternatively, some of the urethra can be used to reinforce the urethroplasty because in either form of megalourethra the spongiosum is deficient.

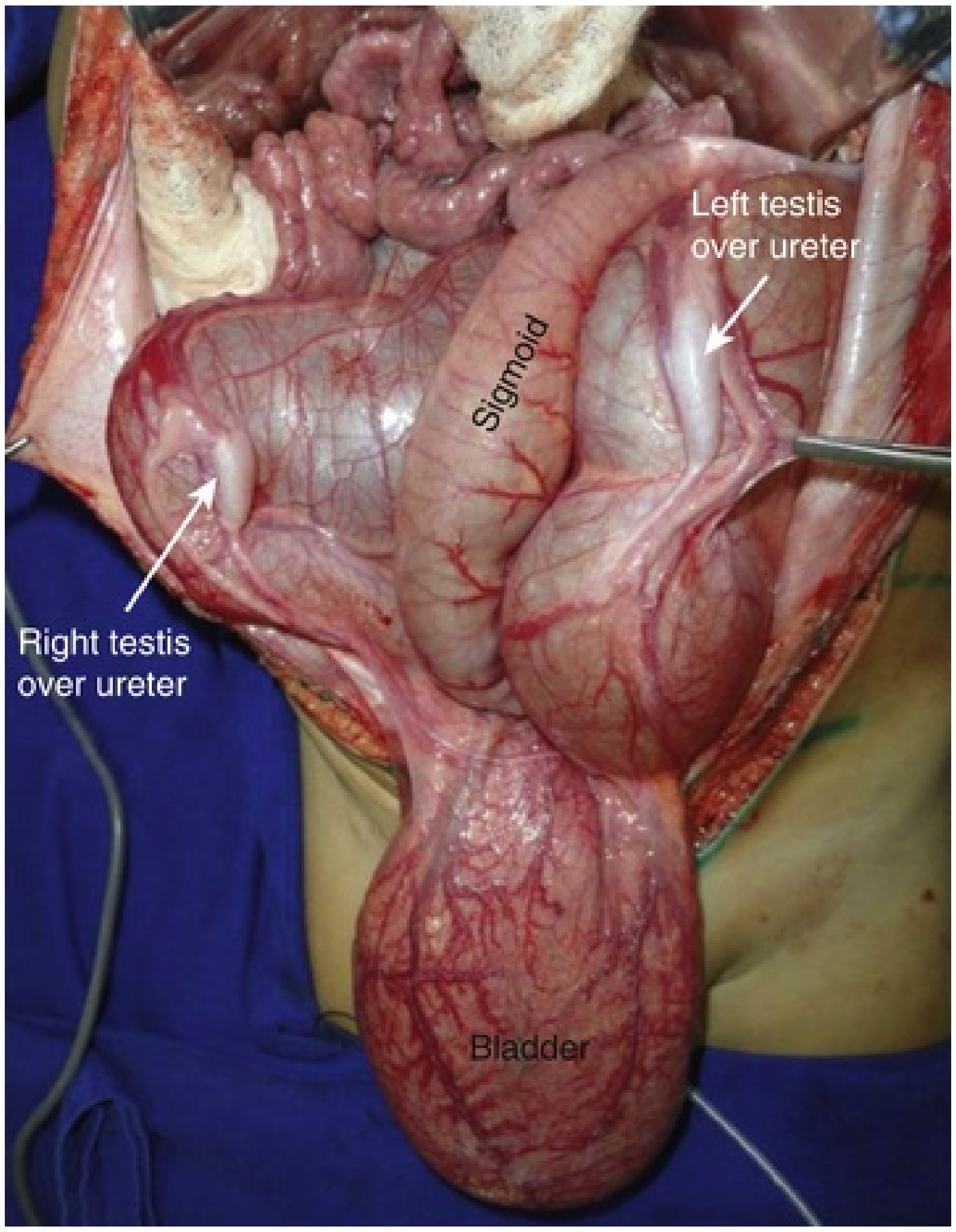

FIG. 32.19 Intra-abdominal testes *(arrows)* overlying massively dilated ureters.

Circumcision.

As in other boys who are at risk of developing recurrent urinary tract infection because of lower urinary tract abnormalities such as posterior urethral valves and vesicoureteral reflux, patients with PBS certainly benefit from circumcision as a means to decrease the incidence of recurring urinary tract infections. Lopes et al. (2015) incorporated circumcision in all their patients with PBS who were submitted to urinary tract reconstruction, orchidopexy, or abdominoplasty.

Testes: Orchidopexy

The timing of orchidopexy is dictated by our current understanding of the need for early treatment of the undescended testis in patients both with and without PBS along with the need of individual patients with PBS for either temporary or reconstructive surgery. Although the fertility potential of the patient with PBS is known to be compromised, germ cells are present in the testes of infants with PBS, and spermatozoa were found in the semen and post-ejaculatory urine samples of adult patients who underwent orchidopexy early in infancy (Dénes et al., 2017). In addition, the prognosis for normal hormonal function at puberty is excellent. These factors, along with the potential risk of testicular carcinoma (Massad et al., 1991; Uehling et al., 1984), would justify early orchidopexy. Because the testes are uniformly located in the abdomen, most commonly on a broad mesorchium overlying the iliac vessels (Coplen et al., 1996), standard inguinal approaches are not usually successful in achieving a satisfactory scrotal position. Four alternative approaches may be considered.

Transabdominal Orchidopexy.

Woodard, Parrott, and other researchers noted that if an orchidopexy is done in the neonatal period and up to 6 months of age by a transabdominal approach, adequate spermatic vessel mobilization can usually be achieved for scrotal placement (Fallat et al., 1989; Randolph et al., 1981a; Woodard and Parrott, 1978a, 1978b). **Transabdominal bilateral orchidopexy at about 6 months of age is currently considered the approach of choice** (Fig. 32.20). This approach is often used in conjunction with other abdominal surgeries, either a vesicostomy, urinary tract reconstruction, or abdominal wall reconstruction. In the absence of need for other abdominal surgeries, this can be accomplished laparoscopically (Philip et al., 2011).

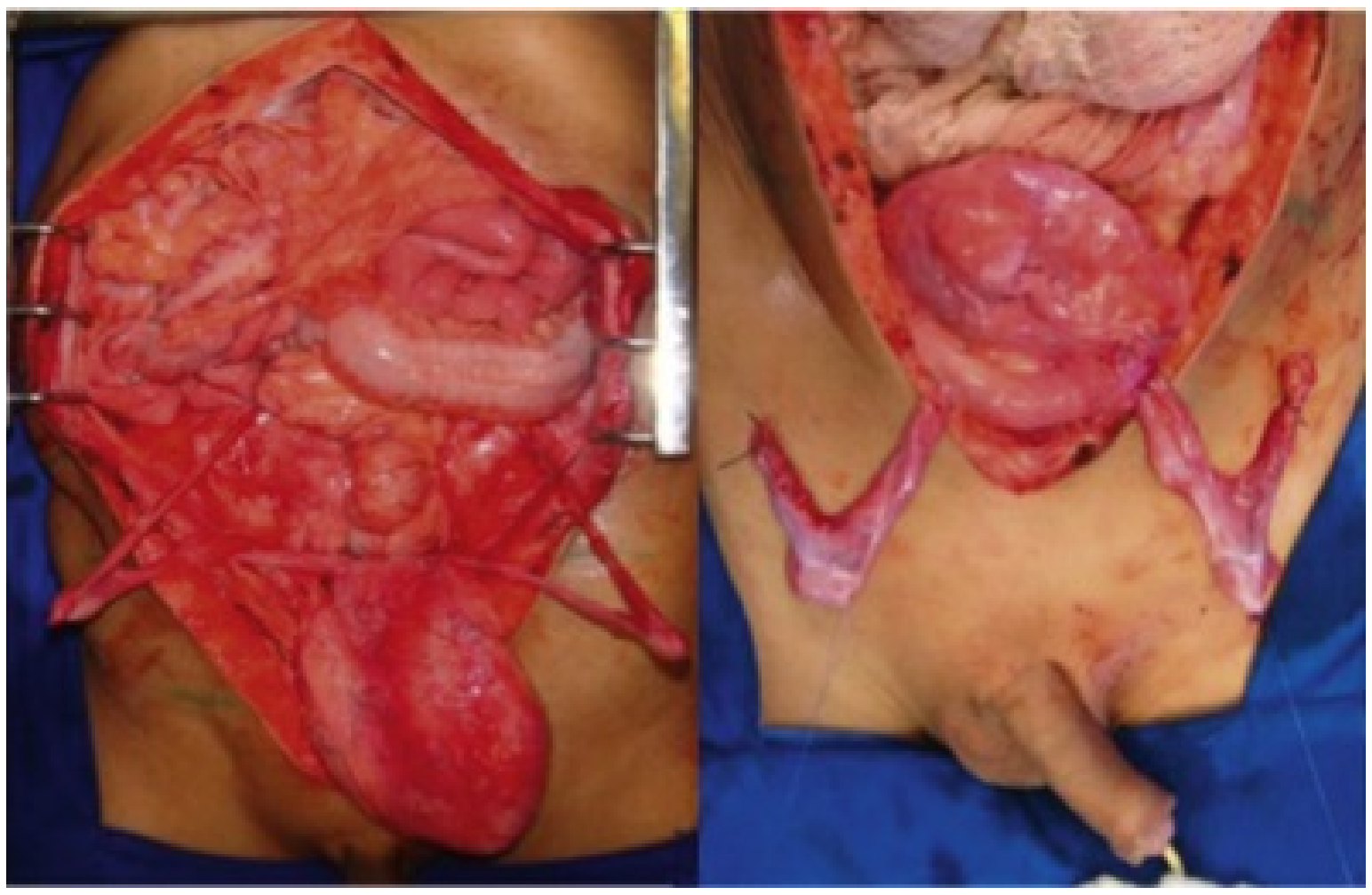

FIG. 32.20 Transabdominal orchidopexy with and without preservation of the vascular pedicle in patients with the prune belly syndrome.

Spermatic Vessel Ligation.

When successful transabdominal orchidopexy cannot be accomplished in the first few months of life, the other options that may be considered are (1) Fowler-Stephens orchidopexy (Boddy et al., 1991; Fowler and Stephens, 1959; Gibbons et al., 1979; Kirsch et al., 1998), **(2) staged Fowler-Stephens orchidopexy** (see Fig. 32.18) (Bloom, 1991; Caldamone and Amaral, 1994; Docimo, 1995; Ransley et al., 1984; Yu et al., 1995), and **(3) microvascular autotransplantation** (Boddy et al., 1991; MacMahon et al., 1976; Wacksman et al., 1980). A meta-analysis report by Docimo (1995) indicated comparative success rates of 67% and 77% for standard and staged Fowler-Stephens techniques, respectively.

Laparoscopic Orchidopexy.

In a multi-institutional report of laparoscopic orchidopexy, Baker et al. (2001) noted a success rate of 81% for a standard Fowler-Stephens approach compared with 90% for a staged approach. In a long-term follow-up report, Patil et al. (2004) reported a satisfactory outcome in PBS with a one- or two-stage Fowler-Stephens orchidopexy (Fig. 32.21). Some authors have recommended several technical adjustments during laparoscopic orchiopexy in children with PBS, particularly port placement because there is little resistance to cannula placement in these children (Saxena and Brinkmann, 2007).

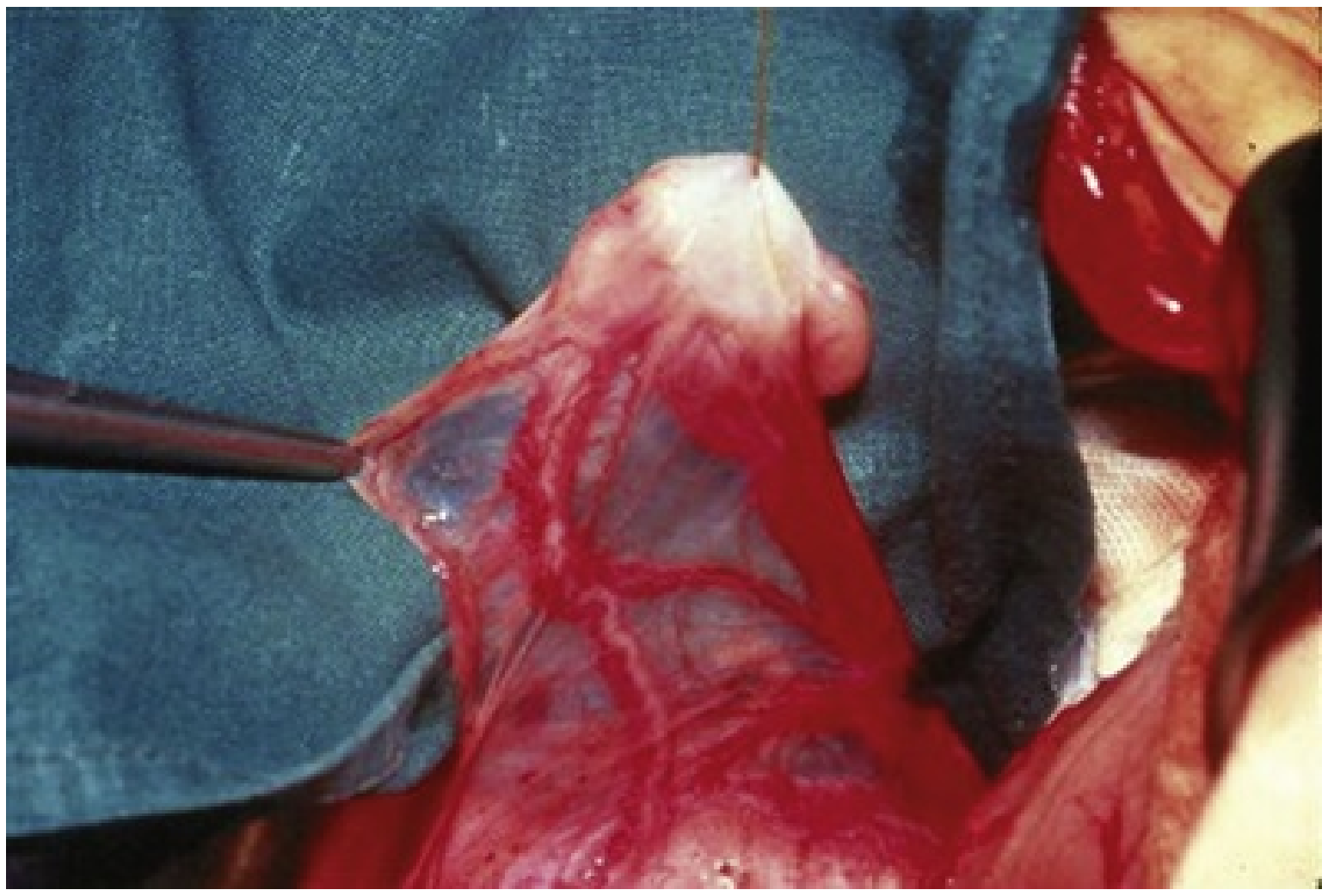

FIG. 32.21 Operative photograph showing increased vascularity along vas deferens 4 months after first-stage Fowler-Stephens orchidopexy.

Abdomen: Reconstruction of the Abdominal Wall

Indications.

Children with mild degrees of abdominal muscular deficiency may show improvement in the abdominal wall laxity as they mature. However, most others with moderate to severe degrees of abdominal wall laxity are left with a potentially physically and psychologically crippling defect (Ehrlich et al., 1986; Parrott and Woodard, 1992). An elasticized corset can improve the external appearance when the patients are fully clothed as well as improve the respiratory and gastrointestinal problems, even in the neonatal period (Satar et al., 2016). Nevertheless, these corsets may become inconvenient to use in the long term, particularly in regions with warm climate.

There is general agreement about the cosmetic benefit of abdominal wall reconstruction. However, whether it improves bladder, bowel, and pulmonary function is controversial (Smith et al., 1998; Woodard, 1998). Smith et al. demonstrated improved bladder emptying after abdominal wall reconstruction; nevertheless, some of their reconstructed patients underwent concomitant urinary tract remodeling as well. Potential effects include a more effective cough and improvement in defecation. The timing of abdominal wall reconstruction should be dictated by the need for other surgical interventions, particularly if upper urinary tract remodeling is necessary. If upper tract remodeling is not anticipated, the abdominal wall can be addressed at any time and has been done as young as 6 months of age along with transabdominal orchidopexy (Smith and Woodard, 2002). However, if the procedure is done in infancy, the infant may have to be placed on a respirator postoperatively for a period of time.

Techniques

Randolph Technique.

Randolph et al. (1981a), first popularized a technique for abdominal wall reconstruction based on electromyographic mapping, which indicated that the most severely affected area of the abdomen is the infraumbilical regions, whereas the lateral and supraumbilical regions are generally least affected. This technique makes a transverse incision from the 12th rib to the pubic symphysis to the opposite 12th rib with a full-thickness removal of the skin, lower abdominal musculature, and peritoneum. The healthy fascia is then approximated to the anterior iliac spines, pubic tubercle, and inferior fascia.

Although this technique is successful in establishing a waistline, lateral abdominal bulging often persists. Of the 16 patients reported, 9 had excellent cosmetic results and there was some residual protuberance in 7 (Fallat et al., 1989).

Ehrlich Technique.

The technique described by Ehrlich used a vertical midline incision and allows preservation of the umbilicus on a vascular pedicle from the inferior epigastric artery (Ehrlich et al., 1986; Ehrlich and Lesavoy, 1993). The skin and subcutaneous tissues are elevated off the muscle and fascial layers, and an overlapping, vest-over-pants advancement of each side to the contralateral flank is performed, preserving the less affected lateral muscles and fascia. Excellent long-term follow-up of this technique has been reported (Lesavoy et al., 2012).

Monfort Technique.

Monfort described a technique that is vertically oriented similar to that of Ehrlich's approach; however, an elliptically oriented incision is used to isolate the redundant skin (Monfort et al., 1991). The incision extends from the tip of the xyphoid to the pubis. A second incision is made around the umbilicus to preserve it in situ. The skin and subcutaneous tissue are dissected off the attenuated fascia and muscle with the dissection extending laterally to the anterior axillary line. Vertical fascial incisions are made lateral to the superior epigastric arteries, leaving a central fascial bridge. If intra-abdominal surgery is necessary, excellent exposure to the urinary tract or abdominal testes is afforded through these lateral fascial incisions. After urinary reconstruction and/or orchidopexy, the lateral fascial is then advanced over the central fascial bridge from both sides, alleviating the redundancy and increasing the thickness of the abdominal wall (Fig. 32.22). Recently incorporated modifications, such as the use of diagnostic laparoscopy to define the topography of the abdominal wall defect, initial midline rather than elliptical skin incision to defer retailoring of the skin coverage until the final step of the procedure, varying the width of the central plate to correct side-to-side asymmetry in redundancy, plication of the central plate to reduce vertical redundancy and allow reposition of the umbilicus, and plication of focal areas of fascial weakness in the flank region, have improved the results of this abdominoplasty technique (Smith et al., 2017). A modification of the Monfort technique uses laparoscopy to protect the abdominal contents (Franco, 2005).

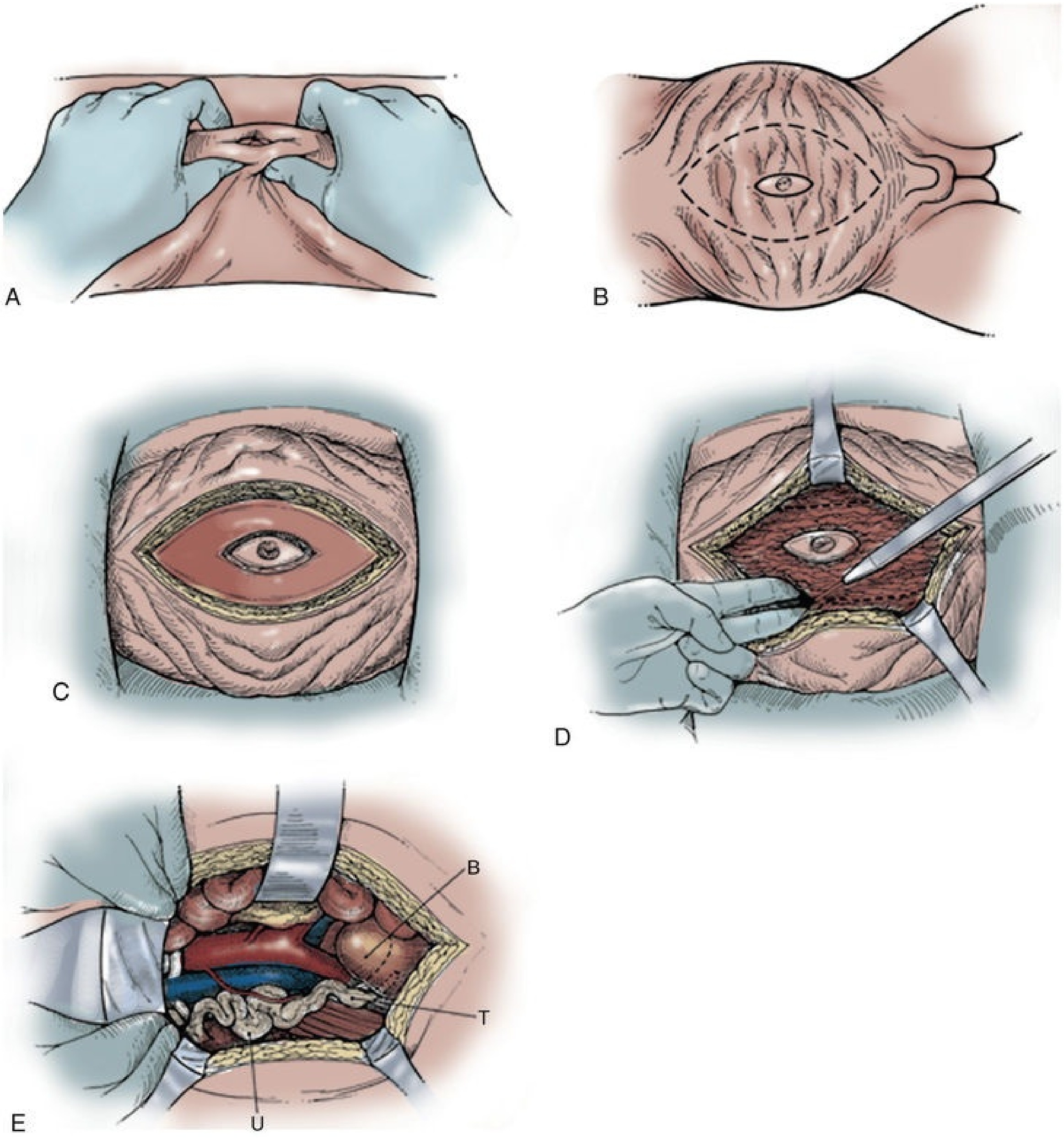
A
B
C
D
B
T
E
U

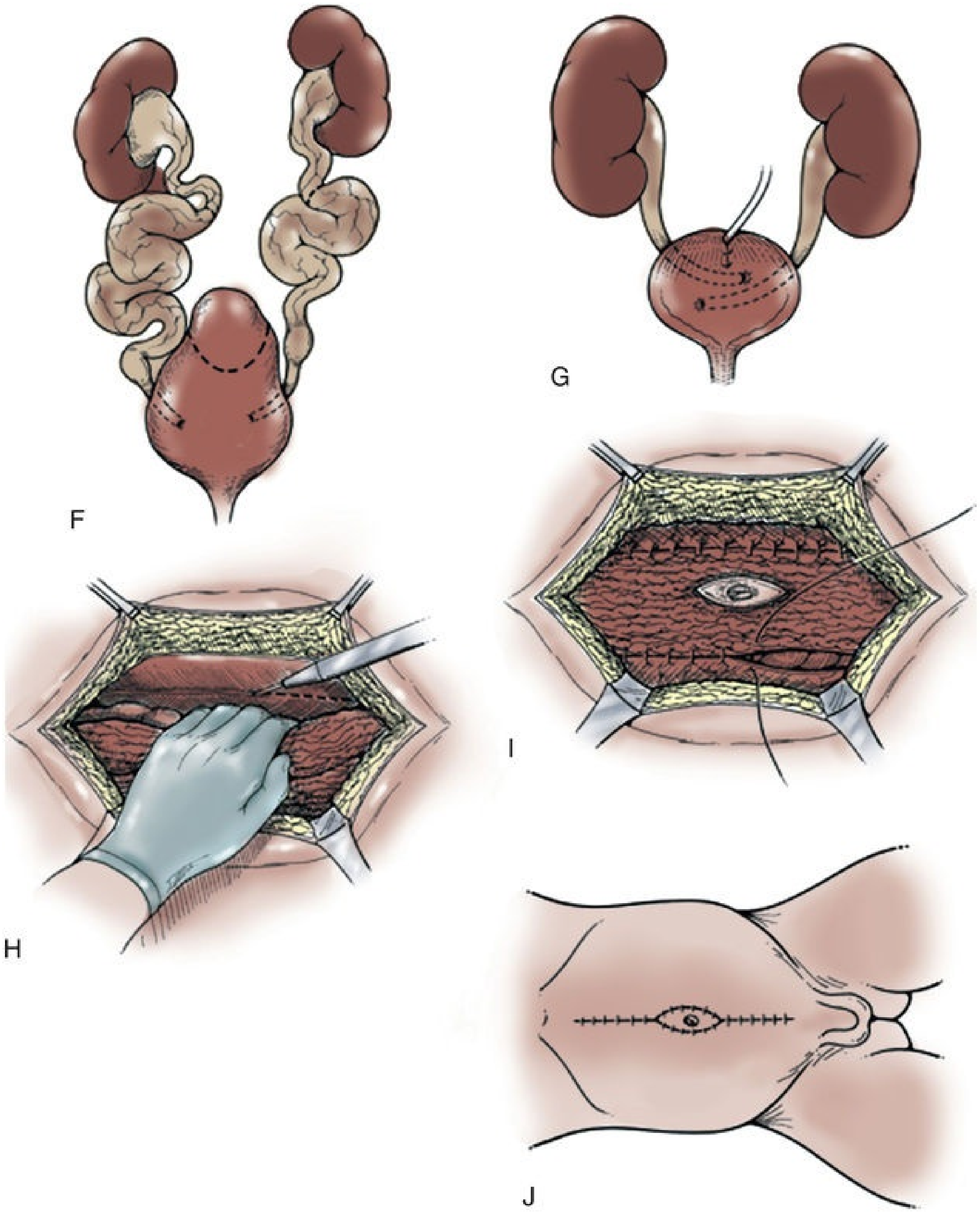

FIG. 32.22 Surgical technique for Monfort abdominoplasty and concomitant reconstruction of prune-belly uropathy. (A) Delineation of redundancy by tenting up abdominal wall. (B) Skin incisions are outlined with a separate circumscribing incision to isolate the umbilicus. (C) Skin (epidermis and dermis only) is excised with electrocautery. (D) Abdominal wall central plate is incised at the lateral border of the rectus muscle on either side, from the superior epigastric to the inferior epigastric vessels, creating a central musculofascial plate. (E) Adequate exposure is provided

for concomitant transperitoneal genitourinary procedures. *B,* Bladder; *T,* testis; *U,* ureter.(F) Only the more normal proximal ureter is preserved for vesicoureteral reimplantation, and the urachal diverticulum is excised. (G) Transtrigonal ureteral reimplantation is performed with or without ureteral tapering as needed. The bladder is closed in two layers, and ureteral stents (not shown) and a cystostomy tube are used. (H) Completion of abdominoplasty by scoring of the parietal peritoneum overlying the lateral abdominal wall musculature with electrocautery. (I) The edges of the central plate are sutured to the lateral abdominal wall musculature along the scored line. (J) Lateral flaps are brought together in the midline, with closed suction drains placed between the lateral flaps and the central plate. Skin is brought together in the midline, enveloping the previously isolated umbilicus. (From Woodard JR, Perez LM: Prune-belly syndrome. In Marshall FF, ed: *Operative urology,* Philadelphia, 1996, Saunders.)

Dénes Technique.

Another modification of the Ehrlich and Monfort techniques was reported in which, after the fusiform longitudinal resection of the mid-abdominal skin and subcutaneous tissue with preservation of the musculo-aponeurotic fascia and umbilicus, one elliptical xyphopubic incision is made in the more flaccid side of the abdominal fascia, producing one wide and one narrow fascial flap, with the umbilicus kept intact in the wide flap. Closure is made by suturing the wide flap laterally to the inner side of the narrow flap, followed by vest-over-pants suture of this flap over the wide, now “inner” flap, with a buttonhole exposing the umbilicus, which is then fixed in place. After slight undermining of both skin edges, they are approximated and sutured with incorporation of the umbilicus (Dénes et al., 2014) (Fig. 32.23). Abdominal appearance and tonus were improved in 90% of the children after the primary surgery and 100% after reoperation (Lopes et al., 2015) (Fig. 32.24).

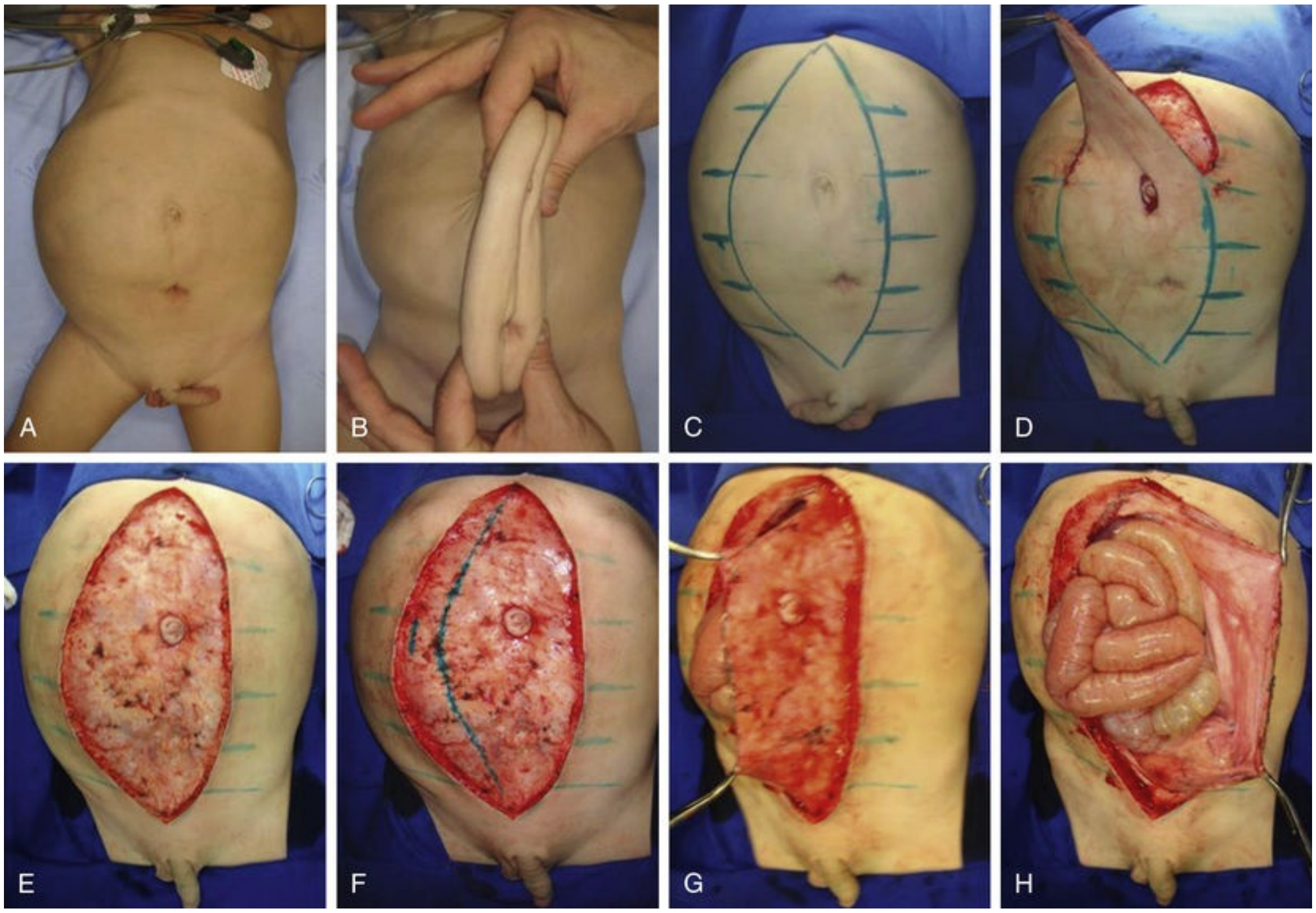
A
B
C
D
E
F
G
H

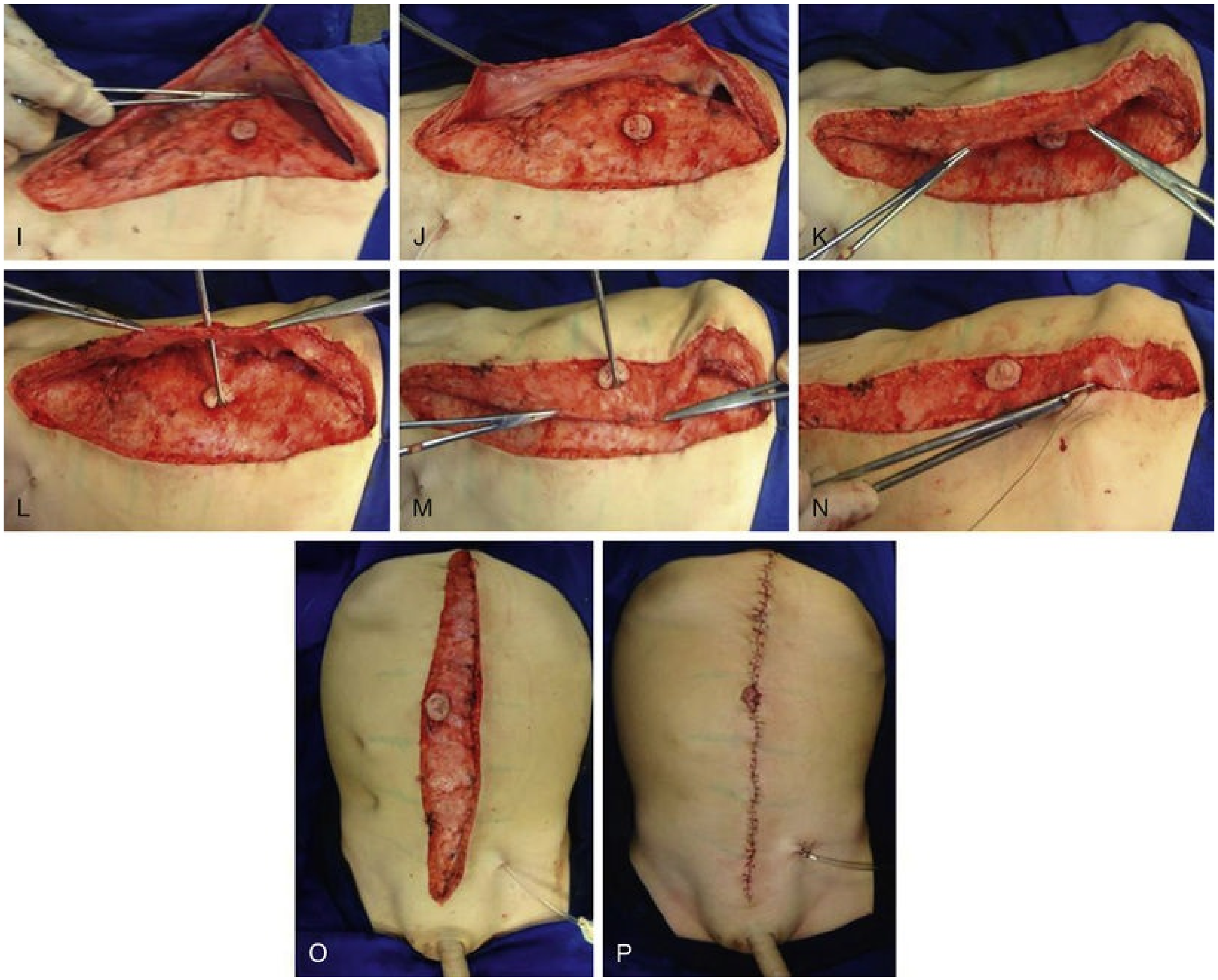

FIG. 32.23 Abdominoplasty with the Dénes technique: (A) initial aspect; (B) estimation of the extension of abdominal wall resection; (C) demarcation of the incisional limits; (D and E) elliptical excision of skin and subcutaneous tissue with preservation of umbilicus; (F and G) eccentric elliptical incision of the musculo-aponeurotic fascia on the more flaccid side, creating one broad and one narrow flap; (H) excellent exposure of the abdominal cavity. Abdominoplasty closure: (I through J) suture of broad flap to inner side of narrow flap; (K through O) Pants-over-vest fixation of narrow flap over the broad flap (now inner flap), with a buttonhole for umbilicus. (P) Final aspect after approximation of subcutaneous and skin.

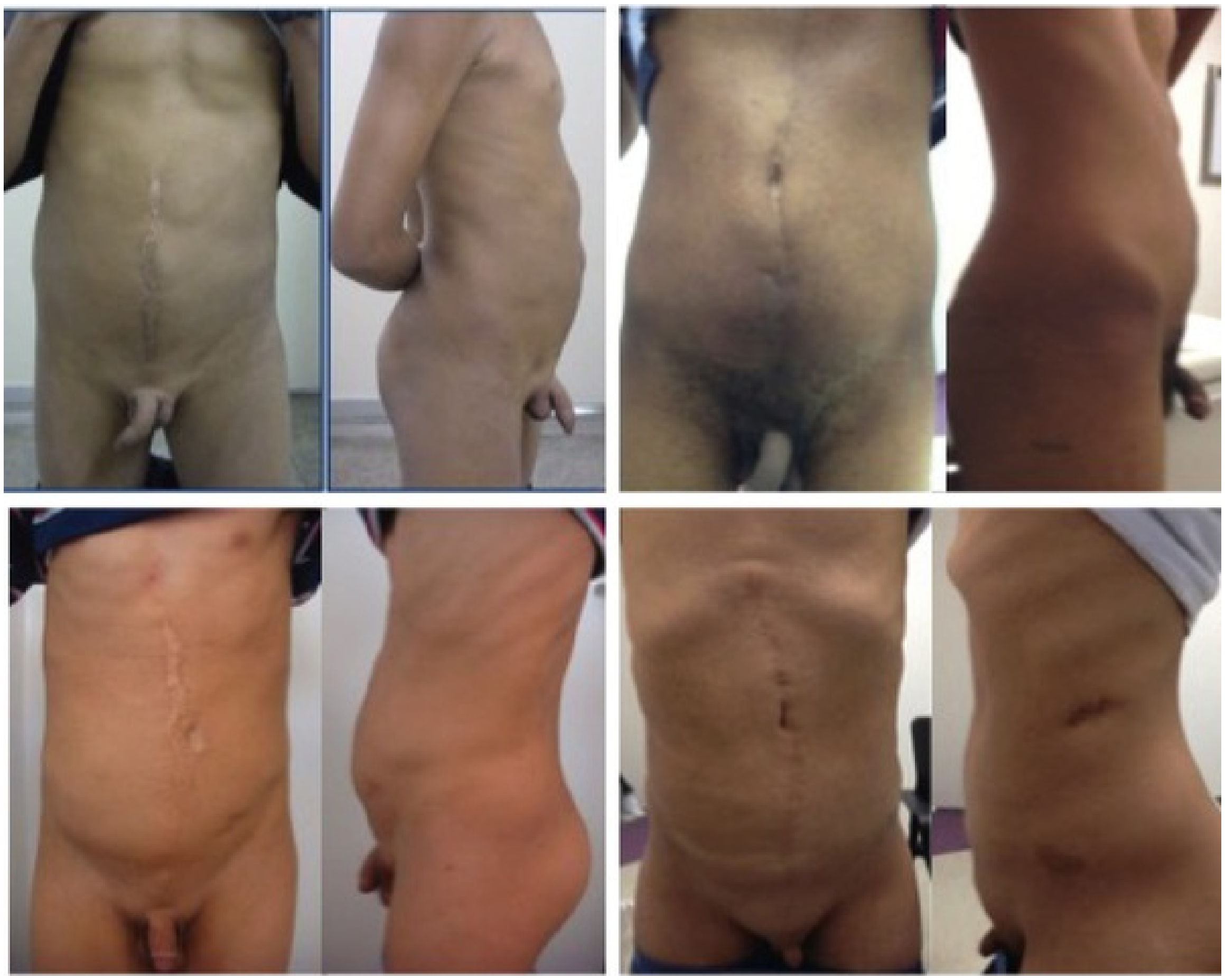

FIG. 32.24 Postoperative front and lateral images of patients with prune-belly syndrome submitted to abdominoplasty with the Dénes technique.

Furness Technique.

Furness et al. (1998) described a modified midline approach with less abdominal wall dissection that avoids entering the peritoneum, which is useful if an intra-abdominal surgery is not planned. A modification of the Monfort technique uses laparoscopy to protect the abdominal contents (Franco, 2005).

Key Points: Surgical Reconstruction

- Upper urinary tract reconstruction is controversial but clearly indicated for evidence of declining renal function in the presence of recurrent upper tract infections or progression of the hydroureteronephrosis.
- Orchidopexy is best performed early in life because this affords the most

likely prospect of a successful single-stage procedure, as well as the perspective of preservation of germ cells.

- Abdominal wall reconstruction, besides the obvious cosmetic and psychosocial benefits, has demonstrated improved bladder emptying, a more effective cough, and improved defecation.
- Comprehensive surgery that includes the all the above mentioned points, as well as circumcision, is feasible in most patients.

Long-Term Outlook

Quality of Life

The overall outlook for the patient with PBS for survival and for quality of life has improved considerably, largely through advances in medical, surgical, and urodynamic management. However, despite these advances in care of children with PBS, there continues to be a high perinatal mortality rate in patients of group I, largely because of associated prematurity, renal dysplasia, and pulmonary hypoplasia (Routh, 2010).

PBS profoundly affects health-related quality of life in affected children as well as in their caregivers. The patients have compromised physical, emotional, social, and school functioning, and the caregivers report an overall lower quality of life because of the burdens that families with chronically ill children often face (Arlen et al., 2016). Another study demonstrated that surviving individuals with PBS had a significantly high incidence of orthopedic, gastrointestinal, and cardiopulmonary conditions that negatively affected their quality of life, whereas treatment of these non-GU conditions improves their lives.

These studies stress the fact that, as primarily responsible for the overall health of these medically complex patients, the pediatric urologist must be aware and prepared not only to treat the late genitourinary complications of PBS but also to evaluate and diagnose the nongenitourinary comorbidities that directly affect their medical and surgical treatment and quality of life, as they pass through puberty into adulthood (Grimsby et al., 2015).

Renal Function

The nadir creatinine value during infancy has proven to be a useful predictor of long-term renal function. If the nadir value is less than 0.7 mg/dL, renal function tends to be stable during childhood unless there is further renal compromise by pyelonephritis (Geary et al., 1986; Noh et al., 1999; Reinberg et al., 1991b). Reconstruction of the upper and lower urinary tract has been proven to maintain stabilized renal function in most patients (Lopes et al., 2015), but the importance of urinary tract monitoring by periodic imaging and cultures and prompt treatment of urinary tract infections, with or without prior surgery of the urinary tract, cannot be overemphasized. Unfortunately, the risk of infection is constant in the setting of persistent urinary tract dilation and stasis. Up to 30% of patients, generally those with impaired renal function at initial evaluation, develop chronic renal failure during childhood or adolescence (Geary et al., 1986). Furthermore, kidney dysplasia and polyuria may also play a deleterious role in the long-term renal function (Lopes et al., 2015). Renal transplantation is necessary for these patients to ensure normal growth and development, and success with transplantation in patients with PBS can be expected to equal that in other age-matched groups (Reinberg et al., 1989). Fusaro et al. (2004) have reported on five boys with PBS who underwent renal transplantation. The 5-year graft survival rate was 66.7%, with all maintaining their native urinary tracts.

The key to management of the urinary tract in the patient with PBS is individualization of care because some require major urologic reconstruction, and others require little if any intervention. Long-term surveillance of the urinary tract is essential because functional dynamics can change over time.

Bladder Function

As mentioned before, urodynamic studies of patients with PBS generally show normal compliance with decreased sensibility and contractile activity. As consequence, some patients tend to retain large volumes in the bladder, which develops progressive capacity associated to significant postvoid residual (Snyder et al., 1976). The lack of abdominal support, the eventual association of polyuria, and the negative behavior of some patients in regard to timed voiding usually increase this tendency (Kinahan et al., 1992). Therefore, to prevent further bladder dilation and upper urinary tract deterioration, all patients, even those who underwent lower urinary tract reconstruction and abdominoplasty, have to be trained as early as possible and constantly reinforced to empty their bladders on schedule, eventually associating it to double or triple voiding and Valsalva's or Credé's maneuvers. In the case of progressive unbalanced voiding, if such a program is not feasible or ineffective, intermittent bladder catheterization is mandatory, either per urethra or through a Mitrofanoff channel. Eventually, effective voiding is achieved with growth and improved proprioceptive sensation, as well as increased abdominal support. In the series of Lopes et al. (2015), 17.4% of the patients submitted to reconstruction of the urinary tract required intermittent catheterization through urethra or a Mitrofanoff channel. Rarely, some of these children reacquire normal voiding with good bladder emptying.

Growth and Musculoskeletal Development

Normal growth can be expected in most of the patients with normal renal function, although growth retardation in the absence of renal compromise was observed in one-third of patients in one series (Geary et al., 1986). Patients with the syndrome may present musculoskeletal abnormalities that impair function and cosmesis. As many patients now reach adulthood, these abnormalities gain significance (Loder et al., 1992). As the abdominal flaccidity, either after previous surgical repair or not, generally improves with age, there is no restriction to physical activities appropriate for the age of the patient. The correct use of corsets may be useful in this situation. Some sport activities, such as swimming, may reinforce the thoracic, limb, and even abdominal musculature, without exerting undue strain on the abdomen. Thoracic deformities, such as *pectus excavatum*, usually do not compromise pulmonary function in the older child and may show some improvement with growth and exercise. If not, thoracoplasty may be requested by some patients in early adulthood because of cosmetic reasons. Significant scoliosis and lordosis associated with the abdominal flaccidity may require orthopedic management early in childhood to stabilize and improve the condition. Ankle abnormalities are also detected early in infancy, and some are better treated surgically at that age. Hip abnormalities that impair correct ambulation may be identified late in childhood, sometimes requiring surgical treatment. In a recent study, older patients and their families were informed that the correction of musculoskeletal problems through abdominoplasty and/or orthopedic surgeries was the most common way for health providers to improve their patients' quality of life (Grimsby et al., 2015).

Sexual Function and Fertility

A normal pattern of secondary sexual development can be expected as hormonal production by the testes is preserved (Woodhouse and Snyder, 1985), but sexual function may be impaired by retrograde ejaculation. Spontaneous paternity has not been reported to date; therefore primary infertility is usually taken for granted. In a recent study, 15 patients with a mean age of 18.2 years, who underwent successful orchidopexy early in childhood, were evaluated in regard to fertility. Of these, 14 had both testes in the scrotum, and FSH, LH, and testosterone levels were normal in all patients; 8 patients were able to provide semen samples, 6 by antegrade and 2 by retrograde ejaculation. Of these patients 5 had spermatozoa in the specimen, and 4 of them had motile spermatozoa (Dénes et al., 2017). This and other promising works stress the fact that assisted reproductive techniques may be feasible in those having had successful early orchidopexy (Fleming et al., 2013; Kolettis et al., 1999).

Key Points: Long-Term Follow-Up

- Up to one-third of the patients may develop chronic renal insufficiency during childhood or adolescence.
- Recurrent pyelonephritis as well as renal dysplasia and polyuria are major factors associated with renal function decline.
- Adequate emptying of the bladder is necessary to avoid recurrent infection and prevent upper tract deterioration associated to poliuria.
- A normal pattern of sexual development is expected after orchidopexies, although no spontaneous paternity has been reported to date.
- There is significant spontaneous improvement of abdominal tonus in most cases with growth, but the skeletal abnormalities often require surgical correction.

Suggested Readings

Dénes FT, Lopes RI, Oliveira LM, et al. Modified abdominoplasty for patients with the Prune Belly Syndrome. *Urology*. 2014;83:451–454.

Fusaro F, Zanon GF, Ferreli AM, et al. Renal transplantation in prune belly syndrome. *Transpl Int*. 2004;17(9):549–552.

Grimsby GM, Harrison SM, Granberg CF, et al. Impact and frequency of extra-genitourinary manifestations of prune belly syndrome. *J Pediatr Urol*. 2015;11:1–6.

Lopes RI, Tavares A, Srougi M, et al. 27 years of experience with the comprehensive surgical treatment of prune belly syndrome. *J Pediatr Urol*. 2015;11(5):276.e1–276.e7.

Monfort G, Guys JM, Bocciardi A, et al. A novel technique for reconstruction of the abdominal wall in the prune belly syndrome. *J Urol*. 1991;146(2 Pt 2):639–640.

Noh PH, Cooper CS, Winkler AC, et al. Prognostic factors for long-term renal function in boys with the prune-belly syndrome. *J Urol*. 1999;162:1399–1401.

Reinberg Y, Manivel JC, Pettinato G, et al. Development of renal failure in children with the prune belly syndrome. *J Urol*. 1991;145:1017–1019.

Routh JC, Huang L, Retik AB, et al. Contemporary epidemiology and characterization of newborn males with prune belly syndrome. *Urology*. 2010;76:44–48.

Smith CA, Smith EA, Parrott TS, et al. Voiding function in patients with prune belly syndrome after Monfort abdominoplasty. *J Urol*. 1998;159:80–89.

Stephens FD, Gupta D. Pathogenesis of the prune belly syndrome. *J Urol*. 1994;152:2328–2331.

Woodard JR, Smith EA. Prune belly syndrome. Walsh PC, Retik AB, Vaughan ED Jr, et al. *Campbell's urology*. WB Saunders:

Philadelphia; 1998:1917–1938.

Woodhouse CR, Ransley PG, Innes Williams D. Prune belly syndrome—report of 47 cases. *Arch Dis Child*. 1982;57:856–859.

References

Adebonojo FO. Dysplasia of the anterior abdominal musculature with multiple congenital anomalies: Prune-belly or triad syndrome. *J Natl Med Assoc*. 1973;65:327–333.

Adeyokunnu AA, Familusi JB. Prune belly syndrome in two siblings and a first cousin. Possible genetic implications. *Am J Dis Child*. 1982;136:23–25.

Afifi AK, Rebeiz J, Mire J, et al. The myopathology of the prune belly syndrome. *J Neurol Sci*. 1972;15:153–165.

Alford BA, Peoples WM, Resnick JS, et al. Pulmonary complications associated with the prune-belly syndrome. *Radiology*. 1978;129:401–407.

Amacker EA, Grass FS, Hickey DE, et al. An association of prune belly anomaly with trisomy 21. *Am J Med Genet*. 1986;23:919–923.

Appel RA, Kaplan GW, Brock WA, et al. Megalourethra. *J Urol*. 1986;135:747–751.

Arlen AM, Kirsch SS, Seidel NE, et al. Health-related quality of life in children with Prune-belly Syndrome and their caregivers. *Urology*. 2016;87:224–227.

Asplund J, Laska J. Prune belly syndrome at the age of 37. Case report. *Scand J Urol Nephrol*. 1975;9:297–300.

Awad K, Lall A. It's not all doom and gloom: prune belly syndrome associated with VACTERL. *J Neonatal Surg*. 2016;3:33.

Baird PA, Sadovnick AD. Prune belly anomaly in Down syndrome [letter]. *Am J Med Genet*. 1987;26:747–748.

Baker LA, Docimo SG, Surer I, et al. A multi-institutional analysis of laparoscopic orchidopexy. *BJU Int*. 2001;87:484–489.

Basso MD, Favretto CO, Cunha RF. The association of prune belly syndrome and dental anomalies. *BMC Oral Health*. 2012;12:56–60.

Beasley SW, Bettenay F, Hutson JM. The anterior urethra provides clues to the aetiology of prune belly syndrome. *Pediatr Surg Int*. 1988;3:169–172.

Bellah RD, States LJ, Duckett JW. Pseudoprune-belly syndrome: imaging findings and clinical outcome. *Am J Roentgenol*. 1996;167:1389–1393.

Berdon WE, Baker DH, Wigger HJ, et al. The radiologic and pathologic spectrum of the prune belly syndrome. The importance of urethral obstruction in prognosis. *Radiol Clin North Am*. 1977;15:83–92.

Biard JM, Johnson MP, Carr MC, et al. Long-term outcomes in children treated by prenatal vesicoamniotic shunting for lower urinary tract obstruction. *Obstet Gynecol*. 2005;106:503–508.

Blaicher W, Häusler M, Gembruch U, et al. Feto-amniotic shunting. Experience of six centres. *Ultraschall Med*. 2005;26:134–141.

Bloom DA. Two step orchiopexy with pelviscopic clip ligation of the spermatic vessels. *J Urol*. 1991;145:1030–1033.

Boddy SA, Gordon AC, Thomas DF, et al. Experience with the Fowler Stephens and microvascular procedures in the management of intraabdominal testes. *Br J Urol*. 1991;68:199–202.

Bovicelli L, Rizzo N, Orsini LF, et al. Prenatal diagnosis of the prune belly syndrome. *Clin Genet*. 1980;18:79–82.

Bukowski TP, Perlmutter AD. Reduction cystoplasty in the prune belly syndrome: a long-term follow-up. *J Urol*. 1994;152:2113–2116.

Burbige KA, Amodio J, Berdon WE, et al. Prune belly syndrome: 35 years of experience. *J Urol*. 1987;137:86–90.

Burke EC, Shin MH, Kelalis PP. Prune-belly syndrome. Clinical findings and survival. *Am J Dis Child*. 1969;117:668–671.

Caldamone AA, Amaral JF. Laparoscopic stage 2 Fowler-Stephens orchidopexy. *J Urol*. 1994;152:1253–1256.

Cazorla E, Ruiz F, Abad A, et al. Prune belly syndrome: early antenatal diagnosis. *Eur J Obstet Gynecol Reprod Biol*. 1997;72:31–33.

Christopher CR, Spinelli A, Severt D. Ultrasonic diagnosis of prune-belly syndrome. *Obstet Gynecol*. 1982;59:391–394.

Coplen DE, Snow BW, Duckett JW. Prune belly syndrome. Gillenwater JY, Grayhack JT, Howards SS, et al. *Adult and pediatric urology*. Mosby: St. Louis; 1996:2297–2316.

Cukier J. Resection of the urethra with the prune belly syndrome. *Birth Defects Orig Artic Ser*. 1977;5:95–96.

Culp DA, Flocks RH. Congenital absence of abdominal musculature: report of two cases. *J Iowa State Med Soc*. 1954;44:155–159.

Dénes FT, Lopes RI, Oliveira LM, et al. Modified abdominoplasty for patients with the Prune Belly syndrome. *Urology*. 2014;83:451–454.

Dénes FT, Tavares A, Cocuzza M, et al. Gonadal function and reproductive system anatomy in post puberal prune belly syndrome patients. *J Urol*. 2017;197:e863.

Docimo SG. The results of surgical therapy for cryptorchidism: a literature review and analysis. *J Urol*. 1995;154:1148–1152.

Dorairajan T. Defects of spongy tissue and congenital diverticula of the penile urethra. *Aust NZ J Surg*. 1963;32:209–214.

Duckett JW Jr. Cutaneous vesicostomy in childhood. The Blocksom technique. *Urol Clin N Am*. 1974;1:485–495.

Duckett JW Jr, Knutrud O, Hohenfellner R, et al. Prune belly syndrome. *Dialog Pediatr Urol*. 1980;3:1–7.

Eagle JF Jr, Barrett GS. Congenital deficiency of abdominal musculature with associated genitourinary abnormalities: a syndrome. Report of 9 cases. *Pediatrics*. 1950;6:721–736.

Ehrlich RM, Lesavoy MA. Umbilicus preservation with total abdominal wall reconstruction in the prune-belly syndrome. *Urology*. 1993;41:231–232.

Ehrlich RM, Lesavoy MA, Fine RN. Total abdominal wall reconstruction in the prune belly syndrome. *J Urol*. 1986;136:282–285.

Elder JS. Current status of intrauterine intervention for obstructive uropathy. *Kidney*. 1990;22:19–24.

Elder JS, Duckett JW Jr, Snyder HM. Intervention for fetal obstructive uropathy: has it been effective? *Lancet*. 1987;2:1007–1010.

Estes JM, Harrison MR. Fetal obstructive uropathy. *Semin Pediatr Surg*. 1993;2:129–135.

Ewig JM, Griscom NT, Wohl ME. The effect of the absence of abdominal muscles on pulmonary function and exercise. *Am J Respir Crit Care Med*. 1996;153:1314–1321.

Fallat ME, Skoog SJ, Belman AB, et al. The prune belly syndrome: a comprehensive approach to management. *J Urol*. 1989;142:802–805.

Favorito LA, Costa SF, Costa WS, et al. Study of testicular structure in fetuses with prune belly syndrome. *Adv Urol*. 2017;2017:3254980.

Fleming SD, Varughese E, Hua VK, et al. Normal live births after intracytoplasmic sperm injection in a man with the rare condition of Eagle-Barrett syndrome (prune-belly syndrome). *Fertil Steril*. 2013;100:1532–1535.

Fowler R, Stephens FD. The role of testicular vascular anatomy in the salvage of the high undescended testes. *Aust NZ J Surg*. 1959;29:92–106.

Franco I. Laparoscopic assisted modification of the Firlit abdominal wall plication. *J Urol*. 2005;174:280–283.

Freedman AL, Johnson MP, Smith CA, et al. Long-term outcome in children after antenatal intervention for obstructive uropathies. *Lancet*. 1999;354:374–377.

Frolich F. *Der Mangel der Muskeln, insbesondere der Seitenbauchmuskeln. Dissertation*. CA Zurn: Wurzburg; 1839.

Frydman M, Cohen HA, Ashkenazi A, et al. Familial segregation of cervical ribs, Sprengel anomaly, preaxial polydactyly, anal atresia, and urethral obstruction: a new syndrome? *Am J Med Genet*. 1993;45:717–720.

Furness PD III, Cheng EY, Franco I, et al. The prune-belly syndrome: a new and simplified technique of abdominal wall reconstruction. *J Urol*. 1998;160:1195–1197.

Fusaro F, Zanon GF, Ferreli AM, et al. Renal transplantation in prune belly syndrome. *Transpl Int*. 2004;17(9):549–552.

Gadziala NA, Kawada CY, Doherty FJ, et al. Intrauterine decompression of megalocystis during the second trimester of pregnancy. *Am J Obstet Gynecol*. 1982;144:355–356.

Garcia-Roig ML, Grattan-Smith JD, Arlen AM, et al. Detailed evaluation of the upper urinary tract in patients with prune belly syndrome using magnetic resonance urography. *J Pediatr Urol*. 2016;12:1–7.

Garlinger P, Ott J. Prune belly syndrome. Possible genetic implications. *Birth Defects Orig Artic Ser*. 1974;10:173–180.

Gearhart JP, Lee BR, Partin AW, et al. A quantitative histological evaluation of the dilated ureter of childhood. II: ectopia, posterior urethral valves and the prune belly syndrome. *J Urol*. 1995;153:172–176.

Geary DF, MacLusky IB, Churchill BM, et al. A broader spectrum of abnormalities in the prune belly syndrome. *J Urol*. 1986;135:324–326.

Gibbons DM, Cromie WJ, Duckett JW Jr. Management of the abdominal undescended testicle. *J Urol*. 1979;122:76–79.

Glazer GM, Filly RA, Callen PW. The varied sonographic appearance of the urinary tract in the fetus and newborn with urethral obstruction. *Radiology*. 1982;144:563–568.

Gonzalez R, Reinberg Y, Burke B, et al. Early bladder outlet obstruction in fetal lambs induces renal dysplasia and the prune-belly syndrome. *J Pediatr Surg*. 1990;25:342–345.

Green NE, Lowery ER, Thomas R. Orthopaedic aspects of prune belly syndrome. *J Pediatr Orthop*. 1993;13:496–501.

Greskovich FJ 3rd, Nyberg LM Jr. The prune belly syndrome: a review of its etiology, defects, treatment and prognosis. *J Urol*. 1988;140:707–712.

Grimsby GM, Harrison SM, Granberg CF, et al. Impact and frequency of extra-genitourinary manifestations of prune belly syndrome. *J Pediatr Urol*. 2015;11:1–6.

Grover H, Sethi S, Garg J, et al. Pseudo prune belly syndrome: diagnosis revealed by imaging - a case report and brief review. *Pol J Radiol*. 2017;7:252–257.

Heydenrych JJ, Du Toit DF. Torsion of the spleen and associated prune belly syndrome. A case report and review of the literature. *S Afr Med J*. 1978;53:637–639.

Hillman RT, Garabedian MJ, Wallerstein RJ. Pregnancy outcome in a woman with prune belly syndrome. *BMJ Case Rep*. 2012;2012.

Hoagland MH, Hutchins GM. Obstructive lesions of the lower urinary tract in the prune belly syndrome. *Arch Pathol Lab Med*. 1987;111:154–156.

Hutson JM, Beasley SW. Re: Association between abdominal wall defects and cryptorchidism [letter]. *J Urol*. 1988;139:388.

Ives EJ. The abdominal muscle deficiency triad syndrome—experience with ten cases. *Birth Defects Orig Artic Ser*. 1974;10:127–135.

Jeffs RD, Comisarow RH, Hanna MK. The early assessment for individualized treatment in the prune belly syndrome. *Birth*

Defects Orig Artic Ser. 1977;13:97–99.

Joseph DB. Triad syndrome and other disorders of abnormal detrusor development. Gonzales ET, Bauer SB. *Pediatric urology practice*. Williams & Wilkins: Philadelphia; 1999:323–337.

Julio Junior HR, Costa SF, Costa WS, et al. Structural study of the bladder in fetuses with prune belly syndrome. *Neurourol Urodyn*. 2017;37(1):148–152.

Kajbafzadeh AM, Rasouli MR, Dianat S, et al. Urethral hydrodistension for management of urethral hypoplasia in prune belly syndrome: long-term results. *J Pediatr Surg*. 2010;45:2217–2221.

Kaplan LM, Koyle MA, Kaplan GW, et al. Association between abdominal wall defects and cryptorchidism. *J Urol*. 1986;136:645–647.

Kerbl K, Pauer W. Renal failure and uraemia leading to the diagnosis of prune belly syndrome. *Br J Anaesthesiol*. 1993;46:897.

Kinahan TJ, Churchill BM, McLorie GA, et al. The efficiency of bladder emptying in the prune belly syndrome. *J Urol*. 1992;148:600–603.

Kirsch AJ, Escala J, Duckett JW, et al. Surgical management of the nonpalpable testis: the Children's Hospital of Philadelphia experience. *J Urol*. 1998;159:1340–1343.

Kolettis PN, Ross JH, Kay R, et al. Sperm retrieval and intracytoplasmic sperm injection in patients with prune-belly syndrome. *Fertil Steril*. 1999;72(5):948–949.

Kramer SA. Current status of fetal intervention for congenital hydronephrosis. *J Urol*. 1983;130:641–646.

Kroovand RL, Al-Ansari RM, Perlmutter AD. Urethral and genital malformations in prune belly syndrome. *J Urol*. 1982;127:94–96.

Lattimer JK. Congenital deficiency of the abdominal musculature and associated genitourinary anomalies: a report of 22 cases. *J Urol*. 1958;79:343–352.

Lee SM. Prune-belly syndrome in a 54-year-old man. *J Am Med Assoc*. 1977;237:2216–2217.

Leeners B, Sauer I, Schefels J, et al. Prune-belly syndrome: therapeutic options including in utero placement of a vesicoamniotic shunt. *J Clin Ultrasound*. 2000;28:500–507.

Lesavoy MA, Chang EI, Suliman A, et al. Long-term follow-up of total abdominal wall reconstruction for prune belly syndrome. *Plast Reconstr Surg*. 2012;129:104–109.

Lockhart JL, Reeve HR, Bredael JJ, et al. Siblings with prune belly syndrome and associated pulmonic stenosis, mental retardation, and deafness. *Urology*. 1979;14:140–142.

Loder RT, Guiboux JP, Bloom DA, et al. Musculoskeletal aspects of prune-belly syndrome. Description and pathogenesis. *Am J Dis Child*. 1992;146:1224–1229.

Lopes RI, Tavares A, Srougi M, et al. 27 years of experience with the comprehensive surgical treatment of prune belly syndrome. *J Pediatr Urol*. 2015;11(5):276.e1–276.e7.

MacMahon RA, O'Brien MC, Cussen LJ. The use of microsurgery in the treatment of the undescended testis. *J Pediatr Surg*. 1976;11:521–526.

Manivel JC, Pettinato G, Reinberg Y, et al. Prune belly syndrome: clinicopathologic study of 29 cases. *Pediatr Pathol*. 1989;9:691–711.

Massad CA, Cohen MB, Kogan BA, et al. Morphology and histochemistry of infant testes in the prune belly syndrome. *J Urol*. 1991;146:1598–1600.

McMullin ND, Hutson JM, Kelly JH. Minimal surgery in the prune belly syndrome. *Pediatr Surg Int*. 1988;3:51–54.

Mininberg DT, Montoya F, Okada K, et al. Subcellular muscle studies in the prune belly syndrome. *J Urol*. 1973;109:524–526.

Moerman P, Fryns JP, Goddeeris P, et al. Spectrum of clinical and autopsy findings in trisomy 18 syndrome. *J Genet Hum*. 1982;30:17–38.

Monfort G, Guys JM, Bocciardi A, et al. A novel technique for reconstruction of the abdominal wall in the prune belly syndrome. *J Urol*. 1991;146(Pt 2):639–640.

Monie IW, Monie BJ. Prune belly syndrome and fetal ascites. *Teratology*. 1979;19:111–117.

Morgan CL Jr, Grossman H, Novak R. Imperforate anus and colon calcification in association with the prune belly syndrome. *Pediatr Radiol*. 1978;7:19–21.

Mortensen PH, Johnson HW, Coleman GU, et al. Megalourethra. *J Urol*. 1985;134:358–361.

Nakayama DK, Harrison MR, Chinn DH, et al. The pathogenesis of prune belly. *Am J Dis Child*. 1984;138:834–836.

Noh PH, Cooper CS, Zderic SA, et al. Prognostic factors in patients with prune belly syndrome. *J Urol*. 1999;162:1399–1401.

Nunn IN, Stephens FD. The triad syndrome: a composite anomaly of the abdominal wall, urinary system and testes. *J Urol*. 1961;86:782–794.

Okulski TA. The prenatal diagnosis of lower urinary tract obstruction using B scan ultrasound: a case report. *J Clin Ultrasound*. 1977;5:268–270.

Orvis BR, Bottles K, Kogan BA. Testicular histology in fetuses with the prune belly syndrome and posterior urethral valves. *J Urol*. 1988;139:335–337.

Osler WO. Congenital absence of abdominal muscles, with distended and hypertrophied urinary bladder. *Bull Johns Hopkins Hosp*. 1901;12:331–333.

Pagon RA, Smith DW, Shepard TH. Urethral obstruction malformation complex: a cause of abdominal muscle deficiency and the “prune belly. *J Pediatr*. 1979;94:900–906.

Pak LK, Ruchelli E, Ewalt D, et al. Testicular histology in prune belly syndrome: just another intraabdominal testis? *J Urol*. 1993;149:226A.

Palmer JM, Tesluk H. Ureteral pathology in the prune belly syndrome. *J Urol*. 1974;111:701–707.

Parker RW. Case of an infant in whom some of the abdominal muscles were absent. *Trans Clin Soc Lond*. 1895;28:201–203.

Parra RO, Cummings JM, Palmer DC. Testicular seminoma in a long-term survivor of the prune belly syndrome. *Eur Urol*. 1991;19:79–80.

Parrott TS, Woodard JR. The Monfort operation for abdominal wall reconstruction in the prune belly syndrome. *J Urol*. 1992;148:688.

Passerini-Glazel G, Araguna F, Chiozza L, et al. The P.A.D.U.A. (Progressive Augmentation by Dilating the Urethra Anterior) procedure for the treatment of severe urethral hypoplasia. *J Urol*. 1988;140:1247–1249.

Patil KK, Duffy PG, Woodhouse CR, et al. Long-term outcome of Fowler-Stephens orchiopexy in boys with prune-belly syndrome. *J Urol*. 2004;171:1666–1669.

Perez-Brayfield MR, Gatti J, Berkman S, et al. In utero intervention in a patient with prune-belly syndrome and severe urethral hypoplasia. *Urology*. 2001;57:1178.

Perlman M, Levin M. Fetal pulmonary hypoplasia, anuria, and oligohydramnios: clinicopathologic observations and review of the literature. *Am J Obstet Gynecol*. 1974;118:1119–1122.

Perlmutter AD. Reduction cystoplasty in prune belly syndrome. *J Urol*. 1976;116:356–362.

Perrotin F, Ayeva-Derman M, Lardy H, et al. Prenatal diagnosis and postnatal outcome of congenital megalourethra. Report of two cases. *Fetal Diagn Ther*. 2001;16:123–128.

Pescia G, Cruz JM, Weihs D. Prenatal diagnosis of prune belly syndrome by means of raised maternal alpha-fetoprotein level. *J Genet Hum*. 1982;30:271–274.

Pessoa L, Galvão V. Oral manifestations associated with systemic complications of prune belly syndrome. *Oral Surg Oral Med Oral Pathol Oral Radiol*. 2013;115:37–40.

Petersen DS, Fish L, Cass AS. Twins with congenital deficiency of abdominal musculature. *J Urol*. 1972;107:670–672.

Philip J, Mullassery D, Craigie RJ, et al. Laparoscopic orchidopexy in boys with prune belly syndrome: outcome and technical considerations. *J Endourol*. 2011;25:1115–1117.

Popek EJ, Tyson RW, Miller GJ, et al. Prostate development in prune belly syndrome (PBS) and posterior urethral valves (PUV): etiology of PBS—lower urinary tract obstruction or primary mesenchymal defect? *Pediatr Pathol*. 1991;11:1–29.

Potter EL. Abnormal development of the kidney. Potter EL. *Normal and abnormal development of the kidney*. Year Book Medical: Chicago; 1972:154–220.

Rabinowitz R, Schillinger JF. Prune belly syndrome in the female subject. *J Urol*. 1977;118:454–456.

Ramagopal G, Narayana G, Rathod A. Prune belly syndrome with situs inversus abdominus. *J Neonatal Surg*. 2016;3:38.

Ramasamy R, Haviland M, Woodard JR, et al. Patterns of inheritance in familial prune belly syndrome. *Urology*. 2005;65:1227.

Randolph J, Cavett C, Eng G. Abdominal wall reconstruction in the prune-belly syndrome. *J Pediatr Surg*. 1981;16:960–964.

Randolph J, Cavett C, Eng G. Surgical correction and rehabilitation for children with prune-belly syndrome. *Ann Surg*. 1981;193:757–762.

Randolph JG. Total surgical reconstruction for patients with abdominal muscular deficiency (“prune-belly”) syndrome. *J Pediatr Surg*. 1977;12:1033–1043.

Ransley PG, Vordermark JS, Caldamone AA, et al. Preliminary ligation of the gonadal vessels prior to orchidopexy for the intra-abdominal testicle: a staged Fowler-Stephens procedure. *World J Urol*. 1984;2:266–269.

Reinberg Y, Chelimsky G, Gonzalez R. Urethral atresia and the prune belly syndrome. Report of 6 cases. *Br J Urol*. 1993;72:112–114.

Reinberg Y, Manivel JC, Fryd D, et al. The outcome of renal transplantation in children with the prune belly syndrome. *J Urol*. 1989;142:1541.

Reinberg Y, Manivel JC, Pettinato G, et al. Development of renal failure in children with the prune belly syndrome. *J Urol*. 1991;145(5):1017–1019.

Reinberg Y, Shapiro E, Manivel JC, et al. Prune belly syndrome in females: a triad of abdominal musculature deficiency and anomalies of the urinary and genital systems. *Pediatr*. 1991;118:395–398.

Riccardi VM, Grum CM. The prune belly anomaly: heterogeneity and superficial X-linkage mimicry. *J Med Genet*. 1977;14:266–270.

Rogers LW, Ostrow PT. The prune belly syndrome. Report of 20 cases and description of a lethal variant. *J Pediatr*. 1973;83:786–793.

Routh JC, Huang L, Retik AB, et al. Contemporary epidemiology and characterization of newborn males with prune belly syndrome. *Urology*. 2010;76:44–48.

Satar M, Özlü F, Yapıcıoğlu H, et al. Corset usage for gastrointestinal and respiratory problems in a newborn with prune belly syndrome. *Indian J Pediatr*. 2016;83:717–719.

Saxena AK, Brinkmann OA. Unique features of prune belly syndrome in laparoscopic surgery. *J Am Coll Surg*. 2007;205:217–221.

Sayre R, Stephens R, Chonko AM. Prune belly syndrome and retroperitoneal germ cell tumor. *Am J Med*. 1986;81:895–897.

Scarborough PR, Files B, Carroll AJ, et al. Interstitial deletion of chromosome 1 [del(1)(q25q32)] in an infant with prune belly sequence. *Prenat Diagn*. 1988;8:169–174.

Schneider-Monteiro ED, Dénes FT, Hampel C, et al. Immunoexpression of adrenergic receptors in detrusor from patients with prune belly syndrome: a digital quantification. *J Pediatr Urol*. 2010;6:282–287.

Shih WJ, Greenbaum LD, Baro C. In utero sonogram in prune belly syndrome. *Urology*. 1982;20:102–105.

Shimizu T, Ihara Y, Yomuro W, et al. Antenatal diagnosis of prune belly syndrome. *Arch Gynecol Obstet*. 1992;251:211–214.

Sholder AJ, Maizels M, Depp R, et al. Caution in antenatal intervention. *J Urol*. 1988;139:1026–1029.

Short KL, Groff DB, Cook L. The concomitant presence of gastroschisis and prune belly syndrome in a twin. *J Pediatr Surg*. 1985;20:186–187.

Shrom SH, Cromie WJ, Duckett JW. Megalourethra. *Urology*. 1981;17:152–156.

Silengo M, Barberis L, Ferrero GB, et al. A possible relationship between Beckwith-Wiedemann syndrome and prune belly syndrome. *Clin Dysmorphol*. 2002;11:293–294.

Silverman FM, Huang N. Congenital absence of the abdominal muscle associated with malformation of the genitourinary and alimentary tracts: report of cases and review of the literature. *Am J Dis Child*. 1950;80:91–124.

Sinico M, Touboul C, Haddad B, et al. Giant omphalocele and “prune belly” sequence as components of the Beckwith-Wiedemann syndrome. *Am J Med Genet A*. 2004;129:198–200.

Skoog SJ. Prune belly syndrome. Kelalis PP, King LR, Belman AB. *Clinical pediatric urology*. WB Saunders: Philadelphia; 1992:943–976.

Smith CA, Smith EA, Parrott TS, et al. Voiding function in patients with prune belly syndrome after Monfort abdominoplasty. *J Urol*. 1998;159:1675–1679.

Smith EA, Srinivasan A, Scherz HC, et al. Abdominoplasty in prune belly syndrome: modifications in Monfort technique to address variable patterns of abdominal wall weakness. *J Pediatr Urol*. 2017;13(5):502.e1–502.e6.

Smith EA, Woodard JR. Prune belly syndrome. 8th ed. WB Saunders: Philadelphia; 2002:2117. Retik AB, Vaughan ED, Wein AJ. *Campbell's urology*. vol 3.

Smith EB. Congenital absence of abdominal muscles and other defects. *Proc R Soc Med*. 1913;6:186–187.

Smythe AR 2nd. Ultrasonic detection of fetal ascites and bladder dilation with resulting prune belly. *J Pediatr*. 1981;98:978–980.

Snow BW, Duckett JW. Prune belly syndrome. Gillenwater JY, et al. *Adult and pediatric urology*. Yearbook Medical Publishers: Chicago; 1987:1921–1938.

Snyder HM, Harrison NW, Whitfield HN, et al. Urodynamics in the prune belly syndrome. *Br J Urol*. 1976;48:663–670.

Steinhardt G, Hogan W, Wood E, et al. Long-term survival in an infant with urethral atresia. *J Urol*. 1990;143:336–337.

Stephens FD. Triad (prune belly) syndrome. Stephens FD. *Congenital malformations of the urinary tract*. Praeger: New York; 1983:485–511.

Stephens FD, Gupta D. Pathogenesis of the prune belly syndrome. *J Urol*. 1994;152:2328–2331.

Strumme EG. Über die symmetrischenkongenitalenBauchmuskeldefekte undüber die KombinationderselbenmitanderenBildungsanomalien des Rumpfes. *Mitt Grenzgeb Med Chir*. 1903;11:548–551.

Symonds DA, Driscoll SG. Massive fetal ascites, urethral atresia, and cytomegalic inclusion disease. *Am J Dis Child*.

1974;127:895–897.

Tank ES, McCoy GB. Limited surgical intervention in the prune belly syndrome. *J Pediatr Surg*. 1983;18:688–691.

Tayakkanonta K. The gubernaculum and its nerve supply. *Aust NZ J Surg*. 1963;33:61–67.

Teramoto R, Opas LM, Andrassy R. Splenic torsion with prune belly syndrome. *J Pediatr*. 1981;98:91–92.

Texter JH, Koontz WW. Prune-belly syndrome seen in the adult. *Soc Pediatr Urol Newsletter*. 1980.

Tran S, Grossman E, Barsness KA. Prune belly syndrome, splenic torsion, and malrotation: a case report. *J Pediatr Surg*. 2013;48:41–43.

Uehling DT, Zadina SP, Gilbert E. Testicular histology in triad syndrome. *Urology*. 1984;23:364–366.

Volmar KE, Fritsch MK, Perlman EJ, et al. Patterns of congenital lower urinary tract obstructive uropathy: relation to abnormal prostate and bladder development and the prune belly syndrome. *Pediatr Dev Pathol*. 2001;4:467–472.

Wacksman J, Dinner M, Staffon RA. Technique of testicular autotransplantation using a microvascular anastomosis. *Surg Gynecol Obstet*. 1980;150:399–401.

Waldbaum RS, Marshall VF. The prune belly syndrome: a diagnostic therapeutic plan. *J Urol*. 1970;103:668–674.

Walker J, Prokurat AI, Irving IM. Prune belly syndrome associated with exomphalos and anorectal agenesis. *J Pediatr Surg*. 1987;22:215–217.

Wheatley JM, Stephens FD, Hutson JM. Prune-belly syndrome: ongoing controversies regarding pathogenesis and management. *Semin Pediatr Surg*. 1996;5:95–106.

Wigger HJ, Blanc WA. The prune belly syndrome. *Pathol Annu*. 1977;12:17–39.

Wilbert C, Cohen H, Yu YT, et al. Association of prune belly syndrome and gastroschisis. *Am J Dis Child*. 1978;132:526–

527.

Williams DI. Prune-belly syndrome. Harrison JH, Gittes RF, Perlmutter AD, et al. *Campbell's urology*. 4th ed. WB Saunders: Philadelphia; 1979:1743.

Williams DI, Burkholder GV. The prune belly syndrome. *J Urol*. 1967;98:244–251.

Williams DI, Parker RM. The role of surgery in the prune belly syndrome. Johnston JH, Goodwin WF. *Reviews of paediatric urology. Amsterdam: ExcerptaMedica*. 1974:315.

Woodard JR. Lessons learned in 3 decades of managing the prune belly syndrome [editorial]. *J Urol*. 1998;159:1680.

Woodard JR. Prune belly syndrome. Kelalis PP, King LR, Belman AB. *Clinical pediatric urology*. WB Saunders: Philadelphia; 1985:805–824.

Woodard JR, Parrott TS. Orchiopexy in the prune belly syndrome. *Br J Urol*. 1978;50:348–351.

Woodard JR, Parrott TS. Reconstruction of the urinary tract in prune belly uropathy. *J Urol*. 1978;119:824–828.

Woodard JR, Smith EA. Prune belly syndrome. Walsh PC, Retik AB, Vaughan ED Jr, et al. *Campbell's urology*. WB Saunders: Philadelphia; 1998:1917–1938.

Woodard JR, Trulock TS. Prune belly syndrome. Walsh PC, Gittes RF, Perlmutter AD, et al. *Campbell's urology*. 5th ed. WB Saunders: Philadelphia; 1986:2159–2167.

Woodard JR, Zucker I. Current management of the dilated urinary tract in prune belly syndrome. *Urol Clin North Am*. 1999;17:407–418.

Woodhouse CR, Ransley PG. Teratoma of the testis in the prune belly syndrome. *Br J Urol*. 1983;55:580–581.

Woodhouse CR, Ransley PG, Innes-Williams D. Prune belly syndrome—report of 47 cases. *Arch Dis Child*. 1982;57:856–859.

Woodhouse CR, Snyder IIIHM. Testicular and sexual function in adults with prune belly syndrome. *J Urol*. 1985;133:607–609.

Woodhouse RJ, Kellett MJ, Williams DI. Minimal surgical interference in the prune belly syndrome. *Br J Urol*. 1979;51:475.

Workman SJ, Kogan BA. Fetal bladder histology in posterior urethral valves and the prune belly syndrome. *J Urol*. 1990;144:337–339.

Wright JR Jr, Barth RF, Neff JC, et al. Gastrointestinal malformations associated with prune belly syndrome: three cases and a review of the literature. *Pediatr Pathol*. 1986;5:421–448.

Yamamoto H, Nishikawa S, Hayashi T, et al. Antenatal diagnosis of prune belly syndrome at 11 weeks of gestation. *J Obstet Gynaecol Res*. 2001;27:37–40.

Yu TJ, Lai MK, Chen WF, et al. Two stage orchiopexy with laparoscopic clip ligation of the spermatic vessels in prune belly syndrome. *J Pediatr Surg*. 1995;30:870–872.

33

Posterior Urethral Valves

Aseem Ravindra Shukla MD, Arun K. Srinivasan MD

Background

Few afflictions of the newborn male share in the irony of being readily diagnosed and treated with a straightforward initial surgical intervention, yet imply the significant long-term consequences of posterior urethral valves (PUVs). As the most common cause of bladder outlet obstruction in infants, the presentation of PUV is often rendered antenatally, and pathognomonic findings on postnatal imaging confirm the diagnosis. **Although an endoscopic ablation or urinary diversion will address the immediate uropathy, the embryologic insult to the bladder and kidneys is profound and requires that these infant boys remain under the extended care of urologists and nephrologists.**

Description

A congenital obstruction of the posterior urethra ascribed to valvelike leaflets was recognized as early as 1769, by Morgagni, then confirmed by Langenbeck in 1802, both based on postmortem dissections. It was Hugh Hampton Young, however, who described the first endoscopic diagnosis of a urethral obstruction that he termed “posterior urethral valves” (Young et al., 1919). Despite the rudimentary nature of the early endoscopic instruments, in 1920 Randall carried out the first endoscopic resection of valves, providing a description that remarkably encapsulates the visual findings of the posterior urethra even today (Randall, 1921):

> *The prostatic urethra is markedly dilated. The vesical neck raised and bladder orifice relaxed. Deep pittings penetrate down into either lateral wall of the prostatic urethra and at the extremity the verumontanum is seen a fine frenulum which extends distally for about 1 cm, and in dividing, forms what is apparently a definite valve on either side of the urethra, rising from the floor to each side wall.*

Young was the first to propose a classification system for the lesion in 1919 based on an initial 12 patients that remains a widely used contemporary nomenclature (Fig. 33.1). **The type 1 lesion, pertinent to 95% of cases, is theorized as a hypertrophied variant of the inferior urethral crest formed by the insertion of the distal ends of the Wolffian ducts into the**

anterolateral walls of the cloaca (Field & Stephens, 1974). **The urethral valves are actually leaflets that arise from the verumontanum, take an anterior course, and then fuse in the midline just proximal to the external striated urethral sphincter.** Some argue that the cleft seen in the midline—the "two forklike processes" as Young described, or the leaflets fanning out from the verumontanum—is actually iatrogenic and created by retrograde instrumentation in the perinatal period (Dewan et al., 1994).

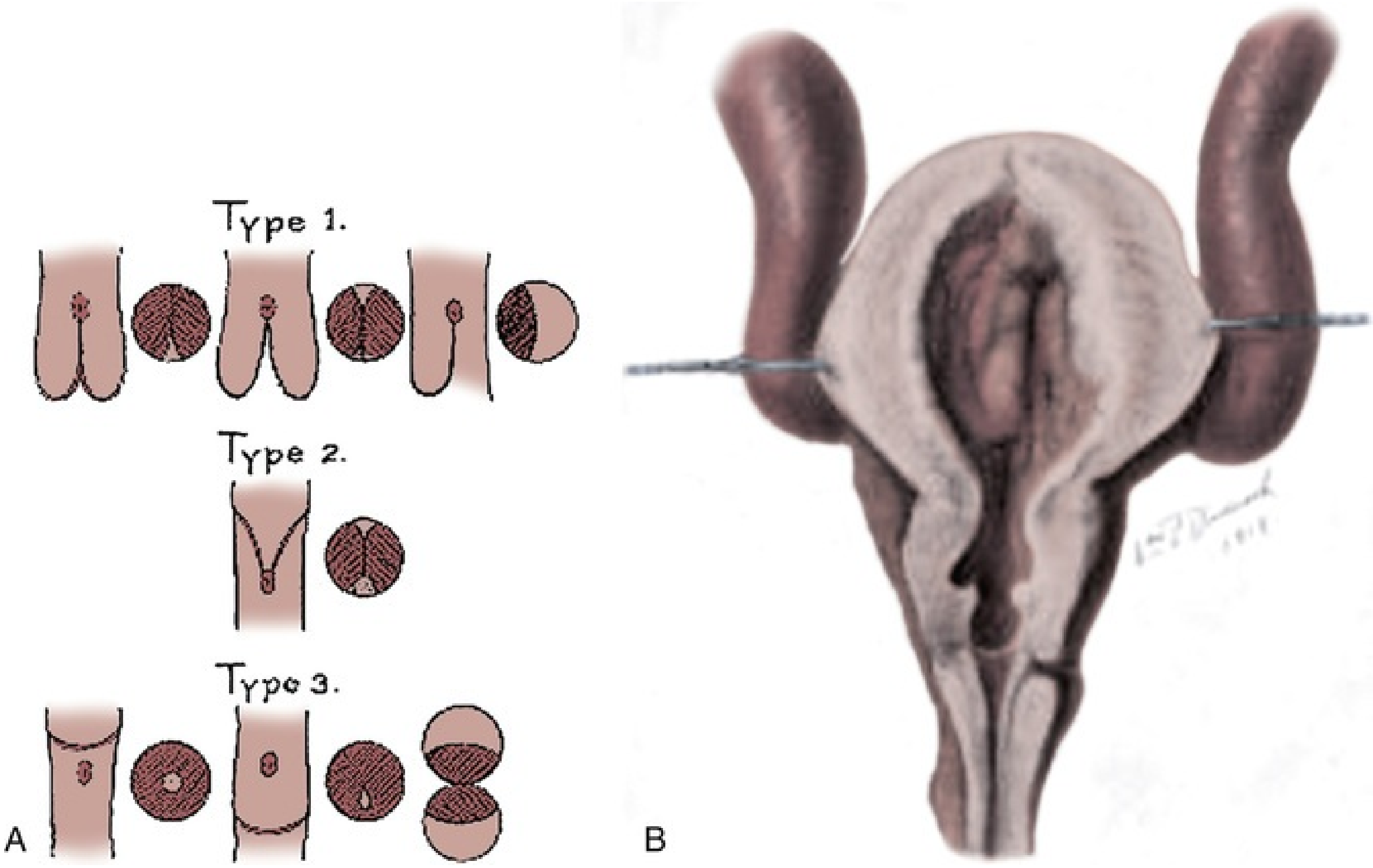

FIG. 33.1 (A) Young's original figures from his 1919 article describing three types of posterior urethral valves. (B) William P. Didusch illustrates the pathognomonic findings associated with posterior urethral valves: the thickened bladder with elevated bladder neck, dilated prostatic urethra, and the valve leaflets commonly ascribed to type 1 valves. The ureters are shown to be dilated. (From Young HH, Frontz WA, Baldwin JC. Congenital obstruction of the posterior urethra. *J Urol* 1919;3:289.)

The type 2 valve of Young, described as arising from the verumontanum and extending posteriorly and superiorly to the bladder neck, is not obstructing and **has not been reported definitively since early reports.** Stephens reported seeing no type 2 valves in 210 boys with PUV examined with cystoscopy and suggested that the description was that of the secondary effects at the bladder neck of more distal obstruction (Stephens, 1955).

The type 3 valve is another contentious diagnosis, but **is most commonly described as an annular ring similar to that seen with a congenital urethral stricture. Young described a complete obstruction “attached to the entire circumference of the urethra, there being a small opening in the center.”** The embryologic origin for this variant affecting 5% to 10% of cases of outlet obstruction is felt to be a persistence of the urogenital membrane after the urorectal septum divides the cloacal membrane (Stephens et al., 2002).

A consensus view on the embryologic origins of PUVs remains elusive, although various mechanisms have been proposed. The earliest theory held that hypertrophy of the urethral mucosal folds were the cause of obstruction, which was furthered later to suggest cloacal remnants caused the appearance of valves after division by the urogenital membrane (Krishnan et al., 2006). Lowsley placed the origin of PUVs in an abnormal development of the Wolffian and Müllerian ducts based on an autopsy study in 1914; but a more recent autopsy study corroborates the presence of what is termed a “congenital obstructing posterior urethral membrane (COPUM),” consistent with a persistent, oblique urogenital membrane that is punctured at the time of catheter or feeding tube placement in the immediate postpartum period by the medical practitioner (Dewan et al., 1994, Krishnan et al., 2006). Although the premise of COPUM is an interesting, even provocative hypothesis, convincing, corroborative evidence is lacking.

Genetic Basis of Posterior Urethral Valves

An understanding of the genetic etiology for PUVs is still in its infancy. Chiarmonte et al. reported a familial incidence of PUVs, identifying that affected siblings shared a partial duplication in the short arm of chromosome 11 (Chiaramonte et al., 2016). Other studies similarly implicated chromosome 11, along with chromosome 1 (Weber et al., 2005). The majority of cases described in the literature are sporadic, but **because the anomaly is known to affect siblings, inheritance of PUVs may be autosomal recessive, x-linked recessive, or by multifactorial inheritance. A recent genome-wide population-based study of copy number variants in isolated PUV identified novel candidate gene regions in 57% of cases examined** (Boghossian et al., 2016). Faure et al. examined the phenotypic effect of copy number variants in PUVs and concluded that affected children have a higher nadir creatinine and increased likelihood of progressing to stage V chronic kidney disease (Faure et

al., 2016).

Epidemiology

Congenital anomalies of the urinary tract affect up to 1 in 500 pregnancies, and obstructive uropathy accounts for most of these cases. (Lissauer et al., 2007; Ruano, 2011). A large population-based registry study from the United Kingdom demonstrated that lower urinary tract obstruction (LUTO) has an incidence of 2.2 per 10,000 births, of which PUVs was the most common pathology (1.4/10,000 births) followed by urethral atresia and prune-belly syndrome (Anumba et al., 2005). Because birth incidence requires the often inaccurate count of early spontaneous pregnancy loss, a latter study following a similar cohort based in the West Midlands between 1995 to 2007 calculated **a prevalence ratio of PUVs—number of affected births divided by the total number of live births and stillbirths—of 2.10 per 10,000 births** (Malin et al., 2012). This prevalence was also significantly higher in black and minority ethnic groups when compared with white Europeans.

A review of the Kids' Inpatient Database (KID)—a national database of inpatient pediatric hospitalizations in the United States—found 578 newborn males diagnosed with PUV between 1997 to 2009, that when divided by 10.0 million live male births in hospitals over that interval, gave a weighted prevalence rate of 1.6 per 10,000 in hospital live male births (Lloyd et al., 2013).

A more recent Australian study calculated a live birth incidence of PUVs as 1.28 per 10,000 in New South Wales. No association between PUVs and maternal or socioeconomic factors was found (Thakkar et al., 2014).

Considering that the United States alone may expect 300 to 500 new cases of PUVs born annually—of which one third will go on to end-stage renal failure (Heikkilä et al., 2011)—the economic repercussions in terms of dialysis and renal transplantation arising from this congenital anomaly are enormous.

Key Points

- Type 1 valves are the most common variant of PUVs, and appear as leaflets that arise from the verumontanum and fuse anteriorly just proximal to the external urethral sphincter.
- Type 3 valves present as a congenitally obstructing membrane that is likely

perforated at the time of the initial postnatal catheterization.

- The incidence of PUVs is between 1.6 to 2.1 per 10,000 births.
- There is an emerging understanding of the genetic basis for PUVs, particularly associated with chromosome 11 and copy number variants.

Pathophysiology of Posterior Urethral Valves

Although the initial treatment of PUVs—cystoscopy and valve ablation—is a relatively simple and reproducible procedure with adequate training, the bladder outlet obstruction during early fetal development creates downstream consequences that afflict an individual, often for a lifetime (Table 33.1). The long-term sequelae of valvular disease can be correlated to bladder dysfunction, renal dysplasia, polyuria, and multiple other anatomic and physiologic factors. Simply put, the bladder exposed to developmental obstruction becomes hypertrophied and empties well during the compensated phase. Over time, polyuria caused by renal dysplasia and continuing glomerular damage leave the bladder without adequate periods of bladder emptying, leading to decompensation. This phase leads to increased bladder residuals that are causally linked to exacerbation of hydronephrosis and further glomerular damage.

TABLE 33.1

Damage Caused by Posterior Urethral Valves

ORGAN	EFFECT	NATURAL HISTORY
Lung	Pulmonary hypoplasia	May be fatal in newborns; limited data on long-term natural history of survivors
Kidney		
Glomerular injury		
Obstructive uropathy	Reversible renal insufficiency	Usually improves with initial treatment but can recur with bladder dysfunction
Dysplasia	Irreversible renal insufficiency	Permanent level of renal damage that limits growth; leads to progressive renal failure and hypertension
Tubular injury	Inability to limit sodium and water loss	Progressive with age; nephrogenic diabetes insipidus
Bladder	Poor sensation, hypercontractility, low compliance, and eventual myogenic	Bladder problems are lifelong and change with age and

	failure all may contribute to incontinence and poor emptying	management
Ureters	Poor contractility and inability to coapt and transport urine	Many will improve initially, but most have chronic hydronephrosis

Lower Urinary Tract

It cannot be overstated that the potential comorbidities arising from PUVs—renal dysfunction, urine reflux, worsening hydronephrosis—are directly related to bladder dysfunction.

Understanding the embryologic impact of PUVs on bladder development—and subsequent bladder dysfunction—remains an area of continuing investigation. The storage and voiding of urine at high pressures has been simulated in fetal sheep and rabbit models in vitro to investigate the cascade of events effectuating bladder smooth muscle alterations**. Increased bladder compliance is seen following partial bladder outlet obstruction** (**Kirsch et al., 2003**), **and more compliant bladders (simulating the decompensated bladder) lead to more upper tract dilation. So increased bladder dilation places the upper urinary tract at risk.** This model, and the work of others confirmed that extracellular matrix elements line the detrusor smooth muscle cells of the bladder after obstruction—as noted in valve bladders (Workman and Kogan, 1990). Importantly, the pathologically significant elevated storage pressures must be distinguished from the normal neonatal and infantile elevated voiding pressures that are a normal feature of bladder development (Sillen et al., 1992).

There remains some controversy whether the changes in bladder morphology in the valve-affected bladder are reversible, as opposed to the phenotypic changes in neurogenic bladders that are more permanent (Hutcheson et al., 2004; Keating, 1994; Rink, 1994).

The deposition in the extracellular matrix causes altered contraction and passive relaxation of the bladder, which may cause multiple intracellular changes ranging from a reduction in detrusor blood flow causing ischemia to free radical toxicity. These changes alter the phenotype of detrusor muscle myosin bundles and actin-associated filaments (Ghafar et al., 2002; Shukla et al., 2004; Levin et al., 2005).

The valvular obstruction will also lead to marked dilation of the posterior

urethra, hypertrophy of the bladder neck, and flattening of the verumontaum with dilation of ejaculatory ducts—the pathognomic findings on voiding cystourethrogram of this diagnosis (Figs. 33.2A–D and 33.3AB). These changes seem to return to a more normal appearance after valve ablation as the offending distal obstruction is removed.

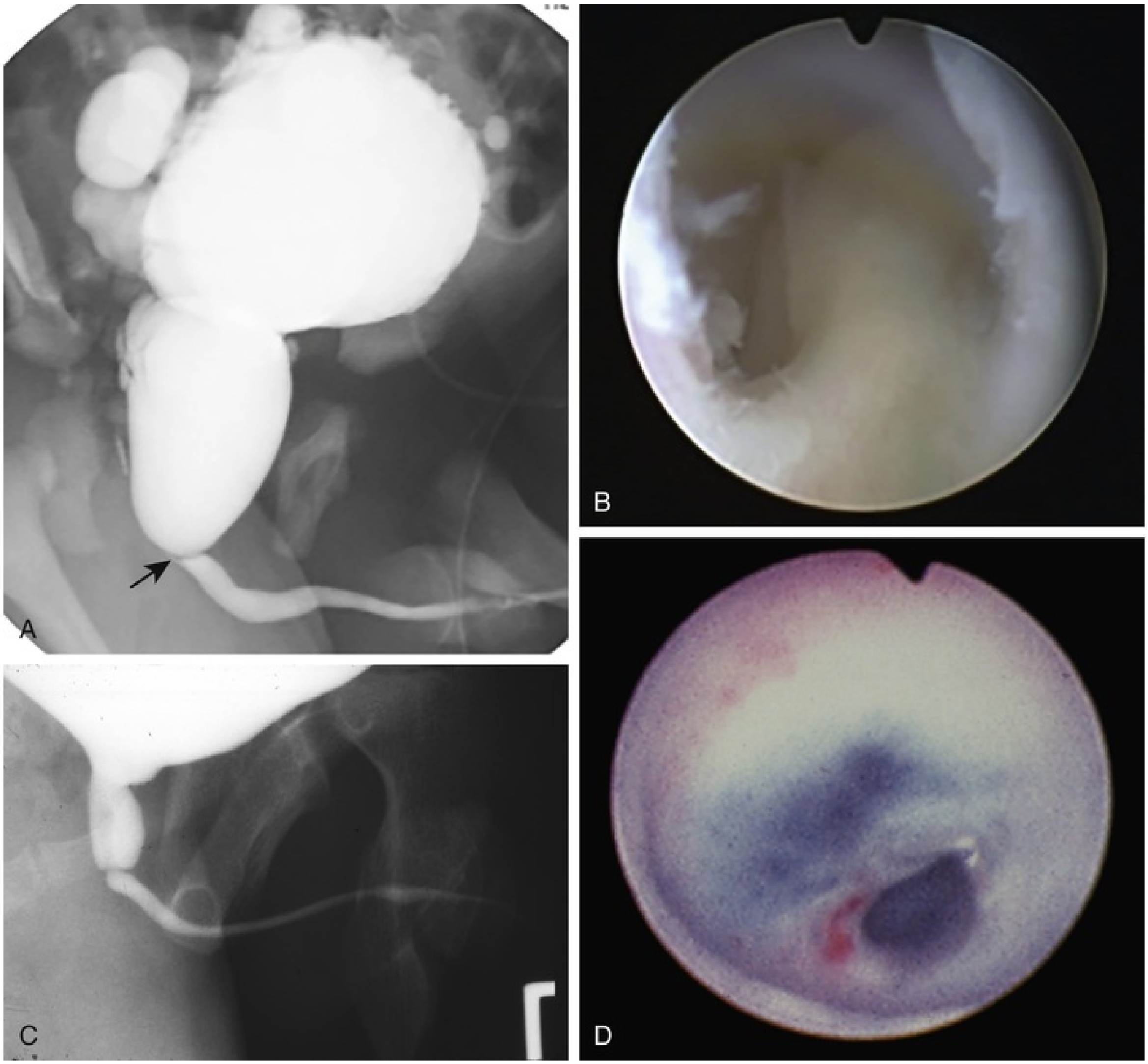

FIG. 33.2 (A) Voiding cystourethrogram image shows a bladder affected by multiple diverticuli and a dilated posterior urethra narrowing at the site of valvular obstruction. *Arrows* indicate valve leaflet that would be fulgurated at time of valve ablation. (B) Cystoscopic image corresponding to the point of obstruction in (A). The urethral valves are seen as leaflets arising from the verumontaum and fusing in the midline, just proximal to the striated sphincter. The verumontanum is noted just proximal to the valve leaflets. (C) Voiding cystourethrogram image shows an elevated bladder neck and dilated posterior urethral funneling to a point of obstructed flow. These are

typical radiologic findings of posterior urethral valves. (D) Cystoscopic image corresponding to point of obstruction in (A). The concentric narrowing is classically associated with a type 3 valve, but also considered consistent with the congenital obstructing posterior urethral membrane (COPUM) that may have been perforated at time of initial catheter placement.

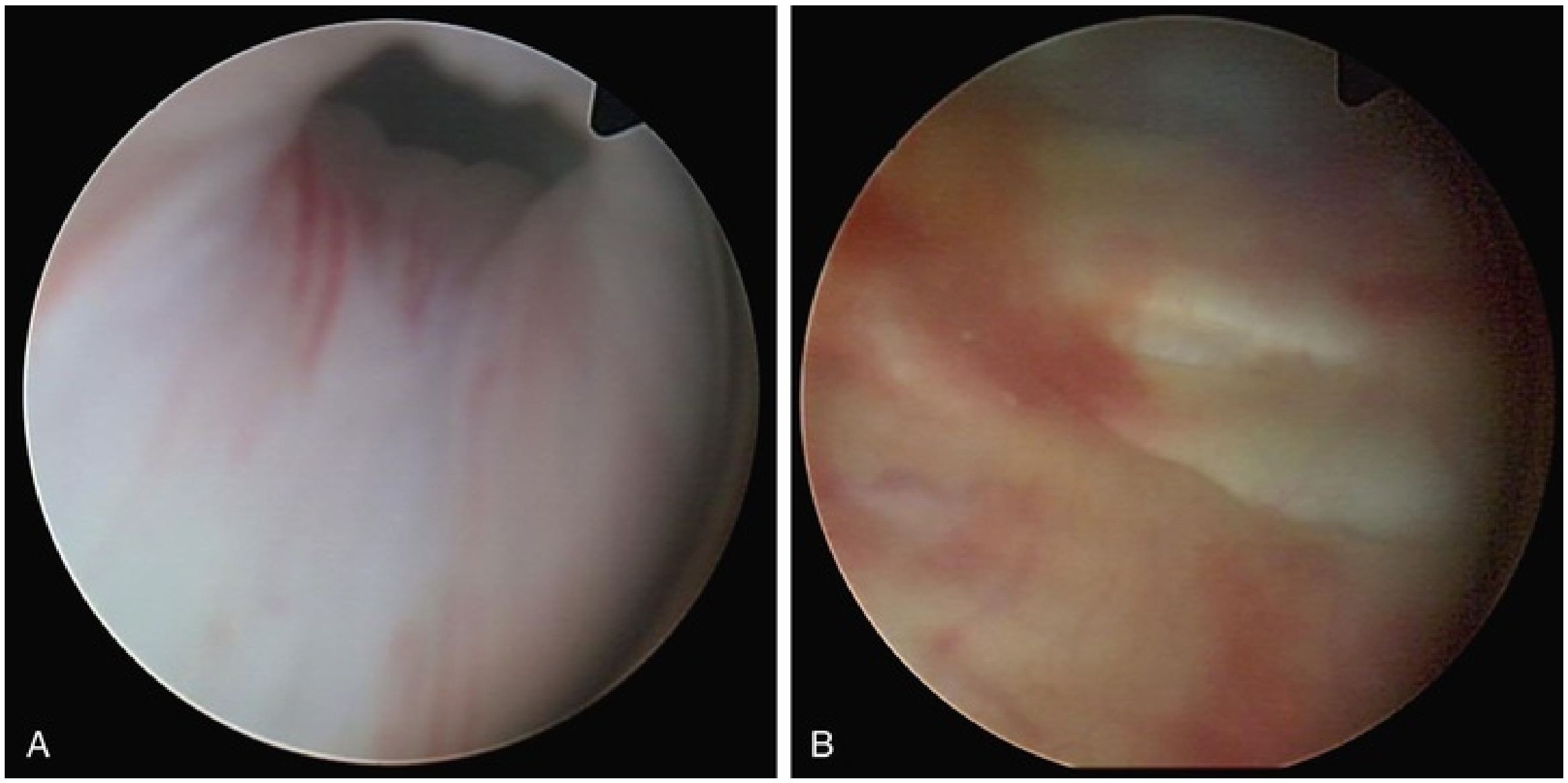

FIG. 33.3 Cystoscopic view in an infant with posterior urethral valves of (A) elevated bladder neck and (B) trabeculations in affected bladder consistent with obstructive uropathy.

Mitchell coined the term “valve bladder syndrome” in 1982, when he described 11 patients in whom bladder filling and emptying were noted to be intricately related to the extent of renal pelvicaliectasis and overall renal function and dysfunction (Mitchell, 1982). This concept was subsequently illustrated as a “vicious cycle” leading to the valve bladder syndrome. **Bladder hypertrophy secondary to fetal obstruction results in higher voiding pressures that maintain complete bladder emptying in the compensated phase. The increased voiding pressures lead to gradual remodeling of the bladder wall, increasing voiding pressures, and ultimately higher postvoid residuals (PVRs) as emptying begins to fail.** The rise in urine output with normal growth and development, combined with the latent polyuria of existing renal dysplasia and increased glomerular pressure caused by poor bladder emptying, conspire to increase urine volumes stored in the upper urinary tracts. As this bolus of urine fills the bladder, even as the bladder empties partially, a lack of extended periods of an empty, relaxed bladder push the compensated bladder toward decompensation. This, of course, leads to even greater PVRs, overflow incontinence, and further renal damage (Close et al., 1997). Underscoring the significance of the incontinence wrought by a valve bladder, Parkhouse et al. described a higher incidence of renal deterioration in boys presenting with incontinence after 5 years, even when renal function was normal in infancy (Parkhouse et al., 1988).

Upper Urinary Tract

A bladder exposed to PUVs undergoes a cascade of changes that alter the organ's normal function in storing and emptying urine. This bladder dysfunction manifests in varied ways during infancy, and will be discussed later in this chapter. **But what is apparent is that a sustained increase in intravesical storage pressures over prolonged time intervals transmits that pressure to the ureter, renal pelvis and, ultimately, the glomerular units—causing architectural and functional changes at each ascending structure** (Koff et al., 2002). These architectural changes can be inferred clinically by the severe hydroureteronephrosis that is often seen in the setting of PUVs. Increased echogenicity, parenchymal thinning with cortical cysts, and lack of corticomedullary differentiation similarly imply significant renal dysplasia (Fig. 33.4A).

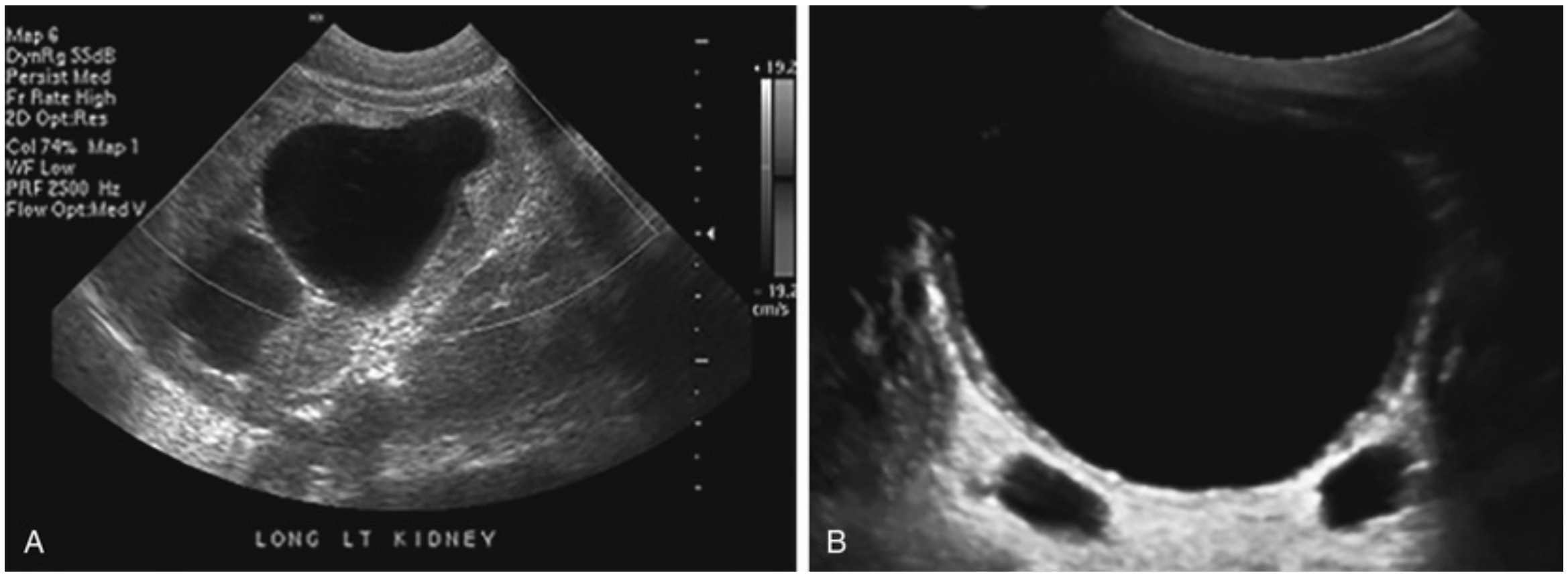

FIG. 33.4 (A) Left renal ultrasound for a newborn with posterior urethral valves. Severe pelvicaliectasis with thinning of the parenchyma with increased echogenicity, and loss of corticomeduallary differentiation is seen. (B) Pelvic view of the same patient, not yet catheterized, shows a distended bladder with dilation of bilateral distal ureters.

Ureteral dilation occurs as a direct transmission of pressure from the dysfunctional bladder and the vesicoureteral reflux that is seen in up to 70% of patients with PUVs (Puri and Kumar, 1996; Sarhan et al., 2011). Polyuria caused by progressive renal damage and congenital renal dysplasia compound ureteral dilation as well (Smyth et al., 1991). **The chronicity of ureteral dilation is classically believed to cause ureteral wall thickening, loss of peristalsis, and loss of mucosal coaptation, increasing the risk for urine stasis, infection, and increased pressures in the renal units** (see Fig. 33.4B; Parkhouse et al., 1988; Glassberg, 2001).

The elevated renal pelvic pressures secondary to increase in bladder and ureteral pressure lead to significant alterations in renal morphology and function. **The renal dysfunction seen in PUVs has two specific etiologies: (1) obstructive uropathy and (2) renal dysplasia.**

Obstructive uropathy causing renal damage is a well-known phenomenon in various models. Fetal sheep ureteral obstruction models clearly demonstrate that although hydronephrosis occurs rapidly after obstruction, irreversible dysplastic changes in the renal architecture are seen by term, and these changes were confirmed after bladder outlet obstruction in the same model (Peters et al., 1992; Chevalier, 2004). Apoptosis and increased oxidative stress in mouse kidneys with ureteral obstruction is also seen in the face of bladder outlet obstruction (Kawada et al., 1999; Chevalier, 2004).

The increased pressure from obstruction damages luminal cells in the renal tubules and also leads to poorly concentrated urine production (Li et al., 2004, Nguyen et al., 2005). Obstruction may also affect urinary concentration by reducing blood flow to the medulla, causing a loss in the medullary concentration gradient and resulting in significant polyuria, and even the postobstructive diuresis seen after catheter placement in infants with PUVs (Dinneen et al., 1995).

Although some debate about whether the entirety of renal damage seen in PUVs is actually a secondary phenomenon caused by obstruction, the observation that even early prenatal intervention does not necessarily forestall long-term renal disease posits that renal dysplasia may be concurrent with—rather than a consequence of—PUVs (Haecker et al., 2002). Others have demonstrated known primary dysplastic malformations of fetal cartilage tissue or dysplastic glomeruli and tubules in PUV–affected renal tissue at time of nephrectomy (Haecker et al., 2002).

A correlation between severe renal dysplasia with decreased activity of the renin-angiotensin system that modulates renal development has been noted in PUVs, and a decrease in the angiotensin receptor type 1 genetic polymorphisms (Peruzzi et al., 2005). Bajpai et al. found that plasma rennin activity increases precede common clinical findings of renal damage such as rising serum creatinine, renal scars, and lowering glomerular filtration rate (Bajpai et al., 2005). Although angiotensin II contributes to renal damage by hemodynamic alterations in glomerular flow, it also induces profibrogenic actions and inflammation through the induction of transforming growth factor-β_1 and tumor necrosis factor-α (Kagami et al., 1994; Furness et al., 1999; MacRae Dell et al., 2000). These cytokines are considered potential biomarkers that seem to decrease with improvement in renal function after valve ablation, and elevations imply worsening outcomes.

Administering an angiotensin-converting enzyme inhibitor (ACE-I) shows therapeutic potential in experimental studies by reducing fibrosis (Yu et al., 2004; Gagliardini and Benigni, 2006) and seems to reduce expression of biomarkers such as transforming growth factor-β_1 and tumor necrosis factor-α in another clinical study, suggesting a potential role in selected children with PUVs (Mandelia et al., 2013). Further corroborating the hypothesis that renal damage in valves is due, in part, to congenital dysplasia and not only obstruction, is the finding that the *ACE II* gene is expressed significantly more, and the angiotensin receptor gene *(ATR)* less, in patients with PUVs compared with those with other types of renal dysplasia and in controls (Peruzzi et al., 2005; Laksmi et al., 2010). Fetal sheep experiments, in contrast, demonstrated increased renin mRNA expression, angiotensinogen-2 mRNA along with upregulation of AT2 receptor expression with partial bladder outlet obstruction (Gobet et al., 1999). These alterations imply that renal dysfunction in children with PUV is multifactorial, and that both congenital renal dysplasia and secondary changes caused by obstruction in developing kidneys mediate the renal dysfunction that is a consequence of PUV.

Vesicoureteral Reflux and Dysplasia

Hoover and Duckett observed that the high-grade vesicoureteral reflux seen in children with PUVs was usually noted in an ipsilateral poorly functioning renal unit and that the contralateral renal unit appeared to have preserved renal function (Fig. 33.5) (Hoover and Duckett, 1982). **They hypothesized that the reflux served as a “pop-off” mechanism in which the dysplastic kidney with**

reflux served as a pressure reservoir mitigating damage to the contralateral kidney and coined the term, "vesicoureteral reflux and dysplasia (VURD)." This relationship, in that original series, was found in 13% of patients with valves, and the theory that these children would have better long-term renal function as a result of the pop-off phenomenon was widely affirmed.

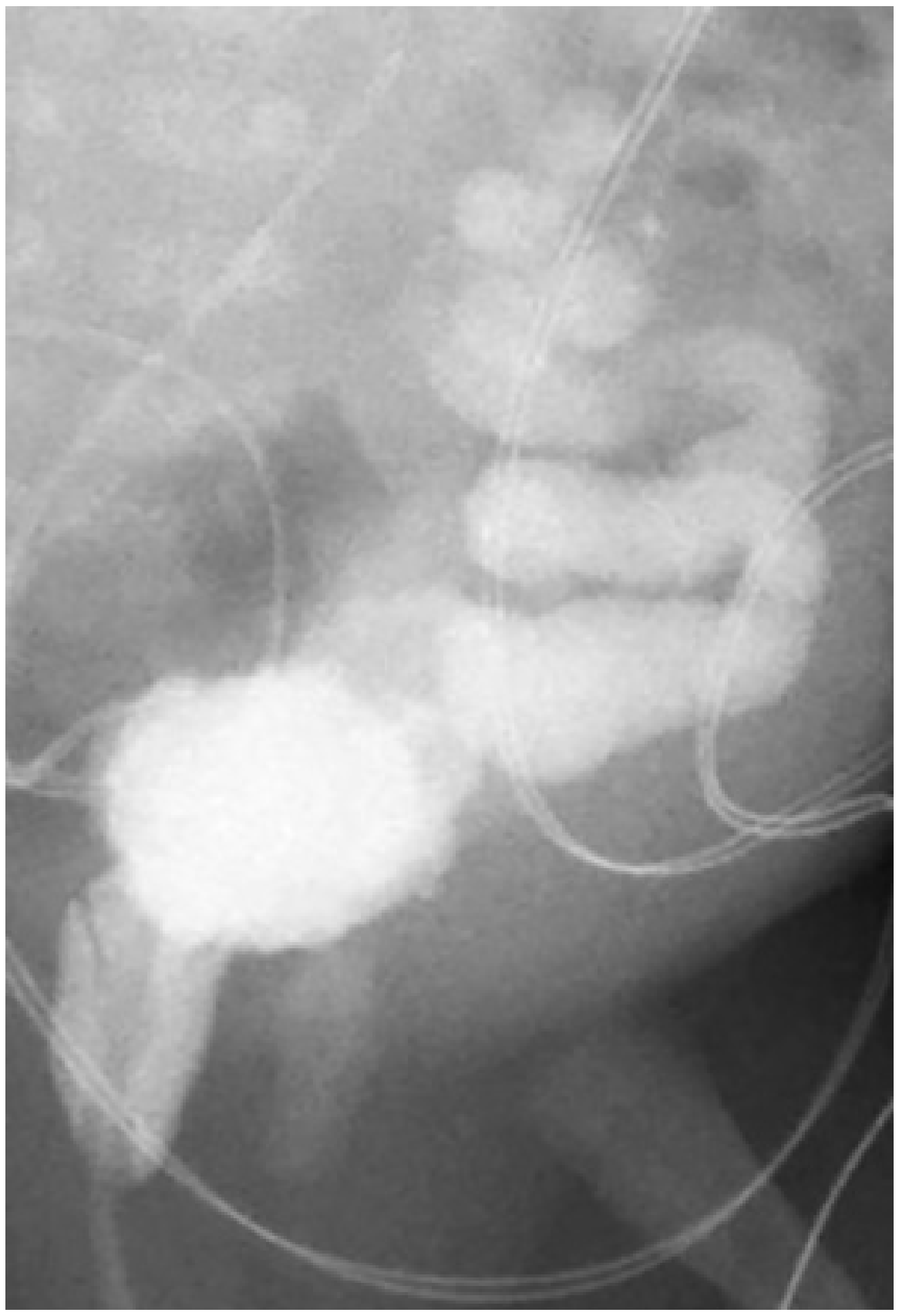

FIG. 33.5 Massive, dilating vesicoureteral reflux is seen on the left side on this voiding cystourethrogram and, in this case, is typically associated with a poorly functioning kidney on the ipsilateral side, referred to as the vesicoureteral reflux with dysplasia (VURD) syndrome.

Longer-term studies have confirmed, however, that the VURD does not improve renal prognosis. Fifteen years after the VURD was first described, Cuckow et al. found that although 67% of patients affected by VURD during the second year of life had a normal serum creatinine, only 30% of these children had normal values between 8 and 10 years of age (Cuckow et al., 1997). The glomerular filtration rate, importantly, was already abnormal in 75% of these patients, even in the first two years of life. Another observation that even the contralateral, nonrefluxing renal unit in VURD patients carries a high risk for congenital renal scarring (implying poorer long-term prognosis) means that VURD should never be allowed to create a false sense of security, and that close follow-up is mandatory, as with any cohort with PUVs (Narasimhan et al., 2005).

Key Points

- The renal dysfunction, vesicoureteric reflux, and voiding dysfunction seen in children with PUVs is mediated by a dysfunctional bladder.
- Renal impairment in PUV patients is caused by renal dysplasia and obstructive uropathy.
- The VURD syndrome confers no protective benefit on long-term renal prognosis.

Diagnosis

Antenatal Diagnosis

Ultrasonography

With widespread access to antenatal sonography, PUVs and other LUTOs such as urethral atresia or stenosis are increasingly detected during the fetal period**. PUV is detected in approximately 1/1250 ultrasound screenings, accounting for 10% of significant antenatally detected genitourinary disease and afflicting one third of surviving infants with bilateral renal disease** (Gunn et al., 1995; Thomas and Gordon, 1989). **The pathognomonic ultrasound findings of a thickened, dilated bladder along with bilateral hydroureter and pelvicaliectasis do carry a high sensitivity (95%) and specificity (80%), and oligohydramnios and the dilated posterior urethra displaying the "keyhole sign" further corroborate the presence of LUTO** (Figs. 33.6 and 33.7) (Peters, 1998; Robyr et al., 2005). Renal echogenicity will be increased in PUVs, and is a reliable indicator to infer renal damage as well.

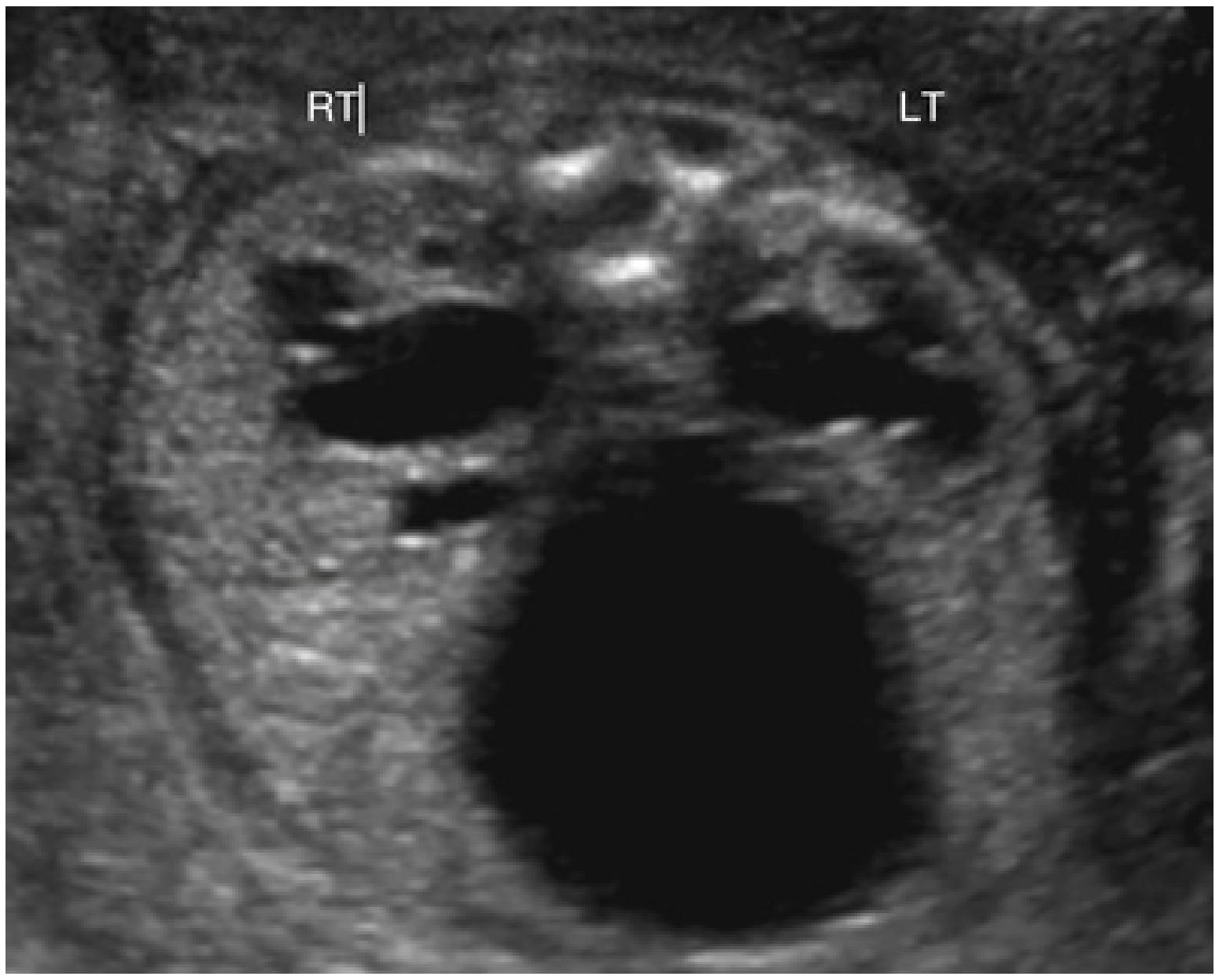

FIG. 33.6 (A) Antenatal ultrasound examination demonstrates bilateral severe pelvicaliectasis with dilated bladder in fetus. (Courtesy of Dr. Mark P. Johnson, Children's Hospital of Philadelphia.)

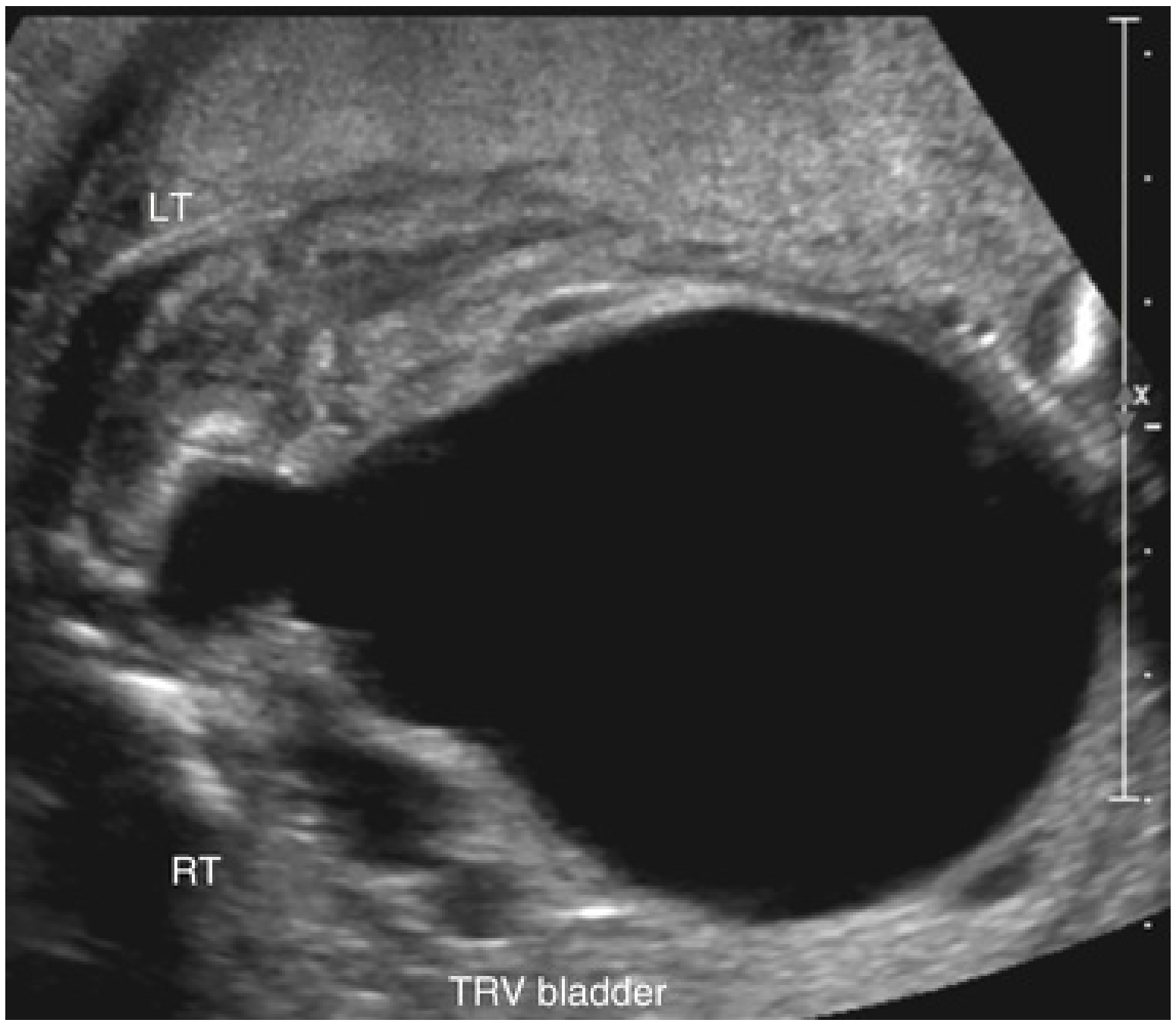

FIG. 33.7 Ultrasound of fetal bladder shows a thickened bladder with dilated posterior urethra below, suggesting the “keyhole sign.” (Courtesy of Dr. Mark P. Johnson, Children's Hospital of Philadelphia.)

Although LUTO may be diagnosed prenatally, differentiating valves from urethral atresia or prune-belly syndrome, high-grade vesicoureteral reflux or bilateral primary obstructing megaureters is much more problematic, reducing the accuracy of diagnosing PUVs with prenatal sonography alone to as low as 50% (Abbott et al., 1998). Still, **the antenatal finding of a thickened, enlarged bladder, bilateral ureterectasis with pelvicaliectasis with or without oligohydramnios in a male infant requires an early postnatal ultrasound and voiding cystourethrogram before the infant's discharge from the postpartum unit** (Lee et al., 2006; **Herndon, 2012**; St Aubin et al., 2013).

A review of all births with PUVs over 5 years in New South Wales, Australia, found that 53% of cases were diagnosed antenatally. Of the remaining births, one half were diagnosed in the neonatal period, and the other half presented with urinary tract infections (Thakkar et al., 2014).

Fetal Magnetic Resonance Imaging

Fetal magnetic resonance imaging (MRI) is an adjunct in prenatal diagnosis and increasingly available at major centers. As with ultrasonography, fetal MRI is used to distinguish the degree of obstruction based on urethral dilation, bladder distention with thickened bladder wall, and reduced amniotic fluid levels (Fig.

33.8). Lung hypoplasia and cystic changes in renal parenchyma are also apparent on MRI, although the rate of renal dysplasia does not necessarily correlate with microcystic or macrocystic changes (Chauvin et al., 2012). One study of fetal MRI in early gestation showed that the modality altered the initial sonographic diagnosis in 30% of the cases (Poutamo et al., 2000). **Although MRI does provide added information as to the cause of obstruction in select cases, the utility of MRI is limited as with sonography in diagnosing the actual cause of LUTO** (Miller et al., 2002).

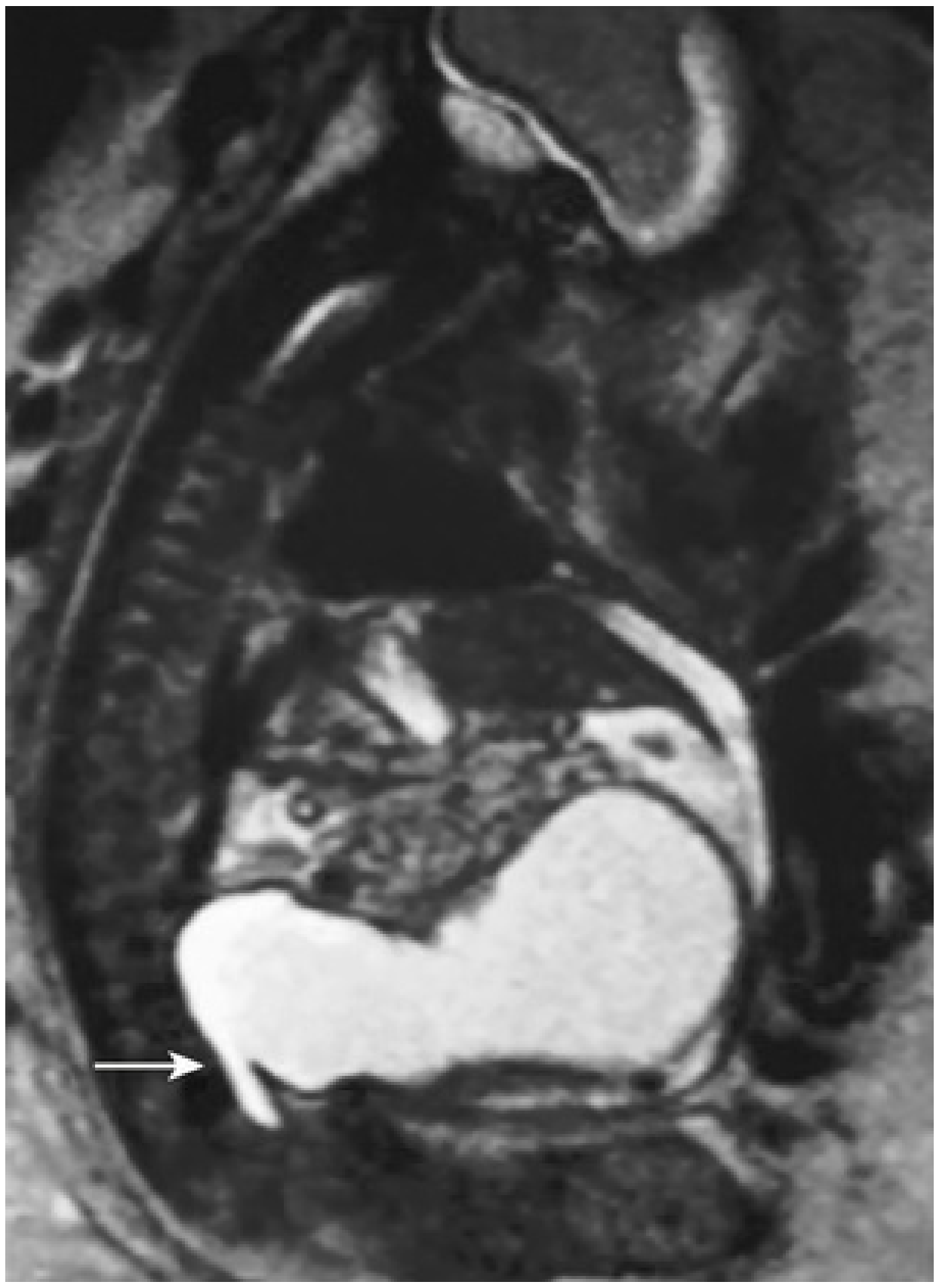

FIG. 33.8 Fetal magnetic resonance imaging demonstrating lower urinary tract obstruction that was postnatally diagnosed as posterior urethral valves. A dilated bladder funneling to a visible posterior urethra is seen on this T2 image *(arrow).*

Postnatal Diagnosis

Ultrasonography.

Much like the antenatal period, classic findings on ultrasound suggest PUVs are a distended bladder with thickened bladder wall, presence of bladder diverticula, dilated posterior urethra, and a high bladder neck with hyperplasia. The classic “keyhole sign” is often evident as well. These lower tract changes may be associated with upper tract changes such as a dilated ureter with or without dysplastic changes of kidney, which include cyst proliferation, loss of corticomedullary differentiation, and abnormal echogenicity. In the newborn period, a urinoma may be inferred by free fluid around one or both kidneys. In our practice, we consider a bladder wall to be thickened if it measures more than 3 mm when it is distended or more than 5 mm when it is empty.

Voiding Cystourethrography

The voiding cystourethrography remains the definitive radiologic study in confirming the diagnosis of PUV. This study should be completed in the early postnatal period after renal and bladder sonography and as soon as an infant with suspected prenatal findings of valves is hemodynamically stabilized and able to undergo the contrast study.

The bladder often appears thickened and trabeculated with multiple diverticuli, mimicking the appearance of a neuropathic bladder. High-grade vesicoureteral reflux may be seen in approximately 50% of patients with valves at the time of diagnosis (Hassan et al., 2003). **Images obtained during the voiding phase will show contrast traveling across a hypertrophied, elevated bladder neck and grossly dilated posterior urethra (Fig. 33.9AB).** The urethra funnels abruptly at a transverse membrane, or cusp, **representing the obstructing valve leaflets seen at cystoscopy. These are the pathognomonic signs for PUV.**

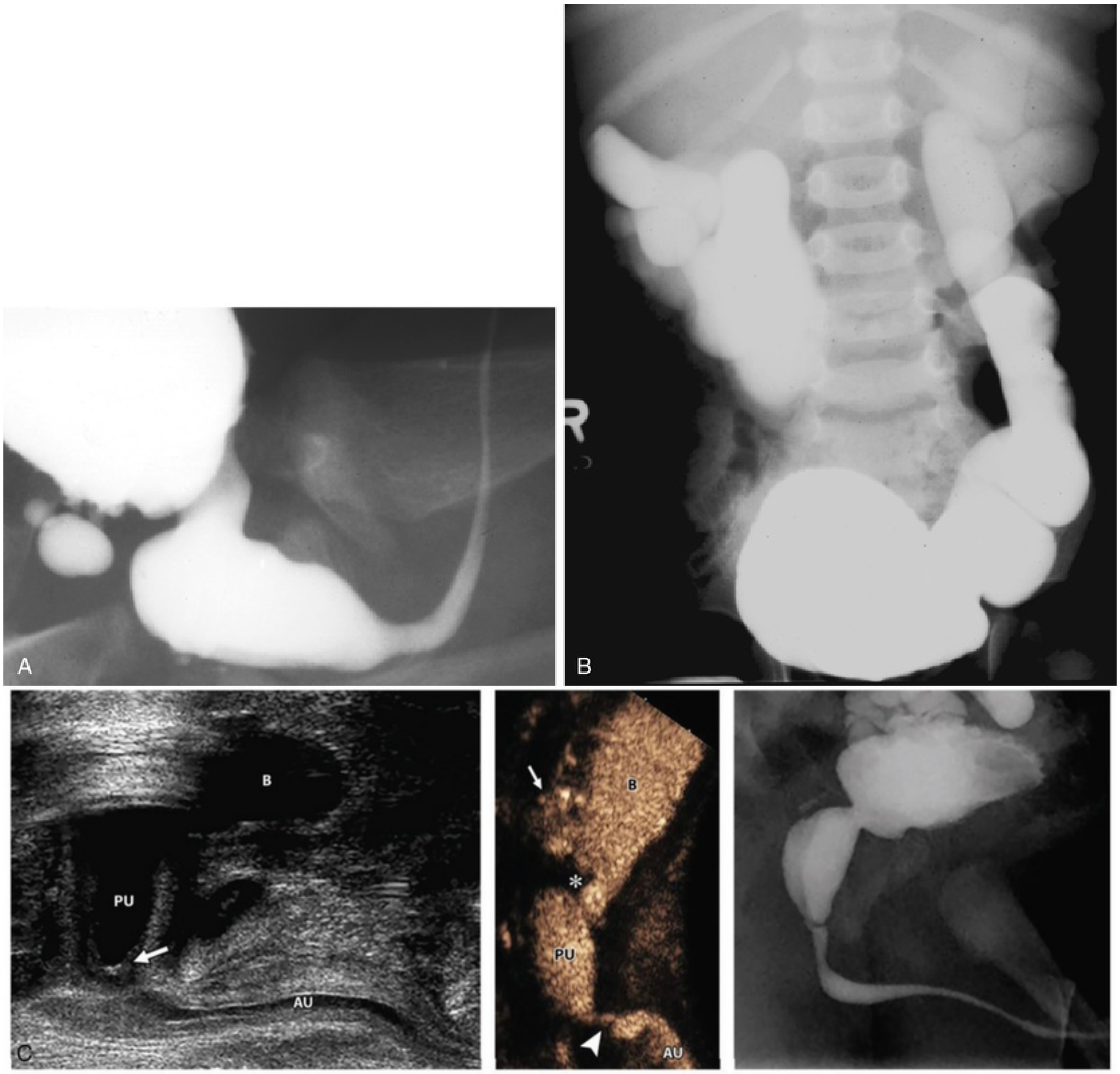

FIG. 33.9 (A) Voiding cystourethrogram image demonstrates a dysmorphic, elongated bladder with dilated posterior urethra and classic appearance of posterior urethral valves. (B) Dilating vesicoureteral reflux is seen bilaterally. (C) Contrast-enhanced voiding ultrasonogram (ceVUS) image of an infant with posterior urethral valves *(arrows; middle panel)* compared with standard sonography *(left panel)* and fluoroscopic voiding cystouretherogram *(far-right panel). B,* Bladder; *PU,* posterior urethra; *AU,* anterior urethra. (From Duran C, Beltrán VP, González A, et al. Contrast enhanced voiding urosonography for vesicoureteral reflux diagnosis in children. *Radiographics* 2017;37(6):1865.)

The study commences with the insertion of an 8-Fr feeding tube into the urethra, and this tube may curl within the capacious posterior urethra or hypertrophied bladder neck, requiring the use of a coudé catheter to advance into the bladder. Often a catheter may already be in place at the time of the study, and it is important that the catheter be withdrawn gradually distal to the posterior urethra during the voiding phase of the study to offer unobstructed views of that segment.

Voiding Urosonography (VUS)

Second-generation ultrasound contrast has enabled ultrasound-guided dynamic imaging of the lower urinary tract. This has been well established in the diagnosis of reflux with contrast-enhanced voiding ultrasonography (ceVUS) with some studies reporting sensitivity exceeding the present standard of care of fluoroscopic voiding cystourethrogram (Kis et al., 2010). This has led to an interest in imaging the urethra to diagnose urethral pathology. There is significant evidence today to use ceVUS for imaging the urethra and reliably diagnose PUV (see Fig. 33.9C) and other pathologic conditions such as a urethral diverticulum (Mate et al., 2003; Berrocal et al., 2005; Duran et al., 2009). At our institution, a significant proportion of lower urinary tract imaging is completed using contrast ultrasound–based imaging as a concerted effort to reduce radiation exposure in children and find it to be a useful modality.

Radionuclide Renal Scan

The radionuclide renal scan offers quantification of differential renal function, and cortical deficits seen on the study may imply renal dysplasia when completed in the neonatal period. Mercaptoacetyltriglycine (MAG3) is a useful agent to evaluate renal functional contribution, although delayed emptying of nuclear tracer from the often dilated collecting systems should not be necessarily interpreted as ureterovesical junction obstruction requiring intervention. Placement of a urinary catheter is essential in a patient with vesicoureteral reflux to minimize error in the calculation of renal function.

Laboratory Evaluation

Laboratory evaluation of a newborn with a diagnosis of PUV will, as with any newborn, reflect maternal values and must be interpreted with caution. After 48 hours, the maternal blood mediated through the placenta should clear, and the infant's kidney baseline function will be apparent. Both these values represent the infant's baseline values, and subsequent values and trends may be monitored to infer effective renal function. The nadir creatinine value at various intervals—1 month of age, 6 months of age, and 1 year of age—are considered important diagnostic tools, and this value may be plotted to evaluate immediate response to treatment in the neonatal period. But the serum creatinine plateau even in unaffected children may not be seen until days 65 and 220 of life (DeFoor et al., 2008; Boer et al., 2010).

Key Points

- Antenatal diagnosis is primarily by fetal ultrasound sometimes aided by fetal MRI. Combination of thickened dilated bladder with upper tract dilation along with oligohydramnios has a high sensitivity for PUVs.
- Postnatal diagnosis is with ultrasound and finding confirmed by fluoroscopic voiding cystourethrogram. More recently, contrast-enhanced VUS is emerging as a good alternative.
- Biochemical evaluation centers on electrolyte and creatinine values. Nadir creatinine value is en effective prognostic indicator for long-term kidney function.

Clinical Presentation and Initial Management

Antenatal Presentation and Management

With widely available advanced ultrasound technology, a significant proportion of children with PUVs are diagnosed antenatally and may present to the urologist for prenatal advice and management. Along with the previously discussed common markers of bladder outlet obstruction, important considerations are the presence of oligohydramnios, degree and laterality of hydronephrosis, and gestational age.

Antenatal intervention in cases of suspected LUTO was popularized in the mid-1980s (Glick et al., 1984, 1985) as advances in fiber optics and endoscopic miniaturization enabled even complex fetal procedures. Although ultrasound remains the mainstay of diagnosis in the antenatal period, fetoscopy has been shown to offer better sensitivity than ultrasound, although with the considerable additional risks of intervention (Welsh et al., 2003). **Historically, intervention is considered in some centers when antenatal sonography detects evidence of oligohydramnios, a dilated bladder, and severe hydroureteronephrosis—without renal cortical cystic lesions—in a fetus with a normal karyotype** (Ruano, 2011). A fetal urine sample obtained after 20 weeks' gestation demonstrating **favorable prognosis is suggested by a urinary sodium <100 mEq/L, chloride <90 mEq/L, osmolarity <200 mEq/L, and β_2 microglobulin <6 mg/L** (Nicolini and Spelzini, 2001). **Johnson et al. showed that triple serial sampling in 48- to 72-hour intervals is a more accurate proxy to assess irreversible renal damage, with sequential rises in values of the above variables portending an unfavorable prognosis** (Johnson et al., 1994).

The Society of Fetal Urology held a multidisciplinary panel discussion in 2016 on appropriate patient selection for antenatal intervention (Farrugia et al., 2017). The panel suggested a standardized classification based on the severity of LUTO based on various factors. Ruano et al. suggested stratifying antenatally detected bladder outlet obstruction into discrete categories, with the most favorable outcomes associated with intervention in a fetus with: (1) oligohydramnios, but absence of anhydramnios; (2) severe hydronephrosis; (3) favorable fetal urine biochemistry; and (4) absence of renal cortical cysts (Ruano et al., 2016). Peters urged selective cautious intervention, given that some children do well in spite of significant obstruction and others might be taken through the intrauterine period by these interventions but ultimately not fare well.

Nevertheless, vesicoamniotic shunting to treat oligohydramnios offers potential ameliorative effects on pulmonary function and represents the first stage in fetal intervention with several hundred shunt procedures reported in the literature (Ruano, 2011). This approach is corroborated by fetal sheep models demonstrating that restoration of amniotic fluid volume prevents lung hypoplasia, although the lack of controlled studies in the literature constrains conclusions as to its effectiveness (Kitagawa et al., 2006).

And although a systematic review demonstrated a survival advantage in infants having undergone vesicoamniotic shunting, randomized trials were lacking (Clark et al., 2003). The percutaneous vesicomaniotic shunting versus conservative management for lower urinary tract obstruction (PLUTO) trial attempted to fill this paucity of data but was limited by poor recruitment and pregnancy terminations, with only 12 live births in each group studied. The results showed a trend toward improved survival at 28 days in the shunted group, but overall survival was very poor in both groups, with only two infants surviving to 2 years of age with normal renal function. There was a high mortality as a result of pulmonary hypoplasia. There was also a greater risk for pregnancy loss in the shunt group caused by procedure-related complications and early rupture of membranes (Morris et al., 2013).

There have been no studies similar to the PLUTO trial attempted for even more complex fetal interventions such as fetal cystoscopy with valve ablation or even fetal surgery. Fetal cystoscopy, performed using a 1.0-mm fetoscope, is carried out in an antegrade fashion by a transuterine percutaneous incision into the bladder. When the posterior urethra is entered through the bladder neck, a ND:YAG laser, or cauterizing wire, is used to perforate the obstructing membrane (Quintero et al., 1995, 2000; Ruano, 2011). Holmes et al. reported a series of 14 fetal surgical procedures for PUVs including antenatal valve ablation, vesicoamniotic shunting, cutaneous ureterostomy, and vesicostomy (Holmes et al., 2001). Six infants died as a result of premature delivery and respiratory failure, and 5 of 8 surviving children at a mean 11.6 years follow-up were in renal failure. The 43% fetal mortality rate for fetal surgery must be an essential part of any prenatal counseling before considering fetal intervention that offers potential, although yet unproven, benefits for a very select group of pregnancies.

Parental counseling for the possible diagnosis of PUVs is an important role that the pediatric urologist performs in the setting of antenatal diagnosis. In this role, we take the opportunity to educate parents about possible outcomes, possible diagnoses, expected course for the rest of the pregnancy, and where the child should be delivered, and we plot management once the child is born to broadly explain prognosis. It is an important role that reassures parents that all care is taken to provide their child the best care possible. Parents' perception of adequacy of information should be sought and any gaps of knowledge bridged. A recent study on patient perception of counseling shows a work in progress (Marokakis et al., 2017).

Key Points

- Up to 50% of infants with PUVs are diagnosed in the antenatal period.
- Severity of obstruction can be objectively assessed by the volume of amniotic fluid, degree of renal dysplasia, and fetal urinary makers.
- Vesicoamniotic shunting may have a survival benefit for the infant in select cases, but there is no clear benefit in the risk for renal failure.

Postnatal Management

Infants with PUVs may be affected by serious comorbidities such as pulmonary hypoplasia and physical stigmata of oligohydramnios, including Potter facies, club feet and deformed hands, and poor visceral muscle tone, and they may require intensive initial management. The infant may be noted to have difficulty with voiding, and the urinary stream may be weak or intermittent. A 5- or 7-Fr feeding tube, or similar-caliber urinary catheter, should be inserted per urethra in an infant presenting to the neonatal intensive care unit with a presumed diagnosis of LUTO. **Catheter placement into the bladder may be impeded by the hypertrophied and often elevated bladder neck and curling of the catheter within the dilated posterior urethra. In such cases, a coudé tip catheter, or alternatively, using a stylet to curl the tip of the feeding tube dorsally, will facilitate bladder drainage.** Minimizing any type of catheter balloon filling is important to prevent inducing bladder spasms in the small, hypertrophic bladder and potentially occluding the ureteral orifices (Jordan and

Hoover, 1985). Placement of the catheter within the bladder may be confirmed by bladder sonography, or in some instances, a one-shot cystogram.

An important consideration is that infants with PUV may be diagnosed with hyponatremia, sometimes triggered by a urinary tract infection. The hyponatremia is readily corrected with sodium supplementation and may be secondary to a transient pseudohypoaldosteronism (Deshpande 2018).

Pulmonary Hypoplasia

Although the focus in PUVs is too often on the lower urinary tract and kidneys, the most profound complication, and cause of perinatal mortality in infants affected by severe LUTO remains pulmonary hypoplasia. The often cyanotic baby requires complex ventilatory support and is often the factor delaying definitive surgical intervention to address the valves. Pulmonary hypoplasia seen in infants with a history of antenatally detected oligohydramnios may be the contributing factor to perinatal mortality in these children, requiring intensive and rapid supportive treatment (Pinar, 2004).

The association between PUVs, oligohydramnios, and pulmonary hypoplasia is recognized, but the etiology of hypoplasia is unclear and likely multifactorial. Grossly hydronephrotic kidneys and a dilated bladder combined with increased uterine pressure on the developing fetus caused by oligohydramnios may reduce diaphragmatic expansion and affect lung volume and growth (Fig. 33.10). This reduced expansion adversely affects the development of the fetal pulmonary tree that requires intraluminal pressure, volume, and flow while providing cellular signaling to the developing alveoli (Husain and Hessel, 1993; Laudy et al., 2002).

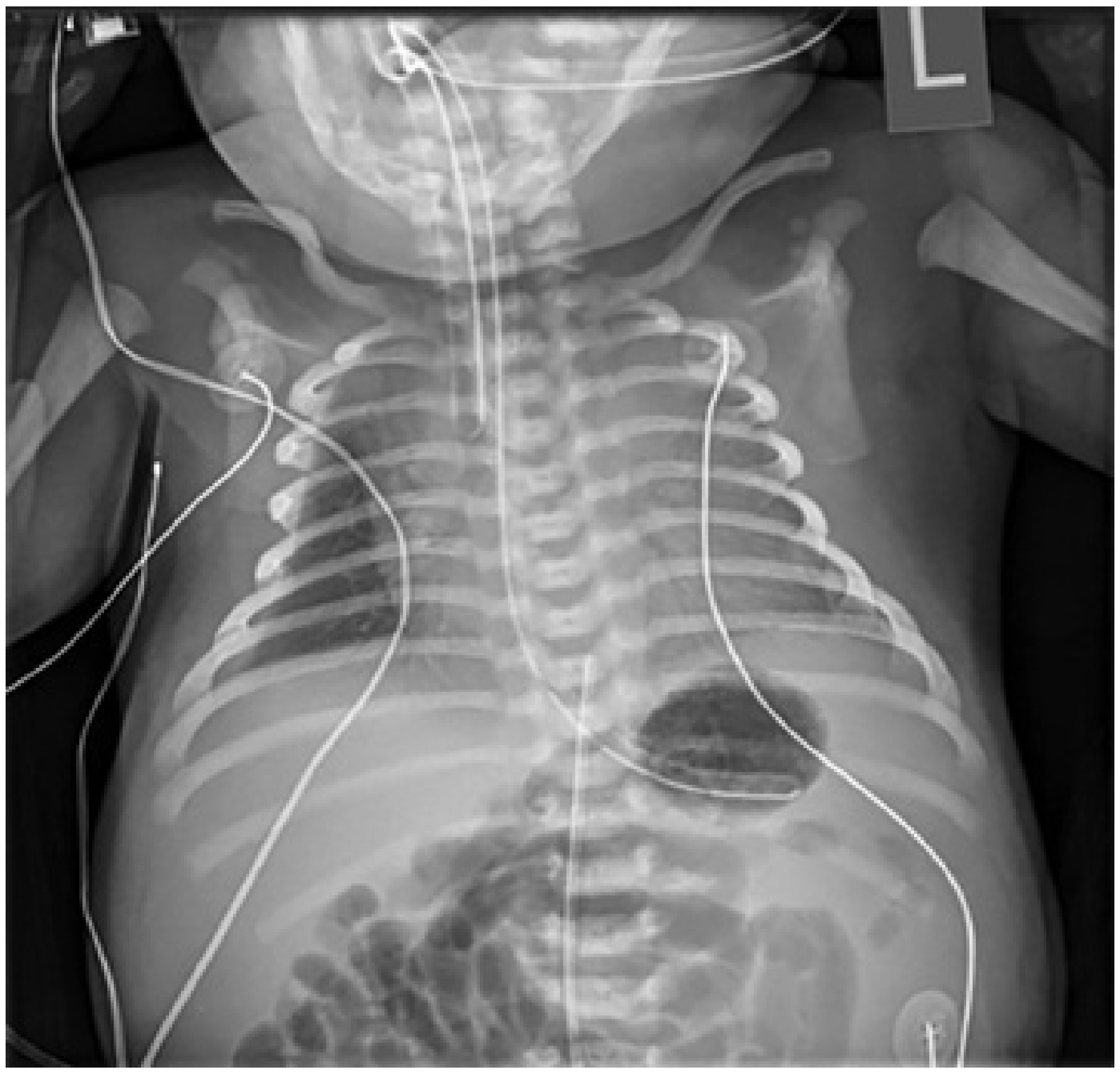

FIG. 33.10 Plain radiograph of a 5-day-old infant with posterior urethral valves and bronochopulmonary dysplasia, requiring airway support, shows reduced lung volume and left upper and lower lobe atelectasis.

Urinomas

A urinoma is associated with PUVs in 3% to nearly 10% of cases (Fig. 33.11) (Greenfield et al., 1982; Patil et al., 2003). The introduction of renal ultrasonography since 1979 increased the detection of urinomas to 15% in one study (Heikkilä et al., 2011). Forniceal rupture will appear on renal ultrasound as distorted renal parenchyma caused by fluid trapped within the renal capsule, and transperitoneal transudation of fluid or bladder rupture will present as neonatal ascites (Greenfield et al., 1982). Although voiding cystourethrogram or radionuclide cystography may delineate the site of leakage for ascites, the cause is often difficult to determine (Patil et al., 2003).

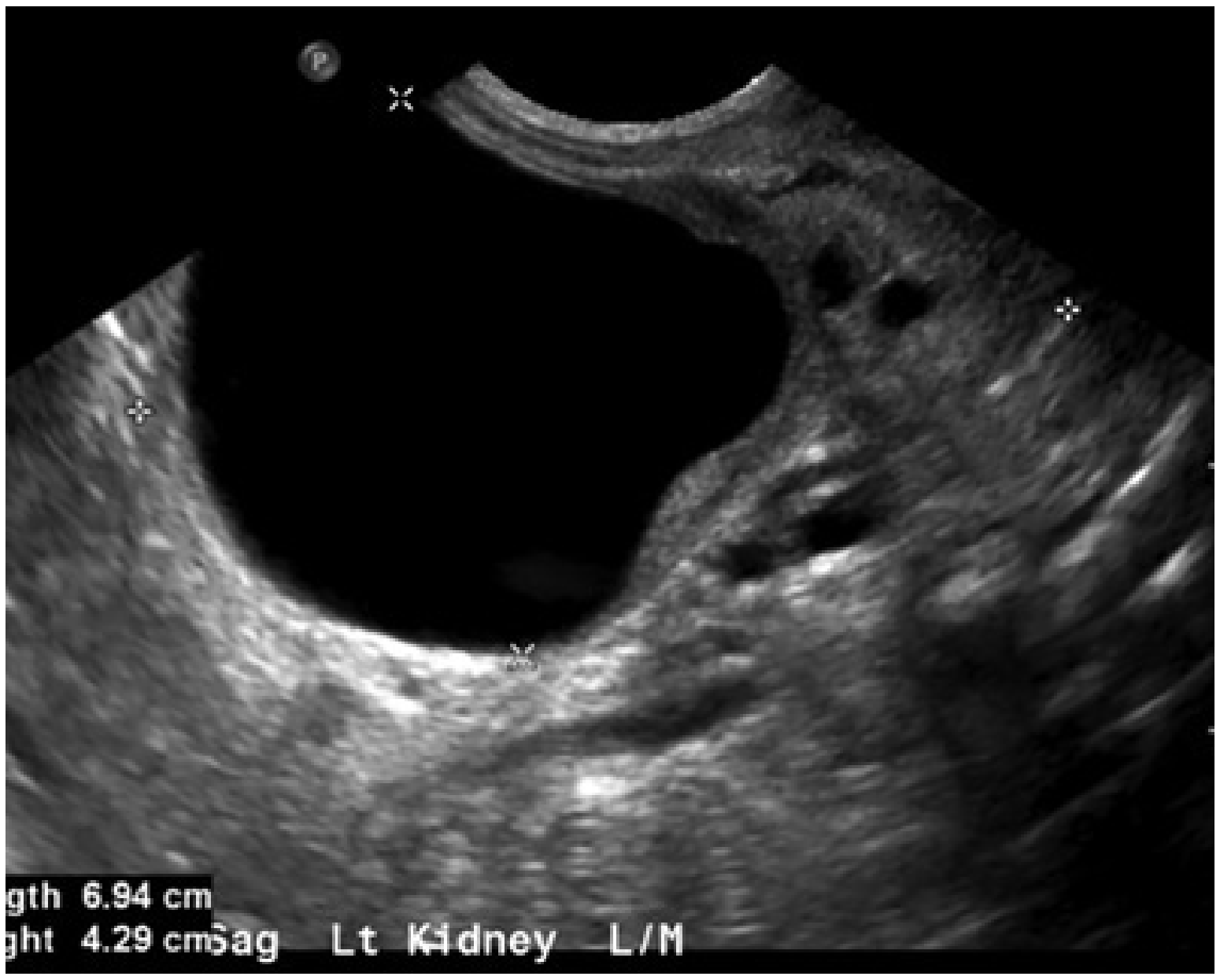

FIG. 33.11 Sonographic image of left kidney in a newborn diagnosed with posterior urethral valves shows a large urinoma. The urinoma compresses the renal parenchyma inferiorly, and is contained within the renal capsule.

Urinomas are usually addressed by restoring urinary flow and treating the proximate cause of LUTO, allowing the fluid to be reabsorbed. It is only in cases in which the ascites is causing respiratory distress, severe abdominal distension, or other clinical symptoms that percutaneous drainage or tapping ascites becomes necessary, but these interventions are uncommon.

There is some debate as to whether a urinoma heralds better or worse renal function for the affected side. Numerous studies have postulated that the urinoma serves as a pop-off mechanism, thereby reducing renal dysplasia on a given side, and others demonstrate globally preserved renal function, including an index of long-term renal severity (Rittenberg et al., 1988; Wells et al., 2010). Others hold that the urinoma, especially one retained within the renal capsule and compressing the kidney, impairs ipsilateral renal function and is a harbinger for worsened renal prognosis or has no bearing at all on long-term renal function (Patil et al., 2003; Kleppe et al., 2006; Heikkilä et al., 2011).

Delayed Presentation

In the age of extensive antenatal ultrasonography, delayed, postinfancy presentation of PUVs is assumed to be less common. Still, Engel et al. reported that 141 of 228 (62%) children undergoing valve ablation presented with PUVs with a clinical presentation other than prenatal hydronephrosis or oligohydramnios (Engel et al., 2011). Up to 64% of these children had a normal prenatal ultrasound, and most presented with urinary tract infections, voiding complaints, and acute renal failure in 10% (Engel et al., 2011). Another recent study at the Children's Hospital of Philadelphia followed a cohort of 138 patients presenting with PUVs between 1988 and 2011, of which 60 (43%) presented after 6 months of life (Pulido et al., 2014). **A high degree of suspicion for PUVs is therefore still warranted in boys presenting with lower urinary tract symptoms, especially recurrent urinary tract infections, but also overflow incontinence, gross hematuria, renal dysfunction, and less commonly, ejaculatory dysfunction** (Bomalaski et al., 1999; Schober et al., 2004). A renal ultrasound in these patients often detects the telltale bladder wall thickening, distal ureteral dilation that requires a voiding cystourethrogram for confirmation.

Key Points

- Antenatal finding of a thickened bladder and bilateral ureterectasis should be evaluated with early postnatal ultrasound and voiding cystourethrogram.
- Voiding cystourethrogram in valve patient will show bladder wall irregularity; hypertrophied, elevated bladder neck; and dilated and elongated posterior urethra.
- The most common cause of early mortality in infants with PUVs is pulmonary hypoplasia.

Surgical Intervention

Valve Ablation

Today, cystoscopy with ablation of PUVs is considered the preferred initial surgical option in any neonate diagnosed with PUVs. The treatment goal is to restore flow of urine through the urethra and enable normal cyclic filling and emptying of the bladder, which is superior to urinary diversion and passive urine drainage (Smith et al., 1996; Close et al., 1997). Experimental models corroborate clinical evidence of the importance of bladder cycling, and one model of urinary diversion and undiversion demonstrated the changes that occur in a diverted bladder prevented from cycling (Chun et al., 1989). A fetal sheep model developed an increase in expression of extracellular matrix elements and apoptosis after a high diversion (Chun et al., 1989).

There are several approaches to valve ablation. Historically, it had even been successfully performed with a crochet hook passed retrograde into the urethra and feeling the hook catch the obstructing tissue. Innes Williams first described the engagement of valves with a hook, and Whitaker and Sherwood modified the hook by insulating the wire except for the very distal portion of the hook, which measures 6 to 7 Fr and could be passed at the bedside without general anesthesia while applying a small amount of diathermy when ablating the valves (Whitaker and Sherwood, 1986).

With the miniaturization of endoscopes in the age of fiberoptic and, now, digital technology, cystoscopy can be accomplished in even the smallest neonate, and endoscopic valve ablation is the preferred approach at most centers today. **Availability of a 7.5-Fr or 9-Fr infant cystoscope with an offset lens facilitates passage of a variety of ablating devices, including a Bugbee electrode that can be used to incise the valves at the ventral 5 o'clock and 7 o'clock positions with or without an incision on the dorsal 12 o'clock position. Alternatively, a 12 o'clock alone might suffice** (Video 33.1). A wire bent at the tip and passed through a 3-Fr ureteric catheter is another option, as is the visually guided fogarty embolectomy catheter (Soliman, 2009). In an infant with a normal caliber urethra, the 9.5-Fr resectoscope may be used with a Collins knife working element (Fig. 33.12).

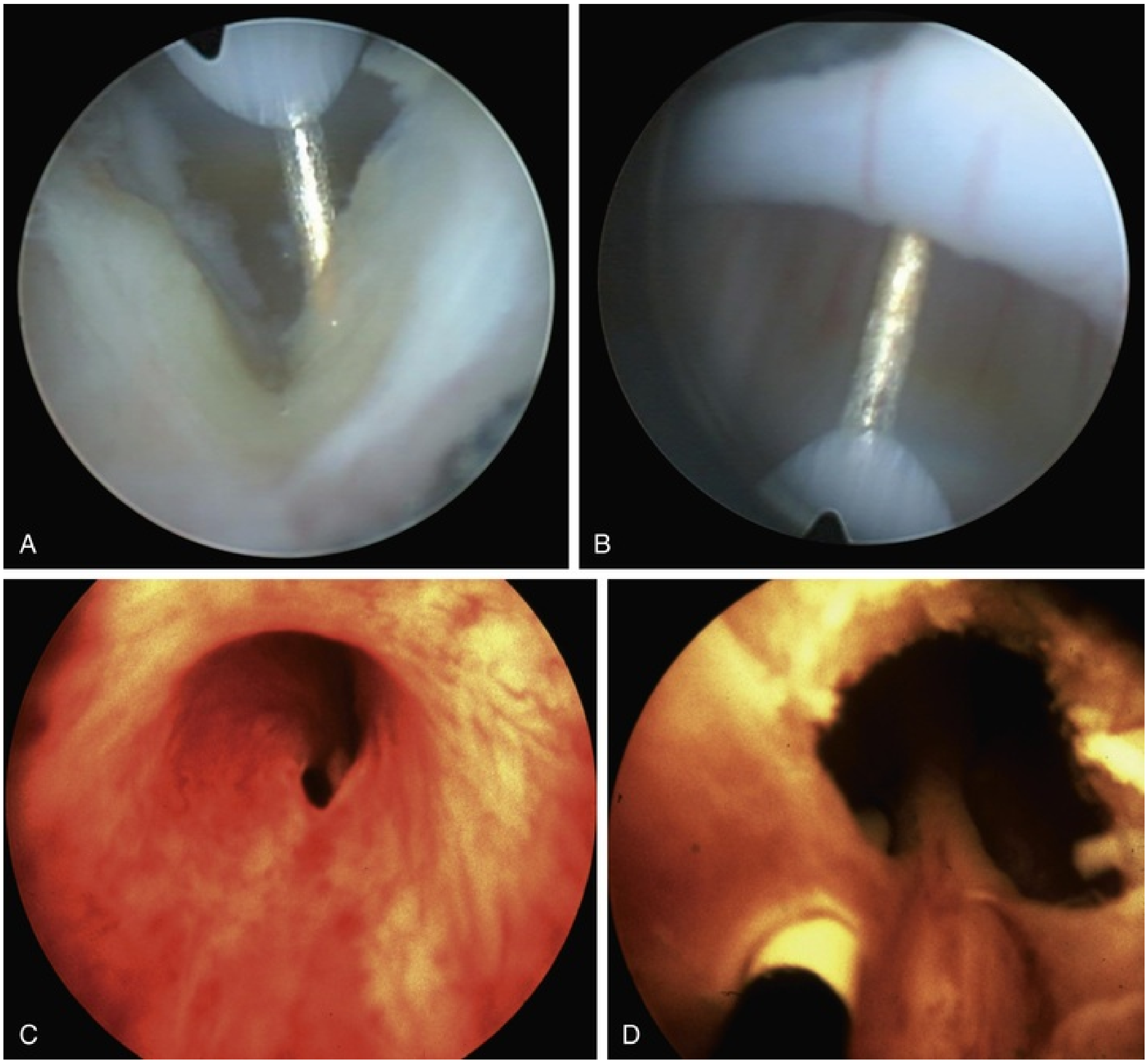

FIG. 33.12 Cystoscopic images of incision of posterior urethral valves. Incision with a Collins knife being made at the 5 o'clock position (A) and at the dorsal 12 o'clock position (B). Before incision (C) and after incision (D) with Bugbee wire. The ureteral catheter has been passed through a perforation in the valve leaflet.

Valves are thin and associated with minimal vascularity, and aggressive resection should be avoided. Use of a hot loop resectoscope for valve ablation, primarily in older children where a resectoscope can be readily inserted, seems to be associated with a higher risk for urethral stricture, and caution should be exercised with its use (Sarhan et al., 2010).

A urethral catheter is typically placed for at least 24 hours after the procedure and is not necessary to be kept longer, although it is not uncommon for the catheter to be left in for a longer period while the infant continues to be monitored for improvements in renal parameters or respiratory issues, often in an intensive care environment. A voiding cystourethrogram must be repeated after valve ablation within 1 month to ensure that the valves are no longer visible. It is not uncommon to see immediate signs of diminished bladder pressures, including some improvement in renal dilation and in the volume of vesicoureteric reflux.

Bladder neck hypertrophy and the subsequent elevation of the bladder neck proximal to the posterior urethra, along with the incomplete emptying that seems to persist on imaging in some boys after valve ablation, prompted an interest in transurethral incision of the bladder neck during or after primary valve ablation. The earliest reports of procedures to address this bladder neck hypertrophy included a Y-V plasty and bladder neck incision (Bauer et al., 1979). But subsequent to Mitchell's elaboration of the concept of the valve bladder, the concept was widely accepted as a plausible explanation for persistent bladder dysfunction in children with a history of PUV. Still, the concept of bladder neck obstruction and bladder neck incision is still offered as a surgical option (Androulakakis et al., 2005; Kajbafzadeh et al., 2007). Although some studies confirm that the bladder neck incision benefits emptying in children with a neurogenic bladder, the concerns of retrograde ejaculation and lack of improvement compared with controls in even short-term pilot studies have limited the adoption of this technique (Christensen et al., 1985; Sarin and Sinha, 2013). There is a dearth of studies from multiple institutions confirming the extended durability and advantage of bladder neck incision. One long-term study limited to 21 patients older than 18 years of age who underwent bladder neck incision in infancy reported no incontinence in adulthood and a lack of significant ejaculatory dysfunction (Keihani et al., 2017). Injection of botulinum toxin (Botox) into the hypertrophied bladder neck is another postulated modality proposed to address bladder dysfunction in PUVs—and it too failed to improve voiding dynamics in affected boys (Mokhless et al., 2014)

Vesicostomy

With miniaturization of endoscopic technology, vesicostomy is reserved primarily for the very low birth weight infant whose urethra cannot accommodate an endoscope and for a child with continued impaired renal function, high bladder urine volumes, and upper tract deterioration after valve ablation or urethral catheterization. The vesicostomy does reduce bladder storage pressures and may optimize glomerular filtration rate in some cases (Kim et al., 1997). The argument that the vesicostomy defunctionalizes the bladder and leads to decreased compliance in the long term has been refuted, as a properly created vesicostomy allows bladder filling and preserves contractile function as urine must be expulsed through the stoma, albeit at a reduced leak point pressure (Hutcheson et al., 2001). The vesicostomy is best seen as a temporary diversion in children with PUVs as it does not alter clinical outcomes as compared with primary ablation, nor does it prevent a bladder from acting as an adequate reservoir for renal transplant (Fine et al., 2011).

The vesicostomy is classically created with a 2-cm midline transverse incision made midway between the pubic symphysis and the umbilicus. The rectus muscles are separated, the bladder is exposed with traction sutures, and the peritoneum is mobilized cephalad and away from the posterior wall and dome of the bladder. The bladder dome is identified by isolating the urachus, which is ligated, so that the dome can be exposed through the fascial incision. The urachus and small portion of the bladder dome are excised, and then the detrusor is sutured to the fascia 1 cm below the edge of the cystotomy. **The key operative step in creation of the vesicostomy is to ensure that the posterior wall of the bladder is taut—accomplished by bringing the dome of the bladder to the skin—to prevent prolapse of the back wall of the bladder through the incision** (Fig. 33.13; Hutcheson et al., 2001).

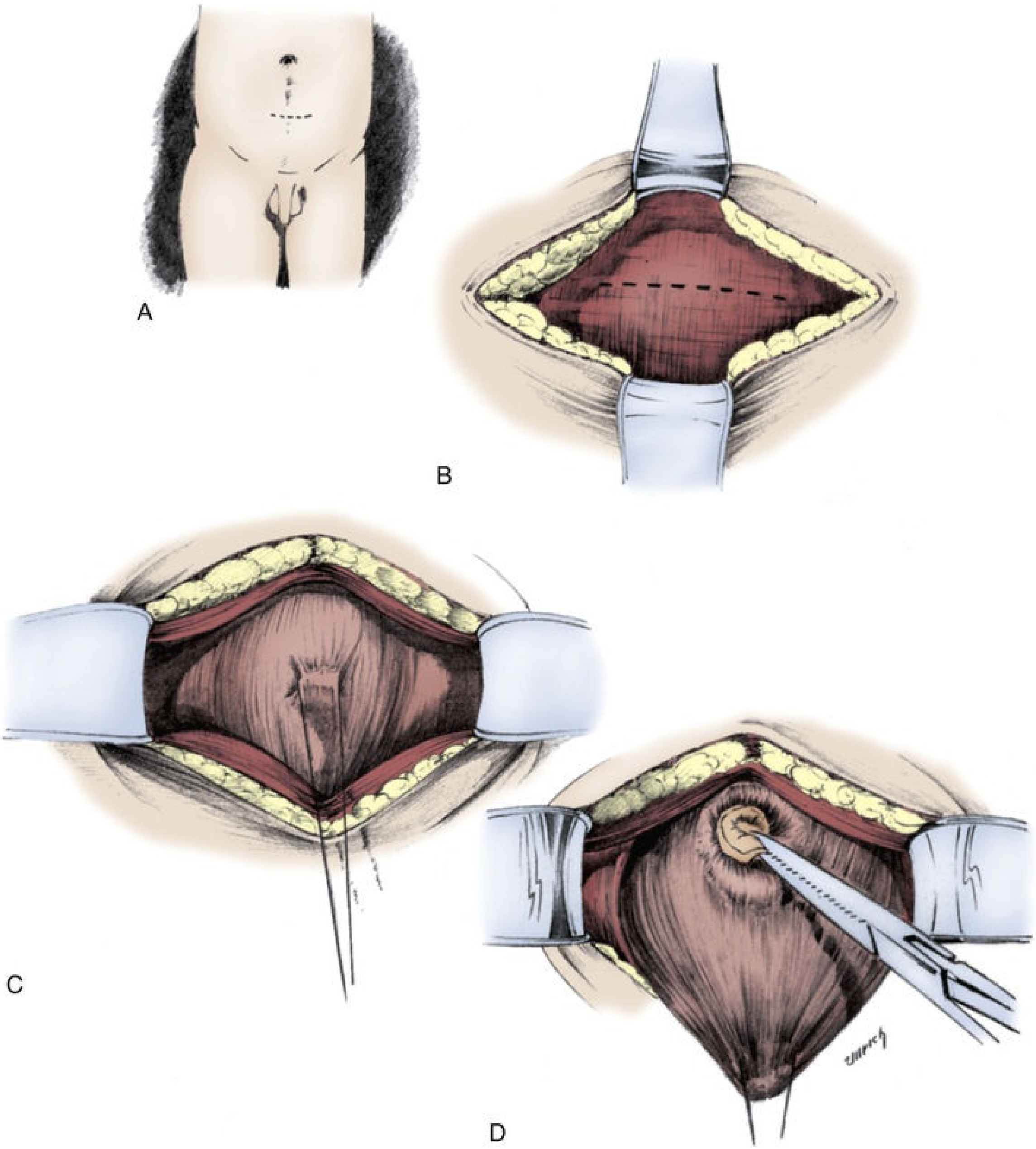
A
B
C
D

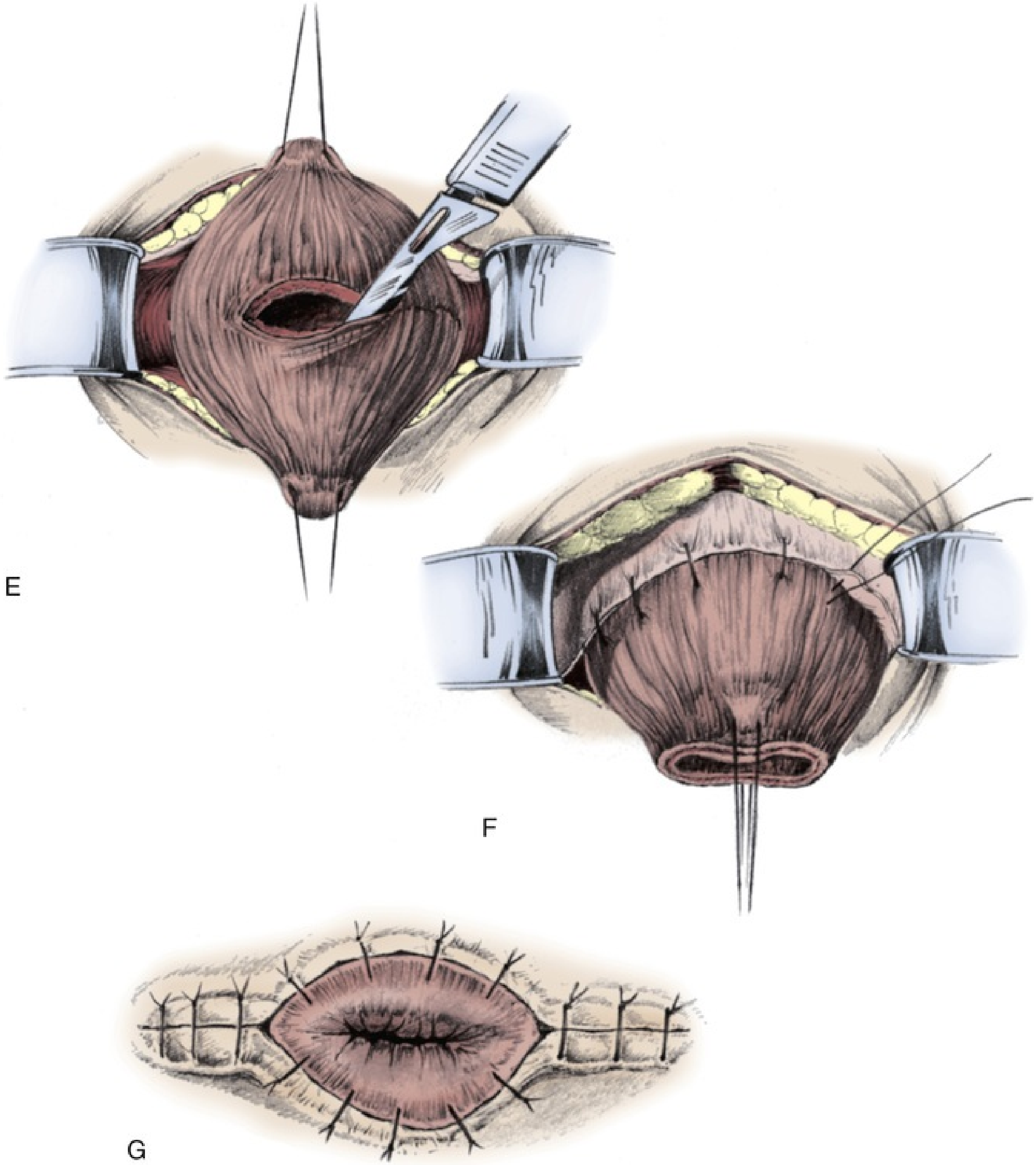

FIG. 33.13 Blocksom technique for performance of cutaneous vesicostomy. (A) An incision is made at a point midway between the umbilicus and pubis that corresponds to the upper limit of the filled bladder. (B) A transverse incision is made in the rectus fascia, and the bladder detrusor muscle is exposed. (C) Stay sutures or noncrushing clamps are used to mobilize the bladder while dissecting the peritoneum away from the bladder dome. (D) The dome of the bladder is identified by ligating the urachal remnant. (E) A transverse incision is then made in the dome of the bladder. (F) The bladder detrusor is sutured to the rectus fascia, placing these sutures 1 cm away from the edge of the bladder incision. (G) The bladder opening is sutured to the skin. (From Walsh PC, Retik AB, Vaughan ED, Wein AJ. eds. *Campbell's urology.* 8th ed. Philadelphia, PA:

Saunders; 2002.)

Upper Tract Diversion

Proponents of supravesical urinary diversion hold that direct decompression of the kidney by a cutaneous ureterostomy or pyelostomy will effectuate direct, low-pressure urinary drainage, allowing optimization of renal function (Fig. 33.14). High diversion, when renal dilation and biochemical markers of renal function fail to improve despite maximal bladder drainage, historically was felt to protect the upper urinary tract from ureterovesical junction obstruction caused by a tortuous intramural ureter passing through a thickened valve-affected bladder. In these cases, a loop diversion of the ureter or renal pelvis, for example, also allows bladder filling and bladder cycling, mitigating the concern of defunctionalizing the bladder (Pinto et al., 1978; Churchill et al., 1990; Kim et al., 1997).

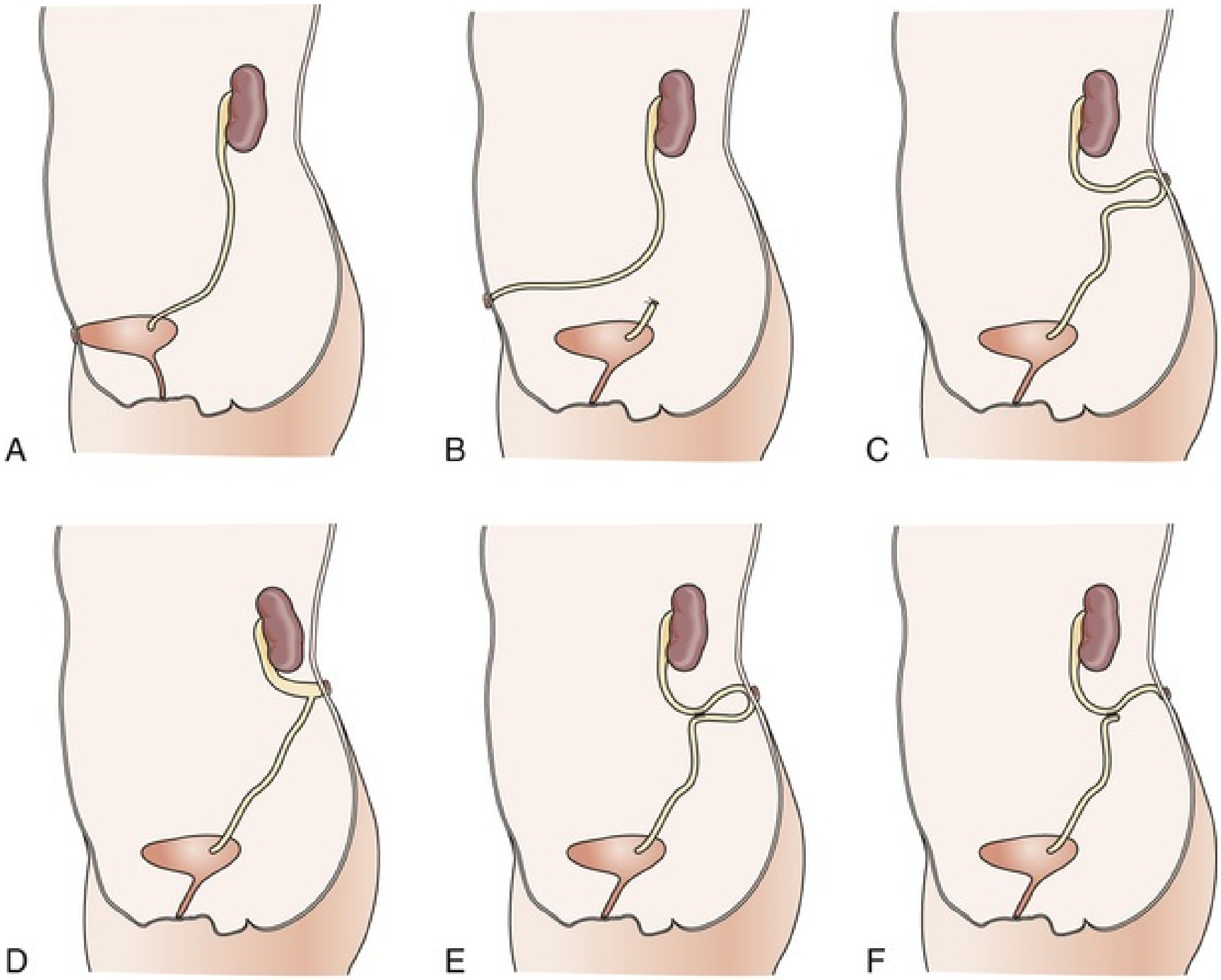

FIG. 33.14 The variety of urinary tract diversions useful in posterior urethral valves. (A) Vesicostomy. (B) Distal ureterostomy. (C) Proximal loop ureterostomy. (D) Cutaneous pyelostomy. (E) Ring ureterostomy. (F) Sober Y ureterostomy. (From Glassberg KI, Horowitz M. Urethral valves and other anomalies of the male urethra. In: Belman AB, King LR, Kramer SA, eds. *Clinical pediatric urology.* 4th ed. London: Martin Dunitz; 2002:899–945.)

Contemporary studies and long-term follow-up of these patients, however, failed to detect long-term renal protective benefit of high diversion, and necessarily require an often complicated undiversion procedure as the child matures (Smith et al., 1996). Moreover, the finding that renal biopsies taken at the time of high urinary diversion uniformly show renal dysplasia, while the diversion does not seem to protect from renal failure, suggests that renal dysplasia occurring in early fetal development is the primary mediator of renal outcome, rather than any type of complex surgical undertaking in the neonate (Tietjen et al. 1997).

Upper urinary tract diversion is a rare undertaking in an infant with complete decompression of the lower urinary tract but worsening renal function, increasing upper tract dilation, and, possibly, a clinical picture of sepsis. Diversion would be considered with the clear understanding that any expectation of improved renal outcome is not borne out by available evidence. A complex secondary surgery will be required, and the bladder may be exposed to a potentially extended period of defunctionalization with attendant risks of impairment in compliance and contractility (Close et al., 1997). The preferred initial surgical intervention for infants with PUVs should be considered endoscopic valve ablation, followed by a properly constructed vesicostomy when primary valve ablation is impossible or bladder decompression is not achieved by urethral catherization or valve ablation alone. In the unique case in which upper tract dilation persists after vesicostomy and is accompanied by worsening renal parameters, upper urinary tract diversion with a cutaneous ureterostomy or renal pyelostomy is considered after multispecialty consultation with pediatric nephrologists and radiologists.

Circumcision

A urinary tract infection can quickly progress to pyelonephritis and sepsis in an infant with PUVs caused by the associated morbidities of vesicoureteral reflux, incomplete bladder emptying, and severe upper urinary tract dilation. **The overall risk for urinary tract infection in children with PUVs is 50% to 60%**

—several magnitudes greater than the 1% risk for unaffected boys (Mukherjee et al., 2009; Bader and McCarthy, 2013). **Circumcision reduces this risk for urinary tract infection by 83% to 92%, a risk reduction similar to that for uncircumcised boys** (Wiswell et al., 1988; Mukherjee et al., 2009). It is recommended that a circumcision be strongly considered as a prophylactic measure for any boy diagnosed with PUVs and should certainly be completed before giving any consideration to a ureteral reimplant in a scenario of frequent febrile urinary tract infections despite conservative measures.

Nephroureterectomy

Nephroureterectomy was historically considered an appropriate intervention for valve patients manifesting elements of the VURD syndrome discussed previously. The nonfunctioning renal unit in association with dilating urinary reflux was long considered a potential source for infection and sepsis, and prophylactic excision was considered appropriate. In contemporary practice, a focus on proper bladder emptying and circumcision has decreased the incidence of urinary tract infections sufficiently that nephroureterectomy is rarely considered. Indeed, renal preservation for even poorly functioning renal units contributing moderate polyuria are easier to manage than anuria**. If frequent urinary tract infections localizing to the nonfunctioning renal unit necessitate a nephrectomy, preserving the ureter for potential subsequent reconstruction, such as a ureteral augmentation, is recommended** (Husmann et al., 2004).

Key Points

- Cystoscopy with valve ablation is the preferred initial treatment for PUVs.
- Vesicostomy does not inhibit bladder cycling, as the bladder continues to contract, but is reserved for select cases in which valve ablation is not possible.
- High urinary diversion offers no renal protective benefit and requires a complex secondary procedure to reverse the diversion.
- Circumcision should be encouraged as a prophylactic measure for any boy with PUVs, and especially any boy with a history of urinary tract infection.

Management of Vesicoureteral Reflux

A voiding cystourethrogram will reveal vesicoureteral reflux (see Fig. 33.9) in 50% to 80% of infants undergoing a workup for PUVs (Puri and Kumar, 1996; Tourchi et al., 2014). As discussed in the previous section, infants with valves are also at an increased risk for urinary tract infections, and the co-existence of reflux and valves presents a clinical scenario that may suggest a role for ureteral reimplantation. However**, it is important to understand that reflux in these infants is a consequence of obstruction and that the secondarily elevated bladder pressures are critical to management and should dissuade a ureteral reimplantation in nearly all cases.** Indeed, ablation of the valves or vesicostomy alone will resolve ureteral reflux in 25% to 40% of patients with urinary reflux before ablation (Hassan et al., 2003; Tourchi et al., 2014).

Reflux resolves more readily in lower grades of reflux and also when associated with a kidney with adequate renal function. Hassan et al. found that the presence of urinary reflux did not correlate with renal outcomes, underscoring that the presence of reflux alone should not be seen as an indication for intervention (Hassan et al., 2003). All efforts in a symptomatic valve patient with vesicoureteral reflux must focus on addressing any persistent bladder outlet obstruction, reducing intravesical pressures by considering anticholinergic treatment, and treating underlying bladder dysfunction that is common in bladders exposed to fetal bladder outlet obstruction. Urodynamic evaluation may help guide management in this regard (Kim et al., 1997).

In the rare event that a clinical scenario of recurrent urinary tract infections mandates intervention in a child with PUVs, bladder management in advance of intervention is a critical component in ensuring favorable surgical outcomes (Hunziker et al., 2012).

Surgical correction is considered recognizing also the higher complication rate of stricture and persistent reflux associated with reimplanting dilated ureters into thick-walled bladders that are not properly rehabilitated before surgery (Coleman and McGovern, 1978; Atwell, 1983). Indeed, any treatment of urinary reflux in a child with profound bowel dysfunction potentially puts an already compromised renal unit at risk for further deterioration (Sillen et al., 2010; Tekgul et al., 2012). Endoscopic correction of reflux seems to carry less of the risks of myogenic disruption and renal deterioration seen with ureteroneocystotomy in children with valves, but the overall surgical success rate is lower than that for children without valves (Puri and Kumar, 1996; Tourchi et al., 2014).

Bladder Dysfunction and Valve Bladder Syndrome

Consequent to exposure to obstruction from its earliest development, the bladder is necessarily the focus of management and rehabilitation throughout the life of a boy diagnosed with PUVs (Parkhouse et al., 1988). **The extent of remodeling and subsequent functional compromise may vary, but the bladder and its dysfunction begins a cascade of pathophysiologic changes including voiding dysfunction, urinary reflux, and worsening of renal dysplasia and obstructive uropathy. The ultimate manifestation of this dysfunction is the valve bladder syndrome.**

Urodynamics plays an important role in monitoring an affected child's progression through various well-described changes in bladder function throughout childhood. **The bladder evolves through three distinct contractility patterns throughout childhood: (1) detrusor hyperreflexia in infancy and early childhood; (2) decreasing intravesical pressures and improved compliance bladder in childhood; and (3) increased capacity bladder with hypocontractility and atony in adolescence** (Peters et al., 1990; De Gennaro et al., 2000). Holmdahl et al. stressed that the pattern outlined here overlaps in most children, emphasizing that the patterns described earlier are not arbitrary or destined to happen, but rather useful guideposts in monitoring and helpful in offering management solutions and assessing the effectiveness of intervention over the long-term (Holmdahl et al., 1995).

Mitchell conceptualizes a vicious circle in voiding dysfunction in which the outlet obstruction begins a cascade of events leading to the end-stage bladder, or valve bladder. Bladder outlet obstruction leads to detrusor hypertrophy, which increases the voiding pressures initially as the bladder strives to complete emptying. As further remodeling of the bladder occurs, however, the PVR begins to increase as the urine output increases. Ultimately, the bladder cannot meet the demand of emptying and the detrusor decompensates. This is not to state that the devolution to a valve bladder is unavoidable nor uniformly applicable and expected. One may hypothesize that active, appropriate intervention to effectively drain the overdistended bladder could alter the course toward decompensation and preserve bladder functionality.

Boys with PUVs were noted to achieve daytime and nighttime continence later than peers without this issue (5.5 years vs. 2.9 years; Jalkanen et al., 2016). Bladder dysfunction, even when not detected on clinical history alone, must always be suspected in children with a history of valve ablation. One systematic review of 34 studies describing renal function, vesicoureteral reflux, and urodynamic findings after endoscopic valve ablation in 1474 patients found that although the self-reported history of incontinence ranged widely between 0% and 70%, the mean incidence was 19%. But when urodynamic outcomes were examined, the incidence of bladder dysfunction rose to a mean of 55% (Hennus et al., 2012). **Reliance on clinical examination or patient questionnaires alone may grossly underestimate bladder dysfunction, and obtaining a uroflow and checking PVRs should be a routine part of follow-up in toilet-trained children with a history of PUVs** (Lopez Pereira et al., 2013).

Bladder Management

The typical follow-up for children with valves after ablation for bladder dysfunction has focused on observation, clinical history, and urodynamics. Education of parents and growing children is a critical component of bladder management and success of any prescribed behavioral modifications**. Families are counseled to not aggressively push an affected child toward toilet training and to expect a lag compared with the normal population. Daytime incontinence is not uncommon, ranging from 7% to 35%, and nocturnal enuresis is expected in 1 of 4 children with a history of valve ablation** (Hennus et al., 2012). **Once toilet training is achieved, children and caregivers are educated to ensure adequate fluid intake, void on a timed regimen, and practice double-voiding. Biofeedback therapy and home pelvic floor exercises have also shown to be useful** (Ansari et al., 2008).

The role of adjunctive medications is unclear. The preferred intervention is predicated also on varying proposed etiologies of voiding dysfunction after valve ablation: (1) functional obstruction at the bladder neck caused by hypertrophy or (2) bladder wall thickening caused by detrusor wall thickening from increased collagen deposition. One study suggests the use of α-adrenergic blockade to relieve sphincteric hypertonicity and relax the bladder neck in children with high PVRs, finding a significant reduction in residual volumes (Abraham et al., 2009). In contrast, Casey et al. administered oxybutynin at 0.1 mg/kg twice daily in 18 consecutive infants undergoing urodynamics at 3 months post–valve ablation, showing high voiding pressures or small bladder capacity (Casey et al., 2012). Although the study found that both parameters improved significantly with oxybutynin, the lack of a control group in both studies and the fact that detrusor hypercontractility and elevated voiding pressures are a normal finding in neonates necessitate more rigorous, prospective studies (Sillen et al., 1992; Casey et al., 2012). If oxybutynin is chosen, its use must be closely monitored for effect, and if a growing child begins to demonstrate higher bladder residual volumes and capacity, oxybutynin should be stopped. Therapy was ceased in 4 of 18 patients in the Casey et al. study, and another found that myogenic failure required clean intermittent catheterization (CIC; Kim et al., 1997; Casey et al., 2012). It is unclear whether the myogenic failure was a consequence of evolving bladder dysfunction inherent to PUVs or secondary to oxybutynin, but caution, nevertheless, should be exercised during the treatment period.

Role of Urodynamics

As outlined earlier, bladder contractility changes as the child ages and must be considered a dynamic condition. The clinician must carefully monitor the bladder function of a child affected by PUVs, and urodynamics is an important modality to facilitate this goal. Combining fluoroscopy to standard urodynamics, or videourodynamics, is especially useful in properly assessing storage and emptying in dynamic conditions, and in offering an understanding of the contribution of vesicoureteral reflux to bladder function (Fig. 33.15AB). Urodynamics may be most useful when there is a change in the clinical scenario, such as worsening upper tract dilation or presence of urinary tract infections. Yet, any putative benefit of videourodynamics must be understood in the context of known disadvantages of radiation exposure and infection (Concodora et al., 2017).

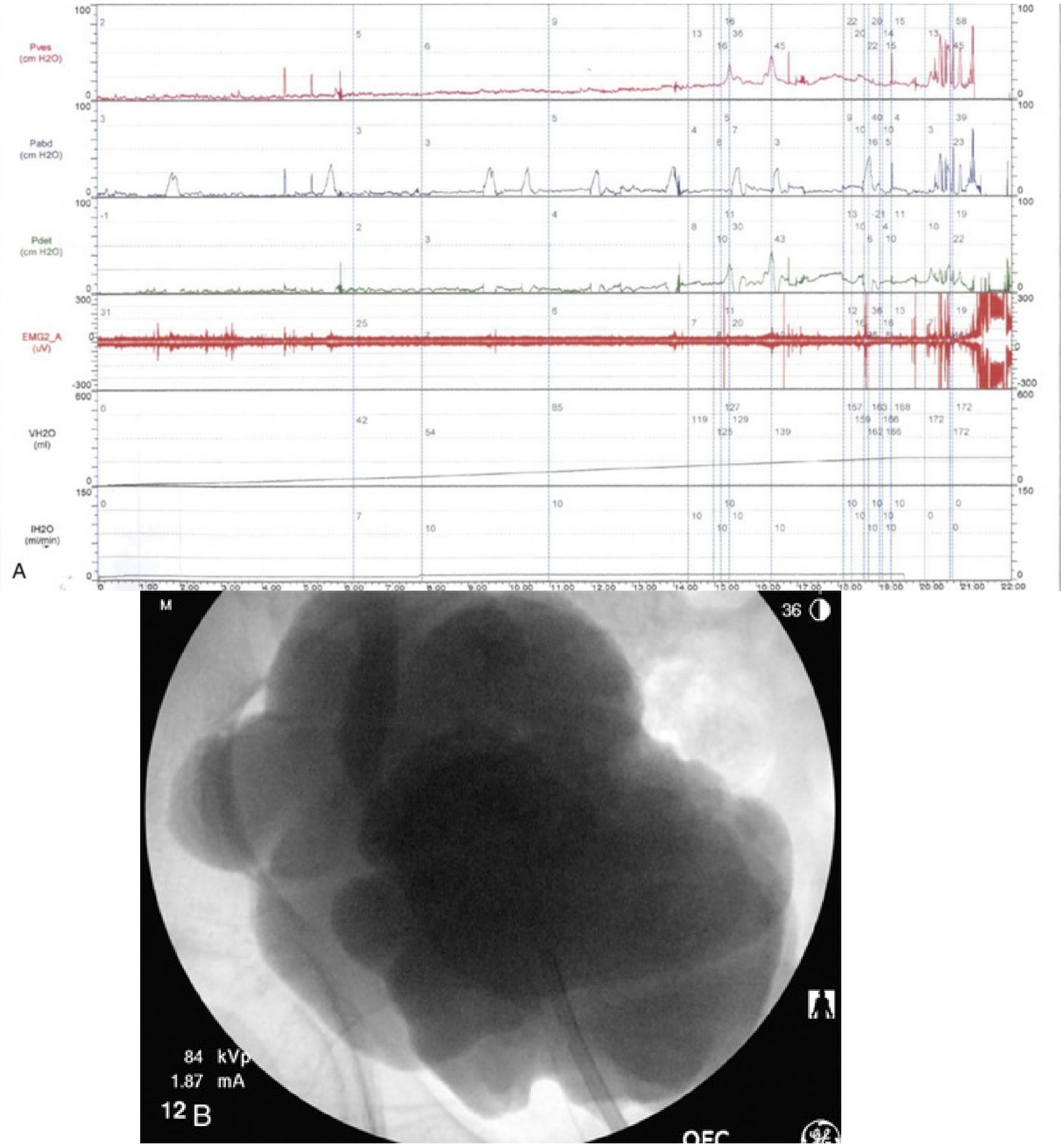

FIG. 33.15 The valve bladder "vicious cycle" illustrated. An affected bladder will lead to increasing postvoid residuals. The sustained stretch will cause increasing collagen deposition and other changes that cause increased pressures being transmitted to the renal pelvis. Subsequent renal tubular injury causes polyuria and increased volume in the bladder that already empties poorly, and the cycle continues leading to additive damage. (A) Urodynamic tracing obtained in 7-year-old boy with a history of posterior urethral valves shows a bladder with preserved compliance, frequent uninhibited contractions, and poor contractility. (B) Fluroscopic image of the same patient during videourodyamics demonstrates a severely trabeculated bladder with right-sided vesicoureteral reflux.

Valve Bladder Syndrome

The term “valve bladder syndrome” was coined by Mitchell in 1982 after reviewing his experience with 11 patients in whom hydroureteronephrosis and renal function continued to worsen despite no clinical evidence of residual bladder outlet. **Mitchell's concept, which is illustrated in Fig. 33.15 and described earlier, holds that although the bladder initially compensates for outlet obstruction by generating high voiding pressures, it begins to experience higher volumes of urine caused by increasing urine production as the child grows. The polyuria caused by nephrogenic diabetes insipidus secondary to evolving renal impairment augments the urine volumes entering a bladder that is increasingly unable to empty completely. As the PVRs increase, the bladder no longer enjoys periods of complete relaxation, and the detrusor fibers are continuously in a state of partial or complete stretch, beginning a cascade of genotypic and phenotypic changes that further impair contractility of the bladder** (Kirsch et al., 2003; Hutcheson et al., 2004; Shukla et al., 2004). And when the bladder does empty partially, the urine already stored in the hydronephrotic kidneys quickly empties into the bladder, once again denying the detrusor muscle periods of relaxation. The impaired contractility and increasing PVRs then transmit the increasing bladder pressures to the kidneys, potentially worsening the already impaired renal function.

In sum then, **there are three processes that contribute toward the devolution of a bladder into a valve bladder:** (1) polyuria; (2) bladder insensitivity; and (3) residual urine volume. These three factors—all secondary to the original insult of impaired bladder compliance creating high wall tension caused by increases in collagen and matrix—conspire to sustain bladder overdistension that ultimately leads to the valve bladder (Koff et al., 2002). Although the goal of intensive management of bladder dysfunction is to arrest the progression toward full expression of late-term manifestations of valve bladder syndrome, *valve bladder syndrome* is actually a broad term describing a continuum of symptoms of bladder dysfunction. As described in the previous section, monitoring urine PVRs, flow rates, and voiding pressures, along with timed voiding, double voiding, and anticholinergics or α-blockers compose the mainstay of treatment. CIC becomes necessary if residual volume increases despite initial interventions with anticholinergics to deter the progression toward decompensation.

Overnight bladder drainage is an important adjunct in therapy and is increasingly adopted as a standard intervention in children with classic evidence of developing a valve bladder syndrome (Koff et al., 2002; Nguyen et al., 2005). Nocturnal bladder drainage is instituted if ureteral dilation and hydronephrosis does not respond to behavioral modification or an affected child develops worsening renal function or recurrent urinary tract infections. The continuous bladder drainage, achieved by leaving a urinary catheter in the bladder over a 7- to 10-hour period, allows an extended period of bladder decompression, even as the kidneys empty urine without encountering the increased voiding or resting bladder pressures they face during the day. This simple step interrupts the “vicious cycle” of bladder remodeling and consequent renal effects caused by chronic bladder distension. Koff et al. and Nguyen et al. noted significant improvements in hydronephrosis, continence, and urinary tract infections after instituting overnight bladder drainage (Koff et al., 2002; Nguyen et al., 2005).

When CIC or overnight bladder drainage is difficult because of an elevated bladder neck or sensate urethra, an appendicovesicostomy utilizing the Mitrofanoff principle presents a useful option (Mitrofanoff, 1980). King et al. followed 24 patients with a valve bladder who underwent the Mitrofanoff procedure to enable CIC for a median of 6.2 years. The study demonstrated that pelvicaliectasis decreased and bladder compliance improved, although renal deterioration still developed in 35% of cases (King et al., 2014).

Minimally invasive approaches to create this catheterizable channel, utilizing both laparoscopic and robotic assisted approaches, are increasingly being adopted at many centers (Mitrofanoff 1980; Hsu and Shortliffe, 2004; Nguyen et al., 2009; Famakinwa and Gundeti, 2013; Famakinwa et al., 2013) (Fig. 33.16A–C). A large, multi-institutional review of the robotic-assisted laparoscopic Mitrofanoff procedure confirmed its safety with a revision rate of 12.5% (Famakinwa and Gundeti, 2013) The robotic-assisted approach potentially limits the field of dissection and could, in older children, make it difficult to mobilize the appendix and perform bladder mobilization with anastomosis of the appendix through a single robot docking. In such situations, a pure laparoscopic approach could be used to mobilize the appendix, followed by docking of the robot with standard triangulation of port sites focused on the pelvic midline for anastomosis of the appendix.

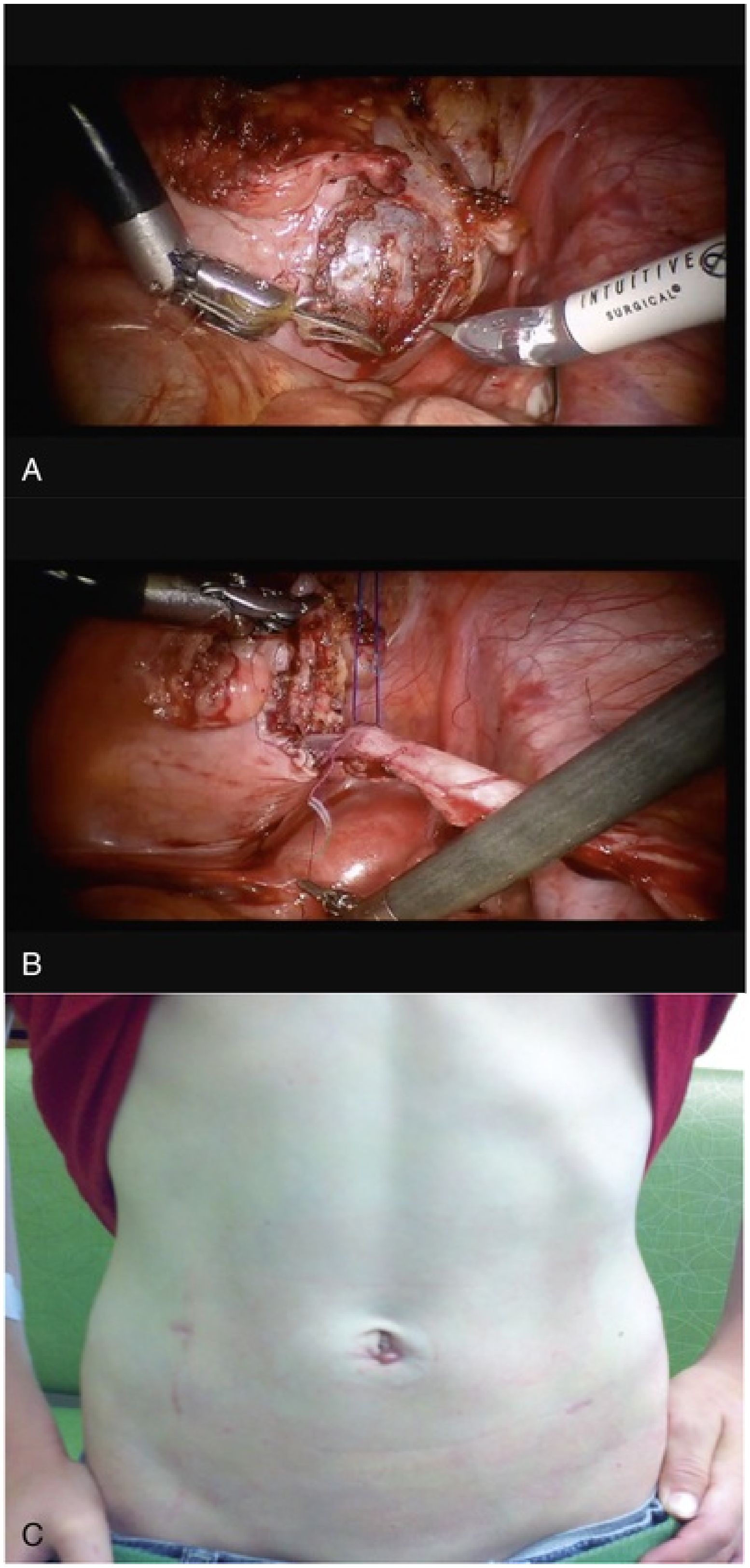
INTUITIVE SURGICAL
A
B
C

FIG. 33.16 Robot-assisted laparoscopic appendicovesicostomy in a child with valve bladder syndrome and a history of posterior urethral valves. (A)

The detrusor muscle is incised in the posterior bladder wall to allow tunneled anastomosis of the appendix. (B) Anastomosis of the appendix to the bladder with a feeding tube traversing the appendix into a cystotomy along the posterior wall of the bladder. (C) Postoperative appearance with appendicovesicostomy stoma visible just inside the umbilicus.

Augmentation cystoplasty is rarely utilized for a valve bladder in the contemporary era, perhaps as a result of improved understanding of bladder dysfunction, behavior modification, and timely institution of overnight bladder drainage. But when faced with a small-capacity, high-pressure, and thick-walled valve bladder with worsening upper tract anatomy refractory to conservative measures, augmentation may be considered. Ureteral augmentation is preferred in children with PUVs as it reduces the risk for mucous production, acidosis, and stones that are common to ileal augmentation. Moreover, severe ureteral dilation or unilateral VURD seen in boys with valves offers an ideal clinical scenario where the ureter can be detubularized and patched on a bisected bladder without bowel manipulation. Johal et al. reported lasting benefits of increased capacity and decreased filling pressures at a mean follow-up of 4.5 years after ureteral augmentation (Johal et al., 2008).

Key Points

- The focus of management for vesicoureteric reflux in a child with valves should be centered on the bladder, and ureteral reimplantation is rarely offered.
- The bladder evolves through three patterns in boys with valves: (1) detrusor hyperreflexia in infancy and early childhood; (2) decreasing intravesical pressures and improved compliance bladder in childhood; and (3) increased capacity bladder with hypocontractility and atony in adolescence.
- Videourodynamics is completed in boys with valves especially when there is a clinical change: increasing upper tract dilation or recurrent urinary tract infections.
- Overnight bladder drainage is considered in the scenario of increasing PVRs, urinary tract infection, or worsening hydronephrosis and renal function.

Prognostic Indicators for Renal Function

Despite numerous advances in antenatal diagnosis and intervention and rapid postnatal evaluation and treatment, the lifetime prevalence of end-stage renal disease in boys with PUVs is between 20% to 50% (Parkhouse et al., 1988, Smith et al., 1996; Sarhan et al., 2011). Risk factors known to affect the prognosis of an infant diagnosed with PUVs include age at diagnosis, renal dysplasia with or without vesicoureteral reflux, nadir creatinine during 1 year of life, recurrent urinary tract infections, and bladder dysfunction.

Nadir creatinine has long been considered a relatively easy method of predicting long-term renal outcome in affected children. The nadir creatinine value measured at 1 year of life appears to be more accurate as a predictive tool than the value obtained at 1 month of age (Drozdz et al., 1998; Lal et al., 1999; Heikkilä et al., 2011). **A serum creatinine of less than 0.8 mg/dL appears to indicate a minimal risk, and a value greater than 1.2 mg/dL at 1 year of age predicts a higher risk for developing end-stage renal failure** (Drozdz et al., 1998; DeFoor et al., 2008). In those studies suggesting that a 1-month post-treatment serum creatinine is a more accurate predictor of renal function, again, the value of less than 0.8 mg/dL at 1 month after treatment seems to indicate better long-term outcomes (Rittenberg et al., 1988). Coleman et al. concluded that a nadir creatinine at 1 month of greater than 0.85 mg/dL implies a higher risk for renal failure, and values of less than 0.4 mg/dL may be considered lower risk (Coleman et al., 2015a, 2015b). Creatinine velocity (the rate of change of creatinine over time) in the first 30 days of life has also been postulated to be a predictor of renal failure (Coleman et al., 2015a, 2015b).

Age at presentation remains an unclear predictor of future renal outcomes. The assumption that antenatal diagnosis would lead to more rapid diagnosis of PUVs and, therefore, forestall renal injury has not been sustained. Indeed, Heikkilä et al. found that patients diagnosed in the presonography era before 1982 had a risk for end-stage renal disease of 16.8%, as compared with 36.6% developing renal failure if diagnosed during the postsonography era (Heikkilä et al., 2011). Another review found a similar variation, with 41% of those presenting before 1 year of age having poor long-term renal outcome compared with 15% of those presenting after 1 year of age (Parkhouse et al., 1988). This difference in outcomes may be explained by the assumption that the critically ill infants in the presonography era likely died before diagnosis was complete, and early interventions, including fetal measures in the current era increased survival dramatically. These infants born after 1982, then, may previously have died and tended to have more severe manifestations of valve disease and related comorbidities contributing to poorer renal outcomes.

Another common assumption, not corroborated, was that the later presenting children likely had a milder variant of valve disease, allowing them to go undetected for some years before presenting with more vague symptoms of voiding dysfunction. But some reports found much poorer outcomes in children presenting outside of the neonatal period with PUVs, with delayed presentation associated with a significantly higher risk for azotemia, higher serum creatinine, and poorer long-term renal outcomes (El-Sherbiny et al., 2002; Ziylan et al., 2006; Sarhan et al., 2011).

Quantifying renal dysplasia without a renal biopsy requires reliance on available imaging technology including renal sonography and nuclear scintigraphy. Hyperechogenic kidneys, cystic changes in the cortex, and loss of corticomedullary differentiation are considered to portend a poor prognosis (Robyr et al., 2005). Pulido et al. examined the association of the renal parenchymal area—defined as the area of the kidney minus the area of the pelvicalyceal system on the first postnatal ultrasound—with end-stage renal disease. Reviewing the first postnatal ultrasound images of 60 patients followed for 393 person-years, the authors found that for infants with a 1-month-of-life serum creatinine between 0.8 mg/dL and 1.1 mg/dL, each 1-cm^2 increase in renal parenchymal area was associated with a lower risk for end-stage renal disease (Pulido et al., 2013). Odeh et al. concluded that there is a significant difference in parenchymal area between children who proceed to renal failure versus those who do not (21.41 cm^2 vs. 16 cm^2), along with a difference in the corticomedullary differentiation index (Odeh et al., 2016). Recently, fetal MRI (Faure et al., 2017), postnatal ultrasound findings (Hochart et al., 2016), and genetic markers (Faure et al., 2016) have been used to predict risk for renal deterioration. These studies highlight the need for novel ways of predicting renal outcomes in children with valves and certainly more definitive and powerful predictive tools that incorporate genetic and biochemical markers (Farrugia et al., 2006).

Transplantation in Valve Patients

The prevalence of end-stage renal disease in boys with a history of end-stage renal disease is up to 50%, and the 2006 annual report of the North American Pediatric Renal Trials and Collaborative Studies listed obstructive uropathy as the second most common cause for transplantation, accounting for 1424 of 8990 transplant cases (15.8%) since 1987 (Smith et al., 2007).

Patients with PUVs receiving renal transplant compose an especially difficult cohort for receiving a renal transplant. These boys are likely to have several comorbidities including high-grade vesicoureteral reflux into native, nonfunctioning kidneys and valve bladder syndrome with a thick-walled, poorly contractile or hypercontractile bladder. A pediatric urologist must be a critical component of the transplant team and should carefully examine the prospective recipient as part of the pretransplant evaluation. Recipients have significantly higher complication rates and graft loss rates in boys in whom bladder dysfunction is incompletely managed or bladder reservoir is not optimized (Sheldon et al., 1994; Mendizabal et al., 2005).

Outcomes after renal transplant in children with PUVs have been mixed. **The thickened bladder wall of PUV patients may contribute to the significantly increased incidence of ureteral obstruction on univariate and multivariate analysis compared with a non–PUV transplant cohort, but recent studies saw no risk for increased graft loss or patient death despite ureteral obstruction, stenting, or dilation** (Indudhara et al., 1998; DeFoor et al., 2003; Smith et al., 2010; Fine et al., 2011). Fine et al. reported on 59 valve patients that underwent renal transplant with 8-year follow-up and found that outcomes were similar whether a boy underwent an initial valve ablation, vesicostomy, or supravesical diversion; and although bladder dysfunction increased the risk for graft failure, the effect did not reach significance (Fine et al., 2011).

Videourodynamics should be obtained for transplant candidates to determine the safe storage pressures and contractile function of the future reservoir. Overnight bladder drainage or CIC may be initiated before transplant to optimize the reservoir and establish proper bladder management skills that will be essential for graft success after transplant. Pretransplant nephrectomy is rarely required and is only considered in cases where proteinuria or severe polyuria is creating hemodynamic challenges.

If augmentation is felt necessary based on unsafe storage pressures in the bladder, this reconstruction can be considered before or after transplantation. Although previous dogma suggested that a pretransplant augmentation is preferable to prevent the undertaking in an immunocompromised child or one too young to take responsibility for catheterization and pouch management, recent experience argues that transplantation into even a vesicostomy is a safe alternative until the child grows to an appropriate age for cystoplasty and the attendant reliance on CIC (Rigamonti et al., 2005; Christman et al., 2013). A recent meta-analysis confirmed this reluctance to proceed with prerenal transplant augmentation cystoplasty, finding that augmentation cystoplasty does increase the risk for urinary tract infection in children with PUVs. The authors also noted that if augmentation cystoplasty is deemed necessary, it can be performed after transplant with surgical outcomes no different from doing it before transplantation (Jesus and Pippi Salle, 2015). Still, Lopez Pereira et al. found that augmentation cystoplasty did not compromise transplant kidneys and that the infection rate is very similar between children who were augmented versus those who were not as long as they are compliant with their catheterization protocol (Lopez Pereira et al., 2014).

Quality of Life With Posterior Urethral Valves

It must be emphasized that PUVs is an illness with lifetime repercussions. Understanding these long-term risk factors and their impact on quality of life is necessary for counseling, preparing, and treating valve patients as they reach adulthood.

The evolution of the valve bladder and the associated comorbidities of renal transplantation that many valve patients face are associated with well-known risks including erectile dysfunction and infertility. The lower urinary tract symptoms that affect children with valves will affect them as adults two to three times more often than in the general population (Tikkinen et al., 2011). A survey of 67 adult patients with valves found that the overall rate of erectile dysfunction or infertility was not different than the general population (Taskinen et al., 2012). But a subgroup analysis of these same patients with urinary incontinence or renal insufficiency showed that valve patients had the greatest evidence of impaired quality of life, underscoring the necessity of long-term follow-up and active treatment well into adulthood (Jalkanen et al., 2013). **Indeed, the chronicity of bladder dysfunction, risk for urinary tract infections, and sequelae of renal dysfunction require communication between pediatric and adult urologists, even as the adult urologist should be knowledgeable of the pathophysiology of PUVs and well prepared to provide care to these patients after their transition into adulthood.**

Key Points

- An antenatal vesicoamniotic shunt can be considered in select patients with bladder wall thickening, hydroureteronephrosis, and oligohydramnios. Although it may reduce the severity of pulmonary hypoplasia, the procedure confers no protection from renal impairment.
- A nadir serum creatinine at 1 year of less than 0.8 mg/dL confers a significantly decreased risk for developing end-stage renal disease.
- Transplantation into a valve-affected bladder may carry a higher risk for

ureteral obstruction, but there is no increased risk for graft loss compared with controls.

Anterior Urethral Valves

Anterior urethral valves are the most common congenital obstructive lesion of the anterior urethra but are 25 to 30 times less common than PUVs (Confer et al., 2010). Because the condition is often found in association with a large anterior urethral diverticulum, the valve itself is varyingly described as an obstruction resulting from a wall of the diverticulum obstructing flow, or a semilunar fold draping down from the wall of the anterior urethra interrupting urinary flow (Tank, 1987; Paulhac et al., 2003). The embryology of anterior urethral valves is not clear, but hypoplastic corpus spongiosum over the affected portion of the anterior urethra indicates a place on the hypospadias spectrum or a faulty union between urethral mucosa and the epithelium of the fossa navicularis. A rupture of dilated bulbourethral glands has also been suggested as an etiology (McLellan et al., 2004). The valves may be located at the bulbar urethra, penoscrotal junction, or penile urethra (Firlit et al., 1978).

Patients present with anterior urethral valves at different ages based on the severity of the obstructive process. **Symptoms may consist of postvoid dribbling and mild incontinence, significant bulging of the distal penis, palpable bladder with obstruction, or even renal insufficiency and urinary tract infections** (Cruz-Diaz et al., 2013). Diagnosis requires a careful examination of the external genitalia, and compression of the distal shaft may result in expressing urine as seen in a diverticulum (see Fig. 33.16A). The voiding cystourethrogram is required to confirm the diagnosis and may demonstrate a dilated anterior urethra with proximal signs of chronic obstruction including bladder diverticula and massive vesicoureteral reflux (see Fig. 33.16B).

The treatment approach to anterior urethral valves varies according to age of presentation, extent of upper tract damage, and extent of anterior urethral deformity. In a premature or small infant, a vesicostomy may be required to facilitate relief of obstruction until the infant can accommodate a cystoscope or undergo further reconstruction. **In the majority of cases, cystoscopy with valve ablation using a bugbee electrode or laser is possible as an initial treatment, and when successful, no further surgery of the urethra is required** (Cruz-Diaz et al., 2013). In more severe cases in which a gross urethral diverticulum is seen, **surgical reconstruction over a urethral catheter may be required.**

Up to 80% of children with anterior urethral valves will develop bladder

dysfunction, and bladder instability, hyperreflexia, and diminished compliance and capacity will be seen on urodynamics (Kajiwara et al., 2007). As with PUVs, long-term renal function is contingent on preoperative creatinine and glomerular filtration rate. Routh et al. performed a multivariate analysis of data available from 97 studies including 229 patients with anterior urethral valves and found that pretreatment azotemia, vesicoureteral reflux, and urinary tract infection together increased the risk for poor renal outcome 25-fold (Routh et al., 2010). Still, because of the milder and more subtle presentation, the overall incidence of preserved renal function in anterior urethral valves is better than PUVs, with 78% of patients having normal renal function after treatment (Routh et al., 2010).

Urethral Atresia

Urethral atresia, or the congenital urethral stricture, is a rarely described entity likely caused by its high associated mortality (Fig. 33.17). When an infant survives—because the obstruction is incomplete or because there was decompression caused by an antenatal shunt placement or a patent urachus—the outcome can be similar to a child with obstructing PUVs (Gonzalez et al., 2001). **An obstructing membrane is typically seen at the distal end of the prostatic urethra, and the urethra distal to that point may be hypoplastic. As a part of the LUTO spectrum seen in antenatally detected anomalies of the lower urinary tract, the obstruction is confirmed after birth with cystoscopy, and a vesicostomy is usually required** (Freedman et al., 1999).

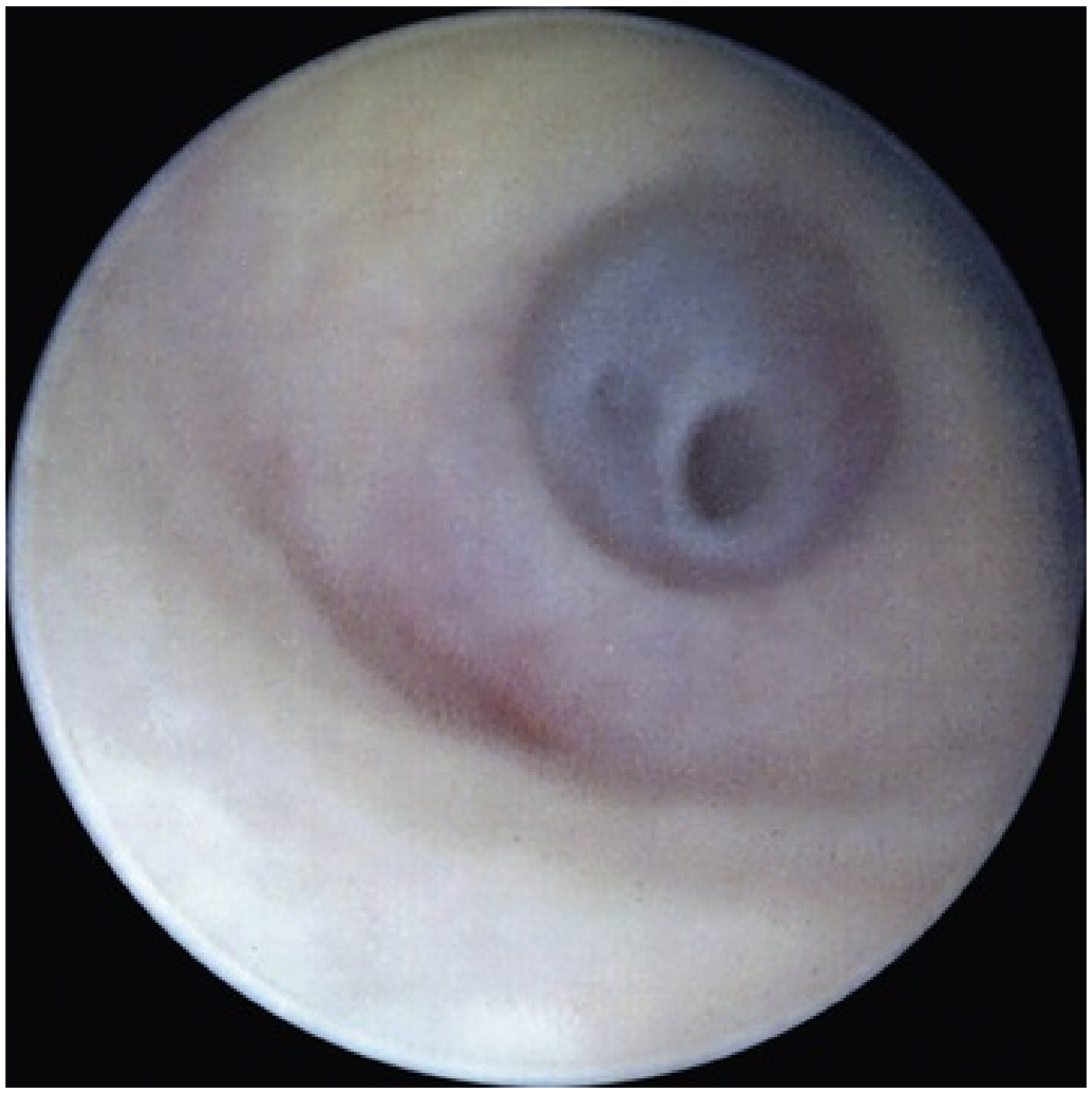

FIG. 33.17 Image obtained during cystoscopy on day 2 of life in a neonate with a prenatal history of lower urinary tract obstruction (LUTO). Cystoscopy demonstrates a near-complete urethral obstruction in the mid-bulbar urethra most consistent with urethral atresia.

Whether urethral atresia is a precipitating factor for development of prune-belly syndrome in certain cases remains controversial, but infants with urethral atresia or congenital urethral stricture often will present with oligohydramnios, bilateral hydroureteronephrosis, and weak abdominal wall musculature. The Progressive Augmentation by Dilation Urethra Anterior (PADUA) initially reported by Firlit, is considered a safe alternative for restoring urethral continuity in select cases without complex reconstructive surgery (Passerini-Glazel et al. 1988), but long-term data is lacking.

Urethral Duplication

Urethral duplication is another rare anomaly of the urethra with several known anatomic variants. The duplication may begin at the bladder neck or within the more distal urethra. **Although one urethra usually terminates on the glans near its orthotopic position, another urethra may end in a meatus placed on the glans or more ventrally along the shaft of the penis. In the most severe cases, the duplicated urethra may even be as proximal as the anal sphincter. The duplication occurs in a sagittal plane, with the ventral urethra, usually the functional meatus, containing the sphincteric complex and verumontanum.**

Effmann et al. are credited with the most widely used classification system for urethral duplications (Effmann et al., 1976) (Fig. 33.18A-J). Broadly, **the type I abnormality includes a blind incomplete urethral duplication or accessory urethra. Type II is a complete patent urethral duplication with four subytpes, and type III refers to urethral duplication as a component of partial or complete caudal duplication.** The “Y” type duplication refers to a type IIA2 type in which the duplicated urethra arises from the first but diverges away to open into a second meatus that opens as ventral as the rectum.

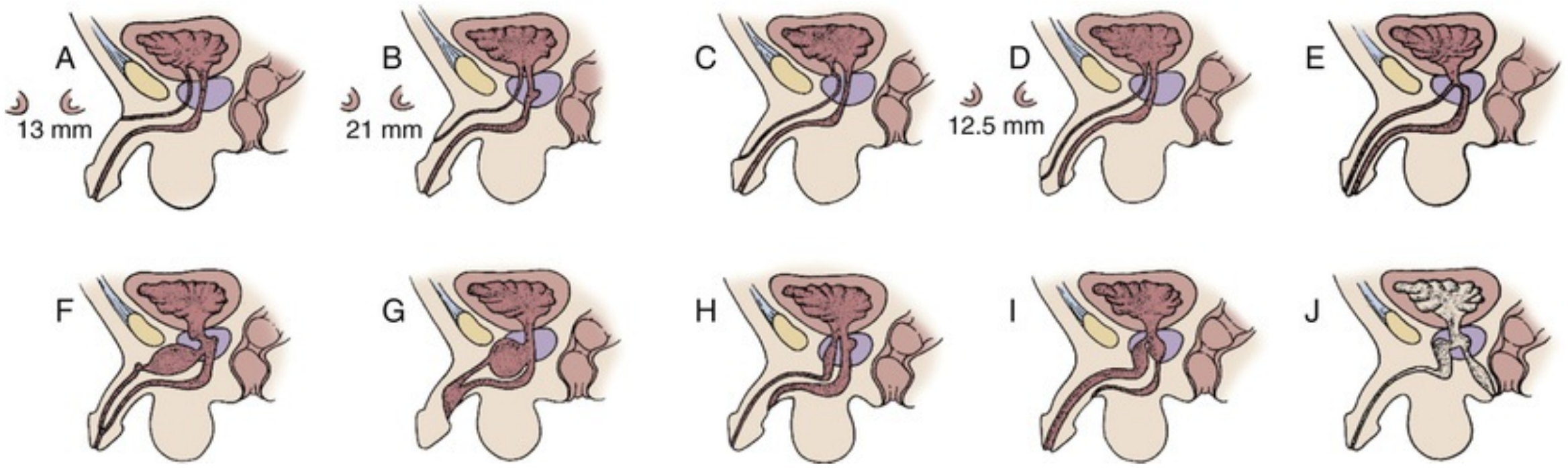

FIG. 33.18 Illustration of different types of urethral diverticulum. (A to J) Variations of urethral duplications shown in the sagittal plane. Each of these drawings illustrate that the ventral urethra is the functional one as it passes through the orthotopic prostate and sphincter.

Diagnosis is readily made in some cases when two distinct meatal openings are seen on the glans, but in other cases requires a high index of suspicion when examining what appears to be an atypical case of proximal hypospadias with a patent appearing opening on the glans. A voiding cystourethrogram will confirm the diagnosis during the voiding phase in many cases, although a retrograde injection of the distinct urethra can also be accomplished (Fig. 33.19AB; Hoekstra and Jones, 1985; Podesta et al., 1998).

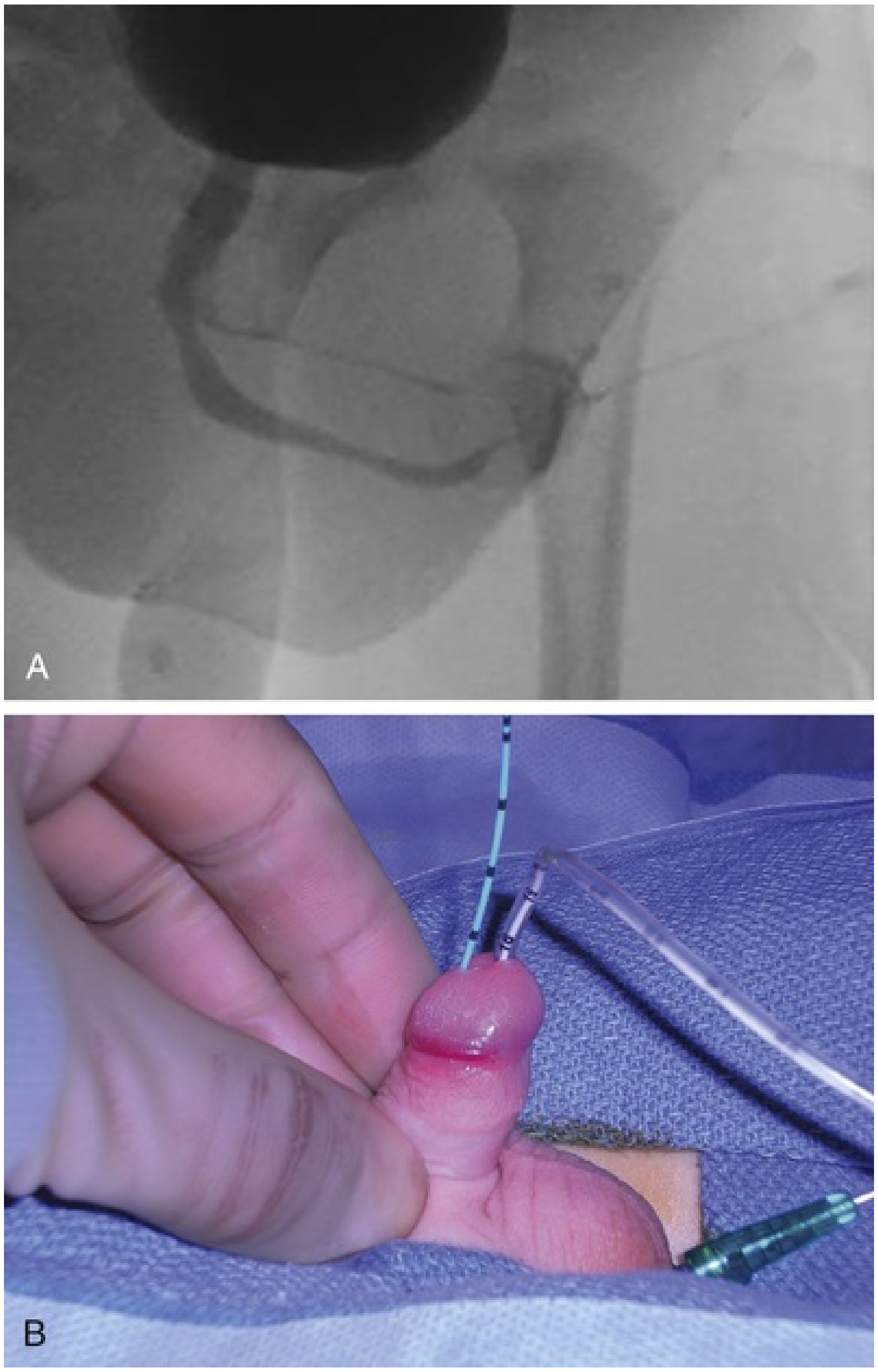

FIG. 33.19 (A) Voiding cystourethrogram in a male child showing urethral duplication. (B) Clinical demonstration of the same child in the operating room with the larger-caliber ventral urethra and the narrower dorsal urethra.

Surgical management is complex and may require a variety of single- or multiple-stage repairs. A small, blind-ending accessory urethra may be conservatively monitored or treated expeditiously with simple coagulation of the mucosal tract with a bugbee electrode. A patent duplicated urethra connected to the bladder with a distinct bladder neck will require a planned reconstruction. When two urethral openings are found on the glans, the more dorsal urethra may mimic the appearance of a distal epispadias. Alanee et al. described a technique by which the septum between the two urethral channels is incised and the dorsal defect is repaired with reverse glans wings to cover a dorsal urethroplasty (Alanee et al., 2012). In cases in which the urethral openings are separated by the “Y”-type arrangement, a staged reconstruction using preputial or buccal mucosa flaps may be required to bring the more ventral but functional meatus to the glans penis, where it can be insinuated into the dorsal, usually atretic, urethra.

The anterior sagittal trans-ano-rectal approach (ASTRA) is another option for select cases as a means to mobilize the ventral, functional meatus placed in the anal sphincter (Macedo et al., 2012). The ventral urethra may be mobilized to bridge the gap with the rest of the urethra reconstructed using preputial skin as reported by Kaye et al. (Kaye et al., 2012) (▶Video 33.2). In our experience, if the distal aspect of the orthotopic, or dorsal, urethra is of sufficient caliber, then the ventral urethra may be mobilized sufficiently enough to be directly anastomosed to the dorsal, orthotopic urethra. It is essential to recognize that treatment strategies vary significantly in cases of duplex urethra, and surgical strategy needs to be devised based on individual anatomy.

Urethrorrhagia

Urethrorrhagia, usually referred to as idiopathic urethrorrhagia, describes a spotting of blood on the underwear after urination or voiding of clear urine followed by a few drops of blood. The visible blood tends to raise alarm within families, but the condition is typically considered a benign and self-limited condition. Urethrorrhagia is most commonly seen in peripubertal boys.

The etiology of urethrorrhagia is unclear, although various hypotheses have been offered. Meatal stenosis and dysfunctional elimination syndrome have been suggested as inciting factors (Herz et al., 2005). Proponents of voiding dysfunction as the etiology of urethrorrhagia hold that increased voiding pressures caused by incomplete relaxation of the external urethral sphincter leads to turbulent flow that creates a negative intraluminal urethral pressure. That negative pressure causes an engorgement of the sinuses of the urethral mucosa and small extravasation of blood (Docimo et al., 1998; Herz et al., 2005). Meatal stenosis is similarly proposed as a cause of increased voiding pressures.

Adult urologists consider cystoscopy and upper urinary tract evaluation a necessary step for the evaluation of hematuria, **but the high rate of spontaneous resolution of urethrorrhagia in symptomatic adolescent males —up to 92%—means that routine cystoscopy is not necessary.** Rather, evaluation should focus on a detailed history of bowel and bladder function, renal and bladder ultrasound, and an office evaluation of urinary flow rate and PVRs. If urethrorrhagia becomes atypical—accompanied by symptoms of urethral stricture or increased urethral bleeding—then cystoscopy should be performed.

Although the majority of cases of urethrorrhagia will have an idiopathic origin, urethral strictures are diagnosed after or during evaluation in 14% to 28% of patients presenting with urethrorrhagia (Dewan and Wilson, 1996; Poch et al., 2007). This strong association has led to some debate as to whether cystoscopy itself, in traversing abnormal, inflamed epithelium, initiates stricture formation. Poch et al., in a review of 66 boys with urethrorrhagia, found that cystoscopy in atypical cases of urethrorrhagia identified varying levels of bulbar urethral inflammation, with 24% of patients having a white membranous exudate noted at cystoscopy subsequently diagnosed with a urethral stricture over a mean of 5 years (Poch et al., 2007). In the same cohort, 12% had a stricture found on cystoscopy without any prior history of instrumentation. These findings seem to support a perspective that although cystoscopy is benign in most cases, the procedure may exacerbate the inflammation of an already inflamed urethra in a small population that cannot readily be distinguished by any radiologic modality. A careful analysis of voiding habits and baseline uroflow is, therefore, imperative before cystoscopy is considered (Poch et al., 2007).

Urinary Fistula in Boys With Anorectal Malformation

The vast majority of boys born with an anorectal malformation will have a fistula to the urinary tract (Hong et al., 1992; Fig. 33.20). **Because the initial diverting colostomy is completed during the neonatal period, the fistula tract is usually seen on distal colostogram during subsequent workup before anorectoplasty.**

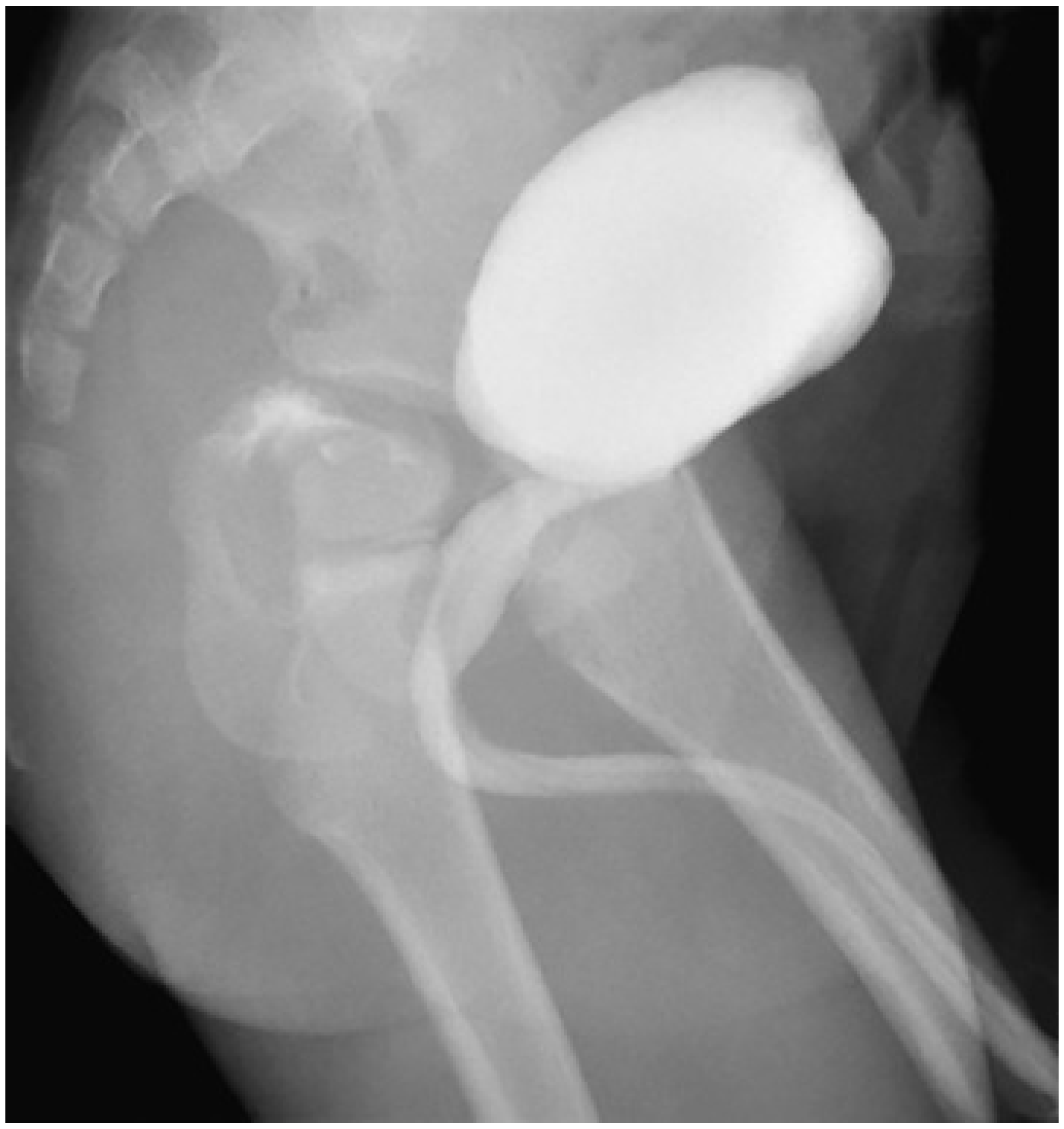

FIG. 33.20 Voiding cystourethrogram in a male infant with an anorectal malformation demonstrates passage of contrast into the rectum via a patent, although small, urethrorectal fistula visualized on the voiding phase of the study.

Pediatric urologists are an integral part of any multidisciplinary team caring for children with anorectal malformations. **Because associated genitourinary anomalies range from 25% to 50%, routine diagnostic imaging to determine the presence of renal anomalies and vesicoureteral reflux is recommended** (Hoekstrar et al., 1983). In an analysis of 190 patients with anorectal malformations, 31 (16.3%) developed a febrile urinary tract infection, of whom 51.6% had a diagnosis of vesicoureteral reflux. On multivariate analysis, the presence of genitourinary malformations was associated with a urinary tract infection, but the association did not reach statistical significance (Sanchez et al., 2014).

When definitive surgical repair is planned in association with general pediatric surgeons, a posterior sagittal approach is preferred to address the rectourinary fistula concurrently. Care must be taken to properly identify the fistula tract and ensure that the tract is excised in its entirety adjacent to the urethra and the rectum to prevent a diverticulum.

A urologist is present at the time of anorectoplasty and fistula repair, and the procedure begins with cystoscopy with an attempt to pass an open-ended ureteral catheter through the fistula tract. A guidewire may also be passed if the caliber of the fistula is small. A urethral catheter is then placed into the bladder, across the urethra. Once the child is placed prone and posterior sagittal anorectoplasty begins, the rectum is adequately mobilized away from the urethra using the previously placed catheter as a guide to location. The fistula tract is excised completely, and the urethral defect is approximated as close to the urethra as possible, reducing the risk for a urethral diverticulum. The rectal defect may be closed primarily, but if redundant intestinal tissue is available, then the fistulous portion of intestine is excised. Healthy adjacent tissue is interposed, and the catheter is left in place for at least 1 week to ensure healing of the urethroplasty.

Key Points

- Anterior urethral valves and urethral atresia are less common causes of LUTO, and long-term outcomes can be similar to those of PUVs if the neonate survives.
- Dysfunctional voiding causing a turbulent urinary flow may lead to urethrorrhagia.
- Treatment for urethrorrhagia should focus on improving voiding habits and conservative management, reserving cystoscopy for refractory cases and when there is significant straining during voiding.
- An infant diagnosed with anorectal malformation should undergo a renal ultrasound and a voiding cystourethrogram because of the high risk for

associated genitourinary anomalies.

Suggested Readings

Fine MS, Smith KM, et al. Posterior urethral valve treatments and outcomes in children receiving kidney transplants. *J Urol*. 2011;185(6 Suppl):2507–2511.

Heikkilä J, Holmberg C, Kyllönen L, et al. Long-term risk of end stage renal disease in patients with posterior urethral valves. *J Urol*. 2011;186(6):2392–2396.

Koff SA, Mutabagani KH, Jayanthi VR. The valve bladder syndrome: pathophysiology and treatment with nocturnal bladder emptying. *J Urol*. 2002;167(1):291–297.

Mitchell ME. Persistent ureteral dilatation. *Dialogues Pediatr Urol*. 1982;5(4).

Peters CA, Bolkier M, Bauer SB, et al. The urodynamic consequences of posterior urethral valves. *J Urol*. 1990;144(1):122–126.

Smith GH, Canning DA, Schulman SL, et al. The long-term outcome of posterior urethral valves treated with primary valve ablation and observation. *J Urol*. 1996;155(5):1730–1734.

Young HH, Frontz WA, Baldwin JC. Congenital obstruction of the posterior urethra. *J Urol*. 1919;3:289.

References

Abbott JF, Levine D, Wapner R. Posterior urethral valves: inaccuracy of prenatal diagnosis. *Fetal Diagn Ther*. 1998;13(3):179–183.

Abraham MK, Nasir AR, Sudarsanan B, et al. Role of alpha adrenergic blocker in the management of posterior urethral valves. *Pediatr Surg Int*. 2009;25(12):1113–1115.

Alanee S, Gupta P, Gleich P, et al. Complete urethral duplication: description of surgical approach mimicking distal epispadias repair. *J Pediatr Urol*. 2012;8(4):343–347.

Androulakakis PA, Karamanolakis DK, Tsahouridis G, et al. Myogenic bladder decompensation in boys with a history of posterior urethral valves is caused by secondary bladder neck obstruction? *BJU Int*. 2005;96(1):140–143.

Ansari MS, Srivastava A, Kapoor R, et al. Biofeedback therapy and home pelvic floor exercises for lower urinary tract dysfunction after posterior urethral valve ablation. *J Urol*. 2008;179(2):708–711.

Anumba DO, Scott JE, Plant ND, et al. Diagnosis and outcome of fetal lower urinary tract obstruction in the northern region of England. *Prenat Diagn*. 2005;25(1):7–13.

Atwell JD. Posterior urethral valves in the British Isles: a multicenter BAPS review. *J Pediatr Surg*. 1983;18(1):70–74.

Bader M, McCarthy L. What is the efficacy of circumcision in boys with complex urinary tract abnormalities? *Pediatr Nephrol*. 2013;28(12):2267–2272.

Bajpai M, Pratap A, Tripathi M, et al. Posterior urethral valves: preliminary observations on the significance of plasma Renin activity as a prognostic marker. *J Urol*. 2005;173(2):592–594.

Bauer SB, Dieppa RA, Labib KK, et al. The bladder in boys with posterior urethral valves: a urodynamic assessment. *J*

Urol. 1979;121(6):769–773.

Berrocal T, Gaya F, Arjonilla A. Vesicoureteral reflux: can the urethra be adequately assessed by using contrast-enhanced voiding US of the bladder? *Radiology*. 2005;234(1):235–241.

Boer DP, de Rijke YB, Hop WC, et al. Reference values for serum creatinine in children younger than 1 year of age. *Pediatr Nephrol*. 2010;25(10):2107–2113.

Boghossian NS, Sicko RJ, Kay DM, et al. Rare copy number variants implicated in posterior urethral valves. *Am J Med Genet A*. 2016;170(3):622–633.

Bomalaski MD, Anema JG, Coplen DE, et al. Delayed presentation of posterior urethral valves: a not so benign condition. *J Urol*. 1999;162(6):2130–2132.

Casey JT, Hagerty JA, Maizels M, et al. Early administration of oxybutynin improves bladder function and clinical outcomes in newborns with posterior urethral valves. *J Urol*. 2012;188(4 Suppl):1516–1520.

Chauvin NA, Epelman M, Victoria T, et al. Complex genitourinary abnormalities on fetal MRI: imaging findings and approach to diagnosis. *AJR Am J Roentgenol*. 2012;199(2):W222–W231.

Chevalier RL. Biomarkers of congenital obstructive nephropathy: past, present and future. *J Urol*. 2004;172(3):852–857.

Chiaramonte C, Bommarito D, Zambaiti E, et al. Genetic basis of posterior urethral valves inheritance. *Urology*. 2016;95:175–179.

Christensen MG, Nordling J, Andersen JT, et al. Functional bladder neck obstruction. Results of endoscopic bladder neck incision in 131 consecutive patients. *Br J Urol*. 1985;57(1):60–62.

Christman MS, Canning DA, Schast AP, et al. Renal transplantation into a diverted urinary system—Is it safe in children? *J Urol*. 2013;190(2):678–682.

Chun AL, Ruzich JV, Wein AJ, et al. Functional and pharmacological effects of ureteral diversion. *J Urol*. 1989;141(2):403–407.

Churchill BM, McLorie GA, Khoury AE, et al. Emergency treatment and long-term follow-up of posterior urethral valves. *Urol Clin North Am*. 1990;17(2):343–360.

Clark TJ, Martin WL, Divakaran TG, et al. Prenatal bladder drainage in the management of fetal lower urinary tract obstruction: a systematic review and meta-analysis. *Obstet Gynecol*. 2003;102(2):367–382.

Close CE, Carr MC, Burns MW, et al. Lower urinary tract changes after early valve ablation in neonates and infants: is early diversion warranted? *J Urol*. 1997;157(3):984–988.

Coleman JW, McGovern JH. Ureterovesical reimplantation in children. Surgical results in 491 children. *Urology*. 1978;12(5):514–518.

Coleman R, King T, Nicoara CD, et al. Combined creatinine velocity and nadir creatinine: a reliable predictor of renal outcome in neonatally diagnosed posterior urethral valves. *J Pediatr Urol*. 2015;11(4):214.e211–214.e213.

Coleman R, King T, Nicoara CD, et al. Nadir creatinine in posterior urethral valves: how high is low enough? *J Pediatr Urol*. 2015;11(6):356.e351–356.e355.

Concodora CW, Reddy PP, VanderBrink BA. The role of video urodynamics in the management of the valve bladder. *Curr Urol Rep*. 2017;18(3):24.

Confer SD, Galati V, Frimberger D, et al. Megacystis with an anterior urethral valve: case report and review of literature. *J Pediatr Urol*. 2010;6(5):459–462.

Cruz-Diaz O, Salomon A, Rosenberg E, et al. Anterior urethral valves: not such a benign condition. *Front Pediatr*. 2013;1:35.

Cuckow PM, Dinneen MD, Risdon RA, et al. Long-term renal function in the posterior urethral valves, unilateral reflux and renal dysplasia syndrome. *J Urol*. 1997;158(3 Pt 2):1004–1007.

De Gennaro M, Capitanucci ML, Mosiello G, et al. The changing urodynamic pattern from infancy to adolescence in boys with posterior urethral valves. *BJU Int*. 2000;85(9):1104–1108.

DeFoor W, Clark C, Jackson E, et al. Risk factors for end stage renal disease in children with posterior urethral valves. *J Urol*. 2008;180(4 Suppl):1705–1708 [discussion 1708].

DeFoor W, Tackett L, Minevich E, et al. Successful renal transplantation in children with posterior urethral valves. *J Urol*. 2003;170(6 Pt 1):2402–2404.

Deshpande AV. Current strategies to predict and manage sequelae of posterior urethral valves in children. *Pediatr Nephrol*. 2018;33(10):1651–1661.

Dewan PA, Keenan RJ, Morris LL, et al. Congenital urethral obstruction: Cobb's collar or prolapsed congenital obstructive posterior urethral membrane (COPUM). *Br J Urol*. 1994;73(1):91–95.

Dewan PA, Wilson TM. Idiopathic urethritis in the adolescent male. *Eur Urol*. 1996;30(4):494–497.

Dinneen MD, Duffy PG, Barratt TM, et al. Persistent polyuria after posterior urethral valves. *Br J Urol*. 1995;75(2):236–240.

Docimo SG, Silver RI, Gonzalez R, et al. Idiopathic anterior urethritis in prepubertal and pubertal boys: pathology and clues to etiology. *Urology*. 1998;51(1):99–102.

Drozdz D, Drozdz M, Gretz N, et al. Progression to end-stage renal disease in children with posterior urethral valves. *Pediatr Nephrol*. 1998;12(8):630–636.

Duran C, Valera A, Alguersuari A, et al. Voiding urosonography: the study of the urethra is no longer a limitation of the technique. *Pediatr Radiol*. 2009;39(2):124–131.

Effmann EL, Lebowitz RL, Colodny AH. Duplication of the urethra. *Radiology*. 1976;119(1):179–185.

El-Sherbiny MT, Hafez AT, Shokeir AA. Posterior urethral valves: does young age at diagnosis correlate with poor renal function? *Urology*. 2002;60(2):335–338 [discussion 338].

Engel DL, Pope JC 4th, Adams MC, et al. Risk factors associated with chronic kidney disease in patients with posterior urethral valves without prenatal hydronephrosis. *J Urol*. 2011;185(6 Suppl):2502–2506.

Famakinwa O, Gundeti MS. Robotic assisted laparoscopic Mitrofanoff appendicovesicostomy (RALMA). *Curr Urol Rep*. 2013;14(1):41–45.

Famakinwa OJ, Rosen AM, Gundeti MS. Robot-assisted laparoscopic Mitrofanoff appendicovesicostomy technique and outcomes of extravesical and intravesical approaches. *Eur Urol*. 2013;64(5):831–836.

Farrugia MK, Braun MC, Peters CA, et al. Report on The Society for Fetal Urology panel discussion on the selection criteria and intervention for fetal bladder outlet obstruction. *J Pediatr Urol*. 2017;13(4):345–351.

Farrugia MK, Godley ML, Woolf AS, et al. Experimental short-term partial fetal bladder outflow obstruction: II Compliance and contractility associated with urinary flow impairment. *J Pediatr Urol*. 2006;2(4):254–260.

Faure A, Bouty A, Caruana G, et al. DNA copy number variants: a potentially useful predictor of early onset renal failure in boys with posterior urethral valves. *J Pediatr Urol*. 2016;12(4):227.e221–227.e227.

Faure A, Panait N, Panuel M, et al. Predicting postnatal renal function of prenatally detected posterior urethral valves using fetal diffusion-weighted magnetic resonance imaging with apparent diffusion coefficient determination. *Prenat Diagn*. 2017;37(7):666–672.

Field PL, Stephens FD. Congenital urethral membranes causing urethral obstruction. *J Urol*. 1974;111:250.

Fine MS, Smith KM, Shrivastava D, et al. Posterior urethral valve treatments and outcomes in children receiving kidney transplants. *J Urol*. 2011;185(6 Suppl):2507–2511.

Firlit RS, Firlit CF, King LR. Obstructing anterior urethral valves in children. *J Urol*. 1978;119(6):819–821.

Freedman AL, Johnson MP, Smith CA, et al. Long-term outcome in children after antenatal intervention for obstructive uropathies. *Lancet*. 1999;354(9176):374–377.

Furness PD 3rd, Maizels M, Han SW, et al. Elevated bladder urine concentration of transforming growth factor-beta1 correlates with upper urinary tract obstruction in children. *J Urol*. 1999;162(3 Pt 2):1033–1036.

Gagliardini E, Benigni A. Role of anti-TGF-beta antibodies in the treatment of renal injury. *Cytokine Growth Factor Rev*. 2006;17(1–2):89–96.

Ghafar MA, Shabsigh A, Chichester P, et al. Effects of chronic partial outlet obstruction on blood flow and oxygenation of the rat bladder. *J Urol*. 2002;167(3):1508–1512.

Glassberg KI. The valve bladder syndrome: 20 years later. *J Urol*. 2001;166(4):1406–1414.

Glick L, Harrison MR, Golbus MS, et al. Management of the fetus with congenital hydronephrosis II: prognostic criteria and selection for treatment. *J Pediatr Surg*. 1985;20(4):376–387.

Glick PL, Harrison MR, Halks-Miller M, et al. Correction of congenital hydrocephalus in utero II: efficacy of in utero shunting. *J Pediatr Surg*. 1984;19(6):870–881.

Gobet R, Park JM, Nguyen HT, et al. Renal renin-angiotensin system dysregulation caused by partial bladder outlet obstruction in fetal sheep. *Kidney Int*. 1999;56(5):1654–1661.

Gonzalez R, De Filippo R, Jednak R, et al. Urethral atresia: long-term outcome in 6 children who survived the neonatal period. *J Urol*. 2001;165(6 Pt 2):2241–2244.

Greenfield SP, Hensle TW, Berdon WE, et al. Urinary extravasation in the newborn male with posterior urethral valves. *J Pediatr Surg*. 1982;17(6):751–756.

Gunn TR, Mora JD, Pease P. Antenatal diagnosis of urinary tract abnormalities by ultrasonography after 28 weeks' gestation: incidence and outcome. *Am J Obstet Gynecol*. 1995;172(2 Pt 1):479–486.

Haecker FM, Wehrmann M, Hacker HW, et al. Renal dysplasia in children with posterior urethral valves: a primary or secondary malformation? *Pediatr Surg Int*. 2002;18(2–3):119–122.

Hassan JM, Pope JC 4th, Brock JW 3rd, et al. Vesicoureteral reflux in patients with posterior urethral valves. *J Urol*. 2003;170(4 Pt 2):1677–1680 [discussion 1680].

Heikkilä J, Holmberg C, Kyllönen L, et al. Long-term risk of end stage renal disease in patients with posterior urethral valves. *J Urol*. 2011;186(6):2392–2396.

Hennus PM, van der Heijden GJ, Bosch JL, et al. A systematic review on renal and bladder dysfunction after endoscopic treatment of infravesical obstruction in boys. *PLoS ONE*. 2012;7(9):e44663.

Herndon CD. Fetal urology. *J Pediatr Urol*. 2012;8(2):120.

Herz D, Weiser A, Collette T, et al. Dysfunctional elimination syndrome as an etiology of idiopathic urethritis in childhood. *J Urol*. 2005;173(6):2132–2137.

Hochart V, Lahoche A, Priso RH, et al. Posterior urethral valves: are neonatal imaging findings predictive of renal function during early childhood? *Pediatr Radiol*.

2016;46(10):1418–1423.

Hoekstra I, Jones B. Duplication of the male urethra: report of three cases. *Clin Radiol*. 1985;36(5):529–531.

Hoekstra WJ, Scholtmeijer RJ, Molenaar JC, et al. Urogenital tract abnormalities associated with congenital anorectal anomalies. *J Urol*. 1983;130(5):962–963.

Holmdahl G, Sillen U, Bachelard M, et al. The changing urodynamic pattern in valve bladders during infancy. *J Urol*. 1995;153(2):463–467.

Holmes N, Harrison MR, Baskin LS. Fetal surgery for posterior urethral valves: long-term postnatal outcomes. *Pediatrics*. 2001;108(1):E7.

Hong AR, Croitoru DP, Nguyen LT, et al. Congenital urethral fistula with normal anus: a report of two cases. *J Pediatr Surg*. 1992;27(10):1278–1280.

Hoover DL, Duckett JW Jr. Posterior urethral valves, unilateral reflux and renal dysplasia: a syndrome. *J Urol*. 1982;128(5):994–997.

Hsu TH, Shortliffe LD. Laparoscopic Mitrofanoff appendicovesicostomy. *Urology*. 2004;64(4):802–804.

Hunziker M, Mohanan N, D'Asta F, et al. Incidence of febrile urinary tract infections in children after successful endoscopic treatment of vesicoureteral reflux: a long-term follow-up. *J Pediatr*. 2012;160(6):1015–1020.

Husain AN, Hessel RG. Neonatal pulmonary hypoplasia: an autopsy study of 25 cases. *Pediatr Pathol*. 1993;13(4):475–484.

Husmann DA, Snodgrass WT, Koyle MA, et al. Ureterocystoplasty: indications for a successful augmentation. *J Urol*. 2004;171(1):376–380.

Hutcheson JC, Cooper CS, Canning DA, et al. The use of vesicostomy as permanent urinary diversion in the child with myelomeningocele. *J Urol*. 2001;166(6):2351–2353.

Hutcheson JC, Stein R, Chacko S, et al. Murine in vitro whole bladder model: a method for assessing phenotypic responses to pharmacologic stimuli and hypoxia. *Neurourol Urodyn*. 2004;23(4):349–354.

Indudhara R, Joseph DB, Perez LM, et al. Renal transplantation in children with posterior urethral valves revisited: a 10-year followup. *J Urol*. 1998;160(3 Pt 2):1201–1203 [discussion 1216].

Jalkanen J, Heikkila J, Kyrklund K, et al. Controlled outcomes for achievement of urinary continence among boys treated for posterior urethral valves. *J Urol*. 2016;196(1):213–218.

Jalkanen J, Mattila AK, Heikkila J, et al. The impact of posterior urethral valves on adult quality of life. *J Pediatr Urol*. 2013;9(5):579–584.

Jesus LE, Pippi Salle JL. Pre-transplant management of valve bladder: a critical literature review. *J Pediatr Urol*. 2015;11(1):5–11.

Johal NS, Hamid R, Aslam Z, et al. Ureterocystoplasty: long-term functional results. *J Urol*. 2008;179(6):2373–2375 [discussion 2376].

Johnson MP, Bukowski TP, Reitleman C, et al. In utero surgical treatment of fetal obstructive uropathy: a new comprehensive approach to identify appropriate candidates for vesicoamniotic shunt therapy. *Am J Obstet Gynecol*. 1994;170(6):1770–1776 [discussion 1776–1779].

Jordan GH, Hoover DL. Inadequate decompression of the upper tracts using a Foley catheter in the valve bladder. *J Urol*. 1985;134(1):137–138.

Kagami S, Border WA, Miller DE, et al. Angiotensin II stimulates extracellular matrix protein synthesis through induction of transforming growth factor-beta expression in rat glomerular mesangial cells. *J Clin Invest*. 1994;93(6):2431–2437.

Kajbafzadeh AM, Payabvash S, Karimian G. The effects of bladder neck incision on urodynamic abnormalities of children with posterior urethral valves. *J Urol*. 2007;178(5):2142–2147 [discussion 2147–2149].

Kajiwara M, Inoue K, Kato M, et al. Anterior urethral valves in children: a possible association between anterior urethral valves and Cowper's duct cyst. *Int J Urol*. 2007;14(2):156–160.

Kawada N, Moriyama T, Ando A, et al. Increased oxidative stress in mouse kidneys with unilateral ureteral obstruction. *Kidney Int*. 1999;56(3):1004–1013.

Kaye JD, Srinivasan AK, Koyle MA, et al. Rotation of the amputated fistula tract for the management of congenital urethral-enteric fistula with severe urethral stenosis: a novel technique with long-term outcomes. *J Pediatr Urol*. 2012;8(2):166–173.

Keihani S, Kajbafzadeh AM, Kameli SM, et al. Long-term impacts of concurrent posterior urethral valve ablation and bladder neck incision on urinary continence and ejaculation. *Urology*. 2017;99:278–280.

Kim YH, Horowitz M, Combs AJ, et al. Management of posterior urethral valves on the basis of urodynamic findings. *J Urol*. 1997;158(3 Pt 2):1011–1016.

King T, Coleman R, Parashar K. Mitrofanoff for valve bladder syndrome: effect on urinary tract and renal function. *J Urol*. 2014;191(5 Suppl):1517–1522.

Kirsch AJ, Macarak EJ, Chaqour B, et al. Molecular response of the bladder to obstruction. *Adv Exp Med Biol*. 2003;539(Pt A):195–216.

Kis E, Nyitrai A, Varkonyi I, et al. Voiding urosonography with second-generation contrast agent versus voiding cystourethrography. *Pediatr Nephrol*. 2010;25(11):2289–2293.

Kitagawa H, Pringle KC, Koike J, et al. Early bladder wall changes after creation of obstructive uropathy in the fetal lamb. *Pediatr Surg Int*. 2006;22(11):875–879.

Kleppe S, Schmitt J, Geipel A, et al. Impact of prenatal urinomas in patients with posterior urethral valves and postnatal renal function. *J Perinat Med*. 2006;34(5):425–428.

Koff SA, Mutabagani KH, Jayanthi VR. The valve bladder syndrome: pathophysiology and treatment with nocturnal bladder emptying. *J Urol*. 2002;167(1):291–297.

Krishnan A, de Souza A, Konijeti R, et al. The anatomy and embryology of posterior urethral valves. *J Urol*. 2006;175(4):1214–1220.

Laksmi NK, Khullar M, Kaur B, et al. Association of angiotensin converting enzyme and angiotensin type 2 receptor gene polymorphisms with renal damage in posterior urethral valves. *J Pediatr Urol*. 2010;6(6):560–566.

Lal R, Bhatnagar V, Mitra DK. Long-term prognosis of renal function in boys treated for posterior urethral valves. *Eur J Pediatr Surg*. 1999;9(5):307–311.

Laudy JA, Tibboel D, Robben SG, et al. Prenatal prediction of pulmonary hypoplasia: clinical, biometric, and Doppler velocity correlates. *Pediatrics*. 2002;109(2):250–258.

Lee RS, Cendron M, Kinnamon DD, et al. Antenatal hydronephrosis as a predictor of postnatal outcome: a meta-analysis. *Pediatrics*. 2006;118(2):586–593.

Levin RM, Agartan CA, Leggett RE, et al. Effect of partial outlet obstruction on nitrotyrosine content and distribution within the rabbit bladder. *Mol Cell Biochem*. 2005;276(1–2):143–148.

Li C, Klein JD, Wang W, et al. Altered expression of urea transporters in response to ureteral obstruction. *Am J Physiol Renal Physiol*. 2004;286(6):F1154–F1162.

Lissauer D, Morris RK, Kilby MD. Fetal lower urinary tract obstruction. *Semin Fetal Neonatal Med*. 2007;12(6):464–470.

Lloyd JC, Wiener JS, Gargollo PC, et al. Contemporary epidemiological trends in complex congenital genitourinary anomalies. *J Urol*. 2013;190(4 Suppl):1590–1595.

Lopez Pereira P, Miguel M, Martinez Urrutia MJ, et al. Long-term bladder function, fertility and sexual function in patients with posterior urethral valves treated in infancy. *J Pediatr Urol*. 2013;9(1):38–41.

Lopez Pereira P, Ortiz R, Espinosa L, et al. Does bladder augmentation negatively affect renal transplant outcome in posterior urethral valve patients? *J Pediatr Urol*. 2014;10(5):892–897.

Macedo A Jr, Rondon A, Bacelar H, et al. Urethral duplication II-A Y type with rectal urethra: ASTRA approach and tunica vaginalis flap for first stage repair. *Int Braz J Urol*. 2012;38(5):707 [discussion 708].

MacRae Dell K, Hoffman BB, Leonard MB, et al. Increased urinary transforming growth factor-beta(1) excretion in children with posterior urethral valves. *Urology*. 2000;56(2):311–314.

Malin G, Tonks AM, Morris RK, et al. Congenital lower urinary tract obstruction: a population-based epidemiological study. *BJOG*. 2012;119(12):1455–1464.

Mandelia A, Bajpai M, Agarwala S, et al. The role of urinary TGF-beta(1), TNF-alpha, IL-6 and microalbuminuria for monitoring therapy in posterior urethral valves. *Pediatr Nephrol*. 2013;28(10):1991–2001.

Marokakis S, Kasparian NA, Kennedy SE. Parents’ perceptions of counselling following prenatal diagnosis of congenital anomalies of the kidney and urinary tract: a qualitative study. *BJU Int*. 2017;119(3):474–481.

Mate A, Bargiela A, Mosteiro S, et al. Contrast ultrasound of the urethra in children. *Eur Radiol*. 2003;13(7):1534–1537.

McLellan DL, Gaston MV, Diamond DA, et al. Anterior urethral valves and diverticula in children: a result of ruptured Cowper's duct cyst? *BJU Int*. 2004;94(3):375–378.

Mendizabal S, Estornell F, Zamora I, et al. Renal transplantation in children with severe bladder dysfunction. *J Urol*. 2005;173(1):226–229.

Miller OF, Lashley DB, McAleer IM, et al. Diagnosis of urethral obstruction with prenatal magnetic resonance imaging. *J Urol*. 2002;168(3):1158–1159.

Mitchell ME. Persistent ureteral dilatation. *Dialogues Pediatr Urol*. 1982;5(4).

Mitrofanoff P. Trans-appendicular continent cystostomy in the management of the neurogenic bladder. *Chir Pediatr*. 1980;21(4):297–305.

Mokhless I, Zahran AR, Saad A, et al. Effect of Botox injection at the bladder neck in boys with bladder dysfunction after valve ablation. *J Pediatr Urol*. 2014;10(5):899–904.

Morris RK, Malin GL, Quinlan-Jones E, Percutaneous vesicoamniotic shunting in Lower Urinary Tract Obstruction Collaborative Group, et al. Percutaneous vesicoamniotic shunting versus conservative management for fetal lower urinary tract obstruction (PLUTO): a randomised trial. *Lancet*. 2013;382(9903):1496–1506.

Mukherjee S, Joshi A, Carroll D, et al. What is the effect of circumcision on risk of urinary tract infection in boys with posterior urethral valves? *J Pediatr Surg*. 2009;44(2):417–421.

Narasimhan KL, Mahajan JK, Kaur B, et al. The vesicoureteral reflux dysplasia syndrome in patients with posterior urethral valves. *J Urol*. 2005;174(4 Pt 1):1433–1435 [discussion 1435].

Nguyen HT, Hsieh MH, Gaborro A, et al. JNK/SAPK and p38 SAPK-2 mediate mechanical stretch-induced apoptosis via caspase-3 and -9 in NRK-52E renal epithelial cells. *Nephron Exp Nephrol*. 2005;102(2):e49–e61.

Nguyen HT, Passerotti CC, Penna FJ, et al. Robotic assisted laparoscopic Mitrofanoff appendicovesicostomy: preliminary experience in a pediatric population. *J Urol*. 2009;182(4):1528–1534.

Nguyen MT, Pavlock CL, Zderic SA, et al. Overnight catheter drainage in children with poorly compliant bladders improves post-obstructive diuresis and urinary incontinence. *J Urol*. 2005;174(4 Pt 2):1633–1636 [discussion 1636].

Nicolini U, Spelzini F. Invasive assessment of fetal renal abnormalities: urinalysis, fetal blood sampling and biopsy. *Prenat Diagn*. 2001;21(11):964–969.

Odeh R, Noone D, Bowlin PR, et al. Predicting risk of chronic kidney disease in infants and young children at diagnosis of posterior urethral valves: initial ultrasound kidney characteristics and validation of parenchymal area as forecasters of renal reserve. *J Urol*. 2016;196(3):862–868.

Parkhouse HF, Barratt TM, Dillon MJ, et al. Long-term outcome of boys with posterior urethral valves. *Br J Urol*. 1988;62(1):59–62.

Passerini-Glazel G, Araguna F, Chiozza L, et al. The PADUA (progressive augmentation by dilating the urethra anterior) procedure for the treatment of severe urethral hypoplasia. *J Urol*. 1988;140(5 Pt 2):1247–1249.

Patil KK, Wilcox DT, Samuel M, et al. Management of urinary extravasation in 18 boys with posterior urethral valves. *J Urol*. 2003;169(4):1508–1511 [discussion 1511].

Paulhac P, Fourcade L, Lesaux N, et al. Anterior urethral valves and diverticula. *BJU Int*. 2003;92(5):506–509.

Peruzzi L, Lombardo F, Amore A, et al. Low renin-angiotensin system activity gene polymorphism and dysplasia associated with posterior urethral valves. *J Urol*. 2005;174(2):713–717.

Peters CA. Lower urinary tract obstruction: clinical and experimental aspects. *Br J Urol*. 1998;81(Suppl 2):22–32.

Peters CA, Bolkier M, Bauer SB, et al. The urodynamic consequences of posterior urethral valves. *J Urol*. 1990;144(1):122–126.

Peters CA, Carr MC, Lais A, et al. The response of the fetal kidney to obstruction. *J Urol*. 1992;148(2 Pt 2):503–509.

Pinar H. Postmortem findings in term neonates. *Semin Neonatol*. 2004;9(4):289–302.

Pinto MH, Markland C, Fraley EE. Posterior urethral valves managed by cutaneous ureterostomy with subsequent ureteral reconstruction. *J Urol*. 1978;119(5):696–698.

Poch MA, Handel LN, Kaplon DM, et al. The association of urethrorrhagia and urethral stricture disease. *J Pediatr Urol*. 2007;3(3):218–222.

Podesta ML, Medel R, Castera R, et al. Urethral duplication in children: surgical treatment and results. *J Urol*. 1998;160(5):1830–1833.

Poutamo J, Vanninen R, Partanen K, et al. Diagnosing fetal urinary tract abnormalities: benefits of MRI compared to ultrasonography. *Acta Obstet Gynecol Scand*. 2000;79(1):65–71.

Pulido JE, Furth SL, Zderic SA, et al. Renal parenchymal area and risk of ESRD in boys with posterior urethral valves. *Clin J Am Soc Nephrol*. 2014;9(3):499–505.

Puri P, Kumar R. Endoscopic correction of vesicoureteral reflux secondary to posterior urethral valves. *J Urol*. 1996;156(2 Pt 2):680–682.

Quintero RA, Hume R, Smith C, et al. Percutaneous fetal cystoscopy and endoscopic fulguration of posterior urethral valves. *Am J Obstet Gynecol*. 1995;172(1 Pt 1):206–209.

Quintero RA, Shukla AR, Homsy YL, et al. Successful in utero endoscopic ablation of posterior urethral valves: a new dimension in fetal urology. *Urology*. 2000;55(5):774.

Randall A. Congenital valves of the posterior urethra. *Ann Surg*. 1921;73(4):477–480.

Rigamonti W, Capizzi A, Zacchello G, et al. Kidney transplantation into bladder augmentation or urinary diversion: long-term results. *Transplantation*. 2005;80(10):1435–1440.

Rink RC, Adams MC, Keating MA. The flip-flap technique to lengthen the urethra (Salle procedure) for treatment of neurogenic urinary incontinence. *J Urol*. 1994;152(2 Pt 2):799–802.

Rittenberg MH, Hulbert WC, Snyder HM 3rd, et al. Protective factors in posterior urethral valves. *J Urol*. 1988;140(5):993–996.

Robyr R, Benachi A, Daikha-Dahmane F, et al. Correlation between ultrasound and anatomical findings in fetuses with lower urinary tract obstruction in the first half of pregnancy. *Ultrasound Obstet Gynecol*. 2005;25(5):478–482.

Routh JC, McGee SM, Ashley RA, et al. Predicting renal outcomes in children with anterior urethral valves: a systematic review. *J Urol*. 2010;184(4 Suppl):1615–1619.

Ruano R. Fetal surgery for severe lower urinary tract obstruction. *Prenat Diagn*. 2011;31(7):667–674.

Ruano R, Sananes N, Wilson C, et al. Fetal lower urinary tract obstruction: proposal for standardized multidisciplinary prenatal management based on disease severity. *Ultrasound Obstet Gynecol*. 2016;48(4):476–482.

Sanchez S, Ricca R, Joyner B, et al. Vesicoureteral reflux and febrile urinary tract infections in anorectal malformations: a retrospective review. *J Pediatr Surg*. 2014;49(1):91–94 [discussion 94].

Sarhan O, El-Ghoneimi A, Hafez A, et al. Surgical complications of posterior urethral valve ablation: 20 years experience. *J Pediatr Surg*. 2010;45(11):2222–2226.

Sarhan OM, El-Ghoneimi AA, Helmy TE, et al. Posterior urethral valves: multivariate analysis of factors affecting the final renal outcome. *J Urol*. 2011;185(6 Suppl):2491–2495.

Sarin YK, Sinha S. Efficacy of bladder neck incision on urodynamic abnormalities in patients with posterior urethral valves. *Pediatr Surg Int*. 2013;29(4):387–392.

Schober JM, Dulabon LM, Woodhouse CR. Outcome of valve ablation in late-presenting posterior urethral valves. *BJU Int*. 2004;94(4):616–619.

Sheldon CA, Gonzalez R, Burns MW, et al. Renal transplantation into the dysfunctional bladder: the role of adjunctive bladder reconstruction. *J Urol*. 1994;152(3):972–975.

Shukla AR, Nguyen T, Zheng Y, et al. Over expression of smooth muscle specific caldesmon by transfection and intermittent agonist induced contraction alters cellular morphology and restores differentiated smooth muscle phenotype. *J Urol*. 2004;171(5):1949–1954.

Sillen U, Brandstrom P, Jodal U, et al. The Swedish reflux trial in children: v. Bladder dysfunction. *J Urol*. 2010;184(1):298–304.

Sillen U, Hjalmas K, Aili M, et al. Pronounced detrusor hypercontractility in infants with gross bilateral reflux. *J Urol*. 1992;148(2 Pt 2):598–599.

Smith GH, Canning DA, Schulman SL, et al. The long-term outcome of posterior urethral valves treated with primary valve ablation and observation. *J Urol*. 1996;155(5):1730–1734.

Smith JM, Stablein DM, Munoz R, et al. Contributions of the Transplant Registry: the 2006 annual report of the North American Pediatric Renal Trials and Collaborative Studies (NAPRTCS). *Pediatr Transplant*. 2007;11(4):366–373.

Smith KM, Windsperger A, Alanee S, et al. Risk factors and treatment success for ureteral obstruction after pediatric renal transplantation. *J Urol*. 2010;183(1):317–322.

Smyth TB, Shortliffe LM, Constantinou CE. The effect of urinary flow and bladder fullness on renal pelvic pressure in a rat model. *J Urol*. 1991;146(2 Pt 2):592–596.

Soliman SM. Primary ablation of posterior urethral valves in low birth weight neonates by a visually guided fogarty embolectomy catheter. *J Urol*. 2009;181(5):2284–2289 [discussion 2289-2290].

St Aubin M, Willihnganz-Lawson K, Varda BK, et al. Society for fetal urology recommendations for postnatal evaluation of prenatal hydronephrosis—will fewer voiding cystourethrograms lead to more urinary tract infections? *J Urol*. 2013;190(4 Suppl):1456–1461.

Stephens FD. Urethral obstruction in childhood; the use of urethrography in diagnosis. *Aust N Z J Surg*. 1955;25:89.

Stephens FD, Smith ED, Hutson JM. Congenital intrinsic lesions of the posterior urethra. Stephens FD, Smith ED, Hutson JM. *Congenital anomalies of the kidney, urinary, and genital tracts*. Martin Dunitz: London, UK; 2002:91–106.

Tank ES. Anterior urethral valves resulting from congenital urethral diverticula. *Urology*. 1987;30(5):467–469.

Taskinen S, Heikkila J, Santtila P, et al. Posterior urethral valves and adult sexual function. *BJU Int*. 2012;110(8 Pt B):E392–E396.

Tekgul S, Riedmiller H, Hoebeke P, European Association of Urology, et al. EAU guidelines on vesicoureteral reflux in children. *Eur Urol*. 2012;62(3):534–542.

Thakkar D, Deshpande AV, Kennedy SE. Epidemiology and demography of recently diagnosed cases of posterior urethral valves. *Pediatr Res*. 2014;76(6):560–563.

Thomas DF, Gordon AC. Management of prenatally diagnosed uropathies. *Arch Dis Child*. 1989;64(1 Spec No):58–63.

Tietjen DN, Gloor JM, Husmann DA. Proximal urinary diversion in the management of posterior urethral valves: is it necessary? *J Urol*. 1997;158(3 Pt 2):1008–1010.

Tikkinen KA, Heikkila J, Rintala RJ, et al. Lower urinary tract symptoms in adults treated for posterior urethral valves in childhood: matched cohort study. *J Urol*. 2011;186(2):660–666.

Tourchi A, Kajbafzadeh AM, Aryan Z, et al. The management of vesicoureteral reflux in the setting of posterior urethral valve with emphasis on bladder function and renal outcome: a single center cohort study. *Urology*. 2014;83(1):199–205.

Weber S, Mir S, Schlingmann KP, et al. Gene locus ambiguity in posterior urethral valves/prune-belly syndrome. *Pediatr Nephrol*. 2005;20(8):1036–1042.

Wells JM, Mukerji S, Chandran H, et al. Urinomas protect renal function in posterior urethral valves—a population based study. *J Pediatr Surg*. 2010;45(2):407–410.

Welsh A, Agarwal S, Kumar S, et al. Fetal cystoscopy in the management of fetal obstructive uropathy: experience in a single European centre. *Prenat Diagn*. 2003;23(13):1033–1041.

Whitaker RH, Sherwood T. An improved hook for destroying posterior urethral valves. *J Urol*. 1986;135(3):531–532.

Wiswell TE, Miller GM, Gelston HM Jr, et al. Effect of circumcision status on periurethral bacterial flora during the first year of life. *J Pediatr*. 1988;113(3):442–446.

Workman SJ, Kogan BA. Fetal bladder histology in posterior urethral valves and the prune belly syndrome. *J Urol*. 1990;144(2 Pt 1):337–339.

Young HH, Frontz WA, Baldwin JC. Congenital obstruction of the posterior urethra. *J Urol*. 1919;3:289.

Yu L, Border WA, Anderson I, et al. Combining TGF-beta inhibition and angiotensin II blockade results in enhanced antifibrotic effect. *Kidney Int*. 2004;66(5):1774–1784.

Ziylan O, Oktar T, Ander H, et al. The impact of late presentation of posterior urethral valves on bladder and renal function. *J Urol*. 2006;175(5):1894–1897 [discussion 1897].

Neuromuscular Dysfunction of the Lower Urinary Tract in Children

Carlos R. Estrada MD, MBA, Stuart B. Bauer MD

Neuromuscular dysfunction of the lower urinary tract (LUT) may be either congenital or acquired. The most common cause of congenital dysfunction encountered by the urologist is the condition of neural tube defect (NTD) (Table 34.1). Before 1960, the outcome of children with NTDs was poor, with less than 10% surviving infancy (Rinck et al., 1989). Advances in neurosurgical and urologic care have resulted in a significant improvement in the survival rate such that in the mid-1990s, more than 85% of children survived infancy (Rinck et al., 1989). The most important intervention in this population was the institution of clean intermittent catheterization (CIC) for the prevention of upper urinary tract deterioration (Lapides et al., 1971). A longitudinal cohort study reveals that one-third of children will die before 5 years of age, and a further one-fourth die before 40 years of age (Oakeshott et al., 2010). The risk for death correlates with a higher level of neurologic deficit (Oakeshott et al., 2010). As these patients live longer, renal failure becomes an important cause of mortality, and thus lifelong monitoring and management of the urinary tract is necessary from infancy onward (McDonnell and McCann, 2000; Mitchell, 2005; Singhal and Mathew, 1999). For those children that survive, challenges persist for the achievement of bowel and bladder continence (Bomalaski et al., 1995; Metcalfe et al., 2011) and satisfactory sexual function (Lassmann et al., 2007).

TABLE 34.1

Causes of Neuromuscular Dysfunction of the Lower Urinary Tract

CONGENITAL	ACQUIRED	
NEURAL TUBE DEFECT	**EXTENSIVE PELVIC SURGERY**	
Occult forms of neural tube defect (Lipomeningocele and other spinal	Central nervous	Cerebral palsy
		Conditions of the brain

dysraphisms)	system insults	(tumors, infarcts, encephalopathies)
Sacral agenesis	Spinal cord insults	Trauma
		Transverse myelitis
Anorectal malformations		

Neural Tube Defects

Epidemiology of Neural Tube Defects

The most common cause of neurogenic bladder dysfunction in children is abnormal development of the spinal canal and consequently, the enveloped spinal cord. See Fig. 34.1 for an example of an open myelomeningocele. Formation of the spinal cord and vertebral column begins at about the 18th day of gestation. Closure of the canal proceeds in a caudal direction from the cephalad end and is complete by 35 days. The exact mechanism that results in closure and what produces a dysraphic state are yet to be elucidated, but numerous causative factors have been implicated. NTDs have a worldwide incidence of 0.3 to 4.5 per 1000 births (de Jong et al., 2008). In the United States, the birth prevalence of spina bifida has plateaued at approximately 30 per 100,000 (Snow-Lisy et al., 2015). Non-Hispanic white children have a risk of 3.22 per 10,000 births. The risk for children of non-Hispanic black or African-American descent is the lowest at 2.64 per 10,000 births (Boulet et al., 2008). There is geographic and temporal variation in the incidence of NTDs (Olney and Mulinare, 1998, 2002).

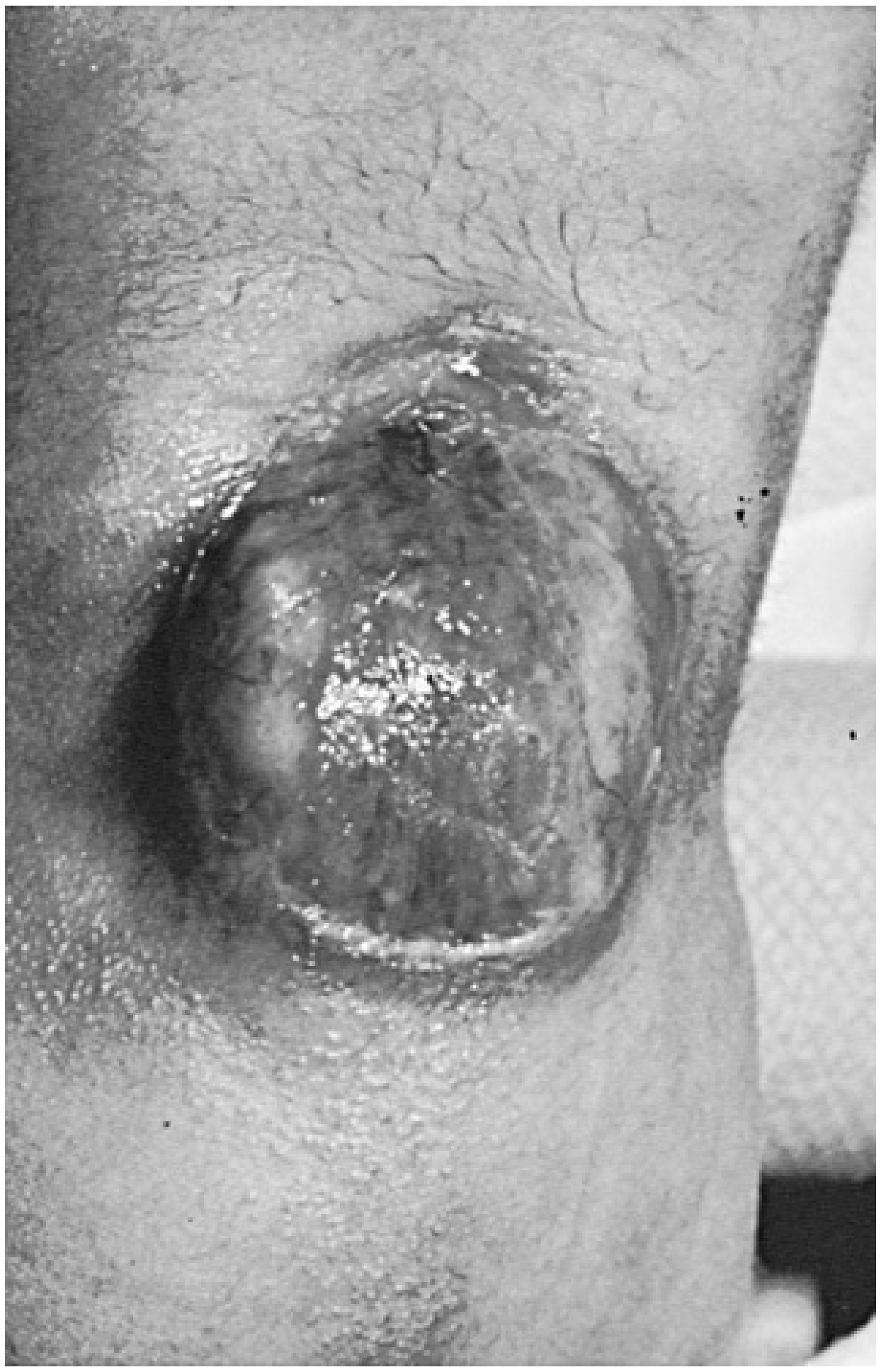

FIG. 34.1 Typical appearance of an open myelomeningocele in a neonate.

Women with low levels of folic acid and impairment of folate-mediated pathways or antibodies to folate are known to be at increased risk for NTDs (Botto and Mulinare, 1999). Folic acid supplementation in prospective randomized trials resulted in a 50% to 70% decrease in the prevalence of NTDs (Botto and Mulinare, 1999; Czeizel and Dudás, 1992; MRC Vitamin Study Research Group, 1991). In 1992, the U.S. Public Health Service recommended that women of childbearing age take a folic acid supplement (400 mcg daily) (MMWR, 1992) because the neural tube develops early in gestation, before most women realize that they are pregnant (Botto and Mulinare, 1999). Thus, it is suggested that the optimal time for folic acid supplementation is at least 4 weeks before and during the first month of pregnancy (Czeizel and Dudás, 1992; Dawson et al., 2001). However, only one-third of women take a folic acid supplement as recommended (Honein et al., 2001). Therefore, governments regulated the fortification of flour and pasta with folic acid in the late 1990s

(Food and Drug Regulations, 1998). Fortification of grains with folic acid has resulted in a 20% to 50% decrease in the prevalence of NTDs (Godwin et al., 2008; Honein et al., 2001).

Risk Factors for the Development of Neural Tube Defects

There is a strong familial risk for neural tube defects. A mother with one affected child has a 20 to 50 times increased risk for having another child with an NTD, and for an individual with spina bifida it is a 40 times greater than normal risk (Scarff and Fronczak, 1981; Stein et al., 1982).

Other, well-documented risk factors include young and advanced maternal age (Vieira and Castillo Taucher, 2005); maternal obesity (Stothard et al., 2009); maternal diabetes (Soler et al., 1976); maternal fever or flu (Lynberg et al., 1994); maternal caffeine consumption (Schmidt et al., 2009); specific maternal occupational exposures (Blanco Muñoz et al., 2005); maternal low educational level and socioeconomic status (Blanco Muñoz et al., 2005); maternal passive smoking (Wang et al., 2013); maternal periconceptual stressful event (Li et al., 2013); low maternal weight gain (Shaw et al., 2001); maternal use of folic acid antagonists such as valproic acid and/or carbamazepine (Hernández-Díaz et al., 2001; Lammer et al., 1987); preceding history of maternal miscarriage (Blanco Muñoz et al., 2006) or other birth defects (Yin et al., 2010); and higher birth order (Vieira, 2004).

Pathogenesis

Almost all infants born with spina bifida have an Arnold-Chiari malformation, which includes hindbrain herniation, brainstem abnormalities, low-lying venous sinuses, and a small posterior fossa (Adzick et al., 2011). This malformation is also associated with hydrocephalus and developmental brain abnormalities (Adzick et al., 2011). This affects motor, cranial nerve, and cognitive functioning. Hydrocephalus has traditionally been managed by diverting cerebral spinal fluid to the peritoneal cavity with a surgically placed shunt (Adzick et al., 2011). Endoscopic third ventriculostomy combined with choroid plexus cauterization effectively manages hydrocephalus in more than 70% of patients with myelomeningocele, avoids the need for placement of a ventriculoperitoneal (VP) shunt, and has similar neurocognitive outcomes as the VP shunt (Warf and

Campbell, 2008; Warf et al., 2009).

The neurologic lesion produced by the myelomeningocele can be variable, depending on what neural elements, if any, have everted with the meningocele sac. The bony vertebral level often provides little or no clue to the exact neurologic level or lesion produced. The height of the bony level may differ from the highest extent of the neurologic lesion for one to three vertebrae in either direction (Bauer et al., 1977). **Therefore, the neurologic lesion produced by this condition influences LUT function in a variety of ways and cannot be predicted just by looking at the spinal abnormality or the neurologic function of the lower extremities.** (Table 34.7 notes the distribution of spinal levels affected in myelomeningocele.)

Perinatal Concerns

Antenatal ultrasonography suggests the insult to central and peripheral nervous systems of a fetus with spina bifida is progressive, such that lower limb movement may be lost and hindbrain herniation and hydrocephalus may worsen during gestation (Korenromp et al., 1986; Sival et al., 1997). Animal studies have demonstrated that prenatal coverage of spina bifida–like lesions can preserve neurologic function and limit hindbrain herniation (Meuli et al., 1995). It is postulated that the ultimate neurologic deficit in spina bifida is the result of "two-hits": (1) the initial failure of neural tube formation and (2) ongoing injury to the exposed neural tissue in the intrauterine environment that results from mechanical and chemical trauma (Adzick et al., 2011; Meuli et al., 1995). Thus, it is suggested that in-utero intervention may improve outcomes for children with spina bifida.

To further evaluate this theory, a **randomized trial of prenatal surgery** before 26 weeks' gestation or standard postnatal repair of myelomeningocele, Management of Myelomeningocele Study (MOMS), was completed. The primary outcome (a composite of fetal or neonatal death or the need for a cerebrospinal fluid shunt) was reduced in the prenatal surgery group (relative risk 0.70). However, 40% of the prenatal closure group still required shunting, and not all experienced improved neuromotor function or complete resolution of hindbrain herniation. The second primary outcome (a composite score of mental development and motor function at 30 months) was also better in the prenatally treated group. No maternal deaths were reported. Fetal and neonatal deaths did not differ between the two groups. However, pregnancy complications, including oligohydramnios, chorioamniotic separation, placental abruption, need for transfusion at the time of delivery, and spontaneous membrane rupture, were more common in the prenatally treated group. One-third of women with prenatal surgery had an area of dehiscence or a very thin uterine surgical scar at the time of delivery. The fetuses that underwent prenatal surgery were much more likely to be preterm, with an average gestational age of 34.1 weeks (with 13% delivered before 30 weeks) compared with 37.3 weeks' gestation in the postnatal surgery group (with none delivered before 30 weeks). In addition, infants in the prenatal surgery group underwent more procedures for delayed spinal cord tethering and had a much higher rate of respiratory distress syndrome and a lower birth weight (Adzick et al., 2011).

Bladder Function After Prenatal Closure of Spina Bifida

Several early studies of a small number of children who underwent closure of the NTD in utero found that urodynamic parameters were similar to those published in the literature for children undergoing standard postnatal closure (Holmes et al., 2001; Holzbeierlein et al., 2000). A case-control series found that those with prenatal closure had a higher incidence of complete denervation of the external urinary sphincter and detrusor overactivity compared with those with postnatal closure (Koh et al., 2006). A recent small study of 8 patients reported lower rates of CIC and febrile urinary tract infections (UTIs) in children whose defects were closed prenatally (Horst et al., 2017). Larger studies with a comparative postnatal closure group confirmed that there is no difference in the need for CIC, bladder capacity, detrusor overactivity (Clayton et al., 2011; Lee et al., 2012b), incontinence between catheterizations, antimuscarinic use, antibiotic use, detrusor sphincter dyssynergia (Lee et al., 2012b), incidence of detrusor leak point pressure greater than 40 cm H_2O, vesicoureteral reflux (VUR), need for a comprehensive bowel regimen, or need for surgery including augmentation cystoplasty, continent catheterizable urinary channel procedure, or Malone antegrade continence procedure (Clayton et al., 2011). Minimally invasive fetoscopic repair of myelomeningocele also has been reported to be associated with similar urinary tract functional outcomes as patients are being repaired postnatally (Huang et al., 2017).

In summary, prenatal closure of spina bifida appears to improve neuromotor function and decrease the need for ventriculo-peritoneal shunting. However, this advantage comes with an increased risk for maternal morbidity and preterm labor with its resultant complications. In addition, there is clear evidence that bowel and bladder function are not improved and in some cases may be hindered with prenatal closure of spina bifida when compared with postnatal closure.

Initial Postnatal Management

Ideally, it would be best to perform urodynamic testing immediately after the infant is born, but the risk for spinal infection and the need for prompt spinal closure have not made this a viable option. However, it was accomplished in one study, and the results showed that 1 in 30 children (3.2%) experienced a change in neurologic status as a result of the spinal canal closure (Kroovand et al., 1990). Therefore, **renal ultrasonography and measurement of residual urine are performed as early as possible after birth,** typically after the spinal defect is closed and the patient has sufficiently recovered from surgery. Residual urine may be measured by ultrasonography or catheterization after the patient voids or leaks urine with the Valsalva maneuver (Bauer et al., 2012). Urodynamic studies (UDS) are delayed until it is safe to transport the child to the urodynamic suite and place him or her on the back or side for the test. However, it may not be practical to obtain UDS before initial discharge, and recent guidelines suggest UDS can be safely performed at 3 months without detriment to the infant (Routh et al., 2016). If the infant cannot empty the bladder after a spontaneous void, CIC is begun even before UDS are conducted. The normal bladder capacity in the newborn period is 10 to 15 mL; therefore, a residual urine volume of less than 5 mL is acceptable. A careful neurologic examination of the lower extremities should be undertaken as well. A serum creatinine and blood pressure are obtained at 3 months. Urine cultures are obtained as clinically indicated (Routh et al., 2016).

Once the spinal closure has healed sufficiently, renal ultrasonography is performed to assess upper urinary tract architecture and function. If voiding cystourethrography (VCUG) is not performed as part of a video urodynamic study, a separate VCUG should be obtained at 3 months. Evaluation for VUR is particularly important if hydronephrosis, ureteral dilation, renal size or contour discrepancy, or increased bladder wall thickness are observed on ultrasonography and/or detrusor overactivity, poor compliance, elevated leak point pressure, or detrusor-sphincter dyssynergia (DSD) (Bauer et al., 2012) are noted on UDS. A screening dimercaptosuccinic acid (DMSA) renal scan is recommended at 3 months (Routh et al., 2016). **These studies meet several objectives: they provide baseline information about the radiologic appearance of the upper and lower urinary tracts as well as the condition of the sacral spinal cord and the central nervous system (CNS); they provide information that can be compared with findings on subsequent assessments, so that early signs of deterioration of urinary tract function and drainage, or of progressive neurologic denervation, can be detected; they help identify infants at risk for urinary tract deterioration as a result of a poorly compliant or overactive detrusor or outflow obstruction from DSD, which predetermines the need to initiate prophylactic measures before any deterioration in upper urinary tract architecture and function actually takes place; and they help the physician to counsel parents about the child's future bladder and sexual function** (Bauer et al., 1984; Lais et al., 1993; McGuire et al., 1981; Bauer, 1984; Sidi et al., 1986)**.** The DMSA scan provides a different baseline, primarily the potential to determine progressive changes in upper urinary tract changes in relations to LUT dysfunction. Strategies to address inadequate bladder emptying are found in Table 34.2.

TABLE 34.2

Strategies to Address Inadequate Bladder Emptying in Children With Neurogenic Bladder Dysfunction

CAUSE OF INADEQUATE EMPTYING	MINIMALLY INVASIVE TREATMENT OPTIONS	MORE INVASIVE TREATMENT OPTIONS
Inadequate bladder contractions	CIC Overnight catheter drainage	Neuromodulation
Detrusor sphincter dyssynergia	CIC Antimuscarinic therapy Overnight catheter drainage	Intravesical and/or sphincteric botulinum toxin Augmentation cystoplasty Urinary diversion Neuromodulation

CIC, Clean intermittent catheterization.

Key Points: Evaluation of the Newborn With

Neurogenic Bladder Dysfunction

- Renal ultrasonography and measurement of residual urine are performed as early as possible after birth.
- Initial evaluation can be compared with findings on subsequent assessments so that early signs of deterioration of urinary tract function and drainage, or of progressive neurologic denervation, can be detected.
- Infants at risk for urinary tract deterioration as a result of a poorly compliant or overactive detrusor or outflow obstruction from DSD need to be identified. This determines the need to initiate prophylactic measures before any deterioration in upper urinary tract architecture and function take place.
- Three categories of LUT dynamics may be detected: synergic (26%), dyssynergic with and without poor detrusor compliance (37%), and complete denervation (36%).

Findings

When first evaluated on radiologic examination, 5% to 10% of newborns have an abnormal urinary tract (Bauer, 1985), 3% have hydroureteronephrosis secondary to spinal shock, probably from spinal canal closure (Chiaramonte et al., 1986), and 15% have abnormalities that developed in utero as a result of abnormal LUT function in the form of outlet obstruction (Bauer, 2003).

UDS in the newborn period have shown that 63% of infants have bladder contractions. This is also true for an equivalent number of children with upper lumbar or thoracic lesions in whom the sacral spinal cord is spared, 50% of whom have detrusor overactivity (Pontari et al., 1995). Thirty-seven percent have an acontractile detrusor with compliance during filling that is either good (20%) or poor (17%) in this subgroup (Bauer, 2003; Bauer et al., 1984). Electromyographic (EMG) assessment of the external urethral sphincter demonstrates an intact sacral reflex arc with no evidence of lower motor neuron denervation in 40% of newborns; partial denervation is seen in 24%, and complete loss of sacral cord function is noted in 36% (Bauer, 2003; Lais et al., 1993).

Prediction of Risk for Upper Urinary Tract Deterioration

A combination of bladder contractility and external sphincter activity results in **three categories of LUT dynamics: synergic (26%), dyssynergic with and without poor detrusor compliance (37%), and complete denervation (36%)** (Figs. 34.2 and 34.3) (Bauer, 2003; Sidi et al., 1986). DSD occurs when the external sphincter fails to decrease or actually increases its activity during a detrusor contraction or a sustained increase in intravesical pressure as the bladder is filled to capacity (Blaivas et al., 1981). Frequently, a poorly compliant bladder with high intravesical pressure occurs in conjunction with a dyssynergic sphincter, resulting in a bladder that empties only at high intravesical pressure (Sidi et al., 1986) (Fig. 34.4). Synergy is characterized by complete silencing of the sphincter during a detrusor contraction or when capacity is reached at the end of filling. Voiding pressures are usually within the normal range. Complete denervation is noted when no bioelectric potentials are detectable in the region of the external sphincter at any time during the micturition cycle or in response to sacral stimulation or the Credé maneuver.

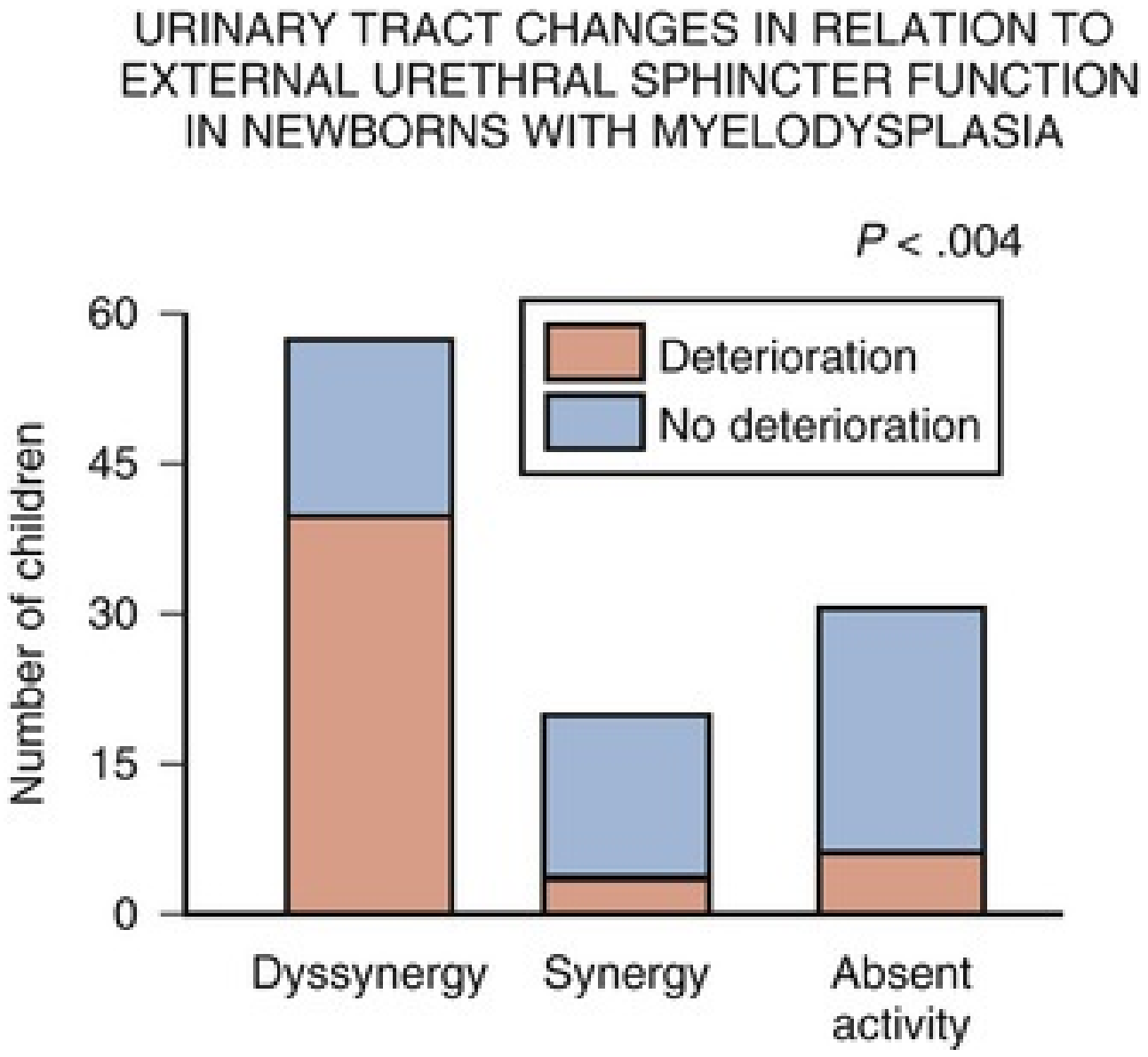

FIG. 34.2 Urinary tract deterioration is related to outflow obstruction and is most often associated with dyssynergy. Children with synergy converted to dyssynergy, and patients with complete denervation developed fibrosis with a fixed high outlet resistance in the external sphincter before any changes occurred in the urinary tract. (From Bauer SB. Early evaluation and management of children with spina bifida. In: King LR, ed. *Urologic surgery in neonates and young infants.* Philadelphia, PA: WB Saunders; 1988:252–264.)

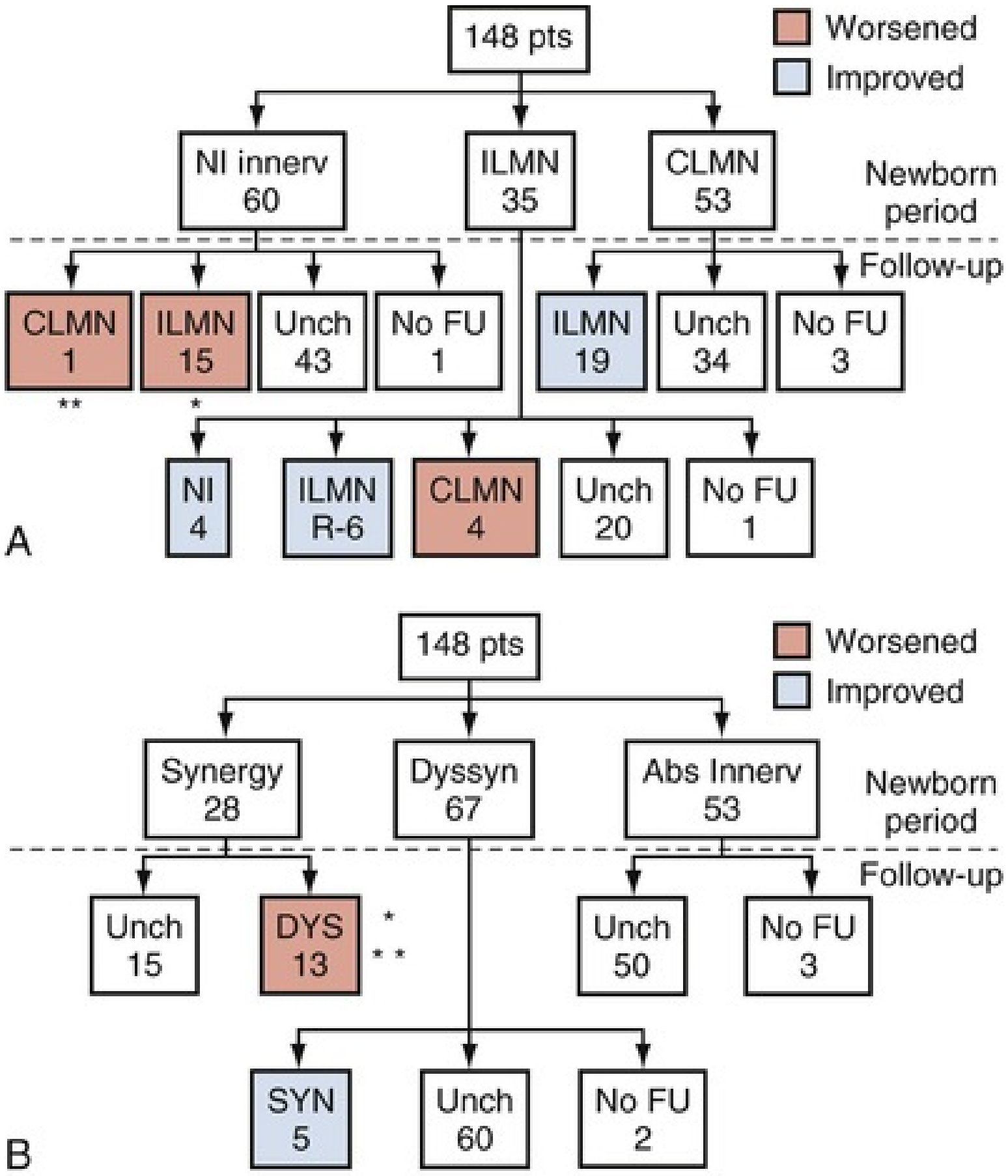
148 pts
Worsened
Improved
Nl innerv 60
ILMN 35
CLMN 53
Newborn period
Follow-up
CLMN 1
**
ILMN 15
*
Unch 43
No FU 1
ILMN 19
Unch 34
No FU 3
NI 4
ILMN R-6
CLMN 4
Unch 20
No FU 1
A
148 pts
Worsened
Improved
Synergy 28
Dyssyn 67
Abs Innerv 53
Newborn period
Follow-up
Unch 15
DYS 13
*
* *
Unch 50
No FU 3
SYN 5
Unch 60
No FU 2
B

FIG. 34.3 Changes in innervation of the purely sacral (A) and pontine-sacral (B) reflex arc pathways that occurred in a group of children with spina bifida who were monitored with sequential urodynamic studies beginning in the newborn period. *ILMN,* Incomplete lower motor neuron lesion; *CLMN,* complete lower motor neuron lesion; *NI,* normal innervation; *Unch,* unchanged; *FU,* follow-up; *DYS,* dyssynergy; *Syn,* synergy. A, The *double asterisk* indicates 1 patient changed from synergy to dyssynergy, and the *single asterisk* indicates 4 of 15 patients so changed. B, The *single asterisk* indicates 1 patient changed from normal to partial and then complete denervation, and the double asterisk indicates 4 patients changed from normal to partial denervation. (From Lais A, Kasabian NG, Dyro FM, et al. The neurosurgical implications of continuous neurourological surveillance of children with myelodysplasia. *J Urol* 150(6):1879–1883, 1993.)

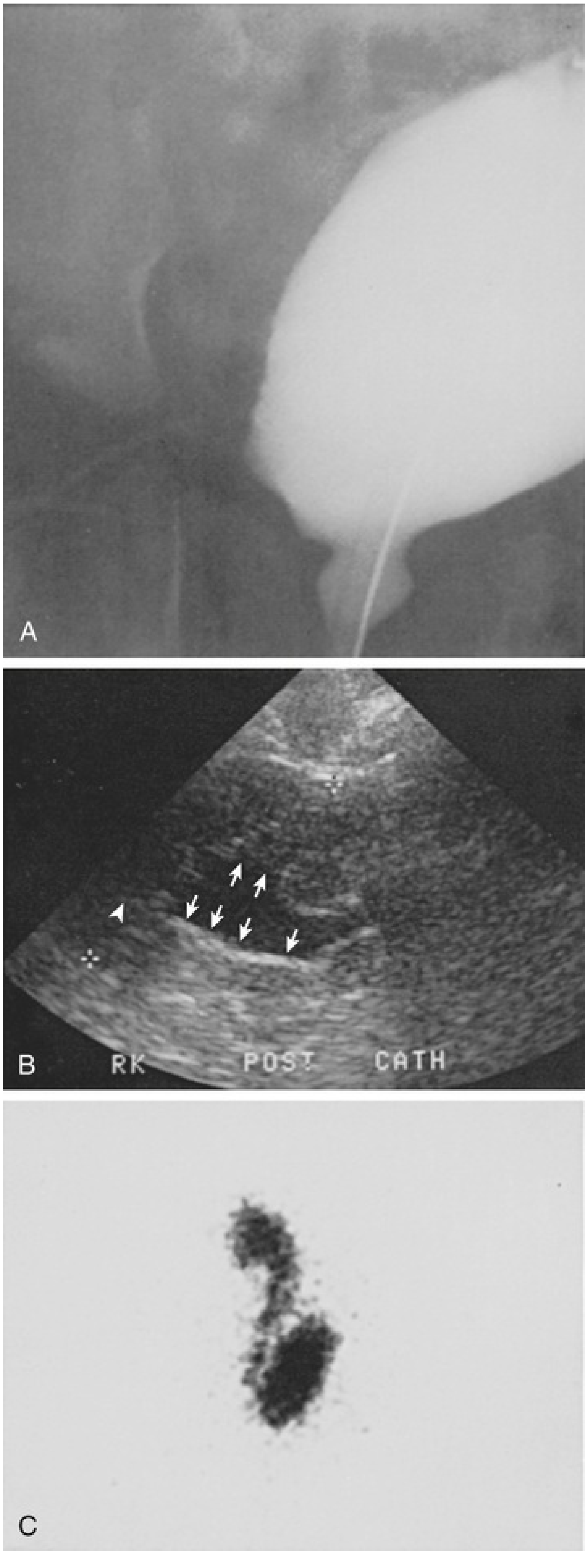
A
B
RK
POST
CATH
C

FIG. 34.4 (A) A voiding cystourethrogram in a female neonate with dyssynergy and elevated voiding pressures demonstrates no reflux and a smooth-walled bladder. The initial renal echogram was normal. The patient was started on clean intermittent catheterization and oxybutynin chloride (Ditropan) but did not respond. Within 1 year, she developed right hydronephrosis (B, *arrows*) and severe reflux, evident on a radionuclide cystogram (C).

Categorizing LUT function in this way has been extremely useful because it reveals which children are at risk for urinary tract changes, who should be treated prophylactically, and who need close surveillance. Within the first 3 years of life, 71% of newborns with DSD had urinary tract deterioration on initial assessment or subsequent studies, whereas only 17% of synergic children and 23% of completely denervated individuals developed similar changes (see Fig. 34.2). Infants in the synergic group who showed deterioration did so only after they converted to a dyssynergic pattern of sphincter function. Among the infants with complete denervation, the ones who showed deterioration were those who had increased levels of urethral resistance, presumably caused by fibrosis of the skeletal muscle component of the external sphincter. Therefore, it appears that bladder outlet obstruction is a major contributor to the development of urinary tract deterioration in these children. Poor detrusor compliance plays an important role in this regard, especially when bladder outlet resistance exceeds 40 cm H_2O (Landau et al., 1994; McGuire et al., 1981; Tanaka et al., 1999) and the patient is not on a CIC program that empties the bladder regularly. Detrusor compliance seems to be poorer in children with high levels of outlet resistance (Ghoniem et al., 1989).

It may be that detrusor filling pressures need to be looked at in a more critical way to determine whether they are an important factor in upper urinary tract deterioration. **Landau et al.** (1994) **developed the concept of low detrusor filling pressure (< 30 cm H_2O) at specific volumes adjusted for age and not at maximal capacity.** Applying this notion, they reported significantly improved sensitivity in predicting upper urinary tract deterioration. Recently, a Centers for Disease Control and Prevention (CDC)-sponsored spina bifida management protocol categorized UDS into four groups: hostile bladder, intermediate risk, abnormal but safe, and normal. Hostile bladder was defined as end filling pressure or detrusor leak point pressure (DLPP) 40 cm H_2O or greater or neurogenic detrusor overactivity (NDO) with detrusor sphincter dyssynergia.

Intermediate risk was defined as NDO, reduced compliance, and end filling pressure or DLPP 25 to 39 cm H_2O. Abnormal but safe was defined as end filling pressure or DLPP less than 25 cm H_2O. Normal bladder was defined as normal capacity, compliance greater than 15 cm H_2O, no NDO, no detrusor sphincter dyssynergia, and minimal postvoid residual.

Early Intervention in Children With Spina Bifida

The concept of early intervention for children with detrusor sphincter dyssynergia, poor detrusor compliance, high bladder outlet pressures, and outflow obstruction was introduced in the early 1990s (Bauer et al., 1984; McGuire et al., 1981; Sidi et al., 1986). Early intervention is herein defined as CIC and antimuscarinic therapy. There has been some controversy about the benefit of early intervention in children with spina bifida; however, **there is a plethora of data that document its beneficial effects on long-term outcomes in this population.**

Effect of Early Intervention on Bladder Function

In one study of 26 newborns with DSD and high bladder pressures treated with CIC and oxybutynin, this drug eliminated overactive contractions in 2 of 14 children and lowered peak contractile pressure in the remaining 12 children (Fig. 34.5). It was also noted to lower bladder filling pressure at capacity in all 12 patients with poor compliance (Kasabian et al., 1992). Minimal side effects were noted from its use and none from CIC (Kasabian et al., 1992). Early intervention also results in improved continence (Kaefer et al., 1999). One study found that up to 44% of children treated with early intervention were dry at 6 years of age (Dik et al., 2006).

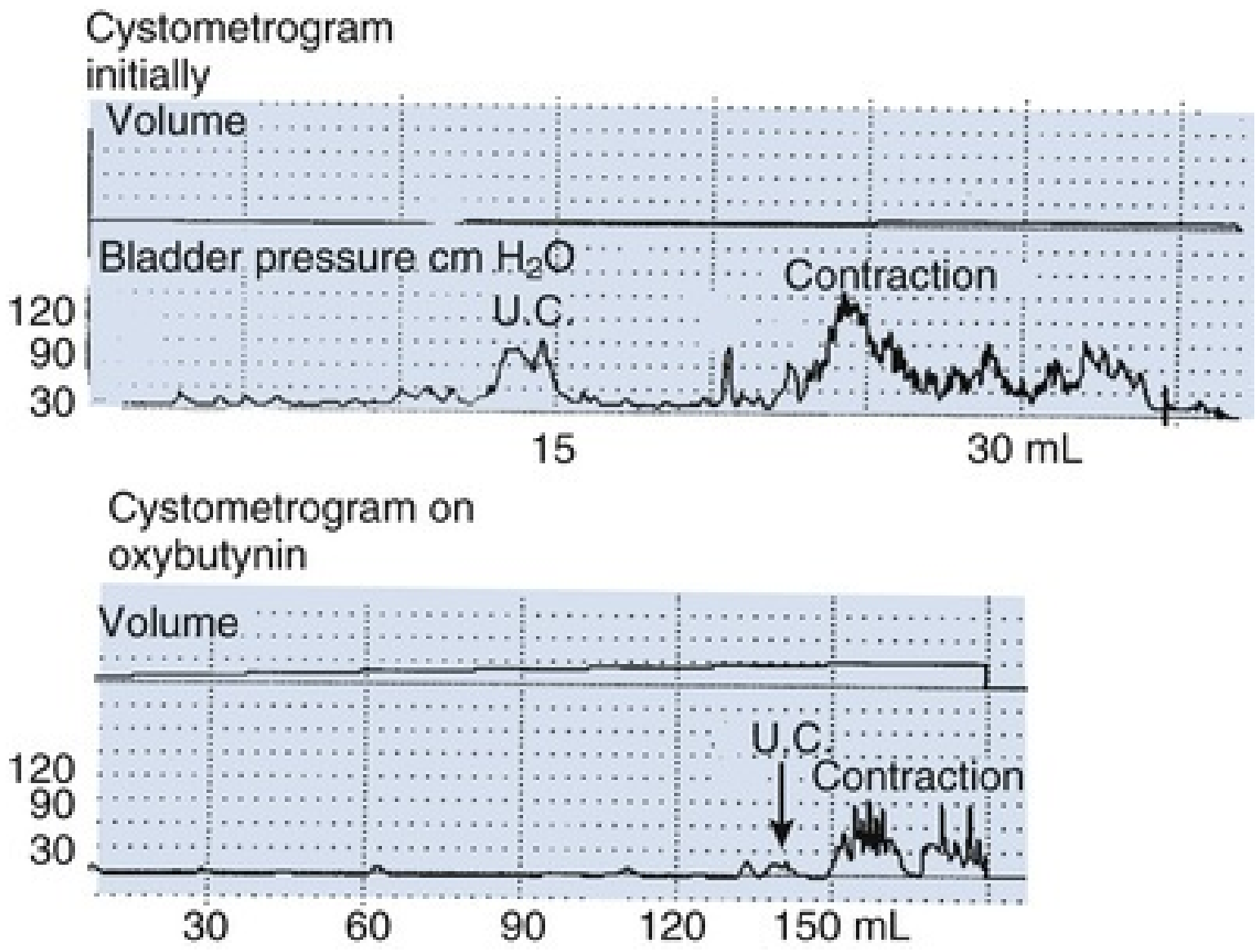

FIG. 34.5 Oxybutynin is a potent anticholinergic agent that dramatically delays detrusor contractions and lowers contraction pressure, as demonstrated on these two graphs. *U.C.,* Uninhibited contraction.

Early Initiation of Clean Intermittent Catheterization Decreases the Rate of Urinary Tract Infection

Studies of expectant management document UTI in 50% of children by 15 months of life and 81% by 15 years of age. In addition, recurrent UTIs are common, with more than 44% of children having 5 episodes of UTI and almost 10% having more than 20 episodes (Filler et al., 2011). However, in children following early institution of CIC, the mean number of infections is 0.3 per year (Wide et al., 2012). Several studies have demonstrated a decreased rate of UTI when CIC is utilized, either within the same patient (Olandoski et al., 2011) or in contrast with a comparative group (Kari et al., 2009).

Early Intervention Decreases Upper Urinary Tract Deterioration

The potential for development of hydroureteronephrosis in children with high-risk bladders including DSD is well established. In one study, 72% with dyssynergia later developed hydronephrosis (Bauer et al., 1984). Other studies note the risk for development of hydroureteronephrosis varied from 18% to 80% in children with high-risk bladders who were treated expectantly (Edelstein et al., 1995; Geraniotis et al., 1988; Kaefer et al., 1999; Kochakarn et al., 2004).

Development of hydrouteronephrosis is much less common in trials of early intervention, ranging from 0% to 15% (Dik et al., 2006; Edelstein et al., 1995; Geraniotis et al., 1988; Kaefer et al., 1999). The importance of preventing upper urinary tract deterioration is underscored by one study that reported renal impairment in 6.6% and DMSA abnormalities in 30% of newborns with spina bifida at their initial evaluation (Sager et al., 2017).

Early Intervention Reduces the Rate of Vesicoureteral Reflux

Studies of expectant management of children with myelodyspasia and high-risk bladders identify VUR in up to 50% of patients by 9 years of age (Filler et al., 2011). In children managed with CIC from birth, the development of VUR is much less common (28%) (Wide et al., 2012). Another study also found that children treated with CIC early had a much lower incidence of VUR than those who were not on therapy or were noncompliant with therapy (62% vs. 92%) (Kari et al., 2009).

Early Intervention Decreases the Need for Surgery

Several studies comparing early intervention to expectant therapy have noted a lower need for surgery in children with high-risk bladders. Up to 11% of children treated expectantly may require urinary diversion (Filler et al., 2011). Comparatively, no child required renal protective surgery in a group of 41 children treated with early intervention. In fact, only 1 child in this group required surgery for incontinence, and 6 had injection of botulinum A toxin (BTA) (Wide et al., 2012). Others have documented an 18% to 24% reduction in the need for bladder augmentation when early intervention is compared with expectant management (Kaefer et al., 1999; Kochakarn et al., 2004).

Early Intervention Decreases the Incidence of Renal Scarring and End-Stage Renal Disease

Early intervention does not appear to be advantageous for those children who can empty their bladder spontaneously (Torre et al., 2011). Studies of historical cohorts document evidence of renal scarring in 27% to 50% of children (Filler et al., 2011; Lewis et al., 1994; Müller et al., 2002). The rate of renal scarring in children treated with early intervention is much lower, ranging from 4% to 12% (Dik et al., 2006; Torre et al., 2011; Wide et al., 2012). As anticipated, the decrease in renal scarring relates to a decreased incidence of end-stage renal disease (ESRD) in children treated with early intervention (0% to 1.6%) (Dik et al., 2006; Malakounides et al., 2013; Torre et al., 2011) compared with those managed expectantly (30%) (Rickwood et al., 1984).

Assessment of Renal Function in Children With Neuromuscular Dysfunction of the Lower Urinary Tract

Although serum creatinine is a widely used marker of glomerular filtration rate (GFR), it is known to be a poor marker of renal function in children with neurogenic bladder dysfunction. Its serum level is dependent on age, gender, height, and, most importantly, muscle mass (Pham-Huy et al., 2003). Individuals with reduced muscle mass may demonstrate a low endogenous creatinine release that may not result in an elevated creatinine level despite a decrease in GFR (Quan, 1997). Numerous studies have confirmed that serum creatinine is not an accurate reflection of GFR in children with spina bifida, who often have diminished muscle mass (Filler and Lepage, 2003; Pham-Huy et al., 2003; Quan, 1997). **The gold standard for measuring GFR is the renal scan, which is invasive and exposes the patient to radiation.** Thus it is preferable to have a serum marker that will closely reflect GFR in this specific population with a high risk for renal functional impairment.

Small–molecular-weight proteins, such as cystatin C, have been suggested as alternative markers of GFR for children with neuromuscular dysfunction of the urinary tract (Pham-Huy et al., 2003). As cystatin C is determined primarily by glomerular filtration, these levels correlate more closely with GFR than that obtained when estimated by the Schwarz formula or other small–molecular-weight proteins (Abrahamsson et al., 2008; Pham-Huy et al., 2003). However, cystatin C is not widely available, and it is limited by inflammation and changes in protein catabolism (Filler and Lee, 2018).

Kidney Size in Children With Spina Bifida

Sutherland et al. noted that children with spina bifida had smaller kidneys than their normal peers and generated a nomogram for renal size in this population (Sutherland et al., 1997). Others have confirmed this finding of small renal size in some children with spina bifida (del Gado et al., 2003; Montaldo et al., 2014).

It was initially suggested that a potential cause could be low levels of growth hormone, but this has been excluded by the demonstration of normal levels of insulin-like growth factor-1 (del Gado et al., 2003; Montaldo et al., 2014). A study of newborns with spina bifida found those with small kidneys and their mothers had high serum levels of homocysteine. Specifically, children and mothers with homocysteine levels greater than 10 µmol/L were more than twice as likely to have small kidneys and to give birth to children with small kidneys (Montaldo et al., 2014). These infants also had a higher incidence of intrauterine growth restriction. As hyperhomocysteinemia has been linked to placental vasculopathy, it has been postulated that the mechanism for small renal size in children with spina bifida might be related to abnormal placental function (Montaldo et al., 2014). Small renal size in children with spina bifida has been associated with decreased renal function (del Gado et al., 2003).

Renal Dysfunction in Spina Bifida

Several studies have identified that surrogate markers of renal dysfunction in children with spina bifida are frequently abnormal. For example, 54% and 19% of children referred to nephrologists for recurrent UTI were noted to have microalbuminuria and metabolic acidosis, respectively (Olandoski et al., 2011). The rate of hypertension in myelodyspastic children ranges from 12% to 41% (Rickwood et al., 1984; Mazur et al., 2011; Olandoski et al., 2011). This is significantly higher than national age-matched control groups (3%) (Mazur et al., 2011). The risk for hypertension is positively correlated with maximum body mass index (Mazur et al., 2011). Hypertension is more frequently noted after puberty and in those with renal scarring (Rickwood et al., 1984).

Some degree of renal dysfunction has been detected in 30% to 50% of children with spina bifida (Malakounides et al., 2013; Müller et al., 2002). Historical studies determined an incidence of end-stage renal disease (ESRD) in 18% of children before and 30% of children after puberty (Rickwood et al., 1984). Others have found that ESRD is an outcome in 15% of those with spina bifida (Lee, 2010). More contemporary studies in which early intervention with CIC and antimuscarinics were used noted much lower rates of renal dysfunction (6%) and ESRD (0% to 1.6%) (Dik et al., 2006; Malakounides et al., 2013; Torre et al., 2011).

Determinants of Risk for Renal Dysfunction in Spina Bifida.

There has been much investigation regarding the determinants of renal functional loss in children with spina bifida. In most studies, renal deterioration or dysfunction is defined as altered renal function as measured by creatinine, creatinine clearance, or renal scarring noted on DMSA renal scans. Urodynamic findings associated with increased incidence of renal deterioration, such as hydronephrosis, VUR, and renal scarring include detrusor sphincter dyssynergia (Bauer et al., 1984; Ozel et al., 2007); high detrusor pressures (Arora et al., 2007; Ozel et al., 2007; Wide et al., 2012); and detrusor overactivity (Ozel et al., 2007). The association between history of febrile UTI and renal scarring in this population is well documented (Ozel et al., 2007; Shiroyanagi et al., 2009). The presence of hydronephrosis (Arora et al., 2007; DeLair et al., 2007; Ozel et al., 2007; Torre et al., 2011) and VUR (Arora et al., 2007; DeLair et al., 2007; Ozel et al., 2007; Torre et al., 2011) is also associated with renal scarring. However, one study using multivariate analysis demonstrated that a high-pressure bladder and hydronephrosis in the absence of VUR was not associated with renal cortical loss (DeLair et al., 2007). Lack of compliance with recommended therapy has also been shown to be an important factor in the development of renal scarring in this population (Kari et al., 2009; Wide et al., 2012).

Key Points: Early Intervention and Renal Function in Neural Tube Defects

- Early intervention with CIC and antimuscarinics improves urodynamic parameters; decreases the rate of UTI, VUR, and upper urinary tract deterioration; and decreases the incidence of ESRD.
- Cystatin C is superior to serum creatinine in monitoring renal function in children with neural tube defects. Renography is the gold standard for estimating GFR.
- Determinants of risk for renal dysfunction in spina bifida include detrusor sphincter dyssynergia, high detrusor pressures, detrusor overactivity, febrile UTI, and VUR. These entities should be actively managed to minimize the risk for renal functional decline.

Sexual Function

Sexuality in this population is becoming an increasingly important issue as more individuals reach adulthood and want to have intimate relationships

(Cromer et al., 1990). Many psychosocial factors play a role in the development and sexual maturation of children with spina bifida. Parents and health care workers are often reluctant to discuss sexual development with adolescents (Joyner et al., 1998; Sandler et al., 1996; Woodhouse, 1998). In addition, teens with spina bifida often experience social isolation (Dorner, 1977; Joyner et al., 1998). This is supported by studies showing that children with spina bifida are less likely than those without spina bifida to have peers acting as their main source of sexual education (Decter et al., 1997; Dorner, 1977). Some children with spina bifida are dependent on others for their activities of daily living and therefore often live with parents or an alternative caregiver (Börjeson and Lagergren, 1990). Young men with spina bifida reported better erectile function and intercourse satisfaction when they lived independently (Gamé et al., 2006). **Parents of children with spina bifida tend to be more overprotective than parents of normal children and are less willing to grant autonomy to them for adequate peer and sexual development** (Holmbeck et al., 2002). When asked about sexual function, many teens with spina bifida report that their parents are often very overprotective (Dorner, 1977). Parental permissiveness in social participation and age-appropriate treatment by parents contribute positively to high self-esteem in these adolescents (Wolman et al., 1994). In a study of life satisfaction of Dutch young adults with spina bifida, the highest proportion of dissatisfaction was found for partnership relations (49%) and sex life (55%). **More than 50% of young adults with spina bifida report that they are dissatisfied with their current sex life** (Barf et al., 2007; Verhoef et al., 2005a).

Boys reach puberty at an age similar to the age for boys without spina bifida, whereas breast development and menarche tend to start as much as 2 years earlier than usual in girls with spina bifida compared with girls without spina bifida. The average age at menarche in girls with spina bifida varies between 10.9 and 11.4 years of age (Trollmann, 1998). The cause of this early hormonal transformation is uncertain, but it may be related to changes in pituitary function in girls secondary to hydrocephalus (Hayden et al., 1979).

Sexual education specific to individuals with spina bifida should be provided. Latex-free condoms are mandatory for those with latex allergy or those adhering to latex avoidance recommendations. The use of estrogen/progestin contraceptives may increase the risk for thromboembolic events in those with decreased mobility, and using intrauterine devices for contraception is unsafe because of the risk for pelvic infections (Jackson and

Mott, 2007).

The degree of sexuality is inversely proportional to the level of neurologic dysfunction (Gatti et al., 2009; Joyner et al., 1998; Palmer et al., 1999). In addition, lower occurrence of sexual activity seemed to be noted in populations with greater rates of incontinence and more severe disability (Barf et al., 2007; Börjeson and Lagergren, 1990; Cardenas et al., 2008; Gatti et al., 2009; Sandler et al., 1996; Verhoef et al., 2005a). Those with the lowest lesion levels are most likely to form partnerships (Gatti et al., 2009). Increasing age is associated with increased likelihood of having a partner; those older than 26 years of age were 2.1 times more likely to have a partner than those 18 to 25 years of age (Gatti et al., 2009). The absence of hydrocephalus is a positive predictor of sexual activity (Barf et al., 2007; Verhoef et al., 2005a). This effect is more pronounced for women than for men (Cardenas et al., 2008). Females are more likely than males to be sexually active (Barf et al., 2007; Cardenas et al., 2008; Sawyer and Roberts, 1999; Verhoef et al., 2005a), **but females with spina bifida are at risk for sexual abuse.** Unwanted sexual attention was reported by 37% and unwanted sexual touching was noted by 30% of women with spina bifida, whereas 4% of men with spina bifida have experienced improper sexual touching (Sawyer and Roberts, 1999).

In several studies, researchers interviewed groups of teenagers with spina bifida and reported that **28% to 40% of them had had one or more sexual encounters, and almost all of them had a desire to marry and ultimately to bear children** (Cromer et al., 1990; Palmer et al., 1999). Seventy percent of those with spina bifida desire sexual contact (Barf et al., 2007; Verhoef et al., 2005a). Common features of studies evaluating sexual function in adolescents and young people with spina bifida include low participation rates because of patient/parental refusal and elimination of patients with severe physical disabilities and/or severely compromised intellectual function. This results in a very select population in which only highly functioning individuals are investigated. Five of six studies found that **more than 70% of young men with spina bifida were able to obtain an erection** (range 70% to 92%) (Börjeson and Lagergren, 1990; Cass et al., 1986; Decter et al., 1997; Diamond et al., 1986; Sandler et al., 1996). A more recent study reported that only 40% of men with spina bifida had normal erections, with ambulatory status the likely collolary associated with erectile function, and 63% of ambulators more likely to report normal erections compared with 15.8% of nonambulators (Roth et al., 2017). In another series, **the ability to ejaculate ranged from approximately 40% to**

75% (Börjeson and Lagergren, 1990; Cass et al., 1986; Decter et al., 1997; Sandler et al., 1996). In some cases, retrograde ejaculation was noted (Sandler et al., 1996). Self-report of sexual activity varied greatly with different study populations, ranging from 8% to 83% for males (Börjeson and Lagergren, 1990; Cass et al., 1986; Decter et al., 1997; Laurence and Beresford, 1975; Sandler et al., 1996) and 23% to 69% for females (Börjeson and Lagergren, 1990; Cass et al., 1986).

Reports suggest that **70% to 80% of women with spina bifida were able to become pregnant and to have an uneventful pregnancy and delivery,** although urinary incontinence in the latter stages of gestation was common in many, as was delivery by cesarean section (1975 Arata et al., 2000; Bomalaski et al., 1995; Cass et al., 1986; Laurence and Beresford, 1975). In the same studies, 17% to 39% of male subjects claimed that they were able to father children, and another 25% had a favorable prognosis for fathering them (Bomalaski et al., 1995; Decter et al., 1997; Laurence and Beresford, 1975). **Both women and men with spina bifida have an increased risk for having a child with spina bifida** compared with individuals without spina bifida (3.7% incidence of spina bifida in offspring) (Bong, 2007). This effect is more pronounced in women (Chatkupt et al., 1992). If both parents have spina bifida, the risk for having a child with spina bifida increases to 15% (Cameron and Moran, 2009). To reduce this risk, women with spina bifida should be counseled about taking a 4- to 5-mg supplement of folic acid daily before even contemplating getting pregnant (Visconti et al., 2012). It is more likely that men will have problems with erectile and ejaculatory function because the sacral spinal cord is frequently involved, whereas reproductive function in women, which is under hormonal control, is not affected. Men with neurologic lesions at S1 or lower are likely to have normal or adequate reproductive sexual function, but only 50% of those with lesions above that level have adequate function (Woodhouse, 1994, 2005). Poor semen quality (Hultling et al., 2000) and Sertoli cell only histology on testis biopsy (Glass and Soni, 1999) have been reported as reasons (in addition to erectile dysfunction) for infertility in men with spina bifida.

One study used a validated questionnaire, the International Index of Erectile Function (IIEF) to evaluate sexual function in men older than 18 years of age with spina bifida (Gamé et al., 2006). Overall, 75% had erectile dysfunction. Of 16 men who recently had sexual intercourse, 4 had no erectile dysfunction, 3 had mild dysfunction, 4 had mild to moderate dysfunction, and 5 had severe dysfunction. Erectile function was directly related to the ability to maintain erections and the presence of a sacral nerve root lesion (Gamé et al., 2006). A more recent study of 47 men using the IIEF reported a 51.1% rate of sexual intercourse, but 87% reported more than mild sexual dysfunction; however, 67% and 50% had normal erectile and orgasmic function, respectively. Furthermore, sexual function and quality of life were associated statistically (Choi et al., 2017). The role of intact pelvic parasympathetic reflex activity has a positive correlate in men with spina bifida (Diamond et al., 1986; Sandler et al., 1996). The Female Sexual Function Index (FSFI) has been used to evaluate sexual function in women with spina bifida (Choi et al., 2018). In this study, sexual dysfunction was noted in 55.5% of women. In sexually active women, VP shunt, mobility status, and CIC did not show a significant difference among each subdomain (desire, arousal, lubrication, orgasm, satisfaction, and pain) and the total FSFI score. However, women who did not have urinary incontinence experienced better sexual function in terms of lubrication and pain scores. Both the physical and mental composites of quality of life were positively correlated with the arousal score of FSFI. Another recent study using the IIEF and FSFI to determine sexual function in 45 patients with spina bifida reported sexual dysfunction in 89% of women and 59% of men (Lee et al., 2015). Individuals with spina bifida of either gender tended to have more severe dysfunction compared with those who had sexual dysfunction of other etiologies, except with similar sexual desire scores. Thus, patients of both genders with spina bifida experienced high rates of sexual dysfunction.

Medical therapy for erectile dysfunction has been shown to be effective in this population. Sildenafil improved erectile function in 80% of men with myelomeningocele in a randomized, double-blind, placebo-controlled trial (Palmer et al., 1999). Some promise has been achieved with attempts to restore penile sensation in men with spina bifida by connecting the sensory ilioinguinal nerve microsurgically to the ipsilateral dorsal nerve of the penis in men with normal groin sensation (Jacobs et al., 2013; Overgoor et al., 2013) Preliminary results in small case series showed increased sensation of the ipsilateral glans penis, better overall sexual function, and increased satisfaction (Overgoor et al., 2013), but these findings await long-term studies.

Management of Neurogenic Bowel Dysfunction in Spina Bifida

Options for the management of constipation traditionally include dietary modification, digital stimulation, laxatives, enemas, and biofeedback therapy.

Management in children with neurogenic bowel must to be tailored to the individual's ability to address mobility/balance, ability for self-care, manual dexterity, and anal sphincter tone.

Two-thirds of children 6 years of age and older and one-third of children 16 to 25 years of age with spina bifida report fecal incontinence, which has a substantial impact on their quality of life (Krough et al., 2003; Verhoef et al., 2005b). Most recommend a **graduated approach** to the management of constipation in this population (Burgers et al., 2013; Choi et al., 2013a, 2013b; Velde et al., 2007). **Initially, treatment is directed toward high dietary fiber and osmotic laxatives** (Choi et al., 2013b; Velde et al., 2007). Polyethylene glycol has been shown to be more effective in this population than lactulose (Rendeli et al., 2006). An option for those who are unable to sit on the toilet is **controlled constipation with manual evacuation of stool** as large-volume enemas cannot easily be delivered in these children (Velde et al., 2007). In those who are able sit independently, with some anal sphincter activity, a regular postprandial toilet-sitting regime 3 times a daily after meals has been effective, as it employs the gastrocolic reflex to initiate a bowel movement (Velde et al., 2007). When continence is not achieved by defecation, **digital stimulation** is suggested (Velde et al., 2007). If manual evacuation fails or if the anal sphincter is nonfunctioning, **retrograde enemas** (tap water with irrigation cone followed by kneading of the abdomen or alternative transanal irrigation devices (Ausili et al., 2010) are instituted (Shandling and Gilmour, 1987; Velde et al., 2007). Initially, enemas are given daily, and, if successful, the frequency can be decreased to every second day. Initial enema volume is 500 mL and increased to 1L, if required. If fecal incontinence persists at this point, the **antegrade continence enema (ACE)** is considered the next step in management. An ACE can be instituted on a daily basis initially, but can be reduced to 4 to 5 times a week depending on its effectiveness. Volumes used range between 1 to 2 liters (Velde et al., 2007). This stepwise approach to fecal pseudocontinence was successful in 69% of patients with spina bifida, and 10% achieved full fecal continence. Of those who were pseudocontinent, 16% used manual evacuation, 10% used a toileting scheme, 42% used a retrograde enema, and 32% used an ACE (Velde et al., 2007). The addition of polyethylene glycol (GoLYTELY), mineral oil, polyethylene glycol 3350 (MiraLAX), or glycerin to tap water enemas has successfully increased the continence rate for ACE regimens (Bani-Hani et al., 2008).

Malone was first to describe an ACE delivered through a surgically placed appendicostomy or cecostomy in children with spina bifida or anorectal malformation (Malone et al., 1990). It has been shown to significantly improve fecal continence, not increase the amount of time dedicated to bowel care, and improve quality of life (Ok and Kurzrock, 2011). Anal plugs may be effective for some patients during specific activities, such as swimming (Velde et al., 2007). Long-term studies indicate that approximately 40% of children discontinue using their surgically created cecostomies after a median of 11 years. Reasons for non-use include lack of effectiveness, complications, psychological issues, and poor compliance (Yardley et al., 2009). In those who continue using the cecostomy, their level of satisfaction is very high (Yardley et al., 2009). Shandling described placement of a percutaneous cecostomy under fluoroscopic guidance for delivery of the ACE in children with spina bifida (Shandling et al., 1996). This provides the advantage of avoiding laparotomy or laparoscopy.

Initial Diagnostic Evaluation and Follow-Up of Congenital Neurogenic Dysfunction in Children

The initial diagnostic evaluation of neurogenic bladder dysfunction will be discussed as it relates to specific pathologic processes throughout this chapter. The International Children's Continence Society (ICCS) has published general recommendations for follow-up of congenital neurogenic bladder, which are a compilation of best practices resulting from a paucity of high-level evidence (Bauer et al., 2012). The recommendations are based on developmental stages and associated growth spurts in the first 2 years of life and during early adolescence that may increase the risk for spinal cord tethering, and are summarized in Table 34.3. An example of the magnetic resonance imaging (MRI) findings in a case of spinal tethering is shown in Fig. 34.6. A recent study has noted that in adulthood, patients followed at a multidisciplinary spina bifida clinic presented with a urologic issue at a median of 12 months, and 40% had an asymptomatic urologic issue at 36 months. This suggests that a follow-up period of 12 to 18 months in adulthood may be prudent (Duplisea et. al., 2014).

TABLE 34.3

Summary of the International Children's Continence Society Recommendations for the Diagnostic Evaluation and Follow-Up of Congenital Neurogenic Bladder

RECOMMENDED

AGE GROUP	TYPE OF INVESTIGATION	FREQUENCY OF INVESTIGATION	INDICATION FOR INVESTIGATION
Newborn to toddler	Ultrasonography	Every 6 months until 2 years of age	High risk for tethering with rapid growth
	UDS	Every 12 months	UTIs or lower extremity changes
	DMSA renal scan	When indicated	Consider if VUR on initial VCUG/RNC or febrile UTIs
Toddler to adolescent	Ultrasonography	Every 12 to 24 months	Low risk for tethering with slower growth
	UDS	When indicated	Change in ambulation or lower extremity function
	DMSA renal scan	When indicated	Febrile UTIs
Adolescent to adult	Ultrasonography	Every 12 months	Low risk for tethering with slower growth; may decrease to every 24 months once growth velocity has decreased
	UDS	When indicated	Development of hydronephrosis, more frequent CIC required for continence, new wetting, recurrent UTI
	VCUG/RNC	When indicated	Recurrent UTI
Adult	Ultrasonography	Every 36 months	Low risk for tethering without ongoing somatic growth
	UDS	When indicated	Development of hydronephrosis, more frequent CIC required for continence, new wetting, recurrent UTI

CIC, Clean intermittent catheterization; *DMSA,* dimercaptosuccinic acid; *RNC* radionuclide cystography; *UTI,* urinary tract infection; *UDS,* urodynamic studies; *VCUG,* voiding cystourethrography; *VUR,* vesicoureteral reflux.

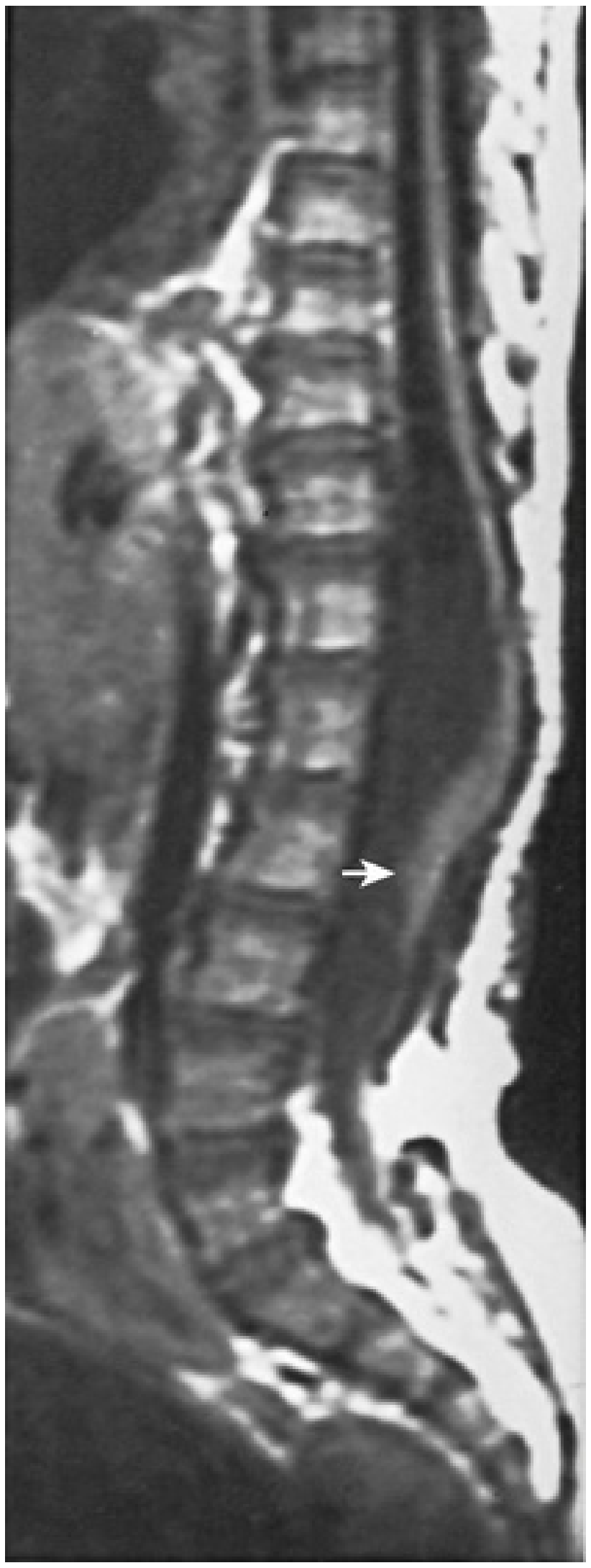

FIG. 34.6 Magnetic resonance image for a 9-year-old girl who developed a tethered cord after myelomeningocele repair reveals the conus opposite the L3–L4 vertebrae *(arrow).*

Management of Neuromuscular Dysfunction of the Lower Urinary Tract

The primary principle in management of neuromuscular dysfunction of the LUT is preservation of renal function. Secondary goals include attaining urinary continence, avoiding UTI, and facilitating sexual function and fertility. **Preservation of renal function is best achieved by maintaining low bladder pressures, avoiding hydronephrosis, and actively managing VUR, especially if recurrent UTIs are present.** The ICCS has published general recommendations for the evaluation and follow-up of patients with congenital neurogenic bladder, which are a compilation of expert opinions resulting from a paucity of high-level evidence (Bauer et al., 2012). These recommendations are based on developmental stages and associated growth spurts in the first 2 years of life and during early adolescence that may increase the risk for spinal cord tethering and are summarized in Table 34.3. More recently, a multicenter group endorsed by the Centers for Disease Control and Prevention (CDC) published a protocol for the urologic management of children birth to 5 years of age (Table 34.4). As of this writing, 22 sites in the United States are participating in the CDC National Spina Bifida Patient Registry (NSBPR).

TABLE 34.4

Summary of the Centers for Disease Control and Prevention Urologic and Renal Protocol of the Newborn and Young Child With Spina Bifida

	AGE OF CHILD						
DIAGNOSTIC PROCEDURE OR INTERVENTION	**BIRTH**	**3 MONTHS**	**6 MONTHS**	**9 MONTHS**	**1 YEAR**	**2 YEARS**	**3 YE**
Foley catheter placement–intermittent catheterization	X						
Teach family CIC technique	X						

	AGE OF CHILD						
DIAGNOSTIC PROCEDURE OR INTERVENTION	**BIRTH**	**3 MONTHS**	**6 MONTHS**	**9 MONTHS**	**1 YEAR**	**2 YEARS**	**3 YE**
Medical history	X	X	X	X	X	X	X
Physical examination	X	X	X	X	X	X	X
Blood pressure		X			X	X	X
Serum		X			X	X	X
RBUS	X	X	X	X	X	X	X
Urodynamics		X			X	X	X
DMSA nuclear scan		X					
GFR nuclear scan							

CIC, Clean intermittent catheterization; *DMSA,* dimercaptosuccinic acid; *GFR,* glomerular filtration rate; *RBUS,* renal and bladder ultrasonography.

From Bauer, 2012.

Initial efforts to reduce bladder pressures include minimally invasive therapy to reduce bladder pressures such as CIC and antimuscarinic therapy. If this is unsuccessful, overnight indwelling catheter drainage has been shown to improve or resolve hydronephrosis, increase bladder capacity, and decrease the frequency of UTI (Koff et al., 2005; Nguyen et al., 2005). Those who have failed conservative management require surgical intervention. When choosing a surgical intervention, consideration must be given to the patient's ambulatory status, body habitus, manual dexterity, compliance with therapy, and capacity to provide self-care.

The normal bladder functions by storing urine at low pressures and empties by coordinating decreased outlet resistance with a bladder contraction. In neuropathic dysfunction, incontinence may result from failure of proper storage, emptying, or both. Storage may be compromised by low compliance, low capacity, overactive bladder contractions, and low bladder outlet resistance. Emptying may be compromised by inadequate bladder contractions or detrusor sphincter dyssynergia. Tables 34.2 and 34.5 indicate some possible options to address the failure of storage and emptying, respectively, in neuropathic dysfunction of the LUT in children, and the specific medical and surgical treatment options are described.

TABLE 34.5

Strategies to Address Inadequate Bladder Storage in Children With Neurogenic Bladder Dysfunction

CAUSE OF INADEQUATE STORAGE	MINIMALLY INVASIVE TREATMENT OPTIONS	MORE INVASIVE TREATMENT OPTIONS
Low compliance	CIC Antimuscarinic therapy Overnight catheter drainage	Intravesical botulinum toxin Augmentation cystoplasty Urinary diversion
Low capacity	Antimuscarinic therapy Overnight catheter drainage	Intravesical botulinum toxin Augmentation cystoplasty Urinary diversion
Overactive bladder contractions	CIC Antimuscarinic therapy Overnight catheter drainage	Intravesical botulinum toxin Augmentation cystoplasty Urinary diversion
Low bladder outlet resistance	Sympathomimetic therapy	Bladder neck sling Bladder neck procedure Injection of bulking agents into bladder neck

CIC, Clean intermittent catheterization.

Key Points: Management of Neuropathic Dysfunction of the Lower Urinary Tract

- The primary goal of management is preservation of renal function.
- Secondary goals of management include urinary/fecal continence, avoidance of UTI, and facilitation of sexual function and fertility.
- Preservation of renal function is achieved by maintaining low bladder filling pressures, active management of VUR, and avoiding UTI.
- The ICCS recommendations for follow-up are based on developmental stages and the relative risk for secondary spinal cord tethering.
- The CDC-endorsed multicenter collaborative has published a protocol for the management of patients with neurogenic bladder from birth to 5 years of age.
- Minimally invasive approaches should precede the use of more invasive therapies to address bladder failure to store urine efficiently or empty

effectively.

Medical Management of Neuropathic Dysfunction of the Lower Urinary Tract

See Table 34.6 for a summary of medications. Antimuscarinic drugs are the first-line treatment for detrusor overactivity (Hood and Andersson, 2013). The detrusor smooth muscle has M_2 and M_3 receptors, but M_2 predominate in number; however, $M_{3,}$ receptors mediate the direct contractile effects of acetylcholine in the detrusor (Hegde and Eglen, 1999). Initial response rates are favorable, but adverse effects and decreasing efficacy result in dwindling long-term compliance (Hood and Andersson, 2013). Use of antimuscarinics in children with detrusor overactivity results in increased bladder capacity, increased bladder volume to first detrusor contraction, and decreased number of incontinence episodes and number of catheterizations (Alloussi et al., 2010; Bolduc et al., 2010; Christoph et al., 2007; Ellsworth et al., 2005; Nijman et al., 2005; Reddy et al., 2008). Common adverse events include dry mouth, constipation, blurred vision, facial flushing, dizziness, and headache (Alloussi et al., 2010; Bolduc et al., 2010; Christoph et al., 2007; Ellsworth et al., 2005; Nijman et al., 2005; Reddy et al., 2008). There have been concerns about potential adverse cognitive effects of antimuscarinics, but a prospective, randomized, double-blind trial showed no negative effect of antimuscarinic medications on attention or memory (Giramonti et al., 2008).

TABLE 34.6

Medications for Management of Neuropathic Lower Urinary Tract Dysfunction

TYPE	MINIMUM DOSAGE	MAXIMUM DOSAGE
ANTICHOLINERGIC		
Oxybutynin (Ditropan)	0.2 mg/kg bid	0.2 mg/kg qid
Glycopyrrolate (Robinul)	0.01 mg/kg bid	0.03 mg/kg tid
Hyoscyamine (Levsin)	0.03 mg/kg bid	0.1 mg/kg qid
Tolterodine (Detrol)	0.01 mg/kg bid	0.04 mg/kg bid
Trospium (Sanctura)	0.1 mg/kg bid	0.3 mg/kg bid
Fesoterodine (Toviaz)	0.06 mg/kg qd	0.12 mg/kg qd
SYMPATHOMIMETIC		

Pseudoephedrine (alpha) (Sudafed)	0.4 mg/kg bid	0.9 mg/kg tid
Mirabegron (beta 3) (Myrbetriq)	0.3 mg/kg qd	0.3 mg/kg bid
Sympatholytic		
Doxazosin (alpha) (Cardura)	0.01 mg/kg qd	0.02 mg/kg qd
Tamsulosin (Flomax)	0.01 mg/kg qd	0.02 mg/kg qd
Terazosin (Hytrin)	0.015 mg/kg qd	0.06 mg/kg qd
Other		
Imipramine (Tofranil)	0.7 mg/kg bid	1.2 mg/kg tid

bid, Twice a day; *tid,* three times a day; *qd,* once a day; *qid,* four times a day.

The most commonly used antimuscarinic agent in children is oxybutynin, a tertiary amine with primary affinity for M_3 receptors. It may be delivered orally, transcutaneously (Cartwright et al., 2009), or intravesically (Guerra et al., 2008). Oral dosing is usually done at 0.2 mg/kg/dose given up to three times daily. Oral preparations include tablets, syrup, and extended-release tablets. All three have been shown to be safe and effective in children (Franco et al., 2005). The transdermal doses is 3.9 mg daily (Cartwright et al., 2009). The transdermal route has been shown to be well-tolerated and an effective alternative to oral oxybutynin in children with neurogenic detrusor overactivity. Skin irritation is noted in some patients, which leads to discontinuation of treatment in 20% of children (Cartwright et al., 2009; Gleason et al., 2014). A systematic review noted a low level of evidence for the intravesical use of oxybutynin that is thought to result in fewer adverse effects by avoiding first-pass metabolism. It did increase maximum bladder capacity and decrease bladder fill pressure with lower side effects than oral administration; however, 9% of children discontinued using it as a result of adverse effects and 22% because of other issues such as inconvenience of administration (crushing pills to prepare the solution) (Guerra et al., 2008).

Tolterodine, a tertiary amine (antimuscarinic), has been noted to inhibit nonvoiding bladder activity and the amplitude of voiding contractions (Gillespie et al., 2012). In children with neurogenic detrusor overactivity, tolterodine was shown to be well tolerated, with minimal treatment-related adverse events because of its inability to cross the blood-brain barrier, and to increase functional bladder capacity in children younger than 10 years of age while decreasing the mean number of incontinence episodes with long-term (12 month) use (Reddy et al., 2008).

Fesoterodine is a tertiary amine antimuscarinic with affinity to M_3 receptors. Its active metabolite, 5-hydroxy-methyltolteride, is the same as tolterodine, but fesoterodine has less pharmacokinetic variability and fewer adverse events than tolterodine (Malhotra et al., 2011). It has been shown to be safe and tolerable in children with daily doses of 4 mg and 8 mg (Malhotra et al., 2012). Its main benefit is that a methyl group has been added, which allows the drug to bypass the cytochrome oxidase enzymes that convert tolterodine to its active form, thus providing a more effective antimuscarinic drug (Chapple et al., 2007).

Trospium, a quaternary amine antimuscarinic, crosses the blood brain-barrier but has minimal affinity for intracerebral M_1 receptors, so its rate of adverse events is markedly diminished. It has a considerably prolonged mechanism of action compared with oxybutynin ($T_{1/2}$ of 8 vs. 2 hours). Its improvement in LUT urodynamic parameters and clinical symptoms are significant, with only 8% reporting any adverse event (Lopez Pereira et al., 2003).

Solifenacin is a once-daily tertiary amine antimuscarinic, also with affinity for M_3 receptors, that has been shown to increase urodynamic bladder capacity, decrease overactive contractions, and improve continence with acceptable tolerability and safety in an open-label study of children with neurogenic and non-neurogenic detrusor overactivity who were recalcitrant to oxybutynin or tolterodine therapy (Bolduc et al., 2010). In this study, 21% had mild effects, 4% had moderate effects, and 5% withdrew because of intolerable adverse effects.

Propiverine is a calcium channel blocker. Preventing intracellular influx of calcium inhibits Rho kinase action on actomyosin fibrils and limits the enzymatic action on actomyocin ATPase by binding to calmodulin. In several studies, LUT symptoms (Allousi et al., 2009) and especially urodynamic parameters were improved to a greater extent than with oxybutynin, with a statistically significant change for patients receiving propiverine versus either their own pretreatment UDS or compared with those given oxybutynin, respectively (Madersbacher et al., 2009; Schulte-Baukloh et al., 2006). In another prospective analysis, 17 children had increased bladder capacity and reduced detrusor pressure greater than 60%, with incontinence improving in 53% of those who were incontinent before treatment (Schulte-Baukloh et al., 2012).

Mirabegron is a novel β_3-adrenegic receptor agonist that decreases the number of micturitions and continence (Yamaguchi et al., 2014). It works by stimulating β_3 receptors located throughout the fundus of the bladder that, when stimulated, elicit relaxation of the detrusor muscle by activating adenylyl cyclase, causing increases in the intracellular levels of cyclic AMP and calcium (Chapple et al., 2014). It is effective in adults but has not yet been approved by the U.S. Food and Drug Administration (FDA) for use in children. Two recent studies using mirabegron alone or in combination with solifenacin in children with idiopathic overactive bladder reported acceptable tolerability and efficacy (Blais et al., 2016; Morin et al., 2017).

Sympathomimetic Agents (Fig. 34.7)

If incontinence results from inadequate urethral resistance, sympathomimetic agents such as ephedrine HCl (0.5 to 1 mg/kg/day three times a day and pseudoephedrine (0.4 mg/kg twice a day to 0.9 mg/kg three times a day) act to increase tone at the bladder neck, where the concentration of alpha-adrenergic receptors is highest, thereby raising outlet resistance and improving continence. It is hard to predict which children might respond to these drugs that potentially increase bladder outlet resistance by stimulating receptors in the trigone and bladder neck, but in some cases there is a dramatic increase leading to continence between CIC (Bauer, 2014). Regular use of sympathomimetic agents, however, may be limited by their adverse effects, which include dizziness, nausea, nervousness, insomnia, loss of appetite, headache, mood changes, and urinary retention.

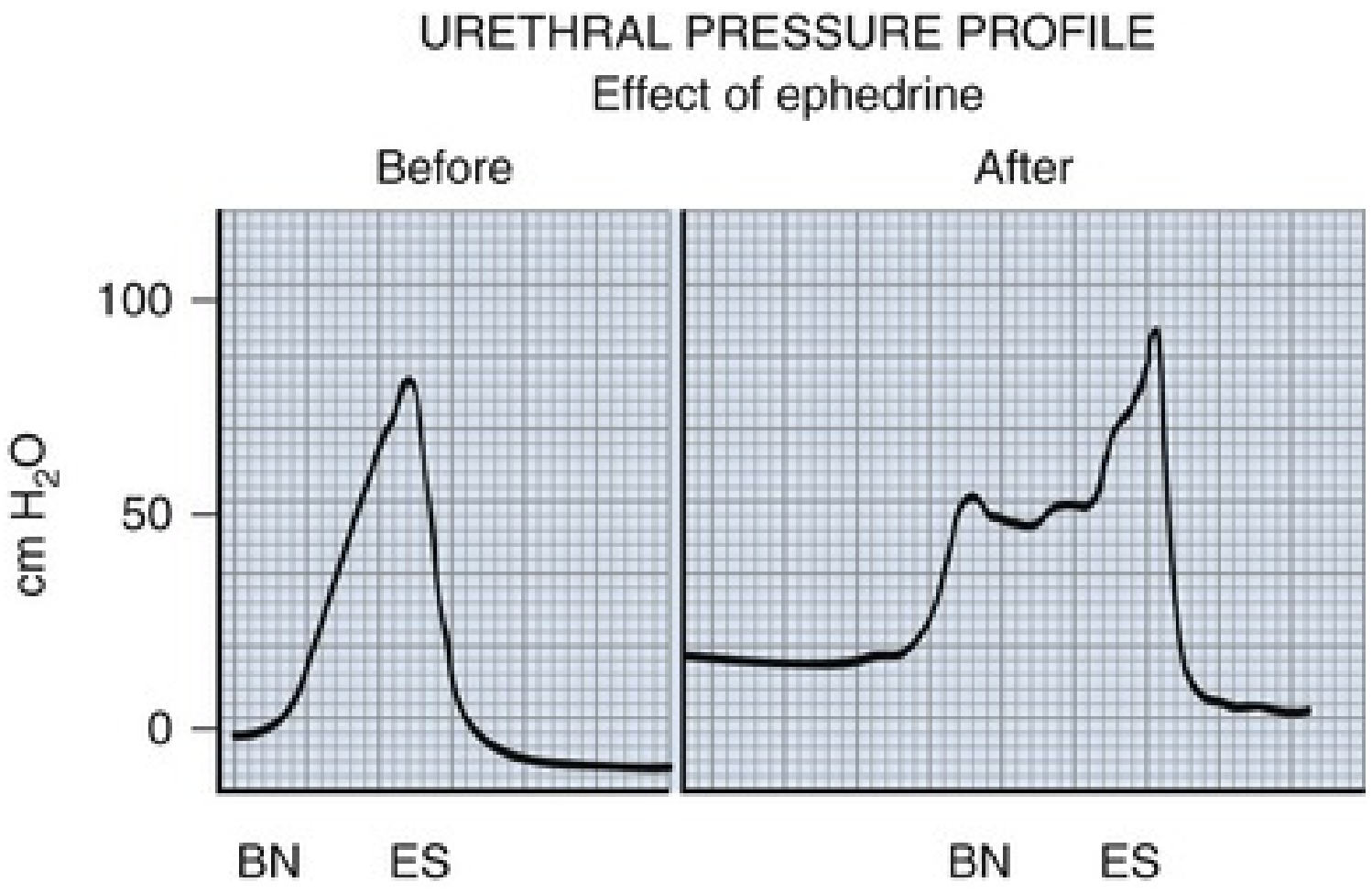

FIG. 34.7 α-Sympathomimetic agents potentially have their greatest effect in the bladder neck region, where the highest concentration of α-adrenergic receptor sites exists. They can raise outlet resistance and improve continence in many individuals. *BN,* Bladder neck; *ES,* external sphincter.

Surgical Treatment Options for Neuropathic Dysfunction of the Lower Urinary Tract

Botulinum Toxin

An alternative option for detrusor overactivity in neurogenic bladder is the intravesical injection of BTA. BTA is a neurotoxin protein produced by the gram-positive bactrium, *Clostridium botulinum;* it acts by inhibiting acetylcholine release resulting in muscle paralysis. BTA has also been found to inhibit the release of other neurotransmitters including adenosine triphosphate and neuropeptides such as substance P, and to downregulate the expression of purinergic and capsaicin receptors on afferent neurons within the bladder (Apostolidis et al., 2006; Chapple and Patel, 2006). Specifically, it substantially reduces muscle cell expression for M_2, M_3, P2x2 and P2x3 receptors that lead to detrusor muscular paralysis (Schulte-Baukloh et al., 2013). The first use of BTA to treat neurogenic detrusor was in adults with spinal cord injury (SCI) (Dykstra and Sidi, 1990). The first use in children with neuropathic bladder was documented in 2002 (Schulte-Baukloh et al., 2002). The most commonly injected dose varies from 5 to 9.6 *IU*/kg with a maximum dose of 360 *IU*. Most studies use 30 injection sites, sparing the trigone with rigid cystoscopy under general anesthesia. Sixty-five percent to 87% of children who have failed conservative medical management and CIC achieved dryness with a BTA injection (Riccabona et al., 2004). Improvements in urodynamic parameters include decreased maximum detrusor pressure (33% to 57%); increased maximum cystometric capacity (34% to 165%); and improved compliance (121% to 183%). The duration of response ranges from 6 to 10.5 months (Gamé et al., 2009; Hascoet et al., 2018). The most common minimal age for injection was 2 years, which corresponds to that approved by the FDA for the treatment of cerebral palsy (CP) (Gamé et al., 2009).

Overall patient and caregiver satisfaction with this treatment is greater than 70% (Figueroa et al., 2014). Injection of BTA may allow approximately 25% of patients to discontinue antimuscarinic therapy after the first injection and an additional 10% after a second injection (Figueroa et al., 2014). Side effects from BTA are infrequently reported by patients (Kask et al., 2014). Side effects of intravesical BTA injection include urinary retention, UTI, hematuria, transient muscle weakness, dysuria, and pain (Duthie et al., 2011; Hascoet et al., 2018). It appears that repeated injections continue to be effective, with the interval between repeated injections increasing with each series of injections (Altaweel et al., 2006; Schulte-Baukloh et al., 2005). A reduction of dose in repeat injections (from 300 *IU* to 200 *IU*) was associated with recurrence of symptoms, which resolved with reinstitution of the original dosing regimen (Figueroa et al., 2014). Injection of intradetrusor BTA avoided bladder augmentation in close to 90% of children who had failed first-line treatment with CIC and antimuscarinics (Figueroa et al., 2014). Serial injections of BTA show additional, significant improvement in urodynamic parameters, suggesting that tachyphylaxis, neutralizing antibody formation, or progressive fibrosis are not considerations with repeat BTA injections (Figueroa et al., 2014). This finding is supported by histopathologic examination of the detrusor. One study found no significant difference in edema, inflammation, or fibrosis when comparing children with neurogenic dysfunction before their first injection with those having had a previous intradetrusor injection of BTA. Repeated injections were associated with a significant decrease in the amount of fibrosis compared with those who had no history of injection (Pascali et al., 2011).

Children who respond poorly to BTA intradetrusor injection may have preexisting poor bladder compliance (Kask et al., 2014). Complete lack of response to BTA injection has been linked to the presence of BTA antibodies (Schulte-Baukloh et al., 2008, 2011), but another study found no differences in antibody formation and response to BTA despite the number of injections (Kajbafzadeh et al., 2010). One study compared injection of BTA in the detrusor to injection in both the detrusor and external urinary sphincter in 60 children with neurogenic dysfunction who had failed CIC and antimuscarinic therapy. More than 90% of this cohort had DSD documented before injection of BTA. They found those with BTA injected into the external urethral sphincter had a significant improvement in postvoid residual urine measurement and the presence of DSD on follow-up UDS. Additionally, clinical parameters including constipation and incontinence trended toward improvement in the group with injections into the external urethral sphincter, although this improvement was not statistically significant (Safari et al., 2010). A larger study is required to confirm these preliminary findings.

For a thorough discussion of more invasive surgical options for neurogenic bladder in children including augmentation, autoaugmentation, urinary diversion, bladder neck procedures, and the artificial urinary sphincter (AUS), please refer to ExpertConsult.com.

Surgical Management of Neuropathic Dysfunction of the Lower Urinary Tract

Augmentation

A persistent poorly compliant, small-capacity, and/or overactive bladder may be treated with enterocystoplasty (Mitchell and Piser, 1987; Sidi et al., 1987). It is estimated that in the early 2000s, approximately 5.4% of children with spina bifida underwent augmentation cystoplasty (Lendvay et al., 2006). Sigmoid, cecum, stomach, and small intestine have been used to enlarge the bladder. The ileocecal segment is avoided in children with spina bifida because removing it might aggravate the bowel dysfunction in these children (Bauer, 2014). Detubularization of the bowel is needed to minimize the intrinsic contractions of the intestinal segment and prevent it from causing intractable incontinence once it has been added to the bladder (Goldwasser et al., 1987; Hinman, 1988).

Most studies evaluating outcomes for augmentation cystoplasty have patient populations that compromise mixed etiologies (primarily neurogenic bladder caused by spina bifida, but also other causes; exstrophy-epispadias; and posterior urethral valves) and are performed with and without concomitant procedures such as continent catheterizable channels, antireflux surgery, and bladder outlet surgery, thus there is limited data that reflect the outcomes specifically in those with neurogenic bladder treated with augmentation cystoplasty in isolation. Continence is achieved in 90% or more (Husmann and Cain, 2001; Quek and Ginsberg, 2003; Shekarriz et al., 2000; Veenboer et al., 2013). Mean bladder capacity (Krishna et al., 1995; Quek and Ginsberg, 2003), improved compliance (Veenboer et al., 2013), and safe storage pressures (Krishna et al., 1995; Quek and Ginsberg, 2003) are achieved in most patients. Preexisting hydronephrosis resolves in up to 92% (Krishna et al., 1995).

Postoperative UDS may reveal regular phasic contractions (Robertson et al., 1991). It is unclear if these contractions arise from the bowel segment or the remaining bladder. These contractions are generally of low-amplitude activity (<40 cmH_2O) and are volume dependent, occurring only at volumes greater than 200 mL (Quek and Ginsberg, 2003). Zero percent to 29% of patients require antimuscarinics after augmentation (Chartier-Kastler et al., 2000; Herschorn and Hewitt, 1998; Luangkhot et al., 1991; Mitchell et al., 1986; Quek and Ginsberg, 2003).

Complications of Augmentation Cystoplasty.

The complication rate of augmentation cystoplasty is approximately 30% (Metcalfe et al., 2006b; Schlomer et al., 2013). Approximately one-half of those are considered to be major (Schlomer et al., 2013), and they include small bowel obstruction (Schlomer et al., 2013), bleeding requiring transfusion (in cases using gastric segments) (Schlomer et al., 2013), fistula (Schlomer et al., 2013), bladder perforation (Metcalfe et al., 2006b), and recurrent UTIs/pyelonephritis (Bertschy et al., 2000; DeFoor et al., 2004; Flood et al., 1995). The need for further surgery is estimated to be 0.04 operations per patient per year. Additional surgery may include intervention for stones (11% to 63%) (DeFoor et al., 2004; Flood et al., 1995; Metcalfe et al., 2006a), laparotomy for bowel obstruction (3.2% to 4%) (Flood et al., 1995; Metcalfe et al., 2006a), closure of bladder perforation (4% to 13%) (Bauer et al., 1992; Bertschy et al., 2000; DeFoor et al., 2003; Flood et al., 1995; Krishna et al., 1995; Metcalfe et al., 2006b; Shekarriz et al., 2000), and revision of or repeat augmentation (9.4% to 16%) (Flood et al., 1995; Metcalfe et al., 2006a).

Risk factors for development of stones in augmented bladders include excessive mucus production from enteric segments (Hensle et al., 2004), use of the ileal segment (DeFoor et al., 2004; Metcalfe et al., 2006b), presence of an abdominal stoma (Hensle et al., 2004), and an immobile patient with sensory impairment (Hensle et al., 2004). Stone formation recurs in up to 30% (DeFoor et al., 2004; Flood et al., 1995). Periodic irrigation with water or saline is recommended to decrease the rate of stone formation related to mucus (Hensle et al., 2004).

Bladder perforation is a life-threatening complication of bladder augmentation that requires prompt diagnosis and treatment. In some individuals, it is a recurring problem (Metcalfe et al., 2006b). Presenting symptoms include abdominal distension and pain, septic shock, and shoulder pain related to diaphragmatic irritation from extravasated urine (Bauer et al., 1992). Sepsis has resulted in death of 25% presenting with bladder perforation (Bauer et al., 1992). Those with a history of bladder outlet surgery seem to be at increased risk (Bauer et al., 1992; Metcalfe et al., 2006b). It appears that individuals with a catheterizable abdominal stoma are at lower risk for perforation (Metcalfe et al., 2006b), perhaps as a result of increased compliance with catheterization schedules (Horowitz et al., 1995). Controversy exists regarding which bowel segment has the highest risk for rupture. Some studies have identified the sigmoid colon as the most likely to perforate, although most of the sigmoid segments in this series were not detubularized (Metcalfe et al., 2006b), and others have identified the ileum as most likely to rupture (Bauer et al., 1992). With this risk for sepsis and death, diagnosis and treatment must be immediate. Cystography (either fluoroscopic or computed tomography [CT]) is diagnostic in most but not all cases (Bauer et al., 1992; Slaton and Kropp, 1994). Overdistension and relative ischemia related to bowel detubularization are important factors in the pathophysiology of rupture (Bauer et al., 1992). The gold standard approach to management is exploratory laparotomy and closure of the perforation; however, conservative management with drainage of the urinary reservoir and percutaneous drainage of abdominal urinoma, in those without hemodynamic instability or worsening symptoms has been described, especially if the leak is extraperitoneal (Leyland and Masters, 2003; Slaton and Kropp, 1994).

Long-term metabolic complications are also common with augmentation cystoplasty. **Concerns have surfaced about gastric segments because they can cause hyponatremic hypochloremic metabolic alkalosis** (Gosalbez et al., 1993) or the hematuria dysuria syndrome (Castellan et al., 2012). Except for children with progressive or end-stage renal failure, gastrocystoplasty is not recommended currently as a routine form of augmentation (Chadwick Plaire et al., 2000; Leonard et al., 2000). Augmentation cystoplasty with any segment of the gastrointestinal tract can lead to long-term consequences in acid-base balance, vitamin B_{12} deficiency, fat absorption, renal function changes, aberrant bone metabolism, and growth retardation (Gilbert and Hensle, 2005).

There seems to be an increased risk for bladder cancer in patients with spina bifida who have been augmented (Austin et al., 2007). Proposed risk factors for the development of malignancy in spina bifida include chronic UTI, stone disease, repeat catheterization, and incorporating enteric segments (Mehan et al., 2011). Early reports suggested that intestinal and gastric bladder augmentation were associated with an increased risk for bladder cancer. The largest study found that bladder cancer developed in 0.6% of patients undergoing augmentation (Metcalfe et al., 2006a). Most studies note a 10-year minimum lag time between the augmentation and presentation of disease. Presenting symptoms are often atypical and may include vague abdominal pain, gross hematuria, urosepsis, renal failure, difficult catheterization, increasing frequency of UTI, new-onset hydronephrosis, and bladder wall thickening (Austin et al., 2007; Castellan et al., 2007; Veenboer and de Kort, 2011; Vemulakonda et al., 2008). Patients also present at a younger age than is typical for these cancers (Austin et al., 2007; Veenboer and de Kort, 2011). One study found that almost

90% of patients presented with locally advanced disease or lymph node metastases (Austin et al., 2007). Urothelial cell carcinoma accounts for close to 60% of the tumors, followed by squamous cell carcinoma in 21%, adenocarcinoma in 16%, and signet cell tumor of the gastric augment in 5% (Austin et al., 2007). Some studies have disputed the association of enteric augmentation with increased risk for malignancy as there have also been reports of malignancy in those with autoaugmentation without incorporation of enteric segments (Mehan et al., 2011; Veenboer and de Kort, 2011). In addition, several studies have found that enteric augmentation in this group does not result in a greater risk for developing malignancy than in a comparable group of patients without augmentation (Austin et al., 2007; Higuchi et al., 2010). Most of these studies are compromised because of relatively small study numbers and confounding factors, such as a history of smoking, exposure to known carcinogens, and family history, all of which are not addressed. A recent systematic review reported on the outcomes in 52 patients with spina bifida from 28 studies that included patients with and without bladder augments (Rove et al., 2017). In this review, it was reported that the overall risk for bladder cancer in patients with spina bifida in 2% to 4%. Overall survival at 1 and 2 years was 48.5% and 31.5%, respectively, and there was no difference in overall survival based on age, management with an indwelling catheter, diversion with an ileal conduit, or being on a surveillance program. However, overall survival was poorer for those with augmentation. Thus, it is clear that patients with neurogenic bladder affected by bladder malignancy present at a young age, with atypical symptoms and with advanced disease. Some, including the ICCS, have recommended annual surveillance cystoscopy and cytology starting 5 to 10 years after augmentation (Castellan et al., 2007; Rawashdeh et al., 2012; Soergel et al., 2004; Vemulakonda et al., 2008). However, there is insufficient evidence to determine the efficacy of screening for bladder cancer in this population (Kokorowski et al., 2011). In fact, 4 of 6 cases diagnosed with bladder cancer had no discernible mass noted during routine cystoscopic surveillance (Castellan et al., 2007; Vemulakonda et al., 2008). In addition, hypothetical models predict that screening for bladder cancer after augmentation cystoplasty is not cost-effective (Kokorowski et al., 2011).

Alternatives to standard augmentation cystoplasty have been sought to avoid the short- and long-term complications associated with this procedure. Although initial reports of autologous tissue–engineered bladder augmentation using cell-seeded polyglycolic acid–collagen scaffolds was promising (Atala et.al., 2006), a recent phase II study showed that bladder capacity and compliance were not improved and the incidence of serious adverse events was unacceptable (Joseph et al., 2014). Similar unsatisfactory results were noted with bladder augmentation using small intestine submucosa (SIS) (Schaeffer et al., 2013).

Autoaugmentation

As augmentation with enteric segments has a significant risk for short- and long-term complications, some have advocated autoaugmentation or detrusorectomy (with or without demucosalized enteric segments) to treat small and poorly compliant neurogenic bladders (Cartwright and Snow, 1989a; 1989b). Although some have shown short-term improvement in bladder capacity, compliance, and maximum detrusor pressures (Hansen et al., 2013), when compared with enteric augmentation, those who have had autoaugmentation are more apt to be incontinent, use antimuscarinics, and have poorer compliance (MacNeily et al., 2003; Marte et al., 2002; Veenboer et al., 2013). The incidence of de novo hydronephrosis (30%) (MacNeily et al., 2003) and VUR (Marte et al., 2002) in autoaugmentation is unacceptably high. The failure rate of autoaugmentation and need for subsequent augmentation cystoplasty ranges from 15% to 45% (Hansen et al., 2013; MacNeily et al., 2003; Marte et al., 2002; Veenboer et al., 2013). The lack of long-term improvement in urodynamic parameters and continence, combined with the high failure rate, make autoaugmentation an undesirable option.

Urinary Diversion

Urinary diversion, once considered a panacea for children with spina bifida, has turned out to be a Pandora's box of new clinical problems (Schwarz and Jeffs, 1975; Shapiro et al., 1975). Pyelonephritis and renal scarring, urinary tract calculi, ureterointestinal obstruction, strictures of the conduit, and stomal stenosis are often encountered in children who are monitored on a long-term basis. In recent times, urinary diversion is rarely performed, unless accompanied by a continent catheterizable stoma.

Incontinent Urinary Diversion.

Button vesicostomy was first described in 1996 using a gastrostomy button (de Badiola et al., 1996). It has the advantage of being readily reversible and can be used as a temporary solution. The incidence of minor complications such as transient leakage, wound infection, and overgranulation are expected in 40% of patients, with 17% requiring removal or replacement of the device for infection, device failure, and significant leakage (Bradshaw et al., 2014).

Vesicostomy drainage (Duckett, 1974; Mandell et al., 1981) is rarely required today but is reserved for those infants (1) who have such severe reflux that CIC and antimuscarinic medication fail to improve upper urinary tract drainage, (2) whose parents cannot adapt to the catheterization program, or (3) who are not good candidates for augmentation cystoplasty (Morrisroe et al., 2005). It has been shown to improve renal function, hydronephrosis, and VUR in almost all patients undergoing the procedure (Queipo Zaragozá et al., 2003). Complications include bladder stomal prolapse, stomal stenosis, peristomal irritation, and vesical lithiasis (Queipo Zaragozá et al., 2003).

Ileovesicostomy is suggested to be advantageous over vesicostomy because an external appliance can be applied to the stoma that eliminates the need for diapers (Ching et al., 2014). Although short-term results look promising (Ching et al., 2014), long-term follow-up reveals over one-half of children require reoperation or additional procedures (Hellenthal et al., 2009; Tan et al., 2008).

Urethral Dilation.

External urethral dilation (up to 36 F in infants or up to number 18 Hegar dilators in older children) under general anesthesia has been described to address elevated leak point pressures in select children with neurogenic bladder dysfunction who have not responded to CIC and antimuscarinic therapy (Bloom et al., 1990). The mean number of dilations needed per patient is 1.6 (Park et al., 2001). The dilation in males can be achieved via perineal urethrostomy (Bloom et al., 1990; Miller et al., 2003). Durable (mean follow-up of 8 years) improvement has been demonstrated in mean leak point pressure, capacity, and initial and terminal compliance (Bloom et al., 1990; Park et al., 2001). Those with an elevated leak point pressure and good initial compliance seem to have the most long-lasting results from the procedure. However, upper urinary tract deterioration was noted in 20%, by about 9.5 years after the dilation (Park et al., 2001). Approximately 43% have improvement in VUR, and 64% have an improvement or resolution of hydronephrosis (Kiddoo et al., 2006). Thus, urethral dilation may benefit a select group of children with neurogenic bladder who fail initial conservative measures, but long-term follow-up is compulsory.

Bladder Neck Procedures

Artificial Urinary Sphincter.

In children with low bladder outlet resistance, the AUS provides increased outlet resistance while maintaining the ability to catheterize per urethra. In children, the sphincter may be placed at the bladder neck or bulbar urethra (in males). It is often performed in conjunction but not simultaneously with other procedures such as augmentation cystoplasty to address poor compliance and low bladder volumes. Continence rates range from 63% to 86% (Catti et al., 2008; Herndon, 2003; Simeoni et al., 1996; Spiess et al., 2002). The need for revision ranges from 16% to 61% (Catti et al., 2008; Herndon, 2003; Simeoni et al., 1996; Spiess et al., 2002), with erosion of the cuff noted in 16% to 20% (Castera, 2001; Catti et al., 2008; Herndon, 2003; Simeoni et al., 1996). Worsening bladder function is noted in 4% to 30% (Catti et al., 2008; Castera, 2001; Simeoni et al., 1996). This is seen more commonly in those with a preexisting poorly compliant or with overactive bladder. Long-term surveillance is required in all patients as they may develop bladder hypertonicity after outlet resistance is increased, which can lead to upper urinary tract changes and eventual renal failure (Castera, 2001). Patients with an AUS are less likely to void spontaneously if the sphincter is implanted before puberty or in conjunction with augmentation cystoplasty (Catti et al., 2008). Mean operational life of the AUS ranges from 4.6 to 12.7 years (Castera, 2001; Simeoni et al., 1996; Spiess et al., 2002). Better continence outcomes are noted in those without a history of a prior bladder neck procedure (Castera, 2001).

Bladder Neck Slings.

It is difficult to compare published data concerning the effectiveness of bladder neck slings in the treatment of bladder outlet incompetence, as most published series include patients with varied preoperative bladder function and previous or concurrent procedures, such as augmentation cystoplasty, bladder neck reconstruction, and continent catheterizable channels. As well, there is no standardized definition of continence. In addition, varied materials are utilized to perform the sling including rectus fascia (Bauer et al., 1989; Walker et al., 1995), bladder wall (Albouy et al., 2007), and small intestinal submucosa (Colvert, 2002; Misseri et al., 2005a). Success rates for continence appear to be similar despite varied sling materials, although rectus fascia is used most commonly. Both *U*-shaped and 360-degree type slings are described (Bauer et al., 1989; Snodgrass et al., 2007). Irrespective of technique, similar continence rates are noted. In those with decreased bladder compliance or overactivity, bladder neck slings are usually performed in conjunction with augmentation cystoplasty, yielding continence rates of 30% to 93%, with most studies noting success in excess of 70% (Albouy et al., 2007; Barthold et al., 1999; Churchill et al., 2010; Dik et al., 2006; Walker, 1995). Continence rates for females tend to be better than for males with a bladder neck sling (Barthold et al., 1999; Colvert, 2002). Most studies note that bladder neck slings do not lead to difficulty with catheterization (Albouy et al., 2007; Churchill et al., 2010; Dean and Kunkle, 2009). Some have advocated using a bladder neck sling alone, without augmentation in children with neurogenic sphincter deficiency, bladder underactivity, and a low detrusor leak point pressure less than 25 cm H_2O (Snodgrass et al., 2007). Continence, defined as two or fewer wet pads per day, is noted in 83% (Snodgrass et al., 2007). However, as noted in those with increased outlet resistance after placement of an AUS (Bauer et al., 1986), these patients are at risk for developing overactivity and decreased bladder compliance. Approximately one-third of patients treated with a tight 360-degree bladder neck sling developed increased bladder pressures and/or overactive detrusor contractions (Snodgrass and Barber, 2010; Snodgrass et al., 2007). Most of these children responded to antimuscarinic treatment, although augmentation cystoplasty was required in 2 of 37 patients (5%) (Snodgrass and Barber, 2010; Snodgrass et al., 2010). Therefore, if bladder neck sling is done in isolation, long-term surveillance is required to monitor for changes in bladder function to prevent upper urinary tract deterioration. When compared with those having a bladder neck sling without augmentation, patients with augmentation have a longer interval between catheterizations, require less antimuscarinic medication, and scored higher on a health-related quality of life survey for achieving independence for self-directed care (Snodgrass et al., 2009). For children who do not achieve continence with a bladder neck sling, placement of an AUS is likely to be more effective than injection of periurethral bulking agents (Barthold et al., 1999).

Injection of Periurethral Bulking Agents

Over time, the type of material injected to increase outlet resistance at the bladder neck has changed; currently, the most common agent used is dextranomer/hyaluronic acid (Alova et al., 2012; DaJusta et al., 2013). Success rates for achieving complete continence with retrograde, transurethral injection of the bladder neck are low, ranging from 7% to 50%, with deterioration in results over time (Alova et al., 2012; DaJusta et al., 2013; De Vocht et al., 2010;

Godbole et al., 2003; Guys et al., 2001, 2006; Lottmann et al., 2006; Misseri, Casale, et al., 2005b). Repeat injections do not appear to be beneficial (Alova et al., 2012; De Vocht et al., 2010). Success in those with antegrade injection of bulking agent and suprapubic catheter drainage postinjection is much better, ranging from 70% to 78% (Alova et al., 2012; Dean et al., 2007; Kaye et al., 2010). Thus, although the success rates are low, bladder neck injection of bulking agents does achieve dryness for some children with neurogenic sphincter deficiency. Antegrade injection has superior success rates than retrograde injection.

Electrostimulation

Most studies of electrostimulation in pediatric neurogenic bladder involve a small sample size, often lack a control group, and have varied methods of electrostimulation and different outcome measures. Although some studies have shown improvement in clinical and urodynamic parameters, larger, prospective, randomized trials are required (Balcom et al., 1997; Choi et al., 2013a; Cirović et al., 2009; Decter et al., 1992, 1994; Godec and Cass, 1978; Han et al., 2004; Kajbafzadeh et al., 2009; 2010; Marshall and Boston, 1997).

Sacral Neuromodulation

Sacral neuromodulation has been used extensively in children with non-neurogenic bladder dysfunction. Its use in children with neurogenic dysfunction has been limited. One prospective, randomized study of 42 children with spina bifida comparing standard conservative management and sacral neuromodulation found that urodynamic variables did not differ between the two groups, with the exception of better functional bladder capacity in the control group and lower leak point pressure in the neuromodulation group (Guys et al., 2004). Some of those in the implant group noted improved intestinal transit, resolution of UTI, and better sensation of a persistently full bladder (Guys et al., 2004). Seven percent of the neuromodulation group required revision surgery (Guys et al., 2004). Thus, sacral neuromodulation in this population appears to be safe with some limited benefits over standard therapy, but a larger study is required to determine its efficacy.

Artificial Somatic-Autonomic Reflex Pathway

Procedure

The artificial somatic-autonomic reflex pathway is a procedure involving a limited laminectomy and a lumbar ventral root to S3 ventral root microanastomosis. The L5 dorsal root is left intact as the afferent branch of the somatic-autonomic reflex pathway after axonal regeneration (Xiao et al., 2005). Despite reported improvements in urinary and bowel function in early small series (Peters et al., 2010; Xiao et al., 2005), a prospective, randomized, double-blind study showed no benefit (Tuite et al., 2016). In addition, significant postoperative complications that have been reported included prolonged wound drainage, ipsilateral foot drop, and temporary lower extremity muscle weakness (Peters et al., 2010). Thus this procedure has been largely abandoned.

Key Points: Medical and Surgical Treatment Options

- Antimuscarinic therapy and CIC are the mainstay of therapy.
- Bladder filling pressures should be maintained below 30 cm H_2O as much as possible to prevent upper urinary tract deterioration.
- Intravesical injection of BTA is well tolerated and avoids the need for more invasive treatment options in a high proportion of children with minimal side effects.
- Enterocystoplasty is an effective option to prevent upper urinary tract deterioration but comes with a high risk for complications.
- Patients undergoing isolated bladder neck procedures (AUS and bladder neck sling) may develop detrusor overactivity and poor compliance that leads to upper urinary tract deterioration, mandating close follow-up.

Management of Vesicoureteral Reflux in Neuropathic Dysfunction of the Lower Urinary Tract

VUR occurs in 3% to 5% of neonates with spina bifida, usually in association with poor detrusor compliance, detrusor overactivity, and/or DSD (Flood et al., 1994). It is rare to find reflux in any neonate without these urodynamic findings (Bauer, 1984; Edelstein et al., 1995; Geraniotis et al., 1988). If left untreated, the incidence of reflux in these infants at risk increases with time until 30% to 40% are afflicted by 5 years of age (Bauer, 1984a; Seki et al., 1999). In children with reflux grades 1 to 3 (International Classification) who void spontaneously or have a complete lesion with little or no bladder outlet resistance and empty their bladder completely, management consists solely of prophylaxis with antibiotics to prevent recurrent infection. In children with high-grade reflux (grade 4 or 5), CIC is begun to ensure complete emptying. Children who cannot empty their bladder spontaneously, regardless of the grade of reflux, are treated with CIC to improve emptying efficiency.

Children with poor detrusor compliance with or without hydroureteronephrosis are also started on antimuscarinic agents to lower intravesical pressure and ensure adequate upper urinary tract decompression (Flood et al., 1994). When reflux is managed thusly, there has been a dramatic response, with resolution in 30% to 55% of individuals (Agarwal et al., 1997 Bauer, 1984; Flood et al., 1994; Hopps and Kropp, 2003; Joseph et al., 1989; Kass and Koff, 1981). Although bacteriuria can be seen in as many as 56% of children on CIC, it is not harmful except in the presence of high-grade reflux, because symptomatic urinary infection and renal scarring rarely occur with lesser grades of reflux (Cohen et al., 1990; Kass and Koff, 1981).

Credé voiding should be avoided in children with reflux, especially those with a reactive external urethral sphincter. In this circumstance, the Credé maneuver results in a reflex response in the external sphincter that increases urethral resistance and raises the pressure needed to expel urine from the bladder (Barbalias et al., 1983) (Fig. 34.8). This has the effect of aggravating the degree of reflux and accentuating its waterhammer effect on the kidneys.

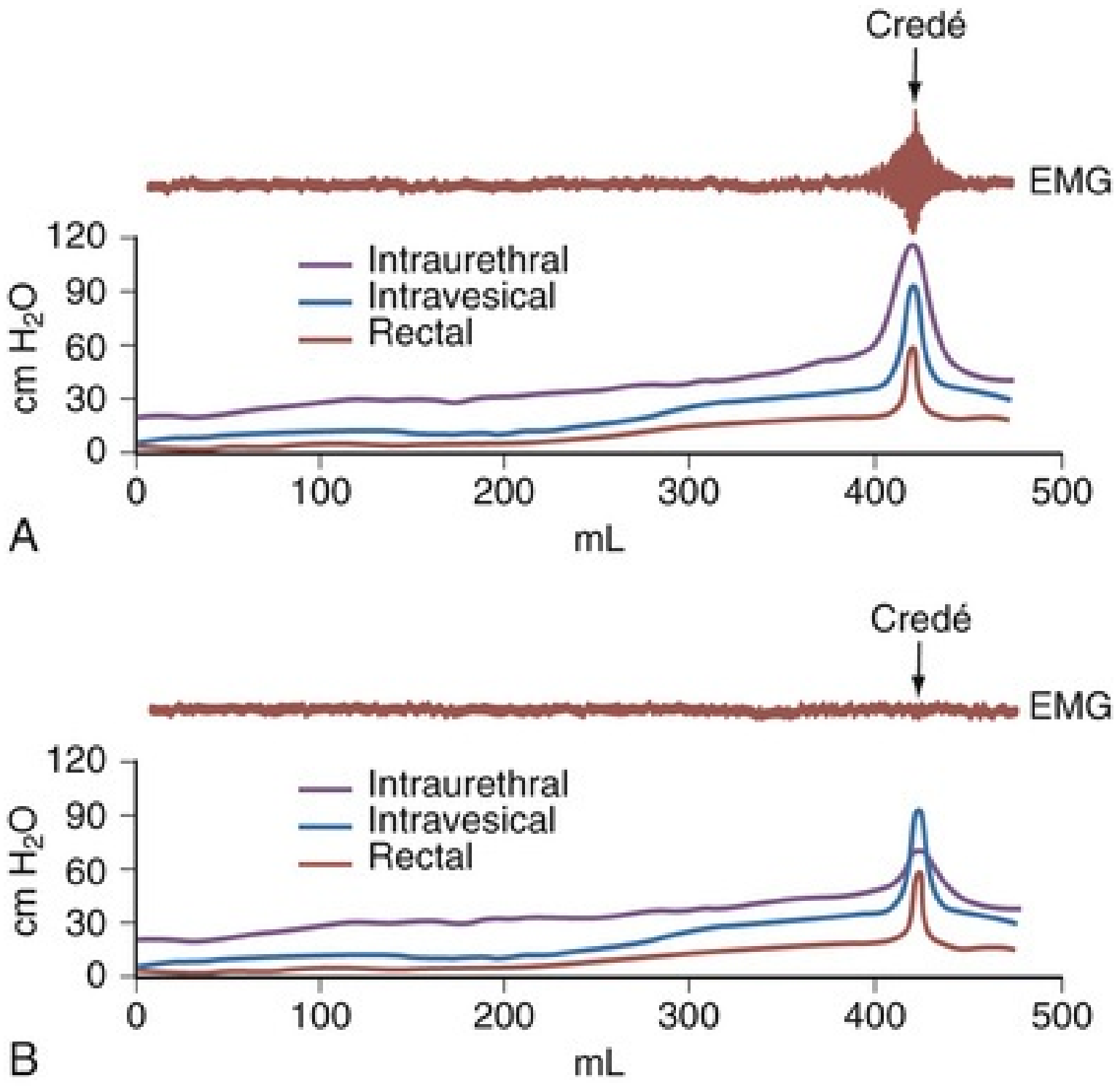

FIG. 34.8 When the external sphincter is reactive (A), the Credé maneuver produces a reflex increase in electromyographic (EMG) activity of the sphincter and a concomitant rise in urethral resistance, resulting in high voiding pressure. A child whose sphincter is denervated and nonreactive (B) will not have a corresponding rise in EMG activity, urethral resistance, or voiding pressure. The Credé maneuver here will not be detrimental. (From Bauer SB. Early evaluation and management of children with spina bifida. In: King LR, ed. *Urologic surgery in neonates and young infants.* Philadelphia, PA: WB Saunders; 1988:252–264.)

The indications for antireflux surgery in this group of children are not very different from those applicable to children with normal bladder function. They include recurrent symptomatic (febrile) urinary infection while receiving adequate antibiotic therapy and appropriate catheterization techniques; persistent hydroureteronephrosis despite effective emptying of the bladder and lowering of intravesical pressure; and severe reflux with an anatomic abnormality at the ureterovesical junction.

Jeffs et al. were the first to show that **antireflux surgery can be very effective in children with neurogenic bladder dysfunction as long as it is combined with measures to ensure complete bladder emptying** (Jeffs et al., 1976). Before this observation was made, the results of ureteral reimplantation were so dismal that most physicians treating these children advocated urinary diversion as a means of managing reflux (Cass, 1976; Smith, 1972). Since the advent of CIC, success rates for antireflux surgery have approached 95% (Kaplan and Firlit, 1983; Kass and Koff, 1981; Woodard et al., 1981). Bilateral surgery for unilateral disease need not be done, because contralateral reflux does not occur postoperatively (Bauer, 1984).

In patients with low-grade reflux who are undergoing augmentation cystoplasty, most clinicians have found acceptable resolution rates of VUR without ureteral reimplantation (Helmy and Hafez, 2013; López Pereira et al., 2001; Morioka et al., 1998). However, for those with dilating reflux (grades 3 and greater), augmentation cystoplasty alone reveals persistence of VUR ranging from 20% to 47% (Helmy and Hafez, 2013; Morioka et al., 1998; Wang et al., 2011). Thus, children with dilating grade reflux who are undergoing augmentation cystoplasty should have concurrent ureteral reimplantation (Helmy and Hafez, 2013; Morioka et al., 1998; Wang et al., 2011).

The endoscopic injection of various materials has altered the management of reflux in children with myelomeningocele (Schlussel, 2004). Success rates of 73% with one injection and 91% with two injections have been reported for the endoscopic management of VUR in those with neurogenic bladder dysfunction (Estornell Moragues et al., 2008; Misra et al., 1996). It has been suggested that success rates of endoscopic therapy in children with neurogenic bladder does not differ from those with a normal bladder (Routh et al., 2008). Higher success rates, approaching 95% have been noted when endoscopic treatment of VUR is paired with intravesical injection of BTA (Neel, 2010; Neel et al., 2008).

However, the durability of this approach has been questioned, with one study showing 40% of those with initial success with endoscopic management had VUR recur at a mean of 4.5 years after the initial treatment (Polackwich et al., 2012). Studies comparing the effectiveness of open surgical to endoscopic management in this population show a significantly greater success rate for traditional open procedures (84.3% to 95.5% vs. 61% to 72.5%) (Engel et al., 1997; Granata et al., 1999). Thus, the endoscopic approach is a reasonable alternative to ureteroneocystotomy; however, long-term outcomes raise concerns about its durability in those with neurogenic bladder dysfunction.

Key Points: Management of Vesicoureteral Reflux

- Low-grade reflux in patients who are emptying well without outlet resistance can be managed with antibiotic prophylaxis alone.

- Patients with high-grade reflux or those who do not empty well also require CIC.
- Patients with poor compliance with or without hydronephrosis should be started on antimuscarinics.
- The Credé maneuver is contraindicated in patients with reflux who have a reactive external urethral sphincter.
- Indications for antireflux surgery are similar to those for children without neurogenic bladder. Success rates are similar if effective bladder emptying is addressed.

Lipomeningocele and Other Spinal Dysraphisms

Presentation

There is a group of congenital defects that affect the formation of the spinal column but do not result in an open vertebral canal (Table 34.7). They occur in 1 in 4000 live births, but with the ease of MRI screening of children with suspected lesions, the detected incidence of these defects is increasing (Bruce and Schut, 1979). The incidence of lipomeningocele in families was calculated to be 0.043% (Sebold et al., 2005). These lesions can be very subtle and have no obvious outward signs, but in more than 90% of children there is a cutaneous abnormality overlying the lower spine (Anderson, 1975; Pierre-Kahn et al., 1997). This varies from a small dimple or skin tag to a tuft of hair, a dermal vascular malformation, a very noticeable subcutaneous lipoma, or an asymmetrically curving gluteal cleft (Fig. 34.9). In addition, on careful inspection of the legs, one may note a high arched foot or feet; hammer or claw toes; a discrepancy in muscle size, leg length, and decreased strength in one leg compared with the other, typically at the ankle; and/or a gait abnormality, especially in older children (Dubowitz et al., 1965; Jindal and Mahapatra, 2000; Weissert et al., 1989). Absent perineal sensation, back pain, and secondary incontinence after a period of dryness are common symptoms in older children and young adults (Linder et al., 1982; Weissert et al., 1989; Yip et al., 1985). LUT function is abnormal in 40% to 90% of affected older individuals, with the incidence of an abnormality increasing proportionately with age (Koyanagi et al., 1997; Mandell et al., 1980; Pierre-Kahn et al., 1997; Sarica et al., 2003). The child may experience difficulty with toilet training, urinary incontinence after an initial period of dryness once toilet trained (especially during the pubertal growth spurt), recurrent urinary infection, and/or fecal soiling. Occasionally, some patients without an obvious back lesion escape detection until they develop urinary (66%) or lower extremity (19%) symptoms or back pain (14%) after puberty caused by delayed traction on the spinal cord (Satar et al., 1995).

TABLE 34.7

Spinal Level of Myelomeningocele

LOCATION	INCIDENCE (%)
Cervical–high thoracic	2
Low thoracic	5
Lumbar	26
Lumbosacral	47
Sacral	20

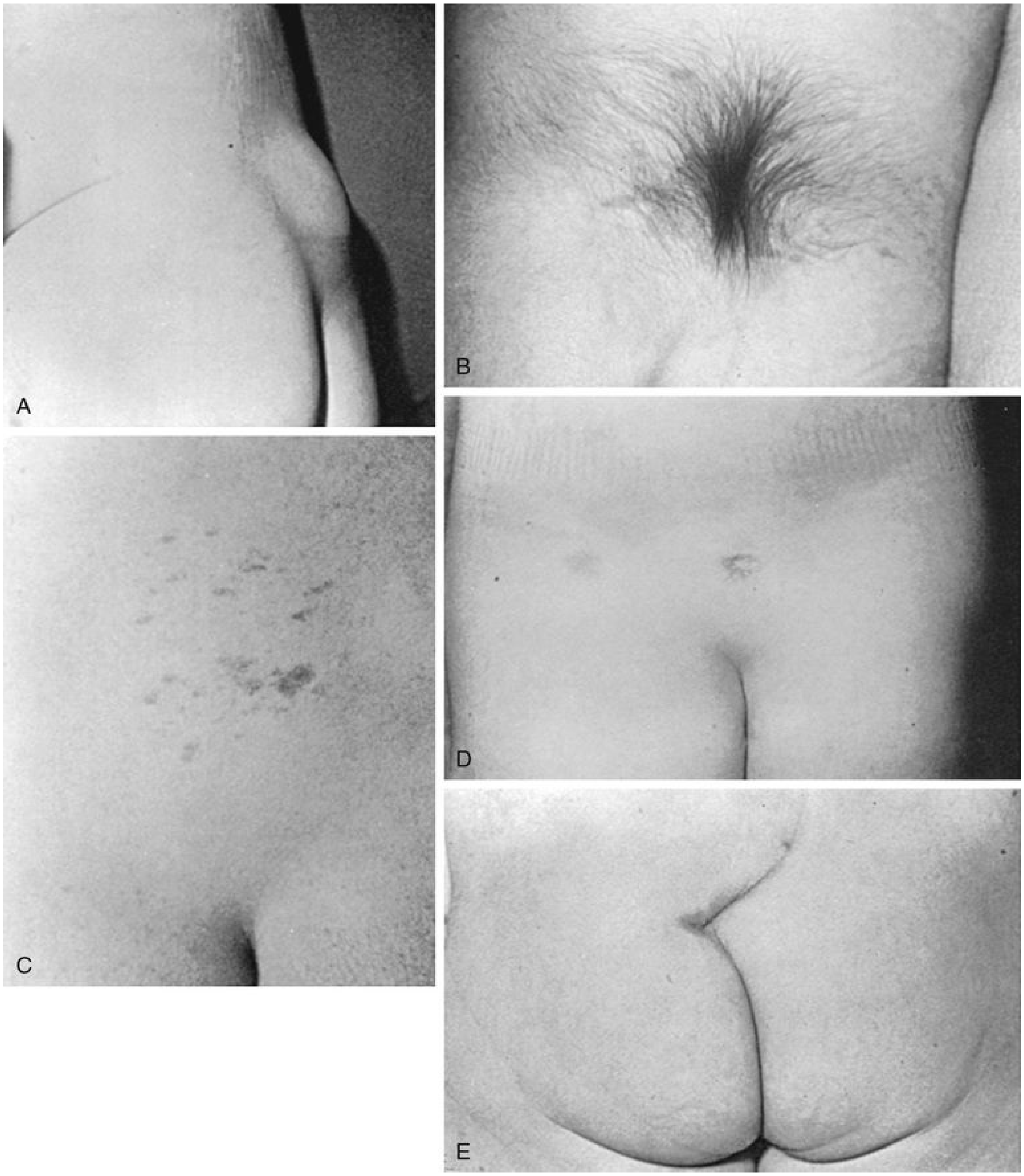

FIG. 34.9 Cutaneous lesions occur in 90% of children with various occult dysraphic states. These lesions vary from a small lipomeningocele (A) to a hair patch (B), a dermal vascular malformation (C), a dimple (D), or an abnormal gluteal cleft (E).

When these children are evaluated in the neonatal period or early infancy, **a majority have a perfectly normal neurologic examination** (Atala et al., 1992). Urodynamic testing, however, reveals abnormal LUT function in about one-third of infants younger than 18 months of age (Keating et al., 1988) (Fig. 34.10). Such studies may provide the only evidence of a neurologic injury involving the lower spinal cord (Atala et al., 1992; Foster et al., 1990; Keating et al., 1988; Nogueira et al., 2004; Satar et al., 1995). When present, the most likely abnormality is an upper motor neuron lesion characterized by an overactive detrusor and/or hyperactive sacral spinal cord reflexes (Fone et al., 1997; Pierre-Kahn et al., 1997); mild forms of DSD are rarely noted. Lower motor neuron signs with denervation potentials in the sphincter or an acontractile detrusor occur in only 10% of young children.

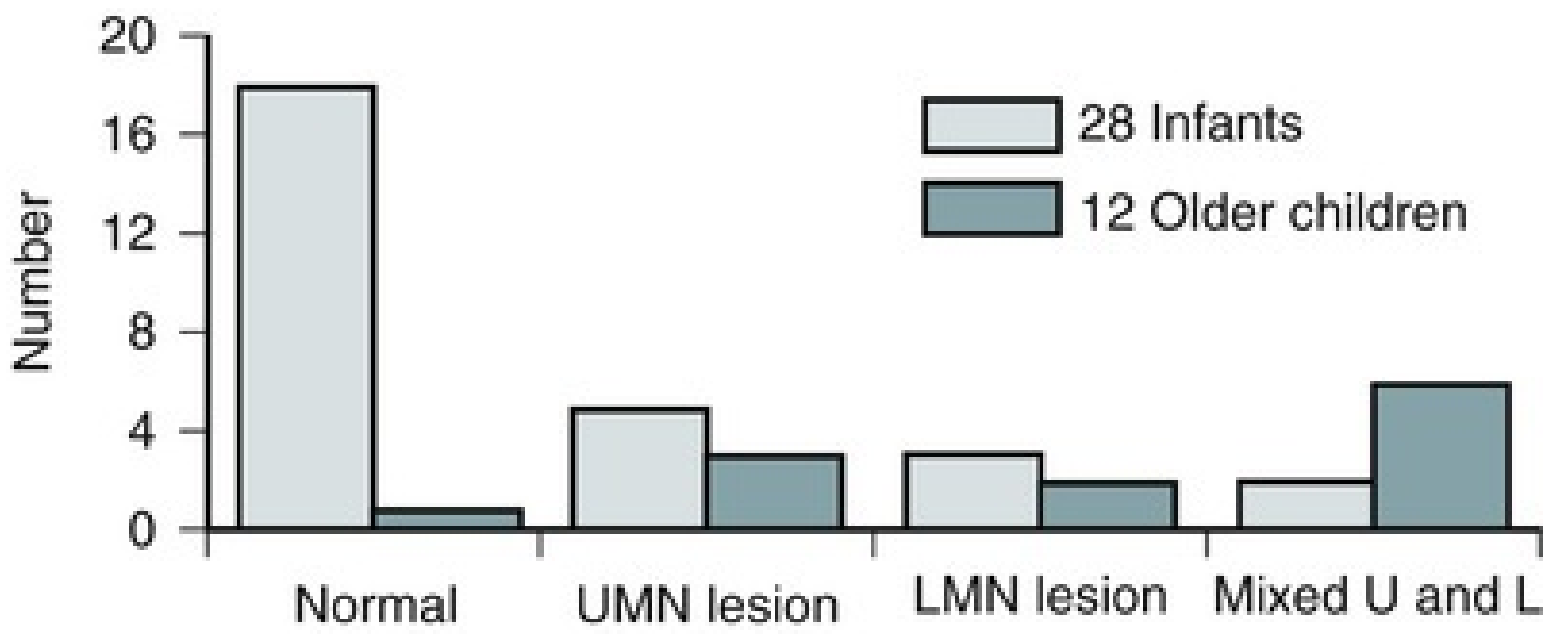

FIG. 34.10 Most neonates with occult spinal dysraphism have normal lower urinary tract function, whereas older children tend to have both upper motor neuron *(UMN)* and lower motor neuron *(LMN)* lesions.

In contrast, practically all individuals older than 3 years of age who have not been operated on or in whom an occult dysraphism has been belatedly diagnosed have either an upper or lower motor neuron lesion or a combination thereof on UDS (92%) (see Fig. 34.10) or neurologic signs of lower extremity dysfunction (Atala et al., 1992; Keating et al., 1988; Kondo et al., 1986; Nogueira et al., 2004; Satar et al., 1995; Yip et al., 1985). When such children were observed expectantly from infancy after the diagnosis was made, 58% experienced deterioration of their disorder within 2 years (Andar et al., 1997; Cornette et al., 1998). There does not seem to be a preponderance of one type of lesion over another (i.e., upper vs. lower motor neuron), and often the child shows signs of both (Hellstrom et al., 1986; Kondo et al., 1986). In one study of children older than 3 years of age, 43% had denervation in the sphincter and 52% had an acontractile detrusor, with a total of 81% having an abnormality (Satar et al., 1995).

Pathogenesis

Various occult spinal dysraphic lesions produce different neurourologic findings. When they do cause an abnormality, lipomas of the cauda equina invariably cause an upper motor neuron lesion (70%), alone or in combination with a lower motor neuron deficit (30%) (Satar et al., 1995). The split cord syndrome results in an isolated upper or lower motor neuron lesion in 25% each or a combined lesion in 50% (Proctor et al., 2000).

The reason for this difference in neurologic findings may be related to (1) compression of the cauda equina or sacral nerve roots by an expanding lipoma or lipomeningocele (Yamada et al., 1983)**; (2) tension on the spinal cord from tethering secondary to differential growth rates in the bony vertebrae and neural elements, and the lower end of the cord is held in place by the lipoma or by a thickened filum terminale** (Dubowitz et al., 1965)**; or (3) fixation of the split lumbosacral cord by an intravertebral bony spicule or fibrous band** (Andar et al., 1997; Pang, 1992; Pang et al., 1992). The overt stretching that invariably occurs when there is a forcible flexion and/or extension of the spinal cord with normal movement leads to changes in oxidation/reduction of cytochrome oxidase, most notably in the lumbosacral spinal neurons when there is no intraspinal pathologic process (Henderson et al., 2005; Yamada et al., 1983). Under normal circumstances the conus medullaris ends just below the L2 vertebra at birth and “recedes” upward to T12 by adulthood (Barson, 1970). When the cord does not “rise” or is fixed in place as a result of one of these lesions, ischemic injury may ensue (Yamada et al., 1981, 2004). Correcting the lesion in infancy has resulted not only in stabilization but also in improvement in the neurologic picture in many instances (Cornette et al., 1998; Koyanagi et al., 1997; Proctor et al., 2000) (Fig. 34.11). Sixty percent of infants with abnormal urodynamic findings preoperatively revert to normal postoperatively, with improvement noted in 30%; 10% become worse with time. In older children there is a less dramatic change after surgery, with only 27% becoming normal, 27% improving, 27% stabilizing, but 19% actually becoming worse with time (see Fig. 34.11) (Keating et al., 1988; Satar et al., 1995). Older children with an overactive detrusor tend to improve, whereas those with acontractile bladders do not (Flanigan et al., 1989; Hellstrom et al., 1986; Kondo et al., 1986). Finally, 5% to 27% of children operated on in early childhood develop secondary tethering when observed for several years, suggesting that early surgery has both beneficial and sustaining effects in patients with this condition (Pierre-Kahn et al., 1997; Proctor et al., 2000; Satar et al., 1995).

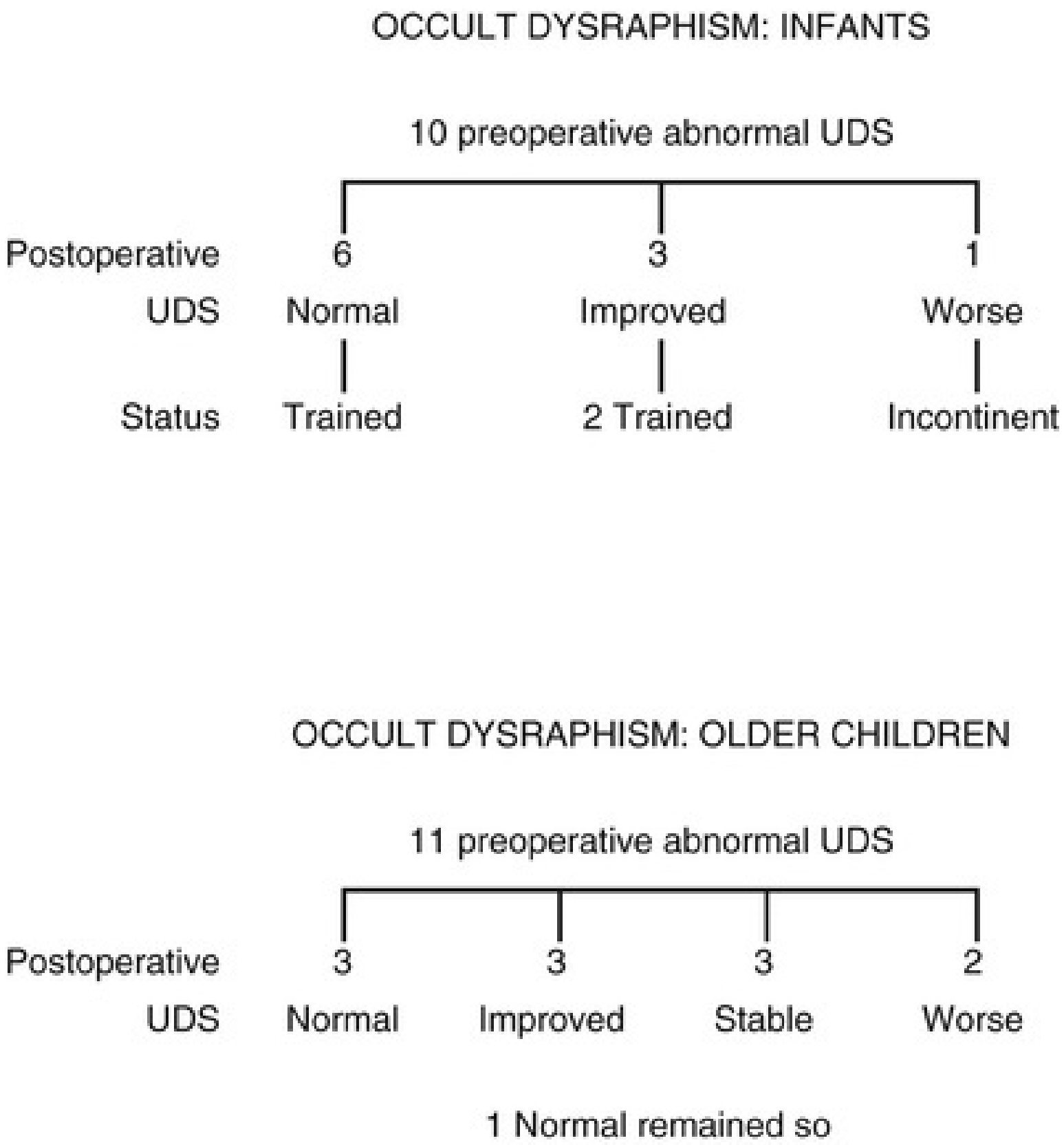
OCCULT DYSRAPHISM: INFANTS
10 preoperative abnormal UDS
Postoperative
UDS
Status
6
Normal
Trained
3
Improved
2 Trained
1
Worse
Incontinent
OCCULT DYSRAPHISM: OLDER CHILDREN
11 preoperative abnormal UDS
Postoperative
UDS
3
Normal
3
Improved
3
Stable
2
Worse
1 Normal remained so

FIG. 34.11 The potential for recoverable function is greatest in infants (6 of 10, 60%) and less so in older children (3 of 11, 27%). The risk for damage to neural tissue at the time of exploration to those with normal function is small (2 of 19, 11%). *UDS,* Urodynamic study.

As a result of these findings, it is apparent that urodynamic testing may be the only way to document that an occult spinal dysraphism is actually affecting lower spinal cord function (Keating et al., 1988; Khoury et al., 1990; Pierre-Kahn et al., 1997; Sarica et al., 2003). The serial use of electromyography of the external urethral sphincter using a needle electrode to monitor individual motor unit action potentials provides a precise mechanism for measuring changes in innervation that may occur over time. Some investigators have shown that posterior tibial somatosensory evoked potentials are an even more sensitive indicator of tethering and should be an integral part of the urodynamic evaluation (Roy et al., 1986). The implication of these findings lies in the fact that **early detection and early intervention can either reverse or at least stabilize the progression of the lesion, which does not happen in older children** (Kaplan et al., 1988; Yamada et al., 1983), and offers a degree of protection from subsequent tethering (Pierre-Kahn et al., 1997; Proctor et al., 2000; Satar et al., 1995), which seems to be a frequent occurrence when the lesion is not dealt with expeditiously in infancy (Chapman, 1982; Seeds and Jones, 1986) (see Fig. 34.11). Improvement of urodynamic parameters is most likely to occur in those undergoing neurosurgical repair for lipomeningocele in the first 12 months of life compared with those 12 to 36 months of age. Those children undergoing surgery after 36 months of age were least likely to have improvement in their urodynamic findings (Rendeli et al., 2007). Thus, early intervention provides more favorable outcomes for motor and bladder function (Tuite et al., 2016).

Specific Recommendations

In addition to MRI studies (Tracy and Hanigan, 1990), urodynamic testing including EMG of the external urethral sphincter should be performed in every child who has a questionable cutaneous or bony abnormality of the lower spine, especially if there is a radiologic abnormality of the spinal cord (Campobasso et al., 1988; Hall et al., 1988; Meyrat et al., 2003; Packer et al., 1986). This test provides the most accurate measure of sacral spinal cord function at diagnosis and provides a basis for comparison with subsequent studies when the children are either operated on or carefully observed. **In children younger than 3 months of age, the vertebral bones have not ossified; thus a window of opportunity exists for ultrasonography to be a useful screening tool in visualizing the spinal canal** (Fig. 34.12) (Raghavendra et al., 1983; Scheible et al., 1983)**. At this age, there is good correlation between the ultrasound imaging and MRI findings; however, if a spinal cord abnormality is identified, the latter provides a better definition of the spinal cord lesion. Consequently, ultrasonography should not be used as the definitive imaging modality** (Hughes et al., 2003). Older children with an occult spinal cord lesion may have urologic symptoms in 20% of cases (Hsieh et al., 2006), and 50% to

60% may have abnormal urodynamic findings preoperatively (Guerra et al., 2006). Resolution of abnormal urodynamic parameters is noted in 50% to 60% of cases after detethering (Guerra et al., 2006; Hsieh et al., 2006). **Therefore, urodynamic testing is recommended for all children with an occult spinal dysraphism before and after spinal cord detethering procedures.** In addition to UDS, all children should have renal/bladder ultrasonography at presentation (Bauer et al., 2012).

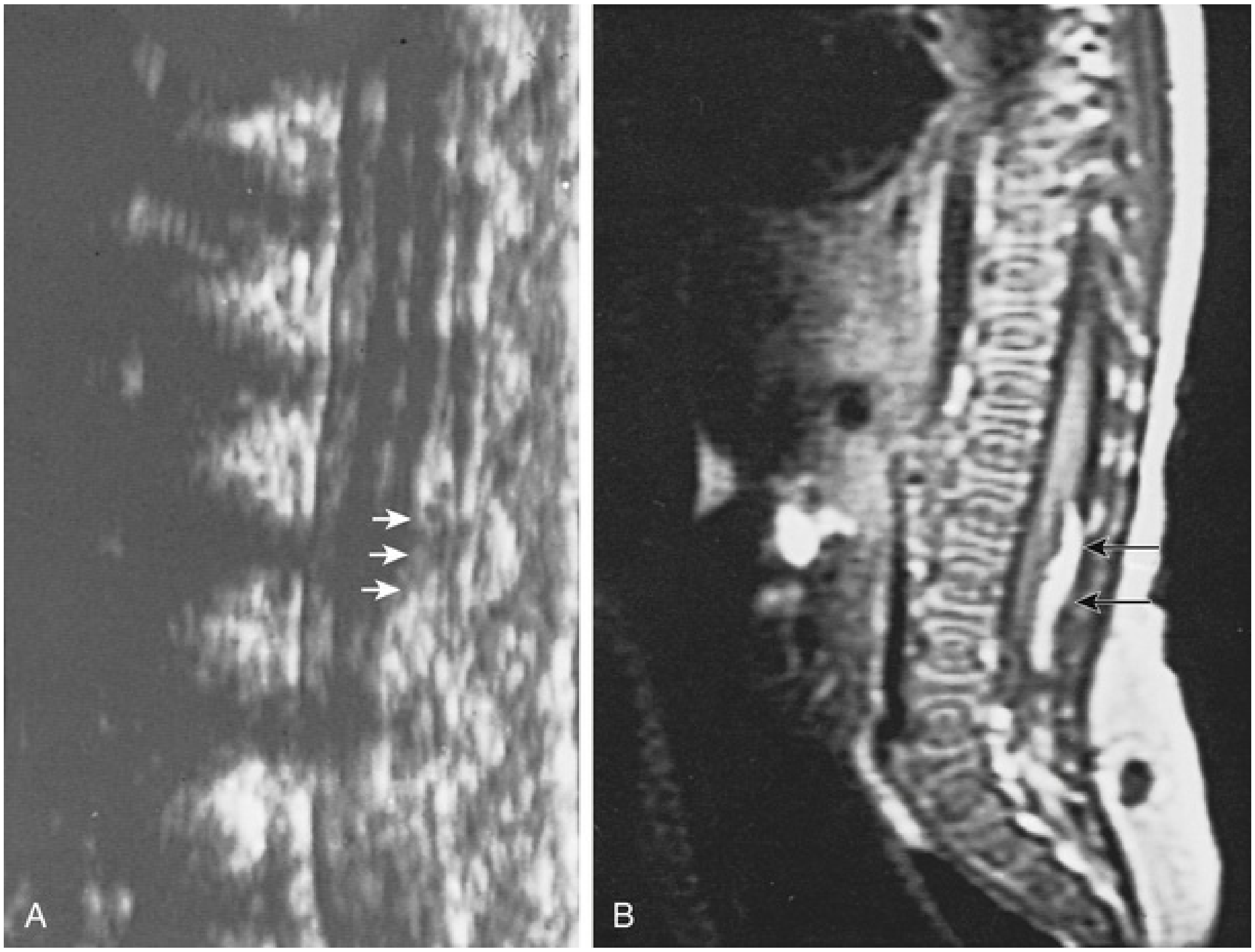

FIG. 34.12 (A) During the first few months of life, ultrasonography can clearly demonstrate intravertebral anatomy because the posterior arches have not completely ossified. Note that the spinal cord along with its central canal is displaced anteriorly *(white arrows)* beginning at L3 because of an intradural lipoma. (B) The MRI scan is juxtaposed to confirm the ultrasound findings. The longitudinal white intraspinal mass *(black arrows)* is the lipoma; the longitudinal gray mass is the spinal cord.

In the past, most of these conditions were treated by excising the superficial skin lesion without dissecting further into the spinal canal to remove or repair the entire abnormality. Currently, most neurosurgeons advocate laminectomy and removal of the intraspinal process as completely as possible without injuring the nerve roots or cord to release the tether and prevent further injury with subsequent growth (Atala et al., 1992; Foster et al., 1990; Kaplan et al., 1988; Kondo et al., 1986; Linder et al., 1982; Pierre-Kahn et al., 1997; Proctor et al., 2000). Long-term urologic follow-up is recommended, according to the guidelines put forth by the ICCS, which are summarized in Table 34.3 (Bauer et al., 2012).

Key Points: Lipomeningocele and Other Spinal Dysraphisms

- Children with an occult neural tube defect often present after 3 or 4 years of age with incontinence or constipation. They may present with new urologic symptoms after a growth spurt related to tethering of the spinal cord. Most have a cutaneous abnormality overlying the spine.
- Radiologic examination of the spine, MRI, and renal ultrasonography are indicated in the initial evaluation. Spinal ultrasonography may be used as a screening investigation before MRI in those younger than 3 months of age.
- UDS should be done before and after spinal cord detethering.
- Intervention with spinal cord detethering early in life is associated with more favorable outcomes than when done later.

Sacral Agenesis

Presentation

Sacral agenesis has been defined as the absence of part or all of two or more lower vertebral bodies. The presentation is bimodal, with more than three-fourths of children being detected in early infancy and the remainder discovered between 4 and 5 years of age (Wilmshurst et al., 1999). With the increased use of prenatal ultrasonography, it is being diagnosed with increased frequency before birth. Sacral vertebral bony ossification begins at 15 weeks, so it is possible to detect the lesion after 18 weeks' gestation on a prenatal ultrasound examination and then to confirm it by fetal MRI (De Biasio et al., 2003). When not detected prenatally or at birth, the diagnosis is often delayed until failed attempts at toilet training bring the child to the attention of a physician. Presenting urinary symptoms in those 4 years of age and older include urinary incontinence or constant dribbling in 85% and recurrent UTI in 74%. VUR may be seen in up to 65% (Emami-Naeini et al., 2012). Sensation, including that in the perianal dermatomes, is usually intact, and lower extremity function is normal (Capitanucci et al., 1997; Koff and Deridder, 1977). Because these children have normal sensation and little or no orthopedic deformity in the lower extremities (although high arched feet or claw toes or hammer toes may be present), the underlying lesion is often overlooked. In fact, 20% escape detection until 3 or 4 years of age (Guzman et al., 1983). The only clue, besides a high index of suspicion, is flattened buttocks and a low, short gluteal cleft (Bauer, 1990) (Fig. 34.13). Palpation of the coccyx is helpful in detecting the absent vertebrae (White and Klauber, 1976). The diagnosis is most easily confirmed with a lateral film of the lower spine, because this area is often obscured by overlying gas and fecal matter on an anteroposterior projection (Guzman et al., 1983; White and Klauber, 1976) (Fig. 34.14). MRI has been used to visualize the spinal cord in these cases; its imaging reveals a sharp cutoff of the conus at T12 as a consistent finding (Diel et al., 2001; Pang, 1993) (Fig. 34.15).

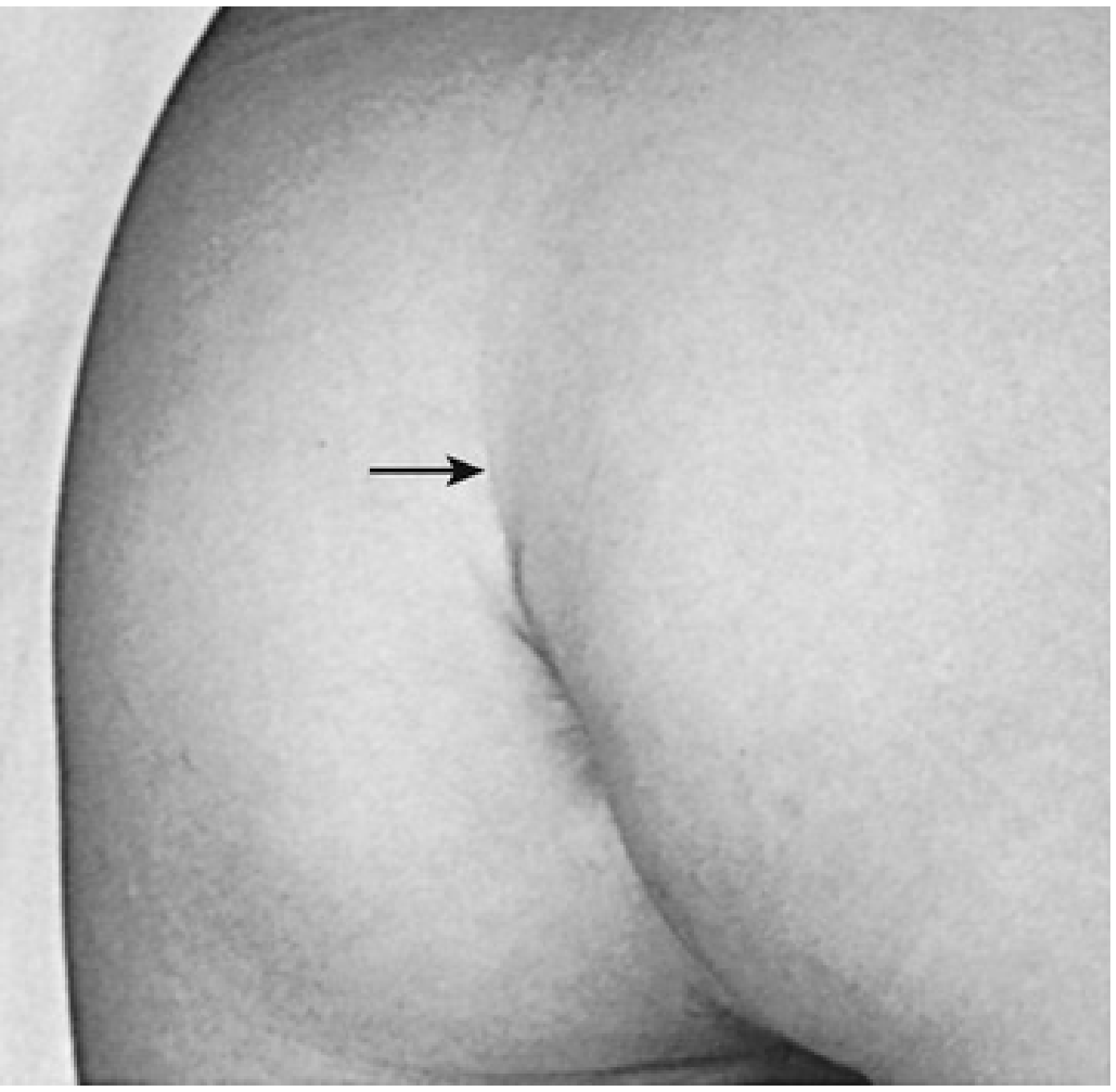

FIG. 34.13 Characteristically, in sacral agenesis the gluteal crease is short and is seen only inferiorly *(below arrow)* because of the flattened buttocks.

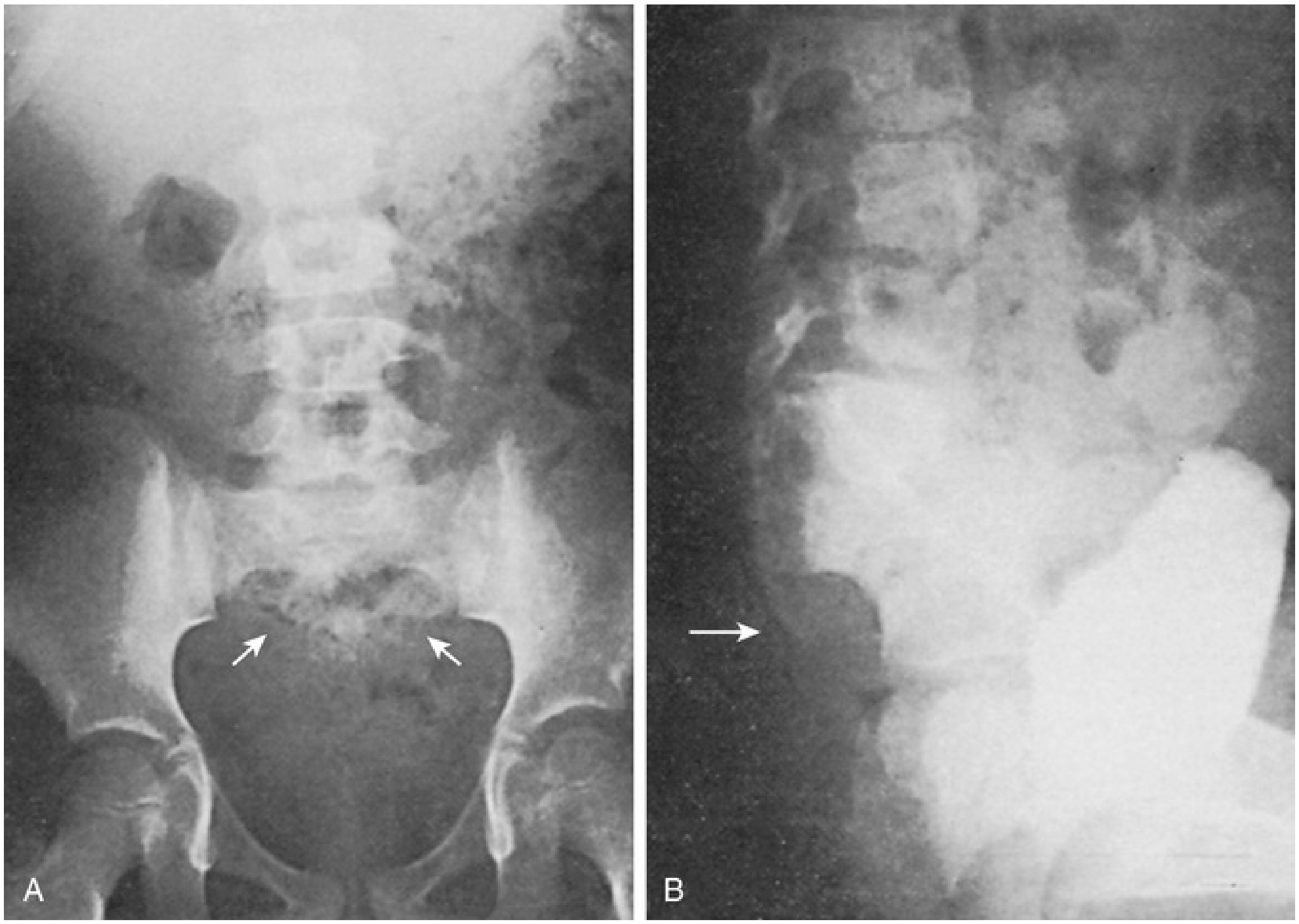

FIG. 34.14 The diagnosis of partial or complete sacral agenesis *(arrows)* is easily confirmed on an anteroposterior (A) or lateral (B) radiograph of the spine if bowel gas obscures the sacral area. (From Bauer SB. Early evaluation and management of children with spina bifida. In: King LR, ed. *Urologic surgery in neonates and young infants.* Philadelphia, PA: WB Saunders; 1988:283–310.)

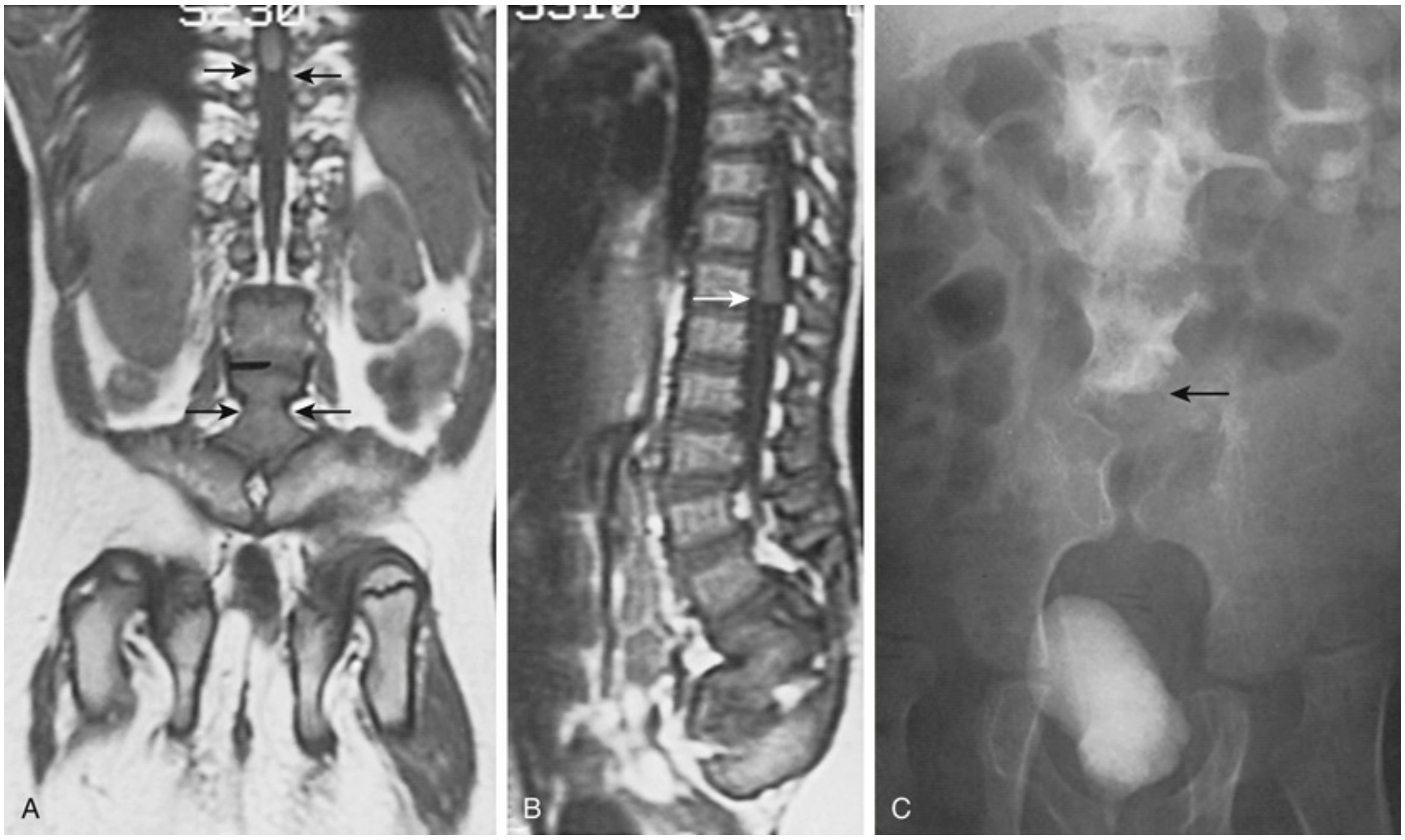

FIG. 34.15 Coronal (A) and sagittal (B) MRI scan in a 10-year-old boy with sacral agenesis beginning at L5. Note the squared lower limit of the cord adjacent to T11 (A, *upper arrows;* B, *white arrow*) and the two sacroiliac joints (A, *lower arrows*), which are in the midline because of absence of the sacrum. (C) An anteroposterior radiograph from an excretory urogram shows no vertebral bodies below L4 *(arrow).*

On urodynamic evaluation, an almost equal number of individuals manifest either an upper or lower motor neuron lesion (35% vs. 40%, respectively); 20 to 25% have no sign of denervation (Boemers et al., 1994a; Guzman et al., 1983). The number of affected vertebrae does not seem to correlate with the type of motor neuron lesion present (Boemers et al., 1994a) (Fig. 34.16). The injury appears to be stable and rarely shows signs of progressive denervation as the child grows. Sacral sensation is relatively spared, even in the presence of extensive sacral motor deficits (Boemers et al., 1994a). UTI may be detected in 75% of children over time, with VUR diagnosed in 37%. Reflux is most likely to occur in those with an upper motor neuron lesion (75%) (irrespective of whether they have synergy or dyssynergy) versus a lower motor neuron lesion (40%) (Wilmshurst et al., 1999).

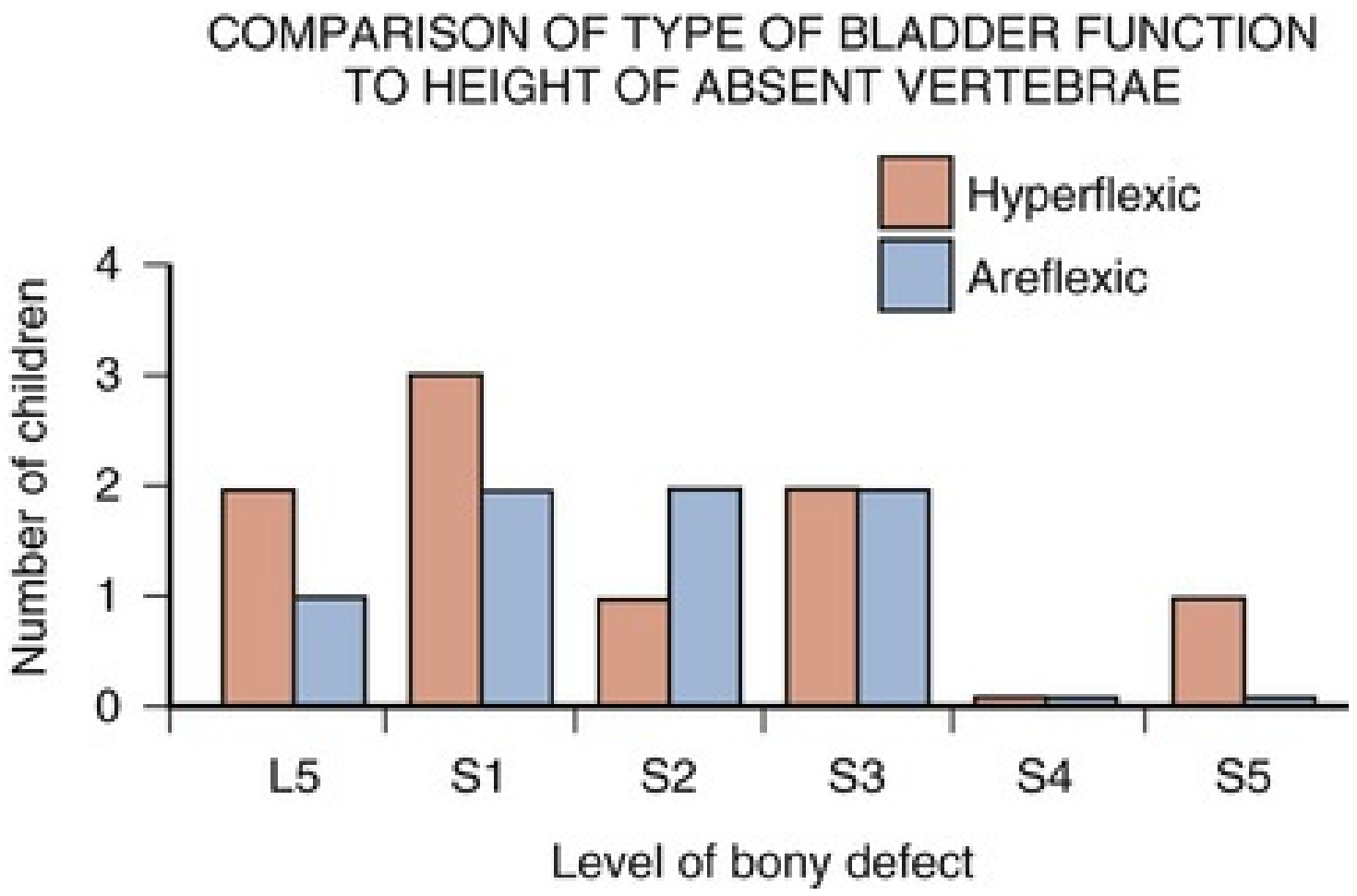

FIG. 34.16 Bladder contractility is unrelated to the number of absent vertebrae. (From Bauer SB. Early evaluation and management of children with spina bifida. In: King LR, ed. *Urologic surgery in neonates and young infants.* Philadelphia, PA: WB Saunders; 1988:283–310.)

Pathogenesis

The cause of this condition is still uncertain, but teratogenic factors may play a role, because insulin-dependent diabetic mothers have a 1% chance of giving birth to a child with this disorder. Conversely, 16% or more of children with sacral agenesis have a mother who is insulin dependent with diabetes mellitus (Guzman et al., 1983; Passarge and Lenz, 1966; Wilmshurst et al., 1999). In cases of gestational insulin-dependent diabetes, this dependency is present before conception or begun early in the first trimester. The disease has been reproduced in chicks by exposing embryos to insulin (Landauer, 1945; White and Klauber, 1976). Maternal insulin-antibody complexes have been noted to cross the placenta, and their concentration in the fetal circulation is directly correlated with macrosomia (Menon et al., 1990). It is possible that a similar cause-and-effect phenomenon occurs in sacral agenesis. There is evidence that a deletion of the seventh chromosome (7q36) leading to the absence of a transcription factor may be responsible for this anomaly (Papapetrou et al., 1999). In addition, maternal drug exposure (i.e., minoxidil) has been reported to cause sacral agenesis (Rojansky et al., 2002).

In familial cases of sacral agenesis associated with the Currarino syndrome (presacral mass, sacral agenesis, and anorectal malformation), deletions in chromosome 7 (7q) resulting in *HLXB9* genetic mutations have been found (Ross et al., 1998). A mutation in *HLXB9*, a homeodomain gene of a 403–amino acid protein that appears to be responsible for neural plate infolding, has been identified in 20 of 21 patients with familial cases and in 2 of 7 sporadic cases of Currarino syndrome (Hagan et al., 2000; Köchling et al., 2001). Heterozygote carriers within these families have also been identified (Lynch et al., 2000). Thus, sacral agenesis may represent one point on a spectrum of abnormalities that encompass sacral meningoceles and anorectal malformations (Bernbeck et al., 2004).

Specific Recommendations

Because most children who are diagnosed with this condition have a neurologic deficit, urodynamic testing is mandatory at the time of diagnosis. **Renal ultrasonography and nuclear or conventional cystography should be included as part of the evaluation process, especially if the child has a history of UTI or findings of an upper motor neuron lesion on urodynamic testing.** Additional imaging studies may be required based on the child's history and findings from baseline studies.

Management depends on the specific type of neurourologic dysfunction seen on urodynamic testing (Choi et al., 2016). Antimuscarinic agents should be given to children with upper motor neuron findings of detrusor overactivity, whereas CIC and α-sympathomimetic medications may have to be given to individuals with lower motor neuron deficits who cannot empty their bladders or stay dry between catheterizations. When antimuscarinic medication is ineffective in controlling the overactive detrusor, augmentation cystoplasty may be required to attain an adequate organ for urinary storage. Failure of α-sympathomimetic agents may require either endoscopic injection of bulking agents, AUS implantation, bladder neck sling, or bladder neck reconstruction with or without bladder neck sling to increase bladder outlet resistance. The bowels manifest a similar picture of dysfunction and need as much characterization and treatment as the LUT. Anorectal manometry has identified abnormalities in the internal anal sphincter and in voluntary anal sphincter squeeze pressure, leading to weakness of the muscle and concomitant fecal incontinence (Morera and Nurko, 2003). It is important to identify these individuals as early as possible so that they can become continent and out of diapers at an appropriate age, thus avoiding the social stigma of fecal or urinary incontinence.

Key Points: Sacral Agenesis

- The index of suspicion for sacral agenesis should be high in children presenting with incontinence or UTIs with a short gluteal cleft and/or flattened buttocks.
- The children of diabetic mothers or those with gestational diabetes are at increased risk.
- Initial investigation includes UDS, renal ultrasonography, and nuclear cystography.
- Long-term follow-up is required.

Conditions of the Pelvis

Anorectal Malformations

Presentation

Anorectal malformations encompass a wide spectrum of diseases involving the distal anus and rectum and the urinary and genital tracts. The abnormalities may be minor with excellent prognosis or very complex with poor functional outcomes (Levitt and Peña, 2007). This malformation occurs in approximately 1 in 5000 live births (Levitt and Peña, 2007). The International (Krickenbeck) Classification of anorectal malformations separates entities into major clinical groups according to the location of fistula and rare or regional variants (Table 34.8) (Holschneider et al., 2005). Urinary tract abnormalities have been noted in 26% to 52% of affected children, with renal agenesis (primarily left-sided) and VUR as the most common associated findings (Parrott, 1985). The highest incidence of an abnormality is in those children with a high (70%) (supralevator insertion of fistula) versus a low (infralevator) (35%) lesion (Emir and Söylet, 1998; Shaul and Harrison, 1997), with boys more prone than girls to having an anomaly (50% vs. 29%) (Metts et al., 1997).

TABLE 34.8

Types of Occult Spinal Dysraphisms

Lipomeningocele
Intradural lipoma
Diastematomyelia
Tight filum terminale
Dermoid cyst/sinus
Aberrant nerve roots
Anterior sacral meningocele

Spinal bony abnormalities range in incidence from 30% to 44%, but patients with a high lesion are more likely to be affected (48% to 54%) than those with a low lesion (15% to 27%) (Carson et al., 1984; Long et al., 1996; Tsakayannis and Shamberger, 1995). Spinal cord abnormalities including tethered cord, thickened or fatty filum terminale, and lipoma have been noted in 18% to 50% of patients, with the incidence varying proportionately in relation to the height of the rectal lesion (Shaul and Harrison, 1997). Neurogenic bladder dysfunction is a frequent finding (Kakizaki et al., 1994), usually manifesting as incontinence, but its occurrence is rare when no spinal cord malformation exists (Hulthén de Medina et al., 2004) (Fig. 34.17). It often manifests when the child is older and the parents have difficulty with toilet training. Cutaneous malformations suggesting an underlying occult spinal dysraphism is rarely, if ever, present.

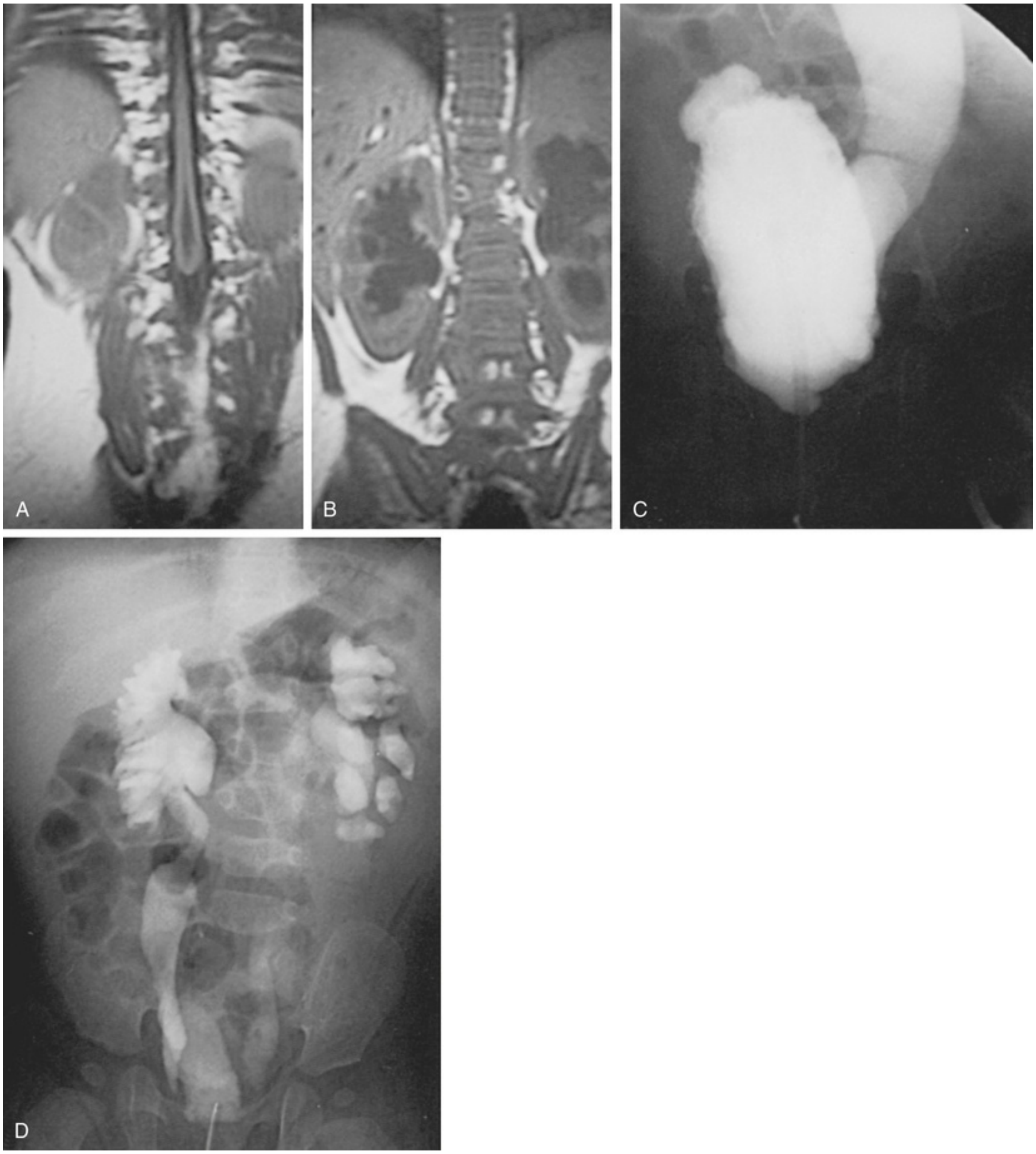

FIG. 34.17 (A, B) A 1-year-old girl with an imperforate anus and bony vertebral abnormalities has a tethered cord and bilateral hydronephrosis on magnetic resonance imaging. (C) Voiding cystourethrogram reveals significant trabeculation and reflux on the left. (D) Excretory urogram demonstrates bilateral hydronephrosis secondary to the reflux on the left and a ureterovesical junction obstruction on the right. Subsequent urodynamic study revealed poor detrusor compliance and dyssynergy.

Anorectal malformations may be nonsyndromic or occur in conjunction with many different conditions (Levitt and Peña, 2007). Important examples of syndromic anorectal malformations include VACTERL syndrome (**v**erterbral anomalies, **a**nal atresia, **c**ardiac malformations, **t**racheo**e**sophageal fistula, **r**enal anomalies, and **l**imb abnormalities), MURCS (**Mü**llerian duct aplasia, **r**enal aplasia, and **c**ervicothoracic **s**omite dysplasia), OEIS (**o**mphalocele, **e**xstrophy, **i**mperforate anus, and **s**pinal defects), and Currarino syndrome (anorectal malformation, sacrococcygeal defect, presacral mass) (Currarino et al., 1981; Levitt and Peña, 2007).

The most common finding on urodynamic testing is an upper motor neuron lesion with an overactive detrusor and/or DSD (Boemers et al., 1994b; Borg et al., 2009; Taskinen et al., 2002) but a lower motor neuron lesion with an acontractile detrusor and a denervated sphincter may be seen as well (see Fig. 34.17) (Greenfield and Fera, 1991; Taskinen et al., 2002). Leak point pressures in excess of 40 cm H_2O, decreased compliance, and low bladder capacity has been noted (De Filippo et al., 1999; Stathopoulos et al., 2012). Normal UDS do not exclude a vertebral anomaly or spina bifida (Stathopoulos et al., 2012).

Children with Currarino syndrome are noted to have a tethered spinal cord in more than 80% of cases (Lee et al., 2012a). Postoperative voiding complaints including urgency, frequency, incontinence, and UTI are noticed in approximately 80% (Lee et al., 2012a). Upper urinary tract changes such as hydronephrosis and VUR are not uncommon (Lee et al., 2012a). Surgical untethering of the spinal cord results have variable outcomes for urodynamic abnormalities, with some showing improvement, worsening, or no change (Lee et al., 2012a). Urodynamic abnormalities include small capacity, poor compliance, detrusor overactivity, detrusor sphincter dyssynergia, and/or high voiding pressure (Lee et al., 2012a).

Pathogenesis

The etiology of anorectal malformations remains unclear. It is most likely multifactorial, with some genetic component (Levitt and Peña, 2007). Although evidence for risk factors in the development of anorectal malformations is limited, paternal smoking, maternal obesity, and maternal pregestational and gestational diabetes are associated with increased risk (Zwink et al., 2011). **The etiology of neurogenic bladder in these children is most commonly associated with a spinal cord abnormality.** The posterior sagittal anorectoplasty (PSARP) approach espoused by Peña (1986) minimizes the chances of injuring the pelvic nerves that innervate the pelvic floor muscles and does not appear to result in iatrogenic neurogenic bladder dysfunction (Borg et al., 2009; De Filippo et al., 1999). Eighteen percent to 35% of those with anorectal malformations are noted to have neurogenic bladder (Borg et al., 2009; Mosiello et al., 2003a; Stathopoulos et al., 2012). Almost all have abnormal urodynamic findings before PSARP (Borg et al., 2009) and are usually (Borg et al., 2009) but not always (De Filippo et al., 1999; Stathopoulos et al., 2012) associated with a spinal cord abnormality.

Specific Recommendations

Initial evaluation in the neonatal period should include careful inspection of the perineum looking for a fistulous site from the bowel, an examination of the upper and lower extremities, and an assessment of the spine and spinal cord (Carson et al., 1984; Mosiello et al., 2003a). Because of the high rate of associated genitourinary abnormalities, **renal-bladder ultrasonography is indicated in all children with an anorectal malformation** (Levitt and Peña, 2007). Abnormalities of the renal ultrasound scan such as hydronephrosis and renal asymmetry should be further investigated with VCUG.

Not all patients with a spinal cord abnormality have a bony defect, so intraspinal imaging in all children with anorectal malformations is recommended to ensure the presence of a normal spinal cord. (Miyasaka et al., 2009; Mosiello et al., 2003a; Rivosecchi et al., 1995). To rule out any abnormal intraspinal process, ultrasonography of the spine in children younger than 3 months of age (because the vertebral bodies have not ossified) or spinal MRI in those older than 3 months of age is recommended (see Figs. 34.12 and 34.17) (Barnes et al., 1986; Emir and Söylet, 1998; Mosiello et al., 2003a; Tunell et al., 1987).

UDS are reserved for children with either a bony abnormality of the spine, a spinal cord defect, or the telltale signs of dysfunction on VCUG or renal ultrasonography (Mosiello et al., 2003a; Taskinen et al., 2002). These studies should be conducted early in infancy before the child has had any definitive surgery for the imperforate anus and again after a pull-through operation has been performed on the rectum to determine, respectively, the true incidence of neurogenic bladder dysfunction and any changes that might have occurred as a result of the surgery (Borg et al., 2009). The presence of an abnormality on urodynamic testing in early infancy may warrant either intervention at that time to correct a spinal cord defect or watchful waiting to determine whether the lesion is progressive. UDS are repeated subsequently or performed for the first time if secondary urinary or fecal incontinence ensues (Taskinen et al., 2002). Long-term follow-up reveals that ESRD is rare, but may occur in just under 2% of those children with anorectal malformation (Giuliani et al., 2013). Thus, if neurogenic bladder dysfunction is noted, long-term follow-up with annual ultrasonography and repeat urodynamic or other imaging studies as specified in Table 34.3 is recommended.

Pelvic Surgery

Presentation

In children, exenterative pelvic surgery for sacrococcygeal teratoma (Ozkan et al., 2006), pelvic rhabdomyosarcoma/other pelvic neoplasms (Yeung et al., 1994), and Hirschprung disease (Holschneider et al., 2005) is well known to have deleterious effects on LUT function.

Children who have surgical resection of sacrococcygeal teratomas are noted to develop neurogenic bladder dysfunction in 35% to 45% of cases (Gabra et al., 2006; Le et al., 2011). Common presenting symptoms include UTI and incomplete bladder emptying (Ozkan et al., 2006). Urodynamic profiles reveal normal findings in 28% (Ozkan et al., 2006), detrusor overactivity in 57% to 81% (Boemers et al., 1994a; Ozkan et al., 2006), detrusor underactivity in 14% to 27% (Boemers et al., 1994a; Ozkan et al., 2006), poor compliance in 33% (Le et al., 2011), and detrusor sphincter dyssynergia in 18% to 38% (Boemers et al., 1994a; Ozkan et al., 2006). Upper urinary tract deterioration may include renal scarring or decreased GFR (25%) (Le et al., 2011), VUR (25% to 50%) (Le et al., 2011; Ozkan et al., 2006), and hydronephrosis (30% to 43%) (Le et al., 2011; Ozkan et al., 2006). A tethered spinal cord can contribute to the neurogenic bladder abnormality in a small proportion of patients with sacrococcygeal teratoma (Boemers et al., 1994a; Mosiello et al., 2003b).

Children presenting with genitourinary rhabdomyosarcomas in the past were uniformly treated with cystectomy. Currently, bladder preservation is attempted when feasible (Raney et al., 2006). Children who are treated for pelvic neoplasms are noted to have normal bladder function postoperatively in 27% to 40% (Arndt et al., 2004; Hishiki et al., 2013; Mosiello et al., 2003b). Those who are symptomatic with their LUT dysfunction present with nocturnal enuresis (26%) (Raney et al., 2006), daytime incontinence (14% to 27%) (Raney et al., 2006), urinary urgency (Soler et al., 2005), suprapubic pain with bladder filling (Soler et al., 2005), and UTIs (55%) (Raney et al., 2006). UDS reveal markedly reduced functional bladder capacity (Soler et al., 2005; Yeung et al., 1994), detrusor overactivity (Mosiello et al., 2003b; Soler et al., 2005), detrusor underactivity (Mosiello et al., 2003b), and detrusor sphincter dyssynergia (Mosiello et al., 2003b). Those children treated with bladder preservation strategies for pelvic rhabdomyosarcoma, especially those who receive radiation therapy, are at high risk for LUT symptoms and upper urinary tract deterioration (Raney et al., 2006; Soler et al., 2005; Yeung et al., 1994). Abnormal renal function was noted in one-third and hydronephrosis in 15% (Raney et al., 2006). Urinary tract reconstruction or diversion was ultimately required in close to 20% of children in one large series (Raney et al., 2006).

Up to 45% of children with Hirschsprung disease will have unstable detrusor contractions that often resolve after the abnormal bowel is resected (Boemers et al., 2001). Transient urinary retention was noted in up to 7% of children undergoing surgery for Hirschsprung disease (Ateş et al., 2007). From to 0% to 6% of children had urinary incontinence postoperatively with long-term follow-up (Holschneider et al., 1982; Boemers et al., 2001). Approximately one-third of these children had normal urodynamic findings postoperatively (Boemers et al., 2001). Two-thirds had an increased maximum cystometric capacity (Boemers et al., 2001), and 55% to 78% had a high postvoid residual urine (Ateş et al., 2007; Boemers et al., 2001). Poor compliance was rarely noted (Boemers et al., 2001). Different surgical approaches are noted to have varying effects on bladder function (Ateş et al., 2007).

Pathogenesis

Surgery of the pelvic viscera can result in damage to the pelvic splanchnic nerves, the hypogastric nerves, or the pelvic nerve plexus, resulting in autonomic denervation. Parasympathetic denervation (injury to the pelvic splanchnic nerves) may result in an acontractile bladder. Sympathetic denervation (injury to the hypogastric nerves) may cause a loss of bladder compliance and diminished or unresponsive changes in bladder neck resistance when increases in abdominal pressure occur. Mixed patterns of LUT dysfunction may be seen with injury to the pelvic plexus (Blaivas and Barbalias, 1983; Chang and Fan, 1983; Leveckis et al., 1995; Woodside and Crawford, 1980; Yalla and Andriole, 1984).

Specific Recommendations

The risk for upper urinary tract deterioration in those having resection of pelvic sacrococcygeal teratomas is high, therefore preoperative and postoperative UDS are recommended for all (Le et al., 2011; Ozkan et al., 2006). Long-term urologic follow-up is required with annual ultrasonography and clinical review in those who demonstrate urodynamic abnormalities or symptoms. Those who are asymptomatic and/or demonstrate normal postoperative investigations do not require further long-term evaluation unless symptoms arise.

As the risk for upper tract deterioration in those undergoing surgery for pelvic rhabdomyosarcomas is relatively high, it is recommended that all survivors, particularly those who had radiation therapy, be carefully monitored for upper and LUT dysfunction (Yeung et al., 1994). This screening should be carried out with a frequency volume chart (Yeung et al., 1994), with urodynamic and ultrasound investigation limited to those with dysfunction. Long-term urologic follow-up is required with annual ultrasonography and clinical review in those who demonstrate urodynamic abnormalities or symptoms. Those who are asymptomatic and/or demonstrate normal postoperative investigations do not require further long-term evaluation unless symptoms arise.

As children undergoing surgery for Hirschprung disease are usually only symptomatic if bladder function is altered, routine postoperative urodynamic testing is not recommended for everyone. However, all patients should have clinical preoperative and postoperative screening for abnormal LUT function and undergo a urinary tract ultrasound examination (Boemers et al., 2001). Those who are symptomatic preoperatively warrant UDS before surgery. Those who are symptomatic after surgery should have UDS completed 6 months after surgery to allow resolution of temporary neuropraxia (Boemers et al., 2001). Long-term urologic follow-up is required with annual ultrasound examinations and clinical review in those who demonstrate urodynamic abnormalities or symptoms. Those who are asymptomatic and/or demonstrate normal postoperative investigations do not require further long-term evaluation unless symptoms arise.

Central Nervous System Insults

Presentation

CP is the most common physical disability in childhood. A recent study in the United States found that approximately 3.3 of 1000 8-year-old children are variably affected. Its prevalence varies by region. It is more common in black children and white children than in those who are Hispanic, and it is 1.2 times more common in boys than in girls (Kirby et al., 2011). CP is a disorder of the development of movement and posture causing limitations in activities that are the result of nonprogressive disturbances of the fetal or infant brain. Sensation, perception, cognition, communication, and behavior may also be affected (Richards, 2013; Richards and Malouin, 2013) The Gross Motor Function Classification System – Expanded and Revised in 2007 (GMFCS – E&R) (https://canchild.ca/en/resources/42-gross-motor-function-classification-system-expanded-revised-gmfcs-e-r) is based on self-initiated movement, with emphasis on sitting, transferring, and mobility. This is a five-level scale that ranges from 1 (walks without limitations) to 5 (transported in a manual wheelchair). Specific descriptions with relevant age band categories exist for each level.

Affected children will often achieve urinary continence although later than their age-adjusted normal peers (Roijen et al., 2001). Generally, daytime continence is achieved first, followed by nighttime continence within the next year. Overall, 14% (Silva et al., 2009) to 34% (Richardson and Palmer, 2009) of children are continent of urine. The median age for achieving continence in those with high intellectual capacity and diplegia or hemiplegia is 3.6 to 4.1 years. For those with low intellectual capacity and tetraplegia, this milestone is achieved much later (10.1 to 13.2 years) (Roijen et al., 2001). Most studies do not correlate mobility (or GMFCS level) with the achievement of continence (Ersoz et al., 2009; Murphy et al., 2012; Silva et al., 2009). One study of 97 children who were evaluated using a standardized dysfunction voiding symptom survey found that 1 of 4 who were able to walk had LUT dysfunction compared with 3 of 4 who were unable to do so ($P < 0.001$) (Silva et al., 2009). LUT symptoms were more prevalent as the children aged (Murphy et al., 2012; Silva et al., 2009).

The incidence of urinary symptoms in children with CP varies among studies, ranging from 16% (Murphy 2012) to 94% (Gündoğdu et al., 2013). Females are more likely than males to present with LUT symptoms (Ersoz et al., 2009; Silva et al., 2009). The most common symptom is incontinence, ranging from 23% to 94%; most noted a prevalence of 35% to 45% (Gündoğdu et al., 2013; Murphy et al., 2012; Richardson and Palmer, 2009; Roijen et al., 2001). Urgency and frequency was also reported (Murphy et al., 2012). Monosymptomatic (nighttime only) enuresis is seen in 3% (Richardson and Palmer, 2009) to 13% (Silva et al., 2009). UTI was also variable occurring in 5% to 57% (Ersoz et al., 2009; Gündoğdu et al., 2013; Silva et al., 2009, 2010). When evaluated, constipation was detected in 33% to 66% (Gündoğdu et al., 2013; Silva et al., 2009, 2010). Upper urinary tract deterioration, defined primarily as hydronephrosis, is uncommon, occurring in less than 5%, with a range of 0.5% to 12% (Gündoğdu et al., 2013; Murphy et al., 2012; Silva et al., 2009, 2010). Other parameters of deterioration include asymmetric renal size, VUR, and microlithiasis (Gündoğdu et al., 2013; Murphy et al., 2012; Silva et al., 2009). Factors raising the risk for upper urinary tract deterioration include increasing age, clinical symptoms of detrusor sphincter dyssynergia (retention, interrupted voiding, hesitancy), and recurrent UTI (Gündoğdu et al., 2013).

Pathogenesis

The etiology of urinary tract symptoms in some children with CP may be related to abnormal LUT function rather than to decreased mobility or ability to communicate.

Normal UDS are found in one-third of children with CP (Silva et al., 2009). Detrusor overactivity is noted in approximately 30% (Gündoğdu et al., 2013; Murphy et al., 2012) to 61% (Decter et al., 1987). Detrusor underactivity is documented in 6% (Murphy et al., 2012). Bladder capacity is less than expected in 42% to 93% (Ersoz et al., 2009; Gündoğdu et al., 2013; Silva et al., 2009). Detrusor sphincter dyssynergia is found in approximately 12% (Decter et al., 1987; Gündoğdu et al., 2013).

Thirteen percent may have an elevated postvoid residual urine volume (Silva et al., 2009). Uroflow patterns include a bell-shaped curve in 63%, a staccato pattern in 17%, an intermittent pattern in 13%; a plateau-shaped pattern in 3%, and a tower-shaped pattern in 3%) (Ersoz et al., 2009).

Specific Recommendations

Although many affected children may have LUT symptoms, upper urinary tract deterioration is rare. Therefore, most can be managed initially with minimal investigation and conservative management. In those with frequency, urgency, and/or incontinence, **initial investigation should include a urinalysis and culture to rule out UTI, and a minimally invasive uroflow and postvoid residual urine measurement.** Conservative measures such as timed voiding with or without antimuscarinic therapy may be instituted**. If these measures fail, further investigation with UDS may be indicated. In addition, children presenting with factors known to be associated with upper urinary tract deterioration, such as recurrent UTI or clinical symptoms of detrusor sphincter dyssynergia (urinary retention, interrupted voiding, hesitancy), warrant a more aggressive investigation including renal/bladder ultrasonography and UDS. VCUG is indicated in the presence of UTI or DSD.** In patients with severe CP (GMFCS grade IV and V), selective dorsal rhizotomy has been used to treat severe limb spasticity, but has also been shown to significantly improve bladder function in the same patients (D'Aquino et al., 2018).

Conditions of the Brain (Tumors/Infarcts/Encephalopathies)

Presentation

Children with neurogenic bladder resulting from central nervous system (CNS) tumors most commonly present with urinary incontinence and urinary retention (Nguyen et al., 2010; Soler and Borzyskowski, 1998). Other presenting symptoms include UTI, straining/difficulty voiding, hydronephrosis, and urinary urgency (Nguyen et al., 2010; Soler and Borzyskowski, 1998). In some children, development of bladder symptoms heralds progression or recurrence of the disease (Soler and Borzyskowski, 1998).

Pathogenesis

UDS of children with neurogenic bladder resulting from CNS tumors demonstrate poor compliance, inability to void, high voiding pressures, detrusor overactivity, elevated postvoid residual urine, and abnormal urinary sphincter function (Nguyen et al., 2010; Soler and Borzyskowski, 1998). There was no correlation between tumor location and any specific urodynamic parameter, nor was there a difference in urodynamic findings in patients with intracranial versus extracranial tumors or in those with suprasacral versus sacral involvement (Nguyen et al., 2010).

There is little literature related to neurogenic dysfunction that arises from other brain conditions such as encephalopathies and infarcts in children. One study noted that voided volume and rate of consciousness with voiding was significantly lower in newborns with hypoxic ischemic encephalopathy (HIE) than those without HIE (Wen et al., 2012). Those with HIE had significantly higher postvoid residual urine volumes and voiding frequency (Wen et al., 2012)

Specific Recommendations

Because various types of storage and voiding dysfunction can occur independent of tumor location, routine urologic investigation including renal ultrasonography and UDS in all children with CNS tumors is recommended (Nguyen et al., 2010; Soler and Borzyskowski, 1998). Children with encephalopathy may be at risk for bladder dysfunction and should be screened with clinical history. Those who are symptomatic warrant investigation with renal ultrasonography and UDS.

Conditions of the Spinal Cord

Traumatic Injuries

Presentation

Despite increased exposure to and the potential for traumatic SCI, **such injuries are rarely encountered in children.** The incidence in Sweden is 2.6 cases per 1 million children per year (Augutis and Levi, 2003). In the United States, the estimated incidence of hospital admission for SCI is 170 per 1 million in the population younger than 21 years of age, and the incidence of SCI is 24 per 1 million (Piatt, 2015). **The incidence tends to increase geometrically with age, and the incidence of SCI is six times greater for adolescents than for children** (Anderson and Schutt, 1980; Piatt and Imperato, 2018) (Fig. 34.18). When an injury does occur, it is more likely to happen in a male than a female child, and it is usually the result of a motor vehicle or bicycle accident (24% to 52%), a fall from a high place, a gunshot wound, or a diving or sports incident (Augutis and Levi, 2003; Brown et al., 2001; Cass et al., 1984; Cirak et al., 2004; Decter and Bauer, 1993; Hadley et al., 1988). The type of causative injuries varies with age, with infants more prone to injury from a motor vehicle accident (71%), toddlers and children injured secondary to a fall (48% and 34%, respectively) and adolescents having a sports-related event (29%) (Cirak et al., 2004). An injury may also occur iatrogenically after surgery to correct scoliosis, kyphosis, or other intraspinal processes or congenital aortic anomalies or after ligation of a patent ductus arteriosus (Batista et al., 1995; Cass et al., 1984). Neonates are particularly prone to a hyperextension injury during a high forceps delivery (Adams et al., 1988; Lanska et al., 1990). Among younger children, girls are affected as often as boys (Ruge et al., 1988).

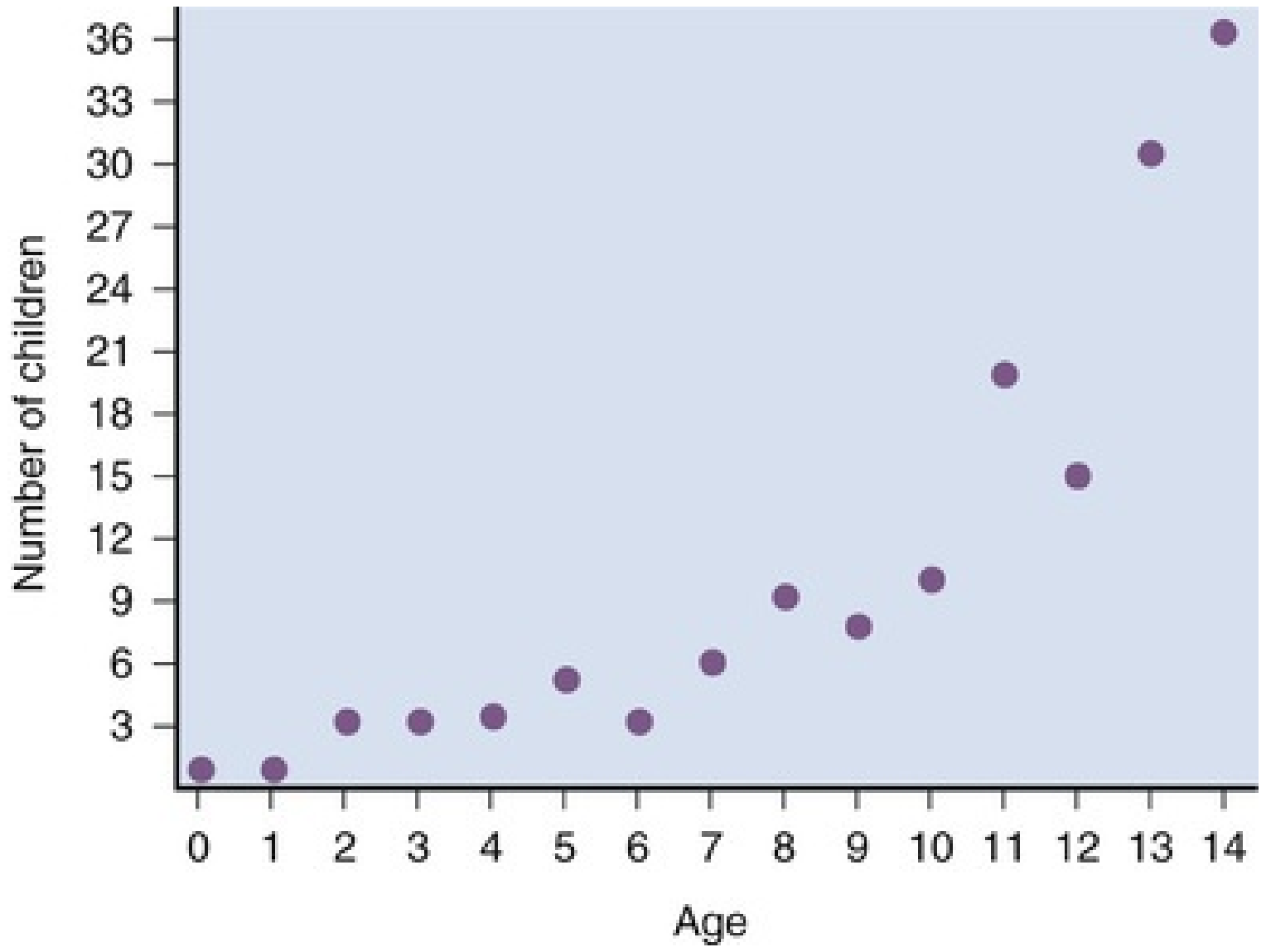

FIG. 34.18 Increasing frequency of spinal injury with age. (From Anderson JM, Schutt AH. Spinal injury in children: a review of 156 cases seen from 1950 through 1978. *Mayo Clin Proc* 55(8):499–504, 1980.)

Pathogenesis

SCIs in children are intrinsically different from those in adults because of a variety of factors, including the mechanism of injury and the difference in configuration of the brainstem and spinal cord in children compared with adults. In addition, the horizontal versus vertical orientation of the facet joints in vertebral bodies that predisposes to anteroposterior subluxation in children, the delayed supportive effect of the paraspinous musculature and ligaments, and the relative heaviness of the head, which causes a fulcrum of maximal flexion of the upper cervical region in infants and young children, all contribute to a high degree of hypermobility that places the child's spinal cord at risk for ischemic necrosis (Decter and Bauer, 1993).

Specific Recommendations

The LUT dysfunction that ensues is not likely to be an isolated event but is usually associated with loss of sensation and paralysis of the lower limbs. Radiologic investigation of the spine may not reveal any bony abnormality, although momentary subluxation of osseous structures resulting from the elasticity of the vertebral ligaments can result in a neurologic injury (Pollack et al., 1988). This condition has been seen only in children (usually younger than 8 years of age) and has been labeled **S**pinal **C**ord **I**njury **W**ith**O**ut **R**adiologic

Abnormality (SCIWORA) (Pang and Pollack, 1989; Pang and Wilberger, 1982). Overall, SCIWORA can account for up to 38% of SCIs in children (Brown et al., 2001). Myelography and CT show swelling of the cord below the level of the lesion (Adams et al., 1988; Lanska et al., 1990). **Often, what appears to be a permanent lesion initially turns out to be a transient phenomenon with time.** Although sensation and motor function in the lower extremities may be restored relatively quickly, the dysfunction involving the LUT and rectum may persist considerably longer.

During the acute phase of the injury, the bladder is often acontractile and the urethral sphincter nonreactive, although normal-appearing bioelectric potentials can be recorded on sphincter EMG (spinal shock). Over a variable period, detrusor contractility and sphincter reactivity return as spinal cord edema subsides. With this return of function, an **overactive detrusor and bladder-sphincter dyssynergy develop if the lateral reticulospinal cord pathways to and from the brainstem have been disrupted. When the lesion affects the cauda equina, there is probably little to no return of bladder or urethral sphincter function.** Sacral sensation and peripheral reflexes are not good indicators of ultimate LUT function (Shenot et al., 1998). Over time, the predominant urodynamic pattern in patients with a thoracic-level lesion is an overactive detrusor with DSD, high voiding pressures, eventual hydronephrosis, and VUR. Often children exhibit a highly compliant bladder for a portion of bladder filling but then have C-fiber–mediated, small, ineffective rhythmic contractions of the detrusor with simultaneous waxing and waning of external urethral sphincter activity. Some urinary leakage may occur with these contractions, but in general the bladder does not empty with them. **Patients with an upper thoracic (above T6) or cervical lesion are likely to exhibit autonomic dysreflexia with a spontaneous discharge of α_1-stimulants during bladder filling and with contractions of the detrusor. Monitoring blood pressure and availability of α-antagonists are mandatory during VCUG or UDS** (Perkash, 1997; Vaidyananthan et al., 1998b).

If urinary retention occurs immediately after the injury, an indwelling Foley catheter is passed into the bladder and left in place for as short a time as possible until the patient's condition is stable and aseptic intermittent catheterization can be started safely on a regular basis (Barkin et al., 1983; Guttmann and Frankel, 1966). There is no difference in the incidence of urinary infection or in the development of stones in patients using sterile versus clean catheterization techniques to empty the bladder (Prieto-Fingerhut et al., 1997;

Van Hala et al., 1997). Rates of infection range as high as 60% to 80% (Biering-Sørensen et al., 1999), and stone formation occurs in 1.5% to 3% within the first 5 years after the trauma (Donnellan and Bolton, 1999; McKinley et al., 1999). When the child starts to void again, the timing of catheterization can be regulated so that it is used as a means of measuring the residual urine after a spontaneous void. Residual urine volumes of 25 mL or less are considered safe enough to allow reducing the frequency or even stopping the catheterization program (Barkin et al., 1983). If there is no improvement in LUT function after 4 to 6 weeks, UDS are conducted to determine whether the condition is the result of spinal shock or an actual nerve root or SCI. An acontractile detrusor is not uncommon under these circumstances (Iwatsubo et al., 1985). On the other hand, EMG recording of the sphincter often reveals normal motor units without fibrillation potentials but absent sacral reflexes and a nonrelaxing sphincter with bladder filling, a sign that transient spinal shock has occurred (Iwatsubo et al., 1985). The outcome of this situation is guarded but good, because most cases resolve completely as edema of the cord in response to the injury subsides, leaving no permanent damage (Fanciullacci et al., 1988; Iwatsubo et al., 1985).

Incomplete emptying may be enhanced by the judicious use of α-sympatholytic agents (Al-Ali et al., 1999). **The goal is balanced voiding at pressures lower than 40 cm H_2O,** which reduces the 30% risk for urinary tract deterioration seen in poorly managed patients (Giannantoni et al., 1998; Kim et al., 1998). If this cannot be achieved, then CIC is continued. Antimuscarinics, either orally or intravesically (Vaidyananthan et al., 1998a; Wein, 1998), or capsaicin (an inhibitor of C-fiber stimulation (Wiart et al., 1998) have been added and are effective in reducing an overactive detrusor, but at the cost of significant side effects. Alternative treatments that have been effective to ensure complete emptying at low pressure include external urethral sphincterotomy (Kim et al., 1998), urethral stent placement (Chancellor et al., 1999), or injection of BTA into the external sphincter (Kuo, 2003; Schurch et al., 1997). In some cases, a continent catheterizable abdominal urinary stoma may be created to facilitate self-catheterization in patients with low cervical or upper thoracic lesions who cannot easily catheterize themselves (Sylora et al., 1997).

Most permanent traumatic injuries involve either the upper thoracic or the cervical spinal cord but some affect the cauda equina region. The sacral cord injury most likely produces a lower motor neuron deficit of the striated urethral sphincter that usually leads to low pressure bladder emptying with little risk for upper urinary tract deterioration. However, it probably necessitates medical and/or surgical management to achieve continence. On the other hand, upper SCIs produce an upper motor neuron lesion with an overactive detrusor and DSD. The potential danger from this outflow obstruction is obvious (Donnelly et al., 1972). Substantial residual urine volumes, high-pressure reflux, urinary infections, and their sequelae are the leading causes of long-term morbidity and mortality in patients with SCI (Giannantoni et al., 1998). Even patients who voluntarily urinate and are continent or who involuntarily but spontaneously void to completion are not immune to urinary tract changes (Decter and Bauer, 1993). **UDS are imperative to identify which patients are at risk** (Barkin et al., 1983)**. These studies should be performed within 2 to 3 months after the injury, again 6 to 9 months later, and possibly at 2 years after the trauma** to determine the stability of LUT function, the need for continued CIC, and whether adjuvant drug or surgical therapy should be added (or continued) to achieve good long-term success. When these measures are employed judiciously, effective management can be achieved (Pannek et al., 1997). **Renal ultrasonography early in the course and, if video UDS are not available, a VCUG if signs of bladder outlet obstruction are present or if recurrent urinary infection ensues are also recommended. Investigation for VUR is indicated if the patient has repeated febrile UTI or develops hydronephrosis** (Phillips et al., 1997)**. Because stone formation can be insidious, periodic ultrasonographic imaging of the kidneys and bladder is necessary**. Early identification and proper management may prevent the signs and effects of bladder outlet obstruction before they become apparent on radiographic examination of the urinary tract (Ogawa et al., 1988; Pearman, 1976).

Tranverse Myelitis

Presentation

Transverse myelitis is a clinical syndrome caused by an immune-mediated inflammatory process that affects the spinal cord (DaJusta et al., 2008). Approximately 1400 new cases are diagnosed in the United States annually, and 28% of affected individuals are children (Krishnan et al., 2004). The incidence peaks between 10 and 19 years of age and again in the third decade of life (Krishnan et al., 2004). Males and females have an equal incidence (DaJusta et al., 2008). The diagnosis is made by accepted criteria, including sensory, motor, or autonomic dysfunction attributable to the spinal cord, bilateral neurologic signs and/or symptoms, a clearly defined sensory level, and inflammation in the spinal cord as demonstrated by cerebrospinal fluid pleocytosis or an increased T2 signal on MRI (Fig. 34.19) (Krishnan et al., 2004).

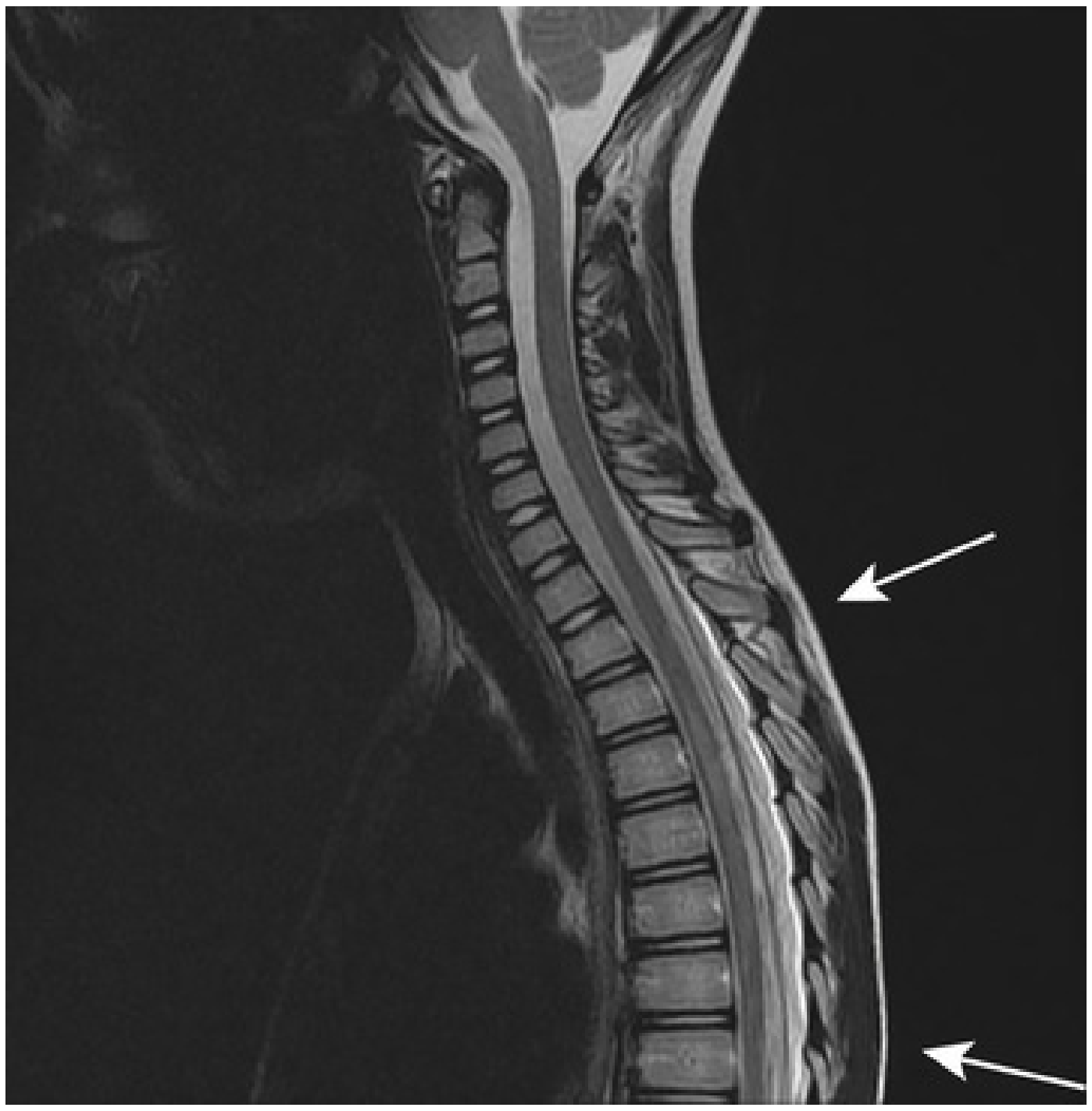

FIG. 34.19 T2-weighted sagittal MRI scan of the spine of an 8-year-old boy who presented with lower extremity weakness and urinary retention. Increased signal intensity of the spinal cord is noted from T3 to T8 *(arrows).*

Transverse myelitis usually presents with sudden lower back pain or lower extremity muscle weakness that rapidly progresses to paralysis and often to urinary retention (Knebusch et al., 1998). Bladder dysfunction may present simultaneously with the motor dysfunction or more commonly follows it (DaJusta et al., 2008). Bowel dysfunction is also likely to occur at presentation (DaJusta et al., 2008). In the acute stage of transverse myelitis, there may be a varying period of spinal shock that may persist for up to 6 weeks (Guttmann, 1970) and which gradually progresses to spasticity if total resolution does not occur. The segment of the spinal cord affected by the disease determines the motor deficit (DaJusta et al., 2008). During the acute phase of the disease, treatment options include steroids, plasma exchange, and intravenous IgG (DaJusta et al., 2008). Recovery from the disease usually commences within 2 weeks to 3 months after the onset of symptoms. The most substantial recovery occurs within the first 6 months (DaJusta et al., 2008), but sometimes improvement continues up to 2 years postevent (Krishnan et al., 2004).

Pathogenesis

It is well documented that the most common urinary symptom in children with transverse myelitis is **urinary retention;** in fact, more than 95% of affected children will have urinary retention during the acute phase of the disease (DaJusta et al., 2008; Gatti et al., 2001; Kalita et al., 2002). **The most common urodynamic finding in the acute phase is areflexia or detrusor underactivity, found in close to 70%** (Kalita et al., 2002). Detrusor overactivity is noted in the acute phase in approximately 13%; 30% have decreased compliance, and 20% may have detrusor sphincter dyssynergia (Kalita et al., 2002). **After resolution of spinal shock, the urodynamic patterns identifiable are detrusor overactivity (59% to 90%), decreased compliance (47%), DSD (17% to 80%), and detrusor leak point pressure greater than 40 cm H_2O (12% to 33%). Detrusor underactivity is noted rarely after resolution of the acute phase of the disease** (Ganesan and Borzyskowski, 2001; Kalita et al., 2002; Tanaka et al., 2006).

Approximately one-third of children will be able to void spontaneously after the acute phase (DaJusta et al., 2008; Tanaka et al., 2006). Some children (57% to 73%) will require CIC to empty their bladder (DaJusta et al., 2008; Tanaka et al., 2006). Antimuscarinic medications are needed to manage symptoms of detrusor overactivity in 14% to 64% (DaJusta et al., 2008; Ganesan and Borzyskowski, 2001; Tanaka et al., 2006). For children whose incontinence is not resolved with CIC and antimuscarinics because of small capacity/poor compliance or unremitting overactivity, injection of BTA and bladder augmentation has been helpful (Tanaka et al., 2006). Up to 77% may have persistent bowel dysfunction; consequently, most require active bowel management (Tanaka et al., 2006).

Although some reports have not correlated LUT function with recovery of motor function (Ganesan and Borzyskowski, 2001; Tanaka et al., 2006), other larger studies have demonstrated an association (DaJusta et al., 2008; Dunne et al., 1986; Kalita et al., 2002). One study found that children with full motor recovery were likely to also have full recovery of LUT symptoms, that is, normal voiding with continence and no requirement for antimuscarinic medication. It was also noted that partial recovery of motor function was associated with partial recovery of LUT function, meaning that children could void spontaneously but required antimuscarinics for incontinence. Children with no motor recovery or those who were wheelchair dependent were likely to require CIC and possibly antimuscarinics (DaJusta et al., 2008).

Profound urologic complications have been noted infrequently in children with transverse myelitis including UTI (DaJusta et al., 2008), VUR, hydroureteronephrosis, chronic renal insufficiency, and bladder calculi and diverticula (Kalita et al., 2002). One study documented an association between late initiation of CIC and increased risk for decreased bladder compliance and upper urinary tract deterioration. In this series, upper urinary tract deterioration, where hydronephrosis or VUR was noted, occurred in 5% of children. In this series, neither neurologic examination nor urinary symptoms were able to predict the risk for upper urinary tract deterioration. In addition, ambulatory status did not correlate with urodynamic findings (Tanaka et al., 2006).

Specific Recommendations

UDS and a baseline renal/bladder ultrasound examination, once the acute phase of the neurologic injury has stabilized, are suggested to identify those patients who may have DSD. Children with bladder underactivity and/or DSD will benefit from the early introduction of CIC and antimuscarinic therapy, respectively (Tanaka et al., 2006). UDS should be performed again after resolution of the acute phase (at approximately 6 months) to guide therapy for incontinence and preservation of the upper urinary tract. Voiding or radionuclide cystography is indicated in the presence of DSD or febrile UTIs if video UDS are not available. As these children are at risk for upper urinary tract deterioration, annual follow-up evaluation including renal ultrasonography is recommended as outlined in Table 34.3. UDS are advisable if there is a change in LUT symptoms or in ultrasound images.

Key Points: Conditions of the Pelvis, Central Nervous System Insults, and Conditions of the Spinal Cord

- Spinal cord abnormalities including tethered spinal cord, thickened or fatty filum terminale, and lipoma occur in 18% to 50% of patients with an anorectal malformation.
- The incidence of LUTS in children with CP is 16% to 94%, and the most common symptom is urinary incontinence.

- In patients with SCI, there is an acute phase of spinal shock wherein the bladder is often acontractile and the urethral sphincter nonreactive; with resolution of spinal shock, an overactive detrusor and bladder-sphincter dyssynergy most commonly develop.
- Patients with a cervical or thoracic spine lesion above T6 are likely to exhibit autonomic dysreflexia during bladder filling and detrusor contractions.

Suggested Readings

Bauer SB, Austin PF, Rawashdeh YF, et al. International Children's Continence Society. International Children's Continence Society's recommendations for initial diagnostic evaluation and follow-up in congenital neuropathic bladder and bowel dysfunction in children. *Neurourol Urodyn*. 2012;31(5):610–614.

Lapides J, Diokno AC, Silber SJ, et al. Clean intermittent self-catheterization in the treatment of urinary tract disease. *J Urol*. 1972;107(3):458–461.

McGuire EJ, Woodside JR, Borden TA, et al. The prognostic value of urodynamic testing in myelodysplastic patients. *J Urol*. 1981;126(2):205–209.

Rawashdeh YF, Austin P, Siggaard C, et al. International Children's Continence Society. International Children's Continence Society's recommendations for therapeutic intervention in congenital neuropathic bladder and bowel dysfunction in children. *Neurourol Urodyn*. 2012;31(5):615–620.

References

Abrahamsson K, Jodal U, Sixt R, et al. Estimation of renal function in children and adolescents with spinal dysraphism. *J Urol*. 2008;179(6):2407–2409.

Adams C, Babyn PS, Logan WJ. Spinal cord birth injury: value of computed tomographic myelography. *Pediatr Neurol*. 1988;4(2):105–109.

Adzick NS, Thom EA, Spong CY, et al. A randomized trial of prenatal versus postnatal repair of myelomeningocele. *N Engl J Med*. 2011;364(11):993–1004.

Agarwal SK, McLorie GA, Grewal D, et al. Urodynamic correlates of resolution of reflux in meningomyelocele patients. *J Urol*. 1997;158(2):580–582.

Al-Ali M, Salman G, Rasheed A, et al. Phenoxybenzamine in the management of neuropathic bladder following spinal cord injury. *Aust N Z J Surg*. 1999;69(9):660–663.

Albouy B, Grise P, Sambuis C, et al. Pediatric urinary incontinence:evaluation of bladder wall wraparound sling procedure. *J Urol*. 2007;177(2):716–719.

Alloussi S, Mürtz G, Braun R, et al. Efficacy, tolerability and safety of propiverine hydrochloride in comparison to oxybutynin in children with urge incontinence due to overactive bladder: results of a multicentre observational cohort study. *BJU Int*. 2010;106:550–556.

Alova I, Margaryan M, Bernuy M, et al. Long-term effects of endoscopic injection of dextranomer/ hyaluronic acid based implants for treatment of urinary incontinence in children with neurogenic bladder. *J Urol*. 2012;188(5):1905–1909.

Altaweel W, Jednack R, Bilodeau C, et al. Repeated intradetrusor botulinum toxin type A in children with neurogenic bladder due to myelomeningocele. *J Urol*.

2006;175(3 Pt 1):1102–1105.

Andar UB, Harkness WF, Hayward RD. Split cord malformations of the lumbar region. A model for the neurosurgical management of all types of ‘occult’ spinal dysraphism? *Pediatr Neurosurg*. 1997;26(1):17–24.

Anderson FM. Occult spinal dysraphism: a series of 73 cases. *Pediatrics*. 1975;55(6):826–835.

Anderson JM, Schutt AH. Spinal injury in children: a review of 156 cases seen from 1950 through 1978. *Mayo Clin Proc*. 1980;55(8):499–504.

Apostolidis A, Dasgupta P, Fowler CJ. Proposed mechanism for the efficacy of injected botulinum toxin in the treatment of human detrusor overactivity. *Eur Urol*. 2006;49(4):644–650.

Arata M, Grover S, Dunne K, et al. Pregnancy outcome and complications in women with spina bifida. *J Reprod Med*. 2000;45(9):743–748.

Arndt C, Rodeberg D, Breitfeld PP, et al. Does bladder preservation (as a surgical principle) lead to retaining bladder function in bladder/prostate rhabdomyosarcoma? Results from intergroup rhabdomyosarcoma study iv. *J Urol*. 2004;171(6 Pt 1):2396–2403.

Arora G, Narasimhan KL, Saxena AK, et al. Risk factors for renal injury in patients with meningomyelocele. *Indian Pediatr*. 2007;44(6):417–420.

Atala A, Bauer SB, Dyro FM, et al. Bladder functional changes resulting from lipomyelomeningocele repair. *J Urol*. 1992;148(2 Pt 2):592–594.

Atala A, Bauer SB, Soker S, et al. Tissue-engineered autologous bladders for patients needing cystoplasty. *Lancet*. 2006;367(9518):1241–1246.

Ateş O, Hakgüder G, Kart Y, et al. The effect of dilated ganglionic segment on anorectal and urinary functions during 1-stage transanal endorectal pull through for Hirschsprung's disease. *J Pediatr Surg*. 2007;42(7):1271–1275.

Augutis M, Levi R. Pediatric spinal cord injury in Sweden: incidence, etiology and outcome. *Spinal Cord*. 2003;41(6):328–336.

Ausili E, Focarelli B, Tabacco F, et al. Transanal irrigation in myelomeningocele children: an alternative, safe and valid approach for neurogenic constipation. *Spinal Cord*. 2010;48(7):560–565.

Austin JC, Elliott S, Cooper CS. Patients with spina bifida and bladder cancer: atypical presentation, advanced stage and poor survival. *J Urol*. 2007;178(3 Pt 1):798–801.

Balcom AH, Wiatrak M, Biefeld T, et al. Initial experience with home therapeutic electrical stimulation for continence in the myelomeningocele population. *J Urol*. 1997;158(3 Pt 2):1272–1276.

Bani-Hani AH, Cain MP, King S, et al. Tap water irrigation and additives to optimize success with the Malone antegrade continence enema: the Indiana University algorithm. *J Urol*. 2008;180(4 Suppl):1757–1760 [discussion 1760].

Barbalias GA, Klauber GT, Blaivas JG. Critical evaluation of the Credé maneuver: a urodynamic study of 207 patients. *J Urol*. 1983;130(4):720–723.

Barf HA, Post MW, Verhoef M, et al. Life satisfaction of young adults with spina bifida. *Dev Med Child Neurol*. 2007;49(6):458–463.

Barkin M, Dolfin D, Herschorn S, et al. The urologic care of the spinal cord injury patient. *J Urol*. 1983;129(2):335–339.

Barnes PD, Lester PD, Yamanashi WS, et al. MRI in infants and children with spinal dysraphism. *Am J Roentgenol*. 1986;147(2):339–346.

Barson AJ. The vertebral level of termination of the spinal cord during normal and abnormal development. *J Anat*. 1970;106(Pt 3):489–497.

Barthold JS, Rodriguez E, Freedman AL, et al. Results of the rectus fascial sling and wrap procedures for the treatment of neurogenic sphincteric incontinence. *J Urol*. 1999;161(1):272–274.

Batista JE, Bauer SB, Shefner JM, et al. Urodynamic findings in children with spinal cord ischemia. *J Urol*. 1995;154(3):1183–1187.

Bauer S, Labib K, Dieppa R, et al. Urodynamic evaluation in the boy with myelodysplasia and incontinence. *Urology*. 1977;10:354–362.

Bauer SB. Vesico-ureteral reflux in children with neurogenic bladder dysfunction. Williams & Wilkins: Baltimore; 1984:159–177. Johnston JH. *International perspectives in urology*. vol 10.

Bauer SB. The management of spina bifida from birth onwards. Whitaker RH, Woodard JR. *Paediatric urology*. Butterworth-Heinemann: London; 1985:87–112.

Bauer SB. Early evaluation and management of children with spina bifida. King. *Urologic surgery in neonates and young infants*. WB Saunders: Philadelphia, PA; 1988:252–264.

Bauer SB. Bladder neck reconstruction. Glenn JF, Graham SD. *Urologic surgery*. JB Lippincott: Philadelphia; 1990:509–522.

Bauer SB: Urodynamics in myelodysplasia. Presented at the Bladder and Bowel Dysfunction in Myelodysplasia Symposium, Aachen, Germany, April 3, 2003.

Bauer SB. *Personal communication*. 2014.

Bauer SB, Hallett M, Khoshbin S, et al. Predictive value of urodynamic evaluation in newborns with myelodysplasia. *JAMA*. 1984;252(5):650–652.

Bauer SB, Reda EF, Colodny AH, et al. Detrusor instability: a delayed complication in association with the artificial sphincter. *J Urol*. 1986;135(6):1212–1215.

Bauer SB, Peters CA, Colodny AH, et al. The use of rectus fascia to manage urinary incontinence. *J Urol*. 1989;142(2 Pt 2):516–519 [discussion 520–521].

Bauer SB, Hendren WH, Kozakewich H, et al. Perforation of the augmented bladder. *J Urol*. 1992;148(2 Pt 2):699–703.

Bauer SB, Austin PF, Rawashdeh YF, et al. International Children's Continence Society. International Children's Continence Society's recommendations for initial diagnostic evaluation and follow-up in congenital neuropathic bladder and bowel dysfunction in children. *Neurourol Urodyn*. 2012;31(5):610–614.

Bernbeck B, Schürfeld-Fürstenberg K, et al. Unilateral pulmonary atresia with total sacral agenesis and other congenital defects. *Clin Dysmorphol*. 2004;13(1):47–48.

Bertschy C, Bawab F, Liard A, et al. Enterocystoplasty complications in children. A study of 30 cases. *Eur J Pediatr Surg*. 2000;10(1):30–34.

Biering-Sørensen F, Nielans HM, Dørflinger T, et al. Urological situation five years after spinal cord injury. *Scand J Urol Nephrol*. 1999;33(3):157–161.

Blais AS, Nadeau G, Moore K, et al. Prospective pilot study of mirabegron in pediatric patients with overactive bladder. *Eur Urol*. 2016;70(1):9–13.

Blaivas JG, Barbalias GA. Characteristics of neural injury after abdominoperineal resection. *J Urol*. 1983;129(1):84–87.

Blaivas JG, Sinha HP, Zayed AA, et al. Detrusor-external sphincter dyssynergia: a detailed electromyographic study. *J Urol*. 1981;125(4):545–548.

Blanco Muñoz J, Lacasaña M, Borja Aburto VH, et al. Socioeconomic factors and the risk of anencephaly in a Mexican population: a case-control study. *Public Health Rep*. 2005;120(1):39–45.

Blanco Muñoz J, Lacasaña M, Borja Aburto VH. Maternal miscarriage history and risk of anencephaly. *Paediatr Perinat Epidemiol*. 2006;20(3):210–218.

Bloom DA, Knechtel JM, McGuire EJ. Urethral dilation improves bladder compliance in children with myelomeningocele and high leak point pressures. *J Urol*. 1990;144(2 Pt 2):430–433 [discussion 443–444].

Boemers TM, van Gool JD, de Jong TP, et al. Lower urinary tract dysfunction in children with benign sacrococcygeal teratoma. *J Urol*. 1994;151(1):174–176.

Boemers TM, van Gool JD, de Jong TP, et al. Urodynamic evaluation of children with the caudal regression syndrome (caudal dysplasia sequence). *J Urol*. 1994;151(4):1038–1040.

Boemers TM, Bax NM, van Gool JD. The effect of rectosigmoidectomy and Duhamel-type pull-through procedure on lower urinary tract function in children with Hirschsprung's disease. *J Pediatr Surg*. 2001;36(3):453–456.

Bolduc S, Moore K, Nadeau G, et al. Prospective open label study of solifenacin for overactive bladder in children. *J Urol*. 2010;184(4 Suppl):1668–1673.

Bomalaski MD, Teague JL, Brooks B. The long-term impact of urological management on the quality of life of children with spina bifida. *J Urol*. 1995;154(2 Pt 2):778–781.

Bong GW, Rovner ES. Sexual health in adult men with spina bifida. *ScientificWorldJournal*. 2007;7:1466–1469.

Borg H, Holmdahl G, Olsson I, et al. Impact of spinal cord malformation on bladder function in children with anorectal malformations. *J Pediatr Surg*. 2009;44(9):1778–1785.

Börjeson MC, Lagergren J. Life conditions of adolescents with myelomeningocele. *Dev Med Child Neurol*. 1990;32(8):698–706.

Botto LD, Mulinare J. Re: “Maternal vitamin use, genetic variation of infant methylenetetrahydrofolate reductase, and risk for spina bifida”. *Am J Epidemiol*. 1999;150(3):323–324.

Boulet SL, Yang Q, Mai C, et al. Trends in the postfortification prevalence of spina bifida and anencephaly in the United States. *Birth Defects Res A Clin Mol Teratol*. 2008;82(7):527–532.

Bradshaw CJ, Gray R, Downer A, et al. Button vesicostomy: 13 years of experience. *J Pediatr Urol*. 2014;10(1):80–87.

Brown RL, Brunn MA, Garcia VF. Cervical spine injuries in children: a review of 103 patients treated consecutively at a level 1 pediatric trauma center. *J Pediatr Surg*. 2001;36(8):1107–1114.

Bruce DA, Schut L. Spinal lipomas in infancy and childhood. *Childs Brain*. 1979;5(3):192–203.

Burgers RE, Mugie SM, Chase J, et al. Management of functional constipation in children with lower urinary tract symptoms: report from the Standardization Committee of the International Children's Continence Society. *J Urol*. 2013;190(1):29–36.

Cameron M, Moran P. Prenatal screening and diagnosis of neural tube defects. *Prenat Diagn*. 2009;29(4):402–411.

Campobasso P, Galiani E, Verzerio A, et al. A rare cause of occult neuropathic bladder in children: the tethered cord syndrome]. *Pediatr Med Chir*. 1988;10(6):641–645.

Capitanucci ML, Silveri M, Nappo S, et al. Total agenesis of the sacrum and neurogenic bladder dysfunction]. *Pediatr Med Chir*. 1997;19(2):113–116.

Cardenas DD, Topolski TD, White CJ, et al. Sexual functioning in adolescents and young adults with spina bifida. *Arch Phys Med Rehabil*. 2008;89(1):31–35.

Carson JA, Barnes PD, Tunell WP, et al. Imperforate anus: the neurologic implication of sacral abnormalities. *J Pediatr Surg*. 1984;19(6):838–842.

Cartwright PC, Coplen DE, Kogan BA, et al. Efficacy and safety of transdermal and oral oxybutynin in children with neurogenic detrusor overactivity. *J Urol*. 2009;182(4):1548–1554.

Cartwright PC, Snow BW. Bladder autoaugmentation: early clinical experience. *J Urol*. 1989;142(2 Pt 2):505–508 [discussion 520–521].

Cartwright PC, Snow BW. Bladder autoaugmentation: partial detrusor excision to augment the bladder without use of bowel. *J Urol*. 1989;142(4):1050–1053.

Cass AS. Urinary tract complications in myelomeningocele patients. *J Urol*. 1976;115(1):102–104.

Cass AS, Luxenberg M, Johnson CF, et al. Management of the neurogenic bladder in 413 children. *J Urol*. 1984;132(3):521–525.

Cass AS, Bloom BA, Luxenberg M. Sexual function in adults with myelomeningocele. *J Urol*. 1986;136(2):425–426.

Castellan M, Gosalbez R, Perez-Brayfield M, et al. Tumor in bladder reservoir after gastrocystoplasty. *J Urol*. 2007;178(4 Pt 2):1771–1774 [discussion 1774].

Castellan M, Gosalbez R, Bar-Yosef Y, et al. Complications after use of gastric segments for lower urinary tract reconstruction. *J Urol*. 2012;187(5):1823–1827.

Castera R, Podestá ML, Ruarte A, et al. 10-Year experience with artificial urinary sphincter in children and adolescents. *J Urol*. 2001;165(6 Pt 2):2373–2376.

Catti M, Lortat-Jacob S, Morineau M, et al. Artificial urinary sphincter in children—voiding or emptying? An evaluation of functional results in 44 patients. *J Urol*. 2008;180(2):690–693.

Chadwick Plaire J, Snodgrass WT, Grady RW, et al. Long-term followup of the hematuria-dysuria syndrome. *J Urol*. 2000;164(3 Pt 2):921–923.

Chancellor MB, Bennett C, Simoneau AR, et al. Sphincteric stent versus external sphincterotomy in spinal cord injured men: prospective randomized multicenter trial. *J Urol*. 1999;161(6):1893–1898.

Chang PL, Fan HA. Urodynamic studies before and/or after abdominoperineal resection of the rectum for carcinoma. *J Urol*. 1983;130(5):948–951.

Chapman PH. Congenital intraspinal lipomas: anatomic considerations and surgical treatment. *Childs Brain*. 1982;9(1):37–47.

Chapple C, Patel A. Botulinum toxin—new mechanisms, new therapeutic directions? *Eur Urol*. 2006;49(4):606–608.

Chapple CR, Cardozo L, Nitti VW, et al. Mirabegron in overactive bladder: a review of efficacy, safety, and tolerability. *Neurourol Urodyn*. 2014;33(1):17–30.

Chapple CR, Fianu-Jonsson A, Indig M, et al. Treatment outcomes in the STAR study: a subanalysis of solifenacin 5 mg and tolterodine ER 4 mg. *Eur Urol*. 2007;52(4):1195–1203.

Chartier-Kastler EJ, Mongiat-Artus P, Bitker MO, et al. Long-term results of augmentation cystoplasty in spinal cord injury patients. *Spinal Cord*. 2000;38(8):490–494.

Chatkupt S, Lucek PR, Koenigsberger MR, et al. Parental sex effect in spina bifida: a role for genomic imprinting? *Am J Med Genet*. 1992;44(4):508–512.

Chiaramonte RM, Horowitz EM, Kaplan GW, et al. Implications of hydronephrosis in the newborn with myelodysplasia. *J Urol*. 1986;136(2):427–429.

Ching CB, Stephany HA, Juliano TM, et al. Outcomes of incontinent ileovesicostomy in the pediatric patient. *J Urol*. 2014;191(2):445–450.

Choi PS, Bauer SB, Pennison M, et al. Sacral agenesis and neurogenic bladder: long-term outcomes of bladder and fidkey function. *J Pediatr Urol*. 2016;158:158.e1–158.e7.

Choi EK, Hong CH, Kim MJ, et al. Effects of intravesical electrical stimulation therapy on urodynamic patterns for children with spina bifida: a 10-year experience. *J Pediatr Urol*. 2013;9(6 Pt A):798–803.

Choi EK, Shin SH, Im YJ, et al. The effects of transanal irrigation as a stepwise bowel management program on the quality of life of children with spina bifida and their caregivers. *Spinal Cord*. 2013;51(5):384–388.

Choi EK, Ji Y, Han SW. Sexual function and quality of life in young men with spina bifida: could it be neglected aspects in clinical practice? *Urology*. 2017;108:225–232.

Choi EK, Kim SW, Ji Y, et al. Sexual function and qualify of life in women with spina bifida: are the women with spina bifida satisfied with their sexual activity? *Neurourol Urodyn*. 2018;37(5):1785–1793.

Christoph F, Moschkowitsch A, Kempkensteffen C, et al. Long-term efficacy of tolterodine and patient compliance in pediatric patients with neurogenic detrusor overactivity. *Urol Int*. 2007;79(1):55–59.

Churchill BM, Bergman J, Kristo B, et al. Improved continence in patients with neurogenic sphincteric incompetence with combination tubularized posterior urethroplasty and fascial wrap: the lengthening, narrowing and tightening procedure. *J Urol*. 2010;184(4 Suppl):1763–1767.

Cirak B, Ziegfeld S, Knight VM, et al. Spinal injuries in children. *J Pediatr Surg*. 2004;39(4):607–612.

Cirović D, Petronić I, Nikolić D, et al. Effects of electrotherapy in treatment of neurogenic bladder in children with occult spinal dysraphism. *Srp Arh Celok Lek*. 2009;137(9–10):502–505.

Clayton DB, Tanaka ST, Trusler L, et al. Long-term urological impact of fetal myelomeningocele closure. *J Urol*. 2011;186(4 Suppl):1581–1585.

Cohen RA, Rushton HG, Belman AB, et al. Renal scarring and vesicoureteral reflux in children with myelodysplasia. *J Urol*. 1990;144(2 Pt 2):541–544 [discussion 545].

Colvert JR III, Kropp BP, Cheng EY, et al. The use of small intestinal submucosa as an off-the-shelf urethral sling material for pediatric urinary incontinence. *J Urol*. 2002;168:1872–1876.

Cornette L, Verpoorten C, Lagae L, et al. Tethered cord syndrome in occult spinal dysraphism: timing and outcome of surgical release. *Neurology*. 1998;50(6):1761–1765.

Cromer BA, Enrile B, McCoy K, et al. Knowledge, attitudes and behavior related to sexuality in adolescents with chronic disability. *Dev Med Child Neurol*. 1990;32(7):602–610.

Currarino G, Coln D, Votteler T. Triad of anorectal, sacral, and presacral anomalies. *AJR Am J Roentgenol*. 1981;137(2):395–398.

Czeizel AE, Dudás I. Prevention of the first occurrence of neural-tube defects by periconceptional vitamin supplementation. *N Engl J Med*. 1992;327(26):1832–1835.

DaJusta DG, Wosnitzer MS, Barone JG. Persistent motor deficits predict long-term bladder dysfunction in children following acute transverse myelitis. *J Urol*. 2008;180(4 Suppl):1774–1777.

DaJusta D, Gargollo P, Snodgrass W. Dextranomer/hyaluronic acid bladder neck injection for persistent outlet incompetency after sling procedures in children with neurogenic urinary incontinence. *J Pediatr Urol*. 2013;9(3):278–282.

D'Aquino D, Moussa AA, Ammar A, et al. Selective dorsal rhizotomy for the treatment of severe spastic cerebral palsy: efficacy and therapeutic durability in GMFCS grade IV and V children. *Acta Neurochir (Wien)*. 2018;160(4):811–821.

Dawson LE, Pham B, Hunter AG. Low rate of adequate folic acid supplementation in well-educated women of high socioeconomic status attending a genetics clinic. *CMAJ*.

2001;164(8):1149–1150.

de Badiola FI, Denes ED, Ruiz E, et al. New application of the gastrostomy button for clinical and urodynamic evaluation before vesicostomy closure. *J Urol*. 1996;156(2 Pt 2):618–620.

De Biasio P, Ginocchio G, Aicardi G, et al. Ossification timing of sacral vertebrae by ultrasound in the mid-second trimester of pregnancy. *Prenat Diagn*. 2003;23(13):1056–1059.

De Filippo RE, Shaul DB, Harrison EA, et al. Neurogenic bladder in infants born with anorectal malformations: comparison with spinal and urologic status. *J Pediatr Surg*. 1999;34(5):825–827 [discussion 828].

de Jong TP, Chrzan R, Klijn AJ, et al. Treatment of the neurogenic bladder in spina bifida. *Pediatr Nephrol*. 2008;23(6):889–896.

De Vocht TF, Chrzan R, Dik P, et al. Long-term results of bulking agent injection for persistent incontinence in cases of neurogenic bladder dysfunction. *J Urol*. 2010;183(2):719–723.

Dean GE, Kirsch AJ, Packer MG, et al. Antegrade and retrograde endoscopic dextranomer/hyaluronic Acid bladder neck bulking for pediatric incontinence. *J Urol*. 2007;178(2):652–655.

Dean GE, Kunkle DA. Outpatient perineal sling in adolescent boys with neurogenic incontinence. *J Urol*. 2009;182(4 Suppl):1792–1796.

Decter RM, Bauer SB. Urologic management of spinal cord injury in children. *Urol Clin North Am*. 1993;20(3):475–483.

Decter RM, Bauer SB, Khoshbin S, et al. Urodynamic assessment of children with cerebral palsy. *J Urol*. 1987;138(4 Pt 2):1110–1112.

Decter RM, Snyder P, Rosvanis TK. Transurethral electrical bladder stimulation: initial results. *J Urol*. 1992;148(2 Pt

2):651–653 [discussion 654].

Decter RM, Snyder P, Laudermilch C. Transurethral electrical bladder stimulation: a followup report. *J Urol*. 1994;152(2 Pt 2):812–814.

Decter RM, Furness PD, Nguyen TA, et al. Reproductive understanding, sexual functioning and testosterone levels in men with spina bifida. *J Urol*. 1997;157(4):1466–1468.

DeFoor W, Tackett L, Minevich E, et al. Risk factors for spontaneous bladder perforation after augmentation cystoplasty. *Urology*. 2003;62(4):737–741.

DeFoor W, Minevich E, Reddy P, et al. Bladder calculi after augmentation cystoplasty: risk factors and prevention strategies. *J Urol*. 2004;172(5 Pt 1):1964–1966.

del Gado R, Perrone L, del Gaizo D, et al. Renal size and function in patients with neuropathic bladder due to myelomeningocele: the role of growth hormone. *J Urol*. 2003;170(5):1960–1961.

DeLair SM, Eandi J, White MJ, et al. Renal cortical deterioration in children with spinal dysraphism: analysis of risk factors. *J Spinal Cord Med*. 2007;30(Suppl 1):S30–S34.

Diamond DA, Rickwood AM, Thomas DG. Penile erections in myelomeningocele patients. *Br J Urol*. 1986;58(4):434–435.

Diel J, Ortiz O, Losada RA, et al. The sacrum: pathologic spectrum, multimodality imaging, and subspecialty approach. *Radiographics*. 2001;21(1):83–104.

Dik P, Klijn AJ, van Gool JD, et al. Early start to therapy preserves kidney function in spina bifida patients. *Eur Urol*. 2006;49(5):908–913.

Donnellan SM, Bolton DM. The impact of contemporary bladder management techniques on struvite calculi associated with spinal cord injury. *BJU Int*. 1999;84(3):280–285.

Donnelly J, Hackler RH, Bunts RC. Present urologic status of the World War II paraplegic: 25-year followup. Camparison with status of the 20-year Korean War paraplegic and 5-year Vietnam paraplegic. *J Urol*. 1972;108(4):558–562.

Dorner S. Sexual interest and activity in adolescents with spina bifida. *J Child Psychol Psychiatry*. 1977;18(3):229–237.

Dubowitz V, Lorber J, Zachary RB. Lipoma of the cauda equina. *Arch Dis Child*. 1965;40:207–213.

Duckett JW. Cutaneous vesicostomy in childhood. The Blocksom technique. *Urol Clin North Am*. 1974;1(3):485–495.

Dunne K, Hopkins IJ, Shield LK. Acute transverse myelopathy in childhood. *Dev Med Child Neurol*. 1986;28(2):198–204.

Duthie JB, Vincent M, Herbison GP, et al. Botulinum toxin injections for adults with overactive bladder syndrome. *Cochrane Database Syst Rev*. 2011;(12) [CD005493].

Dykstra DD, Sidi AA. Treatment of detrusor-sphincter dyssynergia with botulinum A toxin: a double-blind study. *Arch Phys Med Rehabil*. 1990;71(1):24–26.

Edelstein RA, Bauer SB, Kelly MD, et al. The long-term urological response of neonates with myelodysplasia treated proactively with intermittent catheterization and anticholinergic therapy. *J Urol*. 1995;154(4):1500–1504.

Ellsworth PI, Borgstein NG, Nijman RJ, et al. Use of tolterodine in children with neurogenic detrusor overactivity: relationship between dose and urodynamic response. *J Urol*. 2005;174(4 Pt 2):1647–1651 [discussion 1651].

Emami-Naeini P, Nejat F, Rahbar Z, et al. Urological manifestations of sacral agenesis. *J Pediatr Urol*. 2012;8(2):181–186.

Emir H. Söylet Y. Neurovesical dysfunction in patients with anorectal malformations. *Eur J Pediatr Surg*. 1998;8(2):95–97.

Engel JD, Palmer LS, Cheng EY, et al. Surgical versus endoscopic correction of vesicoureteral reflux in children with neurogenic bladder dysfunction. *J Urol*. 1997;157(6):2291–2294.

Ersoz M, Kaya K, Erol SK, et al. Noninvasive evaluation of lower urinary tract function in children with cerebral palsy. *Am J Phys Med Rehabil*. 2009;88(9):735–741.

Estornell Moragues F, Serrano Durbá A, Domínguez Hinarejos C. Endoscopic treatment of vesicoureteral reflux in pediatric patients with the diagnosis of neurogenic bladder. Results and long-term outcome]. *Arch Esp Urol*. 2008;61(2):278–283.

Fanciullacci F, Zanollo A, Sandri S, et al. The neuropathic bladder in children with spinal cord injury. *Paraplegia*. 1988;26(2):83–86.

Figueroa V, Romao R, Pippi Salle JL, et al. Single-center experience with botulinum toxin endoscopic detrusor injection for the treatment of congenital neuropathic bladder in children: effect of dose adjustment, multiple injections, and avoidance of reconstructive procedures. *J Pediatr Urol*. 2014;10(2):368–373.

Filler G, Lee M. Educational review: measurement of GFR in special populations. *Pediatr Nephrol*. 2018;33(11):2037–2046.

Filler G, Lepage N. Should the Schwartz formula for estimation of GFR be replaced by cystatin C formula? *Pediatr Nephrol*. 2003;18(10):981–985.

Filler G, Gharib M, Casier S, et al. Prevention of chronic kidney disease in spina bifida. *Int Urol Nephrol*. 2011;44(3):817–827.

Flanigan RC, Russell DP, Walsh JW. Urologic aspects of tethered cord. *Urology*. 1989;33(1):80–82.

Flood HD, Ritchey ML, Bloom DA, et al. Outcome of reflux in children with myelodysplasia managed by bladder pressure monitoring. *J Urol*. 1994;152(5 Pt 1):1574–1577.

Flood HD, Malhotra SJ, O'Connell HE, et al. Long-term results and complications using augmentation cystoplasty in reconstructive urology. *Neurourol Urodyn*. 1995;14(4):297–309.

Fone PD, Vapnek JM, Litwiller SE, et al. Urodynamic findings in the tethered spinal cord syndrome: does surgical release improve bladder function? *J Urol*. 1997;157(2):604–609.

Food and Drug Regulations. *Amendment SOR/96-527*. 1998.

Foster LS, Kogan BA, Cogen PH, et al. Bladder function in patients with lipomyelomeningocele. *J Urol*. 1990;143(5):984–986.

Franco I, Horowitz M, Grady R, et al. Efficacy and safety of oxybutynin in children with detrusor hyperreflexia secondary to neurogenic bladder dysfunction. *J Urol*. 2005;173(1):221–225.

Gabra HO, Jesudason EC, McDowell HP, et al. Sacrococcygeal teratoma—a 25-year experience in a UK regional center. *J Pediatr Surg*. 2006;41(9):1513–1516.

Gamé X, Moscovici J, Gamé L, et al. Evaluation of sexual function in young men with spina bifida and myelomeningocele using the International Index of Erectile Function. *Urology*. 2006;67(3):566–570.

Gamé X, Mouracade P, Chartier-Kastler E, et al. Botulinum toxin-A (Botox) intradetrusor injections in children with neurogenic detrusor overactivity/neurogenic overactive bladder: a systematic literature review. *J Pediatr Urol*. 2009;5(3):156–164.

Ganesan V. Borzyskowski M. Characteristics and course of urinary tract dysfunction after acute transverse myelitis in. *Dev Med Child Neurol*. 2001;43(7):473–475.

Gatti JM, Perez-Brayfield M, Kirsch AJ, et al. Acute urinary retention in children. *J Urol*. 2001;165(3):918–921.

Gatti C, Del Rossi C, Ferrari A, et al. Predictors of successful sexual partnering of adults with spina bifida. *J Urol*.

2009;182(4 Suppl):1911–1916.

Geraniotis E, Koff SA, Enrile B. The prophylactic use of clean intermittent catheterization in the treatment of infants and young children with myelomeningocele and neurogenic bladder dysfunction. *J Urol*. 1988;139(1):85–86.

Ghoniem GM, Bloom DA, McGuire EJ, et al. Bladder compliance in meningomyelocele children. *J Urol*. 1989;141(6):1404–1406.

Giannantoni A, Scivoletto G, Di Stasi SM, et al. Clean intermittent catheterization and prevention of renal disease in spinal cord injury patients. *Spinal Cord*. 1998;36(1):29–32.

Gilbert SM, Hensle TW. Metabolic consequences and long-term complications of enterocystoplasty in children: a review. *J Urol*. 2005;173(4):1080–1086.

Gillespie JI, Palea S, Guilloteau V, et al. Modulation of non-voiding activity by the muscarinergic antagonist tolterodine and the β3-adrenoceptor agonist mirabegron in conscious rats with partial outflow obstruction. *BJU Int*. 2012;110(2 Pt 2):E132–E142.

Giramonti KM, Kogan BA, Halpern LF. The effects of anticholinergic drugs on attention span and short-term memory skills in children. *Neurourol Urodyn*. 2008;27(4):315–318.

Giuliani S, Midrio P, De Filippo RE, et al. Anorectal malformation and associated end-stage renal disease: management from newborn to adult life. *J Pediatr Surg*. 2013;48(3):635–641.

Glass C, Soni B. ABC of sexual health: sexual problems of disabled patients. *BMJ*. 1999;318(7182):518–521.

Gleason JM, Daniels C, Williams K, et al. Single center experience with oxybutynin transdermal system (patch) for management of symptoms related to non-neuropathic overactive bladder in children: an attractive, well tolerated alternative form of administration. *J Pediatr Urol*. 2014;10(4):753–757.

Godbole P, Bryant R, MacKinnon AE, et al. Endourethral injection of bulking agents for urinary incontinence in children. *BJU Int*. 2003;91(6):536–539.

Godec CJ, Cass AS. Electrical stimulation for incontinence in myelomeningocele. *J Urol*. 1978;120(6):729–731.

Godwin KA, Sibbald B, Bedard T. Kuzeljevic B. Changes in frequencies of select congenital anomalies since the onset of folic acid fortification in a Canadian birth defect registry. *Can J Public Health*. 2008;99(4):271–275.

Goldwasser B, Barrett DM, Webster GD, et al. Cystometric properties of ileum and right colon after bladder augmentation, substitution or replacement. *J Urol*. 1987;138(4 Pt 2):1007–1008.

Gosalbez R, Woodard JR, Broecker BH, et al. Metabolic complications of the use of stomach for urinary reconstruction. *J Urol*. 1993;150(2 Pt 2):710–712.

Granata C, Buffa P, Di Rovasenda E, et al. Treatment of vesico-ureteric reflux in children with neuropathic bladder: a comparison of surgical and endoscopic correction. *J Pediatr Surg*. 1999;34(12):1836–1838.

Greenfield SP, Fera M. Urodynamic evaluation of the patient with an imperforate anus: a prospective study. *J Urol*. 1991;146(2 Pt 2):539–541.

Guerra LA, Pike J, Milks J, et al. Outcome in patients who underwent tethered cord release for occult spinal dysraphism. *J Urol*. 2006;176(4 Pt 2):1729–1732.

Guerra LA, Moher D, Sampson M, et al. Intravesical oxybutynin for children with poorly compliant neurogenic bladder: a systematic review. *J Urol*. 2008;180(3):1091–1097.

Gündoğdu G, Kömür M, Avlan D, et al. Relationship of bladder dysfunction with upper urinary tract deterioration in cerebral palsy. *J Pediatr Urol*. 2013;9(5):659–664.

Guttmann L, Frankel H. The value of intermittent catheterisation in the early management of traumatic paraplegia and tetraplegia. *Paraplegia*. 1966;4(2):63–84.

Guttmann L. Spinal shock and reflex behaviour in man. *Paraplegia*. 1970;8(2):100–116.

Guys JM, Fakhro A, Louis-Borrione C, et al. Endoscopic treatment of urinary incontinence: long-term evaluation of the results. *J Urol*. 2001;165(6 Pt 2):2389–2391.

Guys JM, Haddad M, Planche D, et al. Sacral neuromodulation for neurogenic bladder dysfunction in children. *J Urol*. 2004;172(4 Pt 2):1673–1676.

Guys JM, Breaud J, Hery G, et al. Endoscopic injection with polydimethylsiloxane for the treatment of pediatric urinary incontinence in the neurogenic bladder: long-term results. *J Urol*. 2006;175(3 Pt 1):1106–1110.

Guzman L, Bauer SB, Hallett M, et al. Evaluation and management of children with sacral agenesis. *Urology*. 1983;22(5):506–510.

Hadley MN, Zabramski JM, Browner CM, et al. Pediatric spinal trauma. Review of 122 cases of spinal cord and vertebral column injuries. *J Neurosurg*. 1988;68(1):18–24.

Hagan DM, Ross AJ, Strachan T, et al. Mutation analysis and embryonic expression of the HLXB9 Currarino syndrome gene. *Am J Hum Genet*. 2000;66(5):1504–1515.

Hall WA, Albright AL, Brunberg JA. Diagnosis of tethered cords by magnetic resonance imaging. *Surg Neurol*. 1988;30(1):60–64.

Han SW, Kim MJ, Kim JH, et al. Intravesical electrical stimulation improves neurogenic bowel dysfunction in children with spina bifida. *J Urol*. 2004;171(6 Pt 2):2648–2650.

Hansen EL, Hvistendahl GM, Rawashdeh YFH, et al. Promising long-term outcome of bladder autoaugmentation in children with neurogenic bladder dysfunction. *J Urol*. 2013;190(5):1869–1875.

Hascoet J, Peyronnet B, Forin V, et al. Intradetrusor injections of botulinum toxin type A in children with spina bifida: a multicenter study. *Urology*. 2018;116:161–167.

Hayden PW, Davenport SL, Campbell MM. Adolescents with myelodysplasia: impact of physical disability on emotional maturation. *Pediatrics*. 1979;64(1):53–59.

Hegde SS, Eglen RM. Muscarinic receptor subtypes modulating smooth muscle contractility in the urinary bladder. *Life Sci*. 1999;64(6–7):419–428.

Hellenthal NJ, Short SS, O'Connor RC, et al. Incontinent ileovesicostomy: Long-term outcomes and complications. *Neurourol Urodyn*. 2009;28(6):483–486.

Hellstrom WJ, Edwards MS, Kogan BA. Urological aspects of the tethered cord syndrome. *J Urol*. 1986;135(2):317–320.

Helmy TE, Hafez AT. Vesicouretral reflux with neuropathic bladder: studying the resolution rate after ileocystoplasty. *Urology*. 2013;82(2):425–428.

Henderson FC, Geddes JF, Vaccaro AR, et al. Stretch-associated injury in cervical spondylotic myelopathy: new concept and review. *Neurosurgery*. 2005;56(5):1101–1113 [discussion 1101–1113].

Hensle TW, Bingham J, Lam J, et al. Preventing reservoir calculi after augmentation cystoplasty and continent urinary diversion: the influence of an irrigation protocol. *BJU Int*. 2004;93(4):585–587.

Hernández-Díaz S, Werler MM, Walker AM, et al. Neural tube defects in relation to use of folic acid antagonists during pregnancy. *Am J Epidemiol*. 2001;153(10):961–968.

Herndon CD, Rink RC, Shaw MB, et al. The Indiana experience with the artificial urinary sphincter in children and young adults. *J Urol*. 2003;169(2):650–654.

Herschorn S, Hewitt RJ. Patient perspective of long-term outcome of augmentation cystoplasty for neurogenic bladder. *Urology*. 1998;52(4):672–678.

Higuchi TT, Granberg CF, Fox JA, et al. Augmentation cystoplasty and risk of neoplasia: fact, fiction and controversy. *J Urol*. 2010;184(6):2492–2497.

Hinman F. Selection of intestinal segments for bladder substitution: physical and physiological characteristics. *J Urol*. 1988;139(3):519–523.

Hishiki T, Saito T, Mitsunaga T, et al. Optimal surgical treatment and urological outcomes in boys with pelvic and urogenital rhabdomyosarcomas and soft tissue sarcomas. *Pediatr Surg Int*. 2013;29(10):1077–1082.

Holmbeck GN, Johnson SZ, Wills KE, et al. Observed and perceived parental overprotection in relation to psychosocial adjustment in preadolescents with a physical disability: the mediational role of behavioral autonomy. *J Consult Clin Psychol*. 2002;70(1):96–110.

Holmes NM, Nguyen HT, Harrison MR, et al. Fetal intervention for myelomeningocele: effect on postnatal bladder function. *J Urol*. 2001;166(6):2383–2386.

Holschneider AM, Kraeft H, Scholtissek C. Urodynamic investigations of bladder disturbances in imperforate anus and Hirschsprung's disease (author's transl). *Z Kinderchir*. 1982;35(2):64–68.

Holschneider A, Hutson J, Peña A, et al. Preliminary report on the International Conference for the Development of Standards for the Treatment of Anorectal Malformations. *J Pediatr Surg*. 2005;40(10):1521–1526.

Holzbeierlein J, Pope JC IV, Adams MC, et al. The urodynamic profile of myelodysplasia in childhood with spinal closure during gestation. *J Urol*. 2000;164(4):1336–1339.

Honein MA, Paulozzi LJ, Mathews TJ, et al. Impact of folic acid fortification of the US food supply on the occurrence of neural tube defects. *JAMA*. 2001;285(23):2981–2986.

Hood B, Andersson KE. Common theme for drugs effective in overactive bladder treatment: inhibition of afferent signaling from the bladder. *Int J Urol*. 2013;20(1):21–27.

Hopps CV, Kropp KA. Preservation of renal function in children with myelomeningocele managed with basic newborn evaluation and close followup. *J Urol*. 2003;169:305–308.

Horowitz M, Kuhr CS, Mitchell ME. The Mitrofanoff catheterizable channel: patient acceptance. *J Urol*. 1995;153(3 Pt 1):771–772.

Horst M, Mazzone L, Schraner T, et al. Prenatal myelomeningocele repair: do bladders better? *Neurourol Urodyn*. 2017;36(6):1651–1658.

Hsieh MH, Perry V, Gupta N, et al. The effects of detethering on the urodynamics profile in children with a tethered cord. *J Neurosurg*. 2006;105(5 Suppl):391–395.

Huang GO, Belfort MA, Whitehead WE, et al. Early postnatal bladder function in fetoscopic myelomeningocele repair patients. *J Pediatr Rehabil Med*. 2017;10(3–4):327–333.

Hughes JA, De Bruyn R, Patel K, et al. Evaluation of spinal ultrasound in spinal dysraphism. *Clin Radiol*. 2003;58(3):227–233.

Hulthén de Medina V, Mellstam L, Amark P, et al. Neurovesical dysfunction in children after surgery for high or intermediate anorectal malformations. *Acta Paediatr*. 2004;93(1):43–46.

Hultling C, Levi R, Amark SP, et al. Semen retrieval and analysis in men with myelomeningocele. *Dev Med Child Neurol*. 2000;42(10):681–684.

Husmann DA, Cain MP. Fecal and urinary continence after ileal cecal cystoplasty for the neurogenic bladder. *J Urol*. 2001;165(3):922–925.

Iwatsubo E, Iwakawa A, Koga H, et al. Functional recovery of the bladder in patients with spinal cord injury—prognosticating programs of an aseptic intermittent catheterization. *Hinyokika Kiyo*. 1985;31(5):775–783.

Jackson AB, Mott PK. Reproductive health care for women with spina bifida. *ScientificWorldJournal*. 2007;7:1875–1883.

Jacobs MA, Avellino AM, Shurtleff D, et al. Reinnervating the penis in spina bifida patients in the United States: ilioinguinal-to-dorsal-penile neurorrhaphy in two cases. *J Sex Med*. 2013;10(10):2593–2597.

Jeffs RD, Jonas P, Schillinger JF. Surgical correction of vesicoureteral reflux in children with neurogenic bladder. *J Urol*. 1976;115(4):449–451.

Jindal A, Mahapatra AK. Spinal lipomatous malformations. *Indian J Pediatr*. 2000;67(5):342–346.

Joseph DB, Bauer SB, Colodny AH, et al. Clean, intermittent catheterization of infants with neurogenic bladder. *Pediatrics*. 1989;84(1):78–82.

Joseph DB, Borer JG, De Filippo RE, et al. Autologous cell seeded biodegradable scaffold for augmentation cystoplasty: phase II study in children and adolescents with spina bifida. *J Urol*. 2014;191(5):1389–1395.

Joyner BD, McLorie GA, Khoury AE. Sexuality and reproductive issues in children with myelomeningocele. *Eur J Pediatr Surg*. 1998;8(1):29–34.

Kaefer M, Pabby A, Kelly M, et al. Improved bladder function after prophylactic treatment of the high risk neurogenic bladder in newborns with myelomeningocele. *J Urol*. 1999;162(3 Pt 2):1068–1071.

Kajbafzadeh AM, Sharifi-Rad L, Baradaran N, et al. Effect of pelvic floor interferential electrostimulation on urodynamic parameters and incontinency of children with myelomeningocele and detrusor overactivity. *Urology*. 2009;74(2):324–329.

Kajbafzadeh AM, Sharifi-Rad L, Dianat S. Efficacy of transcutaneous functional electrical stimulation on urinary incontinence in myelomeningocele: results of a pilot study. *Int Braz J Urol*. 2010;36(5):614–620.

Kakizaki H, Nonomura K, Asano Y, et al. Preexisting neurogenic voiding dysfunction in children with imperforate anus: problems in management. *J Urol*. 1994;151(4):1041–1044.

Kalita J, Shah S, Kapoor R, et al. Bladder dysfunction in acute transverse myelitis: magnetic resonance imaging and neurophysiological and urodynamic correlations. *J Neurol Neurosurg Psychiatry*. 2002;73(2):154–159.

Kaplan WE, Firlit CF. Management of reflux in the myelodysplastic child. *J Urol*. 1983;129(6):1195–1197.

Kaplan WE, McLone DG, Richards I. The urological manifestations of the tethered spinal cord. *J Urol*. 1988;140(5 Pt 2):1285–1288.

Kari JA, Safdar O, Jamjoom R. Anshasi W. Renal involvement in children with spina bifida. *Saudi J Kidney Dis Transpl*. 2009;20(1):102–105.

Kasabian NG, Bauer SB, Dyro FM, et al. The prophylactic value of clean intermittent catheterization and anticholinergic medication in newborns and infants with myelodysplasia at risk of developing urinary tract deterioration. *Am J Dis Child*. 1992;146(7):840–843.

Kask M, Rintala R, Taskinen S. Effect of onabotulinumtoxinA treatment on symptoms and urodynamic findings in pediatric neurogenic bladder. *J Pediatr Urol*. 2014;10(2):280–283.

Kass EJ, Koff SA. The management of vesicoureteral reflux in children with neurogenic bladders. *Z Kinderchir*.

1981;34(4):379–383.

Kaye JD, Jafri SM, Cuda SP, et al. Same setting laparoscopic antegrade continence enema and antegrade bladder neck injection for constipation and urinary incontinence in the spina bifida population. *J Urol*. 2010;184(4 Suppl):1644–1650.

Keating MA, Rink RC, Bauer SB, et al. Neurourological implications of the changing approach in management of occult spinal lesions. *J Urol*. 1988;140(5 Pt 2):1299–1301.

Khoury AE, Hendrick EB, McLorie GA, et al. Occult spinal dysraphism: clinical and urodynamic outcome after division of the filum terminale. *J Urol*. 1990;144(2 Pt 2):426–428 [discussion 428–429, 443–444].

Kiddoo DA, Canning DA, Snyder HM 3rd, et al. Urethral dilation as treatment for neurogenic bladder. *J Urol*. 2006;176(4 Pt 2):1831–1833 [discussion 1834].

Kim YH, Kattan MW, Boone TB. Bladder leak point pressure: the measure for sphincterotomy success in spinal cord injured patients with external detrusor-sphincter dyssynergia. *J Urol*. 1998;159(2):493–496 [discussion 496–497].

Kirby RS, Wingate MS, Van Naarden Braun K, et al. Prevalence and functioning of children with cerebral palsy in four areas of the United States in 2006: a report from the Autism and Developmental Disabilities Monitoring Network. *Res Dev Disabil*. 2011;32(2):462–469.

Knebusch M, Strassburg HM, Reiners K. Acute transverse myelitis in childhood: nine cases and review of the literature. *Dev Med Child Neurol*. 1998;40(9):631–639.

Kochakarn W, Ratana-Olarn K, Lertsithichai P, et al. Follow-up of long-term treatment with clean intermittent catheterization for neurogenic bladder in children. *Asian J Surg*. 2004;27(2):134–136.

Köchling J, Karbasiyan M, Reis A. Spectrum of mutations and genotype-phenotype analysis in Currarino syndrome. *Eur J Hum Genet*. 2001;9(8):599–605.

Koff SA, Deridder PA. Patterns of neurogenic bladder dysfunction in sacral agenesis. *J Urol*. 1977;118(1 Pt 1):87–89.

Koff SA, Gigax MR, Jayanthi VR. Nocturnal bladder emptying: a simple technique for reversing urinary tract deterioration in children with neurogenic bladder. *J Urol*. 2005;174(4 Pt 2):1629–1631 [discussion 1632].

Koh CJ, DeFilippo RE, Borer JG, et al. Bladder and external urethral sphincter function after prenatal closure of myelomeningocele. *J Urol*. 2006;176(5):2232–2236.

Kokorowski PJ, Routh JC, Borer JG, et al. Screening for malignancy after augmentation cystoplasty in children with spina bifida: a decision analysis. *J Urol*. 2011;186(4):1437–1443.

Kondo A, Kato K, Kanai S, et al. Bladder dysfunction secondary to tethered cord syndrome in adults: is it curable? *J Urol*. 1986;135(2):313–316.

Korenromp MJ, van Gool JD, Bruinese HW, et al. Early fetal leg movements in myelomeningocele. *Lancet*. 1986;1(8486):917–918.

Koyanagi I, Iwasaki Y, Hida K, et al. Surgical treatment supposed natural history of the tethered cord with occult spinal dysraphism. *Childs Nerv Syst*. 1997;13(5):268–274.

Krishna A, Gough DC, Fishwick J, et al. Ileocystoplasty in children: assessing safety and success. *Eur Urol*. 1995;27(1):62–66.

Krishnan C, Kaplin AI, Deshpande DM, et al. Transverse myelitis: pathogenesis, diagnosis and treatment. *Front Biosci*. 2004;9:1483–1499.

Kroovand RL, Bell W, Hart LJ, et al. The effect of back closure on detrusor function in neonates with myelomeningocele. *J*

Urol. 1990;144(2 Pt 2):423–425 [discussion 443–444].

Krough K, Lie HR, Bilenberg N, et al. Bowel function in Danish children with myelomeningocele. *APMIS Suppl*. 2003;109:81–85.

Kuo HC. Botulinum A toxin urethral injection for the treatment of lower urinary tract dysfunction. *J Urol*. 2003;170(5):1908–1912.

Lais A, Kasabian NG, Dyro FM, et al. The neurosurgical implications of continuous neurourological surveillance of children with myelodysplasia. *J Urol*. 1993;150(6):1879–1883.

Lammer EJ, Sever LE, Oakley GP Jr. Teratogen update: valproic acid. *Teratology*. 1987;35(3):465–473.

Landau EH, Churchill BM, Jayanthi VR, et al. The sensitivity of pressure specific bladder volume versus total bladder capacity as a measure of bladder storage dysfunction. *J Urol*. 1994;152(5 Pt 1):1578–1581.

Lanska MJ, Roessmann U, Wiznitzer M. Magnetic resonance imaging in cervical cord birth injury. *Pediatrics*. 1990;85(5):760–764.

Lapides J, Diokno AC, Silber SJ, et al. Clean, intermittent self-catheterization in the treatment of urinary tract disease. *Trans Am Assoc Genitourin Surg*. 1971;63:92–96.

Lassmann J, Garibay Gonzalez F, Melchionni JB, et al. Sexual function in adult patients with spina bifida and its impact on quality of life. *J Urol*. 2007;178(4 Pt 2):1611–1614.

Laurence KM, Beresford A. Continence, friends, marriage and children in 51 adults with spina bifida. *Dev Med Child Neurol Suppl*. 1975;35:123–128.

Le LD, Alam S, Lim FY, et al. Prenatal and postnatal urologic complications of sacrococcygeal teratomas. *J Pediatr Surg*. 2011;46(6):1186–1190.

Lee CY, Lee CY. Long-term renal outcome in patients with lumbar meningomyelocele. Abstract 864. *Pediatr Nephrol*. 2010;25:1967.

Lee NG, Gana R, Borer JG, et al. Urodynamic findings in patients with Currarino syndrome. *J Urol*. 2012;187(6):2195–2200.

Lee NG, Gomez P, Uberoi V, et al. In utero closure of myelomeningocele does not improve lower urinary tract function. *J Urol*. 2012;188(4 Suppl):1567–1571.

Lee NG, Andrews E, Rosoklija I, et al. The effect of spinal cord level on sexual function in the spina bifida population. *J Pediatr Urol*. 2015;11(3):142 [e1–e6].

Lendvay TS, Cowan CA, Mitchell MM, et al. Augmentation cystoplasty rates at childrens hospitals in the US. *J Urol*. 2006;176(4 Pt 2):1716–1720.

Leonard MP, Dharamsi N, Williot PE. Outcome of gastrocystoplasty in tertiary pediatric urology practice. *J Urol*. 2000;164(3 Pt 2):947–950.

Leveckis J, Boucher NR, Parys BT, et al. Bladder and erectile dysfunction before and after rectal surgery for cancer. *Br J Urol*. 1995;76(6):752–756.

Levitt MA, Peña A. Anorectal malformations. *Orphanet J Rare Dis*. 2007;2:33.

Lewis MA, Webb NJ, Stellman-Ward GR, et al. Investigative techniques and renal parenchymal damage in children with spina bifida. *Eur J Pediatr Surg*. 1994;4(Suppl 1):29–31.

Leyland JW, Masters JG. Conservative management of an intraperitoneal rupture of an augmentation cystoplasty and continent urinary diversion in an adult. *J Urol*. 2003;170(2 Pt 1):524.

Li Z, Zhang L, Li H, et al. Maternal severe stressful life events and risk of neural tube defects among rural Chinese. *Birth Defects Res A Clin Mol Teratol*. 2013;97(2):109–114.

Linder M, Rosenstein J, Sklar FH. Functional improvement after spinal surgery for the dysraphic malformations. *Neurosurgery*. 1982;11(5):622–624.

Long FR, Hunter JV, Mahboubi S, et al. Tethered cord and associated vertebral anomalies in children and infants with imperforate anus: evaluation with MR imaging and plain radiography. *Radiology*. 1996;200(2):377–382.

López Pereira P, Martinez Urrutia MJ, Lobato Romera R, et al. Should we treat vesicoureteral reflux in patients who simultaneously undergo bladder augmentation for neuropathic bladder? *J Urol*. 2001;165(6 Pt 2):2259–2261.

Lopez Pereira P, Miguelez C, Caffarati J, et al. Trospium chloride for the treatment of detrusor instability in children. *J Urol*. 2003;170(5):1978–1981.

Lottmann HB, Margaryan M, Bernuy M, et al. Long-term effects of dextranomer endoscopic injections for treatment of urinary incontinence: an update of a prospective study of 31 patients. *J Urol*. 2006;175(4):1485–1489.

Luangkhot R, Peng BC, Blaivas JG. Ileocecocystoplasty for the management of refractory neurogenic bladder: surgical technique and urodynamic findings. *J Urol*. 1991;146(5):1340–1344.

Lynberg MC, Khoury MJ, Lu X, et al. Maternal flu, fever, and the risk of neural tube defects: a population-based case-control study. *Am J Epidemiol*. 1994;140(3):244–255.

Lynch SA, Wang Y, Strachan T, et al. Autosomal dominant sacral agenesis: currarino syndrome. *J Med Genet*. 2000;37(8):561–566.

MacNeily AE, Afshar K, Coleman GU, et al. Autoaugmentation by detrusor myotomy: its lack of effectiveness in the management of congenital neuropathic bladder. *J Urol*. 2003;170(4 Pt 2):1643–1646 [discussion 1646].

Madersbacher H, Mürtz G, Alloussi S, et al. Propiverine vs oxybutynin for treating neurogenic detrusor overactivity in children and adolescents: results of a multicentre observational cohort study. *BJU Int*. 2009;103(6):776–781.

Malakounides G, Lee F, Murphy F, et al. Single centre experience: long term outcomes in spina bifida patients. *J Pediatr Urol*. 2013;9(5):585–589.

Malhotra B, Darsey E, Crownover P, et al. Comparison of pharmacokinetic variability of fesoterodine vs. tolterodine extended release in cytochrome P450 2D6 extensive and poor metabolizers. *Br J Clin Pharmacol*. 2011;72(2):226–234.

Malhotra B, El-Tahtawy A, Wang EQ, et al. Dose-escalating study of the pharmacokinetics and tolerability of fesoterodine in children with overactive bladder. *J Pediatr Urol*. 2012;8(4):336–342.

Malone PS, Ransley PG, Kiely EM. Preliminary report: the antegrade continence enema. *Lancet*. 1990;336(8725):1217–1218.

Mandell J, Bauer SB, Hallett M, et al. Occult spinal dysraphism: a rare but detectable cause of voiding dysfunction. *Urol Clin North Am*. 1980;7(2):349–356.

Mandell J, Bauer SB, Colodny AH, et al. Cutaneous vesicostomy in infancy. *J Urol*. 1981;126(1):92–93.

Marshall DF, Boston VE. Altered bladder and bowel function following cutaneous electrical field stimulation in children with spina bifida—interim results of a randomized double-blind placebo-controlled trial. *Eur J Pediatr Surg*. 1997;7(Suppl 1):41–43.

Marte A, Di Meglio D, Cotrufo AM, et al. A long-term follow-up of autoaugmentation in myelodysplastic children. *BJU Int*. 2002;89(9):928–931.

Mazur L, Lacy B, Wilsford L. The prevalence of hypertension in children with spina bifida. *Acta Paediatr*. 2011;100(8):e80–e83.

McDonnell GV, McCann JP. Why do adults with spina bifida and hydrocephalus die? A clinic-based study. *Eur J Pediatr Surg*. 2000;10(Suppl 1):31–32.

McGuire EJ, Woodside JR, Borden TA, et al. Prognostic value of urodynamic testing in myelodysplastic patients. *J Urol*. 1981;126(2):205–209.

McKinley WO, Jackson AB, Cardenas DD, et al. Long-term medical complications after traumatic spinal cord injury: a regional model systems analysis. *Arch Phys Med Rehabil*. 1999;80(11):1402–1410.

Mehan R, Misseri R, Vanderbrink B, et al. Metastatic transitional cell carcinoma of the bladder arising in a patient with bladder autoaugmentation. *J Pediatr Urol*. 2011;7(2):137–139.

Menon RK, Cohen RM, Sperling MA, et al. Transplacental passage of insulin in pregnant women with insulin-dependent diabetes mellitus. Its role in fetal macrosomia. *N Engl J Med*. 1990;323(5):309–315.

Metcalfe PD, Cain MP, Kaefer M, et al. What is the need for additional bladder surgery after bladder augmentation in childhood? *J Urol*. 2006;176(4 Pt 2):1801–1805 [discussion 1805].

Metcalfe PD, Casale AJ, Kaefer MA, et al. Spontaneous bladder perforations: a report of 500 augmentations in children and analysis of risk. *J Urol*. 2006;175(4):1466–1470 [discussion 1470–1471].

Metcalfe P, Gray D, Kiddoo D. Neuropathic bladder management of the urinary tract in spina bifida cases varies with lesion level and shunt presence. *J Urol*. 2011;185(6 Suppl):2547–2551.

Metts JC, Kotkin L, Kasper S, et al. Genital malformations and coexistent urinary tract or spinal anomalies in patients with imperforate anus. *J Urol*. 1997;158(3 Pt 2):1298–1300.

Meuli M, Meuli-Simmen C, Hutchins GM, et al. In utero surgery rescues neurological function at birth in sheep with spina bifida. *Nat Med*. 1995;1(4):342–347.

Meyrat BJ, Tercier S, Lutz N, et al. Introduction of a urodynamic score to detect pre- and postoperative neurological deficits in children with a primary tethered cord. *Childs Nerv Syst*. 2003;19(10–11):716–721.

Miller DC, Bloom DA, McGuire EJ, et al. Temporary perineal urethrostomy for external sphincter dilation in a male patient with high risk myelomeningocele. *J Urol*. 2003;170(4 Pt 2):1606–1608 [discussion 1608–1609].

Misra D, Potts SR, Brown S, et al. Endoscopic treatment of vesico-ureteric reflux in neurogenic bladder—8 Years' experience. *J Pediatr Surg*. 1996;31(9):1262–1264.

Misseri R, Cain MP, Casale AJ, et al. Small intestinal submucosa bladder neck slings for incontinence associated with neuropathic bladder. *J Urol*. 2005;174(4 Pt 2):1680–1682 [discussion 1682].

Misseri R, Casale AJ, Cain MP, et al. Alternative uses of dextranomer/hyaluronic acid copolymer: the efficacy of bladder neck injection for urinary incontinence. *J Urol*. 2005;174(4 Pt 2):1691–1693 [discussion 1693–1694].

Mitchell LE. Epidemiology of neural tube defects. *Am J Med Genet C Semin Med Genet*. 2005;135C(1):88–94.

Mitchell ME, Piser JA. Intestinocystoplasty and total bladder replacement in children and young adults: followup in 129 cases. *J Urol*. 1987;138(3):579–584.

Mitchell ME, Kulb TB, Backes DJ. Intestinocystoplasty in combination with clean intermittent catheterization in the management of vesical dysfunction. *J Urol*. 1986;136(1 Pt 2):288–291.

Miyasaka M, Nosaka S, Kitano Y, et al. Utility of spinal MRI in children with anorectal malformation. *Pediatr Radiol*. 2009;39(8):810–816.

Montaldo P, Montaldo L, Iossa AC, et al. Small renal size in newborns with spina bifida: possible causes. *Clin Exp Nephrol*. 2014;18(1):120–123.

Morera C, Nurko S. Rectal manometry in patients with isolated sacral agenesis. *J Pediatr Gastroenterol Nutr*. 2003;37(1):47–52.

Morin F, Blais AS, Nadeua G, et al. Dual therapy for refractory overactive bladder in children: a prospective open-label study. *J Urol*. 2017;197(4):1158–1163.

Morioka A, Miyano T, Ando K, et al. Management of vesicoureteral reflux secondary to neurogenic bladder. *Pediatr Surg Int*. 1998;13(8):584–586.

Morrisroe SN, O'Connor RC, Nanigian DK, et al. Vesicostomy revisited: the best treatment for the hostile bladder in myelodysplastic children? *BJU Int*. 2005;96(3):397–400.

Mosiello G, Capitanucci ML, Gatti C, et al. How to investigate neurovesical dysfunction in children with anorectal malformations. *J Urol*. 2003;170(4 Pt 2):1610–1613.

Mosiello G, Gatti C, De Gennaro M, et al. Neurovesical dysfunction in children after treating pelvic neoplasms. *BJU Int*. 2003;92(3):289–292.

Müller T, Arbeiter K, Aufricht C. Renal function in meningomyelocele: risk factors, chronic renal failure, renal replacement therapy and transplantation. *Curr Opin Urol*. 2002;12(6):479–484.

Murphy KP, Boutin SA, Ide KR. Cerebral palsy, neurogenic bladder, and outcomes of lifetime care. *Dev Med Child Neurol*. 2012;54(10):945–950.

Neel KF. Total endoscopic and anal irrigation management approach to noncompliant neuropathic bladder in children: a good alternative. *J Urol*. 2010;184(1):315–318.

Neel KF, Salem M, Soliman S. Total endoscopic management (TEM approach) of children with non-compliant neuropathic bladder: a preliminary report. *J Pediatr Urol*. 2008;4(2):124–126.

Nguyen HT, Sencan A, Silva A, et al. Urodynamic studies are recommended in children with central nervous system tumors regardless of location. *J Urol*. 2010;184(6):2516–2520.

Nguyen MT, Pavlock CL, Zderic SA, et al. Overnight catheter drainage in children with poorly compliant bladders improves post-obstructive diuresis and urinary incontinence. *J Urol*. 2005;174(4 Pt 2):1633–1636 [discussion 1636].

Nijman RJ, Borgstein NG, Ellsworth P, et al. Tolterodine treatment for children with symptoms of urinary urge incontinence suggestive of detrusor overactivity: results from 2 randomized, placebo controlled trials. *J Urol*. 2005;173(4):1334–1339.

Nogueira M, Greenfield SP, Wan J, et al. Tethered cord in children: a clinical classification with urodynamic correlation. *J Urol*. 2004;172(4 Pt 2):1677–1680 [discussion 1680].

Oakeshott P, Hunt GM, Poulton A, et al. Expectation of life and unexpected death in open spina bifida: a 40-year complete, non-selective, longitudinal cohort study. *Dev Med Child Neurol*. 2010;52(8):749–753.

Ogawa T, Yoshida T, Fujinaga T. Bladder deformity in traumatic spinal cord injury patients]. *Hinyokika Kiyo*. 1988;34(7):1173–1178.

Ok J, Kurzrock EA. Objective measurement of quality of life changes after ACE Malone using the FICQOL survey. *J Pediatr Urol*. 2011;7(3):389–393.

Olandoski KP, Koch V, Trigo-Rocha FE. Renal function in children with congenital neurogenic bladder. *Clinics*. 2011;66(2):189–195.

Olney R, Mulinare J. Epidemiology of neural tube defects. *Ment Retard Dev Disabil Res Rev*. 1998;4:241–246.

Olney RS, Mulinare J. Trends in neural tube defect prevalence, folic acid fortification, and vitamin supplement use. *Semin Perinatol*. 2002;26(4):277–285.

Overgoor MLE, de Jong TPVM, Cohen-Kettenis PT, et al. Increased sexual health after restored genital sensation in male patients with spina bifida or a spinal cord injury: the TOMAX procedure. *J Urol*. 2013;189(2):626–632.

Ozel SK, Dokumcu Z, Akyildiz C, et al. Factors affecting renal scar development in children with spina bifida. *Urol Int*. 2007;79(2):133–136.

Ozkan KU, Bauer SB, Khoshbin S, et al. Neurogenic bladder dysfunction after sacrococcygeal teratoma resection. *J Urol*. 2006;175(1):292–296 [discussion 296].

Packer RJ, Zimmerman RA, Sutton LN, et al. Magnetic resonance imaging of spinal cord disease of childhood. *Pediatrics*. 1986;78(2):251–256.

Palmer JS, Kaplan WE, Firlit CF. Erectile dysfunction in spina bifida is treatable. *Lancet*. 1999;354(9173):125–126.

Pang D, Dias MS. Ahab-Barmada M. Split cord malformation: Part I: a unified theory of embryogenesis for double spinal cord malformations. *Neurosurgery*. 1992;31(3):451–480.

Pang D, Pollack IF. Spinal cord injury without radiographic abnormality in children—the SCIWORA syndrome. *J Trauma*. 1989;29(5):654–664.

Pang D, Wilberger JE Jr. Spinal cord injury without radiographic abnormalities in children. *J Neurosurg*. 1982;57(1):114–129.

Pang D. Sacral agenesis and caudal spinal cord malformations. *Neurosurgery*. 1993;32(5):755–778 [discussion 778–779].

Pang D. Split cord malformation: Part II: clinical syndrome. *Neurosurgery*. 1992;31(3):481–500.

Pannek J, Diederichs W, Bötel U. Urodynamically controlled management of spinal cord injury in children. *Neurourol Urodyn*. 1997;16(4):285–292.

Papapetrou C, Drummond F, Reardon W, et al. A genetic study of the human T gene and its exclusion as a major candidate gene for sacral agenesis with anorectal atresia. *J Med Genet*. 1999;36(3):208–213.

Park JM, McGuire EJ, Koo HP, et al. External urethral sphincter dilation for the management of high risk myelomeningocele: 15-year experience. *J Urol*. 2001;165(6 Pt 2):2383–2388.

Parrott TS. Urologic implications of anorectal malformations. *Urol Clin North Am*. 1985;12(1):13–21.

Pascali MP, Mosiello G, Boldrini R, et al. Effects of botulinum toxin type a in the bladder wall of children with neurogenic bladder dysfunction: a comparison of histological features before and after injections. *J Urol*. 2011;185(6 Suppl):2552–2557.

Passarge E, Lenz W. Syndrome of caudal regression in infants of diabetic mothers: observations of further cases. *Pediatrics*. 1966;37(4):672–675.

Pearman JW. Urological follow-up of 99 spinal cord injured patients initially managed by intermittent catheterisation. *Br J Urol*. 1976;48(5):297–310.

Peña A. Posterior sagittal approach for the correction of anal rectal malformations. *Adv Surg*. 1986;19:69.

Perkash I. Autonomic dysreflexia and detrusor-sphincter dyssynergia in spinal cord injury patients. *J Spinal Cord Med*. 1997;20(3):365–370.

Peters KM, Girdler B, Turzewski C, et al. Outcomes of lumbar to sacral nerve rerouting for spina bifida. *J Urol*. 2010;184(2):702–708.

Pham-Huy A, Leonard M, Lepage N, et al. Measuring glomerular filtration rate with cystatin c and β-trace protein in children with spina bifida. *J Urol*. 2003;169(6):2312–2315.

Phillips JR, Jadvar H, Sullivan G, et al. Effect of radionuclide renograms on treatment of patients with spinal cord injuries.

AJR Am J Roentgenol. 1997;169:1045–1047.

Piatt JH Jr. Pediatric spinal injury in the US: epidemiology and disparities. *J Neurosurg Pediatr*. 2015;16(4):463–471.

Piatt J, Imperato N. Epidemiology of spinal injury in childhood and adolescence in the United States: 1997-2012. *J Neurosurg Pediatr*. 2018;21(5):441–448.

Pierre-Kahn A, Zerah M, Renier D, et al. Congenital lumbosacral lipomas. *Childs Nerv Syst*. 1997;13(6):298–334 [discussion 335].

Polackwich AS, Skoog SJ, Austin JC. Bladder long-term followup after endoscopic treatment of vesicoureteral reflux with dextranomer/hyaluronic acid copolymer in patients with neurogenic bladder. *J Urol*. 2012;188(4 Suppl):1511–1515.

Pollack IF, Pang D, Sclabassi R. Recurrent spinal cord injury without radiographic abnormalities in children. *J Neurosurg*. 1988;69(2):177–182.

Pontari MA, Keating M, Kelly M, et al. Retained sacral function in children with high level myelodysplasia. *J Urol*. 1995;154(2 Pt 2):775–777.

Prevention of neural tube defects: results of the Medical Research Council Vitamin Study. MRC Vitamin Study Research Group. *Lancet*. 1991;338(8760):131–137.

Prieto-Fingerhut T, Banovac K, Lynne CM. A study comparing sterile and nonsterile urethral catheterization in patients with spinal cord injury. *Rehabil Nurs*. 1997;22(6):299–302.

Proctor MR, Bauer SB, Scott RM. The effect of surgery for split spinal cord malformation on neurologic and urologic function. *Pediatr Neurosurg*. 2000;32(1):13–19.

Quan A, Adams R, Ekmark E, et al. Serum creatinine is a poor marker for glomerular filtration rate in patients with spina bifida. *Dev Med Child Neurol*. 1997;39:808–810.

Queipo Zaragozá JA, Domínguez Hinarejos C, Serrano Durbá A, et al. Vesicostomy in children. Our experience with 43 patients]. *Actas Urol Esp*. 2003;27(1):33–38.

Quek ML, Ginsberg DA. Long-term urodynamics followup of bladder augmentation for neurogenic bladder. *J Urol*. 2003;169(1):195–198.

Raghavendra BN, Epstein FJ, Pinto RS, et al. The tethered spinal cord: diagnosis by high-resolution real-time ultrasound. *Radiology*. 1983;149(1):123–128.

Raney B, Anderson J, Jenney M, et al. Late effects in 164 patients with rhabdomyosarcoma of the bladder/prostate region: a report from the international workshop. *J Urol*. 2006;176(5):2190–2194 [discussion 2194–2195].

Rawashdeh YF, Austin P, Siggaard C, et al. International Children's Continence Society. International Children's Continence Society's recommendations for therapeutic intervention in congenital neuropathic bladder and bowel dysfunction in children. *Neurourol Urodyn*. 2012;31(5):615–620.

Recommendations for the use of folic acid to reduce the number of cases of spina bifida and other neural tube defects. *MMWR Recomm Rep*. 1992;41(RR–14):1–7.

Reddy PP, Borgstein NG, Nijman RJ, et al. Long-term efficacy and safety of tolterodine in children with neurogenic detrusor overactivity. *J Pediatr Urol*. 2008;4(6):428–433.

Rendeli C, Ausili E, Tabacco F, et al. Polyethylene glycol 4000 vs. lactulose for the treatment of neurogenic constipation in myelomeningocele children: a randomized-controlled clinical trial. *Aliment Pharmacol Ther*. 2006;23(8):1259–1265.

Rendeli C, Ausili E, Tabacco F, et al. Urodynamic evaluation in children with lipomeningocele: timing for neurosurgery, spinal cord tethering and followup. *J Urol*. 2007;177(6):2319–2324.

Riccabona M, Koen M, Schindler M, et al. Botulinum-A toxin injection into the detrusor: a safe alternative in the treatment of children with myelomeningocele with detrusor hyperreflexia. *J Urol*. 2004;171(2 Pt 1):845–848 [discussion 848].

Richards CL, Malouin F. Cerebral palsy: definition, assessment and rehabilitation. *Handb Clin Neurol*. 2013;111:183–195.

Richardson I, Palmer LS. Clinical and urodynamic spectrum of bladder function in cerebral palsy. *J Urol*. 2009;182(4 Suppl):1945–1948.

Rickwood AM, Hodgson J, Lonton AP, et al. Medical and surgical complications in adolescents and young adults with spina bifida. *Health Trends*. 1984;16:91–95.

Reilly JM, Oates RD. Preliminary investigation of the potential fertility status of post pubertal males with myelodysplasia. *J Urol*. 1992;147:75.

Rinck C, Berg J, Hafeman C. The adolescent with myelomeningocele: a review of parent experiences and expectations. *Adolescence*. 1989;24(95):699–710.

Rivosecchi M, Lucchetti MC, Zaccara A, et al. Spinal dysraphism detected by magnetic resonance imaging in patients with anorectal anomalies: incidence and clinical significance. *J Pediatr Surg*. 1995;30(3):488–490.

Robertson AS, Davies JB, Webb RJ, et al. Bladder augmentation and replacement. Urodynamic and clinical review of 25 patients. *Br J Urol*. 1991;68(6):590–597.

Roijen LE, Postema K, Limbeek VJ, et al. Development of bladder control in children and adolescents with cerebral palsy. *Dev Med Child Neurol*. 2001;43(2):103–107.

Rojansky N, Fasouliotis SJ, Ariel I, et al. Extreme caudal agenesis. Possible drug-related etiology? *J Reprod Med*. 2002;47(3):241–245.

Ross AJ, Ruiz-Perez V, Wang Y, et al. A homeobox gene, HLXB9, is the major locus for dominantly inherited sacral agenesis. *Nat Genet*. 1998;20(4):358–361.

Roth JD, Misseri R, Cain MP, et al. Mobility, hydrocephalus and quality of erections in men with spina bifida. *J Pediatr Urol*. 2017;13(3):264.e1–264.e6.

Routh JC, Kramer SA, Inman BA, et al. Utility of dextranomer/hyaluronic acid injection in setting of bladder and ureteral anomalies. *Urology*. 2008;71(3):435–438.

Routh JC, Cheng EY, Austin JC, et al. Design and methodological considerations of the centers for disease control and prevention urologic and renal protocol for the newborn and young child with spina bifida. *J Urol*. 2016;196(6):1728–1734.

Rove KO, Husmann DA, Wilcox DT, et al. Systematic review of bladder cancer outcomes in patients with spina bifida. *J Pediatr Urol*. 2017;13(5):456.

Roy MW, Gilmore R, Walsh JW. Evaluation of children and young adults with tethered spinal cord syndrome. Utility of spinal and scalp recorded somatosensory evoked potentials. *Surg Neurol*. 1986;26(3):241–248.

Ruge JR, Sinson GP, McLone DG, et al. Pediatric spinal injury: the very young. *J Neurosurg*. 1988;68(1):25–30.

Safari S, Jamali S, Habibollahi P, et al. Intravesical injections of botulinum toxin type A for management of neuropathic bladder: a comparison of two methods. *Urology*. 2010;76(1):225–230.

Sager C, Burek C, Corbetta JP, et al. Initial urological evaluation and management of children with neurogenic bladder due to myelomeningocele. *J Pediatr Urol*. 2017;13(3):271 [e1–e5].

Sandler AD, Worley G, Leroy EC, et al. Sexual function and erection capability among young men with spina bifida. *Dev Med Child Neurol*. 1996;38(9):823–829.

Sarica K, Erbağci A, Yağci F, et al. Multidisciplinary evaluation of occult spinal dysraphism in 47 children. *Scand J Urol*

Nephrol. 2003;37(4):329–334.

Satar N, Bauer SB, Shefner J, et al. The effects of delayed diagnosis and treatment in patients with an occult spinal dysraphism. *J Urol*. 1995;154(2 Pt 2):754–758.

Sawyer SM, Roberts KV. Sexual and reproductive health in young people with spina bifida. *Dev Med Child Neurol*. 1999;41(10):671–675.

Scarff TB, Fronczak S. Myelomeningocele: a review and update. *Rehabil Nurs*. 1981;6(6):26–29.

Schaeffer M, Kaiser A, Stehr M, et al. Bladder augmentation with small intestinal submucosa leads to unsatisfactory long-term results. *J Pediatr Urol*. 2013;9(6 Pt A):878–883.

Scheible W, James HE, Leopold GR, et al. Occult spinal dysraphism in infants: screening with high-resolution real-time ultrasound. *Radiology*. 1983;146(3):743–746.

Schlomer BJ, Saperston K, Baskin L. National trends in augmentation cystoplasty in the 2000s and factors associated with patient outcomes. *J Urol*. 2013;190(4):1352–1358.

Schlussel R. Cystoscopic correction of reflux. *Curr Urol Rep*. 2004;5(2):127–131.

Schmidt RJ, Romitti PA, Burns TL, et al. Maternal caffeine consumption and risk of neural tube defects. *Birth Defects Res A Clin Mol Teratol*. 2009;85(11):879–889.

Schulte-Baukloh H, Michael T, Schobert J, et al. Efficacy of botulinum-a toxin in children with detrusor hyperreflexia due to myelomeningocele: preliminary results. *Urology*. 2002;59(3):325–327 [discussion 327–328].

Schulte-Baukloh H, Knispel HH, Stolze T, et al. Repeated botulinum-A toxin injections in treatment of children with neurogenic detrusor overactivity. *Urology*. 2005;66(4):865–870 [discussion 870].

Schulte-Baukloh H, Mürtz G, Henne T, et al. Urodynamic effects of propiverine hydrochloride in children with neurogenic detrusor overactivity: a prospective analysis. *BJU Int*. 2006;97(2):355–358.

Schulte-Baukloh H, Bigalke H, Miller K, et al. Botulinum neurotoxin type A in urology: antibodies as a cause of therapy failure. *Int J Urol*. 2008;15(5):407–415 [discussion 415].

Schulte-Baukloh H, Herholz J, Bigalke H, et al. Results of a BoNT/A antibody study in children and adolescents after onabotulinumtoxin A (Botox) detrusor injection. *Urol Int*. 2011;87:434–438.

Schulte-Baukloh H, Mürtz G, Heine G, et al. Urodynamic effects of propiverine in children and adolescents with neurogenic bladder: results of a prospective long-term study. *J Pediatr Urol*. 2012;8(4):386–392.

Schulte-Baukloh H, Priefert J, Knispel HH, et al. Botulinum Toxin A detrusor injections reduce postsynaptic muscular M2, M3, P2x2, and P2x3 receptors in children and adolescents who have neurogenic detrusor overactivity: a single-blind study. *Urology*. 2013;81:1052–1057.

Schurch B, Hodler J, Rodic B. Botulinum A toxin as a treatment of detrusor-sphincter dyssynergia in patients with spinal cord injury: MRI controlled transperineal injections. *J Neurol Neurosurg Psychiatry*. 1997;63(4):474–476.

Schwarz GR, Jeffs RD. Ileal conduit urinary diversion in children: computer analysis of followup from 2 to 16 years. *J Urol*. 1975;114(2):285–288.

Sebold CD, Melvin EC, Siegel D, et al. Recurrence risks for neural tube defects in siblings of patients with lipomyelomeningocele. *Genet Med*. 2005;7(1):64–67.

Seeds JW, Jones FD. Lipomyelomeningocele: prenatal diagnosis and management. *Obstet Gynecol*. 1986;67(3 Suppl):34S–37S.

Seki N, Akazawa K, Senoh K, et al. An analysis of risk factors for upper urinary tract deterioration in patients with myelodysplasia. *Br J Urol*. 1999;84(6):679–682.

Shandling B, Gilmour RF. The enema continence catheter in spina bifida: successful bowel management. *J Pediatr Surg*. 1987;22(3):271–273.

Shandling B, Chait PG, Richards HF. Percutaneous cecostomy: a new technique in the management of fecal incontinence. *J Pediatr Surg*. 1996;31(4):534–537.

Shapiro SR, Lebowitz R, Colodny AH. Fate of 90 children with ileal conduit urinary diversion a decade later: analysis of complications, pyelography, renal function and bacteriology. *J Urol*. 1975;114(2):289–295.

Shaul DB, Harrison EA. Classification of anorectal malformations—initial approach, diagnostic tests, and colostomy. *Semin Pediatr Surg*. 1997;6(4):187–195.

Shaw GM, Todoroff K, Carmichael SL, et al. Lowered weight gain during pregnancy and risk of neural tube defects among offspring. *Int J Epidemiol*. 2001;30(1):60–65.

Shekarriz B, Upadhyay J, Demirbilek S, et al. Surgical complications of bladder augmentation: comparison between various enterocystoplasties in 133 patients. *Urology*. 2000;55(1):123–128.

Shenot PJ, Rivas DA, Watanabe T, et al. Early predictors of bladder recovery and urodynamics after spinal cord injury. *Neurourol Urodyn*. 1998;17(1):25–29.

Shiroyanagi Y, Suzuki M, Matsuno D, et al. The significance of 99mtechnetium dimercapto-succinic acid renal scan in children with spina bifida during long-term followup. *J Urol*. 2009;181(5):2262–2266.

Sidi AA, Dykstra DD, Gonzalez R. The value of urodynamic testing in the management of neonates with myelodysplasia: a prospective study. *J Urol*. 1986;135(1):90–93.

Sidi AA, Aliabadi H, Gonzalez R. Enterocystoplasty in the management and reconstruction of the pediatric neurogenic bladder. *J Pediatr Surg*. 1987;22(2):153–157.

Silva JA, Alvares RA, Barboza AL, et al. Lower urinary tract dysfunction in children with cerebral palsy. *Neurourol Urodyn*. 2009;28(8):959–963.

Silva JA, Gonsalves MC, Saverio AP, et al. Pediatric urology. *Urology*. 2010;76:942–945.

Simeoni J, Guys JM, Mollard P, et al. Artificial urinary sphincter implantation for neurogenic bladder: a multi-institutional study in 107 children. *Br J Urol*. 1996;78(2):287–293.

Singhal B, Mathew KM. Factors affecting mortality and morbidity in adult spina bifida. *Eur J Pediatr Surg*. 1999;9(Suppl 1):31–32.

Sival DA, Begeer JH, Staal-Schreinemachers AL, et al. Perinatal motor behaviour and neurological outcome in spina bifida aperta. *Early Hum Dev*. 1997;50(1):27–37.

Slaton JW, Kropp KA. Conservative management of suspected bladder rupture after augmentation enterocystoplasty. *J Urol*. 1994;152(2 Pt 2):713–715.

Smith ED. Urinary prognosis in spina bifida. *J Urol*. 1972;108(5):815–817.

Snodgrass W, Barber T. Comparison of bladder outlet procedures without augmentation in children with neurogenic incontinence. *J Urol*. 2010;184(4 Suppl):1775–1780.

Snodgrass WT, Elmore J, Adams R. Bladder neck sling and appendicovesicostomy without augmentation for neurogenic incontinence in children. *J Urol*. 2007;177(4):1510–1514 [discussion 1515].

Snodgrass W, Keefover-Hicks A, Prieto J, et al. Comparing outcomes of slings with versus without enterocystoplasty for neurogenic urinary incontinence. *J Urol*. 2009;181(6):2709–2714 [discussion 2714–2716].

Snodgrass W, Barber T, Cost N. Detrusor compliance changes after bladder neck sling without augmentation in children with neurogenic urinary incontinence. *J Urol*. 2010;183(6):2361–2366.

Snow-Lisy DC, Yerkes EB, Cheng EY. Update on urological management of spina bifida from prenatal diagnosis to adulthood. *J Urol*. 2015;194(2):288–296.

Soergel TM, Cain MP, Misseri R, et al. Transitional cell carcinoma of the bladder following augmentation cystoplasty for the neuropathic bladder. *J Urol*. 2004;172(4 Pt 2):1649–1651 [discussion 1651–1652].

Soler D. Borzyskowski M. Lower urinary tract dysfunction in children with central nervous system tumours. *Arch Dis Child*. 1998;79(4):344–347.

Soler NG, Walsh CH, Malins JM. Congenital malformations in infants of diabetic mothers. *Q J Med*. 1976;45(178):303–313.

Soler R, Macedo A, Bruschini H, et al. Does the less aggressive multimodal approach of treating bladder-prostate rhabdomyosarcoma preserve bladder function? *J Urol*. 2005;174(7):2343–2346.

Spiess PE, Capolicchio JP, Kiruluta G, et al. Is an artificial sphincter the best choice for incontinent boys with spina bifida? Review of our long term experience with the AS-800 artificial sphincter. *Can J Urol*. 2002;9(2):1486–1491.

Stathopoulos E, Muehlethaler V, Rais M, et al. Preoperative assessment of neurovesical function in children with anorectal malformation: association with vertebral and spinal malformations. *J Urol*. 2012;188(3):943–947.

Stein SC, Feldman JG, Friedlander M, et al. Is myelomeningocele a disappearing disease? *Pediatrics*. 1982;69(5):511–514.

Stothard KJ, Tennant PW, Bell R, et al. Maternal overweight and obesity and the risk of congenital anomalies: a systematic review and meta-analysis. *JAMA*. 2009;301(6):636–650.

Sutherland RW, Wiener JS, Roth DR, et al. A renal size nomogram for the patient with myelomeningocele. *J Urol*. 1997;158(3 Pt 2):1265–1267.

Sylora JA, Gonzalez R, Vaughn M, et al. Intermittent self-catheterization by quadriplegic patients via a catheterizable Mitrofanoff channel. *J Urol*. 1997;157(1):48–50.

Tan HJ, Stoffel J, Daignault S, et al. Ileovesicostomy for adults with neurogenic bladders: complications and potential risk factors for adverse outcomes. *Neurourol Urodyn*. 2008;27(3):238–243.

Tanaka H, Kakizaki H, Kobayashi S, et al. The relevance of urethral resistance in children with myelodysplasia: its impact on upper urinary tract deterioration and the outcome of conservative management. *J Urol*. 1999;161(3):929–932.

Tanaka ST, Stone AR, Kurzrock EA. Transverse myelitis in children: long-term urological outcomes. *J Urol*. 2006;175(5):1865–1868 [discussion 1868].

Taskinen S, Valanne L, Rintala R. Effect of spinal cord abnormalities on the function of the lower urinary tract in patients with anorectal abnormalities. *J Urol*. 2002;168(3):1147–1149.

Torre M, Guida E, Bisio G, et al. Risk factors for renal function impairment in a series of 502 patients born with spinal dysraphisms. *J Pediatr Urol*. 2011;7(1):39–43.

Tracy PT, Hanigan WC. Spinal dysraphism: use of magnetic resonance imaging in evaluation. *Clin Pediatr (Phila)*. 1990;29(4):228–233.

Trollmann R, Strehl E, Dörr HG. Precocious puberty in children with myelomeningocele: treatment with gonadotropin-releasing hormone analogues. *Dev Med Child Neurol*. 1998;40(1):38–43.

Tsakayannis DE, Shamberger RC. Association of imperforate anus with occult spinal dysraphism. *J Pediatr Surg*.

1995;30(7):1010–1012.

Tuite GF, Homsy Y, Polsky EG, et al. Urological outcome of the Xiao procedure in children with myelomeningocele and lipomyelomeningocele undergoing spinal cord detethering. *J Urol*. 2016;196(6):1735–1740.

Tunell WP, Austin JC, Barnes PD, et al. Neuroradiologic evaluation of sacral abnormalities in imperforate anus complex. *J Pediatr Surg*. 1987;22(1):58–61.

Vaidyananthan S, Soni BM, Brown E, et al. Effect of intermittent urethral catheterization and oxybutynin bladder instillation on urinary continence status and quality of life in a selected group of spinal cord injury patients with neuropathic bladder dysfunction. *Spinal Cord*. 1998;36(6):409–414.

Vaidyananthan S, Soni BM, Sett P, et al. Pathophysiology of autonomic dysreflexia: long-term treatment with terazosin in adult and paediatric spinal cord injury patients manifesting recurrent dysreflexic episodes. *Spinal Cord*. 1998;36(11):761–770.

Van Hala S, Nelson VS, Hurvitz EA, et al. Bladder management in patients with pediatric onset neurogenic bladders. *J Spinal Cord Med*. 1997;20(4):410–415.

Veenboer PW, de Kort LM. Bladder carcinoma in a 31-year-old female spina bifida patient with an auto-augmented bladder. *Int Urol Nephrol*. 2011;44(4):1027–1030.

Veenboer PW, Nadorp S, de Jong TP, et al. Enterocystoplasty vs detrusorectomy: outcome in the adult with spina bifida. *J Urol*. 2013;189(3):1066–1070.

Velde SV, Van Biervliet S, Van Renterghem K. Achieving fecal continence in patients with spina bifida: a descriptive cohort study. *J Urol*. 2007;178(6):2640–2644 [discussion 2644].

Vemulakonda VM, Lendvay TS, Shnorhavorian M, et al. Metastatic adenocarcinoma after augmentation gastrocystoplasty. *J Urol*. 2008;179(3):1094–1096 [discussion 1097].

Verhoef M, Barf HA, Vroege JA, et al. Sex education, relationships, and sexuality in young adults with spina bifida. *Arch Phys Med Rehabil*. 2005;86(5):979–987.

Verhoef M, Lurvink M, Barf HA, et al. High prevalence of incontinence among young adults with spina bifida: description, prediction and problem perception. *Spinal Cord*. 2005;43(6):331–340.

Vieira AR. Birth order and neural tube defects: a reappraisal. *J Neurol Sci*. 2004;217(1):65–72.

Vieira AR, Castillo Taucher S. Maternal age and neural tube defects: evidence for a greater effect in spina bifida than in anencephaly]. *Rev Med Chil*. 2005;133(1):62–70.

Visconti D, Noia G, Triarico S, et al. Sexuality, pre-conception counseling and urological management of pregnancy for young women with spina bifida. *Eur J Obstet Gynecol Reprod Biol*. 2012;163(2):129–133.

Landauer W. Rumplessness of chicken embryos produced by the injection of insulin and other chemicals. *J Exp Zool*. 1945;98(1):65–77.

Walker RD 3rd, Flack CE, Hawkins-Lee B, et al. Rectus fascial wrap: early results of a modification of the rectus fascial sling. *J Urol*. 1995;154(2 Pt 2):771–774.

Wang JB, Liu CS, Tsai SL, et al. Augmentation cystoplasty and simultaneous ureteral reimplantation reduce high-grade vesicoureteral reflux in children with neurogenic bladder. *J Chin Med Assoc*. 2011;74(7):294–297.

Wang M, Wang ZP, Gao LJ, et al. Periconceptional factors affect the risk of neural tube defects in offspring: a hospital-based case-control study in China. *J Matern Fetal Neonatal Med*. 2013;26(11):1132–1138.

Warf BC, Campbell JW. Combined endoscopic third ventriculostomy and choroid plexus cauterization as primary treatment of hydrocephalus for infants with myelomeningocele: long-term results of a prospective intent-to-treat study in 115 East African infants. *J Neurosurg Pediatr*. 2008;2(5):310–316.

Warf B, Ondoma S, Kulkarni A, et al. Neurocognitive outcome and ventricular volume in children with myelomeningocele treated for hydrocephalus in Uganda. *J Neurosurg Pediatr*. 2009;4(6):564–570.

Wein AJ. Pharmacologic options for the overactive bladder. *Urology*. 1998;51(2A Suppl):43–47.

Weissert M, Gysler R, Sörensen N. The clinical problem of the tethered cord syndrome—a report of 3 personal cases]. *Z Kinderchir*. 1989;44(5):275–279.

Wen JG, Yang L, Xing L, et al. A study on voiding pattern of newborns with hypoxic ischemic encephalopathy. *Urology*. 2012;80(1):196–199.

White RI, Klauber GT. Sacral agenesis. Analysis of 22 cases. *Urology*. 1976;8(6):521–525.

Wiart L, Joseph PA, Petit H, et al. The effects of capsaicin on the neurogenic hyperreflexic detrusor. A double blind placebo controlled study in patients with spinal cord disease. Preliminary results. *Spinal Cord*. 1998;36(2):95–99.

Wide P, Glad Mattsson G, Mattsson S. Renal preservation in children with neurogenic bladder-sphincter dysfunction followed in a national program. *J Pediatr Urol*. 2012;8(2):187–193.

Wilmshurst JM, Kelly R. Borzyskowski M. Presentation and outcome of sacral agenesis: 20 years' experience. *Dev Med Child Neurol*. 1999;41(12):806–812.

Wolman C, Resnick MD, Harris LJ, et al. Emotional well-being among adolescents with and without chronic conditions. *J Adolesc Health*. 1994;15(3):199–204.

Woodard JR, Anderson AM 3rd, Parrott TS. Ureteral reimplantation in myelodysplasia children. *J Urol*. 1981;126(3):387–388.

Woodhouse CR. The sexual and reproductive consequences of congenital genitourinary anomalies. *J Urol*. 1994;152(2 Pt 2):645–651.

Woodhouse CR. Sexual function in boys born with exstrophy, myelomeningocele, and micropenis. *Urology*. 1998;52(1):3–11.

Woodhouse CRJ. Myelomeningocele in young adults. *BJU Int*. 2005;95(2):223–230.

Woodside JR, Crawford ED. Urodynamic features of pelvic plexus injury. *J Urol*. 1980;124(5):657–658.

Xiao CG, Du MX, Li B, et al. An artificial somatic-autonomic reflex pathway procedure for bladder control in children with spina bifida. *J Urol*. 2005;173(6):2112–2116.

Yalla SV, Andriole GL. Vesicourethral dysfunction following pelvic visceral ablative surgery. *J Urol*. 1984;132(3):503–509.

Yamada S, Zinke DE, Sanders D. Pathophysiology of “tethered cord syndrome”. *J Neurosurg*. 1981;54(4):494–503.

Yamada S, Knierim D, Yonekura M, et al. Tethered cord syndrome. *J Am Paraplegia Soc*. 1983;6(3):58–61.

Yamada S, Won DJ, Yamada SM. Pathophysiology of tethered cord syndrome: correlation with symptomatology. *Neurosurg Focus*. 2004;16(2):E6.

Yamaguchi O, Marui E, Kakizaki H, et al. Phase III, randomized, double-blind, placebo-controlled study of the β3 -adrenoceptor agonist, mirabegron 50 mg once-daily, in Japanese patients with overactive bladder. *BJU Int*. 2014;113(6):951–960.

Yardley IE, Pauniaho SL, Baillie CT, et al. After the honeymoon comes divorce: long-term use of the antegrade continence enema procedure. *J Pediatr Surg*. 2009;44(6):1274–1276 [discussion 1276–1277].

Yeung CK, Ward HC, Ransley PG, et al. Bladder and kidney function after cure of pelvic rhabdomyosarcoma in childhood. *Br J Cancer*. 1994;70(5):1000–1003.

Yin Z, Xu W, Xu C, et al. A population-based case-control study of risk factors for neural tube defects in Shenyang, China. *Childs Nerv Syst*. 2010;27(1):149–154.

Yip CM, Leach GE, Rosenfeld DS, et al. Delayed diagnosis of voiding dysfunction: occult spinal dysraphism. *J Urol*. 1985;134(4):694–697.

Zwink N, Jenetzky E, Brenner H. Parental risk factors and anorectal malformations: systematic review and meta-analysis. *Orphanet J Rare Dis*. 2011;6:25.

35

Functional Disorders of the Lower Urinary Tract in Children

Paul F. Austin MD, Abhishek Seth MD

Clinical Significance

Functional disorders of the lower urinary tract (LUT) encompass abnormalities in the filling and/or emptying phases of the bladder and include a broad spectrum of clinical entities that vary in their cause and prognosis. These are functional disorders in children that do not have a readily identifiable neurologic or anatomic abnormality. These LUT disorders are thought to originate from behavioral factors that affect toilet training and inhibit the development of normal urinary control. *Lower urinary tract dysfunction (LUTD), bladder and bowel dysfunction*, and the antiquated *dysfunctional elimination syndrome* are terms that describe the common array of symptoms that include overactive bladder (OAB), voiding postponement, underactive bladder, dysfunctional voiding, primary bladder neck dysfunction, giggle incontinence, vaginal reflux, pollakiuria, and enuresis.

Evidence-based medicine lends support to the hypothesis that LUTD can predispose children to recurrent urinary tract infections (UTIs) and vesicoureteral reflux (VUR), with a potential for significant impact on subsequent LUT and renal function. Beyond these largely urologic sequelae, however, the impact of symptoms such as daytime incontinence are profound and can affect the behavioral, emotional, and social aspects of a child's daily life. Timely diagnosis and a coherent therapeutic approach are therefore paramount in the successful treatment of these physically and emotionally distressing disorders.

Epidemiology

LUTD is commonly encountered in daily practice, accounting for up to 40% of pediatric urology clinic visits annually (Feldman and Bauer, 2006). Cross-sectional studies confirm that functional LUT problems are prevalent, with 22% of school-age children reporting at least one LUT symptom. The most common urinary symptoms cited included holding maneuvers (19.1%) and urgency (13.7%) (Vaz et al., 2012).

United States

Daytime incontinence is estimated to affect up to 7 million children in the United States 6 years of age or older (Franco, 2012). To date, studies have focused primarily on daytime versus nighttime incontinence and have not attempted to differentiate the type of daytime incontinence. OAB, characterized by urgency, is the most commonly encountered LUT disorder in children and appears to have a peak incidence between 5 and 7 years of age, although its true prevalence is difficult to determine (Franco, 2007). Chandra (1998) reported the responses to 583 questionnaires completed by families of children between 5 and 9 years of age and found that urinary urgency and pelvic tightening maneuvers to postpone voiding and prevent incontinence were the voiding issues most frequently reported. Urge incontinence was present in 7% of girls and 3% of boys.

International

A study by Hellström et al. (1990) of 7-year-old Swedish children entering school revealed that 21% of girls and 18% of boys had moderate-to-severe urinary urgency. Daytime urinary incontinence occurred once weekly in 3.1% of girls and 2.1% of boys. A Japanese study of 6917 school-age children demonstrated an overall prevalence rate of 17.8% for OAB (Kajiwara et al., 2006). Interestingly, this epidemiologic survey found a nearly equal prevalence of OAB between boys and girls of 19.1% and 16.6%, respectively. An Australian study addressed the frequency of voiding disorders in school-age children (Sureshkumar et al., 2009). This study of 2856 students reported that 19.2% of children had experienced at least one episode of daytime incontinence in the previous 6 months, with 16.5% having experienced more than one wetting episode and only 0.7% experiencing wetting on a daily basis. Independent risk factors for daytime incontinence included nocturnal enuresis, female sex, history of UTI, and encopresis (Sureshkumar et al., 2009).

A large cross-sectional study of more than 19,000 children between 5 and 13 years of age was performed in the Republic of Korea and evaluated the prevalence of OAB by parental questionnaire (Chung et al., 2009). The overall prevalence of OAB was 16.6% and decreased with age from 23% to 12% by 13 years of age (Chung et al., 2009). Compared with other children, those with OAB had a greater prevalence of nocturnal enuresis, constipation, fecal incontinence, UTI, delayed bladder control, and poor toilet facilities.

Gender and Age-Related Demographics

Robson (1997) found that **daytime incontinence varies with both age and gender.** This group reported that the prevalence of daytime wetting at least once every 2 weeks was 10% from 5 to 6 years of age, 5% from 6 to 12 years of age, and 4% from 12 to 18 years of age. In a population survey of 1192 individuals 1.5 to 27 years of age, daytime incontinence occurred in 13% of children 4 years of age, 7% of children 5 years of age, 10% of children 6 years of age, and 5% of children 7 years of age (Bloom et al., 1993). **Studies on the prevalence of voiding disorders in school-age children indicate that daytime urinary incontinence is two to five times more common in girls** (Sureshkumar et al., 2009). Girls also tend to have a lower incidence of frequency, more incontinence, and a larger percent expected bladder capacity (EBC) than boys (Van Batavia et al., 2017). Hellström et al. (1990) found that daytime incontinence was more common in girls (6.7%) than in boys (3.8%) and that most children with incontinence had other lower urinary tract symptoms (LUTS). A retrospective analysis by Arlen et al. identified an association between body mass index (BMI) and LUT or bowel-bladder dysfunction (BBD) in school-age children. Furthermore, children with a BMI greater than the 85th percentile were more likely to experience treatment failure (Arlen et al., 2017).

Self-Esteem and Quality-of-Life Issues

Multiple epidemiologic and cross-sectional studies demonstrate that between 5% and 20% of children suffer with daytime incontinence (Hellström et al., 1990; Kajiwara et al., 2004; Joinson et al., 2006; Sureshkumar et al., 2009). The reported incidence of incontinence ranges from 1.2% daily to 3.6% at least twice per week (Hellström et al., 1990). Remarkably, the majority of parents surveyed did not seek medical attention for their child's incontinence, and teachers recognized only 3% of the children in their classroom who actually suffered from daytime wetting (Sureshkumar et al., 2009). These statistics would make it appear that LUTD and its sequelae are of nominal consequence in the daily lives of young children. Various studies examining the impact of symptoms like urinary incontinence on self-esteem and quality of life (QoL) in children would suggest otherwise. In a literature review analysis, Collis et al. found that a majority of pediatric studies demonstrated a reduced QoL in children with nocturnal enuresis, bladder dysfunction, bowel dysfunction, and combined BBD (Collis et al., 2019). Furthermore, they found that parents' QoL and socioemotional functioning were also negatively affected.

Given the emerging recognition of patient perspectives in health care over the past decade, QoL assessment is an important part of incontinence research. Measurement of QoL in children with urinary incontinence gives a child-centric estimate of the impact that incontinence makes in daily life. In a survey of 1185 children, both in the United States and Australia, school-age children were asked to grade the severity of 20 different stressful life events (Ollendick et al., 1989). Of the different situations examined, "wetting pants in class" was rated as the third most stressful, which underscores the importance of urinary control in school-age children and their peers. Additionally, attention has been raised with associated school bullying and pediatric LUTS (Ching et al., 2015).

Thibodeau et al. (2013) prospectively studied 40 children (10 males and 30 females), between 5 and 11 years of age with non-neurogenic daytime wetting. The Dysfunctional Voiding Symptom Score (DVSS), originally put forth by Farhat et al., (2000) was used to quantify the severity of LUTS and was completed by both parents and children. Parents and their children also completed the Pediatric Urinary Incontinence Quality of Life Score tool (Pin-Q), originally developed by Bower et al. (2006), which measures the emotional impact that urinary incontinence has on a child. There was no statistically significant difference between parent and child scores for symptoms (DVSS) and quality of life (Pin-Q), supporting the parent's awareness and accurate perception of the child's symptoms and the shared impact on their QoL. DVSS and Pin-Q responses were positively correlated (i.e., as DVSS scores increased, the Pin-Q showed a corresponding rise). Similarly, Noordhoff et al. examined the efficacy of The Dutch Vancouver Symptom Score for Dysfunctional Elimination Syndrome (VSSDES) and the PinQ in assessing QoL in 64 children who had received urotherapy. The PinQ questionnaire was able to detect clinically important changes over time, suggesting that symptoms had improved with extended urotherapy. In contrast, the VSSDES was not useful in detecting clinically important changes, over time, in response to therapy (Noordhoff et al., 2018). This study demonstrates the heterogeneity existing in questionnaires and psychometric testing used in the diagnosis and management of bladder and bowel dysfunction, which was summarized by Jiang et al., thus validating the need for standardization (Jiang et al., 2018).

Comorbidities

Urinary Tract Infections

A clear and consistent relationship has been repeatedly demonstrated in multiple studies between LUTD and UTIs (Yang et al., 2018). Bauer (2002) suggested that UTIs are not only an effect of dysfunctional voiding but also may precipitate the development of LUTD, specifically OAB.

Hellström et al. (1990) disseminated a questionnaire to analyze the micturition habits and UTI history of more than 3500 school-age children. Girls with daytime wetting, urgency, and emptying difficulties had a higher prevalence of UTI history than those without symptoms. Hoebeke et al. (2001a) prospectively studied 1000 children during a 4-year study period with video-urodynamics to ascertain the cause and epidemiology of LUTD. The incidence of UTI was significantly higher in girls than in boys. In addition, boys with LUTD had no greater risk for UTI. In girls with underactive bladder, there was a significantly higher incidence of UTI.

Chen et al. (2004) performed a multivariate analysis on 2759 children to elucidate the relationships among LUTD, UTI, and VUR. Their data demonstrated a higher rate of LUTD in girls (43.7%) than in boys (23.8%), with 44% of children who had a history of UTIs also having concomitant LUTD. Interestingly, they observed no association of UTI or VUR individually, but rather found that LUTD was noted only when both UTI and VUR were present.

In a recent retrospective review, Van Batavia et al. (2013) determined how many children who initially presented with LUTD had a history of UTIs. Of 623 children diagnosed with LUTD, one-third had a history of UTIs, with the prevalence rate being significantly higher in girls than in boys. When stratified by specific LUT conditions, girls with underactive bladder and dysfunctional voiding had the highest UTI rates. Not surprisingly, **the association between UTIs and LUTD was most often noted for LUT conditions in which urinary stasis occurs.**

Vesicoureteral Reflux

There is a known association between LUTD and VUR, and VUR may be secondary to the LUT condition. Lapides and Diokono (1970) **first described**

the association between dysfunctional voiding and VUR. Since that time, a number of authors have expanded on the description and nature of the association. In the late 1970s, **Koff et al.** (1979) **demonstrated that voiding against a closed sphincter can increase bladder pressure and may contribute to the development and persistence of VUR. The incomplete bladder emptying that occurs in children with LUTD can lead to urinary stasis with subsequent UTI causing inflammatory changes in the bladder wall that stimulate hypertrophy and overactivity. This is particularly true in older children who manifest with febrile UTIs after toilet training has been completed. It has been theorized that detrusor hypertrophy can alter the closure mechanism at the ureterovesical junction, leading to reflux** (Yeung et al., 1998)**. Gaither et al.** (2018) **provided further evidence that dilating reflux and female sex were risk factors for development of LUTD; however, BMI and prophylactic antibiotics were not significant risk factors**.

One of the first studies to systematically address the relationship between LUTD and VUR was performed by Van Gool et al. (1992), who distributed a questionnaire to all children enrolled in the European arm of the International Reflux Study in Children. Extrapolating from the questionnaire results, the prevalence of dysfunctional voiding was approximately 18%. **A strong association was observed between recurrent UTI and LUTD, and in those children with spontaneous resolution of their reflux, the prevalence of LUTD was much lower.**

Koff et al. (1998) reported their experience on 143 children with primary VUR who either resolved spontaneously or were surgically treated. LUTD was present in 66 (43% of the cohort), with 54 (82%) of these children having a breakthrough UTI and undergoing reimplantation compared with only 18% without LUTD. Of 70 children who had a breakthrough UTI, LUTD was present in 54 children (77%); in 73 patients who did not have a breakthrough infection, LUTD was present in only 12 (16%) children. Additionally, if VUR resolution did occur, the time for resolution lagged by 1.6 years in those with LUTD compared with those without LUTD. Finally, **unsuccessful surgical outcomes involving persistent, recurrent, and contralateral reflux occurred only in children with BBD.**

The association between LUTD and treatment failure after surgical correction for reflux has been borne out in a number of clinical studies. Regardless of surgical treatment modality (i.e., endoscopic vs. open reimplantation), ongoing LUTD has been shown to be associated with a higher failure rate (Peters et al., 2010; Tekgül et al., 2012). Capozza et al. (2002) treated a total of 320 children between 3 and 11 years of age with subureteral injection for grades II to IV VUR. They found untreated LUTD to be highly associated with endoscopic treatment failure at 6-month follow-up.

Targeted treatment for LUTD has been demonstrated to improve spontaneous resolution rates for VUR (Fast et al., 2013; Willemsen and Nijman, 2000). In a recent study by Fast et al. (2013), patients diagnosed and treated for LUTD who had concomitant VUR at or near the time of diagnosis underwent targeted treatment for their specific dysfunction along with antibiotic prophylaxis. VUR was monitored with serial voiding cystourethrogram or video-urodynamics. After a mean of 3.1 years of treatment, VUR resolved with targeted therapy in 26 of 58 ureters. All of these patients had a history of UTIs before starting targeted intervention. Interestingly, they found that resolution rates for VUR were similar regardless of VUR grade. Resolution or significant improvement of reflux was greater in patients with dysfunctional voiding (70%) compared with those who had OAB (38%) or underactive bladder (40%). The outcomes of children with and without BBD was compared in two longitudinal studies (Randomized Intervention of Children with Vesicoureteral Reflux and Careful Urinary Tract Infection Evaluation), concluding that patients with combined BBD and VUR are at higher risk for developing recurrent UTIs than children with BBD or VUR alone (Shaikh et al., 2016).

Psychological Associations

Recently, there has been an emerging awareness of the strong association that exists between neuropsychiatric comorbidities and LUTD in children. In fact, **functional causes of LUTD are believed by many to originate from behavioral issues that evolve from personal stressors and/or adverse events that occurred around the time of toilet training** (Feldman and Bauer, 2006)**. A study of nonbiologic determinants of BBD performed by Martins et al. reported that more severe symptoms were observed in urology outpatient clinics when the children were from an unplanned pregnancy, attended daycare, or had school problems. This suggests that environmental factors, including personal and familial interactions, had an important effect on continence of school-age children** (Martins et al., 2016).

Between 20% and 40% of children with daytime urinary incontinence are affected by comorbid behavioral disorders (Joinson et al., 2006; von Gontard et al., 1998b). Additionally, a number of epidemiologic studies have reported clinically significant behavioral problems in up to one-third of children with enuresis (Hirasing et al., 1997; Liu et al., 2000). This is two to four times higher than in children without enuresis and is comparable with rates of psychosocial problems in other pediatric chronic illness groups. Other studies have investigated the psychological problems associated with specific syndromes responsible for daytime urinary incontinence. These investigators found a higher rate of behavioral problems in children with voiding postponement compared with those who had urge incontinence as their major complaint (Lettgen et al., 2002; von Gontard et al., 2011). Moreover, some have suggested that voluntary holding with postponement of voiding is acquired and may be reflective of ongoing behavioral issues (von Gontard et al., 1999). Using a Child Behavior Checklist (CBCL), Marciano et al. (2018) evaluated the prevalence of internalizing and externalizing behavioral problems in children with LUTD. Having enuresis in addition to LUTD was associated with higher frequency of externalizing problems including aggressive behaviors. The presence of a behavioral problem was further associated with a poorer QoL.

Oliver et al. (2013) explored the prevalence of psychosocial comorbidities and their relationship to children presenting with LUTD. Data were prospectively collected on patients 6 to 17 years of age. Parents completed a 21-question LUTS score based on a validated questionnaire and a psychosocial questionnaire that screened for stressful life events and psychological diagnoses. Of the 358 patients examined, 32% had a recent life stressor and 23% had a comorbid psychiatric disorder. Younger age correlated with a higher LUTS score. Children with a recent life stressor, psychiatric disorder, or the two comorbidities had a significantly higher LUTS score than children without comorbidities. This study lends support to the recommendation for screening of psychosocial comorbidities during the evaluation of pediatric LUTD.

In perhaps one of the largest epidemiologic studies to look at the association between daytime urinary incontinence and neuropsychiatric issues in children, researchers found a significantly increased rate of psychological problems among children who wet themselves compared with those who were dry (Joinson et al., 2006). Of the over 8000 children between 7.5 and 9 years of age who were studied, those with daytime wetting had significantly increased rates of attention deficit/hyperactivity disorder (ADHD) (24.8%), conduct disorders (11.8%), separation anxiety (11.4%), and oppositional behavior (10.9%). The increased vulnerability to psychological problems in children with daytime urinary incontinence underscores the importance of parents seeking early intervention for the condition to help prevent later psychological problems. Comorbidity of ADHD with nocturnal enuresis and daytime urinary incontinence has been shown to arise from nongenetic factors and are likely caused by etiologic and pathogenetic links (von Gontard and Equit, 2015). Moreover**, clinicians should be cognizant of the association with disorders such as ADHD in children with daytime wetting, because this is likely to interfere with treatment success.** In addition to an association with more severe nocturnal enuresis, Kovacevic et al. (2018) found that patients with ADHD were significantly more responsive to medication for nocturnal enuresis compared with behavior modification, suggesting that early intervention by pharmacologic treatment is beneficial for children with ADHD.

Bowel Dysfunction

It has long been recognized that an intimate association exists between both hindgut and LUT function. Indeed, LUTS are seen in approximately 30% of children who present with constipation (Belman, 1998). Previous reports have indicated a significant overlap in these conditions in the primary care setting, with nearly one-fourth of children with functional fecal retention also reporting daytime urinary incontinence (Loening-Baucke, 2004). As one would expect, the prevalence of these comorbid conditions is even higher at tertiary care centers. Burgers et al. (2013a) recently reported that nearly one-half of patients seen at their pediatric urology clinic for LUTS also met criteria for functional constipation.

The relationship between abnormal bowel and bladder activity is termed *bowel-bladder dysfunction (BBD)* and is part of an entity originally described by Koff et al. (1998) **as *the dysfunctional elimination syndrome*.** The International Children's Continence Society discourages using the term *dysfunctional elimination syndrome* as this connotes a particular abnormality or condition (Austin et al., 2014). *BBD* is a more descriptive comprehensive term that does not necessarily explain pathogenesis but rather encompasses this parallel dysfunction. In any event, Koff recognized the significance of bowel dysfunction; if present, its clear identification and management were paramount if treatment of the LUT condition was to be successful. Koff et al. (1998) recommended that each LUT condition be treated specifically while addressing any concomitant bowel dysfunction, often before treatment of the LUT condition.

Although an exact pathophysiologic basis for BBD has not been clearly elucidated, a number of different theories have been put forth. One theory espouses that rectal distention from fecal retention puts direct pressure on the posterior bladder wall and that this constant force in turn leads to detrusor instability, which can precipitate bladder overactivity and impair efficient bladder emptying (Lucanto et al., 2000). A second theory assumes that both the urethral and anal sphincters share a common neural input. With chronic contraction of the anal sphincter from rectal stool impaction, the pelvic floor musculature similarly contracts inappropriately, leading to secondary detrusor–external urinary sphincter dyssynergia. This vicious cycle of discoordination is what is thought to induce bladder overactivity, urinary incontinence, recurrent UTIs, and VUR (O'Regan et al., 1985).

In a recent study by Burgers et al. (2013a), researchers assessed the prevalence of functional defecation disorders in children referred to a tertiary pediatric urology outpatient clinic for LUTS. They analyzed the records of 113 patients between 4 and 17 years of age who presented with LUTS. Rome III criteria for functional constipation and functional nonretentive fecal incontinence were fulfilled by 47% and 11% of patients with LUTS, respectively. Not surprisingly, children with dysfunctional voiding were more likely to fulfill the criteria for functional constipation, and children with urge incontinence more often fulfilled the criteria for nonretentive fecal incontinence. This last point is intriguing in that it supports the notion that children with fecal incontinence and urge urinary incontinence often will not respond to a standard bowel program, which could potentially exacerbate the situation. Perhaps these children would be better served by a centrally acting agent to aid in suppression of overactivity or lack of inhibition. Clearly, there continues to be a void in our understanding of the bowel and bladder interaction in higher cortical centers and the spinal cord.

In a similar study by Combs et al. (2013), researchers sought to better illuminate the relationship between LUT and bowel dysfunction by studying 368 consecutive children who presented with LUTD. In a secondary analysis, they also sought to determine if constipation and encopresis, which are often presumed to coexist, also coexisted for their specific cohort. Overall, children with dysfunctional voiding had the highest incidence of bowel dysfunction, with constipation alone being the most frequently observed form. Somewhat surprisingly, nearly 50% of patients reporting encopresis did not have associated constipation. The majority of patients with encopresis with or without associated constipation had idiopathic detrusor overactivity, and those with the worst urgency were the ones reporting encopresis. Interestingly, in children with encopresis, severe urgency was commonly reported and after initiation of anticholinergic therapy the encopresis frequently resolved, even before the urgency had fully subsided. This finding is similar to the results of Burgers et al. (2013a), and perhaps may be secondary to an overactivity of the detrusor and the rectal wall musculature, or a lack of inhibition of detrusor and rectal muscular activity. Whether this is a centrally mediated phenomenon is unclear.

Key Points: Epidemiology, Self-Esteem and Quality-of-Life Issues, and Comorbidities

- LUTD is commonly encountered in daily practice.
- Daytime incontinence varies with both age and gender in school-age children and seems to be more common in girls.
- There is a clear and consistent relationship between LUTD and UTI, especially when urinary stasis occurs.
- There is a known association between LUTD and VUR. Continued LUTD is a risk factor for treatment failure after surgical correction for reflux. Targeted treatment for LUTD has been demonstrated to improve spontaneous resolution rates for VUR.
- Clinicians should be aware of the association between neuropsychiatric disorders and LUTD. Failure to adequately address these comorbidities is likely to interfere with treatment success.
- The relationship between abnormal bowel and bladder activity is termed *bowel-bladder dysfunction (BBD)*, and, if present, clear identification and management of any concomitant bowel dysfunction is paramount if treatment of the LUT condition is to be successful.

Terminology

The International Children's Continence Society (ICCS) is a global, multidisciplinary organization of clinicians involved in the care of children with LUTD (Austin et al., 2014). Perhaps one of the most significant impacts of the ICCS on the pediatric LUT function community was its initial terminology document (Nevéus et al., 2006). Before the publication of this document, the nomenclature used in LUTD had been endemic with transposable terms that in some cases were not completely accurate and were often confusing. Moreover, this fostered uncertainty and made it rather difficult to compare research and study outcomes among different groups. The standardization of the nomenclature for pediatric and adolescent LUT function is thus critical in providing a platform for optimal comprehension and more effective interaction and treatment among multiple health care providers who care for these patients. The ICCS revised the original terminology document to provide a current and consensus update reflecting refinement and current advancement of knowledge on pediatric and adolescent LUT function (Austin et al., 2014).

The terminology used for LUTS focuses on descriptive (as opposed to quantitative) language because quantitative data are currently lacking. This can lead to subjective and variable information requiring expertise of the caretaker for proper categorization of the condition through the use of evidence-based diagnostic tools including guidelines and algorithms (van den Heijkant and Bogaert, 2017). Of particular relevance is the age of the child when applying terminology to describe pediatric LUT function. The reference point used by the ICCS is 5 years of age or older (4 years of age for bowel dysfunction), because this age is used by the *Diagnostic and Statistical Manual of Mental Disorders,* 5th Edition (DSM-V) (American Psychiatric Association, 2013) and the International Classification of Diseases 10 (ICD-10) to characterize urinary incontinence disorders (World Health Organization, 2008). The ICCS terminology document authors do stipulate, however, that there is variability and maturational aspects that certainly will affect LUT function and that there are, in fact, children who have voluntary control over LUT function before 5 years of age. As a result, it is at the discretion of the provider to selectively apply these terms in younger cohorts of children. **(See the Terminology Document by Austin et al. [2014] for specific terms and their definition.)**

Daytime Urinary Incontinence and Bladder Dysfunction

Treatment

The ICCS has published treatment guidelines on various LUT conditions and their associated comorbidities (Austin et al., 2014; Burgers et al., 2013b; Chase et al., 2010; Franco et al., 2013; Hoebeke et al., 2010; Yang et al., 2018). **The management of a child or adolescent who suffers from LUTD is primarily directed at improving symptoms (e.g., urinary and/or fecal incontinence, recurrent UTIs) and protecting the upper urinary tract from permanent damage.** Methods for treating children with BBD must be tailored to the specific LUTD and the child's symptomatology. Therapeutic considerations include the underlying cause, patient age, motivation and maturity level, symptom severity and duration, prior interventions, and potential risk factors for upper urinary tract damage (i.e., elevated intravesical storage pressures, VUR, recurrent UTIs).

We use a stepwise approach to the treatment of children presenting with symptoms concerning for BBD (Thom et al., 2012). Our algorithm generally moves from least to most invasive with conservative measures (e.g., treatment of constipation, behavior modification) exhausted before initiating medications, physical therapy, biofeedback, neuromodulation, or surgical intervention.

According to the ICCS, researchers and/or clinicians should recognize three basic principles of treatment outcomes (Austin et al., 2014). First, the symptom *frequency* during baseline and after treatment each should be documented. Second, the assessment of treatment response must be based on *pretreatment baseline* registration symptom frequency. Third, the response *during* treatment should be noted, as well as the response *after cessation* of treatment for a *specified period;* and these two responses may not be the same. This has been outlined as follows:

- **Initial success** (based on symptom frequency)
  - No response: Less than 50% reduction
  - Partial response: 50% to 99% reduction
  - Complete response: 100% reduction
- **Long-term success**

- Relapse: More than one symptom recurrence per month
- Continued success: No relapse in 6 months after cessation of treatment
- Complete success: No relapse in 2 years after cessation of treatment

Urotherapy

Urotherapy is conservative-based therapy and treatment of LUTD that rehabilitates the LUT and encompasses a very wide field of health care professionals (Austin terminology document [Austin et al., 2014]). It primarily involves behavior modification of voiding (i.e., timed voiding schedules), lifestyle modification, and treatment of constipation. Although there are no randomized controlled trials comparing the efficacy of conservative intervention to other therapies, several retrospective studies suggest a reduction in symptoms of up to 70% with a strictly conservative approach (Allen et al., 2007; Wiener et al., 2000).

Urotherapy can be divided into standard therapy and specific interventions. **Standard components** include the following:

1. *Information and demystification*. It is often helpful to explain normal LUT function to parents and children and how the particular child deviates from normal.
2. *Instruction* on how to resolve LUTD (i.e., behavior modification, timed voiding, treatment of constipation).
3. *Lifestyle advice*. Encompasses balanced fluid intake and diet modification; diminished dietary irritants such as caffeine, carbonation, citrus, chocolate, and spicy foods; regular bladder- and bowel-emptying patterns; and skin care for those with perineal irritation from incontinence. It is also helpful to review optimal posture during voiding (i.e., sitting in the middle of the toilet with heels flat on the ground or supported on a footstool). One useful aid to teach correct upright posture is to have children straddle the toilet seat and face the toilet bowl during voiding, because this spreads the legs apart (preventing holding maneuvers such as forcefully crossing the legs) and forces them to straighten the back as they balance themselves on the toilet seat. This maneuver also can be used to successfully correct vaginal reflux.

4. *Registration* of symptoms and voiding habits, using bladder diaries or frequency-volume charts and potentially mobile applications.
5. *Support* and *encouragement* via regular follow-up with the caregiver.

Specific interventions of urotherapy include various forms of pelvic floor muscle retraining (i.e., biofeedback), neuromodulation, and intermittent catheterization.

In a randomized controlled trial of 150 patients with BBD, Braga et al. (2017) found that using bladder-training videos was similarly effective to the use of urotherapy in reducing symptoms at 3-month follow-up. Brownrigg et al. (2017) performed an assessment of QoL in the same group of patients. QoL changes from baseline were similarly significant with both the bladder-training video and urotherapy at time of follow-up. Bladder training is therefore considered a noninferior method to standard urotherapy in improving QoL.

Conservative Management

Bowel Dysfunction

One of our first steps is to decipher whether concomitant bowel dysfunction exists based on history, physical examination, and pelvic ultrasonography. As mentioned earlier, anorectal and LUT function are closely interrelated. If evidence of bowel dysfunction is indeed present (as is often the case), we generally initiate a bowel regimen that includes high fiber and increased fluid intake. Our rule of thumb for **daily fiber intake is age in years plus 15 to 20 for total number of grams to be ingested. Parents are reminded that without concurrent increased fluid intake, increased fiber could actually make matters worse by allowing smaller stool balls to bind together and subsequently increase the severity of their child's constipation.**

If increased fiber is not a feasible solution, we usually recommend titrating polyethylene glycol such that children are eventually having daily Bristol type 4 stools. In severe cases, we recommend a complete bowel cleanse (i.e., chemical disimpaction) consisting of what we term “magic mousse” supplementing with tap water enemas to relieve any distal obstruction by impacted stool in the rectal vault. Magic mousse consists of three simple ingredients: 1 cup ice cream, 1 cup prepared pudding, 6 oz. mineral oil, that are mixed and frozen (Campigotto, personal communication, 2014). Children younger than 6 years of age are given 60 mL twice daily, and those 6 years of age or older receive 120 mL twice daily.

This is generally done over a weekend for children who are in school or daycare because this routine is fairly intense and children may have multiple, somewhat unpredictable bowel movements. **It is imperative that the bowel regimen be continued throughout the treatment course to both maximize therapeutic efficacy for the bladder dysfunction component and counteract the constipating side effect of anticholinergic medications.**

The importance of addressing constipation in those with BBD is substantiated by the findings of a large retrospective study of 234 chronically constipated and encopretic children who were treated for constipation and reassessed at least 12 months after initiation of therapy (Loening-Baucke, 1997). Of these children, 29% complained of daytime urinary incontinence, and 34% had enuresis. UTI was present in 11% of the cohort and was more common in girls. **Relief of constipation resulted in disappearance of daytime urinary incontinence in 89% and enuresis in 63% of patients. There were no reported UTIs in any patient who had no anatomic abnormality of the urinary tract.**

Behavior Modification

The ultimate goal of any structured behavior modification program is to return the child to normal micturition habits. With this goal in mind, it is important to set an individualized voiding regimen to establish a consistent voiding routine. **The classic regimen entails *timed voiding* with frequent voids scheduled every 2 hours during the day.** This strategy is crucial in aiding to avoid bladder overactivity and urge symptoms, which can occur as the bladder fills and begins to reach the critical volume that triggers the urge to void. We recommend wristwatch alarms to all patients because these can readily assist older, more independent children to comply with timed voiding (Hagstroem et al., 2010). The use of a vibratory watch is also a good option because it does not disturb peers, with only the patient knowing that it has indicted the set time. Regardless of what regimen is used, children are encouraged to urinate before they have a sense of urgency, empty their bladders completely, and avoid abdominal straining.

The timed voiding regimen is often linked to a positive reinforcement program using a diary in which the child tracks the number of times voided during the day. It has been demonstrated that the establishment of a reward system can significantly improve the child's self-esteem and compliance (Allen et al., 2007). Specifically, the incentive scheme should focus on rewarding the child for following the recommended program (e.g., stickers each time the child voids during the day) as opposed to “not wetting” themselves. Not surprisingly, behavior modification has been shown to be more successful in older children (older than 8 years of age), who, in general, will be more motivated by peer pressure and are mature enough to respond to and follow instruction (Curran et al., 2000; Heilenkötter et al., 2006).

Biofeedback

Biofeedback is a treatment modality that uses electronic or mechanical instruments to relay perceptual evidence to assist a person in gaining control over a physiologic process or function (Liberati, 2005). This method has been used for over three decades in the urologic setting and employs noninvasive urodynamic instrumentation to measure, record, and provide direct, instantaneous information to the child about voiding function (Maizels et al., 1979). Real-time uroflowmetry allows the patient to observe the urine flow rate. Concurrent placement of adhesive pads on the perineum measures sphincter and/or pelvic floor activity. Abdominal electromyography (EMG) also can be performed if desired. Each session lasts approximately 45 minutes with a trained practitioner overseeing therapy. The visual and auditory feedback allows the child to become aware of and gain control over LUT function by teaching them how to voluntarily relax their sphincter and pelvic floor musculature during voiding, thus preventing detrusor-sphincter dyscoordination. In fact, many biofeedback programs have been tailored to children by using interactive computer games controlled by pelvic floor contraction and relaxation along with urinary flow rate (McKenna et al., 1999). This system has facilitated the training process and lowered the age at which children can be successfully treated; however, one should bear in mind that most children younger than 5 years of age are typically incapable of receiving biofeedback regularly.

A number of observational studies have documented the utility of biofeedback therapy in reducing the symptoms associated with LUTD (Chin-Peuckert and Salle, 2001; Klijn et al., 2006; Nelson et al., 2004; Yamanishi et al., 2000), expediting the resolution of VUR (Kibar et al., 2007; Palmer et al., 2002), and eliminating recurrent UTIs (Nelson et al., 2004). In a systematic review evaluating the efficacy of biofeedback in the treatment of children with BBD, 27 pooled studies (1 randomized controlled trial and 26 case series) showed an 83% and 80% improvement in UTI and daytime urinary incontinence, respectively (Desantis et al., 2011). The only included randomized study favored biofeedback over standard urotherapy (relative risk [RR] 1.4, 95% confidence interval [CI]

0.98 to 2), but this was not statistically significant. On analysis of all included studies, there also was improvement in constipation (18% to 100%), frequency (67% to 100%), urgency (71% to 88%), and VUR (21% to 100%).

A study evaluating the use of biofeedback in children for treatment of refractory OAB and dysfunctional voiding found that children with dysfunctional voiding have a better improvement of symptoms than children with OAB, although biofeedback was an effective treatment in both groups (Tugtepe et al., 2015). Three months of biofeedback in children with dysfunctional voiding resulted in improvement in UTIs, urge incontinence, fractionated voiding, constipation, voided volume, maximum flow rate, average flow rate, and postvoid residual (PVR), and children with OAB only improved maximum flow rate, average flow rate, voiding time, and PVR. As a single first-line treatment, Alyami et al. found biofeedback to be a potentially effective treatment for children with dysfunctional voiding and diurnal enuresis. In a cohort of 61 patients (52 with diurnal enuresis, 16 with UTI, and 38 with voiding discomfort), 77% were satisfied, with a disappearance of EMG signals in 65.5% after 6 months of biofeedback treatment (Alyami et al., 2018). A more recent systematic review evaluating the effectiveness of biofeedback in voiding dysfunction looked at 12 studies and also found biofeedback to be moderately successful in treating bladder and bowel dysfunction when used in conjunction with behavior modification (Tremback-Ball et al., 2018). In contrast with the studies mentioned earlier, Fazeli et al. did not find evidence to support the effectiveness of biofeedback in management of children with non-neuropathic voiding disorders after conducting a systematic review of five eligible studies. The results of this review concluded that there was no significant difference in the mean maximum urinary flow rate or likelihood of urinary infection compared with the control group, and the proportion of cases with resolved incontinence at 6 months was similar between the biofeedback and control groups (Fazeli et al., 2015). Fernandez-Ibieta and Ayuso-Gonzalez reviewed the efficacy of biofeedback in voiding dysfunction and noted the absence of PVR at the end of treatment and adequate or aggressive constipation management as a variable associated with clinical success (Fernandez-Ibieta and Ayuso-Gonzalez, 2016).

Clean Intermittent Catheterization

Lapides et al. (1972) first introduced the concept of clean intermittent catheterization (CIC) as a method of emptying the bladder in neurologically impaired patients. Since its initial description, this treatment strategy has gradually been employed in neurologically intact individuals with various types of LUTD. In the setting of dysfunctional voiding and in children who postpone micturition, the detrusor muscle stretches and the bladder becomes chronically overdistended. This repeated action over time can lead to two types of changes of the detrusor muscle: (1) bladder wall thickening caused by hyperplasia and hypertrophy resulting in OAB or (2) an underactive bladder with the end result of myogenic failure. In these cases, bladder emptying is often incomplete, resulting in large PVR urine volumes, urinary incontinence, and recurrent UTIs from stasis. CIC is a safe, effective, and well-tolerated treatment strategy to attain continence and reduce the rate of recurrent UTI in children with LUTD (Pohl et al., 2002). It is particularly crucial to discuss the merits of this intervention with sensate patients and their families to maximize adherence.

Pharmacotherapy

Pharmacologic intervention in the treatment of children with LUTD has traditionally encompassed anticholinergic agents and α-adrenergic receptor antagonists (i.e., α-blockers) to enhance bladder filling and emptying, respectively. We will generally initiate one or both of these medications once all other conservative measures have been exhausted. In some instances, we will start α-blockers concomitantly with biofeedback, and this management decision is ultimately left up to the discretion of the provider.

Anticholinergic Agents

Anticholinergics (i.e., antimuscarinics) are the current gold standard in the treatment of patients with symptoms referable to OAB. Muscarinic receptors are found in the human detrusor muscle, and bladder contractions are initiated by stimulation of these receptors with the release of acetylcholine from cholinergic nerves. The main action of anticholinergics is on the M1 and M3 receptor subtypes, which are thought to be responsible for the pathogenesis of detrusor overactivity (Chapple et al., 2002). **These agents act by reducing the frequency and intensity of uninhibited detrusor contractions during the filling phase of the bladder, resulting in an increase in functional bladder capacity and compliance** (Finney et al., 2006; Nijman, 2004). The clinical efficacy depends on various factors such as receptor affinity, pharmacokinetics, and the specificity for the bladder.

Oxybutynin was among the first generation of modern antimuscarinic medications available for treating incontinence in children. Five anticholinergic agents are currently approved in the United States for the treatment of OAB (darifenacin, oxybutynin, solifenacin, tolterodine, and trospium), with only two of these (oxybutynin and tolterodine) having formally achieved approval for use in children. Oxybutynin has antimuscarinic, antispasmodic, and analgesic properties. It causes the antispasmodic effect by acting as a calcium channel blocker. The analgesic and antispasmodic properties make the medication particularly attractive; however, these effects occur only with supraphysiologic doses that would render them useless secondary to side-effect profile (Chapple, 2000).

The nonselective pattern of activity and penetration of the blood-brain barrier are known to induce systemic and central side effects, respectively. The longer-acting extended-release formulation (Oxybutynin XL) is also approved by the U.S. Food and Drug Administration (FDA) for use in children and uses a novel delivery system resulting in absorption in the large intestine (Youdim and Kogan, 2002). **The main side effects include constipation, dry mouth, blurred vision, reduced sweating, flushing, and altered behavior and cognition. Oxybutynin is lipid-soluble and therefore likely to cross the blood-brain barrier** and in adults has been reported to interfere with cognition. However, in a nonrandomized trial of 25 children, Sommer et al. (2005) found that treatment with oxybutynin was not associated with cognitive impairment. Additionally, in a study by Veenboer et al. (2013), no significant differences in behavior were found between children with spinal dysraphism with and without long-term use of antimuscarinics.

Other methods of delivery of oxybutynin are intravesical and transdermal. These delivery systems avoid first-pass metabolism in the liver, leading to a decrease in the active metabolite *N*-desethyloxybutynin, thought to be responsible for many of the adverse effects associated with the use of oxybutynin. Intravesical delivery in the non-neurogenic, sensate population is limited, however, because of the need for catheterization. **The transdermal patch is as efficacious as the immediate-release oral form but with nearly one-half the incidence of dry mouth** (Davila et al., 2001)**. Local skin erythema and pruritus are side effects unique to this route of administration that can be seen in over one-third of patients** (Gleason et al., 2014).

The ideal patient for treatment of OAB with anticholinergics is the small-capacity, OAB with complete emptying. In children with significant PVR and incomplete emptying, anticholinergic treatment for OAB is not as efficacious, and therapy should be aimed at improving emptying and avoidance of overdistension that may be responsible for the OAB symptoms (Thom et al., 2012). In a retrospective analysis of children first prescribed anticholinergic substances for OAB between 2007 and 2008, Blais et al. (2016) determined that after 4 years of treatment, rates of discontinuation of antimuscarinic therapy in children were comparable to those reported in adults however, children persisted on the medication for longer.

α-Adrenergic Receptor Antagonists

α-Adrenoreceptors have been demonstrated in the LUT, with a large concentration located at the bladder neck and urethra (Ek, 1978). **α-Adrenergic blockade results in smooth muscle relaxation and decreased bladder outlet resistance.** Limitations of early α-adrenergic receptor antagonists (α-blockers) included their side-effect profile with hypotension and dizziness. With subsequent development of more “selective” α-blockers in the 1980s that targeted α_{1A}-adrenergic receptors rather than both α_{1A}- and α_{1B}-adrenergic receptors, these side effects were greatly diminished. Examples of selective α-blockers include alfuzosin, doxazosin, prazosin, silodosin, tamsulosin, and terazosin.

Currently, α-blockers are a mainstay drug used to facilitate bladder emptying in the adult population, particularly in adult males with benign prostatic hyperplasia. Early work on the benefits of α-blockers on pediatric LUTD by Austin et al. (1999) pioneered the introduction of α-blockers into the armamentarium of drugs that can be used to treat voiding issues in children. In this pilot report, there was an 82% improvement in the measured parameters of 17 patients treated with α-blocker therapy. In a follow-up of their initial study, the group continued to see improvement in multiple LUTS, daytime incontinence episodes, and PVR measurements in 55 children treated with doxazosin for dysfunctional voiding (Cain et al., 2003).

Kramer et al. (2005) conducted the first randomized, placebo-controlled study of selective α-blocker therapy in children with dysfunctional voiding. In this study, 38 children were randomized to either placebo or 0.5 mg of doxazosin. Unlike in previous studies, they found no significant difference in the PVR and uroflow measurements between the treatment groups. There was a trend toward a significant improvement in urinary incontinence (4 vs. 14 incontinent episodes per week from a median baseline of 18 weekly episodes) and the DVSS parental survey in the α-blocker group compared with the placebo group. There was a significant difference in parental satisfaction, with a higher parental satisfaction in the children treated with α-blockade.

Vanderbrink et al. (2009) reported an observational study of 23 children with bladder neck dysfunction who were treated for an average of 10 months with tamsulosin. The number of incontinent episodes decreased from over 5.5 to less than 1 episode on average per day. In addition, increases in Qavg and Qmax and a reduction in PVR urine and abnormal uroflow patterns were observed during therapy. The safety profile for α-blockade in this pediatric population also was assessed, and the results were consistent with those in other reports using selective α-blockers in children. Although orthostatic hypotension was not formally evaluated, the authors did not find any significant alterations of blood pressure measurements, and there were no reports of any symptomatology suggestive of hypotension.

α-Blocker treatment selection of children with LUTD is done through a comprehensive treatment program that involves an escalating treatment paradigm (Chase et al., 2010; Thom et al., 2012) or identifying patients with characteristic uroflow abnormalities (Van Batavia et al., 2010). The uroflow finding of a prolonged “EMG lag time” is associated with bladder neck and internal urethral sphincter discoordination and may be used to select patients for α-blocker therapy (Van Batavia et al., 2010, 2011). The EMG lag time is the time duration after the external sphincter relaxes and the flow of urine. A prolonged lag time of greater than 6 seconds is suggested as a reliable indicator of tailoring LUTD treatment with α-blocker therapy (Van Batavia et al., 2014). Further validation is needed to investigate the reliability and reducibility of these uroflow findings.

Botulinum Toxin

A relatively recent investigational pharmacologic approach in refractory cases of LUTD is botulinum neurotoxin type A (BoNTA). The toxin acts by inhibiting acetylcholine (ACh) release at the presynaptic neuromuscular junction. Inhibited ACh release results in regionally decreased muscle contractility and atrophy at the injection site. The chemical denervation that ensues is a reversible process, and eventually the toxin is inactivated and removed. Clinical effects begin within 5 to 7 days of injection, with maximal effects reached within 4 to 6 weeks (Gamé et al., 2009). The duration of induced paralysis varies depending on the type of muscle treated, with duration of treatment effect lasting between 3 and

12 months (Riccabona et al., 2004).

Clinically, BoNTA injections have been used safely in the treatment of a number of clinical disorders (Maria et al., 2005), including neurogenic LUTD (Gamé et al., 2009). BoNTA has been subsequently applied to non-neurogenic LUTD, and there are a number of reports of BoNTA used to treat children with OAB and dysfunctional voiding (Franco et al., 2007; Hoebeke et al., 2006; Mokhless et al., 2006; Petronijevic et al., 2007; Radojicic et al., 2006; Steinhardt et al., 1997; Vricella et al., 2014). BoNTA is directly injected into the detrusor muscle (in patients with OAB) or external urinary sphincter (in patients with dysfunctional voiding) under cytoscopic guidance. One of the main drawbacks of this therapeutic modality is the need for retreatment given the reversible nature of this chemical denervation secondary to synaptic terminal resprouting within 6 months of injection. Fortunately, preliminary studies suggest that repeated BoNTA injections are safe in children and do not induce additional fibrosis in the bladder wall (Pascali et al., 2011). In a retrospective review of 20 patients evaluating outcomes of BoNTA in the external urethral sphincters from 2010 to 2013, 't Hoen et al. (2015) found PVR to be decreased by 75%. Furthermore, 16 patients achieved complete dryness, and 5 of 11 patients improved in frequency of UTI.

Neuromodulation

During the past two decades, electrical nerve stimulation, also known as *neuromodulation*, has been applied to the treatment of non-neurogenic LUTD in children (Table 35.1). Several of the reported changes after treatment with neuromodulation include significantly increased bladder capacity, decreased severity of urgency, improved continence, and decreased UTIs (Bower et al., 2001; Hoebeke et al., 2001b; Roth et al., 2008). A significant improvement in urodynamic parameters of bladder compliance, number of involuntary contractions, and bladder volume at first detrusor contraction also has been noted (De Gennaro et al., 2004).

TABLE 35.1

Studies Evaluating Neuromodulation in Treatment of Children With Lower Urinary Tract Dysfunction

REFERENCE	ES	LUTD	NO.	TREATMENT	FREQUENCY/AMPI

	TYPE		PATIENTS	SCHEME	
Hoebeke et al., 2001b	TENS	OAB	41	S3: 2 h/day	2 Hz/not stated
Bower et al., 2001	TENS	OAB	14	Suprapubic/S2–S3: 1 h, 2 times/day	10 or 150 Hz/not state
Barroso et al., 2006	TENS	OAB	19	S3: 20 min, 3 times/week	10 Hz/6–42 mA
Hagstroem et al., 2009	TENS	OAB	25	S2–S3: 2 h/day	10 Hz/37.5 mA
Malm-Buatsi et al., 2007	TENS	OAB	18	S2–S3: 20 min, 2 times/day	100 Hz/0–60 mA
Lordêlo et al., 2010	TENS	OAB	37	S2–S3: 20 min, 3 times/week	10 Hz/not stated
Hoebeke et al., 2002	PTNS	DV	31	30 min, weekly	20 Hz/not stated
De Gennaro et al., 2004	PTNS	OAB DV	10 7	30 min, weekly	20 Hz/0–10 mA
Capitanucci et al., 2009	PTNS	OAB DV	14 14	30 min, weekly + maintenance (once/mo)	20 Hz/0–10 mA
Humphreys et al., 2006	SNM	BBD	23	S3	Not stated
Roth et al., 2008	SNM	BBD	20	S3	Not stated

Stephany et al., 2013	SNM	BBD	14	S3	Not stated

BBD, Bowel-bladder dysfunction; *DV,* dysfunctional voiding; *ES,* electrical stimulation; *LUTD,* lower urinary tract dysfunction; *mo,* month; *OAB,* overactive bladder; *PTNS,* percutaneous tibial nerve stimulation; *SNM,* sacral nerve modulation; *TENS,* transcutaneous electrical nerve stimulation; *UI,* urinary incontinence; *UR,* urinary retention.

In neuromodulation, electrical stimuli are exerted in a noninvasive manner to alter the existent neural transmission pattern and modulate detrusor activity. The putative mechanism involves acting centrally by rebalancing excitatory and inhibitory information and returning the neural drive toward a more neutral status. A number of modalities have been studied in children, including sacral neuromodulation, pudendal nerve stimulation, and tibial nerve stimulation. Although preliminary results have been promising, electrical nerve stimulation's role in children with non-neurologic LUTD is controversial because of the lack of controlled trials and largely obscure mechanism of action. Two randomized controlled trials, however, were performed using transcutaneous electrical nerve stimulation (TENS) for OAB (Lordelo et al., 2010; Quintiliano et al., 2015). Children were randomized to either parasacral TENS or scapular TENS (sham), and no significant improvement in bladder function or LUTS was seen in the sham group as compared with the parasacral TENS group (Lordelo et al., 2010). In the randomized intragroup and intergroup comparison trial between parasacral TENS and oxybutynin, parasacral TENS was as effective as oxybutynin in treating OAB in children (Quintiliano et al., 2015). With TENS, superficial electrodes are placed on each side of the S3 and S2 spinal cord segments. In general, therapy consists of 20-minute sessions three times per week. Percutaneous tibial nerve stimulation (PTNS) is performed with a 34-gauge stainless steel needle inserted approximately 5 cm cephalad to the medial malleolus, and a grounding pad is placed just posterior to the medial malleolus. Proper needle placement in children is confirmed by observing ipsilateral plantar and/or toe flexion or fanning. Although the purported mechanism of action differs somewhat, neuromodulation by PTNS is based on the traditional Chinese practice using the Sanyinjiao acupuncture point, which overlies the posterior tibial nerve (van Balken et al., 2004). The posterior tibial nerve is a mixed sensory and motor nerve originating from the L4 to S3 spinal roots that also contributes to sensory and motor control of the bladder, urinary sphincter, and pelvic floor musculature. Therapy has been invariably applied once weekly, usually for 30-minute outpatient treatment sessions. A prospective study of 69 children by Veiga et al. (2016) determined that a complete resolution of symptoms occurred within 10 to 20 sessions of TENS, with some patients experiencing complete resolution as early as the third session.

Since its initial description, a significant number of reports have been generated on sacral nerve root stimulation via implantable electrodes. In the past decade, sacral nerve modulation (SNM) has gained widespread recognition in adults and was approved by the FDA for use in urology for urinary urgency/frequency, urge incontinence, pelvic floor dysfunction, and nonobstructive urinary retention. Despite off-label use, a number of groups have reported on their experience with SNM in children with non-neurogenic LUTD (Humphreys et al., 2006; McGee et al., 2009; Roth et al., 2008; Stephany et al., 2013; Tanagho, 1992).

Before sacral implantation can be performed, percutaneous transforaminal access to the S3 spinal nerve must be achieved. Once the correct responses are obtained, the quadripolar tined lead of the neurostimulator device can be implanted. This lead can then be connected to an external neurostimulator device via a tunneled subcutaneous extender for programming and trial assessments. If this is successful, the patient undergoes a second procedure to implant the permanent neurostimulator device into a subadipose pocket in the upper gluteal region. Complications commonly cited with implantable SNM devices are device and/or wound infection, electrode migration, loss of effect, and lead fracture. Revision rates range between 7% and 18%, secondary to lead migration, faulty connection, and infection. In a prospective analysis of predictors of outcomes in 83 children with isolated OAB treated with parasacral TENS, Hoffmann et al. (2018) found a significant response to parasacral TENS treatment in 96.4% of cases, with complete resolution of symptoms achieved in 56.6% of cases. Nocturnal enuresis was identified as the only predictor of poor outcome after parasacral TENS, with only a partial resolution being observed in 54.5% of cases; no other factor was associated with response treatment.

Key Points: Management of Daytime Urinary Incontinence and Bladder Dysfunction

- The management of a child or adolescent with LUTD is primarily directed at improving symptoms (e.g., urinary and/or fecal incontinence, recurrent UTIs) and protecting the upper urinary tract from permanent damage.
- In general, a stepwise approach is used with an algorithm that progresses from least to most invasive with conservative measures (e.g., treatment of constipation, behavior modification) exhausted before initiating medications, physical therapy, biofeedback, neuromodulation, or surgical intervention.
- In one large study, relief of constipation alone resulted in the disappearance of daytime urinary incontinence in 89% and enuresis in 63% of patients studied (Loening-Baucke, 1997).
- Anticholinergics are the current gold standard in the treatment of patients with symptoms referable to OAB and ideally for patients with efficient bladder emptying with low PVR. These agents act by reducing the frequency and intensity of uninhibited detrusor contractions during the filling phase of the bladder, resulting in an increase in functional bladder capacity and compliance. The main side effects include constipation, dry mouth, blurred vision, reduced sweating, flushing, and altered behavior and cognition.
- α-Adrenergic blockade results in smooth muscle relaxation and decreased bladder outlet resistance to facilitate bladder emptying.
- In neuromodulation, electrical stimuli are exerted in a noninvasive manner to alter the existent neural transmission pattern and modulate detrusor activity. The putative mechanism involves acting centrally by rebalancing excitatory and inhibitory information and returning the neural drive toward a more neutral status. A number of modalities have been studied in children, including SNM, pudendal nerve stimulation, and tibial nerve stimulation.

Special Conditions of Lower Urinary Tract Dysfunction and Their Treatment

Giggle Incontinence (Enuresis Risoria)

Enuresis risoria is an uncommon form of daytime incontinence classically seen in school-age females. Typically, moderate-to-large amounts of urinary leakage are triggered by laughing alone. The accepted theory is that of a central nervous system (CNS) inactivation (i.e., cataplexy) in association with laughter resulting in urinary incontinence (Sher and Reinberg, 1996). It should be emphasized that the incontinence episodes are invariably significant, and often the entire bladder volume is drained. Daytime urinary incontinence in conjunction with laughter is also seen in children with OAB and is more common than true giggle incontinence. It is a diagnosis of exclusion, and it is usually established on history and supplemented by the absence of other voiding symptoms and normal investigations. Giggle incontinence has a significant adverse effect on the social life, and this is often why medical assistance is sought. Currently, available treatment strategies include biofeedback or methylphenidate (Berry et al., 2009; Richardson and Palmer, 2009).

Pollakiuria (Extraordinary Daytime Urinary Frequency)

This is a disorder characterized by a very high daytime frequency of micturition (sometimes as high as 50 times per day). A key aspect of this syndrome, which differentiates it from OAB and often can clinch the diagnosis, is that the symptoms are limited only to the daytime. It is seen in early childhood (4 to 6 years of age) in both genders and associated with a history of recent death or life-threatening event in the family. Usually it runs a benign, self-limited course over a period of approximately 6 months (Bergmann et al., 2009). No specific treatment, apart from reassurance, is necessary. Children presenting with frequency, however, merit clinical investigation to exclude other pathologic causes.

Underactive Bladder

As the name suggests, underactive bladder describes a child who is required to raise intra-abdominal pressure to initiate, maintain, and complete voiding. Once a functional or anatomic cause for bladder outlet obstruction has been ruled out, there are two main approaches to this entity. The first is with timed voiding and double voiding to more efficiently empty the bladder and lower the ultimate PVR volume of urine. If this treatment strategy fails to achieve the desired effect, we often recommend CIC with frequency dependent on symptom severity. Obviously, this requires appropriate counseling and thoughtful guidance of both the patient and caregiver, especially in the child who is neurologically intact.

Vaginal Reflux (Vaginal Entrapment and Vaginal Voiding)

Vaginal reflux is characterized by incontinence after normal voiding in the absence of other LUTS. It is commonly seen in prepubertal girls, and the typical history is that of wetting of undergarments approximately 10 to 15 minutes after a normal void. It often can be associated with labial adhesions as a result of chronic irritation and inflammation from skin exposure to relatively caustic urine. Reassurance and postural modification to ensure complete vaginal emptying is the only treatment required.

Enuresis

Over the past several decades, much has changed in our understanding of enuresis. Previous notions of voluntary control have been replaced by an appreciation of genetic and pathophysiologic mechanisms. What is known with certainty is that enuresis is a common medical condition in children (Shreeram et al., 2009). It affects millions of children throughout the world and is associated with a significant negative impact on self-esteem and health-related QoL (Wolfe-Christensen et al., 2013).

Terminology and Background

The term *enuresis* is synonymous with *nocturnal enuresis* and is defined as discrete episodes of urinary incontinence during sleep in children older than 5 years of age in the absence of congenital or acquired neurologic disorders. The term *diurnal enuresis* has been eliminated completely. The child who wets during the day and night can be said to have daytime urinary incontinence and enuresis or nonmonosymptomatic enuresis.

Enuresis is categorized as monosymptomatic enuresis (MSE) or nonmonosymptomatic enuresis (NMSE). ***MSE* is defined as enuresis in children without any other LUTS and without a history of bladder dysfunction. MSE is further subdivided into *primary* and *secondary* forms. Children who have *never* achieved a satisfactory period of nighttime dryness (~80% of enuretic children fit this definition) have primary MSE** (Friman and Warzack, 1990)**. Children who develop enuresis after a dry period of at least 6 months are said to have secondary enuresis** (von Gontard and Nevéus, 2006). Secondary enuresis often is ascribed to an unusually stressful event (e.g., parental divorce, birth of a sibling, sexual abuse); an organic cause (e.g., UTI, diabetes, obstructive sleep apnea, neurogenic bladder); or a psychological cause (e.g., ADHD or conduct disorder) at a time of vulnerability in a child's life. These children are more likely to have NMSE (see next paragraph) and do not respond as well to treatment. The exact cause of secondary MSE, however, remains largely unknown. The clinical presentations of children with primary and secondary MSE are otherwise similar, which suggests a common pathogenesis (Robson et al., 2005). Moreover, large family studies have demonstrated that secondary MSE is usually no different etiologically from primary MSE, with undue emphasis on their difference being unwarranted (Schaumburg et al., 2008).

Enuresis with any daytime LUTS is defined as NMSE (Franco et al., 2013). Daytime LUTS suggesting NMSE include daytime incontinence (not obligatory), frequency, genital or LUT pain, and holding maneuvers (i.e., strategies to postpone voiding). A careful history is often required to elicit these symptoms, which usually indicate either OAB (i.e., a storage issue) such as urgency, or dysfunctional voiding (i.e., emptying problems) such as hesitancy, straining, weak stream, intermittency, or a feeling of incomplete emptying.

The pathogenesis, evaluation, and treatment of MSE and NMSE overlap considerably (Nevéus et al., 2010). Approximately 15% to 30% of enuretic children experience daytime LUTS; however, these reported numbers are likely grossly underestimated (Gumus et al., 1999; Järvelin et al., 1988). In fact, **most experts in the field would estimate the proportion of children with enuresis that are truly monosymptomatic to represent fewer than one-half of all bedwetting children** (Franco et al., 2013).

Our initial approach to NMSE is nearly identical to our approach for children with LUTD. Obviously one begins with a thorough history and physical examination, along with the appropriate laboratory and imaging studies. In terms of NMSE therapy, we also begin by identification and treatment of constipation. As discussed earlier in this chapter, effective treatment of bowel problems can lead to the spontaneous remission of daytime incontinence (Loening-Baucke, 1997). We also will treat the underlying LUTD symptoms first, because effective treatment of OAB (or dysfunctional voiding) can lead to cessation of the enuresis entirely (Franco et al., 2013). If comorbid behavioral disorders are present, these should be addressed by an appropriate provider. If enuresis persists after the previously mentioned interventions, standard treatment for MSE can follow. The remaining section of this chapter will focus specifically on MSE and its epidemiology, cause, evaluation, and treatment strategies.

Epidemiology and Natural History

Enuresis is a common problem, with an estimated 7 million children in the United States alone with this condition. According to a recent large longitudinal study in the United Kingdom, at least 20% of children in the first grade occasionally wet the bed, and 4% wet the bed two or more times per week (Butler and Heron, 2008). Prevalence varies with age, suggesting an immaturity of the LUT and nervous system (Fig. 35.1). In a study of almost 11,000 children in the United States, the prevalence of enuresis in boys at 7 and 10 years of age was 9% and 7%, respectively, and in girls at those ages it was 6% and 3%, respectively (Byrd et al., 1996). It is currently generally accepted that in the West **approximately 15% of children will have some degree of nighttime wetting at 5 years of age, with a spontaneous resolution rate of approximately 15% per year** (Forsythe and Redmond, 1974)**. Consequently, at 15 years of age only 1% to 2% of teenagers will still wet the bed** (Klackenberg, 1981). It has also been shown that **the longer the enuresis persists, the lower the probability is that it will resolve spontaneously** (Bakker et al., 2002; Forsythe and Redmond, 1974).

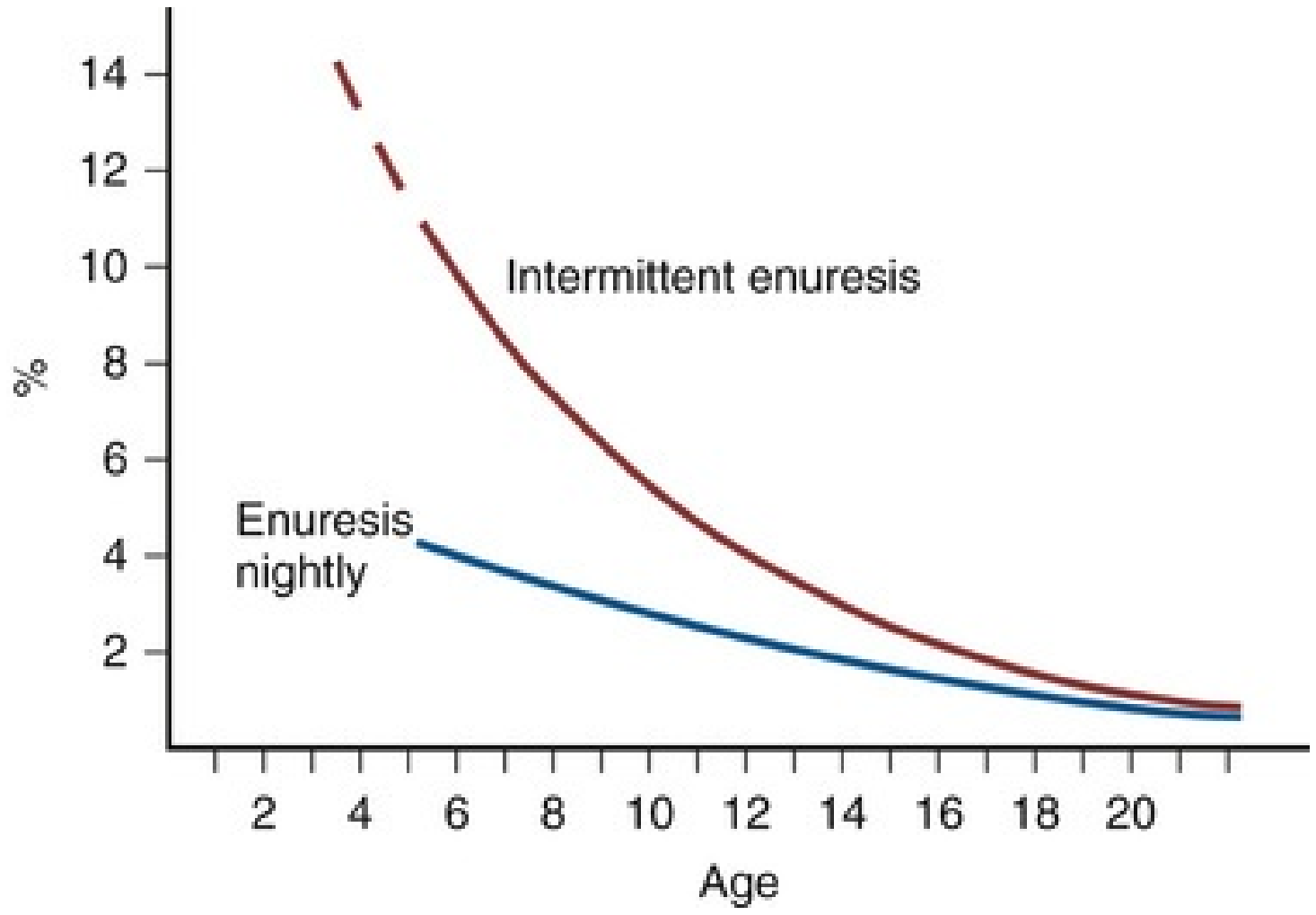

FIG. 35.1 Prevalence rate of enuresis from childhood through young adulthood. (From Austin PF, Nevéus T. Evaluation and management of enuresis. *AUA Update Series* 2012;XXI.)

Enuresis seems to be more common in boys than in girls, with most reports revealing a 2:1 ratio. Although this finding has been disputed by other groups, it is well accepted that by adolescence the prevalence in both males and females reaches equipoise (Yeung et al., 2004).

Enuresis is also known to be common in children with comorbid behavioral issues such as ADHD, oppositional-defiant disorder, conduct disorder, anxiety, and depression (Baeyens et al., 2004; von Gontard et al., 2011). It is estimated that 20% to 30% of children with enuresis have comorbid clinical behavioral disorders that fulfill the criteria for *DSM-V* psychiatric disorders and may subsequently have a negative impact on compliance and ultimate outcome if left untreated (von Gontard et al., 2011).

Genetics

Enuresis has a complex and multifactorial pathophysiology with a strong genetic underpinning (Schaumburg et al., 2008; von Gontard et al., 1998a). When one or both parents have a history of prolonged nighttime wetting, approximately 43% and 77%, respectively, of the offspring will be affected (Bakwin, 1973). When neither parent has a history of nocturnal enuresis, only 15% of offspring will be affected (Bakwin, 1973). Moreover, the concordance among monozygotic twins is almost twice that among dizygotic twins (68% vs. 36%) (Bakwin, 1971). **Linkage of enuresis to markers on chromosomes 12, 13, and 22 has been reported, with autosomal dominant inheritance and high penetrance suggested; however, a major gene locus has yet to be identified** (Arnell et al.,1997; Eiberg 1998; Eiberg et al., 1995). Family and twin studies suggest locus heterogeneity and poor phenotype-genotype correlation (von Gontard et al., 2011). The identification of these genes certainly lifts the burden of guilt from children who have enuresis and helps dispel the theory that enuresis is behavioral in origin and completely under their control.

Pathophysiology

It is generally accepted that **enuresis stems from a maturational delay in the ultimate development of bladder control** (Järvelin, 1989; Light, 1998). This contention is rooted in the fact that most children eventually attain nocturnal dryness regardless of what intervention is used and even if enuresis is left untreated. The hypothesis that there is a difference in the CNS maturation in children with primary enuresis compared with controls is supported by neurophysiologic data (Iscan et al., 2002). Many children who have enuresis are noted to have progressive maturation of bladder stability in conjunction with electroencephalography (EEG) findings that suggest increased CNS recognition of bladder fullness and the ultimate ability to suppress the onset of bladder contraction (Watanabe and Azuma, 1989). This would further lend credence to the premise that delayed maturation of bladder control plays a role in MSE.

Put very simply, **the three organ systems implicated in the pathogenesis of enuresis include the bladder (i.e., a reduced nocturnal bladder capacity)** (Yeung et al., 2002), **the kidney (i.e., nocturnal polyuria)** (Nørgaard et al., 1989a; Vande Walle et al., 2007), **and the brain (i.e., a disorder affecting arousal from sleep)** (Iscan et al., 2002; Watanabe and Azuma, 1989). Enuresis is logically thought to result from a disruption or maturational lag in one or more of these critical domains (Fig. 35.2).

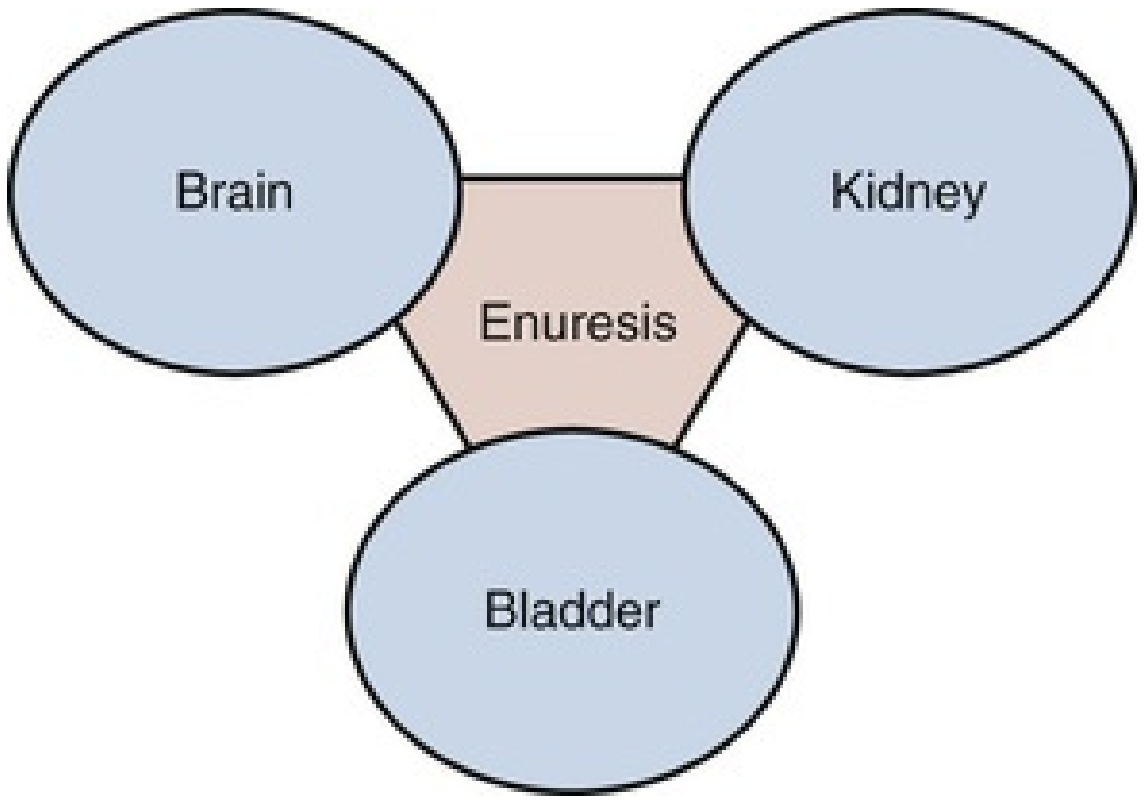

FIG. 35.2 Organ system involvement in pathogenesis of enuresis.

Bladder Overactivity and Reduced Nocturnal Bladder Capacity

There seems to be a subset of children with primary MSE who have nocturnal bladder overactivity regardless of amount of urine production. Yeung et al. (1999) found that nearly one-half of treatment failures with standard therapy (i.e., desmopressin or moisture alarm) had normal daytime bladder function but marked detrusor overactivity during sleep that resulted in enuresis. Almost none of these children had nocturnal polyuria.

When urodynamic studies are performed during sleep, the only difference between children with and without MSE is the increased rate of bladder contractions that occur in association with the enuretic episode (Nørgaard et al., 1989b). In addition, urodynamic studies during sleep demonstrate a relationship between nocturnal enuresis and pelvic floor activity. When pelvic floor activity increased in association with detrusor contractions, wetting was usually avoided, and patients often would awaken subsequently to void. In contrast, when pelvic floor activity did not increase, the detrusor contraction usually was associated with a wetting episode (Nørgaard et al., 1989b).

Children with enuresis (even those without daytime symptoms) have been noted to have a smaller bladder capacity than age-matched controls (Starfield, 1967). The reduced bladder capacity appears to be functional rather than anatomic. This was illustrated by a study in which bladder capacity was measured in the awake state as well as under general anesthesia in children with enuresis and compared with functional bladder capacity among controls (Troup et al., 1971). Compared with controls, the average volume of urine voided by enuretic children in the awake state was reduced. However, when volumes were measured during general anesthesia, enuretic children had similar mean bladder volumes to awake controls. In a somewhat contradictory study, Kawauchi et al. (2003) found that the maximal endurable bladder capacity during the daytime was similar between children with enuresis and controls. However, among children with enuresis, the maximum voided volume during the night (measured using a diaper and enuresis alarm) was significantly smaller than the maximal daytime bladder capacity. They concluded that inability to hold urine during sleep may be an important factor in MSE. A number of trials have noted functional bladder capacity to be a strong predictor of response to desmopressin in MSE (Eller et al., 1998; Rushton et al., 1996). As a result, a refractory response to desmopressin may suggest either unrecognized nocturnal OAB or that the decreased nocturnal urine production elicited by desmopressin continues to overwhelm a functionally undersized bladder. A recent study found that there is a reduction of the nocturnal bladder capacity in selected children despite normal daytime bladder function (Borg et al., 2018).

Whether this situation is a result of reduced nocturnal functional bladder capacity or nocturnal detrusor overactivity, however, may not be critical because the treatment strategy employed would largely be the same (i.e., anticholinergic medications).

Nocturnal Polyuria

Increased nighttime urine output appears to play an important role in nocturnal enuresis (Nevéus et al., 2010). In children and adolescents without enuresis, the diurnal pattern of urine production results in a relative reduction in nocturnal diuresis to approximately 50% of daytime levels (Rittig et al., 1995, 2010). The prevailing mechanism for how this occurs is thought to result from a nocturnal circadian peak of antidiuretic hormone (ADH) release from the posterior pituitary gland that regulates free water excretion. Other purported mechanisms for increased nocturnal urine production may include increased fluid intake before bedtime (Robson, 2001), a blunted response to ADH, increased evening dietary solute load with high nocturnal urine osmolarity (Dehoorne et al., 2006), abnormal renal sodium handling (related to release of angiotensin II, aldosterone, and natriuretic peptide), abnormal circadian rhythm of glomerular filtration rate (De Guchtenaere et al., 2007), abnormal sodium and calcium excretion (Raes et al., 2006), and obstructive sleep apnea/hypoventilation (Su et al., 2011).

Regardless of the mechanism, urine production that normally decreases at night secondary to these circadian systems fails to do so and will subsequently result in nocturnal polyuria, which can exceed the functional capacity of the bladder and result in an enuretic episode. Proof of this concept was demonstrated by Rasmussen et al. (1996), who were able to actually induce enuresis in normal healthy children by increasing nocturnal urine output. Despite this seemingly simple causal relationship, however, it is clear that nocturnal polyuria and ADH responsiveness are highly complex phenomena, because not all children with enuresis have nocturnal polyuria, and, in those who do, nocturnal ADH may be normal (Steffens et al., 1993). In fact, it has been observed that the urine osmolality of children with and without MSE is similar and that early morning osmolality tends to increase with age (Kawauchi et al., 1996). This suggests that the ADH secretion response may be a maturational one and lend further support to the maturation hypothesis.

Arousal and Sleep

Regardless of whether the child has detrusor overactivity and/or nocturnal polyuria, neither observation explains why a child with enuresis is unable to awaken from sleep to void before a wetting episode. Given that both bladder distention and detrusor contractions are robust arousal stimuli (Koyama et al., 1998), it is curious that an enuretic child will not wake up during the night to the sensation of a full or contracting bladder. Parents invariably describe their children with enuresis as excessively deep sleepers (Nevéus et al., 1999a; Wille, 1994). This situation is often experienced by family members of patients exposed to alarm therapy as parents awaken from sleep while their enuretic child will sleep through the alarm. Nevéus et al. (1999a) obtained questionnaire data from 1413 schoolchildren between 6 and 10 years of age and noted that enuresis was associated with subjectively high arousal threshold and significant confusion on awakening from sleep. Wolfish et al. (1997) performed a laboratory study of 33 boys 7 to 12 years of age (15 with enuresis and 18 age-matched controls) and found that attempts at arousal were more often successful in control subjects than in boys with enuresis (40% vs. 9%, respectively). In a comparison control study, sleep was investigated by one overnight video-polysomnography. Children with enuresis displayed higher sleep fragmentation and periodic limb movements in sleep than the control children with a possible sleep disorder without nocturnal enuresis (Dhondt et al., 2014). These findings emphasize the central involvement of the pathophysiology of nocturnal enuresis and the multifactorial nature of the condition.

A subjectively deep sleep, however, is not the same as an objectively deep sleep, as measured by EEG. Freitag et al. studied brainstem evoked potentials in 37 children with MSE and compared these children to 40 age-matched controls (Freitag et al., 2006). They found that interpeak latencies of the brainstem evoked potentials were increased in children with MSE, suggesting a maturational defect of the brainstem to account for this finding. Other sleep studies, however, show that sleep patterns among children with and without enuresis are similar (Bader et al., 2002; Ritvo et al., 1969). These studies indicate that enuretic episodes may occur at random throughout the night, but primarily during non–rapid eye movement (non-REM) sleep (Nevéus et al., 1999b) and when the bladder is at a volume equivalent to the maximal daytime functional capacity (Mikkelsen et al., 1980; Nørgaard et al., 1989b). A study of 35 children with therapy-resistant MSE in Hong Kong demonstrated that although appearing to be heavy sleepers, these children had, in fact, more overall light sleep (stage I/II non-REM) with sleep fragmentation, rather than deep sleep (stage III/IV non-REM). The cerebral cortex received afferent input of sleep OAB with frequent cortical arousals that failed to wake the children, which was presumed to be a paradoxic elevation in the conscious awakening threshold. OAB-associated cortical arousals may cause a shift from deep to light sleep but not to complete awakening, perhaps because of long-term overstimulation of the sleep arousal center by signals from the bladder. In summary, these studies suggest that children who wet the bed sleep normally (i.e., the distribution and proportion of the various stages of sleep are within normal limits) but are unable to awaken in response to nocturnal detrusor contractions or bladder fullness.

Evaluation

The basic evaluation of the child with MSE includes **history, physical examination, and urinalysis. The history, including a voiding diary, is the mainstay of the evaluation** (Nevéus et al., 2010; Robson, 2009). (See Chapter 28 and the discussion of bladder and bowel diaries earlier in this chapter.) **The**

principal objective of the evaluation is to rule out BBD (NMSE) or enuresis as a manifestation of an underlying medical disease (e.g., posterior urethral valves, spinal dysraphism, diabetes mellitus) and to identify that the enuresis is truly monosymptomatic. If there is BBD and the child has NMSE, treatment is aimed at BBD before consideration or initiation of therapy for MSE (Franco et al., 2013).

Once MSE is confirmed, it is often helpful to characterize the enuresis further, such as frequency and volume. Distinguishing between primary and secondary MSE should be attempted, mainly for prognostic purposes because treatment is generally the same. One important point to ask about is the presence of nocturia; this would suggest that the child is not extremely difficult to arouse from sleep. The social history is also particularly germane because somatic and psychological comorbid conditions are more common in children who were previously dry than in those with primary MSE (Robson et al., 2005). A family history of enuresis is often helpful in establishing a genetic pattern. Interventions the family has already tried also should be determined.

Treatment

Conventional therapies for enuresis include behavior modification, the enuresis "moisture" alarm, and pharmacologic therapy (e.g., desmopressin, anticholinergics, imipramine). The evidence for the efficacy of much of the care that we provide to children with enuresis is weak (Nevéus et al., 2010). Given the self-limiting nature of enuresis, one treatment option is to observe and allow the natural history to follow its predetermined course. However, enuresis that occurs as infrequently as once per month is associated with reduced self-esteem, and treatment has been reported to improve self-worth, regardless of the type or the success of therapy (Hägglöf et al., 1998; Longstaffe et al., 2000).

The decision about when to start treatment generally should be guided by the degree of concern and motivation on the part of the child rather than the parents. For the child, nocturnal enuresis usually becomes significant when it interferes with his or her ability to socialize with peers (e.g., sleepovers, summer camps) (Jalkut et al., 2001). **It is important to determine whether the child is mature enough to assume responsibility for treatment.** Treatment probably should be delayed if it seems that the parents are more interested in treatment than the child and the child is unwilling or unable to assume some responsibility for the treatment program. The child must be highly motivated to participate in a treatment program that may take months to achieve successful results. Although general advice should be given to all bedwetting children, active treatment should usually not be started before 6 years of age (Nevéus et al., 2010). However, age should not be the only criterion for initiation of active treatment. In a recent meta-analysis evaluating 18 RCTs with 1649 subjects, Song et al. concluded that desmopressin had a higher relapse rate with a comparable efficacy to bed alarm. A combination of desmopressin plus anticholinergic agent produced a better efficacy to desmospressin alone; however, a similar relapse rate was observed (Song et al., 2019).

Behavioral Therapy

Data from randomized trials on the efficacy of behavioral therapy are lacking (Caldwell et al., 2013; Pennesi et al., 2004), but clinical experience (i.e., level 4 evidence) suggests that this approach is beneficial (Nevéus et al., 2010). Likewise, although the influence of the clinician's behavior has not been formally studied, clinical experience suggests that the ability to establish a rapport with the child and to engender and sustain motivation is important for successful behavioral therapy. **The fundamental goal of behavioral therapy is much like the treatment of daytime urinary incontinence and centers around the practice of good bladder and bowel habits.**

Children should attempt to void regularly during the day and just before going to bed for a total of six to seven times daily. High-sugar and caffeine-based drinks should be avoided, particularly in the evening hours. Daily fluid intake should be concentrated in the morning and early afternoon, and both fluid and solute intake should be minimized during the evening. Isolated nighttime fluid restriction, without compensatory increase in daytime fluid consumption, may prevent the child from meeting his or her daily fluid requirement and is usually unsuccessful.

In practice, compliance improves when parents and children understand normal bladder function and the pathogenesis of enuresis. **Children should be reassured that enuresis is not their fault, and children should not be punished for bedwetting, because this practice is often counterproductive** (van Londen et al., 1993). An individualized program with a series of realistic goals between appointments and monthly follow-up to sustain motivation improves the outcome (Glazener and Evans, 2004). A personalized calendar for recording daytime incontinence and enuresis episodes and the frequency and timing of bowel movements aids the family and child to follow their progress.

When initiating active treatment for primary MSE, there is level 1 evidence to support the use of the enuresis alarm (Glazener et al., 2005)**, desmopressin** (Glazener and Evans, 2002)**, anticholinergics** (Austin et al., 2008)**, and tricyclic antidepressants (TCAs; e.g., imipramine)** (Glazener and Evans, 2000)**, either alone or in combination.** Generally, in addition to behavioral therapy, the two contemporary first-line therapies for MSE include the enuresis alarm and desmopressin. They are both valid treatment options, but patient, caregiver, and disease-related parameters exist that may aid in offering prognostic information in terms of which therapeutic modality should be first entertained (Fig. 35.3). **The enuresis alarm seems best fit for motivated families and for children without polyuria but with low PVR** (Nevéus et al., 2010)**. Desmopressin seems best suited for children with nocturnal polyuria and normal bladder reservoir function** (Hunsballe et al., 1998)**, those with infrequent wet episodes, and for families in whom alarm treatment has failed or who have refused alarm treatment** (Nevéus et al., 2010)**. Children in whom one first-line treatment has failed should be offered the other, and for those in whom both have failed, second- and third-line treatments can be tried, either alone or in combination (e.g., desmopressin plus oxybutynin).**

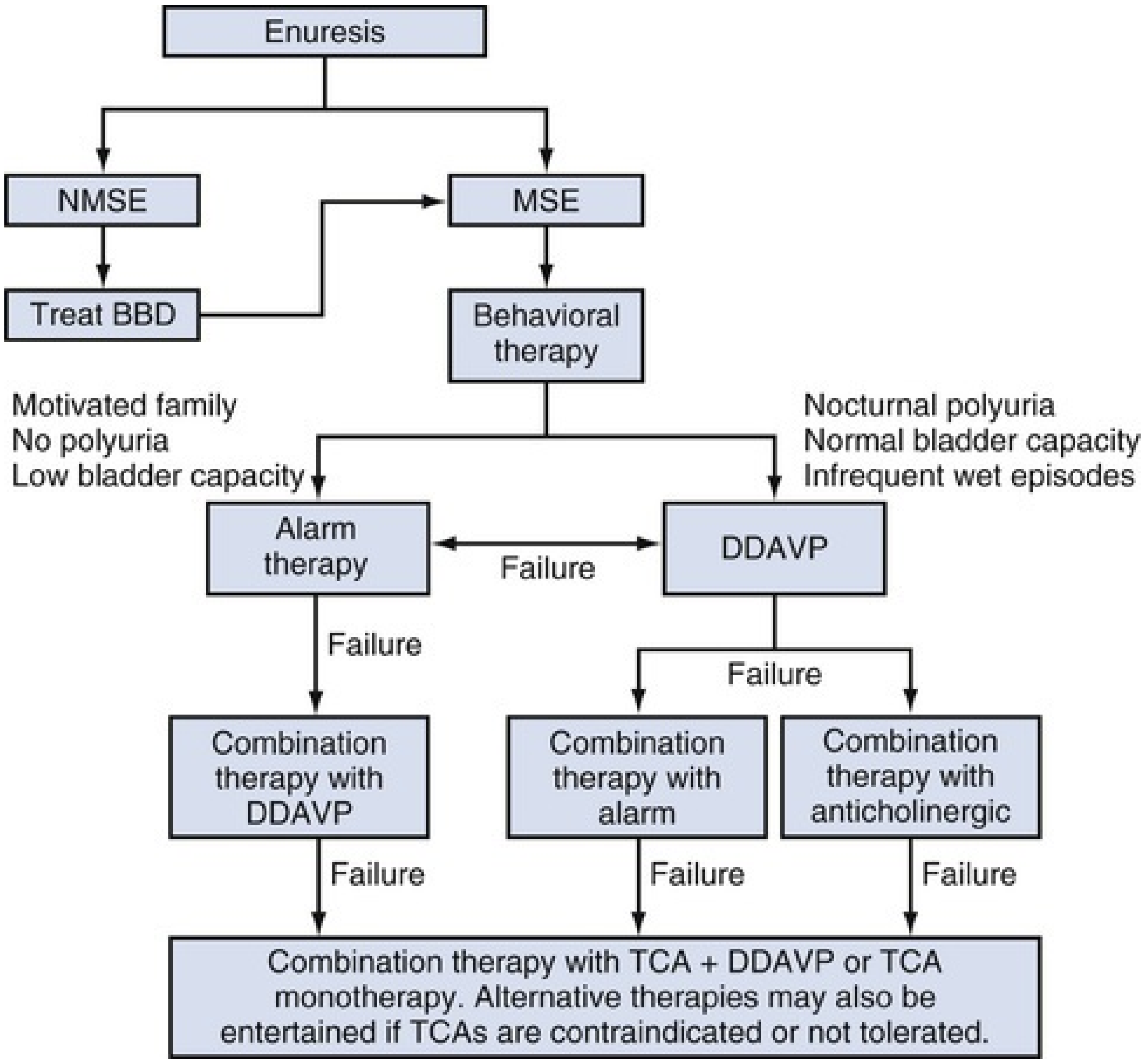
Enuresis
NMSE
MSE
Treat BBD
Behavioral therapy
Motivated family
No polyuria
Low bladder capacity
Nocturnal polyuria
Normal bladder capacity
Infrequent wet episodes
Alarm therapy
Failure
DDAVP
Failure
Failure
Combination therapy with DDAVP
Combination therapy with alarm
Combination therapy with anticholinergic
Failure
Failure
Failure
Combination therapy with TCA + DDAVP or TCA monotherapy. Alternative therapies may also be entertained if TCAs are contraindicated or not tolerated.

FIG. 35.3 Algorithm of the evaluation and treatment of a pediatric patient with enuresis. *BBD,* Bowel-bladder dysfunction; *DDAVP,* 1-desamino-8-D-arginine vasopressin (desmopressin); *MSE,* monosymptomatic enuresis; *NMSE,* nonmonosymptomatic enuresis; *TCA,* tricyclic antidepressant.

Enuresis Alarm

Alarm training has been shown to be the most effective long-term therapeutic modality in the treatment of MSE (Glazener et al., 2005). Alarms have been used since the 1930s and represent classic Pavlovian conditioning techniques, but exactly how the alarm works remains somewhat of a mystery because, strictly speaking, classical conditioning mechanisms should not be functional during sleep. Proposed mechanisms include suppression of bladder emptying during sleep, increasing nocturnal bladder volume (Hansen and Jørgensen, 1997), and waking to void by signaling when they urinate. Interestingly, most children who become dry with the use of the enuresis alarm actually sleep through the night and do not necessarily wake to void. The response is more gradual and sustained than for desmopressin, with approximately two-thirds of children becoming dry during active treatment and nearly one-half remaining dry after treatment completion (Glazener et al., 2005). In a large, multisite study of 2861 enuretic children (5 to 16 years of age), the overall success rate of bell-and-pad alarm therapy was 76%, irrespective of age (Apos et al., 2018). Enuresis alarms are activated when a sensor, placed in the undergarment or on a bed pad, detects moisture, with both types demonstrated to be equally effective (Butler and Robinson, 2002). The arousal device is usually an auditory alarm and/or a vibrating belt.

The family should be instructed that the child is in charge of the alarm. After the alarm goes off, only the child should turn off the alarm, get up, and finish voiding in the toilet. We often remind parents that at the initiation of therapy, the child may fail to awaken and that parents should wake the child when the alarm sounds. The child being fully awake and cognizant of what is happening is critical to the success of alarm therapy. The child should then return to the bedroom, change the bedding and underwear, replace the sensor, and reset the alarm before returning to sleep. A diary should be kept of wet and dry nights, with positive reinforcement given for dry nights and successful completion of the sequence of events. Approximately 30% of patients discontinue enuresis alarms for various reasons, including skin irritation, disturbance of other family members, and/or failure to wake the child (Schmitt, 1997). Adverse effects of alarms include alarm failure, false alarms, disruption of the lives of other family members, and lack of adherence because of difficulty using the alarm (Glazener et al., 2005).

Alarm treatment should be continued until the child has had a minimum of 14 consecutive dry nights (Nevéus et al., 2010). Children who do not continue to improve after 6 weeks of alarm training are unlikely to become completely dry with this technique (Taylor and Turner, 1975), and alternative interventions may be warranted. Therapy with the alarm can be reinitiated for relapse (more than two wet nights in 2 weeks). Children who relapse after discontinuation of the alarm usually can achieve a rapid secondary response because of preconditioning as a result of the first treatment program (Tuncel et al., 2008).

In a review of 1502 children in 15 randomized controlled trials comparing an enuresis alarm and desmopressin in managing children with MSE, the enuresis alarm outperformed desmopressin in achieving at least a partial response (>50% reduction in wet nights) in per-protocol analysis (odds ratio [OR] 1.53, 95% CI 1.05 to 2.23) but not in intention-to-treat analysis (OR 0.97, 95% CI 0.73 to 1.30) as the alarm was hampered by a high dropout rate (OR 2.20, 95% CI 3.41 to 4.29). In the intention-to-treat analysis, the results revealed that alarm and desmopressin therapy are comparable in efficacy with regard to achieving a greater than 50% reduction in baseline wet nights in enuretic children (Peng et al., 2018).

Pharmacotherapy

Desmopressin

Desmopressin (1-desamino-8-D-arginine vasopressin [DDAVP]) is a synthetic analogue of ADH released by the posterior pituitary gland that reduces urine production by increasing water reabsorption by the collecting tubules. DDAVP has been used to treat enuresis for the past 40 years. Desmopressin is fairly easy to administer, and its clinical effects appear immediately, with a serum half-life of approximately 2 to 3 hours when taken in oral form (the duration of pharmacodynamic action approximates the average duration of sleep for a child in the age range for elementary school). It is available in the United States in oral (crushable) tablets and in sublingual and intranasal spray formulations. The main safety issue is the risk for water intoxication with resultant hyponatremic seizures should the drug be taken with excessive fluids. This risk seems to be somewhat higher with the intranasal form, which has a prolonged half-life, and thus use of the spray is discouraged (Robson et al., 2007). Treatment should be interrupted during episodes of fluid and/or electrolyte imbalance (e.g., fevers, vomiting or diarrhea, vigorous exercise, or other conditions associated with increased water consumption).

The usual starting dose is 0.2 mg orally 1 hour before bedtime, and the drug can be titrated up incrementally by 0.2 mg to a maximum dose of 0.6 mg at bedtime. Children are instructed to void directly before going to bed. Fluid intake is reduced to a maximum of one 8-oz glass at the time of ingestion, with absolutely no more fluids until morning, decreasing the risk for significant hyponatremia to virtually zero (Glazener and Evans, 2002).

Desmopressin is most efficient in children with nocturnal polyuria (defined by the ICCS as nocturnal urine production >130% of expected bladder capacity for age) and normal bladder reservoir function (maximum voided volume >70% of expected bladder capacity for age) (Austin et al., 2014; Hunsballe et al., 1998; Rushton et al., 1996). There is a wide range of efficacy among studies, most likely because of heterogeneous patient populations (MSE vs. NMSE), differences in concomitant behavioral therapy recommendations, and differences in the dosage or formulation of DDAVP, without taking into account nocturnal urine volume. Overall, approximately 30% of patients achieve total dryness, and another 40% exhibit a significant decrease in nighttime wetting (Nevéus et al., 2010). However, the relapse rate after discontinuation is high (60% to 70%) (Wille, 1986). In a systematic review of 47 randomized trials (3448 children), researchers noted that compared with placebo, children treated with desmopressin were more likely to become dry and had a reduction in bedwetting by 1.34 nights per week (Glazener and Evans, 2002). In contrast with the enuresis alarm, however, treatment effects were not sustained after discontinuation of therapy, with a relapse rate of 65% versus 46% with DDAVP versus the alarm, respectively (Glazener and Evans, 2002).

The response to desmopressin should be assessed within 2 weeks (Schmitt, 1997). Treatment should be continued if there is a positive response (e.g., smaller wet patches, fewer wetting episodes). If enuresis improves or remits with desmopressin, the family and child can determine whether to use it every night or just for special occasions (e.g., sleepovers, summer camp). When DDAVP is administered daily, we generally give patients regular scheduled drug holidays of approximately 1 week every 3 to 6 months to assess whether the medication is still needed.

Tricyclic Antidepressants

TCAs have been demonstrated to decrease the amount of time spent in REM sleep, stimulate ADH secretion, and relax the detrusor muscle via weak anticholinergic properties. Its anti-enuretic effect has been theorized to be less likely because of its action at the kidney or bladder level and more likely a result of noradrenergic stimulation at the brainstem, specifically the locus coeruleus (Gepertz and Nevéus, 2004). Given the efficacy and safety of enuresis alarms and DDAVP, TCAs (e.g., imipramine, amitriptyline, and desipramine) are considered a third-line treatment for therapy-resistant MSE (Nevéus et al., 2010).

Level 1 evidence demonstrates that, compared with placebo, TCAs are more effective at reducing the number of wet nights and at achieving 14 consecutive dry nights (i.e., cure) but essentially become ineffective once treatment is discontinued.

In a recent systematic review, treatment with TCAs was associated with a reduction of approximately one wet night per week compared with placebo (Glazener and Evans, 2000). Approximately 20% of children became dry during therapy versus 5% with placebo. The rate of relapse was 96% after discontinuation of therapy. In an observational study of children who were refractory to first-line therapy, researchers found that approximately one-third of children became dry on monotherapy, one-third became dry after adding DDAVP, and the remaining one-third were nonresponders (Gepertz and Nevéus, 2004).

Although other TCAs are effective, imipramine is used most often in the treatment of enuresis. Imipramine is available in 10-, 25-, and 50-mg tablets. The initial dose is 10 to 25 mg 1 hour before bedtime; it may be increased by 25 mg if there is no response after 1 week (Schmitt, 1997). On average, the bedtime dose is 25 mg for children 5 to 8 years of age and 50 mg for older children. The dose should not exceed 50 mg in children between 6 and 12 years of age and 75 mg in children older than 12 years of age (Glazener and Evans, 2000).

The response to imipramine should be assessed after 1 month. If there is no improvement after 3 months, it should be discontinued as a gradual taper (as is done with other TCAs). As is the case with other pharmacotherapy for enuresis, we give patients a drug holiday every 3 to 6 months, gradually tapering the dose over a 2-week period (Gepertz and Nevéus, 2004).

Imiprimine is also an effective method of treating refractory daytime incontinence; in a pediatric population of 163 patients, 53% experienced complete treatment response as assessed by the Vancouver Symptom Score (VSS). Of the patients included in this retrospective study, only 13.3% experienced adverse effects (Franco et al., 2018).

Adverse effects of TCA therapy are relatively uncommon. Approximately 5% of children treated with TCAs develop neurologic symptoms, including nervousness, personality change, and disordered sleep. TCAs (as with other antidepressants) are required by the FDA to carry a black box warning regarding the possibility of increased suicidality, particularly in individuals with preexisting depressive symptoms. **The most serious adverse effects of TCAs involve the cardiovascular system: cardiac conduction disturbances and myocardial depression, particularly in cases of overdose** (Swanson et al., 1997). Before initiation of therapy with a TCA, a thorough cardiac history (e.g., palpitations, syncope) and family cardiac history (e.g., arrhythmias, sudden cardiac death) should be obtained with a baseline electrocardiogram to rule out a prolonged QT interval if history or physical examination raises suspicion. In an assessment of 64 trials in a Cochrane review covering the effects of tricyclic and related drugs in the treatment of enuresis, Caldwell et al. concluded that there was evidence for the effectiveness of TCAs in reducing the number of wet nights, but the effect was not sustained after treatment ceased. Combination of tricyclics and anticholinergics may also be more effective than monotherapy with tricyclics. Common side effects of dizziness, headache, mood changes, gastrointestinal discomfort, and neutropenia were observed (Caldwell et al., 2016).

Anticholinergics

Monotherapy with anticholinergic drugs, such as oxybutynin or tolterodine, has been demonstrated not to be effective as a first-line treatment for MSE (Lovering et al., 1988; Persson-Jünemann et al., 1993). Although evidence of efficacy from randomized trials is lacking, uncontrolled studies do show improvement in some children with NMSE, presumably because many of these children have a reduced functional bladder capacity (Caione et al., 1997; Nevéus, 2001). There is also some evidence that nocturnal detrusor overactivity (especially without nocturnal polyuria) plays a role in the pathogenesis of enuresis and therefore makes anticholinergics an attractive pharmacotherapeutic option (Nevéus, 2001).

Where anticholinergics clearly do have a role is combination therapy in the treatment of children who are refractory to DDAVP monotherapy. In the first randomized, placebo-controlled study of combination therapy with anticholinergics, Austin et al. (2008) studied 34 children with primary MSE who failed maximal-dose DDAVP monotherapy and assigned them, in a double-blind manner, to receive either extended-release tolterodine or placebo while all children continued to take DDAVP. Patients were reassessed after 1 month of therapy with a 1-week nocturnal record. They found a significant reduction in the mean number of wet nights in the combination therapy group compared with the placebo group. Furthermore, there was a 66% reduction in the risk for a wet episode compared with the placebo group. Montaldo et al. (2012) reported their results in 206 children with MSE refractory to DDAVP monotherapy who were randomized to 5 mg of oxybutynin or placebo and followed for 1 month. As predictive factors, bladder volume and wall thickness index, nocturnal polyuria, and voiding latency were considered. Corroborating the original study by Austin et al., the oxybutynin group showed a higher rate of full and partial responses than the placebo group. The responders to combined oxybutynin and desmopressin had a significantly lower bladder volume and wall thickness index than nonresponders.

Combination Therapy

The efficacy of the enuresis alarm plus desmopressin combination has been investigated in a number of studies (Bradbury, 1997; Fai-Ngo et al., 2005; Leebeek-Groenewegen et al., 2001; Sukhai et al., 1989).

Sukhai et al. (1989) reported a crossover trial of 28 children with primary MSE who were blindly allocated at random to a combination of enuresis alarm plus 20 mcg intranasal DDAVP or alarm plus placebo for 2 weeks. Patients received the other therapy after a 2-week treatment-free period. The combined treatment of desmopressin plus enuresis alarm resulted in significantly more dry nights per week during the 2 weeks of observation than the placebo plus the alarm. Although there was a significant difference between groups, the treatment period of 2 weeks was most likely too short for alarm therapy to contribute significantly to the outcome variable.

Bradbury compared the efficacy of enuresis alarm monotherapy to alarm treatment in combination with 40 mcg DDAVP nasal spray (Bradbury, 1997). At the end of the treatment period, children receiving combination therapy had more dry nights per week (mean: 6.1) than children using an alarm alone (mean: 4.8). In addition, more children achieved an initial success (4 weeks of dryness) after combination treatment (27 children [75%]) compared with alarm monotherapy (16 children [46%]). Interestingly, this improvement was most pronounced in children with severe wetting (>5 nights per week), family problems, or behavioral problems.

In a placebo-controlled study containing 93 patients with MSE, Leebeek-Groenewegen et al. (2001) compared 9 weeks of desmopressin plus alarm therapy with alarm monotherapy. They showed a significant decrease in the number of wet nights per week with combination therapy. After 6 months of follow-up, however, they reported that there was no significant difference between the two treatment groups regarding the efficacy and number of children who relapsed.

In a recent multicenter randomized controlled trial, Fai-Ngo et al. (2005) compared the efficacy of the enuresis alarm, oral DDAVP, and combined treatment in children with primary MSE. They assigned 105 children equally among groups to receive treatment for 12 weeks, and patients were then followed for 12 weeks after treatment. They found that the mean number of wet nights per week was significantly lower in the combination group than in the other groups at the conclusion of therapy. Desmopressin produced an immediate effect, but relapses were most common in the DDAVP monotherapy and combination therapy groups (60% and 40%, respectively). Alarms took several weeks to produce a benefit, but this was sustained on follow-up (20% relapse rate).

A reduction in the number of wet nights is consistently observed when using combination therapy of desmopressin and the moisture alarm compared with monotherapy. Enuresis relapse, however, is noted in some patients with long-term follow-up.

Alternative Therapies

Other drugs, including indomethacin, ephedrine, atropine, furosemide, and diclofenac, have been tried in the treatment of enuresis. A recent systematic review of randomized trials of drugs other than TCAs and DDAVP found that although indomethacin, diclofenac, and diazepam were better than placebo in reducing the number of wet nights, none of the drugs was better than desmopressin (Deshpande et al., 2012). A second recent review of complementary approaches such as hypnosis, psychotherapy, and acupuncture found limited evidence from small trials with methodologic limitations to support the use of such modalities for the treatment of enuresis (Huang et al., 2011).

Key Points: Enuresis

- The majority of children who present with enuresis have the nonmonosymptomatic form.
- The spontaneous resolution rate of enuresis is approximately 15% annually, such that only approximately 1% of teenagers will continue to be afflicted.
- Enuresis stems from a maturational delay in the ultimate development of bladder control, with three organ systems implicated in its pathogenesis: the bladder, the kidney, and the brain.
- The basic evaluation of the child with MSE includes history (including a voiding diary), physical examination, and urinalysis. The principal objective of the evaluation is to rule out BBD or enuresis as a manifestation of an underlying medical disease (e.g., posterior urethral valves, spinal dysraphism, diabetes mellitus) and to identify that the enuresis is truly monosymptomatic.
- Conventional therapies for enuresis include behavior modification, the

enuresis moisture alarm, and pharmacologic therapy (e.g., desmopressin, anticholinergics, imipramine).

Suggested Readings

Austin PF, Bauer SB, Bower W, et al. The standardization of terminology of lower urinary tract function in children and adolescents: update report from the Standardization Committee of the International Children's Continence Society. *J Urol*. 2014;191(6):1863–1865.

Burgers RE, Mugie SM, Chase J, et al. Management of functional constipation in children with lower urinary tract symptoms: report from the Standardization Committee of the International Children's Continence Society. *J Urol*. 2013;190(1):29–36.

Chase J, Austin P, Hoebeke P, et al. The management of dysfunctional voiding in children: a report from the Standardisation Committee of the International Children's Continence Society. *J Urol*. 2010;183(4):1296–1302.

Franco I, von Gontard A, De Gennaro M, et al. Evaluation and treatment of nonmonosymptomatic nocturnal enuresis: a standardization document from the International Children's Continence Society. *J Pediatr Urol*. 2013;9(2):234–243.

Nevéus T, Eggert P, Evans J, et al. Evaluation of and treatment for monosymptomatic enuresis: a standardization document from the International Children's Continence Society. *J Urol*. 2010;183(2):441–447.

von Gontard A, Baeyens D, Van Hoecke E, et al. Psychological and psychiatric issues in urinary and fecal incontinence. *J Urol*. 2011;185(4):1432–1436.

Yang S, Chua ME, Bauer S, et al. Diagnosis and management of bladder bowel dysfunction in children with urinary tract infections: a position statement from the International Children's Continence Society. *Pediatr Nephrol*. 2018;33(12):2207–2219.

References

Allen HA, Austin JC, Boyt MA, et al. Initial trial of timed voiding is warranted for all children with daytime incontinence. *Urology*. 2007;69(5):962–965.

Alyami F, Ewida T, Alhazmi H, et al. Biofeedback as single first-line treatment for non-neuropathic dysfunctional voiding children with diurnal enuresis. *Can Urol Assoc J*. 2018; 10.5489/cuaj.5209.

American Psychiatric Association. *Diagnostic and statistical manual of mental disorders*. ed 5. American Psychiatric Publishing: Arlington, VA; 2013.

Apos E, Schuster S, Reece J, et al. Enuresis management in children: retrospective clinical audit of 2861 cases treated with practitioner-assisted bell-and-pad alarm. *J Pediatr*. 2018;193:211–216.

Arlen AM, Cooper CS, Leong T. Role of body mass index in school-aged children with lower urinary tract dysfunction: does weight classification predict treatment outcome? *J Pediatr Urol*. 2017;13(5):454.e1–454.e5.

Arnell H, Hjälmas K, Jägervall M, et al. The genetics of primary nocturnal enuresis: inheritance and suggestion of a second major gene on chromosome 12q. *J Med Genet*. 1997;34(5):360–365.

Austin PF, Bauer SB, Bower W, et al. The standardization of terminology of lower urinary tract function in children and adolescents: update report from the Standardization Committee of the International Children's Continence Society. *J Urol*. 2014;191(6):1863–1865.

Austin PF, Ferguson G, Yan Y, et al. Combination therapy with desmopressin and an anticholinergic medication for nonresponders to desmopressin for monosymptomatic nocturnal enuresis: randomized, double-blind, placebo-controlled trial. *Pediatrics*. 2008;122(5):1027–1032.

Austin PF, Homsy YL, Masel JL, et al. alpha-Adrenergic blockade in children with neuropathic and nonneuropathic voiding dysfunction. *J Urol*. 1999;162(3 Pt 2):1064–1067.

Bader G, Nevéus T, Kruse S, et al. Sleep of primary enuretic children and controls. *Sleep*. 2002;25(5):579–583.

Baeyens D, Roeyers H, Hoebeke P, et al. Attention deficit/hyperactivity disorder in children with nocturnal enuresis. *J Urol*. 2004;171(6 Pt 2):2576–2579.

Bakker E, van Sprundel M, van der Auwera JC, et al. Voiding habits and wetting in a population of 4,332 Belgian schoolchildren aged between 10 and 14 years. *Scand J Urol Nephrol*. 2002;36(5):354–362.

Bakwin H. Enuresis in twins. *Am J Dis Child*. 1971;121(3):222–225.

Bakwin H. The genetics of enuresis. Kolvin RM, Meadows SR. *Bladder control and enuresis*. Medical Books: London; 1973:73.

Barroso U Jr, Lordêlo P, Lopes AA, et al. Nonpharmacological treatment of lower urinary tract dysfunction using biofeedback and transcutaneous electrical stimulation: a pilot study. *BJU Int*. 2006;98(1):166–171.

Bauer SB. Special considerations of the overactive bladder in children. *Urology*. 2002;60(5 Suppl 1):43–48.

Belman AB. Urinary tract infection, wetting, and constipation. *Pediatrics*. 1998;102(1 Pt 1):158.

Bergmann M, Corigliano T, Ataia I, et al. Childhood extraordinary daytime urinary frequency: a case series and a systematic literature review. *Pediatr Nephrol*. 2009;24(4):789–795.

Berry AK, Zderic S, Carr M. Methylphenidate for giggle incontinence. *J Urol*. 2009;182(4 Suppl):2028–2032.

Blais AS, Bergeron M, Nadeau G, et al. Anticholinergic use in children: persistence and patterns of therapy. *Can Urol Assoc J*. 2016;10(3–4):137–140.

Bloom DA, Seeley WW, Ritchey ML, et al. Toilet habits and continence in children: an opportunity sampling in search of normal parameters. *J Urol*. 1993;149(5):1087–1090.

Borg B, Kamperis K, Olsen LH, et al. Evidence of reduced bladder capacity during nighttime in children with monosymptomatic nocturnal enuresis. *J Pediatr Urol*. 2018;14(2):160.e1–160.e6.

Bower WF, Moore KH, Adams RD. A pilot study of the home application of transcutaneous neuromodulation in children with urgency or urge incontinence. *J Urol*. 2001;166(6):2420–2422.

Bower WF, Wong EMC, Yeung CK. Development of a validated quality of life tool specific to children with bladder dysfunction. *Neurourol Urodyn*. 2006;25(3):221–227.

Bradbury M. Combination therapy for nocturnal enuresis with desmopressin and an alarm device. *Scand J Urol Nephrol Suppl*. 1997;183:61–63.

Braga LH, Rickard M, Farrokhyar F, et al. Bladder training video versus standard urotherapy for bladder and bowel dysfunction: a noninferiority randomized, controlled trial. *J Urol*. 2017;197(3 Pt 2):877–884.

Brownrigg N, Braga LH, Rickard M, et al. The impact of a bladder training video versus standard urotherapy on quality of life of children with bladder and bowel dysfunction: a randomized controlled trial. *J Pediatr Urol*. 2017;13(4):374.e1–374.e8.

Burgers R, de Jong TP, Visser M, et al. Functional defecation disorders in children with lower urinary tract symptoms. *J Urol*. 2013;189(5):1886–1891.

Burgers RE, Mugie SM, Chase J, et al. Management of functional constipation in children with lower urinary tract symptoms: report from the Standardization Committee of the International Children's Continence Society. *J Urol*. 2013;190(1):29–36.

Butler RJ, Heron J. The prevalence of infrequent bedwetting and nocturnal enuresis in childhood: a large British cohort. *Scand J Urol Nephrol*. 2008;42(3):257–264.

Butler RJ, Robinson JC. Alarm treatment for childhood nocturnal enuresis: an investigation of within-treatment variables. *Scand J Urol Nephrol*. 2002;36(4):268–272.

Byrd RS, Weitzman M, Lanphear NE, et al. Bed-wetting in US children: epidemiology and related behavior problems. *Pediatrics*. 1996;98(3 Pt 1):414–419.

Cain MP, Wu SD, Austin PF, et al. Alpha blocker therapy for children with dysfunctional voiding and urinary retention. *J Urol*. 2003;170(4 Pt 2):1514–1515 [discussion 1516–1517].

Caione P, Arena F, Biraghi M, et al. Nocturnal enuresis and daytime wetting: a multicentric trial with oxybutynin and desmopressin. *Eur Urol*. 1997;31(4):459–463.

Caldwell PH, Nankivell G, Sureshkumar P. Simple behavioural interventions for nocturnal enuresis in children. *Cochrane Database Syst Rev*. 2013;(7) [CD003637].

Caldwell PH, Sureshkumar P, Wong WC. Tricyclic and related drugs for nocturnal enuresis in children. *Cochrane Database Syst Rev*. 2016;(1) [CD002117].

Capitanucci ML, Camanni D, Demelas F, et al. Long-term efficacy of percutaneous tibial nerve stimulation for different types of lower urinary tract dysfunction in children. *J Urol*. 2009;182(Suppl 4):2056–2061.

Capozza N, Lais A, Matarazzo E, et al. Influence of voiding dysfunction on the outcome of endoscopic treatment for vesicoureteral reflux. *J Urol*. 2002;168(4 Pt 2):1695–1698.

Chandra M. Voiding and its disorders in children. Trachtman H, Gauthier B. *Monographs in clinical pediatrics*. Harwood Academic Publishers: The Netherlands; 1998:217–229.

Chapple CR. Muscarinic receptor antagonists in the treatment of overactive bladder. *Urology*. 2000;55(5A Suppl):33–46 [discussion 50].

Chapple CR, Yamanishi T, Chess-Williams R. Muscarinic receptor subtypes and management of the overactive bladder. *Urology*. 2002;60(5 Suppl 1):82–88 [discussion 88–89].

Chase J, Austin PF, Hoebeke P, et al. The management of dysfunctional voiding in children: a report from the Standardisation Committee of the International Children's Continence Society. *J Urol*. 2010;183(4):1296–1302.

Chen JJ, Mao W, Homayoon K, et al. A multivariate analysis of dysfunctional elimination syndrome, and its relationships with gender, urinary tract infection and vesicoureteral reflux in children. *J Urol*. 2004;171(5):1907–1910.

Chin-Peuckert L, Salle JL. A modified biofeedback program for children with detrusor-sphincter dyssynergia: 5-year experience. *J Urol*. 2001;166(4):1470–1475.

Ching CB, Lee H, Mason MD, et al. Bullying and lower urinary tract symptoms: why the pediatric urologist should care about school bullying. *J Urol*. 2015;193(2):650–654.

Chung JM, Lee SD, Kang DI, et al. Prevalence and associated factors of overactive bladder in Korean children 5–13 years old: a nationwide multicenter study. *Urology*. 2009;73(1):63–67 [discussion 68–69].

Combs AJ, Van Batavia JP, Chan J, et al. Dysfunctional elimination syndromes—how closely linked are constipation and encopresis with specific lower urinary tract conditions? *J Urol*. 2013;190(3):1015–1020.

Collis D, Kennedy-Behr A, Kearney L. The impact of bowel and bladder problems on children's quality of life and their parents: a scoping review. *Child Care Health Dev*.

2019;45(1):1–14.

Curran MJ, Kaefer M, Peters C, et al. The overactive bladder in childhood: long-term results with conservative management. *J Urol*. 2000;163(2):574–577.

Davila GW, Daugherty CA, Sanders SW. A short-term, multicenter, randomized double-blind dose titration study of the efficacy and anticholinergic side effects of transdermal compared to immediate release oral oxybutynin in the treatment of patients with urge urinary incontinence. *J Urol*. 2001;166(1):140–145.

De Gennaro M, Capitanucci ML, Mastracci P, et al. Percutaneous tibial nerve neuromodulation is well tolerated in children and effective for treating refractory vesical dysfunction. *J Urol*. 2004;171(5):1911–1913.

De Guchtenaere A, Vande Walle C, Van Sintjan P, et al. Nocturnal polyuria is related to absent circadian rhythm of glomerular filtration rate. *J Urol*. 2007;178(6):2626–2629.

Dehoorne JL, Raes AM, van Laecke E, et al. Desmopressin resistant nocturnal polyuria secondary to increased nocturnal osmotic excretion. *J Urol*. 2006;176(2):749–753.

Desantis DJ, Leonard MP, Preston MA, et al. Effectiveness of biofeedback for dysfunctional elimination syndrome in pediatrics: a systematic review. *J Pediatr Urol*. 2011;7(3):342–348.

Deshpande AV, Caldwell PH, Sureshkumar P. Drugs for nocturnal enuresis in children (other than desmopressin and tricyclics). *Cochrane Database Syst Rev*. 2012;(12) [CD002238].

Dhondt K, Baert E, Van Herzeele C, et al. Sleep fragmentation and increased periodic limb movements are more common in children with nocturnal enuresis. *Acta Paediatr*. 2014;103(6):e268–e272.

Eiberg H. Total genome scan analysis in a single extended family for primary nocturnal enuresis: evidence for a new locus (ENUR3) for primary nocturnal enuresis on chromosome 22q11. *Eur Urol*. 1998;33(Suppl 3):34–36.

Eiberg K, Berendt I, Mohr J. Assignment of dominant inherited nocturnal enuresis (ENUR1) to chromosome 13q. *Nat Genet*. 1995;10(3):354–356.

Ek A. Adrenergic innervation and adrenergic mechanisms: a study of the human urethra. *Acta Pharmacol Toxicol (Copenh)*. 1978;43(Suppl 2):35–40.

Eller DA, Austin PF, Tanguay S, et al. Daytime functional bladder capacity as a predictor of response to desmopressin in monosymptomatic nocturnal enuresis. *Eur Urol*. 1998;33(Suppl 3):25–29.

Fai-Ngo Ng C, Wong SN, Hong Kong Childhood Enuresis Study Group. Comparing alarms, desmopressin, and combined treatment in Chinese enuretic children. *Pediatr Nephrol*. 2005;20(2):163–169.

Farhat W, Bägli DJ, Capolicchio G, et al. The dysfunctional voiding scoring system: quantitative standardization of dysfunctional voiding symptoms in children. *J Urol*. 2000;164(3 Pt 2):1011–1015.

Fast AM, Nees SN, Van Batavia JP, et al. Outcomes of targeted treatment for vesicoureteral reflux in children with nonneurogenic lower urinary tract dysfunction. *J Urol*. 2013;190(3):1028–1032.

Fazeli MS, Lin Y, Nikoo N, et al. Biofeedback for nonneuropathic daytime voiding disorders in children: a systematic review and meta-analysis of randomized controlled trials. *J Urol*. 2015;193(1):274–279.

Feldman AS, Bauer SB. Diagnosis and management of dysfunctional voiding. *Curr Opin Pediatr*. 2006;18(2):139–147.

Fernandez-Ibieta M, Ayuso-Gonzalez L. Dysfunctional voiding in pediatrics: a review of pathophysiology and current treatment modalities. *Curr Pediatr Rev*. 2016;12(4):292–300.

Finney SM, Andersson KE, Gillespie JI, et al. Antimuscarinic drugs in detrusor overactivity and the overactive bladder syndrome: motor or sensory actions? *BJU Int*. 2006;98(3):503–507.

Forsythe WI, Redmond A. Enuresis and spontaneous cure rate: study of 1129 enuretics. *Arch Dis Child*. 1974;49(4):259–263.

Franco I. Overactive bladder in children. I. Pathophysiology. *J Urol*. 2007;178(3 Pt 1):769–774 [discussion 774].

Franco I. Functional bladder problems in children: pathophysiology, diagnosis, and treatment. *Pediatr Clin North Am*. 2012;59(4):783–817.

Franco I, Arlen AM, Collett-Gardere T, et al. Imipramine for refractory daytime incontinence in the pediatric population. *J Pediatr Urol*. 2018;14(1):58.e1–58.e5.

Franco I, Landau-Dyer L, Isom-Batz G, et al. The use of botulinum toxin A injection for the management of external sphincter dyssynergia in neurologically normal children. *J Urol*. 2007;178(4 Pt 2):1775–1779 [discussion 1779–1780].

Franco I, von Gontard A, De Gennaro M, et al. Evaluation and treatment of nonmonosymptomatic nocturnal enuresis: a standardization document from the International Children's Continence Society. *J Pediatr Urol*. 2013;9(2):234–243.

Freitag CM, Röhling D, Seifen S, et al. Neurophysiology of nocturnal enuresis: evoked potentials and prepulse inhibition of the startle reflex. *Dev Med Child Neurol*. 2006;48(4):278–284.

Friman PC, Warzak WJ. Nocturnal enuresis: a prevalent, persistent, yet curable parasomnia. *Pediatrician*. 1990;17(1):38–45.

Gaither TW, Cooper CS, Kornberg Z, et al. Risk factors for the development of bladder and bowel dysfunction. *Pediatrics*.

2018;141(1) [pii: e20172797].

Gamé X, Mouracade P, Chartier-Kastler E, et al. Botulinum toxin-A intradetrusor injections in children with neurogenic detrusor overactivity/neurogenic overactive bladder: a systematic literature review. *J Pediatr Urol*. 2009;5(3):156–164.

Gepertz S, Nevéus T. Imipramine for therapy resistant enuresis: a retrospective evaluation. *J Urol*. 2004;171(6 Pt 2):2607–2610 [discussion 2609–2610].

Glazener CM, Evans JH. Tricyclic and related drugs for nocturnal enuresis in children. *Cochrane Database Syst Rev*. 2000;(3) [CD002117].

Glazener CM, Evans JH. Simple behavioural and physical interventions for nocturnal enuresis in children. *Cochrane Database Syst Rev*. 2004;(2) [CD003637].

Glazener CM, Evans JH. Desmopressin for nocturnal enuresis in children. *Cochrane Database Syst Rev*. 2002;(3) [CD002112].

Glazener CM, Evans JH, Peto RE. Alarm interventions for nocturnal enuresis in children. *Cochrane Database Syst Rev*. 2005;(2) [CD002911].

Gleason JM, Daniels C, Williams K, et al. Single center experience with oxybutynin transdermal system (patch) for management of symptoms related to non-neuropathic overactive bladder in children: an attractive, well tolerated alternative form of administration. *J Pediatr Urol*. 2014;10(4):753–757.

Gumus B, Vurgun N, Lekili M, et al. Prevalence of nocturnal enuresis and accompanying factors in children aged 7-11 years in Turkey. *Acta Paediatr*. 1999;88(12):1369–1372.

Hägglöf B, Andrén O, Bergström E, et al. Self-esteem in children with nocturnal enuresis and urinary incontinence: improvement of self-esteem after treatment. *Eur Urol*.

1998;33(Suppl 3):16–19.

Hagstroem S, Mahler B, Madsen B, et al. Transcutaneous electrical nerve stimulation for refractory daytime urinary urge incontinence. *J Urol*. 2009;182(4 Suppl):2072–2078.

Hagstroem S, Rittig S, Kamperis K, et al. Timer watch assisted urotherapy in children: a randomized controlled trial. *J Urol*. 2010;184(4):1482–1488.

Hansen AF, Jørgensen TM. Alarm treatment: influence on functional bladder capacity. *Scand J Urol Nephrol Suppl*. 1997;183:59–60.

Heilenkötter K, Bachmann C, Janhsen E, et al. Prospective evaluation of inpatient and outpatient bladder training in children with functional urinary incontinence. *Urology*. 2006;67(1):176–180.

Hellström AL, Hanson E, Hansson S, et al. Micturition habits and incontinence in 7-year-old Swedish school entrants. *Eur J Pediatr*. 1990;149(6):434–437.

Hirasing RA, van Leerdam FJ, Bolk-Bennink LB, et al. Bedwetting and behavioural and/or emotional problems. *Acta Paediatr*. 1997;86(10):1131–1134.

Hoebeke P, Van Laecke E, Van Camp C, et al. One thousand video-urodynamic studies in children with non-neurogenic bladder sphincter dysfunction. *BJU Int*. 2001;87(6):575–580.

Hoebeke P, Van Laecke E, Everaert K, et al. Transcutaneous neuromodulation for the urge syndrome in children. *J Urol*. 2001;166(6):2416–2419.

Hoebeke P, Renson C, Petillon L, et al. Percutaneous electrical nerve stimulation in children with therapy resistant nonneuropathic bladder sphincter dysfunction: a pilot study. *J Urol*. 2002;168(6):2605–2607 [discussion 2607–2608].

Hoebeke P, De Caestecker K, Vande Walle J, et al. The effect of botulinum-A toxin in incontinent children with therapy resistant overactive detrusor. *J Urol*. 2006;176(1):328–330

[discussion 330–331].

Hoebeke P, Bower W, Combs A, et al. Diagnostic evaluation of children with daytime incontinence. *J Urol*. 2010;183(2):699–703.

Hoffmann A, Sampaio C, Nascimento AA, et al. Predictors of outcome in children and adolescents with overactive bladder treated with parasacral transcutaneous electrical nerve stimulation. *J Pediatr Urol*. 2018;14(1):54.e1–54.e6.

Huang T, Shu X, Huang YS, et al. Complementary and miscellaneous interventions for nocturnal enuresis in children. *Cochrane Database Syst Rev*. 2011;(12) [CD005230].

Humphreys MR, Vandersteen DR, Slezak JM, et al. Preliminary results of sacral neuromodulation in 23 children. *J Urol*. 2006;176(5):2227–2231.

Hunsballe JM, Hansen TK, Rittig S, et al. The efficacy of DDAVP is related to the circadian rhythm of urine output in patients with persisting nocturnal enuresis. *Clin Endocrinol (Oxf)*. 1998;49(6):793–801.

Iscan A, Ozkul Y, Unal D, et al. Abnormalities in event-related potential and brainstem auditory evoked response in children with nocturnal enuresis. *Brain Dev*. 2002;24(7):681–687.

Jalkut MW, Lerman SE, Churchill BM. Enuresis. *Pediatr Clin North Am*. 2001;48(6):1461–1488.

Järvelin MR. Developmental history and neurological findings in enuretic children. *Dev Med Child Neurol*. 1989;31(6):728–736.

Järvelin MR, Vikeväinen-Tervonen L, Moilanen I, et al. Enuresis in seven-year-old children. *Acta Paediatr Scand*. 1988;77(1):148–153.

Jiang R, Kelly MS, Routh JC. Assessment of pediatric bowel and bladder dysfunction: a critical appraisal of the literature. *J Pediatr Urol*. 2018;14(6):494–501.

Joinson C, Heron J, von Gontard A, et al. Psychological problems in children with daytime wetting. *Pediatrics*. 2006;118(5):1985–1993.

Kajiwara M, Inoue K, Kato M, et al. Nocturnal enuresis and overactive bladder in children: an epidemiological study. *Int J Urol*. 2006;13(1):36–41.

Kajiwara M, Inoue K, Usui A, et al. The micturition habits and prevalence of daytime urinary incontinence in Japanese primary school children. *J Urol*. 2004;171(1):403–407.

Kawauchi A, Tanaka Y, Naito Y, et al. Bladder capacity at the time of enuresis. *Urology*. 2003;61(5):1016–1018.

Kawauchi A, Watanabe H, Miyoshi K. Early morning urine osmolality in nonenuretic and enuretic children. *Pediatr Nephrol*. 1996;10(6):696–698.

Kibar Y, Ors O, Demir E, et al. Results of biofeedback treatment on reflux resolution rates in children with dysfunctional voiding and vesicoureteral reflux. *Urology*. 2007;70(3):563–566 [discussion 566–567].

Klackenberg G. Nocturnal enuresis in a longitudinal perspective: a primary problem of maturity and/or a secondary environmental reaction? *Acta Paediatr Scand*. 1981;70(4):453–457.

Klijn AJ, Asselman M, Vijverberg MA, et al. The diameter of the rectum on ultrasonography as a diagnostic tool for constipation in children with dysfunctional voiding. *J Urol*. 2004;172(5 Pt 1):1986–1988.

Klijn AJ, Uiterwaal CS, Vijverberg MA, et al. Home uroflowmetry biofeedback in behavioural training for dysfunctional voiding in school-age children: a randomized control trial. *J Urol*. 2006;175(6):2263–2268 [discussion 2268].

Koff SA, Lapides J, Piazza D. Association of urinary tract infection and reflux with uninhibited bladder contraction and voluntary sphincteric obstruction. *J Urol*. 1979;122(3):373–376.

Koff SA, Wagner TT, Jayanthi VR. The relationship among dysfunctional elimination syndromes, primary vesicoureteral reflux and urinary tract infections in children. *J Urol*. 1998;160(3 Pt 2):1019–1022.

Kovacevic L, Wolfe-Christensen C, Rizwan A, et al. Children with nocturnal enuresis and attention deficit hyperactivity disorder: a separate entity? *J Pediatr Urol*. 2018;14(1):47.e1–47.e6.

Koyama Y, Imada N, Kayama Y, et al. How does the distention of urinary bladder cause arousal? *Psychiatry Clin Neurosci*. 1998;52(2):142–145.

Kramer SA, Rathbun SR, Elkins D, et al. Double-blind placebo controlled study of alpha-adrenergic receptor antagonists (doxazosin) for treatment of voiding dysfunction in the pediatric population. *J Urol*. 2005;173(6):2121–2124 [discussion 2124].

Lapides J, Diokono AC. Persistence of the infant bladder as a cause for urinary infection in girls. *J Urol*. 1970;103(2):243–248.

Lapides J, Diokono AC, Silber SJ, et al. Clean, intermittent self-catheterization in the treatment of urinary tract disease. *J Urol*. 1972;107(3):458–461.

Leebeek-Groenewegen A, Blom J, Sukhai R, et al. Efficacy of desmopressin combined with alarm therapy for monosymptomatic nocturnal enuresis. *J Urol*. 2001;166(6):2456–2458.

Lettgen B, von Gontard A, Olbing H, et al. Urge incontinence and voiding postponement in children: somatic and psychosocial factors. *Acta Paediatr*. 2002;91(9):978–984 [discussion 895–896].

Liberati J. Biofeedback therapy in pediatric urology. *Urol Nurs*.

2005;25(3):206–210 [quiz 211].

Light L. Children with enuresis: most cases of primary nocturnal enuresis are caused by isolated developmental immaturity. *BMJ*. 1998;316(7133):777–778.

Liu X, Sun Z, Uchiyama M, et al. Attaining nocturnal urinary control, nocturnal enuresis and behavioral problems in Chinese children aged 6 through 16 years. *J Am Acad Child Adolesc Psychiatry*. 2000;39(12):1557–1564.

Loening-Baucke V. Urinary incontinence and urinary tract infection and their resolution with treatment of chronic constipation of childhood. *Pediatrics*. 1997;100(2 Pt 1):228–232.

Loening-Baucke V. Functional fecal retention with encopresis in childhood. *J Pediatr Gastroenterol Nutr*. 2004;38(1):79–84.

Longstaffe S, Moffatt MEK, Whalen JC. Behavioral and self-concept changes after six months of enuresis treatment: a randomized, controlled trial. *Pediatrics*. 2000;105(4 Pt 2):935–940.

Lordêlo P, Teles A, Veiga ML, et al. Transcutaneous electrical nerve stimulation in children with overactive bladder: a randomized clinical trial. *J Urol*. 2010;184(2):683–689.

Lovering JS, Tallett SE, McKendry JB. Oxybutynin efficacy in the treatment of primary enuresis. *Pediatrics*. 1988;82(1):104–106.

Lucanto C, Bauer SB, Hyman PE. Function of hollow viscera in children with constipation and voiding difficulties. *Dig Dis Sci*. 2000;45(7):1274–1280.

Maizels M, King LR, Firlit CF. Urodynamic biofeedback: a new approach to treat vesical sphincter dyssynergia. *J Urol*. 1979;122(2):205–209.

Malm-Buatsi E, Nepple KG, Boyt MA, et al. Efficacy of transcutaneous electrical nerve stimulation in children with overactive bladder refractory to pharmacotherapy. *Urology*.

2007;70(5):980–983.

Marciano RC, Cardoso MGF, Vasconcelos MA, et al. Behavioral disorders and impairment of quality of life in children and adolescents with lower urinary tract dysfunction. *J Pediatr Urol*. 2018;14(6):568.e1–568.e7.

Maria G, Cadeddu F, Brisinda D, et al. Management of bladder, prostatic, and pelvic floor disorders with botulinum neurotoxin. *Curr Med Chem*. 2005;12(3):247–265.

Martins G, Minuk J, Varghese A, et al. Non-biological determinants of paediatric bladder bowel dysfunction: a pilot study. *J Pediatr Urol*. 2016;12(2):109.e1–109.e6.

McGee SM, Routh JC, Granberg CF, et al. Sacral neuromodulation in children with dysfunctional elimination syndrome: description of incisionless first stage and second stage without fluoroscopy. *Urology*. 2009;73(3):641–644 [discussion 644].

McKenna PH, Herndon CD, Connery S, et al. Pelvic floor muscle retraining for pediatric voiding dysfunction using interactive computer games. *J Urol*. 1999;162(3 Pt 2):1056–1062 [discussion 1062–1063].

Mikkelsen EJ, Rapoport JL, Nee L, et al. Childhood enuresis. I. Sleep patterns and psychopathology. *Arch Gen Psychiatry*. 1980;37(10):1139–1144.

Mokhless I, Gaafar S, Fouda K, et al. Botulinum A toxin urethral sphincter injection in children with nonneurogenic neurogenic bladder. *J Urol*. 2006;176(4 Pt 2):1767–1770 [discussion 1770].

Montaldo P, Tafuro L, Rea M, et al. Desmopressin and oxybutynin in monosymptomatic nocturnal enuresis: a randomized, double-blind, placebo-controlled trial and an assessment of predictive factors. *BJU Int*. 2012;110(8 Pt B):E381–E386.

Nelson JD, Cooper CS, Boyt MA, et al. Improved uroflow parameters and post-void residual following biofeedback therapy in pediatric patients with dysfunctional voiding does not correspond to outcome. *J Urol*. 2004;172(4 Pt 2):1653–1656.

Nevéus T. Oxybutynin, desmopressin and enuresis. *J Urol*. 2001;166(6):2459–2462.

Nevéus T, Eggert P, Evans J, et al. Evaluation of and treatment for monosymptomatic enuresis: a standardization document from the International Children's Continence Society. *J Urol*. 2010;183(2):441–447.

Nevéus T, Hetta J, Cnattingius S, et al. Depth of sleep and sleep habits among enuretic and incontinent children. *Acta Paediatr*. 1999;88(7):748–752.

Nevéus T, Stenberg A, Läckgren G, et al. Sleep of children with enuresis: a polysomnographic study. *Pediatrics*. 1999;103(6 Pt 1):1193–1197.

Nevéus T, von Gontard A, Hoebeke P, et al. The standardization of terminology of lower urinary tract function in children and adolescents: report from the Standardisation Committee of the International Children's Continence Society. *J Urol*. 2006;176(1):314–324.

Nijman RJ. Role of antimuscarinics in the treatment of nonneurogenic daytime urinary incontinence in children. *Urology*. 2004;63(3 Suppl 1):45–50.

Noordhoff TC, 't Hoen LA, van den Hoek J, et al. Urotherapy in children with dysfunctional voiding and the responsiveness of two condition-specific questionnaires. *Neurourol Urodyn*. 2018;37(4):1494–1500.

Nørgaard JP, Hansen JH, Nielsen JB, et al. Nocturnal studies in enuretics: a polygraphic study of sleep-EEG and bladder activity. *Scand J Urol Nephrol Suppl*. 1989;125:73–78.

Nørgaard JP, Hansen JH, Wildschiøtz G, et al. Sleep cystometries in children with nocturnal enuresis. *J Urol*.

1989;141(5):1156–1159.

Oliver JL, Campigotto MJ, Coplen DE, et al. Psychosocial comorbidities and obesity are associated with lower urinary tract symptoms in children with voiding dysfunction. *J Urol*. 2013;190(4 Suppl):1511–1515.

Ollendick TH, King NJ, Frary RB. Fears in children and adolescents: reliability and generalizability across gender, age and nationality. *Behav Res Ther*. 1989;27(1):19–26.

O'Regan S, Yazbeck S, Schick E. Constipation, bladder instability, urinary tract infection syndrome. *Clin Nephrol*. 1985;23(3):152–154.

Palmer LS, Franco I, Rotario P, et al. Biofeedback therapy expedites the resolution of reflux in older children. *J Urol*. 2002;168(4 Pt 2):1699–1702 [discussion 1702–1703].

Pascali MP, Mosiello G, Boldrini R, et al. Effects of botulinum toxin type a in the bladder wall of children with neurogenic bladder dysfunction: a comparison of histological features before and after injections. *J Urol*. 2011;185(6 Suppl):2552–2557.

Peng CC, Yang SS, Austin PF, et al. Systematic review and meta-analysis of alarm versus desmopressin therapy for pediatric monosymptomatic enuresis. *Sci Rep*. 2018;8(1):16755.

Pennesi M, Pitter M, Bordugo A, et al. Behavioral therapy for primary nocturnal enuresis. *J Urol*. 2004;171(1):408–410.

Persson-Jünemann C, Seemann O, Köhrmann KU, et al. Comparison of urodynamic findings and response to oxybutynin in nocturnal enuresis. *Eur Urol*. 1993;24(1):92–96.

Peters CA, Skoog SJ, Arant BS Jr, et al. Summary of the AUA Guideline on Management of Primary Vesicoureteral Reflux in Children. *J Urol*. 2010;184(3):1134–1144.

Petronijevic V, Lazovic M, Vlajkovic M, et al. Botulinum toxin type A in combination with standard urotherapy for children with dysfunctional voiding. *J Urol*. 2007;178(6):2599–2602 [discussion 2602–2603].

Pohl HG, Bauer SB, Borer JG, et al. The outcome of voiding dysfunction managed with clean intermittent catheterization in neurologically and anatomically normal children. *BJU Int*. 2002;89(9):923–927.

Quintiliano F, Veiga ML, Moraes M, et al. Transcutaneous parasacral electrical stimulation vs oxybutynin for the treatment of overactive bladder in children: a randomized clinical trial. *J Urol*. 2015;193(5 Suppl):1749–1753.

Radojicic ZI, Perovic SV, Milic NM. Is it reasonable to treat refractory voiding dysfunction in children with botulinum-A toxin? *J Urol*. 2006;176(1):332–336 [discussion 336].

Raes AM, Dehoorne JL, Hoebeke P, et al. Abnormal circadian rhythm of diuresis or nocturnal polyuria in a subgroup of children with enuresis and hypercalciuria is related to increased sodium retention during daytime. *J Urol*. 2006;176(3):1147–1151.

Rasmussen PV, Kirk J, Borup K, et al. Enuresis nocturna can be provoked in normal healthy children by increasing the nocturnal urine output. *Scand J Urol Nephrol*. 1996;30(1):57–61.

Riccabona M, Koen M, Schindler M, et al. Botulinum-A toxin injection into the detrusor: a safe alternative in the treatment of children with myelomeningocele with detrusor hyperreflexia. *J Urol*. 2004;171(2 Pt 1):845–848 [discussion 848].

Richardson I, Palmer LS. Successful treatment for giggle incontinence with biofeedback. *J Urol*. 2009;182(4 Suppl):2062–2066.

Rittig S, Kamperis K, Siggard C, et al. Age-related nocturnal urine volume and maximum voided volume in healthy children: reappraisal of International Children's Continence Society definitions. *J Urol*. 2010;183(4):1561–1567.

Rittig S, Matthiesen TB, Hunsballe JM, et al. Age-related changes in the circadian control of urine output. *Scand J Urol Nephrol Suppl*. 1995;173:71–74 [discussion 74–75].

Ritvo ER, Ornitz EM, Gottlieb F, et al. Arousal and nonarousal enuretic events. *Am J Psychiatry*. 1969;126(1):77–84.

Robson WL. Diurnal enuresis. *Pediatr Rev*. 1997;18(12):407–412 [quiz 412].

Robson WL. Enuresis. *Adv Pediatr*. 2001;48:409–438.

Robson WL. Clinical practice: evaluation and management of enuresis. *N Engl J Med*. 2009;360(14):1429–1436.

Robson WL, Leung AK, Nørgaard JP. The comparative safety of oral versus intranasal desmopressin for the treatment of children with nocturnal enuresis. *J Urol*. 2007;178(1):24–30.

Robson WL, Leung AK, Van Howe R. Primary and secondary nocturnal enuresis: similarities in presentation. *Pediatrics*. 2005;115:956–959.

Roth TJ, Vandersteen DR, Hollatz P, et al. Sacral neuromodulation for the dysfunctional elimination syndrome: a single center experience with 20 children. *J Urol*. 2008;180(1):306–311.

Rushton HG, Belman AB, Zaontz MR, et al. The influence of small functional bladder capacity and other predictors on the response to desmopressin in the management of monosymptomatic nocturnal enuresis. *J Urol*. 1996;156(2 Pt 2):651–655.

Schaumburg HL, Kapilin U, Blåsvaer C, et al. Hereditary phenotypes in nocturnal enuresis. *BJU Int*. 2008;102(7):816–821.

Schmitt BD. Nocturnal enuresis. *Pediatr Rev*. 1997;18(6):183–190 [quiz 91].

Shaikh N, Hoberman A, Keren R, et al. Recurrent urinary tract infections in children with bladder and bowel dysfunction. *Pediatrics*. 2016;137(1); 10.1542/peds.2015-2982.

Sher PK, Reinberg Y. Successful treatment of giggle incontinence with methylphenidate. *J Urol*. 1996;156(2 Pt 2):656–658.

Shreeram S, He JP, Kalaydjian A, et al. Prevalence of enuresis and its association with attention-deficit/hyperactivity disorder among U.S. children: results from a nationally representative study. *J Am Acad Child Adolesc Psychiatry*. 2009;48(1):35–48.

Sommer BR, O'Hara R, Askari N, et al. The effect of oxybutynin treatment on cognition in children with diurnal incontinence. *J Urol*. 2005;173(6):2125–2127.

Song P, Huang C, Wang Y, et al. Comparison of desmopressin, alarm, desmopressin plus alarm, and desmopressin plus anticholinergic agents in the management of paediatric monosymptomatic nocturnal enuresis: a network meta-analysis. *BJU Int*. 2019;123(3):388–400.

Starfield B. Functional bladder capacity in enuretic and nonenuretic children. *J Pediatr*. 1967;70(5):777–781.

Steffens J, Metzer M, Isenberg E, et al. Vasopressin deficiency in primary nocturnal enuresis: results of a controlled prospective study. *Eur Urol*. 1993;24(3):366–370.

Steinhardt GF, Naseer S, Cruz OA. Botulinum toxin: novel treatment for dramatic urethral dilatation associated with dysfunctional voiding. *J Urol*. 1997;158(1):190–191.

Stephany HA, Juliano TM, Clayton DB, et al. Prospective evaluation of sacral nerve modulation in children with validated questionnaires. *J Urol*. 2013;190(4 Suppl):1516–1522.

Su MS, Li AM, So HK, et al. Nocturnal enuresis in children: prevalence, correlates, and relationship with obstructive sleep apnea. *J Pediatr*. 2011;159(2) [238.e1–242.e1].

Sukhai RN, Mol J, Harris AS. Combined therapy of enuresis alarm and desmopressin in the treatment of nocturnal enuresis. *Eur J Pediatr*. 1989;148(5):465–467.

Sureshkumar P, Jones M, Cumming R, et al. A population based study of 2,856 school-age children with urinary incontinence. *J Urol*. 2009;181(2):808–815.

Swanson JR, Jones GR, Krasselt W, et al. Death of two subjects due to imipramine and desipramine metabolite accumulation during chronic therapy: a review of the literature and possible mechanisms. *J Forensic Sci*. 1997;42(2):335–339.

't Hoen LA, van den Hoek J, Wolffenbutte KP, et al. Breaking the vicious circle: onabotulinum toxin A in children with therapy-refractory dysfunctional voiding. *J Pediatr Urol*. 2015;11(3):119.e1–119.e6.

Tanagho EA. Neuromodulation in the management of voiding dysfunction in children. *J Urol*. 1992;148(2 Pt 2):655–667.

Taylor PD, Turner RK. A clinical trial of continuous, intermittent and overlearning “bell and pad” treatments for nocturnal enuresis. *Behav Res Ther*. 1975;13(4):281–293.

Tekgül S, Riedmiller H, Hoebeke P, et al. EAU guidelines on vesicoureteral reflux in children. *Eur Urol*. 2012;62(3):534–542.

Thibodeau BA, Metcalfe P, Koop P, et al. Urinary incontinence and quality of life in children. *J Pediatr Urol*. 2013;9(1):78–83.

Thom M, Campigotto M, Vemulakonda V, et al. Management of lower urinary tract dysfunction: a stepwise approach. *J Pediatr Urol*. 2012;8(1):20–24.

Tremback-Ball A, Gherghel E, Hegge A, et al. The effectiveness of biofeedback therapy in managing Bladder Bowel Dysfunction in children: a systematic review. *J Pediatr Rehabil Med*. 2018;11(3):161–173.

Troup CW, Hodgson NB. Nocturnal functional bladder capacity in enuretic children. *Wis Med J*. 1971;70(7):171–173.

Tugtepe H, Thomas DT, Ergun R, et al. Comparison of biofeedback therapy in children with treatment-refractory dysfunctional voiding and overactive bladder. *Urology*. 2015;85(4):900–904.

Tuncel A, Mavituna I, Nalcacioglu V, et al. Long-term follow-up of enuretic alarm treatment in enuresis nocturna. *Scand J Urol Nephrol*. 2008;42(5):449–454.

van Balken MR, Vergunst H, Bemelmans BL, et al. The use of electrical devices for the treatment of bladder dysfunction: a review of methods. *J Urol*. 2004;172(3):846–851.

Van Batavia JP, Ahn JJ, Fast AM, et al. Prevalence of urinary tract infection and vesicoureteral reflux in children with lower urinary tract dysfunction. *J Urol*. 2013;190(4 Suppl):1495–1499.

Van Batavia JP, Combs AJ, Fast AM, et al. Overactive bladder (OAB): a symptom in search of a disease—its relationship to specific lower urinary tract symptoms and conditions. *J Pediatr Urol*. 2017;13(3):277.e1–277.e4.

Van Batavia JP, Combs AJ, Horowitz M, et al. Primary bladder neck dysfunction in children and adolescents III: results of long-term alpha-blocker therapy. *J Urol*. 2010;183(2):724–730.

Van Batavia JP, Combs AJ, Hyun G, et al. Simplifying the diagnosis of 4 common voiding conditions using uroflow/electromyography, electromyography lag time and voiding history. *J Urol*. 2011;186(Suppl 4):1721–1726.

van den Heijkant M, Bogaert G. Lower urinary tract terminology in daytime lower urinary tract symptoms in children: a view of the pediatric urologist. *Eur Urol Focus*. 2017;3(2–3):189–197.

Van Gool JD, Hjälmåas K, Tamminen-Möbius T, et al. Historical clues to the complex of dysfunctional voiding, urinary tract infection and vesicoureteral reflux. *J Urol*. 1992;148(5 Pt 2):1699–1702.

van Londen A, van Londen-Barentsen MW, van Son MJ, et al. Arousal training for children suffering from nocturnal enuresis: a 2½ year follow-up. *Behav Res Ther*. 1993;31(6):613–615.

Vande Walle J, Vande Walle C, Van Sintjan P, et al. Nocturnal polyuria is related to 24-hour diuresis and osmotic excretion in an enuresis population referred to a tertiary center. *J Urol*. 2007;178(6):2630–2634.

Vanderbrink BA, Gitlin J, Toro S, et al. Effect of tamsulosin on systemic blood pressure and nonneurogenic dysfunctional voiding in children. *J Urol*. 2009;181(2):817–822.

Vaz GT, Vasconcelos MM, Oliveira EA, et al. Prevalence of lower urinary tract symptoms in school-age children. *Pediatr Nephrol*. 2012;27(4):597–603.

Veenboer PW, Huisman J, Chrzan RJ, et al. Behavioral effects of long-term antimuscarinic use in patients with spinal dysraphism: a case control study. *J Urol*. 2013;190(6):2228–2232.

Veiga ML, Queiroz AP, Carvalho MC, et al. Parasacral transcutaneous electrical stimulation for overactive bladder in children: an assessment per session. *J Pediatr Urol*. 2016;12(5):293.e1–293.e5.

von Gontard A, Nevéus T. *Management of disorders of bladder and bowel control in childhood*. MacKeith Press: London; 2006:xi [355].

von Gontard A, Equit M. Comorbidity of ADHD and incontinence in children. *Eur Child Adolesc Psychiatry*. 2015;24(2):127–140.

von Gontard A, Eiberg H, Hollman E, et al. Molecular genetics of nocturnal enuresis: clinical and genetic heterogeneity. *Acta Paediatr*. 1998;87(5):571–578.

von Gontard A, Lettgen B, Olbing H, et al. Behavioural problems in children with urge incontinence and voiding postponement: a comparison of a paediatric and child psychiatric sample. *BJU Int*. 1998;81(Suppl 3):100–106.

von Gontard A, Mauer-Mucke K, Plück J, et al. Clinical behavioral problems in day and night-wetting children. *Pediatr Nephrol*. 1999;13(8):662–667.

von Gontard A, Heron J, Joinson C. Family history of nocturnal enuresis and urinary incontinence: results from a large epidemiological study. *J Urol*. 2011;185(6):2303–2306.

Vricella GJ, Campigotto M, Coplen DE, et al. Long-term efficacy and durability of botulinum-A toxin for refractory dysfunctional voiding in children. *J Urol*. 2014;191(5 Suppl):1586–1591.

Watanabe H, Azuma Y. A proposal for a classification system of enuresis based on overnight simultaneous monitoring of electroencephalography and cystometry. *Sleep*. 1989;12(3):257–264.

Wiener JS, Scales MT, Hampton J, et al. Long-term efficacy of simple behavioral therapy for daytime wetting in children. *J Urol*. 2000;164(3 Pt 1):786–790.

Wille S. Comparison of desmopressin and enuresis alarm for nocturnal enuresis. *Arch Dis Child*. 1986;61(1):30–33.

Wille S. Nocturnal enuresis: sleep disturbance and behavioural patterns. *Acta Paediatr*. 1994;83(7):772–774.

Willemsen J, Nijman RJ. Vesicoureteral reflux and videourodynamic studies: results of a prospective study. *Urology*. 2000;55(6):939–943.

Wolfe-Christensen C, Kovacevic LG, Mirkovic J, et al. Lower health related quality of life and psychosocial difficulties in children with monosymptomatic nocturnal enuresis: is snoring a marker of severity? *J Urol*. 2013;190(4 Suppl):1501–1504.

Wolfish NM, Pivik RT, Busby KA. Elevated sleep arousal thresholds in enuretic boys: clinical implications. *Acta Paediatr*. 1997;86(4):381–384.

World Health Organization. *Multiaxial classification of child and adolescent psychiatric disorders: the ICD-10 classification of mental and behavioral disorders in children and adolescents*. Cambridge University Press: New York; 2008:viii [302].

Yamanishi T, Yasuda K, Murayama N, et al. Biofeedback training for detrusor overactivity in children. *J Urol*. 2000;164(5):1686–1690.

Yang S, Chua ME, Bauer S, et al. Diagnosis and management of bladder bowel dysfunction in children with urinary tract infections: a position statement from the International Children's Continence Society. *Pediatr Nephrol*. 2018;33(12):2207–2219.

Yeung CK, Godley ML, Dhillon HK, et al. Urodynamic patterns in infants with normal lower urinary tracts or primary vesico-ureteral reflux. *Br J Urol*. 1998;81(3):461–467.

Yeung CK, Chiu HN, Sit FK. Bladder dysfunction in children with refractory nocturnal monosymptomatic primary nocturnal enuresis. *J Urol*. 1999;162(3 Pt 2):1049–1054 [discussion 1054–1055].

Yeung CK, Sihoe JD, Sit FK, et al. Urodynamic findings in adults with primary nocturnal enuresis. *J Urol*. 2004;171(6 Pt 2):2595–2598.

Yeung CK, Sit FK, To LK, et al. Reduction in nocturnal functional bladder capacity is a common factor in the pathogenesis of refractory nocturnal enuresis. *BJU Int*. 2002;90(3):302–307.

Youdim K, Kogan BA. Preliminary study of the safety and efficacy of extended-release oxybutynin in children. *Urology*. 2002;59(3):428–432.

36

Management of Defecation Disorders

Martin A. Koyle MD, FAAP, FACS, FRCSC, FRCS (Eng), Armando J. Lorenzo MD, MSc, FRCSC, FAAP, FACS

At first glance, a bowel management chapter may appear out of place in a urology textbook. However, clinical experience has called attention to a deep interrelation between urinary and bowel function. The past decade has witnessed a greater understanding of the pelvic floor working as a functional unit that blends artificial barriers sets by specialty training. The lower gastrointestinal and genitourinary tract share embryologic origin, anatomic location, innervation (motor and sensory), volitional control with normal development, and sphincteric mechanisms. On clinical grounds this is evidenced during careful history and exam, with frequent dual dysfunction in neurologic conditions (neuropathic bladder and bowel in disease processes of the lower spinal cord), bladder capacity compromise resulting from a distended rectum (Fig. 36.1), and dysfunctional elimination rarely affecting only one system (instead often seeing concurrent urinary and bowel symptomatology in affected children). Thus understanding of urinary tract dysfunction is incomplete without considering and addressing all aspects of elimination, including defecation.

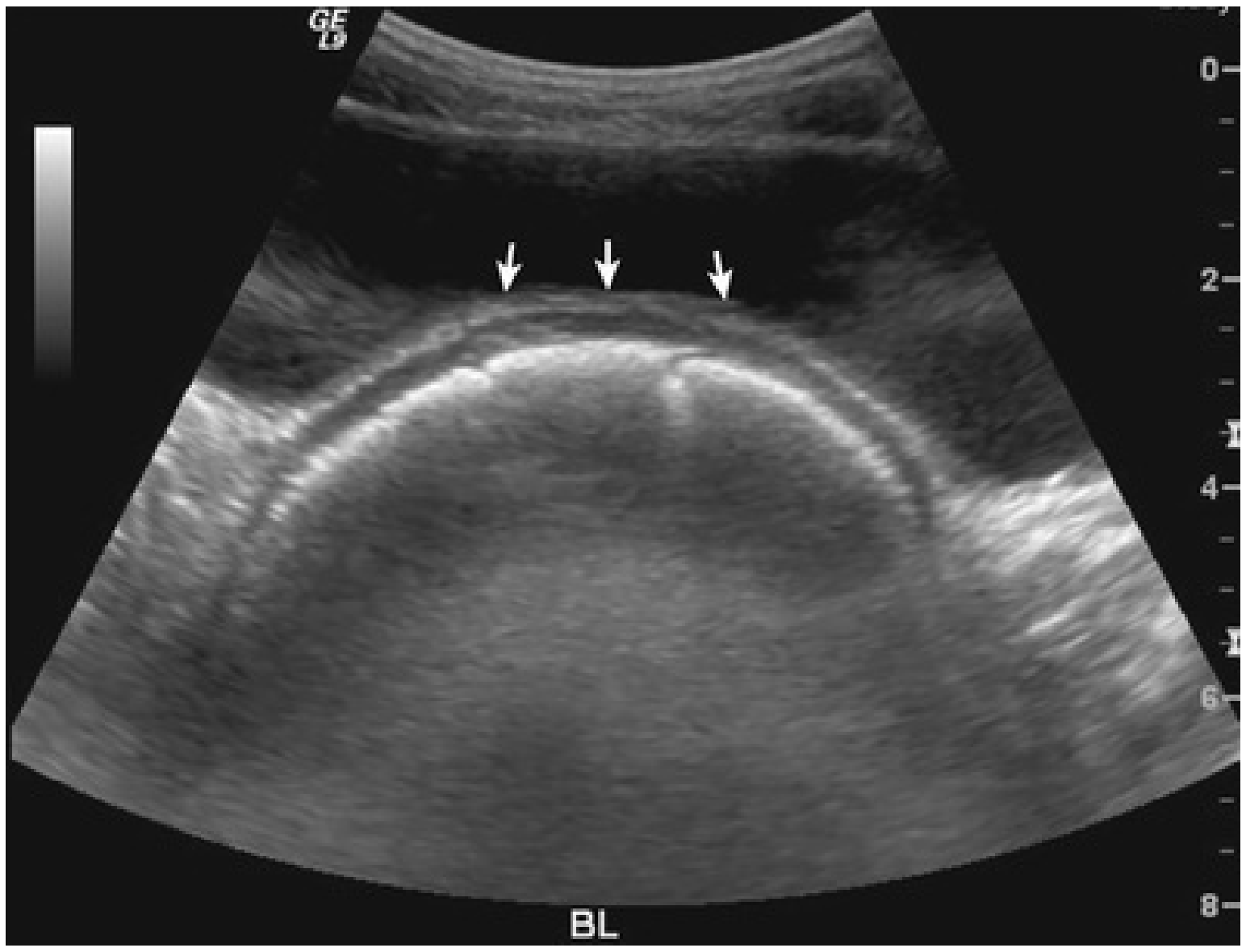

FIG. 36.1 Pelvic ultrasound demonstrates anterior displacement of the bladder wall with decrease in functional bladder capacity resulting from a large amount of fecal material in the rectum *(arrows).*

Anomalies of the bowel and urinary tract frequently coexist, whether functional, anatomic, and/or neuropathic. Constipation and rectal distention may adversely affect bladder function (Burgers et al., 2010), leading to low functional bladder capacity, incontinence, predisposition to urinary tract infections, and triggering or exacerbating vesicoureteral reflux (eFig. 36.2; Loening-Baucke, 1997; Yazbeck et al., 1987). In addition, constipation is a common side effect of medications employed to deal with lower urinary tract symptoms (anticholinergics). Because of this common association, pediatric urologists have become comfortable with assessing and managing bowel problems in the everyday care of children and adolescents with genitourinary complaints. Contemporary management of children with dysfunctional elimination calls for routine simultaneous assessment of the gastrointestinal and genitourinary tracts. Good understanding of medical and surgical options is also warranted because it is often the urologist who is in a position to manage urinary and fecal problems synchronously (Burgers et al., 2013).

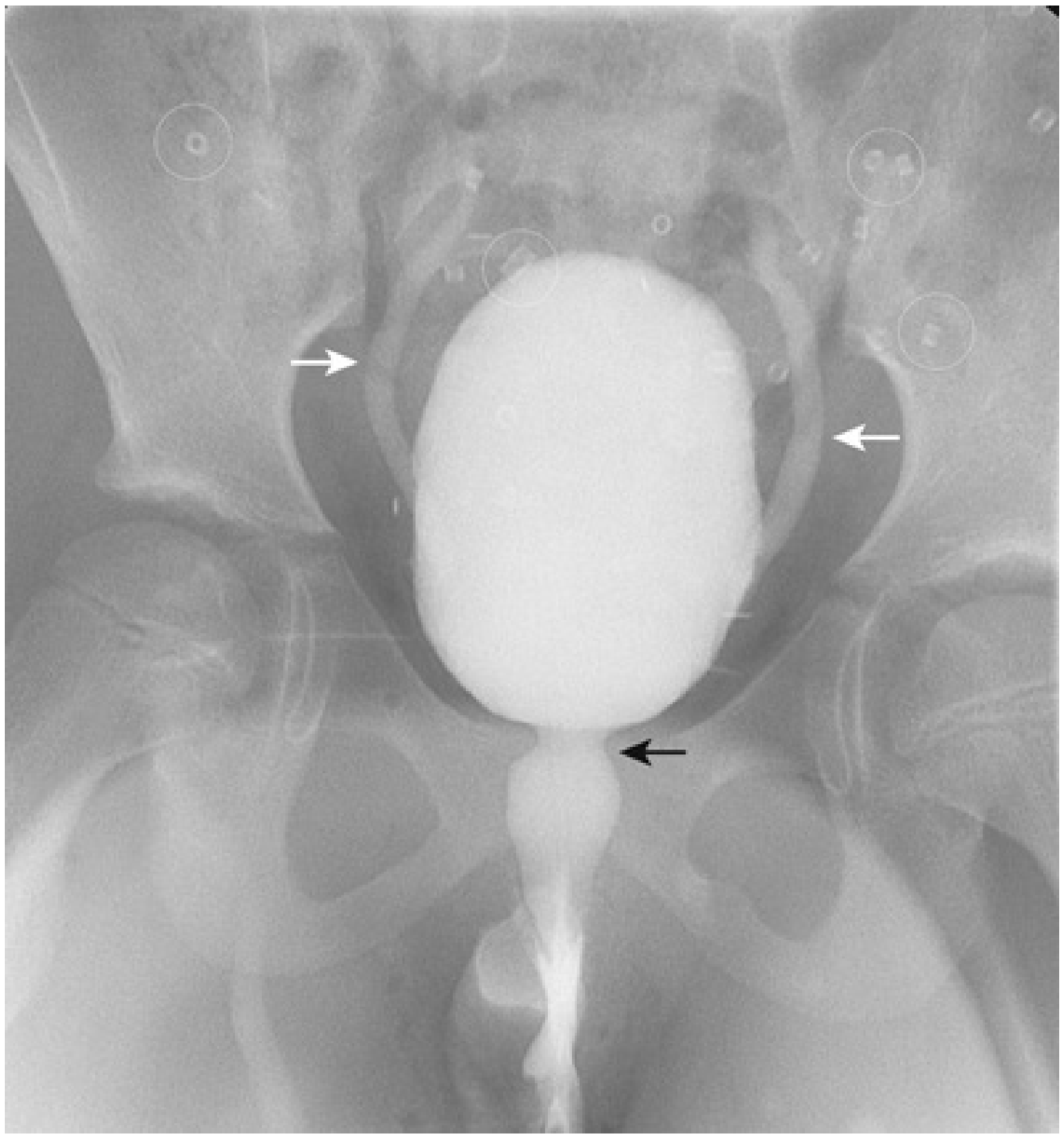

EFIG. 36.2 Voiding cystourethrogram in a patient with dysfunctional elimination and recurrent episode of pyelonephritis. Note the presence of bilateral vesicoureteral reflux *(white arrows)* and “spinning top” deformity of the bladder neck during voiding *(black arrow).* Patient previously underwent a motility study because of persistent constipation despite stool softeners (note encircled radio-opaque markers).

Key Points

- The bladder is not an isolated organ. On the contrary, it works in a close functional and anatomic relationship with surrounding structures, including the lower gastrointestinal tract.
- Constipation is common yet hard to ascertain just by asking children or parents.
- Neurologic problems can affect urinary and bowel systems, as seen in patients with neuropathic bladder dysfunction.
- Medications commonly employed for bladder management (most notably, anticholinergics) have an adverse impact on bowel function.

- Pediatric urologists are in a privileged position to effectively address bowel function and positively affect the child's well-being and quality of life.

Epidemiology and Classification of Disorders of Defecation

Defecation disorders are common throughout life, including childhood. **In children, these are most often manifested as infrequent bowel movements without a specific underlying organic cause, thus labeled as "functional" constipation.** Reported prevalence in the pediatric population ranges between 0.7% and 29.6%, with no significant difference in rates for boys and girls (van den Berg et al., 2006). It is a frequent reason for evaluation by family medicine health care providers, pediatricians, pediatric gastroenterologists, pediatric surgeons, and, because of associated lower urinary tract symptoms, pediatric urologists. Common presenting symptomatology includes infrequent defecation, abdominal bloating or distention, painful bowel movements, abdominal pain, and fecal incontinence (Nurko and Scott, 2011). Although there are multiple potential causes (Table 36.1), most children have a negative assessment for associated conditions. Functional constipation is, in essence, a diagnosis of exclusion, defined as a defecation disorder not associated with congenital or acquired abnormalities or specific medications. Nevertheless, concerns over an organic cause often trigger an overtly extensive, occasionally invasive, and expensive workup.

TABLE 36.1

Differential Diagnosis of Chronic Constipation

Idiopathic or functional
Behavioral: Dysfunctional elimination due to defecation avoidance, intellectual disability, psychological problems, adverse life event
Poor dietary habits: Low fluid and fiber intake
Structural defects: Anorectal malformation, anal stenosis, Hirschsprung disease, extrinsic compression by pelvic mass, deficient abdominal musculature (most notably, prune-belly syndrome)
Neurologic disorders: Isolated to spinal cord (myelomeningocele, tethered cord, trauma, transverse myelitis, postsurgical, tumors), cerebral palsy, muscular dystrophy, neurodegenerative disorders

Endocrine disorders associated with chronic dehydration (such as diabetes insipidus) and electrolyte disorders (most notably hypercalcemia and hypokalemia), hypothyroidism, hypervitaminosis D

Cystic fibrosis

Celiac disease

Connective tissue disorders (such as Ehlers-Danlos syndrome)

Food intolerance (cow's milk) and other food allergies

Medications: Anticholinergics, opioid analgesics, anticonvulsants, antidepressants and antipsychotics, iron and calcium supplements, antispasmodics, diuretics

Other bowel motility disorders: Colonic dysmotility, chronic pseudo-obstruction

Of all the functional gastrointestinal disorders of childhood (e.g., irritable bowel syndrome, functional bloating, functional constipation, and functional diarrhea [Longstreth et al., 2006]), constipation is the one most frequently encountered by pediatric urologists. It demands expertise in management along with ruling out other pathologies that require specialized assessment and treatment. Thus pediatric health care providers in modern specialized centers should be comfortable with addressing constipation.

Normal Versus Abnormal Bowel Function

The definition of normal bowel function has to be framed within the context of age, developmental issues, and cultural expectations. Although seemingly simple, normal bowel function is often difficult to define and ascertain. Despite expected variation in toilet-training age, children are expected to begin experimentation at age 2 and completely gain control of the defecation process by age 3 (Wald et al., 2009). Past this age, bowel movement normal frequency varies from three stools per week to three stools per day. The majority of children 5 to 8 years of age have a bowel movement daily or every other day, without straining or withholding (Fontana et al., 1989; Wald et al., 2009). Unfortunately, children with irregular, incomplete, and/or infrequent defecation may not report symptoms, and parents are often surprisingly unaware of their child's bowel routine. To aid with assessment, the presence of constipation should be ascertained with standardized diagnostic tools, such as the Rome IV criteria (Table 36.2; Hyman et al., 2006; Rasquin et al., 2006; Zeevenhooven et al., 2017). These criteria take into account three important considerations:

absence of an organic underlying cause, developmental stage (toilet trained vs. not toilet trained), and duration of symptoms.

TABLE 36.2

Rome IV Diagnostic Criteria for Functional Constipation

Must include 1 month of at least 2 of the following in infants up to 4 years of age:

1. 2 or fewer defecations per week
2. History of excessive stool retention
3. History of painful or hard bowel movements
4. History of large-diameter stools
5. Presence of a large fecal mass in the rectum

In toilet-trained children, the following *additional* criteria may be used:

6. At least 1 episode/week of incontinence after the acquisition of toileting skills
7. History of large-diameter stools that may obstruct the toilet

From Benninga MA, Faure C, Hyman PE, et al: Childhood functional gastrointestinal disorders: neonate/toddler. *Gastroenterology* 2016 (online journal): https://doi.org/10.1053/j.gastro.2016.02.016.

Evaluation of Abnormalities of Defecation

A good history and physical examination are the cornerstone of evaluation and may suffice for diagnosis and initial management of most children. A detailed previous medical history is clearly relevant. Critical information to be actively gathered includes age of onset of symptoms, failure to toilet train within an age-appropriate and developmental timeframe, frequency of bowel movements, stool consistency (assessed by appearance, and preferably recorded with existing stool scales, such as the Bristol stool form scale [Lewis and Heaton, 1997; Longstreth et al., 2006] as shown in Fig. 36.3 or modifications [Chumpitazi et al., 2010; Lane et al., 2011]), pain with defecation, bleeding per rectum, presence and characteristics of associated abdominal pain, fecal incontinence, holding behaviors, dietary history, changes in appetite, nausea or vomiting, weight loss, growth pattern (including height and weight), developmental delay, and failure to thrive. **The age of onset of symptoms is one of the easiest and most important pieces of information to obtain,** because it can be an important indicator for underlying pathology (Table 36.3). A detailed previous surgical history is also of great value, and attention should be paid to prior correction of anorectal malformations, resection of sacrococcygeal teratomas or other pelvic tumors, closure of spinal dysraphism, spinal cord untethering, and genitourinary reconstruction for conditions such as prune-belly syndrome.

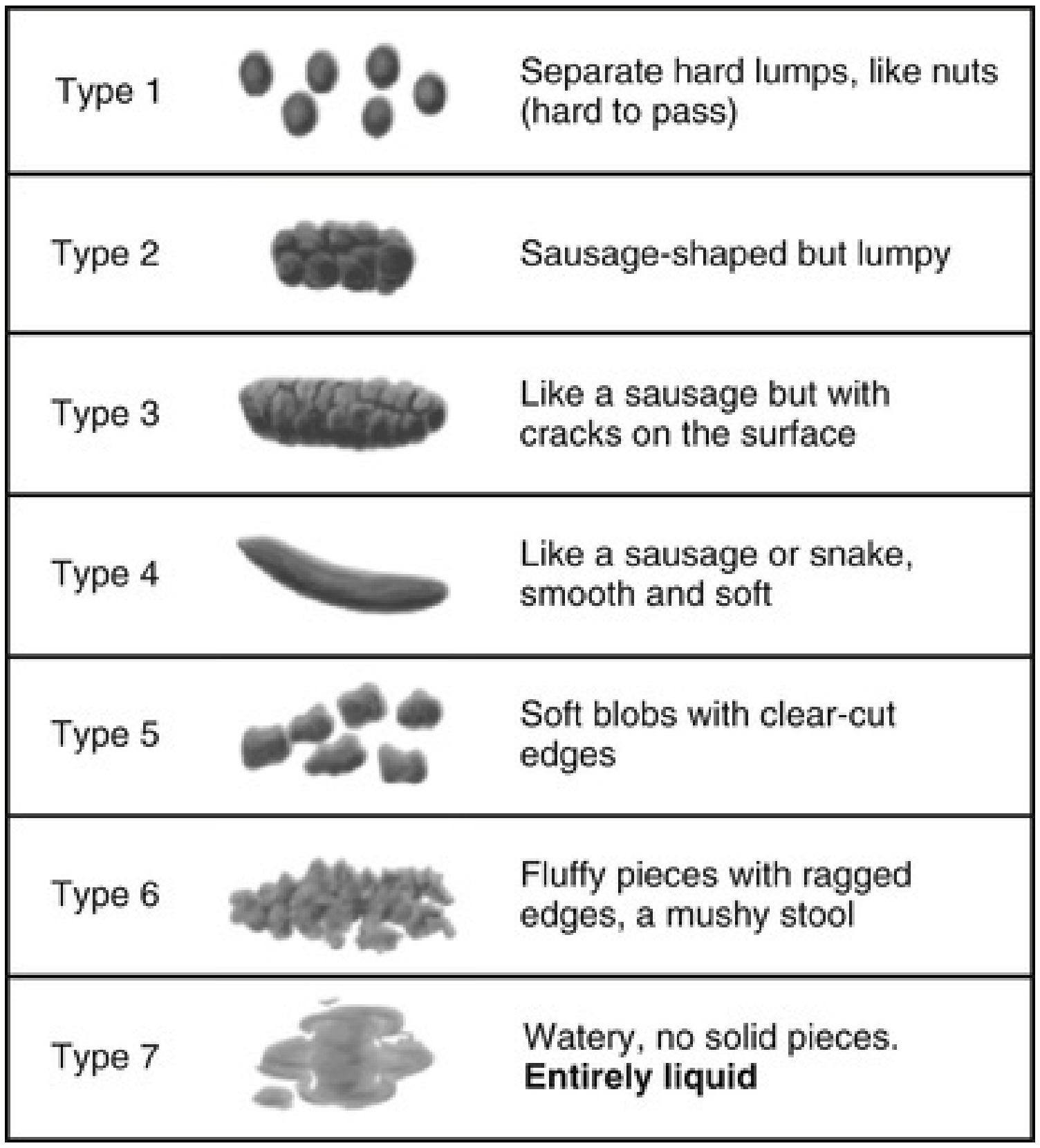
Type 1
Separate hard lumps, like nuts (hard to pass)
Type 2
Sausage-shaped but lumpy
Type 3
Like a sausage but with cracks on the surface
Type 4
Like a sausage or snake, smooth and soft
Type 5
Soft blobs with clear-cut edges
Type 6
Fluffy pieces with ragged edges, a mushy stool
Type 7
Watery, no solid pieces. **Entirely liquid**

FIG. 36.3 The Bristol stool form scale.

TABLE 36.3

Warning Signs and Symptoms

Constipation, fecal impaction that predates bowel training, particularly in the first year of life[a]

Chronic or recurrent respiratory problems[b]

Need for medications or rectal stimulation in the first year of life, particularly breastfed infants

Bloody stools

Alternating constipation and diarrhea

Severe or constant abdominal pain

History of bowel obstruction
Associated weight loss, growth retardation, failure to thrive[c]
Hypotonia, developmental delay[d]
Decreased appetite, early satiety
Bilious vomiting
Ribbon-like stools
Fecal and urinary incontinence beyond age of toilet training
Associated neurologic symptoms, particularly in the lower extremities (weakness, gait abnormalities, muscle atrophy, sensory abnormalities)
Lower back abnormalities (sacral dimple, lipoma, hair tuft, gluteal cleft deviation)
Explosive stool and air from rectum after stimulation (digital, suppository) or after rectal exam

[a] Onset of symptoms in infants <1 month old or delayed passage of meconium by 48 hours in a term neonate should raise suspicion for an organic condition, specifically Hirschsprung disease (Ghosh and Griffiths, 1998); a consideration should be given to ruling out the diagnosis with a rectal biopsy.

[b] Suspect cystic fibrosis.

[c] Suspect celiac disease, hypothyroidism, and Hirschsprung disease.

[d] Associated with hypothyroidism and trisomy 21.

Critical components of physical exam include appearance of the perianal region and perineum, abdominal exam (including presence of palpable masses, muscle tone, distention, pain on palpation), presence of a cremasteric and anal reflex, gluteal and sacral region assessment (for hair tufts, deviated gluteal cleft [eFig. 36.4], sacral dimples, [eFig. 36.5], flat buttocks [eFig. 36.6]), and lower extremity exam (weakness, coordination, muscle atrophy, decreased muscle strength, abnormal deep tendon reflexes, gait abnormalities). Although often an obvious diagnosis on physical exam, the presence of cryptorchidism (or prior bilateral orchidopexies for intra-abdominal gonads), lax abdominal wall, and lower urinary tract problems should raise concern for prune-belly syndrome and have appropriate assessment to consider abdominoplasty as a means to address difficulty generating increased intra-abdominal pressure for defecation.

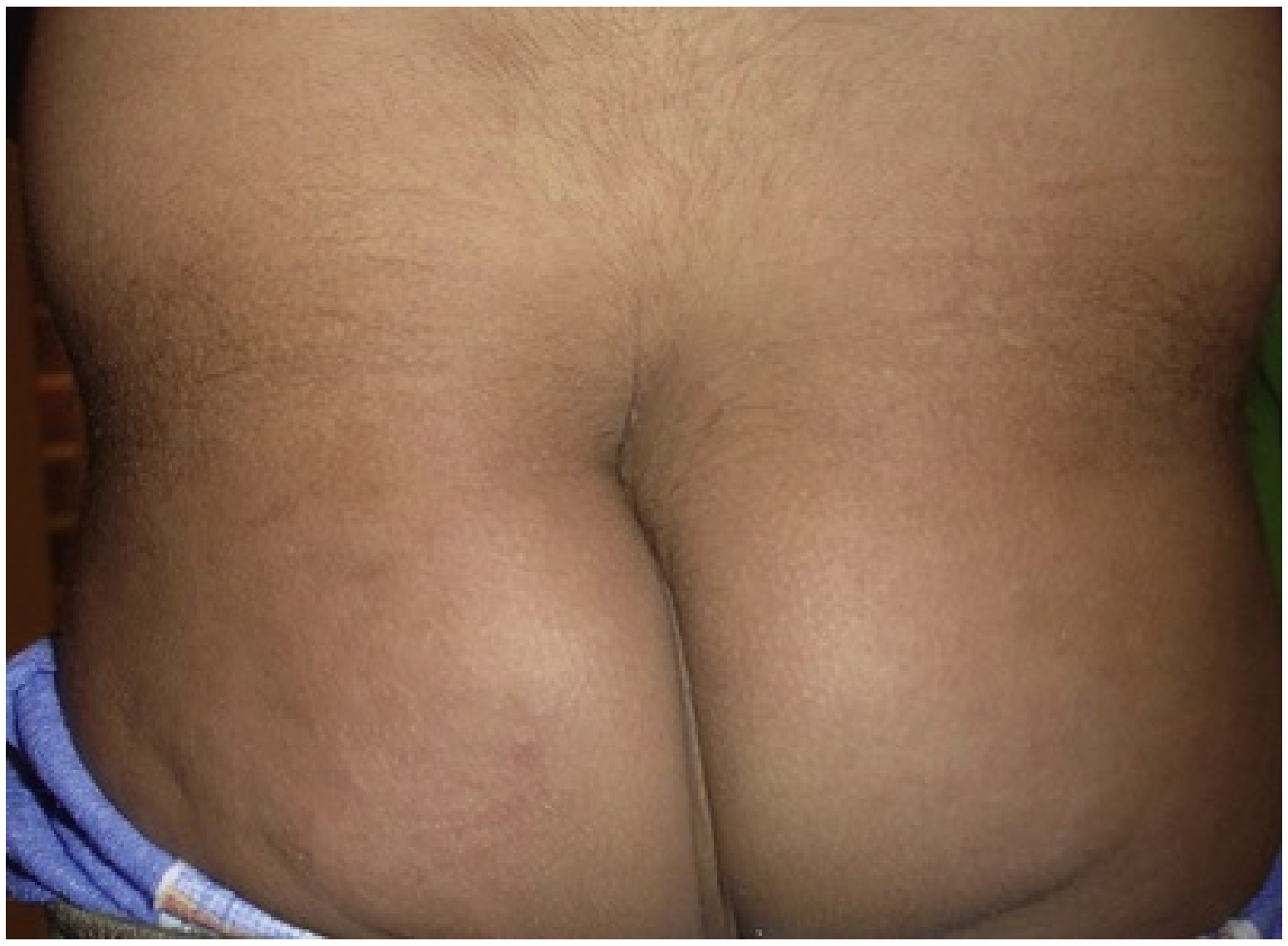

EFIG. 36.4 Deviated gluteal cleft in a child with neuropathic bladder and bowel dysfunction secondary to cord tethering and occult dysraphism.

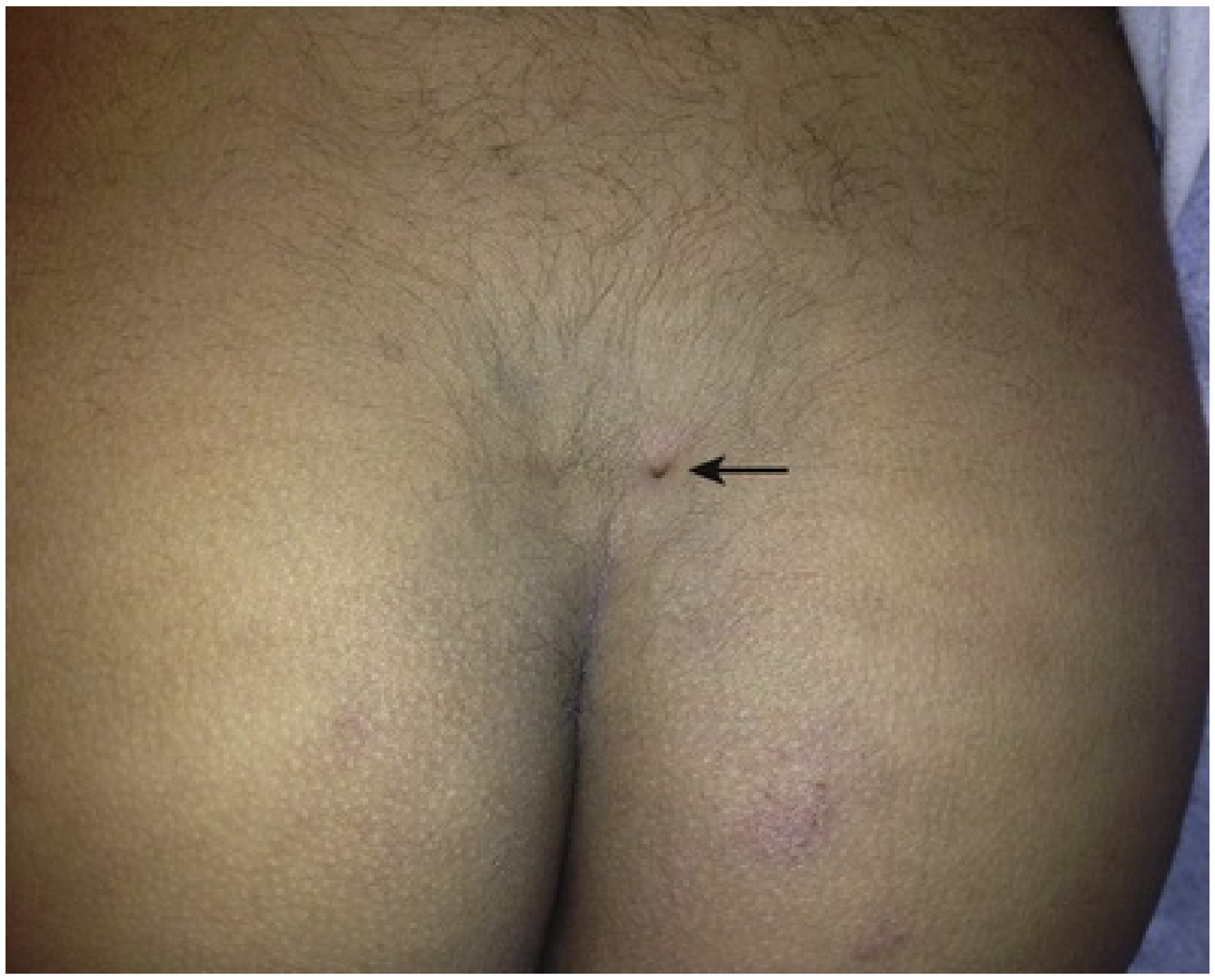

EFIG. 36.5 Sacral dimple *(arrow).*

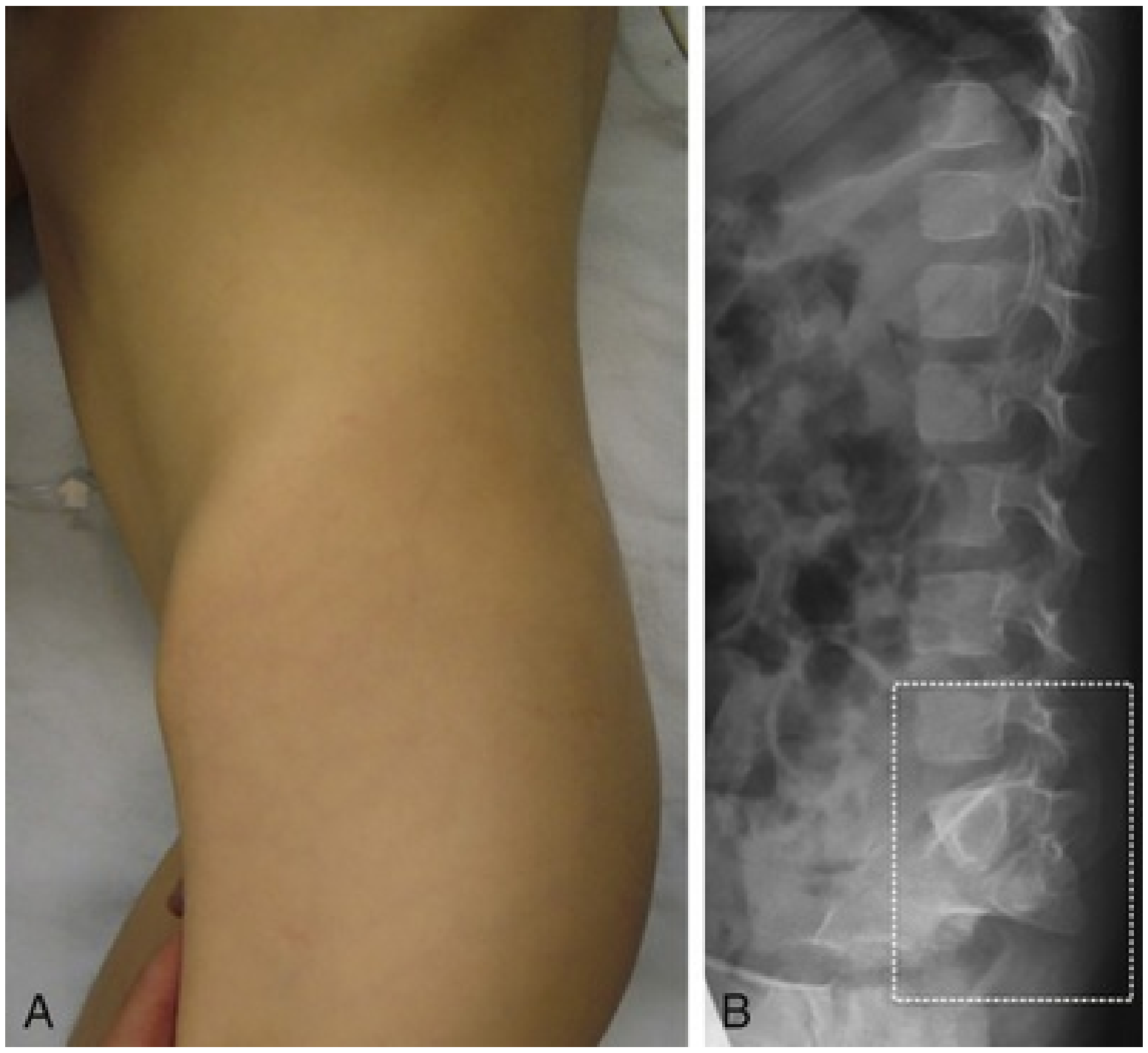

EFIG. 36.6 Sacral agenesis. (A) Findings on physical exam, including a “flat” appearance of the buttocks, associated with neuropathic bladder and bowel. (B) Lateral view lumbosacral radiograph with bony defects of the lower spine consistent with sacral agenesis (or caudal regression syndrome).

Physical exam should also include weight and height (parameters graphed against normal growth curves) and inspection of the anal region (anal position, stool present around the anus or on the underwear, signs of trauma, anal fissures, sensation). Although potentially considered to be an integral part of a complete physical exam, **digital rectal examination should not routinely be performed in children**. It is reserved for difficult-to-treat cases and should be conducted by health care professionals comfortable with interpreting features of anorectal anatomic abnormalities (Mugie et al., 2011), to specifically evaluate for anal stenosis, a large fecal mass, or an empty rectum. **Extreme fear during anal inspection, fissures, or signs of trauma should raise suspicion for sexual abuse.**

Assessment of patients with functional constipation should be fairly normal. Expected findings are those of a well-appearing child, with weight and height within normal limits, normal appearance of anus and surrounding area, a soft abdomen (occasionally distended or with a palpable fecal mass in the left lower abdominal quadrant), normal appearance of the skin and anatomic structures of lumbosacral/gluteal regions, normal gait, tone strength, and lower limb reflexes.

In addition, these patients should not have clinical manifestations until at least a few months of life, having a history of normal passage of meconium (within the first 24 to 48 hours after birth). Presentation sometimes coincides or worsens with precipitating factors, such as change in diet (e.g., transitioning out of breastfeeding), new medications (e.g., anticholinergics for management of urinary frequency), or psychosocial stressors (i.e., moving, starting, or changing school, parents separating, new sibling, major illness in family, travel).

Aside from abnormalities on physical exam, based on history and ancillary tests, selected children need a focused workup for organic conditions that manifest themselves or are associated with elimination problems. These include cystic fibrosis, hypothyroidism, celiac disease, dietary allergies, Hirschsprung disease or colonic aganglionosis, anal stenosis, and trisomy 21. Laboratory evaluation in refractory cases or those with associated worrisome findings include celiac screening and thyroid function tests (TSH, T_4). In older children and teenagers, other conditions should be added to the differential, such as mental health issues (depression), eating disorders, sexual abuse, and irritable bowel syndrome (IBS) (Longstreth et al., 2006). IBS, a functional bowel disorder, is characterized by abdominal pain associated with defecation or a change in bowel habits. Diagnosis depends on key temporal relationships: recurrent abdominal discomfort at least 3 days per month in the past 3 months associated with improvement with defecation and onset or worsening with a change in frequency or stool form (appearance).

Imaging Studies

Although of modest clinical value, along with exposure to a very low dose of radiation, abdominal radiographs are commonly employed in the diagnosis and management of defecation disorders, particularly constipation. The sensitivity and specificity of abdominal radiography in diagnosing childhood constipation is far from optimal, ranging between 60% and 80% and 40% and 90%, respectively (Mugie et al., 2011; Reuchlin-Vroklage et al., 2005). The test's interpretation can be subjective, and findings can be affected by timing since the child's last evacuation. Nevertheless, scales have been devised to help standardize evaluations, based on estimated bowel dilation, as well as the pattern, amount, and distribution of feces in the colon, which provides scores that can be useful for diagnosis, monitoring, and research purposes (Barr et al., 1979; Blethyn et al., 1995; Leech et al., 1999; van den Bosch et al., 2006). Proponents in favor of routine radiologic assessment argue that the study can clearly demonstrate the amount of fecal loading, delineate stool distribution throughout the colon and rectum (Fig. 36.7), as well as help ascertain for the presence of fecal impaction (which has important therapeutic implications) (Fig. 36.8). In addition, it may also reveal associated pathologies, such as bony abnormalities indicative of occult spinal dysraphism or sacral agenesis (eFig. 36.9), and help provide a visual aid for family and patient recognition of stool retention despite a history of regular defecation. In turn, this can be useful to maximize adherence to treatment in cases in which there is disagreement or disbelief with the presence of constipation (particularly if consulting solely for lower urinary tract symptoms or urinary tract infections). Serial exams may also provide an objective way to monitor response to disimpaction and/or maintenance treatment (taking the *ALARA*, *A*s *L*ow *A*s *R*easonably *A*chievable, radiation exposure principle into account), although many would contend that considering symptomatic improvement alone is sufficient. In some circumstances, the study can be replaced or enhanced by conducting ultrasound evaluation of the lower abdomen and pelvis, assessing fecal loading behind the bladder as an alternative or adjunct marker for constipation (Joensson et al., 2008; Klijn et al., 2004; Fig. 36.10). Ultimately, **if constipation and fecal impaction or loading are obvious on history and physical examination, management based on clinical grounds without imaging studies is reasonable and recommended in routine practice** (Tabbers et al., 2014).

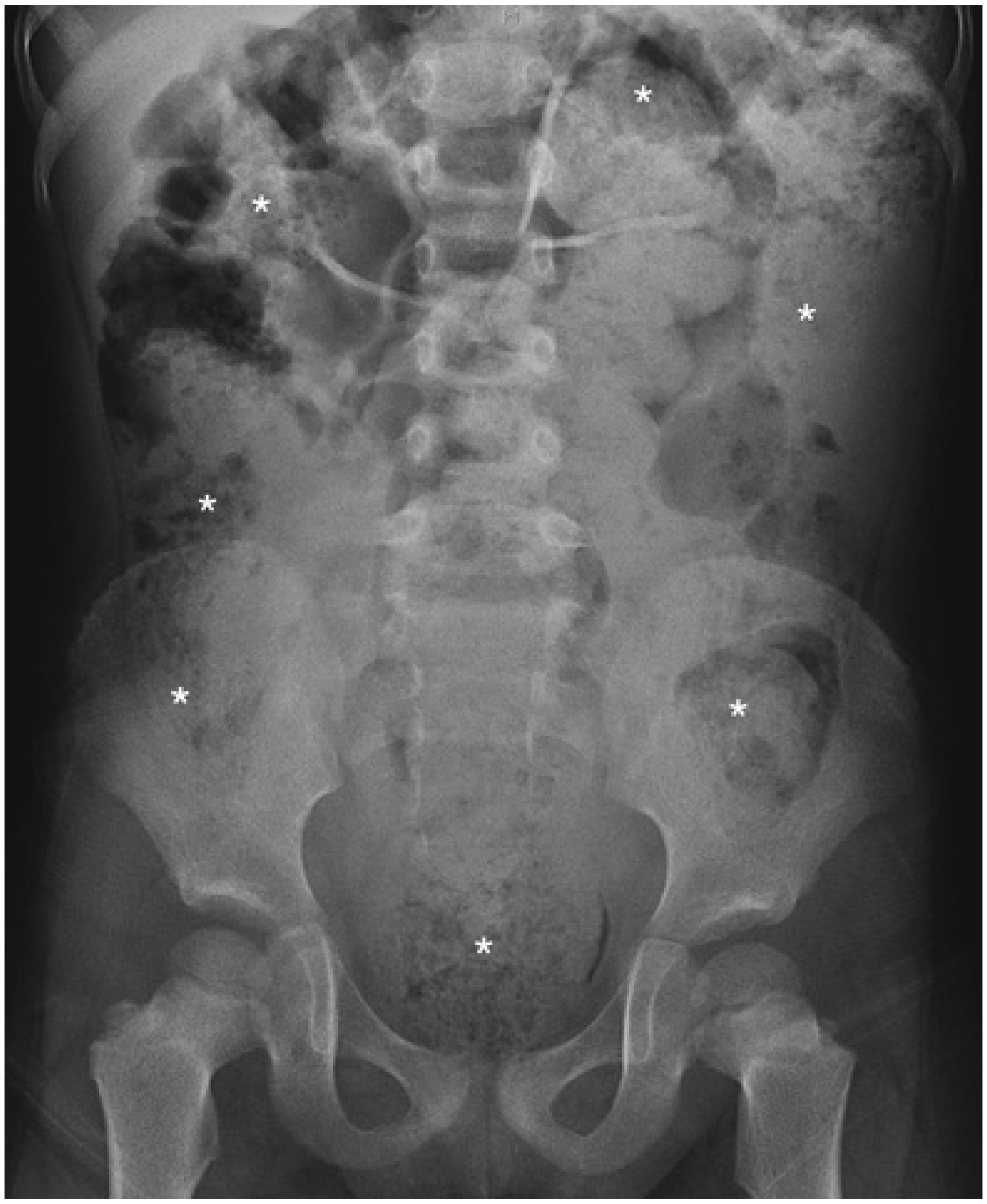

FIG. 36.7 Abdominal radiograph demonstrating fecal loading throughout the colon (*) in a child abdominal distention, encopresis, and urinary frequency.

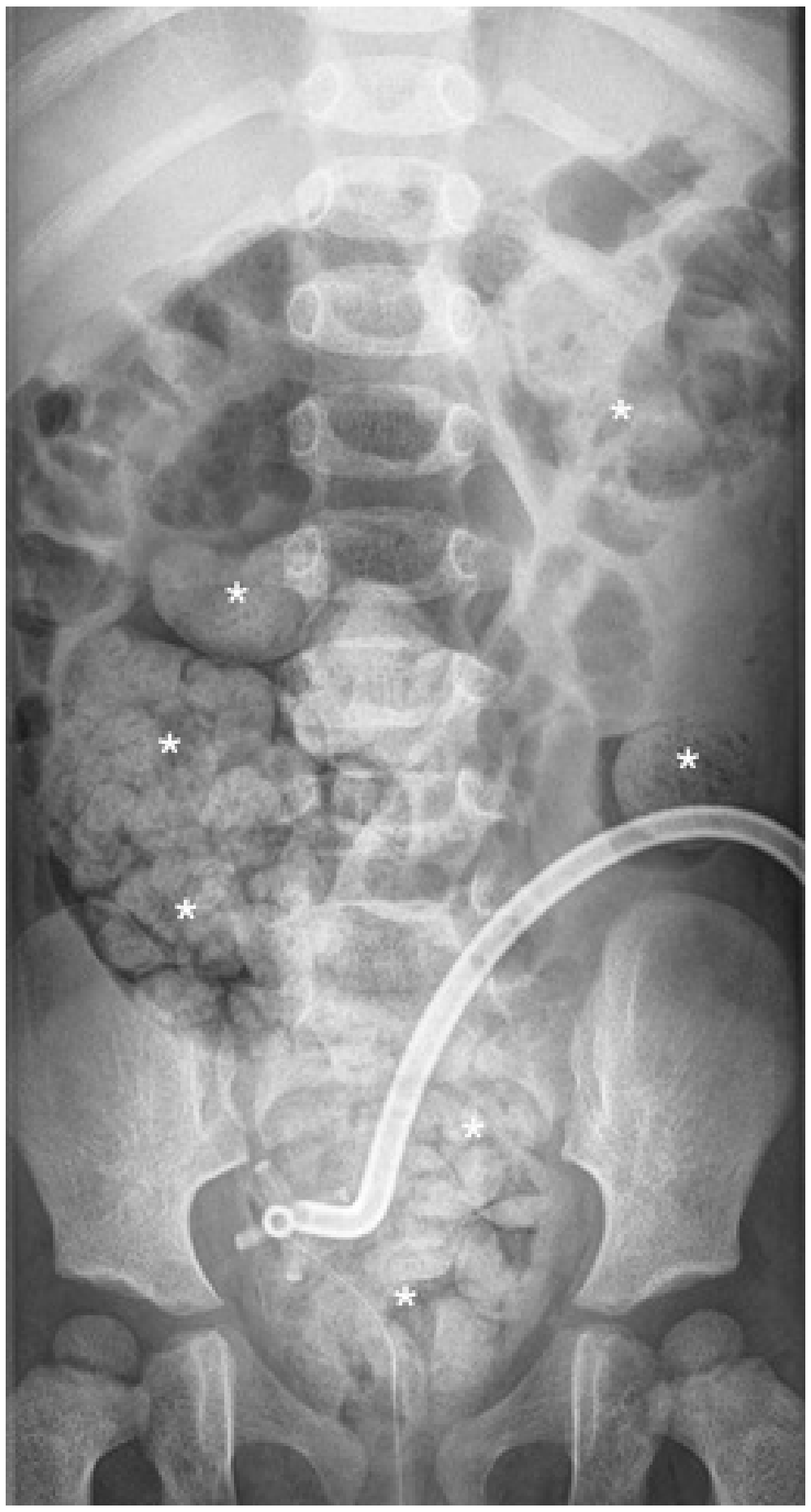

FIG. 36.8 Abdominal x-ray with evidence of fecal impaction in a child who presented with acute urinary retention (note placement of suprapubic tube for bladder management).

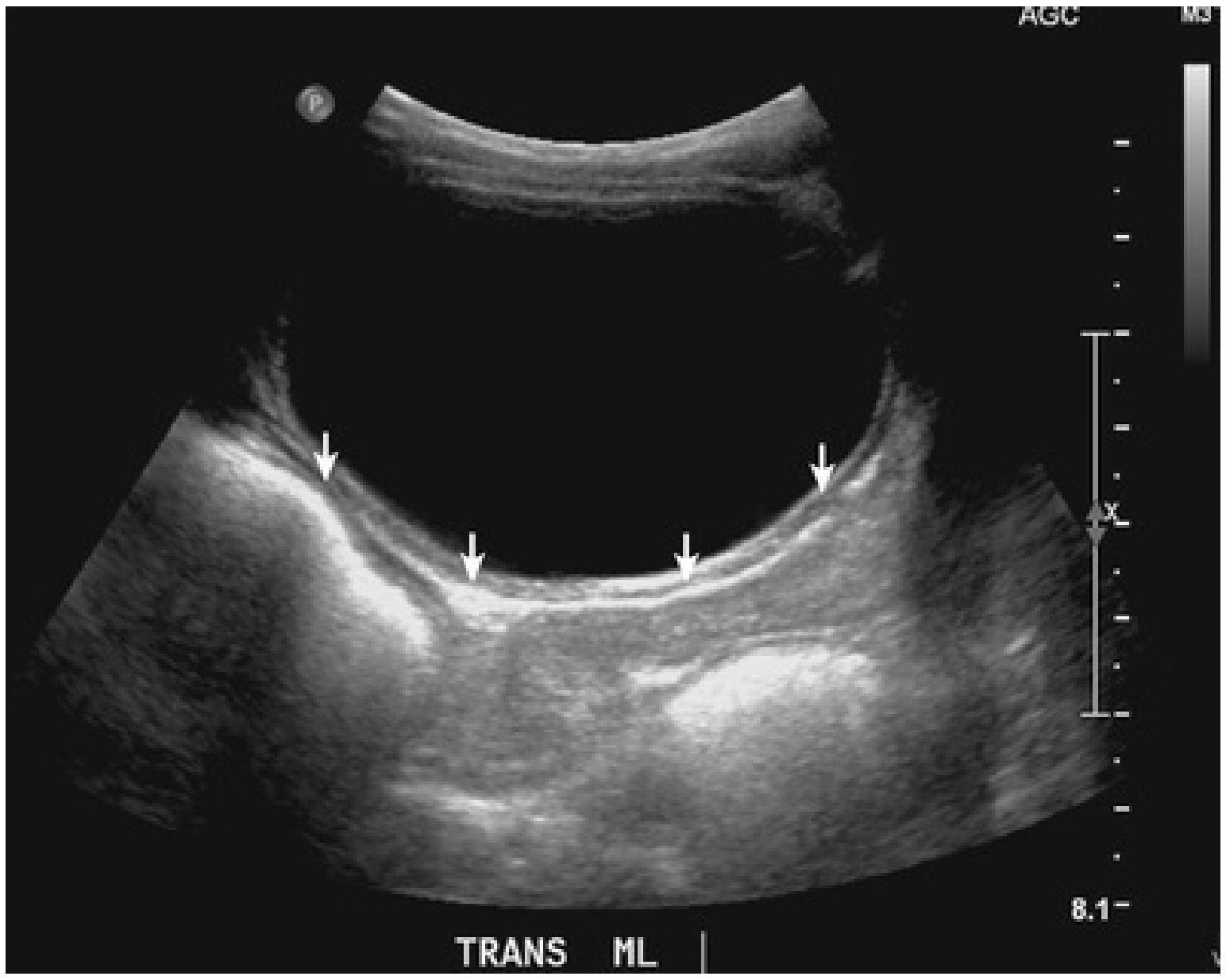

FIG. 36.10 Assessment of fecal load in rectum during pelvic ultrasound. Stool is seen behind the bladder *(arrows).* Note bladder distention due to incomplete emptying and infrequent voiding because of toilet avoidance secondary to pain with defecation.

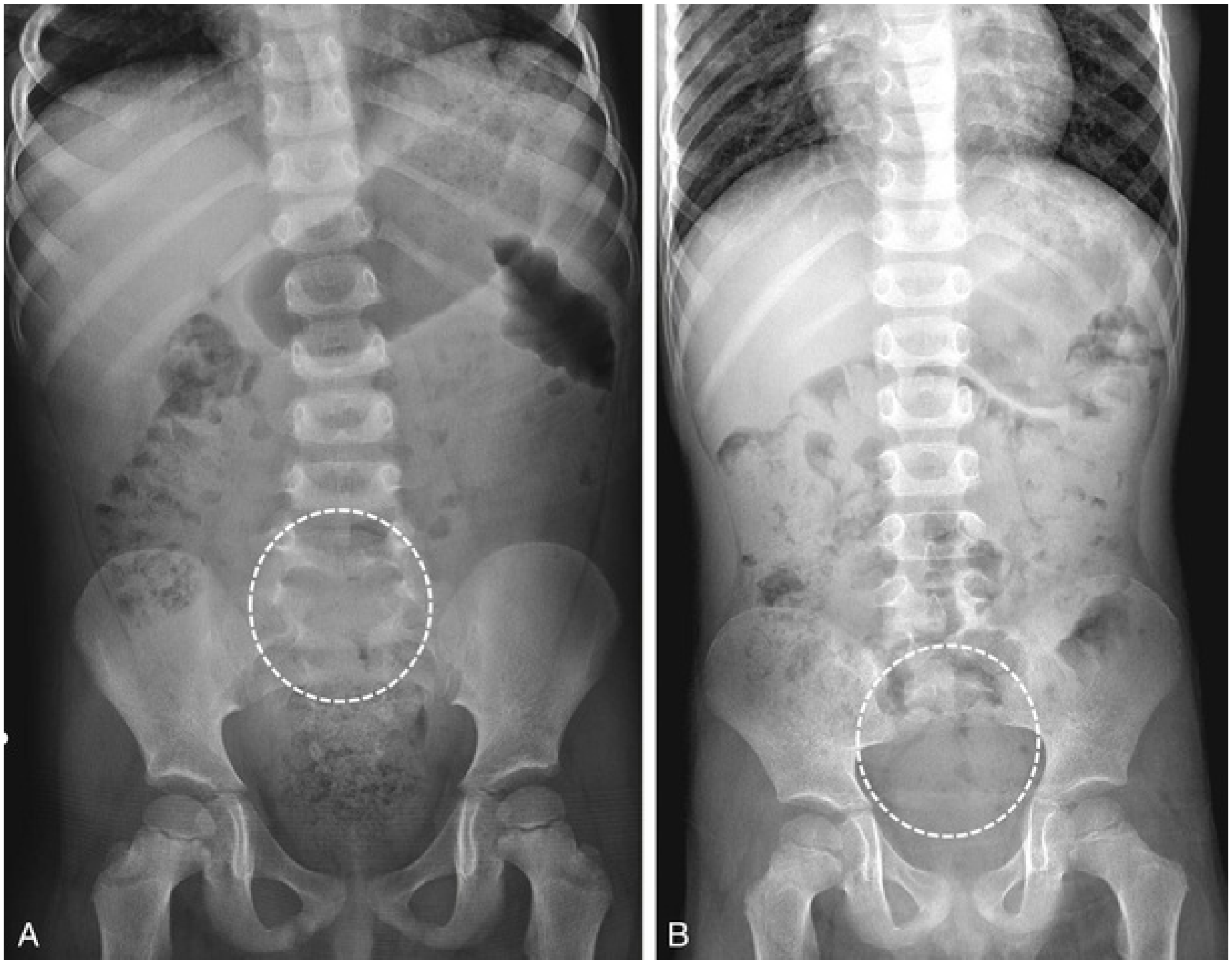

EFIG. 36.9 Bony abnormalities detected on abdominal x-ray during assessment of difficult-to-treat constipation. (A) Lumbar bony defects consistent with occult spinal dysraphism. (B) Absent sacrum, suggestive of sacral agenesis.

Colonic transit time studies, which evaluate the progression of radio-opaque markers along the gastrointestinal tract on serial radiographs, are not recommended for routine diagnosis of functional constipation. However, in difficult to treat or unresponsive cases this study may have some value: a normal evaluation in the setting of fecal incontinence would suggest either a nonretentive defecation disorder or an unreliable medical history. Additional studies are selectively obtained based on suspicion for an underlying condition. A contrast enema series can be of value in the evaluation of children with characteristics suggestive of Hirschsprung disease (Langer, 2013; Reid et al., 2000; Fig. 36.11) and repaired congenital anatomic abnormalities (i.e., anorectal malformation). Concern for a neuropathic process and/or lower spine stigmata should be evaluated with a spine ultrasound (if detected before calcification of the vertebral bodies in the first 3 to 6 months of life, eFig. 36.12) or a lumbosacral MRI in older children (eFig. 36.13). Suspicion for sacral agenesis should be further assessed with a lateral view lower spine/pelvis radiograph (see Fig. 36.6).

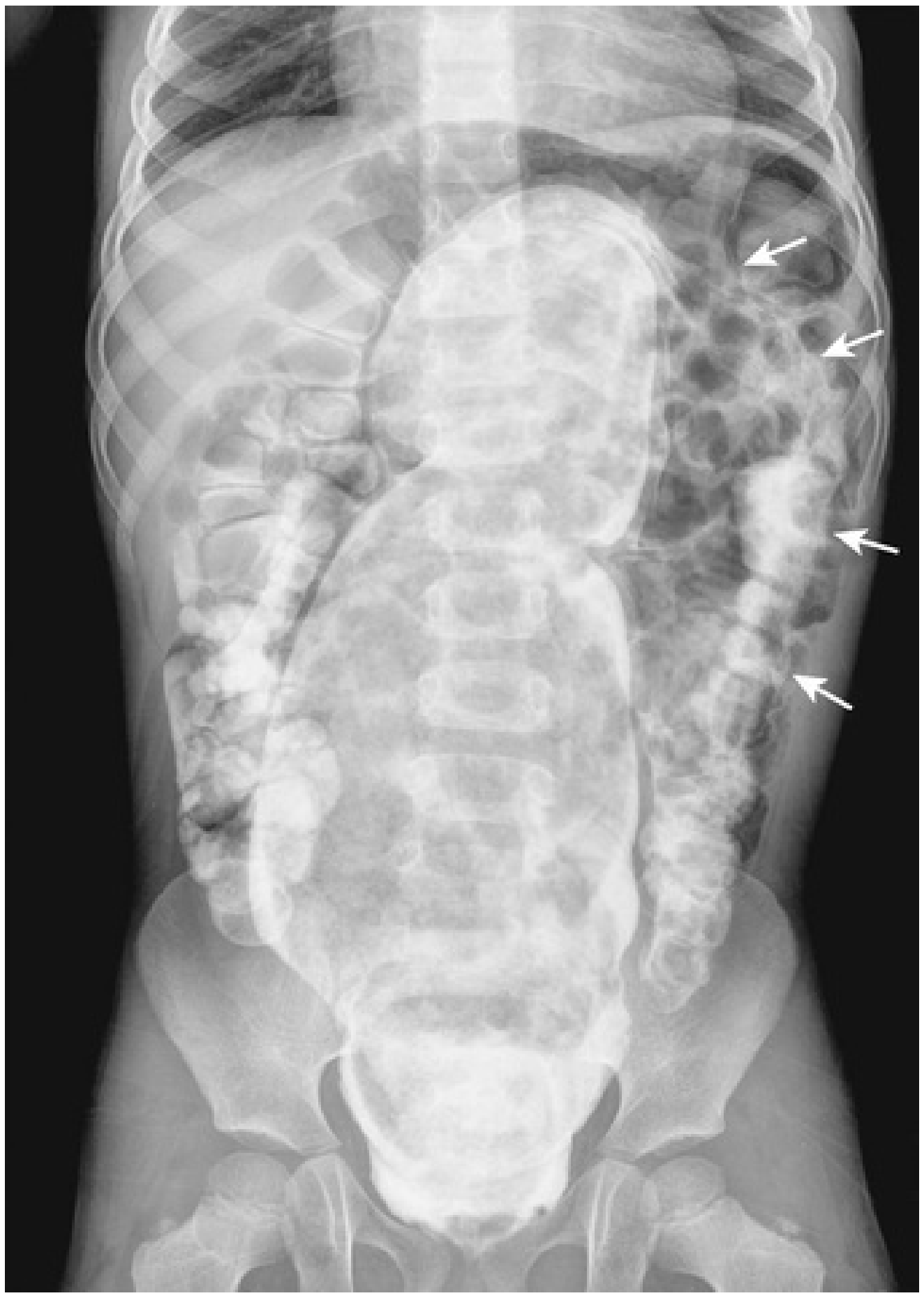

FIG. 36.11 Soluble contrast enema for evaluation of child with defecation problems since birth. Findings suggestive of Hirschsprung disease, including massively distended colon and rectum than can progress toward more normal-appearing large bowel *(arrows).* This child was subsequently assessed with a rectal biopsy to confirm the diagnosis.

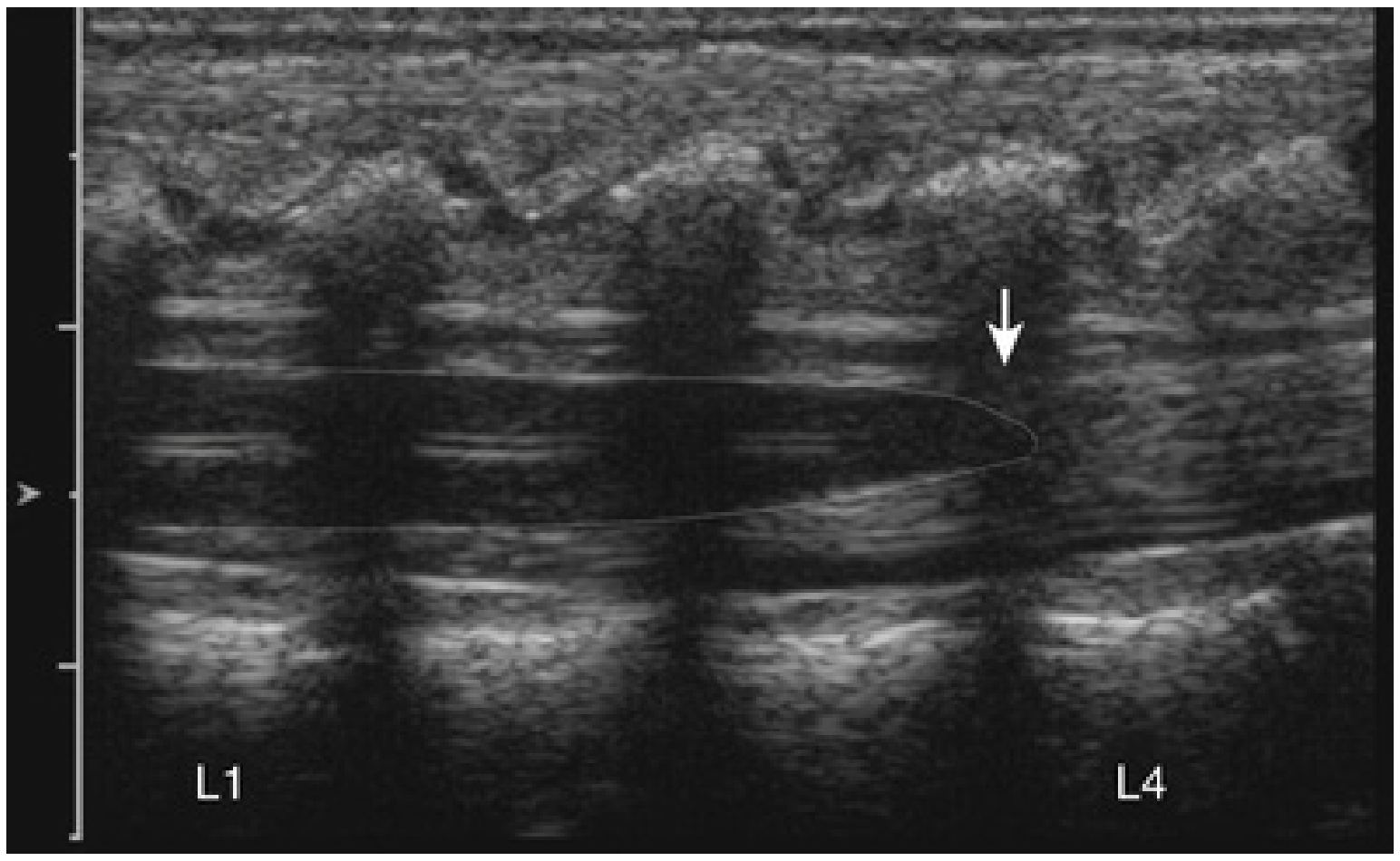

EFIG. 36.12 Spine ultrasound performed in a child with a sacral dimple, demonstrating a low-lying conus (at L4 level, *arrow*). Note shadow by bony component of vertebral bodies.

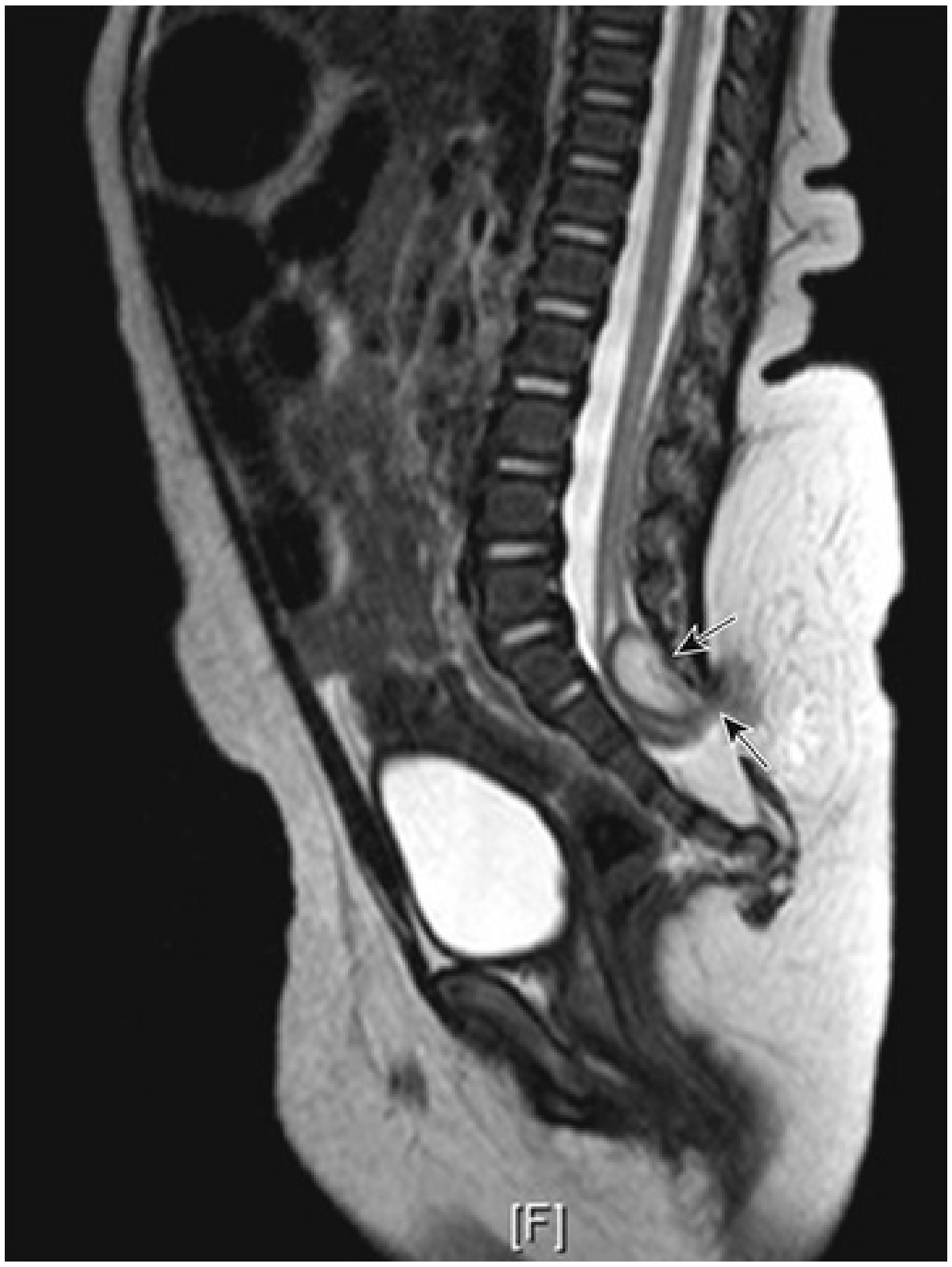

EFIG. 36.13 MRI of lumbosacral region in a child with abnormal lower back exam during initial assessment of constipation and urinary frequency.

Note presence of lipoma extending into the spinal canal *(arrows).*

If Hirschsprung disease or colon aganglionosis is suspected, a deep rectal suction biopsy (including submucosal) should be obtained (Langer, 2013), favoring a transanal approach and aiming at a location 2 to 3 cm from the dentate line. Diagnosis is supported by absence of ganglion cells, hypertrophied nerve fibers, and increase in acetylcholinesterase activity in the lamina propria and muscularis mucosa. Anorectal manometry is useful only in very selected cases (Noviello et al., 2009), such as suspected Hirschsprung disease and internal sphincter achalasia. In these conditions, the rectoanal relaxation reflex is absent. Nevertheless, in most patients suspected of having functional constipation, manometry adds little to the diagnosis or therapeutic strategy (van Ginkel et al., 2001).

Key Points

- The Rome IV criteria are recommended for diagnosis of functional constipation in children.
- The diagnosis of functional constipation should be based on a good medical history and physical examination.
- The presence of alarm signs or symptoms or intractable constipation should trigger a focused assessment to diagnose underlying medical conditions.
- Routine use of abdominal radiographs is of limited value and should be reserved for selected cases, such as suspected fecal impaction and difficult or unreliable history and physical examination.

Management

As is the case with many other conditions, careful thought and consideration must be first given to more conservative, nonoperative management alternatives (see management algorithm, Fig. 36.14). A medical plan, consisting of behavioral interventions, dietary changes, stool softeners and laxatives, and judicious use of retrograde enemas is often sufficient to manage most patients with chronic constipation. In addition, education about defecation and demystification of toilet training (in children with a developmental age of at least 4 years) are crucial yet often overlooked components of successful management (van der Plas et al., 1997). Clearly, whether a functional problem or associated with an organic underpinning, especially considering the spectrum of associated urologic disorders, an individualized approach to each patient is preferred.

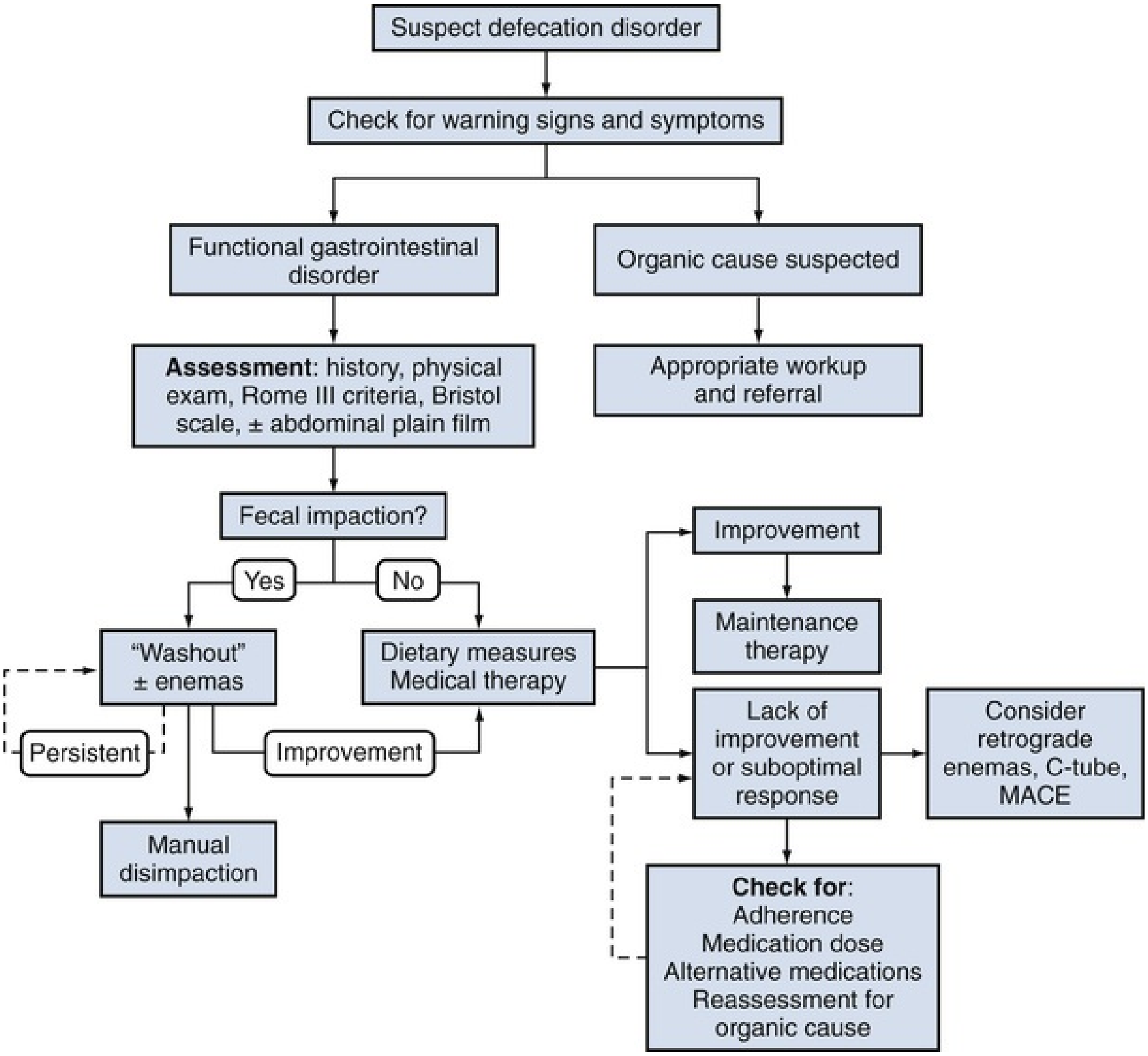

Suspect defecation disorder
Check for warning signs and symptoms
Functional gastrointestinal disorder
Organic cause suspected
Assessment: history, physical exam, Rome III criteria, Bristol scale, ± abdominal plain film
Appropriate workup and referral
Fecal impaction?
Yes
No
"Washout" ± enemas
Dietary measures Medical therapy
Persistent
Improvement
Manual disimpaction
Improvement
Maintenance therapy
Lack of improvement or suboptimal response
Consider retrograde enemas, C-tube, MACE
Check for: Adherence Medication dose Alternative medications Reassessment for organic cause

FIG. 36.14 Management algorithm for childhood defecation disorders seen in a pediatric urology practice. Lack of improvement or intractable constipation should be diagnosed based on worsening or absence of suboptimal response to adequate medical treatment for at least 3 months.

Treatment of constipation is often started within the context of lower urinary tract symptoms. The association between the two has gained acceptance, and simultaneous assessment is part of the comprehensive evaluation offered in many pediatric urology practices, often run by nurse practitioners and other health care providers. The concept's popularity is based on data from a landmark study by Loening-Baucke, who reported on 234 consecutive patients with constipation and encopresis and associated urinary incontinence and urinary tract infections. Successful relief of constipation in 52% was associated with resolution of daytime urinary incontinence in 89%, of nocturnal enuresis in 63%, and a resolution of infections (Loening-Baucke, 1997). Although backed up by experience and other subsequent case series, demonstrating improvement in incontinence episodes, voided volume, and postvoid residuals (Erickson et al., 2003), the value of universal use of laxatives in children requiring treatment of overactive bladder symptoms has been called into question (Bush et al., 2013). Nevertheless, if constipation is suspected, treatment should be recommended, as highlighted in the 2013 report from the Standardization Committee of the International Children's Continence Society (Burgers et al., 2013).

Nonpharmacologic Interventions

If screening and imaging studies are negative, thus restricting the diagnosis to a functional elimination problem and/or slow colonic transit time, medical management follows a stepwise process that begins with medical therapy coupled with behavioral modifications: adequate fluid and fiber intake, regular defecation, scheduled post-meal defecation attempts to take advantage of an increase in colon motility in response to gastric distention and digestive process (so-called gastrocolic reflex), relaxation techniques, and proper positioning on the toilet (with good foot support and forward leaning to flex thighs closer to the abdomen and better generate an increase in abdominal pressure). Obviously, in cases in which an underlying organic cause is suspected, specific therapy should be sought after a directed workup.

Behavioral and dietary recommendations are often implemented first and may suffice as a stand-alone strategy or as an adjunct to medical or surgical interventions. The impact of these is difficult to measure because of wide differences in employed protocols, a high placebo response rate in some subgroups (Bush et al., 2013), and attrition (patient lost for follow-up). Nevertheless, lack of benefit is often based on limited data, families commonly attempt therapeutic trials without recommendation or supervision by a health care provider, parents often favor nonpharmacologic strategies despite unproven benefit, and side effects are often mild or negligible. Thus the expectation is that early on, children will be asked to implement generous fluid intake (in accordance with expectations for children with lower urinary tract symptoms), optimize diet (including liberal fiber intake in the form of fruits and vegetables), establish a bowel routine taking advantage of the gastrocolic reflex, ensure active lifestyle (promoting physical activity and avoid sedentary tendencies), and consider the use of pre- and/or probiotics (Chmielewska and Szajewska, 2010; Korterink et al., 2013), additional fiber intake (Castillejo et al., 2006;

Chmielewska et al., 2011; Loening-Baucke et al., 2004; Staiano et al., 2000), or biofeedback (van der Plas et al., 1996a,b). Unfortunately, any positive effect on functional constipation is hard to defend based on high-quality data (Tabbers et al., 2011), and treatment algorithms tend to be based on opinion rather than evidence (Pijpers et al., 2010).

The chronic nature of defecation disorders, in combination with fears of adverse effects or irreversible reliance on daily medication use, contributes to parents seeking some form of alternative treatment in approximately 40% of children with functional constipation (Vlieger et al., 2008). Many of these, aside from having unknown effectiveness, can be associated with important complications or discomfort (hypnotherapy, acupuncture, homeopathy, and osteopathic or chiropractic musculoskeletal manipulations, transcutaneous nerve stimulation) and should be avoided or only employed under a research setting until backed up by well-designed studies. In particular, phytotherapy (favored by parents who equate "natural" with safety) can elicit severe adverse reactions because of contamination, inability to quantify active compounds, unknown adulteration, or direct toxic effects.

Disimpaction and Large Bowel and Rectum Washout

Decreasing fecal load in the large intestine and rectal vault is the first step toward establishing an optimal medical regimen. Impaction is defined as the presence of a hard mass in the lower abdomen and/or left lower quadrant, or a dilated rectum filled with a large amount of stool as determined by rectal examination, pelvic ultrasound, or abdominal radiography, irrespective of the ability to produce bowel movements. **The child may be able to pass some stool without effectively emptying, and on occasion may have loose bowel movements that can be paradoxically (and erroneously) labeled or treated as diarrhea.** Approximately 30% of children with long-lasting functional constipation have fecal impaction, frequently associated with stool incontinence (Mugie et al., 2011; Nurko and Scott, 2011). The presence of fecal impaction demands attention before initiation of maintenance medical management; otherwise treatment will fail or paradoxically worsen gastrointestinal symptoms.

Disimpaction and bowel washout, as the names imply, attempt to address the problem in a relatively short period of time, accepting the need for enemas or stimulants, and tolerating temporary worsening of fecal incontinence, abdominal distention, and discomfort. In stark contrast to maintenance therapy, enemas and suppositories are acceptable as routine interventions during this period and may facilitate evacuation of a large/hard fecal load in the rectum. Although subject to variability based on the amount of fecal material, distribution within the colon, child's age, tolerance for medication administration per anus, provider experience and cultural barriers, common programs include “high-dose” polyethylene glycol (or PEG, 1–1.5 g/kg/day for 3–6 days) with or without sodium chloride, sodium phosphate, or mineral oil enemas (daily for 3–6 days) (Tabbers et al., 2014). The ultimate goal is to produce soft, watery bowel movements with correction of abdominal distention, palpable fecal mass on abdominal or rectal exam, and clearance of fecal load as determined by abdominal plain film or pelvic ultrasound.

In rare circumstances clearance can only be achieved with more aggressive medication administration, conducted during admission to the hospital, and aided by nasogastric tube delivery and intravenous fluids to prevent dehydration (similar to local protocols for preoperative bowel preparation). If failed, not tolerated, or associated with severe pelvic pain because of difficulty in passing a hard, large rectal fecaloma, digital disimpaction under anesthesia may be required. Subsequent outpatient management requires regular (often daily) visits and consists of monitoring response while modifying the volume and content of the retrograde enemas to suit the individual needs of each patient. Normal saline is commonly used as the solution for enemas, with additives employed based on preference and familiarity with use (glycerin, soap, or phosphate). Commercial sodium phosphate formulations (such as Fleet enema) can be added in difficult cases but should be employed with caution in children with renal impairment. Dosage is adjusted by age: 30 mL for children younger than 4 years old, 60 mL for children 4 to 10 years old, and 120 mL for children older than 10 years of age. The total volume of the enema must be tailored to effect, with constipated patients often requiring up to 500 to 1000 mL. Management is considered successful when the underwear remains clean for 24 hours.

Maintenance Therapy

Before beginning any maintenance protocol, the provider should verify that the rectosigmoid is not impacted again, despite what was thought to be an adequate washout. Failure to do so means management is bound to fail, paradoxically leading to overflow fecal incontinence or triggering pain and cramping with oral medications. In contrast to management of fecal impaction, routine rectal administration of medications is avoided as first-line maintenance therapy. Although tolerated by some children, the use of enemas over optimal oral medical therapy does not appear to provide added benefit (Bongers et al., 2009). There is, however, limited place for routine use of enemas, suppositories, or rectal stimulation in selected, severe, difficult-to-treat cases.

Osmotic laxatives, such as lactulose, milk of magnesia, and polyethylene glycol (PEG), are usually sold as solutions or powders to be dissolved in water, thus making them relatively easy to administer to children and thus preferred agents. They act as poorly absorbed hyperosmolar molecules, increasing stool water content (making feces softer and easier to pass), and increasing colonic peristalsis. Stimulant laxatives (sodium picosulfate, senna, and bisacodyl), which act directly on the intestinal mucosa, increase water and electrolyte secretion and are often reserved for second-line or adjuvant (intermittent) protocols, employed only in selected (otherwise refractory) circumstances.

With the introduction of PEG into routine clinical practice, tolerance of medical management has improved and is currently the preferred agent in many centers. PEG is better tolerated and easier to administer than alternative medications such as lactulose, mineral oil, and milk of magnesia (magnesium hydroxide) (Gordon et al., 2012, 2013). Maintenance PEG dose is 0.2 to 0.8 g/kg/day, further adjusted based on clinical response, and given with fluids either once or twice a day. It is tasteless and dissolves easily within seconds. The most common side effect, watery stools or diarrhea, can be easily addressed by scaling back the daily administered dose. As an alternative, if PEG is not available, lactulose (1–2 g/kg, once or twice/day) can be employed (Tabbers et al., 2014).

New medications are being introduced in the therapeutic armamentarium. These have been studied mostly in the adult population yet are expected to slowly transition into pediatrics. New molecules include lubiprostone, linaclotide, plecanatide, and prucalopride (Koliani-Pace and Lacy, 2017; Tabbers et al., 2014). Prucalopride, an oral selective high-affinity $5HT_4$ receptor antagonist with gastrointestinal prokinetic activities, shows particular promise and may represent a reasonable choice for children who fail to respond to more conservative measures (Diederen et al., 2015; Winter et al., 2013).

Maintenance treatment should continue for at least 2 months, and symptoms should be completely resolved for at least 1 month before attempting gradual slow discontinuation. If the child is in the process of toilet training, medication should only be stopped once this developmental milestone has been completely achieved without evidence of further defecation problems. Lack of improvement or worsening should alert the provider to the possibility of reimpaction, lack of adherence with the prescribed medications, insufficient dose, or the introduction of new medications that may worsen constipation. The development of new symptoms, new findings on physical exam, or failure to improve should also renew consideration for underlying organic causes. Refractory cases are most commonly characterized by recurrent fecal impaction, likely because of retentive posturing, anal sphincter dyssynergia, and abnormal rectal motility or function (Bongers et al., 2009; Voskuijl et al., 2006; Youssef and Di Lorenzo, 2002).

Prognosis

Functional constipation can be difficult to treat and a long-lasting problem for some children. Nevertheless, with adequate management close to 50% of patients monitored for 6 to 12 months can recover and successfully discontinue medications, whereas up to 80% can be adequately controlled with routine interventions (Pijpers et al., 2010). Unfortunately, **subsequent recurrences are fairly common, with up to 50% of children experiencing one in the first 5 years after successful treatment** (Loening-Baucke, 1993; van Ginkel et al., 2003). There is a paucity of data on reliable prognostic factors, such as defecation frequency, that could identify patients at risk (Pijpers et al., 2010). Reported figures are clearly affected by the included patient population, and referral specialized centers may evidence lower cure rates despite intensive medical and behavioral therapy, with some children experiencing persistent symptoms beyond puberty, particularly those with older age of onset and initial delay in treatment (Bongers et al., 2010). Importantly, approximately 80% of children adequately managed early in their course recover without need for medications at 6-month follow-up, compared with only 30% with a delay in treatment (i.e., initial medical treatment postponed for >3 months) (Pijpers et al., 2010). Ultimately, data clearly suggest that constipation does not improve without treatment with time or after puberty (van Ginkel et al., 2003). **Early adequate therapeutic interventions are beneficial and may contribute to a successful long-term outcome while improving the child's quality of life.**

Key Points

- Adequate fluid and fiber intake, nonsedentary (active) physical activity, education, and guidance for toilet training should be presented as first-line interventions for all children of adequate developmental age.

- Although of debatable value, interventions with low-risk for adverse effects, such as behavioral therapy or biofeedback, can be considered for interested families.
- PEG should be considered as first-line treatment for constipation (for initiation and maintenance).
- Enemas are of value in the short-term management of children with fecal impaction but are not recommended for routine maintenance treatment.
- Treatment can be gradually discontinued in patients who remain symptom free for at least 1 to 2 months, being vigilant about recurrence.

Surgical Management

A small group of children fail medical management and may be considered candidates for more invasive options. Surgical management of difficult to treat defecation disorders is not a new concept, which has progressed from diversion (colostomy) for the most severe cases to liberal use of enemas and aggressive colon evacuation. With the introduction of the antegrade continence enema (ACE) or Malone (MACE) procedure in 1989, in an attempt to treat the intractable fecal incontinence associated with spina bifida, a new and highly successful option became available (Malone et al., 1990). Koyle subsequently introduced the technique in North America in 1991 (Koyle et al., 1995). The concept behind it is elegant and simple: to provide access to the colon (often at the level of the cecum) to allow regular emptying by means of antegrade instillation of fluid (so-called bowel washout; Fig. 36.15).

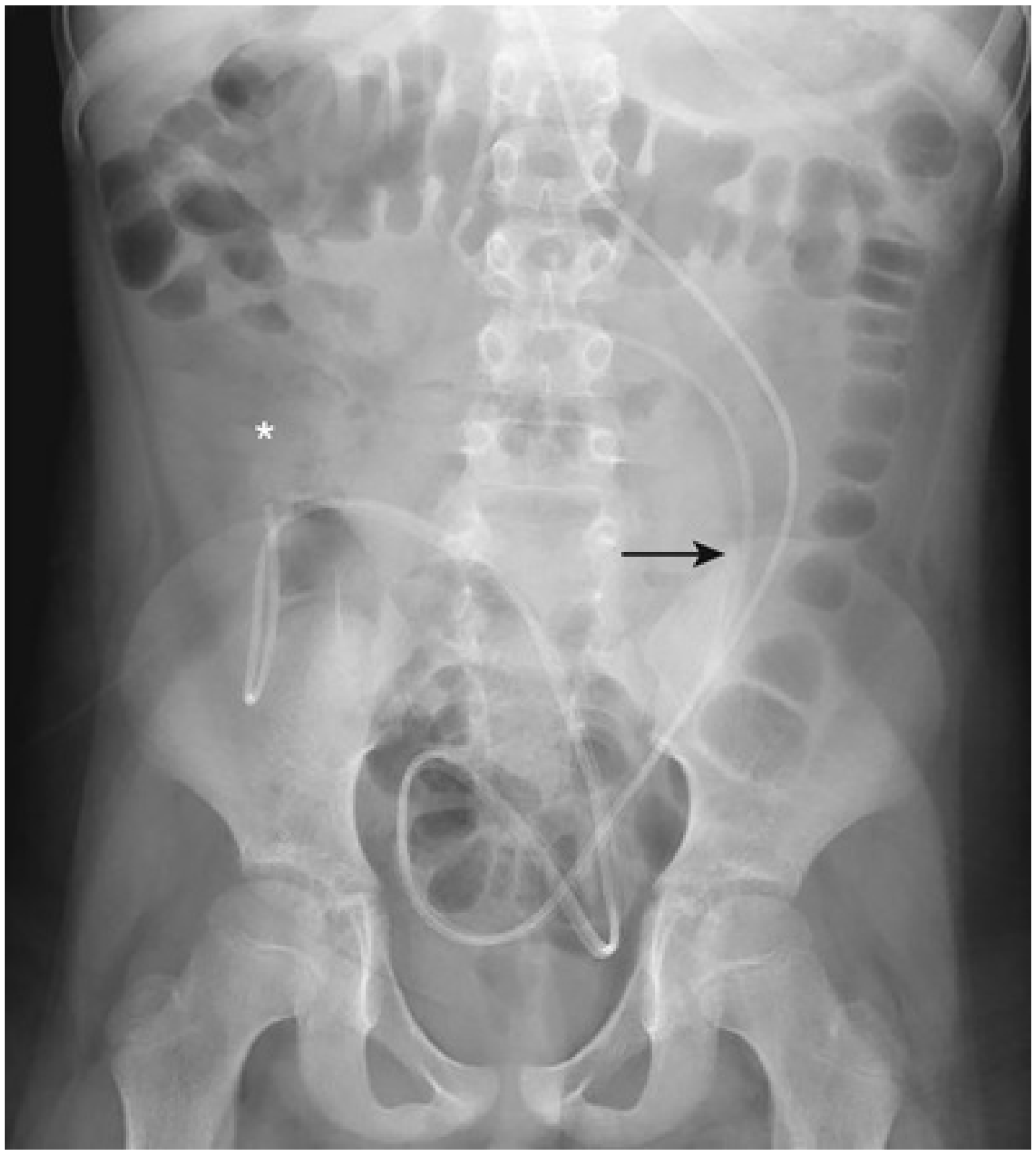

FIG. 36.15 Clearance of large bowel contents with antegrade enemas. Abdominal radiograph taken 12 hours after washout, demonstrating absent fecal material except for early accumulation in the cecum and ascending colon (*). Note presence of a ventriculoperitoneal shunt *(arrow).*

In essence, the MACE combines three well-recognized surgical principles familiar to pediatric urologists and surgeons: (1) complete colonic emptying can achieve bowel continence, (2) antegrade colonic emptying is feasible, and (3) the Mitrofanoff principle of continent cutaneous access to the bladder or bowel is highly successful and reproducible. Based on these, continent intermittent catheter access to the colon for the administration of antegrade enemas while the patient sits on the toilet produces colonic emptying and fecal continence. Success with this approach has been reported in numerous series, and it is now a procedure commonly practiced around the world (Dick et al., 1996; Gerharz et al., 1997a; Griffiths and Malone, 1995; Koyle et al., 1995; Malone, 1995; Peeraully et al., 2014; Schell et al., 1997; Squire et al., 1993).

The initial series described excising the appendix on its pedicle and then reimplanting into the taenia of the cecum, as popularized with the Penn pouch continent urinary reservoir. Modifications have progressed to leaving the appendix in situ and retroverting it (so that the serosa of the colon can be imbricated around it in an anti-refluxing fashion), to not imbricate the appendix (Chan et al., 2018). The procedure can be achieved in an open, laparoscopic, or robotic-assisted fashion (Zee et al., 2017; Fig. 36.16).

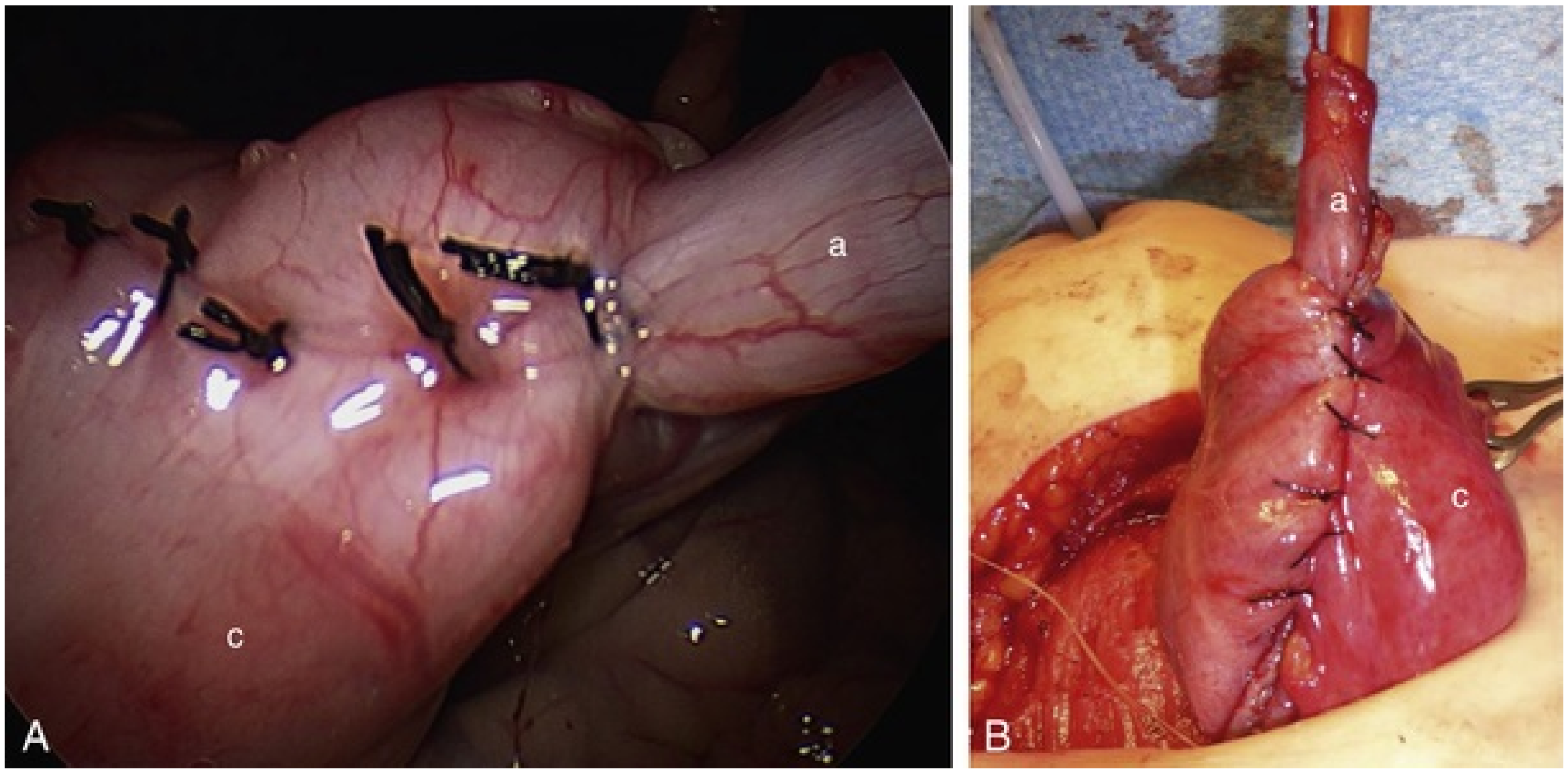

FIG. 36.16 Cecal wrap performed during laparoscopic (A) and open (B) MACE procedure. Note appendix in situ, retroverted with colon serosa imbricated around it in an antirefluxing fashion (*a,* appendix; *c,* cecum).

Nonsurgical Alternatives

In recent years, retrograde washouts have regained interest as a noninvasive way to gain fecal continence in neuropathic and non-neuropathic severe constipation with or without soiling. Although the use of retrograde enemas dates back centuries, the initial concept of using a large-volume saline enema administered through a balloon catheter was developed (Shandling and Gilmour, 1987). In more recent years, commercially available devices (such as the Peristeen transanal irrigation system or the cone-shaped enema tip) have gained some popularity because they provide a more streamlined and patient-friendly way to administer the enemas. The procedure reliably evacuates the descending and rectosigmoid colon in most patients with a variety of defecation disorders (Christensen and Krogh, 2010). Despite a high success rate and growing acceptance, use has been affected by costs and some difficulty with self-administration (Alhazmi et al., 2019; Corbett et al., 2014; Kelly et al., 2017;

López Pereira et al., 2010; Pacilli et al., 2014). This option is a reasonable first step in potential surgical patients, because it may delay or avoid the need for more invasive interventions or provide evidence that regular washouts lead to improvement before committing to antegrade enemas.

Patient Selection and Preparation

For those children in whom conservative measures fail, retrograde enema compliance becomes an issue, or in those who experience successful bowel management through rectal enemas but desire a more convenient means of administration, surgical MACE may be considered an option. Although fecal continence is comparable whether enemas are administered rectally versus antegrade (Matsuno et al., 2010), procedural independence is often optimal for patients performing antegrade enemas. As such, the MACE procedure should be seen as an option that allows patient independence and avoids rectal instrumentation. The underlying diagnosis is important as it influences the success rate. Other issues that may be considered include the presence, length, and quality of the appendix; need and timing of urinary tract reconstruction; patient age and potential intellectual capacity, as well as dexterity, ambulatory status, and body habitus.

Patients with a neuropathic bowel and anorectal malformations seem to fare better than those with chronic idiopathic constipation (Curry et al., 1998). Nevertheless, with increasing experience, modest success rates appear to be improving (Curry et al., 1999; Kokoska et al., 2001; Peeraully et al., 2014). Age at operation is also important, with failures more commonly seen in younger patients irrespective of the diagnosis (Curry et al., 1998). This may reflect inability of young children to sit on a toilet for up to 1 hour before emptying is complete or lack of drive to achieve continence (as seen in older children because of school and peer pressure). Favorable outcomes appear to decrease again after puberty (Christison-Lagay et al., 2010; Gerharz et al., 1997b; Sturkenboom et al., 2018). This may reflect the impact of changes in body habitus associated with transferring issues in those with neurologic conditions, combined attempts at independence with less caregiver support, and compliance issues with the washout regimen.

Just like any other catheterizing protocol, understanding and reinforcing information to the patient and her or his caregivers are essential. It cannot be overemphasized how important ongoing detailed counseling and continued support, pre- and postoperatively (ideally provided by a well-trained dedicated member of the team, such as a nurse practitioner), are to ensure adequate and continued motivation, without which the procedure is set for failure. The ideal patient for a MACE should be between the ages of 5 and 12 years of age, have a diagnosis of neuropathic bowel, anorectal malformation, or Hirschsprung disease, be well motivated with a dedicated family, and have tried and failed all conservative measures.

Operative Technique

Although preoperative bowel preparation may facilitate the initiation of postoperative enemas, an aggressive cleanout is not necessary for the purpose of performing the procedure. Appropriate prophylactic antibiotics are always administered perioperatively and may be adjusted based on any concurrent urinary tract reconstruction. In most instances where coincidental urinary tract surgery is to be performed, a lower midline or Pfannenstiel incision is selected, depending upon the patient's body habitus, prior surgical scars, and surgeon preference. Laparoscopy allows for identification of the appendix and mobilization of the colon, being particularly useful when the cecum is located high in the abdomen, close to the liver (Fig. 36.17). In such cases (often spina bifida patients with prior abdominal incisions and ventriculoperitoneal shunts), a large incision is avoided. In addition, the presence and status of the appendix can be confirmed. If only a MACE channel is to be performed, a pure laparoscopic or robotic approach, or an open appendectomy incision, can be employed, depending on the individual situation and surgeon experience and comfort.

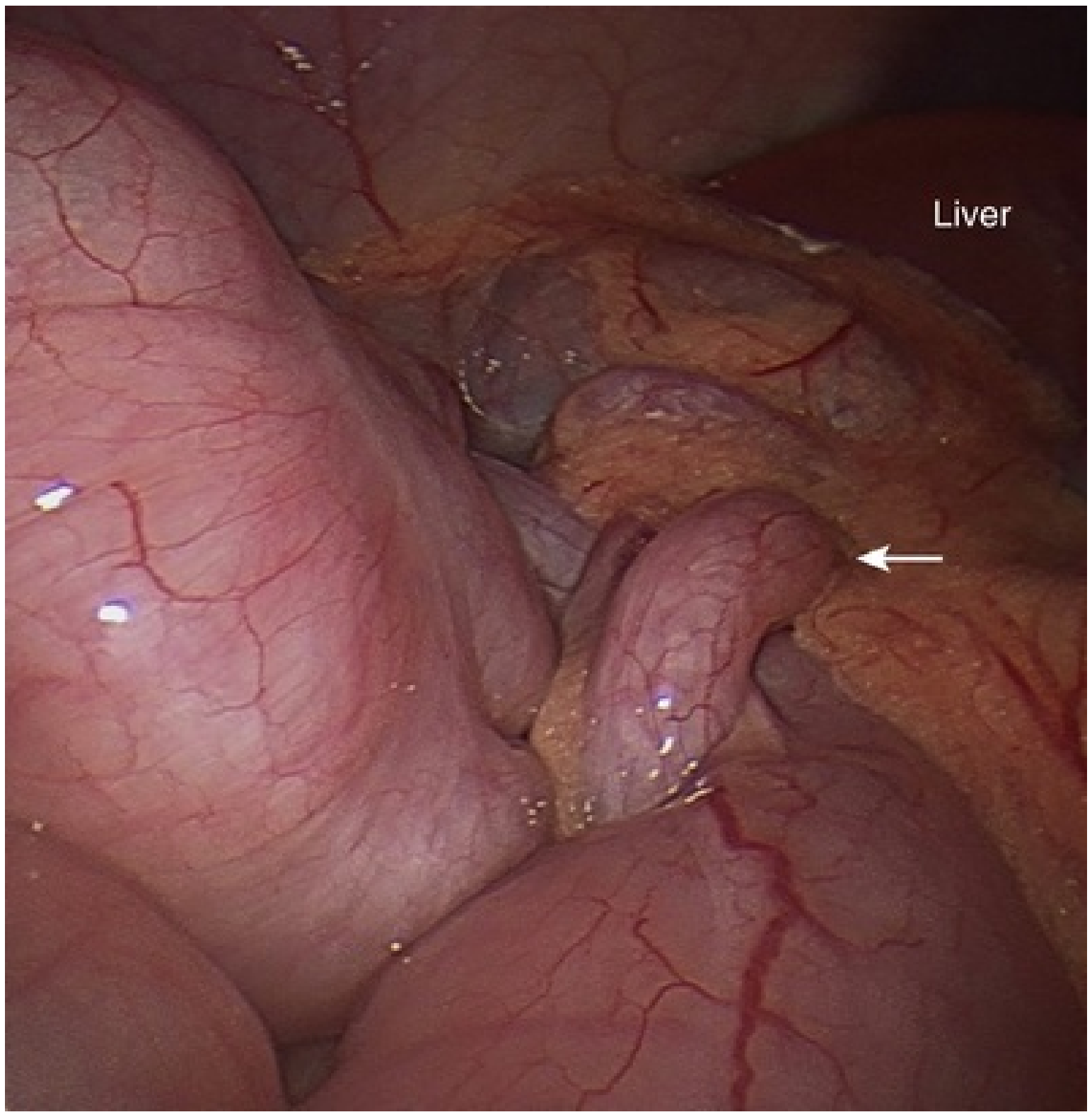

FIG. 36.17 Diagnostic laparoscopy as the initial step to laparoscopic or laparoscopic-assisted MACE procedure. Presence, quality, and location of the appendix can be easily determined. Note location of cecum and appendix *(arrow)* close to the liver in a child with spinal dysraphism.

In most descriptions of the ACE procedure an “antireflux” valve mechanism is fashioned to prevent leakage of bowel contents via the cutaneous stoma. Because the tendency is to maintain the appendix in situ, this is achieved by wrapping it with the cecal wall, an adaptation that follows the principle of the Nissen fundoplication (Koyle et al., 1995). This can be done in a minimally invasive way (Lawal et al., 2011; Nanigian and Kurzrock, 2008; Webb et al., 1997). To reduce the risk of compromising blood supply to the appendix, its mesentery is fenestrated to allow passage of sutures and tissue without entrapping the vessels (Fig. 36.18). The colon can also be sutured to the posterior aspect of the anterior abdominal wall to ensure that the catheterizable conduit is not lying free in the peritoneal cavity, preventing kinking and difficulties with catheterization. Recently it has been suggested that it is not necessary to construct an antireflux mechanism, and some have advocated avoiding this step and simply mobilizing the appendiceal-cecal unit to the abdominal stoma site, a procedure that is amenable to a purely laparoscopic or robotic-assisted approach (Fig. 36.19; Chan et al., 2018; Thakre et al., 2008;

Webb et al., 1997). Thus far, data appear to support similar rates of stomal bowel incontinence, based on retrospective reviews comparing MACE with and without cecal wrap (Chan et al., 2018; Koivusalo et al., 2006; Nanigian and Kurzrock, 2008).

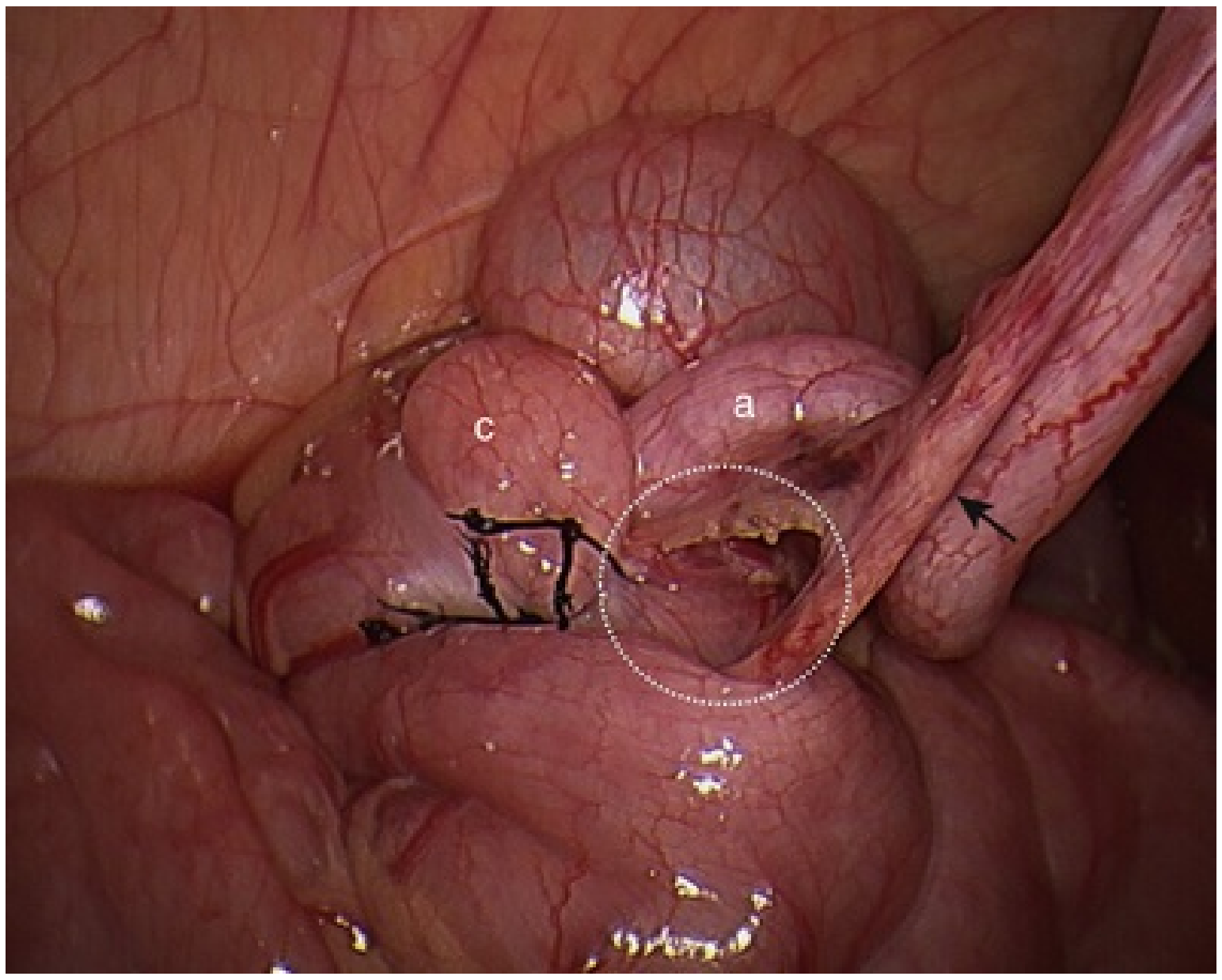

FIG. 36.18 Fenestration of the appendix mesentery during laparoscopic MACE procedure, allowing passage of suture and creation of a cecal wrap without compromise of the blood supply *(arrow)* (*a,* appendix; *c,* cecum).

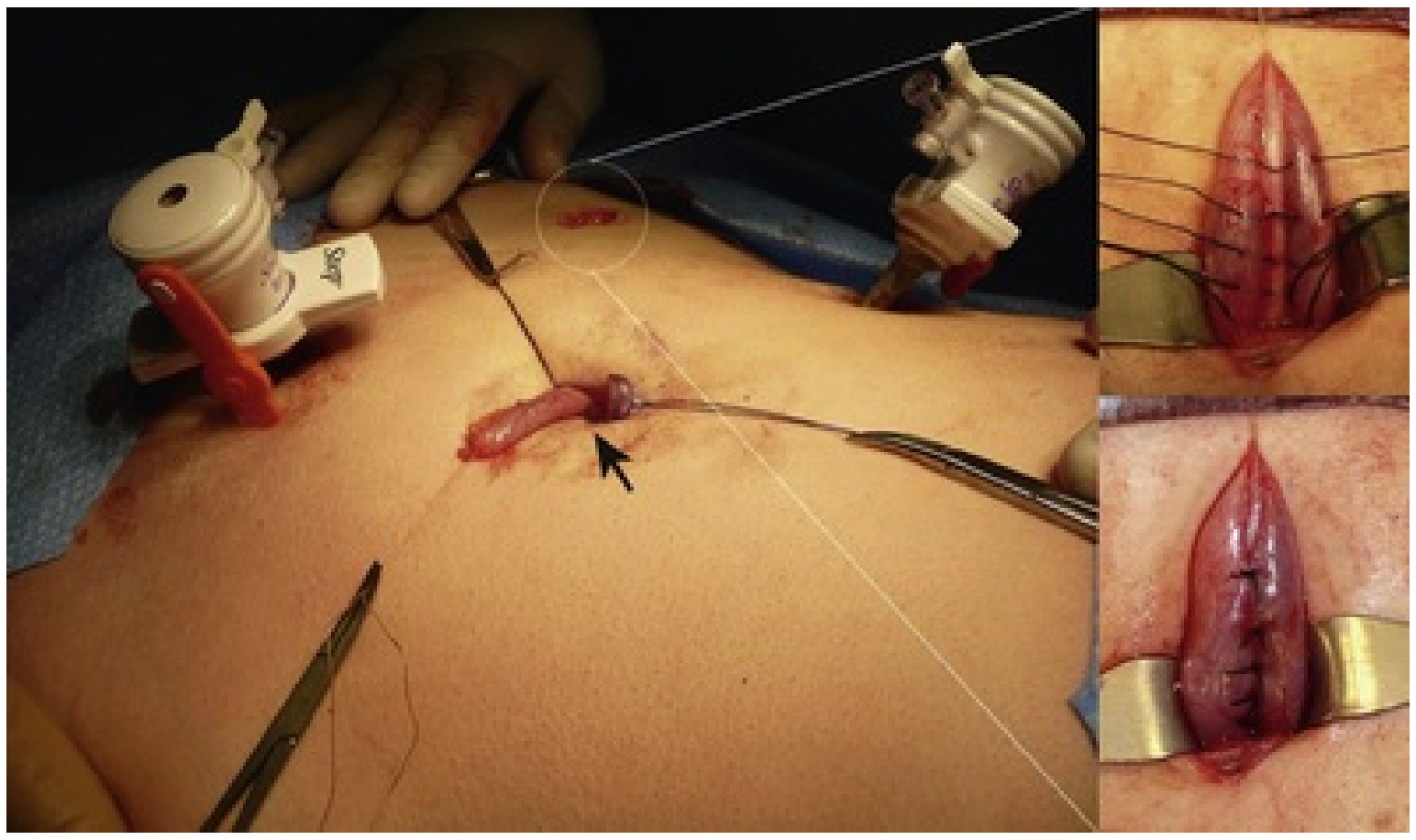

FIG. 36.19 Laparoscopic-assisted cecostomy tube take-down and creation of MACE channel with appendix. Open imbrication through C-tube scar allows creation of “antireflux” mechanism. Note tip of appendix delivered through camera port at umbilicus *(arrow).*

If the patient requires synchronous bladder reconstruction, simultaneous MACE and Mitrofanoff urinary diversion offers patients the chance for complete dual fecal and urinary continence (Casale et al., 2006; Roberts et al., 1995; Wedderburn et al., 2001). The technique must be modified if MACE and appendicovesicostomy procedures are being considered. If the appendix is long enough and the vascular anatomy is suitable, it is possible to split the appendix (Fig. 36.20). If the appendix is not suitable to be split or is absent, alternative options must be considered. In these cases tubularized colon flaps (Fig. 36.21) or cecal extension of the appendiceal stump with a surgical stapler (Fig. 36.22) can be done with relative ease, achieving good results with acceptable complication rates (Anselmo et al., 2017; Herndon et al., 2005; Kiely et al., 1994). The Monti-Yang procedure can also be employed as an alternative conduit (Monti et al., 1997), following the Mitrofanoff flap valve principle to implant in the bowel wall. Some advocate this option as the procedure of choice when the appendix is not available (Sugarman et al., 1998); it can be particularly advantageous in very obese patients, because the use of a spiral or two segments of bowel will produce a conduit long enough for almost all patients.

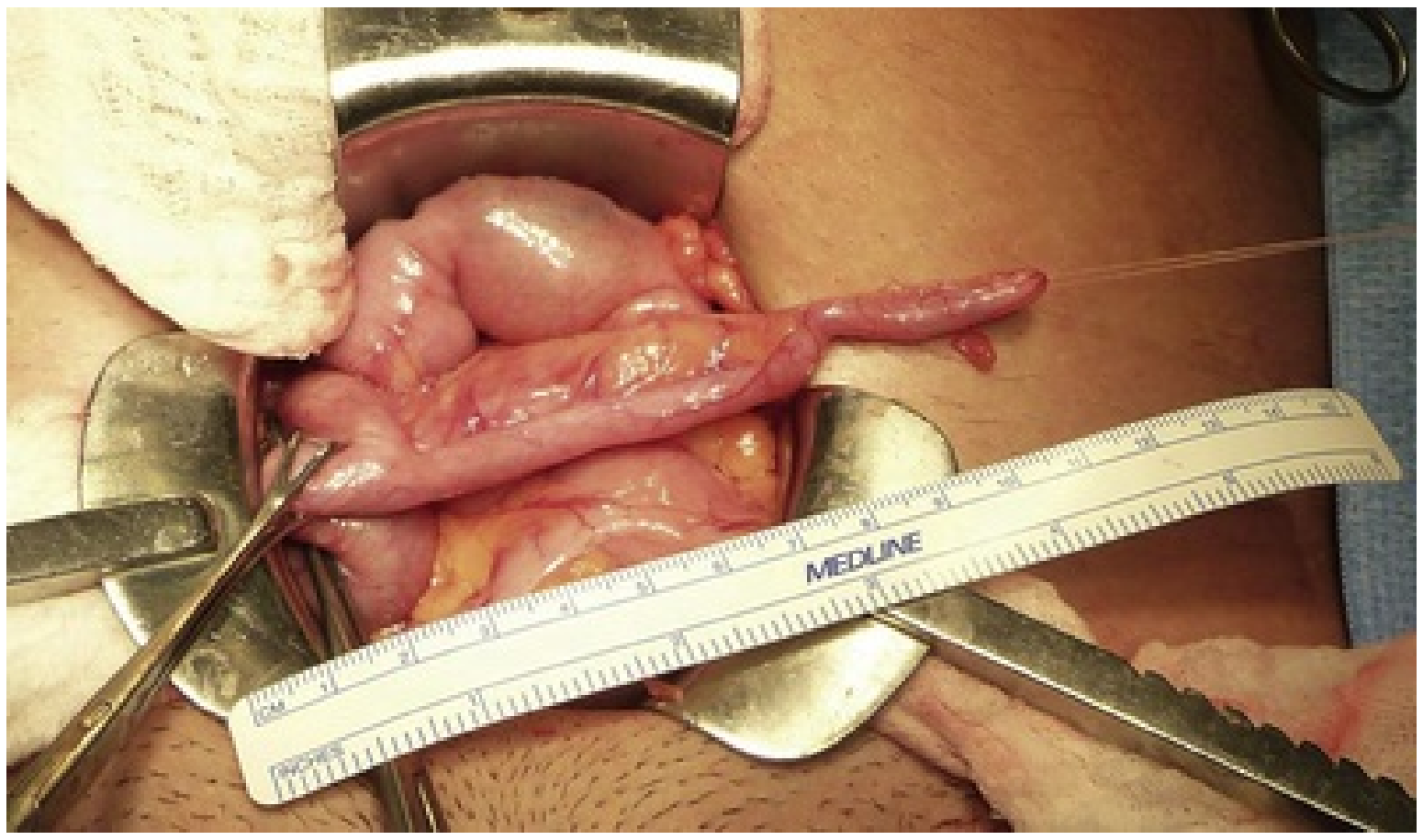

FIG. 36.20 Long appendix with robust blood supply, amenable to split for simultaneous MACE channel and appendicovesicostomy.

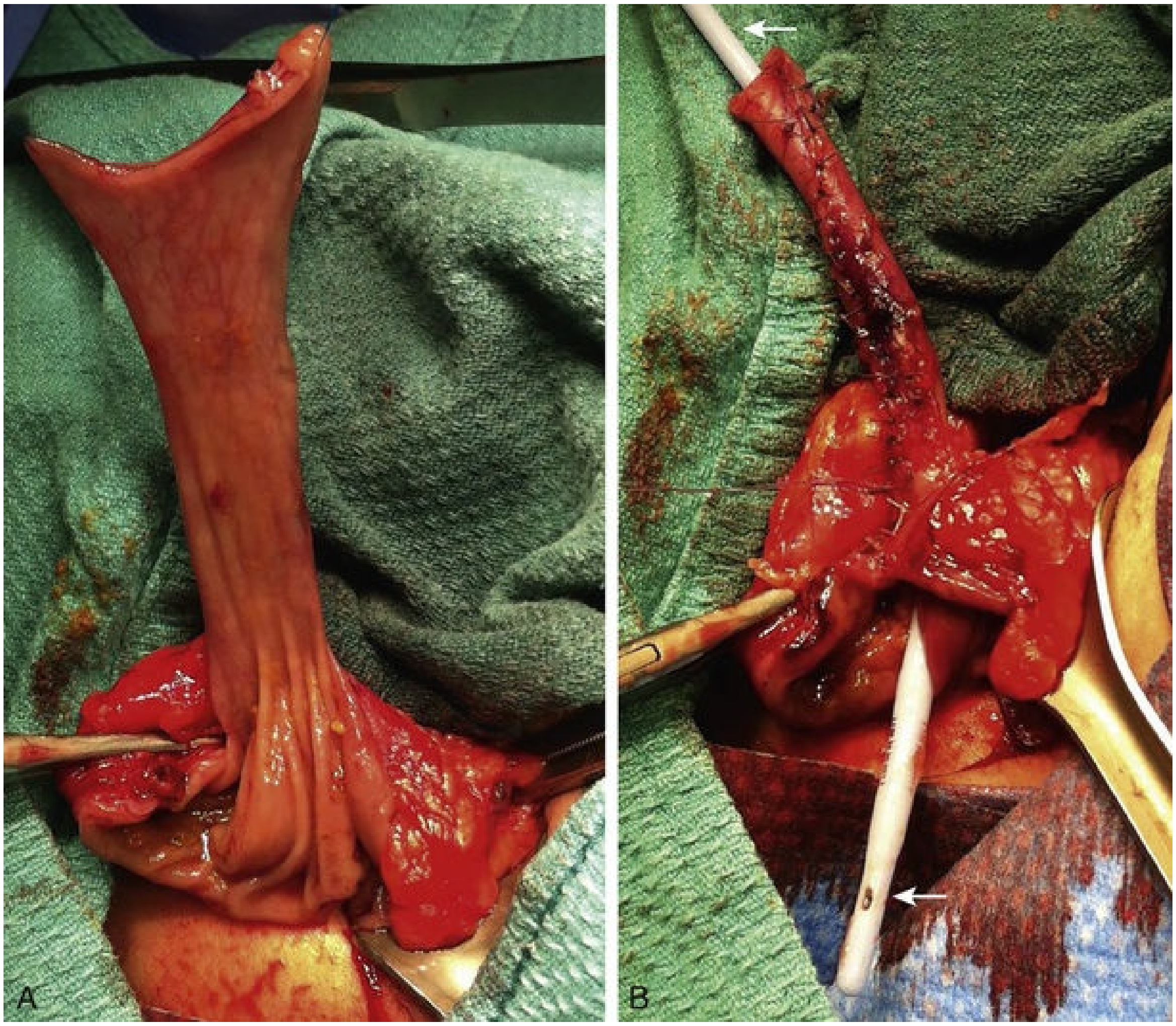

FIG. 36.21 Creation of access with a colon flap (A), tubularized and subsequently imbricated (B). This is suitable for catheterization for flushes to the left or right colon.

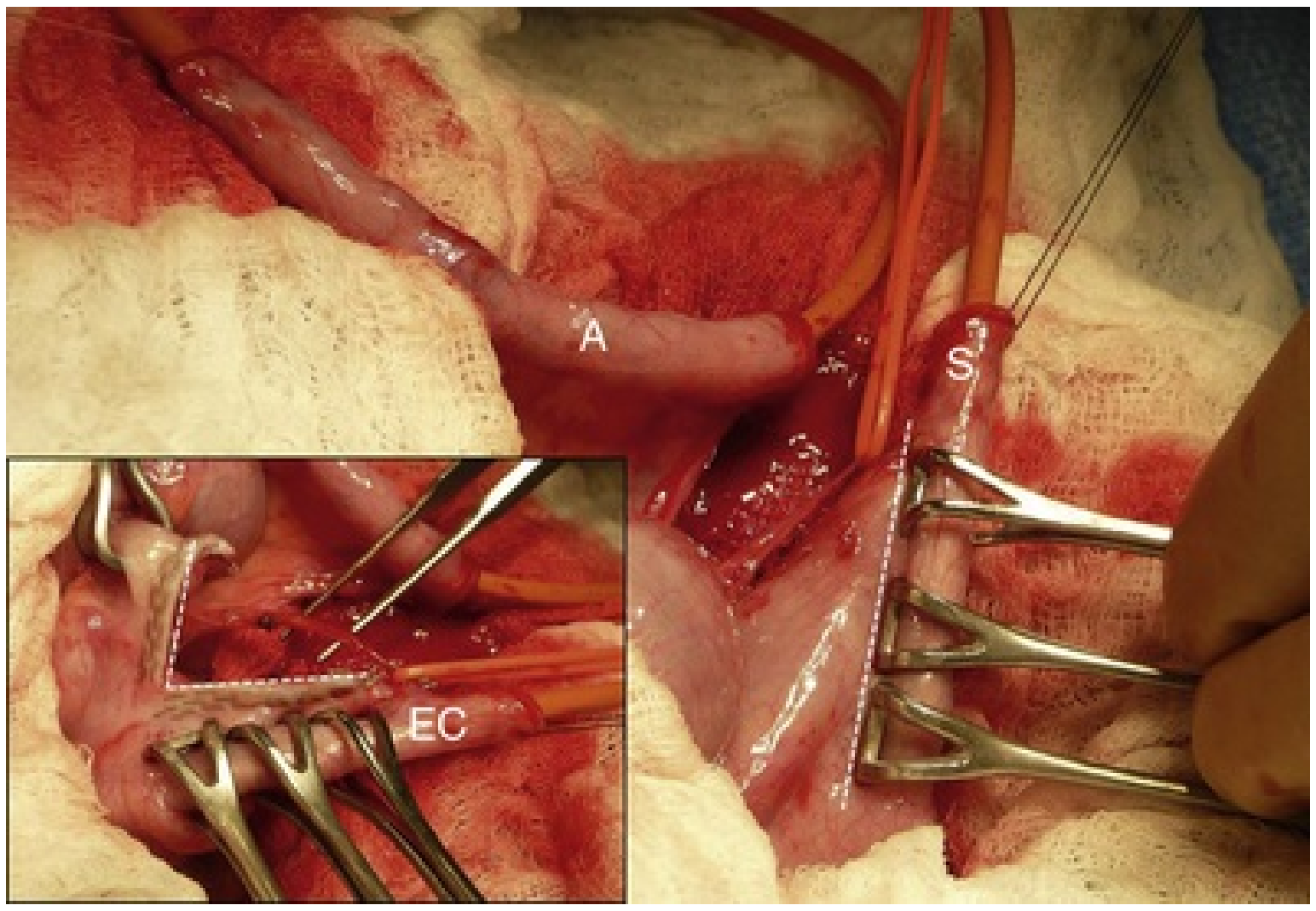

FIG. 36.22 Technique for cecal elongation of appendiceal stump with a surgical stapler effectively lengthening the channel, which is subsequently imbricated to prevent leakage (*A,* distal segment of appendix preserved for appendicovesicostomy; *EC,* elongated cecum; *S,* appendiceal stump).

Another option worthy of consideration is the use of either a cecostomy tube (C-tube or cecal button). Since the description by Chait et al. (Chait et al., 1997a,b), the technique for percutaneous placement of a cecal tube that can be regularly exchanged as a permanent, low-profile cecal button (similar to a gastrostomy button) has been refined. The cecostomy tube option is favored when the appendix is known to be absent (i.e., postappendectomy), when the patient refuses to perform intermittent bowel catheterization, for patients who develop stomal complications such as stenosis (as an alternative to revision of the MACE channel), as a temporary therapeutic challenge to determine response to antegrade enemas, or to determine if ideal placement of a permanent MACE should be in the right or left colon, and as a permanent option in cases in which a nonoperative access is favored. Long-term outcomes reported by Chait et al. (1997a), who performed the procedure percutaneously under fluoroscopic guidance, show successful placement in a large number of children with satisfactory outcomes, certainly similar to other approaches (Chait et al., 2003). The tube can also be placed open or under laparoscopic guidance at the time of concomitant appendicovesicostomy (Lorenzo et al., 2007). The main drawback is that the tube entry site can become unsightly, with granulation tissue and occasional fecal leakage (Fig. 36.23). In these cases, patients may opt for subsequent formal conversion to a bowel-based MACE, either laparoscopic or open (Fig. 36.24). Regardless, the tube or button can always be converted to a formal ACE with time, thus providing a reasonable initial option and bail out in complicated cases.

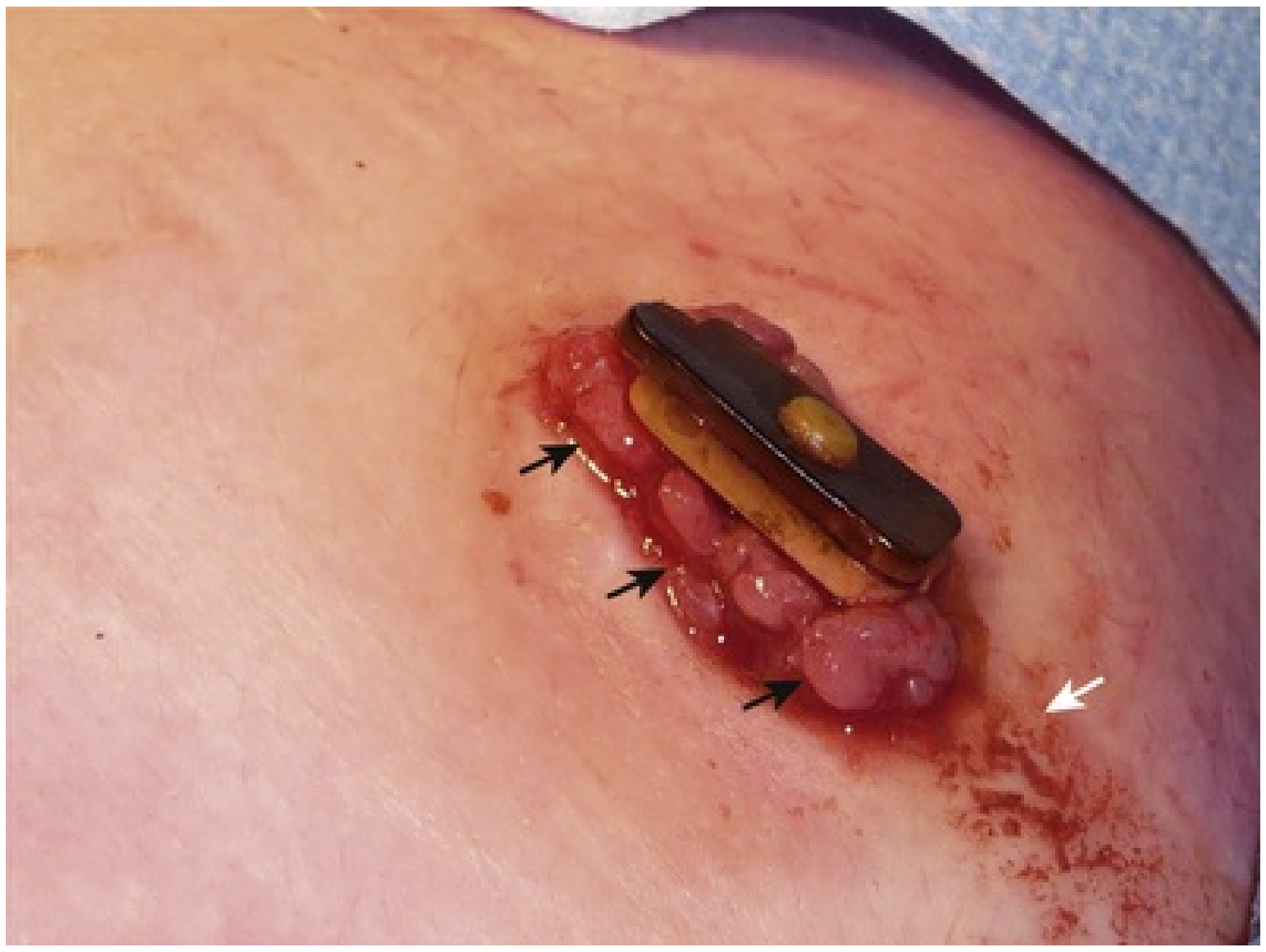

FIG. 36.23 Granulation tissue *(black arrows)* and leakage *(white arrow)* around cecostomy tube. Unsightly appearance and soiling can occur over time, which can lead to removal or conversion to a MACE channel.

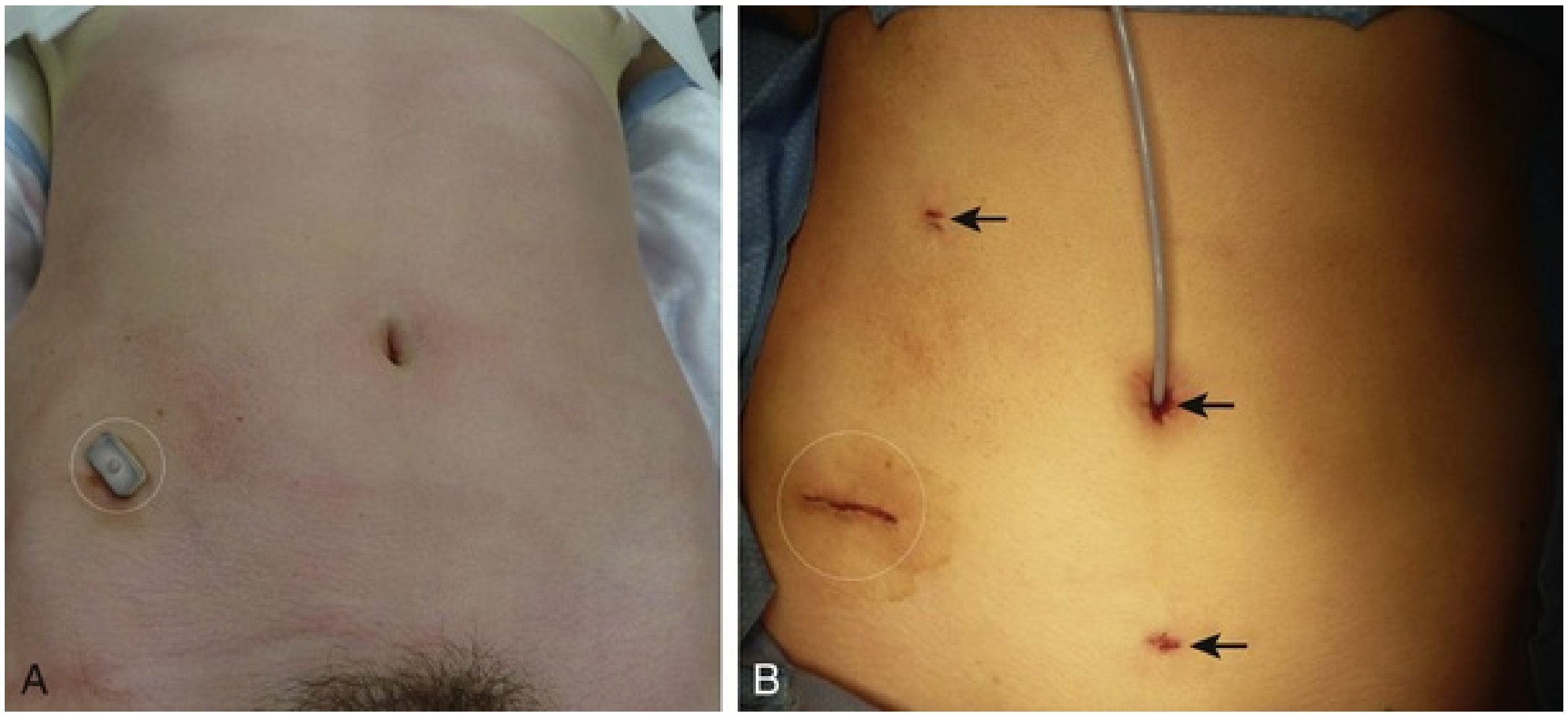

FIG. 36.24 Port placement *(arrows)* and cosmetic outcome of C-tube takedown and laparoscopic-assisted MACE creation (preop [A] and immediate postop [B]).

One of the problems occasionally encountered, particularly in children and adolescents with severe constipation and a redundant colon (Fig. 36.25), is the long time for the washout to actually work. This issue can lead to frustration, failure, and abandonment of the irrigations (Griffiths and Malone, 1995). In an attempt to rectify this problem, some have advocated placing the conduit in the left colon, rather than the cecum (Ellison et al., 2013). By doing so, the length of bowel that has to be washed through is reduced and theoretically so is the time taken for successful enema completion. Results using this approach have been encouraging, with similar outcomes and complication rates compared with traditional MACE (Blackburn et al., 2012; Churchill et al., 2003; Liloku et al., 2002; Meyer et al., 2008; Sinha et al., 2008), yet with less enema fluid requirements and shorter transit times (Sinha et al., 2008). A left MACE should strongly be considered in patients suffering from severe constipation. The decision between left or right access may be a difficult one and can be settled by temporarily placing a cecostomy or percutaneous colostomy tube. If equivalent or better on the right, then the in situ appendix is the simpler option.

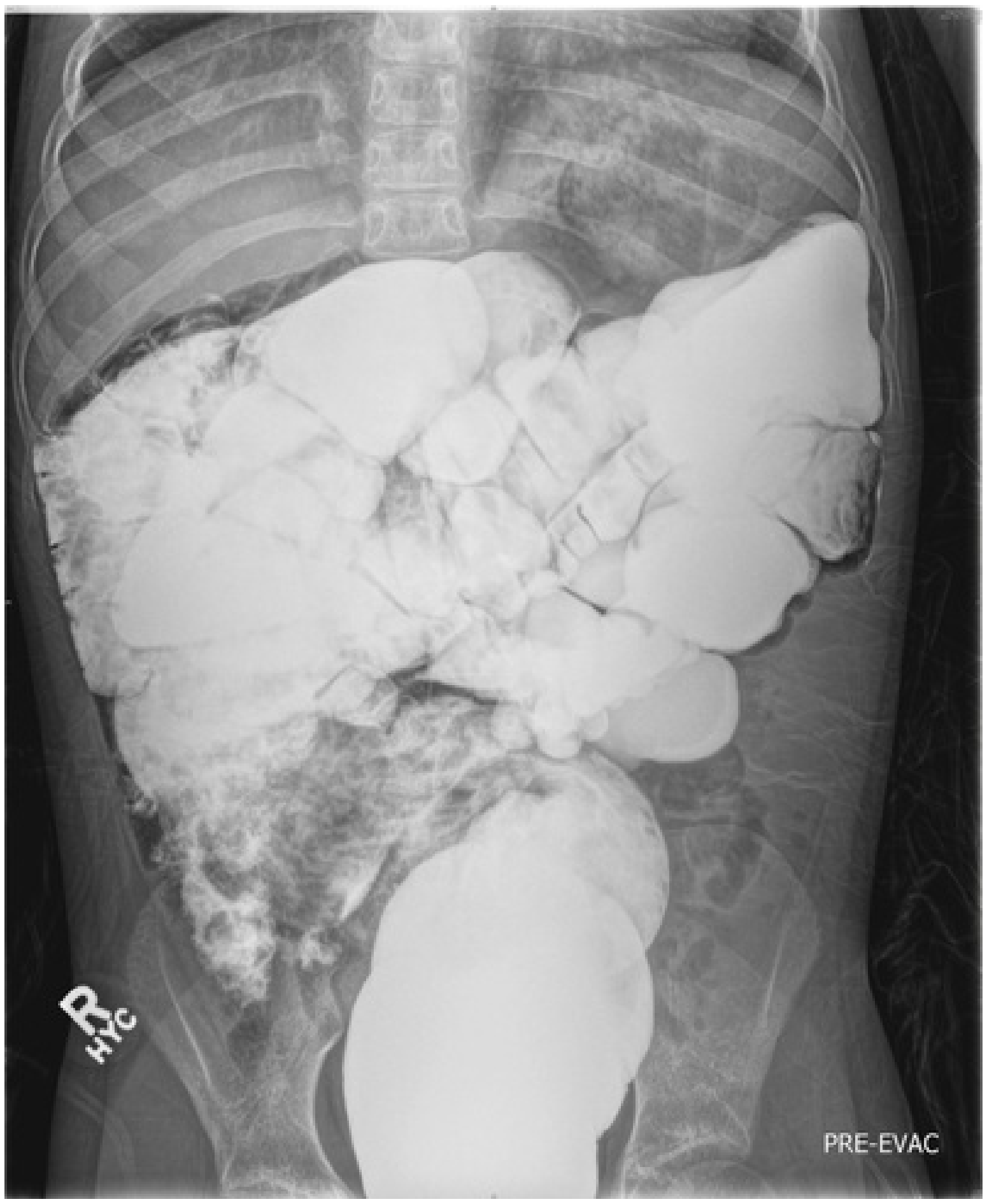

FIG. 36.25 Contrast enema study in a child with long-standing constipation demonstrating redundant colon without associated anatomic abnormalities or radiologic evidence of Hirschprung disease.

Enema Regimen

Although protocols differ, the first enema is commonly administered via the indwelling catheter or percutaneously placed tube after the postoperative ileus resolves, followed by a progressive escalation titrated to the desired effect. Considering individual patient needs and variable response, there is much “trial and error” involved. One of the most important points, especially in the early weeks and months after surgery, is to advise patients not to expect immediate success, because early disappointment can lead to frustration and failure. In fact, many children may not achieve a steady state or a reliable enema routine for a period of up to 6 months (Curry et al., 1998). Patients may also experience a degree of rectal leakage within the first few hours after the washout, but this does not appear to be a long-term problem. Although the washout regimen is established outside the hospital, it is vital to maintain regular contact with the nurse specialist who helps manage the process.

Enema protocols differ among centers, and patients and families frequently modify them to suit their own particular needs. Initially, daily washouts with 20 mL/kg of solution are encouraged, but once the patient is comfortable with the process and a routine has been established, they may attempt to decrease frequency to alternate days. The time of day that the enema is administered is patient dependent, although most families prefer to give the enema during the early evening hours, after dinner. This time is chosen to allow a sufficient interval to achieve the desired result before bedtime. Rarely, others learn that twice-daily cleanouts are necessary and adjust their frequency accordingly. Washout times range between 30 and 60 minutes. Because patients have to sit on the toilet for a long time, buttock pressure sores may develop, a complication that can be minimized with the use of padded toilet seats. Purges can be done with large-volume tap (Koyle et al., 1995; Yerkes et al., 2001) or salt water, with the judicious mix of additives such as glycerin, Bisacodyl, phosphate, magnesium citrate, mineral oil, or polyethylene glycol. Although uncommon, and depending on the solution used, water intoxication and/or electrolyte abnormalities may occur (Hunter et al., 1993; Schreiber and Stone, 1999). Changes and experimentation should only be done under supervision to minimize this risk. Once a steady state is achieved, there is little benefit from dramatically interfering or modifying the regimen.

Several difficulties can be experienced during enema infusion. The most common problem is pain or discomfort during instillation (Curry et al., 1998). In the majority of patients, this is a transient phenomenon that subsides during the first 3 months. Persistence beyond this time period can contribute to discontinuation. Warming the solution, lowering additive concentration, reducing the rate of the infusion, adding sodium chloride, or using an antispasmodic before the enema can be tried in these cases. It is always important to ensure that the pain is not due to distal fecal impaction (Fig. 36.26), which can occur despite regular washouts. These patients may require occasional retrograde cleanouts or be candidates for re-positioning the location of the access channel in the colon (cecum vs. right colon) (Churchill et al., 2003; Liloku et al., 2002).

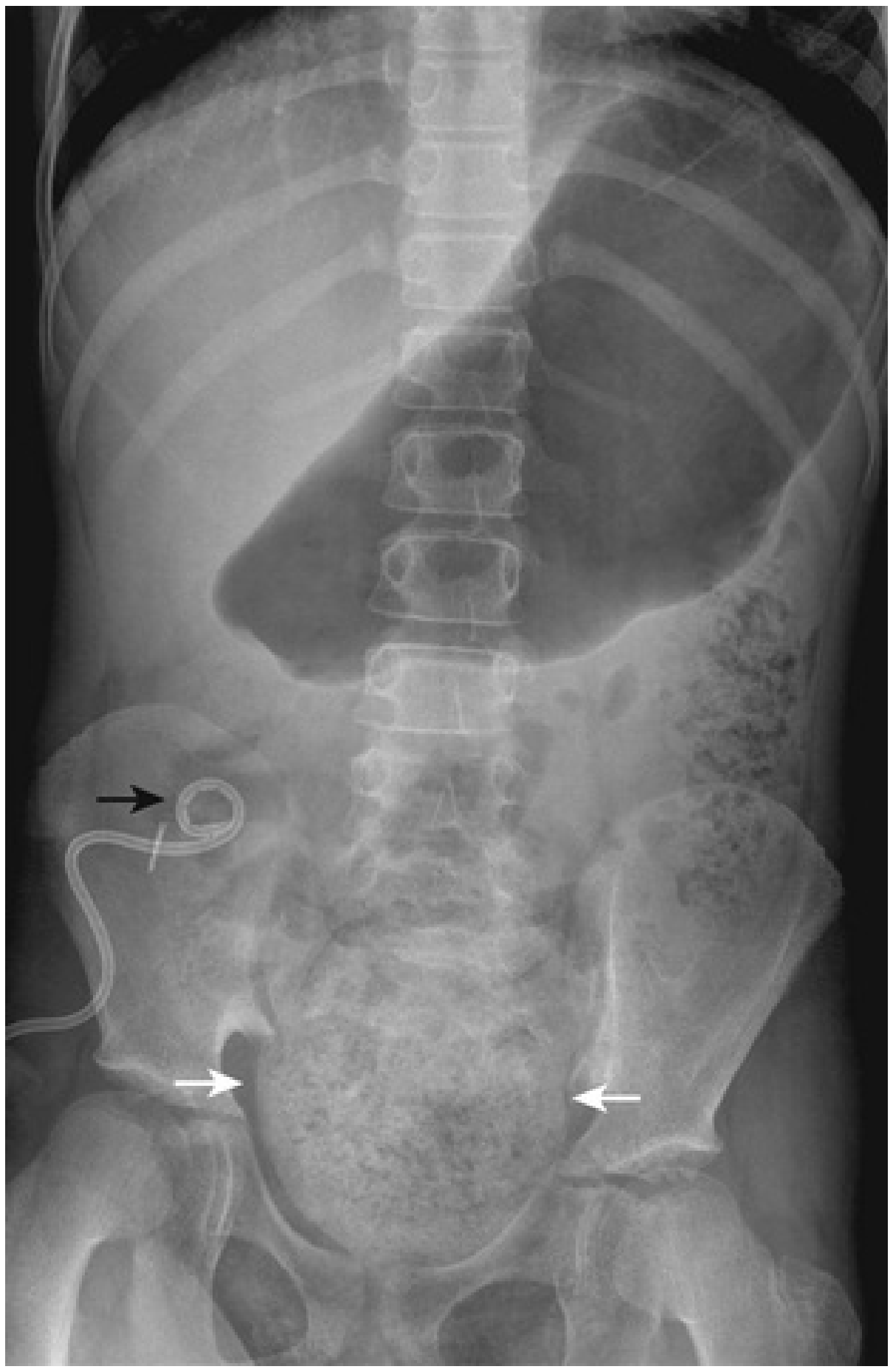

FIG. 36.26 Presence of a large amount of fecal material in the distal colon and rectum *(white arrows).* This patient became impacted while doing infrequent antegrade enemas through a cecostomy access *(black arrow).*

Attempts at clearing this fecal load with antegrade flushes only led to abdominal pain, lack of tolerance, and poor response. Improvement was achieved with disimpaction and retrograde enemas followed by diligent, regular antegrade flushes to achieve complete washout.

Surgical Outcomes

In a survey of 300 ACE procedures performed by members of the British Association of Paediatric Surgeons (BAPS), Curry et al. (1999) reported that success rates were dependent on the original diagnosis (Table 36.4). This large national series reported an overall full and partial success rate of 79%, with complication rates that were lower than in earlier historical series. In particular, stomal stenosis rates were reduced to 30%.

TABLE 36.4

MACE Procedure Success and Failure[a] Based on Underlying Condition

DIAGNOSIS	FULL SUCCESS %	PARTIAL %	FAILURE %
Spina bifida	63	21	16
Anorectal malformation	72	17	11
Hirschsprung disease	82	9	9
Idiopathic constipation	52	10	38
Other	44	25	31

[a] Surgical results have been classified as follows (16): Full success: totally clean or minor rectal leakage on the night of the washout; partial success: clean but significant rectal leakage, occasional major leak, still wearing protection, but perceived by the parent or child to be an improved; failure: regular soiling or constipation persists, no perceived improvement, and the irrigations are abandoned.

Standardized tools have been employed to reflect improvements in quality of life (Shankar et al., 1998), self-esteem, psychosocial function (Aksnes et al., 2002), and fecal incontinence and constipation-related quality of life (including anxiety and family worry) (Ok and Kurzrock, 2011). Nonvalidated questionnaires have shown high satisfaction rates, with a majority of respondents recommending the procedure to others with intractable defecation disorders (Hoekstra et al., 2011).

For patients undergoing synchronous bladder reconstruction and ACE procedures, a high percentage of fecal and urinary continence should be expected, with variable complication rates (Kajbafzadeh and Chubak, 2001; Wedderburn et al., 2001) and no adverse impact compared with patients undergoing staged reconstruction (Casale et al., 2006). Stomal complications and difficulty catheterizing the conduits remain the most important postoperative problems (Barqawi et al., 2004). For example, Curry et al. (1998) reported an incidence of 55% for stomal complications. Ransley's VQZ-flap has been advocated as a technique to reduce the incidence of stenosis when the MACE is directed to a position other than the umbilicus (Landau et al., 2008; Malone et al., 1998; McAndrew and Malone, 2002). Conduit perforation and intraperitoneal enema instillation occurs rarely (3.7% over a 13-year period) but can result in significant morbidity and need for emergency surgical exploration (DeFoor et al., 2005). If suspected, a contrast study through the channel may help establish the diagnosis (Fig. 36.27).

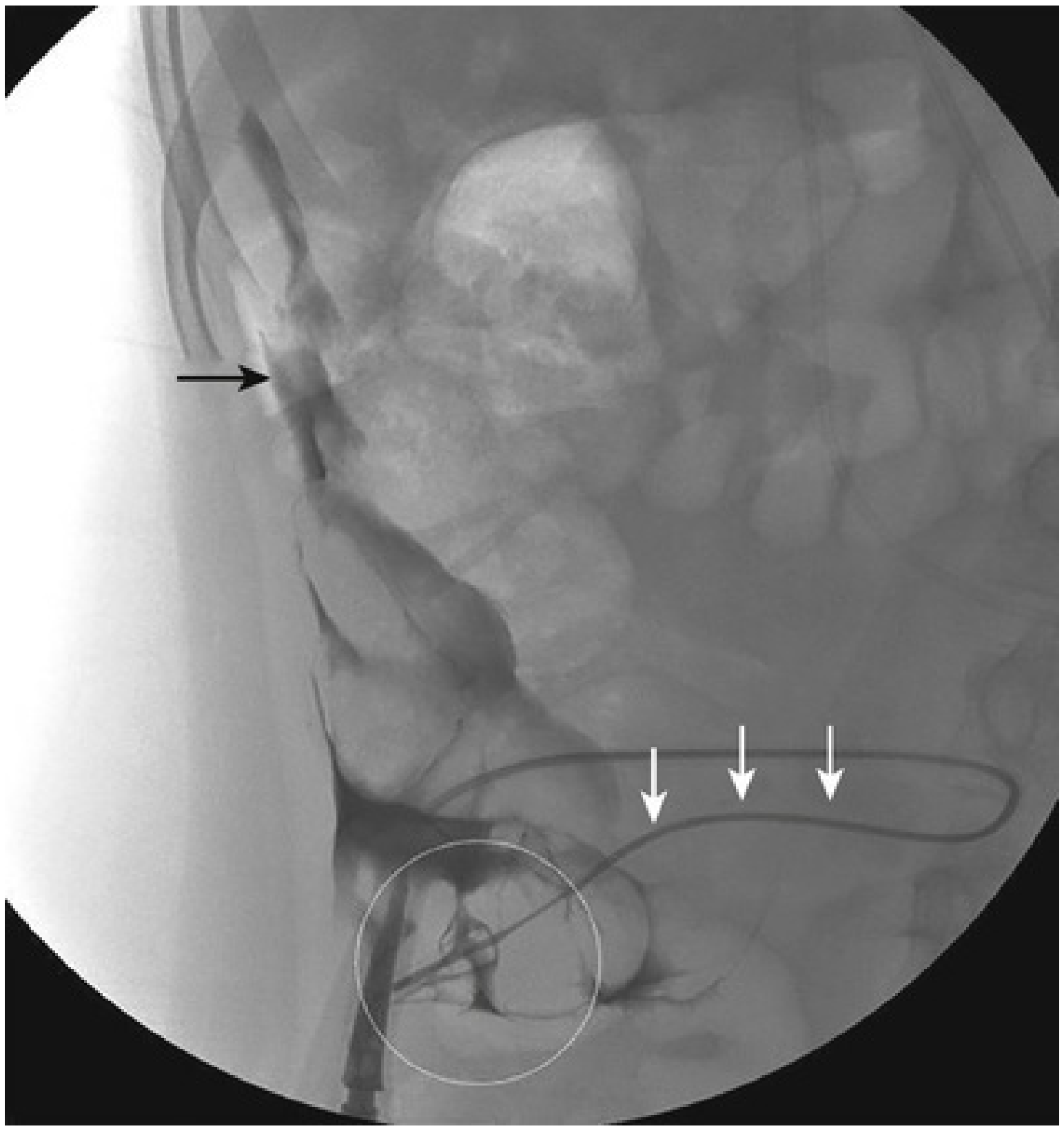

FIG. 36.27 Water-soluble contrast study through catheter placed in MACE channel *(white arrows)* to evaluate possible perforation *(black arrow).*

Key Points

- Surgical management of defecation disorders has been revolutionized with the concept of antegrade enemas, delivered through a catheterizable channel (MACE) or a cecostomy tube. This enables the patient to evacuate the colon at regular intervals, avoiding impaction and reducing fecal incontinence.
- Retrograde (transanal) washouts with a balloon catheter in the rectum represent a viable and less invasive alternative, which is gaining popularity in the management of neuropathic and non-neuropathic defecation disorders.
- Patient selection is critical, and candidates should have failed maximal conventional measures before proceeding to invasive options.
- Although individual variations are expected, patients commonly do washouts on a regular basis (daily or every other day) to achieve continence.
- Concurrent reconstruction of the gastrointestinal and genitourinary tract is feasible in most cases, with adaptations to fashion access to bladder and bowel employing available bowel segments.
- Surgical options include open, laparoscopic, robotic-assisted, and percutaneous techniques.

Suggested Readings

Curry JI, Osborne A, Malone PS. The MACE procedure: experience in the United Kingdom. *J Pediatr Surg*. 1999;34(2):338–340.

DeFoor W, Minevich E, Reddy P, et al. Perforation of Malone antegrade continence enema: diagnosis and management. *Juro*. 2005;174(4 Pt 2):1644–1646.

Koyle MA, Kaji DM, Duque M, et al. The Malone antegrade continence enema for neurogenic and structural fecal incontinence and constipation. *Juro*. 1995;154(2 Pt 2):759–761.

Lorenzo AJ, Chait PG, Wallis MC, et al. Minimally invasive approach for treatment of urinary and fecal incontinence in selected patients with spina bifida. *Urology*. 2007;70(3):568–571 [(online journal)] http://doi.org/10.1016/j.urology.2007.04.026.

Malone PS, Curry JI, Osborne A. The antegrade continence enema procedure why, when and how? *World J Urol*. 1998;16(4):274–278.

Malone PS, Ransley PG, Kiely EM. Preliminary report: the antegrade continence enema. *Lancet*. 1990;336(8725):1217–1218.

Nurko S, Scott SM. Coexistence of constipation and incontinence in children and adults. *Best Pract Res Clin Gastroenterol*. 2011;25(1):29–41 [(online journal)] http://doi.org/10.1016/j.bpg.2010.12.002.

Pijpers MAM, Bongers MEJ, Benninga MA, et al. Functional constipation in children: a systematic review on prognosis and predictive factors. *J Pediatr Gastroenterol Nutr*. 2010;50(3):256–268 [(online journal)] http://doi.org/10.1097/MPG.0b013e3181afcdc3.

Sinha CK, Butler C, Haddad M. Left Antegrade Continent Enema (LACE): review of the literature. *Eur J Pediatr Surg*. 2008;18(4):215–218 [(online journal)] http://doi.org/10.1055/s-2008-1038499.

Sturkenboom R, van der Wilt AA, van Kuijk SMJ, et al. Long-term outcomes of a Malone antegrade continence enema (MACE) for the treatment of fecal incontinence or constipation in adults. *Int J Colorect Dis*. 2018;33(10):1341–1348 [(online journal)] http://doi.org/10.1007/s00384-018-3088-5.

Sugarman ID, Malone PS, Terry TR, et al. Transversely tubularized ileal segments for the Mitrofanoff or Malone antegrade colonic enema procedures: the Monti principle. *Br J Urol*. 1998;81(2):253–256.

van den Berg MM, Benninga MA, Di Lorenzo C. Epidemiology of childhood constipation: a systematic review. *Am J Gastroenterol*. 2006;101(10):2401–2409 http://doi.org/10.1111/j.1572-0241.2006.00771.x.

Yerkes EB, Rink RC, King S, et al. Tap water and the Malone antegrade continence enema: a safe combination? *Juro*. 2001;166(4):1476–1478.

Youssef NN, Di Lorenzo C. Treatment options for refractory childhood constipation. *Curr Treat Options Gastroenterol*. 2002;5(5):377–387.

Zeevenhooven J, Koppen IJN, Benninga MA. The new Rome IV Criteria for functional gastrointestinal disorders in infants and toddlers. *Pediatr Gastroenterol Hepatol Nutr*. 2017;20(1):1–13 [(online journal)] http://doi.org/10.5223/pghn.2017.20.1.1.

References

Aksnes G, Diseth TH, Helseth A, et al. Appendicostomy for antegrade enema: effects on somatic and psychosocial functioning in children with myelomeningocele. *Pediatrics*. 2002;109(3):484–489.

Alhazmi H, Trbay M, Alqarni N, et al. Long-term results using a transanal irrigation system (Peristeen®) for treatment of stool incontinence in children with myelomeningocele. *J Pediatr Urol*. 2019;15(1) [(online journal)] http://doi.org/10.1016/j.jpurol.2018.08.013.

Anselmo CB, do Amaral RDR, Oliveira DEG, et al. Left-colon antegrade enema (LACE): Long-term experience with the Macedo-Malone approach. *Neurourol Urodyn*. 2017;36(1):111–115 [(online journal)] http://doi.org/10.1002/nau.22880.

Barqawi A, de Valdenebro M, Furness PD, et al. Lessons learned from stomal complications in children with cutaneous catheterizable continent stomas. *BJU Int*. 2004;94(9):1344–1347 [(online journal)] http://doi.org/10.1111/j.1464-410X.2004.05171.x.

Barr RG, Levine MD, Wilkinson RH, et al. Chronic and occult stool retention: a clinical tool for its evaluation in school-aged children. *Clin Pediatr*. 1979;18(11):674–679.

Benninga MA, Faure C, Hyman PE, et al. Childhood functional gastrointestinal disorders: neonate/toddler. *Gastroenterology*. 2016;150(6):1443–1445 [(online journal)] http://doi.org/10.1053/j.gastro.2016.02.016.

Blackburn SC, Fishman JR, Geoghegan N, et al. The first 5-year follow up of distal antegrade continence enema stomas. *J Pediatr Urol*. 2012;8(1):17–19 [(online journal)] http://doi.org/10.1016/j.jpurol.2011.01.005.

Blethyn AJ, Verrier Jones K, Newcombe R, et al. Radiological assessment of constipation. *Arch Dis Childhood*. 1995;73(6):532–533.

Bongers MEJ, van den Berg MM, Reitsma JB, et al. A randomized controlled trial of enemas in combination with oral laxative therapy for children with chronic constipation. *Clin Gastroenterol Hepatol*. 2009;7(10):1069–1074 [(online journal)] http://doi.org/10.1016/j.cgh.2009.06.018.

Bongers MEJ, van Wijk MP, Reitsma JB, et al. Long-term prognosis for childhood constipation: clinical outcomes in adulthood. *Pediatrics*. 2010;126(1) [(online journal): e156–62] http://doi.org/10.1542/peds.2009-1009.

Burgers RE, Mugie SM, Chase J, et al. Management of functional constipation in children with lower urinary tract symptoms: report from the Standardization Committee of the International Children's Continence Society. *J Urol*. 2013;190(1):29–36 [(online journal)] http://doi.org/10.1016/j.juro.2013.01.001.

Burgers R, Liem O, Canon S, et al. Effect of rectal distention on lower urinary tract function in children. *J Urol*. 2010;184(4 Suppl):1680–1685 [(online journal)] http://doi.org/10.1016/j.juro.2010.03.120.

Bush NC, Shah A, Barber T, et al. Randomized, double-blind, placebo-controlled trial of polyethylene glycol (MiraLAX®) for urinary urge symptoms. *J Pediatr Urol*. 2013;9(5):597–604 [(online journal)] http://doi.org/10.1016/j.jpurol.2012.10.011.

Casale AJ, Metcalfe PD, Kaefer MA, et al. Total continence reconstruction: a comparison to staged reconstruction of neuropathic bowel and bladder. *Juro*. 2006;176(4 Pt 2):1712–1715 [(online journal)] http://doi.org/10.1016/j.juro.2006.04.086.

Castillejo G, Bulló M, Anguera A, et al. A controlled, randomized, double-blind trial to evaluate the effect of a supplement of cocoa husk that is rich in dietary fiber on colonic transit in constipated pediatric patients. *Pediatrics*. 2006;118(3):e641–e648 [(online journal)] http://doi.org/10.1542/peds.2006-0090.

Chait PG, Shandling B, Richards HF. The cecostomy button. *J Pediatr Surg*. 1997;32(6):849–851.

Chait PG, Shandling B, Richards HM, et al. Fecal incontinence in children: treatment with percutaneous cecostomy tube placement–a prospective study. *Radiology*. 1997;203(3):621–624 [(online journal)] http://doi.org/10.1148/radiology.203.3.9169678.

Chait PG, Shlomovitz E, Connolly BL, et al. Percutaneous cecostomy: updates in technique and patient care. *Radiology*. 2003;227(1):246–250 [(online journal)] http://doi.org/10.1148/radiol.2271020574.

Chan YY, Gonzalez R, Kurzrock EA. Malone antegrade continence enema: is cecal imbrication essential? *J Pediatr Urol*. 2018;14(6):546.e1–546.e2 [(online journal)] http://doi.org/10.1016/j.jpurol.2018.05.019.

Chmielewska A, Szajewska H. Systematic review of randomised controlled trials: probiotics for functional constipation. *World J Gastroenterol*. 2010;16(1):69–75.

Chmielewska A, Horvath A, Dziechciarz P, et al. Glucomannan is not effective for the treatment of functional constipation in children: a double-blind, placebo-controlled, randomized trial. *Clin Nutr*. 2011;30(4):462–468 [(online journal)] http://doi.org/10.1016/j.clnu.2011.01.012.

Christensen P, Krogh K. Transanal irrigation for disordered defecation: a systematic review. *Scand J Gastroenterol*. 2010;45(5):517–527 [(online journal)] http://doi.org/10.3109/00365520903583855.

Christison-Lagay ER, Rodriguez L, Kurtz M, et al. Antegrade colonic enemas and intestinal diversion are highly effective in the management of children with intractable constipation. *J Pediatr Surg*. 2010;45(1):213–219 [(online journal)] http://doi.org/10.1016/j.jpedsurg.2009.10.034.

Chumpitazi BP, Lane MM, Czyzewski DI, et al. Creation and initial evaluation of a Stool Form Scale for children. *J Pediatr*. 2010;157(4):594–597 [(online journal)] http://doi.org/10.1016/j.jpeds.2010.04.040.

Churchill BM, De Ugarte DA, Atkinson JB. Left-colon antegrade continence enema (LACE) procedure for fecal incontinence. *J Pediatr Surg*. 2003;38(12):1778–1780.

Corbett P, Denny A, Dick K, et al. Peristeen integrated transanal irrigation system successfully treats faecal incontinence in children. *J Pediatr Urol*. 2014;10(2):219–222 [(online journal)] http://doi.org/10.1016/j.jpurol.2013.08.006.

Curry JI, Osborne A, Malone PS. How to achieve a successful Malone antegrade continence enema. *J Pediatr Surg*. 1998;33(1):138–141.

Curry JI, Osborne A, Malone PS. The MACE procedure: experience in the United Kingdom. *J Pediatr Surg*. 1999;34(2):338–340.

DeFoor W, Minevich E, Reddy P, et al. Perforation of Malone antegrade continence enema: diagnosis and management. *Juro*. 2005;174(4 Pt 2):1644–1646.

Dick AC, McCallion WA, Brown S, et al. Antegrade colonic enemas. *Br J Surg*. 1996;83(5):642–643.

Diederen K, Mugie SM, Benninga MA. Efficacy and safety of prucalopride in adults and children with chronic constipation. *Exp Opin Pharmacother*. 2015;16(3):407–416 [(online journal)] http://doi.org/10.1517/14656566.2015.996547.

Ellison JS, Haraway AN, Park JM. The distal left Malone antegrade continence enema–is it better? *J Urol*. 2013;190(4 Suppl):1529–1533 [(online journal)] http://doi.org/10.1016/j.juro.2013.01.092.

Erickson BA, Austin JC, Cooper CS, et al. Polyethylene glycol 3350 for constipation in children with dysfunctional elimination. *Juro*. 2003;170(4 Pt 2):1518–1520 [(online journal)] http://doi.org/10.1097/01.ju.0000083730.70185.75.

Fontana M, Bianchi C, Cataldo F, et al. Bowel frequency in healthy children. *Acta Paediatr Scand*. 1989;78(5):682–684.

Gerharz EW, Vik V, Webb G, et al. The in situ appendix in the Malone antegrade continence enema procedure for faecal incontinence. *Br J Urol*. 1997;79(6):985–986.

Gerharz EW, Vik V, Webb G, et al. The value of the MACE (Malone antegrade colonic enema) procedure in adult patients. *J Am Coll Surg*. 1997;185(6):544–547.

Ghosh A, Griffiths DM. Rectal biopsy in the investigation of constipation. *Arch Dis Child*. 1998;79(3):266–268.

Gordon M, Naidoo K, Akobeng AK, et al. Osmotic and stimulant laxatives for the management of childhood constipation. *Cochrane Database Syst Rev*. 2012;(7) [CD009118; (online journal)] http://doi.org/10.1002/14651858.CD009118.pub2.

Gordon M, Naidoo K, Akobeng AK, et al. Cochrane Review: osmotic and stimulant laxatives for the management of childhood constipation (Review). *Evid Based Child Health*. 2013;8(1):57–109 [(online journal)] http://doi.org/10.1002/ebch.1893.

Griffiths DM, Malone PS. The Malone antegrade continence enema. *J Pediatr Surg*. 1995;30(1):68–71.

Herndon CDA, Cain MP, Casale AJ, et al. The colon flap/extension Malone antegrade continence enema: an alternative to the Monti-Malone antegrade continence enema. *Juro*. 2005;174(1):299–302 [(online journal)] http://doi.org/10.1097/01.ju.0000161215.67278.99.

Hoekstra LT, Kuijper CF, Bakx R, et al. The Malone antegrade continence enema procedure: the Amsterdam experience. *J Pediatr Surg*. 2011;46(8):1603–1608 [(online journal)] http://doi.org/10.1016/j.jpedsurg.2011.04.050.

Hunter MF, Ashton MR, Griffiths DM, et al. Hyperphosphataemia after enemas in childhood: prevention and treatment. *Arch Dis Child*. 1993;68(2):233–234.

Hyman PE, Milla PJ, Benninga MA, et al. Childhood functional gastrointestinal disorders: neonate/toddler. *Gastroenterology*. 2006;130(5):1519–1526 [(online journal)] http://doi.org/10.1053/j.gastro.2005.11.065.

Joensson IM, Siggaard C, Rittig S, et al. Transabdominal ultrasound of rectum as a diagnostic tool in childhood constipation. *J Urol*. 2008;179(5):1997–2002 [(online journal)] http://doi.org/10.1016/j.juro.2008.01.055.

Kajbafzadeh AM, Chubak N. Simultaneous Malone antegrade continent enema and Mitrofanoff principle using the divided appendix: report of a new technique for prevention of stoma complications. *Juro*. 2001;165(6 Pt 2):2404–2409.

Kelly MS, Dorgalli C, McLorie G, et al. Prospective evaluation of Peristeen® transanal irrigation system with the validated neurogenic bowel dysfunction score sheet in the pediatric population. *Neurourol Urodyn*. 2017;36(3):632–635 [(online journal)] http://doi.org/10.1002/nau.22979.

Kiely EM, Ade-Ajayi N, Wheeler RA. Caecal flap conduit for antegrade continence enemas. *Br J Surg*. 1994;81(8):1215.

Klijn AJ, Asselman M, Vijverberg MAW, et al. The diameter of the rectum on ultrasonography as a diagnostic tool for constipation in children with dysfunctional voiding. *Juro*. 2004;172(5 Pt 1):1986–1988.

Koivusalo A, Pakarinen M, Rintala RJ. Are cecal wrap and fixation necessary for antegrade colonic enema appendicostomy? *J Pediatr Surg*. 2006;41(2):323–326 [(online journal)] http://doi.org/10.1016/j.jpedsurg.2005.11.007.

Kokoska ER, Keller MS, Weber TR. Outcome of the antegrade colonic enema procedure in children with chronic constipation. *Am J Surg*. 2001;182(6):625–629.

Koliani-Pace J, Lacy BE. Update on the management of chronic constipation. *Curr Treat Options Gastroenterol*. 2017;15(1):126–134 [(online journal)] http://doi.org/10.1007/s11938-017-0118-2.

Korterink JJ, Ockeloen L, Benninga MA, et al. Probiotics for childhood functional gastrointestinal disorders: a systematic review and meta-analysis. *Acta Paediatr*. 2013 [(online journal)] http://doi.org/10.1111/apa.12513.

Koyle MA, Kaji DM, Duque M, et al. The Malone antegrade continence enema for neurogenic and structural fecal incontinence and constipation. *Juro*. 1995;154(2 Pt 2):759–761.

Landau EH, Gofrit ON, Cipele H, et al. Superiority of the VQZ over the tubularized skin flap and the umbilicus for continent abdominal stoma in children. *J Urol*. 2008;180(4 Suppl):1761–1766 [(online journal)] http://doi.org/10.1016/j.juro.2008.04.070.

Lane MM, Czyzewski DI, Chumpitazi BP, et al. Reliability and validity of a modified Bristol Stool Form Scale for children. *J Pediatr*. 2011;159(3):437–441.e1 [(online journal)] http://doi.org/10.1016/j.jpeds.2011.03.002.

Langer JC. Hirschsprung disease. *Curr Opin Pediatr*. 2013;25(3):368–374 [(online journal)] http://doi.org/10.1097/MOP.0b013e328360c2a0.

Lawal TA, Rangel SJ, Bischoff A, et al. Laparoscopic-assisted Malone appendicostomy in the management of fecal incontinence in children. *J Laparoendosc Adv Surg Tech A*. 2011;21(5):455–459 http://doi.org/10.1089/lap.2010.0359.

Leech SC, McHugh K, Sullivan PB. Evaluation of a method of assessing faecal loading on plain abdominal radiographs in children. *Pediatr Radiol*. 1999;29(4):255–258.

Lewis SJ, Heaton KW. Stool form scale as a useful guide to intestinal transit time. *Scand J Gastroenterol*. 1997;32(9):920–924 [(online journal)] http://doi.org/10.3109/00365529709011203.

Liloku RB, Mure PY, Braga L, et al. The left Monti-Malone procedure: preliminary results in seven cases. *J Pediatr Surg*. 2002;37(2):228–231.

Loening-Baucke V. Constipation in early childhood: patient characteristics, treatment, and longterm follow up. *Gut*. 1993;34(10):1400–1404.

Loening-Baucke V. Urinary incontinence and urinary tract infection and their resolution with treatment of chronic constipation of childhood. *Pediatrics*. 1997;100(2 Pt 1):228–232.

Loening-Baucke V, Miele E, Staiano A. Fiber (glucomannan) is beneficial in the treatment of childhood constipation. *Pediatrics*. 2004;113(3 Pt 1):e259–e264.

Longstreth GF, Thompson WG, Chey WD, et al. Functional bowel disorders. *Gastroenterology*. 2006;130(5):1480–1491 [(online journal)] http://doi.org/10.1053/j.gastro.2005.11.061.

Lorenzo AJ, Chait PG, Wallis MC, et al. Minimally invasive approach for treatment of urinary and fecal incontinence in selected patients with spina bifida. *Urology*. 2007;70(3):568–571 [(online journal)] http://doi.org/10.1016/j.urology.2007.04.026.

López Pereira P, Salvador OP, Arcas JA, et al. Transanal irrigation for the treatment of neuropathic bowel dysfunction. *J Pediatr Urol*. 2010;6(2):134–138 [(online journal)] http://doi.org/10.1016/j.jpurol.2009.07.004.

Malone PS. The management of bowel problems in children with urological disease. *Br J Urol*. 1995;76(2):220–225.

Malone PS, Curry JI, Osborne A. The antegrade continence enema procedure why, when and how? *World J Urol*. 1998;16(4):274–278.

Malone PS, Ransley PG, Kiely EM. Preliminary report: the antegrade continence enema. *Lancet*. 1990;336(8725):1217–1218.

Matsuno D, Yamazaki Y, Shiroyanagi Y, et al. The role of the retrograde colonic enema in children with spina bifida: is it inferior to the antegrade continence enema? *Pediatr Surg Int*. 2010;26(5):529–533 [(online journal)] http://doi.org/10.1007/s00383-010-2585-6.

McAndrew HF, Malone PSJ. Continent catheterizable conduits: which stoma, which conduit and which reservoir? *BJU Int*. 2002;89(1):86–89.

Meyer KF, Macedo M, Filho HS, et al. The Malone Antegrade Continence Enema (MACE) principle in children: is it important if the conduit is implanted in the left or the right colon? *Int Braz J Urol*. 2008;34(2):206–213.

Monti PR, Lara RC, Dutra MA, et al. New techniques for construction of efferent conduits based on the Mitrofanoff principle. *Urology*. 1997;49(1):112–115 [(online journal)] http://doi.org/10.1016/S0090-4295(96)00503-1.

Mugie SM, Di Lorenzo C, Benninga MA. Constipation in childhood. *Nat Rev Gastroenterol Hepatol*. 2011;8(9):502–511 [(online journal)] http://doi.org/10.1038/nrgastro.2011.130.

Nanigian DK, Kurzrock EA. Intermediate-term outcome of the simplified laparoscopic antegrade continence enema procedure: less is better. *J Urol*. 2008;179(1):299–303 [(online journal)] http://doi.org/10.1016/j.juro.2007.08.161.

Noviello C, Cobellis G, Papparella A, et al. Role of anorectal manometry in children with severe constipation. *Colorectal*

Dis. 2009;11(5):480–484 http://doi.org/10.1111/j.1463-1318.2008.01654.x.

Nurko S, Scott SM. Coexistence of constipation and incontinence in children and adults. *Best Pract Res Clin Gastroenterol*. 2011;25(1):29–41 [(online journal)] http://doi.org/10.1016/j.bpg.2010.12.002.

Ok J-H, Kurzrock EA. Objective measurement of quality of life changes after ACE Malone using the FICQOL survey. *J Pediatr Urol*. 2011;7(3):389–393 http://doi.org/10.1016/j.jpurol.2011.02.012.

Pacilli M, Pallot D, Andrews A, et al. Use of Peristeen® transanal colonic irrigation for bowel management in children: a single-center experience. *J Pediatr Surg*. 2014;49(2):269–272 [(online journal)] http://doi.org/10.1016/j.jpedsurg.2013.11.036.

Peeraully MR, Lopes J, Wright A, et al. Experience of the MACE procedure at a regional pediatric surgical unit: a 15-year retrospective review. *Eur J Pediatr Surg*. 2014;24(1):113–116 [(online journal)] http://doi.org/10.1055/s-0033-1357502.

Pijpers MAM, Bongers MEJ, Benninga MA, et al. Functional constipation in children: a systematic review on prognosis and predictive factors. *J Pediatr Gastroenterol Nutr*. 2010;50(3):256–268 [(online journal)] http://doi.org/10.1097/MPG.0b013e3181afcdc3.

Rasquin A, Di Lorenzo C, Forbes D, et al. Childhood functional gastrointestinal disorders: child/adolescent. *Gastroenterology*. 2006;130(5):1527–1537 [(online journal)] http://doi.org/10.1053/j.gastro.2005.08.063.

Reid JR, Buonomo C, Moreira C, et al. The barium enema in constipation: comparison with rectal manometry and biopsy to exclude Hirschsprung's disease after the neonatal period. *Pediatr Radiol*. 2000;30(10):681–684.

Reuchlin-Vroklage LM, Bierma-Zeinstra S, Benninga MA, et al. Diagnostic value of abdominal radiography in constipated children: a systematic review. *Arch Pediatr Adolesc Med*. 2005;159(7):671–678 [(online journal)] http://doi.org/10.1001/archpedi.159.7.671.

Roberts JP, Moon S, Malone PS. Treatment of neuropathic urinary and faecal incontinence with synchronous bladder reconstruction and the antegrade continence enema procedure. *Br J Urol*. 1995;75(3):386–389.

Schell SR, Toogood GJ, Dudley NE. Control of fecal incontinence: continued success with the Malone procedure. *Surgery*. 1997;122(3):626–631.

Schreiber CK, Stone AR. Fatal hypernatremia associated with the antegrade continence enema procedure. *Juro*. 1999;162(4).

Shandling B, Gilmour RF. The enema continence catheter in spina bifida: successful bowel management. *J Pediatr Surg*. 1987;22(3):271–273.

Shankar KR, Losty PD, Kenny SE, et al. Functional results following the antegrade continence enema procedure. *Br J Surg*. 1998;85(7):980–982 [(online journal)] http://doi.org/10.1046/j.1365-2168.1998.00733.x.

Sinha CK, Butler C, Haddad M. Left Antegrade Continent Enema (LACE): review of the literature. *Eur J Pediatr Surg*. 2008;18(4):215–218 [(online journal)] http://doi.org/10.1055/s-2008-1038499.

Squire R, Kiely EM, Carr B, et al. The clinical application of the Malone antegrade colonic enema. *J Pediatr Surg*. 1993;28(8):1012–1015.

Staiano A, Simeone D, Del Giudice E, et al. Effect of the dietary fiber glucomannan on chronic constipation in neurologically impaired children. *J Pediatr*. 2000;136(1):41–45.

Sturkenboom R, van der Wilt AA, van Kuijk SMJ, et al. Long-term outcomes of a Malone antegrade continence enema (MACE) for the treatment of fecal incontinence or constipation in adults. *Int J Colorect Dis*. 2018;33(10):1341–1348 [(online journal)] http://doi.org/10.1007/s00384-018-3088-5.

Sugarman ID, Malone PS, Terry TR, et al. Transversely tubularized ileal segments for the Mitrofanoff or Malone antegrade colonic enema procedures: the Monti principle. *Br J Urol*. 1998;81(2):253–256.

Tabbers MM, Boluyt N, Berger MY, et al. Nonpharmacologic treatments for childhood constipation: systematic review. *Pediatrics*. 2011;128(4):753–761 http://doi.org/10.1542/peds.2011-0179.

Tabbers MM, DiLorenzo C, Berger MY, et al. Evaluation and treatment of functional constipation in infants and children. *J Pediatr Gastroenterol Nutr*. 2014;58(2):265–281 [(online journal)] http://doi.org/10.1097/MPG.0000000000000266.

Thakre AA, Yeung CK, Peters C. Robot-assisted Mitrofanoff and Malone antegrade continence enema reconstruction using divided appendix. *J Endourol*. 2008;22(10):2393–2396 [(online journal)] http://doi.org/10.1089/end.2008.0256.

van den Berg MM, Benninga MA, Di Lorenzo C. Epidemiology of childhood constipation: a systematic review. *Am J Gastroenterol*. 2006;101(10):2401–2409 [(online journal)] http://doi.org/10.1111/j.1572-0241.2006.00771.x.

van den Bosch M, Graafmans D, Nievelstein R, et al. Systematic assessment of constipation on plain abdominal radiographs in children. *Pediatr Radiol*. 2006;36(3):224–226 [(online journal)] http://doi.org/10.1007/s00247-005-0065-2.

van der Plas RN, Benninga MA, Büller HA, et al. Biofeedback training in treatment of childhood constipation: a randomised controlled study. *Lancet*. 1996;348(9030):776–780.

van der Plas RN, Benninga MA, Redekop WK, et al. Randomised trial of biofeedback training for encopresis. *Arch Dis Child*. 1996;75(5):367–374.

van der Plas RN, Benninga MA, Taminiau JA, et al. Treatment of defaecation problems in children: the role of education, demystification and toilet training. *Eur J Pediatr*. 1997;156(9):689–692.

van Ginkel R, Büller HA, Boeckxstaens GE, et al. The effect of anorectal manometry on the outcome of treatment in severe childhood constipation: a randomized, controlled trial. *Pediatrics*. 2001;108(1):E9.

van Ginkel R, Reitsma JB, Büller HA, et al. Childhood constipation: longitudinal follow-up beyond puberty. *Gastroenterology*. 2003;125(2):357–363.

Vlieger AM, Blink M, Tromp E, et al. Use of complementary and alternative medicine by pediatric patients with functional and organic gastrointestinal diseases: results from a multicenter survey. *Pediatrics*. 2008;122(2):e446–e451 [(online journal)] http://doi.org/10.1542/peds.2008-0266.

Voskuijl WP, van Ginkel R, Benninga MA, et al. New insight into rectal function in pediatric defecation disorders: disturbed rectal compliance is an essential mechanism in pediatric constipation. *J Pediatrics*. 2006;148(1):62–67 [(online journal)] http://doi.org/10.1016/j.jpeds.2005.08.061.

Wald ER, Di Lorenzo C, Cipriani L, et al. Bowel habits and toilet training in a diverse population of children. *J Pediatr Gastroenterol Nutr*. 2009;48(3):294–298.

Webb HW, Barraza MA, Crump JM. Laparoscopic appendicostomy for management of fecal incontinence. *J Pediatr Surg*. 1997;32(3):457–458.

Wedderburn A, Lee RS, Denny A, et al. Synchronous bladder reconstruction and antegrade continence enema. *Juro*. 2001;165(6 Pt 2):2392–2393.

Winter HS, Di Lorenzo C, Benninga MA, et al. Oral prucalopride in children with functional constipation. *J Pediatr Gastroenterol Nutr*. 2013;57(2):197–203 [(online journal)] http://doi.org/10.1097/MPG.0b013e318292f9ea.

Yazbeck S, Schick E, O'Regan S. Relevance of constipation to enuresis, urinary tract infection and reflux. A review. *Eur Urol*. 1987;13(5):318–321.

Yerkes EB, Rink RC, King S, et al. Tap water and the Malone antegrade continence enema: a safe combination? *Juro*. 2001;166(4):1476–1478.

Youssef NN, Di Lorenzo C. Treatment options for refractory childhood constipation. *Curr Treatment Options Gastroenterol*. 2002;5(5):377–387.

Zee RS, Kern NG, Herndon CDA. Robotic-assisted laparoscopic MACE. *J Pediatr Urol*. 2017;13(5):525–526 [(online journal)] http://doi.org/10.1016/j.jpurol.2017.03.042.

Zeevenhooven J, Koppen IJN, Benninga MA. The New Rome IV Criteria for functional gastrointestinal disorders in infants and toddlers. *Pediatr Gastroenterol Hepatol Nutr*. 2017;20(1):1–13 [(online journal)] http://doi.org/10.5223/pghn.2017.20.1.1.

37

Lower Urinary Tract Reconstruction in Children

John C. Thomas MD, FAAP, FACS, Douglass B. Clayton MD, FAAP, Mark C. Adams MD, FAAP

Although children with anomalies affecting the bladder and outlet are managed with a primary goal of minimizing the need for operative intervention, the basic functions of a “normal” lower urinary tract—to protect renal function, avoid urinary tract infection (UTI), and eventually provide urinary continence—must be achieved. Surgical reconstruction remains an important and effective tool for some children. When reconstruction is considered, it is imperative that the patient be thoroughly evaluated. Each child is unique, and his or her particular pathophysiology must be understood so that surgical techniques available may be used thoughtfully to optimize results while minimizing morbidity.

The scope of this chapter is large. Augmentation cystoplasty is reviewed in detail. In few areas of urology have intestinal segments been used as extensively. Complex patients with bladder dysfunction may also have bladder neck and external sphincteric problems, and this chapter covers techniques that increase bladder neck and external urinary sphincter resistance in the pediatric population. **Perhaps the most important contribution affecting lower urinary tract reconstruction was the introduction of clean intermittent catheterization (CIC) by Lapides et al.** (1972, 1976) **based on the work of Guttmann and Frankel** (1966). Because many pediatric patients with bladder and sphincteric dysfunction do not void adequately after reconstruction, creation of a reliable means to easily catheterize may be essential; ways to do so are presented, along with related results in children.

Most pediatric lower tract reconstructive procedures are undertaken primarily to correct hostility in the native lower urinary tract unresponsive to medical management. Children with bladder and sphincteric dysfunction are among the most complex seen in pediatric urology, and those with spina bifida make up the majority of patients requiring this type of surgical

intervention. The results discussed herein therefore focus on the neurogenic population. **The most important factor influencing the outcome of urinary tract reconstruction in children is the commitment of the patient and family to achieving good care.** Determining that commitment may at times be difficult, but its importance should not be underestimated.

“Functional” Urinary Tract

Bladder physiology can be characterized in two dynamic phases: passive and active. During the passive storage phase, the bladder functions as a reservoir, allowing for urine to be stored at low pressure without leakage. In the active voiding phase, the bladder contracts and efficiently eliminates urine.

Dysfunction

Upper Urinary Tract

It is critical to understand the dynamics of the entire urinary tract before any major reconstructive procedure. In the presence of hydronephrosis, upper tract obstruction must be excluded. Upper tract obstruction may be secondary to severe, long-standing bladder hostility involving poor bladder compliance and emptying. Nuclear renography with a urethral catheter may be useful to rule out a primary upper tract obstruction. Upper tract obstruction, if present, should be corrected at the time of bladder and sphincter reconstruction.

Vesicoureteral reflux in the presence of bladder hostility may be primary or secondary, and differentiating the two may be difficult. If reflux was not present during earlier evaluation, new onset is likely secondary to bladder hostility. Reflux in children with neurogenic dysfunction is often secondary. Previous work has suggested that reflux secondary to bladder hostility may not need surgical correction if the bladder is adequately managed. Neurogenic bladder requiring augmentation in children who did not undergo reimplantation for secondary reflux resolved with augmentation alone (Juhasz et al., 2008; López Pereira et al., 2001; Morioka et al., 1998; Nasrallah and Aliabadi, 1991; Soylet et al., 2004). It is interesting to speculate whether reflux is even a significant problem if a large, compliant bladder is achieved (Soylet et al., 2004). Bacteria may ascend with or without reflux after reconstruction, and certain forms of continent diversion have not shown an increased risk of pyelonephritis in the absence of any antireflux mechanism when compliance is adequate (Gonzalez and Reinberg, 1987; Helal et al., 1993; Pantuck et al., 2000). We agree that most secondary reflux will likely resolve with adequate reconstruction of the bladder but will correct high-grade reflux if present. Caution is warranted when considering the treatment of chronically dilated and scarred ureters. Correcting reflux in that setting is appropriate but can result in obstruction if overly aggressive tapering or tunneling is performed (Hendren, 1998).

Dysfunction in the upper urinary tract usually manifests with hydronephrosis, pyelonephritis, or impairment of renal function. When such problems are present in patients with lower tract dysfunction, thoughtful evaluation and treatment are necessary. All problems should be addressed before and at the time of reconstructive surgery to achieve the best result.

Bladder Dysfunction

Bladder dysfunction is a composite of physiologic abnormalities, and it is helpful to assess each component of passive and active bladder function independently. **Elevated passive filling pressure becomes clinically pathogenic when a pressure greater than 40 cm H_2O is chronically reached** (McGuire et al., 1981; Wang et al., 1988; Weston et al., 1989). Pressures at this level sustained over a period of time impair ureteral drainage that may result in pyelocalyceal changes, hydroureteronephrosis, and decreased glomerular filtration rate. In addition, persistent elevation in filling pressure can result in acquired vesicoureteral reflux (Cohen et al., 1990; Sidi et al., 1986a).

Pharmacologic management can play a role in decreasing filling pressure, particularly when overactive detrusor contractions are present. A combination of medications and intermittent catheterization have a positive impact, particularly in children with neurogenic dysfunction (Aslan and Kogan, 2002; Rink and Mitchell, 1984; Verpoorten and Buyse, 2008). When compliance is unaffected by medical management, augmentation cystoplasty may be required to improve the storage characteristics. After reconstruction, the likelihood of efficient detrusor contractions and effective emptying of the bladder is diminished. Intermittent catheterization should be taught and accepted by the patient and caretaker preoperatively. CIC allows the reconstructive surgeon to aggressively correct storage problems through augmentation. Spontaneous voiding, although a goal, is not imperative because CIC can be used for emptying.

Urinary incontinence is a prominent sign of bladder dysfunction. Continence requires outflow resistance generated by the bladder neck and external urinary sphincter. Outflow resistance must remain greater than bladder pressure during storage throughout normal daily activity. When outflow resistance is diminished because of an abnormal bladder neck and external urinary sphincter, incontinence often occurs. Pharmacologic management with α-adrenergic agents can enhance outflow resistance, but more commonly operative reconstruction is required.

When incontinence occurs during the filling phase because of poor outlet resistance, it is essential to evaluate not only the bladder neck and external urinary sphincter but also detrusor characteristics. Clinical experience has shown that once appropriate resistance is achieved at the bladder neck through operative intervention, adverse detrusor characteristics may become unmasked and result in high pressure urinary storage or uninhibited contractions not previously documented (Bauer et al., 1986; Churchill et al., 1987; Dave and Salle, 2008). For that reason, provocative urodynamic assessment with occlusion of the bladder neck is important before any bladder neck reconstruction in an attempt to identify children who will be at risk.

Normal synergistic voiding occurs when the bladder neck descends, relaxes, and opens, followed by relaxation of the external urinary sphincter and subsequent detrusor contraction resulting in low pressure voiding. Dysfunctional voiding during this active bladder phase occurs as a result of uncoordinated activity of the bladder neck, external urinary sphincter, and detrusor. With such dyssynergy, high-pressure voiding results that chronically can negatively affect the bladder and upper urinary tract (Bauer et al., 1984; Mundy et al., 1982). A similar clinical situation occurs with a fixed, fibrotic external sphincter. Initial treatment involves pharmacologic management and CIC in an attempt to bypass the abnormal voiding mechanics.

Other Considerations

Renal function should be assessed in any patient undergoing bladder reconstruction, particularly if hydronephrosis or severe renal scarring is present. **Demos** (1962) **and Koch and McDougal** (1985) **have demonstrated that urinary solutes, particularly chloride, are absorbed from urine in contact with the mucosa of small and large bowel.** For patients with normal renal function, the kidneys are able to handle the reabsorbed load of chloride and acid without obvious difficulty. Patients with decreased renal function, however, may develop significant metabolic acidosis secondary to such reabsorption. If acidosis exists preoperatively, it will invariably worsen if urine is stored in small or large intestinal segments (Mitchell and Piser, 1987). The first component of renal function to deteriorate after obstruction or infection is concentrating ability. Patients with compromised function may generate enormous volumes of urine. **The bladder volume achieved through bladder reconstruction must accommodate the patient's urinary output for an acceptable period of time,**

usually 4 hours. Patients with renal failure or other medical problems may conversely develop oliguria. Low urinary output may affect an augmented bladder or bowel reservoir with greater collection and inspissation of mucus.

Abnormal function of other organ systems also influences the risk of bladder reconstruction using intestinal segments. Reabsorption of ammonia by large or small intestinal segments in contact with urine may be dangerous for patients with hepatic failure (McDougal, 1992a). Some medications excreted in urine may be reabsorbed by bowel mucosa (Savauagen and Dixey, 1969). Therefore liver function tests and arterial blood gas studies may be appropriate. Careful history should be taken regarding the patient's preoperative bowel function; this is particularly true of patients who may have acquired or secondary gastrointestinal problems. Short gut syndrome is a concern among children with cloacal exstrophy, prior bowel resections, or a history of significant radiation. A history of chronic diarrhea or fecal incontinence preoperatively should signal concern about use of the ileocecal valve in urinary reconstruction.

A critical factor to consider is the commitment of the patient and family. Urinary incontinence, at times, protects some patients from infection and upper tract deterioration. Effective storage can put the patient at risk for problems if emptying is not accomplished on a regular basis. All must be aware of the responsibility that goes along with bladder reconstruction and urinary continence.

The timing of surgical intervention varies dramatically among patients. It may be necessary to perform reconstruction early when the upper tracts and renal function are threatened. This situation may occur in the presence of high outflow resistance and poor bladder compliance. Although work has suggested that augmentation cystoplasty to correct bladder hostility may slow deterioration of renal function even when renal insufficiency resulting from secondary upper tract damage is already established (Ivancic et al., 2010), early intervention to prevent such damage is preferable. More commonly, reconstruction is undertaken later to achieve urinary continence. The age at which urinary incontinence, or the presence of a urinary stoma after temporary diversion, becomes socially unacceptable varies among patients and families.

It is beneficial for the patient and family to wait for bladder reconstruction until all needs of the child are identified. This is not always possible when intervening because of infection or hydronephrosis. When reconstruction is undertaken to achieve continence, it is most efficient to identify all reconstructive issues and address them with one operation. Urodynamic assessment is usually necessary to determine whether a procedure to increase outflow resistance is necessary in addition to bladder augmentation or replacement. Introducing CIC preoperatively is mandatory in that it allows the patient to demonstrate the ability and desire to continue on a regular basis. It is also helpful in determining whether a continent abdominal wall stoma may be required to improve the reliability of catheterization and increase the patient's independence. Likewise in the neurogenic population, it is advantageous to identify the child who may benefit from an antegrade colonic enema. It is certainly better for the patient and surgeon to address all of these issues at one time rather than with sequential procedures that may add morbidity.

Patient Evaluation

Each patient should have upper tract imaging before bladder reconstruction; most will have had routine ultrasonography as part of their surveillance. **When hydronephrosis is present, imaging should be performed to assess for obstruction or vesicoureteral reflux.** Nuclear renography with a catheter in the bladder is usually adequate to rule out primary upper tract obstruction. Reflux should be excluded with an independent voiding study or as part of video urodynamics. In the presence of hydronephrosis, patients should have obtained baseline levels of serum electrolytes, blood urea nitrogen (BUN), and serum creatinine. Patients with elevation of the serum creatinine or significant hydronephrosis benefit from nephrologic evaluation and a 24-hour urine collection for creatinine clearance and urine volume.

Special attention must be given to patients after prior urinary diversion. Permanent intestinal diversions in children are now typically confined to patients requiring cystectomy for cancer. Most urinary diversions performed today are temporary. **The key to urinary undiversion is to understand the original pathology that led to diversion.**

Urodynamics

Bladder Dynamics: Capacity and Compliance

Urodynamic testing of the lower urinary tract plays an essential role when considering bladder reconstruction. Results in infants and children are reproducible but require meticulous attention to detail (Joseph, 1994). Several mechanical factors adversely influence urodynamic data, creating artifacts that, if not recognized, can have a negative impact on the validity of the evaluation. Testing is typically performed with transurethral catheter placement. The size of the catheter can influence the measured leak point pressure, voiding pressure, and ability to empty completely, particularly in infants and young boys (Decter and Harpser, 1992). Suprapubic catheter placement circumvents this problem but is not practical in most cases. The testing medium and infusion rate can influence the results. Carbon dioxide is not as reliable as fluid infusion, particularly when evaluating bladder compliance and capacity. Most commonly, saline or iodinated contrast is used at body temperature to provide reproducible results (Joseph, 1993, 1996). End filling pressure, and therefore bladder compliance, can be dramatically affected by simply changing the filling rate (Joseph, 1992). Bauer (1979) suggested that the cystometrogram be performed at a fill rate of no greater than 10% of the predicted bladder capacity per minute. Despite these advancements and contributions made to improve the reliability and validity of urodynamics in this patient population, significant interrater interpretative variability still exists even amongst providers at the same institution (Dudley et al., 2017). In a follow-up multi-institutional study, the same author confirmed only fair agreement among providers with electromyleography (EMG) synergy and/or presence of detrusor overactivity (Dudley et al., 2018).

Special nuances may be necessary after diversion by vesicostomy. Any bladder is likely to show small capacity in that setting. A repeated study after several days of bladder cycling by occlusion of the vesicostomy may be more predictive of bladder function; the bladder may respond to cycling quickly (Errando et al., 2005; McGuire, personal communication, 1996). Temporary occlusion of the ostomy with a gastrostomy button may be informative (de Badiola et al., 1995).

Sphincter Dynamics: Outflow Resistance

The bladder neck and external urinary sphincter work in synergy, but only one is required for maintenance of urinary continence. Neurogenic dysfunction often leads to abnormalities of the bladder neck and external urinary sphincter, resulting in diminished outlet resistance during storage and/or dyssynergic function with voiding. Monitoring of external urinary sphincter electrical activity is required for evaluation of coordinated voiding and dyssynergic detrusor sphincter activity. Perineal surface electrodes, abdominal wall sensors, anal plugs, vaginal monitors, electrical wires, and concentric needle electrodes have been used for electromyography (Joseph, 1996). In children with neurogenic dysfunction, a concentric needle electrode or dual needle electrodes placed through a 25-gauge needle increase accuracy when measuring sphincter activity (Blaivas et al., 1977; Joseph, 1996).

The functional length of the external urinary sphincter also plays a role in outflow resistance, and its measurement can be undertaken with urethral pressure profilometry (UPP). Unfortunately, the short length and small diameter of the pediatric urethra makes this study technically challenging because the mechanical pulling device is not practical for pediatric use. To perform UPP, a constant infusion of testing medium at a rate of 2 mL/min using a continuous Harvard pump is required (Joseph, 1996), eliminating pressure wave artifacts noted with the standard roller ball infusion pumps. Hand withdrawal of the catheter is used, marking every 5 mm on the recording strip. With experience and a cooperative patient, reliable measurements can be obtained. There is limited value comparing specific UPP results for a patient against standard nomograms; however, preoperative UPP for a given patient provides baseline information that can be beneficial when assessing the intraoperative and postoperative functional urethral length.

Some surgeons use leak point pressure to evaluate outflow resistance during passive filling and Valsalva. The leak point pressure may be artifactually elevated by the urodynamics catheter in a small male urethra (Decter and Harpster, 1992). Work remains to determine how well such measurable parameters correlate. Khoury et al. (2008) suggest that the presence of bladder trabeculation often predicts that outlet resistance is adequate and that such patients are likely to do well with augmentation cystoplasty alone.

Bladder Emptying

The patient's ability to empty the bladder before reconstruction should be assessed carefully. Parameters influencing bladder emptying include synergistic relaxation of the external sphincter on electromyography, urinary flow rates, and residual postvoid urine. Neurologically intact patients able to empty their bladder well preoperatively are much more likely to do so after reconstruction than are patients with neurogenic dysfunction. **No test ensures that a patient will be able to void spontaneously and empty well after bladder augmentation or other reconstruction.** Therefore all patients must be prepared to perform CIC postoperatively. The native urethra should be examined for the ease of catheterization. Ideally, the patient should learn CIC and practice it preoperatively until the patient, family, and surgeon are comfortable that catheterization can and will be done reliably. Physical and psychosocial limitations of the patient must be considered with regard to the ability to self-catheterize and perform independent care. **Failure to catheterize and empty reliably after bladder reconstruction may result in upper tract deterioration, UTI, or bladder perforation despite a technically perfect operation.** Most patients who may catheterize per native urethra or an abdominal wall stoma overwhelmingly prefer the latter (Horowitz et al., 1995).

Patient Preparation

Bladder and sphincter reconstructive procedures remain challenging. The patient's general status should be optimized to afford the best chance to achieve a good result with the least risk of morbidity. General nutritional and hydration status should be determined and corrected, if necessary, before surgery. Coexisting medical problems, particularly cardiac and pulmonary issues, should be well managed preoperatively.

Bowel Preparation

Each patient undergoes preoperative bowel preparation to minimize the potential risk of surgery if the use of any bowel is required. Even when ureterocystoplasty or other alternatives are planned, intraoperative findings may dictate the need for use of a bowel segment. Two days of a clear liquid diet before bowel preparation aid in clearing of solid stool. The patient should then undergo full mechanical bowel preparation the day before surgery. Such bowel preparations have usually been done in the hospital (O'Donnell, 2007); however, recent trends find this changing to an outpatient setting. A recent retrospective analysis showed a significantly shorter length of stay and lower median hospital cost for patients undergoing outpatient bowel preparation. In addition, the authors did not report an increase in postoperative complications (Weatherly et al., 2018). Major reconstructive procedures often require many hours of operative time with large fluid shifts. It is critical that the patient be well hydrated at the time of surgery even if it necessitates the use of intravenous fluids during the preoperative day. The use of oral antibiotics in bowel preparation, once dogma, is now a matter of personal preference. Special attention must be paid to the bowel preparation of patients with neurogenic dysfunction. Most of these patients have chronic constipation, and effective bowel cleansing can be difficult in such patients. Several days of oral cathartics at home may be helpful before formal preparation. Children with renal insufficiency should be observed carefully during bowel preparation for dehydration and electrolyte disturbances.

Theoretically, gastric contents are sterile, and administration of parenteral antibiotics or a routine bowel preparation is not necessary before gastrocystoplasty. Gundeti et al. (2006) suggested that routine bowel preparation may not be necessary before ileocystoplasty in children.

Urine Culture

All patients should have a urine culture performed several days before bladder reconstruction. Any patient with a positive preoperative urine culture should undergo treatment with either oral or intravesical antibiotics and have a second culture documenting sterile urine before the procedure. Many pediatric patients undergoing augmentation cystoplasty have spina bifida and a ventriculoperitoneal shunt. With a negative urine culture and good bowel preparation, the incidence of shunt infection or problems should be very low (Hayashi et al., 2008; Yerkes et al., 2001). In contrast, a recent report using the Pediatric Health Information System (PHIS) database showed an increase in shunt failures in patients undergoing bladder augmentation. The exact explanation for this association is unclear and likely multifactorial (Gonzalez et al., 2017).

Cystoscopy

Preoperative cystoscopy may be the final step in evaluating the native bladder, outflow, or ureteral orifices in pediatric patients. Endoscopy, if done, should be performed immediately before bladder reconstruction under the same anesthetic. Based on history, occasionally a patient may warrant endoscopic or radiographic gastrointestinal evaluation preoperatively.

Key Points: Evaluation and Preparation

- Evaluation for renal function, upper tract obstruction, and vesicoureteral reflux should be performed if hydronephrosis is present, although most such changes are secondary to the bladder dysfunction.
- Careful urodynamic evaluation is critical to understand all problems that may contribute to the dysfunction.
- The patient will likely require CIC to empty after reconstruction and must be capable of performing it on a reliable basis.
- Commitment of the patient and family is essential.
- Basic preoperative preparation includes sterile urine and thorough bowel cleansing.

Antireflux

Ureteral reimplantation into bladder, whether the ureter is dilated or not, is a standard procedure familiar to all pediatric urologists and reconstructive surgeons. The long-term success rate is good and complications rare. Such reimplantation is certainly preferable and usually possible during lower tract reconstruction. Special attention must be given to chronically scarred, short ureters sometimes found after urinary diversion. In Hendren's extensive experience with urinary undiversion (1998), most complications were related to those ureters.

Transureteroureterostomy and Single Ureteral Reimplant

Occasionally, the urinary bladder is so small that it is inadequate for bilateral reimplantation, and alternatives must be considered. It is preferable to reimplant both ureters separately, although **if the native urinary bladder is small and adequate for only a single ureteral tunnel, transureteroureterostomy (TUU) and a single reimplant may be helpful** (Fig. 37.1). Typically, the better ureter should be implanted into the bladder. The crossing ureter should be mobilized to swing gently across the abdomen to the recipient side in a smooth course without tension. It should be carefully mobilized with all of its adventitia and as much periureteral tissue as possible to preserve blood supply. Care must be taken not to angulate the crossing ureter immediately beneath the inferior mesenteric artery. The crossing ureter is widely anastomosed to the posteromedial aspect of the recipient ureter. The recipient is not mobilized or brought medially to meet the end of the other ureter. TUU, when fashioned appropriately, is successful and carries minimal risk for leakage or obstruction (Hendren and Hensle, 1980; Hodges, et al., 1963; Iwaszko et al., 2010; Mure et al., 2000; Noble et al., 1997). A history of previous calculi remains a relative contraindication to TUU.

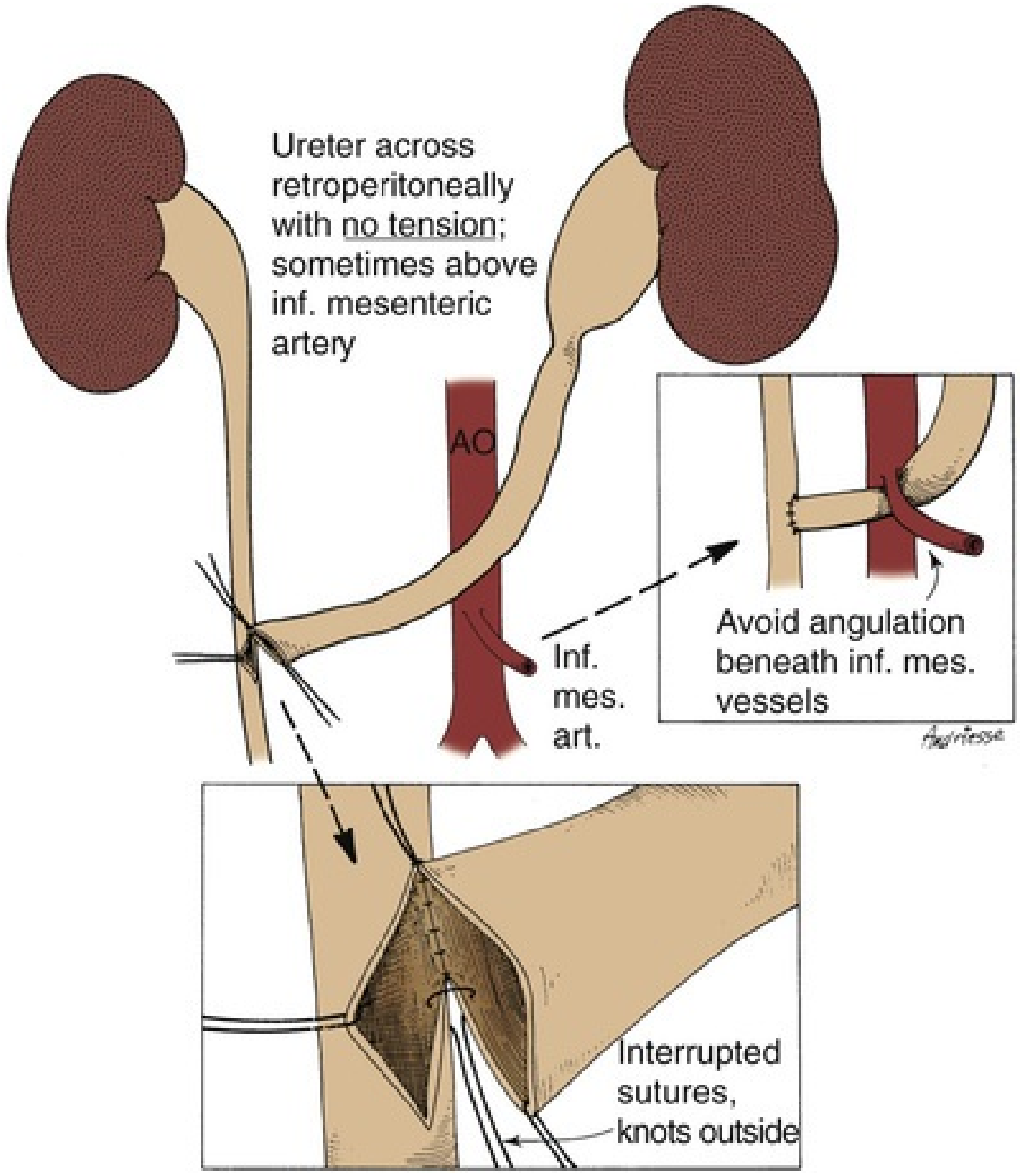
Ureter across
retroperitoneally
with no tension;
sometimes above
inf. mesenteric
artery
AO
Inf.
mes.
art.
Avoid angulation
beneath inf. mes.
vessels
Andriesse
Interrupted
sutures,
knots outside

FIG. 37.1 Technique for transureteroureterostomy. *AO,* Aorta; *inf. mes. art.,* inferior mesenteric artery. (Courtesy W. Hardy Hendren.)

The manner in which the bladder is opened may optimize its use for a single reimplant. Rather than incising the bladder in the anterior midline, a wide, anterior U-shaped incision based cephalad can be made. This potentially elongates the bladder as a posterior plate that can be brought to one side or the other to meet a single ureter. For ureteral reimplantation after such an incision, a psoas hitch of the bladder fixes the bladder in position for a long, straight ureteral tunnel. Incision of the bladder in this way may also be useful in placing a continent catheterizable stoma to the umbilicus.

Psoas Hitch

Fixation of the bladder to the psoas muscle allows for precise control of the length and direction of a ureteral reimplant. A psoas hitch should prevent any angulation of the ureter with bladder filling. Such angulation may be particularly problematic or obstructive with a dilated and scarred ureter. The bladder should be secured to the psoas muscle and fascia using nonabsorbable sutures. Those sutures must not enter the bladder lumen or stones will occur. Broad, shallow purchases of the psoas muscle and fascia should be used to hold long term without trapping the sciatic nerve. The hitching sutures should not be tied so tightly that they cut through either bladder or psoas muscle. The contralateral bladder pedicle may be divided to increase bladder mobility and the length of the hitch on occasion. Although Hendren and Hensle (1980) suggested that the ureteral reimplant is more easily performed before the bladder hitch (Fig. 37.2), the steps should be performed in whichever order allows each to be done precisely with good visualization.

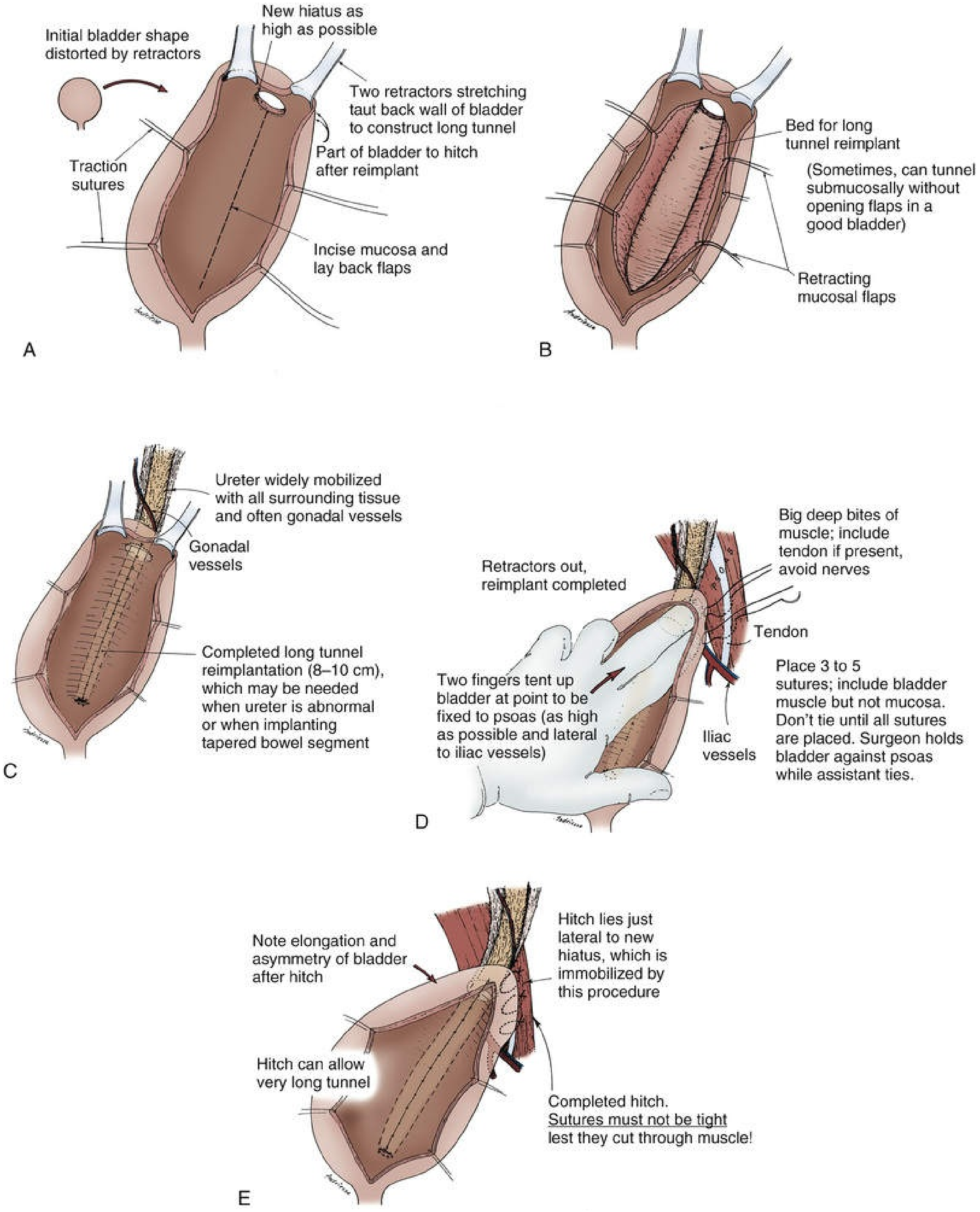
Initial bladder shape distorted by retractors
New hiatus as high as possible
Two retractors stretching taut back wall of bladder to construct long tunnel
Part of bladder to hitch after reimplant
Traction sutures
Incise mucosa and lay back flaps
A
Bed for long tunnel reimplant
(Sometimes, can tunnel submucosally without opening flaps in a good bladder)
Retracting mucosal flaps
B
Ureter widely mobilized with all surrounding tissue and often gonadal vessels
Gonadal vessels
Completed long tunnel reimplantation (8–10 cm), which may be needed when ureter is abnormal or when implanting tapered bowel segment
C
Big deep bites of muscle; include tendon if present, avoid nerves
Retractors out, reimplant completed
Tendon
Two fingers tent up bladder at point to be fixed to psoas (as high as possible and lateral to iliac vessels)
Iliac vessels
Place 3 to 5 sutures; include bladder muscle but not mucosa. Don't tie until all sutures are placed. Surgeon holds bladder against psoas while assistant ties.
D
Note elongation and asymmetry of bladder after hitch
Hitch lies just lateral to new hiatus, which is immobilized by this procedure
Hitch can allow very long tunnel
Completed hitch. Sutures must not be tight lest they cut through muscle!
E

FIG. 37.2 Technique for psoas hitch, which allows the construction of a long reimplantation tunnel and prevents angulation of the ureter or tapered bowel segment when the bladder fills. Monofilament nonabsorbable suture material is used to fix the bladder to psoas muscle. Care must be taken to avoid entering the bladder, which may cause stone formation on a suture. (Courtesy W. Hardy Hendren.)

Antireflux With Intestinal Segments

Necessity of ureteral reimplantation into an intestinal segment may occasionally determine the segment to be used for bladder augmentation or replacement. Long experience with ureterosigmoidostomy and colon conduit diversion has established an effective means of creating antireflux into a colonic segment; a flap valve mechanism can be created by tunneling the ureter beneath a tenia. Principles learned from ureterosigmoidostomy include a direct mucosal-to-mucosal anastomosis and a submucosal tunnel of adequate length. This technique has provided favorable long-term results since the 1950s (Goodwin et al., 1953; Leadbetter and Clarke, 1954; Nesbit, 1949) and is based on the initial work of Coffey (1911). Implantation may be done from within the reservoir or from without after the intestinal segment has been completely reconfigured and closed.

If a gastric segment is used for bladder augmentation or replacement, ureters may be reimplanted into the stomach in a manner remarkably similar to that used in the native bladder. The same principles for choosing the length of tunnel relative to the width of the ureter are used as with bladder. Creating an effective antireflux mechanism into an ileal segment is more difficult. The split nipple technique described by Griffith may prevent reflux at least at low reservoir pressure (Patil et al., 1976; Sagalowsky, 1995; Stone and MacDermott, 1989; Turner-Warwick and Ashken, 1967). A short longitudinal incision is made in the distal ureter, and the ureteral wall is turned back on itself. The nipple should be at least twice as long as the width of the ureter. The cuff is stabilized by suturing the ureter to itself. The adventitia of the ureter immediately proximal to the cuff is then approximated to the full thickness of the ileal wall at the hiatus so that the cuff protrudes into the lumen. Le Duc et al. (1987) described a technique in which the ureter is brought through a hiatus in the ileal wall. From that hiatus, the ileal mucosa is incised and the edges are mobilized to create a trough for the ureter. The spatulated ureter is laid into the trough and approximated to the mucosa at the distal end. The ileal mucosa is sutured to the lateral edges of the ureter and should eventually grow over it. Long-term results with these two techniques have been conflicting but in general have not proven as reliable as a tunneled ureterocolonic anastomosis in preventing reflux (Bihrle, 1997; Le Duc et al., 1987; Patil et al., 1976; Rowland, 1996), with one exception (Lugagne et al., 1997). It is also possible to create an antirefluxing, serosally lined tunnel between two limbs of ileum as described by Abol-Enein and Ghoneim (1999; Soygur et al., 2005).

Reinforced nipple valves of ileum have been used extensively for antireflux with the Kock pouch (Skinner et al., 1989). After several modifications by Skinner, good long-term results have been achieved. His technique requires a relatively long segment of ileum and use of permanent staples. Attempts have been made to secure the nipple long term without staples or mesh (Gosalbez and Gousse, 1998; Hanna and Bloiso, 1987; Tsuchiya et al., 2004). Maintenance of the intussuscepted cuff is the key to a successful result. The same forces that compress the nipple to achieve antireflux or continence tend to evert or destabilize it. An ileal nipple valve may be particularly useful with short, dilated ureters; an isoperistaltic segment of ileum may be left with the nipple to replace a short ureter. The antireflux mechanism is based on the ileal segment and not the ureter. In some neobladders, an isoperistaltic limb of ileum is positioned between the reservoir and ureters to discourage reflux, at least at low pressures (Studer and Zingg, 1997).

Key Points: Antireflux

- Ureteral reimplantation into native bladder is preferable when necessary; the initial bladder incision may facilitate such a procedure.
- An antireflux mechanism can be created with any bowel segment but is most challenging with ileum.

Bladder Neck Reconstruction

One of the greatest technical challenges facing the surgeon regarding bladder reconstruction is reliably providing adequate outflow resistance to achieve continence. The cause of bladder neck dysfunction may be neurogenic in origin or anatomic as noted with exstrophy, bilateral ectopic ureters, or ureteroceles. Each unique problem must be considered when addressing outlet resistance. Many operative techniques have been described for bladder neck reconstruction, indicating that no single option is best for all patients (Cole et al., 2003; Kryger et al., 2000; Lemelle et al., 2006). **Preoperative evaluation and thorough knowledge of the patient's specific physiologic limitations are required.**

The capability for a sustained bladder contraction to result in complete emptying by voiding or the absence of hyperreflexic contractions influences the technique selected for gaining outlet resistance. All operative techniques that create an increase in outlet resistance do so at the expense of detrusor contractibility. For reasons not clearly defined, increasing outlet resistance can result in a noncompliant hostile detrusor environment (Bauer et al., 1986; Burbige et al., 1987; Churchill et al., 1987). Provocative cystometry may uncover only some patients at risk, and close postoperative observation is mandatory (Kronner et al., 1998b).

Multiple techniques are available to tighten the bladder neck and include creation of a flap valve mechanism and placement of artificial or autologous bulking agents, slings, and the artificial urinary sphincter (AUS). **The selected option is individualized to the patient's pathologic process, needs, goals, and desire for independence.**

An important consideration is the patient's ability to empty well before reconstruction and the likelihood that he or she will be able to do so afterward. Many of the repairs prohibit spontaneous voiding. Some patients with neurogenic dysfunction require bladder augmentation and an increase in bladder outflow resistance, resulting in the need for CIC. Other diagnoses, especially when augmentation cystoplasty is not necessary, may allow for spontaneous voiding.

The following section covers operative techniques used to achieve urinary continence through bladder neck and external urinary sphincter reconstruction. Most of the results are based on experience in individuals with spinal dysraphism, but the techniques are used in children with other pathogenic conditions. All techniques have a learning curve that necessitates careful analysis of results and forthright reporting. An evidence-based review of operative bladder neck procedures found assessment of results to be limited by several factors, including the lack of a true, consistent definition of “success” and “continence,” consideration of patients with and without concomitant bladder augmentation, and consideration of small patient populations with mixed pathologic conditions (Joseph et al., 2003).

Young-Dees-Leadbetter Repair

The Young-Dees-Leadbetter bladder neck reconstruction is one of the most recognized operative techniques to increase outlet resistance. The original Young procedure has evolved and remains of primary consideration when reconstructing the exstrophic bladder neck (Ferrer et al., 2001).

Technique

Young's initial description (Young, 1919) of excising a portion of the bladder neck and tightening the bladder neck over a silver probe was modified by Dees (1949), who extended the length of excised tissue through the trigone. Leadbetter (1964) followed by elevating the ureters off the trigone and placing them in a more cephalad position on the bladder floor. This allowed for tubularization of the trigone and enhanced lengthening of the urethra. A detailed description and illustrations are found in the chapter on bladder exstrophy.

Results

Reports of success with the Young-Dees-Leadbetter bladder neck reconstruction in children with neurogenic sphincter dysfunction are limited, not only in the number of patients but also in overall improvement. Tanagho (1981) and Leadbetter (1985) independently reviewed their long-term results and showed minimal success in individuals with neurogenic dysfunction. They speculated that the outcomes were the result of a lack of muscle tone and activity in the wrapped muscle related to the underlying neurogenic problem. Many patients in the early series did not undergo bladder augmentation, possibly compromising the continence achieved. Contrary to the results reported in exstrophy patients, most individuals with neurogenic deficiency of the bladder neck require bladder augmentation and intermittent catheterization. Sidi et al. (1987b) documented a 4-hour continence interval in 7 of 11 patients after such repair, although 10 required catheterization and 9 augmentation. Of the 7 patients, 5 needed a second surgery to achieve continence. This small series is one of the more recent showing long-term results of the Young-Dees-Leadbetter reconstruction in children with neurogenic dysfunction; it has largely fallen out of favor. In an attempt to enhance the Young-Dees-Leadbetter procedure, Mitchell and Rink (1983) described the addition of external support and compression achieved through the placement of a silicone sheath around the reconstructed bladder neck. This was done to establish a plane for future placement of an artificial sphincter cuff, if necessary. The sheath improved the function of the repair by either increasing coaptation or maintaining the repair in a better anatomic position. Unfortunately, most of the thicker Silastic sheaths eventually eroded into the bladder or urethra (Kropp et al., 1993). Quimby et al. (1996) used a thinner Silastic sheath with interposed omentum and reported less risk of erosion. The authors noted improved continence and felt placement of an artificial sphincter cuff was easier when needed.

Donnahoo et al. (1999) reviewed one of the largest series of this repair used in neurogenic incontinence (38 children, 25 of whom were girls). A primary repair was performed in 24 children, a secondary procedure in 6, and a primary repair in conjunction with a silicone sheath in 8. Partial continence was achieved after the initial repair in 26 children (68%). All children with the silicone sheath were initially continent, but erosion occurred in 5. In addition, 35 (92%) of the children required augmentation cystoplasty to become continent without hostile detrusor characteristics. The authors found that, although continence could be achieved with this technique, it was at the expense of augmentation cystoplasty and multiple procedures. Their results are similar to those reported by Cole et al. (2003).

Fascial Sling

Sling procedures were developed in an attempt to increase resistance at the bladder neck. Artificial tissue and autologous fascia have been used. Continence is based on coaptation and elevation of the bladder neck that approximates opposing epithelial surfaces and increases outlet resistance greater above resting bladder pressure and the pressure reached during stressful activity or Valsalva behavior. With sling coaptation, the bladder neck remains fixed, and although a strong detrusor contraction can establish a voiding pressure leading to urinary flow, it rarely allows adequate bladder emptying in the face of anatomic or neurologic problems. The majority of pediatric patients who undergo a sling procedure must be prepared for CIC. The resistance achieved with bladder neck slings can potentially be overcome by overactive bladder contractions or elevated pressure caused by diminished bladder compliance. Therefore simultaneous bladder augmentation has again been reported in 55% to 100% of patients who achieve urinary continence after a sling procedure (Bauer et al., 1989; Bugg and Joseph, 2003; Elder, 1990; Cole et al., 2003; Decter, 1993; Dik et al., 1999; Dik et al., 2003; Godbole and Mackinnon, 2004; Kakizaki et al., 1995; Perez et al., 1996a; Walker et al., 2000). Only Snodgrass et al. have reported good results of bladder neck reconstruction without augmentation cystoplasty in these patients (Snodgrass et al., 2007, 2010; Snodgrass and Barber, 2010). Furthermore, this group found that 35% of children with sustained pressures of more than 40 cm H_2O on anticholinergic therapy for more than 1 year developed either reflux or hydronephrosis at a mean of 23 months. These upper tract changes resolved with a combination of overnight catheter drainage and the addition of intravesical anticholinergic and Deflux. Only one patient was augmented, and the authors concluded that end filling pressures of more than 40 cm should not be used as criteria for augmentation after bladder neck procedure alone (Snodgrass et al., 2014). Long-term assessment from 2000 to 2014 of 109 patients from this same patient population found that 70% required an additional continence procedure, 30% have required augmentation, 50% developed upper tract changes, and 20% developed chronic kidney disease (Grimsby et al., 2015). Alternatives to fascia, such as an expanded fluorocarbon polymer (Gore-Tex) have been used in a similar fashion, although early continence has not been maintained (Godbole and Mackinnon, 2004). Good early results have been noted with some biodegradable scaffolds (Colvert et al., 2002).

Technique

The bladder neck is exposed by clearing fatty tissue overlying the bladder neck and the lateral endopelvic fascia. An incision is made within the endopelvic fascia for approximately 2 cm. The junction between the bladder neck and proximal urethra can be identified by placing a transurethral catheter into the bladder and gently pulling down on the catheter to lodge the balloon at the bladder neck. Using blunt dissection, a plane between the posterior bladder neck and vagina in girls or rectal wall in boys is developed. The proper plane may be more easily developed from the cul-de-sac by dissecting behind the bladder and ureters from above (Badiola et al., 2000; Lottmann et al., 1999). If the landmarks are not easily defined, as in a secondary repair, the dissection becomes difficult. It may be appropriate to open the bladder to help prevent inadvertent dissection into the urethra or posterior structures. Dik et al. (2003) proposed use of a transvaginal approach, eliminating the need to open the bladder or dissect between the bladder neck and anterior vagina.

When fascial tissue is used, the technique is based on that described by McGuire and Lytton (1978) for stress urinary incontinence. Rectus abdominus fascia 1 cm in width and of an appropriate length is harvested. This fascia can be taken either in vertical or horizontal fashion depending on the initial skin incision. Fascia from other sites has been used in a similar fashion but requires a second incision. Cadaveric tissue or biodegradable scaffolds may also be used (Albouy et al., 2007; Colvert et al., 2002; Misseri et al., 2005). All are usually secured to the anterior rectus fascia on either side. Autologous fascial tissue has been used combining the benefits of a compressive wrap and suspension of the proximal urethra and bladder neck. Several variations of fascial placement and configuration have been described (Bugg and Joseph, 2003; Dik et al., 2003; Elder, 1990; McGuire et al., 1986; Perez et al., 1996a; Woodside and Borden, 1982). When fascial slings and wraps are used for neurogenic sphincter incontinence, there is not as much concern for creating a wrap or sling that is too tight because most patients are preferentially managed with CIC. Placement of a bladder neck sling using laparoscopic and robotic assistance is currently being explored by minimally invasive surgeons (Bagrodia and Gargollo, 2011; Mattioli et al., 2010; Storm et al., 2008). In a small retrospective study, although the robotic approach took significantly longer to perform, there did not appear to be differences in overall complication rate, length of stay, and number of additional procedures required (Grimsby et al., 2016). The length of operative time may be a reflection of the overall learning curve, whereas magnification and access to the bladder neck in the deep pelvis appear to aid in the dissection and placement.

Results

Fascial slings have been used more extensively and with better results in girls with neurogenic sphincter incompetence, although recently some success has been reported in boys. Overall, long-term success with fascial slings in the neurogenic population has varied greatly from 40% to 100% (Kryger et al., 2000). A variation thought to contribute to a higher success includes a circumferential fascia wrap around the bladder neck. A circumferential wrap may equalize the compressive pressure over a greater surface area of bladder neck and posterior urethra (Strang et al., 2006; Walker et al., 1995). With the wrap, simultaneous suspension has also been used (Bugg and Joseph, 2003). Success rates have varied so much that it is difficult to determine whether any modification of the sling accounts for an increase in continence. Most patients who have undergone a fascial sling or wrap have also had simultaneous bladder augmentation. **Success of the sling, as with most repairs, apparently is improved with augmentation cystoplasty in this patient population by almost all reports** (Castellan et al., 2005). Perez et al. (1996a) reviewed the outcome of sling cystourethropexy in 39 children, 15 of whom were boys; 1 of 4 various techniques was performed. In evaluation of postoperative continence based on age, sex, underlying diagnosis, preoperative urodynamics, surgical technique, and enterocystoplasty, only concomitant enterocystoplasty was predictive of a successful outcome. This was not the experience of Snodgrass, who reported successful outcome of bladder neck sling without the need for enterocystoplasty. Snodgrass et al. (2010) reported manageable bladder hostility in their determination, but no need for augmentation, in 26 patients who underwent a sling only. They achieved continence in 46% of 35 patients undergoing a sling alone and 82% of 17 patients undergoing a sling combined with a Leadbetter-Mitchell bladder neck repair (Snodgrass and Barber, 2010).

Unlike with the Silastic sheath, erosion rarely occurs with fascial slings. Gormley et al. (1994) reported a revision rate with fascial slings of 15%. Placement of a fascial sling does not eliminate the possibility of later placement of an AUS (Barthold et al., 1999; Decter, 1993). It is not unreasonable to consider placing a fascial sling in a child with a marginally competent bladder neck and deficient external sphincter if the child is undergoing augmentation cystoplasty and already requires intermittent catheterization.

Bladder Neck Bulking Agents

Vorstman et al. (1985) reported one of the initial descriptions of injection therapy with a bulking agent into the bladder neck of incontinent children. The initial enthusiasm for use of polytetrafluoroethylene was quickly tempered because of concern over migration of particles to regional and distant sites including pelvic nodes, lungs, brain, kidney, and spleen found in animal models (Malizia et al., 1984). The technique remains of interest, and several alternatives to polytetrafluoroethylene have been assessed, including glutaraldehyde cross-linked collagen, dextranomer/hyaluronic acid copolymer, and polydimethylsiloxane (Alova et al., 2012a; Dean et al., 2007; Guys et al., 2006; Knudson et al., 2006; Leonard et al., 1990a; Lottmann et al., 2006). Bovine collagen should not be used in latex-sensitive children with spina bifida because the product is not latex free (Kryger et al., 2000). In an attempt to achieve an ideal substance for injection, investigation is ongoing using autologous cartilage cells harvested from a separate site then grown in an alginate matrix for endoscopic implantation (Bent et al., 2000). Preliminary results show a positive effect in women with stress incontinence. Whether this or other materials are appropriate alternatives for neurogenic sphincter incontinence in children is unknown.

To alleviate the risks of injecting a foreign biologic product, alternatives to collagen and bovine have been investigated. Polydimethylsiloxane is one such agent. It is composed of sterile solid textured silicone particles, with an average size of 200 µg, suspended in a biologic hydrogen carrier. The large size of the particles should almost eliminate lymphatic and distant migration (Beisang and Ersek, 1992; Guys et al., 1999; Guys et al., 2006; Halachmi et al., 2004). Contemporary reports favor the use of dextranomer/hyaluronic acid (Alova et al., 2012a; Dean et al., 2007; Dyer et al., 2007; Kaye et al., 2010; Kitchens et al., 2007; Lottmann et al., 2006).

Technique

Endoscopic exposure is used for localizing the proximal urethra and bladder neck. Injection can be done directly through the working channel of the endoscope, often one with an offset lens system. Ideal placement of the material is in a subepithelial space, mobilizing the epithelium toward the lumen of the bladder neck. When completed in a circumferential fashion, adequate epithelial coaptation may occur, which can raise outlet resistance. Alternatively, periurethral injection in women through a long needle placed from the perineum or via a suprapubic approach has been used. Dean et al. (2007) advocate a combined antegrade and retrograde approach. Evidence is lacking regarding whether the exact approach affects success, but accurate placement is important and transurethral injection is usually preferred.

Results

The durability and success of bladder neck and proximal urethral injection remain in doubt for the pediatric population, particularly those with neurogenic dysfunction. True continence, as defined by a 4-hour dry period between voidings or catheterizations, has been reported to be at most 78% and has ranged as low as 5% (Alova et al., 2012a; Bomalaski et al., 1996; Capozza et al., 1995; DaJusta et al., 2013; Dean et al., 2007; De Vocht et al., 2010; Godbole et al., 2003; Guys et al., 2001; Halachmi et al., 2004; Kaye et al., 2010; Kitchens et al., 2007; Leonard et al., 1990a; Perez et al., 1996b; Silveri et al., 1998; Sundaram et al., 1997). Several factors play a role in the outcome, one of which is a history of any previous operative bladder neck repair. Success is enhanced by elevation of the epithelium of the bladder neck, which may be compromised by scarring from previous operative procedures. **The concept of a minimally invasive operation used to enhance a marginal result gained from a more formal bladder neck repair is enticing; unfortunately, the data are lacking to show that bladder neck injection is of lasting value or that repeat treatments are warranted in that setting** (Alova et al., 2012a; DaJusta et al., 2013; De Vocht et al., 2010).

Sundaram et al. (1997) reported on the efficacy and durability of glutaraldehyde cross-linked bovine collagen in 20 children, 12 of whom had neurogenic sphincter dysfunction. More than half of the children required two or three independent injections. Success was achieved in only 1 patient (5%) who was considered dry; 5 had some improvement, and 10 had either no change or transient improvement for only 2 to 90 days. In the hands of these researchers, collagen therapy only delayed the ultimate need for bladder neck reconstruction. Submucosal bladder neck injection of bovine dermal collagen was used by Perez et al. (1996b) in 32 patients. Continence was achieved after a single injection in only 20% of the children with neurogenic dysfunction. The authors concluded that even though their success was limited, the low morbidity and ease of placement justified a trial of submucosal injection in selected children.

Guys et al. (2006) treated 49 children with polydimethylsiloxane, 41 of whom had neurogenic bladder neck and sphincter incontinence. The level of continence deteriorated through 18 months after the procedure then stabilized. After an average follow-up of 73 months, success had been achieved in 16 (33%), and 7 (14%) were improved. Godbole et al. (2003), Halachmi et al. (2004), and Dyer et al. (2007) independently came to the conclusion that regardless of the material injected (polytetrafluoroethylene, collagen, polydimethylsiloxane, dextranomer/hyaluronic acid), short-term success is not long lasting. Alova et al. (2012b) determined that failure after 1 year using dextranomer and hyaluronic acid was primarily caused by neurogenic bladder dysfunction and deterioration.

However, failure after injection therapy does not preclude a successful outcome when it is salvaged by more invasive measures (Alova et al., 2012b).

The cost of the bulking agents can be excessive, and there does not appear to be any financial benefit over a formal repair (Kryger et al., 2000). **At present, bulking agents play a limited role for increasing outlet resistance and should be reserved for a select group of patients. The exact criteria that define that group have not been well established.** Patients with marginal native outflow resistance are probably better candidates than those with minimal preoperative function.

Artificial Urinary Sphincter

The AUS has been recognized as a device that can result in prompt continence in select children while preserving their ability to void spontaneously. The AUS was introduced by Scott et al. (1974). The general concept and design of the initial model have been retained; however, improvements and enhancements have evolved that have a positive impact on the long-term success of the AUS. The current AS800 model includes a seamless, pressurized balloon reservoir, nonkink tubing, and changes in the cuff that facilitate its placement and effectiveness with coaptation of the bladder neck and proximal urethra (Barrett et al., 1993; Catti et al., 2008; Lai et al., 2007; Light and Reynolds, 1992; Ruiz et al., 2006). Alternatives to the AS800 model have also been explored (de O Vilar et al., 2004; Farrugia et al., 2012).

Technique

Placement of the cuff should be at the level of the bladder neck in all females and prepubertal boys. It is also the most desirable and effective location in pubertal and adult males with neurogenic sphincter incompetence. The bulbar urethra can be used as an alternative site in men with mature spongiosum. Levesque et al. (1996) have indicated that age is not a factor regarding placement of the cuff around the bladder neck. They found that children do not outgrow the AUS as they progress through puberty and that replacement of the cuff is not routinely necessary. The AUS cuff can be positioned around intestinal segments used in total urinary reconstruction but is more prone to erosion there. Several authors have described the successful placement of the cuff around a bowel segment, particularly when omentum is interposed between the cuff and the segment (Burbige et al., 1987; Light et al., 1995; Weston et al., 1991).

Placement of an AUS in children is the same as that described for adults. Development of the proper plane for the cuff is virtually identical to that described for a fascial sling. The cuff should be sized snugly, but not tightly, around the bladder neck. Obviously a sterile environment is critical when considering placement of the AUS to avoid infection. For that reason, preoperative antibiotics are a necessity, and confirmation of sterile urine required. With those precautions, there is freedom to open the bladder when dissecting around the bladder neck. This often facilitates the dissection and ensures proper placement. The AS800 model has a locking mechanism in the pump that permits the AUS to be deactivated and activated without a second operative procedure. Experience has shown that leaving the unit deactivated with the cuff deflated after placement allows formation of a pseudocapsule around the cuff and decreases the risk of erosion (Furlow, 1981; Hanna, 1981; Sidi et al., 1984). The noncycled AUS occasionally may provide enough resistance for continence, eliminating the disadvantages of activation (Herndon et al., 2004).

Results

There are substantial short- and long-term data regarding continence after placement of the AUS; the largest series was presented by Herndon et al. (2004). **In investigation of continence, it must be placed in context of the cost experienced by the patient, defined by mechanical malfunctions resulting in secondary operative procedures and more catastrophic complications such as device infection or erosion.** Dramatic improvement regarding the need for secondary procedures has occurred because of the technical refinements in the device. Ten- to 15-year long-term follow-up of the AUS in children has been reported (Castera et al., 2001; Hafez et al., 2002; Herndon et al., 2003; Kryger et al., 1999; Kryger et al., 2001; Levesque et al., 1996; López Pereira et al., 2006; Ruiz et al., 2006). All groups report an impressive continence rate of 80% and a functioning sphincter in 95% of patients. Herndon et al. (2003) present the most comprehensive long-term data. They achieved overall continence in 86% of 142 patients with an average follow-up of 10 years. Age at implementation does not appear to affect continence (Kryger et al., 2001).

Although the AUS is one of the few surgically created continence mechanisms that does not negatively affect spontaneous voiding, CIC remains an important adjunct in approximately 75% of children with neurogenic sphincter incompetence and can be performed successfully through the cuff (Castera et al., 2001; Catti et al., 2008; Diokno and Sonda, 1981; Gonzalez et al., 1995; Hafez et al, 2002; Herndon et al., 2003; Kryger et al., 1999; Kryger et al., 2001; Levesque et al., 1996; Ruiz et al., 2006).

Herndon et al. (2003) reported device malfunction with 64% of the pre-AS800 model and 30% with the AS800. Sphincter erosion was similar for the pre-AS800 and AS800, occurring at 19% and 16%, respectively, in their experience, similar to the reports of others (Bauer, 2008; Ruiz et al., 2006). Fastidious attention to detail and sterile technique diminish the risk of infection but do not eliminate it. When infection occurs without erosion, the unit can be removed and later replaced (Nurse and Mundy, 1988). Infections are minimized by sterilizing the urine preoperatively, meticulously cleaning the wound site, using a preoperative bowel preparation, administering perioperative parenteral antibiotics, and performing copious antibiotic wound irrigation. Newer cuff design and a 6-week delay in activation of the device help formation of a thickened pseudocapsule that substantially decreases bladder neck and proximal urethral erosion. Kryger et al. (1999) indicated that erosion can be virtually eliminated when the cuff is placed as the primary treatment for bladder neck incompetence.

Upper urinary tract changes including hydronephrosis have been reported to occur in up to 15% of children after placement of the AUS (Churchill et al., 1987; Gonzalez et al., 1995; Kryger et al., 1999; Levesque et al., 1996; Light and Pietro, 1986). In extreme cases, renal insufficiency has resulted. **It is now recognized that occlusion of the bladder neck in children with neurogenic sphincter incompetence can result in the unmasking or development of detrusor hostility manifesting with a decrease in bladder compliance or increase in detrusor overactivity** (Bauer, 2008; Bauer et al., 1986). **Careful preoperative urodynamic assessment helps to identify only some of the children who are at risk** (Dave et al., 2008; Kronner et al., 1998b). When hostile bladder characteristics are found preoperatively, anticholinergic medications can be beneficial for hyperreflexic contractions, but augmentation cystoplasty is usually required for diminished compliance. Churchill et al. (1987) showed that favorable parameters can be maintained after placement of the AUS; however, close observation is still recommended in any child undergoing bladder neck reconstruction to identify any early deterioration in bladder dynamics before upper tract changes.

Some children undergoing sphincter placement need bladder augmentation as well, and the timing of the two procedures may be questioned because of the concern for AUS infection. Light et al. (1995) reported a 50% infection rate with simultaneous augmentation compared with 9.5% when the procedures were staged. To the contrary, a contemporary review by Miller et al. (1998) found infection necessitating removal of the device occurred in only 2 of 29 such patients (7%). This low rate is similar to that noted by others (Gonzalez et al., 1989; Strawbridge et al., 1989). Although infection of the AUS is a concern, placement can be successfully undertaken when bowel is simultaneously used for total continent reconstruction of the bladder and bowel (Bar-Yosef et al., 2011).

The ultimate benefits of the AUS lie in its ability to achieve a high rate of continence while maintaining the potential for spontaneous voiding. For practical purposes, when intermittent catheterization is required along with augmentation cystoplasty, use of native tissue for continence eliminates the long-term concern for infection or erosion and the risk of mechanical failure.

Urethral Lengthening

Young's original description of bladder neck reconstruction (1919) consisted of two components: excision of a segment of anterior urethral bladder neck tissue and narrowing of the adjacent remaining posterior portion. However, this ultimately led to failure because the tubularized segment remained unsupported within the bladder. Refinements by Dees (1949) and Leadbetter (1964) maximized good muscle tone at the bladder neck and extension of the urethral tube through the trigone.

Tanagho (1981) described a cephalad-based anterior detrusor wall tube. Closure of the tubularized bladder neck created circularly oriented muscle fibers, which Tanagho described as a sphincter mechanism. However, he cautioned against the use of this technique in the neurogenic population. Because of potential breakdown of that tubularized bladder neck and poor results, other techniques have been developed based on the concept of a flap valve mechanism for urinary retention. Kropp and Angwafo (1986) described urethral lengthening and creation of a flap valve for neurogenic bladder neck and sphincter dysfunction. The technique is based on an anterior detrusor wall tube that is kept in continuity with the urethra, tubularized, and implanted into a submucosal tunnel within the trigone. Conceptually this is effective; however, difficulty with catheterization is a common problem and significant concern.

Technique

A Foley catheter is placed intravesically and the bladder filled to capacity. The bladder is exposed through either a midline or low transverse abdominal incision. The bladder neck is then identified with application of gentle catheter traction. A 6- × 2-cm rectangular flap based on the bladder neck and urethra is then isolated. Stay sutures are placed, and the flap is mobilized in continuity with the proximal urethra. The detrusor musculature at the bladder neck is divided, separating the bladder and urethra, or the muscle may be left intact at the 5 and 7 o'clock positions. In girls, the anterior vaginal wall is exposed; in boys, the seminal vesicles. The rectangular strip based on the urethra is tubularized posteriorly around the urethral catheter with a continuous absorbable suture. The distal portion of the tubularized strip should be approximated in an interrupted fashion to facilitate excision of excessive tissue without jeopardizing the suture line. A capacious submucosal tunnel through the trigone is then created posteriorly for the neourethra (Fig. 37.3). A wide tunnel is required to prevent kinking at the level of the bladder neck, which would impede catheterization. It is important to eliminate dead space at the entrance of the urethra into the bladder; this can be accomplished by placing lateral anchoring sutures in the region of the bladder neck. The detrusor tube must be pulled straight through the tunnel without curve or deviation to facilitate catheterization. Waters et al. (1997) and Kropp (1999) have not found it necessary to reimplant all ureters in a cephalic location; they now typically reimplant only refluxing ureters (Kropp, 1999). When closing the bladder, the lateral wings in the region of the bladder neck are approximated and incorporate adventitia of the tubularized urethra. This enhances a watertight closure and is continued for 2 to 3 cm anteriorly, often up to the area of augmentation. The tubularized neourethra should be long enough to reach the true lumen of the bladder, where it is exposed to pressure as an effective flap valve.

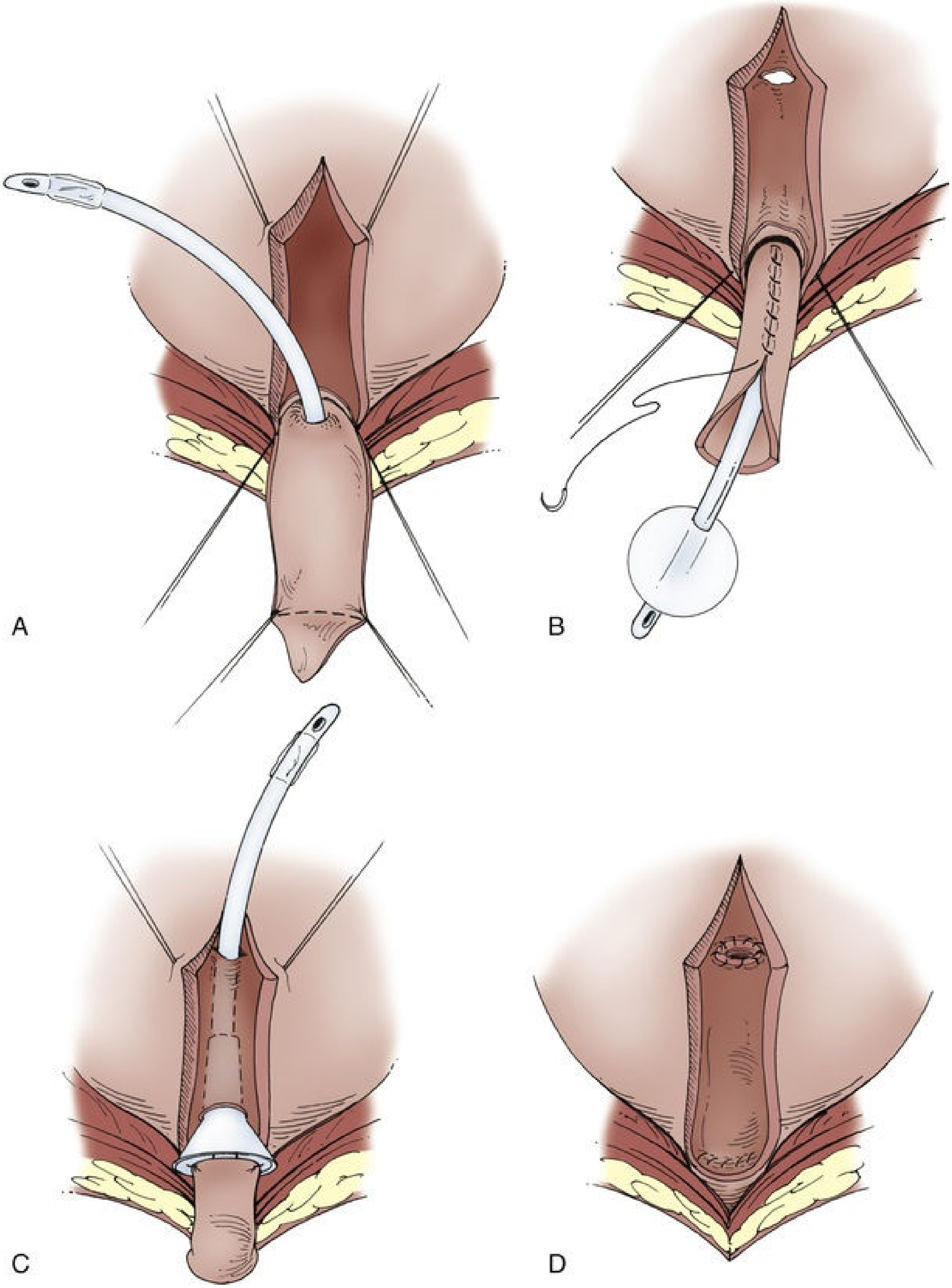

FIG. 37.3 Kropp anterior detrusor tube. (A) An anterior flap of bladder (2 cm wide × 5 to 6 cm long) is developed in continuity with the urethra. (B) The anterior flap is tubularized over a catheter. A tunnel beneath the mucosa of the trigone is made between the ureteral orifices for the length

of the tube. (C) The tubularized flap is brought through the tunnel. (D) The detrusor tube is secured to the floor of the trigone with interrupted absorbable suture in a straight course.

Because of the difficulties with catheterization, modifications of the Kropp bladder neck procedure have been described. Belman and Kaplan (1989) suggested a simplified approach. They harvested a rectangular strip from the anterior bladder wall similar to that described by Kropp. The lateral and posterior musculature at the bladder wall, however, is not incised, and the proximal urethra and bladder are not separated. The flap is tubularized over an 8-Fr catheter. The epithelium on the floor of the bladder is incised contrary to the tunnel made by Kropp. The tube is placed within the trough with the proximal meatus secured on the floor of the bladder. The epithelial edges of the trough are then secured to the lateral aspect of the tube. As with the initial description, the suture line for tubularization of the urethra lies posteriorly against trigonal muscle. Closure of the bladder begins with reapproximation of the lateral walls of the bladder to the tube until the bladder edges meet. The remaining portion of the bladder is covered by an augmentation. Regardless of any modification to the Kropp bladder neck procedure, catheterization potentially remains problematic, and therefore the patient should be prepared for a catheterizable abdominal-vesicle channel.

An innovative trial by Chrzan et al. (2013) was undertaken in 18 patients, using laparoscopic techniques that allowed for “vesicoscopic” exposure of the bladder neck. Chrzan et al. were able to lengthen the urethra by creating a U incision around the bladder neck and onto the epithelial surface of the bladder dome. This prevented interference of the ureteral orifices and could be undertaken in patients in whom other bladder neck procedures had failed. Unfortunately, a long-term benefit has not been achieved.

Results

Snodgrass (1997) examined the results in 23 children, 22 of whom had neurogenic sphincter incompetence, and noted continence in more than 90% of the children. The most common complication was difficult catheterization, particularly in boys. Less than half of the boys in Snodgrass's series catheterized through the native urethra; the majority did so via an abdominal wall stoma. Postoperative vesicoureteral reflux was identified in 9 of 18 children, and Snodgrass speculated this was because of lateral retraction of the ureters. Their recommendation was made to leave the posterior bladder wall open and flat when receiving the augmentation to prevent this distortion. Kropp (1999) has not had as much difficulty with catheterizations in his patients and likewise has achieved a high rate of continence without a high incidence of new reflux.

Some patients with an effective flap valve mechanism created by urethral lengthening never leak per urethra. This potentially puts them at risk for upper tract deterioration or bladder rupture, particularly if they do not or cannot catheterize reliably. Snodgrass (1997) thought his modification was beneficial in that it resulted in a shorter intravesical tunnel for the neourethra, allowing for leakage per urethra with overfilling.

Pippi Salle Procedure

In an attempt to maximize the benefits of the Kropp technique and decrease problems with catheterization, Salle et al. (1994) **reported an anterior bladder onlay flap.** With this technique, the posterior wall of the neourethra is intact, theoretically providing less potential hang-up during catheterization. Since the first report, modifications have been made to improve flap viability, minimize fistula formation, and extend the indications for the procedure beyond that of the neurogenic bladder (Salle et al., 1997).

Technique

An anterior, full-thickness bladder wall flap 5 × 1 cm is mobilized to the bladder neck with 0.1 cm of its epithelial edges excised to avoid overlapping suture lines. Two parallel incisions down to the level of the muscle are made in the mucosa of the trigone from the native bladder neck. The anterior flap is secured to the midline strip of trigone mucosa to create a tube or lengthened urethra using absorbable suture. The muscle on either side of the posterior epithelial strip may be incised superficially to provide an edge to which the muscle of the anterior flap may be approximated with a second layer of suture in an effort to avoid fistula (Fig. 37.4). The more lateral mucosa of the trigone is mobilized and closed over the midline urethra. Distally, the muscle of the bladder neck is wrapped tightly around the urethra with closure. Proximally, the lengthened urethra should extend well into the lumen of the bladder.

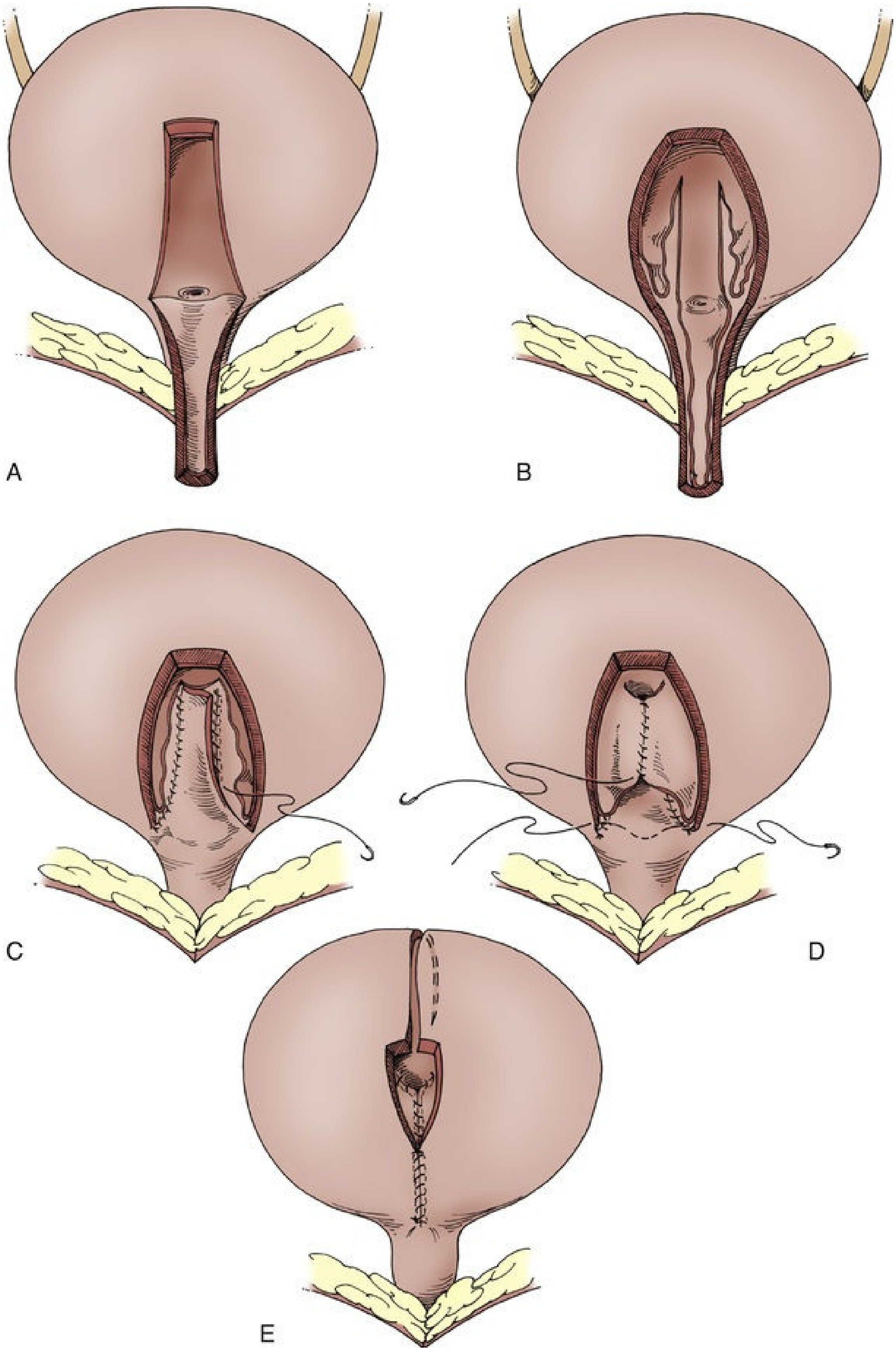
A
B
C
D
E

FIG. 37.4 Pippi-Salle anterior detrusor tube onlay. (A) An anterior detrusor tube (1 cm × 4 to 5 cm) is mobilized to the level of the bladder neck. (B) A central strip on the floor of the bladder is developed by incision of the epithelium on either side. (C) The anterior detrusor flap is secured to the strip in a two-layer fashion, approximating the epithelium with the first layer and muscle with the second. (D) The lateral mucosa of the trigone is mobilized and secured over the lengthened urethra. Distally, the bladder is closed to itself and should incorporate a portion of the anterior detrusor flap to ensure a watertight seal. (E) After distal closure the remaining portion of the bladder is left open if augmentation cystoplasty is necessary.

Results

Initial complications of this procedure included persistent incontinence, urethrovesical fistula, and partial necrosis of the intravesical neourethra. Widening the base of the urethra at the level of the bladder neck may minimize these problems. Children who have previously undergone bladder surgery can have a secondary Salle repair if the anterior bladder flap is lateralized slightly to avoid any old midline suture line.

Salle et al. (1997) found that continence was achieved in 12 of 17 patients (71%) for more than 4 hours. Catheterization difficulties occurred in only 3 of 17 children, 1 of whom subsequently underwent an appendicovesicostomy. Fistula formation at the base of the flap between the proximal, intravesical urethra and bladder occurred in 2 children and resulted in recurrent incontinence. This problem appears to be diminished by creating a wider base to the flap and generously trimming the epithelial edges there. Jawaheer and Rangecroft (1999) reported a diurnal continence rate of 61% for 3 or more hours with the Salle procedure. However, only 44% of their patients were dry through the night. Less trouble with catheterization has occurred relative to the Kropp technique and rarely remains a problem. Continence rates have not been as high in most series (Cole et al., 2003; Mouriquand et al., 1995; Rink et al., 1994).

Canales et al. (2006) used a miniature intravesical lengthening of shorter length (3 cm) and radius (8 Fr) with the intent of enhancing resistance, minimizing the use of bladder, and avoiding need for ureteral reimplantation. After 2½ years of follow-up, 8 of 9 children were continent and had an average leak point pressure of 71 cm H_2O. A recent comparison between the Kropp and Pippe-Salle procedures showed similar dry intervals without the need for additional bladder neck procedure. However, the rate of delayed augmentation was high for both groups who did not have a concomitant augment at the time of bladder neck procedure. In addition, both procedures were associated with a high rate of secondary surgeries unrelated to the bladder neck (Szymanski KM et al., 2016).

Bladder Neck Division

The ultimate procedure to increase bladder outlet resistance is to divide the bladder neck so that it is no longer in continuity with the urethra. It must be accompanied by creation of a continent abdominal wall stoma and should be performed only in patients who will reliably catheterize. If effective, it prevents any leakage or pop-off per urethra and increases the risk for upper tract deterioration or bladder rupture if emptying is not performed. Division is seldom performed as a primary procedure but may be considered if the previously mentioned repairs fail (Baradaran et al., 2012; Bergman et al., 2006; De Troyer et al., 2011; Kavanagh et al., 2012; Khoury et al., 1999; Landau et al., 2009).

Closing the bladder neck moves the reconstructive effort into the realm of continent urinary diversion. The bladder neck is abandoned from a physiologic standpoint, although the bladder may be used as part of the reservoir. Effective division of the bladder neck is not a simple procedure. The bladder must be aggressively mobilized away from the urethra. The bladder should be closed distally in several layers after the posterior lip of bladder neck and trigone are rolled anteriorly and widely separated from the distal urethra. Omentum has usually been interposed, as has rectus abdominus muscle (Smith et al., 2010). Without these steps, fistulization and leakage per urethra can occur (Khoury et al., 1999; Nguyen and Baskin, 2003). With aggressive mobilization, the fistula rate can be low (Thomasch et al., 2009). Although eliminating secondary access to the bladder creates a concern, long-term follow-up indicates that a successful outcome is achieved in almost all patients (De Troyer et al., 2011; Kavanagh et al., 2012; Landau et al., 2009).

Key Points: Bladder Neck Reconstruction

- Any repair other than placement of an AUS, particularly if combined with cystoplasty, is likely to make spontaneous voiding inadequate.
- Young-Dees-Leadbetter repair in the spina bifida population has variable

success related to the underlying neurogenic dysfunction.

- Fascial slings have been used more extensively and with better results in girls than boys with neurogenic dysfunction, although those results vary widely.
- Experience does not yet suggest that injection of bladder neck bulking agents has a lasting effect on severe neurogenic sphincter incompetence.
- A functioning, well-positioned artificial sphincter provides good resistance and is best reserved for patients who can empty adequately with spontaneous voiding.
- Urethral lengthening procedures use a flap valve mechanism for continence that disrupts any chance of voiding and may make catheterization per urethra difficult.
- The success of most bladder neck repairs in the neurogenic population improves if combined with augmentation cystoplasty.
- Bladder neck repair may unmask or result in new bladder hostility; careful follow-up is mandatory.

Bladder Reconstruction

Cutaneous Vesicostomy

Cutaneous vesicostomy is used to “vent” the bladder, thus minimizing the effect of high intravesical pressures to the upper tracts. This technique is an excellent temporary or permanent diversion in patients with worsening upper tract dilation, recurrent febrile UTIs with high grade reflux, and a high pressure bladder despite maximal medical therapy (Donmez et al., 2017). Vesicostomy is typically used in young patients and has proven to be a safe alternative until definitive reconstruction can take place. Disadvantages include stenosis, prolapse, and incontinence (which can be difficult to manage as children get older).

Augmentation Cystoplasty

The initial approach to the patient for augmentation cystoplasty is similar regardless of the bowel segment to be used. Cystoscopy may be performed preoperatively to identify any unsuspected anatomic abnormalities that may affect the surgery or postoperative care. If other bladder procedures such as ureteral reimplantation are to be performed, the bladder is left full after cystoscopy. If not, the bladder is emptied to allow easy access to the peritoneal cavity.

As a general rule, a midline incision is preferred for intestinal cystoplasty, although these procedures can be performed through a lower transverse incision if there has been no previous abdominal surgery. Laparoscopic assistance with mobilization of the intestine may allow augmentation through a smaller, lower incision (Hedican et al., 1999). Associated bladder procedures should be performed before opening the peritoneal cavity to minimize third space fluid loss. For gastrocystoplasty, the incision extends from the pubis to the xiphoid to allow more cephalad exposure. Augmentation cystoplasty may be performed completely by laparoscopy with or without use of a robotic system (Lorenzo et al., 2007; Passerotti et al., 2008; Wang et al., 2007). For such cases, a 12-mm camera port is placed periumbilically or supraumbilically, and up to four 5- to 8-mm working ports are used; one working port should be larger if an endostapler is to be used. Assistant ports are optional, and the use of the fourth robotic arm may aid with retraction or passage of sutures (Gundeti et al., 2008).

Management of the Native Bladder

In the past, it was recommended that the majority of the “diseased” bladder be excised in preparation for augmentation. This meant removal of the supratrigonal bladder, leaving only a small cuff for anastomosis to the intestinal segment. Despite the cuff, a relatively small area was left for anastomosis to the bowel segment; most of the bowel was approximated to itself. **Most surgeons now preserve the native bladder as long as it is widely opened to prevent a narrow-mouthed anastomosis, which can result in the augmentation segment behaving as a diverticulum** (Fig. 37.5). A sagittal incision to bivalve the bladder is generally useful (Fig. 37.6). The incision is carried from a point several centimeters cephalad to the bladder neck anteriorly to a position just above the trigone posteriorly. Such an incision allows a technically easier anastomosis to the bowel segment and leaves the native bladder to add to the overall capacity. A greater circumference for the anastomosis can be provided if need be by opening the bladder in a stellate fashion with a second transverse incision into the two bladder halves. There have been reports of penile or perineal pain in sensate boys after augmentation with preservation of the native bladder (Phelps and Malone, 2004). Although four such patients required secondary removal of bladder, similar problems have not been frequent enough to warrant routine excision at the time of augmentation.

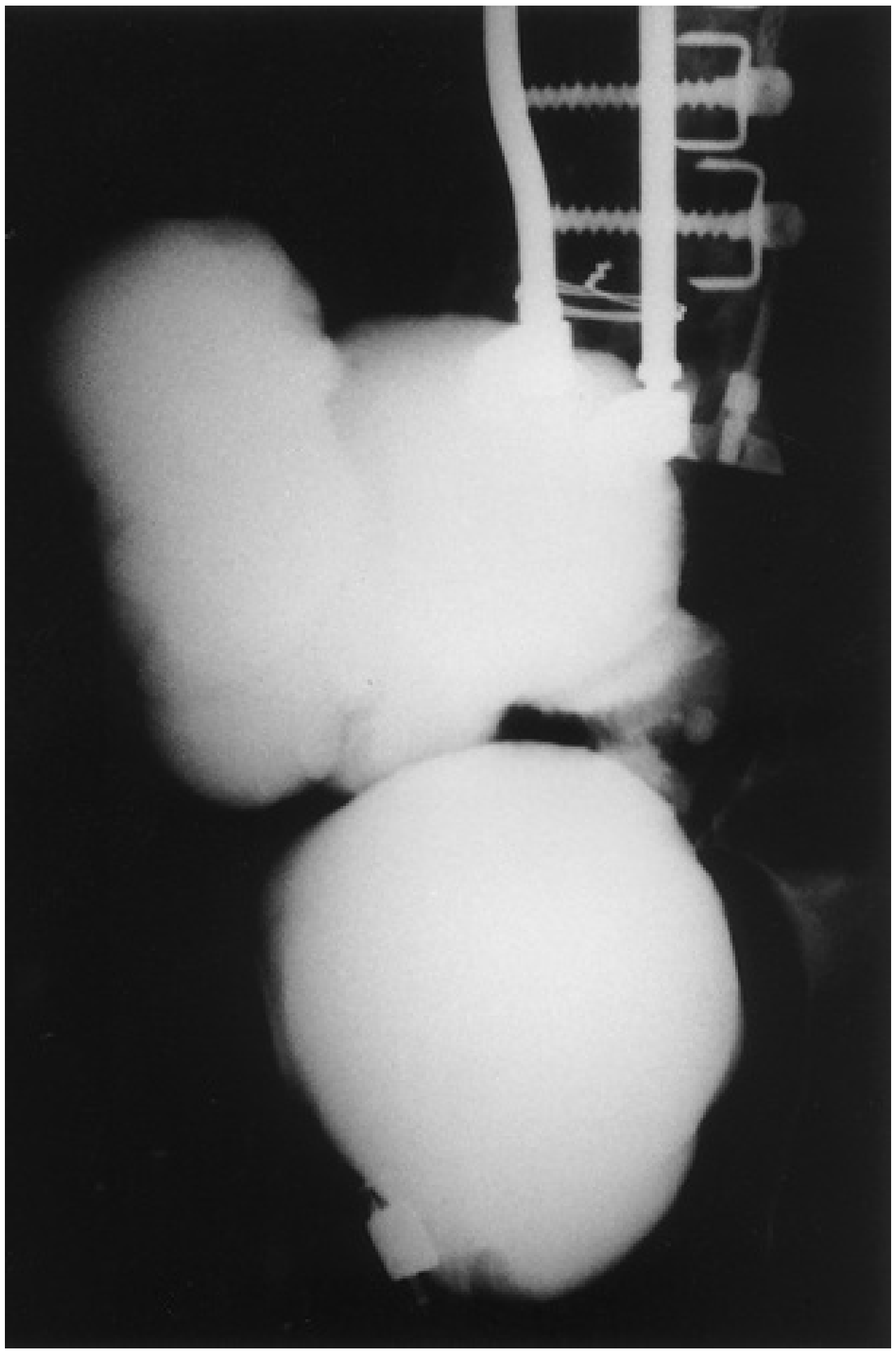

FIG. 37.5 Cystogram after augmentation demonstrates a narrow anastomosis of the bowel segment to bladder. The segment behaves like a diverticulum.

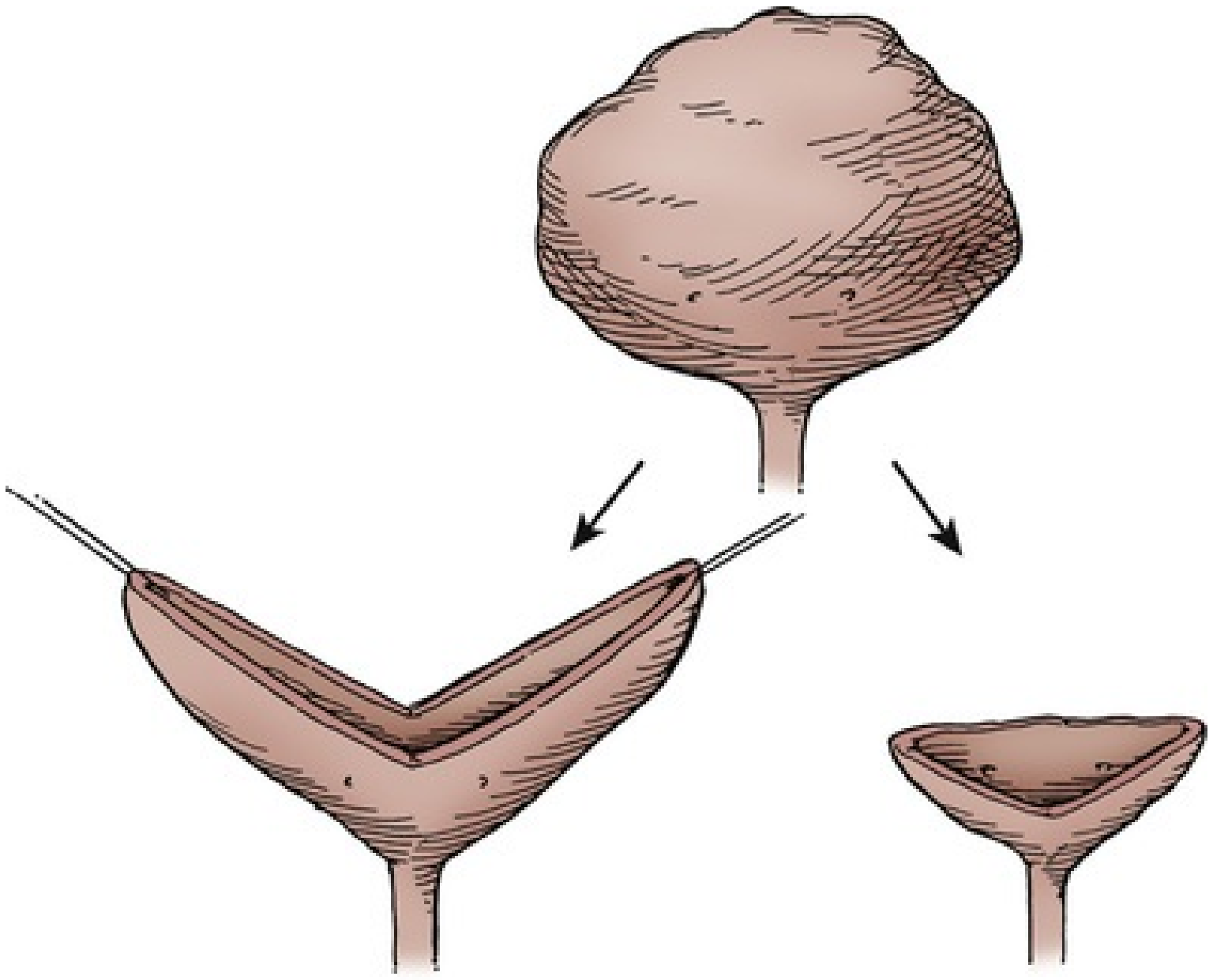

FIG. 37.6 The native bladder can be managed by supratrigonal excision of the diseased bladder. More typically, the bladder is opened widely in a sagittal plane *(left)*.

Management of Intestinal Segments

Hinman (1988) and Koff (1988) demonstrated the advantages of opening a bowel segment on its antimesenteric border with subsequent detubularization and reconfiguration of that intestinal segment. **Reconfiguration into a spheric shape provides multiple advantages, including maximization of the volume achieved for any given surface area, blunting of bowel contractions, and improvement of overall capacity and compliance.** All intact, tubular intestinal segments have been noted to generate pressures of 60 to 100 cm H_2O with contractions (Camey et al., 1991; Fowler, 1988; Kock, 1969; Light and Engelmann, 1985). Detubularization lowered the maximal contractile pressure from 63 to 42 cm H_2O in the right colon and 81 to 28 cm H_2O in ileum (Goldwasser et al., 1987). Furthermore, a shorter intestinal segment can be used to achieve the same capacity as that when left in tubular form. **Detubularization and reconfiguration should always be performed during augmentation cystoplasty.**

Mathematical models based on the length and width of the bowel segment used may predict the volume needed but are cumbersome (Rink and Mitchell, 1990). Depending on the volume needed, 20 to 40 cm of ileum or approximately

20 cm of colon are typically used for cystoplasty. This somewhat depends on the volume of the native bladder being augmented. If the cystoplasty is being done on a bladder of moderate volume that generates high pressure by uninhibited contractions, less bowel is necessary than for one that is tiny in capacity. Unless otherwise contraindicated, the surgeon should err by making the bladder too large rather than too small. Appreciation of the patient's urinary volumes also should influence the size of the bladder required. Patients with upper tract damage may make huge volumes of urine and require a larger capacity.

Ileocystoplasty

Goodwin et al. (1959) were among the first to demonstrate the numerous ways to anastomose a patch of ileum to the native bladder after the ileum was detubularized and reconfigured to achieve the most spheric shape possible.

Technique

A segment of ileum at least 15 to 20 cm proximal to the ileocecal valve should be selected. The distal portion of terminal ileum is unique from a physiologic standpoint and should be avoided. The isolated segment should be 20 to 40 cm in length, depending on patient size, native bladder capacity, and the desired final capacity. With short ureters, an extra tail of isoperistaltic ileum can be useful to reach the foreshortened ureters. This would require creation of an ileal nipple valve to prevent reflux as in the Kock or hemi-Kock pouch; this type of construction may require up to 60 cm of small intestine. **The segment to be used should have an adequate mesentery to reach the native bladder without tension.** After selection of the appropriate segment, the mesentery is cleared from the bowel at either end for a short distance to create a window. The bowel is divided at those ends, and a hand-sewn ileoileostomy or stapled anastomosis is performed. The mesenteric window at the bowel anastomosis is closed to prevent an internal hernia. The harvested ileal segment is irrigated clear with 0.25% neomycin solution and opened on its antimesenteric border (Fig. 37.7A). **The ileum is folded in a** U **shape most commonly, although longer segments can be folded further into an** S **or** W **configuration.** The ileum is anastomosed to itself with running absorbable sutures (Fig. 37.7B). The suture line should approximate the full thickness of ileum to ileum while inverting the mucosa. The anastomosis of the ileum to native bladder is easily done when started posteriorly. The anastomosis may be done in a one- or two-layer fashion, always using absorbable suture and inverting the mucosa to the lumen (Fig. 37.7C). Permanent sutures should never be used for any cystoplasty because they serve as a nidus for stone formation. A suprapubic tube is brought through the native bladder when possible and secured. The anterior aspect of the anastomosis is then completed. A drain is placed near the bladder and brought out of the pelvis through a separate stab incision. It should be removed promptly if not draining urine, particularly in neurogenic patients with a ventriculoperitoneal shunt.

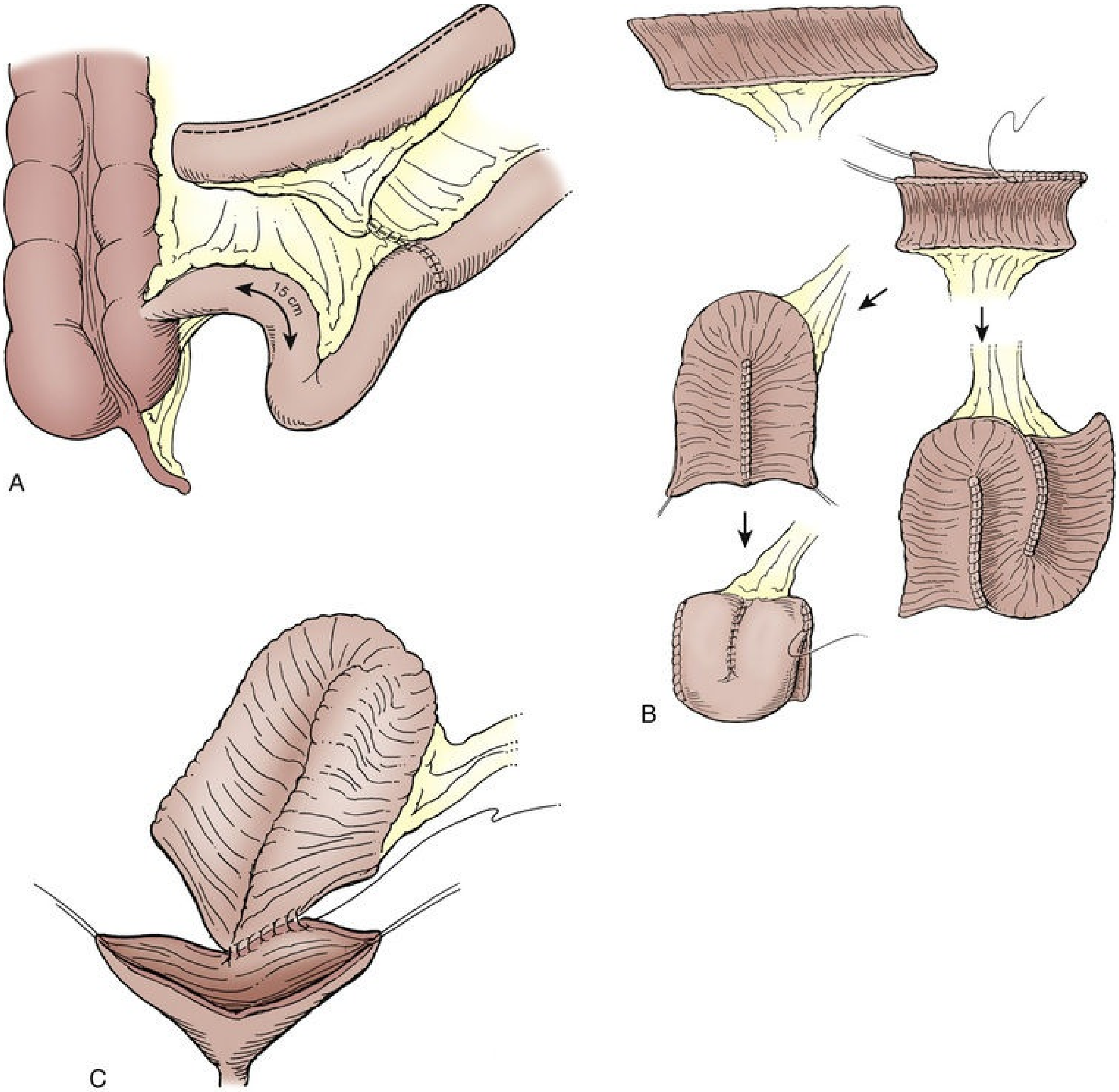

FIG. 37.7 (A) Ileocystoplasty. A 20- to 40-cm segment of ileum at least 15 cm from the ileocecal valve is removed and opened on its antimesenteric border. Ileoileostomy reconstitutes the bowel. (B) The opened ileal

segment should be reconfigured. This can be done in a U, S, or W configuration. It can be further folded as a cup patch. (C) The reconfigured ileal segment is anastomosed widely to the native bladder.

Cecocystoplasty and Ileocecocystoplasty

Couvelaire (1950) described the use of the cecum for augmentation cystoplasty, and numerous reports followed. Presently, cecocystoplasty is an uncommon operative procedure and will not be discussed because it has largely been replaced by various forms of ileocecocystoplasty. With this technique, the cecum is opened, reconfigured, and used to augment the bladder alone, leaving a segment of ileum to reach the ureters or create a continent abdominal wall stoma. Conversely, the ileal segment can be opened and used as a patch on the cecal segment before augmentation cystoplasty.

Technique

Many modifications of the technique exist, but all start with mobilization of the cecum and right colon by incising the peritoneum along the white line of Toldt up to the hepatic flexure. Between 15 and 30 cm of the terminal ileum are used. The length of the ileal segment depends on the technique used. As with all intestinal cystoplasties, before division of the bowel segment, it will reach the bladder without tension (Fig. 37.8A).

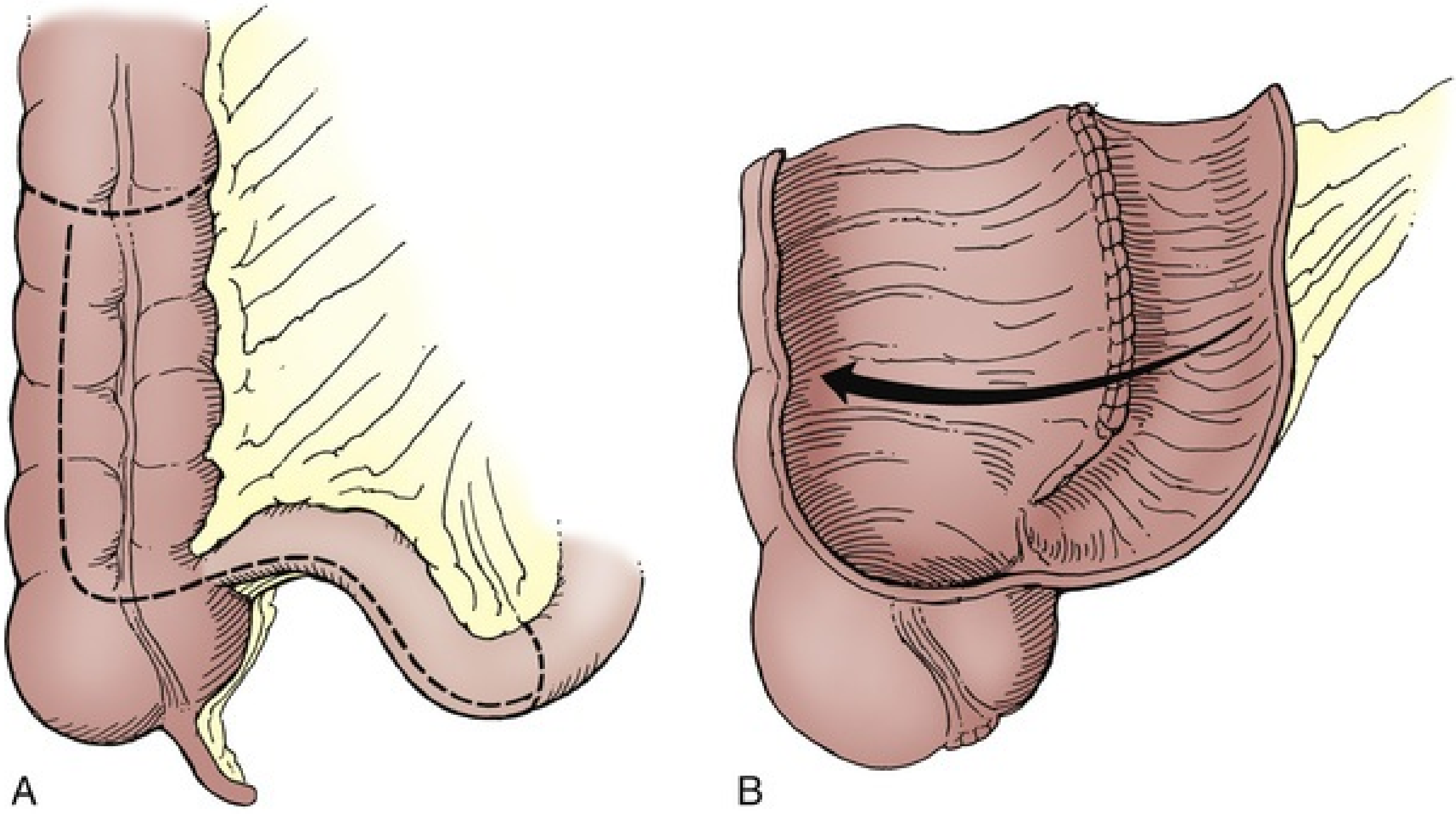

FIG. 37.8 Ileocecocystoplasty. (A) An ileocecal segment is selected. The length of segment chosen depends on the technique used. After removal, it is opened on the antimesenteric border *(dashed lines).* (B) The opened ileal and cecal segments are anastomosed to form a cup in the standard ileocecal cystoplasty.

The isolated ileocecal segment is irrigated clear with neomycin solution and opened on its antimesenteric border through the ileocecal valve for its entire length. In the typical ileocecal augmentation, the ileal and cecal segments are of equivalent length so that the borders of the open segment can be anastomosed and then folded on themselves to form a cup cystoplasty (Fig. 37.8B). The anastomosis of the reconfigured segments is done in either a one- or two-layer closure with absorbable suture. The opening should be left large enough to provide a wide anastomosis to the bivalved bladder. **If more volume is necessary, the ileal segment can be significantly longer, allowing it to be folded before anastomosis to the cecum.** The Mainz ileocecocystoplasty uses an ileal segment twice the length of the cecal segment. The compound ileocecal patch is then anastomosed to the bladder (Fig. 37.9). The mesenteric window is closed, and a suprapubic tube is placed through the native bladder and secured through the abdominal wall.

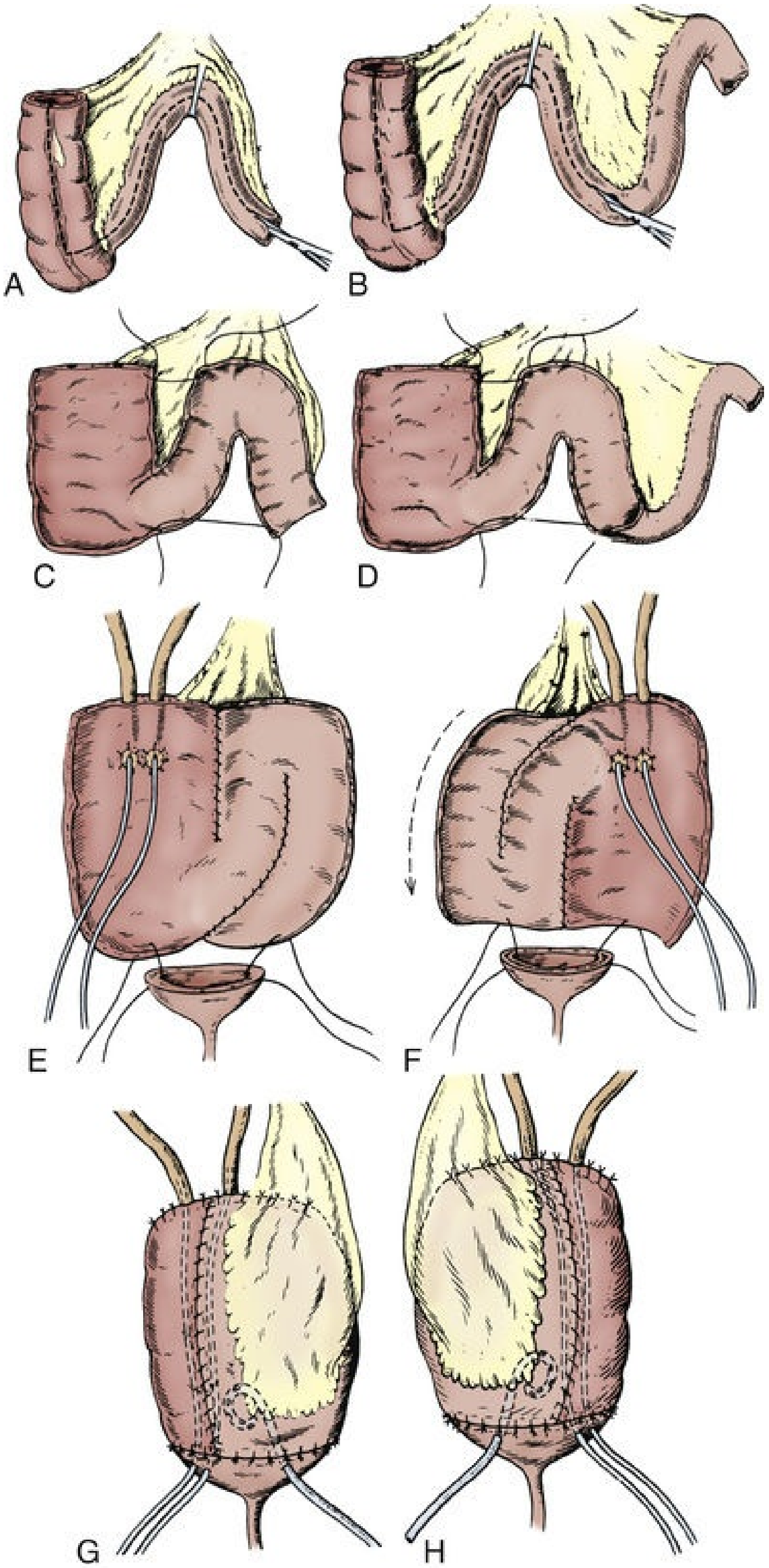

FIG. 37.9 The Mainz ileocecocystoplasty. (A and B) The ileal segment is twice the length of the cecal segment. (C and D) It is opened on the antimesenteric border. (E and F) The ureters can be reimplanted into the opened cecal segment if necessary. (G and H) The ileocecal segment is

anastomosed to the native bladder. (From Thuroff JW, Alken P, Hohenfellner R: The Mainz pouch (mixed augmentation with ileum and cecum) for bladder augmentation and continent diversion. In King LR, Stone AR, Webster GD, editors: *Bladder reconstruction and continent urinary diversion,* Chicago, 1987, Year Book, p 252.)

Appendix

One potential advantage of ileocecocystoplasty is the presence of the appendix. Particularly in children, the appendix is useful in creation of a reliable continent abdominal wall stoma. The appendix may be removed with a small cuff of cecal wall and tunneled into the native bladder or a tenia of the cecal segment to provide a continence mechanism. Likewise, it may be left in situ and the base safely tunneled beneath a tenia. If the appendix is not to be used, an appendectomy is performed with standard ileocecocystoplasty.

Ileocecal Valve

The ileocecal segment has been used extensively in the adult population undergoing reconstruction and bladder replacement. It has been used less frequently in children because the majority of patients undergoing augmentation cystoplasty do so for neurogenic dysfunction affecting bladder and bowel. Removal of the ileocecal valve in such children can result in intractable diarrhea (Gonzalez and Cabral, 1987; King, 1987). Use of the ileocecal valve in such patients should be avoided unless other advantages of the segment outweigh the risk of diarrhea and fecal incontinence.

There are potential advantages to the use of the ileocecal segment. Antireflux tunnels can easily be performed into the tenia of the cecum when necessary. Again for the short ureter, a tail of ileum can be left intact to bridge the gap and the imbricated ileocecal valve used for antireflux. The same imbrication technique can be used to create a continent abdominal wall stoma similar to that used in the Indiana Pouch (Cain and Husmann, 1994; Cain et al., 1999).

Sigmoid Cystoplasty

Use of the sigmoid colon for augmentation cystoplasty was first reported by Lemoine in 1912 (Charghi et al., 1967), and it continues to be used commonly. **Because of the strong unit contractions of the sigmoid, it is imperative to detubularize and reconfigure the segment to provide maximal compliance**

and disruption of contractions.

Technique

Between 15 and 20 cm of sigmoid colon are identified and mobilized. The mesentery is transilluminated to identify the vascular arcade to the segment. After identification of this blood supply, the surgeon must ensure that the segment can reach the bladder without tension. The bowel segment is divided between clamps, and a colocolostomy performed (Fig. 37.10A). The remainder of the abdominal cavity should be carefully packed to prevent contamination from the open sigmoid segment. Detubularization and reconfiguration are done in a fashion determined by the surgeon's preference. The sigmoid patch is anastomosed to the bivalved bladder in a manner similar to that previously described for ileocystoplasty. Again, a large suprapubic tube is brought out through the native bladder and secured to the bladder and skin exit sites.

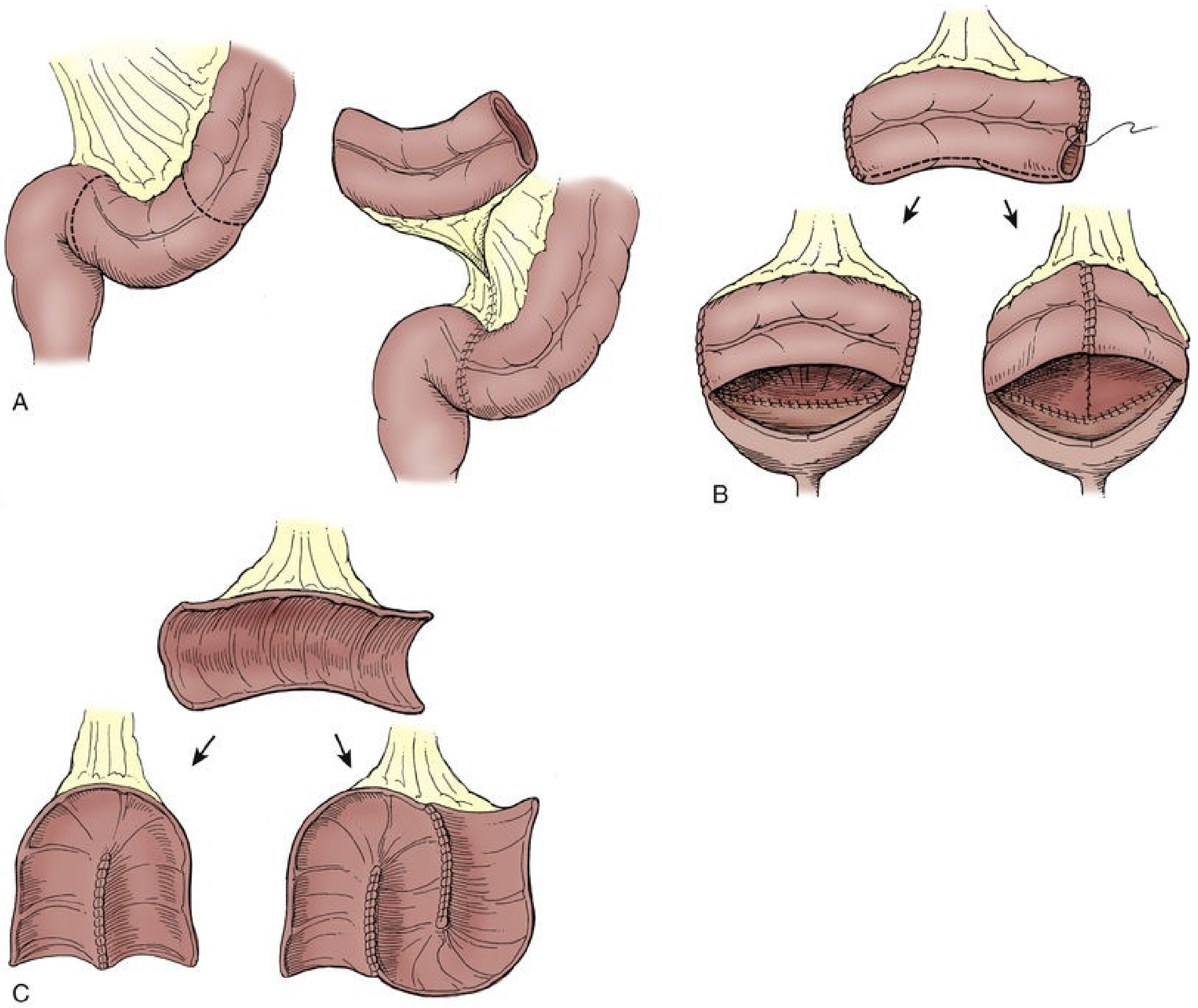

FIG. 37.10 Sigmoid cystoplasty. (A) A sigmoid segment of adequate length is removed from the gastrointestinal tract, and a colocolostomy is performed. (B) In the Mitchell technique the two opened ends are closed. The antimesenteric border is incised, and the segment is anastomosed to the bivalved bladder. It may be rotated 180 degrees to allow an easy fit. (C) The opened sigmoid segment can be reconfigured into a U or S configuration, which may lower pressure.

Reconfiguration of Sigmoid.

In general, sigmoid colon segments are reconfigured in one of two ways. Mitchell (1986) suggested closing the two ends and then opening the segment longitudinally opposite its blood supply. The segment easily fits on the bivalved bladder in either the sagittal or coronal plane (Fig. 37.10B). More radical reconfiguration, and perhaps breakup of unit contractions, may be achieved by folding the sigmoid segment in a U shape similar to that described for ileocystoplasty (Sidi et al., 1987a) (Fig. 37.10C). A slightly longer segment of sigmoid may be necessary for effective reconfiguration in this manner.

Gastrocystoplasty

Two techniques have been described for gastrocystoplasty. Leong and Ong (1972) described the use of the entire antrum with a small rim of body for gastric replacement. Continuity of the upper gastrointestinal tract was restored by Billroth I gastroduodenostomy. A wedge-shaped segment of body based on the midportion of the greater curvature may also be used (Adams et al., 1988) but contains a higher concentration of acid-producing cells. For several reasons, the use of gastrocystoplasty in children has been abandoned except in rare cases, and it consequently is not discussed in any detail. Interested readers may refer to prior editions of this chapter.

Postoperative Management

Early Management

Care of patients after cystoplasty is similar regardless of the segment used in the procedure. **Typically, all patients have been maintained on nasogastric decompression until bowel function recovers, although two studies** (Erickson et al., 2007; Gundeti et al., 2006) **have suggested that nasogastric suction may not be necessary after ileocystoplasty. Attention to fluid and electrolyte management is important because third space losses may be significant after extensive reconstructive surgery.** Although increasingly common in the adult literature, an enhanced recovery after surgery (ERAS) protocol was recently analyzed for pediatric patients undergoing reconstructive procedures. Specifically, this protocol was employed prospectively in patients who had a bowel anastomosis with the intent on earlier recovery of bowel function, reduced length of stay, and decreased overall complication rate. The protocol included no bowel preparation, administration of preoperative oral carbohydrate liquid, avoidance of opioids, regional anesthesia, laparoscopy in select cases, lack of postoperative nasogastric decompression, early feeding, and early stoppage of intravenous fluids (Rove et al., 2018). Despite some inherent biases noted by the authors, this single-center prospective study showed excellent adherence to the protocol by hospital staff and concluded that maintenance of euvolemia and early feeding contributed to early return of bowel function. Opioid usage was less, patients left the hospital almost 2½ days sooner, complication grade per patient decreased, and there was no difference in 90-day complication rates or early postoperative emergency department admission if ERAS was employed. Although these findings were not statistically significant, they suggest the need for a multi-institutional study with larger numbers to confirm these important trends.

Continuous drainage of the bladder is achieved by suprapubic cystostomy. Mucus production from small or large bowel may be excessive and can potentially occlude the drainage catheter. **The suprapubic tube should be irrigated at least three times daily and whenever drainage is slowed by mucus.** Extravesical drains may be removed after several days, if drainage of urine is not apparent. The drains are usually removed more promptly in patients with a ventriculoperitoneal shunt to minimize risk of infection. Some surgeons prefer to perform a cystogram before patient discharge; others wait approximately 3 weeks for the study before clamping the suprapubic tube. All patients should begin CIC every 2 to 3 hours during the day and one or two times at night initially. The suprapubic tube is removed after regular catheterization is successfully underway. The duration between catheterizations is gradually increased over several weeks but should not exceed 4 to 5 hours during the day. Patients without neurologic impairment may eventually attempt to void spontaneously. All should check postvoid residual volumes and continue catheterizations if the residuals are significant.

Late Management

Routine radiographic surveillance of the upper urinary tract is indicated at 6 weeks, 6 months, and 1 year after augmentation cystoplasty. Most of such surveillance may be done with ultrasonography. Serum electrolytes, BUN, and creatinine levels along with urine cultures are performed several times in the first year after surgery. All positive urine cultures need not be treated in patients on CIC. Certainly symptomatic cystitis or infections involving urea-splitting organisms should be cleared. Evaluation by ultrasonography and serum chemistries is then appropriate once a year. Eventually, yearly endoscopy for tumor surveillance may be performed. No consensus exists about the timing or frequency of cystoscopic examination. Higuchi et al. (2010) have suggested that surveillance may be of greater yield in patient populations at greater risk, such as valve patients who are on immunosuppression after transplantation or exstrophy patients with their inherent increased risk for bladder adenocarcinoma. After the report of Castellan et al. (2012), surveillance may be of higher yield after gastrocystoplasty. No experience demonstrates that routine surveillance is cost effective or successful in this population (Higuchi et al., 2011; Kokorowski et al., 2011), and the Mayo Clinic group has suggested that such surveillance be discontinued (Higuchi et al., 2011).

Results and Complications of Augmentation Cystoplasty

The effect of cystoplasty on the patient should be considered in two ways. One must first consider the effect of removing a relatively small portion of the gastrointestinal tract for use in urinary reconstruction. **Any more than rare development of gastrointestinal problems would be prohibitive, even if results were perfect from the standpoint of the urinary bladder.** Second, the effect of augmentation cystoplasty on the urinary bladder must be reviewed. The primary goal of augmentation is to provide a compliant urinary reservoir. **Therefore the main considerations after augmentation are the storage pressure and capacity that are achieved. Any other effects on the urinary bladder are side effects or complications that exist because bowel is not a perfect physiologic substitute for native bladder. Approximately one-third of patients require further surgery after augmentation cystoplasty because of various problems** (Kispal et al., 2011; Metcalfe et al., 2006).

Gastrointestinal Effects

Postoperative bowel obstruction is uncommon after augmentation cystoplasty, occurring in approximately 3% of patients after augmentation (Gearhart et al., 1986; Hollensbe et al., 1992; King, 1987; Mitchell and Piser, 1987; Rink et al., 1995a). **The rate of obstruction is equivalent to that noted after conduit diversion or continent urinary diversion** (McDougal, 1992b). Delicate handling of tissues, closure of mesenteric windows, and elimination of sites of internal herniation help to avoid obstruction. Occasional series have suggested differing rates of bowel obstruction depending on the segment used. These differences have not been consistent in most series and are therefore likely not significant.

Reports of chronic diarrhea after bladder augmentation alone have been rare. Diarrhea can occur after removal of large segments of ileum from the gastrointestinal tract, although the length of the segments typically used for augmentation rarely is problematic unless other problems coexist. The use of a typical colonic segment for augmentation only rarely results in a change in bowel function. **Removal of a segment from the gastrointestinal tract including the ileocecal valve is more likely to cause diarrhea.** Some children with neurogenic impairment depend on constipation for fecal continence. Removal of the ileocecal valve from the gastrointestinal tract may significantly decrease bowel transit time. Loss of the valve can also allow bacterial backflow into the ileum, and the organisms may interfere with fat and vitamin B_{12} metabolism. Studies have noted chronic diarrhea in 10% to 23% of patients with neurogenic dysfunction after displacement of the ileocecal valve (King, 1987; Roth et al., 1995), although the risk may be lower for carefully selected patients (Husmann and Cain, 1999).

Ileum is the sole site of vitamin B_{12} absorption. **Removal of the distal ileum from the gastrointestinal tract may therefore result in vitamin B_{12} deficiency and megaloblastic anemia. The terminal 15 to 20 cm of ileum should not be used for augmentation, although problems may arise even if that segment is preserved** (Racioppi et al., 1999; Steiner and Morton, 1991). Again, the risk is greater if longer segments of ileum are used as with continent diversion. Of patients followed over 5 years after a Kock pouch procedure, 35% were found to be deficient in vitamin B_{12} in one series (Akerlund et al., 1989). In general, the length of ileum used for augmentation is less than one-half that used for a Kock pouch, so vitamin B_{12} deficiency seems unlikely after routine bladder augmentation. Canning et al. evaluated 26 patients after bladder augmentation or replacement and found no patients with either fat malabsorption or vitamin B_{12} deficiency (Canning et al., 1989). However, only three patients were followed for longer than 3 years, and longer observation is necessary because existing body vitamin B_{12} storage may last considerably longer (Stein et al., 1997a). VanderBrink et al. (2010) found low or low-normal B_{12} levels in 41% of patients evaluated a mean of 83 months after ileocystoplasty and were able to increase those levels by giving the oral vitamin.

Early satiety may occur after gastrocystoplasty but usually resolves with time. Disorders of gastric emptying should be extremely rare, particularly when gastric body is used.

Bladder Compliance After Augmentation

An early lesson of past clinical experience with augmentation cystoplasty has been the value of detubularization and reconfiguration of the bowel segment (Hinman, 1988; Koff, 1988). Some surgeons with extensive experience in augmentation cystoplasty have concluded that ileum is superior to other segments in terms of compliance after augmentation, although controlled experimental examination of similarly sized bowel segments is lacking (Goldwasser and Webster, 1986; Rink and McLaughlin, 1994; Studer and Zingg, 1997). On the contrary, one report has suggested superior results with colon compared with ileum (Shekarriz et al., 2000) when a longer colonic segment reconfigured in a U shape was used. Good results have been achieved with all segments in most cases, and it is more important to use a bowel segment well than to choose a particular bowel segment for every patient.

Occasional problems with pressure after augmentation cystoplasty occur from uninhibited contractions, apparently in the bowel segment. It is extremely rare not to achieve an adequate capacity or flat tonus limb unless a technical error has occurred with use of the bowel segment. When pressure contractions occur in the bladder after augmentation, they are often noted in a rhythmic or sinusoidal pattern, occasionally with increasing amplitude (Fig. 37.11). Contractions that begin at low amplitude later in filling and progress only near capacity may be of no clinical significance. Early contractions of higher pressure may result in persistent incontinence, delayed perforation, hydronephrosis, or vesicoureteral reflux. If patients have such clinical problems after augmentation, repeat urodynamic testing is indicated because one cannot assume the bladder is compliant after augmentation. **Rhythmic contractions have been noted postoperatively with all bowel segments, although ileum seems the least likely to demonstrate remarkable urodynamic abnormalities, and the stomach the most likely.**

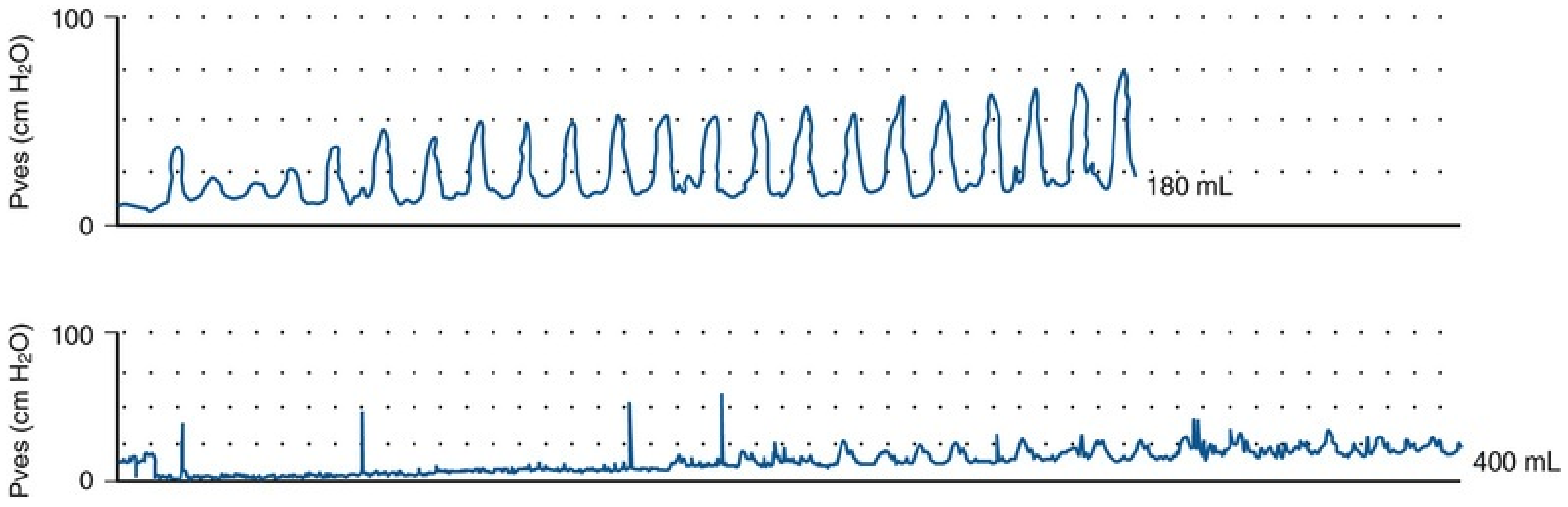

FIG. 37.11 Rhythmic, sinusoidal contractions *(top)* may occur after bladder augmentation, in this case with stomach. Contractions of significant amplitude early in filling occasionally require secondary augmentation. After secondary augmentation with ileum *(bottom)*, urodynamics show that contractions still occur but are much lower in pressure and occur later in filling.

After bladder augmentation or replacement, some urodynamic evaluation has suggested that colonic segments, whether cecum or sigmoid, still generate more pressure than ileum despite detubularization (Berglund et al., 1987; Jakobsen et al., 1987; Lytton and Green, 1989; Studer and Zingg, 1997; Thuroff et al., 1987), although other work has suggested that pressure contractions from the colon decrease with time (Hedlund et al., 1984; Sidi et al., 1986b). Goldwasser's review of enterocystoplasty demonstrated contractions greater than 15 cm H_2O in 42% of patients after ileocystoplasty versus in 60% of those after colocystoplasty (Goldwasser et al., 1987). Significant contractions, defined as those above 40 cm H_2O at a volume below 200 mL, were not noted in any of the ileal augmentations but persisted in 10% of cystoplasties. Their work agreed with that of Berglund et al. (1987) and Studer and Zingg (1997) in suggesting that ileal reservoirs have lower basal pressures and less motor activity. None of these studies critically controlled for the size of the bowel segment or the technique in which they were used. In fact, a canine model of partial bladder replacement using identically sized segments failed to demonstrate in vitro or in vivo differences between the gastrointestinal segments (Nelson et al., 2005).

Rhythmic contractions after gastrocystoplasty have been noted in up to 62% of patients (Adams et al., 1988; Atala et al., 1993; Gosalbez et al., 1993a; Roth et al., 2000), although the use of antrum or a larger gastric segment may have lessened the risk for such contractions (Adams et al., 1995; DeFoor et al., 2003a; Koraitim et al., 1999; Kurzrock et al., 1998; Leong, 1988).

In perhaps the most extensive experience with pediatric bladder augmentation, Hollensbe et al. at Indiana University found that approximately 5% of patients had significant uninhibited contractions after augmentation cystoplasty causing clinical problems (1992). Pope and Rink (1999) found that 6% of more than 300 patients required secondary augmentation of a previously augmented bladder for similar problems. With longer follow-up, the same group has eventually performed reaugmentation in 9% of patients (Metcalfe et al., 2006). These secondary augmentations represent true failures of the cystoplasty to achieve their primary objectives, capacity, and compliance. In that series, sigmoid colon followed by stomach and then ileum were more likely to require reaugmentation. A colonic segment closed at the ends and not reconfigured otherwise was typically used in that experience. Other studies have suggested that stomach is more likely than colon to require secondary intervention (Castellan et al., 2012; El-Ghoneimi et al., 1998).

Metabolic Complications

Chloride Absorption and Acidosis.

The first recognized metabolic complication related to storage of urine within intestinal segments was the development of hyperchloremic metabolic acidosis after ureterosigmoidostomy (Ferris and Odel, 1950). Patients with this metabolic derangement were noted to have fatigue, weakness, anorexia, and polydipsia. **Koch and McDougal** (1985) **demonstrated the mechanisms by which acid is absorbed from urine in contact with intestinal mucosa.** Resorption in the form of ammonium results in chronic acid loading. Patients with normal renal function are usually able to handle the resorbed load of chloride and acid without frank acidosis. **Mitchell and Piser (1987) noted that almost every patient after augmentation with an intestinal segment had an increase in serum chloride and a decrease in serum bicarbonate level, although full acidosis was rare if renal function was normal.** Acidosis and electrolyte disturbances requiring treatment have been reported despite normal renal function (Schmidt et al., 1973; Whitmore and Gittes, 1983). Such derangements may be debilitating to the patient if not recognized and treated (Heidler et al., 1979). **Hall et al.** (1991) **noted that there is an increase in the urinary acid load with wasting of bony buffers even in the absence of frank acidosis**. Such wasting may result in bone demineralization and could cause retarded growth in children after augmentation cystoplasty (Abes et al., 2003; Hafez et al., 2003; Vajda et al., 2003). Patients with acidosis should receive bicarbonate therapy. Nurse and Mundy (1989) have suggested that arterial blood gas values may be more sensitive than serum bicarbonate or chloride levels for detecting acidosis. Stein et al. (1998) felt that measurements of arterial blood gas for base deficit allowed early treatment of acidosis and avoidance of bone demineralization. In severe cases of acidosis, chloride transport can be blocked with chlorpromazine and nicotinic acid.

Although jejunum is rarely used for bladder reconstruction, storage of urine in this segment results in a unique metabolic pattern of hyponatremic,

hypochloremic, and hyperkalemic metabolic acidosis. The problem is often associated with significant hypovolemia.

Hyperchloremic, metabolic acidosis was avoided by gastrocystoplasty (Adams et al., 1988; Ganesan et al., 1991; Kurzrock et al., 1998) even in patients with impaired renal function; however, acid secretion was found to result in several unique complications after gastrocystoplasty. Episodes of hypokalemic and hypochloremic alkalosis were noted in some patients, particularly during an acute gastrointestinal illness with dehydration (Ganesan et al., 1991; Gosalbez et al., 1993b; Hollensbe et al., 1992). Acidic urine could irritate the native bladder and any exposed skin and was particularly bothersome in patients with intact sensation. Mitchell's group described this hematuria-dysuria syndrome well (Nguyen et al., 1993; Plaire et al., 1999). Ironically, stomach in the urinary tract may have performed best in the most complex of patients when combined with ileum to result in a more metabolically neutral reservoir (Austin et al., 1997, 1999, 2001).

Patient Growth.

Delayed or slowed growth in some children after intestinal cystoplasty has previously been recognized (Mundy and Nurse, 1992; Wagstaff et al., 1991; Wagstaff et al., 1992). A delay in linear growth was noted in 20% of almost 200 pediatric patients without any gross biochemical abnormalities. However, no control patients were included in that series. Body habitus and growth are difficult to predict in children with myelodysplasia, who make up the majority in most series of augmentation cystoplasty. Gros et al. (2000) evaluated growth in exstrophy patients. Patients requiring augmentation were matched retrospectively with a similar group not requiring bladder augmentation. Only 1 patient was noted to have acidosis in either group. Other factors that may affect growth, such as UTI, were not controlled. Of 17 patients with adequate measurements before and after cystoplasty, 14 (82%) had a decline in percentile height postoperatively. The decline corresponded to a ½-inch decrease in expected height. The pattern of growth was significantly different between patients with and without augmentation in the series. That series is small, and no evaluation of familial growth patterns or ultimate height was possible; however, the findings are worrisome, particularly because Feng et al. (2002) noted similar differences in exstrophy patients. In the absence of any serum abnormalities, the exact mechanism of delayed growth was not evident, although it seems likely to be related to subclinical acidosis (Bushinsky, 1989; Koch and McDougal, 1988;

Hochstetler et al., 1997). Taskinen et al. (2008) found no adverse effect on longitudinal growth after bladder augmentation in the exstrophy population.

Three recent series did show effect of bowel cystoplasty on bone mineral density in some patients (Abes et al., 2003; Hafez et al., 2003; Vajda et al., 2003), whereas two others did not (Haas et al., 2012; Mingin et al., 2002). One must be careful to determine whether any such changes are the result of augmentation cystoplasty or the underlying pathology (Boylu et al., 2006; Haas et al., 2012; Taskinen et al., 2007). Better analysis of subtle metabolic alterations after enterocystoplasty may establish better understanding of the effect on growth, minimize changes, or aid in early treatment to avoid the complication (Brkovic et al., 2004).

Alkalosis.

The secretory nature of gastric mucosa may at times be detrimental to the patient and can result in two unique complications of gastrocystoplasty. Episodes of hypokalemic, hypochloremic metabolic alkalosis after acute gastrointestinal illnesses were noted in 5 of 37 patients after gastrocystoplasty (Hollensbe et al., 1992). The episodes were significant enough to require hospitalization in all patients and were recurrent in 2 patients. Of the 5 patients who developed the complication 3 had renal insufficiency and would not have been good candidates for augmentation with other segments because of acidosis. Ganesan et al. (1991) noted similar episodes of alkalosis in 5 of 21 patients with renal insufficiency after gastrocystoplasty. **Patients with the primary indication for consideration of gastrocystoplasty may be the ones at greatest risk for this unusual complication.** It has been proposed that the alkalosis results from ongoing chloride loss from the gastric segment in the bladder in the face of decreased oral intake. Gosalbez et al. (1993b) demonstrated persistently increased fractional excretion of chloride despite profound hypochloremia, suggesting that inappropriate gastric secretion is likely the primary mediator. One patient in their series eventually required resection of three quarters of the gastric segment in the bladder because of recurrent problems with alkalosis, and several required therapy with H_2 blockers or H^+/K^+ ion pump inhibitors. All patients and families should be made aware of this potential problem because it has been reported to occur intermittently in 3% to 24% of patients. A composite reservoir of stomach and ileum or colon may provide a more metabolically neutral reservoir (Austin et al., 1997, 1999, 2001; McLaughlin et al., 1995), although these have typically been constructed in only very complex patients or circumstances.

Hematuria-Dysuria Syndrome.

Acid secretion by gastric mucosa may result in another unique problem after gastrocystoplasty, the hematuria-dysuria syndrome. Mitchell's group characterized this syndrome well (Nguyen et al., 1993; Plaire et al., 1999). **Almost all patients after gastrocystoplasty with normal sensation have occasional hematuria or dysuria with voiding or catheterization beyond what is expected with other intestinal segments** (Leonard et al., 1999). All patients should be warned of this potential problem, although in most patients these symptoms are intermittent and mild and do not require treatment. The problem led one group to recommend avoiding gastrocystoplasty in patients with bladder exstrophy (El-Ghoneimi et al., 1998). The dysuria is not as problematic in patients with neurogenic dysfunction. In the experience of Nguyen et al. (1993), 36% of patients developed signs or symptoms of the hematuria-dysuria syndrome after gastrocystoplasty; 14% of patients required treatment with medications, including 9% on a regular basis. Patients who are incontinent or have decreased renal function are at increased risk. Others have noted a similar requirement for short-term and chronic medical therapy (Adams et al., 1995; Castellan et al., 2012; Hollensbe et al., 1992). The symptoms of the hematuria-dysuria syndrome do respond well to H_2 blockers and hydrogen ion pump blockers. Bladder irrigation with baking soda may also be effective. It has been demonstrated that urinary pH may decrease remarkably after meals in patients who have undergone gastrocystoplasty (Bogaert et al., 1995). The signs and symptoms of the hematuria-dysuria syndrome are most likely secondary to acid irritation. Work has suggested that *Helicobacter pylori* may play a role in this complication (Celayir et al., 1999). Such problems can occur but are less frequent after antral cystoplasty because there is a smaller load of parietal cells (Ngan et al., 1993).

Acid in the urine may also cause external irritation. Leong first noted glanular excoriation after gastrocystoplasty in a patient with voiding symptoms (Ngan et al., 1993). Nguyen et al. noted skin excoriation in 8 of 57 patients after gastrocystoplasty; all 8 patients had some element of urinary incontinence (Nguyen et al., 1993). **It is imperative to achieve reliable urinary continence in patients undergoing gastrocystoplasty because urinary leakage may result in the exposure of the skin to gastric secretions and in gastric secretions that are poorly diluted.** Dilution is important; Reinberg et al. (1992) reported a perforation of a gastric segment in a defunctionalized bladder after gastrocystoplasty. They evaluated the influence of urine on gastrocystoplasties in dogs (Castro-Diaz et al., 1992). The animals developed marked inflammation of the gastric segment and native bladder after creation of a dry gastrocystoplasty; 3 of 9 dogs developed ulceration and perforation. Use of H_2 blockers resulted in some protection for the animals; however, such a clinical situation should certainly be avoided. Rare perforations and ulcerations have been noted clinically without defunctionalization (El-Ghoneimi et al., 1998; Mingin et al., 1999a).

Mucus

Intestinal segments continue to produce mucus after placement in the urinary tract. The material can potentially impede bladder drainage during voiding or CIC, particularly in pediatric patients in whom the use of small-caliber catheters is necessary. Mucus may serve as a nidus for infection or stone formation when it remains in the bladder for long periods of time. Mucus production often increases after cystoplasty in the presence of cystitis. Kulb et al. (1986) showed experimentally in dogs that colonic segments produce more mucus than ileum and that gastric segments produce the least amount. This has been noted clinically as well; most patients do not require any routine bladder irrigations for mucus after gastrocystoplasty. Villous atrophy in the ileum has been documented after placement in the urinary tract. It has been suggested that such atrophy may result in decreased mucus production (Gearhart, 1987), although laboratory demonstration of any decrease in production with time has not been evident (Murray et al., 1987). Hendren and Hendren (1990) noted a decrease in mucus production from colonic segments over years; however, others have not been impressed with such changes (Rink et al., 1995a). Glandular atrophy in colonic mucosa has not been noted histologically (Mansson et al., 1984). **Routine use of daily bladder irrigations to prevent mucus buildup may minimize complications of enterocystoplasty such as UTI and calculi** (Hensle et al., 2004).

Urinary Tract Infection

Bacteriuria is common after intestinal cystoplasty, particularly in patients requiring intermittent catheterization (Gearhart et al., 1986; Hendren and Hendren, 1990; King, 1991). Recent experience with bowel neobladders has demonstrated that patients who are able to spontaneously void to completion often maintain sterile urine. **It appears that use of CIC is a prominent factor**

in the development of bacteriuria in patients who have undergone augmentation cystoplasty. Bacteriuria has been noted even when patients are maintained on daily oral antibiotics or antibiotic irrigation (Casale et al., 1999; Gearhart et al., 1986). In Hirst's (1991) experience, persistent or recurrent bacteriuria occurred in 50% of patients augmented with sigmoid colon versus 25% of those after ileocystoplasty. Hollensbe et al. (1992) noted bacteriuria much more commonly in patients requiring CIC regardless of the segment considered. The incidence of symptomatic cystitis after cystoplasty likely depends on the length of follow-up and the diligence with which symptoms are sought. All patients and families should be told to expect some signs or symptoms of cystitis. Recurrent episodes of symptomatic cystitis requiring treatment occurred in 23% of patients after ileocystoplasty, 17% of patients after sigmoid cystoplasty, 13% after cecocystoplasty, and 8% after gastrocystoplasty at Indiana University (Hollensbe et al., 1992). Febrile UTIs occurred in 13% of those 231 patients after augmentation. The same trend among different bowel segments was noted for febrile infections, although there was no statistically significant difference among the various segments. **The incidence of pyelonephritis after augmentation cystoplasty, as long as upper tract problems are corrected, is similar to that noted for conduit diversion, whether refluxing or not** (McDougal, 1992b). Infections may occasionally be more problematic in an immunocompromised patient (Alfrey et al., 1997), but that has not always proven to be the case (Traxel et al., 2011).

Not every episode of asymptomatic bacteriuria requires treatment in patients performing CIC. Bacteriuria should be treated in the presence of significant symptoms such as incontinence or suprapubic pain and may be treated if hematuria, foul-smelling urine, or remarkably increased mucus production occurs. **Bacteriuria should be treated if the urine culture demonstrates growth of a urea-splitting organism that may lead to stone formation.** To minimize infection, patients requiring CIC must perform it on a regular basis to avoid increased reservoir pressures and must work to empty the bladder completely. Special care must be taken by patients catheterizing through a continent abdominal wall stoma. Such patients may have more difficulty completely emptying the bladder from a nondependent stoma. Most can do so with effort (Ludlow et al., 1995). Although catheterization is not routinely a sterile technique, use of proper clean technique should be emphasized.

Calculi

Another long-term complication of augmentation cystoplasty is bladder calculus formation. In the early 1990s, several series reported calculi in 18% of patients after augmentation cystoplasty (Hendren and Hendren, 1990; Hirst, 1991). Blyth et al. noted calculus formation in 30% of such patients; they found that patients catheterizing through an abdominal wall stoma have the highest risk, likely because of incomplete emptying (Blyth et al., 1992). Palmer et al. (1993) noted urolithiasis in 52% of patients after augmentation cystoplasty. Metcalfe et al. (2006) noted a 15% rate of bladder stone formation in 500 patients with long-term follow-up after enterocystoplasty; the reasons for these remarkable differences are not clear. **Most bladder stones in this patient population are composed of struvite, and bacteriuria is an important risk factor.** Any infection with a urea-splitting organism should therefore be treated. All patients requiring CIC, particularly those who have already formed stones, should make every effort to empty the bladder completely with each catheterization. If stones are found in patients voiding spontaneously after augmentation, the adequacy of emptying should be re-evaluated. The association of urinary stasis with stone formation is well established. Routine bladder irrigations to avoid buildup of inspissated mucus may remove a nidus for stone formation. The group at Indiana and others have stressed irrigations and asked patients and families to routinely irrigate the bladder several times a day after augmentation (Hensle et al, 2004; Rink et al., 1995a). Stones have been noted after the use of all intestinal segments with no significant difference noted between small and large intestine. Struvite stones are less likely after gastrocystoplasty (Kaefer et al., 1998; Kronner et al., 1998a), likely because of decreased mucus production and acid that minimizes bacteriuria. Uric acid calculi have been noted in the bladder after gastrocystoplasty (Kaefer et al., 1998). Clearly, any foreign body will serve as a nidus for stone formation; the use of permanent sutures or staples in the urinary tract should be avoided during enterocystoplasty. In a case control analysis, the presence of bladder stones and use of intestinal interposition may be independent risk factors for the development of upper tract stones in children with neuropathic bladders (Stephany, 2014). Khoury et al. (1997) looked for metabolic problems in patients after augmentation and noted low urinary citrate levels in patients with and without stones. They thought that poor emptying and mucus were more significant factors.

Tumor Formation

A well-recognized complication of ureterosigmoidostomy has been the development of tumors, primarily adenocarcinoma, at the ureterocolonic anastomotic site. In Husmann and Spence's (1990) review of reported tumors after ureterosigmoidostomy, the latency for development of such tumors averaged 26 years and ranged from 3 to 53 years. Adenocarcinomas were the prominent tumors that developed, but benign polyps and other types of carcinoma were also found. Eraklis and Folkman (1978) estimated that the risk for developing such tumors is increased by 7000-fold over age-matched controls after ureterosigmoidostomy. Pettersson et al. (2013) reviewed their experience with 24 patients who had undergone ureterosigmoidostomy from 1944 to 1961; most had eventually been undiverted. Invasive colorectal adenocarcinoma developed in 7 patients, 5 of whom died as a result. The risk for tumor formation was 42 times that of the general Swedish population.

The basis for the increased risk is unknown; however, *N*-nitroso compounds thought to originate from a mixture of urine and feces may be carcinogenic. These compounds have been noted in the urine of patients with conduit diversion and augmentation (Treiger and Marshall, 1991). Husmann and Spence (1990) suggested that those compounds are more likely enhancing agents rather than a lone cause for tumor development. It has been proposed that inflammatory reaction at the anastomotic site may induce growth factor production, which, in turn, increases cellular proliferation. **Filmer and Spencer** (1990) **identified 14 patients who have developed adenocarcinoma in an augmented bladder, and several more have been reported since then;** 9 of those tumors occurred after ileocystoplasty and 5 after colocystoplasty. One study has noted a relatively high incidence of tumor after gastrocystoplasty (Castellan et al., 2007). Experimental work in the rat demonstrated hyperplastic growth in the augmented bladder using all intestinal segments, with no segment showing any particular increased risk (Buson et al., 1993; Kispal et al., 2012; Klee et al., 1990; Little et al., 1994; Spencer et al., 1993). The long latency noted for tumor development after ureterosigmoidostomy suggests that short-term follow-up after augmentation cystoplasty is not adequate to evaluate tumor formation. The earliest reported tumor after augmentation was found only 4 years after cystoplasty (Carr and Hershorn, 1997). **Patients undergoing augmentation cystoplasty should be made aware of a potential increased risk for tumor development.** This increased risk has been confirmed by others but may not be secondary to augmentation, rather thought to be due to an inherent cancer risk associated with the underlying congenital abnormality (Higuchi et al., 2010; Husmann, 2009).

Yearly surveillance of the augmented bladder with endoscopy may eventually be performed; the latency period until such procedures are necessary is not well defined (Higuchi et al., 2011; Vajda et al., 2002). Transitional cell carcinoma, hyperplasia, and dysplasia have also been noted near the anastomosis in humans (Barrington et al., 1997; Gregoire et al., 1993; Soergel et al., 2004). Transitional cell carcinomas associated with augmentation cystoplasty have been aggressive; often the patients have metastatic disease at presentation (Higuchi et al., 2010; Metcalfe et al., 2006). Urothelium adjacent to the anastomosis was demonstrated to be genetically unstable on biopsy in one study (Appanna et al., 2007). Castellan et al. (2012) noted a sobering experience with three cases of fatal adenocarcinoma within the gastric segment among only 29 patients who had undergone gastrocystoplasty. A benign lesion, nephrogenic adenoma, may actually be the most common tumor found after cystoplasty (Franke et al., 2011).

Delayed Spontaneous Bladder Perforation

Another disturbing complication of augmentation cystoplasty is delayed bladder perforation. Patients with spontaneous perforation after augmentation cystoplasty are typically ill with abdominal pain, distention, and fever. Sepsis has been common. Nausea, decreased urine output, and shoulder pain from diaphragmatic irritation have also been noted. Perforations have been found in evaluation of asymptomatic pelvic masses (Pope et al., 1999; Fig. 37.12). **Patients with neurogenic dysfunction often have impaired lower abdominal sensation and are seen later in the course of the illness; severe sepsis and death have occurred.** Patients with perforation after gastrocystoplasty often seek care promptly because of acid irritation. **A high index of suspicion for perforation is necessary. Contrast cystography is diagnostic in most cases** (Bauer et al., 1992; Braverman and Lebowitz, 1991; Rosen and Light, 1991) (see Fig. 37.12). Thorough technique is important to identify as many true positives as possible with cystography (Braverman and Lebowitz, 1991). Some reports have noted a significant false-negative rate on cystography (Pope et al., 1999; Rushton et al., 1988; Sheiner and Kaplan, 1988) and suggested that ultrasonography and computed tomography improve diagnostic accuracy. They recommended that one of those studies be done in any child suspected to have a perforation if the initial cystogram is negative.

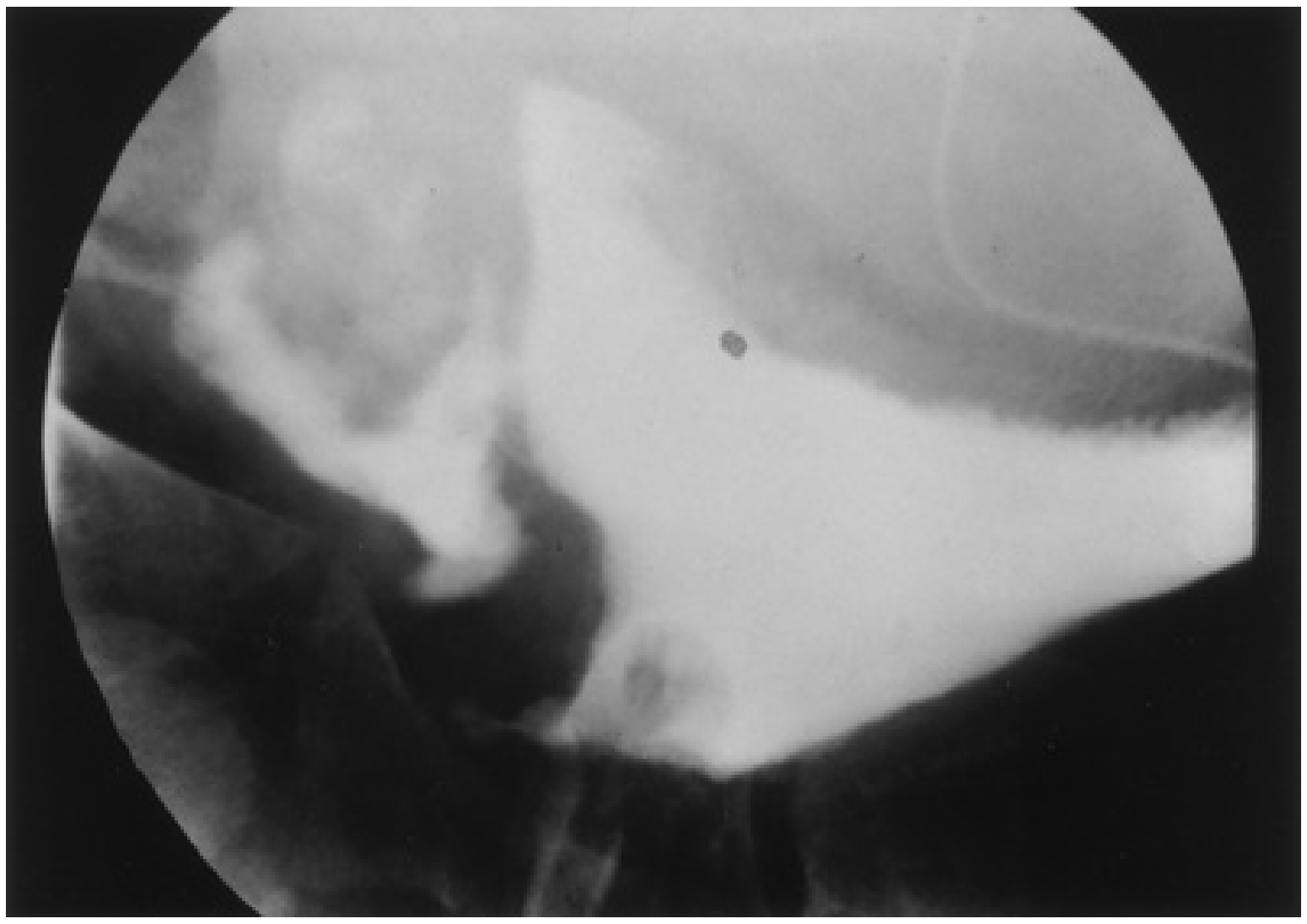

FIG. 37.12 After complete filling, a sagittal view on the cystogram demonstrates a spontaneous bladder perforation on the postdrain view.

Etiology.

The cause of delayed perforations within a bowel segment is unknown. It has been suggested that some perforations may be secondary to traumatic catheterization (Elder et al., 1988; Rushton et al., 1988). Perforation of a bladder not previously augmented has been recognized after CIC (Reisman and Preminger, 1989). It seems unlikely that catheterization trauma is the lone cause in most patients. The location of the perforations has been variable among patients and even in a single patient with multiple perforations. Perforations have occurred in patients after augmentation who did not catheterize at all. Other authors have suggested that trauma to the bowel because of fixed adhesions resulting in sheering forces with emptying and filling may result in perforation (Elder et al., 1988). Transmural infection of the bladder wall has also been proposed as a cause. **Histologic examination of areas of perforation has noted necrosis, vascular congestion, hemorrhage, and hemosiderin deposition compatible with chronic bowel wall ischemia** (Crane et al., 1991). **Chronic overdistention of the bladder may result in such ischemia.** Decreased perfusion in dog bowel used for augmentation can be induced experimentally with high intravesical pressure (Essig et al., 1991); changes were noted more prominently at the antimesenteric border of the bowel. Anderson and Rickwood (1991) have reported perforations occurring in bladders with significant uninhibited contractions after augmentation, as have others (Pope et al., 1998). **High outflow resistance may maintain bladder pressure rather than**

allowing urinary leakage and venting of the pressure, potentially increasing ischemia (Martinez del Castillo et al., 2005). Hyperreflexia alone is likely not a solitary cause of perforation; the complication was not recognized in the era before bowel detubularization and reconfiguration when persistent pressure contractions were more common. **However, once bowel is reconfigured, it may be more prone to ischemia if high pressure does persist.** Failure to perform CIC on a regular basis when needed to empty may exacerbate such issues (DeFoor et al., 2003b; Martinez del Castillo et al., 2005).

The majority of patients who develop perforations after augmentation cystoplasty have had myelodysplasia. The incidence of perforation has been lower in series of patients with other diagnoses requiring bladder reconstruction (Hendren and Hendren, 1990). The role of neurogenic dysfunction in the cause of these perforations is unclear. No matter what the cause, there is likely some field effect on the entire segment. Once a patient has sustained a spontaneous perforation, the chance of recurrence is significant (Hollensbe et al., 1992; Martinez del Castillo et al., 2005), perhaps occurring in one-quarter of patients (Metcalfe et al., 2006). Consideration must eventually be given to removal of the original segment and replacement with another after repeated perforation.

Incidence.

Early postoperative leaks from the bowel-to-bowel or bowel-to-bladder anastomoses after augmentation cystoplasty are rare and represent a technical error or problem with early healing. **Delayed perforations more commonly occur within the bowel segment and represent a problem with long-term storage of urine within an intestinal segment.** There may be no particular increased risk of one intestinal segment over another. At Indiana University, perforations were noted in 43 of 500 patients (8.6%) undergoing cystoplasty (Metcalfe et al., 2006) an average of 4.3 years after augmentation. Analysis of this experience suggested that the use of sigmoid colon was the only significantly increased risk factor. Several other large series of patients with sigmoid cystoplasty have noted a low incidence of delayed perforation (Hendren and Hendren, 1990; Shekarriz et al., 2000; Sidi et al., 1987a). At Children's Hospital (Boston), the incidence of perforation after augmentation was reportedly highest in ileum (9.3%) and less frequent in ileocecal, sigmoid, and gastric segments (Bauer et al., 1992). **With inconsistent differences across multiple large series, it is unlikely that any given enteric segment is at significantly increased risk for perforation and that multiple factors**

influence the risk for the complication. A recent analysis of morbidity in patients undergoing augmentation cystoplasty using the Pediatric Health Information System database showed that the risk of perforation was doubled in those who had bladder outlet procedures (Schlomer and Copp, 2014). In summary, the highest rate of perforation noted was 16.6% in one relatively small series (Martinez del Castillo et al., 2005); however, it is reasonable to present an expected risk of about 9% to patients and families based on experience at Indiana University (Metcalfe et al., 2006).

Treatment.

The standard treatment of spontaneous perforation of the augmented bladder is immediate surgical repair. There are reported series of conservative management for suspected perforation (Slaton and Kropp, 1994). Conservative management including catheter drainage, antibiotics, and serial abdominal examinations was successful in 87% of patients, although only 2 of the 13 patients with suspected ruptures had x-ray documentation unequivocally identifying a perforation. In a more recent study, Lee et al. support a conservative approach in the absence of clinical deterioration, severe peritonitis, and extensive extravasation. Those stable patients were initially managed with maximal bladder drainage and image-guided percutaneous drains placed in loculated fluid collections (Lee et al., 2017). Even patients who do well with conservative management during the acute episode often require eventual surgical intervention (Pope et al., 1999). Such management may be a consideration in a stable patient with sterile urine, but there should be a very low threshold for surgical repair. Most patients with perforations have myelodysplasia and are seen late in the course of the disease because of impaired sensation. Increasing sepsis and death of the patient may result from a delay in diagnosis or treatment.

Pregnancy

Limited information exists regarding the outcome of pregnancy in women who have undergone augmentation cystoplasty. Three issues are raised in the context of pregnancy after bladder reconstruction: how the expanding uterus will affect the pedicle of the reconstruction; how to manage bacteriuria in the setting; and whether cesarean section is necessary in all or some patients.

Hatch et al. (1991) and Schumacher et al. (1997) noted that the mesenteric pedicle to bladder augmentations did not appear to be stretched at the time of cesarean section. In those cases the pedicle was not located near the exposed anterior uterus but deflected laterally. Schilling et al. (1996) recognized similar deflection away from the uterus after urinary diversion but did occasionally find the uterus covered by the vascular pedicle after bladder augmentation. Neither process prevented the rise of the uterus during pregnancy. Those authors speculated that the mesentery underwent changes that enabled deflection or stretch without any adverse effect on circulation. Loss of the augmentation from a mechanical effect on the pedicle from the enlarging uterus has not been reported. The group from Indiana reviewed their experience with 18 pregnancies in 11 women who previously underwent lower urinary tract reconstruction. A high rate of complications were noted and included new or worsening hydronephrosis (87%), of which almost half required percutaneous nephrostomy tube placement. This was noted as the preferred method over indwelling stent to avoid difficult placement because of altered anatomy as well as eliminate the risk for plugging of the stent with mucus. Other reported complications included difficult catheterization in half, in one-third with incontinence, and in two-thirds with UTI. Urology was involved during each cesarean section and this was important as 40% of patients experienced intraoperative complications with the most common being cystotomy during emergent cesarean section. Urinary fistula developed in three patients (Roth et al., 2018).

UTIs may be problematic during pregnancy in women who have undergone urinary reconstruction including bladder augmentation. Ureteral dilation, increased residual urine, and diminished tone to the upper tract may be important risk factors (Hatch et al., 1991; Hill et al., 1990). Asymptomatic bacteriuria is usually treated immediately in pregnant women because of an increased rate of progression to symptomatic infection and pyelonephritis and because of the potentially significant consequences of pyelonephritis. There is little consensus about the role of antibiotics and the risk of asymptomatic bacteriuria in women on CIC after cystoplasty once pregnant (Thomas and Adams, 2009). Antibiotics, if used, must not be teratogenic.

Successful pregnancy with spontaneous vaginal delivery has been observed in some patients with bladder augmentations (Quenneville et al., 2003) and other forms of urinary reconstruction (Asif and Uehling, 1969; Pedlow, 1961). Schumacher et al. (1997) reviewed their experience with pregnancy and delivery in patients who had undergone continent catheterizable ileocecal diversion and found no major complications. This would likely be true for other forms of reconstruction (Wren et al., 2003). Late difficulty with catheterization has been noted with Kock continent ileostomies (Ojerskog et al., 1988) and can occur with any continent abdominal wall stoma (Greenwell et al., 2003).

The need for cesarean section is likely not universal after bladder reconstruction. Flaccid, distensible pelvic tissues, perhaps necessary for progression to spontaneous vaginal delivery, may not be present after extensive pelvic surgery. It is not known if tissues fixed from previous operative repairs can undergo the trauma of delivery and resume the same level of function found before the pregnancy. Our bias would be that woman having undergone extensive bladder neck repair should consider cesarean delivery, particularly if the progression toward spontaneous vaginal delivery is slowed or difficult. Although there are reports of spontaneous vaginal delivery in the presence of an AUS (Creagh et al., 1995; Fishman and Scott, 1993), the presence of such a prosthetic device raises a concern for erosion with a long, difficult delivery.

If cesarean section is required or selected, it is imperative to protect the augmentation or continent stoma and its vascular pedicle. The anterior uterus can typically be exposed atraumatically, although some time and patience may be required to protect the bladder. Such exposure may be more difficult if multiple abdominal stomas are present. The reconstructive urologist familiar with the patient and her anatomy should be present during cesarean section.

Choice of Segment and Approach

Enterocystoplasty improves bladder capacity and compliance in most cases when medical management fails. It is obvious from the previous discussion that there is no one single bowel segment that is perfect for augmentation in all patients. All gastrointestinal segments have been used and continue to be used with good results. Unremitting medical problems are relatively rare after augmentation cystoplasty if used appropriately in well-selected patients. No one bowel segment has a clear advantage over others when all such problems are considered. Patient diagnosis, anatomy, and physiology may suggest that one bowel segment is preferable for a particular patient. Each surgeon interested in augmentation cystoplasty should be familiar with the advantages and disadvantages of each segment in different settings.

In many routine cases, any gastrointestinal segment may be chosen for cystoplasty based purely on the personal preference and familiarity of the surgeon. The surgeon's experience and confidence in using a segment are important. **We believe that no one bowel segment is the best choice in all**

patients and that optimal results are achieved when the bowel segment is chosen based on the needs of the particular patient. The segment must then be used correctly. Ileum is preferred if there is no clear advantage or reason to use another segment. Stomach is reserved for very select children with renal insufficiency and acidosis, short gut syndrome, and heavy irradiation; even then, the potential complications of gastrocystoplasty must be considered (Castellan et al., 2012). Sigmoid cystoplasty is used in select patients without reservation; good results can be expected for most patients with any segment if it is used properly.

The use of laparoscopy, usually with robotic assistance, to achieve augmentation cystoplasty evolved from early work on autoaugmentation to full intracorporeal enterocystoplasty (Ehrlich and Gershman, 1993; Docimo et al., 1995; Gundeti et al., 2008; Lorenzo et al., 2007). Intraoperative times vary greatly among these reports and are related to surgeon experience and inherent patient factors such as prior surgery, working space availability, and whether a pure laparoscopic or robotic-assisted approach is used. Outcomes have been similar to those of open reconstruction in early follow-up (Gundeti et al., 2013; Traxel et al., 2010). Potential advantages of a minimally invasive approach include faster recovery and improved cosmesis (Hasan et al., 2011). Experience with these approaches is already accumulating rapidly, and thorough evaluation will be needed to determine if a minimally invasive approach is cost effective, particularly in the neurogenic population.

A Decreasing Necessity?

Although augmentation cystoplasty works well for most patients who require it, and although work on alternatives to bowel cystoplasty may lower morbidity for the patient, a primary goal for every pediatric urologist is to minimize the number of patients needing cystoplasty. Newer medical regimens, botulinum toxin A injections (Altaweel et al., 2006; Game et al., 2009; Pascali et al., 2011; Schulte-Baukloh et al., 2005; Stoehrer et al., 2009), and neuromodulation may prove effective for some patients who at present do not respond to conservative measures (Aslan and Kogan, 2002; Lansen-Koch et al., 2012). Xiao et al. (2005; Peters et al., 2010) continue to refine an artificial somatic-autonomic reflex pathway in children with neurogenic dysfunction. No matter what the diagnosis, earlier and more aggressive treatment of bladder dysfunction may minimize the insult to the bladder and maximize recovery as well as ultimate bladder function.

Early urodynamic evaluation of boys with posterior urethral valves may identify treatable bladder problems and improve the prognosis from the standpoint of the kidneys and bladder (Casey et al., 2012; Misseri et al., 2002). Grady et al. (2003) suggested that complete primary repair of bladder exstrophy results in early bladder cycling that improves eventual bladder function and decreases the likelihood of augmentation cystoplasty.

With perhaps the most compelling evidence to date, Kaefer et al. (1999a) found that only 17% of patients with hostile neurogenic bladder dysfunction treated immediately on diagnosis required augmentation cystoplasty as compared with 41% of similar patients treated expectantly. Although the series included no collaborative urodynamic data and may be subject to lag time bias, the authors felt that there was a significant difference in the outcomes for the two groups. Because there are no prospective, randomized trials evaluating early evaluation and treatment of pediatric bladder dysfunction, suggestions that expectant treatment may lower the necessity for augmentation cystoplasty (Bauer, 2003; Mitchell, 2003) remain unproven. On early examination, early bladder management had not decreased the rate of augmentation cystoplasty (Lendvay et al., 2006); however, more recent re-evaluation (Schlomer et al., 2013) suggested that augmentation rates have fallen by 25% in the past decade. Critical, prospective evaluation of such treatment is needed and will hopefully demonstrate how to successfully manage these patients. It is likely that such improvements will minimize the need for cystoplasty but not completely remove it (Cain and Rink, 2010).

Improving Quality of Life?

Reconstruction to achieve continence has been assumed to improve health-related quality of life. Early evaluation of small numbers of patients undergoing reconstruction including augmentation cystoplasty does not always show improved status on objective questionnaires compared with preoperative studies or control patients without surgery despite what generally would be considered to be good clinical results (MacNeily et al., 2005; Parekh et al., 2006). Assessment of the social impact of using a catheterizable channel instead of urethra is limited (Kari et al., 2013). Patient-reported scores also do not always correlate with those noted by their parents. Most evaluation of surgical techniques to date has focused on results and complications from the perspective of surgeons. Future evaluation should include objective, patient-reported consideration. Tools to acquire that information must be validated for longitudinal study of these patients and their disease processes.

Key Points: Augmentation Cystoplasty

- Any gastrointestinal segment should be reconfigured and widely anastomosed to the bladder to maximize capacity and compliance.
- Failures to achieve adequate compliance are rare (5% to 10%) and are usually related to rhythmic pressure contractions.
- Gastrointestinal effects are rare, although chronic diarrhea may occur if the ileocecal segment is used in the neurogenic population.
- Ammonium resorption can cause metabolic acidosis, particularly among patients with renal insufficiency.
- Bacteriuria is common after cystoplasty and does not always require treatment.
- Bladder calculi occur in 10% to 30% of patients after augmentation.
- Aggressive adenocarcinomas have been reported as early as 4 years after augmentation but thus far have not occurred with the frequency noted after ureterosigmoidostomy.
- Delayed perforation of the bowel segment can be expected in 5% of patients after augmentation. It has occurred most frequently in colonic segments used in the neurogenic population.
- Good early care for underlying bladder dysfunction may lower the need for augmentation cystoplasty.

Ileovesicostomy

This alternative approach certainly has a role in the management of pediatric patients with neurogenic bladder. Because of its incontinent nature, proper counseling and education of parents and older patients is necessary to achieve the desired outcome. This technique may be best for those patients who are mentally, physically, or socially unable to catheterize via a continent channel. Other indications may include a hyperreflexic detrusor and small bladder capacity (Ching et al., 2014). The main advantage over a regular vesicostomy is the ability to be dry via the urethra while using a bag appliance to avoid constant urinary leakage and the need for diapers. Advantages over continent diversion includes a low-pressure reservoir, thus greatly lowering risk for perforation, potential avoidance of sphincteric surgery, lack of catheterization, and possibility of conversion to continent diversion if desired. Shared risks include risk of bowel related complications, stomal stenosis or prolapse, formation of stones, UTIs, and upper tract deterioration.

Technique and Results

The technique involves the isolation and use of a 10- to 15-cm channel of small intestine, similar to that employed for an ileal conduit, which is then anastomosed in an isoperistaltic fashion to the dome of the native bladder and brought out as a rosebud stoma on the skin. This acts as a passive channel for urine to flow down the path of least resistance. Outcomes in the pediatric population are not as well documented as those in the adult population. Ching et al. reported the first known outcome study in pediatric patients highlighting similar complication rates of postoperative UTI, stomal issues, wound infection, bowel-related issues, and need for additional postoperative procedures as in the adult literature (Ching et al., 2014). This was a small, retrospective study in a carefully selected group of patients, so long-term complications could not be assessed. This is important as length of follow-up and patient body mass index have been directly associated with number of complications. Obesity is common among children with spina bifida during the transition into adulthood. Tan et al. noted the association of obesity with the need for additional procedures or reoperations in 27/50 patients (Tan et al., 2008). Based on this data, these patients must be regularly followed to avoid potentially devastating consequences to the upper tracts.

Key Point: Ileovesicostomy

- Ileovesicostomy is a viable option for a carefully selected group of patients but carries increased risk for long-term complications if not followed appropriately.

Alternatives to Gastrointestinal Cystoplasty

Largely because of the complications just reviewed, alternative methods that can achieve a large-capacity, compliant reservoir remain attractive. Efforts have covered the spectrum from synthetic materials and autologous grafts through creation of a bladder diverticulum (autoaugmentation) to various forms of neural stimulation. **Some of these alternatives appear to hold promise, but none have stood the test of time in comparison with intestinal cystoplasty.**

An ideal tissue for increasing capacity and improving compliance would have transitional epithelium to be relatively impermeable and avoid metabolic changes. The lining would also not produce mucus and would carry no increased potential for tumor development. Two such alternative procedures are ureterocystoplasty and autoaugmentation. With ureterocystoplasty, there is good muscle backing to transitional epithelium, whereas collagen eventually backs the transitional mucosa of an autoaugmentation.

Ureterocystoplasty

In patients with posterior urethral valves, unilateral reflux may behave as a pop-off valve to lower intravesical pressures (Hoover and Duckett, 1982; Kaefer et al., 1995; Rittenberg et al., 1988). **It was a logical extension to use ureteral tissue in that setting to augment the bladder.**

Technique.

Ureterocystoplasty may be performed through a midline, intraperitoneal incision. This incision provides access to the intestine should mobilization of the ureter for augmentation be unsatisfactory. **Bellinger** (1993), **Dewan et al.** (1994), **and Reinberg et al.** (1995) **have shown that ureterocystoplasty can be done through two incisions, remaining completely extraperitoneal.** The general technique is the same. A standard nephrectomy is performed with great care to preserve the renal pelvic and upper ureteral blood supply. All adventitia and periureteral tissue are swept from the peritoneum toward the ureter during mobilization to protect the ureteral blood supply. Proximally, this blood supply typically arises medially. As the ureter enters the true pelvis, the blood supply arises posterior and laterally. After mobilization of the ureter into the pelvis, the bladder is opened in the sagittal plane. Posteriorly, this incision has typically been carried off-center directly into and through the ureteral orifice of the ureter used for cystoplasty. The ureter is *not* detached from the bladder but is opened longitudinally along its entire length, taking care to avoid its main blood supply (Fig. 37.13). The incision in the bladder and distal ureter should avoid branches of the superior vesical artery, which serve as an important blood supply. The ureter is folded on itself, and the ureter-to-ureter and ureter-to-bladder anastomosis is performed with running absorbable suture. A suprapubic tube is left indwelling through the native bladder for 3 weeks during healing. After cystography documents the absence of leakage, CIC is started. Any patient attempting to void must prove that he or she can empty adequately through a check of postvoid residuals.

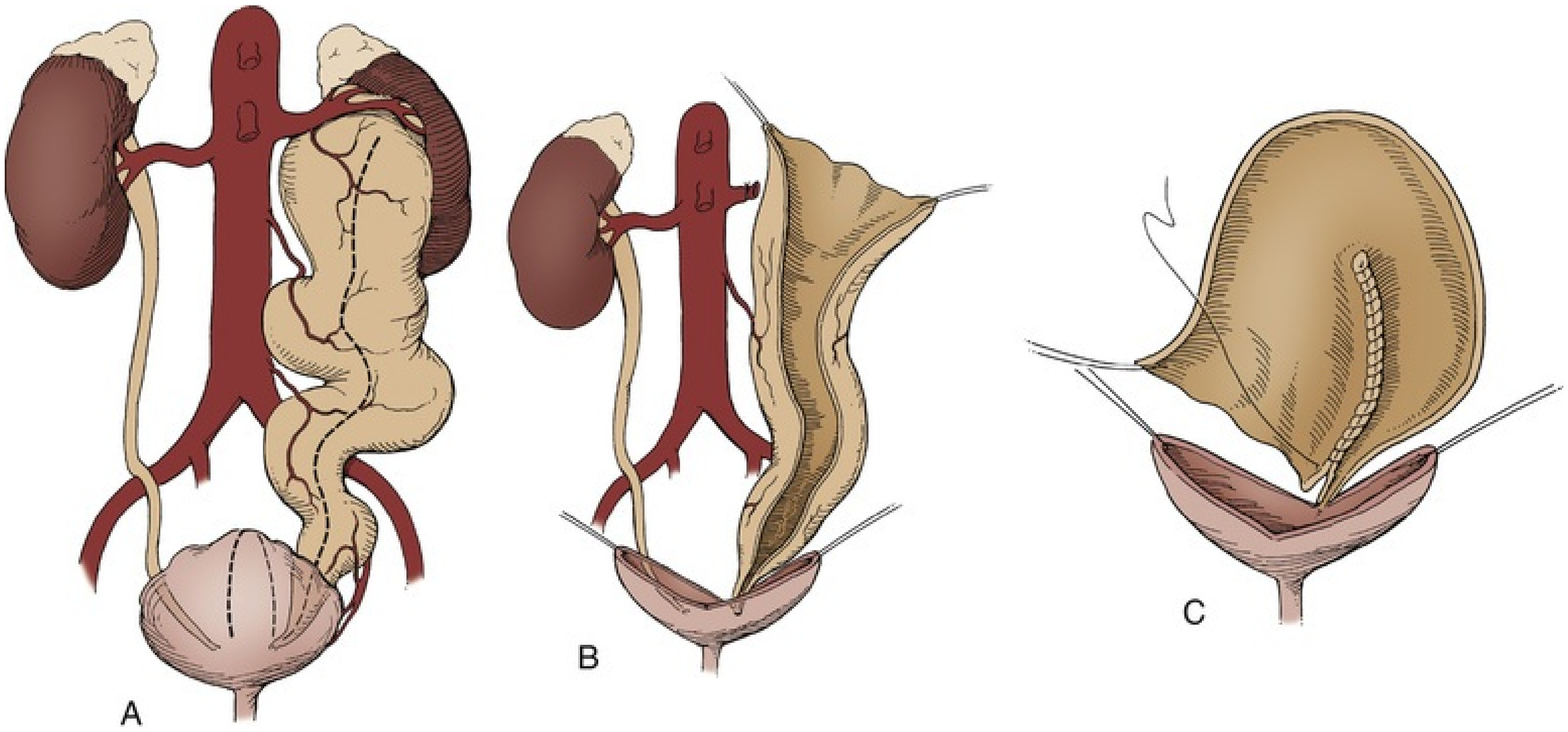

FIG. 37.13 Ureterocystoplasty. (A) After nephrectomy, the bladder is bivalved, with the posterior aspect of the incision carried off the midline to enter the ureteral orifice. The ureter is not detached from the bladder. (B) The ureter is opened opposite its main blood supply. (C) The ureter is reconfigured as in intestinal cystoplasty before anastomosis to the bladder.

Alternatively, the bladder incision can be stopped approximately 2 cm from the orifice, and a similar length of distal ureter left in situ and intact without incision. The resulting small loop of intact ureter does not create clinical problems or adversely affect the end volume in a significant manner (Adams et al., 1998). This modification of technique is easier and may be safer in that it avoids potential injury to the blood supply of the ureter.

Results.

Early experience with the procedure noted that the entire renal pelvis could be preserved, allowing more tissue for cystoplasty (Churchill et al., 1993; Landau et al., 1994; McKenna and Bauer, 1995; Reinberg et al., 1995). As with intestinal cystoplasty, folding the ureter into a more spheric configuration maximizes the volume to be achieved. If a massively dilated ureter drains a functioning kidney, the distal ureter may be used for augmentation, with the proximal ureter either reimplanted into the bladder or anastomosed to the contralateral ureter (Bellinger, 1993). Numerous series have reported good results after augmentation using ureter. The upper tracts have remained stable or improved in almost all patients. Complications have been uncommon. Landau et al. (1994) compared age-matched and diagnosis-matched children undergoing ureterocystoplasty or ileocystoplasty. **The total mean bladder capacity was 470 mL in the ureterocystoplasty group and 381 in the ileocystoplasty group. Bladder volumes at 30 cm H_2O were 413 mL and 380 mL after ureterocystoplasty and ileocystoplasty, respectively.** Ureter effectively enhanced volume and compliance. There was one failure in the group, which occurred in a child in whom the distal ureter did not provide enough volume. Work has shown that one dilated ureter typically is enough for cystoplasty (Kajbafzadeh et al., 2010; Zubieta et al., 1999).

The main disadvantage to ureterocystoplasty is the limited patient population with a nonfunctioning kidney draining into a megaureter. McKenna and Bauer (1995) reported the use of a normal-sized ureter. The ultimate success of ureterocystoplasty using normal-sized ureter requires further follow-up, particularly because Gonzalez (1999) stated that in one-quarter of his patients with posterior urethral valves, ureterocystoplasty with a dilated ureter has failed because of their huge urinary volume. Husmann et al. (2004) noted even worse results if the ureter used was less than 1.5 cm in diameter. Patients can have a good long-term result with ureterocystoplasty but must be carefully selected (Johal et al., 2008). Atala et al. (1994) presented an experimental technique to slowly dilate a normal ureter for later use. Work continued in porcine models (Desai et al., 2003; Stifelman et al., 1998); however, the principle has not yet proven to be clinically feasible.

Autoaugmentation

Techniques and Results.

Cartwright and Snow (1989a, 1989b) described a method to improve bladder compliance and capacity through use of native urothelial tissue. In their procedure, known as *autoaugmentation*, the detrusor muscle was excised over the dome of the bladder, leaving the mucosa intact to protrude as a wide-mouthed diverticulum. Initially they made a midline incision through the bladder muscle (Fig. 37.14A). With the bladder distended with saline so that mucosa bulged from the incision, the muscle was then mobilized and excised laterally in each direction (Fig. 37.14B). The lateral edges of the detrusor muscle were then secured to the psoas muscle bilaterally to prevent collapse of the diverticulum (Fig. 37.14C). Their early experience noted improved compliance in most and increased capacity in some patients (Cartwright and Snow, 1989a).

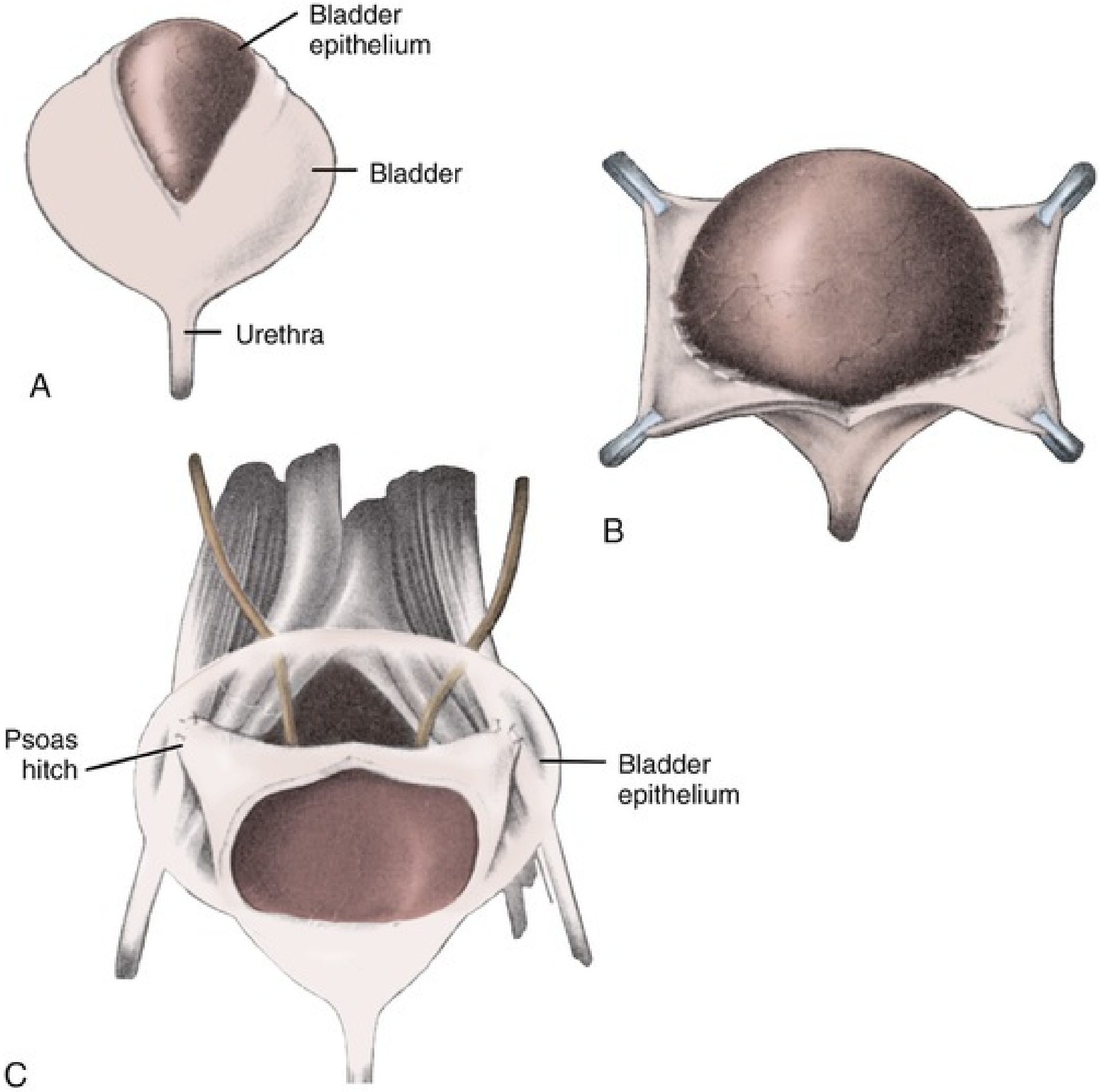

FIG. 37.14 Autoaugmentation. (A) The detrusor is incised. (B) Detrusor is stripped and excised from mucosa. (C) The detrusor muscle is anchored bilaterally so that the mucosa bulges with bladder filling. (From Cartwright PC, Snow BW: Bladder autoaugmentation: early clinical experience. *J Urol* 142:505, 1989.)

This procedure has since been modified by a number of surgeons, each applying a different name for the procedure depending on whether the detrusor muscle was simply incised or was excised to create the

diverticulum. In an effort to determine if incision or excision provided superior results, Johnson et al. (1994) performed 16 vesicomyotomies and 16 vesicomyectomies in rabbits after previously reducing bladder capacity. Functional bladder capacity in the animals increased by 43.5%, and there was no statistical difference between the two techniques. They then performed vesicomyotomies (incision) in 12 patients with neurogenic bladder dysfunction and demonstrated a mean increase in capacity of 40% (Stothers et al., 1994). They concluded that detrusor excision offered no advantage over incision. All patients demonstrated some increase in capacity (15% to 70%), and no patient in early follow-up clinically deteriorated and required enterocystoplasty.

Detrusorectomy, leaving a small cap of muscle at the dome through which a suprapubic tube can be placed, was proposed by Landa and Moorhead (1994). **They were concerned that although these procedures usually improve compliance, increase in volume is "modest at best," a concern shared by others** (Snow and Cartwright, 1996; Cartwright and Snow, personal communication, 1998). In a report of 12 detrusorectomies, 5 patients were considered to have excellent results, 2 to have acceptable results, and 1 was lost to follow-up. Failures occurred in 4 patients, of whom 3 underwent conventional augmentation (Landa and Moorhead, 1994). In a combined series at those two institutions, only 52% of patients had a good result with autoaugmentation, whereas 20% had a poor outcome (Snow and Cartwright, 1996). Reoperative enterocystoplasty was not hampered by the prior detrusorectomy. The urothelial diverticulum at the time of augmentation cystoplasty was noted to be thick and fibrous, similar to a leather bag.

In general, complications from the procedures are uncommon. Perforation, a major concern after intestinal cystoplasty, has not been reported. Inadvertent opening of the mucosa during the procedure can make subsequent mobilization more difficult and may promote prolonged postoperative extravasation. Such extravasation usually stops with bladder drainage (Landa and Moorhead, 1994: Stothers et al., 1994). Prolonged drainage, however, may result in compromised results because of collapse of the diverticulum. Rocha et al. (2011) suggested that early use of a silicone balloon to maintain distention may improve results. If concomitant ureteral reimplantation or bladder neck surgery is necessary, various authors have recommended that it be done first and the bladder then closed before detrusorectomy (Stothers et al., 1994).

Ehrlich and Gershman (1993) first reported laparoscopic myotomy (incision). A laparoscopic approach uses a smaller incision and perhaps shortens postoperative hospitalization; it may allow effective fixation of the detrusor muscle in an open fashion to make good bulging more difficult.

Concerns.

The main disadvantage of autoaugmentation is a limited increase in bladder capacity such that adequate preoperative volume may be the most important predictor of success (Landa and Moorhead, 1994). If the maximum capacity and the volume of urine held at 40 cm H_2O are similar, the patient may be better served by immediate intestinal cystoplasty. Some patients have demonstrated clinical improvement after these procedures without a significant change in urodynamics. The reason for improvement in that setting is unknown.

In most series of autoaugmentation, no matter what the technique, occasional patients have been noted or concern has existed at the time of the initial procedure that adequate expansion was not achieved. In many series, the autoaugmentation procedure, regardless of technique, has not provided adequate increase in bladder capacity, leading surgeons to proceed with formal enterocystoplasty instead. In most such cases it was elected to proceed with enterocystoplasty immediately at the time (Landa and Moorhead, 1994). The patient and surgeon must be prepared for such an event on occasion. Stoehrer's group (1999) as well as Leng et al. (1999) reported good results with the technique among patients with hyperreflexia. In terms of capacity, even if adequate expansion is achieved initially, there is concern that any improvement may not persist long term (Dewan et al., 1994). In animals, the surface area of the autoaugmentation site was noted to decrease approximately 50% by 12 weeks. Progressive thickening and contracture of the site have been noted because of collagenous infiltrate (Johnson et al., 1994). Milam (personal communication, 2000) noted that almost one-half of his adult patients with hyperreflexia who had a good early result after autoaugmentation failed with longer follow-up. Similar delayed failures have been noted in pediatric patients (Lindley et al., 2003), including one series with very poor results (MacNeily et al., 2003). To the contrary, Hansen et al. (2013) found that early decreases in capacity improvement may reverse with longer follow-up.

At this point, autoaugmentation should likely be considered only in patients who have reasonable capacity but refractory uninhibited contractions. Those same patients may respond to Botox injection or neural stimulation. **If a significant increase in capacity is needed, autoaugmentation may not be definitive.**

Seromuscular Enterocystoplasty

Based on concerns about collagen deposition and contraction around autoaugmentation, efforts have been made to cover the bulging urothelium with demucosalized enteric segments. Use of bowel segments stripped of their mucosa within the bladder is not new. If exposed submucosa was left facing the bladder lumen, re-epithelialization with urothelium was noted in animals. Despite re-epithelization, patch contracture often occurred (Oesch, 1988; Salle et al., 1990). Several series evaluated demucosalized augmentation in humans, with care taken to preserve the submucosa. Some encouraging results were noted (Dayanc et al., 1999; de Badiola et al., 1999; Lima et al., 1998; Lima et al., 2004), although regrowth of metaplastic enteric mucosa was found in the second study. Early placement of a silicone balloon or mold may help prevent contracture (Lima et al., 2004).

Technique and Results.

To avoid contracture, a combination of autoaugmentation after detrusorectomy and coverage with a demucosalized enteric segment has now been used. Buson et al. (1994) used reconfigured, demucosalized sigmoid colon placed over the urothelium (seromuscular colocystoplasty lined with urothelium [SCLU]). They, and others, noted that the intestinal submucosa should be preserved to avoid contracture (Buson et al., 1994; Vates et al., 1997; Fig. 37.15). This procedure has been performed clinically with early reports of good results in most patients (Gonzalez et al., 1994). Endoscopic biopsy of the segments has been interesting. Of 10 biopsy specimens, 1 was noted to contain urothelium with islands of colonic mucosa, whereas 2 others were found to contain only colonic mucosa. Removal of all of the enteric mucosa is important when using sigmoid to prevent mucoceles or overgrowth of intestinal mucosa (Gonzalez et al., 1994; Lutz and Frey, 1994). Dewan et al. (1997) felt preservation of the submucosa eventually promoted regrowth of bowel mucosa. The interaction of the two different tissues will be interesting to follow. The long-term effects on the urothelium by the seromuscular segment and vice versa are unknown. Work has shown that persistent transitional lining will protect from metabolic problems and mucus production (Denes et al., 1997).

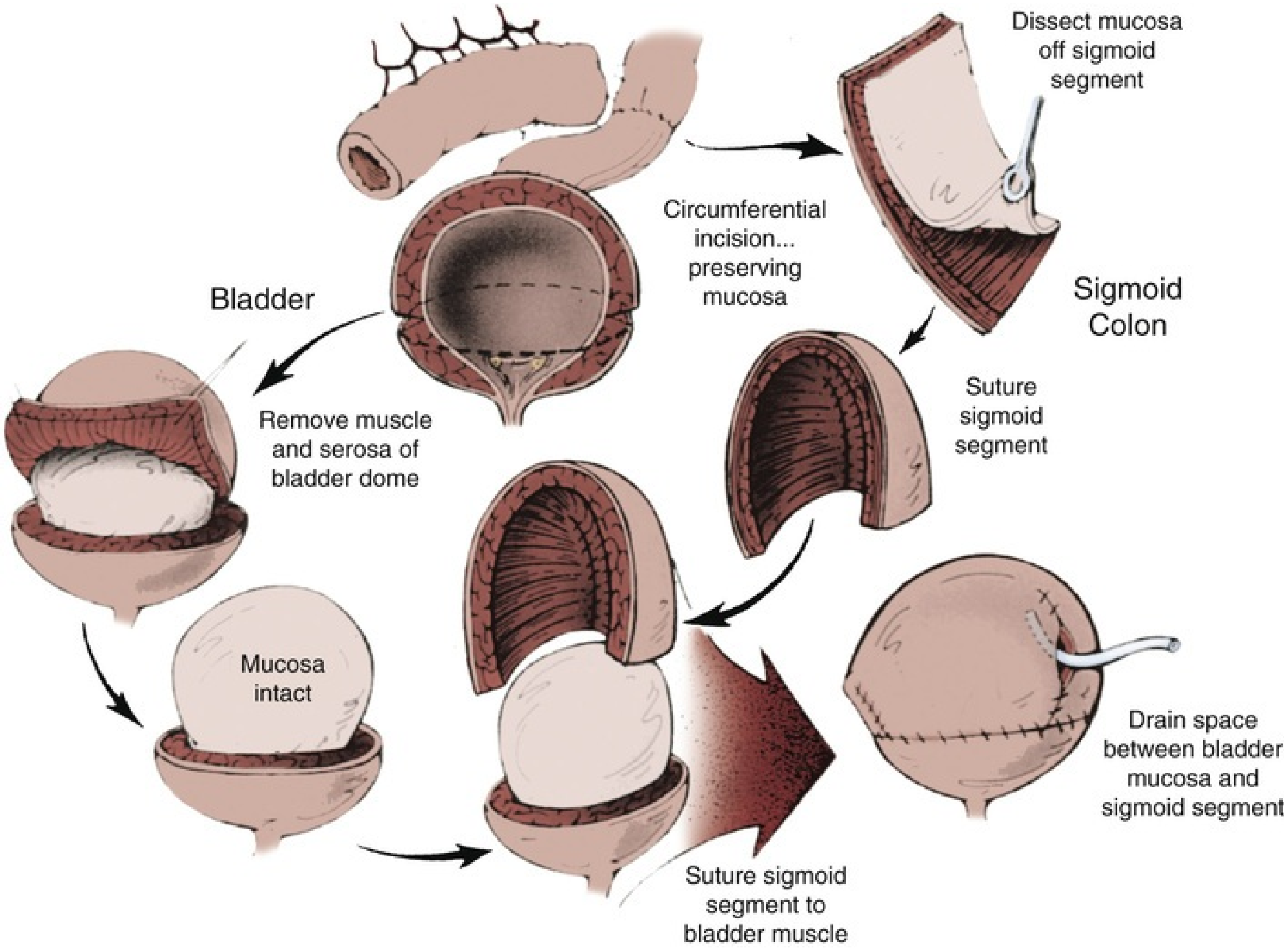
Dissect mucosa off sigmoid segment
Circumferential incision... preserving mucosa
Sigmoid Colon
Bladder
Remove muscle and serosa of bladder dome
Suture sigmoid segment
Mucosa intact
Drain space between bladder mucosa and sigmoid segment
Suture sigmoid segment to bladder muscle

FIG. 37.15 Seromuscular enterocystoplasty with use of sigmoid colon. Detrusor incision is performed as in autoaugmentation; however, the bulging mucosa is covered with a demucosalized segment of sigmoid colon. (From Buson H, Manivel JC, Dayanc M, et al.: Seromuscular colocystoplasty lined with urothelium: experimental study. *Urology* 44:745, 1994.)

These procedures are technically more demanding than simple augmentation or autoaugmentation and are associated with more blood loss and a longer operative time (Gonzalez et al., 1994; Horowitz et al., 1995). Increased bleeding is particularly true when stomach is used. These urothelial-lined, seromuscular augmentations are theoretically attractive. Thus far, the failure and reoperation rate after such procedures remains higher than that noted for standard enterocystoplasty at most centers (Carr et al., 1999; Jung et al., 2012; Shekarriz et al., 2000; Vates et al., 1997). The best results have been reported with use of colon and a mold to minimize contracture (Lima et al., 2008). They noted bladder capacity to rise from a median of 73 mL to 250 mL, an increase of 349%. Only 12.6% of patients were thought to have failed after nonsecretory intestine-cystoplasty (Lima et al., 2008).

Bladder Regeneration

Efforts to find alternatives to intestinal cystoplasty in the 1950s included the use of alloplastic materials for bladder substitution (Gleeson and Griffith, 1992; Kanematsu et al., 2007; Kropp et al., 1995b, 2004; Lewis and Cheng, 2007; Roth et al., 2011; Yamzon et al., 2008). Early research efforts met with very limited success because of foreign body complications but provided a foundation for regenerative medicine. This led to focus on biodegradable, collagen-rich tissues serving as scaffold with and without cell "seeding" for bladder regeneration (Atala et al., 1992; Fishman et al., 1987; Harrington et al., 2008; Kambic et al., 1992; Kelami, 1971; Kropp et al., 1995a; Zhang et al., 2004). Atala et al. (2006) provided the first reported data regarding use of a seeded biodegradable construct for augmentation in the neurogenic population. This work led to an industry-supported prospective multi-institution investigation using a neobladder construct (Joseph et al., 2009). Unfortunately, compliance improved in only 4 patients after 12 months and in 5 at 36 months, but in none to a clinically or statistically significant degree. Capacity did not improve either (Joseph et al., 2014).

Using autologous tissue from a neuropathic source may result in lower yield of cells for use (Subramaniam et al., 2011) or could potentiate growth of abnormal tissue; an alternate cell source for regenerative tissue such as stem cells might circumvent those concerns. The use of stem cells carries its own set of obstacles (Aboushwareb and Atala, 2008; Aitken and Bägli, 2009; Chen et al., 2011; Soler et al., 2009). Further investigation into the clinical applicability of regenerative tissue engineering is required, but this technology could alter the field of reconstructive bladder surgery.

Key Points: Alternatives to Gastrointestinal Cystoplasty

- Ureterocystoplasty avoids complications associated with bowel segments but may not provide adequate volume if the ureter is not remarkably dilated.
- Autoaugmentation seldom adds significant capacity and may not always improve compliance long term.

Continent Urinary Diversion

The frequency with which continent urinary diversion is performed in children depends on the definition of continent diversion. Tumors resulting in cystectomy among children are much less common than in adults. Thus, in the setting cystectomy for cancer or severe congenital abnormality of the bladder, a pure continent urinary diversion, such as a Kock or Indiana pouch, may be performed. Very good results with continent diversion in children have been achieved, equivalent to those reported in adults (Stein et al., 2005). Orthotopic neobladders in children are performed very infrequently because neurogenic or anatomic problems at the outlet prevent spontaneous voiding in many cases. Occasionally a child with neurogenic dysfunction may be a candidate for orthotopic bladder substitution (Stein et al., 2000, 2005), but it is not clear how many of those patients with neurogenic dysfunction can be expected to void adequately.

Some authors have defined combinations of bladder augmentation, continent abdominal wall stoma, and some procedure at the outlet as continent diversions (Kaefer et al., 1997b). Division and closure of the bladder neck to prevent incontinence per native urethra has typically meant inclusion. These procedures typically have been performed in complex patients with multiple problems that must be addressed, often after numerous previous surgeries.

Considerations

The amount of bowel used in continent urinary diversion may vary depending on the patient. Total bladder replacement requires much more intestine than simple augmentation. Typically a 40-cm segment of small bowel is used for an ileal reservoir in a Kock pouch compared with the 20 cm often used for augmentation. Likewise, the entire right colon with the hepatic flexure may be used in an Indiana pouch, whereas only 15 to 20 cm of colon are needed for colocystoplasty. Because of the potential morbidity associated with use of a larger intestinal segment, the native bladder is often used in children if it provides any significant volume. To do so, however, may require repair of the outlet if outflow resistance is low.

Imbrication of the ileocecal valve and terminal ileum has proven to be a simple and reliable means for construction of an effective efferent limb in continent diversion among adults and children. Despite reports to the contrary in select patients (Husmann and Cain, 1999), concern about fecal incontinence secondary to use of the ileocecal valve persists for patients with neurogenic dysfunction. The flap valve continence mechanism provides numerous alternatives for those surgeons with such concerns in continent diversion. Good results achieved with use of the appendix or tapered intestinal segments have led to their increased use.

Whereas maintenance of the native urethra for catheterization is ideal, it may not be appropriate or possible in all individuals. Urethras after reconstructive bladder neck procedures are often subject to difficulty with catheterization. **Children with neurogenic sphincter incompetence may have associated neurologic limitations that prevent easy access to the native urethra. This is particularly true for the wheelchair-bound child. For children without neurologic deficits, normal sensation in the native urethra can prevent compliance with a routine catheterization schedule because of discomfort. For these reasons, a continent catheterizable stoma provides an adequate and sometimes a more reliably useful alternative.**

Continence Mechanisms and Catheterizable Stoma

Ureterosigmoidostomy and Its Variants

Ureterosigmoidostomy can be an effective form of continent urinary diversion in some patients. Its advantage is the spontaneous evacuation of urine with stool. The significant complications of hyperchloremic acidosis, infection, hydronephrosis, and colonic malignancies have led to disfavor and disuse, particularly in the United States. **Although good results with standard ureterosigmoidostomy have been reported in some children, the procedure is rarely performed as originally described. The morbidity of acidosis and upper tract changes may increase with time, making those complications particularly worrisome for children with a long life expectancy. The significant risk of adenocarcinoma commits the patients to a lifetime of close surveillance for an avoidable tumor.** It is unlikely that ureterosigmoidostomy, as classically described, will regain acceptance for children.

Several modifications of ureterosigmoidostomy have been developed in an attempt to decrease the significant complication rate. **The most basic of the modifications is the sigma rectum or the Mainz II pouch.** The colon is incised along the antimesenteric border for 6 cm proximal and distal to the rectosigmoid junction. The ureters are implanted in an antirefluxing fashion, and that portion of colon is then reconfigured and closed. This is done to create a rectosigmoid reservoir of lower pressure to protect the upper tracts. The Mainz II pouch has been used in children with bladder exstrophy (Stein et al., 1997a). Continence in appropriately selected patients is good, although acidosis is still a significant problem because of exposure of the entire colon to urine (Fisch et al., 1996; Gerharz et al., 1999; Mingin et al., 1999b). The risk for development of adenocarcinoma is unaltered with this technique. Long-term follow-up is necessary to determine if the reconfiguration of the sigmoid in the area of ureteral implantation is truly effective for protection of the upper tracts. Stricture at the ureterocolonic anastomosis has been the most common complication in relatively short follow-up (Fisch et al., 1996).

In an effort to control the amount of colon to which urine is exposed, Kock et al. (1988) **described creation of a colorectal valve to confine urine distally.** The intussuscepted nipple valve was stabilized with permanent staples. The distal rectal segment was opened and patched with ileum to lower pressure. With short-term follow-up, the valve was effective in that no necessity for sodium bicarbonate or potassium citrate therapy was noted (Kock et al., 1988; Mahran et al., 1999). Urodynamic evaluation revealed low pressure in the rectal reservoir (Kock et al., 1988), but long-term follow-up in children is needed to see if it is truly less morbid in terms of infection and upper tract deterioration.

If placement of a colorectal valve avoids most complications of metabolic acidosis from ureterosigmoidostomy and creation of a reservoir with lower pressure better protects the upper tracts, the last remaining major concern about ureterosigmoidostomy is tumor development. The concern is significant; of 94 children followed in Boston after ureterosigmoidostomy, 7 developed adenocarcinoma, of whom 4 died of the tumor (Rink and Retik, 1991). Kock et al. (1988), followed by Skinner et al. (1989), used a hemi-Kock pouch to augment the distal rectal segment. A colorectal valve was created to isolate urine to the distal colonic reservoir. The afferent nipple valve kept stool away from the ureteroileal anastomoses, perhaps lowering the risk for tumor development. Simoneau and Skinner (1995) reported their results with the procedure in 15 patients, including 4 children. Their complication rate, both early and late, was relatively high. This is not surprising, considering the relatively complex nature of the procedure. They did think that pediatric patients were better suited for the procedure. Rink and Retik (1991) suggested that the rectum could be augmented with a nonrefluxing ileocecal conduit in a similar fashion.

Before any variant of ureterosigmoidostomy is considered, competence of the anal sphincter must be ensured. Tests used to assess sphincter integrity include manometry, electromyography, and practical evaluation of the ability to retain an oatmeal enema in the upright position for a period of time without soilage. Incontinence of a mixture of stool and urine results in foul soilage and must be avoided. Most patients with neurogenic dysfunction who are incapable of fecal continence in the presence of diarrhea are not candidates for these procedures. Procedures that separate the fecal and urinary streams within the rectal sphincter have been described but have not been widely used in children.

Nipple Valves

The most extensive experience with nipple valves used to achieve urinary continence has been with the Kock pouch. Skinner et al. (1989) made a series of modifications to aid in maintenance of the efferent nipple. Despite experience and use of these modifications, a failure rate of 15% or higher can be expected (Benson and Olsson, 1998; Fig. 37.16A). Several authors have reported a reoperative rate of approximately 33% with the Kock pouch, most frequently related to the efferent nipple (deKernion et al., 1985; Waters et al., 1987). Equivalent results with the nipple valve and a Kock pouch have been achieved in children (Abd-El-Gawad et al., 1999; Hanna and Bloiso, 1987; Kaefer et al., 1997b; Skinner et al., 1988). The last report noted a significant incidence of hyperchloremic acidosis and new hydronephrosis, although those complications were likely related to the complex nature of the patients rather than the particular continent diversion used.

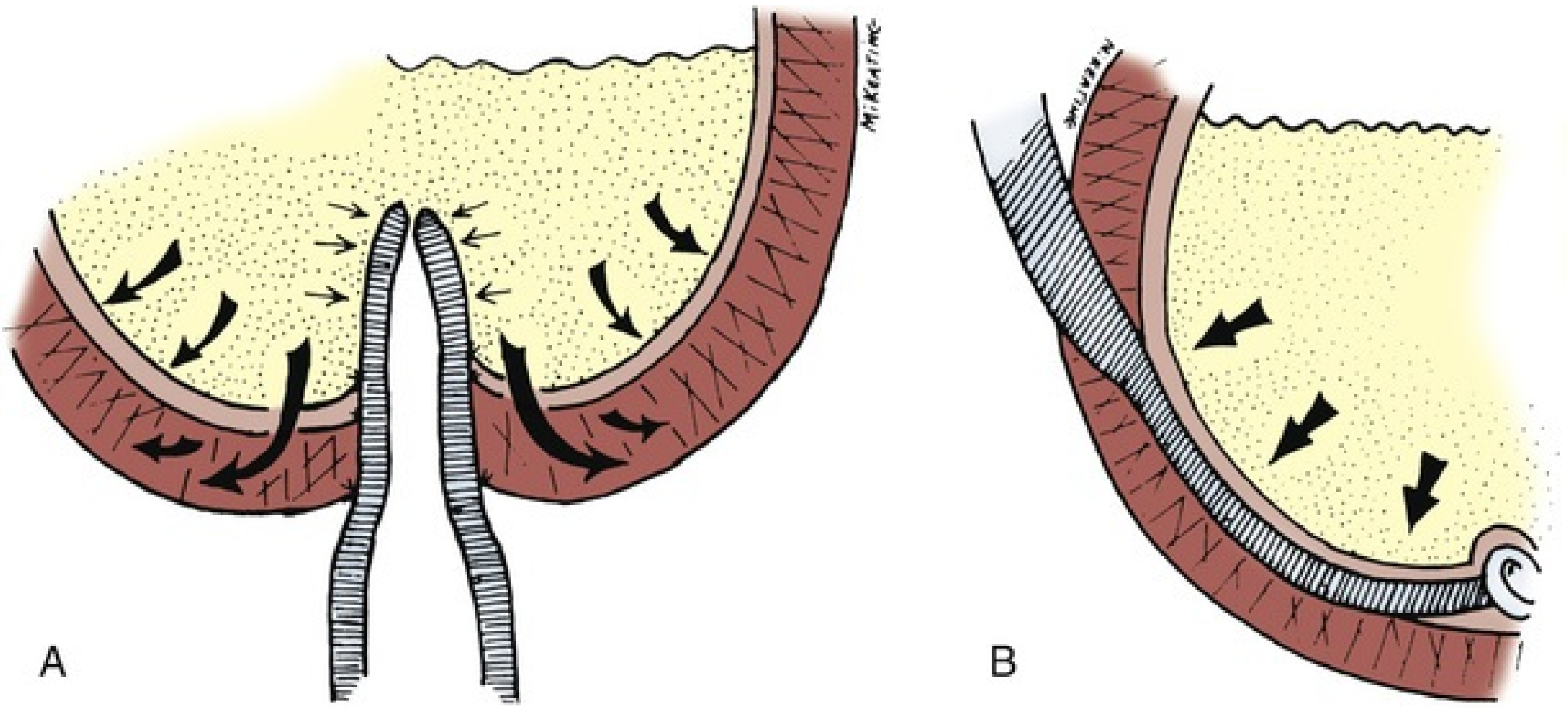

FIG. 37.16 Continence mechanisms. (A) The same pressures that create continence tend to efface nipple valves. (B) This is not true of flap valves, which have been more reliable in pediatric reconstruction.

Intussuscepted nipple valves have also been used with colonic and ileocolonic reservoirs, particularly the Mainz I pouch. Evolution of the nipple valve in the Mainz pouch also occurred over time (Hohenfellner et al., 1990; Stein et al., 1995; Thuroff et al., 1986, 1988). Most recently, the intussuscepted ileum was fixed with staples, passed through the intact ileocecal valve, and fixed again. Much as with the Kock pouch, the incidence of incontinence decreased with experience and modifications. The Mainz I pouch has been used in children with good results and low rates of incontinence using the latest modifications (Stein et al., 1995, 1997a; Stein et al., 2000; Steiner et al., 1998). Maintenance of normal upper tracts has been good, and metabolic problems rare (Stein et al., 1997b).

Flap Valves and the Mitrofanoff Principle

Mitrofanoff (1980) described a continence mechanism using the appendix and ureter to create a flap valve. He recognized that any tubular structure could be implanted effectively into a low-pressure reservoir. This continence mechanism circumvents many of the secondary potential complications associated with harvesting the ileocecal valve or using other gastrointestinal segments.

The foundation for the success of the Mitrofanoff principle is based on creating a submucosal tunnel for a supple, small-diameter conduit. As the reservoir fills, the rise in intravesical pressure is transmitted through the epithelium and to the implanted conduit, coapting its lumen (Fig. 37.16B). The **appendix is an ideal tubular structure that can be safely removed from the**

gastrointestinal tract without significant morbidity. The small caliber of the appendix facilitates creation of a short functional tunnel within the bladder wall. Experience has shown that continence can be achieved with only a 2-cm appendiceal tunnel (Kaefer and Retik, 1997). Whether implanted into a bowel segment or native bladder, the appendix has been used as an efferent limb with very good results (Cain et al., 1999; Jayanthi et al., 1995; Kaefer et al., 1997b; Mollard et al., 1997; VanderBrink et al., 2011). The appendix has been particularly useful in children because it is relatively longer and the abdominal wall generally thinner. The flap valve is likely the most reliable of all of the surgically constructed continence mechanisms. Some patients with a flap valve almost never leak per stoma; this potentially puts them at risk for upper tract deterioration or spontaneous rupture of the bladder or reservoir if catheterization is not routinely performed.

If the appendix is used in situ as a continence mechanism in a continent urinary reservoir, the reservoir by necessity will include the right colon. Duckett and Snyder (1986, 1987) used the right colon and appendix with good results in children. The mesoappendix, in most cases, allows mobilization of the appendix for use in the native bladder or virtually any reservoir.

Technique.

In most children good exposure to the appendix and reservoir can be achieved through a low midline or a transverse incision. On occasion, the cecum may be high in the abdomen, and mobilization of the ascending colon along the line of Toldt may be required to gain access to the appendix and its mesentery. Cadeddu and Docimo (1999) have used laparoscopy to aid in the mobilization of the ascending colon and cecum. Once the cecum has been mobilized, the base of the appendix is amputated, leaving a small cuff of cecum with the appendix. Use of the cecal cuff at the stoma may decrease the risk of stenosis. The cecum is closed in a fashion similar to an open appendectomy. If the length of the appendix is marginal, a greater portion of the cecum can be harvested to effectively increase the functional length of the appendix (Bruce and McRoberts, 1998; Cromie et al., 1991).

After harvesting, a location is selected for implantation of the appendix into the bladder. The location is based on the length of the appendix, the mobility of the bladder, and the location for the appendiceal stoma. Typically the distal end of the appendix is tunneled into a posterolateral position within the bladder (see Fig. 37.17), although an anterior site may be useful as well depending on anatomy. Creating a tunnel is easily done whether the bladder is opened or not (VanderBrink et al., 2011). Successful continence has also been achieved by developing an extravesical trough with or without a serosal base and then covering the channel with laterally mobilized serosa (Baradaran et al., 2013; Elshal et al., 2011).

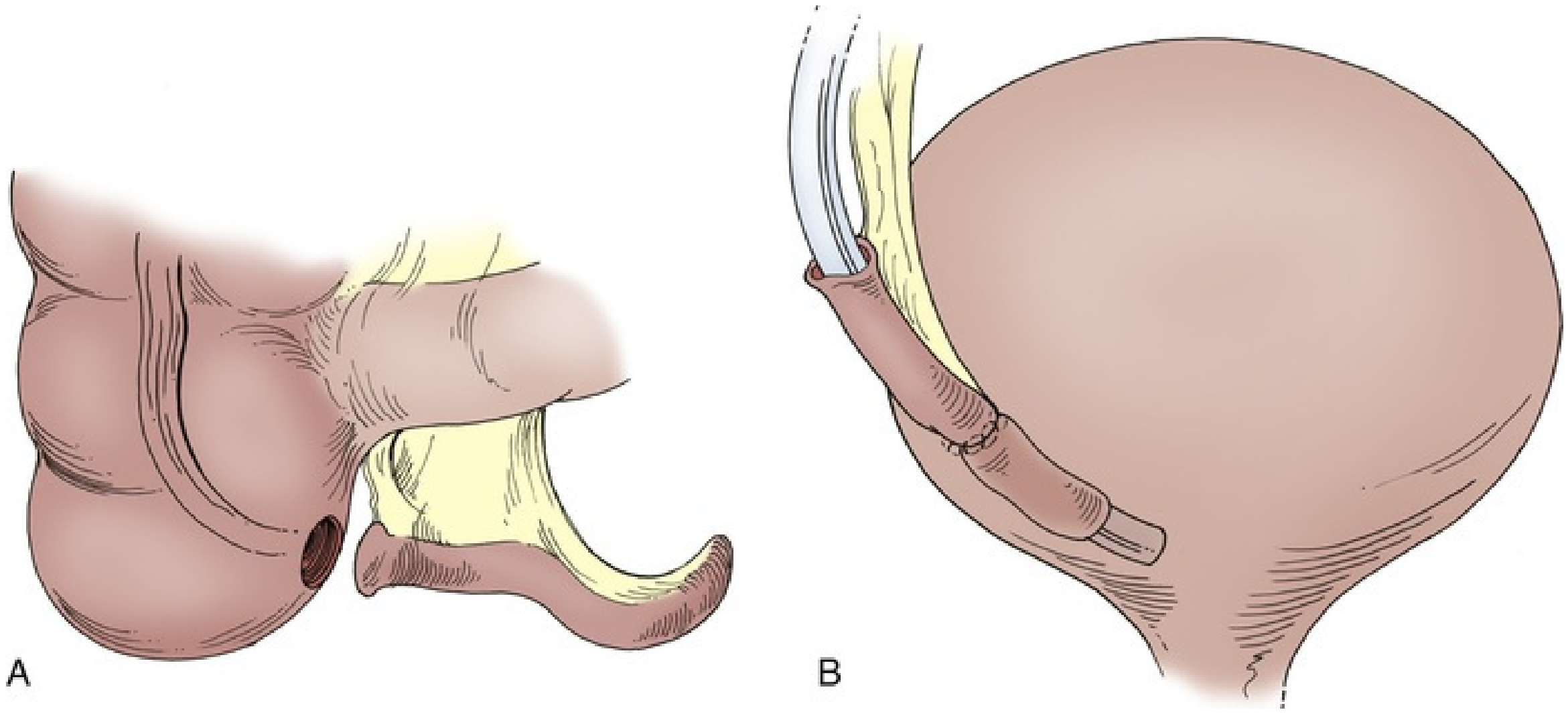

FIG. 37.17 Appendicovesicostomy. (A) The appendix is harvested with a cuff of cecum on a wide pedicle based on the appendiceal artery. A flap of cecum can be harvested in continuity with the appendix and tubularized to increase the length. (B) The distal appendix is tunneled into the bladder to provide continence after the end is amputated. The proximal end of the appendix, the cecal cuff, is brought to the umbilicus or right lower quadrant as a catheterizable stoma.

The base of the appendix is brought to the abdominal wall in a location chosen preoperatively to suit the patient. It should be brought up to reach the skin without tension. Care must be taken not to twist the pedicle or occlude it as it passes through the abdominal wall fascia. The base of the appendix can often be hidden within the umbilicus, which allows for elimination of a small but obvious abdominal stoma. Because of the small circular diameter of the appendiceal base, stomal stenosis is common, and techniques have been described to prevent this problem. Various flaps have been described as a method for avoiding stomal stenosis (Berrettini et al., 2008; Frane-Guimond et al., 2006; Kajbafzadeh et al., 1995; Kaefer and Retik, 1997; Keating et al., 1993; Landau et al., 2008). Weikert et al. (2012) described a rotational umbilical flap to enhance mobility and decrease tension when anastomosing to a channel with a short mesentery.

Regardless of the technique, stomal stenosis remains the most common of complications. Chronic nighttime use of a stent through the channel may decrease that risk (Mickelson et al., 2009).

For prevention of kinking and problems with catheterization, it is advisable to maintain as short a conduit as possible. Securing the appendix and bladder wall to the peritoneum beneath the fascia will help diminish the problem of conduit kinking with reservoir filling. When appendix or any catheterizable stoma is used, it is advisable to repeatedly catheterize the channel after each step in reconstruction to confirm easy passage. If the catheter does not pass easily into the reservoir, the prior step must be revised. Problems with catheterization by the surgeon during the operative procedure usually result in more difficulty for the patient afterward. It is also beneficial to catheterize at variable reservoir volumes to confirm proper fixation of the reservoir and the absence of any kinking. The basic principles used for open reconstruction of a catheterizable channel can be used laparoscopically and with robotic assistance to achieve the same level of success (Badawy et al., 2013; Famakinwa et al., 2013; Hsu and Shortliffe, 2004; Rey et al., 2013; Wille et al., 2011).

A 6-Fr to 12-Fr stent is typically left for 10 to 14 days within the efferent catheterizable channel during the healing process. It is then advisable for the surgeon to personally catheterize the efferent limb before the patient or family members do so. Catheterization should be repeated at least every 4 hours during the day for reservoir drainage, maintenance of patency, and minimalization of the risk of stomal stenosis.

The appendix may not be available for use in all patients because of previous appendectomy, its location or length, congenital absence, involvement with adhesions, or its use for continence enemas. Histologic abnormalities of the appendix have been reported to occur in as many as 30% of patients (Liebovitch et al., 1992) and to increase with age. They rarely are of enough clinical significance to preclude use (Mulvihill et al., 1983).

Results.

Several papers have reviewed large series of patients after appendicovesicostomy (Cain et al., 1999; Kaefer et al., 1997b; Harris et al., 2000; Thomas et al., 2006; VanderBrink et al., 2011; Welk et al., 2008). Inability to use the appendix, other than because it was needed for use in situ for antegrade continence enemas, has been rare. The results, in terms of continence, have been superb, usually above 95% (Baradaran et al., 2012; Cain et al., 1999;

Castellan et al., 1999; Elshal et al., 2011; Gerharz et al., 1998; Gosalbez et al., 1998; Kaefer and Retik, 1997; Liard et al., 2001; Mor et al., 1997; Suzer et al., 1997; VanderBrink et al., 2011). **Incontinence is a rare event with the Mitrofanoff principle and may result from inadequate length of the flap valve mechanism or persistently elevated reservoir pressure.** Urodynamic evaluation is required to evaluate the cause of the incontinence. Injection of a bulking agent is a possible treatment for inadequate outflow resistance, with success reported up to 50% in the short term (Welk et al., 2008).

A more formal approach with takedown and revision of the leaking Mitrofanoff valve is often required (Kaefer and Retik, 1997). **The most common complication has been stomal stenosis, which in general has occurred in 6% to 10% of patients** (Ardelt et al., 2012; Leslie et al., 2011; Thomas et al., 2006; Welk et al., 2008;). Stenosis resulting in difficult catheterization may occur early in the postoperative course and require formal revision (Harris et al., 2000). Mickelson et al. (2009) have described the successful use of an “L stent” with topical steroid cream as an effective noninvasive treatment. Another recognized complication has been appendiceal perforation. Most problems with stomal stenosis and creation of a false passage (perforation) occur in the first few years after reconstruction, but long-term problems do occur, resulting in the need for lifelong monitoring (Leslie et al., 2011; Thomas et al., 2006). Benign fibroepithelial polyps and inflammatory granulomatous tissue have recently been reported in all types of catheterizable channels. Groth et al. (2013) reported an incidence of polyps occurring in 20% of their patients at a 7-year follow-up; 50% were symptomatic and 45% had a recurrence after resection. Stricture and necrosis, particularly of cecal extensions of the appendix, have occurred rarely. Abdominal stomas may be associated with a higher risk of reservoir calculi because of the potential for incomplete emptying.

Follow-up in the recent series has averaged approximately 4 years. Patients from Mitrofanoff's early experience (1980) now have follow-up of more than 30 years, suggesting that the appendix may provide a durable alternative for pediatric patients, a finding also noted by others (Cain et al., 1999; Harris et al., 2000; Liard et al., 2001). Similar outcomes have been achieved in smaller series of adults (Ardelt et al., 2012; Gowda et al., 2008; Van der Aa et al., 2009).

Alternatives.

When the appendix is unavailable for use, other tubular structures can provide a similar mechanism for catheterization and continence. Mitrofanoff (1980) described a similar technique using a ureter (Kaefer et al., 1997b). Care must be taken to preserve the distal blood supply to prevent ischemia. Refluxing ureters have even been used after extravesical reimplantation (Ashcraft and Dennis, 1986; Duel et al., 1996; Kaefer et al., 1997b). Stomal stenosis seems to be more problematic with use of the ureter compared with the appendix, possibly because of compromised blood supply. In addition, distention of the ureter from catheter passage has caused discomfort in some individuals (Duckett and Lofti, 1993).

Woodhouse and MacNeily (1994) used the fallopian tube, which can accommodate catheterization. Stenosis again appears to be a significant problem with the fallopian tube. The effect on fertility should be considered when there is a normal ipsilateral gonad. Ileum has been tapered to create a similar uniform tube of adequate length (Adams et al., 1992). By narrowing the ileal segment longitudinally along the mesenteric border using permanent staplers in series, the surgeon constructed a surrogate that was easy to catheterize and provided good continence. Others (Hampel et al., 1995; Woodhouse and MacNeily, 1994) have shown similar success with tapered ileum. The catheterizable channel must be long enough to reach from the reservoir to skin without tension but kept as short and straight as possible to facilitate easy catheterization. An unnecessarily long, mobile catheterizable channel can kink and result in difficult catheterization or perforation.

Yang and Monti have been credited with a novel modification of the tapered intestinal segment that can be reimplanted according to the Mitrofanoff principle (Monti et al., 1997; Yang, 1993). A very short (1 to 2 cm) segment of small bowel is opened longitudinally along the antimesenteric border and then closed transversely (Fig. 37.18). By this reconfiguration, the initial circumference of the segment is converted to length and the original length to circumference. A uniform tube is created with a small mesentery toward the center. The two ends are devoid of mesentery, making them easy to tunnel into bladder and bring through the abdominal wall. If the first incision is made directly at the antimesenteric border, both limbs are of equal length. Because the incision is made off of midline and to one side, one limb may be created much longer than the other. Experience has shown that a long tunnel in the bladder or reservoir is not needed to achieve continence with such a small-diameter channel, and the longer limb has typically been used to reach the skin through a thick abdominal wall.

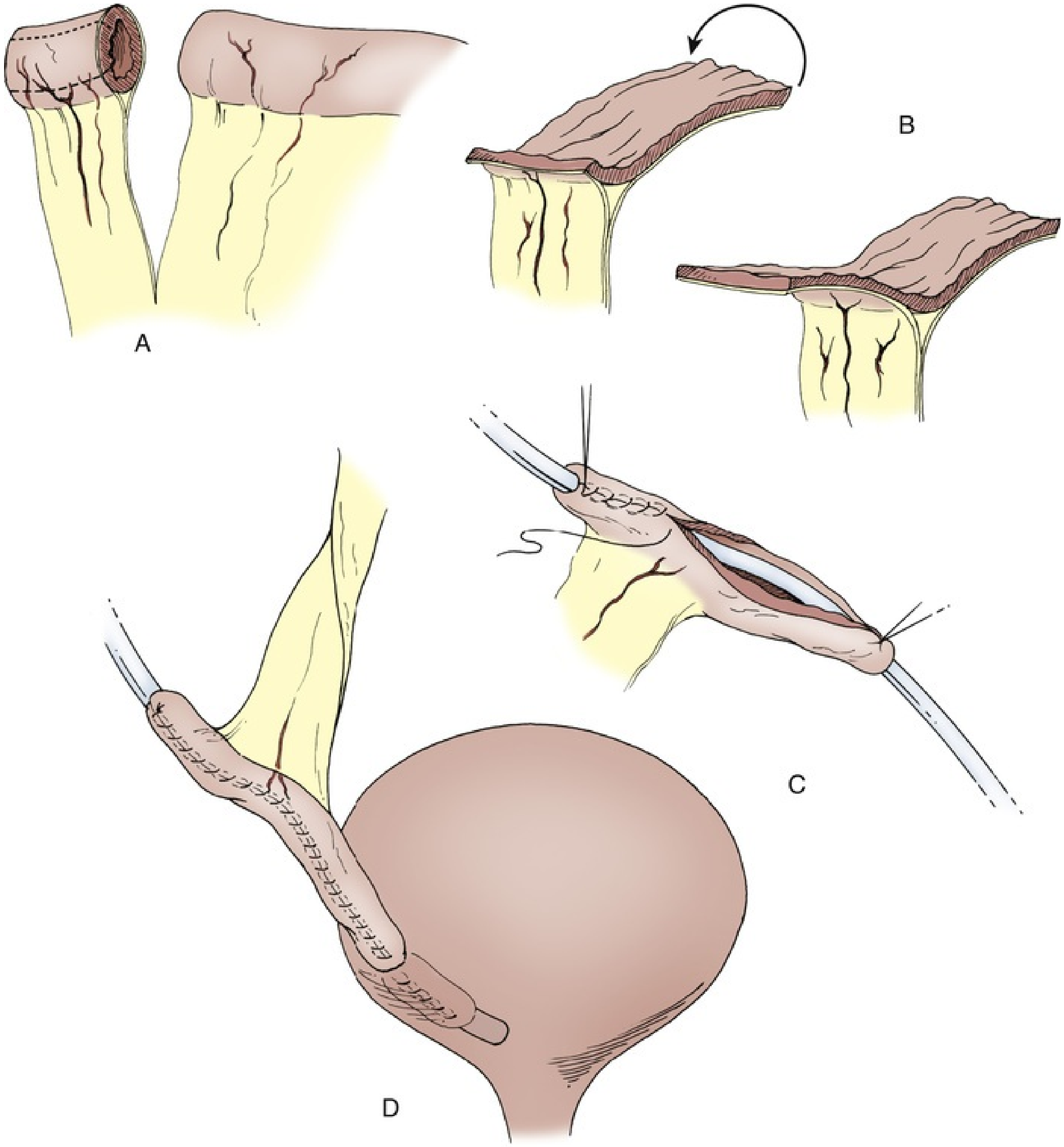

FIG. 37.18 Yang-Monti technique to efficiently construct a catheterizable tube. (A) A 2-cm length of ileum is harvested either independently or next to a segment for augmentation cystoplasty. The segment is opened horizontally and tubularized in a longitudinal fashion. (B) If the segment is opened directly on the antimesenteric border, two equal-length limbs result with a central mesenteric pedicle. Initial incision may be made to one side to form a shorter limb for implantation in the bladder and a longer one to be brought through the abdominal wall. (C) The reconfigured ileal segment is tubularized over a 12-Fr catheter in a two-layer technique with absorbable sutures. (D) A continent catheterizable stoma is constructed.

Very good results have been achieved using the Yang-Monti channel as a catheterizable stoma, and it is certainly an efficient use of bowel (Leslie et al., 2011; Nerli et al., 2013; VanderBrink et al., 2011). Some surgeons have suggested that it may be easier to catheterize than an ileal segment tapered longitudinally because circular mucosal folds are redirected longitudinally in the direction of catheter passage. Stomas created with ileum may have a lower rate of stenosis than those created with appendix (Kaefer et al., 1999b). The one potential disadvantage of the Yang-Monti channel is that it remains relatively short and may not reach the skin without tension in obese patients. Despite extensive use of skin flaps, such tension may lead to stomal stenosis. Two separate reconfigured channels can be anastomosed together for increased length (Kaefer and Retik, 1997). Casale (1999) used an initial segment that was twice as long that was partially split in the middle and then opened in a spiral fashion on opposite sides to create a longer strip that could be tubularized in continuity. A direct comparison of these channel modifications showed similar results in terms of continence, stenosis, and revision rate; however, spiral Monti channels were more likely to need subfascial revision if located at the umbilicus (Whittam et al., 2015). Narayanaswamy et al. (2001) noted difficulty with catheterizations through Yang-Monti channels in 28% of a large series of patients as a result of “pouch-like dilatation.” Such a problem, to that degree, has been avoidable in most series. Excessive length of the extravesical limb may make such dilation more problematic.

Ileocecal Valve

Use of the ileocecal valve as a continence mechanism began with Gilchrist et al. (1950) and was popularized by the Indiana group (Bihrle, 1997; Rowland et al., 1985). Various modifications have been developed. In general, a short segment of terminal ileum, whether imbricated or tailored, is used as an efferent limb. This segment should be kept as short and straight as possible to facilitate easy intermittent catheterization. Continence is based on the imbricated ileocecal valve, not the length of the efferent limb. The imbrication is usually secured with interrupted, permanent sutures, involving the very distal ileum and ileocecal valve, and the imbrication is carried onto the cecum.

The Indiana pouch has been used in children with excellent results as in adults. Besides the appendix, this continence mechanism is perhaps the simplest and has the shortest learning curve to achieve reliable results. Continence rates have been reported as high as 95% with preservation of normal upper tracts (Hensle and Ring, 1991; Kaefer et al., 1997b; Lockhart et al., 1990; Rink and

Bihrle, 1990; Rowland et al., 1985; Rowland, 1995). One report noted a higher rate of incontinence (Canning, 1998). Husmann and Cain (1999) have used the cecal segment for bladder augmentation and the efferent limb to construct a continent catheterizable stoma with good results. They noted a very low incidence of detrimental effect on gastrointestinal function in a select group of patients with neurogenic dysfunction.

Hydraulic Valves

Benchekroun (Benchekroun, 1982; Benchekroun et al., 1989) developed a hydraulic valve as a continence mechanism that was modified by Guzman et al. (1989). Urine from the reservoir and generated pressure is allowed to enter a sleeve of ileum around the catheterizable channel. Compression of the inner tube theoretically provides continence, and early experience was encouraging. Initial continence rates approached 75% and then 90% with a single revision (Benchekroun et al., 1989). Others have been unable to duplicate those results (Leonard et al., 1990b; Sanda et al., 1988). Koff et al. (1989) added a similar hydraulic sleeve around the efferent limb of an Indiana pouch, but the use of such valves has largely been abandoned.

Continent Vesicostomy

Yachia (1997) described creation of a bladder tube fashioned from a wide flap of the anterior bladder wall. An attempt to provide a continence mechanism was fashioned by weaving the bladder tube through the rectus muscle for compression and continence. Continence in their small, short-term series was reported to be 100%, but this has not been duplicated.

Hanna et al. (1999) described a continence mechanism based on either a flap of bladder or intestinal tissue fashioned after prior enterocystoplasty and used it on a very small series of patients. A rectangular flap in continuity with the bladder is tubularized over a 14-Fr to 16-Fr catheter. The bladder is plicated around the proximal 3 cm of the tube using nonabsorbable suture to create a type of nipple similar to gastric fundoplication. Macedo and Srougi (2000) described a similar continence mechanism created at the time of initial augmentation. They achieved acceptable continence in eight of their first nine patients. Their technique is potentially appealing for patients requiring augmentation and having no appendix because of the simplicity; however, continence is based on a type of nipple valve that historically has been difficult to keep fixed. The same forces that create continence tend to efface the continence mechanism.

Casale (1991) has described a form of continent vesicostomy in which the continence mechanism is based on a flap valve created from a tubularized strip of bladder mucosa. It is particularly suitable when the bladder is compliant and of large capacity. An anterior detrusor strip is used to create a catheterizable limb.

Technique.

Parallel incisions 3 cm apart are made into the anterior bladder and used to create a long rectangular flap. The abdominal wall should be measured to ensure that the strip is long enough to reach the skin without tension. The full-thickness strip is tubularized down to the bladder in two layers. The muscle portion is left broad to come around without tension and provide good blood supply. The mucosa may be trimmed in width before tubularization to avoid redundancy. A strip of mucosa within the bladder, 2 to 3 cm in length and 1.5 cm in width, is incised in a direct line and in continuity with the mobilized bladder tube. The edges of this strip are mobilized until it can be tubularized along its entire length. It may be beneficial to mobilize only one edge over to the other side to avoid overlapping suture lines. Casale (1991) originally incised the mucosa transversely at the end of the intravesical strip to be tubularized; Rink et al. (1995b) then suggested that it could be left intact (Fig. 37.19). The bladder mucosa from either side of the channel is then mobilized and closed over the mucosal tube to create a flap valve. More extensive mobilization of the side opposite that mobilized for the inner tube allows closure without overlapping suture lines, which may help avoid fistula formation and incontinence. A stent is left in the channel for 3 weeks to prevent stenosis. It does tend to stricture if not catheterized regularly—more so than other catheterizable channels (Cain et al., 2002; Thomas et al., 2005).

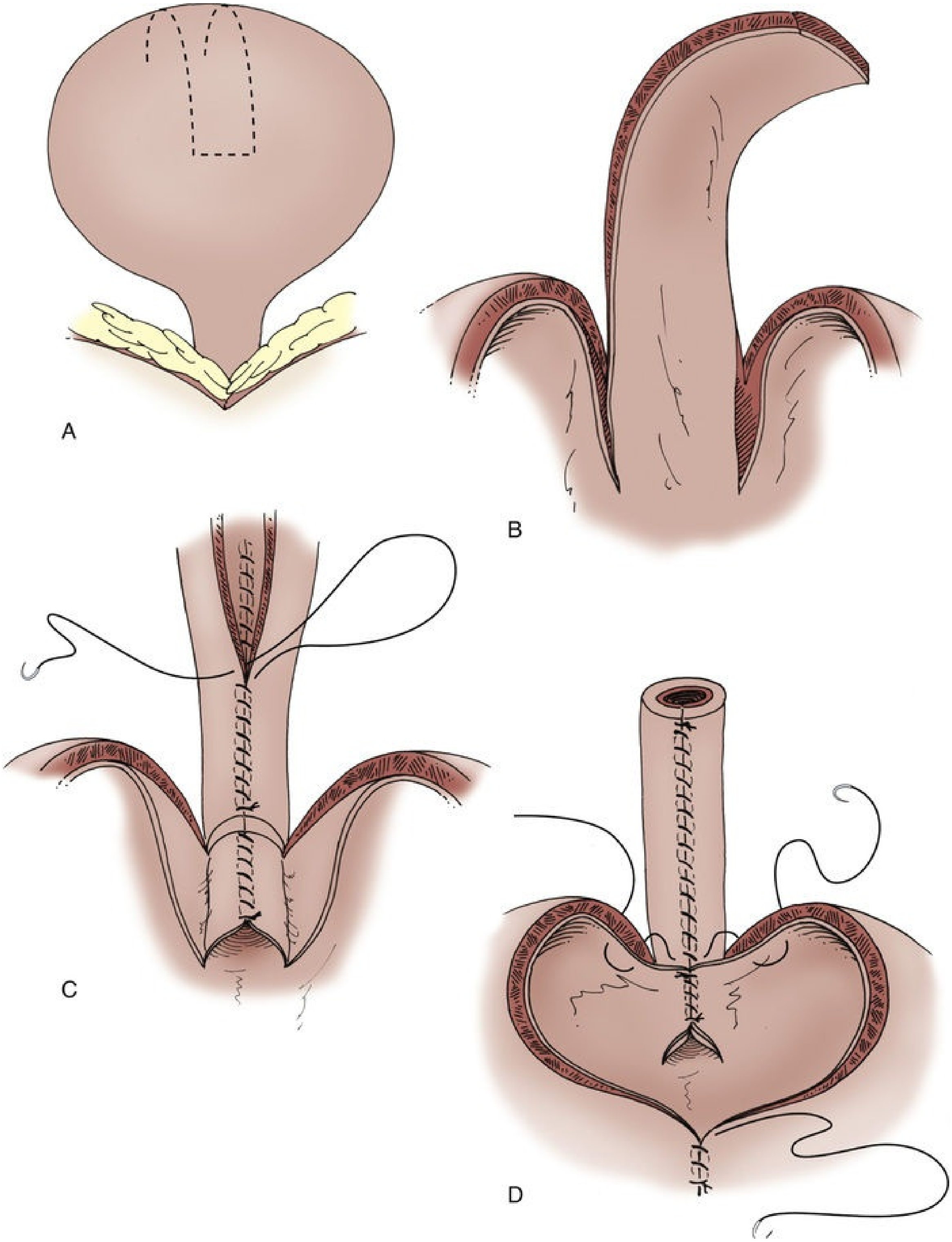

FIG. 37.19 Casale continent catheterizable stoma. (A) Parallel incisions are made in the bladder dome, forming a full-thickness bladder strip. (B) The epithelium of the bladder is then incised for an additional 2.5 cm. The edges of the epithelium are mobilized, allowing tubularization. (C) The

epithelium is tubularized from the bladder out to the tip of the strip with an absorbable suture. The muscle of the bladder strip is then tubularized with an absorbable suture. (D) The lateral edges of the epithelium within the bladder are reapproximated over the tubularized bladder segment with absorbable suture. The bladder is then closed with absorbable suture, incorporating the bladder tube with the initial sutures to prevent kinking.

Results.

Continence rates have been good, as with most flap valves (Cain et al., 1999, 2002). Stomal stenosis remains a significant problem for 45% in the experience at Indiana University (Cain et al., 2002). Skin flaps and avoidance of tension to reach the skin may minimize this risk but do not eliminate it. Advantages include avoidance of an intraperitoneal procedure and bowel anastomosis; the appendix can be reserved for use with enemas. It does use some bladder and decrease capacity, which may not be appropriate for many patients.

Results With Pediatric Continent Diversion

The most challenging aspect of continent diversion in children remains construction of an efferent limb that provides reliable continence and easy catheterization (Ardelt et al., 2012). The continence mechanism most familiar to pediatric urologists is the flap valve. The appendix is simple to use, suitable for most children, and associated with very good continence rates. If the appendix is not present or is to be used for antegrade colonic enemas, tapered intestinal segments provide a nice alternative. Nipple valves are the most complex continence mechanism and therefore have a longer learning curve. Continence rates approaching 85% can be expected with stapled nipple valves (Benson and Olsson, 1998; Kaefer et al., 1997b) after extensive experience. With use of the other efferent limbs, continence rates above 90% and approaching 95% have been reported in children (Ardelt et al, 2012; Duckett and Snyder, 1986; Hensle and Ring, 1991; Kaefer et al., 1997b; Surer et al., 2003).

Children undergoing continent diversion have a long life expectancy. With proper patient selection and appropriately performed continent diversion, postoperative hydronephrosis in children is rare and is not increased when compared with conduit diversion (Stein et al., 2000). In cases of catheterization not being performed reliably, however, new hydronephrosis was reported (Abd-El-Gawad et al., 1999). The incidence of complications after continent diversion will undoubtedly increase with longer follow-up. These patients will be subject to the same complications seen with bladder augmentation. All of those complications, including infection, hydronephrosis, calculi, spontaneous perforation, and tumor, have been reported after continent diversion in adults if not in children. These are largely a function of the use of intestine as a urinary reservoir. Because more intestine is usually required in continent diversion than bladder augmentation, the incidence of complications may ultimately be higher than with simple augmentation. Already, serum changes of increased chloride, decreased bicarbonate, and acidosis have been noted in some patients after continent diversion (Allen et al., 1985; Ashken, 1987; Boyd et al., 1989; McDougal, 1992a; Thuroff et al., 1987). Spontaneous perforation has occurred in up to 1.5% of patients (Mansson et al., 1997).

The most common complication in pediatric continent diversion thus far has been stomal stenosis. Stenosis occurs more commonly at the umbilicus with use of appendix compared with tapered ileal segments (Fichtner et al., 1997; Kaefer et al., 1999b). Various skin flaps may be placed into the terminal end of the appendix or intestinal segment to lower the rate of stenosis, but they do not eliminate stenosis (Kajbafzadeh et al., 1995; Landau et al., 2008). Ardelt et al., after extensive review (2012), found no consensus that a single type of efferent limb is superior and suggested that the choice of technique should be individualized according to the case.

Key Points: Continent Urinary Diversion

- "Pure" continent diversions have been used in children with good results similar to those expected in adults.
- Flap valves provide a reliable continence mechanism with appendix or reconfigured intestinal segments.
- The efferent limb should always be kept as short and straight as possible to facilitate catheterization.

Stomal stenosis is the most common complication of pediatric continent diversion.

Other Considerations

Use of Buttons as Alternative Means to Empty Bladder

The Mic-Key button (Ballard Medical Products, Avanos Medical, Alpharetta, GA) and Mini balloon button (Applied Medical Technology, Brecksville, OH) can be used as an alternative means to empty the bladder in patients with neurogenic bladders. The ideal patient is one who is not a candidate for augmentation and/or CIC. A variety of sizes are available. This technique only allows for bladder drainage, either intermittent or continuous, depending on whether the drainage adaptor is in place (Lopes and Lorenzo, 2016).

Technique.

Although these buttons can be placed percutaneously under cystoscopic guidance as a primary approach, we have found it helpful to initially place a suprapubic tube to allow for an established tract. The button can then be placed with or without a guidewire in the outpatient setting. The appropriate size can be chosen with the included sizing tool, and one can change the length of the button over time depending on the patient's body habitus.

Transitional Care Considerations

As children with spina bifida and other similar conditions age, the need for adult care of pediatric urologic problems has grown in concert. This patient care need has led to the emergence of a new field of urologist, the transitional urologist, the detail of which will be covered in greater degree elsewhere in this book. However, when considering transitional care associated with patients who have undergone lower urinary tract reconstruction, certain factors must be considered. Such factors include the mortality that can arise from medical noncompliance. Several important studies from Husmann highlight the role of the transitional urologist in patients who have been reconstructed. One study from Husmann (2017) draws attention to the various causes of morbidity and mortality in a contemporary population of patients after lower urinary tract reconstruction. In this report of 385 patients with a history of bladder augmentation, significant long-term complications include spontaneous bladder rupture in 3% of patients with rupture leading to death in 1 patient. Factors that contributed to bladder rupture include substance abuse, mental/physical deficits, and noncompliance with catheterization. In another report by Husmann from 2016, the author further highlights the scrutiny needed in transition patients who have been augmented. Reporting on the same population of patients as the 2017 article, the study finds that 240 mL of saline bladder irrigation daily was highly effective in reducing bladder calculi in the post-augmented patient. Furthermore, the article draws attention to a population of 80 patients undergoing bladder augmentation and concomitant bladder neck procedures. At 14 years of follow-up, 40% of these patients developed new renal scars, and 32% of those patients went on to develop stage 3 chronic renal disease or higher. Yet again, compliance with catheterization was a driving factor in the development of upper tract deterioration, further underscoring the need for routine follow-up of patients in late adolescence and adulthood. Another concern in the augmented patient is the development of bladder cancer and the possible effect that augmentation has on this risk. Several studies show that the overall risk for bladder cancer in spina bifida patients is approximately 2% to 4% (Husmann, 2017; Rove et al., 2017). A recent systematic review examined 28 studies, most of which were case reports, totaling 52 spina bifida patients with a bladder cancer diagnosis. Notably, 71% of these patients had aggressive disease with stage III or stage IV cancer at the time they were diagnosed. Yet, the presence of a bladder augmentation with segments other than stomach did not appear to increase the risk for developing bladder cancer. The authors encourage physicians to counsel their patients on the risk of developing cancer given the aggressive disease at the time of presentation (Rove et al., 2017). In conclusion, it is clear that pediatric patients undergoing bladder augmentation remain at lifelong risk for complications and that a well-trained adult urology provider must play a role in their care. Providers caring for adult patients must keenly assess for compliance with catheterization, maintenance of a daily bladder irrigation program, and signs of upper tract deterioration, particularly in those who have had augmentation with bladder outlet procedures.

Summary

Every effort should be made to treat pediatric bladder dysfunction, no matter what the cause, early and aggressively to minimize the number of patients requiring reconstructive surgery for bladder and sphincter dysfunction. Some such surgery will still be necessary, and the patients must be carefully evaluated so that all problems are identified and addressed. The surgeon should then be flexible and prepared to use the bowel segments and techniques that best fit each patient. **Although a given surgeon's results using any technique may improve with experience and confidence, each patient's unique problems and anatomy may make some choices better than others. Forcing one procedure to fit every patient should be avoided.**

Preoperative evaluation should identify upper tract obstruction or vesicoureteral reflux. Such problems should be corrected at the time of surgery, although low-grade secondary reflux usually resolves spontaneously with correction of bladder dysfunction. It is imperative to provide the patient with an adequate bladder or reservoir, one capable of holding at low pressure a urinary volume that will be produced between voidings or catheterizations. This can be accomplished by either augmentation or construction of a continent reservoir using any gastrointestinal segment. Each has its own set of advantages and disadvantages that should be considered. If adequate outflow resistance is lacking, it should be created at the bladder neck to prevent incontinence. Any patient undergoing reconstructive surgery for bladder or sphincter dysfunction must be prepared and capable of performing intermittent catheterization on a reliable basis; most will require it routinely. This is particularly true of those patients with neurogenic dysfunction.

As much of the patient's native urinary tract as possible should be preserved in pediatric urologic reconstruction. The urothelial lining avoids much of the morbidity associated with intestinal segments. If necessary, however, virtually any portion of the lower urinary tract may be reconstructed or replaced using intestine. Unfortunately, occasional complications do occur when intestinal segments are used in that manner. They are not perfect physiologic substitutes. Patients after reconstruction require a lifetime of follow-up, and that observation should include careful evaluation of their true quality of life. The most important factor in avoiding problems with such complex pediatric patients is the motivation of the patient and family to achieve a successful outcome.

Assessment of that commitment is critical.

See Videos 37.1▶, 37.2▶, and 37.3▶ for procedures related to this chapter.

Suggested Readings

Ardelt PU, Woodhouse CR, Riedmiller H, et al. The efferent segment in continent urinary diversion: a comprehensive review of the literature. *BJU Int*. 2012;109(2):288–297.

Cain MP, Casale AJ, King SJ, et al. Appendicovesicostomy and newer alternatives for the Mitrofanoff procedure: results in the last 100 patients at Riley Children's Hospital. *J Urol*. 1999;162:1749–1752.

Filmer RB, Spencer JR. Malignancies in bladder augmentations and intestinal conduits. *J Urol*. 1990;143:671.

Hendren WH. Urinary tract refunctionalization after long-term diversion: a 20 year experience with 177 patients. *Ann Surg*. 1990;212:478–495.

Herndon CD, Rink RC, Shaw MB, et al. The Indiana experience with artificial urinary sphincters in children and young adults. *J Urol*. 2003;169:650–654.

Husmann DA, Snodgrass WT, Koyle MA, et al. Ureterocystoplasty: indications for a successful augmentation. *J Urol*. 2004;171:376–380.

Koch MO, McDougal WS. The pathophysiology of hyperchloremic metabolic acidosis after urinary diversion through intestinal segments. *Surgery*. 1985;98:561–570.

Kropp KA, Angwafo FF. Urethral lengthening and reimplantation for neurogenic incontinence in children. *J Urol*. 1986;135:533.

Kryger JV, Gonzalez R, Spencer Barthold J. Surgical management of urinary incontinence in children with neurogenic sphincteric incompetence. *J Urol*. 2000;163:256–263.

Lapides J, Diokno AC, Gould FR, et al. Further observations on self-catheterization. *J Urol*. 1976;116:169–171.

Liard A, Seguier-Lipszyc E, Mathiot A, et al. The Mitrofanoff procedure: 20 years later. *J Urol*. 2001;165:2394–2398.

McGuire EJ, Woodside JR, Borden TA, et al. Prognostic value of urodynamic testing in myelodysplastic patients. *J Urol*. 1981;126:205–209.

Rink RC, Hollensbe D, Adams MC. Complications of augmentation in children and comparison of gastrointestinal segments. *AUA Update Series*. 1995;14:122–128.

References

Abd-El-Gawad G, Abrahamsson K, Hanson E, et al. Early and late metabolic alterations in children and adolescents with a Kock urinary reservoir. *BJU Int*. 1999;83:285–289.

Abes M, Sarihan H, Madenci E. Evaluation of bone mineral density with dual x-ray absorptiometry for osteoporosis in children with bladder augmentation. *J Pediatr Surg*. 2003;38:230–232.

Abol-Enein H, Ghoneim MA. Serous lined extramural ileal valve: a new continent urinary outlet. *J Urol*. 1999;161:786–791.

Aboushwareb T, Atala A. Stem cells in urology. *Nat Clin Pract Urol*. 2008;5(11):621–631.

Adams MC, Bihrle R, Foster RS, et al. Conversion of an ileal conduit to a continent, catheterizable stoma. *J Urol*. 1992;147:126.

Adams MC, Bihrle R, Rink RC. The use of stomach in urologic reconstruction. *AUA Update Series*. 1995;27:218–223.

Adams MC, Brock JW 3rd, Pope JC 4th, et al. Ureterocystoplasty: is it necessary to detubularize the distal ureter? *J Urol*. 1998;160:851–853.

Adams MC, Mitchell ME, Rink PC. Gastrocystoplasty: an alternative solution to the problem of urological reconstruction in the severely compromised patient. *J Urol*. 1988;140:1152–1156.

Aitken KJ, Bägli DJ. The bladder extracellular matrix II: regenerative applications. *Nat Rev Urol*. 2009;6:612–621.

Akerlund S, Lelin K, Kock NG, et al. Renal function and upper tract configuration following urinary diversion to a continent ileal reservoir (Kock pouch): a prospective 5 to 11 year follow up after reservoir construction. *J Urol*. 1989;142:964.

Albouy B, Grise P, Sambuis C, et al. Pediatric urinary incontinence: evaluation of bladder wall wraparound sling procedure. *J Urol*. 2007;177:716–719.

Alfrey EJ, Salvatierra O Jr, Tanney DC, et al. Bladder augmentation can be problematic with renal failure and transplantation. *Pediatr Nephrol*. 1997;11:672–675.

Allen T, Peters PC, Sagalowsky A. The Camey procedure: preliminary results in 11 patients. *World J Urol*. 1985;3:167.

Alova IA, Margaryan MB, Bernuy MC, et al. Long-term effects of endoscopic injection of dextranomer/hyaluronic acid based implants for treatment of urinary incontinence in children with neurogenic bladder. *J Urol*. 2012;188(5):1905–1909.

Alova IA, Margaryan MB, Verkarre V, et al. Outcome of continence procedures after failed endoscopic treatment with dextranomer-based implants (DEFLUX). *J Ped Urol*. 2012;8:40–46.

Altaweel W, Jednack R, Bilodeau C, et al. Repeated intradetrusor botulinum toxin type A in children with neurogenic bladder due to myelomeningocele. *J Urol*. 2006;175(3):1102–1105.

Anderson PA, Rickwood AM. Detrusor hyperreflexia as a factor in spontaneous perforation of augmentation cystoplasty for neuropathic bladder. *Br J Urol*. 1991;67:210–212.

Appanna TC, Doak SH, Jenkins SA, et al. Comparative genomic hybridization (CGH) of augmentation cystoplasties. *Int J Urol*. 2007;14(6):539–544.

Ardelt PU, Woodhouse CRJ, Reidmiller H, et al. The efferent segment in continent cutaneous urinary diversion: a comprehensive review of the literature. *BJU Int*. 2012;109(2):288–297.

Ashcraft KW, Dennis PA. The reimplanted ureter as a catheterizing stoma. *J Pediatr Surg*. 1986;21:1042.

Ashken MH. Urinary cecal reservoir. King LR, Stone AR, Webster GD. *Bladder reconstruction and continent urinary diversion*. Year Book: Chicago; 1987:238–251.

Asif S, Uehling DT. Successful pregnancy following ureteroileostomy. *Am J Obstet Gynecol*. 1969;105:641.

Aslan AR, Kogan BA. Conservative management in neurogenic bladder dysfunction. *Curr Opin Urol*. 2002;12:473–477.

Atala A, Bauer SB, Hendren WH, et al. The effect of gastric augmentation on bladder function. *J Urol*. 1993;149:1099.

Atala A, Bauer SB, Soker S, et al. Tissue-engineered autologous bladders for patients needing cystoplasty. *Lancet*. 2006;367:1241–1246.

Atala A, Lailas NG, Cilento BG, et al. *Progressive ureteral dilation for subsequent ureterocystoplasty*. [Presented at: Section on Urology meeting, American Academy of Pediatrics. Dallas, TX] 1994.

Atala A, Vacanti JP, Peters CA, et al. Formation of urothelial structures in vivo from disassociated cells attached to biodegradable polymer scaffolds. *J Urol*. 1992;148:658.

Austin PF, DeLeary G, Homsy YL, et al. Long-term metabolic advantages of a gastrointestinal composite urinary reservoir. *J Urol*. 1997;158:1704–1707.

Austin PF, Lockhart JL, Bissada NK, et al. Multi-institutional experience with the gastrointestinal composite reservoir. *J Urol*. 2001;165:2018–2021.

Austin PF, Rink RC, Lockhart JL. The gastrointestinal composite urinary reservoir in patients with myelomeningocele and exstrophy: long-term metabolic follow-up. *J Urol*. 1999;162:1126–1128.

Badawy H, Eid A, Dawood W, et al. Safety and feasibility of laparoscopic appendicovesicostomy in children. *J Ped Urol*. 2013;9:427–431.

Badiola F, Gosalbez R, Ruiz E, et al. The posterior approach for bladder neck dissection. *Br J Urol*. 2000;85:59.

Bagrodia A, Gargollo P. Robot-assisted bladder neck reconstruction, bladder neck sling, and appendicovesicostomy in children: description of technique and initial results. *J Endourol*. 2011;25(8):1299–1305.

Bar-Yosef Y, Castellan M, Joshi D, et al. Total continence reconstruction using the artificial urinary sphincter and the Malone antegrade continence enema. *J Urol*. 2011;185:1444–1448.

Baradaran N, Stec AA, Gupta A, et al. Using a serosal trough for fashioning a continent catheterizable stoma: technique and outcomes. *BJU Int*. 2013;111(5):828–833.

Baradaran N, Stec AA, Wang M, et al. Urinary diversion in early childhood: indications and outcomes in the exstrophy patients. *Urol*. 2012;80:191–195.

Barrett DM, Parulkar BG, Kramer SA. Experience with AS800 artificial sphincter in pediatric and young adult patients. *Urology*. 1993;42:431.

Barrington JW, Fulford S, Griffiths D, et al. Tumors in bladder remnant after augmentation enterocystoplasty. *J Urol*. 1997;157:482–486.

Barthold JS, Rodriquez E, Freedman AL, et al. Results of the rectus fascial sling and wrap procedures for the treatment of neurogenic sphincteric incontinence. *J Urol*. 1999;161:272.

Bauer SB. The management of the myelodysplastic child: a paradigm shift. *BJU Int*. 2003;92(Suppl 1):23–28.

Bauer SB. Long-term efficacy of artificial urinary sphincters in children. *J Urol*. 2008;180:441.

Bauer SB, Hallett M, Khoshbin S, et al. Predictive value of urodynamic evaluation in newborns with myelodysplasia. *J Am Med Assoc*. 1984;252:650.

Bauer SB, Hendren WH, Kozakewich H, et al. Perforation of the augmented bladder. *J Urol*. 1992;148:699.

Bauer SB, Peters CA, Colodny AH, et al. The use of rectus fascia to manage urinary incontinence. *J Urol*. 1989;142:516.

Bauer SB, Reda EF, Colodny AH, et al. Detrusor instability: a delayed complication in association with the artificial sphincter. *J Urol*. 1986;135:1212.

Bauer SB. Pediatric neurology. Krane RJ, Sioky MB. *Clinical neurourology*. Little Brown: Boston; 1979:275–294.

Beisang AA, Ersek RA. Mammalian response to subdermal implantation of textured microimplants. *Aesthet Plast Surg*. 1992;16:83.

Bellinger MF. Ureterocystoplasty: a unique method for vesical augmentation in children. *J Urol*. 1993;149:811–813.

Belman AB, Kaplan GW. Experience with the Kropp anti-continence procedure. *J Urol*. 1989;141:1160.

Benchekroun A. Continent cecal bladder. *Br J Urol*. 1982;54:505–506.

Benchekroun A, Essakalli N, Faik M, et al. Continent urostomy with hydraulic valve in 136 patients: 13 years of experience. *J Urol*. 1989;142:46.

Benson MC, Olsson CA. Continent urinary diversion. Walsh PC, Retik AB, Vaughn ED Jr, et al. *Campbell's urology*. ed 7. Saunders: Philadelphia; 1998:3190–3245.

Bent AE, Tutrone RF, Lloyd K, et al. Treatment of intrinsic sphincter deficiency using autologous ear cartilage as a periurethral bulking agent. *J Urol*. 2000;163:75.

Berglund B, Kock NG, Norlen L, et al. Volume capacity and pressure characteristics of the continent ileal reservoir used for urinary diversion. *J Urol*. 1987;137:29.

Bergman J, Lerman SE, Kristo B, et al. Outcomes of bladder neck closure for intractable urinary incontinence in patients with neurogenic bladders. *J Pediatr Urol*. 2006;2:528–533.

Berrettini A, Rigamonti W, Castagnetti M. Modified VQZ-plasty for the creation of a catheterizable stoma suitable as a neoumbilicus in selected bladder exstrophy patients. *Urology*.

2008;72:1073–1076.

Bihrle R. The Indiana pouch continent urinary reservoir. *Urol Clin North Am*. 1997;24:773.

Blaivas JG, Labib KB, Bauer SB. A new approach to electromyography of the external urethral sphincter. *J Urol*. 1977;117:773.

Blyth B, Ewalt DH, Duckett JW, et al. Lithogenic properties of enterocystoplasty. *J Urol*. 1992;148:575.

Bogaert GA, Mevorach RA, Kim J, et al. The physiology of gastrocystoplasty: once a stomach, always a stomach. *J Urol*. 1995;153:1977.

Bomalaski MD, Bloom DA, McGuire EJ, et al. Glutaraldehyde cross-lined collagen in the treatment of urinary incontinence in children. *J Urol*. 1996;155:699.

Boyd SD, Schiff WM, Skinner DG, et al. Prospective study of metabolic abnormalities in patients with continent Kock pouch urinary diversion. *Urology*. 1989;33:85–88.

Boylu U, Horasanli K, Tanriverdi O, et al. Evaluation of bone mineral density after ileocystoplasty in children without myelomeningocele. *Pediatr Surg Int*. 2006;22(4):375–379.

Braverman RM, Lebowitz RL. Perforation of the augmented urinary bladder in nine children and adolescents: importance of cystography. *Am J Roentgenol*. 1991;157:1059.

Brkovic D, Seibel M, Juchem R, et al. Effect of augmentation cystoplasty on bone metabolism in chronic uremic rats. *J Urol*. 2004;171:921–925.

Bruce RG, McRoberts JW. Cecoappendicovesicostomy: conduit-lengthening technique for use in continent urinary reconstruction. *Urology*. 1998;52:702–704.

Bugg CE, Joseph DB. Bladder neck cinch for pediatric neurogenic outlet deficiency. *J Urol*. 2003;170:1501–1504.

Burbige KA, Reitelman C, Olsson CA. Complications of artificial urinary sphincter around intestinal segments in reconstructed exstrophy patients. *J Urol*. 1987;138:1123.

Bushinsky DA. Net calcium efflux from live bone during chronic metabolic but not respiratory acidosis. *Am J Physiol*. 1989;256:F836.

Buson H, Castro-Diaz D, Manivel JC, et al. The development of tumors in experimental gastroenterocystoplasty. *J Urol*. 1993;150:730.

Buson H, Manivel JC, Dayanc M, et al. Seromuscular colocystoplasty lined with urothelium: experimental study. *Urology*. 1994;44:743–748.

Cadeddu JA, Docimo SG. Laparoscopic-assisted continent stoma procedures: our new standard. *Urology*. 1999;54:909–912.

Cain MP, Casale AJ, King SJ, et al. Appendicovesicostomy and newer alternatives for the Mitrofanoff procedure: results in the last 100 patients at Riley Children's Hospital. *J Urol*. 1999;162:1749–1752.

Cain MP, Husmann DA. *Cecal bladder augmentation with a tapered catheterizable stoma: a modification of the Indiana pouch*. Presented at Urology Section meeting, American Academy of Pediatrics: Dallas; 1994.

Cain MP, Rink RC. Augmentation for neuropathic bladder—a thing of the past? *J Urol*. 2010;183(6):2124–2125.

Cain MP, Rink RC, Yerkes EB, et al. Long-term followup and outcome of continent catheterizable vesicostomy using the Rink modification. *J Urol*. 2002;168:2583–2585.

Camey M, Richard F, Botto H. Ileal replacement of bladder. King LS, Stone AR, Webster GD. *Bladder reconstruction and continent urinary diversion*. Mosby–Year Book: St. Louis; 1991:389.

Canales B, Fung L, Elliott S. Miniature intravesical urethral lengthening procedure for treatment of pediatric neurogenic urinary incontinence. *J Urol*. 2006;176:2663–2667.

Canning DA, Perman JA, Jeffs RD, et al. Nutritional consequences of bowel segments in the lower urinary tract. *J Urol*. 1989;142:509.

Canning DC. Continent urinary diversion. King LR. *Urologic surgery in infants and children*. Saunders: Philadelphia; 1998:139–161.

Capozza N, Caione P, De Gennaro M, et al. Endoscopic treatment of vesico-ureteric reflux and urinary incontinence: technical problems in the paediatric patient. *Br J Urol*. 1995;75:538.

Carr LK, Herschorn S. Early development of adenocarcinoma in a young woman following augmentation cystoplasty for undiversion. *J Urol*. 1997;157:2255–2256.

Carr MC, Docimo SG, Mitchell ME. Bladder augmentation with urothelial preservation. *J Urol*. 1999;162:1133–1137.

Cartwright PC, Snow BW. Bladder autoaugmentation: early clinical experience. *J Urol*. 1989;142:505.

Cartwright PC, Snow BW. Bladder augmentation: partial detrusor excision to augment the bladder without use of bowel. *J Urol*. 1989;142:1050.

Casale AJ, Such RS, DeMarco RT, et al. *The microbiology of bladder augmentation in children*. [Presented at Section on Urology meeting, American Academy of Pediatrics, Washington, DC] 1999.

Casale AJ. A long continent ileovesicostomy using a single piece of bowel. *J Urol*. 1999;162:1743–1745.

Casale AJ. *Continent vesicostomy: a new method utilizing only bladder tissue [abstract 72]*. [Presented at 60th annual meeting of the American Academy of Pediatrics, New Orleans] 1991.

Casey JT, Hagerty JA, Maizels MA, et al. Early administration of oxybutynin improves bladder function and clinical outcomes with posterior urethral valves. *J Urol*. 2012;188(4

Suppl):1516–1520.

Castellan M, Gosalbez R, Bar-Yosef Y, et al. Complications after use of gastric segments for lower urinary tract reconstruction. *J Urol*. 2012;187(5):1823–1827.

Castellan M, Gosalbez R, Labbie A, et al. Clinical applications of the Monti procedure as a continent catheterizable stoma. *Urology*. 1999;54:152–156.

Castellan M, Gosalbez R, Labbie A, et al. Bladder neck sling for treatment of neurogenic incontinence in children with augmentation cystoplasty: long-term followup. *J Urol*. 2005;173:2128–2131 [discussion 2131].

Castellan M, Gosalbez R, Perez-Brayfield M, et al. Tumor in bladder reservoir after gastrocystoplasty. *J Urol*. 2007;178(4):1771–1774.

Castera R, Podesta ML, Ruarte A, et al. 10-year experience with artificial urinary sphincter in children and adolescents. *J Urol*. 2001;165:2372–2376.

Castro-Diaz D, Froemming C, Manivel JC, et al. The influence of urinary diversion on experimental gastrocystoplasty. *J Urol*. 1992;148:571–574.

Catti M, Lortat-Jacob S, Morineau M, et al. Artificial urinary sphincter in children—voiding or emptying? An evaluation of functional results in 44 patients. *J Urol*. 2008;180(2):690–693.

Celayir S, Goksel S, Buyukunal SN. The relationship between *Helicobacter pylori* infection and acid-hematuria syndrome in pediatric patients with gastric augmentation-II. *J Pediatr Surg*. 1999;34:532–535.

Charghi A, Charbonneau J, Gauthier G. Colocystoplasty for bladder enlargement and bladder substitution: a study of late results in 31 cases. *J Urol*. 1967;97:849.

Chen BS, Xie H, Zhang SL, et al. Tissue engineering of bladder using vascular endothelial growth factor gene-modified endothelial progenitor cells. *Int J Art Org*. 2011;34(12):1137–1146.

Ching CB, Stephany HA, Juliano TM, et al. Outcomes of incontinent ileovesicostomy in the pediatric patient. *J Urol*. 2014;191:445–450.

Chrzan R, Dik P, Klijn AJ, et al. Vesicoscopic bladder neck procedure in children: what we have learned from the first series. *J Laparoendosc Adv Surg Tech A*. 2013;23(9):803–807.

Churchill BM, Aliabadi H, Landau EH, et al. Ureteral bladder augmentation. *J Urol*. 1993;150:716–720.

Churchill BM, Gilmour RF, Khoury AE, et al. Biological response of bladders rendered continent by insertion of artificial sphincter. *J Urol*. 1987;138:1116.

Coffey RC. Physiologic implantation of the severed ureter or common bile duct into the intestine. *J Am Med Assoc*. 1911;56:387.

Cohen RA, Rushton HG, Belman AB, et al. Renal scarring and vesicoureteral reflux in children with myelodysplasia. *J Urol*. 1990;144:541.

Cole EE, Adams MC, Brock JW 3rd, et al. Outcome of continence procedures in the pediatric patient: a single institutional experience. *J Urol*. 2003;170:560–563.

Colvert JR 3rd, Kropp BP, Cheng EY, et al. The use of small intestinal submucosa as an off-the-shelf urethral sling material for pediatric urinary incontinence. *J Urol*. 2002;168:1872–1875.

Couvelaire R. La “petite vessie” des tuberculeaux genitourinaires: essai de classification place et variantes des cysto-intestinoplasties. *J Urol*. 1950;56:381.

Crane JM, Scherz HS, Billman GF, et al. Ischemic necrosis: a hypothesis to explain the pathogenesis of spontaneously ruptured enterocystoplasty. *J Urol*. 1991;146:141–144.

Creagh TA, McInerney PD, Thomas PJ, et al. Pregnancy after lower urinary tract reconstruction in women. *J Urol*. 1995;154:1323–1324.

Cromie WJ, Barada JH, Weingarten JL. Cecal tubularization: lengthening technique for creation of catheterizable conduit. *Urology*. 1991;37:41.

DaJusta D, Gargollo P, Snodgrass W. Dextranomer/hyaluronic acid bladder neck injection for persistent outlet incompetency after sling procedures in children with neurogenic urinary incontinence. *J Ped Urol*. 2013;9:278–282.

Dave S, Pippi Salle JL, Lorenzo AJ, et al. Is long-term bladder deterioration inevitable following successful isolated bladder outlet procedures in children with neuropathic bladder dysfunction? *J Urol*. 2008;179(5):1991–1996.

Dave S, Salle JL. Current status of bladder neck reconstruction. *Curr Opin Urol*. 2008;18:419–424.

Dayanc M, Kilciler M, Tan O, et al. A new approach to bladder augmentation in children: seromuscular enterocystoplasty. *BJU Int*. 1999;84:103–107.

de Badiola F, Ruiz E, Denes E, et al. *New application of the gastrostomy button for clinical and urodynamic evaluation prior to vesicostomy closure*. [Presented at Section on Urology meeting, American Academy of Pediatrics, San Francisco] 1995.

de Badiola F, Ruiz E, Puigdevall J, et al. *Seromuscular sigmoidcystoplasty*. [Presented at: Section on Urology meeting, American Academy of Pediatrics, Washington, DC] 1999.

de O Vilar F, Araújo LA, Lima SV. Periurethral constrictor in pediatric urology: long-term followup. *J Urol*. 2004;171:2626–2628.

De Troyer B, Van Laecke E, Groen L, et al. A comparative study between continent diversion and bladder neck closure versus continent diversion and bladder neck reconstruction in children. *J Ped Urol*. 2011;7:209–212.

De Vocht T, Chrzan R, Dik P, et al. Long-term results of bulking agent injection for persistent incontinence in cases of neurogenic bladder dysfunction. *J Urol*. 2010;183:719–723.

Dean GE, Kirsch AJ, Packer MG, et al. Antegrade and retrograde endoscopic dextranomer/hyaluronic acid bladder neck bulking for pediatric incontinence. *J Urol*. 2007;178:652–655.

Decter RM, Harpster L. Pitfalls in determination of the leak point pressure. *J Urol*. 1992;148:588–591.

Decter RM. Use of the fascial sling for neurogenic incontinence: lessons learned. *J Urol*. 1993;150(Pt 2):683.

Dees JE. Congenital epispadias with incontinence. *J Urol*. 1949;62:513.

DeFoor W, Minevich E, Reeves D, et al. Gastrocystoplasty: long-term followup. *J Urol*. 2003;170:1647–1649.

DeFoor W, Tackett L, Minevich E, et al. Risk factors for spontaneous bladder perforation after augmentation cystoplasty. *Urology*. 2003;62:737–741.

deKernion JB, Den Besten L, Kaufman J, et al. The Kock pouch as a urinary reservoir: pitfalls and perspectives. *Am J Surg*. 1985;150:83.

Demos MP. Radioactive electrolyte absorption studies of small bowel comparison of different segments for use in urinary diversion. *J Urol*. 1962;88:638.

Denes ED, Vates TS, Freedman AL, et al. Seromuscular colocystoplasty lined with urothelium protects dogs from acidosis during ammonium chloride loading. *J Urol*. 1997;158:1075–1080.

Desai MM, Gill IS, Goel M, et al. Ureteral tissue balloon expansion for laparoscopic bladder augmentation: survival study. *J Endourol*. 2003;17:283–293.

Dewan PA, Blose CE, Byard RW, et al. Enteric mucosal regrowth after bladder augmentation using demucosalized gut segments. *J Urol*. 1997;158:1141–1146.

Dewan PA, Nicholls EA, Goh DW. Ureterocystoplasty: an extraperitoneal urothelial bladder augmentation technique. *Eur Urol*. 1994;26:85–89.

Dik P, Klijn AJ, van Gool JD, et al. Transvaginal sling suspension of the bladder neck in female patients with neurogenic sphincter incontinence. *J Urol*. 2003;170:580–582.

Dik P, Van Gool JD, de Jong TP. Urinary continence and erectile function after bladder neck sling suspension in male patients with spinal dysraphism. *BJU Int*. 1999;83:971–975.

Diokno AC, Sonda LP. Compatibility of genitourinary prostheses and intermittent self-catheterization. *J Urol*. 1981;125:659.

Docimo SG, Moore RG, Adams J, et al. Laparoscopic bladder

augmentation using stomach. *Urology*. 1995;46:565–569.
Donmez MI, Carrasco A Jr, Saltzman AF, et al. Long term outcomes of cutaneous vesicostomy in patients with neuropathic bladder caused by spina bifida. *J Pediatr Urol*. 2017;13:622.
Donnahoo KK, Rink RC, Cain MP, et al. The Young-Dees-Leadbetter bladder neck repair for neurogenic incontinence. *J Urol*. 1999;161:1946–1949.
Duckett JW, Lofti AH. Appendicovesicostomy (and variations) in bladder reconstruction. *J Urol*. 1993;149:567.
Duckett JW, Snyder HM III. Continent urinary diversion: variation on the Mitrofanoff principle. *J Urol*. 1986;135:58.
Duckett JW, Snyder HM III. The Mitrofanoff principle in continent urinary reservoirs. *Semin Urol*. 1987;5:55.
Dudley AG, Adams MC, Brock JW 3rd, et al. Interrater reliability in interpretation of neuropathic pediatric urodynamic tracings: an expanded multicenter study. *J Urol*. 2018;199:1337–1343.
Dudley AG, Casella DP, Lauderdale CJ, et al. Interrater reliability in pediatric urodynamic tracings: a pilot study. *J Urol*. 2017;197:865–870.
Duel BP, Hendren WH, Bauer SB, et al. Reconstructive options in genitourinary rhabdomyosarcoma. *J Urol*. 1996;156:1798.
Dyer L, Franco I, Firlit CF, et al. Endoscopic injection of bulking agents in children with incontinence: dextranomer/hyaluronic acid copolymer versus polytetrafluoroethylene. *J Urol*. 2007;178:1628–1631.
Ehrlich RM, Gershman A. Laparoscopic seromyotomy (autoaugmentation) for non-neurogenic neurogenic bladder in a child: initial case report. *Urology*. 1993;42:175–178.
El-Ghoneimi A, Muller C, Guys JM, et al. Functional outcome and specific complications of gastrocystoplasty for failed bladder exstrophy closure. *J Urol*. 1998;160(Pt 2):1186–

1189.

Elder JS, Snyder HM, Hulbert WC, et al. Perforation of the augmented bladder in patients undergoing clean intermittent catheterization. *J Urol*. 1988;140:1159–1162.

Elder JS. Periurethral and puboprostatic sling repair for incontinence in patients with myelodysplasia. *J Urol*. 1990;144:434.

Elshal A, Abol-Enein H, Sarhan O, et al. Catheterizable serous lined urinary outlet in children and adolescents: a choice when other treatments fail. *J Urol*. 2011;185:1083–1087.

Eraklis AJ, Folkman MJ. Adenocarcinoma at the site of ureterosigmoid-ostomies for exstrophy of the bladder. *J Pediatr Surg*. 1978;13:730.

Erickson BA, Dorin RP, Clemens JO. Is nasogastric tube drainage required after reconstructive surgery for neurogenic bladder dysfunction? *Urology*. 2007;69(5):885–888.

Errando C, Batista JE, Caparros J, et al. Is bladder cycling useful in the urodynamic evaluation previous to renal transplantation? *Urol Int*. 2005;74:341–345.

Essig KA, Sheldon CA, Brandt MT, et al. Elevated intravesical pressure causes arterial hypoperfusion in canine colocystoplasty: a fluorometric assessment. *J Urol*. 1991;146:551–553.

Famakinwa O, Rosen A, Gundeti M. Robot-assisted laparoscopic Mitrofanoff appendicovesicostomy technique and outcomes of extravesical and intravesical approaches. *Eur Urol*. 2013;64:831–836.

Farrugia MK, Lottmann HB, Neilson AB, et al. Outcome of the Lima periurethral constrictor in children and adolescents: a European prospective. *J Urol*. 2012;188(4 Suppl):1555–1560.

Feng AH, Kaar S, Elder JS. Influence of enterocystoplasty on linear growth in children with exstrophy. *J Urol*. 2002;167:2552–2555.

Ferrer FA, Tadros YE, Gearhart J. Modified Young-Dees-Leadbetter bladder neck reconstruction: new concepts about old ideas. *Urology*. 2001;58:791–796.

Ferris DO, Odel HM. Electrolyte pattern of the blood after bilateral ureterosigmoidostomy. *JAMA*. 1950;142:634–641.

Fichtner J, Fischer R, Hohenfellner R. Appendiceal continence mechanisms in continent urinary diversion. *World J Urol*. 1997;157:635–637.

Filmer RB, Spencer JR. Malignancies in bladder augmentations and intestinal conduits. *J Urol*. 1990;143:671.

Fisch M, Wammack R, Hohenfellner R. The Sigma rectum pouch (Mainz pouch II). *World J Urol*. 1996;14:68–72.

Fishman IJ, Flores FN, Scott FB, et al. Use of fresh placental membranes for bladder reconstruction. *J Urol*. 1987;138:1291–1294.

Fishman IJ, Scott FB. Pregnancy in patients with an artificial urinary sphincter. *J Urol*. 1993;150:340.

Fowler JE Jr. Continent urinary reservoirs. *Surg Annu*. 1988;20:201–225.

Frane-Guimond J, Gonzalez R. Simplified technique to create a concealed catheterizable stoma: the VR flap. *J Urol*. 2006;175:1088–1091.

Franke EI, Misseri R, Cain MP, et al. Nephrogenic adenoma in the augmented bladder. *J Urol*. 2011;186(4 Suppl):1586–1589.

Game X, Mouracade P, Chartier-Kastler E, et al. Botulinum toxin A intradetrusor injections in children with neurogenic detrusor overactivity: a systematic literature review. *J Ped Urol*. 2009;5(3):156–160.

Ganesan GS, Mitchell ME, Adams MC, et al. *Use of stomach for reconstruction of the lower urinary tract in patients with compromised renal function*. [Presented at Urology Section meeting, American Academy of Pediatrics, New Orleans]

1991.

Gearhart JP. Mucus secretions in augmented bladder. *Dialogues Pediatr Urol*. 1987;10:6.

Gearhart JP, Albertsen PC, Marchall FF, et al. Pediatric applications of augmentation cystoplasty: the Johns Hopkins experience. *J Urol*. 1986;136:430.

Gerharz EW, Kohl UN, Weingartner K, et al. Experience with the Mainz modification of ureterosigmoidostomy. *Br J Surg*. 1999;86:427.

Gerharz EW, Tassadaq T, Pickard RS, et al. Transverse retubularized ileum: early clinical experience with a new second line Mitrofanoff tube. *J Urol*. 1998;159:525–528.

Gilchrist RK, Merricks JW, Hamlin HH, et al. Construction of a substitute bladder and urethra. *Surg Gynecol Obstet*. 1950;90:752.

Gleeson MJ, Griffith DP. The use of alloplastic biomaterials in bladder substitution. *J Urol*. 1992;148:1377–1382.

Godbole P, Bryant R, Mackinnon AE, et al. Endourethral injection of bulking agents for urinary incontinence in children. *BJU Int*. 2003;91:536–539.

Godbole P, Mackinnon AE. Expanded PTFE bladder neck slings for incontinence in children: the long-term outcome. *BJU Int*. 2004;93:139–141.

Goldwasser B, Barrett DM, Webster GD, et al. Cystometric properties of ileum and right colon after bladder augmentation, substitution or replacement. *J Urol*. 1987;138:1007.

Goldwasser B, Webster GD. Augmentation and substitution enterocystoplasty. *J Urol*. 1986;135:215–224.

Gonzalez DO, Cooper JN, McLeod DJ. Effect of bladder augment on VP shunt failure rates in spina bifida. *J Pediatr Rehabil Med*. 2017;10:249–255.

Gonzalez R. Clinical and urodynamic evaluation after

ureterocystoplasty [discussion]. *J Urol*. 1999;162:1132.
Gonzalez R, Buson H, Reid C, et al. Seromuscular colocystoplasty lined with urothelium: experience with 16 patients. *Urology*. 1994;45:124–129.
Gonzalez R, Cabral BH. Rectal continence after enterocystoplasty. *Dialogues Pediatr Urol*. 1987;10:3–4.
Gonzalez R, Merino FG, Vaughn M. Long-term results of the artificial urinary sphincter in male patients with neurogenic bladder. *J Urol*. 1995;154:769.
Gonzalez R, Nguyen DH, Koleilat N, et al. Compatibility of enterocystoplasty and the artificial urinary sphincter. *J Urol*. 1989;142:502.
Gonzalez R, Reinberg Y. Localization of bacteriuria in patients with enterocystoplasty and nonrefluxing conduits. *J Urol*. 1987;138:1104–1105.
Goodwin WE, Harris AP, Kaufman JJ, et al. Open, transcolonic ureterointestinal anastomosis. *Surg Gynecol Obstet*. 1953;97:295–330.
Goodwin WE, Winter CC, Barker WF. “Cup-patch” technique of ileocystoplasty for bladder enlargement of partial substitution. *Surg Gynecol Obstet*. 1959;108:240–244.
Gormley EA, Bloom DA, McGuire EJ, et al. Pubovaginal slings for the management of urinary incontinence in female adolescents. *J Urol*. 1994;152:822.
Gosalbez R Jr, Gousse AE. Reconstruction and undiversion of the short or severely dilated ureter: the antireflux ileal nipple revisited. *J Urol*. 1998;159:530–534.
Gosalbez R Jr, Woodard JR, Broecker BH, et al. Metabolic complications of the use of stomach for urinary reconstruction. *J Urol*. 1993;150:710–712.
Gosalbez R Jr, Woodard JR, Broecker BH, et al. The use of stomach in pediatric urinary reconstruction. *J Urol*. 1993;150:438.

Gosalbez R, Wei D, Gousse A, et al. Refashioned short bowel segments for the construction of catheterizable channels (the Monti procedure): early clinical experience. *J Urol*. 1998;160:1099–1102.

Gowda BD, Agrawal V, Harrison SC. The continent, catheterizable abdominal conduit in adult urological practice. *BJU Int*. 2008;102:1688–1692.

Grady RW, Joyner BD, Roedel M, et al. *The complete primary repair of exstrophy (CPRE) technique for repair of bladder exstrophy and epispadias: long-term follow-up*. [Presented at: American Academy of Pediatrics, Urology Section Meeting. New Orleans] 2003.

Greenwell TJ, Venn SN, Greighton S, et al. Pregnancy after lower urinary tract reconstruction for congenital abnormalities. *BJU Int*. 2003;92:773.

Gregoire M, Kantoff P, DeWolf WC. Synchronous adenocarcinoma and transitional cell carcinoma of the bladder associated with augmentation: case report and review of the literature. *J Urol*. 1993;149:115.

Grimsby GM, Jacobs MA, Menon M, et al. Perioperative and short term outcomes of robotic versus open bladder neck procedures for neurogenic incontinence. *J Urol*. 2016;195:1088–1092.

Grimsby GM, Menon V, Schlomer BJ, et al. Long term outcomes of bladder neck reconstruction without augmentation cystoplasty in children. *J Urol*. 2015 [Epub ahead of print].

Gros DA, Dodson JL, Lopatin UA, et al. Decreased linear growth associated with intestinal bladder augmentation in children with bladder exstrophy. *J Urol*. 2000;164:917.

Groth T, Mitchell M, Balcom A. Polyps in continent catheterizable bladder channels. *J Ped Urol*. 2013;9:46–50.

Gundeti MS, Eng MK, Reynolds WS, et al. Pediatric robotic-assisted laparoscopic augmentation ileocystoplasty and Mitrofanoff appendicovesicostomy: complete intracorporeal-initial case report. *Urology*. 2008;72:1144–1147.

Gundeti MS, Godbole PP, Wilcox DT. Is bowel preparation required before cystoplasty in children? *J Urol*. 2006;176(4 Pt 1):1574–1576 [discussion 1576–1577].

Gundeti MS, Kojima Y, Haga N, et al. Robotic-assisted laparoscopic reconstructive surgery in the lower urinary tract. *Curr Urol Reports*. 2013;14:333–341.

Guttmann L, Frankel H. The value of intermittent self catheterization in the early management of traumatic paraplegia and tetraplegia. *Paraplegia*. 1966;4:63–84.

Guys JM, Breaud J, Hery G, et al. Endoscopic injection with polydimethylsiloxane for the treatment of pediatric urinary incontinence in the neurogenic bladder: long-term results. *J Urol*. 2006;175:1106–1110.

Guys JM, Fakhro A, Louis-Borrione C, et al. Endoscopic treatment of urinary incontinence: long-term evaluation of the results. *J Urol*. 2001;165:2389–2391.

Guys JM, Simeoni-Alias J, Fakhro A, et al. Use of polydimethylsiloxane for endoscopic treatment of neurogenic urinary incontinence in children. *J Urol*. 1999;162:2133–2135.

Guzman JM, Montes de Oca L, Gonzalez R, et al. Modified Benchekroun technique for continent ileal stoma. *J Urol*. 1989;142:1431.

Haas RE, Kecskemethy HH, Lopiccolo MA, et al. Lower extremity bone mineral density in children with congenital spinal dysfunction. *Dev Med Child Neurol*. 2012;54(12):1133–1137.

Hafez AT, McLorie G, Bägli D, et al. A single-centre long-term outcome analysis of artificial urinary sphincter placement in children. *BJU Int*. 2002;89:82–85.

Hafez AT, McLorie G, Gilday D, et al. Long-term evaluation of metabolic profile and bone mineral density after ileocystoplasty in children. *J Urol*. 2003;170:1639–1641.

Halachmi S, Farhat W, Metcalfe P, et al. Efficacy of polydimethylsiloxane injection to the bladder neck and leaking diverting stoma for urinary continence. *J Urol*. 2004;171:1287–1290.

Hall MC, Koch MO, McDougal WS. Metabolic consequences of urinary diversion through intestinal segments. *Urol Clin North Am*. 1991;18:725.

Hampel N, Hasan ST, Marshall C, et al. Continent urinary diversion using the Mitrofanoff principle. *Br J Urol*. 1995;74:454–459.

Hanna MK. Artificial urinary sphincter for incontinent children. *Urol*. 1981;18:370.

Hanna MK, Bloiso G. Continent diversion in children: modification of Kock pouch. *J Urol*. 1987;137:1206.

Hanna MK, Richter F, Stock JA. Salvage continent vesicostomy after enterocystoplasty in the absence of the appendix. *J Urol*. 1999;162:826–828.

Hansen EV, Hvistendahl GM, Rawashdeh YF, et al. Promising long-term outcome of bladder autoaugmentation in children with neurogenic bladder dysfunction. *J Urol*. 2013;190(5):1869–1875.

Harrington DA, Sharma AK, Erickson BA, et al. Bladder tissue engineering through nanotechnology. *World J Urol*. 2008;26:315–322.

Harris CF, Cooper CS, Hutcheson JC, et al. Appendicovesicostomy: the Mitrofanoff procedure—a 15-year perspective. *J Urol*. 2000;163:1922–1926.

Hasan MN, Schumacher MC, Wiklund PN, et al. Robotic-assisted reconstructive urology. *Curr Opin Urol*. 2011;21(6):483–487.

Hatch TR, Steinberg RW, Davis LE. Successful term delivery by cesarean section in a patient with a continent ileocecal urinary reservoir. *J Urol*. 1991;146:1111.

Hayashi Y, Okazaki T, Kobayashi H, et al. Shunt conversion before bladder augmentation can prevent shunt infection. *Asian J Surg*. 2008;31:207–210.

Hedican SP, Schulam PG, Docimo SG. Laparoscopic assisted reconstructive surgery. *J Urol*. 1999;161:267–270.

Hedlund H, Lindstrom K, Mansson W. Dynamics of a continent cecal reservoir for urinary diversion. *Br J Urol*. 1984;56:366–372.

Heidler H, Marberger M, Hohenfellner R. The metabolic situation in ureterosigmoidostomy. *Eur Urol*. 1979;5:39–44.

Helal M, Pow-Sang J, Sanford E, et al. Direct (nontunneled) ureterocolonic reimplantation in association with continent reservoirs. *J Urol*. 1993;150:835–837.

Hendren WH, Hendren RB. Bladder augmentation: experience with 129 cases in children and young adults. *J Urol*. 1990;144:445–453.

Hendren WH, Hensle TW. Transureteroureterostomy: experience with 75 cases. *J Urol*. 1980;123:826–833.

Hendren WH. Urinary undiversion: refunctionalization of the previously diverted urinary tract. Walsh PC, Retik AB, Vaughan ED Jr, et al. *Campbell's urology*. Saunders: Philadelphia; 1998:3247.

Hensle TW, Bingham J, Lam J, et al. Preventing reservoir calculi after augmentation cystoplasty and continent urinary diversion: the influence of an irrigation protocol. *BJU Int*. 2004;93:585–587.

Hensle TW, Ring KS. Urinary tract reconstruction in children. *Urol Clin North Am*. 1991;18:701–715.

Herndon CD, Rink RC, Shaw MB, et al. Experience with non-cycled artificial urinary sphincter. *BJU Int*. 2004;93:1049–

1052.

Higuchi TT, Fox JA, Husmann DA. Annual endoscopy and urine cytology for surveillance of bladder tumors after enterocystoplasty for congenital bladder anomalies. *J Urol*. 2011;186(5):1791–1795.

Higuchi TT, Granberg CF, Fox JA, et al. Augmentation cystoplasty and risk of neoplasm: fact, fiction and controversy. *J Urol*. 2010;184:2492–2496.

Hill DE, Chantigian PM, Kramer SA. Pregnancy after augmentation cystoplasty. *Surg Gynecol Obstet*. 1990;170:485.

Hinman F Jr. Selection of intestinal segments for bladder substitution: physical and physiological characteristics. *J Urol*. 1988;139:519.

Hirst G. Ileal and colonic cystoplasties. *Probl Urol*. 1991;5:223.

Hochstetler JA, Flanigan MJ, Kreder KJ. Impaired bone growth after ileal augmentation cystoplasty. *J Urol*. 1997;157:1873–1879.

Hodges CV, Moore RJ, Lehman TH, et al. Clinical experiences with transureteroureterostomy. *J Urol*. 1963;90:552–562.

Hohenfellner R, Riedmiller H, Thuroff JW. Commentary: the Mainz pouch. Whitehead ED. *Current operative urology*. JB Lippincott: Philadelphia; 1990:168.

Hollensbe DW, Adams MC, Rink RC, et al. *Comparison of different gastrointestinal segments for bladder augmentation*. [Presented at American Urological Association meeting, Washington, DC] 1992.

Hoover DL, Duckett JW. Posterior urethral valves, unilateral reflux and renal dysplasia: a syndrome. *J Urol*. 1982;128:994.

Horowitz M, Kuhr CS, Mitchell ME. The Mitrofanoff catheterizable channel: patient acceptance. *J Urol*. 1995;153:771.

Hsu TH, Shortliffe LD. Laparoscopic Mitrofanoff

appendicovesicostomy. *Urology*. 2004;64:802–804.
Husmann DA, Cain M. *Colocecal bladder augmentation with a tapered continent ileal limb: use in the neuropathic bladder*. [Presented at Section on Urology Meeting, American Academy of Pediatrics, Washington, DC] 1999.
Husmann DA, Snodgrass WT, Koyle MA, et al. Ureterocystoplasty: indications for a successful augmentation. *J Urol*. 2004;171:376–380.
Husmann DA, Spence HM. Current status of tumor of the bowel following ureterosigmoidostomy: a review. *J Urol*. 1990;144:607.
Husmann DA. Malignancy after gastrointestinal augmentation in childhood. *Ther Adv Urol*. 2009;1:5–11.
Husmann DA. Mortality following augmentation cystoplasty: a transitional urologist's viewpoint. *J Pediatr Urol*. 2017;13(4):358–364.
Husmann DA. Long-term complications following bladder augmentations in patients with spina bifida: bladder calculi, perforation of the augmented bladder and upper tract deterioration. *Transl Androl Urol*. 2016;5(1):3–11.
Ivancic V, DeFoor W, Jackson E, et al. Progression of renal insufficiency in children and adolescents with neuropathic bladder is not accelerated by lower urinary tract reconstruction. *J Urol*. 2010;184(4 Suppl):1768–1774.
Iwaszko MR, Krambeck AE, Chow GK, et al. Transureteroureterostomy revisited: long-term surgical outcomes. *J Urol*. 2010;183(3):1055–1059.
Jakobsen H, Steven K, Stigsby B, et al. Pathogenesis of nocturnal urinary incontinence after ileocecal bladder replacement: continuous measurement of urethral closure pressure during sleep. *Br J Urol*. 1987;59:148–152.
Jawaheer G, Rangecroft L. The Pippi Salle procedure for neurogenic urinary incontinence in childhood: a three-year

experience. *Eur J Pediatr Surg*. 1999;9:9–11.

Jayanthi VR, Churchill BM, McLorie GA, et al. Concomitant bladder neck closure and Mitrofanoff diversion for the management of intractable urinary incontinence. *J Urol*. 1995;154:886.

Johal NS, Hamid R, Aslam Z, et al. Ureterocystoplasty: long-term functional results. *J Urol*. 2008;179:2373–2375.

Johnson HW, Nigro MK, Stothers L, et al. Laboratory variables of autoaugmentation in an animal model. *Urology*. 1994;44:260–263.

Joseph DB. The effect of medium-fill and slow-fill saline cystometry on compliance and detrusor pressure in infants and children with myelodysplasia. *J Urol*. 1992;143:441–446.

Joseph DB. Neurogenic bladder dysfunction and myelodysplasia. Krane RJ, Siroky MB, Fitzpatrick JM. *Clinical urology*. JB Lippincott: Philadelphia; 1994.

Joseph DB, Adams MC, Bauer SB, et al. *Urologic review*. [Presented at Evidence-Based Practice in Spina Bifida: Developing a Research Agenda meeting, Washington, DC] 2003.

Joseph DB, Borer JG, De Filippo RE, et al. A phase 2 study—Tengion autologous neo-bladder augment (NBA) for augmentation cystoplasty in subjects with neurogenic bladder secondary to spina bifida. *J Urol*. 2009;181(4):555–556.

Joseph DB, Borer JG, DeFilippo RE, et al. Autologous cell-seeded biodegradable scaffold for augmentation cystoplasty: phase 2 study in children and adolescents with spina bifida. *J Urol*. 2014;191:1389–1395.

Joseph DB. The use of iothalamate meglumine 17.2% as an effective testing medium in lower urinary tract urodynamic assessment of children. *J Urol*. 1993;149:92.

Joseph DB. Urodynamics in the pediatric population: indication and techniques. Elder JS. *Pediatric urology for the general* *urologist*. Igaku-Shoin: New York; 1996.

Juhasz F, Somogyl R, Vajda P, et al. Does the type of bladder augmentation influence the resolution of pre-existing vesicoureteral reflux? Urodynamic studies. *Neurourol Urodyn*. 2008;27(5):412–416.

Jung HJ, Lee H, Im YJ, et al. Prerequisite for successful surgical outcome in urothelium lined seromuscular enterocystoplasty. *J Urol*. 2012;187(4):1416–1421.

Kaefer M, Hendren WH, Bauer SB, et al. Reservoir calculi: a comparison of reservoirs constructed from stomach and other enteric segments. *J Urol*. 1998;160:2187–2190.

Kaefer M, Keating MA, Adams MC, et al. Posterior urethral valves, pressure pop-offs and bladder function. *J Urol*. 1995;154:708–711.

Kaefer M, Pabby A, Kelly M, et al. Improved bladder function after prophylactic treatment of the high risk neurogenic bladder in newborns with myelomeningocele. *J Urol*. 1999;162:1068–1071.

Kaefer M, Retik AB. The Mitrofanoff principle in continent urinary reconstruction. *Urol Clin North Am*. 1997;24:795–811.

Kaefer M, Rink RC, Cain MP, et al. *Stomal stenosis: is ileum the ideal substrate for efferent limb construction?*. [Presented at American Academy of Pediatrics meeting, Washington, DC] 1999.

Kaefer M, Tobin MS, Hendren WH, et al. Continent urinary diversion: the Children's Hospital experience. *J Urol*. 1997;157:1394–1399.

Kajbafzadeh AM, Duffy PG, Carr MC, et al. *A review of 100 Mitrofanoff stomas and reports of the VQZ technique for prevention of complications at the stomal level*. [Presented at European Society of Pediatric Urology meeting, Toledo, Spain] 1995.

Kajbafzadeh AM, Farrokhi Y, Ostovaneh M, et al. Teapot ureterocystoplasty and ureteral Mitrofanoff channel for bilateral megaureters: technical points and surgical results of neurogenic bladder. *J Urol*. 2010;183(3):1168–1174.

Kakizaki H, Shibata T, Shinno Y, et al. Fascial sling for the management of urinary incontinence due to sphincter incompetence. *J Urol*. 1995;153:644.

Kambic H, Kay R, Chen JF, et al. Biodegradable pericardial implants for bladder augmentation: a 2.5 year study in dogs. *J Urol*. 1992;148:539–543.

Kanematsu A, Yamamoto S, Ogawa O. Changing concepts of bladder regeneration. *Int J Urol*. 2007;14:673–678.

Kari J, Al-Deek B, Elkhatib L, et al. Is Mitrofanoff a more socially accepted clean intermittent catheterization (CIC) route for children and their families? *Euro J Ped Surg*. 2013;23(5):405–410.

Kavanagh A, Afshar K, Scott H, et al. Bladder neck closure in conjunction with enterocystoplasty and Mitrofanoff diversion for complex incontinence: closing the door for good. *J Urol*. 2012;188:1561–1566.

Kaye J, Jafri S, Cuda S, et al. Same setting laparoscopic antegrade continence enema and antegrade bladder neck injection for constipation and urinary incontinence in the spina bifida population. *J Urol*. 2010;184:1644–1650.

Keating MA, Rink RC, Adams MC. Appendicovesicostomy: a useful adjunct to continent reconstruction of the bladder. *J Urol*. 1993;149:1091.

Kelami A. Lyophilized human dura as a bladder wall substitute: experimental and clinical results. *J Urol*. 1971;105:518–522.

Khoury AE, Agarwal S, Bägli D, et al. Concomitant modified bladder neck closure and Mitrofanoff urinary diversion. *J Urol*. 1999;162:1746–1748.

Khoury AE, Dave S, Peralta-Del Valle MH, et al. Severe bladder trabeculation obviates the need for bladder outlet procedures during augmentation cystoplasty in incontinent patients with neurogenic bladder. *BJU Int*. 2008;101:223–226.

Khoury AE, Salomon M, Doche R, et al. Stone formation after augmentation cystoplasty: the role of intestinal mucus. *J Urol*. 1997;158:1133–1137.

King LR. Cystoplasty in children. King LR, Stone AR, Webster GD. *Bladder reconstruction and continent urinary diversion*. ed 2. Mosby–Year Book: St. Louis; 1991:115–125.

King LR. Protection of the upper tracts in children. King LR, Stone AR, Webster GD. *Bladder reconstruction and continent urinary diversion*. Year Book: Chicago; 1987:127.

Kispal ZF, Balogh D, Erdei O, et al. Complications after bladder augmentation or substitution in children: a prospective study in 86 patients. *BJU Int*. 2011;108(2):282–289.

Kispal ZF, Vajda P, Kereskai L, et al. Composite urinary reservoir in dogs: histological findings. *J Urol*. 2012;187(3):1110–1115.

Kitchens D, Minevich E, DeFoor W, et al. Incontinence following bladder neck reconstruction—is there a role for endoscopic management? *J Urol*. 2007;177:302–306.

Klee LW, Hooever DM, Mitchell ME, et al. Long-term effects of gastrocystoplasty in rats. *J Urol*. 1990;144:1283.

Knudson MJ, Cooper CS, Block CA, et al. Calcification of glutaraldehyde cross-linked collagen in bladder neck injections in children with incontinence: a long-term complication. *J Urol*. 2006;176:1143–1146 [discussion 1146].

Koch MO, McDougal WS. Bony demineralization following ureterosigmoid anastomosis: an experimental study in rats. *J Urol*. 1988;140:856.

Koch MO, McDougal WS. The pathophysiology of hyperchloremic metabolic acidosis after urinary diversion through intestinal segments. *Surgery*. 1985;98:561–570.

Kock NG, Ghoneim MA, Lycke KG, et al. Urinary diversion to the augmented and valved rectum: preliminary results with a novel surgical procedure. *J Urol*. 1988;140:1375–1379.

Kock NG. Internal "reservoir" in patients with permanent ileostomy: preliminary observations on a procedure resulting in fecal "continence" in five ileostomy patients. *Arch Surg*. 1969;99:223.

Koff SA, Cirulli C, Wise HA. Clinical and urodynamic features of a new intestinal urinary sphincter for continent urinary diversion. *J Urol*. 1989;142:293.

Koff SA. Guidelines to determine the size and shape of intestinal segments used for reconstruction. *J Urol*. 1988;140:1150.

Kokorowski PJ, Routh JC, Borer JG, et al. Screening for malignancy after augmentation cystoplasty in children with spina bifida: a decision analysis. *J Urol*. 2011;186(4):1437–1443.

Koraitim MM, Khalil MR, Ali GA, et al. Micturition after gastrocystoplasty and gastric bladder replacement. *J Urol*. 1999;161:1480–1484.

Kronner KM, Casale AJ, Cain MP, et al. Bladder calculi in the pediatric augmented bladder. *J Urol*. 1998;160:1096–1098.

Kronner KM, Rink RC, Simmons G, et al. Artificial urinary sphincter in the treatment of urinary incontinence: preoperative urodynamics do not predict the need for future bladder augmentation. *J Urol*. 1998;160:1093–1095.

Kropp BP, Badylak S, Thor KB. Regenerative bladder augmentation: a review of the initial preclinical studies with porcine small intestinal submucosa. *Adv Exp Med Biol*. 1995;385:229–235.

Kropp BP, Cheng EY, Lin HK, et al. Reliable and reproducible bladder regeneration using unseeded distal small intestinal submucosa. *J Urol*. 2004;172(4 Pt 2):1710–1713.

Kropp BP, Eppley BL, Prevel CD, et al. Experimental assessment of small intestine submucosa as a bladder wall substitute. *Urology*. 1995;46:396–400.

Kropp BP, Rink RC, Adams MC, et al. Bladder outlet reconstruction: fate of the silicone sheath. *J Urol*. 1993;150:703.

Kropp KA, Angwafo FF. Urethral lengthening and reimplantation for neurogenic incontinence in children. *J Urol*. 1986;135:533.

Kropp KA. Bladder neck reconstruction in children. *Urol Clin North Am*. 1999;26:661–672.

Kryger JV, Leverson G, Gonzalez R. Long-term results of artificial urinary sphincters in children are independent of age at implantation. *J Urol*. 2001;165:2377–2379.

Kryger JV, Spencer Barthold J, Fleming P. The outcome of artificial urinary sphincter placement after a mean 15 years' follow-up in a paediatric population. *Br J Urol*. 1999;83:1026–1031.

Kryger JV, Gonzalez R, Spencer Barthold J. Surgical management of urinary incontinence in children with neurogenic sphincteric incompetence. *J Urol*. 2000;163:256–263.

Kulb TB, Rink RC, Mitchell ME. *Gastrocystoplasty in azotemic canines*. [Presented at American Urological Association, North Central Section meeting, Palm Springs, FL] 1986.

Kurzrock EA, Baskin LS, Kogan BA. Gastrocystoplasty: long-term follow-up. *J Urol*. 1998;160(Pt 1):2182–2186.

Lai HH, Hsu E, Teh BS, et al. 13 years of experience with artificial urinary sphincter implantation at Baylor College of Medicine. *J Urol*. 2007;177:1021–1025.

Landa HM, Moorhead JD. Detrusorectomy. *Probl Pediatr Urol*. 1994;8:204–209.

Landau EH, Gofrit O, Pode D, et al. Bladder neck closure in children: a decade of followup. *J Urol*. 2009;182:1797–1801.

Landau EH, Gofrit ON, Cipele H, et al. Superiority of the VQZ over the tubularized skin flap and the umbilicus for continent abdominal stoma in children. *J Urol*. 2008;180:1761–1765 [discussion 1765–1766].

Landau EH, Jayanthi VR, Khoury AE, et al. Bladder augmentation: ureterocystoplasty versus ileocystoplasty. *J Urol*. 1994;152:716–719.

Lansen-Koch SM, Govaert B, Oerlemans D, et al. Sacral nerve modulation for defecation and micturition disorders in patients with spina bifida. *Colorect Dis*. 2012;14(4):508–514.

Lapides J, Diokno AC, Gould FR, et al. Further observations on self-catheterization. *J Urol*. 1976;116:169–171.

Lapides J, Diokno AC, Silbert SJ, et al. Clean intermittent self-catheterization in the treatment of urinary tract disease. *J Urol*. 1972;107:458.

Le Duc A, Camey M, Teillac P. An original antireflux ureteroileal implantation technique: long-term follow-up. *J Urol*. 1987;137:1156–1158.

Leadbetter GW. Surgical correction of total urinary incontinence. *J Urol*. 1964;91:261.

Leadbetter GW. Surgical reconstruction for complete urinary incontinence: a 10 to 22 year follow-up. *J Urol*. 1985;133:205.

Leadbetter WF, Clarke BG. Five years' experience with uretero-enterostomy by the "combined" technique. *J Urol*. 1954;73:67–82.

Lee T, Kozminski DJ, Bloom DA, et al. Bladder perforation after sugmentation cystoplasty: determining the best management option. *J Pediatr Urol*. 2017;13:274.

Lemelle JL, Guillemin F, Aubert D, et al. A multicenter evaluation of urinary incontinence management and outcome in spina bifida. *J Urol*. 2006;175:208–212.

Lendvay TS, Cowan CA, Mitchell ME, et al. Augmentation cystoplasty rates at Children's Hospital in the United States: a Pediatric Health Information System database study. *J Urol*. 2006;176(4):1716–1720.

Leng WW, Blalock HJ, Fredriksson WH, et al. Enterocystoplasty or detrusor myectomy? Comparison of indications and outcomes for bladder augmentation. *J Urol*. 1999;161:758–763.

Leonard MP, Canning DA, Epstein JI, et al. Local tissue reaction to the suburethral injection of glutaraldehyde cross-linked bovine collagen in humans. *J Urol*. 1990;143:1209.

Leonard MP, Dharamsi N, Williot PE. *Outcome of gastrocystoplasty in tertiary pediatric urology practice*. [Presented at Section on Urology meeting, American Academy of Pediatrics, Washington, DC] 1999.

Leonard MP, Gearhart JP, Jeffs RD. Continent urinary reservoirs in pediatric urological practice. *J Urol*. 1990;144:330.

Leong CH. The use of gastrocystoplasty. *Dialogues Pediatr Urol*. 1988;11:3–5.

Leong CH, Ong GB. Gastrocystoplasty in dogs. *Aust N Z J Surg*. 1972;41:272–279.

Leslie B, Lorenzo A, Moore K, et al. Long-term followup and time to event outcome analysis of continent catheterizable channels. *J Urol*. 2011;185:2298–2302.

Levesque PE, Bauer SB, Atala A, et al. Ten-year experience with the artificial urinary sphincter in children. *J Urol*. 1996;156:625–628.

Lewis JM, Cheng EY. Non-traditional management of the neurogenic bladder: tissue engineering and neuromodulation. *Sci World J*. 2007;7:1230–1241.

Liard A, Seguier-Lipszyc E, Mathiot A, et al. The Mitrofanoff procedure: 20 years later. *J Urol*. 2001;165:2394–2398.

Liebovitch I, Avigad I, Nativ O, et al. The frequency of histopathological abnormalities in incidental appendectomy in urological patients: the implications for incorporation of the appendix in urinary tract reconstruction. *J Urol*. 1992;148:41.

Light JK, Engelmann UH. Reconstruction of the lower urinary tract: observations on bowel dynamics and the artificial urinary sphincter. *J Urol*. 1985;133:594–597.

Light JK, Pietro T. Alteration in detrusor behavior and the effect on renal function following insertion of the artificial urinary sphincter. *J Urol*. 1986;136:632.

Light JK, Reynolds JC. Impact of the new cuff design on reliability of the AS800 artificial urinary sphincter. *J Urol*. 1992;147:609.

Light JK, Lapin S, Vohra S. Combined use of bowel and the artificial urinary sphincter in reconstruction of the lower urinary tract: infectious complications. *J Urol*. 1995;153:331.

Lima SV, Araujo LA, Vilar FO. Nonsecretory intestinocystoplasty: a 10-year experience. *J Urol*. 2004;171:2636–2639.

Lima SV, Araujo LA, Vilar FO, et al. Nonsecretory intestinocystoplasty: a 15-year prospective study of 183 patients. *J Urol*. 2008;179:1113–1116.

Lima SV, Montoro AM, Maciel A, et al. The use of demucosalized bowel to augment small contracted bladders. *Br J Urol*. 1998;82:436–439.

Lindley RM, Mackinnon AE, Shipstone D, et al. Long-term outcome in bladder detrusorectomy augmentation. *Eur J Pediatr Surg*. 2003;13(Suppl 1):7–12.

Little JS, Klee LW, Hoover DM, et al. Long-term histopathologic changes observed in rats subjected to augmentation cystoplasty. *J Urol*. 1994;152:720–724.

Lockhart JL, Pow-Sang JM, Persky L, et al. A continent colonic reservoir: the Florida pouch. *J Urol*. 1990;144:864–867.

Lopes RI, Lorenzo A. Recent advances in urinary tract reconstruction for neuropathic bladder in children. *F1000Res*. 2016;204:1–10.

López Pereira P, Martinez Urrutia MJ, Lobato Romera R, et al. Should we treat vesicoureteral reflux in patients who simultaneously undergo bladder augmentation for neuropathic bladder? *J Urol*. 2001;165:2259–2261.

López Pereira P, Somoza Ariba I, Martínez Urrutia MJ, et al. Artificial urinary sphincter: 11-year experience in adolescents with congenital neuropathic bladder. *Eur Urol*. 2006;50:1096–1101 [discussion 1101].

Lorenzo AJ, Cerveira J, Farhat WA. Pediatric laparoscopic ileal cystoplasty: complete intracorporeal surgical technique. *Urology*. 2007;69(5):977–981.

Lottmann H, Traxer O, Aigrain X, et al. Posterior approach to the bladder for implantation of the 800 AMS artificial sphincter in children and adolescents: technique and results in 8 patients. *Ann Urol (Paris)*. 1999;33:357–363.

Lottmann H, Margaryan M, Bernuy M, et al. Long-term effects of dextranomer endoscopic injections for treatment of urinary incontinence: an update of a prospective study of 31 patients. *J Urol*. 2006;175:1485–1489.

Ludlow J, McLaughlin KP, Rink RC, et al. *Do appendicovesicostomies empty effectively?*. [Presented at North Central Section, American Urological Association meeting, Minneapolis, MN] 1995.

Lugagne PM, Herve JM, Lebret T, et al. Ureteroileal implantation in orthotopic neobladder with the Le Duc-Camey mucosal-through technique: risk of stenosis and long-term follow-up. *J Urol*. 1997;158:765–767.

Lutz N, Frey P. *Evaluation of modified enterocystoplasties using a pediculated detubularized and demucosed sigmoid patch in* *the mini-pig*. [Presented at Section on Urology meeting, American Academy of Pediatrics, Dallas] 1994.

Lytton B, Green DF. Urodynamic studies in patients undergoing bladder replacement surgery. *J Urol*. 1989;141:1984.

Macedo A Jr, Srougi M. A continent catheterizable ileum-based reservoir. *BJU Int*. 2000;85:160–162.

MacNeily AE, Afshar K, Coleman GU, et al. Autoaugmentation by detrusor myotomy: its lack of effectiveness in the management of congenital neuropathic bladder. *J Urol*. 2003;170:1643–1646.

MacNeily AE, Morrell J, Secord S. Lower urinary tract reconstruction for spina bifida—does it improve health related quality of life? *J Urol*. 2005;179(4):1637–1643.

Mahran MR, Dawaba MS, Ghoneim MA. Evaluation of the functional significance of the colorectal valve used in rectal urinary diversion in children: a comparative study between cases with and without the valve. *Urology*. 1999;53:1215–1218.

Malizia AA Jr, Reiman HM, Myers RP, et al. Migration and granulomatous reaction after periurethral injection of Polytef (Teflon). *J Am Med Assoc*. 1984;251:3277.

Mansson W, Bakke A, Bergman B, et al. Perforation of continent urinary reservoirs. Scandinavian experience. *Scand J Urol Nephrol*. 1997;31:529–532.

Mansson W, Colleen S, Sundin R. The continent cecal reservoir for urine. *Scand J Urol Nephrol*. 1984;85(Suppl):8.

Martinez del Castillo ML, Miguelez Lago C, Garcia Merida M, et al. Spontaneous urinary bladder perforation after pediatric cystoplasty. *Actas Urol Esp*. 2005;29(9):869–878.

Mattioli G, Buffa P, Torre M, et al. Preperitoneoscopic approach for bladder neck sling suspension in a boy: preliminary experience. *J Laparoendosc Adv Surg Tech A*. 2010;20(5):497–501.

McDougal WS. Metabolic complications of urinary intestinal diversion. *J Urol*. 1992;147:1199–1208.

McDougal WS. Use of intestinal segments in the urinary tract: basic principles. Walsh PC, Retik AB, Stamey TA, et al. *Campbell's urology*. ed 6. Saunders: Philadelphia; 1992:2595–2629.

McGuire EJ, Lytton B. Pubovaginal sling procedure for stress incontinence. *J Urol*. 1978;119:82.

McGuire EJ, Wang CC, Usitalo H, et al. Modified pubovaginal sling in girls with myelodysplasia. *J Urol*. 1986;135:94.

McGuire EJ, Woodside JR, Borden TA, et al. Prognostic value of urodynamic testing in myelodysplastic patients. *J Urol*. 1981;126:205–209.

McKenna PH, Bauer SB. Bladder augmentation with ureter. *Dialogues Pediatr Urol*. 1995;18:4.

McLaughlin KP, Rink RC, Adams MC, et al. Stomach in combination with other intestinal segments in pediatric lower urinary tract reconstruction. *J Urol*. 1995;154:1162–1168.

Metcalfe PD, Cain MP, Kaefer M, et al. What is the need for additional bladder surgery after bladder augmentation in childhood? *J Urol*. 2006;176(4):1801–1805.

Mickelson J, Cheng E, Meyer T, et al. Use of the “L-stent” for the management of stomal stenosis in catheterizable channels. *J Urol*. 2009;182(4 Suppl):1786–1791.

Miller EA, Mayo M, Kwan D, et al. Simultaneous augmentation cystoplasty and artificial urinary sphincter placement: infection rates and voiding mechanisms. *J Urol*. 1998;160:750–753.

Mingin GC, Nguyen HT, Mathias RS, et al. Growth and metabolic consequences of bladder augmentation in children with myelomeningocele and bladder exstrophy. *Pediatrics*. 2002;110:1193–1198.

Mingin GC, Stock JA, Hanna MK. Gastrocystoplasty: long-term complications in 22 patients. *J Urol*. 1999;162:1122–1125.

Mingin GC, Stock JA, Hanna MK. The Mainz II pouch: experience in 5 patients with bladder exstrophy. *J Urol*. 1999;162(Pt 1):846–848.

Misseri R, Cain MP, Casale AJ, et al. Small intestinal submucosa bladder neck slings for incontinence associated with neuropathic bladder. *J Urol*. 2005;174:1680–1682 [discussion 1682].

Misseri R, Combs AJ, Horowitz M, et al. Myogenic failure in posterior urethral valve disease: real or imagined? *J Urol*. 2002;168:1844–1848.

Mitchell ME, Piser JA. Intestinocystoplasty and total bladder replacement in children and young adults: followup in 129 cases. *J Urol*. 1987;138:579–584.

Mitchell ME, Rink RC. Experience with the artificial urinary sphincter in children and young adults. *J Pediatr Surg*. 1983;18:700–706.

Mitchell ME. Bladder augmentation in children: where have we been and where are we going? *BJU Int*. 2003;92(Suppl 1):29–34.

Mitchell ME. Use of bowel in undiversion. *Urol Clin North Am*. 1986;13:349.

Mitrofanoff P. Cystotomie continente trans-appendiculaire dans le traitement des vessies neurologiques. *Chir Pediatr*. 1980;21:297–305.

Mollard P, Gauriau L, Bonnet JP, et al. Continent cystostomy (Mitrofanoff's procedure) for neurogenic bladder in children and adolescent (56 cases: long-term results). *Eur J Pediatr Surg*. 1997;7:34–37.

Monti PR, Lara RC, Dutra MD, et al. New techniques for construction of efferent conduits based on the Mitrofanoff principle. *Urology*. 1997;49:112–115.

Mor Y, Kajbafzadeh AM, German K, et al. The role of ureter in the creation of Mitrofanoff channels in children. *J Urol*. 1997;157:635–637.

Morioka A, Miyano T, Ando K, et al. Management of vesicoureteral reflux secondary to neurogenic bladder. *Pediatr Surg Int*. 1998;13:584–586.

Mouriquand PD, Sheard R, Phillips N, et al. The Kropp-onlay procedure (Pippi Salle procedure): a simplification of the technique of urethral lengthening: preliminary results in eight patients. *Br J Urol*. 1995;75:656.

Mulvihill S, Goldthorn J, Woolley MM. Incidental appendectomy in infants and children. Risk vs. rationale. *Arch Surg*. 1983;118:714.

Mundy AR, Borzyskowski M, Saxton HM. Videourodynamic evaluation of neuropathic vesicourethral dysfunction in children. *Br J Urol*. 1982;54:645.

Mundy AR, Nurse DE. Calcium balance, growth and skeletal mineralization in patients with cystoplasties. *J Urol*. 1992;69:257–259.

Mure PY, Mollard P, Mouriquand P. Transureteroureterostomy in childhood and adolescence: long-term results in 69 cases. *J Urol*. 2000;163:946–948.

Murray K, Nurse D, Mundy AR. Secreto-motor function of intestinal segments used in lower urinary tract reconstruction. *Br J Urol*. 1987;60:532.

Narayanaswamy B, Wilcox DT, Cuckow PM, et al. The Yang-Monti ileovesicostomy: a problematic channel? *BJU Int*. 2001;87:861–865.

Nasrallah PF, Aliabadi HA. Bladder augmentation in patients with neurogenic bladder and vesicoureteral reflux. *J Urol*. 1991;146:563–566.

Nelson BA, DeMarco RT, Pope JC, et al. *Augmentation cystoplasty: a comparative analysis of different bowel* *segments and stomach*. [Presented at: American Academy of Pediatric Urology Section Meeting. Washington, DC] 2005.

Nerli R, Patil S, Hiremath M, et al. Yang-Monti's catheterizable stoma in children. *Nephrourol Mon*. 2013;5(3):801–805.

Nesbit RM. Ureterosigmoid anastomosis by direct elliptical connection: a preliminary report. *J Urol*. 1949;61:728–734.

Ngan JH, Lau JL, Lim ST, et al. Long-term results of antral gastrocystoplasty. *J Urol*. 1993;149:731–734.

Nguyen DH, Bain MA, Salmonson KL, et al. The syndrome of dysuria and hematuria in pediatric urinary reconstruction with stomach. *J Urol*. 1993;150:707–709.

Nguyen HT, Baskin LS. The outcome of bladder neck closure in children with severe urinary incontinence. *J Urol*. 2003;169(3):1114–1116.

Noble IG, Lee KT, Mundy AR. Transuretero-ureterostomy: a review of 253 cases. *Br J Urol*. 1997;79:20–23.

Nurse DE, Mundy AR. Metabolic complications of cystoplasty. *Br J Urol*. 1989;63:165–170.

Nurse DE, Mundy AR. One hundred artificial sphincters. *Br J Urol*. 1988;61:318.

O'Donnell E. Inpatient surgical bowel preps: making them work. *J Pediatr Nursing*. 2007;22:245–250.

Oesch I. Neourothelium in bladder augmentation: an experimental rat model. *Eur Urol*. 1988;14:328.

Ojerskog B, Kock NG, Philipson BM, et al. Pregnancy and delivery in patients with continent ileostomy. *Surg Gynecol Obstet*. 1988;167:61–64.

Palmer LS, Franco I, Koan SJ, et al. Urolithiasis in children following augmentation cystoplasty. *J Urol*. 1993;150:726.

Pantuck AJ, Han KR, Perrotti M, et al. Ureteroenteric anastomosis in continent urinary diversion: long-term results and complications of direct versus nonrefluxing techniques. *J Urol*. 2000;163:450–455.

Parekh AD, Trusler LA, Pietsch JB, et al. Prospective, longitudinal evaluation of health related quality of life in the pediatric spina bifida population undergoing reconstructive urological surgery. *J Urol*. 2006;176(4):1878–1882.

Pascali MP, Mosiello G, Boldrini R, et al. Effects of botulinum toxin A in the bladder wall of children with neurogenic dysfunction: a comparison of histological features before and after infections. *J Urol*. 2011;185(6 Suppl):2552–2557.

Passerotti CC, Nguyen HT, Lais A. Robot-assisted laparoscopic ileal bladder augmentation: defining techniques and potential pitfalls. *J Endourol*. 2008;22(2):355–360.

Patil U, Glassberg KI, Waterhouse K. Ileal conduit surgery with nippled ureteroileal anastomoses. *Urology*. 1976;7:594–597.

Pedlow PR. Pregnancy associated with uretero-sigmoid anastomosis. *J Obstet Gynaecol Br Emp*. 1961;68:822.

Perez LM, Smith EA, Broecker BH, et al. Outcome of sling cystourethropexy in the pediatric population: a critical review. *J Urol*. 1996;156:642–646.

Perez LM, Smith EA, Parrott TS, et al. Submucosal bladder neck injection of bovine dermal collagen for stress urinary incontinence in the pediatric population. *J Urol*. 1996;156:633–636.

Peters KM, Girdler B, Turzewski C, et al. Outcomes of lumbar to sacral nerve rerouting for spina bifida. *J Urol*. 2010;184:702–708.

Pettersson L, Tranberg J, Abrahamsson K, et al. Half century of followup after ureterosigmoidostomy performed in early childhood. *J Urol*. 2013;189:1870–1875.

Phelps SE, Malone PS. Severe perineal pain after enterocystoplasty in bladder exstrophy. *BJU Int*. 2004;93:835–837.

Plaire JC, Snodgrass WT, Mitchell ME. *Long-term follow-up of the hematuria-dysuria syndrome*. [Presented at: Section on

Urology meeting, American Academy of Pediatrics. Washington, DC] 1999.

Pope JC 4th, Albers P, Rink RC, et al. *Spontaneous rupture of the augmented bladder from silence to chaos*. [Presented at European Society of Pediatric Urologists meeting, Istanbul, Turkey] 1999.

Pope JC 4th, Keating MA, Casale AJ, et al. Augmenting the augmented bladder: treatment of the contractile bowel segment. *J Urol*. 1998;160(Pt 1):854–857.

Pope JC 4th, Rink RC. Surgical management of the neurogenic bladder. Gonzalez ET, Bauer SB. *Pediatric urology practice*. Lippincott-Raven: Philadelphia; 1999:401–416.

Quenneville V, Beurton D, Thomas L, et al. Pregnancy and vaginal delivery after augmentation cystoplasty. *BJU Int*. 2003;91:893–894.

Quimby GF, Diamond DA, Mor Y, et al. Bladder neck reconstruction: long-term followup of reconstruction with omentum and silicone sheath. *J Urol*. 1996;156:629–632.

Racioppi M, D'Addessi A, Fanasca A, et al. Acid-base and electrolyte balance in urinary intestinal orthotopic reservoir: ileocecal neobladder compared with ileal neobladder. *Urology*. 1999;54:629–635.

Reinberg Y, Manivel JC, Froemming C, et al. Perforation of the gastric segment of an augmented bladder secondary to peptic ulcer disease. *J Urol*. 1992;148:369–371.

Reinberg Y, Allen RC, Vaughn M, et al. Nephrectomy combined with lower abdominal extraperitoneal ureteral bladder augmentation in the treatment of children with the vesicoureteral reflux dysplasia syndrome. *J Urol*. 1995;153:777–779.

Reisman EM, Preminger GM. Bladder perforation secondary to clean intermittent catheterization. *J Urol*. 1989;142:1316–1317.

Rey D, Oderda M, El Helou E, et al. Feasibility of robotic double Yang-Monti ileal conduit with bladder augmentation: surgical technique. *Urol*. 2013;82:480–484.

Rink RC, Adams MC, Keating MA. The flip-flap technique to lengthen the urethra (Salle procedure) for treatment of neurogenic urinary incontinence. *J Urol*. 1994;152:799.

Rink RC, Bihrle R. Continent urinary diversion in children and the Indiana pouch. *Probl Urol*. 1990;4:663–675.

Rink RC, Hollensbe D, Adams MC. Complications of augmentation in children and comparison of gastrointestinal segments. *AUA Update Series*. 1995;14:122–128.

Rink RC, McLaughlin KP, Adams MC, et al. Modification of the Casale vesicostomy: continent diversion without the use of bowel [abstract 442]. *J Urol*. 1995;153:339A.

Rink RC, McLaughlin KP. Indications for enterocystoplasty and choice of bowel segment. *Probl Urol*. 1994;8:389–403.

Rink RC, Mitchell ME. Role of enterocystoplasty in reconstructing the neurogenic bladder. Gonzales ET, Roth D. *Common problems in pediatric urology*. Mosby–Year Book: St Louis; 1990:192–204.

Rink RC, Mitchell ME. Surgical correction of urinary incontinence. *J Pediatr Surg*. 1984;19:637–641.

Rink RC, Retik AB. Ureteroileocecal sigmoidostomy and avoidance of carcinoma of the colon. King LR, Stone AR, Webster GD. *Bladder reconstruction and continent urinary diversion*. Mosby–Year Book: St Louis; 1991:221.

Rittenberg MH, Hulbert WC, Snyder HM 3rd, et al. Protective factors in posterior urethral valves. *J Urol*. 1988;140:993.

Rocha FT, Bruschini H, Figueiredo JA, et al. Use of an inflatable silicone balloon improves the success rate of bladder autoaugmentation in long-term followup. *J Urol*. 2011;185(6 Suppl):2576–2581.

Rosen MA, Light JK. Spontaneous bladder rupture following augmentation enterocystoplasty. *J Urol*. 1991;146:1232–1234.

Roth CC, Mondalek FG, Kibar Y, et al. Bladder regeneration in a canine model using hyaluronic acid-poly(lactic-co-glycolic-acid) nanoparticle modified porcine small intestine submucosa. *BJU Int*. 2011;108(1):148–155.

Roth JA, Borer JG, Hendren WH, et al. *Is gastric augmentation a good long-term urodynamic solution to the poorly functioning bladder?*. [Presented at American Academy of Pediatrics, Urology Section meeting, Chicago] 2000.

Roth JD, Casey JT, Whittam BM, et al. Complications and outcomes of pregnancy and cesarean delivery in women with neuropathic bladder and lower urinary tract reconstruction. *Urology*. 2018;114:236–243.

Roth S, Semjonow A, Waldner M, et al. Risk of bowel dysfunction with diarrhea after continent urinary diversion with ileal and ileocecal segments. *J Urol*. 1995;154:1696–1699.

Rove KO, Brockel MA, Saltzman AF, et al. Prospective study of enhanced recovery after surgery protocol in children undergoing reconstructive operations. *J Pediatr Urol*. 2018;14(3):252.

Rove KO, Husmann DA, Wilcox DT, et al. Systematic review of bladder cancer outcomes in patients with spina bifida. *J Pediatr Urol*. 2017;13(5):456.e1–456.e9.

Rowland RG, Mitchell ME, Bihrle R. The cecoileal continent urinary reservoir. *World J Urol*. 1985;3:185.

Rowland RG. Complications of continent cutaneous reservoirs and neobladder—series using contemporary techniques. *AUA Update Series*. 1995;14:202–207.

Rowland RG. Present experience with the Indiana pouch. *World J Urol*. 1996;14:92–98.

Ruiz E, Puigdevall J, Moldes J, et al. 14 years of experience with the artificial urinary sphincter in children and adolescents without spina bifida. *J Urol*. 2006;176:182–185.

Rushton HG, Woodard JR, Parrott TS, et al. Delayed bladder rupture after augmentation enterocystoplasty. *J Urol*. 1988;140:344.

Sagalowsky AI. Early results with split-cuff nipple ureteral reimplants in urinary diversion. *J Urol*. 1995;154:2028.

Salle JL, Fraga JC, Amarante A, et al. Urethral lengthening with anterior bladder wall flap for urinary incontinence: a new approach. *J Urol*. 1994;152:803.

Salle JL, Fraga JC, Lucib A, et al. Seromuscular enterocystoplasty in dogs. *J Urol*. 1990;144:454–456.

Salle JL, McLorie GA, Bägli DJ, et al. Urethral lengthening with anterior bladder wall flap (Pippi Salle procedure): modifications and extended indications of the technique. *J Urol*. 1997;158:585–590.

Sanda MC, Jeffs RD, Gearhart JP. Evolution of outcomes with the ileal hydraulic continent diversion: reevaluation of the Bechekroun catheterizable stoma. *World J Urol*. 1988;14:108–111.

Savauagen F, Dixey GM. Syncope following ureterosigmoidostomy. *J Urol*. 1969;101:844.

Schilling A, Krawczak G, Friesen A, et al. Pregnancy in a patient with an ileal substitute bladder followed by severe destabilization of the pelvic support. *J Urol*. 1996;155:1389–1390.

Schlomer BJ, Copp HL. Cumulative incidence of outcomes and urologic procedures after augmentation cystoplasty. *J Pediatr Urol*. 2014;10:1043–1450.

Schlomer BJ, Saperton K, Baskin L. National trends in augmentation cystoplasty in the 2000s and factors associated with outcomes. *J Urol*. 2013;190(4):1352–1357.

Schmidt JD, Hawtrey CE, Flocks RH, et al. Complications, results, and problems of ileal conduit diversions. *J Urol*. 1973;109:210–216.

Schulte-Baukloh H, Knispel HH, Stolze T, et al. Repeated botulinum toxin A injections in treatment of children with neurogenic detrusor overactivity. *Urol*. 2005;66(4):865–870.

Schumacher S, Fichtner J, Stein R, et al. Pregnancy after Mainz pouch urinary diversion. *J Urol*. 1997;158:1362–1364.

Scott FB, Bradley WE, Timm GW. Treatment of urinary incontinence by an implantable prosthetic urinary sphincter. *J Urol*. 1974;112:75–80.

Sheiner JR, Kaplan GW. Spontaneous bladder rupture following enterocystoplasty. *J Urol*. 1988;140:1157–1158.

Shekarriz B, Upadhyay J, Demirbilek S, et al. Surgical complications of bladder augmentation: comparison between various enterocystoplasties in 133 patients. *Urology*. 2000;55:123–128.

Sidi AA, Sinha B, Gonzalez R. Treatment of urinary incontinence with an artificial sphincter: further experience with the AS791/792 device. *J Urol*. 1984;131:891.

Sidi AA, Aliabadi H, Gonzalez R. Enterocystoplasty in the management and reconstruction of the pediatric neurogenic bladder. *J Pediatr Surg*. 1987;22:153–157.

Sidi AA, Peng W, Gonzalez R. Vesicoureteral reflux in children with myelodysplasia: natural history results of treatment. *J Urol*. 1986;136:329.

Sidi AA, Reinberg Y, Gonzalez R. Comparison of artificial sphincter implantation and bladder neck reconstruction in patients with neurogenic urinary incontinence. *J Urol*. 1987;138:1120.

Sidi AA, Reinberg Y, Gonzalez R. Influence of intestinal segment and configuration on the outcome of augmentation enterocystoplasty. *J Urol*. 1986;136:1201–1204.

Silveri M, Capitanucci ML, Mosiello G, et al. Endoscopic treatment for urinary incontinence in children with a congenital neuropathic bladder. *Br J Urol*. 1998;82:694.

Simoneau AR, Skinner DG. Ileo-anal reservoir. *J Urol*. 1995;153:305A.

Skinner DG, Lieskovsky G, Boyd S. Continent urinary diversion. *J Urol*. 1989;141:1323–1327.

Skinner DG, Lieskovsky G, Boyd S. Continent urinary diversion: a year experience. *Ann Surg*. 1988;208:337–344.

Slaton JW, Kropp KA. Conservative management of suspected bladder rupture after augmentation enterocystoplasty. *J Urol*. 1994;152:713–715.

Smith E, Kaye J, Lee J, et al. Use of rectus abdominis muscle flap as adjunct to bladder neck closure in patients with neurogenic incontinence: preliminary experience. *J Urol*. 2010;183:1556–1560.

Snodgrass W, Barber T, Cost N. Detrusor compliance changes after bladder neck sling without augmentation in children with neurogenic urinary incontinence. *J Urol*. 2010;183:2361–2366.

Snodgrass W, Barber T. Comparison of bladder outlet procedures without augmentation in children with neurogenic incontinence. *J Urol*. 2010;184:1775–1780.

Snodgrass W, Elmore J, Adams R. Bladder neck sling and appendicovesicostomy without augmentation for neurogenic incontinence in children. *J Urol*. 2007;177(4):1510–1514.

Snodgrass W, Villanueva C, Jacobs M, et al. Upper tract changes in patients with neurogenic bladder and sustained pressures > 40 cm following bladder neck surgery without augmentation. *J Pediatr Urol*. 2014;10:744–748.

Snodgrass W. A simplified Kropp procedure for incontinence. *J Urol*. 1997;158:1049–1052.

Snow BW, Cartwright PC. Bladder autoaugmentation. *Urol Clin North Am*. 1996;23:323.

Soergel TM, Cain MP, Misseri R, et al. Transitional cell carcinoma of the bladder following augmentation cystoplasty for the neuropathic bladder. *J Urol*. 2004;172:1649–1651.

Soler R, Fullhase C, Atala A. Regenerative medicine strategies for treatment of neurogenic bladder. *Therapy*. 2009;6(2):177–184.

Soygur T, Arikan N, Zumrutbas AE, et al. Serosal lined extramural tunnel (Ghoneim) principle in the creation of a catheterizable channel in bladder augmentation. *J Urol*. 2005;174(2):696–699.

Soylet Y, Emir H, Ilce Z, et al. Quo vadis? Ureteric reimplantation or ignoring reflux during augmentation cystoplasty. *BJU Int*. 2004;94:379–380.

Spencer JR, Steckel J, May M, et al. Histological and bacteriological findings in long-term ileocystoplasty and colocystoplasty in the rat. *J Urol*. 1993;150:1321.

Stein R, Fisch M, Andreas J, et al. Whole-body potassium and bone mineral density up to 30 years after urinary diversion. *Br J Urol*. 1998;82:798–803.

Stein R, Fisch M, Beetz R, et al. Urinary diversion in children and young adults using the Mainz pouch I technique. *Br J Urol*. 1997;79:354–361.

Stein R, Fisch M, Ermert A, et al. Urinary diversion and orthotopic bladder substitution in children and young adults with neurogenic bladder: a safe option for treatment? *J Urol*. 2000;163:568–573.

Stein R, Fisch M, Stockle M, et al. Urinary diversion in bladder exstrophy and incontinent epispadias: 25 years of experience. *J Urol*. 1995;154:1177–1181.

Stein R, Lotz J, Fisch M, et al. Vitamin metabolism in patients with a Mainz pouch: I. Long-term follow-up. *J Urol*. 1997;157:44–47.

Stein R, Wiesner C, Beetz R, et al. Urinary diversion in children and adolescents with neurogenic bladder: the Mainz experience: I. Bladder augmentation and bladder substitution-therapeutic algorisms. *Pediatr Nephrol*. 2005;20(7):920–925.

Steiner G, Muller SC, Bruhl P. Urinary incontinence in neurogenic defects and urogenital anomalies in childhood. *Wien Med Wochenschr*. 1998;148:299–304.

Steiner MS, Morton RA. Nutritional and gastrointestinal complications of the use of bowel segments in the lower urinary tract. *Urol Clin North Am*. 1991;18:743.

Stephany HA, Clayton DB, Tanaka ST, et al. Development of upper tract stones in patients with congenital neurogenic bladder. *J Pediatr Urol*. 2014;10:112–117.

Stifelman MD, Ikeguchi FF, Hensle TW. Ureteral tissue expansion for bladder augmentation: a long-term prospective controlled trial in a porcine model. *J Urol*. 1998;160:1826–1829.

Stoehrer M, Goepel M, Kramer G, et al. Detrusor myectomy (autoaugmentation) in the treatment of hyper-reflexive low compliance bladder. *Urologe A*. 1999;38:30–37.

Stoehrer M, Wolff A, Kramer G, et al. Treatment of neurogenic detrusor overactivity with botulinum toxin A: the first seven years. *Urol Int*. 2009;83(4):379–385.

Stone AR, MacDermott JA. The split cuff ureteral nipple reimplantation technique: reliable reflux prevention from bowel segments. *J Urol*. 1989;142:707–709.

Storm DW, Fulmer BR, Sumfest JM. Robotic-assisted laparoscopic approach for posterior bladder neck dissection and placement of pediatric bladder neck sling: initial experience. *Urology*. 2008;72:1149–1152.

Stothers L, Johnson H, Arnold W, et al. Bladder autoaugmentation by vesicomyotomy in pediatric neurogenic bladder. *Urology*. 1994;44:110–113.

Strang AM, Herndon CD, Joseph DB. *Is the effectiveness of the* *fascial bladder neck wrap maximized: a review of the double neck wrap in pediatric outlet deficiency [abstract]*. [Presented at American Urological Association meeting] 2006.

Strawbridge LR, Kramer SA, Castillo DA, et al. Augmentation cystoplasty and the artificial genitourinary sphincter. *J Urol*. 1989;142:297.

Studer UE, Zingg EJ. Ileal orthotopic bladder substitutes: what we have learned from 12 years' experience with 200 patients. *Urol Clin North Am*. 1997;24:781–793.

Subramaniam R, Hinley J, Stahlschmidt J, et al. Tissue engineering potential of urothelial cells from diseased bladders. *J Urol*. 2011;186(5):2014–2020.

Sundaram CP, Reinberg Y, Aliabadi HA. Failure to obtain durable results with collagen implantation in children with urinary incontinence. *J Urol*. 1997;157:2306–2307.

Surer I, Ferrer FA, Baker LA, et al. Continent urinary diversion and the exstrophy-epispadias complex. *J Urol*. 2003;169:1102–1105.

Suzer O, Vates TS, Freedman AL, et al. Results in the Mitrofanoff procedure in urinary tract reconstruction in children. *Br J Urol*. 1997;79:279–282.

Szymanski KM, Rink RC, Whittam B, et al. Long-term outcomes of the Kropp and Salle urethral lengthening bladder neck reconstruction procedures. *J Pediatr Urol*. 2016;12:403.

Tan HJ, Stoffel J, Daignault S, et al. Ileovesicostomy for adults with neurogenic bladders: complications and potential risk factors for adverse outcomes. *Neurourol Urodyn*. 2008;27:238–243.

Tanagho EA. Bladder neck reconstruction for total urinary incontinence: 10 years' experience. *J Urol*. 1981;125:321.

Taskinen S, Fagerholm R, Makitie O. Skeletal health after intestinal bladder augmentation: findings in 54 patients. *BJU*

Int. 2007;100(4):906–910.

Taskinen S, Makitie O, Fagerholm R. Intestinal bladder augmentation at school age has no adverse effects on growth. *J Pediatr Urol*. 2008;4(1):40–42.

Thomas JC, Adams MC. Pregnancy following urinary tract reconstruction. *J Urol*. 2009;182:2578–2584.

Thomas JC, Dietrich MS, Trusler L, et al. Continent catheterizable channels and the timing of their complications. *J Urol*. 2006;176:1816–1820 [discussion 1820].

Thomas JC, Donohoe JM, DeMarco RT, et al. *Continent catheterizable channels and the timing of their complications: Vanderbilt Children's Hospital Experience*. [Presented at Southeastern Section of the American Urological Association annual meeting, Charleston, SC] 2005.

Thomasch J, Adams MC, Pope JC, et al. *Vesicourethral fistula formation in pediatric patients undergoing bladder neck closure: a rare event*. [Presented at American Urological Association, Southeastern Section meeting, Mobile, AL] 2009.

Thuroff JW, Alken P, Hohenfellner R. The Mainz pouch (mixed augmentation with ileum and cecum) for bladder augmentation and continent diversion. King LR, Stone AR, Webster GD. *Bladder reconstruction and continent urinary diversion*. Year Book: Chicago; 1987:252.

Thuroff JW, Alken P, Riedmiller H, et al. 100 cases of Mainz pouch: continuing experience and evolution. *J Urol*. 1988;140:283.

Thuroff JW, Alken P, Riedmiller H, et al. The Mainz pouch (mixed augmentation ileum and cecum) for bladder augmentation and continent diversion. *J Urol*. 1986;136:17.

Traxel EJ, DeFoor W, Minevich EA, et al. Low incidence of urinary tract infections following renal transplantation in children with bladder augmentation. *J Urol*. 2011;186(2):667–671.

Traxel EJ, Minevich EA, Noh PH. A review: the application of minimally invasive surgery to pediatric urology: lower urinary tract reconstructive procedures. *Urology*. 2010;76(1):115–120.

Treiger BF, Marshall FF. Carcinogenesis and the use of intestinal segments in the urinary tract. *Urol Clin North Am*. 1991;18:737.

Tsuchiya N, Sato K, Satoh S, et al. A novel antireflux technique using an intussuscepted ileal segment. *Urol Int*. 2004;73:15–18.

Turner-Warwick RT, Ashken MH. The functional results of partial, subtotal, and total cystoplasty with special reference to ureterocaecocysto-plasty selective sphincterotomy and cystocystoplasty. *Br J Urol*. 1967;39:3–12.

Vajda P, Kaiser L, Magyarlaki T, et al. Histological findings after colocystoplasty and gastrocystoplasty. *J Urol*. 2002;168:698–701.

Vajda P, Pinter AB, Harangi F, et al. Metabolic findings after colocystoplasty in children. *Urology*. 2003;62:542–546.

Van der Aa F, Joniau S, De Baets K, et al. Continent catheterizable vesicostomy in an adult population: success at high costs. *Neurourol Urodyn*. 2009;28:1–5.

VanderBrink BA, Cain MP, King S, et al. Is oral vitamin B12 therapy effective for vitamin B12 deficiency in patients with prior ileocystoplasty. *J Urol*. 2010;184(4 Suppl):1781–1785.

VanderBrink BA, Kaefer M, Cain MP, et al. Extravesical implantation of a continent catheterizable channel. *J Urol*. 2011;185:2572–2575.

Vates TS, Denes ED, Rabah R, et al. Methods to enhance in vivo urothelial growth on seromuscular colonic segments in the dog. *J Urol*. 1997;158:1081–1085.

Verpoorten C, Buyse G. The neurogenic bladder: medical treatment. *Pediatr Nephrol*. 2008;23:717–725.

Vorstman B, Lockhart JL, Kaufman M, et al. Polytetrafluoroethylene injection for urinary incontinence in children. *J Urol*. 1985;133:248.

Wagstaff KE, Woodhouse CR, Duffy PG, et al. Delayed linear growth in children with enterocystoplasties. *Br J Urol*. 1992;69:314–317.

Wagstaff KE, Woodhouse CR, Roose GA, et al. Blood and urine analysis in patients with intestinal bladders. *Br J Urol*. 1991;68:311–316.

Walker RD, Erhard M, Starling J. Long-term evaluation of rectus fascial wrap in patients with spina bifida. *J Urol*. 2000;164:485–486.

Walker RD, Flack CE, Hawkins-Lee B, et al. Rectus fascial wrap: early results of a modification of the rectus fascial sling. *J Urol*. 1995;154(Pt 2):771.

Wang DS, Anderson DA, Fretz PC, et al. Laparoscopic augmentation cystoplasty: a comparison between native ileum and small intestinal submucosa in the porcine model. *BJU Int*. 2007;99(3):626–631.

Wang SC, McGuire EJ, Bloom DA. A bladder pressure management system for myelodysplasia: clinical outcome. *J Urol*. 1988;140:1499.

Waters PR, Chehade NC, Kropp KA. Urethral lengthening and reimplantation: incidence and management of catheterization problems. *J Urol*. 1997;158:1053.

Waters WB, Vaughan DJ, Harris RG, et al. The Kock pouch: initial experience and complications. *J Urol*. 1987;137:1151.

Weatherly DL, Szymanski KM, Whittam BM, et al. Comparing inpatient versus outpatient bowel preparation in children and adolescents undergoing appendicovesicostomy. *J Pediatr Urol*. 2018;14:50.

Weikert E, Kraske S, Schott G, et al. Umbilical rotation: a new technique for the cutaneous fixation of continent catheterizable vesicostomies. *J Ped Urol*. 2012;8:87–91.

Welk BK, Afshar K, Rapoport D, et al. Complications of the catheterizable channel following continent urinary diversion: their nature and timing. *J Urol*. 2008;180:1856–1860.

Weston PM, Robinson LQ, Williams S, et al. Poor compliance early in filling in the neuropathic bladder. *Br J Urol*. 1989;63:28.

Weston PM, Morgan JD, Hussain J, et al. Artificial urinary sphincters around intestinal segments-are they safe? *Br J Urol*. 1991;67:150.

Whitmore WF 3rd, Gittes RF. Reconstruction of the urinary tract by cecal and ileocecal cystoplasty: review of a 15-year experience. *J Urol*. 1983;129:494–498.

Whittam BM, Szymanski KM, Flack C, et al. A comparison of the monti and spiral monti procedures: a long-term analysis. *J Pediatr Urol*. 2015;11:1–6.

Wille M, Jayram G, Gundeti M. Feasibility and early outcomes of robotic-assisted laparoscopic Mitrofanoff appendicovesicostomy in patients with prune belly syndrome. *BJU Int*. 2011;109:125–129.

Woodhouse CR, MacNeily AE. The Mitrofanoff principle: expanding upon a versatile technique. *Br J Urol*. 1994;74:447.

Woodside JR, Borden TA. Pubovaginal sling procedure for the management of urinary incontinence in a myelodysplastic girl. *J Urol*. 1982;127:744.

Wren FJ, Reese CT, Decter RM. Durability of the Malone antegrade continence enema in pregnancy. *Urology*. 2003;61:644.

Xiao CG, Du MX, Li B. An artificial somatic-autonomic reflex pathway procedure for bladder control in children with spina bifida. *J Urol*. 2005;173:2112–2116.

Yachia D. A new continent vesicostomy technique: preliminary report. *J Urol*. 1997;157:1633–1637.

Yamzon J, Perin L, Koh CJ. Current status of tissue engineering in pediatric urology. *Curr Opin Urol*. 2008;18:404–407.

Yang W. Yang needle tunneling technique in creating antireflux and continent mechanisms. *J Urol*. 1993;150:830–834.

Yerkes EB, Rink R, Cain M, et al. Shunt infection and malfunction after augmentation cystoplasty. *J Urol*. 2001;165:2262–2264.

Young HH. An operation for the cure of incontinence of urine. *Surg Gynecol Obstet*. 1919;28:84.

Zhang Y, Kropp BP, Lin HK, et al. Bladder regeneration with cell-seeded small intestinal submucosa. *Tissue Eng*. 2004;10:181–187.

Zubieta R, de Badiola F, Escala JM, et al. Clinical and urodynamic evaluation after ureterocystoplasty with different amounts of tissue. *J Urol*. 1999;162:1129–1132.

SECTION D

Upper Urinary Tract Conditions

OUTLINE

38 Anomalies of the Upper Urinary Tract
39 Renal Dysgenesis and Cystic Disease of the Kidney
40 Pathophysiology of Urinary Tract Obstruction
41 Ectopic Ureter, Ureterocele, and Ureteral Anomalies
42 Surgery of the Ureter in Children Ureteropelvic Junction, Megaureter, and Vesicoureteral Reflux
43 Management of Pediatric Kidney Stone Disease

38

Anomalies of the Upper Urinary Tract

Brian A. VanderBrink MD, Pramod P. Reddy MD

Anomalies of Renal Number

Renal function is crucial for sustaining life, and therefore nature provided us with an adequate renal reserve (typically two functioning kidneys) to protect against kidney disease or damage. In this section of the chapter, we will focus on congenital absence of one or both kidneys and the rare instance of supernumerary kidneys. *Agenesis* implies the congenital absence of an organ resulting from failure to develop during embryonic growth and development because of the absence of primordial tissue. Strictly speaking, individuals who have a congenital solitary kidney caused by early involution of a multicystic displastic kidney (MCDK) do not have renal agenesis.

Bilateral Renal Agenesis

Of all the congenital anomalies of the upper urinary tract, bilateral renal agenesis (BRA) has the most profound effect on the fetus, and it is almost always incompatible with life. Although Wolfstrigel first recognized BRA in 1671, it was not until Potter's extensive description of the constellation of associated defects that the full extent of the syndrome could be easily recognized (Potter, 1946a, 1946b, 1952, 1965). Because of the myriad of complex molecular events that are required for normal renal development, there is probably no single underlying etiology for BRA.

Incidence

The incidence of BRA is exceedingly rare, with only about 500 cases reported in the literature (Potter, 1965). It is estimated that BRA occurs once in 4800 to 5000 births, whereas Stroup et al. detected an incidence of 3.5 per 100,000 (Stroup et al., 1990). A study in 8500 pregnancies in Poland documented a higher incidence of 0.25% (Forys et al., 2003). Almost 75% of affected individuals are males. Increasing maternal age may be a risk factor (Bianca et al., 2003), but complications of pregnancy or maternal disease such as diabetes mellitus do not appear to influence the incidence of BRA (Ruhland et al., 1998). An autosomal recessive inheritance pattern may exist (Dicker et al., 1984), although other investigators have suggested an autosomal dominant trait with variable penetrance (Kovacs et al., 1991; Murugasu et al., 1991; Moerman et al., 1994). When siblings and parents of an index child with BRA were screened, 4.5% had unilateral renal agenesis (URA) (Roodhooft et al., 1984) and 3.5% had BRA (McPherson et al., 1987). This is 1000 times higher than in the general population (Stroup et al., 1990). McPherson et al. evaluated renal anomalies in families of individuals with congenital solitary kidneys including renal agenesis or a very poorly functioning kidney resulting from dysplasia/hypoplasia (McPherson, 2007). The empirical risk of 7% for offspring, 4% for parents, and 2.5% for siblings may be an underestimation, because not all relatives underwent ultrasound screening. The incidence of BRA in offspring of congenital solitary kidney probands was approximately 1%, which is significantly greater than the risk found in the general population but less than that for families with a history of BRA. Ultrasound screening has been recommended for parents and siblings of infants born with either URA or BRA or renal dysgenesis (Roodhooft et al., 1984). McPherson reviewed families in whom a first-degree relative had been diagnosed with a solitary kidney and noted a significant incidence of renal anomalies; based on this, he has recommended prenatal and/or postnatal ultrasound examination when either parent or another first-degree relative has a congenital solitary kidney (McPherson, 2007).

Syndromic associations with BRA have been detected in higher than expected proportions in cases with esophageal atresia (Saing et al., 1998), cryptophthalmos, Fraser syndrome (syndactyly, renal abnormalities, genital malformations, and cryptophthalmos) (Fryns et al., 1997), Klinefelter syndrome (Barroeta and Stopyra, 2004), and Kallmann syndrome (Colquhoun-Kerr et al., 1999).

Relevant Renal Embryology and Possible Etiology

The embryologic development of the renal system is closely integrated with the developing genital system, hence abnormalities with renal development are associated with malformations of the genital system in both genders. **The intermediate kidney, or mesonephros, develops and then regresses, leaving behind the mesonephric tubules** (Uetani and Bouchard, 2009; Costantini and Kopan, 2010). In the male, these are the efferent ductules that serve as a link between the gonad and the mesonephric duct or Wolffian duct (WD) structures (the body and tail of the epididymis and vas deferens). In the female, the mesonephric tubules link the ovary through the fimbriated end of the fallopian tube to the reproductive tract. **The definitive kidney differentiates from the**

metanephric blastema, which is a specialized region of the intermediate mesoderm termed the *metanephric mesenchyme (MM)*. This process requires the reciprocal induction between the metanephric blastema and the ureteral bud (UB), which is critical for the kidney to form. The metanephric blastema sends signals to the WD to initiate UB formation from its caudal end between 5 and 7 weeks' gestation. The UB evaginates and invades the metanephric blastema and branches repeatedly in a characteristic pattern to form the renal collecting duct system. The ureteral tips induce nephron differentiation in the adjacent mesenchyme, forming the mature metanephros (Uetani and Bouchard, 2009). The absence of a nephrogenic ridge on the dorsolateral aspect of the coelomic cavity, or the failure of a UB to develop from the WD, will result in ipsilateral renal agenesis. Therefore, for BRA to occur, there must be an alteration in normal molecular development or a mutation that causes renal or ureteral maldevelopment on both sides of the midline.

Mammalian Kidney Organogenesis: New Advances in Developmental Biology

Renal agenesis is the result of a failure of the UB to develop from the mesonephric duct (WD) or a failure of the reciprocal induction of the UB and the metanephric blastema. Mutations in *RET* (Rearranged in Transfection) were found in 7 of 19 fetuses with BRA and in 2 of 10 fetuses with URA. A mutation in *GDNF* was found in 1 fetus with URA who also had mutations in *RET*. No *GFRα1* mutations were observed. These data suggest that congenital renal agenesis results from *RET* mutations that prevent or impede the embryonic development of *RET*-dependent structures. After the GDNF/GFRα1 complex binds to RET, the *Wnt11* gene is activated in the epithelial tips of the UB and is associated with UB branching (Majumdar et al., 2003).

Gremlin 1 (GREM1) is an extracellular BMP antagonist that is expressed in the mesonephric mesenchyme and in the MM (Michos et al., 2004). GREM1 is upregulated in the mesenchyme around the origin of the UB before the initiation of its outgrowth. At this time, BMP activity is reduced locally. **In the *Grem1*-deficient mouse embryo, metanephric development is disrupted at the stage of UB outgrowth initiation, resulting in BRA. This inhibition of UB outgrowth causes progressive loss of *Gdnf* expression, resulting in apoptosis of the MM.** To examine further the relationship of these various ligands and their effects on epithelial-mesenchymal interactions, Michos et al. cultured early *Grem1*-deficient mutant mouse kidney rudiments in a medium supplemented with recombinant GREM1 (Michos et al., 2007). The addition of GREM1 restored UB outgrowth and induced supernumerary epithelial buds that invaded the MM and initiated branching morphogenesis. At the molecular level, GREM1 replacement activated *Wnt11* expression in the epithelial buds and upregulated *Gdnf* expression in the mesenchyme. Because genetic suppression of BMP4 activity in a *Grem1*-deficient mouse model completely restored kidney development, *the local reduction of BMP4 activity by GREM1 was presumed to be critical to the initiation of UB outgrowth and kidney organogenesis*. Because BMP4 signaling by the mesenchyme surrounding the WD prevents the formation of supernumerary epithelial buds, successful initiation of UB outgrowth most likely requires both the antagonism of BMP4 by GREM1 in mesenchyme and the signaling by GDNF from the MM to RET in the ureteric epithelium (Michos et al., 2007). In addition, autoregulatory feedback signaling between GDNF in the mesenchyme and WNT11 in the epithelial tips regulates branching morphogenesis. *Grem1* is essential for both upregulation of *Wnt11* in the ureteric epithelium and *Gdnf* expression in the mesenchyme and the establishment of epithelial-mesenchymal feedback signaling. The renin-angiotensin system (RAS) has also been shown to be essential to normal renal development (Yosypiv, 2014). Gene mutations of the RAS lead to a spectrum of congenital anomalies of the kidney and urinary tract (CAKUT) resulting from defects in UB morphogenesis. UB tips induce surrounding mesenchymal cells to undergo mesenchymal to epithelial transition, forming the glomerulus to the distal tubule. Therefore, a decrease in UB branching efficiency will result in a significant decrease in nephron endowment. Aberrant branching can result in abnormal nephrogenesis and renal dysplasia. In the RAS, renin cleaves angiotensinogen to angiotensin I, which is converted to angiotensin II by the angiotensin-converting enzyme (ACE) (Yosypiv, 2014). Angiotensin II, the primary effector peptide growth factor of the RAS, acts through two major protein receptors: AT1R and AT2R. Angiotensin II acts through the AT2R to stimulate UB branching by upregulating PAX2, a downstream regulator of GDNF that induces the expression of *GDNF/Ret/Wnt11* pathway genes. These genes promote proliferation in UB tip cells and stimulate UB branching. The critical role for the RAS in UB morphogenesis is observed when ACE inhibitors or AT1R antagonists are administered during pregnancy. These inhibitors cause abnormal nephrogenesis, more specifically, renal tubular dysgenesis, which is characterized by absent or underdeveloped proximal tubules. In mice, gene inactivation of angiotensinogen, renin, ACE, or AT1R results in renal pelvic dilation and hypoplastic papilla. Mutations in the *AT2R* gene in mice result in downregulation of the *GNFR/Ret/Wnt11* pathway gene expression, decreased proliferation, and induction of apoptosis of the UB cells. **Clinically, ureteral duplication and vesicoureteral reflux are associated with *AT2R* gene mutations.** These observations in receptor-deficient mice illustrate the need for a critical balance of cell proliferation and cell apoptosis in normal UB branching and nephrogenesis. *SOX* genes are an essential component of the c-RET signaling pathway and are important developmental regulators expressed in the tips of the UB that are thought to direct UB branching.

Gross Pathologic Description of Retroperitoneal Findings in Bilateral Renal Agenesis

In an extensive autopsy analysis by Ashley and Mostofi, the kidneys were completely absent on gross inspection of the entire retroperitoneum (Ashley and Mostofi, 1960). Complete absence of the renal vessels was observed in about 25% of specimens. **Complete ureteral atresia was observed in 39 of the 42 cases of BRA, and partial ureteral absence was noted in three cases.** With complete absence of the ureter, a rudimentary kidney was discovered in only a few instances.

The adrenal gland may appear flattened (“lying down” sign) on ultrasonography and is usually orthotopic in location; only rarely is the adrenal gland malpositioned or absent (Hoffman et al., 1992) **(Fig. 38.1).** A normally located adrenal gland is expected, because the adrenal cortex embryologically develops independent from the kidney, arising from primitive mesoderm, medial to the urogenital ridge. The medulla develops from ectodermal neural crest cells, whereas the metanephros is derived from the intermediate mesoderm (MM). Fused and/or horseshoe-shaped adrenal glands have been noted on prenatal ultrasound screening (Strouse et al., 2002). Potter noted that fused adrenal glands were often found in the presence of spinal anomalies (Potter, 1965). In a small number of autopsies, the gonads were absent, indicating that the insult occurred before the fifth week and affected the development of the urogenital ridge (Carpentier and Potter, 1959). In the Ashley and Mostofi series, about 50% of cases of complete ureteral atresia showed complete absence of the bladder, and in the remainder, a hypoplastic bladder was found consisting only of a muscular tube with a minuscule lumen (Ashley and Mostofi, 1960). In Potter's series, the bladders were also hypoplastic and lacked ureteral orifices. A normally closed urachus was observed. Abnormal development of the bladder is thought to be the result of a lack of stimulation by fetal urine production, which starts at 10 to 12 weeks' gestation. Alternatively, it has been postulated that UB and WD structures migrating into the ventral cloacal region are needed to initiate normal bladder development. The absence of the UB, and not the *lack* of urine, may arrest bladder development (Katz and Chatten, 1974). This theory is supported by the fact that, despite the absence of bladder filling in bladder exstrophy, many of these bladders are functional following surgical closure alone, whereas the bladders associated with bilateral ureteral ectopia (below the bladder neck) almost invariably require augmentation (Jayanthi et al., 1997; Gearhart and Mathews, 2007).

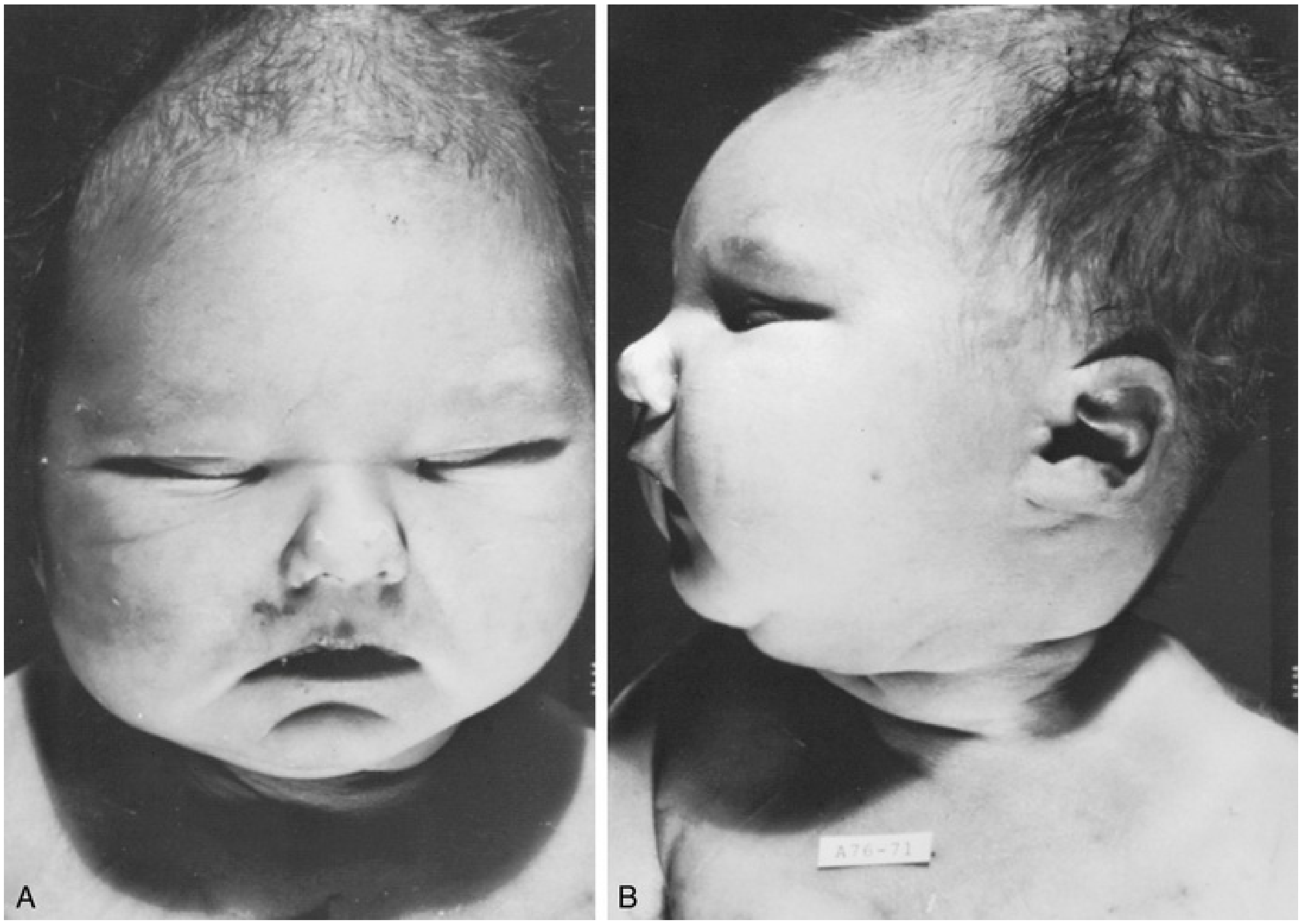

FIG. 38.1 An anephric child who lived 2 days has the typical Potter facial appearance. (A) Note the prominent fold and skin crease beneath each eye, blunted nose, and depression between the lower lip and chin. (B) The ears give an impression of being low set because lobes are broad and drawn forward, but actually the ear canals are located normally.

Phenotypic Features Associated With Bilateral Renal

Agenesis

Potter has extensively described phenotypic features associated with BRA. These infants have low birth weights, ranging from 1000 to 2500 g, and intrauterine growth restriction (IUGR) resulting in part from low iron stores in the liver (Georgieff et al., 1996). **The characteristic facial appearance and deformity of the extremities distinguishes these neonates from healthy newborns (Fig. 38.2).** The infants look prematurely senile and have “a prominent fold of skin that begins over each eye, swings down in a semicircle over the inner canthus and extends onto the cheek” (Potter 1946a, 1946b). This facial feature is a sine qua non of the absence of amniotic fluid, resulting from the lack of functioning renal parenchyma. The nose is blunted, and a prominent depression exists between the lower lip and chin. The ears appear to be low set, are drawn forward, and are often pressed against the side of the head, making the lobes seem unusually broad and exceedingly large. Periauricular pits and tags have been noted (Wang et al., 2001). The skin can be excessively dry and appears too loose for the body. The hands are relatively large and clawlike. The legs are often bowed and clubbed, with excessive flexion at the hip and knee joints (Das et al., 2002). Occasionally the lower extremities are completely fused as seen with sirenomelia (Liatsikos et al., 1999). A lumbar meningocele with or without the Arnold-Chiari malformation and hydrocephalus has been observed (Ashley and Mostofi, 1960). In Potter's series, anomalies of the gastrointestinal tract were found in 60% of fetuses. Anomalies of the external genitalia are commonly encountered (Potter, 1965).

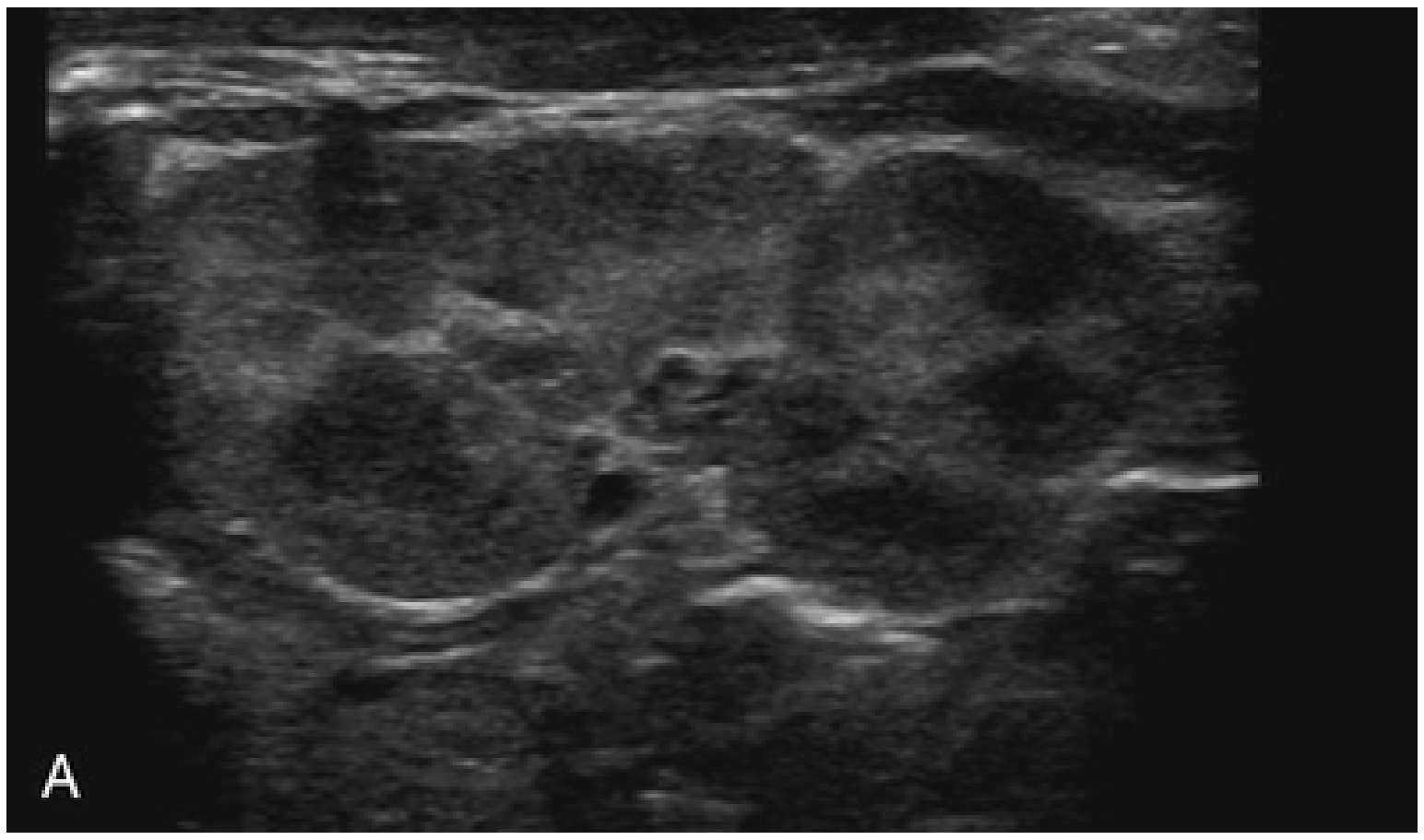

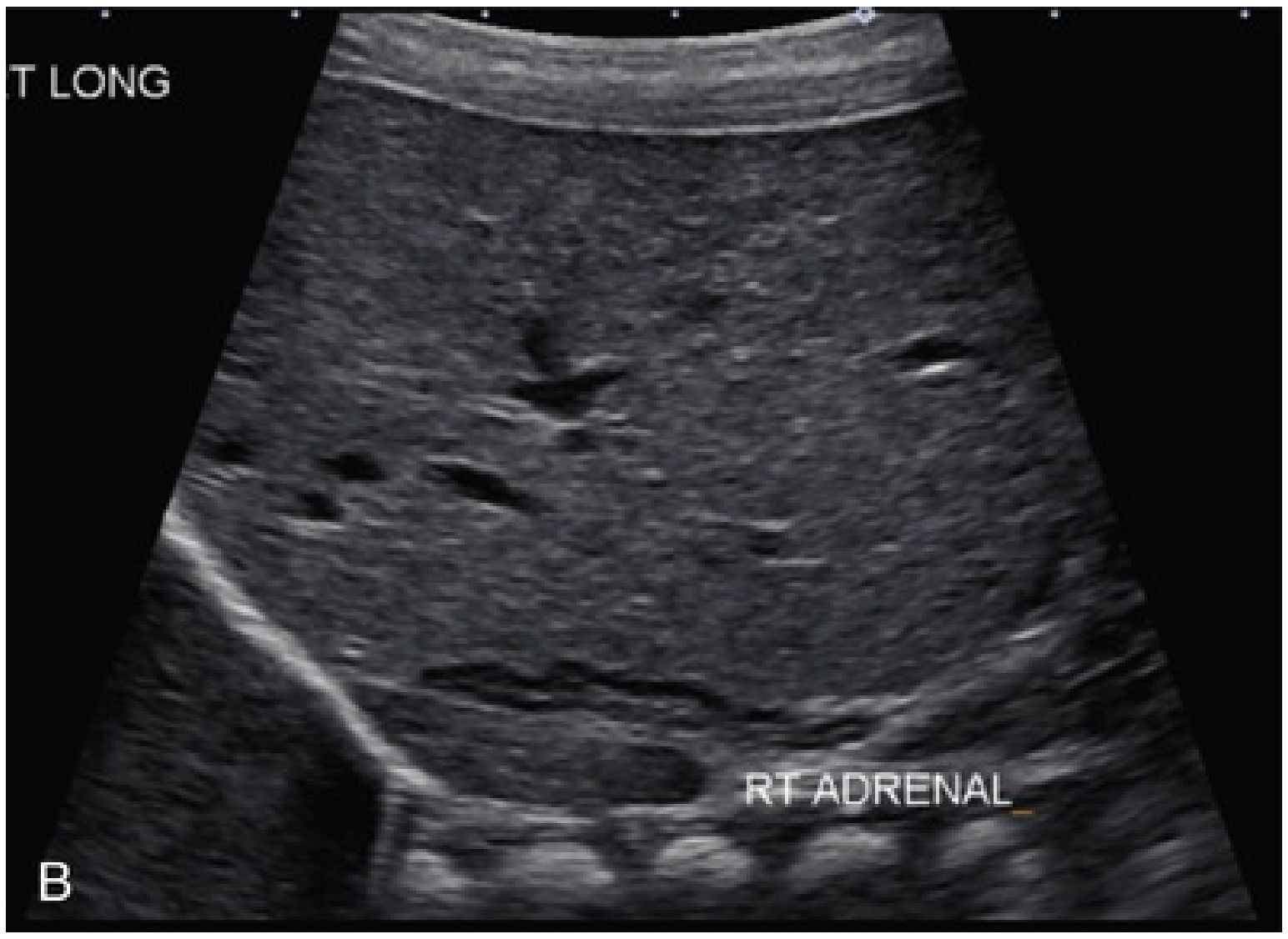

FIG. 38.2 Two-month-old infant with prenatally detected solitary kidney. (A) Postnatal sonogram showing left kidney. (B) Postnatal sonogram showing empty right renal fossa with the "lying down" adrenal sign, a feature seen with renal agenesis or renal ectopia in which the adrenal gland on the affected side appears flattened, elongated, and lying along the spine because of absence of the ipsilateral kidney.

Genital abnormalities in a male fetus with BRA include absence of the scrotum. Penile development is usually normal, but in a few cases, penile agenesis or a rudimentary penis and scrotum has been reported (Potter, 1965; O'Connor et al., 1993). Hypospadias is rare and does not appear to be related to the presence or absence of the testes. **The testes are undescended in 43% of cases** (Carpentier and Potter, 1959). Ashley and Mostofi found testicular agenesis in 10% of cases (Ashley and Mostofi, 1960). The vas deferens is normal in most cases, implying that the factor responsible for the renal agenesis influenced the UB *only after* it formed from a completely elongated WD or that the insult affected the induction of the MM.

Genital abnormalities in a female fetus with BRA include clitoral hypertrophy, which has been noted in a number of cases. There is a relatively high incidence of anomalies of the MD structures and ovaries (Carpentier and Potter, 1959). The ovaries are frequently hypoplastic or absent. The uterus is usually rudimentary or bicornuate but occasionally absent. The vagina is a short, blind-ending pouch or is completely absent.

Role of Amniotic Fluid Production in Fetal Pulmonary Development

The characteristic facial and limb features may result from deformations rather than malformations of structures as a result of the lack of "cushioning" from amniotic fluid (Thomas and Smith, 1974). This observation was confirmed by an experiment in nature, involving a case of mono-amniotic twins, in which one twin with BRA did not have the characteristic Potter facies because it shared the same amniotic sac with the second twin, who had an adequate volume of amniotic fluid (Klinger et al., 1997). Fetal urine is the major source of amniotic fluid, accounting for more than 90% of its volume by the third trimester (Chevalier and Roth, 2007). Pulmonary hypoplasia and a bell-shaped chest are commonly associated findings that were thought to be caused by uterine wall compression of the thoracic cage as a result of oligohydramnios (Bain and Scott, 1960). Fetal lung development begins in the fifth week of gestation with the pseudo-glandular phase and involves branching to form the terminal bronchioles. The critical phase of fetal lung development that is dependent on the presence of amniotic fluid is between 16 and 26 weeks' gestation, which is called the *canalicular phase*. During this phase, terminal bronchioles divide into two or more respiratory bronchioles, which in turn divide into three to six alveolar ducts. Pulmonary airway branching occurs between 12 and 26 weeks' gestation (Reid, 1977; Marszalek et al., 1999; Copland and Post, 2004; Keller et al., 2004). A reduction in the number of branches and a decrease in acini formation in fetuses with BRA imply interference with this process before 16 weeks' gestation (Hislop et al., 1979). It has been suggested that the anephric fetus fails to produce proline, which is a prerequisite for collagen formation in the bronchiolar tree. The fetal kidneys are a primary source of proline, which along with ornithine is required for synthesis of polyamines that are key regulators of gene expression, protein synthesis, and angiogenesis (Clemmons, 1977; Wu et al., 2013). Thus, pulmonary hypoplasia in fetuses with renal abnormalities was thought to mainly result from the absence of renal parenchyma and not from diminished amniotic fluid. This hypothesis is supported by the finding of normal lungs in two infants with prolonged leakage of amniotic fluid beginning at a time when pulmonary hypoplasia would have been expected if the amniotic fluid alone was responsible for the defect (Perlman et al., 1976; Cilento et al., 1994). Peters et al. proposed a two-step process in pulmonary development, with a primary "renal growth factor" influencing early lung development and an amniotic fluid volume–dependent phase influencing later gestational lung growth (Peters et al., 1991a). Smith et al. studied early lung development using a murine knockout model of renal agenesis/dysgenesis and anuria (Smith et al., 2006). They found that pulmonary development occurred early in embryogenesis and showed that hypoplastic lung development preceded the onset of oligohydramnios. These observations support the two-step model proposed by Peters (Peters et al., 1991a). This model is further supported by the fact that oligohydramnios resulting from experimentally induced urinary obstruction is associated with pulmonary hypoplasia in fetal sheep that initially showed normal renal function (Peters et al., 1991a). Restoring amniotic fluid volume only partially restores lung growth. Therefore, uropathy-associated pulmonary hypoplasia appears to be a predominantly the result of oligohydramnios during the canalicular phase of lung development rather than renal dysfunction (Peters et al., 1991b). This observation is further supported by the fact that in some cases of anhydramnios or severe oligohydramnios, serial transabdominal amnioinfusion with saline has improved the fetal lung volume and also postnatal neonatal lung function (Vergani et al., 1997; Szabo et al., 2001).

Prenatal and Postnatal Diagnosis of Bilateral Renal Agenesis

BRA is usually diagnosed by prenatal ultrasonography in the second or third trimester, when severe oligohydramnios is noted and no renal parenchyma can be identified (Forys et al., 2003). Additional diagnostic findings include small lung volumes and chest diameter and abnormal adrenal gland appearance (Heling et al., 2001; Strouse et al., 2002). **The characteristic Potter facies and the presence of oligohydramnios are pathognomonic.** Amnion nodosum—small, white, keratinized nodules on the surface of the amniotic sac—has been considered a placental hallmark of severe oligohydramnios, but the condition is not pathognomonic, and the finding should be interpreted with caution (Adeniran and Stanek, 2007). In a study of 500 infants, every infant voided within the first 24 hours of life, regardless of gestational age (Clark, 1977). After the first 24 hours, anuria without any distention of the bladder is strongly suggestive of BRA.

Postnatal Radiographic Evaluation of a Neonate With Bilateral Renal Agenesis

Renal ultrasonography is the most efficient way to identify and assess the morphology of the kidneys and bladder and to confirm the presence or

absence of urine production. Power Doppler ultrasonography has been highly accurate in determining the status of the renal arteries and documenting blood flow, even in fetuses with suspected BRA (Sepulveda et al., 1998). A flattened orthotopic adrenal gland supports the diagnosis of an absent ipsilateral kidney (Hoffman et al., 1992) (see Fig. 38.1). If abdominal ultrasonography is inconclusive about the presence or absence of kidneys, a radionuclide scan with 99mTc-dimercaptosuccinic acid (^{99m}Tc-DMSA) can be performed at any time after birth. The absence of uptake of the radionuclide in both renal fossae above background activity and in an ectopic location confirms the diagnosis of BRA.

Prognosis for the Patient With Bilateral Renal Agenesis

About 40% of the affected fetuses are stillborn. Of those neonates born alive, most do not survive beyond the first 24 to 48 hours because of respiratory distress and the inability to provide adequate ventilatory support to the profoundly hypoplastic lungs. However, there have been rare instances in the past few years following prenatal interventions for fetuses with BRA permitting the delivery of a "pulmonary survivor," (i.e., fetus with functioning lung tissue and end-stage renal disease [ESRD]) (Sherer et al., 1992; Cameron et al., 1994). These isolated cases of successful deliveries of live neonates with BRA has prompted the ethical dialogue of whether such interventions are appropriate (Sugarman et al., 2018). Cameron et al. reported a case of BRA in which a total of ten amnioinfusions were performed between 17 and 33 weeks' gestation (Cameron et al., 1994). Chorioamnionitis led to preterm delivery at 33 weeks. The infant had no significant pulmonary hypoplasia nor any of the compression effects usually associated with the oligohydramnios sequence. Peritoneal dialysis was provided for the infant with a long-term aim of eventual renal replacement therapy, but dialysis was unsuccessful and the infant died at 23 days of age. Bienstock et al. reported a case of a 34-year-old woman, gravida 1 para 0, who presented at 23 $\frac{5}{7}$ weeks of gestation with a diagnosis of anhydramnios and a female fetus with BRA (Bienstock et al., 2014). The patient underwent weekly serial amnioinfusion with the goal of improving fetal pulmonary development. At 28 weeks' gestation, the patient delivered a live newborn who required minimal respiratory support. The neonate at the time of the case report was 9 months of age and undergoing daily peritoneal dialysis. At the present time, these types of prenatal procedures should be deemed experimental interventions in cases of BRA, and such management can only be undertaken with the oversight of the institutional review board (IRB) and full disclosure of the risks to the expectant mother and the fetus (Polzin, 2017; Sugarman et al., 2018).

Unilateral Renal Agenesis

URA is a condition in which an individual is born with a nonectopic, solitary functioning kidney (SFK) and failure of the contralateral kidney to develop. URA occurs in 1 in 1200 live births. Renal agenesis is most often an isolated event that occurs sporadically, however in a few instances it is actually secondary to an identifiable chromosomal abnormality or as part of a constellation of developmental defects, such as VATER (vertebral, anorectal, tracheoesophageal, renal) or MURCS (Müllerian duct aplasia, uterine hypoplasia, renal aplasia, cervicothoracic somite dysplasia). **Complete absence of one kidney occurs more frequently than BRA but is not easily detected on physical examination and is usually an incidental finding during an imaging study.** The largest study to date of neonates with an isolated single umbilical artery did not find an increased incidence of URA or other malformations (Deshpande et al., 2009). URA may remain undetected unless examination of the external genitalia and/or radiographic evaluation of the female or male pelvis for other reasons shows an anomaly associated with renal agenesis. **Since the mid-1990s, prenatal ultrasound examinations have been performed more routinely, and URA has been detected with increased frequency** (Sipek et al., 1997). **A substantial number of cases thought to be URA were a dysplastic kidney or MCDK that had involuted before birth (5%)** (Hiraoka et al., 2002: Schreuder et al., 2009). MCDK has an incidence of 1 in 4300. Renal aplasia is found in 1 in about 1300 births, which is similar to the incidence of renal agenesis and may be the most common cause of congenital solitary kidney. Renal aplasia includes those units with rudimentary parenchyma and ureter. It is thought to be a result of early regression of the ureteric bud, altered metanephric differentiation, or defects in the reciprocal induction of the branching ureteric duct and the metanephric blastema. Curvilinear calcifications on a plain radiograph or computed tomography (CT) scan are a sign of a previous MCDK that may have involuted and not a true URA (Nakano et al., 1996). **A plain radiograph of the abdomen supports this diagnosis if the splenic or hepatic flexure of the bowel is in its normal location and not in the ipsilateral renal fossa, suggesting that a dysplastic kidney or MCDK may have formed in the renal fossa before involuting** (Matsell, 1998). A flattened adrenal gland or the spleen (on the left) may be mistaken for a kidney on the 20-week structural ultrasound (Woolf and Hillman, 2007).

Incidence

Most autopsy series suggest that URA occurs in 1 of 1100 births (Doroshow and Abeshouse, 1961). Ultrasound screening of 280,000 schoolchildren in Taipei showed the incidence of URA to be 1 in 1200 (Sheih et al., 1990). The high male predominance of BRA is not nearly as striking in the unilateral condition, with a **male-to-female ratio of 1.8 : 1** (Doroshow and Abeshouse, 1961). **Absence of a kidney occurs somewhat more frequently on the left side, and a familial tendency for renal agenesis has been noted** (Cascio et al., 1999). McPherson et al. concluded that inheritance of URA was autosomal dominant with a 50% to 90% penetrance (McPherson et al., 1987). Others who evaluated families with more than one affected individual have confirmed this inheritance pattern (Roodhooft et al., 1984; Battin et al., 1993). Screening recommendations are similar to those for UR (see the Bilateral Renal Agenesis section earlier in this chapter).

Genetic/Syndromic and Other Associations

An absent kidney has been noted in a number of genetic disorders in which there is a deletion of several chromosomal loci: 8q13.3 (Pierides et al., 2002; Dowton et al., 1997), 22q11 (Stewart et al., 1999), and in X-linked and sporadic cases of Kallmann syndrome (Quinton et al., 2001). Several syndromes have been associated with URA, including Turner syndrome, Poland syndrome (Mace et al., 1972), Fraser syndrome (Fryns et al., 1997), branchio-oto-renal (BOR) syndrome (Pierides et al., 2002), and DiGeorge anomaly. Maternal diabetes is associated with a threefold increased risk for renal agenesis and dysplasia (Davis et al., 2010). Animal studies have shown that the developing kidney is adversely affected by a high glucose environment, causing dysmorphogenesis of the metanephros and ureteric bud and disruptions in the normal process of nephrogenesis resulting in a reduced population of nephrons (Kanwar et al., 2005; Cunha et al., 2008). About 30% of children with the VACTERL association (vertebral, imperforate anus, cardiac, tracheoesophageal atresia, renal, and limb anomalies) have URA (Kolon et al., 2000). Children with supernumerary nipples (Urbani and Betti, 1996) and disorders of the ears with hearing loss, especially if it is congenital (Huang et al., 2001), and preauricular pits (Pierides et al., 2002), have been thought to have an increased incidence of URA. Studies have not shown a significant relationship between preauricular pits, minor ear tags, and URA (Arora and Pryce, 2004; Deshpande and Watson, 2006). A renal sonogram is recommended when these ear anomalies are found in the presence of other malformations. In addition, when more than one congenital anomaly is present (e.g., ventricular septal defect and an undescended testis) a renal sonogram is prudent, but when specific complexes of anomalies associated with renal agenesis are present (e.g., VACTERL-associated anomalies), a comprehensive radiographic examination of all organ systems including the spine is mandatory.

Embryology

The embryologic basis for URA and BRA is thought to be similar, and it is most likely caused by abnormalities in the development and/or function of the UB. This observation is supported by the increased incidence of *RET* mutations documented in humans with renal agenesis (Skinner et al., 2008; Davis et al., 2014). Complete absence of a ureteric bud or aborted ureteral development prevents reciprocal induction of the metanephric blastema, which is critical for development into the definitive adult kidney. The metanephros is not likely to be responsible for the majority of cases, because the ipsilateral gonad (derived from adjacent mesenchymal tissue) is rarely absent, malpositioned, or nonfunctioning (Ashley and Mostofi, 1960). **The high incidence of absent or malformed proximal WD structures in the male and anomalies of the MD structures in the female suggest that the embryologic insult affects the UB primarily in its early development and influences the development of WD derivatives.** The abnormality most likely occurs no later than 4 or 5 weeks' gestation, when the UB forms and the WD begins to develop into the ejaculatory duct, seminal vesicle, and vas deferens. The MD in the female begins its medial migration at this time, crossing over the WD (sixth week) during its differentiation into the fallopian tube, uterine horn and body, and proximal vagina (Yoder and Pfister, 1976). **Magee et al. proposed an embryologic classification to explain the association of URA and MD anomalies (Fig. 38.3)** (Magee et al., 1979).

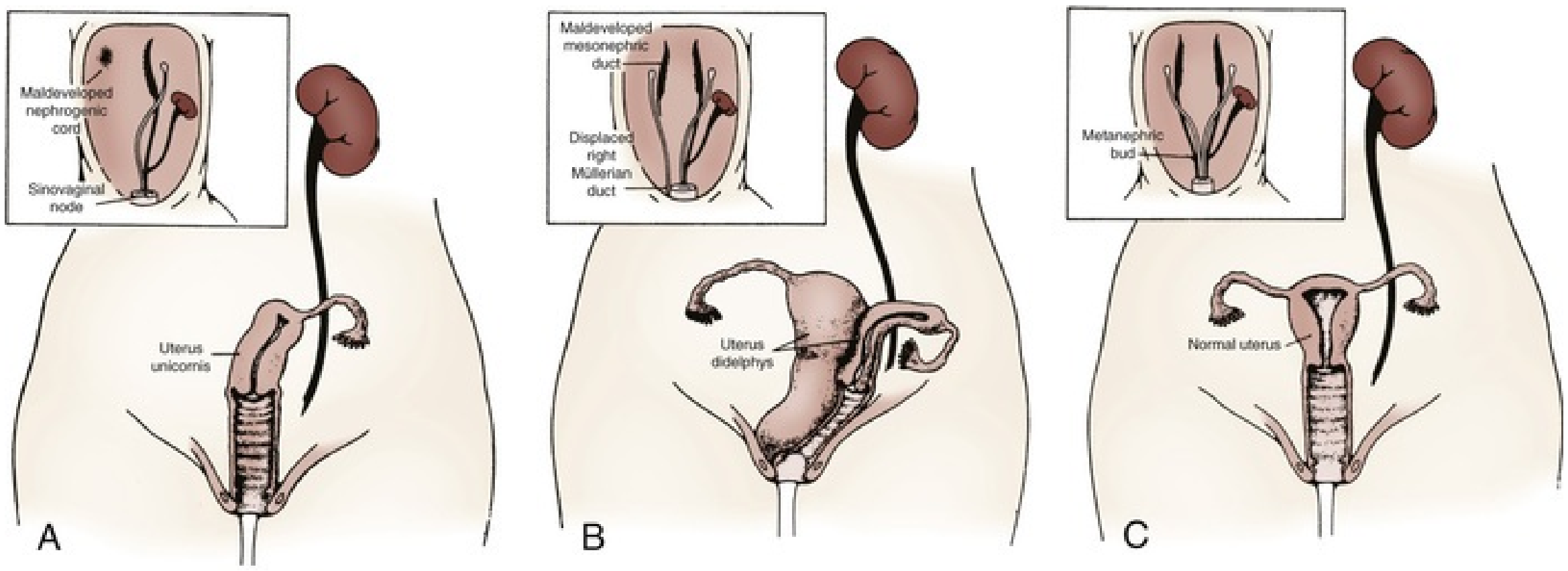
Maldeveloped nephrogenic cord
Sinovaginal node
Uterus unicornis
A
Maldeveloped mesonephric duct
Displaced right Müllerian duct
Uterus didelphys
B
Metanephric bud
Normal uterus
C

FIG. 38.3 A proposed categorization of genital and renal anomalies in females. See text for details. (From Magee MC, Lucey DT, Fried FA. A new embryologic classification for uro-gynecologic malformations: the syndromes of mesonephric duct induced Müllerian deformities. *J Urol*. 1979;121:265–267.)

- In type I URA, the insult occurs before the fourth week of gestation, and there is nondifferentiation of the urogenital ridge structures, including the MD and WD. If unilateral, a uterus consisting of a single MD (unicornuate uterus) will form and will be associated with contralateral renal agenesis.
- In type II URA, the insult occurs early in the fourth week of gestation, affecting both the WD and the UB. Because it is critical that the MD maintains close contact with the WD for MD elongation and subsequent fusion, maldevelopment of the WD affects renal development, MD elongation, contact with the urogenital sinus, and subsequent fusion. Therefore, a didelphys uterus will form with obstruction of the horn and vagina on the side of the URA.
- Finally, in type III URA, the insult occurs after the fourth week of gestation, and the WD and MD elongation and differentiation proceed normally. In this case, only the UB and metanephric blastema are affected, thereby resulting in isolated URA.

Associated Genitourinary and Adrenal Anomalies

Unilateral renal agenesis is usually asymptomatic and often identified on prenatal testing, whereas in the past it was commonly an incidental autopsy finding. The most commonly associated urologic comorbidity is vesicoureteral reflux for both genders, and in females there may also be Müllerian structure abnormalities (Savvidou and Dhillon, 2014). **The ipsilateral ureter is absent in about 60% of cases with URA** (Ashley and Mostofi, 1960). In this series, 19 of 232 with URA had only a portion of the lower end of the ureter present. In most cases of complete absence of the ureters, the bladder showed no evidence of a ureteric orifice with failure of the ipsilateral trigone to develop (Ashley and Mostofi, 1960). Cell lineage studies using a murine model show that the trigone has a urogenital sinus origin and should form normally (Viana et al., 2007; Mendelsohn, 2009). The trigone may not be distinguishable from the surrounding detrusor when the intramural ureter is absent. Therefore, the endoscopic appearance of the trigone in this setting has led to the probable misnomer in the case of the "hemitrigone" (in association with complete ureteral agenesis) or "asymmetrical trigone" (in the presence of a partially developed ureter). Except for ectopia or malrotation, anomalies of the contralateral kidney are infrequent (Chow et al., 2005). **However, abnormalities of the contralateral ureter are not uncommon, including ureteropelvic and ureterovesical junction obstruction in 11% and 7%, respectively** (Cascio et al., 1999), **and reflux in 30%** (Atiyeh et al., 1993; Cascio et al., 1999).

Although the ipsilateral adrenal gland may be flattened (Hoffman et al., 1992), adrenal agenesis occurs in less than 10% of URA cases (Ashley and Mostofi, 1960) and in 17% of individuals with URA undergoing a CT scan (Kenney et al., 1985). Genital anomalies occur much more frequently. The incidence of a reproductive tract malformation for both genders varies from 20% to 40% (Thompson and Lynn, 1966). **Despite the predominance of males with URA, reproductive tract abnormalities in females occur in at least 25% to 50% of cases compared with 10% to 15% in males. Regardless of sex, both gonads are usually normal.** Therefore, the different phenotypes that occur with URA may result from a primary urogenital ridge defect, which explains the finding of gonadal and adrenal agenesis only in the minority of cases, or a primary defect in the development of the UB and WD, which leads to the more common cases of URA and frequently observed abnormalities of the WD, MD, and their derivatives.

Anomalies in the Male

The testis and head of the epididymis, which contain the efferent ductules

derived from the mesonephric tubules, are invariably present; all structures proximal to that point, which develop from the WD (the body and tail of the epididymis, vas deferens, seminal vesicle, ampulla, and ejaculatory duct), are absent in almost 50% of cases with URA (Ochsner et al., 1972). Donohue and Fauver reported that 79% of adult males with an absent vas deferens have an absent ipsilateral kidney; left-sided lesions predominated, with a ratio of 3.5 : 1 (Donohue and Fauver, 1989). However, bilateral absence of the vas has been noted with URA (McCallum et al., 2001). Occasionally, the WD structures are rudimentary or ectopic rather than absent (Holt and Peterson, 1974). Ipsilateral cryptorchidism rarely occurs. A seminal vesicle cyst caused by obstruction (atresia) of the ejaculatory duct may be seen in association with ipsilateral renal agenesis, and it has been referred to as Zinner syndrome (Pereira et al., 2009). Six cases (5%) were noted among 119 boys found to have URA during ultrasound screening (Sheih et al., 1990). Pelvic sonography or magnetic resonance imaging (MRI) in boys diagnosed with URA may demonstrate a seminal vesicle cyst (van den Ouden et al., 1998; Seo et al., 2009). In cases of seminal vesicle cysts and URA, the ureter may insert into the prostatic urethra or seminal vesicle. Cystic dysplasia of the rete testis is a rare benign condition that is often associated with ispsilateral renal anomalies, most commonly URA, and spontaneous regression and conservative treatment in the setting of WD defects have been reported (Jeyaratnam and Bakalinova, 2010). In males evaluated for infertility, the diagnosis of URA should be suspected when the vas deferens or body and tail of the epididymis are impalpable. In children, URA should be considered when vasal and/or epididymal anomalies are incidentally found at the time of scrotal ultrasonography, herniorrhaphy, or orchiopexy.

Anomalies in the Female

A variety of anomalies may result from incomplete MD formation because of alterations in normal WD development. Approximately one-fourth to one-third of women with URA have an abnormality relating to WD development (Thompson and Lynn, 1966; Heinonen, 2004; Friedman et al., 2018). Conversely, 43% of women with internal genital anomalies have URA (Semmens, 1962; Heinonen, 1997). The most common MD anomalies are a unicornuate uterus with complete absence of the ipsilateral horn and fallopian tube or a bicornuate uterus with rudimentary development of the horn on the affected side (Candiani et al., 1997). The fimbriated end of the fallopian tube, however, is usually fully formed and is analogous to the head of the epididymis in the male (Shumaker, 1938). Partial or complete midline fusion of the MD may result in a double (didelphys) or septate uterus with either a single or a duplicated cervix. Complete duplication or separation of the vagina, proximal vaginal atresia associated with a small introital dimple, and complete absence of the vagina have been reported. Obstruction of one side of a duplicated system is not uncommon, and unilateral hematocolpos or hydrocolpos associated with a pelvic mass and/or pain has been described in pubertal girls and has been previously referred to as the Herlyn-Werner-Wunderlich syndrome (Yoder and Pfister, 1976); (Tong et al., 2013). **Smith and Laufer** (Smith and Laufer, 2007) **suggested the acronym OHVIRA to classify the syndrome of *O*bstructed *H*emi*V*agina and *I*psilateral *R*enal *A*nomaly.** In rare instances, this anomalous condition has been mistaken for a large or infected Gartner duct cyst. Sometimes a Gartner duct cyst has been found in a prepubertal girl with an ectopic ureter that is blind ending proximally or one that is connected to a rudimentary kidney (Currarino, 1982). A total of 6% of girls with URA were found to have a Gartner cyst on mass screening of schoolchildren (Sheih et al., 1990). Infertility occurs in as many as 33% of affected women with renal agenesis and unicornuate uterus (Heinonen, 1997). When anomalies of the uterus, including congenital absence of the uterus, unicornuate uterus, and didelphic uterus, are found on ultrasonography or MRI, radiologic investigation of the urinary tract often demonstrates URA or other renal anomalies (Reichman and Laufer, 2010). Based on review of existing literature, Friedman et al. advocated for pelvic ultrasound as a screening tool after thelarche but before menarche to identify Müllerian anomalies in patients with URA (Friedman et al., 2018).

Another anomaly often associated with URA is the Mayer-Rokitansky-Küster-Hauser syndrome (MRKH), which is a complex of malformations occurring in 1 of 4500 newborn females (Guerrier et al., 2006; Oppelt et al., 2012; Pizzo et al., 2013). This syndrome includes not only renal anomalies, but also genital tract anomalies ranging from upper vaginal atresia to total Müllerian agenesis in an otherwise phenotypically normal 46,XX female. There are two main subtypes. Type I is the typical form characterized by the finding of only symmetrical muscular buds or Müllerian remnants and normal fallopian tubes. Type II, which is more common but considered the atypical form, is characterized by asymmetrical hypoplasia of one or two buds with or without dysplasia of the fallopian tubes. Most importantly, the atypical form is often associated with renal anomalies, primarily URA, ectopia of one or both kidneys, or horseshoe kidney in about 40% to 60% (Guerrier et al., 2006). Duncan et al.

reported on the most severe constellation of malformations and referred to this as the MURCS association; this includes Müllerian duct aplasia (96%), renal aplasia or ectopia (86%), and cardiothoracic somite dysplasia (two to four anomalous vertebrae between C5 and T1 [80%]) Duncan et al., 1979).

Anomalies of Other Organ Systems

Dursun et al. found that 44% of individuals with a congenital solitary kidney had various nongenitourinary anomalies including cardiovascular (15%), gastrointestinal (9%), neurologic (3%), and hematologic (6%) (Dursun et al., 2005).

Diagnosis and Radiographic Evaluation

About 90% of fetal kidneys associated with a contralateral URA or MCDK undergo compensatory hypertrophy in utero from 20 weeks' gestation (van Vuuren et al., 2012). Postnatally, retroperitoneal ultrasonography with color Doppler will show an absence of the kidney and ipsilateral renal vessels (see Fig. 38.1). The diagnosis of URA usually can be confirmed with a radionuclide DMSA scan showing absent uptake of the isotope on one side, with the contralateral kidney often showing compensatory hypertrophy. A DMSA scan will also detect an ectopic (usually pelvic) or a crossed ectopic kidney in cases in which the nonvisualized orthotopic kidney is thought to be absent (Volkan et al., 2003). In some cases, crossed fused ectopia may be difficult to distinguish from a congenital solitary kidney that has undergone compensatory hypertrophy or a solitary complete duplication. A small dysplastic kidney or MCDK may be misdiagnosed as URA when a kidney is not seen on ultrasonography (Mesrobian et al., 1993). When a fetus with other suspected organ anomalies undergoes MRI, an absent kidney can be confirmed (Dell'Acqua et al., 2002). **When URA is diagnosed, especially in infants and young children, a voiding cystourethrogram may be performed because there is a 28% incidence of contralateral reflux (Kaneyama et al., 2004).**

Special Considerations

The most common question many parents of a child with URA ask is "Will having only one kidney affect my child's life, and will there be any restrictions on the child's activities?" **Psooy summarized several North American studies, which suggest that whereas bicycling, sledding, downhill**

skiing/snowboarding, and equestrian activities are the more common causes of renal injury, motor vehicle accidents as passenger and pedestrian result in more renal trauma than sports activities (Psooy, 2009). In addition, these sports activities have more than a fivefold relative risk for head injury compared with renal injury. Psooy noted that children are generally not restricted from these activities just because they have "only one head" (Psooy, 2009). Rice and the American Academy of Pediatrics Council on Sports Medicine and Fitness advise that each athlete needs individual assessment for his or her particular sport and that wearing protective padding may reduce the risk for injury to the solitary kidney, thus allowing participation in most sports (Rice and American Academy of Pediatrics Council on Sports Medicine and Fitness, 2008). Since those recommendations were proposed (Grinsell et al., 2012) used data from the National Athletic Trainers' Association High School Injury Surveillance Study, which calculated the rates for sport-specific injuries to select organs. Although more than 4.4 million athlete-exposures, defined as 1 athlete participating in 1 game or practice, and 23,666 injuries were reviewed, only 18 kidney injuries (3 lacerations and 15 contusions) occurred, none of which were catastrophic or required surgery. **So, in summary, having a solitary kidney does not preclude an individual from safely participating in sports and athletic activities.**

Prognosis

In the past, there was no definitive evidence that having a congenital solitary kidney predisposed to long-term problems when compared with outcomes of individuals undergoing nephrectomy for Wilms tumor or donor nephrectomy (Shapiro et al., 2003). It is now well recognized that the latter two groups represent completely different conditions compared with the congenital solitary kidney group in which genetic or environmental events may have altered the development of both kidneys, impacting growth and function throughout life. The remaining kidney is thought to be healthy in living kidney donors who have lower rates of end-stage renal failure (ESRF) than the general population or those undergoing nephrectomy for tumor in childhood (Ibrahim et al., 2009).

Current Concepts Regarding Prognosis in Adults With Unilateral Renal Agenesis

Several studies examine the long-term outcome of children with SFK, although there are no definitive conclusions. These studies are based on the "hyperfiltration hypothesis" of Brenner et al. (Brenner et al., 1996). In their rodent model, unilateral nephrectomy led to hyperfiltration of the remnant nephrons and altered sodium balance with subsequent glomerular hypertension. These hemodynamic changes resulted in glomerular damage with albuminuria and glomerulosclerosis. The hyperfiltration hypothesis may be extrapolated to individuals with SFK who have reduced nephron number, especially when the solitary kidney is also affected by CAKUT (Westland et al., 2012, 2013a). The CAKUT spectrum includes renal agenesis, renal hypoplasia or dysplasia, MCDK, ureteropelvic junction (UPJ) obstruction, megaureter, posterior urethral valves, and vesicoureteral reflux, and occurs in about 1 in 600 births (Wiesel et al., 2005), and it is found in 20% of those with chromosomal abnormalities (Garne et al., 2009). About 10% of those with CAKUT have close relatives with renal abnormalities, but most are asymptomatic (Bulum et al., 2013). **There is now evidence that subtle defects in UB branching can cause reduced nephron number, which may lead to renal disease later in life** (Brenner and Mackenzie, 1997; Costantini and Shakya, 2006; Chevalier, 2009).

In humans, there is an eightfold range in the normal variation of the actual number of glomeruli, ranging from 200,000 to 1.8 million (Hughson et al., 2003). Therefore it is more likely for an individual with nephron numbers at the lower end of the spectrum to be at greater risk for renal insufficiency at any age and from any etiology (Luyckx and Brenner, 2010). Luyckx et al. proposed clinical surrogates for low nephron number and susceptibility to hypertension and renal disease in humans (Luyckx et al., 2013). They included low birth weight, preterm birth, short stature, reduced kidney volume by ultrasonography, low kidney mass by scintigraphy, glomerulomegaly by biopsy, gene polymorphisms (PAX2, RET), and infants of diabetic mothers.

Prenatal renal development may be affected by medications including ACE inhibitors, dexamethasone, antiepileptic medications, aminoglycosides, and IUGR and maternal diabetes. In the past, studies of renal survival in children with CAKUT have been difficult to perform because they involve decades of follow-up, and the phenotypes of these disorders are not uniform (Pope et al., 1999). Sanna-Cherchi et al. evaluated the long-term functional outcomes in individuals with CAKUT, including those with URA from a single pediatric nephrology center (Sanna-Cherchi et al., 2009). A total of 312 patients with CAKUT who had a known defect of the number or size of at least one kidney were followed up for as long as 20 years. Patients with isolated vesicoureteral reflux and duplications were excluded. Dialysis-free survival was evaluated, taking into consideration reflux, age at diagnosis, hypertension, proteinuria, and serum creatinine. Six subgroups were examined, including URA, unilateral and bilateral renal hypoplasia, posterior urethral valves, MCDK, and horseshoe kidney. These investigators found that by 30 years of age, 19% of all patients were on dialysis, most of whom had posterior urethral valves, bilateral renal hypoplasia, or URA. Further analysis showed that patients with a solitary kidney had a 50% probability of requiring dialysis by 30 years of age. Notably, most patients with URA in this study were diagnosed during adolescence and had a normal creatinine level at the time of diagnosis. Interestingly, the patients diagnosed at birth had a slightly elevated creatinine level (0.68 mg/dL). These and other studies point to the fundamental differences in individuals with URA and adults who undergo unilateral nephrectomy. The number of nephrons in children with URA may be abnormally low, and those with fewer nephrons may be at greater risk for developing hypertension, albuminuria, and focal glomerulosclerosis, and ultimately progressing to ESRD.

The KIMONO (Kidney of Monofunctional Origin) study retrospectively evaluated 116 children with congenital or pSFK (primary SFK), 54 with URA, 62 with MCDK, and 90 with sSFK (secondary SFK after unilateral nephrectomy for CAKUT or tumor) (Westland et al., 2011). About 30% had ipsilateral CAKUT (the side of the SFK only) in both groups. Renal injury was defined as hypertension and/or albuminuria and/or the use of renoprotective medication. **Of all children with SFK, 32% had renal injury at a mean age of 9.5 years.** GFR declined as early as 9 years of age, and microalbuminuria developed at about 16 years of age. As expected, children with ipsilateral CAKUT, involving pSFK or sSFK, had more renal injury than those in either group without CAKUT. Although the results of the KIMONO study are similar to those of Sanna-Cherchi et al., the study did not consider the different molecular origin(s) and clinical course of the different conditions of each patient. The estimates of renal injury and the proportion of patients who develop ESRD are most likely overestimated because of several factors including selection bias.

Calderon-Margalit et al. conducted a nationwide, population-based cohort study of over 1 million Israeli adolescents who were examined before compulsory military service and linked this information to the Israeli ESRD registry (Calderon-Margalit et al., 2018). Although only 1% of patients with a history of CAKUT, pyelonephritis, or glomerular disease in childhood, with no apparent sequelae in adolescence, developed ESRD during 30 years of follow-up. The risk in such patients was approximately four times as high as the risk among participants who had no such history. The association between CAKUT and the risk for ESRD in adulthood was similar in magnitude to other renal diseases identified in childhood such as pyelonephritis or glomerular diseases. This study, along with the KIMONO study and the study by Sanna-Cherchi et al. (Sanna-Cherchi 2009), underscores the importance of identifying individuals who are more likely to progress to chronic renal failure in adulthood and ensuring appropriate long-term follow-up.

Current suggestions for children with SKF include annual assessments of blood pressure and microalbuminuria (first morning specimen) when there is no CAKUT and biannually when there is CAKUT, because hypertension and microalbuminuria (>30 mg/24 h) are hallmarks of progressive decrease in glomerular filtration rate (Hegde and Coulthard, 2009; Westland et al., 2013a, 2014).Treatment with an ACE inhibitor may be indicated to slow the progression of renal injury (Puddu et al., 2009). Depending on the age of the patient, dietary changes may also be recommended, including limiting salt and avoiding excessive protein intake. Blood pressure, urinary albumin, and serum creatinine are monitored 2 to 4 times per year when the GFR less than 60 mL/min/1.73 m^2 or the individual is taking medication for hypertension or proteinuria (Westland et al., 2013b, 2014). In addition, periodic ultrasonography is performed for both pSFK and sSFK, especially with CAKUT to assure appropriate compensatory hypertrophy and or growth into adolescence. For those with GFR greater than 60 mL/min/1.73 m^2 who are not on medication, serum creatinine can be performed every 5 years (Westland et al., 2014).

Supernumerary Kidney

Occasionally, there will be more than two kidneys detected within an individual; the additional kidney(s) are called *supernumerary* kidneys (in excess of the normal number). **The supernumerary kidney is truly an accessory organ with its own collecting system, blood supply, and distinct encapsulated parenchymal mass.** Three or more separate kidneys can form with the additional renal units usually being smaller. The two main kidneys are commonly functionally normal, equal in size, and orthotopically located. The supernumerary kidney may be either totally separate from the normal kidney on the same side or connected to it by loose areolar tissue (Geisinger, 1937). The ipsilateral ureters may be bifid or completely duplicated. The condition is not analogous to a single kidney with ureteral duplication in which the collecting systems drain portions of one parenchymatous mass surrounded by a single capsule.

Incidence

The true incidence of this anomaly cannot be determined because only about 100 cases have been reported (McPherson et al., 1987). It affects males and females equally but has a higher predilection for the left side (N'Guessan and Stephens, 1983). Four cases of bilateral supernumerary kidneys have been reported (Oto, Kerimoglu et al. 2002).

Embryology and Molecular Mechanisms Involved in Development of a Supernumerary Kidney

A second UB or a branching from the initial UB appears as a necessary first step. Next, the nephrogenic anlage may divide into two metanephric tails, which separate entirely when induced to differentiate by the separate or bifid UBs (N'Guessan and Stephens, 1983). The two metanephroi develop only after being penetrated by the bifid or separate UBs. Kidney development is initiated when a single UB forms from the WD in response to GDNF secreted by the adjacent metanephric mesenchyme. Posterior restriction of GDNF expression is critical for the development of a UB in the normal position, whereas another intercellular signaling system, including SLIT2 or its receptor ROBO2, is also important in ensuring that a single UB forms in the appropriate location. Grieshammer et al. showed that mutant mice lacking either SLIT2 or its receptor ROBO2 develop supernumerary UBs that are correlated with abnormal maintenance of GDNF expression in anterior MM (Grieshammer 2004). The SLIT2/ROBO2 intercellular signaling system restricts, directly or indirectly, the extent of the GDNF expression and plays a critical role in precisely positioning the site of kidney induction.

Description and Associated Anomalies

The supernumerary kidney is a distinct renal mass that may be either completely separate or only loosely attached to the major kidney on the ipsilateral side. **In about 60% of cases, it is located caudad to the dominant kidney, which is in its orthotopic position in the renal fossa**. When a separate and distinct ureter is present, the supernumerary kidney is more likely to be cranial to the dominant kidney but caudal to the adrenal gland (Bernik et al., 2001). The supernumerary kidney is reniform but generally smaller than the main ipsilateral kidney. In almost one-half of reported cases, the collecting system is severely dilated with thin parenchyma, suggesting obstruction to the outflow of urine. The ipsilateral and contralateral kidneys are usually normal. The ureteral interrelationships on the side of the supernumerary kidney can be variable. Convergence of the ipsilateral ureters distally to form a common stem and a single ureteral orifice occurs in 50% of cases (N'Guessan and Stephens, 1983), which suggests “a bud off of a bud” situation (Fig. 38.4). Two completely independent ureters, each with its own entrance into the bladder, are seen in the other 50% of cases (Fig. 38.5). The Weigert-Meyer principle is usually followed, but in 10% of cases, the caudal kidney has a ureter that does not follow the rule and enters the trigone below the ipsilateral ureter (Tada et al., 1981). Individual case reports have described calyceal communications between the supernumerary and the dominant kidney or fusion of the dominant kidney's ureter with the pelvis of the supernumerary kidney to create a single distal ureter that then enters the bladder (Kretschmer, 1929). The vascular supply to the supernumerary kidney is anomalous, depends on its position in relation to the major ipsilateral kidney, and should be separate to be considered a true supernumerary kidney (Fig. 38.6) (Kaneoya et al., 1989).

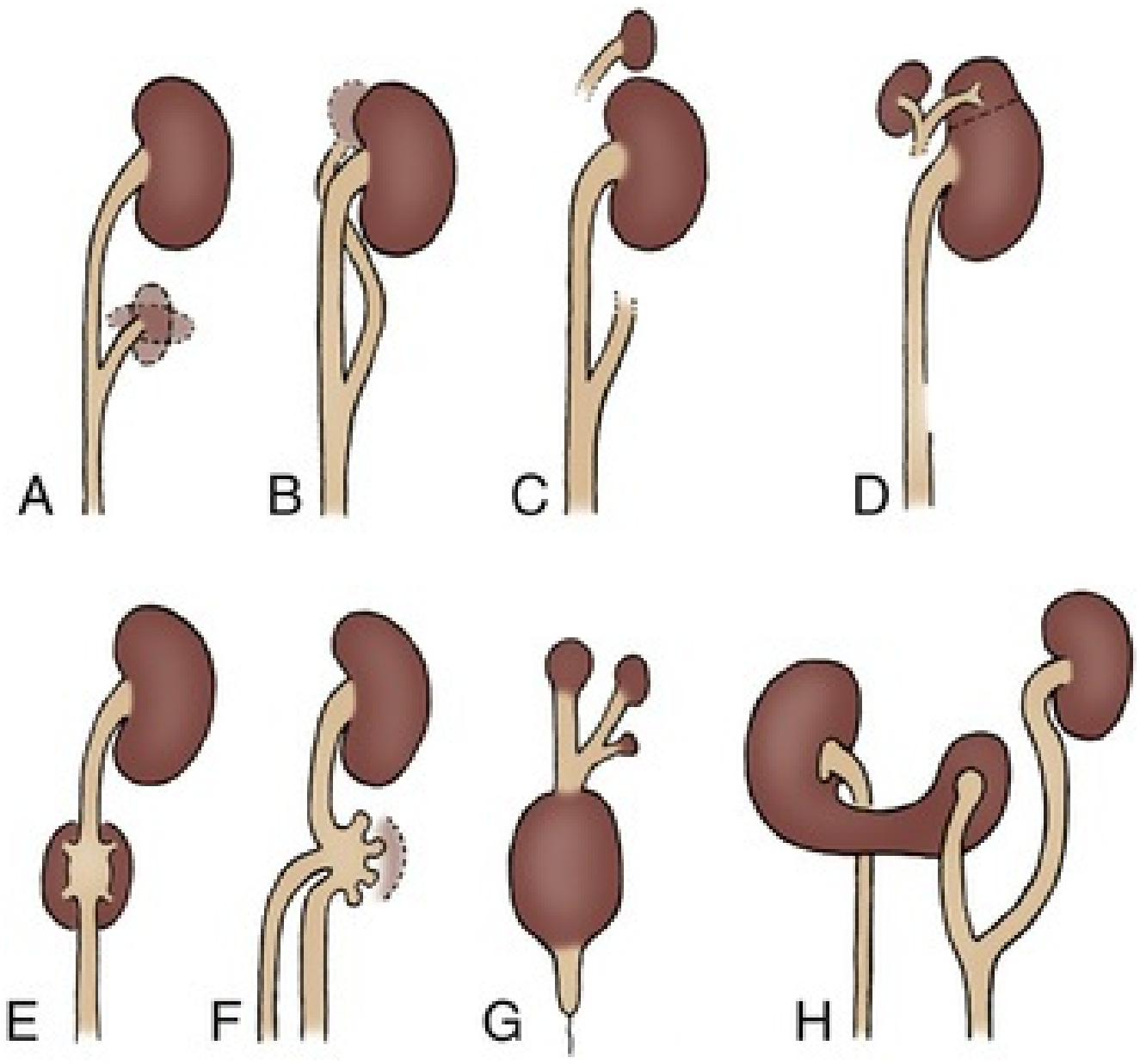

FIG. 38.4 (A to H) Various patterns of urinary drainage when ureters form a common stem. All kidney positions are relative only and are depicted on the left side for ease of interpretation. *Dashed lines* indicate that detail was not defined. (From N'Guessan G, Stephens FD. Supernumerary kidney. *J*

Urol. 1983;130:649–653.)

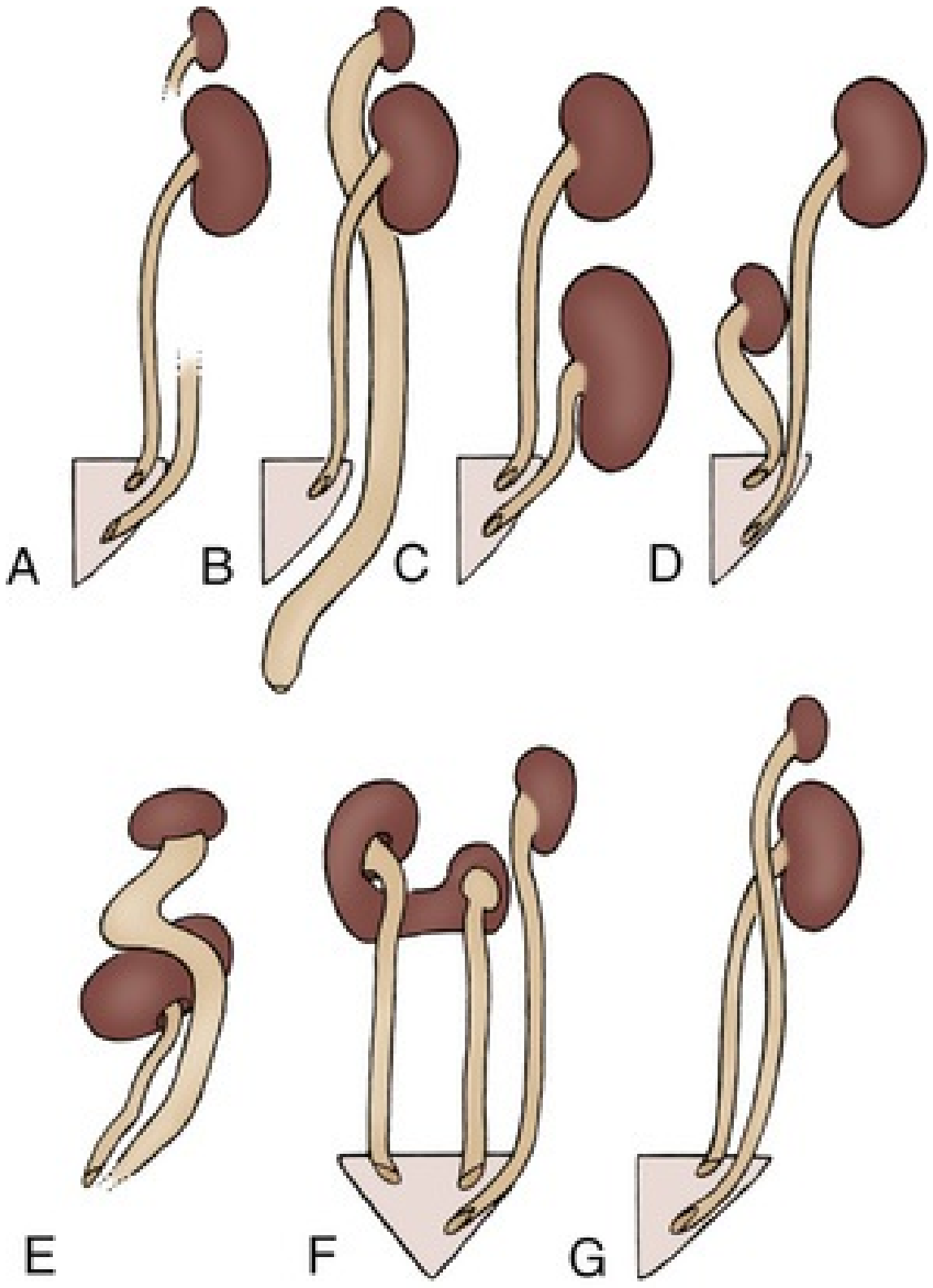

FIG. 38.5 (A to G) Various patterns of urinary drainage of supernumerary and ipsilateral kidneys when ureters are completely separated. All kidney positions are relative only and are depicted on the left side for ease of interpretation. *Dashed lines* indicate that detail was not defined. (From N'Guessan G, Stephens FD. Supernumerary kidney. *J Urol.* 1983;130:649–653.)

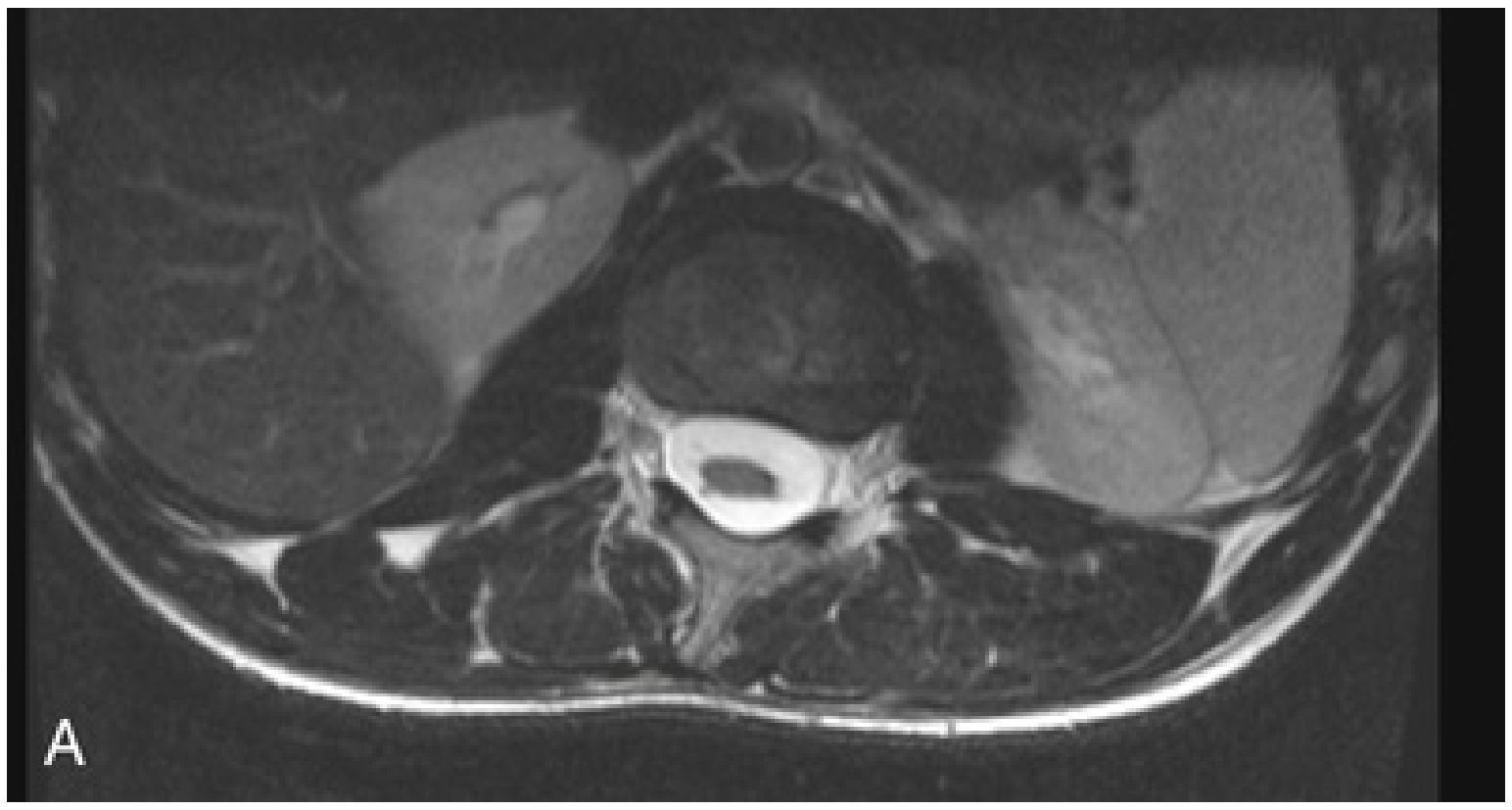

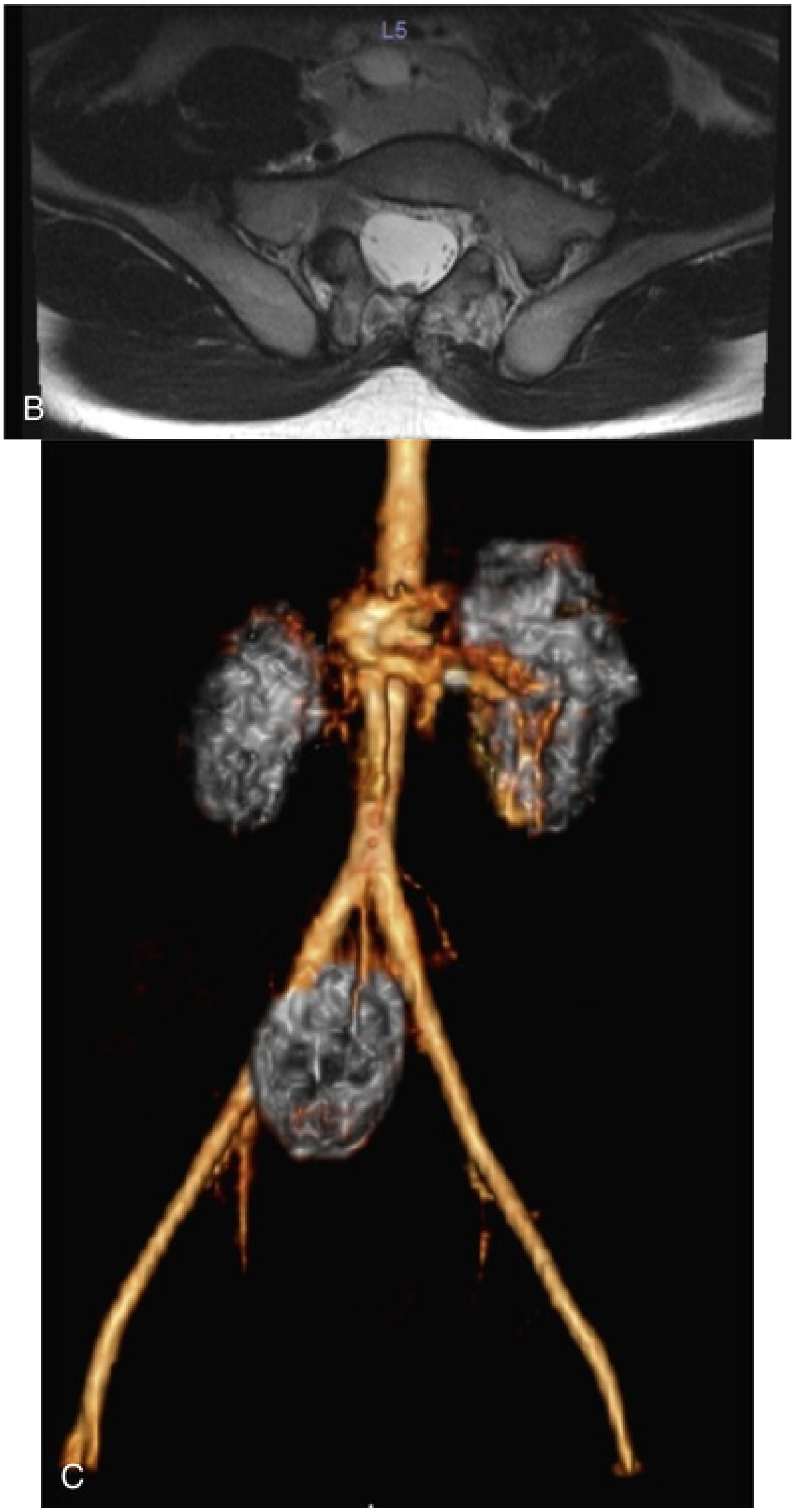

FIG. 38.6 A 12-year-old child with cloacal exstrophy. (A) Magnetic resonance (MR) axial images of bilateral orthotopic kidneys in a patient with supernumerary kidney. (B) MR axial images of pelvic supernumerary kidney overlying the sacrum. (C) Three-dimensional coronal reconstruction of MR images. Blood supply to the pelvic kidney is from the right internal iliac artery, and venous drainage is into the inferior vena cava.

Associated Symptoms

This anomaly is rarely symptomatic, but it may become symptomatic in early adulthood. The average age at diagnosis is 36 years. Pain, fever, hypertension, and a palpable abdominal mass are the usual presenting complaints. Urinary infection, obstruction, or both, are the major conditions that lead to evaluation. Ureteral ectopia from the supernumerary kidney may produce urinary incontinence, but this is extremely rare. A palpable abdominal mass secondary to a carcinoma in the supernumerary kidney has been described in two patients. In 25% of all reported cases, the supernumerary kidney is discovered only at autopsy (Carlson, 1950).

Diagnosis

If the supernumerary kidney is normal and asymptomatic, it is usually diagnosed when radiographic studies are performed for other reasons. The kidney may be inferior and distant enough from the ipsilateral kidney so that it does not alter the position of the normal kidney (Conrad and Loes, 1987). If it is in close proximity, it may displace the predominant kidney or its ureter very slightly. A supernumerary kidney may become symptomatic because of obstruction from a stone (Koureas et al., 2000). In this case, ultrasonography may demonstrate distortion of the normal ipsilateral kidney and ureter. If the collecting system is bifid, the dominant kidney on that side will usually be involved in the same disease process. If the ureters are separate, the ipsilateral kidney may show the effects of an abnormal supernumerary kidney. Magnetic resonance urography (MRU) and retrograde pyelography may be needed to delineate the anomaly. Radionuclide imaging provides information about relative function in the supernumerary and the normal kidneys (Conrad and Loes, 1987). Cystoscopy reveals one or two ureteral orifices on the ipsilateral side, depending on whether the ureters are completely duplicated. Ureteral ectopia may exist in or outside the bladder. Occasionally, a supernumerary kidney is not accurately diagnosed until the time of surgery or at autopsy, or it may mimic a duplication (Kaneoya et al., 1989).

Key Points: Anomalies of Renal Number

- BRA is rare, estimated at 1 in 5000 births, and is almost always incompatible with life because of associated pulmonary hypoplasia.

- URA occurs in 1 in 1200 births. It predominates in males and occurs more frequently on the left side.
- Despite the predominance of males with URA, Müllerian duct abnormalities occur in 25% to 50% of cases of females with URA compared with WD anomalies in 10% to 15% of males with URA.
- Patients with solitary kidney carry a risk for CKD.
- The supernumerary kidney is a definitive accessory organ with its own blood supply and encapsulated parenchyma. The ureteral interrelationships on the side of the supernumerary kidney can be variable.

Anomalies of Renal Ascent

Simple Renal Ectopia

The fetal kidney ascends to its usual location from its origin in the pelvis in a predictable timeframe during gestation. The UB arises from the WD at the end of the fourth week, grows cranially toward the urogenital ridge, and acquires a cap of metanephric blastema by the fifth week. This unit of metanephric tissue and UB migrate cephalad while simultaneously rotating medially on its long axis. **The entire process of renal ascent is completed between 6 and 9 weeks' gestation so that the kidney resides in its usual location in the lumbar retroperitoneum below the adrenal glands.** The precise mechanism for this ascent remains unknown, and a detailed discussion of the molecular mechanisms involved in UB outgrowth and metanephric interactions is presented elsewhere in this textbook (see Chapter 20).

When the mature kidney fails to reach its normal location, the condition is known as *renal ectopia*. The term is derived from the Greek words *ek* ("out") and *topos* ("place"), and it literally means "out of place." An ectopic kidney can be found in one of the following positions: pelvic, iliac, abdominal, thoracic, and contralateral or crossed. There have been many purported factors that may influence the orderly ascent and rotation of the kidneys. Speculations have included UB maldevelopment (Campbell, 1930), defective metanephric tissue that fails to induce ascent (Ward et al., 1965), genetic abnormalities, and maternal illnesses or teratogenic causes (Malek et al., 1971). A vascular barrier that prevents upward migration secondary to persistence of the fetal blood supply has also been postulated (Baggenstoss, 1951), but the existence of an "early" renal blood supply does not prevent the affected kidney's movement to its ultimate position. The aberrant blood supply is probably an observed end result, not the cause, of the renal ectopia.

Incidence

The reported incidence of renal ectopia among autopsy series varies from 1 in 500 (Campbell, 1930) **to 1 in 1200** (Bell, 1946a), **with an average occurrence of about 1 in 900. There is no significant gender difference, and the left side is favored slightly over the right side** (Abeshouse and Bhisitkul, 1959). A solitary ectopic kidney occurred in 1 of 22,000 autopsies (Delson, 1975; Stevens, 1937). Sheih et al. performed a screening study for renal anomalies in schoolchildren and found that approximately 1 in 4000 had the renal anomaly categorized as renal ectopia (Sheih et al., 1989). A screening study in a Kenyan population of residents older than 2 years of age revealed simple renal ectopia in 0.35% (approximately 1 in 300) of the screened population (Magak et al., 2004). This rate is much higher than expected compared with other published rates, leading the authors to speculate either a common teratogenic exposure or genetic conditions. Bilateral ectopic kidneys are rarely observed and accounted for only 10% of all patients with renal ectopia in one study (Malek et al., 1971).

Description and Associated Anomalies

When ectopia occurs below the diaphragm, the classification of ectopia is based on the position of the kidney. The pelvic kidney lies opposite the sacrum, and the kidneys below the aortic bifurcation are the most common sites of ectopia; the lumbar kidney resides near the sacral promontory in the iliac fossa and anterior to the iliac vessels, and the abdominal kidney is above the iliac crest and is adjacent to the second lumbar vertebra (Fig. 38.7). The ectopic kidney typically is smaller than its orthotopic counterpart and, because of persistent fetal lobulations, may not conform to the usual reniform shape. Rotation of the kidney occurs during ascent of the kidney, and with renal ectopia representing an arrestment of ascension, the axis of the kidney is also frequently affected. **The renal pelvis is usually anterior (instead of medial) to the parenchyma, because the kidney has incompletely rotated.** The axis of the ectopic kidney may be slightly medial or vertical, but it may be tilted as much as 90 degrees laterally so that it lies in a true horizontal plane. **As a result of these anomalies of ascension and rotation, hydronephrosis is a common radiographic finding from a variety of causes.** Gleason et al. reported that hydronephrosis in renal ectopia resulted from obstruction in 50% of cases, either at the ureteropelvic or the ureterovesical junction (70% and 30%, respectively), 25% from reflux grade III or greater, and 25% from the malrotation alone (Gleason et al., 1994).

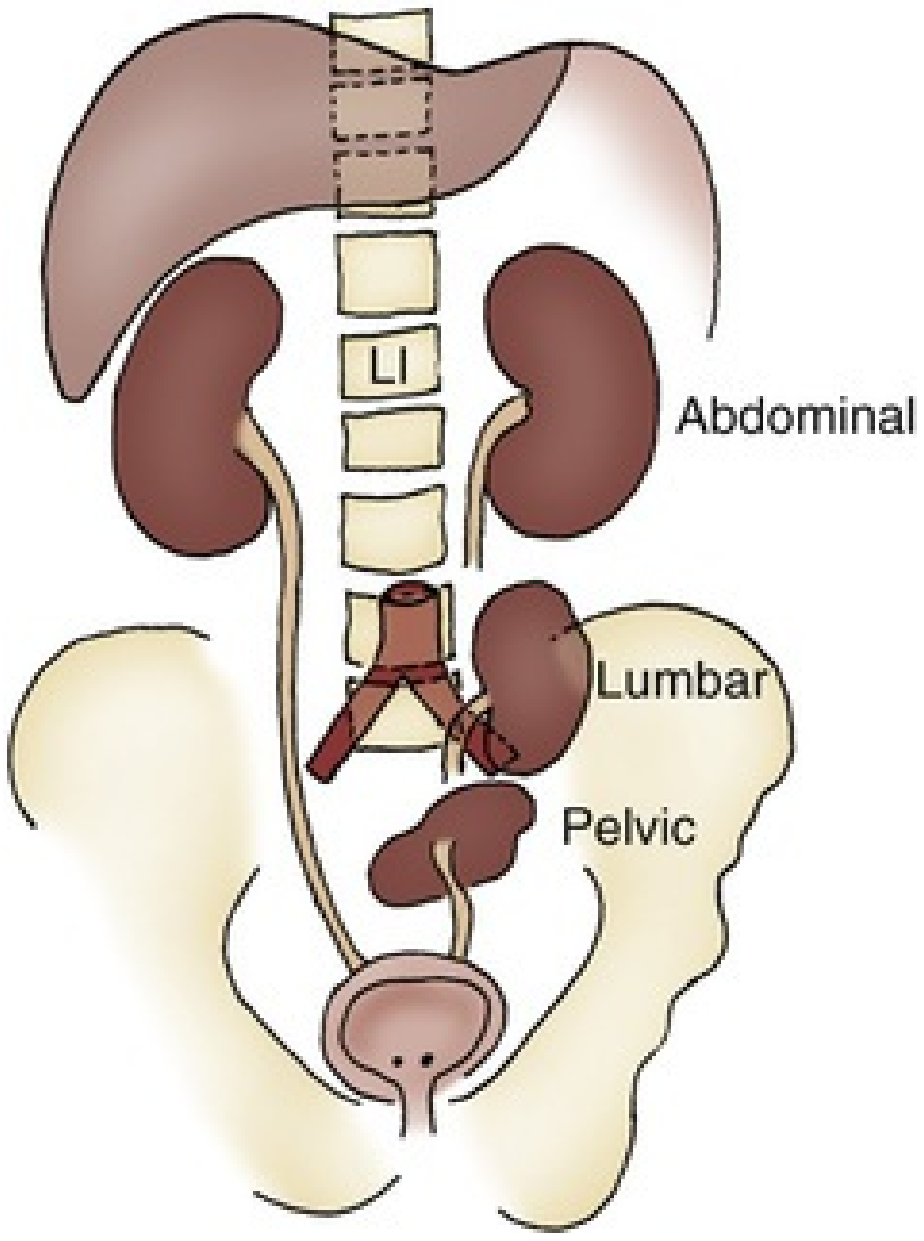

FIG. 38.7 Incomplete ascent of kidney. The kidney may halt at any level of its ascent from the pelvis. (From Gray SW, Skandalakis JE. The kidney and ureter. In: Gray SW, Skandalakis JE, eds. *Embryology for surgeons.* Philadelphia, PA: Saunders; 1972.)

Reflux has been reported in approximately 30% to 50% of children with ectopic kidneys when cystography is performed (Guarino et al., 2004; Dogan et al., 2017, Kramer and Kelalis, 1984). Vesicoureteral reflux occurs in either the ectopic kidney or orthotopic kidney. Guarino et al. observed that 86% of patients had reflux into the orthotopic kidney when reflux was also present in unilateral renal ectopia (Guarino et al., 2004). **The ureter associated with the ectopic renal unit usually enters the bladder on the ipsilateral side with its orifice positioned normally, except for those unusual cases with ectopic ureters** (Borer et al., 1998).

The arterial and venous network is frequently anomalous, and its vascular pattern depends on the ultimate position of the kidney (Dretler et al., 1971; Anson and Riba, 1939). There may be one or two main renal arteries arising from the distal aorta or from the aortic bifurcation, with one or more aberrant arteries emanating from the common or external iliac or even the inferior mesenteric artery. The kidney may be supplied entirely by multiple anomalous branches. **Exact delineation of the anomalous blood supply can be pursued with CT/MR imaging or formal angiography when necessary and can be helpful before surgical intervention (**Kara et al., 2011; Gülsün et al., 2000).

Although the contralateral kidney is usually morphologically normal, it may be associated with a number of congenital defects such as agenesis, ectopia, or vesicoureteral reflux (Malek et al., 1971; Thompson and Pace, 1937; Chow et al., 2005). As mentioned earlier, bilateral renal ectopia occurs infrequently (10%), **and the adrenal gland is not expected to be absent or abnormally positioned as renal ascent does not influence adrenal gland development.**

Renal ectopia has a strong association with reproductive structure anomalies, and the incidence varies from 15% (Thompson and Pace, 1937) **to 45%** (Downs et al., 1973). Twenty percent to 66% of females have one or more of the following abnormalities of the reproductive organs: bicornuate or unicornuate uterus with atresia of one horn, rudimentary or absent uterus and proximal and/or distal vagina, and duplication of the vagina (D'Alberton et al., 1981; Hall-Craggs et al., 2013; McCrea, 1942; Donahoe and Hendren, 1980). Among male patients, Guarino et al. reported an incidence of hypospadias and undescended testicle of 5% for each condition in their series of 60 boys with renal ectopia (Guarino et al., 2004). Others have reported 10% to 20% rates of recognizable associated genital defect; undescended testes; duplication of the urethra; and hypospadias (Thompson and Pace, 1937).

Anomalies of other organ systems have been described in patients with ectopic kidneys (Dogan et al., 2017; Downs et al., 1973); most involve the skeletal or cardiac systems. Fourteen percent of patients with a cloacal malformation have an ectopic kidney (Dursun et al., 2005).

Diagnosis

As imaging modalities have become more widespread in their usage, ectopic kidneys are diagnosed and discovered more frequently. Prenatal ultrasonography can detect ectopic kidneys in a variety of locations such as the pelvis or thorax (Chow et al., 2005; Meizner et al., 1995). The diagnosis of an ectopic lumbar or pelvic kidney is made when whatever renal imaging modality fails to show a kidney in its orthotopic location, and reniform tissue is identified in the lower abdomen or pelvis (Fig. 38.8). **Most ectopic kidneys are asymptomatic.** However, the ectopic kidney can produce a variety of symptoms such as vague abdominal pain, renal colic secondary to an obstruction, or hematuria (Gleason et al., 1994; Livermore and Thiruchelvam, 2010). Renal ectopia may also present with a urinary tract infection (UTI) or a palpable abdominal mass (Karmi, 1977; Gleason et al., 1994). Continuous urinary incontinence in females with normal voiding habits should prompt an evaluation for ectopic ureter. In such a clinical scenario when the initial evaluation yields the diagnosis of a solitary kidney, the potential for renal ectopia with an ectopically draining ureter may exist (Borer et al., 1998). Diagnosis may be difficult because of the diminished function of some ectopic kidneys. An ectopic kidney may be very small and/or dysplastic with essentially no function, leading to the misdiagnosis of URA. DMSA scanning and/or MRU may be necessary to diagnose in such cases (see Fig. 38.8). Cystoscopy, when performed, usually will reveal ureteral orifices that are invariably normal unless the ureteral orifice is also ectopic.

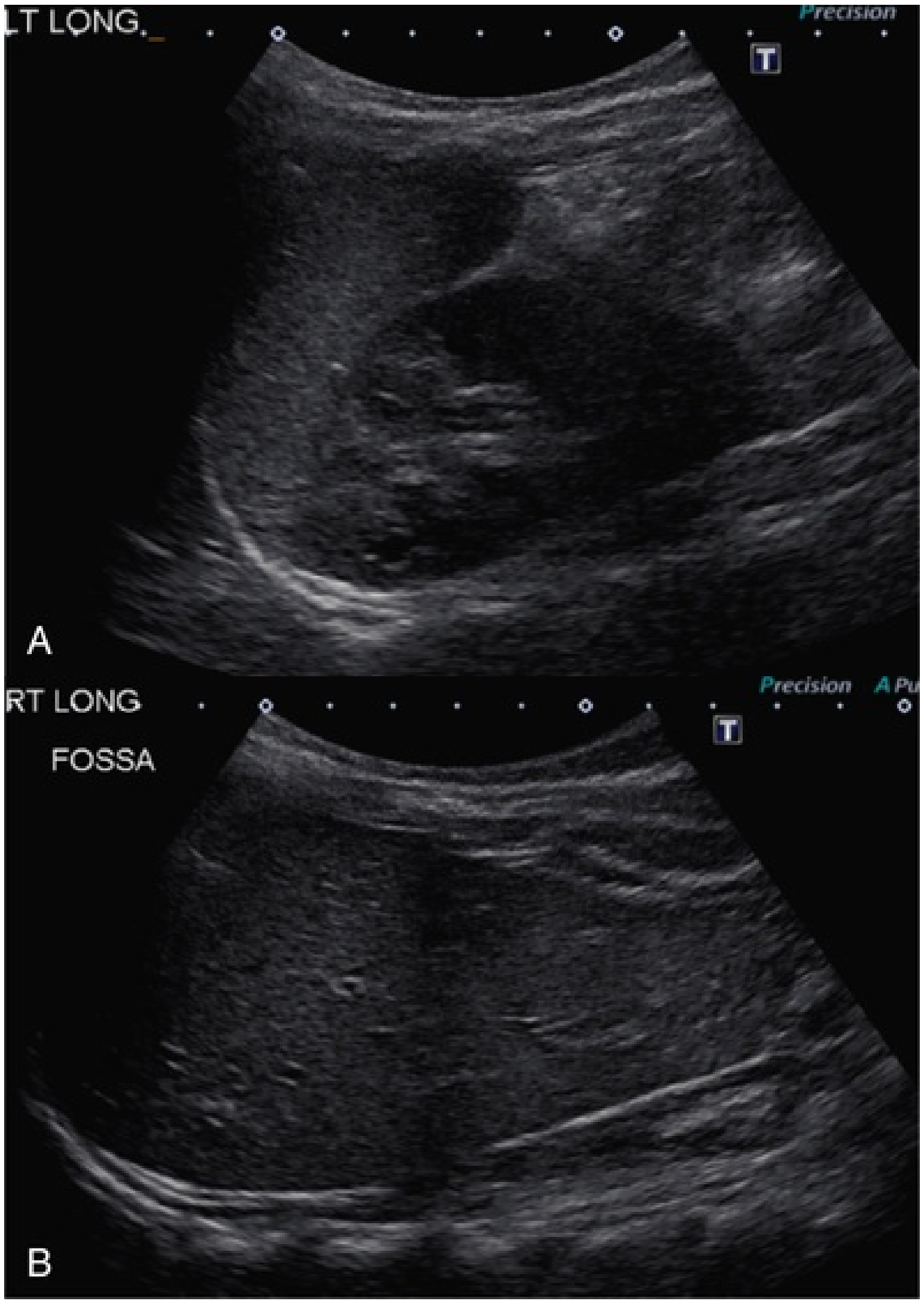

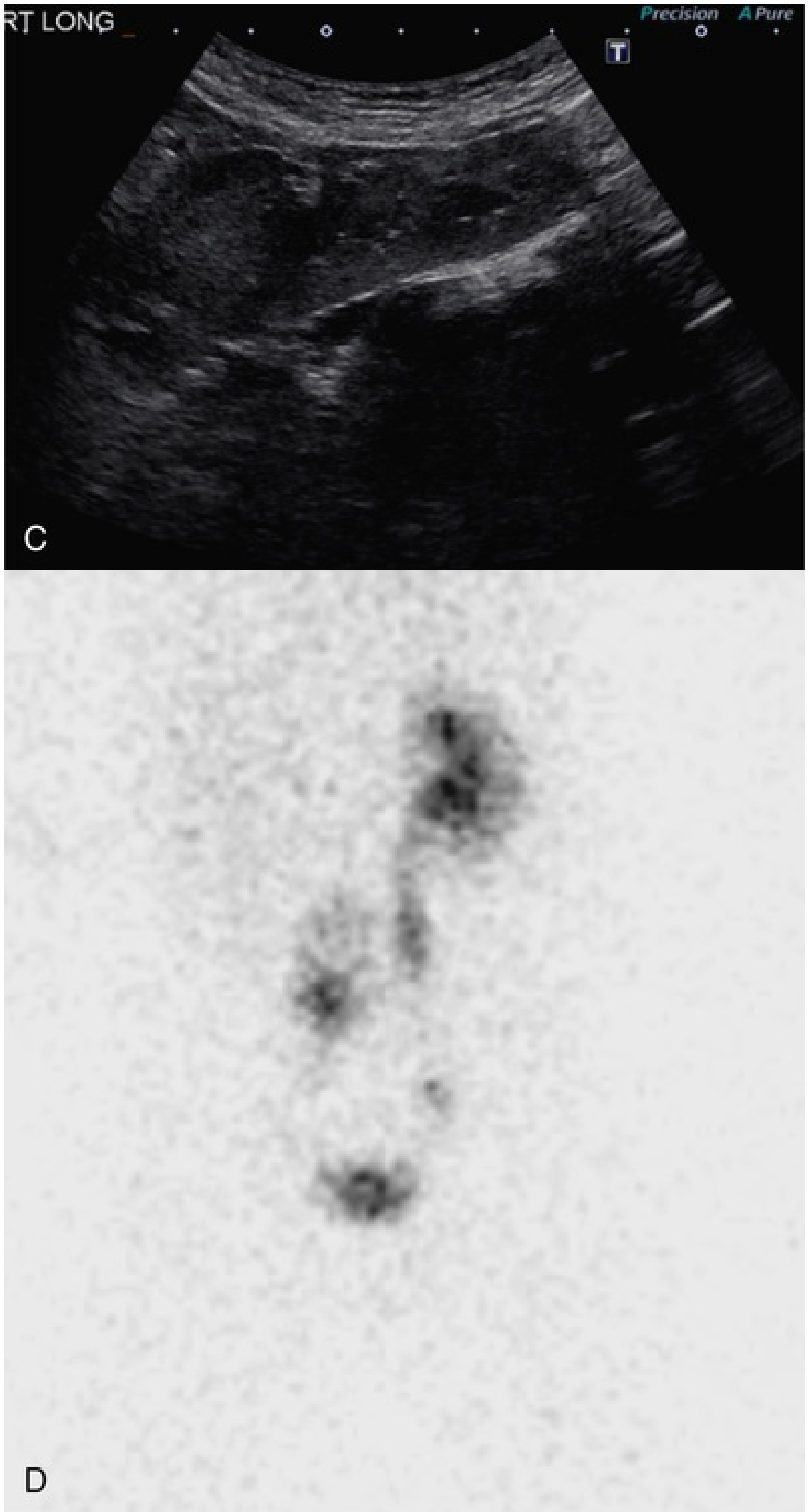

FIG. 38.8 Three-month-old patient with a history of prenatal abnormal renal ultrasound. (A) Sonogram of left orthotopic kidney. (B) Sonogram of right empty renal fossa. (C) Sonogram of right pelvic ectopic kidney. (D) DMSA renal scan of ectopic pelvic kidney revealed 27% differential function relative to 73% of its contralateral orthotopic mate.

Prognosis

The ectopic kidney is no more susceptible to disease than the orthotopic kidney, except for the development of hydronephrosis or stones (Gleason et al., 1994; Benchekroun et al., 2002). This may be a result of the anteriorly placed pelvis and malrotation of the kidney, which may impair drainage of urine from a high insertion of the ureter to the pelvis or anomalous vasculature that partially obstructs one of the major calyces or the upper ureter. In addition, there may be an increased risk for injury from blunt abdominal trauma, because the low-lying kidney is not protected by the rib cage. Van den Bosch et al. examined the urologic and nephrologic consequences of both simple and crossed renal ectopia (Van den Bosch et al., 2010). They found no adverse effects on blood pressure or kidney function during childhood. Many studies have reported that global renal function can be normal in patients with unilateral renal ectopia, however the relative function of the ectopic kidney on DMSA scan may demonstrate decreased function in most instances (Van den Bosch et al., 2010; Guarino et al., 2004; Dogan et al., 2017) (see Fig. 38.8). Pregnant women with renal ectopia found no increased occurrence of maternal or fetal complications related to the ectopic kidney (Anderson and Harrison, 1965; Delson, 1975). Dystocia from a pelvic kidney is rare but may require cesarean section (Freilich and Brint, 1957; Mckenzie, 1950). Before modern imaging, instances have occurred in which solitary ectopic kidneys were mistaken for pelvic malignancies and were removed (Downs et al., 1973).

Cephalad Renal Ectopia

The kidney may be positioned more craniad than normal in a subdiaphragmatic position resulting in cephalad renal ectopia. This can occur when there is an omphalocele and the liver herniates into the omphalocele with the intestines, allowing the kidneys to continue ascension until the diaphragm arrests their ascent (Pinckney et al., 1978). The kidneys are positioned immediately beneath the diaphragm near the level of the 10th thoracic vertebra. The ureters are longer than normal but otherwise normal. A color Doppler sonogram or MR arteriography demonstrates that the origin of each renal artery is more cephalad than normal (Fig. 38.9). Patients usually have no symptoms caused by malposition, and urinary drainage is not impaired. Cephalad renal ectopia has also been described when abdominal wall defects are absent (Kaur and Chawla, 1980; Kundu and Goswami, 1995; Bulgrin and Hokmes, 1955; Baurys and

Servoss, 1949; Zolotas and Krishnan, 2016). Zolotas and Krishnan reported on male infants with a series of antenatal and the first postnatal ultrasound scans demonstrating the right kidney located within the right renal fossa (Zolotas and Krishnan, 2016). On subsequent follow-up imaging during the first 3 months of life, the kidney migrated to a subdiaphragmatic position, which was confirmed on MRI scan (see Fig. 38.9).

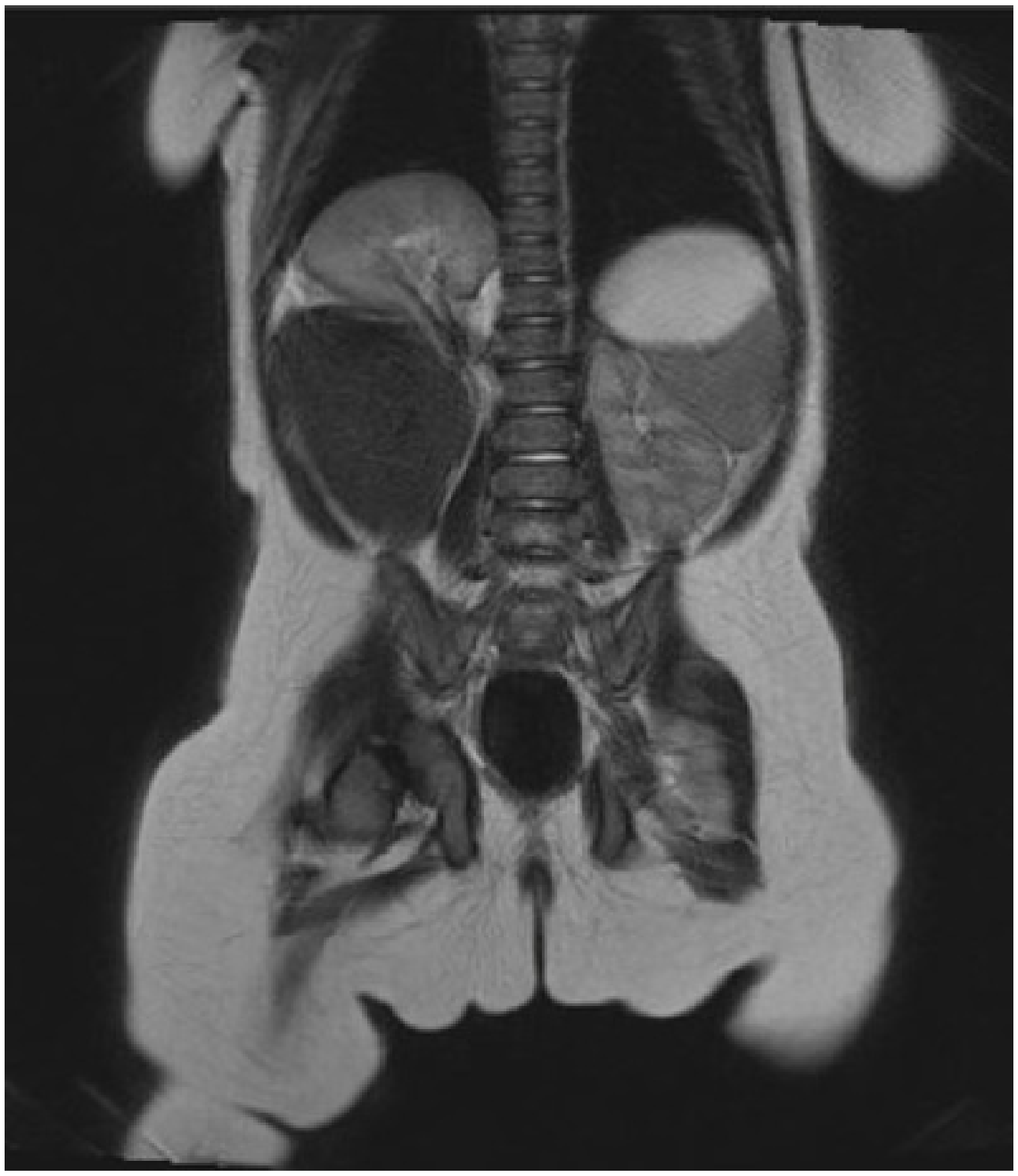

FIG. 38.9 Magnetic resonance image of the coronal view of the abdomen and chest in 4-month-old patient with a history of right ectopic kidney. The right kidney appears in a subdiaphragmatic position. (From Zolotas E, Krishnan RG. Subdiaphragmatic renal ectopia: case report and review of the literature. *Case Rep Nephrol*. 2016;2016:1084917.)

Thoracic Kidney

Intrathoracic ectopia denotes either a partial or a complete protrusion of the kidney above the level of the diaphragm into the posterior mediastinum.

Incidence

This is a rare anomaly, with less than 5% of patients with renal ectopia having an intrathoracic kidney and an estimated incidence of 1 : 13,000 at autopsy (Campbell, 1930). Several case reports of patients with a thoracic kidney have been reported (Lacasta Garcia et al., 1999). Bilateral ectopic thoracic kidneys have also been described (Dingeldein et al., 2008; Liddell et al, 1989). There appears to be a slight left-sided predominance of 1.5 : 1, and the sex ratio favors males by 2 : 1 (Lozano and Rodriguez, 1975). This entity has been found on prenatal ultrasonography (Masturzo et al., 2001) and in all age groups, however, it is more commonly detected in adults undergoing chest radiography for other reasons (Drop et al., 2003).

Embryology

When the kidney reaches its typical location by the end of 8 weeks' gestation, the diaphragmatic leaflets are formed as the pleuroperitoneal membrane, which separates the pleural from the peritoneal cavity. Mesenchymal tissues associated with this membrane eventually form the muscular component of the diaphragm. Two possibilities exist for the occurrence of an ectopic intrathoracic kidney: either delayed closure of the diaphragmatic anlage allows for protracted renal ascent above the level of the future diaphragm or, alternatively, the kidney overshoots its usual position because of accelerated ascent before normal diaphragmatic closure (N'Guessan and Stephens, 1984). Delayed involution of mesonephric tissue has been proposed as the most likely causative factor (Angulo et al., 1992) because intrathoracic kidneys occur in only 0.25% of patients with a diaphragmatic hernia (Donat and Donat, 1988). Renal angiography has demonstrated either a normal site (Lundius, 1975) or a more cranial origin (Franciskovic and Martincic, 1959) of the renal artery from the aorta supplying the thoracic kidney (Fig. 38.10).

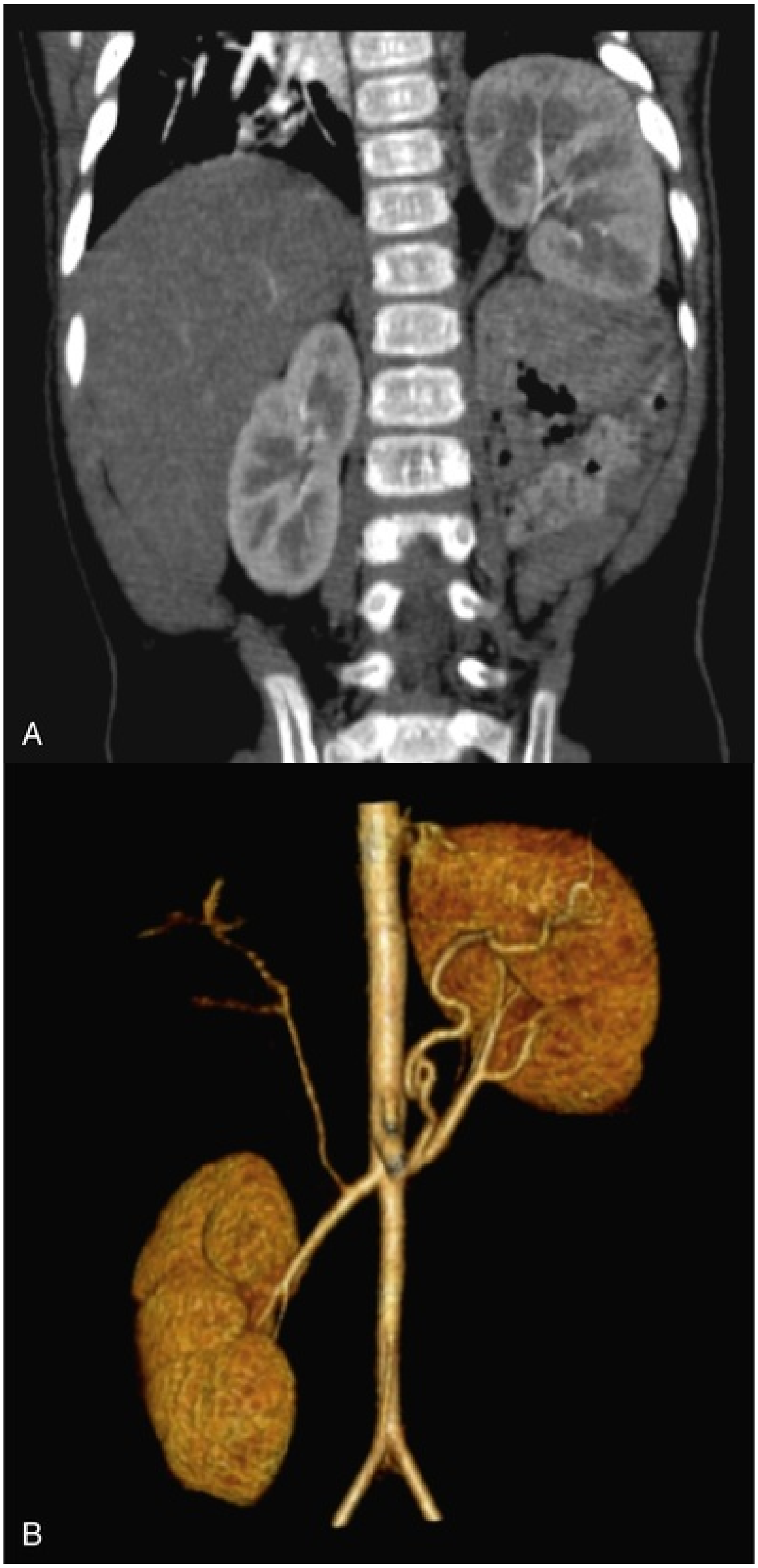

FIG. 38.10 One-year-old female with multiple congenital anomalies including cardiac anomalies. (A) Computed tomography (CT) coronal views after administration of intravenous contrast revealing left intrathoracic

kidney. (B) Three-dimensional CT reconstruction of renal arterial vasculature.

Description

The kidney is situated in the posterior mediastinum and usually has completed the normal rotation process. The renal contour and collecting system are normal. Thoracic kidney has been described in four basic categories: (1) true ectopia; (2) diaphragm eventration; (3) diaphragmatic hernia; and (4) traumatic diaphragm injuries (Donat and Donat, 1988). The kidney usually lies in the posterolateral aspect of the diaphragm in the foramen of Bochdalek. At this point, the diaphragm thins out and a flimsy membrane surrounds the protruding portion of kidney. Therefore the kidney is not within the pleural space (N'Guessan and Stephens, 1984). The lower lobe of the adjacent lung may be hypoplastic secondary to compression by the kidney mass. The renal vasculature and the ureter enter and exit from the pleural cavity through the foramen of Bochdalek.

Associated Anomalies

The ureter is elongated to accommodate the excessive distance to the bladder (N'Guessan and Stephens, 1984). The adrenal gland typically occupies its normal location, and the contralateral kidney is usually normal. However, cases of ectopic adrenal glands in association with thoracic kidneys have been described (Dingeldein et al., 2008; Donat and Donat, 1988). No consistent anomalies have been described in other organ systems.

Symptoms

The vast majority of affected individuals are asymptomatic. Flank pain was the presenting symptom in a case of UPJ obstruction in a thoracic kidney (Hampton and Borden, 2002). Respiratory symptoms have led to the diagnosis of intrathoracic kidney (Langer et al., 2015; Maduekwe et al., 2011). Renal function is typically normal with an ectopic intrathoracic kidney.

Diagnosis

The diagnosis is commonly made after a routine chest radiograph shows the affected hemidiaphragm slightly elevated. A smooth, rounded mass is seen extending into the chest near the midline on an anteroposterior radiograph and along the posterior aspect of the diaphragmatic leaflet on a lateral view. A thoracic kidney may be found at the time of thoracotomy for a suspected mediastinal tumor (DeNoronha et al., 1974). CT or MRU is currently the imaging modality of choice (see Fig. 38.10).

Prognosis

Neither autopsy series nor clinical reports suggest that a thoracic kidney will inevitably lead to serious urinary or pulmonary complications. Therefore surgical intervention is reserved for clinical signs and/or symptoms.

Key Points: Anomalies of Renal Ascent

- The left side is affected slightly more than the right.
- Hydronephrosis is a common finding in ectopic kidneys, with etiology resulting from obstruction at the ureteropelvic or ureterovesical junction, high-grade vesicoureteral reflux, or the malrotation alone.
- Vesicoureteral reflux has been found in 30% to 50% of children with ectopic kidneys, either into the ectopic kidney or the contralateral side.
- The incidence of genital anomalies in the patient with ectopia is about 15%.
- The majority of ectopic kidneys are clinically asymptomatic.
- Differential renal function of the ectopic kidney may show decreased function on nuclear scan.

Anomalies of Renal Form and Fusion

Crossed Renal Ectopia With and Without Fusion

When a kidney is located on the side opposite that in which its ureter inserts into the bladder, the condition is known as *crossed renal ectopia*. **Ninety percent of crossed ectopic kidneys are fused to their ipsilateral mate.** Crossed renal ectopia accounts for the second most common renal fusion anomaly after horseshoe kidney. Renal fusion anomalies are usually diagnosed in children as part of a constellation of malformations, in young adults during evaluation for delayed menarche, and in the elderly as incidental findings (Glodny et al., 2008). **McDonald and McClellan in 1957 proposed the categorization of crossed renal ectopia into four groups: crossed ectopia with fusion, crossed ectopia without fusion, solitary crossed ectopia, and bilaterally crossed ectopia** (McDonald and McClellan, 1957) **(Fig. 38.11).** When crossed renal ectopia with fusion occurs, the fusion anomalies are designated as (1) unilateral fused kidney with inferior ectopia; (2) sigmoid, or *S*-shaped; (3) lump, or cake; (4) *L*-shaped, or tandem; (5) disc, shield, or doughnut; and (6) unilateral fused kidneys with superior ectopia (Fig. 38.12).

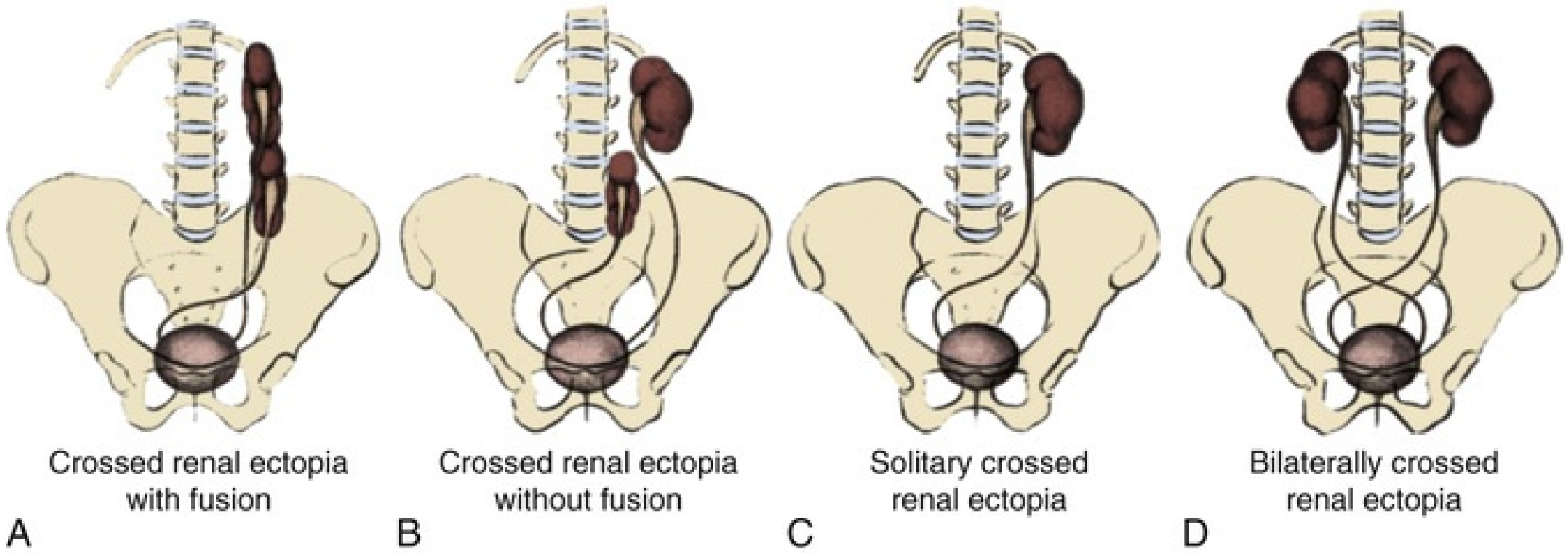
Crossed renal ectopia with fusion
A
Crossed renal ectopia without fusion
B
Solitary crossed renal ectopia
C
Bilaterally crossed renal ectopia
D

FIG. 38.11 (A to D) Four types of crossed renal ectopia.

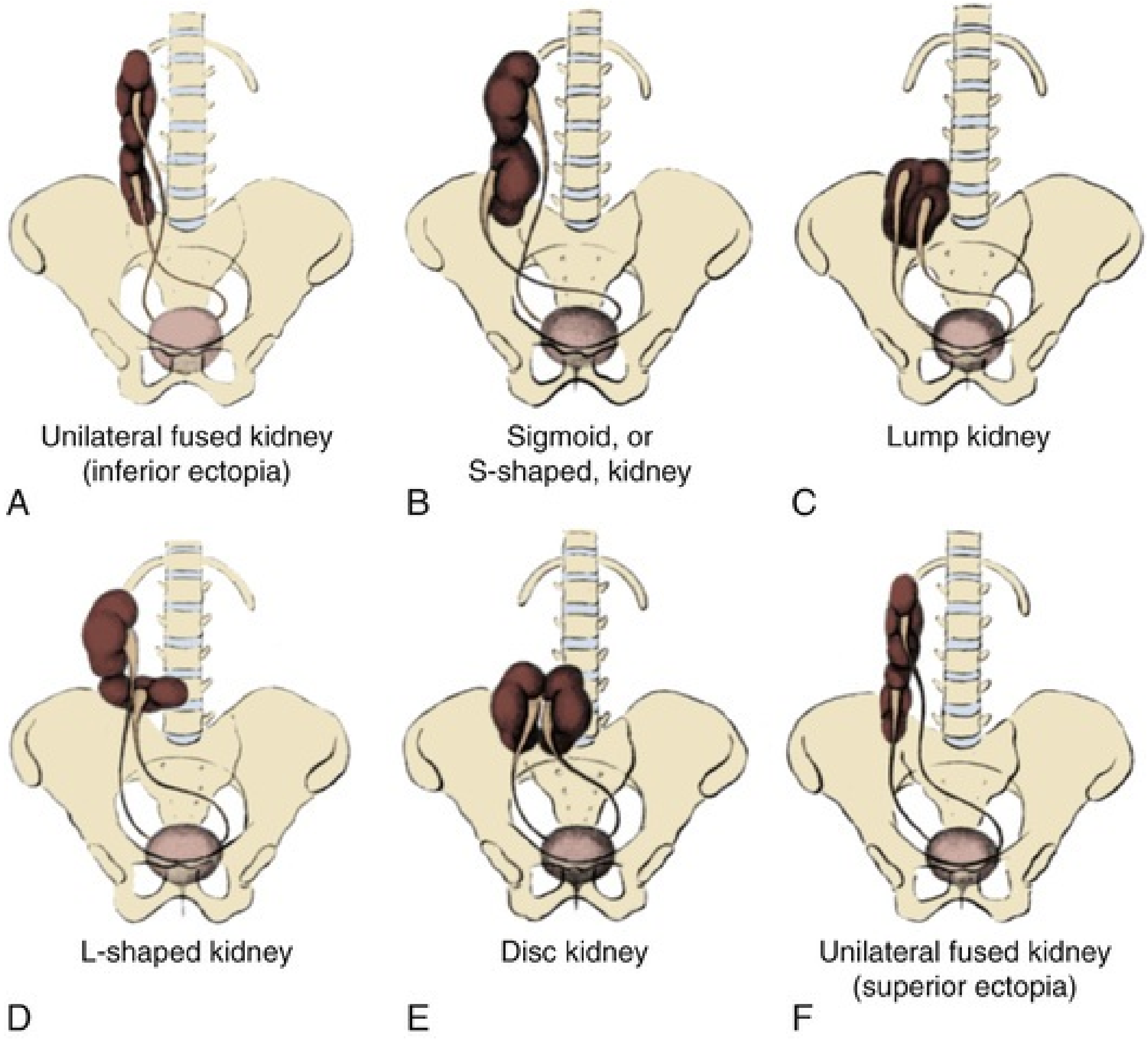
Unilateral fused kidney (inferior ectopia)
A
Sigmoid, or S-shaped, kidney
B
Lump kidney
C
L-shaped kidney
D
Disc kidney
E
Unilateral fused kidney (superior ectopia)
F

FIG. 38.12 (A to F) Six forms of crossed renal ectopia with fusion.

Incidence

Abeshouse and Bhisitkul (1959) reported almost 500 cases of crossed ectopia with and without fusion that presented primarily with clinical symptoms. Glodny et al. reported on 24 crossed fused ectopia found on CT scan performed for non-neurologic indications (Glodny et al., 2008). **Cases of crossed renal ectopia without fusion have been reported** (Ramaema et al., 2012; Pelegrí Gabarró et al., 2014; Felzenberg and Nasrallah, 1991). It is estimated that crossed nonfused renal ectopia represents approximately 10% of all crossed ectopic kidneys (Lee, 1949; Abeshouse and Bhisitkul, 1959). The anomaly occurs more commonly in males with a ratio of 2 : 1, and left-to-right ectopia is seen three times more frequently than right-to-left ectopia (Lee, 1949). **Solitary crossed ectopia has been reported** (Miles et al., 1985; Gu and Alton, 1991; Livermore and Thiruchelvam, 2010). Males predominate with a ratio of 2 : 1. The crossed ectopia involves migration of the left kidney to the right side with absence of the right kidney, rather than the reverse, with a ratio of almost 2 : 1 (Kakei et al., 1976). In most cases, the kidney fails to ascend to an orthotopic location and rotate completely. Bilateral crossed renal ectopia has been described (Abeshouse and Bhisitkul, 1959) and is considered the rarest form.

Abeshouse and Bhisitkul (1959) compiled 443 reports of crossed ectopia with fusion and estimated its occurrence at 1 in 1000 live births. This figure varies with the type of fusion anomaly; **the unilaterally fused kidney with inferior ectopia is the most common variety, whereas fusion with superior ectopia is the least common.** The autopsy incidence has been calculated at 1 in 2000 (Baggenstoss, 1951). There is a slight male predominance (3 : 2). As in renal ectopia without fusion, renal ectopia with fusion has a predilection for left-to-right crossover compared with the contrary.

Embryology

As mentioned earlier, the mechanisms responsible for complete ascent of the kidney remain unknown, and therefore **the cause of crossed ectopia is also unknown.** Several authors have proposed different theories to its development. Cook and Stephens postulated that crossover is the result of malalignment and abnormal rotation of the caudal end of the developing fetus, with the distal curled end of the vertebral column being displaced to one side or the other (Cook and Stephens, 1977). As a result, either the cloaca and WD structures lie to one side of the vertebral column, allowing one ureter to cross the midline and enter the opposite nephrogenic blastema, or the kidney and ureter are transplanted to the opposite side of the midline during "normal" renal ascent (Hertz et al., 1977; Maizels and Stephens, 1979). Some have implicated teratogenic factors given observed incidence of associated genitourinary and other organ system anomalies in one series (Kelalis et al., 1973). Finally, genetic influences may play a role, because familial inheritance of crossed renal ectopia has been reported (Rinat et al., 2001). **Fusion of the metanephric masses can occur in the true pelvis before or at the start of cephalad migration, or it may occur during the latter stages of ascent.** The extent of fusion is determined by the proximity of the developing renal anlagen to one another. After fusion, midline retroperitoneal structures, the aortic bifurcation, the inferior mesenteric artery, and the base of the small bowel mesentery may impede advancement of the kidneys toward their normal location.

Description

Fusion of a crossed ectopic kidney is related to the time it comes in contact with its mate. The crossed kidney usually lies caudad to its normal counterpart on that side. Based on clinical observation and reported frequencies, it is likely that migration of each kidney begins simultaneously, but ascent of the ectopic renal unit lags behind because of crossover time. **Therefore the superior pole of the crossed ectopic kidney usually joins with the inferior aspect of the normal kidney. Ascent continues either until the uncrossed kidney reaches its normal location or until one of the retroperitoneal structures prevents further migration of the fused kidneys. The final shape of the crossed fused ectopic kidney depends on the time, extent of fusion, and the degree of renal rotation that has occurred.** No further rotation is likely after the two kidneys have joined. Orientation of the renal pelvis can provide further insight into the timing of the fusion anomaly. An anteriorly placed pelvis suggests early fusion, whereas a medially positioned renal pelvis indicates that fusion probably occurred after rotation was completed.

When crossed renal ectopia occurs without fusion, the uncrossed kidney usually resides in its orthotopic location with proper orientation, whereas the ectopic kidney is inferior and is in either a diagonal or a horizontal position with an anteriorly placed renal pelvis. A variable distance usually separates the two kidneys, each with its own capsule of Gerota fascia surrounding it. In every case of crossed ectopia without fusion, the ureter from the normal kidney enters the bladder on the same side, and that of the ectopic kidney crosses the midline at the pelvic brim and enters the bladder on the contralateral side (Fig. 38.13). In cases of solitary crossed ectopia, the kidney is usually located somewhat low but in the opposite renal fossa at the level of L1 to L3 and is oriented anteriorly, having incompletely rotated on its vertical axis (Miles et al., 1985; Purpon, 1963). When the kidney remains in the pelvis or ascends only to the lower lumbar region, it may assume a horizontal lie with an anteriorly placed pelvis because it has failed to rotate fully (Trabrisky and Bhisitkul, 1965). The ureter crosses the midline above the S2 vertebra and enters the bladder on the opposite side (Gu and Alton, 1991; Livermore and Thiruchelvam, 2010) (see Fig. 38.13). The contralateral ureter, if present, is often rudimentary (Caine, 1956). Bilateral crossed ectopia may have normal-appearing kidneys and renal pelves, but the ureters cross the midline at the level of the lower lumbar vertebrae (Abeshouse and Bhisitkul, 1959).

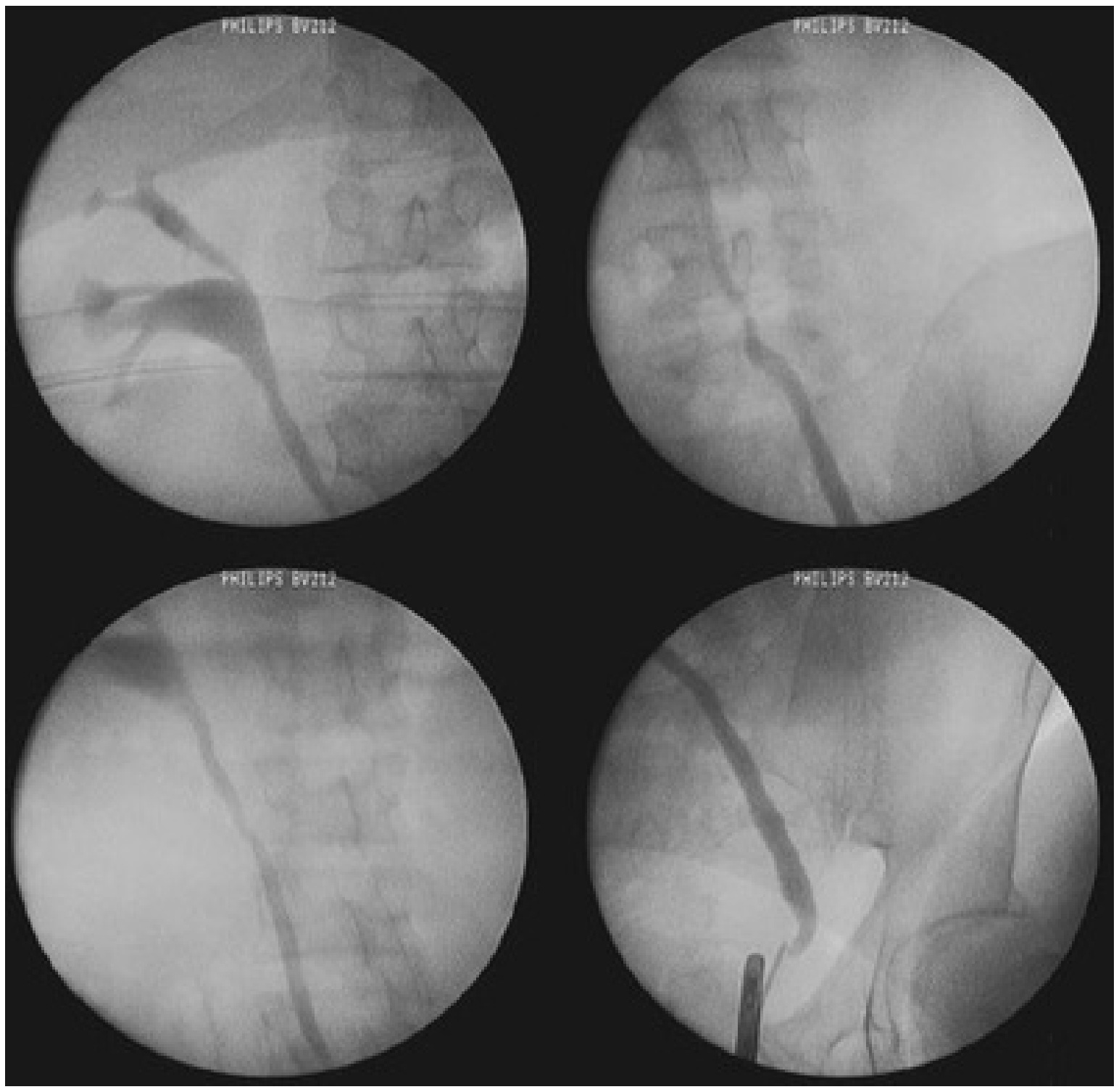
PHILIPS BV212
PHILIPS BV212
PHILIPS BV212
PHILIPS BV212

FIG. 38.13 Retrograde pyelogram showing ureter from solitary crossed ectopic kidney crossing the midline. (From Livermore LJ, Thiruchelvam N. Whose side are you on? The diagnostic conundrum of solitary crossed renal ectopia. *J Ped Urol*. 2010;6:83-86.)

Inferior Ectopic Kidney

Two-thirds of all unilaterally fused kidneys involve inferior ectopia. Both renal pelves are anterior, so fusion probably occurs relatively early (Fig. 38.14).

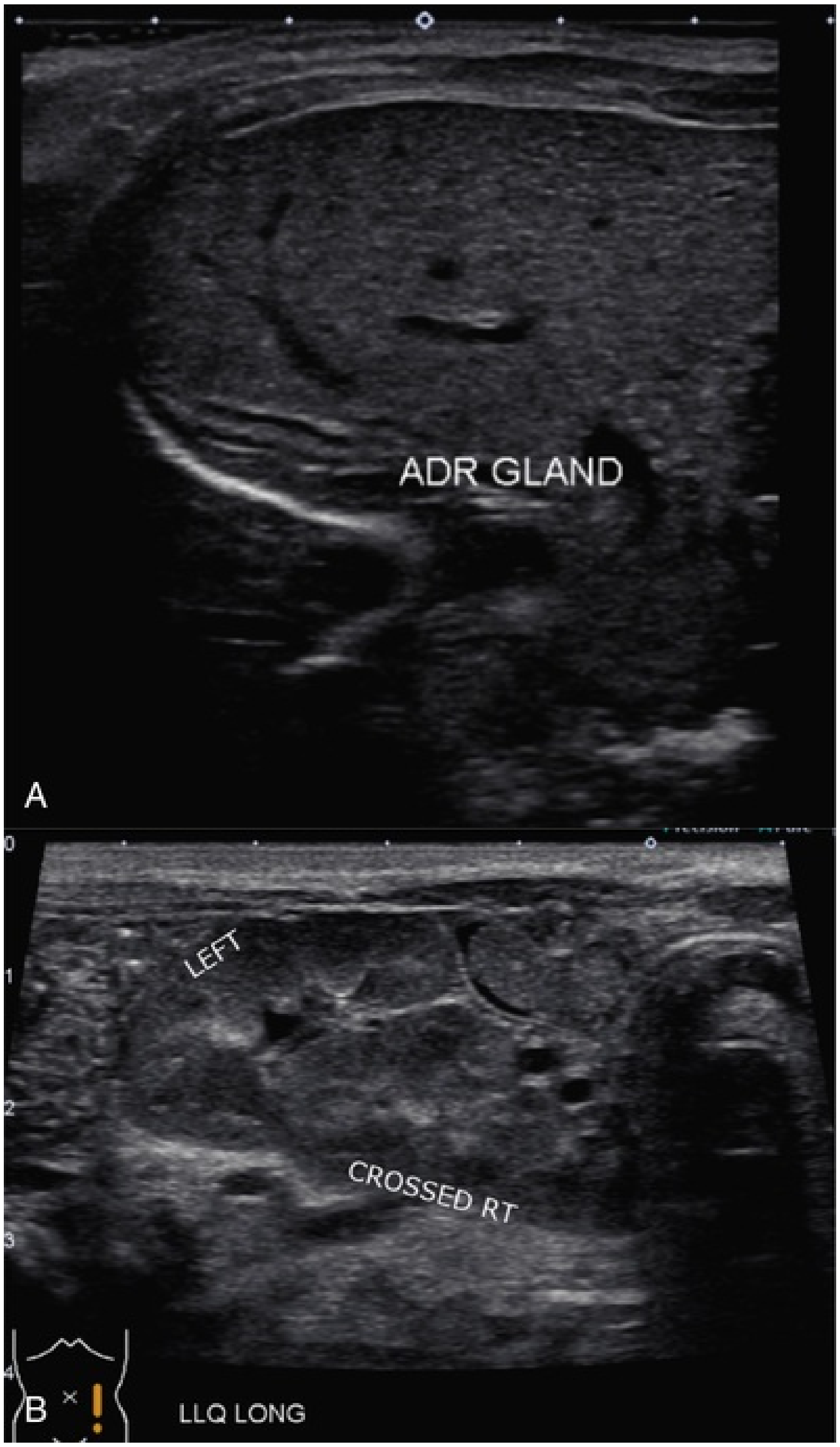
ADR GLAND
A
0
1
2
3
4
LEFT
CROSSED RT
B
LLQ LONG

FIG. 38.14 Neonate with tetralogy of Fallot who underwent screening ultrasound. (A) Sonogram showing empty right renal fossa. (B) Sonogram on patients left side revealed crossed fused renal ectopia with the left kidney in orthotopic location and the right kidney fused to its lower pole.

Sigmoid, or *S*-Shaped, Kidney

The sigmoid, or *S*-shaped, kidney is the second most common anomaly of fusion. The crossed kidney is inferior, with the two kidneys fused at their adjacent poles (see Fig. 38.12). Fusion of the two kidneys occurs relatively late, after complete rotation on the vertical axis has occurred. Therefore, each renal pelvis is oriented correctly, and they face in directions opposite from one another. The lower convex border of one kidney is directly opposite the outer border of its counterpart, creating an *S*-shaped appearance to the entire renal outline. The ureter from the normal kidney courses downward anterior to the outer border of the inferior kidney, and the ectopic kidney's ureter crosses the midline before entering the bladder.

Cake, or Lump, Kidney

The cake, or lump, kidney is a relatively rare form of fusion (Glenn, 1958) (Fig. 38.15). The total kidney is irregular and lobulated, which is contradistinct to the disc kidney (see Fig. 38.12). Ascent usually progresses only as far as the sacral promontory, but in many instances the kidney remains within the true pelvis. Anomalies of the ureteral anatomy have been reported as well; specifically solitary ureter draining both moieties (Brock et al., 1983; Goren and Eidelman, 1987; Calado et al., 2004). Reproductive malformations such as unicornuate uterus and bilateral absence of the vas have been described in association with cake kidney in both males and females (Schwartz et al., 2010; Rosenkrantz et al., 2010).

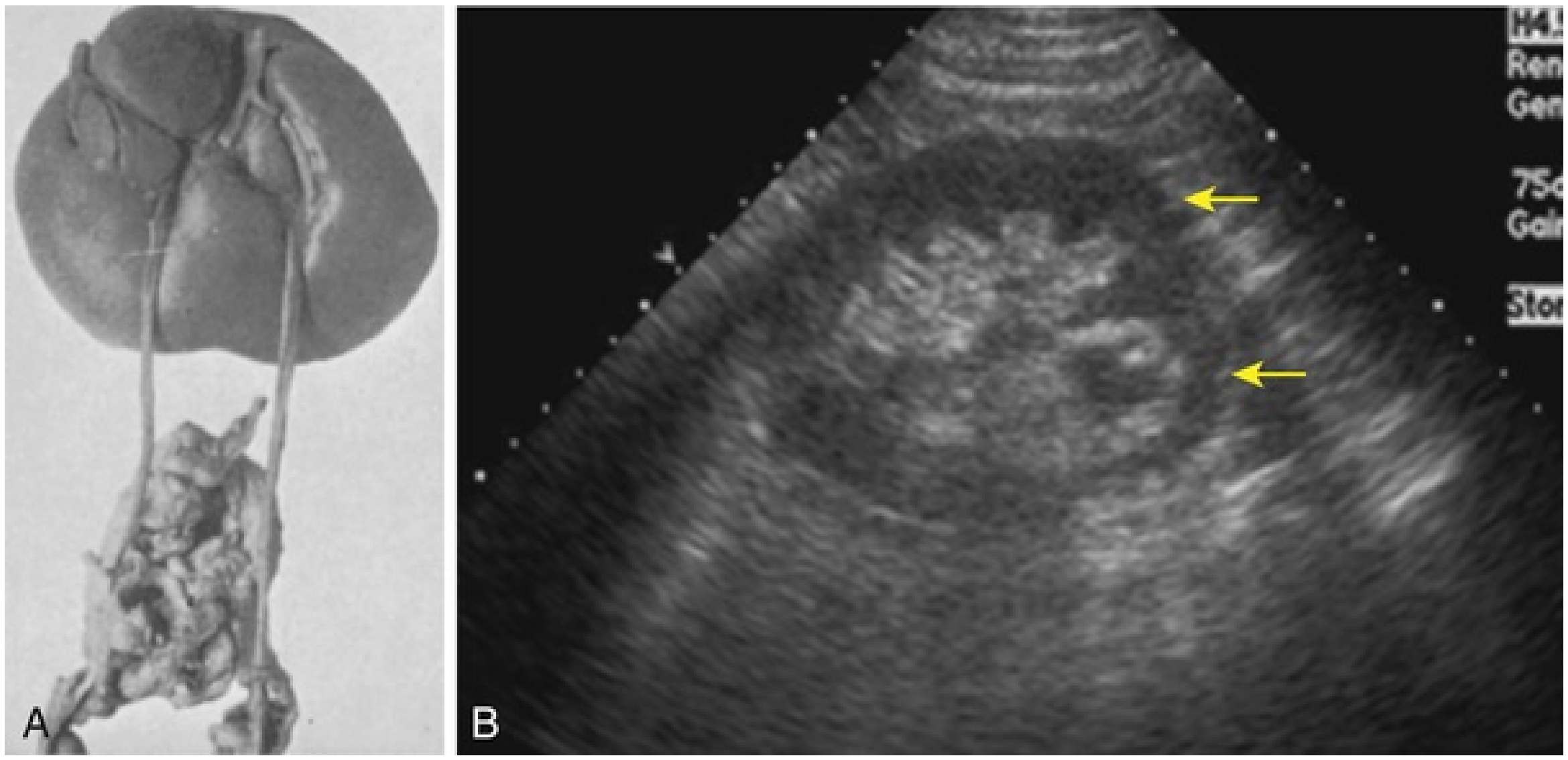

FIG. 38.15 (A) Lump, or cake, kidney showing the unusual anatomy, with

the anterior blood supply coming from above and the ureters leaving from below. (B) Sonogram of cake kidney in sagittal view *(arrows)*. (A, Courtesy of Dr. H.S. Altman. B, Courtesy Dr. Shpetim Telegrafi.)

L-Shaped Kidney

The *L*-shaped, or tandem, kidney occurs when the crossed kidney assumes a transverse position at the time of its attachment to the inferior pole of the normal kidney (see Fig. 38.12). The crossed kidney lies in the midline or in the contralateral paramedian space anterior to the L4 vertebra. Rotation about the long axis of the kidney produces an inverted or a reversed pelvic position. The ureter from each kidney enters the bladder on its respective side (Iwanaga et al., 2018).

Disc Kidney

The disc kidney is known by several other names such as pancake, shield, or doughnut kidney. One of the earliest published reports of this fusion type was by Looney and Dodd; however others have reported it (Looney and Dodd, 1926; Tiwari et al., 2014). It can be described as a renal mass located in the pelvis, which is formed by complete medial fusion of renal parenchyma without intervening septum creating a disc, or shield, shape (see Fig. 38.12). The lateral aspect of each kidney retains its normal contour. This type of fusion differs from the lump, or cake, kidney in that the reniform shape is better preserved because there is a less extensive degree of fusion. Each kidney has its own collecting system and anteriorly oriented ureters that enter the bladder normally. However, there are case reports from autopsies of pancake kidney with two major calyces joined to form a single renal pelvis from both kidneys, which join and continue as a single ureter (Horai et al., 2018; Kanchan et al., 2017; Ghawanmeh et al., 2017).

Superior Ectopic Kidney

The least common variety of renal fusion is the crossed ectopic kidney that lies superior to the normal kidney. The lower pole of the crossed kidney is fused to the upper pole of the normal kidney (see Fig. 38.12). The renal units retain a fetal orientation, with both pelves lying anteriorly, suggesting that fusion occurred very early (Akdogan et al., 2015; Yin et al., 2014).

Regardless of the type of fusion encountered, the vascular supply to the kidneys is variable. The crossed ectopic kidney is supplied by one or more branches from the aorta or common iliac artery (Rubinstein et al., 1976; Glodny et al., 2008). The normal kidney frequently has an anomalous blood supply, with multiple renal arteries originating from various levels along the aorta. The solitary crossed ectopic kidney generally receives its blood supply from the aorta or iliac artery on the side where it is positioned (Tanenbaum et al., 1970).

Associated Anomalies

In all the types of fusion anomalies, the ureteral orifice associated with each kidney is usually orthotopic. Most patients with crossed ectopia have a normal trigone, however the incidence of an ectopic ureteral orifice from the crossed renal unit is about 3% (Abeshouse and Bhisitkul, 1959; Hendren et al., 1976). The ureter from the uncrossed renal segment of a fusion anomaly occasionally has an ectopic orifice or an associated ureterocele (Mishra and Kapoor, 1995; Fishman and Borden, 1982; Hendren et al., 1976). Vesicoureteral reflux is noted in 20% of crossed ectopia and in 71% of bilateral crossed ectopia (Kelalis et al., 1973; Guarino et al., 2004) (Fig. 38.16). Currarino and Weisbruch reported 10 cases of midline renal fusion in which a single ureter divided into two pelves that stretched across the midline to drain one respective half of the total parenchymatous mass (Currarino and Weisbruch, 1989). In 4 of the 10 cases, a second ureter was present that drained a separate duplex system on either the right or left side. Most of the affected individuals had an imperforate anus, an abnormal vertebra, or both.

Several cases of renal tumors have been reported in kidney fusion anomalies of varying histology (Stimac et al., 2004; Grotas and Phillips, 2009; Lee, 1949; Redman and Berry, 1977; Rac et al., 2016; Walther et al., 2013; Gur et al., 2003). Anomalies of the skeletal system and genital organs have been reported in patients with solitary renal ectopia (Gleason et al., 1994). **Genital anomalies described in either renal ectopia with or without fusion are: cryptorchidism, hypospadias, absence of the vas deferens, absence of testicle, vaginal atresia, and a unilateral uterine abnormality** (Drevna et al., 2018; Kakei et al., 1976; Kelalis et al., 1973). Imperforate anus has also been observed in 20% of those with solitary crossed ectopia. In general, the occurrence of an associated nonurologic anomaly in crossed renal ectopia, excluding solitary crossed ectopia, is low; the most frequent are imperforate anus (4%), orthopedic anomalies (4%), skeletal abnormalities, and cardiovascular septal defects.

Symptoms

Most individuals with crossed ectopic anomalies present no symptoms. These anomalies are often discovered incidentally at autopsy, during routine perinatal ultrasound, or during imaging for another clinical indication. When symptoms occur, they usually develop in the third or fourth decade of life, and they include vague lower abdominal pain, pyuria, hematuria, and UTI (Gleason et al., 1994). It is believed that the abnormal kidney position and the anomalous blood supply may impede drainage from the collecting system, creating a predisposition to UTI and calculus formation (Collura et al., 2004) (Fig. 38.16). Romans et al. observed that when a stone in a crossed ureter causes colic, the pain is lateralized to the anephric side or the side of the embryonic origin of the ureter, whereas when there is pyelonephritis or obstruction at the UPJ in the crossed kidney, the lumbar pain is on the side of the kidneys (Romans et al., 1976). These observations suggest ureteral, not renal, migration as a causative factor in crossed ectopia. **An asymptomatic abdominal mass is the presenting sign in one-third of cases** (Abeshouse and Bhisitkul, 1959; Nussbaum et al., 1987; Karmi, 1977). Hypertension evaluation may uncover an ectopic fusion anomaly (Akdogan et al., 2015).

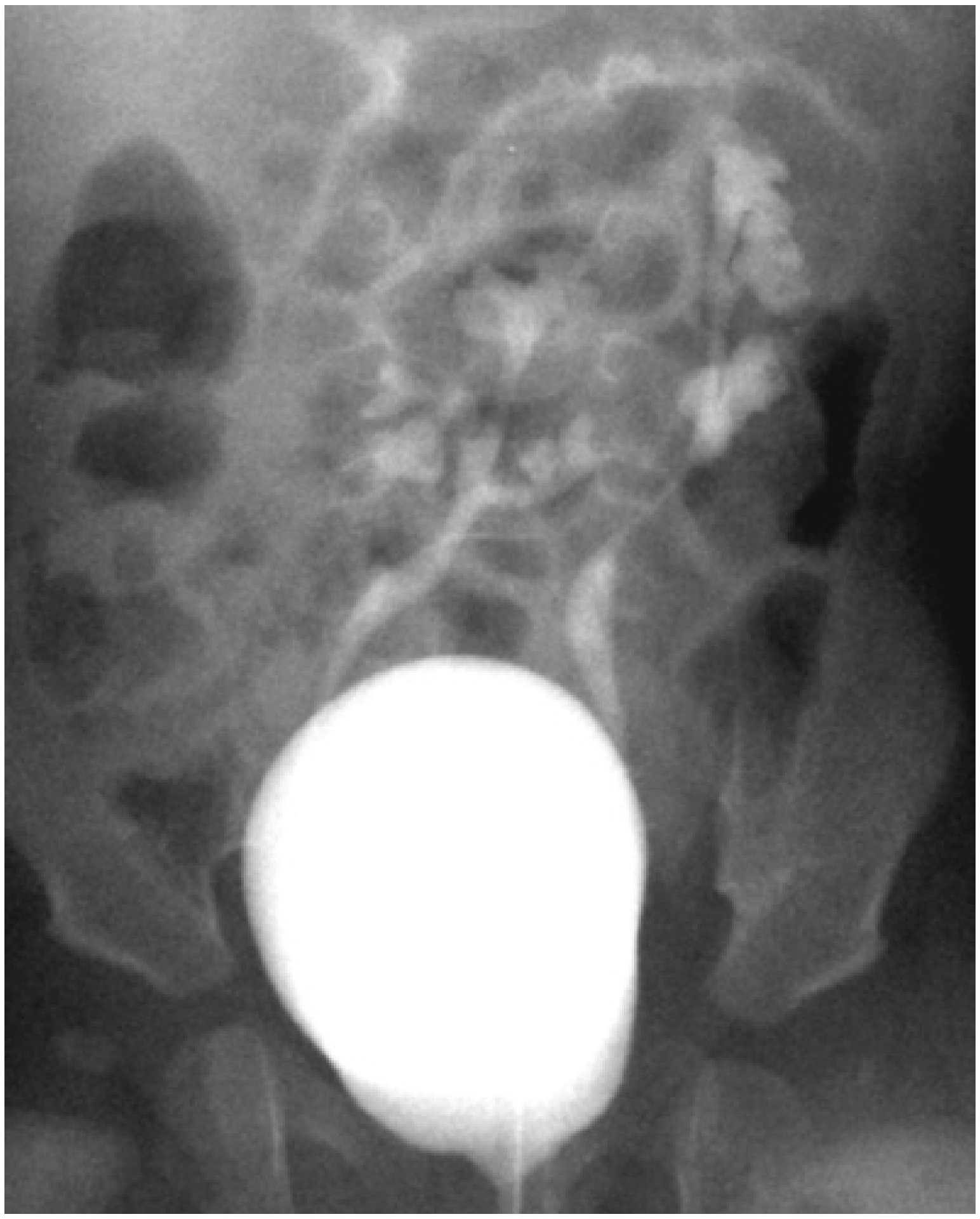

FIG. 38.16 Voiding cystogram demonstrated bilateral grade 3 vesicoureteral reflux into a right-to-left crossed fused renal system.

Diagnosis

Ultrasonography is frequently used to diagnose renal fusion abnormalities in the pediatric population given the higher utilization in this age group compared with adults (Glodny et al., 2008). Indications for pediatric renal imaging may be for screening purposes when syndromic conditions associated with renal anomalies are diagnosed. Nuclear scans can be utilized to identify functioning renal tissue, and diuretic components can assist in determining drainage patterns of associated collecting systems (Volkan et al., 2003; Gambhir et al., 2015). Multidetector three-dimensional CT urography is excellent for delineating the renal parenchyma, collecting system, ureters, and vascular supply of the kidneys whatever the fusion anomaly may be (Türkvatan et al., 2006; Pupca et al., 2014). The main limitation of CT is the increased risk for significant radiation exposure, which is especially problematic for children, pregnant women, and individuals requiring repeat examinations (Türkvatan et al., 2009). MRU and magnetic resonance arteriography (MRA) should be performed in children undergoing extensive surgery on an ectopic kidney to obtain more information while minimizing radiation exposure. Cystoscopy and retrograde pyelography can be useful in mapping the collecting system and pattern of drainage when MRU does not provide sufficient anatomic detail.

Prognosis

Most individuals with crossed renal ectopia have normal longevity. However, those with an obstructive-appearing collecting system are at risk for development of UTI, renal calculi, or both. As is the case with renal cancers in orthotopic kidneys, the prognosis of patients with renal malignancies in cases of renal ectopia is related to the stage and histology of the tumor (Dhillon et al., 2014).

Key Points: Crossed Renal Ectopia With and Without Fusion

- When a kidney is located on the side opposite that in which its ureter inserts into the bladder, the condition is known as crossed ectopia.
- Ninety percent of crossed ectopic kidneys are fused with their mate; the superior pole of the ectopic kidney usually joins with the inferior aspect of the normal kidney.

Horseshoe Kidney

The horseshoe kidney is the most common of all renal fusion anomalies. The anomaly consists of two distinct renal masses lying vertically on either side of the midline and connected at their respective lower poles by a parenchymatous or fibrous isthmus that crosses the midplane of the body (Natsis et al., 2014).

Incidence

Horseshoe kidney occurs in 0.25% of the population, or about 1 in 400 individuals (Campbell, 1970). Reported incidence based on radiographic imaging has shown similar results: between 1 in 474 and 1 in 666 individuals (Weizer et al., 2003; Glodny et al., 2009). Horseshoe kidney is found more commonly in males with a ratio slightly greater than 2 : 1 (Weizer et al., 2003; Glodny et al., 2009). Horseshoe kidneys have been reported in identical twins (Bridge, 1960) and among several siblings (David, 1974). It is doubtful that this anomaly represents a particular genetic predisposition, but it may be the result of a genetic expression with a low degree of penetrance (Leiter, 1972). The abnormality has been discovered in multiple congenital anomalies associated with the horseshoe kidney, some of which are incompatible with long-term survival (Scott, 2002).

Description

In 95% of cases, the kidneys join at the lower pole, which occurs before the kidneys have rotated on their long axes. There may or may not be symmetry to the size of each moiety (Glodny et al., 2009). In one study examining 90 horseshoe kidneys, 36 kidneys had midline fusions (40%), 34 had left lateral fusions (38%), and 20 had right lateral fusions (22%). The pelves and ureters of the horseshoe kidney are usually anteriorly placed, crossing ventrally to the isthmus. Very rarely, the pelves are anteromedial, suggesting that fusion occurred after some rotation occurred. **In a small subset, an isthmus connects both upper poles** (Love and Wasserman, 1975). In addition, cephalad migration is usually incomplete, and it is thought that the inferior mesenteric artery prevents full ascent.

The isthmus is generally bulky and consists of parenchymatous tissue with its own blood supply (Glenn, 1959; Love and Wasserman, 1975). Occasionally it is just a flimsy midline structure composed of fibrous tissue that tends to draw the renal masses close together. The isthmus is located adjacent to the L3 or L4 vertebra just below the origin of the inferior mesenteric artery from the aorta. The isthmus most often lies anterior to the aorta and vena cava, but it has been reported to pass between the inferior vena cava and the aorta or even behind both great vessels (Dajani, 1966). In some instances, the anomalous kidneys are very low, anterior to the sacral promontory or even in the true pelvis behind the bladder (Campbell, 1970).

The calyces are normal in number and are atypical in orientation. Because the kidney fails to rotate, the calyces point posteriorly, and the axis of each pelvis remains in the vertical or obliquely lateral plane (on a line drawn from the lower to the upper poles). The lowermost calyces extend caudally or even medially to drain the isthmus and may overlie the vertebral column (Strauss et al., 2000). The ureter may insert high on the renal pelvis and lie laterally, probably as the result of incomplete renal rotation. It courses downward and has a characteristic bend as it crosses over and anterior to the isthmus (Strauss et al., 2000). The lower ureter enters the bladder normally, however there have been several cases of atypical ureteral course and anatomy such as retrocaval ureter, ureteral ectopia, and duplication (Khong et al., 1996; Knutson and Hawas, 2004; Tyagi et al., 2014; Keskin et al., 2009).

The blood supply to the horseshoe kidney can be variable, and a single artery and vein to each moiety is the exception rather than the norm. CT imaging studies of 90 patients with horseshoe kidneys revealed a highly variable pattern of arterial and renal vasculature related to number (Glodny et al., 2009)**. In the Glodny et al. study, only 5% of the patients had the simple situation of only one artery on each side, whereas others have reported between 20% to 30% of cases with one renal artery to each kidney** (Glodny et al., 2009; Glenn, 1959; Crawford et al., 1988). The blood supply to the isthmus and lower poles is also variable. The isthmus and adjacent parenchymal masses might receive a branch from each main renal artery, or they may have their own arterial supply from the aorta originating either above or below the level of the isthmus. There is tremendous variability to the origin of renal vasculature to a horseshoe kidney. Not infrequently, branches from the inferior mesenteric, common or external iliac, or sacral arteries supply this area (Kolln et al., 1972; Crawford et al., 1988; Glodny et al., 2009).

Associated Anomalies

There are many congenital anomalies and syndromes associated with horseshoe kidney. Je et al. examined their institution's experience over a 24-year period with 366 children and young adults and 14 fetuses with horseshoe kidney (Je et al., 2015). One-half of the subjects had extrarenal diseases or syndromes, and gastrointestinal and vertebral anomalies were the most common. The autopsy incidence of other anomalies is greater in children who die at birth or in early infancy than in those who reach adulthood (Scott, 2002). This implies that a horseshoe kidney occurs more often in association with other serious congenital anomalies. Horseshoe kidney is found in 3% of children with neural tube defects (Whitaker and Hunt, 1987). Anorectal malformations are frequently encountered in these patients as part of the VATER (vertebral, anorectal, tracheoesophageal fistula, renal) anomalies syndrome. Horseshoe kidney is seen in 60% of females with Turner syndrome (Lippe et al., 1988). In the study by Je et al., 13% of the patients had syndromes, with Turner syndrome the most common followed by caudal regression syndrome (Je et al., 2005).

Genitourinary anomalies can be associated with a horseshoe kidney (Je et al., 2005; Boatman et al., 1972). Hypospadias and undescended testes occurred in 4% of the males, and a bicornuate uterus, a septate vagina, or both were noted in 7% of the females. Vesicoureteral reflux has been noted in 8% to 32% of patients with horseshoe kidney (Cascio et al., 2002; Pitts and Muecke, 1975; Segura et al., 1972; Wilson and Azmy, 1986). Management of vesicoureteral reflux in children with horseshoe kidney is no different than in children with normal kidneys. Cascio et al. observed that of the 20 refluxing ureters, 15 spontaneously resolved and 5 needed surgical intervention to correct reflux. Hydronephrosis is not an uncommon radiographic finding with horseshoe kidneys. This can be secondary to nonrefluxing and nonobstructing etiology. Hydronephrosis secondary to UPJ obstruction ranges from 13% to 34% in previously published clinical series (Fig. 38.17) (Whitehouse, 1975; Das and Amar, 1984; Pitts and Muecke, 1975; Segura et al, 1972; Wilson and Azmy, 1986). The UPJ obstruction can be caused by a variety of factors. High insertion of the ureter into the renal pelvis, its abnormal course anterior to the isthmus, and extrinsic compression from the anomalous blood supply to the kidney may individually or collectively contribute to the hydronephrosis.

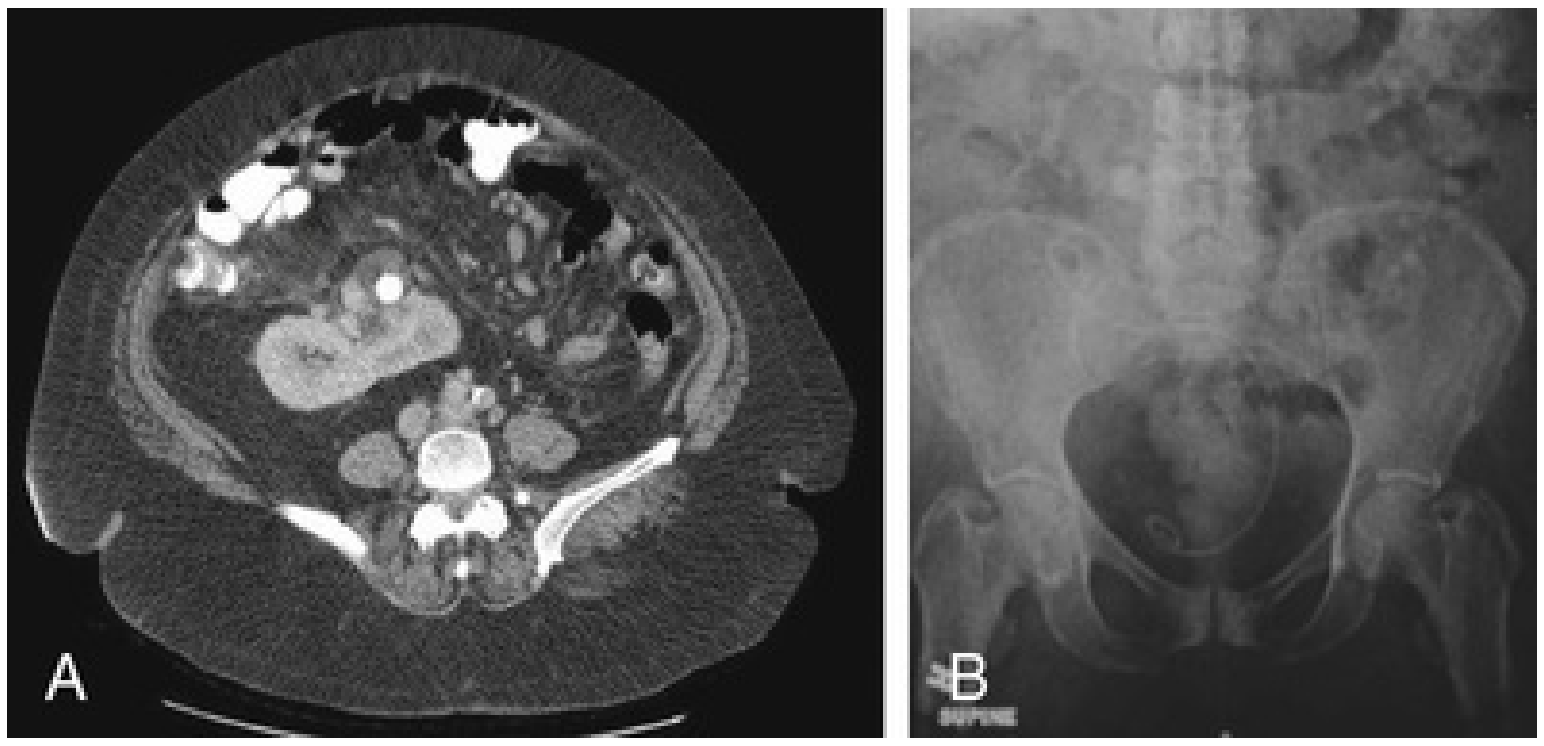

FIG. 38.17 A 42-year-old female presented with abdominal pain and emesis. (A) Computed tomography scan of abdomen and pelvis reveals obstructing stone in left-to-right crossed fused ectopic kidney. (B) Postprocedure abdominal radiograph shows internal ureteral stent within the left crossed ectopic kidney. Note the stent exiting the left ureteral orifice and crossing midline into the renal pelvis located in the right lower quadrant.

In the modern era, horseshoe kidneys are frequently discovered incidentally, and their apparent hydronephrosis more often shows a nonobstructed pattern on radionuclide scanning. Horseshoe kidneys can be incidentally observed on ^{99m}Tc bone scan as a result of renal uptake and excretion of the isotope (O'Brien et al., 2008). Cystic disease, including multicystic dysplasia in one-half (the upper pole) of one side (Boullier et al., 1992) and adult polycystic kidney disease have been reported with horseshoe kidney (Correa and Paton, 1976). DMSA scanning in 22 patients showed asymmetrical function between the two moieties of horseshoe kidney in 63% (Kao et al., 2003).

Stone formation has been commonly seen in horseshoe kidney. In a meta-analysis, Pawar et al. observed that kidney stones are very common in adult patients with horseshoe kidney, with an estimated incidence of 36% (Pawar et al., 2018). Calcium-based stones are the most prevalent kidney stones in adults with horseshoe kidney. Metabolic stone evaluation in 11 of 37 of stone formers with horseshoe kidneys showed at least one abnormality, with an average of 2.68 abnormalities per 24-hour urine collection. Hypovolemia, hypercalciuria, and hypocitraturia were the most common metabolic defects (Raj et al., 2004). The number and types of abnormalities appear similar to those observed in stone formers without horseshoe kidneys.

Symptoms

At least 50% with horseshoe kidneys are asymptomatic, and in most instances the anomaly is an incidental finding at autopsy (Kolln et al., 1972; Pitts and Muecke, 1975). When present, symptoms are typically related to hydronephrosis, infection, tumor, or calculus formation. The most common symptom is vague abdominal pain that may radiate to the lower lumbar region. UTIs occur in 30% of patients, and calculi have been noted in 20% to 80% (Kolln et al., 1972; Pitts and Muecke, 1975; Evans and Resnick, 1981; Sharma and Bapna, 1986; Benchekroun et al., 1998; Cascio et al., 2002). A horseshoe kidney may present as a palpable abdominal mass with or without hydronephrosis (Kolln et al., 1972; Karmi, 1977; Kasper et al., 1976).

Diagnosis and Radiographic Appearance

The classic radiologic features on a plain radiograph of the abdomen include kidneys that are somewhat low lying and close to the vertebral

column and that have a vertical or outward axis with the lower poles being more medial than in the normal kidney (O'Brien et al., 2008). The kidneys may be observed by the delineation of the perinephric fat. Prenatal ultrasonography detects most horseshoe kidneys (Kovo-Hasharoni et al., 1997; Cho et al., 2005). Postnatal ultrasonography detects the isthmus joining the two lower poles of the kidneys in the midline, unless the isthmus is only a thin fibrous band. (Figs. 38.18 and 38.19). Ultrasound diagnosis is made by scanning horizontally along the midline in a craniocaudal direction, especially in children and in thin patients. Radionuclide scanning demonstrates the abnormal axis of a horseshoe kidney. A continuous band across the midline is observed if the isthmus contains functioning parenchyma. CT and MRU can also be used to characterize the isthmus and further evaluate hydronephrosis (see Fig. 38.17). MRA can be used to delineate the vascular anatomy for preoperative planning (O'Brien et al., 2008).

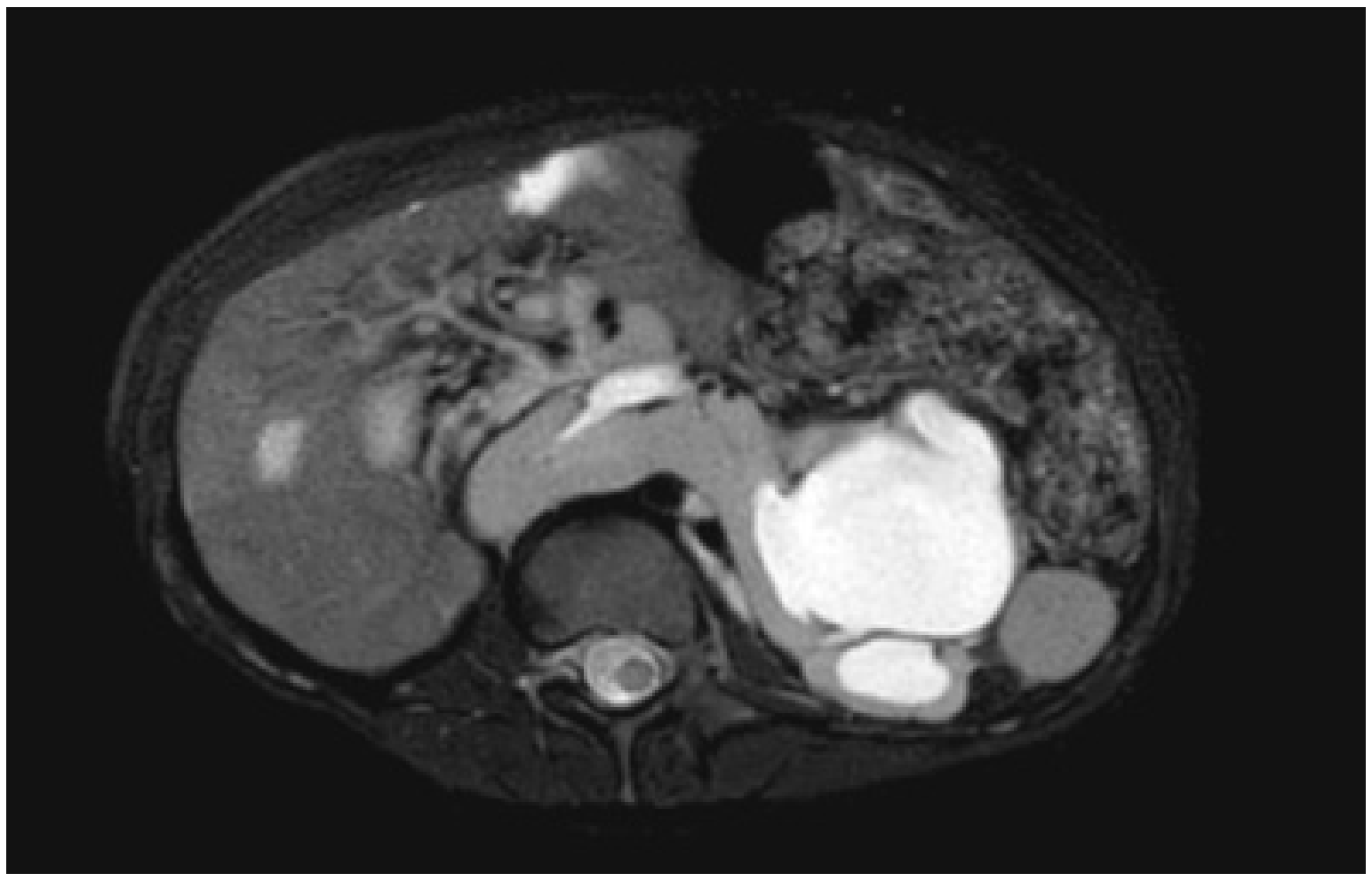

FIG. 38.18 A 16-year-old patient presented with abdominal pain. Computed tomography scan demonstrates horseshoe kidney with severe hydronephrosis of the left side secondary to obstruction of the ureteropelvic junction.

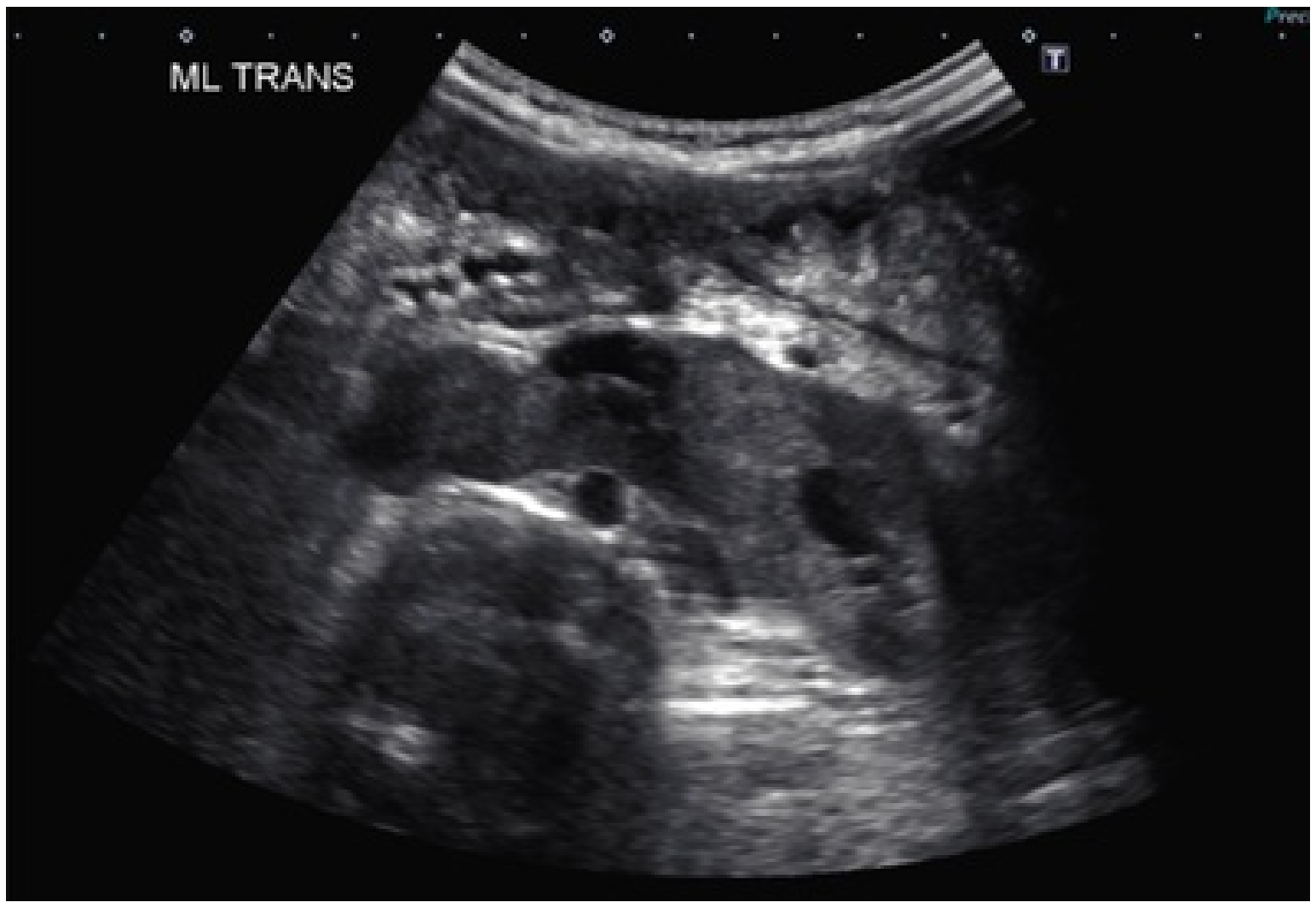

FIG. 38.19 Newborn with cloacal anomaly. Abdominal sonogram shows horseshoe kidney with mild dilation of the right and left collecting system. Note right side with anterior renal pelvis.

Prognosis

Smith and Orkin believed that horseshoe kidneys are almost always associated with disease (Smith and Orkin, 1945); however, **Glenn observed patients with horseshoe kidneys for an average of 10 years after discovery and found that almost 60% of these remained asymptomatic** (Glenn 1959). Only 13% had persistent urinary infection or pain, and 17% developed recurrent calculi. These clinical findings are supported in more contemporary series in which Glodny et al. found that 85% of patients with renal fusion anomalies had no new symptoms appear during follow-up (Glodny et al., 2009). Many disease processes have been described with a horseshoe kidney, but this likely reflects the relative frequency of the congenital defect and subsequent surveillance bias.

Kidney cancers have been reported in patients with horseshoe kidney of varying pathologies (Stimac et al., 2004; Dhillon et al., 2014). **Renal cell carcinoma accounts for about one-half of renal tumors, although the incidence has been found to be no greater than that in the general population** (Buntley, 1976). Cases of bilateral tumors have been reported (Romics et al., 2002). Renal pelvic tumors, Wilms tumors, sarcomas, and carcinoid tumors have also been observed (Isobe et al., 2000; Santiago et al., 2017; Murphy and Zincke, 1982; Nawaz et al., 2014). Overall, 41 of 8617 (0.48%) Wilms tumors in the National Wilms Tumor study occurred in horseshoe kidneys, primarily on the left side, rarely in the isthmus, and practically all with favorable histology (Neville et al., 2002). The incidence of Wilms tumor in horseshoe kidneys is 1.76 to 7.93 times higher than that expected in the general population (Mesrobian et al., 1985). Thirty-seven percent of these Wilms tumors were initially inoperable. However, with preoperative chemotherapy, most patients were salvaged, yielding a 75% preservation rate of renal parenchyma (Neville et al., 2002). Wilms tumor may originate in the isthmus (Beck and Hlivko, 1960). Except for renal pelvic tumors, a surprisingly high number of renal cancers arise in the isthmus (Blackard and Mellinger, 1968). For this reason, it has been suggested that teratogenic factors are responsible for abnormal migration of nephrogenic cells to form an isthmus, which then leads to the horseshoe shape and the predisposition for the development of cancer in this portion of the kidney (Hohenfellner et al., 1992). It has been suggested that the increased occurrence of chronic infection, obstruction, and stone formation explains the higher than expected incidence of renal pelvic tumors because the incidence exceeds that of the general population (Dische and Johnston, 1979). Survival from tumors within the horseshoe kidney is related to the pathology and stage of the tumor at diagnosis and not to the renal anomaly (Dhillon et al., 2014).

Because a horseshoe kidney is located above the pelvic inlet, it should not adversely affect pregnancy or delivery (Bell, 1946b). The development of renal failure associated with adult polycystic kidney disease is no greater in a horseshoe kidney (Correa and Paton, 1976). Because of organ shortage, kidneys with atypical anatomy are frequently considered for transplantation, and renal transplantation has occurred with horseshoe kidneys (Nelson and Palmer, 1975; Zipitis et al., 2003). A horseshoe kidney can be transplanted en bloc, or it can be divided and implanted into two recipients, depending on the anatomy of the vessels and the urinary collecting system. A worldwide review of horseshoe kidney transplant from the Netherlands noted that 23 whole and 57 split horseshoe kidneys have been transplanted, with initial failure rates of only 4.3% and 13.4% for en bloc and for split transplants, respectively. An overall 80% graft survival rate has been reported at 5 years (Stroosma et al., 2001). See Table 38.1.

TABLE 38.1

Summary of Major Anomalies of Renal Number and Position

PATTERN	DESCRIPTION	INCIDENCE	CLINICAL	ASSOCIATE

			ISSUES	**CONDITIONS**
Bilateral renal agenesis	Absence of all renal tissue; 50% incidence of absent ureter/lower urinary tract	Estimated 1 : 5000	Lethal in nearly 100% of cases because of pulmonary hypoplasia	Oligohydramn Potters facies Clubfeet
Unilateral renal agenesis	Absence of unilateral renal tissue, 60% of cases have ipsilateral ureteral agenesis	1 : 1200	Usually asymptomatic Long-term follow-up may have signs of CKD in 30% because of reduced nephron mass	VUR in up to 30% or UPJ obstruction in 10% in contralateral kidney Reproductive anomalies in both sexes in 20% to 40% 30% VACTER patients
Supernumerary kidney	Accessory organ with its own collecting system, blood supply, and distinct encapsulated parenchymal mass	Very rare	Usually asymptomatic	
Simple renal ectopia	Renal tissue that has not fully ascended to orthotopic position and remains on ipsilateral side of which its ureter inserts into the bladder	1 : 900	Hydronephrosis common as a result of anomalies of ascension and rotation	Reproductive anomalies in both sexes in approximately 15
Thoracic kidney	Partial or complete protrusion of the kidney above the	1 : 13,000	Usually asymptomatic	

	kidney above the level of the diaphragm into the posterior mediastinum			
Crossed renal ectopia	Kidney is located on the contralateral side of which its ureter inserts into the bladder	1 : 2000	Potential for hydronephrosis and nephrolithiasis	Anorectal malformations Genitourinary malformations
Horseshoe kidney	Inferiorly fused kidneys at their lower poles, low in abdomen	1 : 400	Potential for hydronephrosis and nephrolithiasis	Anorectal malformations Turner syndro Genitourinary malformations

CKD, Chronic kidney disease; *UPJ,* ureteropelvic junction; *VUR,* vesicoureteral reflux.

Key Points: Horseshoe Kidney

- Horseshoe kidney occurs in 0.25% of the population, or about 1 in 400 individuals.
- The majority of patients with horseshoe kidneys are asymptomatic.
- The calyces, normal in number, are atypical in orientation. Because the kidney fails to rotate, the calyces point posteriorly, and the axis of each pelvis remains in the vertical or obliquely lateral plane.
- Horseshoe kidney is frequently found in association with other congenital anomalies and syndromes.
- The blood supply can be variable, and imaging before surgery may be needed to better delineate.
- UPJ obstruction, causing significant hydronephrosis, occurs in as many as one-third of individuals with horseshoe kidneys, usually from extrinsic compression secondary to atypical ureteral course or crossing aberrant renal vessel.
- Wilms tumors occur more frequently in patients with horseshoe kidneys compared with the general population.

Anomalies of Renal Rotation

The kidney, as it assumes its final position in the "renal" fossa, orients itself so that the calyces point laterally and the pelvis faces medially. When this alignment is not exact, the condition is known as *malrotation*. As mentioned earlier, abnormalities of renal ascent and/or fusion are typically accompanied by abnormalities of renal malrotation. Renal malrotation can occur in orthotopic kidney, and this section focuses on malrotation as an isolated renal entity.

Incidence

Campbell (1963) found renal malrotation in 1 of 939 autopsies, and Smith and Orkin (1945) noted 1 case per 390 hospital admissions. **It is frequently observed in association with Turner syndrome** (Gray and Skandalakis, 1972). Males are affected twice as often as females, but there does not appear to be any predilection for side.

Description

It is thought that medial rotation of the collecting system occurs simultaneously with renal migration. The kidney starts to turn during the sixth week, just when it is leaving the true pelvis, and it completes this process by rotating 90 degrees toward the midline by the time ascent is complete at the end of 9 weeks' gestation. **The kidney and renal pelvis normally rotate 90 degrees ventromedially during ascent.** In a detailed study, Weyrauch categorized the various abnormal phases of medial and reverse rotation according to position of the renal pelvis (Weyrauch, 1939) (see Fig. 38.18).

Ventral Position

The pelvis is ventral and in the same anteroposterior plane as the calyces, which point dorsally because they have undergone no rotation at all. This is the most common form of malrotation.

Ventromedial Position

The pelvis faces ventromedially because of an incompletely rotated kidney. Excursion probably stops during the seventh week of gestation, when the kidney and pelvis normally reach this position. The calyces thus point dorsolaterally.

Dorsal Position

Renal excursion of 180 degrees occurs to produce this rarest position. The pelvis is dorsal to the parenchyma, and the vessels pass behind the kidney to reach the hilum.

Lateral Position

When the kidney and pelvis rotate between 180 degrees and 360 degrees, or when reverse rotation of up to 180 degrees occurs, the pelvis faces laterally and the kidney parenchyma resides medially. The renal vascular supply provides the only clue to the actual direction of excursion. Vessels that course ventral to the kidney to enter a laterally or dorsolaterally placed hilum suggest reverse rotation, whereas a path dorsal to the kidney implies excessive ventral rotation. **In cases of isolated malrotation, other characteristic features may be present** (Patil et al., 2011). The kidney shape may be discoid, elongated, oval, or triangular, with flattened anterior and posterior surfaces. Fetal lobulations are invariably present and are accentuated beyond normal limits. A dense amount of fibrous tissue encases the hilar area, possibly even distorting and fixing the pelvis. The UPJ may be distorted as well. The upper ureter initially courses laterally, and it, too, may be encased in this fibrous matting. The pelvis is elongated and narrow, and calyces, especially the superior calyx, may be stretched. The blood supply may vary widely, depending on the direction and degree of rotation. The vasculature may consist of a single vessel with or without multiple additional branches entering the parenchyma along the course of the renal artery. There also may be a polar vessel in conjunction with the main renal artery. The vascular orientation around the kidney provides the only clue to the type and extent of renal rotation.

Symptoms

Rotation anomalies, per se, do not produce specific symptoms. The excessive amount of fibrous tissue encasing the pelvis, UPJ, and upper ureter, however, may lead to varying degrees of hydronephrosis. Vascular compression from an accessory or main renal artery or distortion of the upper ureter or UPJ may contribute to intermittent obstruction.

Diagnosis

The diagnosis should be considered when a renal calculus is detected in an abnormal location, but confirmation should be obtained from a renal sonogram, CT, MRU, or retrograde pyelogram (Fig. 38.20). These studies show the abnormal orientation of the renal pelvis and calyces, a flattened and elongated pelvis, a stretched superior calyx with blunting of the remaining calyces, and a laterally displaced upper third of the ureter. Bilateral malrotation is not uncommon and may suggest the diagnosis of a horseshoe kidney (Kim et al., 2016). However, careful inspection for an isthmus and observation of the lower pole renal outline should distinguish the two entities.

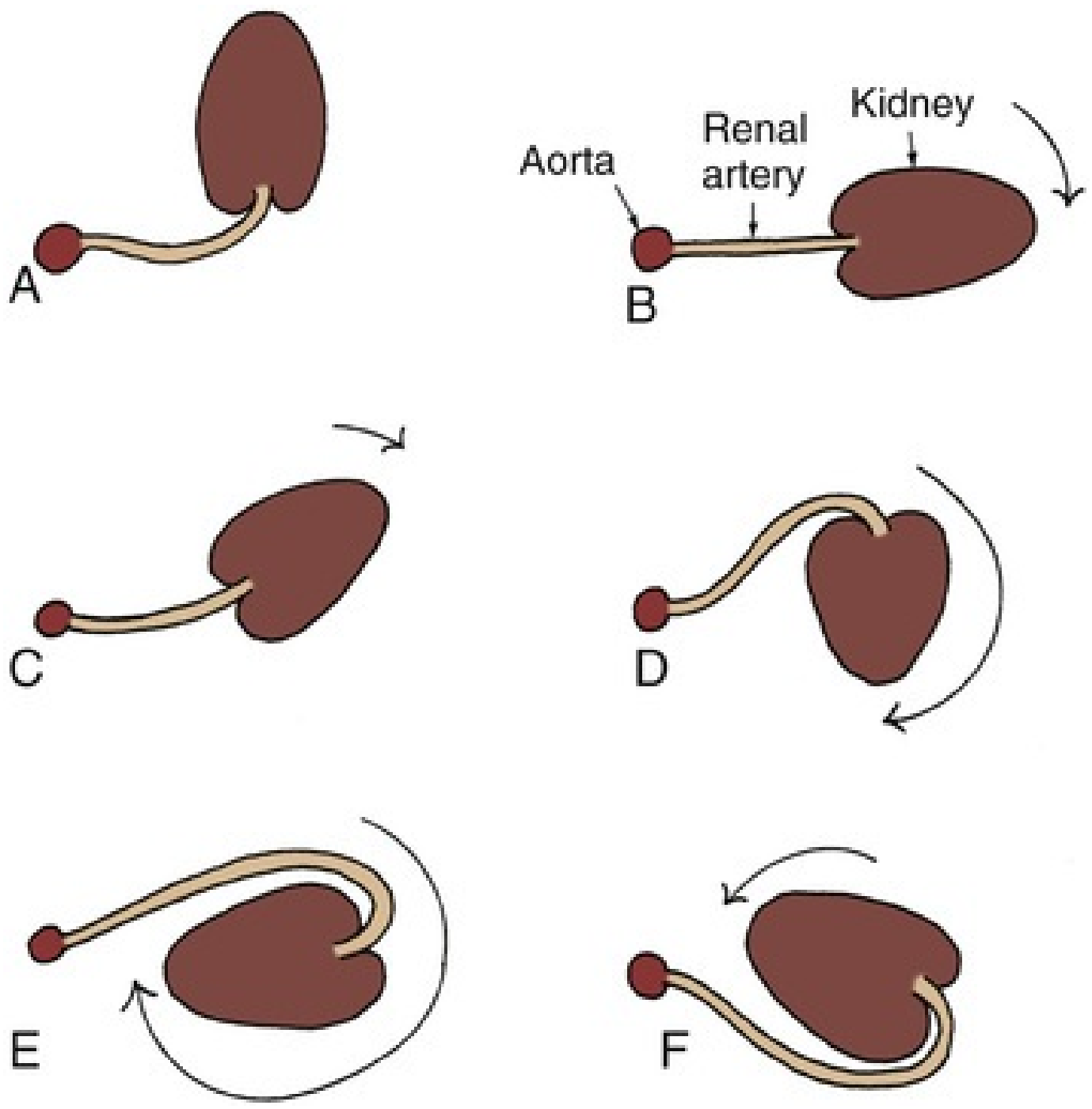

FIG. 38.20 Rotation of the kidney during its ascent from the pelvis. The left kidney with its renal artery and the aorta are viewed in transverse section to show normal and abnormal rotation during its ascent to the adult site. (A) Primitive embryonic position; hilus faces ventrad (anterior). (B) Normal adult position; hilus faces mediad. (C) Incomplete rotation. (D) Hyper-rotation; hilus faces dorsad (posterior). (E) Hyper-rotation; hilus faces laterad. (F) Reverse rotation; hilus faces laterad. (From Gray SW, Skandalakis JE. *Embryology for surgeons.* Philadelphia: Saunders; 1972.)

Prognosis

Malrotation does not impair renal function. Hydronephrosis resulting from impaired urinary drainage may lead to infection and calculus formation (Kim et al., 2016; Tsai et al., 2015).

Key Points: Anomalies of Renal Rotation

- The kidney and renal pelvis normally rotate 90 degrees ventromedially during ascent so that the calyces point laterally and the pelvis faces medially. When this alignment is not exact, the condition is known as malrotation.
- Malrotation is frequently associated with Turner syndrome.

Anomalies of Renal Vasculature

Aberrant, Accessory, or Multiple Vessels

The kidney is divided into various segments, each supplied by a single “end” arterial branch that usually courses from one main renal artery. The preferred term to describe any kidney supplied by more than one vessel originating from the aorta is *multiple renal arteries*. The terms *anomalous vessels* or *aberrant vessels* should be reserved for arteries that originate from vessels other than the aorta or main renal artery. The term *accessory vessels* denotes two or more arterial branches supplying the same renal segment.

Incidence

Between 71% and 85% of kidneys have a single artery that supplies the entire renal parenchyma (Merklin and Michele, 1958; Geyer and Poutasse, 1962). A slightly higher percentage of right-sided kidneys have a single renal artery compared with left-sided organs (Geyer and Poutasse, 1962; Nayak, 2008; Bayramoglu et al., 2003). True aberrant vessels are rare, except in cases with renal ectopia, with or without fusion, and in individuals with a horseshoe kidney (Degani et al., 2010; Glodny et al., 2009; Gesase, 2007).

Embryology

The renal arterial tree is derived from three groups of primitive vasculature that coalesce to form the mature vascular pattern for all retroperitoneal structures. The cranial group consists of two pairs of arteries dorsal to the suprarenal gland that shift dorsally to form the phrenic artery. The middle group is composed of three pairs of vessels that pass through the suprarenal area and retain the same lateral position, becoming the adrenal artery. Finally, the caudal group of four paired arteries cross ventral to the suprarenal area and become the main renal artery. Sometimes the most inferior pair from the middle group joins them (Guggemos, 1962). It is believed that, during renal migration, this network of vessels selectively degenerates, and the remaining adjacent arteries assume a progressively more important function. By a process of elimination, one primitive renal arterial pair eventually becomes the dominant vessel, the completed process being dependent on the final position of the kidney (Graves, 1956). Polar arteries or multiple renal arteries to the normally positioned kidney represent a failure of complete degeneration of all primitive vascular channels. The multiple vessel pattern that has been described for renal ectopia could be considered as an arrested embryonic state for that particular renal position (Gray and Skandalakis, 1972.

Description

Based on vascular supply, the renal parenchyma is divided into five segments: apical, upper, middle, lower, and posterior. The main renal artery divides initially into an anterior and posterior branch. The anterior branch almost always supplies the upper, middle, and lower segments of the kidney. The posterior branch invariably supplies the posterior and lower segments (Sampaio and Aragao, 1990a). The vessel to the apical segment has the greatest variation in origin; it arises from (1) the anterior division (44%), (2) the junction of the anterior and posterior divisions (23%), (3) the mainstem renal artery or aorta (23%), or (4) the posterior division of the main renal artery (10%) (Graves, 1954). Rarely the upper segment is supplied from a branch totally separate from the main renal artery (Merklin and Michele, 1958). Shoja et al. studied the perihilar (extraparenchymal) branching patterns and morphologies of the renal artery (Shoja et al., 2008). A “fork” pattern with a common branching point (usually duplicated) was the most commonly observed extrarenal division and branching pattern of the main renal artery. They conclude that perihilar branching of the main renal artery was highly variable, with predictable patterns in the majority of kidneys. This information is useful for the transplant surgeon when interpreting radiodiagnostics of the renal hilum. **The lower renal segment, however, is often supplied by an accessory vessel.** This vessel is usually the most proximal branch when it arises from the main renal artery or its anterior division (Graves, 1954). However, it may originate directly from the aorta near the main renal artery, or it may be aberrant, arising from the gonadal vessel. Merklin and Michele performed an extensive study of the variant renal and suprarenal blood supply (Merklin and Michele, 1958). Sampaio and Aragao studied the venous drainage of the kidney and noted a close association between the inferior branch to the main renal vein and the anterior inferior aspect of the renal pelvis in 40% of kidneys (Sampaio and Aragao, 1990b).

Symptoms

Symptoms attributable to renal vascular anomalies are those that might result from inadequate urinary drainage at the site of extrinsic compression on the collecting system. Multiple, aberrant, or accessory vessels may constrict an infundibulum, a major calyx, or the UPJ (Addonizio and Patel, 1980; Zambrowicz et al., 1972; Fraley, 1966). Pain and hematuria secondary to hydronephrosis, UTI, or calculus may result.

Diagnosis

Precise anatomic resolution of vascular variants and associated disease states can be obtained using three-dimensional power Doppler ultrasonography, CT, or MRI (Figs. 38.21 and 38.22) (Degani et al., 2010; Leavitt et al., 2013).

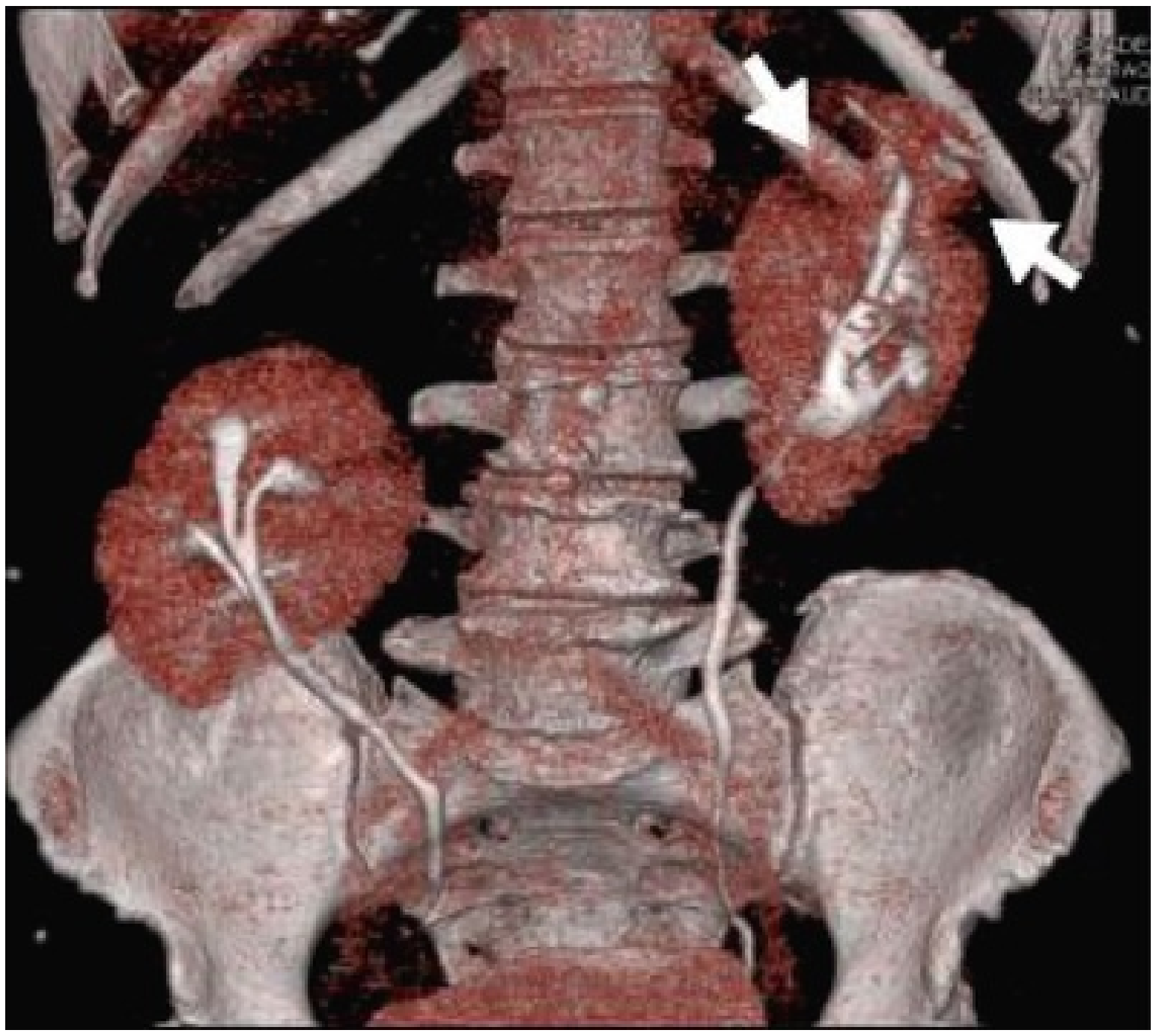

FIG. 38.21 Three-dimensional computed tomography reconstruction image show anteriorly rotated bilateral kidneys in 71-year-old patient with left flank pain caused by acute pyelonephritis. Note wedge-shaped defects in the left upper pole *(arrows).* (From Kim HY, Lee SJ, Bae EH, et al. A case of acute pyelonephritis in bilateral renal malrotation. *Chonnam Med J.* 2016;52:219.)

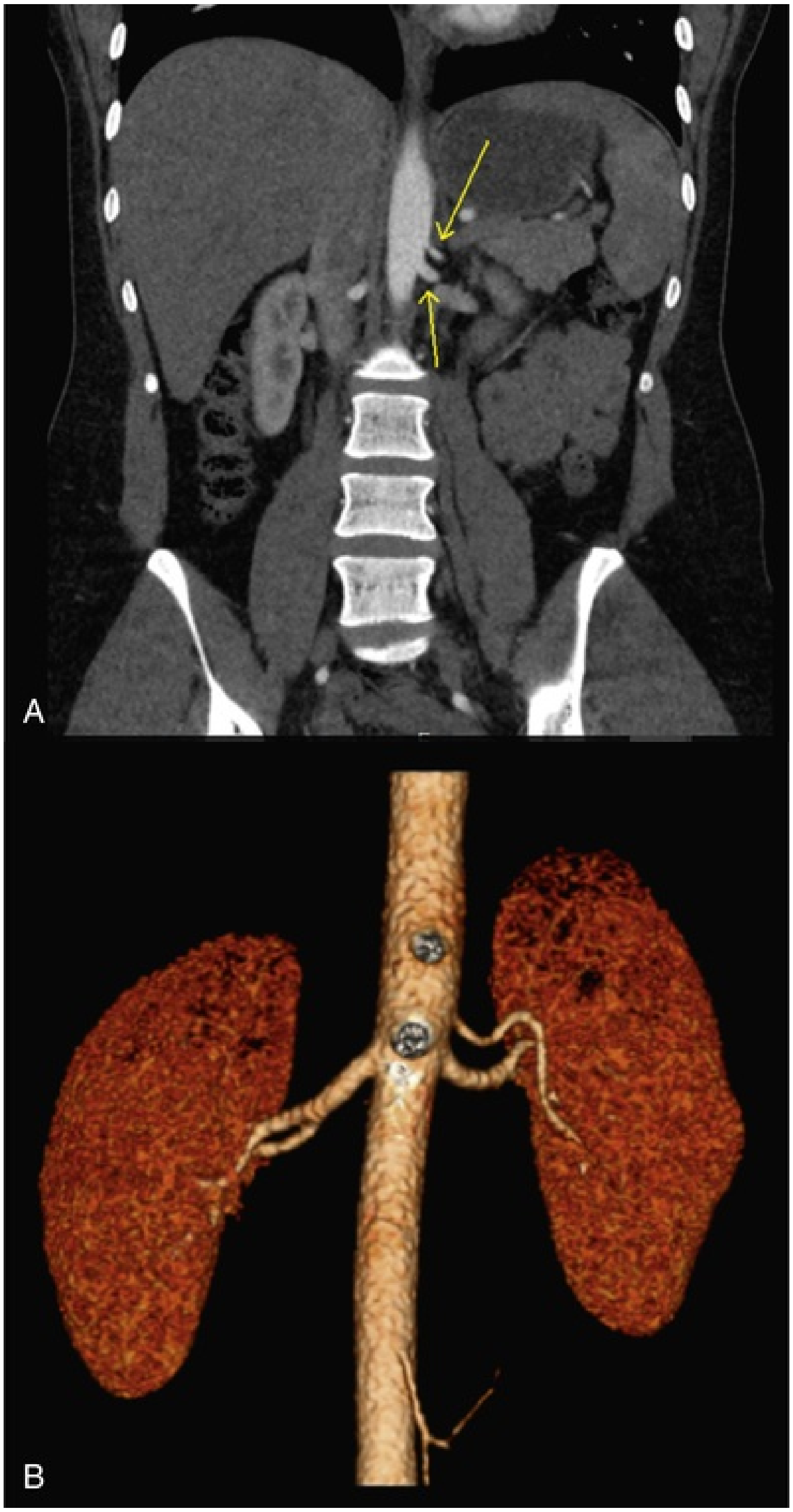

FIG. 38.22 A 29-year-old patient undergoing computed tomography (CT) scanning for living donor renal transplant evaluation. (A) CT scan after administration of intravenous contrast demonstrating renal artery anatomy on coronal images. *Arrows* point to two separate renal arteries arising from aorta. (B) Coronal three-dimensional reconstruction showing single right renal artery and two left renal arteries.

Prognosis

Hydronephrosis secondary to a vascular anomaly such as a lower pole crossing vessel is a very rare finding, especially when one considers the relative frequency of all renal vascular variations. Leavitt et al. reported that the prevalence of crossing vessels in asymptomatic, healthy patients with a radiographically normal ureteropelvic junction was approximately 25% using CT imaging (Leavitt et al., 2013). Zelster et al. used endoluminal ultrasound to identify that a crossing vessel at the UPJ is seen in 19% of patients with a normal UPJ (Zeltser et al., 2004). Hypertension is no more frequent in patients with multiple renal arteries than in those with a single vessel (Geyer and Poutasse, 1962).

Renal Artery Aneurysm

Renal artery aneurysm (RAA) is a rare occurrence, with an estimated incidence of 0.09% in the general population (Stanley et al., 1975). Abeshouse classified RAAs as follows: saccular, fusiform, dissecting, or arteriovenous (Abeshouse, 1951). The saccular aneurysm, a localized outpouching that communicates with the arterial lumen by a narrow or wide opening, is the most common type, accounting for 93% of all aneurysms (Zinman and Libertino, 1982). When the aneurysm is located at the bifurcation of the main renal artery and its anterior and posterior divisions, or at one of the more distal branchings, it is considered to be congenital in origin and is called the *fusiform* type (Poutasse, 1957). The presence of similar aneurysms at branching points in the vasculature of other organ systems attests to this possible origin (Lorentz et al., 1984). Acquired aneurysms may be located anywhere and may result from inflammatory, traumatic, or degenerative factors. A localized defect in the internal elastic tissue and the media allows the vessel to dilate at that point. It is a true aneurysm, because its walls are composed of most of the layers that make up the normal artery (Poutasse, 1957). The outpouchings may vary in size from 1 to 2 cm up to 10 cm (Garritano, 1957), but 90% are smaller than 2 cm. There is no absolute predilection for side, but the right side is more commonly encountered, and bilateral aneurysms are seen in up to 15% (Pfeiffer et al., 2003; Klausner et al., 2015). **In one multi-institutional study in the United States, three-fourths of RAA cases were asymptomatic at diagnosis** (Klausner et al., 2015). **The absence of symptoms predominates when RAA is diagnosed in children** (Sarker et al., 1991). When symptoms are present, they include abdominal or flank pain (6% to 15%), hematuria (microscopic and macroscopic; 5% to 30%), and hypertension (10% to 55%) (Bulbul and Farrow, 1992; Klausner et al., 2015). The hypertension is renin-mediated and secondary to relative parenchymal ischemia (Lorentz et al., 1984). Thirteen cases of hydronephrosis secondary to an adjacent renal vessel aneurysm were noted (Miyagawa et al., 2001). **The diagnosis is suspected when a pulsatile mass is palpated in the region of the renal hilum or when a bruit is heard on abdominal auscultation. A wreathlike calcification in the area of the renal artery or its branches (30%) is highly suggestive** (Silvis et al., 1956). RAAs can be evaluated with color Doppler sonography, spiral CT, three-dimensional MRA, or digital subtraction arteriography (Bunchman et al., 1991; González et

al., 2014).

Many asymptomatic RAAs come to light during a workup of uncontrolled hypertension (35%), whereas 26% are diagnosed when angiography is performed for other reasons (Hupp et al., 1992). **The indications for treatment of RAA remain controversial** (González et al., 2014). **Treatment is indicated for those who present with rupture or are at a high risk for rupture. High risk for rupture is associated with rapidly expanding RAAs and pregnant females, or those who are considering pregnancy.** Several reports exist of a ruptured RAA during pregnancy (Lacroix et al., 2001). The likelihood of spontaneous rupture in the study by Klausner was very low for all RAAs (0.3%), with all ruptured RAAs being larger than 3 cm. Klausner et al., 2015). Among RAAs larger than 3 cm in their study, the rate of rupture was 18%. In addition, intervention is indicated for RAAs larger than 2.0 cm or for individuals with symptoms including uncontrolled hypertension from renal artery stenosis, flank pain, hematuria, or renal ischemia/infarction resulting from embolization from the aneurysm. Open surgical or endovascular techniques should be performed electively for those at high risk for rupture (González et al., 2014; Pfeiffer et al., 2003; Klausner et al., 2015).

Renal Arteriovenous Fistula

Although rare, renal arteriovenous fistulas (AVFs) have been diagnosed with increasing frequency. **Two types exist, congenital and acquired** (Maldonado et al., 1964)**, with the latter (secondary to trauma, inflammation, renal surgery, or percutaneous needle biopsy) accounting for the increase in incidence.** Only the congenital variant is discussed here. **Less than 25% of all AVFs are congenital, with only 91 reported cases** (Takaha et al., 1980; Muraoka et al., 2008)**. They are identifiable by their cirsoid configuration and multiple communications between the main or segmental renal arteries and the venous channels** (Crummy et al., 1965; Cho and Stanley, 1978). Although congenital, they rarely present clinically before the third or fourth decade. Women are affected three times as often as men, and the right kidney is involved slightly more often than the left (Ishikawa et al., 2004). The lesion is usually located in the upper pole (45% of cases), but not infrequently it may be found in the midportion (30%) or in the lower pole (25%) of the kidney (Yazaki et al., 1976). **The condition is thought either to be present at birth or to result from a congenital aneurysm eroding into an adjacent vein** (Thomason et al., 1972).

The pathophysiology involved in the shunting of blood, which bypasses the renal parenchyma and rapidly joins the venous circulation and returns to the heart, results in a varied clinical picture. The symptoms are based on the age and size of the AVF (Messing et al., 1976). **The hemodynamic derangement often produces a loud bruit in 75% of cases. Diminished perfusion of renal parenchyma distal to the fistulous site leads to relative ischemia and renin-mediated hypertension in approximately 50%** (McAlhany et al., 1971). The increased venous return and high cardiac output with concomitant diminution in peripheral resistance may result in left ventricular hypertrophy and subsequent high-output cardiac failure in 50% of cases (Maldonado et al., 1964). Macroscopic and microscopic hematuria occurs in more than 75% of affected individuals because of the proximity of the collecting system (Montoya et al., 2004; Inoue and Hashimura, 2000; Chen et al., 2006; Fogazzi et al., 1997). Although flank or abdominal pain may be present, a mass is rarely palpable (10%). **Three-dimensional Doppler sonography and MRA are accurate and noninvasive tests** (Mohaupt et al., 1999; Macpherson et al., 1991; Ishikawa et al., 2004)**, but selective renal arteriography or digital subtraction angiography is the most definitive method for diagnosing the lesion.** A cirsoid appearance with multiple small, tortuous channels; prompt venous filling; and an enlarged renal, and possibly gonadal, vein are pathognomonic for arteriovenous malformation (AVM) (DeSai and DeSautels, 1973). **The symptomatic nature of this lesion, which causes progressive alterations in the cardiovascular system, often dictates surgical intervention.** The congenital variant rarely behaves like its acquired counterpart, which may disappear spontaneously after several months (Inoue and Hashimura, 2000; Kubota et al., 2003). Nephrectomy, partial nephrectomy, vascular ligation, selective embolization (Bookstein and Goldstein, 1973; Bilge et al., 1999), and balloon catheter occlusion (Bentson and Crandall, 1972) have been used to obliterate the fistula.

Key Points: Anomalies of Renal Vasculature

- The overall incidence of RAA is rare and has been calculated to be 0.1%.
- Most RAAs are silent, especially in children. An asymptomatic RAA may be diagnosed during an evaluation for hypertension.

- Treatment of RAA is indicated for those presenting with rupture or at high risk for rupture. Risk factors for RAA rupture are rapidly expanding RAA, RAA greater than 2 cm, pregnancy, or those considering pregnancy.
- Congenital renal AVM RAAs are very rare but may require treatment if alterations in the cardiovascular system occur resulting in high-output cardiac failure.

Anomalies of the Renal Collecting System

Bifid Pelvis

Approximately 10% of normal renal pelves are bifid, the pelvis dividing to form two major calyces first at, or just within, its entrance to the kidney. A bifid pelvis should be considered a normal variant. Further division of the renal pelvis can occur resulting in triplication of the pelvis, but this is extremely rare (Fig. 38.23).

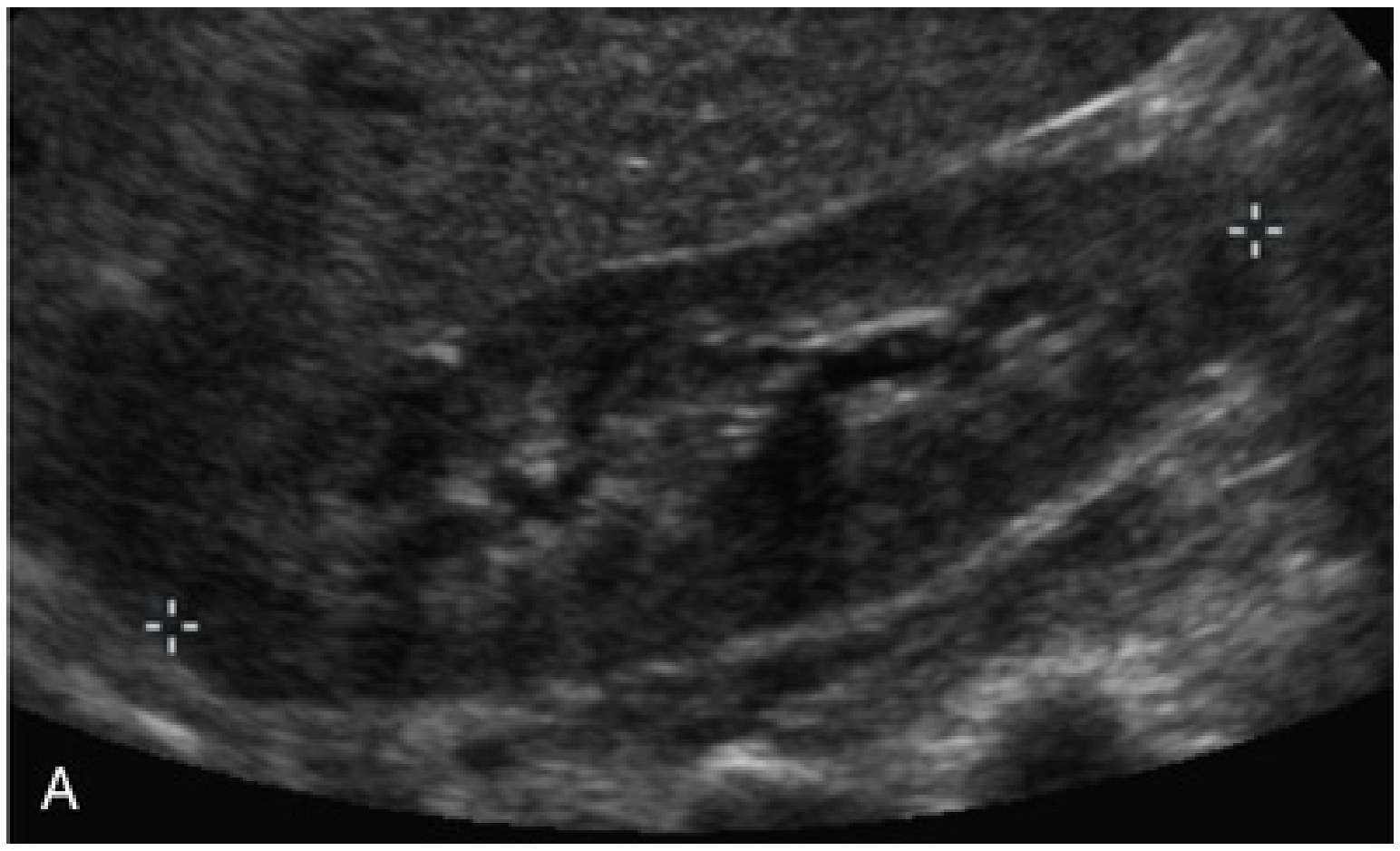

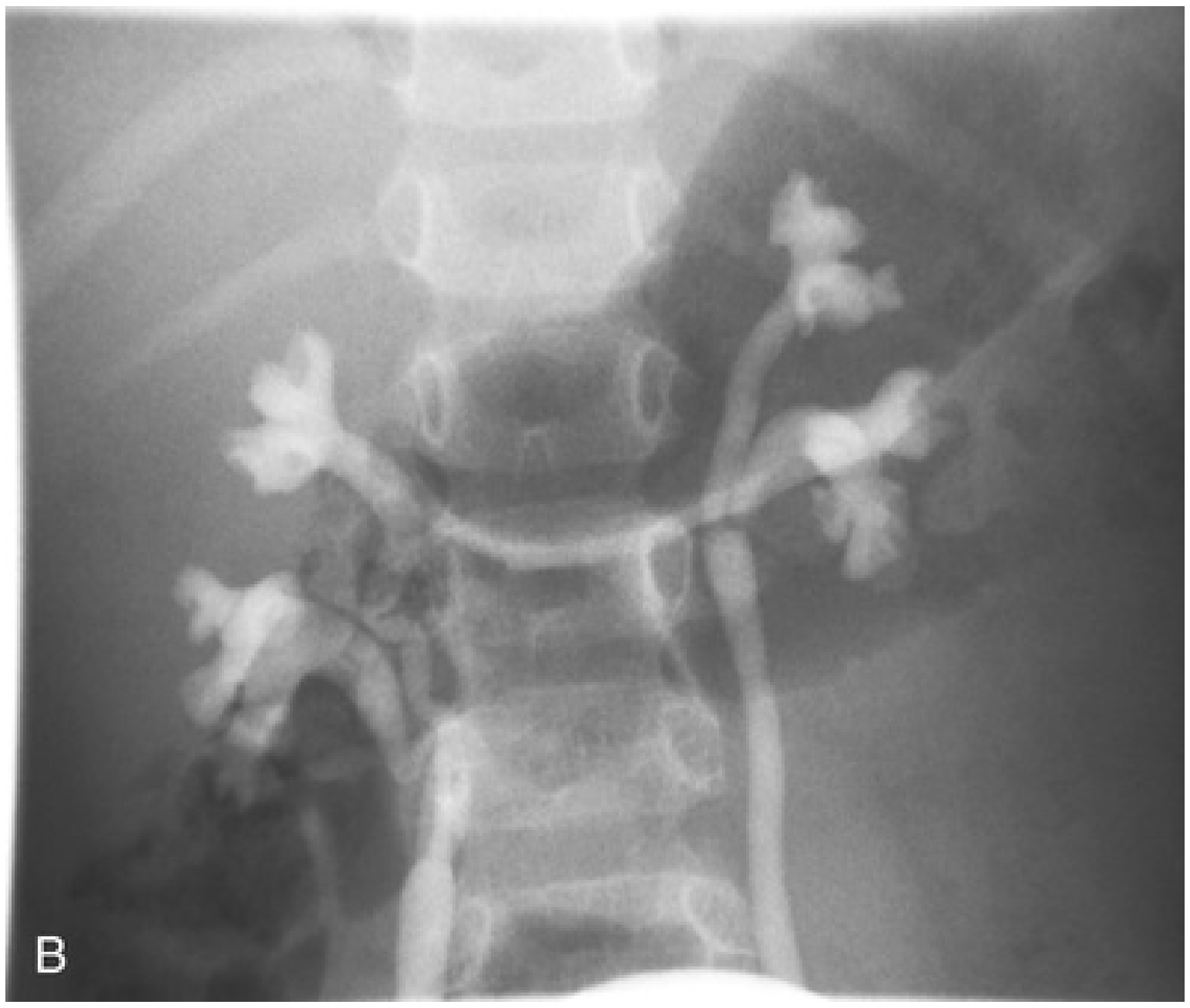

FIG. 38.23 (A) Sonogram showing split hyperechoic region of renal sinus indicative of bifid renal pelvis. (B) Cystogram demonstrating bilateral vesicoureteral reflux into bifid renal pelves.

Calyceal Diverticulum

A calyceal diverticulum is a cystic cavity within the kidney that is lined by transitional epithelium and communicates with a calyx or less commonly with the renal pelvis through a narrow isthmus (Estrada et al., 2009)**. An incidence of 4.5 per 1000 has been reported** (Timmons et al., 1975). A similar incidence was noted both in children and in adults, with no predilection for either side or gender. Most diverticula, labeled type I, occur adjacent to an upper or, occasionally, a lower pole calyx. Type II diverticula are larger, communicate with the renal pelvis, and tend to be symptomatic (Wulfsohn, 1980). **Congenital and acquired factors have been suggested to explain the formation of calyceal diverticula.** The similar incidence in children and adults is consistent with an embryologic etiology (Middleton and Pfister, 1974). At the 5-mm stage of the embryo, ureteral branches of the third and fourth generation, which ordinarily degenerate, may persist as isolated branches, resulting in the formation of a calyceal diverticulum (Lister and Singh, 1973). A localized cortical abscess draining into a calyx has also been postulated as an alternative etiologic factor. Amar postulated that calyceal tubular backflow of infected urine could result in abscess formation and parenchymal injury leading to diverticular formation (Amar, 1975). Other proposed causes include obstruction from stones or infection within a calyx, progressive fibrosis of an infundibular stenosis, renal injury, achalasia, and spasm or dysfunction of one of the supposed sphincters surrounding a minor calyx (Siegel and McAlister, 1979; Patriquin et al., 1985). Vesicoureteral reflux has also been considered an etiologic factor.

Small diverticula are usually asymptomatic and are found incidentally by ultrasonography, CT, or MRI (Fig. 38.24). These diverticula may progressively distend with trapped urine and enlarge over time (Amar, 1975; Siegel and McAlister, 1979; Patriquin et al., 1985). Infection, milk of calcium (Patriquin et al., 1985), or true stone formation are complications of stasis or obstruction that can produce symptoms. Lister and Singh, 1973; Siegel and McAlister, 1979). **Hematuria, pain, and UTI may be seen in the presence of stones, which can occur in almost 40% of patients. The diagnosis is suggested on ultrasonography but is confirmed on CT scan or MRU** (Estrada et al., 2009) **(see Fig. 38.24).** Delayed radiographs demonstrate pooling of contrast material in the diverticulum. When it is filled with microcalculi, ultrasonography characteristically demonstrates a layering effect, within the diverticulum, between clear fluid above and echo-dense debris without shadowing below (Widder and Newhouse, 1982). Ultrasonography will image the milk of calcium within the diverticulum as the patient changes position. **Patients who are asymptomatic do not require treatment but should be followed periodically with ultrasonography.** Estrada et al. reported 10 of 23 calyceal diverticula (43%) that required treatment at a mean of 27 months after initial diagnosis (Estrada et al., 2009). Most commonly, these children presented with febrile UTI.

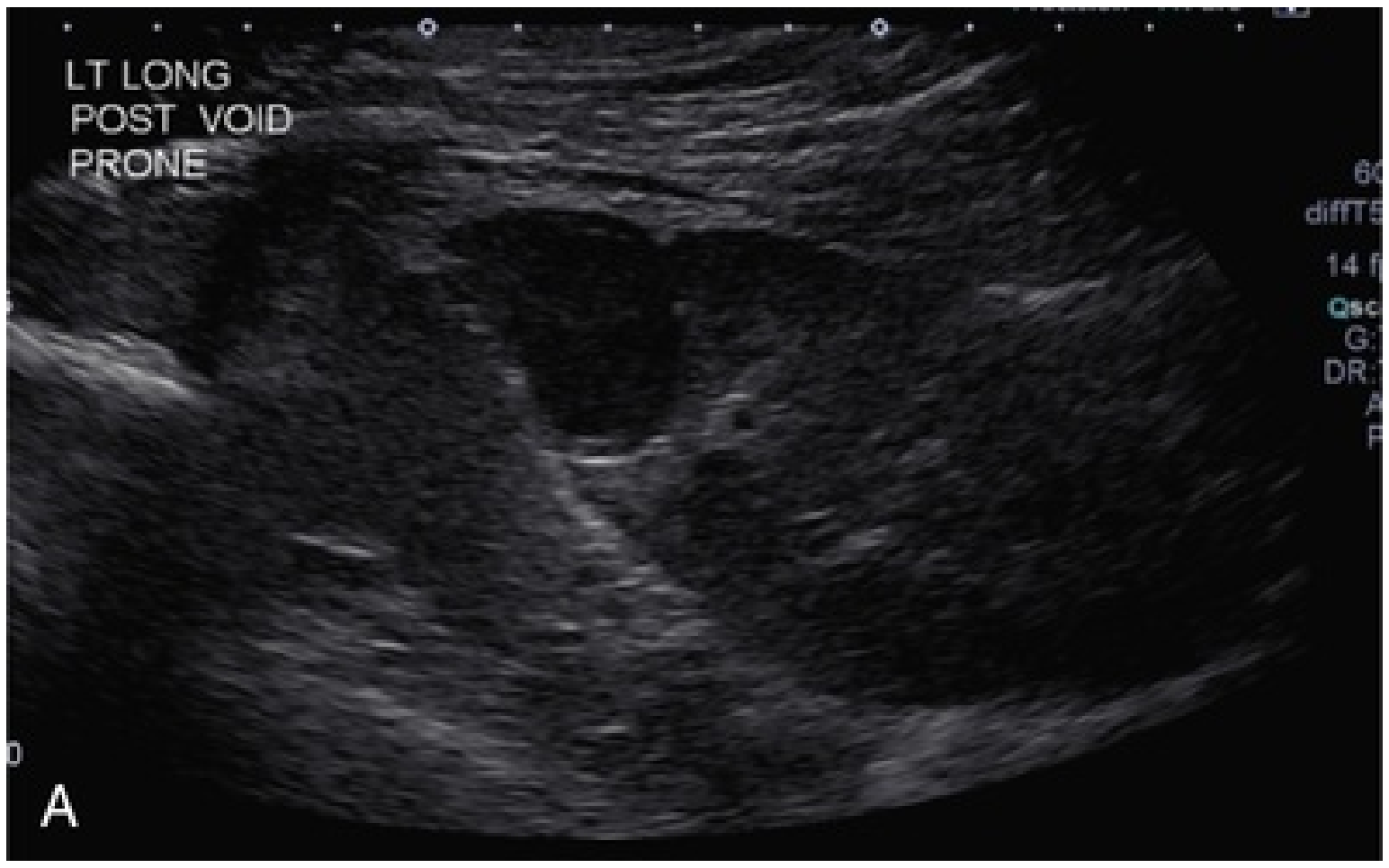

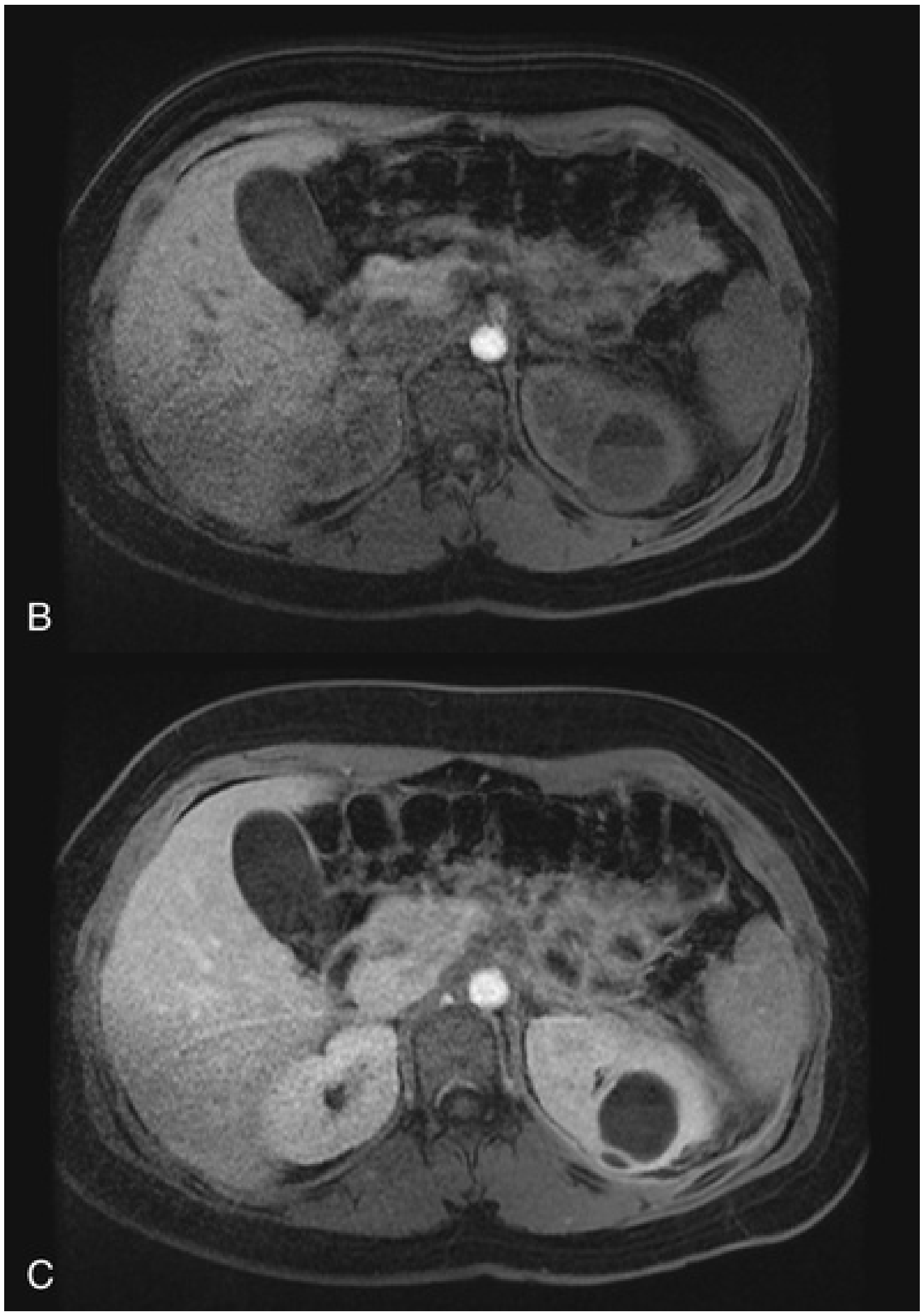
B
C

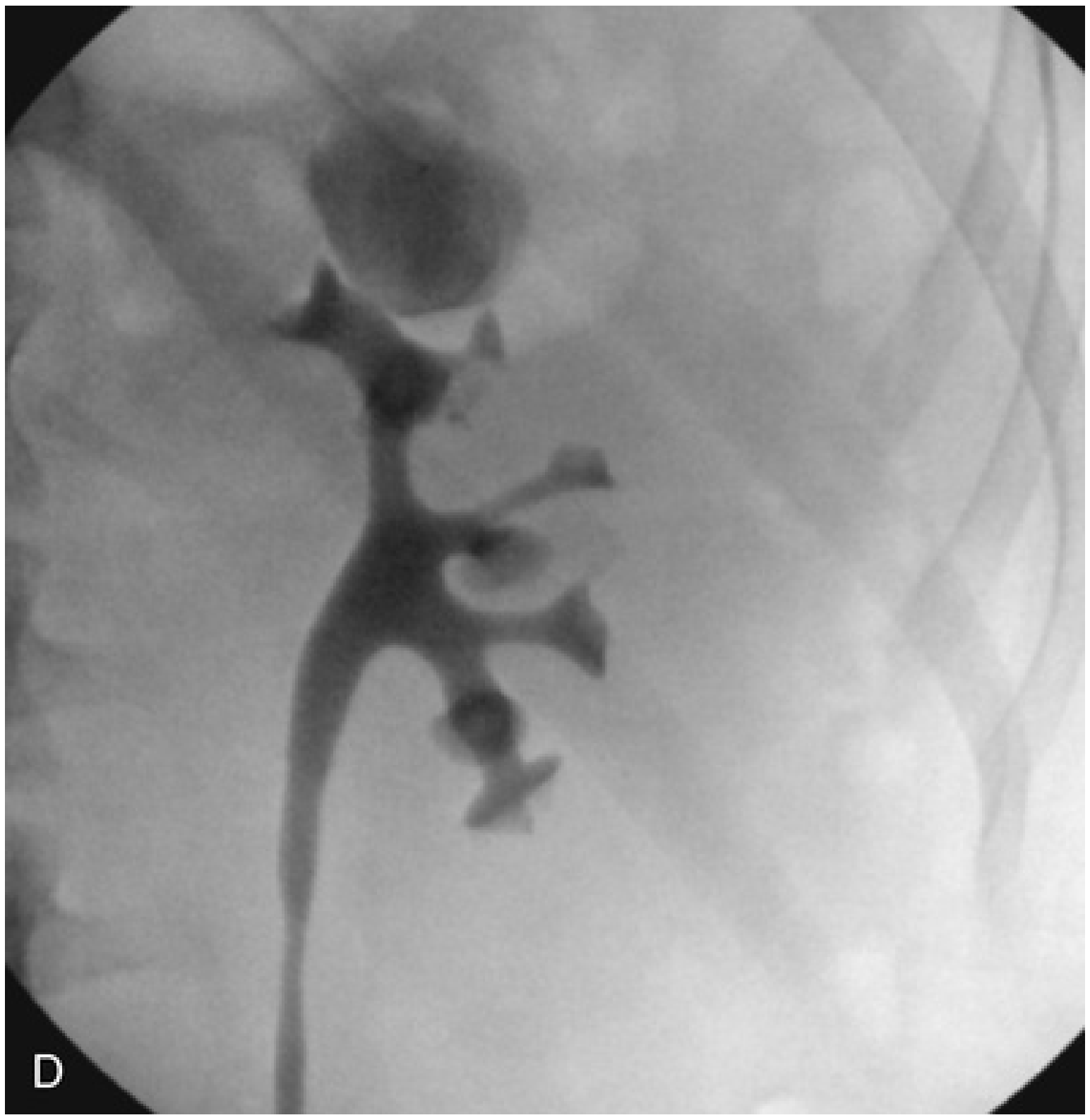

FIG. 38.24 Calyceal diverticulum in a 16-year-old female with recurrent urinary tract infections and left flank pain. (A) Ultrasound of a hypoechoic lesion in the upper pole of the left kidney and no significant hyperemia surrounding the cystic lesion. (B and C) Magnetic resonance axial image of the left kidney precontrast compared with 5 minutes post–intravenous contrast. Images show in upper pole of the left kidney a 3-cm cystic lesion with layering internal contents. (D) Retrograde pyelogram demonstrating injection of contrast into the left ureter and left renal collecting system opacifying the nondilated collecting system and a rounded collection of contrast superior to the collecting system, which was a calyceal diverticulum.

The indications for surgery included enlargement of the diverticulum associated with pain or infection, abscess formation, urosepsis, and symptomatic calculus formation. Retrograde pyelography can delineate the collecting system anatomy before intervention as well (see Fig. 38.24). Ureteroscopy with enlargement of the diverticular communication and removal of the stones has also been reported (Baldwin et al., 1998). Others have performed ureteroscopic ablation of the diverticular cavity to minimize the risk for recurrence (Long et al., 2015). Percutaneous ablation of the communication and fulguration of the diverticular lining is a viable option with favorable long-term results (Monga et al., 2000). Although percutaneous ablation remains a viable treatment alternative, the availability of pediatric laparoscopic equipment has led to the laparoscopic approach for marsupialization of the diverticulum and fulguration of the epithelial lining (Casale et al., 2004; Long et al., 2015; Sripathi et al., 2018).

Hydrocalycosis

Hydrocalycosis is a rare cystic dilation of a major calyx with a demonstrable connection to the renal pelvis. Dilation of the upper calyx resulting from obstruction of the upper infundibulum by vessels or stenosis has been described (Fraley, 1966; Johnston and Sandomirsky, 1972). Cicatrization of an infundibulum may result from infection or trauma or without an obvious etiology (Williams and Mininberg, 1968). It has been postulated that achalasia of a ring of muscle at the entrance of the infundibulum into the renal pelvis causes a functional obstruction (Williams and Mininberg, 1968). Mild upper calyceal dilation caused by partial infundibular obstruction is relatively common but usually asymptomatic. Although the most frequent presenting symptom is upper abdominal or flank pain, hydrocalycosis may be detected on prenatal ultrasonography. On occasion, a mass may be palpated. Stasis can lead to hematuria, urinary infection, or both. Hydrocalycosis must be differentiated from multiple dilated calyces secondary to ureteral obstruction, calyceal clubbing as a result of recurrent pyelonephritis or medullary necrosis, renal tuberculosis, a large calyceal diverticulum, and megacalycosis.

Megacalycosis

Megacalycosis is defined as nonobstructive enlargement of calyces resulting from malformation of the renal papillae (Fig. 38.25). The calyces are generally dilated and malformed and may be increased in number (12 to 20) (Pieretti-Vanmarcke et al., 2009). The renal pelvis is not dilated, nor is its wall thickened, and the UPJ is normally funneled without evidence of obstruction. The cortical tissue around the abnormal calyx is normal in thickness. The medulla, however, is underdeveloped and assumes a falciform (crescent) or semilunar appearance instead of its normal pyramidal shape. The collecting tubules are not dilated but are definitely shorter than normal, and they are oriented transversely rather than vertically from the corticomedullary junction (Puigvert, 1963). A mild disorder of maximal concentrating ability has been reported (Gittes and Talner, 1972), but acid excretion is normal after an acid load

(Vela-Navarrete and Garcia Robledo, 1983). Other functions of the kidney such as glomerular filtration, renal plasma flow, and isotope uptake also are not altered (Gittes, 1984). Turkmen et al. reported of a case of IgA nephropathy diagnosed in the setting of acute kidney injury and bilateral megacalycosis (Turkmen et al., 2013).

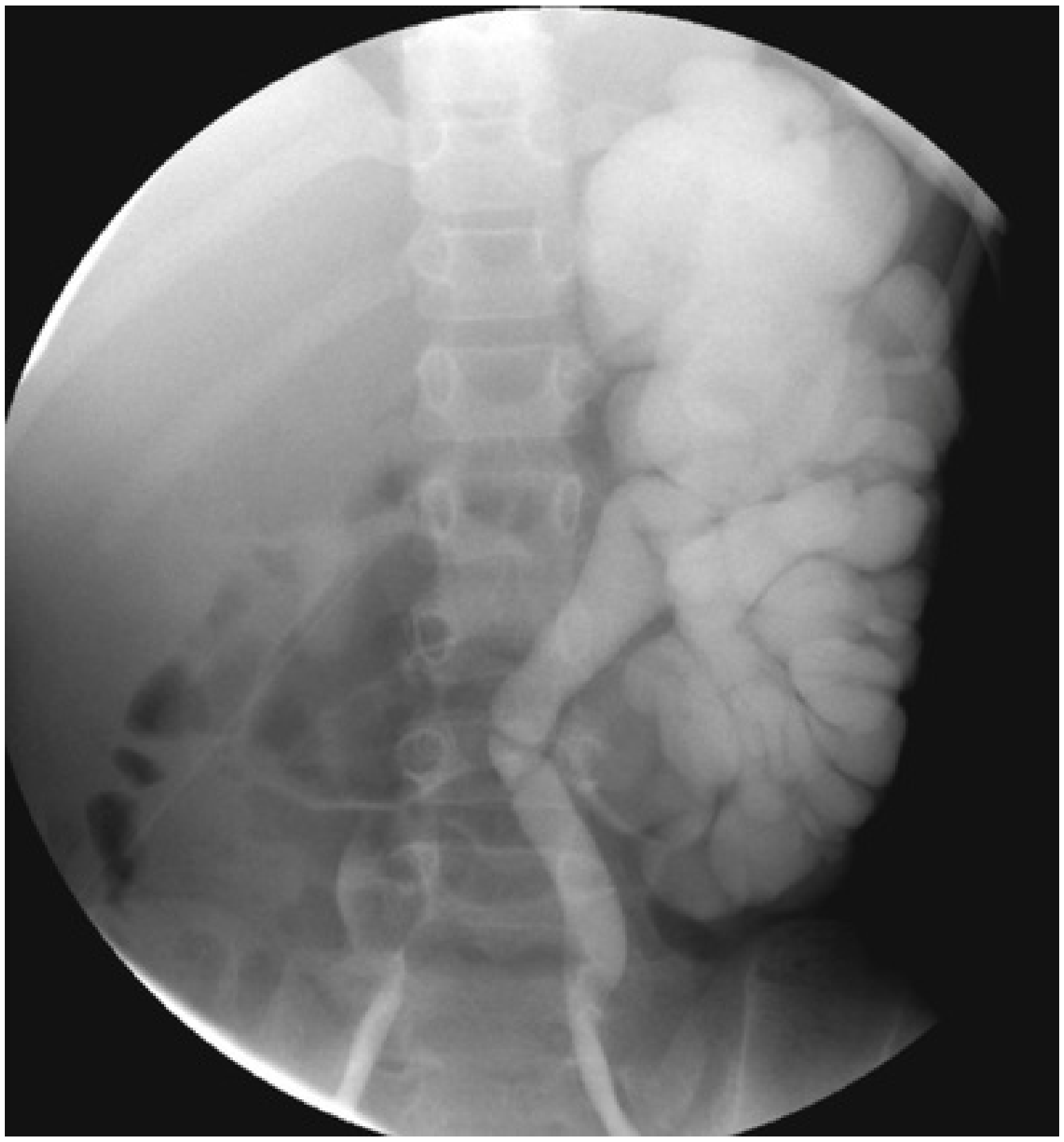

FIG. 38.25 Voiding cystogram demonstrating bilateral vesicoureteral reflux, right grade 1 and left side with innumerable dilated calyces and nondilated renal pelvis diagnostic of megacalycosis.

Megacalycosis is congenital and has been diagnosed prenatally (Hill et al., 2002)**. It occurs predominantly in males with a ratio of 6 : 1 and has been found only in Caucasians. Bilateral disease has been seen almost exclusively in males, whereas segmental unilateral involvement occurs only in females** (Cacciaguerra et al., 1996). It was theorized by Puigvert and endorsed by Johnston and Sandomirsky that there is a transient delay in the recanalization of the upper ureter after the branches of the UB hook up with the metanephric blastema (Puigvert, 1964; Johnston and Sandomirsky, 1972). This produces transient obstruction when the glomeruli start producing urine. The fetal calyces may dilate and retain their obstructed appearance, despite the lack of evidence of obstruction in postnatal life (Gittes and Talner, 1972). **The increased number of calyces may be an aborted response by the branching UB to the obstruction.** The abnormality is usually diagnosed during radiographic evaluation for UTI or other congenital anomalies (Arambasic et al., 2003). Adults frequently present with hematuria secondary to renal calculi. The calyces are dilated and are usually increased in number, but the infundibuli and pelvis may not be enlarged (see Fig. 38.25). Although the UPJ does not appear obstructed, there may be segmental dilation of the distal third of the ureter (Kozakewich and Lebowitz, 1974; Mandell et al., 1987). A normal-caliber ureter was interposed between the two entities. This anatomic picture may be mistaken for congenital ureteropelvic, ureterovesical junction obstruction, or infundibular stenosis (Pieretti-Vanmarcke et al., 2009). Diuretic renography shows a normal pattern for uptake and washout of the isotope (Gómez Tellado et al., 1997). **Long-term follow-up of these patients does not show progression of the anatomic derangement or functional impairment of the kidney** (Gittes, 1984).

Infundibulopelvic Stenosis

Infundibulopelvic stenosis most likely forms a link between cystic dysplasia of the kidney and the grossly hydronephrotic organ (Uhlenhuth et al., 1990). This condition includes a variety of radiographically dysmorphic kidneys with varying degrees of infundibular or infundibulopelvic stenosis that may be associated with renal dysplasia (Fig. 38.26). It is believed that this was the result of extensive dysgenesis of the pyelocalyceal system but with preservation of renal function. **Infundibulopelvic stenosis is usually bilateral and is commonly associated with vesicoureteral reflux, suggesting an abnormality of the entire UB** (Kelalis and Malek, 1981). Patients usually present with urinary infection, hypertension, or flank pain. Sometimes, an asymptomatic child with multiple anomalies is found to have this condition. Dally et al. reported a series of 200 patients with MCDK in which 5 patients had infundibulopelvic stenosis in the contralateral kidney (Dally et al., 2011). The MCDK was diagnosed in the first year of life in four of the five patients in the study. The infundibulopelvic stenosis was diagnosed early (before 1 year of age) in two patients while it was diagnosed later (6, 12, and 16 years of age). Despite extensively dysmorphic kidney features, the function is either normal or only slightly affected (Kelalis and Malek, 1981; Dally et al., 2011). In Husmann's study of 21 patients with the longest follow-up to date (median of 11 years), 90% had bilateral renal disease (Husmann et al., 1994). Ten patients had bilateral infundibulopelvic stenosis, six had a contralateral dysplastic renal unit, and three had contralateral URA. Renal insufficiency or ESRD developed in eight patients (37%), all of whom had bilateral kidney anomalies. Renal biopsies in those with ESRD demonstrated renal dysplasia proximal to the stenotic infundibuli and varying degrees of glomerulosclerosis of the glomeruli that were not involved in the regions with dysplasia. They proposed that the decreased total functional renal tissue leads to hyperfiltration injury. They suggested that endoscopic or percutaneous surgery should be considered for increasing hydronephrosis. Nurzia et al. recommend monitoring of renal function to include a baseline and yearly serum creatinine level, estimation of glomerular filtration rate, and urinalysis (Nurzia et al., 2002). Prevention of hyperfiltration injury with calcium-channel–blocking agents, ACE inhibitors, and dietary restriction of protein should be considered when a decline in renal function occurs (Puddu et al., 2009). Surgical intervention should be reserved for patients in whom obstruction from the infundibulopelvic stenosis is demonstrated to negatively affect renal function. Bayne and Peters reported on three patients who each underwent open repair for declining renal function (Bayne and Peters, 2016). As a surgical strategy to optimize postoperative outcomes, the authors advocate for utilization of preoperative three-dimensional modeling via MRU to guide proper placement of calicocalicostomy drainage to a lower pole ureterocalicostomy.

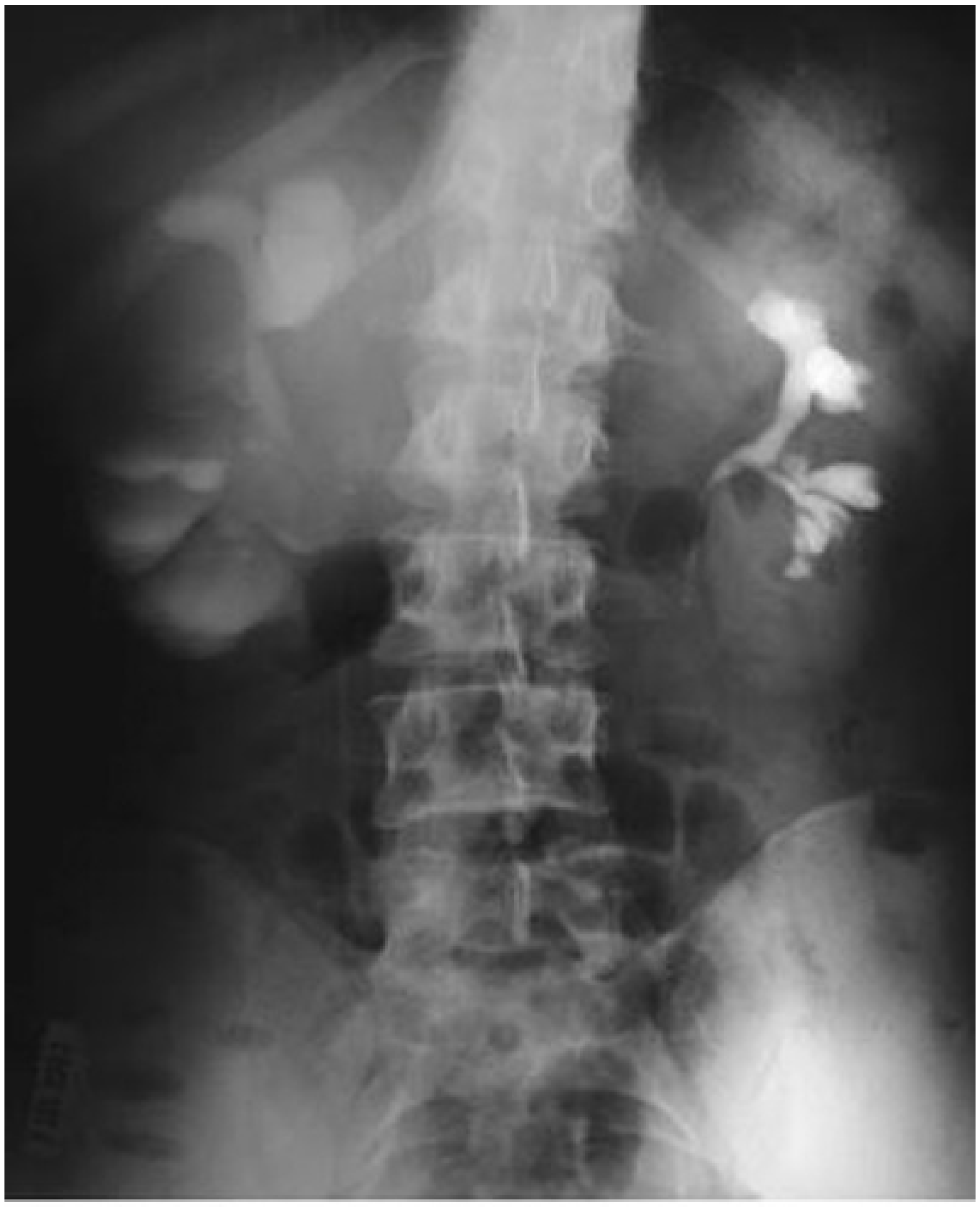

FIG. 38.26 Intravenous pyelogram of a 17-year-old boy showing severe right calyceal dilatation, no dilation of the right renal pelvis, and a small contralateral renal pelvis. The left renal pelvis is slightly atrophic, an infundibulopelvic stenosis variant. (From Bayne CE, Peters CA. Congenital infundibulopelvic stenosis: indications for intervention, surgical technique, and review of literature. *J Ped Urol*. 2016;12:389.)

Key Points: Anomalies of Renal Collecting System

- Calyceal diverticulum is a cystic cavity within the kidney that is lined by transitional epithelium and communicates with a calyx or, less commonly, with the renal pelvis through a narrow isthmus.
- The diagnosis of calyceal diverticulum is best made by CT or MRU.
- Endoscopic or laparoscopic treatment are both effective approaches for treatment of symptomatic calyceal diverticulum.

- Megacalycosis is a congenital, nonobstructive enlargement of calyces resulting from malformation of the renal papillae.
- Infundibulopelvic stenosis is usually bilateral, and despite extensively dysmorphic kidney features, the function is either normal or only slightly affected.

Acknowledgments

The authors would like to acknowledge the efforts and assistance of Dr. Steven Kraus in compiling a portion of the radiographic images included in this chapter. The authors would also like to acknowledge Drs. Ellen Shapiro and Shpetim Telegrafi for their work on this chapter in the previous edition.

References

Abeshouse BS, Bhisitkul I. Crossed renal ectopia with and without fusion. *Urol Int*. 1959;9:63–91.

Abeshouse BS. Renal aneurysm: report of two cases and review of the literature. *Urol Cutaneous Rev*. 1951;55:451–463.

Addonizio JC, Patel RC. Innocent aberrant renal vessels producing ureteropelvic junction obstruction. *Urology*. 1980;16:176–180.

Adeniran AJ, Stanek J. Amnion nodosum revisited: clinicopathologic and placental correlations. *Arch Pathol Lab Med*. 2007;131(12):1829–1833.

Akdogan L, Oguz AK, Ergun T, et al. The rarest of the rare: crossed fused renal ectopia of the superior ectopia type. *Case Rep Nephrol*. 2015;2015:742419.

Amar A. The clinical significance of renal caliceal diverticulum in children: relation to vesicoureteral reflux. *J Urol*. 1975;113:255–257.

Anderson EE, Harrison JH. Surgical importance of the solitary kidney. *N Engl J Med*. 1965;273:683–687.

Angulo JC, Lopez JI, Vilanova JR, et al. Intrathoracic kidney and vertebral fusion: a model of combined misdevelopment. *J Urol*. 1992;147:1351–1353.

Anson BJ, Riba LW. The anatomical and surgical features of ectopic kidney. *Surg Gynecol Obstet*. 1939;68:37.

Arambasic J, Puseljic S, Angebrandt S, et al. Rare renal anomalies in childhood. *Acta Med Croatica*. 2003;57:83–85.

Arora RS, Pryce R. Is ultrasonography required to rule out renal malformations in babies with isolated preauricular tags? *Arch Dis Child*. 2004;89(5):492–493.

Ashley DJ, Mostofi FK. Renal agenesis and dysgenesis. *J Urol*. 1960;83:211–230.

Atiyeh B, Husmann D, Baum M. Contralateral renal abnormalities in patients with renal agenesis and noncystic renal dysplasia. *Pediatrics*. 1993;91(4):812–815.

Baggenstoss AH. Congenital anomalies of the kidney. *Med Clin North Am*. 1951;35:987–1004.

Bain AD, Scott JS. Renal agenesis and severe urinary tract dysplasia: a review of 50 cases, with particular reference to the associated anomalies. *Br Med J*. 1960;1(5176):841–846.

Baldwin DD, Beaghler MA, Ruckle HC, et al. Ureteroscopic treatment of symptomatic caliceal diverticular calculi. *Tech Urol*. 1998;4:92–98.

Barroeta JE, Stopyra GA. 47,XXY with associated bilateral renal agenesis. *Arch Pathol Lab Med*. 2004;128(3):e44–e45.

Battin J, Lacombe D, Leng JJ. Familial occurrence of hereditary renal adysplasia with mullerian anomalies. *Clin Genet*. 1993;43(1):23–24.

Baurys W, Servoss S. Eventration of the diaphragm; report of a case involving the kidney. *Urol Cutaneous Rev*. 1949;53:535.

Bayne CE, Peters CA. Congenital infundibulopelvic stenosis: indications for intervention, surgical technique, and review of literature. *J Pediatr Urol*. 2016;12:389.e1–389.e5.

Bayramoglu A, Demiryurek D, Erbil KM. Bilateral additional renal arteries and an additional right renal vein associated with unrotated kidneys. *Saudi Med J*. 2003;24:535–537.

Beck WC, Hlivko AE. Wilms' tumor in the isthmus of a horseshoe kidney. *Arch Surg*. 1960;81:803–806.

Bell ET. *Renal diseases*. Lea & Febiger: Philadelphia, PA; 1946.

Bell R. Horseshoe kidney in pregnancy. *J Urol*. 1946;56:159–161.

Benchekroun A, Kasmaoui EH, Jira H, et al. Pathological pelvic kidney. *Ann Urol (Paris)*. 2002;36:231–235.

Benchekroun A, Lachkar A, Soumana A, et al. Pathological horseshoe kidney. *Ann Urol (Paris)*. 1998;32:279–282.

Bentson JR, Crandall PH. Use of the Fogarty catheter in arteriovenous malformations of the spinal cord. *Radiology*. 1972;105:65–68.

Bernik TR, Ravnic DJ, Bernik SF, et al. Ectopic supernumerary kidney, a cause of para-aortic mass: case report and review. *Am Surg*. 2001;67(7):657–659.

Bianca S, Ingegnosi C, Ettore G. Reproductive risk factors in unilateral and bilateral renal agenesis. *Congenit Anom (Kyoto)*. 2003;43(1):79–80.

Bienstock JL, Birsner ML, Coleman F, et al. Successful in utero intervention for bilateral renal agenesis. *Obstet Gynecol*. 2014;124(2 Pt 2 Suppl 1):413–415.

Bilge I, Rozanes I, Acunas B, et al. Endovascular treatment of arteriovenous fistulas complicating percutaneous renal biopsy in three paediatric cases. *Nephrol Dial Transplant*. 1999;14:2726–2730.

Blackard CE, Mellinger GT. Cancer in a horseshoe kidney. *Arch Surg*. 1968;97:616–627.

Boatman DL, Kolln CP, Flocks RH. Congenital anomalies associated with horseshoe kidney. *J Urol*. 1972;107:205–207.

Bookstein JJ, Goldstein HM. Successful management of post biopsy arteriovenous fistula with selective arterial embolization. *Radiology*. 1973;109:535–536.

Borer JG, Bauer SB, Peters CA, et al. Single system ectopic ureter draining an ectopic dysplastic kidney: delayed diagnosis in the young female with continuous urinary incontinence. *Br J Urol*. 1998;81:474–478.

Boullier J, Chehval MJ, Purcell MH. Removal of a multicystic half of a horseshoe kidney: significance of pre-operative evaluation in identifying abnormal surgical anatomy. *J Pediatr Surg*. 1992;27:1244–1246.

Brenner BM, Lawler EV, Mackenzie HS. The hyperfiltration theory: a paradigm shift in nephrology. *Kidney Int*.

1996;49(6):1774–1777.

Brenner BM, Mackenzie HS. Nephron mass as a risk factor for progression of renal disease. *Kidney Int*. 1997;(Suppl 63):S124–S127.

Bridge RAC. Horseshoe kidneys in identical twins. *Br J Urol*. 1960;32:32.

Brock JW 3rd, Braren V, Phillips K, et al. Caudal regression with cake kidney and a single ureter: a case report. *J Urol*. 1983;130:535–536.

Bulbul MA, Farrow GA. Renal artery aneurysms. *Urology*. 1992;40:124–126.

Bulgrin JG, Hokmes FH. Eventration of the diaphragm with high renal ectopia; a case report. *Radiology*. 1955;64:249–251.

Bulum B, Ozcakar ZB, Ustuner E, et al. High frequency of kidney and urinary tract anomalies in asymptomatic first-degree relatives of patients with CAKUT. *Pediatr Nephrol*. 2013;28(11):2143–2147.

Bunchman TE, Walker HS, Joyce PF, et al. Sonographic evaluation of renal artery aneurysm in childhood. *Pediatr Radiol*. 1991;21:312–313.

Buntley D. Malignancy associated with horseshoe kidney. *Urology*. 1976;8:146–148.

Cacciaguerra S, Bagnara V, Arena C, et al. Megacalycosis on duplex system upper moiety. *Eur J Pediatr Surg*. 1996;6:42–44.

Caine M. Crossed renal ectopia without fusion. *Br J Urol*. 1956;28:257–258.

Calado AA, Macedo A Jr, Srougi M. Cake kidney drained by single ureter. *Int Braz J Urol*. 2004;30:321–322.

Calderon-Margalit R, Skorecki K, Vivante A. History of childhood kidney disease and risk of adult end-stage renal disease. *N Engl J Med*. 2018;378:1751–1752.

Cameron D, Lupton BA, Farquharson D, et al. Amnioinfusions in renal agenesis. *Obstet Gynecol*. 1994;83(5 Pt 2):872–876.

Campbell MF. Renal ectopy. *J Urol*. 1930;24:187.

Campbell MF. Anomalies of the kidney. 2nd ed. Saunders: Philadelphia, PA; 1963:1589. Campbell MF. *Urology*. vol 2.

Campbell MF. Anomalies of the kidney. 3rd ed. Saunders: Philadelphia, PA; 1970:1447–1452. Campbell MF, Harrison JH. *Urology*. vol 2.

Candiani GB, Fedele L, Candiani M. Double uterus, blind hemivagina, and ipsilateral renal agenesis: 36 cases and long-term follow-up. *Obstet Gynecol*. 1997;90(1):26–32.

Carlson HE. Supernumerary kidney: a summary of 51 reported cases. *J Urol*. 1950;64(2):224–229.

Carpentier PJ, Potter EL. Nuclear sex and genital malformation in 48 cases of renal agenesis, with especial reference to nonspecific female pseudoheramphroditism. *Am J Obstet Gynecol*. 1959;78(2):235–258.

Casale P, Grady RW, Feng WC, et al. The pediatric caliceal diverticulum: diagnosis and laparoscopic management. *J Endourol*. 2004;18:668–671.

Cascio S, Paran S, Puri P. Associated urological anomalies in children with unilateral renal agenesis. *J Urol*. 1999;162(3 Pt 2):1081–1083.

Cascio S, Sweeney B, Granata C, et al. Vesicoureteral reflux and ureteropelvic junction obstruction in children with horseshoe kidney: treatment and outcome. *J Urol*. 2002;167:2566–2568.

Chen KJ, Chen CH, Cheng CH, et al. Renal arteriovenous malformation in a young woman presenting with haematuria and hypertension. *Nephrology (Carlton)*. 2006;11:482–483.

Chevalier RL. When is one kidney not enough? *Kidney Int*. 2009;76(5):475–477.

Chevalier RL, Roth JA. Renal function in the fetus, neonate, and child. Wein AJ, Kavoussi LR, Novick AC, et al. *Campbell-Walsh urology*. Saunders: Philadelphia, PA; 2007:3149–3162.

Cho JY, Lee YH, Toi A, et al. Prenatal diagnosis of horseshoe kidney by measurement of the renal pelvic angle. *Ultrasound Obstet Gynecol*. 2005;25:554–558.

Cho KJ, Stanley JC. Non-neoplastic congenital and acquired renal arteriovenous malformations and fistula. *Radiology*. 1978;129:333–343.

Chow JS, Benson CB, Lebowitz RL. The clinical significance of an empty renal fossa on prenatal sonography. *J Ultrasound*

Med. 2005;24(8):1049–1054.

Cilento BG Jr, Benacerraf BR, Mandell J. Prenatal and postnatal findings in monochorionic, monoamniotic twins discordant for bilateral renal agenesis-dysgenesis (perinatal lethal renal disease). *J Urol*. 1994;151(4):1034–1035.

Clark DA. Times of first void and first stool in 500 newborns. *Pediatrics*. 1977;60(4):457–459.

Clemmons JJW. Embryonic renal injury: a possible factor in fetal malnutrition. *Pediatr Res*. 1977;11:404.

Collura G, De Dominicis M, Patricolo M, et al. Hydronephrosis due to malrotation in a pelvic ectopic kidney with vascular anomalies. *Urol Int*. 2004;72:349–351.

Colquhoun-Kerr JS, Gu WX, Jameson JL, et al. X-linked Kallmann syndrome and renal agenesis occurring together and independently in a large Australian family. *Am J Med Genet*. 1999;83(1):23–27.

Conrad GR, Loes DJ. Ectopic supernumerary kidney. Functional assessment using radionuclide imaging. *Clin Nucl Med*. 1987;12(4):253–257.

Cook WA, Stephens FD. Fused kidneys: morphologic study and theory of embryogenesis. Bergsma D, Duckett JW. *Urinary system malformations in children*. Allen R Liss: New York, NY; 1977.

Copland I, Post M. Lung development and fetal lung growth. *Paediatr Respir Rev*. 2004;5(SupplA):S259–S264.

Correa RJ Jr, Paton RR. Polycystic horseshoe kidney. *J Urol*. 1976;116:802.

Costantini F, Kopan R. Patterning a complex organ: branching morphogenesis and nephron segmentation in kidney development. *Dev Cell*. 2010;18(5):698–712.

Costantini F, Shakya R. GDNF/Ret signaling and the development of the kidney. *Bioessays*. 2006;28(2):117–127.

Crawford ES, Coselli JS, Safi HJ, et al. The impact of renal fusion and ectopia on aortic surgery. *J Vasc Surg*. 1988;8:375–383.

Crummy AB Jr, Atkinson RJ, Caruthers SB. Congenital renal arteriovenous fistulas. *J Urol*. 1965;93:24–26.

Cunha AR, Aguila MB, Mandarim-de-Lacerda CA. Effects of early postnatal hyperglycaemia on renal cortex maturity, endothelial nitric oxide synthase expression and nephron deficit in mice. *Int J Exp Pathol*. 2008;89(4):284–291.

Currarino G. Single vaginal ectopic ureter and Gartner's duct cyst with ipsilateral renal hypoplasia and dysplasia (or agenesis). *J Urol*. 1982;128(5):988–993.

Currarino G, Weisbruch GJ. Transverse fusion of the renal pelves and single ureter. *Urol Radiol*. 1989;11:88–91.

Dajani AM. Horseshoe kidney: a review of twenty-nine cases. *Br J Urol*. 1966;38:388–402.

D'Alberton A, Reschini E, Ferrari N, et al. Prevalence of urinary tract abnormalities in a large series of patients with uterovaginal atresia. *J Urol*. 1981;126:623–624.

Dally EA, Raman A, Webb NR, et al. Unilateral multicystic dysplastic kidney with progressive infundibular stenosis in the contralateral kidney: experience at 1 center and review of literature. *J Urol*. 2011;186:1053–1058.

Das BB, Rajegowda BK, Bainbridge R, et al. Caudal regression syndrome versus sirenomelia: a case report. *J Perinatol*. 2002;22(2):168–170.

Das S, Amar AD. Ureteropelvic junction obstruction with associated renal anomalies. *J Urol*. 1984;131:872–874.

David RS. Horseshoe kidney: a report of one family. *BMJ*. 1974;4:571–572.

Davis EM, Peck JD, Thompson D, et al. Maternal diabetes and renal agenesis/dysgenesis. *Birth Defects Res A Clin Mol Teratol*. 2010;88(9):722–727.

Davis TK, Hoshi M, Jain S. To bud or not to bud: the RET perspective in CAKUT. *Pediatr Nephrol*. 2014;29(4):597–608.

Degani S, Leibovitz Z, Shapiro I, et al. Variations of the origin of renal arteries in the fetus identified on power Doppler and 3D sonography. *J Clin Ultrasound*. 2010;38(2):59–65.

Dell'Acqua A, Mengozzi E, Rizzo F, et al. Ultrafast MR imaging of the foetus: a study of 25 non-central nervous system anomalies. *Radiol Med*. 2002;104(1–2):75–86.

Delson B. Ectopic kidney in obstetrics and gynecology. *N Y State J Med*. 1975;75:2522–2526.

DeNoronha LL, Costa MFE, Godinho MTM. Ectopic thoracic kidney. *Am Rev Respir Dis*. 1974;109:678–681.

DeSai SG, DeSautels RE. Congenital arteriovenous malformation of the kidney. *J Urol*. 1973;110:17–19.

Deshpande SA, Jog S, Watson H, et al. Do babies with isolated single umbilical artery need routine postnatal renal ultrasonography? *Arch Dis Child Fetal Neonatal Ed*. 2009;94(4):F265–F267.

Deshpande SA, Watson H. Renal ultrasonography not required in babies with isolated minor ear anomalies. *Arch Dis Child Fetal Neonatal Ed*. 2006;91(1):F29–F30.

Dhillon J, Mohanty SK, Kim T, et al. Spectrum of renal pathology in adult patients with congenital renal anomalies—a series from a tertiary cancer center. *Ann Diagn Pathol*. 2014;18:14–17.

Dicker D, Samuel N, Feldberg D, et al. The antenatal diagnosis of Potter syndrome (Potter sequence). A lethal and not-so-rare malformation. *Eur J Obstet Gynecol Reprod Biol*. 1984;18(1–2):17–24.

Dingeldein MW, Kane D, Kim AW, et al. Bilateral intrathoracic kidneys and adrenal glands associated with posterior congenital diaphragmatic hernias. *Ann Thorac Surg*. 2008;86:651–654.

Dische MR, Johnston R. Teratoma in horseshoe kidneys. *Urology*. 1979;13:435–438.

Dogan CS, Dorterler ME, Aybar MD, et al. Associated anomalies and clinical outcome in children with ectopic kidney. *Saudi J Kidney Dis Transpl*. 2017;28:330–335.

Donahoe PK, Hendren WH. Pelvic kidney in infants and children: experience with 16 cases. *J Pediatr Surg*. 1980;15:486–495.

Donat SM, Donat PE. Intrathoracic kidney: a case report with a review of the world's literature. *J Urol*. 1988;140:131–133.

Donohue RE, Fauver HE. Unilateral absence of the vas deferens. A useful clinical sign. *JAMA*. 1989;261(8):1180–1182.

Doroshow LW, Abeshouse BS. Congenital unilateral solitary kidney: report of 37 cases and a review of the literature. *Urol Surv*. 1961;11:219–229.

Downs RA, Lane LW, Burns E. Solitary pelvic kidney: its clinical implications. *Urology*. 1973;1:51–56.

Dowton SB, Hing AV, Sheen-Kaniecki V, et al. Chromosome 18q22.2–>qter deletion and a congenital anomaly syndrome with multiple vertebral segmentation defects. *J Med Genet*. 1997;34(5):414–417.

Dretler SP, Olsson C, Pfister RC. The anatomic, radiologic and clinical characteristics of the pelvic kidney: an analysis of 86 cases. *J Urol*. 1971;105:623–627.

Drevna DW, Dankoff J, Van Leeuwen B. A potential link: cross-fused renal ectopia with concomitant absent left testicle. *Rev Urol*. 2018;20:49–51.

Drop A, Czekajska-Chehab E, Maciejewski R. Thoracic ectopic kidney in adults. *Folia Morphol (Warsz)*. 2003;62:313–316.

Duncan PA, Shapiro LR, Stangel JJ, et al. The MURCS association: mullerian duct aplasia, renal aplasia, and cervicothoracic somite dysplasia. *J Pediatr*. 1979;95(3):399–

402.

Dursun H, Bayazit AK, Buyukcelik M, et al. Associated anomalies in children with congenital solitary functioning kidney. *Pediatr Surg Int*. 2005;21(6):456–459.

Estrada CR, Datta S, Schneck FX, et al. Caliceal diverticula in children: natural history and management. *J Urol*. 2009;181(3):1306–1311.

Evans WP, Resnick MI. Horseshoe kidney and urolithiasis. *J Urol*. 1981;125:620–621.

Felzenberg J, Nasrallah PF. Crossed renal ectopia without fusion associated with hydronephrosis in an infant. *Urology*. 1991;38:450–452.

Fishman M, Borden S. Crossed fused renal ectopia with single crossed ectopic ureterocele. *J Urol*. 1982;127(1):117–118.

Fogazzi GB, Moriggi M, Fontanella U. Spontaneous renal arteriovenous fistula as a cause of haematuria. *Nephrol Dial Transplant*. 1997;12:350–356.

Forys S, Wilczynski J, Oszukowski P, et al. [Bilateral renal agenesis at the Department for Diagnosis and Prophylaxis of Fetal Malformation at the Institute Polish Mother's Memorial Hospital with fetal echocardiography in years 1994-2002]. *Ginekol Pol*. 2003;74(10):1083–1087.

Fraley EE. Vascular obstruction of superior infundibulum causing nephralgia. A new syndrome. *N Engl J Med*. 1966;275:1403–1409.

Franciskovic V, Martincic N. Intrathoracic kidney. *Br J Urol*. 1959;31:156–158.

Freilich TH, Brint S. Ectopic kidney obstructing labor. *J Am Osteopath Assoc*. 1957;56:547–548.

Friedman MA, Aguilar L, Heyward Q, et al. Screening for Mullerian anomalies in patients with unilateral renal agenesis: leveraging early detection to prevent complications. *J Pediatr Urol*. 2018;14:144–149.

Fryns JP, van Schoubroeck D, Vandenberghe K, et al. Diagnostic echographic findings in cryptophthalmos syndrome (Fraser syndrome). *Prenat Diagn*. 1997;17(6):582–584.

Gambhir A, James VM, Kumar A, et al. Bilateral crossed unfused renal ectopia. *Clin Nucl Med*. 2015;40:805–807.

Garne E, Loane M, Wellesley D, et al. Congenital hydronephrosis: prenatal diagnosis and epidemiology in Europe. *J Pediatr Urol*. 2009;5(1):47–52.

Garritano AP. Aneurysm of the renal artery. *Am J Surg*. 1957;94:638–648.

Gearhart JP, Mathews R. Exstrophy-epispadias complex. Wein AJ, Kavoussi LR, Novick AC, et al. *Campbell-Walsh urology*. Saunders: Philadelphia, PA; 2007:3497–3553.

Geisinger JF. Supernumerary kidney. *J Urol*. 1937;38:331.

Georgieff MK, Petry CD, Wobken JD, et al. Liver and brain iron deficiency in newborn infants with bilateral renal agenesis (Potter's syndrome). *Pediatr Pathol Lab Med*. 1996;16(3):509–519.

Gesase AP. Rare origin of supernumerary renal vessels supplying the lower pole of the left kidney. *Ann Anat*. 2007;189:53–58.

Geyer JR, Poutasse EF. Incidence of multiple renal arteries on aortography. *JAMA*. 1962;182:120–125.

Ghawanmeh HM, Al-Ghazo M, Halalsheh OM, et al. Pancake kidney found inside abdominal cavity: rare case with literature review. *Urol Case Rep*. 2017;13:123–125.

Gittes RF. Congenital megacalices. *Monogr Urol*. 1984;5:1.

Gittes RF, Talner LB. Congenital megacalyces vs. obstructive hydronephrosis. *J Urol*. 1972;108:833–836.

Gleason PE, Kelalis PP, Husmann DA, et al. Hydronephrosis in renal ectopia: incidence, etiology and significance. *J Urol*. 1994;151:1660–1661.

Glenn JF. Fused pelvic kidney. *J Urol*. 1958;80:7–9.

Glenn JF. Analysis of 51 patients with horseshoe kidney. *N Engl J Med*. 1959;261:684–687.

Glodny B, Petersen J, Hofmann KJ, et al. Kidney fusion anomalies revisited: clinical and radiological analysis of 209 cases of crossed fused ectopia and horseshoe kidney. *BJU Int*. 2008;103:224–238.

Gómez Tellado M, Pais E, Méndez R, et al. [Use of Tc 99m DTPA in the follow-up of 2 pediatric patients diagnosed with megacalycosis or Puigvert's disease]. *Arch Esp Urol*. 1997;50:762–766.

González J, Esteban M, Andrés G, et al. Renal artery aneurysms. *Curr Urol Rep*. 2014;15(1):376.

Goren E, Eidelman A. Pelvic cake kidney drained by single ureter. *Urology*. 1987;30:492–493.

Graves FT. The anatomy of the intrarenal arteries and its application to segmental resection of the kidney. *Br J Surg*. 1954;42:132–139.

Graves FT. The aberrant renal artery. *J Anat*. 1956;90:553–558.

Gray SW, Skandalakis JE. Anomalies of the kidney and ureter. Gray SW, Skandalakis JE. *Embryology for surgeons*. Saunders: Philadelphia, PA; 1972:485.

Grieshammer U, Le M, Plump AS, et al. SLIT2-mediated ROBO2 signaling restricts kidney induction to a single site. *Dev Cell*. 2004;6(5):709–717.

Grinsell MM, Butz K, Gurka MJ, et al. Sport-related kidney injury among high school athletes. *Pediatrics*. 2012;130(1):e40–e45.

Grotas AB, Phillips JL. Renal mass in solitary, crossed, ectopic pelvic kidney. *Urology*. 2009;73(6):1223–1224.

Gu L, Alton DJ. Crossed solitary renal ectopia. *Urology*. 1991;38:556–558.

Guarino N, Tadini B, Camardi P, et al. The incidence of associated urological abnormalities in children with renal ectopia. *J Urol*. 2004;172(4 Pt2):1757–1759.

Guerrier D, Mouchel T, Pasquier L, et al. The Mayer-Rokitansky-Kuster-Hauser syndrome (congenital absence of uterus and vagina)—phenotypic manifestations and genetic approaches. *J Negat Results Biomed*. 2006;5:1.

Guggemos E. A rare case of an arterial connection between the left and right kidneys. *Ann Surg*. 1962;156:940–943.

Gülsün M, Balkanci F, Cekirge S, et al. Pelvic kidney with an unusual blood supply: angiographic findings. *Surg Radiol Anat*. 2000;22:59–61.

Gur U, Yossepowitch O, Baniel J. Transitional cell carcinoma in a fused crossed ectopic kidney. *Urology*. 2003;62:748.

Hall-Craggs MA, Kirkham A, Creighton SM. Renal and urological abnormalities occurring with Mullerian anomalies. *J Pediatr Urol*. 2013;9:27–32.

Hampton LJ, Borden TA. Ureteropelvic junction obstruction in a thoracic kidney treated by dismembered pyeloplasty. *Urology*. 2002;60:164.

Hegde S, Coulthard MG. Renal agenesis and unilateral nephrectomy: what are the risks of living with a single kidney? *Pediatr Nephrol*. 2009;24(3):439–446.

Heinonen PK. Unicornuate uterus and rudimentary horn. *Fertil Steril*. 1997;68(2):224–230.

Heinonen PK. Gestational hypertension and preeclampsia associated with unilateral renal agenesis in women with uterine malformations. *Eur J Obstet Gynecol Reprod Biol*. 2004;114(1):39–43.

Heling KS, Tennstedt C, Chaoui R, et al. Reliability of prenatal sonographic lung biometry in the diagnosis of pulmonary hypoplasia. *Prenat Diagn*. 2001;21(8):649–657.

Hendren WH, Donahoe PK, Pfister RC. Crossed renal ectopia in children. *Urology*. 1976;7:135–144.

Hertz M, Rabenstein ZJ, Shairin N, et al. Crossed renal ectopia: clinical and radiologic findings in 22 cases. *Clin Radiol*. 1977;28:339–344.

Hill LM, Macpherson T, Romano L, et al. Prenatal sonographic findings of fetal megacalycosis. *J Ultrasound Med*. 2002;21:1179–1181.

Hiraoka M, Tsukahara H, Ohshima Y, et al. Renal aplasia is the predominant cause of congenital solitary kidneys. *Kidney Int*. 2002;61(5):1840–1844.

Hislop A, Hey E, Reid L. The lungs in congenital bilateral renal agenesis and dysplasia. *Arch Dis Child*. 1979;54(1):32–38.

Hoffman CK, Filly RA, Callen PW. The lying down adrenal sign: a sonographic indicator of renal agenesis or ectopia in fetuses and neonates. *J Ultrasound Med*. 1992;11(10):533–536.

Hohenfellner M, Schultz-Lampel D, Lampel A, et al. Tumor in the horseshoe kidney: clinical implications and review of embryogenesis. *J Urol*. 1992;147:1098–1102.

Holt SA, Peterson NE. Ectopia of seminal vesicle. Associated with agenesis of ipsilateral kidney. *Urology*. 1974;4(3):322–324.

Horai K, Naito M, Yakura T, et al. A case of pancake kidney with a single ureter in the retroperitoneal space. *Anat Sci Int*. 2018;93(4):563–565.

Huang HM, Yeh RM, Tan CT, et al. Auditory abnormalities associated with unilateral renal agenesis. *Int J Pediatr Otorhinolaryngol*. 2001;60(2):113–118.

Hughson M, Farris AB 3rd, Douglas-Denton R, et al. Glomerular number and size in autopsy kidneys: the relationship to birth weight. *Kidney Int*. 2003;63(6):2113–2122.

Hupp T, Allenberg JR, Post K, et al. Renal artery aneurysm: surgical indications and results. *Eur J Vasc Surg*.

1992;6(5):477–486.

Husmann DA, Kramer SA, Malek RS, et al. Infundibulopelvic stenosis: a long-term follow-up. *J Urol*. 1994;152:837–840.

Ibrahim HN, Foley R, Tan L, et al. Long-term consequences of kidney donation. *N Engl J Med*. 2009;360(5):459–469.

Inoue T, Hashimura T. Spontaneous regression of a renal arteriovenous malformation. *J Urol*. 2000;163:232–233.

Ishikawa T, Fujisawa M, Kawabata G, et al. Assessment of availability of magnetic resonance angiography (MRA) in renal arteriovenous fistula. *Urol Res*. 2004;32:104–106.

Isobe H, Takashima H, Higashi N, et al. Primary carcinoid tumor in a horseshoe kidney. *Int J Urol*. 2000;7:184–188.

Iwanaga J, Watanabe K, Saga T, et al. Anatomical and radiological analyses of L-shaped kidney with vascular anomalies. *Kurume Med J*. 2018;64:21–24.

Jayanthi VR, Churchill BM, Khoury AE, et al. Bilateral single ureteral ectopia: difficulty attaining continence using standard bladder neck repair. *J Urol*. 1997;158(5):1933–1936.

Je BK, Kim HK, Horn PS. Incidence and spectrum of renal complications and extrarenal diseases and syndromes in 380 children and young adults with horseshoe kidney. *AJR Am J Roentgenol*. 2015;205:1306–1314.

Jeyaratnam R, Bakalinova D. Cystic dysplasia of the rete testis: a case of spontaneous regression and review of published reports. *Urology*. 2010;75(3):687–690.

Johnston JH, Sandomirsky SK. Intrarenal vascular obstruction of the superior infundibulum in children. *J Pediatr Surg*. 1972;7:318–323.

Kakei H, Kondo A, Ogisu BI, et al. Crossed ectopia of solitary kidney: a report of two cases and a review of the literature. *Urol Int*. 1976;31:40–45.

Kanchan T, Murlimanju BV, Saralaya VV. Pancake kidney with a single ureter: a rare incidental observation at autopsy. *Anat*

Sci Int. 2017;92:142–146.

Kaneoya F, Gotoh S, Yokokawa M. [Unusual duplication of renal collecting system mimicking supernumerary kidney—a case report]. *Nippon Hinyokika Gakkai Zasshi*. 1989;80(2):270–273.

Kaneyama K, Yamataka A, Satake S, et al. Associated urologic anomalies in children with solitary kidney. *J Pediatr Surg*. 2004;39(1):85–87.

Kanwar YS, Nayak B, Lin S, et al. Hyperglycemia: its imminent effects on mammalian nephrogenesis. *Pediatr Nephrol*. 2005;20(7):858–866.

Kao PF, Sheih CP, Tsui KH, et al. The 99mTc-DMSA renal scan and 99mTc-DTPA diuretic renogram in children and adolescents with incidental diagnosis of horseshoe kidney. *Nucl Med Commun*. 2003;24:525–530.

Kara E, Oztürk NC, Ozgür A, et al. Ectopic kidney with varied vasculature: demonstrated by CT angiography. *Surg Radiol Anat*. 2011;33:81–84.

Karmi SA. Rare urologic pathology presenting as abdominal masses in children. *J Urol*. 1977;118:431–433.

Kasper TE, Osborne RW Jr, Semerdjian HS, et al. Urologic abdominal masses in infants and children. *J Urol*. 1976;116:629–633.

Katz SM, Chatten J. The urethra in bilateral renal agenesis. *Arch Pathol*. 1974;97(5):269–270.

Kaur RP, Chawla D. Right subdiaphragmatic kidney. *Br J Radiol*. 1980;53:809–810.

Kelalis PP, Malek RS. Infundibulopelvic stenosis. *J Urol*. 1981;125:568–571.

Kelalis PP, Malek RS, Segura JW. Observations on renal ectopia and fusion in children. *J Urol*. 1973;110:588–592.

Keller TM, Rake A, Michel SC, et al. MR assessment of fetal lung development using lung volumes and signal intensities.

Eur Radiol. 2004;14(6):984–989.

Kenney PJ, Robbins GL, Ellis DA, et al. Adrenal glands in patients with congenital renal anomalies: CT appearance. *Radiology*. 1985;155(1):181–182.

Keskin S, Erdogan N, Kurt A, et al. Bilateral partial ureteral duplication with double collecting system in horseshoe kidney. *Adv Med Sci*. 2009;54:302–304.

Khong PL, Peh WC, Mya GH, et al. Horseshoe kidney with bilateral single system ectopic ureters. *Aust N Z J Surg*. 1996;66:773–776.

Kim HY, Lee SJ, Bae EH, et al. A case of acute pyelonephritis in bilateral renal malrotation. *Chonnam Med J*. 2016;52:219.

Klausner JQ, Lawrence PF, Harlander-Locke MP, Vascular Low-Frequency Disease Consortium, et al. The contemporary management of renal artery aneurysms. *J Vasc Surg*. 2015;61:978–984.

Klinger G, Merlob P, Aloni D, et al. Normal pulmonary function in a monoamniotic twin discordant for bilateral renal agenesis: report and review. *Am J Med Genet*. 1997;73(1):76–79.

Knutson T, Hawas B. Horseshoe kidney with a circumcaval ureter. *Scand J Urol Nephrol*. 2004;38:348–350.

Kolln CP, Boatman DL, Schmidt JD, et al. Horseshoe kidney: a review of 105 patients. *J Urol*. 1972;107:203–204.

Kolon TF, Gray CL, Sutherland RW, et al. Upper urinary tract manifestations of the VACTERL association. *J Urol*. 2000;163(6):1949–1951.

Koureas AP, Panourgias EC, Gouliamos AD, et al. Imaging of a supernumerary kidney. *Eur Radiol*. 2000;10(11):1722–1723.

Kovacs T, Csecsei K, Toth Z, et al. Familial occurrence of bilateral renal agenesis. *Acta Paediatr Hung*. 1991;31(1):13–21.

Kovo-Hasharoni M, Mashiach R, Levy S, et al. Prenatal sonographic diagnosis of horseshoe kidney. *J Clin Ultrasound*. 1997;25:405–407.

Kozakewich HPW, Lebowitz FL. Congenital megacalices. *Pediatr Radiol*. 1974;2:251–257.

Kramer SA, Kelalis PP. Ureteropelvic junction obstruction in children with renal ectopy. *J Urol (Paris)*. 1984;90:331.

Kretschmer HL. Supernumerary kidney: report of a case with review of the literature. *Surg Gynecol Obstet*. 1929;49:818.

Kubota H, Sakagami H, Kubota Y, et al. Spontaneous disappearance of a renal arteriovenous malformation. *Int J Urol*. 2003;10:547–549.

Kundu AK, Goswami TK. Left subdiaphragmatic kidney: a case report. *J Indian Med Assoc*. 1995;93:153.

Lacasta Garcia JD, Sanz Velez JI, Abad Roger J. Ectopic thoracic kidney. *Actas Urol Esp*. 1999;23:536–538.

Lacroix H, Bernaerts P, Nevelsteen A, et al. Ruptured renal artery aneurysm during pregnancy. *J Vasc Surg*. 2001;33:188–190.

Langer FW, dos Santos D, Dartora EG, et al. Ectopic intrathoracic kidney presenting as recurrent pneumonias in a 1-year-old infant: a case report. *Lung*. 2015;193:839–842.

Leavitt DA, Nicholson AF, Ortiz-Alvarado O, et al. Nature of crossing vessels in patients with radiographically normal ureteropelvic junctions: prevalence and anatomic characteristics. *Urology*. 2013;81:1168–1172.

Lee HP. Crossed unfused renal ectopia with tumor. *J Urol*. 1949;61:333–339.

Leiter E. Horseshoe kidney: discordance in monozygotic twins. *J Urol*. 1972;108:683–684.

Liatsikos EN, Perimenis P, Dandinis K, et al. Mermaid and Potter's syndrome occurring simultaneously. *Int Urol Nephrol*. 1999;31(3):277–281.

Liddell RM, Rosenbaum DM, Blumhaen JD. Delayed radiologic appearance of bilateral thoracic ectopic kidneys. *AJR Am J Roentgenol*. 1989;152:120–122.

Lippe B, Geffner ME, Dietrich RB, et al. Renal malformations in patients with Turner syndrome: imaging in 141 patients. *Pediatrics*. 1988;82:852–856.

Lister J, Singh H. Pelvicalyceal cysts in children. *J Pediatr Surg*. 1973;8:901–905.

Livermore LJ, Thiruchelvam N. Whose side are you on? The diagnostic conundrum of solitary crossed renal ectopia. *J Pediatr Urol*. 2010;6:83–86.

Long CJ, Weiss DA, Kolon TF, et al. Pediatric calyceal diverticulum treatment: an experience with endoscopic and laparoscopic approaches. *J Pediatr Urol*. 2015;11:172.e1–172.e6.

Looney WW, Dodd DL. An ectopic (pelvic) completely fused (cake) kidney associated with various anomalies of the abdominal viscera. *Ann Surg*. 1926;84:522–524.

Lorentz WB Jr, Browning MC, D'Souza VJ, et al. Intrarenal aneurysm of the renal artery in children. *Am J Dis Child*. 1984;138:751–754.

Love L, Wasserman D. Massive unilateral nonfunctioning hydronephrosis in horseshoe kidney. *Clin Radiol*. 1975;26:409–415.

Lozano RH, Rodriguez C. Intrathoracic ectopic kidney: report of a case. *J Urol*. 1975;114:601–602.

Lundius B. Intrathoracic kidney. *AJR Am J Roentgenol*. 1975;125:678–681.

Luyckx VA, Brenner BM. The clinical importance of nephron mass. *J Am Soc Nephrol*. 2010;21(6):898–910.

Luyckx VA, Bertram JF, Brenner BM, et al. Effect of fetal and child health on kidney development and long-term risk of hypertension and kidney disease. *Lancet*. 2013;382(9888):273–283.

Mace JW, Kaplan JM, Schanberger JE, et al. Poland's syndrome. Report of seven cases and review of the literature. *Clin Pediatr (Phila)*. 1972;11(2):98–102.

Macpherson RI, Fyfe D, Aaronson IA. Congenital renal arteriovenous malformations in infancy. The imaging features in two infants with hypertension. *Pediatr Radiol*. 1991;21:108–110.

Maduekwe E, Weinberg B, Samaan B, et al. Right thoracic ectopic kidney in a child with breathing difficulties—sonographic diagnosis. *J Clin Ultrasound*. 2011;39:108–110.

Magak P, King CH, Ireri E, et al. High prevalence of ectopic kidney in Coast Province, Kenya. *Trop Med Int Health*. 2004;9:595–600.

Magee MC, Lucey DT, Fried FA. A new embryologic classification for uro-gynecologic malformations: the syndromes of mesonephric duct induced mullerian deformities. *J Urol*. 1979;21(3):265–267.

Maizels M, Stephens FD. Renal ectopia and congenital scoliosis. *Invest Urol*. 1979;17:209–217.

Majumdar A, Vainio S, Kispert A, et al. Wnt11 and Ret/Gdnf pathways cooperate in regulating ureteric branching during metanephric kidney development. *Development*. 2003;130(14):3175–3185.

Maldonado JE, Sheps SG, Bernatz PE, et al. Renal arteriovenous fistula. *Am J Med*. 1964;37:499–513.

Malek RS, Kelalis PP, Burke EC. Ectopic kidney in children and frequency of association of other malformations. *Mayo Clin Proc*. 1971;46:461–467.

Mandell GA, Snyder HM 3rd, Heyman S, et al. Association of congenital megacalycosis and ipsilateral segmental megaureter. *Pediatr Radiol*. 1987;17(1):28–33.

Marszalek A, Biczysko W, Wasowicz M. Development of the fetal and newborn lung—morphometric studies (rat model).

Pol J Pathol. 1999;50(4):277–288.

Masturzo B, Kalache KD, Cockell A, et al. Prenatal diagnosis of an ectopic intrathoracic kidney in right-sided congenital diaphragmatic hernia using color Doppler ultrasonography. *Ultrasound Obstet Gynecol*. 2001;18:173–174.

Matsell DG. Renal dysplasia: new approaches to an old problem. *Am J Kidney Dis*. 1998;32(4):535–543.

McAlhany JC Jr, Black HC, Hanback LD Jr, et al. Renal arteriovenous fistulas as a cause of hypertension. *Am J Surg*. 1971;122:117–120.

McCallum T, Milunsky J, Munarriz R, et al. Unilateral renal agenesis associated with congenital bilateral absence of the vas deferens: phenotypic findings and genetic considerations. *Hum Reprod*. 2001;16(2):282–288.

McCrea LE. Congenital solitary pelvic kidney. *J Urol*. 1942;48:58.

McDonald JH, McClellan DS. Crossed renal ectopia. *Am J Surg*. 1957;93:995–1002.

McKenzie CH. Dystocia due to solitary pelvic ectopic kidney. *J Lancet*. 1950;70:215–217.

McPherson E. Renal anomalies in families of individuals with congenital solitary kidney. *Genet Med*. 2007;9(5):298–302.

McPherson E, Carey J, Kramer A, et al. Dominantly inherited renal adysplasia. *Am J Med Genet*. 1987;26(4):863–872.

Meizner I, Yitzhak M, Levi A, et al. Fetal pelvic kidney: a challenge in prenatal diagnosis? *Ultrasound Obstet Gynecol*. 1995;5(6):391–393.

Mendelsohn C. Using mouse models to understand normal and abnormal urogenital tract development. *Organogenesis*. 2009;5(1):306–314.

Merklin RJ, Michele NA. The variant renal and suprarenal blood supply with data on the inferior phrenic, ureteral and gonadal arteries: a statistical analysis based on 185 dissections and review of the literature. *J Int Coll Surg*. 1958;29:41–76.

Mesrobian HG, Kelalis PP, Hrabovsky E, et al. Wilms tumor in horseshoe kidneys: a report from the National Wilms Tumor Study. *J Urol*. 1985;133:1002–1003.

Mesrobian HG, Rushton HG, Bulas D. Unilateral renal agenesis may result from in utero regression of multicystic renal dysplasia. *J Urol*. 1993;150(2 Pt 2):793–794.

Messing E, Kessler R, Kavaney RB. Renal arteriovenous fistula. *Urology*. 1976;8:101–107.

Michos O, Goncalves A, Lopez-Rios J, et al. Reduction of BMP4 activity by gremlin 1 enables ureteric bud outgrowth and GDNF/WNT11 feedback signalling during kidney branching morphogenesis. *Development*. 2007;134(13):2397–2405.

Michos O, Panman L, Vintersten K, et al. Gremlin-mediated BMP antagonism induces the epithelial-mesenchymal feedback signaling controlling metanephric kidney and limb organogenesis. *Development*. 2004;131(14):3401–3410.

Middleton AW Jr, Pfister RC. Stone-containing pyelocaliceal diverticulum: embryogenic, anatomic, radiologic and clinical characteristics. *J Urol*. 1974;111:2–6.

Miles BJ, Moon MR, Bellville WD, et al. Solitary crossed renal ectopia. *J Urol*. 1985;133:1022–1023.

Mishra VK, Kapoor R. Crossed fused renal ectopia with crossed single ectopic ureterocele: an unusual presentation. *Arch Esp Urol*. 1995;48:321–323.

Miyagawa Y, Oka T, Takano Y, et al. Renal artery aneurysm causing hydronephrosis. *Int J Urol*. 2001;8:463–466.

Moerman P, Fryns JP, Sastrowijoto SH, et al. Hereditary renal adysplasia: new observations and hypotheses. *Pediatr Pathol*. 1994;14(3):405–410.

Mohaupt MG, Perrig M, Vogt B. 3D ultrasound imaging: a useful noninvasive tool to detect A-V fistulas in transplanted kidneys. *Nephrol Dial Transplant*. 1999;14:940–943.

Monga M, Smith R, Ferral H, et al. Percutaneous ablation of caliceal diverticulum: long-term follow-up. *J Urol*. 2000;163:28–32.

Montoya G, Vega J, Moreno O, et al. Spontaneous renal arteriovenous fistula-caused hematuria. *Gac Med Mex*. 2004;140:85–87.

Muraoka N, Sakai T, Kimura H, et al. Rare causes of hematuria associated with various vascular diseases involving the upper urinary tract. *Radiographics*. 2008;28:855–867.

Murphy DM, Zincke H. Transitional cell carcinoma in the horseshoe kidney: report of 3 cases and review of the literature. *Br J Urol*. 1982;54:484–485.

Murugasu B, Cole BR, Hawkins EP, et al. Familial renal adysplasia. *Am J Kidney Dis*. 1991;18(4):490–494.

N'Guessan G, Stephens FD. Congenital superior ectopic (thoracic) kidney. *Urology*. 1984;24:219–228.

Nakano M, Tada K, Takahashi Y, et al. [Unilateral multicystic dysplastic kidney in an adult: report of a case]. *Hinyokika Kiyo*. 1996;42(5):373–376.

Natsis K, Piaghou M, Skotsimara A, et al. Horseshoe kidney: a review of anatomy and pathology. *Surg Radiol Anat*. 2014;36:517–526.

Nawaz G, Muhammad S, Jamil MI, et al. Neuroblastoma in horseshoe kidney. *J Ayub Med Coll Abbottabad*. 2014;26:404–405.

Nayak BS. Multiple variations of the right renal vessels. *Singapore Med J*. 2008;49:e153–e155.

Nelson RP, Palmer JM. Use of horseshoe kidney in renal transplantation: technical aspects. *Urology*. 1975;6:357–359.

Neville H, Ritchey ML, Shamberger RC, et al. The occurrence of Wilms tumor in horseshoe kidneys. *J Pediatr Surg*.

2002;37:1134–1137.

N'Guessan G, Stephens FD. Supernumerary kidney. *J Urol*. 1983;130(4):649–653.

Nurzia MJ, Costantinescu AR, Barone JG. Childhood infundibular stenosis. *Urology*. 2002;60(2):344.

Nussbaum AR, Hartman DS, Whitley N, et al. Multicystic dysplasia and crossed renal ectopia. *AJR Am J Roentgenol*. 1987;149:407–410.

O'Brien J, Buckley O, Doody O, et al. Imaging of horseshoe kidneys and their complications. *J Med Imaging Radiat Oncol*. 2008;52:216–226.

Ochsner MG, Brannan W, Goodier EH. Absent vas deferens associated with renal agenesis. *JAMA*. 1972;222(8):1055–1056.

O'Connor TA, LaCour ML, Friedlander ER, et al. Penile agenesis associated with urethral and bilateral renal agenesis. *Urology*. 1993;41(6):564–565.

Oppelt PG, Lermann J, Strick R, et al. Malformations in a cohort of 284 women with Mayer-Rokitansky-Kuster-Hauser syndrome (MRKH). *Reprod Biol Endocrinol*. 2012;10:57.

Oto A, Kerimoglu U, Eskicorapci S, et al. Bilateral supernumerary kidney: imaging findings. *JBR-BTR*. 2002;85(6):300–303.

Patil ST, Meshram MM, Kasote AP. Bilateral malrotation and lobulation of kidney with altered hilar anatomy: a rare congenital variation. *Surg Radiol Anat*. 2011;33:941–944.

Patriquin H, Lafortune M, Filiatrault D. Urinary milk of calcium in children and adults: use of gravity-dependent sonography. *AJR Am J Roentgenol*. 1985;144:407–413.

Pawar AS, Thongprayoon C, Cheungpasitporn W, et al. Incidence and characteristics of kidney stones in patients with horseshoe kidney: a systematic review and meta-analysis. *Urol Ann*. 2018;10:87–93.

Pelegrí Gabarró J, Guiote Partido I, Oliva Encina J, et al. Crossed renal ectopia. *Arch Esp Urol*. 2014;67:634–637.

Pereira BJ, Sousa L, Azinhais P, et al. Zinner's syndrome: an up-to-date review of the literature based on a clinical case. *Andrologia*. 2009;41(5):322–330.

Perlman M, Williams J, Hirsch M. Neonatal pulmonary hypoplasia after prolonged leakage of amniotic fluid. *Arch Dis Child*. 1976;51(5):349–353.

Peters CA, Docimo SG, Luetic T, et al. Effect of in utero vesicostomy on pulmonary hypoplasia in the fetal lamb with bladder outlet obstruction and oligohydramnios: a morphometric analysis. *J Urol*. 1991;146(4):1178–1183.

Peters CA, Reid LM, Docimo S, et al. The role of the kidney in lung growth and maturation in the setting of obstructive uropathy and oligohydramnios. *J Urol*. 1991;146(2 Pt 2):597–600.

Pfeiffer T, Reiher L, Grabitz K, et al. Reconstruction for renal artery aneurysm. *J Vasc Surg*. 2003;37:293–300.

Pieretti-Vanmarcke R, Pieretti A, Pieretti RV. Megacalycosis: a rare condition. *Pediatr Nephrol*. 2009;24:1077–1079.

Pierides AM, Athanasiou Y, Demetriou K, et al. A family with the branchio-oto-renal syndrome: clinical and genetic correlations. *Nephrol Dial Transplant*. 2002;17(6):1014–1018.

Pinckney LE, Moskowitz PS, Lebowitz RL, et al. Renal malposition associated with omphalocele. *Radiology*. 1978;129:677–682.

Pitts WR, Muecke EC. Horseshoe kidneys: a 40-year experience. *J Urol*. 1975;113:743–746.

Pizzo A, Lagana AS, Sturlese E, et al. Mayer-Rokitansky-Kuster-Hauser syndrome: embryology, genetics and clinical and surgical treatment. *ISRN Obstet Gynecol*. 2013;2013:628717.

Polzin W. Framing the conversation for exploring innovative techniques in therapy: the example of bilateral renal agenesis. *Issues Law Med*. 2017;32(2):225–232.

Pope JC 4th, Brock JW 3rd, Adams MC, et al. How they begin and how they end: classic and new theories for the development and deterioration of congenital anomalies of the kidney and urinary tract, CAKUT. *J Am Soc Nephrol*. 1999;10(9):2018–2028.

Potter EL. Bilateral renal agenesis. *J Pediatr*. 1946;29:68–76.

Potter EL. Facial characteristics of infants with bilateral renal agenesis. *Am J Obstet Gynecol*. 1946;51:885–888.

Potter EL. *Pathology of the fetus and the newborn*. Year Book: Chicago, IL; 1952.

Potter EL. Bilateral absence of ureters and kidneys: a report of 50 cases. *Obstet Gynecol*. 1965;25:3–12.

Poutasse EF. Renal artery aneurysm: report of 12 cases, two treated by excision of the renal aneurysm and repair of renal artery. *J Urol*. 1957;77:697–708.

Psooy K. Sports and the solitary kidney: what parents of a young child with a solitary kidney should know. *Can Urol Assoc J*. 2009;3(1):67–68.

Puddu M, Fanos V, Podda F, et al. The kidney from prenatal to adult life: perinatal programming and reduction of number of nephrons during development. *Am J Nephrol*. 2009;30(2):162–170.

Puigvert A. Megacalicosis: diagnostico diferencial con la hidrocaliectasia. *Med Clin (Barc)*. 1963;41:294–302.

Puigvert A. Megacalicose: diagnostic differential avec l'hydrocaliectasia. *Helv Chir Acta*. 1964;31:414–419.

Pupca G, Miclăuş GD, Bucuraş V, et al. Left crossed fused renal ectopia L-shaped kidney type, with double nutcracker syndrome (anterior and posterior). *Rom J Morphol Embryol*. 2014;55:1237–1241.

Purpon I. Crossed renal ectopy with solitary kidney: a review of the literature. *J Urol*. 1963;90:13–15.

Quinton R, Duke VM, Robertson A, et al. Idiopathic gonadotrophin deficiency: genetic questions addressed through phenotypic characterization. *Clin Endocrinol (Oxf)*. 2001;55(2):163–174.

Rac G, Ellet JD, Sarkissian H, et al. Open partial nephrectomy for Wilms' tumor in a cross-fused pelvic ectopic kidney. *Urology*. 2016;93:188–190.

Raj GV, Auge BK, Assimos D, et al. Metabolic abnormalities associated with renal calculi in patients with horseshoe kidneys. *J Endourol*. 2004;18:157–161.

Ramaema DP, Moloantoa W, Parag Y. Crossed renal ectopia without fusion—an unusual cause of acute abdominal pain: a case report. *Case Rep Urol*. 2012;2012:728531.

Redman JF, Berry DL. Wilm's tumor in crossed fused renal ectopia. *J Pediatr Surg*. 1977;12:601–603.

Reichman DE, Laufer MR. Congenital uterine anomalies affecting reproduction. *Best Pract Res Clin Obstet Gynaecol*. 2010;24(2):193–208.

Reid L. 1976 Edward BD Neuhauser lecture: the lung: growth and remodeling in health and disease. *AJR Am J Roentgenol*. 1977;129(5):777–788.

Rice SG, American Academy of Pediatrics Council on Sports Medicine and Fitness. Medical conditions affecting sports participation. *Pediatrics*. 2008;121(4):841–848.

Rinat C, Farkas A, Frishberg Y. Familial inheritance of crossed fused renal ectopia. *Pediatr Nephrol*. 2001;16:269–2270.

Romans DG, Jewett MA, Robson CJ. Crossed renal ectopia with colic. A clinical clue to embryogenesis. *Br J Urol*. 1976;48:171–174.

Romics I, Riesz P, Szelepcsenyi J, et al. Bilateral renal cell carcinoma in a horseshoe kidney. *Pathol Oncol Res*.

2002;8:270–271.

Roodhooft AM, Birnholz JC, Holmes LB. Familial nature of congenital absence and severe dysgenesis of both kidneys. *N Engl J Med*. 1984;310(21):1341–1345.

Rosenkrantz AB, Kopec M, Laks S. Pelvic cake kidney drained by a single ureter associated with unicornuate uterus. *Urology*. 2010;76:53–54.

Rubinstein ZJ, Hertz M, Shahin N, et al. Crossed renal ectopia: angiographic findings in six cases. *AJR Am J Roentgenol*. 1976;126:1035–1038.

Ruhland F, Ohlinger R, Radmann D, et al. [Bilateral renal agenesis in insulin-dependent maternal diabetes mellitus (IDDM)—a case report]. *Z Geburtshilfe Neonatol*. 1998;202(6):258–260.

Saing H, Mya GH, Cheng W. The involvement of two or more systems and the severity of associated anomalies significantly influence mortality in esophageal atresia. *J Pediatr Surg*. 1998;33(11):1596–1598.

Sampaio FJ, Aragao AH. Anatomical relationship between the intrarenal arteries and the kidney collecting system. *J Urol*. 1990;143:679–681.

Sampaio FJ, Aragão AH. Anatomical relationship between the renal venous arrangement and the kidney collecting system. *J Urol*. 1990;144:1089–1093.

Sanna-Cherchi S, Ravani P, Corbani V, et al. Renal outcome in patients with congenital anomalies of the kidney and urinary tract. *Kidney Int*. 2009;76(5):528–533.

Santiago T, Clay MR, Azzato E, et al. Clear cell sarcoma of kidney involving a horseshoe kidney and harboring EGFR internal tandem duplication. *Pediatr Blood Cancer*. 2017;64(11).

Sarker R, Coran AG, Cilley RE, et al. Arterial aneurysms in children: clinicopathologic classification. *J Vasc Surg*.

1991;13:47–56 [discussion 56–57].

Savvidou M, Dhillon HK. Urinary tract abnormalities. Coady AM, Bower S. *Twining's textbook of fetal abnormalities*. Churchill Livingstone: London; 2014.

Schreuder MF, Westland R, van Wijk JA. Unilateral multicystic dysplastic kidney: a meta-analysis of observational studies on the incidence, associated urinary tract malformations and the contralateral kidney. *Nephrol Dial Transplant*. 2009;24(6):1810–1818.

Schwartz MJ, Bartolotta R, Brill PW, et al. Pelvic cake kidney with a solitary ureter and bilateral congenital absence of the vas deferens. *Urology*. 2010;75(1):170–172.

Scott JE. Fetal, perinatal, and infant death with congenital renal anomaly. *Arch Dis Child*. 2002;87:114–117.

Segura JW, Kelalis PP, Burke EC. Horseshoe kidney in children. *J Urol*. 1972;108:333.

Semmens JP. Congenital anomalies of female genital tract. Functional classification based on review of 56 personal cases and 500 reported cases. *Obstet Gynecol*. 1962;19:328–350.

Seo IY, Kim HS, Rim JS. Congenital seminal vesicle cyst associated with ipsilateral renal agenesis. *Yonsei Med J*. 2009;50(4):560–563.

Sepulveda W, Corral E, Sanchez J, et al. Sirenomelia sequence versus renal agenesis: prenatal differentiation with power Doppler ultrasound. *Ultrasound Obstet Gynecol*. 1998;11(6):445–449.

Shapiro E, Goldfarb DA, Ritchey ML. The congenital and acquired solitary kidney. *Rev Urol*. 2003;5(1):2–8.

Sharma SK, Bapna BC. Surgery of the horseshoe kidney: an experience of 24 patients. *Aust N Z J Surg*. 1986;56:175–177.

Sheih CP, Hung CS, Wei CF, et al. Cystic dilatations within the pelvis in patients with ipsilateral renal agenesis or dysplasia.

J Urol. 1990;144(2 Pt 1):324–327.

Sheih CP, Liu MB, Hung CS, et al. Renal abnormalities in schoolchildren. *Pediatrics*. 1989;84:1086–1090.

Sherer DM, McAndrew JA, Liberto L, et al. Recurring bilateral renal agenesis diagnosed by ultrasound with the aid of amnioinfusion at 18 weeks' gestation. *Am J Perinatol*. 1992;9(1):49–51.

Shoja MM, Tubbs RS, Shakeri A, et al. Peri-hilar branching patterns and morphologies of the renal artery: a review and anatomical study. *Surg Radiol Anat*. 2008;30(5):375–382.

Shumaker HB Jr. Congenital anomalies of the genitalia associated with unilateral renal agenesis. *Arch Surg*. 1938;37:586–602.

Siegel MJ, McAlister WH. Calyceal diverticula in children: unusual features and complications. *Radiology*. 1979;131:79–82.

Silvis RS, Hughes WF, Holmes FH. Aneurysm of the renal artery. *Am J Surg*. 1956;91:339–343.

Sipek A, Gregor V, Horacek J, et al. [Incidence of renal agenesis in the Czech Republic from 1961 to 1995]. *Ceska Gynekol*. 1997;62(6):340–343.

Skinner MA, Safford SD, Reeves JG, et al. Renal aplasia in humans is associated with RET mutations. *Am J Hum Genet*. 2008;82(2):344–351.

Smith EC, Orkin LA. A clinical and statistical study of 471 congenital anomalies of the kidney and ureter. *J Urol*. 1945;53:11.

Smith NA, Laufer MR. Obstructed hemivagina and ipsilateral renal anomaly (OHVIRA) syndrome: management and follow-up. *Fertil Steril*. 2007;87(4):918–922.

Smith NP, Losty PD, Connell MG, et al. Abnormal lung development precedes oligohydramnios in a transgenic murine model of renal dysgenesis. *J Urol*. 2006;175(2):783–

786.

Sripathi V, Mitra A, Padankatti RL, et al. Robotic treatment of a type 2 calyceal diverticulum in a child: is suture closure and marsupialisation enough for a good outcome? *J Robot Surg*. 2018;12(4):727–730.

Stanley JC, Rhodes EL, Gewertz BL, et al. Renal artery aneurysms. Significance of macroaneurysms exclusive of dissections and fibrodysplastic mural dilations. *Arch Surg*. 1975;110:1327–1333.

Stevens AR. Pelvic single kidneys. *J Urol*. 1937;37:610.

Stewart TL, Irons MB, Cowan JM, et al. Increased incidence of renal anomalies in patients with chromosome 22q11 microdeletion. *Teratology*. 1999;59(1):20–22.

Stimac G, Dimanovski J, Ruzic B, et al. Tumors in kidney fusion anomalies. *Scand J Urol Nephrol*. 2004;38:485–489.

Strauss S, Dushnitsky T, Peer A, et al. Sonographic features of horseshoe kidney: review of 34 patients. *J Ultrasound Med*. 2000;19:27–31.

Stroosma OB, Schurink GW, Smits JM, et al. Transplanting horseshoe kidneys: a worldwide survey. *J Urol*. 2001;166:2039–2042.

Stroup NE, Edmonds L, O'Brien TR. Renal agenesis and dysgenesis: are they increasing? *Teratology*. 1990;42(4):383–395.

Strouse PJ, Haller JO, Berdon WE, et al. Horseshoe adrenal gland in association with asplenia: presentation of six new cases and review of the literature. *Pediatr Radiol*. 2002;32(11):778–782.

Sugarman J, Anderson J, Baschat AA, et al. Ethical considerations concerning amnioinfusions for treating fetal bilateral renal agenesis. *Obstet Gynecol*. 2018;131(1):130–134.

Szabo I, Vizer M, Halvax L. Amnioinfusion to prevent pulmonary hypoplasia after premature rupture of membranes. *Am J Obstet Gynecol*. 2001;184(7):1583–1584.

Tada Y, Kokado Y, Hashinaka Y, et al. Free supernumerary kidney: a case report and review. *J Urol*. 1981;126(2):231–232.

Takaha M, Matsumoto A, Ochi K, et al. Intrarenal arteriovenous malformation. *J Urol*. 1980;124:315–318.

Tanenbaum B, Silverman N, Weinberg SR. Solitary crossed renal ectopia. *Arch Surg*. 1970;101:616–618.

Thomas IT, Smith DW. Oligohydramnios, cause of the nonrenal features of Potter's syndrome, including pulmonary hypoplasia. *J Pediatr*. 1974;84(6):811–815.

Thomason WB, Ross M, Radwin HM, et al. Intrarenal arteriovenous fistulas. *J Urol*. 1972;108:526–529.

Thompson DP, Lynn HB. Genital anomalies associated with solitary kidney. *Mayo Clin Proc*. 1966;41(8):538–548.

Thompson GJ, Pace JM. Ectopic kidney: a review of 97 cases. *Surg Gynecol Obstet*. 1937;64:935.

Timmons JW Jr, Malek RS, Hattery RR, et al. Caliceal diverticulum. *J Urol*. 1975;114:6–9.

Tiwari AK, Choudhary AK, Khowal H, et al. Pancake kidney: a rare developmental anomaly. *Can Urol Assoc J*. 2014;8:E451–E452.

Tong J, Zhu L, Lang J. Clinical characteristics of 70 patients with Herlyn-Werner-Wunderlich syndrome. *Int J Gynaecol Obstet*. 2013;121(2):173–175.

Trabrisky J, Bhisitkul I. Solitary crossed ectopic kidney with vaginal aplasia: a case report. *J Urol*. 1965;94:33–35.

Tsai HY, Lee MH, Chen HC, et al. Sagitally malrotated kidney: a case series of two patients. *Surg Radiol Anat*. 2015;37:551–553.

Turkmen E, Yildirim T, Ciftci T, et al. Congenital megacalycosis with IgA nephropathy: a case report and

review of the literature. *Ren Fail*. 2013;35:155–158.
Türkvatan A, Demir D, Olçer T, et al. Cake kidney: MDCT urography for diagnosis. *Clin Imaging*. 2006;30:420–422.
Türkvatan A, Olcer T, Cumhur T. Multidetector CT urography of renal fusion anomalies. *Diagn Interv Radiol*. 2009;15:127–134.
Tyagi V, Dar TI, Khawaja AR, et al. Horseshoe kidney with complete unilateral duplication of ureter and pelvicalyceal system—a case report. *Urol J*. 2014;10:1162–1164.
Uetani N, Bouchard M. Plumbing in the embryo: developmental defects of the urinary tracts. *Clin Genet*. 2009;75(4):307–317.
Uhlenhuth E, Amin M, Harty JI, et al. Infundibular dysgenesis: a spectrum of obstructive renal disease. *Urology*. 1990;35:334–337.
Urbani CE, Betti R. Accessory mammary tissue associated with congenital and hereditary nephrourinary malformations. *Int J Dermatol*. 1996;35(5):349–352.
van den Bosch CM, van Wijk JA, Beckers GM, et al. Urological and nephrological findings of renal ectopia. *J Urol*. 2010;183:1574–1578.
van den Ouden D, Blom JH, Bangma C, et al. Diagnosis and management of seminal vesicle cysts associated with ipsilateral renal agenesis: a pooled analysis of 52 cases. *Eur Urol*. 1998;33(5):433–440.
van Vuuren SH, van der Doef R, Cohen-Overbeek TE, et al. Compensatory enlargement of a solitary functioning kidney during fetal development. *Ultrasound Obstet Gynecol*. 2012;40(6):665–668.
Vela-Navarrete R, Garcia Robledo A. Polycystic disease of the renal sinus: structural characteristics. *J Urol*. 1983;129:700–703.
Vergani P, Locatelli A, Strobelt N, et al. Amnioinfusion for prevention of pulmonary hypoplasia in second-trimester

rupture of membranes. *Am J Perinatol*. 1997;14(6):325–329.

Viana R, Batourina E, Huang H, et al. The development of the bladder trigone, the center of the anti-reflux mechanism. *Development*. 2007;134(20):3763–3769.

Volkan B, Ceylan E, Kiratli PO. Radionuclide imaging of rare congenital renal fusion anomalies. *Clin Nucl Med*. 2003;28(3):204–207.

Walther A, Cost NG, Garrison AP, et al. Renal rhabdomyosarcoma in a pancake kidney. *Urology*. 2013;82:458–460.

Wang RY, Earl DL, Ruder RO, et al. Syndromic ear anomalies and renal ultrasounds. *Pediatrics*. 2001;108(2):E32.

Ward JN, Nathanson B, Draper JW. The pelvic kidney. *J Urol*. 1965;94:36–39.

Weizer AZ, Silverstein AD, Auge BK, et al. Determining the incidence of horseshoe kidney from radiographic data at a single institution. *J Urol*. 2003;170:1722–1726.

Westland R, Schreuder MF, Bokenkamp A, et al. Renal injury in children with a solitary functioning kidney—the KIMONO study. *Nephrol Dial Transplant*. 2011;26(5):1533–1541.

Westland R, van Wijk JA, Schreuder MF. The reason why mother nature provided us with two kidneys: the risks of a congenital solitary functioning kidney. *Nephrol Dial Transplant*. 2012;27(6):2603–2604.

Westland R, Schreuder MF, Ket JC, et al. Unilateral renal agenesis: a systematic review on associated anomalies and renal injury. *Nephrol Dial Transplant*. 2013;28(7):1844–1855.

Westland R, Kurvers RA, van Wijk JA, et al. Risk factors for renal injury in children with a solitary functioning kidney. *Pediatrics*. 2013;131(2):e478–e485.

Westland R, Schreuder MF, van Goudoever JB, et al. Clinical implications of the solitary functioning kidney. *Clin J Am Soc*

Nephrol. 2014;9(5):978–986.

Weyrauch HM Jr. Anomalies of renal rotation. *Surg Gynecol Obstet*. 1939;69:183.

Whitaker RH, Hunt GM. Incidence and distribution of renal anomalies in patients with neural tube defects. *Eur Urol*. 1987;13:322–323.

Whitehouse GH. Some urographic aspects of the horseshoe kidney anomaly: a review of 59 cases. *Clin Radiol*. 1975;26:107–114.

Widder DJ, Newhouse JH. The sonographic appearance of milk of calcium in renal caliceal diverticuli. *J Clin Ultrasound*. 1982;10:448–450.

Wiesel A, Queisser-Luft A, Clementi M, et al. Prenatal detection of congenital renal malformations by fetal ultrasonographic examination: an analysis of 709,030 births in 12 European countries. *Eur J Med Genet*. 2005;48(2):131–144.

Williams DI, Mininberg DT. Hydrocalycosis: report of three cases in children. *Br J Urol*. 1968;40:541–545.

Wilson C, Azmy AF. Horseshoe kidney in children. *Br J Urol*. 1986;58:361.

Woolf AS, Hillman KA. Unilateral renal agenesis and the congenital solitary functioning kidney: developmental, genetic and clinical perspectives. *BJU Int*. 2007;99(1):17–21.

Wu G, Bazer FW, Satterfield MC, et al. Impacts of arginine nutrition on embryonic and fetal development in mammals. *Amino Acids*. 2013;45(2):241–256.

Wulfsohn M. Pyelocaliceal diverticula. *J Urol*. 1980;123:1–8.

Yazaki T, Tomita M, Akimoto M, et al. Congenital renal arteriovenous fistula: case report, review of Japanese literature and description of non-radical treatment. *J Urol*. 1976;116:415–418.

Yin Z, Yang JR, Wei YB, et al. A new subtype of crossed fused ectopia of the kidneys. *Urology*. 2014;84:e27.

Yoder IC, Pfister RC. Unilateral hematocolpos and ipsilateral renal agenesis: report of two cases and review of the literature. *AJR Am J Roentgenol*. 1976;127(2):303–308.

Yosypiv IV. Renin-angiotensin system in ureteric bud branching morphogenesis: implications for kidney disease. *Pediatr Nephrol*. 2014;29(4):609–620.

Zambrowicz T, Bartkowiak Z, Sarazin O. Hydronephrosis caused by abnormal renal arteries. *Pol Med J*. 1972;11:1196–1202.

Zeltser IS, Liu JB, Bagley DH. The incidence of crossing vessels in patients with normal ureteropelvic junction examined with endoluminal ultrasound. *J Urol*. 2004;172:2304–2307.

Zinman L, Libertino JA. Uncommon disorders of the renal circulation: renal artery aneurysm. Breslin DJ, Swinton NW, Libertino JA, et al. *Renovascular hypertension*. Williams & Wilkins: Baltimore; 1982:110–114.

Zipitis CS, Augustine T, Tavakoli A, et al. Horseshoe kidney transplantation. *Surgeon*. 2003;1:160–163.

Zolotas E, Krishnan RG. Subdiaphragmatic renal ectopia: case report and review of the literature. *Case Rep Nephrol*. 2016;2016:1084917.

39

Renal Dysgenesis and Cystic Disease of the Kidney

John C. Pope IV, MD

Congenital and acquired renal malformations constitute a wide spectrum of clinical entities. This chapter is devoted to those disorders that lead to dysgenesis of the kidney, cystic lesions of the kidney, or both.

Many of these conditions are related to maldevelopment of the kidney and urinary tract and are thus the result of anomalous genetic mechanisms, some of which are understood and others of which are not. A basic knowledge of molecular genetics is required to better understand normal renal development, absence of renal development, and the effects of genetic mutations and abnormal signaling proteins on renal maldevelopment and cystic diseases. Within this chapter, the relevant genetic processes are briefly discussed as they relate to specific disease processes.

Overview of Genetics

Genetic direction of kidney and urinary tract development results when a gene from a specific chromosomal area produces a protein product that then signals certain actions to occur within an individual cell or group of cells. This cellular differentiation is then responsible for the particular action of those cells. In general, when a gene is normal, its protein product is normal as well. When a gene is abnormal, it produces an abnormal protein that can lead to maldevelopment or disease. Obviously, with complex organogenesis, the process is not always this simple. Often **more than one gene can be responsible for a specific disease. For example, an abnormality of one of two genes is responsible for the entity tuberous sclerosis. One tuberous sclerosis gene, *TSC1*, is located on chromosome 9 and the second, *TSC2*, on chromosome 16.**

Each gene within a cell is one of a set of two; each is called an *allele*. One defective allele may be the carrier for the defect**. In Knudson's** (1971) **two-hit theory, the first hit is an inherited mutation that is found in all cells of an individual (i.e., a germline mutation). The second hit occurs when the wild-type, normal allele spontaneously mutates within a specific organ, although it may be a different mutation than in the primarily affected allele**. For example, the typical somatic cells in the kidney and all other cells of a patient with von Hippel-Lindau (VHL) disease typically are heterozygous for the *VHL* gene located on chromosome 3; that is, the mutant *VHL* allele is inherited and its mate is the normal wild-type allele. However, the configuration of wild-type *VHL* makes it prone to spontaneous mutation. If the wild-type allele develops a defect within the cells of a specific organ, those cells no longer are able to produce normal pVHL (VHL protein) with its suppressor properties. That organ then has the propensity to develop a tumor. The variability in manifestations of autosomal dominant polycystic kidney disease (ADPKD) may be related to a two-hit phenomenon as well. For example, ADPKD is a heterozygous condition in which one allele of the *PKD1* or *PKD2* set is responsible for the genetic transmission of the disease but may not be enough for cystogenesis. A spontaneous mutation of the wild-type allele may be responsible for cystogenesis or for other manifestations of the disease.

Renal Agenesis and Dysplasia

Many terms can be used to describe anomalous development of the kidney. These terms are often used interchangeably and can result in great confusion. The definitions as adopted in 1987 by the American Academy of Pediatrics (AAP) Section on Urology (Glassberg et al., 1987) are used in this chapter.

Renal Agenesis

See Chapter 38.

Renal Dysplasia

Definition

Renal dysgenesis is defined as maldevelopment of the kidney that affects its size, shape, or structure. It is composed of two primary subtypes, the first of which is dysplasia. The term *dysplasia*, although literally and most simply is defined as “abnormal tissue,” specifically, as it relates to the kidney, can only truly be defined on the basis of histopathology. **Dysplasia is a histologic diagnosis made by the presence of embryonic, immature mesenchyme, and primitive renal components.** The differentiation of the metanephros into mature renal components halts at some point along the developmental pathway, often because of an error in the wolffian duct–ureteric bud–metanephric blastema interaction. Common histologic features include distortion of renal architecture, immature or primitive glomeruli, nephron precursors such as comma- and S-shaped bodies, and cartilage and tubules encircled by collars of fibromuscular cells (referred to as *primitive ducts*) (Fig. 39.1). Ericsson and Ivemark (1958) considered these primitive ducts to be the sine qua non finding of all dysplasia. Cysts may or may not be present. The cause of the development of dysplasia appears to be twofold: (1) a primary, inherent abnormality in the differentiation of the nephron and collecting duct, often with an underlying genetic cause, and (2) a secondary cause resulting from congenital urinary tract obstruction.

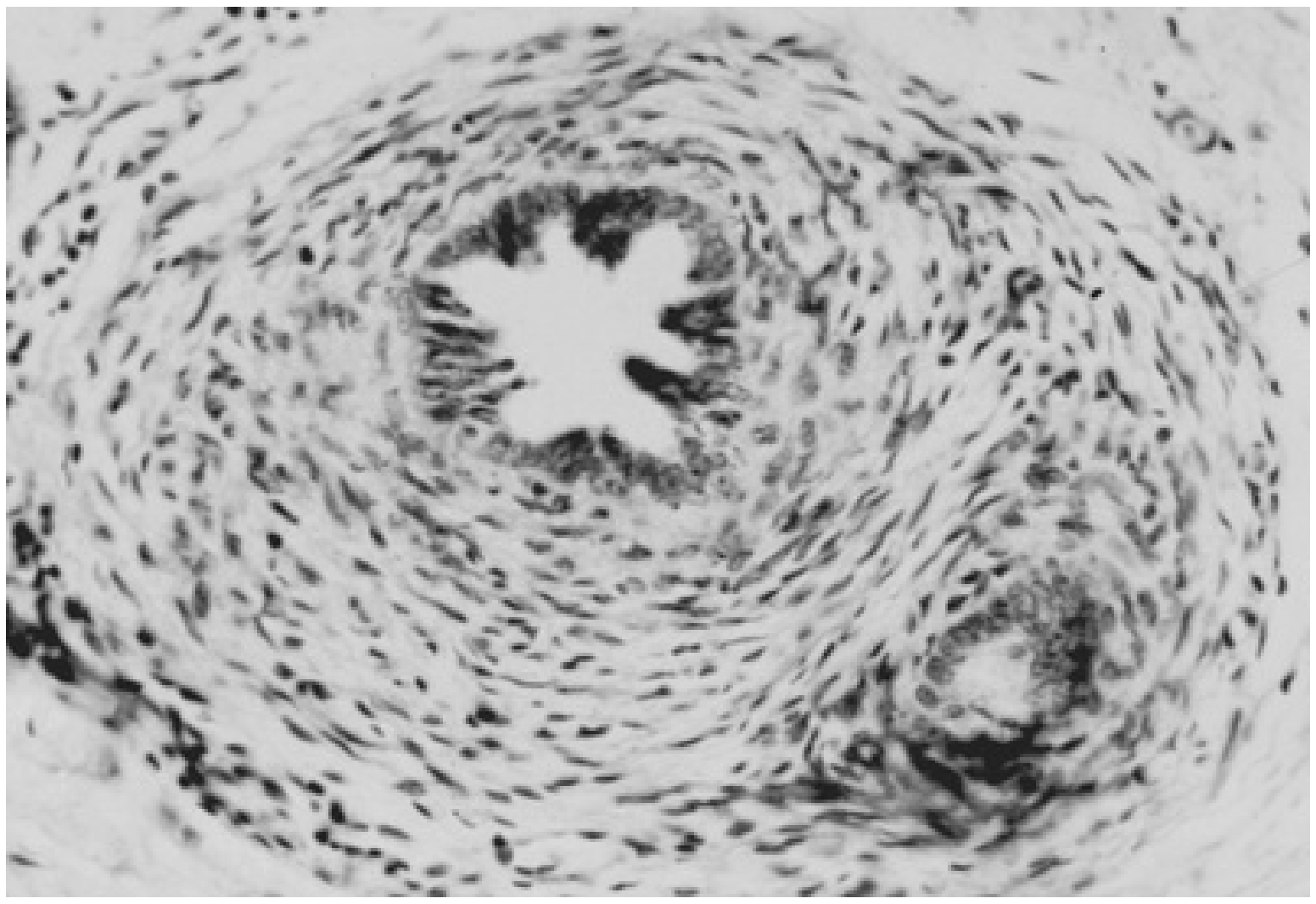

FIG. 39.1 Primitive duct lined with columnar epithelial cells. Note concentric arrangement of spindle mesenchymal cells around the duct. Special staining is required to demonstrate smooth muscle cells.

Key Points: Dysplasia

- The hallmark of dysplasia is the primitive duct, a duct encircled by a collar of fibromuscular cells.
- Dysplasia in its truest form is a histopathologic definition, not a clinical one.
- Dysplasia often is associated with ureteric bud anomalies and/or urinary tract obstruction.

Etiology

Renal dysplasia is the primary cause of childhood end-stage renal disease (ESRD), and two main theories have been considered in its pathogenesis: (1) a primary failure of ureteric bud activity and (2) a disruption in renal development produced by fetal urinary outflow impairment (obstruction). Mackie and Stephens (1975) described the ureteric bud theory, suggesting that ectopic (cephalad or caudal) ureteric bud formation leads to abnormal ureteric orifice location either laterally (often leading to vesicoureteral reflux) or distally (often leading to ureteral obstruction). Normal nephrogenesis is dependent on the ureteric bud meeting the center of the metanephric mesenchyme so that nephrogenesis is appropriately induced by the ureteric bud. However, an abnormally located ureteric bud would be expected to penetrate into a peripheral, degenerating area of the metanephric blastema. The result is a marginal (i.e., hypoplastic or dysplastic) kidney. In cases of dysplasia that are associated with an ectopic ureter, it is not clear if it is the obstruction, aberrant ureteric bud–metanephros interaction, or some other factor that leads to the dysplasia. Dysplasia associated with vesicoureteral reflux would also be included in this category.

Currently, there is no direct experimental evidence to prove that an abnormal ureteric bud site leads to ureteric bud penetration at a peripheral area of the blastema. However, there are substantial data to support the idea that defects in genetic and apoptotic pathways can affect ureteric bud formation, branching morphogenesis within the metanephric blastema, and normal nephrogenesis (Grieshammer et al., 2004; Mendelsohn et al., 1994; Norwood et al., 2000; Pope et al., 2001; Thomas et al., 2005).

Animal studies of fetal urinary tract obstruction generate some but not all of the anatomic and histopathologic features of human renal dysplasia. Findings in these animal studies include dilation at various segments of the nephron and collecting duct, inhibition of nephron development in the nephrogenic zone, architectural disorganization, and the appearance of primitive glomeruli as well as S-shaped bodies and cysts. At times, obstruction in these animal models can even lead to de-differentiation of certain cells. An example is the conversion of renal epithelial cells back into mesenchymal cells and even of mesenchymal cells into myofibroblasts (Matsell and Tarantal, 2002; Nguyen et al., 1999; Peters et al., 1992). Dysplasia arising from obstruction typically appears at the periphery of the kidney, at the nephrogenic zone, and frequently with subcapsular cysts. This type usually develops later in gestation, as in the case of posterior urethral valves (PUVs) (Fig. 39.2).

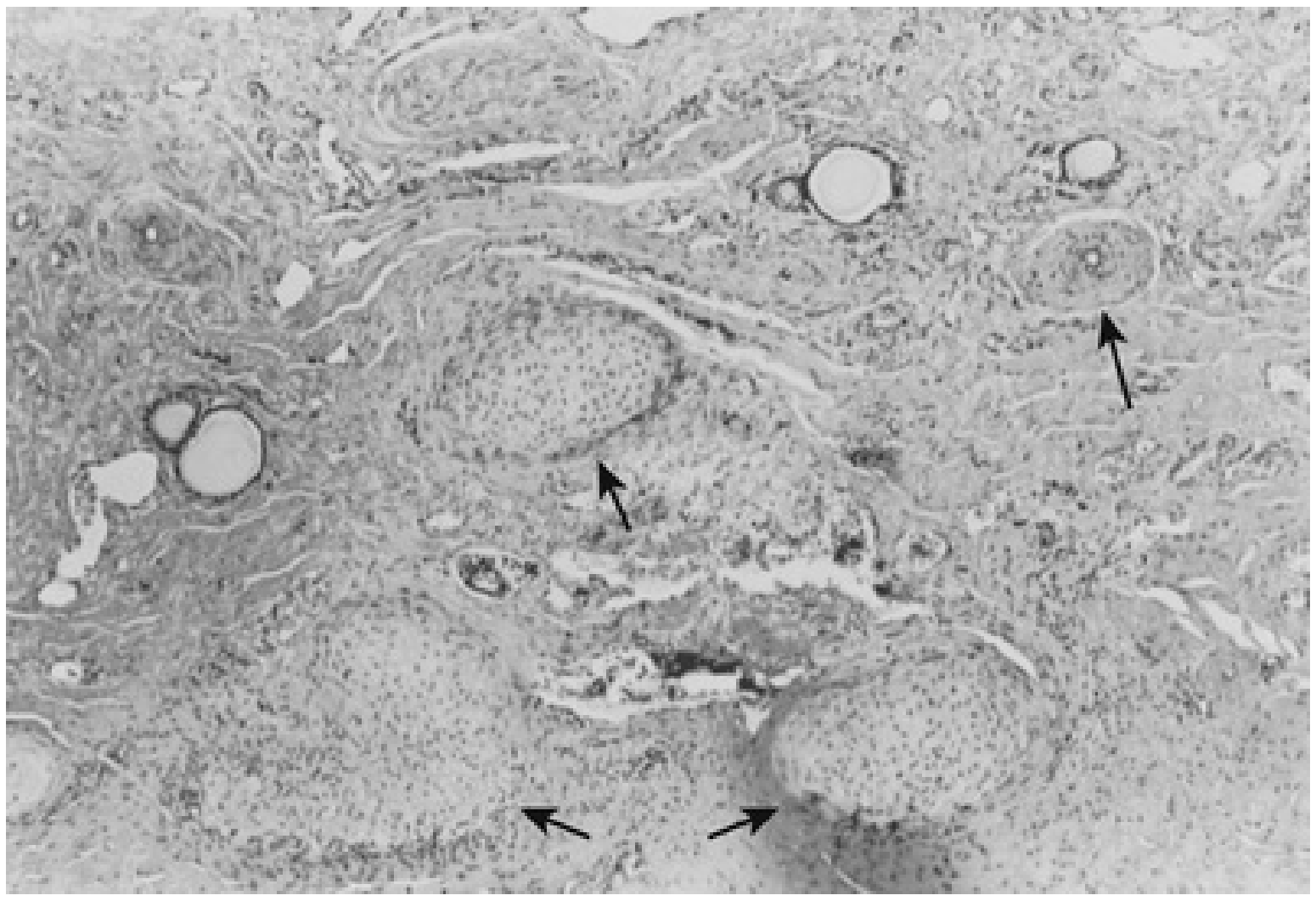

FIG. 39.2 Histologic specimen of a nonfunctioning reflux kidney in a patient with posterior urethral valves. Note presence of nests of cartilage *(short arrows).* Primitive ducts are scattered throughout the specimen *(long arrow)* (100×). The findings are compatible with dysplasia.

Dysplasia is associated with numerous genetic syndromes (e.g., Fraser syndrome; branchio-oto-renal [BOR] syndrome; renal-coloboma syndrome; Kallmann syndrome; Simpson-Golabi-Behmel syndrome; Smith-Lemli-Opitz syndrome; hypoparathyroidism, sensorineural deafness, and renal dysplasia [HDR] syndrome, and Townes-Brocks syndrome). The kidney, in association with these conditions, may be composed mostly of normal functioning parenchyma with areas of dysplasia, or, alternatively, the entire kidney may be dysplastic or entirely absent.

Ultrasonographically, dysplastic kidneys have a distinct appearance. The kidney is typically small and is hyperechogenic when compared with the liver. There is loss of the typical corticomedullary differentiation, and there is minimal distinction of the renal parenchyma and the perirenal fat (Fig. 39.3A). Cysts can be seen in conjunction with parenchymal dysplasia (Fig. 39.3B). The exact cause of the cyst formation is unclear. The important point is that not all cysts are a result of dysplasia, and not all dysplasia is associated with cysts.

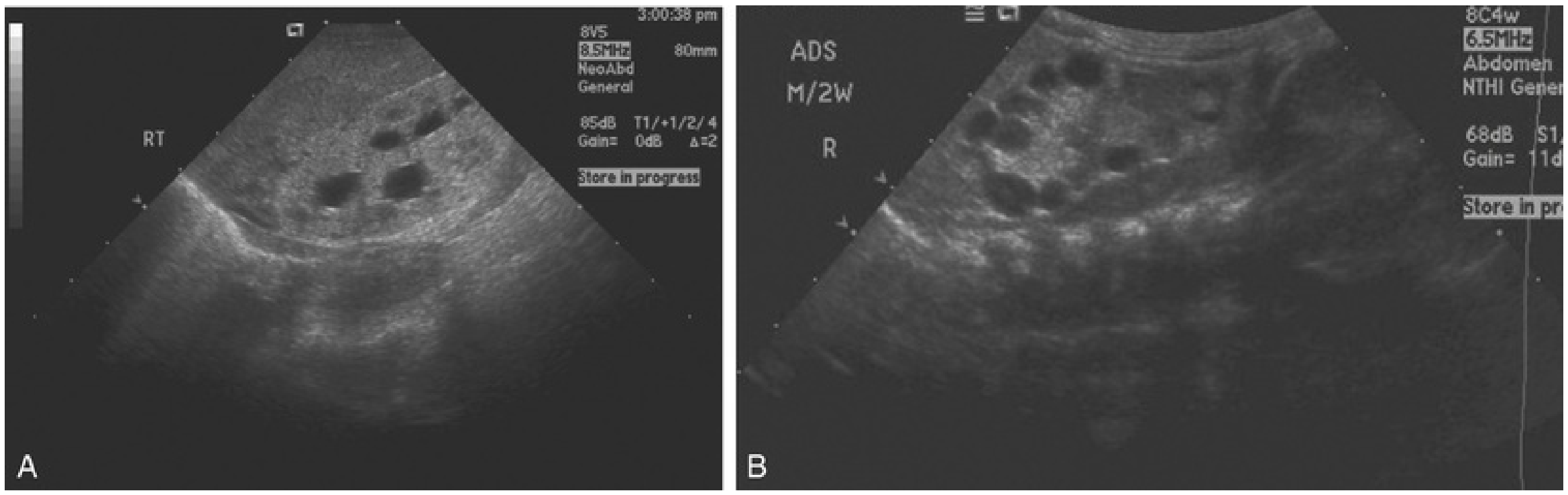
3:00:38 pm
8V5
8.5MHz
80mm
NeoAbd
General
85dB T1/+1/2/4
Gain= 0dB Δ=2
Store in progress
RT
A
ADS
M/2W
R
8C4w
6.5MHz
Abdomen
NTHI Gener
68dB S1
Gain= 11d
Store in pr
B

FIG. 39.3 Ultrasonographic appearance of renal dysplasia. (A) Classic dysplasia with hyperechogenic appearance of the kidney relative to the liver, a loss of normal corticomedullary differentiation, and dysmorphic calyces. (B) Renal dysplasia accompanied by cysts. (Courtesy Marta Hernanz-Schulman, MD.)

Hypoplasia and Hypodysplasia

Renal Hypoplasia

Another form of renal dysgenesis is hypoplasia, which is defined as the underdevelopment of a tissue or organ and is usually caused by a deficiency in the number of cells. Renal hypoplasia is a condition in which there is a reduction in the size of the functioning renal mass. Use of the term *hypoplasia* should be restricted to kidneys that have less than the normal number of calyces and nephrons but are not dysplastic or embryonic. These are kidneys that are morphologically normal but have either a reduced number of nephrons or smaller nephrons, although a hypoplastic kidney may have a normal nephron density despite its small size. Hypoplasia may be bilateral or unilateral. In unilateral cases, the other kidney usually shows greater compensatory growth than is characteristic in patients with renal atrophy caused by acquired disease. Many have used the term *hypoplasia* to describe small kidneys associated with vesicoureteral reflux. These kidneys often do not function and have dysplastic elements histologically. The term *hypoplasia* is thus technically incorrect, and a more appropriate term for these kidneys would be *congenital reflux nephropathy.* The terms *hypoplasia* and *congenital reflux nephropathy* should *not,* however, be used interchangeably. Small kidneys associated with reflux have been called *hypoplastic* in the past; however, now the term *reflux nephropathy* is used to describe the renal changes associated with reflux.

Hypodysplastic kidneys most often occur in conjunction with ectopic ureteric orifices, with the extent of dysplasia correlating with the degree of ectopia (Schwarz et al., 1981). However, hypodysplastic kidneys are seen in a few patients with normal ureteric orifices. In such patients, obstruction may or may not be present.

All forms of hypoplasia can be assessed by ultrasonography with measurement of the kidneys. The size will be reduced in all forms. Dilated calyces may also be seen. Renal function is assessed biochemically and, if there is unilateral hypoplasia, by radionuclide studies.

Oligomeganephronia

First described in 1962 (Habib et al., 1962; Royer et al., 1962), oligomeganephronia is a type of renal hypoplasia that results from a quantitative defect of the renal parenchyma with a reduced number of nephrons and hypertrophy of each nephron. This condition differs histopathologically from simple hypoplasia, in which the renal mass is reduced but the number of nephrons is normal. It is usually a bilateral condition, although a few instances of unilateral oligomeganephronia associated with contralateral renal agenesis have been reported (Forster and Hawkins, 1994; Griffel et al., 1972; Lam et al., 1982).

Etiology

Oligomeganephronia results from arrested development of the metanephric blastema at 14 to 20 weeks' gestation, with subsequent hypertrophy of glomeruli and tubules (Fig. 39.4) in the kidney. This hypertrophy and hyperfiltration results in further nephron injury and sclerosis. Eventually, this progressive loss of nephrons leads to ESRD. Recently, genetic mutations have been described in association with oligomeganephronia (Bohn et al., 2003) as have vascular abnormalities and accidents. The cause of most oligomeganephronia cases is unknown.

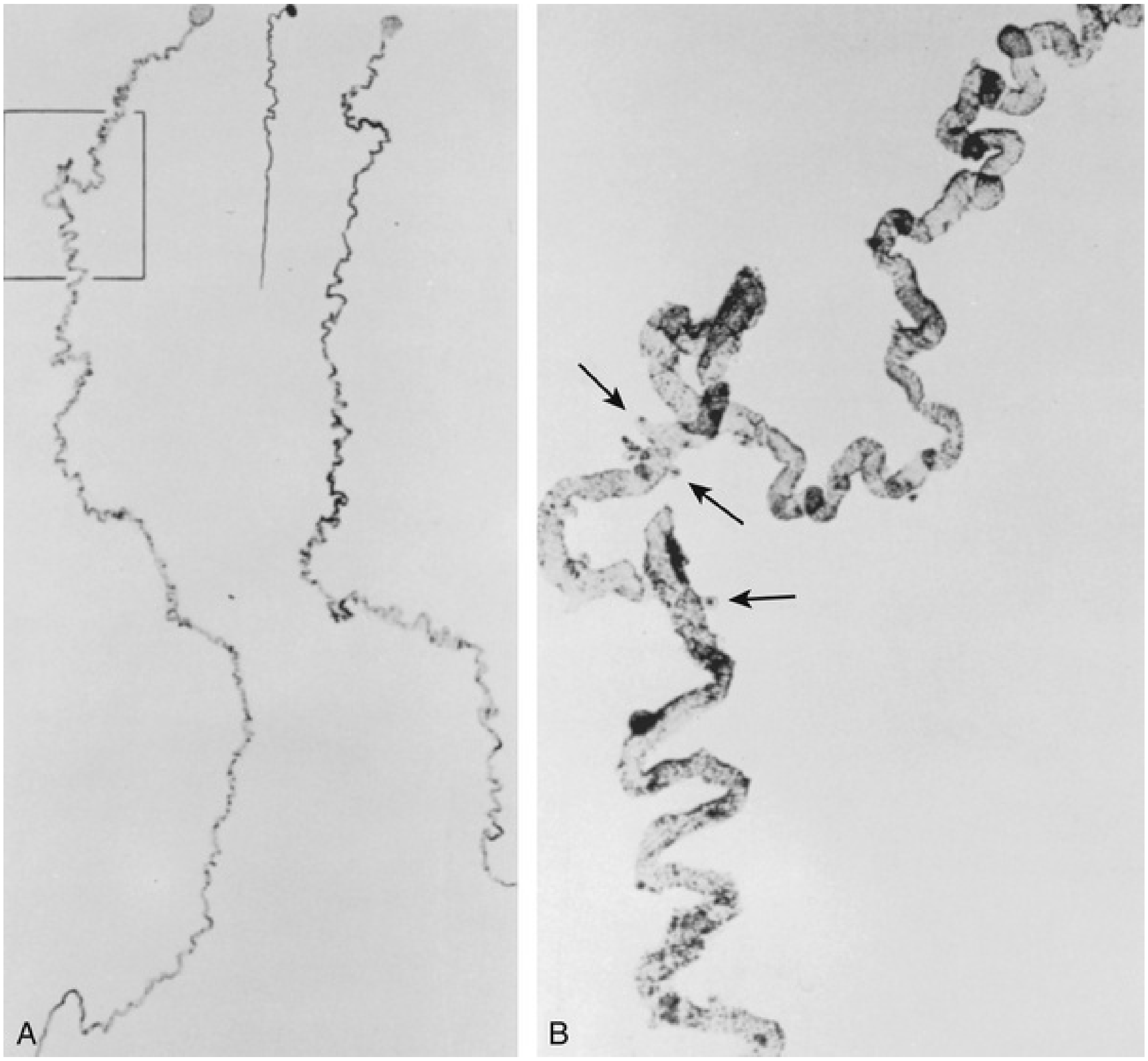

FIG. 39.4 (A) Mosaic photograph of two typical proximal tubules dissected from the kidney of a patient with oligomeganephronia. The silhouette in the top center is a diagrammatic representation to scale of an average proximal tubule from a kidney of an age-matched control. (B) Enlargement of the *inset* in A showing the diverticula along the course of the nephron *(arrows).* (From Fetterman GH, Habib R: Congenital bilateral oligonephronic renal hypoplasia with hypertrophy of nephrons [oligomeganephronia]. *Am J Clin Pathol* 52:199–207, 1969.)

Clinical Features

Oligomeganephronia is a nonheritable congenital disorder, and boys appear to be affected more often than girls. It frequently is associated with low birth weight (2500 g). The condition is usually discovered within the first 2 years of life. In neonates, kidney disease is often suspected with spontaneous pneumothorax, feeding problems, or laboratory abnormalities and may also be incidentally diagnosed when renal anomalies are discovered in the evaluation of another illness. The creatinine clearance is abnormal (10 to 50 mL/min/1.73 m^2), and the maximum specific gravity of the urine is 1.007 to 1.012. Moderate proteinuria may be present, but this is more likely to be a later finding. In neonates with oligomeganephronia, particular attention should be directed to diagnosis of associated syndromes, including BOR syndrome, acrorenal syndrome, and tapetoretinal dystrophia.

After the first year of life, individuals with oligomeganephronia most often have short stature, polyuria and polydipsia, or proteinuria. Renal function remains below normal (although stable) for many years. As the patient enters his or her teens, the creatinine clearance begins to drop rapidly. Marked proteinuria (2 g/24 h) is common. Over a period of years, the kidney continues to atrophy with reduction in the number of tubules. Oligomeganephronia is a progressive disorder, and many patients progress to renal failure in the second decade.

Histopathology

Meticulous histologic examination of the kidney is the only way to establish an absolute diagnosis of oligomeganephronia. There is a reduced number of nephrons and immature glomeruli are often present. Existing glomeruli and tubules are enlarged. As the disease progresses, segmental sclerosis and hyalinosis of glomeruli are present. Tubular atrophy with interstitial fibrosis occurs. The renal artery is small.

Evaluation

Proteinuria is often the first laboratory manifestation of oligomeganephronia and precedes decline in renal function by several years. Other laboratory manifestations of renal failure are frequently present, including elevated blood urea nitrogen (BUN) and creatinine levels, hyponatremia, and metabolic acidosis. Small kidney size depicted on renal ultrasonography (RUS) usually establishes the diagnosis of hypoplasia.

Treatment

In general, treatment is supportive and directed at maintaining normal biochemical balance, hemoglobin, and growth. High fluid intake and correction of salt loss and acidosis are the initial steps. Daily dietary protein should be limited to 1.5 g/kg during the stable phase (Royer et al., 1962). In addition, angiotensin-converting enzyme (ACE) inhibitors may be of benefit in slowing progression of renal failure, even if the patient has a normal blood pressure (BP). ESRD is managed by dialysis and transplantation. The allograft may come from a living related donor because the disease is not familial.

Ask-Upmark Kidney (Segmental Hypoplasia)

Segmental renal hypoplasia, or Ask-Upmark kidney, refers to situations of extreme acquired reflux nephropathy, and the patients (usually young women and girls) most frequently have hypertension. The lesions found in these kidneys are most likely acquired, possibly representing chronic atrophic pyelonephritis caused by vesicoureteral reflux, although some appear to be congenital. Segmental vascular (arterial) anomalies have also been cited as a possible cause for these lesions.

Clinical Features

Most patients are 10 years of age or older at diagnosis. The disease is associated with severe hypertension, sometimes with headaches, either alone or together with hypertensive encephalopathy (Rosenfeld et al., 1973) and with retinopathy in half of the patients (Royer et al., 1971).

Proteinuria and some degree of renal insufficiency may be present if the disease is bilateral. The disorder is usually unilateral, producing a small kidney with deep, narrow, segmental scars (slit-scar) found in the midzone. These slit-scars are the classic radiographic finding. Although the scar can be detected with ultrasonography, computed tomography (CT), or magnetic resonance imaging (MRI), the presence of a deep scar is often overlooked.

Histopathology

The Ask-Upmark kidney is smaller than normal—12 to 35 g (Royer et al., 1971). Its distinctive feature is one or more deep grooves on the lateral convexity, underneath which the parenchyma consists of tubules resembling those in the thyroid gland. Usually, the hypoplastic segments are easily distinguished from adjacent areas. The medulla consists of a thin band, and remnants of the corticomedullary junction and arcuate arteries are seen. Arteriosclerosis is common, and juxtaglomerular hyperplasia may be seen (Fig. 39.5; Arant et al., 1979; Bernstein, 1968; Kaufman and Fay, 1974; Meares and Gross, 1972).

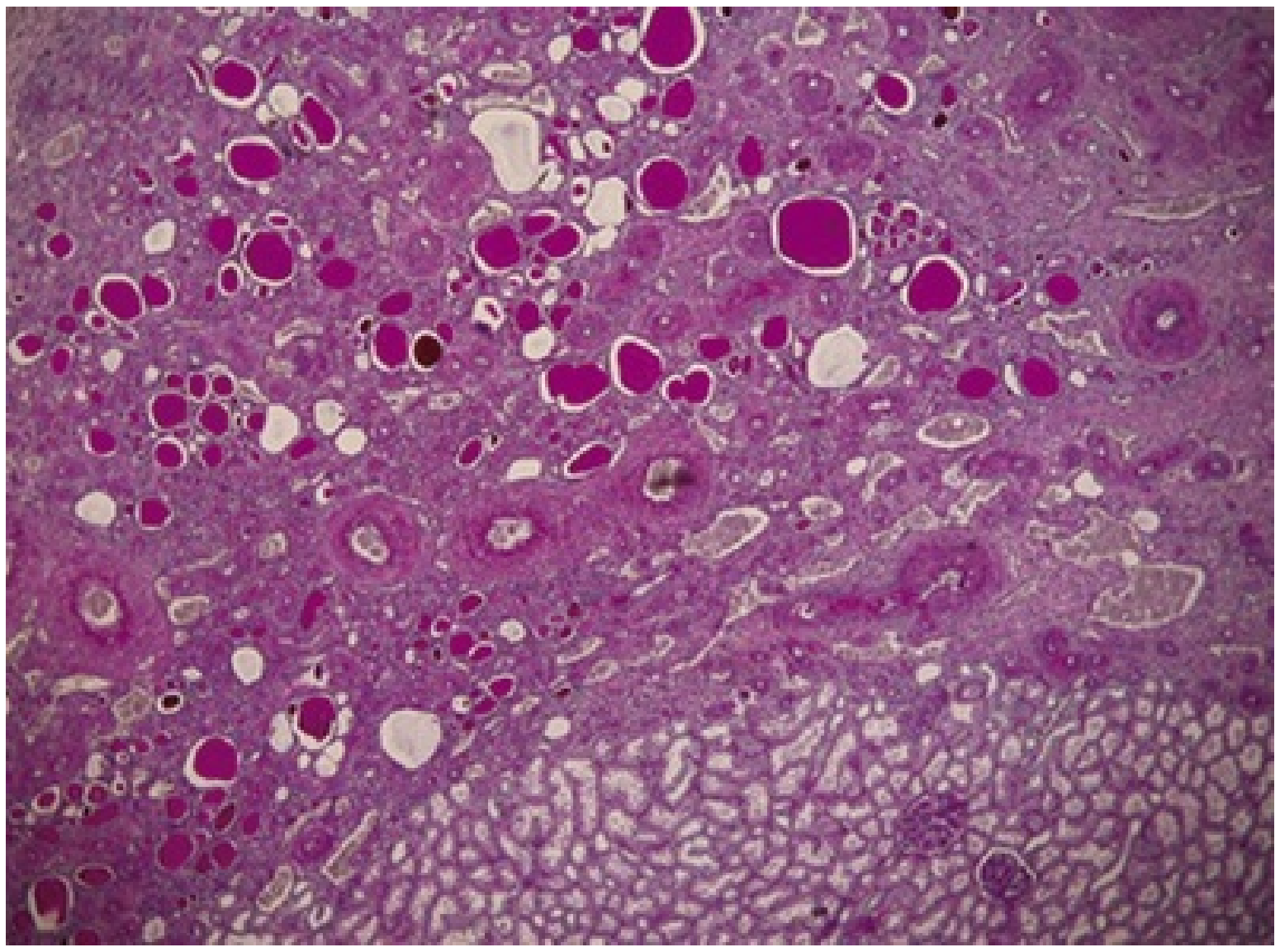

FIG. 39.5 Typical microscopic pattern of segmental hypoplasia affecting the cortex with thyroidlike tubules, thick-walled arteries, and the absence of glomerulus. Note the sharp delineation from the surrounding normal kidney *(bottom)*. Periodic acid–Schiff stain. (From Babin J, Sackett M, Delage C, et al.: The Ask-Upmark kidney: a curable cause of hypertension in young patients. *J Hum Hypertens* 19:315–316, 2005.)

Treatment

Abnormal renin secretion has been proposed as the cause of the hypertension; however, nephrectomy has been shown to normalize BP regardless of plasma renin activities (Babin et al., 2005). In patients with unilateral disease, partial or total nephrectomy may control the hypertension (Meares and Gross, 1972; Royer et al., 1971). Failure of this measure suggests an unrecognized scar or generalized arteriosclerosis in the remaining kidney (Arant et al., 1979). Bilateral disease with renal insufficiency usually is managed medically, although dialysis and transplantation may be needed. Correction of reflux may prevent further renal damage but probably will have no effect on the hypertension.

Renal Hypodysplasia

Hypodysplasia may be associated with a wide spectrum of urologic diseases, such as primary obstructive megaureter, ureterocele, urethral obstruction, or prune-belly syndrome. Lateral ureteral ectopia usually leads to vesicoureteral reflux and its associated forms of hypodysplasia. Medial ureteral ectopia, with or without the presence of a ureterocele, can often result in hypodysplasia as well.

The renal cortex may be thin, secondary to hydronephrosis, or severely dysplastic, and perhaps with numerous small cysts.

According to Osathanondh and Potter (1964), posterior urethral valves may be associated with two types of renal hypodysplasia. In the less severe form, there are small, usually subcapsular cysts and nearly normal renal function. In the second form, the cysts are larger and more widely distributed, and numerous islands of cartilage are present. This form usually is associated with earlier onset and more severe obstruction and reflux (see Fig. 39.2).

The features of prune-belly syndrome (absent abdominal musculature, triad syndrome) include grossly deformed kidneys, which may have various degrees of hypodysplasia. The ureters are wide and tortuous, often with large and laterally placed orifices. Urethral obstruction or atresia may be present in the most severe cases, but usually there is no lower urinary tract obstruction.

Key Points: Hypoplasia and Hypodysplasia

- Hypoplasia and hypodysplasia often are associated with ectopic orifices and sometimes with obstruction.
- Oligomeganephronia is a condition with a reduced number of nephrons and hypertrophy of each nephron.
- Ask-Upmark kidneys have segmented dysplasia, are seen most frequently in association with reflux, and are often the cause of severe hypertension.

Cystic Diseases of the Kidney

The kidney is one of the most common sites in the body for cyst formation. Renal cystic diseases encompass a broad spectrum of sporadic and genetically determined congenital or acquired conditions that have in common the presence of cysts in one or both kidneys. These diseases often require a multidisciplinary approach to evaluation and treatment.

Renal cysts are cavities derived primarily from tubules and are composed of a layer of partially de-differentiated epithelial cells enclosing a cavity filled with urinelike liquid or semisolid material. They may develop in any tubular segment between the Bowman capsule and the tip of the renal papilla, depending on the nature of the underlying disorder. Some cysts are saccular or fusiform structures that resemble diverticula. Other cysts may or may not communicate with a glomerulus, tubule, collecting duct, or calyx, or they may initially have communicated only to become isolated later. **Multicystic dysplasia is an exception in that it arises before formation of the nephron, from abnormal induction of metanephric development, from a primary abnormality of the nephrogenic blastema, or from obstruction occurring early in renal development. Another exception, benign multilocular cyst, represents a neoplastic growth.**

The fundamental processes that are essential for the development and progressive enlargement of renal cysts include (1) proliferation of epithelial cells in segments of renal tubule, (2) accumulation of fluid within the expanding tubule segment, and (3) disturbed organization and metabolism of the extracellular matrix (Fig. 39.6).

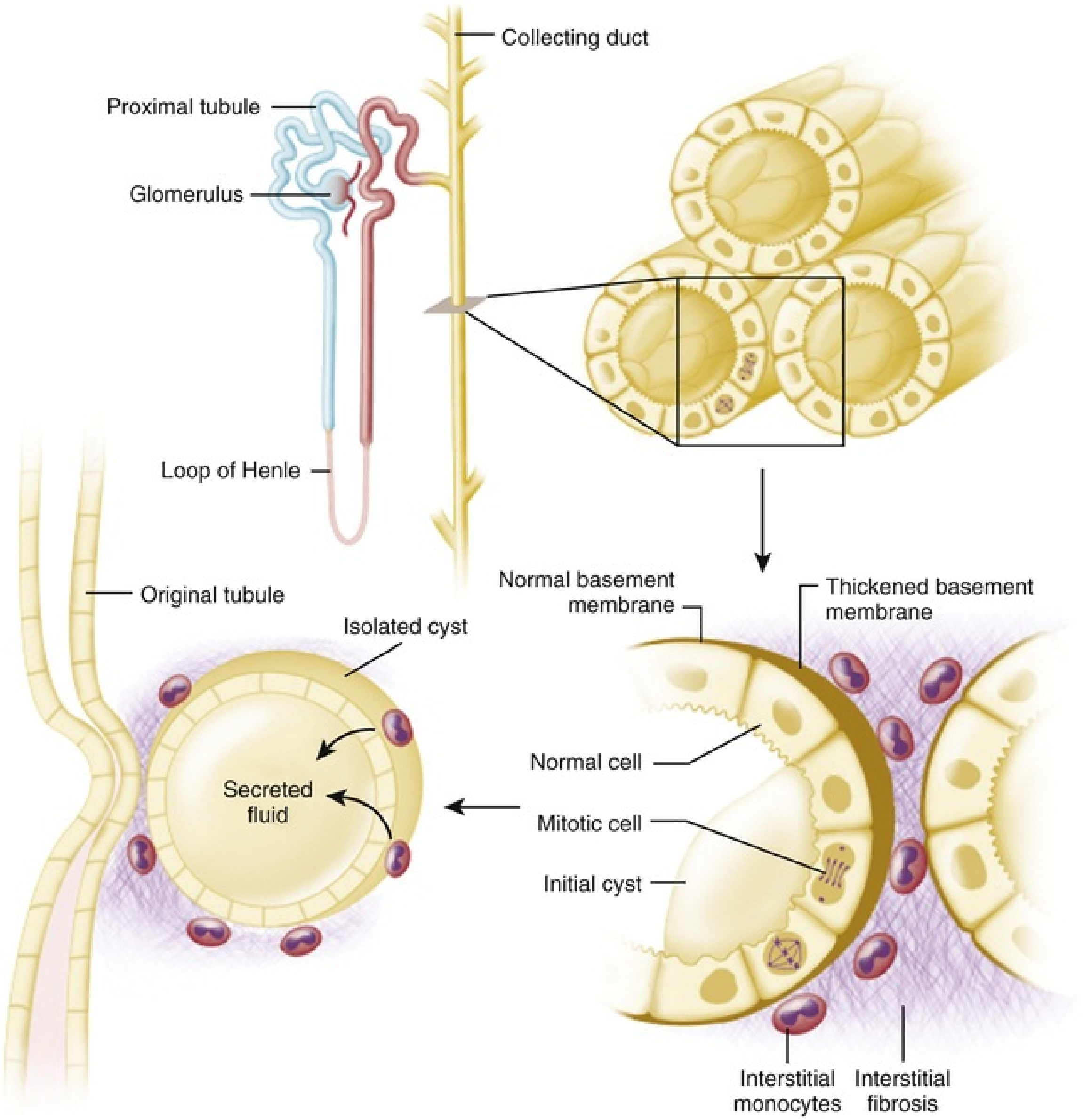
Collecting duct
Proximal tubule
Glomerulus
Loop of Henle
Original tubule
Isolated cyst
Secreted fluid
Normal basement membrane
Thickened basement membrane
Normal cell
Mitotic cell
Initial cyst
Interstitial monocytes
Interstitial fibrosis

FIG. 39.6 Evolution of cysts from renal tubules. Abnormal proliferation of tubule epithelium begins in a single cell after a "second-hit" process disables the function of the normal allele. Repeated cycles of cell proliferation lead to expansion of the tubule wall into a cyst. The cystic epithelium is associated with thickening of the adjacent tubule basement membrane and with an influx of inflammatory cells into the interstitium. The cystic segment eventually separates from the original tubule, and net epithelial fluid secretion contributes to the accumulation of liquid within the cyst cavity. (From Brenner BM, editor: *Brenner and Rector's the kidney,* ed 8, Philadelphia, 2008, Saunders, p 1428.)

An imbalance of the secretory and absorptive properties in proliferating epithelial cells leads to a net accumulation of fluid in otherwise normal renal tubules. Beyond the loop of Henle, tubule cells have the capacity to secrete solutes and fluid on stimulation. This secretory flux operates in competition with the more powerful mechanism by which sodium (Na^+) is absorbed. Under conditions in which Na^+ absorption is diminished, the **net** secretion of sodium chloride (NaCl) and fluid occurs.

Abnormalities of the extracellular matrix in and about renal cysts are seen in all cystic disorders. In the early stages of renal cyst development, changes in expression of collagen I and IV, metalloproteinase activators and inhibitors, integrins, and β-catenin may forecast a vital role for extracellular matrix remodeling in the pathogenesis of renal cysts. A hypomorphic mutation in the mouse laminin α5 gene was found to cause polycystic kidney disease (PKD) (Joly et al., 2006; Shannon et al., 2006).

Until recently, the mechanisms responsible for the abnormal differentiation and functional behavior of the epithelial cells that give rise to the cysts were largely unknown. Evidence now strongly suggests that a long-neglected structure, the primary cilium, is essential in maintaining epithelial cell differentiation. Structural and functional defects in the primary apical cilia of tubular epithelia may have a central role in determining cyst development and the abnormal differentiation and behavior of the cystic epithelium, and in various forms of human and rodent cystic diseases (Torres and Grantham, 2008). There have been several novel signaling pathways identified that are involved in the regulation of these epithelial cells and that are providing new opportunities for targeted therapies to slow and/or prevent cystogenesis (Blanco and Wallace, 2013; Choi et al., 2013; Legué et al., 2019; Ma et al., 2017; Mochizuki et al., 2013; Nikonova et al., 2018; Zhou et al., 2013).

Cystic kidneys of different causes may appear morphologically similar, whereas the same etiologic entity may cause a wide spectrum of renal abnormalities. For example, in ADPKD, tuberous sclerosis, VHL disease, and acquired renal cystic disease (ARCD), the cysts have a hyperplastic lining, sometimes with nodules of hyperplasia or polyps that project into the cyst lumen. However, these hyperplastic conditions are very different from one another. Another example of such similarities is the ectatic collecting ducts seen in two very different clinical entities: autosomal recessive polycystic kidney disease (ARPKD) and medullary sponge kidney.

Classification

In this chapter, the classification of renal cystic disease as outlined in 1987 by the Committee on Classification, Nomenclature, and Terminology of the AAP Section on Urology is used. **The primary distinction is between genetic (inheritable) and nongenetic (nonheritable) disease.** Box 39.1 gives an overview of characteristics associated with the various forms of cystic disease.

Box 39.1

Cystic Diseases of the Kidney

Inheritable

- Autosomal recessive (infantile) polycystic kidney disease
- Autosomal dominant (adult) polycystic kidney disease
  - Juvenile nephronophthisis and medullary cystic disease complex
  - Juvenile nephronophthisis (autosomal recessive)
- Medullary cystic disease (autosomal dominant)
- Congenital nephrosis (familial nephrotic syndrome) (autosomal recessive)
- Familial hypoplastic glomerulocystic disease (autosomal dominant)
- Multiple malformation syndromes with renal cysts (e.g., tuberous sclerosis, von Hippel-Lindau disease)

Nonheritable

- Multicystic kidney (multicystic dysplastic kidney)
- Benign multilocular cyst (cystic nephroma)
- Simple cysts
- Medullary sponge kidney
- Sporadic glomerulocystic kidney disease
- Acquired renal cystic disease
- Calyceal diverticulum (pyelogenic cyst)

The terms *multicystic* and *polycystic* should not be confused, even though both terms literally mean "many cysts." *Multicystic* typically refers to a dysplastic kidney resulting from aberrant renal development. *Polycystic* refers to renal units that developed in a normal fashion, all of which have no dysplasia and have nephrons throughout the kidney. The term *polycystic kidney disease* traditionally is used in reference to two conditions: ARPKD and ADPKD. Many of the PKD entities progress to renal failure as the nephrons become more diseased. In other conditions, such as tuberous sclerosis and VHL disease, there are hyperplastic cysts, and the individual nephrons are normal. Only occasionally do the nephrons become compressed by the cysts or by associated tumors, and only in such situations does renal failure ensue.

Among the nonheritable cystic diseases, benign multilocular cysts, cystic renal cell carcinoma (RCC), and other variants are considered neoplasms. Medullary sponge kidney is a disease principally of dilated ectatic collecting ducts, with cysts playing a lesser role, although the size of the ducts by definition makes them cysts. The nephrons initially are normal.

Inheritable Cystic Disease

Genetic (inheritable) cystic diseases can be classified based on their mode of transmission: autosomal dominant, autosomal recessive, X-linked, and others. Some of these disorders are caused by a single gene defect, some by an X-linked gene defect, and others by chromosomal defects. The modes of inheritance of these diseases and the specific gene or gene locus, where identified, are summarized in Table 39.1.

TABLE 39.1

Characteristics of Major Inheritable and Nonheritable Cystic Kidney Diseases

DISEASE ENTITY	CHROMOSOMAL DEFECT	RENAL FINDINGS	EXTRARENAL MANIFESTATIONS
INHERITABLE			
Autosomal recessive polycystic kidney disease (ARPKD)	Chromosome 6	In newborn usually large, homogeneous, echogenic kidneys	Congenital hepatic fibrosis; biliary dysgenesis
Autosomal dominant polycystic kidney disease (ADPKD)	*PKD1:* chromosome 16 *PKD2:* chromosome 4 *PKD3;* not mapped	Renal cysts scattered throughout parenchyma; large kidneys	Diverticulitis; liver, spleen, pancreatic cysts; mitral valve prolapse; intracranial (berry) aneurysms

Juvenile nephronophthisis and medullary cystic disease complex Juvenile nephronophthisis (autosomal recessive) Medullary cystic disease (autosomal dominant)	Chromosome 2; not mapped	Cysts of corticomedullary junction; develop after onset of renal failure; always thickened tubular basement membrane	Retinitis pigmentosa (16%; also known as Senior-Loken syndrome); rarely skeletal abnormalities, hepatic fibrosis, Bardet-Biedl syndrome, ocular motor apraxia, and other neurologic defects
		Cysts of corticomedullary junction; develop before onset of renal failure; tubular basement membrane may not be thickened	None
Tuberous sclerosis (autosomal dominant)	*TSC1:* chromosome 9 *TSC2:* chromosome 16	Cysts and angiomyolipomas throughout kidney; cysts even present in utero; 3% incidence of RCC	Adenoma sebaceum; epilepsy; mental retardation; cranial tumors
von Hippel-Lindau disease (autosomal dominant)	Chromosome 3	Cysts, adenomas, and clear cell RCC (35%–38% of cases)	Cerebellar hemangioblastomas; retinal angiomas; pheochromocytomas; cysts of pancreas and epididymis
NONHERITABLE			
Multicystic dysplastic kidney	Renal maldevelopment with diffuse cysts and remnants of early metanephros; minimal, if any, nephron development; most		Unusual

	frequent renal cystic disease in newborns		
Benign multilocular cyst	Benign cystic neoplasm of the kidney; remainder of kidney has normal nephrons that may be compromised by growing mass; present more often in males when younger than 4 yr and females when older than 30 yr		None
Simple cysts	Single or multiple cysts; normal nephrons throughout kidney; very common in normal kidneys with increasing age		None
Medullary sponge kidney	Ectatic collecting ducts; nephrons usually normal		None
Acquired renal cystic disease	Diffuse cysts; adenomas; occasionally RCC; increases with duration of ESRD		None

ESRD, End-stage renal disease; *RCC,* renal cell carcinoma.

Autosomal Recessive (Infantile) Polycystic Kidney Disease

ARPKD is typified by relatively rapid, symmetrical, and bilateral enlargement of the kidneys in infants secondary to collecting duct cysts. It is invariably associated with some degree of congenital hepatic fibrosis (Guay-Woodford and Desmond, 2003; MacRae Dell and Avner, 2003; Zerres et al., 1988). ARPKD has been referred to as the "infantile" form in the past; however, the disease can occur in adolescents and young adults, although significantly less frequently. **ARPKD has a spectrum of severity, with the most severe forms appearing earliest in life. If it is not apparent at birth, the disease will become apparent later in childhood (up to age 13 years or, rarely, up to age 20 years).**

The reported incidence of ARPKD varies from 1 in 10,000 to 50,000 live births (Kaplan et al., 1989a; Zerres et al., 1988). However, as many as 50% of affected newborns die in the first few days of life, making for a significantly lower incidence among children who live for at least 1 year. Of those infants who survive the neonatal period, approximately 50% are alive at 10 years of age (Kaplan et al., 1989a).

Genetics

Once the diagnosis of ARPKD is strongly suspected, referral for genetic evaluation and counseling is appropriate. A detailed history should be taken of at least three generations. **Because the disease is transmitted as an autosomal recessive trait, siblings of either sex have a 1 in 4 chance of being affected.**

Despite the clinical variability of ARPKD, it appears that only mutations of a single gene, named *PKHD1* and located on chromosome 6 (6p12), are responsible for the disease. The gene produces a protein called *fibrocystin* (also known as *polyductin*) (Onuchic et al., 2002; Ward et al., 2002). Dysfunction of this protein mediates cystogenesis through dysfunction of the primary cilia of renal epithelial cells. It is highly expressed in the kidney, with levels also present in the liver and pancreas. It is localized to the branching ureteric bud, collecting ducts of the kidney, and biliary ducts, consistent with the phenotype seen in ARPKD, and it is often absent in the patients with ARPKD (Al-Bhalal and Akhtar, 2008; Wilson, 2004).

Clinical Features

Affected children typically have enlarged, echogenic kidneys in utero. Oligohydramnios is common because of the lack of normal urine production by the fetus. The infant often displays Potter facies and deformities of the limbs and may have respiratory distress as a consequence of pulmonary hypoplasia. The affected newborn usually has enormous, kidney-shaped, nonbosselated flank masses that are hard and do not transilluminate. In some cases, the kidneys are large enough to impede delivery. The infant's serum creatinine and BUN begin to rise soon after birth. Of affected individuals 30% to 50% die shortly after birth as a result of uremia or respiratory failure (Capisonda et al., 2003; Guay-Woodford, 2003; Kaplan et al., 1989b). The earlier the age at which the disease is identified, the more severe the disease. **No matter what the severity of the renal disease, all patients with ARPKD have liver involvement in the form of congenital hepatic fibrosis and vary in the degree of biliary ectasia and periportal fibrosis** (Habib and Bois, 1973; Kissane and Smith, 1975).

Patients who survive the neonatal period have a milder form of the disease and are likely to survive into adulthood. Some diagnosed as neonates can live beyond age 3 or 4 years before going into renal failure (Avni et al., 2002; Cole et al., 1987). **Hypertension and renal insufficiency are the major manifestations in surviving children, with liver disease becoming more prevalent in older patients.** The exact cause of hypertension remains unclear. Consequences of chronic renal insufficiency (e.g., growth failure, anemia, osteodystrophy) become more apparent as the children age. Renal calcifications occur commonly in patients with ARPKD.

Patients whose disease appears later in life develop renal failure and hypertension more slowly. In general, their clinical problems are the consequence of liver disease rather than the renal disease, with hepatic fibrosis leading to portal hypertension, esophageal varices, and hepatosplenomegaly. Hepatocellular function is rarely abnormal, with liver enzymes typically remaining normal. The kidneys in these patients are often normal in appearance.

No association of ARPKD with renal neoplasms has been reported.

Histopathology

The kidneys are symmetrically enlarged (up to 20 times their normal size) and retain a reniform configuration. The parenchyma exhibits small subcapsular cysts, representing generalized fusiform dilations of the collecting tubules radiating from the medulla to the cortex with their long axis perpendicular to the renal surface (Bisceglia et al., 2006). Almost 100% of collecting ducts are affected in the most severe cases. The cortex is crowded with minute cysts (Fig. 39.7A). The renal pedicle is normal, as are the renal pelvis and ureter.

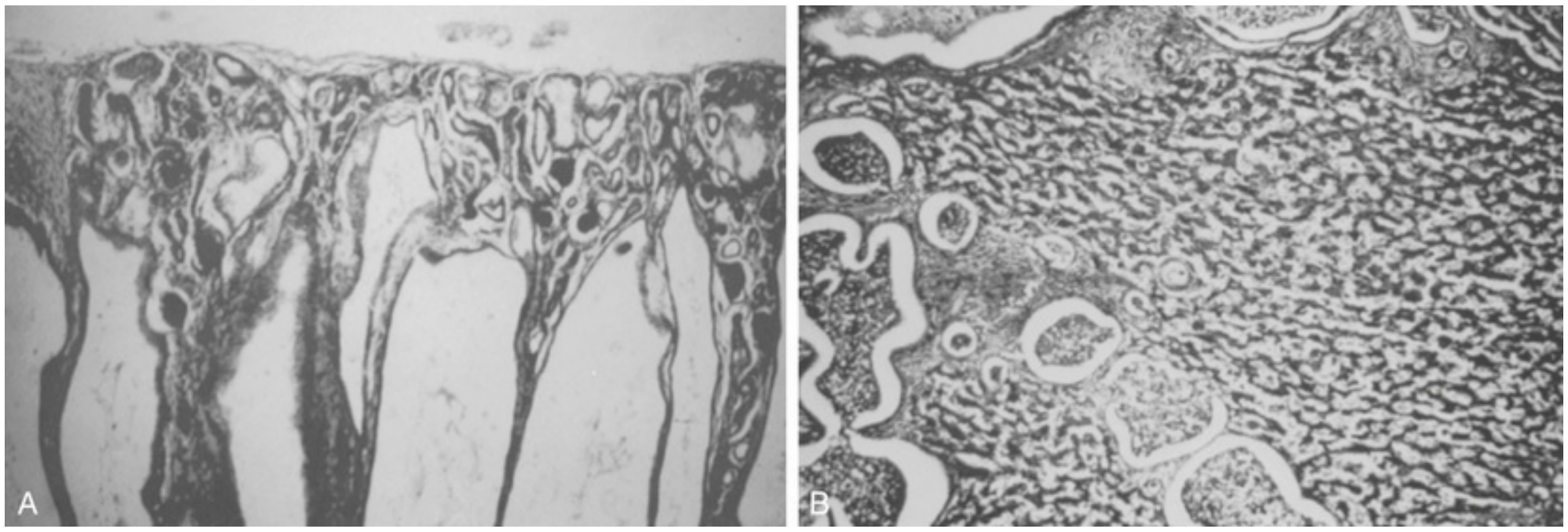

FIG. 39.7 Newborn with abdominal mass and pulmonary hypoplasia. Neither parent had a history of renal cysts. (A) Renal histology demonstrates dilated ducts radiating out to the periphery of the kidney. (B) On liver histology, ectatic biliary ducts are seen in the left half of the figure, and periportal fibrosis is seen at the upper edge. These findings confirm the diagnosis of autosomal recessive polycystic disease.

ARPKD affects the kidneys and the liver in approximately inverse proportions (Torres and Grantham, 2008). The disease may be viewed as a spectrum ranging from severe renal disease and mild liver changes at one extreme to mild renal damage and severe liver disease at the other. The form with severe renal disease is the most common and the one typically seen at or near the time of birth. The form with less severe renal disease and more significant liver damage is present in older children. **All children with ARPKD have lesions in the periportal areas of the liver** (Fig. 39.7B; Habib and Bois, 1973; Kissane and Smith, 1975).

Evaluation

The diagnosis may be suspected from in utero ultrasound examination and may be associated with oligohydramnios, a finding secondary to low urinary output. **In fetus and newborn, ultrasonography identifies bilateral, very enlarged, diffusely echogenic kidneys, especially when compared with the echogenicity of the liver** (Fig. 39.8A)**. The increased echogenicity is due to the presence of**

numerous microcysts (created by tightly compacted, dilated collecting ducts) that result in innumerable interfaces. Compared with normal newborn kidneys, in ARPKD, the pyramids are hyperechogenic because they blend in with the rest of the kidney, and the kidneys typically have a homogeneous appearance (see Fig. 39.8A). In ADPKD, the cysts, if apparent in newborns, are usually diffuse and large (see Fig. 39.8B). Also included in the differential diagnosis are severe bilateral hydronephrosis (the kidneys are enlarged with hypoechogenic calyces), multicystic kidney (hypoechogenic cysts lie within a nonreniform mass that has very little parenchyma), sporadic glomerulocystic kidney disease (GCKD), bilateral mesoblastic nephroma, Wilms tumor, and bilateral renal vein thrombosis. If the diagnosis is in doubt, CT is valuable because it is more sensitive to inhomogeneity (and therefore to tumor) within abdominal masses.

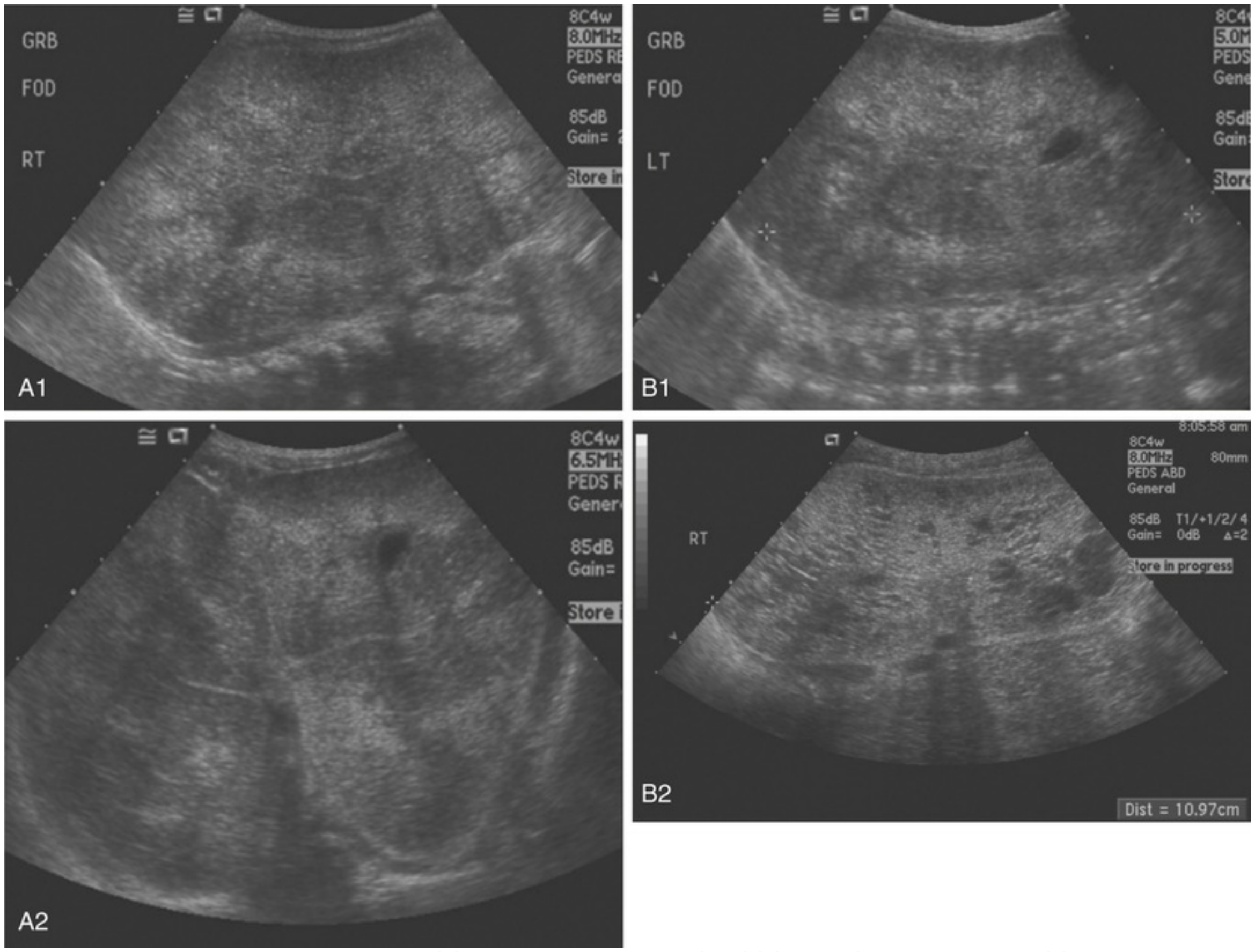
GRB
FOD
RT
8C4w
8.0MHz
85dB
A1
GRB
FOD
LT
8C4
5.0M
85dB
B1
8C4w
6.5MHz
85dB
A2
RT
8:05:58 am
8C4w
8.0MHz
PEDS ABD
General
80mm
85dB
Gain= 0dB
Store in progress
B2
Dist = 10.97cm

FIG. 39.8 Ultrasonographic appearance of the kidneys in neonates with autosomal recessive polycystic kidney disease (ARPKD) and autosomal dominant polycystic kidney disease (ADPKD) can be similar. (A1 and A2) Newborn with ARPKD. Note the large size and hyperechogenic,

homogeneous appearance of the renal parenchyma. A2 is a cross-sectional cut of the baby's abdomen showing both kidneys to be large and occupying a large portion of the abdominal cavity. (B1 and B2) Newborn with ADPKD. Again note the abnormal renal architecture and the hyperechogenic appearance of the kidneys. The parenchyma consists of multiple tiny cysts, with some being slightly larger than others. (Courtesy Marta Hernanz-Schulman, MD.)

Considerable overlap in clinical presentation and imaging findings can occur between ADPKD and ARPKD. Occasionally, a newborn with severe ADPKD can also have enlarged, homogeneously hyperechogenic kidneys. Age at onset can overlap, and typically, when ADPKD manifests at birth, cysts are apparent on the sonographic image. Macrocysts are rare in newborns with ARPKD but do increase in frequency as the child gets older, sometimes producing an appearance similar to that of the dominant disease. Cysts less than 1 cm appear more often than large cysts (Fig. 39.9; Avni et al., 2002). Hepatic fibrosis can rarely occur in patients with ADPKD, as can brain aneurysms with ARPKD (Cobben et al., 1990; Neumann et al., 1999). The correct diagnosis of ARPKD depends on the overall clinical data: a positive family history with a recessive mode of inheritance, a positive liver biopsy, and the lack of the extrarenal malformations often associated with other renal cystic diseases.

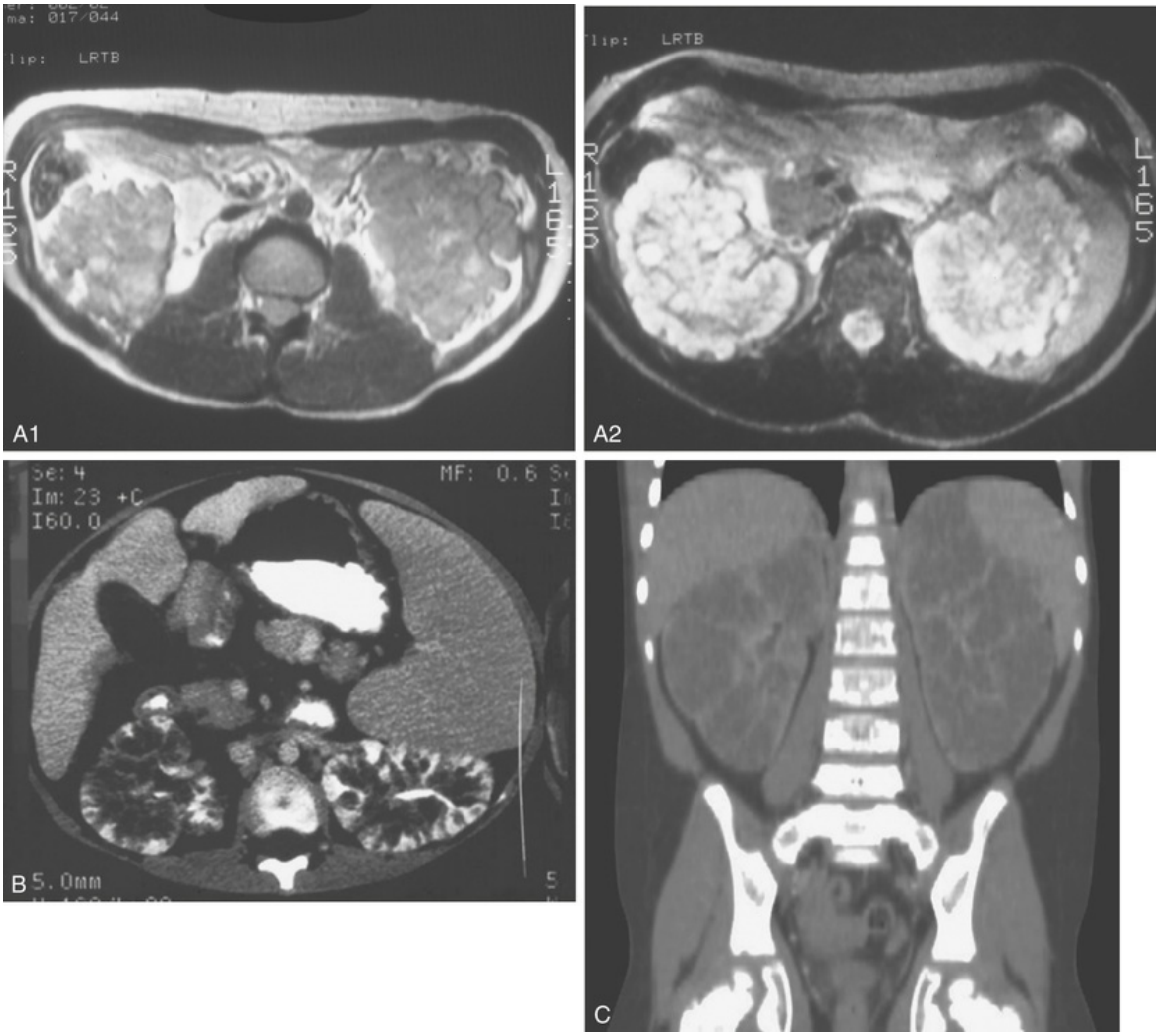

FIG. 39.9 (A1 and A2) Magnetic resonance images of an 8-month-old child with autosomal recessive polycystic kidney disease (ARPKD) demonstrating multiple renal cysts. (A1) On T1-weighted image, fluid content of cysts appears dark. (A2) On T2-weighted image, the fluid content appears white. (B) Computed tomography scan of a child with ARPKD. Horizontal cuts showing contrast puddling in collecting ducts. (C) Coronal cut. Note that the kidneys are enlarged and the enhancing renal parenchyma is effaced by nonenhancing cysts and represents the progression and normal history of the disorder. (A, Courtesy Walter Berdon, MD; B, courtesy Marta Hernanz-Schulman, MD.)

Treatment

No cure has been found for ARPKD. Respiratory care can ease or extend the child's life. Severely affected neonates may require unilateral or bilateral nephrectomy, because of respiratory and nutritional compromise. Patients who survive may require treatment for hypertension, congestive heart failure, and renal and hepatic failure. Portal hypertension may be dealt with by decompressive procedures such as a splenorenal shunt. Esophageal varices may be managed, at least temporarily, by gastric section and reanastomosis. Endoscopic sclerotherapy is widely used in pediatric and adult patients with bleeding varices. Hemodialysis and renal transplantation must eventually be considered in many patients. Often, nephrectomy is required before peritoneal dialysis to make room in the intra-abdominal cavity for dialysate.

Key Points: Autosomal Recessive Polycystic Kidney Disease

- ARPKD is secondary to a mutation of the *PKHD1* gene on chromosome 6.
- The severe form manifests in utero or in infancy; milder cases can manifest later in childhood and rarely up to age 20.
- All affected individuals have some degree of congenital hepatic fibrosis.
- When it manifests early, it is associated most often with very large kidneys that are homogeneously hyperechogenic.
- Discrete cysts appear more often as the child gets older.
- RUS reveals bilateral, very enlarged, diffusely echogenic kidneys, and the increased echogenicity is a result of the presence of numerous microcysts (created by tightly compacted, dilated collecting ducts) that result in innumerable interfaces.
- Considerable overlap in clinical presentation and imaging findings can occur between ADPKD and ARPKD.

Autosomal Dominant (Adult) Polycystic Kidney Disease

ADPKD is by far the most common inheritable form of renal cystic disease, with an incidence of approximately 1 in 400 to 1000 live births (Grantham, 1996; Iglesias et al., 1983). It is an important cause of renal failure, accounting for 7% to 15% of patients who receive hemodialysis (Grantham, 1996; Hildebrandt, 1995; Wilson, 2004). The trait theoretically has a 100% penetrance, and, on average, because it is transmitted in an autosomal dominant fashion, 50% of an affected individual's offspring will likewise be affected. Although a positive family history is one of the major criteria for the diagnosis of ADPKD, 10% of cases occur sporadically. Of affected persons, 96% will manifest the disease clinically by age 90 years (Gabow, 1991).

Although most cases are identified between the fourth and fifth decades of life, the condition has been reported in newborns and infants (Proesmans et al., 1982). All affected individuals manifest the disease (although not necessarily symptomatically) if they live long enough, but renal failure is seldom seen before the age of 40 years, unless the disease manifests during infancy, in which case it is much more aggressive.

A number of associated anomalies are common, including cysts of the liver, pancreas, spleen, and lungs; aneurysms of the circle of Willis (berry aneurysms); colonic diverticula; aortic aneurysms; and mitral valve prolapse (Table 39.2).

TABLE 39.2

Comparison of Autosomal Recessive and Autosomal Dominant Polycystic Kidney Disease

	AUTOSOMAL RECESSIVE POLYCYSTIC KIDNEY DISEASE	AUTOSOMAL DOMINANT POLYCYSTIC KIDNEY DISEASE
Gene defect	Chromosome 6	Chromosomes 4 and 16
Incidence	1 : 5000–40,000	1 : 500–1100
Usual age at clinical presentation	Perinatal	Third to fifth decades

Typical ultrasonographic appearance of kidneys	Symmetrically enlarged, homogeneous, hyperechogenic	Large, cystic kidneys, sometimes asymmetrical
Histology	Collecting duct ectasia; cysts derived principally from collecting duct	Microcysts and macrocysts derived from the entire nephron
Liver	Always with congenital hepatic fibrosis but of varying severity	Cysts, mostly in adults
Other organ system(s) involvement	None	Intracranial (berry) aneurysms, colonic diverticuli; mitral valve prolapse; cysts of other organs (seminal vesicle, arachnoid membrane, pancreas)

Genetics

There are two major genetic forms of ADPKD caused by mutation in the genes *PKD1* and *PKD2* (Breuning et al., 1987; Pieke et al., 1989; Reeders et al., 1985; Ryynanen et al., 1987). *PKD1* has been localized to the short arm of chromosome 16, with its gene product being polycystin-1. Mutations in the *PKD1* gene account for 85% of ADPKD cases. These patients typically have a more rapidly progressive form of the disease, with cysts usually developing by the age of 20 years (64% of children have cysts by the age of 10 years and 90% by the age of 20 years) and ESRD occurring in their 50s (Chakraborty and McHugh, 2005). The *PKD2* gene has been mapped to the long arm of chromosome 4 and it encodes the protein polycystin-2. *PKD2* mutations account for about 15% of ADPKD cases, and in these patients, the disease progresses more slowly. ESRD usually does not occur until these patients are in their 70s (Hateboer et al., 1999). The presence of a third locus *(PKD3)* is now accepted as the cause of disease in a very small percentage of patients who have been found to have neither a *PKD1* nor a *PKD2* gene defect (Dauost et al., 1993). **When either the *PKD1* or the *PKD2* gene is abnormal, cystic kidneys can develop.** Because defects of *PKD1* and *PKD2* manifest similarly, it has been suggested that the gene product of each is involved in the same pathway and that an abnormality of either product results in similar manifestations of the disease (Qian et al., 1996).

Every cell of the nephron and collecting duct has the *PKD1* or *PKD2* mutation; however, only 1% to 2% of these glomerular units are affected by cyst formation. Only those nephrons that undergo a disruption of a second allele undergo cystic enlargement. This is the “second hit” of the Knudson theory, which has been proposed to explain the focal nature of the cysts (Knudson, 1971). In this model, a mutated *PKD1* (or *PKD2*) gene is inherited from one parent, and a wild-type gene is inherited from the unaffected parent. During the lifetime of the individual, the wild-type gene undergoes a somatic mutation and becomes inactivated. Loss of heterozygosity caused by somatic mutations of the *PKD1* and *PKD2* genes has been identified in the cells lining the cysts in the kidney and liver (Qian et al., 1996; Watnick et al., 1998). The phenomenon of genetic anticipation is seen as well; it manifests with progressively earlier presentation and increased severity in subsequent generations of patients with ADPKD (Fick et al., 1994; Zerres et al., 1994). Genetic testing for *PKD1* and *PKD2* is commercially available through polymerase chain reaction amplification and direct DNA sequencing.

Occasionally, the classic ADPKD phenotype is seen in conjunction with tuberous sclerosis. This association is a classic example of a “contiguous gene syndrome,” which is a disorder caused by deletion of multiple gene loci that are adjacent to one another. Contiguous gene syndromes are characterized by multiple, apparently unrelated, clinical features caused by deletion of the multiple adjacent genes. Because of the fact that the *PKD1* gene is immediately adjacent to the *TSC2* gene (the most important gene in tuberous sclerosis) on chromosome 16, large deletions in this area can involve the *PKD1* and *TSC2* genes. Thus these patients have the classic features of tuberous sclerosis in addition to the renal cystic phenotype of ADPKD (Galliani et al., 2015; Murakami et al., 2012; Rito et al., 2017).

Pathogenesis

The *PKD1* and *PKD2* proteins, polycystin-1 (PC1) and polycystin-2 (PC2), are transmembrane proteins that in all likelihood form a functional complex. When working properly, PC1 and PC2 inhibit cell proliferation by several pathways. Polycystin-1 functions as a mechanoreceptor located on the primary cilium of renal tubular cells. These cilia project from the surface of the cell into the lumen of the ducts and tubules. Mutations that block the assembly of these cilia are known to cause many cystic diseases of the kidney. The products of the *ADPKD,* *ARPKD*, and nephronophthisis (NPH) genes are at least partially localized to these primary cilia. Polycystin-1 is linked to polycystin-2, which contains a calcium (Ca^{2+}) channel. When the mechanoreceptor of PC1 is stimulated by calcium-containing urine flowing through the tubule, the calcium channel of PC2 opens and calcium enters the cell (Braun, 2009; Nauli et al., 2003). This process regulates the proliferative state of the renal tubular cells through a variety of signaling pathways (e.g., cAMP, extracellularly regulated kinase [ERK], mammalian target of rapamycin [mTOR]). The cilia likely serve as organization centers for this signal transduction (Pazour, 2004).

In ADPKD, the polycystins do not function properly, and these proliferative pathways are unopposed and cyst formation occurs to varying degrees.

Increased levels of cAMP have been noted in multiple animal models of ADPKD, and biochemical processes that alter cAMP appear to affect the presence and size of renal cysts. For example, cAMP is broken down by phosphodiesterases. Caffeine and methylxanthine products, such as theophylline, interfere with phosphodiesterase activity, raise cAMP in epithelial cell cultures from patients with ADPKD, and increase cyst formation in canine kidney cell cultures (Belibi et al., 2002; Mangoo-Karim et al., 1989). The abnormal response to cAMP is directly linked to alterations in Ca^{2+} channel activity and results in the abnormal response of cyst-derived cells. This has also been shown to be regulated by cAMP stimulation of the mitogen-activated protein kinase/extracellularly regulated kinase (MAPK/ERK) signaling pathways, which leads to abnormal cellular proliferation of the PKD renal epithelial cells.

Upregulation of the vasopressin V_2 receptor (VPV2R) has also been shown to increase cAMP levels. In genetically produced polycystic animals, two antagonists of the vasopressin V_2 receptor (VPV2R), OPC31260 and OPC41061 (tolvaptan), decreased cAMP and ERK, prevented or reduced renal cysts, and preserved renal function (Gattone et al., 2003; Wang et al., 2005). Not surprisingly, simply increasing water intake decreases vasopressin production and the development of PKD in rats (Nagao et al., 2006). Polycystic kidney (PCK) animals with no vasopressin activity had virtually no cAMP or renal cysts, whereas animals with increasing amounts of vasopressin had progressively larger kidneys with more numerous cysts. Administration of synthetic vasopressin to PCK rats that totally lacked vasopressin re-created the full cystic disease (Braun, 2009; Wang et al., 2008). Finally, the absence of polycystin permits excessive kinase activity in the mTOR pathway and the development of renal cysts (Shillingford et al., 2006). The mTOR system can be blocked by rapamycin, which has been shown to slow PKD progression in rats (Wahl et al., 2006).

Clinical Features

Phenotypes associated with ADPKD are highly variable in penetrance. This variability related to the severity of renal disease can range from fetal demise and neonatal death to adequate renal function into old age. Characteristics of the associated liver disease and extrarenal manifestations can also be variable. *PKD1* and *PKD2* gene mutations are obviously critical, but intrafamilial variability also indicates that genetic background and environmental factors can also affect ultimate clinical expression of the disease (Rossetti and Harris, 2007). Now that the families of ADPKD patients are being screened by ultrasonography, large numbers of asymptomatic children with renal cysts are being identified before full-blown disease develops. Bilateral renal involvement is the usual presentation, but 17% of cases are asynchronous or asymmetrical, especially in children. These extreme forms of asymmetry are referred to as *unilateral ADPKD*, with the involvement in the contralateral kidney becoming apparent at a much older age (Bisceglia et al., 2006; Strand et al., 1989).

Typically, signs or symptoms first occur between the ages of 30 and 50 years (Glassberg et al., 1981). These include microscopic and gross hematuria, flank pain, gastrointestinal symptoms (perhaps secondary to renomegaly or associated colonic diverticula), renal colic (secondary either to clots or stones), and hypertension. Microscopic or gross hematuria is seen in 50% of patients, and in 19% to 35% it is the presenting sign (Delaney et al., 1985; Gabow et al., 1992; Milutinovic et al., 1984; Zeier et al., 1988). Because patients with ADPKD have increased renal mass, erythropoietin levels are increased, making anemia unusual even when ESRD is present (Gabow, 1993).

Pain (flank and/or abdominal) is the most common presenting symptom in adults. This results from a number of possible factors: mass effect (cysts impinging on abdominal wall or neighboring organs), bleeding into the cysts, urinary tract infection (including infected cysts), and nephrolithiasis. Twenty percent to 30% of patients with ADPKD develop stones (Fick et al., 1994), and these are treated by conservative means if possible (i.e., urine alkalinization, spontaneous stone passage, extracorporeal shock wave lithotripsy). Uric acid stones and calcium oxalate stones are equally prevalent. The finding of hydronephrosis, which helps make the diagnosis of stones, may not be as useful in ADPKD patients because of the number of cysts camouflaging the findings (Choyke et al., 1995). Urinary tract infections are more frequent in female patients. Cyst aspiration for diagnostic and therapeutic reasons should be considered in the setting of suspected cyst infection.

As BP screening has become more widespread, hypertension has become a very common form of presentation (Zeier et al., 1988). Hypertension is present in roughly 50% of patients 20 to 35 years old having ADPKD with normal renal function. Almost 100% of patients with ESRD have hypertension (Kelleher et al., 2004). The hypertension seems to be renin mediated, secondary to stretching of the intrarenal vessels around cysts, causing distal ischemia (Gabow, 1993). Diagnosis and treatment of this hypertension are critical to slow the progression of renal failure and to decrease morbidity and mortality from heart disease and cerebral aneurysms.

The development of renal failure is highly variable. Renal function is usually maintained, despite increasingly rapid cyst growth, until the fourth to sixth decade of life. Risk factors for earlier onset of ESRD include *PKD1* gene mutation, male gender, first episode of hematuria before age 30 years, onset of hypertension before age 35 years, hyperlipidemia, and sickle cell trait (Johnson and Gabow, 1997; Yium et al., 1994). There is a strong relationship between the decline in renal function and the size of the kidneys and cyst volumes. As the cysts, and thus the kidneys, become larger, renal function declines proportionately (Gabow et al., 1990a). Hypertension and vascular remodeling secondary to cyst expansion also contribute to progressive renal failure.

Extrarenal Manifestations

Hepatic cysts, usually identified incidentally by ultrasonography, are the most common extrarenal manifestation of ADPKD. These cysts are associated with PKD1 and non-PKD1 genotypes. They are rare in children, and their frequency increases with age. They are present in almost all ADPKD patients by the age of 50 years (Bae et al., 2006). Hepatic cysts are more prevalent and their size greater in females (Fick et al., 1994). Several studies have shown an estrogen effect on hepatic cyst growth (Gabow et al., 1990b; Sherstha et al., 1997). Hepatic cysts are usually asymptomatic but can occasionally cause symptoms because of mass effect, complicating infection, or hemorrhage. In rare instances, enlargement of hepatic cysts leads to portal hypertension and bleeding esophageal varices (Campbell et al., 1958). When secondary portal hypertension appears, differentiating ADPKD from ARPKD can be difficult. In ARPKD, portal hypertension is seen much more frequently and is always secondary to congenital hepatic fibrosis. However, congenital hepatic fibrosis, on very rare occasions, may accompany ADPKD as well, particularly when the diagnosis is made perinatally.

Intracranial aneurysms (ICAs)—predominantly aneurysms of the circle of Willis (berry aneurysm)—occur in 10% to 30% of patients, and approximately 9% of these patients die because of subarachnoid hemorrhages (Grantham, 1979; Hartnett and Bennett, 1976; Ryu, 1990; Sedman and Gabow, 1984; Wakabayashi et al., 1983). The most common symptom of subarachnoid hemorrhage is the sudden onset of a severe headache, frequently associated with nausea and vomiting. When this occurs, immediate medical evaluation is obviously imperative. Morbidity and mortality from these aneurysms are strongly influenced by positive family history and the *PKD1* genotype. Now, with MRI, even small berry aneurysms can be detected. These aneurysms, when diagnosed, average only 6.1 mm. Although small aneurysms (1 cm) have a lower risk of rupture, patients with small aneurysms have a greater risk of rupture when there is a positive family history of ruptured ICAs or the presence of ADPKD (Huston et al., 1993). Control of hypertension is critical to minimize the risk of aneurysm rupture. In some patients with ADPKD, hemorrhage follows the rupture of *intracerebral* arteries, which is the usual type of intracranial hemorrhage seen in patients with hypertension who do not have ADPKD.

Cysts may also occur in the seminal vesicles (40%), arachnoid membrane (8%), and pancreas (5%). Seminal vesicle cysts rarely cause infertility; however, many of these men may have problems with sperm motility. Arachnoid membrane and pancreatic cysts are typically asymptomatic. Other abnormalities associated with ADPKD are mitral valve prolapse and colonic diverticulosis (Hossack et al., 1986; Kupin et al., 1987; Scheff et al., 1980). Patients who have diverticulosis are more likely to have hepatic cysts and symptomatic berry aneurysms (Kupin et al., 1987).

Association With Renal Cell Carcinoma

The incidence of renal adenomas is almost as high in ADPKD as in ARCD associated with ESRD (i.e., one in four to five patients). However, whereas ESRD is associated with an increased incidence of RCC, especially when associated with ARCD (three to six times the incidence seen in the general population), **the incidence of RCC in patients with ADPKD is no higher than that in the general population.** However, there are certain findings considered typical of a predisposition to RCC that are seen more frequently in patients with ADPKD than in the general population. For example, RCC in ADPKD is often diagnosed at a younger age, is more often concurrently bilateral (12% vs. 1% to 5% in the general population), multicentric (28% vs. 6%), and sarcomatoid (33% vs. 1% to 5%) (Keith et al., 1994). The diagnosis of RCC in the context of ADPKD can be difficult, because tumor may be masked by the complex cystic appearance of the kidney. In addition, cystic hemorrhage, degenerating blood clots, proteinaceous debris, and infection can also complicate the diagnosis.

Histopathology

ADPKD kidneys typically maintain their reniform shape, and their size can range from minimally enlarged in early disease to massive enlargement in more advanced disease. Both kidneys are usually equally affected, and the cysts range from a few millimeters to a few centimeters in diameter and appear diffusely throughout the cortex and medulla with communications at various points along the nephron (Kissane, 1974). The cysts appear to begin as focal tubular outpouchings, and as they enlarge they usually become detached from their tubule of origin. The first pathological finding in fetuses is focal tubular dilation, which may occur anywhere along the nephron (Fig. 39.10; Choyke et al., 1995).

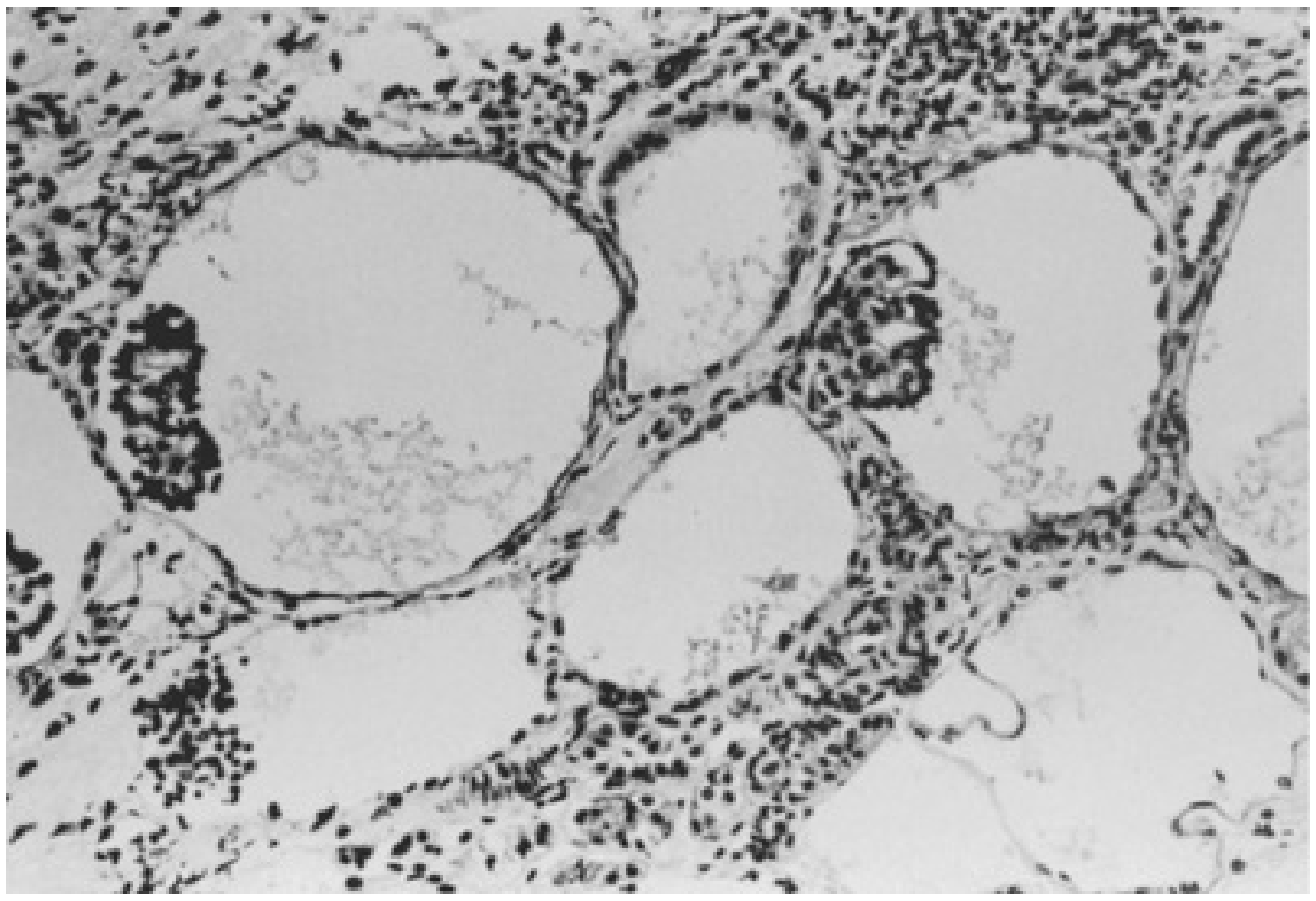

FIG. 39.10 Glomerular cysts with a pattern compatible with autosomal

dominant polycystic kidney disease in early childhood (190×). (From Bernstein J, Gardner KD Jr: Cystic disease and dysplasia of the kidneys. In Murphy WM, editor: *Urological pathology,* Philadelphia, 1989, Saunders, pp 483–524.)

Epithelial hyperplasia or even adenoma formation in the cyst wall is common, and the basement membrane of the wall is thickened. Arteriosclerosis is present in more than 70% of patients with preterminal or terminal renal failure, and interstitial fibrosis, with or without infiltrates, is common (Zeier et al., 1988). This fibrosis may be secondary to infection or to an inflammatory reaction set off by spontaneously rupturing cysts.

Up to 90% of adults with ADPKD have cysts of the liver (Bae et al., 2006). These cysts are lined by a single layer of epithelium resembling that of the biliary tract and contain fluid that resembles the bile salt–independent fraction of the bile.

Evaluation

To make the diagnosis, it is important to have at least three generations of the patient's family history. Questions should be asked about renal disease, hypertension, and strokes. Patients and families should be counseled before any imaging or other testing is undertaken. Genetic testing can be used when the imaging results are equivocal and when a definite diagnosis is required. Benefits of testing include making a diagnosis that may affect family planning, early detection and treatment of disease complications, and selection of genetically unaffected family members for living donor–related renal transplantation. Disadvantages to testing include discrimination in terms of insurability and employment associated with a positive diagnosis, as well as the psychological stress of impending organ failure.

Abdominal ultrasonography may reveal renal cysts (Fig. 39.11) as well as cysts in other organs. **Ultrasonographic diagnostic criteria for individuals at 50% risk for the disease include at least two unilateral or bilateral cysts in individuals younger than 30 years of age, two cysts in each kidney in individuals 30 to 59 years of age, and four cysts in each kidney in individuals 60 years of age or older** (Ravine et al., 1994). The sensitivity of these criteria is nearly 100% for individuals 30 years or older and for younger individuals with *PKD1* mutations but only 67% for individuals with *PKD2* mutations younger than 30 years (Nicolau et al., 1999). When there is no family history to support a diagnosis of ADPKD, a presumptive diagnosis can be made if bilateral renal cysts are present and two or more of the following symptoms are present as well: bilateral renal enlargement, three or more hepatic cysts, cerebral artery aneurysm, and a solitary cyst of the arachnoid, pineal gland, pancreas, or spleen (Grantham, 1993).

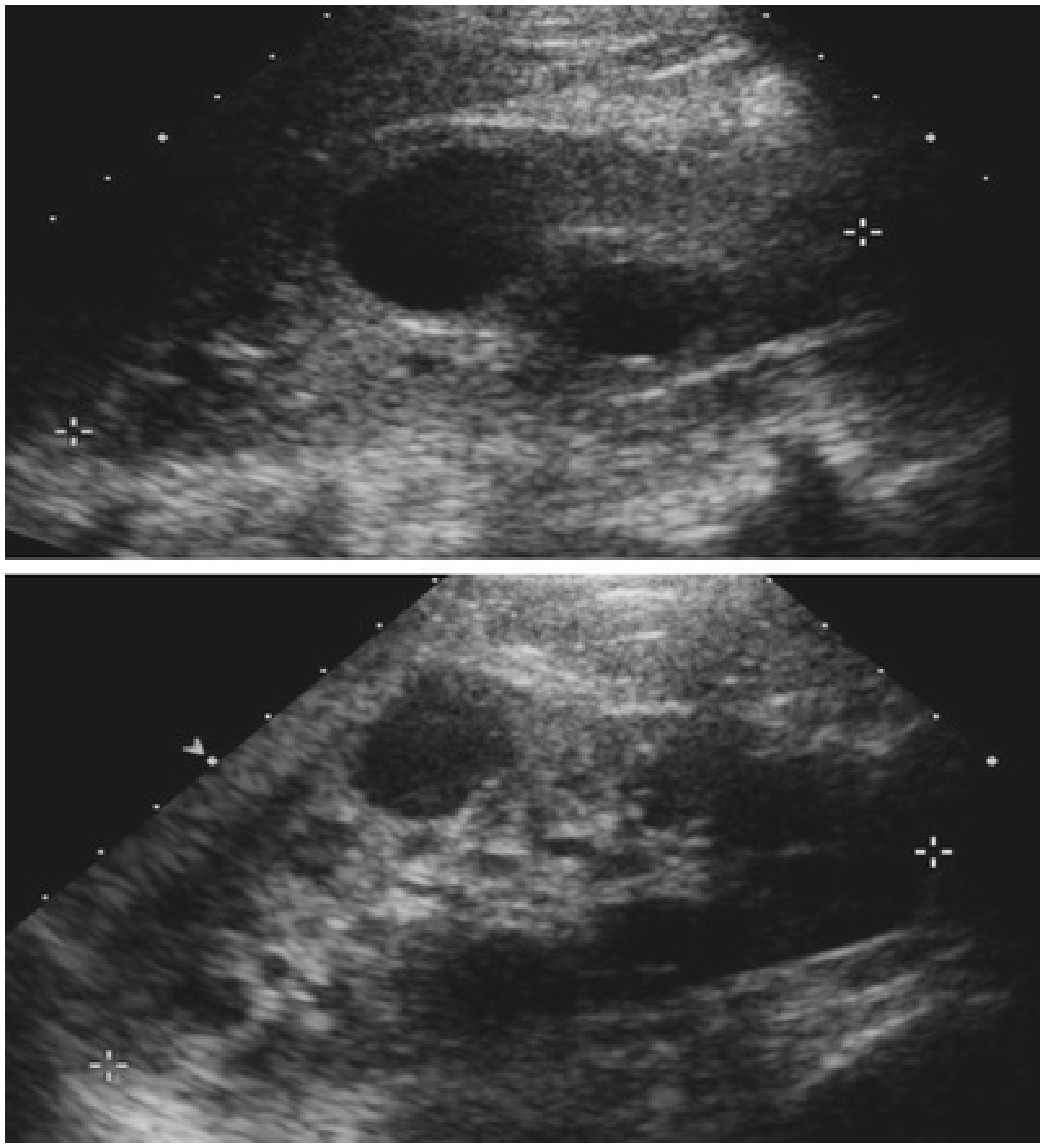

FIG. 39.11 Renal ultrasonogram of 20-year-old patient newly diagnosed with autosomal dominant polycystic kidney disease. Note the presence of multiple cysts in both kidneys. (Courtesy Marta Hernanz-Schulman, MD.)

CT or MRI (or both) may be helpful in some cases and often are superior to ultrasonography for detecting cysts in organs other than the kidney (Fig. 39.12A). CT is helpful in making the diagnosis of hemorrhage within a cyst. More acute hemorrhage has a higher density (50 to 90 Hounsfield units [HU]) than old hemorrhage (Choyke et al., 1995). MRI also may be helpful, particularly in patients with compromised renal function, because no contrast agent is needed (Fig. 39.12B).

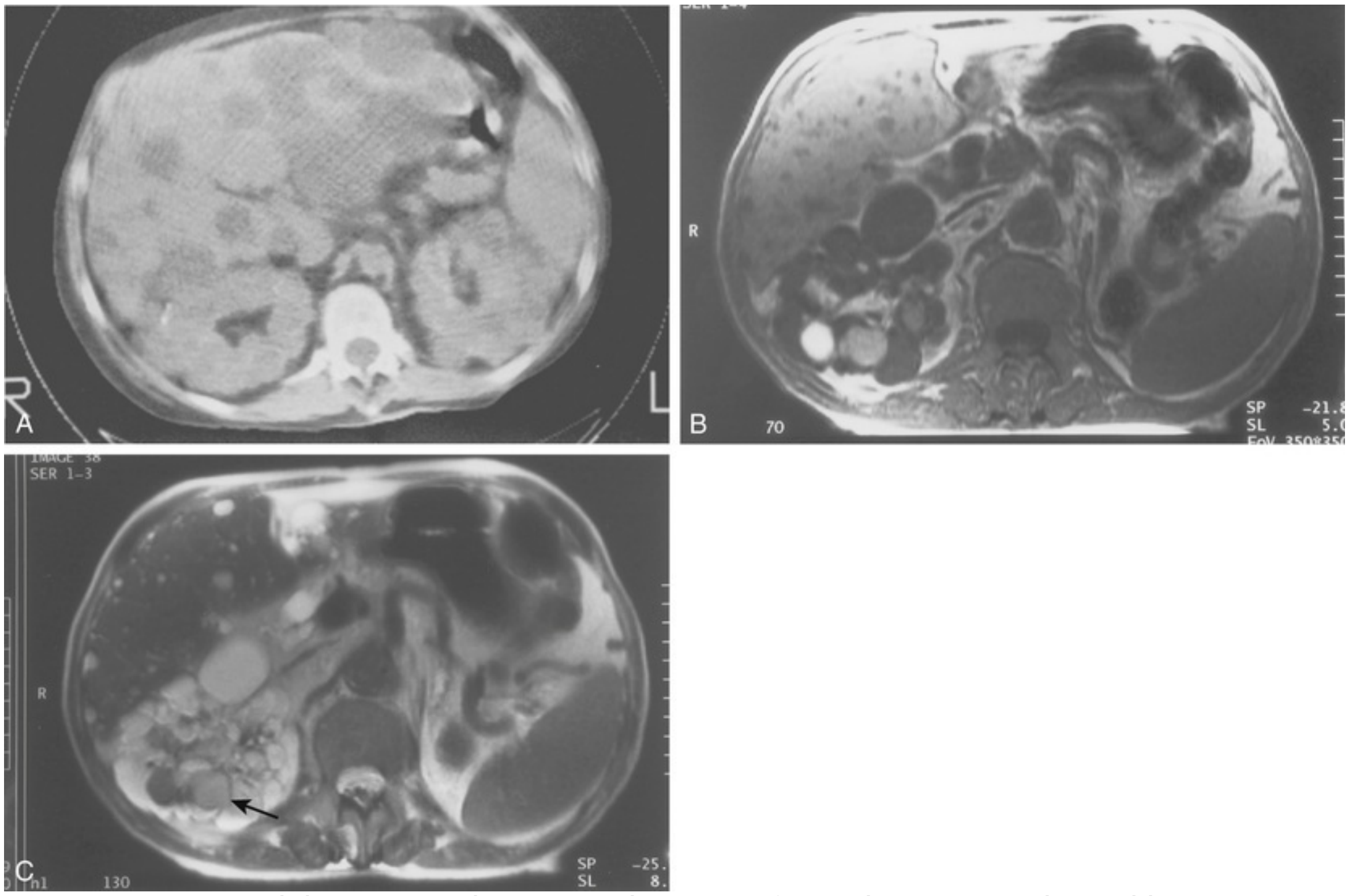

FIG. 39.12 (A) Computed tomography scan of an adult male patient with autosomal dominant polycystic kidney disease (ADPKD). Bilateral renal cysts are seen in enlarged kidneys with calcification. Large asymptomatic cysts are seen throughout the liver as well. (B and C) A 55-year-old woman with ADPKD. Patient has had a left nephrectomy for pain. Right renal and hepatic cysts are seen on both T1- and T2-weighted coronal images. (B) T1-weighted image demonstrates renal cysts with low and high (white) signals. High-signal cysts correlate with intracystic hemorrhage. (C) On T2 weighting, hemorrhagic cysts are dark, and cysts without hemorrhage are white. On T2 weighting with the patient in the supine position, cysts with blood tend to get darker more posteriorly *(arrow).* (Courtesy H. Zinn, MD.)

When ADPKD manifests in utero or in infancy, 50% of affected kidneys are large with identifiable macrocysts (Pretorius et al., 1987). However, the kidneys may appear identical to those seen in ARPKD, having no apparent macrocysts and showing only enlargement and homogeneous hyperechoic features. In such situations, clinicians must look for a parent with ADPKD.

Treatment and Prognosis

Current therapy is directed toward lessening the complications of ADPKD and delaying the onset of ESRD. There is no known cure at this time. More than 60% of patients with ADPKD who do not yet have renal impairment

have hypertension (Gabow et al., 1984), which can worsen renal function, cause cardiac disease, and predispose the patient to intracranial hemorrhage. **The complications of ADPKD can be reduced significantly by controlling hypertension.** There is no proven antihypertensive agent of choice; however, ACE inhibitors or angiotensin receptor antagonists would seem to be logical first-line choices. Not only does the hypertension associated with ADPKD appear to be renin mediated, but these drugs increase renal blood flow, have minimal side effects, and may have renoprotective properties beyond BP control. The optimum BP target is not clear. Ongoing studies will determine whether a low BP target is more protective of renal function than a standard BP target (<130/80 mm Hg) and whether combination drug therapy is more advantageous than single-drug therapy.

Chronic pain must be evaluated and entities such as infection, stone, and tumor treated accordingly. The use of chronic nephrotoxic analgesics (nonsteroidal anti-inflammatory drugs [NSAIDs]) must be avoided. The use of narcotic analgesics should be limited to acute pain episodes, because patient dependence on narcotics is a significant risk in this patient population. When conservative measures fail, surgical management must be considered. Ultrasonography- or CT-guided cyst aspiration is a straightforward procedure and may be diagnostic and therapeutic. Surgical unroofing of multiple or very large cysts can potentially alleviate symptoms of pain and can be performed either laparoscopically or through open flank or dorsal lumbotomy incisions (Elzinga et al., 1992; Lee and Clayman, 2004; Lee and Lee, 2003). The effect of laparoscopic unroofing in those patients with hypertension was variable. Surgical intervention appears only to improve symptoms and does not appear to either accelerate the decline of renal function or preserve declining renal function. Nephrectomy is indicated for symptomatic patients with ESRD.

Upper urinary tract infections are common in patients with ADPKD, especially women, and must be treated appropriately. If a patient with suspected pyelonephritis does not respond to an appropriate antibiotic, clinicians must consider whether the infection may be present in a noncommunicating cyst (Gabow, 1993). Actual cyst infections can be challenging to treat because of poor cyst penetration of many antibiotics. Lipophilic antibiotics, such as trimethoprim-sulfamethoxazole, chloramphenicol, and fluoroquinolones, are the best choices (Bennett et al., 1990; Schwab et al., 1987). If appropriate antibiotic therapy fails, percutaneous or surgical drainage of infected cysts may be required. Complicating factors, such as urinary tract obstruction, renal or perinephric abscess, or urolithiasis, must be excluded.

Screening for asymptomatic berry aneurysms is not currently recommended unless the patient has a family history of aneurysm or subarachnoid hemorrhage, previous aneurysm rupture, need for screening in preparation for major elective surgery, high-risk occupation (e.g., airline pilot), or a high anxiety level over the possibility of ICA (Pirson et al., 2002). CT and magnetic resonance angiography are the imaging studies of choice, although the former requires intravenous contrast. Aneurysm rupture occurs most often in people with larger aneurysms and/or poorly controlled high BP. Screening of low-risk patients is not recommended because aneurysms are rare in this group, and most aneurysms that are found have a low risk of rupture. Conservative management is usually recommended for ADPKD patients with small (<7 mm) aneurysms detected by presymptomatic screening. Aneurysms that are larger than 7 to 10 mm have a higher risk of rupture (up to 2% per year for larger aneurysms). Cerebral aneurysms of this size and those that cause symptoms may be corrected with open surgical clipping or with endovascular procedures, placing a coil within the aneurysm. Smaller aneurysms that do not cause symptoms are much less likely to rupture and are not routinely corrected, except in patients with a history of a bleeding aneurysm.

Emerging Therapeutics

Changing the natural course of the disease by altering the course of cyst growth has received the most attention in recent years. The HALT PKD study is the largest treatment study ever performed on patients with PKD, and the National Institutes of Health (NIH) extended the study because of the valuable information being obtained. This study examined the role of BP control versus the impact of specific medications on the course of the disease and assessed whether combination ACE inhibitor (lisinopril) and angiotensin receptor blocker (ARB; telmisartan) therapy is more effective in slowing cyst progression than ACE inhibition alone. The study was completed in June 2014, and in a recent report by Schrier et al. (2014) showed that in early ADPKD, the combination of lisinopril and telmisartan did not significantly alter the rate of increase in total kidney volume. As compared with standard blood-pressure control (120–130/70–80), rigorous blood-pressure control (95–110/60–75) was associated with a slower increase in total kidney volume, no overall change in the estimated GFR, a greater decline in the left-ventricular-mass index, and greater reduction in urinary albumin excretion (Schrier et al., 2014). From this study, the investigators also hope to learn how to predict when renal insufficiency will occur in individual patients (Steinman, 2011).

Approaches have also been undertaken to reduce the levels of cAMP in the kidneys of ADPKD patients. A recent phase III trial showed that compared with placebo, tolvaptan, a selective vasopressin V_2-receptor antagonist, slowed the increase in total kidney volume and the decline in renal function over a 3-year period in these patients. It was, however, associated with a relatively high discontinuation rate as a result of adverse events, such as increased aquaresis (thirst, polyuria, nocturia, and polydipsia as a result of the excretion of electrolyte-free water) and liver function abnormalities. Serious adverse events associated with chest pain and headache were also slightly more frequent in the tolvaptan group.

Somatostatin, known to inhibit vasopressin-induced cAMP, has also been tested in humans and has shown substantial retardation of the increase in kidney volume (Chapman, 2007). Two studies have evaluated the efficacy of blocking mTOR with rapamycin and have shown a significant reduction in kidney cyst burden (Tao et al., 2005; Wahl et al., 2006). Other drugs shown to be effective in preclinical trials and of potential value for the treatment of human PKD include ErbB1 (epidermal growth factor receptor) and ErbB2 tyrosine kinase inhibitors, Src kinase inhibitors, MEK inhibitors, and cyclin-dependent kinase inhibitors. These drugs, which have been developed for the treatment of neoplastic diseases, may also be considered for the treatment of PKD (Brenner, 2008; Bukanov et al., 2006; Omori et al., 2006; Sweeney et al., 2000; Wilson et al., 2006).

Key Points: Autosomal Dominant Polycystic Kidney Disease

- ADPKD is the most common inheritable form of renal cystic disease.
- ADPKD most often becomes clinically apparent after age 30 years but may manifest at any age, including in utero.
- Ninety-nine percent of affected individuals have a mutation either of the *PKD1* gene on chromosome 16 or, less often, of the *PKD2* gene on chromosome 4.

- The protein products of *PKD1* and *PKD2* are PC1 and PC2, and they inhibit cell proliferation through several pathways.
- Cysts can be identified sonographically before age 20 years in almost all affected individuals.
- ADPKD is associated with a high incidence of liver cysts that increases with age.
- Signs or symptoms first occur between the ages of 30 and 50 years and include hematuria, flank pain, gastrointestinal symptoms, renal colic, and hypertension.
- Hepatic cysts occur in virtually all patients with ADPKD by the age of 50 years and are rarely symptomatic.
- ICAs of the circle of Willis (berry aneurysm) occur in 10% to 30% of patients, and approximately 9% of these patients die because of subarachnoid hemorrhages.
- The incidence of RCC in ADPKD patients is no higher than that of the general population.
- Tight BP control, the use of ACE inhibitors and/or ARB BP medication, and the possible use of tolvaptan are the most current treatment options.

Juvenile Nephronophthisis and Medullary Cystic Disease Complex

Juvenile NPH (first described by Fanconi et al. in 1951) and medullary cystic kidney disease (MCKD) (first reported by Smith and Graham in 1945) describe a group of genetic (inheritable) disorders with similar and unique characteristics. Similarities include the gross and histopathological appearance of the kidneys, with the hallmark being interstitial fibrosis. Distinguishing features are the mode of inheritance, the age of onset of ESRD, and the type of extrarenal organ involvement. Juvenile NPH is the more common condition and is responsible for 10% to 20% of cases of renal failure occurring in children and occurs in 1% to 5% of patients undergoing dialysis or transplantation (Cantani et al., 1986) (see Table 39.1).

Genetics

Although either condition can occur sporadically, **juvenile NPH usually is inherited as an autosomal recessive trait.** It is genetically heterogeneous, and 13 responsible genes have been identified for various forms of NPH (Hildebrandt et al., 1997; Loftus, 2013; Mollet et al., 2005; Olbrich et al., 2003; Otto et al., 2003, 2005; Saunier et al., 1997; Sayer et al., 2006). The *NPHP1* gene encodes nephrocystin; *NPHP2/INVS*, inversin; *NPHP3*, nephrocystin-3; *NPHP4*, nephrocystin-4/nephroretinin; *NPHP5/IQCB1*, nephrocystin-5; and *NPHP6/CEP290*, nephrocystin-6. *NPHP1* mutations are found in approximately one-half of the patients with NPH. The majority of patients are homozygous for an *NPHP1* deletion (Konrad et al., 1996). *NPHP1, NPHP4, NPHP5*, and *NPHP6* mutations may be associated with the Senior-Loken syndrome (a combination of NPH and retinitis pigmentosa).

MCKD usually is inherited in an autosomal dominant fashion (50% of all offspring will have the disease) and is caused by mutations in either the *MCKD1* or *MCKD2* gene. The *UMOD* gene encodes for uromodulin, the most abundant protein found in normal human urine. Mutations in this gene can also lead to MCKD type 2 (Loftus, 2013). Because patients with either condition theoretically can be fertile in their early childbearing years, the risk of transmitting the condition to offspring must be acknowledged: 1% for juvenile

NPH and 50% for MCKD (Neumann et al., 1997).

Clinical Features

Juvenile NPH and MCKD cause polydipsia and polyuria in more than 80% of patients, but not to the extent observed in patients with diabetes insipidus (Cantani et al., 1986; Gardner and Evan, 1984). The polyuria is caused by a renal tubular urinary concentrating defect that leads to salt wasting, and this process is resistant to vasopressin. Subsequently, a large dietary salt intake frequently is necessary. One major difference in the two entities is the presence of hypertension. There is no hypertension associated with juvenile NPH, whereas patients with MCKD can have significant hypertension.

Renal failure usually ensues 5 to 10 years after initial presentation (Cantani et al., 1986). Another important difference between the two entities is that **renal failure develops in patients with NPH at a mean age of 13 years and almost always before 25 years** (Neumann et al., 1997). MCKD is a milder disease when it manifests in early adulthood, but it will manifest in all patients by 50 years of age (Bernstein and Gardner, 1979). **ESRD in patients with MCKD most often develops in the third or fourth decade.** MCKD type 1 manifests as slowly progressive chronic renal disease. There is minimal proteinuria and hematuria, and hypertension and hyperuricemia become more common as the renal disease progresses. Hyperuricemia is characteristic of MCKD2, and gout is a common presentation in teenage males. Proteinuria is minimal (Bleyer, 2003; Loftus, 2013).

Twenty percent of juvenile NPH families have extrarenal manifestations, whereas MCKD usually affects only the kidneys (Neumann et al., 1997). Sixteen percent of patients with juvenile NPH have associated **retinitis pigmentosa** (Hildebrandt et al., 1993). When the two entities coexist, the condition is referred to as *renal-retinal* or *Senior-Loken syndrome*. More rarely, other conditions can also be present, such as skeletal abnormalities; hepatic fibrosis; Bardet-Biedl syndrome (combination of obesity, mental retardation, polydactyly, retinitis pigmentosa, and hypogenitalism); ocular motor apraxia (Cogan syndrome); and other neurologic defects varying from subtle cerebellar involvement to clear Joubert syndrome (JS) phenotypes, peripheral dysostosis (cone-shaped epiphyses), or truncal cerebellar ataxia (Hildebrandt and Orman, 2001).

Pathologically, NPH and MCKD are similar. Grossly, the kidneys are small to normal in size with multiple cysts at the corticomedullary junction. Histologically, there is a characteristic triad present that includes (1) irregular thickening and disintegration of the tubular basement membrane, (2) marked tubular atrophy with cyst development, and (3) interstitial cell infiltration with fibrosis.

Evaluation

Diagnosis of NPH and MCKD can be difficult early in the onset because of the relative vagueness and nonspecificity of symptoms; thus a high index of suspicion is required. Ultrasonography frequently fails to detect cysts because they are small (Ala-Mello et al., 1998; Chang and Udupa, 1989). Ultrasonography may show smaller-than-normal kidneys in juvenile NPH. Cysts may be seen on imaging studies if they are large enough (Rosenfeld et al., 1977), but, early in the disease, cysts are rarely visible. The parenchyma may also appear hyperechogenic secondary to tubulointerstitial fibrosis (Fig. 39.13; Resnick and Hartman, 1990). Contrast-enhanced CT and MRI scans are more sensitive for detecting small corticomedullary and medullary cysts, but failure to detect cysts does not exclude the diagnosis.

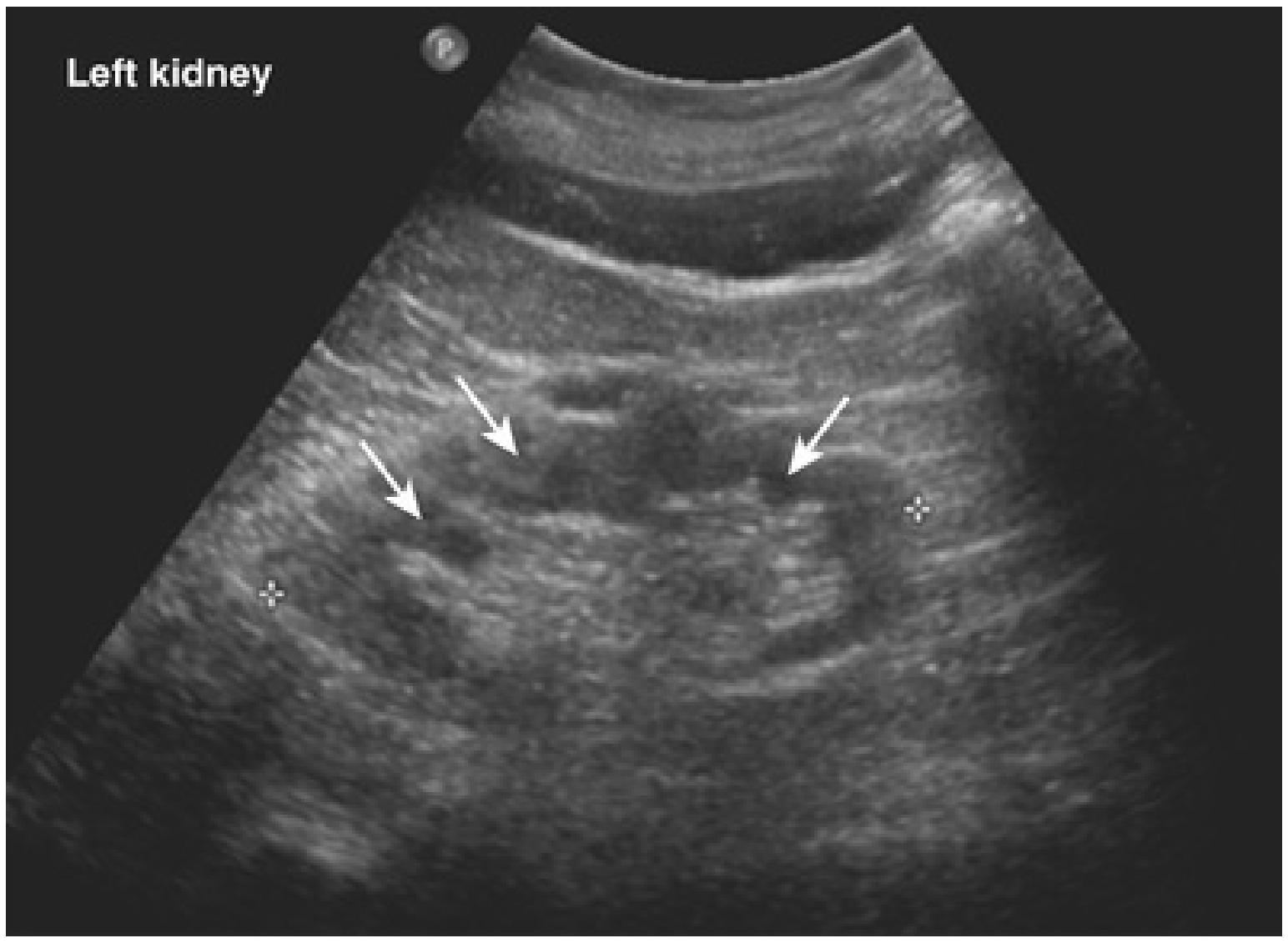

FIG. 39.13 Features of medullary cystic kidney disease. Ultrasonogram demonstrating corticomedullary cysts, some of which are indicated by *arrows.* The hyperechogenicity is secondary to the tubulointerstitial fibrosis. (From Simms RJ, Eley L, Sayer JA: Nephronophthisis. *Eur J Hum Gen* 17:406–416, 2009.)

Treatment

The treatment of NPH is supportive. Because of the tendency for sodium wasting, volume contraction, and renal azotemia, sodium replacement is indicated early in the course of the disease, and unnecessary sodium restriction or use of diuretics should be avoided. Later, dialysis and transplantation must be considered. Allografts apparently are not susceptible to the same process that destroyed the native kidney, because there is no evidence of serum antibodies to the basement membrane or other renal structural proteins (Cantani et al., 1986; Cohen and Hoyer, 1986). If kidneys from siblings are considered for transplant surgery, precautions should be taken to obtain them only from unaffected, older relatives, who should be subjected to meticulous diagnostic evaluation.

Key Points: Juvenile Nephronophthisis and Medullary Cystic Disease Complex

- Juvenile NPH, an autosomal recessive disease, is responsible for 10% to 20% of cases of renal failure in children and leads to early ESRD (early teens).
- MCKD, an autosomal dominant disease, manifests in early adulthood.
- Polyuria, polydipsia, and hypertension are clinical hallmarks of these disease entities.
- Both juvenile NPH and MCKD have almost identical histology, with severe interstitial nephritis; many patients demonstrate cysts at the corticomedullary junction.

Other Inheritable Renal Cystic Diseases (Congenital Nephrosis)

Congenital nephrosis is predominantly of two types. The more common variety is referred to as *congenital nephrotic syndrome of the Finnish type* (CNF) (Lanning et al., 1989; Norio, 1966) and is recessive. The second type is referred to as *diffuse mesangial sclerosis* (DMS), and one-third are familial (Habib and Bois, 1973; Habib et al., 1989). These conditions are associated with dilation of the proximal convoluted tubules, and the patients have profound proteinuria. In infants with CNF, proteinuria is present in the first urinalysis. Without dialysis, half of the patients die by the age of 6 months, and the rest die before their fourth birthday (Huttunen, 1976). In DMS, the onset of symptoms is variable, and the diagnosis is usually made by the age of 1 year. All children have terminal renal failure by the age of 3 years. Approximately one-third of DMS cases are associated with Drash syndrome (nephrotic syndrome and Wilms tumor with or without male pseudohermaphroditism) (Habib et al., 1989). Interstitial fibrosis is present in both conditions but is more pronounced in DMS (Norio and Rapola, 1989). After the kidneys have failed, transplantation is curative. Neither type of disease responds to corticosteroids.

Familial Hypoplastic Glomerulocystic Kidney Disease (Cortical Microcystic Disease)

Cortical microcystic disease is an autosomal dominant disorder described in several families and has been called *hypoplastic glomerulocystic disease* (Rizzoni et al., 1982) and cortical microcystic disease (Kaplan et al., 1989a; Melnick et al., 1984). The diagnosis of familial hypoplastic glomerulocystic disease requires four features: (1) stable or progressive chronic renal failure, (2) small or normal-sized kidneys with irregular calyceal outlines and abnormal papillae, (3) presence of the condition in two generations of a family, and (4) histologic evidence of glomerular cysts.

Multiple Malformation Syndromes With Renal Cysts

Renal cysts are a feature of several syndromes characterized by multiple malformations (see Table 39.1). Tuberous sclerosis and VHL disease are autosomal dominant disorders and are the ones most likely to be encountered by urologists. Meckel syndrome, Jeune asphyxiating thoracic dystrophy, and Zellweger cerebrohepatorenal syndrome are some of the autosomal recessive syndromes. Many of these conditions involve glomerular cysts, and some have cystic dysplasia as a feature.

Tuberous Sclerosis Complex

Bourneville described tuberous sclerosis in 1880. It is usually an autosomal dominant neurocutaneous disorder with an incidence of up to 1 in 6000 individuals (O'Hagan et al., 1996; Webb et al., 1991). It is characterized by benign growths called *hamartomas,* which can develop in nearly every organ of the human body.

Classically, tuberous sclerosis has been described as the triad of Bourneville phakomatosis (epilepsy) (80% of patients), mental retardation (60% of patients), and adenoma sebaceum (facial angiofibromata) (75% of patients) (Lagos and Gomez, 1967; Pampigliana and Moynahan, 1976). It is also associated with autism and other neurocognitive and behavioral disabilities (Kohrman, 2012). Adenoma sebaceum consists of firm, discrete, red or brown telangiectatic papules located in the nasolabial folds, chin, and cheeks. They usually appear after the age of 2 years, gradually become more prominent with time, and persist throughout life. An earlier skin lesion that is a white papule in the shape of an ash leaf is sometimes identified (Shepherd et al., 1991). An examination of the skin with ultraviolet light may reveal cutaneous lesions earlier and should be part of a diagnostic evaluation.

Definitive diagnosis, however, is no longer dependent on this triad but rather on the presence of certain major and minor clinical features (Roach et al., 1998). The diagnosis of tuberous sclerosis complex (TSC) requires two major features (major features include renal angiomyolipoma [AML], facial angiofibromas or forehead plaques, nontraumatic ungual or periungual fibroma, three or more hypomelanotic macules, shagreen patch, multiple retinal nodular hamartomas, cortical tuber, subependymal nodule, subependymal giant cell astrocytoma, cardiac rhabdomyoma, lymphangioleiomyomatosis) or one major plus two minor features (minor features include multiple renal cysts, nonrenal hamartoma, hamartomatous rectal polyps, retinal achromic patch, cerebral white matter radial migration tracts, bone cysts, gingival fibromas, "confetti" skin lesions, multiple enamel pits).

The kidneys of these patients may be free of lesions (Stillwell et al., 1987) or may display cysts, AMLs, or both (Figs. 39.14 and 39.15).

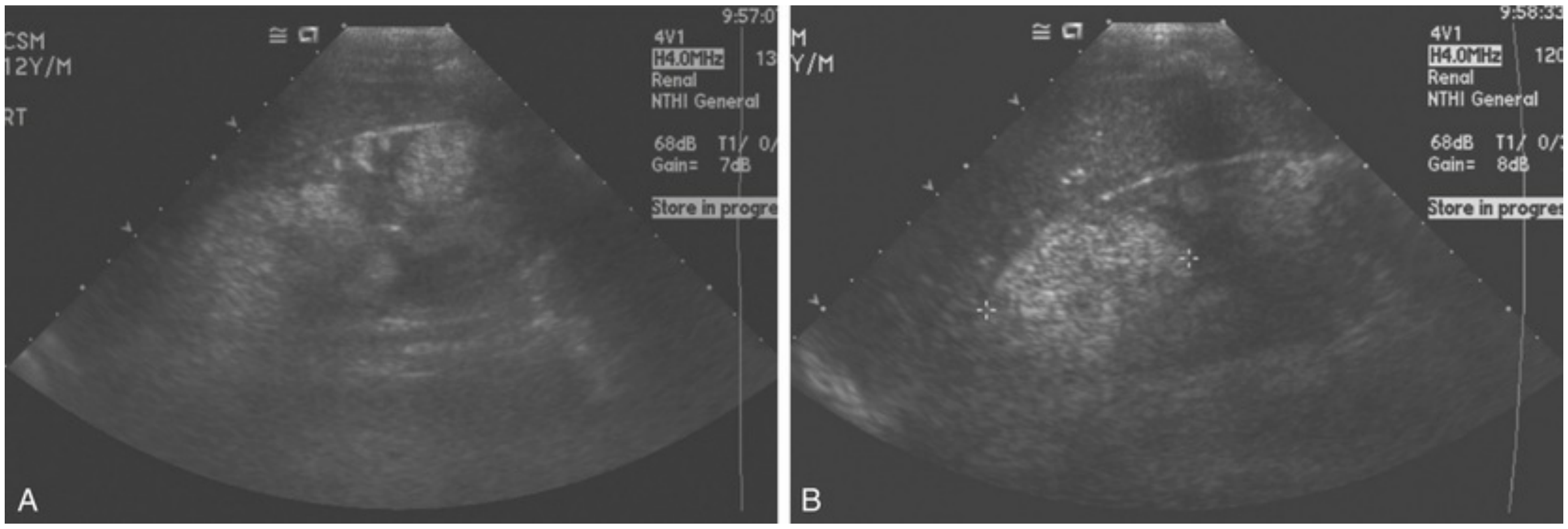
CSM
12Y/M
RT
9:57:0
4V1
H4.0MHz
13
Renal
NTHI General
68dB T1/ 0/
Gain= 7dB
Store in progre
A
M
Y/M
9:58:33
4V1
H4.0MHz
120
Renal
NTHI General
68dB T1/ 0/
Gain= 8dB
Store in progres
B

FIG. 39.14 (A and B) Renal ultrasonogram of 13-year-old patient with tuberous sclerosis. Multiple hyperechoic lesions of varying size are visible, consistent with angiomyolipomas. (Courtesy Marta Hernanz-Schulman, MD.)

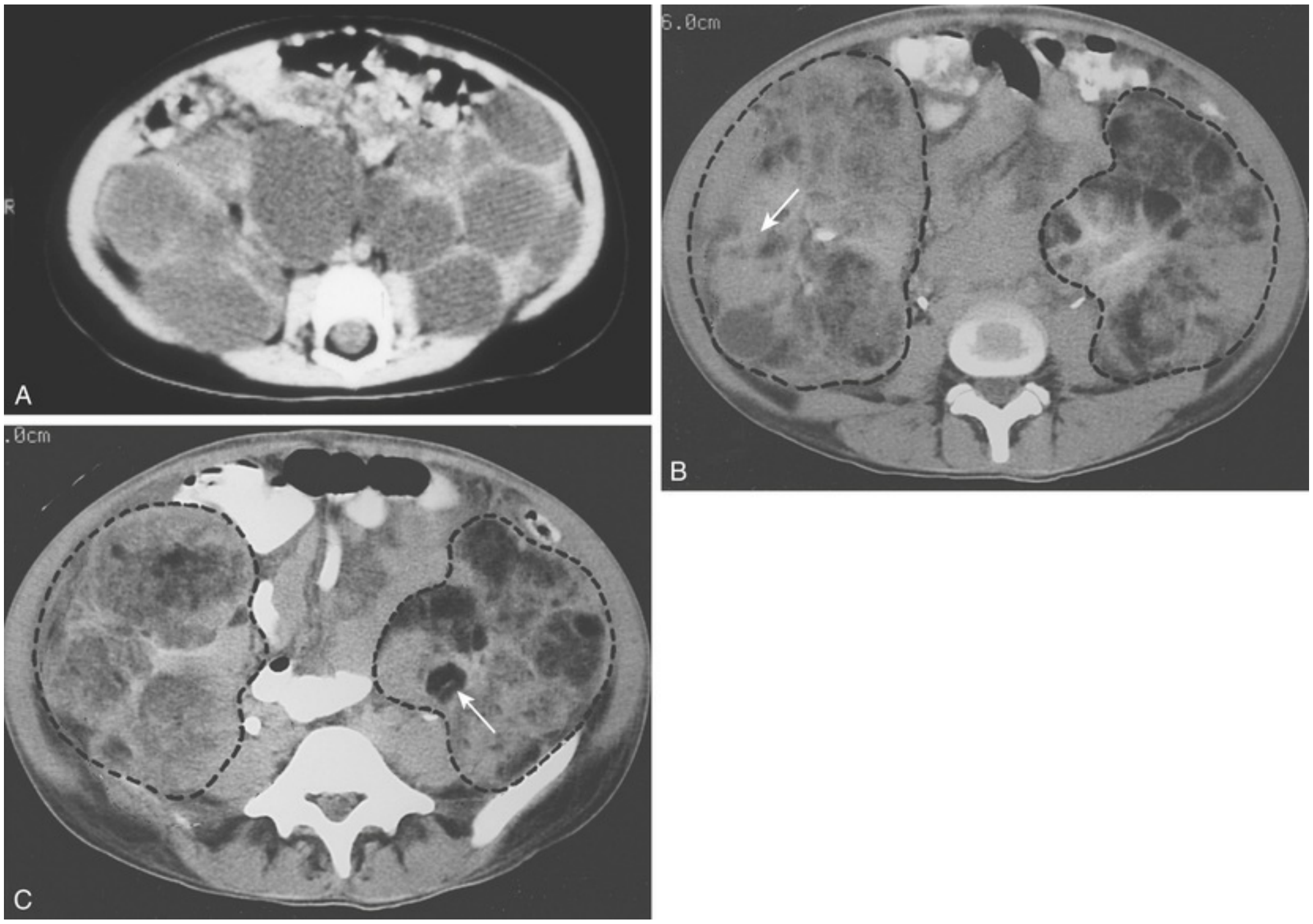

FIG. 39.15 (A) Computed tomography (CT) scan of 4-month-old with tuberous sclerosis complex and diffuse renal cysts. (B and C) A 24-year-old woman was known to have had tuberous sclerosis since early childhood. Enhanced CT scans demonstrate bilateral renomegaly with multiple renal cysts and angiomyolipomas. (B) *Arrow* points to a cyst with a CT value of +10 HU. (C) *Arrow* points to an angiomyolipoma with a negative CT value (−50 HU) secondary to its high fat content. (A, Courtesy Walter Berdon, MD.)

Genetics

Although it is transmitted as an autosomal dominant trait in 25% to 40% of patients, in the remainder, tuberous sclerosis occurs either sporadically or as an example of the genetic condition with variable or incomplete penetrance. Because it is a heterogeneous genetic disorder with variable manifestations, it usually is referred to as TSC. It is caused by mutations in one of two genes. ***TSC1* is located on chromosome 9 (9q34) and encodes the protein hamartin, and *TSC2* is on chromosome 16 (16p13) and encodes the protein tuberin** (Dabora et al., 2001; Jones et al., 1999; Sancak et al., 2005). Both of these genes are characterized as tumor suppressor genes, and the loss of function of either gene leads to hamartoma formation. Hamartin and tuberin function as a complex to inhibit the mTOR pathway. This pathway modulates cell signaling pathways that are important in the regulation of cell growth and migration, as well as cell number and organ size. Therefore a mutation of either gene will lead to similar clinical manifestations (Fig. 39.16).

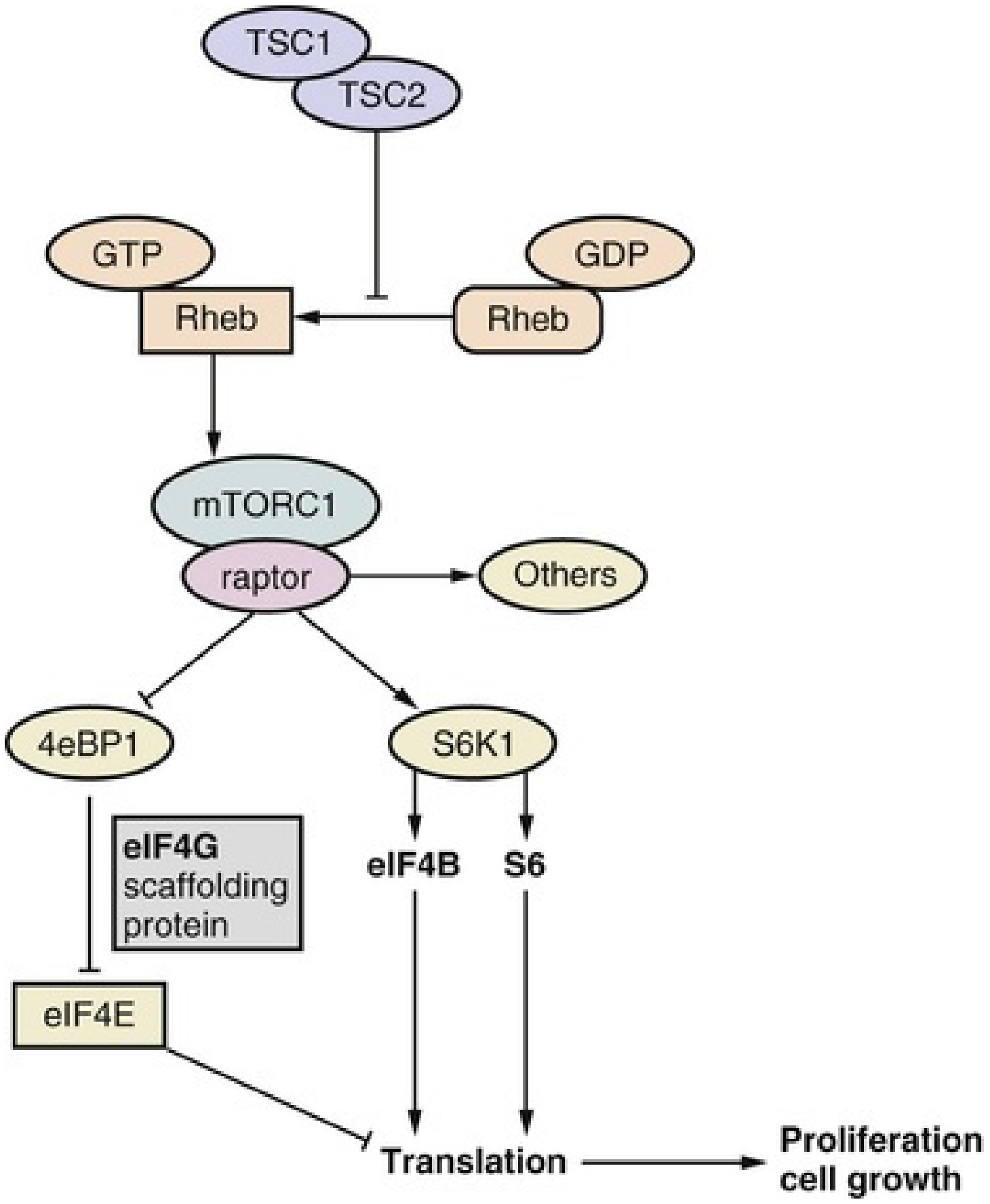
TSC1
TSC2
GTP
GDP
Rheb
Rheb
mTORC1
raptor
Others
4eBP1
S6K1
eIF4G scaffolding protein
eIF4B
S6
eIF4E
Translation
Proliferation cell growth

FIG. 39.16 Features of signaling through the mammalian target of rapamycin complex 1 pathway *(mTORC1)* via the tuberous sclerosis 1/tuberous sclerosis 2 complex. *4eBP1,* Eukaryotic translation initiation factor 4E binding protein 1; *eIF4B,* eukaryotic translation initiation factor 4B; *eIF4E,* eukaryotic translation initiation factor 4E; *eIF4G,* eukaryotic translation initiation factor 4G; *GDP,* guanosine diphosphate; *GTP,* guanosine triphosphate; *Rheb,* Ras homolog enriched in the brain; *S6,* ribosomal protein S6; *S6K1,* ribosomal protein S6 kinase 1; *TSC1,* tuberous sclerosis complex 1 protein; *TSC2,* tuberous sclerosis complex 2 protein.

Clinical Features

Renal involvement in TSC is second only to central nervous system abnormalities and includes predominately AML, renal cysts, and RCCs. AMLs are extremely common in TSC and are usually bilateral and multiple and affect both genders, whereas in the general population they are uncommon, are usually single, and are found mainly in middle-aged women. **Renal AMLs occur in 40% to 80% of patients with TSC** (Chonko et al., 1974; Gomez, 1979). They are rarely identified before the age of 6 years but are common after age 10 years (Bernstein and Gardner, 1986). The primary risk of these lesions relates to their potential for hemorrhage or mass effect. Abdominal or flank mass and tenderness, hypertension, and renal insufficiency can also occur as a result of these lesions. By themselves, these lesions probably do not cause renal failure (Bernstein and Gardner, 1986; Okada et al., 1982). Also, belying their aggressive histologic appearance, which is characterized by pleomorphism and mitoses, no evidence of metastases has been presented.

Unlike AMLs, renal cysts may be present in the first year of life, and cystic disease may be the presenting manifestation of TSC. **Renal cysts develop in approximately 20% of patients and most often manifest before 3 years of age; one-third of children are younger than 1 year of age at presentation.** Patients with large cysts or PKD may be identified by in utero ultrasonography or may demonstrate an abdominal mass and distended abdomen in the first year of life. Most patients with renal cysts do not develop any serious renal compromise, but when the disease is more widespread within the kidney and large cysts are present, renal failure may develop in the milder form with PKD. If any renal failure develops, it is uncommon before the fourth decade (Glazier et al., 1996).

TSC2 and *PKD1* lie adjacent to each other in a tail-to-tail orientation on chromosome 16 at 16p13.3. Deletions inactivating both genes are associated with PCKs diagnosed during the first year of life or early childhood (*TSC2*/*PKD1* contiguous gene syndrome) (Brook-Carter et al., 1994; Sampson et al., 1997). **Therefore TSC should be considered in children with renal cysts and no family history of PKD.** Rarely, *TSC2/PKD1* contiguous gene syndrome can be diagnosed in adults (Martignoni et al., 2002). Patients with the contiguous gene syndrome usually reach ESRD at an earlier age than patients with ADPKD alone. Patients with *TSC1* or *TSC2* mutations without the contiguous gene syndrome also have an increased frequency of renal cysts. The combination of cystic kidneys and AMLs has been said to be virtually pathognomonic for tuberous sclerosis.

Association With Renal Cell Carcinoma

The numerous reports of RCC in patients with tuberous sclerosis make it clear that this association is more than coincidental and may be as frequent as 2% (Bernstein, 1993; Bernstein and Gardner, 1986). However, the incidence of RCC is considerably less than that seen in VHL disease and ARCD of chronic renal failure. Compared with sporadic RCCs, there is a female predominance, earlier age of presentation, and increased bilaterality. Early detection is essential. RCC should be suspected in cases of enlarging lesions without demonstrable fat and in the presence of calcifications within the lesions.

Radiographic Evaluation

Sometimes renal cysts and AMLs can be identified by ultrasonography in tuberous sclerosis, the former lesions being sonolucent and the latter having a fluffy, white appearance. When renal cysts are present without AMLs, the ultrasonographic appearance of the kidneys in tuberous sclerosis is very similar to that in ADPKD. Therefore it is not that unusual for a patient with cysts identified as typical of ADPKD to be diagnosed as having ADPKD, only to develop the stigmata of tuberous sclerosis a few years later. To help make the diagnosis, abdominal CT can be useful in demonstrating AMLs that may be present in the kidney or other organs (findings that are compatible with tuberous sclerosis) and in revealing cysts in other organs (compatible with ADPKD) (see Fig. 39.15). MRI or CT of the head may demonstrate the classic cranial calcifications associated with tubers or gliosis (Okada et al., 1982).

In recent years, it has become increasingly evident that there is a subcategory of AMLs that are “fat poor” and are more difficult to diagnose than the classic AML, which has a characteristic appearance on CT and US. These lesions are benign and do not require extirpative surgery. It is thus important to distinguish these benign lesions from their malignant counterparts. Fat-poor AMLs are subcategorized as follows: (1) hyperattenuating subtype, (2) isoattenuating subtype, and (3) angiomyolipoma with epithelial cyst subtype. The radiologic diagnosis of renal AML is as important as ever. The failure to diagnose the classic and fat-poor types will contribute to unnecessary surgery. Fat-poor AMLs demonstrate specific perfusion features on specialty CT scans allowing their differentiation. It is important to keep this in mind when evaluating unusual renal masses (Chen et al., 2018; Jinzaki et al., 2017; Park, 2017).

Treatment

Because more patients with TCS now survive their central nervous system lesions than in the past, the urologist is more likely to be asked to manage the renal problems (Stillwell et al., 1987). Shepherd et al. (1991) found that renal disease was the leading cause of death in these patients (11 of 40 deaths). Of these 11 patients, 2 died of metastatic RCC, 2 of massive hemorrhage associated with renal AMLs, and 6 of renal failure secondary to the cysts, AMLs, or both.

AMLs are benign lesions that usually are asymptomatic and do not require treatment. Large AMLs are more likely to bleed. van Baal et al. (1994) recommended careful monitoring of the size of AMLs and prophylactic embolization or surgical excision if they enlarge to greater than 4 cm. Annual surveillance with RUS or CT is necessary to assess for growth of the lesions and to detect the development of other complications. Renal-sparing surgery is indicated for symptoms such as pain and hemorrhage, growth of the lesions to the point at which they compromise renal function, and the inability to exclude RCC. Reports of hemorrhagic complications during pregnancy have led to the recommendation that patients with multiple or large AMLs be warned about the potential risk of pregnancy and estrogen administration.

Hypertension and renal failure must also be treated appropriately. Bilateral nephrectomy should be considered before transplantation because of the risk of life-threatening hemorrhage and the development of RCC.

Finally, treatment in rodent models of TSC with rapamycin before the onset of disease reduces the development of renal tumors without affecting the number of precursor lesions (Kenerson et al., 2005). Clinical trials of the mTOR inhibitor rapamycin have demonstrated reduction in the size of tuberous sclerosis–associated renal, lung, and brain tumors. Sirolimus (rapamycin) and everolimus have demonstrated reduction in size of subependymal giant cell astrocytomas, reduction in seizure frequency, and inhibition of AML growth and even reduction of AML size in some reports (Kohrman, 2012). Larger-scale randomized controlled trials of mTOR inhibitors continue.

Elucidation of the TSC protein function at a molecular level and preclinical studies have identified mTOR as a target for intervention in TSC (Budde et al., 2012; Curatolo et al., 2012, Lee et al., 2005). The efficacy of mTOR inhibitors has also been demonstrated in patients with TSC who have subependymal giant cell astrocytomas or pulmonary lymphangioleiomyomatosis (Davies et al., 2011; Franz et al., 2006). Multiple open-label, nonrandomized studies have shown that sirolimus produces a reduction in the volume of renal AMLs, mostly achieved in the first few months of treatment (Bissler et al., 2008; Curatolo et al., 2012; Sasongko et al., 2015), but the effect is not maintained after discontinuation of treatment. The best data on the efficacy of mTOR inhibitors come from the double-blind EXIST-2 study (Everolimus for angiomyolipoma associated with tuberous sclerosis complex or sporadic lymphangioleiomyomatosis) (Bissler et al., 2013), which included 118 patients, 18 years or older, who had a definite diagnosis of TSC ($n = 113$) or sporadic lymphangioleiomyomatosis (LAM) ($n = 5$) and at least one renal AML 3 cm or more in its largest diameter. The patients were randomly assigned in a 2 : 1 ratio to everolimus 10 mg/day or placebo and treated for a median duration of 38 or 34 weeks, respectively. At the data cutoff, therapy had been discontinued in 20 patients, because of disease progression in 9 receiving placebo and because of adverse effects in 1 receiving everolimus and 4 receiving placebo. The primary end point, at least a 50% reduction in the total volume of all target AMLs identified at baseline, was achieved in 42% of the patients treated with everolimus and in none of the patients treated with placebo ($P < 0.001$). The median time to response to everolimus was 2.9 months. Progression of AMLs was significantly more common in the placebo group (21% vs. 4%). The response rate of skin lesions was significantly more common with everolimus (26% vs. 0). The patients treated with everolimus had significantly higher rates of stomatitis (48% vs. 8%) and acnelike skin lesions (22% vs. 5%). On the basis of these findings, the FDA approved everolimus tablets for the treatment of adults with renal AMLs and TSC who do not require immediate surgery. At present, the place of everolimus or other mTOR inhibitors for the treatment of renal AMLs needs to be further defined. Benefits and risks must be balanced, because the administration of mTOR inhibitors can be associated with significant adverse events, the reduction in renal AML volume is reversible after discontinuation of treatment, and long-term outcome results are not available.

von Hippel-Lindau Disease

In 1904 Eugene von Hippel, a German ophthalmologist, first described retinal angiomatosis—angiomatous lesions of the retina that caused blindness in association with similar cerebellar tumors. One of his patients developed renal cancer, and this was reported in 1921. In 1926 Arvid Lindau, a Swedish pathologist, published a series about patients with retinal and cerebellar tumors, with four of his patients also having renal cysts and renal cancer. He was also the first to propose that these lesions had an inherited origin.

VHL disease is an autosomal dominant syndrome manifesting with cerebellar and retinal hemangioblastomas; cysts of the pancreas, kidney, and epididymis; epididymal cystadenoma; pheochromocytoma; and clear cell RCC. It is found in all ethnic groups, both sexes are affected, and it has an incidence ranging from 1 in 30,000 to 1 in 50,000 individuals. It has more than 95% penetrance by the age of 65 years in affected individuals. It is grouped with the phakomatoses (Sturge-Weber-Krabbe syndrome, TSC, and neurofibromatosis), because they all have a common inheritance pattern and propensity for neoplasm.

Etiology

VHL disease is caused by a germline mutation in the tumor suppressor gene known as *VHL*, located on chromosome 3 (3p25) (Kondo and Kaelin, 2001; Latif et al., 1993; Lesho, 1994). A tumor suppressor gene is one in which both copies of the gene must be disabled for a cancer to develop. Seventy percent of patients will have a mutation of one *VHL* allele. As long as one copy of the *VHL* gene is producing functional VHL protein in each cell, tumors do not form. If a mutation occurs in the second copy of the *VHL* gene during a person's lifetime, the cell will have no working copies of the gene and will produce no functional VHL protein. A lack of this protein allows tumors characteristic of VHL syndrome to develop. The discovery and characterization of the *VHL* gene, and its role in cell regulation, is a prime example of how discoveries in the basic science arena can revolutionize treatment of human disease (Clark and Cookson, 2008).

The protein encoded by the *VHL* gene (pVHL) is a tumor suppressor and acts through multiple routes. It forms a complex of proteins that are involved with specific target proteins, typically hypoxia-inducible factors (HIFs), being “marked” for degradation. The most researched of these targets is hypoxia-inducible factor-1α (HIF-1α), a transcription factor that induces the expression of a number of angiogenesis-related factors (Czyzk-Krzeska and Meller, 2004). HIF-1α, when not suppressed, can stimulate the formation of hemangioblastomas and RCC. HIF targets specific genes that encode growth factors that seem to play a role in tumorigenesis, including platelet-derived growth factor (PDGF), transforming growth factor-β (TGF-β), and vascular endothelial growth factor (VEGF), the last of which is particularly prominent in RCC. HIF-1α and pVHL are also involved in a transcriptional system that is a major regulator in oxygen homeostasis. HIF regulation in normoxia depends on VHL-mediated destruction. When the oxygen supply is reduced, the HIF pathway is activated. Together with activation of HIF in normoxia, VHL-deficient cells show a striking defect in extracellular matrix assembly. Thus altered oxygen tension in pathological settings could have major effects on matrix behavior (Esteban et al., 2004). pVHL has also been shown to be a ciliary protein that controls ciliogenesis in kidney cells. Cilia play an important role in several biologic processes, including mechanosensation, photoperception, and osmosignaling. Loss of pVHL appears to impede the formation of cilia in renal cancer cells, whereas the expression of pVHL in VHL-negative renal cancer cells rescued the ciliogenesis defect (Schermer et al., 2006).

Clinical Features

The mean age at presentation is 35 to 40 years (Neumann et al., 1997). There is no sex preference for the disease or for RCC development. Sporadic RCC in individuals without VHL disease occurs more often in males and usually after age 50 years. **Renal cysts, the most common and often earliest manifestation, are seen in 76% of patients** (Levine et al., 1982). The cysts are bilateral in 75% of affected persons and multifocal in 87% (Reichard et al., 1998). RCC occurs in approximately 50% of affected persons. The renal cysts, as well as the tumors, usually are asymptomatic, although large tumors may cause pain or a mass. Hematuria may occur after rupture of the tumor into the pelvicalyceal system. When cysts are present, typically they are large. Only rarely do images demonstrate ADPKD, and even less often do cysts cause renal failure.

Pheochromocytoma occurs in 10% to 17% of affected persons and appears to be confined to specific families (Horton et al., 1976; Levine et al., 1982). Patients may have seizures or dizziness secondary to hemangioblastomas of the central nervous system. **Cerebellar hemangioblastomas** usually become symptomatic between 15 and 40 years of age (Jennings and Gaines, 1988). These lesions are the most frequent, characteristic, and clinically specific tumors seen in VHL (Shehata et al., 2008; Zbar et al., 1996). Although benign tumors, they often result in major morbidity and mortality. They cause a mass effect because of their location, and, because of their vascular nature, they tend to rupture and bleed. **Retinal angiomas** (hemangiomas) frequently manifest early. Bleeding may cause blurred vision, retinal detachment, and blindness. Early diagnosis is important, because these tumors respond to laser therapy or cryotherapy. The pancreas is commonly involved with either cysts or true neoplasms. **Pancreatic cysts** can occur in up to 70% of patients with VHL but are usually asymptomatic and benign. Islet cell tumors occur in approximately 12% of VHL patients, and metastatic RCC of the pancreas is not unusual (Cheng et al., 1997; Kogire et al., 2000). Other clinical findings in patients with VHL can include **endolymphatic sac tumor, which is a papillary tumor of the petrous bone and can cause hearing loss; papillary cystadenomas of the epididymis; and the female counterpart, cystadenoma of the broad ligament** (Shehata et al., 2008; Zbar et al., 1996).

Because of the high incidence of RCC in patients with VHL disease, the urologist's primary role is careful surveillance so that small tumors can be identified and treated before they metastasize. Although central nervous system hemangioblastomas account for more than half of the deaths in these patients, metastatic RCC is also a major cause of mortality and in some accounts is the leading cause of death in this population (Maher et al., 1990; Reichard et al., 1998). Accordingly, annual or perhaps biannual CT examinations are advised.

Classification

Patients with VHL are subdivided into groups based on disease presentation, and each group has a specific *VHL* gene aberration. VHL type 1 is the most common form of the disease and is characterized by a tendency to develop tumors in the eyes, brain, spinal cord, kidney, and pancreas. VHL type 2 is less common. VHL type 2 differs from type 1 in that affected family members are at high risk to develop pheochromocytomas. VHL type 2 is further divided into types 2A, 2B, and 2C. Individuals in families with VHL type 2A develop pheochromocytomas but have a low risk for RCC (this type of VHL is uncommon). Those with VHL type 2B develop pheochromocytomas and have a high risk for RCC. Patients with type 2C VHL have familial pheochromocytoma without hemangioblastomas and clear cell RCCs (Table 39.3; Shehata et al., 2008; Zbar et al., 1996).

TABLE 39.3

Classification of von Hippel-Lindau Disease

TYPE	CLINICAL CHARACTERISTICS
1	Without pheochromocytoma
2	With pheochromocytoma
2A	Without renal cell carcinoma or pancreatic cysts

2B	With renal cell carcinoma and pancreatic cysts
2C	Familial pheochromocytoma without hemangioblastomas and clear cell renal cell carcinoma

Histopathology

When present, renal cysts and tumors often are multiple and bilateral. The cysts usually simulate simple benign cysts, with flattened epithelium that some investigators consider precancerous. In VHL patients, cysts larger than 2 cm are more likely than smaller cysts to have components of RCC (Poston et al., 1993). Frank cancer usually appears between the ages of 20 and 50 years (Jennings and Gaines, 1988). Others found that the hyperplastic cells lining cysts frequently resembled the clear cell type of RCC, the most common type in these patients (Loughlin and Gittes, 1986). Ibrahim et al. (1989) studied the cysts adjacent to carcinomas and found, much as in tuberous sclerosis, that the karyotype resembled that of the tumors. This similarity is evidence that the hyperplastic cells of the cyst lining are precursors of the carcinomas.

Solomon and Schwartz (1988) believed that a spectrum of pathology is found within the kidneys of patients with VHL disease. At one extreme is a simple cyst with a single layer of bland epithelium. The next step is a typical proliferative cyst with layers of epithelial cells. In the ensuing step, there are complex neoplastic projections into the cyst lumen. If the arbitrary distinction between adenoma and carcinoma on the basis of size is agreed upon, the next stage would be adenoma. Finally, there is full-blown RCC. All of these stages may be found within a single kidney (Solomon and Schwartz, 1988).

Evaluation

In patients with a known family history of VHL, the diagnosis can be made based on the presence of a single retinal or cerebellar hemangioblastoma, RCC, or pheochromocytoma (Couch et al., 2000; Melmon and Rosen, 1964). In such families, germline mutations may be present without clinical manifestations, and the patient should be screened for this mutation. For patients who do not have a family history, the diagnosis requires two or more cardinal manifestations, such as retinal or cerebellar hemangioblastomas, or a single hemangioblastoma and an additional characteristic lesion.

Ultrasonography is useful in diagnosing the typical benign renal cystic features of VHL disease: absence of internal echoes, well-defined margins, and acoustic enhancement. On CT, sharp thin walls are seen around homogeneous contents without enhancement after contrast medium injection. Because multiple lesions (cysts, tumors, or both) are often present, CT frequently is more useful than ultrasonography. CT often is useful in examining the adrenal glands for pheochromocytomas.

When the lesions are small, it is impossible to distinguish tumors from cysts. In such cases, patients should have regular CT scans with narrow-screen collimation (Levine et al., 1982). With larger lesions, and whenever RCC is suspected, renal angiography with magnification or subtraction is advisable. This type of study helps to reveal any additional tumors and indicates the appropriateness of conservative surgery (Kadir et al., 1981; Loughlin and Gittes, 1986). Intra-arterial administration of epinephrine is sometimes helpful, because it causes vasoconstriction of the normal vessels but has no effect on tumor neovascularity.

MRI has not been very useful for small tumors of the kidney, unless the shape of the kidney is altered. The lesions on MRI have a signal intensity that is similar to that of normal renal parenchyma on T1- and T2-weighted images. However, gadolinium is useful because it enhances RCC. The heterogeneous nature of the larger tumors makes them more readily diagnosed (Rominger et al., 1992).

Screening

The genetic nature of VHL disease mandates careful screening. However, because of molecular genetic advances, the screening process for the disease in family members can now be more selective. Previously, asymptomatic relatives required routine ophthalmoscopic examination to rule out retinal angiomas, as well as frequent abdominal CT scans. Now only genetically affected family members require screening (Table 39.4).

TABLE 39.4

Screening Protocol for Patients and Families With von Hippel-Lindau Disease

STUDY	AFFECTED PERSONS	RELATIVES AT RISK
Physical examination	Annual	Annual
24-Hour urine collection for metanephrines and	Annual	Annual

normetanephrines		
Funduscopy	Annual	Annual (age 10–60 yr)
Gadolinium MRI brain scan (or CT)	Every 3 yr from age 10-50 yr; every 5 yr thereafter	Every 3 yr from age 15–40 yr then every 5 yr until age 60 yr
Abdominal evaluation	Annual RUS with abdominal CT scan every 3 yr (more frequently if multiple renal cysts present)	Annual RUS with abdominal CT scan every 3 yr from age 20–65

CT, Computed tomography; *MRI,* magnetic resonance image; *RUS,* renal ultrasonography.

From Maher ER, Yates JR, Harris R, et al.: Clinical features and natural history of von Hippel-Lindau disease. *Q J Med* 7:1151–1163, 1990.

Treatment

The treatment of patients with VHL requires a multidisciplinary approach, because the involvement of multiple organ systems and numerous medical problems is inherent to this disease. Because the tumors that characterize VHL disease are frequently multiple, bilateral, and recurrent, the goals of treatment for patients who have VHL disease are not as straightforward as the goals of treatment for patients who have sporadic tumors. Close surveillance and minimization of surgical procedures constitute the mainstay of treatment. **For patients who have VHL disease, and all patients who have hereditary cancer syndromes, the goal of treatment is cancer control, not cancer cure, and preservation of functional parenchyma to avoid the morbidity associated with renal or adrenal loss.** In patients who have VHL disease, surgical resection is performed with the understanding that microscopic disease probably is left behind. At present, open nephron-sparing surgery should be considered the standard of care for treating low-grade RCC in the setting of VHL disease. Patients with high-grade disease are still probably best served with bilateral nephrectomy. With the objective of sparing as much renal parenchyma as possible and preventing metastasis of the lesions already present, it is not curative surgery (Reed and Parekh, 2009). Although this approach does not reduce the risk of recurrence, reported to be 75% to 85%, the 10-year disease-specific survival rates are high (81% to 94%) (Malek et al., 1987; Ploussard et al., 2007; Roupret et al., 2003; Steinbach et al., 1995). Classically, the survival rate after nephrectomy has been only 50%. Because most of these tumors are low grade, a nephron-sparing approach provides very good survival rates while avoiding the diminished quality of life that comes with bilateral nephrectomy and subsequent dialysis and transplantation. Laparoscopic and percutaneous image-guided ablative techniques, such as radiofrequency ablation and cryoablation, have also been used and are currently under investigation.

Given the high risk of multiple and bilateral pheochromocytomas in patients who have VHL disease, bilateral adrenalectomy can lead to the loss of all adrenal function. Preservation of normal adrenocortical function should be a primary surgical goal, because medical replacement therapy is associated with decreased quality of life (Telenius-Berg et al., 1989). Partial adrenalectomy can preserve normal adrenal function and avoid this morbidity. Identification of small pheochromocytomas may enable laparoscopic preservation of adrenal function and maintain quality of life in these complicated patients. The small size and lack of function of these tumors make them ideal for partial adrenalectomy; however, recurrences may develop in 15% of patients (Walther et al., 1999a, 1999b).

Papillary cystadenomas of the epididymis can be unilateral or bilateral and occur in approximately 10% to 26% of men who have VHL disease (Horton et al., 1976; Lamiell et al., 1989). They seem to have no malignant potential. Surgery is not performed for these lesions unless the patient experiences severe pain.

Key Points: Multiple Malformation Syndromes

- Tuberous sclerosis complex is an autosomal dominant condition that includes the triad of epilepsy, mental retardation, and adenoma sebaceum. It is associated with renal cysts (20% of patients), renal AML (40% to 80%), and RCC (2%).
- There are two different gene mutations associated with tuberous sclerosis: *TSC1* on chromosome 9 and *TSC2* on chromosome 16.
- VHL disease is an autosomal dominant syndrome associated with cerebellar and retinal hemangioblastomas; cysts of the pancreas, kidney (76%), and epididymis; pheochromocytoma (10% to 12%); and clear cell RCC (50% incidence, and 30% to 40% incidence of death).
- VHL disease is associated with an inherited mutation of the *VHL* gene on chromosome 3.

- *VHL* is a tumor suppressor gene involved in regulation of HIF target genes, including *VEGF*; abnormal or absent *VHL* leads to increased tissue levels of specific growth factors and, in particular, VEGF, the most prominent growth factor in RCC.

Multicystic Dysplastic Kidney

MCDK is a developmental anomaly resulting in multiple cysts of varying sizes, without identifiable normal renal parenchyma. These kidneys have no function by definition, and usually the contralateral kidney is normal and exhibits compensatory hypertrophy. Only unilateral involvement is compatible with life. The kidney often does not have a reniform appearance, and it is typically associated with an atretic ureter with no connection between glomerulus and calyces. Typically, the kidney has the appearance of a bunch of grapes, with little stroma between the cysts (Fig. 39.17). Renal size is highly variable, ranging from a small nubbin of tissue to a very large mass that fills most of the abdomen. In fact, MCDK is the second most common cause of an abdominal mass in a newborn, after hydronephrosis.

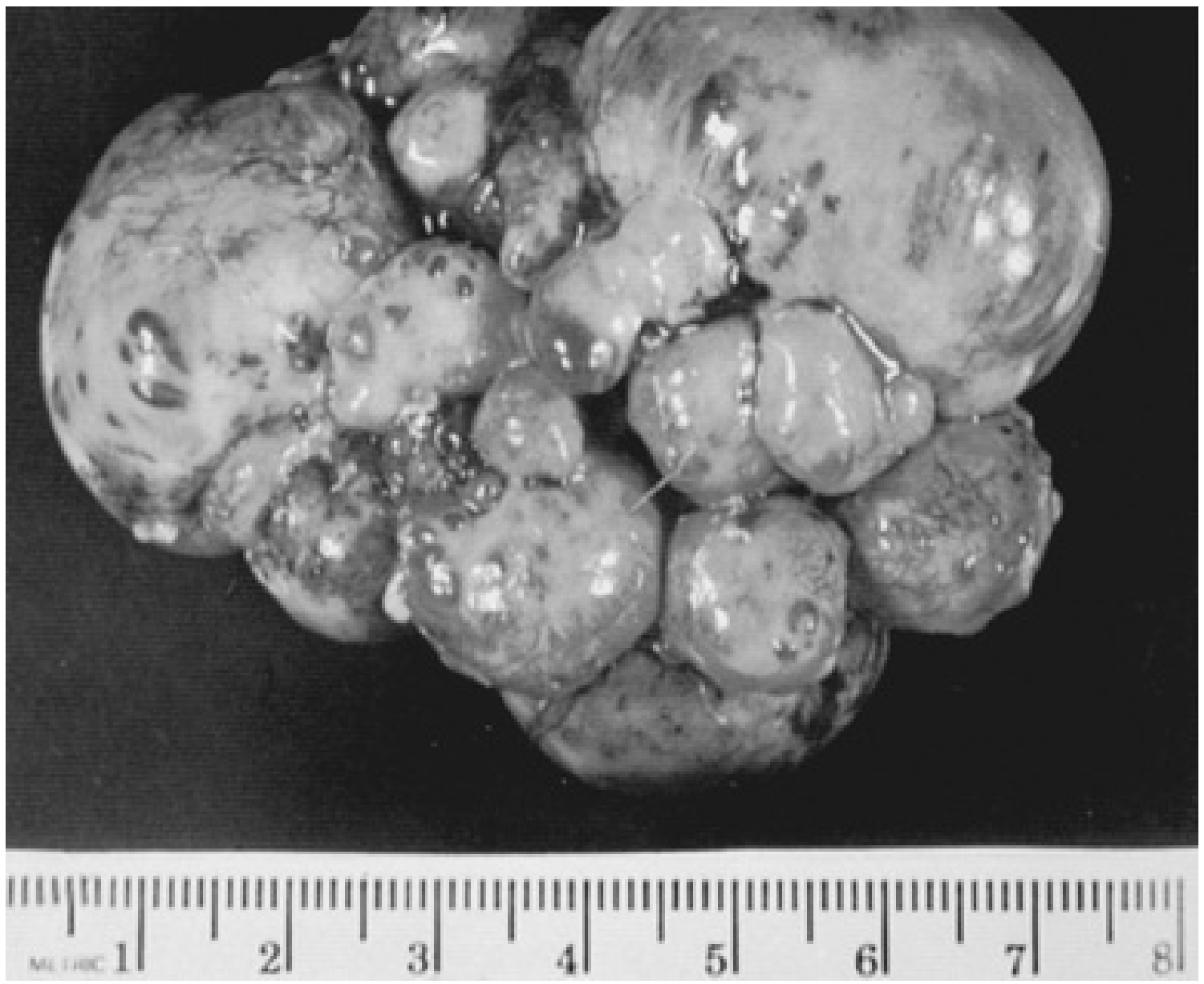

FIG. 39.17 A typical multicystic dysplastic kidney having the appearance of a bunch of grapes. The kidney is composed almost entirely of cysts with very little stroma.

MCDK can be of two types: the infundibulopelvic type, with the atresia involving the renal pelvis and the ureter, and the less common hydronephrotic type, in which only the upper ureter is atretic (Felson and Cussen, 1975). In both cases, the ureters are absent or atretic and the renal vessels are hypoplastic.

MCDK can also rarely be secondary to ureteroceles that have caused complete obstruction. It can rarely be seen in one-half of a duplex kidney (usually the upper pole associated with an ectopic ureter) or in other abnormalities such as a horseshoe kidney.

Etiology

Many theories have been offered to explain the cause of MCDK. Clearly, it is a result of an error in renal development. Some have proposed that the multicystic kidney is an extreme form of obstructive hydronephrosis that occurs secondary to atresia of the ureter or renal pelvis. Several investigators have attempted to establish an animal model of MCDK by ligating the ureter at various points in gestation (Beck, 1971; Fetterman et al., 1974; Tanagho, 1972). This approach is not effective in middle or late gestation; early ligation of the fetal lamb ureter produces renal dysplasia but not multicystic dysplasia (Beck, 1971). Similarly, other investigators have been able to induce dysplasia, but no one as yet has been able to induce an MCDK.

Another theory stems from the “ureteric bud theory” as proposed by Mackie and Stephens (1975). This theory hypothesizes that MCDK may result from abnormal interaction between the ureteric bud and metanephric mesenchyme. Mutations in genes such as *EYA1*, *SIX1*, *WNT*, *WT-1*, *GNF*, *AT2*, and *PAX2* are known to have important roles in ureteric bud development and have been identified in multiple human syndromes with renal dysplasia (Pope et al., 1999). These studies linking genetic mutations with renal dysplasia support the ureteric bud theory in the pathogenesis of MCDK and may also explain its frequent association with other urinary tract anomalies (Hains et al., 2009). This hypothesis, like the obstructive view, is supported by the high incidence of concomitant ureteral atresia.

Although the ureteric bud theory and the obstruction theory may at some level go hand in hand, there is no question that there are several gene-mediated processes that go awry in the process of making a developmentally abnormal MCDK. These genes and their proteins are currently potential targets for therapeutic intervention and research to further elucidate the mechanisms that cause MCDK.

Clinical Features

Multicystic dysplasia is the most common type of renal cystic disease and is the second most common cause of an abdominal mass in infants (Griscom et al., 1975; Longino and Martin, 1958; Melicow and Uson, 1959). Most cases in the current era are diagnosed by prenatal ultrasonography, and the incidence is 1 per 1000 to 4000 live births (Kalyoussef et al., 2006). There is a male preponderance (55% to 70%), and studies conflict as to whether MCDK is more common on the right or left side.

The contralateral system frequently is abnormal. For example, contralateral UPJO is found in 3% to 12% of infants with MCDK, and contralateral vesicoureteral reflux is seen in 18% to 43% of infants (Al-Khaldi et al., 1994; Atiyeh et al., 1992; Flack and Bellinger, 1993; Heikkinen et al., 1980; Wacksman and Phipps, 1993).

The natural history of MCDK is benign; the incidence of complications is extremely rare; and approximately 40% of MCDKs will spontaneously involute. Although anecdotal case reports exist, available large series data indicate that MCDK is not associated with an increased risk for hypertension or neoplasm (Farnham et al., 2005; Narchi, 2005a, 2005b; Onal and Kogan, 2006; Rabelo et al., 2004; Tilemis et al., 2003; Truong et al., 2003; Wacksman and Phipps, 1993). Although hypertension is a rare but recognized sequela of MCDK, it is reasonable to follow patients with MCDK conservatively. The primary care provider should monitor patients with MCDK for hypertension, abdominal mass, and urinary tract infection.

Histopathology

Multicystic kidneys with large cysts tend to be large with little stroma, whereas those with small cysts typically are smaller and more solid. Likewise, the blood supply is variable, ranging from a pedicle with small vessels to no pedicle at all (Parkkulainen et al., 1959). Usually the ureter is partly or totally atretic, and the renal pelvis may be absent. Griscom et al. (1975) referred to the form without a renal pelvis as *pyeloinfundibular atresia* and reported finding no evidence of communication between the cysts. However, others have shown distribution of contrast medium among the cysts by means of connecting tubules (Saxton et al., 1981). Microscopically, the cysts are lined by low cuboidal epithelium, are surrounded by collars of spindle cells, and are filled with proteinaceous or sanguineous fluid. They are separated by thin septa of fibrous tissue and primitive dysplastic elements, especially primitive ducts. Immature-appearing cartilage is often present in the tissue. Frequently, immature glomeruli are present, and on occasion a few mature glomeruli are seen (Fig. 39.18).

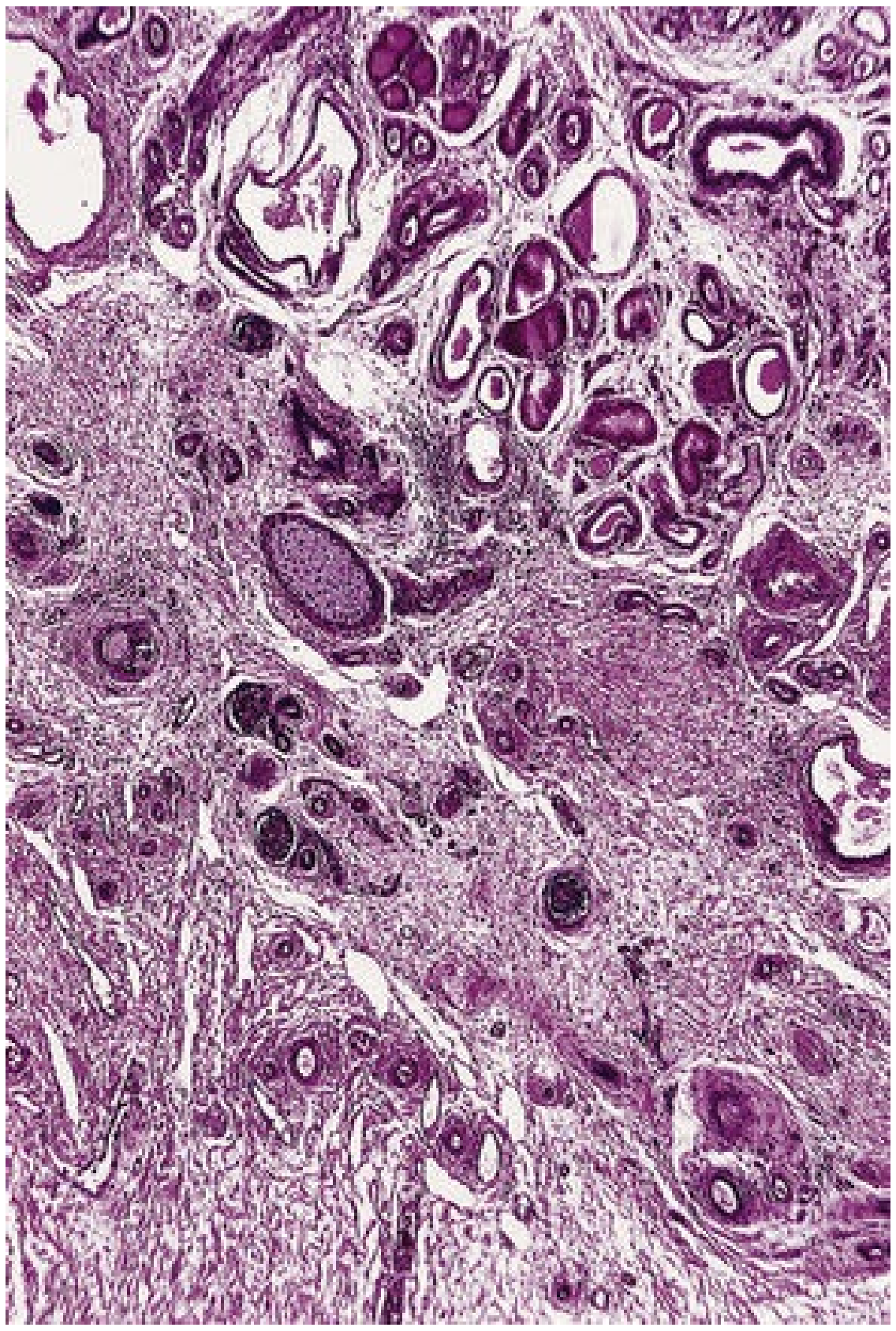

FIG. 39.18 Disorganized development of kidney consistent with multicystic dysplastic kidney showing primitive glomeruli, tubules, and mesenchyme. (From Ordonez NG, Rosai J: Urinary tract. In Rosai J, editor: *Rosai and Ackerman's surgical pathology,* ed 9, Edinburgh, 2004, Mosby.)

Evaluation

MDCK is most often identified by prenatal ultrasonography, and in newborns ultrasonography is usually repeated (once within the first few days of life and again 1 month later) to confirm the diagnosis and to evaluate the contralateral kidney and bladder. In a few cases, it is difficult to differentiate multicystic kidney disease from severe hydronephrosis (Gates, 1980; Hadlock et al., 1981). **In general, the multicystic kidney has a haphazard distribution of cysts of various sizes without a larger central or medial cyst and without visible communications among the cysts. Frequently, very small cysts appear**

among the large cysts. By comparison, in UPJO, the cysts or calyces are organized around the periphery of the kidney, connections usually can be demonstrated between the peripheral cysts and a central or medial cyst that represents the renal pelvis, and there is an absence of small cysts among the larger cysts (Fig. 39.19).

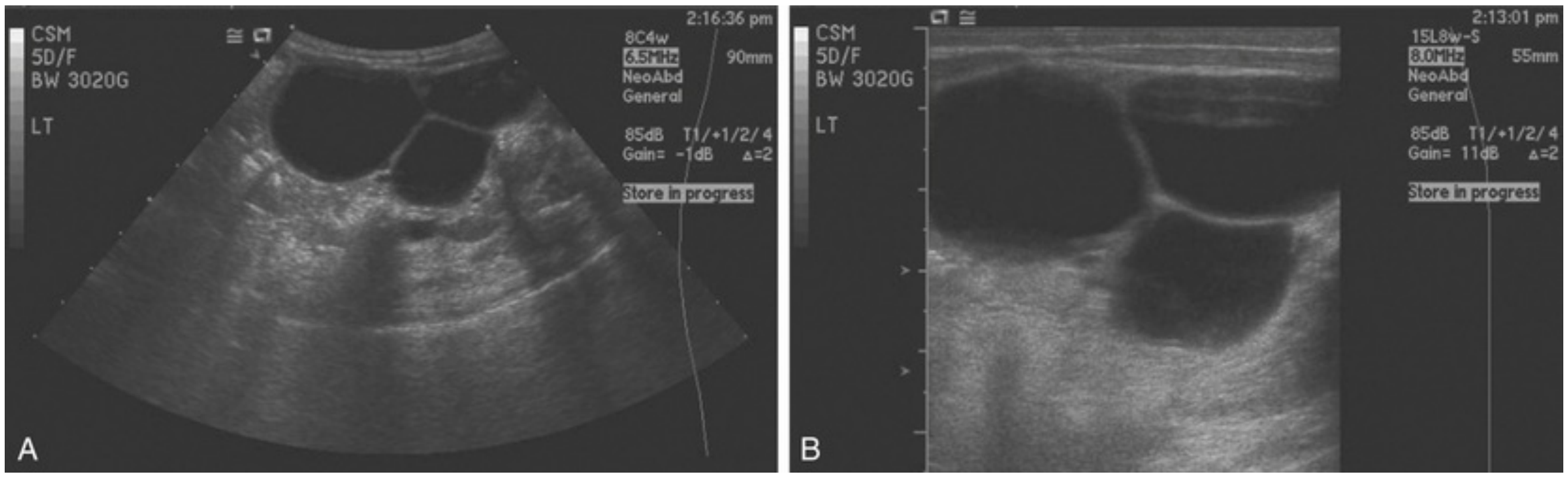
CSM
5D/F
BW 3020G
LT
2:16:36 pm
8C4w
6.5MHz
90mm
NeoAbd
General
85dB T1/+1/2/4
Gain= -1dB Δ=2
Store in progress
A
CSM
5D/F
BW 3020G
LT
2:13:01 pm
15L8w-S
8.0MHz
55mm
NeoAbd
General
85dB T1/+1/2/4
Gain= 11dB Δ=2
Store in progress
B

FIG. 39.19 (A and B) Renal ultrasonogram of large left multicystic dysplastic kidney. There are multiple large cysts. No definite renal cortex is seen.

In these difficult cases, radioisotope studies may be helpful. **Hydronephrotic kidneys usually show some function on a dimercaptosuccinic acid (DMSA) or technetium-99m mercaptoacetyltriglycine (^{99m}Tc-MAG3) scan, whereas renal uptake is seldom seen in multicystic kidneys** (Fig. 39.20). Angiography reveals an absent or small renal artery in the multicystic kidney, but this study is rarely indicated. Cystoscopy may reveal a hemitrigone and absent ureteric orifice on the affected MCDK side; however, more often an orifice is present, but retrograde urography demonstrates ureteral atresia. Again, this study is seldom performed. As mentioned previously, a voiding cystourethrogram (VCUG) is usually indicated in the workup because of the high incidence of reflux into the contralateral single functioning kidney. Some authors, however, have started to advocate that the VCUG is of little value if serial high-quality ultrasound findings are consistent with MCDK and demonstrate a normal bladder and contralateral kidney. A VCUG is not necessary unless clinically indicated later in life (Ismaili et al., 2005; Onal and Kogan, 2006; Welch and Wacksman, 2005).

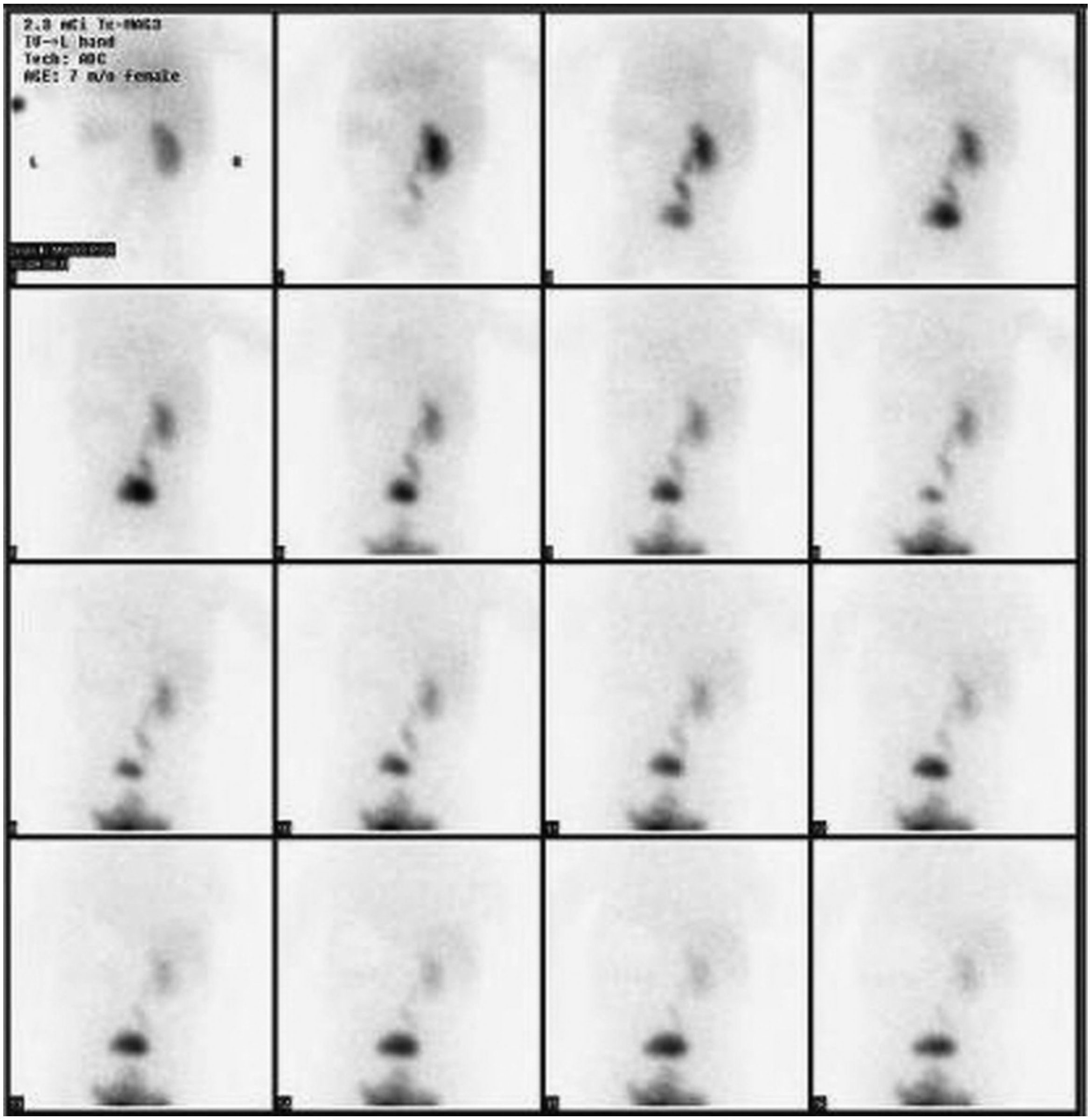

FIG. 39.20 Technetium-99m mercaptoacetyltriglyceride renogram revealing a normally functioning right kidney and no function on the left, which is consistent with a left multicystic dysplastic kidney.

Treatment and Prognosis

It has often been stated that the multicystic kidney can be ignored unless its bulk is inconvenient (Griscom et al., 1975; Pathak and Williams, 1964), and attention should be directed instead to identifying any abnormalities of the contralateral urinary tract. Large MCDKs are known to interfere with respiratory and digestive function simply because of their mass effect. Intervention for these large masses may have to be undertaken to relieve these problems. Nephrectomy for MCDK may also be necessary to correct the rare cases of associated hypertension or if a cyst has ruptured spontaneously or secondary to trauma (to relieve pain or hemorrhage).

A nonfunctioning hydronephrotic kidney could be mistaken for a multicystic kidney, although complete nonfunction on a nuclear medicine study is unusual in kidneys affected by UPJO. Fortunately, if the correct diagnosis is missed in such a case, there are unlikely to be significant consequences, because a totally nonfunctioning hydronephrotic kidney is rarely salvageable and probably will cause no problems other than a predisposition to infection or hypertension.

The probability of malignant transformation is estimated to be extremely low and believed by many to be nonexistent (Avni et al., 1987; Gordon et al., 1988; Narchi, 2005b; Wacksman and Phipps, 1993). Fewer than 15 cases of malignant degeneration have been reported in MCDK. Roughly half have been identified as RCC and half as Wilms tumor, and there has been one reported mesothelioma. Recommendations for addressing this risk range from early nephrectomy of the MCDK to minimal follow-up with no imaging and only periodic abdominal examination by the primary care physician (PCP). Many pediatric urologists will perform ultrasound surveillance every 3 to 12 months, but there has been no conclusive evidence that this is beneficial or cost effective (Onal and Kogan, 2006; Perez et al., 1998).

There has also been much debate in contemporary series regarding hypertension in MCDK. The various case reports and small series that have been reviewed offer conflicting data on the issue. An additional confounding factor is that MCDK is often associated with contralateral abnormalities, such as UPJO and reflux. Thus groups have had difficulty determining if hypertension is associated with contralateral abnormalities or with MCDK. Several small series have reported patients with MCDK and hypertension who were cured with nephrectomy (Angermeier et al., 1992; Javadpour et al., 1970; Snodgrass, 2000; Susskind et al., 1989; Webb et al., 1997). Although these reports demonstrate that hypertension can occur with MCDK, most large series support the rarity of hypertension in association with MCDK. Several studies, including the report from the Multicystic Kidney Registry in 1993, have demonstrated the incidence of hypertension in patients with MCDK and long-term follow-up to be less than 1% (Gough et al., 1995; Farnham et al., 2005; Perez et al., 1998; Wacksman and Phipps, 1993). One study, however, demonstrated a much higher incidence of hypertension than the other MCDK series (Seeman et al., 2001). This could be a result of the more stringent measurement of BP applied, although these patients were examined at a much later age than in other series, which may also have contributed to the higher detected incidence of hypertension. Two of those four patients with hypertension had concomitant abnormalities; thus it was concluded that increased BP is mainly associated with contralateral kidney damage regardless of the presence or absence of the dysplastic kidney (Seeman et al., 2001). In summary, hypertension is a rare but recognized sequela of MCDK. However, there is a suggestion that with more diligent monitoring, its incidence would increase. Therefore it is reasonable to follow patients with MCDK conservatively, realizing that hypertension can exist and should be assessed periodically. Because hypertension can be discovered on an examination by the PCP, the potential for this problem does not require urologic follow-up, only an informed PCP and family (Farnham et al., 2005).

Key Points: Multicystic Dysplastic Kidney

- MCDK is a developmental anomaly resulting in multiple cysts of varying sizes, is without identifiable normal renal parenchyma, is associated with active expression of genes involved with nephrogenesis, and has a changing morphology.
- Kidneys usually get smaller or disappear from view on imaging studies (i.e., renal aplasia), very occasionally increase in size, and very rarely are associated with Wilms tumor.
- There is no clear indication for removal of the kidney, unless an increased amount of solid tissue is identified.
- Large series data indicate that MCDK is not associated with an increased risk for hypertension or neoplasm.
- Fifteen percent of patients have associated contralateral reflux, and debate exists regarding whether or not to obtain a VCUG in all patients or only in those with some degree of fullness in the contralateral collecting system.

Benign Multilocular Cyst (Cystic Nephroma)

Benign multilocular cyst (multilocular cystic nephroma) is a multilocular cystic neoplastic lesion in the kidney that falls in a spectrum of diseases along with multilocular cyst with partially differentiated Wilms tumor, a multilocular cyst with nodules of Wilms tumor, or cystic Wilms tumor (Fig. 39.21). These four lesions form a spectrum, with benign multilocular cyst at the most benign extreme and cystic Wilms tumor at the most malignant extreme. There has been some debate as to whether these lesions represent a spectrum of one disease with a common cause.

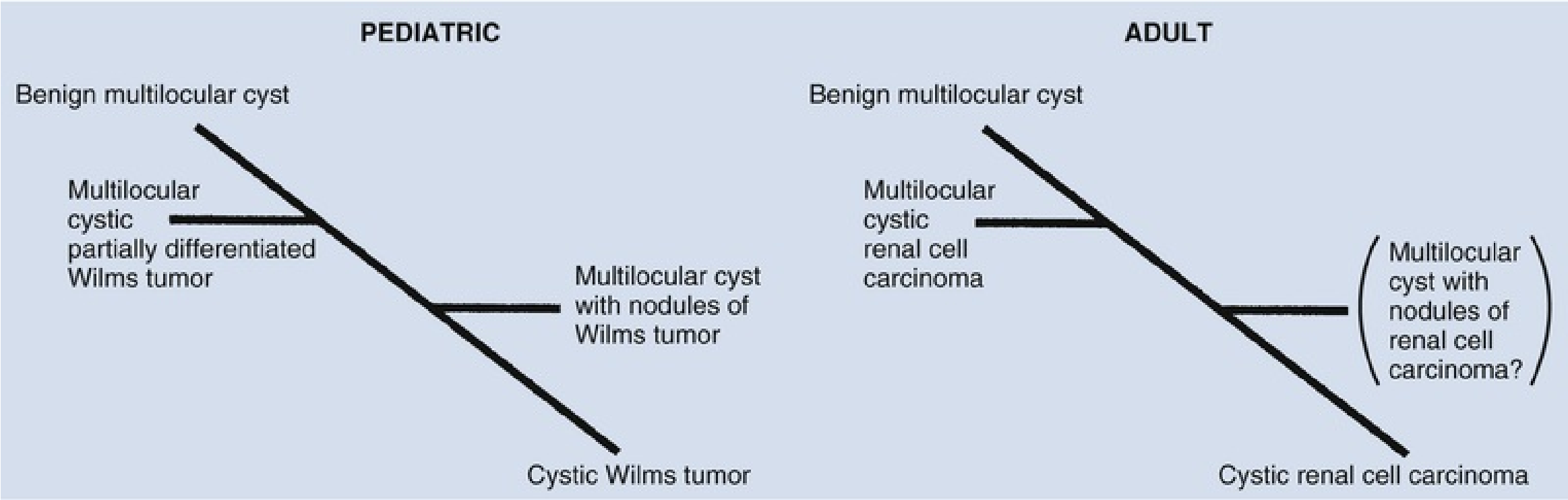
PEDIATRIC
ADULT
Benign multilocular cyst
Multilocular cystic partially differentiated Wilms tumor
Multilocular cyst with nodules of Wilms tumor
Cystic Wilms tumor
Benign multilocular cyst
Multilocular cystic renal cell carcinoma
Multilocular cyst with nodules of renal cell carcinoma?
Cystic renal cell carcinoma

FIG. 39.21 The spectrum of multilocular cystic lesions in children and adults. There is no evidence that one lesion can convert into the other. Benign cystic partially differentiated Wilms tumor and multilocular cystic renal cell carcinoma act as benign lesions. When nodules of tumor are present, the lesion should be considered malignant, although the prognosis of this lesion, as well as cystic Wilms tumor and cystic renal cell carcinoma, seems to be better than that of the corresponding solid lesions. It is not clear whether clinical examples of "multilocular cyst with nodules of renal cell carcinoma" actually exist, but this entity is placed in the spectrum for consideration. For simplicity, the multilocular-appearing lesions of other cystic tumors (e.g., cystic oncocytoma, cystic hamartoma of the renal pelvis) are not included in the figure.

A multilocular cyst is not a renal segment affected by multicystic kidney disease; these conditions differ clinically, histologically, and radiographically. However, controversy continues about whether the multilocular cyst is a segmental form of renal dysplasia (Johnson et al., 1973; Osathanondh and Potter, 1964; Powell et al., 1951), a hamartomatous malformation (Arey, 1959), or a neoplastic disease (Boggs and Kimmelsteil, 1956; Christ, 1968; Fowler, 1971; Gallo and Penchansky, 1977). The confusion arises in part from the variability of the histologic picture: the appearance of the primitive stroma; the maturity of tubular and even on occasion of muscle elements; and the degree of epithelial atypia that differs not only from patient to patient but also within the same lesion.

Clinical Features

The great majority of cases (95%) manifest before the age of 4 years or after 30 years. If younger than 4 years, the patient is twice as likely to be male; if older than 30 years, the patient is eight times as likely to be female (Eble and Bonsib, 1998).

The signs and symptoms differ according to the age at presentation. **In children, an asymptomatic flank mass is the most common finding, whereas most adults have a flank mass, abdominal pain, or hematuria.** The bleeding is felt to be secondary to herniation of the cyst through the transitional epithelium into the renal pelvis (Aterman et al., 1973; Madewell et al., 1983; Uson and Melicow, 1963).

Seven cases of bilateral benign multilocular cysts of the kidney have been described (Castillo et al., 1991), and recurrence after excision has been rarely described (Geller et al., 1979). There are also at least two instances in which multilocular cysts arose in kidneys known to have been normal previously (Chatten and Bishop, 1977; Uson and Melicow, 1963). Such cases support a neoplastic theory of the origin of this lesion.

Histopathology

These lesions are bulky and are circumscribed by a thick capsule. Normal renal parenchyma adjacent to the lesion frequently is compressed by it. The lesion may extend beyond the renal capsule into the perinephric space or renal pelvis. The loculi, which range from a few millimeters to centimeters in diameter, do not communicate. They contain clear, straw-colored or yellow fluid and are lined by cuboidal or low columnar epithelial cells. In some cases, eosinophilic cuboidal cells project into the cyst lumen, creating a hobnail appearance (Madewell et al., 1983). The septa of a benign multilocular cyst are composed of fibrous tissue in which well-differentiated tubules may be present, but poorly differentiated tissues and blastemal cells are not present (Joshi and Beckwith, 1989).

In children, although there may be a continuum from benign multilocular cyst to cystic Wilms tumor, and although all of these lesions may be derived from similar cells or tissues, no evidence suggests that one entity transforms into another. Furthermore, **none of the genetically determined conditions associated with Wilms tumor (e.g., hemihypertrophy, aniridia) has accompanied a benign multilocular cyst** (Banner et al., 1981).

In adults, there also is a spectrum of multilocular cystic lesions. Multilocular cystic RCC in adults falls in the spectrum between a benign multilocular cyst and a cystic malignant tumor, such as a **multilocular cystic RCC, a cystic RCC, a cystic oncocytoma, or a cystic hamartoma of the renal pelvis** (Eble and Bonsib, 1998; Kirsh et al., 1999). The cystic component of the tumor at the carcinomatosis end of the spectrum in children and adults (i.e., cystic Wilms tumor and cystic RCC) improves the prognosis of the malignant lesion (Kirsh et al., 1999). In adults, as in children, there is no evidence that one lesion can convert into another (Fig. 39.22).

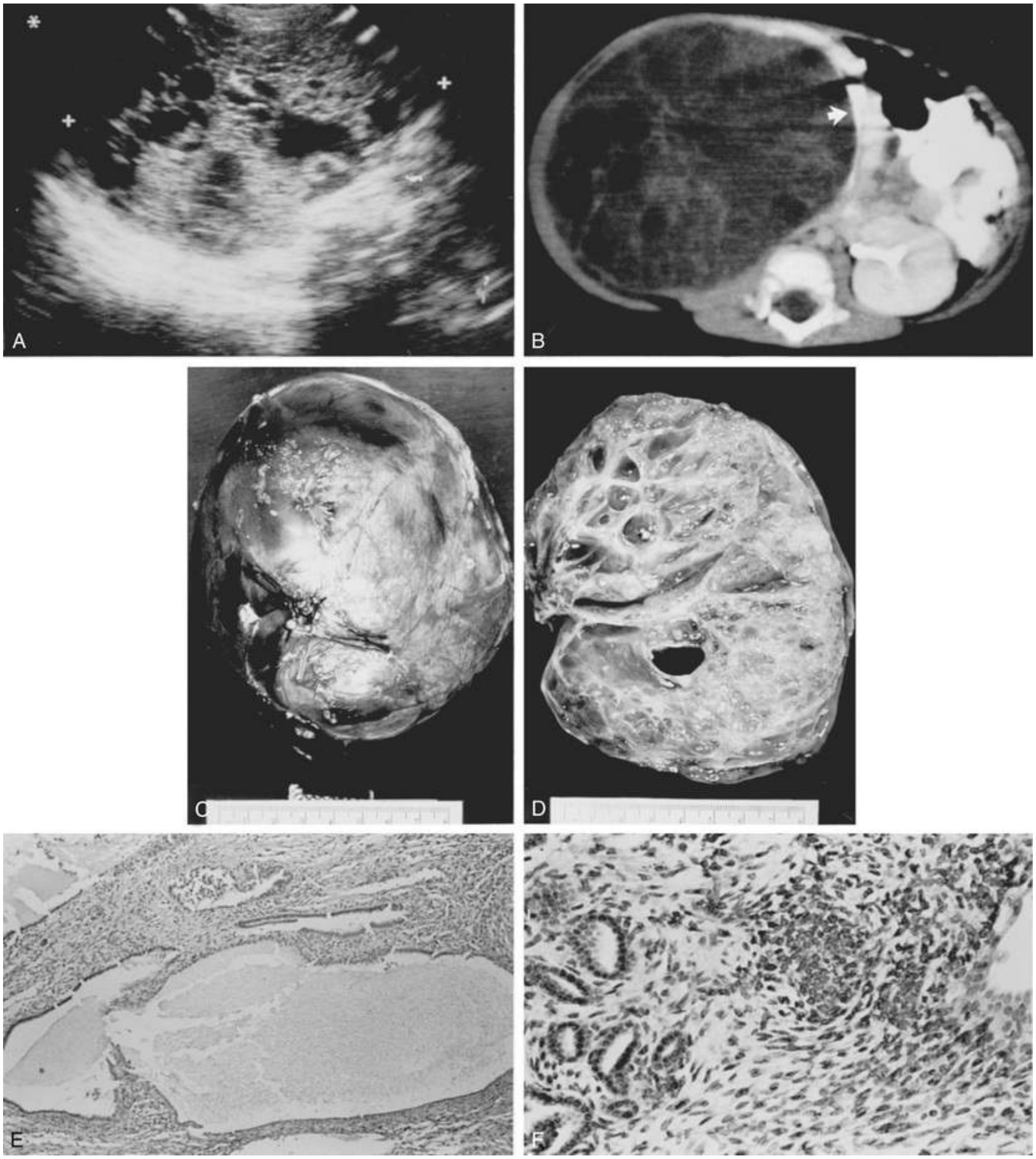

FIG. 39.22 A 4-year-old girl with a right-sided abdominal mass. (A) Renal ultrasonogram shows multiple cysts throughout the left kidney. (B) On contrast medium–enhanced computed tomography scan, a large, smoothly outlined left renal mass is seen with fine septa throughout the mass. Residual preserved parenchyma and the pelvicalyceal system are compressed medially and pushed to the contralateral side *(arrow).* (C) Uncut gross specimen reveals a smooth-walled, encapsulated renal mass. (D) Cross section of mass reveals multiple noncommunicating loculations. (E) On histology, a hypocellular cystic area is seen with monotonous stroma (100×). (F) Between loculi, nests of blastemal cells are visualized

along with tubular elements *(left),* making the diagnosis of multilocular cyst with partially differentiated Wilms tumor (200×).

Evaluation

A number of tests may be useful, including ultrasonography, CT, MRI, cyst puncture with aspiration and double-contrast cystography, and arteriography. **Ultrasonography and CT can distinguish multicystic kidneys from multilocular cysts, but neither study is sufficiently reliable to distinguish among multilocular cysts, multilocular cysts with foci of Wilms tumor or adenocarcinoma, mesoblastic nephromas, cystic Wilms tumors, and clear cell sarcomas.** Typically, the septa are highly echogenic with sonolucent loculi, although if there is debris in a loculus, it may appear more solid. On CT the septa are less dense than normal parenchyma. Calcification is rarely visible in such lesions in children (Madewell et al., 1983).

Treatment

The treatment for any multilocular cystic lesion, even the most benign variant, is nephrectomy. If the lesion is localized enough and there is well-preserved normal tissue, excision of the lesion or partial nephrectomy is feasible. Children who have a multilocular cyst with nodules of Wilms tumor or a cystic Wilms tumor should be treated as for Wilms tumor, according to the National Wilms Tumor Study (NWTS) recommendations for the appropriate stage of disease, recognizing the generally favorable outlook. Similarly, cystic RCC in adults should be managed as a malignant lesion, again recognizing its better prognosis. In adults, benign multilocular cysts more often are associated with larger amounts of normal renal tissue, making partial nephrectomy more often feasible.

If enucleation or partial nephrectomy is chosen, recurrence is possible. However, with more Wilms tumors being treated by local excision, the case for enucleation or partial nephrectomy combined with close follow-up by ultrasonography and CT is stronger, even if malignancy is found within the lesion. By comparison, if a clear cell sarcoma is found after enucleation, the remaining ipsilateral renal tissue should be removed because of the aggressiveness of this cancer. The recurrence of a multilocular cyst not containing malignancy probably reflects inadequate excision of the initial lesion.

Key Points: Benign Multilocular Cyst

- A benign multilocular cyst is a benign, nondysplastic, neoplastic lesion that occurs most commonly either before the age of 4 years, most frequently in males, or after the age of 30 years, predominantly in females.
- The only way to determine the diagnosis of a multilocular cystic lesion identified on imaging studies, in either a child or an adult, is by surgical excision.
- Benign multilocular cyst is thought to fall at the benign end of a spectrum of the same disease process that also includes multilocular cyst with partially differentiated Wilms tumor, multilocular cyst with nodules of Wilms tumor, or cystic Wilms tumor at the most malignant end of the spectrum.

Simple Cysts

Simple cysts are the most common cystic lesions found in the human kidney. They are usually oval to round; may be solitary or multiple, unilateral or bilateral; and are filled with plasmalike clear or straw-colored fluid (Nahm and Ritz, 2000; Terada et al., 2002). They are not connected to any part of the nephron, although they may originate initially from a portion of the nephron.

Simple cysts may manifest at any time in utero and have been diagnosed as early as 14 weeks of gestation. Ultrasonography done on 29,984 fetuses in succession revealed 0.09% of 11,000 pregnancies to have renal cysts (Blazer et al., 1999). Between birth and 18 years of age, the incidence of simple renal cysts is fairly stable, ranging from 0.1% to 0.45%, with an average incidence of 0.22% (McHugh et al., 1991). However, in adults the frequency rises with age, with an incidence of 20% by age 40 years and as high as 50% after age 60 years (Kissane and Smith, 1975; Laucks and McLachlan, 1981).

Clinical Features

In children and adults, cysts are typically discovered incidentally on ultrasonography, CT, or urography. However, cysts can produce an abdominal mass or pain, hematuria secondary to rupture into the pelvicalyceal system, and hypertension secondary to segmental ischemia (Lüscher et al., 1986; Papanicolaou et al., 1986; Rockson et al., 1974). Cysts can cause calyceal or renal pelvic obstruction as well (Barloon and Vince, 1987; Evans and Coughlin, 1970; Hinman, 1978; Wahlqvist and Grumstedt, 1966). They may or may not increase in size with time.

Cysts can rupture into the pelvicalyceal system, maintain a communication, and become a pseudocalyceal diverticulum. The reverse is also possible: closure of the communication of a diverticulum can create a simple cyst (Mosli et al., 1986; Papanicolaou et al., 1986). These two sequences of events can be distinguished only by histologic examination. Theoretically, diverticula should have linings of transitional epithelium, whereas simple cysts should be lined by a single layer of flattened or cuboidal epithelium.

Histopathology

Simple cysts vary considerably in size, ranging from less than 1 cm to greater than 10 cm. The majority are less than 2 cm in diameter, however (Tada et al., 1983). The wall is fibrous and of varying thickness and has no renal elements. The cyst lining is glistening and usually smooth and histologically is a single layer of flattened or cuboidal epithelium, and the cysts are filled with a clear, serous fluid. Because cysts are increasingly common with age, they have been considered an acquired lesion. Some cysts may be trabeculated by partial septa that divide the cavity into broadly interconnecting loculi. These septated simple cysts should not be confused with multilocular cysts. The cysts are often cortical and distort the renal contour, but they may be deep cortical or apparently medullary in origin. They do not communicate with the renal pelvis. The walls typically are thin and transparent but may become thickened, fibrotic, and even calcified, possibly from earlier hemorrhage or infection (Torres and Grantham, 2008).

Evaluation

Most simple cysts are identified incidentally. The clinician can safely make the diagnosis of a classic benign simple cyst by ultrasonography when the following criteria are met: **(1) absence of internal echoes, (2) presence of a sharply defined, thin, distinct wall with a smooth and distinct margin, (3) good transmission of sound waves through the cyst with consequent acoustic enhancement behind the cyst, and (4) a spheric or slightly ovoid shape** (Goldman and Hartman, 1990). If all of these criteria are satisfied, the chance that malignancy is present is negligible (Fig. 39.23; Lingard and Lawson, 1979; Livingston et al., 1981).

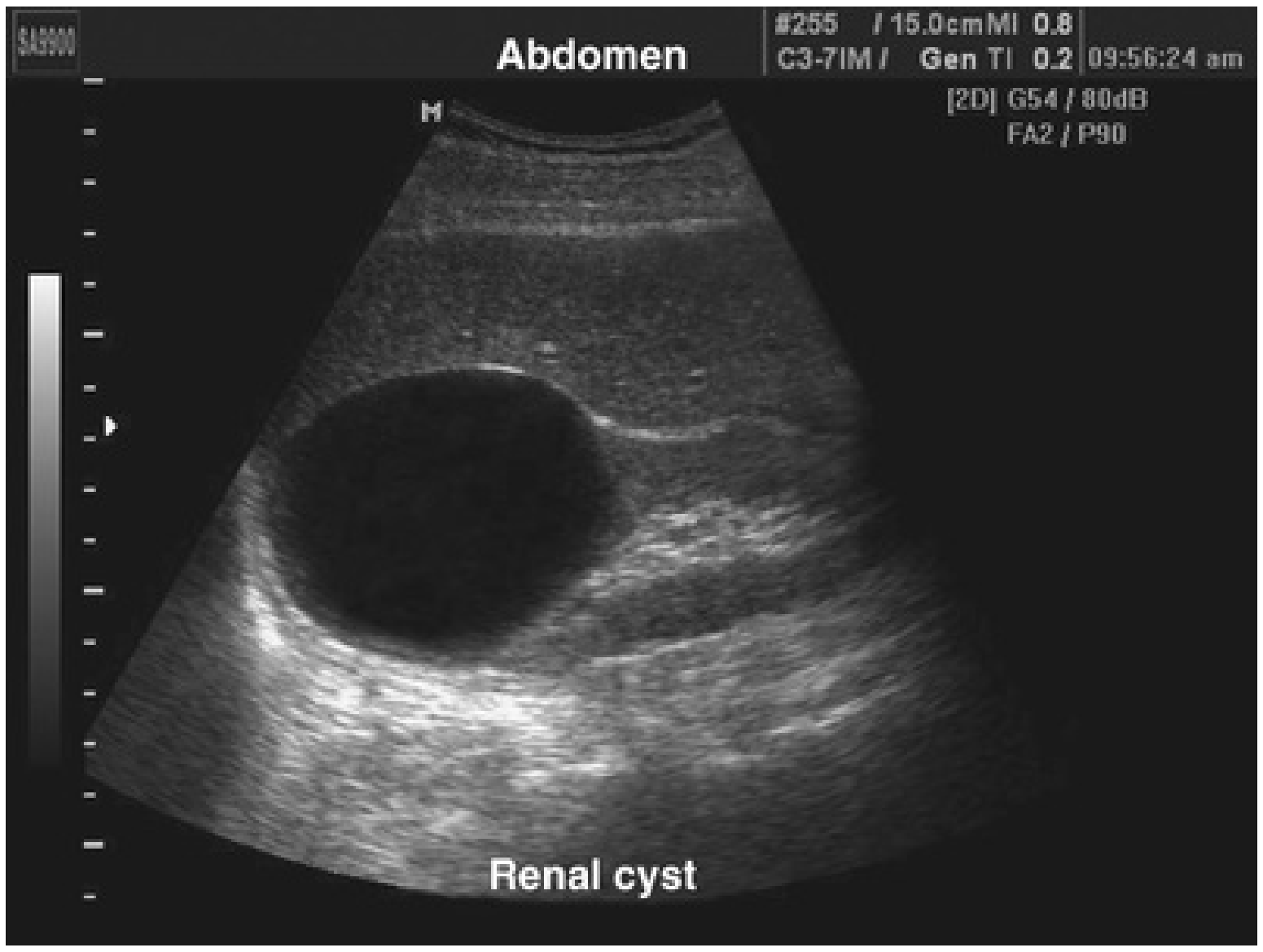

FIG. 39.23 Ultrasonographic appearance of a 4-cm simple renal cyst. This meets the definition of a true simple cyst: (1) absence of internal echoes; (2) sharply defined, thin, distinct wall with a smooth and distinct margin; (3) good transmission of sound waves through the cyst with consequent acoustic enhancement behind the cyst; and (4) spheric or slightly ovoid shape.

When some of these criteria are not met (e.g., when there are septations, irregular margins, calcifications, or suspect areas), further evaluation by CT, or perhaps needle aspiration or MRI, is indicated (Bosniak, 1986). A cluster of cysts is another indication for further study, because they may be hiding a small carcinoma. CT is better than ultrasonography in defining such a camouflaged lesion (Bosniak, 1986). Peripelvic cysts often require CT confirmation, because they frequently are interspersed among structures of the collecting system and hilum, which can create artificial echoes (Bosniak, 1986).

The CT criteria for a simple cyst are similar to those used in ultrasonography: (1) a sharp, thin, distinct, smooth wall and margin, (2) a spheric or ovoid shape, and (3) homogeneous content. When these criteria are respected, the accuracy of diagnosis of a simple cyst by CT approaches 100% (Fig. 39.24; McClennan et al., 1979). The density ranges from −10 to +20 HU, similar to the density of water, and no enhancement should occur after the intravenous injection of contrast medium.

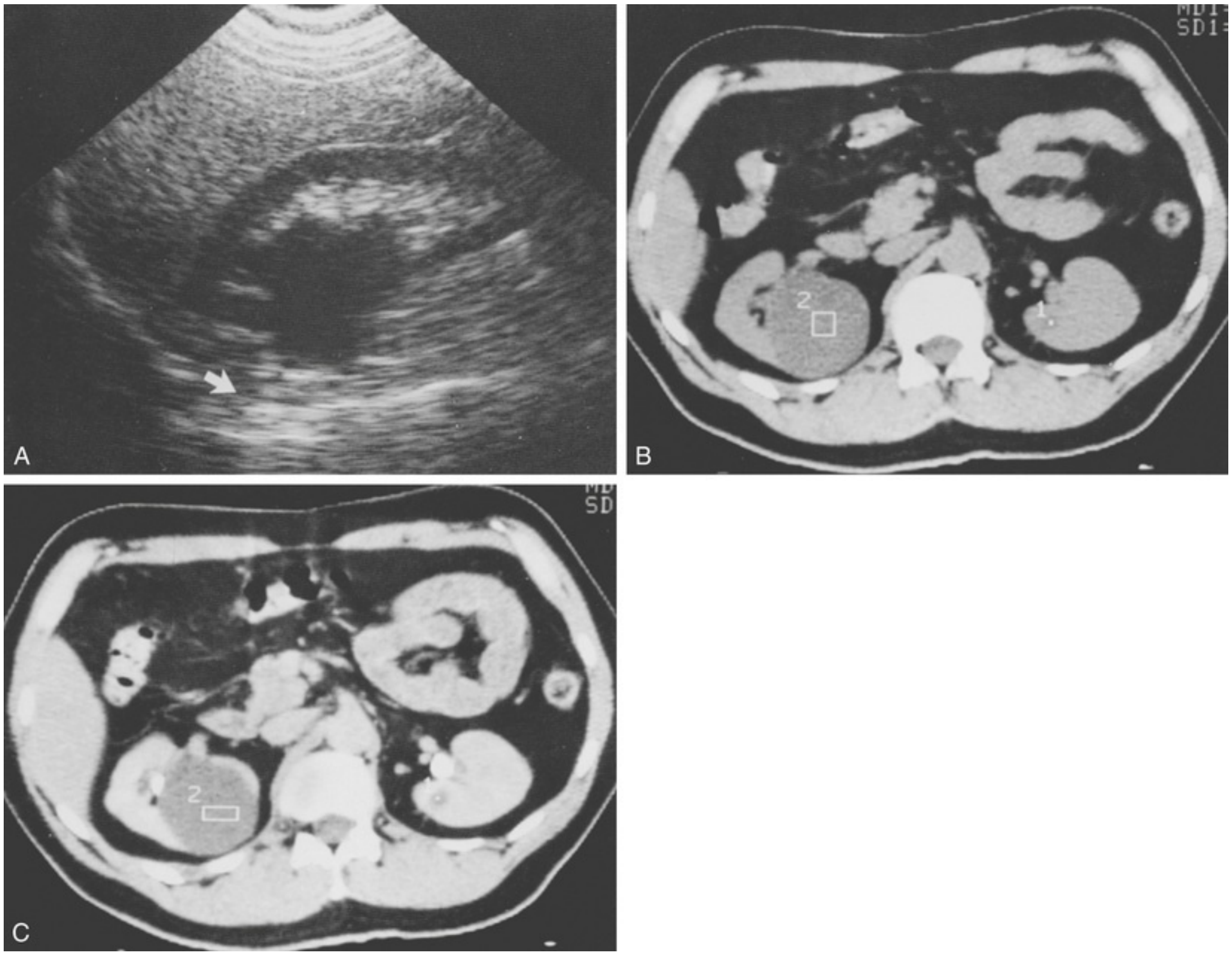

FIG. 39.24 A 56-year-old man with an indeterminate left renal cyst on renal ultrasonography. (A) Note the nonspheric, non–smoothly outlined sonolucent mass in the left kidney. However, there is good sound wave transmission through the cysts (acoustic enhancement), which is illustrated by the intensity (whiteness) of the ultrasonogram image behind the cyst *(arrow).* (B) On precontrast computed tomography (CT) scan, a very small cyst *(1)* is seen in the left kidney. The right renal cyst *(2)* that was identified on ultrasonography measures 17 HU. (C) After contrast agent administration, the CT value *(2)* was 16 HU, signifying no enhancement. CT values between −10 and +20 HU are characteristic of cysts. No enhancement with contrast agent confirms the diagnosis of a simple renal cyst. The small cyst *(1)* was not large enough for determining accurate CT values. (Courtesy G. Laungani, MD.)

When the cyst fluid is hyperdense (i.e., between 20 and 90 HU), the cyst still is likely to be a simple cyst if no enhancement occurs when intravenous contrast agent is injected and if the other criteria of CT and ultrasonography are met. Hyperdense cysts must be evaluated with narrow window settings to make sure that they are homogeneous. Other criteria that must be met to avoid further evaluation of hyperdense cysts (e.g., cyst puncture or exploration) include size (the lesion should be 3 cm or smaller) and location (at least one-fourth of the cyst's circumference should extend beyond the renal contour so that the smoothness of a good portion of the cyst can be evaluated) (Bosniak, 1991; Hartman et al., 1992). **Because cysts have no blood vessels and do not communicate directly with nephrons, they should not enhance; enhancement therefore implies vascular tissue or contrast medium mixing with fluid.** Enhancement of any nodular areas on the wall of the cyst or of a thickened septum within the cyst is taken as proof of vascularity within the lesion, and thus there should be a high index of suspicion for neoplasm.

When ultrasonographic or CT criteria are not met, conditions other than a simple cyst must be considered, such as complicated cysts (i.e., those containing blood, pus, or calcification) and cystic neoplasms. Cyst puncture and aspiration with or without contrast medium injection has been popular in the past, but with current imaging modalities the need for cyst puncture is very rare. The remaining indications for cyst puncture are (1) suspected infection, in which case puncture may be therapeutic as well as diagnostic, (2) the presence of low-level echoes on ultrasonography but a classic cyst on CT, and (3) a borderline lesion in a poor surgical candidate.

Two percent of simple cysts and 10% of RCCs contain calcium deposits, but calcification in simple cysts appears to be peripheral, whereas in tumors it is more central. When the cysts are numerous and bilateral, differentiation from ADPKD may be difficult if liver cysts are not also found. Because of the obvious implications, it is important to avoid a diagnosis of ADPKD in questionable cases unless a familial history consistent with autosomal dominant transmission can be documented or the diagnosis confirmed by genetic testing.

In children, several recent publications support the conclusion that stable (non-growing for 2 years) simple cysts require no additional follow-up unless otherwise indicated clinically (Bayram et al., 2014; Karmazyn, et al., 2015; O'Kelly et al., 2019; Rediger et al., 2019; Saltzman et al., 2018). They found that many renal cysts in children resolve spontaneously or show no growth on subsequent imaging. No cases of malignancy were noted in children found to have simple cysts and the rate of malignancy in complex cysts was also low. From their large study group, they have reasonably proposed that if a simple cyst is less than 15 mm in an asymptomatic patient less than 18 years old, then it is safe to repeat the ultrasound in 2 years and discharge the patient if stability of the cyst is demonstrated. They have continued to recommend surveillance only for patients with large (> 15 mm) cysts, complex cysts, and family history of inheritable cystic disease and patients with concomitant genitourinary anomalies.

MRI offers little information beyond that available from ultrasonography and CT, although it is more specific in identifying the nature of the cyst fluid. Marotti et al. (1987) found that if the fluid has low signal intensity (similar to that of urine) on T1-weighted images, the cyst is benign even if the wall is thick or septa are present. The T2-weighted images identify bloody fluid with an extremely bright image. Some have reported that MRI can lead to changes in category assignment in a significant proportion of cases, possibly because of its superior soft tissue and contrast resolution (Ferreira et al., 2016).

Classification

In an attempt to better categorize surgical and nonsurgical cysts in the kidney, Bosniak suggested a classification in 1986 that was clarified further in 1997 and modified by Israel and Bosniak in 2003 (Box 39.2). In addition, Wallis et al. (2008) suggested a modified Bosniak classification that can be used as a guideline to direct the need for surgical intervention in the pediatric population. They propose that in the absence of change or symptoms Bosniak category II cysts may be safely followed with periodic ultrasound imaging. Patients with Bosniak class III and class IV cysts have a significant chance of harboring malignancy, and surgical resection should be considered (Wallis et al., 2008). In addition, one recent study in children proposed a modified Bosniak classification and found that cystic renal lesions in children with a modified Bosniak class of I or II were most often benign, whereas class III or IVV lesions warranted surgical excision because more than 90% of masses harbored intermediate or malignant pathology. They concluded that the modified Bosniak classification system allows for a reasonable clinical risk stratification of pediatric cystic renal masses (Saltzman et al., 2018).

Box 39.2

Bosniak's Classification of Simple and Complex Cysts

Category I

Simple benign cyst with (1) good through-transmission (i.e., acoustic enhancement), (2) no echoes within the cyst, (3) sharply marginated smooth wall; requires no surgery

Category II

Looks benign with some radiologic concerns, including septation, minimal calcification, and high density; requires no surgery

Category II F

Although calcification in wall of cyst may even be thicker and more nodular than in category II, the septa have minimal enhancement, especially those with calcium; requires no surgery

Category III

More complicated lesion that cannot confidently be distinguished from malignancy, having more calcification, more prominent septation of a thicker wall than a category II lesion; more likely to be benign than malignant; requires surgical exploration and/or removal

Category IV

Clearly a malignant lesion with large cystic components, irregular margins; solid vascular elements; requires surgical removal

Category I cysts are the typical benign cysts. Category II cysts are benign cystic lesions that are minimally complicated, such as by septations, small calcifications, infection, or high density, and do not require surgery. For example, when all the criteria for a simple cyst are met, except that a fine line of calcification or a short segment of slightly thickened calcification is seen in the wall or septa, the lesion should be considered a benign cyst, and exploration is not required. Another example is the cyst with fine traversing strands, perhaps containing calcium. In this case, exploration is not required unless the septa are numerous, irregular, or thick.

Category II F cysts (Israel and Bosniak, 2003) are complex cysts that cannot be classified as either category II or III. These lesions may contain increased calcification. The calcification may even be thicker and nodular, but although the septa may have minimal enhancement, those septa with calcium do not enhance. Calcification seems to represent a less significant finding in making a lesion suspicious as a malignancy than previously thought. More focus is placed on tissue enhancement. There is little concern if calcification increases with time but much concern if the wall or septa becomes thicker or irregular. **Category II F cysts do not necessarily require surgical exploration** (Fig. 39.25; Israel and

Bosniak, 2003). However, more recent reports have shown that malignant progression can occur in 10.9% of cases and requires close follow-up (Hindman et al., 2014).

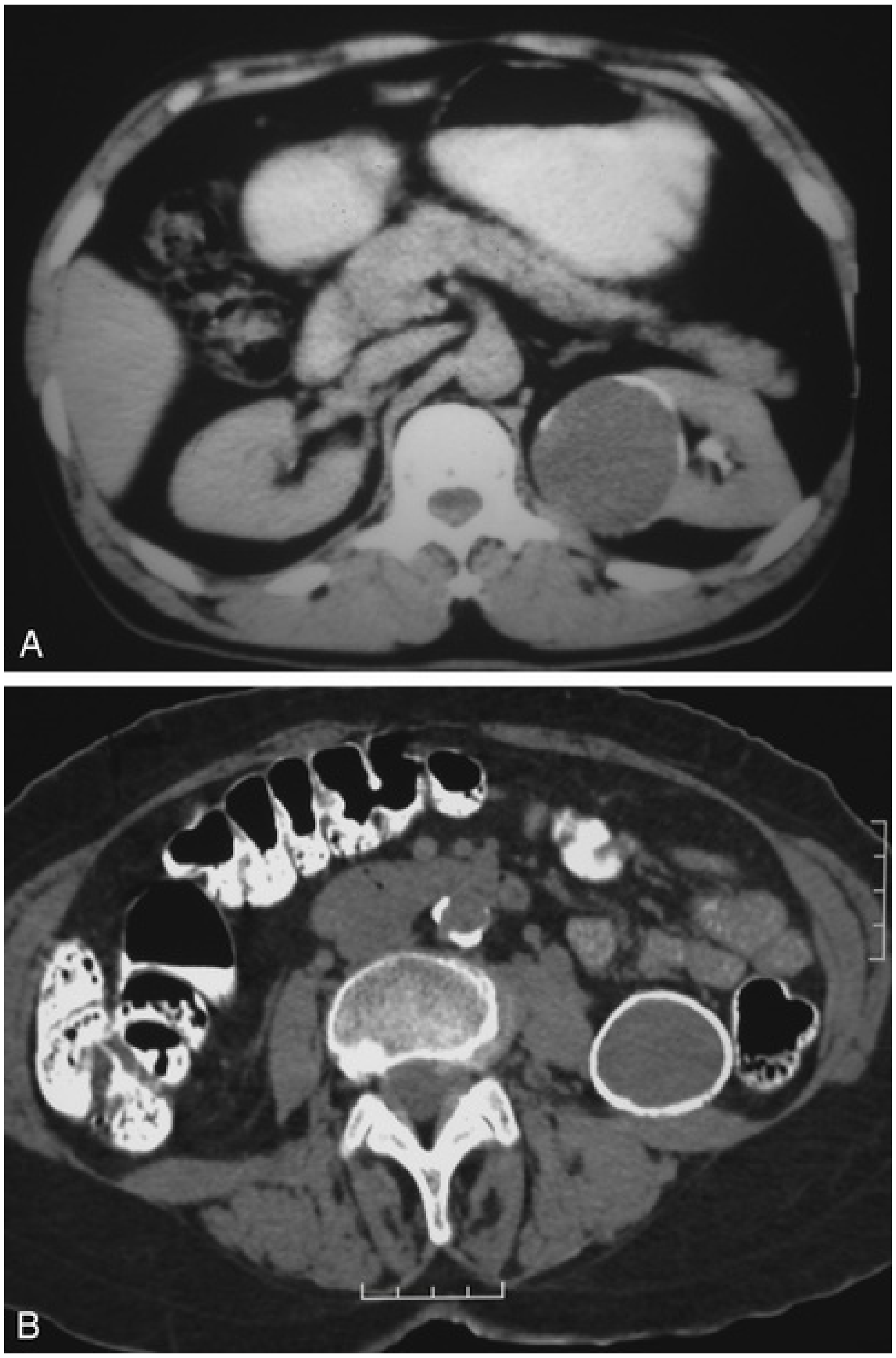

FIG. 39.25 (A and B) Two examples of Bosniak category II F cysts with diffuse calcification but no enhancement of septa on computed tomography. (Courtesy Jeffrey Newhouse, MD.)

Category III cysts are more complicated lesions with radiologic features that are also seen in malignancy. One example is the lesion with more extensive calcification, especially if the wall is not pencil-point thin or is

irregular. Other category III cysts are those with septations, suggesting a multilocular cystic lesion, or chronic infection with a thickened wall. These lesions are more problematic and require a surgical approach that is individualized. In some cases, the clinician may consider violating the Gerota fascia to expose the kidney for examination of the lesion or partial nephrectomy.

Bosniak category IV lesions are cystic malignant tumors and are dealt with as such, namely, by radical nephrectomy.

Treatment and Prognosis

Once malignancy has been ruled out, surgical intervention for an asymptomatic cyst is not indicated (Bartholomew et al., 1980; Gordon et al., 1979; Ravden et al., 1980; Siegel and McAlister, 1980). Large renal cysts may cause abdominal or flank pain, although this pain may be caused by a coexisting problem (e.g., nephrolithiasis), and other sources of pain should be ruled out. Other symptoms that may arise as a result of simple cysts are pain resulting from hemorrhage into the cyst or calyceal or infundibular obstruction caused by cyst impingement. In rare cases, hypertension may occur, presumably from cyst compression causing segmental renal ischemia of the surrounding renal parenchyma. Cyst infection is a rare but potentially severe complication, with patients demonstrating fever, flank pain, and often a sympathetic pleural effusion (Torres and Grantham, 2008). Most of these patients are women, the most common pathogen is *Escherichia coli*, and urine cultures can often be negative.

Treatment of the simple cyst must thus be directed to the symptomatology. When a benign simple cyst causes pyelocalyceal obstruction or hypertension, the problem may be corrected either surgically, by unroofing the cyst, or percutaneously, by aspirating the fluid and perhaps injecting a sclerosing agent, particularly if fluid has reaccumulated after an earlier aspiration. Several sclerosing agents have been used, including glucose, phenol, iophendylate (Pantopaque), bismuth phosphate, and absolute ethanol, but none has been sufficiently impressive for its use to become dominant (Holmberg and Hietala, 1989). Infected cysts must be drained and appropriate antibiotics given. Percutaneous resection, intrarenal marsupialization (Hubner et al., 1990; Hulbert and Hunter, 1990; Meyer and Jonas, 1990), and laparoscopic unroofing (either transperitoneally or retroperitoneally) are reasonable options for the treatment of symptomatic simple cysts.

Unilateral renal cystic disease is characterized by cysts of varying size

appearing side by side, often more numerous at one pole. Except for its unilateral location, lack of extrarenal cyst formation, and the fact that these patients show no genetic background or progressive deterioration in renal function, the gross and histologic findings are indistinguishable from those of asymmetrical ADPKD (Kossow and Meek, 1982; Lee et al., 1978). It is important not to overdiagnose unilateral simple cyst disease, because the entity itself is rare, and when first identified in an individual it is more likely to represent a unilateral asymmetrical presentation of ADPKD. Because the entity seems to represent nothing more than multiple simple cysts lying side by side within a kidney, it seems reasonable to consider it as a variation of the presentation of simple cysts. Now that genetic studies are becoming available for ADPKD, TSC, and VHL disease, the diagnosis of unilateral renal cystic disease can more readily be confirmed (Fig. 39.26).

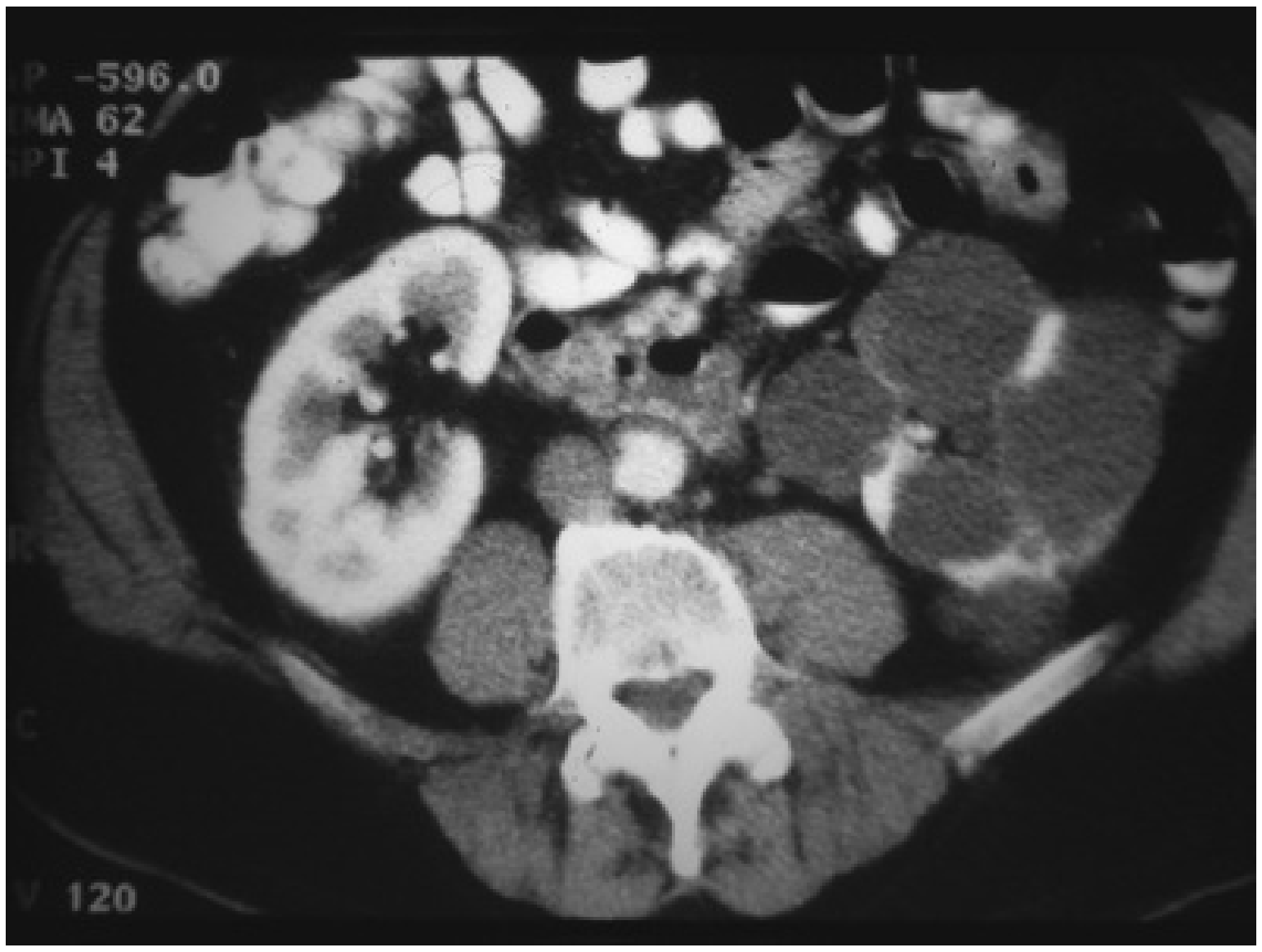

FIG. 39.26 Unilateral renal cystic disease. Diffuse simple cysts were evident in one kidney. There was no discrete mass or evidence of multiple malformation syndrome. (Courtesy Jeffrey Newhouse, MD.)

Key Points: Simple Cysts

- Simple cysts are seldom seen in children; in adults, simple cysts are seen increasingly more frequently with age.

- For diagnosis of a benign simple cyst on ultrasonography, it should (1) have no internal echoes, (2) have a sharply defined, thin, distinct smooth wall, (3) be spheric or oval with no internal echoes, and (4) have good transmission of sound waves with acoustic enhancement behind the cyst. When these criteria are not met, CT with contrast enhancement must be performed.
- Relevant guidelines for determining when to explore or remove a complex cyst are often based on the Bosniak CT classification (see Box 39.2).

Medullary Sponge Kidney

The condition known as *medullary sponge kidney* (MSK; also known as *precalyceal canalicular ectasia*) was recognized by Beitzke in 1908, and its radiographic features were described by Lenarduzzi in 1939. The name of this disorder dates from a 1949 publication by Cacchi and Ricci. **It is characterized by tubular dilation of the distal portion of the collecting ducts with numerous associated cysts and diverticula strictly confined to the medullary pyramids.** These dilated ducts have the appearance of the bristles on a brush and often are more ectatic and filled with calcifications, giving an appearance suggestive of a bouquet of flowers. In general, classic intravenous urography is more sensitive than CT in detecting mild cases of MSK; however, three-dimensional (3D) volume-rendered imaging acquired during the urographic phase of a multidetector CT urogram can also establish the diagnosis (Fig. 39.27). The current literature suggests that single-slice helical CT, ultrasonography, and MRI are not able to detect findings specific to MSK. However, CT urography with 3D volume-rendered imaging is comparable with intravenous pyelography for the diagnosis of MSK (Maw, 2007).

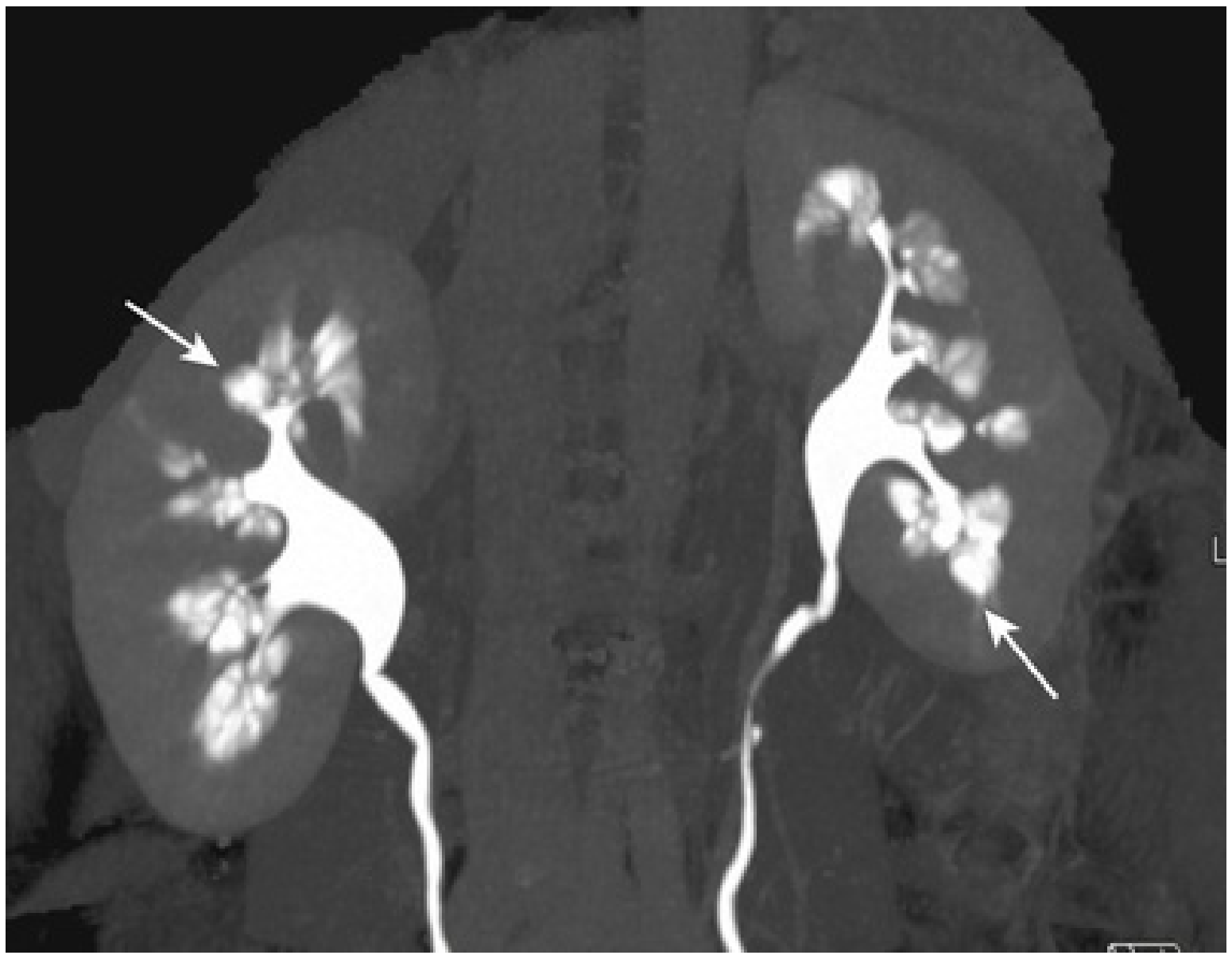

FIG. 39.27 Contrast-enhanced maximum intensity projection three-dimensional image from multidetector-row computed tomography (CT) urogram shows characteristic papillary blush *(arrows)* associated with scattered calculi within the dilated collecting tubules. The CT demonstration

is equivalent to the well-documented intravenous pyelography findings. (From Maw AM, Megibow AJ, Grasso M, et al.: Diagnosis of medullary sponge kidney by computed tomographic urography. *Am J Kid Dis* 50:146–150, 2007.)

A significant number of patients with MSK are asymptomatic, and their condition is never diagnosed. As a result, the true incidence of the condition is unknown. Among patients undergoing intravenous urography for various indications, 1 in 200 were found to have MSK (Myall, 1970; Palubinskas, 1961). MSK is more common in calcium stone formers. It is usually regarded as a nonhereditary disease, and the small number of reported cases in children implies that this is an acquired rather than a congenital disease. There has been some recent evidence, however, that some forms of the disease are inherited in an autosomal dominant fashion. This evidence supports the hypothesis that MSK is caused by a disruption at the ureteric bud–metanephric blastema or RET/GDNF interface (Gambaro, 2013).

Clinical Features

MSK is usually a benign process, and it may remain asymptomatic and undetected for life. Clinical presentation usually occurs after age 20 years, with the most common presentation being renal colic (50% to 60%), followed by urinary tract infection (20% to 33%) and gross hematuria (10% to 18%) (Kuiper, 1976). The incidence of MSK in stone formers differs widely in the reported series, ranging from 2.6% to 21%. The incidence appears to be higher in female than in male stone formers (Lavan et al., 1971; Palubinskas, 1961; Parks et al., 1982; Sage et al., 1982; Vagelli et al., 1988; Wikstrom et al., 1983; Yendt, 1990). Urinary tract infections, likewise, seem to be more common in female patients with MSK (Parks et al., 1982).

One-third to one-half of the patients with MSK have hypercalciuria (Ekstrom et al., 1959; Harrison and Rose, 1979; Parks et al., 1982; Yendt, 1990). Incomplete distal renal tubular acidosis may be found in as many as 30% to 40% of these patients (Torres and Grantham, 2008). In the absence of infection, the stones passed by patients with MSK are composed of calcium oxalate, either alone or in combination with calcium phosphate. MSK has also been reported in association with rare congenital anomalies, such as hemihypertrophy, Beckwith-Wiedemann syndrome (macroglossia, omphalocele, and gigantism), Ehlers-Danlos syndrome, anodontia, and Caroli disease.

Three different clinical pictures of MSK have been described: the typical form characterized by recurrent calcium nephrolithiasis and a number of concomitant tubular defects, including renal acidosis and metabolic bone disease; an indolent form with no or few renal stones and no tubular defects; and a rare but very severe condition dominated by intractable excruciating renal pain (Gambaro, 2013).

Histopathology

The principal finding is dilated intrapapillary collecting ducts and small medullary cysts, which range in diameter from 1 to 8 mm and give the cross-sectioned kidney the appearance of a sponge. The renal size is usually normal or slightly enlarged. The precalyceal canalicular ectasia may involve one or more renal papillae in one or both kidneys. The lesions are bilateral in 70% of cases. The cysts are lined by collecting duct epithelium (Bernstein, 1990) and usually communicate with the collecting tubules. The cysts and the dilated collecting ducts may have concretions mostly made of pure apatite (calcium phosphate) and, less frequently, apatite and calcium oxalate (Ekstrom et al., 1959). The cysts contain a yellow-brown fluid and desquamated cells or calcified material.

Diagnosis

The urographic features of the disorder are as follows: (1) enlarged kidneys, sometimes with calcification, particularly in the papillae; (2) elongated papillary tubules or cavities that fill with contrast medium; and (3) papillary contrast blush and persistent medullary opacification (Gedroyc and Saxton, 1988). Calcium deposits within the tubules may appear as renal calculi or nephrocalcinosis.

In rare cases, MSK can mimic the radiographic appearance of ADPKD. In these instances, the liver should be evaluated before a diagnosis is made. In addition, the absence of family history and a CT showing the absence of cortical cysts help confirm the diagnosis.

When nephrocalcinosis is found, other hypercalciuric states, such as hyperparathyroidism, sarcoidosis, vitamin D intoxication, multiple myeloma, tuberculosis, and milk alkali syndrome, must be ruled out. In these conditions, the calcium deposits are in collecting ducts of normal caliber, whereas in MSK the calcifications occur in dilated ducts (Levine and Grantham, 1990).

Treatment and Prognosis

The complications of MSK, calculus formation and infection, require management. Given the frequent presence of hypercalciuria and hypocitraturia (possibly caused by incomplete renal tubular acidosis), treatment with potassium citrate is effective in reducing the rates of calciuria and stone recurrence (Gambaro, 2013). In addition to liberal fluid intake and a low-sodium diet, **thiazides are effective for lowering hypercalciuria and limiting stone formation. If thiazides cannot be used, inorganic phosphates may be appropriate;** however, they should not be used in patients with urinary tract infections caused by urease-producing organisms, because of the risk of struvite stones. **For patients with renal lithiasis, thiazides should be administered even if hypercalciuria is not present.**

Because infections are not unusual in patients with MSK, especially if stones are present, cultures should be obtained frequently, and long-term prophylaxis should be considered in some cases. Infections by coagulase-positive staphylococci are common in patients with stones and should be treated even when the colony count in the cultures is less than 100,000/mL (Yendt, 1990). Repeated investigations for hematuria should be avoided. When stones require surgical therapy, standard procedures, such as extracorporeal lithotripsy and percutaneous nephrolithotomy, may be used.

Key Points: Medullary Sponge Kidney

- MSK is usually a nonheritable condition associated with dilated collecting ducts that appear as bristles on a brush on IVP, and the ducts are sometimes filled with calcifications.
- There are high incidences of renal colic (50% to 60%), urinary tract infections (20% to 33%), gross hematuria (10% to 18%), and hypercalciuria (33%).

Sporadic Glomerulocystic Kidney Disease

GCKD is a specific entity, but the term has often been used to include all conditions in which there are glomerular cysts, regardless of cause. The term *glomerulocystic* means that cysts of the glomeruli or Bowman space are present diffusely and bilaterally. However, cysts of the glomeruli are present in many forms of renal cystic disease, and they may or may not be the predominant pathology. The specific disease entity, glomerulocystic disease (or “sporadic” glomerulocystic disease), is a nonheritable condition producing bilaterally enlarged kidneys containing small cysts, predominantly of the Bowman space. The clinical significance of this disease process is that it is often **indistinguishable from other conditions in which glomerular cysts are present, namely, autosomal dominant polycystic disease, familial hypoplastic glomerulocystic disease, and juvenile NPH.** Characteristically, with sporadic GCKD, no other family members are affected and no associated anomalies are typically present.

Acquired Renal Cystic Disease

ARCD, also known as *acquired cystic kidney disease* (ACKD), is defined as bilateral cystic renal change in patients with ESRD from causes other than inherited renal cystic disease. A minimum of three cysts in each kidney is required for diagnosis. This disease entity was first described in 1977 in **patients receiving hemodialysis; however, it soon became apparent that the disorder is almost as common in patients receiving peritoneal dialysis** (Dunhill et al., 1977; Thomson et al., 1986). It is now known that dialysis is not a prerequisite of ARCD, and it is likely that the uremic state causes the pathologic changes seen; dialysis merely prolongs patient survival and the amount of time available for the cystic changes to occur (Fisher and Horvath, 1972; Ishikawa et al., 1980; Kutcher et al., 1983; Miller et al., 1989; Truong et al., 2003).

The prevalence and severity of this disease increase with the duration of azotemia and the subsequent need for dialysis. Acquired cysts are found in roughly 10% of patients with ESRD before dialysis. The incidence increases to 44% within 3 years after initiation of dialysis, to 60% at 5 years after initiation of dialysis, and to greater than 90% if the patient is on dialysis for 10 or more years. ARCD is three times more common in men than in women and is generally thought to be unrelated to age or the cause of renal failure. African-Americans and perhaps Japanese are more prone than Americans of European descent to develop ARCD (Reichard et al., 1998). **ARCD can occur in children as well (an incidence of approximately 23% has been reported)** (Hakim et al., 1994). A successful renal transplant was previously thought to delay or even reverse the cystic changes, but this is not supported by more recent data (Doublet et al., 1997; Heinz-Peer et al., 1995; Kliem et al., 1997).

Etiology

Several etiologic theories have been proposed for ARCD, although the exact cause has not been identified. One theory suggests that tubular obstruction resulting from fibrosis, oxalate crystals, vascular occlusion, or ischemia leads to cyst formation. Various other findings suggest a role for toxins. First, the cysts, adenomas, and carcinomas usually are multiple and bilateral, as are the carcinomas induced experimentally in rats by toxins. Second, there is often a regression of the cysts after successful transplantation (Ishikawa et al., 1983), suggesting that some cystogenic or carcinogenic toxin of uremia is being eliminated by the allograft. Third, if transplantation fails and dialysis is resumed, the cysts return even in chronically rejected transplanted kidneys. Another hypothesis suggests that the accumulation of growth factors, such as epidermal growth factor (EGF), and other stimulatory chemicals (present with uremia) leads to the development of cysts (Bisceglia et al., 2006). Yet another theory suggests that loss of functioning renal tissue leads to the production of renotrophic agents that induce hyperplasia of remaining glomeruli, cyst development, and in extreme cases renal tumors (Harris et al., 1983; Yamamoto et al., 1983).

Clinical Features

Most patients with ARCD are asymptomatic. The majority of clinical manifestations result from spontaneous bleeding into one or more of the cysts, making the most common presentation loin pain, hematuria, or both conditions. Bleeding occurs in as many as 50% of patients (Levine, 1996). When significant bleeding occurs, it may cause a subcapsular or retroperitoneal hematoma and may be secondary to renal cysts or to RCC. This bleeding may be complicated by coagulation defects induced by uremia or heparinization during dialysis. Other, much less common, complications are cyst infection, urolithiasis, and a rapid rise in hematocrit, which is probably related to increased renal synthesis of erythropoietin (Mickisch et al., 1984; Ratcliffe et al., 1983; Shalhoub et al., 1982). Patients with microscopic hematuria (more than 5 red blood cells per high-power field), dialysis patients, and transplant recipients should be radiographically evaluated because of the increased risk of tumor formation in these groups.

Renal neoplasms, principally adenomas, occur in 10% of patients receiving chronic hemodialysis, and, when ARCD is present, the incidence of neoplasms is even higher, ranging from 20% to 25% (Gardner and Evan, 1984). The overall prevalence of RCC in hemodialysis patients is approximately 1%. Carcinoma is 3 times more likely in the presence of ARCD and 6 times more common in large cystic kidneys than in small cystic kidneys (Torres and Grantham, 2008). **Overall, the incidence of renal malignancy in dialysis patients is 5 to 50 times greater than in the general population** (Ishikawa, 1993; Levine et al., 1991; Port et al., 1989; Resseguie et al., 1978; Truong et al., 1995).

Compared with the sporadic form, RCC associated with ARCD is characterized by younger patient age, male predominance, frequent multicentricity and bilaterality, and less aggressive behavior (Denton et al., 2002; Gronwald et al., 1999; Truong et al., 2003). Approximately 20% of ARCD-associated RCC metastasizes versus 50% for sporadic RCC. **The risk factors for tumor development include male gender, duration of dialysis, and kidney weight, but not type of dialysis.** Children on dialysis can also develop RCC, despite its rarity in the general pediatric population. Most tumors (86%) are asymptomatic, and the symptomatic ones are related mostly to bleeding from tumor. Many manifest exclusively as persistent hematuria and are not seen by any available imaging techniques. Nephrectomy is recommended for tumors larger than 3 cm or for smaller ones that are associated with persistent hematuria or rapid growth (Ishikawa, 2000; Truong et al., 1995).

Histopathology

Both kidneys are usually smaller than normal, and the cysts are multiple and bilateral. The cysts develop predominantly in the cortex, although the medulla may be affected, especially later in the disease process (Fig. 39.28). The cysts average 0.5 to 1.0 cm in diameter, but some have been reported to reach 5.0 cm (Miller et al., 1989). Larger cysts, a frequent feature of ADPKD, are rare. The cysts are unilocular and contain clear, straw-colored, or gelatinous fluid, with frequent bleeding and/or neoplastic transformation.

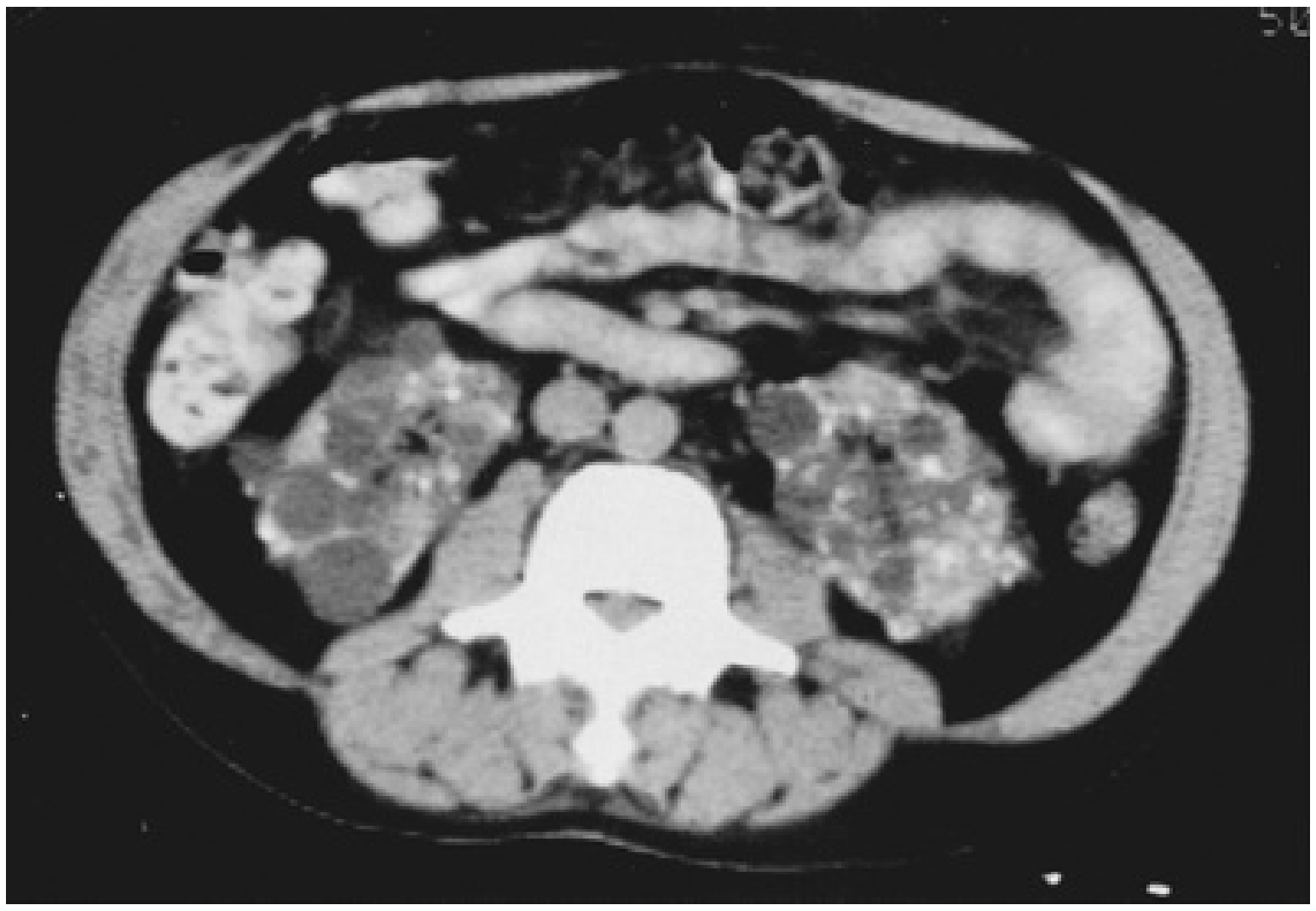

FIG. 39.28 Bilateral multiple renal cysts and diffuse calcification in enlarged kidneys in a patient undergoing chronic hemodialysis. The

findings simulate those of ADPKD. However, cystic disease was not the cause of the uremia, and the diagnosis of acquired renal cystic disease was made. (Courtesy D. Gordon, MD.)

Most cysts are lined by a single layer of epithelium composed of flat nondescript cells, cells with abundant cytoplasm and hyaline droplets, or small cuboidal cells resembling those from distal tubules or collecting ducts. Cysts usually show secondary changes, including luminal deposition of degenerated blood, hemosiderin, or calcium oxalates (Hughson et al., 1986; Ishikawa, 1991; Truong et al., 1995). The nuclei of the epithelial cells in these cases are round and regular, without prominent nucleoli (Hughson et al., 1980). However, some cysts (atypical or hyperplastic) are lined by epithelial cells with larger, irregular nuclei that contain prominent nucleoli and may show mitotic activity. This hyperplastic lining is thought by some to be a precursor of renal tumors. Moreover, some hyperplastic cysts have papillary projections, and to some observers the distinction between cyst and neoplasm becomes blurred when papillary hyperplasia predominates.

Differentiating renal tumors into adenomas and carcinomas is arbitrary at times. Most renal nodules that are smaller than 1 cm in diameter are adenomas, and most that are larger than 3 cm in diameter are carcinomas. Tumors between 1 and 3 cm in diameter must be considered equivocal. It is not clear whether renal adenomas undergo malignant transformation. It is believed that atypical hyperplastic epithelium occurs even without cyst formation and that these cells are the precursors of atypical cysts and adenomas (Hughson et al., 1986). It is thus possible that either hyperplastic cysts or adenomas can become RCCs. Therefore the clinician must not ignore the native kidney left in situ during a renal transplantation. Hyperplastic cyst epithelium has also been considered a possible precursor of RCC in other cystic diseases (VHL disease and tuberous sclerosis) (Fayemi and Ali, 1980).

Evaluation

Ultrasonography is the modality most commonly used to diagnose and monitor patients with ARCD. CT and MRI identify more cysts, and MRI is probably better at demonstrating and characterizing small lesions in particular (Heinz-Peer et al., 1998). Ultrasonography usually shows small, hyperechoic kidneys with cysts of various sizes. Cyst wall calcification may be visible, but it is more readily seen on CT. CT with and without contrast is better for distinguishing kidneys with a few simple cysts from those with multiple acquired cysts and is the most useful for detecting neoplasms. In patients with ESRD not yet on dialysis, however, the use of CT contrast should be avoided for fear of causing further deterioration of renal function. Ultrasonography and MRI with gadolinium enhancement are better alternatives to contrast-enhanced CT in these patients. **A word of caution, however: nephrogenic systemic fibrosis (NSF) is a rare but serious and life-threatening disorder observed in patients with renal impairment and is associated with the infusion of gadolinium as an MRI contrast agent in patients with ESRD. Caution should be used when using gadolinium in these patients.**

In uremic patients with fever, clinicians should consider the diagnosis of ARCD and the possibility of an infected cyst (Bonal et al., 1987). Infection should be suspected if ultrasonographic examination shows internal echoes or a thickened wall. Cyst puncture can be used to confirm the diagnosis and to identify the infecting microorganism. CT examination may identify cyst wall thickening in patients with infection.

In the differential diagnosis of ARCD, the cause of the renal failure must be considered and, in particular, the possibility of ADPKD. Usually, patients with ARCD have smaller kidneys and smaller cysts and are free of the extrarenal manifestations of ADPKD. In patients receiving hemodialysis, kidneys affected by ARCD usually are smaller than 300 g; ADPKD kidneys usually are larger than 800 g (Feiner et al., 1981).

Treatment

Bleeding episodes are often treated conservatively with bed rest and symptom control. Persistent bleeding and pain, however, may require nephrectomy or renal embolization. If heparinization is associated with hematuria during hemodialysis, peritoneal dialysis may be substituted. Because the risk of undetected RCC is high in patients with retroperitoneal hemorrhage, nephrectomy is recommended when carcinoma cannot be ruled out. If a few larger cysts are associated with flank pain, percutaneous aspiration (with cytologic examination) is a reasonable temporizing measure, because ARCD may regress after successful renal transplantation (Torres and Grantham, 2008). For an infected cyst, percutaneous drainage may be effective. When it is not, surgical drainage or nephrectomy should be considered.

Although small renal tumors may metastasize, it is known that those smaller than 3.0 cm in diameter rarely do so (Bell, 1935; Talamo and Shonnard, 1980). Thus it is currently recommended that renal masses larger than 3 cm detected in patients with ACKD be treated by surgical excision. For tumors smaller than 3 cm, some advise nephrectomy for the acceptable surgical candidate, whereas others recommend annual CT follow-up with resection only if the tumors enlarge. Although metastases are statistically less likely to occur from small than from large tumors, small tumor size is not a guarantee against metastasis. Laparoscopic bilateral radical nephrectomy in patients with ESRD, ACKD, and suspicious tumors has been proposed as a more desirable alternative to traditional open surgery (Ghasemian et al., 2005).

It has been recommended that patients who have been receiving hemodialysis for longer than 3 years be screened by ultrasonography and CT and then monitored by ultrasonography every 6 months if the kidneys are without cysts and tumors or by both ultrasonography and CT on the same schedule if cysts or tumors smaller than 2 cm are identified (Sarasin et al., 1995). The benefit of screening in this population continues to be the subject of much debate. It has been proposed that screening be restricted to patients younger than 55 years who have been on dialysis for at least 3 years and are in good general health (Sarasin et al., 1995). Others have suggested that screening of patients should be considered when known risk factors exist, such as prolonged dialysis, presence of ARCD, and male gender (Reichard et al., 1998).

A number of investigators have found that the cysts of ARCD regress after renal transplantation (Ishikawa et al., 1983; Kutcher et al., 1983; Thomson et al., 1986). Therefore it was considered that the incidence of RCC may fall after transplantation as well. Unfortunately, 18% of patients developed new cysts after transplantation, and renal carcinoma can occur in the native kidney 3 to 8 years after transplantation (Ishikawa, 1991; Levine and Gburek, 1994). It appears that the malignant potential of ARCD may persist for many years after transplantation, especially in older transplantation patients and in men (Heinz-Peer et al., 1995). Finally, immunosuppression makes these patients vulnerable to carcinoma. Native kidneys account for 4.5% of all malignancies in renal transplantation recipients (Penn, 1979). After renal transplantation for ESRD, the risk for developing RCC is more than 15-fold increased (Kasiske, 2004). RCC of native kidneys and RCC of the allografts can be distinguished, with more than 70% of the tumors occurring in native kidneys (Klatte, 2011; Tsaur, 2011). It also appears that the clinical significance of RCC in patients undergoing chronic hemodialysis must be questioned because in this population, RCCs rarely cause metastases or death. In contrast, renal cancer in the transplant population behaves aggressively and warrants aggressive evaluation before and after renal transplantation.

Key Points: Acquired Renal Cystic Disease

- ARCD is associated with chronic renal failure and is most often seen in patients on long-term hemodialysis and peritoneal dialysis.
- ARCD consists of hyperplastic renal cysts and frequently adenomas; either can progress to RCC.
- The incidence of renal malignancy in dialysis patients is 5 to 50 times greater than in the general population. If RCC develops, it mostly does so before 10 years of dialysis.
- The cysts usually regress with transplantation. Even when this occurs, there still is some suggestion that the risk of developing RCC still persists, but at a much lower incidence.

Calyceal Diverticulum (Pyelogenic Cyst)

A calyceal diverticulum is an outpouching of the collecting system into the corticomedullary region of the kidney, and it usually arises from the fornix of a calyx. It is a transitional epithelial-lined, smooth-walled, spheric cavity that communicates with the pelvicalyceal system by a thin channel or neck, typically in the upper or lower pole. It is sometimes known as a *pyelogenic cyst*, especially if it arises from the renal pelvis. The size of such lesions can range from a few millimeters to several centimeters. Most diverticula are presumed to be congenital; however, similar lesions may occur as a result of blunt renal trauma or obstruction of a calyceal infundibulum. Diverticula are usually asymptomatic but may occasionally develop calculi. The calculi may be a single larger stone or multiple tiny stones. Occasionally, milk of calcium may be present. Passage of a stone through the narrow channel into the calyx may cause pain and hematuria.

Radiographically, these diverticula are seen as a spheric collection of contrast medium adjacent to a papilla on IVP; however, the connecting channel is often too narrow to be demonstrated. On upright films, the urine and contrast media form a fluid level. Calyceal diverticula can also be seen on CT, MRI, and ultrasonography, but the distinction between an obstructed calyx and a renal cyst may be difficult unless contrast is administered (Fig. 39.29).

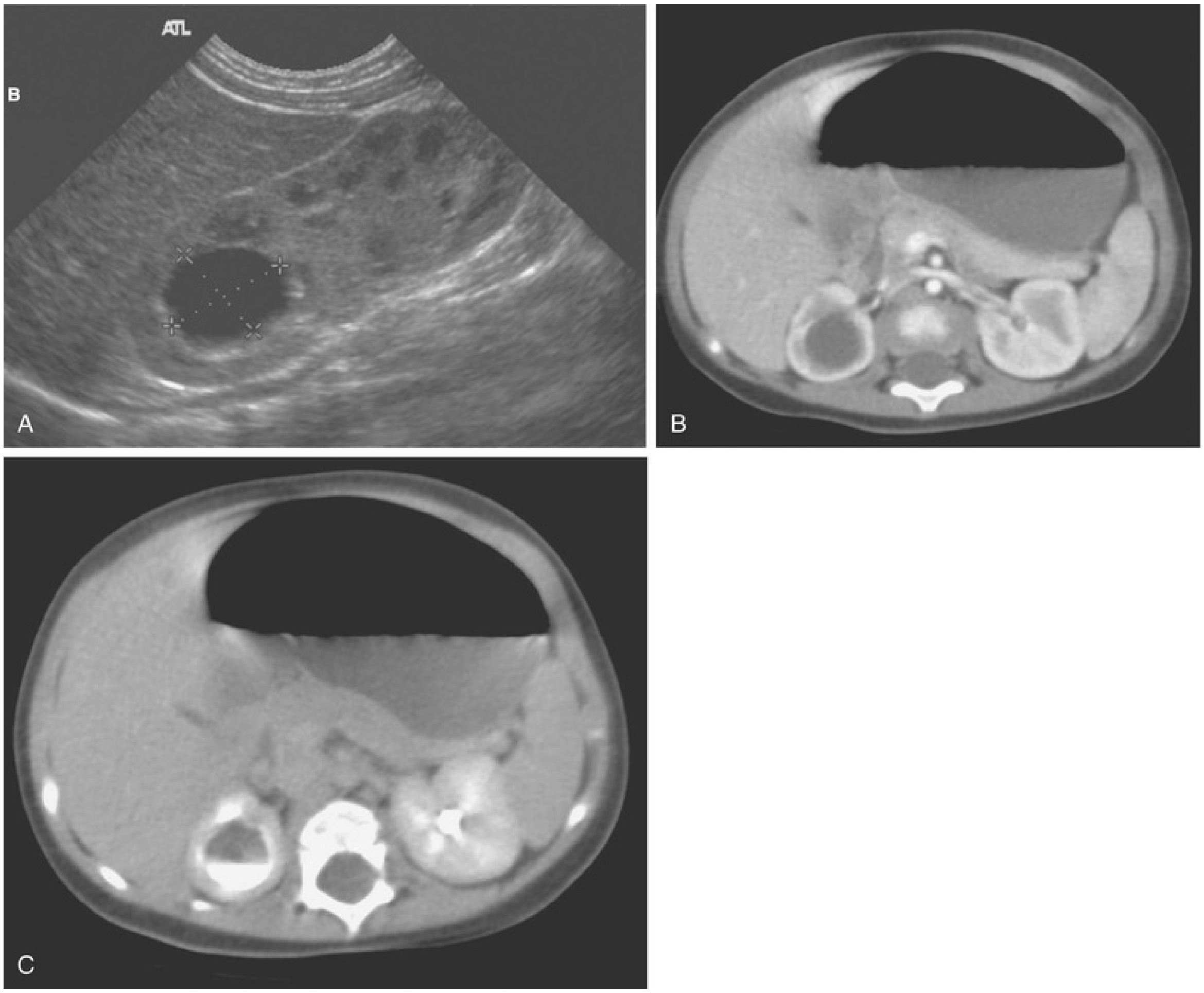

FIG. 39.29 Calyceal diverticulum. (A) Renal ultrasonography reveals a round lesion that could be confused with a renal cyst. Because of the patient's history of recurrent febrile urinary tract infections, contrast computed tomography was performed. (B) Early contrast images reveal no enhancement of the lesion; however, delayed imaging (C) reveals contrast layering in a portion of the collecting system, confirming the diagnosis of calyceal diverticulum.

This entity is discussed in more depth in Chapter 38.

Parapelvic and Renal Sinus Cysts

Parapelvic cysts, renal sinus cyst, peripelvic cyst, pelvic cyst, parapelvic lymphatic cysts, hilus cysts, cysts of the renal hilum, and parapelvic lymphangiectasia are terms used to describe cysts adjacent to the renal pelvis or within the hilum. Although some peripelvic cysts are simple cysts that arise from the renal parenchyma and impinge on the renal pelvis, true cysts derived from the renal sinus have no parenchymal cause. Thus the terms *parapelvic* and *peripelvic* are terms better used to describe the location of parenchymal cysts, and the term *renal sinus cyst* more accurately describes all other cysts in the hilum that are not derived from the renal parenchyma but rather from the other structures of the renal sinus, such as arteries, lymphatics, and fat. These are all benign lesions found in 15% to 20% of patients at autopsy. With modern imaging techniques, they can easily be distinguished from more serious lesions of the renal pelvis or renal parenchyma (Fig. 39.30).

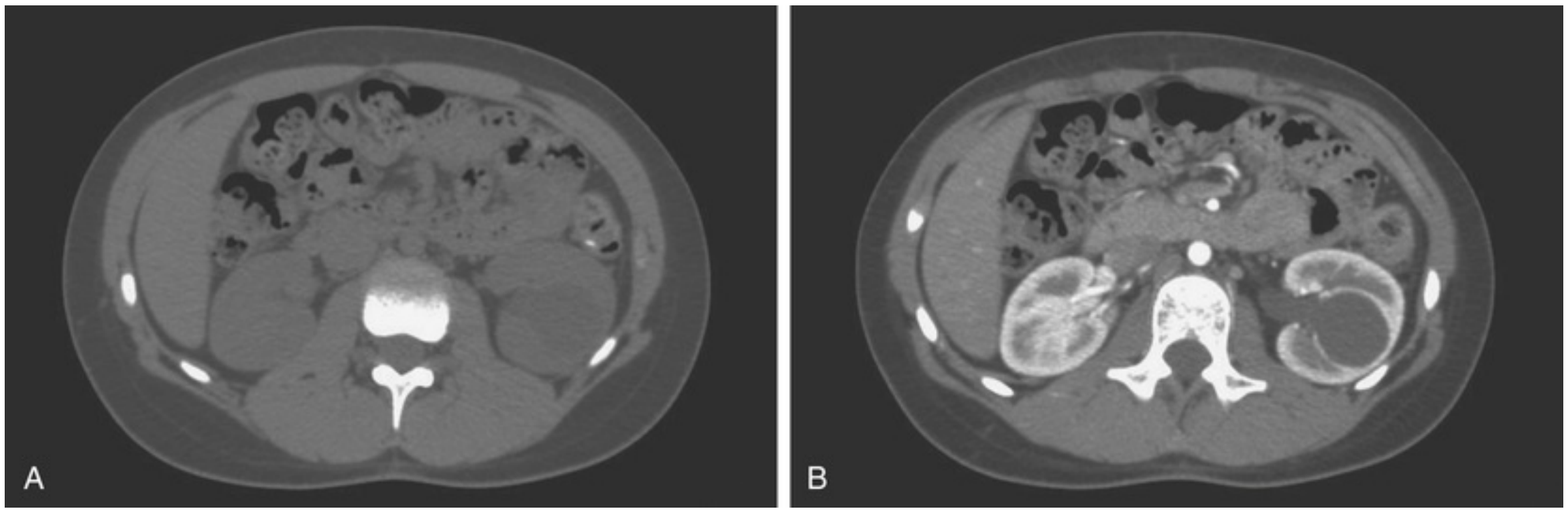

FIG. 39.30 Parapelvic cyst. (A) A hypoechoic, well-circumscribed, round focus in the peripelvic region of the kidney. (B) There is no delayed enhancement after the administration of intravenous contrast. There is no hydronephrosis or hydroureter. Note contrast within the ureter on the contrasted images.

The predominant type of renal sinus cyst appears to be a result of dilation of lymphatics; however, the mechanism responsible for these changes is not known. Most often these cysts are multiple, and often they are bilateral. Other renal sinus cysts are caused by fluid replacing adipose tissue in the renal sinus as the kidney becomes affected by local vascular disease and atrophy.

Patients are usually in their fifth or sixth decades and are almost always asymptomatic. These cysts are usually discovered incidentally in the course of evaluation for other conditions, such as urinary tract infections, nephrolithiasis, hypertension, and prostatism. There are rare instances of obstruction of a collecting system from these cysts. Ultrasonography will show multiple echo-free areas in the region of the renal sinus. Differentiation from hydronephrosis may be difficult. A diagnosis of hydronephrosis is established without question when dilated calyces are seen to communicate with a dilated renal pelvis. On CT, renal sinus cysts have the attenuation value of water, and they can often be seen within the renal sinus as they displace the calyces peripherally. On nonenhanced scans, multiple renal sinus cysts resemble a dilated renal pelvis and thus mimic hydronephrosis. Differential diagnosis should include renal sinus lipomatosis (fat density), lymphoma, hemorrhage, and urinoma. The therapeutic approach to renal sinus cysts should be conservative.

Acknowledgment

I would like to thank Anthony Kallas Chemaly, MD, fellow in Pediatric Urology at Femme Mère-Enfant Hospital (Lyon, France), for his assistance with factual proofreading.

Suggested Readings

Al-Bhalal L, Akhtar M. Molecular basis of autosomal recessive polycystic kidney disease (ARPKD). *Adv Anat Pathol*. 2008;15:54–58.

Avni FE, Guissard G, Hall M, et al. Hereditary polycystic kidney diseases in children. *Pediatr Radiol*. 2002;32:169–174.

Bisceglia M, Galliana CA, Senger C, et al. Renal cystic diseases: a review. *Adv Anat Pathol*. 2006;13:26–56.

Bosniak MA. The use of the Bosniak classification system for renal cysts and cystic tumors. *J Urol*. 1997;157:1852.

Braun WE. Autosomal dominant polycystic kidney disease: emerging concepts of pathogenesis and new treatments. *Cleve Clin J Med*. 2009;76:97–104.

Chakraborty K, McHugh K. Cystic diseases of the kidney in children. *Imaging*. 2005;17:69–75.

Clark PE, Cookson MS. The von Hippel-Lindau gene: turning discovery into therapy. *Cancer*. 2008;113(Suppl 7):1768–1778.

Grantham JJ. The etiology, pathogenesis and treatment of polycystic autosomal dominant polycystic kidney disease: recent advances. *Am J Kidney Dis*. 1996;8:788–803.

Mackie GG, Stephens FD. Duplex kidneys: a correlation of renal dysplasia with position of the ureteral orifice. *J Urol*. 1975;114:274.

Pazour G. Intraflagellar transport and cilia-dependent renal disease: the ciliary hypothesis of polycystic kidney disease. *J Am Soc Nephrol*. 2004;15:2528–2536.

Peters CA, Carr ML, Lais A, et al. The response of the fetal kidney to obstruction. *J Urol*. 1992;148:503–509.

Pope JC 4th, Brock JW 3rd, Adams MC, et al. How they begin and how they end: classic new theories for the development and deterioration of congenital anomalies of the kidney and urinary tract, CAKUT. *J Am Soc Nephrol*. 1999;61:2018–2028.

Reed AB, Parekh DJ. Surgical management of von Hippel-Lindau disease: urologic considerations. *Surg Oncol Clin N Am*. 2009;8(1):157–174.

Shehata BM, Stockwell CA, Castellano-Sanchez AA, et al. von Hippel-Lindau (VHL) disease: an update of the clinicopathologic and genetic aspects. *Adv Anat Pathol*. 2008;15:165–171.

Sweeney WE Jr, Avner ED. Pathophysiology of childhood polycystic kidney diseases: new insights into disease-specific therapy. *Pediatr Res*. 2013;1–2(75):148–157.

Torres VE, Grantham JJ. Cystic diseases of the kidney. Brenner BM. *Brenner and Rector's the kidney*. ed 8. Saunders: Philadelphia; 2008:1428–1462.

References

Ala-Mello S, Sankila EM, Koskimies O, et al. Molecular studies in Finnish patients with familial juvenile nephronophthisis exclude a founder effect and support a common mutation causing mechanism. *J Med Genet*. 1998;35:279–283.

Al-Bhalal L, Akhtar M. Molecular basis of autosomal recessive polycystic kidney disease (ARPKD). *Adv Anat Pathol*. 2008;54–58.

Al-Khaldi N, Watson AR, Zuccollo J, et al. Outcome of antenatally detected cystic dysplastic kidney disease. *Arch Dis Child*. 1994;70:520.

Angermeier KW, Kay R, Levin H. Hypertension as a complication of multicystic dysplastic kidney. *Urology*. 1992;39:55–58.

Arant BS Jr, Sotelo-Avila C, Bernstein J. Segmental hypoplasia of the kidney (Ask-Upmark). *J Pediatr*. 1979;95:931–939.

Arey JB. Cystic lesions of the kidney in infants and children. *J Pediatr*. 1959;54:429.

Aterman K, Boustani P, Gillis DA. Solitary multilocular cysts of the kidney. *J Pediatr Surg*. 1973;8:505.

Atiyeh B, Husmann D, Baum M. Contralateral renal abnormalities in multicystic-dysplastic kidney disease. *J Pediatr*. 1992;121:65.

Avni E, Thova Y, Lalmand B, et al. Multicystic dysplastic kidney: natural history from in utero diagnosis and postnatal followup. *J Urol*. 1987;138:1420.

Avni FE, Guissard G, Hall M, et al. Hereditary polycystic kidney diseases in children. *Pediatr Radiol*. 2002;32:169–174.

Babin J, Sackett M, Delage C, et al. The Ask-Upmark kidney: a curable cause of hypertension in young patients. *J Hum*

Hypertens. 2005;19:315–316.

Bae KT, Zhu F, Chapman AB, et al. Magnetic resonance imaging evaluation of hepatic cysts in early autosomal-dominant polycystic kidney disease. *Clin J Am Soc Nephrol*. 2006;1:64–69.

Banner MP, Pollack HM, Chatten J, et al. Multilocular renal cysts: radiological-pathologic correlation. *AJR Am J Roentgenol*. 1981;136:239.

Barloon JT, Vince SW. Caliceal obstruction owing to a large parapelvic cyst: excretory urography, ultrasound and computerized tomography findings. *J Urol*. 1987;137:270.

Bartholomew TH, Solvis TL, Kroovand RL, et al. The sonographic evaluation and management of simple renal cysts in children. *J Urol*. 1980;123:732.

Bayram MT, Alaygut D, Soylu A, et al. Clinical and radiological course of simple renal cysts in children. *Urology*. 2014;83:433.

Beck AD. The effect of intra-uterine urinary obstruction upon the development of the fetal kidney. *J Urol*. 1971;105:784.

Belibi FA, Wallace DP, Yamaguchi T, et al. The effect of caffeine on renal epithelial cell from patients with autosomal dominant polycystic kidney disease. *J Am Soc Nephrol*. 2002;13:2723–2729.

Bell ET. Cystic disease of the kidneys. *Am J Pathol*. 1935;11:373.

Bennett WM, Elzinga LW, Barry JM. Management of cystic kidney disease. Gardner KD Jr, Bernstein J. *The cystic kidney*. Kluwer Academic: Boston; 1990:247–275.

Bernstein J, Gardner KD Jr. Cystic disease of the kidney and renal dysplasia. Walsh PC, Gittes RF, Perlmutter AD, et al. *Campbell's urology*. ed 5. Saunders: Philadelphia; 1986:1760.

Bernstein J, Gardner KD Jr. Familial juvenile nephronophthisis: medullary cystic disease. Edelman CM Jr. *Pediatric kidney* *disease*. Little, Brown: Boston; 1979:580.

Bernstein J. A classification of renal cysts. Gardner KD Jr, Bernstein J. *The cystic kidney*. Kluwer Academic: Boston; 1990:163.

Bernstein J. Developmental abnormalities of the renal parenchyma: renal hypoplasia and dysplasia. *Pathol Annu*. 1968;3:213.

Bernstein J. Glomerulocystic kidney disease: nosological considerations. *Pediatr Nephrol*. 1993;7:464.

Bisceglia M, Galliana CA, Senger C, et al. Renal cystic diseases: a review. *Adv Anat Pathol*. 2006;13:26–56.

Bissler JJ, Kingswood JC, Radzikowska E, et al. Everolimus for angiomyolipoma associated with tuberous sclerosis complex or sporadic lymphangioleiomyomatosis (EXIST-2): a multicentre, randomised, double-blind, placebo-controlled trial. *Lancet*. 2013;381(9869):817–824.

Bissler JJ, McCormack FX, Young LR, et al. Sirolimus for angiomyolipoma in tuberous sclerosis complex or lymphangioleiomyomatosis. *N Engl J Med*. 2008;358(2):140–151.

Blanco G, Wallace DP. Novel role of ouabain as a cystogenic factor in autosomal dominant polycystic kidney disease. *Am J Physiol Renal Physiol*. 2013;6(305):F797–F812.

Blazer S, Zimmer EZ, Blumefeld Z, et al. Natural history of fetal simple renal cysts detected in pregnancy. *J Urol*. 1999;162:812.

Bleyer AJ, Hart TC. Medullary cystic kidney disease type 2. *Am J Kidney Dis*. 2004;43(6):1142.

Boggs LK, Kimmelsteil P. Benign multilocular cystic nephroma: report of two cases of so-called multilocular cyst of the kidney. *J Urol*. 1956;76:530.

Bohn S, Thomas H, Turan G, et al. Distinct molecular and morphogenetic properties of mutations in the human HNF 1 beta gene. *J Am Soc Nephrol*. 2003;14(8):2033–2041.

Bonal J, Caralps A, Lauzurica R, et al. Cyst infection in acquired renal cystic disease. *BMJ*. 1987;295:25.

Bosniak MA. Difficulties in classifying cystic lesions of the kidney [Commentary]. *Urol Radiol*. 1991;13:91.

Bosniak MA. The current radiological approach to renal cysts. *Radiology*. 1986;158:1.

Braun WE. Autosomal dominant polycystic kidney disease: emerging concepts of pathogenesis and new treatments. *Cleve Clin J Med*. 2009;76:97–104.

Brenner BM. *Brenner and Rector's the kidney*. ed 8. Saunders: Philadelphia; 2008.

Breuning MH, Reeder ST, Brunner H, et al. Improved early diagnoses of adult polycystic kidney disease with flanking DNA markers. *Lancet*. 1987;2:1359.

Brook-Carter PT, Peral B, Ward CJ, et al. Deletion of the *TSC2* and *PKD1* genes associated with severe infantile polycystic kidney disease—a contiguous gene syndrome. *Nat Genet*. 1994;8:328.

Budde K, Gaedeke J. Tuberous sclerosis complex-associated angiomyolipomas: focus on mTOR inhibition. *Am J Kidney Dis*. 2012;59(2):276–283.

Bukanov N, Smith LA, Klinger KW, et al. Long lasting arrest of murine polycystic kidney disease with CDK inhibitor R-roscovitine. *Nature*. 2006;444:949–952.

Campbell GS, Bick HD, Paulsen EP. Bleeding esophageal varices with polycystic liver: report of three cases. *N Engl J Med*. 1958;259:904.

Cantani A, Bamonte G, Ceccoli D, et al. Familial nephronophthisis: a review and differential diagnosis. *Clin Pediatr (Phila)*. 1986;25:90.

Capisonda R, Phan V, Traubuci J, et al. Autosomal recessive polycystic kidney disease outcomes from a single-center experience. *Pediatr Nephrol*. 2003;18:119–126.

Castillo O, Boyle ET, Kramer SA. Multilocular cysts of the kidney: a study of 29 patients and review of the literature. *Urology*. 1991;37:156.

Chakraborty K, McHugh K. Cystic diseases of the kidney in children. *Imaging*. 2005;17:69–75.

Chang K, Udupa J. *Boundary detection in grey level scenes*. Proceedings of the Tenth Annual Conference of the National Computer Graphics Association. 1989 [Fairfax (VA); NCGA].

Chapman A. Autosomal dominant polycystic disease: a time for change? *J Am Soc Nephrol*. 2007;18:1399–1407.

Chatten J, Bishop HC. Bilateral multilocular cysts of the kidney. *J Pediatr Surg*. 1977;12:749.

Chen C, Kang Q, Xu B, et al. Fat poor angiomyolipoma differentiation from renal cell carcinoma at 320-slice dynamic volume CT perfusion. *Abdom Radiol (NY)*. 2018;43(5):1223–1230.

Cheng TY, Su CH, Shyr YM, et al. Management of pancreatic lesions in von Hippel-Lindau disease. *World J Surg*. 1997;21:307–312.

Choi SY, Chacon-Heszele MF, Huang L, et al. Cdc42 deficiency causes ciliary abnormalities and cystic kidneys. *J Am Soc Nephrol*. 2013;9(24):1435–1450.

Chonko AM, Weiss JM, Stein JH, et al. Renal involvement in tuberous sclerosis. *Am J Med*. 1974;56:124.

Choyke PL, Glenn GM, Walther MM, et al. von Hippel-Lindau disease: genetic, clinical and imaging features. *Radiology*. 1995;194:629–642.

Christ ML. Polycystic nephroblastoma. *J Urol*. 1968;98:570.

Clark PE, Cookson MS. The von Hippel-Lindau gene: turning discovery into therapy. *Cancer*. 2008;113(Suppl 7):1768–1778.

Cobben JM, Breuning MH, Schoots C, et al. Congenital hepatic fibrosis in autosomal-dominant polycystic kidney disease. *Kidney Int*. 1990;38:880.

Cohen AH, Hoyer JR. Nephronophthisis. A primary tubular basement membrane defect. *Lab Invest*. 1986;55:564–572.

Cole BR, Conley SB, Stapleton FB. Polycystic kidney disease in the first year of life. *J Pediatr*. 1987;111:693.

Couch V, Lindor MS, Noralane M, et al. von Hippel Lindau disease. *Mayo Clin Proc*. 2000;75:265–272.

Curatolo C, Moavero R. mTOR inhibitors in tuberous sclerosis complex. *Curr Neuropharmacol*. 2012;10(4):404–415.

Czyzk-Krzeska MF, Meller J. von Hippel-Lindau tumor suppressor: not only HIF's executioner. *Trends Mol Med*. 2004;10(4):146–149.

Dabora SL, Jazwiak S, Fran DN, et al. Mutational analysis in a cohort of 224 tuberous sclerosis patients indicates increased severity of TSC2, compared with TSC1, disease in multiple organs. *Am J Hum Genet*. 2001;68(1):64–80.

Dauost MC, Bichet DG, Somlo S. A French-Canadian family with autosomal dominant polycystic kidney disease (ADPKD) unlinked to ADPKD1 or ADPKD2. *J Am Soc Nephrol*. 1993;4:262.

Davies DM, de Vries PJ, Johnson SR, et al. Sirolimus therapy for angiomyolipoma in tuberous sclerosis and sporadic lymphangioleiomyomatosis: a phase 2 trial. *Clin Cancer Res*. 2011;17(12):4071–4081.

Delaney VB, Adler S, Bruns FJ, et al. Autosomal dominant polycystic kidney disease: presentation, complications and progression. *Am J Kidney Dis*. 1985;5:104.

Denton MD, Magee CC, Ovuworie C, et al. Prevalence of renal cell carcinoma in patients with ESRD pre-transplantation of pathologic analysis. *Kidney Int*. 2002;61:2201–2209.

Doublet J, Peraldi M, Gattegno B, et al. Renal cell carcinoma of native kidneys: prospective study of 129 renal transplant patients. *J Urol*. 1997;158:42–44.

Dunhill MS, Milard PR, Oliver DO. Acquired cystic disease of the kidneys: a hazard of long-term intermittent maintenance hemodialysis. *J Clin Pathol*. 1977;30:368.

Eble JN, Bonsib SM. Extensively cystic renal neoplasms: cystic nephroma, cystic partially differentiated nephroblastoma, multilocular cystic renal cell carcinoma and cystic hamartoma of the renal pelvis. *Semin Diagn Pathol*. 1998;15:2.

Ekstrom T, Engfeldt B, Langergren C, et al. *Medullary sponge kidney*. Almquist and Wiksells: Stockholm; 1959.

Elzinga LW, Barry JM, Torres VT, et al. Cyst decompression surgery for autosomal dominant polycystic kidney disease. *J Am Soc Nephrol*. 1992;2:1219.

Ericsson NO, Ivemark BI. Renal dysplasia and pyelonephritis in infants and children I. *Arch Pathol*. 1958;66:255.

Esteban MA, Mandriota SJ, Maxwell PH. The von Hippel-Lindau protein: a key player in oxygen homeostasis and matrix assembly. International Congress Series, Atherosclerosis XIII. *Proceedings of the 13th International Atherosclerosis Symposium*. 2004;1262:450–453.

Evans AT, Coughlin JP. Urinary obstruction due to renal cysts. *J Urol*. 1970;103:277.

Fanconi G, Hanhart E, Ailbertini A, et al. Die familiäre juvenile Nephronophthise (die idiopathische parenchymatose Schrumptniere). *Helv Paediatr Acta*. 1951;6:1.

Farnham S, Adams MC, Brock JW, et al. Pediatric urological causes of hypertension. *J Urol*. 2005;173:697.

Fayemi AD, Ali M. Acquired renal cysts and tumor superimposed on chronic primary diseases: an autopsy study of 24 patients. *Pathol Res Pract*. 1980;68:73.

Feiner HD, Katz LA, Gallo GR. Acquired renal cystic disease of kidney in chronic hemodialysis patients. *Urology*.

1981;17:260.
Felson B, Cussen LJ. The hydronephrotic type of congenital multicystic disease of the kidney. *Semin Roentgenol*. 1975;10:113.
Ferreira AM, Reis RB, Kajiwara PP, et al. MRI evaluation of complex renal cysts using the Bosniak classification: a comparison to CT. *Abdom Radiol (NY)*. 2016;41(10):2011–2019.
Fetterman GH, Ravitch MM, Sherman FE. Cystic changes in fetal kidneys following ureteral ligation: studies of microdissection. *Kidney Int*. 1974;5:111.
Fick GM, Johnson AM, Gabow PA. Is there evidence for anticipation in autosomal-dominant polycystic kidney disease? *Kidney Int*. 1994;43:1153.
Fisher ER, Horvath B. Comparative ultrasound study of so-called renal adenoma and carcinoma. *J Urol*. 1972;108:382.
Flack CE, Bellinger MF. The multicystic dysplastic kidney and contralateral reflex: protection of the solitary kidney. *J Urol*. 1993;150:1873.
Forster SV, Hawkins EP. Deficient metanephric blastema: a cause of oligomeganephronia. *Pediatr Pathol*. 1994;14:935.
Fowler M. Differentiated nephroblastoma: solid, cystic or mixed. *J Pathol*. 1971;105:215.
Franz DN, Leonard J, Tudor C, et al. Rapamycin causes regression of astrocytomas in tuberous sclerosis complex. *Ann Neurol*. 2006;59:490–498.
Gabow PA, Chapman AB, Johnson AM, et al. Renal structure and hypertension in autosomal dominant polycystic kidney disease. *Kidney Int*. 1990;38:1177–1180.
Gabow PA, Duley I, Johnson AM. Clinical profiles of gross hematuria in autosomal polycystic kidney disease. *Am J Kidney Dis*. 1992;20:140.
Gabow PA, Ikle D, Holmes J. Polycystic kidney disease:

prospective analysis of nonazotemic patients and family members. *Ann Intern Med*. 1984;101(2):238–247.

Gabow PA, Johnson AM, Kaehny WD, et al. Risk factors for the development of hepatic cysts in autosomal dominant polycystic kidney disease. *Hepatology*. 1990;11:1033–1037.

Gabow PA. Autosomal dominant polycystic kidney disease. *N Engl J Med*. 1993;329:332–342.

Gabow PA. Polycystic kidney disease: clues to pathogenesis. *Kidney Int*. 1991;40:989.

Galliani CA, Gomez AM, Panniello G, et al. Selected case from the Arkadi M. Rywlin International Pathology Slide Series: asymmetric, segmental glomerulocystic kidney in an infant with tuberous sclerosis complex. *Adv Anat Pathol*. 2015;22(2):135–143.

Gallo GE, Penchansky L. Cystic nephroma. *Cancer*. 1977;39:1322.

Gambaro G, Danza FM, Fabris A. Medullary sponge kidney. *Curr Opin Nephrol Hypertens*. 2013;22(4):421–426.

Gardner KD Jr, Evan AP. Cystic kidneys: an enigma evolves. *Am J Kidney Dis*. 1984;3:403.

Gates GF. Ultrasonography of the urinary tract in children. *Urol Clin North Am*. 1980;7:215.

Gattone VH, Wang X, Harris PC, et al. Inhibition of renal cystic disease development and progression by a vasopressin V2 receptor antagonist. *Nat Med*. 2003;9:1323–1326.

Gedroyc WM, Saxton HM. More medullary sponge variants. *Clin Radiol*. 1988;39(4):423–425.

Geller RA, Pataki KI, Finegold RA. Bilateral multilocular renal cysts with recurrence. *J Urol*. 1979;121:808.

Ghasemian SR, Pedraza R, Sasaki TA, et al. Bilateral laparoscopic radical nephrectomy for renal tumors in patients with acquired cystic disease. *J Laparoendosc Adv Surg Tech A*. 2005;15:606–610.

Glassberg KI, Hackett RE, Waterhouse K. Congenital anomalies of the kidney, ureter and bladder. Kendall AR, Karafin L. *Goldsmith's practice of surgery: urology*. Harper & Row: Hagerstown; 1981:1.

Glassberg KI, Stephens FD, Lebowitz RL, et al. Renal dysgenesis and cystic disease of the kidney: a report of the Committee on Terminology, Nomenclature and Classification, Section on Urology, American Academy of Pediatrics. *J Urol*. 1987;138:1085.

Glazier DB, Fleischer MH, Cummings KB, et al. Cystic renal disease and tuberous sclerosis in infants. *Urology*. 1996;48:613.

Goldman SM, Hartman DS. The simple renal cysts. Pollack HM. *Clinical urography*. Saunders: Philadelphia; 1990:1603.

Gomez MR. *Tuberous sclerosis*. Raven Press: New York; 1979.

Gordon AC, Thomas DF, Arthur RJ, et al. Multicystic dysplastic kidney: is nephrectomy still appropriate? *J Urol*. 1988;140:1231.

Gordon RL, Pollack HM, Popky GL, et al. Simple serous cysts of the kidney in children. *Radiology*. 1979;131:357.

Gough DC, Postlethwaite RJ, Lewis MA, et al. Multicystic renal dysplasia diagnosed in the antenatal period. *J Urol*. 1995;76:244–250.

Grantham JJ. Polycystic kidney disease: hereditary and acquired. *Adv Intern Med*. 1993;38:409.

Grantham JJ. Polycystic renal disease. Early LE, Gottschalk CW. *Strauss and Welt's diseases of the kidney*. ed 3. Little, Brown: Boston; 1979:1123.

Grantham JJ. The etiology, pathogenesis and treatment of autosomal dominant polycystic kidney disease: recent advances. *Am J Kidney Dis*. 1996;28(6):788–803.

Grieshammer U, Ma L, Plump AS, et al. SLIT2-mediated ROBO2 signaling restricts kidney induction to a single site.

Dev Cell. 2004;6:709–717.

Griffel B, Pewzner S, Berandt M. Unilateral "oligomeganephronia" with agenesis of the contralateral kidney, studied by microdissection. *Virchows Arch A Pathol Anat Histopathol*. 1972;357:179.

Griscom NT, Vawter FG, Fellers FX. Pelvoinfundibular atresia: the usual form of multicystic kidney; 44 unilateral and two bilateral cases. *Semin Roentgenol*. 1975;10:125.

Gronwald J, Baur AS, Holtgreve-Grez H, et al. Chromosomal abnormalities in renal cell neoplasms associated with acquired renal cystic disease. *J Pathol*. 1999;187:308–312.

Guay-Woodford L. Autosomal recessive polycystic kidney disease. Flinter F, Saggar-Malik A. *The genetics of renal disease*. Oxford University Press: Oxford, United Kingdom; 2003:239–251.

Guay-Woodford LM, Desmond RA. Autosomal recessive polycystic kidney disease: the clinical experience in North America. *Pediatrics*. 2003;111(5 Pt 1):1072–1080.

Habib R, Bois E. Hétérogèneité des syndromes néphrotiques à début précoce de nourrisson (syndrome néphrotique "infantile"): étude anatomoclinique et génétique de 37 observations. *Helv Paediatr Acta*. 1973;28:91.

Habib R, Courtecuisse V, Mathieu H, et al. Un type anatomoclinique particular, d'insuffisance rénale chronique de l'enfant: l'hypoplasie oligonéphronique congénitale bilaterale. *J Urol Nephrol (Paris)*. 1962;68:139.

Habib R, Gubler M, Niavdet P, et al. Congenital/infantile nephrotic syndrome with diffuse mesangial sclerosis: relationships with Drash syndrome. Alan R Liss: New York; 1989:193. Bartsocas CS. *Genetics of kidney disorders: progress in clinical and biological research*. vol 305.

Hadlock FP, Deter RL, Carpenter P, et al. Sonography of fetal urinary tract abnormalities. *AJR Am J Roentgenol*.

1981;137:261.

Hains DS, Bates CM, Ingram S, et al. Management and etiology of the unilateral multicystic dysplastic kidney. *Pediatr Nephrol*. 2009;42:233–241.

Hakim LS, Adler H, Glassberg KI. Acquired renal cystic disease (ARCD) in the pediatric patient. *J Urol*. 1994;151:330A.

Harris RH, Wise MK, Best CF. Renotrophic factors in urine. *Kidney Int*. 1983;23:616.

Harrison AR, Rose GA. Medullary sponge kidney. *Urol Res*. 1979;7:197.

Hartman DS, Weatherby E 3rd, Laskin WB, et al. Cystic renal cell carcinoma: CT findings simulating a benign hyperdense cyst. *AJR Am J Roentgenol*. 1992;159:1235.

Hartnett M, Bennett W. External manifestations of cystic renal disease. Gardner KD Jr. *Cystic disease of the kidney*. John Wiley & Sons: New York; 1976:201–219.

Hateboer N, van Dijk MA, Bogdanova N, et al. Comparison of phenotypes of polycystic kidney disease types 1 and 2. *Lancet*. 1999;353:103–107.

Heikkinen ES, Herva R, Lanning P. Multicystic kidney: a clinical and histologic study of 13 patients. *Ann Chir Gynaecol*. 1980;69:15.

Heinz-Peer G, Maier A, Eibenberger K, et al. Role of magnetic resonance imaging in renal transplant recipients with acquired cystic kidney disease. *Urology*. 1998;51:534.

Heinz-Peer G, Schoder M, Rand T, et al. Prevalence of acquired cystic kidney disease and tumors in native kidneys of renal transplant recipients: a prospective US study. *Radiology*. 1995;195:667.

Hildebrandt F, Orman H. New insights: nephronophthisis-medullary cystic kidney disease. *Pediatr Nephrol*. 2001;16:168–176.

Hildebrandt F, Otto E, Rensing C, et al. A novel gene encoding an SH3 dominant protein is mutated in nephronophthisis type 1. *Nat Genet*. 1997;17:149–153.

Hildebrandt F, Singh-Sawhney I, Schnieders B, et al. Mapping of a gene for familial juvenile nephronophthisis: refining the map and defining flanking markers on chromosome 2. *Am J Hum Genet*. 1993;53:1256.

Hildebrandt F. Genetic renal diseases in children. *Curr Opin Pediatr*. 1995;7:182.

Hindman NM, Hecht EM, Bosniak MA. Follow-up for Bosniak category 2F cystic renal lesions. *Radiology*. 2014;272(3):757–766.

Hinman JA. Obstructive renal cysts. *J Urol*. 1978;119:681.

Holmberg G, Hietala S. Treatment of simple renal cysts by percutaneous puncture and instillation of bismuth-phosphate. *Scand J Urol Nephrol*. 1989;23:207.

Horton WA, Wong V, Eldridge R. Von Hippel-Lindau disease: clinical and pathological manifestations in nine families with 50 affected members. *Arch Intern Med*. 1976;136:769.

Hossack KF, Leddy CL, Schrier RW, et al. Incidence of cardiac abnormalities associated with autosomal dominant polycystic kidney disease (ADPKD) [abstract]. *Am Soc Nephrol*. 1986;19:46A.

Hubner W, Pfaf R, Porpaczy P, et al. Renal cysts: percutaneous resection with standard urologic instruments. *J Endourol*. 1990;4:61.

Hughson M, Buchwald D, Fox M. Renal neoplasia and acquired cystic kidney disease in patients receiving long term dialysis. *Arch Pathol Lab Med*. 1986;110:592–601.

Hughson MD, Henniger GR, McManus JF. Atypical cysts, acquired renal cystic disease, and renal cell tumors in end stage dialysis kidneys. *Lab Invest*. 1980;42:475.

Hulbert JC, Hunter D. *Percutaneous techniques for intrarenal* *marsupialization of difficult symptomatic renal cysts*. Presented at: 85th Annual Meeting of the American Urological Association. 1990 [May; New Orleans, LA].

Huston J, Torres VE, Wiebers DO. Value of magnetic resonance angiography for detection of intracranial aneurysms in autosomal dominant polycystic kidney disease. *J Am Soc Nephrol*. 1993;3:1871.

Huttunen JR. Congenital nephrotic syndrome of Finnish type: study of 75 patients. *Arch Dis Child*. 1976;51:344.

Ibrahim RE, Weinberg DS, Weidner N. Atypical cysts and carcinomas of the kidneys in the phacomatoses: a quantitative DNA study using static and flow cytometry. *Cancer*. 1989;63:148.

Iglesias CG, Torres VE, Offord KD, et al. Epidemiology of adult polycystic kidney disease. Olmstead County, MN. *Am J Kidney Dis*. 1983;2:630–639.

Ishikawa I, Saito Y, Onouchi Z, et al. Development of acquired cystic disease and adenocarcinoma of the kidney in glomerulonephrotic chronic hemodialysis patients. *Clin Nephrol*. 1980;14:1.

Ishikawa I, Yuri T, Kitada H, et al. Regression of acquired cystic disease of the kidney after successful renal transplantation. *Am J Nephrol*. 1983;3:310.

Ishikawa I. Hemorrhage versus cancer in acquired cystic disease. *Semin Dial*. 2000;13:56.

Ishikawa I. Letter to the editor. *J Urol*. 1993;149:1146.

Ishikawa I. Uremic acquired renal cystic disease. *Nephron*. 1991;58:257–267.

Ismaili K, Avni FE, Alexander M, et al. Routine voiding cystourethrography is of no value in neonates with unilateral multicystic dysplastic kidney. *J Pediatr*. 2005;146:759.

Israel GM, Bosniak MA. Calcification in cystic renal masses: is it important in diagnosis? *Radiology*. 2003;226:47–52.

Javadpour N, Chelouhy E, Moncada L, et al. Hypertension in a child caused by a multicystic kidney. *J Urol*. 1970;104:918.

Jennings CM, Gaines PA. The abdominal manifestations of von Hippel-Lindau disease and a radiological screening protocol for an affected family. *Clin Radiol*. 1988;39:363.

Jinzaki M, Silverman SG, Akita H, et al. Diagnosis of renal angiomyolipomas: classic, fat-poor, and epithelioid types. *Semin Ultrasound CT MR*. 2017;38(1):37–46.

Johnson A, Gabow P. Identification of patients with autosomal dominant polycystic kidney disease at highest risk for end stage renal disease. *J Am Soc Nephrol*. 1997;8:1560–1576.

Johnson DE, Ayala AG, Medellin H, et al. Multilocular renal cystic disease in children. *J Urol*. 1973;109:101.

Joly D, Berissi S, Bertrand A, et al. Laminin 5 regulates polycystic kidney cell proliferation and cyst formation. *J Biol Chem*. 2006;281:29181–29189.

Jones AC, Shyamsundar MM, Thomas MW, et al. Comprehensive mutation analysis of TSC1 and TSC2 and phenotypic correlations in 150 families with tuberous sclerosis. *Am J Hum Genet*. 1999;64:1305–1315.

Joshi VV, Beckwith JB. Multilocular cyst of the kidney (cystic nephroma) and cystic partially differentiated nephroblastoma. *Cancer*. 1989;64:466.

Kadir S, Kerr WS, Athanasoulis CA. The role of arteriography in the management of renal cell carcinoma associated with von Hippel-Lindau disease. *J Urol*. 1981;126:316.

Kalyoussef E, Hwang J, Prasad V, et al. Segmental multicystic dysplastic kidney in children. *Urology*. 2006;68(5):1211.

Kaplan BS, Fay FM, Shah VM, et al. Autosomal recessive polycystic kidney disease. *Pediatr Nephrol*. 1989;3:43–49.

Kaplan BS, Kaplan P, Rosenberg HK, et al. Polycystic kidney disease in childhood. *J Pediatr*. 1989;115:867.

Karmazyn B, Tawadros A, Delaney LR, et al. Ultrasound classification of solitary renal cysts in children. *J Pediatr Urol*. 2015;11:149e1.

Kasiske BL, Snyder JJ, Gilbertson DT, et al. Cancer after kidney transplantation in the United States. *Am J Transplant*. 2004;4(6):905–913.

Kaufman J, Fay R. Renal hypertension in childhood. Johnston JH, Goodwin WE. *Reviews in pediatric urology*. Excerpta Medica: Amsterdam; 1974:201.

Keith DS, Torres VE, King BF, et al. Renal cell carcinoma in autosomal dominant polycystic kidney disease. *J Am Soc Nephrol*. 1994;4:1661.

Kelleher CL, McFann KK, Johnson AM, et al. Characteristics of hypertension in young adults with autosomal dominant polycystic kidney disease compared with the general US population. *Am J Hypertens*. 2004;17:1029–1034.

Kenerson H, Dundon TA, Yeung RS. Effects of rapamycin in the Eker rat model of turberous sclerosis complex. *Pediatr Res*. 2005;57(1):67–75.

Kirsh EJ, Strauss FH II, Goldfischer ER, et al. Benign adenomatous kidney tumor (Perlmann's tumor) and renal cortical carcinoma with adenomatous multicystic features: 12 cases. *Urology*. 1999;53:65.

Kissane JM, Smith MG. *Pathology of infancy and childhood*. ed 2. Mosby: St Louis; 1975:587.

Kissane JM. Congenital malformations. Heptinstall RH. *Pathology of the kidney*. ed 2. Little, Brown: Boston; 1974:69.

Klatte T, Marberger M. Renal cell carcinoma of native kidneys in renal transplant patients. *Curr Opin Urol*. 2011;21(5):376–379.

Kliem V, Kolditz M, Behrend M, et al. Risk of renal cell carcinoma after kidney transplantation. *Clin Transplant*. 1997;11:255–258.

Knudson A. Mutation and cancer: statistical study of retinoblastoma. *Proc Natl Acad Sci USA*. 1971;68:820–823.

Kogire M, Hosotami R, Kondo M, et al. Pancreatic lesions in von Hippel-Lindau syndrome. *Surg Today*. 2000;30:380–382.

Kohrman MH. Emerging treatments in the management of tuberous sclerosis complex. *Pediatr Neurol*. 2012;46(5):267–275.

Kondo K, Kaelin WG Jr. The von Hippel-Lindau tumor suppressor gene. *Exp Cell Res*. 2001;264:117–125.

Konrad M, Sauner S, Heidert L, et al. Large homozygous deletions of the 2q13 region are a major cause of juvenile nephronophthisis. *Hum Mol Genet*. 1996;5:367–371.

Kossow AS, Meek JM. Unilateral polycystic kidney disease. *J Urol*. 1982;127:297.

Kuiper JJ. Medullary sponge kidney. *Perspect Nephrol Hypertens*. 1976;4:151.

Kupin W, Norris C, Levin NW, et al. *Incidence of diverticular disease in patients with polycystic kidney disease (PCKD)*. Presented at 10th International Congress of Nephrology. 1987 [London; July].

Kutcher R, Amodio JR, Rosenblatt R. Uremic renal cystic disease: value of sonographic screening. *Radiology*. 1983;147:833.

Lagos JC, Gomez MR. Tuberous sclerosis: reappraisal of a clinical entity. *Mayo Clin Proc*. 1967;42:26.

Lam M, Halverstadt D, Altshuler G, et al. Congenital oligomeganephronia in a solitary kidney: report of a case. *Am J Kidney Dis*. 1982;1:300.

Lamiell JM, Salazar FG, Hsia YE. von Hippel-Lindau disease affecting 43 members of a single kindred. *Medicine (Baltimore)*. 1989;68(1):1–29.

Lanning P, Uhari M, Kouvalainan K, et al. Ultrasonic features of the congenital nephrotic syndrome of the Finnish type.

Acta Paediatr Scand. 1989;78:717.

Latif F, Tory K, Gnarra J, et al. Identification of the von Hippel-Lindau disease tumor suppressor gene. *Science*. 1993;260:317.

Laucks SP Jr, McLachlan MS. Aging and simple renal cysts of the kidney. *Br J Radiol*. 1981;54:12.

Lavan JN, Neale FC, Posen S. Urinary calculi: clinical, biochemical and radiological studies in 619 patients. *Med J Aust*. 1971;2:1049.

Lee DI, Clayman RV. Hand assisted laparoscopic nephrectomy in autosomal dominant polycystic kidney disease. *J Endourol*. 2004;18:379–382.

Lee JK, McLennan BL, Kissane JM. Unilateral polycystic kidney disease. *AJR Am J Roentgenol*. 1978;130:1165.

Lee L, Sudentas P, Donohue B, et al. Efficacy of a rapamycin analog (CCI-779) and IFN-gamma in tuberous sclerosis mouse models. *Genes Chromosomes Cancer*. 2005;42:213–227.

Lee YR, Lee KB. Ablation of symptomatic cysts using absolute ethanol in 11 patients with autosomal-dominant polycystic kidney disease. *Korean J Radiol*. 2003;4:239–242.

Legué E, Liem KF Jr. Tulp3 is a ciliary trafficking gene that regulates polycystic kidney disease. *Curr Biol*. 2019;29(5):803–812.e5; 10.1016/j.cub.2019.01.054 [Epub 2019 Feb 21].

Lesho EP. Recognition and management of von Hippel-Lindau disease. *Am Fam Physician*. 1994;50:1269–1272.

Levine BS, Knibloe K, Golchini S, et al. Renal adaptation to dietary phosphate deprivation. *Am J Physiol*. 1991;260:F613–F618.

Levine E, Collins DL, Horton WA, et al. CT screening of the abdomen in von Hippel-Lindau disease. *AJR Am J Roentgenol*. 1982;139:505.

Levine E, Grantham JJ. Radiology of cystic kidneys. Gardner KD Jr, Bernstein J. *The cystic kidney*. Kluwer Academic: Boston; 1990:171.

Levine E. Acquired cystic kidney disease. *Radiol Clin North Am*. 1996;34:947.

Levine LA, Gburek BM. Acquired cystic disease and renal adenocarcinoma following renal transplantation. *J Urol*. 1994;151:129.

Lingard DA, Lawson TI. Accuracy of ultrasound in predicting the nature of renal masses. *J Urol*. 1979;122:724.

Livingston WD, Collins TL, Novick DE. Incidental renal masses. *Urology*. 1981;17:257.

Loftus H, Ong ACM. Cystic kidney diseases: many ways to form a cyst. *Pediatr Nephrol*. 2013;28(1):33–49.

Longino LA, Martin LW. Abdominal masses in the newborn infant. *Pediatrics*. 1958;21:596.

Loughlin KR, Gittes RF. Urological management of patients with von Hippel-Lindau disease. *J Urol*. 1986;136:789.

Lüscher TF, Wanner C, Siegenthaler W, et al. Simple renal cyst and hypertension: cause or coincidence? *Clin Nephrol*. 1986;26:91–95.

Ma M, Gallagher AR, Somlo S. Ciliary mechanisms of cyst formation in polycystic kidney disease. *Cold Spring Harb Perspect Biol*. 2017;9(11).

Mackie GG, Stephens FD. Duplex kidneys: a correlation of renal dysplasia with position of the ureteral orifice. *J Urol*. 1975;114:274.

MacRae Dell KM, Avner ED. *Autosomal recessive polycystic kidney disease: genetic disease online reviews at GeneTests-Geneclinics*. University of Washington: Seattle; 2003.

Madewell JE, Goldman SM, Davis CJ Jr. Multilocular cystic nephroma: a radiographic pathologic correlation of 58 patients. *Radiology*. 1983;146:309.

Maher ER, Yates JR, Harris R, et al. Clinical features and natural history of von-Hippel Lindau disease. *Q J Med*. 1990;7:1151–1163.

Malek R, Omess P, Benson R, et al. Renal cell carcinoma in von Hippel-Lindau disease. *Am J Med*. 1987;82:236.

Mangoo-Karim R, Uchich M, Lechene C, et al. Renal epithelial cyst formation and enlargement in vitro: dependence on cAMP. *Proc Natl Acad Sci USA*. 1989;86:6007–6011.

Marotti M, Hricak H, Fritzche P, et al. Complex and simple cysts: comparative evaluation with MR imaging. *Radiology*. 1987;162:679.

Martignoni G, Bennetti F, Pea M, et al. Renal disease in adults with TSC2/PKD1 contiguous gene syndrome. *Am J Surg Pathol*. 2002;26:198–205.

Matsell DG, Tarantal AF. Experimental models of fetal obstructive uropathy. *Pediatr Nephrol*. 2002;17:470–476.

Maw AM, Megibow AJ, Grasso M, et al. Diagnosis of medullary sponge kidney by computed tomographic urography. *Am J Kidney Dis*. 2007;50(1):146–150.

McClennan BL, Stanley RJ, Melson GL, et al. CT of the renal cyst: is a cyst puncture necessary? *AJR Am J Roentgenol*. 1979;133:671.

McHugh K, Stringer DA, Hebert D, et al. Simple renal cysts in children: diagnosis and follow-up with US. *Radiology*. 1991;178:383.

Meares EM Jr, Gross DM. Hypertension owing to unilateral renal hypoplasia. *J Urol*. 1972;108:197.

Melicow MM, Uson AC. Palpable abdominal masses in infants and children: a report based on a review of 653 cases. *J Urol*. 1959;81:705.

Melmon KL, Rosen SW. Lindau's disease. Review of the literature and study of a large kindred. *Am J Med*. 1964;36:595–618.

Melnick SC, Brewer DB, Oldham JS. Cortical microcystic disease of the kidney with dominant inheritance: a previously undescribed syndrome. *J Clin Pathol*. 1984;37:494.

Mendelsohn C, Lohnes D, Decimo D, et al. Function of retinoic acid receptors (RARs) during development: II. Multiple abnormalities at various stages of organ genesis in RAR double mutants. *Development*. 1994;120:2749.

Meyer WM, Jonas D. *Endoscopic percutaneous resection of renal cysts*. Presented at Eighth World Congress on Endourology and ESWL. 1990 [Washington, DC].

Mickisch O, Bommer J, Blackman J, et al. Multicystic transformation of kidneys in chronic renal failure. *Nephron*. 1984;38:93.

Miller LR, Soffer O, Nasser VH, et al. Acquired renal cystic disease in end stage renal disease: an autopsy study of 155 cases. *Am J Nephrol*. 1989;9:322.

Milutinovic J, Fialkow PJ, Agoda LY, et al. Autosomal dominant polycystic kidney disease: symptoms and clinical findings. *Am J Med*. 1984;53:511.

Mochizuki T, Tsuchiya K, Nitta K. Autosomal dominant polycystic kidney disease: recent advances in pathogenesis and potential therapies. *Clin Exp Nephrol*. 2013;3(17):317–326.

Mollet G, Silberman F, Delous M, et al. Characterization of the nephrocystin-4 complex and subcellular localization of nephrocystin-4 to primary cilia and centromes. *Hum Mol Genet*. 2005;14:645–656.

Mosli HA, Macdonald P, Schillinger JF. Caliceal diverticulum developing into simple renal cyst. *J Urol*. 1986;136:658–661.

Murakami A, Gomi K, Tanaka M, et al. Unilateral glomerulocystic kidney disease associated with tuberous sclerosis complex in a neonate. *Pathol Int*. 2012;62(3):209–215.

Myall GF. The incidence of medullary sponge kidney. *Clin Radiol*. 1970;21:171.

Nagao S, Nishi K, Katsuvama M, et al. Increased water intake decreases progression of polycystic kidney disease in the PCK rat. *J Am Soc Nephrol*. 2006;17:2220–2227.

Nahm AM, Ritz E. The simple renal cyst. *Nephrol Dial Transplant*. 2000;15:1702–1704.

Narchi H. Risk of hypertension with multicystic kidney disease. *Arch Dis Child*. 2005;90:921.

Narchi H. Risk of Wilms' tumour with multicystic kidney disease. *Arch Dis Child*. 2005;90:147.

Nauli S, Alenghat FJ, Luo Y, et al. Polycystins 1 and 2 mediate mechanosensation in the primary cilium of kidney cells. *Nat Genet*. 2003;33:129–137.

Neumann HP, Krumme B, van Velthoven V, et al. Multiple intracranial aneurysms in a patient with autosomal recessive polycystic kidney disease. *Nephrol Dial Transplant*. 1999;14:934–939.

Neumann HP, Zauner I, Strahm B, et al. Late occurrence of cysts in autosomal dominant medullary cystic kidney disease. *Nephrol Dial Transplant*. 1997;12:1242.

Nguyen HT, Thomson AA, Kogan BA, et al. Expression of the *Wnt* gene family during late nephrogenesis and complete ureteral obstruction. *Lab Invest*. 1999;79:647–658.

Nicolau C, Torra K, Badenas C, et al. Autosomal dominant polycystic kidney disease types 1 and 2: assessment of US sensitivity for diagnosis. *Radiology*. 1999;213:273–276.

Nikonova AS, Deneka AY, Kiseleva AA, et al. Ganetespib limits ciliation and cystogenesis in autosomal-dominant polycystic kidney disease (ADPKD). *FASEB J*. 2018;32(5):2735–2746.

Norio R, Rapola J. Congenital and infantile nephrotic syndromes. Alan R Liss: New York; 1989:179–192.

Bartsocas CS. *Genetics of kidney disorders: progress in clinical and biological research*. vol 305.

Norio R. Heredity in the congenital nephrotic syndrome: a genetic study of 57 Finnish families with a review of reported cases. *Ann Paediatr Fenn*. 1966;12(Suppl 27):1.

Norwood VF, Morham SG, Smithies O. Postnatal development and progression of renal dysplasia in cyclooxygenase-2 null mice. *Kidney Int*. 2000;58:2291–2300.

O'Kelly F, McAlpine K, Abdeen N, et al. The prevalence, clinico-demographics and outcomes of incidental and symptomatic renal cysts in a paediatric cohort undergoing ultrasonography. *J Urol*. 2019.

O'Hagan AR, Ellsworth R, Secic MS, et al. Renal manifestations of tuberous sclerosis complex. *Clin Pediatr (Phila)*. 1996;35:183.

Okada RD, Platt MA, Fleischman J. Chronic renal failure in patients with tuberous sclerosis: association with renal cysts. *Nephron*. 1982;30:85.

Olbrich H, Fliegant M, Hoefele J, et al. Mutations in a novel gene, *NPHP3* cause adolescent nephronophthisis, tapeto-retinal degeneration and hepatic fibrosis. *Nat Genet*. 2003;34:455–459.

Omori S, Hide M, Fujita H, et al. Extracellular signal-related kinase inhibition slows disease progression in mice with polycystic kidney disease. *J Am Soc Nephrol*. 2006;17:1604–1614.

Onal B, Kogan BA. Natural history of patients with multicystic dysplastic kidney—what followup is needed? *J Urol*. 2006;176:1607–1611.

Onuchic LF, Furu LX, Hou X, et al. *PKHD1*, the polycystic kidney and hepatic disease gene encodes a novel large protein containing multiple immunoglobulin-like plexin-transcription-factor domains and parallel beta helix 1 repeats.

Am J Hum Genet. 2002;70:1305.

Osathanondh V, Potter EL. Pathogenesis of polycystic kidneys: historical survey. *Arch Pathol*. 1964;77:459.

Otto EA, Loeys B, Khanna H, et al. Nephrocystin-5, a ciliary IQ domain protein, is mutated in Senior-Loken syndrome and interacts with RPGR and calmodulin. *Nat Genet*. 2005;37:282–288.

Otto EA, Schermer B, Obarn T, et al. Mutations in INVS encoding cause nephronophthisis type 2 linking renal cystic disease to the function of primary cilia and left-right axis determination. *Nat Genet*. 2003;34:413–420.

Palubinskas AJ. Medullary sponge kidney. *Radiology*. 1961;76:911.

Pampigliana G, Moynahan EJ. The tuberous sclerosis syndrome: clinical and EEG studies in 100 children. *J Neurol Neurosurg Psychiatry*. 1976;39:666.

Papanicolaou N, Pfister RC, Yoder IC. Spontaneous and traumatic rupture of renal cysts: diagnosis and outcome. *Radiology*. 1986;160:99–103.

Park BK. Renal angiomyolipoma: radiologic classification and imaging features according to the amount of fat. *AJR Am J Roentgenol*. 2017;209(4):826–835.

Parkkulainen KV, Hjeldt L, Sirola K. Congenital multicystic dysplasia of kidney: report of nineteen cases with discussion on the etiology, nomenclature and classification of cystic dysplasia of the kidney. *Acta Chir Scand Suppl*. 1959;244:5.

Parks JH, Coe FL, Strauss AL. Calcium nephrolithiasis and medullary sponge kidney in women. *N Engl J Med*. 1982;306:1088.

Pathak IG, Williams DI. Multicystic and cystic dysplastic kidneys. *Br J Urol*. 1964;36:318.

Pazour G. Intraflagellar transport and cilia-dependent renal disease: the ciliary hypothesis of polycystic kidney disease. *J*

Am Soc Nephrol. 2004;15:2528–2536.

Penn I. Tumor incidence in renal allograft recipients. *Transplant Proc*. 1979;11:1047.

Perez LM, Naidu SI, Joseph DB. Outcome and cost analysis of operative versus non-operative management of neonatal multicystic dysplastic kidneys. *J Urol*. 1998;160:1207.

Peters CA, Carr ML, Lais A, et al. The response of the fetal kidney to obstruction. *J Urol*. 1992;148:503–509.

Pieke SA, Kimberling WJ, Kenyon KG, et al. Genetic heterogenicity of polycystic kidney disease: an estimate of the proportion of families unlinked to chromosome 16. *Am J Hum Genet*. 1989;45:458.

Pirson Y, Chauveau D, Torres VE. Management of cerebral aneurysms in autosomal dominant polycystic kidney disease. *J Am Soc Nephrol*. 2002;13:269–276.

Ploussard G, Droupy S, Ferlicot S, et al. Local recurrence after nephron-sparing surgery in von Hippel-Lindau disease. *Urology*. 2007;70(3):435–439.

Pope JC 4th, Brock JW 3rd, Adams MC, et al. Congenital anomalies of the kidney and urinary tract: role of loss of function mutation in the pluripotent angiotensin type 2 receptor gene. *J Urol*. 2001;165:196.

Pope JC 4th, Brock JW 3rd, Adams MC, et al. How they begin and how they end: classic new theories for the development and deterioration of congenital anomalies of the kidney and urinary tract, CAKUT. *J Am Soc Nephrol*. 1999;61:2018–2028.

Port FK, Ragheb NE, Schwartz SH, et al. Neoplasms in dialysis patients: a population-based study. *Am J Kidney Dis*. 1989;14:199.

Poston DO, Jaffes GS, Lubensky IA, et al. Characterization of the renal pathology of a familial form of renal cell carcinoma associated with von Hippel-Lindau's disease. *J Urol*.

1993;153:22.

Powell T, Schackman R, Johnson HD. Multilocular cysts of the kidney. *Br J Urol*. 1951;23:142.

Pretorius DH, Lee ME, Manco-Johnson ML, et al. Diagnosis of autosomal dominant polycystic kidney disease in utero and in the young infant. *J Ultrasound Med*. 1987;6:249.

Proesmans W, Van Damme B, Casaer P, et al. Autosomal dominant polycystic kidney disease in the neonatal period: association with arteriovenous malformations. *Pediatrics*. 1982;70:971–975.

Qian F, Watnick TJ, Onuchic LF, et al. The molecular basis of focal cyst formation in human autosomal dominant polycystic kidney disease type I. *Cell*. 1996;87:979.

Rabelo EA, Oliveria EA, Diniz JS, et al. Natural history of multicystic kidney conservatively managed. *Pediatr Nephrol*. 2004;19:1102.

Ratcliffe PJ, Dunhill MS, Oliver DO. Clinical importance of acquired cystic disease of the kidneys in patients undergoing dialysis. *BMJ*. 1983;287:1855.

Ravden MI, Zuckerman HL, Kay CJ, et al. Evaluation of solitary simple renal cysts in children. *J Urol*. 1980;124:904.

Ravine D, Gibson RN, Walker RG, et al. Evaluation of ultrasonographic diagnostic criteria for autosomal dominant polycystic kidney disease 1. *Lancet*. 1994;343:824.

Rediger C, Guerra LA, Keays MA, et al. Renal cyst evolution in childhood: a contemporary observational study. *J Pediatr Urol*. 2019.

Reed AB, Parekh DJ. Surgical management of von Hippel-Lindau disease: urologic considerations. *Surg Oncol Clin N Am*. 2009;8(1):157–174.

Reeders ST, Bruening MH, Davies KE, et al. A highly polymorphic DNA marker linked to adult polycystic kidney disease on chromosome 16. *Nature*. 1985;317:542.

Reichard EA, Roulindoux MA, Dunnick NR. Renal neoplasms in patients with renal cystic disease. *Abdom Imaging*. 1998;32:237–248.

Resnick JS, Hartman DS. Medullary cystic disease of the kidney. Pollack HM. *Clinical urography*. Saunders: Philadelphia; 1990:1178–1184.

Resseguie LJ, Nobrega FT, Farrow GM, et al. Epidemiology of renal and ureteral cancer in Rochester, Minnesota 1950–1978, with special reference to clinical and pathologic features. *Mayo Clin Proc*. 1978;53:503.

Rito M, et al. Glomerulocystic kidney presenting as a unilateral kidney mass in a newborn with tuberous sclerosis: report of a case and review of the literature. *Pathol Res Pract*. 2017;213(3):286–291.

Rizzoni G, Loirat C, Levy M, et al. Familial hypoplastic glomerulocystic kidneys: a new entity? *Clin Nephrol*. 1982;18:263.

Roach ES, Gomez MR, Northrup H. Tuberous sclerosis complex consensus conference: revised clinical diagnostic criteria. *J Child Neurol*. 1998;13:624–628.

Rockson SG, Stone RA, Gunnels JC Jr. Solitary renal cyst with segmental ischemia and hypertension. *J Urol*. 1974;112:550.

Rominger M, Kenney P, Morgan D, et al. Gadolinium-enhanced MR imaging of renal masses. *Radiographics*. 1992;12:1097.

Rosenfeld AT, Siegel NJ, Kappleman MB. Grey scale ultrasonography in medullary cystic disease of the kidney and congenital hepatic fibrosis with tubular ectasia: new observations. *AJR Am J Roentgenol*. 1977;129:297.

Rosenfeld JB, Cohen L, Garty I, et al. Unilateral renal hypoplasia with hypertension (Ask-Upmark kidney). *BMJ*. 1973;2:217.

Rossetti S, Harris PC. Genotype-phenotype correlations in autosomal recessive polycystic kidney disease. *J Am Soc*

Nephrol. 2007;18:1374–1380.

Roupret M, Hopirtean V, Mejean A, et al. Nephron sparing surgery for renal cell carcinoma and von Hippel-Lindau's disease. *J Urol*. 2003;170(5):1752–1755.

Royer P, Habib R, Broyer M, et al. Segmental hypoplasia of the kidney in children. *Adv Nephrol Necker Hosp*. 1971;1:145.

Royer P, Habib R, Mathieu H, et al. L'Hypoplasie rénale bilaterale congénitale avec réduction du nombre et hypertrophie des néphrons chez l'enfant. *Ann Pediatr (Paris)*. 1962;38:133.

Ryu SJ. Intracranial hemorrhage in patients with polycystic kidney disease. *Stroke*. 1990;21:291–294.

Ryynanen M, Dolata MM, Lampainen E, et al. Localization of mutation producing autosomal dominant polycystic kidney disease without renal failure. *J Med Genet*. 1987;24:462.

Sage MR, Lawson AD, Marshall VR, et al. Medullary sponge kidney and urolithiasis. *Clin Radiol*. 1982;33:435.

Saltzman AF, Carrasco A Jr, Colvin AN, et al. Can a modified Bosniak classification system risk stratify pediatric cystic renal masses? *J Urol*. 2018;200:434.

Sampson JR, Maheshwar MM, Aspinwall R, et al. Renal cystic disease in tuberous sclerosis: role of the polycystic kidney disease 1 gene. *Am J Hum Genet*. 1997;61:843–851.

Sancak O, Nellist M, Goedbloed M, et al. Mutational analysis of the TSC1 and TSC2 genes in a diagnostic setting: genotype-phenotype correlations and comparison of diagnostic DNA techniques in tuberous sclerosis complex. *Eur J Hum Genet*. 2005;13:731–734.

Sarasin FP, Wong JB, Levey AS, et al. Screening for acquired cystic kidney disease. *Kidney Int*. 1995;48:207–219.

Sasongko TH, Ismail NF, Nik Abdul Malik NM, et al. Rapamycin and its analogues (rapalogs) for tuberous sclerosis complex-associated tumors: a systematic review on nonrandomized studies using meta-analysis. *Orphanet J Rare Dis*. 2015;10:95.

Saunier S, Clado J, Helig K, et al. A novel gene that encodes a protein with a putative src homology 3 domain is a candidate gene for familial juvenile nephronophthisis. *Hum Mol Genet*. 1997;17:2317–2323.

Saxton HM, Golding SJ, Chantler C, et al. Diagnostic puncture in renal cystic dysplasia (multicystic kidney): evidence on the aetiology of the cysts. *Br J Urol*. 1981;54:555.

Sayer JA, Otto EA, O'Toole JF, et al. The centrosomal protein nephrocystin-6 is mutated in Joubert syndrome and activates transcription factor ATF4. *Nat Genet*. 2006;38:674–681.

Scheff RT, Zuckerman G, Harter H, et al. Diverticular disease in patients with chronic renal failure due to polycystic kidney disease. *Ann Intern Med*. 1980;92:202.

Schermer B, Ghenoiu C, Bartram M, et al. The von Hippel-Lindau tumor suppressor protein controls ciliogenesis. *J Cell Biol*. 2006;175(4):547–554.

Schrier RW, Abebe KZ, Perrone RD, et al. HALT-PKD Trial Investigators. Blood pressure in early autosomal dominant polycystic kidney disease. *N Engl J Med*. 2014;371:2255–2266.

Schwab SJ, Bander SJ, Klahr S. Renal infection in autosomal dominant polycystic kidney disease. *Am J Med*. 1987;82:714.

Schwarz RD, Stephens FD, Cussen LJ. The pathogenesis of renal hypodysplasia: II. The significance of lateral and medial ectopy of the ureteric orifice. *Invest Urol*. 1981;19:97.

Sedman A, Gabow PA. Autosomal dominant polycystic kidney disease. *Dialogues Pediatr Urol*. 1984;7:4.

Seeman T, John U, Blahova K, et al. Ambulatory blood pressure monitoring in children with unilateral multicystic dysplastic kidney. *Eur J Pediatr*. 2001;160:78–83.

Shalhoub RJ, Rajan U, Kim VV, et al. Erythrocytosis in patients on long-term hemodialysis. *Ann Intern Med*. 1982;97:686.

Shannon MB, Patton BL, Harvey SJ, et al. A hypomorphic mutation in the mouse laminin alpha 5 gene. *J Am Soc Nephrol*. 2006;17:1913–1922.

Shehata BM, Stockwell CA, Castelllano-Sanchez AA, et al. von Hippel Lindau (VHL) disease: an update of the clinicopathologic and genetic aspects. *Adv Anat Pathol*. 2008;15:165–171.

Shepherd CW, Scahill SJ, Stephenson JB, et al. Tuberous sclerosis complex in Olmsted County, Minnesota, 1950–1989. *Arch Neurol*. 1991;48:400.

Sherstha R, McKinley C, Russ P, et al. Postmenopausal estrogen therapy selectively stimulates hepatic enlargement in women with autosomal dominant polycystic disease. *Hepatology*. 1997;26:1282–1286.

Shillingford JM, Murcia NS, Larson CH, et al. The mTOR pathway is regulated by polycystin-1 and its inhibition reverses renal cystogenesis in polycystic kidney disease. *Proc Natl Acad Sci USA*. 2006;103:5466–5471.

Siegel MJ, McAlister WH. Simple cysts of the kidney in children. *J Urol*. 1980;123:75.

Smith C, Graham J. Congenital medullary cysts with severe refractory anemia. *Am J Dis Child*. 1945;69:369–377.

Snodgrass WT. Hypertension associated with multicystic dysplastic kidney in children. *J Urol*. 2000;164:472.

Solomon D, Schwartz A. Renal pathology in von Hippel-Lindau disease. *Hum Pathol*. 1988;19:1072.

Steinbach F, Novick AC, Zincke H, et al. Treatment of renal cell carcinoma in von Hippel-Lindau disease: a multicenter study. *J Urol*. 1995;153:1812–1816.

Steinman TI. Polycystic kidney disease: a 2011 update. *Curr Opin Nephrol Hypertens*. 2012;21(2):189–194.

Stillwell TJ, Gomez MR, Kelalis PP. Renal lesions in tuberous sclerosis. *J Urol*. 1987;138:477.

Strand WR, Rushton HG, Markle BM, et al. Autosomal dominant polycystic kidney disease in infants: asymmetric disease mimicking a unilateral renal mass. *J Urol*. 1989;141:1151–1153.

Susskind MR, Kim KS, King LR. Hypertension and multicystic kidney. *Urology*. 1989;34:362–366.

Sweeney WE Jr, Chen Y, Nakanishi K, et al. Treatment of polycystic kidney disease with a novel tyrosine kinase inhibitor. *Kidney Int*. 2000;57:33–40.

Tada S, Yamagishi J, Kobayashi H, et al. The incidence of simple renal cyst by computed tomography. *Clin Radiol*. 1983;150:207.

Talamo TS, Shonnard JW. Small renal adenocarcinoma with metastases. *J Urol*. 1980;124:132–134.

Tanagho EA. Surgically induced partial urinary obstruction in the fetal lamb: III. Ureteral obstruction. *Invest Urol*. 1972;10:35.

Tao Y, Kim J, Schrier RW, et al. Rapamycin markedly slows disease progression in a rat model of polycystic kidney disease. *J Am Soc Nephrol*. 2005;16:46–51.

Telenius-Berg M, Ponder MA, Berg B, et al. Quality of life after bilateral adrenalectomy in MEN 2. *Henry Ford Hosp Med J*. 1989;37(3–4):160–163.

Terada N, Ichioka K, Matsuta Y, et al. The natural history of simple renal cysts. *J Urol*. 2002;167:21–23.

Thomas JC, DeMarco RT, Pope JC. Molecular biology of ureteral bud and trigonal development. *Curr Urol Rep*. 2005;6(2):146–151.

Thomson BJ, Jenkins DAS, Allan PL, et al. Acquired cystic disease of the kidney in patients with end stage chronic renal failure: a study of prevalence and etiology. *Nephrol Dial Transplant*. 1986;1:38–43.

Tilemis S, Savanelli A, Baltogiannis D, et al. Is the risk of hypertension an indication for prophylactic nephrectomy in patients with unilateral multicystic dysplastic kidney? *Scand J Urol Nephrol*. 2003;37:429.

Torres VE, Grantham JJ. Cystic diseases of the kidney. Brenner BM. *Brenner and Rector's the kidney*. ed 8. Saunders: Philadelphia; 2008:1428–1462.

Truong L, Kirshman B, Cao JT, et al. Renal neoplasms in acquired cystic kidney disease. *Am J Kidney Dis*. 1995;26:1–12.

Truong LD, Choi YJ, Shen SS, et al. Renal cystic neoplasms and renal neoplasms associated with cystic renal diseases. *Adv Anat Pathol*. 2003;10:135.

Tsaur I, Obermüller N, Jonas D, et al. De novo renal cell carcinoma of native and graft kidneys in renal transplant recipients. *BJU Int*. 2011;108(2):229–234.

Uson AC, Melicow MM. Multilocular cysts of the kidney with intrapelvic herniation of a “daughter” cyst: report of 4 cases. *J Urol*. 1963;89:341.

Vagelli G, Ferraris V, Calbrese G, et al. Medullary sponge kidney and calcium nephrolithiasis [Abstract]. *Urol Res*. 1988;16:201.

van Baal JG, Smits NJ, Keeman JN, et al. The evolution of renal angiomyolipomas in patients with tuberous sclerosis. *J Urol*. 1994;152:35.

Wacksman J, Phipps L. Report of the multicystic kidney registry: preliminary findings. *J Urol*. 1993;150:1870.

Wahl PR, Serra AL, Le Hir M, et al. Inhibition of mTOR with sirolimus slows disease progression in Han:SPRD rats with autosomal dominant polycystic kidney disease ADPKD. *Nephrol Dial Transplant*. 2006;21:598–604.

Wahlqvist L, Grumstedt B. Therapeutic effect of percutaneous puncture of simple renal cyst: follow-up investigation of 50 patients. *Acta Chir Scand*. 1966;132:340.

Wakabayashi T, Fujita S, Onbora Y, et al. Polycystic kidney disease and intracranial aneurysms: early angiographic diagnosis and early operation for the unruptured aneurysm. *J Neurosurg*. 1983;58:488.

Wallis MC, Lorenzo AJ, Farhat WA, et al. Risk assessment of incidentally detected complex renal cysts in children: potential role for a modification of the Bosniak classification. *J Urol*. 2008;180(1):317–321.

Walther MM, Keiser HR, Choyke PL, et al. Management of hereditary pheochromocytoma in von Hippel-Lindau kindreds with partial adrenalectomy. *J Urol*. 1999;161(2):395–398.

Walther MM, Reiter R, Keiser HR, et al. Clinical and genetic characterization of pheochromocytoma in von Hippel-Lindau families. *J Urol*. 1999;162:659–664.

Wang W, Wu Y, Ward CJ, et al. Vasopressin directly regulates cyst growth in polycystic kidney disease. *J Am Soc Nephrol*. 2008;19:102–108.

Wang X, Gattone V, Harris PC, et al. Effectiveness of vasopressin V2 receptor antagonists OPC-31260 and OPC-41061 on polycystic kidney disease development in the PCK rat. *J Am Soc Nephrol*. 2005;16:846–851.

Ward CJ, Hogan MC, Rossetti S, et al. The gene mutated in autosomal recessive polycystic kidney disease encodes a large receptor-like protein. *Nat Genet*. 2002;30:259.

Watnick TJ, Torres VE, Grandolph MA, et al. Somatic mutation in individual liver cysts supports a two-hit model of cystogenesis in autosomal dominant polycystic kidney disease. *Mol Cell*. 1998;2:247–251.

Webb DW, Osborne JP, Fryer AE. On the incidence of mental retardation in tuberous sclerosis. *J Med Genet*. 1991;28:385.

Webb NJ, Lewis MA, Bruce J, et al. Unilateral multicystic dysplastic kidney: the case for nephrectomy. *Arch Dis Child*. 1997;76:31.

Welch TR, Wacksman J. The changing approach to multicystic dysplastic kidney in children. *J Pediatr*. 2005;146:723–725.

Wikstrom B, Backman U, Danielson BG. Ambulatory diagnostic evaluation of 38 recurrent renal stone formers: a proposal for clinical classification and investigation. *Klin Wochenschr*. 1983;61:85.

Wilson PD. Polycystic kidney disease: new understanding in the pathogenesis. *Int J Biochem Cell Biol*. 2004;36:1868–1873.

Wilson SJ, Amsler K, Hyink DP, et al. Inhibition of HER-2(neu/ErbB2) restores normal function and structure to polycystic kidney disease (PKD) epithelia. *Biochim Biophys Acta*. 2006;1762:647–655.

Yamamoto N, Kanetake H, Yamara J. In vitro evidence from tissue cultures to prove existence of rabbit and human renotropic growth factor. *Kidney Int*. 1983;23:624.

Yendt ER. Medullary sponge kidney. Gardner KD Jr, Bernstein J. *The cystic kidney*. Kluwer Academic: Boston; 1990:379.

Yium J, Gabow P, Johnson A, et al. Autosomal dominant hemoglobin. *J Am Soc Nephrol*. 1994;4:1670–1674.

Zbar B, Kishida T, Chen F, et al. Germline mutations in the von Hippel-Lindau disease (VHL) gene in families from North America, Europe and Japan. *Hum Mutat*. 1996;8:348.

Zeier M, Geberth S, Ritz E, et al. Adult dominant polycystic kidney disease: clinical problems. *Nephron*. 1988;49:177.

Zerres K, Hansmann M, Mallman R, et al. Autosomal recessive polycystic kidney disease: problems of prenatal diagnosis. *Prenat Diagn*. 1988;8:215.

Zerres K, Mucher G, Bachner L, et al. Mapping of the gene for autosomal recessive polycystic kidney disease (ARPKD) to chromosome 6p21-cen. *Nat Genet*. 1994;7:429.

Zhou X, Fan LX, Sweeney WE Jr, et al. Sirtuin 1 inhibition delays cyst formation in autosomal-dominant polycystic kidney disease. *J Clin Invest*. 2013;7(123):3084–3098.

40

Pathophysiology of Urinary Tract Obstruction

Craig A. Peters MD, Kirstan K. Meldrum MD

Prevalence

Obstructive uropathy accounts for approximately 10% of all cases of renal failure. In an autopsy series of 59,064 individuals ranging from neonates to geriatric subjects, the prevalence of hydronephrosis was originally estimated to be 3.1% (Bell, 1950). Hydronephrosis was found to be more prevalent in women between ages 20 and 60, which was attributed to pregnancy and the development of gynecologic malignancies. In contrast, hydronephrosis was more prevalent in males after age 60 because of the presence of prostatic disease.

In a consecutive autopsy series of 3172 stillbirths, infants, and children performed over a 12-year period, urinary tract malformations were found in 78 cases (2.5%). Hydronephrosis and/or hydroureter accounted for 35.9% of urinary tract abnormalities (Tan et al., 1994). A slightly higher autopsy incidence of hydronephrosis in children (2%) was reported by Campbell (1970). Among children, hydronephrosis appears to be somewhat more prevalent in boys, and the majority of cases occur in subjects younger than 1 year. Indeed, obstructive nephrouropathies constitute the single largest entity leading to renal insufficiency in male children younger than 1 year of age (Benfield, 2003; Seikaly et al., 2003; USRDS, 2015).

Clinical Presentation of Obstruction

The clinical presentation of urinary tract obstruction can be variable depending on the site, degree, and chronicity of the obstruction. Flank pain secondary to stretching of the collecting system is the most common symptom in patients with acute obstruction and is typically an unrelenting, excruciating pain that can radiate to the lower abdomen and testicles or labia on the affected side and is often associated with nausea or vomiting. In contrast, chronic obstruction of the urinary tract is usually a relatively painless phenomenon, and patients may be entirely asymptomatic. Obstruction of the bladder outlet is most often associated with voiding symptoms of frequency, urgency, hesitancy, nocturia, poor urinary stream, and the sensation of incomplete emptying. Anuria is a rare but dramatic and fairly specific presenting sign of urinary tract obstruction.

Obstructive uropathy should always be considered in patients with new-onset hypertension and in patients with renal failure without a previous history of renal disease, diabetes, or hypertension. In addition, urinary tract obstruction should always be investigated as a possible contributing factor in patients with recurrent urinary tract infections (UTIs). Because the clinical signs and symptoms of obstructive uropathy are so variable, the diagnosis is dependent on prompt and appropriate imaging.

Clinical Presentation in Children

Prenatal ultrasonographic diagnosis has radically altered the clinical presentation of obstructive conditions. Today most are detected before birth, and many have no apparent clinical signs. Those with clinical manifestations are often severe obstructive conditions such as posterior urethral valves or massive hydronephrosis of various causes. Children are still found with clinical signs of obstruction, usually infection or pain, and rarely hypertension (de Waard et al., 2008). In the child with obstruction of the entire urinary tract, even when the obstruction is relieved, the functional abnormalities inform us of the effects of obstruction on developing kidneys. Reduced filtration function resulting from glomerular injury can cause a rising serum creatinine, acidosis due to tubular injury, and nephrogenic diabetes insipidus secondary to collecting duct abnormalities. In extreme cases, these may all be present, but on occasion they are noted in isolation and may persist after relief of the obstruction

(Hutcheon et al., 1976). Obstructive hypertension appears to be renin mediated (Mizuiri et al., 1992; Riehle and Vaughan, 1981; Urata et al., 1985) and may be reversible with surgical repair (Al-Mashhadi et al., 2015; de Waard et al., 2008).

Progressive Renal Dysfunction

A major concern regarding obstructive conditions in the urinary tract is the potential for progressive renal dysfunction. Progression may be seen in two forms, one with the uncorrected partially obstructive lesion (i.e., ureteropelvic junction [UPJ] obstruction), and the second with the previously obstructed but corrected obstruction that has produced some degree of renal damage (i.e., posterior urethral valves). In the first, renal function may initially appear intact on imaging tests, yet in time there will be loss of absolute and relative function of the kidney affected by the obstruction. If this were known prospectively, intervention would be appropriate and should be performed early. The challenge is in predicting this situation and few markers are available to do this. The frequency of progressive deterioration in unilateral asymptomatic obstruction likely ranges from 20% to 40%, but severity and duration of follow-up will significantly affect this rate. Every prospective study of obstructive conditions has documented the potential for progressive loss (Koff, 2000; Koff and Campbell, 1992, Palmer et al., 1998; Parkhouse et al., 1988; Ross et al., 2011; Thorup et al., 2003).

The second situation reflects the fact that the damaged kidney does not have the functional reserve of a normal kidney. These kidneys demonstrate a steady decline in function over time, and this is usually evident only in bilateral obstruction. The mechanism may be hyperfiltration of remnant renal units, and clinically this is most often seen with posterior urethral valves (Heikkila et al., 2011; Nguyen and Peters, 1999; Parkhouse et al., 1988). These children may show adequate renal function early in life yet demonstrate a delayed and inexorable progression into renal failure in adolescence (Fig. 40.1). Whether earlier intervention would have protected their renal function is uncertain. Ultimately, specific therapeutic interventions could be targeted toward prevention of this progressive process (Chevalier, 2015).

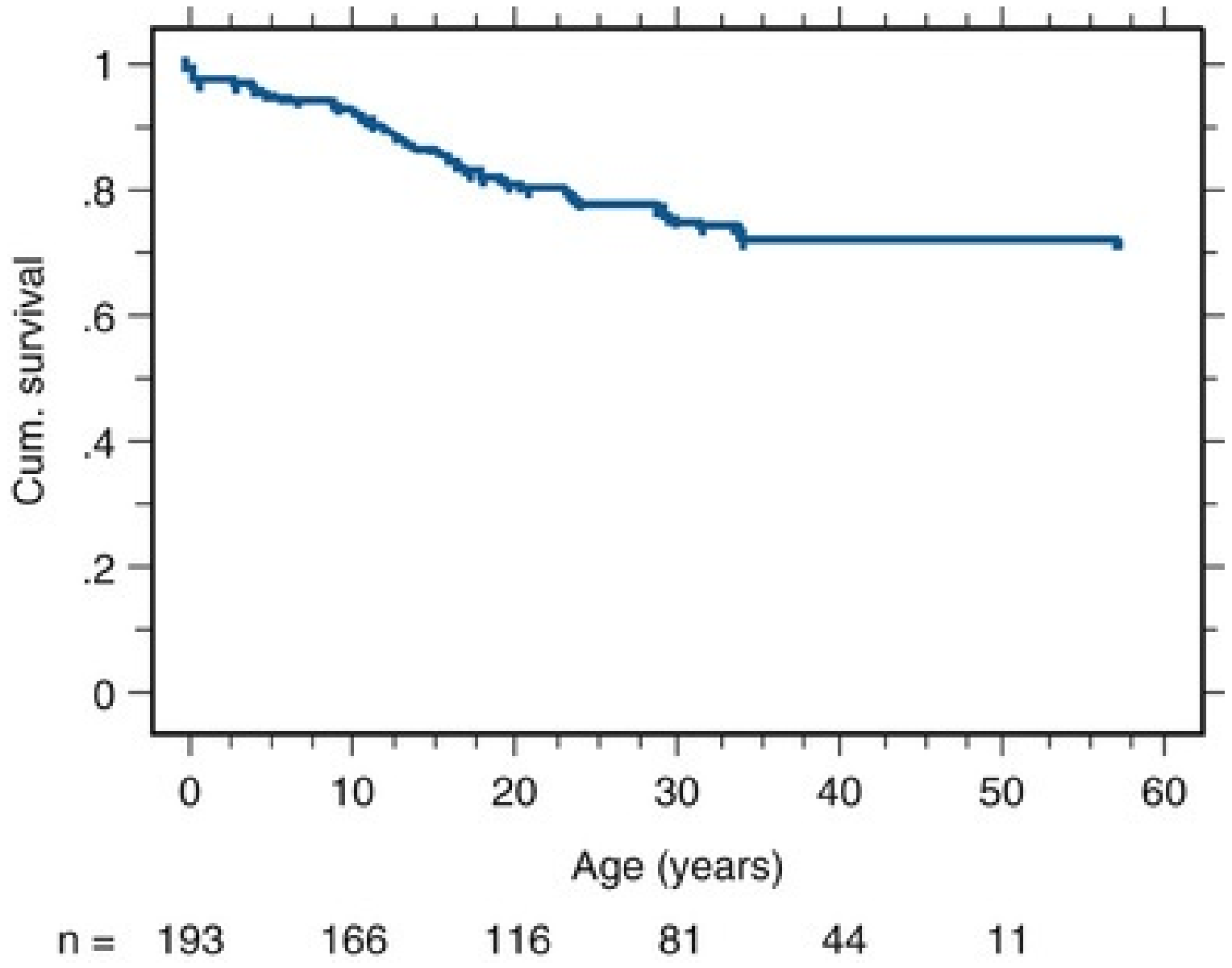

FIG. 40.1 Graph depicting the progressive deterioration in renal function and progression to end-stage renal disease in children with posterior urethral valves. (From Heikkilä J, Holmberg C, Kyllönen L, et al.: Long-term risk of end stage renal disease in patient with posterior urethral valves. *J Urol* 186:2392–2396, 2011. With permission.)

The most obvious marker of progressive renal dysfunction is the serum creatinine. However, this is relatively insensitive in early stages of progression. Radionuclide imaging may be helpful in some cases, but there is no gold standard regarding the best interpretation of potentially progressive disease. Urinary biomarkers have been extensively investigated, yet none are used commonly (Chevalier, 2016; Madsen et al., 2011).

Definition of Obstruction

Although the detection of hydronephrosis is straightforward, the determination of whether this particular condition requires surgical intervention to protect renal function and development is much more difficult. The frequently quoted definition of congenital obstruction (Koff, 1987) is that of “a condition producing a restriction of urinary flow that will lead to deterioration in renal function” seems too limited. In the growing child, renal function is expected to increase significantly, initially in excess of body mass and subsequently in parallel to it. If this increase in function does not occur, renal functional potential is lost, which may be of greater consequence than losing absolute function. Therefore **the impairment of renal functional development should be considered as a determinant of obstruction that warrants intervention** (Peters, 1995).

If this is the case, then an obstructive or hydronephrotic condition associated with less than normal function should be considered as likely functionally obstructive and warranting intervention. The ability to recover function that has not been achieved is unpredictable, however.

A critical element of COU is the recognition that it is distinct from acquired obstruction in the mature animal (or mature kidney). The fact that obstruction develops at the same time the kidney is in the process of formation creates an entirely different paradigm for COU as compared with obstruction of the mature kidney (Peters, 1997). The patterns of renal development are affected by obstruction, and this produces the ultimate functional effects. The mechanisms for these alterations are therefore wholly distinct from mature obstruction. Although there is likely to be some overlap in the critical mechanisms of change, many will be different.

One of the frustrations in the management of clinical congenital obstruction is the dichotomy between therapeutic options, which are currently limited to either observation or surgery. The absence of any medical or pharmacologic therapy to ameliorate or prevent the complications of obstruction has been a major factor in the controversy between those who chose to correct a problem and those who believe it is better to await spontaneous resolution or unambiguous evidence of obstructive injury. The horizon holds promise for medical therapies that may prevent renal injury in various ways, but it will be essential to more completely understand the nature of COU to permit such specific treatment. As medical therapies evolve, the simplistic black and white view of obstructed vs. not obstructed, rooted in our limited treatments, will hopefully fade away as it should.

Diagnosis and Imaging

Laboratory Studies

The initial workup of a patient suspected of having urinary tract obstruction should begin with a urinalysis and microscopic analysis. An assessment of renal function and measurement of serum electrolytes should be performed, and in the patient with acute renal failure, an assessment of urinary diagnostic indices including the fractional excretion of sodium (FENa) should be performed.

Urinalysis

The urinalysis and microscopic analysis is necessary in the complete evaluation of a patient suspected of having urinary tract obstruction and/or renal failure. The urinalysis can provide an estimation of osmolality, evidence of urinary tract infection, insight into stone formation based on crystals that may be present in the urine, and the possible presence of medical renal disease with the presence of protein and/or cellular casts.

Fractional Excretion of Sodium

The FENa is a test often used to differentiate between the three types of acute renal injury: prerenal, intrinsic, and postrenal.

$$\mathrm{FENa} = (P_{Cr} \times U_{Na})/(P_{Na} \times U_{Cr})$$

P_{Cr} is defined as the serum creatinine level, U_{Na} is urine sodium level, P_{Na} is serum sodium level, and U_{Cr} is the urine creatinine level. An FENa less than 1% suggests a prerenal cause of acute renal failure (i.e., hypovolemia, congestive heart failure [CHF], renal artery stenosis, sepsis). An FENa of more than 1% indicates intrinsic causes of acute renal failure (i.e., acute tubular necrosis, glomerulonephritis, acute interstitial nephritis), and an FENa more than 4% indicates postrenal causes of acute renal failure (i.e., BPH, bladder stones, bilateral ureteral obstruction).

Assessment of Renal Function

Measurement of glomerular filtration rate (GFR) is considered the gold standard in identifying patients with renal insufficiency or renal failure. Normal GFR varies and generally decreases with age. The measurement of true GFR can be tedious and impractical; therefore a variety of tests are used to estimate GFR, the most common being serum creatinine. Creatinine remains imprecise, however, because of variability with age, gender, race, and a relationship with muscle mass. In adults, the most accurate estimating equation for GFR is the Chronic Kidney Disease Epidemiology Collaboration equation (CKD-EPI) (Levey et al., 2009):

$$\begin{aligned} \text{eGFR} &= 141 \times \min\left(S_{cr}/\kappa, 1\right)^{\alpha} \times \max\left(S_{cr}/\kappa, 1\right)^{-1.209} \\ &\quad \times 0.993^{\text{Age}} \times 1.018\ [\text{if female}] \times 1.159\ [\text{if black}] \end{aligned}$$

where S_{cr} is serum creatinine in mg/dL, κ is 0.7 for females and 0.9 for males, α is −0.329 for females and −0.411 for males, *min* indicates the minimum of S_{cr}/κ or 1, and *max* indicates the maximum of S_{cr}/κ or 1. The Schwartz equation is most commonly used to estimate GFR in children:

$$\text{eGFR} = 0.413 \times \text{height (cm)}/\text{serum creatinine (mg/dL)}$$

Because creatinine is a waste product of muscle metabolism and is cleared by glomerular filtration and tubular secretion, serum creatinine can be influenced by a number of factors without representing a change in GFR. Cystatin C has recently emerged as a more accurate marker of GFR and can be used in modified CKD-EPI and Schwartz equations to estimate GFR (Pasala and Carmody, 2017). Cystatin C is a cysteine protease inhibitor produced by all nucleated cells in the body and is therefore not influenced by muscle mass. It is also freely filtered at the glomerulus and not secreted by the tubules (Pasala and Carmody, 2017).

In general, a GFR greater than 90 mL/min/1.73 m^2 is considered normal, between 60 and 90 mL/min/1.73 m^2 is considered a mild decline in renal function, between 30 and 60 mL/min/1.73 m^2 is a moderate decline in renal function, between 15 and 30 mL/min/1.73 m^2 is a severe decline in renal function, and less than 15 mL/min/1.73 m^2 is considered renal failure (Siddiqui and McDougal, 2011).

Biomarkers

Biomarkers of renal obstruction may reflect the response of the kidney in a direct manner, such as expression of growth factors that contribute to fibrosis or are associated with increased apoptosis in renal epithelium. They may also be downstream effects reflecting specific alterations mediated by other cytokines and not directly relevant but indicative of the level and pattern of the obstructive effect. An emerging broad approach, proteomics, uses assessment of changes in overall protein expression in the urine. Normal developing kidneys have an evolving protein fingerprint, which can be defined (Lee et al., 2008) and is altered with obstruction. If particular elements of the alteration can be identified and associated with clinical outcomes, these patterns may be diagnostic of functionally significant obstruction. Such patterns may reflect a single protein, which may be an element of a response pattern, or a downstream consequence (Chevalier, 2016; Jianguo et al., 2014; Li et al., 2018; Taranta-Janusz et al., 2013, Tian et al., 2015, Zhao et al., 2016). It may be that a particular pattern of protein expression, involving several factors, will be the best indicator of obstruction (Chevalier, 2016; Decramer et al., 2006, 2008; Stodkilde et al., 2013). Such studies will require development in animal systems and validation in the human. It will be necessary to set limits for what is and is not clinically significant "obstruction" and correlate this with clinical and functional outcomes of relevance. These changes must be correlated with histopathological changes in the developing kidney or more precise measures of renal function.

Diagnostic Imaging

Because the clinical presentation of the patient with urinary tract obstruction can be so variable, prompt and accurate diagnosis of obstruction is dependent on appropriate imaging. A review of the imaging modalities currently available and their advantages and limitations are presented later.

Ultrasonography

Renal ultrasonography remains a first-line imaging modality in the evaluation of a patient suspected of having urinary tract obstruction because of its availability, low cost, and lack ionizing radiation. It also does not require the administration of iodinated contrast and can therefore safely

be performed in patients with renal insufficiency or a contrast allergy. The renal ultrasound primarily provides anatomic information about the kidney including renal size, cortical thickness, corticomedullary differentiation, and the grade of collecting system dilation. **Although the presence of hydronephrosis is suggestive of underlying obstruction, it is important to recognize that hydronephrosis is an anatomic finding, not a functional diagnosis, and that hydronephrosis alone does not indicate urinary tract obstruction.** Significant hydronephrosis can be present in the absence of obstruction (e.g., in the patient with vesicoureteral reflux) and significant obstruction can be present in the absence of severe hydronephrosis, as is often the case very early in the course of acute renal obstruction. Parenchymal thinning and a small renal size can be evidence of chronic renal obstruction, and bladder distention in association with hydronephrosis can be suggestive of bladder outlet obstruction. **Standard renal sonography may appear normal in 50% of patients with acute urinary obstruction, and distinguishing obstructive from nonobstructive collecting system dilation can be difficult, especially when the obstructing agent is not visualized** (Mostbeck et al., 2001; Platt et al., 1989).

The introduction of duplex Doppler sonography was subsequently suggested as a means to improve the ability of ultrasonography to diagnose renal obstruction in patients. In the early 1990s, changes in intrarenal arterial waveforms were shown to be associated with urinary obstruction, and the resistive index (RI) (defined as the peak systolic velocity-end diastolic velocity/peak systolic velocity) was advanced as a technique to improve our detection of urinary obstruction during ultrasonography. After a short period of prostaglandin-mediated vasodilation, renal blood flow decreases and there is an increase in renal vascular resistance in response to obstruction. In general, an RI of 0.70 is considered to be the upper limits of normal in adults (Tublin et al., 2003), although important exceptions to this value have been reported. It is common for the mean RI to exceed 0.70 in children in the first year of life and can exceed 0.70 for at least the first 4 years of life. The RI can also exceed 0.70 in elderly patients without renal insufficiency. Initial clinical studies evaluating the RI threshold of 0.70 in the diagnosis of obstruction were encouraging, with a 92% sensitivity and 88% specificity. The diagnosis of obstruction increased further when the difference in RI (δ RI) between the affected kidney and contralateral kidney was found to be greater than 0.1 (Platt et al., 1989).

Although a number of encouraging studies evaluating RI have been reported, subsequent clinical trials and animal studies investigating RI in the detection of renal obstruction have been discouraging. Chen et al. (1993) demonstrated that the RI is normal in most patients with partial or mild obstruction. Similarly, when discriminatory thresholds for obstruction (mean RI ≥ 0.7, delta RI ≥ 0.1) were used in the detection of patients with acute renal colic, the sensitivity and specificity of the Doppler examination was found to be only 44% and 82%, respectively (Tublin et al., 1994). It has subsequently been demonstrated that radio-contrast can induce vasoconstriction and increase RI during Doppler sonography (Hetzel et al., 2001) and that nonsteroidal anti-inflammatory drugs (NSAIDs) can significantly decrease the RI of acutely obstructed kidneys (Shokeir et al., 1999), both of which may have been factors confounding the results of clinical studies investigating RI in the diagnosis of renal obstruction. Despite these observations, however, there has been increased skepticism over the utility of RI to detect renal obstruction (Gurel et al., 2006), and with widespread acceptance of non-contrast computed tomography (CT) scanning as the gold standard in the detection of renal calculi, the routine use of RI analysis in the evaluation of possible renal obstruction has declined.

Color Doppler ultrasonography has been shown to reliably identify ureteric jet dynamics in the bladder, and this has evolved as another diagnostic tool to distinguish obstructive from nonobstructive hydronephrosis. Burge et al. (1991) demonstrated that there was a significant decrease in the frequency of ureteral jets in patients with obstructing ureteral stones as compared with the normal ureter. More recently, Jandaghi et al. demonstrated that there is a significant decrease in the frequency, duration, and peak velocity of urine jets emanating from the obstructed ureterovesical junction when compared with the contralateral side, and differences of 1.5 jets/min, 2.5 s, and 19.5 cm/s in ureteral jet frequency, duration, and peak velocity, respectively, were proposed as cutoff points between obstructed and normal ureters (Jandaghi et al., 2013). de Bessa et al. (2008) evaluated the frequency of urine jets in children that had obstructive vs. nonobstructive hydronephrosis and demonstrated that a relative jet frequency (RJF = jet frequency of the hydronephrotic side divided by the sum of both ureteral jets over 5 min) of less than 25% had a sensitivity of 87% and a specificity of 96% in detecting obstruction. **Although the analysis of ureteral jets is easily applied during routine ultrasonography and may offer some valuable insight into the presence of obstruction, it does require good hydration of the patient and is limited by the requirement of a normal contralateral collecting system for comparison.**

Quantitative image analysis of renal ultrasounds with hydronephrosis has introduced the potential for more precise delineation of clinically significant hydronephrosis to better define patients needing more complex imaging (Cerrolaza et al., 2016; Kern et al., 2017).

One of the most common causes of urinary tract obstruction is the presence of renal or ureteral calculi. Although ultrasonography does not have the sensitivity of CT in detecting stones, it avoids the cumulative radiation dose from CT and can reveal secondary effects of urolithiasis, including hydronephrosis, infection, or abscess formation. It also has the advantage of detecting radiolucent stones. Ultrasound may detect calculi as small as 0.5 mm under optimal conditions, and stones typically manifest on ultrasound as echogenic foci in the collecting system associated with acoustic shadowing. Use of the twinkling artifact (TwA), an intense alternating color signal behind calcifications and stones, appears to be very useful in detecting stones smaller than 5 mm on ultrasound with a reported sensitivity of 99.12% and specificity of 90.91% (Gliga et al., 2017). **In a pooled analysis, ultrasound was demonstrated to have only a 45% sensitivity and 94% specificity in detecting ureteral stones and a 45% sensitivity and 88% specificity in detecting renal calculi as compared with noncontrast CT** (Ray et al., 2010)**. However, a recent multicenter comparative effectiveness trial demonstrated no difference in serious adverse events, pain scores, return emergency department visits, or hospitalizations when using ultrasonography versus CT for the initial evaluation of suspected nephrolithiasis** (Smith-Bindman et al., 2014)**. It has been shown that ultrasound overestimates renal stone size as compared with CT, particularly for stones 5 mm or smaller** (Sternberg et al., 2016)**, and this may have a significant impact on clinical decision making and counseling decisions** (Ganesan et al., 2017). Direct visualization of stones can be difficult on ultrasound because of the presence of overlying bowel gas and the relative depth of the ureter within the pelvis and can be further complicated in obese patients with large amounts of intervening fat (Cheng et al., 2012). **Because of these limitations, ultrasound is primarily used as a first-line investigative tool in pediatric and pregnant patients but can be used for routine follow-up in all patients with urolithiasis.**

Nuclear Renography

Nuclear medicine plays a critical role in the evaluation of the patient with possible urinary tract obstruction because it is the only imaging modality

that can provide noninvasive information about dynamic renal function. The nuclear study of choice in the evaluation of the obstructed collecting system is diuretic renography, most commonly performed using the radiopharmaceutical technetium-99m-mercaptoacetyltriglycine (^{99m}Tc-MAG3). **^{99m}Tc-MAG3 is preferred for diuretic renography because it has high extraction by the kidneys, rapid clearance, low radiation dose, and tubular secretion.** Renal uptake is 55% compared with 20% uptake by technetium-99m-diethylenetriaminepentaacetic acid (^{99m}Tc-DTPA), the other radiopharmaceutical used for diuretic renography, resulting in better cortical imaging for qualitative and quantitative analysis (He and Fischman, 2008). **As opposed to ^{99m}Tc-MAG3, which is actively secreted by the tubules, ^{99m}Tc-DTPA is removed almost exclusively by glomerular filtration and is therefore the agent most suited to measurement of GFR. Adequate imaging of the collecting system, however, is GFR-dependent with DTPA and is limited in patients with renal insufficiency and those less than 6 months of age because of the immaturity of renal function.**

The normal renogram curve has three distinct phases. The initial phase is characterized by rapid uptake of the radiopharmaceutical by the kidneys reflecting renal perfusion. The second phase is characterized by a more gradual rise in uptake over time, usually peaking after 2 to 5 minutes. It is during the second phase that renal function is primarily evaluated. Urinary obstruction can diminish the rate of uptake of the radiotracer during the second phase and can therefore alter the assessment of differential renal function. The third phase is the excretory phase and is characterized by a gradual decrease in renal counts over time. The third phase is often augmented by the administration of a diuretic (diuretic renogram) to induce high urine flow and prevent the false-positive results that can be caused by urine stasis in a dilated collecting system. **By convention, a kidney is considered unobstructed if the T1/2 (time for one half of the tracer to leave the collecting system) is less than 10 min, is equivocal if the T1/2 is 10 to 20 min, and is considered obstructed if the T1/2 is greater than 20 min.** False-positive results can be seen in the presence of dehydration because of the suboptimal response to diuretic, poor renal function, high-grade reflux, and in the presence of massive collecting system dilation with urinary stasis (Goldfarb et al., 2006). Renal immaturity in neonates may also generate false-positive results (Karam et al., 2003).

To improve the accuracy of diuretic renography and limit false-positive results, patients should be well hydrated for the study. The well-tempered renogram was originally described for children in 1992 as a means to ensure a standardized level of hydration with the administration of IV fluids before and during the course of the study (Conway and Maizels, 1992). Bladder distention and elevated bladder pressures can limit the ability of the upper urinary tract to drain and may artificially prolong the excretory phase of the study. Routine catheter placement is therefore recommended for any patient who is unable to urinate voluntarily and should also be considered for any patient with significant reflux, bladder pathology (i.e., neurogenic bladder), or a low-lying pelvic kidney from which the signal may be obscured by bladder filling. Patient position during the study also appears to affect results, and urine flow may be slow and resemble obstruction when the patient is supine. It is therefore suggested that a later static image be obtained in any patient with prolonged T1/2 after they have assumed an upright gravity-assisted posture (Wong et al., 2000).

Timing of diuretic administration is somewhat controversial, and multiple different protocols have been established. Traditionally, furosemide is injected 20 minutes after the radiopharmaceutical is administered (F+20), although the diuretic can be administered 15 minutes before tracer injection (F−15) or at the time of tracer injection (F+0). The advantages of the F+20 technique are that the modifications to the drainage curve caused by furosemide can be observed, and if adequate kidney washout has occurred during the basic renogram, one can potentially avoid the administration of furosemide (Piepsz, 2011). With earlier administration of furosemide (F−15, F+0), urine flow is increased dramatically throughout the entire study; Turkolmez et al. (2004) found that these protocols allowed clarification of obstruction in cases of equivocal F+20 studies. The disadvantage of the F+0 protocol is that early furosemide injection can result in acceleration of renal transit and an underestimation of renal function on the side with a short transit time (Donoso et al., 2003). A recent study suggested improved results when patients were placed in a seated position and furosemide was administered 10 minutes after the radiopharmaceutical (F+10) (Tartaglione et al., 2013). **It is important to keep in mind that measurement of differential renal function and tracer washout varies depending on the protocol and radiopharmaceutical used, and care should be taken when interpreting results if comparative studies have been performed using different protocols or radiopharmaceuticals.**

Computed Tomography

Cross-sectional imaging provided by CT generates greater anatomic

definition than ultrasonography, and because of its speed, safety, and accuracy, noncontrast helical CT (NCHCT) has become the imaging modality of choice for patients suspected of having ureteral obstruction. In a landmark study, Smith et al. (1995) demonstrated the superiority of unenhanced helical CT in the evaluation of possible ureteral obstruction compared with excretory urography. Unenhanced helical CT gives information about obstructing and non-obstructing stones, and it can reveal signs associated with ureteral obstruction even after stone passage, including hydronephrosis, perinephric stranding, and the "tissue rim sign." These secondary signs have been reported to have a positive predictive value of more than 90% for the presence of acute ureteral obstruction (Heneghan et al., 1997; Smith et al., 1996). **CT has a reported sensitivity of 96% for stone detection with a specificity and positive predictive value of 100%** (Worster et al., 2002) **and can detect most radiolucent stones with the exception of protease inhibitor stones (e.g., indinavir sulfate) and mucoid matrix stones.** In addition, NCHCT has been demonstrated to diagnose a wide spectrum of significant and alternative diagnoses in 10% of patients evaluated for renal colic (Katz et al., 2000).

Although the unenhanced helical CT is the modality of choice in the evaluation of patients with acute renal colic, it has a limited ability to evaluate chronic obstruction of the urinary tract and various causes of obstruction other than calculi. Over the past decade, **multidetector computed tomography urography (CTU) has emerged as the imaging modality of choice for a comprehensive evaluation of the urinary tract** (Washburn et al., 2009). The traditional CTU technique involves three imaging phases using a single intravenous bolus injection of contrast. An unenhanced phase is initially performed followed by a nephrogenic phase obtained approximately 100 to 120 seconds after contrast injection, and an excretory phase is performed after a greater time delay to evaluate the urothelium. With the advent of improved software and high-resolution thin-slice CT scanning, three-dimensional (3D) reconstruction of the urinary tract can be performed and has been helpful in characterizing many obstructive lesions of the urinary tract. In addition to stones, calyceal diverticulum, crossing vessels causing UPJ obstruction, duplication anomalies in nonfunctioning systems, ureteroceles, and ectopic ureteral insertions can be visualized with good accuracy.

The primary concern regarding widespread use of CT is its associated high radiation exposure. The average mean effective dose for a single unenhanced CT has been reported to be 8.5 millisieverts (mSv) (Poletti et al.,

2007) **for a multidetector CT compared with 6.5 mSv for a single detector CT and 1.5 mSv for an excretory urogram series** (Katz et al., 2006). This dose can rapidly accumulate if there are multiple phases to the CT or the patient presents repeatedly. It has been estimated that the risk of fatal cancer is 0.05% or 1 in 2000 for 10 mSv of ionizing radiation (Brenner et al., 2001). **In children, the risks are more concerning because they are more sensitive to radiation-induced carcinogenesis and have a longer period of time for cancer to develop.** A recent study demonstrated that children receiving a cumulative brain dose of 50 mGy or more from CT had a 2.8 times higher risk of developing brain cancer and those receiving a cumulative bone marrow dose of 30 mGy or more from CT had a 3.2 times greater risk of developing leukemia (Miglioretti et al., 2013; Pearce et al., 2012). Because of these risks, low-dose protocols have emerged with very little loss in diagnostic accuracy (Poletti et al., 2007; Sade et al., 2017). Stones smaller than 3 mm, impaction at the UVJ, and patient obesity, however, have been shown to impair diagnostic accuracy of low-dose techniques (Kennish et al., 2010).

Magnetic Resonance Urography

Magnetic resonance urography (MRU) is an imaging modality that integrates excellent anatomic information with functional data and avoids ionizing radiation. Because of its significant cost and restricted availability, it is not a first-line imaging modality in the evaluation of a urinary obstruction at this time, but because of its major advantages over conventional imaging, MRU has the potential to become the imaging study of choice for the evaluation of urinary tract abnormalities in the future. The MRU protocol begins with standard T1- and T2-weighted imaging through the abdomen and pelvis without contrast. Gadolinium-diethylenetriaminepentaacetate dimeglumine (Gd-DTPA) is then administered in conjunction with furosemide, and T1-weighted imaging is performed allowing visualization of the concentrating and excretory functions of the kidney. MRU measurements of differential renal function and contrast excretion have been shown to correlate well with DTPA nuclear scintigraphy (Perez-Brayfield et al., 2003), but MRU has the advantage of providing excellent anatomic visualization of even nonfunctioning renal moieties. **The MRU measurement of contrast excretion is the renal transit time (RTT), which is defined as the time it takes for contrast to pass from the renal cortex to the proximal ureters. It is classified as normal if it is 4 min or less, equivocal if between 4 and 8 min, and obstructed if 8 min or longer** (Jones et al., 2004)**.**

Although the potential for MRU in pediatric obstruction is promising, the clinical correlation of these parameters to conventional diuretic renography and clinical outcomes remains to be defined, however (Grattan-Smith et al., 2011)**.** El-Nahas et al. (2007) reported that MRU has 100% sensitivity in diagnosing upper urinary tract obstruction, and MRU is valuable in diagnosing urinary tract abnormalities when traditional imaging is inconclusive (Payabvash et al., 2008). **Unfortunately, MRU detection of renal and ureteral stones is poor in comparison with CT because of the fact that stones appear as signal voids on T1- and T2-weighted images.** MRU sensitivity for detecting stones has been reported to be 68.9% to 84% (Blandino et al., 2001; Semins et al., 2013; Shokeir et al., 2004), but accuracy is greatly improved with gadolinium-enhanced excretory MRU, with sensitivities approaching 90% to 100% (Cerwinka and Kirsch, 2010). **The biggest risk of MRI is the development of nephrogenic systemic fibrosis (NSF), which was linked to gadolinium-based contrast agents in 2006 and appears to occur only in patients with severe renal impairment** (Thomsen, 2006). The incidence of NSF in patients with risk factors has been demonstrated to be 3% and current recommendations now limit the use of gadolinium in patients with renal impairment (Cerwinka and Kirsch, 2010). Newer agents may be able to reduce the risk of systemic fibrosis (Beam et al., 2017; Schieda et al., 2018; Soares et al., 2017).

Excretory Urography

Excretory urography (EXU) was previously considered the imaging modality of choice in the evaluation of patients suspected of having urolithiasis and/or urinary tract obstruction. Although it has largely been replaced with CTU, it does provide anatomic and functional information and can be useful in certain clinical situations. **Imaging during EXU is dependent on glomerular filtration and renal excretion of iodinated contrast medium; therefore the utility of excretory urography is limited in patients with renal insufficiency. The risk of contrast nephropathy also increases with worsening renal function. Excretory urography should not be performed in patients with a history of contrast allergy or those in whom radiation exposure is a concern (i.e., pregnancy).** A delay in contrast uptake and excretion by the kidney (delayed nephrogram) can be indicative of urinary tract obstruction, and the subsequent opacification of the collecting system with contrast can be helpful in identifying the level and potentially the source of obstruction. In addition, small renal size, parenchymal thinning, calyceal clubbing, and significant ureteral dilation and tortuosity can be signs of chronic urinary tract obstruction.

Whitaker Test

The Whitaker test, first described in 1973, is a urodynamic evaluation of the upper urinary tract that is helpful in differentiating an obstructed collecting system from an unobstructed hydronephrotic collecting system (Whitaker, 1973). Renal scintigraphy can give false-positive results in the face of massive collecting system dilation or poor renal function, because continued filling, rather than drainage, of the collecting system occurs in response to furosemide leading to an apparent prolongation in the calculated washout time. **The Whitaker test involves placement of a percutaneous needle in the collecting system of the kidney and the infusion of contrast at a rate of 10 mL/min. A urodynamic catheter is also placed in the bladder and intravesical pressures are monitored and subtracted from measured intrapelvic pressures during the infusion.** Intrapelvic pressures are noted at the time that contrast is first seen extending past the UPJ and past the ureterovesical junction (UVJ). **Pressures less than 15 cm H_2O are considered normal, greater than 22 cm H_2O is indicative of obstruction, and between 15 and 22 cm H_2O is considered indeterminate.** Although the reproducibility and clinical utility of the Whitaker test has been questioned (Djurhuus et al., 1985), the test has recently been shown to determine or contribute to therapeutic management in 84% of cases of suspected obstruction and to accurately predict obstruction and non-obstruction in 77% of cases (Lupton and George, 2010). A study by Veenboer et al. in 2011 demonstrated a 100% negative predictive value in the ability of the Whitaker test to diagnose the absence of obstruction. **Although the Whitaker test has limited applicability in clinical practice, it continues to have a role in the evaluation of equivocal upper urinary tract obstruction, especially when noninvasive investigations are inconclusive.**

Retrograde Pyelography

Retrograde pyelography refers to the injection of contrast into the upper collecting system through a cystoscopic approach. The technique accurately defines ureteral and upper collecting system anatomy and can determine the location of an obstructive lesion. It is most often used to define the anatomy of the collecting system when it has not been adequately defined by other imaging modalities or when a patient has risk factors for receiving iodinated contrast material. It may also provide more specific insight into the anatomy of the ureter and renal pelvis to better plan the surgical approach. Because retrograde pyelography involves intubation of the ureter with a catheter, bacteria may be introduced into the upper urinary tract during the procedure. The technique is therefore associated with an increased risk of UTI/sepsis in the setting of obstruction if the collecting system is not subsequently drained.

Antegrade Pyelography

Antegrade pyelography is most often used when retrograde pyelography is not technically feasible or when other imaging studies do not adequately define the collecting system.

Key Points: Imaging of Obstruction

- Hydronephrosis is an anatomic finding, not a functional diagnosis, and hydronephrosis alone does not indicate urinary tract obstruction.
- Ultrasound has a limited sensitivity in detecting stones, particularly ureteral stones, as compared with noncontrast CT.
- Ultrasound overestimates renal stone size as compared with CT, particularly for stones 5 mm or smaller, and this may have a significant impact on clinical decision making and counseling decisions. Ultrasound is primarily used as a first-line investigative tool in pediatric and pregnant patients but can be used for routine follow-up in all patients with urolithiasis.
- ^{99m}Tc-MAG3 is preferred for diuretic renography because it has high extraction by the kidneys, rapid clearance, low radiation dose, and tubular secretion.
- ^{99m}Tc-DTPA is removed almost exclusively by glomerular filtration and is therefore the agent most suited to measurement of GFR. Adequate imaging of the collecting system, however, is GFR-dependent with DTPA and is limited in patients with renal insufficiency and those less than 6 months of age because of immaturity of renal function.
- The primary concern regarding widespread use of CT is its high associated radiation exposure. In children, the risks are more concerning because children are more sensitive to radiation-induced carcinogenesis and have a

longer period of time for cancer to develop.

- MRU measurements of differential renal function and contrast excretion have been shown to correlate well with DTPA nuclear scintigraphy. Unfortunately, MRU detection of renal and ureteral stones is poor in comparison with CT because of the fact that stones appear as signal voids on T1- and T2-weighted images.
- The biggest risk of MRI is the development of NSF, which is linked to gadolinium-based contrast agents and appears to occur only in patients with severe renal impairment.

Pathological Changes of Obstruction

Pathological Changes in the Mature Kidney

The gross pathological changes that occur in the mature kidney in response to obstruction have been well described in animal models and parallel findings in humans. After 42 hours of obstruction, there is dilation of the collecting system and blunting of the papillary tips associated with an increased weight of the kidney. Collecting system dilation and renal weight further increase and the parenchyma becomes edematous after 7 days of obstruction. Further collecting system dilation develops after 12 days of obstruction, but after 21 to 28 days the cortex and medullary tissue in the obstructed kidney become diffusely thinned. After 6 weeks, the obstructed kidney is enlarged with a cystic appearance, but lower weight, as compared with the normal contralateral kidney (Ladefoged and Djurhuus, 1976).

The histologic derangements associated with early obstruction are localized primarily to the tubulointerstitial compartment of the kidney and include massive tubular dilation, progressive tubulointerstitial fibrosis, inflammatory cell infiltration, and apoptotic renal tubular cell death. Although the glomeruli of the kidney are relatively spared, damage to the tubulointerstitial compartment of the kidney is severe (Misseri et al., 2004; Nagle et al., 1973; Sharma et al., 1993). Inflammatory cell infiltration occurs early in the course of obstruction (Diamond et al., 1994, 1998) and results in the release of a variety of cytokines and growth factors that stimulate fibroblast proliferation and activation, and an imbalance in extracellular matrix (ECM) synthesis, deposition, and degradation. This results in an expansion of the interstitial space and a disruption in normal cellular communication (Fig. 40.2). Increasing tubular cell death accompanies progressive interstitial fibrosis (Docherty et al., 2006**), and long-standing obstruction ultimately results in glomerulosclerosis (Figs. 40.3 and 40.4), most likely as a result of chronic inflammation** (Steinhardt et al., 1988) **and/or hyperfiltration injury** (Pascual et al., 1998). Although extensive glomerulosclerosis has been shown to correlate well with a decrease in renal function in patients with obstruction, milder degrees of fibrosis and glomerulosclerosis can be seen in up to 25% of patients with obstruction and normal differential function on radionuclide imaging (Elder et al., 1995).

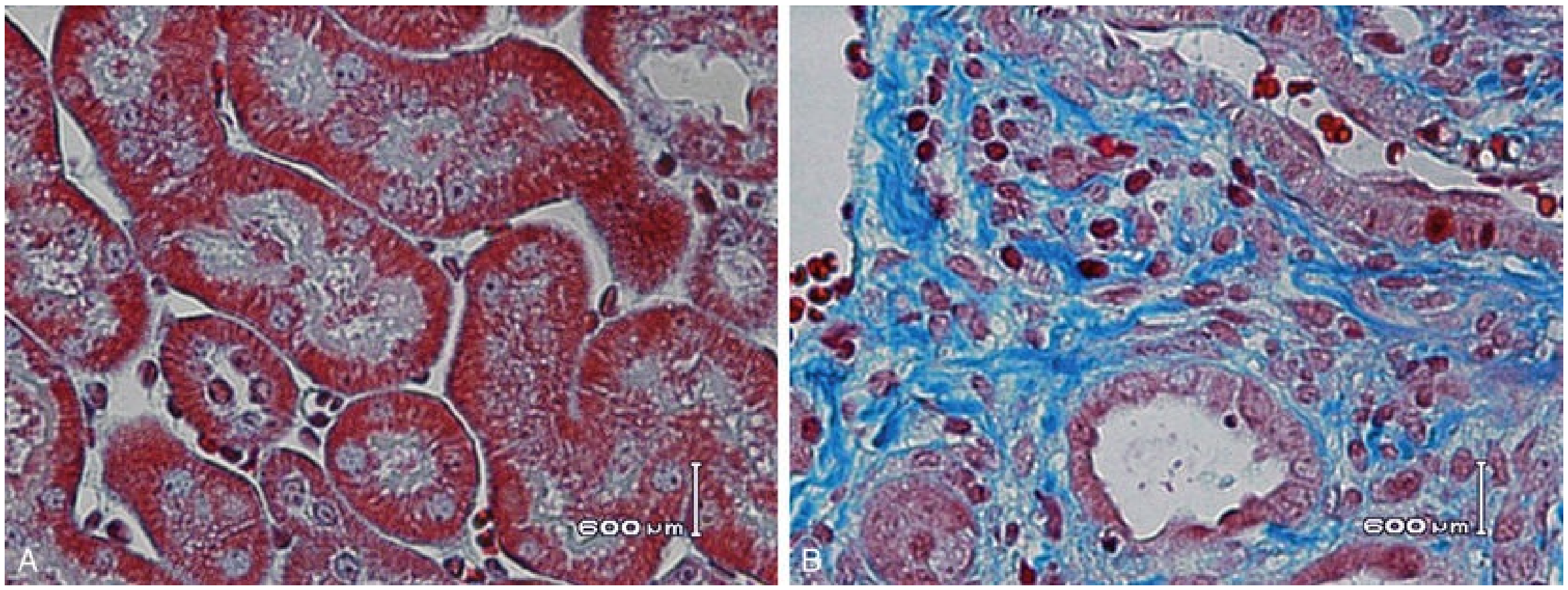

FIG. 40.2 Masson trichrome stained tissue sections from a mouse kidney exposed to sham operation (A) or 2 weeks of unilateral ureteral obstruction (B). Staining depicts significant collagen deposition *(blue)* and expansion of the interstitial space in response to obstruction.

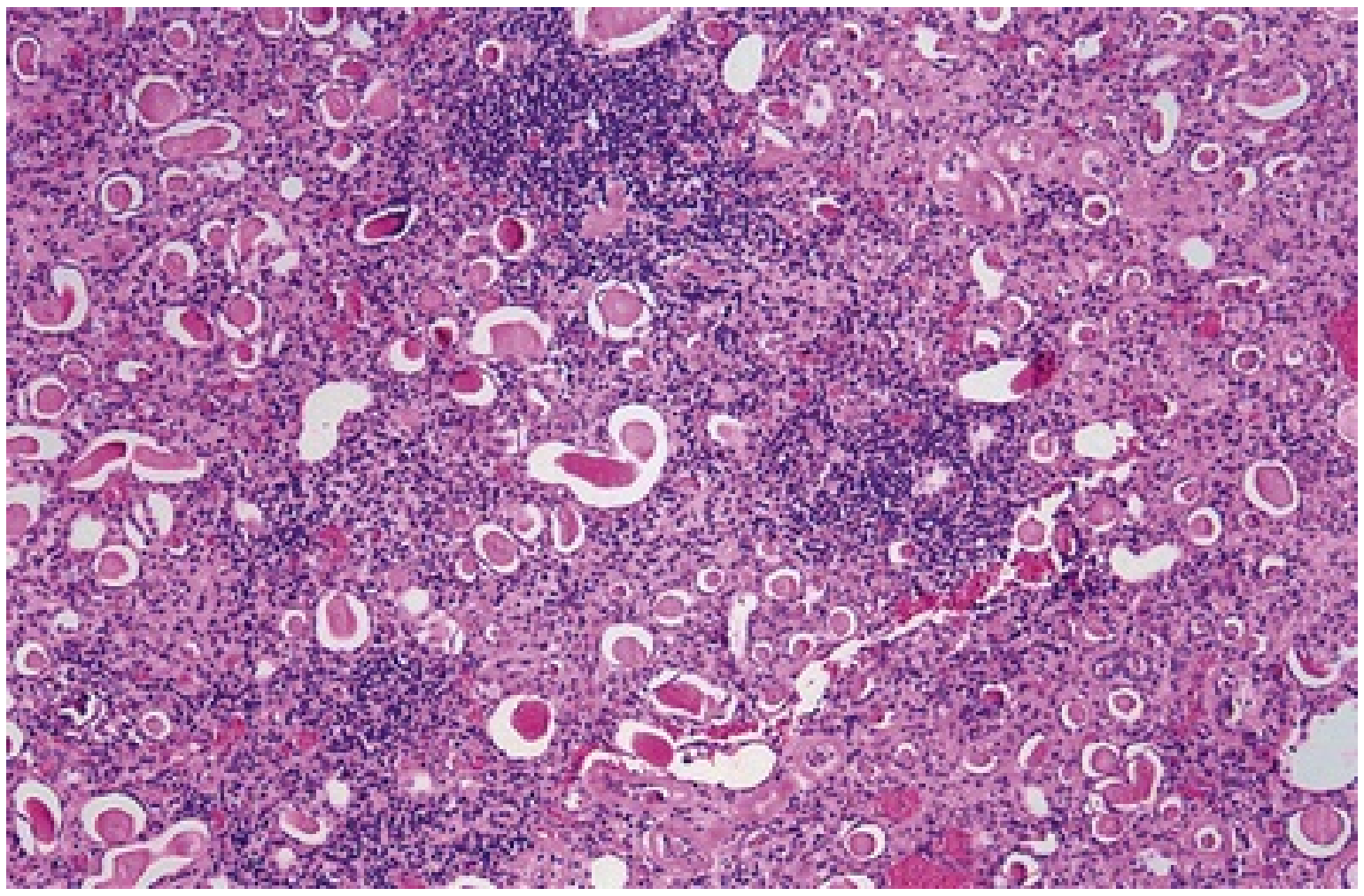

FIG. 40.3 Sections of deep cortex and outer medulla from a patient with chronic obstructive uropathy. Tubules demonstrate thyroidization-type atrophy interspersed with a mononuclear inflammatory infiltrate. Hematoxylin and eosin stain; original magnification, ×25. (Courtesy Dr. Sami Iskandar.)

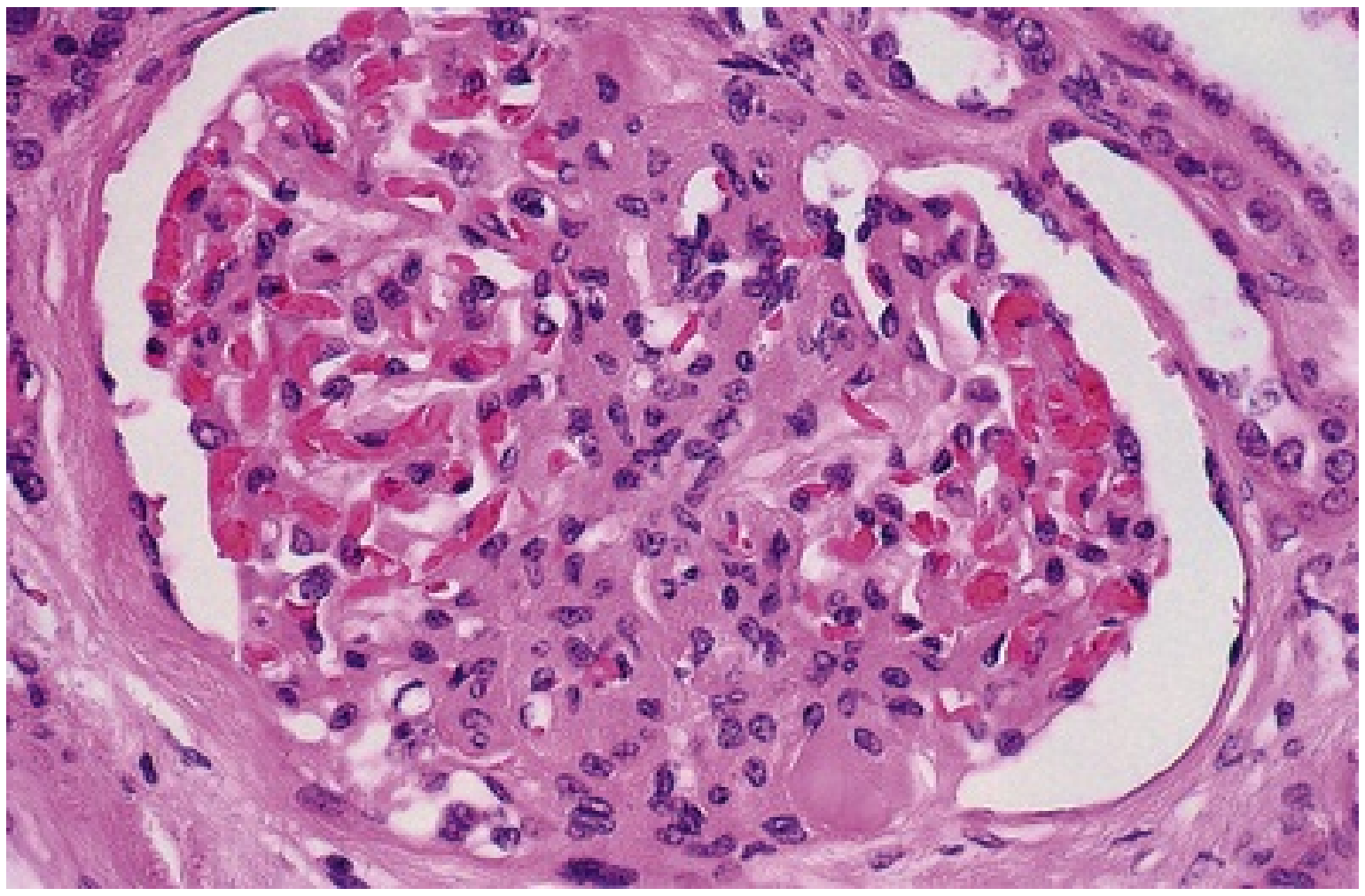

FIG. 40.4 Sections of deep cortex and outer medulla from a patient with chronic obstructive uropathy. Glomerulus with segmental tuft sclerosis *(center)* and hyalinosis is seen. Hematoxylin and eosin stain; original magnification, ×100. (Courtesy Dr. Sami Iskandar.)

Pathological Changes in the Developing Kidney

General Observations

The pathological correlates of congenital obstruction have been described to varying degrees (Elder et al., 1995; Han et al., 1998; Huang et al., 2006; Poucell-Hatton et al., 2000; Stock et al., 1995; Zhang et al., 2000). The pathological changes associated with lesser degrees of obstruction have been less thoroughly investigated, and a spectrum of qualitatively similar alterations have been described. In the absence of overt functional alterations and in unilateral conditions, determining the state of the one affected kidney becomes a clinical challenge.

Histologic examination of obstructed renal tissues has shown disorganization of structure with primitive forms of renal tissues, pathologically defined as dysplasia. Although the definition of dysplasia is not universally agreed upon, evidence of altered renal development in association with obstruction is frequently reported (Bernstein, 1971; Matsell, 1998; Matsell and Tarantal, 2002; Matsell et al., 2002; Peters et al., 1992; Tarantal et al., 2001). Dysplasia is often considered to be an embryonic process and irreversible. It is clear that some dysplasias are due to very early abnormalities of renal development (Winyard and Chitty, 2008) and unrelated to obstruction, but it is equally clear that obstructive processes can produce dysplasia. In some cases, however, usually in lesser degrees of obstruction, there is no dysplasia (Bonsib, 1998; Zhang et al., 2000).

If obstruction can produce dysplasia or abnormal developmental patterns, the character of these alterations may provide insights into the critical mechanisms of obstructive nephropathy. **Development is the controlled process of growth and differentiation of tissues in the formation of an organ or tissue. The factors that regulate these processes are likely targets of obstructive effects.**

Structural alterations with obstruction are obviously evident with hydronephrosis, but this is largely a distortion of normal architecture and relative alterations in the amounts of elements of renal tissues. There may be subtle changes, however, that are functionally important. Other alterations include fibrosis and increased interstitial tissues, as well as the presence of abnormal tubules and glomeruli. The normal layered organization of the kidney with the cortical and medullary areas with inner and outer stripes is often distorted or absent (Zhang et al., 2000). Less obvious are changes in the differentiation of the individual renal cell types that make up the nephron (Huang et al., 2006). Cells are unlikely to perform their normal functions, including communicating with neighboring cells in an integrated fashion. Function may therefore be disrupted.

Closely tied with these altered patterns of structure are distortions of normal growth regulation with either increased or decreased growth of specific structures. In some cases, obstructed kidneys are markedly smaller than normal, and in a developmental context, this does not represent atrophy but hypoplasia. The distinction is important in that renal tissue mass has not been lost but has never been formed. This is growth failure, not atrophy, and the mechanisms are likely distinct.

These observations are supported by clinical and experimental work. Several biopsy studies have shown patterns indicative of altered differentiation and growth in various levels of obstruction, including upper (UPJ obstruction) (Elder et al., 1995; Huang et al., 2006; Stock et al., 1995; Zhang et al., 2000) and lower (posterior urethral valves) (Haecker et al., 2002; Poucell-Hatton et al., 2000). These variations are not well explained and correlation with clinical parameters is imperfect. Experimental studies, however, have shown that obstruction during development will produce changes in patterns of renal differentiation and in growth regulation (Beck, 1971; Cachat et al., 2003; Gonzalez et al., 1990; Mure et al., 2006; Peters et al., 1992; Steinhardt et al., 1988; Wen et al., 2002). These can be seen to vary depending upon the time of onset in experimental models, as well as the severity of obstruction (Chevalier et al., 1988, 1999a,b; Klein et al., 2011; Thornhill et al., 2005; Truong et al., 2011). The latter is difficult to measure accurately. The validity of any of these model systems must be considered conditional, however, until we have more definite correlations. Nonetheless, it is clear that induced obstruction can produce such severe abnormalities of differentiation as to be considered dysplasia and to produce clear disruptions of growth regulation (Peters et al., 1992). It is therefore reasonable to examine the specific patterns observed and the potential mechanisms of those changes, all of which are likely contributing factors in the development of obstructive nephropathy.

The effects of obstruction on the developing kidney may be summarized as producing alterations in the regulation of growth, tissue differentiation, extracellular matrix, and fibrosis, and in altering the functional integration of the kidney. The latter is largely a result of the first three major factors and refers to the mechanisms producing vascular, neural, and humoral homeostasis and in the regulation of inflammatory cascades. Understanding the mechanisms by which these systems are dysregulated by obstruction will permit a better understanding of the outcomes of obstruction, which should improve our diagnostic, prognostic, and therapeutic abilities.

Growth

Growth regulation is a critical part of development, and the obstructed kidney may demonstrate impaired or accelerated growth. It is important to recognize that the small, obstructed kidney is not atrophic as may be seen in the adult, but it is hypoplastic. The growth it should have experienced never occurred. This can be readily seen by prenatal ultrasound and has been shown repeatedly experimentally (Mandell et al., 1994; Peters et al., 1992). This seems to usually be a generalized impairment of all parts of the kidney, with reduced numbers of nephrons as well as smaller nephrons. Differential growth impairment within the nephron segments may be present as well (Cachat et al., 2003; Huang et al., 2006). The functional effects of significant growth impairment are obvious because there are fewer and smaller nephron units. There may be compensatory responses to these changes, and it is difficult to assess their long-term impact. Reduced renal mass can be associated with hypertension as well as reduced filtration function, and loss of tubular mass will affect electrolyte and acid-base homeostasis, as well as water balance.

Growth acceleration can be seen in the larger-than-normal hydronephrotic kidney, although this is difficult to prove in humans, as few of those kidneys are removed. In animal experiments, fetal partial obstruction can increase renal mass (Ayan et al., 2001; Gobet et al., 1999). This is not seen with dysplastic changes and is not a product of edema because the total protein and DNA are increased as well. The factors that predict altered growth appear to be the severity of obstruction and timing of the obstructive effect, although the latter is difficult to ascertain in human situations. The functional consequences of accelerated growth are not known, and this may correlate with the occasional hyperfunction measured on renal scans that is seen in some patients with hydronephrosis (Maenhout et al., 2005; Moon et al., 2003). Compensatory responses to obstruction may not be benign; growth enhancement of the glomeruli occurs in early diabetes and is later associated with glomerular sclerosis.

Growth Regulation of the Kidney.

Regulation of renal growth is extremely complex and dynamic through development. A variety of growth factors are known to influence kidney growth at various stages of renal development and act at different loci of the nephron. Obstructive conditions have been shown to alter expression of growth-regulatory genes as well as the presence of the proteins coded by these genes (Chevalier, 1996). Table 40.1 lists some of the factors reported to be altered in renal obstruction (not all in early or fetal models) and potentially important mechanistic determinants. EGF has been shown to reduce some of the growth effects of obstruction when administered exogenously (Chevalier et al., 1998, 1999; Kennedy et al., 1997; Wen et al., 2009). Many studies have focused on specific growth factors, but it is evident from the complexity of renal development and growth regulation that the interactions of multiple factors and their signaling pathways will be of greater relevance.

TABLE 40.1

Key Factors in Congenital Obstructive Uropathy

APOPTOSIS ACTIVATION	APOPTOSIS INHIBITION
GROWTH	
TGF-β1 (Ayan et al., 2001; Medjebeur et al., 1997)	BMP7 (Klahr and Morrissey, 2002) HGF (Liu, 1999)
RAS (Eskild-Jensen et al., 2007): AT1 receptor	Angiotensin AT2 receptor (Liapis, 2003; Ma et al., 1998)
TNF-α/NF-κB (Misseri et al., 2005; Meldrum et al., 2006)	STAT6 (Yukawa et al., 2005a)

BAD, Bax (Liapis, 2003)	Bcl-2 (Manucha et al., 2007; Manucha and Valles, 2008)
ROS (Ricardo et al., 1997)	Catalase, SOD (Kinter et al., 1999; Truong et al., 2011)
DAPK (Yukawa et al., 2005b)	CD44 (Rouschop et al., 2004)
Tubular stretch (Cachat et al., 2003; Nguyen et al., 2000)	EGF (Chevalier et al., 1999; Bartoli et al., 2000, 2011; Grandaliano et al., 2000)
p53 caspases (Choi et al., 2000; Guerin et al., 2008; Misseri et al., 2005; Nguyen et al., 2006)	P21 (Silverstein et al., 2003)
FAS (Choi et al., 2000)	HO-1 (Kim et al., 2006; Li et al., 2012)
NHE1 downregulation (Manucha et al., 2007)	HB-EGF (Nguyen et al., 2000)
	IGF (Kiley et al., 2003)
	Osteopontin (Yoo et al., 2006)
	PAX2 (Cohen et al., 2007)
	SS-31 (Mizuguchi et al., 2008)
EMT INDUCTION	**EMT INHIBITION**
DIFFERENTIATION	
TGF-β1/Smad2/Smad3 (Chevalier, 2008; Inazaki et al., 2004)	BMP7 (Klahr and Morrissey, 2002)
Snail-1 (Yoshino et al., 2007)	ALK TGF-β1R inhibitor (Galarreta et al., 2013)
PAI-1 (Zhang et al., 2007)	
Leukocytes (Lange-Sperandio et al., 2007)	
Angiotensin (Topcu et al., 2007)	
PROFIBROTIC	**ANTIFIBROTIC**
FIBROSIS	
TIMPs (Ayan et al., 2001; Mure et al., 2006)	MMPs (Gobet et al., 1999a)
TGF-β1 (Lange-Sperandio et al., 2007; Silverstein et al., 2003; Yang et al., 2001)	HGF (Mizuno et al., 2001; Yang et al., 2003a), BMP (Klahr and Morrissey, 2002)
Smad2/Smad3 (Inazaki et al., 2004)	Smad7 (Chung et al., 2004; Fukasawa et al., 2004; Lan et al., 2003)
RAS: AT1 receptor (Manucha et al., 2004)	Angiotensin AT2 receptor (Yoo et al., 1997), bradykinin B2 receptor (Vari et al., 1993)
Ischemia, hypoxia, ROS (Cachat et al., 2003)	iNOS (Ito et al., 2004), eNOS (Chang et al., 2002)
TNF-α (Meldrum et al., 2007)	Decorin (TGF-β inhibitor) (Diamond et al., 1997; Silverstein et al., 2003)
Osteopontin (Yoo et al., 2006)	ALK5 TGF-β1R inhibitor (Moon et al.,

	2006)
PAI-1 (Zhang et al., 2007)	Losartan (Manucha et al., 2004)
PDGF (Liapis et al., 1994; Seseke et al., 2004), CTGF (Yokoi et al., 2004)	Rosuvastatin (Mazzei et al., 2012)
DAPK (Yukawa et al., 2005b)	
PROINFLAMMATORY	**ANTI-INFLAMMATORY**
INFLAMMATION	
MCP-1 (Bartoli et al., 2011; Madsen et al., 2011; Pittock et al., 2005; Silverstein et al., 2003)	Candesartan (AngRec inhibitor) (Topcu et al., 2007)
NF-κB (Seseke et al., 2004)	IκB (Tashiro et al., 2003)
Classically activated macrophage (Liu et al., 2008)	Alternatively activated macrophage
TNF-α/NF-κB (Meldrum et al., 2007; Valles et al., 2003)	Adenosine A2A receptor/PDE4 (Lange-Sperandio et al., 2005)
Krox 24 (Silverstein et al., 2003)	
Integrins, selectins, ICAM-1 (Lange-Sperandio et al., 2006)	
CCR1 (Eis et al., 2004), CCR2 (Kitagawa et al., 2004)	
Chemokines (RANTES, MIP-1β, MIP-1α) (Lange-Sperandio et al., 2007)	

ALK, Activin receptor-like kinase; *AT1,* angiotensin type 1; *AT2,* angiotensin type 2; *BAD,* Bcl-2 associated death; *Bcl-2,* B-cell lymphoma 2; *BMP,* bone morphogenetic protein; *BMP7,* bone morphogenetic protein-7; *CCR1,* chemokine receptor type 1; *CCR2,* chemokine receptor type 2; *CTGF,* connective tissue growth factor; *DAPK,* death-associated protein kinase; *EGF,* epidermal growth factor; *EMT,* epithelial-to-mesenchymal transition; *eNOS,* endothelial nitric oxide synthase; *FAS,* fatty acid synthase; *HB-EGF,* heparin-binding epidermal growth factor; *HGF,* hepatocyte growth factor; *HO-1,* heme oxygenase-1; *ICAM-1,* intercellular adhesion molecule-1; *IGF,* insulin-like growth factor; *IκB,* inhibitor of kappa B; *iNOS,* inducible nitric oxide synthase; *MCP-1,* monocyte chemotactic protein-1; *MIP-1α,* macrophage inflammatory protein-1α; *MIP-1β,* macrophage inflammatory protein-1β; *MMPs,* matrix metalloproteinases; *NF-κB,* nuclear factor kappa B; *PAI-1,* plasminogen activator inhibitor-1; *PDE4,* phosphodiesterase type 4; *PDGF,* platelet-derived growth factor; *RANTES,* regulated on activation normal T cell expressed and secreted; *RAS,* renin-angiotensin system; *ROS,* reactive oxygen species; *SOD,* superoxide dismutase; *TGF-β,* transforming growth factor-β; *TGF-β1,* transforming growth factor-β1; *TGF-β1R,* transforming growth factor-β1 receptor; *TIMPs,* tissue inhibitors of metalloproteinases; *TNF-α,* tumor necrosis factor-α.

Apoptosis Regulation.

A critical component of growth in the developing kidney is apoptosis, regulated cell death. The early fetal kidney is extremely active in terms of

new cell formation as well as turnover (Carr et al., 1995)**. This permits remodeling during development, as well as providing a control system over unregulated growth.** Small increases in the rate of apoptosis, even with normal ongoing growth, would lead to significant reductions in renal mass over time. The role of apoptosis in congenital obstruction has become more firmly established in recent years, including cellular patterns characteristic of apoptosis and enhanced expression of apoptosis regulating molecules (Campbell et al., 2008; Eskild-Jensen et al., 2007; Klein et al., 2011; Yang et al., 2001; Yoo et al., 2006). The changes may be seen heterogeneously, and the precise means by which these alterations occur remains incompletely defined, although apoptotic activity is regulated by cytokines (Campbell et al., 2008; Cohen et al., 2007; Manucha and Valles, 2012; Manucha et al., 2007) as well as mechanical factors (Hsieh and Nguyen, 2005; Nguyen et al., 2000). Inappropriate apoptosis may also be related to interstitial fibrosis as well (Docherty et al., 2006). An important aspect of understanding the role of apoptosis in congenital obstruction is that the mediators may be measurable in the urine or blood, and they may permit therapeutic manipulation (Mizuguchi et al., 2008).

Differentiation

Differentiation is the process of cells attaining specific functional traits to permit specialized functions and organization into tissues and is the basis for the many functions of the kidney. Obstruction affects these finely tuned patterns by gross structural disruption as seen in a severely obstructed dysplastic kidney. More subtle effects may require assessment of tubular or glomerular function, but all are a result of altered differentiation. Disruption of differentiation may begin as early as induction of the nephron or later in development with injury to renal collecting duct cells that regulate urinary concentrating ability. Some of these changes may be reversible, but it is usually presumed that many are not. Some cells will undergo terminal differentiation, and if that does not occur at a particular time point in development, there will not be another opportunity for it to occur. Disruption of normal differentiation of renal elements is unique to congenital obstruction and does not occur in a major way in adult obstruction. Abnormal epithelial-to-mesenchymal transformation (EMT) is one alteration in differentiation that does occur in the adult and can be reversible (Docherty et al., 2006; Forino et al., 2006; Hay and Zuk, 1995; Higgins et al., 2007; Ivanova et al., 2008; Yang et al., 2005). A variety of mediators of EMT have been described, including TGF-β, plasminogen (Zhang et al., 2007), and leukocytes (Lange-Sperandio, Trautmann et al. 2007), as well as inhibitors, such as hepatocyte growth factor (HGF) (Yang et al., 2005; Fig. 40.5). It is likely to be an important factor in fetal obstruction as well, although little is known about its role. Most adult cells may be injured and lose their differentiated capacity, but the cell types rarely change their behavior once differentiated. Understanding the patterns of altered differentiation and its regulators is critical to understanding congenital obstructive nephropathy.

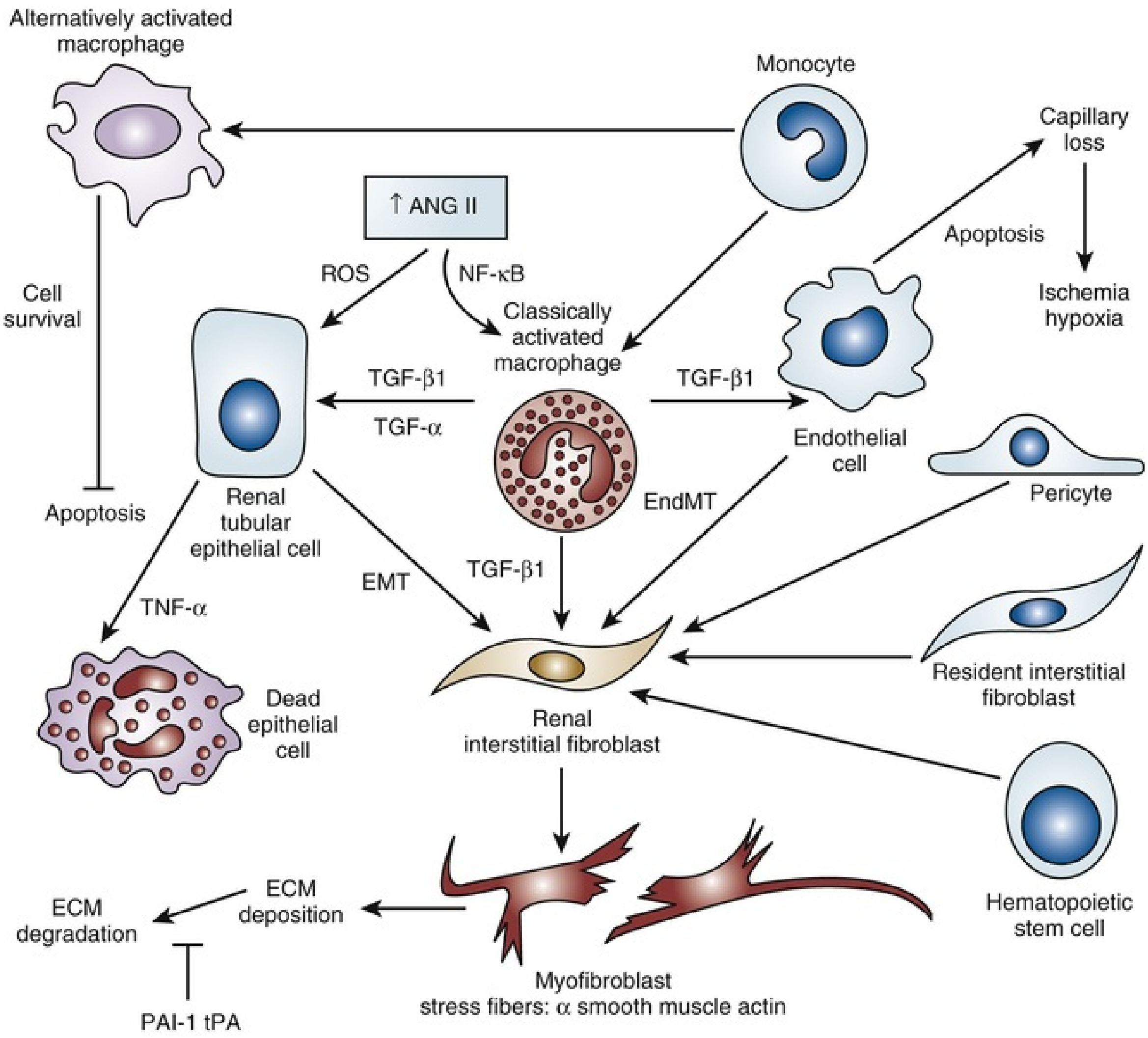
Alternatively activated macrophage
Monocyte
Capillary loss
↑ ANG II
Apoptosis
Ischemia hypoxia
ROS
NF-κB
Cell survival
Classically activated macrophage
TGF-β1
TGF-α
TGF-β1
Endothelial cell
Pericyte
Apoptosis
Renal tubular epithelial cell
EndMT
EMT
TGF-β1
TNF-α
Resident interstitial fibroblast
Dead epithelial cell
Renal interstitial fibroblast
ECM degradation
ECM deposition
Hematopoietic stem cell
PAI-1 tPA
Myofibroblast
stress fibers: α smooth muscle actin

FIG. 40.5 Renal cellular interactions in obstructive nephropathy. The interstitium is infiltrated by monocytes, which are “classically” activated to macrophages that release cytokines such as TGF-β1 and tumor necrosis factor-α (TNF-α). In turn, TGF-β1 promotes a phenotypic response of tubular epithelial cells either to undergo apoptosis (leading to tubular atrophy) or to undergo epithelial-to-mesenchymal transition (EMT), becoming fibroblasts that migrate to the interstitium. Angiotensin II (ANG

II), produced by the activation of monocytes, stimulates the production of nuclear factor kappa B (NF-κB), which leads to the recruitment of more macrophages, as well as to the production of reactive oxygen species (ROS), which aggravates renal tubular injury. In contrast, alternatively activated macrophages can enhance tubular cell survival and proliferation. Endothelial cells can undergo endothelial-mesenchymal transition (EndMT) or apoptosis, which leads to capillary loss and secondary renal ischemia and hypoxia. Resident pericytes and infiltrating hematopoietic stem cells can also differentiate into fibroblasts. Under the stimulus of cytokines such as TGF-β1 produced by macrophages or other cells, fibroblasts synthesize stress fibers and undergo further differentiation to become myofibroblasts. The myofibroblasts are contractile and augment the deposition of extracellular matrix (ECM), leading to progressive interstitial fibrosis. This process is augmented by a decrease in ECM degradation, mediated by plasminogen activator inhibitor-1 (PAI-1) and tissue-type plasminogen activator (tPA). (From Chevalier RL, Forbes MS, Thornhill BA: Ureteral obstruction as a model of renal interstitial fibrosis and obstructive nephropathy. *Kidney Int* 75:1145–1152, 2009).

Induction Process.

Renal differentiation begins with induction and from then on is exquisitely sensitive to various outside effects that may disrupt the normal sequence of cellular changes that results in a kidney. When these may be disturbed by obstruction is unclear, but it can be presumed that some of the variation in the spectrum of obstruction is due to different times of onset of the obstructive effect and to different degrees of severity (Guo et al., 2015). The pattern of effect is likely to reflect the time of onset and be reflected in the number of nephron generations and the degree of dysplastic transformation. Controversy remains as to whether obstruction can produce dysplasia, and it is often stated that if dysplasia is present, then it was because of abnormal induction and not obstruction. Abnormal induction and nephrogenesis may be produced by various factors, including genetic ones, or because of cellular disruption from mechanical forces with subsequent cellular responses. The study of Berman and Maizels (1982) is often cited to indicate that dysplasia in the chick kidney (a mesonephric kidney) was produced only with mechanical disruption of the mesenchyme and not hydronephrosis. The production of “obstruction” in that elegant study was by necessity rather crude, and several of the preparations were not obstructed. It is unclear whether they all were to a sufficient degree. It also suggests that mechanical forces can, in fact, disrupt nephrogenesis enough to produce dysplasia, and there is no inherent reason to believe that this cannot be from obstruction as well. Later mammalian studies in fetal sheep have shown dysplastic changes produced by obstruction (Matsell et al., 1996; Peters et al., 1992; Steinhardt et al., 1988b), and this has been shown in rodent studies as well (Thomasson et al., 1970).

The critical determinant of dysplasia in animal studies has been complete obstruction early in gestation. In the fetal sheep dysplasia was only seen when the obstruction was induced before 50% of gestation (70 days in most sheep species, which have a gestation from 140 to 145 days). Obstruction induced after that point only produces hydronephrotic changes, albeit severe (Beck, 1971). Partial obstructions produced hydronephrosis only, without apparent disruption of the renal architecture. The reason for this is presumably altered sensitivity of the developing nephrons to obstructive effects at this point. Alternatively, the particular signaling systems that are active in the early phases of renal development begin to fade away with ongoing development. It is possible that the pathways sensitive to obstruction, which would inherently alter the pattern of development, have run their course of expression and activity by mid-gestation. Expression of recognized mediators of renal development have been shown to be affected in models of fetal obstruction, including *WT-1* (Liapis, 2003), *Wnt* gene family (Nguyen et al., 1999), and *PAX2* (Attar et al., 1998; Cohen et al., 2007; Fenghua et al., 2009; Galarreta et al. 2013; Manson et al., 2014, 2015a, 2015b; Mure et al., 2006; Wilhide et al., 2016).

One of the histologic hallmarks of renal dysplasia is fibromuscular collars surrounding tubular structures, so-called *primitive ducts*. These have a characteristic appearance, and the smooth muscle surrounding the tubules stains for α-smooth muscle actin (α-SMA) (Fig. 40.6). This pattern suggests an abnormality in the regulation of epithelial-to-mesenchymal transformation (Baum et al., 2008; Butt et al., 2007). The mesenchymal structures of the primitive nephrogenic blastema and the epithelium of the ureteral bud processes interact, and there is differentiation from an epithelial-to-mesenchymal phenotypes and the reverse. It is uncertain whether the presence of the primitive tubules suggests persistence of mesenchyme that should have transformed to epithelium, or inappropriate epithelial-to-mesenchymal transformation. Understanding the signaling pathways involved in these processes (Bani-Hani et al., 2008; Roberts et al., 2006) will directly affect our understanding of obstructive processes. Persistent expression of α-SMA can be seen in partial obstruction without dysplastic patterns and so may be important at several levels of severity (Gobet et al., 1999; Mure et al., 2006). α-SMA expression is regulated by TGF-β1, linking these two proteins to growth as well as fibrotic changes.

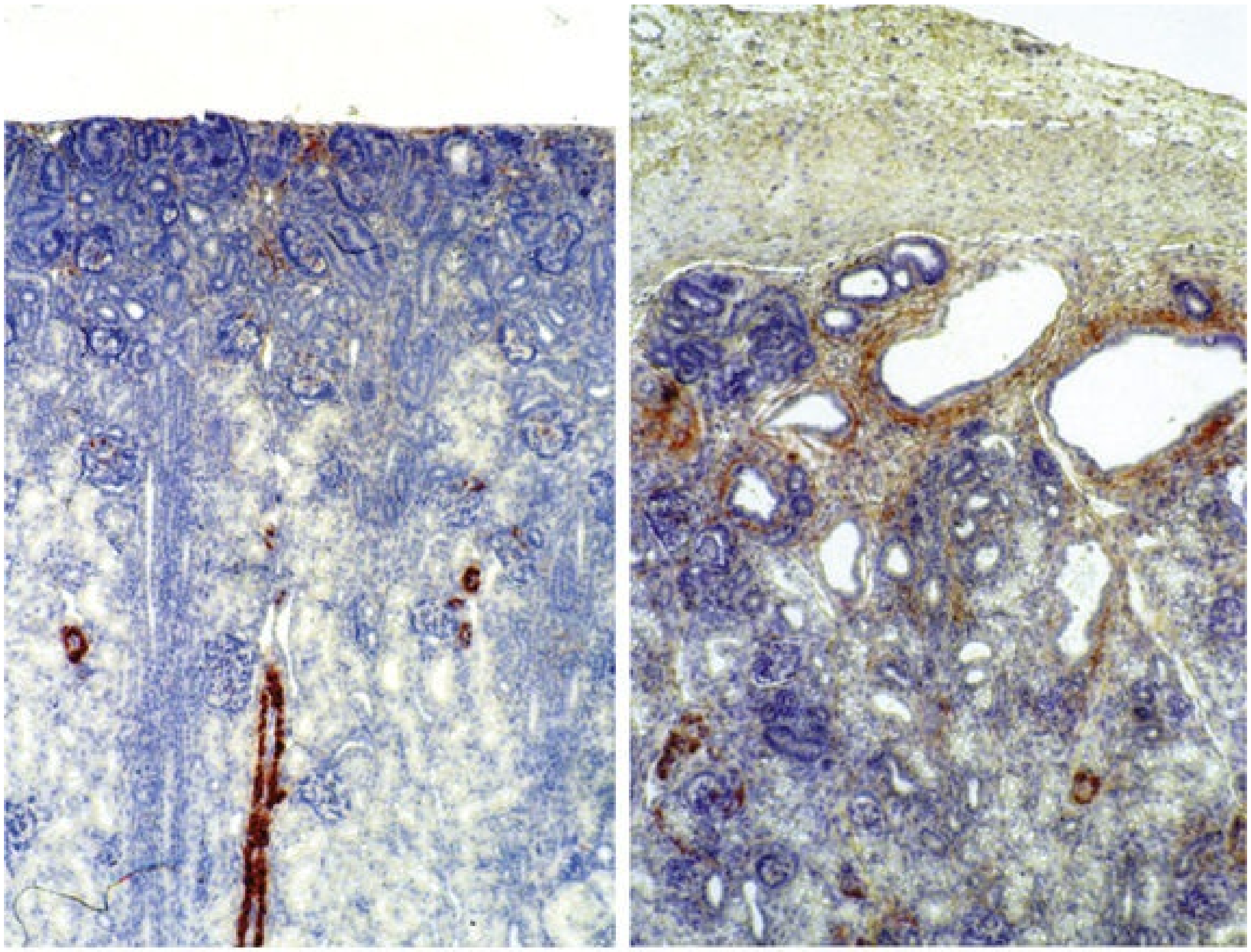

FIG. 40.6 Histologic view of normal and obstructed full-term sheep showing the abnormal structural pattern of the kidney, increased interstitial fibrosis and cells, as well as abnormally persistent α-smooth muscle actin (brown stain). (From Gobet et al.: Fetal partial urethral obstruction causes renal fibrosis and is associated with proteolytic imbalance. *J Urol* 162:854–860, 1999.)

Development of the glomerulus is a tightly regulated process that involves interaction of the mesenchyme and epithelium with a very specific pattern of growth and formation of intermediate structures such as the S-shaped body. In general, primitive glomeruli are not evident in obstructive changes, but markedly abnormal glomeruli are seen as well as hypoplastic glomerular structures (Matsell et al., 2002). In some cases, glomeruli may be enlarged in obstruction, suggestive of the changes seen in hyperfiltration that leads to glomerulosclerosis. Dissociation of the glomerulus from the tubules can be seen in early neonatal rodent obstruction (Thornhill et al., 2007), suggesting severe disruption of the developmental program.

Tubulointerstitial Fibrosis

Tubulointerstitial fibrosis is a major pathological component of obstructive renal injury. In response to kidney obstruction, pro-fibrotic signaling pathways are stimulated to increase production and deposition of extracellular matrix. This causes an expansion of the interstitial space, and ultimately, a disruption in the normal architecture of the kidney. As the tubulointerstitial space expands, intercellular signaling is disrupted and progressive renal dysfunction ensues. Progressive tubulointerstitial fibrosis is, in fact, a hallmark of all kidney diseases that lead to chronic renal failure (Zeisberg and Neilson, 2010).

Inflammatory Cell Infiltration

One of the earliest histologic changes in the obstructed kidney is an increase in inflammatory cell infiltration into the interstitial compartment of the kidney. Macrophage infiltration has been documented as early as 4 hours after the onset of renal obstruction (Schreiner et al., 1988), and the recruitment of macrophages, as well as other inflammatory cells, into the interstitial space appears to be mediated by chemokine production. All types of renal cells can express chemokines in response to immunologic, toxic, ischemic, or mechanical injury, and the interaction of chemokines with specific receptors expressed on immune cells (chemokine receptors) facilitates the migration of leukocytes and macrophages across the endothelium (Anders et al., 2003). The renin-angiotensin system has also been implicated in obstruction-induced inflammatory cell infiltration. Angiotensin II, a potent vasoconstrictor, is rapidly stimulated after the onset of renal obstruction, and studies have demonstrated that angiotensin II participates in the regulation of renal monocyte recruitment, primarily through interactions with the angiotensin II (AT2) receptor and the subsequent stimulation of the nuclear factor-kappa B (NF-κB) pathway (Esteban et al., 2004). NF-κB, in turn, stimulates the expression of chemokines (chemokine ligand 2 [CCL2] and chemokine ligand 5 [CCL5]) and adhesion molecules (vascular cell adhesion molecule-1 [VCAM-1] and intercellular adhesion molecule 1 [ICAM-1]) that facilitate monocyte recruitment (Klein et al., 2011).

Once inflammatory cells populate the interstitium, they begin to elaborate a wide array of proinflammatory cytokines and growth factors that contribute to renal injury, including tumor necrosis factor-α (TNF-α), interleukin-18 (IL-18), and TGF-β (Bani-Hani et al., 2009; Klahr and Morrissey, 2002; Misseri et al., 2004). Increased expression of chemokines has been demonstrated in response to obstruction, including monocyte chemotactic protein-1 (MCP-1 or CCL2), macrophage inflammatory protein-1α (MIP-1α or CCL3), macrophage inflammatory protein-1β (MIP-1β or CCL4), and CCL7, and blockade of CCL2 and CCL7 has further been shown to ameliorate obstruction-induced tubulointerstitial fibrosis (Bani-Hani et al., 2009; Gonzalez et al., 2013; Wada et al., 2004). Indeed, MCP-1 has recently been identified as a potential urinary biomarker of obstruction in children with hydronephrosis (Madsen et al., 2013). Although this inflammatory cell infiltrate is certainly critical to the pathophysiology of urinary tract obstruction, cytokines and proinflammatory mediators can also be produced by renal tubular epithelial cells independent of macrophage infiltration (Franke et al., 2012; Kaneto et al., 1996; Misseri et al., 2004). A variety of other potentially important molecular effectors of fibrosis have been investigated with the potential to therapeutically reduce the impact of fibrosis (Manson et al., 2015; Singh et al., 2016).

Interestingly, models of fetal kidney obstruction demonstrate little evidence of renal inflammation (Peters et al., 1992)**, and inflammatory infiltration is surprisingly sparse in biopsies of human kidneys with congenital obstruction and no history of infection** (Huang et al., 2006). Increased extracellular matrix is seen in fetal obstruction as well (Gobet et al., 1999). It has been demonstrated in animal models, however, that a marked inflammatory cell infiltrate associated with fibrosis is observed if fetal obstruction continues after birth (Mure et al., 2006). This suggests a fundamentally distinct mechanism in the pathophysiology of congenital obstruction as compared with postnatally acquired kidney obstruction. However, similar to postnatal renal obstruction, involvement of the renin angiotensin system is evident in fetal obstructive processes as well and may offer pathways for therapy (Ayan et al., 2001; Gobet et al., 1999; Singh et al., 2016). Although the inflammatory response probably does not have a significant role in the development of renal alterations during fetal life, the development of obstruction-induced inflammation in the newborn kidney may be influenced by the increased renal functional demand of postnatal life (Klein et al., 2011).

Elaboration of Growth Factors and Cytokines

Transforming Growth Factor-β1 (TGF-β1)

TGF-β1 has long been regarded as one of the most critical mediators of obstruction-induced renal injury. Renal TGF-β1 and TGF-β receptor expression increase in fetal and mature kidneys in response to obstruction (Chevalier et al., 2010; Kaneto et al., 1993; Yang et al., 2001)**, and evidence indicates that TGF-β1 is a major regulator of renal fibrosis via stimulation of EMT (a process by which epithelial cells undergo phenotypic transformation into matrix producing myofibroblasts), fibroblast proliferation** (Fan et al., 1999; Postlethwaite et al., 1987; Zeisberg et al., 2003)**, extracellular matrix synthesis (Roberts et al., 1992), and the simultaneous inhibition of collagenase and degradative matrix metalloproteinases** (Border and Noble, 1994; Chandrasekhar and Harvey, 1988). TGF-β1 is expressed by macrophage and resident tubular cells, and upon activation, TGF-β1 will bind to its receptor and stimulate the Smad family of proteins to multimerize into a transcription-regulating complex that translocates into the nucleus and exerts TGF-β1's biologic effects (Massague and Chen, 2000). Smad2 and Smad3 appear to mediate TGF-β1's profibrotic properties, whereas Smad7 is inhibitory and protects against renal fibrosis (Lan et al., 2003; Liu et al., 2017; Sato et al., 2003). It has been demonstrated that TGF-β1 induces proliferation of human renal fibroblasts in vitro by inducing the production and secretion of fibroblast growth factor 2 (FGF-2) (Strutz et al., 2001), and that a competitive inhibitor to the FGF-2 receptor, Klotho, prevents FGF-2–induced fibroblast proliferation and activation, and inhibits TGF-β signaling and obstruction-induced renal fibrosis (Doi et al., 2011; Guan et al., 2014). Several of these pathways have been shown to be present in fetal renal obstruction as well (Gobet et al., 1999a,b).

Bone morphogenic protein-7 (BMP7) is a member of the TGF-β superfamily that stimulates Smad1/5/8 activation and inhibits TGF-β dependent biologic functions after binding to its receptor BMPR1 (Meng et al., 2013); however, the mechanism by which BMP7 counteracts TGF-β activity remains unclear. Several studies have demonstrated that exogenous BMP7 cannot only inhibit TGF-β1–induced EMT and renal fibrosis but actually induce mesenchymal-to-epithelial transition in adult fibroblasts and facilitate regeneration of the injured kidney (Patel and Dressler, 2005; Zeisberg et al., 2005). The BMP7 pathway is activated after correction of renal obstruction, and activation of BMP7 during renal recovery promotes the resolution of fibrosis and the restoration of normal renal architecture (Manson et al., 2011). Although the downstream mechanisms that contribute to BMP7–mediated kidney repair remain unclear, BMP7 has promising therapeutic potential for obstructive renal injury (Manson et al., 2015a,b).

Tumor Necrosis Factor-α

TNF-α is a potent proinflammatory cytokine implicated in the pathophysiology of a wide range of renal disease (Donnahoo et al., 1999; Guo et al., 2001; Klahr and Morrissey, 1998). TNF-α is capable of upregulating its own expression as well as the expression of other inflammatory mediators (i.e., IL-1, nitric oxide, cell adhesion molecules, eicosanoids) and can recruit and stimulate various cells in the immune system. TNF-α is produced by resident renal tubular cells and infiltrating macrophage, and its expression is increased significantly in congenital and acquired renal obstruction (Chevalier et al., 2010; Kaneto et al., 1996; Misseri et al., 2005; Valles et al., 2003). TNF-α has a role in fibrotic renal injury, stimulating ECM accumulation and the upregulation of a number of cytokines and transcription factors involved in tubulointerstitial fibrosis, including TGF-β1. TNF-α is also a cytotoxic cytokine and has a significant role in obstruction-induced renal cell apoptosis (Misseri et al., 2005). Genetic deletion of the TNF-α receptor and inhibition of TNF-α pharmacologically cause a dramatic reduction in obstruction-induced renal fibrosis and apoptosis (Guo et al., 2001; Meldrum et al., 2007; Misseri et al., 2005), and inhibition of TNF-α has been shown to reduce tubulointerstitial fibrosis even when administered late in the course of renal injury (Khan et al., 2005).

Interleukin-18

IL-18 is a proinflammatory cytokine that has been found to be a sensitive and early marker of renal tubular damage; urinary IL-18 levels are predictive of acute tubular injury before creatinine levels and urine output become altered (Parikh et al., 2005). Liang et al. (2007) have also shown that circulating IL-18 levels and renal tubular IL-18 receptor expression is significantly increased in patients with chronic kidney disease. IL-18 expression is dramatically increased in response to obstruction and IL-18 has been shown to directly stimulate EMT in renal tubular cells in vitro and inflammatory cell infiltration and fibrotic injury in vivo via upregulation/activation of Toll-like receptor 4 (TLR4) (Meldrum et al., 2012). Inhibition of IL-18 activity prevents obstruction-induced EMT, fibroblast proliferation, and renal fibrosis independent of TGF-β1 and TNF-α activity, indicating that IL-18 is an important mediator of obstruction-induced renal injury through an alternative signaling mechanism (Bani-Hani et al., 2009).

Angiotensin II

The renin-angiotensin system has also been implicated in the pathophysiology of obstructive uropathy because of the substantial vasoconstriction of the renal vascular bed observed during renal obstruction. **Angiotensin II, a potent vasoconstrictor, is produced after conversion of angiotensin I to angiotensin II by the angiotensin-converting enzyme (ACE). Angiotensin II production is rapidly stimulated after onset of renal obstruction and has been linked to many of the pathophysiologic processes involved in obstruction, including altered hemodynamics and renal fibrosis** (Singh et al., 2016). Angiotensin II upregulates TGF-β1 and TNF-α expression during renal obstruction (Guo et al., 2001; Ishidoya et al., 1995), and ACE inhibition and inhibition of the angiotensin II receptor have been shown to decrease TGF-β1 expression, extracellular matrix deposition, macrophage recruitment, and the extent of obstruction-induced renal fibrosis (Guo et al., 2001; Klahr and Morrissey, 1997; Morrissey and Klahr, 1998). Angiotensin II has also been implicated in the perturbation of interstitial capillary circulation that occurs in fibrotic renal disease, resulting in chronic renal hypoxia and further stimulation of EMT and cytokine production (Norman et al., 2003; Zeisberg and Neilson, 2010). **Indeed, angiotensin II inhibition currently represents the principal clinical therapeutic approach to slowing or preventing the progression of most forms of renal disease** (Chevalier et al., 2009).

The biologic effects of angiotensin II are mediated through its interaction with one of two receptors: angiotensin II type I receptor (AT1) and angiotensin II type 2 receptor (AT2) (Bernstein and Berk, 1993). AT1 receptors, which mediate vasoconstriction and fibrosis, are more abundant and appear to be more biologically significant than AT2 receptors in adult mammalian kidneys (Meister et al., 1993; Sechi et al., 1992). Previous studies have demonstrated that AT1 receptor expression is increased in response to kidney obstruction (Yoo et al., 1998), and ACE inhibition and AT1 receptor blockade cause a significant reduction in obstruction-induced collagen expression, interstitial volume, and renal fibrosis (Guo et al., 2001; Klahr and Morrissey, 1997; Morrissey and Klahr, 1998). AT2 receptors predominate in fetal life, but AT2 receptor expression decreases in the first 3 to 14 days of life (Yoo et al., 1998). In the fetus, AT2 receptors have a vasodilating effect and appear to have a significant role in cellular proliferation and apoptosis (Chevalier et al., 1999a,b). Alterations in the developmental regulation of the renin angiotensin system appear to have a role in fetal obstruction as noted earlier (Ayan et al., 2001; Gobet et al., 1999).

Fibrosis and Extracellular Matrix in Obstructive Nephropathy

A universal characteristic of obstructive nephropathy appears to be renal fibrosis, although it is a nonspecific pattern seen in a variety of pathological conditions affecting the kidney (Eddy, 2000; Klein et al., 2011)**. It is seen as infiltration of the interstitium with abnormal amounts of extracellular matrix, including collagens, fibronectin, and other connective tissue proteins. Their presence disrupts the normal interconnections between cells that permit functional integration of the renal tissues.** Tubular cells may be disrupted and inadequately regulated. Cell:cell signaling by direct connection or paracrine messengers may be disrupted. Tissue oxygenation may be impaired. Fibrosis is a histopathological hallmark of many renal diseases.

The extracellular matrix is essential to normal function of the kidney as well, in terms of providing structural integrity and contributing to normal signaling systems. When abnormally expressed, however, it becomes detrimental (Chevalier, 2015; Klein et al., 2011). ECM homeostasis is a complex balance of synthesis and breakdown. Synthetic regulation is controlled by various mechanisms, including growth factors and signaling systems that are just being discerned. Mechanical forces contribute to these signals in various conditions, including hypertension and hydronephrosis. ECM breakdown is tightly regulated and represents the product of degradative enzymes, the matrix metalloproteinases (MMPs), and their endogenous inhibitors, the tissue inhibitors of metalloproteinases (TIMPs). This product is the proteolytic balance and is regulated by various cytokines, hormones, and mechanical forces. This balance has been studied vigorously in renal disease and to a limited degree in congenital obstruction (Ayan et al., 2001; Engelmyer et al., 1995; Gobet et al., 1999; Mure et al., 2006). In a neonatal murine model of partial obstruction, the degree of fibrosis and contralateral hypertrophy were not correlated with the degree of hydronephrosis in the affected kidney (Botto et al., 2011). The interaction of these systems is complex, and various compensatory pathways are likely to be present (Chevalier et al., 2009; Kim et al., 2001).

Modulation of renal fibrosis may be a significant potential target for managing obstructive nephropathy, but the delicate balance of these factors must be understood to a greater degree than at present (Eddy, 2005; Pap et al., 2017; Singh et al., 2016).

Mechanisms of Fibrosis

The most likely causes of excessive connective tissue include abnormal accumulation resulting from imbalance of synthesis and breakdown. It may also represent abnormal inductive signaling that produces excessive conversion of epithelium to mesenchymal tissue and connective tissues with this (Bascands and Schanstra, 2005; Burns et al., 2007; Zhang et al., 2007). These processes may be normal developmental sequences that persist because of the obstructive effect.

Cytokine Regulation.

Abnormal accumulation may represent simply excessive synthesis with no change in ECM breakdown. Increased collagen synthesis has been shown by upregulation of collagen gene expression in obstructive models (Fu et al., 2006; Liapis et al., 1994). Collagen synthesis is regulated in part by various cytokines, including TGF-β and the RAS. Reduced fibrosis may be seen when angiotensinogen activity is downregulated in an obstructed system (Fern et al., 1999; Kellner et al., 2006; Singh et al., 2016). Similar approaches have been demonstrated in nonobstructive fibrosis as well.

The role of TGF-β is complex and context dependent, yet inhibition of activity will produce less fibrosis as well (El Chaar et al., 2007; Isaka et al., 2000; Miyajima et al., 2000). There is evidence that TGF-β interacts and regulates the activity of the RAS, as well as regulating cellular growth dynamics. Fetal obstruction induces increased expression of TGF-β1 (Ayan et al., 2001; Medjebeur et al., 1997; Yang et al., 2001). Upregulation of the principle TGF-β receptors, TGF-βRI and TGF-βRII, have been demonstrated in fetal sheep ureteral obstruction (Yang et al., 2001). As reviewed earlier, TGF-β1 regulates EMT, thereby contributing to renal dysplasia (Yang et al., 2000). There is considerable interest in the role of TGF-β1 in promoting EMT of differentiated renal tubular epithelial cells in response to chronic ureteral obstruction. As shown in Fig. 40.5, renal interstitial fibroblasts, through transformation to myofibroblasts, play a pivotal role in the deposition of ECM in a hydronephrotic kidney. TGFβ-1 has also been shown to play a role in glomerular response to injury, because receptor inhibition protects glomerular integrity in the obstructed neonatal mouse model (Galarreta et al., 2013; Manson et al., 2014).

Epithelial-Mesenchymal Transition.

Although the role of fibroblasts in renal fibrosis is well accepted, their origin and process of activation remains controversial. Resident interstitial fibroblasts, bone marrow fibroblasts, migrating leukocytes, and vascular endothelial cells are potential sources of renal interstitial fibroblasts. **Growing evidence suggests that under pathological conditions renal tubular epithelial cells can also undergo a phenotypic transformation into matrix-producing myofibroblasts by EMT** (Bani-Hani et al., 2009; Baum et al., 2008; Healy and Brady, 1998; Strutz et al., 1995). These activated fibroblasts acquire mesenchymal markers, migrate into the interstitial space across damaged tubular basement membranes, and become capable of producing extracellular matrix (Liu, 2010). EMT appears to be a major contributing factor to tubulointerstitial fibrosis in the obstructed kidney, and Iwano et al. (2002) have demonstrated that a substantial number of interstitial fibroblasts originate from tubular epithelium during renal obstruction. In fact, selective blockade of EMT in animal models impressively reduces fibrosis after obstructive injury, underscoring the importance of EMT in renal fibrogenesis (Iwano et al., 2002; Yang and Liu, 2002). More recent studies using a cell lineage-tracing technique demonstrate that a substantial number of interstitial fibroblasts are also derived from capillary endothelial cells (Zeisberg et al., 2008). The extent to which EMT contributes to renal fibrosis in human chronic kidney disease is a matter of debate, because it is impossible to use cell lineage-tracing techniques. Although a loss of epithelial markers (i.e.. E-cadherin, zonula occludens-1 [ZO-1]) and an increase in mesenchymal markers (i.e., α-SMA, fibroblast specific protein-1 [FSP-1], vimentin) suggest the existence of EMT in adult and fetal models of kidney obstruction (Lange-Sperandio et al., 2007; Liu, 2010; Mure et al., 2006; Murer et al., 2006), these markers are not absolutely specific for EMT. The early inflammatory phase of renal fibrosis plays a decisive role in initiating EMT (Liu, 2010), as a number of growth factors and cytokines released during this phase regulate EMT, of which TGF-β1 is the chief and most studied mediator. In addition to TGF-β, TNF-α, IL-18, angiotensin II, FGF-2, MMP-2, and MMP-9 have been implicated in renal tubular cell EMT (Bani-Hani et al., 2009; Liu, 2010).

Many of the steps involved in the transformation of tubular epithelial cells are regulated by TGF-β1; these steps include loss of cell adhesion, expression of α-

SMA, disruption of tubular basement membrane, and cell migration to the interstitium (Liu, 2004). Signaling by TGF-β1 is mediated in part by Smads, which are profibrotic (Smad2 and Smad3) and inhibitory (Smad7). Thus targeted deletion of Smad3 reduces apoptosis and fibrosis in mice with ureteral obstruction, whereas gene therapy with Smad7 also reduces fibrosis (Lan et al., 2003; Sato et al., 2003). TGFβ-1 also acts through downregulation of transcriptional co-repressors of the Smads, SnoN and Ski (Yang et al., 2003). In contrast, hepatocyte growth factor (HGF) blocks EMT by blocking Smad2 and Smad3, and gene therapy with HGF reduces fibrosis in rats with ureteral obstruction (Gao et al., 2002; Yang and Liu, 2003). HGF also acts by upregulating the Smad co-repressors SnoN and Ski, countering the action of TGFβ-1 (Yang et al., 2005).

These complex networks of counterbalancing factors provide many potential opportunities for therapeutic intervention to prevent the progression—or even promote the reversal—of interstitial fibrosis resulting from obstructive nephropathy (Fogo, 2003). EMT, as a gene directed process, is uniquely suited to pharmacologic manipulation and may therefore have therapeutic potential in the management of patients with fibrotic renal disease.

Dysregulation of the Proteolytic Balance.

Fibroblasts in the renal interstitium are considered the primary source of extracellular matrix, and tubulointerstitial fibrosis is associated with a significant accumulation of matrix-producing fibroblasts. In response to stimulation from cytokines and growth factors, fibroblasts will secrete collagen, elastin, proteoglycans, and fibronectin into the interstitial space (see Fig. 40.2). This process is normally tightly regulated by MMPs, a family of enzymes responsible for tissue remodeling and the degradation of collagenous and noncollagenous components of extracellular matrix. MMPs are excreted by a variety of cells, including fibroblasts, endothelial cells, macrophage, and lymphocytes, in an inactive form that requires further processing to become active. Control of MMP activity occurs in the activation of the latent enzyme and with direct inhibition of the active enzyme (Ronco et al., 2007). TIMPs are produced by tubular cells and interstitial cells in the kidney, and they function to inhibit the activity of MMPs. Dramatic increases in TIMP expression have been demonstrated in response to obstruction (Engelmyer et al., 1995; Kim et al., 2001). It has been postulated that increased extracellular matrix deposition during obstructive injury is due to increased TIMP inhibition of MMPs.

The role of MMPs in renal fibrosis, however, appears to be much more complex than originally theorized. MMP-2 and MMP-9 have been the focus of most studies in the kidney. Although some studies demonstrate an acceleration of renal fibrosis with pharmacologic inhibition of MMP-2 and MMP-9 (Zeisberg et al., 2006), more recent studies in knockout mice suggest that MMP-9 is an important mediator of obstruction-induced renal fibrosis and EMT independent of TGF-β expression (Wang et al., 2010). MMP-9 has been demonstrated to promote EMT by stimulating E-cadherin shedding and tubular basement membrane degradation, and it can also release and activate a variety of profibrotic growth factors and cytokines sequestered in the ECM upon proteolysis (Matsui et al., 2017). Mice overexpressing MMP-2 similarly exhibit interstitial fibrosis, glomerulosclerosis, tubular atrophy, and renal failure in the absence of superimposed injury (Cheng et al., 2006). In addition to their degradative effect on extracellular matrix, it appears that MMPs can disrupt tubular basement membrane integrity, release cytokines and growth factors sequestered in the ECM, and trigger epithelial-to-mesenchymal transition, all processes that contribute to the development of renal fibrosis.

Altered activity and regulation of the MMPs and TIMPs have been studied in the kidney (Eddy, 1996) in several conditions. It is clear that they are important regulators of the state of the ECM. Their expression has been shown in the developing kidney as well and in postnatal obstruction, they are altered in activity. In prenatal obstruction increased expression (Ayan et al., 2001; Mure et al., 2006), and activity (Gobet et al., 1999) has been shown as well as in congenital reflux-related fibrosis (Gobet et al., 1998). The precise regulators of the MMPs and TIMPs in development and obstruction are not well defined but are likely to be an important element in the development of pathological fibrosis (Pap et al., 2017) and may involve mechano-cellular signaling pathways (Park et al., 1999). There is some evidence of regulation by the RAS and TGF-β as well, which opens therapeutic options for the treatment of fibrosis (Bolbrinker et al., 2006; Diamond et al., 1998; Ding et al., 2005; Yang et al., 2007).

Other Mechanisms.

Oxidative stress in the developing kidney is a probable contributor to fibrotic and inflammatory pathways in obstructive uropathy. The ability of the immature kidney to mount an appropriate response to increased oxidative stress may define the degree of functional and developmental impairment suffered (Chevalier et al., 2014; Manucha and Valles, 2008; Rinaldi et al., 2010).

Hypoxia may be a factor in the development of tissue fibrosis as well in response to induction of hypoxia-inducible factors-1 and 2 (HIF-1 and HIF-2) (Higgins et al., 2008). In vitro stimulation of renal epithelia with HIF-1 increases EMT, known to induce fibrosis. Genetic models that do not express HIF-1α develop less fibrosis and inflammatory infiltration in response to ureteral obstruction in postnatal models (Higgins et al., 2007). The role in prenatal obstruction remains undefined but potentially relevant.

Nitric oxide (NO) has also been shown to regulate the development of obstructive fibrosis in postnatal animals and may play a similar role prenatally (Felsen et al., 2003; Huang et al., 2000; Manucha and Valles, 2008; Yoo et al., 2010). Increased NO generation reduces the degree of interstitial fibrosis (Ito et al., 2004), and in animals without the gene to produce NO synthase, unilateral ureteral obstruction (UUO) produces a greater degree of fibrosis than in those animals with this enzyme intact (Hochberg et al., 2000). Data suggest a greater potential role for nitric oxide derived from endothelial nitric oxide synthase (eNOS) than inducible nitric oxide synthase (iNOS) (Chang et al., 2002; Huang et al., 2000).

Fibrosis is clearly a major component of the pathophysiology of congenital obstruction. Understanding the role and activities of the various components of this system may permit more specific diagnosis through urinary biomarkers reflecting the elements of the system. These elements may also be relevant targets of therapeutic intervention to modulate ECM homeostasis.

Apoptosis.

Apoptosis, or programmed cell death, is the major mechanism by which renal tubular cell death and a reduction in renal mass occur after renal obstruction (Gobe and Axelsen, 1987; Manucha and Valles, 2012; Nilsson et al., 2015; Truong et al., 1998). Apoptosis is present in normal and disease states and can be triggered by either a death receptor signaling pathway (i.e., TNF-α binding to its receptor) or an intrinsic pathway involving disturbances in the mitochondrial membrane and release of cytochrome c. After stimulation of either of these signaling pathways, caspases (cysteinyl aspartate-specific proteinases) become activated, which are a family of 12 enzymes that act as the effector molecules for apoptosis. Caspases cleave various nuclear and cytoplasmic substrates, resulting in nuclear fragmentation and condensation. The cell is then broken down into multiple membrane-bound spheric bodies, called apoptotic bodies, which are phagocytized by adjacent healthy cells. As compared with necrosis, this unique mechanism of cell death maintains cell membrane integrity and thereby minimizes the involvement of inflammatory scavenger cells and the overall inflammatory response (Wyllie et al., 1980). **Renal tubular and interstitial cells are most susceptible to apoptotic cell death during renal obstruction in mature kidneys** (Truong et al., 1998). Choi et al. (2000) demonstrated renal tubular cell apoptosis beginning after 4 days and peaking after 15 days of renal obstruction, whereas interstitial cell apoptosis increased progressively over the duration of renal obstruction. Glomerular cells, on the other hand, appear to be very resistant to obstruction-induced apoptosis, with no evidence of glomerular cell apoptosis occurring after 90 days of renal obstruction (Truong et al., 1998). **In the neonatal kidney, glomerular and tubular cells are susceptible to apoptotic cell death, with progressive apoptosis resulting in a decrease in the number of glomeruli, tubular atrophy, and glomerulotubular disconnection, ultimately resulting in the development of nonfunctioning nephrons** (Cachat et al., 2003; Klein et al., 2011; Thornhill et al., 2005).

Many of the cytokines and vasoactive factors implicated in EMT and tubulointerstitial fibrosis also appear to mediate apoptotic cell death in response to renal obstruction, in part by increasing caspase expression and activation. TGF-β1 directly stimulates renal tubular cell apoptosis in vitro (Schuster and Krieglstein, 2002; Yang et al., 2006), and TGF-β1 inhibition has been shown to prevent obstruction-induced and stretch-induced renal tubular cell apoptosis (Miyajima et al., 2000, 2001). TNF-α is a directly cytotoxic cytokine that induces apoptosis in many cells, including renal tubular cells, through interactions with its membrane-bound receptors, TNFR1 and Fas. The expression of TNF-related apoptotic molecules (e.g., TNFR1 and Fas) increase in parallel to observed increases in obstruction-induced tubular cell apoptosis (Choi et al., 2000). TNF-α neutralization has been shown to ameliorate obstruction-induced apoptosis and pro-apoptotic signaling (Misseri et al., 2005). IL-18 has similarly been demonstrated to be an important mediator of renal tubular cell apoptosis in vitro and in response to UUO (Zhang et al., 2011). The effect of angiotensin II on obstruction-induced apoptosis is less clear. Morrissey and Klahr (1999) demonstrated that an angiotensin II type 2 receptor antagonist inhibits obstruction-induced apoptosis, but other investigators have found no benefit of either ACE inhibitors or angiotensin II type 2 receptor antagonists in preventing obstruction-induced apoptosis in the mature kidney (Chevalier et al., 1999a,b; Radovic et al., 2008). These diverging cellular responses to a single stimulus suggest that renal tubular epithelial cells may undergo an adaptive (EMT) vs. death response (apoptosis) depending on the degree or duration of stimulation.

Emerging Therapeutic Options

Although it has been demonstrated that inhibition of profibrotic cytokines and growth factors can prevent obstruction-induced renal injury, these treatment options often do not translate well into clinical medicine because therapy is nontargeted and can result in unwanted systemic effects on the immune system and other nonpathological organ systems. Stem cell therapy has recently emerged as an exciting alternative therapy. Mesenchymal stem cells (MSCs) have the capacity to home or migrate specifically to injured tissue and produce an array of cytokines and growth factors that act in a paracrine fashion to repair damaged tissue and limit inflammatory injury (Sohni and Verfaillie, 2013). Although mesenchymal stem cell (MSC)-based therapies have been shown to confer renal protection in several clinical trials and animal models of acute kidney injury (AKI) (Herrera et al., 2004; Kim et al., 2012; Tan et al., 2012; Westenfelder and Togel, 2011), the potential of MSC-based therapy to ameliorate chronic kidney disease is only beginning to be elucidated. Exogenous administration of MSCs has been demonstrated to reduce renal tubulointerstitial fibrosis, collagen deposition, and EMT in response to chronic obstructive renal injury (Asanuma et al., 2011; Bai et al., 2013), and MSCs conditioned medium has been shown to rescue kidney function and significantly reduce tubulointerstitial fibrosis and tubular atrophy in animals with established CKD (van Koppen et al., 2012). MSCs secrete BMP7 in vitro, and MSCs have been shown to ameliorate diabetic glomerulosclerosis in vivo and in vitro by inhibiting TGF-β signaling via secretion of BMP7 (Lv et al., 2014). Interestingly, although MSCs are undetectable in the kidney 2 weeks after injection, they appear to confer renal protection and decrease renal fibrosis for up to 3 months after delivery (Semedo et al., 2009). A greater understanding of the mechanisms of MSC-induced renoprotection may facilitate the development of new therapeutic options for patients with irreversible obstruction-induced renal damage.

Key Points: Mechanisms of Obstructive Uropathy

- Chronic ureteral obstruction leads to renal inflammation, increased extracellular matrix formation, tubulointerstitial fibrosis, and apoptosis, thus limiting the potential for return of renal function.
- Inflammatory infiltration is not a prominent characteristic of fetal kidney obstruction, suggesting a fundamentally distinct mechanism for the pathophysiology of congenital obstruction as compared with postnatally acquired kidney obstruction.
- TGF-β1 is a major regulator of renal fibrosis via stimulation of epithelial-to-mesenchymal transition, fibroblast proliferation, extracellular matrix synthesis, and the simultaneous inhibition of collagenase and degradative matrix metalloproteinases.
- BMP7 is a member of the TGF-β superfamily that is activated after correction of renal obstruction and promotes the resolution of fibrosis and the restoration of normal renal architecture.
- Angiotensin II production is rapidly stimulated after the onset of renal obstruction and has been linked to many of the pathophysiologic processes involved in obstruction, including altered hemodynamics, inflammatory infiltration, and renal fibrosis.
- Fibroblasts in the renal interstitium are considered the primary source of extracellular matrix, and tubulointerstitial fibrosis is associated with a significant accumulation of matrix-producing fibroblasts.
- Evidence suggests that under pathological conditions, renal tubular epithelial cells can undergo a phenotypic transformation into matrix-producing myofibroblasts by a process called epithelial-to-mesenchymal transition. These activated fibroblasts acquire mesenchymal markers, migrate into the interstitial space across damaged tubular basement membranes, and become capable of producing extracellular matrix.
- Renal tubular cells are most susceptible to apoptotic cell death during renal obstruction in mature kidneys, whereas glomerular and tubular cells are susceptible to apoptotic cell death in neonatal kidneys.

Hemodyamic Changes With Obstruction

Glomerular Filtration and Renal Blood Flow

There are many functional changes in the kidney associated with obstructive nephropathy that affect renal hemodynamics. To understand the relationship between changes in renal hemodynamics and the alterations in glomerular filtration rate (GFR) that occur during and after obstruction, it is important to understand all of the factors that influence GFR. GFR is defined by the equation

$$\mathrm{GFR} = K_f(P_{GC} - P_T - \pi_{GC})$$

where K_f is a glomerular ultrafiltration coefficient related to the surface area and permeability of the capillary membrane. P_{GC} refers to glomerular capillary pressure, which is influenced by renal plasma flow and the resistances of the afferent and efferent arterioles. The hydraulic pressure driving fluid into Bowman space is resisted by the hydraulic pressure of fluid within the renal tubules (P_T) and $\pi_{GC,}$ which is the oncotic pressure of proteins in the glomerular capillary and efferent arteriole. In addition to tubular hydraulic pressure and the oncotic pressure of proteins in the capillary, glomerular capillary pressure is also influenced by renal plasma flow (RPF): R_{aff}

$$\mathrm{RPF} = (\text{Aortic pressure} - \text{Renal venous pressure})$$

Renal Vascular Resistance

Renal vascular resistance is primarily mediated by changes in the resistance of the afferent and efferent arterioles; therefore constriction of the afferent arteriole will result in a decrease in P_{GC} and GFR, whereas constriction of the efferent arteriole will increase P_{GC}. Renal obstruction can transiently or permanently affect some or all of the determinants of GFR depending on the length and degree of obstruction.

Unilateral Ureteral Obstruction

There are differences in the hemodynamic changes that occur in response to UUO as compared with bilateral ureteral obstruction (BUO). **Animal experiments have demonstrated a triphasic pattern of renal blood flow (RBF) and ureteral pressure changes during UUO (Fig. 40.7).** Initially, there is an increase in pressure within the renal tubules of the affected kidney secondary to obstruction and a subsequent decrease in GFR. **The vasculature of the kidney attempts to compensate for the decreased GFR with an increase in renal blood flow mediated by the release of vasodilators, such as prostaglandin E_2 (PGE_2)** (Allen et al., 1978) **and NO** (Lanzone et al., 1995). This phase lasts 1 to 2 hours. During the second phase, lasting 3 to 4 hours, ureteral pressure remains elevated, but renal blood flow begins to decline, and in the final phase, ureteral pressure and renal blood flow progressively decline, resulting in a gradual loss in renal function (Moody et al., 1975; Vaughan et al., 1970). The late phase decline in RBF and ureteral pressure appears to be mediated by an increase in afferent arteriolar resistance. In addition to impeding RBF, increased afferent arteriolar resistance causes a decrease in effective glomerular capillary pressure and a resulting decrease in renal tubular pressure (Arendshorst et al., 1974). During the late phase of obstruction, there is also a shift in RBF from the outer cortex to the juxtamedullary region of the kidney and large portions of the cortical vascular bed become unperfused or underperfused (Yarger and Griffith, 1974). **Reduced GFR at this stage is therefore not only the result of a reduction in P_{GC} in individual glomeruli because of increased afferent arteriolar resistance but also the result of a global lack of perfusion of many glomeruli.**

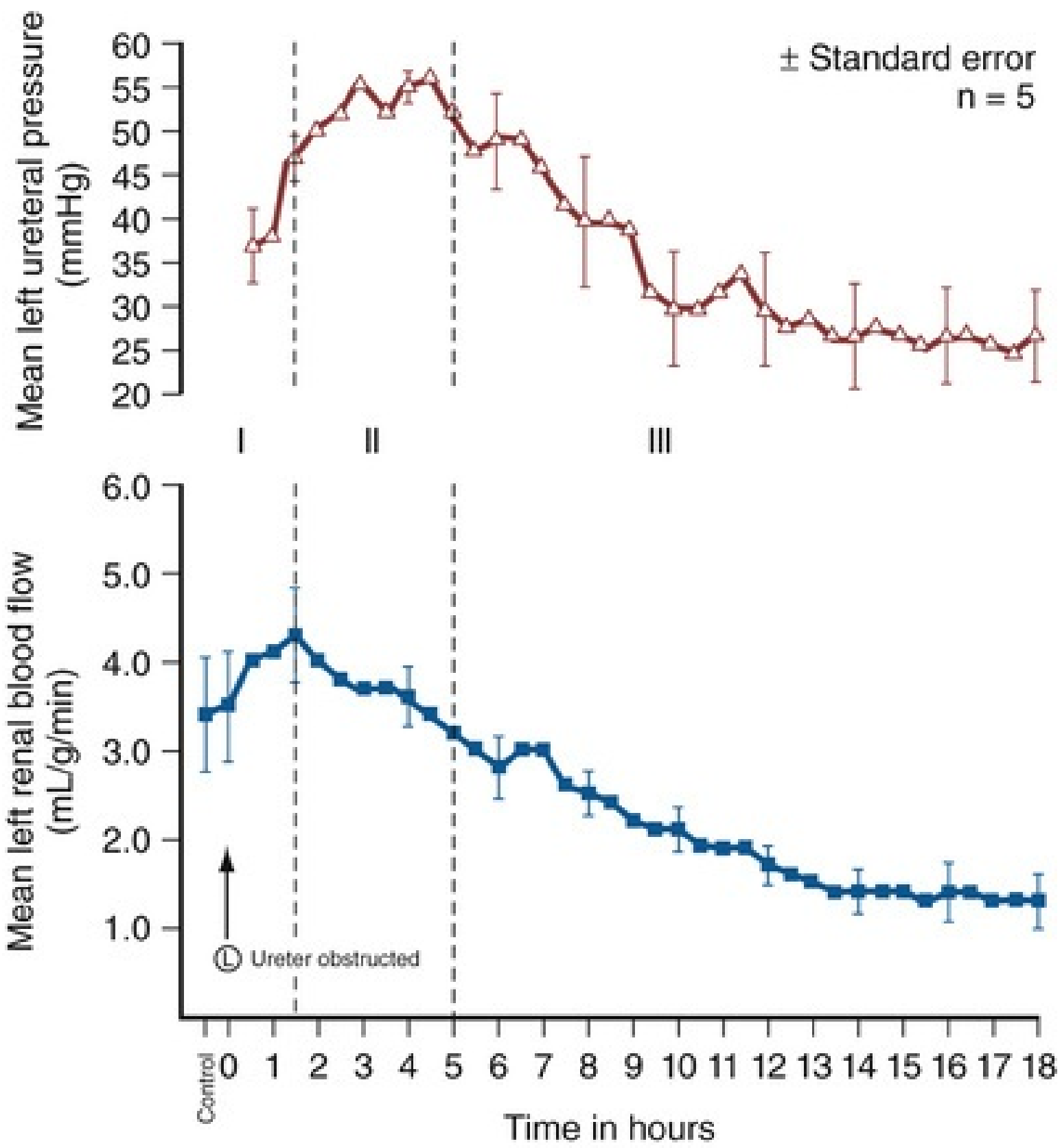

FIG. 40.7 Triphasic relationship between ipsilateral renal blood flow and left ureteral pressure during 18 hours of left ureteral obstruction. The three phases are designated by Roman numerals and separated by *vertical dashed lines*. In phase I, renal blood flow and ureteral pressure rise together. In phase II, the renal blood flow begins to decline and ureteral pressure remains elevated. In phase III, the blood flow and ureteral pressure decline together. (From Moody TE, Vaughan ED JR, Gillenwater JY: Relationship between renal blood flow and ureteral pressure during 18 hours of total ureteral occlusion. Implications for changing sites of increased renal resistance. *Inves Urol* 13:246–251, 1975.)

The mechanism of obstruction-induced increased afferent arteriolar resistance was initially thought to be due to upregulation of the renin-angiotensin system or increased thromboxane A_2 expression, but subsequent studies have not revealed a significant effect of these mediators on the renal hemodynamic response to obstruction (Vaughan et al., 2004). More recently, NO has been implicated in the late renal hemodynamic changes observed during UUO. NO is a vasodilator formed by the conversion of arginine to NO by nitric oxide synthase (NOS). NOS is present in the kidney and iNOS is upregulated in the kidney in response to obstruction (Miyajima et al., 2001). A study by Felsen et al. demonstrated that animals administered L-arginine demonstrated an increase in RBF and ureteral pressure in response to obstruction that was not observed in controls, suggesting that a lack of availability of substrate for NO production may be the mechanism of late phase decreases in RBF and tubular pressure (Felsen et al., 2003).

Bilateral Ureteral Obstruction or Obstruction of a Solitary Kidney

BUO (or obstruction of a solitary kidney) is characterized by only a modest initial increase in renal blood flow lasting about 90 minutes, followed by a decrease in bilateral renal blood flow (Gulmi et al., 1995)**. Unlike UUO, in which the ureteral pressure is initially elevated but quickly decreases to preocclusion pressures by 24 hours, ureteral pressure remains elevated for at least 24 hours with BUO. This prolonged elevation in intratubular pressure contributes to the decrease in GFR observed with BUO.** It has been shown, however, that the decrease in GFR and RBF is more pronounced in animals with UUO compared with BUO (Siegel et al., 1977). The mechanism of these hemodynamic differences appears to be related to the site of vasoconstriction in the glomerulus. During UUO, preglomerular vasodilation is followed by a more prolonged preglomerular vasoconstriction, and this increase in afferent arteriolar resistance causes a reduction in glomerular capillary pressure that, in turn, results in decreased intratubular pressure. **In contrast, during BUO, preglomerular vasodilation is followed by a prolonged postglomerular vasoconstriction. This increase in efferent arteriolar resistance results in increased P_{GC} and intratubular pressure despite a decrease RBF. The positive effect of increased P_{GC} on GFR is offset by the persistent elevation in tubular pressure.** As with UUO, it appears that nitric oxide has an important role in early vasodilation of the afferent arteriole (Reyes and Klahr, 1992). A number of other vasoactive mediators have been implicated in the hemodynamic changes observed during BUO. Inhibition of platelet-activating factor (PAF), a potent vasodilator, has been shown to significantly decrease GFR and effective renal plasma flow (ERPF) in animals with BUO (Reyes and Klahr, 1991), whereas inhibition of endothelin (a vasoconstrictor) in animals with BUO has been shown to attenuate the observed decreases in GFR and ERPF (Reyes and Klahr, 1992). Although a number of different vasoactive mediators likely contribute to the hemodynamic response during BUO, **atrial natriuretic peptide (ANP) appears to have a unique role in BUO and may be largely responsible for the different hemodynamic response observed with**

BUO as compared with UUO. Because there is no second renal unit to compensate for the ureteral obstruction, intravascular volume increases in response to BUO and serves as a stimulus for secretion of ANP. ANP, in turn, increases afferent arteriolar dilation and efferent arteriolar vasoconstriction, leading to an increase in P_{GC} and intratubular pressure (Maack, 1996). It also decreases the sensitivity of tubuloglomerular feedback, inhibits release of renin, and increases the glomerular ultrafiltration coefficient, K_f, which is related to the surface area and permeability of the capillary membrane. Indeed, high plasma levels of ANP have been demonstrated in animals with BUO as compared with control animals or those with UUO (Kim et al., 2001; Purkerson et al., 1989), and it has been postulated that increased levels of ANP may exert a protective effect on GFR during BUO that is not seen with UUO.

The intrarenal distribution of blood flow is also different with BUO as compared with UUO. **Animal studies have demonstrated that there is shift of blood flow from the juxtamedullary region of the kidney to the outer cortex in response to BUO, which is the opposite of that seen with UUO** (Jaenike, 1972; Solez et al., 1976). These alterations in the distribution of renal cortical blood flow may also contribute to the differences in GFR observed between BUO and UUO.

In summary, the hemodynamic changes observed with UUO and BUO involve increases in renal vascular resistance and ureteral pressure. The timing and regulation of these changes; however, are different (Fig. 40.8). During UUO, early renal vasodilation is followed by prolonged preglomerular vasoconstriction that results in normalization of intratubular pressure. In contrast, during BUO there is little early vasodilation and the later postglomerular vasoconstriction is associated with increased intratubular pressures.

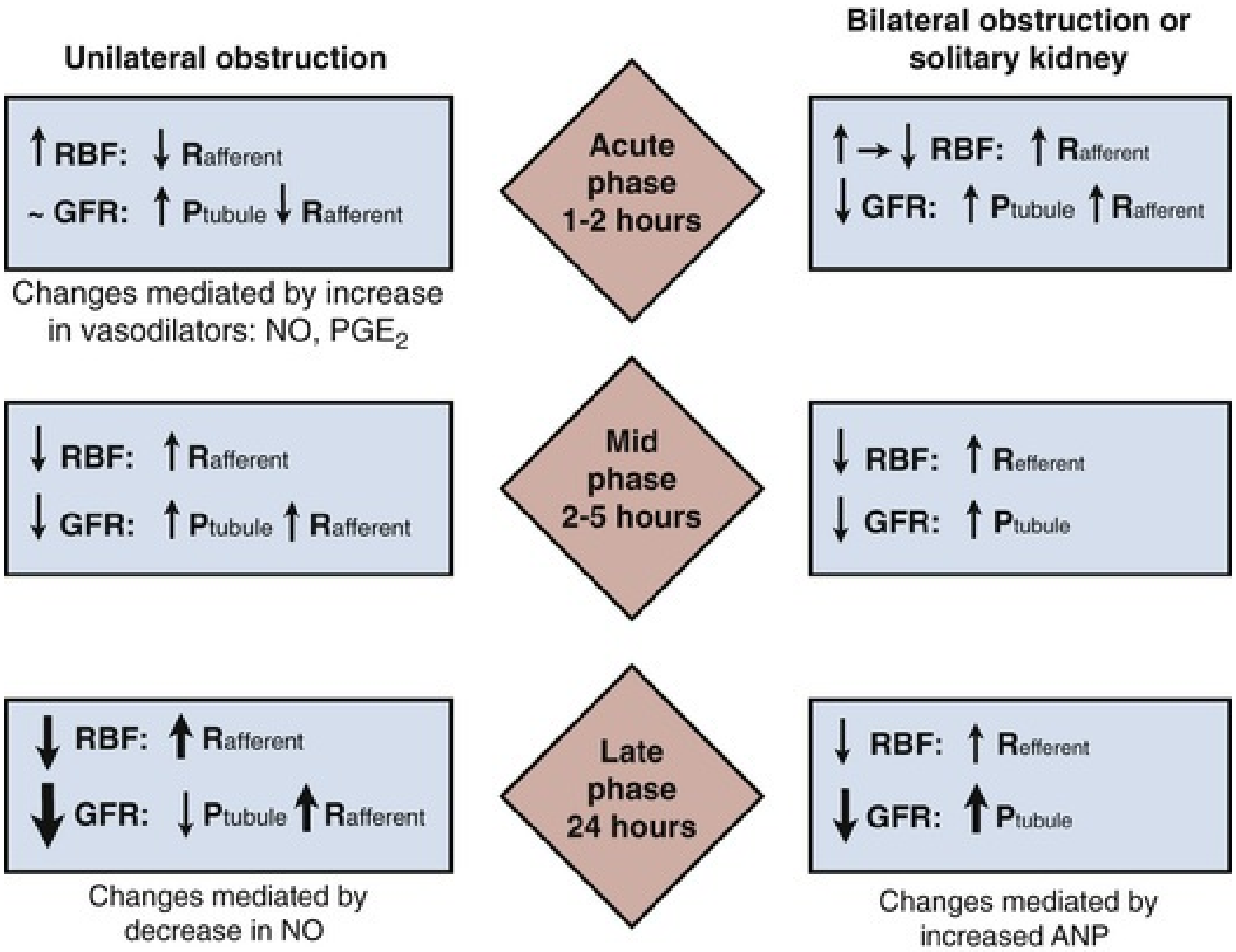
Unilateral obstruction
Bilateral obstruction or solitary kidney
↑RBF: ↓Rafferent
~ GFR: ↑Ptubule ↓Rafferent
Changes mediated by increase in vasodilators: NO, PGE2
Acute phase 1-2 hours
↑→↓ RBF: ↑Rafferent
↓GFR: ↑Ptubule ↑Rafferent
↓RBF: ↑Rafferent
↓GFR: ↑Ptubule ↑Rafferent
Mid phase 2-5 hours
↓RBF: ↑Refferent
↓GFR: ↑Ptubule
↓RBF: ↑Rafferent
↓GFR: ↓Ptubule ↑Rafferent
Changes mediated by decrease in NO
Late phase 24 hours
↓RBF: ↑Refferent
↓GFR: ↑Ptubule
Changes mediated by increased ANP

FIG. 40.8 Summary of the functional changes during ureteral obstruction. ~, Little change; *ANP,* atrial natriuretic peptide; *GFR,* glomerular filtration rate; *NO,* nitric oxide; *PGE_2,* prostaglandin E_2; *Ptubule,* tubular hydrolic pressure; *Rafferent,* afferent arteriolar resistance; *RBF,* renal blood flow; *Refferent,* efferent arteriolar resistance.

Partial Ureteral Obstruction

Although most models of urinary tract obstruction study complete obstruction over variable periods of time, many clinical situations involve partial ureteral obstruction (PUO). The effect of PUO on renal hemodynamics and GFR are variable depending on the severity and the duration of obstruction. In general, PUO results in decreased renal blood flow and GFR in the ipsilateral kidney (Wen, 2002; Wen et al., 1999). Chronic PUO has been reported to decrease RBF to 25% of normal (Stecker and Gillenwater, 1971), and a shift in renal cortical blood flow from the outer cortex to the inner cortex has been documented. It appears that the degree of RBF decline is dependent on the severity of obstruction (Chevalier, 1984; Chevalier and Kaiser, 1984). Although PUO has not been studied as extensively as complete UUO, a similar array of vascular mediators have been implicated in the increased afferent arteriolar resistance that occurs in response to PUO, including prostaglandins (Ichikawa and Brenner,

1979) and the renin-angiotensin system (Beharrie et al., 2004). A major problem with studies involving partial obstruction is the ability to accurately reproduce the degree of obstruction in each animal. Thornhill et al. (2005) describe a method of a ligating the ureter over a wire of calibrated diameter, which can then be removed to create a partial obstruction. The authors found that when the ureter was reduced by 70% to 75% that GFR was reduced by 80% after 28 days of partial UUO.

Key Points: Hemodynamic Changes With Obstruction

- With unilateral ureteral obstruction, renal blood flow increases during the first 1 to 2 hours. It begins to decrease at 3 to 4 hours and markedly declines after 5 hours of obstruction.
- The increase in renal blood flow in UUO is a result of relaxation of afferent arterials in which PGE_2 and NO play a role.
- Reduction in whole-kidney GFR after prolonged obstruction is due to afferent arteriolar vasoconstriction mediated by the renin-angiotensin system.
- In BUO, there is a modest increase in renal blood flow lasting approximately 2 hours, followed by a profound decline in renal blood flow.
- In UUO there is a shift of blood flow from the outer cortex to inner cortex. In bilateral ureteral obstruction, the shift is in the opposite direction toward the outer cortex.

Effects of Obstruction on Tubular Function

Obstruction of one or both kidneys can have profound effects on the concentrating ability of the kidney and on sodium, potassium, and hydrogen excretion. The ability of the kidney to recover normal excretory function after relief of obstruction is dependent on the degree and severity of obstruction. **A postobstructive diuresis often accompanies relief of bilateral ureteral obstruction but is not typically observed with relief of UUO, secondary to the presence of a functional contralateral kidney that can maintain fluid balance.** The eventual correction of abnormal renal tubular function depends on the degree and duration of obstruction.

Urinary Concentrating Ability

Normal urine concentrating ability is dependent on a hypertonic medullary interstitial gradient, which is established by active sodium transport out of the tubule and the countercurrent exchange mechanism. It is also dependent on the variable permeability of the tubules to water, mediated by aquaporin water channels. Obstructive nephropathy can disrupt all or some of these mechanisms and lead to a defect in urine concentrating ability.

Aquaporins (AQPs) are protein channels that form pores in the membrane of renal tubular cells. AQPs selectively conduct water into and out of the cell and are essential for the urine concentrating ability of the kidney. **Aquaporin 2 (AQP2) is exclusively expressed in the principal cells of the collecting tubule and collecting duct and is the predominant vasopressin-regulated water channel.** Vasopressin is secreted into the bloodstream from the posterior pituitary gland in response to increased serum osmolality or a reduction in circulating volume. After vasopressin binding to cell surface receptors in the collecting tubule, cytoplasmic vesicles containing AQP2 channels fuse with the apical membrane of tubular cells to facilitate water movement out of the collecting duct and its subsequent reabsorption.

After 24 hours of bilateral ureteral obstruction there is a marked reduction in AQP2 expression in the kidney (Frokiaer et al., 1996; Stodkilde et al., 2011), which results in an impaired ability of the kidney to reabsorb water once the obstruction has been relieved. It has been demonstrated that AQP2 expression remains 50% of normal levels 7 days after relief of obstruction. AQP1, AQP3, and AQP4 expression levels have also been shown to be downregulated in response to BUO (Li et al., 2001), and although AQP2 and AQP3 expression normalize within 30 days of release of BUO, **AQP1 remains downregulated and may contribute to the long-term polyuria and impaired concentrating ability of obstructive nephropathy.** Downregulation of AQP channels are also observed in response to UUO, but the clinical manifestations are not as evident because the contralateral kidney is able regulate fluid balance. A significant decrease in AQP2 levels are observed in the obstructed kidney (23% normal) and a moderate decrease in AQP2 levels are observed in the nonobstructed kidney (75% normal) after 24 hours of UUO (Frokiaer et al., 1997), suggesting a local and a systemic effect on AQP expression. Angiotensin has been implicated in obstruction-induced AQP2 downregulation, because blockade of the angiotensin I receptor has been shown to prevent the decreased expression of AQP2 (Jensen et al., 2006), and antioxidants, such as N-acetylcysteine, appear to upregulate AQP2 expression and protect against the urinary concentrating defect caused by obstructive injury (Shimizu et al., 2008). Neonatal complete or partial UUO similarly induces a reduction in the expression and distribution of aquaporins (AQP1, AQP2, AQP3, AQP7) (Klein et al., 2011), and AQP1 through AQP4 expression has been shown to be reduced in pediatric patients with congenital hydronephrosis in proportion to the degree of renal functional impairment detected on DTPA renal dynamic imaging (Li et al., 2012).

Sodium Transport

A decrease in sodium transport in the nephron is observed after release of obstruction, and this salt wasting also contributes to the concentrating defect observed in response to obstruction. Previous studies have indicated that the major defects in renal tubular sodium reabsorption localize to the distal segments of the nephron (Jensen et al., 2006; Li et al., 2003). A significant downregulation in major sodium transporters occurs within the nephron 24 hours after the onset of UUO and occurs in the obstructed and unobstructed kidneys. Similarly, a significant downregulation in major sodium transporters occurs in response to BUO, and in both models of injury, the downregulation in sodium transporters has been shown to contribute to the observed natriuresis (Jensen et al., 2006; Li et al., 2003). A significant reduction in the expression and distribution of major sodium transporters has also been demonstrated in neonatal kidneys in response to complete and partial UUO (Klein et al., 2011). **The natriuresis after relief of BUO is typically greater than that after UUO because BUO causes retention of sodium, water, urea nitrogen, and increased production of ANP, all of which stimulate sodium wasting after relief of obstruction.**

Prostaglandin E_2 has an important role in tubular water and salt transport and the regulation of renal hemodynamics (Harris and Breyer, 2001). It has been demonstrated that PGE_2 inhibits NaCl reabsorption in the thick ascending limb of the loop of Henle and vasopressin-induced increases in water permeability in collecting ducts (Aarab et al., 1999; Torikai and Kurokawa, 1983). Cyclooxygenase (COX) is the rate-limiting enzyme in the synthesis of prostaglandin from arachidonic acid, and Norregaard et al. (2005) have demonstrated that COX-2 and PGE_2 synthesis are upregulated in the kidney in response to 24 hours of BUO and that COX-2 inhibition prevents PGE_2 release and the observed downregulation in AQP2 and major sodium channel expression in response to obstruction.

Hydrogen Ion Transport and Urinary Acidification

Obstruction causes a deficit in urinary acidification that has been demonstrated in human subjects as well as animal models. The defect is characterized by the inability of the kidney to lower urinary pH maximally (<5.5) under the stimulus of systemic acidemia. Evidence suggests that the major acidification defect is in the distal nephron, most likely related to defective H+ secretion in the distal tubule and collecting duct, and/or decreased bicarbonate reabsorption in the juxtamedullary nephron. Obstruction has been demonstrated to significantly decrease the expression of multiple acid-base transporters in the kidney, including the type 3 Na^+/H^+ exchanger, the electrogenic Na^+/HCO_3^- cotransporter, the Na^+-K^+ (NH_4^+)-$2Cl^-$ cotransporter, and the electroneutral Na^+/HCO_3^- cotransporter, in addition to decreasing the expression of H^+-ATPase in the kidney (Wang et al., 2009). Valles et al. (2000) demonstrated that the decrease in H^+-ATPase observed during UUO is mediated by an increase in iNOS, which in turn, appears to be regulated by angiotensin II. Neonatal kidney obstruction similarly results in a downregulation of acid-base transporters, resulting in decreased acid secretion and the development of metabolic acidosis in a time- and age-dependent fashion (Wang et al., 2009).

In the proximal tubule, glutamine uptake and ammonia generation are diminished after release of obstruction, resulting in a greater proportion of H^+ that will be buffered as a titratable acid in combination with phosphate, creatinine, and other bases. The largest component of titratable acid is phosphate, and because phosphate excretion may be compromised in response to obstruction, the net result may be a lower urinary pH related to unbuffered protons in spite of a net decrease in total H^+ secretion.

Other Cation Transport

Obstruction has an effect on other cation transport as well. In UUO potassium secretion is decreased in proportion to the decrease in GFR after release of a 24-hour period of UUO (Harris and Yarger, 1975). This may be due to reduced delivery of sodium to the distal nephron and a low-flow state, although other investigations indicate an intrinsic defect in potassium secretion as well (Thirakomen et al., 1976). In contrast, potassium excretion increases in parallel with sodium excretion after relief of BUO, and it appears that proximal reabsorption of potassium remains unchanged, whereas its secretion in the collecting duct is increased after relief of obstruction. This may be related to increased water and sodium delivery to the collecting duct and to the presence of high levels of ANP that can stimulate potassium secretion in the distal nephron (Sonnenberg and Wilson, 1976). Magnesium excretion is also markedly increased after release of either UUO or BUO. This most likely results from compromised transport in the thick limb of Henle. The effects on phosphate reabsorption after the release of obstruction vary depending upon whether it was bilateral or unilateral. When BUO is released, accumulated phosphate is rapidly excreted in proportion to sodium (Beck, 1979). Conversely, a decrease in phosphate excretion and a net retention occur with release of UUO.

Egress of Urine From the Obstructed Kidney

Although normal flow of urine from the kidney through the urinary tract is compromised with obstruction, urine may still egress from the kidney. A rupture of the calyceal fornix and subsequent extravasation of urine can occur during acute obstruction, typically in response to ureteral stones (Stenberg et al., 1988), although it can also be seen with congenital abnormalities such as posterior urethral valves. Extravasation of urine into the venous and lymphatic system may also occur in the setting of urinary obstruction. During chronic obstruction, fluid is thought to exit primarily into the renal venous system.

Clinical Impact of Renal Obstruction

Hypertension

Hypertension can develop in response to urinary tract obstruction and is more common in the presence of BUO as compared with UUO. Vaughan and Gillenwater (1973) noted hypertension in 17 of 22 patients with BUO that was reversible upon relief of obstruction in all but 2 patients. Increased ANP levels and intravascular volume have been documented in patients with BUO and suggest a volume-mediated mechanism for hypertension in these patients. Hypertension is less common in patients with UUO and does not appear to be related to volume overload because the normal contralateral kidney is able to eliminate excess volume and solutes (Al-Mashhadi et al., 2015). The renin-angiotensin system is upregulated in response to UUO and has been implicated as the mechanism of hypertension in these patients. Previous studies have demonstrated that blockade of the angiotensin II type 2 receptor with losartan prevents the rise in systolic blood pressure associated UUO and normalizes systolic blood pressure in chronically hypertensive UUO rats (el-Dahr et al., 1993). **Hypertension is therefore more likely to occur in response to BUO and more likely to be reversed after relief of obstruction in patients with BUO as compared with UUO** (Al-Mashhadi et al., 2015, 2018).

Compensatory Renal Growth

First described by Hinman in 1943, compensatory renal growth refers to the development of increased volume of the contralateral kidney in response to unilateral ureteral obstruction or renal agenesis (Peters et al., 1993; Taki et al., 1983). **The development of contralateral renal growth is influenced by age and the degree and duration of obstruction.** Studies in human subjects subjected to nephrectomy have demonstrated that a reduction in renal compensatory growth occurs with increasing age (Edgren et al., 1976). Compensatory renal growth appears to be directly proportional to the duration of obstruction and is less prominent with partial rather than complete UUO (Chevalier and Kaiser, 1984; Chevalier et al., 1987, 1999a-d; Eskild-Jensen et al., 2001). Interestingly, a recent study also demonstrated that compensatory renal growth, renal hypertrophy, and GFR are increased in response to unilateral nephrectomy in male rats as compared with female rats or gonadectomized groups (Azurmendi et al., 2013), suggesting that sex hormones have a role in this adaptive response as well. **Although the kidney enlarges, an increase in the number of nephrons or glomeruli does not occur in utero, indicating that the increase in renal volume is primarily a consequence of cellular hypertrophy rather than hyperplasia** (Peters et al., 1993). A study in fetal sheep, however, demonstrated that animals subjected to 5/6 nephrectomy had increased cortical thickness, tubular hypertrophy, a lower glomerular density, but a striking increase in glomerular number as compared with animals subjected to 1/2 nephrectomy. Furthermore, the magnitude of the regenerative process appeared to be more dependent on the severity of renal reduction than on the timing of renal reduction (Sammut et al., 2013). This adaptive response allows the remaining kidney to ensure homeostasis and compensate for the lack of functioning contralateral renal tissue; however, the mechanisms behind compensatory renal growth remain poorly understood.

Insulin-like growth factor (IGF-1) appears to be an important mediator of compensatory renal hypertrophy (Cleper, 2012). IGF-1 is a growth factor that has a critical role in renal development, growth, and function (Kamenicky et al., 2013). Exogenous IGF-1 has been shown to increase GFR in normal humans (Guler et al., 1989) and attenuate renal injury resulting from obstruction in animals (Chevalier et al., 2000). IGF-1 levels are significantly elevated in the contralateral kidney after unilateral nephrectomy or after unilateral ureteral obstruction (Serel et al., 2000). Evidence suggests that IGF-1 expression may be increased in immature kidneys as compared with mature kidneys after unilateral nephrectomy (Mulroney et al., 1992). Significant increases in serum IGF-1 levels have also been demonstrated in humans after donor nephrectomy and IGF-1 levels have been positively correlated with the increased renal volume demonstrated on postoperative imaging after donor nephrectomy (Nam, Lee et al., 1999). Other growth factors have been implicated as effectors of this process (i.e. TGF-β1, hepatocyte growth factor [HGF]); however, the sensors of reduced renal mass that stimulate compensatory renal hypertrophy remain unknown.

Key Points: Functional Changes With Obstruction

- After obstruction, there is dysregulation of aquaporin water channels in the proximal tubule, descending loop, and collecting duct, which may contribute to long-term polyuria.

- The excretion of sodium after the relief of bilateral ureteral obstruction is greater than after UUO because in bilateral obstruction there is retention of sodium, water, urea, and other osmotic substances and an increase of atrial natriuretic factor, all of which stimulate a profound natriuresis.
- Recovery of renal function after relief of obstruction is affected by the duration, the degree, the patient's age, baseline renal function, collecting system compliance, and infection.
- Ureteral obstruction may result in prolonged decreases in concentrating ability, urinary acidification, and electrolyte transport long after the obstruction is released.
- Compensatory renal growth decreases progressively with increasing age. Although the kidney does enlarge, there is not an increase in nephrons or number of glomeruli after birth.

Treatment of Renal Obstruction

Pain Management

The first-line approach for the patient with renal colic is the administration of analgesics. Narcotics have a rapid onset of analgesia but may promote nausea and emesis, cause excessive sedation, and have the potential to be abused. Nonsteroidal anti-inflammatory drugs (NSAIDs) are nonopioid analgesics that, unlike narcotics, target the inflammatory basis of pain. Renal colic is thought to arise from increased collecting system pressure and an acute distention of the collecting system (Holmlund, 1983), and NSAIDs have been demonstrated to reduce collecting system pressure. Indomethacin, as well as other NSAIDs, cause a decrease in renal pelvic pressure in response obstruction (Frokiaer et al., 1993; Gasparich and Mayo, 1986; Sjodin et al., 1982) that is thought to be mediated by a reduction in renal blood flow. Perlmutter et al. (1993) demonstrated that ketorolac induces a prompt reduction in RBF and intrapelvic pressure in canines with UUO. COX-2 inhibitors are a form of NSAIDs that block the synthesis of prostaglandins from arachidonic acid. It has previously been shown that COX-2 inhibitors can prevent the PGE-mediated downregulation of aquaporin channels and major sodium channels in response to obstruction (Norregaard et al., 2005), and the resulting decrease in hydrostatic pressure within the tubules may provide an additional mechanism for the NSAID-mediated reduction in intrapelvic pressures.

In clinical trials, NSAIDs have proven to be superior to opioids in managing renal colic and are associated with a greater reduction in pain scores, less need for "rescue" analgesia, and less emesis than opioids (Holdgate and Pollock, 2004). **NSAIDs should not be used in patients with renal insufficiency, however, because renal dysfunction can be exacerbated by the decrease in renal blood flow induced by NSAIDs.** COX-1 inhibitors should also not be used in patients at risk for gastrointestinal bleeding or when optimal platelet function is needed, and COX-2 inhibitors have been linked to an increased risk of myocardial infarction and stroke because of an adverse effect on blood vessels (Cannon and Cannon, 2012). Although opioids have untoward side effects, they still provide excellent analgesia and remain an important tool in the management of the patient with renal colic. The administration of α_1-blockers (e.g., Flomax) have also been used for medical expulsive therapy and studies have demonstrated the ability of α_1-blockers to facilitate stone passage and reduce the requirement for analgesics (Wang et al., 2008).

Renal Drainage

Prompt drainage of the obstructed kidney is important to relieve pain and prevent functional decline. Minimally invasive endourologic and interventional radiologic techniques allow for temporary drainage until a definitive procedure can be performed or, in some circumstances, may be a permanent management option. Urine cultures should be obtained from the obstructed renal unit at the time of relief of obstruction when infection is suspected and antibiotic therapy should be instituted. Ureteral obstruction that is symptomatic, accompanied by fever, complicated by undrained infection, or determined to be high grade, bilateral, or inducing renal failure warrants immediate drainage.

Percutaneous nephrostomy (PCN) tubes and internal stents have been shown to be equally effective in relieving an obstructed collecting system with similar complication rates (Regalado, 2006). PCN tubes are larger caliber and offer the advantage of providing superior drainage, especially if the fluid is more purulent. The catheters can be irrigated to prevent clogging, the urine output of the kidney can be measured, and excessive ureteral manipulation can be avoided, decreasing the risk for sepsis or rupture. The procedure can also be done using ultrasound guidance with local anesthesia and conscious sedation, eliminating the need for an anesthesiologist and ionizing radiation exposure. Internal stents offer the advantage of increased patient comfort with no catheter extending out of the flank, and a lower potential risk for bleeding complications. Internal stent placement should therefore be considered first for patients that are coagulopathic. If thick, purulent fluid is obtained from the kidney at the time of ureteral stenting, placement of a large diameter stent is recommended and/or placement of an external diversion stent that can be irrigated and monitored. Internal stent placement typically requires greater x-ray exposure than percutaneous nephrostomy placement, which may be of concern in pregnant patients (McAleer and Loughlin, 2004; Mokhmalji et al., 2001), and accelerated stent encrustation in this patient population resulting from increased calcium excretion may increase the risk of stent failure (Goldfarb et al., 1989).

Historically, ureteral stenting has not been as effective for treating patients with extrinsic ureteral obstruction. Docimo and Dewolf (1989) reported a 43% failure rate in stents placed for extrinsic obstruction, the majority related to malignancy. Chung et al. (2004) similarly identified a 42% rate of stent failure in these patients, with a diagnosis of cancer, metastatic disease requiring chemotherapy or radiation, and renal insufficiency predictors of stent failure. **New metallic stents composed of a unique continuous unfenestrated coil of nonmagnetic alloy have been proven to be safe and effective for patients with extrinsic compression of the ureter and offer longer indwelling times (3.5 to 11 months).** Age and preoperative serum creatinine levels have been identified as independent risk factors for metallic stent failure, and lower GI cancers have been associated with longer metallic stent duration times than GU cancers (Chow et al., 2014).

Renal Recovery After Obstruction

A number of factors can affect the recovery of renal function after relief of obstruction, including the duration of obstruction, function of the contralateral kidney, age, pyelo-lymphatic backfIow, compliance of the ureter and renal pelvis, presence or absence of infection, and underlying renal disease (Soliman et al., 2011). **When acute complete ureteral obstruction is promptly relieved, full recovery of global GFR can occur, but longer periods of complete ureteral obstruction are associated with diminished return of GFR**. The persistent decrease in GFR and RBF after relief of obstruction is due to persistent vasoconstriction of the afferent arteriole. Vaughan and Gillenwater (1971) performed some of the initial studies on recovery of renal function after obstruction. In a canine model of UUO, researchers noted that full recovery of renal function occurred after 7 days of UUO, whereas only 70% recovery of GFR occurred after 14 days of UUO, 30% after 4 weeks of UUO, and no recovery occurred after 6 weeks of UUO. More recent studies have demonstrated that renal damage can persist despite recovery of renal function. After 3 days of UUO in a rat model of obstruction, GFR and RBF returned to baseline levels within 14 days in the previously obstructed kidney (Ito et al., 2004), but interstitial fibrosis and tubular apoptosis continued to increase after relief of obstruction. Mouse studies suggest that after 7 days of obstruction, normal renal function is not restored in the previously obstructed kidney even after 30 days of recovery, with GFR and RBF reduced by 40% and the urine albumin/protein ratio increased by 2.8-fold. The remaining intact nephrons are hypertrophied and there is evidence of substantial glomerular injury (Chaabane et al., 2013). In humans, delayed relief of obstruction (>2 weeks) has been demonstrated to decrease long-term renal function and increase the risk of hypertension (Lucarelli et al., 2013).

Complete reversal of renal damage is rarely achieved after release of complete obstruction in the neonatal kidney. Glick et al. (1984) **demonstrated that the functional salvageability of an obstructed fetal kidney is dependent on the duration of the obstruction and the gestational age at which the obstruction occurs. It has been demonstrated that glomerular numbers remain low 1 month after release of a 5-day period of complete obstruction, indicating a permanent loss in nephrons** (Chevalier et al., 1999)**. Although glomerular function initially improves with normalization of GFR 1 month after release of neonatal obstruction, GFR subsequently decreases by 80% 1 year after relief of obstruction secondary to progressive glomerular sclerosis** (Chevalier et al., 2000). Tubular deterioration is attenuated but not reversed after release of neonatal obstruction, and tubular function remains abnormal 1 month after release of obstruction, suggesting that renal transporter expression is not corrected after the release (Chevalier et al., 1999).

The presence of increased collagen deposition in the renal parenchyma at the time of pyeloplasty has been shown to have a negative impact on recovery of renal function, as it demonstrates a more advance state of renal fibrosis (Kim et al., 2005; Kiratli et al., 2008). **Thompson and Gough** (2001) **demonstrated that DMSA is superior to MAG3 and DTPA in measuring function of the obstructed kidney and predicting the ultimate outcome of surgical intervention**. MAG3 was found to underestimate the potential of the kidney for recovery and was associated with a large variation in accuracy. The superiority of DMSA in assessing function under these circumstances appears to be related to its fixation to the renal cortex and delayed clearance. In cases in which renal function is significantly depressed on diuresis renography and nephrectomy is being considered, a preoperative DMSA scan may be of additional value in surgical planning.

Choice of Surgical Intervention

Definitive management of urinary tract obstruction is based on the cause of obstruction, the status of the contralateral kidney, the function of the affected kidney, and the patient's age and overall medical status. A number of different endoscopic, open, laparoscopic, and robotically assisted ablative and reconstructive options are available and are discussed elsewhere in this text. In general, a nephrectomy should be considered for an obstructed kidney that contributes less than 10% to the patient's overall renal function. The decision to remove a kidney, however, should only be made after the kidney has been adequately drained for a sufficient period of time to allow maximal recovery and an accurate assessment of renal function (Kerr, 1954). In the setting of global renal insufficiency, the decision is more complicated, and patients may elect management with a chronic indwelling stent or nephrostomy tube to prevent more rapid progression to dialysis.

In children the determination of salvageability may also require a period of decompression and reassessment of relative function. Although no absolute cutoff for renal preservation exists, the typical threshold for function is between 10% and 15%. A large series of pediatric poorly functioning kidneys with less than 20% relative uptake were seen to have significant improvements in function after pyeloplasty (Menon et al., 2016). These authors recommend nephrectomy only when function is less than 5%. The initial assessment of relative renal function, usually by nuclear imaging, may not be completely accurate. Poorly functioning kidneys can improve their relative function after reconstruction; however, this may be only a limited amount, so parents should be provided with realistic expectations (Jiang et al., 2017).

Postobstructive Diuresis

Mechanism of Postobstructive Diuresis

Postobstructive diuresis, defined as a period of significant polyuria, may develop after the relief of urinary tract obstruction. Urine outputs of 200 mL or greater may be encountered. Although this primarily occurs after relief of BUO, it can rarely occur in the presence of a normal contralateral kidney (Roth et al., 2018; Schlossberg and Vaughan, 1984). The diuresis is generally a physiologic response to the accumulated solutes and volume expansion that has occurred during obstruction. Sodium, urea, and free water are eliminated, and the diuresis subsides after homeostasis is achieved. A pathologic postobstructive diuresis may also ensue, characterized by inappropriate renal handling of water and/or solutes. Downregulation of sodium transport channels (Li et al., 2003), downregulation of aquaporin channels (Li et al., 2001), poor responsiveness of the collecting duct to vasopressin, and altered regulation of ANP (Kim et al.,

2001) can result in a disruption of the medullary interstitial solute gradient and profound diuresis and natriuresis.

Postobstructive diuresis is uncommon in children but should be considered with relief of bilateral obstruction. It has been reported in neonates with unilateral obstruction, but this is uncommon (Boone and Allen, 1992; Roth et al., 2018).

Clinical Management of Postobstructive Diuresis

The majority of patients do not demonstrate a clinically significant postobstructive diuresis after relief of urinary tract obstruction, and those who are susceptible typically exhibit signs of fluid overload including edema, congestive heart failure, and hypertension. Most commonly, postobstructive diuresis develops after relief of urinary retention, and the speed at which the bladder is drained has not been shown to have any effect on the development of postobstructive diuresis or hematuria (Nyman et al., 1997).

After relief of obstruction, patients with BUO or an obstructed solitary kidney should be monitored for the development of postobstructive diuresis. Those patients with normal renal function, normal electrolytes, no evidence of fluid overload, and a normal mental status should have their vital signs and urine output monitored regularly and they should be given free access to oral fluids. If evidence of a postobstructive diuresis develops, vital signs, urine output, and electrolytes should be monitored more frequently, and patients should continue to have free access to oral fluids. Generally, patients with a normal mental status should not be given intravenous fluids, because this may prolong the period of diuresis. **This is a physiologic diuresis that, in the majority of cases, resolves when free water and excess solutes are eliminated.** In patients with impaired renal function, altered mental status, and signs of fluid overload, more intense monitoring is indicated. A urine osmolality should be checked, and vital signs and urine output should be checked frequently. Electrolytes should be monitored every 12 hours or more often if necessary. Patients with poor cognitive function should also be given intravenous fluids, although at a rate below maintenance. If a pathological diuresis ensues, the patient can become hypovolemic because of excess water loss and electrolyte abnormalities may develop as result of salt or potassium wasting. Very intense monitoring and careful fluid and electrolyte replacement is indicated in these patients. The urine is usually isosthenuric initially and intravenous fluid replacement with 0.45% saline administration at a rate lower than the urine output is recommended (Frokiaer and Zeidel, 2007). Changes in the type and amount of intravenous fluid administration are based on the patient's clinical status, serum, and urinary electrolytes.

Experimental Modulation of Postobstructive Diuresis

Experimental data do suggest the potential for pharmacologic manipulation of postobstructive diuresis. It remains unclear, however, what role pharmacologic manipulation may play in clinical practice. As discussed previously, BUO is associated with increased COX-2 expression, and selective COX-2 inhibition prevents the downregulation of AQP2 channels in response to obstruction (Norregaard et al., 2005). Norregaard et al. (2007) demonstrated that COX-2 activity increases in the postobstructive phase and that this contributes to polyuria and an impaired urine concentrating ability. After administration of a selective COX-2 inhibitor, the authors demonstrated that urine output was reduced but sodium excretion and GFR remained unchanged 24 hours after release of BUO. There is also evidence that sildenafil citrate (Viagra) can induce accumulation of AQP2 channels in collecting duct cells in vitro, independent of vasopressin stimulation, by activating a parallel cGMP-mediated pathway (Bouley et al., 2005). Clearly, further research is required to identify effective management strategies for postobstructive diuresis and to determine which patients would benefit from pharmacologic manipulation.

Key Points: Treatment of Renal Obstruction

- When acute complete ureteral obstruction is promptly relieved, full recovery of global GFR can occur, but longer periods of complete ureteral obstruction are associated with diminished return of GFR.
- Postobstructive diuresis is a result of (1) a physiologic diuresis that involves volume expansion and solute accumulation and (2) a pathological diuresis that involves derangements of the medullary gradient and transport processes for solutes in the renal tubule.
- Distended bladders should be expeditiously decompressed. There is no role for gradual decompression, because this does not limit hematuria or postobstructive diuresis.

Suggested Readings

Bani-Hani AH, Campbell MT, Meldrum DR, et al. Cytokines in epithelial-mesenchymal transition: a new insight into obstructive nephropathy. *J Urol*. 2008;180:461–468.

Cerwinka WH, Kirsch AJ. Magnetic resonance urography in pediatric urology. *Curr Opin Urol*. 2010;20:323–329.

Cheng PM, Moin P, Dunn MD, et al. What the radiologist needs to know about urolithiasis: part 1–pathogenesis, types, assessment, and variant anatomy. *AJR Am J Roentgenol*. 2012;198:W540–W547.

Chevalier RL. Congenital urinary tract obstruction: the long view. *Adv Chronic Kidney Dis*. 2015;22(4):312–319.

Chevalier RL, Forbes MS, Thornhill BA. Ureteral obstruction as a model of renal interstitial fibrosis and obstructive nephropathy. *Kidney Int*. 2009;75:1145–1152.

Huang WY, Peters CA, Zurakowski D, et al. Renal biopsy in congenital ureteropelvic junction obstruction: evidence for parenchymal maldevelopment. *Kidney Int*. 2005;69:137–143.

Kennish SJ, Wah TM, Irving HC. Unenhanced CT for the evaluation of acute ureteric colic: the essential pictorial guide. *Postgrad Med J*. 2010;86:428–436.

Kerr WS Jr. Effect of complete ureteral obstruction for one week on kidney function. *J Appl Physiol*. 1954;6:762–772.

Klahr S, Morrissey J. Obstructive nephropathy and renal fibrosis. *Am J Physiol Renal Physiol*. 2002;283:F861–F875.

Klein J, Gonzalez J, Miravete M, et al. Congenital ureteropelvic junction obstruction: human disease and animal models. *Int J Exp Pathol*. 2011;92:168–192.

Li C, Wang W, Kwon TH, et al. Altered expression of major renal Na transporters in rats with bilateral ureteral obstruction and release of obstruction. *Am J Physiol Renal Physiol*.

2003;285:F889–F901.

Lucarelli G, Ditonno P, Bettocchi C, et al. Delayed relief of ureteral obstruction is implicated in the long-term development of renal damage and arterial hypertension in patients with unilateral ureteral injury. *J Urol*. 2013;189:960–965.

Meng X-M, Chung ACK, Lan JY. Role of the TGF-β/BMP-7/Smad pathways in renal diseases. *Clin Sci*. 2013;124:243–254.

Miglioretti DL, Johnson E, Willimas A, et al. The use of computed tomography in pediatrics and the associated radiation exposure and estimated cancer risk. *JAMA Pediatr*. 2013;167:700–707.

Misseri R, Rink RC, Meldrum DR, et al. Inflammatory mediators and growth factors in obstructive renal injury. *J Surg Res*. 2004;119:149–159.

Nielsen S, Kwon T-H, Frokiaer J, et al. Regulation and dysregulation of aquaporins in water balance disorders. *J Intern Med*. 2007;261:53–64.

Peters CA. Urinary tract obstruction in children. *J Urol*. 1995;154(5):1874–1883.

Peters CA. Obstruction of the fetal urinary tract. *J Am Soc Nephrol*. 1997;8(4):653–663.

Piepsz A. Antenatal detection of pelviureteric junction stenosis: main controversies. *Semin Nucl Med*. 2011;41:11–19.

Truong LD, et al. Obstructive uropathy. *Contrib Nephrol*. 2011;169:311–326.

Vaughan ED Jr, Gillenwater JY. Recovery following complete chronic unilateral ureteral occlusion: functional, radiographic and pathologic alterations. *J Urol*. 1971;106:27–35.

Vaughan ED Jr, Marion D, Poppas DP, et al. Pathophysiology of unilateral ureteral obstruction: studies from Charlottesville to New York. *J Urol*. 2004;172:2563–2569.

References

Aarab L, Siaume-Perez S, Chabardes D. Cell-specific coupling of PGE2 to different transduction pathways in arginine vasopressin- and glucagon-sensitive segments of the rat renal tubule. *Br J Pharmacol*. 1999;126(4):1041–1049.

Allen JT, Vaughan ED Jr, Gillenwater JY. The effect of indomethacin on renal blood flow and uretral pressure in unilateral ureteral obstruction in a awake dogs. *Invest Urol*. 1978;15(4):324–327.

Al-Mashhadi A, Checa A, Wahlin N, et al. Changes in arterial pressure and markers of nitric oxide homeostasis and oxidative stress following surgical correction of hydronephrosis in children. *Pediatr Nephrol*. 2018;33(4):639–649.

Al-Mashhadi A, Neveus T, Stenberg A, et al. Surgical treatment reduces blood pressure in children with unilateral congenital hydronephrosis. *J Pediatr Urol*. 2015;11(2):91 e91–91 e96.

Anders HJ, Vielhauer V, Schlondorff D. Chemokines and chemokine receptors are involved in the resolution or progression of renal disease. *Kidney Int*. 2003;63(2):401–415.

Arendshorst WJ, Finn WF, Gottschalk CW. Nephron stop-flow pressure response to obstruction for 24 hours in the rat kidney. *J Clin Invest*. 1974;53(5):1497–1500.

Asanuma H, Vanderbrink BA, Campbell MT, et al. Arterially delivered mesenchymal stem cells prevent obstruction-induced renal fibrosis. *J Surg Res*. 2011;168(1):e51–e59.

Attar R, Quinn F, Winyard PJ, et al. Short-term urinary flow impairment deregulates PAX2 and PCNA expression and cell survival in fetal sheep kidneys. *Am J Pathol*. 1998;152(5):1225–1235.

Ayan S, Roth JA, Freeman MR, et al. Partial ureteral obstruction dysregulates the renal renin-angiotensin system in the fetal sheep kidney. *Urology*. 2001;58(2):301–306.

Azurmendi PJ, Oddo EM, Toledo JE, et al. Sexual hormones modulate compensatory renal growth and function. *Medicina (B Aires)*. 2013;73(6):513–519.

Bai ZM, Deng XD, Li JD, et al. Arterially transplanted mesenchymal stem cells in a mouse reversible unilateral ureteral obstruction model: in vivo bioluminescence imaging and effects on renal fibrosis. *Chin Med J*. 2013;126(10):1890–1894.

Bani-Hani AH, Campbell MT, Meldrum DR, et al. Cytokines in epithelial-mesenchymal transition: a new insight into obstructive nephropathy. *J Urol*. 2008;180(2):461–468.

Bani-Hani AH, Leslie JA, Asanuma H, et al. IL-18 neutralization ameliorates obstruction-induced epithelial-mesenchymal transition and renal fibrosis. *Kidney Int*. 2009;76(5):500–511.

Bartoli F, Gesualdo L, Paradies G, et al. Renal expression of monocyte chemotactic protein-1 and epidermal growth factor in children with obstructive hydronephrosis. *J Pediatr Surg*. 2000;35:569–572.

Bartoli F, Penza R, Aceto G, et al. Urinary epidermal growth factor, monocyte chemotactic protein-1, and β2-microglobulin in children with ureteropelvic junction obstruction. *J Pediatr Surg*. 2011;46:530–536.

Bascands JL, Schanstra JP. Obstructive nephropathy: insights from genetically engineered animals. *Kidney Int*. 2005;68(3):925–937.

Baum B, Settleman J, Quinlan MP. Transitions between epithelial and mesenchymal states in development and disease. *Semin Cell Dev Biol*. 2008;19(3):294–308.

Beam AS, Moore KG, Gillis SN, et al. GBCAs and risk for nephrogenic systemic fibrosis: a literature review. *Radiol*

Technol. 2017;88(6):583–589.

Beck AD. The effect of intra-uterine urinary obstruction upon the development of the fetal kidney. *J Urol*. 1971;105:784–789.

Beck N. Phosphaturia after release of bilateral ureteral obstruction in rats. *Am J Physiol*. 1979;237(1):F14–F19.

Beharrie A, Franc-Guimond J, Rodriguez MM, et al. A functional immature model of chronic partial ureteral obstruction. *Kidney Int*. 2004;65(4):1155–1161.

Bell E. *Renal diseases*. Lea & Febiger: Philadelphia; 1950.

Benfield MR. Current status of kidney transplant: update 2003. *Pediatr Clin North Am*. 2003;50(6):1301–1334.

Berman DJ, Maizels M. The role of urinary obstruction in the genesis of renal dysplasia. A model in the chick embryo. *J Urol*. 1982;128(5):1091–1096.

Bernstein J. The morphogenesis of renal parenchymal maldevelopment (renal dysplasia). *Pediatr Clin North Am*. 1971;18(2):395–407.

Bernstein KE, Berk BC. The biology of angiotensin II receptors. *Am J Kidney Dis*. 1993;22(5):745–754.

Blandino A, Gaeta M, Minutoli F, et al. MR pyelography in 115 patients with a dilated renal collecting system. *Acta Radiol*. 2001;42(5):532–536.

Bolbrinker J, Markovic S, Wehland M, et al. Expression and response to angiotensin-converting enzyme inhibition of matrix metalloproteinases 2 and 9 in renal glomerular damage in young transgenic rats with renin-dependent hypertension. *J Pharmacol Exp Ther*. 2006;316(1):8–16.

Bonsib SM. Fetal obstructive uropathy without renal dysplasia: a study of the renal findings in 13 cases presenting with megacystis. *J Urol*. 1998;160(6 Pt 1):2166–2170.

Boone TB, Allen TD. Unilateral post-obstructive diuresis in the neonate. *J Urol*. 1992;147(2):430–432.

Border WA, Noble NA. Transforming growth factor beta in tissue fibrosis. *N Engl J Med*. 1994;331(19):1286–1292.

Botto N, Azoulay R, Peuchmaur M, et al. Renal parenchymal fibrosis and atrophy are not correlated with upper tract dilatation: long-term study of partial unilateral ureteral obstruction in neonatal mice. *J Pediatr Urol*. 2011;7(3):310–316.

Bouley R, Pastor-Soler N, Cohen O, et al. Stimulation of AQP2 membrane insertion in renal epithelial cells in vitro and in vivo by the cGMP phosphodiesterase inhibitor sildenafil citrate (Viagra). *Am J Physiol Renal Physiol*. 2005;288(6):F1103–F1112.

Brenner D, Elliston C, Hall E, et al. Estimated risks of radiation-induced fatal cancer from pediatric CT. *AJR Am J Roentgenol*. 2001;176(2):289–296.

Burge HJ, Middleton WD, McClennan BL, et al. Ureteral jets in healthy subjects and in patients with unilateral ureteral calculi: comparison with color Doppler US. *Radiology*. 1991;180(2):437–442.

Burns WC, Kantharidis P, Thomas MC. The role of tubular epithelial-mesenchymal transition in progressive kidney disease. *Cells Tissues Organs*. 2007;185(1–3):222–231.

Butt MJ, Tarantal AF, Jimenez DF, et al. Collecting duct epithelial-mesenchymal transition in fetal urinary tract obstruction. *Kidney Int*. 2007;72(8):936–944.

Cachat F, Lange-Sperandio B, Chang AY, et al. Ureteral obstruction in neonatal mice elicits segment-specific tubular cell responses leading to nephron loss. *Kidney Int*. 2003;63(2):564–575.

Campbell M. Urinary obstruction. Campbell MF, Harrison JH. *Urology*. WB Saunders: Philadelphia; 1970:1772–1793.

Campbell MT, Dagher P, Hile KL, et al. Tumor necrosis factor-alpha induces intrinsic apoptotic signaling during renal obstruction through truncated bid activation. *J Urol*. 2008;180(6):2694–2700.

Cannon CP, Cannon PJ. Physiology. COX-2 inhibitors and cardiovascular risk. *Science*. 2012;336(6087):1386–1387.

Carr MC, Schlussel RN, Peters CA, et al. Expression of cell growth regulated genes in the fetal kidney: relevance to in utero obstruction. *J Urol*. 1995;154(1):242–246.

Cerrolaza JJ, Peters CA, Martin AD, et al. Quantitative ultrasound for measuring obstructive severity in children with hydronephrosis. *J Urol*. 2016;195(4 Pt 1):1093–1099.

Cerwinka WH, Kirsch AJ. Magnetic resonance urography in pediatric urology. *Curr Opin Urol*. 2010;20(4):323–329.

Chaabane W, Praddaude F, Buleon M, et al. Renal functional decline and glomerulotubular injury are arrested but not restored by release of unilateral ureteral obstruction (UUO). *Am J Physiol Renal Physiol*. 2013;304(4):F432–F439.

Chandrasekhar S, Harvey AK. Transforming growth factor-beta is a potent inhibitor of IL-1 induced protease activity and cartilage proteoglycan degradation. *Biochem Biophys Res Commun*. 1988;157(3):1352–1359.

Chang B, Mathew R, Palmer LS, et al. Nitric oxide in obstructive uropathy: role of endothelial nitric oxide synthase. *J Urol*. 2002;168(4 Pt 2):1801–1804.

Chen JH, Pu YS, Liu SP, et al. Renal hemodynamics in patients with obstructive uropathy evaluated by duplex Doppler sonography. *J Urol*. 1993;150(1):18–21.

Cheng PM, Moin P, Dunn MD, et al. What the radiologist needs to know about urolithiasis: part 1–pathogenesis, types, assessment, and variant anatomy. *AJR Am J Roentgenol*. 2012;198(6):W540–W547.

Cheng S, Pollock AS, Mahimkar R, et al. Matrix metalloproteinase 2 and basement membrane integrity: a unifying mechanism for progressive renal injury. *FASEB J*.

2006;20(11):1898–1900.

Chevalier RL. Chronic partial ureteral obstruction in the neonatal guinea pig. II. Pressure gradients affecting glomerular filtration rate. *Pediatr Res*. 1984;18(12):1271–1277.

Chevalier RL. Growth factors and apoptosis in neonatal ureteral obstruction. *J Am Soc Nephrol*. 1996;7(8):1098–1105.

Chevalier RL. Chronic partial ureteral obstruction and the developing kidney. *Pediatr Radiol*. 2008;38(Suppl 1):S35–S40.

Chevalier RL. Congenital urinary tract obstruction: the long view. *Adv Chronic Kidney Dis*. 2015;22(4):312–319.

Chevalier RL. Prognostic factors and biomarkers of congenital obstructive nephropathy. *Pediatr Nephrol*. 2016;31(9):1411–1420.

Chevalier RL, Kaiser DL. Chronic partial ureteral obstruction in the neonatal guinea pig. I. Influence of uninephrectomy on growth and hemodynamics. *Pediatr Res*. 1984;18(12):1266–1271.

Chevalier RL, Kim A, Thornhill BA, et al. Recovery following relief of unilateral ureteral obstruction in the neonatal rat. *Kidney Int*. 1999;55(3):793–807.

Chevalier RL, Thornhill BA, Chang AY. Unilateral ureteral obstruction in neonatal rats leads to renal insufficiency in adulthood. *Kidney Int*. 2000;58(5):1987–1995.

Chevalier RL, Thornhill BA, Forbes MS, et al. Mechanisms of renal injury and progression of renal disease in congenital obstructive nephropathy. *Pediatr Nephrol*. 2010;25(4):687–697.

Chevalier RL, Thornhill BA, Wolstenholme JT. Renal cellular response to ureteral obstruction: role of maturation and angiotensin II. *Am J Physiol*. 1999;277(1 Pt 2):F41–F47.

Chevalier RL, Thornhill BA, Wolstenholme JT, et al. Unilateral ureteral obstruction in early development alters renal growth: dependence on the duration of obstruction. *J Urol*. 1999;161(1):309–313.

Chevalier RL, Sturgill BC, Jones CE, et al. Morphologic correlates of renal growth arrest in neonatal partial ureteral obstruction. *Pediatr Res*. 1987;21(4):338–346.

Chevalier RL, Forbes MS, Galarreta CI, et al. Responses of proximal tubular cells to injury in congenital renal disease: fight or flight. *Pediatr Nephrol*. 2014;29(4):537–541.

Chevalier RL, Forbes MS, Thornhill BA. Ureteral obstruction as a model of renal interstitial fibrosis and obstructive nephropathy. *Kidney Int*. 2009;75(11):1145–1152.

Chevalier RL, Gomez RA, Jones CE. Developmental determinants of recovery after relief of partial ureteral obstruction. *Kidney Int*. 1988;33(4):775–781.

Chevalier RL, Goyal S, Thornhill BA. EGF improves recovery following relief of unilateral ureteral obstruction in the neonatal rat. *J Urol*. 1999;162(4):1532–1536.

Chevalier RL, Goyal S, Wolstenholme JT, et al. Obstructive nephropathy in the neonatal rat is attenuated by epidermal growth factor. *Kidney Int*. 1998;54(1):38–47.

Choi YJ, Baranowska-Daca E, Nguyen V, et al. Mechanism of chronic obstructive uropathy: increased expression of apoptosis-promoting molecules. *Kidney Int*. 2000;58(4):1481–1491.

Chow PM, Hsu JS, Huang CY, et al. Metallic ureteral stents in malignant ureteral obstruction: clinical factors predicting stent failure. *J Endourol*. 2014;28(6):729–734.

Chung SY, Stein RJ, Landsittel D, et al. 15-year experience with the management of extrinsic ureteral obstruction with indwelling ureteral stents. *J Urol*. 2004;172(2):592–595.

Cleper R. Mechanisms of compensatory renal growth. *Pediatr Endocrinol Rev*. 2012;10(1):152–163.

Cohen T, Loutochin O, Amin M, et al. PAX2 is reactivated in urinary tract obstruction and partially protects collecting duct cells from programmed cell death. *Am J Physiol Renal Physiol*. 2007;292(4):F1267–F1273.

Conway JJ, Maizels M. The “well tempered” diuretic renogram: a standard method to examine the asymptomatic neonate with hydronephrosis or hydroureteronephrosis. A report from combined meetings of The Society for Fetal Urology and members of The Pediatric Nuclear Medicine Council–The Society of Nuclear Medicine. *J Nucl Med*. 1992;33(11):2047–2051.

de Bessa J Jr, Denes FT, Chammas MC, et al. Diagnostic accuracy of color Doppler sonographic study of the ureteric jets in evaluation of hydronephrosis. *J Pediatr Urol*. 2008;4(2):113–117.

de Waard D, Dik P, Lilien MR, et al. Hypertension is an indication for surgery in children with ureteropelvic junction obstruction. *J Urol*. 2008;179(5):1976–1978 [discussion 1978–1979].

Decramer S, Wittke S, Mischak H, et al. Predicting the clinical outcome of congenital unilateral ureteropelvic junction obstruction in newborn by urinary proteome analysis. *Nat Med*. 2006;12(4):398–400.

Decramer S, Zürbig P, Wittke S, et al. Identification of urinary biomarkers by proteomics in newborns: use in obstructive nephropathy. *Contrib Nephrol*. 2008;160:127–141.

Diamond JR, Kees-Folts D, Ding G, et al. Macrophages, monocyte chemoattractant peptide-1, and TGF-beta 1 in experimental hydronephrosis. *Am J Physiol*. 1994;266(6 Pt 2):F926–F933.

Diamond JR, Levinson M, Kreisberg R, et al. Increased expression of decorin in experimental hydronephrosis. *Kidney Int*. 1997;51:1133–1139.

Diamond JR, Ricardo SD, Klahr S. Mechanisms of interstitial fibrosis in obstructive nephropathy. *Semin Nephrol*. 1998;18(6):594–602.

Ding HL, Xu MT, Guo Y, et al. Effect of losartan on the mRNA expressions of MT3-MMP and TIMP-2 in diabetic kidneys. *Rev Diabet Stud*. 2005;2(4):216–220.

Djurhuus JC, Sorensen SS, Jorgensen TM, et al. Predictive value of pressure flow studies for the functional outcome of reconstructive surgery for hydronephrosis. *Br J Urol*. 1985;57(1):6–9.

Docherty NG, O'Sullivan OE, Healy DA, et al. Evidence that inhibition of tubular cell apoptosis protects against renal damage and development of fibrosis following ureteric obstruction. *Am J Physiol Renal Physiol*. 2006;290(1):F4–F13.

Docherty NG, O'Sullivan OE, Healy DA, et al. TGF-beta1-induced EMT can occur independently of its proapoptotic effects and is aided by EGF receptor activation. *Am J Physiol Renal Physiol*. 2006;290(5):F1202–F1212.

Docimo SG, Dewolf WC. High failure rate of indwelling ureteral stents in patients with extrinsic obstruction: experience at 2 institutions. *J Urol*. 1989;142(2 Pt 1):277–279.

Doi S, Zou Y, Togao O, et al. Klotho inhibits transforming growth factor-beta1 (TGF-beta1) signaling and suppresses renal fibrosis and cancer metastasis in mice. *J Biol Chem*. 2011;286(10):8655–8665.

Donnahoo KK, Meng X, Ayala A, et al. Early kidney TNF-alpha expression mediates neutrophil infiltration and injury after renal ischemia-reperfusion. *Am J Physiol*. 1999;277(3 Pt 2):R922–R929.

Donoso G, Ham H, Tondeur M, et al. Influence of early furosemide injection on the split renal function. *Nucl Med*

Commun. 2003;24(7):791–795.
Eddy AA. Molecular insights into renal interstitial fibrosis [editorial]. *J Am Soc Nephrol*. 1996;7(12):2495–2508.
Eddy AA. Molecular basis of renal fibrosis. *Pediatr Nephrol*. 2000;15(3–4):290–301.
Eddy AA. Can renal fibrosis be reversed? *Pediatr Nephrol*. 2005;20(10):1369–1375.
Edgren J, Laasonen L, Kock B, et al. Kidney function and compensatory growth of the kidney in living kidney donors. *Scand J Urol Nephrol*. 1976;10(2):134–136.
El Chaar M, Chen J, Seshan SV, et al. Effect of combination therapy with enalapril and the TGF-beta antagonist 1D11 in unilateral ureteral obstruction. *Am J Physiol Renal Physiol*. 2007;292(4):F1291–F1301.
el-Dahr SS, Gee J, Dipp S, et al. Upregulation of renin-angiotensin system and downregulation of kallikrein in obstructive nephropathy. *Am J Physiol*. 1993;264(5 Pt 2):F874–F881.
Elder JS, Stansbrey R, Dahms BB, et al. Renal histological changes secondary to ureteropelvic junction obstruction. *J Urol*. 1995;154(2 Pt 2):719–722.
El-Nahas AR, Abou El-Ghar ME, Refae HF, et al. Magnetic resonance imaging in the evaluation of pelvi-ureteric junction obstruction: an all-in-one approach. *BJU Int*. 2007;99(3):641–645.
Engelmyer E, van Goor H, Edwards DR, et al. Differential mRNA expression of renal cortical tissue inhibitor of metalloproteinase-1, -2, and -3 in experimental hydronephrosis. *J Am Soc Nephrol*. 1995;5(9):1675–1683.
Eskild-Jensen A, Jacobsen L, Christensen H, et al. Renal function outcome in unilateral hydronephrosis in newborn pigs. II. Function and volume of contralateral kidneys. *J Urol*. 2001;165(1):205–209.

Eskild-Jensen A, Paulsen LF, Wogensen L, et al. AT1 receptor blockade prevents interstitial and glomerular apoptosis but not fibrosis in pigs with neonatal induced partial unilateral ureteral obstruction. *Am J Physiol Renal Physiol*. 2007;292(6):F1771–F1781.

Esteban V, Lorenzo O, Ruperez M, et al. Angiotensin II, via AT1 and AT2 receptors and NF-kappaB pathway, regulates the inflammatory response in unilateral ureteral obstruction. *J Am Soc Nephrol*. 2004;15(6):1514–1529.

Fan JM, Ng YY, Hill PA, et al. Transforming growth factor-beta regulates tubular epithelial-myofibroblast transdifferentiation in vitro. *Kidney Int*. 1999;56(4):1455–1467.

Felsen D, Schulsinger D, Gross SS, et al. Renal hemodynamic and ureteral pressure changes in response to ureteral obstruction: the role of nitric oxide. *J Urol*. 2003;169(1):373–376.

Fenghua W, Junjie S, Gaoyan D, et al. Does intervention in utero preserve the obstructed kidneys of fetal lambs? A histological, cytological, and molecular study. *Pediatr Res*. 2009;66(2):145–148.

Fern RJ, Yesko CM, Thornhill BA, et al. Reduced angiotensinogen expression attenuates renal interstitial fibrosis in obstructive nephropathy in mice. *J Clin Invest*. 1999;103(1):39–46.

Fogo AB. The potential for regression of renal scarring. *Curr Opin Nephrol Hypertens*. 2003;12(3):223–225.

Forino M, Torregrossa R, Ceol M, et al. TGFbeta1 induces epithelial-mesenchymal transition, but not myofibroblast transdifferentiation of human kidney tubular epithelial cells in primary culture. *Int J Exp Pathol*. 2006;87(3):197–208.

Franke EI, Vanderbrink BA, Hile KL, et al. Renal IL-18 production is macrophage independent during obstructive injury. *PLoS ONE*. 2012;7(10):e47417.

Frokiaer J, Nielsen AS, Knudsen L, et al. The effect of indomethacin infusion on renal hemodynamics and on the renin-angiotensin system during unilateral ureteral obstruction of the pig. *J Urol*. 1993;150(5 Pt 1):1557–1563.

Frokiaer J, Christensen BM, Marples D, et al. Downregulation of aquaporin-2 parallels changes in renal water excretion in unilateral ureteral obstruction. *Am J Physiol*. 1997;273(2 Pt 2):F213–F223.

Frokiaer J, Marples D, Knepper MA, et al. Bilateral ureteral obstruction downregulates expression of vasopressin-sensitive AQP-2 water channel in rat kidney. *Am J Physiol*. 1996;270(4 Pt 2):F657–F668.

Frokiaer J, Zeidel ML. Urinary tract obstruction. *Brenner and Rector's the kidney*. WB Saunders: Philadelphia; 2007.

Fu P, Liu F, Su S, et al. Signaling mechanism of renal fibrosis in unilateral ureteral obstructive kidney disease in ROCK1 knockout mice. *J Am Soc Nephrol*. 2006;17(11):3105–3114.

Fukasawa H, Yamamoto T, Togawa A, et al. Down-regulation of Smad7 expression by ubiquitin-dependent degradation contributes to renal fibrosis in obstructive nephropathy in mice. *Proc Natl Acad Sci USA*. 2004;101:8687–8692.

Galarreta CI, Thornhill BA, Forbes MS, et al. Transforming growth factor-beta1 receptor inhibition preserves glomerulotubular integrity during ureteral obstruction in adults but worsens injury in neonatal mice. *Am J Physiol Renal Physiol*. 2013;304(5):F481–F490.

Ganesan V, De S, Greene D, et al. Accuracy of ultrasonography for renal stone detection and size determination: is it good enough for management decisions? *BJU Int*. 2017;119(3):464–469.

Gao X, Mae H, Ayabe N, et al. Hepatocyte growth factor gene therapy retards the progression of chronic obstructive nephropathy. *Kidney Int*. 2002;62(4):1238–1248.

Gasparich JP, Mayo ME. Comparative effects of four prostaglandin synthesis inhibitors on the obstructed kidney in the dog. *J Urol*. 1986;135(5):1088–1090.

Glick PL, Harrison MR, Adzick NS, et al. Correction of congenital hydronephrosis in utero IV: in utero decompression prevents renal dysplasia. *J Pediatr Surg*. 1984;19(6):649–657.

Gliga ML, Chirila CN, Podeanu DM, et al. Twinkle, twinkle little stone: an artifact improves the ultrasound performance!. *Med Ultrason*. 2017;19(3):272–275.

Gobe GC, Axelsen RA. Genesis of renal tubular atrophy in experimental hydronephrosis in the rat. Role of apoptosis. *Lab Invest*. 1987;56(3):273–281.

Gobet R, Bleakley J, Cisek L, et al. Fetal partial urethral obstruction causes renal fibrosis and is associated with proteolytic imbalance. *J Urol*. 1999;162:854–860.

Gobet R, Park JM, Nguyen HT, et al. Renal renin-angiotensin system dysregulation caused by partial bladder outlet obstruction in fetal sheep. *Kidney Int*. 1999;56(5):1654–1661.

Gobet R, Cisek LJ, Zotti P, et al. Experimental vesicoureteral reflux in the fetus depends on bladder function and causes renal fibrosis. *J Urol*. 1998;160(3 Pt 2):1058–1062 [discussion 1079].

Goldfarb CR, Srivastava NC, Grotas AB, et al. Radionuclide imaging in urology. *Urol Clin North Am*. 2006;33(3):319–328.

Goldfarb RA, Neerhut GJ, Lederer E. Management of acute hydronephrosis of pregnancy by ureteral stenting: risk of stone formation. *J Urol*. 1989;141(4):921–922.

Gonzalez J, Mouttalib S, Delage C, et al. Dual effect of chemokine CCL7/MCP-3 in the development of renal tubulointerstitial fibrosis. *Biochem Biophys Res Commun*. 2013;438(2):257–263.

Gonzalez R, Reinberg Y, Burke B, et al. Early bladder outlet obstruction in fetal lambs induces renal dysplasia and the prune-belly syndrome. *J Pediatr Surg*. 1990;25(3):342–345.

Grandaliano G, Gesualdo L, Bartoli F, et al. MCP-1 and EGF renal expression and urine excretion in human congenital obstructive nephropathy. *Kidney Int*. 2000;58:182–192.

Grattan-Smith JD, Jones RA, Little S, et al. Bilateral congenital midureteric strictures associated with multicystic dysplastic kidney and hydronephrosis: evaluation with MR urography. *Pediatr Radiol*. 2011;41(1):117–120.

Guan X, Nie L, He T, et al. Klotho suppresses renal tubulo-interstitial fibrosis by controlling basic fibroblast growth factor-2 signalling. *J Pathol*. 2014;234(4):560–572.

Guerin F, Azoulay R, Berrebi D, et al. Partial unilateral ureteral obstruction in newborn mice: magnetic resonance imaging and pathology studies. *J Urol*. 2008;179:1553–1563.

Guler HP, Eckardt KU, Zapf J, et al. Insulin-like growth factor I increase glomerular filtration rate and renal plasma flow in man. *Acta Endocrinol (Copenh)*. 1989;121(1):101–106.

Gulmi FA, Matthews GJ, Marion D, et al. Volume expansion enhances the recovery of renal function and prolongs the diuresis and natriuresis after release of bilateral ureteral obstruction: a possible role for atrial natriuretic peptide. *J Urol*. 1995;153(4):1276–1283.

Guo G, Morrissey J, McCracken R, et al. Contributions of angiotensin II and tumor necrosis factor-alpha to the development of renal fibrosis. *Am J Physiol Renal Physiol*. 2001;280(5):F777–F785.

Guo Q, Tripathi P, Manson SR, et al. Transcriptional dysregulation in the ureteric bud causes multicystic dysplastic kidney by branching morphogenesis defect. *J Urol*. 2015;193(5 Suppl):1784–1790.

Gurel S, Akata D, Gurel K, et al. Correlation between the renal resistive index (RI) and nonenhanced computed tomography in acute renal colic: how reliable is the RI in distinguishing obstruction? *J Ultrasound Med*. 2006;25(9):1113–1120 [quiz 1121–1123].

Haecker FM, Wehrmann M, Hacker HW, et al. Renal dysplasia in children with posterior urethral valves: a primary or secondary malformation? *Pediatr Surg Int*. 2002;18(2):119–122.

Han SW, Lee SE, Kim JH, et al. Does delayed operation for pediatric ureteropelvic junction obstruction cause histopathological changes? *J Urol*. 1998;160(3 Pt 2):984–988.

Harris RC, Breyer MD. Physiological regulation of cyclooxygenase-2 in the kidney. *Am J Physiol Renal Physiol*. 2001;281(1):F1–F11.

Harris RH, Yarger WE. The pathogenesis of post-obstructive diuresis. The role of circulating natriuretic and diuretic factors, including urea. *J Clin Invest*. 1975;56(4):880–887.

Hay ED, Zuk A. Transformations between epithelium and mesenchyme: normal, pathological, and experimentally induced. *Am J Kidney Dis*. 1995;26(4):678–690.

He W, Fischman AJ. Nuclear imaging in the genitourinary tract: recent advances and future directions. *Radiol Clin North Am*. 2008;46(1):25–43 [v].

Healy E, Brady HR. Role of tubule epithelial cells in the pathogenesis of tubulointerstitial fibrosis induced by glomerular disease. *Curr Opin Nephrol Hypertens*. 1998;7(5):525–530.

Heikkila J, Holmberg C, Kyllonen L, et al. Long-term risk of end stage renal disease in patients with posterior urethral valves. *J Urol*. 2011;186(6):2392–2396.

Heneghan JP, Dalrymple NC, Verga M, et al. Soft-tissue “rim” sign in the diagnosis of ureteral calculi with use of unenhanced helical CT. *Radiology*. 1997;202(3):709–711.

Herrera MB, Bussolati B, Bruno S, et al. Mesenchymal stem cells contribute to the renal repair of acute tubular epithelial injury. *Int J Mol Med*. 2004;14(6):1035–1041.

Hetzel GR, May P, Hollenbeck M, et al. Assessment of radiocontrast media induced renal vasoconstriction by color coded duplex sonography. *Ren Fail*. 2001;23(1):77–83.

Higgins DF, Kimura K, Iwano M, et al. Hypoxia-inducible factor signaling in the development of tissue fibrosis. *Cell Cycle*. 2008;7(9):1128–1132.

Higgins DF, Kimura K, Bernhardt WM, et al. Hypoxia promotes fibrogenesis in vivo via HIF-1 stimulation of epithelial-to-mesenchymal transition. *J Clin Invest*. 2007;117(12):3810–3820.

Hochberg D, Johnson CW, Chen J, et al. Interstitial fibrosis of unilateral ureteral obstruction is exacerbated in kidneys of mice lacking the gene for inducible nitric oxide synthase. *Lab Invest*. 2000;80(11):1721–1728.

Holdgate A, Pollock T. Nonsteroidal anti-inflammatory drugs (NSAIDs) versus opioids for acute renal colic. *Cochrane Database Syst Rev*. 2004;(1) [CD004137].

Holmlund D. The pathophysiology of ureteral colic. *Scand J Urol Nephrol Suppl*. 1983;75:25–27.

Hsieh MH, Nguyen HT. Molecular mechanism of apoptosis induced by mechanical forces. *Int Rev Cytol*. 2005;245:45–90.

Huang A, Palmer LS, Hom D, et al. The role of nitric oxide in obstructive nephropathy. *J Urol*. 2000;163(4):1276–1281.

Huang WY, Peters CA, Zurakowski D, et al. Renal biopsy in congenital ureteropelvic junction obstruction: evidence for parenchymal maldevelopment. *Kidney Int*. 2006;69(1):137–143.

Hutcheon RA, Kaplan BS, Drummond KN. Distal renal tubular acidosis in children with chronic hydronephrosis. *J Pediatr*. 1976;89:372.

Ichikawa I, Brenner BM. Local intrarenal vasoconstrictor-vasodilator interactions in mild partial ureteral obstruction. *Am J Physiol*. 1979;236(2):F131–F140.

Inazaki K, Kanamaru Y, Kojima Y, et al. Smad3 deficiency attenuates renal fibrosis, inflammation,and apoptosis after unilateral ureteral obstruction. *Kidney Int*. 2004;66:597–604.

Isaka Y, Tsujie M, Ando Y, et al. Transforming growth factor-beta 1 antisense oligodeoxynucleotides block interstitial fibrosis in unilateral ureteral obstruction. *Kidney Int*. 2000;58(5):1885–1892.

Ishidoya S, Morrissey J, McCracken R, et al. Angiotensin II receptor antagonist ameliorates renal tubulointerstitial fibrosis caused by unilateral ureteral obstruction. *Kidney Int*. 1995;47(5):1285–1294.

Ito K, Chen J, El Chaar M, et al. Renal damage progresses despite improvement of renal function after relief of unilateral ureteral obstruction in adult rats. *Am J Physiol Renal Physiol*. 2004;287(6):F1283–F1293.

Ito K, Chen J, Khodadadian JJ, et al. Liposome-mediated transfer of nitric oxide synthase gene improves renal function in ureteral obstruction in rats. *Kidney Int*. 2004;66(4):1365–1375.

Ivanova L, Butt MJ, Matsell DG. Mesenchymal transition in kidney collecting duct epithelial cells. *Am J Physiol Renal Physiol*. 2008;294(5):F1238–F1248.

Iwano M, Plieth D, Danoff TM, et al. Evidence that fibroblasts derive from epithelium during tissue fibrosis. *J Clin Invest*. 2002;110(3):341–350.

Jaenike JR. The renal functional defect of postobstructive nephyropathy. The effects of bilateral ureteral obstruction in the rat. *J Clin Invest*. 1972;51(12):2999–3006.

Jandaghi AB, Falahatkar S, Alizadeh A, et al. Assessment of ureterovesical jet dynamics in obstructed ureter by urinary stone with color Doppler and duplex Doppler examinations. *Urolithiasis*. 2013;41(2):159–163.

Jensen AM, Li C, Praetorius HA, et al. Angiotensin II mediates downregulation of aquaporin water channels and key renal sodium transporters in response to urinary tract obstruction. *Am J Physiol Renal Physiol*. 2006;291(5):F1021–F1032.

Jiang D, Tang B, Xu M, et al. Functional and morphological outcomes of pyeloplasty at different ages in prenatally diagnosed society of fetal urology grades 3-4 ureteropelvic junction obstruction: is it safe to wait? *Urology*. 2017;101:45–49.

Jianguo W, Zhenzhen L, Xianghua L, et al. Serum and urinary procollagen III aminoterminal propeptide as a biomarker of obstructive nephropathy in children. *Clin Chim Acta*. 2014;434:29–33.

Jones RA, Perez-Brayfield MR, Kirsch AJ, et al. Renal transit time with MR urography in children. *Radiology*. 2004;233(1):41–50.

Kamenicky P, Mazziotti G, Lombes M, et al. Growth hormone, insulin-like growth factor-1, and the kidney: pathophysiological and clinical implications. *Endocr Rev*. 2013 [er20131071].

Kaneto H, Morrissey J, Klahr S. Increased expression of TGF-beta 1 mRNA in the obstructed kidney of rats with unilateral ureteral ligation. *Kidney Int*. 1993;44(2):313–321.

Kaneto H, Morrissey J, McCracken R, et al. The expression of mRNA for tumor necrosis factor-alpha increases in the obstructed kidney of rats soon after unilateral ureteral ligation. *Nephrology*. 1996;2:161–166.

Karam M, Feustel PJ, Goldfarb CR, et al. Diuretic renogram clearance half-times in the diagnosis of obstructive uropathy:

effect of age and previous surgery. *Nucl Med Commun*. 2003;24(7):797–807.

Katz SI, Saluja S, Brink JA, et al. Radiation dose associated with unenhanced CT for suspected renal colic: impact of repetitive studies. *AJR Am J Roentgenol*. 2006;186(4):1120–1124.

Katz DS, Scheer M, Lumerman JH, et al. Alternative or additional diagnoses on unenhanced helical computed tomography for suspected renal colic: experience with 1000 consecutive examinations. *Urology*. 2000;56(1):53–57.

Kellner D, Chen J, Richardson I, et al. Angiotensin receptor blockade decreases fibrosis and fibroblast expression in a rat model of unilateral ureteral obstruction. *J Urol*. 2006;176(2):806–812.

Kennedy WA 2nd, Buttyan R, Garcia-Montes E, et al. Epidermal growth factor suppresses renal tubular apoptosis following ureteral obstruction. *Urology*. 1997;49(6):973–980.

Kennish SJ, Wah TM, Irving HC. Unenhanced CT for the evaluation of acute ureteric colic: the essential pictorial guide. *Postgrad Med J*. 2010;86(1017):428–436.

Kern AJM, Schlomer BJ, Timberlake MD, et al. Simple visual review of pre- to post-operative renal ultrasound images predicts pyeloplasty success equally as well as geometric measurements: a blinded comparison with a gold standard. *J Pediatr Urol*. 2017;13(4):401 e401–401 e407.

Kerr WS Jr. Effect of complete ureteral obstruction for one week on kidney function. *J Appl Physiol*. 1954;6(12):762–772.

Khan SB, Cook HT, Bhangal G, et al. Antibody blockade of TNF-alpha reduces inflammation and scarring in experimental crescentic glomerulonephritis. *Kidney Int*. 2005;67(5):1812–1820.

Kiley SC, Thornhill BA, Tang SS, et al. Growth factor-mediated phosphorylation of proapoptotic BAD reduces tubule cell death in vitro and in vivo. *Kidney Int*. 2003;63:33–42.

Kim DS, Noh JY, Jeong HJ, et al. Elastin content of the renal pelvis and ureter determines post-pyeloplasty recovery. *J Urol*. 2005;173(3):962–966.

Kim H, Oda T, Lopez-Guisa J, et al. TIMP-1 deficiency does not attenuate interstitial fibrosis in obstructive nephropathy. *J Am Soc Nephrol*. 2001;12(4):736–748.

Kim JH, Park DJ, Yun JC, et al. Human adipose tissue-derived mesenchymal stem cells protect kidneys from cisplatin nephrotoxicity in rats. *Am J Physiol Renal Physiol*. 2012;302(9):F1141–F1150.

Kim JH, Yang JI, Jung MH, et al. Heme oxygenase-1 protects rat kidney from ureteral obstruction via an antiapoptotic pathway. *J Am Soc Nephrol*. 2006;17:1373–1381.

Kim SW, Lee J, Park JW, et al. Increased expression of atrial natriuretic peptide in the kidney of rats with bilateral ureteral obstruction. *Kidney Int*. 2001;59(4):1274–1282.

Kinter M, Wolstenholme JT, Thornhill BA, et al. Unilateral ureteral obstruction impairs renal antioxidant enzyme activation during sodium depletion. *Kidney Int*. 1999;55:1327–1334.

Kiratli PO, Orhan D, Gedik GK, et al. Relation between radionuclide imaging and pathologic findings of ureteropelvic junction obstruction in neonatal hydronephrosis. *Scand J Urol Nephrol*. 2008;42(3):249–256.

Kitagawa K, Wada T, Furuichi K, et al. Blockade of CCR2 ameliorates progressive fibrosis in kidney. *Am J Pathol*. 2004;165:237–246.

Klahr S, Morrissey J. Angiotensin II and gene expression in the kidney. *Am J Kidney Dis*. 1998;31(1):171–176.

Klahr S, Morrissey JJ. Comparative study of ACE inhibitors and angiotensin II receptor antagonists in interstitial scarring.

Kidney Int Suppl. 1997;63:S111–S114.

Klahr S, Morrissey J. Obstructive nephropathy and renal fibrosis. *Am J Physiol Renal Physiol*. 2002;283(5):F861–F875.

Klein J, Gonzalez J, Miravete M, et al. Congenital ureteropelvic junction obstruction: human disease and animal models. *Int J Exp Pathol*. 2011;92(3):168–192.

Klein J, Kavvadas P, Prakoura N, et al. Renal fibrosis: insight from proteomics in animal models and human disease. *Proteomics*. 2011;11(4):805–815.

Koff SA. Problematic ureteropelvic junction obstruction. *J Urol*. 1987;138:390.

Koff SA. Postnatal management of antenatal hydronephrosis using an observational approach. *Urology*. 2000;55(5):609–611.

Koff SA, Campbell K. Nonoperative management of unilateral neonatal hydronephrosis. *J Urol*. 1992;148:525–531.

Ladefoged O, Djurhuus JC. Morphology of the upper urinary tract in experimental hydronephrosis in pigs. *Acta Chir Scand Suppl*. 1976;472:29–35.

Lan HY, Mu W, Tomita N, et al. Inhibition of renal fibrosis by gene transfer of inducible Smad7 using ultrasound-microbubble system in rat UUO model. *J Am Soc Nephrol*. 2003;14(6):1535–1548.

Lange-Sperandio B, Forbes MS, Thornhill B, et al. A2A adenosine receptor agonist and PDE4 inhibition delays inflammation but fails to reduce injury in experimental obstructive nephropathy. *Nephron Exp Nephrol*. 2005;100:e113–e123.

Lange-Sperandio B, Schimpgen K, Rodenbeck B, et al. Distinct roles of Mac-1 and its counter-receptors in neonatal obstructive nephropathy. *Kidney Int*. 2006;69:81–88.

Lange-Sperandio B, Trautmann A, Eickelberg O, et al.

Leukocytes induce epithelial to mesenchymal transition after unilateral ureteral obstruction in neonatal mice. *Am J Pathol*. 2007;171(3):861–871.

Lanzone JA, Gulmi FA, Chou SY, et al. Renal hemodynamics in acute unilateral ureteral obstruction: contribution of endothelium-derived relaxing factor. *J Urol*. 1995;153(6):2055–2059.

Lee RS, Monigatti F, Lutchman M, et al. Temporal variations of the postnatal rat urinary proteome as a reflection of systemic maturation. *Proteomics*. 2008;8(5):1097–1112.

Levey AS, Stevens LA, Schmid CH, et al. A new equation to estimate glomerular filtration rate. *Ann Intern Med*. 2009;150(9):604–612.

Li C, Wang W, Kwon TH, et al. Downregulation of AQP1, -2, and -3 after ureteral obstruction is associated with a long-term urine-concentrating defect. *Am J Physiol Renal Physiol*. 2001;281(1):F163–F171.

Li C, Wang W, Kwon TH, et al. Altered expression of major renal Na transporters in rats with bilateral ureteral obstruction and release of obstruction. *Am J Physiol Renal Physiol*. 2003;285(5):F889–F901.

Li X, Liu X, Li J, et al. Semaphorin-3A and Netrin-1 predict the development of kidney injury in children with congenital hydronephrosis. *Scand J Clin Lab Invest*. 2018;78(1–2):55–61.

Li ZZ, Xing L, Zhao ZZ, et al. Decrease of renal aquaporins 1-4 is associated with renal function impairment in pediatric congenital hydronephrosis. *World J Pediatr*. 2012;8(4):335–341.

Liang D, Liu HF, Yao CW, et al. Effects of interleukin 18 on injury and activation of human proximal tubular epithelial cells. *Nephrology (Carlton)*. 2007;12(1):53–61.

Liapis H. Biology of congenital obstructive nephropathy.

Nephron Exp Nephrol. 2003;93(3):e87–e91.

Liapis H, Nag M, Steinhardt G. Effects of experimental ureteral obstruction on platelet-derived growth factor-A and type I procollagen expression in fetal metanephric kidneys. *Pediatr Nephrol*. 1994;8(5):548–554.

Liu J, Zhong Y, Liu G, et al. Role of Stat3 signaling in control of EMT of tubular epithelial cells during renal fibrosis. *Cell Physiol Biochem*. 2017;42(6):2552–2558.

Liu Y. Hepatocyte growth factor promotes renal epithelial cell survival by dual mechanisms. *Am J Physiol*. 1999;277:F624–F633.

Liu Y. Hepatocyte growth factor in kidney fibrosis: therapeutic potential and mechanisms of action. *Am J Physiol Renal Physiol*. 2004;287(1):F7–F16.

Liu Y. New insights into epithelial-mesenchymal transition in kidney fibrosis. *J Am Soc Nephrol*. 2010;21(2):212–222.

Liu Y, Stewart KN, Bishop E, et al. Unique expression of suppressor of cytokine signaling 3 is essential for classical macrophage activation in rodents in vitro and in vivo. *J Immunol*. 2008;180:6270–6278.

Lucarelli G, Ditonno P, Bettocchi C, et al. Delayed relief of ureteral obstruction is implicated in the long-term development of renal damage and arterial hypertension in patients with unilateral ureteral injury. *J Urol*. 2013;189(3):960–965.

Lupton EW, George NJ. The Whitaker test: 35 years on. *BJU Int*. 2010;105(1):94–100.

Lv S, Liu G, Sun A, et al. Mesenchymal stem cells ameliorate diabetic glomerular fibrosis in vivo and in vitro by inhibiting TGF-beta signalling via secretion of bone morphogenetic protein 7. *Diab Vasc Dis Res*. 2014;11(4):251–261.

Ma J, Nishimura H, Fogo A, et al. Accelerated fibrosis and collagen deposition develop in the renal interstitium of angiotensin type 2 receptor null mutant mice during ureteral obstruction. *Kidney Int*. 1998;53:937–944.

Maack T. Role of atrial natriuretic factor in volume control. *Kidney Int*. 1996;49(6):1732–1737.

Madsen MG, Norregaard R, Frokiaer J, et al. Urinary biomarkers in prenatally diagnosed unilateral hydronephrosis. *J Pediatr Urol*. 2011;7(2):105–112.

Madsen MG, Norregaard R, Palmfeldt J, et al. Epidermal growth factor and monocyte chemotactic peptide-1: potential biomarkers of urinary tract obstruction in children with hydronephrosis. *J Pediatr Urol*. 2013;9(6 Pt A):838–845.

Maenhout A, Ham H, Ismaili K, et al. Supranormal renal function in unilateral hydronephrosis: does it represent true hyperfunction? *Pediatr Nephrol*. 2005;20(12):1762–1765.

Mandell J, Paltiel HJ, Peters CA, et al. Prenatal findings associated with a unilateral nonfunctioning or absent kidney. *J Urol*. 1994;152:176–178.

Manson SR, Song JB, Hruska KA, et al. HDAC dependent transcriptional repression of Bmp-7 potentiates TGF-beta mediated renal fibrosis in obstructive uropathy. *J Urol*. 2014;191(1):242–252.

Manson SR, Song JB, Guo Q, et al. Cell type specific changes in BMP-7 expression contribute to the progression of kidney disease in patients with obstructive uropathy. *J Urol*. 2015;193(5 Suppl):1860–1869.

Manson SR, Austin PF, Guo Q, et al. BMP-7 Signaling and its critical roles in kidney development, the responses to renal injury, and chronic kidney disease. *Vitam Horm*. 2015;99:91–144.

Manson SR, Niederhoff RA, Hruska KA, et al. Endogenous BMP-7 is a critical molecular determinant of the reversibility of obstruction-induced renal injuries. *Am J Physiol Renal Physiol*. 2011;301(6):F1293–F1302.

Manucha W, Carrizo L, Ruete C, et al. Apoptosis induction is associated with decreased NHE1 expression in neonatal unilateral ureteric obstruction. *BJU Int*. 2007;100(1):191–198.

Manucha W, Oliveros L, Carrizo L, et al. Losartan modulation on NOS isoforms and COX-2 expression in early renal fibrogenesis in unilateral obstruction. *Kidney Int*. 2004;65:2091–2107.

Manucha W, Valles PG. Cytoprotective role of nitric oxide associated with Hsp70 expression in neonatal obstructive nephropathy. *Nitric Oxide*. 2008;18(3):204–215.

Manucha W, Valles PG. Apoptosis modulated by oxidative stress and inflammation during obstructive nephropathy. *Inflamm Allergy Drug Targets*. 2012;11(4):303–312.

Massague J, Chen YG. Controlling TGF-beta signaling. *Genes Dev*. 2000;14(6):627–644.

Matsell DG. Renal dysplasia: new approaches to an old problem. *Am J Kidney Dis*. 1998;32(4):535–543.

Matsell DG, Bennett T, Bocking AD. Characterization of fetal ovine renal dysplasia after mid-gestation ureteral obstruction. *Clin Invest Med*. 1996;19(6):444–452.

Matsell DG, Mok A, Tarantal AF. Altered primate glomerular development due to in utero urinary tract obstruction. *Kidney Int*. 2002;61(4):1263–1269.

Matsell DG, Tarantal AF. Experimental models of fetal obstructive nephropathy. *Pediatr Nephrol*. 2002;17(7):470–476.

Matsui F, Babitz SA, Rhee A, et al. Mesenchymal stem cells protect against obstruction-induced renal fibrosis by decreasing STAT3 activation and STAT3-dependent MMP-9 production. *Am J Physiol Renal Physiol*. 2017;312(1):F25–F32.

Mazzei LJ, Garcia IM, Altamirano L, et al. Rosuvastatin preserves renal structure following unilateral ureteric obstruction in the neonatal rat. *Am J Nephrol*. 2012;35:103–113.

McAleer SJ, Loughlin KR. Nephrolithiasis and pregnancy. *Curr Opin Urol*. 2004;14(2):123–127.

Medjebeur AA, Bussieres L, Gasser B, et al. Experimental bilateral urinary obstruction in fetal sheep: transforming growth factor-β1 expression. *Am J Physiol*. 1997;273(3 Pt 2):F372–F379.

Meister B, Lippoldt A, Bunnemann B, et al. Cellular expression of angiotensin type-1 receptor mRNA in the kidney. *Kidney Int*. 1993;44(2):331–336.

Meldrum KK, Metcalfe P, Leslie JA, et al. TNF-alpha neutralization decreases nuclear factor-kappaB activation and apoptosis during renal obstruction. *J Surg Res*. 2006;131:182–188.

Meldrum KK, Misseri R, Metcalfe P, et al. TNF-alpha neutralization ameliorates obstruction-induced renal fibrosis and dysfunction. *Am J Physiol Regul Integr Comp Physiol*. 2007;292(4):R1456–R1464.

Meldrum KK, Zhang H, Hile KL, et al. Profibrotic effect of interleukin-18 in HK-2 cells is dependent on stimulation of the Toll-like receptor 4 (TLR4) promoter and increased TLR4 expression. *J Biol Chem*. 2012;287(48):40391–40399.

Meng XM, Chung AC, Lan HY. Role of the TGF-beta/BMP-7/Smad pathways in renal diseases. *Clin Sci*. 2013;124(4):243–254.

Menon P, Rao KL, Bhattacharya A, et al. Outcome analysis of pediatric pyeloplasty in units with less than 20% differential renal function. *J Pediatr Urol*. 2016;12(3):171.e1–171.e7.

Miglioretti DL, Johnson E, Williams A, et al. The use of computed tomography in pediatrics and the associated radiation exposure and estimated cancer risk. *JAMA Pediatr*.

2013;167(8):700–707.

Misseri R, Meldrum DR, Dinarello CA, et al. TNF-alpha mediates obstruction-induced renal tubular cell apoptosis and pro-apoptotic signaling. *Am J Physiol Renal Physiol*. 2005;288:F406–F411.

Misseri R, Rink RC, Meldrum DR, et al. Inflammatory mediators and growth factors in obstructive renal injury. *J Surg Res*. 2004;119(2):149–159.

Miyajima A, Asano T, Yoshimura I, et al. Tranilast ameliorates renal tubular damage in unilateral ureteral obstruction. *J Urol*. 2001;165(5):1714–1718.

Miyajima A, Chen J, Lawrence C, et al. Antibody to transforming growth factor-beta ameliorates tubular apoptosis in unilateral ureteral obstruction. *Kidney Int*. 2000;58(6):2301–2313.

Miyajima A, Chen J, Poppas DP, et al. Role of nitric oxide in renal tubular apoptosis of unilateral ureteral obstruction. *Kidney Int*. 2001;59(4):1290–1303.

Mizuguchi Y, Chen J, Seshan SV, et al. A novel cell-permeable antioxidant peptide decreases renal tubular apoptosis and damage in unilateral ureteral obstruction. *Am J Physiol Renal Physiol*. 2008;295(5):F1545–F1553.

Mizuiri S, Amagasaki Y, Hosaka H, et al. Hypertension in unilateral atrophic kidney secondary to ureteropelvic junction obstruction. *Nephron*. 1992;61(2):217–219.

Mokhmalji H, Braun PM, Martinez Portillo FJ, et al. Percutaneous nephrostomy versus ureteral stents for diversion of hydronephrosis caused by stones: a prospective, randomized clinical trial. *J Urol*. 2001;165(4):1088–1092.

Moody TE, Vaughn ED Jr, Gillenwater JY. Relationship between renal blood flow and ureteral pressure during 18 hours of total unilateral uretheral occlusion. Implications for changing sites of increased renal resistance. *Invest Urol*.

1975;13(3):246–251.

Moon DH, Park YS, Jun NL, et al. Value of supranormal function and renogram patterns on 99mTc-mercaptoacetyltriglycine scintigraphy in relation to the extent of hydronephrosis for predicting ureteropelvic junction obstruction in the newborn. *J Nucl Med*. 2003;44(5):725–731.

Moon JA, Kim HT, Cho IS, et al. IN-1130, a novel transforming growth factor-beta type I receptor kinase (ALK5) inhibitor, suppresses renal fibrosis in obstructive nephropathy. *Kidney Int*. 2006;70:1234–1243.

Morrissey JJ, Klahr S. Differential effects of ACE and AT1 receptor inhibition on chemoattractant and adhesion molecule synthesis. *Am J Physiol*. 1998;274(3 Pt 2):F580–F586.

Morrissey JJ, Klahr S. Effect of AT2 receptor blockade on the pathogenesis of renal fibrosis. *Am J Physiol*. 1999;276(1 Pt 2):F39–F45.

Mostbeck GH, Zontsich T, Turetschek K. Ultrasound of the kidney: obstruction and medical diseases. *Eur Radiol*. 2001;11(10):1878–1889.

Mulroney SE, Haramati A, Werner H, et al. Altered expression of insulin-like growth factor-I (IGF-I) and IGF receptor genes after unilateral nephrectomy in immature rats. *Endocrinology*. 1992;130(1):249–256.

Mure PY, Gelas T, Dijoud F, et al. Complete unilateral ureteral obstruction in the fetal lamb. Part II: Long-term outcomes of renal tissue development. *J Urol*. 2006;175(4):1548–1558.

Murer L, Benetti E, Centi S, et al. Clinical and molecular markers of chronic interstitial nephropathy in congenital unilateral ureteropelvic junction obstruction. *J Urol*. 2006;176(6 Pt 1):2668–2673 [discussion 2673].

Nagle RB, Bulger RE, Cutler RE, et al. Unilateral obstructive nephropathy in the rabbit. I. Early morphologic, physiologic, and histochemical changes. *Lab Invest*. 1973;28(4):456–467.

Nam UC, Lee CH, Chang SG. Clinical study of insulin-like growth factor-I and compensatory renal growth in patients with donor nephrectomy. *Transplant Proc*. 1999;31(5):2114–2117.

Nguyen HT, Bride SH, Badawy A-B, et al. Heparin-binding EGF-like growth factor is up-regulated in the obstructed kidney in a cell- and region-specific manner and acts to inhibit apoptosis. *Am J Pathol*. 2000;156(3):889–898.

Nguyen HT, Hsieh MH, Gaborro A, et al. JNK/SAPK and p38 SAPK-2 mediate mechanical stretch-induced apoptosis via caspase-3 and -9 in NRK-52E renal epithelial cells. *Nephron Exp Nephrol*. 2006;102:e49–e61.

Nguyen HT, Peters CA. The long-term complications of posterior urethral valves. *BJU Int*. 1999;83(Suppl 3):23–28.

Nguyen HT, Thomson AA, Kogan BA, et al. Expression of the Wnt gene family during late nephrogenesis and complete ureteral obstruction. *Lab Invest*. 1999;79(6):647–658.

Nilsson L, Madsen K, Krag S, et al. Disruption of cyclooxygenase type 2 exacerbates apoptosis and renal damage during obstructive nephropathy. *Am J Physiol Renal Physiol*. 2015;309(12):F1035–F1048.

Norman JT, Stidwill R, Singer M, et al. Angiotensin II blockade augments renal cortical microvascular pO2 indicating a novel, potentially renoprotective action. *Nephron Physiol*. 2003;94(2):p39–p46.

Norregaard R, Jensen BL, Li C, et al. COX-2 inhibition prevents downregulation of key renal water and sodium transport proteins in response to bilateral ureteral obstruction. *Am J Physiol Renal Physiol*. 2005;289(2):F322–F333.

Norregaard R, Jensen BL, Topcu SO, et al. COX-2 activity transiently contributes to increased water and NaCl excretion in the polyuric phase after release of ureteral obstruction. *Am J Physiol Renal Physiol*. 2007;292(5):F1322–F1333.

Nyman MA, Schwenk NM, Silverstein MD. Management of urinary retention: rapid versus gradual decompression and risk of complications. *Mayo Clin Proc*. 1997;72(10):951–956.

Palmer LS, Maizels M, Cartwright PC, et al. Surgery versus observation for managing obstructive grade 3 to 4 unilateral hydronephrosis: a report from the Society for Fetal Urology. *J Urol*. 1998;159(1):222–228.

Pap D, Sziksz E, Kiss Z, et al. Microarray analysis reveals increased expression of matrix metalloproteases and cytokines of interleukin-20 subfamily in the kidneys of neonate rats underwent unilateral ureteral obstruction: a potential role of IL-24 in the regulation of inflammation and tissue remodeling. *Kidney Blood Press Res*. 2017;42(1):16–32.

Parikh CR, Abraham E, Ancukiewicz M, et al. Urine IL-18 is an early diagnostic marker for acute kidney injury and predicts mortality in the intensive care unit. *J Am Soc Nephrol*. 2005;16(10):3046–3052.

Park JM, Adam RM, Peters CA, et al. AP-1 mediates stretch-induced expression of HB-EGF in bladder smooth muscle cells. *Am J Physiol*. 1999;277(2 Pt 1):C294–C301.

Parkhouse HF, Barratt TM, Dillon MJ, et al. Long-term outcome of boys with posterior urethral valves. *Br J Urol*. 1988;62:59–62.

Pasala S, Carmody JB. How to use… serum creatinine, cystatin C and GFR. *Arch Dis Child Educ Pract Ed*. 2017;102(1):37–43.

Pascual L, Oliva J, Vega PJ, et al. Renal histology in ureteropelvic junction obstruction: are histological changes a consequence of hyperfiltration? *J Urol*. 1998;160(3 Pt 2):976–979 [discussion 994].

Patel SR, Dressler GR. BMP7 signaling in renal development and disease. *Trends Mol Med*. 2005;11(11):512–518.

Payabvash S, Kajbafzadeh AM, Saeedi P, et al. Application of magnetic resonance urography in diagnosis of congenital urogenital anomalies in children. *Pediatr Surg Int*. 2008;24(9):979–986.

Pearce MS, Salotti JA, Little MP, et al. Radiation exposure from CT scans in childhood and subsequent risk of leukaemia and brain tumours: a retrospective cohort study. *Lancet*. 2012;380(9840):499–505.

Perez-Brayfield MR, Kirsch AJ, Jones RA, et al. A prospective study comparing ultrasound, nuclear scintigraphy and dynamic contrast enhanced magnetic resonance imaging in the evaluation of hydronephrosis. *J Urol*. 2003;170(4 Pt 1):1330–1334.

Perlmutter A, Miller L, Trimble LA, et al. Toradol, an NSAID used for renal colic, decreases renal perfusion and ureteral pressure in a canine model of unilateral ureteral obstruction. *J Urol*. 1993;149(4):926–930.

Peters CA. Urinary tract obstruction in children. *J Urol*. 1995;154(5):1874–1883 [discussion 1883–1884].

Peters CA. Obstruction of the fetal urinary tract. *J Am Soc Nephrol*. 1997;8(4):653–663.

Peters CA, Carr MC, Lais A, et al. The response of the fetal kidney to obstruction. *J Urol*. 1992;148(2 Pt 2):503–509.

Peters CA, Gaertner RC, Carr MC, et al. Fetal compensatory renal growth due to unilateral ureteral obstruction. *J Urol*. 1993;150(2 Pt 2):597–600.

Piepsz A. Antenatal detection of pelviureteric junction stenosis: main controversies. *Semin Nucl Med*. 2011;41(1):11–19.

Pittock ST, Norby SM, Grande JP, et al. MCP-1 is up-regulated in unstressed and stressed HO-1 knockout mice: pathophysiologic correlates. *Kidney Int*. 2005;68:611–622.

Platt JF, Rubin JM, Ellis JH, et al. Duplex Doppler US of the kidney: differentiation of obstructive from nonobstructive dilatation. *Radiology*. 1989;171(2):515–517.

Poletti PA, Platon A, Rutschmann OT, et al. Low-dose versus standard-dose CT protocol in patients with clinically suspected renal colic. *AJR Am J Roentgenol*. 2007;188(4):927–933.

Postlethwaite AE, Keski-Oja J, Moses HL, et al. Stimulation of the chemotactic migration of human fibroblasts by transforming growth factor beta. *J Exp Med*. 1987;165(1):251–256.

Poucell-Hatton S, Huang M, Bannykh S, et al. Fetal obstructive uropathy: patterns of renal pathology. *Pediatr Dev Pathol*. 2000;3(3):223–231.

Purkerson ML, Blaine EH, Stokes TJ, et al. Role of atrial peptide in the natriuresis and diuresis that follows relief of obstruction in rat. *Am J Physiol*. 1989;256(4 Pt 2):F583–F589.

Radovic N, Cuzic S, Knotek M. Effect of unilateral ureteral obstruction and anti-angiotensin II treatment on renal tubule and interstitial cell apoptosis in rats. *Croat Med J*. 2008;49(5):600–607.

Ray AA, Ghiculete D, Pace KT, et al. Limitations to ultrasound in the detection and measurement of urinary tract calculi. *Urology*. 2010;76(2):295–300.

Regalado SP. Emergency percutaneous nephrostomy. *Semin Intervent Radiol*. 2006;23(3):287–294.

Reyes AA, Klahr S. Role of platelet-activating factor in renal function in normal rats and rats with bilateral ureteral obstruction. *Proc Soc Exp Biol Med*. 1991;198(1):572–578.

Reyes AA, Klahr S. Renal function after release of ureteral obstruction: role of endothelin and the renal artery endothelium. *Kidney Int*. 1992;42(3):632–638.

Ricardo SD, Ding G, Eufemio M, et al. Antioxidant expression in experimental hydronephrosis: role of mechanical stretch and growth factors. *Am J Physiol*. 1997;272:F789–F798.

Riehle RA Jr, Vaughan ED Jr. Renin participation in hypertension associated with unilateral hydronephrosis. *J Urol*. 1981;126(2):243–246.

Rinaldi Tosi ME, Bocanegra V, Manucha W, et al. The Nrf2-Keap1 cellular defense pathway and heat shock protein 70 (Hsp70) response. Role in protection against oxidative stress in early neonatal unilateral ureteral obstruction (UUO). *Cell Stress Chaperones*. 2010;16(1):57–68.

Roberts AB, McCune BK, Sporn MB. TGF-beta: regulation of extracellular matrix. *Kidney Int*. 1992;41(3):557–559.

Roberts AB, Tian F, Byfield SD, et al. Smad3 is key to TGF-beta-mediated epithelial-to-mesenchymal transition, fibrosis, tumor suppression and metastasis. *Cytokine Growth Factor Rev*. 2006;17(1–2):19–27.

Ronco P, Lelongt B, Piedagnel R, et al. Matrix metalloproteinases in kidney disease progression and repair: a case of flipping the coin. *Semin Nephrol*. 2007;27(3):352–362.

Ross SS, Kardos S, Krill A, et al. Observation of infants with SFU grades 3-4 hydronephrosis: worsening drainage with serial diuresis renography indicates surgical intervention and helps prevent loss of renal function. *J Pediatr Urol*. 2011;7(3):266–271.

Roth JD, Lesier JD, Casey JT, et al. Incidence of pathologic postobstructive diuresis after resolution of ureteropelvic junction obstruction with a normal contralateral kidney. *J Pediatr Urol*. 2018;14(6):557.e1–557.e6.

Rouschop KM, Sewnath ME, Claessen N, et al. CD44 deficiency increases tubular damage but reduces renal fibrosis in obstructive nephropathy. *J Am Soc Nephrol*. 2004;15:674–686.

Sade R, Ogul H, Eren S, et al. Comparison of ultrasonography and low-dose computed tomography for the diagnosis of pediatric urolithiasis in the emergency department.*Eurasian J Med*. 2017;49(2):128–131.

Sammut S, Behr L, Hekmati M, et al. Compensatory renal growth after unilateral or subtotal nephrectomy in the ovine fetus. *Pediatr Res*. 2013;74(6):624–632.

Sato M, Muragaki Y, Saika S, et al. Targeted disruption of TGF-beta1/Smad3 signaling protects against renal tubulointerstitial fibrosis induced by unilateral ureteral obstruction. *J Clin Invest*. 2003;112(10):1486–1494.

Schieda N, Blaichman JI, Costa AF, et al. Gadolinium-based contrast agents in kidney disease: comprehensive review and clinical practice guideline issued by the canadian association of radiologists. *Can Assoc Radiol J*. 2018;69(2):136–150.

Schlossberg SM, Vaughan ED Jr. The mechanism of unilateral post-obstructive diuresis. *J Urol*. 1984;131(3):534–536.

Schreiner GF, Harris KP, Purkerson ML, et al. Immunological aspects of acute ureteral obstruction: immune cell infiltrate in the kidney. *Kidney Int*. 1988;34(4):487–493.

Schuster N, Krieglstein K. Mechanisms of TGF-beta-mediated apoptosis. *Cell Tissue Res*. 2002;307(1):1–14.

Sechi LA, Grady EF, Griffin CA, et al. Distribution of angiotensin II receptor subtypes in rat and human kidney. *Am J Physiol*. 1992;262(2 Pt 2):F236–F240.

Seikaly MG, Ho PL, Emmett L, et al. Chronic renal insufficiency in children: the 2001 Annual Report of the NAPRTCS. *Pediatr Nephrol*. 2003;18(8):796–804.

Semedo P, Correa-Costa M, Antonio Cenedeze M, et al. Mesenchymal stem cells attenuate renal fibrosis through immune modulation and remodeling properties in a rat remnant kidney model. *Stem Cells*. 2009;27(12):3063–3073.

Semins MJ, Feng Z, Trock B, et al. Evaluation of acute renal colic: a comparison of non-contrast CT versus 3-T noncontrast HASTE MR urography. *Urolithiasis*. 2013;41(1):43–46.

Serel TA, Savas C, Delibas N, et al. Free insulin-like growth factor-1 and unilateral complete ureteral obstruction in the rat. *Urology*. 2000;56(5):863–866.

Seseke F, Thelen P, Ringert RH. Characterization of an animal model of spontaneous congenital unilateral obstructive uropathy by cDNA microarray analysis. *Eur Urol*. 2004;45:374–381.

Sharma AK, Mauer SM, Kim Y, et al. Interstitial fibrosis in obstructive nephropathy. *Kidney Int*. 1993;44(4):774–788.

Shimizu MH, Danilovic A, Andrade L, et al. N-acetylcysteine protects against renal injury following bilateral ureteral obstruction. *Nephrol Dial Transplant*. 2008;23(10):3067–3073.

Shokeir AA, Abdulmaaboud M, Farage Y, et al. Resistive index in renal colic: the effect of nonsteroidal anti-inflammatory drugs. *BJU Int*. 1999;84(3):249–251.

Shokeir AA, El-Diasty T, Eassa W, et al. Diagnosis of ureteral obstruction in patients with compromised renal function: the role of noninvasive imaging modalities. *J Urol*. 2004;171(6 Pt 1):2303–2306.

Siddiqui MM, McDougal WS. Urologic assessment of decreasing renal function. *Med Clin North Am*. 2011;95(1):161–168.

Siegel NJ, Feldman RA, Lytton B, et al. Renal cortical blood flow distribution in obstructive nephropathy in rats. *Circ Res*. 1977;40(4):379–384.

Silverstein DM, Travis BR, Thornhill BA, et al. Altered expression of immune modulator and structural genes in neonatal unilateral ureteral obstruction. *Kidney Int*. 2003;64:25–35.

Singh S, Manson SR, Lee H, et al. Tubular overexpression of angiopoietin-1 attenuates renal fibrosis. *PLoS ONE*. 2016;11(7):e0158908.

Sjodin JG, Wahlberg J, Persson AE. The effect of indomethacin on glomerular capillary pressure and pelvic pressure during ureteral obstruction. *J Urol*. 1982;127(5):1017–1020.

Smith RC, Rosenfield AT, Choe KA, et al. Acute flank pain: comparison of non-contrast-enhanced CT and intravenous urography. *Radiology*. 1995;194(3):789–794.

Smith RC, Verga M, Dalrymple N, et al. Acute ureteral obstruction: value of secondary signs of helical unenhanced CT. *AJR Am J Roentgenol*. 1996;167(5):1109–1113.

Smith-Bindman R, Aubin C, Bailitz J, et al. Ultrasonography versus computed tomography for suspected nephrolithiasis. *N Engl J Med*. 2014;371(12):1100–1110.

Soares BP, Lequin MH, Huisman T. Safety of contrast material use in children. *Magn Reson Imaging Clin N Am*. 2017;25(4):779–785.

Sohni A, Verfaillie CM. Mesenchymal stem cells migration homing and tracking. *Stem Cells Int*. 2013;2013:130763.

Solez K, Ponchak S, Buono RA, et al. Inner medullary plasma flow in the kidney with ureteral obstruction. *Am J Physiol*. 1976;231(5 Pt 1):1315–1321.

Soliman SA, Shokeir AA, Mosbah A, et al. Recoverability of renal function after relief of chronic partial unilateral ureteric obstruction: the effect of an angiotensin-converting enzyme inhibitor (enalapril). *Arab J Urol*. 2011;9(1):67–71.

Sonnenberg H, Wilson DR. The role of the medullary collecting ducts in postobstructive diuresis. *J Clin Invest*. 1976;57(6):1564–1574.

Stecker JF Jr, Gillenwater JY. Experimental partial ureteral obstruction. I. Alteration in renal function. *Invest Urol*. 1971;8(4):377–385.

Steinhardt GF, Ramon G, Salinas-Madrigal L.

Glomerulosclerosis in obstructive uropathy. *J Urol*. 1988;140(5 Pt 2):1316–1318.

Steinhardt GF, Vogler G, Salinas ML, et al. Induced renal dysplasia in the young pouch opossum. *J Pediatr Surg*. 1988;23(12):1127–1130.

Stenberg A, Bohman SO, Morsing P, et al. Back-leak of pelvic urine to the bloodstream. *Acta Physiol Scand*. 1988;134(2):223–234.

Sternberg KM, Eisner B, Larson T, et al. Ultrasonography significantly overestimates stone size when compared to low-dose, noncontrast computed tomography. *Urology*. 2016;95:67–71.

Stock JA, Krous HF, Heffernan J, et al. Correlation of renal biopsy and radionuclide renal scan differential function in patients with unilateral ureteropelvic junction obstruction. *J Urol*. 1995;154(2 Pt 2):716–718.

Stodkilde L, Madsen MG, Palmfeldt J, et al. Urinary proteome analysis in congenital bilateral hydronephrosis. *Scand J Urol*. 2013;47(1):43–51.

Stodkilde L, Norregaard R, Fenton RA, et al. Bilateral ureteral obstruction induces early downregulation and redistribution of AQP2 and phosphorylated AQP2. *Am J Physiol Renal Physiol*. 2011;301(1):F226–F235.

Strutz F, Okada H, Lo CW, et al. Identification and characterization of a fibroblast marker: FSP1. *J Cell Biol*. 1995;130(2):393–405.

Strutz F, Zeisberg M, Renziehausen A, et al. TGF-beta 1 induces proliferation in human renal fibroblasts via induction of basic fibroblast growth factor (FGF-2). *Kidney Int*. 2001;59(2):579–592.

Taki M, Goldsmith DI, Spitzer A. Impact of age on effects of ureteral obstruction on renal function. *Kidney Int*. 1983;24(5):602–609.

Tan J, Wu W, Xu X, et al. Induction therapy with autologous mesenchymal stem cells in living-related kidney transplants: a randomized controlled trial. *J Am Med Assoc*. 2012;307(11):1169–1177.

Tan PH, Chiang GS, Tay AH. Pathology of urinary tract malformations in a paediatric autopsy series. *Ann Acad Med Singapore*. 1994;23(6):838–843.

Taranta-Janusz K, Wasilewska A, Debek W, et al. Urinary angiotensinogen as a novel marker of obstructive nephropathy in children. *Acta Paediatr*. 2013;102(9):e429–e433.

Tarantal AF, Han VK, Cochrum KC, et al. Fetal rhesus monkey model of obstructive renal dysplasia. *Kidney Int*. 2001;59(2):446–456.

Tartaglione G, D'Addessi A, De Waure C, et al. (99m)Tc-MAG3 diuretic renography in diagnosis of obstructive nephropathy in adults: a comparison between F-15 and a new procedure F+10(sp) in seated position. *Clin Nucl Med*. 2013;38(6):432–436.

Tashiro K, Tamada S, Kuwabara N, et al. Attenuation of renal fibrosis by proteasome inhibition in rat obstructive nephropathy: possible role of nuclear factor kappaB. *Int J Mol Med*. 2003;12:587–592.

Thirakomen K, Kozlov N, Arruda JA, et al. Renal hydrogen ion secretion after release of unilateral ureteral obstruction. *Am J Physiol*. 1976;231(4):1233–1239.

Thomasson BH, Esterly JR, Ravitch MM. Morphologic changes in the fetal rabbit kidney after intrauterine ureteral ligation. *Invest Urol*. 1970;8:261–272.

Thomsen HS. Nephrogenic systemic fibrosis: a serious late adverse reaction to gadodiamide. *Eur Radiol*. 2006;16(12):2619–2621.

Thompson A, Gough DC. The use of renal scintigraphy in assessing the potential for recovery in the obstructed renal tract in children. *BJU Int*. 2001;87:853–856.

Thornhill BA, Burt LE, Chen C, et al. Variable chronic partial ureteral obstruction in the neonatal rat: a new model of ureteropelvic junction obstruction. *Kidney Int*. 2005;67(1):42–52.

Thornhill BA, Forbes MS, Marcinko ES, et al. Glomerulotubular disconnection in neonatal mice after relief of partial ureteral obstruction. *Kidney Int*. 2007;72(9):1103–1112.

Thorup J, Jokela R, Cortes D, et al. The results of 15 years of consistent strategy in treating antenatally suspected pelvi-ureteric junction obstruction. *BJU Int*. 2003;91(9):850–852.

Tian F, Gu C, Zhao Z, et al. Urinary Emmprin, matrix metalloproteinase 9 and tissue inhibitor of metalloproteinase 1 as potential biomarkers in children with ureteropelvic junction narrowing on conservative treatment. *Nephrology (Carlton)*. 2015;20(3):194–200.

Topcu SO, Pedersen M, Norregaard R, et al. Candesartan prevents long-term impairment of renal function in response to neonatal partial unilateral ureteral obstruction. *Am J Physiol Renal Physiol*. 2007;292:F736–F748.

Torikai S, Kurokawa K. Effect of PGE2 on vasopressin-dependent cell cAMP in isolated single nephron segments. *Am J Physiol*. 1983;245(1):F58–F66.

Truong LD, Gaber L, Eknoyan G. Obstructive uropathy. *Contrib Nephrol*. 2011;169:311–326.

Truong LD, Sheikh-Hamad D, Chakraborty S, et al. Cell apoptosis and proliferation in obstructive uropathy. *Semin Nephrol*. 1998;18(6):641–651.

Tublin ME, Bude RO, Platt JF. Review. The resistive index in renal Doppler sonography: where do we stand? *AJR Am J Roentgenol*. 2003;180(4):885–892.

Tublin ME, Dodd GD 3rd, Verdile VP. Acute renal colic: diagnosis with duplex Doppler US. *Radiology*. 1994;193(3):697–701.

Turkolmez S, Atasever T, Turkolmez K, et al. Comparison of three different diuretic renal scintigraphy protocols in patients with dilated upper urinary tracts. *Clin Nucl Med*. 2004;29(3):154–160.

Urata H, Masui S, Ideishi M, et al. A case of hyperreninemic hypertension with unilateral hydronephrosis. *Jpn J Med*. 1985;24(1):44–49.

United States Renal Data System. *2015 Annual Data Report: End-Stage Renal Disease in the United States. Chapter 8: Pediatric ESRD*. 2015 [National Institutes of Health, National Institute of Diabetes and Digestive and Kidney Diseases] https://www.usrds.org.

Valles PG, Manucha WA. H+-ATPase activity on unilateral ureteral obstruction: interaction of endogenous nitric oxide and angiotensin II. *Kidney Int*. 2000;58(4):1641–1651.

Valles PG, Pascual L, Manucha W, et al. Role of endogenous nitric oxide in unilateral ureteropelvic junction obstruction in children. *Kidney Int*. 2003;63(3):1104–1115.

van Koppen A, Joles JA, van Balkom BW, et al. Human embryonic mesenchymal stem cell-derived conditioned medium rescues kidney function in rats with established chronic kidney disease. *PLoS ONE*. 2012;7(6):e38746.

Vari RC, Boineau FG, Lewy JE. Angiotensin or thromboxane receptor antagonism in rats with congenital hydronephrosis. *J Am Soc Nephrol*. 1993;3(8):1522–1529.

Vaughan ED Jr, Gillenwater JY. Recovery following complete chronic unilateral ureteral occlusion: functional, radiographic and pathologic alterations. *J Urol*. 1971;106(1):27–35.

Vaughan ED Jr, Gillenwater JY. Diagnosis, characterization and management of post-obstructive diuresis. *J Urol*.

1973;109(2):286–292.

Vaughan ED Jr, Marion D, Poppas DP, et al. Pathophysiology of unilateral ureteral obstruction: studies from Charlottesville to New York. *J Urol*. 2004;172(6 Pt 2):2563–2569.

Vaughan ED Jr, Sorenson EJ, Gillenwater JY. The renal hemodynamic response to chronic unilateral complete ureteral occlusion. *Invest Urol*. 1970;8(1):78–90.

Veenboer PW, de Jong TP. Antegrade pressure measurement as a diagnostic tool in modern pediatric urology. *World J Urol*. 2011;29(6):737–741.

Wada T, Furuichi K, Sakai N, et al. Gene therapy via blockade of monocyte chemoattractant protein-1 for renal fibrosis. *J Am Soc Nephrol*. 2004;15(4):940–948.

Wang CJ, Huang SW, Chang CH. Efficacy of an alpha1 blocker in expulsive therapy of lower ureteral stones. *J Endourol*. 2008;22(1):41–46.

Wang G, Ring T, Li C, et al. Unilateral ureteral obstruction alters expression of acid-base transporters in rat kidney. *J Urol*. 2009;182(6):2964–2973.

Wang G, Topcu SO, Ring T, et al. Age-dependent renal expression of acid-base transporters in neonatal ureter obstruction. *Pediatr Nephrol*. 2009;24(8):1487–1500.

Wang X, Zhou Y, Tan R, et al. Mice lacking the matrix metalloproteinase-9 gene reduce renal interstitial fibrosis in obstructive nephropathy. *Am J Physiol Renal Physiol*. 2010;299(5):F973–F982.

Washburn ZW, Dillman JR, Cohan RH, et al. Computed tomographic urography update: an evolving urinary tract imaging modality. *Semin Ultrasound CT MR*. 2009;30(4):233–245.

Wen JG. Partial unilateral ureteral obstruction in rats. *Neurourol Urodyn*. 2002;21(3):231–250.

Wen JG, Frokiaer J, Zhao JB, et al. Severe partial ureteric obstruction in newborn rats can produce renal dysplasia. *BJU Int*. 2002;89(7):740–745.

Wen JG, Ringgaard S, Frokiaer J, et al. Contralateral compensatory kidney growth in rats with partial unilateral ureteral obstruction monitored by magnetic resonance imaging. *J Urol*. 1999;162(3 Pt 2):1084–1089.

Wen JG, Wang GX, Chen Y, et al. Long-term EGF treatment partially prevents reduction of renal blood flow in response to neonatally induced partial unilateral ureteral obstruction. *Nephron Exp Nephrol*. 2009;111(2):e51–e59.

Westenfelder C, Togel FE. Protective actions of administered mesenchymal stem cells in acute kidney injury: relevance to clinical trials. *Kidney Int Suppl*. 2011;1(3):103–106.

Whitaker RH. Diagnosis of obstruction in dilated ureters. *Ann R Coll Surg Engl*. 1973;53(3):153–166.

Wilhide ME, Feller JD, Li B, et al. Renal epithelial miR-205 expression correlates with disease severity in a mouse model of congenital obstructive nephropathy. *Pediatr Res*. 2016;80(4):602–609.

Winyard P, Chitty LS. Dysplastic kidneys. *Semin Fetal Neonatal Med*. 2008;13(3):142–151.

Wong DC, Rossleigh MA, Farnsworth RH. Diuretic renography with the addition of quantitative gravity-assisted drainage in infants and children. *J Nucl Med*. 2000;41(6):1030–1036.

Worster A, Preyra I, Weaver B, et al. The accuracy of noncontrast helical computed tomography versus intravenous pyelography in the diagnosis of suspected acute urolithiasis: a meta-analysis. *Ann Emerg Med*. 2002;40(3):280–286.

Wyllie AH, Kerr JF, Currie AR. Cell death: the significance of apoptosis. *Int Rev Cytol*. 1980;68:251–306.

Yang J, Dai C, Liu Y. Hepatocyte growth factor suppresses renal interstitial myofibroblast activation and intercepts Smad signal transduction. *Am J Pathol*. 2003;163:621–632.

Yang J, Dai C, Liu Y. A novel mechanism by which hepatocyte growth factor blocks tubular epithelial to mesenchymal transition. *J Am Soc Nephrol*. 2005;16(1):68–78.

Yang J, Liu Y. Blockage of tubular epithelial to myofibroblast transition by hepatocyte growth factor prevents renal interstitial fibrosis. *J Am Soc Nephrol*. 2002;13(1):96–107.

Yang J, Liu Y. Delayed administration of hepatocyte growth factor reduces renal fibrosis in obstructive nephropathy. *Am J Physiol Renal Physiol*. 2003;284(2):F349–F357.

Yang J, Zhang X, Li Y, et al. Downregulation of Smad transcriptional corepressors SnoN and Ski in the fibrotic kidney: an amplification mechanism for TGF-beta1 signaling. *J Am Soc Nephrol*. 2003;14(12):3167–3177.

Yang Q, Xie RJ, Yang T, et al. Transforming growth factor-beta1 and Smad4 signaling pathway down-regulates renal extracellular matrix degradation in diabetic rats. *Chin Med Sci J*. 2007;22(4):243–249.

Yang SP, Woolf AS, Quinn F, et al. Deregulation of renal transforming growth factor-beta1 after experimental short-term ureteric obstruction in fetal sheep. *Am J Pathol*. 2001;159(1):109–117.

Yang SP, Woolf AS, Yuan HT, et al. Potential biological role of transforming growth factor-beta1 in human congenital kidney malformations. *Am J Pathol*. 2000;157(5):1633–1647.

Yang Y, Ji S, Wang C, et al. Apoptosis of renal tubular cells in congenital hydronephrosis. *Chin Med J*. 2001;114(5):502–505.

Yang Y, Pan X, Lei W, et al. Regulation of transforming growth factor-{beta}1-induced apoptosis and epithelial-to-mesenchymal transition by protein kinase A and signal transducers and activators of transcription 3. *Cancer Res*. 2006;66(17):8617–8624.

Yarger WE, Griffith LD. Intrarenal hemodynamics following chronic unilateral ureteral obstruction in the dog. *Am J Physiol*. 1974;227(4):816–826.

Yokoi H, Mukoyama M, Nagae T, et al. Reduction in connective tissue growth factor by antisense treatment ameliorates renal tubulointerstitial fibrosis. *J Am Soc Nephrol*. 2004;15:1430–1440.

Yoo KH, Norwood VF, el Dahr SS, et al. Regulation of angiotensin II AT1 and AT2 receptors in neonatal ureteral obstruction. *Am J Phys*. 1997;273:R503–R509.

Yoo KH, Thornhill BA, Forbes MS, et al. Inducible nitric oxide synthase modulates hydronephrosis following partial or complete unilateral ureteral obstruction in the neonatal mouse. *Am J Physiol Renal Physiol*. 2010;298(1):F62–F71.

Yoo KH, Thornhill BA, Forbes MS, et al. Osteopontin regulates renal apoptosis and interstitial fibrosis in neonatal chronic unilateral ureteral obstruction. *Kidney Int*. 2006;70(10):1735–1741.

Yoo KH, Thornhill BA, Wolstenholme JT, et al. Tissue-specific regulation of growth factors and clusterin by angiotensin II. *Am J Hypertens*. 1998;11(6 Pt 1):715–722.

Yoshino J, Monkawa T, Tsuji M, et al. Snail1 is involved in the renal epithelial-mesenchymal transition. *Biochem Biophys Res Commun*. 2007;362:63–68.

Yukawa K, Hoshino K, Kishino M, et al. Deletion of the kinase domain in death-associated protein kinase attenuates renal tubular cell apoptosis in chronic obstructive uropathy. *Int J Mol Med*. 2005;13:515–520.

Yukawa K, Kishino M, Goda M, et al. STAT6 deficiency inhibits tubulointerstitial fibrosis in obstructive nephropathy. *Int J Mol Med*. 2005;15:225–230.

Zeisberg EM, Potenta SE, Sugimoto H, et al. Fibroblasts in kidney fibrosis emerge via endothelial-to-mesenchymal transition. *J Am Soc Nephrol*. 2008;19(12):2282–2287.

Zeisberg M, Neilson EG. Mechanisms of tubulointerstitial fibrosis. *J Am Soc Nephrol*. 2010;21(11):1819–1834.

Zeisberg M, Hanai J, Sugimoto H, et al. BMP-7 counteracts TGF-beta1-induced epithelial-to-mesenchymal transition and reverses chronic renal injury. *Nat Med*. 2003;9(7):964–968.

Zeisberg M, Khurana M, Rao VH, et al. Stage-specific action of matrix metalloproteinases influences progressive hereditary kidney disease. *PLoS Med*. 2006;3(4):e100.

Zeisberg M, Shah AA, Kalluri R. Bone morphogenic protein-7 induces mesenchymal to epithelial transition in adult renal fibroblasts and facilitates regeneration of injured kidney. *J Biol Chem*. 2005;280(9):8094–8100.

Zhang G, Kernan KA, Collins SJ, et al. Plasmin(ogen) promotes renal interstitial fibrosis by promoting epithelial-to-mesenchymal transition: role of plasmin-activated signals. *J Am Soc Nephrol*. 2007;18(3):846–859.

Zhang H, Hile KL, Asanuma H, et al. IL-18 mediates proapoptotic signaling in renal tubular cells through a Fas ligand-dependent mechanism. *Am J Physiol Renal Physiol*. 2011;301(1):F171–F178.

Zhang PL, Peters CA, Rosen S. Ureteropelvic junction obstruction: morphological and clinical studies. *Pediatr Nephrol*. 2000;14(8–9):820–826.

Zhao Q, Yang Y, Wang C, et al. ATP5B and ETFB metabolic markers in children with congenital hydronephrosis. *Mol Med Rep*. 2016;14(6):5111–5115.

41

Ectopic Ureter, Ureterocele, and Ureteral Anomalies

Irina Stanasel MD, Craig A. Peters MD

Classification and Anatomic Description

General Patterns

Abnormalities of ureteral development, including ectopic ureters and ureteroceles, represent a large component of clinical urology and continue to challenge clinical management in spite of their wide recognition and well-defined surgical strategies. The wide spectrum of clinical significance of these anomalies and the variable patterns of presentation underlie the clinical challenge and require a thorough understanding of both normal and abnormal embryology of the lower urinary tract. This chapter presents the embryologic pathology, clinical manifestations, and evaluation and management strategies for ectopic ureters and ureteroceles, as well as other less common ureteral anomalies. Obstructive ureteral pathologies including ureteropelvic junction (UPJ) obstruction and ureterovesical junction obstruction are reviewed in Chapter 42.

Although ectopic ureter and ureterocele are typically presented as distinct entities, it is apparent that they share many common features and may well have the same underlying developmental mechanisms, with slight variations that induce the very obvious differences in their appearances. In many ways, they may be approached in a similar manner, with slight variation in management because of their particular differences. It is also apparent that clinical cases may represent manifestations that lie between the two entities, suggesting a continuum of embryologic development.

Ectopic Ureter

By definition, an ectopic ureter is any ureter, single or duplex, that does not enter the trigonal area of the bladder. In a duplex system, this is inevitably the upper pole ureter, presumably because of its budding from the mesonephric duct later than the lower pole with later incorporation into the developing urogenital sinus. If it is simply near the bladder neck, it is not technically ectopic, which requires entry at the level of the bladder neck or distal. In females, the ectopic ureter may enter anywhere from the bladder neck to the perineum and into the vagina, uterus (Ghosh et al., 2016), and even rectum (Fig. 41.1). It may be associated with a cyst of the Gartner duct, the remnant of the Wolffian duct from which the ureter buds, and may include cystic dilation of the duct. The duct typically runs parallel to the vagina (the Müllerian structure), and with rupture of the cystic ductal structure, communication with the vagina is established. This is the basis for incontinence, the frequent presentation of an ectopic ureter in females. In males, the ectopic ureter always enters the urogenital system above the external sphincter or pelvic floor, and usually into the Wolffian structures, including the vas deferens, seminal vesicles, or ejaculatory duct (Fig. 41.2; also see Fig. 41.1). Presentation in male patients does not involve incontinence, but rather infection and pain of the affected organs (testicles and epididymis). When associated with an ipsilateral renal absence and seminal vesicle cyst, it is termed *Zinner syndrome* (Ghonge et al., 2010; Haddock and Wagner, 2015).

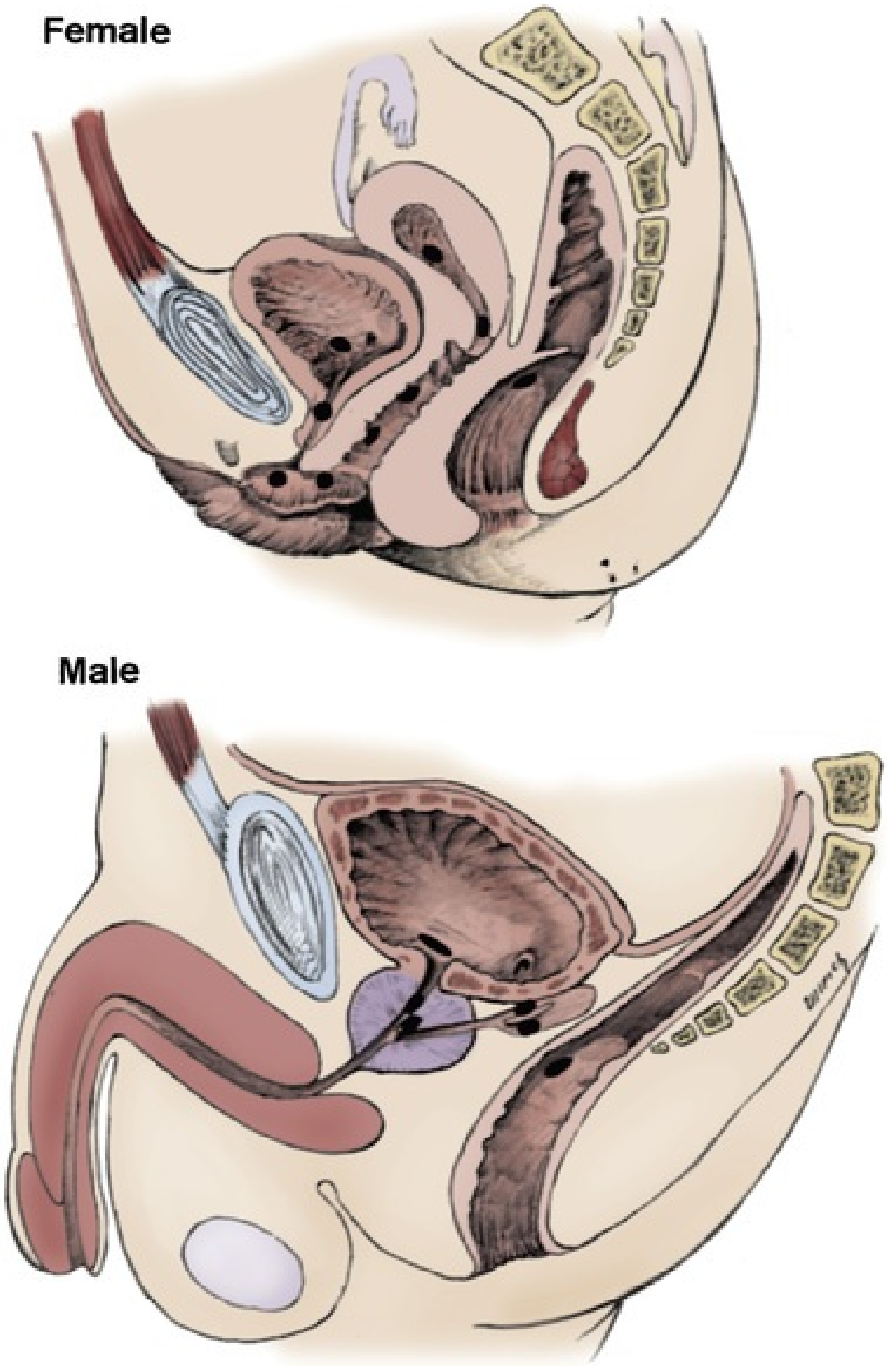

FIG. 41.1 Sites of ectopic ureteral orifices in the male and female.

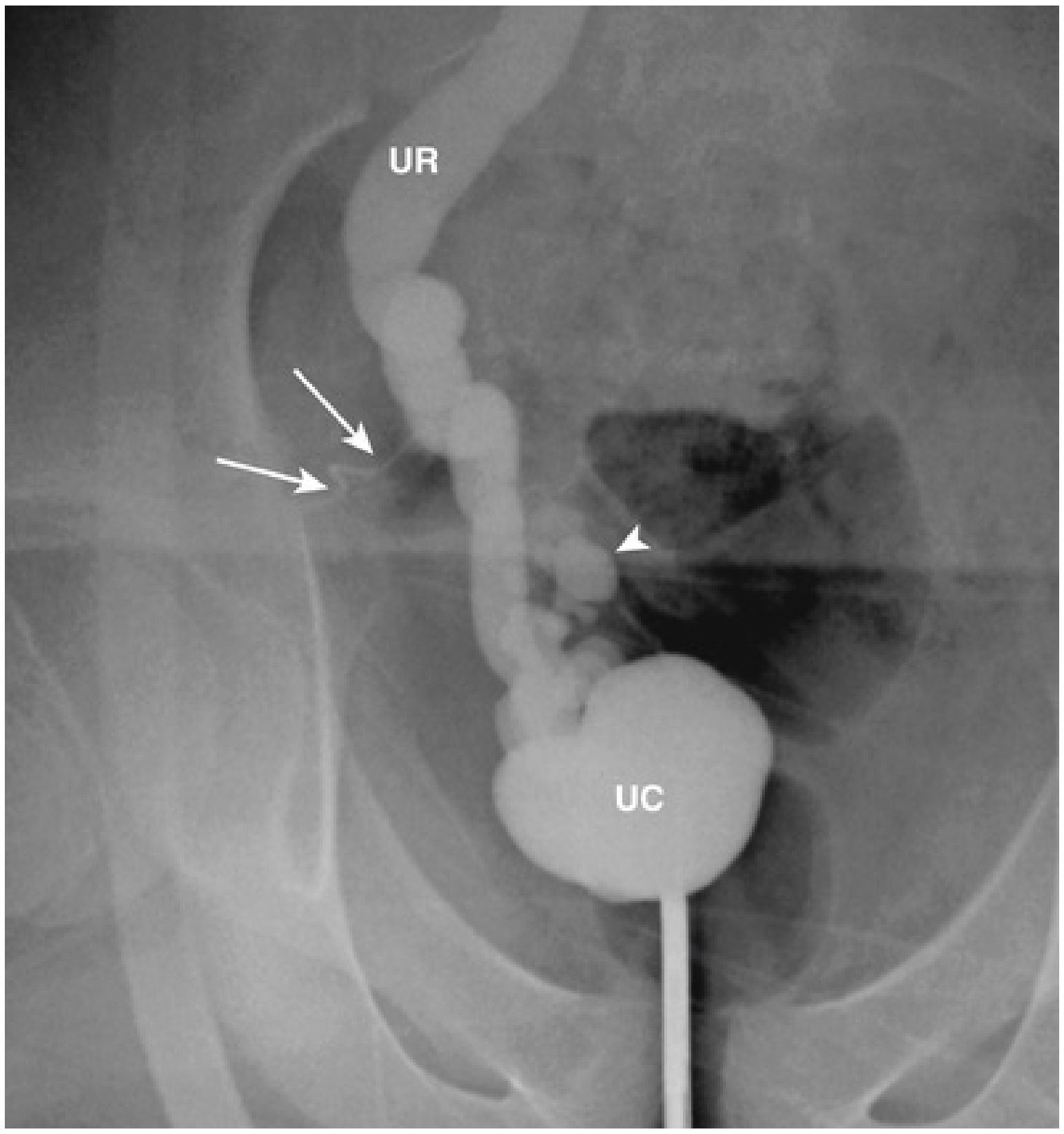

FIG. 41.2 Retrograde injection study of a boy with abdominal pain and a ureterocele associated with a hypoplastic right kidney. The intravesical ureterocele *(UC)* is being injected and demonstrates communication with the right seminal vesicle *(arrowhead)* and vas deferens *(arrows),* with the ureter *(UR)* leading to the dysplastic kidney. At surgical resection, the ureter and vas were joined just above the seminal vesicles.

Single-system ectopic ureters and ureteroceles may manifest in a similar fashion to the ectopic upper pole but may also be associated with an apparently absent kidney. This usually reflects an inability to identify the kidney using ultrasound and has led to the use of computed tomography (CT) imaging with contrast or renal function studies to detect small, poorly functioning renal units associated with an ectopic ureter (Borer et al., 1998). Either single or duplex systems with an ectopic ureter may be associated with severe hydronephrosis reflecting distal obstruction. Severe obstruction may have impaired normal renal development to the point that the affected segment is nonfunctional.

The rare entity of bilateral single-system ectopic ureters may be associated with a hypoplastic bladder and a poorly developed trigone and bladder neck, as well as with bilateral renal abnormalities, typically dysplasia (Koyanagi et al., 1977; Noseworthy and Persky, 1982; Johnin et al., 2007).

Key Points: Ectopic Ureter

- An ectopic ureter is any ureter, single or duplex, that does not enter the trigonal area of the bladder.
- In a duplex system, the ectopic ureter is inevitably the upper pole ureter. This is because budding from the mesonephric duct occurs later (more cephalad) than the lower pole ureteral bud.
- In females, the ectopic ureter may enter anywhere from the bladder neck to the perineum and into the vagina, uterus, and even rectum. One of the classic symptoms is continuous wetting.
- In males, the ectopic ureter always enters the urogenital system above the external sphincter or pelvic floor and usually into the Wolffian structures, including the vas deferens, seminal vesicles, or ejaculatory duct. Clinical presentation is not incontinence.

Ureterocele

Ureteroceles represent a version of the ectopic ureter with a cystic dilation of the distal aspect of the ureter that is located either within the bladder or spanning the bladder neck and urethra. As with the ectopic ureter, ureteroceles may be associated with a single or duplex system, and in duplex systems are associated with the upper pole (Fig. 41.3). Ureteroceles can extend into the urethra but do not form entirely within the urethra, nor do they attach to the Wolffian ductal structures.

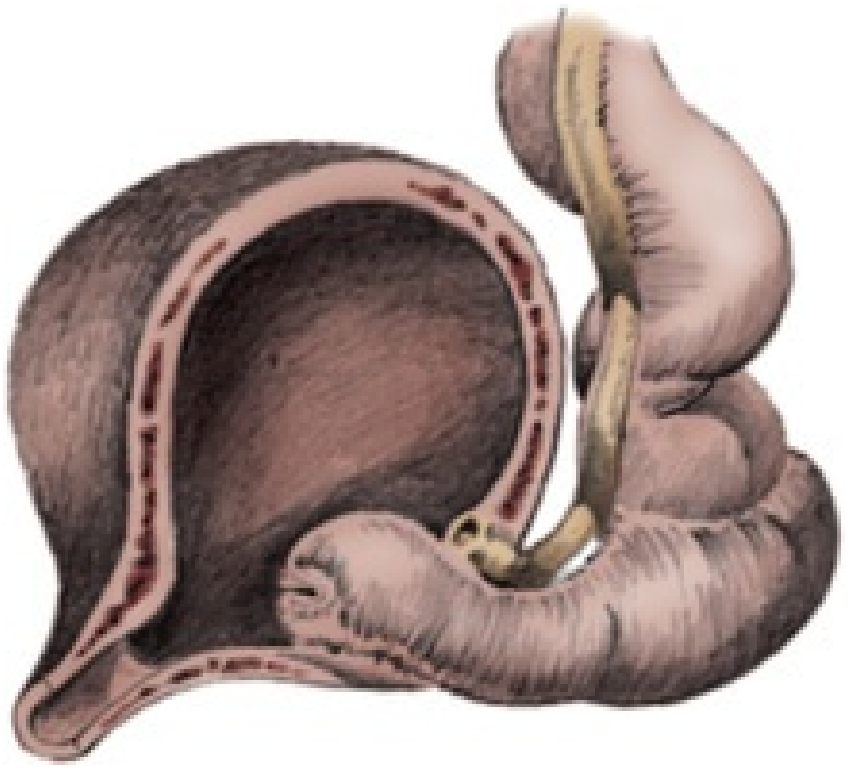

FIG. 41.3 Diagram of intravesical ureter with stenotic orifice just proximal to the bladder neck.

Several classification systems exist for ureteroceles, but the most useful one for clinical practice separates intravesical from extravesical ureteroceles. The intravesical ureterocele is entirely within the bladder and above the bladder neck. This would include a "simple" ureterocele that may be seen in the adult with mild to no upper tract dilation, suggestive of lack of obstruction. This term, however, should be discouraged as it can be confusing; the term *single intravesical ureterocele* should be used in its place (Glassberg et al., 1984). Intravesical ureteroceles can also present with obstruction, severe hydronephrosis, and clinically significant sequelae. Ectopic ureteroceles include those "in which some portion of the ureterocele is situated permanently at the bladder neck or urethra" (Glassberg et al., 1984). The orifice may be in the bladder, at the bladder neck, or in the urethra. This should be distinguished from an intravesical ureterocele that prolapses into the urethra with voiding.

Other notable classifications of ureteroceles have been published (Stephens, 1971). This classification includes cecoureteroceles and stenotic, sphincteric, sphincterostenotic, blind, and nonobstructed ureteroceles (Fig. 41.4). From a clinical perspective, it is critical to recognize the subgroup of cecoureteroceles. In these cases, the orifice of the affected ureter is within the bladder, but the cavity of the ureterocele extends submucosally beyond the bladder neck into the urethra. These may not be readily characterized preoperatively (Smith and Parrott, 1994), and their complexity may create surgical challenges, particularly with endoscopic incision (see later).

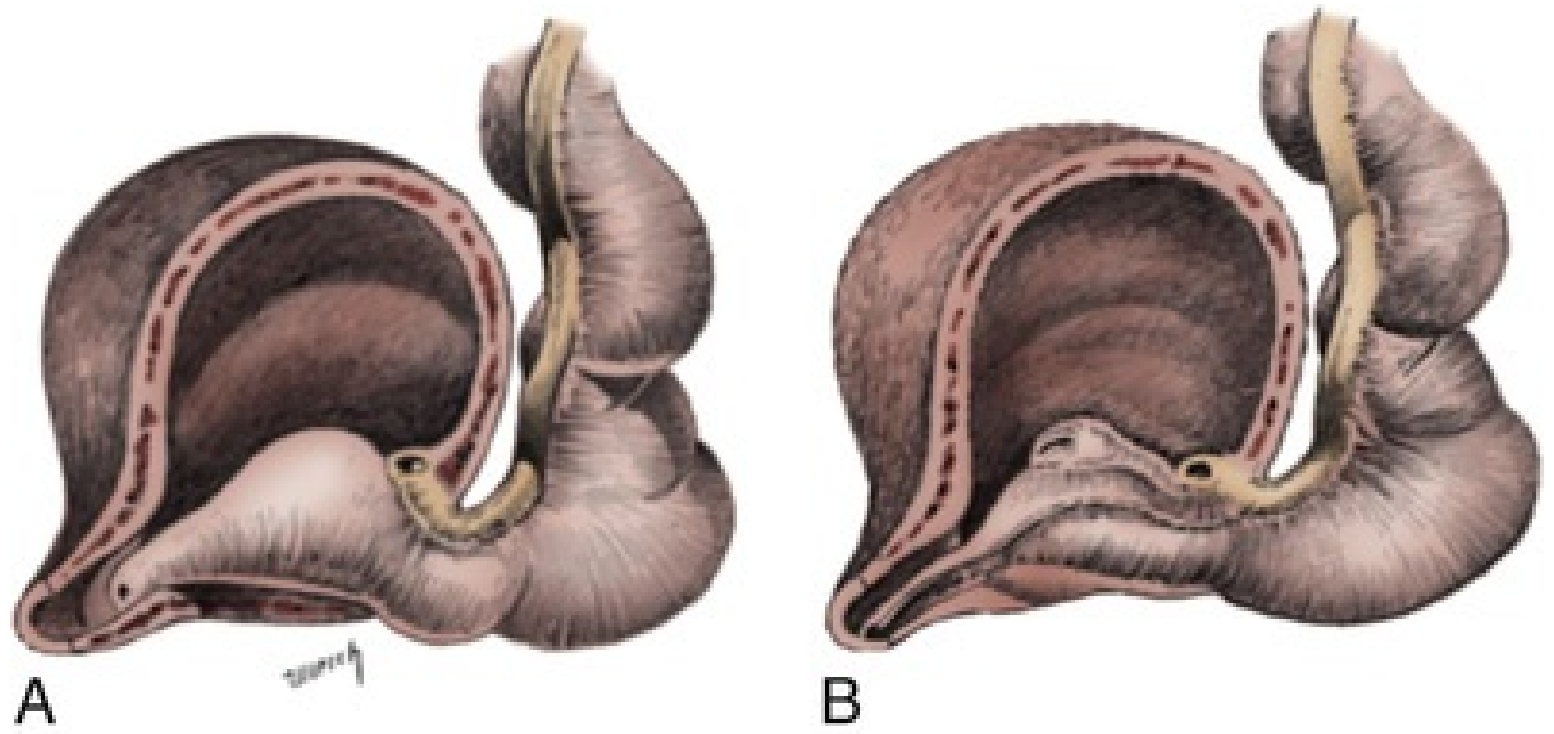

FIG. 41.4 (A) Sphincterostenotic ectopic ureterocele. (B) Cecoureterocele lumen extends distal to the orifice as a long tongue beneath the ureteral submucosa. The orifice communicates with the lumen of the bladder and is large and incompetent.

An unusual but diagnostically challenging ureterocele variant is the nonobstructive ureterocele with duplication (Bauer and Retik, 1978) or “ureterocele disproportion” (Share and Lebowitz, 1989) (Fig. 41.5). These are associated with a duplex kidney, but the affected upper pole is nondilated and typically dysplastic to such a degree that it is not readily detected on most imaging, and the affected ureter is not dilated beyond the bladder. A typical-appearing ureterocele is seen in the bladder, but the ipsilateral kidney appears completely normal.

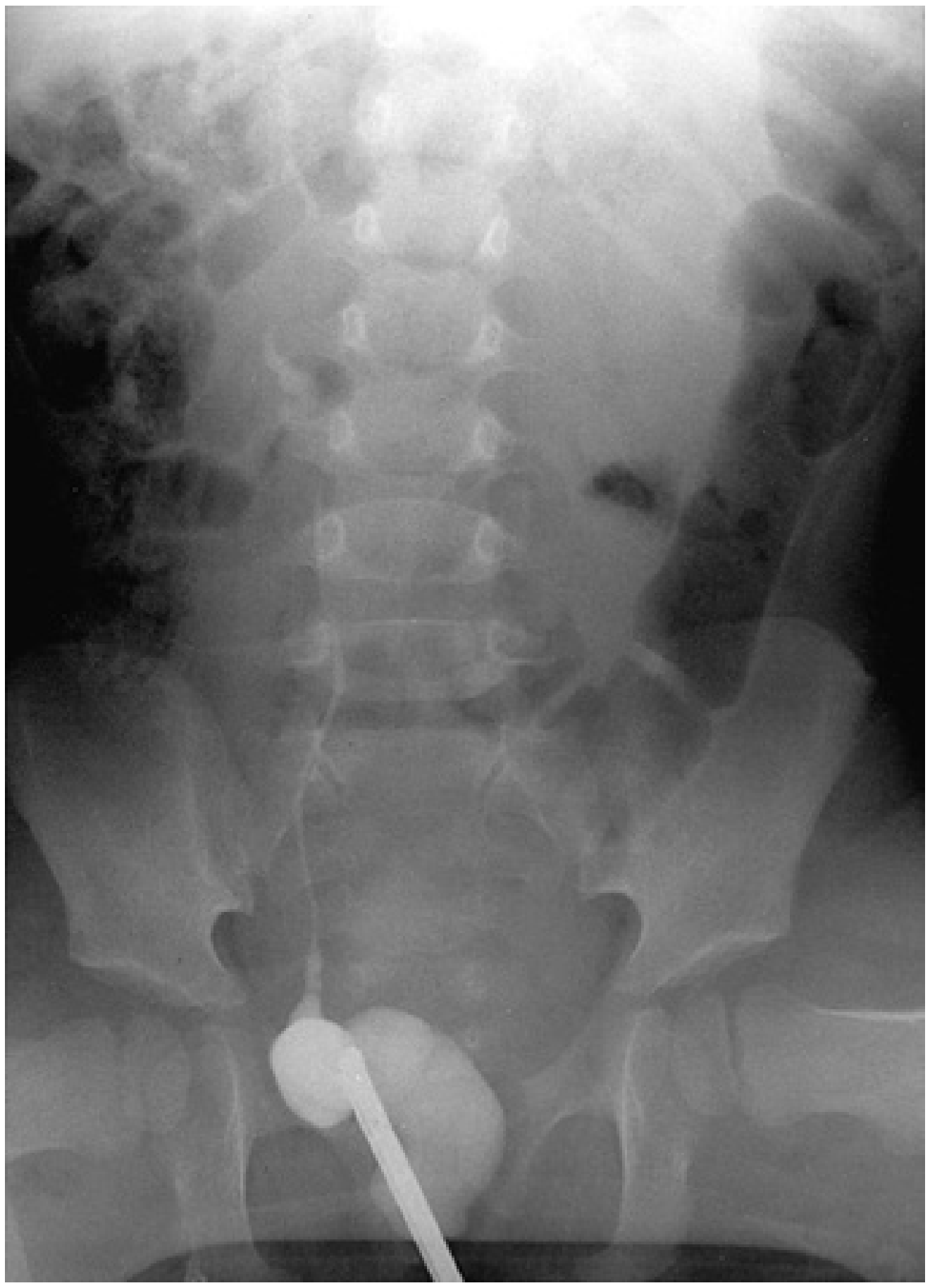

FIG. 41.5 Retrograde pyelogram demonstrating ureterocele disproportion. Note the disparity between the large ureterocele and the thin ureter and nondilated collecting system.

There is some association of ureterocele type with outcomes of various therapeutic measures, but these predictions have not proven to be as reliable as initially reported. Churchill et al. proposed a classification system based on the impact of the ureterocele on the upper urinary tract that included the impact on all of the patient's renal units (Churchill et al., 1992). This functional system separates those in which the upper pole only is in jeopardy, those in which an entire ipsilateral kidney is threatened, and those in which the contralateral system is also at risk because of reflux or bladder outlet obstruction. The last group comprised 26% of the reported cases.

Key Points: Ureterocele

- Ureteroceles represent a version of the ectopic ureter with a cystic dilation of the distal aspect of the ureter that is located either within the bladder or spanning the bladder neck and urethra.

- Several classification systems exist for ureteroceles, but the most useful distinction for clinical practice separates intravesical from extravesical ureteroceles.
- Cecoureteroceles are ones in which the orifice of the affected ureter is within the bladder, but the cavity of the ureterocele extends submucosally beyond the bladder neck into the urethra.

Embryology and Etiology

The specific mechanisms responsible for development of ectopic ureters and ureteroceles remain undefined, but our emerging understanding of normal and abnormal ureterotrigonal development is likely to provide valuable insights (Mendelsohn, 2009). This work provides insight into the cellular basis of renal branching morphogenesis and demonstrates that both *Ret*-dependent cell movements and *Ret*-independent changes in the Wolffian duct epithelium contribute to ureteric bud formation. These molecular mechanisms are of scientific importance and will hopefully permit potential separation among variants of these conditions with therapeutic relevance, as well as ultimately permitting early detection (i.e., in utero) and intervention. At the present time, we remain uncertain as to the fundamental mechanisms, and we need to know which ureteroceles and ectopic ureters are associated with bladder neck and trigonal maldevelopment sufficient to cause functional disturbances such as incontinence. Early identification may lead to early diagnosis and prevention of complications such as infection and renal scarring, as well as early and more effective surgical therapies.

Ureteral-Trigonal-Renal Development

The pathogenesis of ureteral ectopia with or without ureterocele results in renal maldevelopment caused by defective ureterotrigonal connections. At the present time, a growing number of genetic pathways have been identified that are critical in humans and rodents for establishing distal ureter connections, and studies in mouse models have led to a better understanding of the process by which proper distal ureter connections are generated.

Function of the urinary tract depends on patent ureterobladder connections and an antireflux mechanism that prevents backflow of urine to the ureter and kidneys. The antireflux valve is formed by intersecting ureteral and bladder muscle fibers. Therefore, malpositioned ureters that do not follow a precise trajectory through the bladder wall or terminate outside the normal insertion site in the trigone can cause obstruction or vesicoureteral reflux (VUR). Renal defects associated with ureteral ectopia or ureterocele can be caused by obstruction that damages renal cell types (see Chapter 40) or mutations in genes that are required independently for normal kidney development and ureter insertion, including *RET*, *FGFR2*, and *GATA3* (Chia et al., 2011; Liu et al., 2011; Hoshi et al., 2012).

Classic understanding of ureterotrigonal development teaches that the trigone originates from the mesodermal common nephric duct (CND), as do the mesonephric duct and thus ureter, and is distinct from the urogenital sinus, which is of endodermal origin. According to this model, proper ureterobladder connections depend on expansion of the CND and its subsequent insertion into the urogenital sinus epithelium (UGE), both separating the CND and ureter and producing a mature insertion site in the bladder (Wesson, 1920; Tanagho and Pugh, 1963; Woodburne, 1965). However, the observation that the CND degenerates during ureter maturation suggests that the CND may not give rise to the trigone as previously thought (Batourina et al., 2002, 2005; Viana et al., 2007; Chi et al., 2009; Mendelsohn, 2009; Uetani et al., 2009; Tanaka et al., 2010). Consistent with this, lineage studies and tissue recombination studies in mice suggest that the trigone is formed by interconnections between the detrusor and fibers surrounding the intravesical ureter (Viana et al., 2007).

With ureteral bud formation, the mesonephric duct becomes the CND caudally toward the insertion into the urogenital sinus. Studies in animal models indicate that establishing a mature ureterobladder connection depends on a process of ureteral maturation, a complex series of events driven by cellular rearrangements and apoptosis of the CND. Ureteral maturation begins when the most distal portion of the CND begins to merge with the urogenital sinus and undergoes apoptosis, which occurs over the course of several days. This first round of apoptosis results in removal of the most distal portion of the CND and formation of a loop composed of the remaining CND and distal ureter. The loop makes contact with the dorsal UGE, an event that sets the position of the future ureter orifice. Merger of the loop with the UGE and removal of the remaining CND by apoptosis generates a patent connection between the ureter and bladder, which at this stage is at the level of the verumontanum. Subsequent growth and expansion of the bladder and urethra further separate the mesonephric duct and distal ureter. The ureter is initially occluded by cells that undergo apoptosis (Mendelsohn, 2009). These cells correspond to the Chwalle membrane, which in humans is thought to be important for generating a patent ureterobladder connection. If the process of apoptosis is abnormal, this is thought to result in formation of a ureterocele (Chwalle, 1927).

Studies in mouse models suggest that ectopic ureters can arise from defects that cause misalignment of the loop with the dorsal side of the urogenital sinus, altering the position where the ureteral orifice inserts. Potential events include delayed or defective nephric duct insertion into the cloaca, sprouting of the primary ureteric bud from an abnormally high or low position on the nephric duct relative to the urogenital sinus, and defective ureteral maturation. A ureter that inserts in the proper site but is obstructed may reflect failure in regression of the Chwalle membrane. The revised model of ureteral maturation provides possible mechanisms for ureteral ectopia and ureterocele formation. Abnormal apoptosis may maintain the connection between the ureter and the Wolffian duct and prevent incorporation of the ureter and the urogenital sinus. This defect would produce a ureter attached to the Wolffian remnants in girls (Gartner duct) or to the vas deferens or ejaculatory system in boys. Alternately, partial CND regression may result in ureters that join the bladder at an abnormally posterior site, close to or in the urethra.

In duplicated systems, upper pole kidneys derived from ureteric bud branches that formed at an abnormally high position on the mesonephric duct tend to be obstructed, whereas distal ureteral obstruction is rare in lower pole renal moieties that arise from ureteric bud branches that sprout from the mesonephric duct at the appropriate site. This upper pole defect may reflect incomplete CND remodeling, a suggestion supported by observations from mouse models with duplicated systems. In this case, CNDs associated with ureters that form at an abnormally anterior site on the mesonephric duct persist, resulting in obstruction, whereas CNDs associated with ureters that form at the proper site, close to the urogenital sinus, undergo regression. These observations together suggest that signals from the urogenital sinus may normally regulate ureteral maturation by controlling CND remodeling.

These observations suggest that the final position of the ureter depends in large part on the extent of CND remodeling, which can be disrupted by defects in cell movements or apoptosis. If there is no remodeling, the ureter will remain joined to the sex duct (ectopic vas deferens or Gartner duct in girls). Partial CND remodeling could produce a different defect. In this case, distal ureters will be joined to the urogenital sinus at a site that is closer to the nephric duct, which joins at the level of the verumontanum or sinus ridge. Very similar defects are observed in mouse models, including mutants lacking *Ret*. Mutations in *RET* in humans cause Hirschsprung disease, renal abnormalities, VUR, and hydronephrosis. Studies in *Ret*-mutant mice indicate that *Ret* controls ureteric bud formation as well as mesonephric duct insertion and CND regression, suggesting that conserved genetic pathways may be required at independent sites and at different stages for generating a normal urinary system.

Obstruction is unlikely to be a major, and certainly not the only, factor producing ureteral dilation as seen with ureteroceles. Ureteroceles with large orifices and no apparent obstruction are well recognized clinically. Ectopic ureters with insertion into the bladder neck are dilated, but do not have the disproportionate distal dilation characteristic of the ureterocele. Obstruction plays some role in ureterocele pathophysiology, however, as is evident in the frequent occurrence of decompression with ureterocele puncture. Whether this is determined by the degree of muscularization of the ureterocele is undefined. Recent studies support the idea that degeneration of the Chwalle membrane is important for generating a patent connection between the ureter orifice and the bladder (Chwalle, 1927; Mendelsohn, 2009). These studies suggest that the Chwalle membrane, which has been thought to form from the urogenital sinus, may in fact be derived from luminal cells in the ureter that undergo apoptosis at a relatively late stage, before the onset of renal function, which may be important for generating a patent connection between the distal ureter and bladder.

Key Points: Embryology

- In contrast with the classic model in which the CND forms the trigone, the revised model includes regression of the CND in the normal animal through apoptosis and formation of the trigone from the endoderm, like the bladder.
- The classic explanation of ureterocele formation is that of Chwalle, who postulated that distal ureteral expansion is produced by failure of rupture of a distal membrane at the ureteral orifice (Chwalle membrane).
- Because the ureteral bud derives from the Wolffian duct, the ectopic ureter

will not insert directly into the Müllerian structures (vagina, cervix, uterus), but will be associated with them through the remnant of the Wolffian duct, the Gartner duct, which runs alongside the mature Müllerian structures.

- The Weigert-Meyer rule describes the inverse relationship of the duplex ureteral orifices, in which the ectopic ureter or ureterocele associated with the upper pole is caudal to the lower pole ureteral orifice.

Clinical Presentation

Imaging

Prenatal Detection

The majority of ureteroceles and ectopic ureters are detected through prenatal ultrasound imaging, even if only through the identification of hydronephrosis. The abnormality prompts postnatal imaging, leading to better characterization of the condition. The prenatal imaging patterns are identical to those seen postnatally on ultrasound imaging, but are more easily misinterpreted on prenatal imaging. Although these are described in Chapter 22, several elements should be emphasized.

The identification of a duplex system may be difficult except when one of the moieties is dilated. The report of an upper pole "cyst" in a fetus should be interpreted as being upper pole hydronephrosis until proven otherwise. Minor degrees of hydronephrosis may not be readily identified, although changes over time may prompt recognition. The expected ureteral dilation may not be readily detected but can often be traced to the bladder. The bladder must be inspected in all such cases to identify a ureterocele, but it may be necessary to await bladder filling to make this observation. A large ureterocele can fill a bladder and mask its own presence.

The character of the renal parenchyma of the upper pole should be noted, both thickness and echogenicity. The findings may be useful in making clinical decisions.

The ectopic ureter can appear identical to a ureterocele except at the bladder level, with a dilated upper pole and tortuous ureter but no intravesical component. On occasion, a large ectopic ureter may impinge on the bladder and appear as an intravesical structure, termed a *pseudoureterocele* (Sumfest et al., 1995). These patterns are identical to the postnatal appearance, but their recognition does require an experienced maternal-fetal ultrasonographer.

With a tentative diagnosis of a ureterocele or ectopic ureter, careful evaluation of the other renal units and bladder should be made. Ipsilateral lower pole or contralateral dilation suggests reflux or less commonly obstruction from the ureterocele or the dilated ectopic ureter. Bladder outlet obstruction by a ureterocele can occur and manifest as hydronephrosis and possibly obstruction of all renal units (Ogunyemi, 2001; Quintero et al., 2001; Godinho et al., 2013).

Although it is very unusual to identify bladder obstruction from a ureterocele to the extent of producing oligohydramnios, this can occur. Contralateral renal dysplasia may be evident and associated with reduced amniotic fluid. The need for prenatal intervention or early delivery is exceptional and unlikely to provide significant benefit.

A single-system ureterocele or ectopic ureter is suggested by dilation of the entire kidney and ureter. It may be impossible to differentiate this from an obstructive megaureter or severe reflux, but this has little immediate prenatal clinical impact, and differentiation can be made postnatally with additional studies.

Incidental Postnatal Detection

Ectopic ureters and ureteroceles are sometimes diagnosed based on findings of hydronephrosis when imaging studies are performed for unrelated reasons such as trauma or abdominal pain. In some cases, the studies are performed for general abdominal pain that was not considered to have a renal cause but may in fact prove to be of renal origin. It is also possible that the dilated ureter may not be recognized as such. Cases of presumed ovarian cysts have been seen that were actually markedly dilated ureters, so it is important to consider the dilated ureter as part of the differential when diagnosing dilated structures in the pelvis (Mason et al., 2012).

Infection

Infection remains a significant reason for clinical presentation of both ectopic ureters and ureteroceles, which may occur at any age and have a highly variable pattern.

Although there is great variability in the presentation of either ectopic ureter or ureterocele, there are several patterns that may be anticipated. In either case, generalized urosepsis may be the presenting clinical scenario, and renal bladder ultrasonography will usually provide the diagnosis. It has been reported that an acute ultrasound study is unnecessary if a child has a febrile urinary tract infection (UTI) and a history of a normal prenatal ultrasound examination after 30 to 32 weeks (Hoberman et al., 2003). The extreme variability of quality of prenatal imaging makes this recommendation tenuous, and it would seem prudent that an ultrasound study be obtained in all children with urosepsis. In those with a febrile UTI, there is rarely urgency if they are clinically responding.

The value of early detection is the potential for early treatment, which may be a simple drainage procedure.

In the acute setting, with evidence of an ectopic ureter or ureterocele, initial clinical response will determine the timing of intervention. Certainly the child with sepsis who is not responding rapidly to appropriate therapy may require urgent transurethral incision (TUI) of an infected ureterocele or percutaneous or open drainage of an ectopic ureter. Open drainage in this setting is often an end ureterostomy as described later.

Ectopic ureters will frequently manifest with a less acute pattern evidenced by ongoing low-grade fever with periodic spikes. In some cases, a negative urine culture will be present simply because the infected ectopic system is not draining into the bladder. Parents may describe a purulent discharge from the perineum (See and Mayo, 1991). This clinical pattern should prompt an ultrasound study, which will usually reveal a dilated upper pole or entire system. It is rare for the unobstructed ectopic ureter to manifest with infection, but it can be associated with incontinence.

In boys, a similar generalized subacute pattern of infection may be present, but more often these boys have epididymitis on presentation. Although this may be an unusual subset of young boys with an acute scrotum, they can have a true bacterial epididymitis or infected urine. In the setting of suspicion for epididymitis in a young boy, it is prudent to perform a brief ultrasound examination of the upper tracts to ensure no abnormality (Rajfer et al., 1978; Umeyama et al., 1985; Chu et al., 2012). Older males will also present in this manner, although it is unclear why it may be so delayed. Some have had recurrent episodes of epididymitis before the underlying cause is detected.

Incontinence

Urinary incontinence may be caused by an ectopic ureter in a girl, but not in a boy. Untreated ureteroceles are not associated with incontinence. The toilet-trained girl with verified continuous urinary leakage must be evaluated for an ectopic ureter. Imaging studies may not immediately detect this condition because the affected renal moiety may not be dilated, and the level of suspicion must be guided by a careful history and occasionally physical examination. Before toilet training, it may be difficult to detect continuous incontinence, although some parents will note persistent dribbling during changing. In early training, the wetting may be falsely attributed to lack of motivation. Persistence should prompt evaluation, and the characteristic history can be obtained. This is usually one of persistent low-volume dampness at all times. When asked if the child can be dry for 30 to 60 minutes, the parent will usually say no. It is important to be cautious in questioning, because some parents with children who wet for other reasons may state, “She is always wet,” when in fact the child can be dry for periods. The dampness associated with an ectopic ureter typically occurs throughout the day and night and does not relent. It may seem to worsen with activity in some patients. In rare patients, it can be intermittent, perhaps caused by intermittent leakage through a membrane of the Gartner duct.

In older children in whom the diagnosis has not been recognized, attribution of the symptoms may be to dysfunctional voiding, laziness, and even sexual abuse (Lane, 1962; Carrico and Lebowitz, 1998). During the history taking, signs of typical voiding dysfunction such as voiding postponement, posturing, and constipation should be sought to assess the likelihood of these being an explanation for the wetting.

Pain

Pain is uncommonly associated with either an ectopic ureter or a ureterocele. The exceptions are pain related to acute infection, episodic obstruction of the ectopic ureter, and bladder pain caused by an obstructing ureterocele. Occasional cases of intermittent drainage of an ectopic ureter in older children have been described and are characterized by abdominal pain followed by perineal drainage of urine or purulent material. It is presumed that this reflects accumulation of urine in a system that is obstructed at the level of the orifice with subsequent drainage and relief of symptoms.

Prolapse

Ureterocele prolapse is an unusual but distinctive presenting sign that may still confuse the clinician. These are usually smooth, congested mucosal-covered interlabial masses, and the child may be experiencing difficulty voiding. The mass protrudes from the urethra, distinct from the vagina. It is not lobulated as a sarcoma botryoides would appear. An ultrasound examination of the bladder will usually confirm the diagnosis, and kidney images will further support this (Fig. 41.6A and B).

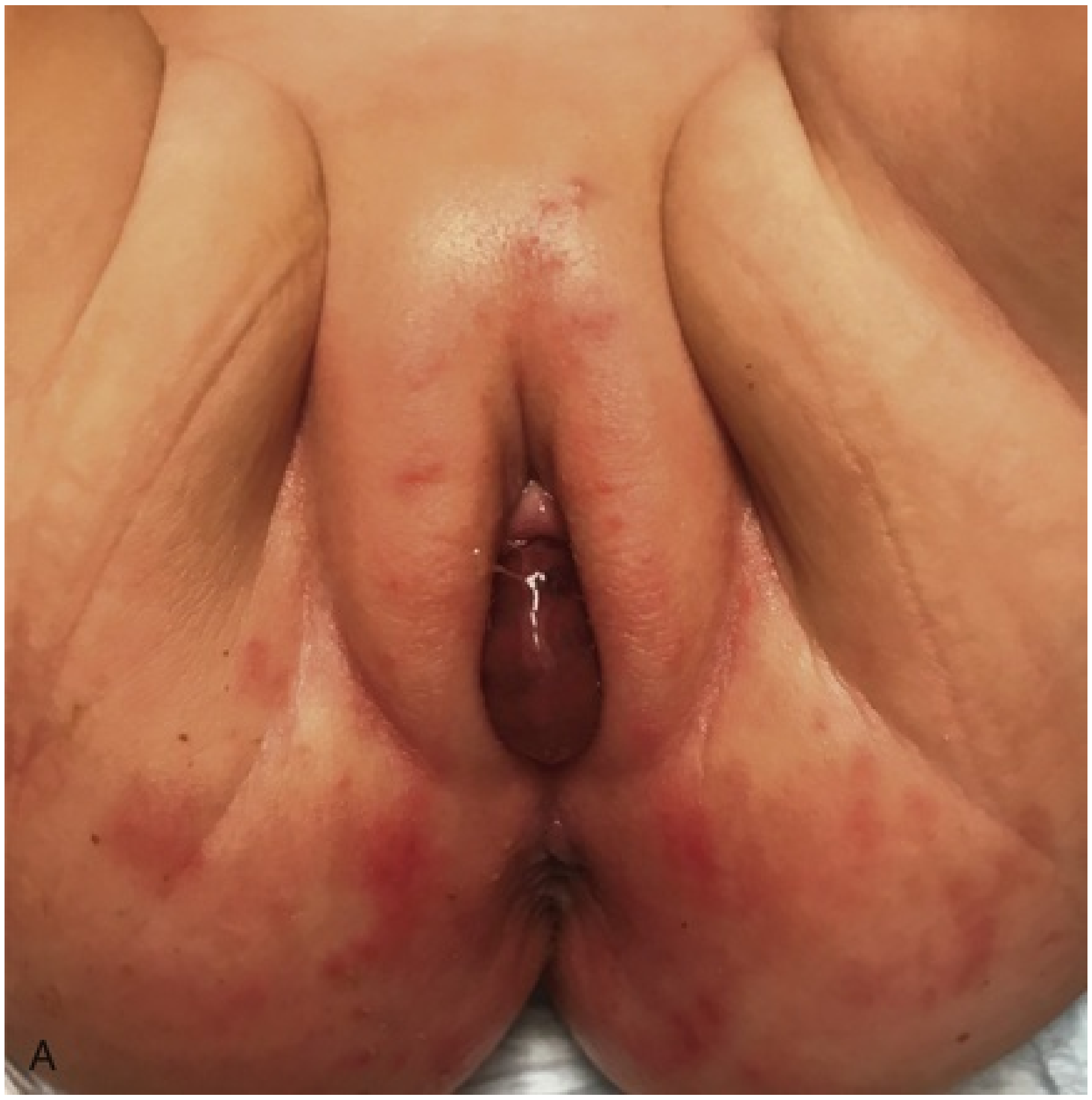
A

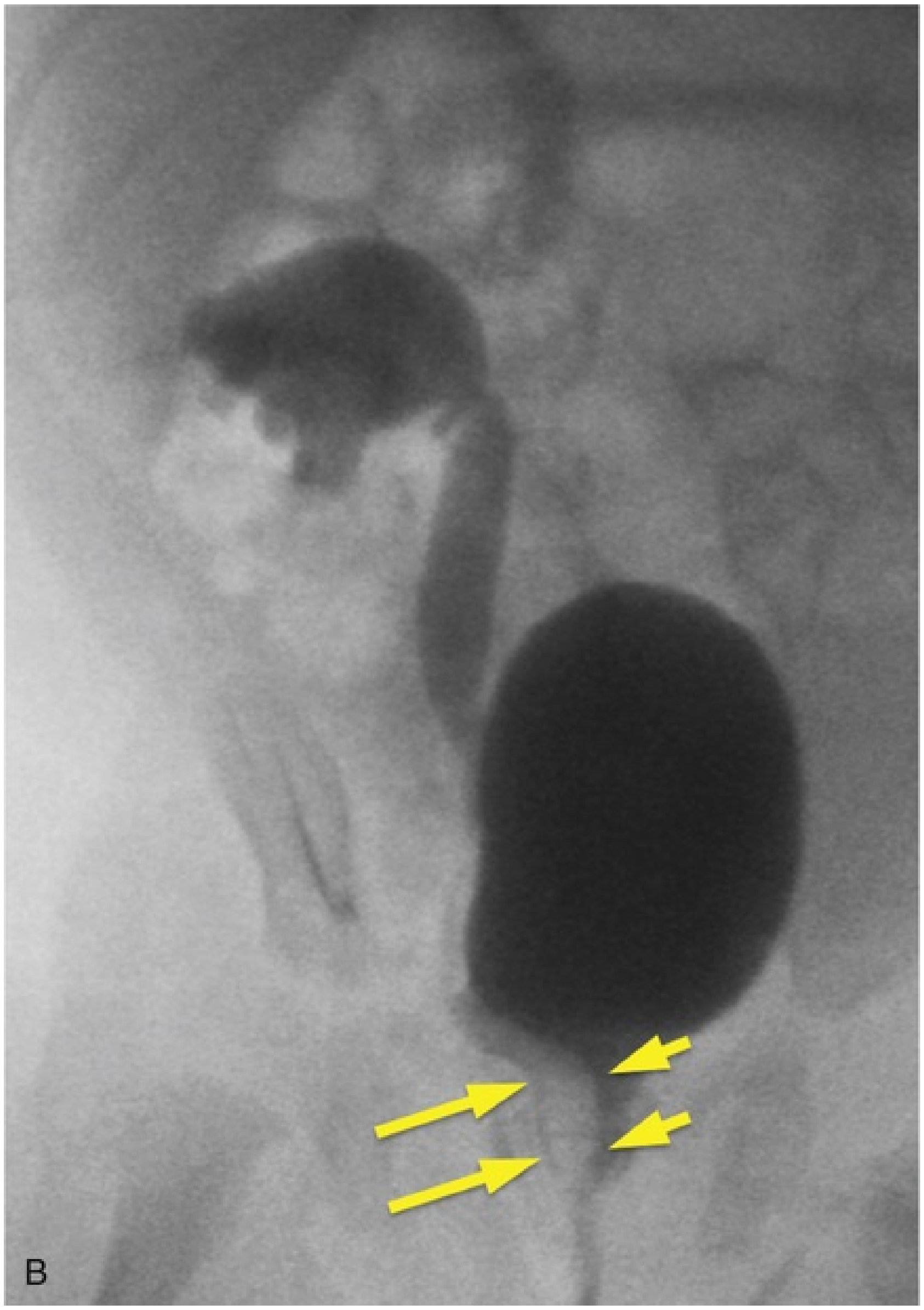

FIG. 41.6 (A) A prolapsed ureterocele presented as an interlabial mass in a 14-month-old girl. (B) Voiding cystourethrogram demonstrates the ureterocele prolapsing into the urethra *(arrows)* with associated lower pole reflux and the classical "drooping lily" appearance of the lower pole, displaced by the dilated upper pole. The prolapse was reduced in the operating room and the ureterocele incised.

Late Presentation

Presentation of both ectopic ureters and ureteroceles in the teen or adult has been reported, usually associated with infection or abdominal pain and rarely incontinence (Idbohrn and Sjostedt, 1954; Abrahamsson et al., 1981; Amitai et al, 1992; Westesson and Goldman, 2013). The nonobstructing ureterocele, often associated with a single system, is well recognized in the adult, often with a stone in the small ureterocele (Singh, 2007; Mizuno et al., 2008). Vaginal wall prolapse has also been associated with an ectopic ureter (Chai et al., 2014). Ureterocele prolapse after incision in adults has been reported (Campobasso et al., 2018). There is usually little to no function associated with the affected renal moiety, and although extirpative therapy with upper pole heminephrectomy has been the mainstay of treatment in these cases, upper to lower pole ureteroureterostomy may also be considered (Brehmer et al, 2007; Mason et al., 2012).

Key Points: Clinical Presentation

- The majority of ureteroceles and ectopic ureters are detected by prenatal ultrasound imaging based on the presence of hydronephrosis, although a specific diagnosis is often not made until after birth.
- Ectopic ureters frequently manifest with a less acute pattern evidenced by ongoing low-grade fever with periodic spikes. In some cases, urine cultures are negative because the infected ectopic system is not draining into the bladder.
- Boys with ectopic ureter can present with a subacute pattern of infection but often have associated epididymitis.
- Urinary incontinence may be caused by an ectopic ureter in a girl but not in a boy.
- The toilet-trained girl with verified continuous urinary leakage must be evaluated for an ectopic ureter.
- Ureterocele prolapse is an unusual but distinctive presenting sign; these are usually smooth, congested mucosa-covered interlabial masses, and the child may experience difficulty voiding.

Evaluation

Management of ectopic ureter or ureterocele is based on a thorough assessment of the affected anatomy and the functional implications of the condition.

Anatomic Assessment

Physical Examination

Physical examination provides invaluable information for the diagnosis of both ectopic ureter and ureterocele. The prolapsed ureterocele is diagnostic and dramatic, but unusual. Further study of the detailed anatomy is necessary. It is unusual to be able to detect an ectopic perineal ureteral orifice in a child, but this does provide much information as to the character of the situation and best treatment when it is identified (Fig. 41.7). A search for the perineal orifice in a child with continuous wetting or a known leaking ectopic ureter is worthwhile. Rarely, the dilated Gartner duct cyst may be detected on careful perineal examination (Fig. 41.8). These orifices or cystic structures may then be imaged by injection of contrast.

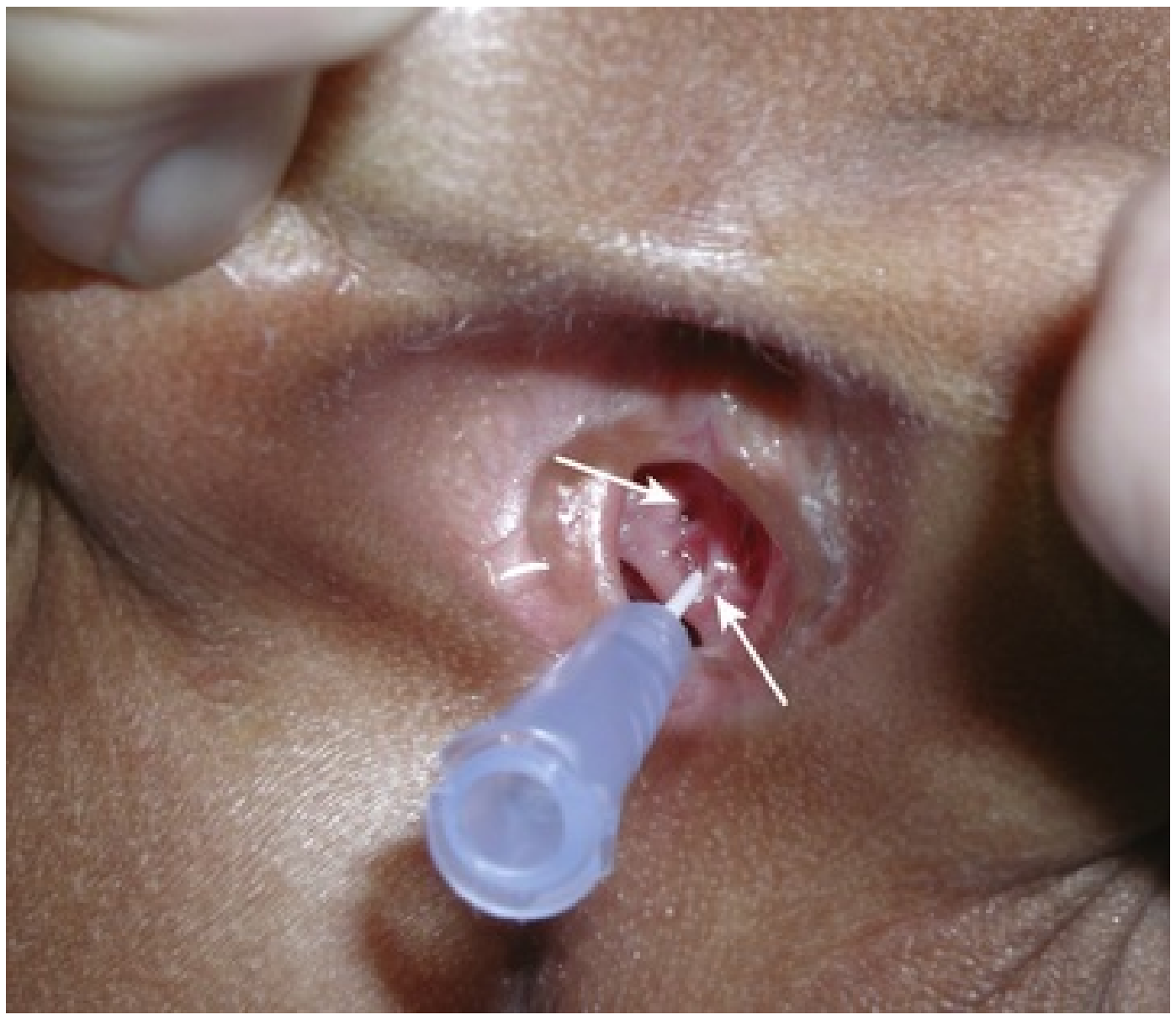

FIG. 41.7 Perineal ectopic ureteral orifice *(bottom arrow)* cannulated with an angiocatheter, situated between the urethral orifice *(top arrow)* and the vagina, just to the left of midline.

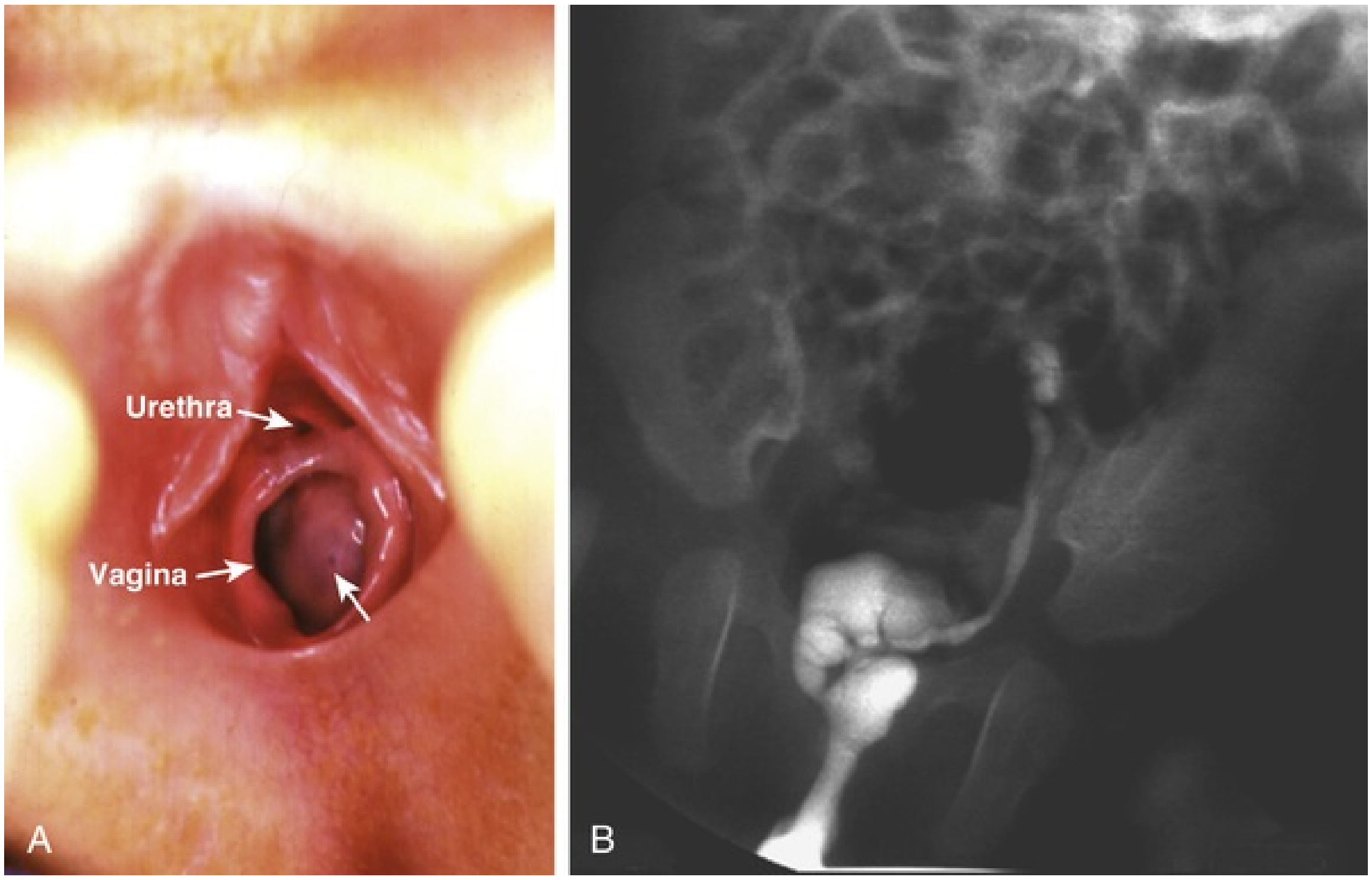

FIG. 41.8 (A) Gartner duct cyst *(bottom right arrow)* in a newborn with a left multicystic dysplastic kidney. (B) Injection of the cyst communicated with the ureter and dysplastic kidney.

The dilated upper pole of either an ectopic ureter or ureterocele may be palpable in the relaxed infant, but this is difficult in the older child.

Ultrasonography

The ultrasound image will usually provide the anatomic diagnosis and permit inference of functional assessment. **The typical findings are as with the prenatal imaging of a dilated upper pole with ureteral dilation or a dilated single system.** The character of the renal parenchyma is more readily seen postnatally, and if it appears healthy, the true need for functional upper tract imaging is controversial. Depending on the chosen treatment algorithm, it may be argued that this is unnecessary if it will not change treatment. The difference between functioning upper poles and those with little to no function is usually apparent (Figs. 41.9 and 41.10).

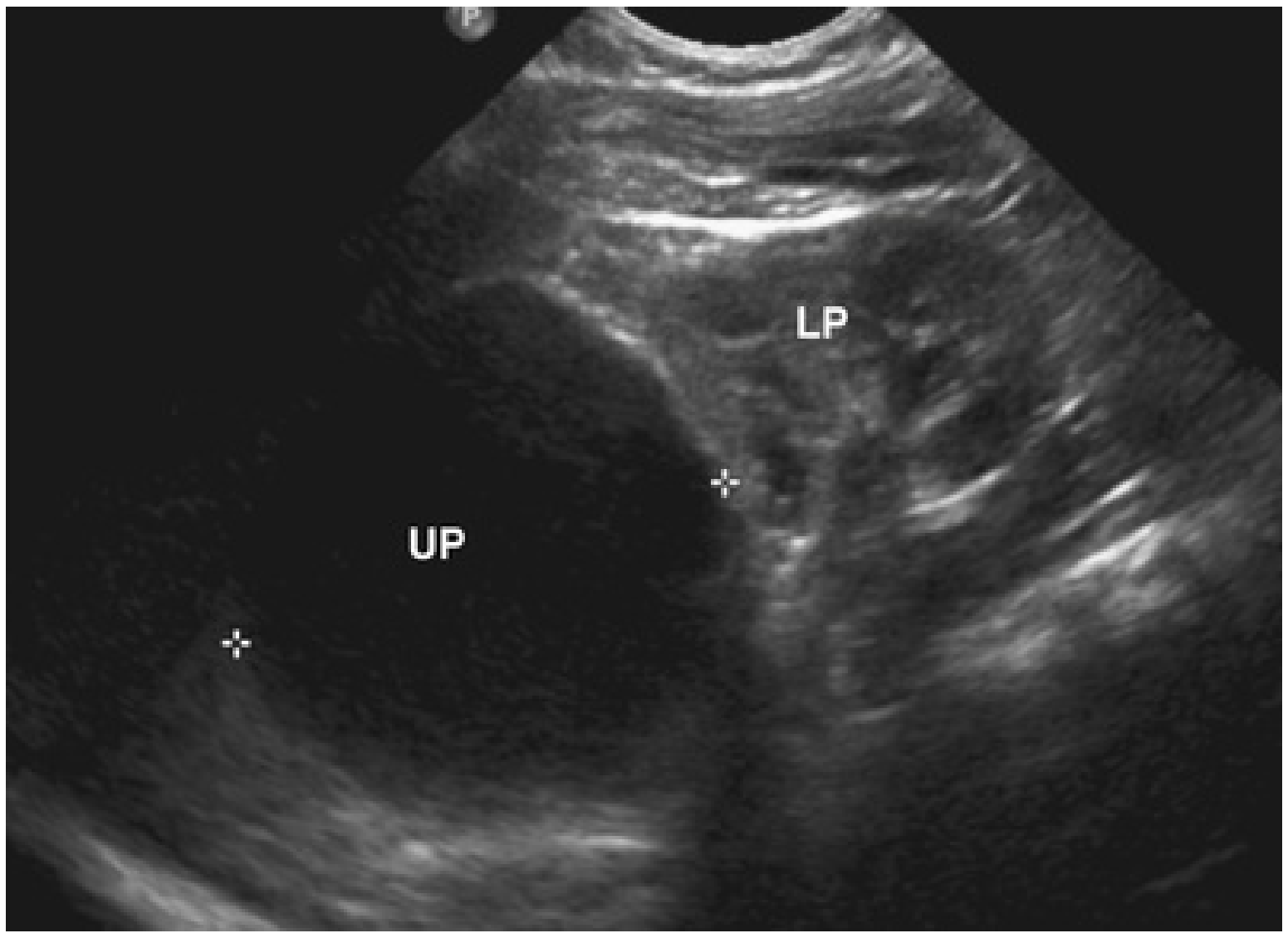

FIG. 41.9 Ultrasound image of dilated upper pole *(UP)* associated with a ureterocele, demonstrating limited renal parenchyma (same patient as in Fig. 41.33). *LP,* Lower pole.

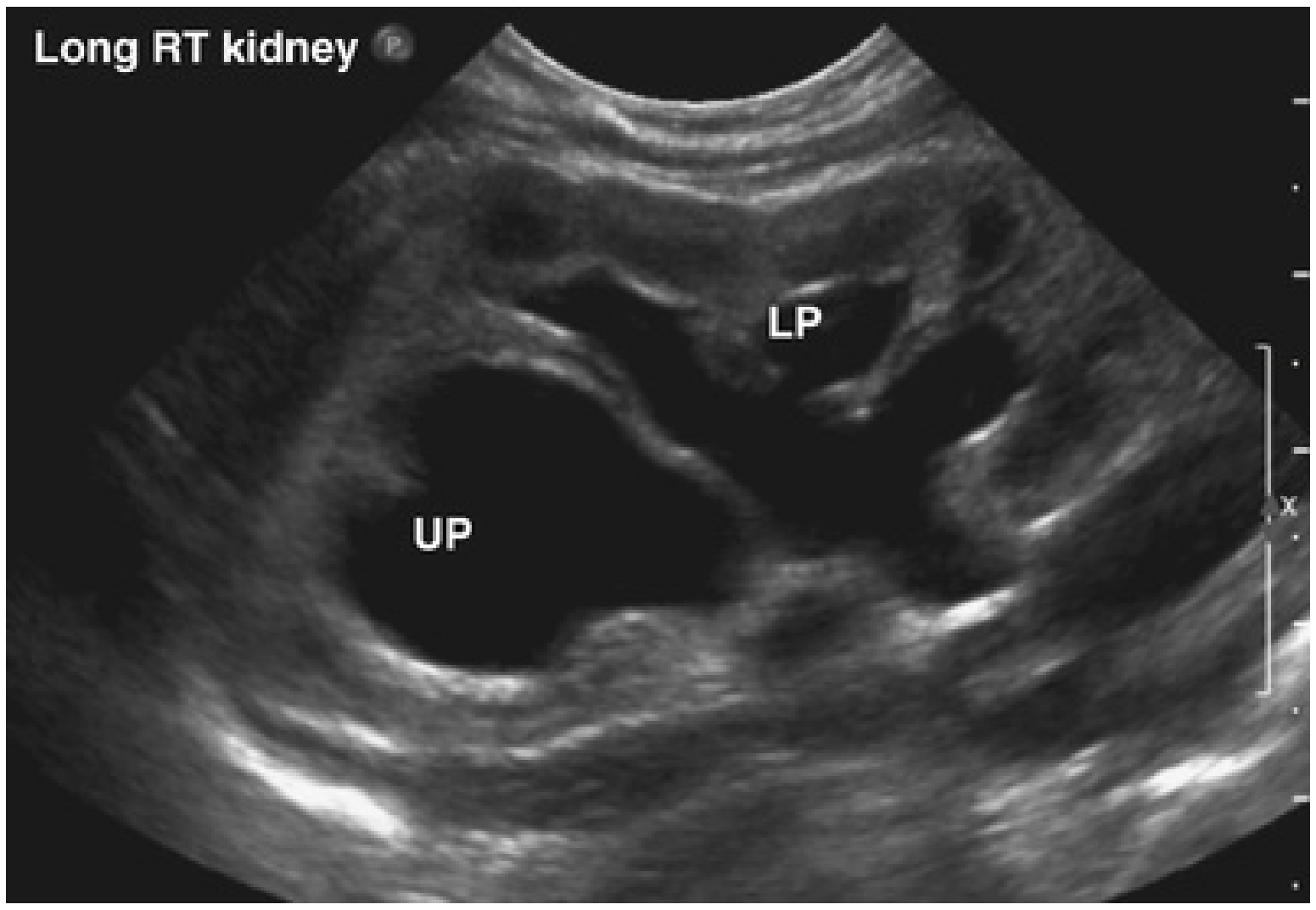

FIG. 41.10 Ultrasound image demonstrating dilated upper pole *(UP)* and lower pole *(LP)* associated with a ureterocele. The upper pole has evident renal parenchyma. The lower pole is dilated because of compression of the dilated upper pole ureter on the lower pole system, creating a partial obstruction.

There are no characteristics that permit differentiation between a dilated ectopic ureter and ureterocele above the level of the bladder. **The bladder images therefore are critically important because management of the two**

entities can be very different.

Bladder views are typically diagnostic in differentiating ureterocele from ectopic ureter by revealing a thin-walled, cystic dilation within the bladder and not extending beyond its walls (Fig. 41.11). The laterality of the ureterocele is usually apparent but may appear midline if large. A lobulated ureterocele may appear as two structures, but careful examination should show communication. It is difficult to visualize extension of a cecoureterocele into the bladder neck, so nonvisualization is not diagnostic.

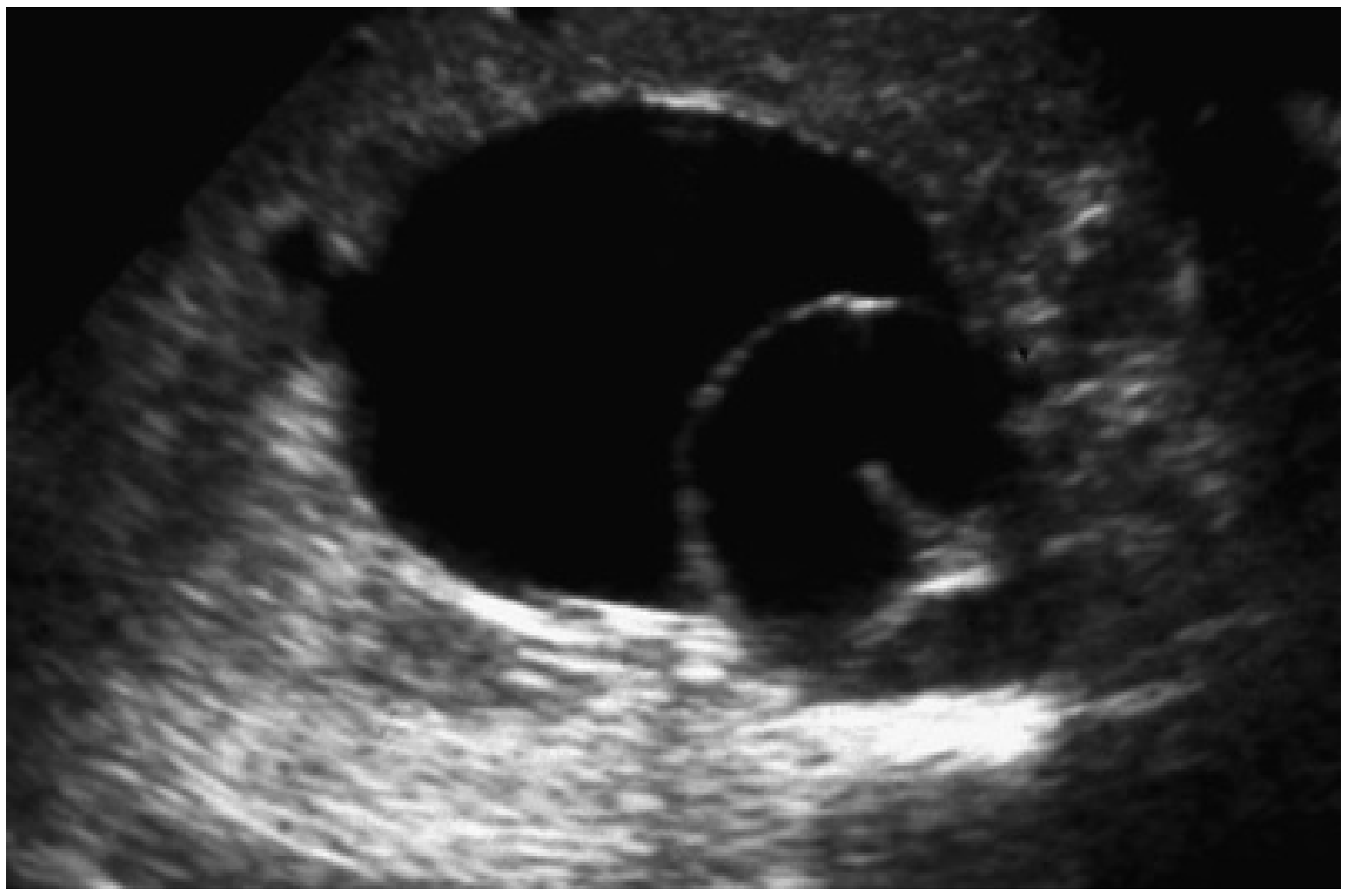

FIG. 41.11 Ultrasound image of an intravesical ureterocele at the bladder level.

Several ultrasound patterns may produce confusion in diagnosis. A large ureterocele may completely fill a bladder with no urine in the bladder itself. A full bladder with an effaced ureterocele may be mistakenly considered an ectopic ureter. Observation of the bladder over time will usually avoid these errors. A very dilated ectopic ureter may produce an impression on the bladder and appear as a ureterocele, but the wall will be bilaminar and much thicker than typically seen with a ureterocele (Fig. 41.12A and B). Furthermore, the lumen of the ectopic ureter will extend well outside the bladder walls. This is referred to as a pseudoureterocele as mentioned earlier.

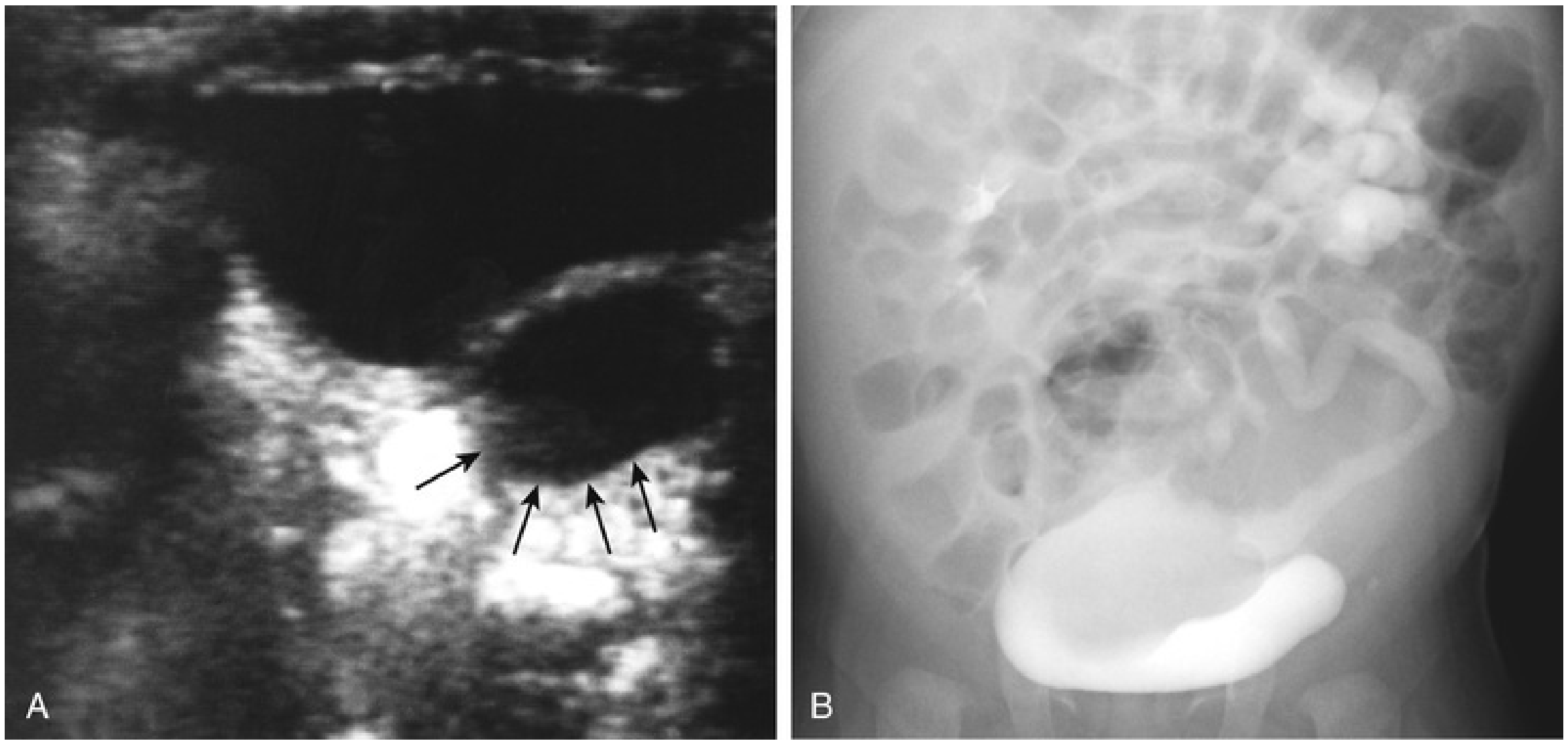

FIG. 41.12 (A) Ultrasound image of a bladder in a child with an ectopic ureter extending into the bladder. The wall of the ureter is thicker than the ureterocele, and the lumen of the ureter extends well outside the bladder lumen, indicating that this is an ectopic ureter rather than a ureterocele. (B) Voiding cystourethrogram of a large ectopic ureter pushing inward on the back of the bladder and appearing as a filling defect in the bladder (pseudoureterocele). (B, Courtesy of Dr. Jeanne Chow, Assistant Professor of Radiology, Harvard Medical School and Children's Hospital, Boston.)

Voiding Cystourethrogram

The voiding cystourethrogram (VCUG) provides the most definitive evaluation of the bladder and urethra and often of the distal ureters and is an obligatory imaging test. This should almost always be obtained before any intervention to define the baseline situation. The unusual situation in which a VCUG may not be obtained would be if decompression of a ureterocele producing bladder outlet obstruction or severe bilateral upper tract obstruction in an infant is urgently indicated. It is unlikely that the findings on VCUG would alter treatment, which would nearly always be transurethral puncture. The presence of reflux may determine initial treatment for some practitioners and is an important parameter in clinical management after initial decompression of the ureterocele. In the setting of an ectopic ureter, ipsilateral lower pole reflux is unlikely to resolve spontaneously and will influence definitive treatment options.

After incision of a ureterocele, the presence of reflux either ipsilaterally or contralaterally will be critical in therapeutic decision making.

Magnetic Resonance Imaging

Magnetic resonance urography can provide the most detailed images of an affected urinary tract, however magnetic resonance imaging (MRI) in young children often requires sedation and typically does not add information not already obtained with less expensive methods. At the present time, the value of MRI rests with patients in whom other imaging cannot define complex anatomy. This may occur in duplicated collecting systems with a nondilated upper pole, one with massive dilation in which the existence of duplication may be uncertain, or one in which anatomic relationships are significantly distorted (Fig. 41.13). If this type of anatomic delineation is needed, MRI offers the addition of functional information that is an important aspect of evaluation (Fig. 41.14).

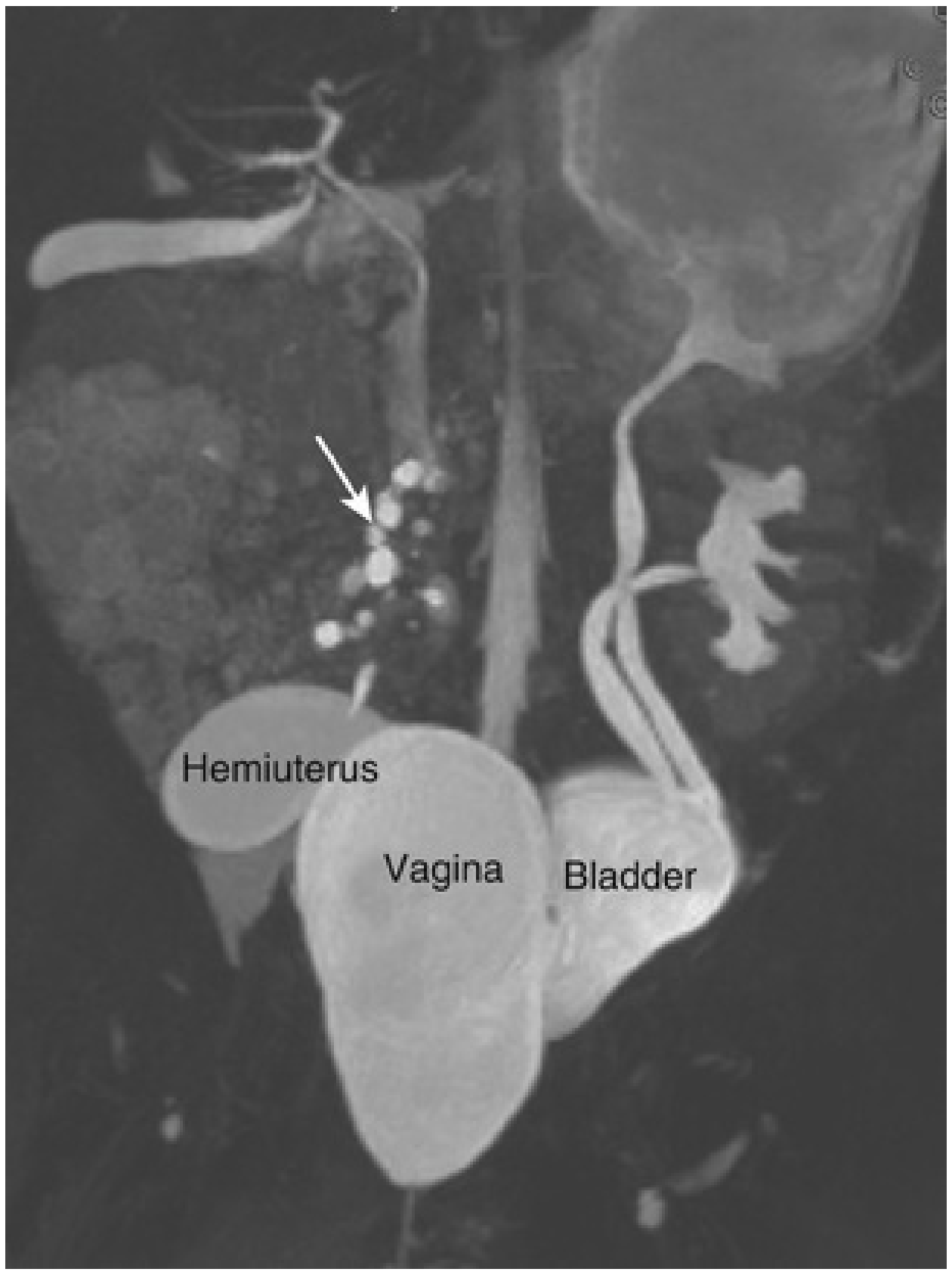

FIG. 41.13 Magnetic resonance image demonstrating the complex anatomy of a child with an ectopic ureter associated with a right dysplastic, cystic kidney *(arrow)* draining into an obstructed hemivagina and producing urinary dilation of the right hemiuterus. Initial therapy constituted creating a distal window between the two vaginae. Subsequently, the patient underwent right nephrectomy.

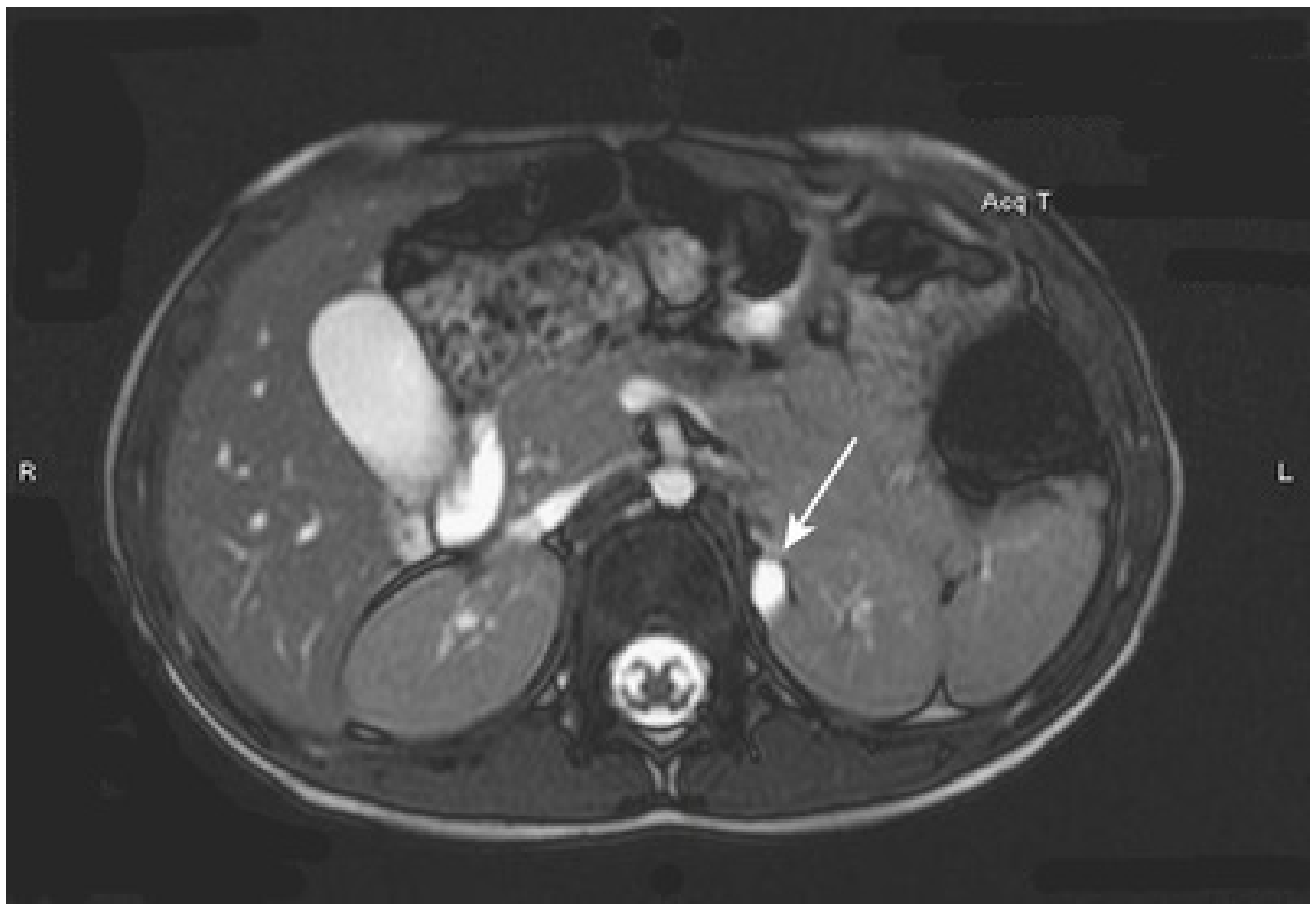

FIG. 41.14 Magnetic resonance urogram demonstrating the presence of an occult upper pole associated with an ectopic ureter producing incontinence. The left upper pole ureter is marked by the *arrow* at the level of the lower pole pelvis.

Functional Assessment

Functional urinary assessment in association with an ectopic ureter or ureterocele is the foundation for both initial management and postoperative care. Both renal and bladder function are affected by the developmental abnormalities of ureteral formation and may ultimately require complex surgical interventions.

Renal Function

Nuclear Imaging.

Radionuclide renal imaging remains the gold standard for renal functional assessment, and this is usually best afforded by dimercaptosuccinic acid (DMSA) imaging (Fig. 41.15A and B). The function of the affected upper pole is the principal focus, but the health of the other renal moieties must be determined as well, particularly if there is lower pole reflux or hydronephrosis of any unit. Although there have been some attempts to define what the “normal” function of an upper pole associated with an ectopic ureter or ureterocele should be, there are no criteria to define this. The clinical impact comes with the decision to preserve the upper tract or not, yet there are no objective parameters to determine what level of functional contribution should be preserved. The functional assessment therefore offers the dichotomy of some function versus no function, and this may or may not determine clinical management (see later). In general, this is clear, but there will always be ambiguous cases. Preoperative assessment is further complicated by the lack of ability to predict the effect of decompression.

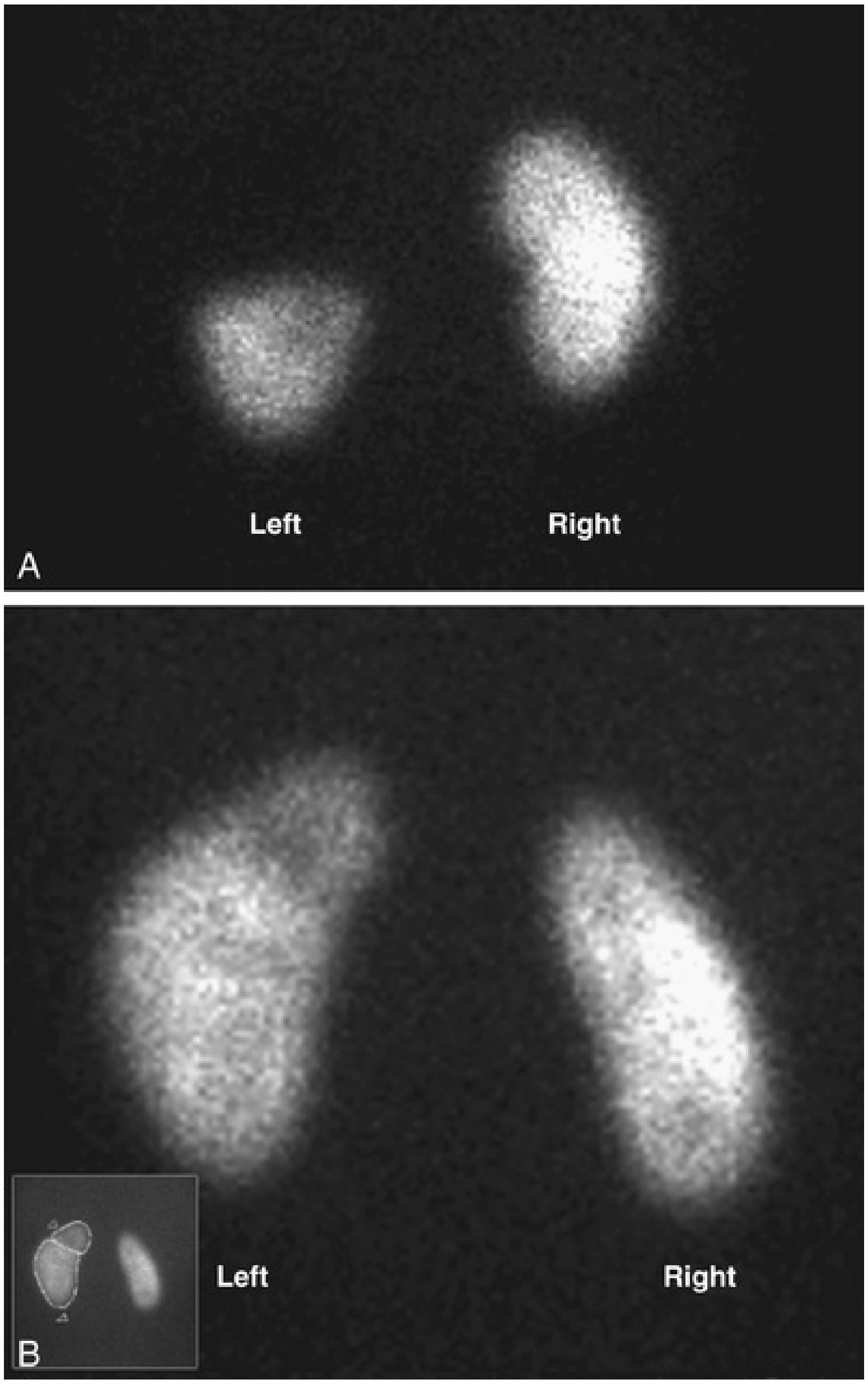

FIG. 41.15 (A) Dimercaptosuccinic acid renal scan in a child with a left ureterocele demonstrating no function in the affected upper pole. (B) Dimercaptosuccinic acid renal scan in a child with a ureterocele with evidence of upper pole function after transurethral incision to decompress the ureterocele. The upper pole was separately assessed as contributing

approximately 18% of total renal function.

The assessment of ureteroceles in which an observational approach may be considered is best accomplished with a diuretic renal scan (Han et al., 2005), which would then replace the DMSA scan. This provides both functional and drainage measurements. This has been shown to be of some clinical value in ureteroceles in which drainage is adequate, and ultimate resolution of the hydronephrosis has been reported (Han et al., 2005). A dilated ectopic ureter is only rarely suitable for observational management, so the value of an assessment of obstruction is limited.

Intravenous Pyelogram.

In unusual situations, the intravenous pyelogram (IVP) may offer adequate functional information with anatomic delineation without the complexities of an MRI. Functional assessment is only qualitative, however, and the IVP is a less useful baseline study except when the anatomy is uncertain or there is uncertainty about an ectopic ureter with no dilation in the setting of incontinence (Fig. 41.16).

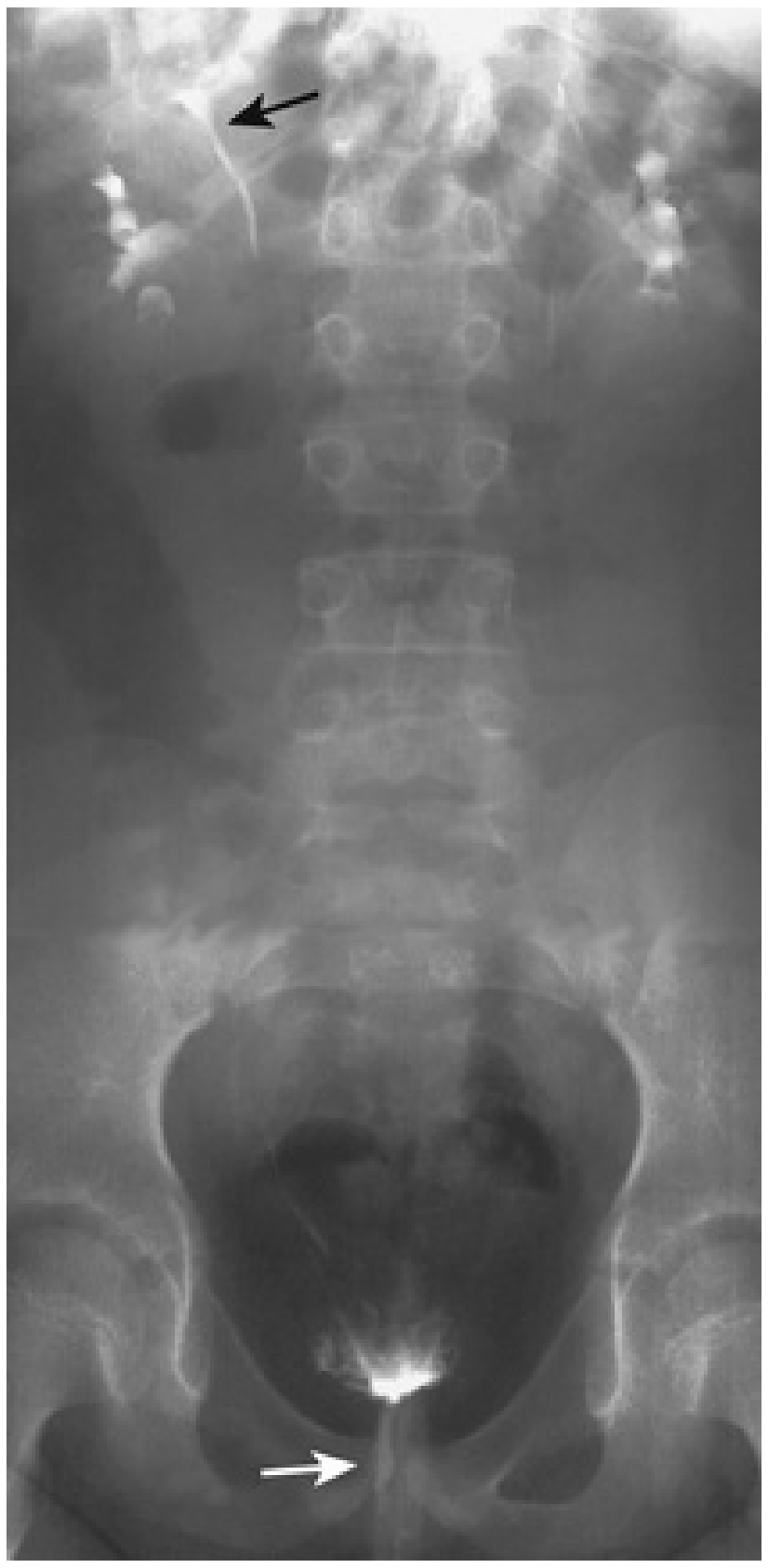

FIG. 41.16 Intravenous pyelogram in a 10-year-old child with lifelong wetting and evidence of ureteral duplication *(black arrow—upper pole)* with no hydronephrosis. The distal ureter *(white arrow)* can be seen passing by the bladder and bladder neck and inserting into the urethra near the perineum.

Bladder Function

Although the bladder is not the principal focus of clinical attention in the evaluation of the ectopic ureter or ureterocele, the potential for impaired bladder function cannot be ignored. This may be caused by bladder outlet obstruction from a ureterocele, or impaired continence resulting from inadequate bladder neck function with an ectopic ureter or ureterocele. In the extreme case of bilateral single-system ectopic ureters, bladder development may be severely impaired because of the absence of fetal bladder filling.

Ultrasound Imaging Interpretation

A simple bladder ultrasound image may be very useful in completing the functional evaluation of these patients. Waiting for bladder filling and emptying may yield information on bladder emptying efficiency and bladder wall thickness (indicative of possible outlet obstruction). The character, location, and size of the ureterocele can usually be assessed as well (see Fig. 41.11). In some cases, the ectopic nature of a dilated ureter may be identified ultrasonographically.

Ureterocele and Bladder Outlet

The appearance of the bladder base with filling and voiding demonstrated on VCUG (Fig. 41.17) is also useful in therapeutic decision making, because significant eversion indicates a weak trigonal floor that may be more likely to require surgical repair. Prolapse of a ureterocele into the urethra or demonstration of a cecoureterocele is an important factor in planning and performing a TUI and may be more predictive of the subsequent need for secondary surgery. **The usual descriptive terms in the context of a ureterocele include *prolapse,* which is movement of the ureterocele into the urethra, eversion, or diverticulum-like protrusion of the bladder base and trigone with filling and voiding (Fig. 41.18), and *intussusception,* or protrusion of the ureterocele back into its ureter (Fig. 41.19).**

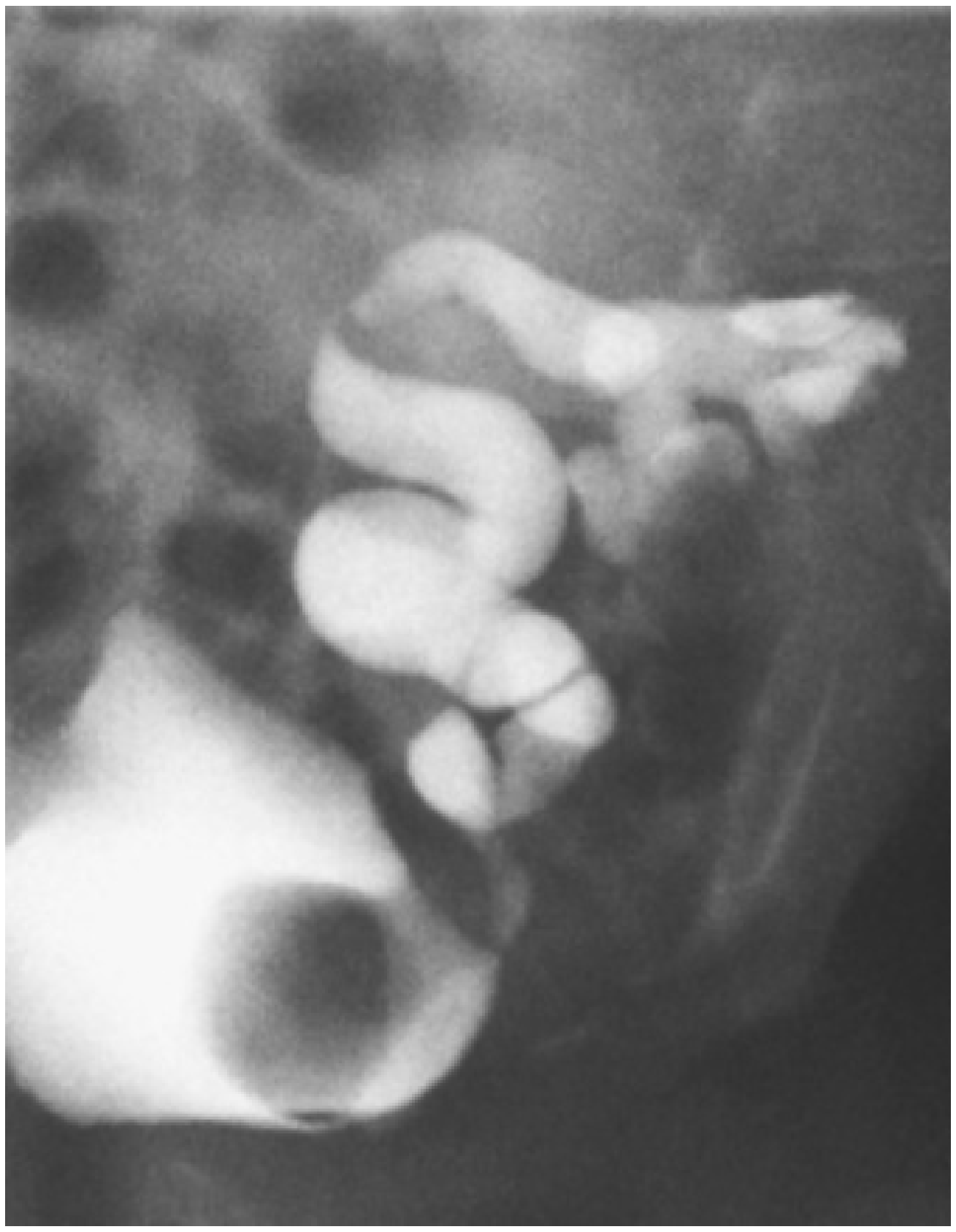

FIG. 41.17 Voiding cystourethrogram in a child with a ureterocele appearing as a filling defect within the bladder and massive ipsilateral lower pole reflux.

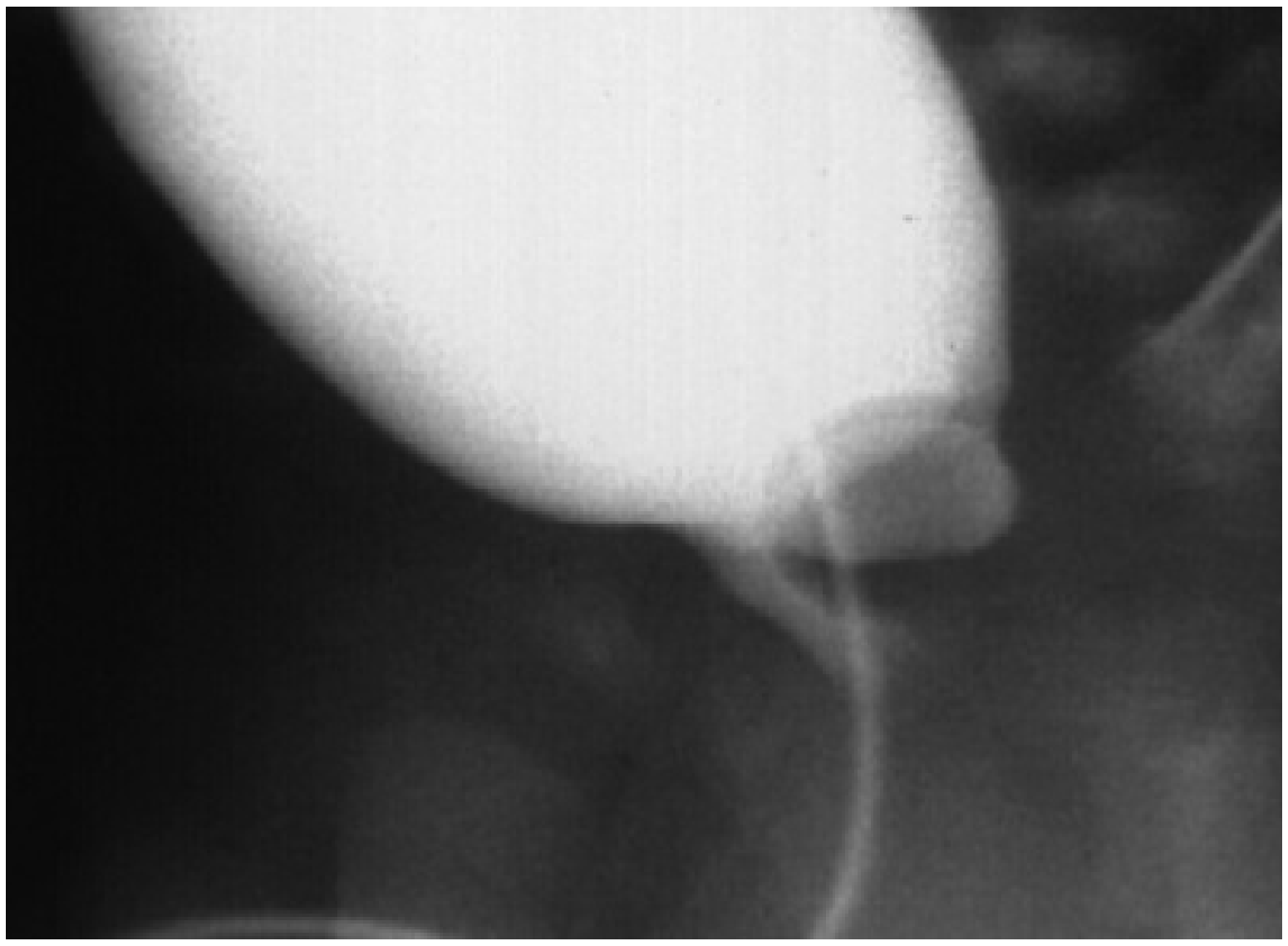

FIG. 41.18 Voiding cystourethrogram in a child with ureterocele and evidence of prolapse of the ureterocele into the bladder neck with voiding.

This is distinct from a cecoureterocele, in which the ureterocele is part of the urethra. This pattern of prolapse can cause bladder outlet obstruction.

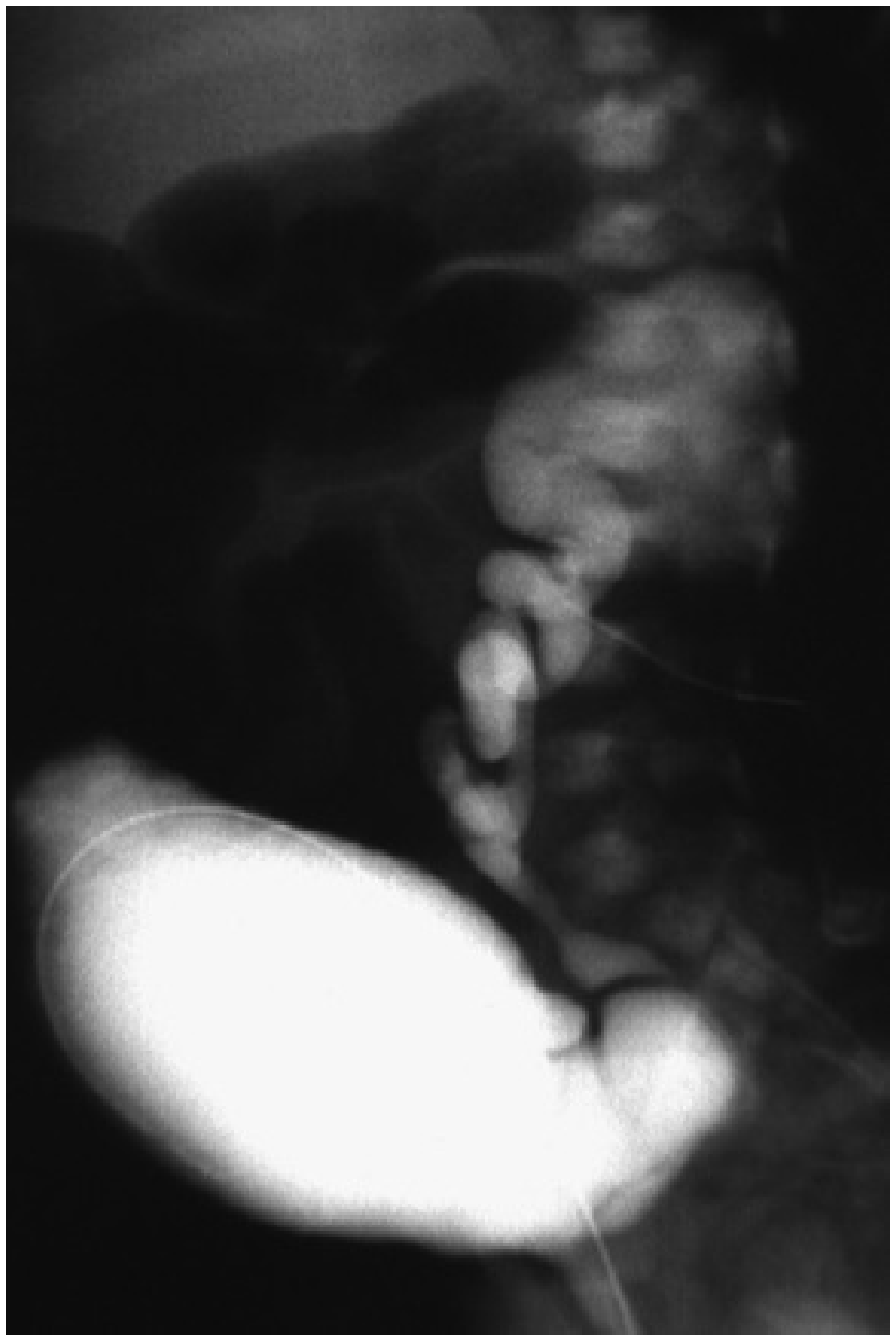

FIG. 41.19 Voiding cystourethrogram in a child with a ureterocele and evidence of ureterocele eversion with voiding. The apparent diverticulum is the ureterocele extending outside the bladder wall with increased intravesical pressure. This pattern may be seen with the ureterocele everting or intussuscepting into its dilated ureter. There is lower pole reflux as well.

Although it is difficult to predict continence at initial presentation, the ureterocele or ectopic ureter associated with a patulous bladder neck may be complicated by later urinary incontinence. Cecoureteroceles are a particular risk factor for incontinence, but we have also observed bladder neck ectopic ureters with wide-open bladder necks and later incontinence after resection of the distal ectopic ureter and external bladder neck reinforcement (Fig. 41.20). These patients may benefit from more aggressive bladder neck tightening at the time of definitive resection of the ureterocele or ectopic ureter; however, this entails some risk for disturbing what may be normal bladder neck function. Videourodynamic evaluation may be helpful in such patients.

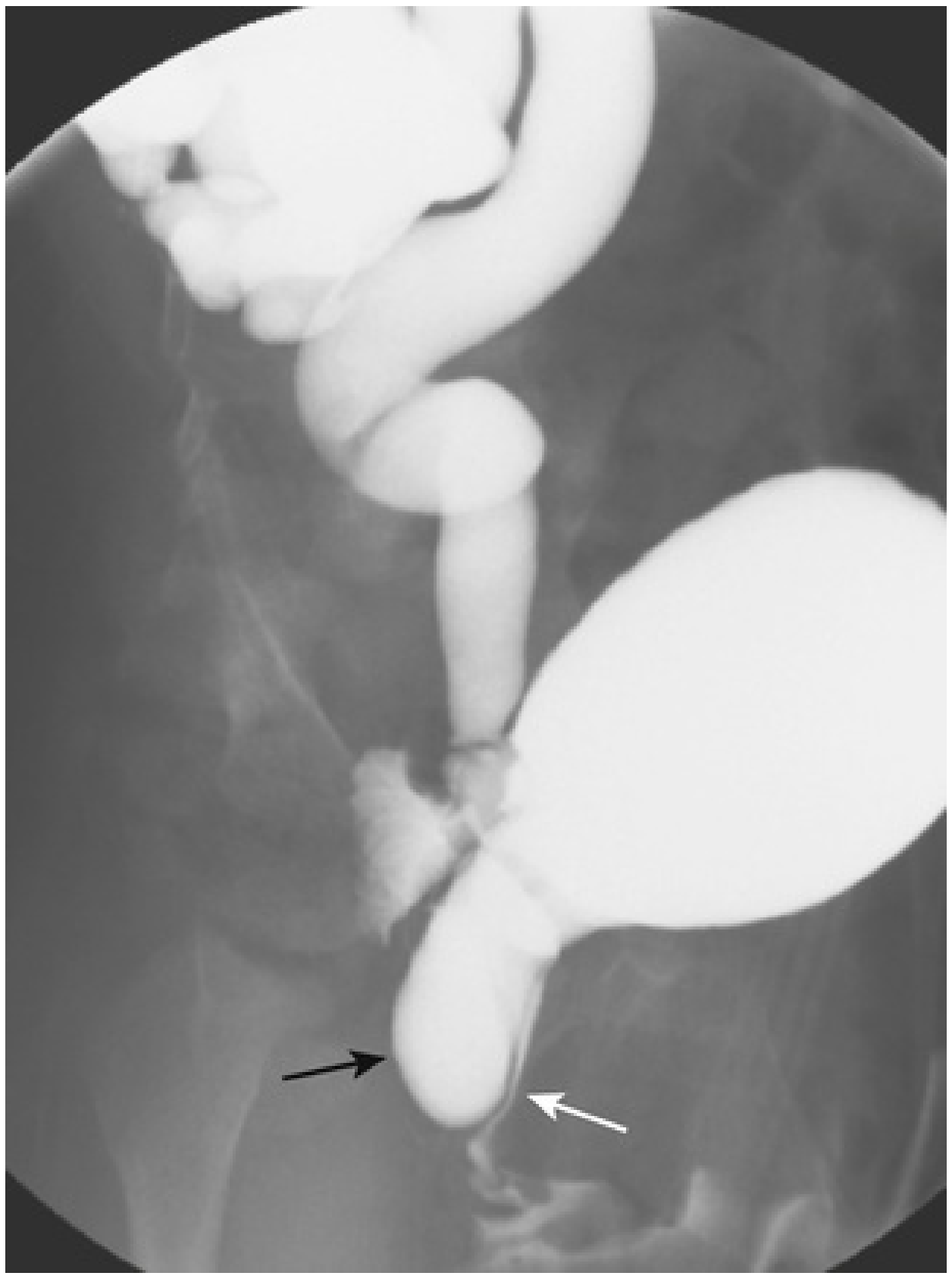

FIG. 41.20 Voiding cystourethrogram of a cecoureterocele in which the ureterocele *(black arrow)* is attached to the urethra *(white arrow)* and the lumen extends into the urethra. These are the most challenging ureteroceles because there is involvement of the bladder neck and urethra.

Endoscopic Evaluation

The final element of evaluation of a ureterocele or ectopic ureter can be endoscopic. Although this is not always essential, most cases of both ureterocele and ectopic ureter will come to operative intervention, and concurrent endoscopic evaluation is important if not essential. Certainly when endoscopic incision is to be performed, this is a critical element and should be performed thoroughly before incision to permit selection of the most effective site.

Endoscopy should take note of the character of the urethra, bladder neck, and trigone relative to the ureterocele or ectopic ureter. The location of the other ureteral orifices should be documented. The orifice of the affected

ureter should be sought but may not be identified. The urethra is examined carefully for the orifice if not seen in the bladder. **The appearance of the ureterocele will vary with bladder filling, and it is best to start with little filling and slowly increase bladder volume (Fig. 41.21).** The ureterocele will be seen to slowly flatten. Its true limits are best appreciated with limited bladder filling; this will expose the lowest portion, which is probably the best site for incision. Extension of the ureterocele into the urethra, indicative of a cecoureterocele, may be detected, and this indicates the need to make sure this section does not cause obstruction with incision. Retrograde contrast injection can confirm the presence of ureterocele disproportion, as there will be only a narrow proximal ureter and no filling of an upper pole segment (see Fig. 41.5). Unusual connections with the genital ducts may also be demonstrated as in the example of a boy with a ureterocele and communication among the ureter, vas deferens, and seminal vesicles (see Fig. 41.2).

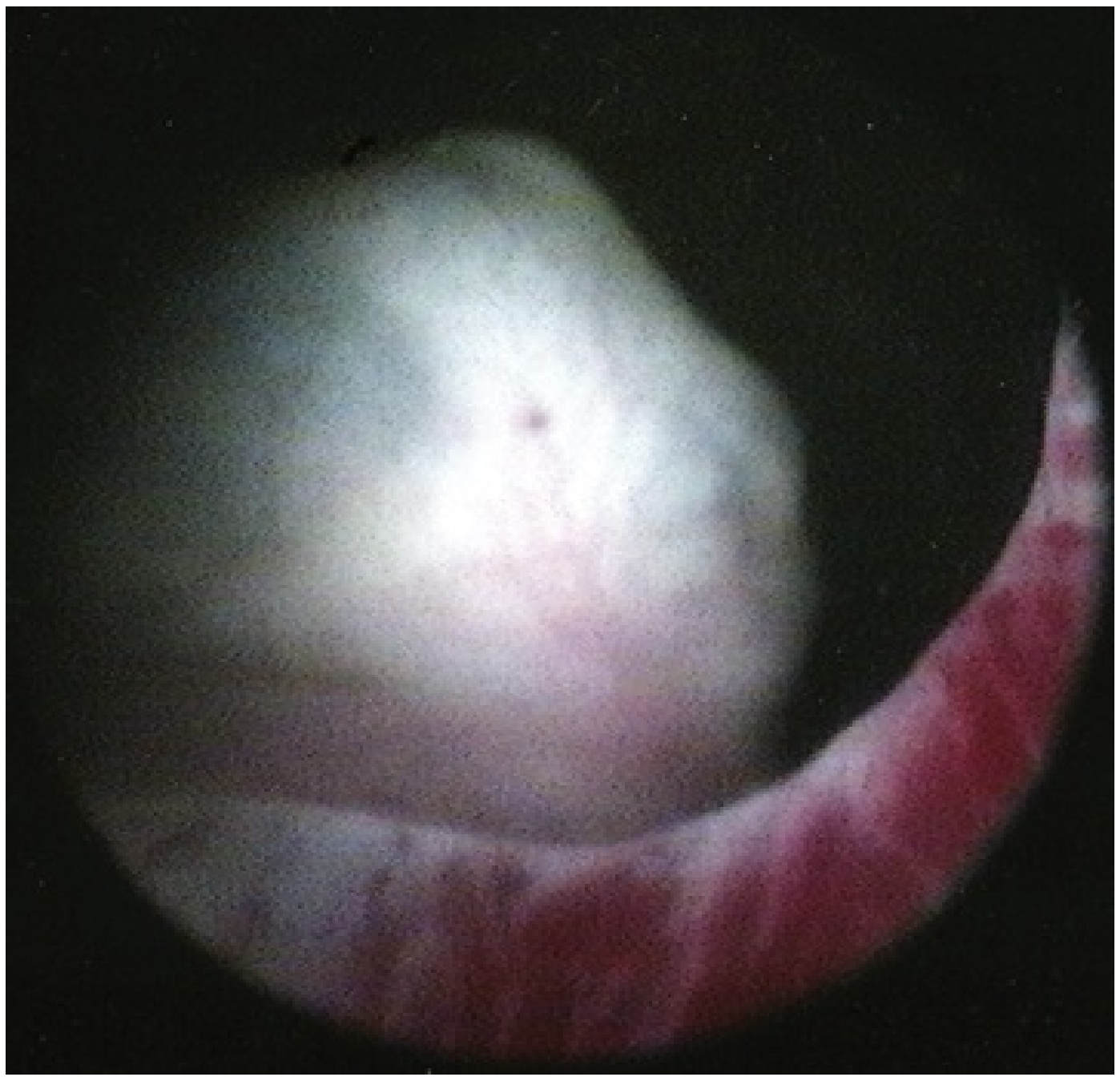

FIG. 41.21 Endoscopic image of an intravesical ureterocele just inside the bladder neck.

An ectopic ureteral orifice may be very difficult to find endoscopically, but if it is in the bladder neck, it is often patulous (Fig. 41.22). The anatomic connections of the ectopic ureter may be demonstrated using retrograde contrast studies. We have identified ectopic ureters that appear to have a very thin layer of tissue separating them from the urethra, looking much more like a ureterocele than an ectopic ureter (Fig. 41.23A and B). These may be associated with defects in the bladder neck and incontinence (see Fig. 41.23C). Consideration for more extensive removal of these patulous segments with reconstruction of the bladder neck may be part of the clinical decision, and their endoscopic appearance can facilitate this decision.

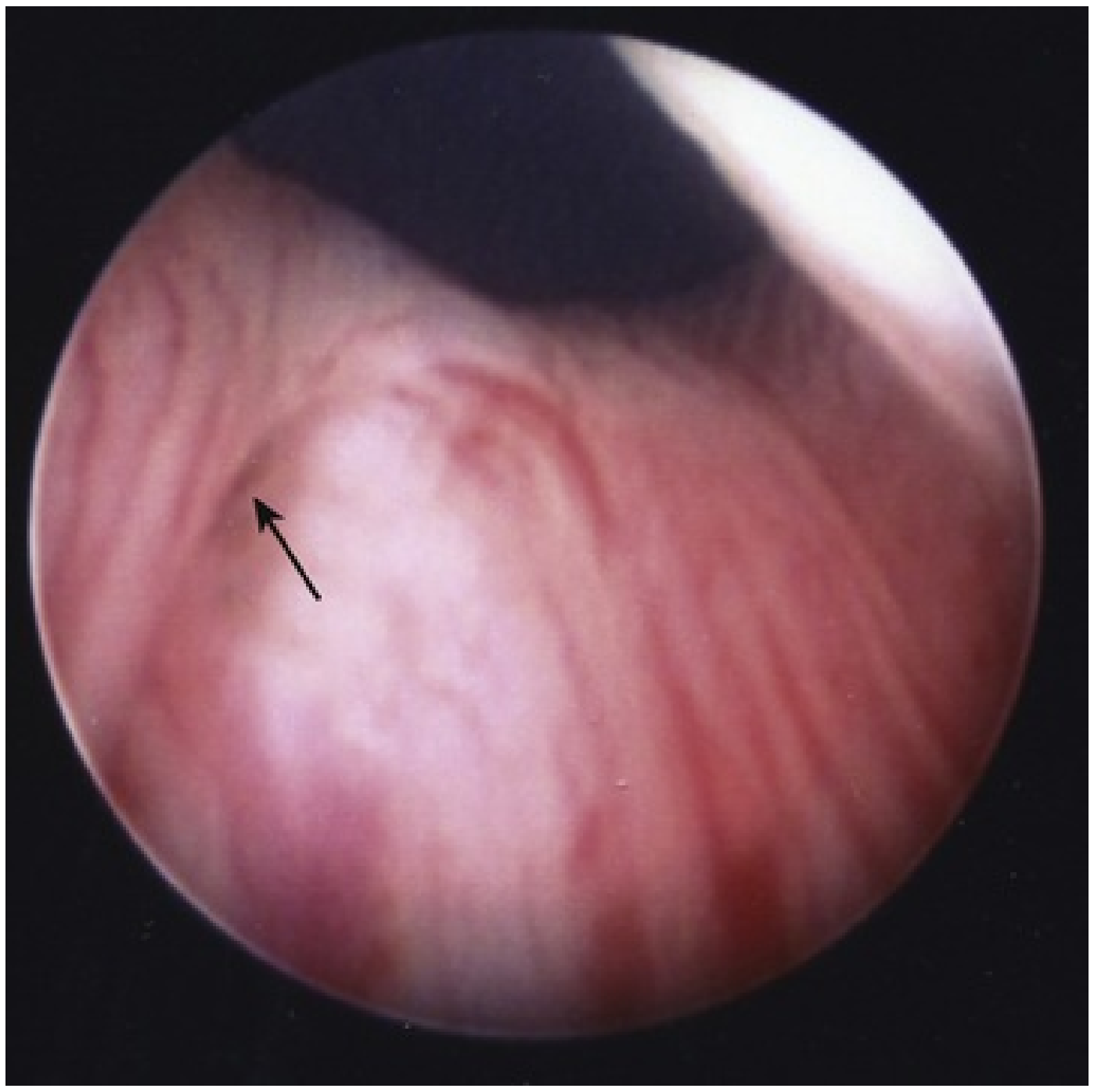

FIG. 41.22 Endoscopic images of a bladder neck and ectopic ureteral orifice *(arrow).* Bladder neck ectopic ureteral orifices are often patulous but do not always reflux.

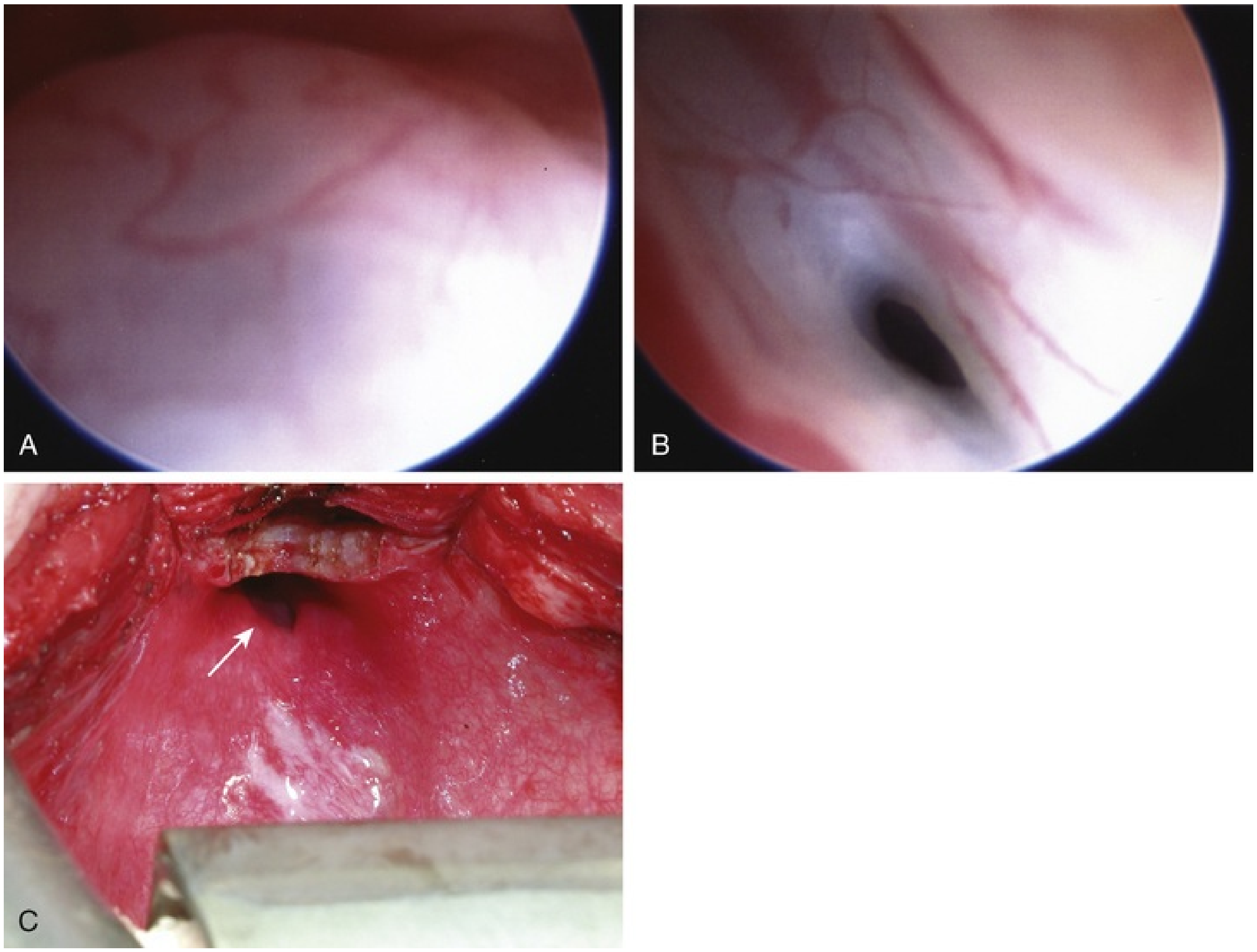

FIG. 41.23 (A, B) Endoscopic images of bladder neck orifices of an ectopic ureter with an appearance similar to that of a ureterocele without the dilated intravesical portion. The membrane overlying the orifice was thin and fluttered with irrigation, just as a ureterocele would be. (C) At open surgery, these bladder neck ectopic ureters can have the appearance of a defect in the bladder neck *(arrow)* and be associated with incontinence. It remains unclear how these ectopic ureters are related to ureteroceles.

Key Points: Evaluation of Ectopic Ureters and Ureteroceles

- An ultrasound image usually provides the anatomic diagnosis of an ectopic ureter or ureterocele and permits an inference of renal function.
- Typical findings are of hydroureteronephrosis in a single system or of a dilated upper pole with ureteral dilation in a duplicated system.
- The ureterocele is characterized by a thin-walled, cystic dilation within the bladder and not extending beyond its walls.

- A very dilated ectopic ureter may produce an impression on the bladder and appear as a ureterocele; this is called a *pseudoureterocele*.
- Radionuclide renal imaging remains the gold standard for renal functional assessment, and this is usually best provided by DMSA imaging. A mercapto-acetyl-triglycine (MAG3) renal function study with Lasix can be considered when need to determine both renal function and degree of obstruction.
- The function of the affected upper pole is the principal focus, but the health of the other renal moieties must be determined as well.
- VCUG provides the most definitive evaluation of the bladder and urethra.
- The appearance of the bladder base with filling and voiding demonstrated on VCUG will also be useful in therapeutic decision making, as massive eversion indicates a weak trigonal floor that may be more likely to require surgical repair.
- Endoscopy should take note of the character of the urethra, bladder neck, and trigone relative to the ureterocele or ectopic ureter.

Clinical Management

Management Goals

It should again be stressed that, before any surgical intervention for ectopic ureters or ureteroceles, the surgeon must obtain as much information as possible regarding the patient's altered anatomy and its potential clinical impact. Only then can a rational treatment plan be devised. Although specific and definitive management for ectopic ureters and ureteroceles differ, the goals of management are the same, and in many cases the approaches are identical.

The goals of therapy should be clearly defined and factored into the clinical decisions. These goals are preservation of renal function; elimination of infection, obstruction, and reflux; and maintenance of urinary continence. Minimizing surgical morbidity is a goal that must be included in this consideration. Although the goals of treatment are generally agreed upon, the means to achieving these goals remain controversial. One area in which there is some general agreement is that early institution of a daily prophylactic antibiotic can reduce the risk for UTIs in patients in whom there is significant hydronephrosis.

Historical Perspective

Initial management for ureterocele and ectopic ureter focused on the same goals as today, and ureterocele excision using open surgery was described in the early 1950s (Gross and Clatworthy 1950; Campbell, 1951). Total reconstruction with removal of nonfunctioning renal tissue and reconstruction at the level of the bladder with ureterocele excision and/or reimplantation was presented as a viable option in the mid-1950s and again became popular in the 1970s with the reports of Hendren et al. and Kroovland et al. (Hendren and Monfort, 1971; Kroovand and Perlmutter, 1979). The upper tract approach for ureteroceles, with upper pole partial nephrectomy to decompress the ureterocele, became the standard approach in the 1980s (King et al., 1983). Endoscopic incision of the ureterocele, initially as a salvage approach in the septic child, gained widespread favor in the 1990s, but its use is now more selectively applied based on imaging criteria in the acute setting and a means of relieving obstruction and preserving renal parenchyma (Tank, 1986; Rich et al., 1990). Observational management has emerged more recently, although this remains controversial and is likely best used in cases of small ureteroceles with minimal hydronephrosis.

Ectopic ureter was usually managed surgically in nearly all patients. An early description of the clinical presentation and management of the ectopic ureter focused on removal of the associated renal unit in patients with incontinence (Alldred and Higgins, 1951). Presentation in most cases was relatively late, and residual renal function was usually limited. Excision was commonly the best option. With prenatal detection, salvage of the affected renal moiety has become a common option, usually with an upper to lower drainage procedure in duplicated systems.

Fetal Management

Widespread use of fetal ultrasonography has resulted in a large portion of ectopic ureters and ureteroceles being diagnosed prenatally. Duplicated systems without hydronephrosis may not be noted prenatally, but when hydronephrosis is present, this is usually easily noted prenatally. There is no role for fetal intervention in the ectopic ureter, however its identification can help plan postnatal management. If there is suspicion of ectopic ureter (or ureterocele) prenatally, a postnatal ultrasound should be obtained and a VCUG considered. A recommendation for prophylactic antibiotics to be started at birth is often made to limit the risk for early UTI. Subsequent workup and management can be determined based on these initial studies. Ureteroceles are also not typically an indication for fetal intervention except in the rare instance when the ureterocele is large and causes obstruction of all renal units. In these patients, cystoscopic laser ablation of the fetal ureterocele has emerged as a management technique, although the procedure is still considered experimental and is only performed in select centers (Chalouhi et al., 2017; Persico et al., 2017).

Neonatal Management

Nonurgent Management

Most ureterocele and ectopic ureter patients are seen in a nonurgent manner, either in consultation after a baby with such an abnormality is born or in the clinic as a neonate. Evaluation should always start with renal ultrasonography. If there is significant hydroureteronephrosis caused either by a ureterocele or ectopic ureter, the start of prophylactic antibiotics should be considered and a

VCUG ordered. The determination for continuation or prophylactic antibiotics can be made thereafter. Even in the absence of reflux, prophylaxis can be considered to minimize the risk for infection in the setting of hydroureteronephrosis with obstruction. A renal function study is often obtained when the child is old enough for the study (generally older than 2 months of age) to assess the degree of renal function in the obstructed segment and other moieties.

In the case of the small ureterocele with minimal degree of hydronephrosis and no or little demonstrable obstruction, observation is one management option. In cases of significant hydronephrosis with obstruction, especially if the parenchyma in the obstructed segment is compromised, consideration should be given to proceeding with TUI. Various methods for puncture have been described. The most commonly used method is a low transverse incision, but a "watering can" technique to the incision of the ureterocele has also been described, in which a holmium laser is used to puncture multiple holes in the ureterocele in the hopes that the risk for *de novo* VUR will be lower than with traditional incision (Haddad et al., 2017). If an endoscopic approach cannot be undertaken, a cutaneous distal ureterostomy can be performed to divert the urine until the child is old enough for formal reimplantation.

Urgent Management

In the child who presents with sepsis of urinary origin in the setting of obstruction caused by an ectopic ureter or ureterocele, antibiotics are usually sufficient to clinically stabilize the patient, however if the child does not respond promptly and appropriately, a TUI of an obstructing ureterocele or a nephrostomy tube drainage of the ectopic ureter should be considered. A cutaneous distal ureterostomy can also be performed in either setting to promptly and reliably establish drainage. Once the child has proven to be prone to infection by presenting in this manner, a drainage procedure should be undertaken in a nonurgent fashion once the child is stabilized (if such a procedure was not required urgently) to prevent future infections.

General Management Principles

For both ectopic ureter and ureterocele associated with a duplicated system, a principle concern is the preservation of functional renal parenchyma. This goal is achieved by correcting obstruction and preventing reflux with its

risk for renal parenchymal damage from infection (Churchill et al., 1992). At times it is necessary to balance one against the other, because relieving the obstruction of an ectopic ureter or ureterocele may induce reflux in either or both poles of the involved kidney. In other instances, the same action may cause existing lower pole reflux to resolve. Several methods of achieving these goals are available. The decision making regarding when and how to intervene is quite subjective however, and decisions regarding how much renal function is worth preserving should be made on an individual basis. **For an ectopic ureter, this can mean ureteral reimplantation or, in case of a duplex kidney, common sheath reimplantation or ureteroureterostomy, either low or proximal near the renal pelvis.**

A recently described technique for management of the ectopic ureter in the young child who is not yet old enough for a formal ureteral reimplantation is to create a side-to-side nondismembered refluxing anastomosis. Alyami et al. described using this technique to manage 29 patients with an average age at the time of surgery of 3.7 months. This group has performed this technique with the intention of considering it definitive in a certain population with a low risk for development of UTI. Long-term data will be necessary to determine the safety of this management technique and to determine how many children do, in fact, require further procedures (Alyami et al., 2017). For a ureterocele, this can be accomplished with TUI as well as ureterocele excision and common sheath reimplantation or ureteroureterostomy. In both cases, acute decompression may be necessary because of sepsis and the age of the child. For the ectopic ureter, acute decompression is best achieved with an end ureterostomy near the bladder, whereas for a ureterocele, TUI is usually effective.

The decision making for renal parenchymal preservation is largely empirical, and there are few objective criteria to indicate how much residual function is worth preserving. The presence of VUR into either of the ureters must be considered as well, and every effort should be made to correct this with the drainage procedure.

Ectopic ureters and ureteroceles are overwhelmingly dealt with postnatally. Although one might reason that a prenatal diagnosis could lead to earlier relief of obstruction and presumably a greater chance of recovery of upper pole function, the evidence in the literature seems to show that there is a limited recovery of function, even with early decompression. The observations by Tank using early endoscopic puncture demonstrated function that had not been detected before drainage (Tank, 1986). Impaired function of the upper pole occurs equally in those diagnosed prenatally and postnatally (Upadhyay et al., 2002). In most instances, the upper pole contributes little to overall renal function, but as discussed earlier, there are no criteria for what should be normal upper pole function.

Key Points: Clinical Management—Goals of Treatment

- The goals of therapy are preservation of renal function; elimination of infection, obstruction, and reflux; and maintenance of urinary continence.
- Minimization of overall procedural morbidity is also a goal of treatment.
- For both ectopic ureter and ureterocele associated with a duplicated system, a primary concern is preservation of functional renal parenchyma.
- Decision making for renal parenchymal preservation is largely empirical, and there are few objective criteria to indicate how much residual function is worth preserving.
- For an ectopic ureter, this can mean common sheath reimplantation or ureteroureterostomy, either low or proximal near the renal pelvis.
- For a ureterocele, this can be accomplished by TUI, as well as ureterocele excision and common sheath reimplantation or ureteroureterostomy.
- Observational management of ureteroceles in carefully selected patients is a reasonable option, with the potential for spontaneous decompression.

Observational Management

Several groups have reported nonoperative management of ureteroceles meeting criteria of no obstruction of the ipsilateral lower pole or contralateral kidney and limited reflux to the lower pole (grade III or less) (Shankar et al., 2001; Direnna and Leonard, 2006), no function of the upper pole, or no obstruction on diuretic renography (Han et al., 2005). Coplen and Austin described a subset of patients with ureteroceles and multicystic dysplastic kidneys in the associated upper tract segment (Coplen and Austin, 2004). This group had either low-grade or no reflux and no ureteral dilation. These prenatally diagnosed patients were managed nonoperatively and had a benign clinical course. Clearly some children will do well for a period without intervention, and in some patients resolution of upper pole dilation and lower pole reflux has been reported. It is challenging to know how to counsel families regarding this approach, as the potential for later, unpredictable acute presentation is real. For that individual, even if with a low statistical incidence, it is very significant clinically. The long-term risk and relative balance of morbidities of this strategy and the robustness of clinical predictors have yet to be determined. Carefully considered, observational management of children with ureteroceles can be an appropriate strategy with careful selection and parental education.

Total Reconstruction

Total reconstruction of both upper and lower tracts has been advocated by some authors as being the most definitive procedure for ureteroceles (Hendren and Mitchell, 1979; Kroovand and Perlmutter, 1979). **Upper pole heminephrectomy with ureterocele excision and reimplantation of the lower pole ureter is definitive but is an extensive operation performed with two incisions.** Although the reported success rates are good, it remains uncertain if this is appropriate in most children when long-term relief from obstruction and reflux may be achieved with one or at most two lesser procedures. The older child with a massive ureterocele and no function of an upper pole with significant lower pole reflux might be reasonably treated with upper pole nephrectomy and ureterocele excision and bladder reconstruction. At the present time, the partial nephrectomy would be reasonably performed laparoscopically or retroperitoneoscopically with a lower Pfannenstiel incision for the bladder reconstruction and reimplantation.

Upper Pole Partial Nephrectomy

Upper pole removal using a partial nephrectomy or heminephrectomy of a duplex system has long been viewed as the preferred treatment when there is clearly no function in the upper pole and if there is concern about how effective a drainage procedure may be because of massive dilation. There are numerous series advocating one or another approach, with variable results dependent on factors such as degree of reflux, age, and underlying pathology, but there are no clear data to indicate that one approach is so definitively better as to be the universal choice.

The surgical methods for partial nephrectomy have been described and remain useful and similar whether being used with open surgery, conventional laparoscopy, or robotic laparoscopy. The techniques are applicable to both ectopic ureters and ureteroceles in duplex systems.

Open Partial Nephrectomy or Heminephrectomy

Heminephrectomy is a standardized procedure with relatively little recent evolution (Mor et al., 1994), but several technical points deserve emphasis (Fig. 41.24). A flank approach for heminephrectomy usually offers better exposure to the upper pole vessels. The procedure may be performed through a dorsal lumbotomy approach, which is both effective and less morbid than a muscle-dividing flank incision. In older children, this exposure can be more challenging, however.

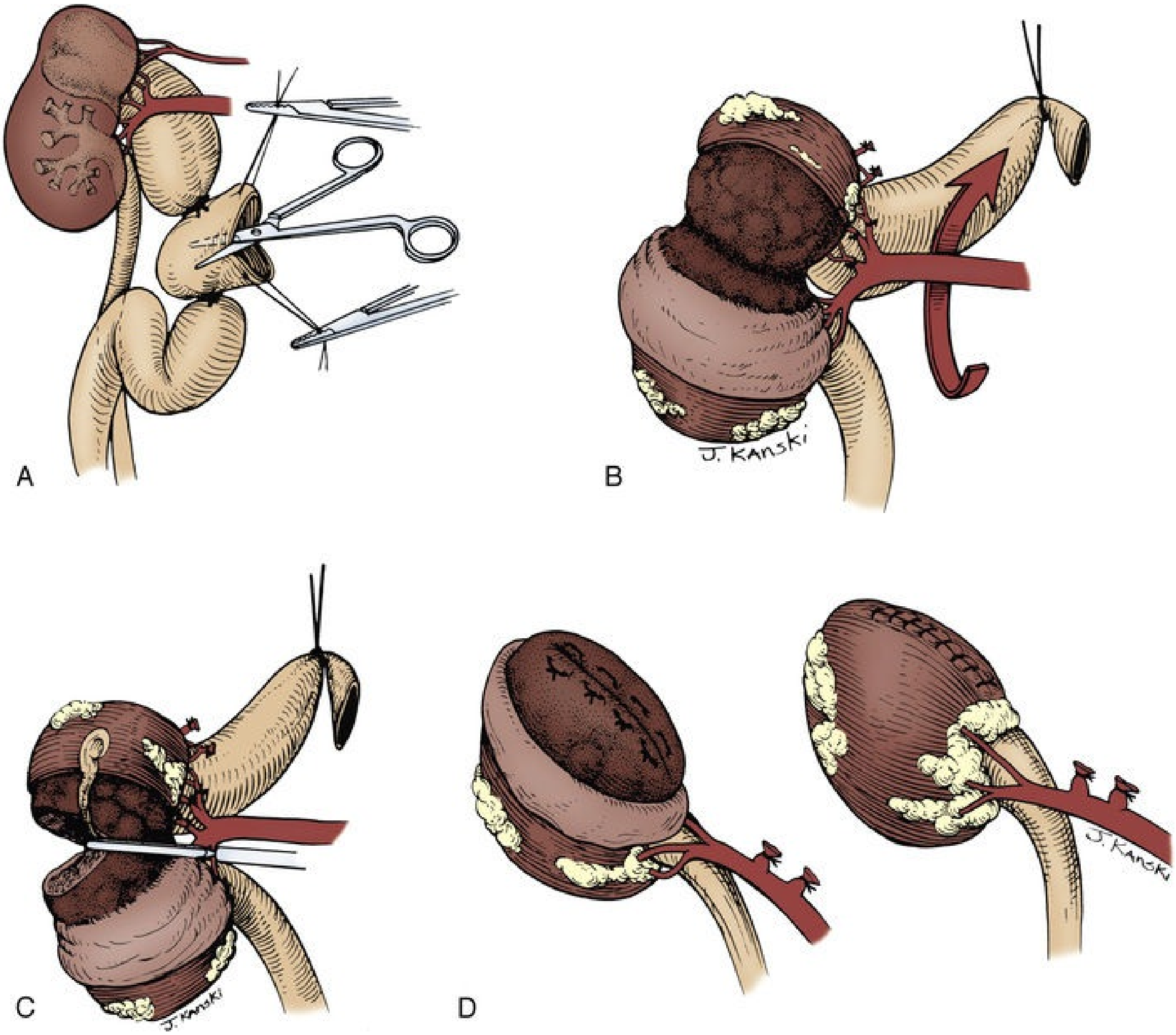

FIG. 41.24 Technique of upper pole nephrectomy. (A) The upper pole ureter is usually dilated and tortuous and can be identified readily at the

lower pole of the kidney. It is separated carefully from the lower pole ureter, divided, and used to improve access to the upper pole moiety. (B) The upper pole ureter is passed beneath the hilar renal vessels and retracted upward. Small feeding vessels to the upper pole are individually ligated and divided. Any larger vessels that may be supplying the upper pole can be temporarily clamped to determine the extent of their distribution. The capsule of the upper pole is bluntly stripped away, exposing the often coarse and cystic parenchyma of the upper pole. This can usually be distinguished from the smooth texture of the normal lower pole. Often, an indented demarcation is seen between the two poles. (C) While traction is applied to the lower pole ureter, the upper pole is excised with the use of electrocautery. Vascular control is achieved by temporary clamping of the lower pole vessels. This may also be accomplished by gentle finger compression of the lower pole. Individual vessels are identified and ligated during this part of the procedure. (D) The parenchyma of the lower pole is approximated at the site of removal of the upper pole with the use of broad mattress sutures. The redundant capsule is then brought over the site of repair and sewn together with a running suture.

In an upper pole nephrectomy, the primary concern is to avoid damaging the viable lower pole. The kidney should be retracted gently so as not to cause any vascular injury through traction and spasm of small vessels. Transecting the upper pole ureter and placing a traction stitch on the proximal portion of this ureter affords the surgeon a good method of retraction and manipulation of the upper pole. Once at the pedicle, dissection of the ureter both below and above the vessels allows for easier, safer freeing of the ureter. The ureter is passed behind the main renal vessels. The dissection *around* the renal vessels should be done carefully to avoid damage to the lower pole. The upper pole vessels (most often two or three in number) are sequentially ligated. Demarcation of the upper pole parenchyma becomes apparent after the upper pole vessels are ligated.

During upper pole nephrectomy, atraumatic clamping of the renal pedicle can be used, enabling work in a bloodless field. Administration of an intravenous osmotic diuretic (e.g., mannitol) moments before and after clamping of the pedicle helps prevent acute tubular necrosis. Topical vasodilating agents (e.g., papaverine) should be available in case vasospasm occurs. In general, vascular control is not essential in upper pole partial nephrectomy because the polar vessels can be identified and controlled. Resection of the upper pole renal tissue can then be carried out with electrocautery or another cutting device. Stripping the capsule off the upper pole in continuity allows it to be used in the closure. Several mattress sutures incorporating a pedicle of retroperitoneal fat are used for closure.

When performing the upper pole ureterectomy, it is of utmost importance to maintain the dissection immediately on the wall of the upper pole ureter as much as possible to preserve the blood supply to the remaining lower pole ureter.

If in addition to obstruction there is concomitant reflux into the ectopic ureter, some recommend a second incision (i.e., a Gibson incision) to resect the ureter in its entirety. Care must be taken to avoid injury to the vas deferens in male patients. To prevent complications that may arise from dissection within a common sheath of two ureters (especially distally), the back wall of the upper pole ureter can be left attached to the lower pole ureter. The remainder of the upper pole ureter should be removed (Fig. 41.25A to C). Such a maneuver prevents damage to the lower pole ureteral blood supply, which courses between both ureters. Resection is carried out to the level of the bladder, where several sutures are placed to close the upper pole ureteral hiatus.

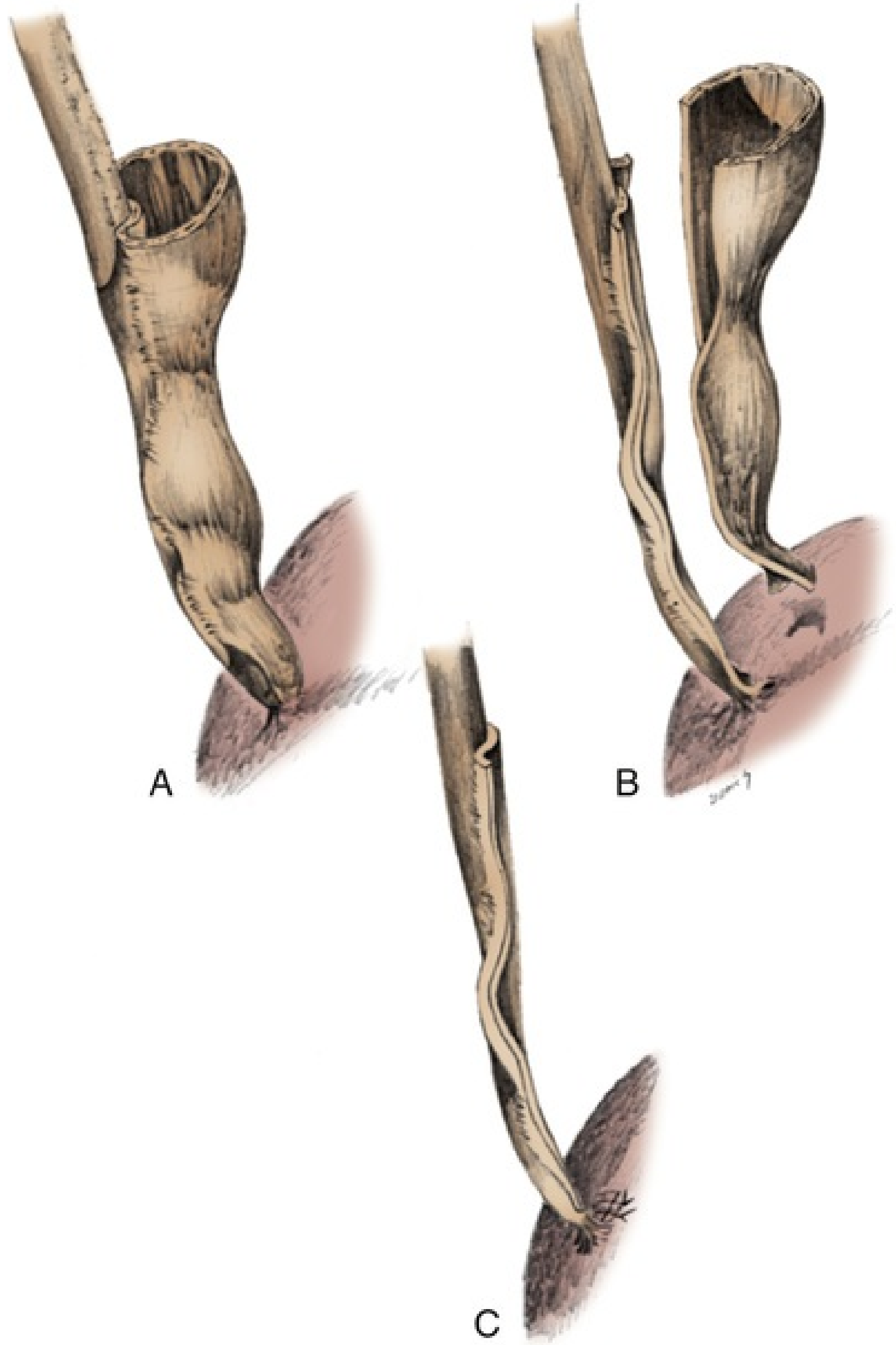

FIG. 41.25 Surgical management of the refluxing ureteral stump. (A) It is difficult to completely separate the distal 2 to 3 cm of the upper pole ureter from the lower pole ureter. The ectopic ureter is excised to this point. (B) The outer wall of the ectopic ureter is excised to the bladder level. (C) A transfixing suture obliterates its lumen, with care taken not to injure the orthotopic ureter.

Other surgeons are comfortable ligating the distal refluxing ureteral stump and leaving it in situ, with few subsequent problems attributed to the small volume of reflux into that stump (Cain et al., 1998; Kim et al., 2001). The refluxing, obstructed ectopic ureter raises the most concern regarding a later infection, and as much of the ureter should be removed as is possible without injury to the bladder neck.

A Penrose drain (brought through a separate counterincision or at the edge of the incision) is placed in such a fashion as to drain the renal fossa and the area of the ureteral dissection. **Postoperative evaluation is best performed with a Doppler sonogram to demonstrate normal postoperative anatomy, absence of a urinoma, and normal blood flow to the lower pole.** Optionally, a functional study such as a nuclear renal scan may be performed if there is concern regarding viability of the lower pole.

Laparoscopic and Robotic Partial Nephrectomy

Another surgical option is laparoscopic or robotic nephrectomy or heminephrectomy. This can be done by either a transabdominal or a retroperitoneal approach, with robotic assistance being increasingly common. These minimally invasive procedures may offer reduced morbidity with less postoperative pain, earlier return of gastrointestinal function, earlier discharge home, and presumably a quicker return to work for the parents (Jordan and Winslow, 1993; Janetschek et al., 1997; El-Ghoneimi et al. 1998b; Lee et al. 2005; Wallis et al., 2006; Lee et al., 2009; You et al., 2010). Other advantages include enhanced visualization and increased magnification of the operative field, improved cosmesis, and avoidance of a second incision that is often needed for the distal ureterectomy of a nephroureterectomy.

Laparoscopic heminephrectomy can be performed in very small infants, and the operative time has decreased as experience and skill have increased (El-Ghoneimi et al., 2003; Lee et al., 2005; Sydorak and Shaul, 2005; Piaggio et al., 2006). Newer energy devices allow for resection of the upper pole in a bloodless field (LigaSure, Valleylab, Boulder, CO; Harmonic scalpel, Ethicon EndoSurgery, Cincinnati, OH; Thunderbeat, Olympus, Tokyo, Japan; and Vessel Sealer, Intuitive Surgical, Sunnyvale, CA).

Laparoscopic heminephroureterectomy performed transperitoneally begins similarly to the open procedure in that the pathologic ureter is grasped as a handle and dissected closely to its wall to avoid compromise of the blood supply to the normal ureter. The upper pole ureter is passed behind the vessels and used to facilitate dissection of the upper pole. The polar renal vessels are then ligated with clips or divided with electrocautery; this allows for a more discernible demarcation of the affected upper pole (Fig. 41.26A). The plane between the upper pole collecting system and the upper parenchyma of the lower pole is developed bluntly to facilitate identifying and transecting the upper pole attachments to the lower pole (see Fig. 41.26B). After the polar element is removed with electrocautery or another energy source, one can check for collecting system leakage with intravenous injection of methylene blue (Yao and Poppas, 2000). Janetschek et al. placed fibrin glue and hemostatic agents on the cut surface and then covered it with Gerota fascia to aid in hemostasis (Janetschek et al., 1997). We have not used these agents but have closed the defect over a pedicle of local fatty tissue (see Fig. 41.26C). Closure of the defect may limit the incidence of postoperative fluid collections (Mason et al., 2014).

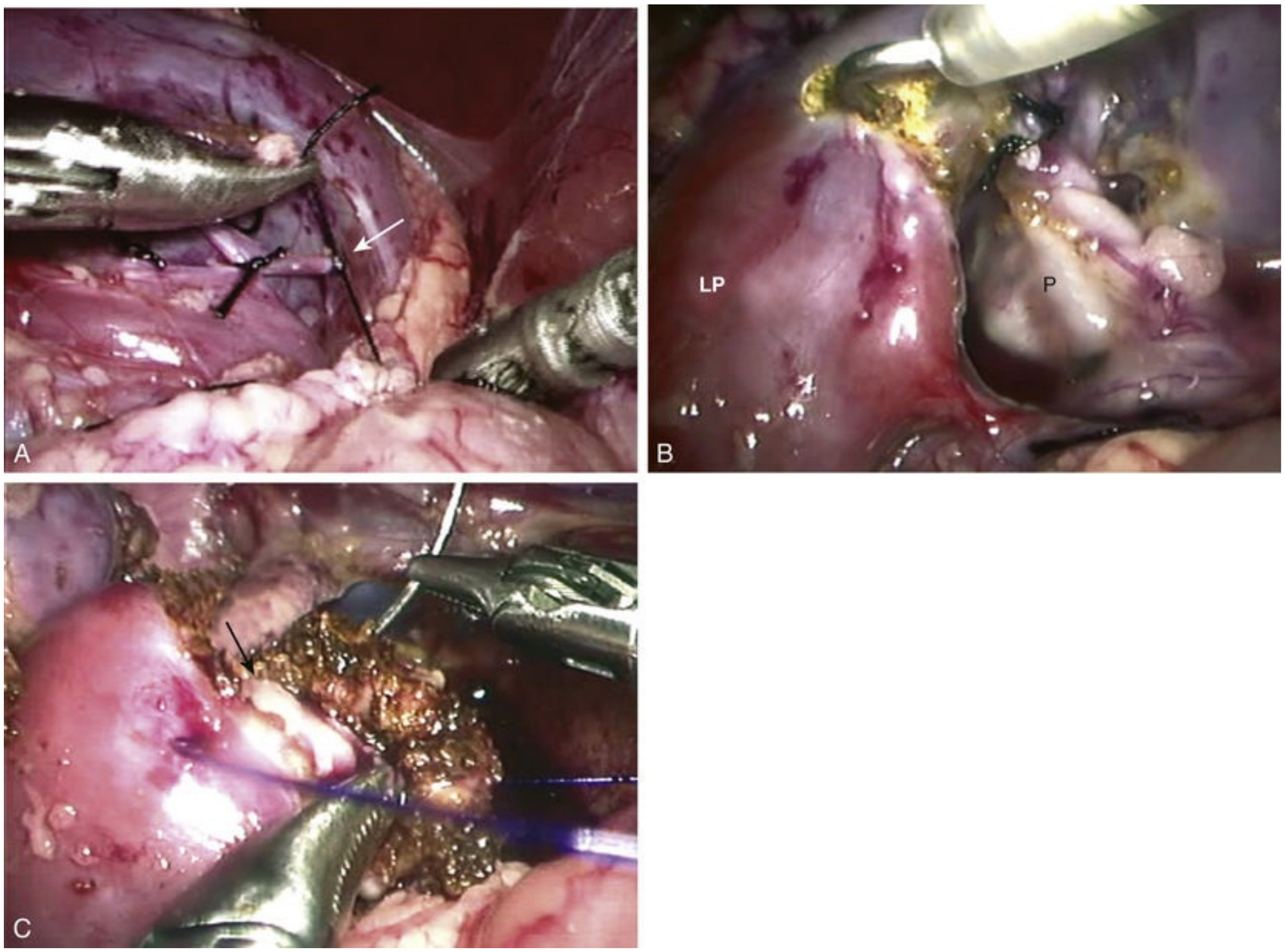

FIG. 41.26 Laparoscopic images of a robotic-assisted upper pole nephrectomy. (A) Isolation and ligation of the multiple vessels to the dilated upper pole *(white arrow).* In some cases, a single vessel is identified, but often these are multiple. (B) The thin dysplastic parenchyma of the upper pole and upper pole pelvis *(P)* is incised using cautery, separating it from the healthy lower pole *(LP).* (C) Mattress sutures are placed over a bolster of fat *(black arrow)* to close the defect in the upper portion of the lower pole.

In performing a partial nephrectomy, robotic-assisted laparoscopy offers advantages over standard laparoscopy (Lee et al., 2009). The magnification is augmented, and the dexterity of the robotic instruments allows for greater precision when working around the renal pedicle and controlling the upper pole vessels, in addition to the visual advantages of a three-dimensional image. Patient and port positioning are the same as for pyeloplasty. Vascular control may be by absorbable or metal clips or even with suture ties. The latter may be preferable by reducing the risk for avulsing a clip during later dissection. The defect is usually closed with a tongue of retroperitoneal fat laid into the defect, which is then closed with two or three mattress sutures of 3-0 polydioxanone suture (PDS) or Vicryl. The robotic approach to heminephrectomy has been described for both upper and lower pole heminephrectomy with successful outcomes (Wiestma et al., 2016).

Laparoendoscopic single-site surgery (LESS) nephrectomy has been described for a single-system ectopic ureter. This technique represents the newest horizon for minimally invasive surgery because only one 22-mm multitrocar port site (recessed in the umbilicus) is used to perform the entire surgical procedure (Park et al., 2009). Newer robotic technology utilizing a single-site platform offers the potential of the precise movement control of robotics with even less surgical morbidity. The current device is too large for smaller children, however.

Ureteral Clipping

A recently described technique for management of nonfunctioning or poorly functioning renal moieties associated with ectopic ureter or obstructive ureteroceles involves laparoscopic clipping of the involved ureter without extirpative surgery. The group encountered two complications in 35 patients including a patient who developed pyonephrosis necessitating nephrectomy and a patient with a duplex system who developed a febrile UTI and persistent upper pole hydronephrosis. The utilization of this technique is still in its infancy, and we advise that caution should be used. Long-term follow-up is unavailable, and these patients should be monitored long term for potential complications such as infection and hypertension (Romao et al., 2014; Lopes et al., 2018).

Laparoscopic vascular ligation of the poorly functioning upper pole vessels has also been reported as effective (Hosseini et al., 2017).

Outcomes

Results of upper pole removal for ectopic ureters and ureteroceles are, in general, very good. The residual stump is rarely problematic in cases of an

ectopic ureter. In cases of ureteroceles in which lower pole reflux is present, resolution may be expected in up to 20% (Husmann et al., 1999)**, and new reflux may be seen in 15% to 50% of patients in whom no reflux was present preoperatively.** The overall secondary surgery rate after primary upper pole nephrectomy for ureterocele is 40% to 50% based on the literature. The difficulty in interpreting the literature rests in variable indications for secondary surgery. In some cases, any presence of reflux postoperatively was considered an indication for further surgery at the level of the bladder, and in other cases reflux was monitored with intervention only in cases of clinical problems such as UTI. Neither of these approaches has been validated by long-term data.

Complications.

The most significant complication related to heminephrectomy is loss of lower pole function (Mandell et al., 1980; Wallis et al., 2006; You et al., 2010). Loss of function may be a long-term issue and may not be recognized immediately. Clinical signs that may suggest problems include fever, increasing pain, and hematuria and may be evident in the first week after surgery. **Development of a postoperative upper pole urinoma has been reported in up to 20% of laparoscopic and robotic cases but is rarely of clinical significance** (Valla et al., 2003; You et al., 2010; Mason et al., 2014). Urinomas have been reported mostly in series in which there is no formal closure of the polar defect. Whether these urinomas are caused by injury to the lower pole or remnant upper pole is unclear. Urinomas, if causing no symptoms and not expanding, can be observed. Other less common problems can include inferior vena cava laceration, duodenal perforation, need for total nephrectomy, and peritoneal tears (if the procedure is done retroperitoneally).

Key Points: Upper Pole Nephrectomy

- In an upper pole nephrectomy, the primary concern is to avoid damaging the viable lower pole.
- Separation of the duplicated ureters during intravesical dissection is discouraged because it can lead to injury of the common blood supply running longitudinally between the two ureters.
- Postoperative evaluation is best performed with Doppler sonography to

assess postoperative anatomy, identify a urinoma, and document normal blood flow to the lower pole.

- Definitive cure by partial nephrectomy for ectopic ureters is usually successful, as the residual stump is rarely problematic.
- For ureteroceles in which lower pole reflux is present, resolution of reflux may be expected in up to 20% of patients, and new reflux may be seen in 15% to 50% of patients in whom no reflux was present preoperatively.
- Complications related to heminephrectomy include loss of lower pole function and development of a postoperative upper pole urinoma.

Lower Tract Reconstruction

A definitive reconstruction at the bladder is suitable for both the ectopic ureter and ureterocele. This approach has the advantage of relieving obstruction and correcting reflux. The disadvantages, however, are the potential for injury to the bladder neck and vagina and the complexity of the procedure. If clinically significant reflux persists after other procedures, lower tract reconstruction may be necessary.

Ureterocele Excision and Common-Sheath Reimplantation

The intravesical approach to the ureterocele begins with a transverse incision of the ureterocele between two stay sutures (Figs. 41.27A to C and 41.28A). Proximally, a plane is obtained between the ureterocele wall and the wall of the bladder. The ureterocele is dissected off the bladder to the point at which it joins the lower pole ureter. Then the two ureters are dissected as a unit, the upper pole ureter is tapered as needed, and both ureters are reimplanted submucosally. The distal portion of the ureterocele is dissected in the same plane (see Figs. 41.27D and 41.28B) to the level of the bladder neck, where it is resected. The detrusor muscle is plicated if it is attenuated, and it appears that it may offer insufficient backing. Bladder mucosal flaps are raised to cover the area of the removed ureterocele (see Figs. 41.27E and F and 41.28C).

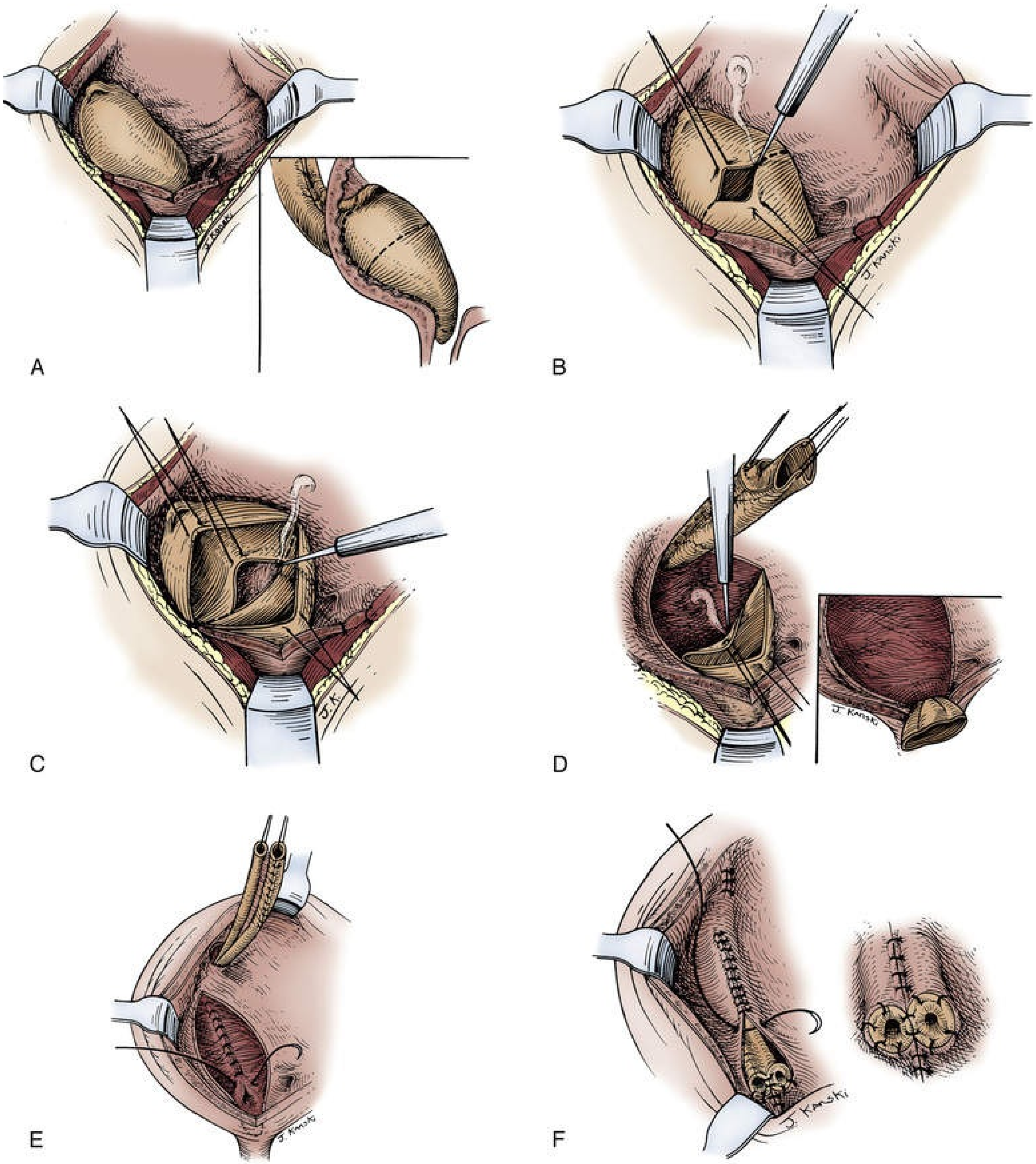

FIG. 41.27 Technique for excision of ectopic ureterocele and common sheath reimplantation of upper and lower pole ureters. (A) Appearance of right-sided ureterocele with open bladder, viewed from below. Note the proximity of the contralateral ureteral orifice. *Inset,* Cutaway side view demonstrating close association of the two polar ureters with a common vascular supply. The *dotted line* indicates the planned initial incision of the ureterocele. (B) After stay sutures are placed, the ureterocele is incised with electrocautery in a transverse direction, exposing the inner cavity of the ureterocele. (C) The posterior mucosal wall of the ureterocele is incised transversely, revealing the often thinned posterior muscular wall of the bladder. This incision is then continued around the bladder mucosal edge

of the ureterocele including the orifice of the lower pole ureter. Stay sutures are important to provide adequate exposure. (D) The upper and lower pole ureters have been mobilized and are retracted into the bladder. The distal aspect of the ureterocele is mobilized in a similar fashion. The bladder mucosal surface is also incised around the edge of the ureterocele to permit complete removal of the ureterocele. *Inset,* The fully mobilized distal ureterocele is retracted caudally, revealing its narrowing attachment at the bladder neck. (E) The dilated upper pole ureter associated with the ureterocele is tapered and remains in continuity with the lower pole ureter. Both are brought into the bladder through a newly formed muscular hiatus to provide adequate tunnel length for the ureteral reimplantation. The thinned-out posterior bladder wall is repaired with multiple interrupted sutures to provide adequate muscular backing for the ureters. The bladder mucosa surrounding the ureterocele defect is mobilized to permit covering of the ureters. (F) *Left,* The ureters are reimplanted into the new ureteral tunnel, sutured distally after spatulation, and covered with bladder mucosa. The lower pole orifice is medial. *Right,* Final appearance of the ureteral tunnel after completion of the reimplantation.

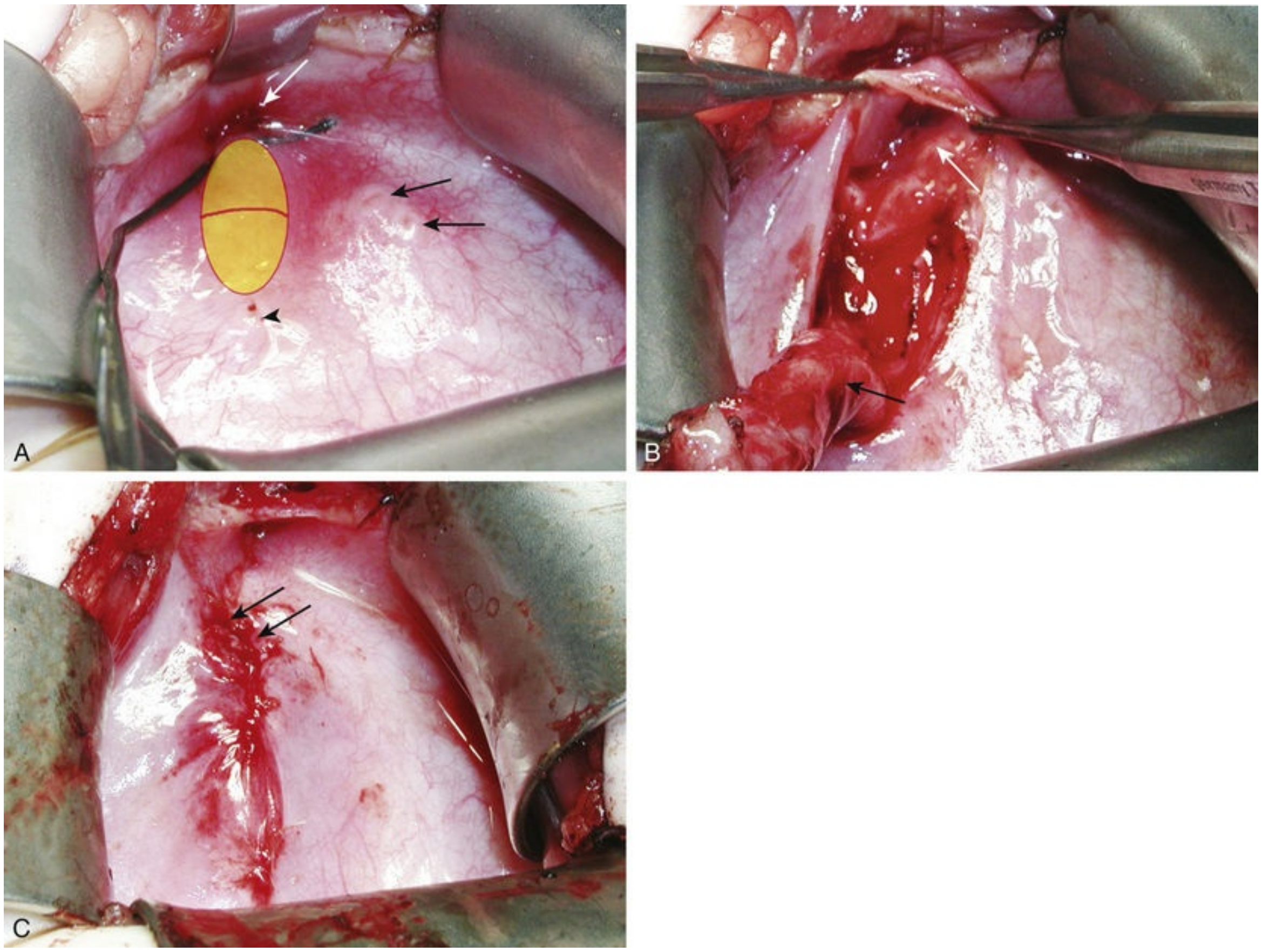

FIG. 41.28 Operative view of ureterocele excision and common sheath reimplantation. (A) View of the decompressed ureterocele *(yellow ellipse)*

after incision (*white arrow* indicates site of incision and the bladder neck orifice) and marking of extent of the ureterocele and the lower pole orifice *(black arrowhead).* The contralateral duplicated ureteral orifices are indicated by *black arrows.* (B) The ureterocele has been divided, and the lower aspect is visible *(white arrow),* going to the bladder neck. This will be excised and the trigonal floor imbricated. The two ureters have been mobilized and are retracted cephalad *(black arrow).* (C) Completed appearance of the reimplanted two ureters *(arrows).*

Once again, several technical points regarding ureterocele excision and common sheath reimplantation deserve mention. **Separation of the duplicated ureters during intravesical dissection is discouraged because it can lead to injury of the common blood supply running longitudinally between the two ureters.** Plication of the detrusor muscle underlying the ureterocele may be necessary to reinforce any areas of muscle deficiency. Furthermore, **the distal portion of the ureterocele may extend below the bladder neck. Extreme care must be taken in this part of the dissection to avoid injury to the sphincter mechanisms. If the entire ureterocele cannot be excised, it can be fulgurated carefully and closed over with two layers.**

Cecoureteroceles present a unique challenge in ureterocele excision and reimplantation in that the distal aspect of the ureterocele can create an obstructive flap-valve with voiding, acting like a windsock behind the urethra. Options for avoidance of this issue includes resection by gentle retraction of the ureterocele if it is not very large, closure of the opening with two layers of tissue, or fulguration of the lumen to cause collapse and closure. Careful postoperative assessment is needed in any case to identify what can be progressive voiding dysfunction if the remnant cecoureterocele creates obstructive voiding (Fig. 41.29).

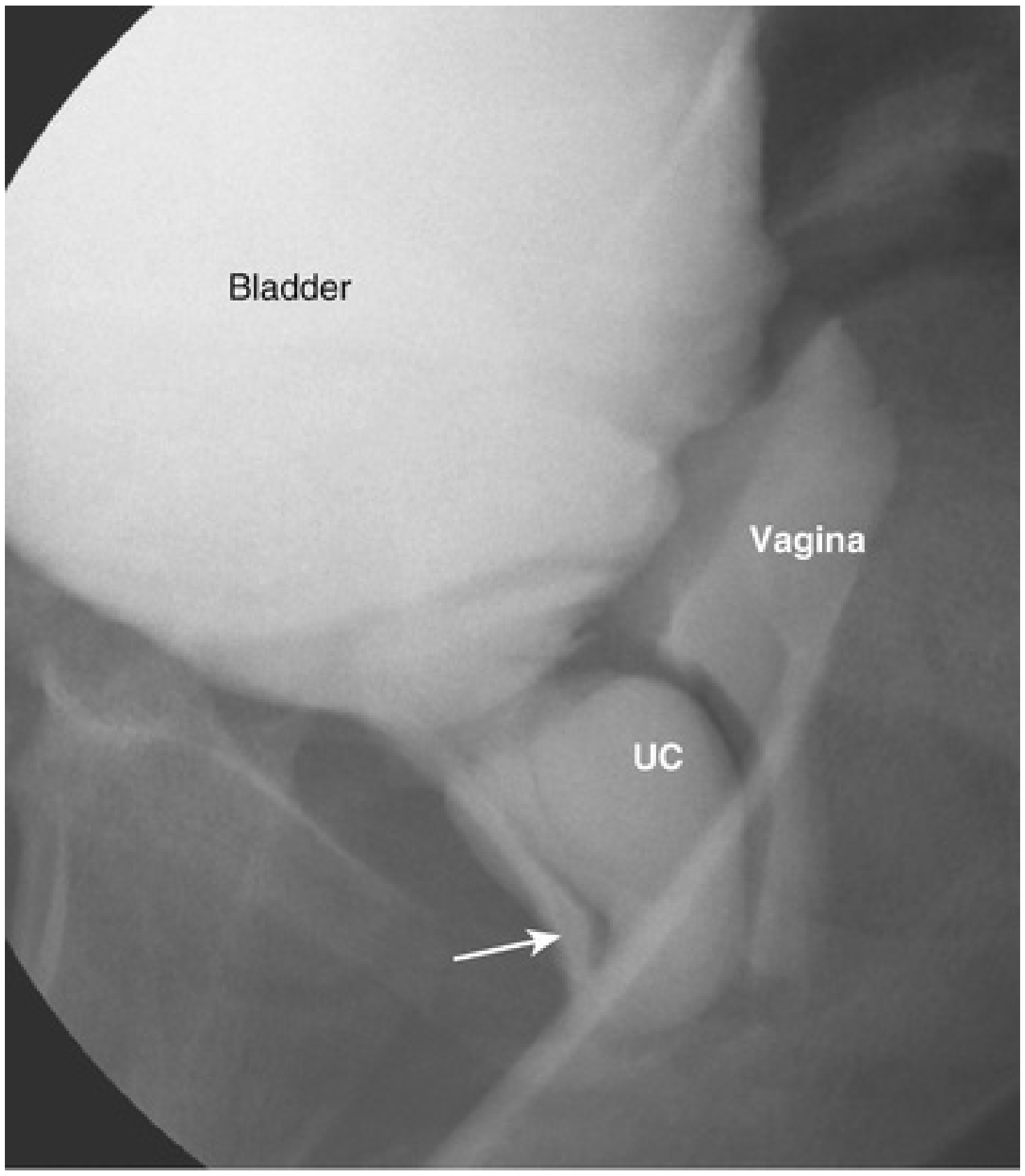

FIG. 41.29 Voiding cystourethrogram demonstrating a large cecoureterocele *(UC)* extending down the urethra and causing bladder outlet obstruction with voiding. The ureterocele fills, acting like an obstructive windsock. The lumen of the urethra is indicated by the *arrow.*

An alternative approach to ureterocele resection is marsupialization, in which the thin intravesical aspect is removed and the edge is sutured. No attempt is made to reinforce the back wall, based on the empirical observation that this is not always needed. Reported results have been satisfactory (Scherz et al., 1989; Lewis et al., 2008). Although this eliminates the need to dissect out the ureterocele and avoids injury to the underlying vagina, it is our impression that this approach has inherent risks that can be avoided by a controlled and predictable surgical approach of trigonal reconstruction. A major problem with marsupialization may be uncommon, but it seems preferable to definitively correct the anatomic and functional defect as certainly as possible on the first open operation when needed.

Reported results of ureterocele excision and common sheath reimplantation are very good, although persisting reflux can be an issue in 5% to 10% of patients. This may be more common when ureteral tapering is needed. Although the clinical significance of this has been called into question, persisting reflux in this context must be viewed with caution.

Key Points: Ureterocele Excision and Reimplantation

- Cecoureteroceles present a unique challenge in ureterocele excision and reimplantation in that the distal aspect of the ureterocele can create an obstructive flap-valve with voiding, acting like a windsock behind the urethra.
- An alternative approach to ureterocele resection is marsupialization, in which the thin intravesical aspect is removed and the edge is sutured.
- The results of ureterocele excision and common sheath reimplantation are very good, although persisting reflux can be an issue in 5% to 10% of patients.
- Total reconstruction including upper pole nephrectomy with ureterocele excision and reimplantation of the lower pole ureter is definitive but is an extensive operation performed with two incisions and may not be necessary in all patients.

Pyeloureterostomy and Ureteroureterostomy

When the upper pole of either an ectopic ureter or ureterocele is to be maintained because of function or surgeon preference, pyeloureterostomy or ureteroureterostomy may be carried out. Both proximal and distal approaches may be used, and these have been described with open and laparoscopic techniques. This management technique has become increasingly used, even in nonfunctioning upper poles, as concerns for long-term problems with hypertension have not been substantiated, and the procedure can be completed through a fairly small incision, often no larger than a herniorrhaphy-type incision (Prieto et al., 2009).

Open Procedure

Ureteroureterostomy can be performed distally to create an anastomosis between the upper pole ureter and the lower pole ureter in an end-to-side fashion. This can be done at the distal ureter via an inguinal, open approach (Huisman et al. 1987; Lashley et al., 2001; Chacko et al., 2007; Prieto et al., 2009). It is critically important in this type of procedure to correctly identify the recipient lower pole ureter, and it is strongly recommended to cystoscopically place a stent into the lower pole ureter at the start of the procedure.

Other options to achieve this goal are the proximal anastomotic technique of ureteroureterostomy or pyeloureterostomy (El Ghoneimi et al., 1998a). This results in the upper pole system draining into the lower pole system. **Such high anastomoses may be preferable to a distal ureteroureterostomy with a dilated upper pole, because the latter may result in more urinary stasis with a distal anastomosis.** Whether the “yo-yo” phenomenon is clinically significant remains uncertain, but we prefer a proximal anastomosis when there is a significant mismatch in ureteral size.

When performing upper tract anastomoses, dissection should be limited to an absolute minimum, especially medially, to prevent disruption of either ureter's blood supply. The upper pole ureter may be considerably larger than the lower pole ureter. A generous longitudinal pyelotomy or ureterotomy is made in the lower recipient pole to overcome such disproportion, and the anastomosis is performed in an end-to-side fashion. The distal portion of the upper pole ureter should be aspirated with a feeding tube to decompress it. The distal upper pole ureter is resected as far inferiorly as possible, with care taken to stay directly on this ureter's wall and avoid the vasculature of the adjacent lower pole ureter. If there is no reflux, the resection is taken as distally as possible and the remnant lower portion of ureter may be left open. If reflux is present in an ectopic ureter, it should be taken as close to the bladder neck as possible. If associated with a ureterocele, it may be possible to avoid resection of the ureterocele as long as it is well decompressed.

Laparoscopic Procedure

Both ureteroureterostomy and pyeloureterostomy can be readily performed laparoscopically (Gonzalez, 2007; Steyaert, 2009), which is aided with robotic control (Kutikov et al., 2007; Smith et al., 2009). A stent is placed in the recipient ureter only and not across the anastomosis (Fig. 41.30). We have reported a series of patients who underwent 25 robotic-assisted laparoscopic ureteroureterostomy (RALUU) procedures and compared it with a series of patients who underwent open ureteroureterostomy during the same period. Operative times and complication rates were comparable, with slightly shorter length of hospitalization in robotic cases. In the robotic cases, cystoscopy with lower pole stenting was consistently performed, however the type of stent varied because of surgeon preference (Lee et al., 2015). Another series with 12 patients who underwent RALUU used an external ureteral stent, which was removed on postoperative day 1. This series similarly showed efficacy of the procedure, with 100% resolution of hydronephrosis postoperatively (Biles et al., 2016).

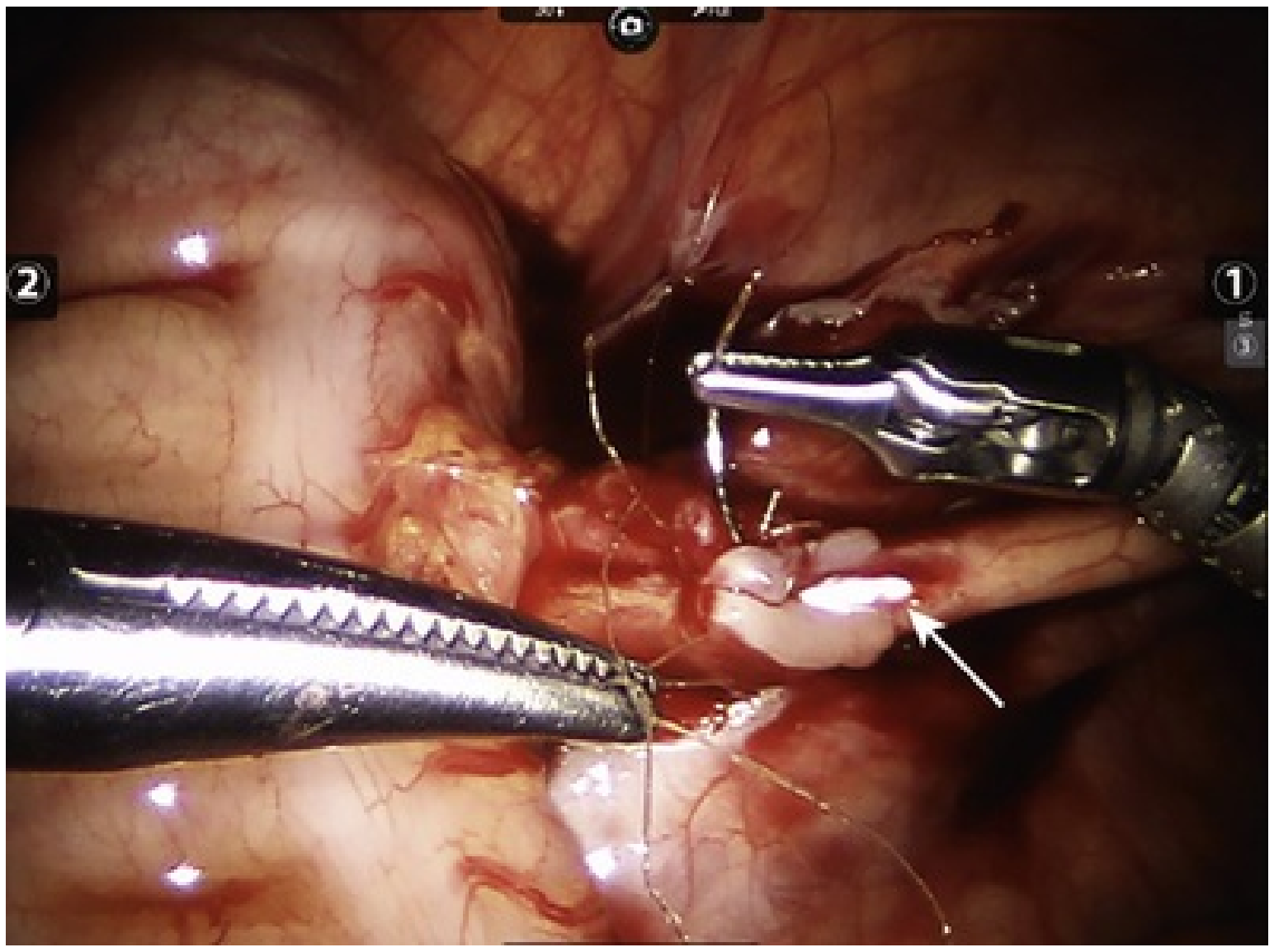

FIG. 41.30 Operative view of robotic ureteroureterostomy for ectopic ureter presenting with incontinence. The procedure is being performed at the level of the iliac vessels. The *arrow* indicates the ureteral stent in the recipient (lower pole) ureter.

Laparoscopy has also been utilized to aid with performing open ureteroureterostomy to improve ease of procedure and minimize size of incision needed for ureteroureterostomy. Grimsby et al. described a technique for identifying the ureters by placing a camera port at the level of the umbilicus for visualization. A babcock was then used through the small incision through which ureteroureterostomy was to be performed to grasp the ureters from the retroperitoneum and deliver them for the surgery (Grimsby et al., 2014). This technique did not increase operative time, and the success of the operation and complication rate was comparable to the traditionally performed procedures.

Key Points: Pyeloureterostomy and Ureteroureterostomy

- Ureteroureterostomy has emerged as a frequently used management technique for the duplicated collecting system with obstructed upper pole in both functioning and nonfunctioning upper poles.
- Size mismatch between the two ureters does not seem to impede achieving a satisfactory anastomosis.

Transurethral Incision for Ureterocele

The simplest means to decompress the obstructed upper pole or single system ureterocele is TUI. Reported rates of relief of obstruction range from 78% to 97% (Rich et al., 1990; Jayanthi and Koff, 1999; Di Renzo et al., 2010; Adorisio et al., 2011; Palmer et al., 2011; Castagnetti et al., 2013). A comparison between TUI and multiple punctures (watering can technique) showed no difference in decompression rates, although multiple punctures induced less reflux into the affected ureter. In the setting of acute sepsis, TUI is the most appropriate intervention, although a percutaneous nephrostomy would be a viable option as well.

Although TUI can reliably relieve obstruction, it carries the risk for inducing reflux into the affected ureter, which may then predispose to upper tract infection and the need for reconstruction. The balance between the minimal morbidity of TUI and its uncertainty is the basis for the clinical controversy as to its usefulness.

Our preferred method of incising the ureterocele is similar to the one described by Rich et al. (Rich et al., 1990): a transverse incision through the full thickness of the ureterocele wall using the cutting current. Making the incision as distally on the ureterocele and as close to the bladder floor as possible lessens the chance of postoperative reflux into the ureterocele. One can use either a Bugbee electrode or an angled-tip wire. We favor the latter instrument because it has a finer tip and allows for more precision, and the angle allows for easier manipulation. In older children, the resectoscope with the Collins hot knife may be used to make the incision. Laser incision has been reported with equivalent results (Marr and Skoog, 2002; Jankowski and Palmer, 2006; Ilic et al., 2018). Cold knife incision has been used as well. The watering can technique has also been recently described (Palmer et al., 2011; Haddad et al., 2017; Ilic et al., 2018).

The ureterocele should be incised deeply because ureteroceles may be thick walled. Adequacy of ureterocele incision is confirmed either by the escape of a jet of urine from the ureterocele or by viewing the urothelium on the inside of the ureterocele (Fig. 41.31). For the ectopic ureterocele that extends into the urethra, adequate drainage may be achieved by either a longitudinal incision that extends down from the intravesical portion into the urethral portion or by two separate punctures, one in the intravesical portion of the ureterocele and one in the urethral portion of the ureterocele.

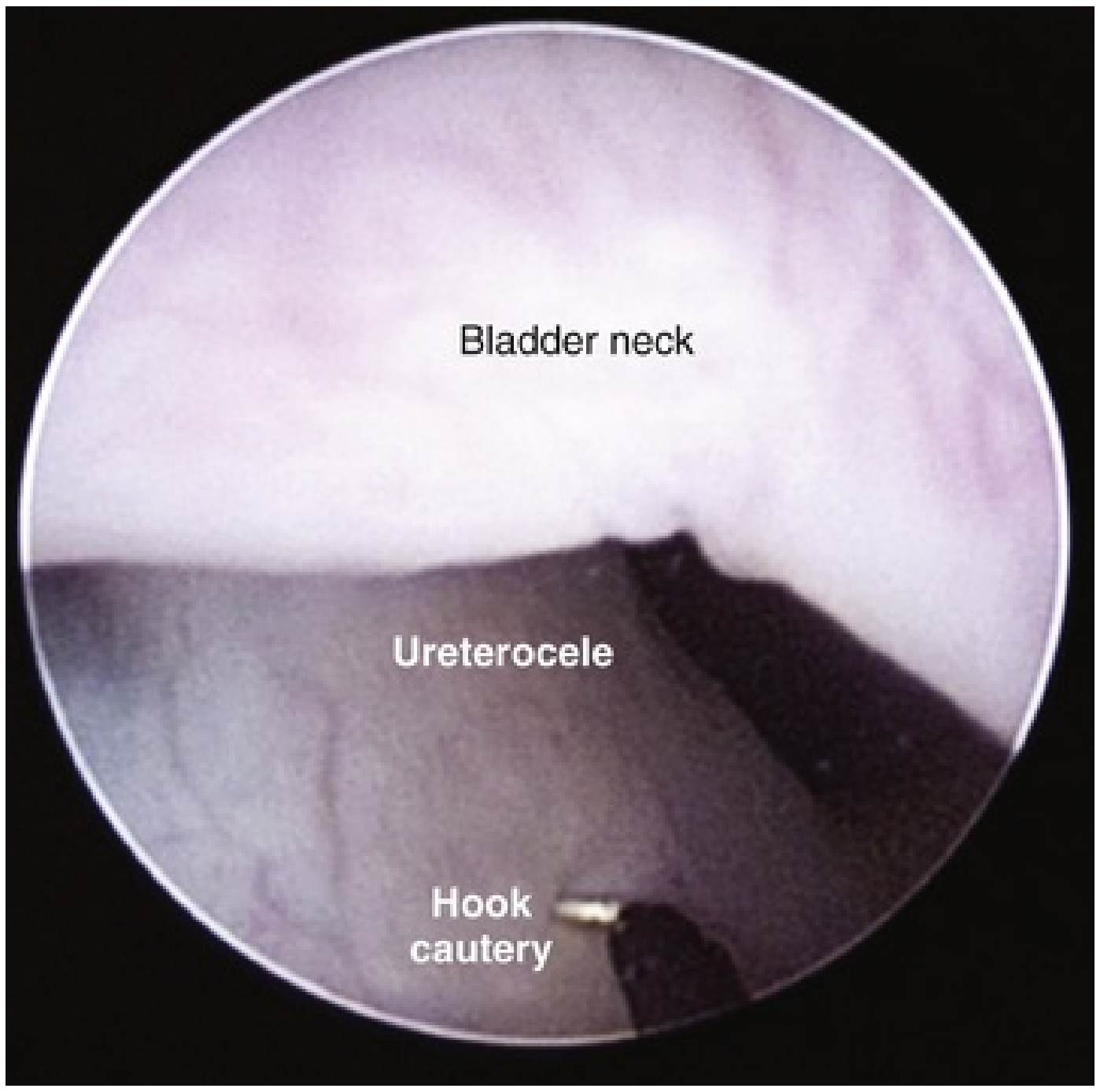

FIG. 41.31 Endoscopic image of a ureterocele about to be incised with hook cautery. The incision should be made inferiorly and medially to limit the risk for reflux, but the key goal is decompression. The ureterocele should be incised with the bladder partially filled, but not so much as to efface the ureterocele.

In the uninfected well child, no bladder catheter is left in place, and most children are treated as outpatients. A follow-up ultrasonography is performed in 4 to 6 weeks to assess the degree of decompression (Fig. 41.32). A voiding cystogram is performed in 2 to 3 months to determine the status of lower pole reflux and whether new reflux has been created into the ureterocele (Fig. 41.33).

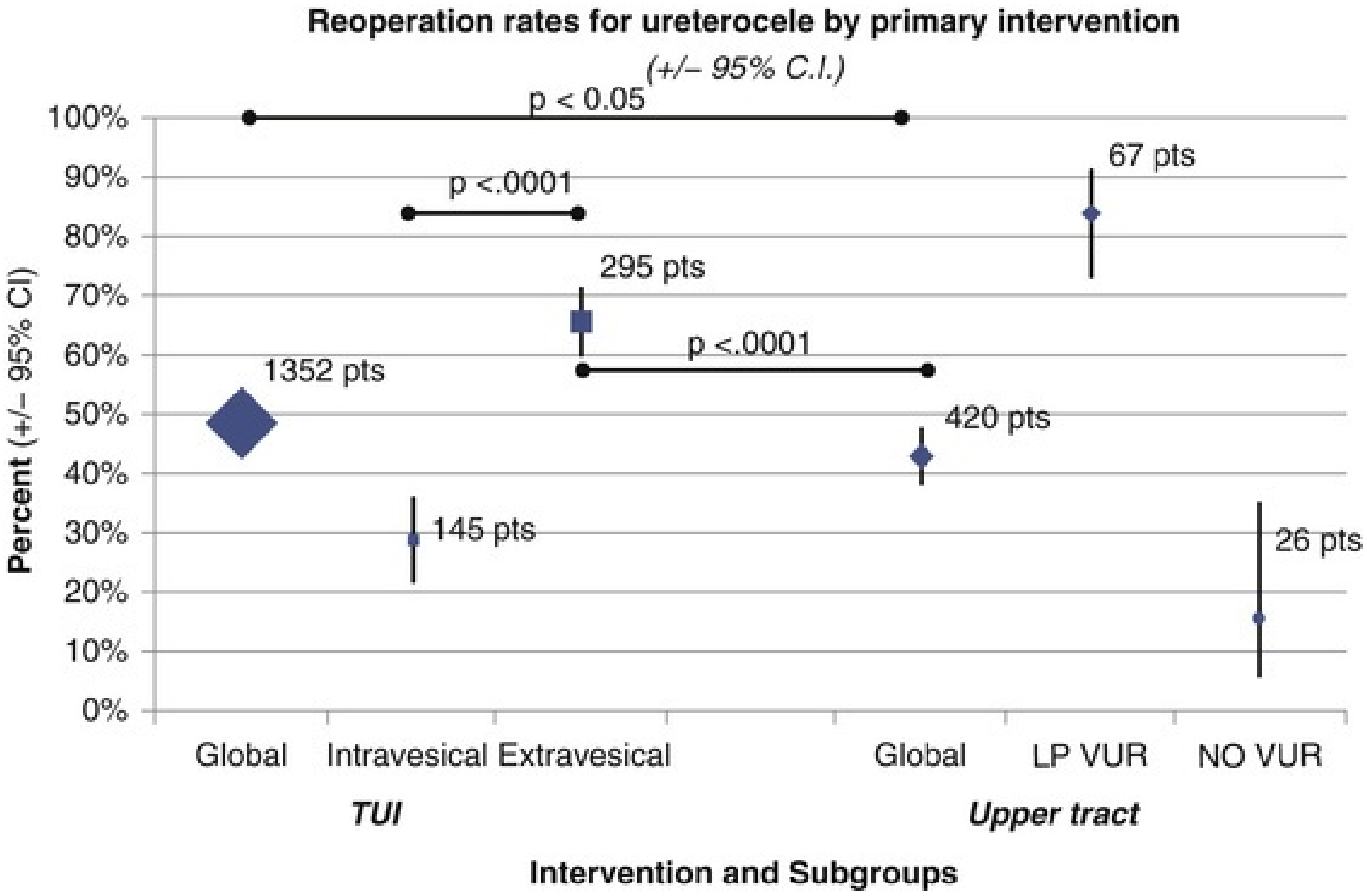

FIG. 41.32 Chart indicating incidence of secondary surgery after either transurethral incision *(TUI)* or upper tract approach (partial nephrectomy or ureteroureterostomy) based on data from multiple sources. The number of patients *(pts)* is indicated adjacent to the data points. Statistical differences are indicated between selected groups based on two-tailed Fisher exact testing. *CI,* Confidence interval; *LP,* lower pole; *VUR,* vesicoureteral reflux.

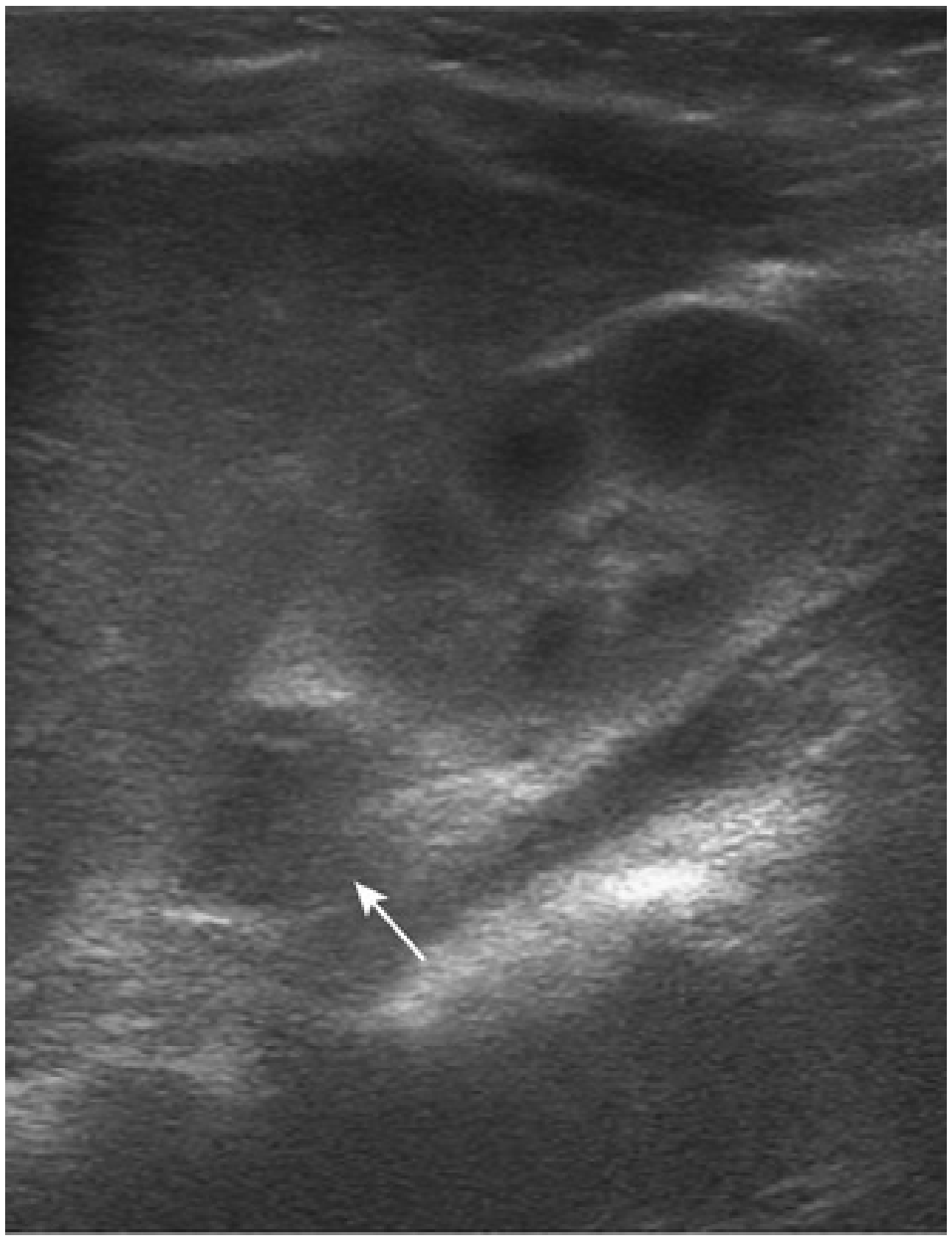

FIG. 41.33 Appearance of the decompressed upper pole *(arrow)* in same patient as in Fig. 41.9, following endoscopic incision of the ureterocele.

The reported incidence of new reflux ranges from 0% to 50%. The risk for reflux may be dependent on the method used for incision (Fig. 41.34) (Tank, 1986; Rich et al., 1990; Blyth et al., 1993; Jelloul et al., 1997; Dahm and King, 1998; Husmann et al., 1999; Jayanthi and Koff, 1999; Shekarriz et al., 1999; Cooper et al., 2000; Singh and Smith, 2001; Upadhyay et al., 2002; Chertin et al., 2007; Rich et al., 1990; Husmann et al., 1999; Jayanthi and Koff, 1999; Shekarriz et al., 1999; Cooper et al., 2000; Singh and Smith, 2001; Upadhyay et al., 2002; Chertin et al., 2007; Di Renzo et al., 2010; Adorisio et al., 2011; Palmer et al., 2011; Castagnetti et al., 2013). Some authors favor puncture instead of incision, but no data are available that demonstrate a clear difference. **The type of ureterocele is a clear determinant of the outcomes of TUI, with intravesical ureteroceles having the highest likelihood of achieving all therapeutic goals with only the incision. Decompression with no reflux can be achieved in 70% to 80% of patients. Extravesical ureteroceles, however, are more likely to have persisting or new reflux and may require secondary surgery based on the presence of reflux in 70% by**

some series (Chowdhary et al., 2017; Hodhod et al., 2017). In the meta-analysis by Byun and Merguerian, the presence of lower pole reflux and the location of the ureterocele are similar in their impact on outcomes (Byun and Merguerian, 2006). In this analysis, the relative risk for reoperation was 1.74 times greater in the presence of reflux than without, and 2.78-fold times higher if extravesical. These factors did not seem to be additive, suggesting they represented similar underlying causes. In comparison with an open approach of any modality, however, the simplicity of ureterocele incision coupled with the potential for definitive cure, even if not in a large fraction, is appealing. **TUI also acts to better prepare the patient for a secondary major surgery, if needed, by decompressing dilated ureters.**

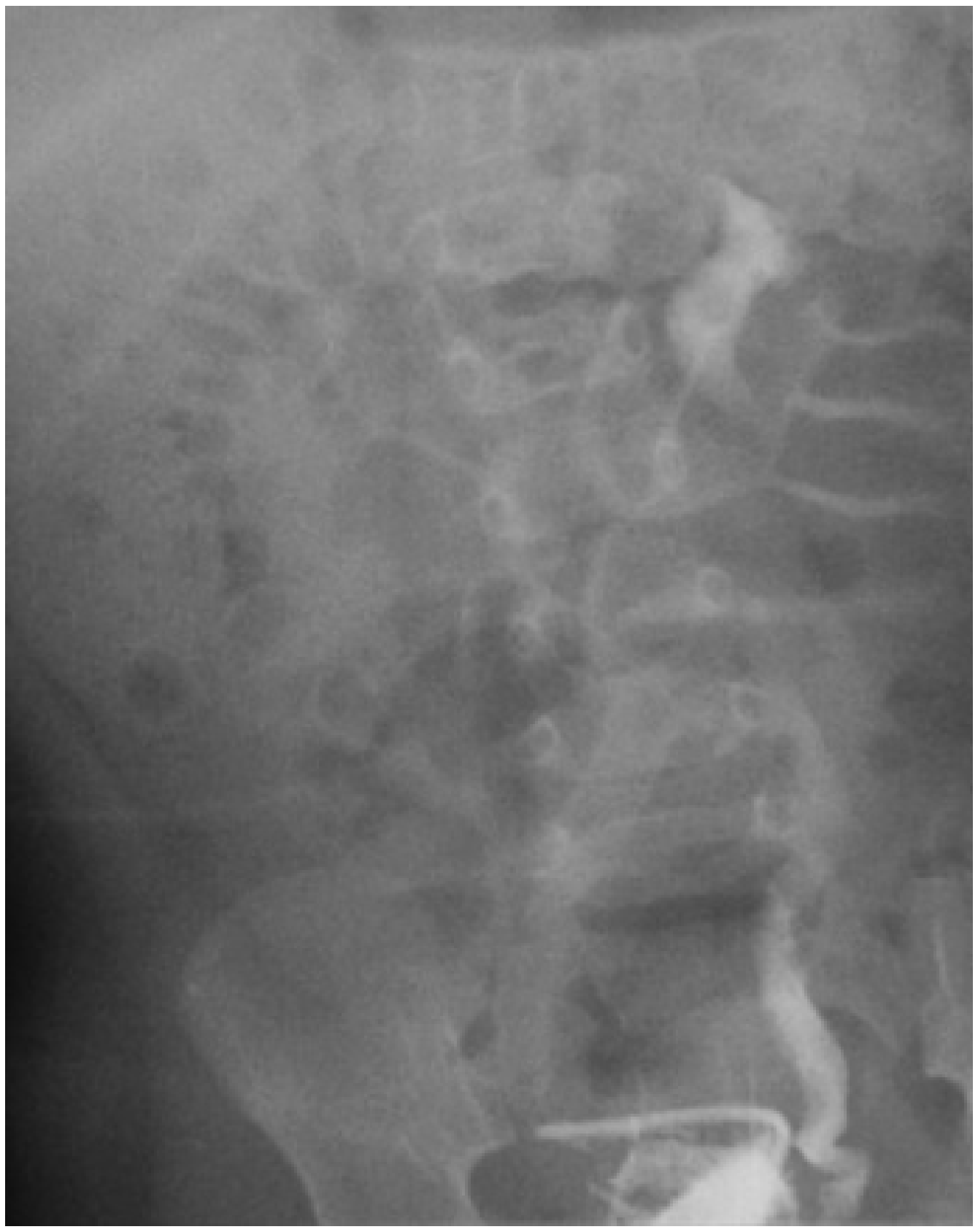

FIG. 41.34 Voiding cystourethrogram demonstrating reflux into the upper pole of a duplex system after ureterocele incision. This type of reflux will rarely resolve spontaneously. Although the clinical risk is uncertain, the reflux is most often repaired.

Reflux Outcomes After Transurethral Incision

The natural history of lower pole reflux after TUI is incompletely defined. In some series an observational approach has been taken, and resolution has been reported in a few series with variable follow-up (Jesus et al., 2011). Sander et al. reported cure rates (improvement of hydronephrosis and absence of VUR) of 55.6% in patients with single-system ureterocele and 14.9% in those with duplex-system ureterocele. Rates of *de novo* reflux into the ureterocele moiety were 27.8% for patients with single-system ureterocele and 56.2% for those with duplex-system ureterocele (Sander et al., 2015; Jawdat et al., 2018). The usefulness of observing these patients is dependent on occurrence of infection and parental preferences.

Key Points: Transurethral Incision of Ureterocele and Drainage Procedures

- The reported incidence of new reflux after TUI of a ureterocele ranges from 0% to 60% and may be dependent on the method used for incision.
- The type of ureterocele is a clear determinant of the outcomes of TUI, with intravesical ureteroceles having the highest likelihood of achieving all therapeutic goals with only the incision.
- TUI also acts to better prepare the patient for a secondary major surgery, if needed, by decompressing dilated ureters.
- Persisting reflux into the upper or lower poles is typically an indication for ureterocele excision and reimplantation, but resolution has been reported.
- In general, it has not been possible to predict with any accuracy how an individual might respond to TUI based on clinical parameters.
- The ectopic ureter in a neonate with sepsis or with massive dilation may be best managed with a temporary end ureterostomy.
- Ureteroureterostomy can be performed distally or proximally to create an anastomosis between the upper pole ureter and the lower pole ureter in an end-to-side fashion.

Ureterostomy for Ectopic Ureter

The ectopic ureter in a neonate with sepsis or with massive dilation may be best managed with a temporary end ureterostomy, although drainage with either endoscopic ureteral incision and stenting or nephrostomy tube is also an option (El Ghoneimi et al., 1996; Ortiz et al., 2017). **This has the advantage of permitting acute decompression to manage sepsis and permit later assessment of any function in the affected renal unit before definitive management.** By performing an end ureterostomy, the ureter can decompress, and it is in position to be reimplanted if the renal unit is felt to be salvageable. No resection of redundant ureter is performed because this will shorten in time, and some length will be needed to perform the reimplantation. The stoma should be positioned at what would be the lateral end of a Pfannenstiel incision. Percutaneous ureterostomy has been reported as well (Bilen et al., 2006). Assessment of functional status is performed shortly before definitive surgery, usually in 4 months or after 6 months of age. DMSA scanning is probably the most efficient means, but differential urine collection is an option as well. If there is no function appreciable, partial or total nephrectomy is performed with removal of the entire ureter to the stoma.

Summary of Clinical Decision Making

For ectopic ureters, clinical decision making is much more straightforward than for ureteroceles and rests on whether to maintain the upper pole of a duplex system. If this is chosen, then the surgical approach depends on the presence of reflux in the lower pole; if present, a common sheath reimplantation or a lower pole reimplantation with distal upper to lower pole ureteroureterostomy is performed. If there is no lower pole reflux, either proximal or distal ureteroureterostomy is performed. If the degree of function is ambiguous, a temporary end ureterostomy can be used to permit assessment out of the acute setting, particularly with a massively dilated ureter. Also, if reflux is present, the need for lower surgery to correct the reflux may influence the choice to avoid upper tract surgery. If removal of the upper pole is chosen based on degree of dilation or the preference for removal of nonfunctioning, dysplastic tissue, an upper pole nephrectomy is performed. For the single-system ectopic ureter, preservation or removal is also based on degree of function and surgeon preference. There are no objective outcome data to advocate clearly for one or another approach.

For a ureterocele in a duplex system, the availability of endoscopic incision creates more options (Table 41.1; see Fig. 41.34). It is important to recognize that although TUI is an operation, it is of a totally different nature than either an upper pole nephrectomy or a lower tract reconstruction. It is inappropriate to equate them as operations in a comparative manner. **In general, it has not been possible to predict with any accuracy how an individual might respond to TUI based on clinical parameters.** Because in some patients significant lower pole reflux and upper tract dilation may be treated with a brief outpatient procedure with documented long-term results, it would seem reasonable to offer this option before moving directly to a more complex upper or lower tract reconstruction. **Even if one-half of these patients may need subsequent surgery, it can be safely deferred until the child is older. There is also the further appeal of TUI in that it may make a subsequent surgical procedure less complex by decompressing a dilated upper pole ureter.** Reimplantation may be much more effective and not require excisional tapering. This lessens overall morbidity, another goal of management. The appeal of TUI may therefore be less in the older child with a massive upper pole in whom removal may be preferable and definitive surgery can be performed at diagnosis.

TABLE 41.1

Options for Ureterocele Management

PROCEDURE	IDEAL INDICATIONS	ADVANTAGES	LIMITATIONS
Transurethral incision	• Infant • Large ureterocele with VUR	• Outpatient procedure • Effective decompression • Occasionally definitive	• May produce reflux into ureterocele segment, necessitating bladder surgery
Upper pole nephrectomy	• Older patient • Large nonfunctioning upper pole • No VUR	• May be definitive • Removes pathology • Avoids bladder-level surgery	• May not be definitive • Significant surgery • Risk to lower pole • May still require lower surgery in bladder
Ureteroureterostomy or ureteropyelostomy	• Older patient • Functioning upper pole • No VUR	• Drains obstructed segment with little risk for obstruction or UTI	• Leaves ureterocele in bladder • May develop reflux
Ureterocele excision and common sheath reimplantation	• Reflux • Functioning upper pole	• Eliminates obstruction and reflux	• Complex surgery • Risk to vagina and bladder neck

	without significant dilation	• Removes ureterocele • No renal risk	• May require ureteral tapering

UTI, Urinary tract infection; *VUR,* vesicoureteral reflux.

Voiding Dysfunction after Ureterocele Repair

Voiding dysfunction after lower urinary tract reconstruction for ureterocele has been reported in some series, but with a low incidence (Abrahamsson et al., 1998; Sherman et al., 2003; Lewis et al., 2008). In other series, there was no evidence of incontinence or significant bladder dysfunction (de Jong et al., 2000; Vereecken and Proesmans, 2000; Beganovic et al., 2007). Abrahamsson et al. reported infrequent voiding with the possibility of infection in 19 of 36 patients, whereas 3 of 36 demonstrated incontinence (Abrahamsson et al., 1998). Vereecken and Proesmans made a similar observation with a lower incidence after complex bladder surgery for duplication anomalies (Vereecken and Proesmans, 2000). Abrahamsson suggested that the bladder dysfunction was the result of an intrinsic bladder abnormality rather than the surgical procedures.

In the child with either recurrent infections or incontinence after surgical repair of a ureterocele, one must consider the type of surgery and if there was the possibility of inadequate trigonal support. This can lead to a weak bladder base, ballooning of the trigone posterior to the bladder neck, and an obstructive process. This can also occur after TUI of a ureterocele with a urethral component. Inadequate bladder emptying and infection as well as upper tract dilation can result.

A VCUG may be needed to assess the bladder anatomy with voiding, and video-urodynamics may be needed. It would be important to recognize the need for lateral views during voiding to identify the bladder pathology. We have also used antegrade cystoscopy via a suprapubic puncture to better assess the bladder neck. Recurrent VUR may occur, particularly if there is obstructed voiding.

Managing bladder dysfunction after ureterocele repair will depend on the cause and may include bladder and trigonal reconstruction or bladder neck repair, intermittent catheterization, or, if there is evidence of bladder neck incompetence, endoscopic injection of bulking agents.

Other Ureteral Anomalies

Anomalies of Number

Bifid Ureters

Ureteral duplication may be associated with ectopia or a ureterocele but is also compatible with a normally functioning renal system if both ureters enter orthotopically or if there is partial duplication. Ureteral duplication is a common condition, described in approximately 1 in 125 people (0.8%) based on autopsy series, which tend to be less selective (Nation 1944; Kaplan and Elkin, 1968; Timothy et al., 1971; Privett et al., 1976). There is a slightly higher incidence in females, estimated to be approximately 1.6 : 1. Duplication is unilateral six times more frequently than bilateral; however, it is clinically prudent to carefully look for contralateral duplication when unilateral duplication is documented. This may be critical in the setting of nonhydronephrotic upper poles and ureteral ectopy causing incontinence. Right and left sides appear to be affected similarly with unilateral duplication.

A bifid renal pelvis includes only a single ureter, but confluence of the upper and lower ureters lower than the UPJ constitutes partial duplication of the ureter or bifid ureter.

An increased incidence of ureterorenal pathology has been documented with duplication anomalies. The clinical implication of duplication depends largely on the ureteral insertion. **A useful clinical approach is to consider that conditions that routinely affect the single-system kidney are those that affect the lower pole, including UPJ obstruction and VUR. The upper pole is more likely affected by conditions resulting from abnormal ureteral formation, including ectopic and ureterocele as discussed earlier.**

Lower pole UPJ obstruction evaluation and management are similar to those for a single-system UPJ obstruction. Lower pole UPJ obstruction may be identified with partial and complete ureteral duplication. Recognition of the presence of the duplication may be challenging with massive hydronephrosis, but in most cases the normal upper pole will be identified on functional imaging such as a renal scan, even if not detected on ultrasonography. Lower pole UPJ obstruction may resolve spontaneously, just as a single system with comparable severity of dilation. Repair may be optionally accomplished with pyeloureterostomy of the dilated renal pelvis of the lower pole to the normal upper pole ureter.

Upper pole UPJ obstruction has been reported, including in association with lower pole UPJ obstruction, but is exceptionally rare (Ho et al., 1995; Ng, 1999; Peters and Pathak, 2014).

Hydronephrosis of the lower pole moiety may also represent VUR, and this is often of high grade. The presence of a dilated ureter on ultrasonographic evaluation will usually be present. This rarely represents ureterovesical obstruction and more often indicates VUR. Lower pole VUR is often associated with significant functional reduction in the lower pole, which is usually congenital but may also be associated with prior infection. Evaluation and management are similar to reflux into a single system, but spontaneous resolution may be more delayed (Afshar et al., 2005). Common sheath ureteral reimplantation and endoscopic injection are surgical options, as well as low ureteroureterostomy of the refluxing lower pole ureter to the upper pole ureter.

Triplication

Triplication of the ureter, either complete or partial, is very rare. These conditions typically have manifested with infection or wetting. The classification by Smith remains useful, in which triplex ureters are divided into four types (Smith, 1946). Type 1 constitutes three entirely separate ureters with unique attachment to the bladder or distally and accounts for 35% of triplications. Type 2 is an incomplete separation with two ureteral orifices, occurring in 21%. Type 3 is a trifid ureter with a single ureteral orifice, seen in 31%. Type 4 describes two ureters with three orifices, seen in 13%. This occurs with an inverted-Y bifurcation similar to that described for duplicated ureters. The positioning of the ureteral orifices typically follows the Weigert-Meyer law (Zaontz and Maizels, 1985).

The ureters may be associated with ureteroceles and may be ectopic to the bladder neck, urethra, or vagina (Park, 2008; Engelstein et al., 1996; Patel et al., 2001). Lower pole and mid-pole UPJ obstruction may be present, as well as ureterovesical obstruction (Sivrikaya et al., 2007; Merlini, 1983). VUR is also described, as well as contralateral duplication (Ander et al., 1997; Srivastava et al., 1996). Fusion anomalies may be present in some patients (Pode et al., 1983; Golomb and Ehrlich, 1989).

Quadruple Ureters

Even more rare is ureteral quadruplication, with only eight cases reported. Most have been in adults, but three recent cases included four ureters draining into a large ureteral cyst and connecting to the bladder through a single ureter (Klinge et al., 2001; Vicentini et al., 2007; Koszutski et al., 2008). One report of a young adult with incontinence describes three of the four ureters merging and entering the bladder orthotopically and the fourth ureter draining to the perineum. This ectopic ureter was associated with the lower mid-calyx, contrary to what the Weigert-Meyer law would predict.

Fibroepithelial Polyps

Polyps of the ureter may manifest clinically with flank pain or hematuria or by incidental detection of hydronephrosis. The most common site of attachment is at the UPJ, although they may originate from any part of the ureter. As a cause of UPJ obstruction, they are very uncommon, reported as 0.5% of all UPJ patients undergoing pyeloplasty (Adey et al., 2003; Kojima et al., 2011). A very large majority of patients were male (89%), and a majority of polyps occurred on the left side (78%). They are uncommonly bilateral, but this has been reported with clinical effects on both kidneys (Bartone et al., 1990; Lavelle et al., 1997; Bhalla et al., 2002; Adey et al., 2003; Romesburg et al., 2009). In a recent series, two of nine patients had bilateral clinically obstructive UPJ polyps. They may also be multiple. We have seen one case in which the polyp protruded from the urethra and produced severe voiding symptoms and was ultimately found to originate from the proximal third of the ureter.

Smaller polyps may not be evident on modern imaging and in a recent series were detected in 22% of patients before surgery for UPJ obstruction (Adey et al., 2003). Ultrasonography may be useful in detecting these polyps (Wang et al., 2012). They would usually be seen on intravenous pyelography but may be mistaken for ureteral blood clots, particularly in the setting of hematuria (Fig. 41.35). Filling defects on retrograde pyelography in anticipation of a pyeloplasty should trigger a search for the polyps (Fig. 41.36). It is unlikely that this would alter the surgical approach unless the polyp was significantly distal to the UPJ.

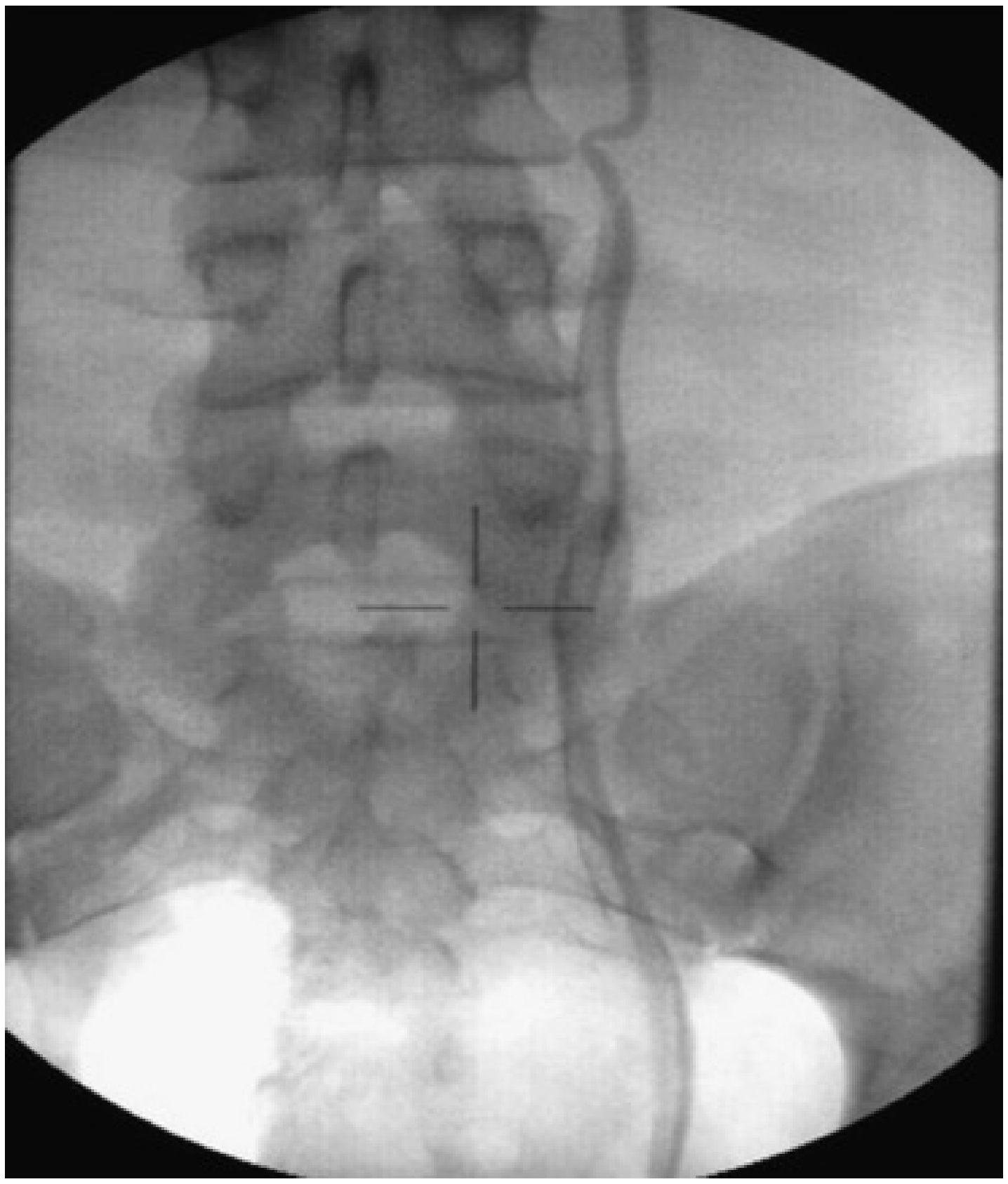

FIG. 41.35 Retrograde ureterogram of an adolescent with a history of hematuria, dysuria, and a fleshy mass protruding from her urethra. The distal segment had been resected by an outside physician. The long-filling defects are typical of fibroepithelial polyps but may be confused for blood clots.

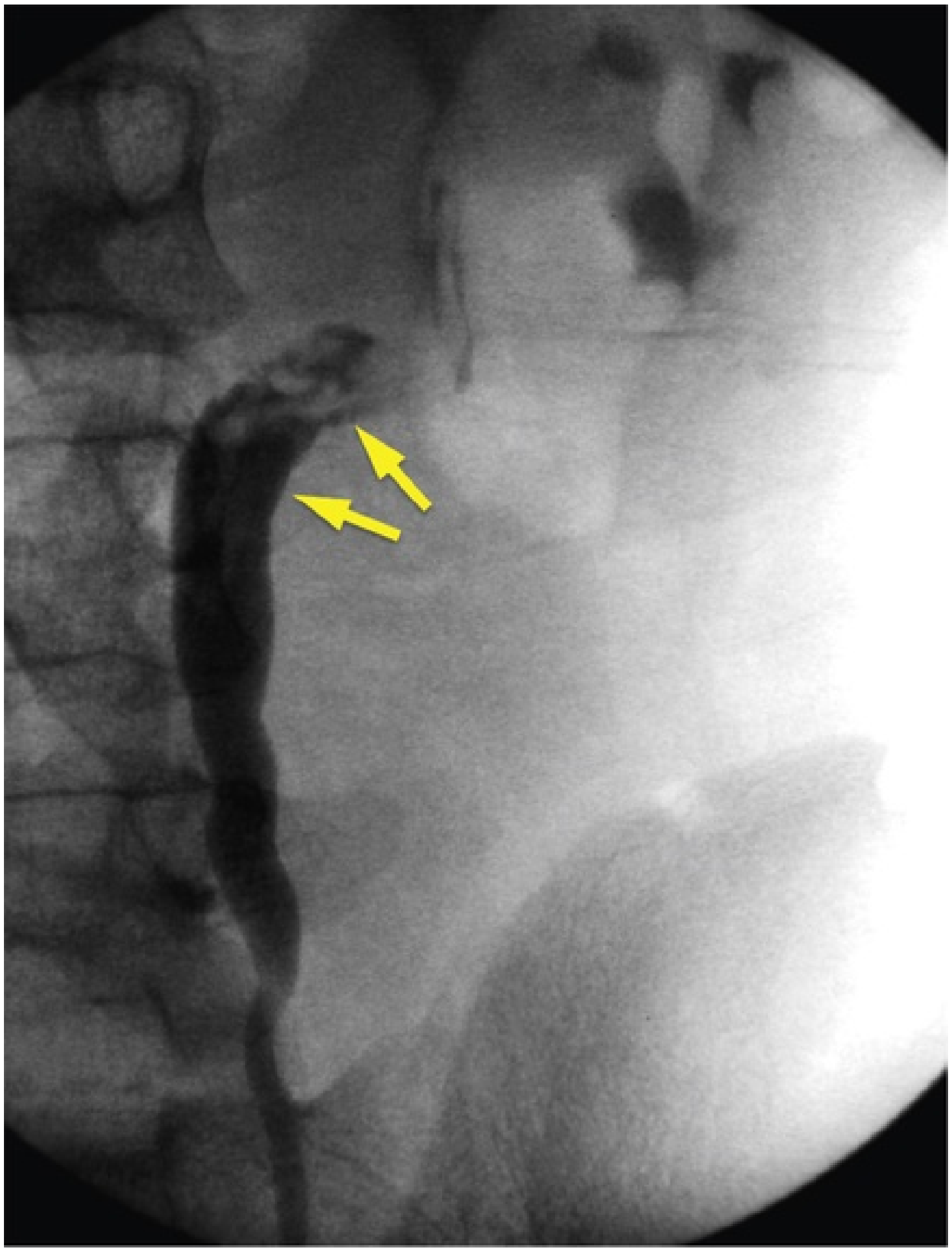

FIG. 41.36 Retrograde pyelogram demonstrating complex filling defects at the ureteropelvic junction in a child with intermittent flank pain and hydronephrosis. The *arrows* show the filling defect at the ureteropelvic junction and the proximal ureter, suggesting a complex multifrondular fibroepithelial polyp.

The cause of fibroepithelial polyps is unclear, although progressive traction resulting from ureteral peristalsis may promote edema and growth. We have seen one in which the ureter was being intussuscepted into itself owing to traction on the polyp in the mid-ureter. Histologically, they are considered benign neoplasms with fibroepithelial and vascular elements, with overlying normal to hypertrophied urothelium. There is usually a fibrovascular core with significant stromal edema. Little inflammation is seen.

Management of the polyp is dictated by the presentation and location. **For**

polyps at the UPJ, most have undergone pyeloplasty, although the question of whether simple endoscopic resection might suffice is not settled, as there are too few cases. Ureteroscopic removal of ureteral polyps is the recommended therapy away from the UPJ, based on combined adult and pediatric reports (Minevich et al., 2005; Childs et al., 2009; Iwatsuki et al., 2010). Earlier reports advocated sleeve resection and reanastomosis of the ureter to prevent recurrence, yet the persisting success with ureteroscopic resection would suggest that to be unnecessary. Even earlier reports recommended nephrectomy, which cannot be justified.

Key Points: Other Ureteral Anomalies

- Ureteral duplication is compatible with a normally functioning renal system if both ureters enter orthotopically or if there is partial duplication.
- It is clinically prudent to look for contralateral duplication when unilateral duplication is documented.
- An increased incidence of ureterorenal pathology has been documented with duplication anomalies.
- Conditions routinely affecting a single system kidney are those that affect the lower pole, including UPJ obstruction and VUR; the upper pole is more likely affected by conditions resulting from abnormal ureteral formation, including ectopia and ureterocele.
- Polyps of the ureter may manifest clinically with flank pain or hematuria or by incidental detection of hydronephrosis.
- The most common site of attachment of a fibroepithelial polyp is at the UPJ, although they may originate from any part of the ureter.
- UPJ polyps are best treated with pyeloplasty, although the question of whether endoscopic resection might suffice is not settled.
- Ureteroscopic removal of ureteral polyps is the recommended therapy away from the UPJ.

Anomalies of Position

Vascular Anomalies Involving the Ureter

A variety of vascular lesions can cause ureteral obstruction. With these lesions, the vascular system rather than the urinary system is anomalous. With the exception of accessory renal blood vessels, all of these lesions are relatively uncommon, although all have clinical relevance.

Preureteral Vena Cava

Anatomy.

Preureteral vena cava is commonly known to urologists as *circumcaval* or *retrocaval ureter,* terms that are anatomically descriptive but misleading with regard to development (Lerman et al., 1956; Dreyfuss, 1959). **The term *preureteral vena cava*** emphasizes that the circumcaval ureter results from altered vascular, rather than ureteral, development. This is the more accurate term.

This disorder involves the right ureter, which typically deviates medially behind (dorsal to) the inferior vena cava, winding about and crossing in front of it from a medial to a lateral direction, to resume a normal course, distally, to the bladder. The renal pelvis and upper ureter are typically elongated and dilated in a *J* or fishhook shape before passing behind the vena cava. The collecting system is not inevitably obstructed. Circumcaval ureters can be classified into two clinical types (Bateson and Atkinson, 1969; Kenawi and Williams, 1976). The more common type I has hydronephrosis and a typically obstructed pattern demonstrating some degree of fishhook-shaped deformity of the ureter to the level of the obstruction. Type II has a lesser degree of hydronephrosis or none at all. Here, the upper ureter is not kinked but passes behind the vena cava at a higher level, with the renal pelvis and upper ureter lying almost horizontal before encircling the vena cava in a smooth curve. In type I, the obstruction appears to occur at the edge of the iliopsoas muscle, at which point the ureter deviates cephalad before passing behind the vena cava.

Embryology.

The definitive inferior vena cava develops on the right side from a plexus of fetal veins (Fig. 41.37). Initially, the venous retroperitoneal pathways consist of symmetrically placed vessels, both central and dorsal. The posterior cardinal and supracardinal veins lie dorsally, and the subcardinal veins lie ventrally. These channels, with their anastomoses, form a collar on each side through which the ascending kidneys pass. Normally the left supracardinal veins and the lumbar portion of the right posterior cardinal vein atrophy. The subcardinal veins become the internal spermatic veins. The definitive right-sided inferior vena cava forms from the right supracardinal vein. **If the subcardinal vein in the lumbar portion fails to atrophy and becomes the primary right-sided vein, the ureter is trapped dorsal to it.**

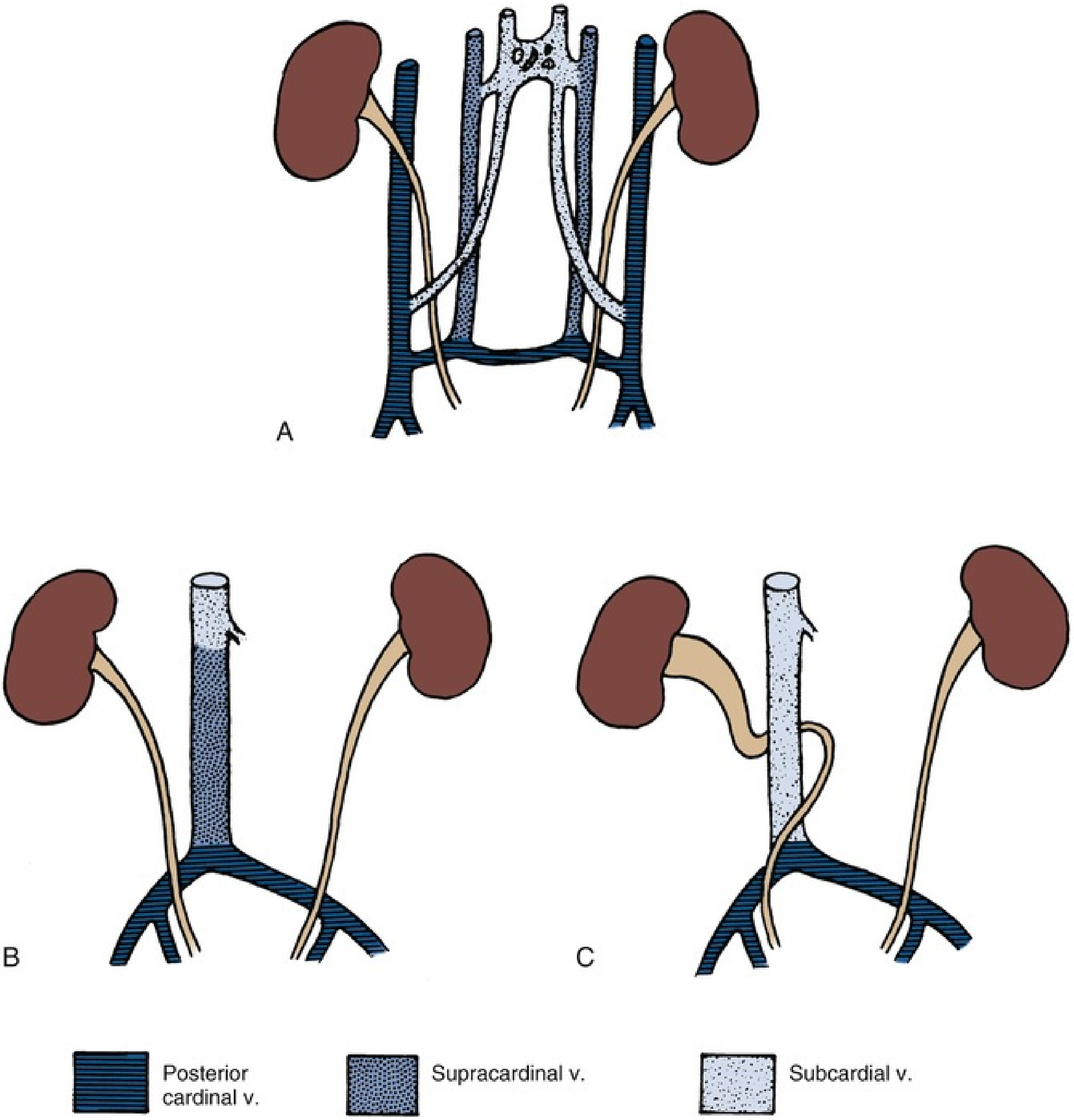

FIG. 41.37 Fetal venous ring (A), normal vena cava (B), and preureteral vena cava (C). (Redrawn from Hollinshead WH. *Anatomy for surgeons.* vol 2. New York, NY: Hoeber Medical Division of Harper and Row; 1956.)

When the definitive vena cava forms normally and the ventral portion of the primitive ring also persists, a double right vena cava is formed because of the persistence of both the right subcardinal vein dorsally and the right subcardinal vein ventrally. This double vena cava traps the right ureter between its limbs (Sasai et al., 1986).

Although bilateral vena cava or left-sided vena cava can occur, a bilateral circumcaval ureter has been described in a case of situs inversus (Clements et al., 1978; Mayo et al., 1983; Brooks, 1962). In cases of bilateral vena cava associated with a circumcaval ureter, the circumcaval ureter has been reported only on the right side, denoting that the right vena cava developed abnormally from a persistent subcardinal vein, whereas the left vena cava developed from the left supracardinal vein but otherwise normally (Pick and Anson, 1940).

Incidence.

The incidence of preureteral vena cava at autopsy is about 1 in 1500. The anomaly is three to four times more common in male than in female cadavers, although a literature review reported a ratio of 114 : 41 male to females (2.8 : 1) (Heslin and Mamonas, 1951; Kenawi and Williams, 1976).

The symptoms of preureteral vena cava are those of obstruction. **Although the lesion is congenital** (Soundappan and Barker, 2004; Acharya et al., 2009)**, presentation in most patients does not occur until the third or fourth decade of life** (Kenawi and Williams, 1976).

Diagnosis.

Clinically, patients may have symptoms of flank or abdominal pain or infection, or the disorder may be discovered incidentally during other radiologic tests. Excretory urography often fails to visualize the portion of the ureter beyond the J hook (i.e., extending behind the vena cava), but retrograde ureteropyelography demonstrates an S curve to the point of obstruction with the retrocaval segment lying at the level of L3 or L4 (Kenawi and Williams, 1976). Cavography is no longer a necessary diagnostic test.

Ultrasonography and CT or MRI also have been useful in defining the vascular malformation (Murphy et al., 1987). CT urography may be the procedure of choice to confirm the diagnosis and avoid retrograde ureteropyelography (Sasai et al., 1986; Kellman et al., 1988). Nuclear renal furosemide scanning can categorize the anomaly as obstructed or nonobstructed (Pienkny et al. 1999) **MRI can demonstrate the course of a preureteral vena cava and may be a more detailed and less invasive imaging modality when**

compared with CT and retrograde pyelography (Uthappa, Anthony et al. 2002).

The diagnosis may not be obvious and we have seen one case in which the obstruction from a pre-ureteral cava was thought to be a ureteropelvic junction obstruction and subsequent pyeloplasty that failed (Junejo et al., 2018).

Treatment.

Surgical correction involves ureteral division, with relocation and ureteroureteral or ureteropelvic reanastomosis, usually with excision or bypass of the retrocaval segment, which can be aperistaltic. It is important to be mindful of the ureter's blood supply from the renal artery and aorta superiorly and the iliac vessels inferiorly. As stated earlier, the preferred approach for the obstructed ureter is ureteral division and relocation. Laparoscopic (Miyazato et al., 2002; Ramalingam and Selvarajan, 2003; Tobias-Machado et al., 2005; Fernandez-Fernandez and Pachano-Arenas, 2008) and robotic (Gundeti et al., 2006; Smith et al., 2009) reconstruction of the ureter in a preureteral vena cava via both the transperitoneal and retroperitoneal approaches in children has been described. Reoperative robotic correction of a missed preureteral cava after pyeloplasty has been described, highlighting the fact that modern imaging may not always permit an accurate diagnosis (Junejo et al., 2018).

Other Anomalies of Position

Several instances of horseshoe kidney have been reported (Cukier et al., 1969; Cendron and Reis, 1972; Heffernan et al., 1978; Taguchi et al., 1986). Anomalies include a variety of left renal anomalies, such as agenesis, hydronephrosis, malrotation, and hypoplasia (Kenawi and Williams, 1976). An obstructing branch of the right spermatic vein and a lumbar vein have mimicked circumcaval ureteral obstruction, as has an anomalous tendon of the iliopsoas muscle (Dreyfuss, 1959; Psihramis, 1987; Guarise et al., 1989).

Preureteral Iliac Artery (Retroiliac Ureter).

A ureter coursing behind the common iliac artery is rare (Corbus et al., 1960; Seitzman and Patton, 1960; Hanna, 1972; Radhkrishnan et al., 1980). Either side can be involved; in two cases, the condition was bilateral (Hanna, 1972; Radhkrishnan et al., 1980). Obstruction occurs at the level of L5 or S1 as the ureter is compressed behind the artery. Coexisting anomalies are common, particularly vasal anomalies (Nguyen et al., 1989; Seitzman and Patton, 1960;

Radhkrishnan et al., 1980).

Like the preureteral cava, the preureteral iliac artery is considered to be of vascular origin without definitive proof. Normally, the primitive ventral root of the umbilical artery is replaced by development of a more dorsal branch between the aorta and the distal umbilical artery. Persistence of the ventral root as the dorsal root fails to form traps the ureter dorsally.

Ureteral or mesonephric duct ectopia is often present (Nguyen et al., 1989). The case of Seitzman and Patton involved an ectopic ureter that emptied, along with the ipsilateral vas deferens, via a persistent common mesonephric duct into the proximal posterior urethra (Seitzman and Patton, 1960). In the case of Radhkrishnan et al., bilateral retroiliac ureters also involved bilateral ectopic termination of the vasa deferentia into the ureters (Radhkrishnan et al., 1980). Iuchtman et al. described ectopic vaginal termination of the involved ureter, with urometrocolpos from an imperforate hymen (Iuchtman et al., 1980).

Taibah et al. reported the unusual finding of left ureteral obstruction from a retrointernal iliac artery ureter in an otherwise normal young woman (Taibah et al., 1987).

Vascular Obstruction of the Distal Ureter.

Obstruction of the distal ureter from uterine, umbilical, obturator, and hypogastric vessels close to the bladder has been described (Campbell, 1936; Young and Kiser, 1965; Scultety and Varga, 1975). However, it is not always clear that vascular impressions on a dilated ureter are the cause of the obstruction. At times, these findings may be an artifact, as when a dilated ureter from an intrinsic obstruction is secondarily compressed against the adjacent vessel. Judging from the paucity of contemporary reports describing this lesion, it is likely that primary terminal ureteral obstruction by vascular lesions is a rare occurrence.

Herniation of the Ureter.

Herniation of the ureter is another extremely rare condition. Dourmashkin reported a series of inguinal, scrotal, and femoral herniations of the ureter (Dourmashkin, 1937). Most of these were paraperitoneal—that is, a loop of herniated ureter extended alongside a peritoneal hernial sac. Only a minority were extraperitoneal (i.e., with no hernial sac present). In paraperitoneal ureteral hernias, the ureteral loop is always medial to the peritoneal sac. Of six scrotal hernias, four did not have peritoneal sacs. When the ureter extended into the scrotum, it was more likely to be dilated, causing upper tract obstruction.

In children, herniated ureters have manifested with hydronephrosis, associated with megaureters and with persistent hydronephrosis after posterior urethral valve ablation (Jewett and Harris, 1953; Powell and Kapila, 1985; Burgu et al., 2009).

Internal hernias of the ureter are even more exceptional. Reports have been published of a sciatic hernia containing a ureter, herniation between the psoas muscle and iliac vessels, and lumbar triangle herniation (Oyen et al., 1987; Witney-Smith et al., 2007; Tsai et al., 2008; Hsu et al., 2010; Page, 1955; Cabello et al., 2008). Ureteral herniation with obstruction has been reported as a rare complication of renal transplantation (Ingber et al., 2007).

Key Points: Preureteral Vena Cava (Circumcaval Ureter, Retrocaval Ureter)

- Preureteral vena cava involves the right ureter, which typically deviates medially behind (dorsal to) the inferior vena cava, winding about and crossing in front of it from a medial to lateral direction, to resume a normal course to the bladder.
- If the subcardinal vein in the lumbar portion fails to atrophy and becomes the primary right-sided vein, the ureter is trapped dorsal to it.
- The preureteral cava may manifest with symptoms of flank or abdominal pain or infection, or the disorder may be discovered incidentally.
- Surgical correction involves ureteral division, with relocation and ureteroureteral or ureteropelvic reanastomosis, usually with excision or bypass of the retrocaval segment, which can be aperistaltic.

Suggested Readings

Adey GS, Vargas SO, Retik AB, et al. Fibroepithelial polyps causing ureteropelvic junction obstruction in children. *J Urol*. 2003;169:1834–1836.

Byun E, Merguerian PA. A meta-analysis of surgical practice patterns in the endoscopic management of ureteroceles. *J Urol*. 2006;176:1871–1877 [discussion 1877].

Castagnetti M, Vidal E, Burei M, et al. Duplex system ureterocele in infants: should we reconsider the indications for secondary surgery after endoscopic puncture or partial nephrectomy? *J Pediatr Urol*. 2013;9(1):11–16.

Chia I, Grote D, Marcotte M, et al. Nephric duct insertion is a crucial step in urinary tract maturation that is regulated by a Gata3-Raldh2-Ret molecular network in mice. *Development*. 2011;138(10):2089–2097.

Churchill BM, Sheldon CA, McLorie GA. The ectopic ureterocele: a proposed practical classification based on renal unit jeopardy. *J Pediatr Surg*. 1992;27:497–500.

Glassberg KI, Braren V, Duckett JW, et al. Suggested terminology for duplex systems, ectopic ureters and ureteroceles. *J Urol*. 1984;132:1153–1154.

Gotoh T, Koyanagi T, Matsuno T. Surgical management of ureteroceles in children: strategy based on the classification of ureteral hiatus and the eversion of ureteroceles. *J Pediatr Surg*. 1988;23:159–165.

Hendren WH, Mitchell ME. Surgical correction of ureteroceles. *J Urol*. 1979;121:590–597.

Husmann D, Strand B, Ewalt D, et al. Management of ectopic ureterocele associated with renal duplication: a comparison of partial nephrectomy and endoscopic decompression. *J Urol*. 1999;162:1406–1409.

Jawdat J, Rotem S, Kocherov S, et al. Does endoscopic puncture of ureterocele provide not only an initial solution, but also a definitive treatment in all children? Over the 26 years of experience. *Pediatr Surg Int*. 2018;34(5):561–565.

Jesus LE, Farhat WA, Amarante AC, et al. Clinical evolution of vesicoureteral reflux following endoscopic puncture in children with duplex system ureteroceles. *J Urol*. 2011;186(4):1455–1458.

Kenawi MM, Williams DI. Circumcaval ureter: a report of four cases in children with a review of the literature and a new classification. *Br J Urol*. 1976;48:183–192.

Le HK, Chiang G. Long-term management of ureterocele in duplex collecting systems: reconstruction implications. *Curr Urol Rep*. 2018;19(2):14.

Lee NG, Corbett ST, Cobb K, et al. Bi-institutional comparison of robot-assisted laparoscopic versus open ureteroureterostomy in the pediatric population. *J Endourol*. 2015;29(11):1237–1241.

Lewis JM, Cheng EY, Campbell JB, et al. Complete excision or marsupialization of ureteroceles: does choice of surgical approach affect outcome? *J Urol*. 2008;180:1819–1822 [discussion 1822–1823].

Mendelsohn C. Using mouse models to understand normal and abnormal urogenital tract development. *Organogenesis*. 2009;5:306–314.

Paye-Jaouen A, Pistolesi F, Botto N, et al. Long-term bladder function after ureterocele decompression in children. *J Urol*. 2015;193(5 Suppl):1754–1759.

Sander JC, Bilgutay AN, Stanasel I, et al. Outcomes of endoscopic incision for the treatment of ureterocele in children at a single institution. *J Urol*. 2015;193(2):662–666.

Shimada K, Matsumoto F, Matsui F. Surgical treatment for ureterocele with special reference to lower urinary tract reconstruction. *Int J Urol*. 2007;14:1063–1067.

Stephens D. Caecoureterocele and concepts on the embryology and aetiology of ureteroceles. *Aust N Z J Surg*. 1971;40:239–248.

Timberlake MD, Corbett ST. Minimally invasive techniques for management of the ureterocele and ectopic ureter: upper tract versus lower tract approach. *Urol Clin North Am*. 2015;42(1):61–76.

References

Abrahamsson K, Hansson E, Sillen U, et al. Bladder dysfunction: an integral part of the ectopic ureterocele complex. *J Urol*. 1998;160(4):1468–1470.

Abrahamsson LO, Rosenkilde Olsen P, Mathiesen FR. Ureterocele in adults. A follow-up study of 28 adult patients treated with transurethral diathermy incision. *Scand J Urol Nephrol*. 1981;15(3):239–242.

Acharya SK, Jindal B, Yadav DK, et al. Retrocaval ureter: a rare cause of hydronephrosis in children. *J Pediatr Surg*. 2009;44(4):846–848.

Adey GS, Vargas SO, Retik AB, et al. Fibroepithelial polyps causing ureteropelvic junction obstruction in children. *J Urol*. 2003;169(5):1834–1836.

Adorisio O, Elia A, Landi L, et al. Effectiveness of primary endoscopic incision in treatment of ectopic ureterocele associated with duplex system. *Urology*. 2011;77(1):191–194.

Afshar K, Papanikolaou F, Malek R, et al. Vesicoureteral reflux and complete ureteral duplication. Conservative or surgical management? *J Urol*. 2005;173(5):1725–1727.

Alldred AJ, Higgins TT. The ectopic ureter in childhood with an account of four personal cases. *Br J Surg*. 1951;38(152):460–466.

Alyami FA, Koyle MA, Bowlin PR, et al. Side-to-Side Refluxing Nondismembered Ureterocystotomy: a novel strategy to address obstructed megaureters in children. *J Urol*. 2017;198(5):1159–1167.

Amitai M, Hertz M, Jonas P, et al. Ectopic ureterocele in adults with a comparison of the anomaly in children. *Urol Radiol*. 1992;13(3):181–186.

Ander H, Ziylan O, Cayan S, et al. A case of ureteral triplication (type 1) associated with vesicoureteral reflux in a solitary kidney. *Int Urol Nephrol*. 1997;29(5):537–540.

Bartone FF, Johansson SL, Markin RJ, et al. Bilateral fibroepithelial polyps of ureter in a child. *Urology*. 1990;35(6):519–522.

Bateson EM, Atkinson D. Circumcaval ureter: a new classification. *Clin Radiol*. 1969;20(2):173–177.

Batourina E, Choi C, Paragas N, et al. Distal ureter morphogenesis depends on epithelial cell remodeling mediated by vitamin A and Ret. *Nat Genet*. 2002;32(1):109–115.

Batourina E, Tsai S, Lambert S, et al. Apoptosis induced by vitamin A signaling is crucial for connecting the ureters to the bladder. *Nat Genet*. 2005;37(10):1082–1089.

Bauer SB, Retik AB. The non-obstructive ectopic ureterocele. *J Urol*. 1978;119(6):804–807.

Beganovic A, Klijn AJ, Dik P, et al. Ectopic ureterocele: long-term results of open surgical therapy in 54 patients. *J Urol*. 2007;178(1):251–254.

Bhalla RS, Schulsinger DA, Wasnick RJ. Treatment of bilateral fibroepithelial polyps in a child. *J Endourol*. 2002;16(8):581–582.

Bilen CY, Aygun C, Ozkaya O, et al. Percutaneous ureterostomy as an effective diversion in a newborn. *Int J Urol*. 2006;13(5):622–624.

Biles MJ, Finkelstein JB, Silva MV, et al. Innovation in Robotics and Pediatric Urology: robotic ureteroureterostomy for duplex systems with ureteral ectopia. *J Endourol*. 2016;30(10):1041–1048.

Blyth B, Passerini-Glazel G, Camuffo C, et al. Endoscopic incision of ureteroceles: intravesical versus ectopic. *J Urol*. 1993;149(3):556–559 [discussion 560].

Borer JG, Bauer SB, Peters CA, et al. A single-system ectopic ureter draining an ectopic dysplastic kidney: delayed diagnosis in the young female with continuous urinary incontinence. *Br J Urol*. 1998;81(3):474–478.

Brehmer B, Makris A, Jakse G. Laparoscopic heminephrectomy and resection of ectopic ureter in an adult. *Urol Int*. 2007;79(3):280–283.

Brooks RE Jr. Left retrocaval ureter associated with situs inversus. *J Urol*. 1962;88:484–487.

Burgu B, Resorlu B, Suer E, et al. Scrotal hernia of the ureter in association with posterior urethral valves. *J Pediatr Urol*. 2009;6(1):87–88.

Byun E, Merguerian PA. A meta-analysis of surgical practice patterns in the endoscopic management of ureteroceles. *J Urol*. 2006;176(4 Pt 2):1871–1877 [discussion 1877].

Cabello R, Cancho MJ, Monzo JI, et al. Herniation of renal pelvis and ureteropelvic junction resulting from superior lumbar triangle hernia. *Scand J Urol Nephrol*. 2008;42(1):81–82.

Cain MP, Pope JC, Casale AJ, et al. Natural history of refluxing distal ureteral stumps after nephrectomy and partial ureterectomy for vesicoureteral reflux. *J Urol*. 1998;160(3 Pt 2):1026–1027.

Campbell M. Ureterocele; a study of 94 instances in 80 infants and children. *Surg Gynecol Obstet*. 1951;93(6):705–718.

Campbell MF. Vascular obstruction of the ureter in children. *J Urol*. 1936;36:366.

Campobasso D, Lanzi A, Pozzoli GL, et al. Prolapsed ureterocele in an adult woman after endoscopic incision. *Urol Ann*. 2018;10(1):100–102.

Carrico C, Lebowitz RL. Incontinence due to an infrasphincteric ectopic ureter: why the delay in diagnosis and what the radiologist can do about it. *Pediatr Radiol*. 1998;28(12):942–

949.

Castagnetti M, Vidal E, Burei M, et al. Duplex system ureterocele in infants: should we reconsider the indications for secondary surgery after endoscopic puncture or partial nephrectomy? *J Pediatr Urol*. 2013;9(1):11–16.

Cendron J, Reis CF. [Retrocaval ureter in children. Apropos of 4 cases]. *J Urol Nephrol (Paris)*. 1972;78(6):375–392.

Chacko JK, Koyle MA, Mingin GC, et al. Ipsilateral ureteroureterostomy in the surgical management of the severely dilated ureter in ureteral duplication. *J Urol*. 2007;178(4 Pt 2):1689–1692.

Chalouhi GE, Morency AM, De Vlieger R, et al. Prenatal incision of ureterocele causing bladder outlet obstruction: a multicenter case series. *Prenat Diagn*. 2017;37(10):968–974.

Chertin B, Mohanan N, Farkas A, et al. Endoscopic treatment of vesicoureteral reflux associated with ureterocele. *J Urol*. 2007;178(4 Pt 2):1594–1597.

Chia I, Grote D, Marcotte M, et al. Nephric duct insertion is a crucial step in urinary tract maturation that is regulated by a Gata3-Raldh2-Ret molecular network in mice. *Development*. 2011;138(10):2089–2097.

Childs MA, Umbreit EC, Krambeck AE, et al. Fibroepithelial polyps of the ureter: a single-institutional experience. *J Endourol*. 2009;23(9):1415–1419.

Chowdhary SK, Kandpal DK, Sibal A, et al. Ureterocele in newborns, infants and children: ten year prospective study with primary endoscopic deroofing and double J (DJ) stenting. *J Pediatr Surg*. 2017;52(4):569–573.

Chu WY, Tsao TF, Chen SL, et al. A 12-year-old boy with an infected ectopic ureter presenting with acute appendicitis-like symptoms and acute scrotum. *Scand J Urol Nephrol*. 2012;46(3):208–211.

Churchill BM, Sheldon CA, McLorie GA. The ectopic ureterocele: a proposed practical classification based on renal unit jeopardy. *J Pediatr Surg*. 1992;27(4):497–500.

Chwalle R. The process of formation of cystic dilatations of the vesical end of the ureter and of diverticula at the ureteral ostium. *Urol Cutan Rev*. 1927;31:499.

Clements JC, McLeod DG, Greene WR, et al. A case report: duplicated vena cava with right retrocaval ureter and ureteral tumor. *J Urol*. 1978;119(2):284–285.

Cooper CS, Passerini-Glazel G, Hutcheson JC, et al. Long-term followup of endoscopic incision of ureteroceles: intravesical versus extravesical. *J Urol*. 2000;164(3 Pt 2):1097–1099 [discussion 1099–1100].

Coplen DE, Austin PF. Outcome analysis of prenatally detected ureteroceles associated with multicystic dysplasia. *J Urol*. 2004;172(4 Pt 2):1637–1639 [discussion 1639].

Corbus BC, Estrem RD, Hunt W. Retro-iliac ureter. *J Urol*. 1960;84:67–68.

Cukier J, Aubert J, Dufour B. [Retrocaval ureter and horseshoe kidney in a 6-year-old hypospadic boy]. *J Urol Nephrol (Paris)*. 1969;75(10):749–757.

de Jong TP, Dik P, Klijn AJ, et al. Ectopic ureterocele: results of open surgical therapy in 40 patients. *J Urol*. 2000;164(6):2040–2043 [discussion 2043–2044].

Di Renzo D, Ellsworth PI, Caldamone AA, et al. Transurethral puncture for ureterocele-which factors dictate outcomes? *J Urol*. 2010;184(4 Suppl):1620–1624.

Direnna T, Leonard MP. Watchful waiting for prenatally detected ureteroceles. *J Urol*. 2006;175(4):1493–1495 [discussion 1495].

Dourmashkin RL. Herniation of the ureter. *J Urol*. 1937;38:455.

Dreyfuss W. Anomaly simulating a retrocaval ureter. *J Urol*. 1959;82:630–632.

El-Ghoneimi A, Farhat W, Bolduc S, et al. Retroperitoneal laparoscopic vs open partial nephroureterectomy in children. *BJU Int*. 2003;91(6):532–535.

el Ghoneimi A, Lottmann H, Odet E, et al. [Ureteropyelostomy for obstructed duplicated ureter an easy and reliable operation in infants]. *Ann Urol (Paris)*. 1998;32(4):241–246.

el Ghoneimi A, Miranda J, Truong T, et al. Ectopic ureter with complete ureteric duplication: conservative surgical management. *J Pediatr Surg*. 1996;31(4):467–472.

El-Ghoneimi A, Valla JS, Steyaert H, et al. Laparoscopic renal surgery via a retroperitoneal approach in children. *J Urol*. 1998;160(3 Pt 2):1138–1141.

Engelstein D, Livne PM, Cohen M, et al. Type II ureteral triplication associated with ectopic ureter. *Urology*. 1996;48(5):786–788.

Fernandez-Fernandez JA, Pachano-Arenas FE. Laparoscopic-assisted correction of a retrocaval ureter. *J Pediatr Surg*. 2008;43(8):1560–1562.

Ghonge NP, Aggarwal B, Sahu AK. Zinner syndrome: a unique triad of mesonephric duct abnormalities as an unusual cause of urinary symptoms in late adolescence. *Indian J Urol*. 2010;26(3):444–447.

Ghosh B, Shridhar K, Pal DK, et al. Ectopic ureter draining into the uterus. *Urol Ann*. 2016;8(1):105–107.

Glassberg KI, Braren V, Duckett JW, et al. Suggested terminology for duplex systems, ectopic ureters and ureteroceles. *J Urol*. 1984;132(6):1153–1154.

Godinho AB, Nunes C, Janeiro M, et al. Ureterocele: antenatal diagnosis and management. *Fetal Diagn Ther*. 2013;34(3):188–191.

Golomb J, Ehrlich RM. Bilateral ureteral triplication with crossed ectopic fused kidneys associated with the VACTERL syndrome. *J Urol*. 1989;141(6):1398–1399.

Gonzalez R, Piaggio L. Initial experience with laparoscopic ipsilateral ureteroureterostomy in infants and children for duplication anomalies of the urinary tract. *J Urol*. 2007;177(6):2315–2318.

Grimsby GM, Merchant Z, Jacobs MA, et al. Laparoscopic-assisted ureteroureterostomy for duplication anomalies in children. *J Endourol*. 2014;28(10):1173–1177.

Gross RE, Clatworthy HW Jr. Ureterocele in infancy and childhood. *Pediatrics*. 1950;5(1):68–77 [illust].

Guarise P, Cimaglia ML, Spata F, et al. [Retrotendinous ureter. An exceptional cause of obstruction in the upper urinary tract]. *Pediatr Med Chir*. 1989;11(1):85–88.

Gundeti MS, Duffy PG, Mushtaq I. Robotic-assisted laparoscopic correction of pediatric retrocaval ureter. *J Laparoendosc Adv Surg Tech A*. 2006;16(4):422–424.

Haddad J, Meenakshi-Sundaram B, Rademaker N, et al. “Watering Can” ureterocele puncture technique leads to decreased rates of de novo vesicoureteral reflux and subsequent surgery with durable results. *Urology*. 2017;108:161–165.

Haddock P, Wagner JR. Seminal vesicle cyst with ipsilateral renal agenesis and ectopic ureter (Zinner syndrome). *Urology*. 2015;85(5):e41–e42.

Han MY, Gibbons MD, Belman AB, et al. Indications for nonoperative management of ureteroceles. *J Urol*. 2005;174(4 Pt 2):1652–1655 [discussion 1655–1656].

Hanna MK. Bilateral retroiliac-artery ureters. *Br J Urol*. 1972;44(3):339–344.

Heffernan JC, Lightwood RG, Snell ME. Horseshoe kidney with retrocaval ureter: second reported case. *J Urol*. 1978;120(3):358–360.

Hendren WH, Mitchell ME. Surgical correction of ureteroceles. *J Urol*. 1979;121(5):590–597.

Hendren WH, Monfort GJ. Surgical correction of ureteroceles in childhood. *J Pediatr Surg*. 1971;6(3):235–244.

Heslin JE, Mamonas C. Retrocaval ureter: report of four cases and review of literature. *J Urol*. 1951;65(2):212–222.

Ho DS, Jerkins GR, Williams M, et al. Ureteropelvic junction obstruction in upper and lower moiety of duplex renal systems. *Urology*. 1995;45(3):503–506.

Hoberman A, Charron M, Hickey RW, et al. Imaging studies after a first febrile urinary tract infection in young children. *N Engl J Med*. 2003;348(3):195–202.

Hodhod A, Jednak R, Khriguian J, et al. Transurethral incision of ureterocele: does the time of presentation affect the need for further surgical interventions? *J Pediatr Urol*. 2017;13(5):501 e501–501 e506.

Hoshi M, Batourina E, Mendelsohn C, et al. Novel mechanisms of early upper and lower urinary tract patterning regulated by RetY1015 docking tyrosine in mice. *Development*. 2012;139(13):2405–2415.

Hosseini Sharifi SH, Nabavizadeh B, Mozafarpour S, et al. Laparoscopic selective clipping of upper moiety vasculature and ureter without partial nephrectomy: a novel technique for pediatric urinary incontinence due to ectopic ureter associated with poor functioning upper renal moiety. *J Pediatr Urol*. 2017;13(2):217–218.

Hsu HL, Huang KH, Chang CC, et al. Hydronephrosis caused by ureterosciatic herniation. *Urology*. 2010.

Huisman TK, Kaplan GW, Brock WA, et al. Ipsilateral ureteroureterostomy and pyeloureterostomy: a review of 15 years of experience with 25 patients. *J Urol*. 1987;138(5):1207–1210.

Husmann D, Strand B, Ewalt D, et al. Management of ectopic ureterocele associated with renal duplication: a comparison of partial nephrectomy and endoscopic decompression. *J Urol*. 1999;162(4):1406–1409.

Idbohrn H, Sjostedt S. Ectopic ureter not causing incontinence until adult life; double kidney with hydronephrosis diagnosed by renal angiography. *Acta Obstet Gynecol Scand*. 1954;33(4):457–464.

Ilic P, Jankovic M, Milickovic M, et al. Laser-puncture Versus Electrosurgery-incision of the Ureterocele in Neonatal Patients. *Urol J*. 2018;15(2):27–32.

Ingber MS, Girdler BJ, Moy JF, et al. Inguinal herniation of a transplant ureter: rare cause of obstructive uropathy. *Urology*. 2007;70(6):1224 e1221–1224 e1223.

Iuchtman M, Assa J, Blatnoi I, et al. Urometrocolpos associated with retroiliac ureter. *J Urol*. 1980;124(2):283–285.

Iwatsuki S, Kojima Y, Mizuno K, et al. Laparoscopic management for fibroepithelial polyp causing ureteropelvic junction obstruction in a child. *Urology*. 2010;76(1):146–148.

Janetschek G, Seibold J, Radmayr C, et al. Laparoscopic heminephroureterectomy in pediatric patients. *J Urol*. 1997;158(5):1928–1930.

Jankowski JT, Palmer JS. Holmium: yttrium-aluminum-garnet laser puncture of ureteroceles in neonatal period. *Urology*. 2006;68(1):179–181.

Jawdat J, Rotem S, Kocherov S, et al. Does endoscopic puncture of ureterocele provide not only an initial solution, but also a definitive treatment in all children? Over the 26 years of experience. *Pediatr Surg Int*. 2018;34(5):561–565.

Jayanthi VR, Koff SA. Long-term outcome of transurethral puncture of ectopic ureteroceles: initial success and late problems. *J Urol*. 1999;162(3 Pt 2):1077–1080.

Jesus LE, Farhat WA, Amarante AC, et al. Clinical evolution of vesicoureteral reflux following endoscopic puncture in children with duplex system ureteroceles. *J Urol*. 2011;186(4):1455–1458.

Jewett HJ, Harris AP. Scrotal ureter. *J Urol*. 1953;69(1):184–

187.

Johnin K, Narita M, Kim CJ, et al. Bilateral single ectopic ureters with hypoplastic bladder: how should we treat these challenging entities? *J Pediatr Urol*. 2007;3(3):243–246.

Jordan GH, Winslow BH. Laparoendoscopic upper pole partial nephrectomy with ureterectomy. *J Urol*. 1993;150(3):940–943.

Junejo N, Vallasciani S, Peters C, et al. High retrocaval ureter: an unexpected intraoperative finding during robotic redo pyeloplasty. *Urol Case Rpt*. 2018;20:19–21.

Kaplan N, Elkin M. Bifid renal pelves and ureters. Radiographic and cinefluorographic observations. *Br J Urol*. 1968;40(2):235–244.

Kellman GM, Alpern MB, Sandler MA, et al. Computed tomography of vena caval anomalies with embryologic correlation. *Radiographics*. 1988;8(3):533–556.

Kenawi MM, Williams DI. Circumcaval ureter: a report of four cases in children with a review of the literature and a new classification. *Br J Urol*. 1976;48(3):183–192.

Kim KS, Kim Y, Oh SJ. Natural history of refluxing distal ureteral stumps following upper tract surgery in children with ectopic ureter or ureterocele. *Urol Int*. 2001;67(2):142–146.

King LR, Kozlowski JM, Schacht MJ. Ureteroceles in children. A simplified and successful approach to management. *JAMA*. 1983;249(11):1461–1465.

Klinge L, Kubiak R, Slongo T. Quadruplication of the ureter in combination with a large ureteral cyst. *Pediatr Surg Int*. 2001;17(7):566–568.

Kojima Y, Lambert SM, Steixner BL, et al. Multiple metachronous fibroepithelial polyps in children. *J Urol*. 2011;185(3):1053–1057.

Koszutski T, Kudela G, Mikosinski M, et al. Quadruplication of dystopic kidney in combination with ureteral cyst. *J Pediatr*

Surg. 2008;43(12):e13–e15.

Koyanagi T, Tsuji I, Orikasa S, et al. Bilateral single ectopic ureter: report of a case. *Int Urol Nephrol*. 1977;9(2):123–127.

Kroovand RL, Perlmutter AD. A one-stage surgical approach to ectopic ureterocele. *J Urol*. 1979;122(3):367–369.

Kutikov A, Nguyen M, Guzzo T, et al. Laparoscopic and robotic complex upper-tract reconstruction in children with a duplex collecting system. *J Endourol*. 2007;21(6):621–624.

Lane V. The ectopic ureter: an elusive cause of urinary incontinence in the female. *Lancet*. 1962;1(7236):937–939.

Lashley DB, McAleer IM, Kaplan GW. Ipsilateral ureteroureterostomy for the treatment of vesicoureteral reflux or obstruction associated with complete ureteral duplication. *J Urol*. 2001;165(2):552–554.

Lavelle JP, Knisely AS, Bellinger MF. Benign fibroepithelial polyps causing symptomatic bilateral intermittent hydroureteronephrosis. *J Urol*. 1997;158(2):569.

Lee NG, Corbett ST, Cobb K, et al. Bi-Institutional comparison of Robot-Assisted laparoscopic versus open ureteroureterostomy in the pediatric population. *J Endourol*. 2015;29(11):1237–1241.

Lee RS, Retik AB, Borer JG, et al. Pediatric retroperitoneal laparoscopic partial nephrectomy: comparison with an age matched cohort of open surgery. *J Urol*. 2005;174(2):708–711 [discussion 712].

Lee RS, Sethi AS, Passerotti CC, et al. Robot assisted laparoscopic partial nephrectomy: a viable and safe option in children. *J Urol*. 2009;181(2):823–828 [discussion 828–829].

Lerman I, Lerman S, Lerman F. Retrocaval ureter. *J Med Soc N J*. 1956;53(2):74–77.

Lewis JM, Cheng EY, Campbell JB, et al. Complete excision or marsupialization of ureteroceles: does choice of surgical approach affect outcome? *J Urol*. 2008;180(4 Suppl):1819–

1822 [discussion 1822–1813].

Liu L, Suzuki K, Nakagata N, et al. Retinoic acid signaling regulates sonic hedgehog and bone morphogenetic protein signalings during genital tubercle development. *Birth Defects Res B Dev Reprod Toxicol*. 2011;95(1):79–88.

Lopes RI, Fernandez N, Koyle MA, et al. Clinical outcomes of the upper urinary tract after ureteral clipping for treatment of low functioning or nonfunctioning renal moieties. *J Urol*. 2018;199(2):558–564.

Mandell J, Colodny AH, Lebowitz R, et al. Ureteroceles in infants and children. *J Urol*. 1980;123(6):921–926.

Marr L, Skoog SJ. Laser incision of ureterocele in the pediatric patient. *J Urol*. 2002;167(1):280–282.

Mason MD, Anthony Herndon CD, Smith-Harrison LI, et al. Robotic-assisted partial nephrectomy in duplicated collecting systems in the pediatric population: techniques and outcomes. *J Pediatr Urol*. 2014;10(2):374–379.

Mason MD, Peters CA, Schenkman NS. Robot-assisted upper pole nephrectomy in adult patients with duplicated renal collecting systems. *J Endourol*. 2012;26(7):838–842.

Mayo J, Gray R, St Louis E, et al. Anomalies of the inferior vena cava. *AJR Am J Roentgenol*. 1983;140(2):339–345.

Mendelsohn C. Using mouse models to understand normal and abnormal urogenital tract development. *Organogenesis*. 2009;5(1):306–314.

Merlini E. Trifid obstructed megaureter. *Urology*. 1983;22(1):62–63.

Minevich E, Defoor W, Reddy P, et al. Ureteroscopy is safe and effective in prepubertal children. *J Urol*. 2005;174(1):276–279 [discussion 279].

Miyazato M, Kimura T, Ohyama C, et al. Retroperitoneoscopic ureteroureterostomy for retrocaval ureter. *Hinyokika Kiyo*. 2002;48(1):25–28.

Mizuno K, Kamisawa H, Hamamoto S, et al. Bilateral single-system ureteroceles with multiple calculi in an adult woman. *Urology*. 2008;72(2):294–295.

Mor Y, Goldwasser B, Ben-Chaim J, et al. Upper pole heminephrectomy for duplex systems in children: a modified technical approach. *Br J Urol*. 1994;73(5):584–585.

Murphy BJ, Casillas J, Becerra JL. Retrocaval ureter: computed tomography and ultrasound appearance. *J Comput Tomogr*. 1987;11(1):89–93.

Nation EF. Duplication of the kidney and ureter: a statistical study of 230 new cases. *J Urol*. 1944;51:456.

Ng JW. Upper-pole pelviureteric junction obstruction: a critical review. *Pediatr Surg Int*. 1999;15(3–4):298–299.

Nguyen DH, Koleilat N, Gonzalez R. Retroiliac ureter in a male newborn with multiple genitourinary anomalies: case report and review of the literature. *J Urol*. 1989;141(6):1400–1403.

Noseworthy J, Persky L. Spectrum of bilateral ureteral ectopia. *Urology*. 1982;19(5):489–494.

Ogunyemi D. Prenatal sonographic diagnosis of bladder outlet obstruction caused by a ureterocele associated with hydrocolpos and imperforate hymen. *Am J Perinatol*. 2001;18(1):15–21.

Ortiz R, Parente A, Burgos L, et al. Endoscopic urinary diversion as initial management of symptomatic obstructive ectopic ureter in infants. *Front Pediatr*. 2017;5:208.

Oyen R, Gielen J, Baert L, et al. CT demonstration of a ureterosciatic hernia. *Urol Radiol*. 1987;9(3):174–176.

Page BH. Obstruction of ureter in internal hernia. *Br J Urol*. 1955;27(3):254–255.

Palmer BW, Greger H, Mannas DB, et al. Comparison of endoscopic ureterocele decompression techniques. Preliminary experience–is the watering can puncture superior? *J Urol*. 2011;186(4 Suppl):1700–1703.

Park BS. Type IV ureteral triplication associated with ipsilateral ureterocele with ureterolithiasis and contralateral duplication with an ectopic ureteral orifice. *Int J Urol*. 2008;15(11):1022.

Park YH, Kang MY, Jeong MS, et al. Laparoendoscopic single-site nephrectomy using a homemade single-port device for single-system ectopic ureter in a child: initial case report. *J Endourol*. 2009;23(5):833–835.

Patel PM, Stock JA, Hanna MK, et al. Ureteral triplication with ectopic upper pole moiety. *Urology*. 2001;58(2):279–280.

Persico N, Berrettini A, Fabietti I, et al. New minimally invasive technique for cystoscopic laser treatment of fetal ureterocele. *Ultrasound Obstet Gynecol*. 2017;50(1):124–127.

Peters CA, Pathak N. Double trouble: a rare case of bilateral upper Pole ureteropelvic junction obstruction. *Urol Case Rep*. 2014;2(5):156–158.

Piaggio L, Franc-Guimond J, Figueroa TE, et al. Comparison of laparoscopic and open partial nephrectomy for duplication anomalies in children. *J Urol*. 2006;175(6):2269–2273.

Pick J, Anson B. Retrocaval ureter. Report of a case with discussion of its clinical significance. *J Urol*. 1940;43:672.

Pienkny AJ, Herts B, Streem SB. Contemporary diagnosis of retrocaval ureter. *J Endourol*. 1999;13(10):721–722.

Pode D, Shapiro A, Lebensart P. Unilateral triplication of the collecting system in a horseshoe kidney. *J Urol*. 1983;130(3):533–534.

Powell MC, Kapila L. Bilateral megaureters presenting as an inguinal hernia. *J Pediatr Surg*. 1985;20(2):175–176.

Prieto J, Ziada A, Baker L, et al. Ureteroureterostomy via inguinal incision for ectopic ureters and ureteroceles without ipsilateral lower pole reflux. *J Urol*. 2009;181(4):1844–1848 [discussion 1848–1850].

Privett JT, Jeans WD, Roylance J. The incidence and importance of renal duplication. *Clin Radiol*. 1976;27(4):521–530.

Psihramis KE. Ureteral obstruction by a rare venous anomaly: a case report. *J Urol*. 1987;138(1):130–132.

Quintero RA, Homsy Y, Bornick PW, et al. In-utero treatment of fetal bladder-outlet obstruction by a ureterocele. *Lancet*. 2001;357(9272):1947–1948.

Radhkrishnan J, Vermillion CD, Hendren WH. Vasa deferentia inserting into retroiliac ureters. *J Urol*. 1980;124(5):746–747.

Rajfer J, Eggleston JC, Sanders RC, et al. Fever and prostatic mass in a young man. *J Urol*. 1978;119(4):555–558.

Ramalingam M, Selvarajan K. Laparoscopic transperitoneal repair of retrocaval ureter: report of two cases. *J Endourol*. 2003;17(2):85–87.

Rich MA, Keating MA, Snyder HM 3rd, et al. Low transurethral incision of single system intravesical ureteroceles in children. *J Urol*. 1990;144(1):120–121.

Romao RL, Figueroa V, Salle JL, et al. Laparoscopic ureteral ligation (clipping): a novel, simple procedure for pediatric urinary incontinence due to ectopic ureters associated with non-functioning upper pole renal moieties. *J Pediatr Urol*. 2014;10(6):1089–1094.

Romesburg JW, Stein RJ, Desai MM, et al. Treatment of child with bilateral ureteropelvic junction obstruction due to fibroepithelial polyps and review of the literature. *Urology*. 2009;73(4):929.e9–929.e11.

Sander JC, Bilgutay AN, Stanasel I, et al. Outcomes of endoscopic incision for the treatment of ureterocele in children at a single institution. *J Urol*. 2015;193(2):662–666.

Sasai K, Sano A, Imanaka K, et al. Right periureteric venous ring detected by computed tomography. *J Comput Assist Tomogr*. 1986;10(2):349–351.

Scherz HC, Kaplan GW, Packer MG, et al. Ectopic ureteroceles:

surgical management with preservation of continence–review of 60 cases. *J Urol*. 1989;142(2 Pt 2):538–541 [discussion 542–533].

Scultety S, Varga B. [Obstructions of the lower ureteral segment caused by vascular anomalies (author's transl). *Urologe A*. 1975;14(3):144–147.

See WA, Mayo M. Ectopic ureter: a rare cause of purulent vaginal discharge. *Obstet Gynecol*. 1991;78(3 Pt 2):552–555.

Seitzman DM, Patton JF. Ureteral ectopia: combined ureteral and vas deferens anomaly. *J Urol*. 1960;84:604–608.

Shankar KR, Vishwanath N, Rickwood AM. Outcome of patients with prenatally detected duplex system ureterocele; natural history of those managed expectantly. *J Urol*. 2001;165(4):1226–1228.

Share JC, Lebowitz RL. Ectopic ureterocele without ureteral and calyceal dilatation (ureterocele disproportion): findings on urography and sonography. *AJR Am J Roentgenol*. 1989;152(3):567–571.

Shekarriz B, Upadhyay J, Fleming P, et al. Long-term outcome based on the initial surgical approach to ureterocele. *J Urol*. 1999;162(3 Pt 2):1072–1076.

Sherman ND, Stock JA, Hanna MK. Bladder dysfunction after bilateral ectopic ureterocele repair. *J Urol*. 2003;170(5):1975–1977.

Singh I. Adult bilateral non-obstructing orthotopic ureteroceles with multiple calculi: endoscopic management with review of literature. *Int Urol Nephrol*. 2007;39(1):71–74.

Singh SJ, Smith G. Effectiveness of primary endoscopic incision of ureteroceles. *Pediatr Surg Int*. 2001;17(7):528–531.

Sivrikaya A, Cay A, Imamoglu M, et al. A case of ureteral triplication associated with ureteropelvic junction obstruction. *Int Urol Nephrol*. 2007;39(3):755–757.

Smith EA, Parrott TS. The unsuspected cecoureterocele. *J Urol*. 1994;152(1):182–184.

Smith I. Triplicate ureter. *Br J Surg*. 1946;34(134):182–185.

Smith KM, Shrivastava D, Ravish IR, et al. Robot-assisted laparoscopic ureteroureterostomy for proximal ureteral obstructions in children. *J Pediatr Urol*. 2009;5(6):475–479.

Soundappan SV, Barker AP. Retrocaval ureter in children: a report of two cases. *Pediatr Surg Int*. 2004;20(2):158–160.

Srivastava DN, Mukhopadhyay S, Agarwal SK. Ureteral triplication with contralateral duplication. *Nephron*. 1996;74(2):427–428.

Stephens D. Caecoureterocele and concepts on the embryology and aetiology of ureteroceles. *Aust N Z J Surg*. 1971;40(3):239–248.

Stephens FD, Smith ED, Hutson JM. *Congenital Anomalies of the Urinary and Genital Tracts*. Isis Medical Media Ltd: Oxford; 1996.

Steyaert H, Lauron J, Merrot T, et al. Functional ectopic ureter in case of ureteric duplication in children: initial experience with laparoscopic low transperitoneal ureteroureterostomy. *J Laparoendosc Adv Surg Tech A*. 2009.

Sumfest JM, Burns MW, Mitchell ME. Pseudoureterocele: potential for misdiagnosis of an ectopic ureter as a ureterocele. *Br J Urol*. 1995;75(3):401–405.

Sydorak RM, Shaul DB. Laparoscopic partial nephrectomy in infants and toddlers. *J Pediatr Surg*. 2005;40(12):1945–1947.

Taguchi K, Shimada K, Mori Y, et al. A case of combined anomaly of horseshoe kidney, retrocaval ureter and pelviureteric stenosis]. *Hinyokika Kiyo*. 1986;32(5):745–750.

Taibah K, Roney PD, McKay DE, et al. Retro-internal iliac artery ureter. *Urology*. 1987;30(2):159–161.

Tanagho EA, Pugh RC. The anatomy and function of the ureterovesical junction. *Br J Urol*. 1963;35:151.

Tanaka ST, Ishii K, Demarco RT, et al. Endodermal origin of bladder trigone inferred from mesenchymal-epithelial interaction. *J Urol*. 2010;183(1):386–391.

Tank ES. Experience with endoscopic incision and open unroofing of ureteroceles. *J Urol*. 1986;136(1 Pt 2):241–242.

Timothy RP, Decter A, Perlmutter AD. Ureteral duplication: clinical findings and therapy in 46 children. *J Urol*. 1971;105(3):445–451.

Tobias-Machado M, Lasmar MT, Wroclawski ER. Retroperitoneoscopic surgery with extracorporeal uretero-ureteral anastomosis for treating retrocaval ureter. *Int Braz J Urol*. 2005;31(2):147–150.

Tsai PJ, Lin JT, Wu TT, et al. Ureterosciatic hernia causes obstructive uropathy. *J Chin Med Assoc*. 2008;71(9):491–493.

Uetani N, Bertozzi K, Chagnon MJ, et al. Maturation of ureter-bladder connection in mice is controlled by LAR family receptor protein tyrosine phosphatases. *J Clin Invest*. 2009;119(4):924–935.

Umeyama T, Kawamura T, Hasegawa A, et al. Ectopic ureter presenting with epididymitis in childhood: report of 5 cases. *J Urol*. 1985;134(1):131–133.

Upadhyay J, Bolduc S, Braga L, et al. Impact of prenatal diagnosis on the morbidity associated with ureterocele management. *J Urol*. 2002;167(6):2560–2565.

Uthappa MC, Anthony D, Allen C. Case report: retrocaval ureter: MR appearances. *Br J Radiol*. 2002;75(890):177–179.

Valla JS, Breaud J, Carfagna L, et al. Treatment of ureterocele on duplex ureter: upper pole nephrectomy by retroperitoneoscopy in children based on a series of 24 cases. *Eur Urol*. 2003;43(4):426–429.

Vereecken RL, Proesmans W. Extensive surgery on the trigone for complete ureteral duplication does not cause incontinence or voiding problems. *Urology*. 2000;55(2):267–270 [discussion 270–261].

Viana R, Batourina E, Huang H, et al. The development of the bladder trigone, the center of the anti-reflux mechanism. *Development*. 2007;134(20):3763–3769.

Vicentini FC, Denes FT, Srougi M. Ureteral quadruplication associated with ureteral cyst and massive vesicoureteral reflux treated by laparoscopic nephroureterectomy. *J Endourol*. 2007;21(7):769–771.

Wallis MC, Khoury AE, Lorenzo AJ, et al. Outcome analysis of retroperitoneal laparoscopic heminephrectomy in children. *J Urol*. 2006;175(6):2277–2280 [discussion 2280–2272].

Wang XM, Jia LQ, Wang Y, et al. Utilizing ultrasonography in the diagnosis of pediatric fibroepithelial polyps causing ureteropelvic junction obstruction. *Pediatr Radiol*. 2012;42(9):1107–1111.

Wesson MB. Anatomical, embryological and physiological studies of the trigone and neck of the bladder. *J Urol*. 1920;4:279.

Westesson KE, Goldman HB. Prolapse of a single-system ureterocele causing urinary retention in an adult woman. *Int Urogynecol J*. 2013;24(10):1761–1763.

Wiestma AC, Cho PS, Hollis MV, et al. Robot-assisted laparoscopic lower pole partial nephrectomy in the pediatric patient. *J Pediatr Urol*. 2016;12(6):428–429.

Witney-Smith C, Undre S, Salter V, et al. An unusual case of a ureteric hernia into the sciatic foramen causing urinary sepsis: successfully treated laparoscopically. *Ann R Coll Surg Engl*. 2007;89(7):W10–W12.

Woodburne RT. The ureter, ureterovesical junction, and vesical trigone. *Anat Rec*. 1965;151:243.

Yao D, Poppas DP. A clinical series of laparoscopic nephrectomy, nephroureterectomy and heminephroureterectomy in the pediatric population. *J Urol*. 2000;163(5):1531–1535.

You D, Bang JK, Shim M, et al. Analysis of the late outcome of laparoscopic heminephrectomy in children with duplex kidneys. *BJU Int*. 2010.

Young JD Jr, Kiser WS. Obstruction of the Lower Ureter by Aberrant Blood Vessels. *J Urol*. 1965;94:101–106.

Zaontz MR, Maizels M. Type I ureteral triplication: an extension of the Weigert-Meyer law. *J Urol*. 1985;134(5):949–950.

Surgery of the Ureter in Children

Ureteropelvic Junction, Megaureter, and Vesicoureteral Reflux

L. Henning Olsen MD, DMSc, Yazan F.H. Rawashdeh MD, PhD

Ureteropelvic Junction Obstruction

Definition

Hydronephrosis in children, defined by an anterior-posterior intrarenal pelvis (AP) diameter of 12 mm (Dhillon, 1998), **differs from that seen later in life and is not necessarily synonymous with true obstruction.** Available diagnostic tools are imprecise, rendering Koff's definition as the only gold standard prognosticator of obstruction. Koff defined obstruction as “any restriction to urinary outflow that if left untreated will lead to progressive kidney damage” (Koff, 1987). Working by this definition, indications for surgery are often amassed retrospectively and at the cost of losing “irrevocably” valuable renal function. So, in an attempt to circumvent use of such diagnostics, numerous guidelines have been published, however, and in the absence of precise diagnostic tools **indications for surgery will always be debatable** (Chertin et al. 2006). The first part of this chapter focuses on open surgical repair of ureteropelvic junction obstruction (UPJO) including retrocaval ureters, mid-ureteral strictures, and UPJO in duplex systems. As there is an evolving interest in minimally invasive procedures such as laparoscopy, retroperitoneoscopy, and robotic procedures, these procedures are also described in detail. The second part of the chapter discusses surgery for vesicoureteral reflux (VUR) and surgery for congenital megaureter.

Clinical Presentation

In many countries, antenatal ultrasound scans are offered at approximately 20 weeks’ gestation. Of the malformations identified, urogenital anomalies are dominant, and of these, dilations in the form of hydronephrosis or hydroureteronephrosis are most common. Postnatal diagnosis is made by ultrasonography, incidentally or in conjunction with the workup for a child presenting with urinary tract infections (UTIs). Febrile infections are often sufficiently treated with antibiotics, with only a minority of patients needing nephrostomy tube diversion in case of concomitant finding of hydronephrosis or hydroureteronephrosis. **Most often, the UPJO in newborns and infants is caused by an *intrinsic* narrowing of the ureteropelvic junction (UPJ) (Fig. 42.1). The typical finding is a narrowed segment of the UPJ with an**

interruption in the development of the circular muscular fibers. This leads to a functional discontinuity of the muscular contractions and ultimately to insufficient emptying of the renal pelvis. **UPJO in childhood and adolescence is often caused by an accessory vessel to the lower pole of the kidney (Fig. 42.2), with the ureter kinking over the lower pole vessel** (Lowe and Marshall 1984) **(*extrinsic)* giving rise to loin pain, nausea, and vomiting.** However, it is unclear whether an intrinsic factor in conjunction with a lower pole vessel is the reason for the symptomatic hydronephrosis (Stephens, 1982). Hydronephrosis is more often seen in boys (Williams and Karlaftis, 1966; Kelalis et al., 1971; Johnston et al., 1977; Olsen et al., 2007), especially in the infant and toddler age groups (Robson et al., 1976; Williams and Kenawi, 1976; Johnston et al., 1977). UPJO predominates on the left side and is bilateral in 10% to 40% (Nixon, 1953; Uson et al., 1968; Robson et al., 1976; Lebowitz and Griscom, 1977; Karnak et al., 2008). There might also be an increased incidence in family members (Cohen et al., 1978).

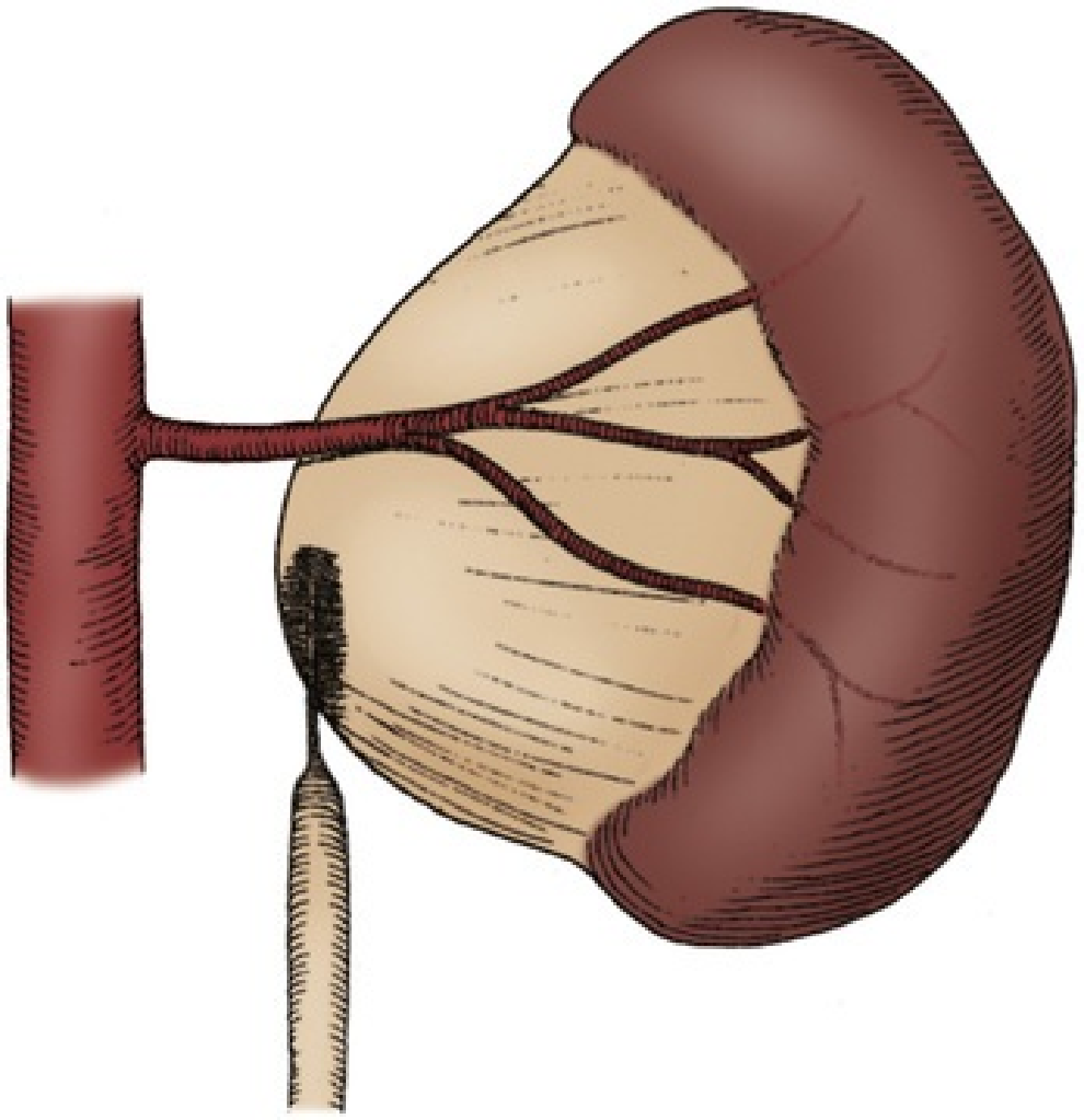

FIG. 42.1 Intrinsic narrowing of upper ureter contributing to ureteropelvic junction obstruction.

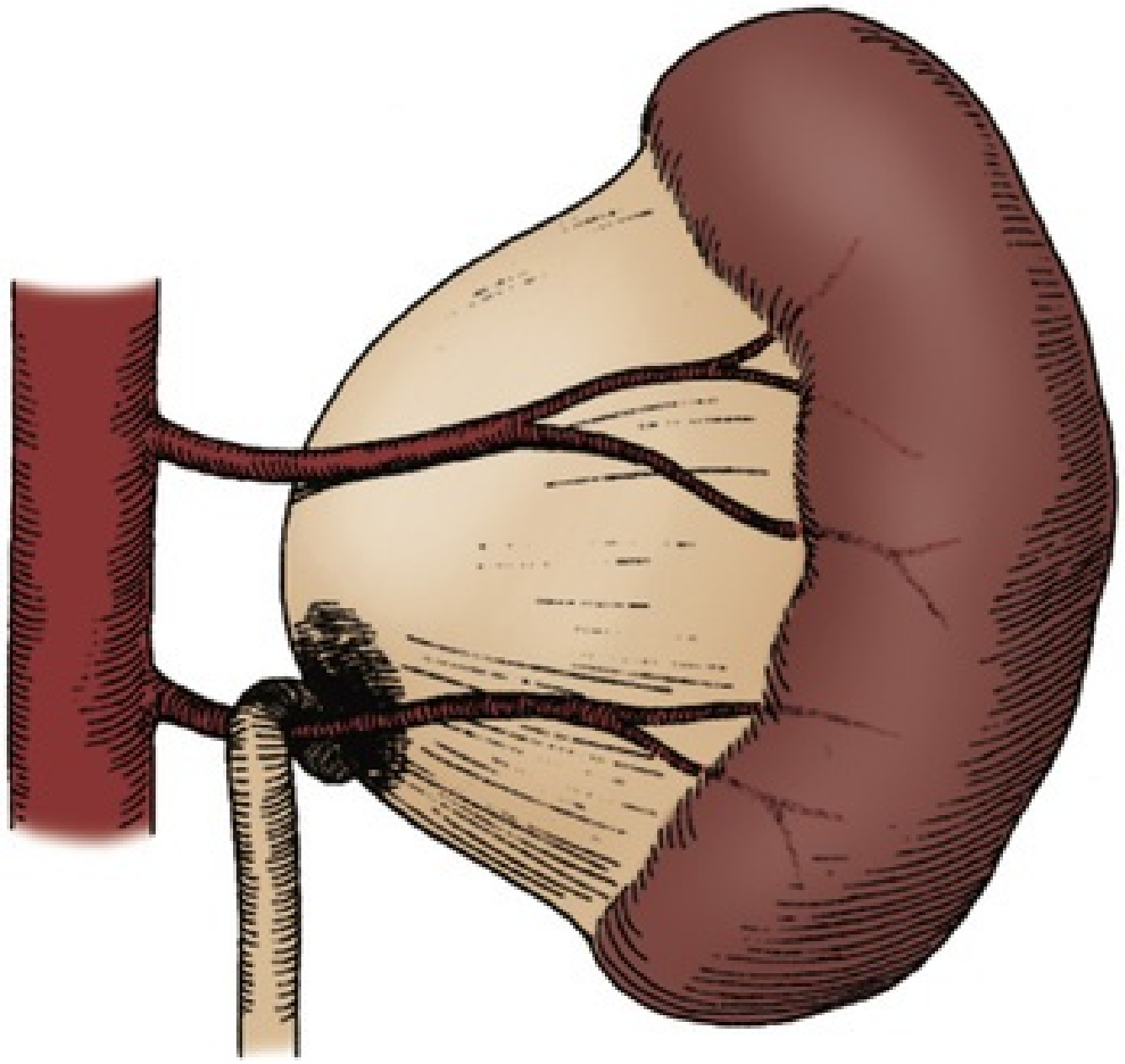

FIG. 42.2 A lower-pole crossing vessel contributes to significant kinking at the ureteropelvic junction and resultant intermittent obstruction. Often, when the ureter is mobilized, no evidence of intrinsic narrowing is found. However, dismembering and moving of the ureter anteriorly to the vessel prevents recurrence of symptoms.

Secondary Ureteropelvic Junction Obstruction

In some cases of high-grade VUR with a torturous dilated ureter, kinking or narrowing of the UPJ can be present. Whether this resolves spontaneously or needs surgical correction of both the VUR and the UPJO is not always clear (Lebowitz and Blickman, 1983; Bomalaski et al., 1997). Because this condition is specific to high-grade reflux, in which surgical correction of the VUR by injectable biomaterials is doubtful, contemplating simultaneous reimplantation and dismembered pyeloplasty is discouraged as there are concerns this may compromise ureteral blood supply. Therefore a conservative approach or operation in two stages is advisable, despite the lack of convincing evidence.

Lower Pole Ureteral Pelvic Junction Obstruction

In uncommon cases of duplex kidneys, a UPJO of the lower moiety is seen (Fig. 42.3) (Privett et al., 1976). In cases of incomplete duplication, a ureteropelvic anastomosis of the upper pole ureter to the lower pole pelvis is possible, either side-to-side or end-to-side. In cases of complete duplication, a standard dismembered pyeloplasty is done, depending on the function of both the upper and lower moiety and the length of the stenosis (Joseph et al., 1989). A nonfunctioning or minimally functioning moiety (i.e., ≤5% to 10% of overall kidney function on nuclear scan) should prompt partial nephrectomy rather than any attempts at repair.

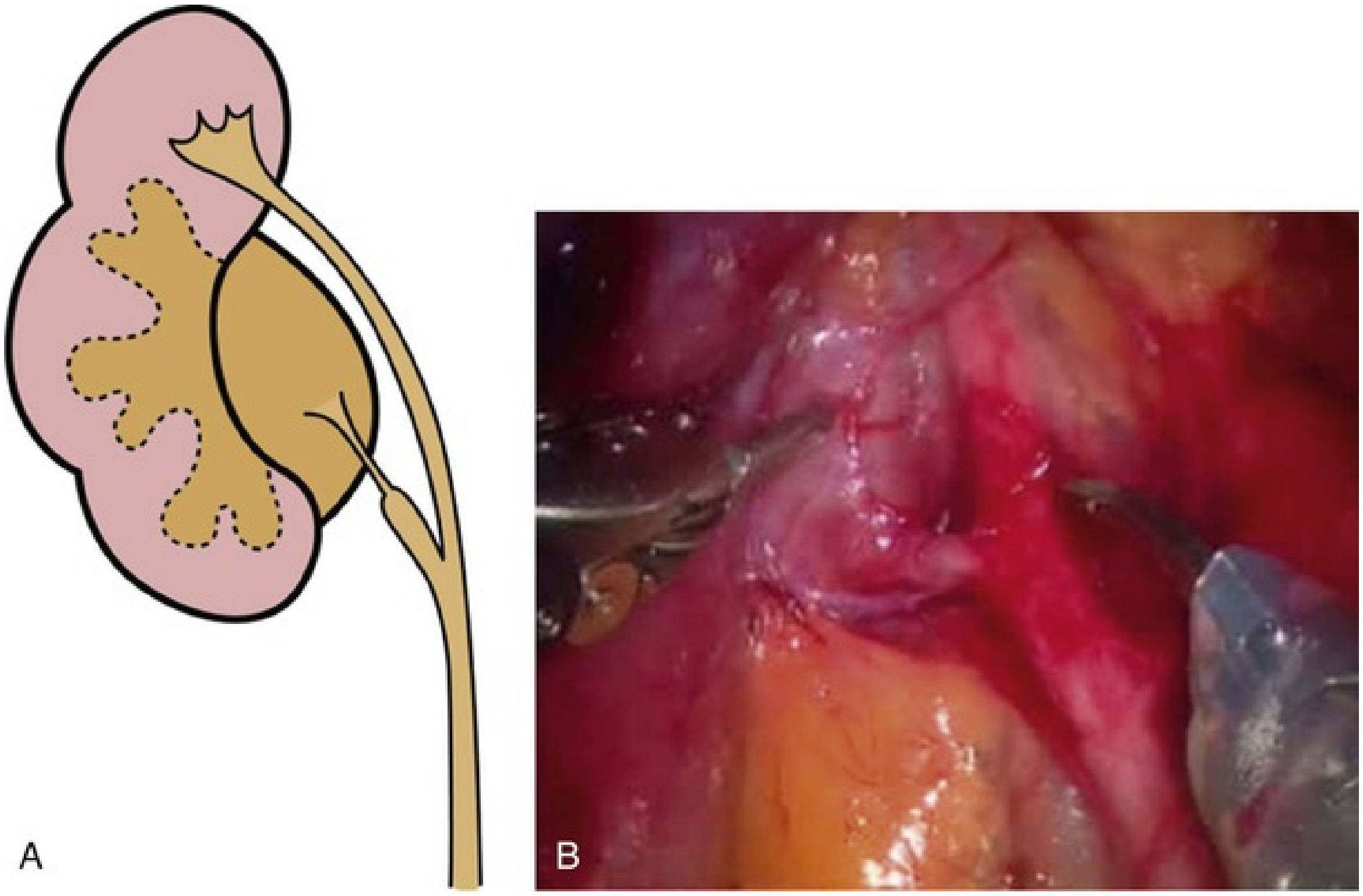

FIG. 42.3 (A and B) Duplex kidney with stenosis of the lower ureteropelvic junction. A V-plasty can resolve the problem.

Associated Anomalies

Congenital renal malformations are commonly seen in association with UPJO. Up to 50% of the affected infants have another urologic abnormality (Uson et al., 1968; Robson et al., 1976; Lebowitz and Griscom, 1977; Lebowitz and Blickman, 1983). Contralateral UPJO is the most common anomaly, seen in 10 % to 40% of cases, followed by renal dysplasia, multicystic dysplastic kidneys, and renal agenesis (Williams and Karlaftis, 1966; Robson et al., 1976; Williams and Kenawi, 1976). Horseshoe kidneys are rare but are in some cases associated with UPJO, both with a genuine stricture or caused by accessory vessels (Glenn, 1959; Blanc et al., 2013; Je et al., 2015). VATER syndrome has also some association with UPJO (Kolon et al., 2000). Furthermore, VUR is seen in up to 40% of children with UPJO, albeit with a high degree of spontaneous resolution (Williams and Kenawi, 1976; Lebowitz and Blickman, 1983; Je et al., 2015).

Surgical Indication

Only approximately one-third of affected children will need surgical intervention (Dhillon, 1998). The widely accepted indications for surgery are an increasing AP diameter on ultrasonography, low or decreasing differential renal function, breakthrough infections while on prophylactic antibiotics, or symptoms such as pain in older infants and children. In infants, UPJO can be a cause of failure to thrive, feeding difficulties, and constipation. However, the majority of cases resolve with time and do not proceed to surgery (Koff, 1998). Hematuria is seen in some cases and is believed to result from disruption or rupture of mucosal vessels in the dilated pelvis (Kelalis et al., 1971; Williams and Kenawi, 1976). UPJO has also been shown to be a rare cause of hypertension most likely caused by renal functional deterioration and activation of the renin-angiotensin axis (Belman et al., 1968; Squitieri et al., 1974; Munoz et al., 1977; Grossman et al., 1981).

Surgical Repair

When indicated, surgical intervention can be performed by open surgery or laparoscopic and robotic-assisted procedures. In infants, open surgery is the preferred procedure because the incision required does not differ significantly from what is necessary for laparoscopic or robotic access. However, the laparoscopic or robotic-assisted route is feasible, and the cosmetic outcome should be superior to the open access (Avery et al., 2015). **There is an ongoing debate on whether minimally invasive procedures should be conducted through the transperitoneal or retroperitoneal routes, even though the majority of pediatric urologists prefer the retroperitoneal approach when performing an open procedure.** However, few proper randomized studies have been published comparing the transabdominal and retroperitoneal laparoscopic routes (Gao et al., 2012; Badawy et al., 2015). The main argument for laparoscopic transperitoneal access is that the procedure is easier, and offers the surgeon familiar anatomic landmarks that assist in orientation. However, ease should not stand alone as an argument for any kind of surgical access. Other variables that need consideration are the potential risk for damage to intra-abdominal organs, postoperative urine leakage, and subsequent prolonged hospital stay, all of which tip the balance toward the retroperitoneal approach (Liu et al., 2017). Despite a longer learning curve for retroperitoneal access, the authors have preferred and advocated the use of retroperitoneoscopic pyeloplasty, as the advantages seem to outweigh many of the potential difficulties encountered during the learning phase (Olsen and Jorgensen, 2004; Olsen, 2006; Olsen et al., 2007; Olsen and Rawashdeh, 2011).

Dismembered Pyeloplasty

Regardless of access, the Anderson-Hynes dismembered pyeloplasty technique is most surgeons’ preferred procedure and the gold standard against which all other interventions are compared. Originally developed for the repair of an obstruction in a retrocaval ureter, the procedure has since gained widespread acceptance as the standard UPJO repair, with a success rate of about 95% (Anderson and Hynes, 1949; Douville and Hollinshead, 1955; Poulsen et al., 1987; MacNeily et al., 1993; Shaul et al., 1994; McAleer and Kaplan, 1999; O'Reilly et al., 2001; Casale et al., 2004). The initial concerns of compromising the blood supply and innervation of the proximal ureter have since been disclaimed (Douville and Hollinshead, 1955). The advantage of dismembering the UPJ is that a lower pole crossing vessel can be preserved, the adynamic part of the ureter excised, and redundant pelvic tissue reduced (Fig. 42.4). In the case of a long dysplastic segment of the upper ureter, complete mobilization of the kidney can bridge the distance between the pelvis and ureter for several centimeters. In addition, a horizontal incision in the lower part of the pelvis can give further length and facilitate tension-free anastomosis (Fig. 42.5). Irrespective of access, the main steps of the Anderson-Hynes dismembered pyeloplasty are as follows (Fig. 42.6): After opening Gerota's fascia, the anterior or posterior aspect of the UPJ is dissected (depending on the access used). The lower pole of the kidney is freed to avoid overlooking an accessory vessel, especially with retroperitoneoscopic access. Electrocautery should be used with caution to minimize damage to the blood supply of both the pelvis and ureter, with preference given to bipolar diathermy. A stay suture can be placed in the pelvis proximal to the anticipated line of dismemberment, and another stay suture can be placed in the ureter at the level of the stenosis. The UPJ is dismembered, and the pelvis is reduced if indicated. A tensely dilated pelvis should be decompressed with a 21-gauge needle before dismembering to avoid excessive pelvic reduction. The ureter is then spatulated along its lateral border, well beyond the dysplastic stenotic segment and carried through adequately into healthy ureteral tissue. At this stage, the stenotic part of the ureter is not removed, as it can serve as a handle that minimizes ureteral tissue manipulation while performing the anastomosis and therefore reduces the risk for mucosal edema. The anastomosis can be completed with interrupted or continuous suturing according to the surgeon's preference. Suture size depends on the prevailing anatomy, but most often a 6-0 or 5-0 absorbable monofilament or polyfilament suture on a round needle is used. Care should be taken at the tip of the *V* at the crotch of the anastomosis, which must be assembled precisely and in a tension-free manner. One should also avoid placing inadvertent excessive tension on the stay sutures while aligning the anastomosis, as this can lead to kinking of the ureter once tension is relieved. Just before completing the anastomosis, the stenotic part of the ureter is removed, and the pelvis is irrigated with saline to avoid blood clots obstructing the ureter. Stenting the anastomosis and the type of stent (either externalized transanastomotic nefro-ureteric or internal pigtail stent) is a matter of choice that differs among surgeons and institutions. In a recent randomized study, Nasser et al. found that stenting with an externalized nefro-ureteric stent reduces complications and length of hospital stay in infants in contrast with no stenting (Nasser et al., 2017). Chu et al. did not find any differences with regard to complications between a pigtail and an externalized stent (Chu et al., 2018). The duration of stenting between 1 to 4 weeks does not seem to affect the outcome (Danuser et al., 2014). The kidney is brought back to its native position, and the anastomosis can be covered with perinephric fat if available. Usually the use of external drainage with a Penrose drain is not indicated.

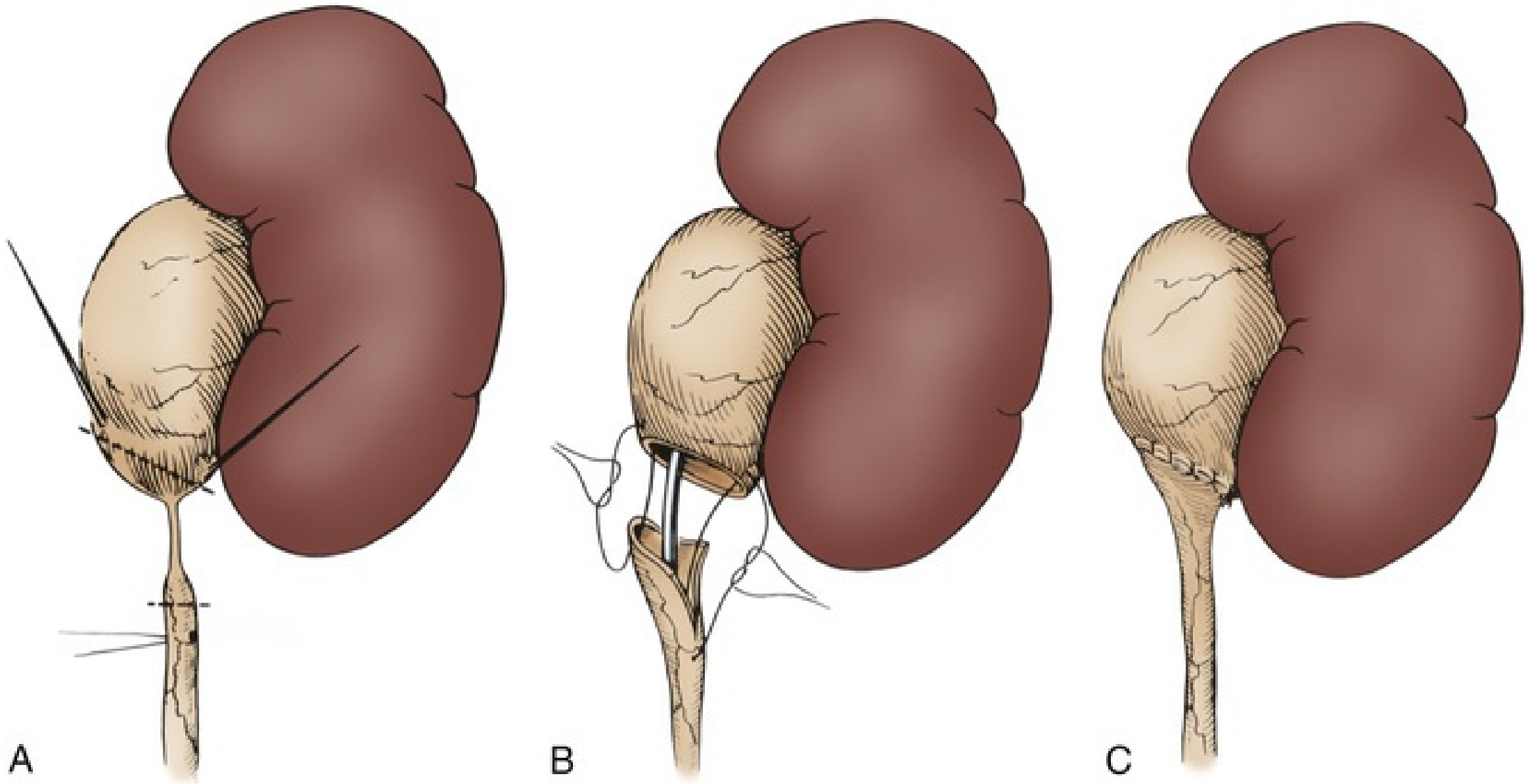

FIG. 42.4 Anderson-Hynes dismembered pyeloplasty. (A) Traction sutures are placed on the medial and lateral aspects of the dependent portion of the renal pelvis in preparation for dismembered pyeloplasty. A traction suture is also placed on the lateral aspect of the proximal ureter below the level of the obstruction. This suture will help maintain proper orientation for the subsequent repair. (B) The ureteropelvic junction is excised. The proximal ureter is spatulated on its lateral aspect. The apex of this lateral, spatulated aspect of the ureter is then brought to the inferior border of the pelvis while the medial side of the ureter is brought to the superior edge of the pelvis. (C) The anastomosis is performed with fine interrupted or running absorbable sutures placed full thickness through the ureteral and renal pelvic walls in a watertight fashion.

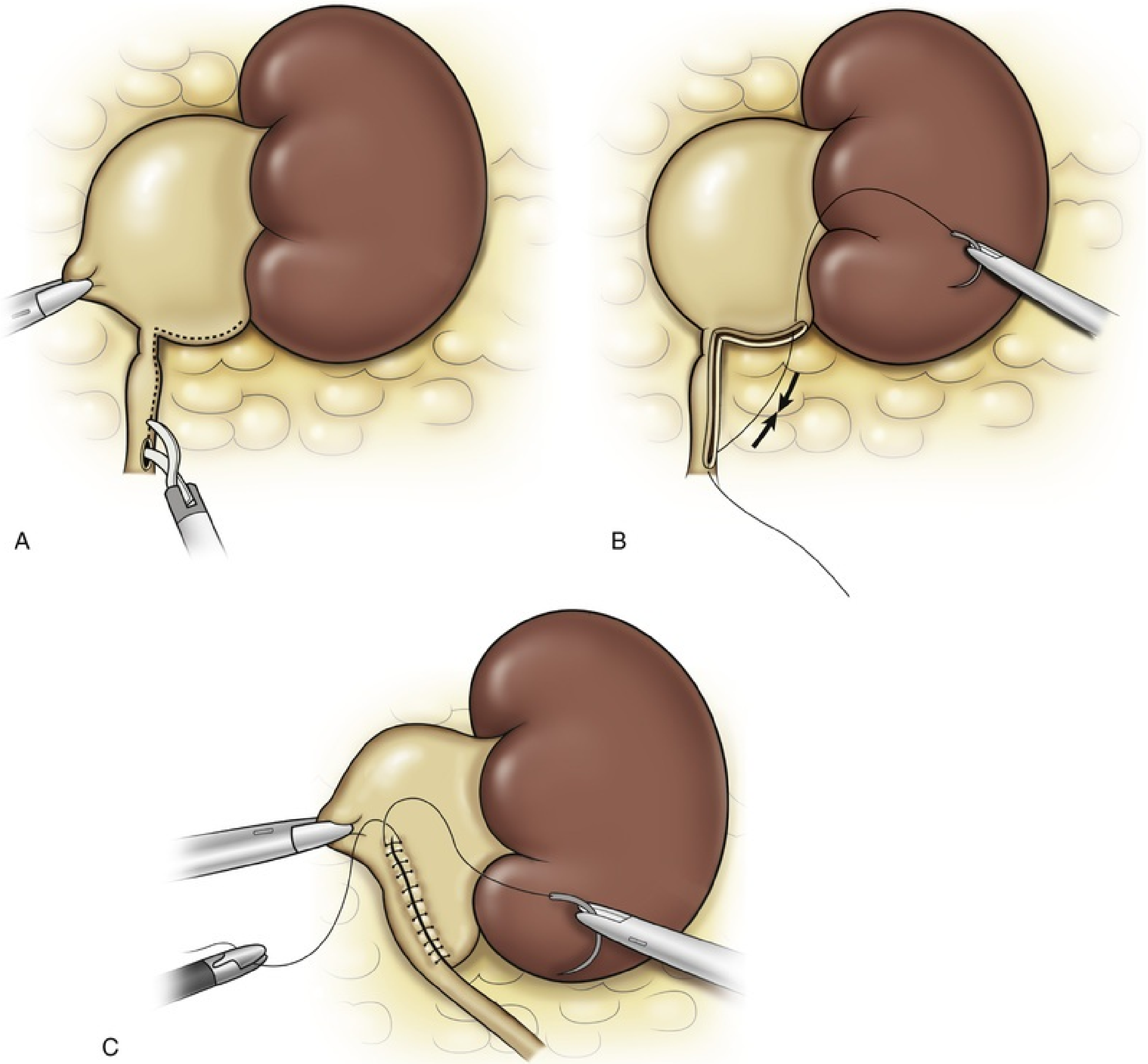

FIG. 42.5 The schematic represents a modified “bypass” pyeloplasty in which a side-to-side anastomosis of the ureter and renal pelvis is performed without transecting the stenotic ureteropelvic junction (UPJ). This allows the new UPJ to be configured within 1 cm of the lower pole parenchyma. It also keeps the ureter oriented by keeping it anchored to the pelvis during reconstruction, encouraging a “no touch” technique.

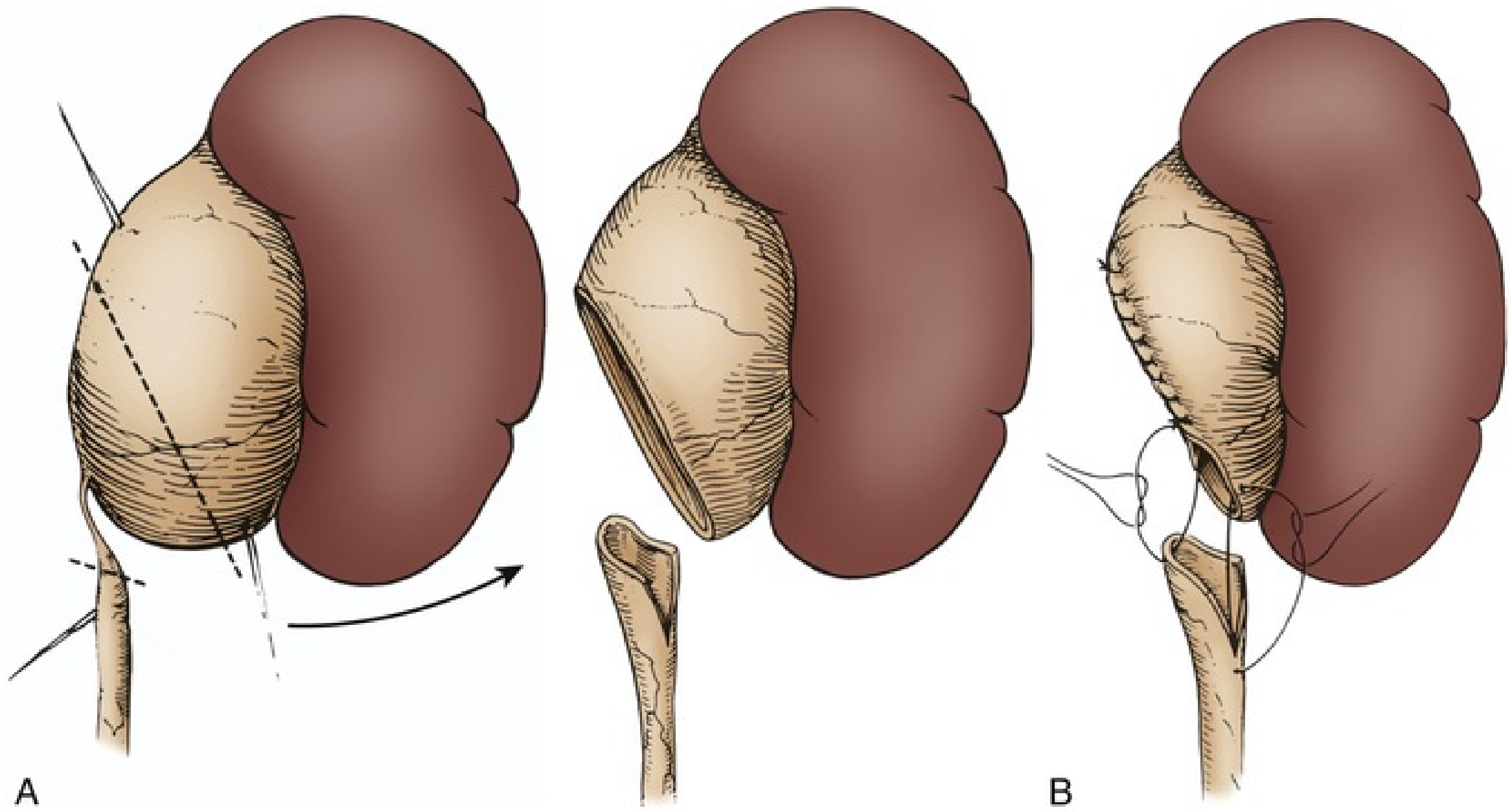

FIG. 42.6 (A) For a large or redundant pelvis, a reduction pyeloplasty is performed by excising the redundant portion between traction sutures. (B) The cephalad aspect of the pelvis is then closed with running absorbable sutures down to the dependent portion. The dependent aspect of the pelvis is anastomosed to the proximal ureter as described in Fig. 42.4.

Nondismembered Pyeloplasty

Several techniques have been described for nondismembered pyeloplasty. In a comparative series of 26 children using the laparoscopic approach, Casale et al. showed that dismembered pyeloplasty gives results superior to those of nondismembered pyeloplasty of the Heineke-Mickulicz fashion (Casale et al., 2004). A feasible alternative is the Foley Y-V plasty, especially in cases with a high insertion of the ureter and no accessory vessels (Fig. 42.7). In a prospective randomized study, Szydełko et al. compared the outcome of Anderson-Hynes pyeloplasty and the Foley Y-V plasty, with success rates of 95% and 86%, respectively, although the difference did not reach statistical significance (Szydełko et al., 2012). A vertical (Fig. 42.8) or spiral flap (Fig. 42.9) technique may be an option in cases of severe hydronephrosis with a long stenotic ureteral segment, which makes tension-free primary anastomosis impossible. The “bypass” pyeloplasty (see Fig. 42.5) might be a feasible alternative, although a systematic review of this technique is not available.

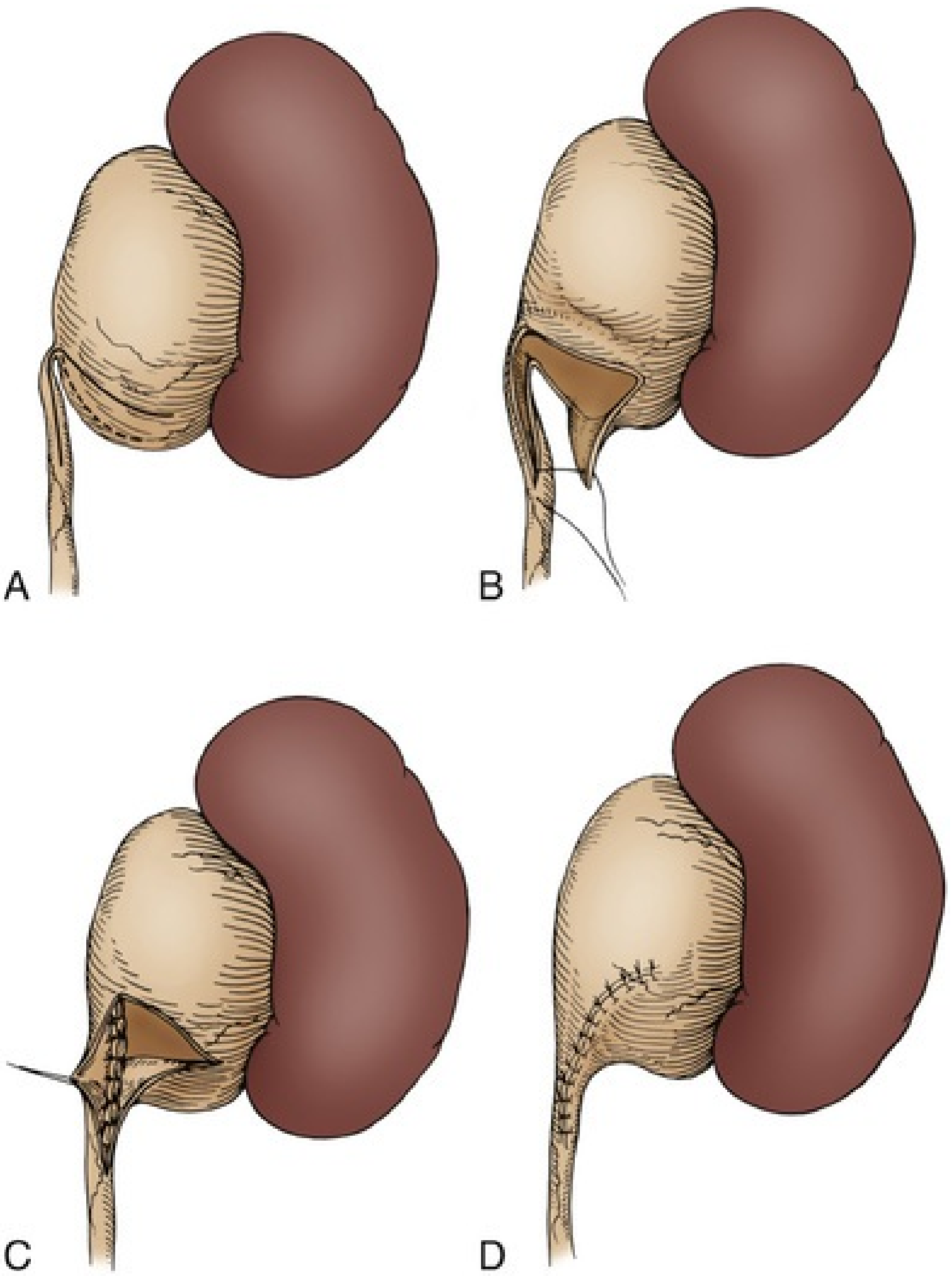

FIG. 42.7 (A) A Foley Y-V plasty is best applied to a ureteropelvic junction obstruction associated with a high insertion of the ureter. The flap is outlined with tissue marker or stay sutures. The base of the V is positioned on the dependent, medial aspect of the renal pelvis and the apex at the ureteropelvic junction. The incision from the apex of the flap, which represents the stem of the Y, is then carried along the lateral aspect of the proximal ureteral wall into an area of normal caliber. (B) The flap is developed with fine scissors. The apex of the pelvic flap is brought to the most inferior aspect of the ureterotomy incision. (C) The posterior walls are approximated using interrupted or running fine absorbable sutures. (D) The anastomosis is completed with approximation of the anterior walls of the pelvic flap and ureterotomy.

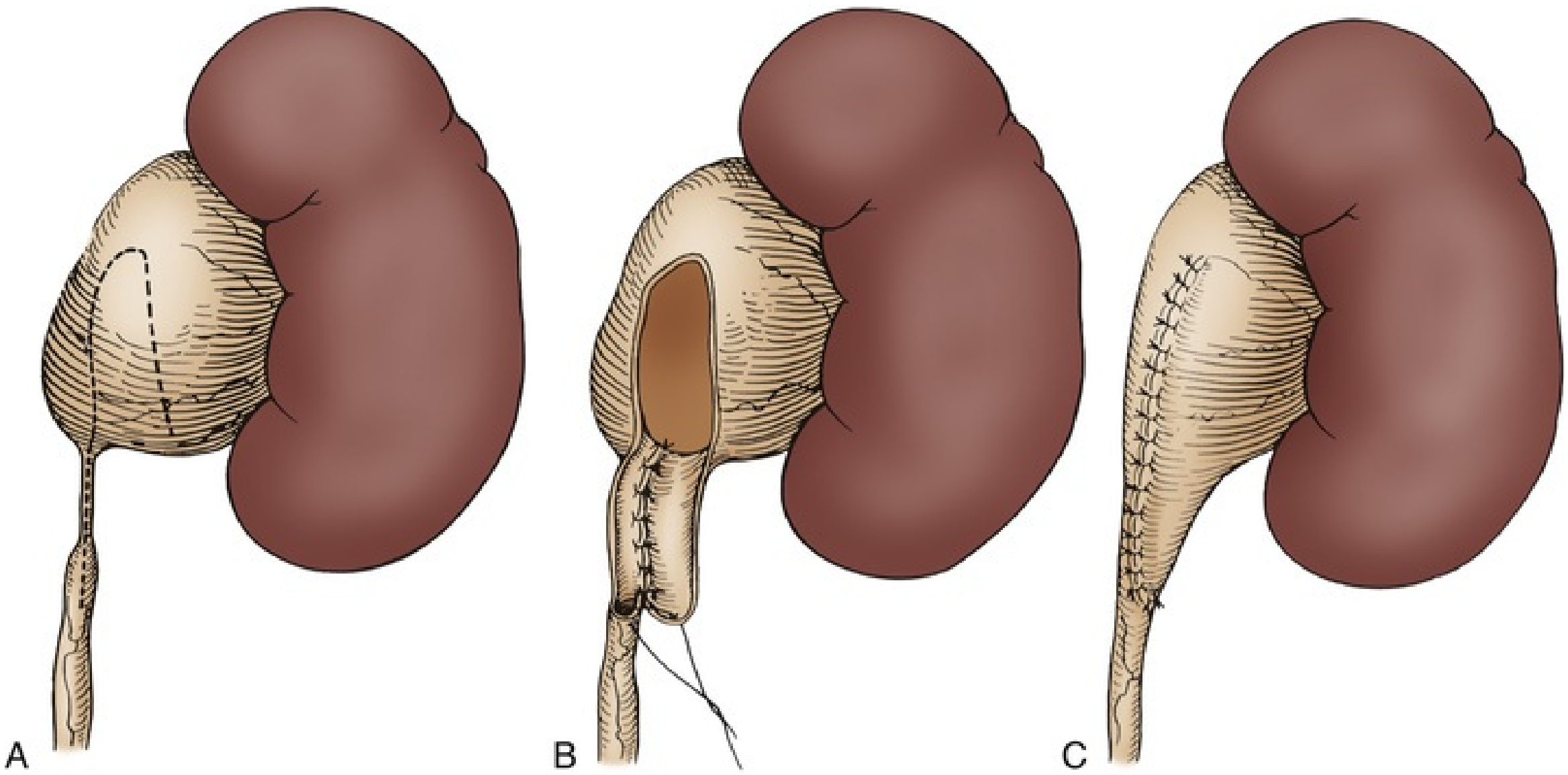

FIG. 42.8 (A) Vertical flap technique may be used when a dependent ureteropelvic junction is situated at the medial margin of a large, box-shaped extrarenal pelvis. In contrast with the spiral flap, the base of the vertical flap is situated more horizontally on the dependent aspect of the renal pelvis, between the ureteropelvic junction and the renal parenchyma. The flap itself is formed by two straight incisions converging from the base vertically up to the apex on either the anterior or posterior aspects of the renal pelvis. As for the spiral flap, the position of the apex determines the length of the flap, which should be a function of the length of proximal ureter to be bridged. The medial incision of the flap is carried down the proximal ureter completely through the strictured area into normal-caliber ureter. (B) The apex of the flap is rotated down to the most inferior aspect of the ureterotomy. (C) The flap is closed by approximating the edges with interrupted or running fine absorbable sutures.

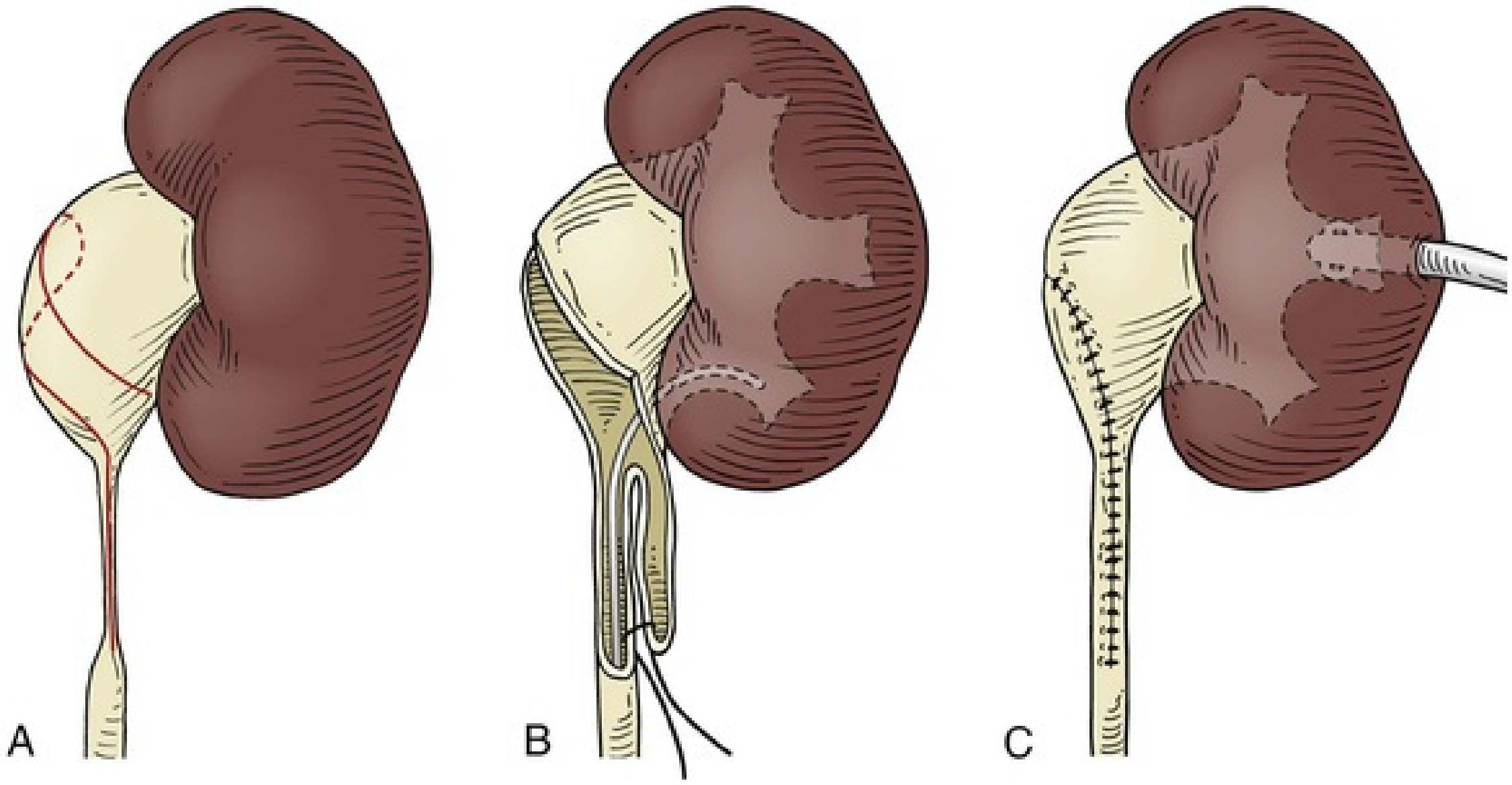

FIG. 42.9 (A) A spiral flap may be indicated for relatively long areas of proximal ureteral obstruction when the ureteropelvic junction is already in a dependent position. The spiral flap is outlined with the base situated obliquely on the dependent aspect of the renal pelvis. The base of the flap is positioned anatomically lateral to the ureteropelvic junction between the ureteral insertion and the renal parenchyma. The flap is spiraled posteriorly to anteriorly, or vice versa. The anatomically medial line of incision is carried down completely through the obstructed proximal ureteral segment into normal-caliber ureter. The site of the apex for the flap is determined by the length of the flap required to bridge the obstruction. The longer the segment of proximal ureteral obstruction, the farther away is the apex because this will make the flap longer. To preserve vascular integrity to the flap, however, the ratio of flap length to width should not exceed 3 to 1. (B) Once the flap is developed, the apex is rotated down to the most inferior aspect of the ureterotomy. (C) The anastomosis is completed, usually over an internal stent, using fine absorbable sutures.

Surgical Approach to Ureteral Pelvic Junction Obstruction

Posterior Lumbotomy

This approach should be reserved for infants and toddlers, because the increasing dorsal musculature with age can make this access difficult if not impossible (Fig. 42.10). In prone position, after a vertical incision is made, the lumbodorsal fascia is incised and retracted laterally. Gerota's fascia is opened, giving direct access to the UPJ. The renal pelvis and the proximal ureter are then stabilized with stay sutures, and the UPJO repair is performed as previously described.

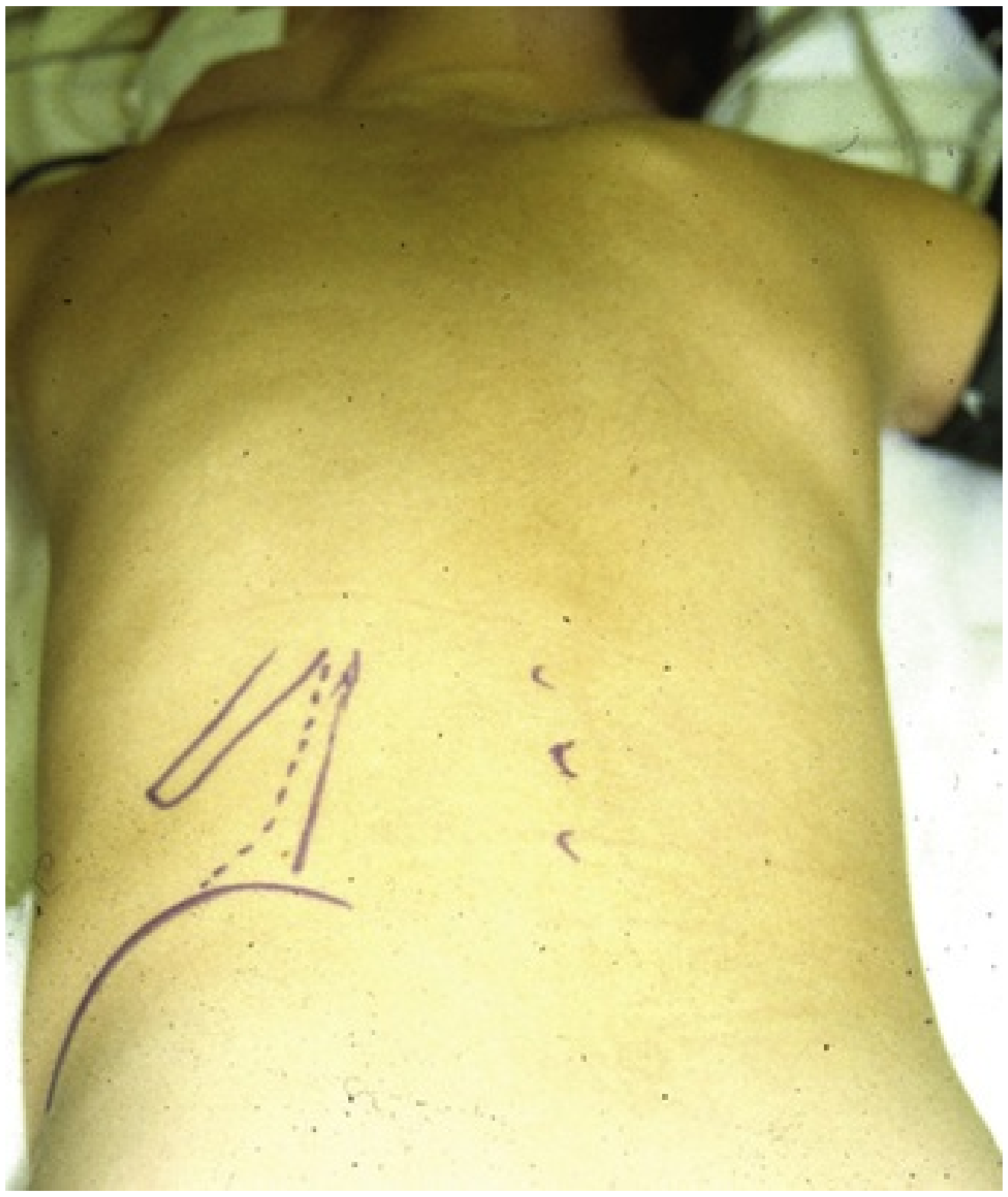

FIG. 42.10 Positioning a patient for left posterior lumbotomy incision. An oblique incision is made from the angle of the 12th rib down to the iliac crest at a point one-third of the distance from the anterior superior iliac spine to the spinal processes.

Flank Approach

In a supine position, the index side is supported by a gel roll. A small transverse incision is made at the level of the tip of the 11th to 12th rib. The fascial and muscle layers are separated in a muscle-splitting fashion. The peritoneum is liberally loosened from the abdominal wall muscles and swept medially, thus giving access to Gerota fascia. The fascia is opened vertically and pushed medially. The UPJ is dissected and stabilized with stay sutures in the pelvis and proximal ureter. The pyeloplasty is then performed as described earlier.

Minimally Invasive Techniques

Endoscopic Approach

The antegrade and retrograde endoscopic approaches to UPJO were popularized in the late 1980s and 1990s with varying results. The reported success rate on long-term follow-up of balloon dilation in patients younger than 18 years of age was 25% (Osther et al., 1998), and the ureteral cutting balloon catheter showed a success rate of 78% in adults, including two patients requiring embolization of a lower pole vessel as a result of gross postoperative hematuria (Kim et al., 1998). Kim et al. recently reported a review of their 25 years of experience with endopyelotomy and found a success rate of 62% in primary UPJO, and the success rate in secondary UPJOs caused by scarring, for example, was as high as 94% (Kim et al., 2012). Antegrade pyelotomy should be reserved for older children and adolescents with moderate hydronephrosis (Figenshau and Clayman, 1998). However, preoperative screening for accessory vessels is required by CT, MRI, or transluminal ultrasonography to avoid vascular injury. Additionally, fluoroscopy is needed during the procedure, which leads to significant radiation exposure, a factor that makes this approach less attractive in pediatrics. **However, endopyelotomy may have a place in the management of failed primary open or laparoscopic procedures (Fig. 42.11) followed by the placement of a double pigtail catheter for 6 weeks. In these cases, the precise anatomy is known from the primary procedure where absence of an accessory vessel is documented. However, patients should be carefully selected and a redo pyeloplasty, either open, laparoscopic, or robotic-assisted, remains the best choice in most cases** (Davis et al., 2016).

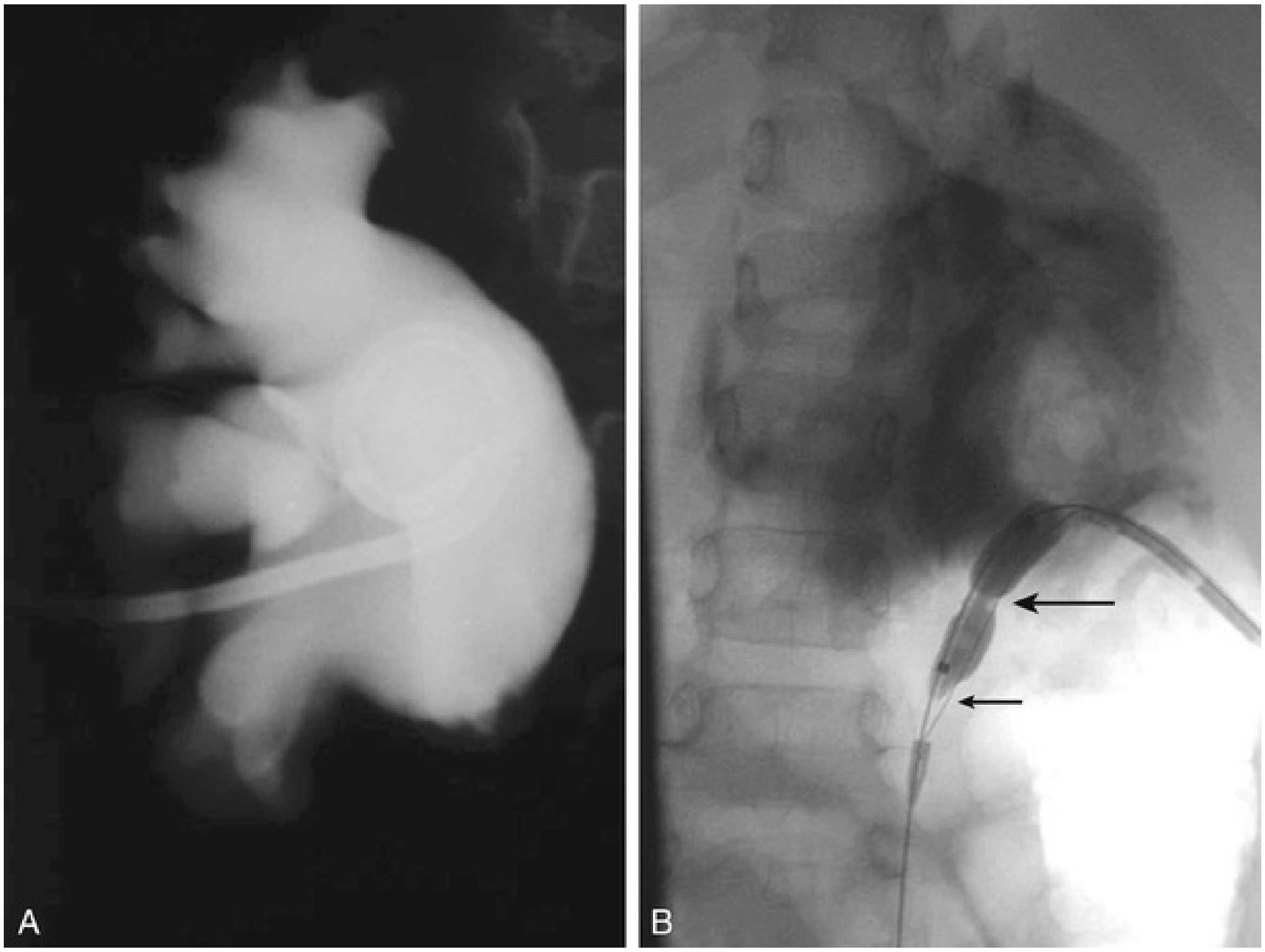

FIG. 42.11 (A) Right antegrade nephrostogram performed 2 months after dismembered pyeloplasty, demonstrating persistent obstruction at the ureteropelvic junction. A nephrostomy tube was placed 2 weeks postsurgery, after which the patient developed flank pain, fever, and *Staphylococcus aureus* urinary tract infection. (B) Acucise balloon is inflated across the ureteropelvic junction narrowing. Note waist present in balloon *(upper arrow)* and cutting wire positioned laterally *(lower arrow).*

Laparoscopic Pyeloplasty

The first cases of laparoscopic pyeloplasty were reported in 1993 (Kavoussi and Peters, 1993). Tan and Roberts reported the first preliminary results of the transabdominal approach, and Yeung et al. described the retroperitoneal approach in infants and children (Tan and Roberts, 1996; Yeung et al., 2001). The evolution of both instruments and video equipment has made the laparoscopic approach widely accepted, and it has become the method of choice at many centers (Metzelder et al., 2006; Sweeney et al., 2011; Blanc et al., 2013). Autorino et al. concluded in a meta-analysis that the laparoscopic approach has a comparable outcome to open surgery, with the robotic technique as an attractive alternative (Autorino et al., 2014).

Transperitoneal or Retroperitoneal Approach.

From a theoretical point of view, the retroperitoneal approach should be safer and is the route of choice in open surgery. However, only a few studies have compared retroperitoneal with transperitoneal access and without noting any significant differences in the outcome and or complications. Abuanz et al. found a higher rate of conversion to open surgery in adults when using the retroperitoneal approach compared with the transabdominal route (Abuanz et al., 2010). This might reflect a more technically challenging procedure in the retroperitoneum. Canon et al. reported a longer operative time for the retroperitoneal approach (Canon et al., 2007a). In a prospective randomized study, Badawy et al. compared the retroperitoneal with the transperitoneal approach and found a significantly shorter operative time for the retroperitoneal approach along with “shorter hospital stay, rapid recovery of intestinal function, and early resumption of oral feeding in favor of the retroperitoneal approach” (Badawy et al., 2015).

Robotic-Assisted Pyeloplasty.

At the beginning of this century, the first publications on robotic pyeloplasty in children emerged (Olsen and Jorgensen, 2004; Kutikov et al., 2006a; Lee et al., 2006). **The transperitoneal approach has gained wide acceptance, but the retroperitoneal approach seems to have attracted fewer proponents, undoubtedly because it is a more technically challenging procedure in children with a confined working space, difficult orientation, and relatively large instruments that need to be maneuvered** (Olsen et al., 2007). Robotic-assisted pyeloplasty has a shorter and more efficient learning curve as compared with laparoscopy, as advanced visualization through three-dimensional vision and the dexterity of the instruments all provide for easier manipulation, precise dissection, and suturing. Barbosa et al. compared open and robotic-assisted pyeloplasty in a larger series and found comparable outcomes but a faster resolution rate in the robotic group (Barbosa et al., 2013). Others have found similar results (Lee et al., 2006; Dangle et al., 2013; Autorino et al., 2014). Peters describes the robotic-assisted transperitoneal technique, and Olsen and Rawashdeh describe the robotic-assisted retroperitoneal technique in detail (Peters, 2011; Olsen and Rawashdeh, 2011).

Technique of Laparoscopic or Robotic-Assisted Pyeloplasty.

With the patient in a 45- to 60-degree flank position, **port placement of the *transperitoneal* approach is shown in Fig. 42.12.** The instrument ports can be placed more medially in cases of large hydronephrosis or in small children/infants. The primary access for the camera port is established using the open Hasson's technique, and instrument ports are placed under direct visual guidance. **On both sides, retrocolic access to the kidney is feasible. However, most surgeons prefer a transmesenteric approach on the left side** (Lee et al., 2006; Gupta, Mukherjee et al., 2009; Sedlacek et al., 2010; Khan et al., 2011; Shadpour et al., 2012) because of shorter operating time, lower morbidity, reduced hospital stay, and no difference in outcome when compared with the retrocolic approach. If the pelvis cannot be identified through the mesocolon, the ureter should be identified and followed to the UPJ while being attentive to the possible presence of any accessory vessel (Peters, 2011). The UPJO can then be stabilized by a stay suture, and surgery is performed as detailed earlier. **Essentially, there is no difference in port placement between a laparoscopic transabdominal or robotic-assisted approach.**

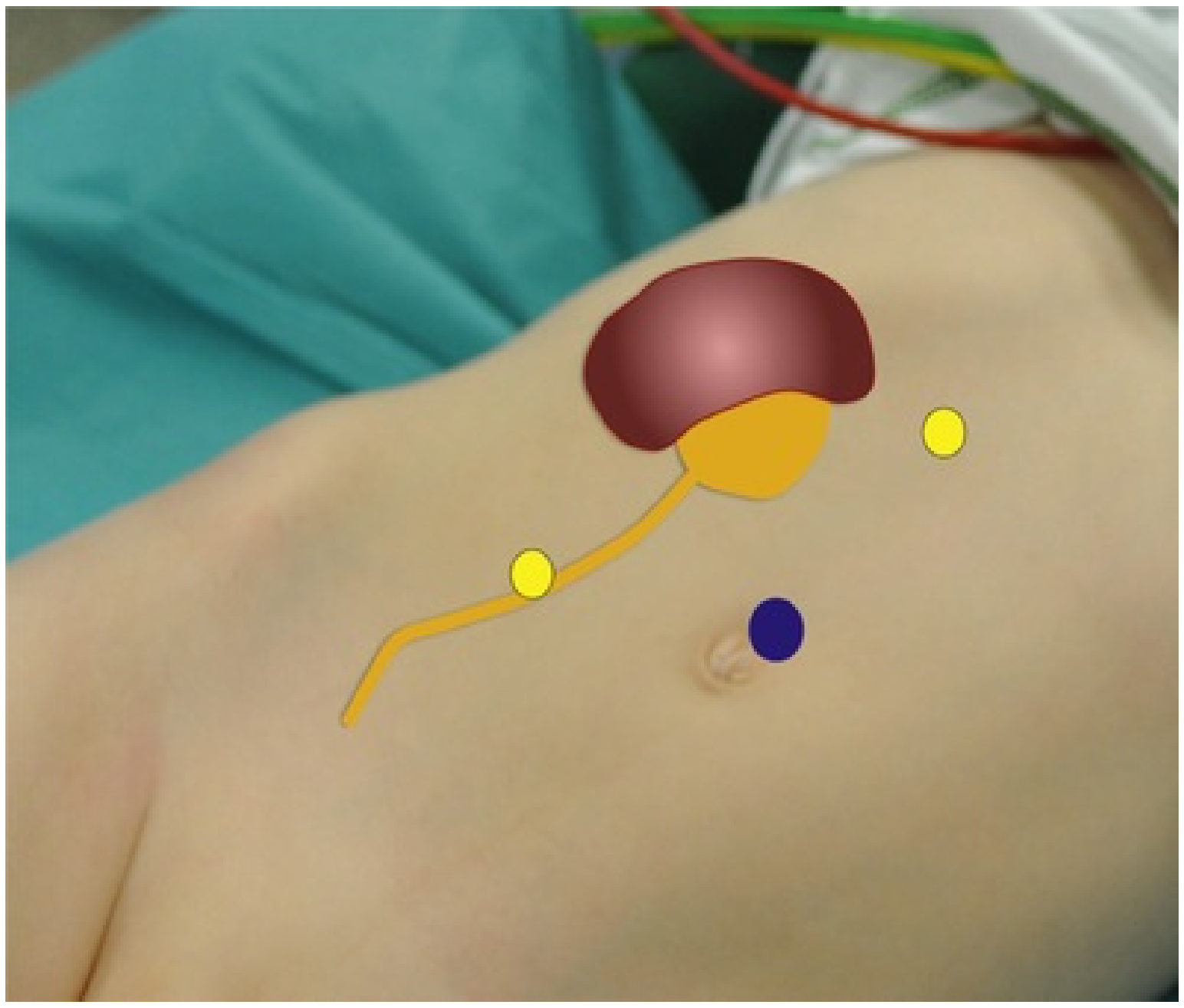

FIG. 42.12 Port placement in transabdominal laparoscopic or robotic-assisted pyeloplasty. *C,* Camera port; *I,* instrument ports.

For the *retroperitoneal* approach, port placement varies in accordance

with the use of laparoscopic or robotic instruments (Fig. 42.13). In both cases, the patient is placed in an 80- to 90-degree flank position. A small gel roll is placed under the contralateral iliac crest, and the upper leg is stretched (Fig. 42.14). The table should not be flexed because this will diminish the AP diameter of the retroperitoneal space. **During the retroperitoneoscopic procedure with standard instruments, the surgeon is positioned behind the patient (dorsally) (see Fig. 42.13A)**, providing better ergonomics (Bonnard et al., 2005). Small children might even be placed diagonally on the table exposing the instruments at a right angle to the surgeon. In the robotic-assisted procedure, the robot is docked from a cranial position and contrary to the case in laparoscopy, camera position is relatively fixed and cannot easily be changed during the procedure. The newest robotic systems are more flexible in this regard. In both cases, a muscle-splitting dissection is carried out at the camera port site, and the lumbodorsal fascia is opened. The retroperitoneal “space” is then developed into 200- to 300-mL working space, depending on the size of the patient. This is done with either a homemade balloon using a 12-Fr catheter with the finger of a latex surgical glove secured to its tip or a commercially available balloon. The latter can be difficult to use in small children because of the large size of these dilators. Additional ports are placed under digital or visual guidance. Use of an extra 5-mm assistance port in the iliac fossa is recommended to facilitate suture delivery and suction during the procedure, as removing and replacing robotic instruments for that same purpose is much more cumbersome and time consuming. After opening Gerota fascia, the UPJ and the pelvis are dissected. A stay suture in the pelvis brought through the abdominal wall or fixed to the psoas muscle provides needed tension and alignment. The pyeloplasty is then performed as described earlier. In case of a UPJO in a horseshoe kidney, the retroperitoneal approach is not advisable because the pelvis is approached from behind. This also applies for the retroperitoneal approach in the rare cases of a retrocaval ureter, at least for the robotic-assisted procedure. Even with standard laparoscopic equipment, retroperitoneal access in these cases is difficult. On the other hand, retroperitoneal access to a UPJO of a lower moiety in a duplex system with the subsequent challenging repair is a perfect case for the robot (see Fig. 42.3).

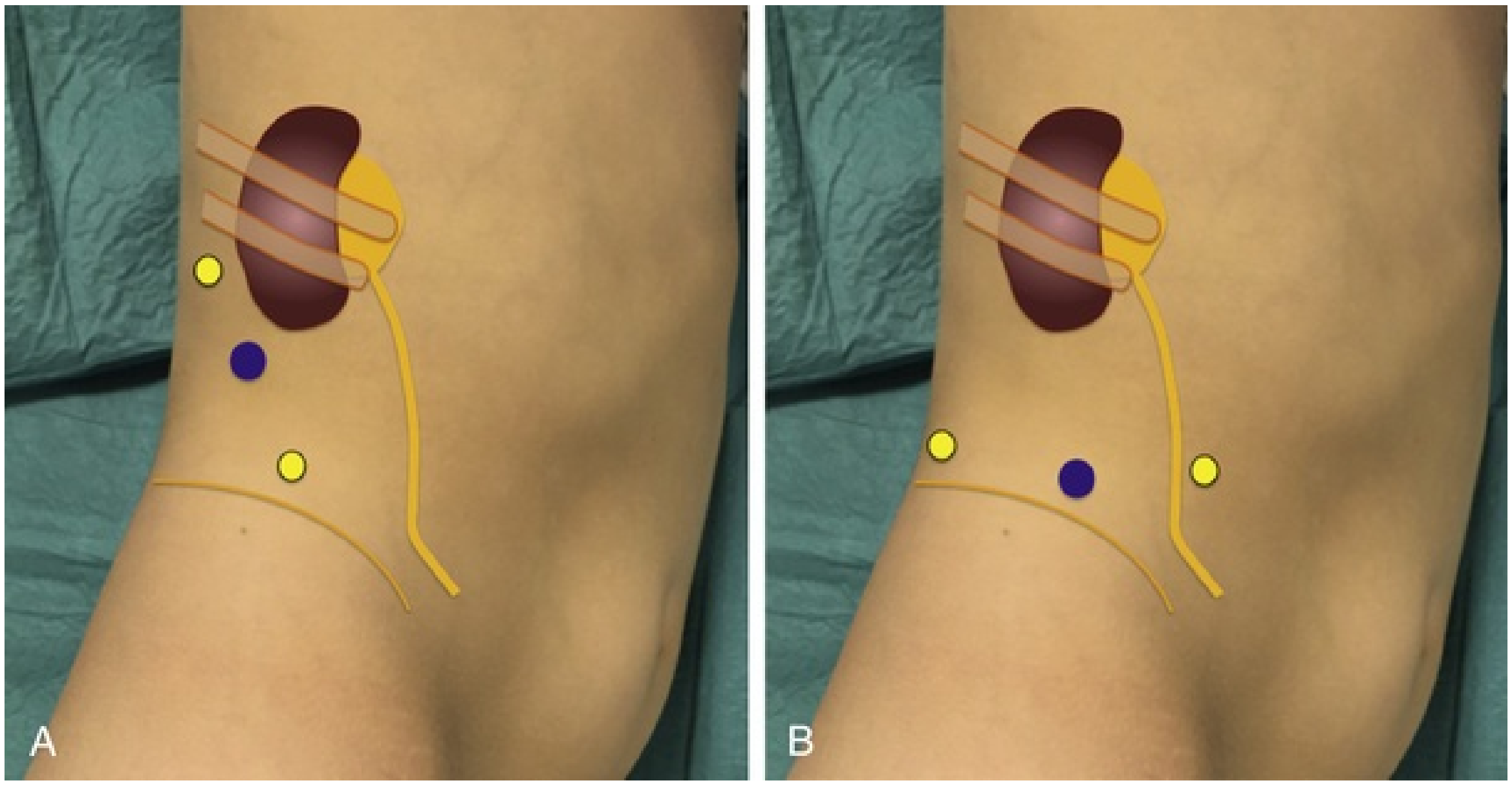

FIG. 42.13 Port placement in retroperitoneal approach. (A) Approach with standard laparoscopic instruments. (B) Approach with robotic assisted instruments. *C,* Camera port. *I,* instrument ports; *a,* assistant port (optional).

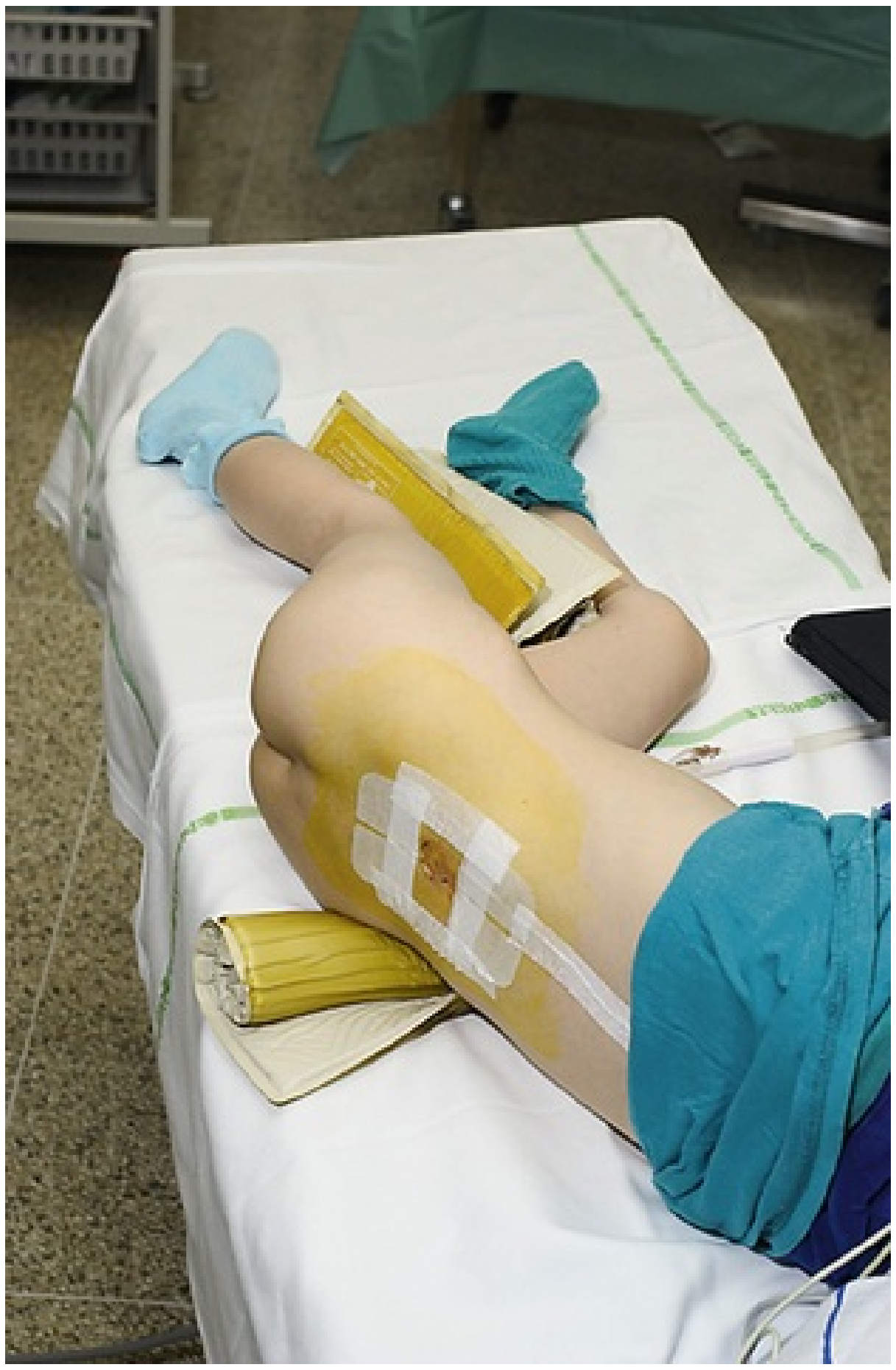

FIG. 42.14 Patient positioning for the retroperitoneal approach. The contralateral iliac crest is supported by a gel role. The table is not flexed to avoid a reduction of the anterior-posterior diameter in the retroperitoneal space. The upper leg is stretched, while the lower leg is bent. This positioning is not advisable for adult patients.

Stones and Congenital Hydronephrosis.

Occasionally pelvic/renal stones are found with congenital hydronephrosis. No matter whether open or laparoscopic/robotic access is used, the treatment of choice is stone removal using a flexible ureteroscope. Alternatively, a flexible cystoscope can be used. The scope can be brought in through either a laparoscopic or robotic port. Standard techniques for stone removal are used as described elsewhere in this book.

Vascular Hitch.

Originally described by Hellstrøm and Vahlquist, the vascular hitch technique (Fig. 42.15) has regained acceptance among laparoscopic surgeons, in part because it is easier to perform than pyeloplasty (Hellstrom and Vahlquist, 1951; Sakoda et al., 2011). However, the technique is only feasible in cases of an anterior lower pole accessory vessel without any intrinsic obstruction of the UPJ. Gundeti et al. conclude that **the vascular hitch should be reserved for cases with “moderate hydronephrosis, no calyceal dilation, a well-preserved cortex, poor renal drainage with preserved split function, and lower pole crossing vessels. Intraoperative criteria included a normal ureter and UPJ with peristalsis”** (Gundeti et al., 2008). Long-term results are limited (Gundeti et al. 2008; Schneider et al., 2013). However, Madec et al. found outcome results in a long-term follow-up comparable to those of dismembered pyeloplasty (Madec et al., 2016). The concern that embedding the lower pole vessels in pelvic tissue gives rise to hypertension has so far not been observed.

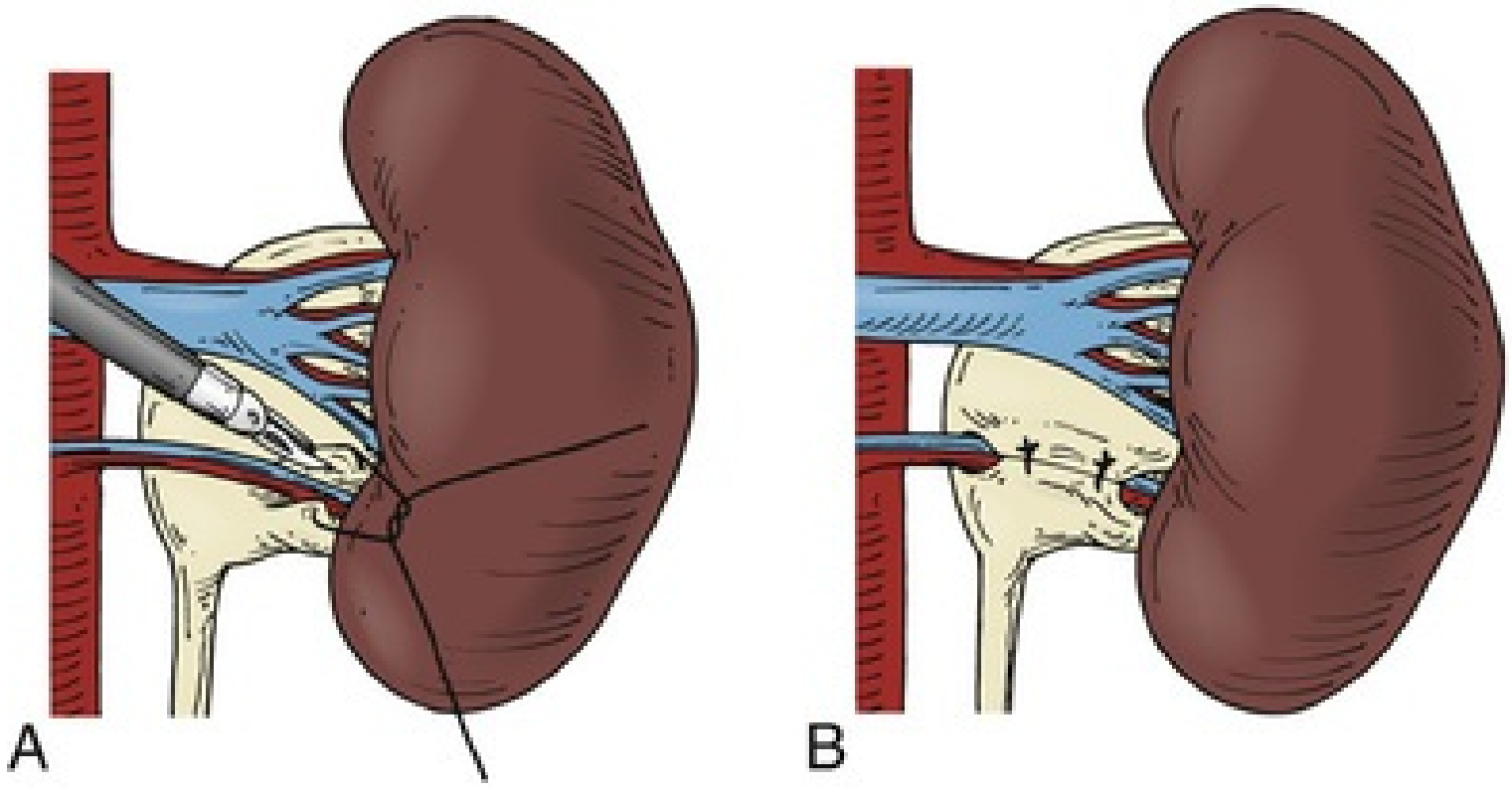

FIG. 42.15 Vascular hitch in cases with crossing vessels and without intrinsic obstruction of the ureteropelvic junction. (A) After removal of all adherences between the ureteropelvic junction and the vessel, the latter is moved cranially on the pelvis and then embedded into pelvic tissue with nonresorbable sutures (B).

Stenting

Most surgeons prefer stenting the UPJ, both in open and minimally invasive surgery (Austin et al., 2000). This decreases the risk for leakage from the anastomosis and subsequent urinoma formation or, if the transperitoneal route is chosen, bowel paralysis caused by urinary ascites. Stentless anastomoses have been advocated by some authors (Liss et al., 2013). This mandates extra careful tissue handling to avoid edema and subsequent obstruction and leakage from the reconstructed UPJ in the postoperative period. Interestingly, Anderson and

Hynes note in their original paper on the dismembered pyeloplasty that; “so-called splinting of any anastomosis is not only unnecessary but is against all the principles of plastic procedure” (Anderson and Hynes, 1949). **Stenting with a double pigtail catheter in children consigns the patient to another anesthesia for stent removal and adds significant time to the procedure when done retrograde in connection with the pyeloplasty.** Use of a stent with an extraction string and placed retrograde can be a feasible alternative. Antegrade intraoperative stenting with a double pigtail catheter can also pose difficulty in passing the ureterovesical junction (UVJ), which can be quite narrow in small infants. For purposes of confirming stent position in the bladder, instillation of methylene blue into the bladder has been advocated. Retrograde stenting immediately before the procedure might make the anastomosis more difficult, and if done days to weeks before surgery (e.g., when emergent diversion is necessary because of obstruction), anastomosis may become more challenging because of local tissue inflammation caused by the catheter traversing the UPJ. It is the authors’ experience to divert with a nephrostomy tube the rare patient with hydronephrosis who needs emergent diversion in close temporal proximity to definitive surgery, as the inflammation caused by a nephrostomy is less severe at the UPJ.

The authors prefer using a transanastomotic nephro-ureteric tube, the so-called “BLUE stent” (Salle Intraoperative Pyeloplasty Stent Set, Cook Medical, Bloomington, IN) (Helmy et al., 2011), **brought out through the renal parenchyma through a middle calyx or directly through the upper part of the anastomosis and the lateral abdominal wall (Fig. 42.16).** This externalized stent is kept open for 12 to 48 hours after which it is knotted and kept in situ for 7 to 14 days and simply pulled out without the need for anesthesia. In cases of obstruction, infection, or postoperative pain, the knot is released and the transanastomotic nephro-ureteric tube drains the system, acting as a nephrostomy tube.

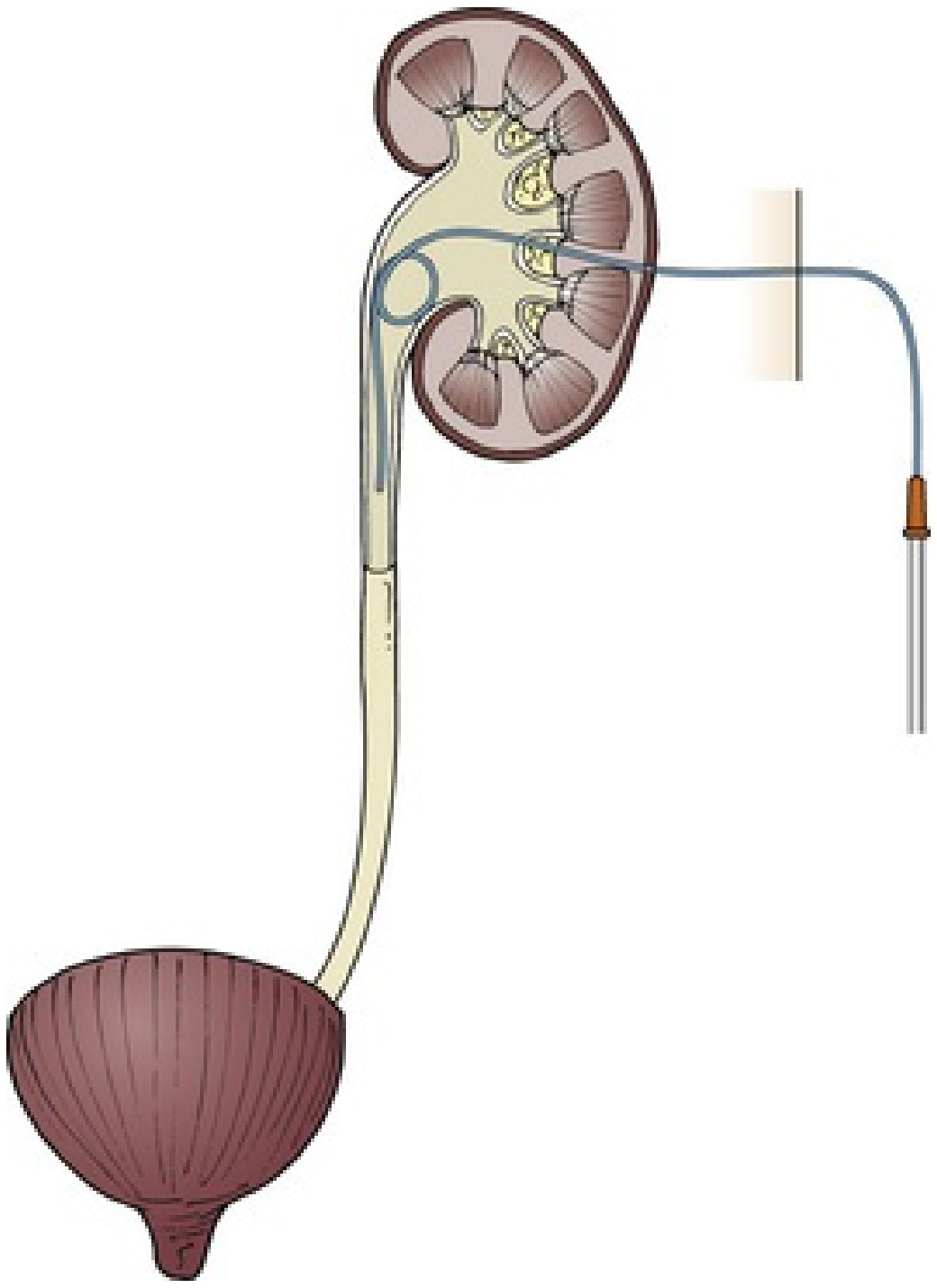

FIG. 42.16 Transanastomotic ureteropyelostomy “Blue Stent.” The lower coil is removed, and the upper end is brought out to the skin, either through the anastomosis or the renal parenchyma. The stent is left open for 24 to 48 hours and then knotted. It can easily be removed after 7 to 14 days without the need for anesthesia.

It is customary to leave the bladder drained by a Foley catheter for up to 24 to 48 hours postoperatively. Although dogmatic and not based on hard evidence, it makes perfect sense when the anastomosis is stented by a double pigtail catheter as VUR will be present transferring bladder pressure unhindered to the renal pelvis. It is however unnecessary when using an externalized transanastomotic nephro-ureteric stent as the lower end of the stent is cut short before placement and does not traverse the UVJ.

Outcome and Complications

In general, pyeloplasty is a safe procedure with few complications and a high success rate between 90% and 100% (Poulsen et al., 1987; O'Reilly, 1989; Macneily et al., 1993; Shaul et al., 1994, Salem et al., 1995; Ragan et al., 1999; Austin et al., 2000; Houben et al., 2000; Casale et al., 2004; Bonnard et al., 2005; Peters, 2011; Autorino et al., 2014). However, the definition of “success” is wide ranging and covers everything from cessation of symptoms to improvement or at least stability of function of the affected kidney, to decreasing

AP diameter of the hydronephrosis on ultrasonography, and more rigidly failure as the need for reoperation or reintervention. This makes the comparison among different outcome studies difficult if not impossible.

Perioperative complications include bleeding from ureteral or pelvic vessels, which can be handled preferably by bipolar diathermy in most cases. Bleeding is the most commonly reported reason for conversion in minimally invasive procedures, followed by lack of progression or difficulties dissecting the UPJ. Postoperatively, infection, pain, and increasing dilation might be early signs of a failed reconstruction (Lindgren et al., 2012). However, blood clots and edema may be the cause and will usually resolve within a few days but may require temporary diversion by a nephrostomy tube. In the long term, decreasing kidney function and increasing dilation may indicate the need for further intervention, initially by balloon dilation/incision of the stenotic UPJ (see Fig. 42.11) and stenting for 4 to 6 weeks, but may ultimately require a redo pyelopasty. In such cases, retroperitoneal access can be cumbersome as a result of scarring, and a transperitoneal approach is preferred. If scarring of the ureter is severe and mobilization of the kidney and ureter does not allow for an appropriate length to perform a tension-free anastomosis, a ureterocalicostomy should be considered. This can be done openly or with a laparoscopic or robotic-assisted procedure (Fig. 42.17) (Davis et al., 2016).

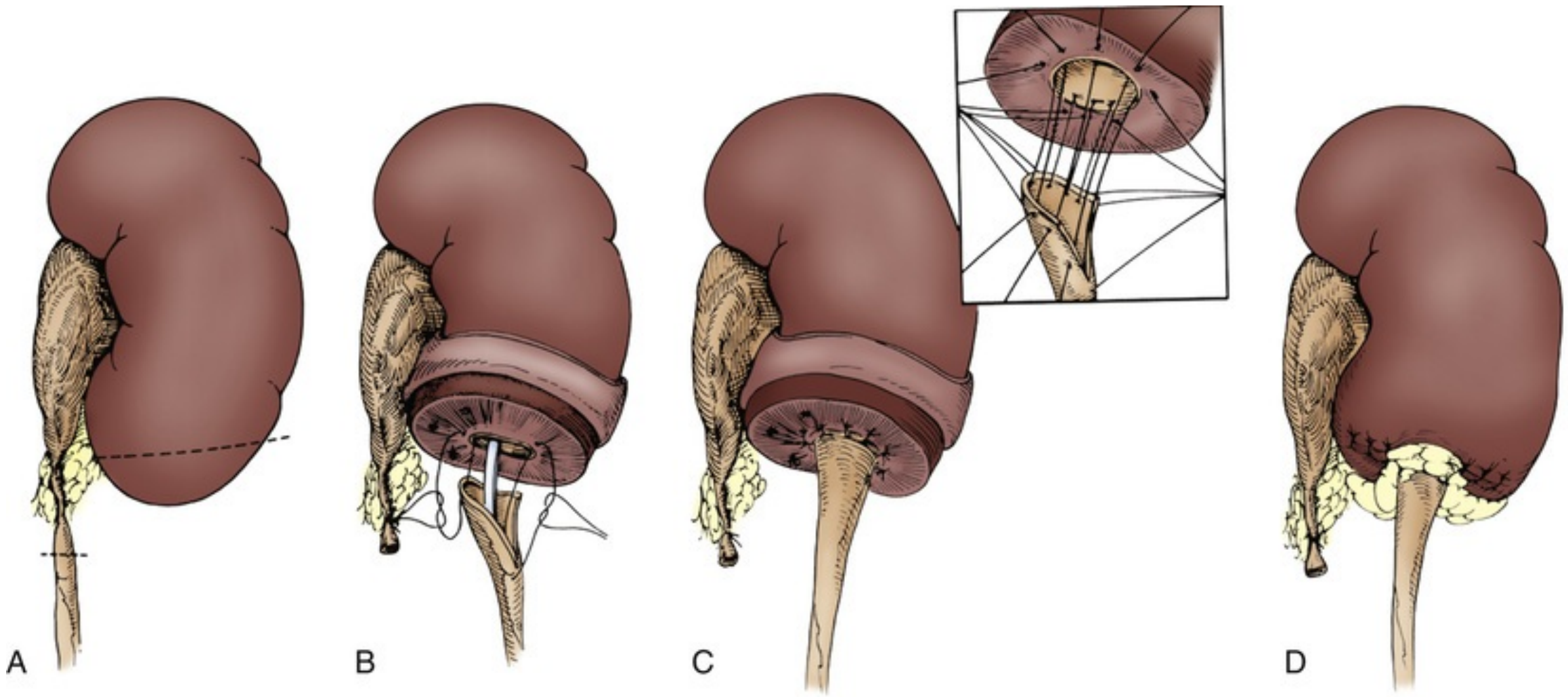

FIG. 42.17 Ureterocalicostomy. (A) The ureter is identified in the retroperitoneum and dissected proximally as far as possible. The kidney is mobilized as much as necessary to gain access to the lower pole and to subsequently perform the anastomosis without tension. A lower pole

nephrectomy is performed, removing as much parenchyma as necessary to widely expose a dilated lower pole calyx. (B) The proximal ureter is spatulated laterally. The anastomosis should subsequently be performed over an internal stent and consideration given to leaving a nephrostomy tube. The initial suture is placed at the apex of the ureteral spatulation and the lateral wall of the calyx, with another suture placed 180 degrees from that. (C) The anastomosis is completed in an open fashion, placing each suture circumferentially but not securing them until the anastomosis has been completed. (D) The renal capsule is closed over the cut surface of the parenchyma whenever possible. However, the capsule should not be closed close to the anastomosis itself because this may compromise the lumen by extrinsic compression. Instead, the anastomosis should be protected with a graft of perinephric fat or with a peritoneal or an omental flap.

Key Points: Pyeloplasty

- UPJO is typically caused by either an intrinsic narrowing in which the ureteral segment has an interruption in the development of the circular musculature of the UPJ; an alteration in collagen fibers in and around the muscular cells; or an extrinsic obstruction that is seen in association with aberrant, accessory, or an early branching lower pole vessel that passes anteriorly to the UPJ or proximal ureter and contributes to mechanical obstruction.
- Congenital renal malformations can be commonly seen in association with a UPJ, with a contralateral UPJO being the most common anomaly, followed by renal dysplasia and multicystic dysplastic kidneys.
- The surgical procedure favored in the repair of a UPJO is the dismembered pyeloplasty, which has been shown to be effective because of its broad applicability, means of allowing excision of the pathologic segment in question, and facilitation of a reduction pyeloplasty when necessary.
- Laparoscopic pyeloplasties provide excellent visualization of the anatomy, enhance cosmesis, and duplicate the results of open pyeloplasties with short-term follow-up. The technical challenges of this approach have been facilitated by the use of a robotic-assisted procedure that improves the anastomotic repair.
- Pyeloplasty complications include prolonged urinary drainage postoperatively, lack of improvement in renal function or improvement in

washout, and, occasionally, worsening hydronephrosis and diminished renal function postoperatively. Such a situation may lend itself to a repair using endoscopic procedures or preferably a repeat dismembered pyeloplasty.

Ureteral Strictures

Congenital ureteral strictures are rare anomalies that have been described causing hydroureteronephrosis. Dilation is identified antenatally but because of their extreme rarity, these patients are usually misdiagnosed as having hydronephrosis or megaureter. Postnatal diagnostics with ultrasonography, MRI, and retrograde pyelography subsequently confirm the diagnosis as being the result of usually a mid-ureteral stricture. Management entails excision of the stenotic ureteral segment and reanastomosis by ureteroureterostomy; excised segments range in length from 1 to 3 cm and are histologically characterized by increased collagen deposition and muscular hypertrophy (Hwang et al., 2005; Brugnara et al., 2007).

Ureteral Polyps

Ureteral polyps are another rare anomaly that may lead to obstruction and dilation. The polyps are most frequently seen in the upper third of the ureter and usually lead to UPJO. They are more common in males and on the left side, can be single or multiple, and can reach several centimeters in diameter. Although they may cause antenatal dilation, they tend to present symptomatically with pain and hematuria later in childhood because of their slow growth and benign nature. Diagnosis can be made by ultrasonography, contrast-based CT scan, and MR urography. Confirmation is usually attained by retrograde pyelography or ureteroscopy. Management options include endoscopic polypectomy, dismembered pyeloplasty with resection of afflicted part of the ureter when polyps are near the UPJ, or ureteral resection and ureteroureterostomy by open and even laparoscopic or robotic surgery. Histologically, they are classified as fibroepithelial benign polyps (Kanamori et al., 2010; Bian et al., 2011; Shive et al., 2012; Li et al., 2015; Osbun et al., 2016).

Vesicoureteric Reflux

Definition and Clinical Presentation

As discussed in Chapter 29, **VUR represents the abnormal retrograde flow of urine from the bladder to the upper urinary tract**. When symptomatic, VUR can give rise to UTIs, pyelonephritic scars, and, at worst, end-stage renal disease. High-grade VUR may also lead to voiding dysfunction, although the exact mechanism is unclear in that there are conflicting interpretations as to whether VUR causes voiding dysfunction or vice versa (Lackgren et al., 2007). **Surgical management of VUR aims at creating one-way, nonobstructed, antegrade flow of urine through the ureter into the bladder by reimplanting the ureter into the bladder in an antirefluxing fashion**. A multitude of surgical procedures and their laparoscopic counterparts have been described. Additionally, minimally invasive endoscopic procedures are also widely in use.

Surgical Management

Key Points: Surgical Principles of Vesicoureteral Reflux Correction

- Excluding causes of secondary reflux.
- Gentle handling of the ureter upon dissection to preserve blood supply and minimize tissue injury.
- Gentle handling of the bladder to minimize postoperative bladder symptoms such as hematuria and bladder spasms.
- Adequate mobilization of the ureter to allow for tension-free anastomosis.
- Establishing an adequate length-to-diameter ratio of 5 : 1 when reimplanting the ureter (Paquin, 1959).
- Maintaining a straight course for the reimplanted ureter, with consideration taken in regard to the distensibility of the bladder and its potential for causing angulations and kinks at either extreme of bladder filling.

The surgical procedures can be classified according to the access and approach used to mobilize the ureter and according to the position of the created submucosal tunnel in relation to the original hiatus of the ureteric orifice. Thus the procedure can be laparoscopic or open, intravesical or extravesical, and the tunnel can be infrahiatal or suprahiatal.

For open surgical procedures, patients are placed in the supine position with slightly abducted hips, and the lower abdomen is raised by placing an appropriate sized gel pad behind the level of the sacrum to facilitate exposure. All pressure points are appropriately padded. The abdomen and perineum are prepped and draped to include the genitalia in the prepared field to allow for sterile urethral catheterization. Prophylactic intravenous antibiotics are given in most cases.

Incision

A Pfannenstiel incision is made along a skin crease 2 cm above the symphysis pubis extending to the edges of the underlying rectus muscles (Fig. 42.18A). The anterior rectus fascia is opened transversely and lifted off the recti to the level of the symphysis pubis inferiorly and to just below the umbilicus superiorly. The rectus abdominis muscles are separated in the midline vertically along the linea alba by blunt dissection, thereby exposing the perivesical space. Alternatively, and in redo cases a vertical lower abdominal incision may be preferable because it allows for more extensive cranial mobilization of the ureters. A moderately filled bladder allows for easier identification and mobilization of the bladder.

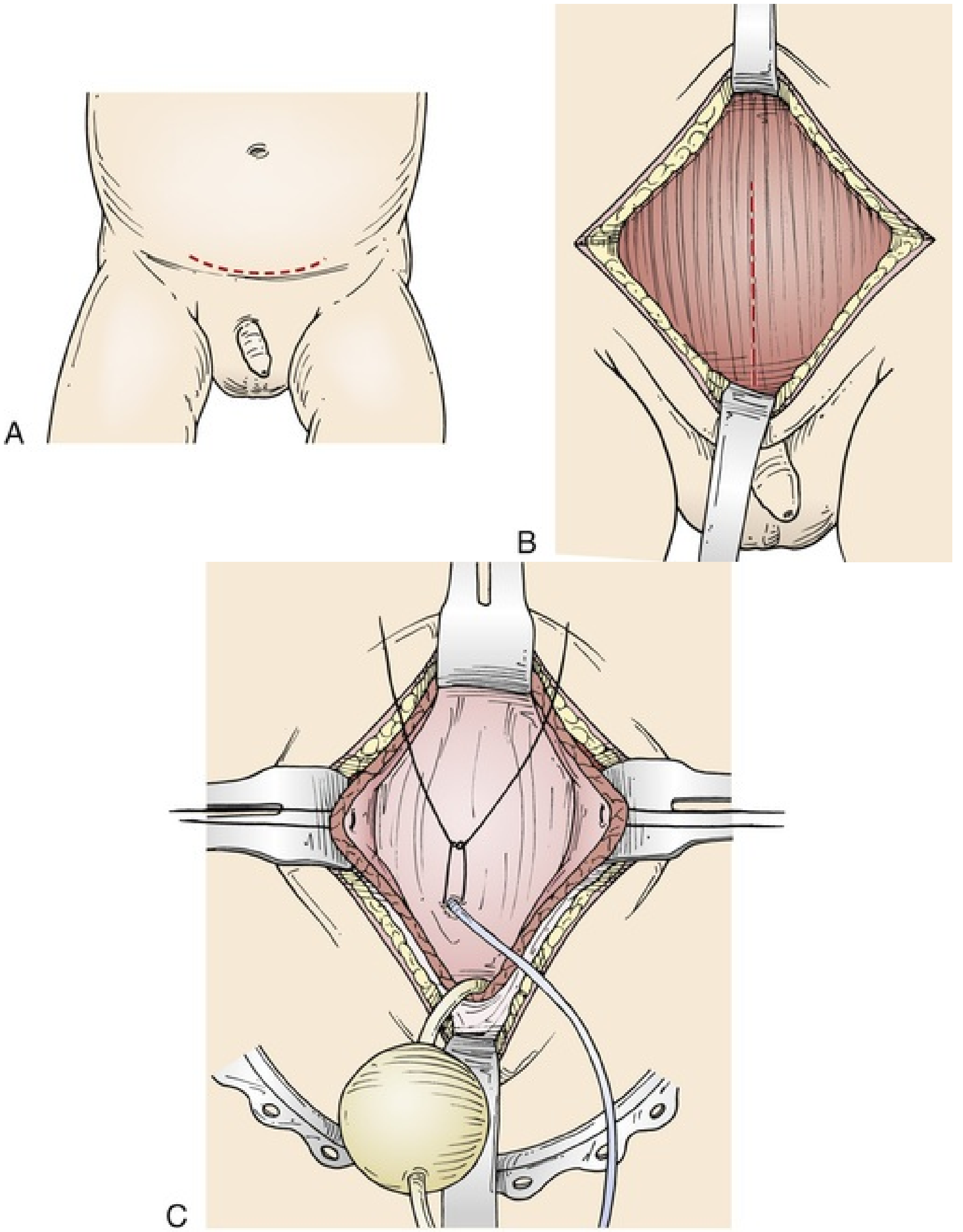
A
B
C

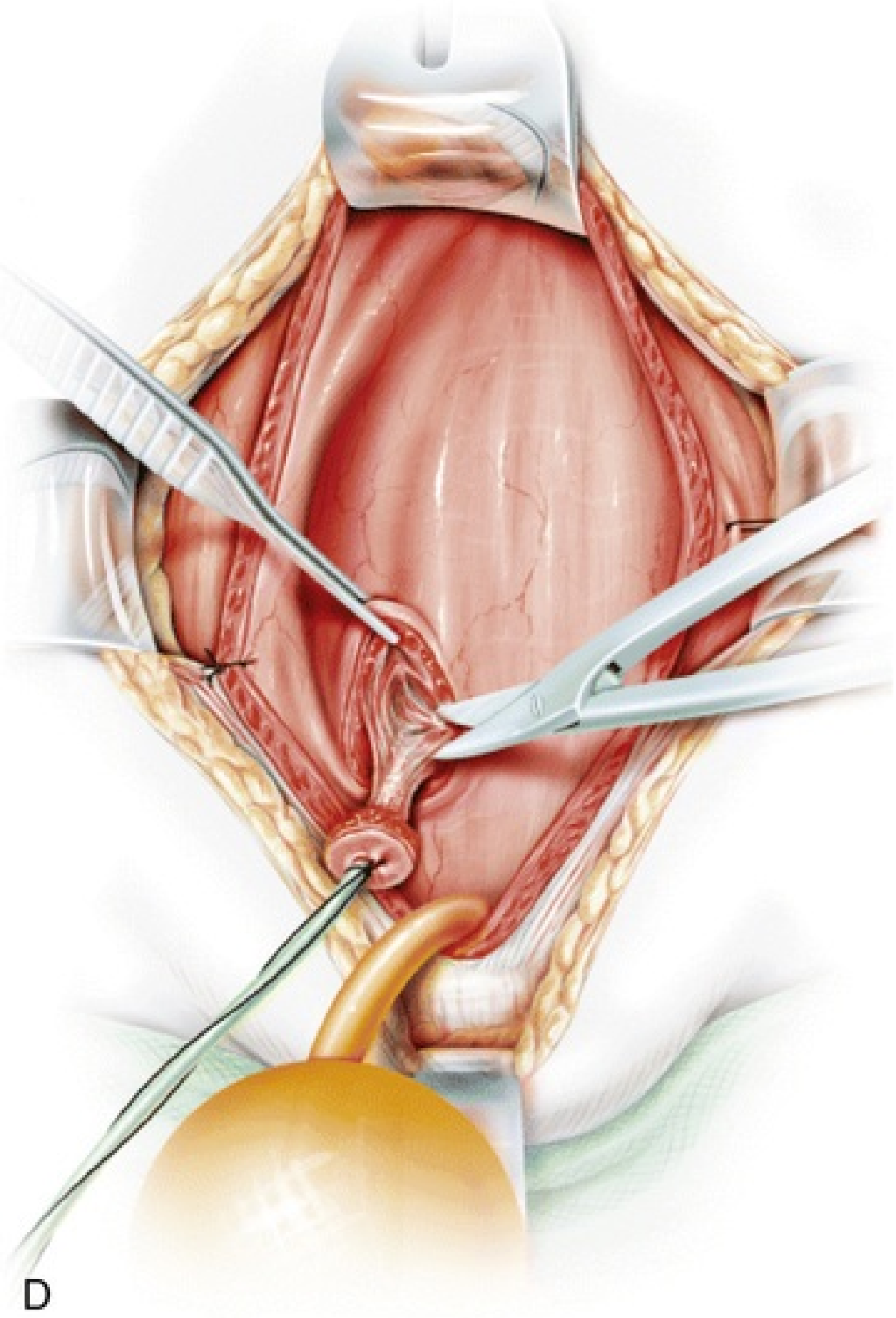
D

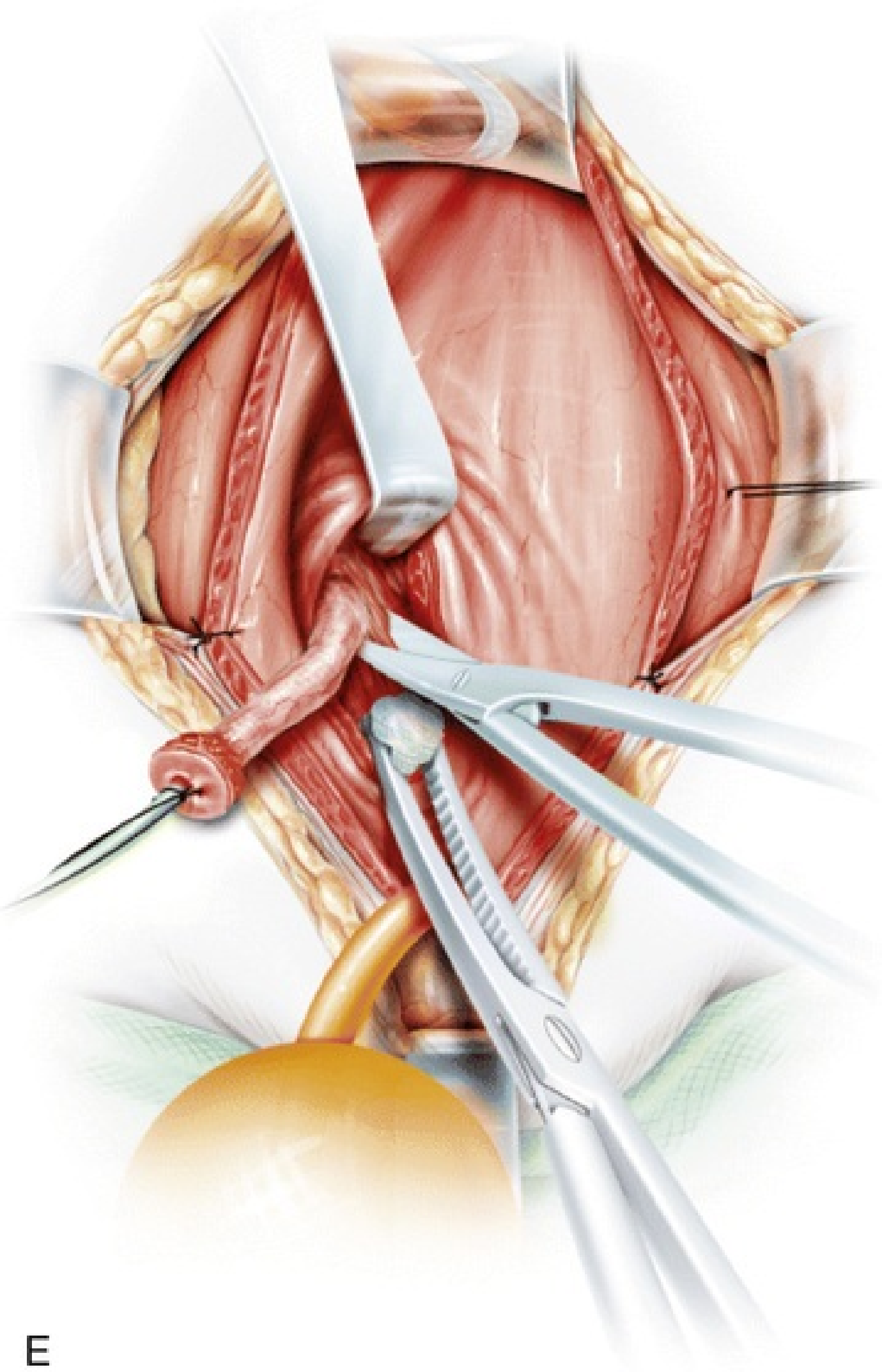

E

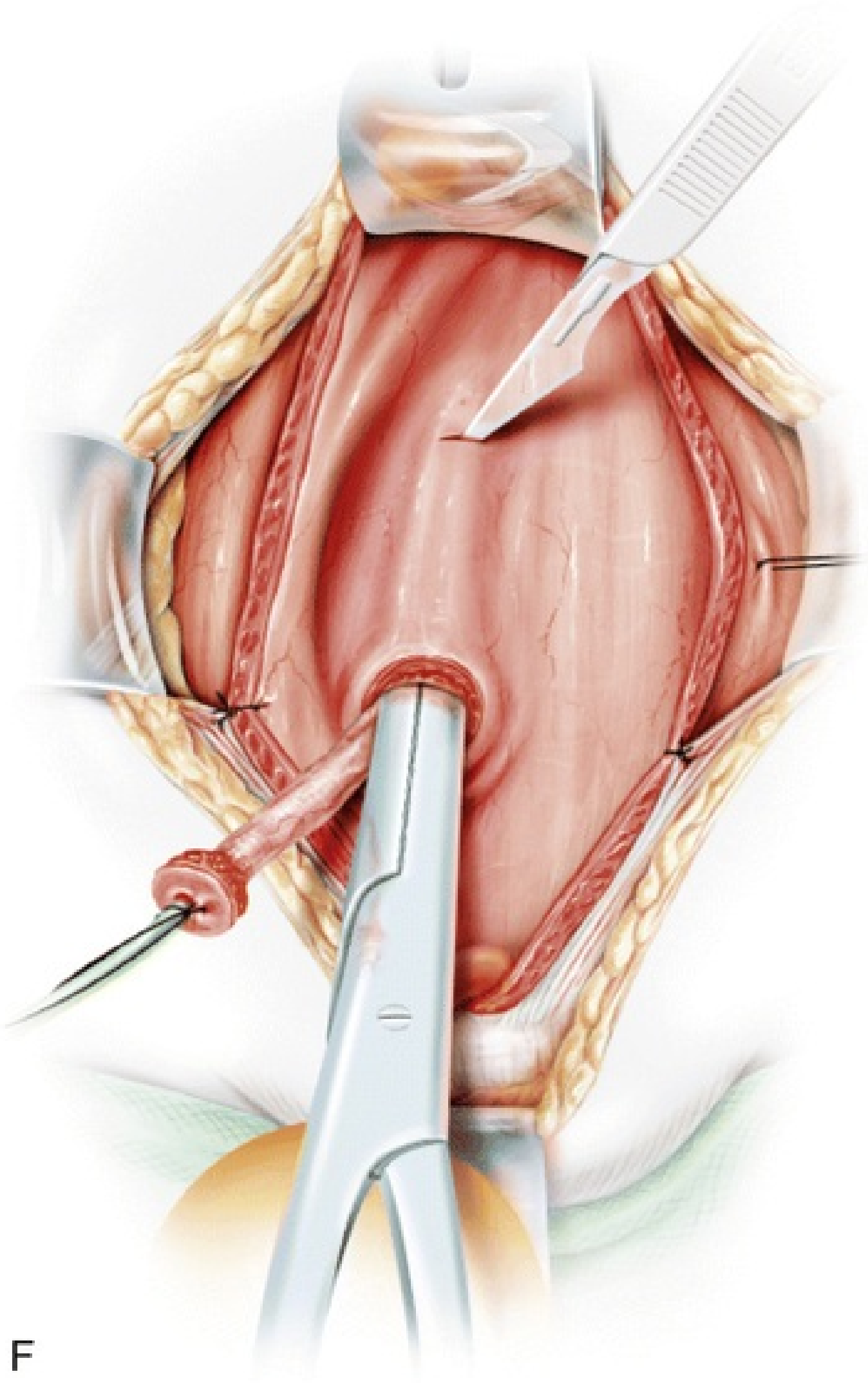

F

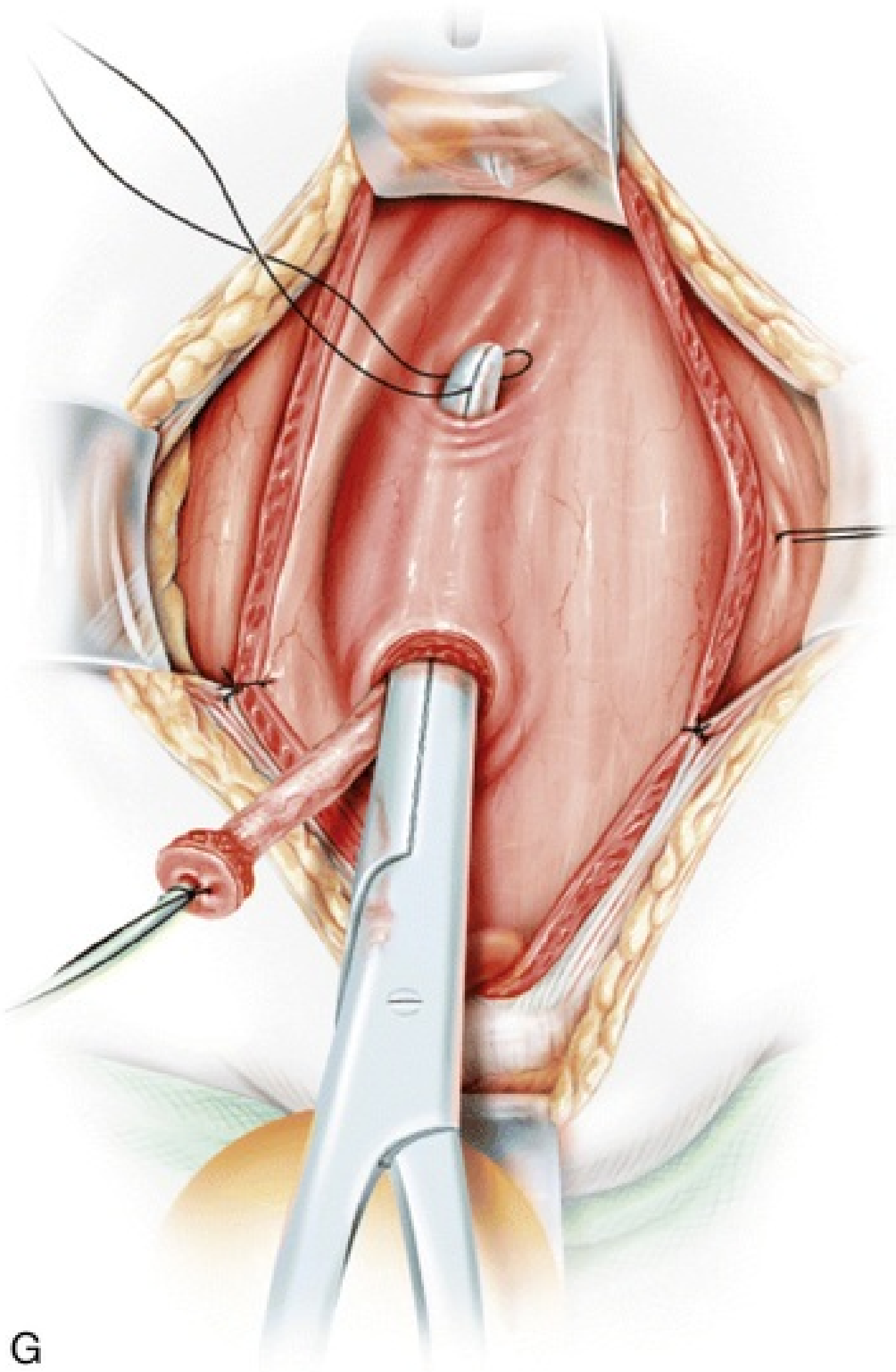

G

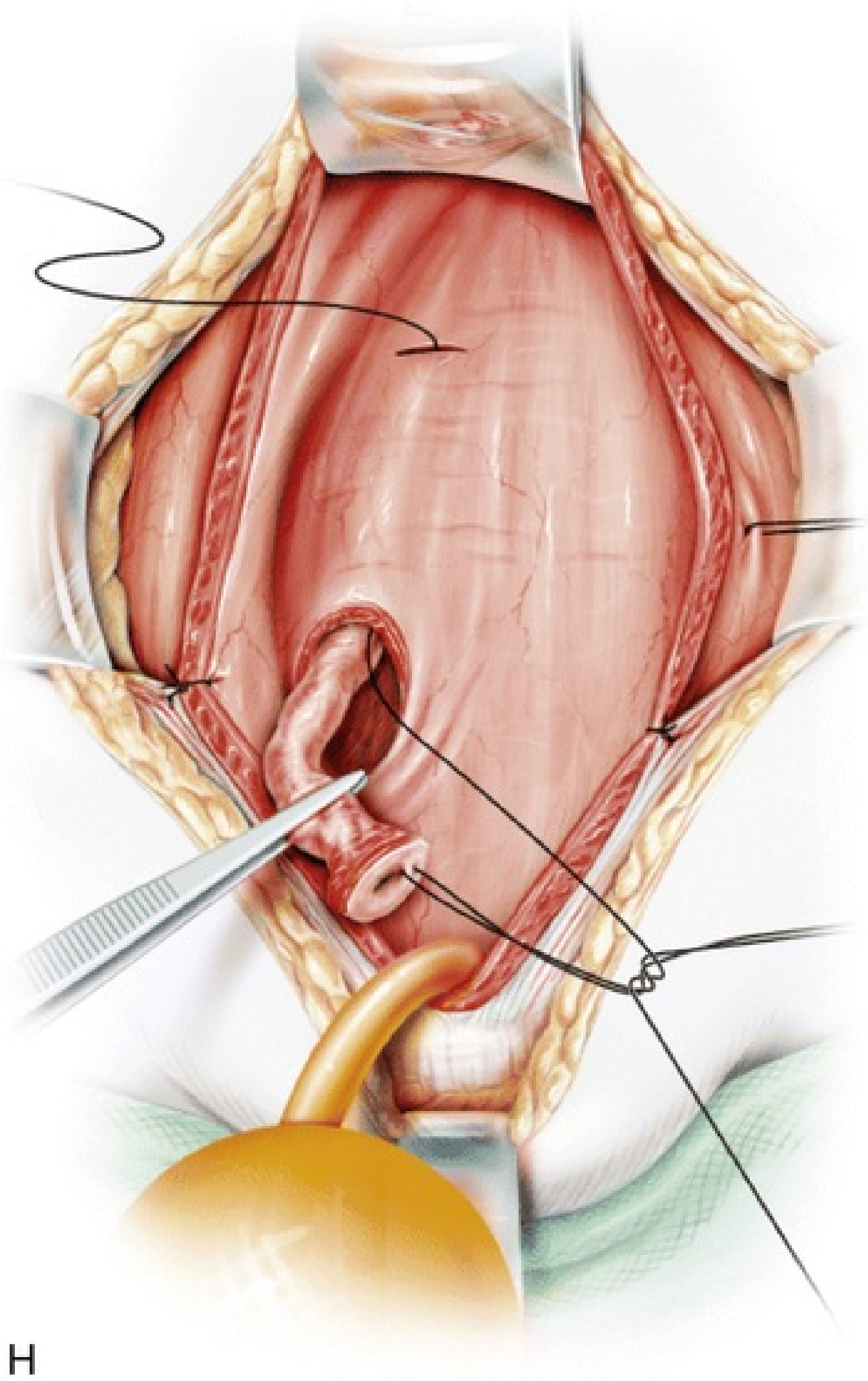

H

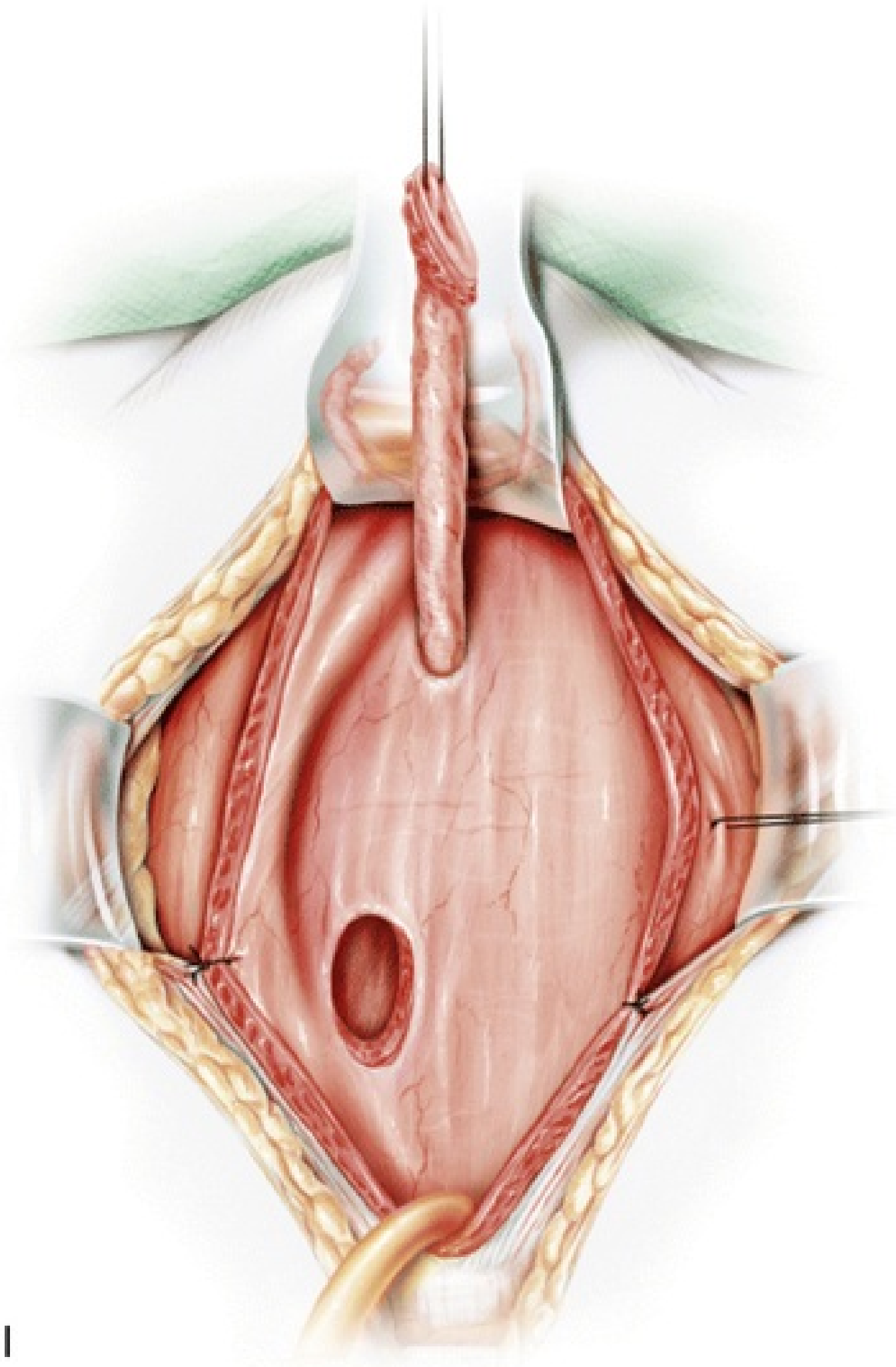

I

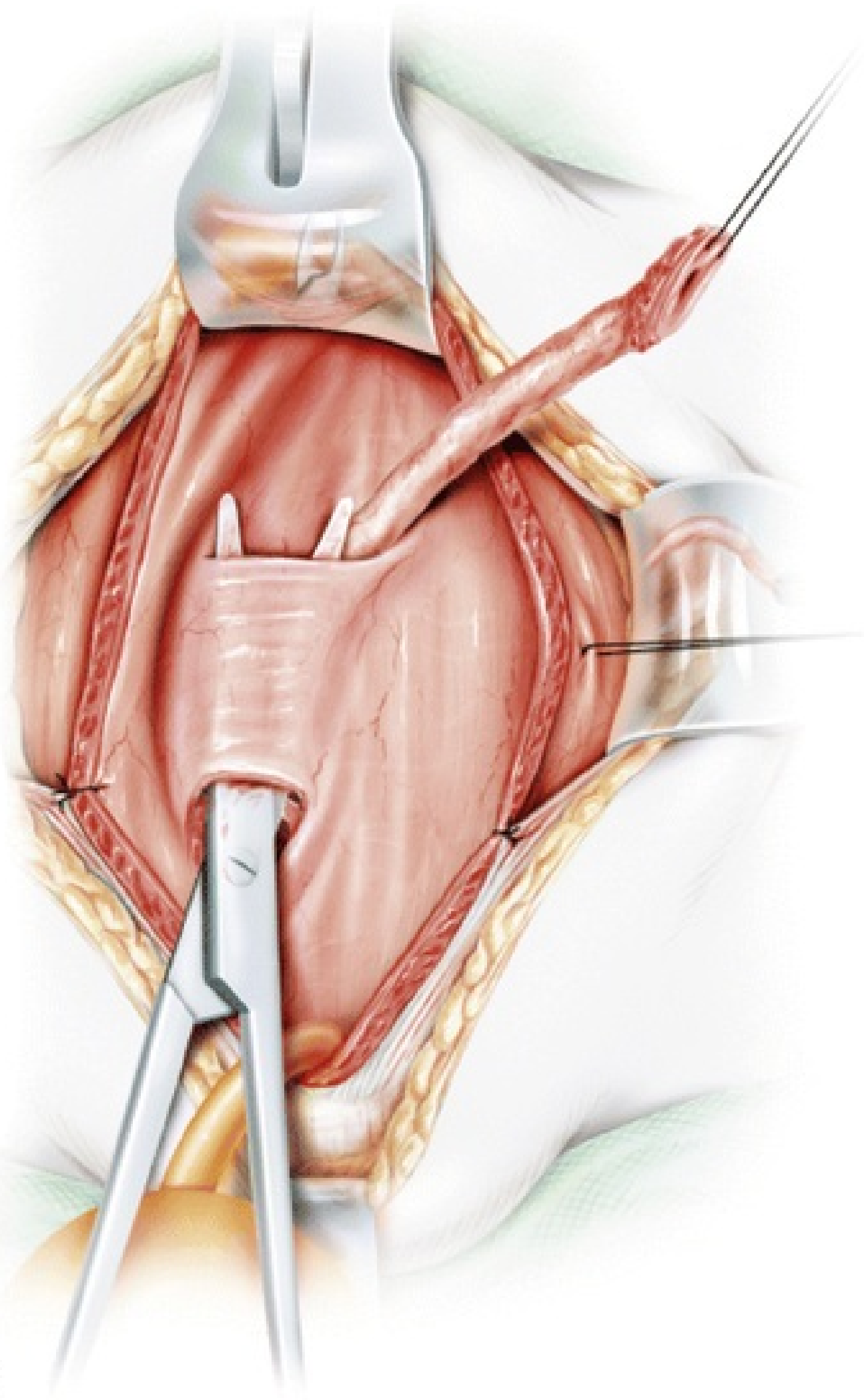
J

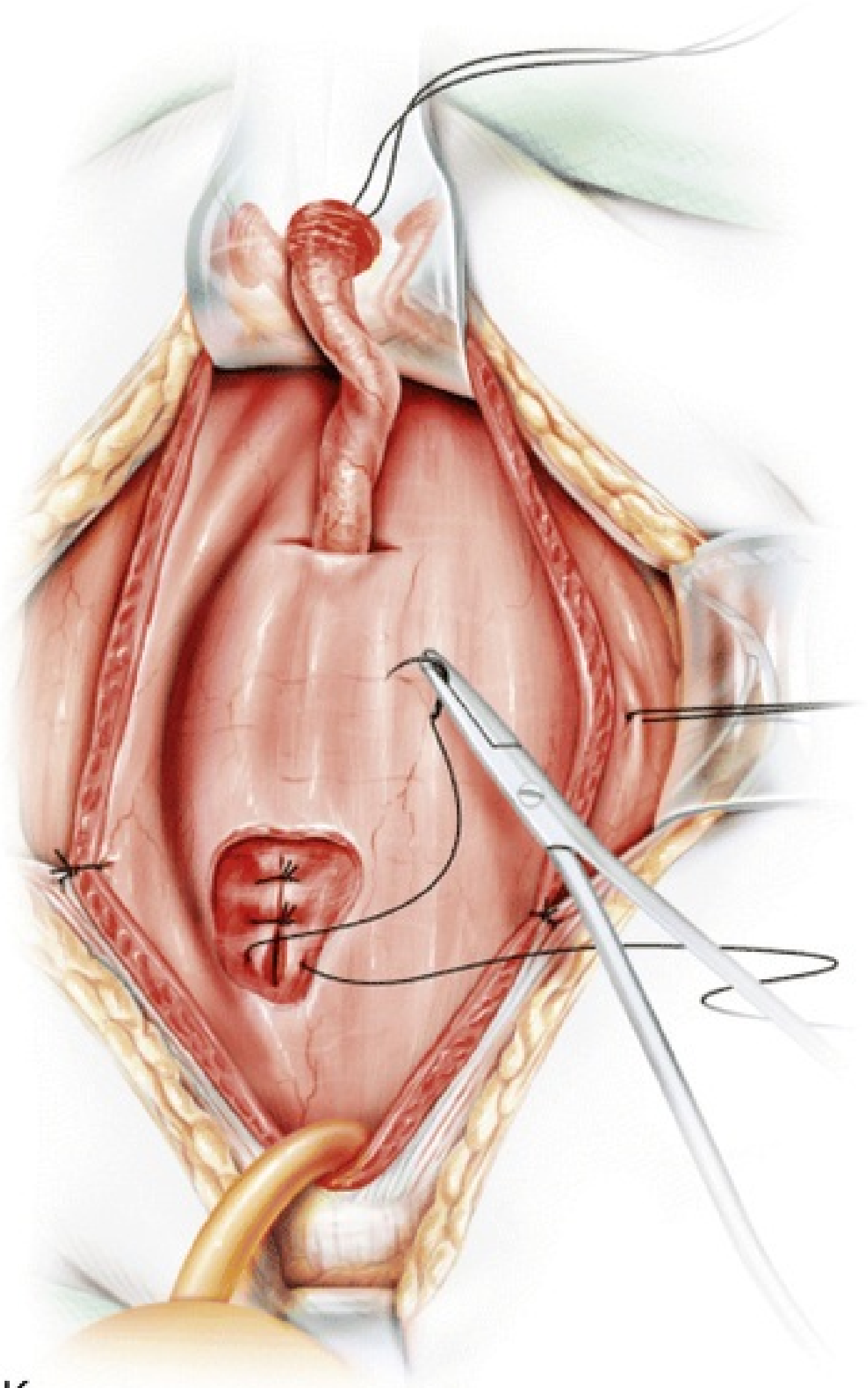

K

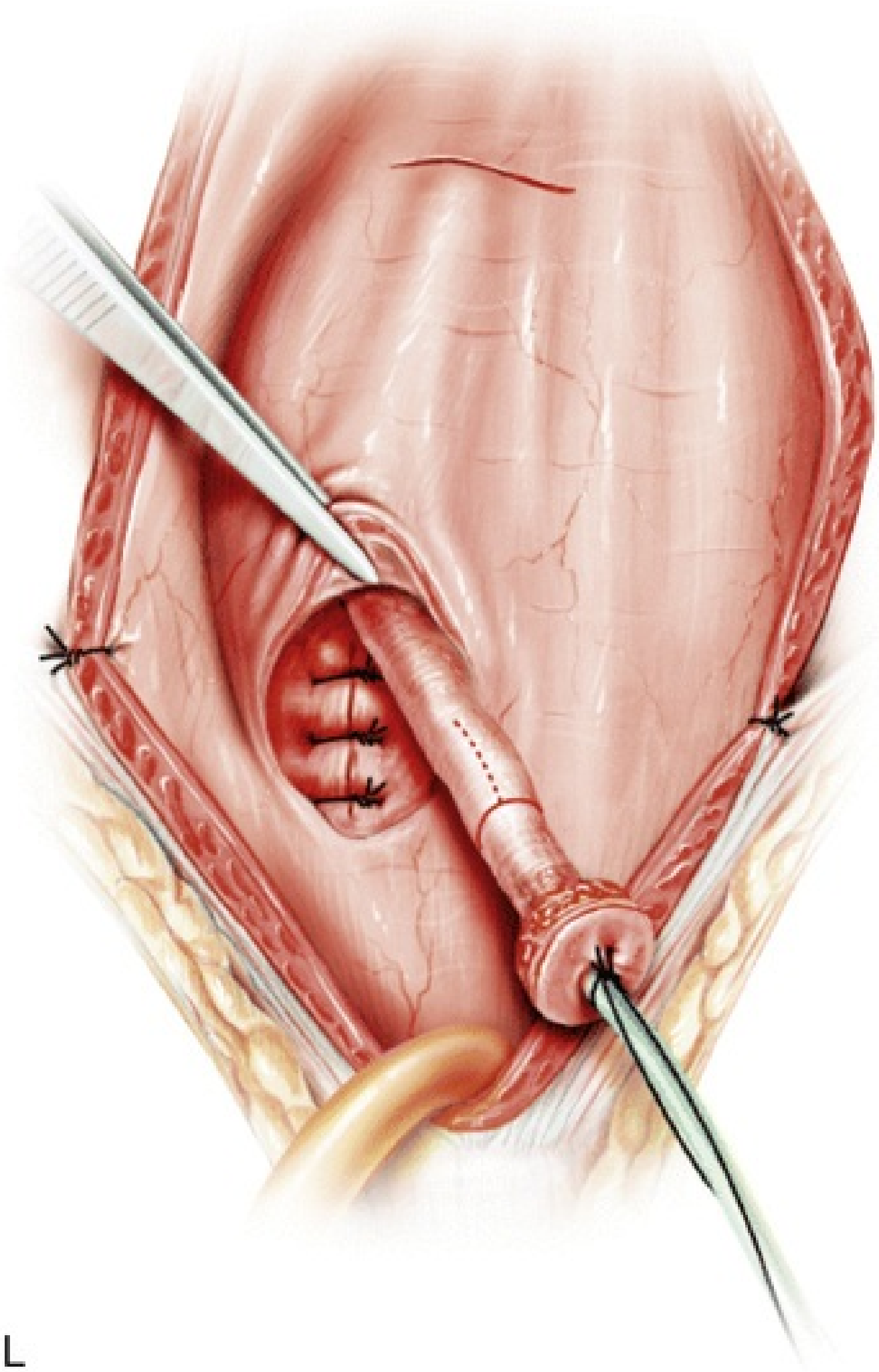

L

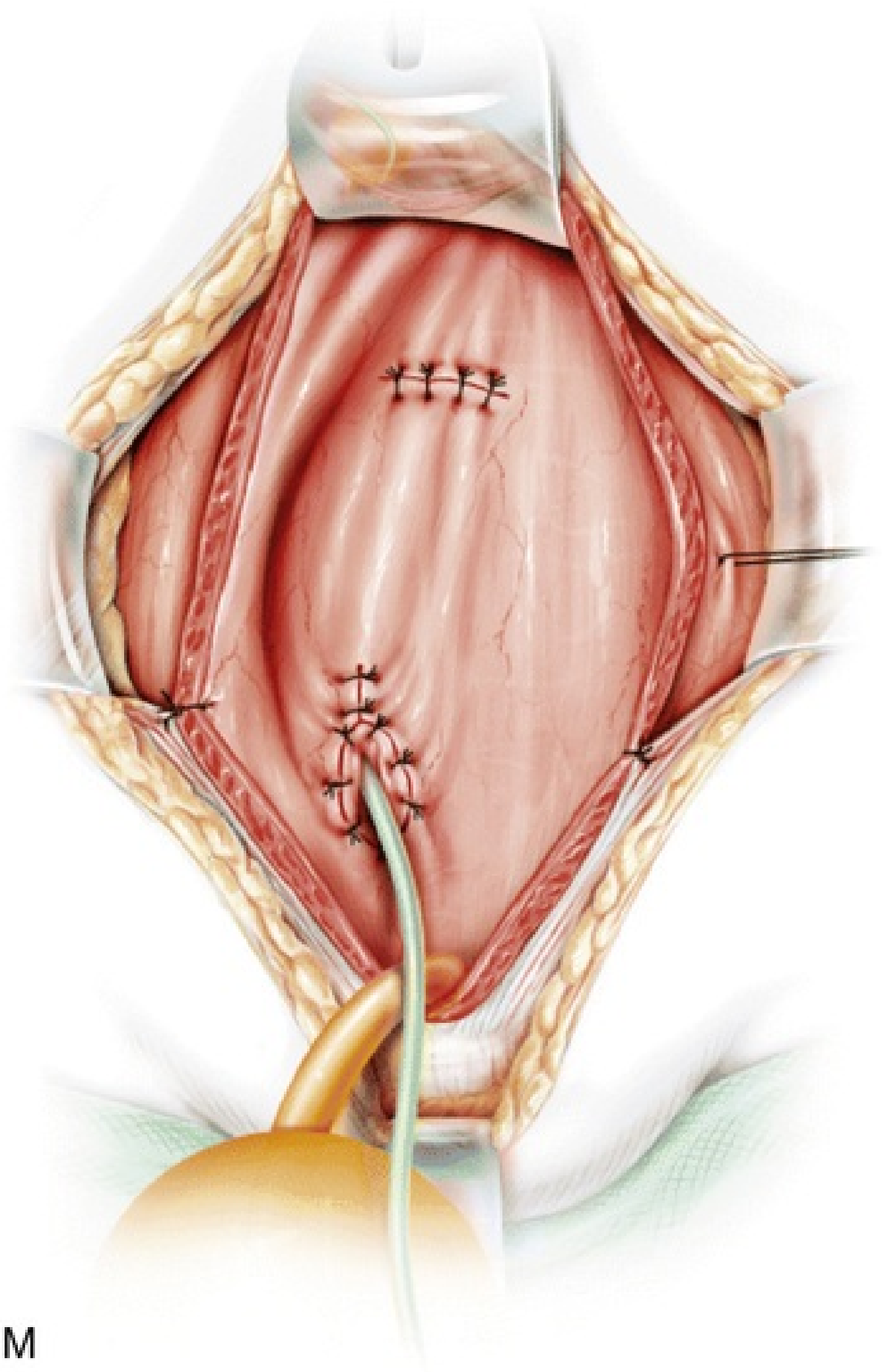

FIG. 42.18 Politano-Leadbetter reimplantation. The bladder is approached extraperitoneally (A) through a Pfannenstiel incision and opened vertically (B) between stay sutures. The refluxing ureteral orifice (C) is identified and cannulated with a 5-Fr baby feeding tube, which is fixed to the ureter with a stay suture that allows handling and traction. The ureter is now mobilized into the bladder (D) by dividing intravesical and extravesical attachments using tenotomy scissors and bipolar diathermy. The superior lip of the original hiatus is retracted with a Langenbeck (E) to sweep off peritoneal attachments and structures from the posterior aspect of the bladder, under direct vision in a superiomedial direction toward the planned neo-hiatus. A right-angled clamp can then be advanced toward the neo-hiatus, incised upon, and dilated appropriately, and a suture is passed from the new to the original hiatus extravesically (F and G). Using the suture as a guide trail, the ureter is now guided out of the bladder and pulled in through the neo-hiatus (H and I). A submucosal tunnel of adequate width is created from the neo-hiatus to the original hiatus, which is closed using 4-0 monofilament absorbable sutures, and the ureter is pulled through the tunnel and shortened appropriately. The ureter is hitched to the detrusor with a 5-0 monofilament absorbable suture at the 6 o'clock

position, and the mucosa is adapted circumferentially to the bladder mucosa in the new position with 6-0 interrupted monofilament absorbable sutures. The mucosal defect at the neo-hiatus is closed with 5-0 absorbable monofilament sutures (J to M).

Intravesical Procedures

When the bladder is identified, the peritoneum is gently swept off the dome. The bladder is opened vertically in the midline between stay sutures, the incision extends to within 2 cm of the bladder neck, and enough of the bladder dome convexity is left, as this allows for packing the bladder dome with saline-soaked surgical gauze, which aids in retraction and presentation of the trigone area (see Fig. 42.18B). The surgical incision is best kept open by using a Denis Brown ring retractor with the blades placed so they retract the bellies of the rectus abdominis muscles laterally on both sides and an additional blade placed cranially within the bladder exerting gentle countertraction on the gauze-packed bladder dome. The lateral bladder walls are retracted laterally by the pull of stay sutures, thereby minimizing trauma incurred by retractor blades directly applied to the friable mucosal lining of the bladder. The ureteric orifice is now cannulated with an appropriately sized baby feeding tube, usually a 5-Fr catheter, which, in turn, is secured to the ureter at its mucosal lip in the bladder with a 5-0 monofilament absorbable suture. The stay suture acts as a handle for traction and aids in dissecting and mobilizing the ureter (see Fig. 42.18C). A circumscribing incision is then made 1 to 2 mm from the orifice using fine-needle–point cautery on low wattage. By applying gentle traction on the stay suture, the ureter can then be mobilized into the bladder by dividing its intravesical and extravesical attachments with tenotomy scissors and bipolar diathermy. **Care must be taken to preserve the blood supply of the distal ureter by confining dissection to the right plane circumferentially**. A narrow retractor (e.g., Langenbeck) can then be introduced at the 12 o'clock position to expose the peritoneal reflection attached to the ureter, which can be gently swept off using a pledget. At this point, the ureter is released and can be mobilized fully into the bladder and will reach the contralateral bladder wall without tension. Depending on the surgeon's preference, experience, and patient in question, the choice of submucosal tunnel is now decided on (see Fig. 42.18D–E).

Politano-Leadbetter Technique

Originally described by Politano and Leadbetter in 1958, this suprahiatal procedure aims at creating a vertical submucosal tunnel from a new hiatus created superiomedial in a straight line down to the native hiatus (Politano and Leadbetter, 1958). The technique is useful in cases of high-grade VUR in which a long submucosal tunnel is needed.

Once the ureter is mobilized within the bladder, an appropriate site for the new hiatus superiomedially is identified and a blunt right-angled clamp is carefully passed through the original hiatus. The clamp is probed toward the new planned hiatus while taking care to sweep off the peritoneal attachments from the posterior aspect of the bladder. Once the clamp is in position and can be felt digitally from inside the bladder, the clamp's right angle is pushed inward opened slightly and incised upon, thereby creating the new hiatus that now can be widened appropriately. **In this step, care must be taken not to injure the bowel, vas deferens, or vagina. The inexperienced surgeon is therefore advised to retract the superior lip of the original hiatus to sweep off the structures under direct vision**. A 3-0 suture can then be passed from the new to the original hiatus extravesically; this will act as a guide rail for the ureter that can then be guided out of the bladder and pulled back in through the new hiatus using the guide suture. The detrusor defect at the original hiatus is closed using 4-0 monofilament absorbable sutures, and a submucosal tunnel is created from the new location to the location of the original hiatus, which is capacious enough to accommodate the ureter without causing constriction. The ureter is then pulled through, shortened adequately to the length of the tunnel, and may be spatulated. The ureter is hitched to the detrusor with a 5-0 monofilament absorbable suture at the 6 o'clock position, and the mucosa is adapted circumferentially to the bladder mucosa in the new position with 6-0 interrupted monofilament absorbable sutures. The mucosal defect at the neo-hiatus is closed with 5-0 monofilament absorbable sutures, and the bladder wall is then closed in one layer using 4-0 monofilament absorbable sutures and decompressed with a Foley catheter for 1 to 3 days. Bladder closure in two layers allows for shorter catheter drainage times. Ureteral stents are only left in complex cases (see Fig. 42.18F–M).

Glenn-Anderson Technique

This technique was described by Glenn and Anderson in 1967 (Glenn and Anderson, 1967). The ureter is mobilized intravesically as mentioned earlier, but the submucosal tunnel is created infrahiatally in the direction of the bladder neck (Fig. 42.19). **A clear advantage over the Politano-Leadbetter operation is the fact that the course of the reimplanted ureter is less liable to angulation and kinking,** whereby obstruction is avoided. The length of the tunnel is however limited by the distance to the bladder neck. As with the other procedures, the outcomes of this technique have been excellent, with reported success rates of up to 98% (Gonzales et al., 1972).

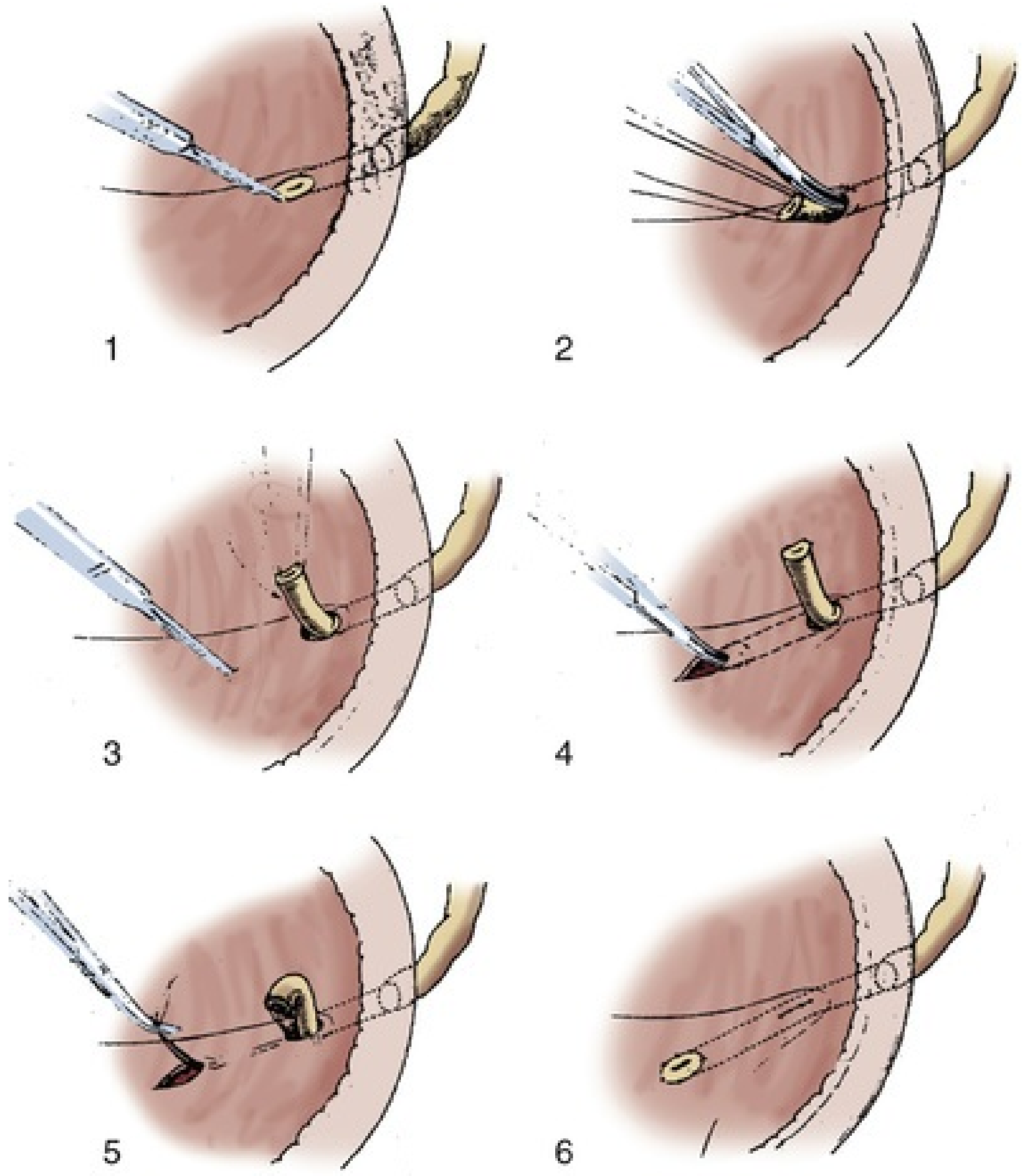

FIG. 42.19 Glenn-Anderson Reimplantation; The ureter is mobilized and advanced beneath a new submucosal tunnel.

Cohen Cross-Trigonal Technique

Cohen's procedure allows for a longer tunnel length by directing it toward the opposite ureteric orifice across the trigone/transhiatally. The technique was originally described in 1977 and has become the most common intravesical procedure because of its versatility, simplicity, and reliable results, with success rates upward of 98% (Cohen, 1977; McCool and Joseph, 1995; El-Ghoneimi et al., 1999; Androulakakis et al., 2003). The technique is especially suited for thick-walled trabeculated bladders as the trigone is typically spared from distortion, and when concomitant bladder neck reconstruction is planned as the transverse tunneling of ureters allows for an increased length, for bladder neck reconstruction. One major critique of the procedure relates to future difficult endourologic retrograde catheterization of the ureters for radiographic studies, stent placement, and management of urolithiasis. This shortcoming can be overcome by negotiating the reimplanted ureteric orifice with a modern flexible ureteroscope or combining cystoscopy with suprapubic cystostomy by trocar or an intravenous cannula directed toward the ureteric orifice, through which a guidewire is introduced under cystoscopic vision (Wallis et al., 2003; De Castro et al., 2011; Emiliani et al., 2017).

After intravesical mobilization of the ureter, a submucosal tunnel is developed using tenotomy scissors in the direction of the opposite ureteric orifice. When only one ureter is reimplanted, the tunnel is directed superior to the contralateral orifice. If bilateral reimplantation is contemplated, the tunnel for the more laterally displaced ureter is directed superior to the contralateral orifice. The second ureter is directed toward the inferior edge of the orifice of the laterally displaced ureter. Reimplantation in a common tunnel has also been described with excellent outcomes (Androulakakis et al., 2003). After pulling the ureter through the new tunnel, it is hitched in place as mentioned earlier (Fig. 42.20).

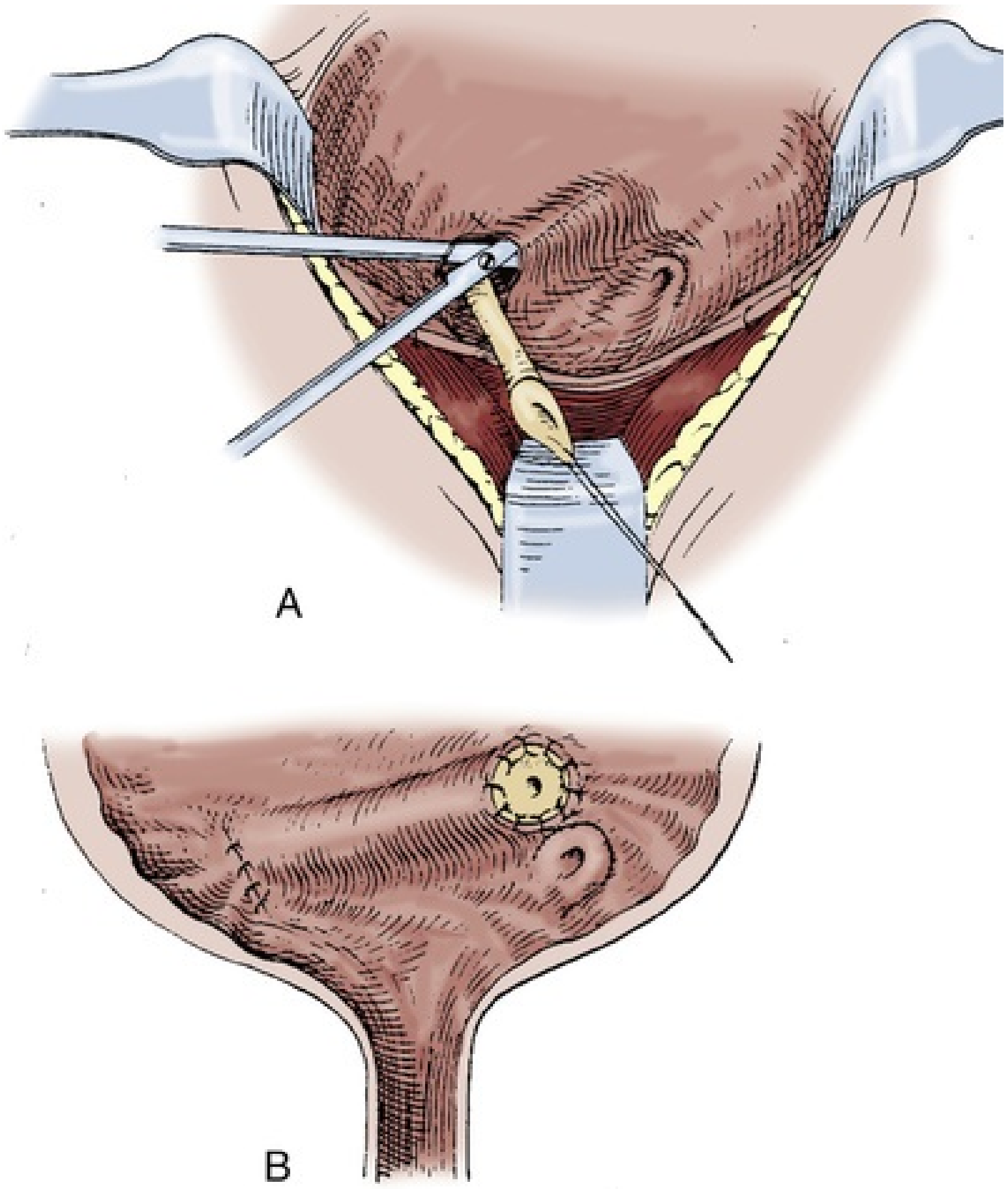
A
B

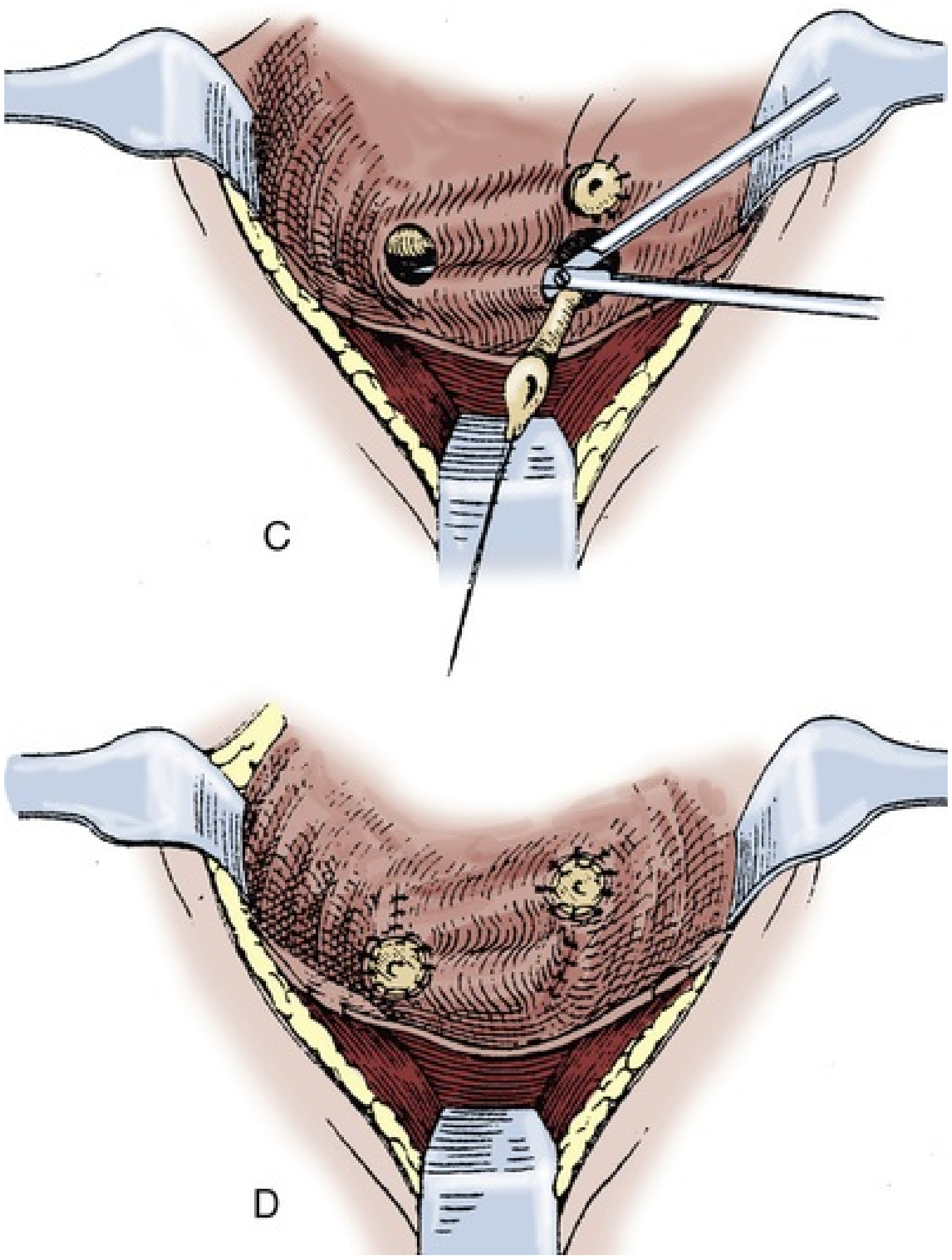

FIG. 42.20 Cohen cross-trigonal unilateral reimplantation technique. After the ureter is freed (A), a submucosal tunnel is made, with the new mucosal hiatus just above the contralateral ureteral orifice (B). Bilateral reimplant. (C) The more superior ureter is tunneled transversely, with its new orifice just above the contralateral orifice. (D) The other ureter is tunneled inferiorly, with its new orifice located at the inferior-most portion of the contralateral hiatus.

Extravesical Procedures

In the 1960s, Lich and Gregoir independently described an extravesical approach for ureteric reimplantation, which has since eponymously borne their names and become a widespread and popular procedure (Lich et al., 1961; Gregoir, 1964). Several consequent modifications have been introduced helping to popularize the method (Daines and Hodgson, 1971; Zaontz et al., 1987), although ensuing neuroanatomic studies by Leissner et al. and Yucel and Baskin have swung the pendulum back to the original description (Leissner et al., 2001; Yucel and Baskin, 2003). **In this extravesical procedure, the bladder is not opened, thus avoiding problems of postoperative hematuria and bladder spasms**. The detrusor along the course of the ureter is incised down to the urothelium, which is left intact, and the ureter is placed and secured in the detrusorotomy, thereby creating an antireflux tunnel. Concerns with this procedure relate to development of postoperative, usually transient, bladder dysfunction and voiding difficulty in up to 20% necessitating catheterization, especially after bilateral procedures (Fung et al., 1995; Lipski et al., 1998; Barrieras et al., 1999; Marotte and Smith, 2001). This has been related to injury of the neural innervation of the detrusor and trigone occurring during dissection of the ureter and subsequent detrusorotomy. To overcome this, elegant studies by Leissner and Yucel delineating the neuroanatomic topography of the UVJ have enabled better understanding of the surgical anatomy of this very intricate region and allowed for modifications that have lessened the incidence of postoperative voiding dysfunction (David et al., 2004; Palmer, 2009). **In Leissner's cadaveric study, it was shown that the main portion of the pelvic plexus is located approximately 1.5 to 2 cm dorsal and medial to the UVJ in adult specimens**. Smaller nerve branches travel along the medial aspect of the ureter outside the thin layer of tissue (mesoureter), which surrounds the ureter. Therefore according to the findings of this study, neural injury can be minimized by staying close to the ureter when dissecting and by avoiding the area dorsomedial to the UVJ (Leissner et al., 2001). These findings were further supported by fetal autopsy studies conducted by Yucel and Baskin using immunohistochemical staining and three-dimensional imaging, **which confirmed the localization of the nerves on the medial border of the ureter just outside the Waldeyer sheath and showed them to extend circumferentially around the ureter and beyond its entry point in the bladder distal and lateral to the UVJ along the detrusor** (Yucel and Baskin, 2003).

The procedure itself can be performed through a standard Pfannenstiel incision or through and inguinal incision for the unilateral cases (Howe and Palmer, 2017). The bladder, which should be filled to about one-third of its volume, is cleared of its peritoneal attachments. The obliterated umbilical artery is identified and divided, thereby facilitating the dissection and mobilization of the distal ureter. The peritoneum is teased off the anterior surface of the ureter, with the dissection staying close to the ureter to avoid injuring the nerves but also minding the ureter's blood supply. A vessel loop can then be passed behind the ureter and used as a handle for gentle traction. The ureter can then be mobilized to the level of the UVJ, where dissection should stop to avoid injuring the small nerves that circumscribe the ureter and branch out to the detrusor lateral and distal to the UVJ. Once the ureter is mobilized, and with the moderately distended bladder in its normal anatomic position, the planned 5-cm tunnel is identified along the natural course of the ureter and marked with a surgical pen. The bladder can then be retracted medially to facilitate dissection. The detrusor is incised with monopolar diathermy at low wattage. As the incision is carried deeper, the assistant can pick up individual detrusor fibers with forceps to be divided by the surgeon. This will result in the formation of a uniform mucosal bulge through the detrusorotomy. The detrusor can then be separated from the mucosa on both sides by gentle blunt dissection with a pledget, to create detrusor flaps that can accommodate the ureter without causing constriction. In Zaontz's modification of the original Lich-Gregoir procedure, the detrusorotomy is continued around the UVJ to allow for placement of advancement sutures from the ureter into the trigone (Zaontz et al., 1987). This step may have been responsible for some of the voiding dysfunction reported in the era where this modification was popularized as this dissection encroaches on vital neural innervation of the detrusor and is generally now avoided as is the case when the procedure is done laparoscopically. It can be helpful to place a stay suture at the cranial apex of the incision to maintain traction and to control tunnel length. Once complete, the tunnel can then accommodate the ureter, and the detrusor can be reapproximated using interrupted 4-0 monofilament absorbable sutures in a caudocranial direction, remembering to incorporate the ureteral adventitia in several of these sutures, especially at the apex, so as to stabilize tunnel length and to prevent prolapse or slippage of the ureter (Fig. 42.21). Postoperatively, the bladder is drained by a Foley catheter for 24 to 48 hours, and the child can be discharged as soon as spontaneous voiding has commenced.

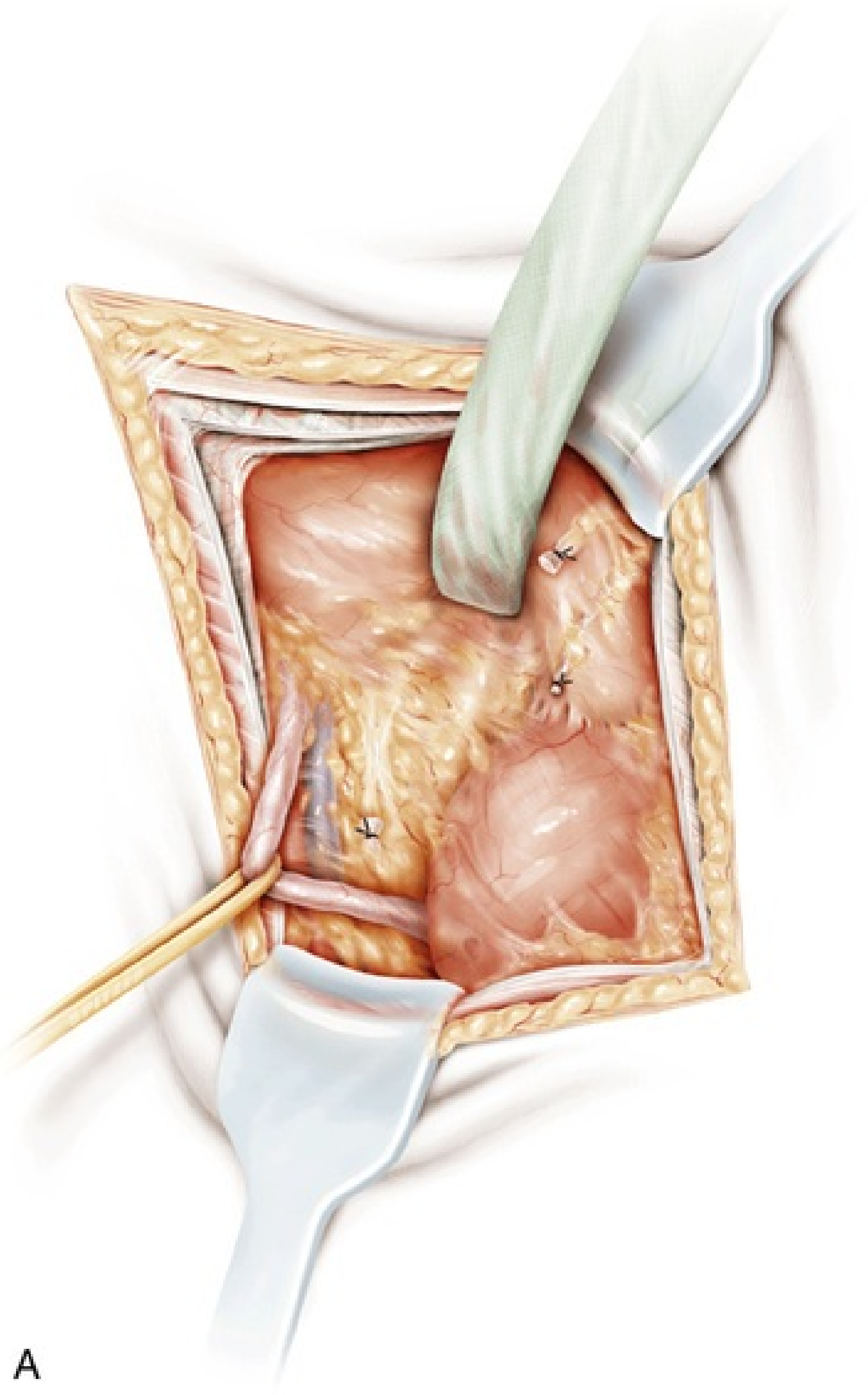
A

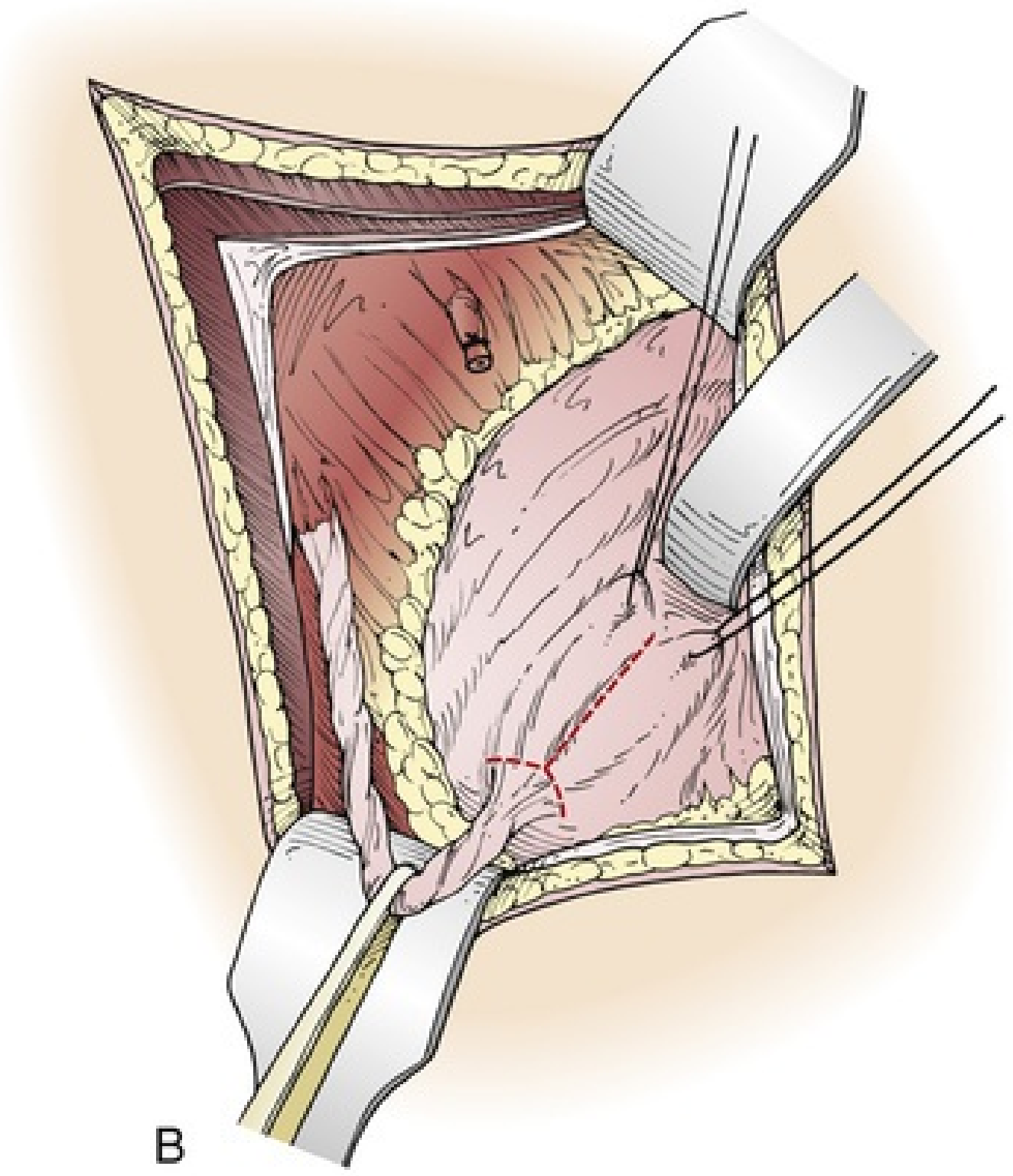
B

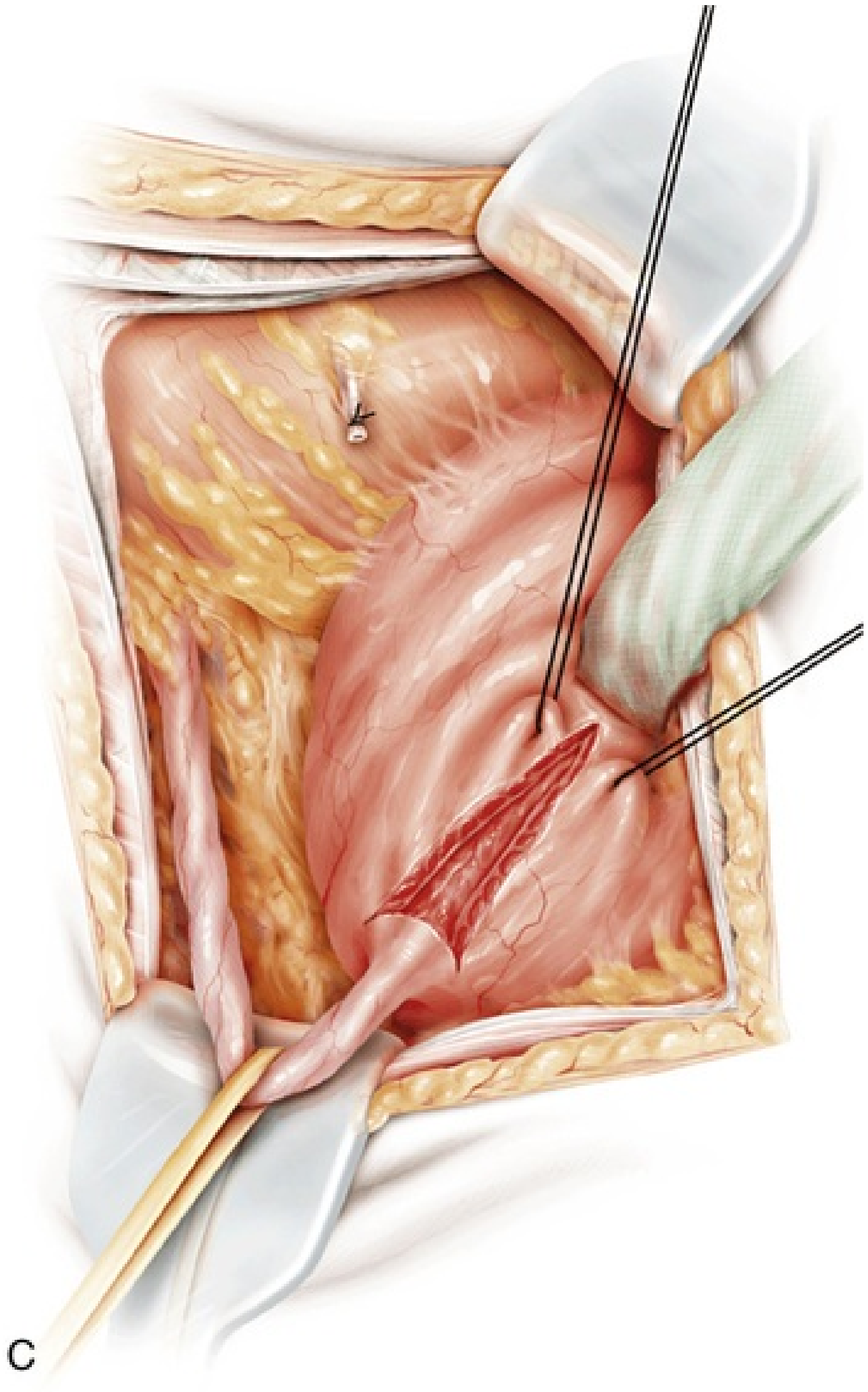

C

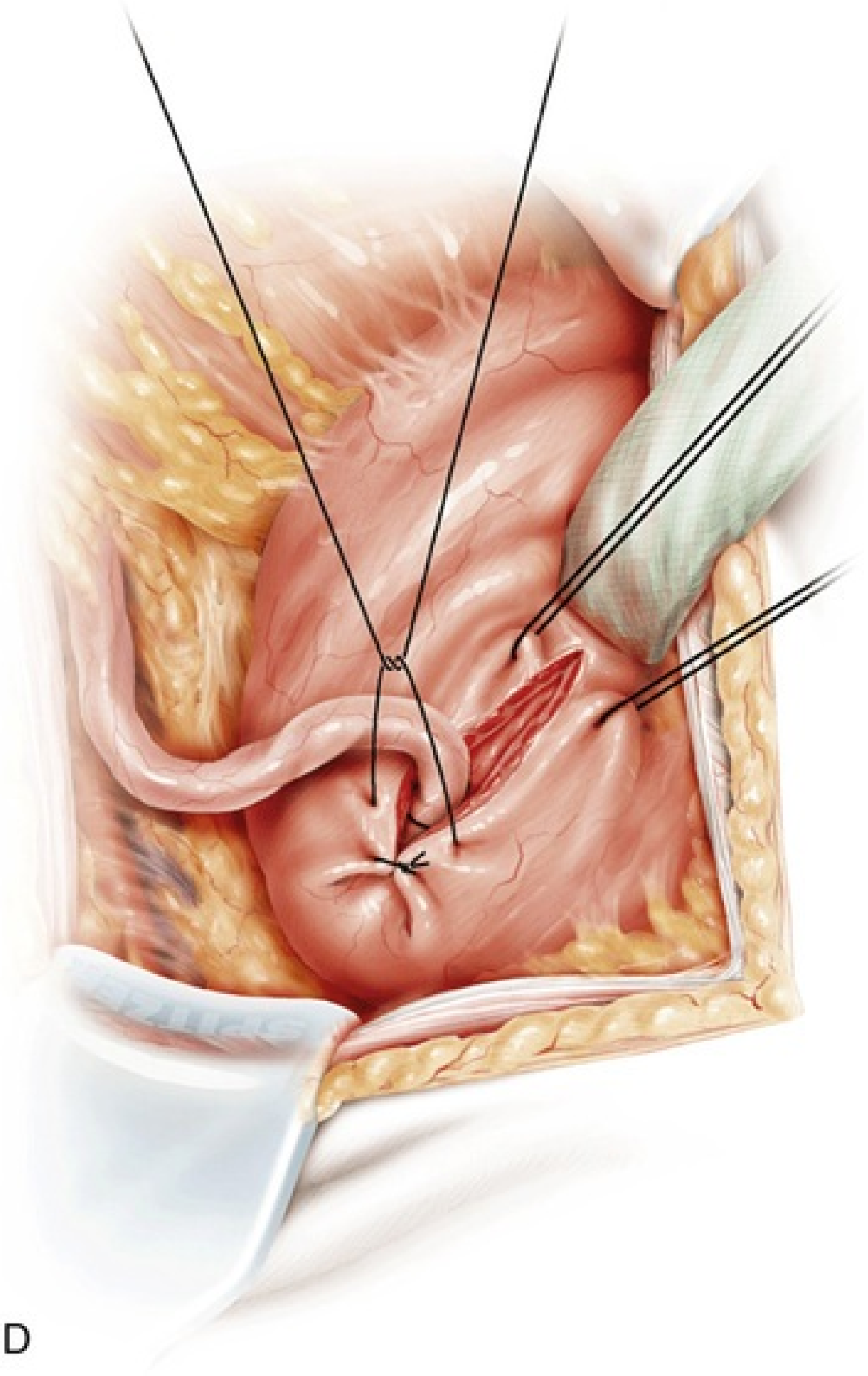

D

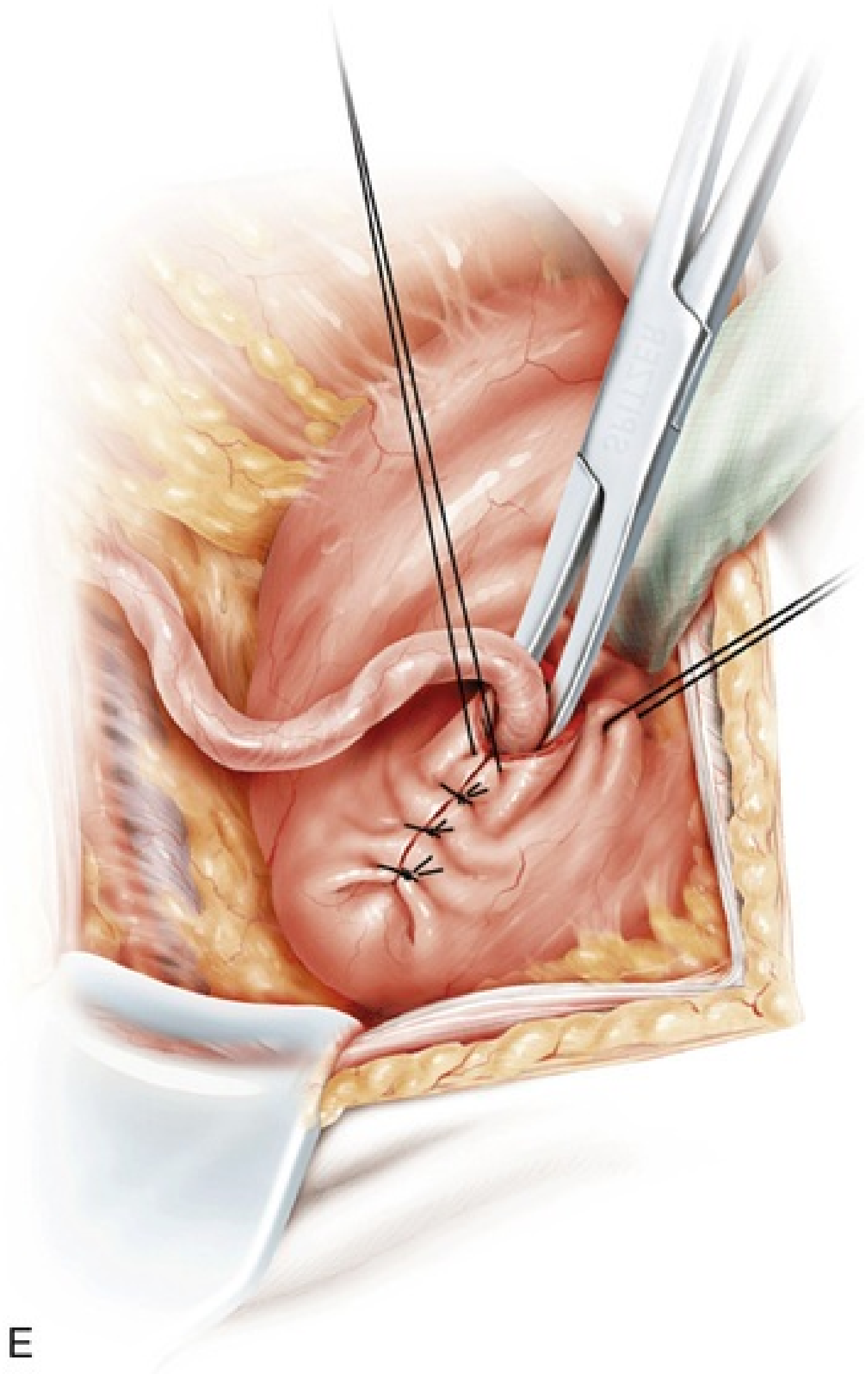

FIG. 42.21 Lich-Gregoir technique. After the obliterated umbilical vessels are divided and tied off, the ureter is identified and the peritoneum is teased off its anterior surface. A vessel loop can then be passed behind the ureter and used as a handle for gentle traction (A). Along the course of the ureter, the planned tunnel of 5 cm can be marked on the detrusor (B). The bladder can then be retracted medially to facilitate dissection of the detrusor along the marked line down to the urothelium, allowing detrusor flaps to be raised (C). The ureter is now placed in the detrusorotomy, and the flaps are closed over it incorporating ureteral adventitia in several of the stiches (C to E). A stay suture at the apex of the detrusorotomy maintains orientation and detrusor tunnel length.

Minimally Invasive Procedures

Since the initial reports by Ehrlich and Janetschek in the mid-1990s, which showed the feasibility of applying the then-emerging concept and technology of laparoscopic surgery for successful extravesical reimplantation of refluxing ureters, an almost exponential interest and rise in minimally invasive procedures has been evident (Ehrlich et al., 1994; Janetschek et al., 1995). However, because of its long learning curve and the cumbersomeness of especially intracorporeal suturing, laparoscopic antireflux surgery never saw widespread adoption, with percentages never exceeding 20% of all minimally invasive procedures performed in the United States, which generally only represented a mere 6.3% of all ureteral reimplants in 2012 (Bowen et al., 2016). **Initial reports seemed however to indicate benefits associated with minimally invasive procedures such as decreased pain, hematuria, and bladder spasms in addition to shorter length of hospital stay** (Lakshmanan and Fung, 2000; Gill et al., 2001; Yeung et al., 2005; Canon et al., 2007b). This spurred on the adoption of robotic-assisted laparoscopic techniques with the advent of the da Vinci Surgical System (Intuitive Surgical, Mountain View, CA). After a porcine study by Olsen et al. showed the feasibility of robotic-assisted intravesical cross-trigonal ureteral reimplantation, Peters and Woo used the robotic system for performing bilateral intravesical Cohen ureteral reimplantation in six children (Olsen et al., 2003; Peters and Woo, 2005). This was soon followed by reports of successful robotic-assisted laparoscopic extravesical reimplantations (Casale et al., 2008; Marchini et al., 2011; Smith et al., 2011; Bayne et al., 2012; Kasturi et al., 2012; Schomburg et al., 2014).

Even though both laparoscopic and robotic-assisted ureteral antireflux surgery apply the same surgical principles as those of open surgery, albeit using minimal access, early reports failed to reproduce the high success rates reported by classical open surgeons of 95.9% shown in a review of 86 studies reporting on 6472 patients (8563 ureters) (Elder et al., 1997). Reflux resolution rates of 83% to 92% were not uncommon, and outcomes were marred by “high” complication rates that were unusual after open procedures such as ureteral injury, obstruction, and urinary leakage especially after the intravesical vesicoscopic procedures (Peters and Woo, 2005; Kutikov et al., 2006b; Canon et al., 2007a; Kurtz et al., 2016). More recent multi-institutional reviews have also documented success rates that continue to fall short of the gold standard approach of open reconstruction and higher complication rates (Grimsby et al., 2015; Boysen et al., 2017). It can however be argued that laparoscopic and robotic-assisted laparoscopic procedures have been subject to more rigorous postoperative radiographic follow-up for documentation of reflux resolution than what historically has been the case for open procedures and that the trend with increasing experience has been that of success and complication rates slowly but surely approaching those of open reconstruction. With laparoscopic ureteral reimplantation procedures confined to few centers, robotic-assisted ureteral reimplants appear to have overtaken the field, and their adoption, though still limited, seems to be increasing steadily in number as has been evident within the past two decades (Bowen et al., 2016). Due to inherent problems with creating and maintaining pneumovesicum, in addition to the very confined working space for the articulating instruments of the robot inside the bladder, extravesical methods are gaining momentum with ever-increasing cohort size reports and improving results (Smith et al., 2011; Akhavan et al., 2014; Schomburg et al., 2014; Gundeti et al., 2016; Boysen et al., 2018).

Robotic-Assisted Laparoscopic Ureteral Reimplantation–Extravesical (RALUR-EV)

The patient is placed in the low lithotomy position, all pressure points are padded, and the skin is prepped and draped from the xiphoid to the perineum. A bladder catheter is inserted in the sterile field, for urine drainage and filling of the bladder. A 12-mm camera port trocar is placed intraperitoneally through the lower umbilical fold by Hasson's open technique. Under direct vision, two 8-mm robotic trocar ports are placed in the midclavicular line just below the level of the umbilicus. Use of an extra 5-mm assistance port is adantageous for delivering sutures and suction. The robot is docked between the legs, with bipolar diathermy used on the left and monopolar scissors on the right when the surgeon is right handed. The ureter is identified at the pelvic brim and mobilized down to the UVJ taking care not to injure the vas deferens, which is easily identified. Dissection is kept close to the ureter to avoid the neurovascular bundle dorsomedially. A stay stitch in the bladder for traction may be placed to enhance visualization. Saline is instilled to partially fill the bladder to facilitate detrusorotomy. A 4- to 5-cm *Y*-shaped detrusorotomy in line with the course of the ureter is created, and detrusor flaps are raised to allow enough space for accommodation of the ureter without constriction. The ureter is placed within the tunnel, and the flaps are closed using a running 4-0 absorbable monofilament suture in a caudocranial direction. Again, as in the classical open Lich-Gregoir procedure, the ureteral adventitia is incorporated in several of these sutures, especially at the apex, to stabilize tunnel length and to prevent prolapse or slippage of the ureter (Fig. 42.22).

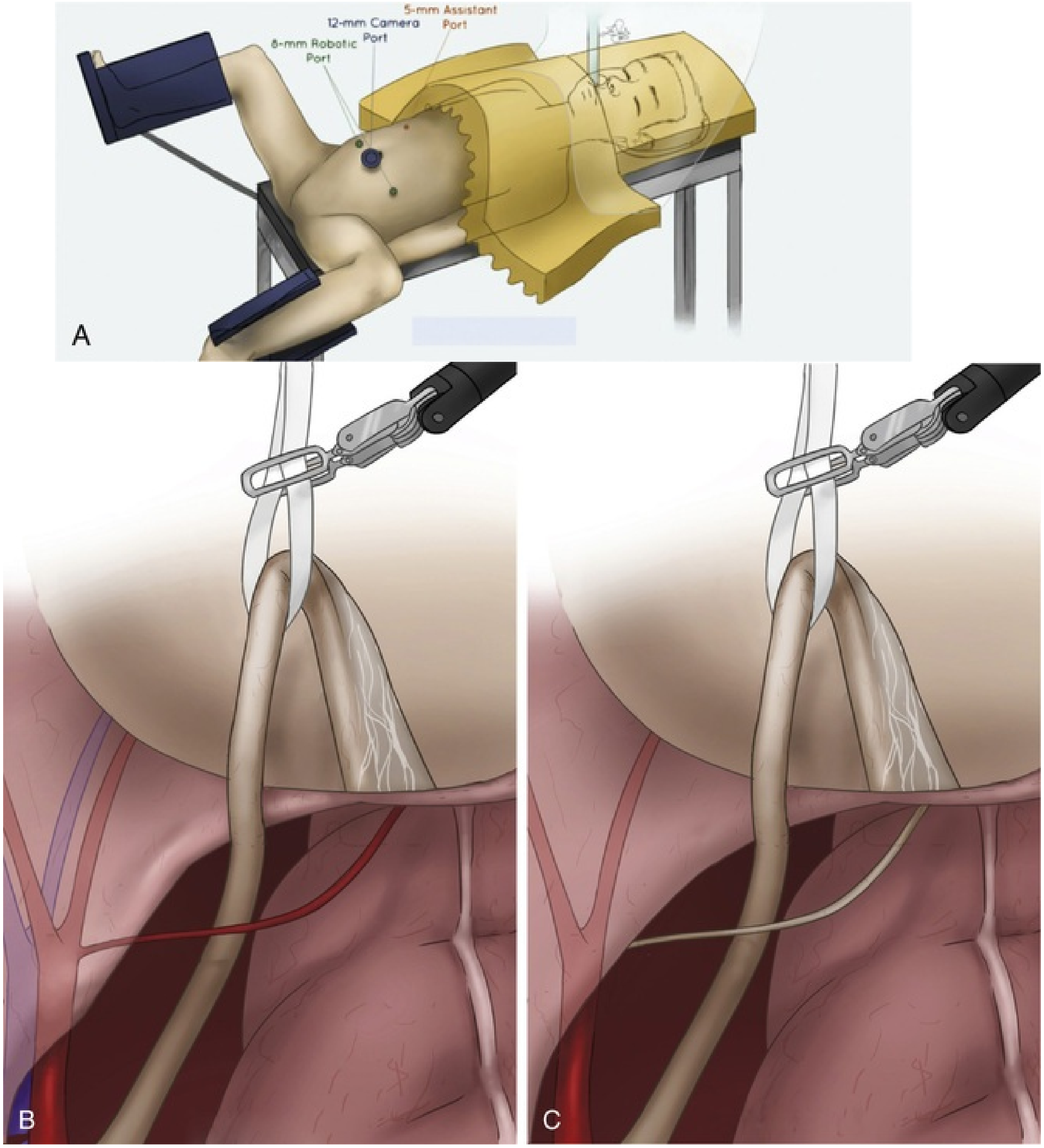
5-mm Assistant Port
12-mm Camera Port
8-mm Robotic Port
A
B
C

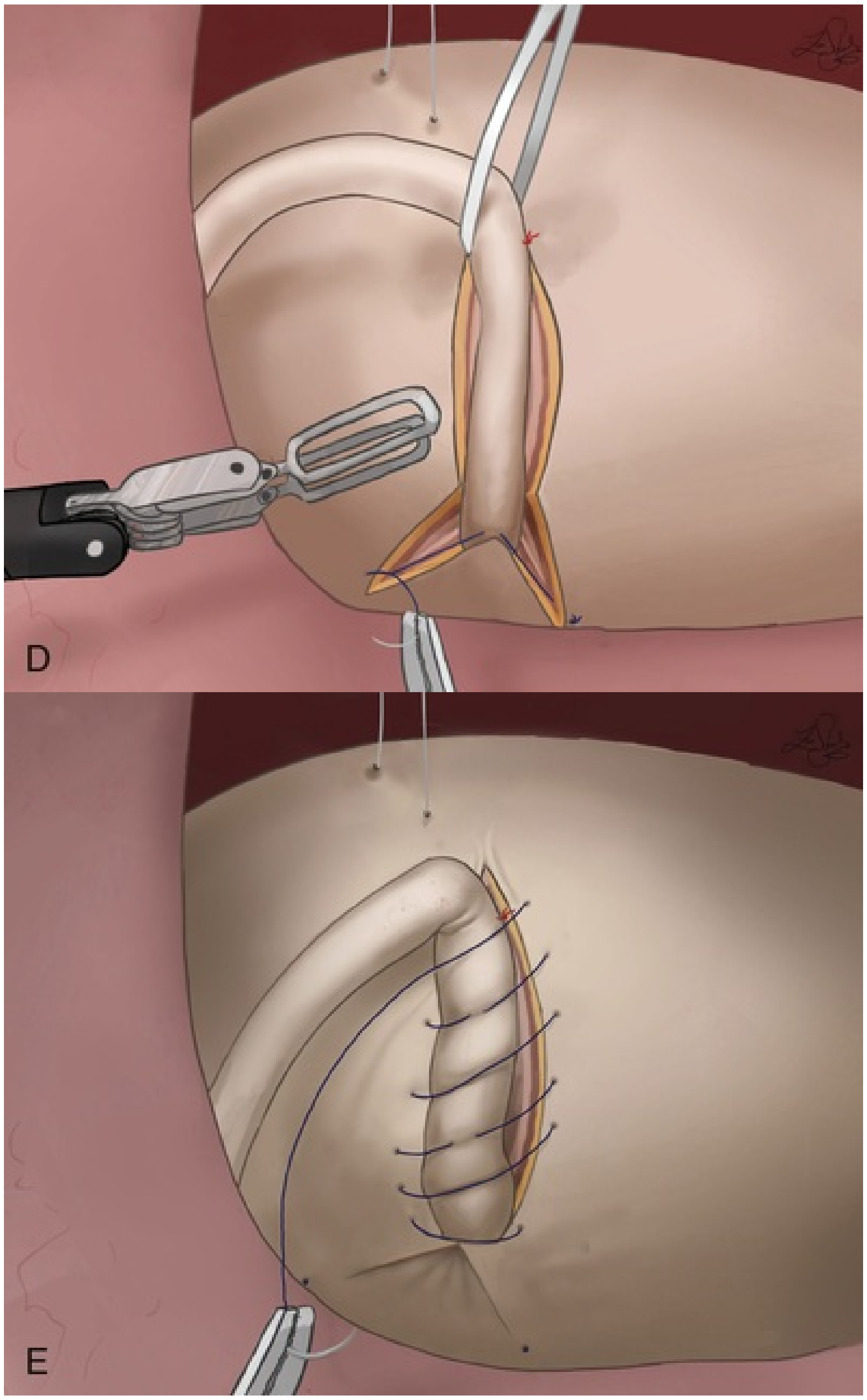

FIG. 42.22 Robotic Assisted Laparoscopic Ureteral Reimplantation–Extravesical (RALUR-EV) technique. The patient is positioned, prepped, and draped in the low lithotomy position, with port placement as in (A). The ureter is identified at the pelvic brim, and an umbilical tape is passed to allow atraumatic handling taking care not to injure the uterine artery (B) or the vas deferens (C). As in the open technique, a *Y*-shaped detrusorotomy along the natural course of the ureter is created about 5 cm long. (D, E) The ureter is then embedded into the tunnel, which is closed with a running 4-0 resorbable suture in a caudocranial direction, again incorporating ureteral adventitia into the running stich. A stay suture at the apex of the detrusorotomy maintains orientation and detrusor tunnel length. (A, from Gundeti MS, Boysen WR, Shah A. Robot-assisted laparoscopic extravesical ureteral reimplantation: technique modifications contribute to optimized outcomes. *Eur Urol* 2016;70(5):818-823.)

Postoperative Evaluation

In expert hands, the success rate for ureteroneocystostomy in patients with low-grade primary VUR approaches 100%. As a result of these outstanding outcomes, several centers have evaluated the need for postoperative invasive imaging. Most agree that a sonogram is necessary at 6 to 12 weeks postoperatively, as also indicated in the most recent AUA Guidelines on Vesicoureteral Reflux (Peters et al., 2010). In a large study by Barrieras et al., 723 renal units were evaluated (Barrieras et al., 2000). At 1 year postoperatively, there was a significant difference between children who had undergone surgery for low-grade primary VUR (99% resolution) versus those with high-grade reflux (94%). Thus, in patients who initially had low-grade primary reflux and in whom the preoperative and postoperative ultrasound examinations were normal and do not have voiding dysfunction or recurrent UTIs (Lavine et al., 2001), the success rate with uncomplicated ureteroneocystostomy approaches 100% (El-Ghoneimi et al., 1999; Barrieras et al., 2000; Grossklaus et al., 2001; Canning, 2002). On the basis of these reports, it has been suggested that the postoperative voiding cystourethrogram (VCUG) can be avoided in this group of patients. It may, however, be reasonable to perform postoperative studies in children with a dysfunctional bladder or in those who develop postoperative hydronephrosis or UTIs. The lower success rate for high-grade reflux would still support complete postoperative studies in most cases.

Complications of Ureteral Reimplantation

Early Complications

Persistent Reflux.

Early reflux after ureteroneocystostomy usually is not a significant clinical problem and commonly resolves by 1 year on repeat cystography. In the report by Barrieras et al., 49 of 723 renal units had reflux at 3 months, 11 of which were contralateral (Barrieras et al., 2000). At 12 months follow-up, reflux resolved spontaneously in 20 of the 38 ipsilateral ureters and in 8 of the 11 contralateral ureters. Persistent reflux at 1 year was more common in patients who had high-grade reflux preoperatively. In their study, 30% of patients undergoing surgery had high-grade reflux. Two-thirds of those with persistent reflux at 1 year (12 of 18) were from that group. **Thus the majority of low-grade postoperative reflux detected by the initial VCUG at the 3-month follow-up point disappeared spontaneously**, likely because of the resolution of the bladder inflammation and improvement in bladder dysfunction that may be present in the early postoperative period.

Contralateral Reflux.

A small percentage of patients undergoing unilateral ureteral reimplantation have been known to develop postoperative contralateral reflux. Given that bilateral reimplantation is highly successful, it can be argued that all patients with VUR should undergo a bilateral procedure regardless of the laterality or bilaterality of the condition. Studies specifically looking at this subgroup of patients have documented a high-resolution rate of contralateral VUR, thereby contradicting the need for such an aggressive stance. **In a study by Hubert et al. detailing the results of 395 patients, contralateral VUR was documented in 9.9%, of which 77.8% resolved spontaneously at a median of 21.5 months** (Hubert et al., 2014). Similarly, Minevich et al. and Burno et al. found low rates of contralateral VUR in 5.6% and 11.6% in their respective cohorts with spontaneous resolution occurring in the overwhelming majority with observation alone (Minevich, et al. 1998; Burno et al., 1998). Contralateral VUR was found more likely in young patients (<6 years of age) and in those with low bladder capacity (<50% of expected) or reimplantation of a refluxing duplex system. There was also a tendency toward higher grades of corrected reflux being associated with contralateral VUR (Diamond et al., 1996; Hubert et al., 2014), however, no association was found with regard to the surgical procedure employed. The exact mechanisms underlying new-onset contralateral VUR remains speculative. It has been attributed to a distortion of the contralateral hemitrigone, the result of a pop-off mechanism, or that contralateral VUR in fact is synchronous (i.e., bilateral) but missed on the initial cystogram or that the natural history of unilateral or bilateral reflux may involve intermittent appearance and disappearance of VUR on one side (Sparr et al., 1998). Recommendations for management of contralateral VUR range from observation in the majority of cases to intervention for control of clinical pyelonephritis episodes. In asymptomatic children younger than 4 to 5 years of age, prophylactic antibiotics are warranted for postoperative contralateral reflux, particularly if one is to be consistent with the medical therapy for the previous ipsilateral reflux. If the child remains asymptomatic and infection free, repeat VCUGs may not be necessary because contralateral reflux resolves spontaneously in the majority of children.

Obstruction.

It is not unusual to detect a mild to moderate degree of hydronephrosis in the early postoperative period by ultrasonography. This should resolve spontaneously with time. Acute postoperative obstruction may be related to technical issues such as twisting or kinking of the ureter in its new tunnel, intramural blood clots, or extramural compression by submucosal hematoma or edema at the site of anastomosis. Progressive, significant obstruction usually becomes apparent in the first 2 weeks after surgery. The children typically present with symptoms of acute ureteral obstruction, including acute abdominal pain, nausea, and vomiting. Although infection is less common, if it occurs it is quite significant in the obstructed system. The diagnosis is readily made on ultrasonography, and the severe hydroureteronephrosis is confirmed by delayed function and excretion on renal scintigraphy. In the more significant cases, drainage of the system either by retrograde insertion of a double pigtail catheter or a percutaneous nephrostomy tube may be necessary. The nephrostomy tube should be internalized as early as possible to avoid a dry reimplant. Many of these cases resolve without requiring additional surgery.

Long-Term Complications

Obstruction.

Progressive dilation and obstruction of the reimplanted ureter can result from ischemia of the distal ureter, which can occur if dissection has been aggressive and carried too close to the ureter's delicate blood supply. Angulation of the ureter at its entry into the bladder can likewise cause obstruction especially if the neo-hiatus is positioned too laterally or anteriorly on the bladder wall. This will result in kinks that worsen as the bladder fills. This situation might resolve spontaneously; alternatively, it might need stenting or redo surgery. Other causes of obstruction include an underdeveloped submucosal tunnel, which may lead to constriction of the ureter within the tunnel, and stenosis of the neo-ureteral orifice. Management options include balloon dilation and stenting, or unroofing the distal few millimeters of the tunneled ureter to relieve the obstruction while maintaining the antireflux mechanism. If these interventions fail reimplantation is indicated.

Recurrent or Persistent Reflux.

Failure of antireflux procedures in primary low-grade reflux is extremely rare. Most failures are caused by either high-grade reflux or an inadequate ratio of tunnel length to ureteral diameter. Development of a short tunnel and failure to taper the excessively wide ureter are obvious important factors. Another significant cause of persistent or recurrent reflux is failure to recognize secondary reflux, especially associated with neurogenic bladders and posterior urethral valve bladders. **Reflux in these situations is secondary to the poor storage or emptying characteristics of the bladder. These issues need to be addressed and optimized before reimplant surgery is attempted** (Peters et al., 2010). In most situations, improving bladder storage and/or emptying with a combination of an anticholinergic agent and intermittent self-catheterization results in spontaneous resolution of secondary reflux (Agarwal et al., 1997). Proceeding with reimplantation surgery in the presence of an abnormal bladder results only in worsening of the ureteral dilation and deposition of scar tissue in the pelvis, which would render future attempts at correcting the reflux even more difficult.

Reoperative Reimplantation

Redo reimplantation is technically more challenging and requires careful attention to detail and meticulous surgical technique. Dissection of the ureter and extensive mobilization are required to achieve an adequate submucosal tunnel. Careful dissection of the ureter is best accomplished by a combination of extravesical and intravesical mobilization as needed. The ureter should be carefully evaluated and ischemic segments excised. Free bleeding from the divided distal end should be observed in addition to peristaltic activity, ensuring normal musculature and blood supply. It is preferable to create a new hiatus and submucosal tunnel. If the ureter is short, a psoas hitch can be used to facilitate the creation of the antireflux mechanism. The psoas hitch should be carried out with a nonabsorbable suture before creation of the submucosal tunnel. The bladder is fixed to the psoas muscle sheath on either side of the iliac vessels, providing a stable posterior bladder wall. In children, the bladder can be mobilized sufficiently to bring it up almost to the bifurcation of the common iliac vessels. This may provide adequate bridging for a distal ureteral defect. A psoas hitch can be achieved only on one side. Attempting a psoas hitch on both sides will not provide adequate length on either side and thus should be avoided. If both ureters are shortened, consider a psoas hitch on one side to achieve a satisfactory antireflux mechanism with a transureteroureterostomy for the other ureter.

Other techniques to consider for the short ureter include the Boari flap, in which a flap extending from the dome to the anterior wall of the bladder based on the posterior wall can be rotated proximally. The flap should be wide enough to allow creation of a submucosal tunnel and tubularization of this flap. In the short ureter, a nipple valve can be created in association with a short submucosal tunnel (Routh et al., 2009). The nipple valve is particularly useful in dilated ureters and is fashioned by spatulating the ureter and folding it back onto itself (Paquin, 1959).

In situations in which the ureter is significantly foreshortened, it can be replaced using a reconfigured segment of bowel as described by Pope and Koch (Pope and Koch, 1996). The colon or ileum is reconfigured similar to the Monti procedure. This technique offers important advantages over the classic tapered ileal ureter, allowing a long tube to be created from a short segment of colon without tapering, thus eliminating the metabolic consequences; additionally, the mesentery is in the center of the tube, which facilitates creation of the submucosal tunnel.

Endoscopic Treatment of Vesicoureteral Reflux

In 1981, the German urologist Matouscheck introduced the concept of endoscopic injection in the treatment of VUR (Matouschek, 1981). Using Teflon, his technique was popularized by O'Donnell and Puri, who coined the acronym STING (Subureteric Teflon Injection) to describe their procedure (O'Donnell and Puri, 1986). Teflon injection was used in many countries but never achieved FDA approval in the United States because of concerns regarding migration of PTFE particles. However, the simplicity of the endoscopic procedure together with high success rates in resolving VUR invigorated the search for and development of safer materials. Currently, Dextranomer/hyaluronic acid (Dx/HA) (Deflux™) is the most commonly used material, with initial resolution rates of 90% for the treatment of low-grade primary VUR after a single treatment (Kirsch et al., 2004). Subsequent results have been less consistent, probably because of variations in technique and the definition of successful outcome.

Technique of Endoscopic Injection

Läckgren and Kirsch have meticulously described both the traditional STING technique and the hydrodistension implantation technique (HIT) including the double HIT (Brandstrom et al., 2010). O'Donnell and Puri originally described the classic STING technique (O'Donnell and Puri, 1984). Prophylactic antibiotics are usually administered with induction of anesthesia. A cystoscopy should be carried out before unpacking the injectable materials in case the procedure cannot be performed because of inflammatory changes in the bladder. If a rigid needle is used, an offset lens injection scope is the appropriate choice. A flexible needle can however easily be inserted through a standard 0- or 30-degree lens cystoscope. The size of the needle varies depending on the viscosity of the material and ranges from 3.7 to 5 Fr. The viscosity of the material also determines whether injecting the material can be carried out using a regular syringe or if it requires a ratcheted metal syringe holder. A 3-Fr ureteral catheter may be introduced to lift up the anterior wall of the ureter and identify the axis of the tunnel. The needle is inserted with the bevel facing up at the 6 o'clock position. The original description by O'Donnell and Puri suggested entering the mucosa 2 to 3 mm distal to the UVJ and advancing the needle in the submucosal plane for a distance of 4 to 5 mm. Kirsch et al. popularized this approach (submucosal implantation within the intramural ureter) and reported improved results with all grades of reflux compared with the classic technique (92% vs. 79% of ureters) (Kirsch et al., 2004). They further modified the technique with addition of a second injection inside the orifice and named it the double hydrodistention implantation technique (double HIT), resulting in further improvement (93%) in intermediate and long-term results (Kalisvaart et al., 2012).

The accuracy of the needle entry point and needle placement is paramount for successful outcome of the procedure (Fig. 42.23). An improper puncture may not result in the desired mound formation and thus may not provide adequate support for the UVJ. If the needle requires repositioning, the implanted material may leak out of the first puncture site, resulting in failure of the procedure.

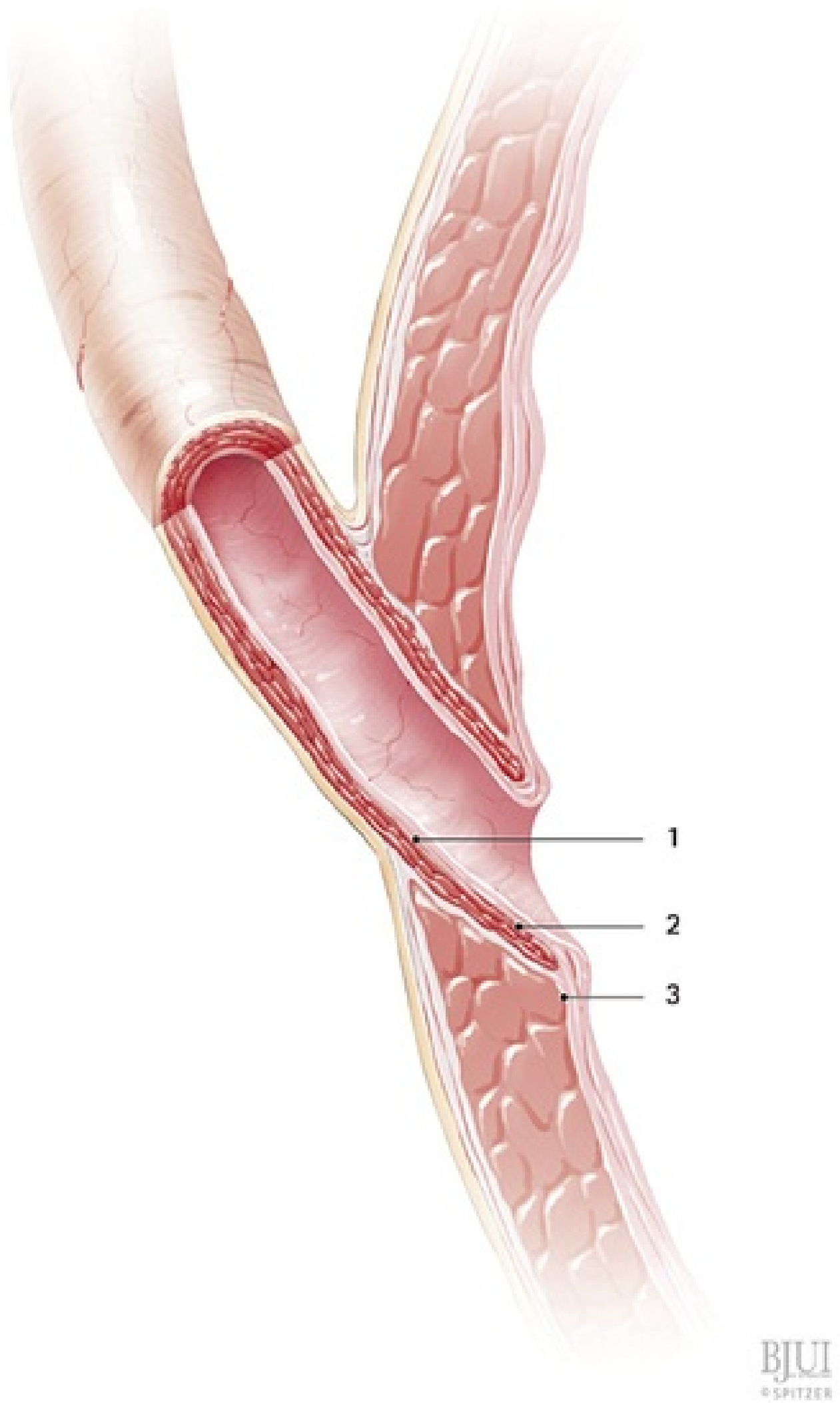

FIG. 42.23 Injection sites for endoscopic treatment of vesicoureteral reflux. *1* and *2*, Hydrodistension (double HIT) technique with submucosal injection of the material in the transmural ureter. *3*, The classic STING technique with the material injected under the bladder mucosa just below the ureteral orifice.

Injection should be carried out slowly. If the needle is positioned in the submucosal plane, the mound becomes apparent with the initial injection of 0.1 to 0.2 mL. This is a key point in the procedure; unsatisfactory mound formation and location after this initial injection is an indicator that the tip of the needle is not in the proper position. Repositioning of the needle by withdrawing it slowly and then advancing it while injecting, in addition to rotating the bevel gently (depending on the lateral location of the mound), should help achieve the desired effect. **Once a volcano appearance, with the ureteral meatus on top of the mound, is achieved, additional volume is injected until the ureteric orifice**

becomes crescent or slit shaped (Fig. 42.24). The shape of the mound was found to be a significant predictor of a successful outcome. Achieving a volcano-shaped mound was associated with an 87% success rate, whereas other morphologies were associated with only a 53% success rate (Lavelle et al., 2005). For most materials, the needle should be kept in place for 1 minute at the end of the injection to reduce extrusion of the material at the injection site. With Deflux, this step is not essential. The bladder is emptied, and the mound is inspected with an empty and a full bladder to ensure that adequate support of the ureter is persistent. Rarely, bleeding occurs at the puncture site. This is best dealt with by emptying the bladder and applying gentle pressure with the tip of the cystoscope until the bleeding stops. Cauterizing the area is not advisable as it may result in sloughing of the mucosa and extrusion of the injected material. At the end of the procedure, lidocaine gel may be instilled in the urethra; catheter drainage is not necessary. In general, the child spends a brief amount of time in the recovery room, followed by discharge. All activities can be resumed immediately.

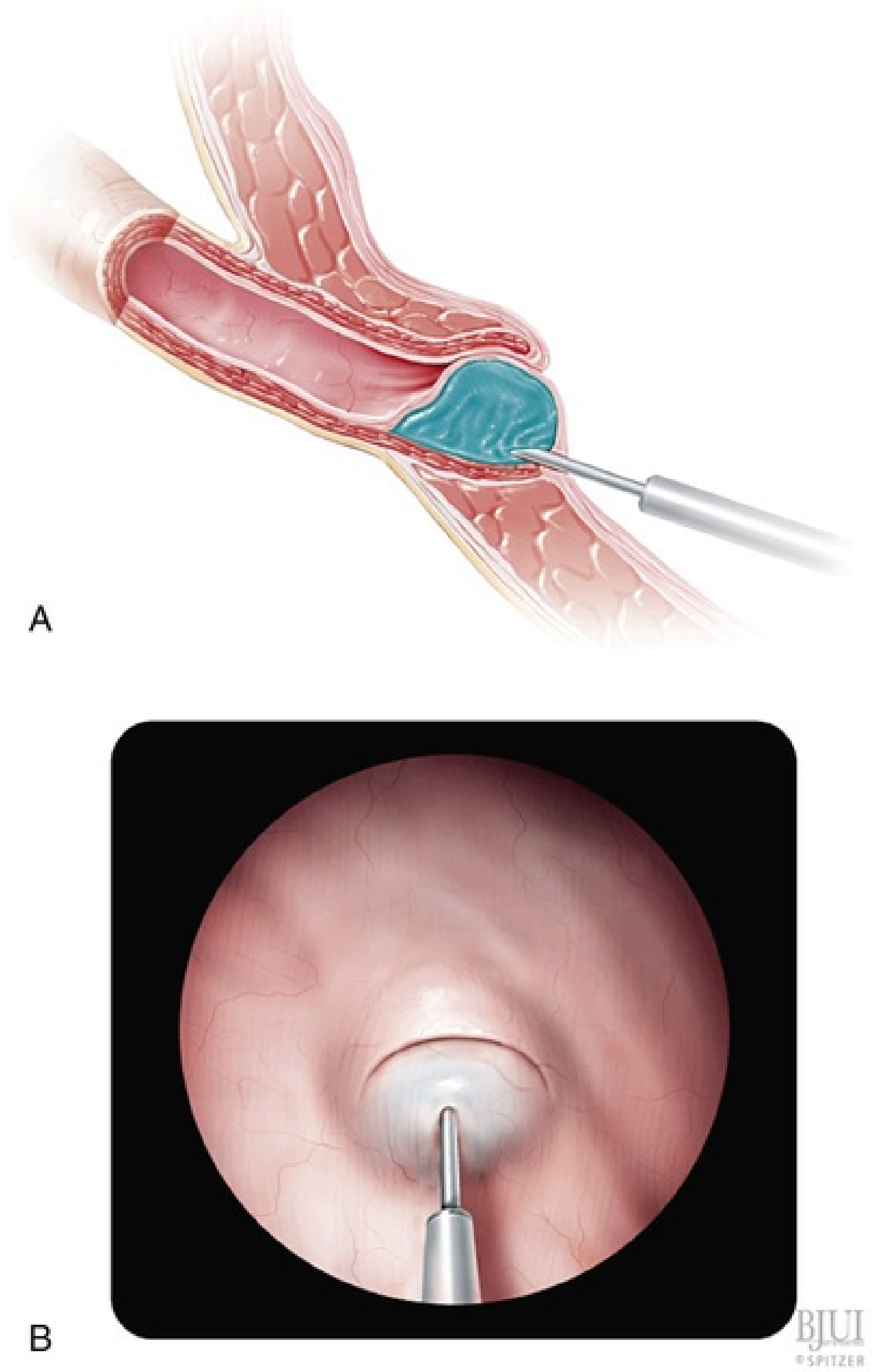

FIG. 42.24 Intraureteral injection (HIT) technique. The material is injected under the intramural ureteral mucosa (A). Appearance of the mound after completion of the injection with a slit-like orifice (B).

There is a significant learning curve with endoscopic correction of VUR (Herz et al., 2001). Although the technique is quite simple once learned, there are some technical nuances and details that require specific attention.

Follow-Up

The child is maintained on antibiotics for 3 months. An early ultrasonography 2 to 4 weeks after treatment is advisable to exclude acute obstruction caused by the bulking substance. A follow-up sonogram and VCUG are obtained after 3 months. However, this depends on the clinical situation. When the clinical situation is improved, simple follow-up by ultrasonography should be sufficient. If VUR persists, one to two repeat injections can be considered. If there is still no resolution, open, laparoscopic, or robotic surgery is recommended. A significant number of late-onset ureteric obstructions have recently been reported, which may argue for long-term follow-up with ultrasonography (Karakus et al., 2016; Kocaoglu, 2016; Ben-Meir et al., 2017; Warchol et al., 2017).

Most reports to date have not indicated any significant difficulty with open surgery after endoscopic correction using Deflux (Herz et al., 2001; Lackgren et al., 2001; Friedlander et al., 2018), but some have experienced difficulty with other substances (Crozier et al., 2016). At open surgery, the injected material is either not seen at all or is found well encapsulated but in an incorrect plane or location inside or outside the bladder. The material is easily removed en bloc and the reimplant procedure carried out without difficulty in most cases.

Materials Used for Endoscopic Correction of Reflux

For an injectable biomaterial to be ideal, it must be nontoxic and stable without migration to vital organs. It should cause minimal local inflammation, while being well encapsulated by normal fibrous tissue and fibrocytes. The material should be easy to inject through a long needle that passes easily through most standard endoscopic instruments. It must be viscous enough to prevent leakage from the puncture site and maintain its injected volume and the mound shape after the normal process of exchange and excretion of any carrier molecules.

The concern with the particulate agents is migration and with degradable agents is durability. Distant migration can occur by two mechanisms. The first is expansion of the injected bolus, which may lead to disruption of the small vessels in the area of the distal ureter and trigone, resulting in the material gaining intravascular access. Particles smaller than 50 μm may bypass the pulmonary vascular bed and thus access the systemic circulation and reach other organs in the body. The second migration mechanism is by phagocytosis of the injected particles by tissue macrophages or blood-borne monocytes. The particle size determines whether phagocytosis can occur, because it is generally agreed that phagocytosis requires a particle less than 80 µm in diameter.

Most of the agents used for endoscopic treatment of VUR are **nonautologous materials.**

Polytetrafluoroethylene paste (Teflon paste) has been widely used for many years in various surgical procedures and as a component in grafts and sutures and as a bulking agent for urinary incontinence. This inexpensive material was advocated for the endoscopic treatment of VUR, with success rates of 86% after one to four injections (Puri et al., 1995; Chertin and Puri, 2002) and a durability of 95% after 11 to 17 years on long-term follow-up (Chertin and Puri, 2002). The material has all but been abandoned because of concerns with migration of the small Teflon paste particles (90% of the particles are less than 40 µm in diameter).

Polydimethylsiloxane (PDS) (Macroplastique) is a solid silicone elastomer that has been used as a soft tissue bulking agent. The injectable material is composed of soft, flexible, highly textured implants of heat-vulcanized PDS suspended in a bioextractable carrier gel. The carrier gel is a water-soluble low–molecular-weight polyvinylpyrrolidone hydrogel (Povidone). The carrier gel is absorbed and replaced with host fibroblasts that subsequently deposit collagen, encapsulating the implant. The implant retains its size and shape. To minimize the risk for migration, PDS is engineered to create an elastomer, instead of the less cross-linked silicone gels or non–cross-linked silicone oils. Although 76% of particles are greater than 100 µm in diameter, **7% are less than 50 µm in diameter.** The smaller particles and possible intramuscular injection of the agent are responsible for migration of particles to the lungs, kidneys, brain, and lymph nodes demonstrated in animal models. Unlike Teflon paste, Macroplastique does not cause an intense local inflammatory response. In patients requiring open surgery after failed injection with Macroplastique, the injectable bolus was found encapsulated and easily removed without adherence to the ureter or bladder (Herz et al., 2001). Histologic examination of the bladder muscle biopsies and pelvic lymph nodes at the time of open surgery revealed a mild inflammatory reaction with no evidence of PDS particle migration in either the wall of the bladder or the draining lymph nodes.

The efficacy of PDS as a bulking agent for correction of reflux is well documented. Dodat et al. reported on the long-term outcomes of Macroplastique injections for correction of VUR (Dodat et al., 2004). Results in 590 refluxing ureters in 389 patients who were injected with a minimum follow-up of 5 years revealed a sustained success rate of 79.4%. Herz et al. demonstrated a reflux resolution rate of 81% after a single injection and 90% after a second injection with a 12-month follow-up (Herz et al., 2001).

The main advantage of PDS is that it is a permanent material that remains well encapsulated, causing minimal local inflammatory changes. Another report, however, draws attention to the development of a Macroplastique bolus calcification occurring in 2 of 31 children presenting with irritative lower urinary tract symptoms 30 and 36 months after injection. At the time of surgery, the calcified material was extracted after unroofing the overlying necrotic mucosa (Bae et al., 2010). Eyssartier et al. made similar observations (Eyssartier et al., 2012). These reports underscore the importance of long-term monitoring after the injection of foreign materials in growing children. Despite its demonstrated long-term track record, PDS has yet to achieve FDA approval for correction of VUR in the United States, possibly because of concerns regarding migration, particularly the presence of particles smaller than 80 µm and the negative connotations associated with silicone implants.

Dx/HA (Deflux) is formed of cross-linked dextranomer microspheres (80 to 250 µm in diameter) suspended in a carrier gel of stabilized sodium hyaluronate. Dx/HA is biodegradable, the carrier gel is reabsorbed, and the dextranomer microspheres are capsulated by fibroblast migration and collagen ingrowth. Dx/HA loses approximately 23% of its volume beyond 3 months of follow-up (Stenberg and Lackgren, 1995).

Deflux was first introduced by the Swedish group of Stenberg and Lackgren and received FDA approval in 2001 (Stenberg and Lackgren, 1995). Since then, several clinical reports from Europe and the United States have documented success rates ranging from 68% to 89% (Lackgren et al., 2001; Puri et al., 2003; Kirsch et al., 2004; Lavelle et al., 2005). The introduction of the double HIT by the Atlanta group has resulted in higher reflux resolution rates of 90% in 336 children (Kalisvaart et al., 2012).

In a long-term follow-up study by Lackgren et al., 68% of 221 children injected using the classic STING technique and followed for a mean of 5 years maintained grade 1 VUR or less at the last VCUG (Lackgren et al., 2001). No significant long-term adverse effects were noted. Other groups have, however, reported the risk for late-onset ureteral obstruction with Dx/HA (Rubenwolf et al., 2013; Christen et al., 2014; Papagiannopoulos et al., 2017). Salvage ureteral reimplantation after failed endoscopic correction with Dx/HA can be accomplished, usually without difficulty. The implant bolus is frequently observed in the periureteral space outside the bladder and is well encapsulated, with mild inflammatory changes (Sparks et al., 2011).

The appeal of Dx/HA is that it is a natural product that is easily administered without a ratcheted syringe through a smaller-gauged needle. It is currently the preferred agent for endoscopic correction in most centers; however, the durability of correction of VUR with Dx/HA remains to be proven.

Polyacrylate polyalcohol copolymer (PPC) (Vantris) is a new nonbiodegradable tissue-augmenting agent belonging to the family of acrylics described by Ormaechea in 2008. The particles of PPC are immersed in a glycerol and physiologic solution carrier (Ormaechea et al., 2008). The particles have a size of 300 µm and should therefore not migrate. PPC particles are encapsulated by fibrotic tissue giving little rise to inflammatory reactions. Initial results reported by Ormaechea and Chertin revealed high reflux resolution rates after one treatment (Ormaechea et al., 2010; Chertin et al., 2011). A recent multicenter survey found resolution rates of 98% (Kocherov et al., 2014). Warchol et al. found higher resolution rates for PPC than for Dx/HA in a comparative study, and in a recent follow-up study the success rate after PPC remained high even for high-grade reflux (Warchol et al., 2016, 2017). The length of follow-up in this study is sparsely described but reaches up to 4.5 years. Late-onset ureteral obstruction, however, remains a major concern offsetting the trade-off of higher resolution rates compared with other bulking agents (Ben-Meir et al., 2017; Warchol et al., 2017). PPC has not yet been approved by the FDA.

A number of other nonautologous and autologous substances are under development but have not yet been introduced to clinical practice.

Recurrence of Vesicoureteral Reflux After Endoscopic Correction

The true incidence of recurrent VUR after successful endoscopic correction with any specific material is difficult to determine because a repeat VCUG is not obtained beyond the initial negative study except in the context of a research protocol. Only a handful of series have reported long-term follow-up with repeat VCUG beyond the initial negative study. Chertin and Puri reported a 5% recurrence rate using Teflon paste with follow-up of up to 17 years (Chertin and Puri, 2002). In the Swedish Reflux Trial, 20% of previously successfully treated children had a recurrence after 2 years of follow-up (Holmdahl et al., 2010).

The higher recurrence rate with Deflux, an absorbable agent, is not unexpected. However, in the absence of UTI, the significance of confirming the long-term absence of VUR is less important. Furthermore, even if absorbable bulking materials were to lose volume or reabsorb completely over time, VUR resolution may be maintained by growth of the child and maturation of the UVJ. The injectable agent may just have bought time for this process to conclude. The implication of recurrent reflux in young adulthood for these patients is inadequately defined at the present time. More recent evidence suggests that children undergoing endoscopic correction with a preinjection history of multiple febrile UTIs, bladder and bowel dysfunction, and renal scarring are at a higher risk for recurrent infections and late recurrence of VUR despite initial negative VCUG (Sedberry-Ross et al., 2008).

Endoscopic correction of VUR is a reasonable alternative for children being considered for surgical correction; however, families should be informed of the varied success rates across centers and that outcomes may not be durable.

Megaureter

Definition

The term *megaureter* is a descriptive one denoting dilation of the ureter irrespective of cause. Originally coined by Caulk in 1923 as *megaloureter,* other synonyms in use include wide ureter and hydroureter and in general refer to a ureter that has a diameter ≥7 mm based on the studies of Cussen and Hellstrom, which defined the upper limit of the range of normal ureteral diameters in children up to 16 years of age as being 0.50 to 0.65 mm (Cussen 1967; Hellstrom et al., 1985). Etiology of megaureters is either primary, representing a condition intrinsic to the ureter itself, or secondary to bladder pathology, such as neurogenic bladder dysfunction, bladder outlet obstruction, and/or infection. **Megaureters have been subclassified into four categories based on causality: obstructed, refluxing, nonobstructed nonrefluxing, and refluxing with obstruction** (Smith, 1977; King, 1980). In circumventing the refluxing type, which is easily diagnosed and has been dealt with previously, distinguishing between obstructed megaureters and those that are nonobstructed nonrefluxing can be somewhat challenging. For as is the case with hydronephrosis, the mere presence of ureteral dilation, which at times can be quite alarming on imaging, does not necessarily indicate significant obstruction. **The challenge is in the balance between early identification and management of the obstructed ureters to prevent renal functional deterioration and to not consign ureters with balanced stable dilations to unnecessary intervention.**

Etiology, Occurrence, and Presentation

The pathophysiology of primary obstructed megaureters (POMs) has not been fully ascertained, but there is general agreement that obstruction results from the presence of an abnormal adynamic segment at the terminal end of the ureter near or at the UVJ. Absent or inefficient peristalsis at the UVJ leads to obstruction and upstream dilation. Fetal animal studies by Tanagho and Pirker have demonstrated that the ureteral muscular layers develop in a craniocaudal direction, leaving the juxtavesical part of the ureter to develop last, with maturation of this terminal part continuing postnatally (Tanagho, 1973; Pirker et al., 2007). This corresponds well with studies in human fetuses that showed a similar directional maturation with typical fetal circular muscular fibers first maturing to the double muscle layer of the full-term infant well past delivery, a fact that may explain transient dysfunction at the UVJ and the spontaneous resolution of some POMs with age (Matsuno et al., 1984; McLellan et al., 2002). Other studies point to the presence of excessive and abnormal collagen deposition at the narrow part of the ureter (Notley, 1968; Gosling and Dixon, 1978) or presence of a thick enveloping sleeve of muscle surrounding the muscle bundles of the terminal ureter (Dixon et al., 1998). Most recently, Kang demonstrated abnormalities in the interstitial cells of Cajal in POM cells whose primary function is related to smooth muscle contractility, pacemaker activity, and ultimately peristalsis (Kang et al., 2009).

The true incidence of POM is not known but is thought to average 10% to 23% of antenatally detected upper urinary tract dilations (Brown et al., 1987; Gokce et al., 2012). The anomaly has a predilection for boys and the left side. It is bilateral in 25% of cases and is associated with contralateral dysplasia or obstruction in 10% to 15% of cases (Joseph, 2007). Most POMs are detected by antenatal ultrasound screening, with the vast majority being asymptomatic. In an interesting paper from 1987 by Brown et al., the role of prenatal ultrasonography was documented in that the majority (79%) of patients with POM (constituting 23% of antenatally detected dilations) were detected antenatally as opposed to the pre-ultrasound era, when only 8% of patients presenting symptomatically and consequently found to have upper urinary tract dilation were diagnosed with POM (Brown et al., 1987; Rubenwolf et al., 2016). Symptoms when present include those of UTI, abdominal pain, and microscopic hematuria, even in the absence of infection. This is believed to result from the disruption of urothelial microvasculature caused by distention or calculi. In rare instances, previously undiagnosed patients can present with an abdominal mass, although this is more of a pre-ultrasound era feature in contrast with the very infrequent presentation with signs and symptoms of renal impairment currently (Shokeir and Nijman, 2000).

Surgical Indications

By historical account, it can be deduced that the majority of nonrefluxing megaureters run a benign course and resolve spontaneously within the first few years of life (Matsuno et al., 1984; Brown et al., 1987; McLellan et al., 2002; Shukla et al., 2005; Rubenwolf et al., 2016). This has been confirmed in a prospective observational study by Ranawaka et al., who showed that complete resolution and time to resolution were inversely related to ureteral diameter with minimal complications or febrile episodes during follow-up for those with a ureteral diameter <10 mm while maintained on antibiotic prophylaxis, and virtually none proceeded to surgery. On the other hand, patients with ureteral diameters >10 mm were more prone to complications such as recurring febrile UTIs, stone formation, and abdominal pain, with only 17% resolving completely and an overall 21% of them requiring surgical intervention (Ranawaka and Hennayake, 2013). Persistence of dilation therefore warrants continued close follow-up with periodic ultrasound examinations supplanted with functional studies when deemed necessary until resolution or stability of dilation is confirmed. The role of extended follow-up into early adulthood has also been advocated based on worsening of some previously stable megaureters at or beyond puberty (Shukla et al., 2005).

As a result, there has been a steady trend toward conservative management of patients with megaureters during the past 25 years. An increased understanding of the pathophysiology of this condition combined with advances in minimally invasive procedures has also shifted management in a more minimally invasive direction. **Surgery in the case of POM is to be considered when patients are symptomatic and have recurring UTIs, progressive unremitting dilation on ultrasonography, differential renal function <40%, and/or significant decreases in differential renal function of ≥ 5% on sequential “comparable” renal nuclear functional studies** (Farrugia et al., 2014). Several studies cite prolonged washout or drainage curves on diuretic renograms as being an indication to intervene, as prolongation of T½ is equated with significant obstruction. Relying on renographic washout curves as a measure of obstruction is, however, problematic and can be misleading, as it has been shown that washout curves in neonates and infants can be affected by many factors other than “restriction of flow”: renal function and the ability to respond to diuretic stimulation, hydration status, posture, distensibility and volume of the collecting system, in addition to matters related to procedural and technical aspects, such as the timing of diuretic administration and curve interpretation. Collectively, these variables limit the usefulness of drainage curves as has been documented in a study that reported false-positive results in up to 44% of renographies (O'Reilly, 1989; Shokeir and Nijman, 2000).

Surgical Management

Basic principles of megaureter correction are simple and straightforward; the surgical procedure can be quite demanding, however, and should be reserved for the pediatric urologist with experience in bladder and ureteral surgery and in whose hands favorable results can be achieved. **In summary, the stenotic distal part of the ureter is excised, and the megaureter is straightened and then tapered to facilitate reimplantation in a nonrefluxing fashion with an adequate length-to-diameter ratio of 5 : 1 so as to improve coaptation of the ureteral lumen whereby effective peristalsis and urine transportation is achieved** (Paquin, 1959). Several eponymous procedures have been described for ureteral remodeling and its reimplantation, and with time numerous modifications and refinements have emerged. **And as the laparoscopic and robotic envelope continues to be pushed, the same basic principles are increasingly being achieved by laparoscopic and robotic-assisted techniques, albeit at a limited number of centers**.

If prompt decompression of a POM is necessary, this can be achieved by nephrostomy tube diversion, however, nephrostomy tubes are difficult to maintain in infants for prolonged periods and carry the risk for leakage, infection, and displacement. A better temporizing option would in this case be distal cutaneous ureterostomy. This simple technique allows rapid decompression of the dilated and potentially infected system and allows a delay in definitive reconstruction, which is usually warranted in infants in whom incongruity between the small bladder and the severely dilated ureter does not allow for safe nonrefluxing reimplantation. Also there is a general reluctance to perform reimplantations in infants for fear of inducing bladder dysfunction, a claim that may be overstated according to a study by de Kort et al. (de Kort et al., 2002). The ureter can hence be approached through a small oblique inguinal incision, carried through muscle splitting dissection to the perivesical space (Fig. 42.25). The distal part of the dilated tortuous ureter is identified and picked up by nontraumatic forceps or a noncrushing Allis clamp. Peritoneal adhesions may have to be swept off using a pledget, and a vascular loop is then pulled under the ureter to allow atraumatic handling. The ureter can then be pulled out into the incision as a loop secured to the fascia with several absorbable monofilament 5-0 sutures, whereafter the fascia is approximated to the distended ureter with the same suture. The ureter can then be opened transversely and the edges everted and secured to the skin using 5-0 or 6-0 absorbable monofilament sutures. A drainage catheter can be left in situ for the first 24 to 48 hours to aid in drainage and decompression of the redundant dilated system. Because of the dimensions of the ureter, stenosis of the stoma is a rare occurrence (Rabinowitz et al., 1977; Kitchens et al., 2007). Another temporizing procedure in the infant that is gaining acceptance is that of internal diversion by means of a refluxing reimplantation. The dilated ureter is transected proximal to the stenotic terminal part and is anastomosed directly in a freely high-grade refluxing fashion whereby “dangerous” obstruction is converted into the “lesser evil” of VUR. Preliminary studies have shown promising results of this temporizing procedure, however, long-term outcomes with regard to effect of reflux on renal function are awaited (Lee et al., 2005; Farrugia et al., 2014; Kaefer et al., 2014; Babu, 2016).

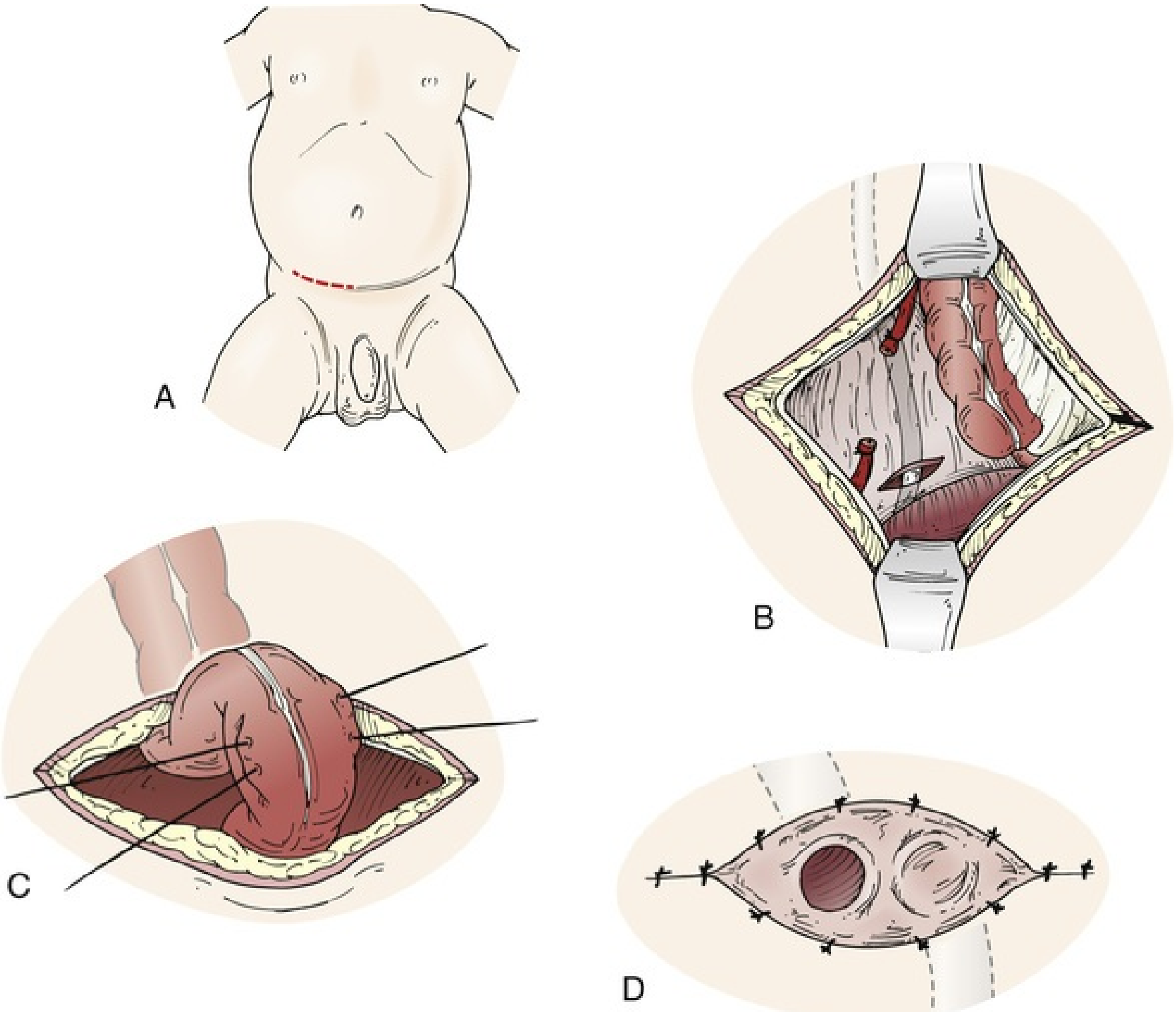

FIG. 42.25 Diversion with ureterostomy. (A) A small oblique or transverse inguinal incision is made. (B) Muscles are separated bluntly, and the perivesical space is accessed. The dilated tortuous ureter is identified, the

obliterated umbilical artery being divided and ligated if necessary. (C) The ureter is mobilized and brought out as a loop to the incision, where it is fixed to the fascia, and the incision is approximated to the ureteral wall. (D) The ureter is now opened, and the edges are everted and fixed to the skin with fine absorbable monofilament interrupted sutures.

Definitive reconstruction entails remodeling and reimplanting the ureter in a nonrefluxing fashion. The bladder is accessed through a low transverse Pfannenstiel incision, and the dilated ureter can then be mobilized into the bladder as shown previously (see Fig. 42.18A–E). Once completely mobilized within the bladder, the technique of reimplantation and remodeling must be decided on, as it dictates the next steps. In case of choosing an intravesical reimplant such as the Cohen cross-trigonal or the Politano-Leadbetter, work can be continued from within the bladder. **It is however advisable to move outside the bladder in cases of a very large ureter or to perform the whole dissection, transection, and remodeling of the ureter extravesically and proceed with an extravesical form of reimplantation, especially if the discrepancy between ureteral diameter and bladder is significant, so as to avoid excessive bladder dissection and creation of a very large hiatus in the trigone area** (Perovic, 1994).

Tailoring of the ureter can be achieved by one of two basic methods: plication or excisional tapering. With plication, the megaureter is imbricated or folded around an 8- or 10-Fr catheter depending on patient age. Ureteral redundancy is marked by brief placement of atraumatic Allis clamps around the ureter containing the medialized catheter. After removing the clamps, the Starr plication technique (Fig. 42.26) includes imbricating the redundant lateral edge of the dilated ureter by multiple interrupted 5-0 monofilament absorbable sutures in the Lembert fashion along the clamp impressions (Starr, 1979). In the Kalicinski plication (Fig. 42.27), a 6-0 monofilament absorbable suture is woven in a continuous fashion craniocaudally through the ureteral wall along the clamp impressions, thereby defunctionalizing the redundant lateral aspect, which, in turn, is folded back and fixed along the catheterized lumen with multiple 6-0 interrupted sutures (Kalicinski et al., 1977). In plication techniques, the blood supply to the ureter is preserved as the ureteral walls are kept intact, thereby decreasing the risk for ischemia and stenosis (Bakker et al., 1988). **Folding techniques are, however, only suitable for the moderately dilated ureter (<1.75 cm in diameter)** (Fretz et al. 2004) **as too big a diameter will result in a bulky remodeled ureter that is difficult to reimplant and significantly**

increases complications and failure rates (Parrott et al., 1990). In general, favorable results have been reported with folding techniques with success rates of 90% to 95% (Ehrlich, 1985; Perdzynski and Kalicinski, 1996; Daher et al., 1999; Fretz et al., 2004). Postoperatively stents in the form of baby feeding tubes or double pigtail catheters are left in situ for 7 days and 4 weeks, respectively, for drainage purposes. Follow-up pyelography via stentograms is not indicated at stent removal.

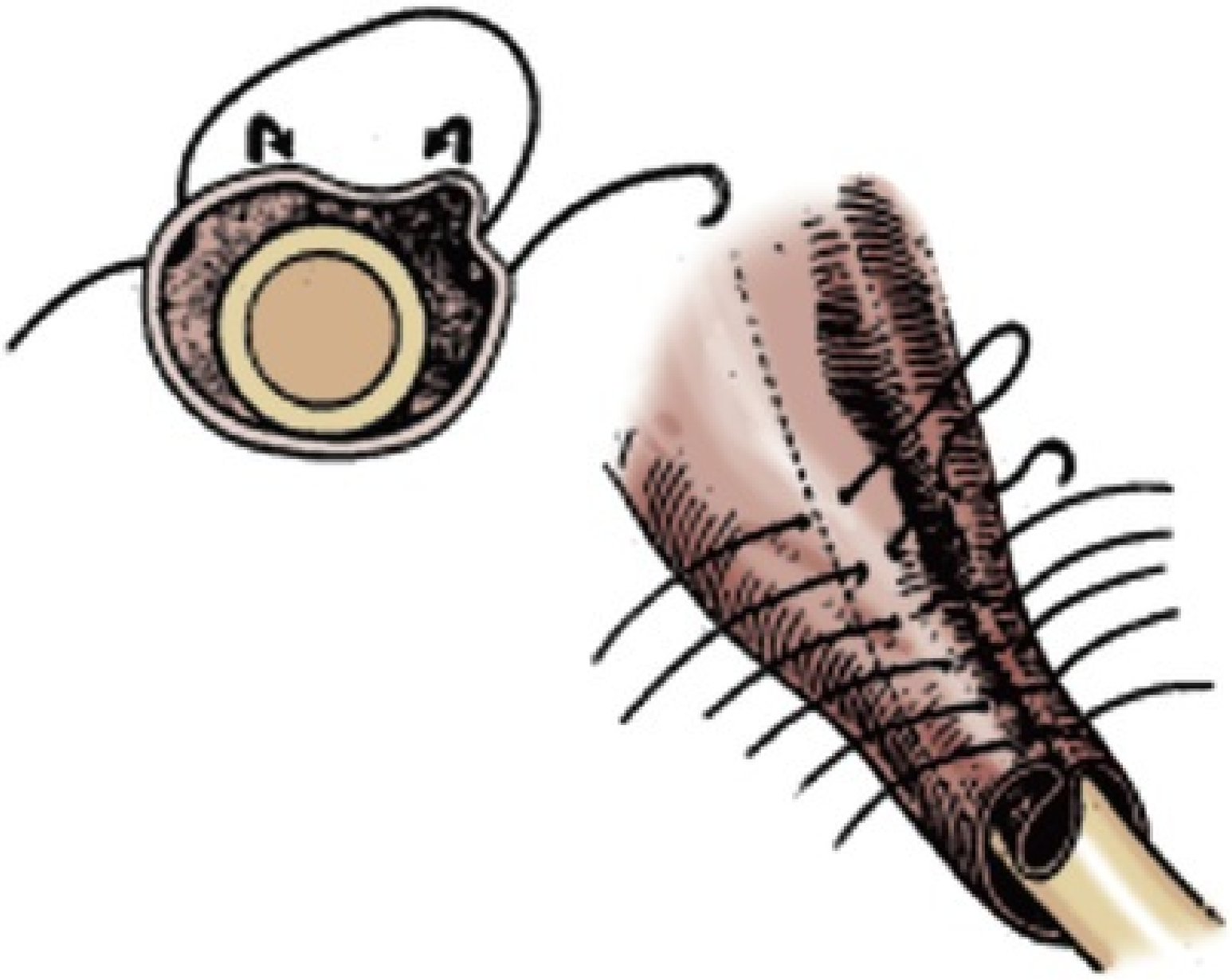

FIG. 42.26 Starr plication. Ureteral plication is performed over the appropriate catheter, with interrupted 5-0 monofilament absorbable sutures placed in Lembert fashion (after Starr). (From Keating MA, Retik AB. Management of failures of ureteroneocystostomy. In: McDougal WS, ed. *Difficult problems in urologic surgery*. Chicago, IL: Year Book; 1989).

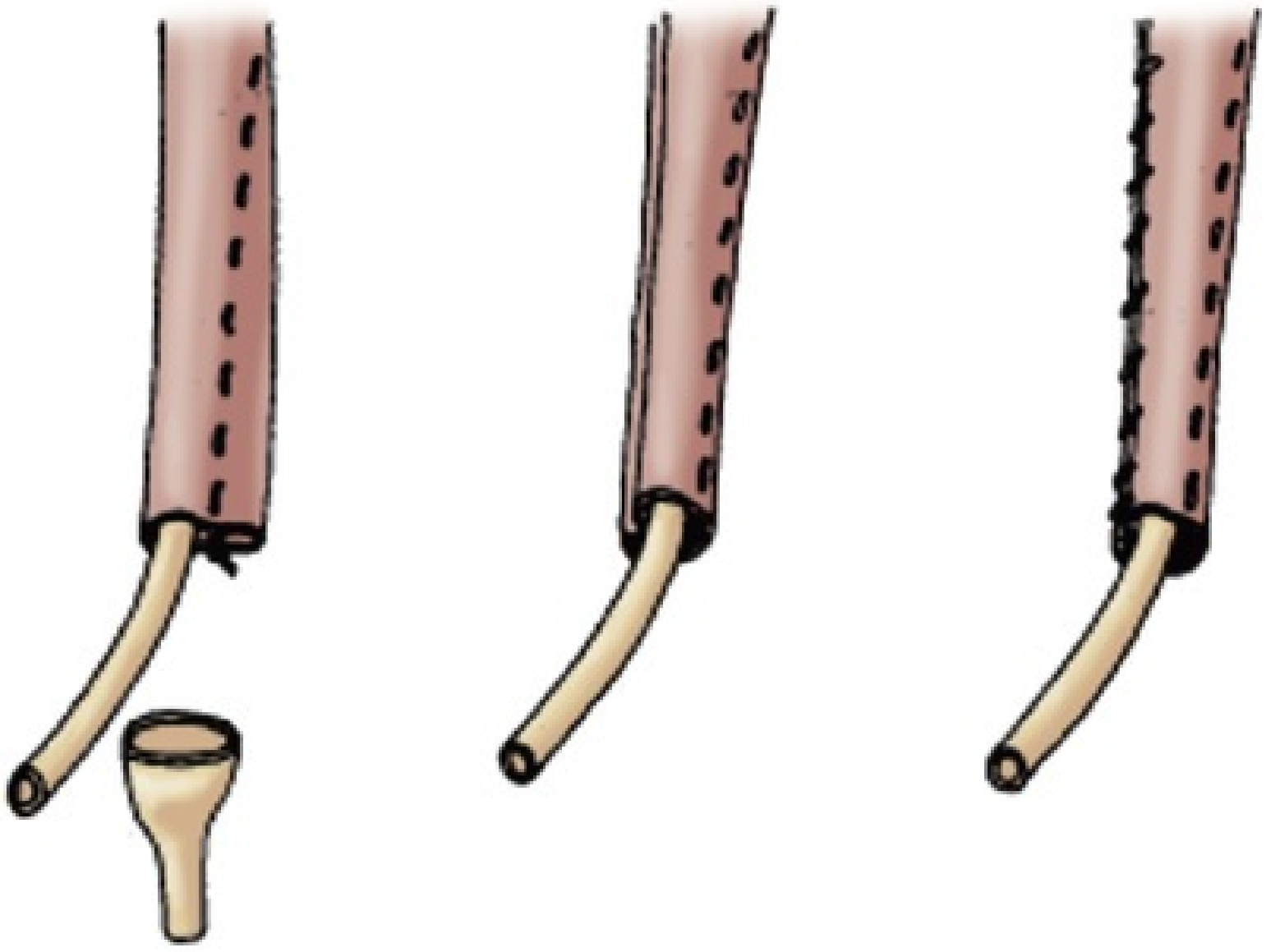

FIG. 42.27 Kalicinski folding technique. Ureteral folding technique. A running suture is longitudinally woven through the megaureter to create two lumens. This isolates the best-vascularized portion as a functional ureter (catheter within) and excludes redundancy. The redundant portion is then folded, and the two are tacked together with interrupted sutures.

Excisional tapering as described by Hendren was the forerunner for the later modifications of folding techniques, as it is believed and has been shown that excisional tapering may jeopardize ureteral vasculature with all its attendant complications (Hendren, 1969; Bakker et al., 1988; Whitmore and Ehrlich, 1988; Parrott et al., 1990). Nonetheless the Hendren procedure has its advantages, especially when dealing with massively dilated ureters that are not amenable to folding. The procedure (Fig. 42.28) follows the same principle steps of defining the redundant less vascular lateral part of the ureter around an 8- to 10-Fr catheter. Instead of folding, the excess ureteral tissue is excised and closed with a running locking 6-0 absorbable monofilament suture along the proximal two-thirds of the ureteral length to be remodeled. The distal third is closed by interrupted sutures of the same kind to allow for appropriate shortening of the ureter at reimplantation without violating the integrity of the running anastomosis (Hendren, 1969). The same postoperative regimen is followed as with the folding techniques. Athough success rates with this method have generally been excellent, exceeding 90% in many studies (Hendren, 1969; Parrott et al., 1990; DeFoor et al., 2004), refinements aimed at preserving vasculature by limiting excision to the mucosal and muscular parts of the redundant ureter, leaving behind the vascular-rich adventitial layers, may even improve on these outcomes by lowering the risk for ischemia (Ossandon et al., 2005). It is pertinent for all types of ureteral remodeling that tapering be gradual so as not to cause an abrupt change in ureteral caliber, which may cause a form of obstruction. After ureteral remodeling is completed, one can proceed with reimplantation in accordance with the same surgical principles of VUR reimplantation.

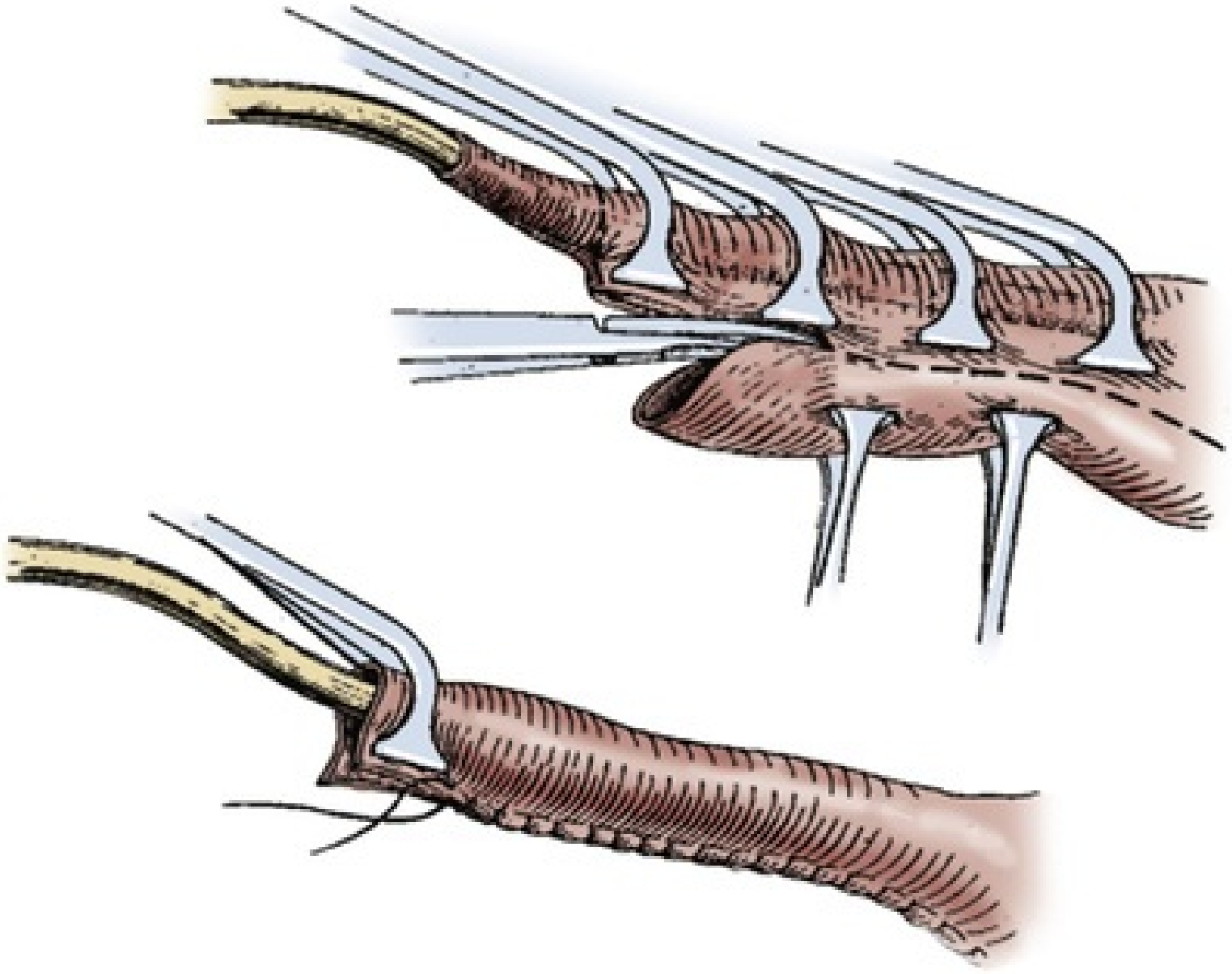

FIG. 42.28 Excisional tapering. Tapering is done over an 8-Fr red rubber catheter in infants or a 10-Fr catheter in older children and adults. After vascularity is defined, special atraumatic clamps are placed over the catheter. Baby Allis clamps help retract the portion of ureter to be resected, which is usually lateral. It is important not to resect too much ureter. Running 5-0 monofilament resorbable sutures are used to reapproximate the proximal two-thirds of the ureter. Its distal third is closed with interrupted sutures to allow for shortening.

Laparoscopic ureteral remodeling and reimplantation follow the same general principles set for open techniques. An increasing number of reports are demonstrating the feasibility and success of these minimally invasive techniques with excellent short- to medium-term outcomes fully comparable with those of open procedures (Abraham et al., 2012; Bi and Sun, 2012; Bondarenko, 2013). Extravesical reimplantations seem to dominate as technical limitations impede tapering from within the bladder (Abraham et al., 2012; Bondarenko, 2013), although a recent report has shown pneumovesical laparoscopic excisional tapering and transtrigonal reimplantation to be achievable (Bi and Sun, 2012).

Outcomes

In general, techniques of ureteral remodeling and reimplantation for POM have stood the test of time, producing excellent and durable results of over 90% success rates in several studies. Interestingly, outcomes for patients with POM have generally been more favorable than those for patients with refluxing megaureters, a fact that may be explained by histologic changes in the collagen to smooth muscle ratios in the UVJ of refluxing ureters, which may result in a stiffer, less compressible ureter (Lee et al., 1998; DeFoor et al., 2004). Poorer outcomes have also been reported in patients with dysfunctional voiding, neurogenic bladders, and other concomitant lower urinary tract pathology such as posterior urethral valves and obstructed flow (DeFoor et al., 2004; Carr and Casale, 2012). **The major reported complications are obstruction, vesicoureteric reflux, and persistent dilation.** Obstruction is initially managed by stenting as it is sometimes the result of postoperative edema; however, it can also be the result of ischemic stricturing especially after excisional tapering, in which case redo ureterneocystostomy is indicated with the attendant risks associated with revision surgery. Conservative management of vesicoureteric reflux is warranted, especially with the lower grades, as reflux has a tendency to resolve spontaneously in many cases. However, successful management with subureteric injection has been reported with minimal complication (DeFoor et al., 2004; Kitchens et al., 2006). Should subureteric injections fail, especially in cases of recurrent febrile UTIs, proceeding to revision surgery may be the only available option. A transureteroureterostomy may offer a valuable management option for unilateral cases in which there is severe ureteral scarring or concern regarding compromised blood supply.

Dilation and Stenting

Endoscopic dilation and stenting of the UVJ in POM has garnered increasing interest during the past decade or so. The method is less invasive than formal open or laparoscopic surgical intervention, with short- to medium-term success rates in the vicinity of 70% to 80% in most studies (Angerri et al., 2007; Carroll et al., 2010; Farrugia et al., 2011; Bujons et al., 2015; Capozza et al., 2015; Casal Beloy et al., 2018). The procedure is however not without complications; stent migration, infection, hematuria, and stone formation have been reported in up to 31% of cases in one series (Farrugia et al., 2011). Furthermore, the need for restenting, stenting by open surgical access in difficult cases, and ureteral injuries requiring emergent reimplantation may limit widespread use before long-term outcomes are documented (Carroll et al., 2010, Farrugia et al., 2011). In essence, the ureteral orifice of the POM is accessed endoscopically and dilated by a ureteral catheter or high-pressure balloon under fluoroscopic guidance until the indentation or waisting on the balloon disappears. Thereafter, a double pigtail catheter is left for 2 to 6 months before removal. Persistent dilation or renal function deterioration at follow-up has successfully been treated by restenting in some patients, and others have required reimplantation (Farrugia et al., 2014).

Key Points: Megaureter

- The term *megaureter* is a descriptive one denoting dilation of the ureter irrespective of cause.
- Megaureters have been subclassified into four categories based on causality: obstructed, refluxing, nonobstructed nonrefluxing, and refluxing with obstruction.
- The challenge is to prevent renal functional deterioration with either conservative or surgical treatment.
- Surgery is indicated for recurring UTIs, progressive unremitting dilation on ultrasonography, differential renal function <40%, and/or significant decreases in differential renal function of ≥5% on sequential “comparable” renal nuclear functional studies.
- During the surgical procedure, the stenotic distal part of the ureter is excised, and the megaureter is straightened and then tapered to facilitate reimplantation in a nonrefluxing fashion with an adequate length-to-diameter ratio of 5 : 1 so as to improve coaptation of the ureteral lumen whereby effective peristalsis and urine transportation is achieved.
- Most surgeons advocate temporary postoperative stenting.

Suggested Readings

Autorino R, Eden C, El-Ghoneimi A, et al. Robot-assisted and laparoscopic repair of ureteropelvic junction obstruction: a systematic review and meta-analysis. *Eur Urol*. 2014;65(2):430–452.

Cohen SJ. The Cohen reimplantation technique. *Birth Defects Orig Artic Ser*. 1977;13(5):391–395.

Farrugia MK, Hitchcock R, Radford A, et al. British Association of Paediatric Urologists consensus statement on the management of the primary obstructive megaureter. *J Pediatr Urol*. 2014;10(1):26–33.

Gundeti MS. *Pediatric robotic and reconstructive urology: a comprehensive guide*. Wiley-Blackwell; 2012.

Gundeti MS, Boysen WR, Shah A. Robot-assisted laparoscopic extravesical ureteral reimplantation: technique modifications contribute to optimized outcomes. *Eur Urol*. 2016;70(5):818–823.

Hendren WH. Operative repair of megaureter in children. *J Urol*. 1969;101:491–507.

Joseph DB. Megaureter. Docimo SD, Canning DA, Khoury AE. *The Kelalis-King-Belman textbook of clinical pediatric urology*. Informa Healthcare; 2007:577–592.

Koff SA. Pathophysiology of ureteropelvic junction obstruction. Clinical and experimental observations. *Urol Clin North Am*. 1990;17(2):263–272.

Läckgren G, Kirsch AJ. Surgery Illustrated—Surgical atlas endoscopic treatment of vesicoreteral reflux. *BJU Int*. 2010;105(9):1332–1347.

Olsen LH, Rawashdeh YF. *Pyeloplasty: a retroperitoneal approach. pediatric robotic and reconstructive urology*. Wiley-Blackwell; 2011:125–128.

Peters CA. Pediatric robot-assisted pyeloplasty. *J Endourol*. 2011;25:179–185.

References

Abraham GP, Das K, Ramaswami K, et al. Laparoscopic reconstruction for obstructive megaureter: single institution experience with short- and intermediate-term outcomes. *J Endourol*. 2012;26(9):1187–1191.

Abuanz S, Game X, Roche JB, et al. Laparoscopic pyeloplasty: comparison between retroperitoneoscopic and transperitoneal approach. *Urology*. 2010;76(4):877–881.

Agarwal SK, Khoury AE, Abramson RP, et al. Outcome analysis of vesicoureteral reflux in children with myelodysplasia. *J Urol*. 1997;157(3):980–982.

Akhavan A, Avery D, Lendvay TS. Robot-assisted extravesical ureteral reimplantation: outcomes and conclusions from 78 ureters. *J Pediatr Urol*. 2014;10(5):864–868.

Anderson JC, Hynes W. Retrocaval ureter; a case diagnosed pre-operatively and treated successfully by a plastic operation. *Br J Urol*. 1949;21(3):209–214.

Androulakakis PA, Stefanidis AA, Karamanolakis DK, et al. The long-term outcome of bilateral Cohen ureteric reimplantation under a common submucosal tunnel. *BJU Int*. 2003;91(9):853–855.

Angerri O, Caffaratti J, Garat JM, et al. Primary obstructive megaureter: initial experience with endoscopic dilatation. *J Endourol*. 2007;21(9):999–1004.

Austin PF, Cain MP, Rink RC. Nephrostomy tube drainage with pyeloplasty: is it necessarily a bad choice? *J Urol*. 2000;163(5):1528–1530.

Autorino R, Eden C, El-Ghoneimi A, et al. Robot-assisted and laparoscopic repair of ureteropelvic junction obstruction: a systematic review and meta-analysis. *Eur Urol*. 2014;65(2):430–452.

Avery DI, Herbst KW, Lendvay TS, et al. Robot-assisted laparoscopic pyeloplasty: Multi-institutional experience in infants. *J Pediatr Urol*. 2015;11(3):139e1–139e5.

Babu R. “Mini reimplantation” for the management of primary obstructed megaureter. *J Pediatr Urol*. 2016;12(2):103.e1–103.e4.

Badawy H, Zoaier A, Ghoneim T, et al. Transperitoneal versus retroperitoneal laparoscopic pyeloplasty in children: randomized clinical trial. *J Pediatr Urol*. 2015;11(3):122 e1–122e6.

Bae YD, Park MG, Oh MM, et al. Endoscopic subureteral injection for the treatment of vesicoureteral reflux in children: polydimethylsiloxane (Macroplastique®) versus Dextranomer/Hyaluronic Acid Copolymer (Deflux®). *Korean J Urol*. 2010;51(2):128–131.

Bakker HH, Scholtmeijer RJ, Klopper PJ. Comparison of 2 different tapering techniques in megaureters. *J Urol*. 1988;140(5 Pt 2):1237–1239.

Barbosa JA, Kowal A, Onal B, et al. Comparative evaluation of the resolution of hydronephrosis in children who underwent open and robotic-assisted laparoscopic pyeloplasty. *J Pediatr Urol*. 2013;9(2):199–205.

Barrieras D, Lapointe S, Reddy PP, et al. Urinary retention after bilateral extravesical ureteral reimplantation: does dissection distal to the ureteral orifice have a role? *J Urol*. 1999;162(3 Pt 2):1197–1200.

Barrieras D, Lapointe S, Reddy PP, et al. Are postoperative studies justified after extravescial ureteral reimplantation? *J Urol*. 2000;164(3 Pt 2):1064–1066.

Bayne AP, Shoss JM, Starke NR, et al. Single-center experience with pediatric laparoscopic extravesical reimplantation: safe and effective in simple and complex anatomy. *J Laparoendosc Adv Surg Tech A*. 2012;22(1):102–106.

Belman AB, Kropp KA, Simon NM. Renal-pressor hypertension secondary to unilateral hydronephrosis. *N Engl J Med*. 1968;278(21):1133–1136.

Ben-Meir D, Bahouth Z, Halachmi S. Late-onset uretero-vesical junction obstruction following endoscopic injection of bulking material for the treatment of vesico-ureteral reflux. *Urology*. 2017;101:60–62.

Bi Y, Sun Y. Laparoscopic pneumovesical ureteral tapering and reimplantation for megaureter. *J Pediatr Surg*. 2012;47(12):2285–2288.

Bian Z, Liu X, Hua Y, et al. Laparoscopic management of multiple ureteral polyps in children. *J Urol*. 2011;186(4):1444–1449.

Blanc T, Muller C, Abdoul H, et al. Retroperitoneal laparoscopic pyeloplasty in children: long-term outcome and critical analysis of 10-year experience in a teaching center. *Eur Urol*. 2013;63(3):565–572.

Bomalaski MD, Hirschl RB, Bloom DA. Vesicoureteral reflux and ureteropelvic junction obstruction: association, treatment options and outcome. *J Urol*. 1997;157(3):969–974.

Bondarenko S. Laparoscopic extravesical transverse ureteral reimplantation in children with obstructive megaureter. *J Pediatr Urol*. 2013;9(4):437–441.

Bonnard A, Fouquet V, Carricaburu E, et al. Retroperitoneal laparoscopic versus open pyeloplasty in children. *J Urol*. 2005;173(5):1710–1713.

Bowen DK, Faasse MA, Liu DB, et al. Use of pediatric open, laparoscopic and robot-assisted laparoscopic ureteral reimplantation in the United States: 2000 to 2012. *J Urol*. 2016;196(1):207–212.

Boysen WR, Akhavan A, Ko J, et al. Prospective multicenter study on robot-assisted laparoscopic extravesical ureteral reimplantation (RALUR-EV): outcomes and complications. *J*

Pediatr Urol. 2018;14(3):262e1–262e6.

Boysen WR, Ellison JS, Kim C, et al. Multi-institutional review of outcomes and complications of robot-assisted laparoscopic extravesical ureteral reimplantation for treatment of primary vesicoureteral reflux in children. *J Urol*. 2017;197(6):1555–1561.

Brandstrom P, Esbjorner E, Herthelius M, et al. The Swedish reflux trial in children: I study design and study population characteristics. *J Urol*. 2010;184(1):274–279.

Brown T, Mandell J, Lebowitz RL. Neonatal hydronephrosis in the era of sonography. *AJR Am J Roentgenol*. 1987;148(5):959–963.

Brugnara M, Cecchetto M, Manfredi R, et al. Prenatal diagnosis of a rare form of congenital mid-ureteral stricture: a case report and literature revisited. *BMC Urol*. 2007;7:8.

Bujons A, Saldana L, Caffaratti J, et al. Can endoscopic balloon dilation for primary obstructive megaureter be effective in a long-term follow-up? *J Pediatr Urol*. 2015;11(1):37.e1–37.e6.

Burno DK, Glazier DB, Zaontz MR. Lessons learned about contralateral reflux after unilateral extravesical ureteral advancement in children. *J Urol*. 1998;160(3 Pt 2):995–997 [discussion 1038].

Canning DA. Is postoperative cystography necessary after ureteral reimplantation? *J Urol*. 2002;168(4 Pt 1):1646.

Canon SJ, Jayanthi VR, Lowe GJ. Which is better—retroperitoneoscopic or laparoscopic dismembered pyeloplasty in children? *J Urol*. 2007;178(4 Pt 2):1791–1795 [discussion 1795].

Canon SJ, Jayanthi VR, Patel AS. Vesicoscopic cross-trigonal ureteral reimplantation: a minimally invasive option for repair of vesicoureteral reflux. *J Urol*. 2007;178(1):269–273 [discussion 273].

Capozza N, Torino G, Nappo S, et al. Primary obstructive megaureter in infants: our experience with endoscopic balloon dilation and cutting balloon ureterotomy. *J Endourol*. 2015;29(1):1–5.

Carr MC, Casale P. Anomalies and surgery of the ureter in children. *Campbell-Walsh urology*. Saunders: Philadelphia, PA; 2012:3212–3235.

Carroll D, Chandran H, Joshi A, et al. Endoscopic placement of double-J ureteric stents in children as a treatment for primary obstructive megaureter. *Urol Ann*. 2010;2(3):114–118.

Casal Beloy I, Somoza Argibay I, Garcia Gonzalez M, et al. Endoscopic balloon dilatation in primary obstructive megaureter: Long-term results. *J Pediatr Urol*. 2018;14(2):167.e1–167.e5.

Casale P, Grady RW, Joyner BD, et al. Comparison of dismembered and nondismembered laparoscopic pyeloplasty in the pediatric patient. *J Endourol*. 2004;18(9):875–878.

Casale P, Patel RP, Kolon TF. Nerve sparing robotic extravesical ureteral reimplantation. *J Urol*. 2008;179(5):1987–1989 [discussion 1990].

Chertin B, Arafeh WA, Zeldin A, et al. Preliminary data on endoscopic treatment of vesicoureteric reflux with polyacrylate polyalcohol copolymer (Vantris®): surgical outcome following single injection. *J Pediatr Urol*. 2011;7(6):654–657.

Chertin B, Pollack A, Koulikov D, et al. Conservative treatment of ureteropelvic junction obstruction in children with antenatal diagnosis of hydronephrosis: lessons learned after 16 years of follow-up. *Eur Urol*. 2006;49(4):734–738.

Chertin B, Puri P. Endoscopic management of vesicoureteral reflux: does it stand the test of time? *Eur Urol*. 2002;42(6):598–606 [discussion 606].

Christen S, Mendoza M, Gobet R, et al. Late ureteral obstruction after injection of dextranomer/hyaluronic acid copolymer. *Urology*. 2014;83(4):920–922.

Chu DI, Shrivastava D, Van Batavia JP, et al. Outcomes of externalized pyeloureteral versus internal ureteral stent in pediatric robotic-assisted laparoscopic pyeloplasty. *J Pediatr Urol*. 2018 [pii: S1477-5131(18)30182-7].

Cohen B, Goldman SM, Kopilnick M, et al. Ureteropelvic junction obstruction: its occurrence in 3 members of a single family. *J Urol*. 1978;120(3):361–364.

Cohen SJ. The Cohen reimplantation technique. *Birth Defects Orig Artic Ser*. 1977;13(5):391–395.

Crozier J, Aw I, Tan PH, et al. Taking the STING out of ureteral obstruction. *J Endourol Case Rep*. 2016;2(1):166–168.

Cussen LJ. Dimensions of the normal ureter in infancy and childhood. *Invest Urol*. 1967;5(2):164–178.

Daher P, Diab N, Ghorayeb Z, et al. The Kalicinski ureteral folding technique for megaureter in children. Experience in 23 cases. *Eur J Pediatr Surg*. 1999;9(3):163–166.

Daines SL, Hodgson NB. Management of reflux in total duplication anomalies. *J Urol*. 1971;105(5):720–724.

Dangle PP, Kearns J, Anderson B, et al. Outcomes of infants undergoing robot-assisted laparoscopic pyeloplasty compared to open repair. *J Urol*. 2013;190(6):2221–2226.

Danuser H, Germann C, Pelzer N, et al. One- vs 4-week stent placement after laparoscopic and robot-assisted pyeloplasty: results of a prospective randomised single-centre study. *BJU Int*. 2014;113(6):931–935.

David S, Kelly C, Poppas DP. Nerve sparing extravesical repair of bilateral vesicoureteral reflux: description of technique and evaluation of urinary retention. *J Urol*. 2004;172(4 Pt 2):1617–1620 [discussion 1620].

Davis TD, Burns AS, Corbett ST, et al. Reoperative robotic pyeloplasty in children. *J Pediatr Urol*. 2016;12(6):394.e1–

394.e7.

De Castro R, Hubert KC, Palmer JS. Retrograde ureteral access after cross-trigonal ureteral reimplantation: a straightforward technique. *J Pediatr Urol*. 2011;7(1):57–60.

de Kort LM, Klijn AJ, Uiterwaal CS, et al. Ureteral reimplantation in infants and children: effect on bladder function. *J Urol*. 2002;167(1):285–287.

DeFoor W, Minevich E, Reddy P, et al. Results of tapered ureteral reimplantation for primary megaureter: extravesical versus intravesical approach. *J Urol*. 2004;172(4 Pt 2):1640–1643 [discussion 1643].

Dhillon HK. Prenatally diagnosed hydronephrosis: the Great Ormond Street experience. *Br J Urol*. 1998;81(Suppl 2):39–44.

Diamond DA, Rabinowitz R, Hoenig D, et al. The mechanism of new onset contralateral reflux following unilateral ureteroneocystostomy. *J Urol*. 1996;156(2 Pt 2):665–667.

Dixon JS, Jen PY, Yeung CK, et al. The vesico-ureteric junction in three cases of primary obstructive megaureter associated with ectopic ureteric insertion. *Br J Urol*. 1998;81(4):580–584.

Dodat H, Aubert D, Chavrier Y, et al. [Vesicoureteric reflux in children: long-term results of endoscopic treatment by Macroplastique injection]. *Prog Urol*. 2004;14(3):380–384.

Douville E, Hollinshead WH. The blood supply of the normal renal pelvis. *J Urol*. 1955;73(6):906–912.

Ehrlich RM. The ureteral folding technique for megaureter surgery. *J Urol*. 1985;134(4):668–670.

Ehrlich RM, Gershman A, Fuchs G. Laparoscopic vesicoureteroplasty in children: initial case reports. *Urology*. 1994;43(2):255–261.

Elder JS, Peters CA, Arant BS Jr, et al. Pediatric Vesicoureteral Reflux Guidelines Panel summary report on the management of primary vesicoureteral reflux in children. *J Urol*. 1997;157(5):1846–1851.

El-Ghoneimi A, Odet E, Lamer S, et al. Cystography after the Cohen ureterovesical reimplantation: is it necessary at a training center? *J Urol*. 1999;162(3 Pt 2):1201–1202.

Emiliani E, Talso M, Audouin M, et al. Modern flexible ureteroscopy in Cohen cross-trigonal ureteral reimplantations. *J Pediatr Urol*. 2017;13(3):329–331.

Eyssartier E, Mourtada H, Dieckmann AK, et al. [Chronic limping due to calcification in a subureteric Macroplastique® implant]. *Arch Pediatr*. 2012;19(12):1337–1339.

Farrugia MK, Hitchcock R, Radford A, British Association of Paediatric Urologists, et al. British Association of Paediatric Urologists consensus statement on the management of the primary obstructive megaureter. *J Pediatr Urol*. 2014;10(1):26–33.

Farrugia MK, Steinbrecher HA, Malone PS. The utilization of stents in the management of primary obstructive megaureters requiring intervention before 1 year of age. *J Pediatr Urol*. 2011;7(2):198–202.

Figenshau RS, Clayman RV. Endourologic options for management of ureteropelvic junction obstruction in the pediatric patient. *Urol Clin North Am*. 1998;25(2):199–209.

Fretz PC, Austin JC, Cooper CS, et al. Long-term outcome analysis of Starr plication for primary obstructive megaureters. *J Urol*. 2004;172(2):703–705.

Friedlander DA, Ludwig WW, Jayman JR, et al. The effect of prior endoscopic correction of vesicoureteral reflux on open ureteral reimplantation: surgical outcomes and costs. *J Pediatr Urol*. 2018;14(3):268.e1–268.e5.

Fung LC, McLorie GA, Jain U, et al. Voiding efficiency after ureteral reimplantation: a comparison of extravesical and intravesical techniques. *J Urol*. 1995;153(6):1972–1975.

Gao F, Gu Y, Huang J, et al. Radiofrequency ablation of retroperitoneal metastatic lymph nodes from hepatocellular carcinoma. *Acad Radiol*. 2012;19(8):1035–1040.

Gill IS, Ponsky LE, Desai M, et al. Laparoscopic cross-trigonal Cohen ureteroneocystostomy: novel technique. *J Urol*. 2001;166(5):1811–1814.

Glenn JF. Analysis of 51 patients with horseshoe kidney. *N Engl J Med*. 1959;261:684–687.

Glenn JF, Anderson EE. Distal tunnel ureteral reimplantation. *J Urol*. 1967;97(4):623–626.

Gokce I, Biyikli N, Tugtepe H, et al. Clinical spectrum of antenatally detected urinary tract abnormalities with respect to hydronephrosis at postnatal ultrasound scan. *Pediatr Surg Int*. 2012;28(5):543–552.

Gonzales ET, Glenn JF, Anderson EE. Results of distal tunnel ureteral reimplantation. *J Urol*. 1972;107(4):572–575.

Gosling JA, Dixon JS. Functional obstruction of the ureter and renal pelvis. A histological and electron microscopic study. *Br J Urol*. 1978;50(3):145–152.

Gregoir W. [The surgical treatment of congenital vesico-ureteral reflux]. *Acta Chir Belg*. 1964;63:431–439.

Grimsby GM, Dwyer ME, Jacobs MA, et al. Multi-institutional review of outcomes of robot-assisted laparoscopic extravesical ureteral reimplantation. *J Urol*. 2015;193(5 Suppl):1791–1795.

Grossklaus DJ, Pope JC, Adams MC, et al. Is postoperative cystography necessary after ureteral reimplantation? *Urology*. 2001;58(6):1041–1045.

Grossman IC, Cromie WJ, Wein AJ, et al. Renal hypertension secondary to ureteropelvis junction obstruction. Unusual presentation and new therapeutic modality. *Urology*. 1981;17(1):69–72.

Gundeti MS, Boysen WR, Shah A. Robot-assisted laparoscopic extravesical ureteral reimplantation: technique modifications contribute to optimized outcomes. *Eur Urol*. 2016;70(5):818–823.

Gundeti MS, Reynolds WS, Duffy PG, et al. Further experience with the vascular hitch (laparoscopic transposition of lower pole crossing vessels): an alternate treatment for pediatric ureterovascular ureteropelvic junction obstruction. *J Urol*. 2008;180(4 Suppl):1832–1836 [discussion 1836].

Gupta NP, Mukherjee S, Nayyar R, et al. Transmesocolic robot-assisted pyeloplasty: single center experience. *J Endourol*. 2009;23(6):945–948.

Hellstrom B, Vahlquist B. Experimental inoculation of roseola infantum. *Acta Paediatr*. 1951;40(3):189–197.

Hellstrom M, Hjalmas K, Jacobsson B, et al. Normal ureteral diameter in infancy and childhood. *Acta Radiol Diagn (Stockh)*. 1985;26(4):433–439.

Helmy T, Blanc T, Paye-Jaouen A, et al. Preliminary experience with external ureteropelvic stent: alternative to double-J stent in laparoscopic pyeloplasty in children. *J Urol*. 2011;185(3):1065–1069.

Hendren WH. Operative repair of megaureter in children. *J Urol*. 1969;101(4):491–507.

Herz D, Hafez A, Bagli D, et al. Efficacy of endoscopic subureteral polydimethylsiloxane injection for treatment of vesicoureteral reflux in children: a North American clinical report. *J Urol*. 2001;166(5):1880–1886.

Holmdahl G, Brandstrom P, Lackgren G, et al. The Swedish reflux trial in children: II Vesicoureteral reflux outcome. *J Urol*. 2010;184(1):280–285.

Houben CH, Wischermann A, Borner G, et al. Outcome analysis of pyeloplasty in infants. *Pediatr Surg Int*. 2000;16(3):189–193.

Howe AS, Palmer LS. An inguinal approach to complex extravesical ureteral reimplantation. *Urology*. 2017;106:178–182.

Hubert KC, Kokorowski PJ, et al. New contralateral vesicoureteral reflux after unilateral ureteral reimplantation: predictive factors and clinical outcomes. *J Urol*. 2014;191(2):451–457.

Hwang AH, McAleer IM, Shapiro E, et al. Congenital mid ureteral strictures. *J Urol*. 2005;174(5):1999–2002.

Janetschek G, Radmayr C, Bartsch G. Laparoscopic ureteral anti-reflux plasty reimplantation. First clinical experience. *Ann Urol (Paris)*. 1995;29(2):101–105.

Je BK, Kim HK, Horn PS. Incidence and spectrum of renal complications and extrarenal diseases and syndromes in 380 children and young adults with horseshoe kidney. *Am J Roentgenol*. 2015;205(6):1306–1314.

Johnston JH, Evans JP, Glassberg KI, et al. Pelvic hydronephrosis in children: a review of 219 personal cases. *J Urol*. 1977;117(1):97–101.

Joseph DB. Megaureter. Docimo SD, Canning DA, Khoury AE. *The Kelalis-King-Belman textbook of clinical pediatric urology*. 5th ed. Informa Healthcare UK: Abington; 2007:577–592.

Joseph DB, Bauer SB, Colodny AH, et al. Lower pole ureteropelvic junction obstruction and incomplete renal duplication. *J Urol*. 1989;141(4):896–899.

Kaefer M, Misseri R, Frank E, et al. Refluxing ureteral reimplantation: a logical method for managing neonatal UVJ obstruction. *J Pediatr Urol*. 2014;10(5):824–830.

Kalicinski ZH, Kansy J, Kotarbinska B, et al. Surgery of megaureters—modification of Hendren's operation. *J Pediatr Surg*. 1977;12(2):183–188.

Kalisvaart JF, Scherz HC, Cuda S, et al. Intermediate to long-term follow-up indicates low risk of recurrence after Double

HIT endoscopic treatment for primary vesico-ureteral reflux. *J Pediatr Urol*. 2012;8(4):359–365.

Kanamori Y, Iwanaka T, Sugiyama M, et al. Antenatally diagnosed, intermittently worsened hydronephrosis caused by a ureteral polyp. *Pediatr Int*. 2010;52(1):e11–e13.

Kang HJ, Lee HY, Jin MH, et al. Decreased interstitial cells of Cajal-like cells, possible cause of congenital refluxing megaureters: histopathologic differences in refluxing and obstructive megaureters. *Urology*. 2009;74(2):318–323.

Karakus SC, User IR, Kilic BD, et al. The comparison of dextranomer/hyaluronic acid and polyacrylate-polyalcohol copolymers in endoscopic treatment of vesicoureteral reflux. *J Pediatr Surg*. 2016;51(9):1496–1500.

Karnak I, Woo LL, Shah SN, et al. Prenatally detected ureteropelvic junction obstruction: clinical features and associated urologic abnormalities. *Pediatr Surg Int*. 2008;24(4):395–402.

Kasturi S, Sehgal SS, Christman MS, et al. Prospective long-term analysis of nerve-sparing extravesical robotic-assisted laparoscopic ureteral reimplantation. *Urology*. 2012;79(3):680–683.

Kavoussi LR, Peters CA. Laparoscopic pyeloplasty. *J Urol*. 1993;150(6):1891–1894.

Kelalis PP, Culp OS, Stickler GB, et al. Ureteropelvic obstruction in children: experiences with 109 cases. *J Urol*. 1971;106(3):418–422.

Khan M, Ahangar S, Nazir SS, et al. Laparoscopic trans-mesocolic pyeloplasty in children: initial experience from a center in India. *Saudi J Kidney Dis Transpl*. 2011;22(4):841–846.

Kim EH, Tanagho YS, Traxel EJ, et al. Endopyelotomy for pediatric ureteropelvic junction obstruction: a review of our 25-year experience. *J Urol*. 2012;188(4 Suppl):1628–1633.

Kim FJ, Herrell SD, Jahoda AE, et al. Complications of acucise endopyelotomy. *J Endourol*. 1998;12(5):433–436.

King LR. Megaloureter: definition, diagnosis and management. *J Urol*. 1980;123(2):222–223.

Kirsch AJ, Perez-Brayfield M, Smith EA, et al. The modified sting procedure to correct vesicoureteral reflux: improved results with submucosal implantation within the intramural ureter. *J Urol*. 2004;171(6 Pt 1):2413–2416.

Kitchens D, Minevich E, DeFoor W, et al. Endoscopic injection of dextranomer/hyaluronic acid copolymer to correct vesicoureteral reflux following failed ureteroneocystostomy. *J Urol*. 2006;176(4 Pt 2):1861–1863.

Kitchens DM, DeFoor W, Minevich E, et al. End cutaneous ureterostomy for the management of severe hydronephrosis. *J Urol*. 2007;177(4):1501–1504.

Kocaoglu C. Endoscopic treatment of grades IV and V vesicoureteral reflux with two bulking substances: dextranomer hyaluronic acid copolymer versus polyacrylate polyalcohol copolymer in children. *J Pediatr Surg*. 2016;51(10):1711–1715.

Kocherov S, Ulman I, Nikolaev S, et al. Multicenter survey of endoscopic treatment of vesicoureteral reflux using polyacrylate-polyalcohol bulking copolymer (Vantris). *Urology*. 2014;84(3):689–693.

Koff SA. Problematic ureteropelvic junction obstruction. *J Urol*. 1987;138(2):390.

Koff SA. Neonatal management of unilateral hydronephrosis. Role for delayed intervention. *Urol Clin North Am*. 1998;25(2):181–186.

Kolon TF, Gray CL, Sutherland RW, et al. Upper urinary tract manifestations of the VACTERL association. *J Urol*. 2000;163(6):1949–1951.

Kurtz MP, Leow JJ, Varda BK, et al. Robotic versus open pediatric ureteral reimplantation: costs and complications from a nationwide sample. *J Pediatr Urol*. 2016;12(6):408.e1–408.e6.

Kutikov A, Guzzo TJ, Canter DJ, et al. Initial experience with laparoscopic transvesical ureteral reimplantation at the Children's Hospital of Philadelphia. *J Urol*. 2006;176(5):2222–2225 [discussion 2225–2226].

Kutikov A, Nguyen M, Guzzo T, et al. Robot assisted pyeloplasty in the infant—lessons learned. *J Urol*. 2006;176(5):2237–2239 [discussion 2239–2240].

Lackgren G, Skoldenberg E, Stenberg A. Endoscopic treatment with stabilized nonanimal hyaluronic acid/dextranomer gel is effective in vesicoureteral reflux associated with bladder dysfunction. *J Urol*. 2007;177(3):1124–1128 [discussion 1128–1129].

Lackgren G, Wahlin N, Skoldenberg E, et al. Long-term followup of children treated with dextranomer/hyaluronic acid copolymer for vesicoureteral reflux. *J Urol*. 2001;166(5):1887–1892.

Lakshmanan Y, Fung LC. Laparoscopic extravesicular ureteral reimplantation for vesicoureteral reflux: recent technical advances. *J Endourol*. 2000;14(7):589–593 [discussion 593–584].

Lavelle MT, Conlin MJ, Skoog SJ. Subureteral injection of Deflux for correction of reflux: analysis of factors predicting success. *Urology*. 2005;65(3):564–567.

Lavine MA, Siddiq FM, Cahn DJ, et al. Vesicoureteral reflux after ureteroneocystostomy: indications for postoperative voiding cystography. *Tech Urol*. 2001;7(1):50–54.

Lebowitz RL, Blickman JG. The coexistence of ureteropelvic junction obstruction and reflux. *Am J Roentgenol*. 1983;140(2):231–238.

Lebowitz RL, Griscom NT. Neonatal hydronephrosis: 146

cases. *Radiol Clin North Am*. 1977;15(1):49–59.

Lee BR, Silver RI, Partin AW, et al. A quantitative histologic analysis of collagen subtypes: the primary obstructed and refluxing megaureter of childhood. *Urology*. 1998;51(5):820–823.

Lee RS, Retik AB, Borer JG, et al. Pediatric robot assisted laparoscopic dismembered pyeloplasty: comparison with a cohort of open surgery. *J Urol*. 2006;175(2):683–687 [discussion 687].

Lee SD, Akbal C, Kaefer M. Refluxing ureteral reimplant as temporary treatment of obstructive megaureter in neonate and infant. *J Urol*. 2005;173(4):1357–1360 [discussion 1360].

Leissner J, Allhoff EP, Wolff W, et al. The pelvic plexus and antireflux surgery: topographical findings and clinical consequences. *J Urol*. 2001;165(5):1652–1655.

Li R, Lightfoot M, Alsyouf M, et al. Diagnosis and management of ureteral fibroepithelial polyps in children: a new treatment algorithm. *J Pediatr Urol*. 2015;11(1):22.e1–22.e6.

Lich R, Howerton LW, Davis LA. Recurrent urosepsis in children. *J Urol*. 1961;86(5):554.

Lindgren BW, Hagerty J, Meyer T, et al. Robot-assisted laparoscopic reoperative repair for failed pyeloplasty in children: a safe and highly effective treatment option. *J Urol*. 2012;188(3):932–937.

Lipski BA, Mitchell ME, Burns MW. Voiding dysfunction after bilateral extravesical ureteral reimplantation. *J Urol*. 1998;159(3):1019–1021.

Liss ZJ, Olsen TM, Roelof BA, et al. Duration of urinary leakage after open non-stented dismembered pyeloplasty in pediatric patients. *J Pediatr Urol*. 2013;9(5):613–616.

Liu D, Zhou H, Ma L, et al. Comparison of laparoscopic approaches for dismembered pyeloplasty in children with ureteropelvic junction obstruction: critical analysis of 11-year experiences in a single surgeon. *Urology*. 2017;101:50–55.

Lowe FC, Marshall FF. Ureteropelvic junction obstruction in adults. *Urology*. 1984;23(4):331–335.

MacNeily AE, Maizels M, Kaplan WE, et al. Does early pyeloplasty really avert loss of renal function? A retrospective review. *J Urol*. 1993;150(2 Pt 2):769–773.

Madec FX, Faraj S, Villemagne T, et al. Laparoscopic transposition of lower-pole crossing vessels: Long-term follow-up of 33 patients at puberty. *J Pediatr Urol*. 2016;12(4):226.e1–226.e6.

Marchini GS, Hong YK, Minnillo BJ, et al. Robotic assisted laparoscopic ureteral reimplantation in children: case matched comparative study with open surgical approach. *J Urol*. 2011;185(5):1870–1875.

Marotte JB, Smith DP. Extravesical ureteral reimplantations for the correction of primary reflux can be done as outpatient procedures. *J Urol*. 2001;165(6 Pt 2):2228–2231.

Matouschek E. [Treatment of vesicorenal reflux by transurethral teflon-injection (author's transl)]. *Urologe A*. 1981;20(5):263–264.

Matsuno T, Tokunaka S, Koyanagi T. Muscular development in the urinary tract. *J Urol*. 1984;132(1):148–152.

McAleer IM, Kaplan GW. Renal function before and after pyeloplasty: does it improve? *J Urol*. 1999;162(3 Pt 2):1041–1044.

McCool AC, Joseph DB. Postoperative hospitalization of children undergoing cross-trigonal ureteroneocystostomy. *J Urol*. 1995;154(2 Pt 2):794–796.

McLellan DL, Retik AB, Bauer SB, et al. Rate and predictors of spontaneous resolution of prenatally diagnosed primary nonrefluxing megaureter. *J Urol*. 2002;168(5):2177–2180 [discussion 2180].

Metzelder ML, Schier F, Petersen C, et al. Laparoscopic transabdominal pyeloplasty in children is feasible irrespective of age. *J Urol*. 2006;175(2):688–691.

Minevich E, Wacksman J, Lewis AG, et al. Incidence of contralateral vesicoureteral reflux following unilateral extravesical detrusorrhaphy (ureteroneocystostomy). *J Urol*. 1998;159(6):2126–2128.

Munoz AI, Baralt JF, Melendez MT. Arterial hypertension in infants with hydronephrosis. Report of six cases. *Am J Dis Child*. 1977;131(1):38–40.

Nasser FM, Shouman AM, ElSheemy MS, et al. Dismembered pyeloplasty in infants 6 months old or younger with and without external trans-anastomotic nephrostent: a prospective randomized study. *Urology*. 2017;101:38–44.

Nixon HH. Hydronephrosis in children; a clinical study of seventy-eight cases with special reference to the role of aberrant renal vessels and the results of conservative operations. *Br J Surg*. 1953;40(164):601–609.

Notley RG. Electron microscopy of the upper ureter and the pelvi-ureteric junction. *Br J Urol*. 1968;40(1):37–52.

O'Donnell B, Puri P. Treatment of vesicoureteric reflux by endoscopic injection of Teflon. *Br Med J (Clin Res Ed)*. 1984;289(6436):7–9.

O'Donnell B, Puri P. Endoscopic correction of primary vesicoureteric reflux. *Br J Urol*. 1986;58(6):601–604.

Olsen LH. Robotics in paediatric urology. *J Pediatr Urol*. 2006;2(1):40–45.

Olsen LH, Deding D, Yeung CK, et al. Computer assisted laparoscopic pneumovesical ureter reimplantation a.m. Cohen: initial experience in a pig model. *APMIS*. 2003;109:23–25.

Olsen LH, Jorgensen TM. Computer assisted pyeloplasty in children: the retroperitoneal approach. *J Urol*. 2004;171(6 Pt

2):2629–2631.

Olsen LH, Rawashdeh YF. Pyeloplasty: a retroperitoneal approach. Gundeti MS. *Pediatric robotic and reconstructive urology*. Wiley-Blackwell; 2011:125–128.

Olsen LH, Rawashdeh YF, Jorgensen TM. Pediatric robot assisted retroperitoneoscopic pyeloplasty: a 5-year experience. *J Urol*. 2007;178(5):2137–2141 [discussion 2141].

O'Reilly PH. Functional outcome of pyeloplasty for ureteropelvic junction obstruction: prospective study in 30 consecutive cases. *J Urol*. 1989;142(2 Pt 1):273–276.

O'Reilly PH, Brooman PJ, Mak S, et al. The long-term results of Anderson-Hynes pyeloplasty. *BJU Int*. 2001;87(4):287–289.

Ormaechea M, Paladini M, Pisano R, et al. Vantris, a biocompatible, synthetic, non-biodegradable, easy-to-inject bulking substance. Evaluation of local tissular reaction, localized migration and long-distance migration. *Arch Esp Urol*. 2008;61(2):263–268.

Ormaechea M, Ruiz E, Denes E, et al. New tissue bulking agent (polyacrylate polyalcohol) for treating vesicoureteral reflux: preliminary results in children. *J Urol*. 2010;183(2):714–717.

Osbun N, Ellison JS, Lendvay TS. Robot-assisted laparoscopic excision of ureteral and ureteropelvic junction fibroepithelial polyps in children. *J Endourol*. 2016;30(8):896–900.

Ossandon F, Romanini MV, Torre M. A modified technique of ureteroplasty for megaureter in children. *J Urol*. 2005;174(4 Pt 1):1417–1420.

Osther PJ, Geertsen U, Nielsen HV. Ureteropelvic junction obstruction and ureteral strictures treated by simple high-pressure balloon dilation. *J Endourol*. 1998;12(5):429–431.

Palmer JS. Bilateral extravesical ureteral reimplantation in toilet-trained children: short-stay procedure without urinary retention. *Urology*. 2009;73(2):285–288.

Papagiannopoulos D, Rosoklija I, Cheng E, et al. Delayed obstruction with asymptomatic loss of renal function after dextranomer/hyaluronic acid copolymer (deflux) injection for vesicoureteral reflux: a close look at a disturbing outcome. *Urology*. 2017;101:63–66.

Paquin AJ Jr. Ureterovesical anastomosis: the description and evaluation of a technique. *J Urol*. 1959;82:573–583.

Parrott TS, Woodard JR, Wolpert JJ. Ureteral tailoring: a comparison of wedge resection with infolding. *J Urol*. 1990;144(2 Pt 1):328–329.

Perdzynski W, Kalicinski ZH. Long-term results after megaureter folding in children. *J Pediatr Surg*. 1996;31(9):1211–1217.

Perovic S. Surgical treatment of megaureters using detrusor tunneling extravesical ureteroneocystostomy. *J Urol*. 1994;152(2 Pt 2):622–625 [discussion 626–627].

Peters CA. Pediatric robot-assisted pyeloplasty. *J Endourol*. 2011;25(2):179–185.

Peters CA, Skoog SJ, Arant BS Jr, et al. Summary of the AUA guideline on management of primary vesicoureteral reflux in children. *J Urol*. 2010;184(3):1134–1144.

Peters CA, Woo R. Intravesical robotically assisted bilateral ureteral reimplantation. *J Endourol*. 2005;19(6):618–621 [discussion 621–612].

Pirker ME, Rolle U, Shinkai T, et al. Prenatal and postnatal neuromuscular development of the ureterovesical junction. *J Urol*. 2007;177(4):1546–1551.

Politano VA, Leadbetter WF. An operative technique for the correction of vesicoureteral reflux. *J Urol*. 1958;79(6):932–941.

Pope J, Koch MO. Ureteral replacement with reconfigured colon substitute. *J Urol*. 1996;155(5):1693–1695.

Poulsen EU, Jorgensen TM, Taagehoj-Jensen F, et al. The functional outcome of Anderson-Hynes pyeloplasty for hydronephrosis. *Scand J Urol Nephrol*. 1987;21(3):213–217.

Privett JT, Jeans WD, Roylance J. The incidence and importance of renal duplication. *Clin Radiol*. 1976;27(4):521–530.

Puri P, Chertin B, Velayudham M, et al. Treatment of vesicoureteral reflux by endoscopic injection of dextranomer/hyaluronic acid copolymer: preliminary results. *J Urol*. 2003;170(4 Pt 2):1541–1544.

Puri P, Ninan GK, Surana R. Subureteric Teflon injection (STING). Results of a European survey. *Eur Urol*. 1995;27(1):71–75.

Rabinowitz R, Barkin M, Schillinger JF, et al. Surgical treatment of the massively dilated ureter in children. Part I. management by cutaneous ureterostomy. *J Urol*. 1977;117(5):658–662.

Ragan DC, Casale AJ, Rink RC, et al. Genitourinary anomalies in the CHARGE association. *J Urol*. 1999;161(2):622–625.

Ranawaka R, Hennayake S. Resolution of primary non-refluxing megaureter: an observational study. *J Pediatr Surg*. 2013;48(2):380–383.

Robson WJ, Rudy SM, Johnston JH. Pelviureteric obstruction in infancy. *J Pediatr Surg*. 1976;11(1):57–61.

Routh JC, Tollefson MK, Ashley RA, et al. Iatrogenic ureteral injury: can adult repair techniques be used on children? *J Pediatr Urol*. 2009;5(1):53–55.

Rubenwolf P, Herrmann-Nuber J, Schreckenberger M, et al. Primary non-refluxive megaureter in children: single-center experience and follow-up of 212 patients. *Int Urol Nephrol*. 2016;48(11):1743–1749.

Rubenwolf PC, Ebert AK, Ruemmele P, et al. Delayed-onset ureteral obstruction after endoscopic dextranomer/hyaluronic acid copolymer (Deflux) injection for treatment of vesicoureteral reflux in children: a case series. *Urology*. 2013;81(3):659–662.

Sakoda A, Cherian A, Mushtaq I. Laparoscopic transposition of lower pole crossing vessels (‘vascular hitch’) in pure extrinsic pelvi-ureteric junction (PUJ) obstruction in children. *BJU Int*. 2011;108(8):1364–1368.

Salem YH, Majd M, Rushton HG, et al. Outcome analysis of pediatric pyeloplasty as a function of patient age, presentation and differential renal function. *J Urol*. 1995;154(5):1889–1893.

Schneider A, Ferreira CG, Delay C, et al. Lower pole vessels in children with pelviureteric junction obstruction: laparoscopic vascular hitch or dismembered pyeloplasty? *J Pediatr Urol*. 2013;9(4):419–423.

Schomburg JL, Haberman K, Willihnganz-Lawson KH, et al. Robot-assisted laparoscopic ureteral reimplantation: a single surgeon comparison to open surgery. *J Pediatr Urol*. 2014;10(5):875–879.

Sedberry-Ross S, Rice DC, Pohl HG, et al. Febrile urinary tract infections in children with an early negative voiding cystourethrogram after treatment of vesicoureteral reflux with dextranomer/hyaluronic acid. *J Urol*. 2008;180(4 Suppl):1605–1609 [discussion 1610].

Sedlacek J, Kocvara R, Molcan J, et al. Transmesocolic laparoscopic pyeloplasty in children: a standard approach for the left-side repair. *J Pediatr Urol*. 2010;6(2):171–177.

Shadpour P, Nayyeri RK, Daneshvar R, et al. Prospective clinical trial to compare standard colon-reflecting with transmesocolic laparoscopic pyeloplasty. *BJU Int*. 2012;110(11):1814–1818.

Shaul DB, Cunningham JA, Lowe P, et al. Infant pyeloplasty is a low-risk procedure. *J Pediatr Surg*. 1994;29(2):343–347.

Shive ML, Baskin LS, Harris CR, et al. Ureteral fibroepithelial polyp causing urinary obstruction. *J Radiol Case Rep*. 2012;6(7):23–28.

Shokeir AA, Nijman RJ. Primary megaureter: current trends in diagnosis and treatment. *BJU Int*. 2000;86(7):861–868.

Shukla AR, Cooper J, Patel RP, et al. Prenatally detected primary megaureter: a role for extended followup. *J Urol*. 2005;173(4):1353–1356.

Smith ED. Report of Working Party to establish the international nomenclature for the large ureter. *Birth Defects Orig Artic Ser*. 1977;13(5):3–8.

Smith RP, Oliver JL, Peters CA. Pediatric robotic extravesical ureteral reimplantation: comparison with open surgery. *J Urol*. 2011;185(5):1876–1881.

Sparks S, Decambre M, Christman M, et al. Salvage ureteral reimplantation after failure of dextranomer/hyaluronic acid injection. *J Urol*. 2011;186(1):257–260.

Sparr KE, Balcom AH, Mesrobian HG. Incidence and natural history of contralateral vesicoureteral reflux in patients presenting with unilateral disease. *J Urol*. 1998;160(3 Pt 2):1023–1025.

Squitieri AP, Ceccarelli FE, Wurster JC. Hypertension with elevated renal vein renins secondary to ureteropelvic junction obstruction. *J Urol*. 1974;111(3):284–287.

Starr A. Ureteral plication. A new concept in ureteral tailoring for megaureter. *Invest Urol*. 1979;17(2):153–158.

Stenberg A, Lackgren G. A new bioimplant for the endoscopic treatment of vesicoureteral reflux: experimental and short-term clinical results. *J Urol*. 1995;154(2 Pt 2):800–803.

Stephens FD. Ureterovascular hydronephrosis and the aberrant renal vessels. *J Urol*. 1982;128(5):984–987.

Sweeney DD, Ost MC, Schneck FX, et al. Laparoscopic pyeloplasty for ureteropelvic junction obstruction in children. *J Laparoendosc Adv Surg Tech A*. 2011;21(3):261–265.

Szydelko T, Kasprzak J, Lewandowski J, et al. Dismembered laparoscopic Anderson-Hynes pyeloplasty versus nondismembered laparoscopic Y-V pyeloplasty in the treatment of patients with primary ureteropelvic junction obstruction: a prospective study. *J Endourol*. 2012;26(9):1165–1170.

Tan HL, Roberts JP. Laparoscopic dismembered pyeloplasty in children: preliminary results. *Br J Urol*. 1996;77(6):909–913.

Tanagho EA. Intrauterine fetal ureteral obstruction. *J Urol*. 1973;109(2):196–203.

Uson AC, Cox LA, Lattimer JK. Hydronephrosis in infants and children. I. Some clinical and pathological aspects. *JAMA*. 1968;205(6):323–326.

Wallis MC, Brown DH, Jayanthi VR, et al. A novel technique for ureteral catheterization and/or retrograde ureteroscopy after cross-trigonal ureteral reimplantation. *J Urol*. 2003;170(4 Pt 2):1664–1666 [discussion 1666].

Warchol S, Krzemien G, Szmigielska A, et al. Comparison of results of endoscopic correction of vesicoureteral reflux in children using two bulking substances: Dextranomer/hyaluronic acid copolymer (Deflux) versus polyacrylate-polyalcohol copolymer (Vantris). *J Pediatr Urol*. 2016;12(4):256.e1–256.e4.

Warchol S, Krzemien G, Szmigielska A, et al. Endoscopic correction of vesicoureteral reflux in children using polyacrylate-polyalcohol copolymer (Vantris): 5-years of prospective follow-up. *Cent European J Urol*. 2017;70(3):314–319.

Whitmore KE, Ehrlich RM. Vascular integrity of the distal ureter following combined tapering and cross trigonal reimplantation. *J Urol*. 1988;139(3):621–624.

Williams DI, Karlaftis CM. Hydronephrosis due to pelvi-ureteric obstruction in the newborn. *Br J Urol*.

1966;38(2):138–144.

Williams DI, Kenawi MM. The prognosis of pelviureteric obstruction in childhood: a review of 190 cases. *Eur Urol*. 1976;2(2):57–63.

Yeung CK, Sihoe JD, Borzi PA. Endoscopic cross-trigonal ureteral reimplantation under carbon dioxide bladder insufflation: a novel technique. *J Endourol*. 2005;19(3):295–299.

Yeung CK, Tam YH, Sihoe JD, et al. Retroperitoneoscopic dismembered pyeloplasty for pelvi-ureteric junction obstruction in infants and children. *BJU Int*. 2001;87(6):509–513.

Yucel S, Baskin LS. Neuroanatomy of the ureterovesical junction: clinical implications. *J Urol*. 2003;170(3):945–948.

Zaontz MR, Maizels M, Sugar EC, et al. Detrusorrhaphy: extravesical ureteral advancement to correct vesicoureteral reflux in children. *J Urol*. 1987;138(4 Pt 2):947–949.

43

Management of Pediatric Kidney Stone Disease

Gregory E. Tasian MD, MSc, MSCE, Lawrence A. Copelovitch MD

Kidney stone disease (nephrolithiasis) is a disorder of mineral metabolism characterized by acute symptomatic events that often recur. Nephrolithiasis affects 9% of the US population (Scales et al., 2012) and results in health care costs of more than $10 billion annually (Pearle et al., 2005), exceeding the treatment costs for prostate cancer and urinary tract infection (UTI) in women by more than 3 billion and 5 billion dollars, respectively (Khan et al., 2016). The prevalence of nephrolithiasis in the United States increased from 5% (1988 to 1994) to 9% (2007 to 2010) (Scales et al., 2012; Stamatelou et al., 2003). During this time, disproportionate increases in the incidence of nephrolithiasis of 5% to 10% per year have been reported for youth. **Among all age groups, the greatest increases in kidney stone disease have been observed among adolescents, particularly females** (Dwyer et al., 2012; Routh et al., 2010a, 2010b; Sas et al., 2010). The annual incidence of nephrolithiasis among girls 15 to 19 years of age increased from 75 per 100,000 in 1997 to 120 per 100,000 in 2012 (Tasian et al., 2016).

Although the gender gap has narrowed among adults (Scales et al., 2007), kidney stones are still more common among men (Scales et al., 2012). Among children and adolescents, however, girls have consistently been observed to have a higher frequency of stones compared with boys (Sas et al., 2010; Bush et al., 2010; Matlaga et al., 2010). The reasons for this are unclear, in part because of the lack of robust cohort studies in which the interaction of sex and putative stone risk factors could be explored. Nephrolithiasis among children and adolescents is most common among non-Hispanic Caucasians, followed by Hispanic Caucasians and African-Americans (Routh et al., 2010a, 2010b; Sas et al., 2010; Bush et al., 2010).

The increasing incidence of pediatric nephrolithiasis has resulted in increasing hospitalizations, emergency department visits, surgeries, and health care expenditures (Routh et al., 2010a, 2010b; Bush et al., 2010). Pediatric nephrolithiasis was estimated to cost the United States at least $375 million annually in hospital and emergency department care in 2010 (Wang et al., 2015). The true economic burden is higher when outpatient visits, medications, and diagnostic imaging are considered. In addition, indirect costs of missed work and lost wages by caregivers are substantial. Saigal estimated that management of nephrolithiasis resulted in an average of 19 hours per year of work loss, including 5 hours associated with ambulatory care visits (Saigal et al., 2005). The average work loss for an inpatient admission for stones was 48 hours. This increase in the incidence of nephrolithiasis in children has implications for future health care spending and for health services allocation and will increase the prevalence of what, for many, is a chronic condition associated with substantial pain and morbidity (Ljunghall and Danielson, 1984).

Given the emergence of nephrolithiasis as a pediatric disease, urologists will evaluate and treat a growing number of adult patients whose kidney stone disease began during childhood. To reduce the burden of disease across the lifespan, it is necessary that primary care providers and specialists understand the optimal evaluation and treatment strategies for children with nephrolithiasis. Stones should always be collected for analysis at the time of surgery or, when possible, when patients pass stones spontaneously. Knowledge of stone composition informs targeted therapy to decrease stone recurrence and also identifies those patients with rare, monogenic causes of kidney stones, such as cystinuria and primary xanthinuria. In adults, approximately 75% to 80% of stones are composed of predominantly calcium oxalate, 5% are predominantly calcium phosphate, 10% to 20% are struvite, and 5% are pure uric acid (Coe et al., 1992). **Contemporary analyses of stones that formed during childhood show a similar distribution, with calcium phosphate stones being slightly more common and uric acid stones being less common** (Kirejczyk et al., 2014). These differences may be caused, in part, by children's more alkaline urine. The notion that most stones that form during childhood are caused by rare genetic causes, inborn errors of metabolism, or infection is no longer true. Children with calcium oxalate stones have the same anatomic characteristics of the renal papillae as adults (Fig. 43.1). These include Randall's plaques, which are composed of hydroxyapatite (Evan et al., 2003, 2006), and are the platform on which most idiopathic calcium oxalate stones grow (see Fig. 43.1).

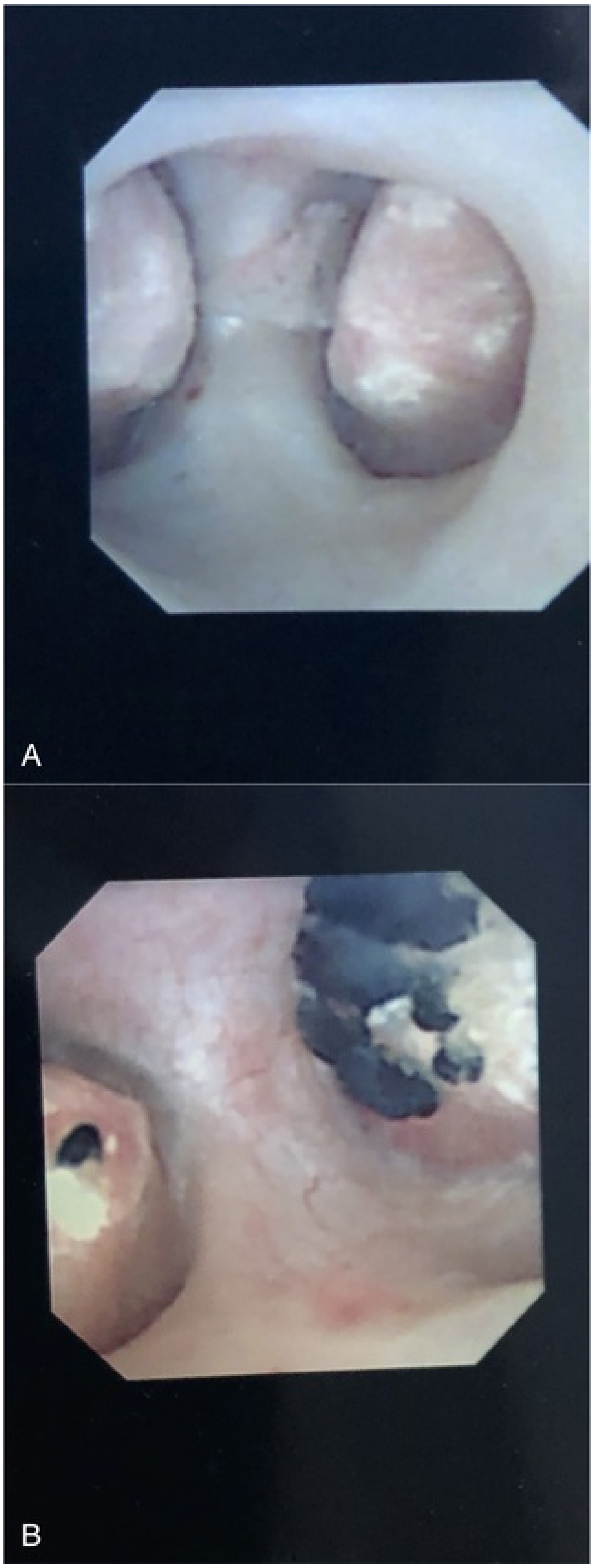

FIG. 43.1 Randall's plaques in a 16-year-old girl with calcium oxalate stones. Randall's plaques (A) appear as white deposits on the renal

papillae and are the sites on which idiopathic calcium oxalate stone attach (B).

Kidney stone disease that begins during childhood has a high risk for recurrence. Approximately 50% of patients who develop kidney stone disease during childhood will develop a recurrent stone within 3 to 5 years of the index stone (Lao et al., 2014; Tasian et al., 2017; Tekin et al., 2002), which is similar to or higher than rates reported for adults (Ljunghall and Danielson, 1984; Johnson et al., 1979). Contemporary studies of stone recurrence among pediatric patients have reported a higher probability of recurrence compared with historic studies (Pietrow et al., 2001; Diamond et al., 1989). These differences may be attributed to differential follow-up, inclusion of many patients with infectious stones (Diamond et al., 1989), and cohorts who don't reflect the current epidemiology of the disease. It is probable that many patients who have recurrent stone episodes during childhood will continue to recur during adulthood; however, there are no existing cohorts that allow for examination of the epidemiology of kidney stone disease across the lifespan.

Extrarenal Manifestations

In addition to a greater lifetime burden of disease as a result of recurrent stone events, exposure to ionizing radiation, and morbidity from surgical interventions, **patients who develop kidney stone disease during childhood are at risk for development of comorbidities such as decreased bone mineral density** (Letavernier et al., 2011; Asplin et al., 2006)**, chronic kidney disease** (Denburg et al., 2016)**, and heart disease** (Ristau et al., 2015). Using the well-characterized Health Professionals Follow-up Study, Nurses' Health Study I, and Nurses' Health Study II, Ferraro et al. (2013) reported that nephrolithiasis was associated with an 18% and 48% increased risk for coronary heart disease among older and younger women, respectively, after adjusting for known cardiovascular risk factors including hypertension, diabetes, hyperlipidemia, and BMI. No association was found for men. In addition to cardiac disease, nephrolithiasis has been associated with loss of kidney function (Alexander et al., 2012). In a Canadian cohort, one or more stone episodes was associated with an increased risk for chronic kidney disease, including a two-times greater risk for end-stage renal disease, compared with those without kidney stones (Alexander et al., 2012). The risk for chronic kidney disease was greater for patients with multiple stone episodes. In a population-based study in the United Kingdom, Denburg et al. (2016) reported similar findings; nephrolithiasis was associated with a 170% increased risk for incident chronic kidney disease (95% CI, 1.67 to 1.98). In the same dataset, Denburg et al. (2016) also demonstrated that nephrolithiasis was associated with a 42% increased risk for hypertension (95% CI, 1.35 to 1.51), which is very similar to the risk estimated by Madore et al. (1998) in the Health Professionals Follow-Up Study and Nurses' Health Study I and II. Although the causal pathway has not yet been elucidated, alterations in renal calcium and sodium handling may be important determinants of nephrolithiasis and hypertension (Obligado and Goldfarb, 2008). Nephrolithiasis has also been associated with an increased risk for fracture among children and adults. The greatest risk was estimated for those patients 10 to 19 years of age (Denburg et al., 2014). Decreased bone mineral density resulting from hypercalciuria and a negative calcium balance may underlie this association (Pietschmann et al., 1992; Jaeger et al., 1994; Cauley et al., 2005; Schwaderer et al., 2008). Accordingly, citrate and thiazides may help reduce the risk for osteoporosis as an adult (Schwaderer et al., 2014, 2011). Given that childhood is the critical period for acquisition of bone mass, identifying children at risk for low bone mineral density is essential to prevent fractures later in life. Although many studies of extrarenal manifestations of kidney stone disease were conducted among adult patients, these associations raise the concern that children may be at particular risk because early onset of nephrolithiasis may represent a more severe phenotype, and children have a long lifetime over which comorbid disease may develop.

Key Points: Epidemiology of Kidney Stone Disease

- There has been a dramatic increase in the incidence of pediatric kidney stone disease, especially among adolescent girls.
- There is a female predominance of kidney stone disease in childhood and adolescence.
- Approximately 80% of kidney stones in children are composed predominantly of calcium oxalate, which is similar to adults, but calcium phosphate stones are slightly more common and pure uric acid stones are less common in children.
- Kidney stone disease is best conceptualized as a disorder of mineral metabolism and is associated with cardiovascular disease, chronic kidney disease, and decreased bone mineral density.

Evaluation

Child With Suspected Nephrolithiasis

The European Association of Urology and a technical paper by the American Urological Association support using ultrasound as the initial imaging study for children with suspected nephrolithiasis and obtaining a noncontrast computed tomography (CT) scan only for children with a nondiagnostic ultrasound in whom the clinical suspicion for stones remains high (Fig. 43.2; Türk et al., 2013, 2016; Fulgham et al., 2013). Additionally, the Image Gently Alliance began its campaign in 2007 to lower radiation exposure among children who need diagnostic imaging (Goske et al., 2008). Currently, it is not known whether these guidelines will reduce unnecessary CT utilization.

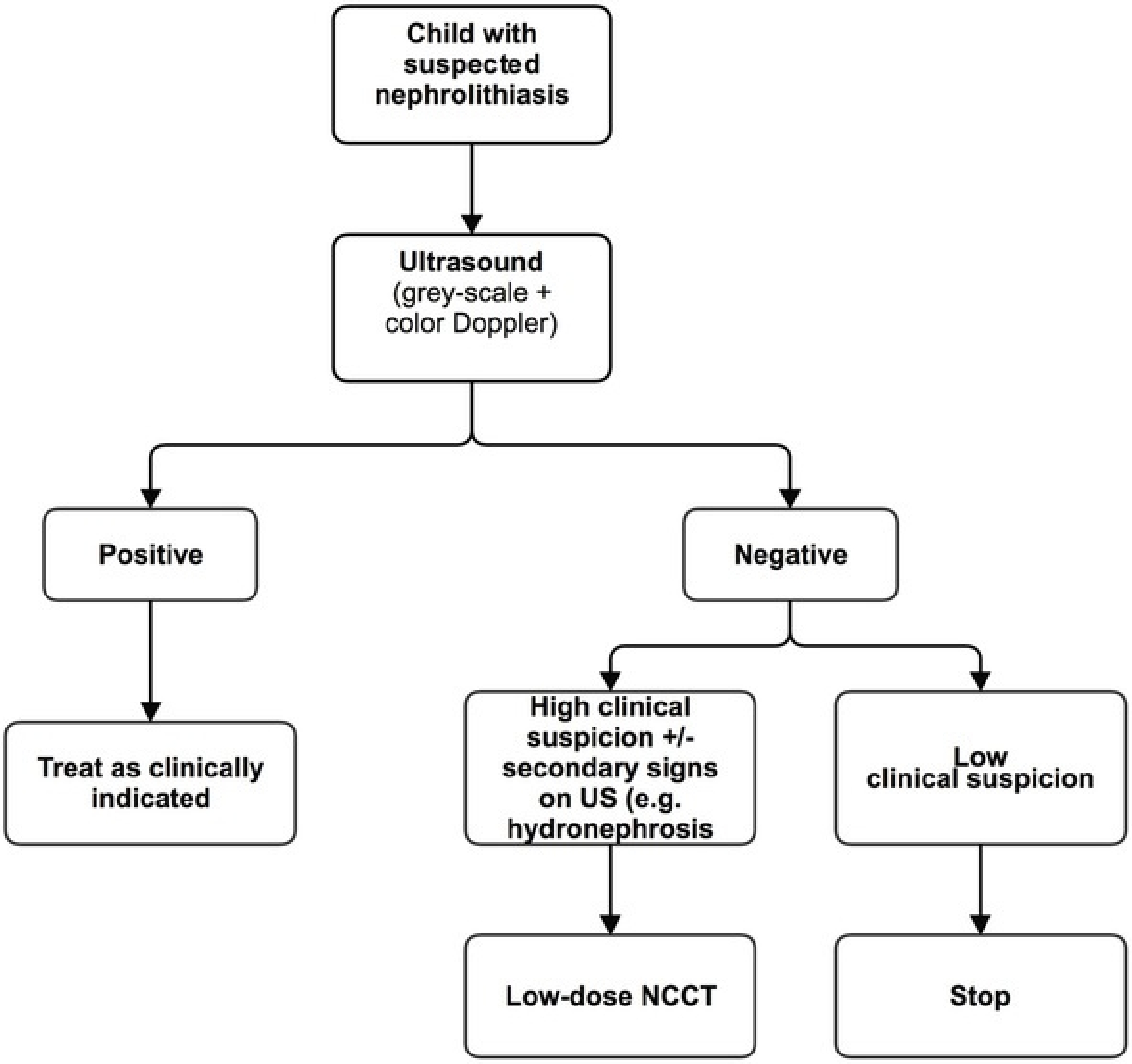
Child with suspected nephrolithiasis
Ultrasound (grey-scale + color Doppler)
Positive
Negative
Treat as clinically indicated
High clinical suspicion +/- secondary signs on US (e.g. hydronephrosis
Low clinical suspicion
Low-dose NCCT
Stop

FIG. 43.2 Diagnostic imaging algorithm for pediatric patients with suspected kidney or ureteral stones.

Although ultrasound is less sensitive and specific than CT (Johnson et al., 2011; Passerotti et al., 2009), ultrasound accurately identifies clinically significant kidney stones in children. The criteria for defining a stone on ultrasound are (1) hyperechoic focus in the renal papillae, calyces, or renal pelvis and (2) confirmatory twinkle artifact (Fig. 43.3). Twinkle artifact, an intense multicolor signal overlying stones generated by Doppler, improves the accurate detection of kidney stones (Masch et al., 2016; Gliga et al., 2017). Importantly, Doppler pulse repetition frequency (PRF) should be increased maximally to reduce noise from normal vascular flow and thereby improve accurate detection of stones (Tchelepi and Ralls, 2009). Although historically the presence of a posterior acoustic shadow was considered to be a necessary diagnostic criterion for defining a kidney stone on ultrasound, modern harmonic and spatial compounding ultrasound technology does not generate shadows as readily, particularly for stones less than 4 mm. **Ultrasound has >70% sensitivity and >95% specificity for detecting urinary tract stones, including stones located in the mid-ureter, which are poorly visualized on ultrasound** (Passerotti et al., 2009). Stones missed on ultrasound are often clinically insignificant (i.e., small in size or nonobstructing; Johnson et al., 2011; Passerotti et al., 2009). A recent cross-sectional study that incorporated twinkle artifact on Doppler ultrasonography reported 67% sensitivity, 97% specificity, 95% positive predictive value, and 79% negative predictive value for the detection of kidney stones. However, these patients in the study underwent ultrasound and then CT because of uncertainty of findings on ultrasound, which would decrease the sensitivity of ultrasound. The use of additional criteria such as renal resistive indices has been investigated in adults to help improve the diagnostic accuracy of ultrasound for nephrolithiasis (Dillman et al., 2011; Granata et al., 2009; Kielar et al., 2012). In addition, the resolution of modern ultrasound is higher than in many CT scans. This high resolution may lead to the detection of small foci (~2 mm) that twinkle and are too small for CT to detect. In our experience, these foci often reflect Randall's plaques with or without small attached stones (Fig. 43.4). These plaques are reflected as hyperdense papillae on CT (Deshmukh et al., 2015) but do not appear as distinct calculi on CT. The appearance of Randall's plaques or papillary deposits as distinct stones on ultrasound are consistent with studies that have demonstrated that ultrasound overestimates the size of stones by 1 to 2 mm.

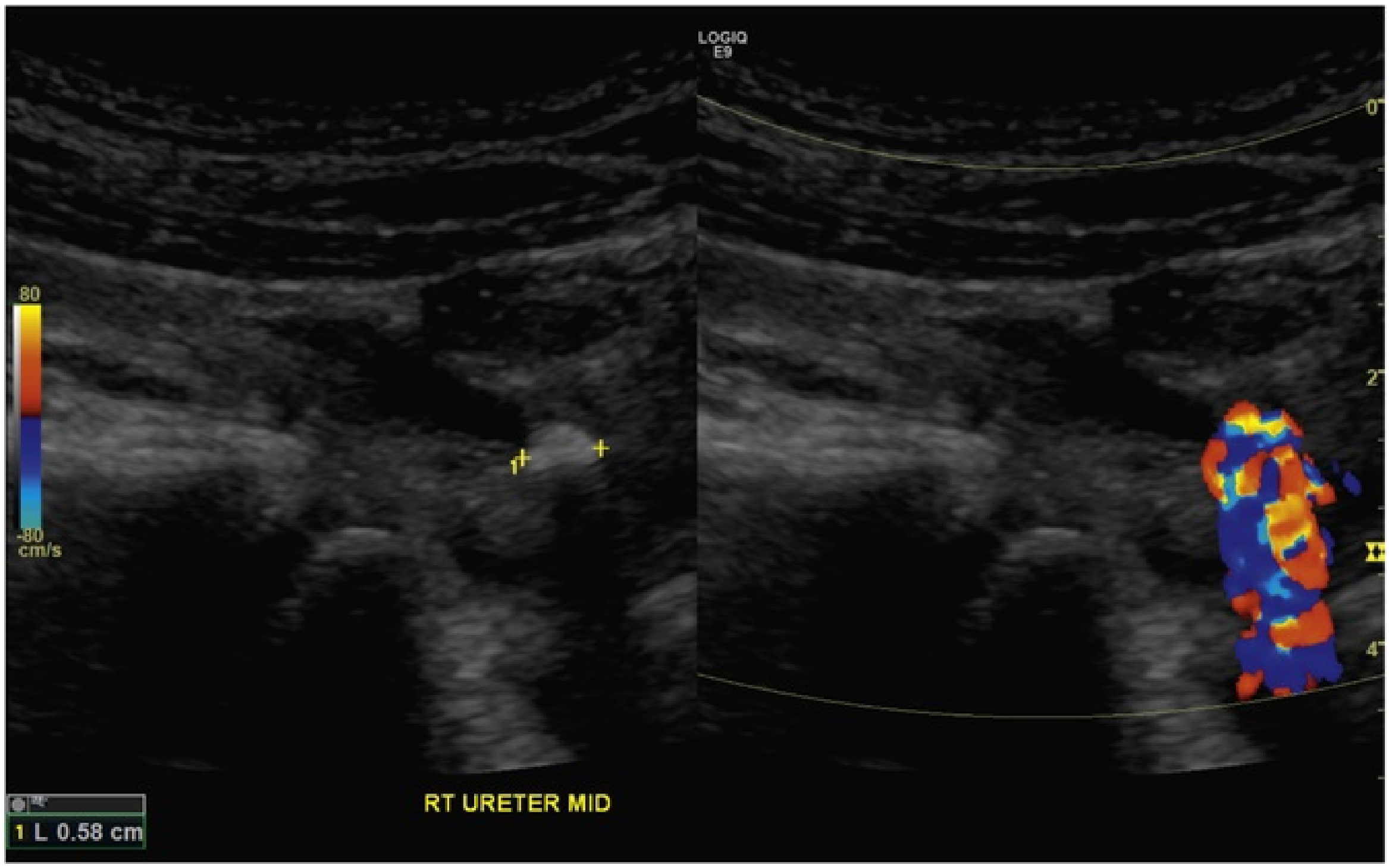
LOGIQ
E9
80
-80
cm/s
1
0
2
4
RT URETER MID
1 L 0.58 cm

FIG. 43.3 Ultrasonographic appearance of ureteral stone. A stone appears as an echogenic focus on gray-scale with confirmatory “twinkle artifact” on color Doppler. The pulse repetition frequency should be maximized when evaluating with Doppler. Stones smaller than 4 mm typically do not have an associated posterior acoustic shadow using modern ultrasound machines, transducers, and software packages.

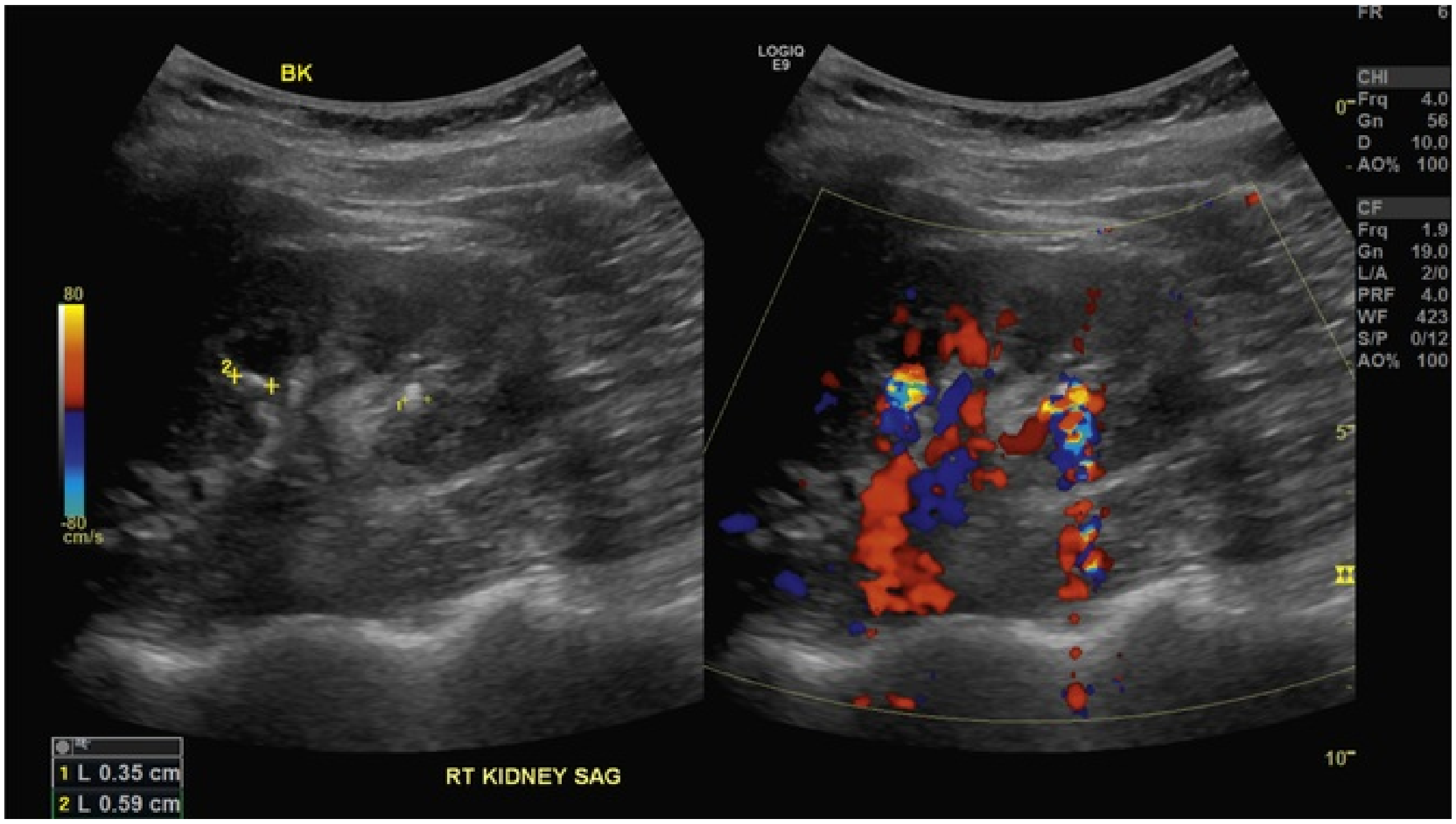
BK
LOGIQ
E9
FR 6
CHI
Frq 4.0
Gn 56
D 10.0
AO% 100
CF
Frq 1.9
Gn 19.0
L/A 2/0
PRF 4.0
WF 423
S/P 0/12
AO% 100
0
5
10
80
-80
cm/s
2
1
RT KIDNEY SAG
1 L 0.35 cm
2 L 0.59 cm

FIG. 43.4 Ultrasonographic appearance of Randall's plaques. Randalls plaques (visualized on ureteroscopy in Fig. 43.1) have the same ultrasound characteristics as stones, although they typically are <4 mm.

Noncontrast CT has nearly 100% sensitivity and specificity to identify kidney stones. CT, however, delivers ionizing radiation, which is associated with an increased risk for malignancy (Katz et al., 2006). Although the attributable risk for cancer from a single CT scan performed for kidney stones is small (0.2% to 0.3% above baseline), the cumulative risk is higher for those undergoing repeated studies (Kuhns et al., 2011). Highlighting the cumulative risk for radiation exposure, Routh et al. (2010a, 2010b) analyzed 7921 children with kidney stones treated at hospitals within the Pediatric Hospital Inpatient Sample and observed that more than 2600 children underwent a median of two CT scans for a single kidney stone episode. Additionally, the risk may be higher in children than in adults because of a longer life expectancy and greater sensitivity of developing tissues to the effects of radiation. Computer-simulated dose reduction has been useful in determining diagnostic thresholds in children. When necessary (e.g., stone not visualized on ultrasound but with secondary signs of obstruction such as hydronephrosis), a low-dose noncontrast CT of the abdomen and pelvis should be performed. Compared with standard protocols, halving the dose to 40 mA for children weighing 50 kg or less does not significantly affect the diagnosis of pediatric renal stones (Karmazyn et al., 2009). Spielmann et al. (2002) reported excellent detection of calculi measuring between 2 and 8 mm using much lower amperage, with an almost threefold decreased estimated radiation dose compared with standard protocols.

Medical History and Physical Examination

A detailed medical history and physical examination are essential. Information pertaining to a family history of nephrolithiasis, hematuria, and chronic kidney disease can be essential in identifying patients at highest risk for inherited metabolic or genetic conditions such as cystinuria, primary hyperoxaluria, *CYP24A1* gene mutations, or Dent disease. **A focused dietary history with special emphasis on fluid and salt intake, vitamin (A, C, D) and mineral supplementation, and special diets (e.g. ketogenic diet) is indicated in every patient.** Obtaining a detailed medication history with special emphasis on corticosteroids, diuretics (furosemide, acetazolamide), protease inhibitors (indinavir), antibiotics (Tasian et al., 2018), and anti-epileptics (e.g., topiramate) can be instructive. Children with a history of prematurity, urinary tract abnormalities, UTIs, intestinal malabsorption, and prolonged immobility are all at increased risk for calculi formation. Detailed physical examination of the child for dysmorphic features (William syndrome), rickets (Dent disease, hereditary hypophosphatemic rickets with hypercalciuria), tetany (familial hypomagnesemia with hypercalciuria and nephrocalcinosis, autosomal dominant hypocalcemic hypercalciuria), or gout (hypoxanthine-guanine phosphoribosyltransferase deficiency, phosphoribosyl pyrophosphate synthetase superactivity) can be helpful.

Metabolic Investigations

Children with an identifiable metabolic abnormality have an up to fivefold increased risk for recurrence compared with children with no identifiable metabolic disorder (Pietrow et al., 2002). Consequently, all children should undergo a comprehensive metabolic evaluation. Whenever possible, analysis should begin with an infrared spectroscopy or radiograph diffraction analysis of a passed stone. If a cystine or struvite stone is found, the analysis will be diagnostic.

Serum and urine studies should be obtained in patients in whom stone analysis could not be performed or for those with either calcium or uric acid–based stones. A serum creatinine is essential to evaluate for possible acute kidney injury or chronic kidney disease. Serum calcium, phosphorous, bicarbonate, magnesium, and uric acid levels are effective in screening for hypercalcemia/hypocalcemia-associated calculi (see Urinary Metabolic Abnormalities later in this chapter and Table 43.1 for diagnostic evaluation characteristics of rare stones), hyperuricemia/hypourcemia, and genetic conditions associated with normocalcemic hypercalciuria including hereditary hypophosphatemic rickets with hypercalciuria, Bartter syndrome, distal renal tubular acidosis (dRTA), and familial hypomagnesemia with hypercalciuria and nephrocalcinosis. Unlike in adults, primary hyperparathyroidism is rare in children, and an intact parathyroid hormone level is not a universally accepted part of the initial evaluation unless there is evidence of hypercalcemia and hypophosphatemia. A 25-hydroxyvitamin D level should be evaluated in hypercalcemic and or hyperphosphatemic patients with a relevant history of exposure. Rarely biallelic loss of function mutations in the *CYP24A1* gene result in the loss of peripheral catabolism of vitamin D and persistently high levels of 1,25-dihydroxyvitamin D, which can mimic vitamin D intoxication. A ratio of

24,25 dihydroxyvitamin D to 25 hydroxyvitamin D (normal <25 to 30) may be a useful screen and should be considered in children with hypercalcemia and associated hypercalciuria in whom other causes have been excluded. Finally, a spot urine β_2-microglobulin or retinol-binding protein (low–molecular-weight protein) is a useful screening test for Dent disease and should be considered in males if there are recurrent calcium-based calculi in the setting of proteinuria or a family history of renal failure, focal segmental glomerulosclerosis, or recurrent calculi.

TABLE 43.1

When to Suspect Rare Inherited Metabolic or Genetic Conditions as a Cause of Nephrolithiasis in Children

---

HISTORY/PHYSICAL EXAMINATION	**CONDITION(s)**
History of polyhydramnios	Bartter syndrome
Growth failure/failure to thrive	Distal renal tubular acidosis
Rickets	Hereditary hypophosphatemic rickets with hypercalciuria, distal renal tubular acidosis, Dent disease
Ocular abnormalities	Familial hypomagnesemia with hypercalciuria and nephrocalcinosis
Tetany/seizures	Familial hypomagnesemia with hypercalciuria and nephrocalcinosis
Gout	Hypoxanthine-guanine phosphoribosyltransferase deficiency, phosphoribosyl pyrophosphate synthetase superactivity
Family history of renal disease or nephrocalcinosis	Cystinuria, primary hyperoxaluria, Dent disease
LABS	
Elevated serum creatinine	Dent disease, cystinuria, primary hyperoxaluria
Hypercalcemia/hypocalcemia	Biallelic *CYP24A1* mutations/autosomal dominant hypocalcemic hypercalciuria
Hypokalemia	Distal renal tubular acidosis/Bartter syndrome
Acidosis/alkalosis	Distal renal tubular acidosis/Bartter syndrome
Hyperuricemia/hypouricemia	Hereditary renal hypouricemia/hypoxanthine-guanine phosphoribosyltransferase deficiency, phosphoribosyl pyrophosphate synthetase superactivity
Hypomagnesemia	Familial hypomagnesemia with hypercalciuria and nephrocalcinosis

Proteinuria	Dent disease
Abnormal urinary crystals	Cystinuria
IMAGING	
Nephrocalcinosis	Hereditary hypophosphatemic rickets with hypercalciuria, distal renal tubular acidosis, Dent disease, Familial hypomagnesemia with hypercalciuria and nephrocalcinosis, Bartter syndrome
Radiolucent stones	Uric acid, cystine, or xanthine calculi

A 24-hour urine collection should be analyzed for calcium, oxalate, uric acid, sodium, citrate, creatinine, volume, pH, and cystine (cyanide-nitroprusside screening test). Results must be evaluated with respect to weight, body surface area, or creatinine to be properly interpreted in children. Urine creatinine excretion (normal 15 to 25 mg/kg/day for adults) is useful in assessing the adequacy of the urine collection. Supersaturations for calcium oxalate, calcium phosphate, and uric acid can be calculated from computer models based on the results of the urine collection. There is ongoing controversy as to whether a single 24-hour urine collection at the time of diagnosis is sufficient for proper evaluation (Castle et al., 2010) or whether two separate collections yield a greater number of specific diagnoses (Parks et al., 2002). Several commercial companies offer these 24-hour urine stone chemistry profiles. Although less precise, when children are not yet toilet trained, the evaluation may be performed by measuring the ratio of calcium, uric acid, citrate, and oxalate to creatinine in a random spot urine sample (Table 43.2). Repeat urine testing should be performed several weeks to months after a change in diet or after the initiation of a medication. Microscopic urinalysis for crystalluria is generally not diagnostic unless hexagonal crystals (cystine) or coffin lid–shaped triple phosphate crystals (struvite) are observed.

TABLE 43.2

Normal Values for Urinary Solute Excretion

METABOLITE	AGE	SPOT (mg/mg)	24-HOUR INDEXED (ALL AGES)	24-HOUR TOTAL EXCRETION
Calcium	0–6 months 7–12 months	<0.8 <0.6 <0.21	<4 mg/kg	Male: <250 mg/d Female: <200 mg/d

	>24 months			
Oxalate	0–6 months 7–24 months 2–5 years 5–14 years >16 years	<0.26 <0.11 <0.08 <0.06 <0.03	<50 mg/1.73 m^2 BSA	20–40 mg/day
Citrate	0–5 years >5 years	>0.2–0.42	Male: >180 mg/g creatinine Female: >300 mg/g creatinine	Male: >450 mg/d Female: >550 mg/d
Cystine	>6 months	<0.075	<50 mg/1.73 m^2 BSA	Male: <0.8 g/d Female: <0.75 g/d
Uric acid	>2 years	0.56 mg/dL GFR	<815 mg/1.73 m^2 BSA	

Urinary Metabolic Abnormalities

Hypercalciuria

Hypercalciuria is found in approximately 30% to 50% of stone-forming children (Milliner and Murphy, 1993; Stapleton et al., 1987). Hypercalciuria is not a single entity but rather a condition associated with many causes. The most common cause in both children and adults is idiopathic hypercalciuria. Idiopathic hypercalciuria is defined as hypercalciuria that occurs in the absence of hypercalcemia in patients in whom no other cause can be identified. The gene (or genes) responsible for familial idiopathic hypercalciuria have not been identified, but they appear to be transmitted in an autosomal dominant fashion with incomplete penetrance. Approximately 4% of asymptomatic healthy children demonstrate evidence of idiopathic hypercalciuria (Kruse et al., 1984), and 40% to 50% of those children have a positive family history of urolithiasis (Coe et al., 1979). **Hypercalciuria is formally defined as calcium excretion of greater than 4 mg/kg/day in children older than 2 years of age. In many**

children, a 24-hour urine collection is not practical, and a urine calcium/creatinine ratio is used to estimate daily calcium excretion. In school-age children, a calcium/creatinine ratio of 0.21 mg/mg or less is considered normal, although calcium excretion is higher for younger children. See Table 43.2 for reference values for urine chemistries.

When hypercalciuria is observed, several conditions must be excluded before establishing a diagnosis of idiopathic hypercalciuria. By definition, the patient should be normocalcemic. In hypercalcemic hypercalciuric patients, the possibility of hyperparathyroidism, biallelic *CYP24A1* mutations, and hypervitaminosis D should be investigated, and, when clinically indicated, a diagnosis of prolonged immobilization, sarcoidosis, malignancy, juvenile idiopathic arthritis, corticosteroid excess, adrenal insufficiency, or William's syndrome should be considered. Children with hypocalcemic hypercalciuria should be evaluated for hypoparathyroidism and autosomal dominant hypocalcemic hypercalciuria (gain-of-function mutation in the calcium-sensing receptor). Although the vast majority of normocalcemic hypercalciuric patients will ultimately be diagnosed with idiopathic hypercalciuria, it is critical during the initial evaluation to consider and exclude other associated conditions such as prematurity, diuretic exposure (furosemide, acetazolamide), anticonvulsant usage (topiramate), the ketogenic diet, Dent disease, Bartter syndrome, familial hypomagnesemia with hypercalciuria and nephrocalcinosis, dRTA, hereditary hypophosphatemic rickets with hypercalciuria, and possibly medullary sponge kidney.

Hyperoxaluria

Oxalate is an end product of the metabolic pathways for glyoxylate and ascorbic acid and is primarily excreted by the kidneys. The vast majority (80% to 85%) of daily urinary oxalate excretion is derived from normal metabolic homeostasis, and the remainder (10% to 15%) is from dietary intake. Daily urine oxalate excretion is generally less than 40 mg/day/1.73 m^2 of body surface area. The impracticality of performing 24-hour urine collections in very young patients requires the use of a random urine oxalate/creatinine ratio, which can be used to estimate oxalate excretion (see Table 43.2). Increased urinary oxalate excretion may be caused by an inherited metabolic disorder (primary hyperoxaluria) or, more commonly, as a secondary phenomenon caused by increased oxalate absorption or excessive intake of oxalate precursors.

Primary Hyperoxaluria

Primary hyperoxaluria (PH) types 1, 2, and 3 are relatively rare autosomal recessive disorders of endogenous oxalate production. Overproduction of oxalate by the liver causes excessive urinary oxalate excretion with resultant nephrocalcinosis and nephrolithiasis. The calcium oxalate deposition results in progressive chronic kidney disease, however the clinical presentation can vary from end-stage renal failure in the neonate to occasional stone passage into adulthood. As a result of this variability, the diagnosis is often overlooked and may be realized only after the loss of a transplanted kidney (Spasovski et al., 2010).

PH1 is caused by mutations in the *AGXT* gene that result in a functional defect of the hepatic peroxisomal enzyme alanine-glyoxylate aminotransferase (AGT). The deficit leads to accumulation of glyoxylate, glycolate, and oxalate in the urine. Importantly, pyridoxine is an essential cofactor for proper AGT activity and, rarely, profound vitamin B_6 deficiency can mimic PH1. PH type 2 is caused by mutations in the *grhpr* gene, with resultant deficient glyoxylate reductase-hydroxypyruvate reductase (GRHPR) enzyme activity causing excessive amounts of oxalate and L-glyceric acid to be excreted by the kidney (Hoppe et al., 2009). PH2 is somewhat milder compared with PH1 but is not benign. Recently, a third variant, PH3, has been described with mutations in the *HOGA1* gene (Belostotsky et al., 2010; Monico et al., 2011). *HOGA1* encodes a mitochondrial 4-hydroxy-2-oxoglutarate aldolase that catalyzes the fourth step in the hydroxyproline pathway (Monico et al., 2011). If urinary oxalate levels are noted to be elevated on a 24-hour urine collection, the diagnosis of PH1, 2, and 3 can be evaluated by measuring the urinary concentrations of glycolate (elevated in PH1), glycerate (elevated in PH2), and 4-hydroxy-2-oxoglutarate (elevated in PH3). Notably, increased concentrations of oxalate with normal concentrations of glycolate, glycerate, and 4-hydroxy-2-oxoglutarate is highly suggestive of secondary hyperoxaluria (see later).

Secondary Hyperoxaluria

In secondary hyperoxaluria, there is either dietary exposure to large amounts of oxalate (or oxalate precursors), or here is an underlying disorder that causes increased absorption of dietary oxalic acid from the intestinal tract. **Gastrointestinal absorption varies inversely with dietary calcium intake,**

and, as a result, calcium-deficient diets may increase oxalate absorption and hyperoxaluria (Polinsky et al., 1987). Oxalate is a by-product of ascorbic acid metabolism, and high doses of vitamin C have also been associated with hyperoxaluria. Increased dietary absorption is usually characterized by fat malabsorption or a chronic diarrheal disorder. Among secondary causes of hyperoxaluria, those attributable to gastrointestinal disease are inflammatory bowel disease, celiac disease, exocrine pancreatic insufficiency (cystic fibrosis), biliary tract disease, and small bowel resection/short bowel syndrome. The causal pathway is the presence of free fatty acids that bind calcium in the intestinal lumen resulting in more unbound oxalate that is free to be absorbed.

Hypocitraturia

Citrate is normally present in the urine and regulated through a process of both absorption and metabolism at the level of the proximal tubule. **Hypocitraturia is generally defined as a citrate-to-creatinine ratio of <128 mg/g in males and <300 mg/g in females on a 24-hour collection. Intracellular acidosis of the proximal tubule, caused either by metabolic acidosis or hypokalemia results in increased citrate absorption in the proximal tubule and resultant hypocitraturia.** The ketogenic diet, certain medications (topiramate, acetazolamide), dRTA, and chronic diarrhea are commonly associated with hypocitraturia. Given that an incomplete dRTA can occur in the absence of an overt systemic acidosis or hypokalemia, the condition can often be overlooked in the face of hypocitraturia if provocative acid-load testing is not readily available. In spite of these known associations, most cases of hypocitraturia are idiopathic, although a diet rich in animal protein and low in vegetable fiber and potassium seems to promote lower citrate excretion (Hess et al., 1994; Kok et al., 1990).

Cystinuria

Cystinuria is an autosomal recessive disorder caused by mutations in either the *SLC3A1* or *SLC7A9* gene, resulting in disordered amino acid transport in the proximal tubule (Ettinger et al., 1997). It is characterized by lack of reabsorption of cystine and the dibasic amino acids lysine, ornithine, and arginine. Normal individuals excrete <60 mg of cystine/day/1.73 m^2 of body surface area, whereas patients who are homozygous for cystinuria often excrete >400 mg/day/1.73 m^2 of body surface area (Coward et al., 2003). Patients typically present with renal colic and stones in the second or third decade of life;

however, they may present as early as infancy with staghorn calculi. The poor solubility of cystine in the urine causes precipitation in the collecting system which, if left untreated, usually results in recurrent episodes of calculi and long-term risk for renal failure. Associated UTIs may occur, and combined cystine/struvite calculi have been observed (Evans et al., 1982).

Hyperuricosuria

Uric acid excretion is greater in children than in adults, with the highest urinary fractional excretion (Fe) found in neonates (Fe 30% to 50%) and levels reaching adult values (Fe 8% to 12%) in adolescence (Cameron et al., 1993). Interestingly, in spite of the higher uric acid excretion observed in children, uric acid nephrolithiasis is rather rare in childhood, accounting for <5% of all renal calculi. Epitaxy, in which the presence of uric acid promotes calcium oxalate crystallization, may be found in patients with hyperuricosuric calcium oxalate nephrolithiasis (Coe, 1978). Epitaxy is the process by which the crystal base of one material allows the growth of a second mineral that it is in the same crystalline orientation. Hyperuricosuria is defined as >815 mg/day/1.73 m^2 of body surface area. When adjusted for glomerular filtration rate (GFR), relative uric acid excretion is fairly constant after 2 years of age (see Table 43.2). In children who are not yet toilet trained but are older than 2 years of age, hyperuricosuria can be defined as >0.56 mg/dL of GFR on a spot urine collection. This value may be calculated with the following equation:

$$\text{Urine uric acid (mg/dL)} \times \text{Plasma creatinine (mg/dL)}/ \\ \text{Urine creatinine (mg/dL)}.$$

Hyperuricosuria in the setting of low urinary pH is the greatest risk factor for uric acid stone formation. Hyperuricosuria associated with significant hyperuricemia is usually associated with inherited disorders of purine metabolism (hypoxanthine-guanine phosphoribosyltransferase deficiency, phosphoribosyl pyrophosphate synthetase superactivity), lymphoproliferative disorders, or polycythemia. Rarely, a condition known as hereditary renal hypouricemia characterized by low serum uric acid, hyperuricosuria, nephrolithiasis, and exercise-induced acute renal failure has been observed. Mutations in either the *SLC22A12* or *SLC2A9* genes, both of which encode urate transporters expressed in the proximal tubule, are known to be causative

(Ettinger et al., 1997). Other causes of hyperuricosuria include excessive purine intake (animal protein, anchovies, mussels), hemolysis, uricosuric medications (probenecid, salicylates, losartan), cyanotic congenital heart disease, melamine toxicity, and idiopathic (familial).

Key Points: Evaluation of Children With Kidney Stone Disease

- Children with an identifiable metabolic abnormality have an increased risk for stone recurrence.
- All children should undergo a comprehensive initial evaluation including a 24-hour urine collection for calcium, oxalate, uric acid, sodium, citrate, creatinine, volume, pH, and cystine.
- Idiopathic hypercalciuria is found in approximately 30% to 50% of stone-forming children.
- Hypocitraturia, hyperoxaluria, hyperusicosuria, and cystinuria remain important causes of childhood nephrolithiasis and need to be identified.

Management of Children and Adolescents With Kidney and Ureteral Stones

Medical Expulsion Therapy

Management options in pediatric patients with a ureteral stone include observation with pain control, medical expulsion therapy (MET), and surgery. MET is the use of α-blockers or, less commonly, calcium-channel blockers to facilitate passage of a ureteral stone. The mechanism for MET in increasing stone passage is that type 1a and 1d α-receptors are found in high concentrations in the smooth muscle of the distal one-third of the ureter and at the ureterovesical junction. Spontaneous stone passage without MET is higher among older patients and for smaller (especially less than 5 mm) and distal ureteral stones (Pietrow et al., 2002; Dangle et al., 2016). Although the greatest number and highest-quality studies of the efficacy and effectiveness of MET have been performed in adult patients, the weight of the evidence that indicates that α-blockers increase stone passage has led to the use of both in the pediatric population (Hollingsworth et al., 2006). Blockage of these receptors leads to dilation of the ureter and, presumably, increased passage of ureteral stones. To date, there are only four small, poor-quality randomized controlled trials of α-blockers for children with distal ureteral stones less than 12 mm, which generally demonstrated that α-blockers improved stone passage (Aydogdu et al., 2009; Mokhless et al., 2012; Aldaqadossi et al., 2015; Erturhan et al., 2013). Erturhan reported a significantly higher stone expulsion rate, reduction in pain, and shorter time to stone passage among patients receiving doxazosin (71%) than controls (29%) (Erturhan et al., 2013). Similarly, in the most recent trial, Aldaqadossi et al. reported 87% of children treated with tamsulosin (0.4 mg) passed stones compared with 63% of children treated with analgesics alone ($p = 0.025$). This study also reported a reduced mean time to stone expulsion in the tamsulosin group compared with the analgesic cohort (7.7 vs. 18.0 days; $p < 0.001$). In addition, a multi-institutional retrospective cohort study demonstrated that tamsulosin was associated with higher stone passage (56%) compared with those treated with analgesics alone (44%) (Tasian et al., 2014). These results were pooled in a systemic review and meta-analysis, which demonstrated that

MET with an α-blocker was associated with increased odds of stone passage compared with placebo or analgesic alone (OR 2.21, 95% CI, 1.40 to 3.49) (Velazquez et al., 2015). Overall, tamsulosin was safe in children despite its off-label use, with only three patients reporting mild nasal congestion and no patients stopping treatment secondary to side effects (Mokhless et al., 2011; Aldaqadossi et al., 2015). **The AUA and Endourological Society Guideline for the surgical management of urinary stones recommends that pediatric patients with uncomplicated ureteral stones ≤10 mm should be offered “observation with or without MET using alpha-blockers”** (Assimos et al., 2016a). This recommendation is categorized as moderate with a grade B level of evidence based on the RCTs described earlier. The guideline states that parents should be informed that the use of α-blockers is off-label and that the maximum duration of MET is unknown but should not exceed 6 weeks. Whereas α-blockers seem to be most effective for adults with ureteral stones greater than 5 mm (Ye et al., 2018), the size of the stone for which α-blockers provide the greatest benefit for pediatric patients is unknown.

Surgical Management

Up to 60% of children with kidney or ureteral stones require surgery (Routh et al 2010a, 2010b; Dangle et al., 2016; Tasian et al., 2014). However, among ten major areas in kidney disease, kidney stones have the fewest proportion of citations that are randomized controlled trials, demonstrating both the difficulty in completing randomized trials for nephrolithiasis and indicating the need for high-quality evidence to inform clinical practice (Strippoli et al., 2004). Despite the increasing incidence of pediatric nephrolithiasis, the comparative effectiveness of surgical interventions for pediatric patients with kidney stones is particularly unclear, and the evidence for or against any given surgery is especially poor. **As for adults, surgical options for pediatric patients include ureteroscopy (URS), shock wave lithotripsy (SWL), and percutaneous nephrolithotomy (PCNL), all of which require anesthesia and, traditionally, radiation exposure** (Routh et al 2010a, 2010b). A recent review reported stone clearance ranging from 70% to 97% for PCNL, 85% to 88% for URS, and 80% to 83% for SWL; however, the indications for surgery, methods of ascertaining residual fragments, and consideration of repeat procedures varied (Hernandez et al., 2015). Open stone surgery such as nephrolithotomy is rarely used in the contemporary era. Although historically most stones in children were treated with SWL, miniaturization and improvement in the optics of endoscopy resulted in increases in URS and PCNL utilization (Long and Srinivasan, 2015; Salerno et al., 2013). Endoscopic techniques initially utilized in adult populations have been increasingly utilized for children and adolescents as technologic advances have produced smaller, more flexible equipment. Introduction of flexible and smaller ureteroscopes have enabled treatment of proximal ureteral and renal stones, primarily for stones less than 15 to 20 mm.

In 2016, the American Urological Association and the Endourological Society published guidelines for the surgical management of kidney stones (Table 43.3) (Assimos et al., 2016a, 2016b). Of the 90 recommendations, only eight addressed children. Of the eight pediatric-specific recommendations, none were guided by level A evidence and four were based on expert opinion alone. For example, the recommendation for either URS or SWL for children with renal stones ≤2 cm was based on small, single-center studies, and the underlying evidence was noted to be of "low certainty." In addition, based only on expert opinion, either PCNL or SWL were recommended for children with stones greater than 2 cm. However, this recommendation is not consistent with the poor stone clearance of SWL for large stones among adults and contradicts the same guideline's recommendation for PCNL and against SWL for adults with stones greater than 2 cm. In response to this knowledge gap, the 2017 National Urology Research Agenda prioritized studies of pediatric patients with kidney stones (Ellison et al., 2018; Penniston et al., 2007, 2017).

TABLE 43.3

2016 American Urological Association and Endourological Society Recommendations for the Surgical Management of Urinary Stones for Pediatric Patients

RECOMMENDATION	STRENGTH OF RECOMMENDATION	LEVEL OF EVIDENCE
In pediatric patients with uncomplicated ureteral stones <10 mm, clinicians should offer observation with or without medical expulsive therapy using α-blockers.	Moderate: Net benefit or harm moderate	B: Moderate certainty
Clinicians should offer URS or SWL for pediatric patients with ureteral stones who are unlikely to pass the stones or who failed observation and/or MET, based on patient-	Strong: Net benefit or harm substantial	B: Moderate certainty

specific anatomy and body habitus.		
Clinicians should obtain a low-dose CT scan on pediatric patients before performing PCNL.	Strong: Net benefit or harm substantial	C: Low certainty
In pediatric patients with ureteral stones, clinicians should not routinely place a stent before URS.	Panel consensus, based on members' clinical training, experience, knowledge, and judgment for which there is no evidence.	Expert opinion
In pediatric patients with a total renal stone burden ≤20 mm, clinicians may offer SWL or URS as first-line therapy.	Moderate: Net benefit or harm moderate	C: Low certainty
In pediatric patients with a total renal stone burden >20 mm, both PCNL and SWL are acceptable treatment options. If SWL is utilized, clinicians should place an internalized ureteral stent or nephrostomy tube.	Panel consensus, based on members' clinical training, experience, knowledge, and judgment for which there is no evidence.	Expert opinion
In pediatric patients, except in cases of coexisting anatomic abnormalities, clinicians should not routinely perform open/laparoscopic/robotic surgery for upper tract stones.	Panel consensus, based on members' clinical training, experience, knowledge, and judgment for which there is no evidence.	Expert opinion
In pediatric patients with asymptomatic and nonobstructing renal stones, clinicians may utilize active surveillance with periodic ultrasonography.	Panel consensus, based on members' clinical training, experience, knowledge, and judgment for which there is no evidence.	Expert opinion

CT, Computed tomography; *MET,* medical expulsive therapy; *PCNL,* percutaneous nephrolithotomy; *SWL,* shock wave lithotripsy; *URS,* ureteroscopy.

Goals of Therapy

The goals of surgical intervention for nephrolithiasis are the same for children as they are for adults: to achieve stone clearance with the minimal number of procedures, risk conferred, and complications. **The choice of intervention is determined primarily by the size and location of the stone, patient anatomy, and patient (and provider) preference.** Secondary considerations include patient comorbidities, composition of stone (if known), and equipment availability. Currently, the choice of the type of surgical intervention is heavily influenced by the site where the child obtains care (Wang et al., 2012).

Stone Clearance Definition

Stone clearance is generally considered the most important clinical outcome of surgery. Although children may have a greater capacity to clear residual fragments than adults (Gofrit et al., 2001), the presence of residual fragments has been associated with adverse clinical outcomes, including residual fragment growth or clinical symptoms. There is currently no consensus regarding the maximum size of residual fragments that are considered clinically significant for children, and as a result there is no clear definition as to what constitutes “stone-free” status. In addition, the method of assessing stone clearance varies by study and ranges from visual inspection at the time of URS to postoperative ultrasound or CT. It is thus difficult to directly compare the results and complications associated with different techniques, stone sizes, stone locations, and methods of outcome ascertainment.

Radiation

Patients with nephrolithiasis are exposed to radiation during diagnostic evaluation, operative treatment, and for surveillance after surgery (Routh et al., 2010a, 2010b; National Research Council, 2006; Kokorowski et al., 2012). URS and PCNL both typically use fluoroscopy, which delivers ionizing radiation, as does SWL unless ultrasound is used to target the stone. One single-institution study reported the median fluoroscopy times for unilateral URS, bilateral URS, and PCNL were 1.6 minutes, 2.5 minutes, and 11.7 minutes, respectively (Ristau et al., 2015). This was equivalent to 3 mSv for URS and 16.8 mSv for PCNL. Each patient received a median of one (IQR 1 to 3) CT scan and three (IQR 1 to 8) abdominal radiographs for the associated stone episode. The average cumulative radiation exposure for a patient who underwent a CT scan, PCNL, and three radiographs in a 1-year period was 32 mSv. Current guidelines recommend a maximum dose of 50 mSv in a 12-month period, and an average of <20 mSv/year over a 5-year period (Wrixon, 2008). Thus a therapeutic plan for a single large stone requiring PCNL may approach the limits of recommended ionizing radiation exposure.

Cumulative radiation exposure is a particularly important consideration for children with nephrolithiasis given they are more likely than adults to require future diagnostic imaging and surgical interventions that use ionizing radiation

(Katz et al., 2006; Kuhns et al., 2011). Additionally, the cumulative risk for radiation exposure may be higher in children than in adults because of a longer life expectancy and greater sensitivity of developing tissues to the effects of radiation.

Nelson et al. demonstrated substantial radiation exposure for children undergoing URS. Fluoroscopy time was the most important determinant of radiation exposure. However, other modifiable factors such as source-to-skin distance and fluoroscopy settings could be adjusted to decrease delivered radiation (Kokorowski et al., 2012). Consistent with the radiation safety concept that As Low As Reasonably Achievable (ALARA) emphasizes, recent techniques that utilize ultrasound for URS (Deters et al., 2014) and PCNL decrease radiation exposure in children. Checklists designed to reduce radiation exposure may also reduce fluoroscopy time, improve skin-to-image intensifier distance, and increase utilization of appropriate dose settings for children undergoing URS (Kokorowski et al., 2013). At our institution, ultrasound is used to obtain PNCL access. We also use intermittent, low-dose rather than continuous fluoroscopy when fluoroscopy is needed for URS and PCNL. Fluoroscopy technicians also operate the C-arm and reduce kVp, use pulse dosing, maximize skin-to-source distance, and narrow the image window to minimize radiation exposure while maintaining image integrity. We avoid routine magnification and, for smaller children, use pulse settings.

Ancillary Procedures/Anesthesia

Children requiring surgery to remove stones often need multiple anesthetics to complete the operative plan. For URS, the smaller size of children's ureters often precludes direct access with a ureteroscope. Because of the risk of ureteral perforation and stricture associated with active dilation in children, a ureteral stent may need to be placed if the ureteroscope cannot be introduced to allow for passive dilation of the ureter (Raza et al., 2005a; Minevich et al., 2005). However, a “pre-stent” increases the number of anesthetics needed to remove the stone. Similarly, SWL often requires retreatment to clear the stone. The need for multiple anesthetics is a concern considering the potential risk for neurotoxicity in the developing brain. Future comparative and cost-effectiveness studies should examine the disadvantages and potential harms of surgical interventions along with the efficacy. Such studies will be critical for shared decision making and understanding the impact of alternative interventions on outcomes that are important to patients and their families.

Surgical Antimicrobial Prophylaxis

Consistent with the 2008 AUA best practice statement on antibiotic prophylaxis and the 2014 AUA practice guide, prophylaxis is indicated in all patients undergoing URS or PCNL and is indicated for patients undergoing SWL who are at increased risk for infection (Wolf et al., 2008). There are no pediatric-specific recommendations. A urine culture should be obtained before all upper tract procedures to determine if the urine is sterile, and culture results are used to guide preoperative antibiotic therapy, particularly for patients undergoing percutaneous procedures, patients with high-grade obstruction, or patients with an indwelling stent (Wu and Docimo, 2004). In our practice, children with a negative urine culture undergoing uncomplicated SWL and ureteroscopy procedures receive perioperative cefazolin, and all children undergoing a percutaneous procedure or who have a preexisting ureteral stent or nephrostomy tube receive a fluoroquinolone or ampicillin/gentamicin. Antibiotics should not be continued for greater than 24 hours postoperatively unless there is a clinical concern for infection.

Ureteroscopic Management of Upper Urinary Tract Calculi

Historically, URS was used for stones below the iliac crest and for upper tract calculi after SWL failure (Wu and Docimo, 2004). URS was not considered primary therapy for upper tract stones in children because of complications from ureteral ischemia, perforation, stricture, and potential for development of vesicoureteral reflux as a result of dilation of small-caliber ureteric orifices. However, the indications for primary ureteroscopic management of upper tract calculi in children have significantly expanded because of continued miniaturization and availability of endourologic instrumentation and training of pediatric urologists in endourology. Stone clearance exceeding 85% with complications similar to the adult population have been reported for ureteroscopic management of renal calculi (Table 43.4). A recent systemic review reported the results of 14 studies of children 4 months to 18 years of age who underwent more than 1700 ureteroscopic stone removals (Ishii et al., 2015). The average stone clearance was 87.5%, and 10% of patients experienced complications less than or equal to Clavien 3. In another recent systematic review, overall stone clearance for URS was 85.5%, and complications occurred in 12% of patients. See Table 43.4 for outcomes of URS reported for pediatric patients.

TABLE 43.4

Historic and Contemporary Outcomes of Ureteroscopy for Pediatric Patients

AUTHOR	PATIENTS	PROCEDURES/PATIENT	MEAN AGE IN YEARS, (RANGE), (RANGE)	MEAN STONE SIZE, IN MM (RANGE)	STON LOCA
Al- Busaidy et al., 1997	43	1.2	6.2 (0.5–12)	12.6 (4–22)	Uretera
Satar et al., 2004	33	1.1	7.4 (0.8–15)	5.3 (3–10)	Uretera
Nerli et al., 2011	80	1.1	9.5 (6–12)	10 (7–16)	70 ure 30 kid
Dogan et al., 2011	642	1.1	7.4 (0.3–17)	8.9 (NR)	Uretera
Yucel et al., 2011	48	1.1	7.6 (0.8–18)	6.6 (4–20)	Uretera
Tiryaki et al., 2013	32	1.7	5.9 (0.6–17)	8.8 (4–18)	Uretera
Erkurt et al., 2014	65	1.1	4.3 (0.5–7)	26 (7–30)	Kidney
Kocaoglu and Ozkan, 2014	36	1	5.3 (1–13)	8.4 (4–18)	Uretera
Chedgy et al., 2015	21	1.5	8.6 (1.4–16)	9.6 (5–20)	Kidney uretera
Featherstone et al., 2017	18	1.8	10.4 (3.6–15)	13.3 (10–25)	Kidney uretera

NR, Not recorded.

There is weak evidence that location may modify the efficacy of URS. Cannon et al. (2007) reported a 76% stone clearance in 21 children with lower pole calculi and a mean stone diameter of 12 mm. Similarly, age may also be a determinant of URS outcomes. Children younger than 6 years of age were reported to have lower treatment success and higher complications (24.0% vs. 7.1%). Among children weighing less than 20 kg, Berrettini et al. (2018) reported that 37% of patients undergoing URS had complications, with a greater risk observed for younger and smaller children.

Even with modern ureteroscopes, pediatric ureters may require a period of stenting before definitive treatment because of the risk for ureteral perforation and stricture associated with active ureteral dilation or forcing a ureteroscope into a ureter that does not accommodate it (Long and Srinivasan, 2015; Dogan et al., 2011). These risks may be greater when a ureteral access sheath is used in younger children (Berrettini et al., 2017). **Approximately 25% of children undergoing URS required staged procedures** (Corcoran et al., 2007)**. However, the AUA and Endourological Society Guidelines do not recommend routine "presenting" before URS** (Assimos et al., 2016a).

There are only a limited number of studies directly comparing URS with SWL in children to help guide evidence-based practice. A recent retrospective, single-institution cohort study comparing URS to SWL reported that URS was associated with a 3.7 times greater odds of stone clearance after a single treatment among children with kidney stones (Freton et al., 2017). Mokhless et al. (2014) in Egypt performed a prospective, randomized trial of URS versus SWL in preschool children and reported similar stone clearance, complications, and operative times. The AUA/Endourological Society Guidelines also reported results of an unpublished meta-analysis that found similar stone clearance between SWL and URS in pediatric patients (Assimos et al., 2016a). These limited results are the basis for the recommendation in the 2016 AUA and Endourological Society Guidelines that **either SWL or URS should be first-line treatment for children with ureteral stones who have failed observation/MET or renal stone burden of ≤20 mm**.

Despite the increased utilization of URS for pediatric patients with ureteral and kidney stones, the optimal technique has not yet been defined. Laser dusting (high frequency of >50 Hz, low energy of <0.4 J) creates small <1-mm particles to enable spontaneous passage of the dust. In the fragmentation and extraction technique (low frequency, high energy), stones are fragmented into 1- to 4-mm pieces that are extracted from the kidney. The questions that emerge from dusting versus fragmentation are related to stone clearance and the patient experience. Preliminary reports from ongoing multicenter studies of adults have demonstrated that dusting is associated with lower stone clearance, but lower ureteral stent use, and similar unplanned health care encounters (Chew et al., 2016; Humphreys et al., 2018).

Equipment

A state-of-the art endourology suite that is familiar to the operative staff is important to effective and safe surgical treatment of the child with urinary stones. This setup includes semirigid and flexible ureteroscopes. In general, semirigid ureteroscopes usually have a 2.4-Fr to 3.5-Fr working port, and flexible ureteroscopes have a 1.8-Fr to 3.6-Fr working port. With flexible ureteroscopes, distal tip deflection up to 270 degrees facilitates access to most lower pole stones (Fig. 43.5). **However, smaller working areas and larger laser fibers may limit deflection, particularly for smaller children in which intrarenal angles are narrow and the collecting system is small (see Fig. 43.5C).**

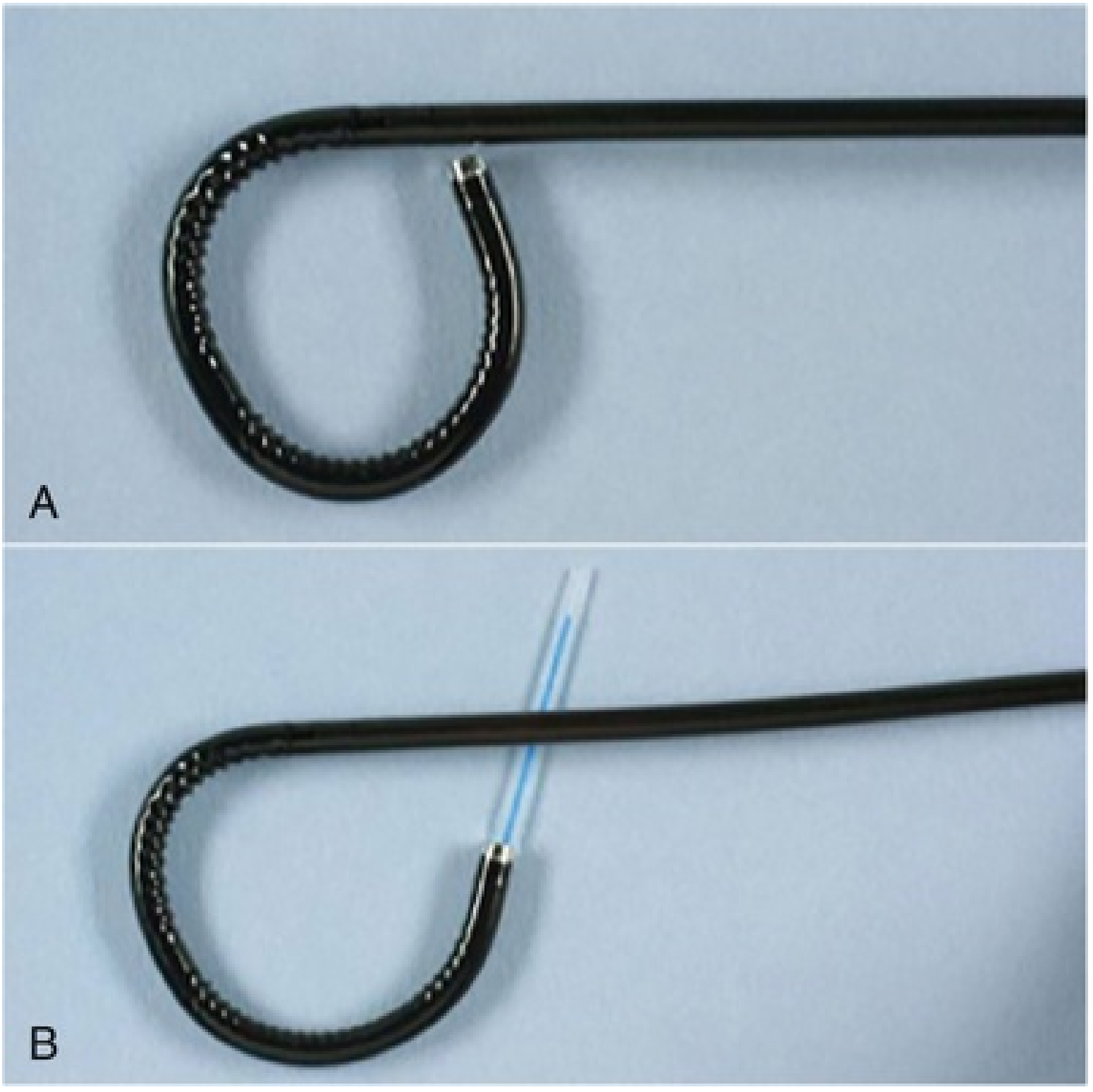

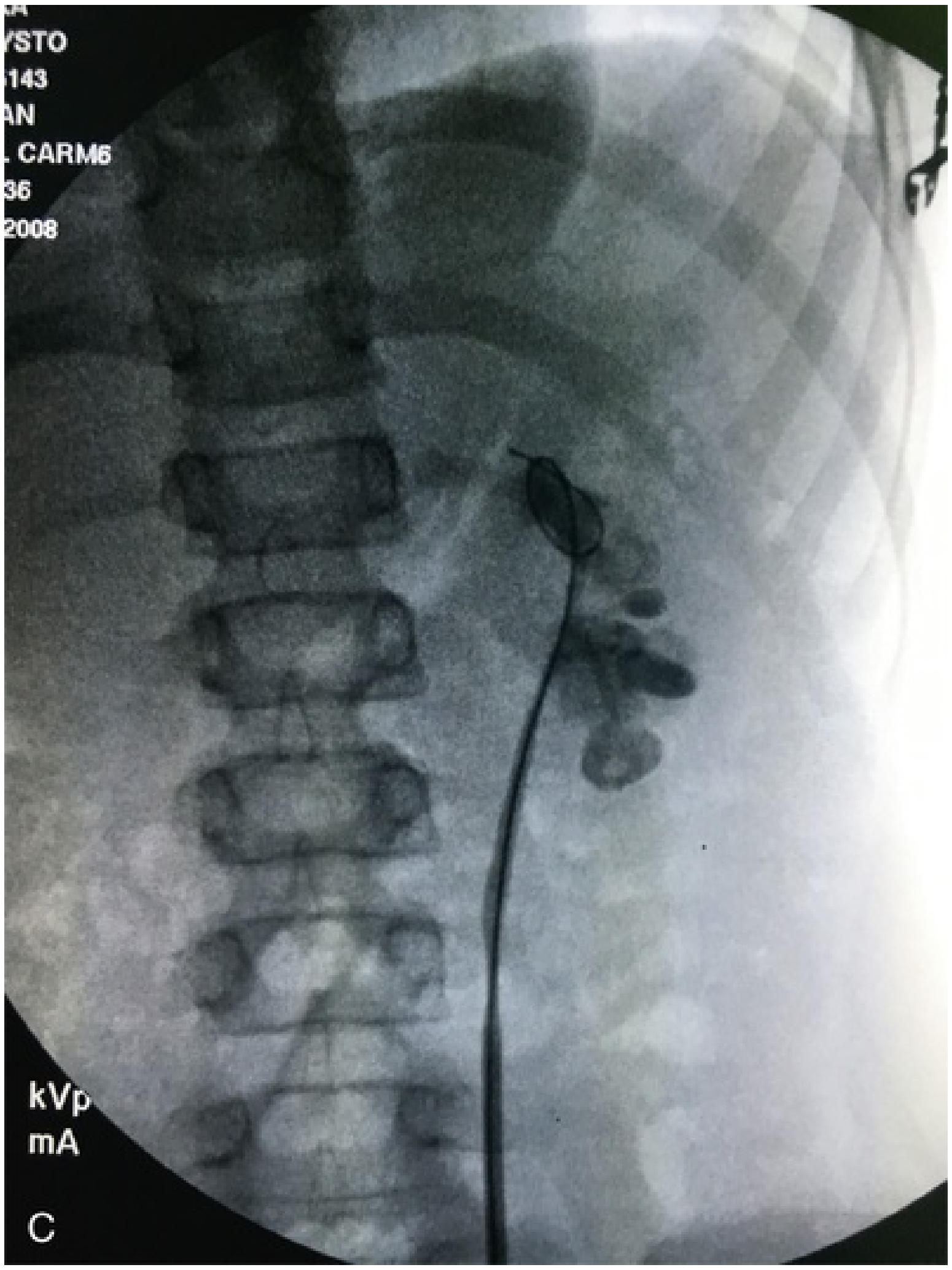

FIG. 43.5 Flexible ureteroscopes have 270-degree deflection of the distal tip (A), although tip deflection is compromised by passage of laser fibers (B), which may make accessing lower pole calyxes with sharp angles difficult (C).

The contents of a basic endourology suite are as follows:

- Ureteroscopes:
  - 7.5- to 8-Fr flexible ureteroscope
  - 4.5-Fr and 6.5-Fr semirigid ureteroscope
- Endourologic equipment:
  - Guidewires (minimum):
    - 0.035-inch guide wire with floppy hydrophilic tip (straight and angled)
    - 0.018- to 0.025-inch Glidewire (straight and angled)
  - Open-ended ureteral catheters (3-Fr, 4-Fr, and 5-Fr)

Dual-lumen catheter
Holmium laser
Basket devices: Zero-tip 4-wire, 16-wire
8- to 10-Fr coaxial ureteral dilators
Ureteral access sheaths (9.5-Fr and 12-Fr internal diameter)
Ureteral stents: 3.7-Fr, 4.6 to 4.7-Fr, 6-Fr, and 8-Fr

Ureteroscopic Technique in Children

All ureteroscopic procedures are performed under general anesthesia. A sterile urine culture should be confirmed before surgery. Children undergoing URS are placed in lithotomy position, similar to adults, using the appropriate size stirrups to avoid pressure wounds and nerve injuries. For infants, gel rolls underneath the knees can be used to provide a modified lithotomy position. Care is taken to ensure all pressure points are padded and the weight of the legs rests on the heels and not the calves or the knees where peroneal nerve injuries may occur. Following broad-spectrum antibiotic prophylaxis, rigid cystoscopy (7.5 Fr, 10 Fr, or 14 Fr) is performed to obtain a retrograde pyelogram and place a wire under fluoroscopic guidance. Initial ureteric orifice calibration is performed, and a safety wire is placed under C-arm fluoroscopic guidance with a 8- to 10-Fr dual-lumen catheter in ureters that have not been stented previously or when the rigid/flexible ureteroscope cannot be advanced easily. We do not use balloon dilation of the ureteric orifice because of concern for development of ureteral stricture from ischemia. If we encounter difficulty passing the 8- to 10-Fr dilator easily, we place a 4.6- or 4.7-Fr ureteral stent to passively dilate the ureter for at least 10 days before returning for the formal URS. We recommend against active dilation of the distal ureter because of the risk for ureteral injury and because the diameter of the ureter proximal to the ureteral orifice also limits safe ureteroscopy, particularly if an access sheath is used.

The decision to use a flexible or semirigid ureteroscope is determined primarily based on location of the stone and anatomic factors. Semirigid ureteroscopy for ureteral calculi and flexible ureteroscopy for proximal ureteral or renal calculi are routinely performed with a safety wire in place. Ureteral access sheaths (10 to 12-Fr or 12 to 14-Fr) are routinely used to facilitate flexible URS, especially in cases of large proximal ureteral stones and larger renal stone burdens when basketing is required. Initially described in eight children, ureteral access sheaths have been reported to facilitate repetitive upper tract access, reduce intrarenal pressures, decrease operative time, and improve stone clearance in adults (Singh et al., 2006). **Access sheaths also may facilitate flexible ureteroscopy when altered anatomy or tortuous ureters are encountered.**

Although the efficacy of URS is less dependent on stone position than SWL, consideration must be given to the smaller size of children's kidneys when operating for a lower pole stone. Smaller kidneys have less room to maneuver a ureteroscope and have sharper angles, which may make accessing stones in the lower pole difficult (see Fig. 43.5C). Given these technical considerations, we use a 150-µm Holmium laser fiber to access stones in the lower pole, which improves deflection compared with larger fibers (Kuo et al., 1998). We routinely use a 200-µm fiber for ureteral stones and stones located in the mid and upper pole calyces.

Irrigating fluid should be isotonic and body temperature to avoid hyponatremia and hypothermia. Calculi are basket-extracted when feasible or fragmented using a holmium : YAG laser to facilitate removal. **The decision to place a ureteral stent postoperatively is based on the duration of the procedure, the number of passes with the ureteroscope, and the degree of visible ureteral trauma or edema at the conclusion of the procedure.** Although the tendency in some series was to leave a stent in place after URS in most children, several authors reported no short- or long-term sequelae despite leaving a postoperative stent in less than 20% of cases (Herndon et al., 2006). In our experience, the decision to place a stent after ureteroscopy is made on an individual patient basis and depends on surgeon experience and degree of visible ureteral trauma at the conclusion of the procedure. If the child can tolerate leaving a urethral string in place for 5 to 7 days, the patient's parents are asked to remove the stent at home; otherwise, the stent is removed under brief anesthesia after 7 days.

Limitations and Complications

The complications of URS include ureteral injury, urinary tract infection, and bleeding. Serious complications (greater than Clavien 3) are uncommon. These include unrecognized ureteral injury including mucosal flaps and tears, perforation, false passage, and partial to complete ureteral avulsion. Should a ureteral injury occur, the procedure should be aborted and a ureteral stent should be placed to mitigate shear force injury on the ureter, ischemic damage, and extravasation of irrigant or urine. Injury can occur during introduction of the ureteroscope or either antegrade or retrograde passage of instrumentation (guidewires, baskets, dilators), especially in the area of an impacted ureteral calculus. Attempting to withdraw a basket-entrapped calculus too large for the ureter to accommodate can result in any of the injuries discussed earlier.

If a ureteral stricture is encountered or develops after ureteroscopy, a retrograde pyelogram can show the degree, length, and location of narrowing. Short mid-ureteral strictures can undergo prolonged stent placement, although the long-term success of this is uncertain. Balloon dilation of ureteral strictures is not used by the authors, with laser incision being preferred. We recommend formal reconstruction, which can often be performed robotically, for longer, denser, or recurrent strictures. Distal strictures may be treated with a ureteroneocystostomy. Proximal or mid-ureteral strictures may necessitate pyeloplasty or excision and primary anastomosis, respectively.

Key Points: Ureteroscopic Management of Upper Tract Calculi

- Miniaturization of endoscopic instruments with modification of techniques used for adults has allowed children with calculi less than 15 mm to be treated effectively and safely.
- Routine prestenting before URS is not recommended.
- Postoperative stenting is based on the duration of the procedure, number of passes with the ureteroscope, and degree of visible ureteral trauma or edema at the conclusion of the procedure.
- The most common complications involve unrecognized ureteral injury, including mucosal flaps and tears, perforation, false passage, and partial to complete avulsion.

Shock Wave Lithotripsy

The introduction of SWL during the early 1980s revolutionized minimally invasive treatment of urolithiasis. Since the initial report on successful SWL use in children in 1986 (Newman et al., 1986), large series have reported complication, safety, and stone clearance comparable to adult cohorts (Myers et al., 1995; Muslumanoglu et al., 2003; Raza et al 2005b; Rizvi et al., 2003; Aksoy et al., 2004; Demirkesen et al., 2006; Elsobky et al., 2000). SWL may be more effective in children than in adults, possibly caused by smaller body size and shorter skin-to-stone difference (Kurien et al., 2009). However, SWL outcomes are difficult to interpret from the existing literature because of variation in the type of lithotripter, number of shocks administered, and retreatment rates.

Along with URS, SWL is a treatment option for upper tract calculi 15 mm or smaller in children (Assimos et al., 2016a)**. When used as a primary treatment option for upper tract calculi, SWL efficacy ranges from 68% to 84%** (Myers et al., 1995; Rizvi et al., 2003; Defoor et al., 2005). In a series of 216 children (mean age of 6.6 years) with a mean stone size of 15 mm undergoing SWL with the Dornier HM3 lithotripter, Landau reported stone clearance of 80% at 3 months. However, stone clearance in children with a history of a urologic anomaly or urinary tract reconstruction is low (Landau et al., 2009). Depending on body habitus, stone size, and stone location, URS or PCNL may be better treatment options for these children (Nelson et al., 2008).

Stone size is an important determinant of stone clearance after SWL. Ather and Noor examined whether size modified the efficacy of SWL efficacy among 105 children younger than 14 years of age. They reported overall stone clearance of 95% after a mean of 1.7 SWL treatments (Ather and Noor, 2003). Demonstrating the importance of stone size in determining efficacy of SWL, Elsobky et al. (2000) reported a 91% stone clearance for mean stone diameter less than 10 mm versus 75% stone clearance for stone size greater than 10 mm. Although it is possible to treat very large stone burdens with SWL, concerns include the need for more shocks delivered, frequent retreatment sessions, and increased risk for postoperative obstruction. Further study delineating a clear size cutoff for uncomplicated upper tract stone burden is required to counsel parents regarding the most effective first-line therapy for renal calculi between 10 and 15 mm.

Although SWL is considered a treatment option for pediatric patients

with renal stones greater than 20 mm, the probability of clearance is lower than PCNL and requires multiple treatments (Al-Busaidy et al., 2003; Lottmann et al., 2001). For pediatric patients who undergo SWL for stones greater than 20 mm, the AUA and Endourological Society Guidelines recommend placing a ureteral stent to decrease the risk for major complications (Assimos et al., 2016a, 2016b). Because of the abundance of studies that have demonstrated poor efficacy of SWL for large renal stone burdens in adults and the safety and high efficacy of PCNL in this clinical setting, it is the authors' practice not to perform SWL for stones greater than 15 mm in pediatric patients.

Stone location is also an important determinant of SWL outcomes; however, the most effective management of lower pole calculi has yet to be determined in children, and there are no location-specific guidelines for pediatric patients. Stone clearance for lower pole stones in small retrospective series range from 56% to 61% with retreatment rates of 40% (Onal et al., 2004; Özgür Tan et al., 2003). A recent systematic review and meta-analysis comparing SWL, URS, and PCNL in adults for lower pole stones less than 2 cm favored PCNL over SWL and URS over SWL, particularly in stones 10 to 20 mm (Donaldson et al., 2015). Whether these results in adults are generalizable to children is uncertain.

SWL failure and retreatment rates were associated with increased mean stone burden, increased infundibular length, and infundibulopelvic angle greater than 45 degrees (Onal et al., 2004; Özgür Tan et al., 2003). Although CT is not necessary before SWL or in the management of most pediatric stone disease, stone attenuation on CT has been associated with stone fragmentation. Stone attenuation less than 1000 HU was associated with treatment success in children (El-Assmy et al., 2013; McAdams et al., 2010).

Stone composition is also an important effect modifier of SWL efficacy. Cystine stones are uniquely challenging because of their hardness and high recurrence rates. In a small series, Slavkovic reported stone clearance of 50% in six children with cystine stone burden ranging from 2 to 25 mm (Slavkovic et al., 2002). Other authors have proposed that cystine stones formed within 2 years of therapy may be more easily fragmented with SWL and that stone number may be more closely associated with stone clearance than stone diameter.

Shock Wave Lithotripsy Technique in Children

SWL is typically performed under general anesthesia, although intravenous sedation has been successfully employed in some older children (Aldridge et al., 2006). Bowel preparation is seldom used to avoid dehydration and electrolyte imbalance postoperatively. Ureteral catheters with retrograde opacification are occasionally employed by some clinicians to aid in the localization of radiolucent calculi. **Increased shock frequency and energy level have been associated with lower stone clearance among adults** (Ozkan et al., 2015)**, but the optimal settings for children are unknown.** A retrospective cohort study of children treated with SWL in Turkey reported similar stone clearance and complications for shock frequencies of 60 and 90 shocks per minute (Kaygisiz et al., 2018).

The 2016 AUA and Endourological Society Guidelines recommended placement of a ureteral stent or nephrostomy for SWL for stones greater than 20 mm. Although indications for stent placement before SWL are poorly defined, **additional relative indications include solitary kidneys, obstruction, or abnormal anatomy.**

Limitations and Concerns

The short-term effects of SWL, which are usually self-limiting, include hematuria (up 44%) and subcapsular or perirenal hematoma (Yucel et al., 2012). In addition, children treated with SWL need to pass stone fragments and are at risk for intermittent renal colic, emergency department visits for pain control, and steinstrasse. Difficulty with focusing SWL can lead to injury to adjacent structures including the colon, vasculature, lung, spleen, and pancreas (Yucel et al., 2012).

In addition, as noted earlier, stone clearance after single SWL treatment is low. As a result, children are subjected to multiple treatments requiring general anesthesia (Aldridge et al., 2006). The need for multiple treatment sessions is concerning because the effects of shock waves on renal tissue are unclear. A growing body of evidence in adults indicates that shock waves result in renal vessel vasoconstriction and that renal tubular injury and subcapsular hematoma from cavitation and shear forces are dependent on the kilovoltage applied (Lingeman et al., 2003). In a large series of 340 adult patients with a mean follow-up period of 19 years after SWL, Krambeck et al. reported an increased risk for hypertension and diabetes mellitus related to bilateral treatment, number of administered shocks, and treatment intensity (Krambeck et al., 2008). **Despite some studies showing no long-term effects of SWL, a recent population-based cohort study of adults also demonstrated that SWL was associated**

with 40% increased risk for incident hypertension (Denburg et al., 2016; Yucel et al., 2012; Griffin et al 2010; Akin and Yucel, 2014; Fayad et al., 2010). It is our practice to discuss with patients and caregivers the potential risk for hypertension associated with SWL during the shared decision-making process considering the possibility that children's kidneys may be more vulnerable to injury, the independent association between kidney stone disease and hypertension, and the longer lifespan over which hypertension may develop following surgical treatment. Long-term prospective data in children are needed.

Key Points: Conservative Management and Shock Wave Lithotripsy

- Smaller and more distal stones have a higher probability of spontaneous passage.
- α-Blockers may increase spontaneous passage of ureteral stones in pediatric patients.
- Although the overall stone clearance of SWL approaches that of URS for stones less than 15 mm, there is a greater need for retreatment.
- SWL has been associated with an increased risk for hypertension.

Percutaneous Nephrolithotomy

The safety and efficacy of PNCL for large stone burdens have been well established in adults. Urologists initially were reluctant to perform PCNL in children because of concerns regarding the use of large instruments in pediatric kidneys and parenchymal damage and the associated effects on renal function, radiation exposure, and the risk for major complications including sepsis and bleeding. However, with significantly accumulated experience, **PCNL is considered first-line therapy for renal stones greater than 20 mm in children, with stone clearances of approximately 90%** (Assimos et al., 2016b). PCNL has replaced open surgery as the treatment of choice for large stone burdens in all children (Table 43.5).

TABLE 43.5

Historic and Contemporary Outcomes of PCNL for Pediatric Patients

---

AUTHOR	YEAR	*N*	MEAN AGE (YEARS)	TRACT SIZE	FRAGMENTATION METHOD	STONE CLEARANC (%)
Yadav et al.	2017	639	12.2	≤2–4 Fr	Pneumatic Holmium	94
Citamak et al.	2015	346	8.5	14–30 Fr	Pneumatic Holmium	73
Daw et al.	2015	26	3.7	14 Fr	Holmium	77
Dede et al.	2015	39	5.8	12 Fr	Pneumatic Holmium	82
Goyal et al.	2014	158	10	24–30 Fr	Pneumatic	85
Zeng et al.	2013	331	7.8	14–20 Fr	Pneumatic Holmium	80
Ozden et al.	2008	53	9.7	20–30 Fr	Ultrasonic Pneumatic	74
Jackman et al.	1998	11	3.4	11 Fr	Electrohydraulic lithotripsy	85

NR, Not recorded.

The earliest pediatric PCNL series were performed using standard adult-sized instruments. Woodside et al. (1985) first reported a series of seven patients (age range 5 to 18 years) who were rendered stone-free without complications using adult percutaneous techniques and equipment. Mor et al. (1997) subsequently reported another pediatric PCNL series using adult-sized instruments. These early series avoided performing PCNL in small children (younger than 5 years of age) because of concerns of parenchymal damage.

PCNL for pediatric patients using an access tract of up to 30 Fr and adult-sized instruments reported high stone clearance (Bilen et al., 2007; Salah et al., 2004; Samad et al., 2006; Zeren et al., 2002). However, Desai et al. (2004) demonstrated that the risk for bleeding increases with access tract size. This risk may be higher in children because the relative size of a 24- to 30-Fr access tract to children's smaller kidneys has been estimated to be 72 Fr (Jackman et al., 1998). The continued miniaturization of access sheaths and nephroscopes and improvements in stone fragmentation technology have allowed use of smaller access tracts, which mitigates the risk for bleeding while maintaining stone-free rates at or above 75%. Mini- and micro-PCNL have become increasingly common for large renal stones for both children and adults. Mini-PCNL usually refers to access tracts of less than 20 to 24 Fr, whereas micro-PCNL refers to tracts less than 10 Fr. The comparative effectiveness of and indications for newer techniques such as mini-PCNL, ultra-mini-PCNL, and micro-PCNL among pediatric patients is an active area of investigation (Dede et al., 2015). With continued improvement in technology and technique, the indications for PCNL in children are expected to continue to increase.

Despite the AUA guidelines that state both SWL and PCNL are options for children with renal stones greater than 20 mm, we recommend PCNL for these patients because SWL is less effective than PCNL for large renal stones. In addition, it is possible that the recently reported association between SWL to the kidney and hypertension (Denburg et al., 2016) may be greater among children because of the larger area of the kidney affected by the shock waves and the longer lifespan over which hypertension may develop. However, PCNL and percutaneous renal access in children should be performed only by experienced urologists who have the necessary training and equipment.

Percutaneous Nephrolithotomy Planning for Pediatric Patients

PCNL is technically challenging, and surgeon experience with PCNL is paramount in developing treatment plans to optimize efficacy with minimal morbidity. The AUA and Endourological Society Guidelines recommend CT before PCNL (Assimos et al., 2016b). Films must be reviewed carefully to determine if stones are amenable to a percutaneous procedure and to determine the optimal calyx to access the stone. Stone size, stone location, and adjacent organs should be considered. In addition, any alteration in renal anatomy caused by scoliosis, lordosis, or kyphosis should be considered. **The risks associated with PCNL must be reviewed with the consenting parent or guardian, including bleeding requiring transfusion, delayed renal hemorrhage requiring angioembolization, sepsis, pneumothorax, hemothorax, urothorax, incomplete stone clearance, and injuries to adjacent organs.**

Urinary tract infections should be treated before PCNL. A urine culture and antibiotic sensitivities should be checked 2 to 3 weeks before the procedure. A positive culture requires a full course of antibiotics. However, it should be noted that bladder cultures may not reflect stone cultures or urine cultures obtained from the renal pelvis. Empiric treatment with ciprofloxacin among adults 1 week before PCNL may reduce infectious complications (Mariappan et al., 2006). Broad-spectrum intravenous antibiotics (e.g., ampicillin and gentamicin) should be given at the time of the procedure.

Percutaneous Nephrolithotomy Technique for Pediatric Patients

PCNL is performed under general anesthesia. A warm operating room, warmed isotonic irrigation solution, shorter operative times, proper draping, and monitoring of body temperature should decrease the incidence of hypothermia. We first perform cystoscopy and place a 4- or 5-Fr open-ended ureteral catheter just below the ureteropelvic junction, which can be used for retrograde pyelograms or instillation of saline to distend the collecting system. We then position the patient prone over gel bolsters and obtain renal access with ultrasound, although fluoroscopy is commonly used (Figs. 43.6 and 43.7). Assessing the degree of mobility in the trunk and extremities is important for positioning patients for PCNL. Patients must be placed in the most comfortable position possible without excessive contortion or flexion of the joints. Special attention must be paid to latex precautions in patients with myelomeningocele, and, in all cases, proper padding of pressure points is mandatory.

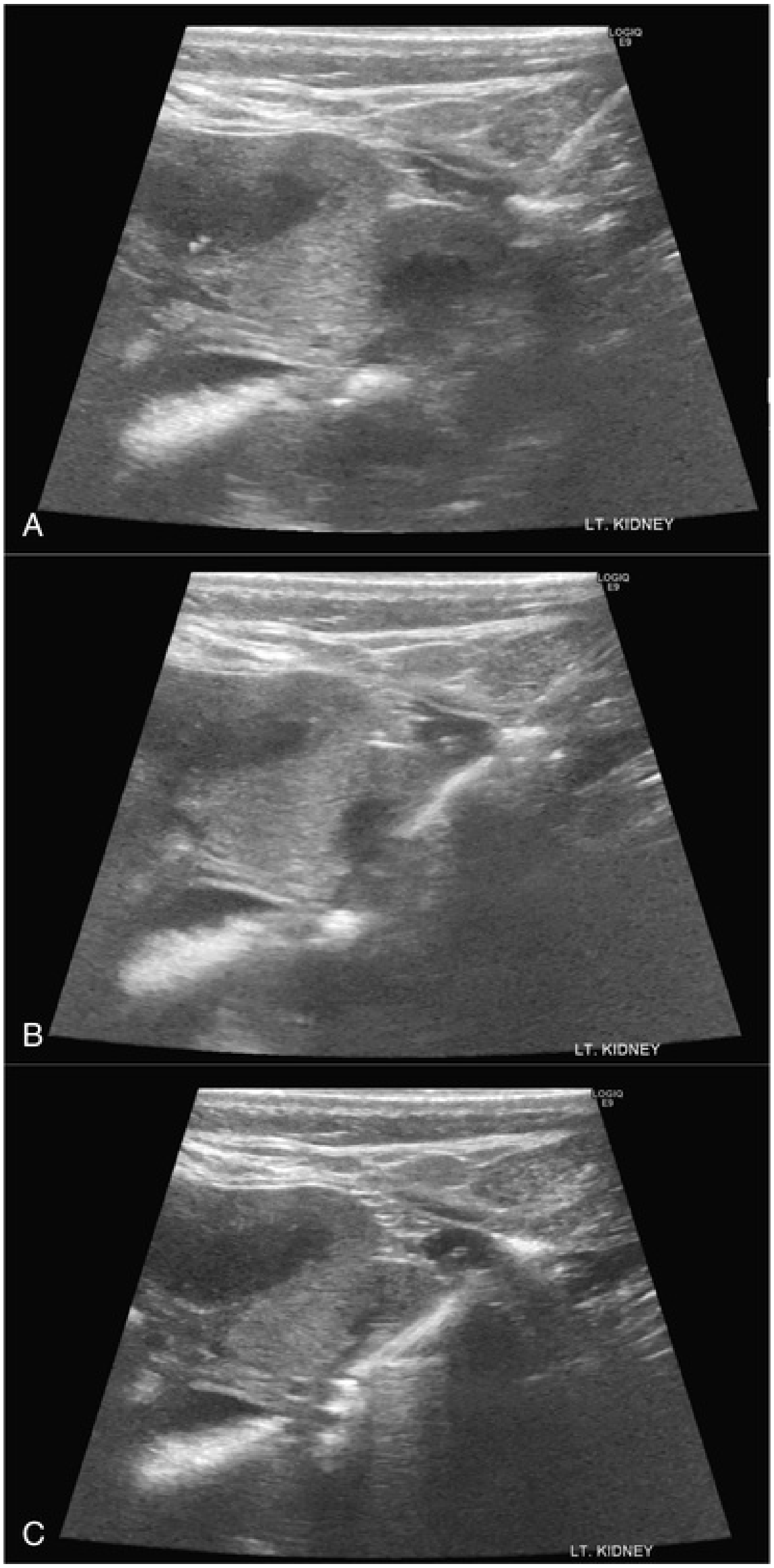
LOGIQ E9
A
LT. KIDNEY
LOGIQ E9
B
LT. KIDNEY
LOGIQ E9
C
LT. KIDNEY

FIG. 43.6 (A–C) Lower pole access for mini-percutaneous nephrolithotomy obtained using ultrasound. The needle appears as a linear echogenic focus on the right side of the image.

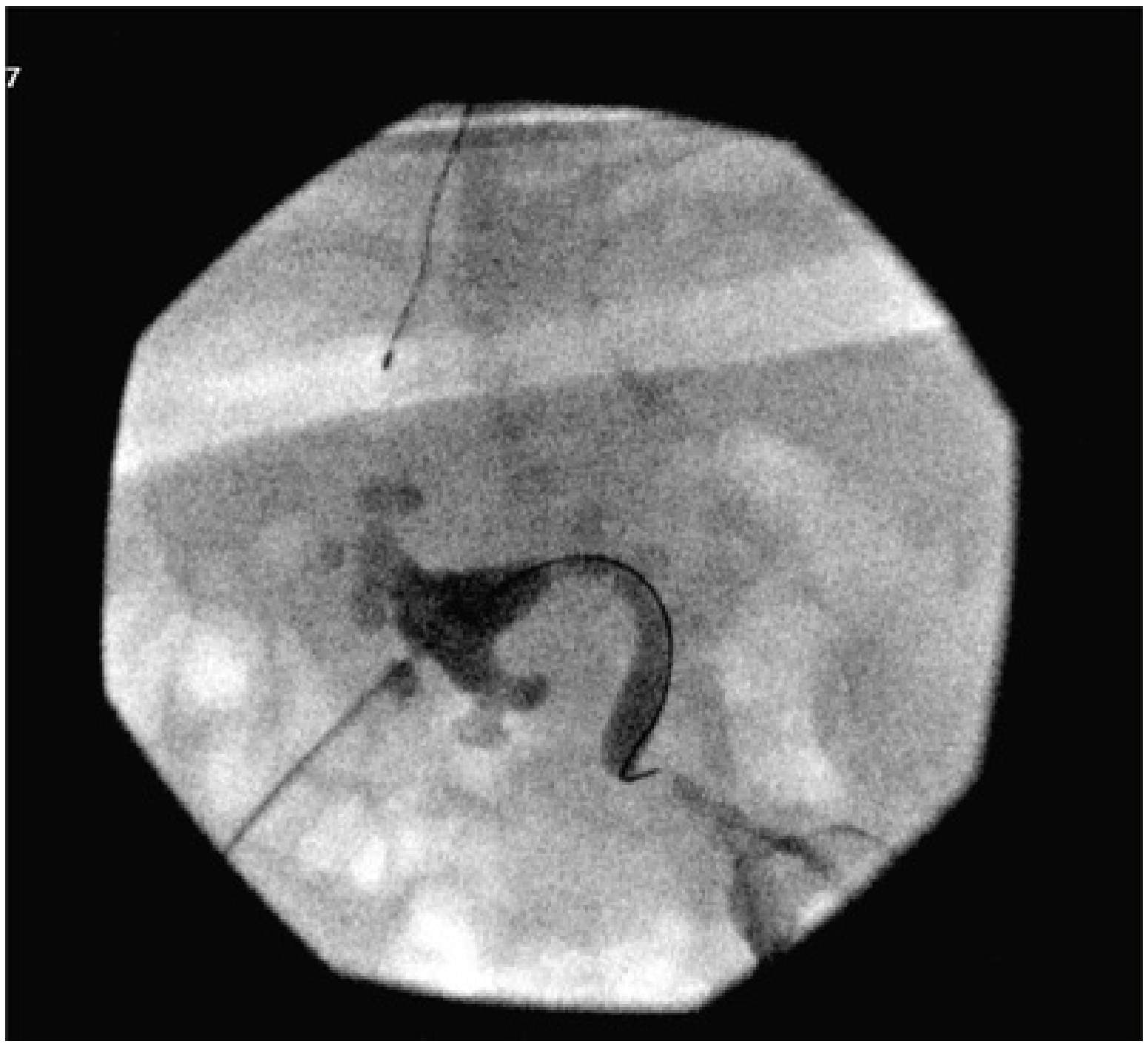

FIG. 43.7 Mid-pole access for mini-percutaneous nephrolithotomy for a pelvis stone in an infant.

After selection of the desired calyx, a 16- or 18-gauge spinal needle is placed with the assistance of fluoroscopy or ultrasound. The authors obtain access with ultrasound using the technique described by Chu et al. (2016). For lower pole access, the posterior calyx is identified, which, in >90% of patients, is the calyx immediately superior to the most inferior calyx on anteroposterior fluoroscopy (Miller et al., 2013). Upper pole is obtained below the 11th rib and in the medial calyx to decrease the risk for pneumothorax. If CT guidance is required for renal access in a child with spinal dysraphism or an aberrantly positioned kidney, Interventional Radiology obtains renal access.

A small skin incision is made with a No. 11 scalpel, and 8-Fr and 10-Fr coaxial dilators are passed over the guidewire into the collecting system. A safety wire introducer or dual-lumen catheter is used to place a safety wire. After placement of two wires (with the safety wire preferentially down the ureter), we use an 18-Fr balloon dilator and PTFE sheath for renal access. **Children's kidneys, and especially infant's kidneys, are more mobile than adult kidneys and often push away when obtaining initial needle access and placing the access sheath.** Attention to the location of the tip of the balloon in the collecting system and bony landmarks is critical when advancing the sheath under fluoroscopy. A retrograde pyelogram is performed using the ureteral catheter to redefine the collecting system anatomy. Before placing a sheath in small children, we trim it to shorten the extracorporal component, which we find improves maneuverability and limits torque on the kidney. After obtaining access, we use a 15- to 18-Fr rigid nephroscope, and our preference is a lithotripter, which uses both ultrasonic and mechanical energy to fragment and remove the stone(s). We use the Olympus ShockPulse lithotripter because it combines the greater efficacy of the ACMI/Olympus Cyberwand (compared with Holmium laser) with probes that are small enough (2.1 to 11.3 Fr) to be used in mini-nephroscopes and semirigid ureteroscopes. Because of the sharper angles and narrower infundibula of children's kidneys, we use a flexible pediatric cystoscope and/or flexible ureteroscope to confirm stone clearance and access mid-pole calyces for residual fragments. Following stone clearance, we routinely place a nephrostomy tube, the size of which depends on the child's age. The authors use a 10- to 12-Fr Malecot in infants and a 14-Fr Malecot in adolescents, or an 8.5-Fr Cope loop nephrostomy tube. If there is substantial stone burden and/or substantial edema at the UPJ, we place a ureteral stent in addition to the nephrostomy tube. In this setting, the nephrostomy tube is removed after the urine clears and the patient is safe for discharge, usually on postoperative day 1. At this time, there is insufficient evidence that tubeless PCNL is a safe option for children.

Historically, primary PCNL with adjunctive SWL to clear residual fragments was often performed for children (“sandwich therapy”; Samad et al., 2006; Mahmud and Zaidi, 2004). However, with efficacy of PCNL around 90% for large stone burdens, miniaturization of nephroscopes, and the concerns of hypertension for SWL, the indications for sandwich therapy are limited.

Percutaneous Nephrolithotomy Complications

The proportion of children who experience some complication after PCNL ranges from 15% to 39%. Although most of these complications are minor, complications greater than or equal to Clavien 3 occur in 1% to 16% (see Table 43.5). The probability of operative blood loss requiring transfusion is consistently <10%. Complications included postoperative fever (30%) and need for transfusion (24%). **Transfusion was associated with operative time, sheath size, and stone burden** (Zeren et al., 2002). In 135 children with a mean age of 8.9 years and a mean stone burden of 507 mm^2, Salah et al. (2004) reported a 98.5% stone-free rate using ultrasonography through a 26-Fr nephroscope.

Complications were low (8% urine leak rate and 0.7% transfusion rate), with only one patient requiring a second procedure. When stratified by tract size (14 Fr, 20 Fr, and 24 Fr), efficacy rates were similar in all groups, but there were no complications or transfusions in the 14-Fr tract group (Bilen et al., 2007). A large multicenter study demonstrated that the most significant determinants affecting complication rates were operative time, sheath size, mid-calyceal puncture, and partial staghorn formation (Onal et al., 2014). PCNL has not been shown to cause loss of kidney function or scarring (Mor et al., 1997).

Should significant bleeding occur, the operation should be aborted and either a Foley catheter or re-entry catheter should be placed in the collecting system through the nephrostomy tract, and treated as clinically indicated for adult patients. Should a renal pelvis injury occur, the operation should be stopped and an antegrade ureteral stent should be placed, if feasible. **Treatment of known complications of PCNL in children, including hydrothorax, colonic injury, and postoperative bleeding, is similar to adults**. Because of the possibility of bleeding requiring embolization or hydrothorax requiring a chest tube, we recommend that PCNL only be performed at children's hospitals with a pediatric interventional radiology team capable of performing these procedures.

Key Points: Percutaneous Nephrolithotomy

- PCNL is indicated for treatment of a large upper tract stone burden (>20 mm) in children.
- Fluoroscopy or ultrasound can be used to obtain access for PCNL.
- Despite efficacy rates approaching 90%, PCNL is associated with risks including bleeding, delayed renal hemorrhage, sepsis, pneumothorax, hemothorax, urothorax, incomplete stone treatment, and injuries to organs adjacent to each respective kidney.

Laparoscopic and Robotic-Assisted Pyelolithotomy

Consistent with the recommendations in the 2016 AUA and Endourological Society recommendations against routine open, laparoscopic, and robotic surgery for pediatric kidney stones, laparoscopy and robotic-assisted surgery is not indicated for upper tract stones in pediatric patients with normal urinary tract anatomy (Assimos et al., 2016b). The rationale for this recommendation is that URS, SWL, and PCNL have high rates of success and lower risks for serious complications. The primary exception to this is in children or adolescents with renal or ureteral stones and a coexisting anatomic anomaly, such as UPJ obstruction. In these patients, robotic (or laparoscopic) pyeloplasty with concomitant stone removal is indicated (Lee et al., 2007).

Secondary Prevention

Fluid

Fluid intake is a critical component of stone prevention by effectively reducing the concentration of lithogenic factors including calcium, oxalate, uric acid, and cystine. Although it has been clearly shown that high daily fluid intake reduces the risk for recurrent stone formation (Borghi et al., 1996), the exact prescription is unknown. Most clinicians recommend intake at least equal to calculated maintenance rates in children and greater than 2 to 2.5 L in adolescents and adults. Even higher fluid intake levels (1.5 to 2 L/m^2) may be recommended for children with cystinuria or primary hyperoxaluria. Increased intake requirements may be required during periods of increased insensible water loss. As to fluids other than water, reports suggest that fluids that increase urinary pH and citrate excretion such as orange juice, lemonade, and black currant juice, as well as those that increase urinary volume such as coffee, tea, beer, and wine, reduce the risk for calcium stone formation. Conversely, grapefruit juice appears to increase the risk for calcium-based stones. Whether or not soft drinks increase lithogenic potential remains controversial (Borghi et al., 2006; Taylor and Curhan, 2006).

Sodium

There is an association between increased sodium intake, urinary calcium excretion, and calcium stone formation (Taylor and Curhan, 2006). Increased sodium intake promotes calciuria by competing for reabsorption at the level of the renal tubules. A low-salt diet corresponding to less than 2 to 3 mEq/kg/day in children or less than 2.4 g/day in adolescents or adults is generally recommended for patients with hypercalciuria or calcium-containing stones. A low-salt diet may also reduce urinary cystine excretion in patients with cystinuria.

Calcium

Higher calcium intake was initially thought to increase the risk for stone formation; however, there now is substantial evidence that a higher calcium diet is associated with a reduced risk for stone formation (Curhan et al., 1997). A potential mechanism that might explain this paradox is that higher calcium intake effectively binds dietary oxalate in the gut, thereby reducing intestinal absorption and eventual urinary oxalate excretion. The current recommendation for stone formers is not to restrict dietary calcium intake, in part also because of the long-term risk for osteoporosis. Excess consumption of vitamin D with or without calcium supplements can also induce excessive urinary calcium excretion, although the association with stone formation is uncertain.

Animal Protein

There is evidence for a role of dietary animal proteins (meat, fish, and poultry) in calcium oxalate stone formation. The metabolism of sulfur-containing amino acids in animal meat generates an acid load in the form of sulfuric acid. As a result, excessive dietary animal protein intake causes increased urinary calcium excretion and reduced urinary citrate excretion and pH. Vegetable and dairy protein sources do not appear to carry the same lithogenic potential. Consumption of excessive amounts of dietary animal protein also results in increased purine load and increased uric acid production, and it may contribute to both uricosuria and more acidic urine. In cystinuric patients, there is little evidence to support the dietary restriction of proteins high in cystine content; however, reducing animal protein intake might be helpful by increasing urinary pH. **It is generally recommended that children with calculi should not eat excessive amounts of protein but should aim for 100% of the daily recommended allowance for age to supply adequate substrate for growth**

and nutrition.

Oxalate

The role of dietary oxalate in stone formation is controversial because only approximately 10% to 20% of urinary oxalate excretion is derived from the diet. As a precautionary measure, most clinicians recommend limiting dietary oxalate ingestion in calcium oxalate stone formers who demonstrate evidence of hyperoxaluria. High oxalate-containing foods include certain nuts (almonds, peanuts, cashews, walnuts, and pecans), spinach, soy beans, tofu, rhubarb, beets, sweet potatoes, wheat bran, okra, parsley, chives, black raspberries, star fruit, green tea, and chocolate. Vitamin C supplements have been associated with increased risk for calcium oxalate stone formation because, as mentioned earlier, oxalate is a by-product of ascorbic acid metabolism, therefore these supplements should be discontinued in calcium oxalate stone formers with hyperoxaluria (Taylor et al., 2004).

Citrate

Potassium-rich foods such as fruits and vegetables usually contain large amounts of citrate, which are protective against calcium oxalate stone formation. In many studies, a diet high in potassium is protective against urolithiasis (Curhan et al., 1997). In addition a potassium-deficient diet can cause increased urinary calcium excretion, overt hypokalemia, and hypocitraturia. One recent study suggests that chronically low potassium intake in the absence of overt hypokalemia may also result in low urinary potassium and citrate levels (Domrongkitchaiporn et al., 2006). As a result, a diet containing potassium-rich fruits and vegetables can theoretically increase urinary citrate excretion directly because of the citrate content found in these foods and indirectly through the dietary potassium content.

Others

Magnesium complexes with oxalate and may prevent enteric oxalate absorption and decrease calcium oxalate supersaturation in the urine. In some studies, higher dietary magnesium has been associated with a lower risk for stone formation in men (Taylor et al., 2004), and supplementation may be helpful in the treatment of children with secondary hyperoxaluria. Carbohydrate ingestion has been associated with hypercalciuria, and sucrose ingestion has been found to be associated with urolithiasis (Curhan et al., 1997). Phytate, a dietary factor found in many high-fiber foods (e.g., cereals, legumes, vegetables, nuts), appears to bind calcium avidly and may inhibit calcium oxalate stone formation.

Medications

Pharmacotherapy is warranted for children in whom fluid/dietary therapy is ineffective in controlling stone formation.

Diuretics

A thiazide diuretic is often required for children with hypercalciuria that does not respond to a restricted sodium diet. The usual recommendation is hydrochlorothiazide 1 to 2 mg/kg per day (adult 25 to 100 mg/day). Potassium citrate can be added to mitigate the effects of potassium depletion.

Alkali Agents

Treatment with either potassium citrate (2 to 4 mEq/kg/day, adults 30 to 90 mEq/day) (Barcelo et al., 1993) **or potassium-magnesium citrate** (Ettinger et al., 1997) **has been shown to reduce the recurrence of calcium oxalate stone formation in patients with low or normal citrate excretion.** Sodium citrate is generally considered less ideal as it is associated with increased sodium delivery to the nephron. Treatment is considered safe with only minor gastrointestinal side effects; however, one potential concern is that overtreatment with alkali may increase the risk for calcium phosphate stone formation by increasing the urinary pH >6.5, thereby decreasing the calcium phosphate supersaturation product. Potassium citrate is also used to alkalinize the urine in patients with uric acid lithiasis (goal of urine pH >6.5), cystinuria (goal of urine pH >7), and hyperoxaluria.

Thiol-Containing Agents

These agents are used exclusively for patients with cystinuria in whom fluid/dietary modifications and urinary alkalinization are ineffective in preventing stone recurrences. The two most common agents are D-penicillamine and α-mercaptopropionylglycine (tiopronin). Cystine is formed as a dimer of cysteine, and these agents work by reducing the disulfide bond that bridges two molecules of cysteine. The thiol group combines with cysteine to form a more soluble cysteine–drug product combination that can be excreted. Unfortunately, D-penicillamine has a large number of adverse side effects including febrile reactions, gastrointestinal discomfort, liver dysfunction, impaired taste, bone marrow suppression, trace metal deficiencies, membranous glomerulopathy, myasthenia gravis, and skin eruptions (elastosis perforans serpiginosa). The incidence of adverse effects for alpha-mercaptopropionylglycine is similar but may be slightly less. Monitoring of liver enzymes, complete blood count, urinalysis, and copper and zinc levels should be performed regularly. Special assays (solid-phase assay or high performance liquid chromatography) can readily distinguish between urinary cystine and cysteine–drug complexes and may help in guiding long-term medical therapy.

Allopurinol

The mainstay of therapy for most children with uric acid calculi is a combination of high urine flow rate and alkalinization of the urine. Allopurinol (4 to 10 mg/kg/day, adult maximum 300 mg/day) is indicated in patients with both hyperuricemia and hyperuricosuria such as PRPSS or HPRT deficiency. Inhibition of xanthine dehydrogenase by allopurinol may lead to accumulation and urinary excretion of xanthine. Rarely, a secondary xanthinuria with xanthine calculi is observed in children on chronic therapy. Allopurinol may also be the agent of choice for treating hyperuricosuric calcium oxalate urolithiasis if there is no concomitant evidence of hypercalciuria, hyperoxaluria, or hypocitraturia (van Woerden et al., 2004).

Pyridoxine

Pyridoxine is an important cofactor of the AGT enzyme. Approximately 10% to 30% of children with PH1 are pyridoxine sensitive (>30% reduction of urinary oxalate excretion). In particular, patients who are homozygous for *Gly170Arg* or *Phe152Ile* mutations are more likely to respond and have preserved renal function over time with adequate treatment (van Woerden et al., 2004). In patients with suspected PH1, treatment should be initiated (2 to 5 mg/kg/day) and titrated upward (8 to 10 mg/kg/day) until a diagnosis can be made and response assessed. Large doses of pyridoxine have been known to induce sensory neuropathies. There is currently no evidence to suggest that pyridoxine supplementation is beneficial in the treatment of other forms of hyperoxaluria unless a true pyridoxine deficiency exists.

References

Akin Y, Yucel S. Long-term effects of pediatric extracorporeal shockwave lithotripsy on renal function. *Res Rep Urol*. 2014;6:21–25.

Aksoy Y, Ozbey I, Atmaca AF, et al. Extracorporeal shock wave lithotripsy in children: experience using a mpl-9000 lithotriptor. *World J Urol*. 2004;22:115.

Al-Busaidy SS, Prem AR, Medhat M. Paediatric ureteroscopy for ureteric calculi: a 4-year experience. *Br J Urol*. 1997;80(5):797–801.

Al-Busaidy SS, Prem AR, Medhat M. Pediatric staghorn calculi: the role of extracorporeal shock wave lithotripsy monotherapy with special reference to ureteral stenting. *J Urol*. 2003;169:629.

Aldaqadossi HA, Shaker H, Saifelnasr M, et al. Efficacy and safety of tamsulosin as a medical expulsive therapy for stones in children. *Arab J Urol*. 2015;13(2):107–111.

Aldridge RD, Aldridge RC, Aldridge LM. Anesthesia for pediatric lithotripsy. *Paediatr Anaesth*. 2006;16:236.

Alexander RT, Hemmelgarn BR, Wiebe N, et al. Kidney stones and kidney function loss: a cohort study. *BMJ*. 2012;345:e5287.

Asplin JR, Donahue S, Kinder J, et al. Urine calcium excretion predicts bone loss in idiopathic hypercalciuria. *Kidney Int*. 2006;70(8):1463–1467.

Assimos D, Krambeck A, Miller NL, et al. Surgical management of stones: American Urological Association/Endourological Society Guideline, Part I. *J Urol*. 2016;196(4):1153–1160.

Assimos D, Krambeck A, Miller NL, et al. Surgical management of stones: American Urological

Association/Endourological Society Guideline, Part II. *J Urol*. 2016;196(4):1161–1169.

Ather MH, Noor MA. Does size and site matter for renal stones up to 30-mm in size in children treated by extracorporeal lithotripsy? *Urology*. 2003;61:212.

Aydogdu O, Burgu B, Gucuk A, et al. Effectiveness of doxazosin in treatment of distal ureteral stones in children. *J Urol*. 2009;182(6):2880–2884.

Barcelo P, Wuhl O, Servitge E, et al. Randomized double-blind study of potassium citrate in idiopathic hypocitraturic calcium nephrolithiasis. *J Urol*. 1993;150(6):1761–1764.

Belostotsky R, Seboun E, Idelson GH, et al. Mutations in DHDPSL are responsible for primary hyperoxaluria type III. *Am J Hum Genet*. 2010;87(3):392–399.

Berrettini A, Boeri L, Montanari E, et al. Retrograde intrarenal surgery using ureteral access sheaths is a safe and effective treatment for renal stones in children weighing <20 kg. *J Pediatr Urol*. 2018;14(1):59.e1–59.e6.

Bilen CY, Kocak B, Kitirci G, et al. Percutaneous nephrolithotomy in children: lessons learned in 5 years at a single institution. *J Urol*. 2007;177:1867.

Borghi L, Meschi T, Amato F, et al. Urinary volume, water and recurrences in idiopathic calcium nephrolithiasis: a 5-year randomized prospective study. *J Urol*. 1996;155(3):839–843.

Borghi L, Meschi T, Maggiore U, et al. Dietary therapy in idiopathic nephrolithiasis. *Nutr Rev*. 2006;64(7 Pt 1):301–312.

Bush NC, Xu L, Brown BJ, et al. Hospitalizations for pediatric stone disease in United States, 2002-2007. *J Urol*. 2010;183(3):1151–1156.

Cameron JS, Moro F, Simmonds HA. Gout, uric acid and purine metabolism in paediatric nephrology. *Pediatr Nephrol*. 1993;7(1):105–118.

Cannon GM, Smaldone MC, Wu HY, et al. Ureteroscopic management of lower-pole stones in a pediatric population. *J Endourol*. 2007;21:1179.

Castle SM, Cooperberg MR, Sadetsky N, et al. Adequacy of a single 24-hour urine collection for metabolic evaluation of recurrent nephrolithiasis. *J Urol*. 2010;184(2):579–583.

Cauley JA, Fullman RL, Stone KL, et al. Factors associated with the lumbar spine and proximal femur bone mineral density in older men. *Osteoporos Int*. 2005;16(12):1525–1537.

Chedgy EC, Griffin SJ, Dyer JP, et al. Ureteroscopy for paediatric renal tract stones—outcomes from a tertiary European centre. *Urol Int*. 2015;95(3):320–323.

Chew BH, Shah O, Sur RL, et al. Dusting versus basketing during ureteroscopic lithotripsy—What is more efficacious? *J Urol*. 2016;195(4S):e407.

Chu C, Masic S, Usawachintachit M, et al. Ultrasound-guided renal access for percutaneous nephrolithotomy: a description of three novel ultrasound-guided needle techniques. *J Endourol*. 2016;30(2):153–158.

Citamak B, Altan M, Bozaci AC, et al. Percutaneous nephrolithotomy in children: 17 years of experience. *J Urol*. 2016;195(4 Pt 1):1082–1087.

Coe FL. Hyperuricosuric calcium oxalate nephrolithiasis. *Kidney Int*. 1978;13:418.

Coe FL, Parks JH, Asplin JR. The pathogenesis and treatment of kidney stones. *N Engl J Med*. 1992;327(16):1141–1152.

Coe FL, Parks JH, Moore ES. Familial idiopathic hypercalciuria. *N Engl J Med*. 1979;300(7):337–340.

Corcoran A, Mally D, Smaldone M, et al. Flexible ureteroscopy for proximal stones in pediatric patients: how complete access simplifies the surgical approach. *J Endourol*. 2007;21:A84.

Coward RJ, Peters CJ, Duffy PG, et al. Epidemiology of paediatric renal stone disease in the UK. *Arch Dis Child*. 2003;88(11):962–965.

Curhan GC, Willett WC, Speizer FE, et al. Comparison of dietary calcium with supplemental calcium and other nutrients as factors affecting the risk for kidney stones in women. *Ann Intern Med*. 1997;126(7):497–504.

Dangle P, Ayyash OT, Shaikh H 3rd, et al. Predicting spontaneous stone passage in prepubertal children: a single institution cohort. *J Endourol*. 2016;30(9):945–949.

Daw K, Shouman AM, Elsheemy MS, et al. Outcome of mini-percutaneous nephrolithotomy for renal stones in infants and preschool children: a prospective study. *Urology*. 2015;86(5):1019–1026.

Dede O, Sancaktutar AA, Dağguli M, et al. Ultra-mini-percutaneous nephrolithotomy in pediatric nephrolithiasis: both low pressure and high efficiency. *J Pediatr Urol*. 2015;11(5):253.e251–253.e256.

Defoor W, Dharamsi N, Smith P, et al. Use of mobile extracorporeal shock wave lithotripter: experience in a pediatric institution. *Urology*. 2005;65:778.

Demirkesen O, Onal B, Tansu N, et al. Efficacy of extracorporeal shock wave lithotripsy for isolated lower caliceal stones in children compared with stones in other renal locations. *Urology*. 2006;67:170.

Denburg MR, Jemielita TO, Tasian GE, et al. Assessing the risk of incident hypertension and chronic kidney disease after exposure to shock wave lithotripsy and ureteroscopy. *Kidney Int*. 2016;89(1):185–192.

Denburg MR, Leonard MB, Haynes K, et al. Risk of fracture in urolithiasis: a population-based cohort study using the health improvement network. *Clin J Am Soc Nephrol*. 2014;9(12):2133–2140.

Desai MR, Kukreja RA, Patel SH, et al. Percutaneous nephrolithotomy for complex pediatric renal calculus disease. *J Endourol*. 2004;18(1):23–27.

Deshmukh S, Kambadakone A, Sahani DV, et al. Hounsfield density of renal papillae in stone formers: analysis based on stone composition. *J Urol*. 2015;193(5):1560–1563.

Deters LA, Dagrosa LM, Herrick BW, et al. Ultrasound guided ureteroscopy for the definitive management of ureteral stones: a randomized, controlled trial. *J Urol*. 2014;192(6):1710–1713.

Diamond DA, Menon M, Lee PH, et al. Etiological factors in pediatric stone recurrence. *J Urol*. 1989;142(2 Pt 2):606–608 [discussion 619].

Dillman JR, Kappil M, Weadock WJ, et al. Sonographic twinkling artifact for renal calculus detection: correlation with CT. *Radiology*. 2011;259(3):911–916.

Dogan HS, Onal B, Satar N, et al. Factors affecting complication rates of ureteroscopic lithotripsy in children: results of multi-institutional retrospective analysis by Pediatric Stone Disease Study Group of Turkish Pediatric Urology Society. *J Urol*. 2011;186(3):1035–1040.

Domrongkitchaiporn S, Stitchantrakul W, Kochakarn W. Causes of hypocitraturia in recurrent calcium stone formers: focusing on urinary potassium excretion. *Am J Kidney Dis*. 2006;48(4):546–554.

Donaldson JF, Lardas M, Scrimgeour D, et al. Systematic review and meta-analysis of the clinical effectiveness of shock wave lithotripsy, retrograde intrarenal surgery, and percutaneous nephrolithotomy for lower-pole renal stones. *Eur Urol*. 2015;67(4):612–616.

Dwyer ME, Krambeck AE, Bergstralh EJ, et al. Temporal trends in incidence of kidney stones among children: a 25-year population based study. *J Urol*. 2012;188(1):247–252.

El-Assmy A, El-Nahas AR, Abou-El-Ghar ME, et al. Kidney stone size and hounsfield units predict successful shockwave lithotripsy in children. *Urology*. 2013;81:880.

Ellison JS, Williams M, Keeley FX Jr. Patient-reported outcomes in nephrolithiasis: can we do better? *J Endourol*. 2018;32(1):10–20.

Elsobky E, Sheir KZ, Madbouly K, et al. Extracorporeal shock wave lithotripsy in children: experience using two second-generation lithotripters. *BJU Int*. 2000;86:851.

Erkurt B, Caskurlu T, Atis G, et al. Treatment of renal stones with flexible ureteroscopy in preschool age children. *Urolithiasis*. 2014;42(3):241–245.

Erturhan S, Bayrak O, Sarica K, et al. Efficacy of medical expulsive treatment with doxazosin in pediatric patients. *Urology*. 2013;81(3):640–643.

Ettinger B, Pak CY, Citron JT, et al. Potassium-magnesium citrate is an effective prophylaxis against recurrent calcium oxalate nephrolithiasis. *J Urol*. 1997;158(6):2069–2073.

Evan A, Lingeman J, Coe FL, et al. Randall's plaque: pathogenesis and role in calcium oxalate nephrolithiasis. *Kidney Int*. 2006;69(8):1313–1318.

Evan AP, Lingeman JE, Coe FL, et al. Randall's plaque of patients with nephrolithiasis begins in basement membranes of thin loops of Henle. *J Clin Invest*. 2003;111(5):607–616.

Evans WP, Resnick MI, Boyce WH. Homozygous cystinuria—evaluation of 35 patients. *J Urol*. 1982;127(4):707–709.

Fayad A, El-Sheikh MG, Abdelmohsen M, et al. Evaluation of renal function in children undergoing extracorporeal shock wave lithotripsy. *J Urol*. 2010;184(3):1111–1114.

Featherstone NC, Somani BK, Griffin SJ. Ureteroscopy and laser stone fragmentation (URSL) for large (≥1 cm) paediatric stones: outcomes from a university teaching hospital. *J Pediatr Urol*. 2017;13(2):202.e1–202.e7.

Ferraro PM, Taylor EN, Eisner BH, et al. History of kidney stones and the risk of coronary heart disease. *JAMA*. 2013;310(4):408–415.

Freton L, Peyronnet B, Arnaud A, et al. Extracorporeal shockwave lithotripsy versus flexible ureteroscopy for the management of upper tract urinary stones in children. *J Endourol*. 2017;31(1):1–6.

Fulgham PF, Assimos DG, Pearle MS, et al. Clinical effectiveness protocols for imaging in the management of ureteral calculous disease: AUA technology assessment. *J Urol*. 2013;189(4):1203–1213.

Gliga ML, Chirila CN, Podeanu DM, et al. Twinkle, twinkle little stone: an artifact improves the ultrasound performance!. *Med Ultrason*. 2017;19(3):272–275.

Gofrit ON, Pode D, Meretyk S, et al. Is the pediatric ureter as efficient as the adult ureter in transporting fragments following extracorporeal shock wave lithotripsy for renal calculi larger than 10 mm. *J Urol*. 2001;166:1862.

Goske MJ, Applegate KE, Boylan J, et al. The Image Gently campaign: working together to change practice. *Am J Roentgenol*. 2008;190(2):273–274.

Goyal NK, Goel A, Sankhwar SN, et al. A critical appraisal of complications of percutaneous nephrolithotomy in paediatric patients using adult instruments. *BJU Int*. 2014;113(5):801–810.

Granata A, Andrulli S, Bigi MQ, et al. Predictive role of duplex Doppler ultrasonography in the diagnosis of acute renal obstruction in patients with unilateral renal colic. *Clin Nephrol*. 2009;71(6):680–686.

Griffin SJ, Margaryan M, Archambaud F, et al. Safety of shock wave lithotripsy for treatment of pediatric urolithiasis: 20-year experience. *J Urol*. 2010;183(6):2332–2336.

Hernandez JD, Ellison JS, Lendvay TS. Current trends, evaluation, and management of pediatric nephrolithiasis. *JAMA Pediatr*. 2015;169(10):964–970.

Herndon CD, Viamonte L, Joseph DB. Ureteroscopy in children: is there a need for ureteral dilation and postoperative stenting? *J Pediatr Urol*. 2006;2:290.

Hess B, Michel R, Takkinen R, et al. Risk factors for low urinary citrate in calcium nephrolithiasis: low vegetable fibre intake and low urine volume to be added to the list. *Nephrol Dial Transplant*. 1994;9(6):642–649.

Hollingsworth JM, Rogers MA, Kaufman SR, et al. Medical therapy to facilitate urinary stone passage: a meta-analysis. *Lancet*. 2006;368(9542):1171–1179.

Hoppe B, Beck BB, Milliner DS. The primary hyperoxalurias. *Kidney Int*. 2009;75(12):1264–1271.

Humphreys MR, Shah OD, Monga M, et al. Dusting versus basketing during ureteroscopy—Which technique is more efficacious? A prospective multicenter trial from the EDGE Research Consortium. *J Urol*. 2018;199(5):1272–1276.

Ishii H, Griffin S, Somani BK. Ureteroscopy for stone disease in the paediatric population: a systematic review. *BJU Int*. 2015;115(6):867–873.

Jackman SV, Hedican SP, Peters CA, et al. Percutaneous nephrolithotomy in infants and preschool age children: experience with a new technique. *Urology*. 1998;52(4):697–701.

Jaeger P, Lippuner K, Casez JP, et al. Low bone mass in idiopathic renal stone formers: magnitude and significance. *J Bone Min Res*. 1994;9(10):1525–1532.

Johnson CM, Wilson DM, O'Fallon WM, et al. Renal stone epidemiology: a 25-year study in Rochester, Minnesota. *Kidney Int*. 1979;16(5):624–631.

Johnson EK, Faerber GJ, Roberts WW, et al. Are stone protocol computed tomography scans mandatory for children with suspected urinary calculi? *Urology*. 2011;78(3):662–666.

Karmazyn B, Frush DP, Applegate KE, et al. CT with a computer-simulated dose reduction technique for detection of pediatric nephroureterolithiasis: comparison of standard and reduced radiation doses. *Am J Roentgenol*. 2009;192:143.

Katz SI, Saluja S, Brink JA, et al. Radiation dose associated with unenhanced CT for suspected renal colic: impact of repetitive studies. *Am J Roentgenol*. 2006;186(4):1120–1124.

Kaygisiz O, Kilicarslan H, Mert A, et al. Comparison of intermediate- and low-frequency shock wave lithotripsy for pediatric kidney stones. *Urolithiasis*. 2018;46(4):391–395.

Khan SR, Pearle MS, Robertson WG, et al. Kidney stones. *Nat Rev Dis Primers*. 2016;2:16008.

Kielar AZ, Shabana W, Vakili M, et al. Prospective evaluation of Doppler sonography to detect the twinkling artifact versus unenhanced computed tomography for identifying urinary tract calculi. *J Ultrasound Med*. 2012;31(10):1619–1625.

Kirejczyk JK, Porowski T, Filonowicz R, et al. An association between kidney stone composition and urinary metabolic disturbances in children. *J Pediatr Urol*. 2014;10(1):130–135.

Kocaoglu C, Ozkan KU. The effectiveness of 4.5F ultrathin semirigid ureteroscope in the management of ureteral stones in prepubertal children: is there a need for any ureteral dilatation? *Urology*. 2014;84(1):202–205.

Kok DJ, Iestra JA, Doorenbos CJ, et al. The effects of dietary excesses in animal protein and in sodium on the composition and the crystallization kinetics of calcium oxalate monohydrate in urines of healthy men. *J Clin Endocrinol Metab*. 1990;71(4):861–867.

Kokorowski PJ, Chow JS, Strauss K, et al. Prospective measurement of patient exposure to radiation during pediatric ureteroscopy. *J Urol*. 2012;187(4):1408–1414.

Kokorowski PJ, Chow JS, Strauss KJ, et al. Prospective systematic intervention to reduce patient exposure to radiation during pediatric ureteroscopy. *J Urol*. 2013;190(4 Suppl):1474–1478.

Krambeck AE, LeRoy AJ, Patterson DE, et al. Long-term outcomes of percutaneous nephrolithotomy compared to shock wave lithotripsy and conservative management. *J Urol*. 2008;179:2233.

Kruse K, Kracht U, Kruse U. Reference values for urinary calcium excretion and screening for hypercalciuria in children and adolescents. *Eur J Pediatr*. 1984;143(1):25–31.

Kuhns LR, Oliver WJ, Christodoulou E, et al. The predicted increased cancer risk associated with a single computed tomography examination for calculus detection in pediatric patients compared with the natural cancer incidence. *Pediatr Emerg Care*. 2011;27(4):345.

Kuo RL, Aslan P, Zhong P, et al. Impact of holmium laser settings and fiber diameter on stone fragmentation and endoscope deflection. *J Endourol*. 1998;12(6):523–527.

Kurien A, Symons S, Manohar T, et al. Extracorporeal shock wave lithotripsy in children: equivalent clearance rates to adults is achieved with fewer and lower energy shock waves. *BJU Int*. 2009;103:81.

Landau EH, Shenfeld OZ, Pode D, et al. Extracorporeal shock wave lithotripsy in prepubertal children: 22-year experience at a single institution with a single lithotriptor. *J Urol*. 2009;182:1835.

Lao M, Kogan BA, White MD, et al. High recurrence rate at 5-year followup in children after upper urinary tract stone surgery. *J Urol*. 2014;191(2):440–444.

Lee RS, Passerotti CC, Cendron M, et al. Early results of robot assisted laparoscopic lithotomy in adolescents. *J Urol*. 2007;177:2306.

Letavernier E, Traxer O, Daudon M, et al. Determinants of osteopenia in male renal-stone-disease patients with idiopathic hypercalciuria. *Clin J Am Soc Nephrol*. 2011;6(5):1149–1154.

Lingeman JE, Kim SC, Kuo RL, et al. Shockwave lithotripsy: anecdotes and insights. *J Endourol*. 2003;17:687.

Ljunghall S, Danielson BG. A prospective study of renal stone recurrences. *Br J Urol*. 1984;56(2):122–124.

Long CJ, Srinivasan AK. Percutaneous nephrolithotomy and ureteroscopy in children: evolutions. *Urol Clin North Am*. 2015;42(1):1–17.

Lottmann HB, Traxer O, Archambaud F, et al. Monotherapy extracorporeal shock wave lithotripsy for the treatment of staghorn calculi in children. *J Urol*. 2001;165:2324.

Madore F, Stampfer MJ, Rimm EB, et al. Nephrolithiasis and risk of hypertension. *Am J Hypertens*. 1998;11(1 Pt 1):46–53.

Mahmud M, Zaidi Z. Percutaneous nephrolithotomy in children before school age: experience of a Pakistani centre. *BJU Int*. 2004;94:1352.

Mariappan P, Smith G, Moussa SA, et al. One week of ciprofloxacin before percutaneous nephrolithotomy significantly reduces upper tract infection and urosepsis: a prospective controlled study. *BJU Int*. 2006;98(5):1075–1079.

Masch WR, Cohan RH, Ellis JH, et al. Clinical effectiveness of prospectively reported sonographic twinkling artifact for the diagnosis of renal calculus in patients without known urolithiasis. *Am J Roentgenol*. 2016;206(2):326–331.

Matlaga BR, Schaeffer AJ, Novak TE, et al. Epidemiologic insights into pediatric kidney stone disease. *Urol Res*. 2010;38(6):453–457.

McAdams S, Kim N, Dajusta D, et al. Preoperative stone attenuation value predicts success after shock wave lithotripsy in children. *J Urol*. 2010;184:1804.

Miller J, Durack JC, Sorensen MD, et al. Renal calyceal anatomy characterization with 3-dimensional in vivo computerized tomography imaging. *J Urol*. 2013;189(2):562–567.

Milliner DS, Murphy ME. Urolithiasis in pediatric patients. *Mayo Clin Proc*. 1993;68(3):241–248.

Minevich E, Defoor W, Reddy P, et al. Ureteroscopy is safe and effective in prepubertal children. *J Urol*. 2005;174(1):276–279 [discussion 279].

Mokhless I, Zahran AR, Youssif M, et al. Tamsulosin for the management of distal ureteral stones in children: a prospective randomized study. *J Pediatr Urol*. 2012;8(5):544–548.

Mokhless IA, Abdeldaeim HM, Saad A, et al. Retrograde intrarenal surgery monotherapy versus shock wave lithotripsy for stones 10 to 20 mm in preschool children: a prospective, randomized study. *J Urol*. 2014;191(5 Suppl):1496–1499.

Monico CG, Rossetti S, Belostotsky R, et al. Primary hyperoxaluria type III gene HOGA1 (formerly DHDPSL) as a possible risk factor for idiopathic calcium oxalate urolithiasis. *Clin J Am Soc Nephrol*. 2011;6(9):2289–2295.

Mor Y, Elmasry YE, Kellett MJ, et al. The role of percutaneous nephrolithotomy in the management of pediatric renal calculi. *J Urol*. 1997;158:1319.

Muslumanoglu AY, Tefekli A, Sarilar O, et al. Extracorporeal shock wave lithotripsy as first line treatment alternative for urinary tract stones in children: a large scale retrospective analysis. *J Urol*. 2003;170:2405.

Myers DA, Mobley TB, Jenkins JM, et al. Pediatric low energy lithotripsy with the Lithostar. *J Urol*. 1995;153:453.

National Research Council. *Health risks from exposure to low levels of ionizing radiation. BEIR VII, Phase 2*. National Academies Press: Washington, DC; 2006.

Nelson CP, Diamond DA, Cendron M, et al. Extracorporeal shock wave lithotripsy in pediatric patients using a late generation portable lithotriptor: experience at Children's Hospital Boston. *J Urol*. 2008;180:1865.

Nerli RB, Patil SM, Guntaka AK, et al. Flexible ureteroscopy for upper ureteral calculi in children. *J Endourol*. 2011;25(4):579–582.

Newman DM, Coury T, Lingeman JE, et al. Extracorporeal shock wave lithotripsy experience in children. *J Urol*. 1986;136:238.

Obligado SH, Goldfarb DS. The association of nephrolithiasis with hypertension and obesity: a review. *Am J Hypertens*. 2008;21(3):257–264.

Onal B, Demirkesen O, Tansu N, et al. The impact of caliceal pelvic anatomy on stone clearance after shock wave lithotripsy for pediatric lower pole stones. *J Urol*. 2004;172:1082.

Onal B, Dogan HS, Satar N, et al. Factors affecting complication rates of percutaneous nephrolithotomy in children: results of a multi-institutional retrospective analysis by the Turkish Pediatric Urology Society. *J Urol*. 2014;191:777.

Ozden E, Sahin A, Tan B, et al. Percutaneous renal surgery in children with complex stones. *J Pediatr Urol*. 2008;4(4):295–298.

Özgür Tan M, Karaoğlan Ü, Şen İ, et al. The impact of radiological anatomy in clearance of lower calyceal stones after shock wave lithotripsy in paediatric patients. *Eur Urol*. 2003;43:188.

Ozkan B, Dogan C, Can GE, et al. Does ureteral stenting matter for stone size? A retrospective analyses of 1361 extracorporeal shock wave lithotripsy patients. *Cent European J Urol*. 2015;68(3):358–364.

Parks JH, Goldfisher E, Asplin JR, et al. A single 24-hour urine collection is inadequate for the medical evaluation of nephrolithiasis. *J Urol*. 2002;167(4):1607–1612.

Passerotti C, Chow JS, Silva A, et al. Ultrasound versus computerized tomography for evaluating urolithiasis. *J Urol*. 2009;182(4 Suppl):1829–1834.

Pearle M, Calhoun E, Curhan G. Urologic diseases in America project: urolithiasis. *J Urol*. 2005;173(3):848–857.

Penniston KL, Antonelli JA, Viprakasit DP, et al. Validation and reliability of the wisconsin stone quality of life questionnaire. *J Urol*. 2017;197(5):1280–1288.

Penniston KL, Nakada SY. Health related quality of life differs between male and female stone formers. *J Urol*. 2007;178(6):2435–2440 [discussion 2440].

Pietrow PK, Pope JC, Adams MC, et al. Clinical outcome of pediatric stone disease. *JURO*. 2001;167(2 Pt 1):670–673.

Pietrow PK, Pope JC 4th, Adams MC, et al. Clinical outcome of pediatric stone disease. *J Urol*. 2002;167(2 Pt 1):670–673.

Pietschmann F, Breslau NA, Pak CY. Reduced vertebral bone density in hypercalciuric nephrolithiasis. *J Bone Min Res*. 1992;7(12):1383–1388.

Polinsky MS, Kaiser BA, Baluarte HJ. Urolithiasis in childhood. *Pediatr Clin North Am*. 1987;34(3):683–710.

Raza A, Smith G, Moussa S, et al. Ureteroscopy in the management of pediatric urinary tract calculi. *J Endourol*. 2005;19(2):151–158.

Raza A, Turna B, Smith G, et al. Pediatric urolithiasis: 15 years of local experience with minimally invasive endourological management of pediatric calculi. *J Urol*. 2005;174(2):682–685.

Ristau BT, Dudley AG, Casella DP, et al. Tracking of radiation exposure in pediatric stone patients: the time is now. *J Pediatr Urol*. 2015;11(6):339.e331–339.e335.

Rizvi SA, Naqvi SA, Hussain Z, et al. Management of pediatric urolithiasis in Pakistan: experience with 1,440 children. *J Urol*. 2003;169:634.

Routh JC, Graham DA, Nelson CP. Epidemiological trends in pediatric urolithiasis at United States freestanding pediatric hospitals. *J Urol*. 2010;184(3):1100–1104.

Routh JC, Graham DA, Nelson CP. Trends in imaging and surgical management of pediatric urolithiasis at American pediatric hospitals. *J Urol*. 2010;184(4 Suppl):1816–1822.

Saigal CS, Joyce G, Timilsina AR, et al. Direct and indirect costs of nephrolithiasis in an employed population: opportunity for disease management? *Kidney Int*. 2005;68(4):1808–1814.

Salah MA, Toth C, Khan AM, et al. Percutaneous nephrolithotomy in children: experience with 138 cases in a developing country. *World J Urol*. 2004;22:277.

Salerno A, Nappo SG, Matarazzo E, et al. Treatment of pediatric renal stones in a Western country: a changing pattern. *J Pediatr Surg*. 2013;48(4):835–839.

Samad L, Aquil S, Zaidi Z. Paediatric percutaneous nephrolithotomy: setting new frontiers. *BJU Int*. 2006;97:359.

Sas DJ, Hulsey TC, Shatat IF, et al. Increasing incidence of kidney stones in children evaluated in the emergency department. *J Pediatr*. 2010;157(1):132–137.

Satar N, Zeren S, Bayazit Y, et al. Rigid ureteroscopy for the treatment of ureteral calculi in children. *J Urol*. 2004;172(1):298–300.

Scales CD Jr, Curtis LH, Norris RD, et al. Changing gender prevalence of stone disease. *J Urol*. 2007;177(3):979–982.

Scales CD Jr, Smith AC, Hanley JM, et al. Prevalence of kidney stones in the United States. *Eur Urol*. 2012;62(1):160–165.

Schwaderer AL, Cronin R, Mahan JD, et al. Low bone density in children with hypercalciuria and/or nephrolithiasis. *Pediatr Nephrol*. 2008;23(12):2209–2214.

Schwaderer AL, Kusumi K, Ayoob RM. Pediatric nephrolithiasis and the link to bone metabolism. *Curr Opin Pediatr*. 2014;26(2):207–214.

Schwaderer AL, Srivastava T, Schueller L, et al. Dietary modifications alone do not improve bone mineral density in children with idiopathic hypercalciuria. *Clin Nephrol*. 2011;76(5):341–347.

Singh A, Shah G, Young J, et al. Ureteral access sheath for the management of pediatric renal and ureteral stones: a single center experience. *J Urol*. 2006;175:1080.

Slavkovic A, Radovanovic M, Siric Z, et al. Extracorporeal shock wave lithotripsy for cystine urolithiasis in children: outcome and complications. *Int Urol Nephrol*. 2002;34:457.

Spasovski G, Beck BB, Blau N, et al. Late diagnosis of primary hyperoxaluria after failed kidney transplantation. *Int Urol Nephrol*. 2010;42(3):825–829.

Spielmann AL, Heneghan JP, Lee LJ, et al. Decreasing the radiation dose for renal stone CT: a feasibility study of single- and multidetector CT. *Am J Roentgenol*. 2002;178:1058.

Stamatelou KK, Francis ME, Jones CA, et al. Time trends in reported prevalence of kidney stones in the United States: 1976-1994. *Kidney Int*. 2003;63(5):1817–1823.

Stapleton FB, McKay CP, Noe HN. Urolithiasis in children: the role of hypercalciuria. *Pediatr Ann*. 1987;16(12):980–981 [984–992].

Strippoli GF, Craig JC, Schena FP. The number, quality, and coverage of randomized controlled trials in nephrology. *J Am Soc Nephrol*. 2004;15(2):411–419.

Tasian GE, Cost NG, Granberg CF, et al. Tamsulosin and spontaneous passage of ureteral stones in children: a multi-institutional cohort study. *J Urol*. 2014;192(2):506–511.

Tasian GE, Jemielita T, Goldfarb DS, et al. Oral antibiotic exposure and kidney stone disease. *J Am Soc Nephrol*. 2018;29:1731.

Tasian GE, Kabarriti AE, Kalmus A, et al. Kidney stone recurrence among children and adolescents. *J Urol*. 2017;197(1):246–252.

Tasian GE, Ross ME, Song L, et al. Annual incidence of nephrolithiasis among children and adults in South Carolina from 1997 to 2012. *Clin J Am Soc Nephrol*. 2016;11(3):488–496.

Taylor EN, Curhan GC. Diet and fluid prescription in stone disease. *Kidney Int*. 2006;70(5):835–839.

Taylor EN, Stampfer MJ, Curhan GC. Dietary factors and the risk of incident kidney stones in men: new insights after 14 years of follow-up. *J Am Soc Nephrol*. 2004;15(12):3225–3232.

Tchelepi H, Ralls PW. Color comet-tail artifact: clinical applications. *Am J Roentgenol*. 2009;192(1):11–18.

Tekin A, Tekgul S, Atsu N, et al. Oral potassium citrate treatment for idiopathic hypocitruria in children with calcium urolithiasis. *J Urol*. 2002;168(6):2572–2574.

Tiryaki T, Azili MN, Ozmert S. Ureteroscopy for treatment of ureteral stones in children: factors influencing the outcome. *Urology*. 2013;81(5):1047–1051.

Türk C, Knoll T, Petrik A, et al. *Guidelines on Urolithiasis*. https://uroweb.org/wp-content/uploads/21_Urolithiasis_LRV4.pdf; 2013.

Türk C, Petrik A, Sarica K, et al. EAU guidelines on interventional treatment for urolithiasis. *Eur Urol*. 2016;69(3):475–482.

van Woerden CS, Groothoff JW, Wijburg FA, et al. Clinical implications of mutation analysis in primary hyperoxaluria type 1. *Kidney Int*. 2004;66(2):746–752.

Velazquez N, Zapata D, Wang HH, et al. Medical expulsive therapy for pediatric urolithiasis: systematic review and meta-analysis. *J Pediatr Urol*. 2015;11(6):321–327.

Wang HH, Huang L, Routh JC, et al. Shock wave lithotripsy vs ureteroscopy: variation in surgical management of kidney stones at freestanding children's hospitals. *J Urol*. 2012;187(4):1402–1407.

Wang HH, Wiener JS, Lipkin ME, et al. Estimating the nationwide, hospital based economic impact of pediatric urolithiasis. *J Urol*. 2015;193(5 Suppl):1855–1859.

Wolf JS Jr, Bennett CJ, Dmochowski RR, et al. Best practice policy statement on urologic surgery antimicrobial prophylaxis. *J Urol*. 2008;179:1379.

Woodside JR, Stevens GF, Stark GL, et al. Percutaneous stone removal in children. *J Urol*. 1985;134:1166.

Wrixon AD. New ICRP recommendations. *J Radiol Prot*. 2008;28(2):161–168.

Wu HY, Docimo SG. Surgical management of children with urolithiasis. *Urol Clin North Am*. 2004;31:589.

Yadav SS, Aggarwal SP, Mathur R, et al. Pediatric percutaneous nephrolithotomy—experience of a tertiary care center. *J Endourol*. 2017;31(3):246–254.

Ye Z, Zeng G, Yang H, et al. Efficacy and safety of tamsulosin in medical expulsive therapy for distal ureteral stones with renal colic: a multicenter, randomized, double-blind, placebo-controlled trial. *Eur Urol*. 2018;73(3):385–391.

Yucel S, Akin Y, Danisman A, et al. Complications and associated factors of pediatric extracorporeal shock wave lithotripsy. *J Urol*. 2012;187(5):1812–1816.

Yucel S, Akin Y, Kol A, et al. Experience on semirigid ureteroscopy and pneumatic lithotripsy in children at a single center. *World J Urol*. 2011;29(6):719–723.

Zeng G, Zhao Z, Wan S, et al. Comparison of children versus adults undergoing mini-percutaneous nephrolithotomy: large-scale analysis of a single institution. *PLoS ONE*. 2013;8(6):e66850.

Zeren S, Satar N, Bayazit Y, et al. Percutaneous nephrolithotomy in the management of pediatric renal calculi. *J Endourol*. 2002;16:75.

SECTION E

Genitalia

OUTLINE

44 Management of Abnormalities of the External Genitalia in Boys

45 Hypospadias

46 Etiology, Diagnosis, and Management of the Undescended Testis

47 Management of Abnormalities of the Genitalia in Girls

48 Disorders of Sexual Development Etiology, Evaluation, and Medical Management

Management of Abnormalities of the External Genitalia in Boys

Lane S. Palmer MD, FACS, Jeffrey S. Palmer MD, FACS, FAAP

The normal anatomy of the penis includes the prepuce (foreskin), glans, urethral meatus, coronal sulcus, and penile shaft. The ventral surface of the penile skin has the median raphe that is contiguous with the scrotal raphe and ends at the edge of the outer prepuce. Anomalies of the penis and scrotum are common and may be congenital, acquired, or iatrogenic. **The congenital anomalies may result from a disorder of sexual differentiation, genital differentiation, or genital growth and may be associated with other syndromes** (eTable 44.1) or organ systems. For example, up to 50% of children with congenital anorectal malformations also have an associated urologic malformation.

eTABLE 44.1

Male Genital Anomalies That Commonly Occur in Various Syndromes (Microphallus, Hypospadias, Ambiguous Genitalia, and Bifid Scrotum)

ANOMALY	FEATURES
Anencephaly	
Aniridia–Wilms tumor association	WAGR syndrome: Wilms tumor, aniridia, genitourinary abnormalities or gonadoblastoma, and mental retardation
Bladder exstrophy	
Börjeson-Forssman-Lehmann syndrome	Microcephaly, mental retardation, large ears
Carpenter syndrome	Acrocephaly, polydactyly and syndactyly of feet, congenital heart disease
CHARGE association	Coloboma, heart malformation, atresia choanae, retarded growth and development, genital anomalies, ear anomalies and/or deafness
Cloacal syndrome	

Fraser syndrome	Cryptophthalmos, mental retardation, ear anomalies
Johanson-Blizzard syndrome	Hypoplastic alae nasi, hypothyroidism, mental retardation, pancreatic insufficiency, deafness
Meckel-Gruber syndrome	Occipital encephalomeningocele, micrognathia, polydactyly, cystic renal dysplasia
Noonan syndrome	Webbed neck, pectus excavatum, pulmonic stenosis, short stature
Opitz syndrome	Hypertelorism, hypospadias, mild-to-moderate mental retardation
Pallister-Hall syndrome	Hypothalamic hamartoblastoma, hypopituitarism, imperforate anus
Popliteal pterygium syndrome	Popliteal web, cleft palate, lower lip pits
Prader-Willi syndrome	Hypotonia, obesity, small hands and feet, mild to moderate mental retardation
Rapp-Hodgkin ectodermal dysplasia syndrome	Hypohidrosis, oral clefts, dysplastic nails
Rieger syndrome	Iris dysplasia, hypodontia
Robinow syndrome	“Fetal face syndrome”; flat facial profile, hypertelorism, short forearms, thoracic hemivertebrae
Schinzel-Giedion syndrome	Growth deficiency, mental retardation, widely patent fontanelles, short forearms and legs, renal anomalies
Smith-Lemli-Opitz syndrome	Ptosis of eyelids, syndactyly of second and third toes, microcephaly, failure to thrive with short stature, mental retardation
Triploidy syndrome	
Trisomy 4p, 9p, 18, 20p, 21, 22, 9p, 10q, 11p, or 15q deficiency	
XXY, XXXXY	

From Jones KL: *Smith's recognizable patterns of human malformation,* ed 5, Philadelphia, 1997, Saunders.

Although ultrasonographic technology has evolved in the past decade, permitting earlier fetal sex determination (Efrat et al., 2006), it is insufficiently accurate to recommend before 12 weeks of gestation (Odeh et al., 2009). However, ultrasonography after 13 weeks of gestation accurately assesses sex determination in 99% to 100% of cases without malformed external genitalia (Odeh et al., 2009) (eFig. 44.1). In utero ultrasonography has identified abnormal male genitalia, including ambiguous genitalia and penoscrotal transposition (Cheikhelard et al., 2000; Pinette et al., 2003; Vijayaraghavan et al., 2002). More recent ultrasonographic technology, including three-dimensional (3D) ultrasonography, is being used to evaluate the fetal external genitalia, but there are no definitive results suggesting this as an enhanced diagnostic modality (Abu-Rustum and Chaaban, 2009; Bamberg et al., 2011; Verwoerd-Dikkeboom et al., 2008).

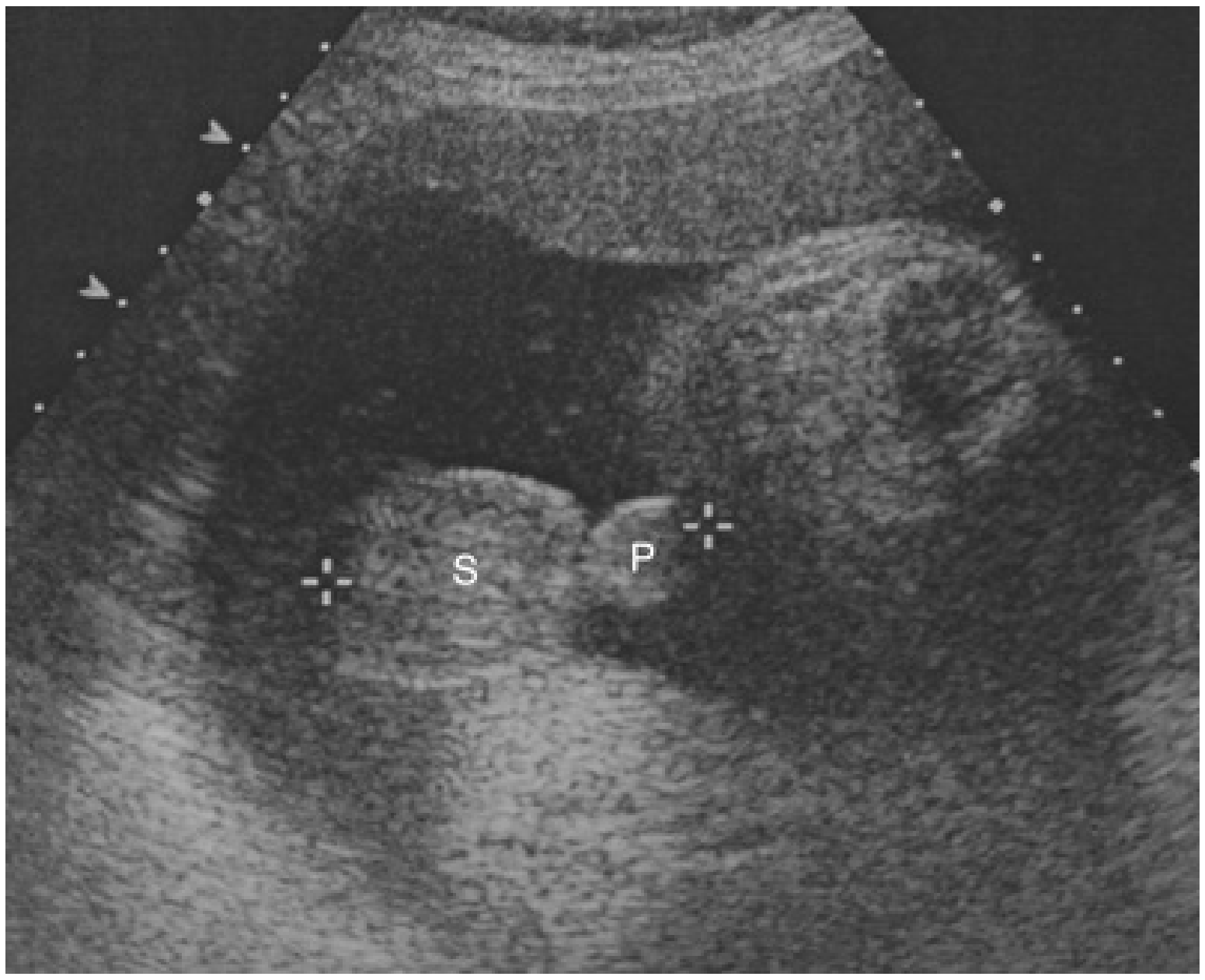

EFIG. 44.1 Fetal ultrasound of male genitalia. *P,* Penis; *S,* scrotum.

The understanding of the normal anatomy and embryologic development of the male external genitalia is essential to recognizing and treating penile and scrotal anomalies. Most genital abnormalities noted in neonates do not result in an ambiguous appearance but rather more common conditions such as inconspicuous penis or abnormal penile orientation. The American Academy of Pediatrics (AAP) Committee on Genetics and Sections on Endocrinology and Urology (2000) **published a guide to the normal embryology of the external genitalia and the altered embryology, evaluation, and management of ambiguous genitalia.**

Normal Male External Genitalia

Embryology

The early development of the external genitalia in the two sexes is similar before the ninth week of gestation (Ammini et al., 1997). Understanding factors and sequential steps in normal embryogenesis is fundamental in understanding the pathogenesis of male genital anomalies. **These factors include testosterone synthesis by the Leydig cells of the fetal testis and its enzymatic conversion into dihydrotestosterone (DHT) by 5α-reductase and the presence of androgen receptors able to recognize the androgenic hormones. The influence of DHT on androgen receptors during weeks 9 to 13 of gestation results in the differentiation of the genital tubercle, genital (labioscrotal) folds, and genital swelling into the male structures of the glans penis, penile shaft, and scrotum, respectively.**

The male develops in a proximal-to-distal manner. As the penis forms from the elongation and enlargement of the phallus, the lateral walls of the urethral groove form from the ventrally located genital folds, which then fuse in the midline. The long-held theory that the glanular urethra forms from the ingrowth of surface epithelium has been challenged by evidence suggesting that it is a result of the fusion of the urethral plate (Ammini et al., 1997; Glenister, 1921). The scrotum forms through the inferomedial migration and midline fusion of the genital folds as delineated by the scrotal raphe. **In females and in males with abnormalities in testosterone and/or DHT production, 5α-reductase deficiency, or androgen-receptor insufficiency, the genital tubercle, genital folds, and genital swellings passively become the clitoris, labia minora, and labia majora, respectively.**

Penile Length and Tanner Classification

Penile length significantly increases with gestational age (6 mm at 16 weeks to 26.4 mm at 38 weeks) (Johnson and Maxwell, 2000; Zalel et al., 2001) and during the first 3 months of life. The latter growth is a result of an increase in Leydig cell production of testosterone caused by the loss of the inhibitory effect of maternal estrogens on the fetal pituitary at birth, thereby causing a surge in gonadotropins (minipuberty). During the remainder of childhood, penile length increases more slowly until adolescence, when the length extensively increases again until the final size is reached. **The normal penile size in a full-term male neonate is 3.5 ± 0.7 cm in the stretched length and 1.1 ± 0.2 cm in diameter compared with 13.3 ± 1.6 cm at adulthood.** The penile stretched lengths (measured from meatus to penopubic junction) from birth to adulthood are listed in Table 44.2. Sharony et al. (2012) demonstrated a positive correlation between prenatal penile length measurements and postnatal measurements.

TABLE 44.2

Stretched Penile Length (cm) in Normal Male Subjects

AGE	MEAN ± SD	MEAN − 2.5 SD
Neonate, 30-wk gestation	2.5 ± 0.4	1.5
Neonate, 34-wk gestation	3.0 ± 0.4	2.0
0–5 mo	3.9 ± 0.8	1.9
6–12 mo	4.3 ± 0.8	2.3
1–2 yr	4.7 ± 0.8	2.6
2–3 yr	5.1 ± 0.9	2.9
3–4 yr	5.5 ± 0.9	3.3
4–5 yr	5.7 ± 0.9	3.5
5–6 yr	6.0 ± 0.9	3.8
6–7 yr	6.1 ± 0.9	3.9
7–8 yr	6.2 ± 1.0	3.7
8–9 yr	6.3 ± 1.0	3.8
9–10 yr	6.3 ± 1.0	3.8
10–11 yr	6.4 ± 1.1	3.7
Adult	13.3 ± 1.6	9.3

SD, Standard deviation.

Data from Feldman KW, Smith DW: Fetal phallic growth and penile standards for newborn male infants. *J Pediatr.* 86:895, 1975; Schonfeld WA, Beebe GW: Normal growth and variation in the male genitalia from birth to maturity. *J Urol.* 30:554, 1987; Tuladhar R, Davis PG, Batch J, et al.: Establishment of a normal range of penile length in preterm infants. *J Paediatr Child Health.* 34:471, 1998.

Tanner stages are a set of recognizable changes that occur to pubic hair, penis, and testes during puberty that are helpful in evaluating patients (Table 44.3). The stages range from preadolescent penis and testes with no pubic hair (stage 1) to adult-size penis and scrotum with adult pubic hair distribution (stage 5).

TABLE 44.3

Tanner Classification of Sexual Maturity Stages in Boys

STAGE	**PUBIC HAIR**	**PENIS**	**TESTES**
1	None	Preadolescent	Preadolescent
2	Scanty, long	Slight enlargement; slightly pigmented	Enlarged scrotum, pink, texture altered
3	Darker, starts to curl, small amount	Longer	Larger
4	Resembles adult type but less in quantity; coarse, curly	Larger; glans and breadth increase in size	Larger, scrotum dark
5	Adult distribution, spread to medial surface of thighs	Adult size	Adult size

Data from Tanner JM: *Growth at adolescence,* ed 2, Oxford, UK, 1962, Blackwell Scientific Publications.

Penile Anomalies

Prepuce (Foreskin)

Phimosis and Paraphimosis

At birth, a physiologic phimosis (Fig. 44.2A) with either partial or complete inability to retract the prepuce exists because of natural adhesions between the glans and inner preputial skin and/or a preputial ring. Two factors are involved in the separation of the prepuce from the glans: (1) accumulation of smegma (epithelial debris) under the prepuce during the first 3 to 4 years of age and (2) intermittent penile erections. Preputial retractability increases with age, with 90% of uncircumcised boys 3 years of age with completely retractable prepuces and less than 1% by 17 years of age with phimosis (Kayaba et al., 1996; Oster, 1968). Thus primary phimosis commonly resolves during childhood. Secondary phimosis may result from several causes, including forceful retraction and balanitis xerotica obliterans (BXO). Forceful preputial retraction should be discouraged to avert cicatrix formation.

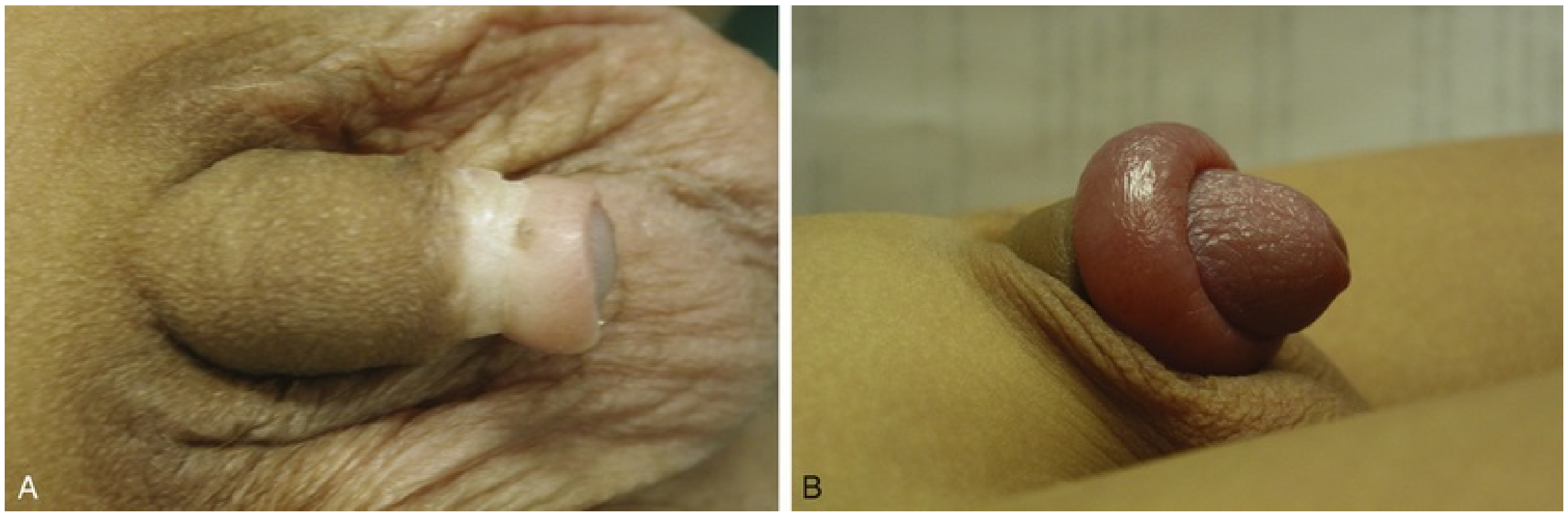

FIG. 44.2 Conditions associated with the uncircumcised penis. (A) Phimosis caused by a preputial ring. (B) Paraphimosis with associated entrapped prepuce behind the glans penis.

Conditions associated with the uncircumcised penis include paraphimosis, infection, urinary tract infection (UTI), and cancer. Paraphimosis (Fig. 44.2B), the entrapment of the prepuce behind the glans penis, can result in gangrene if not reduced in a timely fashion by manipulation, dorsal slit procedure, or circumcision. Severe edema of the foreskin occurs within several hours, depending on the tightness of the tip of the foreskin, making reduction more difficult. In most cases, manual compression of the glans with placement of distal traction on the edematous foreskin allows reduction of the paraphimotic ring. Other treatments include application of an iced glove for 5 minutes, application of granulated sugar for 1 to 2 hours, and placement of multiple punctures in the edematous skin (Mackway-Jones and Teece, 2004).

Indications to enhance preputial retractability include persistent primary phimosis, secondary phimosis, balanitis, posthitis (i.e., inflammation of the prepuce), BXO, and UTIs. Several topical corticosteroid creams with different regimens have been successfully used to treat phimosis with a relatively small number of side effects. Palmer and Palmer (2008) compared the efficacy of two different topical betamethasone (0.05%) treatment regimens (twice daily for 30 days or three times daily for 21 days) and found an 84.5% and 87% response rate, respectively. The response of the prepuce using topical steroids may be seen within 2 weeks (Reddy et al., 2012). Failure to respond to topical steroids (about 15%) may be related to the histologic observation that there is increased density of collagen and decreased density of elastic in the prepuce (Favorito et al., 2012).

Circumcision

Circumcision dates back more than 6000 years, with the oldest documented evidence thought to date to sixth dynasty (2345–2181 BCE) tomb artwork in Egypt. Since that time, different religions, countries, and cultures have adopted various views on circumcision (Palmer, 2009a). Many theories have been proposed regarding the origin of circumcision, including as a religious sacrifice, a rite of passage, an aid to hygiene, a way to differentiate cultural groups, and a method to discourage masturbation.

Elective circumcision in the neonate remains controversial. The AAP has historically weighed in on this subject. In 1989 the AAP concluded that neonatal circumcision offered potential medical benefits and advantages as well as disadvantages and risks, which should be explained to parents (AAP Task Force on Circumcision, 1989). In 1999 the AAP updated its policy statement (AAP Task Force on Circumcision, 1999; Lannon et al., 2000) emphasizing the importance of local anesthesia for the procedure. Most recently, the AAP stated, **“Although health benefits [significant reductions in the risk of UTI, risk of heterosexual acquisition of human immunodeficiency virus, and the transmission of other sexually transmitted infections] are not great enough**

to recommend routine circumcision for all male newborns, the benefits of circumcision are sufficient to justify access to this procedure for families choosing it and to warrant third-party payment for circumcision of male newborns" (AAP Task Force on Circumcision, 2012).

There are several techniques and devices for performing neonatal circumcision, including the Gomco clamp, Mogen clamp, and Plastibell device. There should be complete separation of the prepuce from the glans and complete inspection of the meatus and the corona to confirm the absence of anomalies, including hypospadias. **When neonatal circumcision is performed, local anesthesia is recommended.** Available options include the topical application of a cream containing eutectic mixture of local anesthetic (EMLA; lidocaine and prilocaine), a dorsal penile nerve block, and a penile ring block (Hardwick-Smith et al., 1998). Randomized controlled trials demonstrate the superiority of a dorsal penile nerve block to EMLA cream (Howard et al., 1999; Taddio et al., 2000), and prilocaine in the EMLA cream poses a low risk for methemoglobinemia (Couper, 2000). Typically, older infants and children are circumcised under general anesthesia, rather in the office, using freehand resection techniques.

Circumcision should not be performed in neonates with other penile conditions that require surgical correction using the intact skin. These conditions include hypospadias, penile curvature, dorsal hood deformity, buried penis, and webbed penis (see the corresponding sections). Other conditions commonly seen in neonates that could cause the penile skin to be pushed forward should be taken into consideration, such as large hydroceles or inguinal hernias; these conditions increase the risk of developing secondary phimosis, buried penis, and trapped penis, and thus circumcision should be deferred. A known coagulopathy in a neonate is another contraindication. Performance of circumcision in the neonatal intensive care unit is associated with more complications (Srinivasan et al., 2015).

Circumcision has several potential benefits, including the prevention of penile cancer, UTIs, sexually transmitted diseases including human immunodeficiency virus (HIV) infection, and phimosis, as well as lessening of the risk of balanitis. The allegation that neonatal circumcision can lead to sexual dysfunction is not supported by long-term studies (Bleustein et al., 2005; Fink et al., 2002). Schoen et al. (2006a) determined that neonatal circumcision has a cost benefit compared with postneonatal circumcision, including procedure charges and reduction in future health care costs.

Carcinoma of the penis develops almost exclusively in men who are not circumcised at birth. Phimosis is a significant risk factor (Tsen et al., 2001). Schoen et al. (2000b) reported that of 89 men in a large health maintenance organization with invasive penile cancer, only 2 (2%) had been circumcised at birth. Furthermore, of 116 men with penile carcinoma in situ, 16 (14%) had had a neonatal circumcision.

Uncircumcised neonates and infants are predisposed to UTIs (Singh-Grewal et al., 2005). In a study of 100 neonates with a UTI, Ginsburg and McCracken (1982) found that only 3 (5%) of the 62 boys who developed a UTI were circumcised. Subsequently, Wiswell et al. (1985) studied more than 2500 male infants and found that 41 had symptomatic UTIs; 88% of these infants were uncircumcised. Uncircumcised boys were almost 20 times more likely than circumcised neonates to develop a UTI. Other studies of larger groups of infants confirm these reports (Wiswell, 2000; Zorc et al., 2005) and demonstrate that neonatal circumcision is less costly than treating UTIs in uncircumcised boys (Schoen et al., 2000a). The increased risk seems to affect boys at least through 5 years of age (Craig et al., 1996), and the incidence of epididymitis is also reduced (Bennett et al., 1998). The increased risk of UTIs can be attributed to colonization of the prepuce by urinary pathogens (Bonacorsi et al., 2005; Gunsar et al., 2004). It has been calculated that it takes 111 neonatal circumcisions to prevent one UTI (Singh-Grewal et al., 2005). However, Shim et al. (2009) evaluated 190 infants with confirmed normal urinary systems and diagnosed with their first febrile UTI for recurrent UTI during the following year. Thirty-four percent of infants with persistent nonretractile prepuces developed recurrent UTI, compared with 17.6% of infants with retractile prepuces.

Whether circumcision reduces the risk of sexually transmitted diseases has been controversial. Several recent large series have demonstrated reduced incidence of HIV infection among men, with a protective effect of 60% (Bailey et al., 2007; Gray et al., 2007). However, a recent study compared HIV transmission with HIV-uninfected female partners among 922 uncircumcised, HIV-infected, asymptomatic men, of whom 474 underwent immediate circumcision and 448 remained uncircumcised (Wawer et al., 2009). After 24 months of follow-up, 18% and 12% of women acquired HIV, respectively, concluding that circumcision of HIV-infected men did not reduce HIV transmission to female partners. It has been reported that circumcision may reduce the risk of ulceration, bacterial vaginosis, and trichomoniasis in female partners (Gray et al., 2009).

Several clinical trials of the effect of circumcision on the prevention of human papillomavirus (HPV) infection, herpes simplex virus type 2 (HSV-2) infection, and other sexually transmitted diseases (Auvert et al., 2009; Nielson et al., 2009; Tobian et al., 2009) have been done. Tobian et al. (2009) evaluated 5534 HIV-negative, uncircumcised males, with 3393 being HSV-2 seronegative at enrollment. Of the 3393 men, 1684 underwent immediate circumcision and 1709 were not circumcised to evaluate HSV-2 and HPV transmission. At 24 months' follow-up, HSV-2 seroconversion was 7.8% and 10.3%, respectively, whereas prevalence of high-risk (carcinogenic) HPV genotypes was 18.0% and 27.9%, respectively. This study underscores the benefit of circumcision in reducing the incidence of HSV-2 infection and the prevalence of HPV infection.

Key Points: Circumcision

- Primary phimosis resolves spontaneously in the vast majority of boys; fewer than 1% of 17-year-old boys have a phimotic prepuce.
- Indications to facilitate preputial retractility include persistent primary phimosis, secondary phimosis, balanitis, posthitis, BXO, and UTI.
- The American Academy of Pediatrics acknowledges the potential health benefits of the circumcised penis, thus warranting access to circumcision for families choosing it and endorsing third-party payment for circumcision of male newborns.
- Local or topical anesthetics should be administered for circumcisions performed in the neonatal period.
- Circumcisions should be deferred in the presence of other penile abnormalities detected in the newborn period that may require surgery.
- Health benefits of circumcision include reduction in rates of penile cancer, and sexually transmitted diseases including HIV, UTIs, balanitis, and phimosis.
- Topical application of corticosteroids can relax the phimotic ring in 70% to 80% of cases.

Circumcision Complications.

The risk of complications after circumcision is 0.2% to 5% (Baskin et al., 1996; Ben Chaim et al., 2005; Christakis et al., 2000). Complications can occur immediately or months to years after a circumcision. **The most common complication is bleeding, which occurs in 0.1% and is more common in older children.** Bleeding is usually localized from the frenulum or, less frequently, from a large blood vessel on the penile shaft or from a skin edge between the suture. Although bleeding is usually self-limited or may require compression, occasionally cautery with an ophthalmic cautery or silver nitrate stick or a suture may be necessary. Wound infection is a rare complication, but antibiotic ointment (e.g., bacitracin) use after circumcision usually prevents its development. Penile degloving caused by excess skin removal or the edges of the penile skin not adhering to the mucosal collar can occur after circumcision. The penile shaft usually epithelizes, bridging the defect without any intervention other than the use of antibiotic ointment to the denuded region and warm baths to prevent eschar formation. Immediate suturing of the skin edges and skin grafting are not recommended to bridge the gap.

Penile Skin Complications.

The amount of penile skin excised can also lead to complications after circumcision. Insufficient or asymmetrical prepuce excision can result in health, cosmetic, and social dilemmas for the parents and child, especially as the child gets older (Fig. 44.3A). **Unlike neonatal circumcision, circumcision revision requires general anesthesia.** Several techniques have been described (Brisson et al., 2002; Ching and Palmer, 2008a; Redman, 1995). Excessive skin excision can result in penile chordee, torsion, and lateral deviation. These conditions, if necessary to repair, may require penile skin flaps or Z-plasty for closure. Excessive skin removal can also result in a trapped penis from a cicatricial scar. The trapped penis can be managed with betamethasone (Palmer et al., 2005), vertical relaxation incision, and formal repair using penile skin flaps or Z-plasty. The use of 0.05% betamethasone in conjunction with manual retraction in children with a trapped penis resulting from a dense cicatrix of the residual foreskin distal to the glans has a 79% success rate in softening of the cicatrix with easy exposure of the glans or mild persistence of the cicatrix amenable to vertical relaxation incision (Palmer et al., 2005).

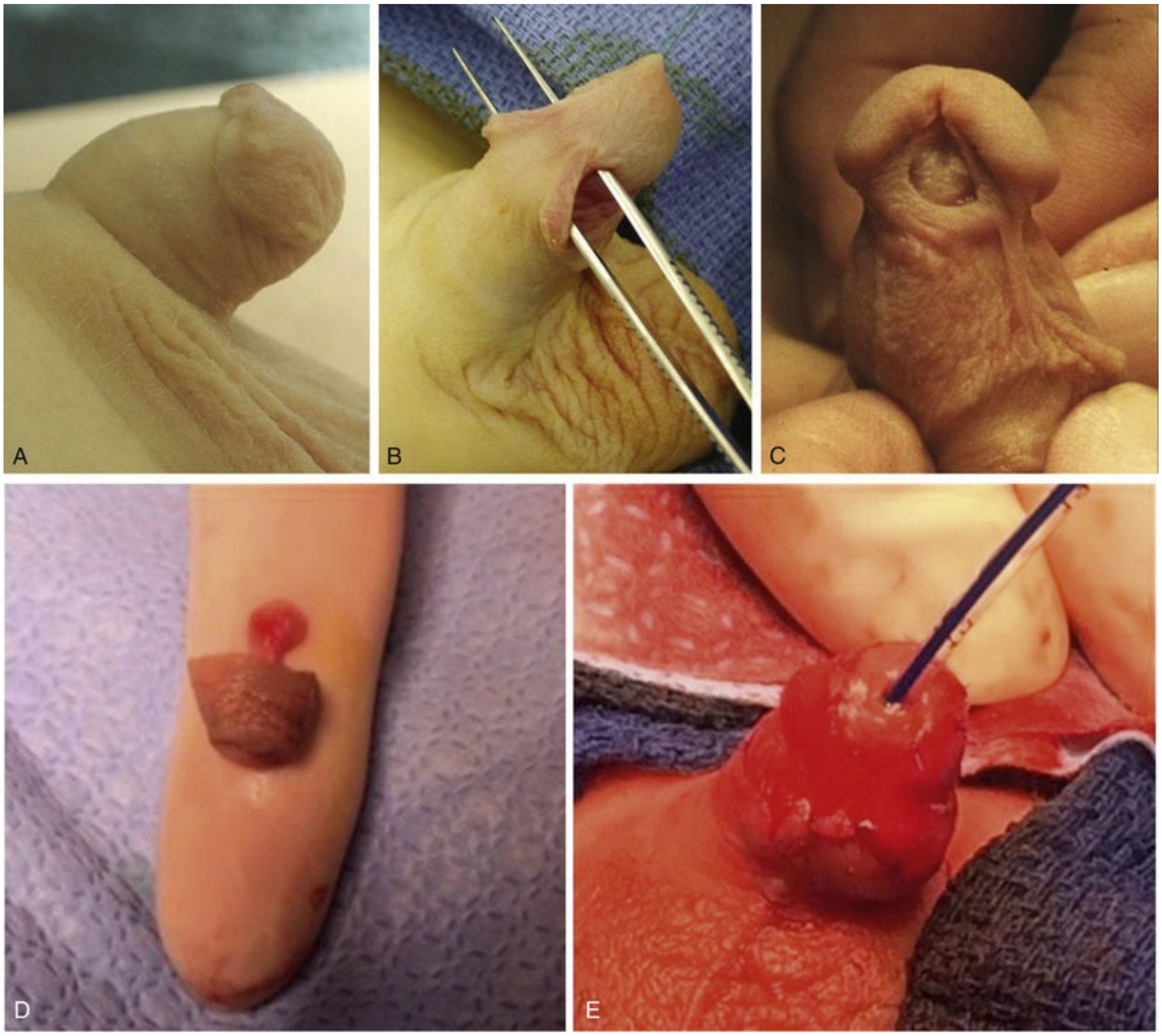

FIG. 44.3 Complications associated with circumcision. (A) Asymmetrical redundant penile skin. (B) Penile skin bridge. (C) Urethral and glanular resection. (D) Flap of amputated glans attached to prepuce. (E) Reattached flap of glans amputated during circumcision.

Glanular Adhesions and Skin Bridges.

Glanular adhesions and skin bridges, attachments of the glans and penile shaft, are common complications associated with circumcision and are usually noticed by the caregiver or primary medical provider. **Both can occur in the well-circumcised penis and are usually the result of the physiologic retraction of the penis caused by a suprapubic fat pad and diaper irritation of the penis.** Glanular adhesions are attachments between the inner prepuce or circumcision incision line attaching to the glans, with an incidence decreasing with age because of epithelial separation of the adhesions (71% of infants, 28% of 1- to 5-

year-olds, 8% of 1- to 9-year-olds, and 2% of children older than 9 years) (Ponsky et al., 2000; Van Howe, 1997). **Persistent adhesions can be lysed in the office with the application of a topical analgesic such as EMLA cream or Pain Ease** (Gebauer Company, Cleveland, OH) **(1,1,1,3,3-pentafluoropropane and 1,1,1,2-tetrafluoroethane)** (Palmer, 2009b). **Use of low-dose corticosteroids has been relatively unsuccessful in lysing adhesions.** Skin bridges (Fig. 44.3B) are epithelized adhesions that can lead to penile chordee and torsion, which can be excised in the office with the application of an analgesic (Palmer, 2009b) or in the operating room when the bridges are broad or thick and may require suturing of the glanular and shaft defects.

The most common acquired cystic lesion of the penis is entrapped smegma under the unretractable prepuce or under the glanular adhesions. The mass may appear yellow because of smegma. Release of the smegma occurs with resolution of the adhesions, either spontaneously or with manual lysis of adhesions.

Meatal Stenosis.

Meatal stenosis occurs in children almost only after circumcision during infancy (Fig. 44.4A). It can be congenital, occurring primarily in neonates with hypospadias, or acquired. **The normal urethral meatus is 10 Fr before 4 years of age, 12 Fr from 4 to 10 years of age, and 14 Fr after 10 years of age** (Litvak et al., 1976)**; this can be calibrated with a bougie à boule or sound.** There are several proposed causes of secondary meatal stenosis. One theory purports that after disruption of the normal adhesions between the prepuce and glans and removal of the foreskin, a significant inflammatory reaction ensues, resulting in a severe meatal inflammation and cicatrix formation. Other theories include frenular devascularization or chronic meatitis from diaper irritation of the exposed, unprotected meatus (Hensle, 1996; Persad et al., 1995). BXO is another cause of meatal stenosis (see following). A relatively small percentage of children will develop symptomatic meatal stenosis after neonatal circumcision. **Symptoms include (1) urinary stream deviation in an upward direction resulting from a meatal baffle** (Fig. 44.4B) **or ventral web located at the inferior of the meatus, (2) a narrow, high-velocity stream, and (3) penile pain at the initiation of micturition.** Urinary tract imaging usually does not reveal any obstructive changes in the urinary tract without other urologic issues but may be indicated for associated UTI or urinary incontinence. Meatotomy or meatoplasty to treat secondary meatal stenosis can be performed in the office with the use of topical lidocaine and prilocaine (EMLA) (Cartwright et al., 1996) or with general anesthesia by making a ventral incision long enough to create a normal meatal caliber. The suturing of the urethral mucosa to the glans with fine, rapidly absorbable sutures tends to reduce the risk of recurrence. An alternative but equally efficacious technique involves meatal tailoring using clamps without the need for suture (Cubillos et al., 2012).

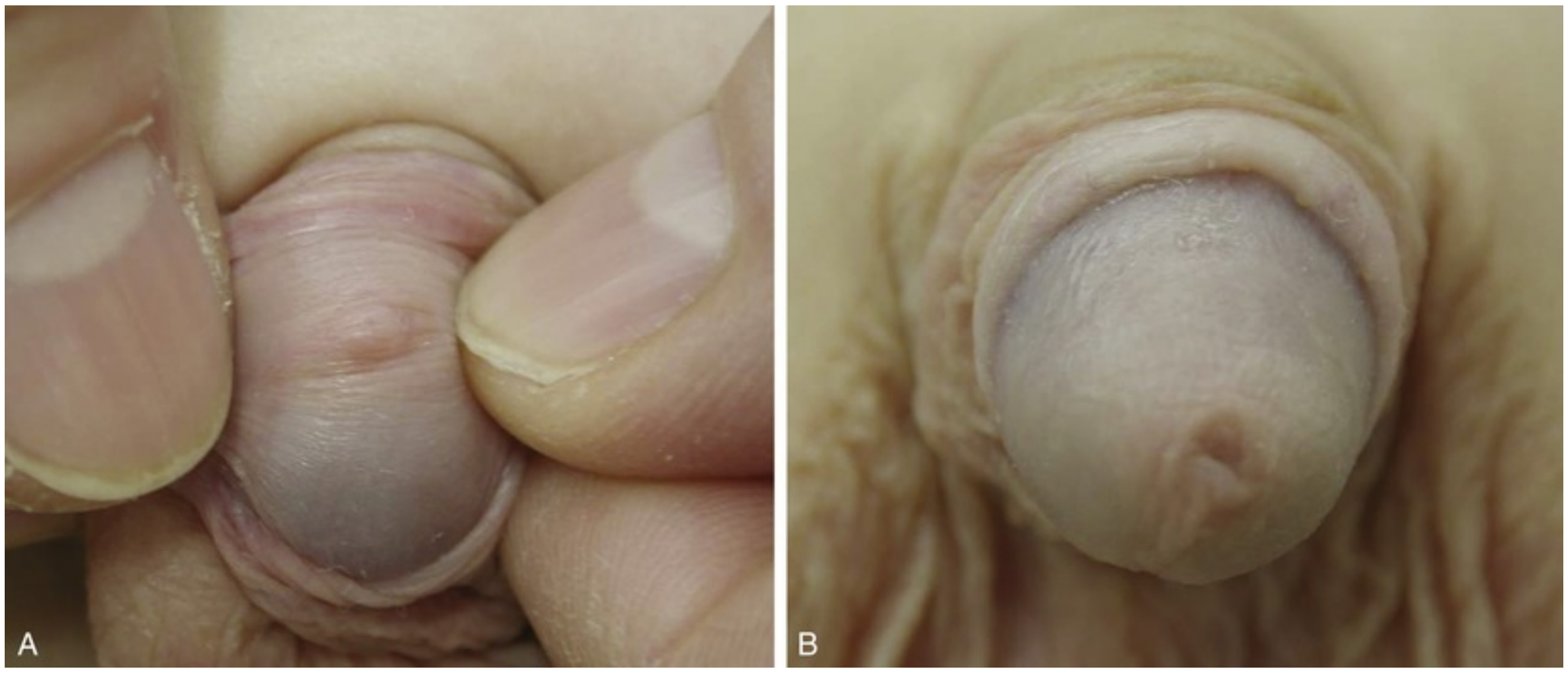

FIG. 44.4 Meatal complications associated with circumcision. (A) Meatal stenosis. (B) Meatal baffle.

Penile Trauma.

The most serious complications associated with circumcision are penile trauma, including urethral injury, excision of the glans and/or penile shaft, and penile necrosis (see Fig. 44.3C). Urethral injury requires urethroplasty, with the technique dependent on the severity of the excision. **Excision of the glans can be repaired by suturing the excised tissue back to the penis, often without the need for microscopic repair** (Sherman et al., 1996), **yielding good results when performed within 8 hours** (see Fig. 44.3D and E). Penile necrosis can result from thermal injury from several causes, including cautery contacting the metal ring applied to the prepuce being excised or the inappropriate use of lasers to perform a circumcision. Several options are available without ideal outcomes, including penile reconstruction and female gender reassignment with bilateral orchiectomy (Bradley et al., 1998; Gearhart and Rock, 1989). Although the cosmetic and functional results of phallic reconstruction have advanced, they are still being refined (De Castro et al., 2007; Monstrey et al., 2009). The issues with gender reassignment can include these children growing up with a male identity believed to result from in utero and neonatal androgen imprinting (Diamond, 1999; Diamond and Sigmundson, 1997; Reiner, 1996).

Balanitis Xerotica Obliterans.

Lichen sclerosus et atrophicus, or BXO, is a chronic infiltrative and cicatrizing skin condition resulting in pathologic phimosis (Chalmers et al., 1984; Fig. 44.5). **BXO can affect the glans and meatus as well as the urethra.** The inability to retract the prepuce is the common presentation at puberty and is rare in children younger than 5 years of age (Oster, 1968). Other symptoms include local infection, irritation, discomfort after micturition, bleeding, and occasionally acute urinary retention or urinary incontinence (Bale et al., 1987). Older patients and those with BXO involving the meatus may have a more severe clinical course (Gargollo et al., 2005). The cause of BXO remains unknown without an identified viral or bacterial cause or a familial predisposition. The association of BXO and penile cancer in children is also not established.

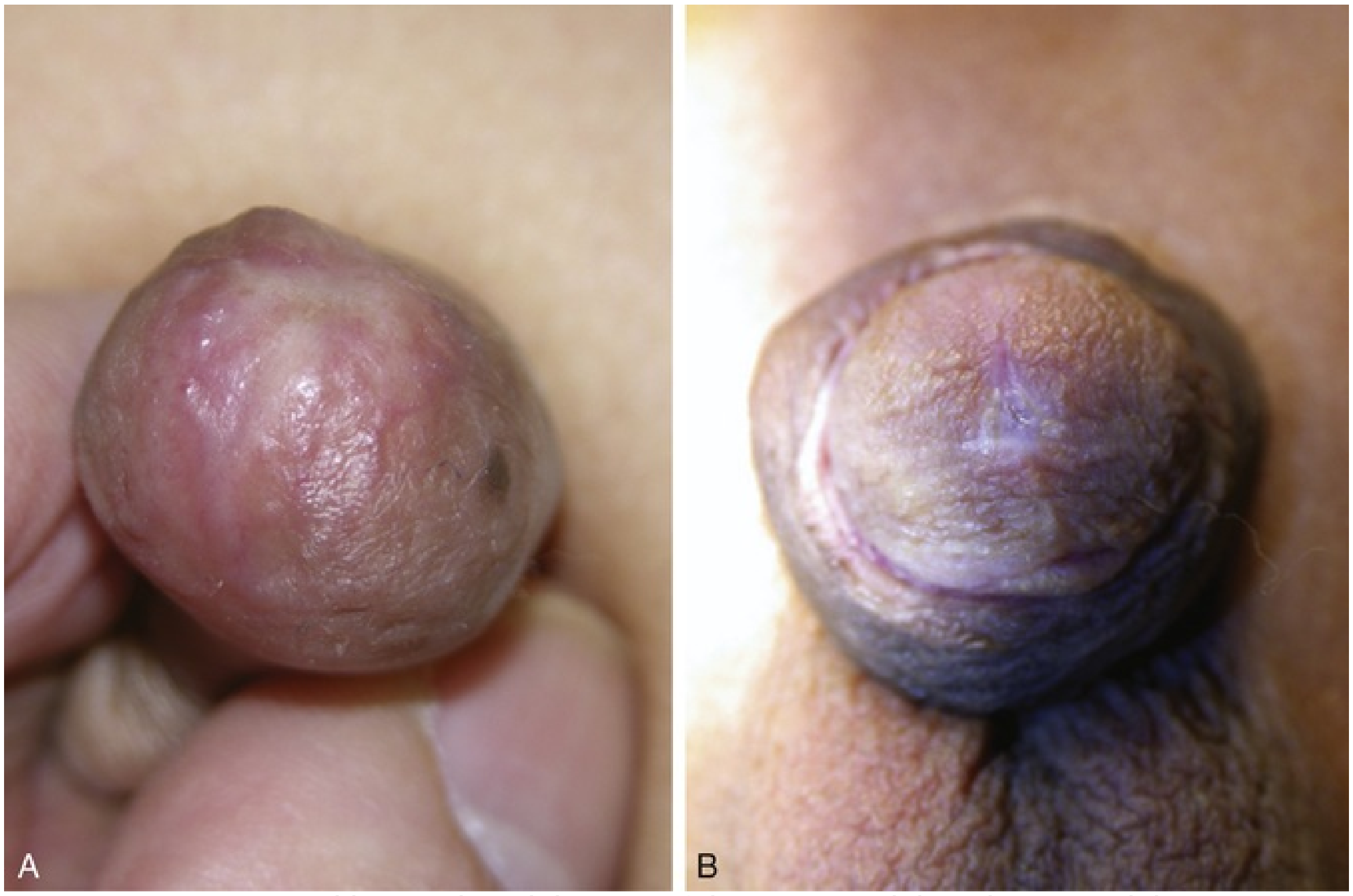

FIG. 44.5 Balanitis xerotica obliterans of the prepuce (A) and meatus (B). (Courtesy Warren Snodgrass, MD.)

Treatment of BXO includes medical and surgical options. The use of topical corticosteroids has had limited benefit to treat mild BXO of the prepuce with minimal scar formation (Vincent and Mackinnon, 2005). **Circumcision is the preferred treatment along with meatotomy or meatoplasty in cases of meatal involvement.** Children with meatal involvement should be observed postoperatively because of the risk of recurrent meatal stenosis, but 20% may require subsequent meatal surgery (Homer et al., 2014). A prepuce-sparing approach was described by Wilkinson et al. in 104 uncircumcised boys for whom triradiate preputial incisions and injection of triamcinolone intralesionally were performed. This resulted in 81% having a fully retractile prepuce without macroscopic evidence of BXO; 13% developed recurrent symptoms or BXO requiring circumcision or repeat foreskin preputioplasty. The development of meatal stenosis occurred in significantly fewer boys than in those who underwent initial circumcision (Wilkinson et al., 2012).

Key Points: Circumcision Complications

- The risk of complications from circumcision is 0.2% to 5%; bleeding is the most common.
- Circumcision revisions require the child to be under general anesthesia.
- Meatal stenosis occurs only in the circumcised penis.
- Topical corticosteroids fail to resolve penile adhesions.
- BXO is a chronic infiltrative and cicatrizing skin condition.

Abnormal Penile Number

Aphallia

Penile agenesis results from failure of development of the genital tubercle (Roth et al., 1981; Fig. 44.6). The disorder is rare, with an estimated incidence of 1 in 10 million to 30 million births. **The karyotype almost always is 46,XY, and the usual appearance is that of a well-developed scrotum with descended testes and an absent penile shaft.** The anus is usually displaced anteriorly. The urethra often opens at the anal verge adjacent to a small skin tag or may open into the rectum. The incidence of stillbirth or neonatal death is approximately one in three cases (Gilbert et al., 1990).

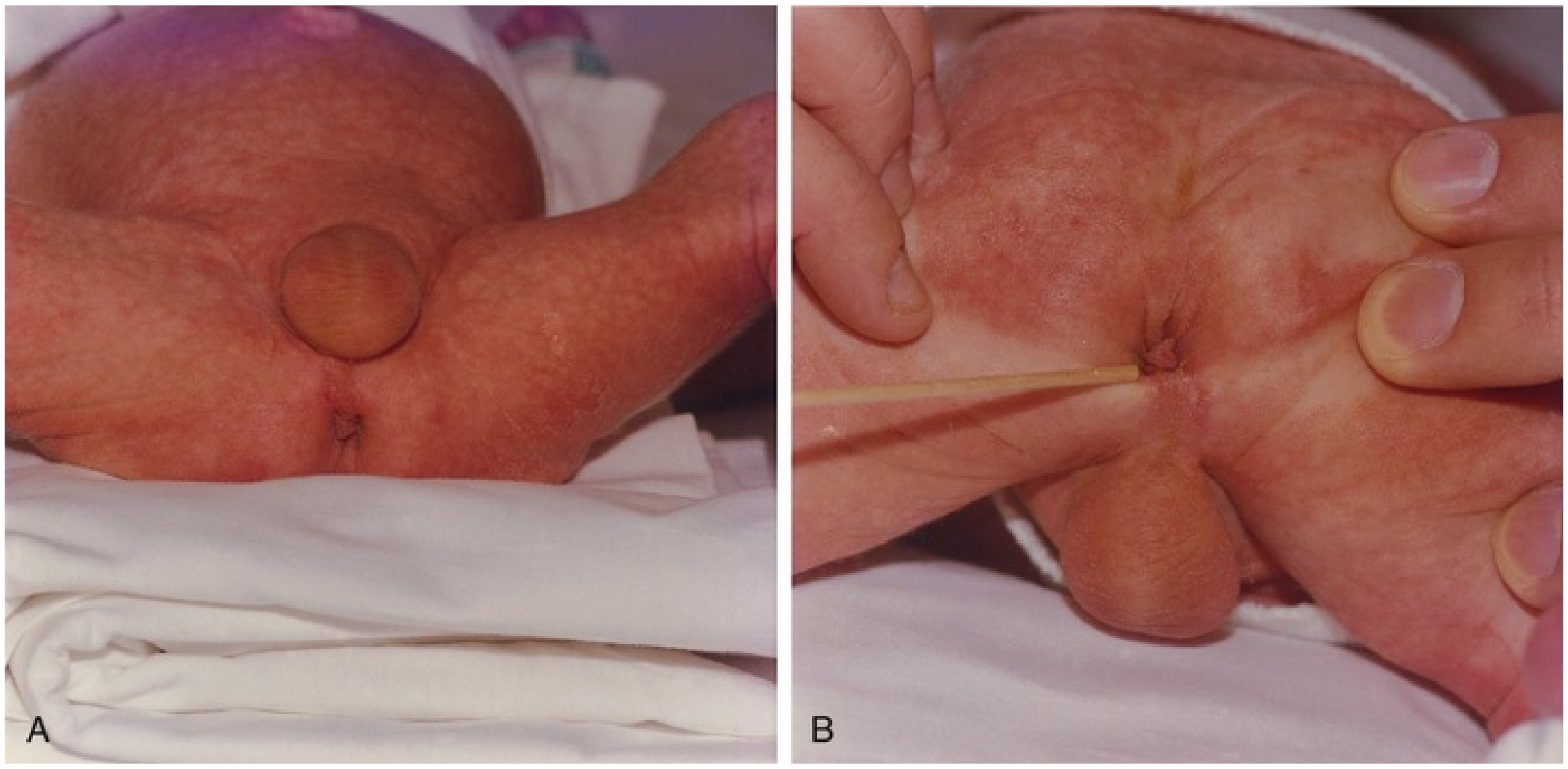

FIG. 44.6 (A) Neonate with aphallia. (B) Urethral meatus at skin tag on anal verge.

Associated malformations are common and include cryptorchidism, vesicoureteral reflux, horseshoe kidney, renal agenesis, imperforate anus, and musculoskeletal and cardiopulmonary abnormalities (Evans et al., 1999; Friedman et al., 2016c; Skoog and Belman, 1989). The connection between the genitourinary and gastrointestinal tract is variable. Skoog and Belman (1989) reviewed 60 reports of aphallia and found that the more proximal the urethral meatus, the greater the likelihood of neonatal death and the incidence of other anomalies. In this study 60% of patients had a postsphincteric meatus located on a peculiar appendage at the anal verge; these patients had the highest survival rate (87%) and the lowest incidence of other anomalies (1.2 per patient). Of those patients studied, 28% had presphincteric urethral communications (prostatorectal fistula), and there was a 36% neonatal mortality rate. Twelve percent had urethral atresia and a vesicorectal fistula for drainage. This group had the highest incidence of other anomalies and a 100% mortality rate. Friedman et al. (2016) noted that aphallia should be considered in girls with severe urinary tract dysplasia and genital ambiguity and recommended imaging of the urinary tract (ultrasound cystography).

Children with this lesion should be evaluated immediately with a multidisciplinary approach. Testing should include a karyotype and other

appropriate studies to detect associated malformations of the urinary tract or other organ systems. Magnetic resonance imaging (MRI) may be beneficial in determining the severity of the defect (Lapointe et al., 2001).

Advances in neophallus reconstruction offer these children an alternative to gender reassignment. As a male, the patient would potentially be fertile; although current advances in phalloplasty and urethroplasty allow for sexual and voiding function (De Castro et al., 2013; Garaffa et al., 2014; Oliveira et al., 2016), reproductive function is unknown. **A recommendation to perform gender reassignment should be made carefully and only after full evaluation by a multidisciplinary team and parental counseling.** Some of these patients have a male gender identity despite reconstruction as a female, presumably because of in utero or postnatal sex steroid imprinting (Diamond, 1999; Diamond and Sigmundson, 1997; Reiner, 1996). Gender reassignment involves orchiectomy and feminizing genitoplasty in the neonatal period (Bruch et al., 1996; Gluer et al., 1998) and neovagina at a later age. Urinary tract reconstruction with simultaneous construction of an intestinal neovagina through a posterior sagittal and abdominal approach in patients with penile agenesis has been described (Hendren, 1997; Hensle and Dean, 1992).

Diphallia

Duplication of the penis (Fig. 44.7) **is a rare anomaly with an incidence of 1 in 5 million live births** (Hollowell et al., 1977) **and has a range of appearances from a small accessory penis to complete duplication** (Gyftopoulos et al., 2002). In some cases, each phallus has only one corporal body and urethra, whereas others seem to be a variant of twinning, with each phallus having two corpora cavernosa and a urethra. The penises are usually unequal in size and situated adjacently. Other associated anomalies are common, including hypospadias, bifid scrotum, bladder duplication, renal agenesis or ectopia, and diastasis of the pubic symphysis (Maruyama et al., 1999). Anal and cardiac anomalies are also common. **Evaluation should include imaging of the entire urinary tract, including a renal ultrasound and voiding cystourethrogram.** Ultrasonography and MRI can also be done to assess penile development (Lapointe et al., 2001; Marti-Bonmati et al., 1989). The cause has not been delineated. Treatment must be individualized, with consideration of the associated anomalies with the goal of attaining a satisfactory functional and cosmetic result (Dean and Horton, 1991).

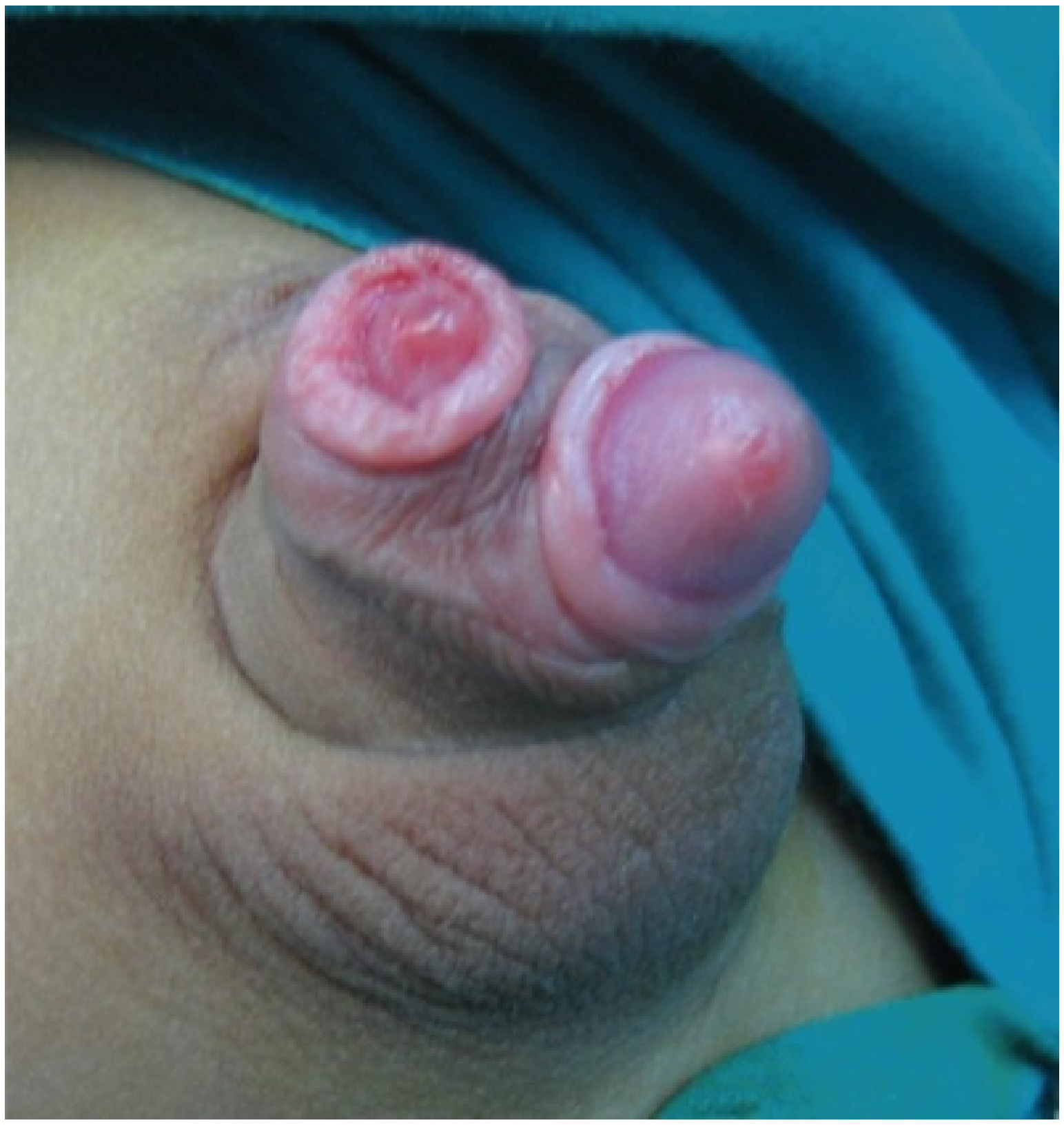

FIG. 44.7 Child with diphallia. Both phalluses sat on a common mons but had separate urethras.

Inconspicuous Penis

An inconspicuous penis is one that appears to be small but with normal stretched penile length measured from the pubic symphysis to the tip of the glans (see Table 44.2) **and normal diameter of the penile shaft** (Bergeson et al., 1993). This condition can be congenital or acquired and is usually of great concern for parents. Several entities are included in this disorder, including buried penis, trapped penis, and webbed penis (Palmer and Kogan, 1995). **These conditions must be differentiated from micropenis, in which the penis is abnormally small.** When an infant has an inconspicuous penis, evaluation is necessary for proper treatment and counseling of the family as to whether the penis is or is not normal.

Buried Penis

A buried penis, also referred to as a *hidden* or *concealed penis*, is a form of inconspicuous penis (Cromie et al., 1998). A buried penis is a normally developed penis that is hidden by the suprapubic fat pad. **This condition can be classified into three categories based on cause of the concealment** (Casale et al., 1999; Maizels et al., 1986): **(1) poor penopubic and/or penoscrotal fixation of the skin at the base of the penis, (2) obesity, and (3) a trapped penis from cicatricial scarring after penile surgery, typically a circumcision.**

The congenital form of buried penis is believed to result from the inelasticity of the dartos fascia, which normally allows the penile skin to slide freely on the deep layers of the shaft, with restricted extension of the penis because the penile skin is not anchored to the deep fascia (Fig. 44.8). The acquired form from obesity typically seen in older children and adolescents is caused by abundant fat on the abdominal wall hiding the penile shaft. The other acquired form, a trapped penis, results from embedding of the penis in the suprapubic fat pad from scar formation over the glans. This deformity may occur after neonatal circumcision in an infant with significant scrotal swelling as a result of a hernia or hydrocele or after routine circumcision in an infant with a webbed penis. Also, in some neonates the penile shaft seems to retract naturally into the scrotum, and if circumcision is performed in this situation, the skin at the base of the penis may form a cicatrix over the retracted phallus. This condition should be differentiated from a transient buried penis resulting from a large suprapubic fat pad noted in early childhood that resolves with increased age and ambulation (Eroglu et al., 2009).

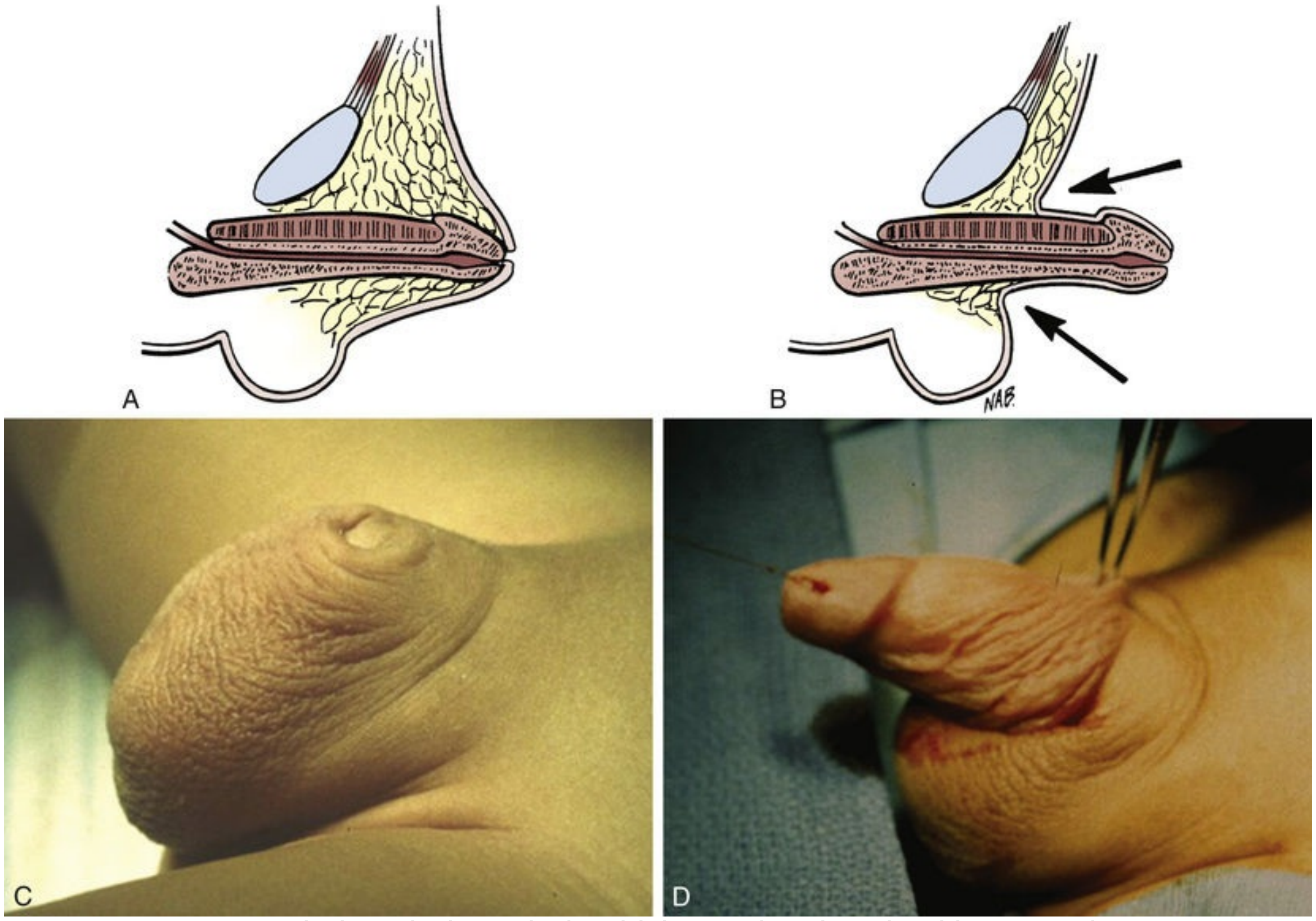

FIG. 44.8 Buried penis (A and C), which may be visualized by retraction of the skin lateral to the penile shaft (B and D).

On examination, a buried penis must be differentiated from a micropenis with an abnormal penile stretched length. The clinician should determine whether the glans can be exposed by retracting the skin covering the glans (see Fig. 44.8). If so, it remains the surgeon's judgment whether correction is warranted. However, if the penis is trapped by physiologic phimosis in the uncircumcised penis or cicatricial scarring (Fig. 44.9A) in the circumcised penis, this increases the chance of difficulty voiding, maintaining proper hygiene, balanitis, UTIs, and psychosocial issues (Fig. 44.9B; Kon, 1983).

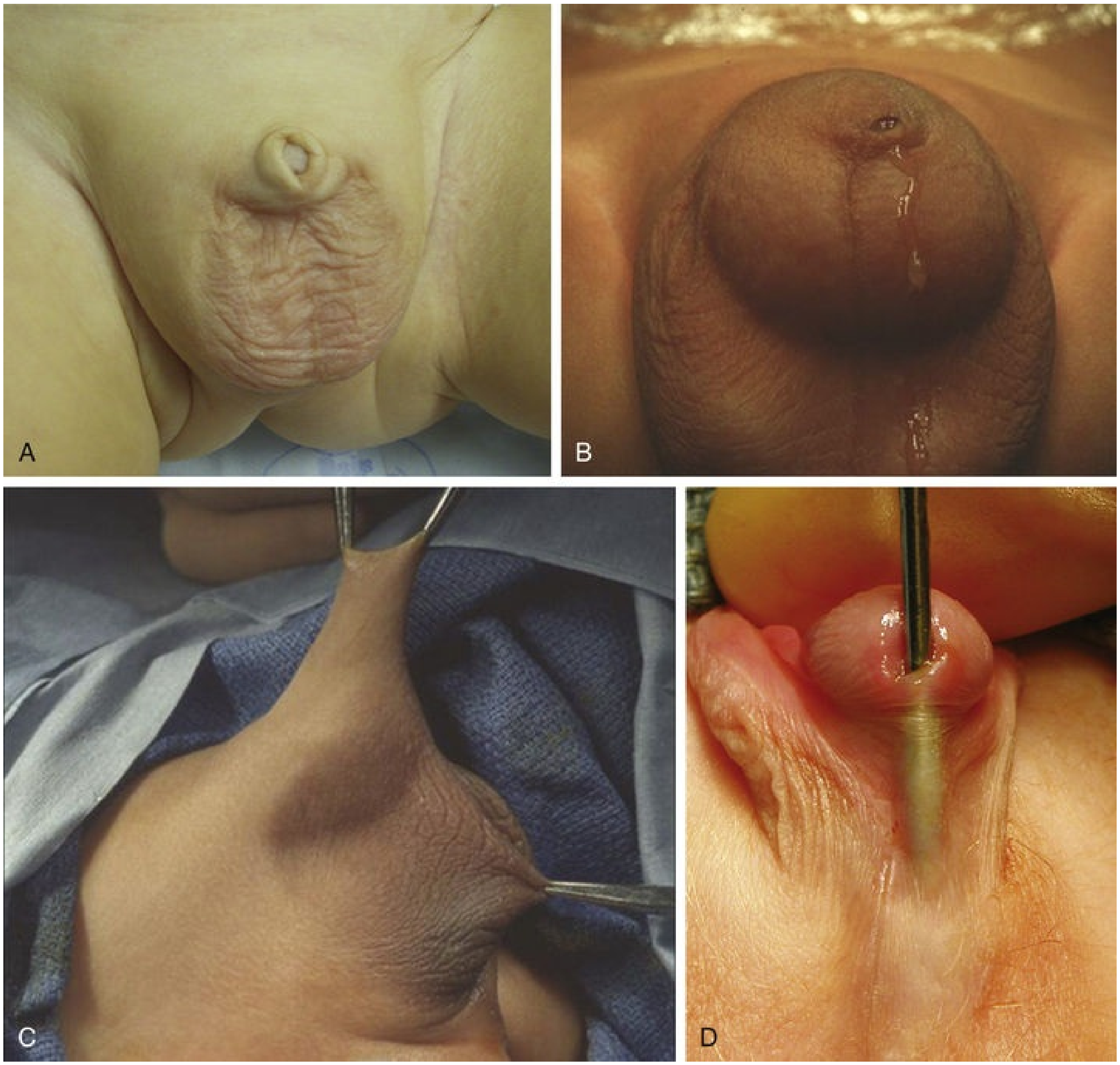

FIG. 44.9 Inconspicuous penis. (A) Trapped penis by cicatricial scarring resulting from neonatal circumcision. (B) Urine pooling caused by cicatricial scarring, increasing susceptibility to urinary tract infections. (C) Penoscrotal web resulting in a webbed penis. (D) Webbed penis with hypoplastic distal urethra.

The treatment options for children with buried penis are centered on the anatomic cause. Patients with buried penis secondary to obesity should have the underlying condition treated with referral back to the primary care provider for a weight loss and exercise program. The child should then be reevaluated to assess whether surgery is needed. Young children with secondary cicatricial scarring after penile surgery can be managed with forceful dilation of the cicatrix with a fine hemostat in the office after the application or injection of analgesic. Another option is the combination of topical betamethasone and manual retraction

(Palmer et al., 2005), which yielded complete resolution in the majority of boys or released the closing cicatrix, allowing for a simple incision of the phimotic ring; this reduced the need for formal surgical repair by 79%. If topical corticosteroid application is ineffective, correction under general anesthesia is necessary, with the usual recommendation of elective repair when the child is at least 6 months of age. The surgical technique is similar to that for the congenital buried penis.

A number of surgical techniques have been described to correct the buried penis (Borsellino et al., 2007; Casale et al., 1999; Elder, 2001; Frenkl et al., 2004; Gillett et al., 2005; Karapetian and Palmer, 2007, Liu et al., 2016; Maizels et al., 1986). The indications and timing for reconstructive surgery are controversial. In moderately severe cases the dysgenic bands of tissue, which are located primarily on the proximal dorsal surface of the shaft of the penis, must be removed. The prepuce should be unfurled and used for ventral skin coverage. In addition, the subcutaneous tissue on the dorsal aspect of the penis should be fixed to the pubic fascia, and then the subcutaneous tissue of the scrotum should be fixed to the ventral aspect of the base of the penile shaft. During correction the surgeon must be careful to avoid injury to the neurovascular bundles (Baskin, 1999; Baskin et al., 2000). Skin coverage can also be accomplished by penoscrotal Z-plasty, lateral penile shaft Z-plasty, island pedicle of ventral preputial skin, or a skin graft. Rarely, in the most severe cases the suspensory ligament of the penis must be divided, the suprapubic fat excised, and the spermatic cords protected. The benefit of liposuction has been reported in severe cases (Maizels et al., 1986; Shenoy et al., 2000). However, this technique should be reserved for adolescent boys because prepubertal boys may lose their fat pad simply with somatic growth.

Webbed Penis

Webbed penis, also known as *penoscrotal fusion*, is a congenital or acquired condition resulting from the scrotal skin extending onto the ventrum of the penis. The congenital form of a penoscrotal web represents an abnormality of the attachment between the penis and the scrotum, whereas the penis, urethra, and remainder of the scrotum are normal (Fig. 44.9C). The acquired condition results from circumcision or other penile surgery, as a result of excessive removal of ventral penile skin.

Although the penoscrotal web is usually asymptomatic, the appearance is often unacceptable. There are several surgical techniques to correct this condition. Similar to the treatment of a buried penis, one technique involves the fixation of the subcutaneous tissue of the scrotum to the ventral aspect of the base of the penile shaft. On occasion, this condition may be corrected by incision of the web transversely, separation of the penis from the scrotum, and closure of the skin vertically. In other cases, a circumferential incision is made 1.5 cm proximal to the coronal sulcus, a Byar preputial skin flap is transferred to the ventral surface of the penis, and the redundant foreskin is excised. In rare cases the distal urethra is hypoplastic, necessitating urethral reconstruction (Fig. 44.9D).

Micropenis

Micropenis is a normally formed penis that is at least 2.5 standard deviations (SD) below the mean size in stretched length for age (Aaronson, 1994; Fig. 44.10). The ratio of the length of the penile shaft to its circumference is usually normal, but occasionally the corpora cavernosa are severely hypoplastic. The testes are usually small and frequently cryptorchid, whereas the scrotum is usually fused and often diminutive.

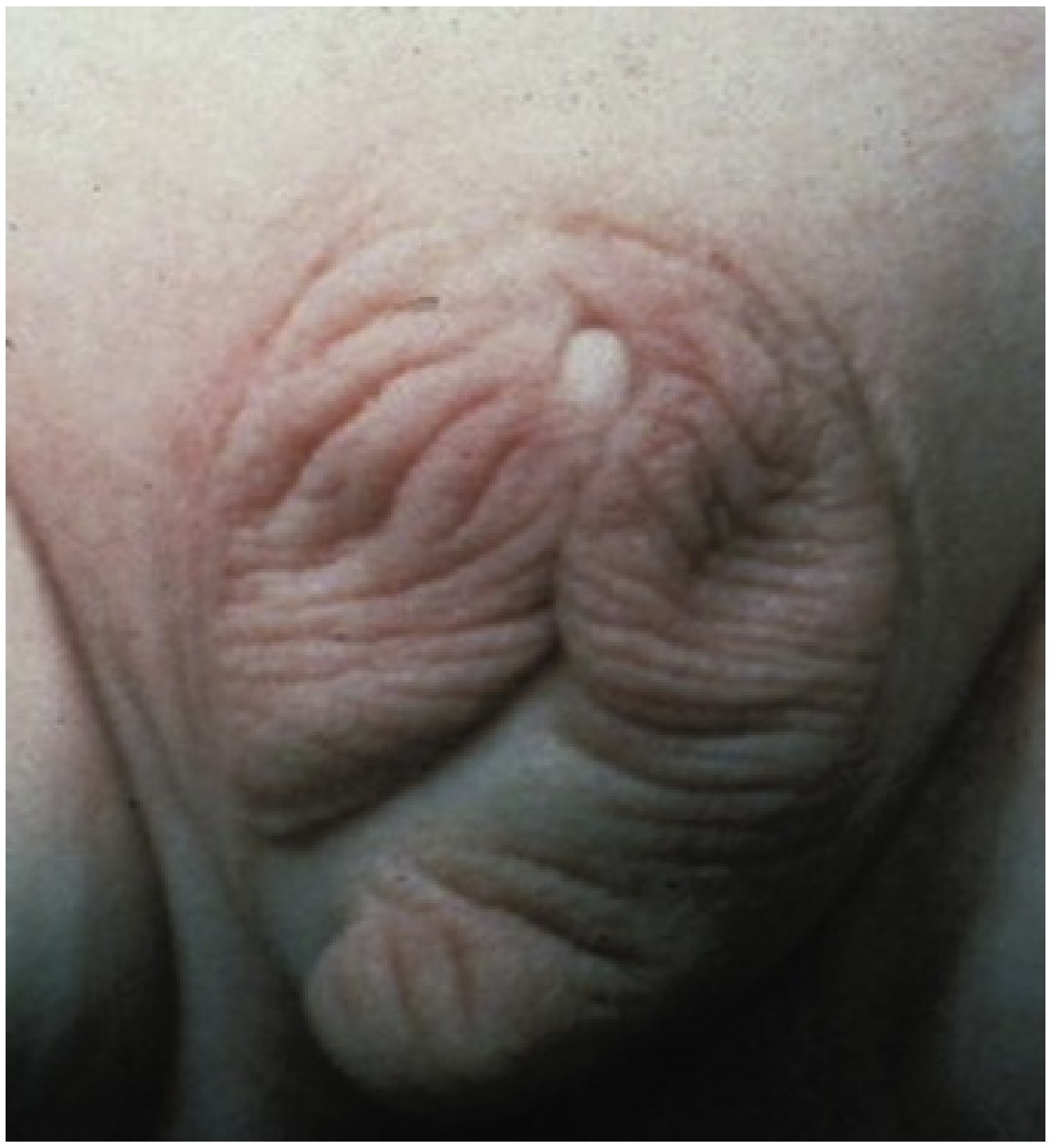

FIG. 44.10 Micropenis resulting from hypogonadotropic hypogonadism.

Stretched penile length correlates more closely with erectile length than does the relaxed penile length and should be compared with standards for penile length (see Table 44.2). Stretched penile length is determined by measuring the penis from its attachment to the pubic symphysis to the tip of the glans. The suprapubic fat pad must be depressed completely for an accurate measurement to be obtained, especially in an obese infant or child. **In general, the penis of a full-term neonate should be at least 1.9 cm long.** One must differentiate buried penis or webbed penis from the micropenis, with the former having a normal penile shaft.

Micropenis results from a hormonal abnormality that occurs after 14 weeks of gestation. Differentiation of the male external genitalia is complete by the 12th week of gestation and requires a normal testis producing testosterone, stimulated by maternal human chorionic gonadotropin (hCG). During the second and third trimesters, growth of the penis occurs under the direction of fetal androgen controlled by the secretion of fetal luteinizing hormone (LH). An abnormality in the production or use of testosterone results in a small penis and hypospadias, whereas a true micropenis often seems to be a consequence of a deficiency of gonadotropic hormones.

The causes of micropenis are many (eBox 44.1) and include isolated gonadotropin defects and generalized endocrinopathies that may be associated with central nervous system defects. **The most common causes of micropenis are hypogonadotropic hypogonadism, hypergonadotropic hypogonadism (primary testicular failure), and idiopathic** (Lee et al., 1980b). Micropenis is often associated with major chromosomal defects, including Klinefelter syndrome (47,XXY) and other X polysomy syndromes, deletions, translocations, and trisomy involving chromosomes 8, 13, and 18 (Aaronson, 1994).

eBox 44.1

Etiology of Micropenis

Deficient Testosterone Secretion

- Hypogonadotropic hypogonadism
  - Isolated, including Kallmann syndrome
  - Associated with other pituitary hormone deficiencies (e.g., CHARGE association)

- Prader-Willi syndrome
    - Laurence-Moon syndrome
    - Bardet-Biedl syndrome
    - Rud syndrome
- Primary hypogonadism
    - Anorchia
    - Klinefelter syndrome and poly X syndrome
    - Gonadal dysgenesis (incomplete)
    - Luteinizing hormone receptor defects (incomplete)
    - Genetic defects in testosterone steroidogenesis (incomplete)
    - Noonan syndrome
    - Down syndrome
    - Robinow syndrome
    - Bardet-Biedl syndrome
    - Laurence-Moon syndrome

Defects in Testosterone Action

- Growth hormone/insulin-like growth factor 1 deficiency
- Androgen receptor defects (incomplete)
- 5α-Reductase deficiency (incomplete)
- Fetal hydantoin syndrome

Developmental Anomalies

- Aphallia
- Cloacal exstrophy

Idiopathic

- Associated with other congenital malformations

Data from Bin-Abbas B, Conte FA, Grumbach MM, et al. Congenital hypogonadotropic hypogonadism and micropenis: effect of testosterone treatment on adult penile size—why sex reversal is not indicated. *J Pediatr.* 134:579, 1999.

The most common cause of micropenis is hypogonadotropic hypogonadism, that is, failure of the hypothalamus to produce adequate quantities of gonadotropin-releasing hormone (GnRH). This condition may result from hypothalamic dysfunction, which can occur in Prader-Willi syndrome, Kallmann syndrome (genital-olfactory dysplasia), Laurence-Moon-Biedl syndrome (Danish et al., 1980; Walsh et al., 1978), and the CHARGE association (Ragan et al., 1999). Other causes include an associated growth hormone deficiency or neonatal hypoglycemia secondary to congenital hypopituitarism, congenital pituitary aplasia, and midline brain defects, such as agenesis of the corpus callosum and occipital encephalocele.

Primary testicular failure **hypergonadotropic hypogonadism** is another cause of micropenis and may result from rudimentary testes syndrome or gonadal dysgenesis. It also occurs in Robinow syndrome (Lee et al., 1980b). **The test most frequently used to identify this subgroup is the failure of serum testosterone concentration to rise appropriately after stimulation by hCG.** However, in patients with Kallmann syndrome and cryptorchidism, the serum testosterone level may not increase after the administration of hCG. Rarely, a patient with partial androgen insensitivity syndrome has micropenis, but sexual ambiguity is more common. Micropenis may also result from improper timing or delayed onset of gonadotropin stimulation in the fetus (Lee et al., 1980a). These patients have an idiopathic form of micropenis and a normal hypothalamic-pituitary-testicular axis.

The initial evaluation of a child with micropenis should include a thorough medical history, physical examination, and a karyotype at birth. Accurate measurement of the penile length, palpation of the corporal bodies, and evaluation for cryptorchidism are important elements of the physical examination. Concurrent evaluation with a pediatric endocrinologist assists in determining the cause of the micropenis (central or testicular), assessing for other abnormalities, and helping to determine penile growth potential. **Testicular function is assessed by measuring serum testosterone levels before and after hCG stimulation. Primary testicular failure produces an absent response and elevated basal concentrations of LH and follicle-stimulating hormone (FSH).** In some cases, a GnRH stimulation test is also performed. Anterior pituitary screening tests include serial measurements of serum glucose, sodium, and potassium; serum cortisol concentrations; and thyroid function tests. MRI of the head assesses the anatomic integrity of the hypothalamus, anterior pituitary gland, and midline structures of the midbrain.

Before extensive evaluation of the hypothalamic-pituitary-testicular axis, androgen therapy should be administered to determine the end-organ response. In general, intramuscular testosterone enanthate is given for 3 months. Although prolonged treatment may advance skeletal maturation, short courses of treatment do not affect height. Transdermal testosterone also has been used in these patients (Choi et al., 1993). If androgen treatment in a neonate successfully increases the penis so that its size falls within the normal range, the effects at puberty have not been clearly delineated. In a mouse model of hypogonadotropic hypogonadal micropenis, significant prepubertal exposure of the penis to androgens reduced the ultimate growth response to androgens (Husmann and Cain, 1994; McMahon et al., 1995). Bin-Abbas et al. (1999) described eight boys with micropenis treated with androgens at birth and at puberty. The final penile stretched length averaged 10.3 cm and was in the normal range in all cases. Therefore exogenous stimulation at birth and at puberty with testosterone enanthate seems most reasonable (Tietjen et al., 1998) and is recommended until longer-term studies are available.

If the penis does not respond to testosterone, gender reassignment remains a controversial option. Previously, gender reassignment was recommended, but this position has come under criticism because of the implication that biologic factors, such as testosterone-induced male brain imprinting, during the prenatal period may affect gender identity (Diamond and Sigmundson, 1997). The lack of long-term data regarding the risks and benefits of reassigning these patients to a female gender (Calikoglu, 1999; Diamond, 1999) has resulted in a conservative use of this treatment option. Husmann (2004) described 20 adult men born with micropenis who had a suboptimal response to testosterone therapy and were raised as males. At adulthood, 90% had a micropenis and all had a male gender identity; 5 were undergoing psychiatric counseling for fear of rejection, and 8 had not been sexually active.

Several studies demonstrate that although ultimate penile size may be below the normal range, men born with micropenis have male gender identity and most have satisfactory sexual function. Reilly and Woodhouse (1989) described 20 patients with a primary diagnosis of micropenis in infancy. Almost all had received androgen therapy during childhood, but as adults none had a penis within the normal range of size. All of the boys stood to void. Parents of patients in the prepubertal group considered their children to be normal boys with a satisfactory penile appearance but did express concern about penile size and future sexual function. All of the patients in the adult group had a strong male identity, and 9 of the 12 patients were sexually active. In a study of 22 men born with micropenis, Lee and Houk (2004) had similar findings. Wisniewski and Migeon (2002) reported that their patients had a male gender identity but in general were dissatisfied with their genital appearance and function.

Key Points: Micropenis

- Micropenis is a normally formed penis that measures at least 2.5 SD below the mean size in the stretched length for age (<1.9 cm in neonates).
- Buried penis is not synonymous with micropenis because the buried penis is of normal stretched length.
- The most common causes of micropenis include hypogonadotropic hypogonadism and hypergonadotropic hypogonadism.
- Patient evaluation includes karyotype, determination of serum LH and FSH concentrations; measurement of testosterone levels before and after hCG stimulation; serum studies of anterior pituitary function; MRI of the brain to assess hypothalamus, anterior pituitary, and midbrain.
- In adulthood, most men with micropenis have male gender identity and satisfactory sexual function.

Abnormal Penile Orientation

Penile Curvature

Curvature of the penis may occur along the vertical (i.e., ventral or dorsal direction) or horizontal (i.e., lateral direction) plane of the penis. Penile curvature may be congenital or acquired after penile surgery (circumcision, hypospadias repair) or trauma and has consequences related to cosmesis and body image as well as future sexual difficulties. The indications for surgical repair include known associated sexual dysfunction, concurrent penile surgery, and surgeon's discretion regarding the likelihood of future sexual dysfunction with worsening curvature associated with penile growth.

Penile curvature is most commonly in the ventral direction, referred to as *chordee,* and is commonly associated with hypospadias. However, isolated chordee may occur with or without a dorsal hooded prepuce (Fig. 44.11) and is commonly associated with a deficiency of the ventral skin (Cendron and Melin, 1981). Ventral curvature in boys without hypospadias can usually be corrected by degloving of the penis, excision of fibrous tissue that is usually confined to the region superficial to Buck fascia, and development of Byar flaps for penile skin coverage, as necessary. In more severe cases, simple dorsal plication, Nesbit dorsal excision, or corporal rotation may be necessary. Urethral catheterization may be helpful in averting urethral injury during degloving. In the most severe cases the urethra is short and urethral reconstruction must be performed. Intraoperative artificial erection with injectable saline confirms complete chordee correction. Some cases of chordee may be aggravated by a prominent frenulum, resulting in distal penile chordee with ventral glanular deflection. In these cases, the addition of frenulotomy will improve or correct the chordee.

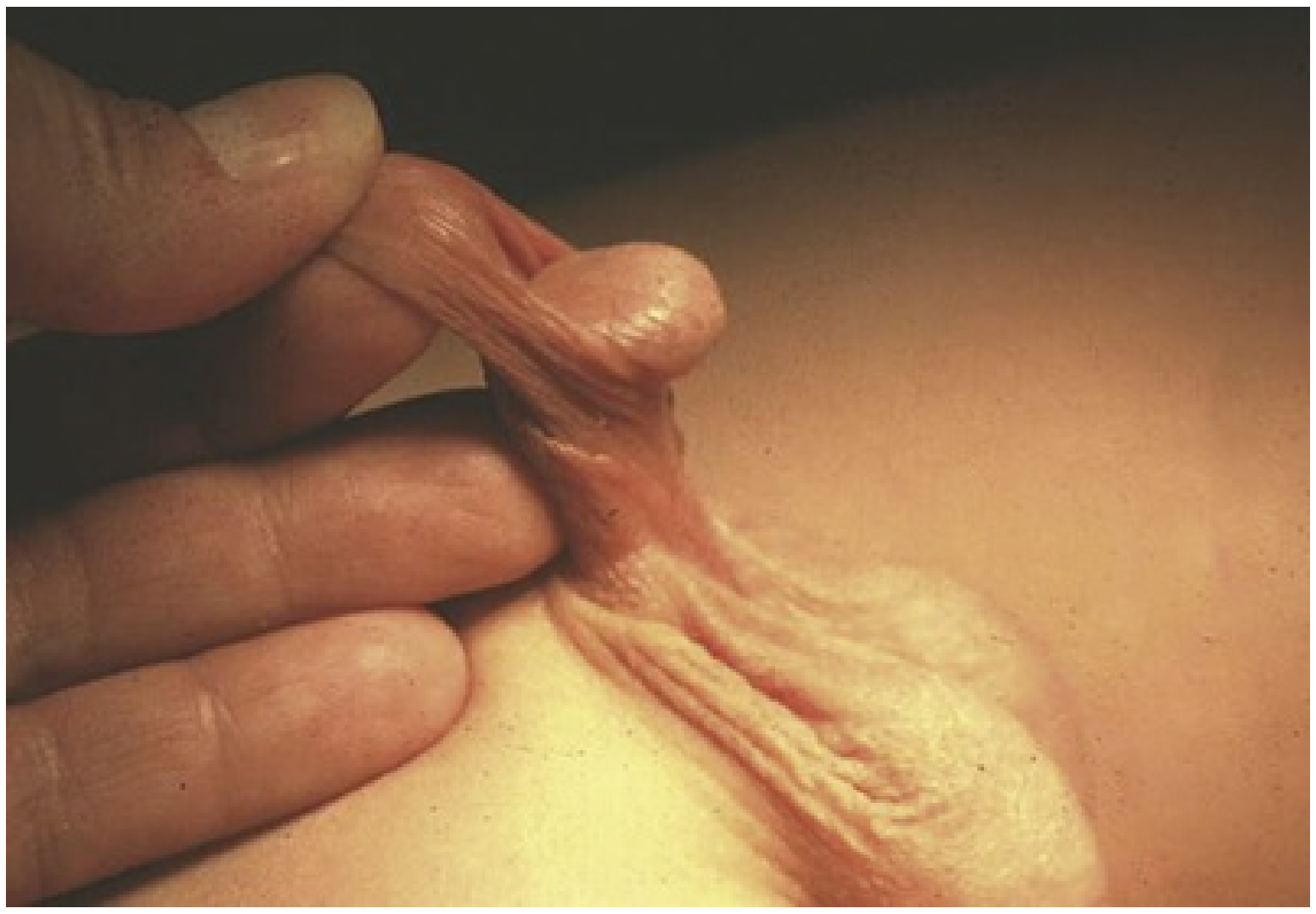

FIG. 44.11 Penile chordee and dorsal hood of foreskin without hypospadias.

Congenital dorsal penile curvature may be an isolated condition with or without asymmetrical penile skin or associated with epispadias and a ventral hood of prepuce. Some individuals may have hypospadias. Surgical repair of this condition without associated urethral anomalies is similar to chordee correction, involving degloving of the penis, excision of fibrous tissue that is usually confined to the region superficial to the Buck fascia, and development of skin flaps for penile skin coverage, as necessary. During correction, the surgeon must be careful to avoid injury to the neurovascular bundles (Baskin, 1999; Baskin et al., 2000). More severe cases involve plication and/or excision of ellipses from the ventral corporal bodies. Intraoperative artificial erection aids in determining the apex of the curvature and confirming chordee correction.

Lateral penile curvature is usually congenital and caused by overgrowth or hypoplasia of one corporal body. However, asymmetrical penile skin excision or postoperative scarring after circumcision or other penile surgery may be a secondary cause. Lateral penile curvature may be unrecognized until later in childhood because the penis is normal when flaccid and only recognized as being curved when erect. Surgical repair of congenital lateral penile curvature involves degloving the penis and performing a plication and/or excision of ellipses from the corporal bodies from the area of maximum curvature to allow straightening of the penis. Secondary lateral penile curvature follows the same principles as for vertical curvature, with degloving of the penis, excision of fibrous tissue that is usually confined to the region superficial to the Buck fascia, and development of skin flaps for penile skin coverage as necessary. Intraoperative artificial erection may be necessary as described earlier.

Penile Torsion

Penile torsion is a rotational deformity of the penile shaft, usually in the counterclockwise direction (i.e., to the left side) (Fig. 44.12). In most cases, penile size is normal and the condition is unrecognized until circumcision is performed or until the foreskin is retracted. Penile torsion may also be associated with hypospadias, chordee, and other abnormalities involving the penile skin shaft, such as dorsal hood deformity without a urethral abnormality. In most cases the median raphe spirals obliquely around the shaft and inserts atypically rather than at the base of the glans in line with the urethral meatus. The cause of penile torsion has not been clearly delineated but may be the result of an anomalous arrangement of penile shaft skin.

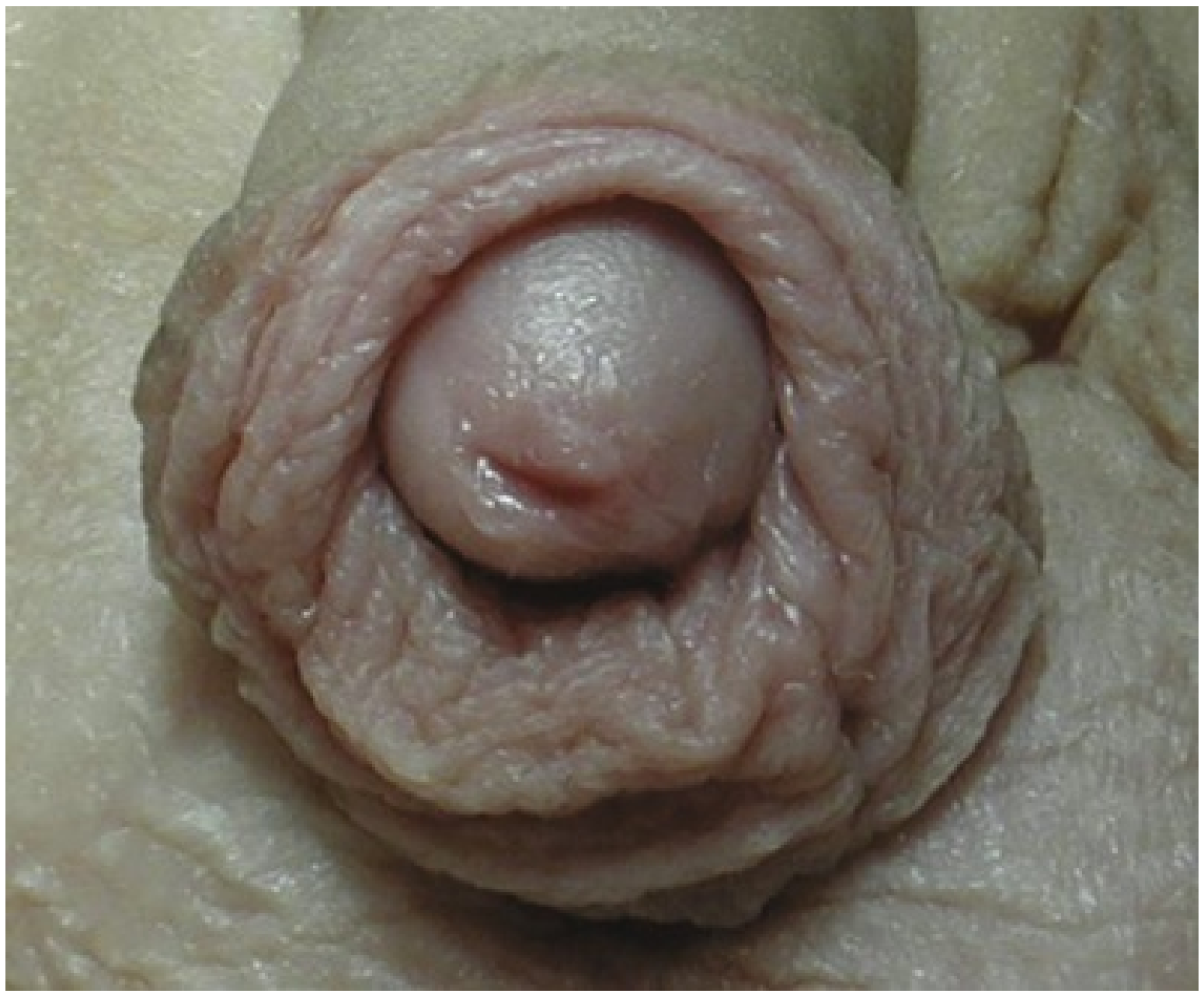

FIG. 44.12 Penile torsion. Patient also has redundant penile skin after a neonatal circumcision.

Most forms of penile torsion are less than 60 degrees. If surgical repair is being considered, neonatal circumcision is discouraged and then performed at the time of penile detorsion. Although the glans may be directed more than 90 degrees from the midline, the orientation of the corporal bodies and the corpus spongiosum at the base of the penis is normal. In mild forms of penile torsion, correction typically involves degloving the penile skin, rotating the glans in the direction opposite to the defect (i.e., clockwise rotation for a counterclockwise abnormality), and suturing the glans to the penile skin, resulting in a glans in a normal configuration (Bar-Yosef et al., 2007). In some instances, the median raphe may take a serpentine course that prevents restoration to a normal position; this is not critical as long as the meatus has a normal configuration. However, in boys with penile torsion of 90 degrees or more, simple shaft skin rearrangement is insufficient. Instead, the base of the penis must be mobilized so that dysgenic bands of fibrous tissue can be identified and incised. If the penis still remains rotated, correction may be accomplished by placing nonabsorbable anchoring sutures at the base of the corpora cavernosa (Elder, 2001; Pomerantz et al., 1978; Slawin et al., 1992), rotating a dorsal dartos flap (Bauer and Kogan, 2009), or mobilizing the urethral plate and urethra (Bhat et al., 2009).

Penile Masses

Penile cysts, congenital or acquired, are the most common penile masses in children. A history of onset, previous surgery, and changes in appearance or size are important in the evaluation of these lesions.

Parameatal Urethral Cyst

The parameatal urethral cyst is a rare anomaly and appears as a small blister in proximity to the urethral meatus (Fig. 44.13A). Shiraki (1975) suggested that these cysts may result from occlusion of paraurethral ducts or in other cases from faulty preputial separation from the glans along the coronal sulcus. The cyst wall may consist of transitional and squamous or columnar epithelium. Treatment is complete excision of the cyst with the patient under anesthesia, with care taken not to cause meatal stenosis (Willis et al., 2011).

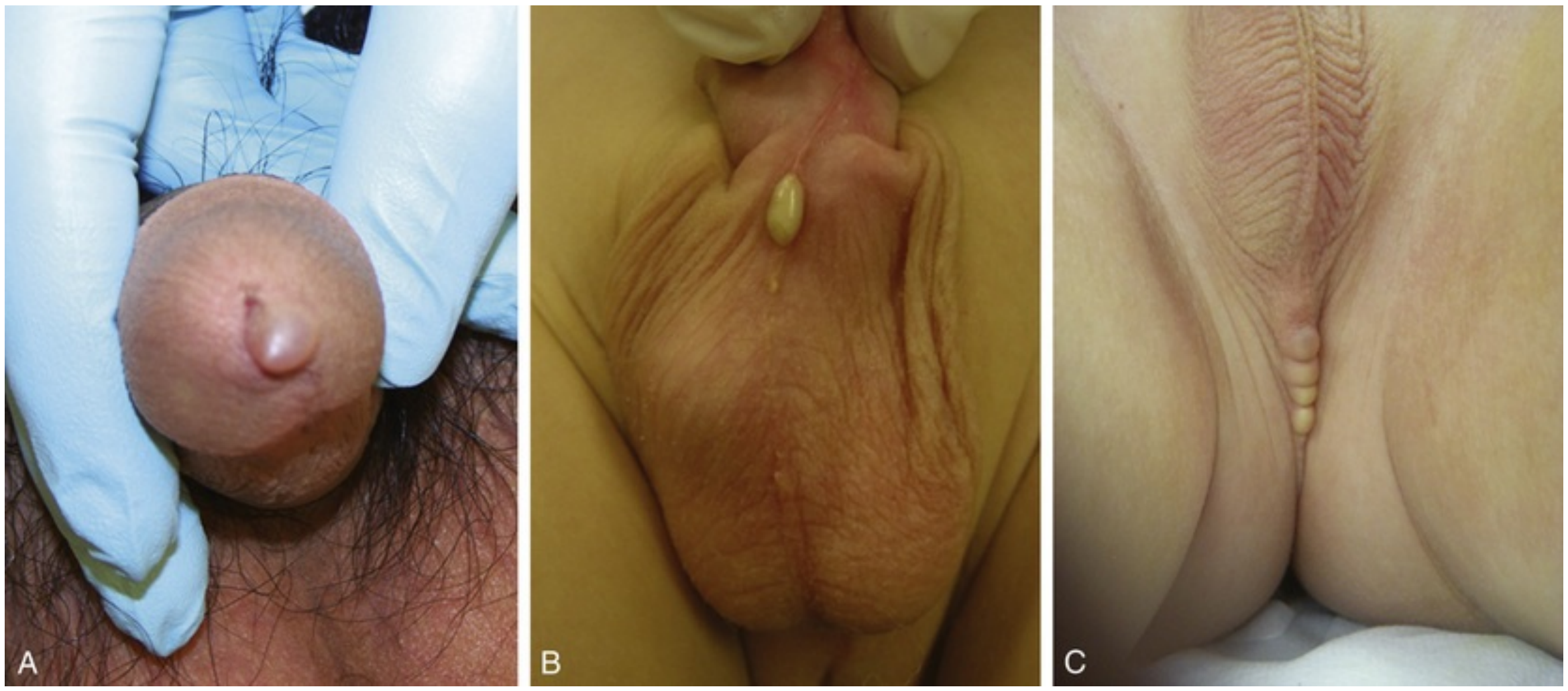

FIG. 44.13 Penile cysts. (A) Parameatal urethral cyst appearing as a small blister. (B) Cyst of the penoscrotal junction raphe. (C) Cysts of the perineal raphe.

Cyst of the Median Raphe

Congenital epidermal cysts tend to form along the median penile raphe on the glans or penile shaft, scrotum, or perineum (Fig. 44.13B and C) (Krauel et al., 2008; Little et al., 1992). These congenital lesions may result from epithelial rests that become buried during the urethral infolding process or represent a monodermal teratoma. Rare cases of cysts enlarging and extending into the pelvis are reported (Huang et al., 1999). Excision with the use of general anesthesia is recommended unless the cysts are small and asymptomatic.

Inclusion Cysts

Epidermal inclusion cysts may form after penile surgery, including circumcision and hypospadias repair, as a result of islands of epithelium within the subcutaneous tissue (Fig. 44.14). Excision of the epidermal inclusion is recommended because these lesions increase in size with time, causing distortion of the skin and possible discomfort during sexual activity.

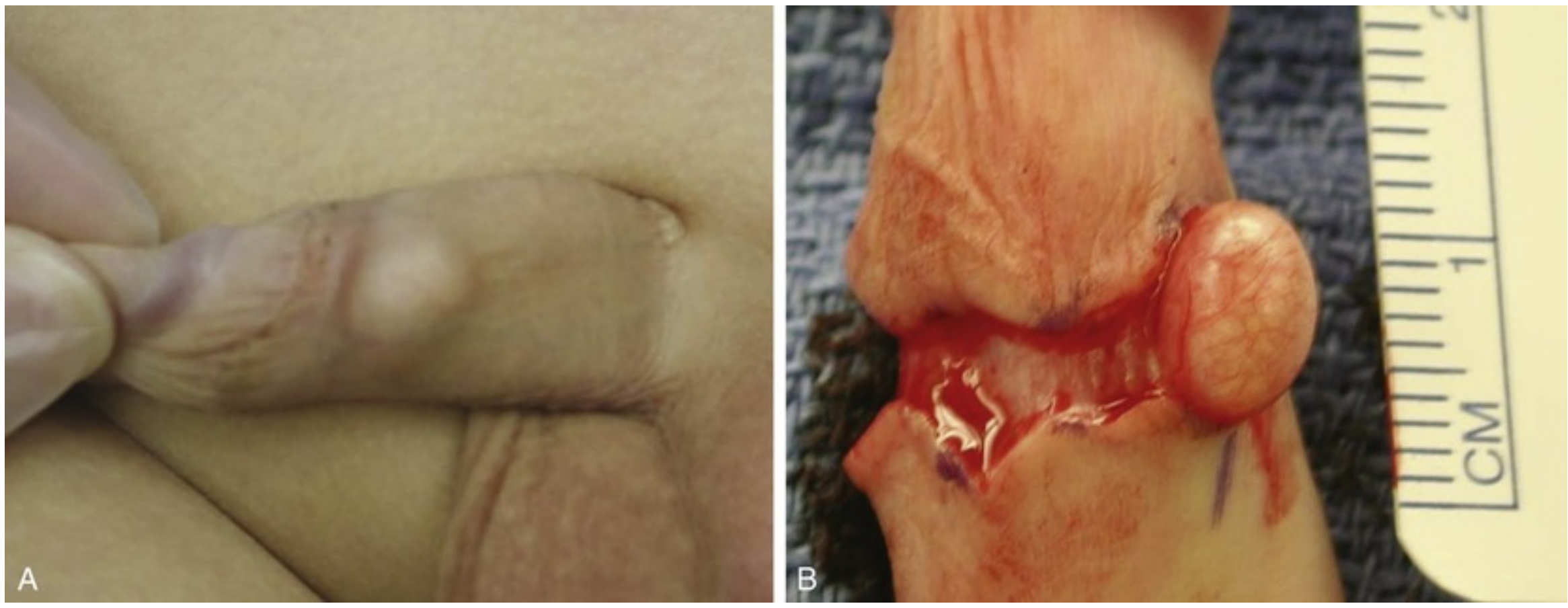

FIG. 44.14 (A) Epidermal inclusion cyst acquired after neonatal circumcision. (B) Cyst exposed and excised intact through an incision of the circumcision scar.

Congenital Penile Nevi

Congenital penile nevi are pigmented lesions that form on the glans and penile shaft (Fig. 44.15). Nevi can be classified based on the location of melanocytes: dermal (involving only the dermis), junctional (involving only the dermal-epidermal junction), and compound (involving the dermis and dermal-epidermal junction). **They tend to be superficial and benign and should be excised** (Papali et al., 2008).

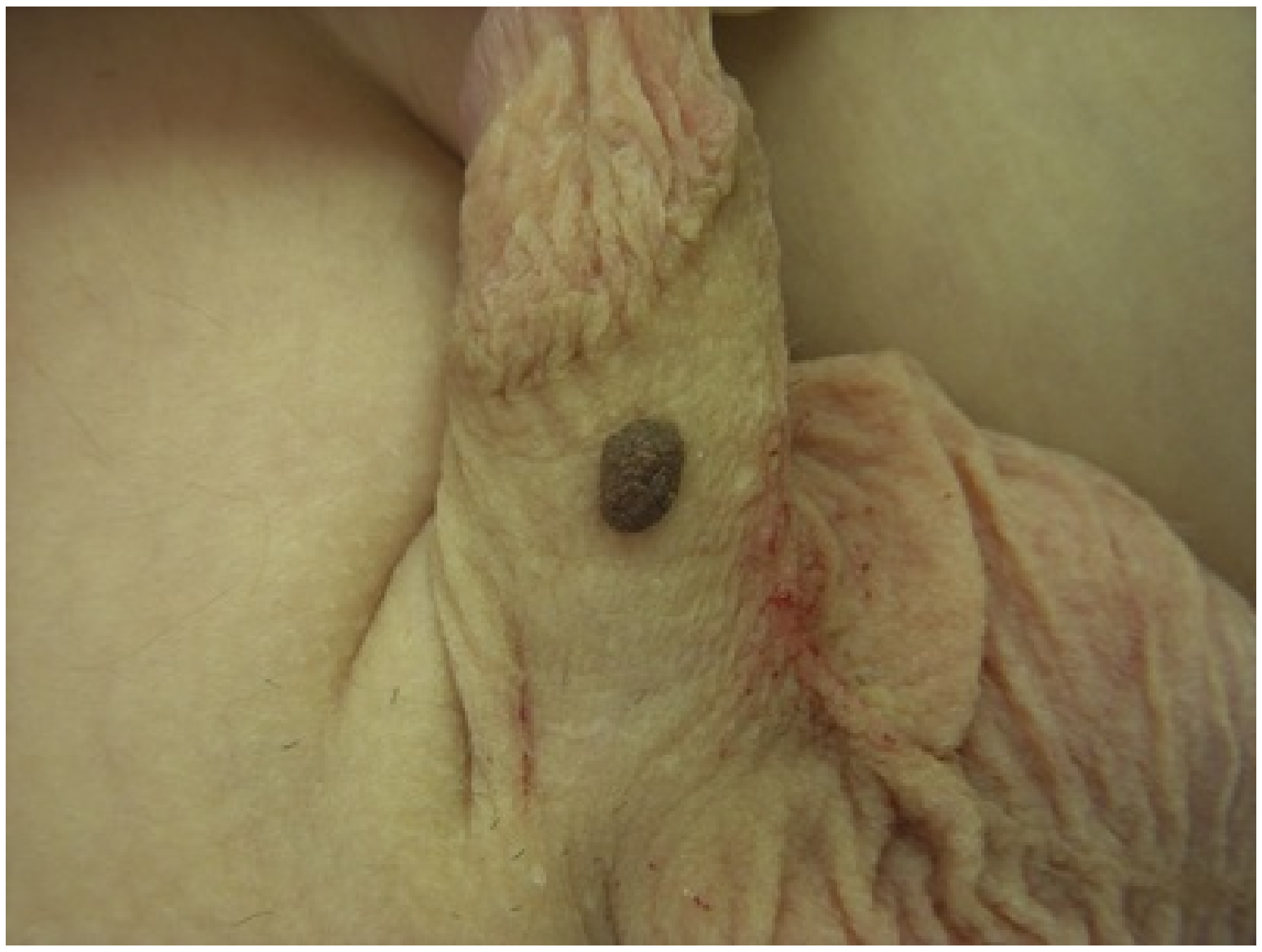

FIG. 44.15 Congenital penile nevus on the penile shaft.

Juvenile Xanthogranuloma

Juvenile xanthogranuloma is an uncommon benign, self-limiting lesion of the penis predominantly seen in infancy or early childhood. These lesions appear as solitary or multiple pigmented (yellow, orange, gold, brown, or red) nodules of rapid onset. They measure 2 to 20 mm in diameter and are well demarcated, firm, and rubbery. These lesions can affect the penis (Bradford and Choudhary, 2009; Hautmann and Bachor, 1993) or scrotum (Dehner, 2003; Goulding and Traylor, 1983), with as many as 20% present at birth. The lesion is often self-limited, and a period of 1 year of expectant monitoring is advised to avoid potentially unnecessary ablative genital surgery.

Accessory Urethral Openings

Congenital Urethral Fistula

Congenital urethral fistula is a condition in which the urethra and meatus are normal and a urethrocutaneous fistula is present, typically located in the coronal or subcoronal position (Fig. 44.16). **This abnormality is usually an isolated deformity** (Tennenbaum and Palmer, 1994) **but may be associated with imperforate anus or ventral chordee** (Ritchey et al., 1994). In a series of 14 such cases, 4 patients had distal hypospadias and 2 had chordee (Caldamone et al., 1999). The cause is unknown but may involve a focal defect in the urethral plate preventing the urethral folds from fusing. The diagnosis is made after circumcision in some cases (Caldamone et al., 1999), raising the possibility that the fistula is instead an iatrogenic injury. Surgical correction may require circumscription of the fistula and closure in multiple layers, similar to a urethrocutaneous fistula after hypospadias repair; or if the glans bridge is thin, the ventral glans can be opened through the distal urethra and then repaired by Thiersch-Duplay tubularization and incision of the urethral plate as needed.

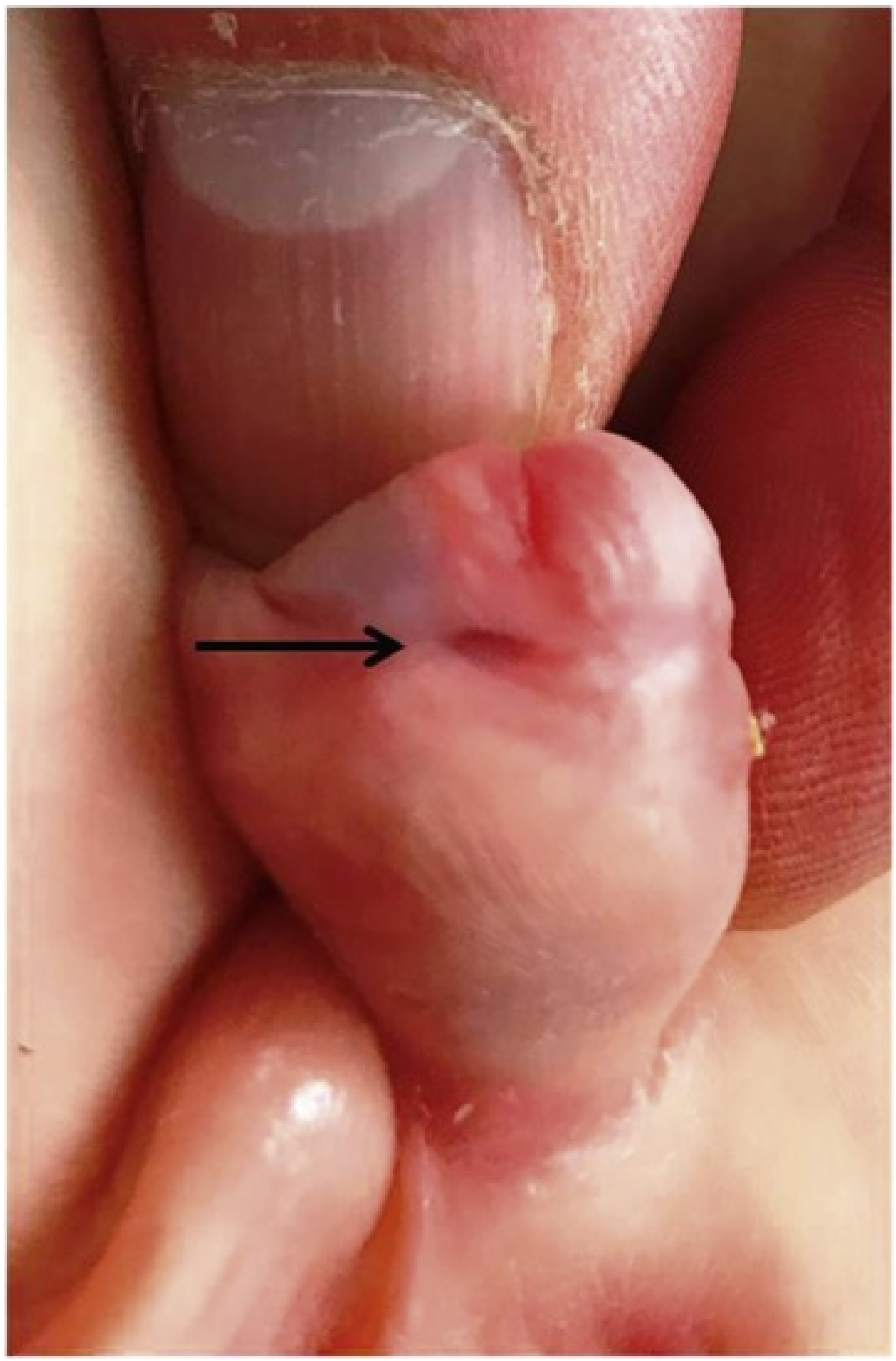

FIG. 44.16 Congenital urethral fistula. The fistula tract *(black arrow)* was noted immediately after circumcision without bleeding noted after the procedure. Urine was noted to come from the fistula and terminal meatus. (Courtesy Moneer Hanna, MD.)

Urethral Duplication

Urethral duplication is a rare congenital anomaly, with roughly 200 reported cases (Salle et al., 2000; Slavov et al., 2007). **The duplication most commonly occurs in the sagittal plane with one urethra located ventrally and the other dorsally** (Fig. 44.17). **Collateral urethral duplication in which urethral duplication occurs in the same horizontal plane is extremely rare** (Ching and Palmer, 2008b). In a series by Salle et al. (2000), sagittal plane duplication accounted for 94% of urethral duplication. Usually the dorsal urethra is considered the accessory urethra with or without a urinary stream, whereas the ventral urethra carries the urine stream and the anatomic landmarks such as the external sphincter and verumontanum. The most commonly used classification of urethral duplication is that of Effman (Fig. 44.18), which describes three types: types I and II distinguish between partial and complete urethral duplication; type III describes urethral duplication as part of bladder duplication (Effman et al., 1976). The embryology of urethral duplication is not well established, with explanations including ischemia (Podesta et al., 1998; Woodhouse and Williams, 1979) and abnormal müllerian duct termination (Das and Brosman, 1977). Effman et al. (1976) suggested that caudal duplication may be related to division of the notochord with subsequent formation of two hindguts, allantoises, and cloacae.

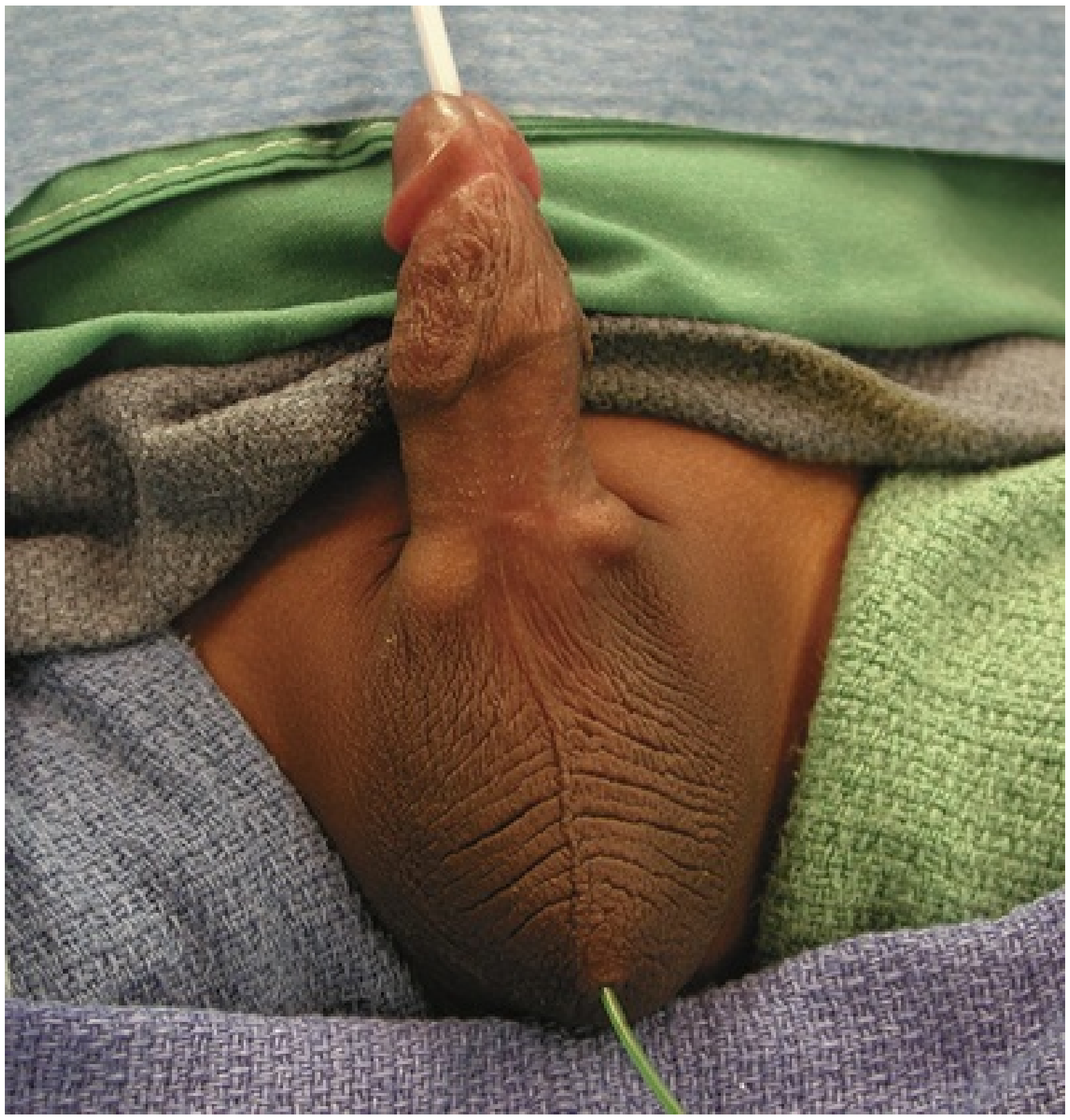

FIG. 44.17 Urethral duplication with catheters through meatus at tip of the glans penis and at perineum.

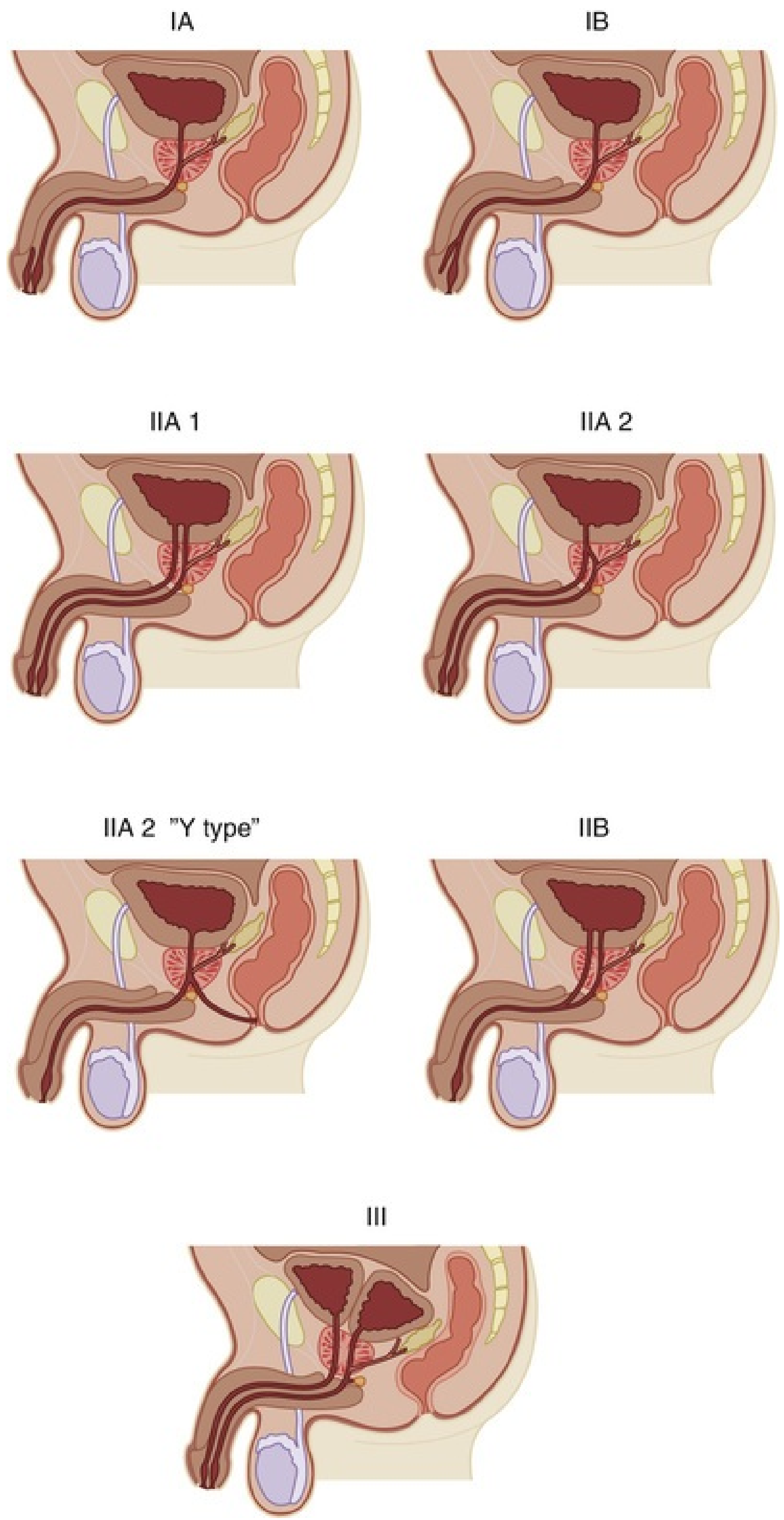
IA
IB
IIA 1
IIA 2
IIA 2 "Y type"
IIB
III

FIG. 44.18 Effman classification.

Associated genitourinary, gastrointestinal, and musculoskeletal anomalies may be present. In the review by Podesta et al. (1998), six of seven patients with urethral duplication had other associated anomalies, the most common vesicoureteral reflux. Other anomalies included renal agenesis, bilateral cryptorchidism, sacral agenesis, imperforate anus, radial hypoplasia, and tracheoesophageal fistula. There appears to be an association with other midline defects such as duplicated bladder, duplicated colon, imperforate anus and anorectal agenesis, bifid glans, thoracic hemivertebrae, and partial sacral agenesis (Fenster et al., 1980; Kennedy et al., 1988; Salle et al., 2000; Woodhouse and Williams, 1979).

The most common presentation of urethral duplication is a double meatus and double urinary stream (Kennedy et al., 1988; Salle et al., 2000; Urakami et al., 1999). Incontinence and recurrent UTIs are other common presentations. Less common conditions include penile chordee and urinary obstruction secondary to a mucosal flap at the urethral bifurcation acting as an occluding valve during voiding (Das and Brosman, 1977; Effman et al., 1976; Salle et al., 2000). The presence of incontinence is dependent on the site of origin of the accessory urethra; the more proximal the site of urethral duplication, the higher the incidence and the greater the degree of incontinence (Farrell and Sparnon, 1987).

Patient evaluation should include a voiding cystourethrogram, retrograde urethrogram, and direct visualization of the anatomy during cystourethroscopy. Evaluation of the other associated anomalies should also be undertaken. Treatment of urethral duplication is usually reserved for the symptomatic child (Urakami et al., 1999). Cosmesis alone, however, has been advocated by some as a valid indication for intervention (Middleton and Melzer, 1992). The accessory urethra should not be used as the primary urethra secondary to being hypoplastic with the risk of inadequate urine flow (Salle et al., 2000). Surgical repair includes complete accessory tract excision, electrofulguration or injection of sclerosing agents into the accessory tract, septotomy if the septum between the two urethras is thin, and urethrourethrostomy of the accessory tract into the functional urethra. Management is dependent on the anatomy of the urethral duplication (Farrell and Sparnon, 1987; Podesta et al., 1998).

Genital Lymphedema

Lymphedema of the genitalia, congenital or acquired, is a disfiguring disorder characterized by impaired lymphatic drainage that causes progressive penile or scrotal swelling. Congenital lymphedema may be sporadic (85%) or inherited (15%) and can be expressed at various ages (McDougal, 2003). Milroy disease is an autosomal dominant inherited trait, whereas Meige disease is probably autosomal dominant with variable penetrance and occurs in the first or second decade (Wheeler et al., 1981). Anogenital granulomatomosis is a rare condition that has a delayed presentation and is associated with Crohn's disease. Azathioprine treatment resulted in complete or partial resolution of the edema in 60% of patients in one study (Alexakis et al., 2017). If the genital lymphedema occurs at puberty and is sporadic, it is termed *lymphedema praecox.* Approximately 80% of patients with congenital lymphedema demonstrate onset of the disease at puberty (McDougal, 2003). The lymphedema may involve the penis, the scrotum, or both. Congenital lymphedema has been associated with several syndromes, including Turner, Noonan, Klinefelter, and intestinal lymphangiectasia syndromes. Lower extremity involvement may also occur.

Initial management involves observation, but surgical therapy is necessary if the lymphedema remains significant or progresses. The goal of surgical treatment is to remove all involved tissue. On the penile shaft, the penis is degloved and all tissue between the Buck fascia and the skin as well as redundant penile skin must be excised. If the patient is uncircumcised, the prepuce may be unfurled to provide coverage of the penile shaft (Shenoy et al., 2001). If the scrotum is involved, the scrotal skin must be excised, with the exception of the posterior skin, and the spermatic cords and testes should be preserved (Ross et al., 1998). The penis may be covered with local skin flaps, and the scrotal contents may be covered with uninvolved posterior skin flaps (Bolt et al., 1998; Ross et al., 1998). Split-thickness skin flaps may be needed to cover the penis and scrotum if inadequate healthy skin is available (McDougal, 2003). Parents should be counseled that lymphedema in adjacent areas may recur after definitive surgical therapy.

Priapism

Priapism is fortunately an uncommon condition in the general pediatric population. It is defined as a prolonged, commonly painful penile erection sustained for longer than 4 hours with the absence of physical and psychological stimulation. Tumescence is usually restricted to the corpora cavernosa (Montague et al., 2003), and in some cases the corpus spongiosum involves the glans. Priapism can be categorized into three types:

1. Ischemic (veno-occlusive, low-flow) priapism is characterized by little or no cavernous blood flow, and cavernous blood gases are hypoxic, hypercapnic, and acidotic. The corpora are rigid and tender to palpation.
2. Nonischemic (arterial, high-flow) priapism is caused by unregulated cavernous arterial inflow. Typically, the penis is neither fully rigid nor painful. There is often a history of antecedent trauma resulting in a cavernous artery or corpora cavernosa fistula.
3. Stuttering (intermittent) priapism is a recurrent form of ischemic priapism with painful erections of shorter duration and intervening periods of detumescence.

The evaluation and management of priapism is similar to that in adults with accommodations made for children as outlined in the guidelines offered by the American Urological Association (Montague et al., 2003) **and European Association of Urology** (Salonia et al., 2014). **Low-flow priapism is most commonly secondary to homozygous sickle cell disease,** which is characterized by predominance of sickle hemoglobin (HbS). Other causes include leukemia, other hemoglobinopathies, and local malignancy (Dewan et al., 1989; Friedman, 1998). Sickle cell–induced priapism occurs in 2% to 29% of males with the disease (Hamre et al., 1991; Mantadakis et al., 1999; Miller et al., 1995; Tarry et al., 1987). The priapism associated with sickle cell disease is generally related to sickling of red blood cells within the sinusoids of the corpora cavernosa during normal erection, resulting in venous stasis. The resulting decreased pH and local oxygen tension potentiates further stasis and sickling (Bruno et al., 2001). Priapism typically occurs during sleep, when mild hypoventilatory acidosis depresses oxygen tension and pH in the corpora or as a result of oxyhemoglobin desaturation (Roizenblatt et al., 2012). The pain that is experienced is a sign of ischemia.

Transient prolonged erections lasting less than 2 hours, stuttering priapism, is more common than prolonged erections in the patient with sickle cell disease. Pseudoephedrine, an oral α-adrenergic agent, given at bedtime promotes muscle contraction within the erectile tissue. If this treatment is unsuccessful, other agents can be used, including an oral β agonist. Recently, preliminary findings have suggested that the use of continuous, long-term oral phosphodiesterase type 5 (PDE5) inhibitor therapy may prevent recurrent priapism based on the hypothesis that PDE5 dysregulation may be involved in priapism (Burnett, 2008; Burnett et al., 2006).

The initial treatment of low-flow priapism resulting from sickle cell disease is conservative, with hydration, oxygenation, alkalization, analgesia, and exchange transfusion aimed at reducing HbS concentration (Hamre et al., 1991; Miller et al, 1995; Seeler, 1973). **Evacuation of blood and irrigation of the corpora cavernosa along with intracavernous injections of α-adrenergic sympathomimetic agents, such as phenylephrine or epinephrine solution, can be a concurrent therapy** (Montague et al., 2003). Surgical shunt procedures to facilitate corporal drainage are indicated in the absence of response to medical therapy (Chakrabarty et al., 1996; Miller et al., 1995; Tarry et al., 1987). Surgical shunting bypasses the veno-occlusive mechanism of the corpora cavernosa and thereby enhances blood drainage. Shunt procedures include distal cavernoglanular shunt (Winter, Ebbehoj, and Al-Ghorab shunts) (Ebbehoj, 1974; Ercole et al., 1981; Winter, 1976), proximal cavernospongiosal shunt (Quackels and Sacher shunts) (Quackels, 1964; Sacher et al., 1972), or saphenous vein anastomosis to one of the corpora cavernosa (Grayhack shunt; Grayhack et al., 1964). Parents should be educated on the potential side effects from intervention, including cavernosal fibrosis and erectile dysfunction.

High-flow priapism is usually a result of perineal trauma, such as a straddle injury. Other causes include Fabry disease and sickle cell anemia (Callewaert et al., 1998; Ramos et al., 1995; Volkmer et al., 2001). Corporal irrigation is diagnostic and therapeutic. Typically, the aspirated blood is bright red and the aspirate is similar to arterial blood on blood gas analysis. Color Doppler ultrasonography (CDUS) often shows the fistula. The initial management is observation (Montague et al., 2003) because spontaneous resolution may occur. Superselective embolization of cavernous and penile arteries (Callewaert et al., 1998; Kuefer et al., 2005; Montague et al., 2003; Volkmer et al., 2001) is the next line of therapy.

A fourth type of priapism is a spontaneously resolving form observed in neonates (Walker and Casale, 1997). Causes may include idiopathic factors, birth trauma, and polycythemia. No intervention is necessary because the priapism usually resolves in 2 to 6 days without adverse results.

Key Points: Priapism

- Priapism can be ischemic (veno-occlusive, low flow), nonischemic (arterial, high flow), and stuttering (intermittent).

- The most common cause for priapism in children is sickle cell disease.
- The initial treatment of low-flow priapism resulting from sickle cell disease is conservative with hydration, oxygenation, alkalinization, and transfusion. Evacuation of blood and irrigation of the corpora cavernosa along with intracavernous injection of α-adrenergic sympathomimetic agents can be done concurrently or after failure of conservative measures.
- High-flow priapism is usually due to perineal trauma, such as a straddle injury. Angiographic embolization should be performed if spontaneous resolution fails to occur.
- Transient but potentially prolonged periods (less than 2 hours) of erection or stuttering priapism can be treated with pseudoephedrine given at bedtime.

Penoscrotal Transposition (Scrotal Engulfment)

Penoscrotal transposition may be partial or complete (Fig. 44.19), with its less severe forms having been termed *doughnut scrotum*, *prepenile scrotum*, and *shawl scrotum*. The embryologic cause may result from incomplete or failed inferomedial migration of the labioscrotal swellings. The use of 2D and 3D ultrasound during gestation has been successful in identifying the condition in utero (Wang et al., 2011). **Frequently, it occurs in conjunction with perineal, scrotal, or penoscrotal hypospadias with chordee** (Pinke et al., 2001). Penoscrotal transposition has also been associated with caudal regression (Lage et al., 1987), sex chromosome abnormalities (Yamaguchi et al., 1989), and Aarskog-Scott syndrome (Shinkawa et al., 1983). As many as 75% of patients with complete penoscrotal transposition and a normal scrotum have a significant urinary tract abnormality, including renal agenesis and dysplasia (MacKenzie et al., 1994; Parida et al., 1995), and other nongenitourinary anomalies have been reported. These patients should be evaluated with renal ultrasonography and voiding cystourethrography.

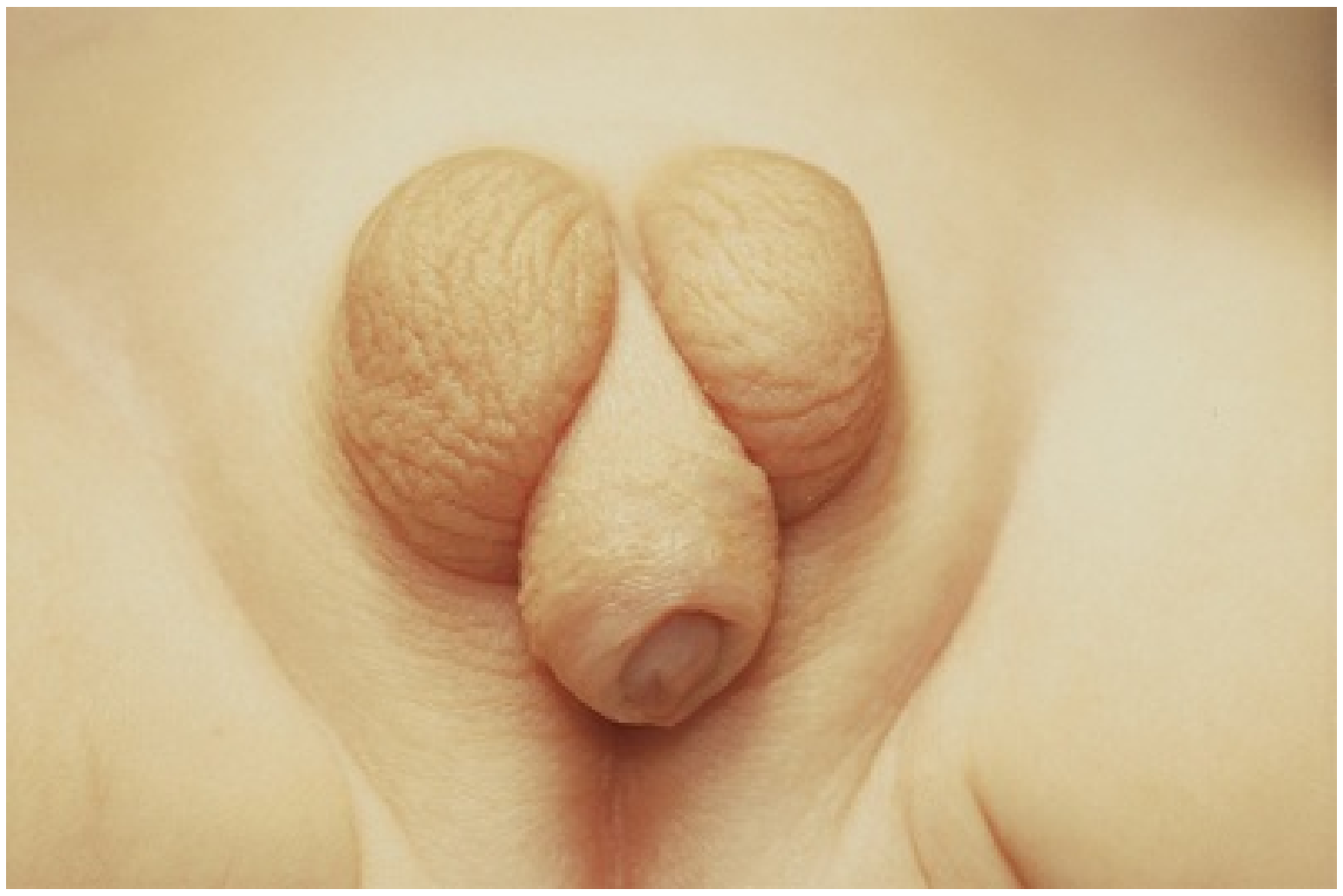

FIG. 44.19 Penoscrotal transposition.

Surgical repair is usually performed during hypospadias or other penile repair. Several scrotoplasty techniques have been described (Ehrlich and Scardino, 1982; Glenn and Anderson, 1973; Levy et al., 1997) with the goal of freeing the penis from the scrotum, developing skin flaps, relocating the scrotum to a dependent position, and moving the penis superiorly. Scrotoplasty is performed by circumscribing the superior aspects of each half of the vertical aspect of the scrotum and extending these incisions laterally to include at least half of the scrotum (Fig. 44.20). The medial aspects of the incision are joined on the ventral aspect of the penis, and the incision is carried down the midline along the median raphe. The injection of a solution of lidocaine with epinephrine into the subcutaneous tissue can be used to develop tissue planes and also help to diminish bleeding. Care must be taken not injure the tunica vaginalis and spermatic cord during deeper dissection. The scrotal wings are rotated medially under the penis and sutured together in the midline in an everted manner. Although in most cases there is no deficiency of the ventral penile shaft skin, in more severe cases of penoscrotal transposition dorsal interposition flaps may be necessary, allowing caudal advancement of the skin of the abdominal wall (Pinke et al., 2001).

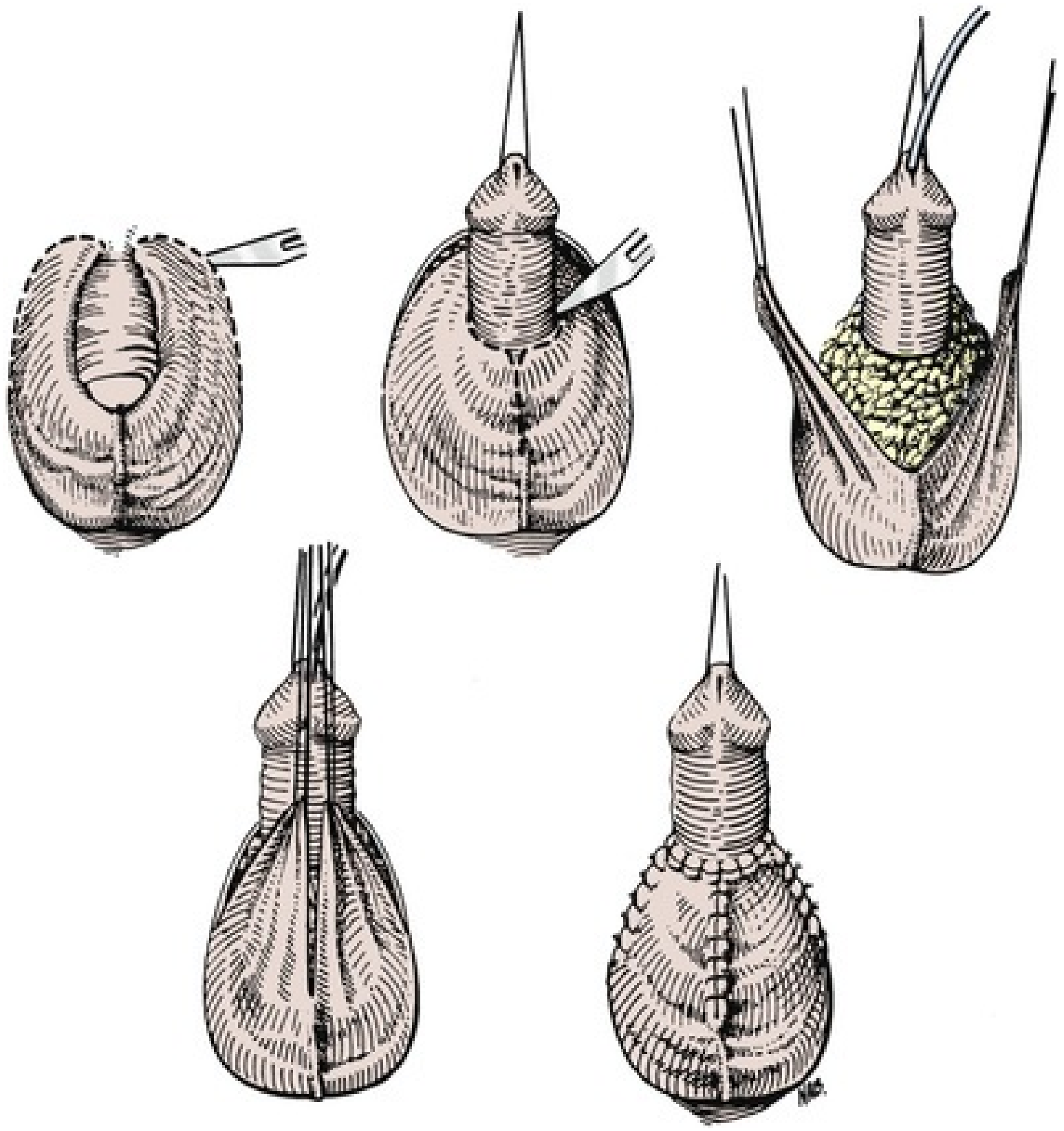

FIG. 44.20 Repair of penoscrotal transposition using rotation flaps of the scrotum (see discussion in text).

An alternative technique is to identify the correct position for the penis and make a buttonhole by excising a plug of epidermis, dermis, and suprapubic fat (Kolligian et al., 2000). The penis is then degloved, and the penile shaft is brought through the buttonhole. The penile shaft skin remains behind, is split down the ventrum, and is mobilized superiorly to the penile shaft. A window of the dartos pedicle is made, and the penile shaft is brought through this window. The degloved penis is then resurfaced with shaft skin (Fig. 44.21).

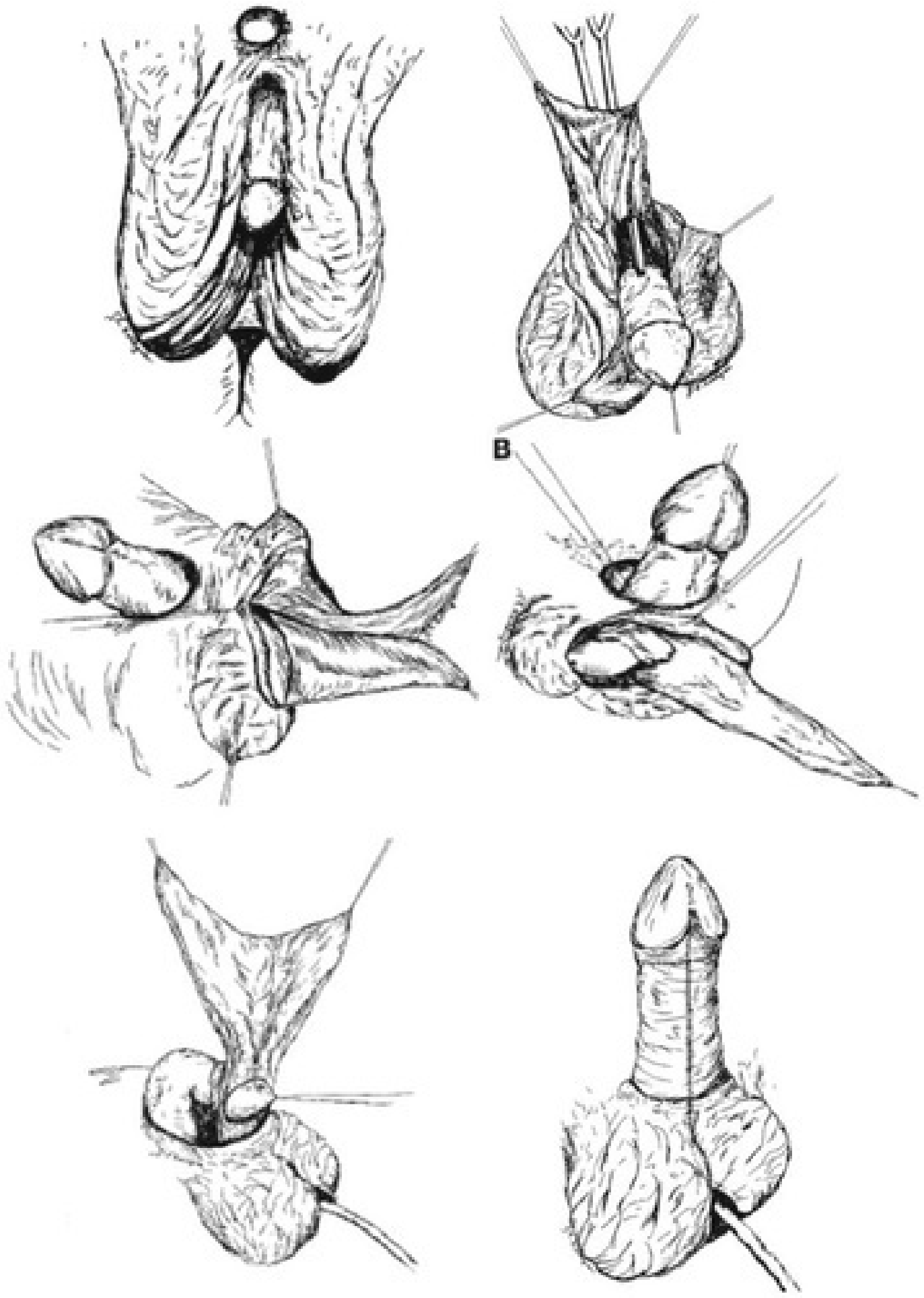

FIG. 44.21 Repair of penoscrotal transposition by relocating the position of the penis (see discussion in text).

Scrotal Anomalies

Bifid Scrotum

Bifid scrotum refers to the deformity in which the labioscrotal folds are completely separated and without a median raphe. This anomaly is most often associated with proximal hypospadias. Surgical repair is usually performed during hypospadias repair. The technique is similar to that used for repair of penoscrotal transposition. An alternative is the use of single or multiple Z-plasty procedures to correct the defect (Mokhless et al., 2011; Fig. 44.22).

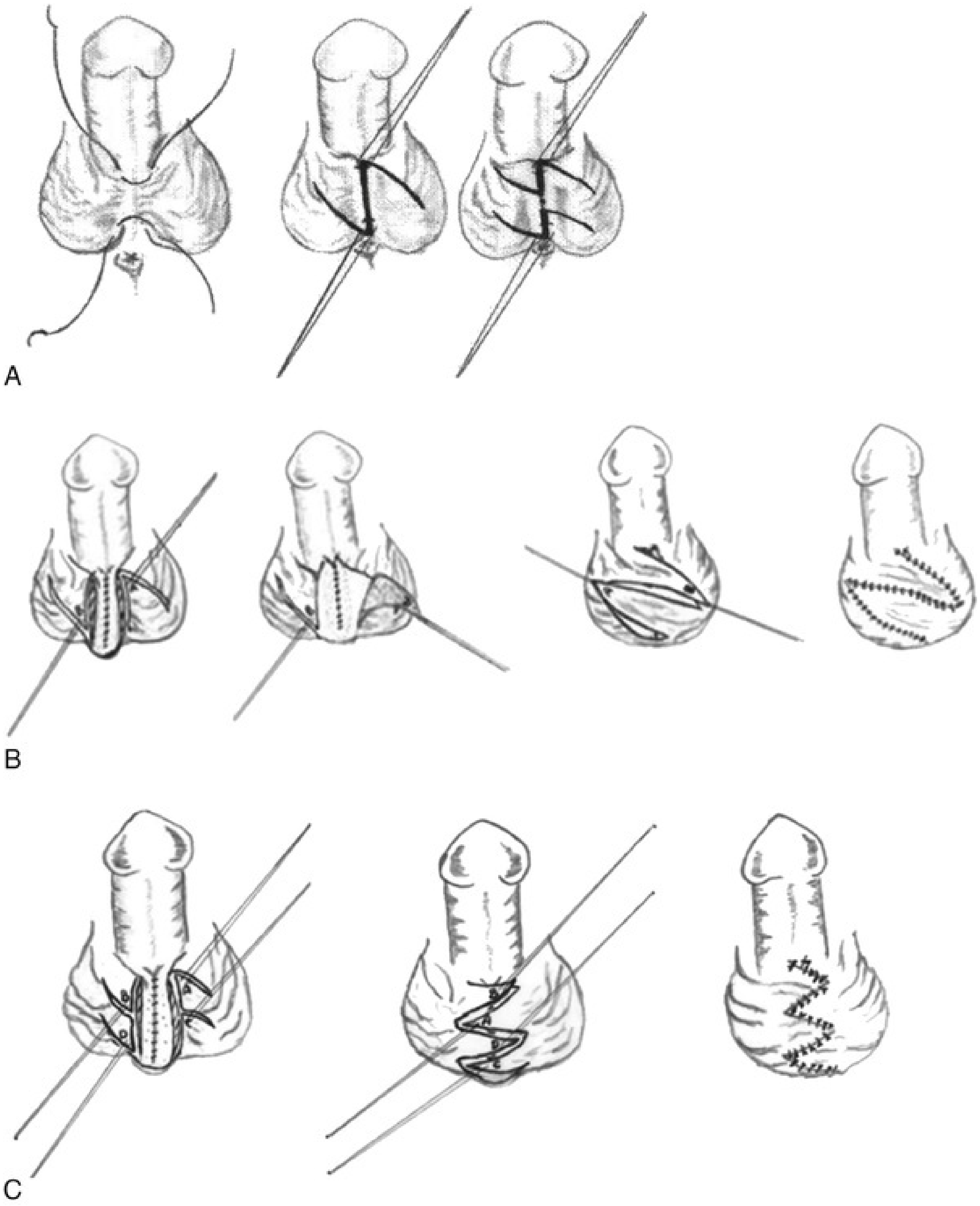

FIG. 44.22 Use of Z-plasties to correct the bifid scrotum. (A) The placement of initial stay sutures *(left)* and drawing lines of simple *(middle)* or multiple Zs *(right)*. The development of the flaps and their rearrangement are seen for a simple Z-plasty (B) and multiple Zs (C). (From Mokhless I, Youssif M, Eltayeb M, et al.: Z-plasty for sculpturing of the bifid scrotum in severe hypospadias associated with penoscrotal transposition. *J Pediatr Urol* 7:305–309, 2011.)

Ectopic Scrotum

Ectopic scrotum (Fig. 44.23), the anomalous position of one hemiscrotum, is a rare condition. The location can be suprainguinal (most common), infrainguinal, or perineal (Elder and Jeffs, 1982; Lamm and Kaplan, 1977). This anomaly has been associated with cryptorchidism, inguinal hernia, and bladder exstrophy as well as with the popliteal pterygium syndrome (Cunningham et al., 1989). In one review, 70% of boys with a suprainguinal ectopic scrotum exhibited ipsilateral upper urinary tract anomalies, including renal agenesis, renal dysplasia, and ectopic ureter (Elder and Jeffs, 1982). Another study indicated that an associated perineal lipoma was found in 83% of these children; 68% of those with a lipoma had no associated anomalies, whereas 100% of those without a lipoma had associated genital or renal malformations (Sule et al., 1994). **Patients with an ectopic scrotum should undergo upper urinary tract imaging with ultrasonography.** Because the embryology of the gubernaculum and of the scrotum are intimately related chronologically and anatomically, the ectopic scrotum may result from a defect in gubernacular formation that prevents migration of the labioscrotal swellings (Hoar et al., 1998). Scrotoplasty and orchiopexy may be performed at 6 to 12 months of age or earlier if other surgical procedures are necessary for associated anomalies.

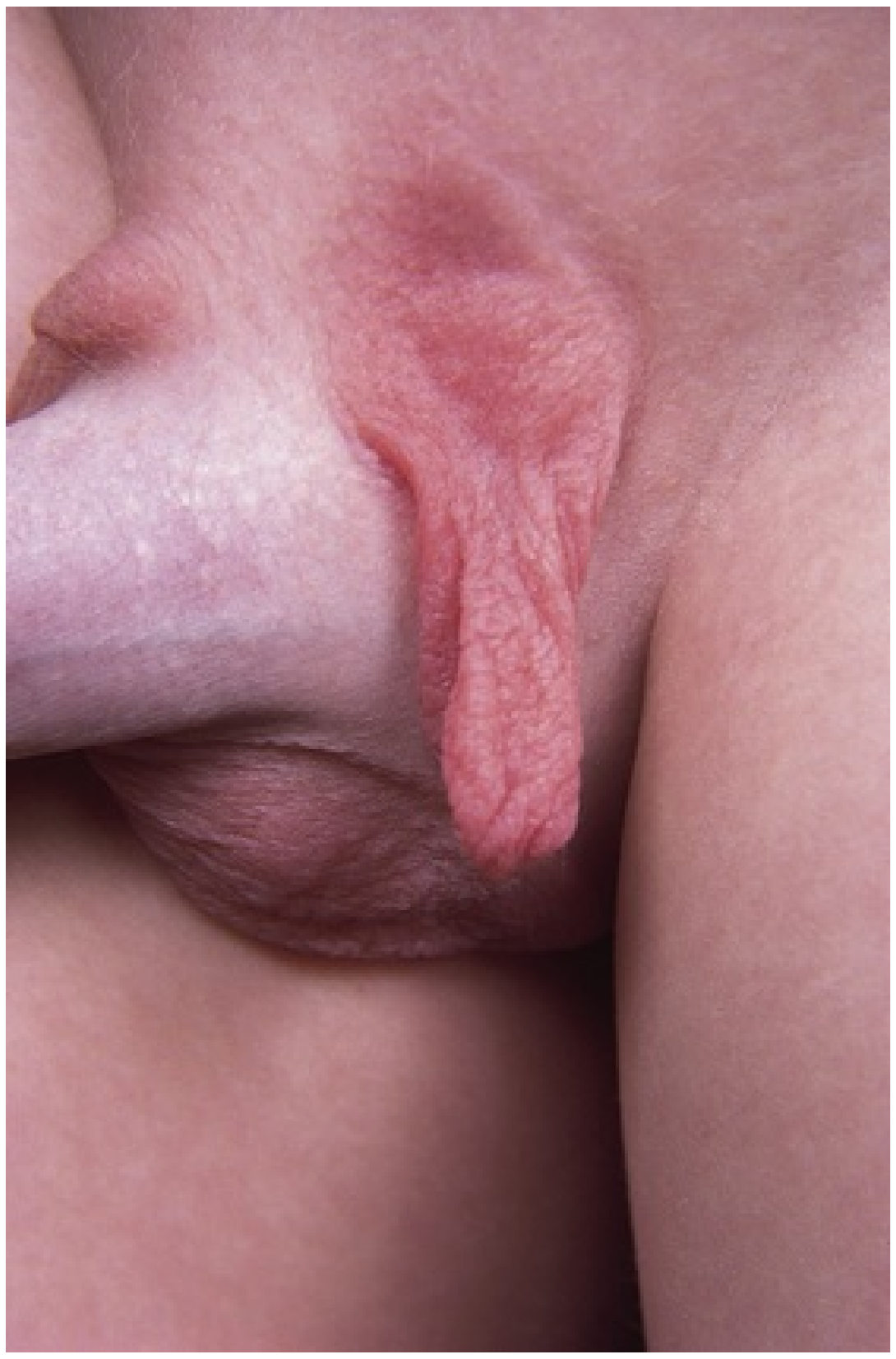

FIG. 44.23 Ectopic scrotum.

Scrotal Hypoplasia

Scrotal hypoplasia, the underdevelopment of one or both sides of the scrotum, **occurs most commonly in boys with an undescended testis** and in infants with genital ambiguity. The deformity may result from lack of gubernacular swelling of the labioscrotal folds.

Scrotal Agenesis

The absence of the scrotum or hemiscrotum is rare (eFig. 44.24). All seven of the reported cases of scrotal agenesis had XY karyotype and bilateral undescended testes; the presence of the median raphe; and other anomalies such as cognitive impairment, bilateral nystagmus, cleft palate, and syndactyly (Silay et al., 2013). Two cases of hemiscrotal agenesis have been reported. In one case, multiple anomalies were found; in the second case an isolated hemiscrotal agenesis was reported. In both cases the penis and contralateral hemiscrotum and contents were normal. In addition, the testes on the affected side were in what would have been the normal location (Flum et al., 2012; Yilmaz et al., 2013).

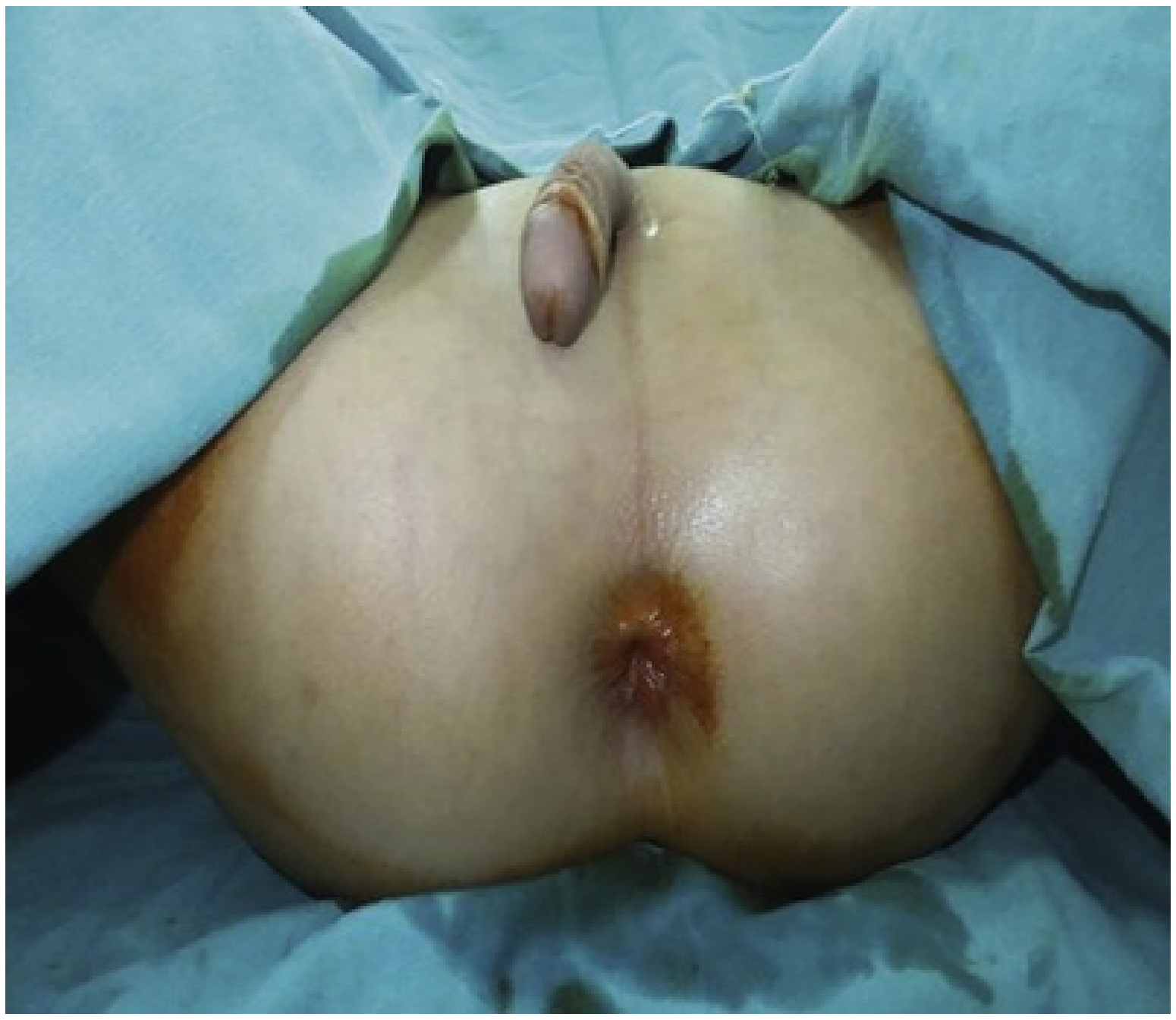

EFIG. 44.24 Congenital agenesis of the scrotum. (From Silay MS, Yesil G, Yildiz K, et al.: Congenital agenesis of scrotum and labia majora in siblings. *Urology* 81:421–423, 2013.)

Scrotoschisis

Meconium peritonitis may occasionally cause genital manifestations, including meconium hydrocele (Ring et al., 1989) and congenital rupture of the scrotum, termed *scrotoschisis* (Chun and St-Vil, 1997; Gongaware et al., 1991; Kojori and Demaria, 2007; Premkumar et al., 2009; Salle et al., 1992). This can result in one or both testes being extruded from the scrotal sac. When scrotoschisis is detected, the clinician should suspect meconium peritonitis and proceed with the appropriate evaluation. Treatment involves scrotal exploration with orchiopexy and primary closure of the scrotal wall defect (eFig. 44.25).

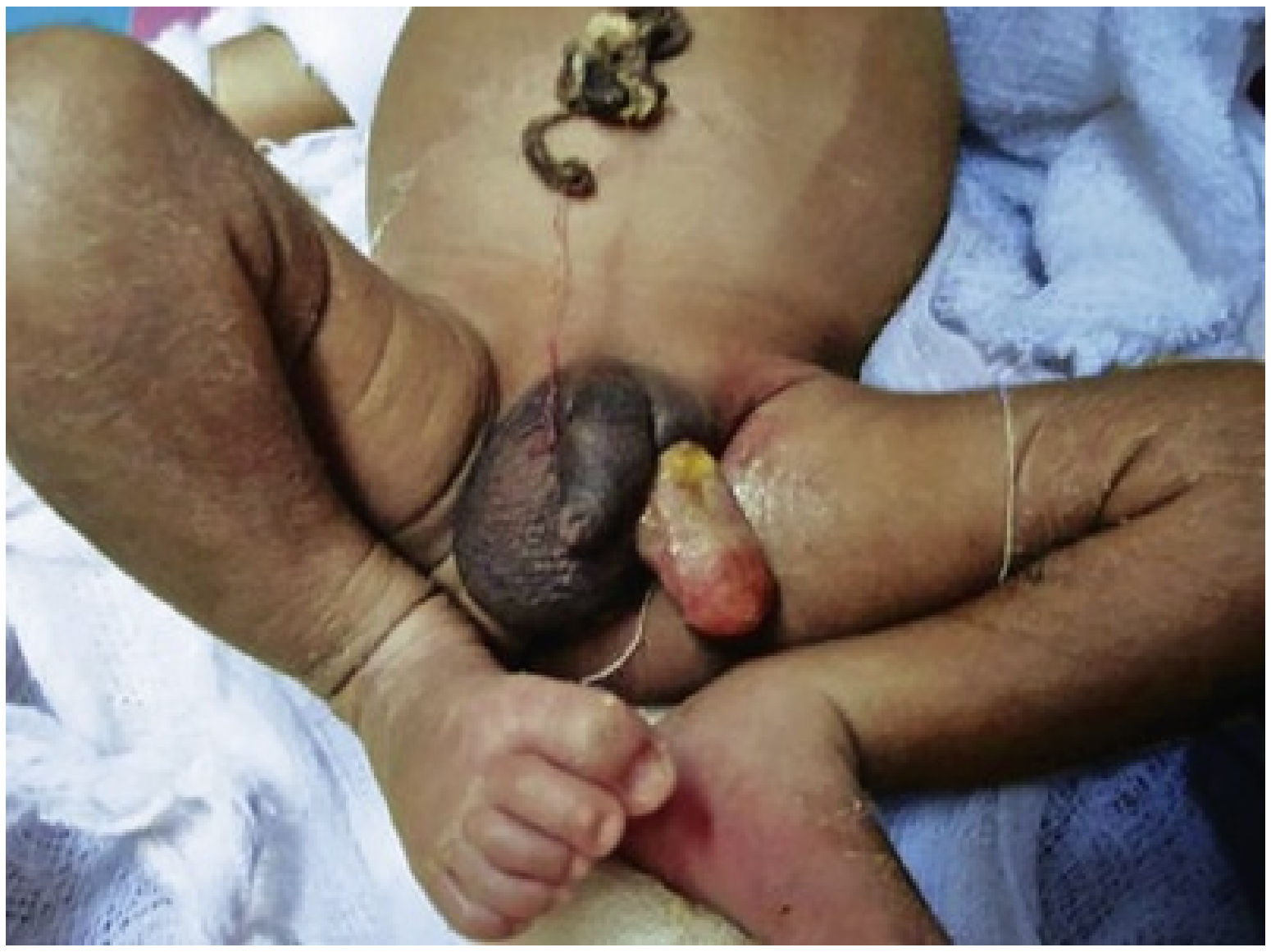

EFIG. 44.25 Congenital scrotoschisis and exposed testis. (From Shukla RM, Mandal KC, Roy D, et al.: Scrotoschisis: an extremely rare congenital anomaly. *J Indian Assoc Pediatr Surg* 17:176–177, 2012.)

Vascular Lesions of the Genitalia

Vascular lesions of the genitalia are uncommon without a consensus on classification, cause, and treatment. These deformities include hemangiomas and vascular malformations. **Hemangiomas are on the skin**, are often congenital, and may show significant growth in the postnatal period followed by slow involution. **Vascular malformations are present at birth in the subcutaneous tissues** and tend to persist or to enlarge, which can occur secondary to trauma, sepsis, or hormonal changes (Ramos et al., 1999). **Vascular malformations can be subdivided into either slow-flow (capillary, lymphatic, venous) or fast-flow (arterial, arteriovenous) types.**

Congenital Hemangiomas

Congenital hemangiomas are common and affect the genitalia in approximately 1% of all hemangiomas (Alter et al., 1993). The origin of these lesions and the mechanisms regulating their growth and involution are controversial (Ritter et al., 2007). **Strawberry hemangiomas are the most common type and result from proliferation of immature capillary vessels.** These are also categorized as cutaneous hemangiomas because they occur on the skin. Although the lesions may undergo a period of rapid growth lasting 3 to 6 months, gradual involution is common, and most lesions require no treatment (Casale and Menashe, 1989; Girard et al., 2006). If ulceration develops, intervention is necessary to prevent complications from bleeding. The most popular form of therapy is short-term oral corticosteroid therapy or propranolol (Tran et al., 2016).

Treatment with laser therapy allows selective photothermolysis and destruction of superficial blood vessels (Kennedy et al., 1993; Ward et al., 1998). In some cases, surgical excision is necessary.

Subcutaneous Hemangiomas

Subcutaneous hemangiomas, also referred to as *cavernous hemangiomas*, are much less common than the cutaneous variety (Ferrer and McKenna, 1995; Sule et al., 1993) and are probably more appropriately classified as a vascular malformation. They may be detected at birth or later in life. In contrast to cutaneous hemangiomas, which tend to involute, cavernous hemangiomas tend to enlarge gradually and should be treated with care. Physical examination reveals a “bag of worms” sensation similar to that of a varicocele, although the lesions tend to be firm and do not decompress when the patient is recumbent. Ultrasonography with color Doppler imaging, computed tomography (CT), or MRI is recommended to delineate the size of the hemangioma (Aizenstein et al., 1996) because examination does not disclose the extent of the lesion. Definitive treatment by en bloc resection is advised, and preoperative angioembolization may reduce the size of the mass and the risk of bleeding.

Klippel-Trénaunay-Weber Syndrome

Klippel-Trénaunay-Weber syndrome is a triad of cutaneous vascular malformation, most commonly nevus flammeus, in combination with soft tissue and bone hypertrophy. The anomaly manifests at birth, usually involving a lower extremity, but it may also involve the trunk or face. These vascular lesions have a propensity to bleed. In a review of 214 patients from a single institution, Husmann et al. (2005) found that 30% had genitourinary cutaneous or visceral involvement. Of the 48 (22%) who had cutaneous genital involvement, 29% developed intractable bleeding. Excision of the hemangiomas was associated with significant blood loss.

Vascular Malformations

The penis may also be affected by vascular malformations (Fig. 44.26). These lesions are congenital but are usually not diagnosed until the teenage years or young adulthood. The lesions are characterized as a faint blue patch or a soft blue mass. Careful excision is effective (Kaufman et al., 2010), but if the lesion affects the glans penis, the neodymium:yttrium-aluminum-garnet laser may yield a better result (Ramos et al., 1999).

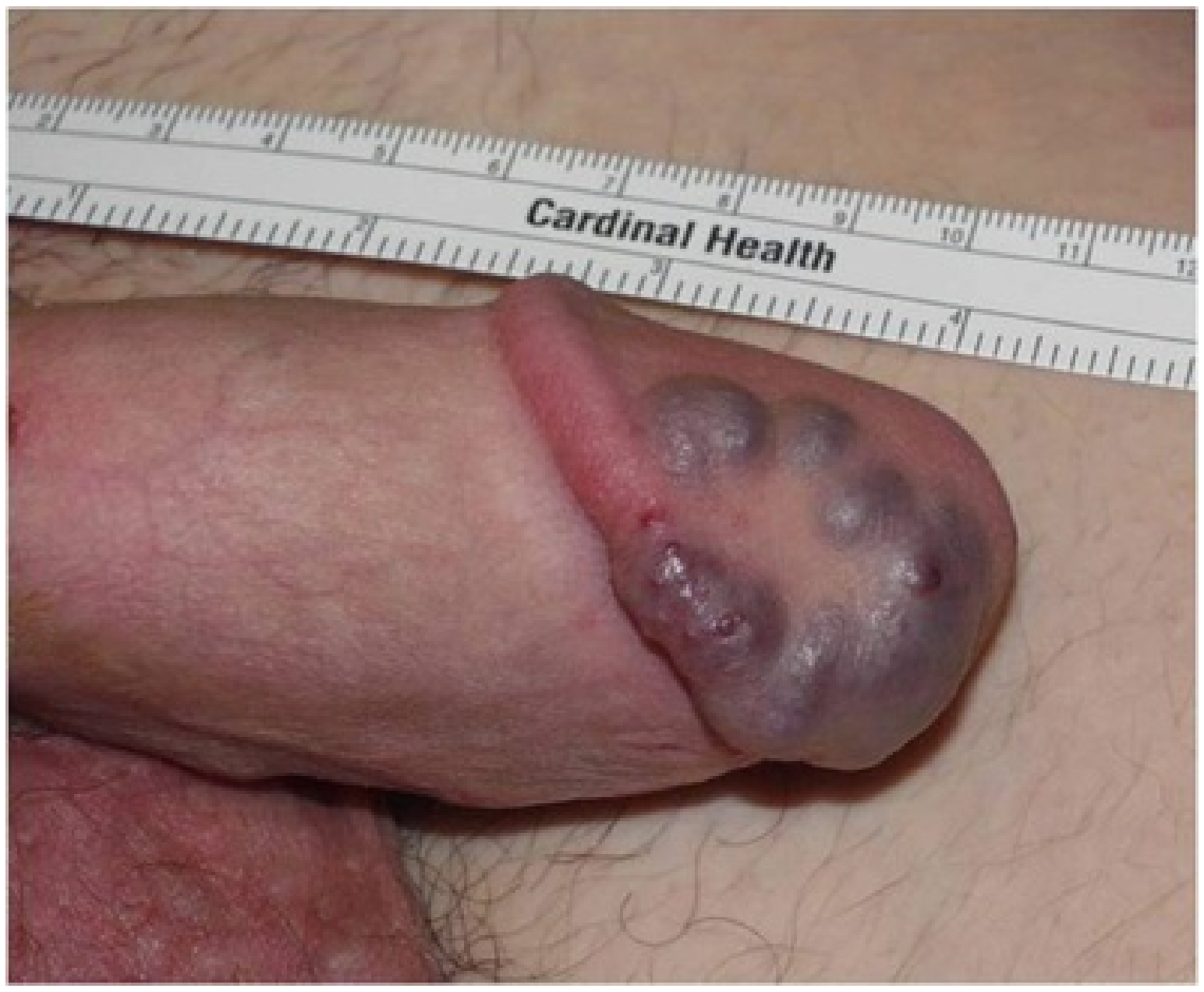
Cardinal Health

FIG. 44.26 Venous malformation of the glans.

Hernia and Hydroceles

Embryology

Patients with inguinoscrotal pathology, namely inguinal hernias and hydroceles, are commonly referred to pediatric urologists for diagnostic confirmation and management. **The processus vaginalis forms during the third month of gestation as the peritoneum bulges into the inguinal canal just before the onset of testicular descent.** On completion of testicular descent, the processus vaginalis obliterates and the portion adjacent to the testes becomes the tunica vaginalis. Obliteration of the processus vaginalis continues postnatally, and its failure to obliterate accounts for nearly all inguinoscrotal abnormalities seen in infancy and childhood. In an autopsy series, Mitchell found closure of the processus vaginalis in 18% of full-term infants at birth (Mitchell, 1939). Among 1965 children undergoing unilateral inguinal hernia repair, Rowe identified a patent contralateral processus vaginalis in 63% of patients younger than 2 months and about 40% of those 1 to 2 years of age, with similar frequency up until age 16 years (Rowe et al., 1969). The incidence of incidental patency observed in older children and adults at autopsy or laparoscopy is about 20% (Ajmani and Ajmani, 1983; van Wessem et al., 2003).

Definitions (Fig. 44.27)

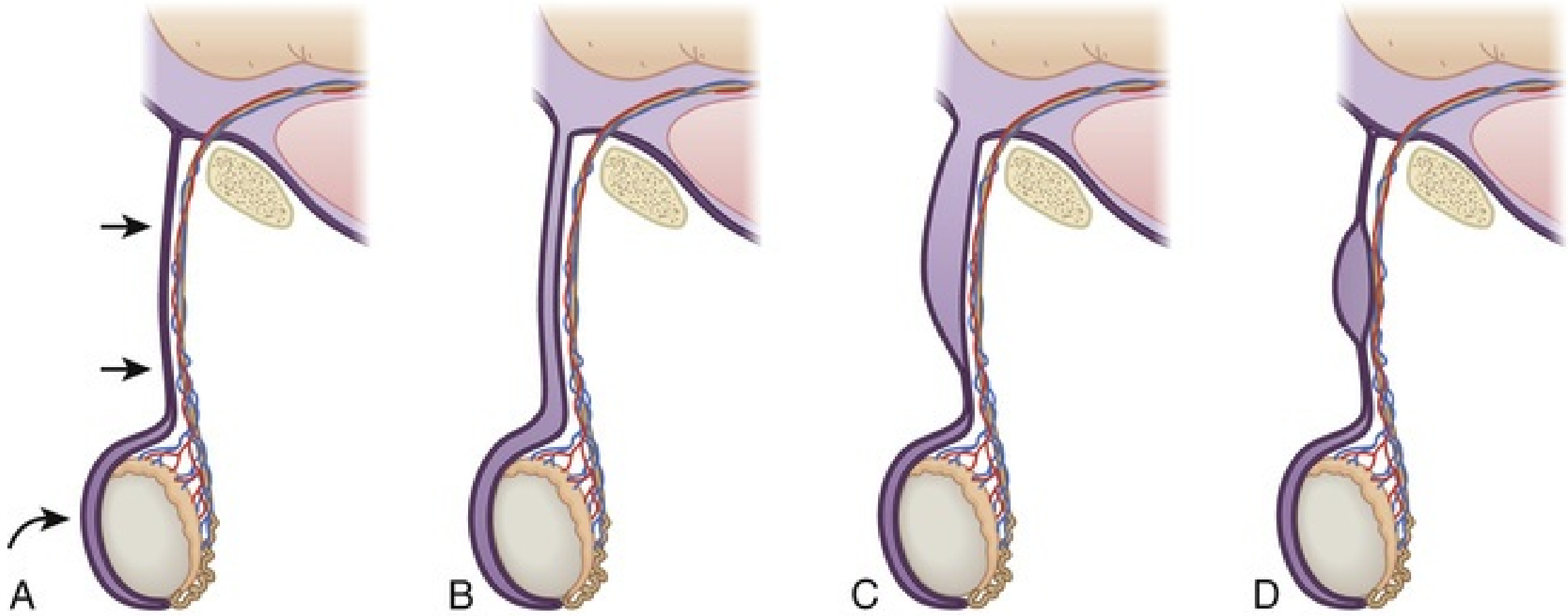

FIG. 44.27 Anatomy of the processus vaginalis in hydrocele. (A) Normal closure of the processus vaginalis; *straight arrows* indicate the funicular process; *curved arrow* is the tunica vaginalis. (B) Communicating hydrocele

with complete patency of the processus vaginalis. (C) Funicular hydrocele with distal closure of the processus vaginalis; communication with the peritoneal cavity may also result in hernia. (D) Encysted hydrocele of the spermatic cord. (From Martin LC, Share JC, Peters C, et al.: Hydrocele of the spermatic cord: embryology and ultrasonographic appearance. *Pediatr Radiol* 26:528–530, 1996.)

Indirect inguinal hernia: a widely patent processus vaginalis extending beyond the internal inguinal ring containing abdominal contents (peritoneal fluid, bowel, omentum, gonads), which may pass into the inguinal canal, labia, or scrotum

Communicating hydrocele: a patent processus vaginalis extending beyond the internal inguinal ring containing peritoneal fluid alone, which extends to the testis, with fluid within the tunica vaginalis

Hydrocele of the spermatic cord: fluid contained within a segment of patent processus vaginalis with obliterated processus distally and proximally

Scrotal hydrocele: fluid contained within the tunica vaginalis surrounding the testis without communication proximally

Abdominoscrotal hydrocele: a large scrotal hydrocele that extends proximally across the internal inguinal ring into the abdomen without communication with the peritoneum

Epidemiology and Pathogenesis

Inguinal Hernia and Communicating Hydrocele

Inguinal hernias develop in 1% to 5% of children. The incidence is 5 to 10 times more common in boys and significantly more common among premature infants (13% of babies born before 32 weeks and nearly 30% of babies weighing less than 1 kg). The propensity for the right side (3:1) is attributed to the later descent of the right testicle (Brandt, 2008; Burgmeier et al., 2015; Jones et al., 1998). **Female gender, prematurity, age younger than 1 year, and history of cryptorchidism are risk factors for bilaterality** (Brandt, 2008; Ein et al., 2006). One study suggests a protective effect of breastfeeding against the development of inguinal hernias (Pisacane et al., 1995). Whereas hernias may occur at any time during childhood, the **average age at presentation is 3 to 4 years,** with nearly one-third of cases manifesting before age 6 months (Kapur et al., 1998). Concomitant hydroceles are frequently seen; 19% of 6361 cases were found by Ein et al. (2006) (70% scrotal, 26% cord, and 4% both).

The majority of new hydroceles occurring after birth and before puberty are associated with a patent processus vaginalis (i.e., communicating hydrocele). In an observational study, 59% of 302 newly identified hydroceles in patients 1 to 18 (mean 4.4) years of age were clinically communicating (clear history of fluctuation), and 6% were spermatic cord hydroceles (Christensen et al., 2006). Seventy (65%) of the apparently noncommunicating and 5 (29%) of the cord hydroceles were followed, and spontaneous resolution was noted in 39 and 3, respectively. Among boys undergoing hydrocele repair, complete obliteration of the processus vaginalis was noted in 0 to 22% of cases (Barthold and Redman, 1996; Elder, 1992; Han and Kang, 2002).

Noncommunicating Hydroceles

Hydroceles that spontaneously resolve during infancy or appear during or after puberty are more commonly noncommunicating. These form from delayed fluid absorption or abnormal fluid dynamics within the tunica vaginalis or less commonly in response to tumor, trauma, or inflammation. Simple scrotal hydroceles occur in at least 5% of male neonates (Osifo and Osaigbovo, 2008), are typically bilateral, and resolve with fluid reabsorption.

Genetics and Associated Conditions

A genetic predisposition to developing inguinal hernias exists, and potential genome sites have been identified. Among probands, there is a 28% risk in other family members and a higher relative risk in first-degree relatives (6.9), particularly female siblings (17.8) of affected girls (Gong et al., 1994; Jones et al., 1998). Genetic transmission appears to be autosomal dominant with reduced penetrance. Zhang has implicated DNA sequence variants (DSVs) within T-box transcription factor 1 (TBX1) and TBX2 as rare causes (Zhang et al., 2014a, 2014b). Sezer identified polymorphisms of the collagen type I α1 (COL1A1). The Sp1 binding site was associated with a higher risk of developing inguinal hernias (Sezer et al., 2014).

Hernias are associated with other diseases and anomalies. These include bladder exstrophy, epididymal anomalies, connective tissue disorders, cystic fibrosis, and posterior urethral valves. Inguinal hernia is also a component of more than 200 syndromes, many of which have known specific genetic alterations (Winter-Baraitser Dysmorphology Database, www.lmdatabases.com).

Other genital anomalies such as polyorchidism, transverse testicular ectopia with or without persistent müllerian ducts, and splenogonadal fusion may be seen at the time of hernia repair. Abnormal epididymal-testicular attachment correlates with degree of closure of the processus vaginalis (Barthold and Redman, 1996; Elder, 1992). Finally, the presence of abdominal ascites or a ventriculoperitoneal shunt increases the chances of developing an inguinal hernia (Grosfeld et al., 1991).

Diagnosis

Signs and Symptoms

Inguinal hernias and communicating hydroceles typically manifest as a painless bulge found in the groin or extending along the cord to the scrotum. The bulge may be present only during periods of increased intra-abdominal pressure (crying or bowel movements); the supine position facilitates reduction of peritoneal fluid and intra-abdominal contents. **The presence of an intermittent bulge helps to distinguish a reducible inguinal hernia and communicating hydrocele from a scrotal hydrocele or hydrocele of the spermatic cord.** The child with an incarcerated inguinal hernia will be irritable or inconsolable and have a persistent or larger bulge without spontaneous reduction and may have decreased appetite and signs of bowel obstruction (abdominal distention, vomiting, and lack of flatus or stool).

The scrotal hydrocele may be seen as a chronic or acute scrotal swelling after an inflammatory, infectious, or traumatic event. The hydrocele size is typically stable but may decrease over time. The hydrocele of the spermatic cord is also usually painless and variable in size. It may be confused for the testis because of its round-oval shape.

Physical Examination

Physical examination starts with a child standing (Fig. 44.28), if age appropriate, otherwise supine. Inspection proceeds from the lower abdominal skin crease and along the inguinal canal to the scrotum. If the child is crying, the bulge should be assessed to emerge or increase in size and then improve or disappear when the child is consoled. Techniques to increase intra-abdominal pressure may induce protrusion of the bulge (immobilizing the extremities to induce crying in infants, and jumping, coughing, laughing, blowing bubbles, or blowing up balloons in older children) (Brandt, 2008). **If a bulge is not elicited at the time of examination, photographs of the bulge taken by family members are diagnostically reliable** (Kawaguchi and Shaul, 2009).

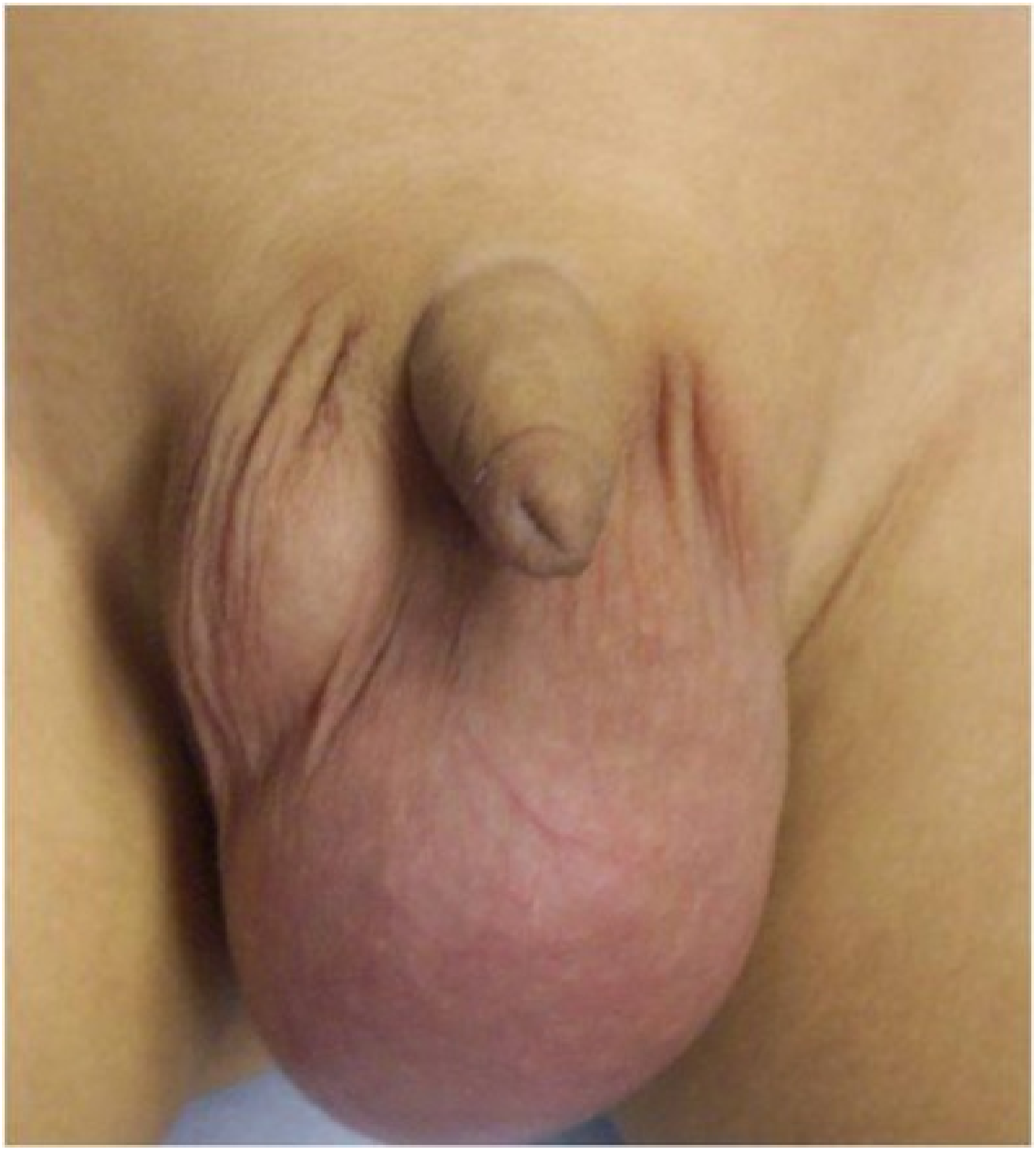

FIG. 44.28 Inguinoscrotal swelling of the left side with child in the standing position. The fluid-filled area was reduced into the abdomen with the child in the supine position.

Palpation proceeds craniocaudally from superior-lateral to the pubic tubercle down to the scrotum to determine the proximal and distal extent of the swelling. Communicating hydroceles and hernias start at the level of the internal ring and end variably. The silk-stocking sign (sensation of rubbing silk together), sought by rubbing the cord structures side to side near the pubic tubercle, implies thicker cord structures. A hydrocele of the spermatic cord may be confused with a testis or large epididymal cyst, but normal cord structures are palpable above and below, and a testis will also be palpated. Scrotal hydroceles may elicit a blue hue through the scrotal skin. Normal cord structures are palpable superior to the hydrocele but may be difficult to distinguish if it extends up to or across (abdominoscrotal) the internal ring, in which case abdominal examination should reveal a ballotable mass. **The hydrocele fluid surrounding the testicle should transilluminate; however, neonatal bowel may also transilluminate.** The testis should be palpable within a soft scrotal hydrocele but may be difficult to discern within a tense hydrocele.

Radiologic Imaging

Although imaging is not commonly needed, ultrasound can be helpful in ascertaining large elongated echolucent area from the groin extending anteromedially in the spermatic cord in the more obese child, confirming the presence of bowel or omentum in an incarcerated hernia, distinguishing tense hydroceles of the cord from a solid mass or from a large epididymal cyst (Fig. 44.29). **In the presence of a presumed hydrocele, a sonogram can aid in identifying an unpalpable testicle surrounded by hydrocele fluid** (Fig. 44.30).

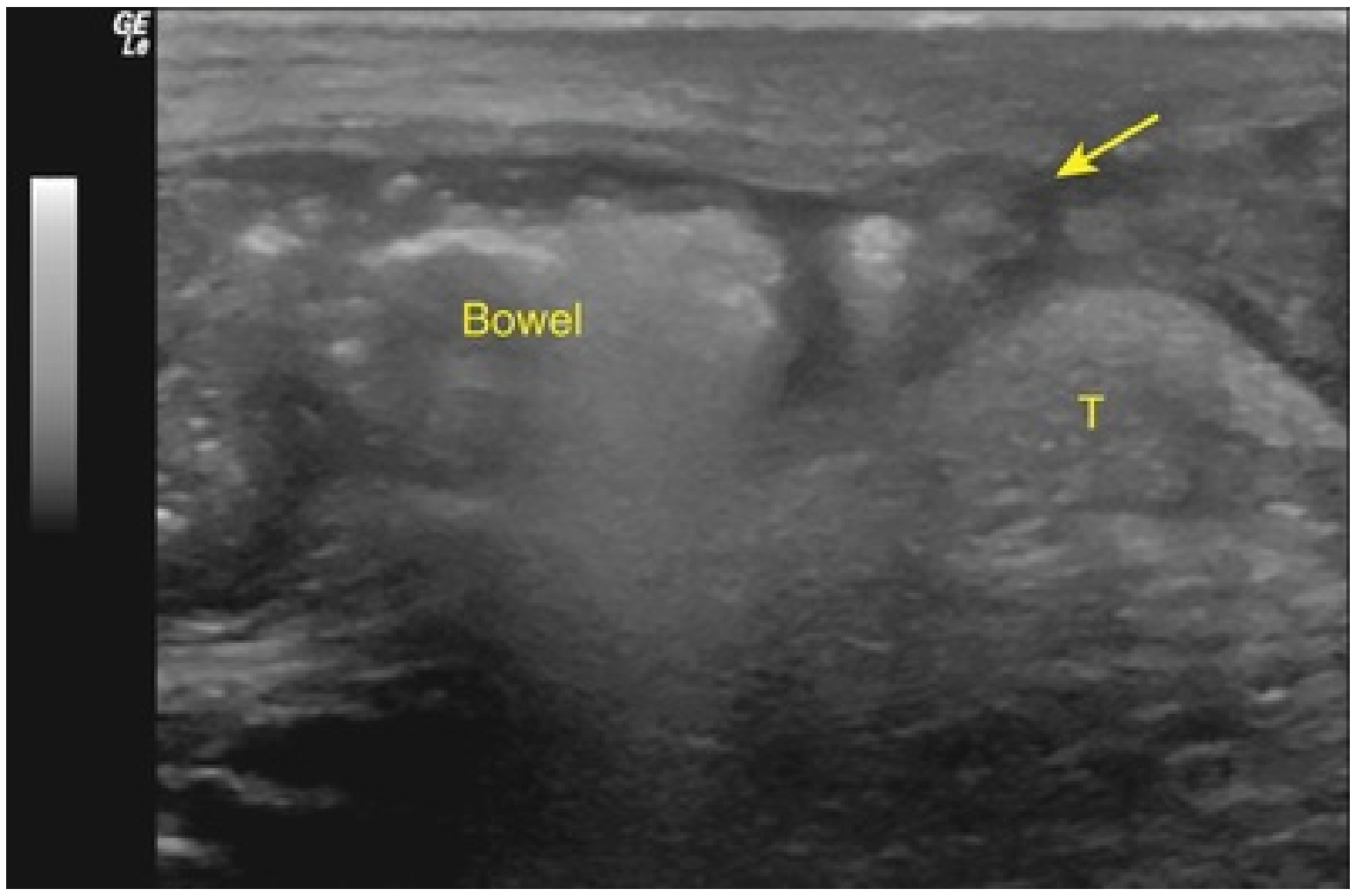

FIG. 44.29 Sagittal image of a scrotal ultrasound in a 4-year-old boy with an inguinoscrotal bulge. Bowel is seen within the hernia sac that ends *(arrow)* superior to the testis *(T)* in the scrotum.

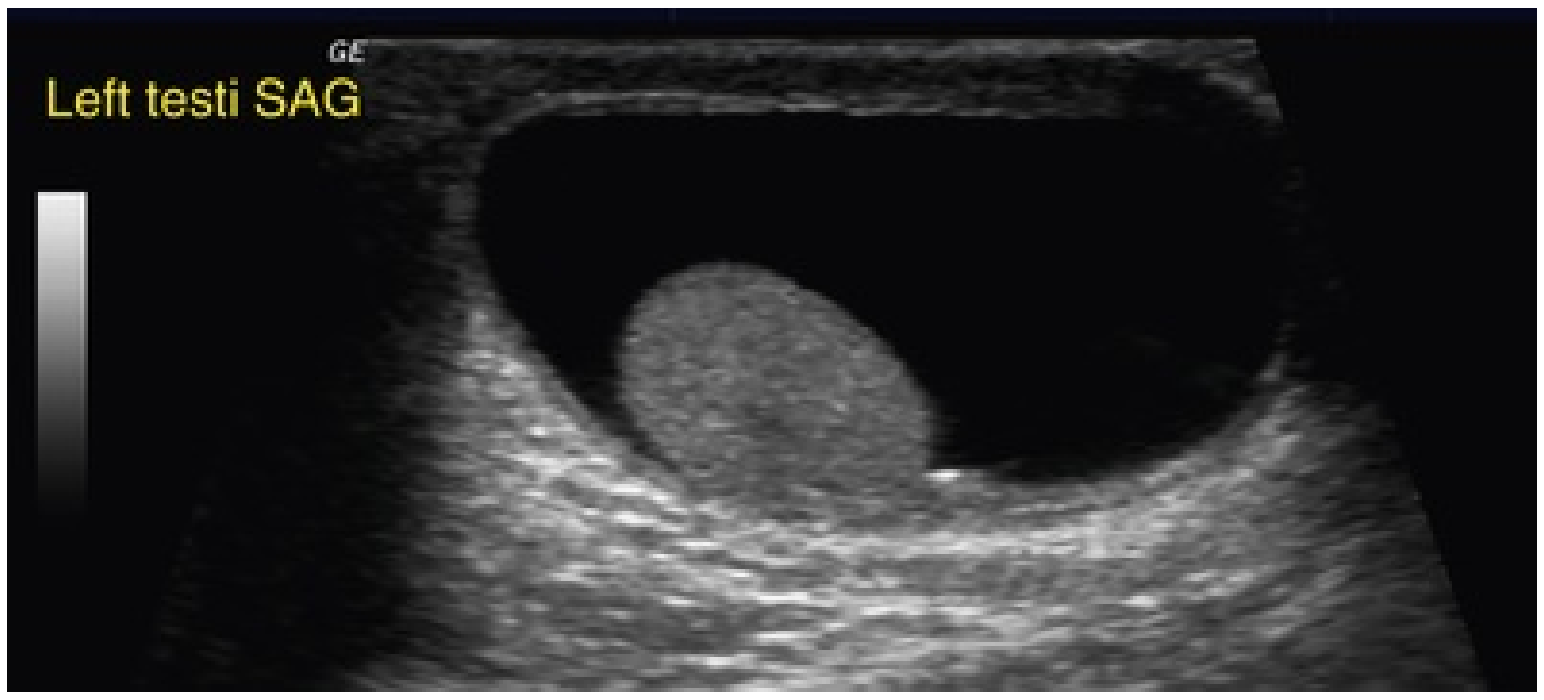

FIG. 44.30 Sagittal *(SAG)* image from a scrotal sonogram of an 8-month-old boy with tense scrotal swelling and indiscernible testis on palpation. Sonogram demonstrates hypoechoic fluid (hydrocele) surrounding the normal testis.

Surgical Repair

Inguinal Hernia

Inguinal hernias require surgical repair shortly after diagnosis, given the significant risk of associated complications. Outpatient surgery can be performed within a few weeks in easily reducible hernias or communicating hydroceles and more urgently if there is moderate difficulty in reducing the hernia contents. Parental counseling regarding the signs and symptoms of incarceration and its possible consequences should occur. An irreducible hernia requires immediate exploration. Hernias in premature infants can be repaired before hospital discharge, but repair may have to be delayed in extremely low–birth-weight (<1500 g) infants or those with congenital heart disease, pulmonary disease, sepsis, or metabolic disease because of the increased risk of anesthesia. Some authors recommend delaying surgery until 50 to 52 weeks postconception rather than performing surgery before hospital discharge (Chen et al., 2009; Stylianos et al., 1993).

Hydroceles

Hydroceles in infants have the potential to resolve spontaneously. If the hydrocele persists by age 1 year or if during the period of observation, the hydrocele enlarges or begins to fluctuate in size, implicating the development of a communicating hydrocele/hydrocele, then surgery is indicated. Hydroceles of the spermatic cord do not tend to resolve spontaneously but rarely require urgent surgery and can also be corrected after age 1 year.

Standard Inguinal Hernia Repair

The traditional surgical approach to repairing an indirect inguinal hernia or communicating hydrocele, high ligation of the hernia sac at the level of the internal inguinal ring, carries high success rate, low morbidity, limited postoperative pain, and good cosmesis. A small incision is made in the Langer lines at the skin crease superolateral to the pubic tubercle (Kogan, 2007). The Scarpa fascia is incised to expose the external oblique fascia, which is then cleared laterally and caudally to the external inguinal ring. The external oblique fascia is opened in the direction of its fibers, with care taken to avoid injuring the ilioinguinal nerve. In young infants, the internal and external inguinal rings are in proximity, providing adequate access without opening of the external oblique fascia (Mitchell-Banks technique; Kurlan et al., 1972). The cremaster muscle fibers are separated perpendicular to the cord to expose the hernia sac anteromedially. The sac is elevated and separated atraumatically from the rest of the cord and then divided between clamps. The proximal limb is elevated and separated from the cord proximally to the internal ring, where it is ligated to avoid risk of recurrence. If there are contents present or suspected, or if the sac is large or thickened, it should be opened before ligation to confirm the absence of any tissue or to reduce bowel, omentum, or a sliding component. The internal ring should be tightened medially without compressing the cord in cases of significant widening (Brandt, 2008; Ein et al., 2006). When the distal sac is short, it may be left in place, and when long, the anterior aspect can be excised. A hydrocele should be excised and any appendages removed.

In peripubertal boys with hydrocele, an inguinal approach is preferred if there is clinical evidence of a communicating hydrocele; otherwise a trans-scrotal hydrocele repair is performed as in adults, and an inguinal incision is made only if a proximal communication is identified. In a retrospective study, Wilson et al. (2008) recorded the intraoperative findings of children undergoing hydrocele repair and found hydroceles were noncommunicating in 82.1% of children older than 10 years and in 86.4% of children older than 12 years. Age was significantly associated with a patent processus vaginalis.

Complications

Early postoperative complications, including bleeding and infection, are rare after standard hernia repair. **The rate of recurrent inguinal hernia after uncomplicated open repair is 0.5% to 1%** (Farrow and Thompson, 1963;

Grosfeld et al., 1991; Vogels et al., 2009; Wright, 1994; Zhang and Li, 1993) and rises to 2% for premature infants (Krieger et al., 1994; Misra et al., 1994) and 3% to 6% after repair of an incarcerated hernia (Clatworthy et al., 1954; Farrow and Thompson, 1963). Recurrence typically occurs within 1 year for 50% of the patients and by 2 years for more than 75% (Grosfeld et al., 1991; Wright, 1994). **The causes of recurrent hernias include failure to properly identify or ligate the sac during the original procedure; a tear in the sac, leaving a strip of peritoneum along the cord; damage to the floor; or a missed direct hernia at the original exploration.** Interestingly, Tabrizian et al. reported on a cohort of patients whose repair did not include high ligation to avoid injury to adjacent organs or vessels, and no hernia recurred over a 1- to 3-year follow-up period (Tabrizian et al., 2013).

Surgical repair of recurrent hernias can usually be accomplished inguinally with ligation of an indirect sac at the level of the internal inguinal ring and/or repair of the floor of the inguinal canal for a direct hernia.

The incidence of complications related to the genital tract, secondary cryptorchidism, testicular atrophy, and vasal injury is not well defined. **If a testis is incompletely descended or retractile, orchidopexy should be performed at the time of herniorrhaphy**. Iatrogenic cryptorchidism is avoidable (Kaplan, 1976; Puri et al., 1984) by confirming proper testis position on completing the herniorrhaphy. The risk of testicular atrophy was 0.3% in the large single center series (Ein et al., 2006) but ranged from 4% to 12% in other series (Clatworthy et al., 1954; Rowe and Clatworthy, 1970), with higher rates among the irreducible cases (Fasching and Hollwarth, 1989). The causes include compression of the gonadal vessels by the irreducible hernia or vascular damage incurred during surgical repair. Young infants are at higher risk with infarction rates of 30% to 33% (younger than 2 or 3 months) (Fasching and Hollwarth, 1989; Slowman and Mylius, 1958). **Portions of vas deferens are found in 0.13% to 0.3% of cases, although embryonal remnants not representing true ductal structures are much more common (1.5% to 2.9%)** (Partrick et al., 1998; Popek, 1990; Steigman et al., 1999). The risk of vasal injury may be higher in young infants and/or cases of incarceration. Vasal injury without transection may manifest as vasal obstruction and infertility later in life (Sheynkin et al., 1998).

Persistence of a hydrocele is rare after decompression at the time of hernia repair (0.1% in the series by Ein et al. [2006]) and should be observed for spontaneous resolution for at least 1 year. If persistent, secondary scrotal hydrocele repair is indicated, or reoperative hernia repair if fluctuation suggests a recurrent hernia.

Scrotal Approach to Inguinal Hernia Repair

Concurrent with reports advocating a scrotal approach to orchidopexy, some authors suggest a similar approach to inguinal hernia and communicating hydrocele (Fearne et al., 2002; Gokcora and Yagmurlu, 2003; Lais and Ferro, 1996). For bilateral inguinal hernias, Shih described a median raphe approach (Shih and Uen, 2012). Initial data suggest no major differences in success rate or morbidity using the scrotal approach compared with standard inguinal surgery but offer a more rapid operation and cosmetic benefit (Alp et al., 2014). Fearne et al. (2002) ligated the processus vaginalis at the level of the external inguinal ring in 195 boys and saw one recurrence (mean follow-up, 13 months). Issues related to the level of sac ligation and patient age have not been fully addressed (Wilson et al., 2008) and deserve longer-term follow-up.

Laparoscopic Inguinal Hernia Repair

Laparoscopic hernia repair uses two major techniques: peritoneal closure of the defect (Schier, 2006) and an extraperitoneal approach (Endo et al., 2009; Takehara et al., 2006), which has gained interest over the past several years. In a meta-analysis of 10 comparative studies of laparoscopic versus open inguinal hernia repair in 2699 infants and children, Alzahem (2011) noted that laparoscopic techniques were associated with a trend toward higher recurrence rate, longer operative time for unilateral repairs, and shorter operative time for bilateral repairs. There was a significant reduction in development of a contralateral metachronous inguinal hernia in the laparoscopic group (Alzahem, 2011). These conclusions have been confirmed in more recent studies, but the recurrence rates have begun to approach those of open repair (Esposito et al., 2014a; Miyake et al., 2016; Timberlake et al., 2015).

Surgery can be performed efficiently, but the recurrence risk remains higher (up to 4%) than with open repair, although it may decrease with increasing experience (Saranga Bharathi et al., 2008). A minimum of 20 cases is suggested to reach the learning curve plateau (Bertozzi et al., 2013). The use of nonabsorbable suture material also decreases the recurrence risk (Grimsby et al., 2015).

Conflicting literature exists regarding levels of pain and operative time after laparoscopic repair (Chan et al., 2005; Koivusalo et al., 2009). Laparoscopic repair of recurrent inguinal hernias was reported by Shalaby et al. (2015b) in 38 patients as efficient, safe, and successful. Despite the growing literature on the utility and possible benefits of laparoscopic hernia repair, a recent survey of 187 European pediatric surgeons, of whom 85% were senior surgeons, 80% of experienced laparoscopists (performed more than 100 cases annually and performed laparoscopy for other conditions) revealed that an open approach was predominantly favored (83%) because of the lower risk of recurrence and of injury to adjacent structures. Only 17% preferred laparoscopic hernia repair, but 58% would perform it on all patients regardless of age, and only 15% would employ this approach for cases of incarceration. Laparoscopy was preferred because of less metachronous contralateral hernias (57%), better cosmesis (41%), easier technique (34%), less vas/vessel injury (31%), and less postoperative pain (22%) (Zani et al., 2014).

Key Points: Hernias and Hydroceles

- Inguinal hernias develop in 1% to 5% of children, more commonly in boys and premature infants. The propensity for the right side (3:1) is attributed to the later descent of the right testicle. Female gender, prematurity, age younger than 1 year, and history of cryptorchidism are risk factors for bilaterality.
- An intermittent bulge helps to distinguish a reducible inguinal hernia and communicating hydrocele from a scrotal hydrocele or hydrocele of the spermatic cord. If a bulge is not elicited at the time of examination, photographs of the bulge taken at home are diagnostically reliable.
- Inguinal hernias should be repaired soon after diagnosis, whereas hydroceles can often resolve spontaneously and warrant a period of observation.
- Surgical repair can be performed through an inguinal, scrotal, or laparoscopic approach. The inguinal approach carries the highest success rates at this time.
- The causes of recurrent hernias (0.5%–1%) include failure to properly dentify or ligate the sac during the original procedure; a tear in the sac, leaving a strip of peritoneum along the cord; damage to the floor; or a

missed direct hernia at the original exploration.

- Transperitoneal diagnostic laparoscopy offers a rapid, direct, and accurate inspection of the contralateral internal inguinal ring.

Despite the previously mentioned considerations, efforts have been made to reduce the size (Turial et al., 2011b) and number of ports and to apply the techniques to younger and more complex patients. Whereas the standard laparoscopic approach uses three ports, some authors report similar outcomes using two ports (Xu et al., 2013) or even a single port (Chang et al., 2012; Li et al., 2012; Shalaby et al., 2015a; Shen et al., 2010). Turial et al. (2011a) reviewed their experience in 147 infants who weighed 5 kg or less, using either a 5-mm scope or a microlaparoscope and 2-mm instruments. The median operative time for the bilateral hernia was 20 minutes. Hernias recurred in 2%, with a higher risk for those with an American Society of Anesthesiologists (ASA) score of 3 or more. No cases of testicular atrophy occurred, and high testes requiring surgery occurred in 4%, which was inversely related to body weight. Esposito et al. (2010) performed outpatient laparoscopic inguinal hernia repair on 50 children younger than 1 year. After division of the sac distal to the ring, the peritoneum was closed using a purse-string suture of a nonabsorbable material. The median operating time was 22 minutes (unilateral, 7 to 30; bilateral, 12 to 42) with one recurrence. Recurrence rates may be equal (Hughes et al., 2016), lower in those younger than 1 year than in older children (Choi et al., 2012). Multiple reports have been published regarding a laparoscopic approach to the incarcerated hernia whereby the bowel is brought back into the abdomen, inspected, and the hernia closed by variable techniques (Zhou et al., 2014). Esposito et al. (2013) reported their experience with 46 patients with an incarcerated hernia (1 month to 8 years), of which more than one-half were irreducible. There were no conversions and two recurrences (4.3%) after a minimum follow-up of 14 months. They purport three main advantages of the laparoscopic approach: aversion of edematous tissue by bypassing the cord structures; bowel reduction performed under direct visual control; and inspection of the incarcerated organ at case end.

Assessment of the Contralateral Internal Ring

The need to assess the patency of the contralateral processus vaginalis or of the internal inguinal ring in children with a unilateral hernia remains

controversial. The goal of contralateral assessment is avoidance of metachronous hernia development and its attendant risks and costs. Historically, routine contralateral exploration was performed and then more selectively in patients considered at high risk for metachronous hernia based on age, prematurity, gender, or associated disease. In a survey, 51% of pediatric general surgeons stated that they routinely perform contralateral exploration in premature infants; 40% perform exploration in boys younger than 2 years, and 13% in boys ages 2 to 5 years (Levitt et al., 2002).

In contrast to older methods, **transperitoneal diagnostic laparoscopy offers a rapid, direct, and accurate inspection of the contralateral internal inguinal ring** (Fig. 44.31). A meta-analysis of 964 laparoscopic evaluations identified a sensitivity of 99.4% and specificity of 99.5%. The incidence of an open contralateral internal ring among boys younger than 1 year without a clinical hernia is 10% undergoing laparoscopic orchidopexy (Palmer and Rastinehad, 2008). Among those undergoing unilateral inguinal hernia repair, the incidence of a contralateral patent processus vaginalis ranges from 57% to 68% during open exploration and 39% to 61% during laparoscopic hernia repair (Miltenburg et al., 1998; Saad et al., 2011; Tepas and Stafford, 1986; Zona, 1996). The incidence is inversely related to age; Chin et al. (1995) found an open contralateral ring in 41% of infants younger than 1 year, in about 30% of toddlers aged 2 to 5 years, and in 19% of children older than 10 years. The incidence in adults at autopsy is 20% (Ajmani and Ajmani, 1983).

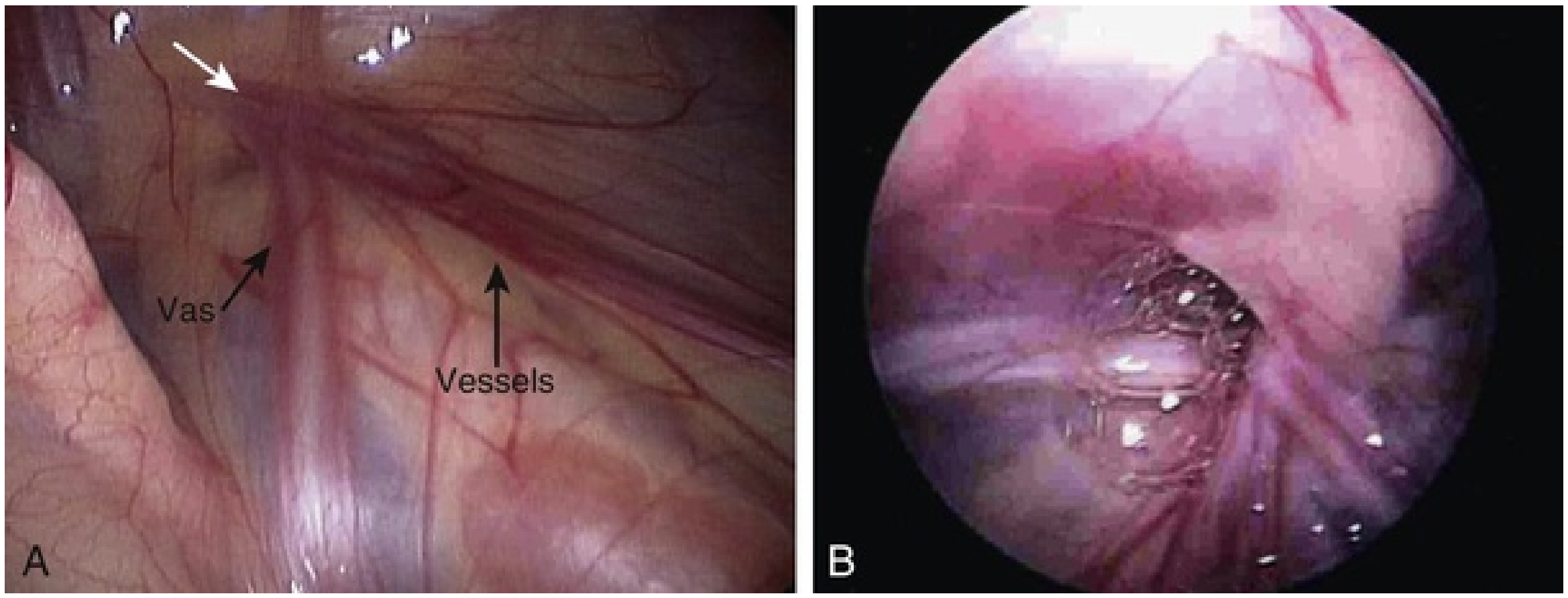

FIG. 44.31 Transinguinal laparoscopic views of (A) a closed *(white arrow)* and (B) an open contralateral internal inguinal ring. Note the bubbles emanating from the air pushed back through the open ring.

The incidence of metachronous development of an inguinal hernia is low. A meta-analysis by Miltenburg et al. (1997) of studies including patients in whom the patency status of the contralateral ring was unknown reported a 7% risk of developing a metachronous contralateral hernia, with 90% developing within 5 years of the initial repair. A systemic review by Ron et al. (2007) confirmed this incidence. Among 1291 children whose contralateral ring was deemed closed by transinguinal laparoscopy, 2.5% had a metachronous contralateral hernia 12.2 months (median) later (Juang et al., 2012), and at the time of unilateral laparoscopic hernia repair 3.1% of 293 children at a median of 24 months of age (range, 6 to 42 months; Tam et al., 2013). **Unfortunately, these studies offer indirect insight into the natural history of an open internal ring, and the question of the natural history of such a ring will remain unanswered until a prospective study of known open contralateral internal inguinal rings is conducted.**

Abdominoscrotal Hydrocele

Abdominoscrotal hydroceles are uncommon, accounting for 1.25% of all hydroceles in a large series (Avolio et al., 2000), and are bilateral in about 30% of cases (Belman, 2001; Bayne et al., 2008; Cozzi et al., 2008; Ferro et al., 1995; Nagar and Kessler, 1998). These noncommunicating scrotal masses are tense and extend into the abdomen, where they may be palpable. Ultrasound may aid in defining the proximal extent (Belman, 2001). Abdominoscrotal hydroceles usually manifest in infancy as such or as scrotal hydroceles that enlarge over time (Celayir et al., 2001; Cuervo et al., 2009), improve (Cozzi et al., 2008), or resolve spontaneously (Upadhyay et al., 2006). Associated diagnoses include cryptorchidism, contralateral hernia, hydrocele, or vanishing testis.

The most likely cause is enlargement and extension of a scrotal hydrocele into the retroperitoneal or properitoneal space after closure of the processus. Bayne et al. (2008) found that abdominoscrotal hydrocele fluid was exudative and theorized that increasing size and pressure would lead to lymphatic obstruction and progression. Massive enlargement could extend into the upper abdomen and be associated with hydroureteronephrosis, lower extremity edema, or appendicitis (reviewed by Cuervo et al., 2009). Chamberlain et al. (1995) first reported dysmorphic elongation of the testis; this was subsequently confirmed (Bayne et al., 2008) but found to be reversible in most cases (Cozzi et al., 2008).

The traditional surgical approach is an inguinal incision with proximal dissection of the sac from its abdominal attachments and distal complete or partial mobilization, with or without orchidopexy. Some authors advocate orchidopexy to avoid iatrogenic cryptorchidism (Bayne et al., 2008; Nagar and Kessler, 1998). Aspiration of the scrotal component may facilitate the proximal dissection (Cuervo et al., 2009). Alternative approaches include a midline abdominal approach for large bilateral cases (Serels and Kogan, 1996) or laparoscopic decompression of the abdominal component followed by inguinal excision (Abel et al., 2009). To avert injury to the spermatic cord or vas, a strip of the lining of the sac may be left along the cord (Cuervo et al, 2009; Ferro et al., 1995). Tightening of a patulous internal ring is described but may be unnecessary because the processus vaginalis is invariably closed.

Belman (2001) described a primary scrotal approach with drainage, excision, and extensive plication with limited dissection. Cozzi et al. (2008) reported reduced morbidity and similar efficacy for the scrotal approach (5 patients) compared with the inguinal approach (13 patients). Persistent scrotal swelling, hematoma, and undescended and/or hypoplastic testis was reported in 11 inguinal cases and infection in 2 scrotal cases.

Acute Scrotum

Acute scrotum refers to the **constellation of new onset of pain, swelling, and/or tenderness of intrascrotal contents.** There is a limited differential diagnosis (Box 44.2) with considerable overlap of signs and symptoms, which may affect the ability to make a definitive diagnosis; some reliable clinical features exist, and adjuvant use of scrotal imaging is helpful in making a diagnosis. **Torsion of the appendix testis is the most common diagnosis** (40% to 60%), followed by spermatic cord torsion (20% to 30% excluding neonates), epididymitis (5% to 15%), and other or no pathology (10%) (Anderson and Giacomantonio, 1985; Mäkelä et al., 2007; Mushtaq et al., 2003; Murphy et al., 2006; Sidler et al., 1997; Van Glabeke et al., 1999). Although all of these diseases can occur at any time during childhood, appendage torsion is typically most common after infancy and before puberty, whereas epididymitis and spermatic cord torsion are most common in the perinatal and pubertal periods. Torsion of an appendage and epididymitis are managed conservatively with limited consequence; prompt surgical exploration for testicular torsion is imperative because the gonad is at considerable risk of ischemic damage or loss, particularly when there is a delay in presentation, evaluation, or management.

Box 44.2

Differential Diagnosis of Pediatric Adolescent Acute Scrotal Pain

- Appendage torsion
  - Appendix testis
  - Other appendage (epididymis, paradidymis, vas aberrans)
- Spermatic cord torsion
  - Intravaginal, acute or intermittent
  - Extravaginal
- Epididymitis
  - Infectious
    - Urinary tract infection
    - Sexually transmitted disease

        - ?Viral
    - Sterile or traumatic
- Scrotal edema or erythema
    - Diaper dermatitis, insect bite, or other skin lesions
    - Idiopathic scrotal edema
- Orchitis
    - Associated with epididymitis with or without abscess
    - Vasculitis (e.g., Henoch-Schönlein purpura)
    - Viral illness (mumps)
- Trauma
    - Hematocele or scrotal contusion or testis rupture
- Hernia or hydrocele
    - Inguinal hernia with or without incarceration
    - Communicating hydrocele
    - Encysted hydrocele with or without torsion
    - Associated with acute abdominal pathology (e.g., appendicitis, peritonitis)
- Varicocele
- Intrascrotal mass
    - Cystic dysplasia or tumor of testis
    - Epididymal cyst, spermatocele or tumor
    - Other paratesticular tumors
- Musculoskeletal pain from inguinal tendonitis or muscle strain
- Referred pain (e.g., ureteral calculus or anomaly)

Delay in presentation for medical attention may stem from patient embarrassment or denial but also from **lack of public awareness regarding torsion and the possible consequences**. Ubee et al. (2014) surveyed parents of 62 boys undergoing emergent scrotal exploration, among whom 66% did not fully appreciate the implications of acute scrotal pain and who overwhelmingly (96%) felt increased public awareness of the condition was needed. In a survey of more than 500 parents in a nonurgent setting, Friedman et al. (2016a) found 34% had heard of testicular twisting/torsion, most commonly through friends, relatives, or knowing someone with torsion (35%) and only 17% from their pediatrician. Only 13% of parents had spoken with their children about torsion. In response, these authors presented an electronic module aimed at educating health care providers on the evaluation and differential diagnosis of acute scrotal pain that was learned within 30 minutes, increased confidence in assessment (Friedman et al., 2016b), and produced a publicly available educational video regarding testis torsion aimed at patients and families (https://www.healthychildren.org/English/health-issues/conditions/genitourinary-tract/Pages/Testicular-Torsion.aspx).

Spermatic Cord Torsion

Acute Intravaginal Spermatic Cord Torsion

Predisposing Factors.

Intravaginal torsion is commonly attributed to excess mobility of the testis within a “bell-clapper deformity,” wherein the tunica vaginalis abnormally fixes proximally on the cord. Although found in 12% of males at autopsy (Caesar and Kaplan, 1994a), the prevalence of torsion is much lower: 8.6 per 100,000 males aged 10 to 19 per year in the United States (Mansbach et al., 2005). There is evidence for a familial predisposition (Collins and Broecker, 1989; Cubillos et al., 2011; Cunningham, 1960) for which the transmission is unknown. Cubillos et al. (2011) found a family history (various relatives) in 10% of probands, including one family with three generations of torsion. **The inciting event for torsion is unknown** but may include cold temperature (Chiu et al., 2012; Lyronis et al., 2009; Srinivasan et al., 2007) even in tropical countries (Gomes et al., 2015) or a change in temperature (Chen et al., 2013) activating the cremasteric reflex, and/or rapid testicular growth at puberty; yet torsion may occur at rest or at sleep. **Cryptorchid testes are at increased risk of torsion and difficult to assess because of the high position.** Torsion after previous orchidopexy may be related to failure of suture (absorbable or nonabsorbable suture) to fix the testis in place (Frank and O'Brien, 2002; Mor et al., 2006; Redman and Barthold, 1995).

Clinical Presentation.

Intravaginal testicular torsion may occur at any age, but the vast majority of cases occur after age 10 years with a peak at 12 to 16 years (Anderson and Giacomantonio, 1985; Mäkelä et al., 2007; Mansbach et al., 2005; Murphy et al., 2006; Mushtaq et al., 2003; Sidler et al., 1997). The prevalence of testicular torsion is 1 in 4000 (Williamson, 1976) with left-sided predominance and rare bilaterality. Classically, boys complain of acute, severe scrotal pain that occurs at rest (even sleep) or with physical activity or after trauma. **A history of prior episodes may be elicited.** Alternatively, patients may have milder, less acute, or even absent scrotal pain or may have inguinal or abdominal pain. Nausea and vomiting occur in 10% to 60% of boys (Jefferson et al., 1997; Knight and Vassy, 1984; Mäkelä et al., 2007; Sessions et al., 2003; Williamson, 1976). Scrotal edema and erythema may be present, depending on the duration or degree of torsion. Dysuria and fever are uncommon.

The most common physical findings are generalized testicular tenderness, abnormal orientation of the testis, and absent cremasteric reflex. Inspection may identify the high-riding testis from a foreshortened cord and horizontally oriented testis. The genitofemoral reflex arc, normally present after age 2 years (Caesar and Kaplan, 1994b), is elicited by scratching the inner thigh with resultant testis elevation. Some studies report reduced or absent reflex in all cases of testicular torsion (Caldamone et al., 1984; Kadish and Bolte, 1998; Rabinowitz, 1984), but it was intact in up to 10% of proven cases of torsion in other series (Hughes et al., 2001; Karmazyn et al., 2005; Murphy et al., 2006; Nelson et al., 2003). The presence of a **cremasteric reflex correlates with intact testicular blood flow but does not unequivocally indicate normal testicular perfusion, especially if the clinical presentation is otherwise suggestive of torsion.** Although anterior epididymal position, thickening of the cord, testicular induration, loss of boundaries between the testis and epididymis, scrotal edema, and/or erythema may be present, landmarks become obliterated and the examination less reliable as the duration of torsion increases.

Several efforts have been made to offer a better clinical assessment of testicular torsion in patients with the acute scrotum. Using a standardized history and physical examination form, Srinivasan et al. (2011) found that absence of ipsilateral cremasteric reflex, nausea or vomiting, and scrotal skin changes on multivariate analysis were predictive of testicular torsion. According to use of a decision tool, patients with acute (<72 hours) scrotal pain and all of the following had no risk of testicular torsion (100% sensitivity and negative predictive value): normal testicular lie, lack of nausea and vomiting, and age 0 to 10 years (Shah et al., 2013). Barbosa et al. (2013) developed a scoring system based on testicular swelling, hard testicle, absent cremasteric reflex, nausea or vomiting, and high-riding testis, which was validated by Sheth et al. (2016). In an effort to reduce in-hospital delay, a standardized process was used at Texas Children's Hospital that included a sign and symptom scoring tool for stratifying risk and improving communication that allowed significantly reduced time from emergency department or ultrasound suite to the operating room (Afsarlar et al., 2016).

Diagnostic Studies.

Urinalysis is of limited usefulness in cases of testicular torsion but is used to identify pyuria and/or bacteriuria associated with epididymitis or hematuria, implicating a urinary tract calculus. Before the advent of reliable and rapid scrotal imaging, immediate scrotal exploration was routine. Radionuclide imaging carried about 90% sensitivity and specificity but was lengthy, was not readily available, and used ionizing radiation, and is currently rarely used. Ultrasound offered a rapid, available, and safe modality to assess testicular architecture, intraparenchymal blood flow, and other anatomic details (hydrocele, scrotal thickening).

CDUS findings consistent with testicular torsion include reduced or absent Doppler color or waveforms and parenchymal heterogeneity compared with the contralateral testis (Fig. 44.32). Kaye et al. (2008b) and later Chmelnik et al. (2010) found that all **testes with heterogeneous echogenicity were necrotic, whereas homogeneous echogenicity predicted a lower risk of orchiectomy.** Lack of demonstrable intratesticular flow on CDUS is 86% sensitive, 100% specific, and 97% accurate in the diagnosis of torsion and ischemia in painful scrotum (Burks et al., 1990) and its use spread (Kass et al., 1993b); even current studies reflect the accuracy of this approach. Altinkilic et al. (2013) prospectively assessed the diagnostic value of CDUS in patients with clinical suspicion of torsion who were explored by a surgeon blinded to the CDUS results. The sensitivity, specificity, and positive and negative predictive values of CDUS for detecting testicular torsion were 100%, 75.2%, 80.4%, and 100%, respectively. The authors concluded that routine surgical exploration was unnecessary if CDUS reveals normal intratesticular perfusion. However, in other studies the sensitivity in confirming decreased or absent blood flow in proven cases of spermatic cord torsion was only 63% to 90%, possibly because of enhanced detection of flow with newer equipment and/or user-dependent characteristics (Bentley et al., 2004; Kalfa et al., 2004; Karmazyn et al., 2005; Stehr and Boehm, 2003; Steinhardt et al., 1993). Cassar et al. (2008) evaluated Doppler waveforms in cases of torsion with decreased or preserved testicular flow and observed subtle waveform abnormalities, including increase or decrease in amplitude relative to the normal testis and reversal of diastolic flow. Increased epididymal size and/or echogenicity and altered epididymal vascularity, usually absent or reduced but occasionally increased, may provide additional support for the diagnosis of torsion (Nussbaum et al., 2006).

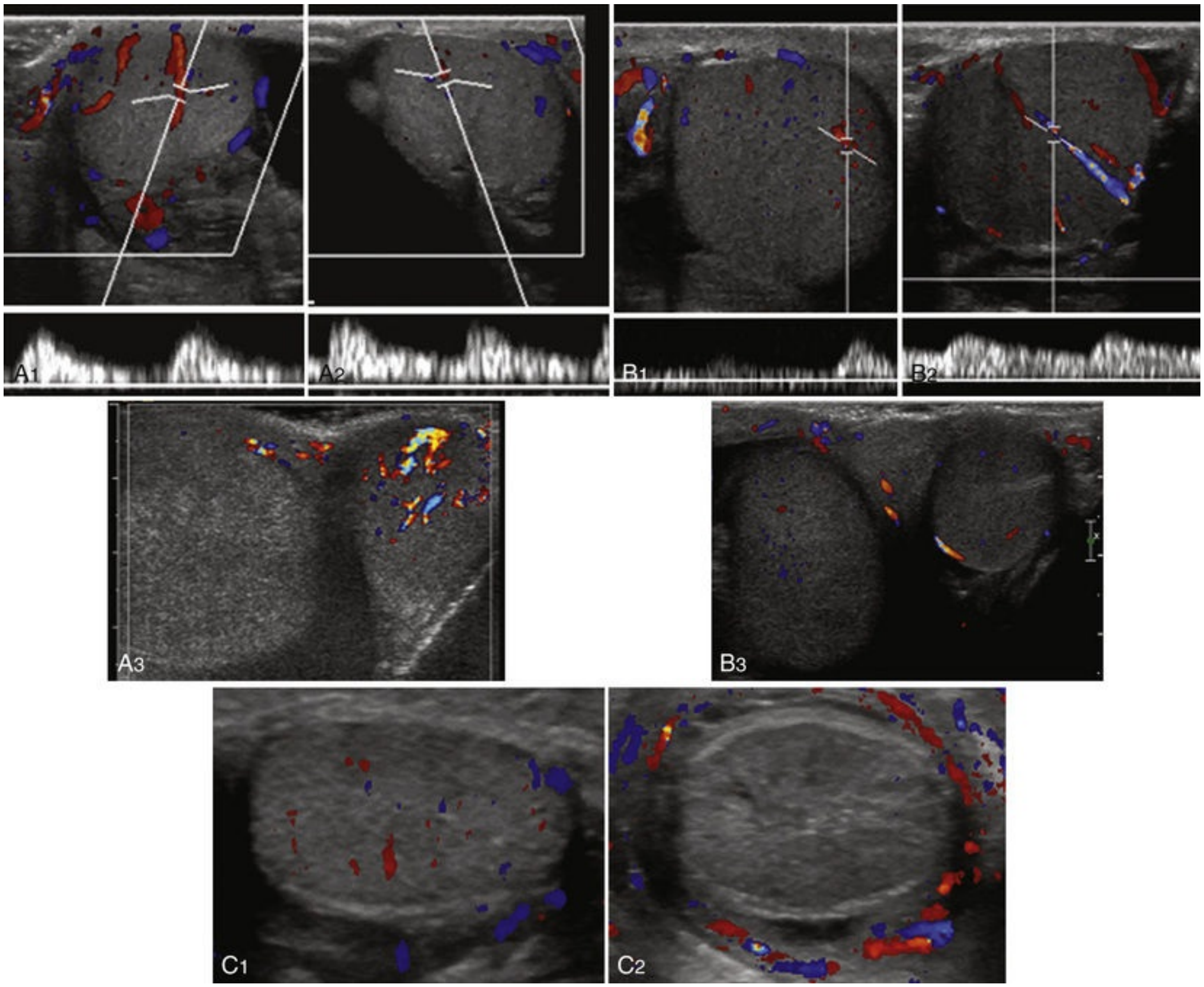

FIG. 44.32 Imaging of intravaginal spermatic cord torsion. (A) Intermittent torsion. Color Doppler ultrasonography (CDUS) demonstrates preserved arterial flow to testis with 12 hours of pain and then loss of flow and parenchymal heterogeneity when child returned later with worsening pain. (B) Acute torsion with reduced arterial flow. (C) Prolonged torsion. CDUS shows heterogeneous testis without arterial or venous flow and a hyperechoic parenchymal ring.

High-resolution (10- to 20-mHz probe) ultrasonography (HRUS) of the length of the spermatic cord may enhance the ability to diagnose torsion. Using HRUS to directly image the cord proximal to the testis, Kalfa et al. (2004) visualized the cord twist as a 1- to 3-cm snail-shaped mass in 43 patients and a completely linear cord in nontorsion cases (Fig. 44.33). In a multi-institutional retrospective series of 919 cases of acute scrotum with cord imaging by HRUS, a cord twist was seen in 96% of cases of surgically proven torsion, and HRUS carried 99% specificity when the cord was linear (Kalfa et al., 2007). However, Karmazyn et al. (2005) observed normal testicular blood flow and no visible spermatic cord twist in 2 of 41 boys with partial or intermittent torsion.

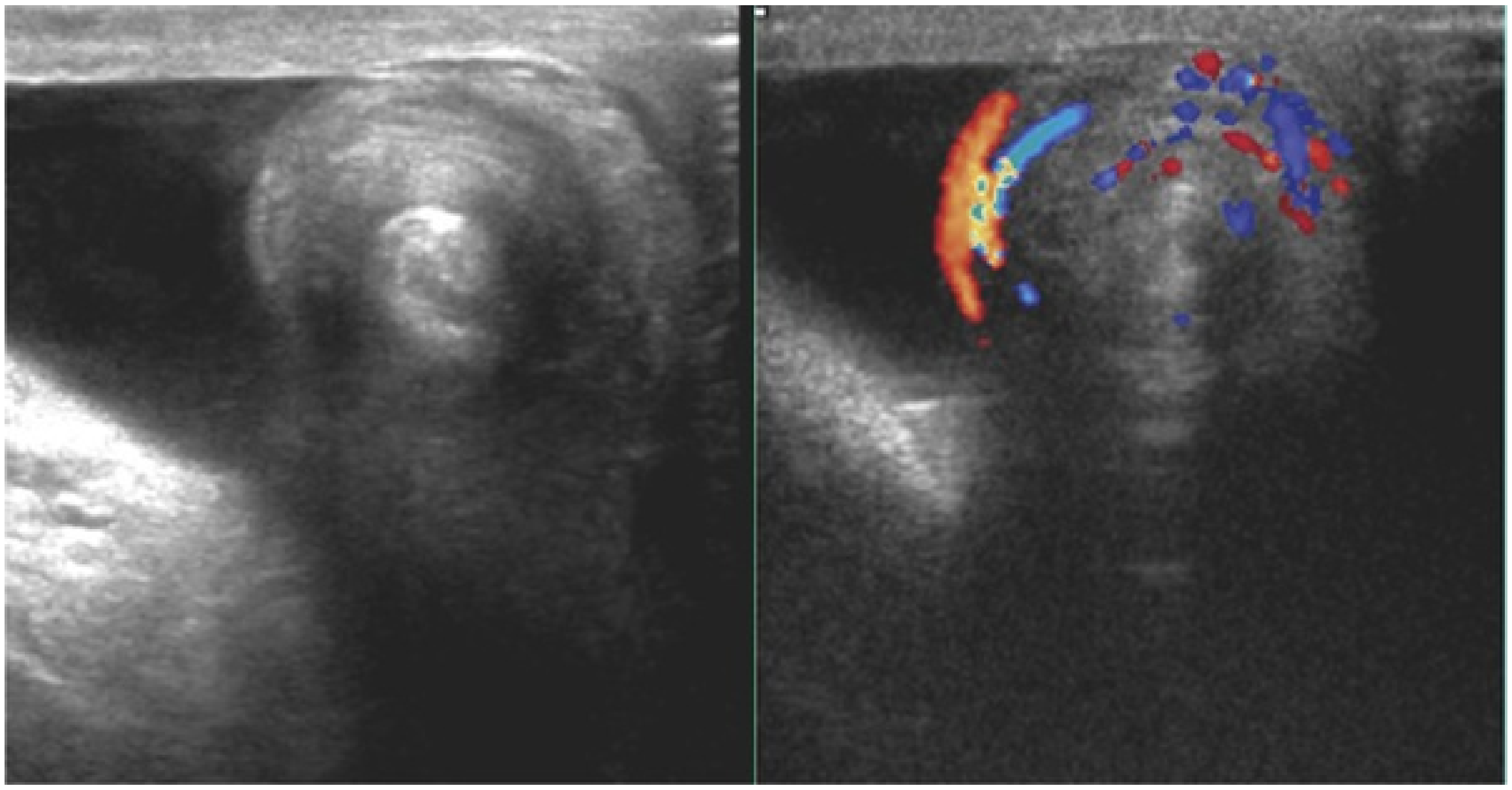

FIG. 44.33 Snail sign. B-Mode *(left)* and color Doppler ultrasonography *(right)* images showing hyperechoic central body of the snail and coiling of blood within the distal spermatic cord around the central echogenic “body.”

Potentially useful diagnostic modalities include contrast-enhanced pulse-inversion ultrasonography (CEUS), infrared thermography and spectroscopy, and scrotal MRI. Pulse-inversion imaging in a rabbit model showed superior quantitative assessment of perfusion of the experimentally torsed testis as compared with conventional CDUS (Paltiel et al., 2006). CEUS was performed in 50 patients with acute scrotal pain or trauma in whom testicular lesion of undefined nature was found at CDUS. Sensitivity and specificity were 76% and 45% for CDUS and 96% and 100% for CEUS, respectively (Valentino et al., 2011). Infrared thermography showed significant reduction in scrotal temperature by 1 hour after 720-degree torsion and prompt normalization with detorsion in a sheep model (Capraro et al., 2008). Transscrotal near infrared spectroscopy was able to reliably discriminate torsion from nontorsion in a select group of children with acute testis pain (Schlomer et al., 2017). MRI has been used in a small series of testicular torsion and may have a role in difficult diagnostic cases with use of dynamic contrast-enhanced MRI, which requires gadolinium (Mäkelä et al., 2011), or diffusion-weighted imaging with findings of a lower testicular apparent diffusion coefficient (ADC) without the need for contrast (Maki et al., 2011).

Management and Surgical Treatment

Testicular torsion is a true surgical emergency because testis viability is inversely related to duration of torsion. Visser and Heyns (2003) amassed data from a published series including 1140 patients and found that the risk of orchiectomy was approximately 5%, 20%, 40%, 60%, 80%, and 90% at 0 to 6, 7 to 12, 13 to 18, 19 to 24, more than 24, and more than 48 hours after onset of pain, respectively. The degree of torsion may provide incomplete vascular occlusion, helping to explain the variability of these data or have a multiplicative effect on the time course to testis loss (Dias et al., 2016).

Orchiectomy after surgical detorsion occurs in 30% to 70% in large studies (Kaye et al., 2008b; Mäkelä et al., 2007; Murphy et al., 2006; Sessions et al., 2003) and in 32% to 42% in database reviews (Cost et al., 2011; Mansbach et al., 2005; Zhao et al., 2011). Sessions et al. (2003) found that the **median degree of rotation was 540 degrees in orchiectomy testes and 360 degrees when the testis was salvaged,** with a range of 180 to 1080 degrees in both groups. The risk of delayed atrophy after orchidopexy was less than 10%, 40%, and 75% after less than 12, 12 to 24, and more than 24 hours of pain, respectively (Visser and Heyns, 2003). Partial (<25%) testicular atrophy may occur after operative detorsion even after 4 hours after the onset of pain (Anderson and Williamson, 1986; Krarup, 1978; Sessions et al., 2003; Tryfonas et al., 1994). Among 37 patients with at least 6 months' follow-up, Lian et al. (2016) found that 54% developed testicular atrophy (>50% compared with contralateral testis) even when deemed viable intraoperatively; duration of pain of more than 1 day and sonographic parenchymal heterogeneity were predictive of subsequent atrophy. **Preoperative manual cord detorsion may relieve symptoms and allow delayed orchidopexy but may incompletely untwist the cord.** Sessions et al. (2003) found that lateral twisting (rather than medial untwisting) occurred in 33% and manual detorsion failed to completely relieve torsion in 32% of orchidopexy cases.

There are two management approaches to the acute scrotum. One is to avoid delay and perform exploration in almost all boys to confirm absence of torsion; this implies many unnecessary surgeries (Anderson and Giacomantonio, 1985; Mäkelä et al., 2007; Mushtaq et al., 2003; Sidler et al., 1997; Watkin et al., 1996). The other approach is more selective of patients for surgical exploration (Caldamone et al., 1984; Kass et al., 1993b; Kalfa et al., 2004; Lam et al., 2005) based on the history, physical examination, and CDUS findings, which may lead to testis loss because of atypical presentation and/or false-negative imaging. **When findings support or raise suspicion for spermatic cord torsion, emergent scrotal exploration is indicated and should not be delayed.**

Surgical exploration of the testis through a hemiscrotal transverse (dartos pouch) or midline raphe incision should first address the affected side. The testis is delivered and the tunica vaginalis opened to note the color of the testis, the number of rotations, and the anatomy of the tunica vaginalis. The testis is untwisted, wrapped in warm soaked gauze, and observed for improvement in color, whereas **the contralateral testis is fixed with nonabsorbable suture to reduce the risk of metachronous torsion.** The affected testis is re-examined for potential viability, and the largely subjective decision for orchidopexy or orchiectomy is made. A Doppler flow probe or incision of the tunica albuginea (Arda and Ozyaylali, 2001) with assessment of bleeding may document intratesticular flow after detorsion; however, the reliability of these assessments lacks validation. If the testis is to be retained, it is fixed either via dartos pouch or directly to the dartos with nonabsorbable suture. Kutikov et al. (2008) have suggested that a compartment syndrome contributes to testicular injury based on the improved appearance and lower intraparenchymal pressures seen after detorsion and tunica albuginea incision in three cases. A patch of vascularized tunica vaginalis was placed in the tunica albuginea defect to maintain lower intraparenchymal pressure and to reduce the likelihood of ongoing ischemia (Fig. 44.34). Figueroa et al. (2012) applied this technique to 11 of 28 testes deemed nonsalvageable at surgery and found that 55% recovered. The long-term outcome of these patients is not available; however, in a rat model of testicular torsion, no significant histologic differences were found between a detorsion group and detorsion with tunica vaginalis flap group after 4 weeks, despite reduction of intratesticular pressure in both groups (Józsa et al., 2016; Oktar et al., 2013).

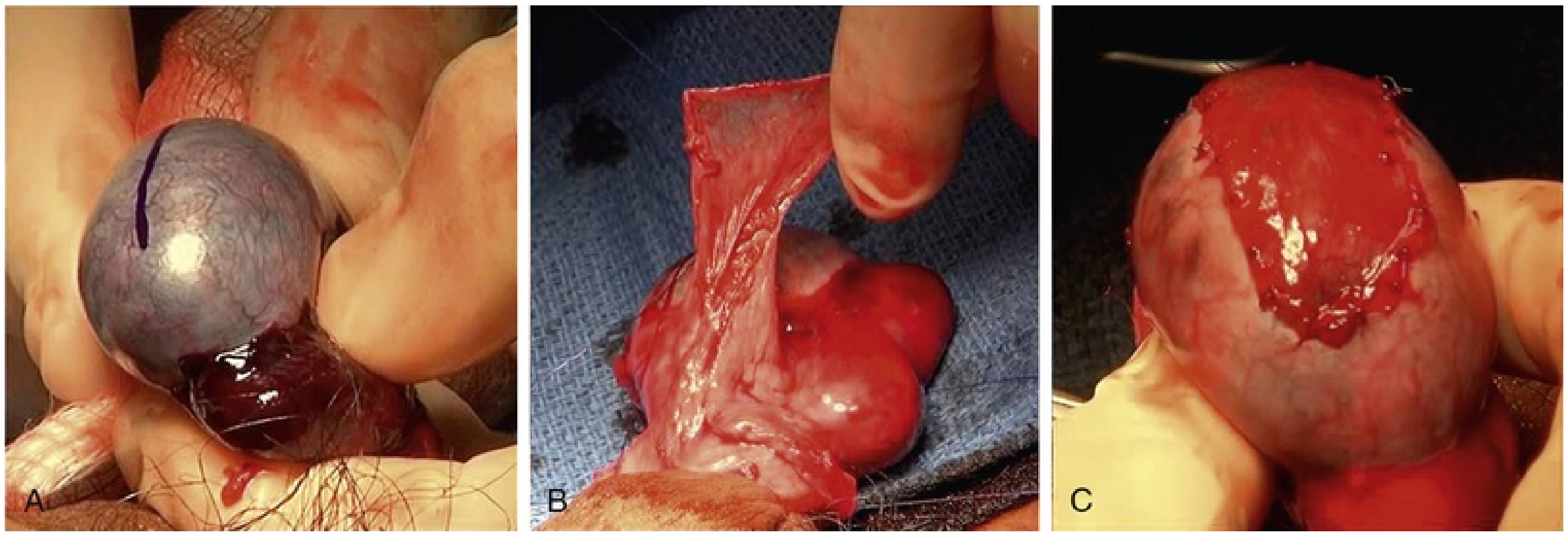

FIG. 44.34 Tunica vaginalis vascularized patch. Tense congestion of the testis (A) was relieved with incision of the tunica albuginea *(marked).* The tunica vaginalis flap on a vascularized pedicle is harvested (B) and used to fill the defect in the tunica albuginea (C). (Courtesy Douglas Canning, MD, and Jason Van Batavia, MD.)

Risk factors for orchiectomy include young age, African-American race, and being on Medicaid or lacking insurance (Cost et al., 2011; Zhao et al., 2011). Zhao et al. (2011) identified surgery at a children's unit to increase the risk of orchiectomy. This may reflect the transfer of patients, which delayed treatment by 75 minutes in the study by Bayne et al. (2010), but did not affect the orchiectomy rate in the study by Ramachandra et al. (2015). Orchiectomy is performed by dividing the cord into segments, each of which is ligated with nonabsorbable suture. In cases of orchiectomy, prosthesis placement is usually offered after complete healing or later in puberty; however, Bush and Bagrodia (2012) demonstrated the feasibility of performing concurrent prosthetic placement and orchiectomy.

Prognosis

Although the impact of testicular torsion on fertility is poorly understood given the inherent difficulty of long-term follow-up in these patients, the few available studies suggest that subtle abnormalities of semen quality are common. **Semen density is often within the normal range but correlates with shorter duration of torsion and reduced atrophy** (Anderson et al., 1992; Arap et al., 2007; Brasso et al., 1993; Fisch et al., 1988; Puri et al., 1985). The observation that increasing duration of torsion inversely correlates with semen quality and limited contralateral testicular biopsy data suggest that global testicular dysfunction may exist after torsion (Visser and Heyns, 2003). The hypothesis of an autoimmune phenomenon (Anderson and Williamson, 1990) was dispelled by analysis of antisperm antibodies in individuals with torsion (Anderson et al., 1992; Arap et al., 2007; Brasso et al., 1993; Puri et al., 1985). Available animal and human data support a role for ischemia-reperfusion injury after release of testicular torsion (Kehinde et al., 2003; Turner et al., 2004). Additional clinical data are needed to determine long-term outcome after testicular torsion and the efficacy of any adjunctive treatment. Romeo et al. (2010) assessed serum levels of FSH and LH (before and after GnRH stimulation), testosterone, and inhibin B in 20 patients 5 years (mean) after testicular torsion and in 15 age-matched controls; 12 patients were treated with detorsion and orchidopexy, and 8 underwent orchidectomy. Serum FSH, LH, and testosterone were within the reference range. Inhibin B levels were significantly reduced in the two torsion groups compared with the controls but not between each other.

Intermittent Intravaginal Spermatic Cord Torsion

Episodes of self-limited acute scrotal pain precede acute testicular torsion in 30% to 50% of patients (Stillwell and Kramer, 1986; Williamson, 1976). These episodes, single or multiple, typically begin and resolve acutely with durations of minutes to hours. Hayn et al. (2008) observed that the frequency of these episodes correlated with the risk for eventual persistent torsion and testicular loss; 71% of patients were previously diagnosed with epididymitis or appendage torsion, and 53% had acute or delayed testicular loss. Nausea and/or vomiting or notation of scrotal swelling may or may not be present. A normal vertical testicular orientation is most common (Hayn et al., 2008), but a horizontal lie may be present (Schulsinger et al., 1991). Physical findings consistent with torsion depend on whether the testis is twisted at the time of the examination. This includes the degree of tenderness and cremasteric reflexes. Eaton et al. (2005) reported absent cremasteric reflex in 3 of 15 patients and reduced or absent intratesticular blood flow by CDUS in only 5 of 12 patients. A whirlpool sign or an abnormal boggy cord and pseudomass formation below the twisted spermatic cord may also signify intermittent torsion (Munden et al., 2013).

There are challenges to confirming the diagnosis of intermittent torsion. **The diagnosis requires a high index of suspicion unless the testis is noted to untwist** during an examination or an ultrasound study shows absent or decreased flow before and normal to increased flow after marked improvement of symptoms. Once the condition is confirmed or highly suspected, **elective bilateral orchidopexy is indicated** to avert torsion and possible organ loss.

Patients and parents should know that absolute confirmation of the diagnosis may not be possible and that symptoms may persist postoperatively.

Extravaginal Spermatic Cord Torsion (Perinatal Testicular Torsion)

Perinatal spermatic cord torsion is a term applied to infants regardless of whether the event occurred prenatally (hours, days, weeks, months), during delivery, or postpartum. Torsion of the entire cord occurs before fixation of the tunica vaginalis and dartos within the scrotum (extravaginal). This event most commonly occurs well before delivery, yielding a “vanishing” testis or a hemosiderin-containing nubbin in the scrotum or less commonly in the inguinal canal. The testis that sustains loss of blood supply close to delivery is a hard, painless testis fixed to the overlying erythematous or dark scrotal skin with or without edema. A coexisting hydrocele complicates the examination. The estimated incidence is 6.1 per 100,000 births (John et al., 2008), and familial cases are reported (Castilla et al., 1975). Predisposing factors such as high birth weight and/or difficult delivery are suggested (John et al., 2008; Kaye et al., 2008a) but unconfirmed by controlled studies. In a minority of cases, symptoms occur after a documented normal scrotal examination. Rarely, neonatal intravaginal torsion occurs or infarction occurs without torsion (John et al., 2008). Bilateral torsion was noted in 5% and 22% in two series (Baglaj and Carachi, 2007; Yerkes et al., 2005) and may occur concurrently or metachronously. Several series indicate that bilateral metachronous torsion may occur in boys in whom the primary event occurs prenatally or postnatally (Al-Salem, 2007; Beasley and McBride, 2005; John et al., 2008; Yerkes et al., 2005).

Scrotal imaging may be obtained in cases of suspected perinatal torsion, but its usefulness and reliability are questionable. Prenatal ultrasonography may show torsion (Herman et al., 2002). Postnatal ultrasound may reveal parenchymal heterogeneity, calcification, and absent blood flow (Fig. 44.35; Arena et al., 2006). Reported cases of testicular blood flow suggest that postnatal CDUS may be unreliable (Al-Salem, 2007; Cuervo et al., 2007; John et al., 2008; Yerkes et al., 2005). Ultrasound helps to differentiate tumors from torsion (Kaye et al., 2008a), but its reliability in this has also been challenged (Al-Salem, 2007; Calonge et al., 2004).

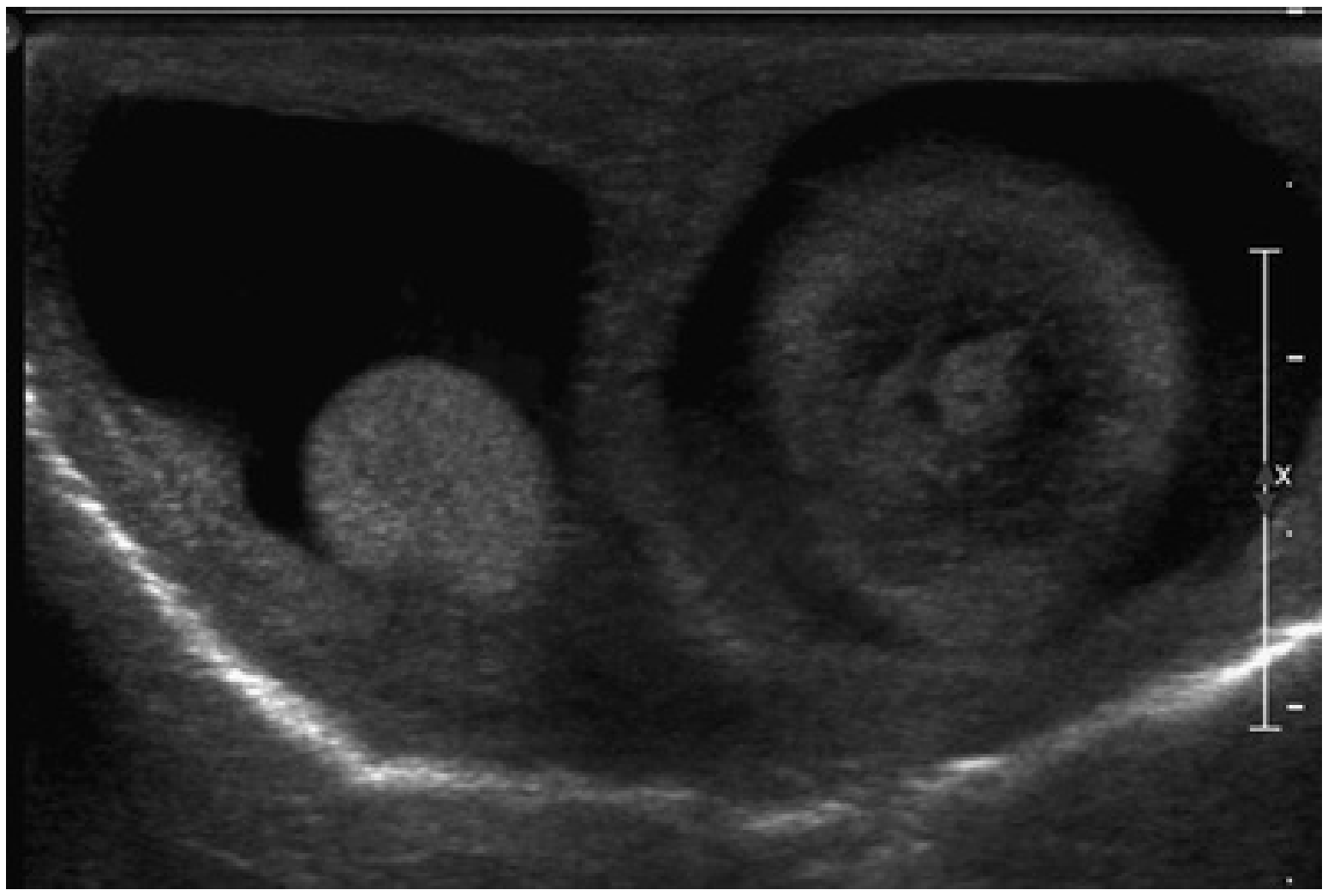

FIG. 44.35 Extravaginal spermatic cord torsion in a neonate. Transverse ultrasound image demonstrates enlarged and heterogeneous left testis and bilateral hydroceles.

There is no consensus regarding the best treatment of perinatal testicular torsion (Snyder and Diamond, 2010). One side advocates elective exploration because of the unsalvageability in most cases, the rarity of metachronous torsion, and the increased anesthetic risk (Brandt et al., 1992; Das and Singer, 1990; Kaye et al., 2008a; Stone et al., 1995). Others advocate for immediate exploration to offer possible partial or complete testicular salvage (Al-Salem, 2007; Cuervo et al., 2007; Sorensen et al., 2003) and point to cases of unexpected contralateral torsion or atrophy found at exploration (Abraham et al., 2016; Al-Salem, 2007; Baglaj and Carachi, 2007; John et al., 2008; Roth et al., 2011; Yerkes et al., 2005). Among 110 pediatric surgeons and urologists surveyed in the United Kingdom and Ireland, few (10.9%) used Doppler ultrasound to guide management or to exclude tumor. Although most (74.5%) performed ipsilateral orchiectomy and contralateral orchidopexy (71.9%), few operated emergently because a viable testis was seldom found (10%) and bilateral torsion was even rarer (7 cases). Some (21.8%) avoided contralateral orchidopexy because of concern for iatrogenic injury (Rhodes et al., 2011). **If torsion is suspected after a normal postnatal scrotal examination, then prompt exploration should be performed as for intravaginal torsion.** Some surgeons use a scrotal approach, whereas others advocate an inguinal approach to ligate a patent processus vaginalis and avoid the theoretic risk of trans-scrotal surgery if a tumor is found.

Torsion of the Appendix Testis and Epididymis

Appendage torsion is the most common cause of acute scrotum in prepubertal children. The appendix testis and appendix epididymis are vestiges of embryologic development without known function. The appendix testis (from the müllerian duct) and appendix epididymis (from the wolffian duct) are present in 76% to 83% and 22% to 28% of testes, respectively (Dresner, 1973; Jacob and Barteczko, 2005). The appendix testis, located at the cranial testicular pole or in the groove between the testis and epididymis, and the appendix epididymis, located along the caput, may be sessile or pedunculated. Although the sessile type may be more common (Jacob and Barteczko, 2005), the pedunculated type may be more prone to torsion (Jones, 1962). The cause of torsion is unknown but may be related to anatomy, trauma, and/or prepubertal enlargement.

The peak age at occurrence is 7 to 12 years (mean 8 to 9 years) (Anderson and Giacomantonio, 1985; Lyronis et al., 2009; Mushtaq et al., 2003), but the condition may occur at any age. Symptoms vary with sudden or insidious onset of pain, which may be mild or severe and intermittent with physical activity. Similarly, physical findings depend on the severity of inflammation and duration of symptoms (Rakha et al., 2006). Early on, **a “blue dot sign”** (Dresner, 1973), **a discoloration at the upper pole of the testis representing the ischemic appendage, may be seen through stretched scrotal skin** in 0 to 52% of patients (Caldamone et al., 1984; Karmazyn et al., 2005; Lyronis et al., 2009; Murphy et al., 2006; Van Glabeke et al., 1999). Murphy reported a false-positive blue dot sign in a patient with testicular torsion (Murphy et al., 2006). Other early signs include a tender nodule superior to the testis with limited testicular tenderness and symmetrical cremasteric reflexes. However, with longer duration and progressive inflammation, increased swelling and tenderness, lack of distinction between testis and epididymis, and marked scrotal wall edema and erythema may make it difficult to distinguish it from testis torsion or epididymitis.

CDUS rarely demonstrates an abnormal appendage but commonly shows hyperperfusion of the epididymis (Baldisserotto et al., 2005). Although the normal appendix testis contains no internal blood flow (Yang et al., 2005), Lev et al. (2015) noted that among 19 patients (ages 3–14 years), CDUS demonstrated a round or oval avascular lesion with heterogeneous echotexture (n = 18), posterior enhancement (n = 13), and hyperemia of the surrounding structures (n = 15). All appendages were adjacent (n = 16) or in close proximity (n = 3) to the upper pole of the testis (Fig. 44.36).

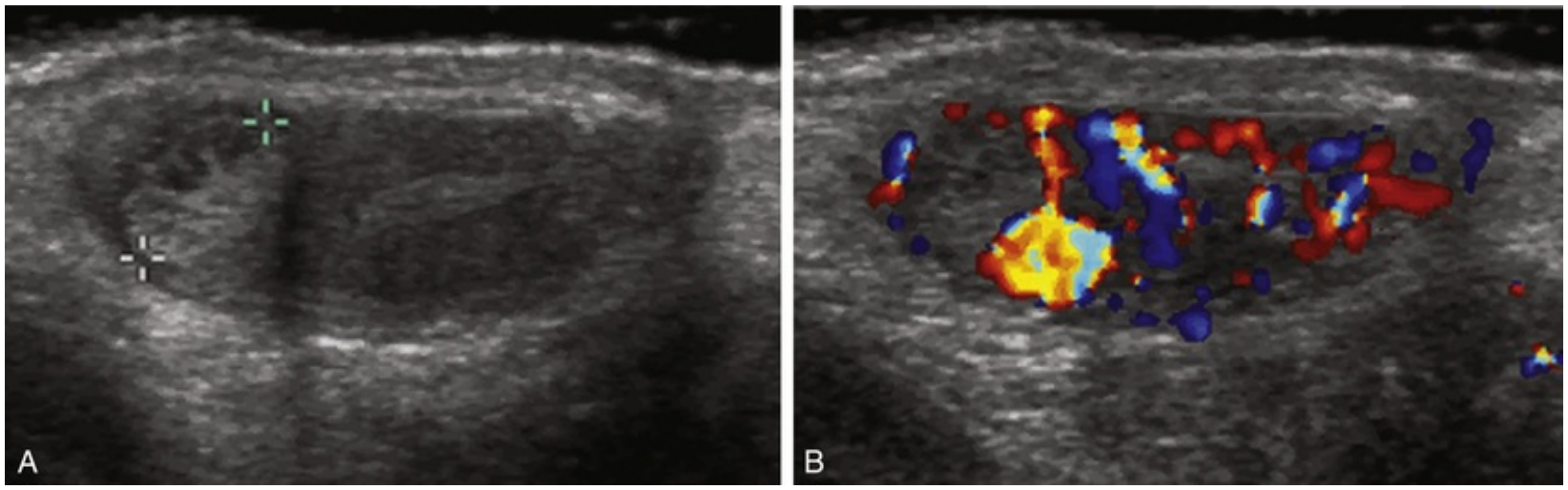

FIG. 44.36 Torsion of testicular appendage. Color Doppler ultrasonography demonstrates (A) enlarged and heterogeneous appendage and (B) absent flow despite increased flow to the epididymis and testis.

Park et al. (2011) found significant differences in the echogenicity correlated with the duration of symptom: hypoechoic in all 17 boys assessed within 24 hours of symptom onset and hypoechoic (6), isoechoic (4), or hyperechoic (8) after 24 hours.

Because **torsion of an appendage is a self-limited process** (Koff and De Ridder, 1976), surgery is rarely indicated. Treatment is aimed at reducing inflammation using ice packs and oral anti-inflammatory agents and limiting physical activity. Surgical exploration is limited to cases in which torsion of the testis is not excluded or, rarely, there is prolonged and severe pain or recurrent episodes.

Epididymitis

Epididymitis, infectious or noninfectious, is a broad category causing an acute scrotum. The incidence is poorly defined (Al-Taheini et al., 2008; Cappele et al., 2000; Lau et al., 1997; Merlini et al., 1998; Sakellaris and Charissis, 2008; Somekh et al., 2004), perhaps because children with a torsed appendage may be diagnosed with epididymitis (Kadish and Bolte, 1998; Lam et al., 2005; Lyronis et al., 2009). In many series, peaks in prevalence occur in infancy and at puberty (Mäkelä et al., 2007; Mushtaq et al., 2003; Sidler et al., 1997). Redshaw et al. (2014) noted that among 252 patients over a 21-year period, the age at first presentation was 10.92 ± 4.08 years with the majority of cases occurring during puberty (11 to 14 years) and few patients (4%) younger than 2 years old. Interestingly, 27.4% of boys experienced a second episode of epididymitis.

Classically, **the symptoms have a more insidious onset than torsion of the cord or an appendage but may present rapidly.** Fever and dysuria may or may not be present, and nausea is rare. A history of UTIs, urethral discharge, sexual activity, intermittent catheterization (Thirumavalavan and Ransley, 1992), dysfunctional voiding (Bukowski et al., 1995), urethral abnormalities (Karmazyn et al., 2009), or congenital anomalies of the ejaculatory duct (Pimpalwar et al., 2002; Yanai et al., 2005) may be present. There is a continuum on examination from localized epididymal enlargement and tenderness to massively swollen and erythematous hemiscrotum without distinct landmarks. **The cremasteric reflex should be intact.** Associated pyuria and/or bacteriuria is reported in 20% to 40% of cases (Anderson and Giacomantonio, 1985; Mäkelä et al., 2007; Murphy et al., 2006; Mushtaq et al., 2003; Sidler et al., 1997). CDUS shows increased epididymal size and blood flow as well as in the testis in some cases.

The management goal is to relieve inflammation and any associated infection. Efforts to reduce the inflammation include the use of ice packs, nonsteroidal anti-inflammatory agents, scrotal elevation, and rest to avoid traumatic exacerbation. In the absence of UTI, symptoms improve spontaneously without antibiotics (Lau et al., 1997). In the presence of pyuria, broad-spectrum antibiotics with gram-negative coverage should be used (Siegel et al., 1987), and in some cases intravenous antibiotics and hospitalization may be required. Treatment for sexually transmitted diseases should be considered, as appropriate, in adolescents.

The need to image the urinary tract has become more selective. Siegel et al. (1987) found that 47% of prepubertal boys had anomalies (urethral anomalies, ureteral ectopia) on imaging. Other clinical series have documented a low risk of urinary tract anomalies in boys with epididymitis, although infants may be at higher risk (Merlini et al., 1998; Sakellaris and Charissis, 2008). Redshaw et al. (2014) noted that anomalies were more commonly found on VCUG among boys with positive urine cultures.

Although some findings (pyelectasis, low-grade vesicoureteral reflux) may not directly contribute to epididymitis, other findings (urethral or ureteral obstruction, ejaculatory duct or vasal anomalies) are important to detect. Some authors recommend renal ultrasonography only (Al-Taheini et al., 2008) or imaging only in recurrent cases (Cappele et al., 2000). However, in **a prepubertal child with a positive urine culture, renal ultrasonography and**

voiding cystourethrography are indicated. In recurrent cases, endoscopy may reveal ejaculatory duct abnormalities undetected on voiding cystourethrography (Pimpalwar et al., 2002; Yanai et al., 2005). Recurrent epididymo-orchitis in these cases may require excision of a utricle or ejaculatory duct cyst with vasovasostomy or vasectomy.

Other Causes of Acute Scrotal Pain

Idiopathic scrotal edema manifests in prepubertal boys with unilateral or bilateral scrotal swelling with minimal or no pain (Klin et al., 2002; Lee et al., 2009). Associated findings may include local spread of erythema or edema to the inguinal or perineal region, inguinal lymphadenopathy, leukocytosis, and/or eosinophilia. The last suggests an allergic origin, although the cause is currently idiopathic. Distinctive characteristics include minimal or no pain, isolated scrotal tenderness, and thickening of the scrotal wall. The “Fountain Sign,” hypervascularity on color Doppler of the thickened scrotum depicted on transverse scans with both testes seen, is highly suggestive of the diagnosis. Because the process is self-limited, no treatment is needed, except perhaps for antihistamines (Geiger et al., 2010).

Henoch-Schönlein purpura is a systemic vasculitis affecting the skin, joints, gastrointestinal tract, and kidneys. The scrotum is involved in 2% to 38% of cases in the form of tenderness, edema, or erythema; testicular hematoma, torsion, or infarction; or cord thrombosis or epididymitis (Diana et al., 2000; Ioannides and Turnock, 2001; Turkish et al., 1976). The typical purpuric rash of the buttocks, perineum, and lower limbs is usually present but may not precede the scrotal findings. Urgent scrotal exploration is indicated if clinical findings suggest concomitant testicular torsion.

Cystic dysplasia of the rete testis is a benign lesion of the testis that was first described in 1973 by Leissring and Oppenheimer. It may present at any age but most commonly around 6 years as acute scrotal swelling and pain (Jeyaratnam and Bakalinova, 2010; Noh et al., 1999; Smith et al., 2008). Rarely, an associated ureteral anomaly may lead to chronic testicular pain (McGee et al., 2009). Ipsilateral renal dysplasia, agenesis, or ureteral anomalies are present in the majority of cases and likely represent maldevelopment of the wolffian duct. Ultrasound will reveal multiple centrally located, small cysts (2–8 mm) surrounded by compressed normal parenchyma but can involve the entire parenchyma. Magnetic resonance has been shown to be helpful (Emam et al., 2012; Landry et al., 1999). Treatment is conservative enucleation, which may be associated with recurrence, or observation; reports of spontaneous regression has been reported (Gelas et al., 2016).

Testicular rupture from trauma may cause acute scrotal pain and swelling and hematocele. CDUS is sensitive in diagnosing testicular fracture. Surgical intervention may be indicated (Adams et al., 2008), or a conservative approach may be considered (Cubillos et al., 2010), reserving surgery for cases of expanding hematoma, symptomatic hydrocele, intractable pain, absent blood flow, or abscess. In their series, Cubillos et al. reported excellent outcomes and testis salvage; slow resumption of all physical activities was reported by a minority of patients in this small cohort.

Key Points: Acute Scrotal Pain

- Delay in presentation for acute scrotal pain may stem not only from patient embarrassment or denial but also from lack of public awareness regarding torsion and the possible consequences.
- In the majority of cases in which a reliable, thorough history is taken and targeted physical examination is performed, a reliable diagnosis should be made; adjunctive ultrasound confirms a diagnosis.
- Ultrasound features suggestive of torsion of the spermatic cord include absent blood flow, a “snail sign,” and heterogeneity of the parenchyma.
- Testicular salvage rates from spermatic cord torsion are inversely related to duration and have some relationship to the degrees of torsion. Thus, in cases in which torsion is highly suspected, emergent surgery should not be delayed by imaging studies.
- Spermatic cord torsion occurring in the perinatal period are rarely salvageable when identified in the nursery and should be managed emergently when a change in physical examination has occurred.
- Appendage torsion is the most common cause of acute scrotum in prepubertal children. A “blue dot sign,” discoloration at the upper pole of the testis, may be seen through stretched scrotal skin. This is a self-limiting process requiring supportive care and analgesia management.

Varicocele

Varicocele, an abnormal dilation and tortuosity of the internal spermatic veins within the pampiniform plexus, is common among adolescents and may contribute significantly to the risk of subfertility in adulthood. Its effect on paternity is less clear because about 85% of men with varicocele in population-based studies have fathered children (Bogaert et al., 2013; Pinto et al., 1994; Safarinejad, 2008).

Epidemiology and Pathogenesis

The prevalence of clinically diagnosed varicoceles in adolescents is 8% to 16%, similar to the 15% prevalence rates in adults (Akbay et al., 2000; Kumanov et al., 2008; Niedzielski et al., 1997; Skoog et al., 1997; Stavropoulos et al., 2002; Zampieri and Cervellione, 2008). Thus the group of adolescents identified as having a varicocele is presumed to be the same group identified as adults, because varicoceles are not known to resolve spontaneously and rarely manifest in older adults.

The frequency and severity of varicoceles vary with age, method of diagnosis, and Tanner development stage. Most varicoceles appear after 10 years of age, progress through puberty, and peak at Tanner stage 3 (Kumanov et al., 2008). Although historically varicoceles were predominantly left sided, recent reports indicate that identification of right-sided varicoceles in boys is increasing. Bilateral palpable varicoceles were repaired in one-third of 10- to 24-year-old males by Decastro et al. (2009), and CDUS identified subclinical left or bilateral varicoceles in 7% to 17% of cases (Akbay et al., 2000; Cervellione et al., 2008; Pfeiffer et al., 2006). Woldu et al. (2013) identified retrograde blood flow in the right side of 40.3% of 503 adolescents with palpable left-sided varicoceles, of which 44% were subclinical. The clinical implication of these subclinical right-sided varicoceles is unclear. In adults, bilaterality is reported in 15% to 50% of cases (Zini and Boman, 2009).

The pathophysiology of the adolescent varicocele is likely to be multifactorial. **The primary factors are believed to be increased venous pressure in the left renal vein, collateral venous anastomoses, and valvular incompetence of the left internal spermatic vein at its junction with the left renal vein.** Varicocele progression may be related to continuous or spontaneous rather than Valsalva-induced spermatic venous reflux (Cervellione et al., 2008; Pfeiffer et al., 2006; Zampieri and Cervellione, 2008). The “nutcracker phenomenon” (compression of the left renal vein between the aorta and superior mesenteric artery) may account for the varicocele in some boys (Coolsaet, 1980; Kim et al., 2006). The reports by Sakamoto and Ogawa of higher peak and antegrade flow and venous diameter in the prostatic venous plexus of men with bilateral varicoceles versus controls and men with unilateral varicoceles (Sakamoto and Ogawa, 2008) and those showing increased risk of saphenofemoral junction incompetence (Karadeniz-Bilgili et al., 2003) and varicose veins (Kilic et al., 2007) reflect a more generalized venous abnormality. Vanlangenhove et al. (2015) compared venographic information between adults and adolescents with left varicoceles and found reflux in adults to be induced via collateral pathways, whereas in adolescents congenital venous abnormalities such as fewer competent valves and more instances of nutcracker phenomenon were more common. Genetic factors may contribute to the risk; the presence of a varicocele was fourfold to eightfold higher among first-degree relatives of men undergoing vasectomy or male kidney donors, and the incidence was especially high in brothers (Mokhtari et al., 2008; Raman et al., 2005). **A tall, thin body habitus (low body mass index [BMI]) is associated with varicoceles in adolescents and adults internationally** (Bae et al., 2014; Handel et al., 2006; Kumanov et al., 2008; Liu et al., 2017; May et al., 2006b; Nielsen et al., 2006; Tsao et al., 2009), perhaps because of increased spermatic vein length and/or hydrostatic pressure, or perhaps resulting from difficulty in identification during physical examination.

Diagnosis and Classification

The majority of varicoceles in children and adolescents are **identified incidentally** by a primary care practitioner or by the patient on self-examination. Less commonly (2% to 11%), adolescents have concerns regarding discomfort (Zampieri et al., 2008a).

The patient should be examined in the supine and standing positions. The scrotum is inspected for visible swelling, followed by palpation of the spermatic cord at rest and during the Valsalva maneuver. The clinical grading system defines varicoceles as *grade 0* (subclinical): nonpalpable and visualized only by CDUS; *grade 1:* palpable only with Valsalva maneuver; *grade 2:* easily palpable but not visible; and *grade 3:* easily visible. **The veins should decompress in the supine position;** failure to do so, particularly on the right side, warrants evaluation (CT or sonogram) for an abdominal or pelvic mass (Roy et al., 1989). Testicular consistency should be assessed; the affected testis may be soft. **Measurement of testicular volume is important because it may predicate surgical intervention.** The volumes should be assessed based on Tanner stage (Table 44.4). Volume can be determined using the Prader orchidometer (chain of 12 solid wooden ellipsoids of increasing volumes that are visually compared with the size of each testis), the Takihara orchidometer (15 elliptical rings with inner dimensions corresponding to ellipsoid volumes placed over the widest testis circumference), or by ultrasound (measure length, width, and depth and use one of several formulas). All three techniques are reliable, but **ultrasound is more sensitive in determining differences in left and right testicular size** (Chipkevitch et al., 1996; Costabile et al., 1992; Diamond et al., 2000). In a canine study, the use of ultrasound and the Lambert formula provided the most accurate and precise testicular volume estimates (Paltiel et al., 2002).

TABLE 44.4

Testicular Volumes Based on Tanner Stage

TANNER STAGE	DANIEL ET AL., 1982				ZACHMANN ET AL., 1974	
	LEFT TESTIS (cm^3)		RIGHT TESTIS (cm^3)		TOTAL (mL)	
	MEAN	SD	MEAN	SD	MEAN	SD
1	4.8	2.8	5.2	3.9	6.0	2.6
2	6.4	3.2	7.1	3.9	6.8	3.6
3	14.6	6.5	14.8	6.1	9.3	3.8
4	19.8	6.2	20.4	6.8	12.6	4.2
5	28.3	8.5	30.2	9.6	16.3	4.6
6					18.9	4.0

SD, Standard deviation.

The ultrasound criteria for diagnosing a varicocele—spermatic vein diameter and retrograde blood flow—are controversial in adults and more so in adolescents. Niedzielski et al. (1997) measured spermatic vein diameter in the standing position and spermatic venous reflux with Valsalva maneuvers in 625 boys with varicoceles and 50 normal controls. They found normal spermatic vein diameter (<2 mm in normal boys) in 95%, 70%, and 4% of boys with grades 1, 2, and 3 varicocele and spermatic venous blood reflux in two-thirds of boys with grade 2 or 3 varicoceles; flow velocity measured while the patient was standing correlated with varicocele grade and sperm motility. Kozakowski et al. (2009) found that spermatic venous diameter measured in the supine position was a poor criterion for clinical varicocele and did not predict risk of testicular volume loss but that peak retrograde spermatic vein flow with Valsalva maneuvers that exceeded 38 cm/sec strongly correlated with testicular volume asymmetry.

Associated Pathological Processes

There is abundant evidence that a varicocele may alter testicular growth, spermatogenesis, and fertility potential. The cause of testicular injury is presumed to be related to increased scrotal temperature, but the pathogenesis remains poorly understood.

Key Points: Varicocele

- The prevalence of varicoceles in adolescent and adult men is similar, approximately 15%.
- Tall, thin males more commonly have varicoceles, implicating a genetic predisposition.
- Varicoceles are commonly identified on examination and least commonly identified as a result of pain.
- Testicular volume is best measured using ultrasound.
- Testicular hypotrophy of 15% to 20% may arise in the presence of an ipsilateral varicocele that commonly resolves after varicocele repair but can resolve spontaneously as well.
- Trends toward poorer sperm quality may be limited to a subset of affected males with varicocele, but grade and postoperative testicular catch-up growth do not reliably predict ultimate semen quality.
- Surgical success rates are similar with retroperitoneal (open or laparoscopic) or subinguinal approaches. Lymphatic sparing techniques offer the lowest rates of hydrocele formation. The majority of hydroceles require surgical intervention.

Testicular Hypotrophy

In the absence of sufficient direct insight into the potential for subfertility (i.e., semen analysis) associated with varicoceles in adolescents, most attention has been on testicular hypotrophy as a surrogate of pathology and indirect marker surgical success. **A decrease in testicular volume has long been associated with varicoceles** (Lipshultz and Corriere, 1977). Steeno et al. (1976) confirmed the finding in adolescents with grade 2 (34.4% had decreased volume) and 3 (81.2% had decreased volume) varicoceles. The correlation between varicocele grade and left testicular hypotrophy has been confirmed in some studies (Thomas and Elder, 2002; Zampieri et al., 2008b) but not others (Alukal et al., 2005; Kolon et al., 2008). Because ipsilateral volume loss may improve or resolve after varicocele repair, it was inferred that hypotrophy reflects significant testicular injury (Kass and Belman, 1987; Lyon et al., 1982). The global impact, and by extension damage, of varicocele was noted by Kass et al. (2001), who found significantly reduced right testicular size compared with control values in Tanner stage 4 or 5 boys with grade 3 left varicoceles. Okuyama et al. (1988) reported right testicular hypotrophy in 22% of patients with grade 2 or 3 left varicoceles, and lower sperm densities among those with bilaterally small testes. Mean right testicular volume increased significantly after left varicocele repair but not in untreated control groups in several other studies (Laven et al., 1992; Paduch and Niedzielski, 1997; Yamamoto et al., 1995).

Significant hypotrophy is variably defined as a 10%, 15%, 20%, or 2- or 3-mL relative difference in testicular size and is found in 10% to 77% of patients (Akbay et al., 2000; Diamond et al., 2004b; Kolon et al., 2008; Lyon et al., 1982; Okuyama et al., 1988; Preston et al., 2008; Thomas and Elder, 2002). This variability is related to the mode of measurement (see following), referral patterns, and the formula used to determine percent differences. Rapid increases in testicular size may occur as early as 10 years of age and persist until age 19, depending on Tanner stage of pubertal development (see Table 44.3) (Daniel et al., 1982; Matsuo et al., 2000; Rundle and Sylvester, 1962; Schonfeld, 1943; Zachmann et al., 1974). Because size variability can vary widely in individuals (Marshall and Tanner, 1970), longitudinal measurements over several years may more accurately define hypotrophy than isolated measurements, particularly in early puberty.

“Catch-up” growth, defined as normalization of left relative to right testicular size, occurs in 32% to 83% of patients after varicocele repair (Barroso et al., 2009; Castagnetti et al., 2008; Cayan et al., 2002; Decastro et al., 2009; Feber and Kass, 2008; Greenfield et al., 2002; Poon et al., 2009; Yaman et al., 2006; Zampieri et al., 2009). The hypothesis that postoperative resolution of left testicular hypotrophy reflects improved testicular function is challenged by observations that testicular size differential may improve spontaneously in untreated patients (Kolon et al., 2008; Paduch and Niedzielski, 1997). In contrast, others report worsening or development of significant hypotrophy in 10% to 26% of boys over time (Kozakowski et al., 2009; Thomas and Elder, 2002; Zampieri and Cervellione, 2008). Finally, Diamond et al. (2004b) reported no statistical difference in either direction in a longitudinal study. Kocvara et al. (2003) posited that lymphatic ligation contributes to increased postoperative testicular volume after lymphatic and arterial ligation, but this was disproved by reports showing no difference in rates of catch-up growth based on lymphatic (Poon et al., 2009) and/or arterial (Barroso et al., 2009) preservation. Laven et al. (1992) noted that varicocele repair increased the volume of small but not normal-sized testes. Postoperative left testicular hypertrophy (>10% size differential relative to the right testis) is attributed to non–lymphatic-sparing procedures or to a rebound effect on spermatogenesis in the affected testis (Cayan et al., 2002; Gershbein et al., 1999; Kocvara et al., 2005).

Significant discrepancy between left and right testicular size remains the primary indication for varicocele correction. Unfortunately, the currently available data are unclear as to the direct relationship between this discrepancy and testicular function with or without correction. **Prospective, randomized studies are needed to clearly establish whether unilateral and/or bilateral testicular hypotrophy or catch-up growth accurately predicts fertility potential in adolescent varicocele.**

Testicular Histology

The histologic effect of varicoceles is better known in adults but is largely absent and inconsistent in adolescents. In adults (reviewed by Hienz et al., 1980), histology findings vary from normal on light and electron microscopy in all men (Fideleff et al., 2000) or even those with severe hypospermatogenesis (Aragona et al., 1994; Kass et al., 1987) to degenerative tubular changes, altered Leydig cell number, and/or proliferative lesions of the vasculature (Hienz et al., 1980). Hadziselimovic et al. (1995) found abnormal tubular maturation and Leydig cell number in a small series of young men who had testicular biopsies at the time of adolescent varicocele repair; these data failed to correlate with ultimate sperm quality in adulthood.

Hormonal Function

The use of hormonal profiles as a proxy to determine if varicoceles are deleterious to testicular function has been inconclusive. Baseline LH and FSH levels are not consistently different in the presence or absence of varicocele in adolescents (Cayan et al., 2005; Ku et al., 2005; Laven et al., 1992; Yamamoto et al., 1995). Basal and stimulated gonadotropin levels were not consistently different in varicocele patients when compared with controls and did not improve after surgery (Fideleff et al., 2000). GnRH stimulation led to an exaggerated LH and FSH response in about 30% of boys with varicoceles but did not correlate with testicular hypotrophy (Kass et al., 1993a). Inhibin B measurements failed to consistently correlate with testicular size or semen parameters in adolescents (Basar et al., 2010; Blevrakis et al., 2016; Carrillo et al., 1999; Romeo et al., 2007; Turkyilmaz et al., 2006). Guarino et al. (2003) observed increased LH, FSH, and simulated FSH levels in 20 boys with varicoceles and abnormal semen parameters compared with 56 with normal semen, but this was confounded by 30% of boys with bilateral varicoceles, a history of inguinal surgery, or cryptorchidism.

Semen Quality

Semen quality is considered the most useful indicator of fertility potential despite many variables associated with collection and interpretation in adolescents. **Progressive improvement in sperm quality may parallel testicular growth and sexual maturation, and so semen analyses may be best obtained at stabilization of testicular growth, which may not depend on age.** In a study of 194 boys aged 12 to 19 years, Janczewski and Bablok (1985a, 1985b, 1985c, 1985d) found that ejaculation began at a bone age of 13 years (within 16 months of the onset of puberty), and normospermia was achieved by a bone age of 17. There were boys at Tanner stage 5 with asthenozoospermia and occasional oligozoospermia. Mean testicular size increased with progression in semen quality but showed a large SD in boys achieving normospermia; LH and FSH levels significantly declined with attainment of normospermia.

Reliable standards for semen quality based on Tanner stage or age do not exist, and therefore recent studies evaluating semen quality among adolescents with varicoceles depend on comparison with adult standards. In the majority of these studies, at least two semen samples were obtained and World Health

Organization criteria were used; however, Tanner stage 5 was not always specified. Christman et al. (2013) recently advocated a single semen analysis, noting sufficient reproducibility of total mobile count (more variability among other parameters) in adolescents at risk for subfertility (varicocele or cryptorchidism). In two randomized studies comparing treated and untreated patients with controls, no differences were found in semen quality at initial or follow-up analysis between groups, except for a significant postoperative increase in sperm concentrations in the treated group (Laven et al., 1992; Yamamoto et al., 1995), hypothesized to be a rebound in spermatogenesis. Correlations between left or total testicular volume and semen parameters were noted by some investigators (Diamond et al., 2007; Haans et al., 1991; Paduch and Niedzielski, 1996) but not others (Guarino et al., 2003). Christman et al. (2014) reported a low total motile count in 48 of 73 patients (66%) followed for 2.7 years (median) by serial scrotal ultrasound evaluating testicular size and semen analysis at Tanner 5, around age 18 years. Testicular volume differential was not predictive of normal semen volume, density, sperm motility, or total motile count, but total testicular volume from the final ultrasound was predictive of total motile count. Kurtz et al. (2015) associated total testis volume and the testicular volume differential with semen analysis outcomes with a testicular volume differential of greater than 20%, doubling the odds of a low total motile sperm count; a total testis volume of less than 30 cc quadruples the odds of a low total motile sperm count.

Investigators were unable to correlate postoperative increases in left testicular volume or varicocele grade with semen analysis data in controlled (Laven et al., 1992) and uncontrolled (Cayan et al., 2002; Diamond et al., 2007; Zampieri and Cervellione, 2008) studies. **The available data suggest that trends toward poorer sperm quality may be limited to a subset of affected males with varicocele, but grade and postoperative testicular catch-up growth do not reliably predict ultimate semen quality.**

Intratesticular Varicocele

In 1% to 2% of adolescents, a varicocele may include an intratesticular component found on CDUS (Diamond et al., 2004a; MacLachlan et al., 2013). The diagnosis is made by identifying venous flow in anechoic structures greater than 2 mm in diameter near the mediastinum testis that increases during Valsalva maneuvers (Bucci et al., 2008). MacLachlan et al. (2013) found worsening testicular asymmetry that responded to surgical correction and progressed in one patient who refused surgery; they concluded that surgery was indicated in adolescents with intratesticular varicoceles and testicular asymmetry.

Treatment

Observation remains the approach of choice for the majority of adolescents with varicocele until a surgical indication is present. **Despite the aforementioned limitations regarding testicular hypotrophy, the main indications for surgical intervention remain significant left (≥20%) or bilateral testicular hypotrophy, pain, or abnormal semen analysis findings; the last is most reliable in boys of Tanner stage 5 and/or at least 18 years of age.** Pain is a rare indication for surgery, reported in only 2% to 10% of patients in most series, and is relieved by the procedure in 68% to 88% of patients (Zampieri et al., 2008a). Despite the aforementioned general principles guiding evaluation and surgical intervention, there is great variability in management approaches in the pediatric urologic community. In separate surveys, Pastuszak et al. (2014) and Coutinho et al. (2014) reported wide variation in intervention indications, preferred surgical approach, follow up, and use of semen analyses. In a survey that specifically assessed the incorporation of semen analysis in practice, Fine et al. (2016) found that only 13% did so routinely. Nearly half had discomfort in addressing the issue with patients and did not order semen analysis.

Surgical Repair of Varicocele

Several approaches exist to correct the adolescent varicocele: inguinal or subinguinal, laparoscopic or retroperitoneal, or venographic. The surgical decision revolves around (1) whether to spare the testicular artery and/or lymphatics using the available approaches and (2) the effect on the rate of recurrence and hydrocele formation (Table 44.5) (Barroso et al., 2009; Castagnetti et al., 2008; Cayan et al., 2005; Diamond et al., 2009; Esposito et al., 2004; Feber and Kass, 2008; Glassberg et al., 2008; Greenfield et al., 2002; Kocvara et al., 2005; Misseri et al., 2001; Poddoubnyi et al., 2000; Schiff et al., 2005; Tong et al., 2009; Yaman et al., 2006). Long-term outcome data are lacking to support any particular approach because the length of postoperative follow-up may be insufficient to identify potential recurrences (Glassberg et al., 2008) or sequelae such as a hydrocele, which may require 2 years or more to develop (Esposito et al., 2004; Feber and Kass, 2008; Misseri et al., 2001).

Whereas many hydroceles may resolve spontaneously, up to one-half may require formal scrotal repair (Diamond et al., 2009; Esposito et al., 2004; Feber and Kass, 2008; Misseri et al., 2001) or aspiration (Esposito et al., 2004) because of large size or symptoms. Yu et al. (2016) demonstrated no difference in improved semen quality when laparoscopic artery sparing and artery ligation techniques were compared.

TABLE 44.5

Results of Adolescent Varicocele Repair

PROCEDURE	RECURRENCE OR PERSISTENCE	HYDROCELE	TESTICULAR ATROPHY
Open suprainguinal (Palomo)	2%–4%	0–30% (10%)[a]	
Laparoscopic:			
Nonlymphatic or artery sparing	0–9%	11%–32% (7%)[a]	
Artery and/or lymphatic sparing	1%–7%	0–4%	
Microscopic subinguinal	0–10%	0–6%	Rare
Nonmicroscopic inguinal	7%–33%	8%–14%	
Sclerotherapy	6%–35%	Occasional	Rare

[a] Number in parentheses refers to meta-analysis of Barroso et al., 2009.

Subinguinal or Inguinal Microsurgical Varicocelectomy

The *subinguinal microscopic approach* provides the advantages of facilitated artery and lymphatic sparing, high rate of success, and low risk of hydrocele but may be time consuming and requires microscopic surgical skills. The procedure used in children is similar to that used in adults as originally published (see Chapter 67). Use of lower degrees of magnification in adolescents (e.g., loupes) may yield inferior results (Cayan et al., 2005; Diamond et al., 2009; Greenfield et al., 2002) than use of an operating microscope. The subinguinal approach is associated in rare cases with testicular atrophy (necrosis), which has not been reported for suprainguinal procedures (Diamond et al., 2009).

Retroperitoneal and Laparoscopic Varicocelectomy

The ligation of the internal spermatic vessels above the level of the internal inguinal ring is a simple procedure performed by open or laparoscopic approaches with high success rates but higher rates of hydrocele formation. Mass ligation, as described by Palomo (1949), offers a highly successful and efficient surgical result. Although potentially more difficult to isolate the arterial and lymphatic vessels, lymphatic- and/or artery-sparing techniques may reduce the incidence of postoperative hydroceles but have an impact on success rate (Kass and Marcol, 1992) and may not benefit catch-up growth (Fast et al., 2014); this was similarly seen in a cohort of adolescents undergoing laparoscopic varicocelectomy (Kim et al., 2014). Zampieri et al. (2007a, 2007b) reported that sparing the artery was associated with improved semen quality; however, randomized prospective data are lacking that clearly define the effect of artery sparing on testicular function. In theory, testis atrophy may follow spermatic artery ligation in patients with prior inguinal surgery (Skoog et al., 1997) but did not occur after laparoscopic Palomo procedures in a small series (Barqawi et al., 2002). Similarly, testis atrophy may occur after non–artery-sparing varicocelectomy and subsequent surgery that compromises the vasal artery or vein (hernia repair, vasectomy).

The Palomo open procedure is performed through a muscle-splitting incision medial to the anterior superior iliac spine. The peritoneum is mobilized medially to expose the bundle of spermatic vessels, which are isolated, clipped, or suture ligated and left as such, or the vessels are divided according to surgeon preference. To reduce the risk of postoperative hydrocele formation, a microscopic lymphatic-sparing procedure through this incision was described by Wong et al., without recurrence (Wong et al., 2009), and shown to be faster and more reliable than a subinguinal approach by Silveri et al. (2015).

Laparoscopic varicocele repair is performed using three ports. The two working ports are placed in variable locations: left midclavicular line inferior to the umbilicus and lower midline/right lower quadrant, or both lower quadrants, or both on the right side at the lateral rectus margin. The peritoneum above the internal ring is opened and the vascular bundle and surrounding tissue are mobilized. To help identify the artery, a laparoscopic Doppler probe or papaverine can be used. The magnification provided by the laparoscope helps to identify lymphatic channels as clear tubular structures accompanying the artery and veins (Fig. 44.37). The use of vital dyes injected into the paratesticular tissue to identify lymphatics has potential technical challenges and risks if the dye is inadvertently injected into the testis (Esposito et al., 2014b, Ishibashi et al., 2014; Makari et al., 2007; Schwentner et al., 2006). The vessels may be ligated using permanent sutures or clips and transected using the harmonic scalpel or vessel-sealing devices. To avoid recurrence, vein(s) accompanying the artery should be identified and ligated. Cimador et al. (2008) used CDUS to search for dilated, refluxing deferential veins in the iliac fossa, which were also ligated. Injury to the genitofemoral nerve has been reported in a limited number of adolescent and adult series and may be more commonly associated with use of electrocautery (Muensterer, 2008). This complication manifests as postoperative paresthesias along the proximal anterior thigh that slowly resolve over weeks or months.

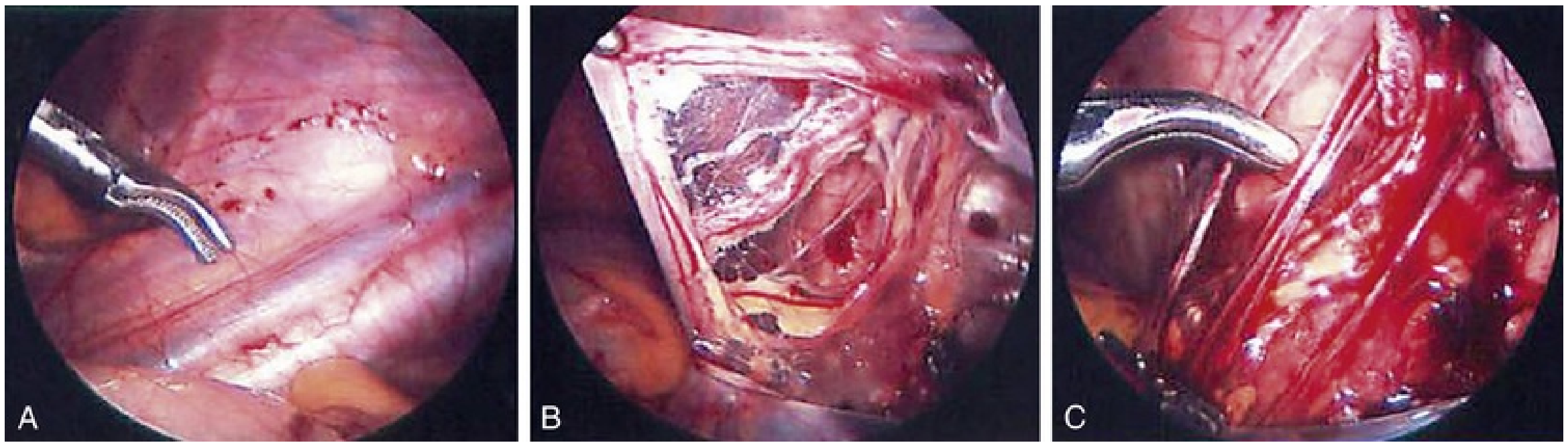

FIG. 44.37 Images from a lymphatic sparing laparoscopic varicocelectomy. (A) Laparoscopic dissector approaches internal spermatic vessels under posterior peritoneum. (B) Vessels have been isolated and elevated off the posterior abdominal wall. (C) Individual lymphatic channels have been teased out and will be spared and the veins divided. (Courtesy Israel Franco, MD.)

Sclerotherapy or Embolotherapy

The published experience with intravascular injection of sclerosant or thrombotic material to occlude varicoceles in adolescents has been limited and mainly applied to cases of recurrent or persistent varicoceles (eFig. 44.38). The **benefit of this approach is to identify and classify the venous collateralization as possible routes of outflow and reflux.** The agents (3% sodium tetradecyl sulfate or polidocanol, with or without intravascular coils or balloons) can be injected in either a retrograde (Alqahtani et al., 2002; Beutner et al., 2007; Granata et al., 2008; May et al., 2006a; Mazzoni et al., 1999; Reiner et al., 2008; Reyes et al., 1994; Sivanathan and Abernethy, 2003) or antegrade fashion. The benefits of the procedure lie in its minimally invasive approach through a transfemoral venous puncture done under local anesthesia (with or without sedation). However, the procedure has generally inferior success rates compared with surgical (open or laparoscopic) procedures, involves radiation exposure, and cannot be completed for technical reasons in 5% to 22% of cases. The follow-up is short in available literature (rarely more than 1 or 2 years), with recurrence rates of 6% to 35%. Self-limiting complications include pain, epididymo-orchitis, phlebitis, or scrotal swelling; partial testicular atrophy and hydrocele occur rarely. Antegrade techniques entail use of a small subinguinal or upper scrotal incision, isolation of a vein or veins amenable to cannulation with or without fluoroscopic confirmation of antegrade flow into the internal spermatic vein, and injection of a sclerosant followed by ligation of the vein (Carmignani et al., 2009; Zaupa et al., 2006). Success rates are reported to be 4% to 12%, lower than for retrograde sclerotherapy, with similar complications. The venographic information gleaned by the procedure identifies aberrant vasculature in about 25% of cases (Malekzadeh et al., 2016; Wong et al., 2014).

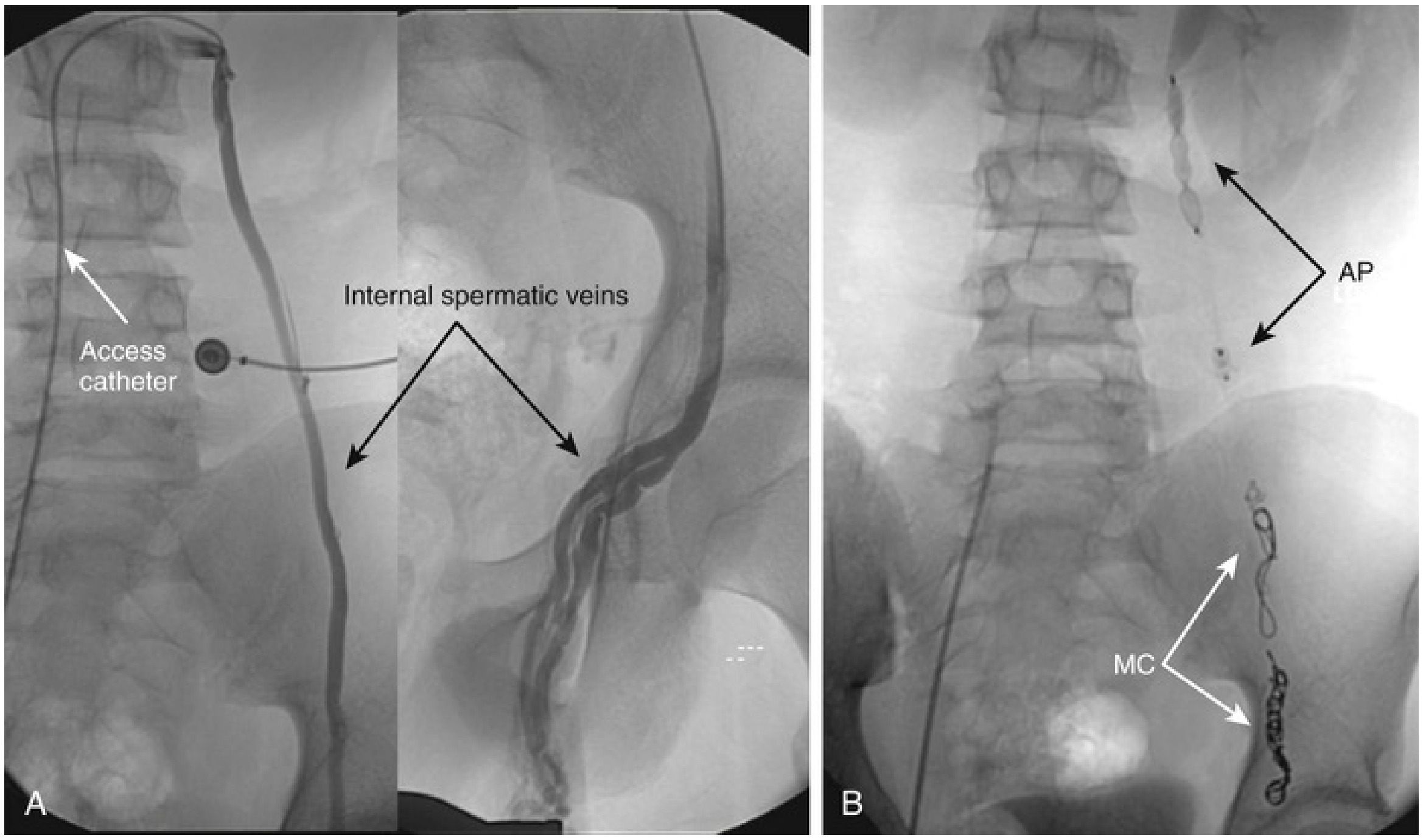

EFIG. 44.38 Antegrade varicocele embolization. (A) The left internal spermatic veins are accessed via the right femoral vein, and venography demonstrates the dilated veins. (B) Postembolization images with two levels of microcoils (MC) and two Amplatzer plugs (AP), representing the typical four levels of embolization. (Courtesy Ardeshir Rastinehad, DO.)

Epididymal and Vasal Anomalies

Congenital anomalies of accessory testicular structures are often associated with primary diseases affecting testicular descent and genital development but may occur as isolated anomalies or as part of syndromes that do not primarily affect the genitalia.

Epididymal cysts are simple cystic structures that may be palpable by the patient or examining physician or found incidentally by ultrasonography (Homayoon et al., 2004). Posey found that over an 8-year period, 14.4% of all boys who underwent scrotal ultrasound had epididymal cyst with increasing incidence with age (35.3% among boys >15 years) (Posey et al., 2010). Epididymal cysts may be clinically indistinguishable from spermatoceles except that the latter occur postpubertally and contain sperm. The pathophysiology of epididymal cysts is unknown but may be related to an altered hormonal environment because they are linked to diethylstilbestrol (DES) exposure (Palmer et al., 2009). These lesions are different ultrasonographically and pathologically from the multicystic, solid epididymal cystadenomas that occur in von Hippel-Lindau disease (Choyke et al., 1997). Homayoon et al. (2004) observed spontaneous resolution of many cysts in their pediatric series, and surgical intervention is rarely needed.

Congenital absence of the vas deferens (CAVD) is in most cases associated with specific mutations of the cystic fibrosis gene *CFTR* (cystic fibrosis transmembrane regulator) that are less severe than those encountered in patients with cystic fibrosis (Kolettis and Sandlow, 2002). The disease can be bilateral (CBAVD) or unilateral (CUAVD) with a normal or obstructed contralateral vas and may be associated with renal agenesis or ectopia and/or partial or complete agenesis of the epididymis and seminal vesicles. *CFTR* mutations are more common in males with CBAVD, and renal anomalies are more common in cases of CUAVD. These patients typically have infertility. Abnormal vasal development may also result in a **persistent mesonephric duct** anomaly that is associated with ipsilateral renal and seminal vesicle agenesis and vasoureteral fusion (Kajbafzadeh and Payabvash, 2006). Reflux into the fused wolffian remnants results in UTI and epididymo-orchitis. Other associated anomalies may include imperforate anus, hypospadias, tracheoesophageal fistula, tetralogy of Fallot, or coarctation of the aorta.

Suggested Readings

Aaronson IA. Micropenis: medical and surgical implications. *J Urol*. 1994;152:4–14.

American Academy of Pediatrics Task Force on Circumcision. Circumcision policy statement. *Pediatrics*. 2012;130(3):585–586.

Baglaj M, Carachi R. Neonatal bilateral testicular torsion: a plea for emergency exploration. *J Urol*. 2007;177:2296–2299.

Barroso U Jr, Andrade DM, Novaes H, et al. Surgical treatment of varicocele in children with open and laparoscopic Palomo technique: a systematic review of the literature. *J Urol*. 2009;181:2724–2728.

Baskin LS, Canning DA, Snyder HM, et al. Treating complications of circumcision. *Pediatr Emerg Care*. 1996;12:62–68.

Baskin LS, Erol A, Li YW, et al. Anatomy of the neurovascular bundle: is safe mobilization possible? *J Urol*. 2000;164:977–980.

Brandt ML. Pediatric hernias. *Surg Clin North Am*. 2008;88:27–43.

Casale AJ, Beck SD, Cain MP, et al. Concealed penis in childhood: a spectrum of etiology and treatment. *J Urol*. 1999;162:1165–1168.

Cost NG, Bush NC, Barber TD, et al. Pediatric testicular torsion: demographics of national orchiopexy versus orchiectomy rates. *J Urol*. 2011;185(6 Suppl):2459–2463.

Cozzi DA, Mele E, Ceccanti S, et al. Infantile abdominoscrotal hydrocele: a not so benign condition. *J Urol*. 2008;180:2611–2615 [discussion 2615].

Cubillos J, Palmer JS, Friedman SC, et al. Familial testicular torsion. *J Urol*. 2011;185(6 Suppl):2469–2472.

Cubillos J, Reda EF, Gitlin J, et al. A conservative approach to testicular rupture in adolescent boys. *J Urol*. 2010;184(4 Suppl):1733–1738.

Diamond DA, Xuewu J, Cilento BG Jr, et al. Varicocele surgery: a decade's experience at a children's hospital. *BJU Int*. 2009;104:246–249.

Eaton SH, Cendron MA, Estrada CR, et al. Intermittent testicular torsion: diagnostic features and management outcomes. *J Urol*. 2005;174:1532–1535 [discussion 1535].

Effman EL, Lebowitz RL, Colodny AH. Duplication of the urethra. *Pediatr Radiol*. 1976;119:179–185.

Esposito C, Turial S, Alicchio F, et al. Laparoscopic repair of incarcerated inguinal hernia. A safe and effective procedure to adopt in children. *Hernia*. 2013;17(2):235–239.

Feber KM, Kass EJ. Varicocelectomy in adolescent boys: long-term experience with the Palomo procedure. *J Urol*. 2008;180:1657–1659.

Friedman AA, Ahmed H, Gitlin JS, et al. Standardized education and parental awareness are lacking for testicular torsion. *J Pediatr Urol*. 2016;12(3):166.e1–166.e8.

Gargollo PC, Diamond DA. Current management of the adolescent varicocele. *Curr Urol Rep*. 2009;10:144–152.

Husmann DA. The androgen insensitive micropenis: long-term follow-up into adulthood. *J Pediatr Endocrinol Metab*. 2004;17:1037–1041.

Kolon TF, Clement MR, Cartwright L, et al. Transient asynchronous testicular growth in adolescent males with a varicocele. *J Urol*. 2008;180:1111–1114.

Laven JS, Haans LC, Mali WP, et al. Effects of varicocele treatment in adolescents: a randomized study. *Fertil Steril*. 1992;58:756–762.

Litvak AS, Morris JA Jr, McRoberts JW. Normal size of the urethral meatus in boys. *J Urol*. 1976;115:736–737.

Maizels M, Zaontz M, Donovan J, et al. Surgical correction of the buried penis: description of a classification system and a technique to correct the disorder. *J Urol*. 1986;136:268–271.

Mansbach JM, Forbes P, Peters C. Testicular torsion and risk factors for orchiectomy. *Arch Pediatr Adolesc Med*. 2005;159:1167–1171.

Misseri R, Gershbein AB, Horowitz M, et al. The adolescent varicocele. II. The incidence of hydrocele and delayed recurrent varicocele after varicocelectomy in a long-term follow-up. *BJU Int*. 2001;87:494–498.

Montague DK, Jarow J, Broderick GA, et al. American Urological Association guideline on the management of priapism. *J Urol*. 2003;170:1318–1324.

Palmer JS. An international view on circumcision. *Dialogues Pediatr Urol*. 2009;4:1.

Palmer JS, Elder JS, Palmer LS. The use of betamethasone to manage the trapped penis following newborn circumcision. *J Urol*. 2005;174:1577–1578.

Redshaw JD, Tran TL, Wallis MC, et al. Epididymitis: a 21-year retrospective review of presentations to an outpatient urology clinic. *J Urol*. 2014;192(4):1203–1207.

Rhodes HL, Corbett HJ, Horwood JF, et al. Neonatal testicular torsion: a survey of current practice amongst paediatric surgeons and urologists in the United Kingdom and Ireland. *J Pediatr Surg*. 2011;46(11):2157–2160.

Ron O, Eaton S, Pierro A. Systematic review of the risk of developing a metachronous contralateral inguinal hernia in children. *Br J Surg*. 2007;94:804–811.

Sessions AE, Rabinowitz R, Hulbert WC, et al. Testicular torsion: direction, degree, duration and disinformation. *J Urol*. 2003;169:663–665.

Sharony R, Bental YA, Eyal O, et al. Correlation between prenatal and postnatal penile and clitoral measurements. *J*

Clin Ultrasound. 2012;40(7):394–398.

Skoog SJ, Belman AB. Aphallia: its classification and management. *J Urol*. 1989;141:589–592.

Visser AJ, Heyns CF. Testicular function after torsion of the spermatic cord. *BJU Int*. 2003;92:200–203.

Walsh PC, Wilson JD, Allen TD, et al. Clinical and endocrinological evaluation of patients with congenital microphallus. *J Urol*. 1978;120:90–95.

Zani A, Eaton S, Hoellwarth M, et al. Management of pediatric inguinal hernias in the era of laparoscopy: results of an international survey. *Eur J Pediatr Surg*. 2014;24(1):9–13.

References

Aaronson IA. Micropenis: medical and surgical implications. *J Urol*. 1994;152:4–14.

Abel EJ, Pettus JA, Snow B. Laparoscopic marsupialization before inguinal repair of large abdominoscrotal hydroceles in infants: observation of natural history and description of technique. *Urology*. 2009;73:507–509.

Abraham MB, Charles A, Gera P, et al. Surgically managed perinatal testicular torsion: a single centre experience. *J Matern Fetal Neonatal Med*. 2016;29(8):1265–1268.

Abu-Rustum RS, Chaaban M. Is 3-dimensional sonography useful in the prenatal diagnosis of ambiguous genitalia? *J Ultrasound Med*. 2009;28:95–97.

Adams RJ, Attia M, Cronan K. Report of 4 cases of testicular rupture in adolescent boys secondary to sports-related trauma. *Pediatr Emerg Care*. 2008;24:847–848.

Afsarlar CE, Ryan SL, Donel E, et al. Standardized process to improve patient flow from the emergency room to the operating room for pediatric patients with testicular torsion. *J Pediatr Urol*. 2016;12(4):233.e1–233.e4.

Aizenstein RI, Wilbur AC, O'Neil HK, et al. Clinical image: MRI of scrotal hemangioma. *J Comput Assist Tomogr*. 1996;20:888–889.

Ajmani ML, Ajmani K. The anatomical basis for the inguinal hernia. *Anat Anz*. 1983;153:245–248.

Akbay E, Cayan S, Doruk E, et al. The prevalence of varicocele and varicocele-related testicular atrophy in Turkish children and adolescents. *BJU Int*. 2000;86:490–493.

Alexakis C, Gordon K, Mellor R, et al. Ano-genital granulomatosis and Crohn's disease: a case series of males presenting with genital lymphoedema. *J Crohns Colitis*.

2017;11(4):454–459.

Alp BF, Irkilata HC, Kibar Y, et al. Comparison of the inguinal and scrotal approaches for the treatment of communicating hydrocele in children. *Kaohsiung J Med Sci*. 2014;30(4):200–205.

Alqahtani A, Yazbeck S, Dubois J, et al. Percutaneous embolization of varicocele in children: a Canadian experience. *J Pediatr Surg*. 2002;37:783–785.

Al-Salem AH. Intrauterine testicular torsion: a surgical emergency. *J Pediatr Surg*. 2007;42:1887–1891.

Al-Taheini KM, Pike J, Leonard M. Acute epididymitis in children: the role of radiologic studies. *Urology*. 2008;71:826–829.

Alter GJ, Trengove-Jones G, Horton CE Jr. Hemangioma of penis and scrotum. *Urology*. 1993;42:205–208.

Altinkilic B, Pilatz A, Weidner W. Detection of normal intratesticular perfusion using color coded duplex sonography obviates need for scrotal exploration in patients with suspected testicular torsion. *J Urol*. 2013;189(5):1853–1858.

Alukal JP, Zurakowski D, Atala A, et al. Testicular hypotrophy does not correlate with grade of adolescent varicocele. *J Urol*. 2005;174:2367–2370.

Alzahem A. Laparoscopic versus open inguinal herniotomy in infants and children: a meta-analysis. *Pediatr Surg Int*. 2011;27(6):605–612.

American Academy of Pediatrics (AAP) Committee on Genetics, Section on Endocrinology, Section on Urology. Evaluation of the newborn with developmental anomalies of the external genitalia. *Pediatrics*. 2000;106:138–142.

American Academy of Pediatrics (AAP) Task Force on Circumcision. Report of the Task Force on Circumcision. *Pediatrics*. 1989;84:388–391.

American Academy of Pediatrics (AAP) Task Force on

Circumcision. Circumcision policy statement. *Pediatrics*. 1999;103:686–693.

American Academy of Pediatrics (AAP) Task Force on Circumcision. Circumcision policy statement. *Pediatrics*. 2012;130(3):585–586.

Ammini AC, Sabherwal U, Mukhopadhyay C, et al. Morphogenesis of the human external male genitalia. *Pediatr Surg Int*. 1997;12:401–406.

Anderson JB, Williamson RC. The fate of the human testes following unilateral torsion of the spermatic cord. *Br J Urol*. 1986;58:698–704.

Anderson JB, Williamson RC. Fertility after torsion of the spermatic cord. *Br J Urol*. 1990;65:225–230.

Anderson MJ, Dunn JK, Lipshultz LI, et al. Semen quality and endocrine parameters after acute testicular torsion. *J Urol*. 1992;147:1545–1550.

Anderson PA, Giacomantonio JM. The acutely painful scrotum in children: review of 113 consecutive cases. *Can Med Assoc J*. 1985;132:1153–1155.

Aragona F, Ragazzi R, Pozzan GB, et al. Correlation of testicular volume, histology and LHRH test in adolescents with idiopathic varicocele. *Eur Urol*. 1994;26:61–66.

Arap MA, Vicentini FC, Cocuzza M, et al. Late hormonal levels, semen parameters, and presence of antisperm antibodies in patients treated for testicular torsion. *J Androl*. 2007;28:528–532.

Arda IS, Ozyaylali I. Testicular tissue bleeding as an indicator of gonadal salvageability in testicular torsion surgery. *BJU Int*. 2001;87:89–92.

Arena F, Nicotina PA, Romeo C, et al. Prenatal testicular torsion: ultrasonographic features, management and histopathological findings. *Int J Urol*. 2006;13:135–141.

Auvert B, Sobngwi-Tambekou J, Cutler E, et al. Effect of male circumcision on the prevalence of high-risk human papillomavirus in young men: results of a randomized controlled trial conducted in Orange Farm, South Africa. *J Infect Dis*. 2009;199:14–19.

Avolio L, Chiari G, Caputo MA, et al. Abdominoscrotal hydrocele in childhood: is it really a rare entity? *Urology*. 2000;56:1047–1049.

Bae K, Shin HS, Jung HJ, et al. Adolescent varicocele: are somatometric parameters a cause? *Korean J Urol*. 2014;55(8):533–535.

Baglaj M, Carachi R. Neonatal bilateral testicular torsion: a plea for emergency exploration. *J Urol*. 2007;177:2296–2299.

Bailey RC, Moses S, Parker CB, et al. Male circumcision for HIV prevention in men in Kisumu, Kenya: a randomized trial. *Lancet*. 2007;369:643–656.

Baldisserotto M, de Souza JC, Pertence AP, et al. Color Doppler sonography of normal and torsed testicular appendages in children. *AJR Am J Roentgenol*. 2005;184:1287–1292.

Bale PM, Lochhead A, Martin HC, et al. Balanitis xerotica obliterans in children. *Pediatr Pathol*. 1987;7:617–627.

Bamberg C, Brauer M, Degenhardt P, et al. Prenatal two- and three-dimensional imaging in two cases of severe penoscrotal hypospadias. *J Clin Ultrasound*. 2011;39(9):539–543.

Barbosa JA, Tiseo BC, Barayan GA, et al. Development and initial validation of a scoring system to diagnose testicular torsion in children. *J Urol*. 2013;189(5):1859–1864.

Barqawi A, Furness P 3rd, Koyle M. Laparoscopic Palomo varicocelectomy in the adolescent is safe after previous ipsilateral inguinal surgery. *BJU Int*. 2002;89:269–272.

Barroso U Jr, Andrade DM, Novaes H, et al. Surgical treatment of varicocele in children with open and laparoscopic Palomo technique: a systematic review of the literature. *J Urol*. 2009;181:2724–2728.

Barthold JS, Redman JF. Association of epididymal anomalies with patent processus vaginalis in hernia, hydrocele and cryptorchidism. *J Urol*. 1996;156:2054–2056.

Bar-Yosef Y, Binyamini J, Matzkin H, et al. Degloving and realignment—simple repair of isolated penile torsion. *Urology*. 2007;69:369–371.

Basar MM, Kisa U, Tuglu D, et al. The effect of varicocele on seminal plasma and serum inhibin-B levels in adolescent and adult men. *Int Urol Nephrol*. 2010;42(1):47–51.

Baskin LS. Fetal genital anatomy reconstructive implications. *J Urol*. 1999;162:527–529.

Baskin LS, Canning DA, Snyder HM, et al. Treating complications of circumcision. *Pediatr Emerg Care*. 1996;12:62–68.

Baskin LS, Erol A, Li YW, et al. Anatomy of the neurovascular bundle: is safe mobilization possible? *J Urol*. 2000;164:977–980.

Bauer R, Kogan BA. Modern technique for penile torsion repair. *J Urol*. 2009;182:286–290.

Bayne A, Paduch D, Skoog SJ. Pressure, fluid and anatomical characteristics of abdominoscrotal hydroceles in infants. *J Urol*. 2008;180:1720–1723.

Bayne AP, Madden-Fuentes RJ, Jones EA, et al. Factors associated with delayed treatment of acute testicular torsion—do demographics or interhospital transfer matter? *J Urol*. 2010;184(4 Suppl):1743–1747.

Beasley SW, McBride CA. The risk of metachronous (asynchronous) contralateral torsion following perinatal torsion. *N Z Med J*. 2005;118:U1575.

Belman AB. Abdominoscrotal hydrocele in infancy: a review and presentation of the scrotal approach for correction. *J Urol*. 2001;165:225–227.

Ben Chaim J, Livne PM, Binyamini J, et al. Complications of circumcision in Israel: a one year multicenter survey. *Isr Med Assoc J*. 2005;7:368–370.

Bennett RT, Gill B, Kogan SJ. Epididymitis in children: the circumcision factor? *J Urol*. 1998;160:1842–1844.

Bentley DF, Ricchiuti DJ, Nasrallah PF, et al. Spermatic cord torsion with preserved testis perfusion: initial anatomical observations. *J Urol*. 2004;172:2373–2376.

Bergeson PS, Hopkin RJ, Bailey RB Jr, et al. The inconspicuous penis. *Pediatrics*. 1993;92:794–799.

Bertozzi M, Melissa B, Magrini E, et al. Laparoscopic herniorrhaphy in the pediatric age group: what about the learning curve? *J Endourol*. 2013;27(7):840–844.

Beutner S, May M, Hoschke B, et al. Treatment of varicocele with reference to age: a retrospective comparison of three minimally invasive procedures. *Surg Endosc*. 2007;21:61–65.

Bhat A, Bhat MP, Saxena G. Correction of penile torsion by mobilization of urethral plate and urethra. *J Pediatr Urol*. 2009;5(6):451–457.

Bin-Abbas B, Conte FA, Grumbach MM, et al. Congenital hypogonadotropic hypogonadism and micropenis: effect of testosterone treatment on adult penile size—why sex reversal is not indicated. *J Pediatr*. 1999;134:579–583.

Bleustein CV, Fogarty JD, Eckholdt H, et al. Effect of neonatal circumcision on penile neurologic sensation. *Urology*. 2005;65:773–777.

Blevrakis E, Chatzidarellis E, Anyfantakis D, et al. Impact of varicocele on biological markers of gonadal function. *Hernia*. 2016;20(3):435–439.

Bogaert G, Orye C, De Win G. Pubertal screening and treatment for varicocele do not improve chance of paternity as adult. *J Urol*. 2013;189(6):2298–2303.

Bolt RJ, Peelen W, Nikkels PG, et al. Congenital lymphoedema of the genitalia. *Eur J Pediatr*. 1998;157:943–946.

Bonacorsi S, Lefevre S, Clermont O, et al. *Escherichia coli* strains causing urinary tract infection in uncircumcised infants resemble urosepsis-like adult strains. *J Urol*. 2005;173:195–197.

Borsellino A, Spagnoli A, Vallasciani S, et al. Surgical approach to concealed penis: technical refinements and outcome. *Urology*. 2007;69:1195–1198.

Bradford RK, Choudhary AK. Imaging findings of juvenile xanthogranuloma of the penis. *Pediatr Radiol*. 2009;39:176–179.

Bradley SJ, Oliver GD, Chernick AB, et al. Experiment of nurture: ablatio penis at 2 months, sex reassignment at 7 months, and a psychosexual follow-up in young adulthood. *Pediatrics*. 1998;102:E9.

Brandt ML. Pediatric hernias. *Surg Clin North Am*. 2008;88:27–43 [vii–viii].

Brandt MT, Sheldon CA, Wacksman J, et al. Prenatal testicular torsion: principles of management. *J Urol*. 1992;147:670–672.

Brasso K, Andersen L, Kay L, et al. Testicular torsion: a follow-up study. *Scand J Urol Nephrol*. 1993;27:1–6.

Brisson PA, Patel HI, Feins NR. Revision of circumcision in children: report of 56 cases. *J Pediatr Surg*. 2002;37:1343–1346.

Bruch SW, Meuli M, Harrison MR. Immediate reconstruction for penile agenesis. *J Pediatr Surg*. 1996;30:1152–1153.

Bruno D, Wigfall DR, Zimmerman SA, et al. Genitourinary complications of sickle cell disease. *J Urol*. 2001;166:803–811.

Bucci S, Liguori G, Amodeo A, et al. Intratesticular varicocele: evaluation using grey scale and color Doppler ultrasound. *World J Urol*. 2008;26:87–89.

Bukowski TP, Lewis AG, Reeves D, et al. Epididymitis in older boys: dysfunctional voiding as an etiology. *J Urol*. 1995;154:762–765.

Burgmeier C, Dreyhaupt J, Schier F. Gender-related differences of inguinal hernia and asymptomatic patent processus vaginalis in term and preterm infants. *J Pediatr Surg*. 2015;50(3):478–480.

Burks DD, Markey BJ, Burkhard TK, et al. Suspected testicular torsion and ischemia: evaluation with color Doppler sonography. *Radiology*. 1990;175:815–821.

Burnett AL. Molecular pharmacotherapeutic targeting of PDE5 for preservation of penile health. *J Androl*. 2008;29:3–14.

Burnett AL, Bivalacqua TJ, Champion HC, et al. Long-term oral phosphodiesterase 5 inhibitor therapy alleviates recurrent priapism. *Urology*. 2006;67:1043–1048.

Bush NC, Bagrodia A. Initial results for combined orchiectomy and prosthesis exchange for unsalvageable testicular torsion in adolescents: description of intravaginal prosthesis placement at orchiectomy. *J Urol*. 2012;188(4 Suppl):1424–1428.

Caesar RE, Kaplan GW. Incidence of the bell-clapper deformity in an autopsy series. *Urology*. 1994;44:114–116.

Caesar RE, Kaplan GW. The incidence of the cremasteric reflex in normal boys. *J Urol*. 1994;152:779–780.

Caldamone AA, Chen SC, Elder JS, et al. Congenital anterior urethrocutaneous fistula. *J Urol*. 1999;162:1430–1432.

Caldamone AA, Valvo JR, Altebarmakian VK, et al. Acute scrotal swelling in children. *J Pediatr Surg*. 1984;19:581–584.

Calikoglu AS. Should boys with micropenis be reared as girls? *J Pediatr*. 1999;134:537–538.

Callewaert P, Stockx L, Bogaert G, et al. Post-traumatic high-flow priapism in a 6 year old boy: management by percutaneous placement of bilateral vascular coils. *Urology*.

1998;52:134–137.

Calonge WM, Heitor F, Castro LP, et al. Neonatal paratesticular neuroblastoma misdiagnosed as in utero torsion of testis. *J Pediatr Hematol Oncol*. 2004;26:693–695.

Cappele O, Liard A, Barret E, et al. Epididymitis in children: is further investigation necessary after the first episode? *Eur Urol*. 2000;38:627–630.

Capraro GA, Coughlin BF, Mader TJ, et al. Testicular cooling associated with testicular torsion and its detection by infrared thermography: an experimental study in sheep. *J Urol*. 2008;180:2688–2693.

Carmignani L, Casellato S, Galasso G, et al. Sclerotherapy of the pampiniform plexus with modified Marmar technique in children and adolescents. *Urol Int*. 2009;82:187–190.

Carrillo A, Gershbein A, Glassberg KI, et al. Serum inhibin B levels and the response to gonadotropin stimulation test in pubertal boys with varicocele. *J Urol*. 1999;162:875–877.

Cartwright PC, Snow BW, McNees DC. Urethral meatotomy in the office using topical EMLA cream for anesthesia. *J Urol*. 1996;156:857–858.

Casale AJ, Beck SD, Cain MP, et al. Concealed penis in childhood: a spectrum of etiology and treatment. *J Urol*. 1999;162:1165–1168.

Casale AJ, Menashe DS. Massive strawberry hemangioma of the male genitalia. *J Urol*. 1989;141:593–594.

Cassar S, Bhatt S, Paltiel HJ, et al. Role of spectral Doppler sonography in the evaluation of partial testicular torsion. *J Ultrasound Med*. 2008;27:1629–1638.

Castagnetti M, Cimador M, Catalano P, et al. Evolving management of adolescent varicocele. *J Pediatr Urol*. 2008;4:107–112.

Castilla EE, Sod R, Anzorena O, et al. Neonatal testicular torsion in two brothers. *J Med Genet*. 1975;12:112–113.

Cayan S, Acar D, Ulger S, et al. Adolescent varicocele repair: long-term results and comparison of surgical techniques according to optical magnification use in 100 cases at a single university hospital. *J Urol*. 2005;174:2003–2006.

Cayan S, Akbay E, Bozlu M, et al. The effect of varicocele repair on testicular volume in children and adolescents with varicocele. *J Urol*. 2002;168:731–734.

Celayir AC, Akyuz U, Ciftlik H, et al. A critical observation about the pathogenesis of abdominoscrotal hydrocele. *J Pediatr Surg*. 2001;36:1082–1084.

Cendron J, Melin Y. Congenital curvature of the penis without hypospadias. *Urol Clin North Am*. 1981;8:389–395.

Cervellione RM, Corroppolo M, Bianchi A. Subclinical varicocele in the pediatric age group. *J Urol*. 2008;179:717–719.

Chakrabarty A, Upadhyay J, Dhabuwala CB, et al. Priapism associated with sickle cell hemoglobinopathy in children: long-term effects on potency. *J Urol*. 1996;155:1419–1423.

Chalmers RJ, Burton PA, Bennett RF, et al. Lichen sclerosus et atrophicus: a common and distinctive cause of phimosis in boys. *Arch Dermatol*. 1984;120:1025–1027.

Chamberlain SA, Kirsch AJ, Thall EH, et al. Testicular dysmorphism associated with abdominoscrotal hydroceles during infancy. *Urology*. 1995;46:881–882.

Chan KL, Hui WC, Tam PK. Prospective randomized single-center, single-blind comparison of laparoscopic vs. open repair of pediatric inguinal hernia. *Surg Endosc*. 2005;19:927–932.

Chang YT, Lin JY, Lee JY, et al. Comparative mid-term results between inguinal herniotomy and single-port laparoscopic herniorrhaphy for pediatric inguinal hernia. *Surg Laparosc Endosc Percutan Tech*. 2012;22(6):526–531.

Cheikhelard A, Luton D, Philippe-Chomette P, et al. How accurate is the prenatal diagnosis of abnormal genitalia? *J Urol*. 2000;164:984–987.

Chen JS, Lin YM, Yang WH. Diurnal temperature change is associated with testicular torsion: a nationwide, population based study in Taiwan. *J Urol*. 2013;190(1):228–232.

Chen LE, Zamakhshary M, Foglia RP, et al. Impact of wait time on outcome for inguinal hernia repair in infants. *Pediatr Surg Int*. 2009;25:223–227.

Chin T, Liu C, Wei C. The morphology of the contralateral internal inguinal rings is age-dependent in children with unilateral inguinal hernia. *J Pediatr Surg*. 1995;30(12):1663–1665.

Ching CB, Palmer JS. Circumcision revision for asymmetric redundant skin resulting in minimal suture lines. *Can J Urol*. 2008;15:4304.

Ching CB, Palmer JS. Collateral urethral duplication. *Dial Ped Urol*. 2008;29:16–17.

Chipkevitch E, Nishimura RT, Tu DG, et al. Clinical measurement of testicular volume in adolescents: comparison of the reliability of 5 methods. *J Urol*. 1996;156:2050–2053.

Chiu B, Chen CS, Keller JJ, et al. Seasonality of testicular torsion: a 10-year nationwide population based study. *J Urol*. 2012;187(5):1781–1785.

Chmelnik M, Schenk JP, Hinz U, et al. Testicular torsion: sonomorphological appearance as a predictor for testicular viability and outcome in neonates and children. *Pediatr Surg Int*. 2010;26(3):281–286.

Choi SK, Han SW, Kim DH, et al. Transdermal dihydrotestosterone therapy and its effects on patients with microphallus. *J Urol*. 1993;150:657–660.

Choi W, Hall NJ, Garriboli M, et al. Outcomes following laparoscopic inguinal hernia repair in infants compared with older children. *Pediatr Surg Int*. 2012;28(12):1165–1169.

Choyke PL, Glenn GM, Wagner JP, et al. Epididymal cystadenomas in von Hippel-Lindau disease. *Urology*. 1997;49:926–931.

Christakis DA, Harvey E, Zerr DM, et al. A trade-off analysis of routine newborn circumcision. *Pediatrics*. 2000;105:246–249.

Christensen T, Cartwright PC, Devries C, et al. New onset of hydroceles in boys over 1 year of age. *Int J Urol*. 2006;13:1425–1427.

Christman MS, Kraft KH, Tasian GE, et al. Reproducibility and reliability of semen analysis in youths at risk for infertility. *J Urol*. 2013;190(2):683–688.

Christman MS, Zderic SA, Canning DA, et al. Active surveillance of the adolescent with varicocele: predicting semen outcomes from ultrasound. *J Urol*. 2014;191(5):1401–1406.

Chun K, St-Vil D. Scrotoschisis associated with contralateral meconium periorchitis. *J Pediatr Surg*. 1997;32:864–866.

Cimador M, Di Pace MR, Castagnetti M, et al. Comprehensive laparoscopic approach to pediatric varicocele based on preoperative color Doppler ultrasound assessment. *Surg Endosc*. 2008;22:701–705.

Clatworthy HW, Thompson AG. Incarcerated and strangulated inguinal hernia in infants: a preventable risk. *J Am Med Assoc*. 1954;154:123.

Collins K, Broecker BH. Familial torsion of the spermatic cord. *J Urol*. 1989;141:128–129.

Coolsaet BL. The varicocele syndrome: venography determining the optimal level for surgical management. *J Urol*. 1980;124:833–839.

Cost NG, Bush NC, Barber TD, et al. Pediatric testicular torsion: demographics of national orchiopexy versus orchiectomy rates. *J Urol*. 2011;185(6 Suppl):2459–2463.

Costabile RA, Skoog S, Radowich M. Testicular volume assessment in the adolescent with a varicocele. *J Urol*. 1992;147:1348–1350.

Coutinho K, McLeod D, Stensland K, et al. Variations in the management of asymptomatic adolescent grade 2 or 3 left varicoceles: a survey of practitioners. *J Pediatr Urol*. 2014;10(3):430–434.

Couper RT. Methaemoglobinaemia secondary to topical lignocaine/prilocaine in a circumcised neonate. *J Paediatr Child Health*. 2000;36:406–407.

Cozzi DA, Mele E, Ceccanti S, et al. Infantile abdominoscrotal hydrocele: a not so benign condition. *J Urol*. 2008;180:2611–2615.

Craig JC, Knight JF, Suresh Kumar P, et al. Effect of circumcision on incidence of urinary tract infection in preschool boys. *J Pediatr*. 1996;128:23–27.

Cromie WJ, Ritchey ML, Smith RC, et al. Anatomical alignment for correction of buried penis. *J Urol*. 1998;160:1482–1484.

Cubillos J, George A, Gitlin J, et al. Tailored sutureless meatoplasty: a new technique for correcting meatal stenosis. *J Pediatr Urol*. 2012;8(1):92–96.

Cubillos J, Palmer JS, Friedman SC, et al. Familial testicular torsion. *J Urol*. 2011;185(6 Suppl):2469–2472.

Cubillos J, Reda EF, Gitlin J, et al. A conservative approach to testicular rupture in adolescent boys. *J Urol*. 2010;184(4 Suppl):1733–1738.

Cuervo JL, Grillo A, Vecchiarelli C, et al. Perinatal testicular torsion: a unique strategy. *J Pediatr Surg*. 2007;42:699–703.

Cuervo JL, Ibarra H, Molina M. Abdominoscrotal hydrocele: its particular characteristics. *J Pediatr Surg*. 2009;44:1766–1770.

Cunningham LN, Keating MA, Snyder HM, et al. Urological manifestations of the popliteal pterygium syndrome. *J Urol*. 1989;141:910–912.

Cunningham RF. Familial occurrence of testicular torsion. *J Am Med Assoc*. 1960;174:1330–1331.

Daniel WA Jr, Feinstein RA, Howard-Peebles P, et al. Testicular volumes of adolescents. *J Pediatr*. 1982;101:1010–1012.

Danish RK, Lee PA, Mazur T, et al. Micropenis: II. Hypogonadotropic hypogonadism. *Johns Hopkins Med J*. 1980;146:177–184.

Das S, Brosman SA. Duplication of the male urethra. *J Urol*. 1977;117:452–454.

Das S, Singer A. Controversies of perinatal torsion of the spermatic cord: a review, survey and recommendations. *J Urol*. 1990;143:231–233.

De Castro R, Merlini E, Rigamonti W, et al. Phalloplasty and urethroplasty in children with penile agenesis: preliminary report. *J Urol*. 2007;177:1112–1116.

De Castro R, Rondon A, Barroso U Jr, et al. Phalloplasty and urethroplasty in a boy with penile agenesis. *J Pediatr Urol*. 2013;9(1):108.e1–108.e2.

Dean JA, Horton CE. Diphallia and duplication. *Plast Reconstr Surg*. 1991;87:358–361.

Decastro GJ, Shabsigh A, Poon SA, et al. Adolescent varicocelectomy—is the potential for catch-up growth related to age and/or Tanner stage? *J Urol*. 2009;181:322–327.

Dehner LP. Juvenile xanthogranulomas in the first two decades of life: a clinicopathologic study of 174 cases with cutaneous and extracutaneous manifestations. *Am J Surg Pathol*. 2003;27:579.

Dewan PA, Tan HL, Auldist AW, et al. Priapism in childhood. *Br J Urol*. 1989;64:541–545.

Diamond DA, Paltiel HJ, DiCanzio J, et al. Comparative assessment of pediatric testicular volume: orchidometer versus ultrasound. *J Urol*. 2000;164:1111–1114.

Diamond DA, Roth JA, Cilento BG, et al. Intratesticular varicocele in adolescents: a reversible anechoic lesion of the testis. *J Urol*. 2004;171:381–383.

Diamond DA, Xuewu J, Cilento BG Jr, et al. Varicocele surgery: a decade's experience at a children's hospital. *BJU Int*. 2009;104:246–249.

Diamond DA, Zurakowski D, Atala A, et al. Is adolescent varicocele a progressive disease process? *J Urol*. 2004;172:1746–1748.

Diamond DA, Zurakowski D, Bauer SB, et al. Relationship of varicocele grade and testicular hypotrophy to semen parameters in adolescents. *J Urol*. 2007;178:1584–1588.

Diamond M. Pediatric management of ambiguous and traumatized genitalia. *J Urol*. 1999;162:1021–1028.

Diamond M, Sigmundson HK. Sex reassignment at birth: long term review and clinical implications. *Arch Pediatr Adolesc Med*. 1997;151:298–304.

Diana A, Gaze H, Laubscher B, et al. A case of pediatric Henoch-Schönlein purpura and thrombosis of spermatic veins. *J Pediatr Surg*. 2000;35:1843.

Dias Filho AC, Alves JR, Filho Buson H, et al. The amount of spermatic cord rotation magnifies the time related orchidectomy risk in intravaginal testicular torsion. *Int Braz J Urol*. 2016;42(6):1210–1219.

Dresner ML. Torsed appendage: diagnosis and management: blue dot sign. [In] Dias AC, Alves JR, Buson H, Oliveira PG. *Urology*. 1973:63–66.

Eaton SH, Cendron MA, Estrada CR, et al. Intermittent testicular torsion: diagnostic features and management outcomes. *J Urol*. 2005;174:1532–1535.

Ebbehoj J. A new operation for priapism. *Scand J Plast Reconstr Surg*. 1974;8:241–242.

Effman EL, Lebowitz RL, Colodny AH. Duplication of the urethra. *Pediatr Radiol*. 1976;119:179–185.

Efrat Z, Perri T, Ramati E, et al. Fetal gender assignment by first-trimester ultrasound. *Ultrasound Obstet Gynecol*. 2006;27:619–621.

Ehrlich RP, Scardino PT. Surgical correction of scrotal transposition and perineal hypospadias. *J Pediatr Surg*. 1982;17:175–177.

Ein SH, Njere I, Ein A. Six thousand three hundred sixty-one pediatric inguinal hernias: a 35-year review. *J Pediatr Surg*. 2006;41:980–986.

Elder JS. Epididymal anomalies associated with hydrocele/hernia and cryptorchidism: implications regarding testicular descent. *J Urol*. 1992;148:624–626.

Elder JS. Circumcision, urethral prolapse, penile torsion, buried penis, webbed penis and megalourethra. Frank JD, Gearhart JP, Snyder HM III. *Operative pediatric urology*. ed 2. Churchill Livingstone: London; 2001:273–285.

Elder JS, Jeffs RD. Suprainguinal ectopic scrotum and associated anomalies. *J Urol*. 1982;127:336–338.

Emam AT, Awad FM, Elsayed EA, et al. Cystic dysplasia of the rete testis: ultrasound and magnetic resonance imaging findings. *Saudi J Kidney Dis Transpl*. 2012;23:559–561.

Endo M, Watanabe T, Nakano M, et al. Laparoscopic completely extraperitoneal repair of inguinal hernia in children: a single-institute experience with 1,257 repairs compared with cut-down herniorrhaphy. *Surg Endosc*. 2009;23:1706–1712.

Ercole CJ, Pontes JE, Pierce JM Jr. Changing surgical concepts in the treatment of priapism. *J Urol*. 1981;125(2):210–211.

Eroglu E, Bastian OW, Ozkan HC, et al. Buried penis after newborn circumcision. *J Urol*. 2009;181:1841–1843.

Esposito C, Montinaro L, Alicchio F, et al. Laparoscopic treatment of inguinal hernia in the first year of life. *J Laparoendosc Adv Surg Tech A*. 2010;20(5):473–476.

Esposito C, St Peter SD, Escolino M, et al. Laparoscopic versus open inguinal hernia repair in pediatric patients: a systematic review. *J Laparoendosc Adv Surg Tech A*. 2014;24(11):811–818.

Esposito C, Iaquinto M, Escolino M, et al. Technical standardization of laparoscopic lymphatic sparing varicocelectomy in children using isosulfan blue. *J Pediatr Surg*. 2014;49(4):660–663.

Esposito C, Turial S, Alicchio F, et al. Laparoscopic repair of incarcerated inguinal hernia. A safe and effective procedure to adopt in children. *Hernia*. 2013;17(2):235–239.

Esposito C, Valla JS, Najmaldin A, et al. Incidence and management of hydrocele following varicocele surgery in children. *J Urol*. 2004;171:1271–1273.

Evans JA, Erdile LB, Greenberg CR, et al. Agenesis of the penis: patterns of associated malformations. *Am J Med Genet*. 1999;84:47–55.

Farrell RW, Sparnon AL. Complete epispadiac urethral duplication. *J Pediatr Surg*. 1987;22(2):175–176.

Farrow GA, Thompson S. Incarcerated inguinal hernia in infants and children: a five year review at the Hospital for Sick Children, Toronto, 1955–1959 inclusive. *Can J Surg*. 1963;6:63.

Fasching G, Hollwarth ME. Risk of testicular lesions following incarcerated inguinal hernia in infants. *Pediatr Surg Int*. 1989;4:265.

Fast AM, Deibert CM, Van Batavia JP, et al. Adolescent varicocelectomy: does artery sparing influence recurrence rate and/or catch-up growth? *Andrology*. 2014;2(2):159–164.

Favorito LA, Balassiano CM, Rosado JP, et al. Structural analysis of the phimotic prepuce in patients with failed topical treatment compared with untreated phimosis. *Int Braz J Urol*. 2012;38(6):802–808.

Fearne C, Abela M, Aquilina D. Scrotal approach for inguinal hernia and hydrocele repair in boys. *Eur J Pediatr Surg*. 2002;12:116–117.

Feber KM, Kass EJ. Varicocelectomy in adolescent boys: long-term experience with the Palomo procedure. *J Urol*. 2008;180:1657–1659.

Fenster H, Jequier S, Mackie GG. Unusual case of urethral duplication. *Urology*. 1980;16:80–81.

Ferrer FA, McKenna PH. Cavernous hemangioma of the scrotum: a rare benign genital tumor of childhood. *J Urol*. 1995;153:1262–1264.

Ferro F, Lais A, Orazi C, et al. Abdominoscrotal hydrocele in childhood: report of four cases and review of the literature. *Pediatr Surg Int*. 1995;10:276–278.

Fideleff HL, Boquete HR, Suarez MG, et al. Controversies in the evolution of paediatric-adolescent varicocele: clinical, biochemical and histological studies. *Eur J Endocrinol*. 2000;143:775–781.

Figueroa V, Pippi Salle JL, Braga LH, et al. Comparative analysis of detorsion alone versus detorsion and tunica albuginea decompression (fasciotomy) with tunica vaginalis flap coverage in the surgical management of prolonged testicular ischemia. *J Urol*. 2012;188(4 Suppl):1417–1422.

Fine RG, Gitlin J, Reda EF, et al. Barriers to use of semen analysis in the adolescent with a varicocele: survey of patient, parental, and practitioner attitudes. *J Pediatr Urol*. 2016;12(1):41.e1–41.e6.

Fink KS, Carson CC, DeVellis RF. Adult circumcision outcomes study: effect on erectile function, penile sensitivity, sexual activity and satisfaction. *J Urol*. 2002;167:2113–2116.

Fisch H, Laor E, Reid RE, et al. Gonadal dysfunction after testicular torsion: luteinizing hormone and follicle-stimulating hormone response to gonadotropin releasing hormone. *J Urol*. 1988;139:961–964.

Flum AS, Chaviano AH, Kaplan WE. Hemiscrotal agenesis: new variation in a rare anomaly. *Urology*. 2012;79(1):210–211.

Frank JD, O'Brien M. Fixation of the testis. *BJU Int*. 2002;89(4):331–333.

Frenkl TL, Agarwal S, Caldamone AA. Results of a simplified technique for buried penis repair. *J Urol*. 2004;171:826–828.

Friedman AA, Ahmed H, Gitlin JS, et al. Standardized education and parental awareness are lacking for testicular torsion. *J Pediatr Urol*. 2016;12(3):166.e1–166.e8.

Friedman AA, Palmer LS, Maizels M, et al. Pediatric acute scrotal pain: a guide to patient assessment and triage. *J Pediatr Urol*. 2016;12(2):72–75.

Friedman AA, Zelkovic PF, Reda EF, et al. Male and female aphallia associated with severe urinary tract dysplasia. *J Pediatr Urol*. 2016;12(4):268.e1–268.e7.

Friedman J. Priapism: an unusual presentation of appendicitis. *Pediatr Emerg Care*. 1998;14:143–144.

Garaffa G, Spilotros M, Christopher NA, et al. Total phallic reconstruction using radial artery based free flap phalloplasty in patients with epispadias-exstrophy complex. *J Urol*. 2014;192(3):814–820.

Gargollo PC, Kozakewich HP, Bauer SB, et al. Balanitis xerotica obliterans in boys. *J Urol*. 2005;174:1409–1412.

Gearhart PJ, Rock JA. Total ablation of the penis after circumcision with electrocautery: a method of management and long-term followup. *J Urol*. 1989;142:799–801.

Geiger J, Epelman M, Darge K. The fountain sign: a novel color Doppler sonographic finding for the diagnosis of acute idiopathic scrotal edema. *J Ultrasound Med*.

2010;29(8):1233–1237.

Gelas T, Margain Deslandes L, Mestrallet G, et al. Spontaneous regression of suspected cystic dysplasia of the rete testis in three neonates. *J Pediatr Urol*. 2016;12(6):387.e1–387.e4.

Gershbein AB, Horowitz M, Glassberg KI. The adolescent varicocele I: left testicular hypertrophy following varicocelectomy. *J Urol*. 1999;162:1447–1449.

Gilbert J, Clark RD, Koyle MD. Penile agenesis: a fatal variation of an uncommon lesion. *J Urol*. 1990;143:338–339.

Gillett MD, Rathbun SR, Husmann DA, et al. Split-thickness skin graft for the management of concealed penis. *J Urol*. 2005;173:579–582.

Ginsburg CM, McCracken GH Jr. Urinary tract infections in young infants. *Pediatrics*. 1982;69:409–412.

Girard C, Bigorre M, Guillot B, et al. PELVIS syndrome. *Arch Dermatol*. 2006;142:884–888.

Glassberg KI, Poon SA, Gjertson CK, et al. Laparoscopic lymphatic sparing varicocelectomy in adolescents. *J Urol*. 2008;180:326–330.

Glenister TW. The origin and fate of the urethral plate in man. *J Anat*. 1921;88:413–423.

Glenn JF, Anderson EE. Surgical correction of incomplete penoscrotal transposition. *J Urol*. 1973;110:603–605.

Gluer S, Fuchs J, Mildenberger H. Diagnosis and current management of penile agenesis. *J Pediatr Surg*. 1998;33:628–631.

Gokcora IH, Yagmurlu A. A longitudinal follow-up using the high trans-scrotal approach for inguinal and scrotal abnormalities in boys. *Hernia*. 2003;7:181–184.

Gomes Dde O, Vidal RR, Foeppel BF, et al. Cold weather is a predisposing factor for testicular torsion in a tropical country. A retrospective study. *Sao Paulo Med J*. 2015;133(3):187–190.

Gong Y, Shao C, Sun Q, et al. Genetic study of indirect inguinal hernia. *J Med Genet*. 1994;31:187–192.

Gongaware RD, Sussman AM, Kraebber DM, et al. Scrotoschisis as a mechanism for extracorporeal testicular ectopia. *J Pediatr Surg*. 1991;26:1430–1431.

Goulding FJ, Traylor RA. Juvenile xanthogranuloma of the scrotum. *J Urol*. 1983;129:841–842.

Granata C, Oddone M, Toma P, et al. Retrograde percutaneous sclerotherapy of left idiopathic varicocele in children: results and follow-up. *Pediatr Surg Int*. 2008;24:583–587.

Gray RH, Kigozi G, Serwadda D, et al. Male circumcision for HIV prevention in men in Rakai, Uganda: a randomized trial. *Lancet*. 2007;369:657–666.

Gray RH, Kigozi G, Serwadda D, et al. The effects of male circumcision on female partners' genital tract symptoms and vaginal infections in a randomized trial in Rakai, Uganda. *Am J Obstet Gynecol*. 2009;200:42.

Grayhack JT, McCullough W, O'Conor VJ Jr, et al. Venous bypass to control priapism. *Invest Urol*. 1964;1:509–513.

Greenfield SP, Seville P, Wan J. Experience with varicoceles in children and young adults. *J Urol*. 2002;168:1684–1688.

Grimsby GM, Keays MA, Villanueva C, et al. Non-absorbable sutures are associated with lower recurrence rates in laparoscopic percutaneous inguinal hernia ligation. *J Pediatr Urol*. 2015;11(5):275.e1–275.e4.

Grosfeld JL, Minnick K, Shedd F, et al. Inguinal hernia in children: factors affecting recurrence in 62 cases. *J Pediatr Surg*. 1991;26:283–287.

Guarino N, Tadini B, Bianchi M. The adolescent varicocele: the crucial role of hormonal tests in selecting patients with testicular dysfunction. *J Pediatr Surg*. 2003;38:120–123.

Gunsar C, Kurutepe S, Alparslan O, et al. The effect of circumcision status on periurethral and glanular bacterial flora. *Urol Int*. 2004;72:212–215.

Gyftopoulos K, Wolffenbuttel KP, Nijman RJ. Clinical and embryologic aspects of penile duplication and associated anomalies. *Urology*. 2002;60:675–679.

Haans LC, Laven JS, Mali WP, et al. Testis volumes, semen quality, and hormonal patterns in adolescents with and without a varicocele. *Fertil Steril*. 1991;56:731–736.

Hadziselimovic F, Herzog B, Jenny P. The chance for fertility in adolescent boys after corrective surgery for varicocele. *J Urol*. 1995;154(2 Pt 2):731–733.

Hamre MR, Harmon EP, Kirkpatrick DV, et al. Priapism as a complication of sickle cell disease. *J Urol*. 1991;145:1–5.

Han CH, Kang SH. Epididymal anomalies associated with patent processus vaginalis in hydrocele and cryptorchidism. *J Korean Med Sci*. 2002;17:660–662.

Handel LN, Shetty R, Sigman M. The relationship between varicoceles and obesity. *J Urol*. 2006;176:2138–2140.

Hardwick-Smith S, Mastrobattista JM, Wallace PA, et al. Ring block for neonatal circumcision. *Obstet Gynecol*. 1998;91:930–934.

Hautmann RE, Bachor R. Juvenile xanthogranuloma of the penis. *J Urol*. 1993;150:456–457.

Hayn MH, Herz DB, Bellinger MF, et al. Intermittent torsion of the spermatic cord portends an increased risk of acute testicular infarction. *J Urol*. 2008;180:1729–1732.

Hendren WH. The genetic male with absent penis and urethrorectal communication: experience with 5 patients. *J Urol*. 1997;157:1469–1474.

Hensle TW. Editorial comment. *J Urol*. 1996;156:858–859.

Hensle TW, Dean GE. Vaginal replacement in children. *J Urol*. 1992;148:677–679.

Herman A, Schvimer M, Tovbin J, et al. Antenatal sonographic diagnosis of testicular torsion. *Ultrasound Obstet Gynecol*.

2002;20(5):522–524.

Hienz HA, Voggenthaler J, Weissbach L. Histological findings in testes with varicocele during childhood and their therapeutic consequences. *Eur J Pediatr*. 1980;133:139–146.

Hoar RM, Calvano CJ, Reddy PP, et al. Unilateral suprainguinal ectopic scrotum: the role of the gubernaculum in the formation of an ectopic scrotum. *Teratology*. 1998;57:64–69.

Hollowell JG Jr, Witherington R, Ballagas AF, et al. Embryologic considerations of diphallus and associated anomalies. *J Urol*. 1977;117:728–732.

Homayoon K, Suhre CD, Steinhardt GF. Epididymal cysts in children: natural history. *J Urol*. 2004;171:1274–1276.

Homer L, Buchanan KJ, Nasr B, et al. Meatal stenosis in boys following circumcision for lichen sclerosus (balanitis xerotica obliterans). *J Urol*. 2014;192(6):1784–1788.

Howard CR, Howard FM, Fortune K, et al. A randomized, controlled trial of a eutectic mixture of local anesthetic cream (lidocaine and prilocaine) versus penile nerve block for pain relief during circumcision. *Am J Obstet Gynecol*. 1999;181:1506–1511.

Huang A, Palmer LS, Levitt SB. Epidermoid cyst of the scrotum extending into the true pelvis. *Urology*. 1999;54(3):561.

Hughes K, Horwood JF, Clements C, et al. Complications of inguinal herniotomy are comparable in term and premature infants. *Hernia*. 2016;20(4):565–569.

Hughes ME, Currier SJ, Della-Giustina D. Normal cremasteric reflex in a case of testicular torsion. *Am J Emerg Med*. 2001;19:241–242.

Husmann D, Rathbun S, Driscol D. Klippel-Trénaunay syndrome: treatment of genitourinary sequelae [abstract]. *J Pediatr Urol*. 2005;1:161.

Husmann DA. The androgen insensitive micropenis: long-term follow-up into adulthood. *J Pediatr Endocrinol Metab*. 2004;17:1037–1041.

Husmann DA, Cain MP. Microphallus: eventual phallic size is dependent on the timing of androgen administration. *J Urol*. 1994;152:734–739.

Ioannides AS, Turnock R. An audit of the management of the acute scrotum in children with Henoch-Schönlein purpura. *J R Coll Surg Edinb*. 2001;46:98–99.

Ishibashi H, Mori H, Yada K, et al. Indigo carmine dye-assisted lymphatic-sparing laparoscopic Palomo varicocelectomy in children. *J Med Invest*. 2014;61(1–2):151–155.

Jacob M, Barteczko K. Contribution to the origin and development of the appendices of the testis and epididymis in humans. *Anat Embryol (Berl)*. 2005;209:287–302.

Janczewski Z, Bablok L. Semen characteristics in pubertal boys. I. Semen quality after first ejaculation. *Arch Androl*. 1985;15:199–205.

Janczewski Z, Bablok L. Semen characteristics in pubertal boys. II. Semen quality in relation to bone age. *Arch Androl*. 1985;15:207–211.

Janczewski Z, Bablok L. Semen characteristics in pubertal boys. III. Semen quality and somatosexual development. *Arch Androl*. 1985;15:213–218.

Janczewski Z, Bablok L. Semen characteristics in pubertal boys. IV. Semen quality and hormone profile. *Arch Androl*. 1985;15:219–223.

Jefferson RH, Perez LM, Joseph DB. Critical analysis of the clinical presentation of acute scrotum: a 9-year experience at a single institution. *J Urol*. 1997;158:1198–1200.

Jeyaratnam R, Bakalinova D. Cystic dysplasia of the rete testis: a case of spontaneous regression and review of published reports. *Urology*. 2010;75(3):687–690.

John CM, Kooner G, Mathew DE, et al. Neonatal testicular torsion—a lost cause? *Acta Paediatr*. 2008;97:502–504.

Johnson P, Maxwell D. Fetal penile length. *Ultrasound Obstet Gynecol*. 2000;15:408–410.

Jones ME, Swerdlow AJ, Griffith M, et al. Risk of congenital inguinal hernia in siblings: a record linkage study. *Paediatr Perinat Epidemiol*. 1998;12:288–296.

Jones P. Torsion of the testis and its appendages during childhood. *Arch Dis Child*. 1962;37:214–226.

Józsa T, Klárik Z, Kiss F, et al. Morphological and microcirculatory evaluation of the rat testis after detorsion with or without a capsular release with a tunica vaginalis flap. *Asian J Androl*. 2016;18(3):462–466.

Juang D, Garey CL, Ostlie DJ, et al. Contralateral inguinal hernia after negative laparoscopic evaluation: a rare but real phenomenon. *J Laparoendosc Adv Surg Tech A*. 2012;22(2):200–202.

Kadish HA, Bolte RG. A retrospective review of pediatric patients with epididymitis, testicular torsion, and torsion of testicular appendages. *Pediatrics*. 1998;102:73–76.

Kajbafzadeh AM, Payabvash S. Endoscopic treatment of vesicovasal and vesicoureteral reflux in infants with persisting mesonephric duct. *J Urol*. 2006;176(6 Pt 1):2657–2662.

Kalfa N, Veyrac C, Baud C, et al. Ultrasonography of the spermatic cord in children with testicular torsion: impact on the surgical strategy. *J Urol*. 2004;172:1692–1695.

Kalfa N, Veyrac C, Lopez M, et al. Multicenter assessment of ultrasound of the spermatic cord in children with acute scrotum. *J Urol*. 2007;177:297–301.

Kaplan GW. Iatrogenic cryptorchidism resulting from hernia repair. *Surg Gynecol Obstet*. 1976;142:671.

Kapur P, Caty MG, Glick PL. Pediatric hernias and hydroceles. *Pediatr Clin North Am*. 1998;45:773–789.

Karadeniz-Bilgili MY, Basar H, Simsir I, et al. Assessment of sapheno-femoral junction continence in patients with primary adolescent varicocoele. *Pediatr Radiol*. 2003;33:603–606.

Karapetian A, Palmer JS. Repair of the buried penis: 3-point technique. *J Am Coll Surg*. 2007;205:S104.

Karmazyn B, Kaefer M, Kauffman S, et al. Ultrasonography and clinical findings in children with epididymitis, with and without associated lower urinary tract abnormalities. *Pediatr Radiol*. 2009;39:1054–1058.

Karmazyn B, Steinberg R, Kornreich L, et al. Clinical and sonographic criteria of acute scrotum in children: a retrospective study of 172 boys. *Pediatr Radiol*. 2005;35:302–310.

Kass EJ, Belman AB. Reversal of testicular growth failure by varicocele ligation. *J Urol*. 1987;137:475–476.

Kass EJ, Chandra RS, Belman AB. Testicular histology in the adolescent with a varicocele. *Pediatrics*. 1987;79:996–998.

Kass EJ, Freitas JE, Salisz JA, et al. Pituitary gonadal dysfunction in adolescents with varicocele. *Urology*. 1993;42:179–181.

Kass EJ, Marcol B. Results of varicocele surgery in adolescents: a comparison of techniques. *J Urol*. 1992;148(2 Pt 2):694–696.

Kass EJ, Stone KT, Cacciarelli AA, et al. Do all children with an acute scrotum require exploration? *J Urol*. 1993;150:667–669.

Kass EJ, Stork BR, Steinert BW. Varicocele in adolescence induces left and right testicular volume loss. *BJU Int*. 2001;87:499–501.

Kaufman D, Feber KM, Palmer LS, et al. Venous malformations of the genitals: a therapeutic dilemma. *Aesthet Surg J*. 2010;30(1):71–73.

Kawaguchi AL, Shaul DB. Inguinal hernias can be accurately diagnosed using the parent's digital photographs when the physical examination is nondiagnostic. *J Pediatr Surg*. 2009;44(12):2327–2329.

Kayaba H, Tamura H, Kitajima S, et al. Analysis of shape and retractability of the prepuce in 603 Japanese boys. *J Urol*. 1996;156:1813–1815.

Kaye JD, Levitt SB, Friedman SC, et al. Neonatal torsion: a 14-year experience and proposed algorithm for management. *J Urol*. 2008;179:2377–2383.

Kaye JD, Shapiro EY, Levitt SB, et al. Parenchymal echo texture predicts testicular salvage after torsion: potential impact on the need for emergent exploration. *J Urol*. 2008;180:1733–1736.

Kehinde EO, Mojiminiyi OA, Mahmoud AH, et al. The significance of measuring the time course of serum malondialdehyde concentration in patients with torsion of the testis. *J Urol*. 2003;169:2177–2180.

Kennedy HA, Steidle CP, Mitchell ME, et al. Collateral urethral duplication in the frontal plane. *J Urol*. 1988;139:332–334.

Kennedy WA 2nd, Hensle TW, Giella J, et al. Potassium thiophosphate laser treatment of genitourinary hemangioma in the pediatric population. *J Urol*. 1993;150:950–952.

Kilic S, Aksoy Y, Sincer I, et al. Cardiovascular evaluation of young patients with varicocele. *Fertil Steril*. 2007;88:369–373.

Kim KS, Lee C, Song SH, et al. Impact of internal spermatic artery preservation during laparoscopic varicocelectomy on recurrence and the catch-up growth rate in adolescents. *J Pediatr Urol*. 2014;10(3):435–440.

Kim WS, Cheon JE, Kim IO, et al. Hemodynamic investigation of the left renal vein in pediatric varicocele: Doppler US, venography, and pressure measurements. *Radiology*. 2006;241:228–234.

Klin B, Lotan G, Efrati Y, et al. Acute idiopathic scrotal edema in children—revisited. *J Pediatr Surg*. 2002;37:1200–1202.

Knight PJ, Vassy LE. The diagnosis and treatment of the acute scrotum in children and adolescents. *Ann Surg*. 1984;200:664–673.

Kocvara R, Dolezal J, Hampl R, et al. Division of lymphatic vessels at varicocelectomy leads to testicular oedema and decline in testicular function according to the LH-RH analogue stimulation test. *Eur Urol*. 2003;43:430–435.

Kocvara R, Dvoracek J, Sedlacek J, et al. Lymphatic sparing laparoscopic varicocelectomy: a microsurgical repair. *J Urol*. 2005;173:1751–1754.

Koff SA, De Ridder P. Conservative management of intrascrotal appendiceal torsion. *Urology*. 1976;7:482–483.

Kogan BA. Communicating hydrocele/hernia repair in children. *BJU Int*. 2007;100:703–714.

Koivusalo AI, Korpela R, Wirtavuori K, et al. A single-blinded, randomized comparison of laparoscopic versus open hernia repair in children. *Pediatrics*. 2009;123:332–337.

Kojori F, Demaria J. Scrotoschisis associated with meconium periorchitis. *J Pediatr Urol*. 2007;3:415–416.

Kolettis PN, Sandlow JI. Clinical and genetic features of patients with congenital unilateral absence of the vas deferens. *Urology*. 2002;60:1073–1076.

Kolligian ME, Franco I, Reda EF. Correction of penoscrotal transposition: a novel approach. *J Urol*. 2000;164:994–996.

Kolon TF, Clement MR, Cartwright L, et al. Transient asynchronous testicular growth in adolescent males with a varicocele. *J Urol*. 2008;180:1111–1114.

Kon M. A rare complication following circumcision: the concealed penis. *J Urol*. 1983;130:573–574.

Kozakowski KA, Gjertson CK, Decastro GJ, et al. Peak retrograde flow: a novel predictor of persistent, progressive and new onset asymmetry in adolescent varicocele. *J Urol*. 2009;181:2717–2722.

Krarup T. The testes after torsion. *Br J Urol*. 1978;50:43–46.

Krauel L, Tarrado X, Garcia-Aparicio L, et al. Median raphe cysts of the perineum in children. *Urology*. 2008;71:830–831.

Krieger NR, Shochat SJ, McGowan V, et al. Early hernia repair in the premature infant: long-term follow-up. *J Pediatr Surg*. 1994;29:978.

Ku JH, Kim SW, Park K, et al. Benefits of microsurgical repair of adolescent varicocele: comparison of semen parameters in fertile and infertile adults with varicocele. *Urology*. 2005;65:554–558.

Kuefer R, Bartsch G Jr, Herkommer K, et al. Changing diagnostic and therapeutic concepts in high-flow priapism. *Int J Impot Res*. 2005;17:109–113.

Kumanov P, Robeva RN, Tomova A. Adolescent varicocele: who is at risk? *Pediatrics*. 2008;121:e53–e57.

Kurlan MZ, Wels PB, Piedad OH. Inguinal herniorrhaphy by the Mitchell Banks Technique. *J Pediatr Surg*. 1972;7:427.

Kurtz MP, Zurakowski D, Rosoklija I, et al. Semen parameters in adolescents with varicocele: association with testis volume differential and total testis volume. *J Urol*. 2015;193(5 Suppl):1843–1847.

Kutikov A, Casale P, White MA, et al. Testicular compartment syndrome: a new approach to conceptualizing and managing testicular torsion. *Urology*. 2008;72:786–789.

Lage JM, Driscoll SG, Bieber FR, et al. Transposition of the external genitalia associated with caudal regression. *J Urol*. 1987;138:387–389.

Lais A, Ferro F. Trans-scrotal approach for surgical correction of cryptorchidism and congenital anomalies of the processus vaginalis. *Eur Urol*. 1996;29:235–238.

Lam WW, Yap TL, Jacobsen AS, et al. Colour Doppler ultrasonography replacing surgical exploration for acute scrotum: myth or reality? *Pediatr Radiol*. 2005;35:597–600.

Lamm DL, Kaplan GW. Accessory and ectopic scrota. *Urology*. 1977;9:149–153.

Landry JL, Dodat H, Pelizzo G, et al. Cystic dysplasia of the rete testis and ipsilateral kidney agenesis in children. *Arch Pediatr*. 1999;6:416–420.

Lannon CM, Bailey A, Fleischman A, et al. Circumcision debate. Task Force on Circumcision, 1999–2000. *Pediatrics*. 2000;105:641–642.

Lapointe SP, Wei DC, Hricak H, et al. Magnetic resonance imaging in the evaluation of congenital anomalies of the external genitalia. *Urology*. 2001;58:452–456.

Lau P, Anderson PA, Giacomantonio JM, et al. Acute epididymitis in boys: are antibiotics indicated? *Br J Urol*. 1997;79:797–800.

Laven JS, Haans LC, Mali WP, et al. Effects of varicocele treatment in adolescents: a randomized study. *Fertil Steril*. 1992;58:756–762.

Lee A, Park SJ, Lee HK, et al. Acute idiopathic scrotal edema: ultrasonographic findings at an emergency unit. *Eur Radiol*. 2009;19:2075–2080.

Lee PA, Danish RK, Major T, et al. Micropenis: III. Primary hypogonadism, partial androgen insensitivity syndrome, and idiopathic disorders. *Johns Hopkins Med J*. 1980;147:175–181.

Lee PA, Houk CP. Outcome studies among men with micropenis. *J Pediatr Endocrinol Metab*. 2004;17:1043–1053.

Lee PA, Mazur T, Danish R, et al. Micropenis: I. Criteria, etiologies and classification. *Johns Hopkins Med J*. 1980;146:156–163.

Leissring JC, Oppenheimer RO. Cystic dysplasia of the testis: a unique congenital anomaly studied by microdissection. *J Urol*. 1973;110(3):362–363.

Lev M, Ramon J, Mor Y, et al. Sonographic appearances of torsion of the appendix testis and appendix epididymis in children. *J Clin Ultrasound*. 2015;43(8):485–489.

Levitt MA, Ferraraccio D, Arbesman MC, et al. Variability of inguinal hernia surgical technique: a survey of North American pediatric surgeons. *J Pediatr Surg*. 2002;37:745.

Levy JB, Darson MF, Bite U. Modified pudendal-thigh flap for correction of penoscrotal transposition. *Urology*. 1997;15:597–600.

Li B, Nie X, Xie H, et al. Modified single-port laparoscopic herniorrhaphy for pediatric inguinal hernias: based on 1,107 cases in China. *Surg Endosc*. 2012;26(12):3663–3668.

Lian BS, Ong CC, Chiang LW, et al. Factors predicting testicular atrophy after testicular salvage following torsion. *Eur J Pediatr Surg*. 2016;26(1):17–21.

Lipshultz LI, Corriere JN Jr. Progressive testicular atrophy in the varicocele patient. *J Urol*. 1977;117:175–176.

Little LS Jr, Keating MA, Rink RC. Median raphe cysts of the genitalia. *J Urol*. 1992;148:1872–1873.

Litvak AS, Morris JA Jr, McRoberts JW. Normal size of the urethral meatus in boys. *J Urol*. 1976;115:736–737.

Liu F, Lin T, He D, et al. New technique for the treatment of buried penis in children. *Urology*. 2016;88:166–169.

Liu J, Zhang S, Liu M, et al. Prevalence of varicocoele and its association with body mass index among 39,559 rural men in eastern China: a population-based cross-sectional study. *Andrology*. 2017;5(3):562–567.

Lyon RP, Marshall S, Scott MP. Varicocele in childhood and adolescence: implication in adulthood infertility? *Urology*. 1982;19:641–644.

Lyronis ID, Ploumis N, Vlahakis I, et al. Acute scrotum—

etiology, clinical presentation and seasonal variation. *Indian J Pediatr*. 2009;76:407–410.

MacKenzie J, Chitayat D, McLorie G, et al. Penoscrotal transposition: a case report and review. *Am J Med Genet*. 1994;49:103–107.

Mackway-Jones K, Teece S. Ice, pins, or sugar to reduce paraphimosis. *Emerg Med J*. 2004;21:77–78.

MacLachlan LS, Nees SN, Fast AM, et al. Intratesticular varicoceles: are they significant? *J Pediatr Urol*. 2013;9(6 Pt A):851–855.

Maizels M, Zaontz M, Donovan J, et al. Surgical correction of the buried penis: description of a classification system and a technique to correct the disorder. *J Urol*. 1986;136:268–271.

Makari JH, Atalla MA, Belman AB, et al. Safety and efficacy of intratesticular injection of vital dyes for lymphatic preservation during varicocelectomy. *J Urol*. 2007;178:1026–1030.

Mäkelä E, Lahdes-Vasama T, Rajakorpi H, et al. A 19-year review of paediatric patients with acute scrotum. *Scand J Surg*. 2007;96:62–66.

Mäkelä E, Lahdes-Vasama T, Ryymin P, et al. Magnetic resonance imaging of acute scrotum. *Scand J Surg*. 2011;100(3):196–201.

Maki D, Watanabe Y, Nagayama M, et al. Diffusion-weighted magnetic resonance imaging in the detection of testicular torsion: feasibility study. *J Magn Reson Imaging*. 2011;34(5):1137–1142.

Malekzadeh S, Fraga-Silva RA, Morère PH, et al. Varicocele percutaneous embolization outcomes in a pediatric group: 7-year retrospective study. *Int Urol Nephrol*. 2016;48(9):1395–1399.

Mansbach JM, Forbes P, Peters C. Testicular torsion and risk factors for orchiectomy. *Arch Pediatr Adolesc Med*.

2005;159:1167–1171.

Mantadakis E, Cavender JD, Rogers ZR, et al. Prevalence of priapism in children and adolescents with sickle cell anemia. *J Pediatr Hematol Oncol*. 1999;12:518–522.

Marshall WA, Tanner JM. Variations in the pattern of pubertal changes in boys. *Arch Dis Child*. 1970;45:13–23.

Marti-Bonmati L, Menor F, Gomez J, et al. Value of sonography in true complete diphallia. *J Urol*. 1989;142:356–357.

Maruyama K, Takahashi A, Kobayashi T, et al. Diphallia and the VATER association. *J Urol*. 1999;162:2144.

Matsuo N, Anzo M, Sato S, et al. Testicular volume in Japanese boys up to the age of 15 years. *Eur J Pediatr*. 2000;159:84–85.

May M, Johannsen M, Beutner S, et al. Laparoscopic surgery versus antegrade scrotal sclerotherapy: retrospective comparison of two different approaches for varicocele treatment. *Eur Urol*. 2006;49:384–387.

May M, Taymoorian K, Beutner S, et al. Body size and weight as predisposing factors in varicocele. *Scand J Urol Nephrol*. 2006;40:45–48.

Mazzoni G, Fiocca G, Minucci S, et al. Varicocele: a multidisciplinary approach in children and adolescents. *J Urol*. 1999;162:1755–1757.

McDougal WS. Lymphedema of the external genitalia. *J Urol*. 2003;170:711–716.

McGee SM, Hutcheson JC, Vandersteen DR, et al. Cystic dysplasia of testis associated with ectopic ureter causing chronic orchalgia. *Urology*. 2009;73:1423 [e7–8].

McMahon DR, Kramer SA, Husmann DA. Micropenis: does early treatment with testosterone do more harm than good? *J Urol*. 1995;154:825–829.

Merlini E, Rotundi F, Seymandi PL, et al. Acute epididymitis and urinary tract anomalies in children. *Scand J Urol*

Nephrol. 1998;32:273–275.

Middleton AW, Melzer RB. Duplicated urethra: an anomaly best repaired. *Urology*. 1992;39(6):538–542.

Miller ST, Rao SP, Dunn EK, et al. Priapism in children with sickle cell disease. *J Urol*. 1995;154:844–847.

Miltenburg DM, Nuchtern JG, Jaksic T, et al. Meta-analysis of the risk of metachronous hernia in infants and children. *Am J Surg*. 1997;174:741–744.

Miltenburg DM, Nuchtern JG, Jaksic T, et al. Laparoscopic evaluation of the pediatric inguinal hernia—a meta-analysis. *J Pediatr Surg*. 1998;33:874–879.

Misra D, Hewitt G, Potts SR, et al. Inguinal herniotomy in young infants, with emphasis on premature neonates. *J Pediatr Surg*. 1994;29:1496.

Misseri R, Gershbein AB, Horowitz M, et al. The adolescent varicocele. II. The incidence of hydrocele and delayed recurrent varicocele after varicocelectomy in a long-term follow-up. *BJU Int*. 2001;87:494–498.

Mitchell GA. The condition of the peritoneal vaginal processes at birth. *J Anat*. 1939;73:658–661.

Miyake H, Fukumoto K, Yamoto M, et al. Comparison of percutaneous extraperitoneal closure (LPEC) and open repair for pediatric inguinal hernia: experience of a single institution with over 1000 cases. *Surg Endosc*. 2016;30(4):1466–1472.

Mokhless I, Youssif M, Eltayeb M, et al. Z-plasty for sculpturing of the bifid scrotum in severe hypospadias associated with penoscrotal transposition. *J Pediatr Urol*. 2011;7(3):305–309.

Mokhtari G, Pourreza F, Falahatkar S, et al. Comparison of prevalence of varicocele in first-degree relatives of patients with varicocele and male kidney donors. *Urology*. 2008;71:666–668.

Monstrey S, Hoebeke P, Selvaggi G, et al. Penile reconstruction:

is the radial forearm flap really the standard technique? *Plast Reconstr Surg*. 2009;124:510–518.

Montague DK, Jarow J, Broderick GA, et al. American Urological Association guideline on the management of priapism. *J Urol*. 2003;170:1318–1324.

Mor Y, Pinthus JH, Nadu A, et al. Testicular fixation following torsion of the spermatic cord—does it guarantee prevention of recurrent torsion events? *J Urol*. 2006;175:171–173.

Muensterer OJ. Genitofemoral nerve injury after laparoscopic varicocelectomy in adolescents. *J Urol*. 2008;180:2155–2157.

Munden MM, Williams JL, Zhang W, et al. Intermittent testicular torsion in the pediatric patient: sonographic indicators of a difficult diagnosis. *AJR Am J Roentgenol*. 2013;201(4):912–918.

Murphy FL, Fletcher L, Pease P. Early scrotal exploration in all cases is the investigation and intervention of choice in the acute paediatric scrotum. *Pediatr Surg Int*. 2006;22:413–416.

Mushtaq I, Fung M, Glasson MJ. Retrospective review of paediatric patients with acute scrotum. *Aust N Z J Surg*. 2003;73:55–58.

Nagar H, Kessler A. Abdominoscrotal hydrocele in infancy: a study of 15 cases. *Pediatr Surg Int*. 1998;13:189–190.

Nelson CP, Williams JF, Bloom DA. The cremasteric reflex: a useful but imperfect sign in testicular torsion. *J Pediatr Surg*. 2003;38:1248–1249.

Niedzielski J, Paduch D, Raczynski P. Assessment of adolescent varicocele. *Pediatr Surg Int*. 1997;12:410–413.

Nielsen ME, Zderic S, Freedland SJ, et al. Insight on pathogenesis of varicoceles: relationship of varicocele and body mass index. *Urology*. 2006;68:392–396.

Nielson CM, Schiaffino MK, Dunne EF, et al. Associations between male anogenital human papillomavirus infection and circumcision by anatomic site sampled and lifetime number of female sex partners. *J Infect Dis*. 2009;199:7–13.

Noh PH, Cooper CS, Snyder HM 3rd. Conservative management of cystic dysplasia of the testis. *J Urol*. 1999;162:2145.

Nussbaum Blask AR, Rushton HG. Sonographic appearance of the epididymis in pediatric testicular torsion. *AJR Am J Roentgenol*. 2006;187:1627–1635.

Odeh M, Granin V, Kais M, et al. Sonographic fetal sex determination. *Obstet Gynecol Surv*. 2009;64:50–57.

Oktar T, Kucukdurmaz F, Erdem S, et al. Tunica albuginea decompression fails to alter the injury of prolonged arterial occlusion during testicular torsion. *J Urol*. 2013;190(1):239–243.

Okuyama A, Nakamura M, Namiki M, et al. Surgical repair of varicocele at puberty: preventive treatment for fertility improvement. *J Urol*. 1988;139:562–564.

Oliveira DE, da Cruz ML, Liguori R, et al. Neophalloplasty in boys with aphallia: a systematic review. *J Pediatr Urol*. 2016;12(1):19–24.

Osifo OD, Osaigbovo EO. Congenital hydrocele: prevalence and outcome among male children who underwent neonatal circumcision in Benin city, Nigeria. *J Pediatr Urol*. 2008;4:178–182.

Oster J. Further fate of the foreskin: incidence of preputial adhesions, phimosis, and smegma among Danish schoolboys. *Arch Dis Child*. 1968;43:200–203.

Paduch DA, Niedzielski J. Semen analysis in young men with varicocele: preliminary study. *J Urol*. 1996;156:788–790.

Paduch DA, Niedzielski J. Repair versus observation in adolescent varicocele: a prospective study. *J Urol*. 1997;158:1128–1132.

Palmer JR, Herbst AL, Noller KL, et al. Urogenital abnormalities in men exposed to diethylstilbestrol in utero: a cohort study. *Environ Health*. 2009;8:37.

Palmer JS. An international view on circumcision. *Dial Ped Urol*. 2009;30(6):1–8.

Palmer JS. *Topical skin refrigerant analgesic spray for office procedures: efficient and highly cost effective*. [Presented at American Academy of Pediatrics meeting, Section of Urology, Washington, DC] 2009.

Palmer JS, Elder JS, Palmer LS. The use of betamethasone to manage the trapped penis following newborn circumcision. *J Urol*. 2005;174:1577–1578.

Palmer LS, Kogan SJ. The small and buried penis. *Adv Urol*. 1995;8:225–247.

Palmer LS, Palmer JS. The efficacy of topical betamethasone for treating phimosis: a comparison of two treatment regimens. *Urology*. 2008;72:68–71.

Palmer LS, Rastinehad A. Incidence and concurrent laparoscopic repair of intra-abdominal testis and contralateral patent processus vaginalis. *Urology*. 2008;72:297–299.

Palomo A. Radical cure of varicocele by a new technique; preliminary report. *J Urol*. 1949;61:604–607.

Paltiel HJ, Diamond DA, Di Canzio J, et al. Testicular volume: comparison of orchidometer and US measurements in dogs. *Radiology*. 2002;222:114–119.

Paltiel HJ, Kalish LA, Susaeta RA, et al. Pulse-inversion US imaging of testicular ischemia: quantitative and qualitative analyses in a rabbit model. *Radiology*. 2006;239:718–729.

Papali AC, Alpert SA, Edmondson JD, et al. A review of pediatric glans malformations: a handy clinical reference. *J Urol*. 2008;180:1737–1742.

Parida SK, Hall BD, Barton L, et al. Penoscrotal transposition and associated anomalies: report of five new cases and review of the literature. *Am J Med Genet*. 1995;59:68–75.

Park SJ, Kim HL, Yi BH. Sonography of intrascrotal appendage torsion: varying echogenicity of the torsed appendage according to the time from onset. *J Ultrasound Med*. 2011;30(10):1391–1396.

Partrick DA, Bensard DD, Karrer FM, et al. Is routine pathological evaluation of pediatric hernia sacs justified? *J Pediatr Surg*. 1998;33:1090–1092.

Pastuszak AW, Kumar V, Shah A, et al. Diagnostic and management approaches to pediatric and adolescent varicocele: a survey of pediatric urologists. *Urology*. 2014;84(2):450–455.

Persad R, Sherma S, McTavish J, et al. Clinical presentation and pathophysiology of meatal stenosis following circumcision. *Br J Urol*. 1995;75:91–93.

Pfeiffer D, Berger J, Schoop C, et al. A Doppler-based study on the prevalence of varicocele in German children and adolescents. *Andrologia*. 2006;38:13–19.

Pimpalwar A, Chowdhary S, Huskisson J, et al. Cysts of the ejaculatory system—a treatable cause of recurrent epididymo-orchitis in children. *Eur J Pediatr Surg*. 2002;12:281–285.

Pinette MG, Wax JR, Blackstone J, et al. Normal growth and development of fetal external genitalia demonstrated by sonography. *J Clin Ultrasound*. 2003;31:465–472.

Pinke LA, Rathbun SR, Husmann DA, et al. Penoscrotal transposition: review of 53 patients. *J Urol*. 2001;166:1865–1868.

Pinto KJ, Kroovand RL, Jarow JP. Varicocele related testicular atrophy and its predictive effect upon fertility. *J Urol*. 1994;152:788–790.

Pisacane A, de Luca U, Vaccaro F, et al. Breast-feeding and inguinal hernia. *J Pediatr*. 1995;127(1):109–111.

Poddoubnyi IV, Dronov AF, Kovarskii SL, et al. Laparoscopic ligation of testicular veins for varicocele in children: a report of 180 cases. *Surg Endosc*. 2000;14:1107–1109.

Podesta ML, Medel R, Castera R, et al. Urethral duplication in children: surgical treatment and results. *J Urol*. 1998;160:1830–1833.

Pomerantz P, Hanna M, Levitt S, et al. Isolated torsion of the penis: report of six cases. *Urology*. 1978;11:37–39.

Ponsky LE, Ross JH, Knipper N, et al. Penile adhesions after neonatal circumcision. *J Urol*. 2000;164:495–496.

Poon SA, Kozakowski KA, Decastro GJ, et al. Adolescent varicocelectomy: postoperative catch-up growth is not secondary to lymphatic ligation. *J Pediatr Urol*. 2009;5:37–41.

Popek EJ. Embryonal remnants in inguinal hernia sacs. *Hum Pathol*. 1990;21:339–349.

Posey ZQ, Ahn HJ, Junewick J, et al. Rate and associations of epididymal cysts on pediatric scrotal ultrasound. *J Urol*. 2010;184(4 Suppl):1739–1742.

Premkumar MH, Colen JS, Roth DR, et al. Could scrotoschisis mimic an iatrogenic injury? A case report. *Urology*. 2009;73:795–796.

Preston MA, Carnat T, Flood T, et al. Conservative management of adolescent varicoceles: a retrospective review. *Urology*. 2008;72:77–80.

Puri P, Barton D, O'Donnell B. Prepubertal testicular torsion: subsequent fertility. *J Pediatr Surg*. 1985;20:598–601.

Puri P, Guiney EJ, O'Donnel B. Inguinal hernia in infants: the fate of the testis following incarceration. *J Pediatr Surg*. 1984;19:44.

Quackels R. Treatment of a case of priapism by cavernospongiosus anastomosis. *Acta Urol Belg*. 1964;32:5–13.

Rabinowitz R. The importance of the cremasteric reflex in acute scrotal swelling in children. *J Urol*. 1984;132:89–90.

Ragan DC, Casale AJ, Rink RC, et al. Genitourinary anomalies in the CHARGE association. *J Urol*. 1999;161:622–625.

Rakha E, Puls F, Saidul I, et al. Torsion of the testicular appendix: importance of associated acute inflammation. *J Clin Pathol*. 2006;59:831–834.

Ramachandra P, Palazzi KL, Holmes NM, et al. Factors influencing rate of testicular salvage in acute testicular torsion at a tertiary pediatric center. *West J Emerg Med*. 2015;16(1):190–194.

Raman JD, Walmsley K, Goldstein M. Inheritance of varicoceles. *Urology*. 2005;65:1186–1189.

Ramos CE, Park JS, Ritchey ML, et al. High flow priapism associated with sickle cell disease. *J Urol*. 1995;153:1619–1621.

Ramos LM, Pavon EM, Barrilero AE. Venous malformation of the glans penis: efficacy of treatment with neodymium:yttrium-aluminum-garnet laser. *Urology*. 1999;53:779–783.

Reddy S, Jain V, Dubey M, et al. Local steroid therapy as the first-line treatment for boys with symptomatic phimosis - a long-term prospective study. *Acta Paediatr*. 2012;101(3):e130–e133.

Redman JF. Circumcision revision in prepubertal boys: analysis of a 2-year experience and description of a technique. *J Urol*. 1995;153:180–182.

Redman JF, Barthold JS. A technique for atraumatic scrotal pouch orchiopexy in the management of testicular torsion. *J Urol*. 1995;154(4):1511–1512.

Redshaw JD, Tran TL, Wallis MC, et al. Epididymitis: a 21-year retrospective review of presentations to an outpatient urology clinic. *J Urol*. 2014;192(4):1203–1207.

Reilly JM, Woodhouse CR. Small penis and the male sexual role. *J Urol*. 1989;142:569–571.

Reiner E, Pollak JS, Henderson KJ, et al. Initial experience with 3% sodium tetradecyl sulfate foam and fibered coils for management of adolescent varicocele. *J Vasc Interv Radiol*. 2008;19:207–210.

Reiner WG. Case study: sex reassignment in a teenage girl. *J Am Acad Child Adolesc Psychiatry*. 1996;35:799–803.

Reyes BL, Trerotola SO, Venbrux AC, et al. Percutaneous embolotherapy of adolescent varicocele: results and long-term follow-up. *J Vasc Interv Radiol*. 1994;5:131–134.

Rhodes HL, Corbett HJ, Horwood JF, et al. Neonatal testicular torsion: a survey of current practice amongst paediatric surgeons and urologists in the United Kingdom and Ireland. *J Pediatr Surg*. 2011;46(11):2157–2160.

Ring KS, Axelrod SL, Burbige KA, et al. Meconium hydrocele: an unusual etiology of a scrotal mass in the newborn. *J Urol*. 1989;141:1172–1173.

Ritchey ML, Sinha A, Argueso L. Congenital fistula of the penile urethra. *J Urol*. 1994;151:1061–1062.

Ritter MR, Butschek RA, Friedlander M, et al. Pathogenesis of infantile haemangioma: new molecular and cellular insights. *Expert Rev Mol Med*. 2007;9:1–19.

Roizenblatt M, Figueiredo MS, Cançado RD, et al. Priapism is associated with sleep hypoxemia in sickle cell disease. *J Urol*. 2012;188(4):1245–1251.

Romeo C, Arrigo T, Impellizzeri P, et al. Altered serum inhibin b levels in adolescents with varicocele. *J Pediatr Surg*. 2007;42:390–394.

Romeo C, Impellizzeri P, Arrigo T, et al. Late hormonal function after testicular torsion. *J Pediatr Surg*. 2010;45(2):411–413.

Ron O, Eaton S, Pierro A. Systematic review of the risk of developing a metachronous contralateral inguinal hernia in children. *Br J Surg*. 2007;94:804–811.

Ross JH, Kay R, Yetman RJ, et al. Primary lymphedema of the genitalia in children and adolescents. *J Urol*. 1998;160:1485–1489.

Roth CC, Mingin GC, Ortenberg J. Salvage of bilateral asynchronous perinatal testicular torsion. *J Urol*. 2011;185(6 Suppl):2464–2468.

Roth JK, Marshall RA, Angel JR, et al. Congenital absence of the penis. *Urology*. 1981;17:579–583.

Rowe MI, Clatworthy HW. Incarcerated and strangulated hernias in children. *Arch Surg*. 1970;101:136.

Rowe MI, Copelson LW, Clatworthy HW. The patent processus vaginalis and the inguinal hernia. *J Pediatr Surg*. 1969;4:102–107.

Roy CR 2nd, Wilson T, Raife M, et al. Varicocele as the presenting sign of an abdominal mass. *J Urol*. 1989;141:597–599.

Rundle AT, Sylvester PE. Measurement of testicular volume. Its application to assessment of maturation, and its use in diagnosis of hypogonadism. *Arch Dis Child*. 1962;37:514–517.

Saad S, Mansson J, Saad A, et al. Ten-year review of groin laparoscopy in 1001 pediatric patients with clinical unilateral inguinal hernia: an improved technique with transhernia multiple-channel scope. *J Pediatr Surg*. 2011;46:1011–1014.

Sacher EC, Sayegh E, Frensilli F, et al. Cavernospongiosum shunt in the treatment of priapism. *J Urol*. 1972;108:97–100.

Safarinejad MR. Infertility among couples in a population-based study in Iran: prevalence and associated risk factors. *Int J Androl*. 2008;31:303–314.

Sakamoto H, Ogawa Y. Is varicocele associated with underlying venous abnormalities? Varicocele and the prostatic venous plexus. *J Urol*. 2008;180:1427–1431.

Sakellaris GS, Charissis GC. Acute epididymitis in Greek children: a 3-year retrospective study. *Eur J Pediatr*. 2008;167:765–769.

Salle JL, de Fraga JC, Wojciechowski M, et al. Congenital rupture of the scrotum: an unusual complication of meconium peritonitis. *J Urol*. 1992;148:1242–1243.

Salle JL, Sibai H, Rosenstein D, et al. Urethral duplication in the male: review of 16 cases. *J Urol*. 2000;163:1936–1940.

Salonia A, Eardley I, Giuliano F, et al. European Association of Urology guidelines on priapism. *Eur Urol*. 2014;65(2):480–489.

Saranga Bharathi R, Arora M, Baskaran V. Minimal access surgery of pediatric inguinal hernias: a review. *Surg Endosc*. 2008;22:1751–1762.

Schier F. Laparoscopic inguinal hernia repair—a prospective personal series of 542 children. *J Pediatr Surg*. 2006;41:1081–1084.

Schiff J, Kelly C, Goldstein M, et al. Managing varicoceles in children: results with microsurgical varicocelectomy. *BJU Int*. 2005;95:399–402.

Schlomer BJ, Keays MA, Grimsby GM, et al. Transscrotal near infrared spectroscopy as a diagnostic test for testis torsion in pediatric acute scrotum: a prospective comparison to gold standard diagnostic test study. *J Urol*. 2017;198(3):694–701.

Schoen EJ, Colby CJ, Ray GT. Newborn circumcision decreases incidence and costs of urinary tract infections during the first year of life. *Pediatrics*. 2000;105:789–793.

Schoen EJ, Colby CJ, To TT. Cost analysis of neonatal circumcision in a large health maintenance organization. *J Urol*. 2006;175:1111–1115.

Schoen EJ, Oehrli M, Colby CJ, et al. The highly protective effect of newborn circumcision against invasive penile cancer. *Pediatrics*. 2000;105:E36.

Schonfeld WA. Primary and secondary sexual characteristics:

study of their development in males from birth through maturity, with biometric study of penis and testes. *Am J Dis Child*. 1943;65:535–549.

Schulsinger D, Glassberg K, Strashun A. Intermittent torsion: association with horizontal lie of the testicle. *J Urol*. 1991;145:1053–1055.

Schwentner C, Oswald J, Lunacek A, et al. Optimizing the outcome of microsurgical subinguinal varicocelectomy using isosulfan blue: a prospective randomized trial. *J Urol*. 2006;175:1049–1052.

Seeler RA. Intensive transfusion therapy for priapism in boys with sickle cell anemia. *J Urol*. 1973;110:360–361.

Serels S, Kogan S. Bilateral giant abdominoscrotal hydroceles in childhood. *Urology*. 1996;47:763–765.

Sessions AE, Rabinowitz R, Hulbert WC, et al. Testicular torsion: direction, degree, duration and disinformation. *J Urol*. 2003;169:663–665.

Sezer S, Simşek N, Celik HT, et al. Association of collagen type I alpha 1 gene polymorphism with inguinal hernia. *Hernia*. 2014;18(4):507–512.

Shah MI, Chantal Caviness A, Mendez DR. Prospective pilot derivation of a decision tool for children at low risk for testicular torsion. *Acad Emerg Med*. 2013;20(3):271–278.

Shalaby R, Ismail M, Shehata S, et al. Shalaby technique for efficient single incision laparoscopic pediatric inguinal hernia repair. *J Pediatr Surg*. 2015;50(11):1995–2000.

Shalaby R, Ismail M, Gouda S, et al. Laparoscopic management of recurrent inguinal hernia in childhood. *J Pediatr Surg*. 2015;50(11):1903–1908.

Sharony R, Bental YA, Eyal O, et al. Correlation between prenatal and postnatal penile and clitoral measurements. *J Clin Ultrasound*. 2012;40(7):394–398.

Shen W, Ji H, Lu G, et al. A modified single-port technique for the minimally invasive treatment of pediatric inguinal hernias with high ligation of the vaginal process: the initial experience. *Eur J Pediatr*. 2010;169(10):1207–1212.

Shenoy MU, Srinivasan J, Sully L, et al. Buried penis: surgical correction using liposuction and realignment of skin. *BJU Int*. 2000;86:527–530.

Shenoy VG, Jawale SA, Oak SN, et al. Primary lymphedema of the penis: surgical correction by preputial unfurling. *Pediatr Surg Int*. 2001;17:169–170.

Sherman J, Borer JG, Horowitz M, et al. Circumcision: successful glanular reconstruction and survival following traumatic amputation. *J Urol*. 1996;156:842–844.

Sheth KR, Keays M, Grimsby GM, et al. Diagnosing testicular torsion before urological consultation and imaging: validation of the TWIST score. *J Urol*. 2016;195(6):1870–1876.

Sheynkin YR, Hendin BN, Schlegel PN, et al. Microsurgical repair of iatrogenic injury to the vas deferens. *J Urol*. 1998;159:139–141.

Shih TY, Uen YH. Single scrotal incision for repair of bilateral inguinal hernias in boys. *Pediatr Surg Int*. 2012;28(4):417–420.

Shim YH, Lee JW, Lee SJ. The risk factors of recurrent urinary tract infection in infants with normal urinary systems. *Pediatr Nephrol*. 2009;24:309–312.

Shinkawa T, Yamauchi Y, Osada Y, et al. Aarskog syndrome. *Urology*. 1983;22:624–626.

Shiraki IW. Parameatal cysts of the glans penis: a report of 9 cases. *J Urol*. 1975;114:544–548.

Sidler D, Brown RA, Millar AJ, et al. A 25-year review of the acute scrotum in children. *S Afr Med J*. 1997;87:1696–1698.

Siegel A, Snyder H, Duckett JW. Epididymitis in infants and boys: underlying urogenital anomalies and efficacy of imaging modalities. *J Urol*. 1987;138(4 Pt 2):1100–1103.

Silay MS, Yesil G, Yildiz K, et al. Congenital agenesis of scrotum and labia majora in siblings. *Urology*. 2013;81(2):421–423.

Silveri M, Bassani F, Adorisio O. Changing concepts in microsurgical pediatric varicocelectomy: is retroperitoneal approach better than subinguinal one? *Urol J*. 2015;12(1):2032–2035.

Singh-Grewal D, Macdessi J, Craig J. Circumcision for the prevention of urinary tract infection in boys: a systematic review of randomised trials and observational studies. *Arch Dis Child*. 2005;90:853–858.

Sivanathan C, Abernethy LJ. Retrograde embolisation of varicocele in the paediatric age group: a review of 10 years' practice. *Ann R Coll Surg Engl*. 2003;85:50–51.

Skoog SJ, Belman AB. Aphallia: its classification and management. *J Urol*. 1989;141:589–592.

Skoog SJ, Roberts KP, Goldstein M, et al. The adolescent varicocele: what's new with an old problem in young patients? *Pediatrics*. 1997;100:112–121.

Slavov C, Donkov I, Popov E. Case of duplicated urethra in an adult male presenting with symptoms of bladder outlet obstruction. *Eur Urol*. 2007;52:1249–1251.

Slawin KM, Nagler HM. Treatment of congenital penile curvature with penile torsion: a new twist. *J Urol*. 1992;14:152–154.

Slowman JG, Mylius RE. Testicular infarction in infancy: its association with irreducible inguinal hernia. *Med J Aust*. 1958;1:242.

Smith PJ, DeSouza R, Roth DR. Cystic dysplasia of the rete testis. *Urology*. 2008;72:230.e7–230.e10.

Snyder HM, Diamond DA. In utero/neonatal torsion: observation versus prompt exploration. *J Urol*. 2010;183(5):1675–1677.

Somekh E, Gorenstein A, Serour F. Acute epididymitis in boys: evidence of a post-infectious etiology. *J Urol*. 2004;171:391–394.

Sorensen MD, Galansky SH, Striegl AM, et al. Perinatal extravaginal torsion of the testis in the first month of life is a salvageable event. *Urology*. 2003;62:132–134.

Srinivasan A, Cinman N, Feber KM, et al. History and physical examination findings predictive of testicular torsion: an attempt to promote clinical diagnosis by house staff. *J Pediatr Urol*. 2011;7(4):470–474.

Srinivasan AK, Freyle J, Gitlin JS, et al. Climatic conditions and the risk of testicular torsion in adolescent males. *J Urol*. 2007;178:2585–2588.

Srinivasan M, Hamvas C, Coplen D. Rates of complications after newborn circumcision in a well-baby nursery, special care nursery, and neonatal intensive care unit. *Clin Pediatr (Phila)*. 2015;54(12):1185–1191.

Stavropoulos NE, Mihailidis I, Hastazeris K, et al. Varicocele in schoolboys. *Arch Androl*. 2002;48:187–192.

Steeno O, Knops J, Declerck L, et al. Prevention of fertility disorders by detection and treatment of varicocele at school and college age. *Andrologia*. 1976;8:47–53.

Stehr M, Boehm R. Critical validation of colour Doppler ultrasound in diagnostics of acute scrotum in children. *Eur J Pediatr Surg*. 2003;13:386–392.

Steigman CK, Sotelo-Avila C, Weber TR. The incidence of spermatic cord structures in inguinal hernia sacs from male children. *Am J Surg Pathol*. 1999;23:880–885.

Steinhardt GF, Boyarsky S, Mackey R. Testicular torsion: pitfalls of color Doppler sonography. *J Urol*. 1993;150:461–462.

Stillwell TJ, Kramer SA. Intermittent testicular torsion. *Pediatrics*. 1986;77:908–911.

Stone KT, Kass EJ, Cacciarelli AA, et al. Management of suspected antenatal torsion: what is the best strategy? *J Urol*. 1995;153:782–784.

Stylianos S, Jacir NN, Harris BH. Incarceration of inguinal hernia in infants prior to elective repair. *J Pediatr Surg*. 1993;28:582–583.

Sule JD, Skoog SJ, Tank ES. Perineal lipoma and the accessory labioscrotal fold: an etiological relationship. *J Urol*. 1994;151:475–477.

Sule JS, Lemmers MJ, Barry JM. Scrotal arteriovenous malformation: case report and literature review. *J Urol*. 1993;150:1917–1919.

Tabrizian F, Raisolsadat SM, Houshmand B, et al. Assessment of the necessity of sac high ligation in inguinal hernia open surgery among children. *J Pediatr Surg*. 2013;48(3):547–549.

Taddio A, Pollock N, Gilbert-MacLeod C, et al. Combined analgesia and local anesthesia to minimize pain during erection. *Arch Pediatr Adolesc Med*. 2000;154:620–623.

Takehara H, Yakabe S, Kameoka K. Laparoscopic percutaneous extraperitoneal closure for inguinal hernia in children: clinical outcome of 972 repairs done in 3 pediatric surgical institutions. *J Pediatr Surg*. 2006;41:1999–2003.

Tam YH, Wong YS, Pang KK, et al. Unexpected metachronous hernia development in children following laparoscopic unilateral hernia repair with negative evaluation for contralateral patent processus vaginalis. *J Laparoendosc Adv Surg Tech A*. 2013;23(3):287–290.

Tarry WF, Duckett JW, Snyder HM. Urological complications of sickle cell disease in a pediatric population. *J Urol*. 1987;138:592–594.

Tennenbaum SY, Palmer LS. Congenital urethrocutaneous fistulas. *Urology*. 1994;43:98–99.

Tepas JJ, Stafford PW. Timing of automatic contralateral groin exploration in male infants with unilateral hernias. *Am Surg*. 1986;52:70–71.

Thirumavalavan VS, Ransley PG. Epididymitis in children and adolescents on clean intermittent catheterisation. *Eur Urol*. 1992;22(1):53–56.

Thomas JC, Elder JS. Testicular growth arrest and adolescent varicocele: does varicocele size make a difference? *J Urol*. 2002;168:1689–1691.

Tietjen DN, Uramoto GY, Tindall DJ, et al. Micropenis in hypogonadotropic hypogonadism: response of the penile androgen receptor to testosterone treatment. *J Urol*. 1998;160:1054–1057.

Timberlake MD, Herbst KW, Rasmussen S, et al. Laparoscopic percutaneous inguinal hernia repair in children: review of technique and comparison with open surgery. *J Pediatr Urol*. 2015;11(5):262.e1–262.e6.

Tobian AA, Serwadda D, Quinn TC, et al. Male circumcision for the prevention of HSV-2 and HPV infections and syphilis. *N Engl J Med*. 2009;360:1298–1309.

Tong Q, Zheng L, Tang S, et al. Lymphatic sparing laparoscopic Palomo varicocelectomy for varicoceles in children: intermediate results. *J Pediatr Surg*. 2009;44:1509–1513.

Tran C, Tamburro J, Rhee A, et al. Propranolol for treatment of genital infantile hemangioma. *J Urol*. 2016;195(3):731–737.

Tryfonas G, Violaki A, Tsikopoulos G, et al. Late postoperative results in males treated for testicular torsion during childhood. *J Pediatr Surg*. 1994;29:553–556.

Tsao CW, Hsu CY, Chou YC, et al. The relationship between varicoceles and obesity in a young adult population. *Int J Androl*. 2009;32:385–390.

Tsen HF, Morgenstern H, Mack T, et al. Risk factor for penile cancer: results of a population-based case-control study in Los Angeles County (United States). *Cancer Causes Control*.

2001;12:267–277.

Turial S, Enders J, Krause K, et al. Laparoscopic inguinal herniorrhaphy in babies weighing 5 kg or less. *Surg Endosc*. 2011;25(1):72–78.

Turial S, Saied A, Schier F. Microlaparoscopic hernia repair in children: initial experiences. *Surg Innov*. 2011;18(4):368–372.

Turkish VJ, Traisman HS, Belman AB, et al. Scrotal swelling in the Schönlein-Henoch syndrome. *J Urol*. 1976;115:317–319.

Turkyilmaz Z, Karabulut R, Sonmez K, et al. Inhibin B levels in peripheral vein do not correlate with inhibin B levels in the spermatic vein in adolescents with varicocele. *Arch Androl*. 2006;52:325–328.

Turner TT, Bang HJ, Lysiak JL. The molecular pathology of experimental testicular torsion suggests adjunct therapy to surgical repair. *J Urol*. 2004;172:2574–2578.

Ubee SS, Hopkinson V, Srirangam SJ. Parental perception of acute scrotal pain in children. *Ann R Coll Surg Engl*. 2014;96(8):618–620.

Upadhyay V, Abubacker M, Teele R. Abdominoscrotal hydrocele—is there a place for conservative management? *Eur J Pediatr Surg*. 2006;16:282–284.

Urakami S, Igawa M, Shiina H, et al. Congenital collateral urethral duplication in the frontal plane. *J Urol*. 1999;162:2097–2098.

Valentino M, Bertolotto M, Derchi L, et al. Role of contrast enhanced ultrasound in acute scrotal diseases. *Eur Radiol*. 2011;21(9):1831–1840.

Van Glabeke E, Khairouni A, Larroquet M, et al. Acute scrotal pain in children: results of 543 surgical explorations. *Pediatr Surg Int*. 1999;15:353–357.

Van Howe RS. Variability in penile appearance and penile findings: a prospective study. *Br J Urol*. 1997;80:776–782.

van Wessem KJ, Simons MP, Plaisier PW, et al. The etiology of indirect inguinal hernias: congenital and/or acquired? *Hernia*. 2003;7:76–79.

Vanlangenhove P, Dhondt E, Van Maele G, et al. Internal spermatic vein insufficiency in varicoceles: a different entity in adults and adolescents? *AJR Am J Roentgenol*. 2015;205(3):667–675.

Verwoerd-Dikkeboom CM, Koning AH, Groenenberg IA, et al. Using virtual reality for evaluation of fetal ambiguous genitalia. *Ultrasound Obstet Gynecol*. 2008;32:510–514.

Vijayaraghavan SB, Muruganand SK, Ravikumar VR, et al. Prenatal sonographic features of penoscrotal transposition. *J Ultrasound Med*. 2002;21:1427–1430.

Vincent MV, Mackinnon E. The response of clinical balanitis xerotica obliterans to the application of topical steroid-based creams. *J Pediatr Surg*. 2005;40:709–712.

Visser AJ, Heyns CF. Testicular function after torsion of the spermatic cord. *BJU Int*. 2003;92:200–203.

Vogels HD, Bruijnen CJ, Beasley SW. Predictors of recurrence after inguinal herniotomy in boys. *Pediatr Surg Int*. 2009;25:235–238.

Volkmer BG, Nesslauer T, Kraemer SC, et al. Prepubertal high flow priapism: incidence, diagnosis and treatment. *J Urol*. 2001;166:1018–1022.

Walker JR, Casale AJ. Prolonged penile erection in the newborn. *Urology*. 1997;50:796–799.

Walsh PC, Wilson JD, Allen TD, et al. Clinical and endocrinological evaluation of patients with congenital microphallus. *J Urol*. 1978;120:90–95.

Wang Y, Cai A, Sun J, et al. Prenatal diagnosis of penoscrotal transposition with 2- and 3-dimensional ultrasonography. *J Ultrasound Med*. 2011;30(10):1397–1401.

Ward JF, Friedlander SF, Kaplan GW. Hemangioma presenting as an ulceration of the scrotum. *J Urol*. 1998;160:182–183.

Watkin NA, Reiger NA, Moisey CU. Is the conservative management of the acute scrotum justified on clinical grounds? *Br J Urol*. 1996;78:623–627.

Wawer MJ, Makumbi F, Kigozi G, et al. Circumcision in HIV-infected men and its effect on HIV transmission to female partners in Rakai, Uganda: a randomized controlled trial. *Lancet*. 2009;18:229–237.

Wheeler ES, Chan V, Wassman R, et al. Familial lymphedema praecox: Meige's disease. *Plast Reconstr Surg*. 1981;67:362–364.

Wilkinson DJ, Lansdale N, Everitt LH, et al. Foreskin preputioplasty and intralesional triamcinolone: a valid alternative to circumcision for balanitis xerotica obliterans. *J Pediatr Surg*. 2012;47(4):756–759.

Williamson RC. Torsion of the testis and allied conditions. *Br J Surg*. 1976;63:465–476.

Willis HL, Snow BW, Cartwright PC, et al. Parameatal urethral cysts in prepubertal males. *J Urol*. 2011;185(3):1042–1045.

Wilson JM, Aaronson DS, Schrader R, et al. Hydrocele in the pediatric patient: inguinal or scrotal approach? *J Urol*. 2008;180:1724–1727.

Winter CC. Cure of idiopathic priapism: new procedure for creating fistula between glans penis and corpora cavernosa. *Urology*. 1976;8:389–391.

Wisniewski AB, Migeon CJ. Long-term perspectives for 46,XY patients affected by complete androgen insensitivity syndrome or congenital micropenis. *Semin Reprod Med*. 2002;20:297–304.

Wiswell TE. The prepuce, urinary tract infections, and the consequences. *Pediatrics*. 2000;106:860–862.

Wiswell TE, Smith FR, Bass JW. Decreased incidence of urinary tract infections in circumcised male infants.

Pediatrics. 1985;75:901–903.

Woldu S, Nees S, Van Batavia J, et al. Physical exam and ultrasound characteristics of right varicocoeles in adolescents with left varicocoeles. *Andrology*. 2013;1(6):936–942.

Wong J, Chan S, Pagala M, et al. Lymphatic sparing microscopic retroperitoneal varicocelectomy: a preliminary experience. *J Urol*. 2009;182(5):2460–2463.

Wong YS, Chung KL, Lo KW, et al. Scrotal antegradesclerotherapy demonstrates anatomical variations on venous drainage in paediatric, adolescent and young adult varicoceles. *Pediatr Surg Int*. 2014;30(1):107–111.

Woodhouse CR, Williams DI. Duplications of the lower urinary tract in children. *Br J Urol*. 1979;51:481–487.

Wright JE. Recurrent inguinal hernia in infancy and childhood. *Pediatr Surg Int*. 1994;9:164.

Xu C, Xiang B, Jin SG, et al. Transumbilical two-port laparoscopic percutaneous extraperitoneal closure: a new technique for inguinal hernia repair in children. *J Laparoendosc Adv Surg Tech A*. 2013;23(4):392–396.

Yamaguchi T, Hamasuna R, Hasui Y, et al. 47,XXY/48,XXY, +21 chromosomal mosaicism presenting as hypospadias with scrotal transposition. *J Urol*. 1989;142:797–798.

Yamamoto M, Hibi H, Katsuno S, et al. Effects of varicocelectomy on testis volume and semen parameters in adolescents: a randomized prospective study. *Nagoya J Med Sci*. 1995;58:127–132.

Yaman O, Soygur T, Zumrutbas AE, et al. Results of microsurgical subinguinal varicocelectomy in children and adolescents. *Urology*. 2006;68:410–412.

Yanai T, Okazaki T, Yamataka A, et al. Cysts of the ejaculatory system: a report of two cases. *Pediatr Surg Int*. 2005;21:939–942.

Yang DM, Lim JW, Kim JE, et al. Torsed appendix testis: gray scale and color Doppler sonographic findings compared with normal appendix testis. *J Ultrasound Med*. 2005;24:87–91.

Yerkes EB, Robertson FM, Gitlin J, et al. Management of perinatal torsion: today, tomorrow or never? *J Urol*. 2005;174:1579–1582.

Yilmaz E, Afşarlar CE, Karaman I, et al. Congenital hemiscrotal agenesis: report of a rare entity. *J Pediatr Urol*. 2013;9(1):e76–e77.

Yu W, Rao T, Ruan Y, et al. Laparoscopic varicocelectomy in adolescents: artery ligation and artery preservation. *Urology*. 2016;89:150–154.

Zachmann M, Prader A, Kind HP, et al. Testicular volume during adolescence. Cross-sectional and longitudinal studies. *Helv Paediatr Acta*. 1974;29:61–72.

Zalel Y, Pinhas-Hamiel O, Lipitz S, et al. The development of the fetal penis—an in utero sonographic evaluation. *Ultrasound Obstet Gynecol*. 2001;17:129–131.

Zampieri N, Cervellione RM. Varicocele in adolescents: a 6-year longitudinal and followup observational study. *J Urol*. 2008;180:1653–1656.

Zampieri N, Corroppolo M, Zuin V, et al. Longitudinal study of semen quality in adolescents with varicocele: to treat or not? *Urology*. 2007;70:989–993.

Zampieri N, Mantovani A, Ottolenghi A, et al. Testicular catch-up growth after varicocelectomy: does surgical technique make a difference? *Urology*. 2009;73:289–292.

Zampieri N, Ottolenghi A, Camoglio FS. Painful varicocele in pediatric age: is there a correlation between pain, testicular damage and hormonal values to justify surgery? *Pediatr Surg Int*. 2008;24:1235–1238.

Zampieri N, Zuin V, Corroppolo M, et al. Varicocele and adolescents: semen quality after 2 different laparoscopic procedures. *J Androl*. 2007;28:727–733.

Zampieri N, Zuin V, Corroppolo M, et al. Relationship between varicocele grade, vein reflux and testicular growth arrest. *Pediatr Surg Int*. 2008;24:727–730.

Zani A, Eaton S, Hoellwarth M, et al. Management of pediatric inguinal hernias in the era of laparoscopy: results of an international survey. *Eur J Pediatr Surg*. 2014;24(1):9–13.

Zaupa P, Mayr J, Hollwarth ME. Antegrade scrotal sclerotherapy for treating primary varicocele in children. *BJU Int*. 2006;97:809–812.

Zhang JZ, Li XZ. Inguinal hernia in infants and children in China. *Pediatr Surg Int*. 1993;8:458.

Zhang Y, Han Q, Fan H, et al. Genetic analysis of the TBX2 gene promoter in indirect inguinal hernia. *Hernia*. 2014;18(4):513–517.

Zhang Y, Han Q, Li C, et al. Genetic analysis of the TBX1 gene promoter in indirect inguinal hernia. *Gene*. 2014;535(2):290–293.

Zhao LC, Lautz TB, Meeks JJ, et al. Pediatric testicular torsion epidemiology using a national database: incidence, risk of orchiectomy and possible measures toward improving the quality of care. *J Urol*. 2011;186(5):2009–2013.

Zhou X, Peng L, Sha Y, et al. Transumbilical endoscopic surgery for incarcerated inguinal hernias in infants and children. *J Pediatr Surg*. 2014;49(1):214–217.

Zini A, Boman JM. Varicocele: red flag or red herring? *Semin Reprod Med*. 2009;27:171–178.

Zona JZ. The incidence of positive contralateral inguinal exploration among preschool children: a retrospective and prospective study. *J Pediatr Surg*. 1996;31:656–660.

Zorc JJ, Levine DA, Platt SL, et al. Clinical and demographic factors associated with urinary tract infection in young febrile infants. *Pediatrics*. 2005;116:644–648.

45

Hypospadias

Christopher J. Long MD, Mark R. Zaontz MD, Douglas A. Canning MD

In 1995 John Duckett, MD, a hypospadias pioneer, wrote: “Hypospadiology requires an in-depth study of the contributions of our predecessors as well as a thorough knowledge of the methods and maneuvers of current experts. To study at a medical center where large numbers of hypospadias cases are managed is more beneficial than the anguish of learning through one's mistakes” (Duckett, 1995). As outlined in this chapter, we have made significant advancements since his passing, but we still have a lot of work to do to improve outcomes. Expanding Dr. Duckett's vision, meticulous documentation, collaboration across multiple centers, and honest outcome reporting will further advance this field.

Embryology

The classic triad of hypospadias, a dorsally hooded foreskin, a proximal urethral meatus, and ventral penile curvature, arises from an arrest in penile development. A more extensive review of penile embryology is covered elsewhere in this volume, so we will focus on the most relevant concepts.

The initial stages of external genital developmental are similar for both sexes. Mesenchymal ingrowth at the cloacal membrane on the ventral surface of the fetus divides it into two halves, forming the foundation for anal and genital anatomy development (Glenister, 1954; Kurzrock et al., 1999). Migrating cells coalesce over the cloacal membrane to form several folds, including the cloacal folds, which merge to form the genital tubercle. The urogenital diaphragm forms below the genital tubercle as the anal and genital systems separate at 7 weeks of gestation. The urogenital folds and the more lateral labioscrotal folds emerge lateral to the urogenital membrane (Fig. 45.1).

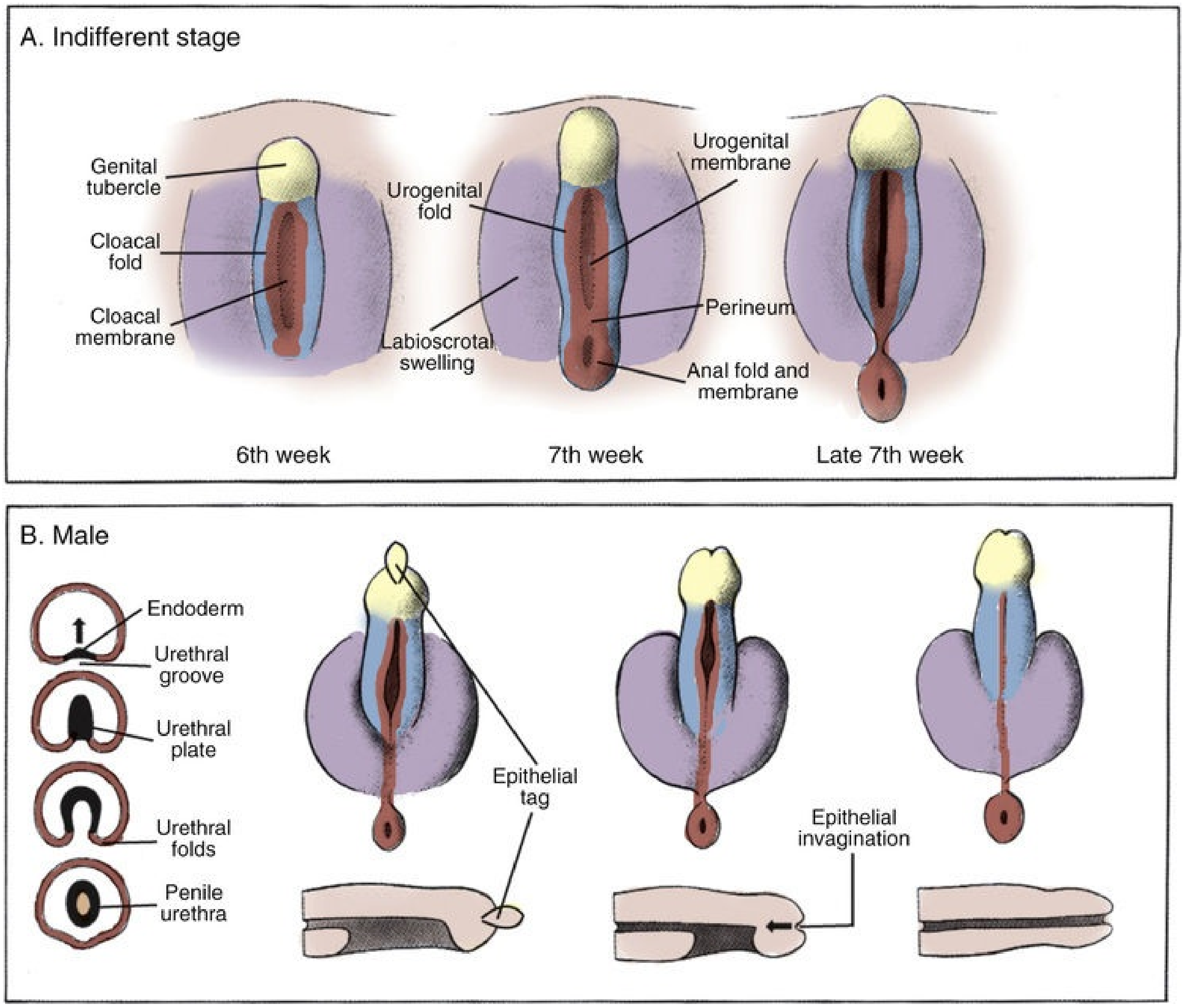
A. Indifferent stage
Genital tubercle
Cloacal fold
Cloacal membrane
Urogenital fold
Labioscrotal swelling
Urogenital membrane
Perineum
Anal fold and membrane
6th week
7th week
Late 7th week
B. Male
Endoderm
Urethral groove
Urethral plate
Urethral folds
Penile urethra
Epithelial tag
Epithelial invagination

FIG. 45.1 (A) The relationship of the genital tubercle, urogenital fold, urogenital membrane, and labioscrotal swellings in the undifferentiated state of development. (B) In males the urogenital folds fuse while the genital tubercle elongates, forming the penis and glans. The lower image depicts the epithelial invagination theory of distal urethra formation, as opposed to the recently proposed endodermal source for formation of the entire urethra. The labioscrotal folds swell and fuse in the midline to form the scrotum.

The exact mechanism of urethral development is debated. In 1954 Glenister proposed the “ectodermal ingrowth theory,” in which the stratified squamous lining of the glanular urethra originates independently via retrograde ectodermal ingrowth from cannulation of the glans. The glanular urethra then fuses at the coronal margin with the endodermal penile urethral plate, which is forming simultaneously as a result of antegrade fusion of the urethral folds (Glenister, 1954). **This process occurs sequentially from the anus to the distal glans during gestation weeks 8 to 16, the critical period for external genitalia**

development.

Alternatively, recent evidence supports an entirely endodermal origin for the urethra (Kurzrock et al., 1999). **According to this newer theory, the urethral plate formation is contiguous from the penile urethra into the glans and undergoes differentiation to form the stratified squamous layer** (Kurzrock et al., 1999). The authors have further refined their theory on urethral development to describe the two-zipper hypothesis of urethral development. This begins with the “unzipping” event, stemming from proliferation of the flat urethral plate into a canalized urethral groove, which is lined with flanking urethral folds. This process is seen in the male and female urethra. **The “closing zipper” is androgen dependent and unique to the male urethra. As opposed to a simple fusion of the urethral folds, the fusion process occurs in an interlacing fashion at varying rates and levels, forming the contiguous urethra** (Li et al., 2015; Shen et al., 2016). Disruption of this process results in the large spectrum of variants of hypospadias (Fig. 45.2).

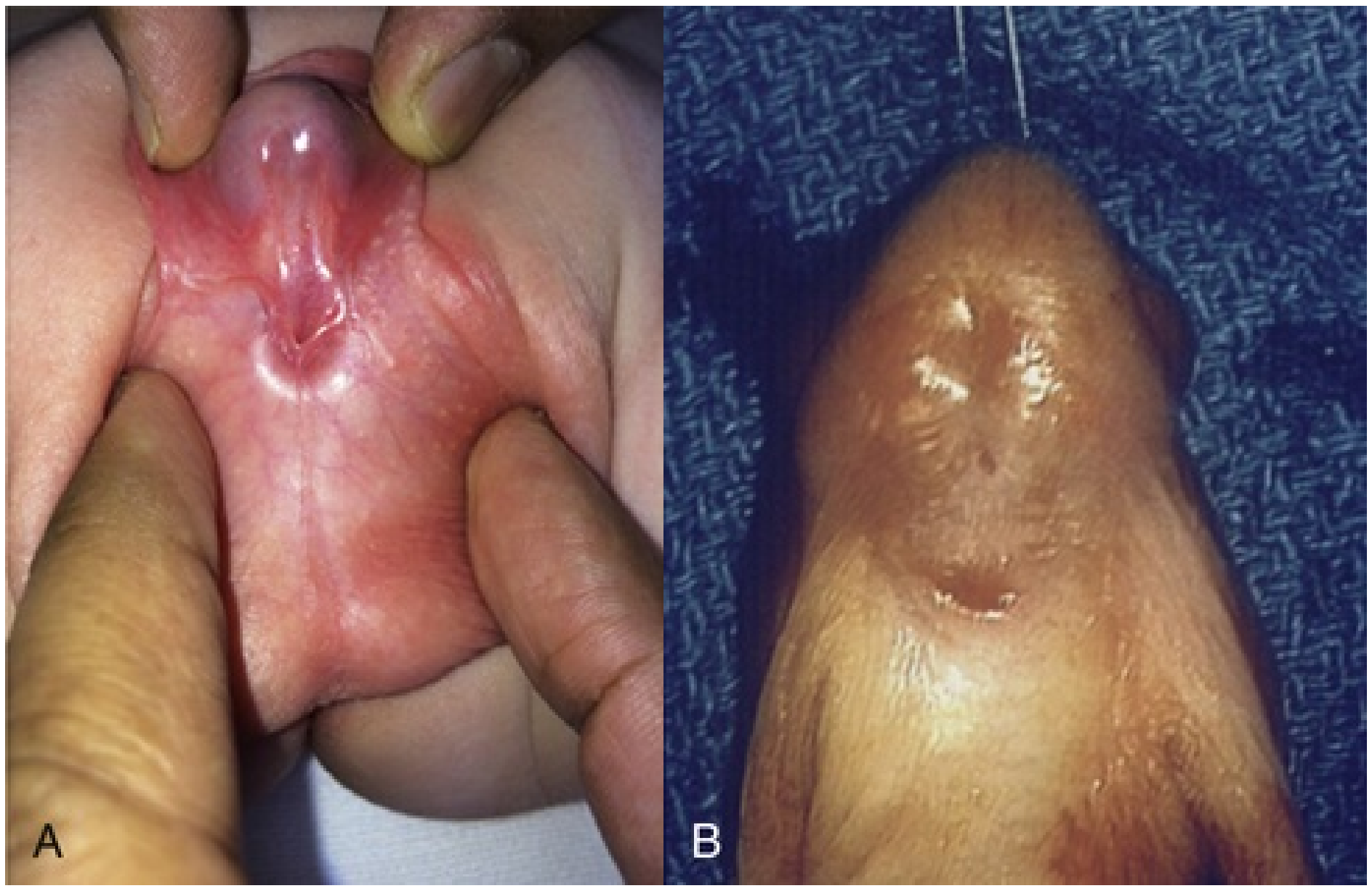

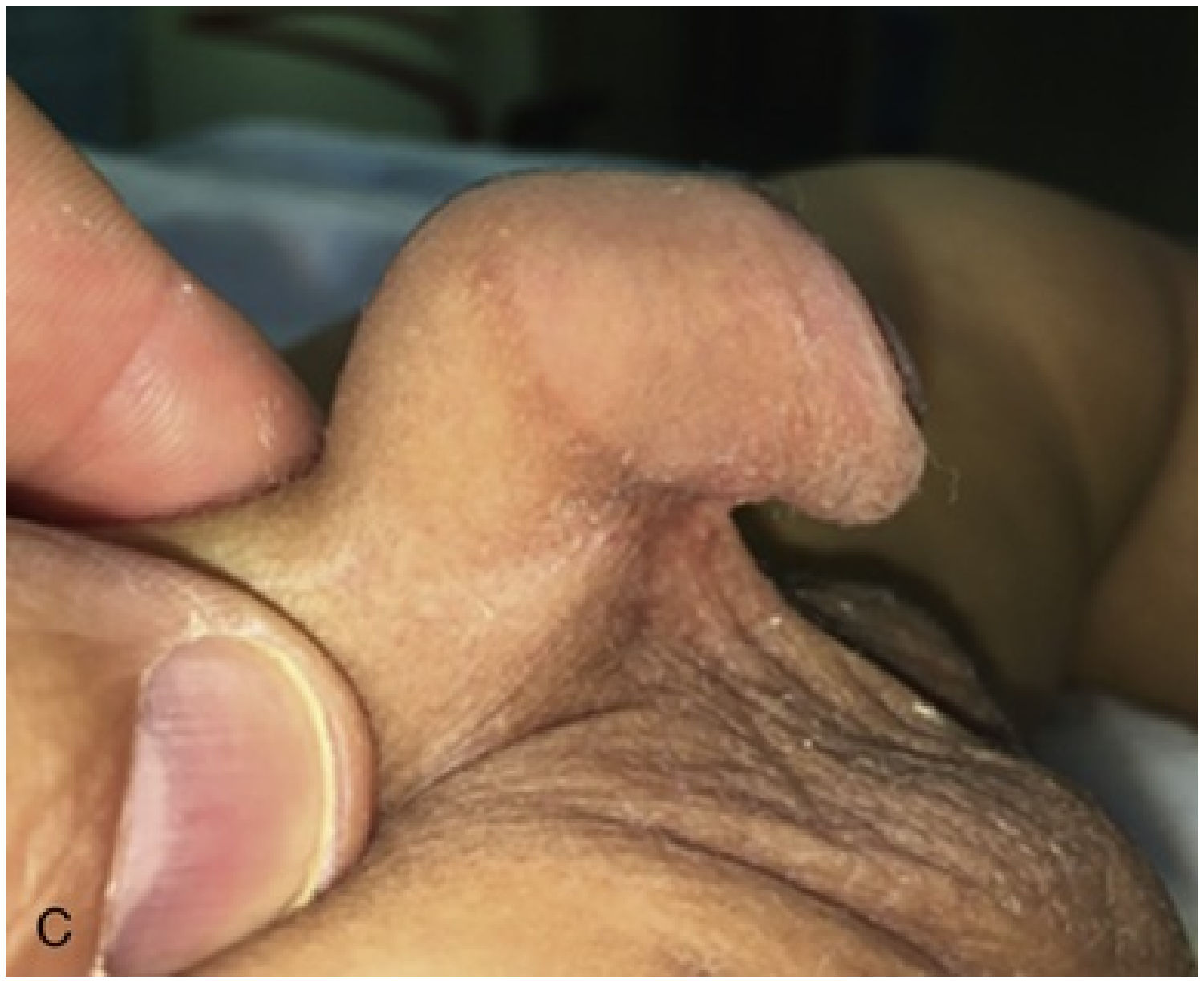

FIG. 45.2 (A) A boy with a proximal hypospadias variant with hypoplastic ventral shaft skin, a penoscrotal meatus, and severe ventral penile curvature. The glans appears small and with a poorly developed groove. (B) A boy who has a subcoronal meatus with a flat glans groove and a lack of ventral foreskin. (C) A boy with severe ventral penile curvature.

Prepuce development coincides with and is dependent on normal urethral development. At approximately 8 weeks of gestation, preputial folds first appear on the distal penile shaft at the base of the corona (Glenister, 1954). These folds first fuse dorsally, then with further penile growth, join ventrally to envelop the developing glans. This process is limited by the developing urethra**. Ventral fusion is not completed until the urethral folds fuse, typically around 20 weeks of gestational age** (Baskin and Ebbers, 2006)**. Therefore incomplete urethral fold fusion results in an ectopic meatus accompanied by incomplete foreskin, seen in 95% of boys with hypospadias** (Baskin and Ebbers, 2006). Contrary to this theory, megameatus with an intact prepuce (MIP) is seen in 5% of cases. The precise cause of this variant, characterized by a widened, distal urethral meatus with a normal foreskin and a lack of severe curvature, is unclear, but we know that complete development and midline fusion of the preputial folds are not always accompanied by an intact urethra (Duckett and Keating, 1989).

External genital development occurs in two phases, a hormone-independent phase and a hormone-dependent stage, beginning at the eighth week of gestation. **Expression of the sex-determining region of *Y* chromosome (SRY) gene product between 7 and 8 weeks of gestation results in masculinization of the**

undifferentiated gonad, testosterone production, regression of female structures, and elongation of the genital tubercle (Baskin and Ebbers, 2006). Leydig cell–produced testosterone is locally converted by 5α-reductase type 2 to dihydrotestosterone (DHT) by cells in the developing external genitalia, further promoting growth (Kim et al., 2002). The growth factor *Sonic Hedgehog (Shh)* plays a critical role in genital tubercle formation and urethral plate formation (Miyagawa et al., 2011). **Androgen receptors have been localized to the penile skin, inner prepuce, urethra, and stromal cells of the corpus spongiosum during the early gestation period, suggesting an equally vital role for androgens in urethral development** (Kim et al., 2002)**. In patients with a lack of androgen receptor stimulation, there is a lack of midline fusion of the scrotal and/or urethral folds, as occurs in female development, which lacks DHT and androgen receptors.**

Key Points

- Dihydrotestosterone at the 8- to 12-week gestational phase is a key mediator in the proper development of the penis.
- Male urethra closure is an androgen-dependent process, contrasting its formation to that of the female urethra.

Diagnosis of Hypospadias

Hypospadias is one of the most common congenital anomalies in boys, occurring in 1 in 150 to 300 live births (Elliott et al., 2011; Springer et al., 2015). **Diagnosis is made on physical exam and includes the following three criteria: an ectopic, ventrally located urethral meatus; ventral penile curvature; and an incomplete, dorsally hooded foreskin.** Hypospadias is a broad term, however, and the severity of each component can vary greatly from boy to boy.

The latter two elements are not always present. Up to 5% of boys with hypospadias have an intact prepuce (the previously mentioned MIP variant) and are not diagnosed until the foreskin becomes retractable or reduced at the time of circumcision (Fig. 45.3). Because the intact prepuce can hide the presence of incomplete urethral development in a newborn infant, it is critical to retract the foreskin before circumcision to avoid missing this anomaly and potentially injuring the incomplete urethra or removing foreskin that could be incorporated in an ensuing urethral reconstruction (Hatch et al., 1989). Some have compared the outcomes of patients with a MIP variant for a prior circumcision to no prior circumcision, concluding that prior circumcision did not negatively affect hypospadias repair (Chalmers et al., 2014; Snodgrass and Khavari, 2006). In our experience a circumcision can be performed if the penis is carefully assessed to rule out a more severe variant of hypospadias with either a ventral skin deficiency or ventral penile curvature. In these instances a circumcision should be avoided because it may be necessary to correct these anomalies.

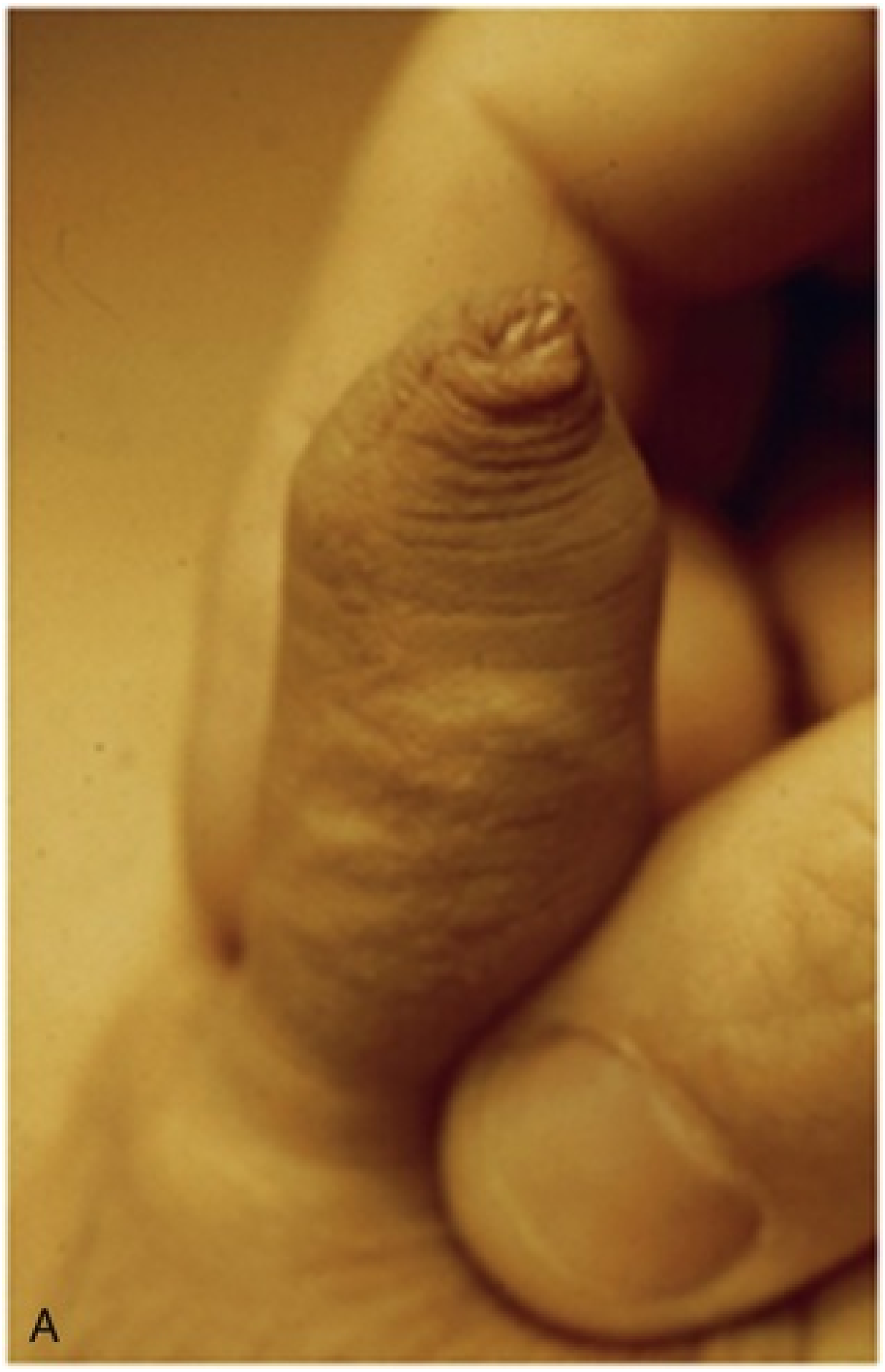
A

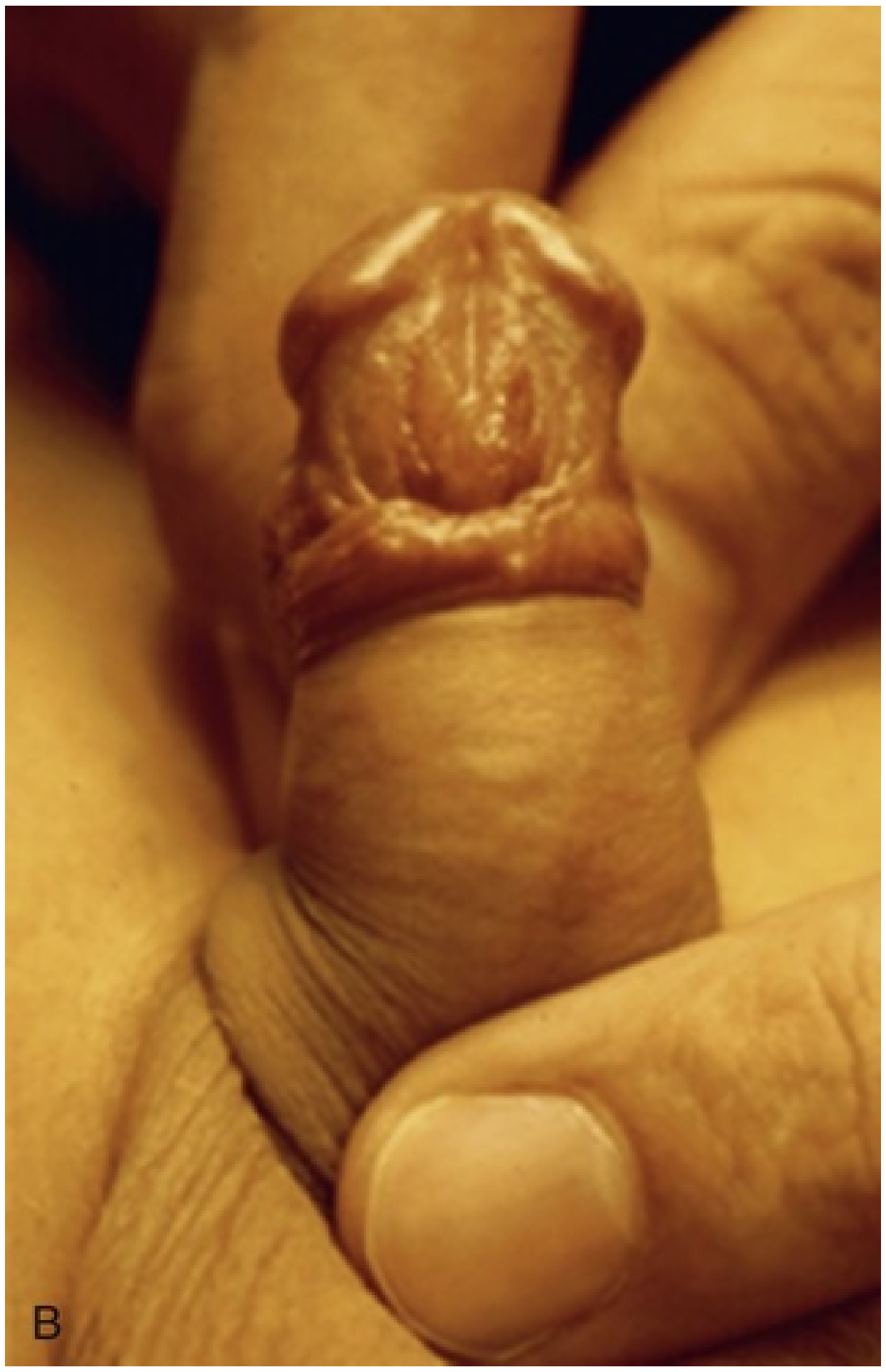

FIG. 45.3 (A) This boy has what appears to be an intact prepuce and normal penis. (B) Once the foreskin is retracted, the hypospadias is obvious. There is separation of the glans wings and a distal penile shaft meatus, representing the megameatus with an intact prepuce (MIP) variant.

Another variant includes boys who have penile curvature without hypospadias. These boys have all the elements of the hypospadias complex but have an orthotopic meatus. In these cases, if circumcision is desired, it should be deferred until definitive surgical management of the curvature can be performed in the operating room because the foreskin may be needed for reconstruction.

The urethral meatus location has classically been used to define severity of hypospadias (Snodgrass et al., 2011). Using this criteria, the majority of boys (70%–85%) have a mild, distal meatus variant (Borer et al., 2001; Duckett, 1989; Pfistermuller et al., 2015; Rushton and Belman, 1998; Fig. 45.4). Proximal hypospadias occurs in 10% to 25% of patients and presents several unique management challenges to the surgeon (Bergman et al., 2015; Manzoni et al., 2004). A classification based solely on the location of the urethral meatus oversimplifies the hypospadias phenotype and may even be misleading. **Boys who have what appears to be a distal urethral meatus may have severe ventral curvature, hypoplastic tissue overlying a more proximal urethral meatus, and a lack of ventral penile shaft skin, increasing the complexity of the repair and the risk of complication (Fig. 45.5).** Thus defining hypospadias complexity simply based upon the location of the urethral meatus underestimates the severity in some boys. **A classification system that includes the location of the urethral meatus as well as the degree of penile curvature after degloving leads to a more definitive and relevant diagnosis.**

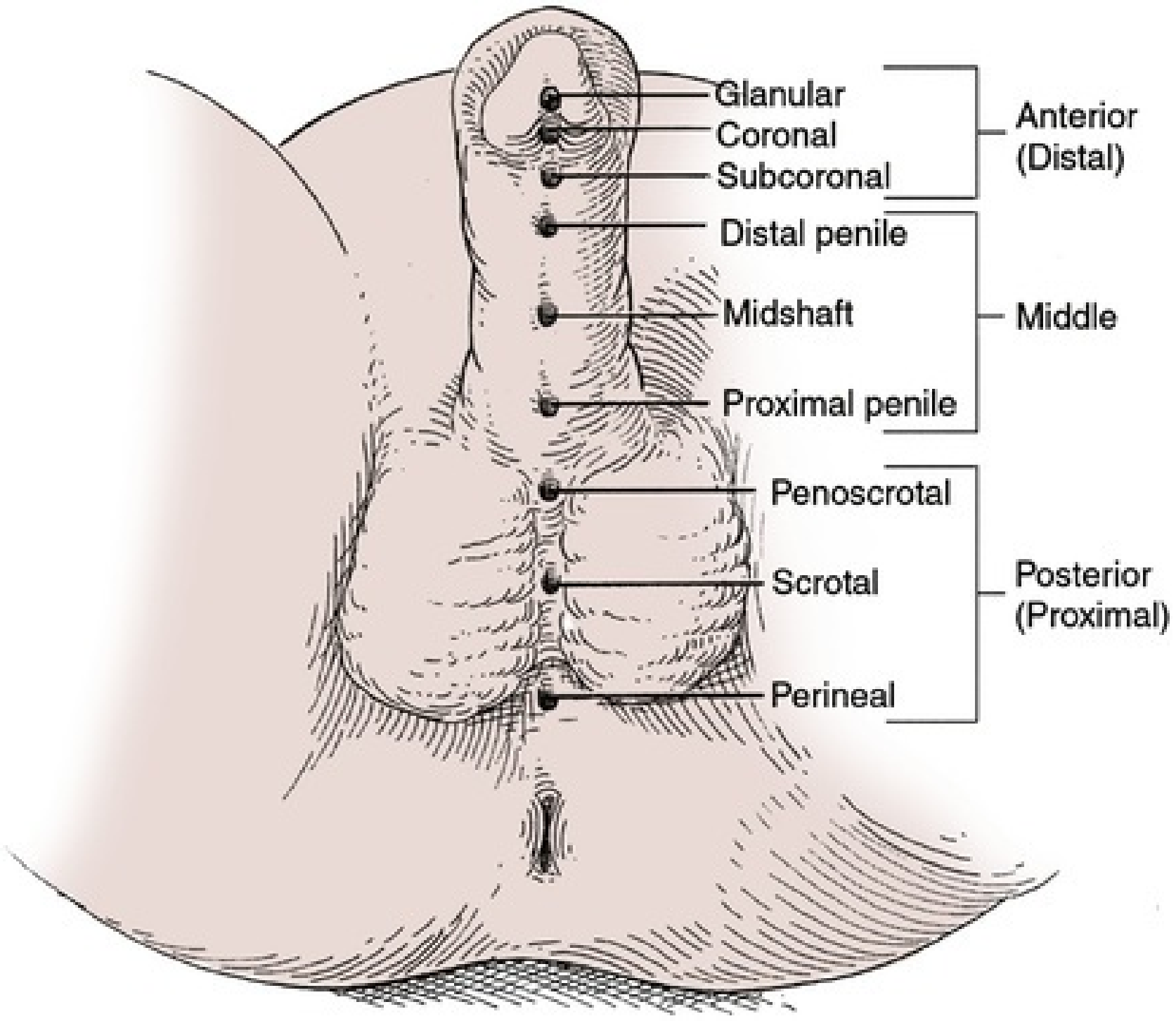
Glanular
Coronal
Subcoronal
Anterior (Distal)
Distal penile
Midshaft
Middle
Proximal penile
Penoscrotal
Scrotal
Posterior (Proximal)
Perineal

FIG. 45.4 Various potential locations for the ectopic urethral meatus in hypospadias. The classical description was based on the location of the urethral meatus and divided into distal, midshaft, and proximal hypospadias.

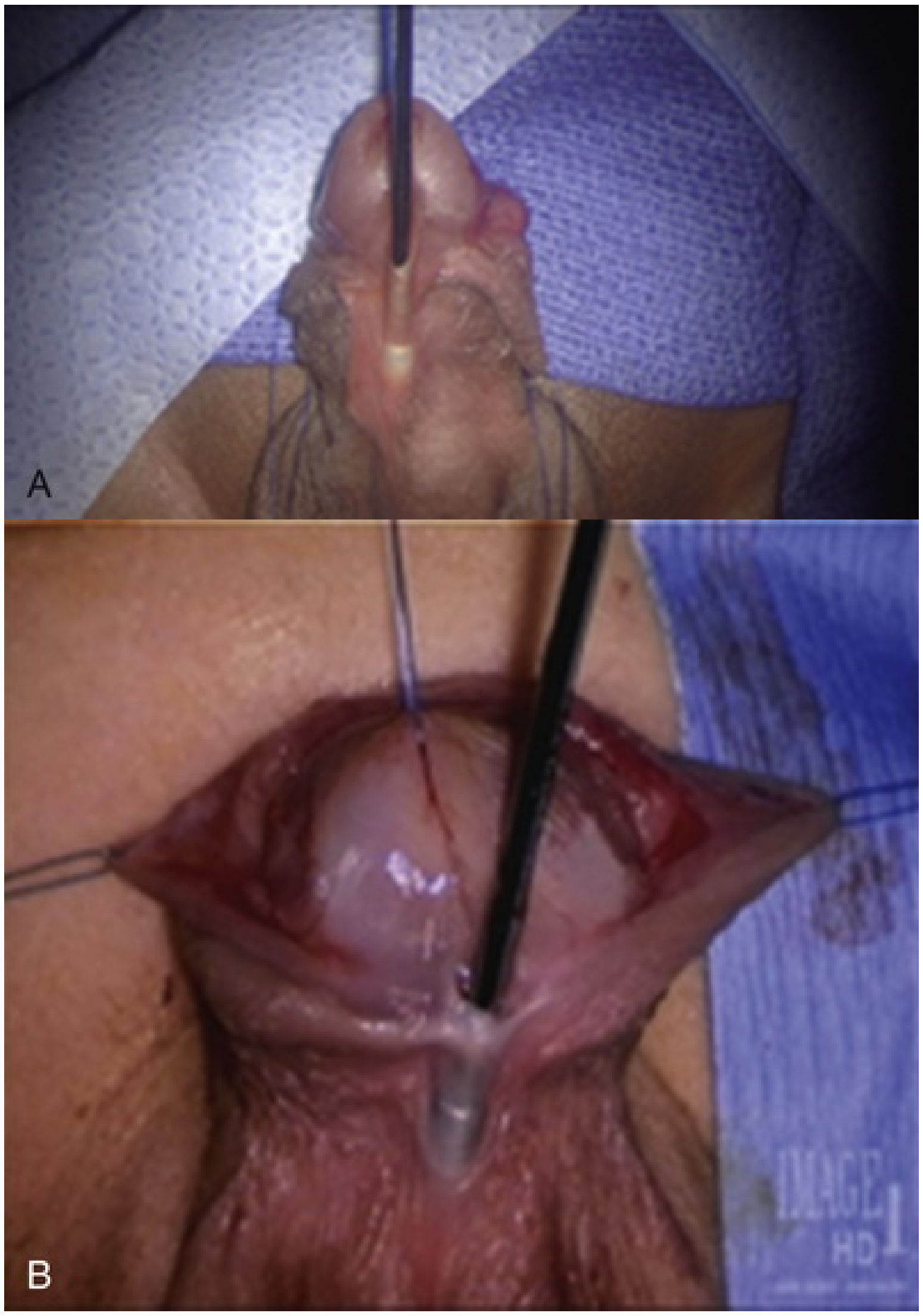

FIG. 45.5 (A and B) Hypospadias classification based solely on the location of the urethral meatus can be deceiving. These two patients have what appears to be a distal hypospadias with a subcoronal meatus, but insertion of a bougie à boule reveals hypoplastic ventral shaft skin and absent corpus spongiosum to the level of the penoscrotal junction. Both of these boys have what we consider to be a severe or proximal hypospadias variant in spite of the initial location of the urethral meatus.

The GMS score (glans meatus and penile shaft [curvature]) incorporates physical exam findings in the operating room, assessing the quality of the glans and urethral plate, the location of the urethral meatus, and the degree of penile curvature, to objectively assign scores to stratify severity (Fig. 45.6; Arlen et al., 2015; Merriman et al., 2013). Indeed, higher GMS scores correlate with an increased risk of developing a complication (Arlen et al., 2015; Merriman et al., 2013). The GMS score assessment was developed for use in the operating room because office measurements have proven to be less accurate at assessing severity, particularly the degree of ventral penile curvature. It remains to be seen whether an office-based exam can provide the same degree of granularity that is obtained in the operating room, but for now the latter remains the gold standard measurement of phenotype severity.

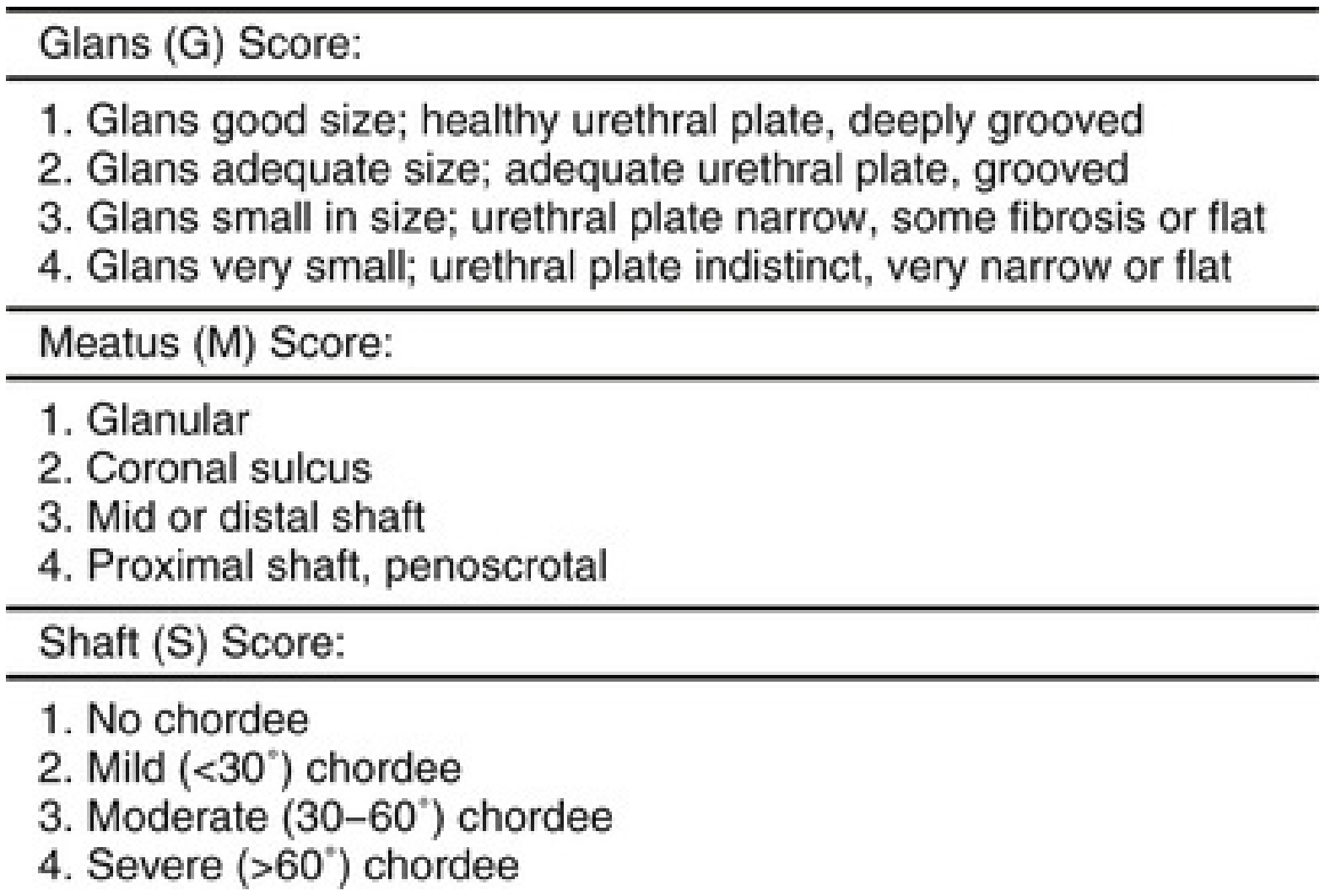

Glans (G) Score:

1. Glans good size; healthy urethral plate, deeply grooved
2. Glans adequate size; adequate urethral plate, grooved
3. Glans small in size; urethral plate narrow, some fibrosis or flat
4. Glans very small; urethral plate indistinct, very narrow or flat

Meatus (M) Score:

1. Glanular
2. Coronal sulcus
3. Mid or distal shaft
4. Proximal shaft, penoscrotal

Shaft (S) Score:

1. No chordee
2. Mild (<30°) chordee
3. Moderate (30–60°) chordee
4. Severe (>60°) chordee

FIG. 45.6 The glans meatus and penile shaft (GMS) score is assessed at the time of the procedure. Each element assigns a higher number score for increasing severity. A small, flatted glans with a poorly defined urethral plate achieves a higher glans score, whereas a proximal location a higher meatus score, and more severe ventral curvature for the shaft score. The components are additive to assign a summary score. (From Merriman LS: The GMS hypospadias score. *J Pediatr Urol* 9:707–712, 2013.)

The initial evaluation of boys with hypospadias requires a careful history and physical examination. In addition to the triad of hypospadias, boys may have associated anomalies, including penile torsion, penoscrotal webbing, and penoscrotal transposition, that must be considered when planning the repair. Physical examination may note dysplastic ventral tissue in boys with hypospadias. Ventral curvature from lack of ventral shaft skin may be immediately obvious on exam. Anatomic studies have shown worsened curvature and shorter penile length in boys with proximal hypospadias. Ultrasonic elastography studies have found less elastic tissue and androgen resistance in boys with proximal hypospadias, suggesting more dysplastic tissue, which not only causes penile curvature but can also complicate surgical reconstruction (Bush et al., 2013a; Camoglio et al., 2016; Snodgrass et al., 2014a).

The most common anomalies associated with hypospadias are inguinal hernia and/or hydrocele and cryptorchidism. Inguinal hernia and/or hydrocele is more common, ranging from 9% to 16%, but no increased incidence is noted with severity of hypospadias (Wu et al., 2002). **Cryptorchidism is found in approximately 7% of patients with hypospadias. This increases to nearly 10% with more proximal hypospadias** (Hjertkvist et al., 1989; John Radcliffe Hospital Cryptorchidism Study Group, 1992; Shima et al., 1979; Sorber et al., 1997; Weidner et al., 1999; Wu et al., 2002). **The AUA cryptorchidism guideline recommends that all boys with unilateral or bilateral undescended testes and severe proximal hypospadias must undergo additional testing to rule out a disorder of sexual differentiation (DSD), which occurs much more frequently in these settings** (Kaefer et al., 1999; Kolon et al., 2014; Moreno-Garcia and Miranda, 2002; Rajfer and Walsh, 1976; Rohatgi et al., 1987).

Guidelines introduced in 2006 included severe hypospadias as a form of 46,XY DSD (Hughes et al., 2006). The concern for DSD is particularly high in a boy with hypospadias and a nonpalpable testis. Kaefer et al. (1999) examined 79 patients with a history of hypospadias and cryptorchidism. **Those with a nonpalpable testis(es), either unilateral or bilateral, had a threefold increased risk for having an underlying DSD diagnosis identified (approximately 50% vs. 15%). There was a significantly increased risk of DSD with proximal hypospadias compared with distal hypospadias (64% vs. 7%)** (Kaefer et al., 1999). A normal 46,XY karyotype may be misleading, particularly in boys with the most severe variants. The surgeon must be alert for contributing diagnoses such as 5α-reductase deficiency, androgen receptor insensitivity, decreased testosterone production associated with testicular dysgenesis, and ovotesticular DSD. Workup may include ultrasound (to rule out müllerian remnants), karyotype, and hormonal analysis (testosterone, FSH, LH, AMH). **These data remind surgeons to look carefully for signs of DSD when planning surgery in a boy with proximal hypospadias.**

Key Points

- Hypospadias is diagnosed by physical exam and includes the following three criteria: an ectopic, ventrally located urethral meatus; ventral penile curvature; and an incomplete, dorsally hooded foreskin.

- The classic definition of hypospadias severity focused on the location of the urethral meatus. A classification system that includes the location of the urethral meatus as well as the degree of penile curvature after degloving leads to a more definitive and relevant diagnosis.
- The presence of hypospadias and unilateral or bilateral cryptorchidism should raise concern for a DSD and prompt an appropriate workup.

Etiology of Hypospadias

Hypospadias is multifactorial in origin, including genetic and environmental concerns. Risk factors include premature birth, infants small for gestational age (<10th percentile for weight, length, and/or head circumference), and intrauterine growth restriction. All have been associated with an increased risk for having a newborn with hypospadias (Gatti et al., 2001; Ghirri et al., 2009; Hussain et al., 2002). In particular there is a trend toward premature birth (<37 weeks) and low birth weight in those with a combination of proximal hypospadias and cryptorchidism (Sekaran et al., 2013). One theory to explain this finding is placental insufficiency, which frequently contributes to small-for-gestational-age boys. Decreased placental weight at birth is associated with a twofold increase in hypospadias development and a 1.5 times risk of cryptorchidism (Arendt et al., 2016). Use of assisted reproduction techniques are also associated with higher rates of hypospadias (Wennerholm et al., 2000). Although these infants also have higher rates of prematurity, low birth weight, and twinning, multivariate analysis suggests that assisted reproduction remains an independent factor (Funke et al., 2010).

Epidemiologic analysis has identified strong familial associations of hypospadias, suggesting a genetic component (Fredell et al., 2002; Schnack et al., 2008). **Studies of twin boys reveal a concordance rate of 9% to 27% in a twin brother, whereas an affected boy has a 9% to 15% chance of having a first-degree relative with hypospadias (brother, father)** (Asklund et al., 2007; Bauer et al., 1979). A nationwide Danish registry of more than 1 million boys identified 5380 boys with hypospadias, implicating maternal and paternal transmission and found an elevated risk for even third-degree relatives (Schnack et al., 2008).

In spite of these findings, attempts at elucidating a “one-hit” gene mutation for sporadic hypospadias have been disappointing, because discrete chromosomal abnormalities are found in only up to 30% of boys with hypospadias (Bouty et al., 2015). Detailed review of the genetic basis of hypospadias is beyond the scope of this chapter but warrants review (Bouty et al., 2015; Kalfa et al., 2011). Various genes have been implicated and segregating them into broader categories is feasible. Homeobox genes (HOX) and fibroblast growth factor (FGF) have been identified as important members of the cascade for penile development. Wilms tumor 1, SOX9, DMRT1, and GATA4 affect gonad development and have been associated with hypospadias. **Finally, mutations within the androgen cascade, androgen production and reception, have been implicated. These include all elements of androgen production, including the luteinizing hormone (LH) receptor gene, 5α-reductase gene, the androgen receptor, and normal testicular development** (Baskin et al., 2001; Fredell et al., 2002; Silver and Russell, 1999).

Nearly 200 syndromes with known genetic causes have an associated hypospadias, although these represent a fraction of those boys with idiopathic forms (Kalfa et al., 2011). The most commonly encountered associations include WAGR (Wilms tumor [WT]), Aniridia genitourinary abnormalities, and developmental delay [R]), Denys-Drash syndrome (genitourinary malformations, renal failure, and high risk for WT), and Smith-Lemli-Opitz syndrome (malformations of the heart, lungs, kidneys, gastrointestinal tract, and genitalia) (Bouty et al., 2015).

Since the 1970s, several large population studies across the world have reported rising rates of hypospadias, some as high as 3% per year (Chul Kim et al., 2011; Lund et al., 2009; Paulozzi, 1999; Toppari et al., 2010). Others have disputed this trend, reporting stable incidence and explaining perceived increased rates reported by others as increased reporting of more mild variants (Bergman et al., 2015; Lane et al., 2017). On the other hand, a study in Sweden over a 40-year period reported a rising trend in incidence for distal and proximal variants (Nordenvall et al., 2014). **Taken together, these data suggest the rate is either stable or increasing. This fact, combined with concerns for a concurrent rise in the rate of cryptorchidism and a decrease in sperm quality, has created concern for a common cause, likely an environmental source, to explain these genital-specific findings**.

The testicular dysgenesis syndrome (TDS) hypothesizes that this series of increasingly frequent male reproductive developmental disorders, including poor semen quality, increased risk of testicular cancer, cryptorchidism, and hypospadias, are secondary to a fetal exposure that directly affects the androgen cascade and genital development (Skakkebaek et al., 2001). This constellation is thought to be multifactorial in origin and includes environmental and genetic insults resulting in testicular dysgenesis, originated from abnormal testicular development in utero (Skakkebaek et al., 2001). **Animal studies have identified a direct correlation between pesticide exposure, disruption of the androgen cascade, and abnormal genital development** (Gray and Kelce, 1996; Hayes et al., 2002; Toppari et al., 1996). Potential causative agents under investigation include pesticides (exposure in the workplace and in foods with elevated levels of pesticides), hormones (birth control medication, diethylstilbestrol [DES]), phthalates (found in plastics and hairspray), and phytoestrogens consumed in a vegetarian diet (Baskin et al., 2001; Kalfa et al., 2015). These environmental disrupting chemicals (EDC), in theory, competitively inhibit androgen receptor binding and disrupt external genital development, although efforts at establishing a link in humans have been unsuccessful (Baskin et al., 2001; Gaspari et al., 2012; Toppari et al., 1996). In a study performed in southern France, after removing patients with hypospadias and age-matched controls, the authors were able to identify a significant risk for developing hypospadias after parental exposure to EDC, specifically detergents, pesticides, and cosmetics, during pregnancy. The authors found an increased risk for environmental exposure alone, but this risk was higher when combined with occupational exposures (Kalfa et al., 2015). Because these chemicals are ubiquitous, it is challenging to avoid them to study them in isolation. Nevertheless, understanding their role in hypospadias development is vital.

The anogenital distance (AGD) is measured from the center of the anus to the most caudad midline border of the penoscrotal junction. **This distance, which is thought to be a measure of disrupted genital development, is shorter in boys with suspected exposure to EDC** (Swan et al., 2005)**. Corroborating reports in animal models, shorter AGD in males has been associated with infertility, cryptorchidism, and hypospadias. In addition, shorter AGD is directly proportional to hypospadias severity** (Cox et al., 2017; Eisenberg et al., 2011; Hsieh et al., 2012; Jain and Singal, 2013).

Key Points

- There is an increased risk of hypospadias in births resulting from assisted reproduction and monozygotic twins.
- The cause of hypospadias is multifactorial, but placental insufficiency and androgen disruption, in part via environmental exposures, are potential culprits in what is thought to be an increasing rate of hypospadias development. Anogenital distance is a reflection of disruption of this cascade and may correlate with phenotype severity.

Surgical Assessment

The goals of surgical reconstruction in boys with hypospadias include correction of penile curvature to ensure a long, straight erection, advancement of the urethra to ensure normal passage of urine and semen through the glans, and the creation of a cosmetically pleasing penis. The surgeon must assess the potential long-term significance of the defect and have an objective discussion with the boy's parents as to whether a surgical repair should be performed. In some cases, in which the penis is straight while erect and the urethral meatus is distal enough to allow for urination while standing, there may be limited benefit to a repair. Repair should be accomplished with the minimum number of procedures to ensure an adequate long-term result, extending into adulthood. **Achievement of this goal includes preparation of the family and patient for the proper procedure, accurate anatomic assessment, and an honest discussion about surgical outcomes and potential complications.**

Surgical timing is important. The timing of the repair should balance the potential adverse psychological effects of surgery, the anesthetic risk to the child, the degree of penile development that will facilitate a successful repair, and wound healing differences as boys age (Bermudez et al., 2011). Genital awareness begins to occur around 18 months of age and progresses with advancing age (Schultz et al., 1983). Boys undergoing earlier repair (usually before 12 months of age) experienced less anxiety and have improved psychosexual outcomes compared with boys undergoing repair at older ages (Belman and Kass, 1982; Perlmutter et al., 2006). Boys operated on at a younger ages may also experience fewer complications, a finding that reinforces the need for early correction (Perlmutter et al., 2006). Comparatively speaking, hypospadias surgery in adults may be associated with a higher complication rate (Hensle et al., 2001). **Based on these studies, in 1996 the American Academy of Pediatrics Section on Urology recommended that elective hypospadias repairs occur between the ages of 6 and 12 months, within which a few exceptions remain in our practice today** (American Academy of Pediatrics, 1996).

Parents frequently ask about the safety of anesthesia when contemplating surgery in their infant son. Data in animals suggest varying degrees of neurotoxicity in response to agents used for general anesthesia (Jevtovic-

Todorovic et al., 2003). Because studies that include brain biopsies in animals are impossible to replicate in human subjects, we must rely on longitudinal observational studies in children. Children exposed to anesthesia (general vs. regional block) for hernia repair had no detectable neurodevelopmental delays at 2 years of age (Davidson et al., 2016). Although research continues, based on current evidence it appears that there are few consequences after a single anesthesia exposure with short-term follow-up (Sun et al., 2016). As additional clinical studies are completed, we will have more information with which to counsel families (Pinyavat et al., 2016). **As a result, the preoperative surgical consultation with the boy's parents must include a careful assessment of the benefits of a surgical repair versus an age-based discussion of the risk of general anesthesia.**

The initial evaluation of boys with hypospadias requires a careful history and physical examination. A focused history should identify prior surgeries (such as circumcision, bladder, or scrotal or hypospadias surgery), urinary tract infections (UTIs), voiding dysfunction, the presence of penile curvature with erection, and any associated medical diseases that may complicate care, such as asthma or a bleeding diatheses. Physical exam should include a measurement of penile length and careful groin examination to assess for undescended testis on either side. Assessment of anogenital distance may also prompt a workup for androgen insensitivity, which could have implications during puberty.

Routine radiographic assessment with voiding cystourethrogram (VCUG) or renal bladder ultrasound (RBUS) in patients with hypospadias is not recommended. In a systematic analysis, the most common associated anomalies included vesicoureteral reflux (VUR), hydronephrosis, and renal position anomalies. These studies were done before the era of routine fetal imaging and the findings were of minimal clinical significance (Chariatte et al., 2013). Boys with a history of other global systemic anomalies should be considered for evaluation with a screening RBUS for the presence of associated urinary tract abnormalities (Khuri et al., 1981). A prostatic utricle may be present, more commonly in boys with proximal hypospadias, and may pose a risk for voiding dysfunction or UTI because of urine entrapment and stasis after the repair (Devine et al., 1980). Surgeons may consider cystoscopy and removal of the utricle at the time of the repair, but the fact that the majority of boys with utricles are asymptomatic and the high risk for injury to the vas deferens make this a rare indication for intervention (Hester and Kogan, 2017).

The preoperative physical examination should assess severity, which will guide surgical planning. The assessment includes the degree of penile curvature, the location of the urethral meatus, the quality of the urethral plate, and the quality of penile skin for reconstruction (Merriman et al., 2013). **Although it is difficult to precisely determine the severity of the phenotype before surgery, particularly the location of the meatus and degree of penile curvature, the surgeon should try to assess the need for a two-stage repair, which is best discussed with the family before the day of surgery** (Snodgrass et al., 2011). If hypospadias is encountered at the time of newborn circumcision, careful evaluation of the severity should be performed and circumcision aborted if there is curvature or skin deficiency. As discussed earlier, boys with unilateral or bilateral undescended testes, perineal hypospadias, or ambiguous genitalia must undergo additional workup to rule out a disorder of sexual differentiation, which occurs much more frequently in this setting (Kaefer et al., 1999; Moreno-Garcia and Miranda, 2002; Rajfer and Walsh, 1976; Rohatgi et al., 1987).

Preoperative Androgen Stimulation

The use of preoperative androgen stimulation in hypospadias surgery is controversial. Bush et al. (2015) reported that a small glans size (defined as a width of less than 14 mm) at the time of surgical repair has been associated with increased risk for complications. Although this group and others have since questioned the importance of glans width and attributed higher complications to technical errors, many surgeons remain concerned that urethroplasty in boys with a small glans results in more complications (Faasse et al., 2016). **Preoperative androgen stimulation, in the form of DHT, human chorionic gonadotrophin (hCG), or testosterone, can be used in prepubertal boys to increase the size of the glans and the penis** (Asgari et al., 2015; Gearhart and Jeffs, 1987; Luo et al., 2003; Nerli et al., 2009)**. Increasing glans size is thought to decrease the amount of tension on the glansplasty and increase the amount of tissue available for urethroplasty, potentially decreasing the complication rate**.

Concerns for androgen stimulation in these boys include aggressive behavior, increased erections, skin discoloration, and secondary male characteristics, all of which are transient and resolve spontaneously within 6 months after the last dose (Asgari et al., 2015; Paiva et al., 2016). Some surgeons prefer to avoid preoperative testosterone because of a perceived increased risk for bleeding as a result of increased angiogenesis. Others believe that poor wound healing may follow androgen exposure (Ashcroft and Mills, 2002; Gilliver et al., 2009). Therefore androgen use is controversial (Gorduza et al., 2011; Menon et al., 2017). To complicate the discussion further, variable degrees of androgen insensitivity may be present in boys with severe proximal hypospadias, which may lead to abbreviated response to androgen stimulation (Snodgrass et al., 2014a).

Several meta-analyses and systemic analyses have been performed in an attempt to answer the question as to whether androgen stimulation reduces or increases the complication rate (Kaya et al., 2008; Netto et al., 2013; Wong and Braga, 2015). Unfortunately, the reported data are variable, specifically the mode of administration, severity of hypospadias, and lack of standardized outcome assessment, precluding meaningful conclusion. Two recent randomized trials have reported fewer complications after preoperative testosterone administration (Asgari et al., 2015; Kaya et al., 2008). A survey of pediatric urologists suggests that preoperative androgen therapy was common before hypospadias repair in boys with proximal hypospadias or in those with a small glans (Malik and Liu, 2014). We use testosterone in some boys, particularly if the glans is small. If we use it, we administer preoperative testosterone cypionate intramuscularly (IM) 5 and 2 weeks before the planned surgery date to boys with a glans width of less than 15 mm. We feel as though the IM route of administration achieves a more consistent increase in glans width and is tolerated well by children.

Intraoperative Assessment and Management

Use of a regional anesthetic is an important feature of a balanced anesthetic in boys undergoing repair for hypospadias. Regional blockade, with either a caudal or circumferential penile block, reduces narcotic requirement during the procedure and improves pain control in the immediate postoperative period (Morrison et al., 2014; Soliman et al., 1978). A survey of practicing urologists found that regional blocks are commonly used in hypospadias surgery, with more urologists preferring a caudal block (Kim et al., 2016). For longer procedures, a second caudal dose can be administered before concluding the case to prolong the analgesic effect in the postoperative period (Chhibber et al., 1997; Samuel et al., 2002). Recently, use of a pudendal nerve block has emerged as an alternative method of regional blockade. The benefits of the pudendal block include a wider coverage area than a penile block, including the ventral penis, perineum, and scrotum. It also reduces the risk of the potential side effects of a caudal block, such as lower extremity weakness, which makes the use of a caudal block less attractive in older children (Kendigelen et al., 2016). In addition, ketorolac (0.5 mg/kg IV), given as a single dose 30 minutes before the conclusion of the procedure, can be an effective adjunctive analgesic, depending upon the surgeon's comfort level with the concern for postoperative bleeding (Morrison et al., 2014; Watcha et al., 1992).

Recent groups have released conflicting reports regarding the secondary effects of caudal anesthesia and surgical hypospadias repair. Kundra et al. (2012) noted a higher rate of fistula formation in boys who underwent caudal compared with penile block (19.2% vs. 0, $P < .001$). **They documented a 27% increase in penile volume 10 minutes after the caudal was placed, theorizing that the penile engorgement leads to increased swelling and compromised wound healing. These authors also found penile block to provide better pain control after distal hypospadias repair. Other single-institution studies have confirmed similar concerns for an increased complication development when a caudal block is administered** (Kim et al., 2016; Saavedra-Belaunde et al., 2017; Taicher et al., 2017). On the other hand, others have found no association between caudal blockade and complications after hypospadias repair (Braga et al., 2017; Zaidi et al., 2015). **Both papers that refute the association between complications and caudal anesthesia believe that boys undergoing caudal had more severe forms of hypospadias and therefore higher complication rates. All of these reports are limited by marginal statistical power, randomization, and patient numbers, leaving the question of an increased complication risk with caudal use unanswered.** We still routinely use caudal blocks for hypospadias repair.

Surgical planning continues after the induction of anesthesia. After antiseptic preparation and administration of intravenous antibiotics, the genitalia are carefully examined to determine surgical approach. We do not perform routine cystoscopy except in cases of severe proximal hypospadias or reoperative procedures. Prostatic utricles, if present, can make catheter placement difficult. Utricles occur more frequently in proximal hypospadias. If a large utricle is suspected, because of severity of the hypospadias or from prior imaging, a cystoscopic examination may be useful to prepare for a more complicated catheter placement (Ciftci et al., 1999).

Preoperative assessment of the hypospadias should proceed as follows. With the boy asleep the preputial glanular adhesions are released and the location of the urethral meatus, quality of ventral shaft tissue, and degree of penile curvature are assessed. Sometimes a proximal hypospadias masquerades as a distal hypospadias with severe penile curvature and a hypoplastic ventral shaft skin (see Fig. 45.5). The surgeon must recognize this before incision to ensure that the appropriate repair is performed. A circumscribing incision is then made and the penis is degloved, partially or completely, depending upon the degree of penile curvature. Care should be taken to develop a mucosal collar, rotating inner shiny preputial tissue from dorsolateral skin to the ventrum where it is lacking. This will aid in ventral shaft skin coverage and yield an improved cosmetic result (Firlit, 1987).

Key Points

- The goals of hypospadias reconstruction include achievement of a straight phallus with proper urinary and sexual function, as well as a cosmetically pleasing appearance.
- The conversation about the risk of hypospadias repair should include the risks of early anesthesia exposure versus the benefits of surgery at a younger age.
- Routine preoperative imaging is not recommended in boys with nonsyndromic hypospadias.
- Preoperative androgen stimulation can transiently increase the penile length and size for surgery. Its impact on complication development is controversial.
- Physical examination in a patient with hypospadias may reveal a ventral deficient prepuce, downward glans tilt, deviation of the median penile raphe, ventral curvature, scrotal encroachment onto the penile shaft, scrotal cleft, and penile scrotal transposition. Each of these must be considered for the surgical reconstruction; each has its own degree of impact.
- Regional blockade is an important adjunct to the surgical procedure. Caudal anesthesia can decrease the amount of anesthetic delivered and does not appear to increase the complication rate.

Assessment and Management of Ventral Penile

Curvature

Penile curvature, or chordee, occurs in the presence or absence of hypospadias. **The degree of curvature is a major determinant in the selection of a one-stage versus a two-stage repair. The decision to treat curvature centers around the potential functional and cosmetic concerns that males can have as they mature into adulthood. Assessment of males with untreated congenital curvature or those with Peyronie disease suggests that as little as 20 to 30 degrees of ventral curvature may result in significant morbidity for patients, including difficulties with intercourse and the patient's dissatisfaction of the appearance of the penis** (Menon et al., 2016; Walsh et al., 2013).

Curvature may result from shortened ventral skin, a short urethra, or from intrinsic curvature of the erectile bodies. The cause of curvature is extremely difficult to assess outside of the operating room. Parents should be asked if they note a history of curvature with erections or may even document this in their son with photos, but **the definitive assessment is done via artificial erection in the operating room after the penis has been degloved.** In 1973 Devine and Horton developed a staging system based on the degree of dysplasia of Buck fascia, dartos, and corpus spongiosum (Devine and Horton, 1973). Donnahoo et al. (1998) expanded this further, dividing curvature into a classification system of 4 groups: skin tethering; dysgenetic Buck and dartos fascia; corporal disproportion; and congenitally short urethra. Each component can be present to varying degrees, increasing the complexity of the defect and repair. Although this system was used to describe chordee in boys without hypospadias, its concepts are relevant to the curvature noted in hypospadias.

An attempt to assess the degree of curvature should be made in the operating room before skin incision. Passage of a catheter or bougie à boule into the meatus will provide an assessment of the overlying tissue, indicating the quality of the urethra and the ventral skin (see Fig. 45.5). A circumscribing incision is made and the penis is degloved as far as the penoscrotal junction, to excise dysplastic dartos tissue. **Artificial erection should then be performed, typically with a tourniquet placed at the penoscrotal junction and injection of sterile normal saline** (Gittes and McLaughlin, 1974)**. Alternatively, in small boys the surgeon can compress the corpora at the base of the penis to approximate an erection without injection.** Curvature can occur at the base of the penis and can be obscured by the presence of a tourniquet. Pharmacologic erection with prostaglandin can be induced as an alternative to saline injection (Kogan, 2000).

Penile curvature has traditionally been treated by the surgeon in a subjective manner, typically categorized as mild (<30 degrees), moderate (30–45 degrees), or severe (≥45 degrees). We, along with several other institutions, use an orthopedic device called a goniometer that functions as a protractor to objectively measure the degree of curvature (Fig. 45.7). Our experience with this device is that the degree of curvature was being underestimated when the “eyeball” test alone was used. Electronic alternatives, which include apps for use on phones and tablet devices, are starting to emerge as well. Regardless of the approach we feel that the assessment should be standardized.

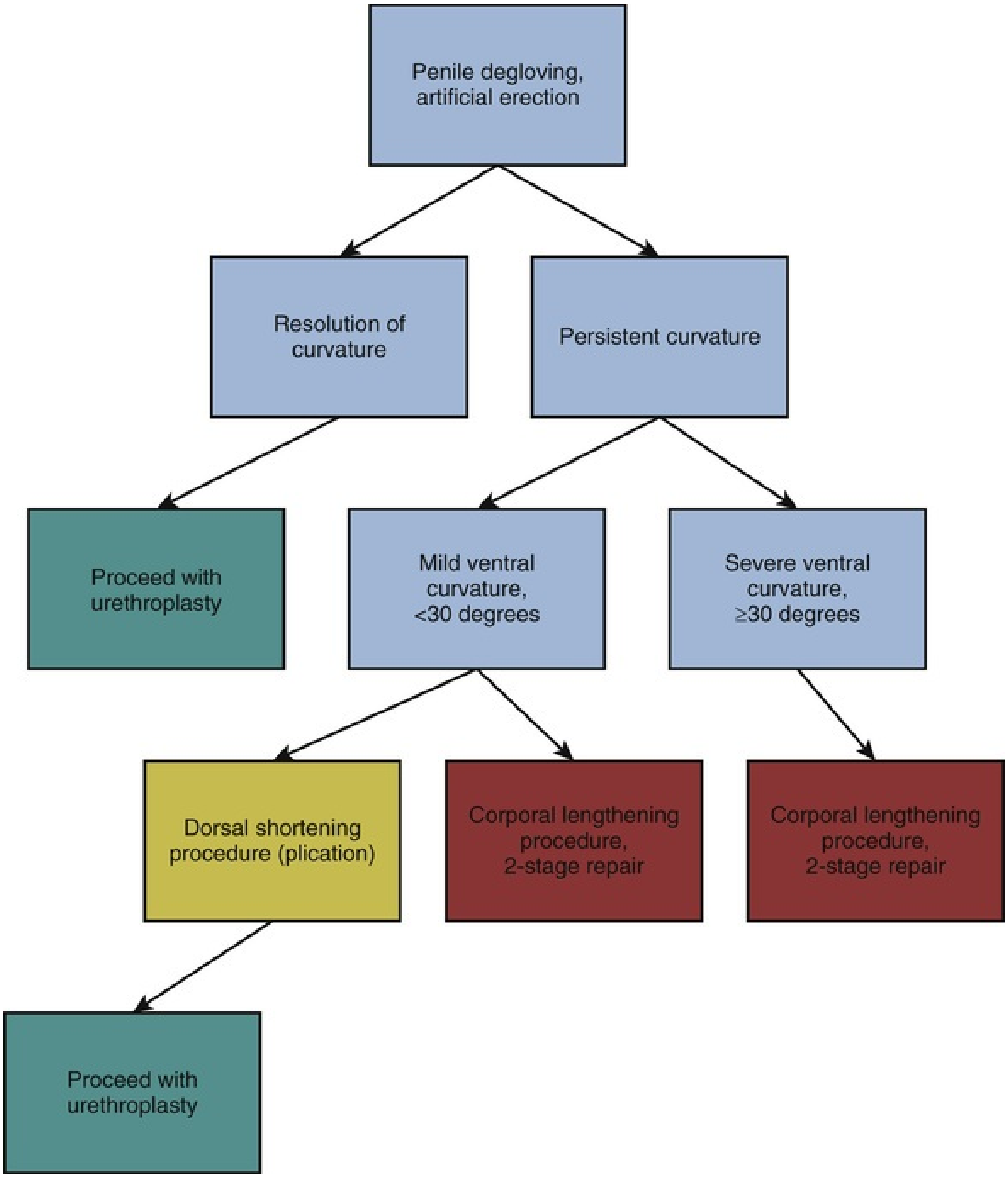
Penile degloving, artificial erection
Resolution of curvature
Persistent curvature
Proceed with urethroplasty
Mild ventral curvature, <30 degrees
Severe ventral curvature, ≥30 degrees
Dorsal shortening procedure (plication)
Corporal lengthening procedure, 2-stage repair
Corporal lengthening procedure, 2-stage repair
Proceed with urethroplasty

FIG. 45.7 Algorithm for management of penile curvature. Once the penis is degloved, artificial erection is performed. If the curvature is resolved, the urethroplasty can be completed. If there is persistent penile curvature, we use a measurement of 30 degrees as the defining measurement for performing a dorsal plication or a corporal lengthening procedure. If the surgeon is concerned about the quality of the ventral shaft skin in spite of curvature of less than 30 degrees, a corporal lengthening procedure can be considered.

The degree of penile curvature drives the decision for a single versus two-stage repair (Fig. 45.8). Although no consensus exists for treatment of specific degrees of curvature, most seem to agree that a dorsal plication is sufficient for curvature less than 30 degrees (Springer et al., 2011). If curvature is more severe than 30 degrees, the next step would be to divide the urethra. Some severe cases of ventral curvature have a meatus proximal to the point of maximal bend so that urethral division is not necessary. Persistent curvature greater than 30 degrees at this point would warrant a corporal lengthening procedure, which in our hands requires transection of the corpora spongiosum distal to the urethra or transection of the urethra (Steven et al., 2013).

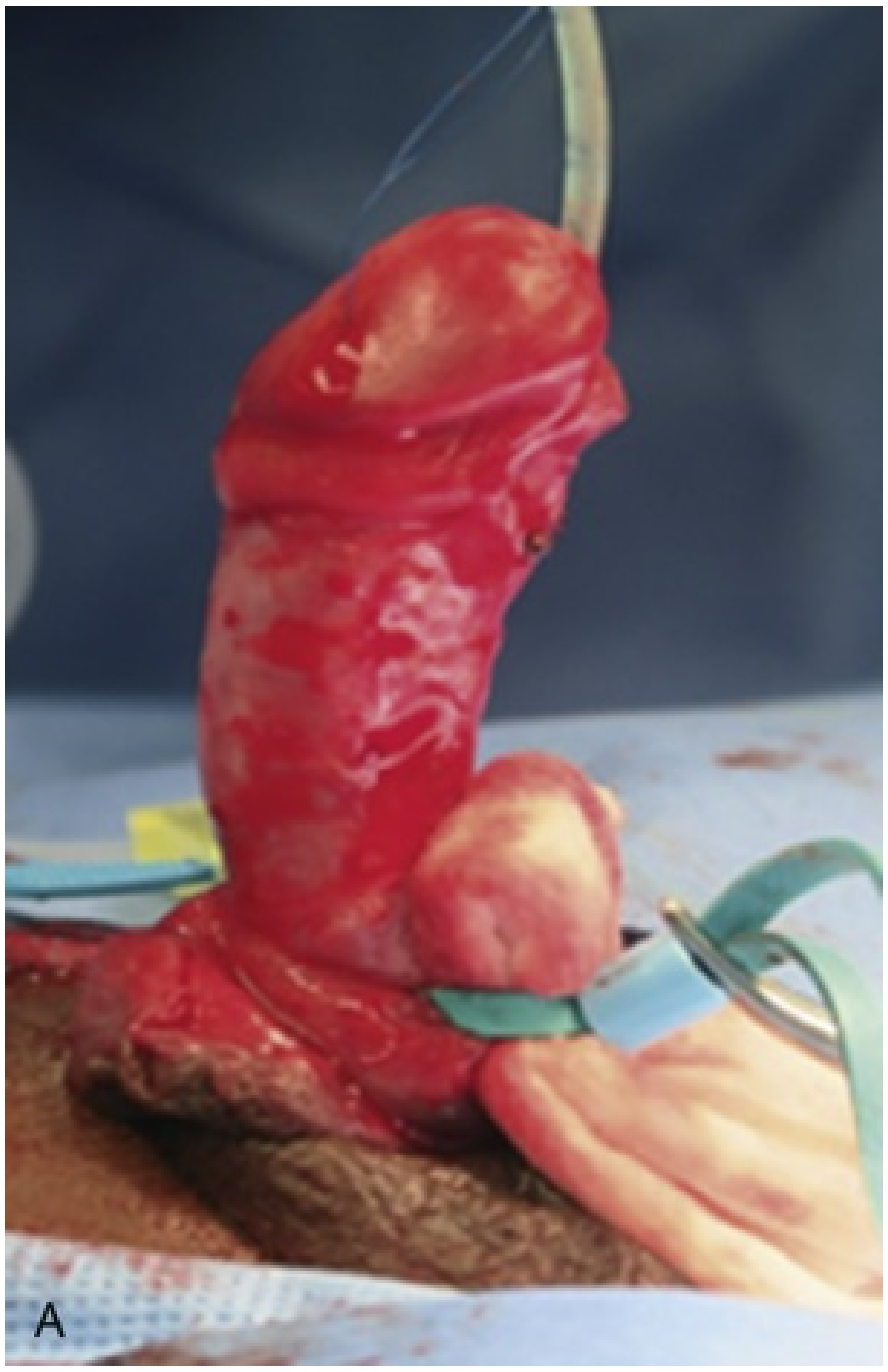

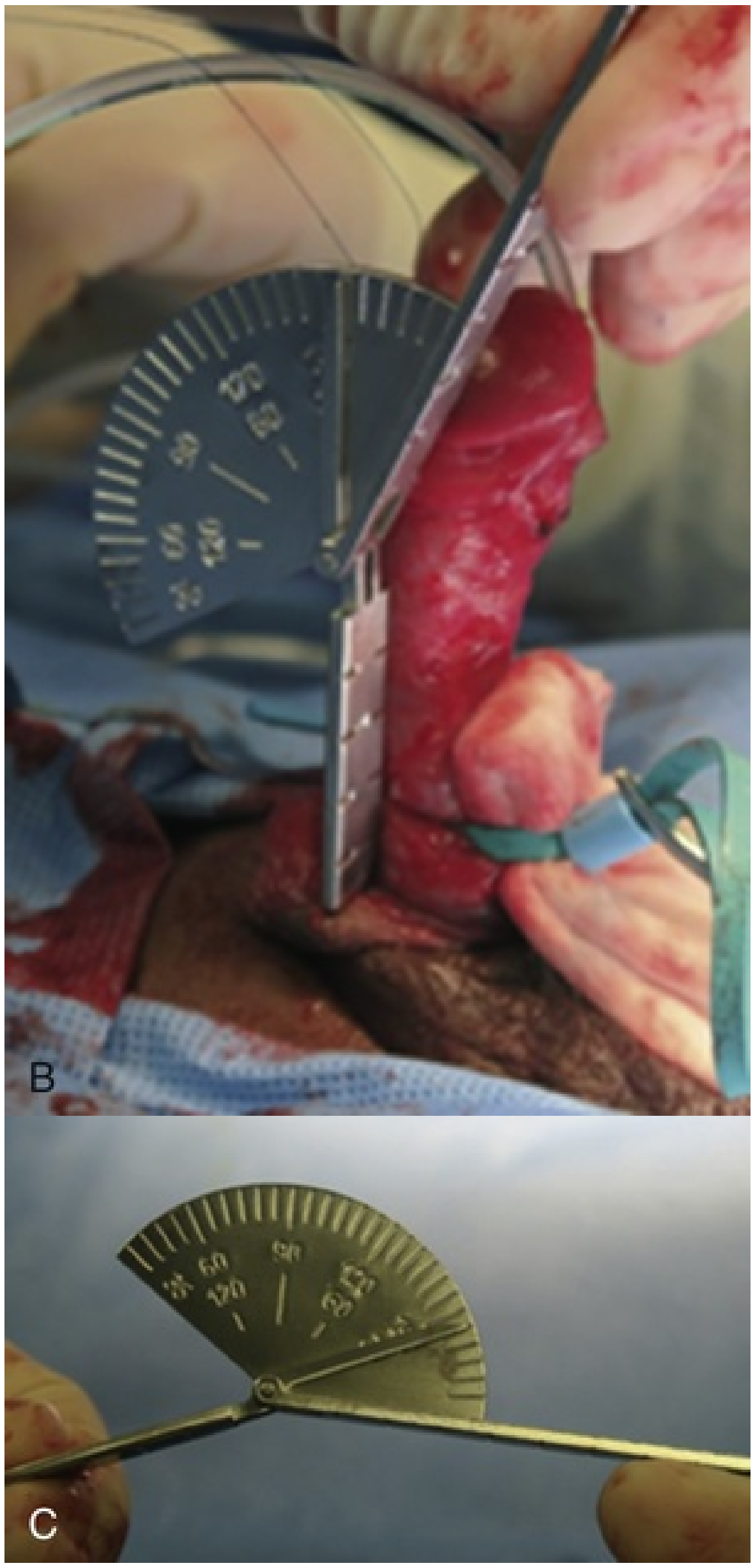
B
C

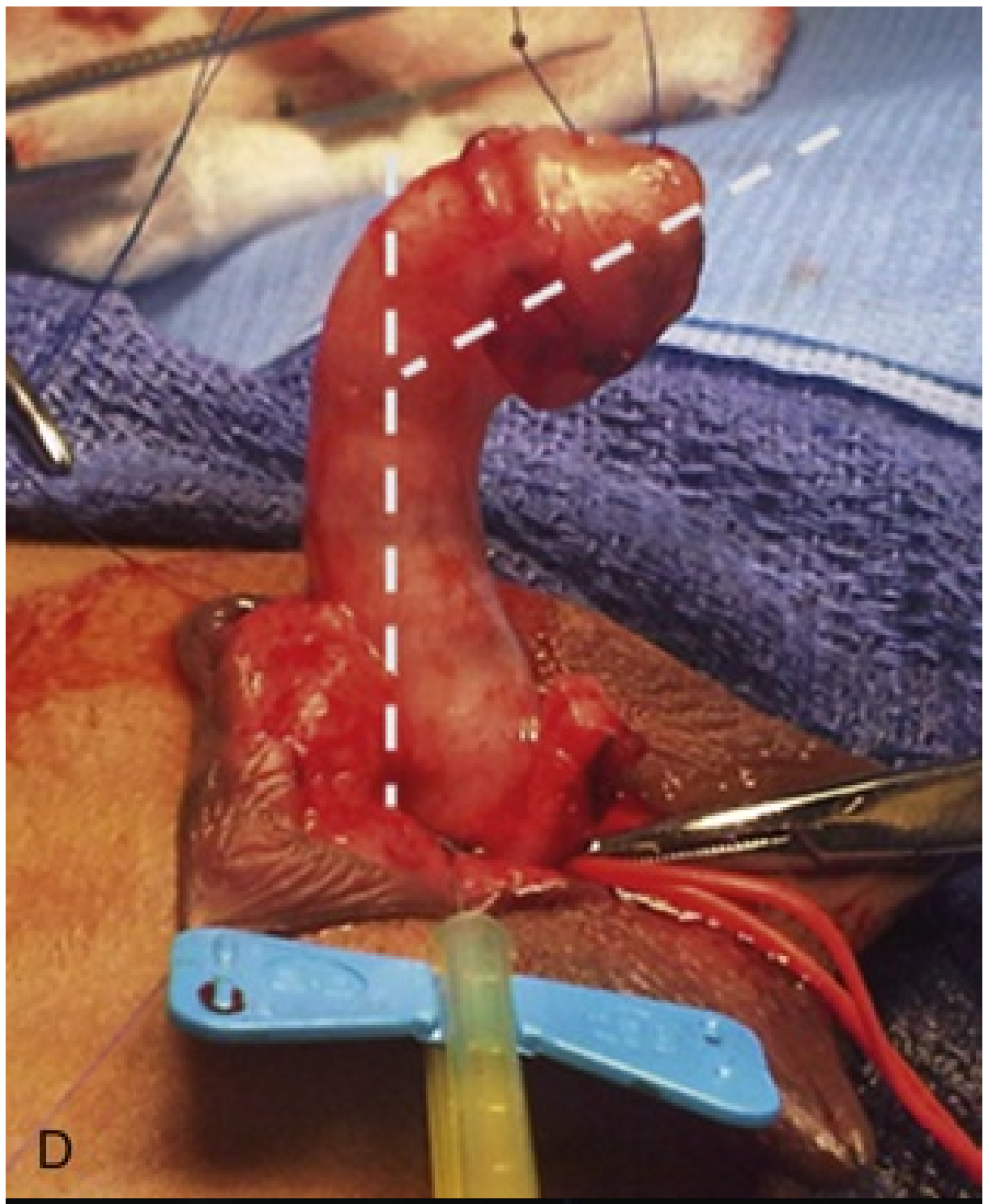
D

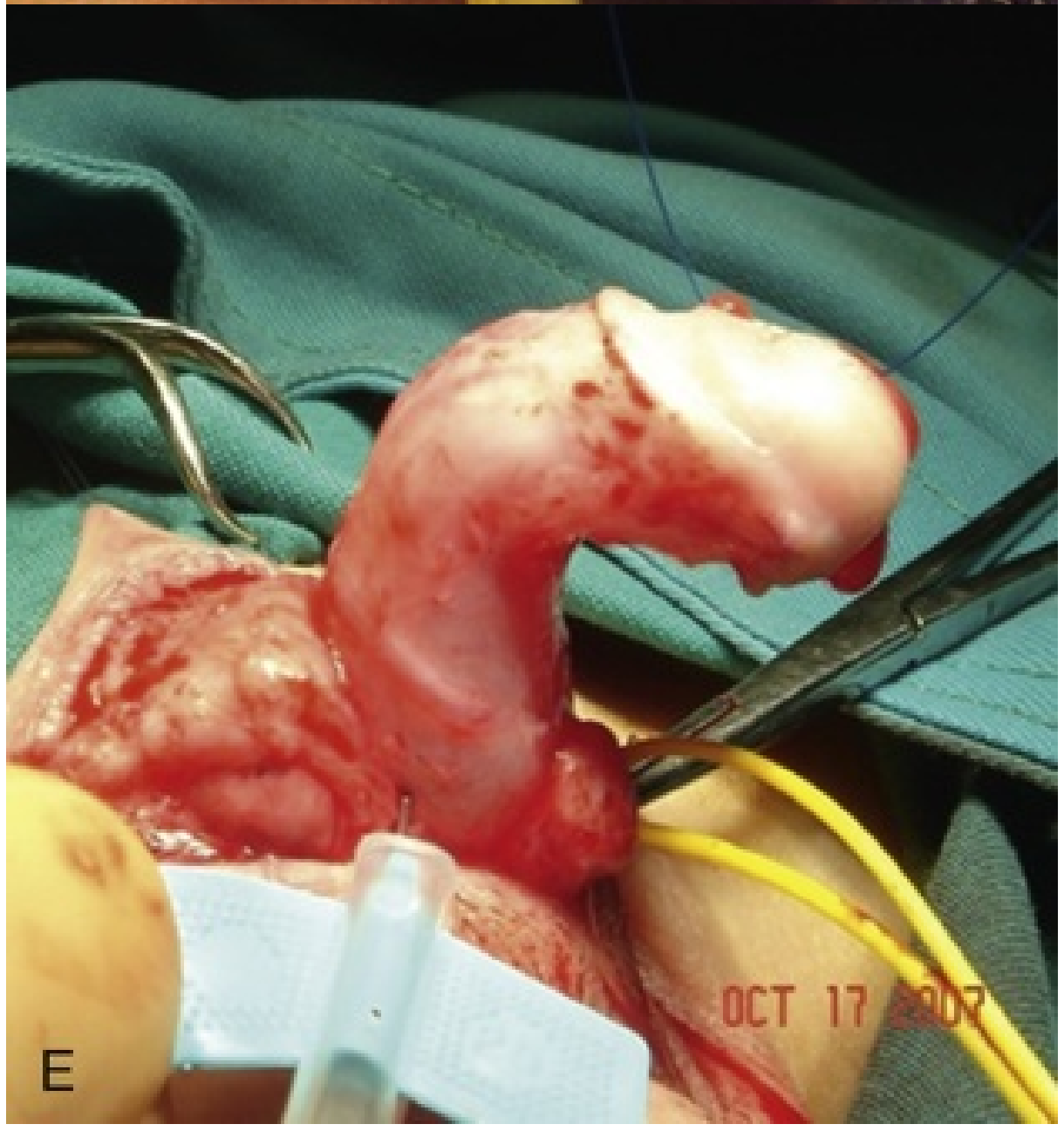
OCT 17 2007
E

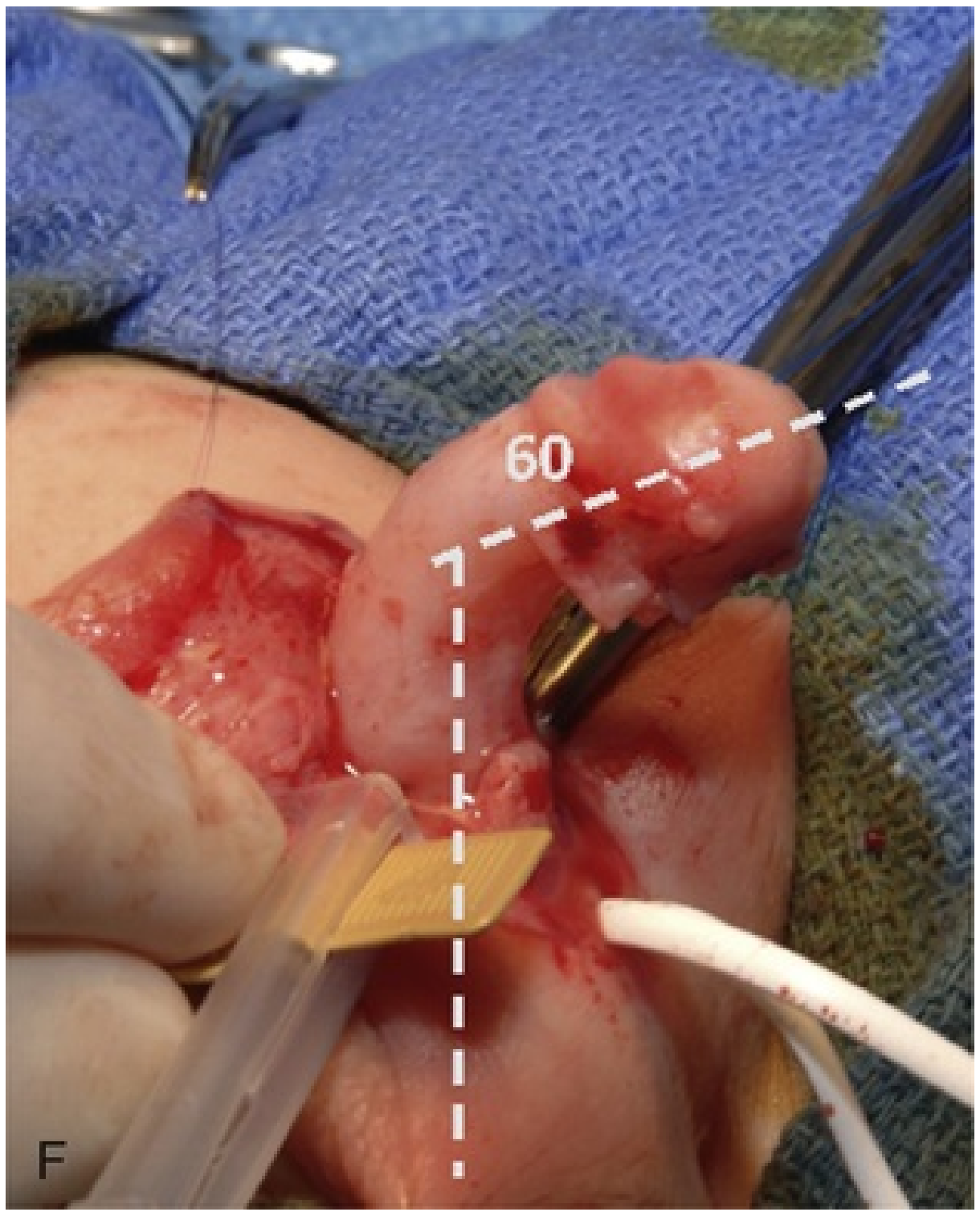

FIG. 45.8 (A) A penis that is degloved to the penoscrotal junction and undergoing artificial erection. Sterile saline is injected via a butterfly needle with a tourniquet in place at the base of the penile shaft. (B,C) The goniometer with a protractor-like element present to precisely measure the degree of penile curvature. (D–F) The degree of penile curvature displayed without a measuring device. (D–F courtesy Rafael Gonzalbez.)

Dorsal shortening techniques, first described by Nesbit, involve excising an ellipsoid segment of tunica albuginea and closing this defect in a transverse orientation, shortening the dorsum of the penis (Fig. 45.9) (Nesbit, 1965). **Anatomic studies by Baskin identified an area on the dorsal midline that was free of any neurovascular tissue, allowing a modified plication by placement of a single, midline plication suture through the tunica albuginea to correct curvature** (Baskin et al., 1998). Contrary to Baskin's original description, we prefer to incise the tunica albuginea in the midline dorsally until the corporal tissue is visualized. The defect is then closed to approximate the raw edges transversely in a Heineke-Mikulicz fashion. This is performed using either a nonabsorbable or a long-lasting absorbable suture. Advantages of the plication approach are that it is a simpler procedure and does not limit subsequent ventral penile shaft skin coverage options. Disadvantages include possible injury to the neurovascular bundle (if the plication is performed off the midline axis) and the potential for recurrence of curvature. Elevating the neurovascular bundle before placing plication sutures may reduce the risk of neural injury (Dean et al., 2000). Plication may be less effective in boys with more severe curvature, particularly when the tunica albuginea is not incised. Of particular concern is that recurrent curvature at puberty is more common after plication compared with ventral lengthening (Ozkuvanci et al., 2017). In our experience, plication works well for mild curvature (<15 degrees), and many use this technique for up to 30 degrees of curvature (see Fig. 45.7).

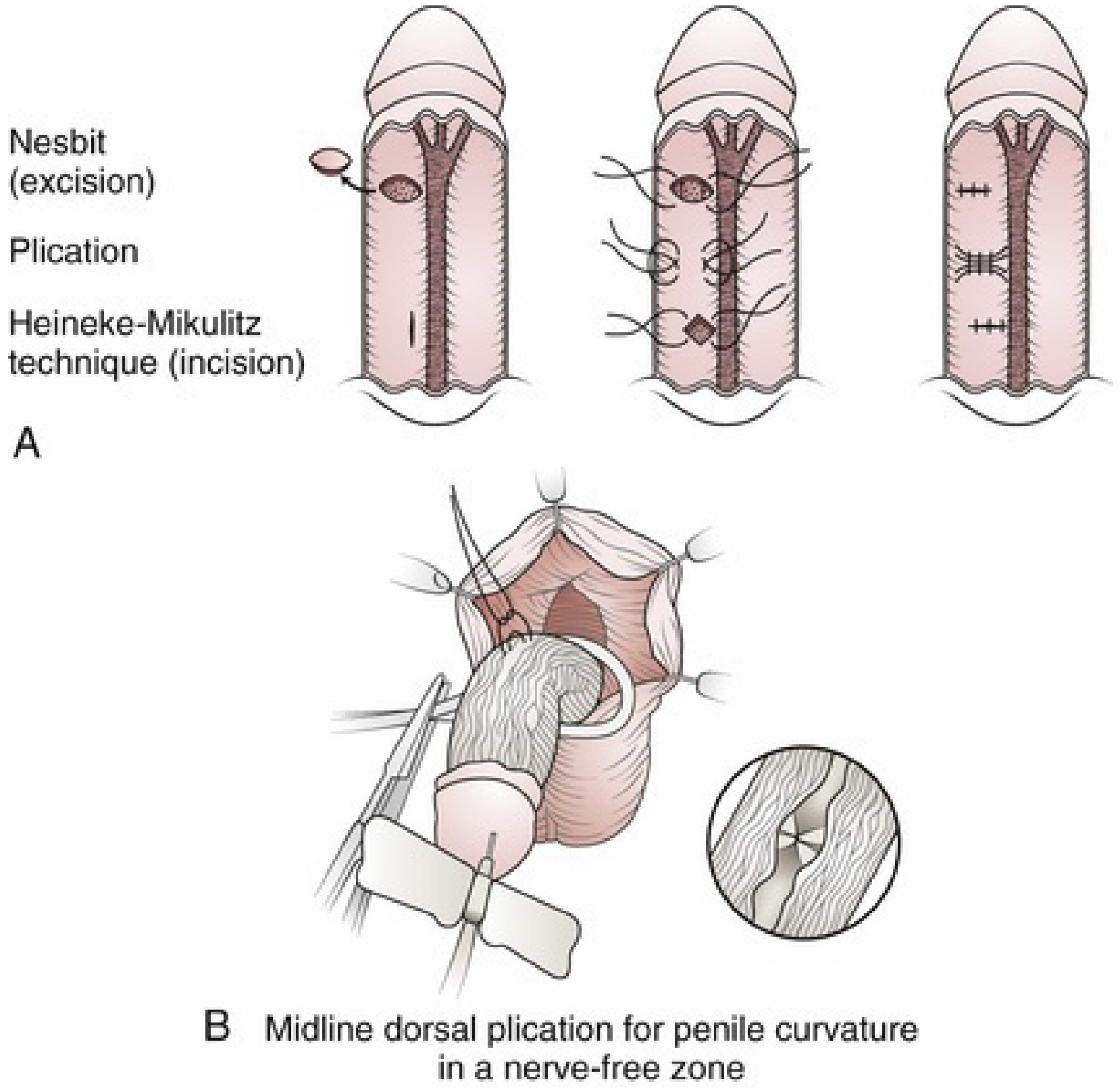

FIG. 45.9 (A) Description of three different plication techniques to correct penile curvature. Nesbit plication technique: an excisional biopsy of dorsal tunica albuginea is made opposite the point of maximal curvature. In a similar fashion, others have described performing a plication without incising the tunica albuginea. The Heineke-Mikulitz technique involves a vertical incision in the tunica albuginea and horizontal closure of the defect to shorten the dorsum of the penis. For each of these techniques the incisions and/or plications are made in parallel on either side of the neurovascular bundle, only one side is displayed for simplicity. (B) The midline (Baskin) plication technique, similar to the Heineke-Mikulitz approach. A single midline plication is performed in the avascular plane of the penis. (A, From Nyirady P: Management of congenital penile curvature. *J Urol* 179:1495–1498, 2008; B, From Baskin LS: Anatomical studies of hypospadias. *J Urol* 160:1108–1115, 1998.)

Several options exist for ventral corporal lengthening procedures (Fig. 45.10). **The basis for each procedure involves single or multiple ventral incisions opposite the point of maximal curvature, releasing the ventral tension on the tunica albuginea to straighten the phallus.** Multiple superficial incisions into, but not through, the tunica albuginea of corpus cavernosa to release the tension on the ventral surface of the penis are called “fairy cuts.” Several (1 to 3) full-thickness incisions into the tunica albuginea without grafting are referred to as transverse corporotomies and have been popularized in the STAG technique, as described in the proximal hypospadias section (see Fig. 45.10A) (Pippi Salle et al., 2016; Snodgrass and Bush, 2017a). A single full-thickness corporotomy extending from 9 o'clock to 3 o'clock or until there is mild reverse hinging of the penis, with subsequent grafting, is our preferred method for ventral lengthening (▶Videos 45.1 and ▶45.2). Subsequent graft options include either autologous tissue (dermal graft [Devine and Horton, 1975], tunica vaginal flap [Braga et al., 2007b] or graft) or nonautologous tissue (AlloDerm, small intestinal submucosa (Braga et al., 2008; Castellan et al., 2011; Fig. 45.10B). The dermal graft procedure is depicted in Fig. 45.10C–F.

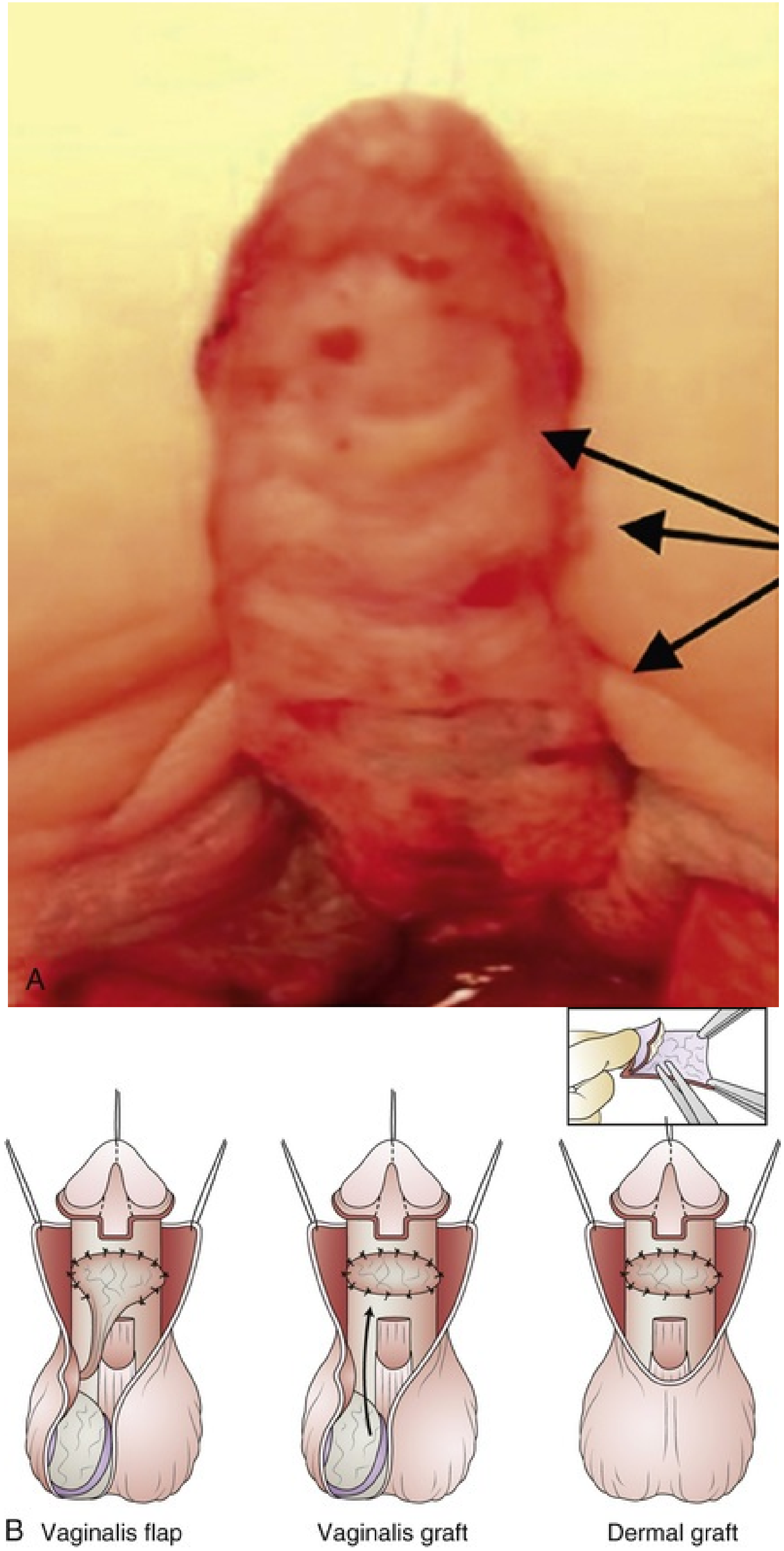
A
B
Vaginalis flap
Vaginalis graft
Dermal graft

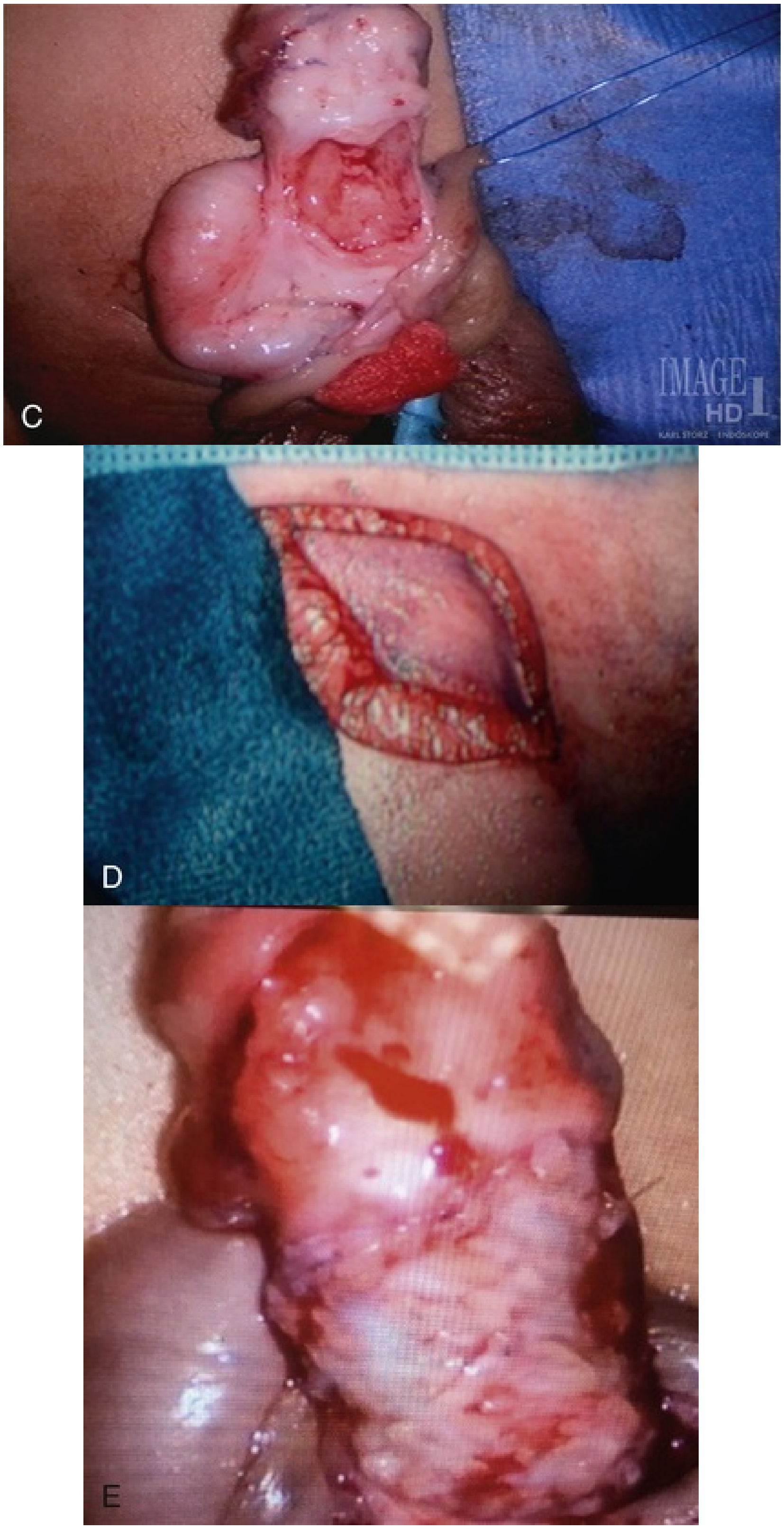
C
IMAGE HD 1
KARL STORZ ENDOSKOPE
D
E

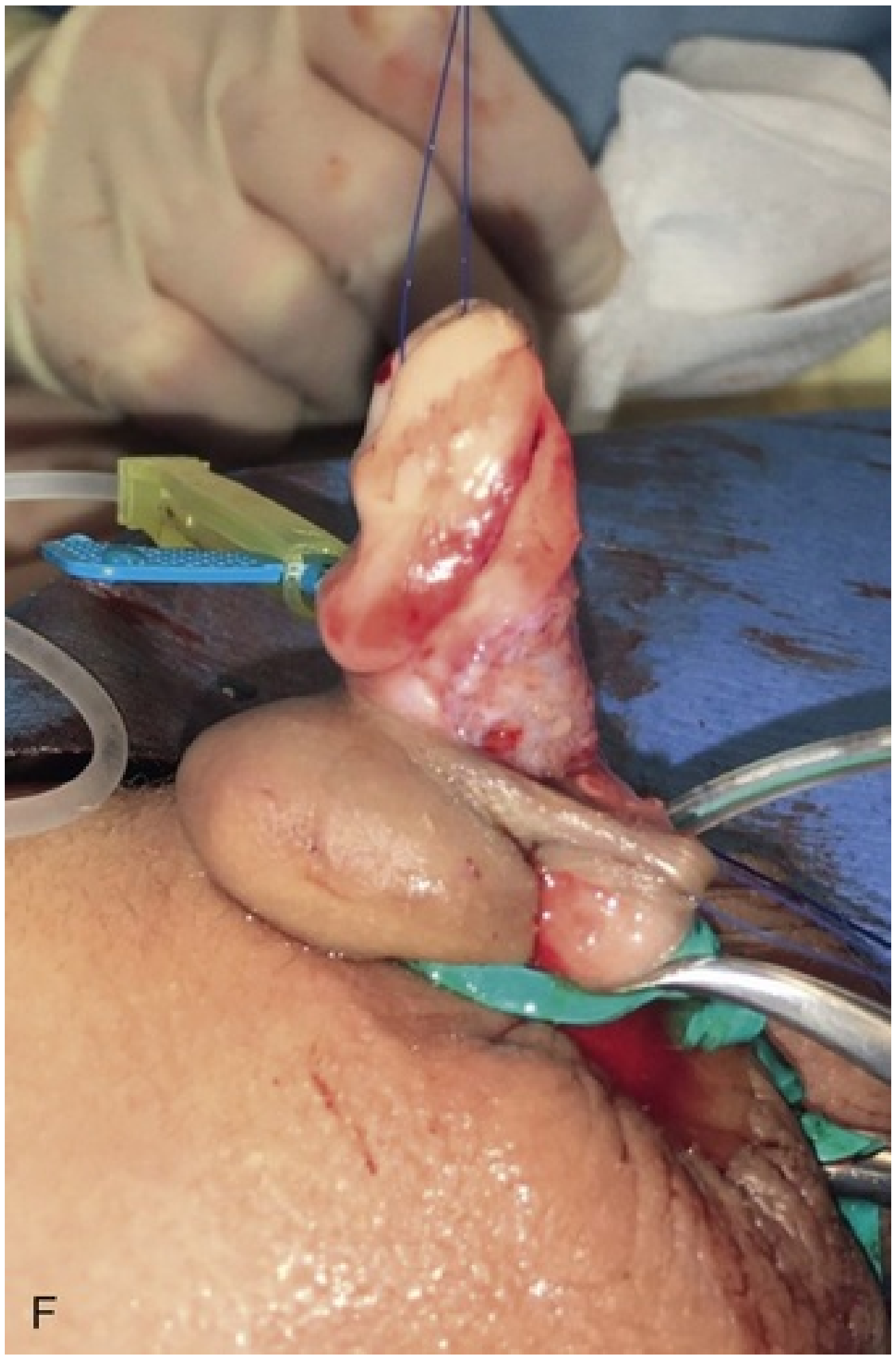

FIG. 45.10 (A) The multiple ventral tunica albuginea corporotomies without grafting as described in the staged tubularized autograft (STAG) repair. *Arrows* are pointing to the transverse corporotomies, which are made full thickness through the albuginea; in this particular example three incisions have been made. (B) Three approaches to ventral penile lengthening. A tunica vaginalis flap, tunica vaginalis graft, and dermal graft are depicted. Each approach is performed after division of the urethral plate and incision of the tunica albuginea. (C–F) show four live surgical images of a dermal graft. First a single, full-thickness transverse incision is made in the tunica albuginea, opposite the point of maximal curvature (C). A dermal graft is then measured 20% larger than the defect in the tunica to allow for graft contracture without shortening the penis (D). This is then sutured in place in a watertight fashion (E). Repeat artificial erection is performed to confirm that penile curvature is fully corrected (F). (A, From Snodgrass W: Staged tubularized autograft repair for primary proximal hypospadias. *J Urol* 198:680–686, 2017. B, From Braga LH: Outcome analysis of severe chordee correction using tunica vaginalis as a flap in boys with proximal hypospadias. *J Urol* 178(suppl4):1693–1697, 2007.)

The choice of corporal lengthening approach is left to the discretion of the

surgeon: no series has formally compared the three ventral lengthening procedures. Benefits of the corporal lengthening procedure(s) include an increase in length of the penis and improved results for severe curvature. Concerns include a longer and more complicated procedure compared with plication, a limitation in ventral skin coverage options, and a potential higher risk of erectile dysfunction. In our experience, patients having undergone pediatric penile lengthening procedures have not had issues in adulthood with erectile function.

Curvature may worsen as these boys progress through puberty and undergo more significant penile growth. Therefore it is important to properly identify and correct curvature at the time of the initial repair (Barbagli et al., 2006; Braga et al., 2008). Direct comparison of the approaches to curvature described earlier is difficult for two reasons: first, there is a lack of standardized definitions of the degree of curvature (lack of objective instrumentation) and second, there are few well-designed and executed comparative studies. In a study of 51 patients with perineal hypospadias with severe ventral curvature with a minimum follow-up of 5 years, 5 of 23 (21%) of patients who underwent dorsal plication developed recurrent curvature, compared with 0 of 11 patients who underwent a two-stage repair with corporal grafting (Gershbaum et al., 2002). **In a series of 100 boys operated upon in Toronto, Braga found an increased rate of recurrent penile curvature after dorsal shortening with plication when compared with boys who had ventral lengthening with corporal grafting (28% vs. 9%, $P = .03$)** (Braga et al., 2008). These results corroborate our clinical experience in that corporal lengthening procedures better correct more severe curvature. This is of particular importance as boys with persistent penile curvature after primary repair, in pre- and postpubertal age groups are challenging to correct, sometimes requiring several staged procedures to achieve an acceptable outcome. This makes it imperative that penile curvature is properly diagnosed and corrected. Long-term assessment is going to be essential for these boys to determine the ideal approach to ensure lasting success and proper function.

Some have referred to boys with severe ventral curvature with a normal urethra as having "congenital penile curvature" (Daskalopoulos et al., 1993; Devine and Horton, 1973; Kramer et al., 1982). Biopsies of tunica albuginea tissue in these boys show that the extracellular matrix and collagen fibers are misaligned and disrupted (Darewicz et al., 2001). Reports have delineated a progressive assessment and treatment algorithm that begins with penile degloving and plication, whereas severe cases may require transection of the urethra at the point of maximal bend, followed by one of the various grafting techniques (Bhat et al., 2008; Tang et al., 2007). This approach requires a staged repair to reconnect the urethra after the chordee has been corrected. **We have developed a successful technique that allows the normal urethra to be mobilized in situ, allowing a corporotomy and graft in one operation, thus avoiding a secondary procedure** (Zaontz and Dean, 2016; Fig. 45.11). We believe this will provide a more secure correction of the curvature while obviating a second repair, an experience shared by others (McQuaid et al., 2016). Recurrent curvature can occur in 2% to 15% of these boys, particularly with plication technique, a reality that should be discussed with parents before repair (Donnahoo et al., 1998; McQuaid et al., 2016; Tang et al., 2007).

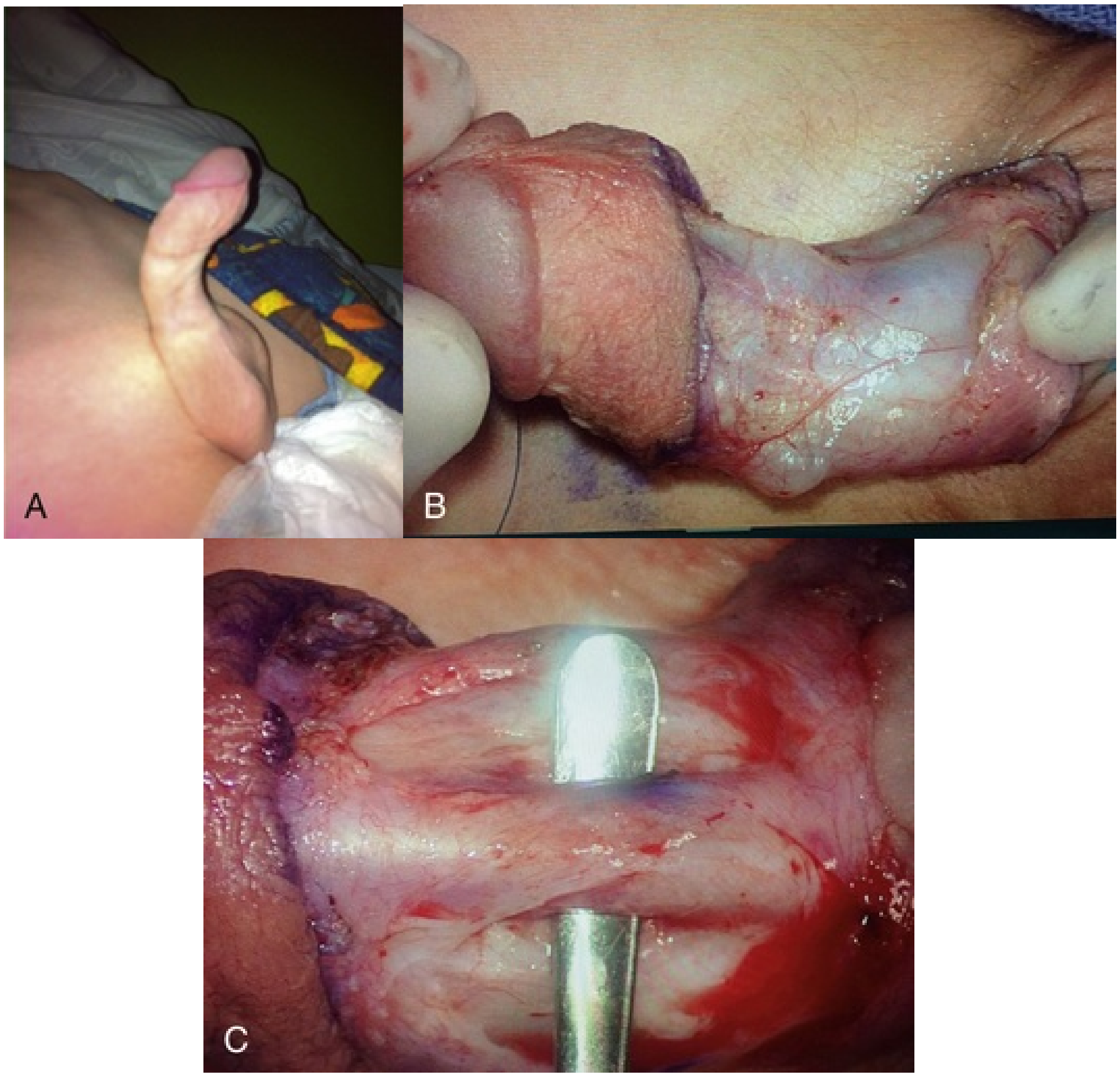

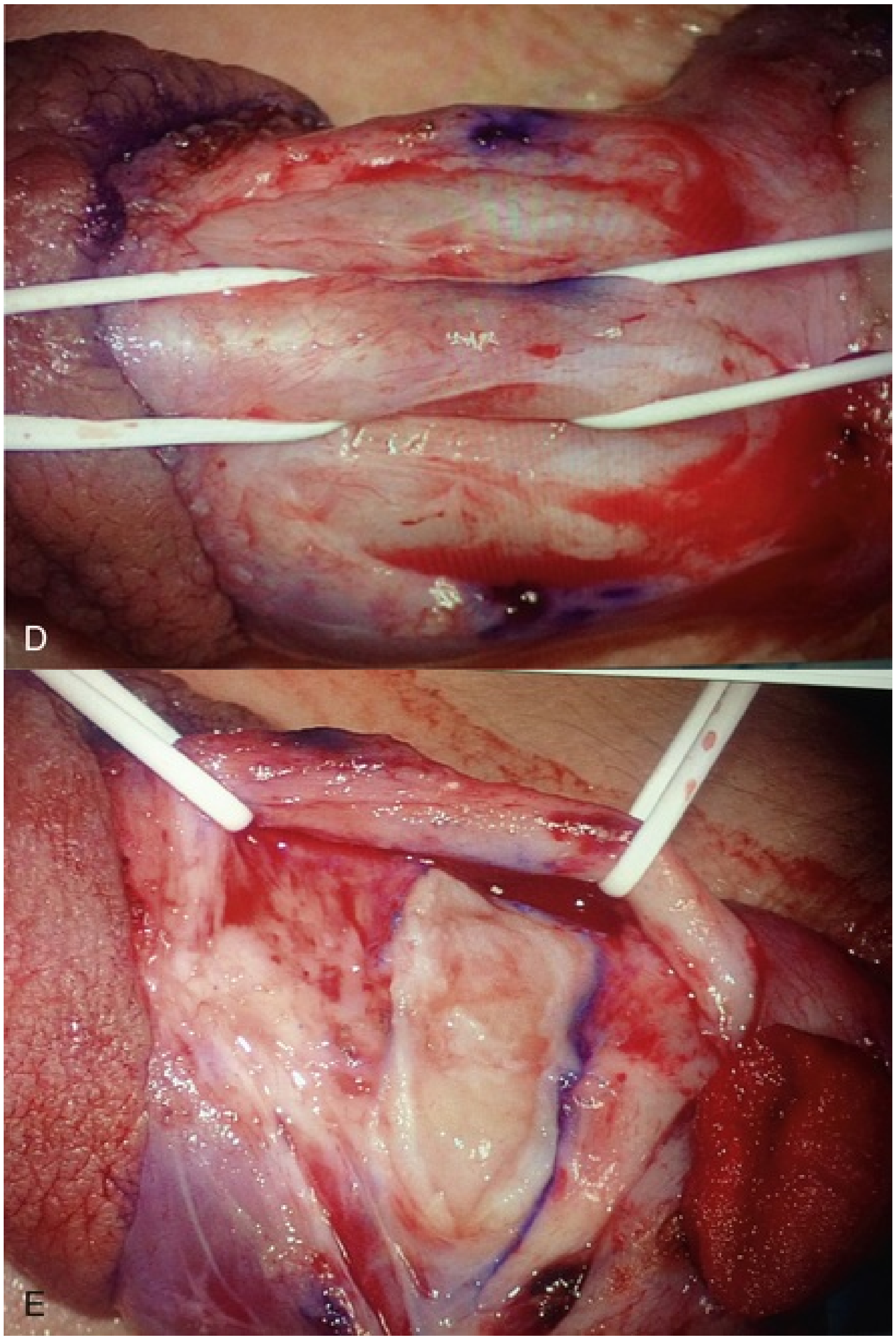
D
E

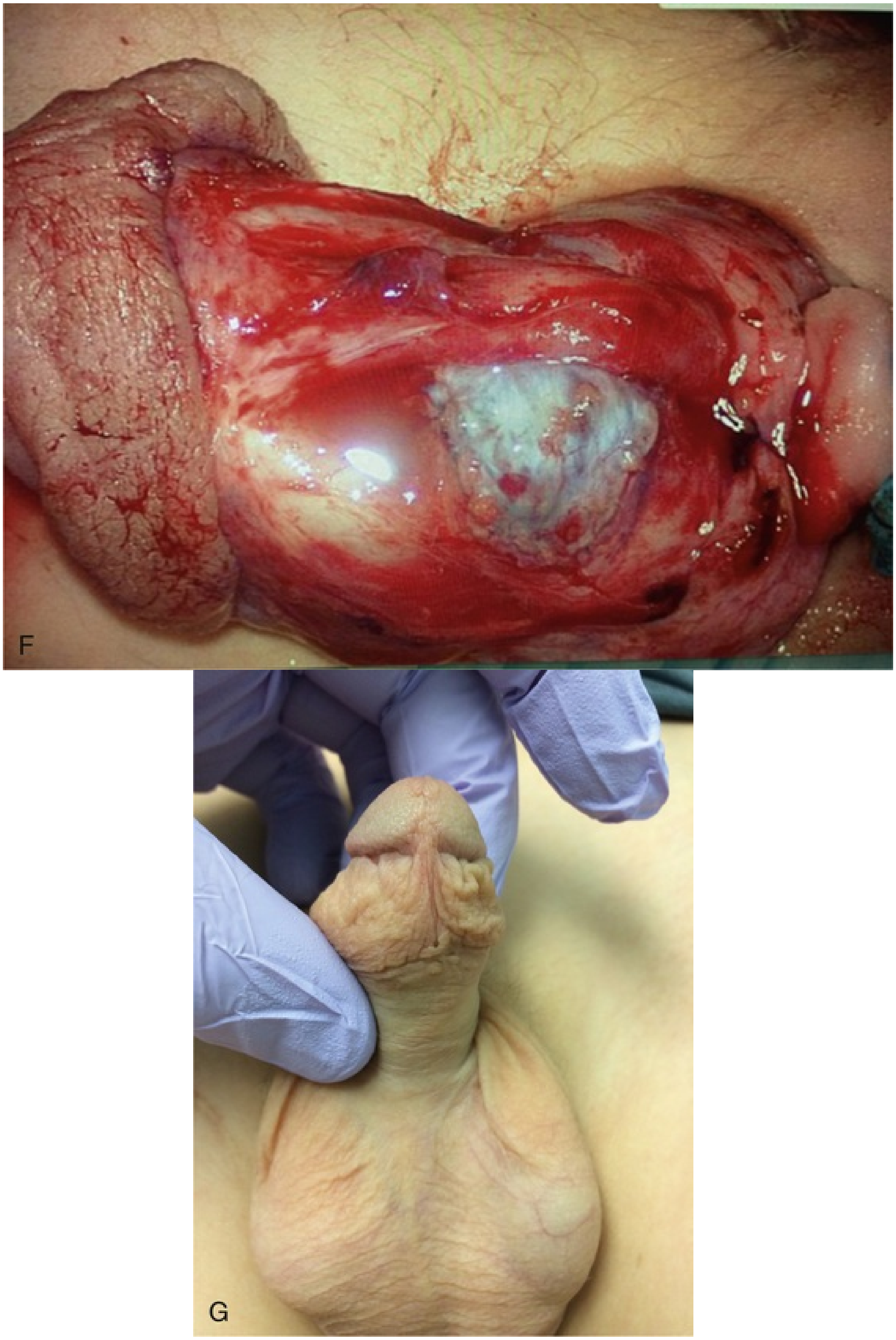

FIG. 45.11 Management of a boy with ventral chordee without hypospadias. (A) Ventral penile curvature is depicted with an erection. Note

that the boy is already circumcised and that the urethral meatus is in a normal position. (B) The penis is degloved, exposing the corpus spongiosum, which is normal. (C,D) The urethra is mobilized off of the corporal bodies, and a transverse incision is made in the tunica. This corrects the penile curvature; therefore the urethra is not divided. (E) A dermal graft is placed into the defect in the tunica albuginea. (F) the urethra is released and the dermal graft is in place. (G) Twelve months after repair, the penis is straight with no evidence of persistent chordee.

Finally, a number of children may have dorsal and/or lateral penile curvature, which can be corrected most of the time with simple plication techniques. However, in rare instances of severe dorsal and or lateral curvature, a patch graft may be necessary as well as the potential need for urethral and/or neurovascular bundle mobilization. Others have noted a higher complication rate with plication in boys with lateral, dorsal, or spiral anomalies that result in a curved penis (McQuaid et al., 2016). These lateral areas of the corpora are theorized to have a thinner albuginea when compared with the dorsum of the penis, limiting the relative effectiveness of plication techniques.

Key Points

- Curvature less than 30 degrees can be straightened by dorsal plication without clinically apparent shortening of the penis.
- Objective measurement of penile curvature, as identified by artificial erection after penile degloving, is a key element of the surgical procedure. Curvature must be assessed and properly corrected.
- Transection of the urethral plate and/or ventral corporal grafting are reserved for cases with curvature greater than 30 degrees after degloving and dartos dissection.
- Improperly corrected penile curvature poses a significant morbidity to the patient, often necessitating several procedures to achieve a straight penis.

General Considerations of Surgical Repair

Aside from the previously mentioned psychological benefits of operating on a young infant, the literature is split on the potential impact that age has on surgical outcomes. Hypospadias repair in boys younger than 6 months of age has been reported as more successful when compared with surgery on

older boys (Perlmutter et al., 2006; Yildiz et al., 2013). **However, two other studies showed no such benefit** (Bush et al., 2013b; Ziada et al., 2011). A systematic review comparing outcomes in North America, Europe, and China, including more than 16,000 patients in 113 manuscripts, identified fewer complications in younger boys at the time of primary repair, and recommended correction by the age of 18 months (Lu et al., 2012). A study by Weber et al. that examined the psychological effects of hypospadias surgery before and after 18 months of age found that later surgery had no negative impact on the long-term emotional impact to the patient (Weber et al., 2009). With this in mind, we recommend beginning the surgical process with the first stage at 6 months. This will likely result in adherence to the AAP-recommended age range of 6 to 18 months for the surgical reconstruction or reconstructions. **Hensle et al.** (2001) **reported that adult hypospadias surgery, for primary and reoperative cases, is associated with a higher than anticipated complication rate, in spite of nearly all patients undergoing a more distal repair. This is in contrast to subsequent studies, which suggest no increased risk of repair in adult patients** (Adayener and Akyol, 2006; Snodgrass et al., 2014b).

Antibiotics are often administered in the perioperative period, preoperatively and as prophylaxis, because of concerns for UTI and/or wound infection (Hsieh et al., 2011). Alternatively, prophylactic antibiotics can be administered at surgery and then at the time of stent removal. Given the shift in concern for overadministration of antibiotics and its role in developing resistant organisms, adverse drug reactions, and changes to the microbiome, several studies have assessed the need for antibiotics in hypospadias repair. The first studies elucidating the role of prophylaxis with an indwelling stent suggested a decrease in the UTI rate, although these boys were asymptomatic and positive cultures represented asymptomatic bacteriuria instead of a true UTI (Shohet et al., 1983; Sugar and Firlit, 1988). A randomized study by Meir and Livne (2004) of patients undergoing the tubularized, incised plate (TIP) procedure found that those who received continuous antibiotic prophylaxis (CAP) were less likely to develop a complicated UTI (3 vs. 12, $P < .05$) and complications (5/52 [9.6%] vs. 13/49 [26.5%], $P < .05$). Others have found CAP to have no impact on complication development, either surgically or infection related, whereas others have even questioned the need for preoperative antibiotics (Baillargeon et al., 2014; Kanaroglou et al., 2013; Smith et al., 2017; Zeiai et al., 2016). Because postoperative UTI or wound infection is so rare after hypospadias repair, this controversy will not likely be sorted out without a large multicenter trial. Our approach varies by surgeon, ranging from daily prophylaxis for the duration of the indwelling urethral stent to a 3-day course starting the day before stent removal.

Sutures used in hypospadias repair must provide sufficient strength while the urethroplasty heals yet should dissolve before suture tracks can epithelialize and lead to fistulous tracts or suture sinuses. Moreover, the suture material should elicit minimal inflammatory response. Hypospadias-specific studies comparing absorbable sutures are few and unfortunately inconclusive. Bartone et al. (1987) found chromic to be superior to polydioxanone (PDS) because of concerns for wound infection, inflammatory reaction, and poor wound healing. In a similar study, DiSandro and Palmer (1996) found the use of rapidly absorbing sutures such as chromic and polyglycolic acid (Vicryl) had a significantly lower complication rate in urethroplasty when compared with the more slowly absorbing PDS. More recent series have also suggested a lower complication rate with Vicryl suture as opposed to monofilament sutures (Snodgrass and Yucel, 2007; Uygur et al., 1998). Regardless of the suture used, modern techniques require use of absorbable, microsurgical-size suture for fine tissue approximation.

Given the complexity of hypospadias repair, even for distal hypospadias, it is not surprising that a learning curve exists. **Higher surgeon volume has been directly correlated to lower complication rates** (Horowitz and Salzhauer, 2006; Lee et al., 2013; Titley and Bracka, 1998)**. Studies comparing experienced surgeons to less experienced surgeons have shown a decreased complication rate for more experienced surgeons** (Snyder et al., 2005a)**. In a similar fashion, comparison of individual surgeon results indicates that time from completion of fellowship training and increase in case volume significantly reduce the incidence of surgical complications** (Horowitz and Salzhauer, 2006). A large population study of 108 surgeons performing distal hypospadias repair found that higher yearly case volume led to a significant decrease in postop complications (Lee et al., 2013).

The use of hair-bearing skin for urethroplasty is discouraged because postpubertal hair growth renders the neourethra susceptible to stone formation and recurrent UTIs. Surgical technique is as important a factor for outcomes as surgical approach. Gentle tissue handling prevents crush injury and preserves blood supply to tissues, which is critical to predictable wound healing. It is imperative that the wounds are closed without tension. Wounds closed under pressure reduce capillary flow and promote ischemia.

Ischemia results in fibrosis and contraction of tissues, predisposes the wound to infection, and potentiates the breakdown of suture lines. Tissue trauma can be minimized by the use of fine forceps, skin hooks, and stay sutures. Intraoperative magnification facilitates this process and helps to identify delicate blood supply and proper tissue approximation. Flaps must be mobilized generously to minimize tension on suture lines and to prevent ischemia. Subcuticular neourethral approximation with epithelial inversion has been shown to decrease complications when compared with full-thickness suturing, as has dual-layer neourethral closure (Cimador et al., 2004; Ulman et al., 1997).

Although use of healthy and well-vascularized tissue is vital, the use of second-layer vascularized tissue coverage over the neourethral repair further reinforces blood supply. The use of multiple overlapping tissue layers is important in the reduction of complications so long as the additional layers do not compromise capillary flow. Dartos interposition flaps increasing the vascularized layers superficial to the urethral closure help reduce fistula formation after TIP repair (Savanelli et al., 2007). This can be done in multiple ways, including the preputial de-epithelialized dartos flap, adjacent de-epithelialized skin flaps in the absence of preputial tissue, tunica vaginalis, and/or the use of the corpus spongiosum for coverage (Fig. 45.12 and ▶Video 45.3; Basavaraju and Balaji, 2017; Chatterjee et al., 2004; Churchill et al., 1996; Smith, 1973; Snow et al., 1995). Belman (1988) initially described a technique of harvesting a dartos flap after transposing Byars flaps around to the ventrum (▶Video 45.4). The point where the excess prepuce reaches the proximal edge of the mucosal collar is measured, and a transverse incision is made (see Fig. 45.12). The harvested vascularized tissue is draped over the entire neourethral repair and secured laterally in a running fashion to offset suture lines.

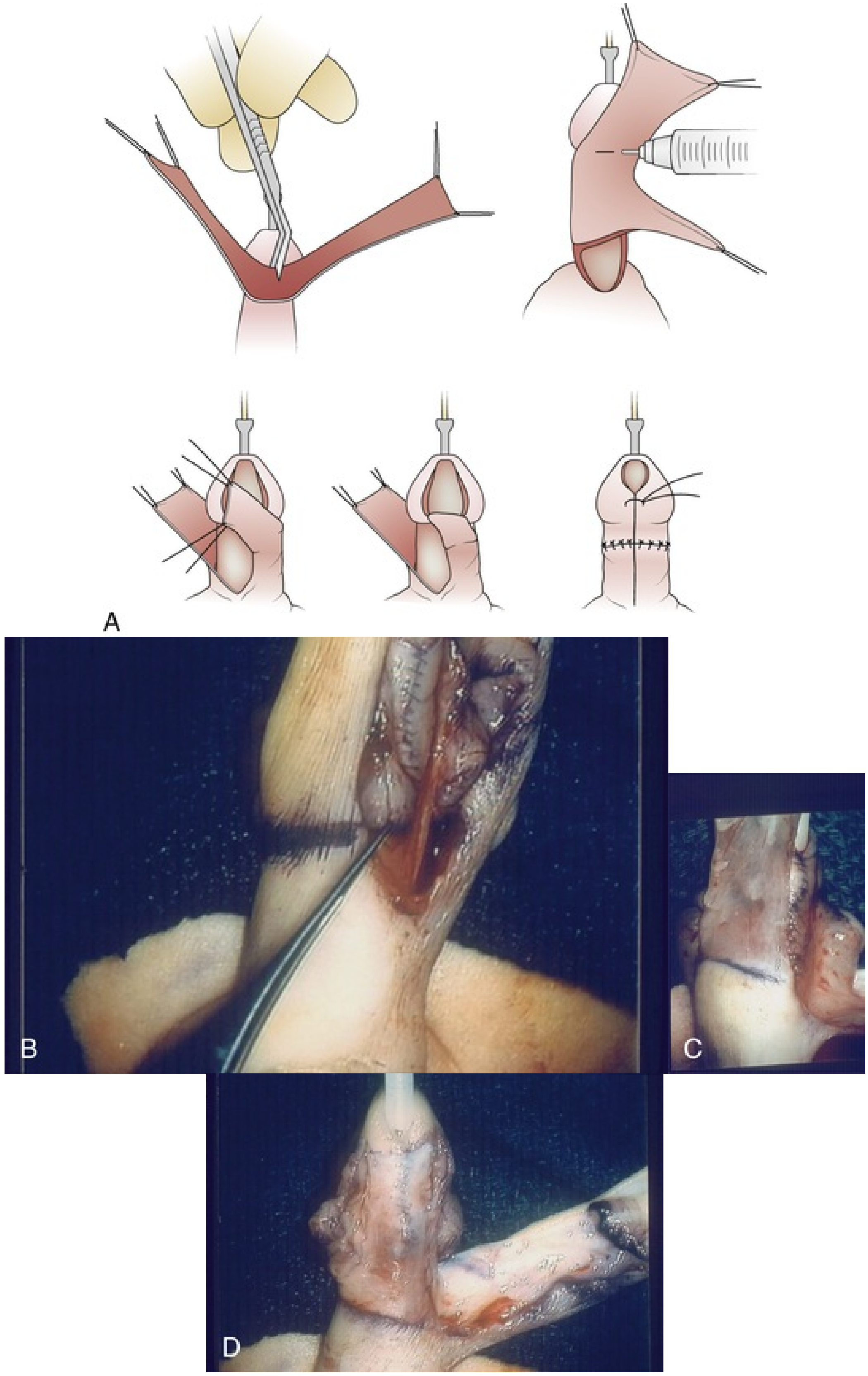
A
B
C
D

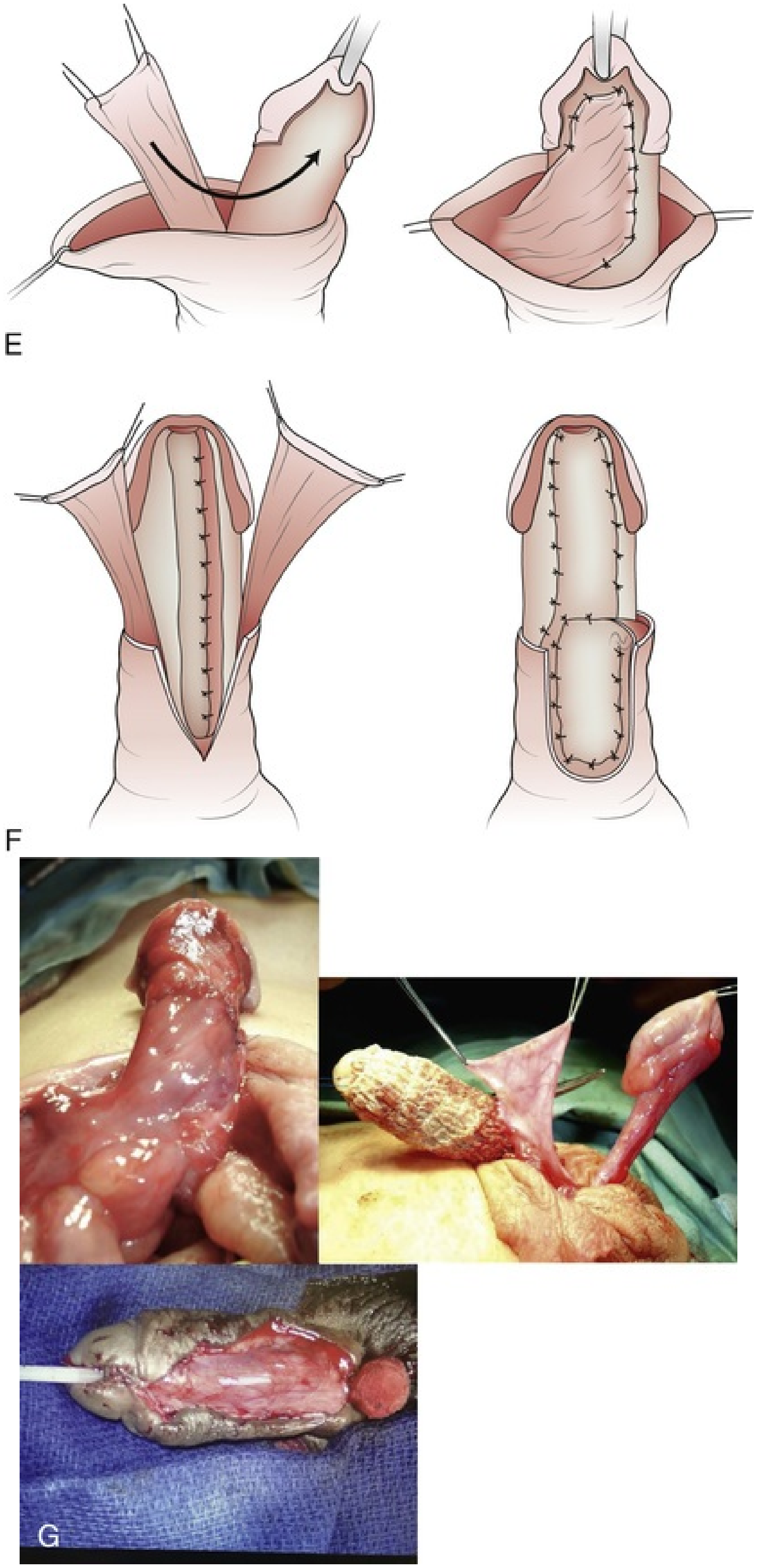

FIG. 45.12 (A) Cartoon depiction of the de-epithelialized Belman flap.

Redundant foreskin is incised dorsally in the midline to the point of yielding a proper skin fit with a circumcision. Byars flaps are rotated ventrally to the midline along either lateral side of the penis. (B–D) represent live surgical pictures depicting the technique. (B) The lateral borders of the redundant skin are marked. (C) The epithelium of the skin is incised and then removed, taking care to preserve the well-vascularized dartos layer. (D) The dartos is then secured as an additional layer of coverage over the urethroplasty, with an offset suture line flanking either side of the urethral closure. (E) Use of bilateral flaps to cover a longer urethroplasty. (F) Depiction of securing the flap in place. (G) Tunica vaginalis flap is harvested as a barrier layer over urethroplasty. Mobilization from the spermatic cord to the external ring prevents subsequent tethering of the testicle and/or penis. (From Belman AB: De-epithelialized skin flap coverage in hypospadias repair. *J Urol* 140[5 Pt 2]:1273–1276, 1988.)

Finally, careful hemostasis should be maintained with the judicious use of pinpoint cautery and a compressive bio-occlusive dressing. Hematoma formation can impede flap healing, resulting in tissue ischemia, and can compromise the repair. The dressing can be formed from an adhesive membrane such as Tegaderm, which is applied circumferentially from the level of the glans to the penoscrotal junction. The glans must be included in the dressing to avoid excessive swelling. Care must be taken to provide even coverage to prevent a constricting ring at the proximal extent of the dressing. Alternatively, a “sandwich” dressing, which provides gentle compression for the first 72 hours postsurgery, can be equally effective (Fig. 45.13). Once the dressing is removed, parents should be counseled that a significant amount of edema and ecchymosis may be present. After dressing removal, application of topical petroleum jelly may help prevent eschar formation and trauma to the tissue as it meets the diaper to further facilitate the healing process.

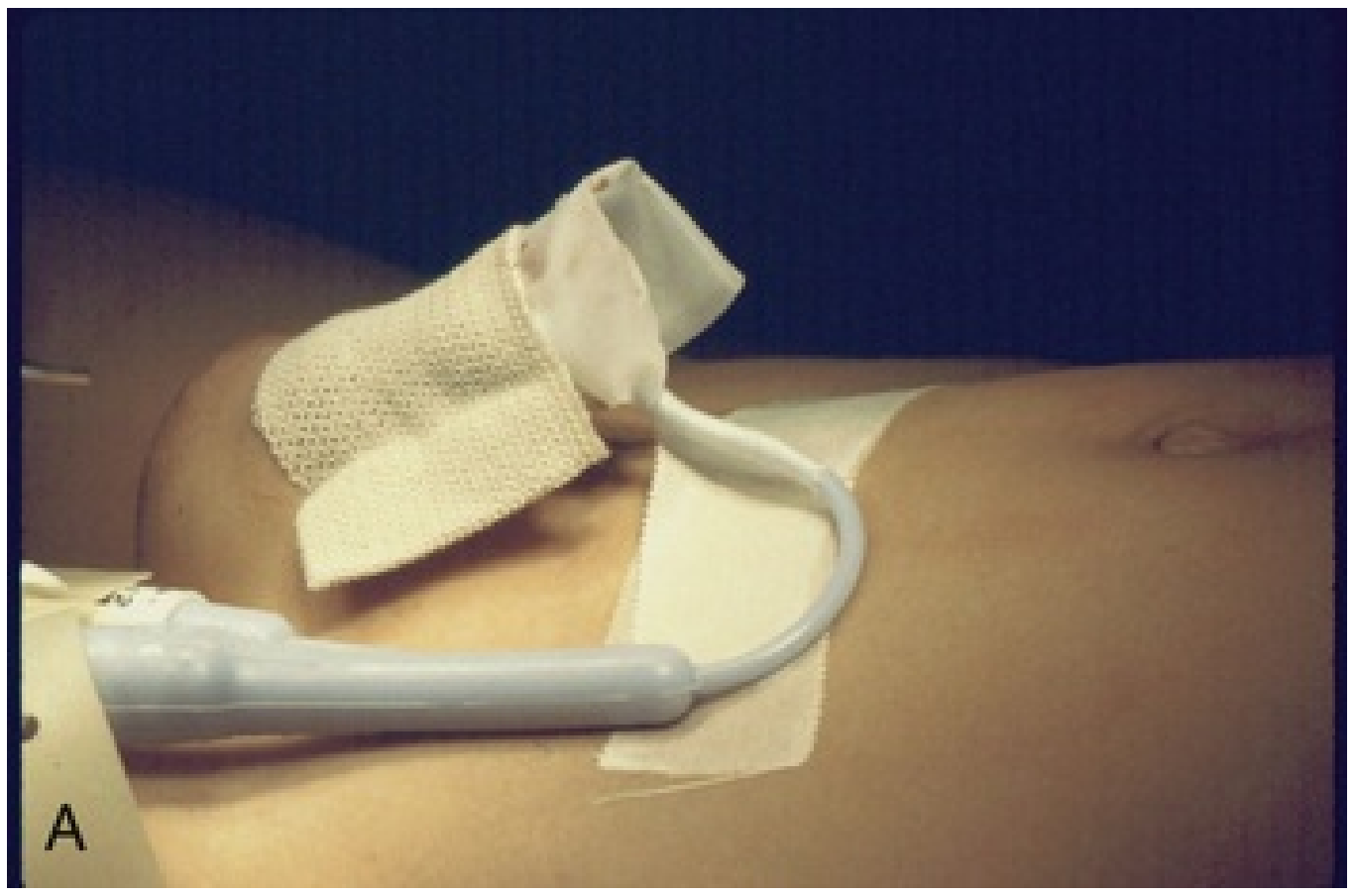

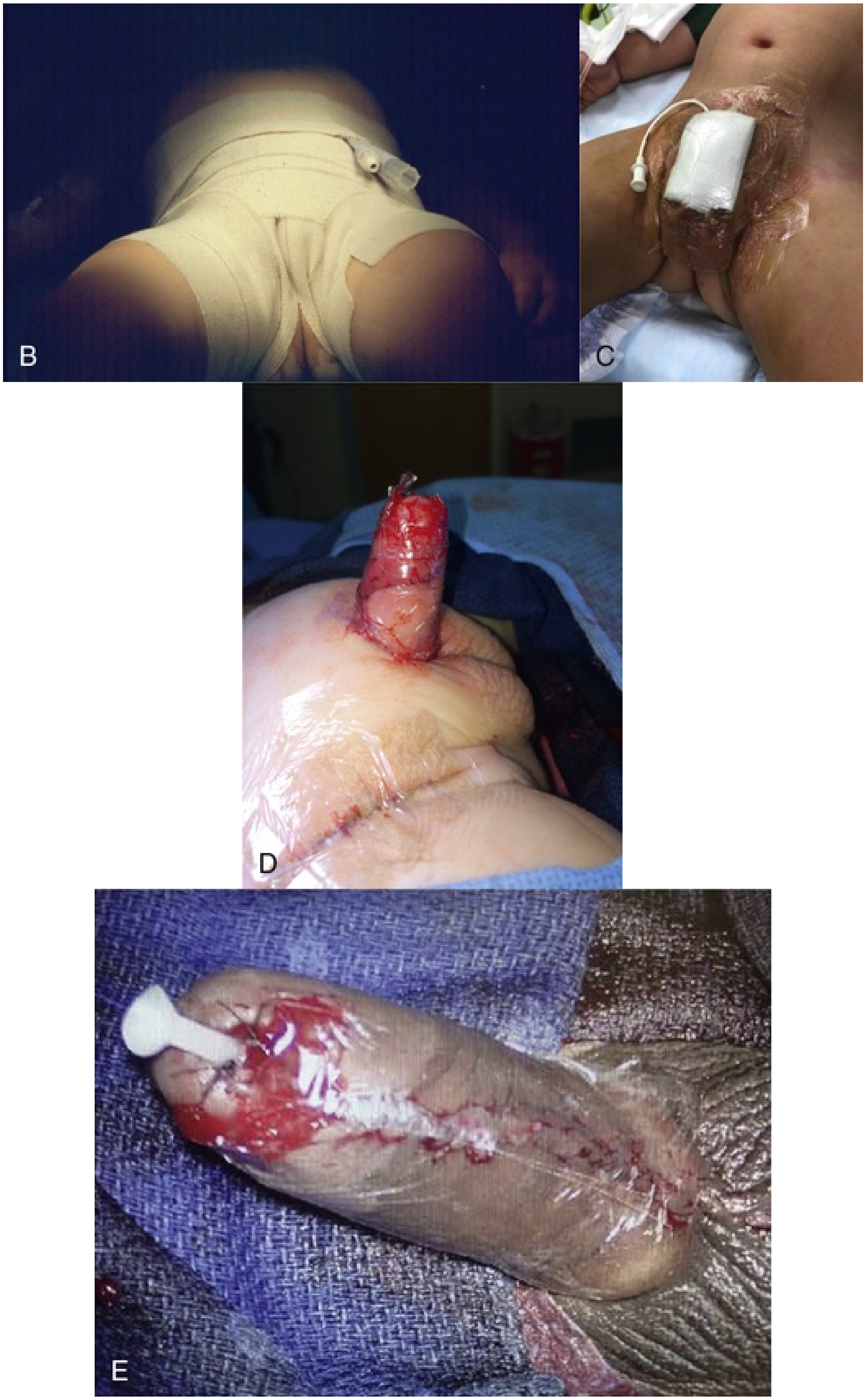

FIG. 45.13 (A,B) Photos of an older type of dressing that includes a Foley catheter in the urethra and subsequently applied extensive amount of

Coban to secure the penis in place. (C) A sandwich dressing, which includes a 6-Fr Kendal stent for the urethra covered by two layers of Tegaderm. (D,E) Simple Tegaderm dressing without a stent and another patient with a drip stent as well.

Key Points

- Higher surgical volume seems to correlate with a lower complication rate in hypospadias repair.
- Nonoverlapping tissue layers, tension-free tissue closure, and barrier layers with well-vascularized tissue increase the success of a repair.

Distal Hypospadias Repair

The literature on hypospadias repairs can be overwhelming, because more than 200 techniques have been described, although the majority are a variation of an established approach. The basic tenets of repair include identification and correction of penile curvature, urethral advancement either with or without urethroplasty, and glansplasty. The skin is then closed, with or without preputioplasty. To simplify the technical variation, urethroplasty techniques can be broadly categorized as those using flaps of local genital skin, those using flaps or grafts of preputial or extragenital tissue, and urethral tubularization. Among the repairs outlined later, a survey of pediatric urologists identified the TIP technique was used more than 90% of the time for distal hypospadias repairs and 80% of the time for midshaft repairs (Cook et al., 2005).

Advancement Procedures

Advancement procedures do not require tubularization of the urethral plate and are typically reserved for only the most distal, glanular meatus with minimal to no penile curvature. Urethromeatoplasty uses the Heineke-Mikulicz principle, in which one makes a longitudinal, vertical incision in the ectopic meatus, the edges of which are then closed in a horizontal fashion (Fig. 45.14A). This flattens the posterior urethral plate and achieves a cosmetically normal meatus. This technique is particularly useful in the setting of a stenotic, distal meatus with an associated blind ending pit in the center of a closed glans.

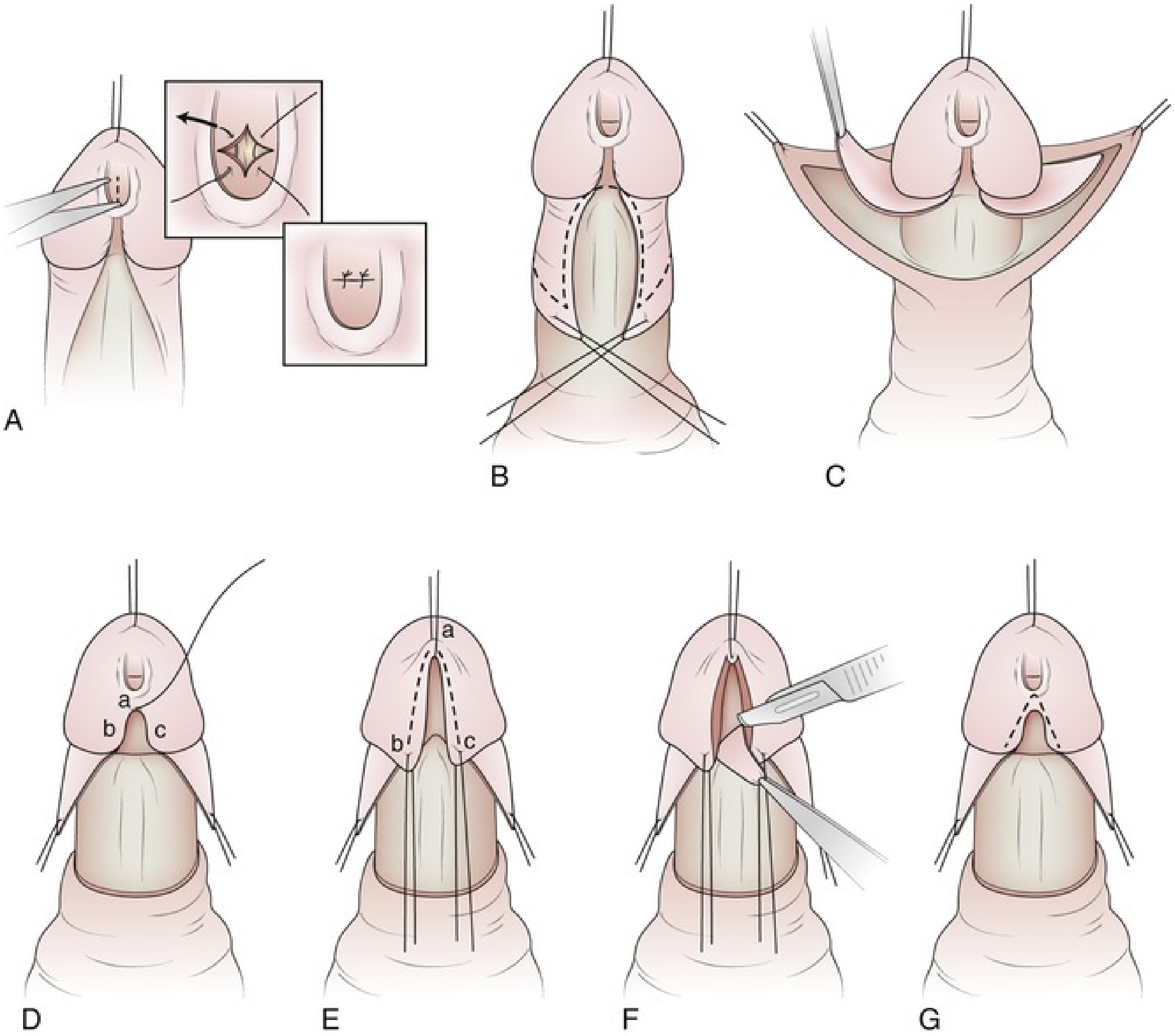

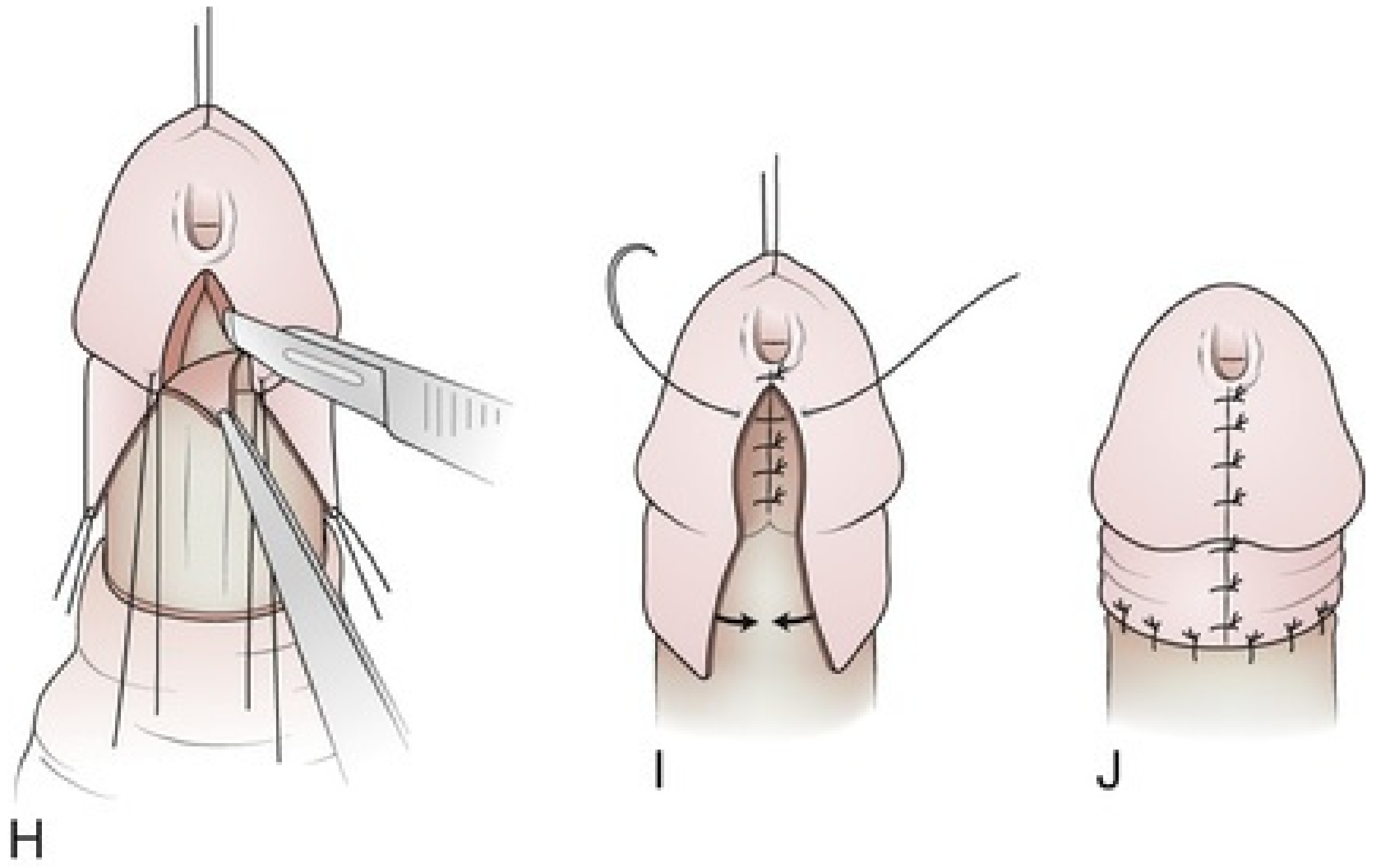

FIG. 45.14 The meatal advancement glanuloplasty (MAGPI) procedure. (A) Heineke-Mikulicz rearrangement with longitudinal incision is made and then closed in a horizontal fashion. (B) Mucosal collar is marked with holding sutures placed. (C) Penis partially degloved. (D) Holding suture placement *(a, b, c).* (E) Distal retraction to provide meatal advancement *(a),* vs. proximal retraction *(b, c).* (F) Glanular spongiosum exposed after excision of glans edges. (G,H) Alternatively marker used to inscribe V along glanular edges and V-shaped tissue segment excised. (I) Approximation of the glans in two layers. (J) Completed repair with mucosal collar. (From Zaontz MR, Dean GE: Glanular hypospadias repair. *Urol Clin N Am* 29:292, 2002.)

Duckett (1981) pioneered what was to become one of the most widely used procedures to correct glanular hypospadias, the meatal advancement glanuloplasty (MAGPI) (Video 45.5). The main objective of this procedure is to advance the meatus distally without formally tubularizing the urethra (Zaontz and Dean, 2002; see Fig. 45.14A). We have since modified the original description (Fig. 45.14B). Although once used for many degrees of distal hypospadias, the best candidates have a meatus located on the glans. **Application of this technique at more proximal locations subjects the repair to undue tension, thus increasing the risk of developing a retrusive meatus and/or an abnormal, flattened distal glans. The evolution of this technique from widespread use to a more selective application reveals the critical role that anatomic assessment and proper approach selection plays in optimizing outcomes.**

In 1991 Decter developed the M inverted V glansplasty (MIV), a repair for proximal glanular or a coronal meatus without urethral tubularization, designed to prevent the meatal retraction and abnormal glans shape sometimes seen in the

MAGPI procedure (Decter, 1991; Fig. 45.15; ●Video 45.6). This technique is used when the parameatal skin is sufficiently compliant to allow tension-free distal mobilization of the meatus and the glans should be of sufficient size for glanuloplasty. In addition, the glans configuration (with ventral medial upward angulation) should be conducive for successful implementation of the MIV (Fig. 45.15B). The glans wings dissection is usually, although not always, less deep than with tubularization techniques. This procedure advances the ventral urethral lip distally with well-apposed glanular tissue proximal to the meatus, whereas a cosmetically pleasing mucosal collar completes the repair.

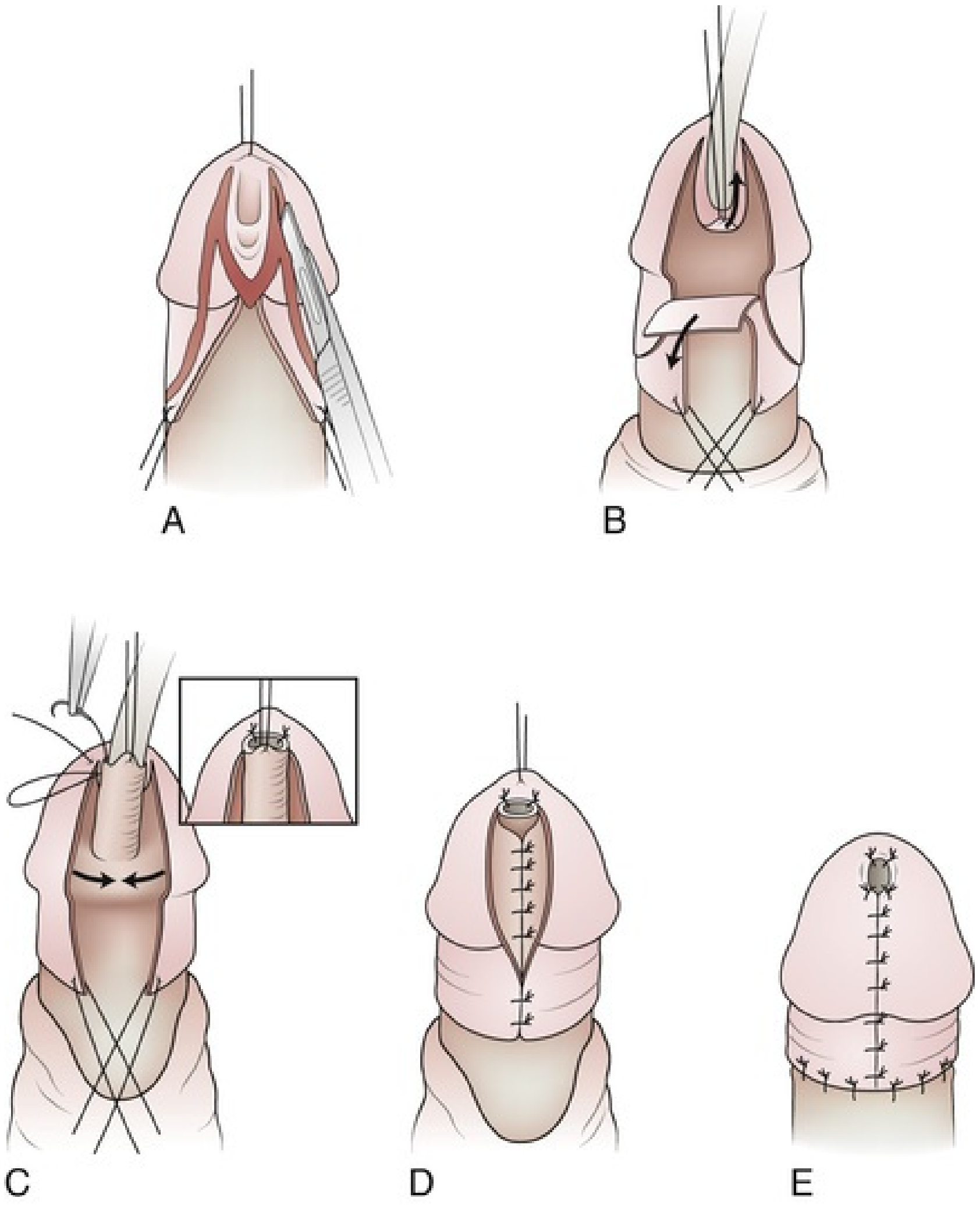

FIG. 45.15 M inverted V glansplasty (MIV) procedure. (A) M-shaped markings made, including mucosal collar followed by incision. (B) Holding suture used to retract meatal tip distally followed by proximal dissection of the ventral tissue. The skin is typically hypoplastic on the distal penile shaft; thus care must be taken to not violate the urethra during this dissection. If

thin but not violated, additional barrier layers can be added to reinforce the repair. (C) Urethromeatoplasty performed followed by ventral approximation of the glans. (D) Two-layer glans closure over the urethral advancement. (E) Completed repair including mucosal collar. (From Zaontz MR, Dean GE: Glanular hypospadias repair. *Urol Clin N Am* 29:292, 2002.)

The urethral advancement procedure, or sleeve technique, incorporates mobilization of the distal urethra by incising the hypospadias meatus at the glans (Koff, 1981). In some instances aggressive mobilization is required. When done in an appropriately selected patient, the mobilization provides increased length to advance the urethra in a tension-free manner into the distal most glans, over which glansplasty is performed (Fig. 45.16). **Concerns for this approach include the potential for devascularization of the mobilized urethra with subsequent urethral stricture and possible retraction of the urethral meatus because of tension caused by the advancement.**

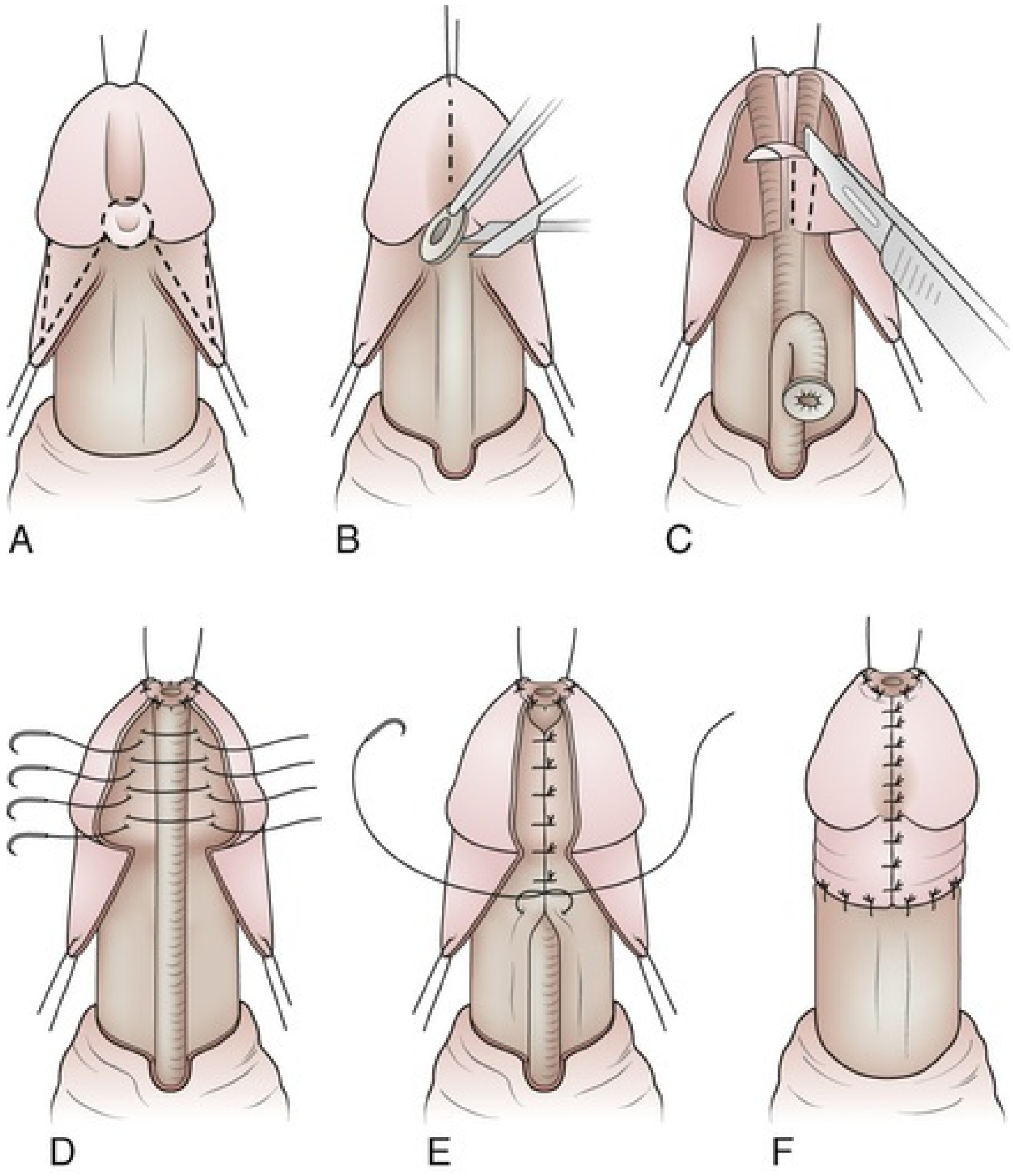

FIG. 45.16 Urethral advancement procedure. (A) Circumferential inscription of meatus and mucosal collar. (B) Degloving of penis followed by mobilization of meatus and urethra. Care is taken to preserve well-perfused urethral tissue, with excision of nonviable segment. (C) Excision of portion of midline spongiosum to allow for proper seating of the urethra in the glans. (D) Proximal deep urethral tissue coverage with glansplasty and approximation of spongiosum. (E) Approximation of superficial glans tissue. (F) Completed repair including mucosal collar. (From Zaontz MR, Dean GE: Glanular hypospadias repair. *Urol Clin N Am* 29:292, 2002.)

Tubularization Techniques

Tubularization techniques incorporate a formal urethroplasty to advance the meatus into a glanular location. These techniques are used in the setting of a more proximal meatus not amenable to advancement, particularly in the setting of curvature that is mild or resolves after penile degloving. These procedures require an astute assessment of the anatomy and application in the appropriate setting, specifically based on the quality of the glans, urethral plate, and periurethral tissue. These anatomic factors can have a big impact on the success of the repair.

The glans approximation procedure (GAP) is a surgical technique designed specifically for patients with proximal glanular/coronal hypospadias who have a wide, deep glanular groove and a noncompliant or “fish-mouth” meatus, which is often present in the MIP variant (Zaontz, 1989; see Fig. 45.3). The pyramid procedure is essentially the GAP with an intact prepuce (Duckett and Keating, 1989). **The glans groove is typically deep and wide enough that if one were to pinch the glans wings together, a normal cosmetic appearance would result. This technique is a modification of the Thiersch-Duplay repair originally described without the extensive mobilization of the glans wings** (Fig. 45.17). **This has since been modified to deeper glans incision and glans wing mobilization, and in our hands, incorporates a two-layer running neourethral mobilization and dartos flap barrier layer**. **As with all reconstructive procedures for hypospadias, attention must be given to the posterior urethral plate to determine the presence of a transverse cleft separating the hypospadias meatus from the distal glans groove.** It is critical that the posterior urethral plate be flat to avoid urine flow deflection as it exits the urethra.

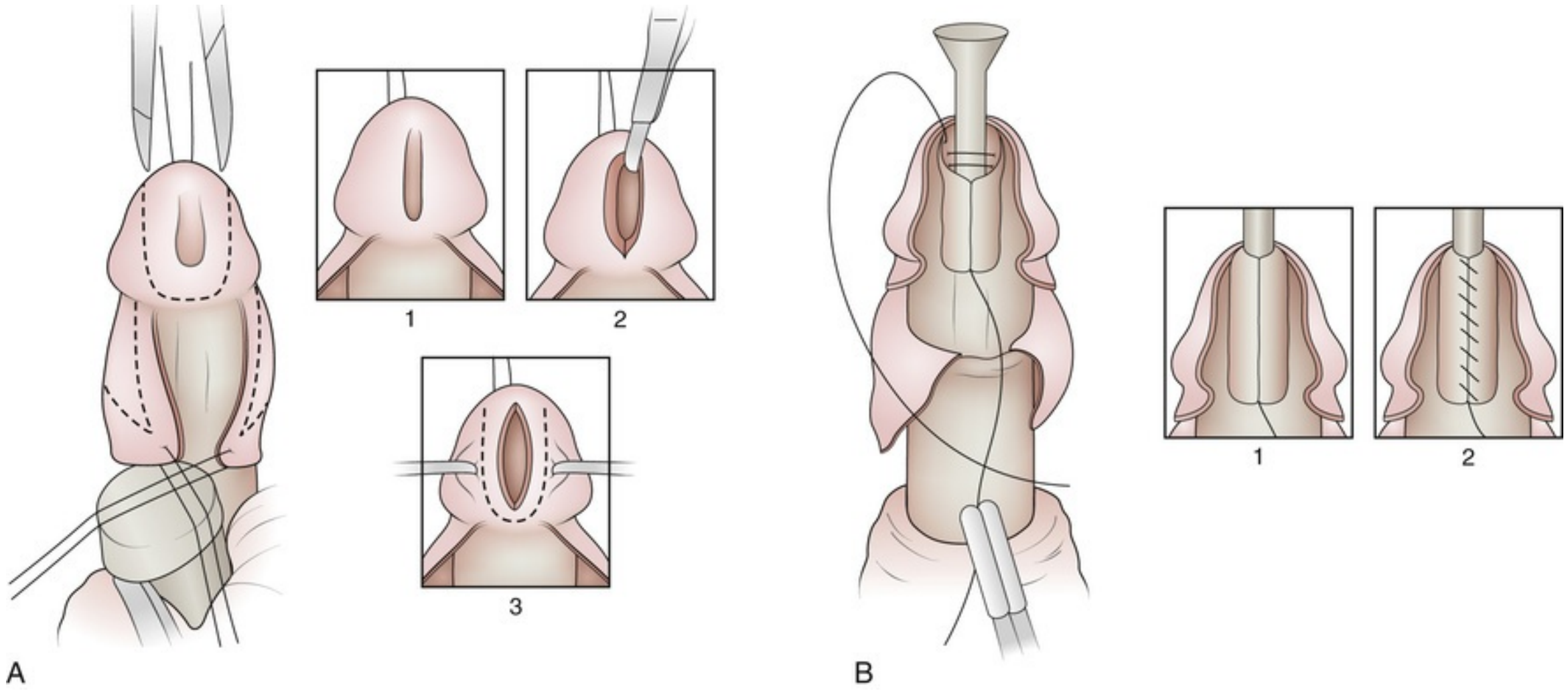

FIG. 45.17 Modified Thiersch-Duplay repair. (A) U-shaped marking line extending down inner prepuce, which is preserved for use in closure of mucosal collar. *Inset* shows narrow urethral plate, which is conducive to TIP modification *(1)* incising urethral plate to determine width *(2)* and lateral marking lines to achieve adequate neourethral lumen *(3).* (B) Tubularization of neourethra. Inset shows first running layer *(1)* and Lembert second running layer *(2).*

Most operations performed in the modern era are modifications of previously developed procedures. The Thiersch Duplay (TD) repair, developed nearly 140 years ago by Thiersch and later Duplay, uses the brilliant concept of urethra tubularization of local tissue distal to the ectopic meatus (Duplay, 1874; Thiersch, 1869). They performed their repair by creating a U-shaped incision made of vascularized skin from the penile shaft, advancing the meatus to the coronal margin. This was later modified for distal hypospadias by covering the repair with a second layer of preputial skin (Allen and Spence, 1968; Belman, 1988). This technique was originally described by Smith and involves de-epithelialization of redundant preputial skin and securing across the repair to provide supplemental blood supply (Smith, 1973). The natural progression was to extend these U-incisions into the distal glans, tubularizing the glans itself over the repair, creating a more cosmetically appealing meatus at the tip of the penis (Firlit, 1987; King, 1970; ▶Videos 45.7 and ▶45.8).

The TD procedure requires a glans of adequate width to allow for an appropriately sized neourethral channel, at least one covering "waterproofing" layer, and glans wings that can loosely approximate over the repair. This technique, which we use frequently in boys with distal hypospadias, is particularly successful if the surgeon adheres to certain parameters (see Fig. 45.17). **Parallel incisions are made lateral to the glans**

groove to equal 12 Fr in diameter; the glans wings must be deeply and widely mobilized to allow for tension-free coverage. Neourethral reconstruction is performed under optical magnification using a double running subcuticular suture. A de-epithelialized pedicle flap is procured from the preputial tissue or the more proximal shaft, should the infant be circumcised, and placed over the entire neourethral repair (Belman and Kass, 1982; Smith, 1973). Should the repair be more proximal, a double dartos flap can be procured from the dorsal prepuce with one flap running distal and one proximal (see Fig. 45.17). **The glans wings are approximated in two layers (spongiosum and then epithelium), followed by the mucosal collar to complete the circumcision defect.**

The TIP procedure, a modification of the TD, is a popular hypospadias surgical technique used worldwide (Cook et al., 2005; Snodgrass, 1994). Rich et al. (1989) noted that the fish-mouth meatal appearance of Mathieu hypospadias repairs or island flap/onlay repairs could be avoided if the posterior urethral plate were incised or hinged, thereby creating a more natural slitlike meatus. The TIP procedure modified the classic TD procedure by incorporating the posterior urethral plate incision as described by Rich. **The midline incision of the posterior urethral plate is designed to improve urethral width to thus allow tubularization of the neourethra in TD fashion, particularly when anatomy would otherwise preclude a tension-free anastomosis with only local tissue. Compared with the superficial incision of a dorsal urethral cleft, the TIP incision is deep and carried to the level just superficial to the corporal bodies, particularly in the setting of a narrow plate or flattened glans. Surgeons must resist the urge to close the urethroplasty too far distally, because this can increase the risk of meatal stenosis. Snodgrass stops his urethral closure 2 to 3 mm proximal to the intended meatal location** (Fig. 45.18). In the original operative description of the TIP procedure, parallel incisions are first made at the lateral edges of the urethral plate followed by a midline longitudinal incision to develop enough width to allow for successful urethroplasty. We have found that no two urethral plates are the same, and obtaining a consistent width throughout the urethroplasty cannot always be achieved in our hands with the TIP. In some cases a narrow plate increases the risk for meatal or urethral stenosis. An experimental animal study demonstrated variable widths upon incising the posterior urethral plate with the additional finding of contraction of the initial incision ultimately leading to a narrower overall width (Eassa et al., 2011). Hence we approach the TIP by first incising the posterior urethral plate, measuring the width obtained, and then making parallel glanular incisions to obtain 12 mm in total width for adequate lumenal diameter. The remainder of the repair proceeds as described for Thiersch Duplay. In our experience, we limit posterior urethral plate incision to situations in which a transverse cleft is present between the meatus and glanular groove to smooth out and flatten the posterior urethral plate to avoid turbulent flow during voiding. **If we consider using the concept of the TIP repair for distal hypospadias, we frequently add an inner preputial graft that we believe protects against future narrowing of the reconstructed distal urethra** (Kolon and Gonzales, 2000).

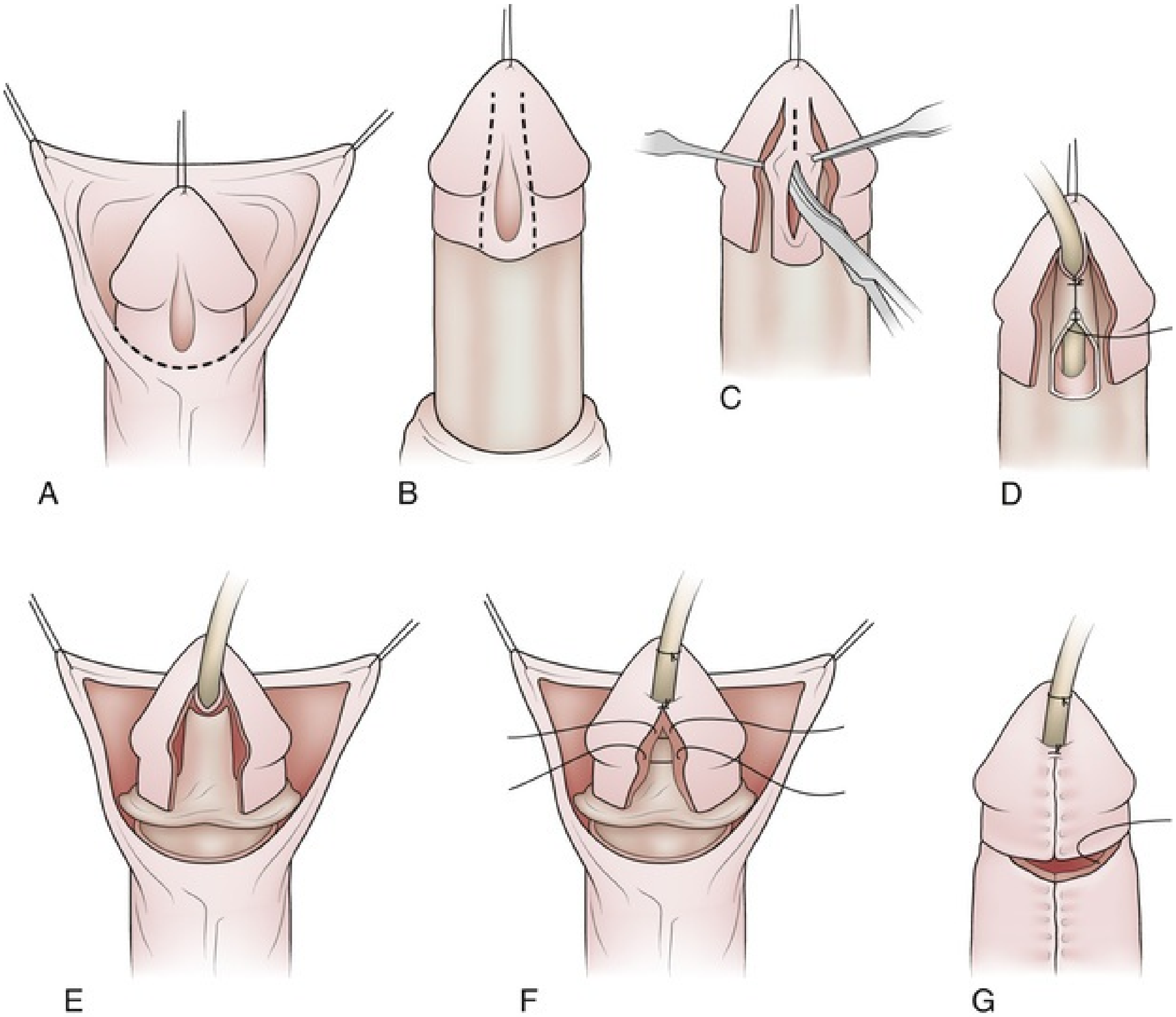

FIG. 45.18 Distal tubularized incised plate (TIP) repair. (A) Circumscribing skin incision. (B) Incision along the visible junction of the glans wings to the urethral plate. (C) Deep, midline incision of the urethral plate extending to the underlying corpora. (D) Tubularizing the urethral plate from distally to

proximally. Note that the first stitch is about 3 mm proximal to the end of the urethral plate, creating an oval opening. (E) The neourethra is covered with a dartos flap. (F) Glansplasty creating the neomeatus and continuing down to the corona. (G) Repair and circumcision completed. (Modified from Snodgrass WT: Snodgrass technique for hypospadias repair. *BJU Int* 95:683–693, 2005.)

The flip-flap technique (Mathieu) is a procedure in which a parameatal-based flap proximal to the meatus is developed, advanced (flipped) onto the deficient urethral plate to augment it, and then closed distally (Devine and Horton, 1973; Mustarde, 1965). Initial incisions are made parallel to the urethral plate and extended proximally for an equal distance such that the raised flap can extend into the distal glans (Fig. 45.19). Theoretical concerns exist regarding the vasculature of the employed flap; if the base of the flap is not sufficiently wide, the blood supply may be compromised, increasing the risk of fistula and stenosis. Others have had concerns for an abnormal, fish-mouth appearance to the meatus. **This technique has been further modified to the so-called slitlike adjusted Mathieu (SLAM) procedure with good outcomes, including an improved appearance to the meatus** (Hadidi, 2012; Fig. 45.20).

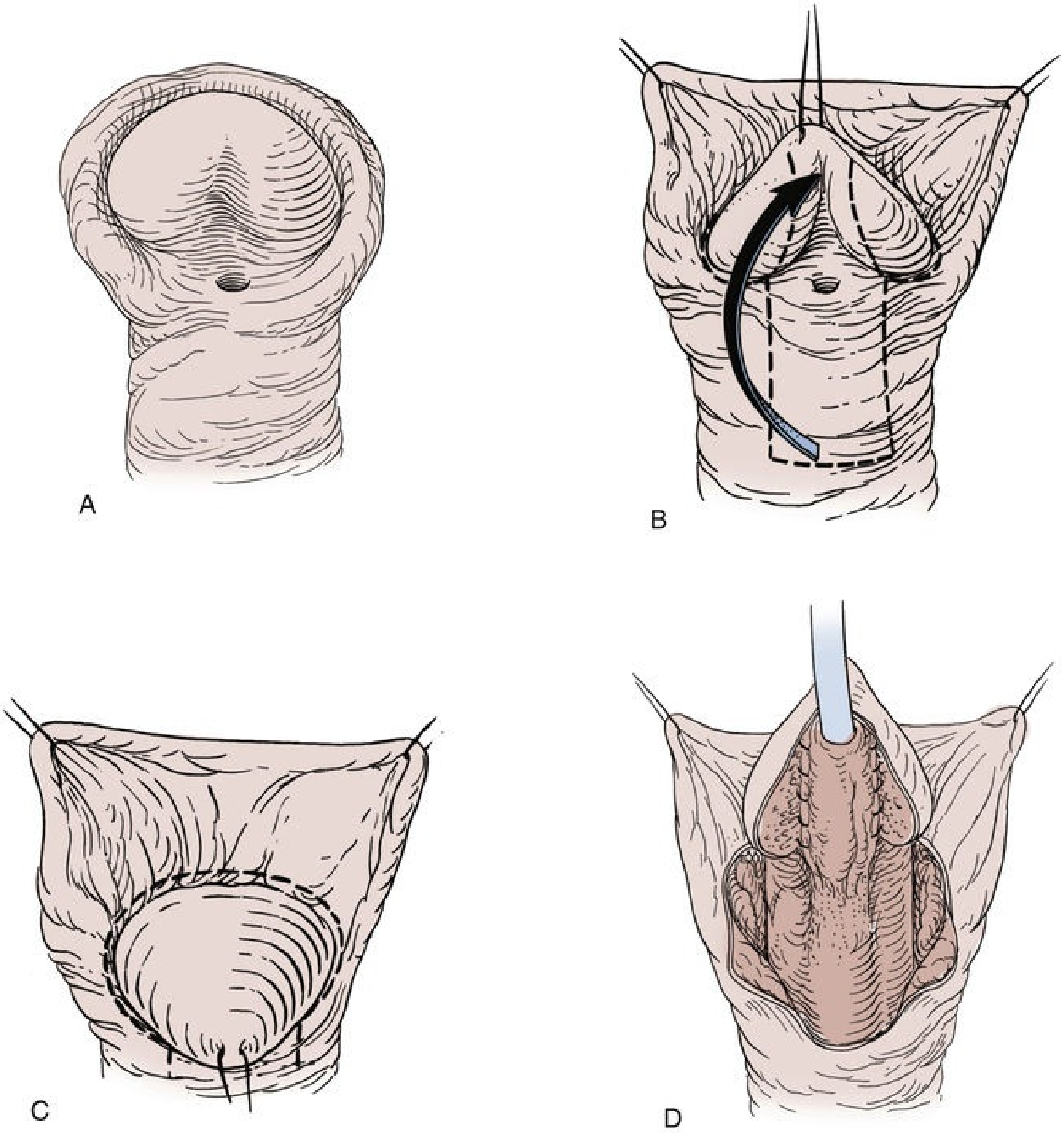

FIG. 45.19 (A,B) Parameatal skin flap is marked and incised. Incisions are extending into the glans. (C) Circumscribing incision is made. (D) Meatal flap is "flipped" onto the urethral plate, with a running suture line running parallel to either side of the late. Once the urethra is closed, glansplasty is performed.

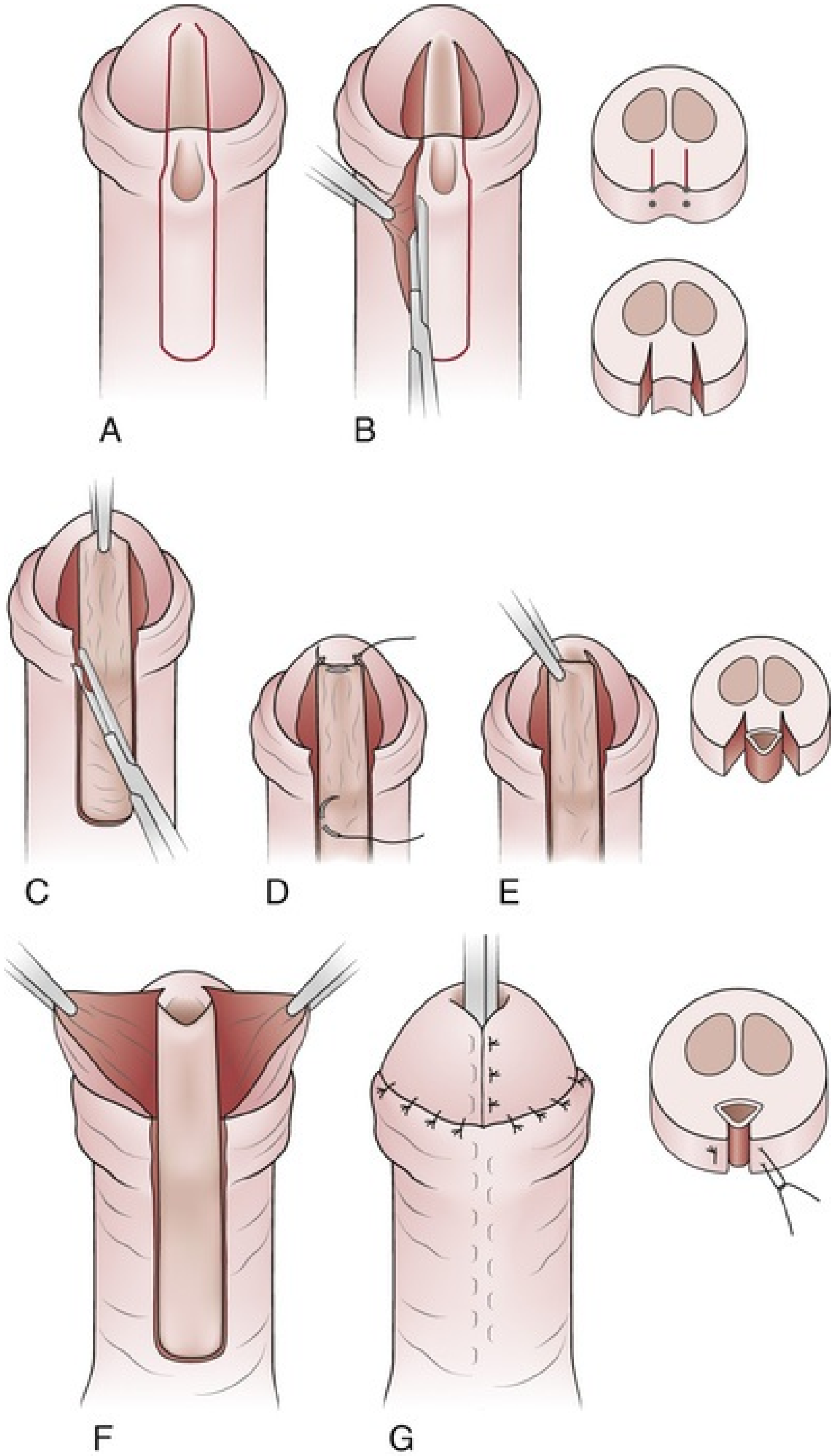

FIG. 45.20 The slitlike adjusted Mathieu (SLAM) technique. (A) A U-shaped incision is marked on the ventral penile shaft. Within the glans, the incisions are made parallel to each other and long the true urethral plate to develop proper glans wings. Proximally, the incisions diverge to create a wide-based flap. (B,C) The flap is mobilized, taking care to preserve spongiosal tissue on the flap. (D) The edges of the flap are sutured in place on either side of the urethral plate. (E) V-shaped excision of the flap is performed to achieve a slitlike meatus. (F,G) Glansplasty is performed. (From Hadidi AT: The slit-like adjusted Mathieu technique for distal hypospadias. *J Pediatr Surg* 47[3]:617–623, 2012.)

The onlay island flap (OIF) procedure is particularly useful in the setting of a narrow urethral plate. To augment the plate, an island flap of dorsal inner preputial skin is harvested, transposed ventrally, and sutured onto the plate to close the urethral defect (Fig. 45.21). Although a popular repair in the 1990s, after introduction of the simpler TIP procedure, this repair fell out of favor except in a few centers. Many surgeons complain that they have difficulty harvesting a consistent flap that will not develop a diverticulum. **We have found that a vertical incision on the ventrum of the penile shaft to the penoscrotal junction facilitates flattening of the dorsal shaft skin, which makes the blood supply to the flap more evident.** The actual harvest begins dorsally at the penopubic junction and progresses distally. This approach facilitates the procurement of a consistent flap. Concerns for this approach compared with the TD or TIP procedures include a fish-mouth or rounded meatus as compared with a more cosmetic oval contour with the TD and/or TIP unless Rich's modification is employed (Rich et al., 1989). After the OIF procedure, these boys are at higher risk for development of a urethral diverticulum because of the elasticity of the inner preputial skin present in the island flap. On the other hand, our impression is that meatal or urethral stenosis is less common in this repair.

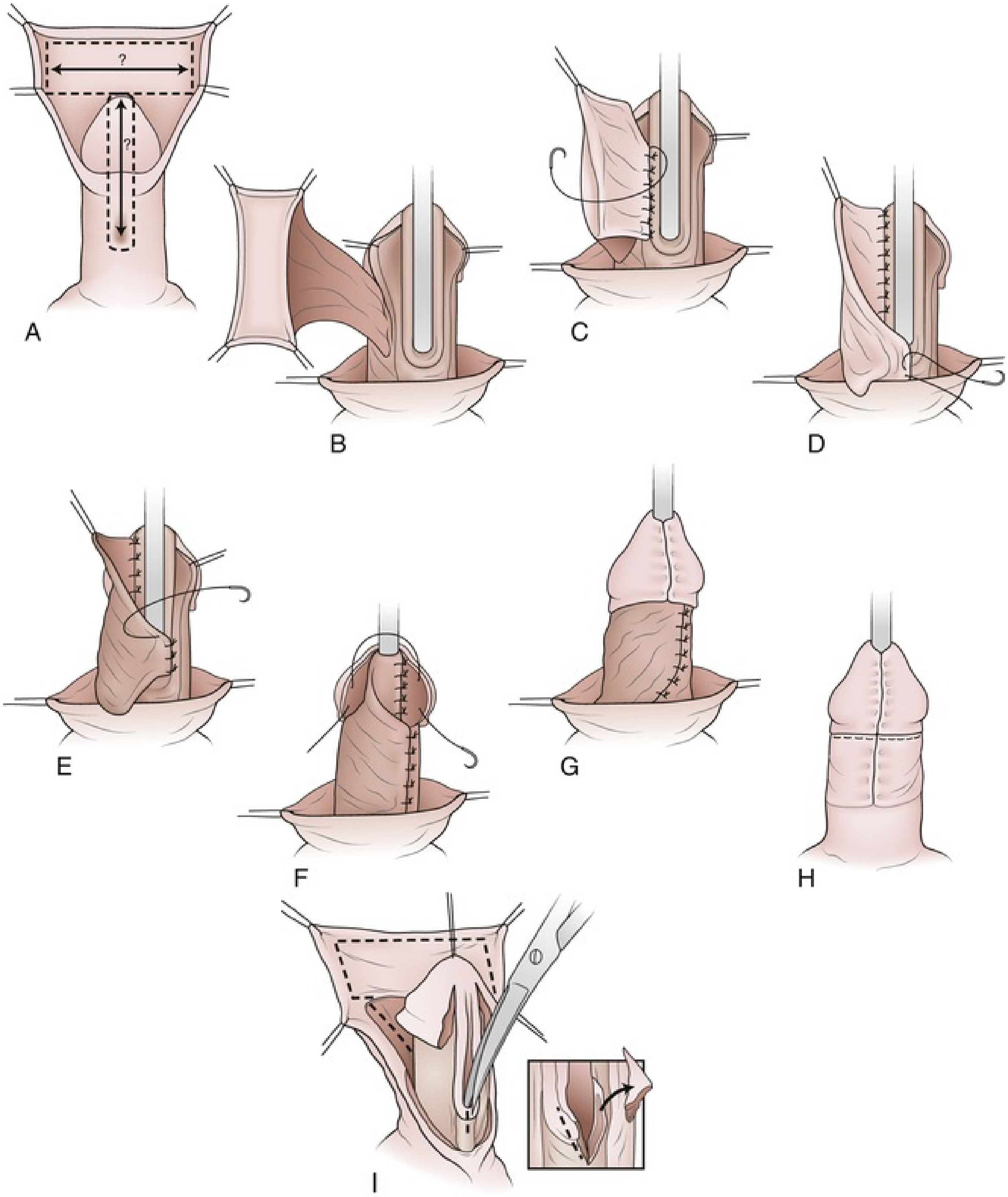

FIG. 45.21 The onlay island flap (OIF) technique. (A) Planned incisions to harvest transverse preputial flap and urethral plate. (B) Isolation of preputial flap on vascularized pedicle. *Inset,* Preparation of meatus for anastomosis, including excision of stenotic or hypoplastic meatal tissue. (C) Initiation of anastomosis of onlay flap and urethral plate. (D) Proximal approximation at the native urethra. (E) Completion of the neourethra channel. (F) Application of second layer of barrier coverage. (G–I) Glansplasty and skin closure.

Key Point

- Many options exist for distal hypospadias repair, many of which are technical variants of each other. Surgeons should use a technique that they feel comfortable with and yields a high success rate.

Proximal Hypospadias

Our appreciation for the importance of careful surgical treatment of curvature has driven a dramatic evolution in our approach to the management of proximal hypospadias. Concerns for recurrence of penile curvature in severe hypospadias when managed with dorsal plication alone have shifted the pendulum toward more aggressive corporal lengthening procedures, and therefore, in the hands of most surgeons, a multistage repair.

One-Stage Hypospadias Repair

In general, the one-stage proximal hypospadias repair involves dorsal plication to correct ventral penile curvature in conjunction with several different urethroplasty techniques. These can be stratified according to the tissue used in the repair, specifically preputial skin versus local skin versus buccal graft.

In 1980 Duckett harvested a preputial island flap, tubularized it into a substitution urethroplasty, and created what is called a transverse preputial island flap (TPIF) or the Duckett tube (Fig. 45.22). We have since modified the technique from its original description (Asopa et al., 1971; ▶Video 45.9). **Rather than tubularizing the flap before securing it to the penile shaft, we now anchor the left side of the flap to the ventral surface of the penile shaft, just to the left of midline. The flap is then closed in the midline, with interrupted Lembert sutures to reduce the risk of exposing epithelium beneath the repair. Both rows of sutures are carried into the midglans. The pedicle of the flap is carefully placed over the suture line. The glans wings are then brought over the urethroplasty and vascular flap. This approach anchors the base of the tubularized flap to the distal extent of the native urethra** (Fig. 45.22E). This provides a point of tension that will guide the subsequent tubularization along the longitudinal axis of the neourethra, removing laxity to reduce the risk of diverticulum development. The tube is closed in a two-layer fashion, maintaining an even caliber throughout its course (Fig. 45.22F). This approach is applicable in the circumstance when the curvature is severe but corrected after skin dissection and division of the urethral plate. **The amount of tissue placed within the glans can hamper glans closure and result in an oval appearance to the meatus, as opposed to a slitlike meatus seen with other repairs, limiting its use.** A higher complication rate with the TPIF resulted in Duckett preferentially using the OIF procedure, even for severe hypospadias (Duckett, 1995).

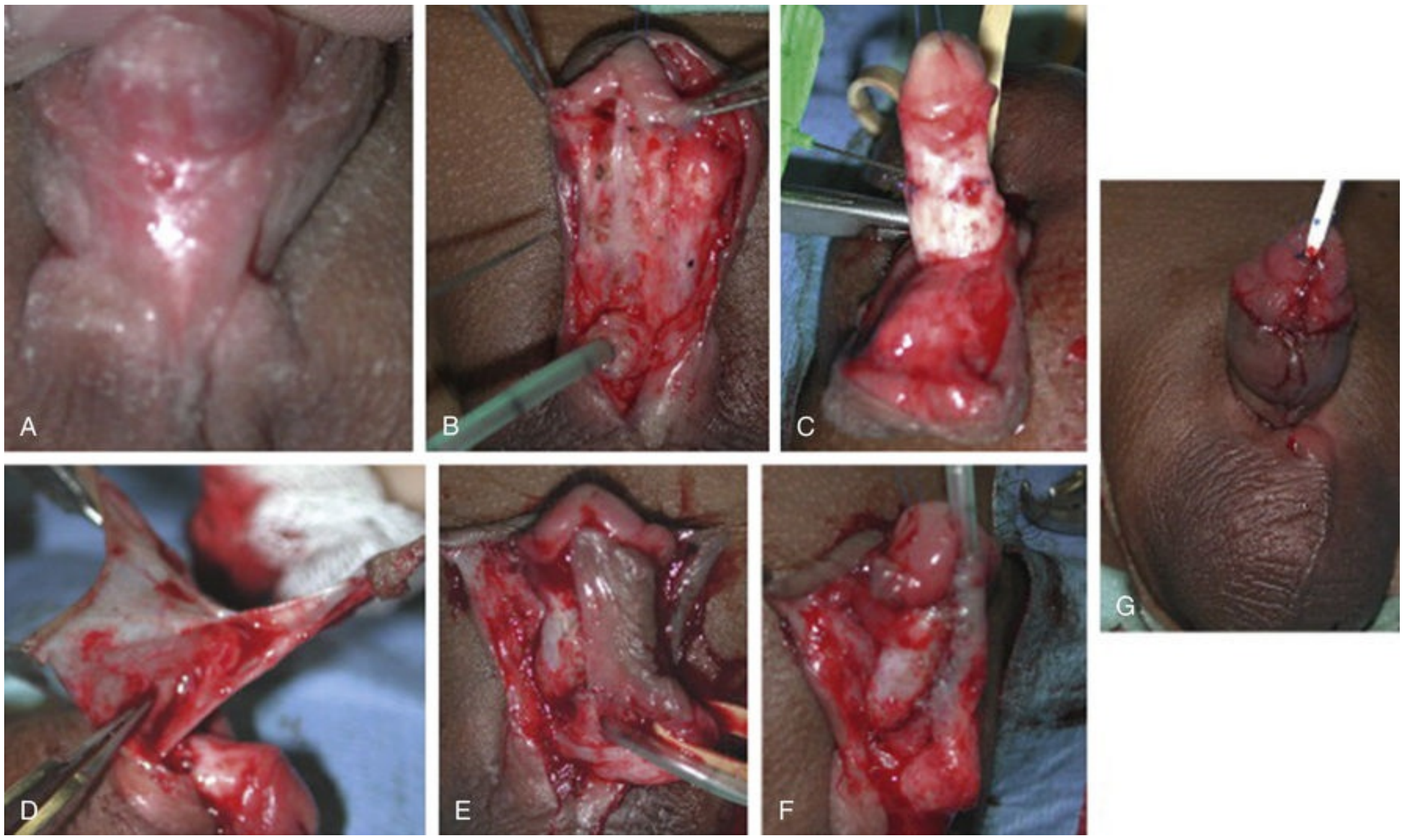

FIG. 45.22 Island tube hypospadias repair. (A) Preoperative appearance. The pink, shiny, ventral skin suggests a thinning of the ventral spongiosum. In spite of the subcoronal meatus, this is a proximal variant. Incisions are marked and made in a similar fashion according to the schematic in Fig. 45.21. (B) After degloving the meatus is located at the penoscrotal junction and is cannulated with an 8-Fr feeding tube. (C) Artificial erection after dorsal plication reveals no residual penile curvature. (D) The preputial island flap is mobilized, with harvest of the supple dartos pedicle off of the shaft skin toward the base of the penis. (E) One edge of the flap is anchored to the tunica albuginea. (F) The flap is measured to a width of 12 mm with excision of redundant epithelium. The flap is then closed over a diversion tube, approximating the epithelial edge to the previously anchored portion of the flap. (G) Completed repair. (From Kraft KH, Shukla AR, Canning DA: Hypospadias. *Urol Clin North Am* 37[2]:167–181, 2010.)

The OIF procedure was described in the previous section for distal hypospadias but evolved from Duckett's experience with the TPIF (see Fig. 45.22). It is a versatile technique and can be used for more proximal variants. **Indications include boys whose curvature is corrected after penile degloving and does not require division of a relatively thin urethral plate that otherwise could not be tubularized. Although at one point used at CHOP in more than 90% of hypospadias repairs, it has since been replaced by other procedures for severe hypospadias and is now most commonly used for midshaft hypospadias repair in which release of skin and division of urethral plate results in correction of curvature.**

Technical aspects of the repair are reviewed in Figs. 45.21 and 45.22. After degloving, incisions along the urethral plate are made in parallel through the glans (see Fig. 45.22A, Video 45.8). Dorsal skin dissection should be in the avascular plane above Buck fascia, preserving the vascular pedicle to the preputial skin. The preputial skin flap is marked with stay sutures (see Fig. 45.22B), then transposed ventrally to align over and to the urethral plate with a full-thickness suture (see Fig. 45.21C). The native urethral meatus is spatulated (see Fig. 45.21). The combined width of the urethral plate and flap should be 12 mm or less, and is trimmed accordingly, in particular to narrow the proximal flap to prevent a diverticulum at the junction of the neo and native urethral anastomosis (see Fig. 45.21D). The remainder of the anastomosis is completed in a running or interrupted Lembert fashion (see Fig. 45.21E).

The TIP repair was previously described in the distal hypospadias section. Extension of this technique to more severe hypospadias was described, particularly in the setting of a boy whose curvature is corrected with skin dissection or plication in combination with an adequate urethral plate (Fig. 45.23; Snodgrass and Lorenzo, 2002). Technical modifications including urethral plate mobilization and transverse corporotomies, in the setting of persistent ventral curvature of greater than 30 degrees after degloving, were proposed to increase the applicability of the TIP for proximal hypospadias (Snodgrass and Bush, 2011). **Subsequent analysis by Snodgrass et al.** (2013) **suggests that aggressive mobilization of the urethral plate leads to devascularization, increasing the risk of stricture formation, which ultimately limits the applicability of proximal TIP in this setting. Because of a higher risk of complications, this technique has since fallen out of favor for other two-stage repairs, such as the Byars flap or STAG repair.**

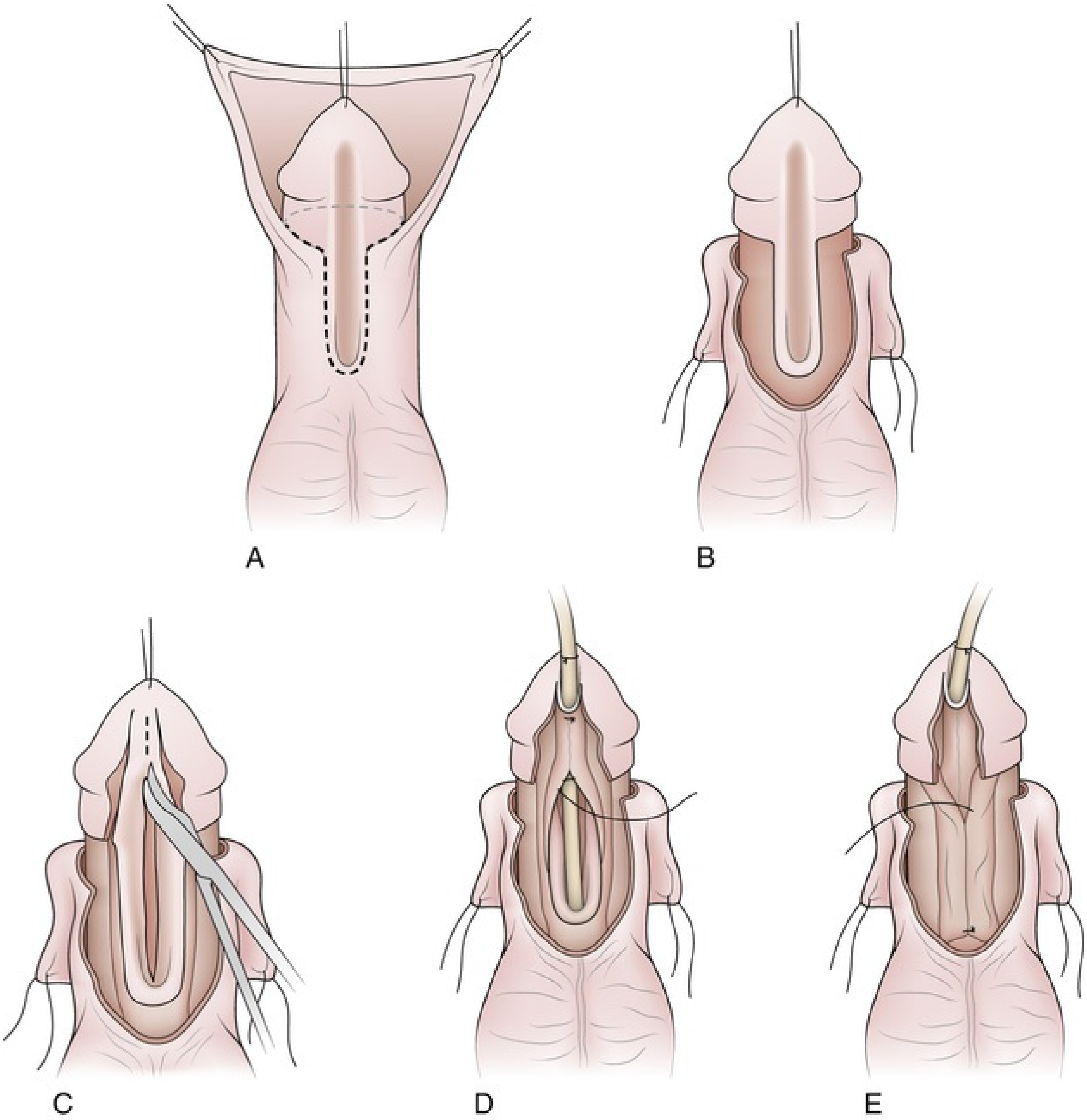

FIG. 45.23 Proximal tubularized incised plate (TIP) repair. (A) Circumscribing incision preserved urethral plate. (B) After degloving, the surgeon separates the glans wings from the urethral plate. Corpus spongiosum is dissected from the cavernosal bodies and released distally from the glans wings for later spongioplasty. Artificial erection is performed, and if curvature is less than 30 degrees and corrected with plication, TIP procedure can be considered. (C) Midline urethral plate incision, extended to the level of the corporal bodies. (D) Two-layer urethral plate tubularization using interrupted subepithelial 7-0 polyglactin suture. (E) Spongioplasty approximates divergent corpus spongiosum over the neourethra before a tunica vaginalis barrier flap is added. (Modified from Snodgrass WT: Snodgrass technique for hypospadias repair. *BJU Int* 95:683–693, 2005.)

The reasoning behind the current trend toward a staged repair for severe hypospadias, in which the curvature is corrected at the first stage and urethroplasty is performed at the second stage, lies with the methods used to correct curvature and while providing supple ventral shaft tissue for tubularization. Concerns for a higher risk of urethroplasty failure when combined with a corporal grafting procedure in a single-stage repair have led to this paradigm shift (Castellan et al., 2011; Mattos et al., 2016). Alternatively, although rarely performed, a corporal lengthening procedure may be combined with urethral closure in a single-stage repair. This is achieved through use of a flap corporoplasty, in contrast to a free graft, which could theoretically prevent contracture and facilitate healing of the overlying urethroplasty. Braga et al. (2007b) reported their approach with simultaneous tunica vaginalis flap for corporal lengthening with subsequent urethroplasty with TPIF to complete the repair in a single operation.

Two-Stage Hypospadias Repair

As the management of severe ventral penile curvature has migrated toward corporal lengthening procedures, the two-stage repair has emerged as the approach of choice for the majority of surgeons in management of proximal hypospadias. Although many technical variations exist, modern two-stage approaches can be divided into three main categories, each separated by fundamental differences to the approach to urethroplasty (Videos 45.1 and 45.10).

Two-Stage Repair With Free Graft

The Bracka two-stage repair uses a free graft, harvested from either the inner preputial skin or buccal mucosa, as a template for urethroplasty (Fig. 45.24; Altarac et al., 2012; Bracka, 1995). **The staged tubularized autograft (STAG) repair is a modification of Bracka's original description** (Pippi Salle et al., 2016; Snodgrass and Bush, 2017a; Fig. 45.25). In the first stage, penile curvature is corrected and the urethral plate is divided**. A midline incision is extended into the glans to act as a receiving bed for the graft. A compression dressing and quilting of the graft into place on the ventral penile shaft can prevent hematoma formation and facilitate graft take.** The second stage is performed at least 6 months later, in which a U-shaped incision, similar to the Thiersch-Duplay approach, is made and the urethra is tubularized and glansplasty is performed (Bracka, 1995). Multilayer closure is performed to maintain vascular flow to aid the healing process. **This technique has since been modified by incorporation of multiple ventral corporotomies, without subsequent graft coverage, as a corporal lengthening procedure. Proximal urethral mobilization and a more extensive glans dissection have also been used to improve the repair** (Pippi Salle et al., 2016; Snodgrass and Bush, 2017a). Caution must be taken when placing a free graft directly over the corporotomies as graft contracture can occur.

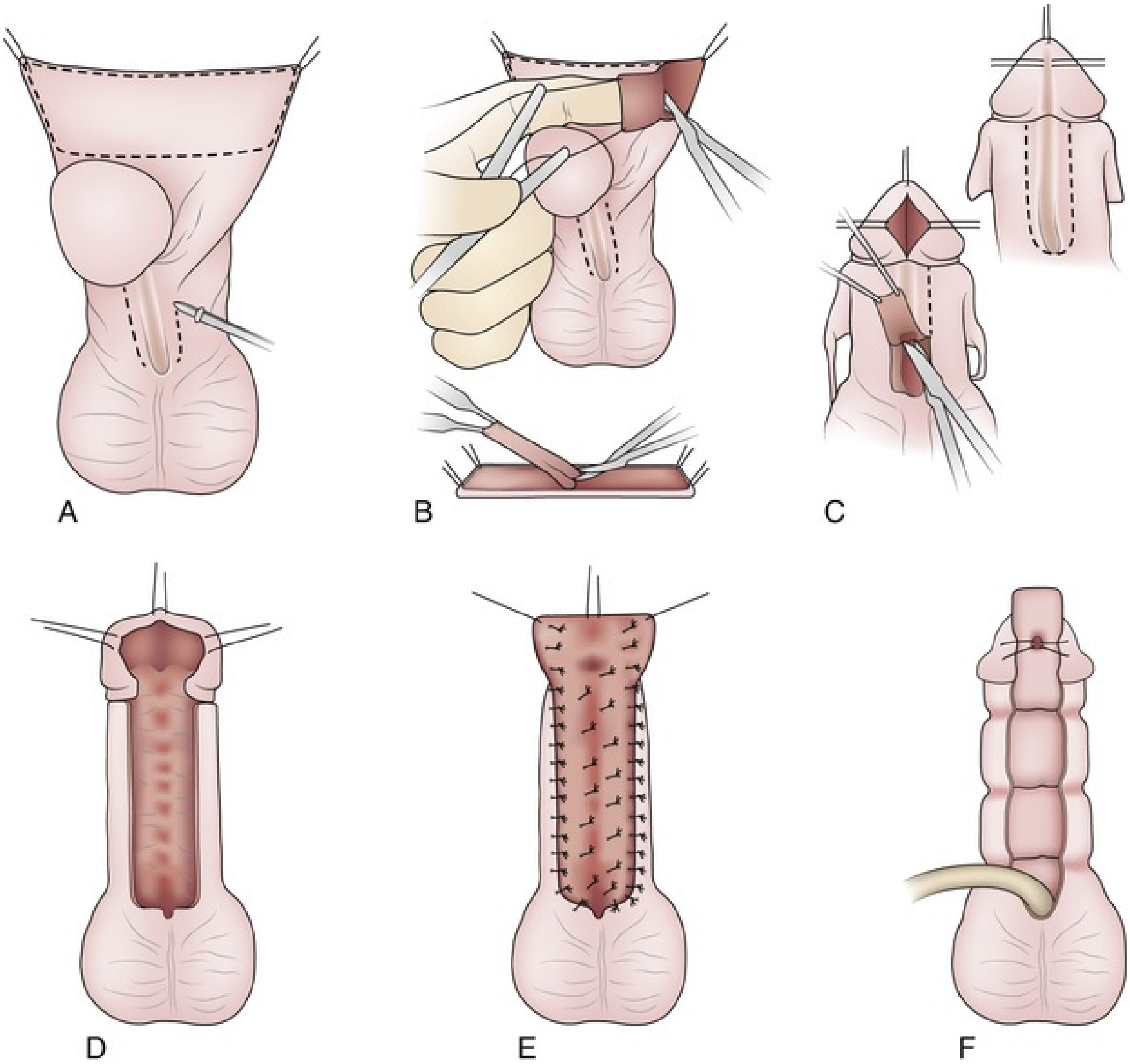

FIG. 45.24 Bracka two-stage free graft repair. (A,B) Inner preputial free graft incision is marked and harvested. (C) Abnormal urethral plate is excised and penis is degloved. (D) Incision is extended into the glans, mobilizing glans wings. (E) Preputial graft is secured into place, including

quilting sutures. (F) Compression dressing is sutured into place over the graft. (Modified from Altarac S, Papeš D, Bracka A: Two-stage hypospadias repair with inner preputial layer Wolfe graft. *BJU Int* 110:460–473, 2012.)

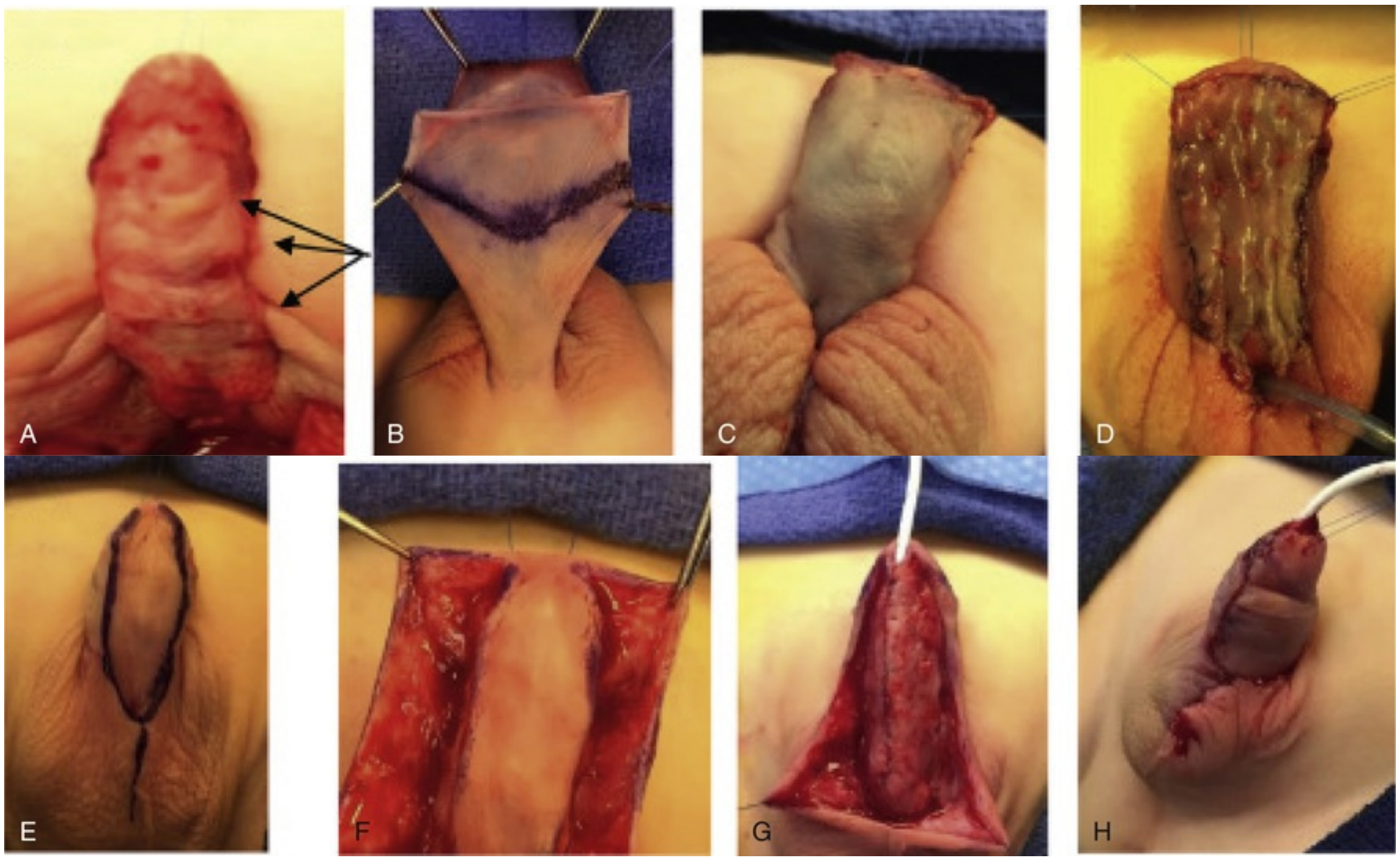

FIG. 45.25 The staged tubularized autograft (STAG) repair. (A) At the time of the first stage, one to three ventral corporotomies are made through the tunica albuginea, with the middle incision opposite the point of maximal curvature. (B) Preputial graft is marked and harvested. (C) Preputial graft is placed on the ventral aspect of the penile shaft and then quilted into place (D). The bottom panel displays the second stage of the repair. (E) Urethroplasty incisions are marked and extended along the midline of the scrotum. (F) Glans wings are developed. (G) Two-layer urethroplasty is performed and subsequently covered with a barrier layer with tunica vaginalis. (H) Appearance after closure. (From Snodgrass W: Staged tubularized autograft repair for primary proximal hypospadias. *J Urol* 198:680–686, 2017.)

Two-Stage Repair With Pedicle Flap

The Byars flap procedure uses redundant dorsal preputial skin, which is transposed ventrally with its vascular pedicle at the first procedure, as the scaffold to form the urethra (Fig. 45.26; Byars, 1951; Retik et al., 1994). The skin can be joined in the midline on the ventral aspect of the penis (Fig. 45.26F) or can be aligned as a single unit as used for the STAG repair (Fig. 45.25; Video 45.11). At the second stage the neourethra is closed by making a long U-shaped incision with glansplasty using a standard Thiersch-Duplay technique. **Some key technical components include creation of a watertight, two-layer closure and establishing a lumen of equal caliber throughout the length of the urethroplasty. Multiple layers of closure are required to ensure that the neourethra maintains adequate blood supply. In particular, establishing a supple dartos bed overlying the corporoplasty at the first stage will provide sufficient vascular flow to allow safe urethroplasty at the second stage** (Video 45.10).

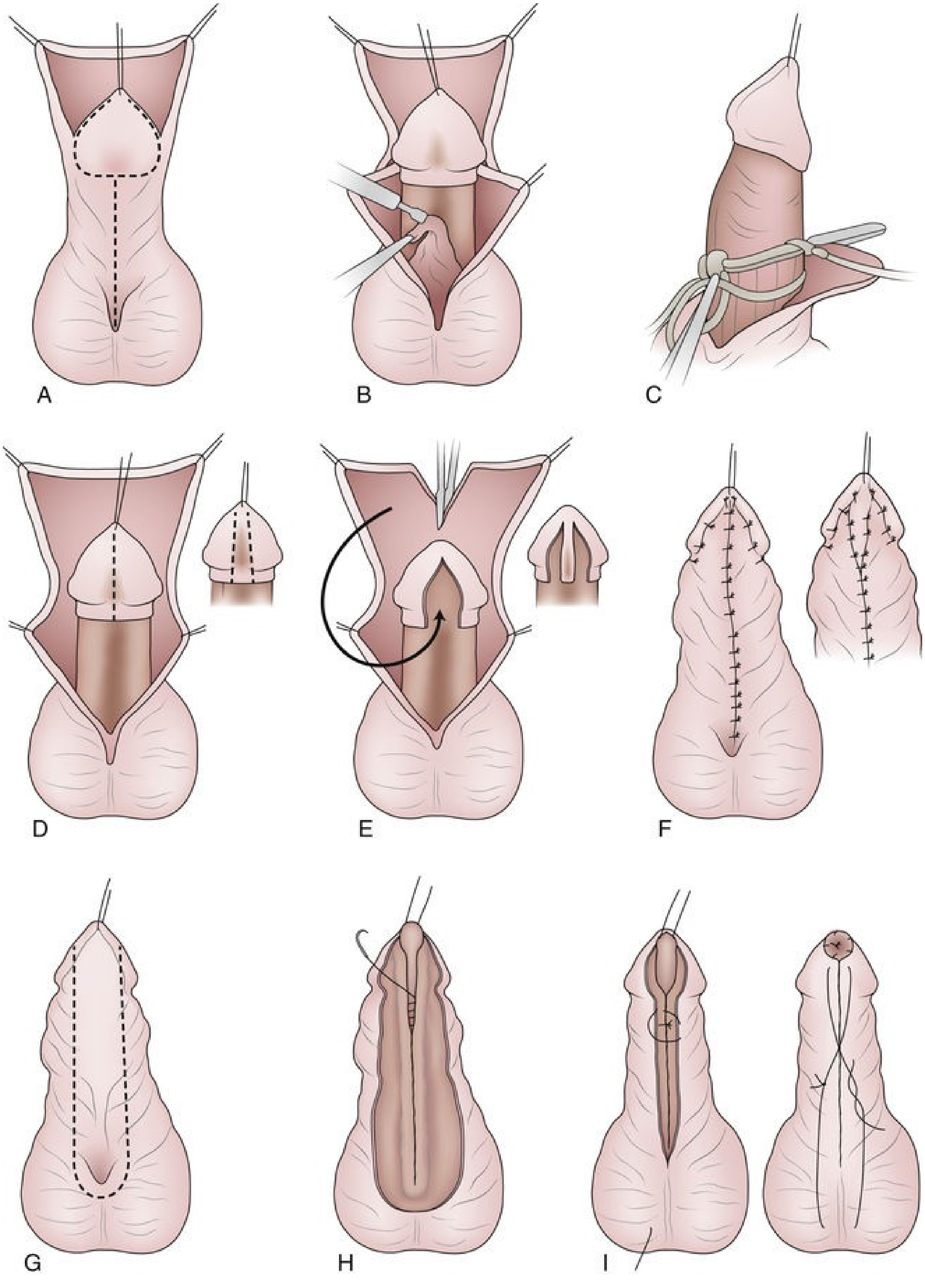

FIG. 45.26 Two-stage hypospadias repair with Byars flap. (A) First stage:

incisions are marked to allow degloving and mobilization of ventral skin. (B) The penis is degloved to the penoscrotal junction. Any dysplastic, or chordee, tissue is removed. (C) Artificial erection to assess penile curvature. For the purpose of the illustration the curvature has already been corrected. (D) Either midline or parallel lateral glans *(inset)* incision(s) is (are) made in the glans and glans wings developed. (E) Byars flaps are developed by incising the dorsal inner preputial skin in the midline to the mucosal collar, yielding a proper skin fit dorsally. (F) The redundant dorsal skin is transposed ventrally and secured in place. (G) Second stage: a U-shaped Thiersch-Duplay incision is made for tubularization. (H) Urethroplasty is performed, either in an interrupted or running fashion, using a two-layer technique. Additional barrier layer with dartos or tunica vaginalis can be performed. (I) Glans and shaft skin are approximated.

The third approach involves correction of the penile curvature with simultaneous closure of the distal urethra and glans at the first stage of the repair. An interposition flap or graft replaces the deficient urethra at the first-stage repair, and the patient is left with a proximal functional meatus after the first procedure. The second stage of the repair involves urethroplasty to close the proximal urethra, joining it with the previously closed distal urethra. One variant of this approach uses a TIP type of distal closure for the urethra and glans in the first stage (Cheng et al., 2003). Alternatively, the Ulaanbaatar repair creates a transverse island interposition tube, which is tunneled into the distal portion of the glans (Dewan et al., 2004; Jayanthi et al., 2017; Fig. 45.27).

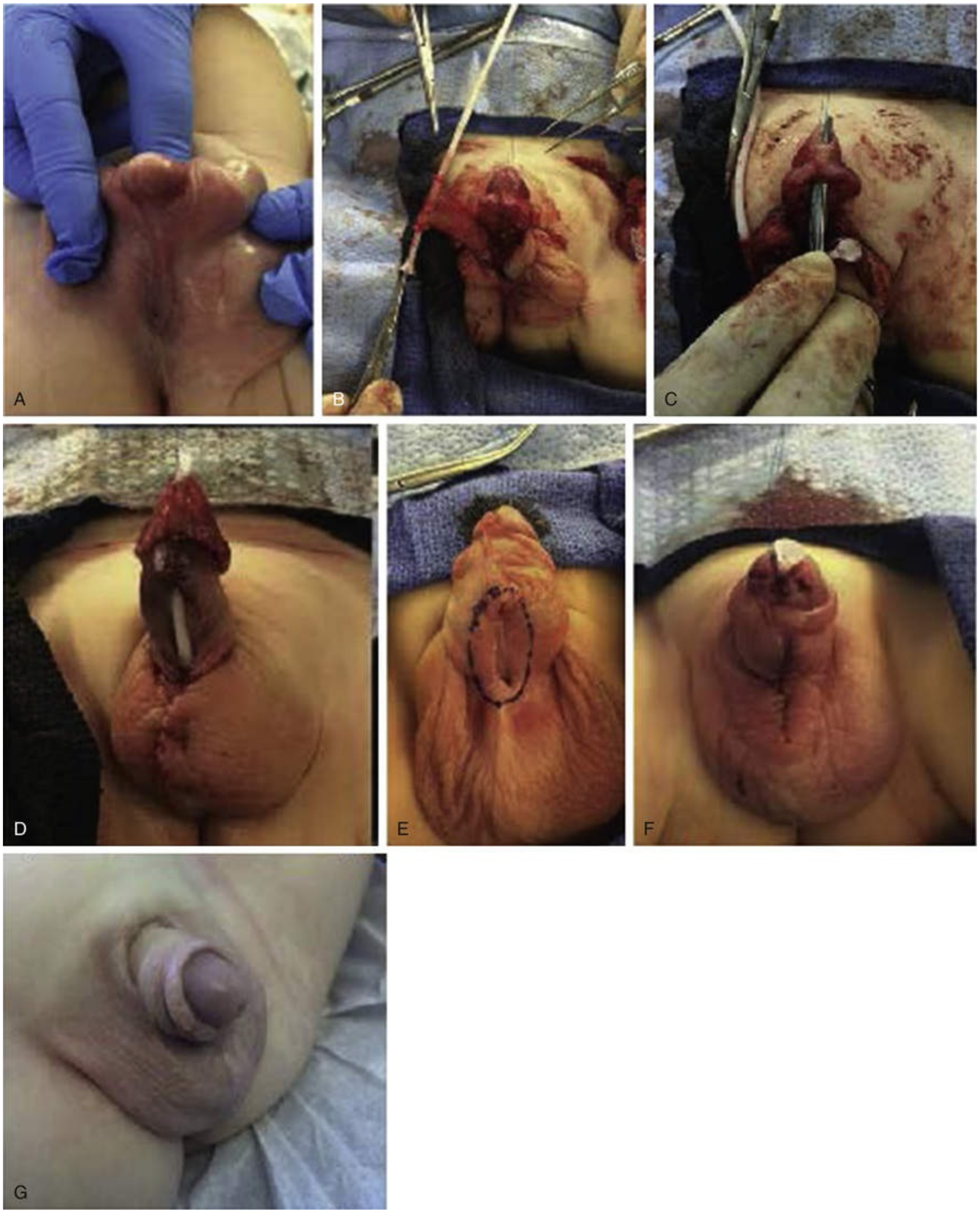

FIG. 45.27 The modified Ulaanbaatar staged hypospadias repair. (A) Initial appearance of the penis before incision. This patient had 46,XY ovotesticular disorder of sexual differentiation, severe ventral penile curvature, and a proximal hypospadias. Incisions are made and curvature is corrected with small intestinal submucosa during the first stage of the operation. (B) A transverse island tube Duckett tube is harvested for a

length that will replace the glanular and distal penile urethra. (C) The neourethra is either tunneled into the glans (if of sufficient size) or a formal glans incision with glansplasty is performed. (D) Byars flaps are rotated ventrally to replace the gap in the urethra between the proximal end of the Duckett tube and the distal extent of the native urethra. A drip stent is left in the closure. (E) After an interval 6 months, an elliptical incision is made around the urethral defect and tubularized. (F,G) The appearance after closure and 3 months postoperatively. (From Jayanthi VR: The modified Ulaanbaatar procedure. *J Pediatr Urol* 13(4): 353, 2017.)

Regardless of the approach, it is important to assess the quality of graft or flap take at the second stage of the repair. In the scenario in which there is skin deficiency or tethering precluding safe closure, an intermediary step of a dorsal inlay buccal mucosal graft may be used (Kolon and Gonzales, 2000) (▶Video 45.12)**. After graft take, the urethra is then reconstructed at a later date when all of the tissues are supple.** Alternatively, a dorsal buccal graft inlay and same-stage urethroplasty may be done at the time of the second-stage repair (Fig. 45.28).

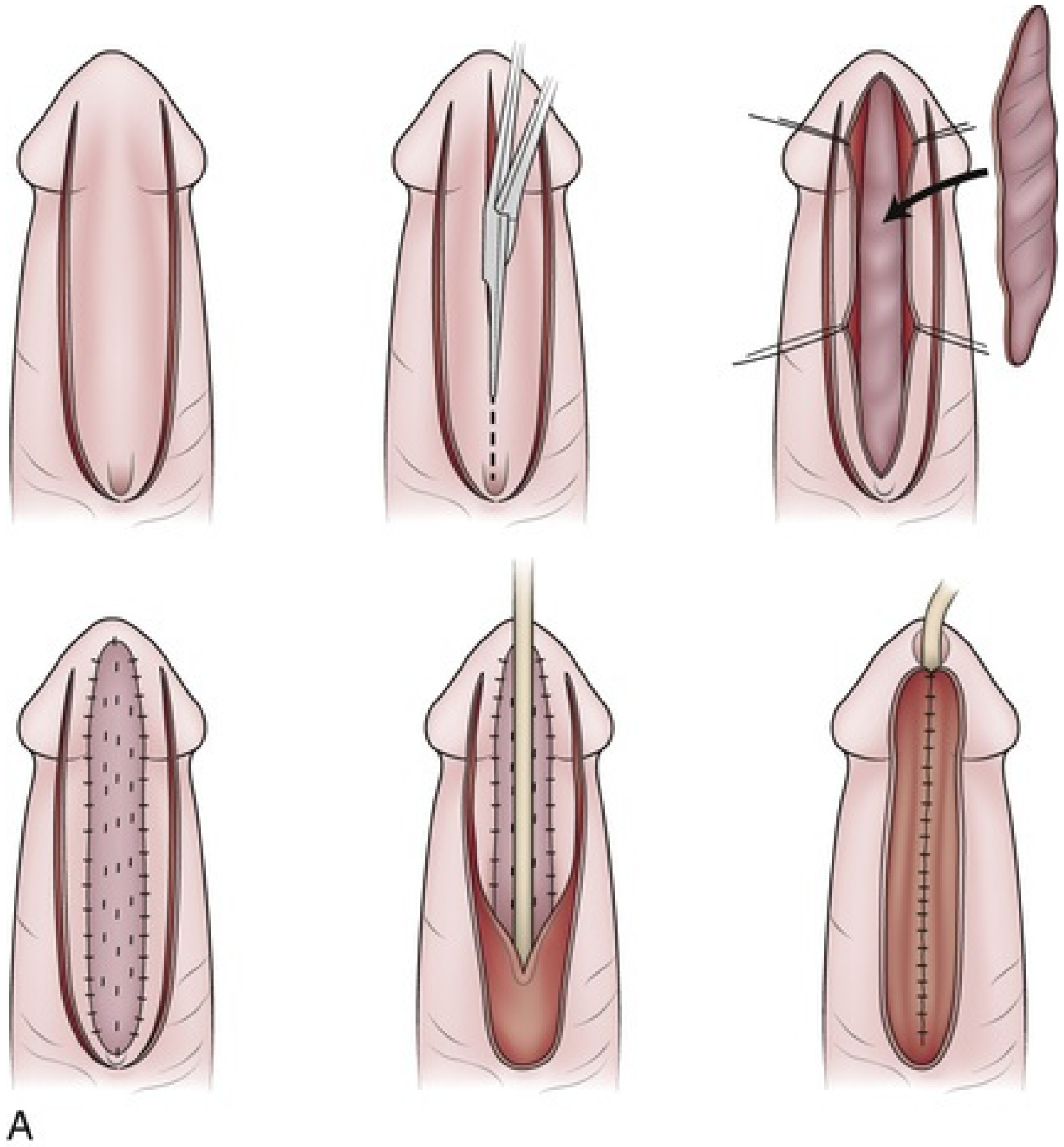

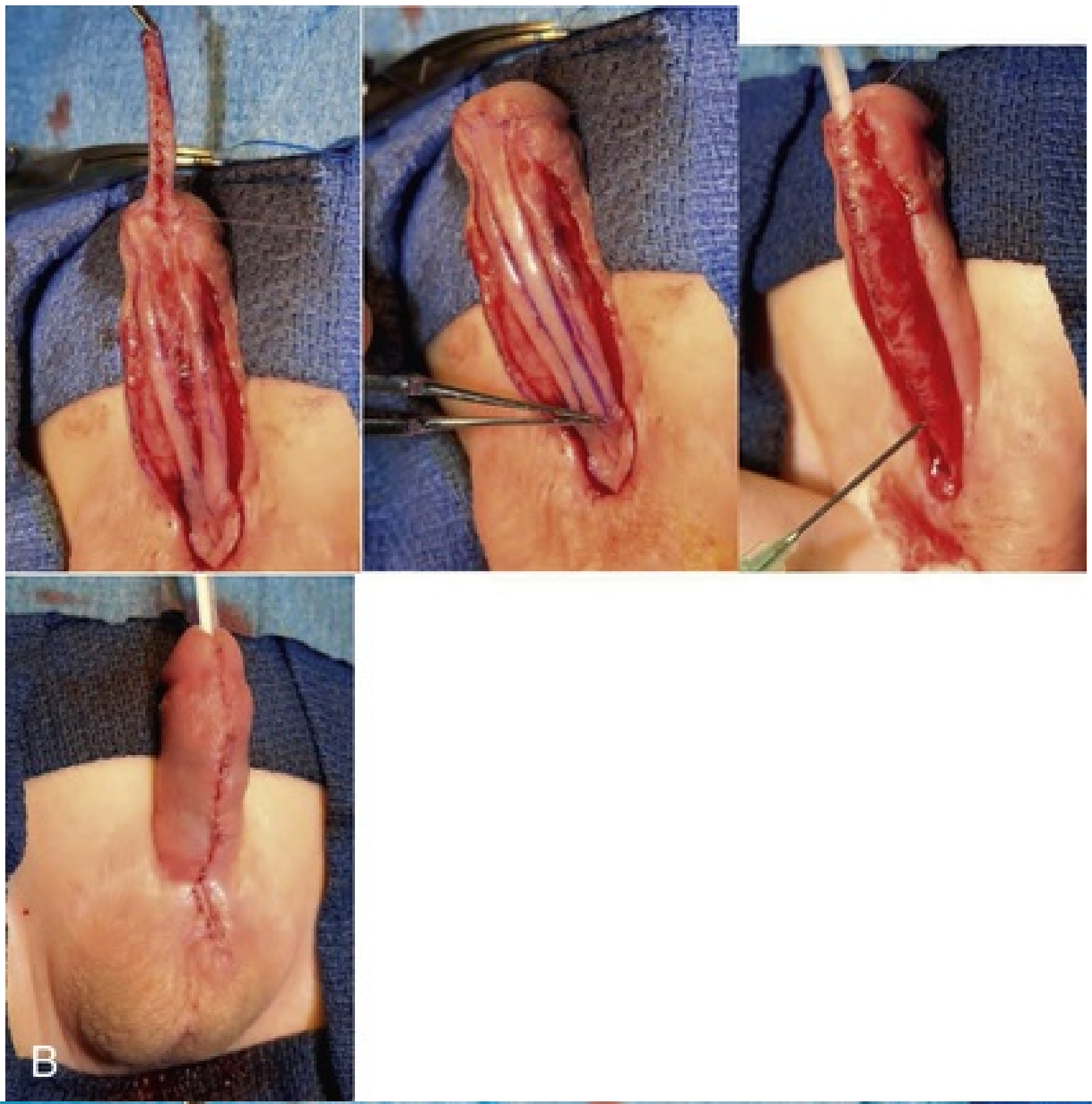
B

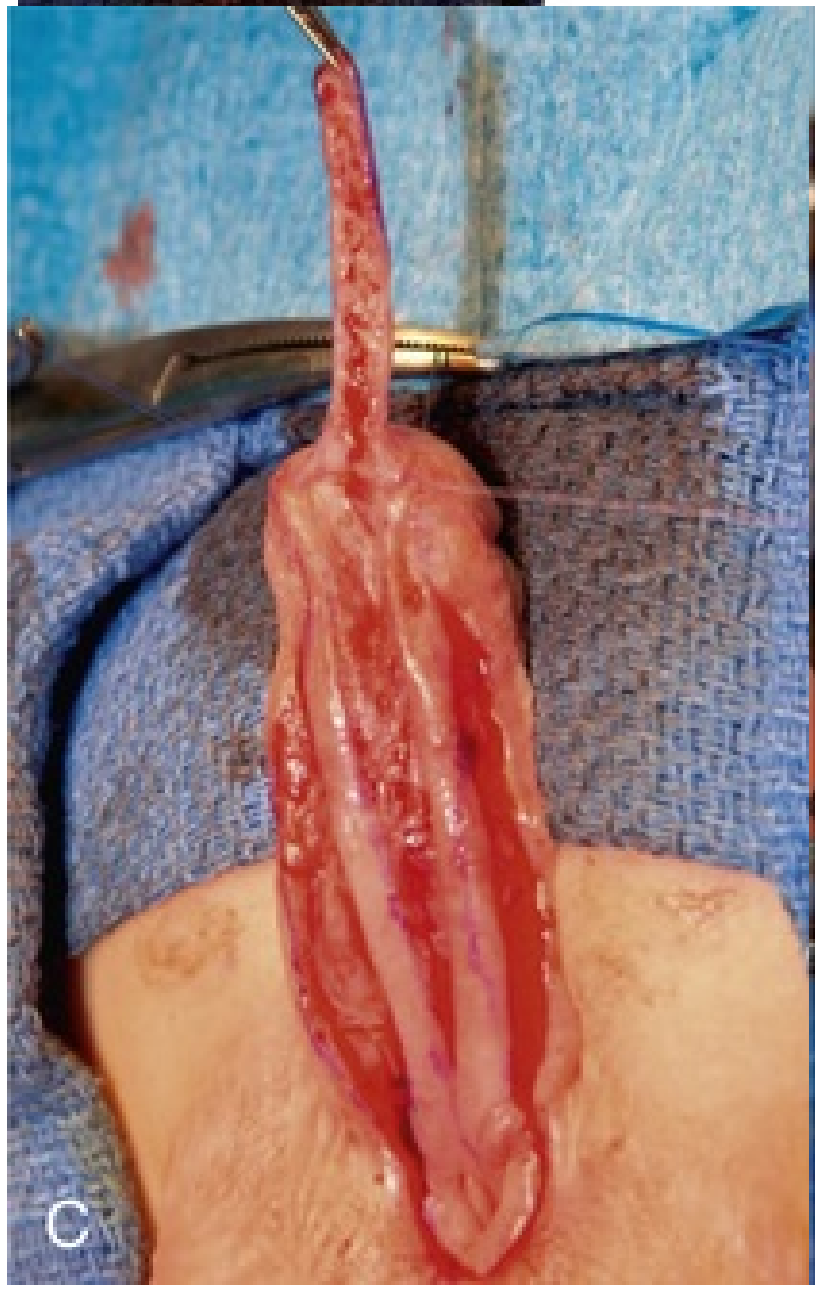
C

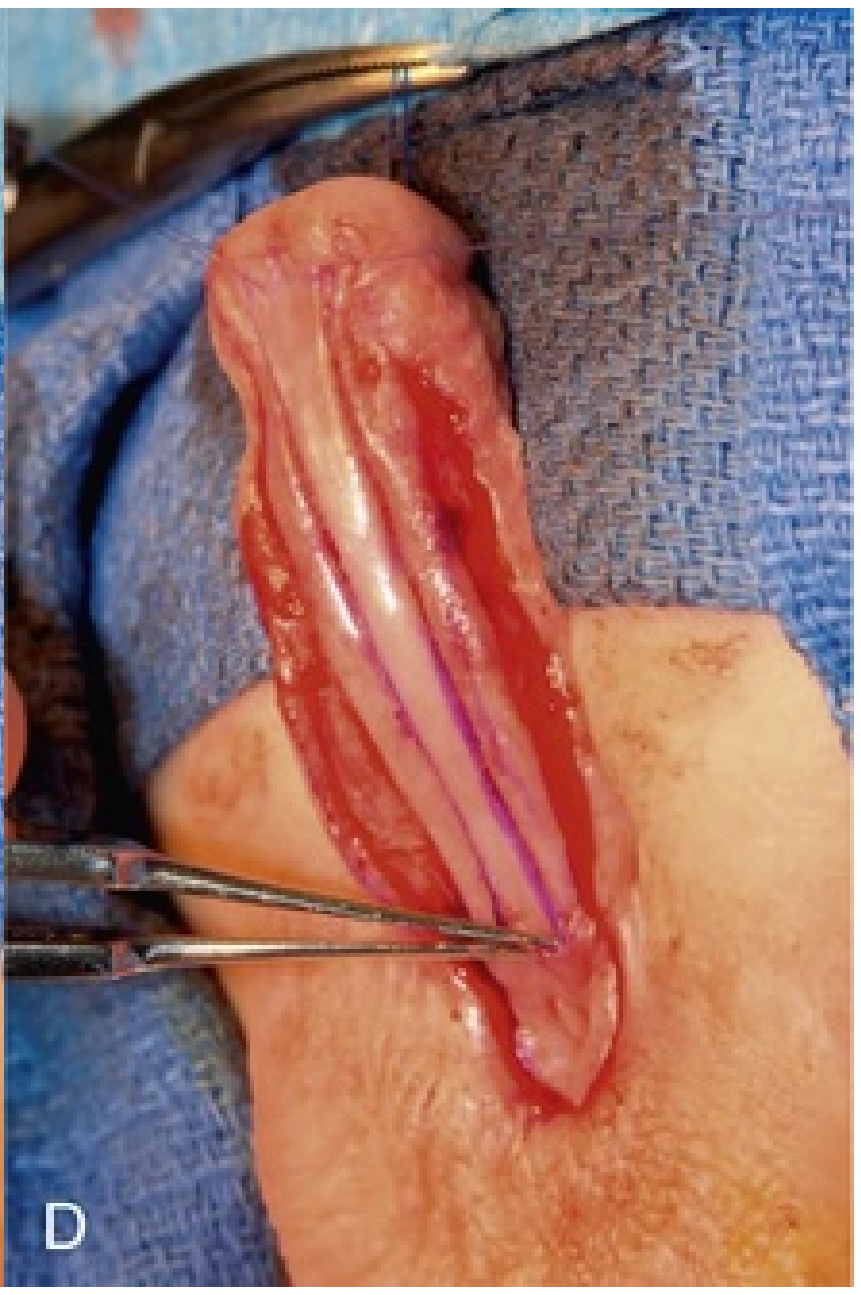
D

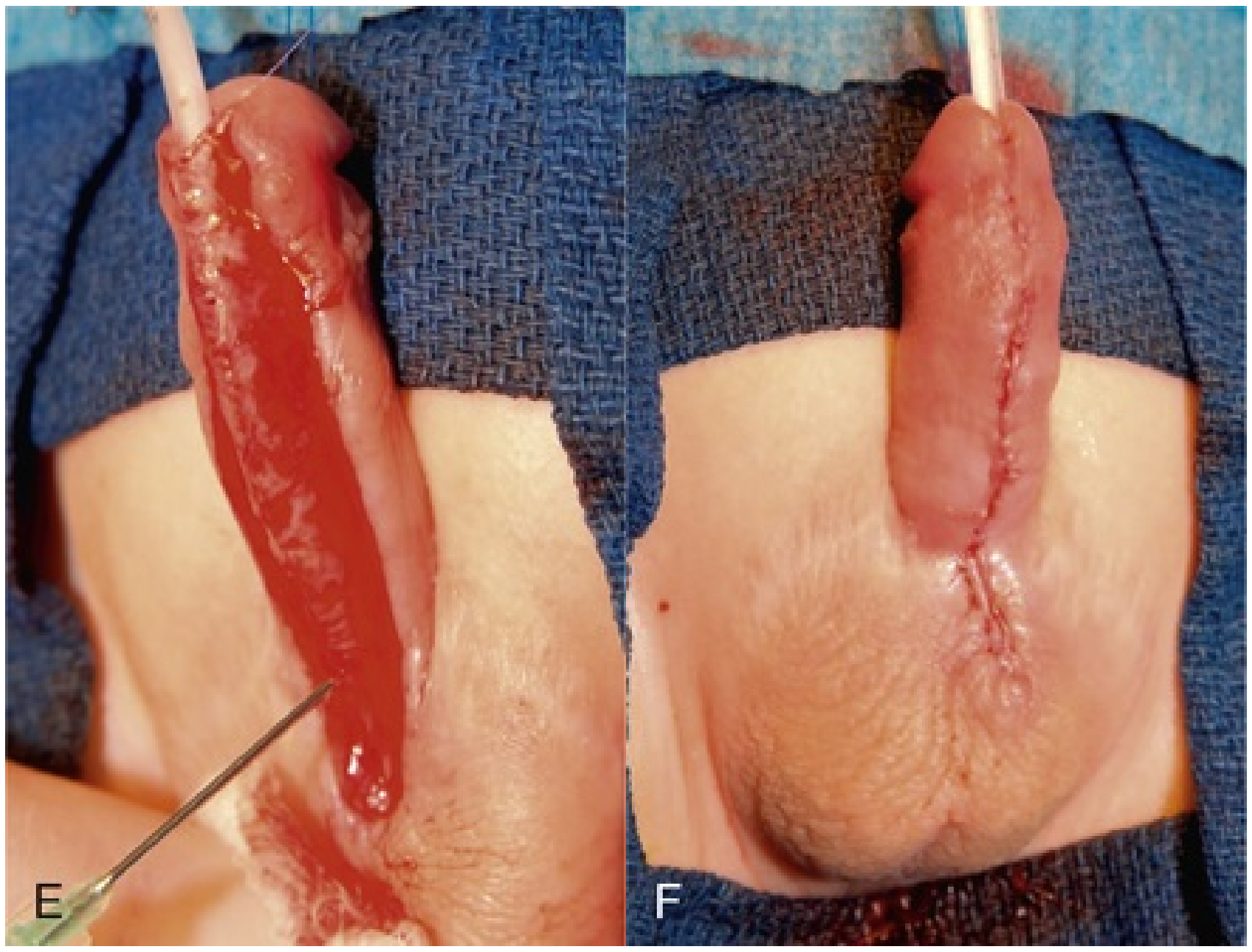

FIG. 45.28 Illustration (A) and live surgery pictures (A–F) depicting a single-stage buccal inlay graft. The penis is assessed and the urethral plate is found to be too narrow for primary tubularization. A U-shaped incision for a Thiersch-Duplay repair is made. A midline incision is made within the future urethral plate and a buccal graft is secured into the midline. Urethroplasty is then performed according to the width of the edges of the initial U-incision. Additional layers of closure are added as a barrier layer and the penis is closed. The final live surgical image represents the closed penis appearance. (Images courtesy Rafael Gosalbez, MD.)

Regardless of the approach to proximal hypospadias repair, it is important to confirm that penile curvature is corrected with repeat artificial erection at the time of the second operation before urethroplasty. If necessary a dorsal plication can be performed to correct minor recurrent curvature or a repeat corporal lengthening procedure if warranted. **A waiting period of at least 6 months should occur between procedures to ensure proper graft and/or flap incorporation and neovascularization.** We often allow 8 to 12 months between procedures, with interval exams to ensure satisfactory graft/flap incorporation, to monitor for recurrent curvature, and to determine if the ventral skin is supple enough to achieve satisfactory urethroplasty.

Comments on Proximal Hypospadias Repair

Analysis of the published literature reveals a recent focus on high complications for proximal hypospadias. Historical data likely

underestimate the complication rate by grouping mild and severe variants, artificially decreasing the understood complication rate for isolated proximal hypospadias (Long and Canning, 2016a). The contemporary rate for needing additional procedures after a planned two-stage repair ranges from 25% to 75%, and additional procedures put these boys at further risk for further complications. As a specialty, although we are effectively correcting 80% of boys who have distal hypospadias, we must direct more efforts to reduce complications in proximal hypospadias.

Why are proximal repairs harder? One reason may be the longer urethroplasty required to repair a proximal hypospadias. This increased length is more technically demanding, requiring precise technique to generate a long urethra of equal caliber throughout its course. One unanswered question is whether the neourethra, from whatever tissue is chosen for reconstruction, is inherently narrowed as a result of reconstruction, limiting its ability for gentle yet repeated expansion to propel the urine bolus as a normal urethra would.

A longer neourethra may more dramatically demonstrate the physics behind laminar flow and fluid dynamics. **According to Poiseuille's law the resistance to flow in a cylinder is proportional to the length of the tube but is inversely proportional to the radius to the fourth power** (Fig. 45.29)**. In plain terms the pressure required to push urine through the lumen of the urethra directly increases with the length of the tube. At the same time minor variations to the radius, either increasing or decreasing in size, will have a much greater impact upon intraluminal pressure. The longer the tube, the greater the risk for stricture. The failure of the reconstructed urethra to expand with voiding increases resistance to urine flow, ultimately resulting in fistula and/or urethral diverticulum formation** (Braga et al., 2007a). In addition, the glans is relatively nondistensible because of densely packed spongiosum tissue. Hence even in situations in which the neourethral lumen is exactly the same caliber throughout, diverticulum formation is a significant risk because of a fixed distal urethra. The penile urethra may distend nicely, but when the urine reaches the glans, poor distention increases turbulent flow, resulting in increased pressure of the proximal urethra and diverticulum development.

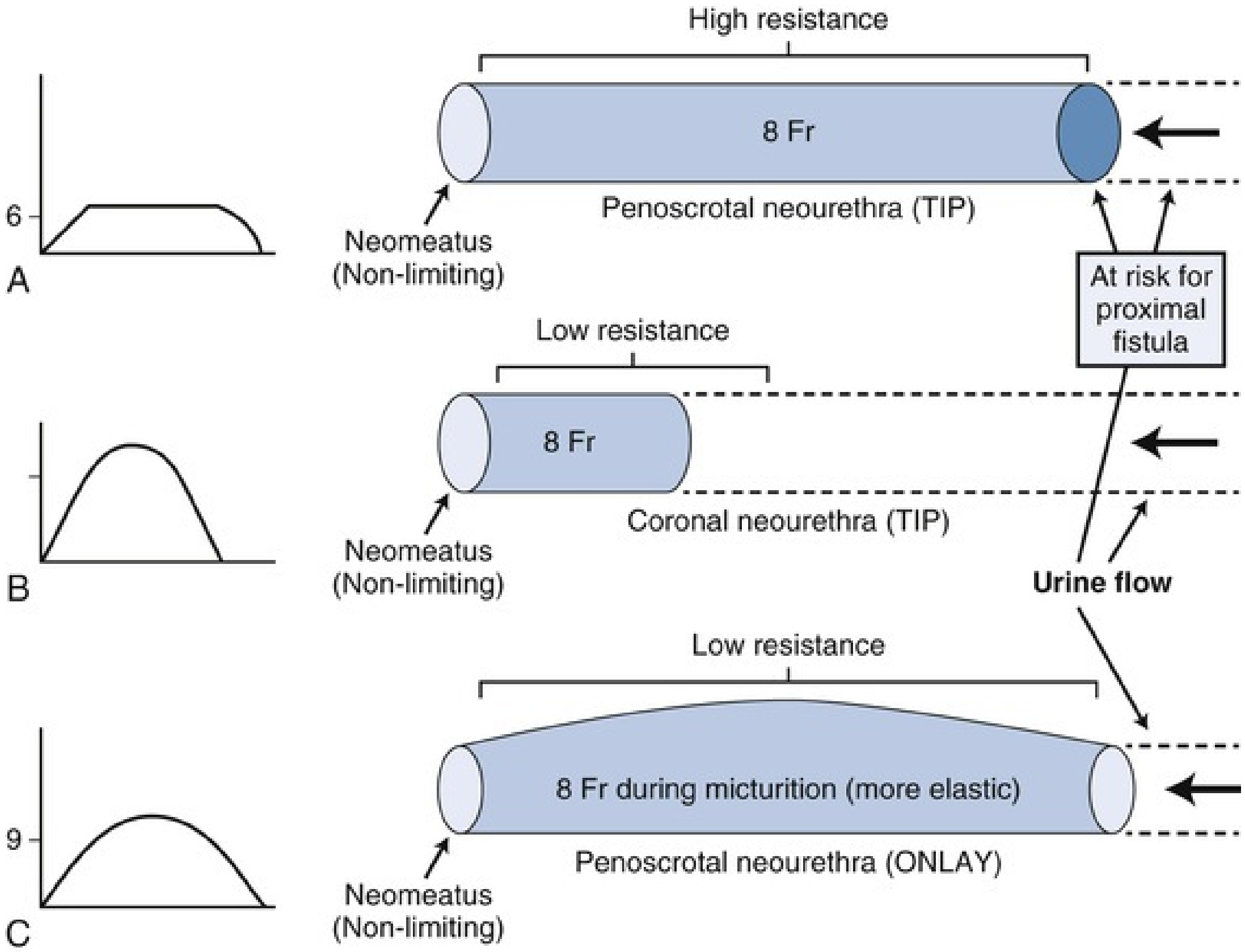
High resistance
8 Fr
Penoscrotal neourethra (TIP)
6
A
Neomeatus
(Non-limiting)
At risk for proximal fistula
Low resistance
8 Fr
Coronal neourethra (TIP)
B
Neomeatus
(Non-limiting)
Urine flow
Low resistance
8 Fr during micturition (more elastic)
Penoscrotal neourethra (ONLAY)
9
C
Neomeatus
(Non-limiting)

FIG. 45.29 Comparison of the urethral resistance and flow patterns for the tubularized incised plate (TIP) repair (A,B) vs. onlay procedure. To the left of the illustration is a corresponding uroflow. All three diagrams assume a patent urethral meatus. (B) The short neourethral length provides a small amount of resistance over a narrow distance, resulting in a relatively normal flow pattern. This is in contrast to (A), where the long TIP repair provides a fixed amount of resistance across a much longer distance. This results in a prolonged void with a dampened velocity. (C) The increased elasticity of the tissue used in the onlay procedure decreases the resistance of the neourethra, allowing a more normal voiding pattern. The fundamental differences between these two repairs are due to the more rigid urethra created with the TIP repair versus the more pliable tissue used in an onlay procedure. (From Braga LP, Pippi Salle JL, Lorenzo AJ, et al: Comparative analysis of TIP versus onlay island flap urethroplasty for penoscrotal hypospadias. *J Urol* 178:1451–1457, 2007.)

It is also possible that the degree of tissue dysplasia, severity of penile curvature, and relative lack of skin may compromise wound healing, compromise vascular flow, or prevent equal tissue growth with time as the boy ages. Given the relatively small number of patients with proximal hypospadias across the world and the increasing number of pediatric urologists performing these procedures, the number of surgeries performed by most surgeons is decreasing. Collaboration is going to be vital for our field to increase patient numbers to provide a measurable advancement in the care of boys with these complex challenges.

Key Points

- Proximal hypospadias has a higher complication rate than distal repairs and represents a unique challenge to the urologist.
- The reasoning behind the current trend toward a staged repair for severe hypospadias, in which the curvature is corrected at the first stage and urethroplasty is performed at the second stage, lies with the methods used to correct curvature and while providing supple ventral shaft tissue for tubularization. Concerns for a higher risk of urethroplasty failure when combined with a corporal grafting procedure in a single-stage repair have led to this paradigm shift.

Postoperative Management

Proper postoperative care is essential. Even a well-planned and technically excellent surgical repair can be compromised with careless postoperative management. Options for methods of urinary diversion, dressings, and perioperative medication administration have varied greatly throughout the history of hypospadias management. Unfortunately, quality data proving a direct influence on outcomes are lacking. During the first 48 hours after surgery, urinary diversion and a compressive dressing are employed by the surgeon. The dressing is designed to minimize stress on the freshly closed neourethra, tamponade bleeding, and minimize swelling. **For complicated repairs, urinary diversion with a soft, pliable urethral stent decreases rates of meatal stenosis and urethrocutaneous fistula development** (Daher et al., 2015; Hakim et al., 1996). In our practice a compressive dressing is left for a 72-hour period, after which petroleum jelly is applied to facilitate healing. A suprapubic tube may be placed, particularly in older children or in redo cases, to maximize urinary diversion.

Urinary diversion is provided for a period of 3 to 21 days and varies according to the complexity of the repair, the length of the urethroplasty, and surgeon preference. In one study, prolonged stent duration has been shown to decrease complication rates (Daher et al., 2015). This finding is not universally accepted. Stent duration must be weighed against patient discomfort and the risk for UTI, which increases with each day of diversion. Some surgeons have performed distal repairs of a short urethroplasty length without a urethral stent without any change in outcomes (Steckler and Zaontz, 1997). Antibiotic prophylaxis is frequently administered, as previously discussed. **Postoperatively, bladder spasm is common and can result in high-pressure voiding around stents and catheters, placing undue stress on the urethroplasty. This can be alleviated with the addition of oxybutynin until stent removal. Longer and stiffer stents that extend well beyond the neomeatus may place undue pressure on the ventral urethral repair, increasing the risk for glanular dehiscence.** A Foley catheter, if placed, must be secured to the anterior abdominal wall in the midline to prevent glans separation. **Unfortunately, these catheters frequently end up with undue lateral or ventral tension from the securing tape releasing prematurely.** Therefore many years ago we moved away from Foley catheters because of the high glans dehiscence rate.

Most surgeons administer acetaminophen for postoperative pain control, whereas close to half of surveyed urologists include nonsteroidal anti-inflammatory drugs (NSAIDs) (Morrison et al., 2014). **Ibuprofen appears safe even in the immediate postoperative period despite concerns for bleeding.** A study by Schroder et al. (2018) suggests that standing doses of acetaminophen and ibuprofen can maximize pain control and minimize the need for supplemental narcotic administration. Around-the-clock dosing can be tapered within 48 to 72 hours of the procedure, after which the surgical pain experienced decreases (Schroder et al., 2018; Wilson et al., 2017).

Complications of Hypospadias Repair

When Duckett discussed hypospadiology, he highlighted the blend of art and science that produces a successful repair, describing it as a humbling process, a time- and energy-consuming task that confounds the surgeon. Pediatric urologists with experience understand this (Duckett, 1995). **Despite continued technical modifications and advances, successful penile reconstruction for boys with hypospadias remains a great challenge. A combination of factors threatens to compromise even the most meticulous repair. The structures are delicate. The healing process is dependent upon fragile neovascularization. Postoperative edema, the risk of infection, and the**

inherent variability in the healing process add to the risk. Anyone who prepares to treat boys with hypospadias must have a broad and deep understanding of the potential risks and be committed to careful preoperative study, meticulous surgical management, and zealous postoperative care.

Today there is a lack of standardized definitions for hypospadias complications, leading to variability in reporting and inconsistency in the literature. Through efforts at multiple centers across the world this is changing, and some standard definitions are represented in Table 45.1.

TABLE 45.1

Complications and Definitions

URETHROPLASTY COMPLICATIONS	SKIN COMPLICATIONS
Fistula	Skin surplus or deficiency with penile tethering
Glans dehiscence	Penile torsion >30 degrees
Meatal stenosis	Preputial fistula
Urethral stricture	Preputial dehiscence
Urethral diverticulum	Postpubertal phimosis
Recurrent curvature >30 degrees	Lichen sclerosus
STANDARDIZED DEFINITIONS	
Urethroplasty Complications: Primary Outcome • Fistula: urethral leak anywhere below the meatus • Glans dehiscence: complete separation of the glans wings resulting in a coronal or more proximal meatus, or complete separation of glans wings with an intervening bridge of skin; objectively: glans fusion measurement <2 mm • Meatal stenosis: obstructive symptoms (straining, prolonged voiding, urinary tract infection, and/or retention) *and* meatal calibration <8 Fr before puberty or <12 Fr after puberty • Urethral stricture: obstructive voiding symptoms (stranguria, prolonged voiding, urinary tract infection, and/or retention) with visual near closure of the urethra on urethroscopy • Urethral diverticulum: visual segmental sacculation of the urethra during voiding • Recurrent curvature: residual ventral, dorsal, or lateral curvature >30 degrees demonstrated on erection (spontaneous or artificial)	
Skin Complications: Secondary Outcome • Skin surplus: Excess skin ≥2 cm in a circumcised patient when the suprapubic fat pad is retracted	

- Penile torsion: angle between the normal and true vertical glanular plane >30 degrees from midline (specify clockwise or counterclockwise)
- Nonretractable reconstructed preputium: cannot visualize meatus (in the absence of lichen sclerosus), acceptable before puberty, abnormal after puberty
- Preputial dehiscence after preputial reconstruction: defect in the preputial skin recreating an incomplete prepuce
- Preputial fistula after preputial reconstruction: fistula-like defect in the preputial skin that has no contact with the urethral lumen
- Lichen sclerosus: white cicatrix, preferably with pathology diagnosis

Courtesy Warren Snodgrass, MD.

Urethrocutaneous Fistula

Urethrocutaneous fistula is the most common reported surgical complication after hypospadias repair, with an incidence just under 10% in short-term follow-up (el-Kassaby et al., 2008; Grosos et al., 2014; Pfistermuller et al., 2015; Snodgrass and Bush, 2011; Fig. 45.30). A fistula can develop anywhere along the length of the urethroplasty, although most often at the site of the original urethral meatus or at the coronal margin. They range from a pinpoint opening with a small urine drip to a large defect through which all urine flows. The development of a fistula is multifactorial, with ischemia, edema, infection, and/or hematoma contributing to improper healing of the neourethra. Distal urethral obstruction from meatal stenosis or urethral stricture results in high urethral pressures and turbulent flow during voiding. This places additional stress on the suture line and can decrease the perfusion of the tissues during wound healing. Technical factors such as overlapping of suture lines, inadequate inversion of the epithelium, or use of poorly absorbable suture material may also contribute (Eardley and Whitaker, 1992). All of these factors become even more evident as the severity of the hypospadias worsens, further increasing the complication rate (Arlen et al., 2015; Bush et al., 2015; Spinoit et al., 2015).

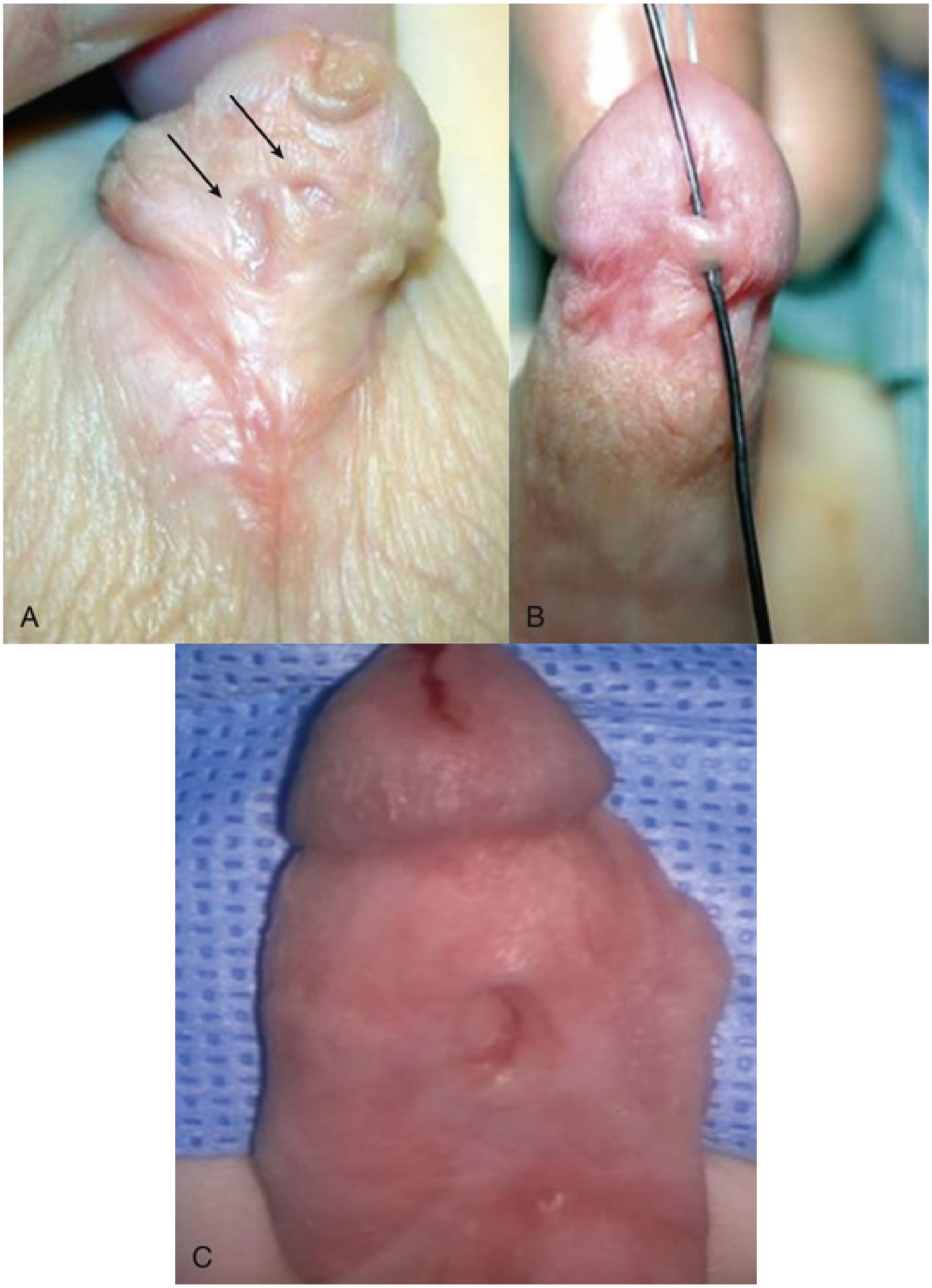

FIG. 45.30 Examples of various urethrocutaneous fistulas, each depicted with *black arrows.* (A) Two fistulas are noted. (B) A lacrimal duct probe lies within the fistulous tract. (C) A midshaft fistula is present.

Management of urethral fistulae depends on the number, size, location, and the presence of additional complications. Multiple urine streams may be noticed by the parent if the child voids during a diaper change, and most are noticed in the first 2 years after surgical repair (Grosos et al., 2014; Spinoit et al., 2013; Wood et al., 2008). Fistula diagnosis may be delayed until toilet training, when voiding is more likely to be observed.

Small fistulas noted in the immediate postoperative period without concomitant inflammation or meatal stenosis rarely close on their own (Chandrasekharam, 2016). The majority of urethrocutaneous fistulas require surgical repair, which is delayed until at least 6 to 12 months after the initial hypospadias repair to allow wound healing and tissue softening.

If a fistula is suspected, a careful evaluation in the operating room may include calibration with a bougie à boule to assess the patency of the urethra and to identify irregularity in the urethral caliber, which commonly accompanies the development of a fistula. If calibration suggests irregularity in the urethra, urethroscopy should be performed. As a further test, a urethral catheter or a venocath may be inserted and saline injected into the urethra with the proximal and distal lumen compressed, performing a “stress test” to identify concealed fistula tracts.

Small-caliber fistulas on the penile shaft proximal to the coronal margin can be closed primarily, taking care to excise the epithelialized tract to the urethra (Santangelo et al., 2003; Fig. 45.31; ▶Video 45.13). The urothelial edges can be closed in a subepithelial fashion. Multiple overlapping layers are placed to prevent recurrence. Larger fistulas, or those that are present in areas where the tissues have thinned, require coverage with a trap-door or island flap of penile shaft skin. Good results depend on a second layer or a vascularized flap coverage, secured in an offset fashion (Cimador et al., 2004; Elbakry et al., 1998; Santangelo et al., 2003).

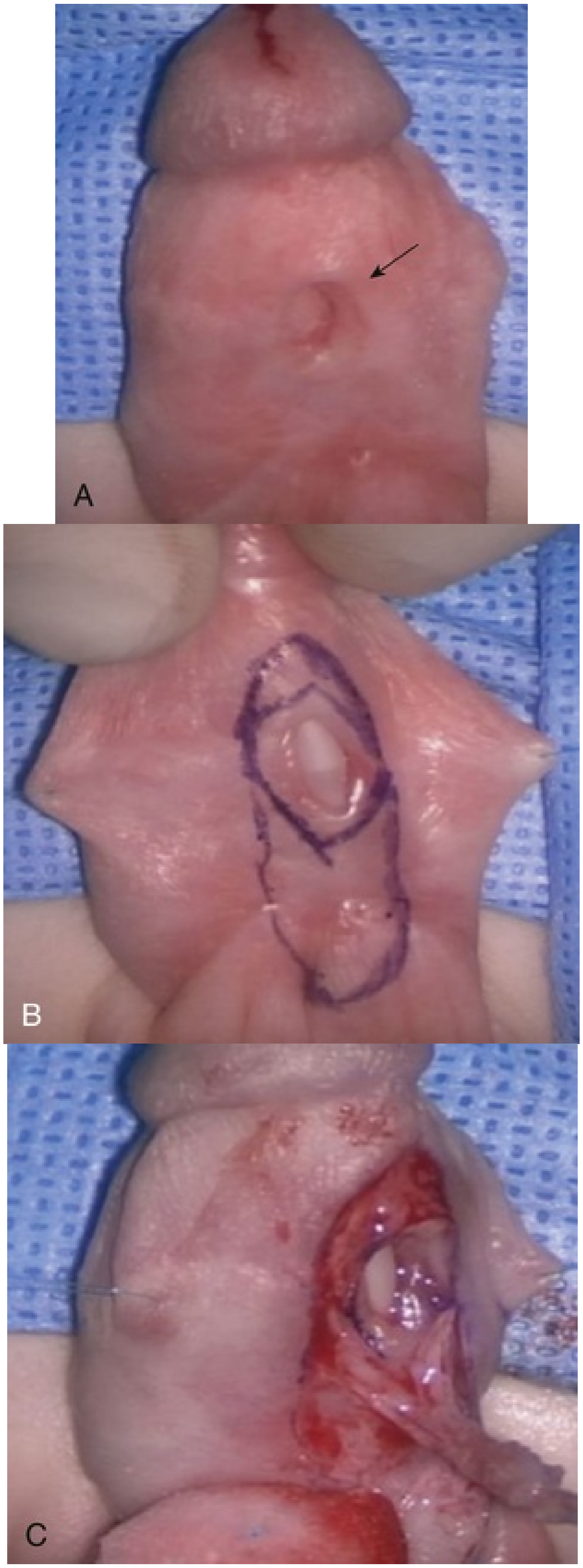
A
B
C

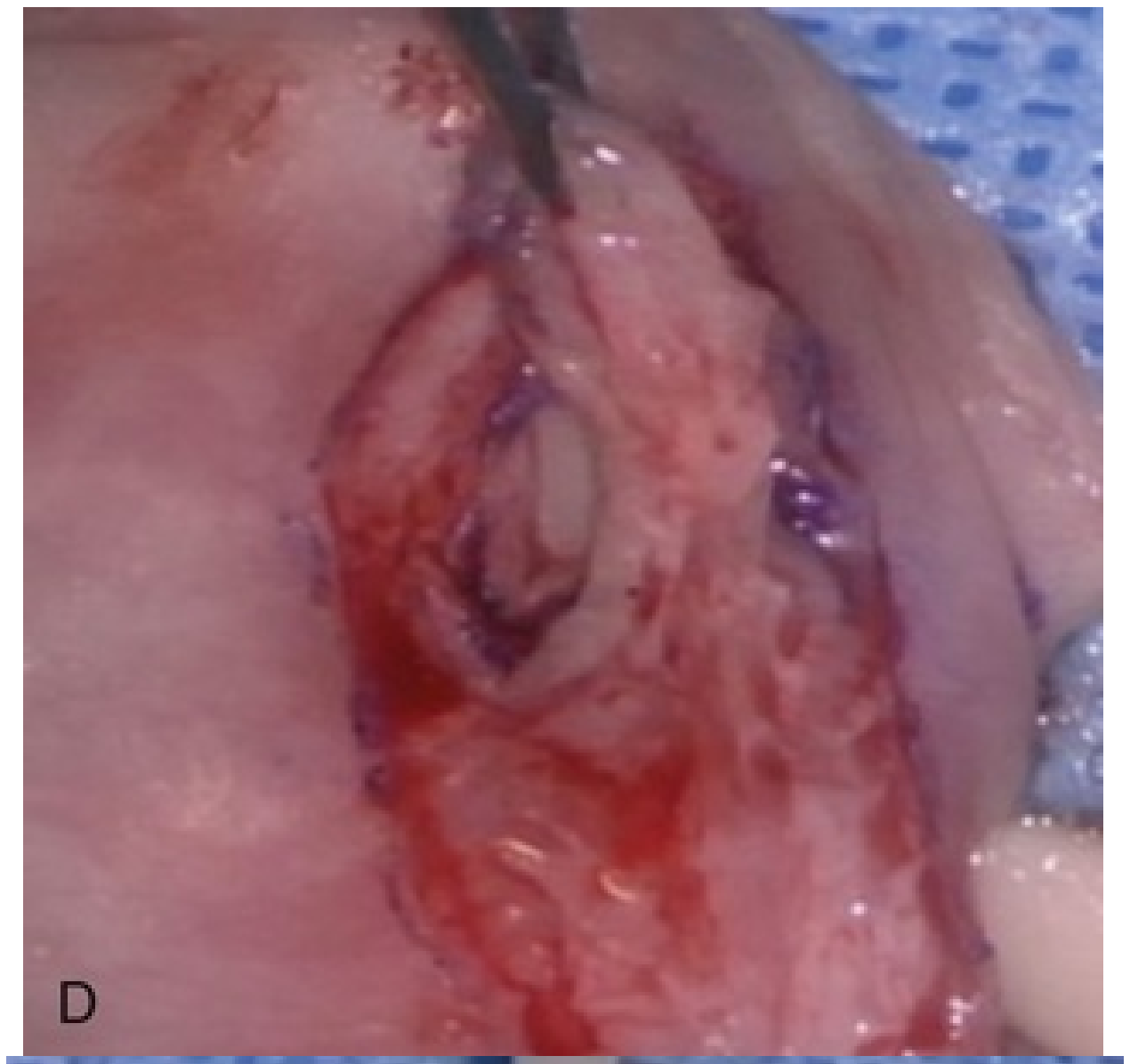
D

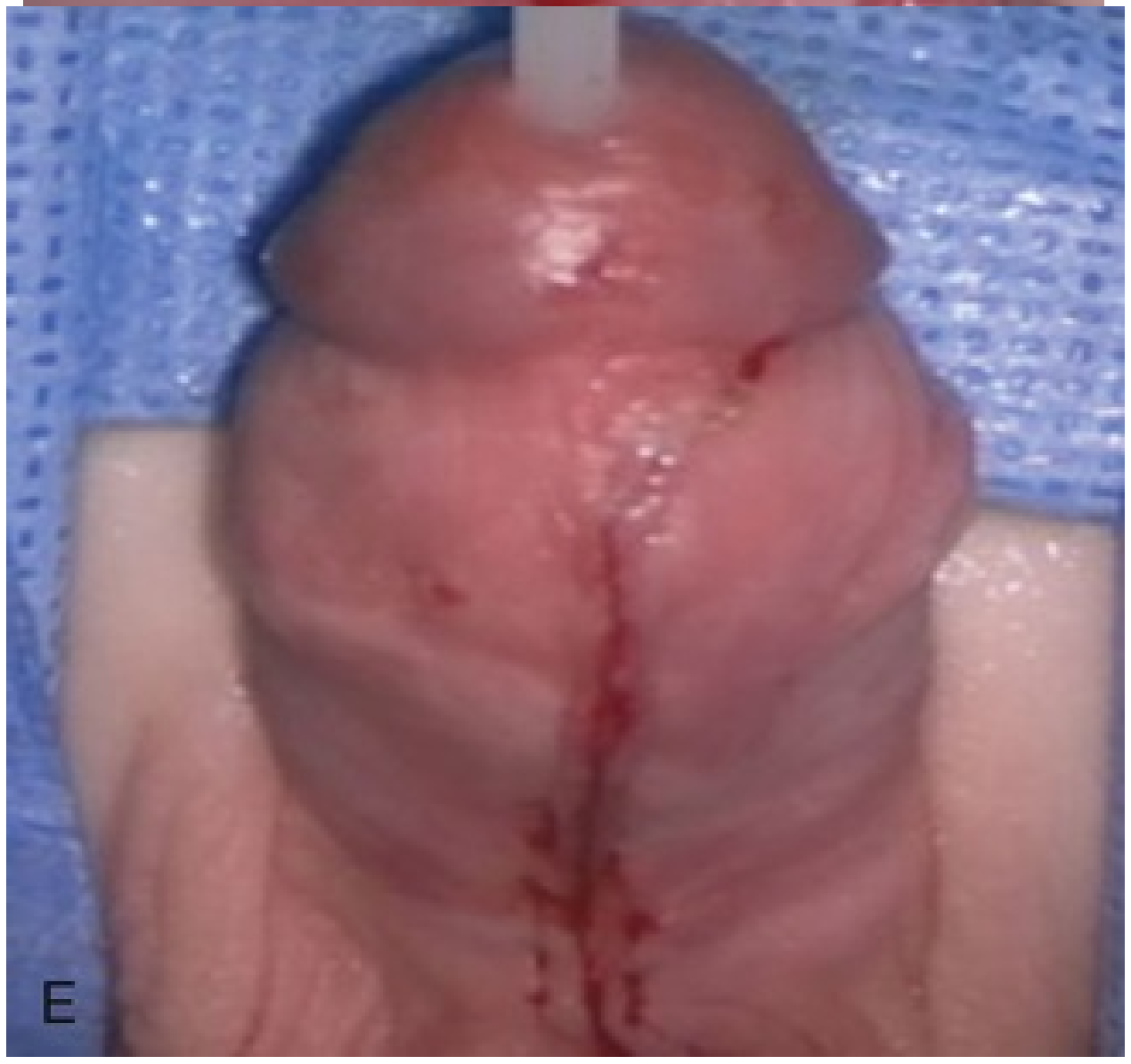
E

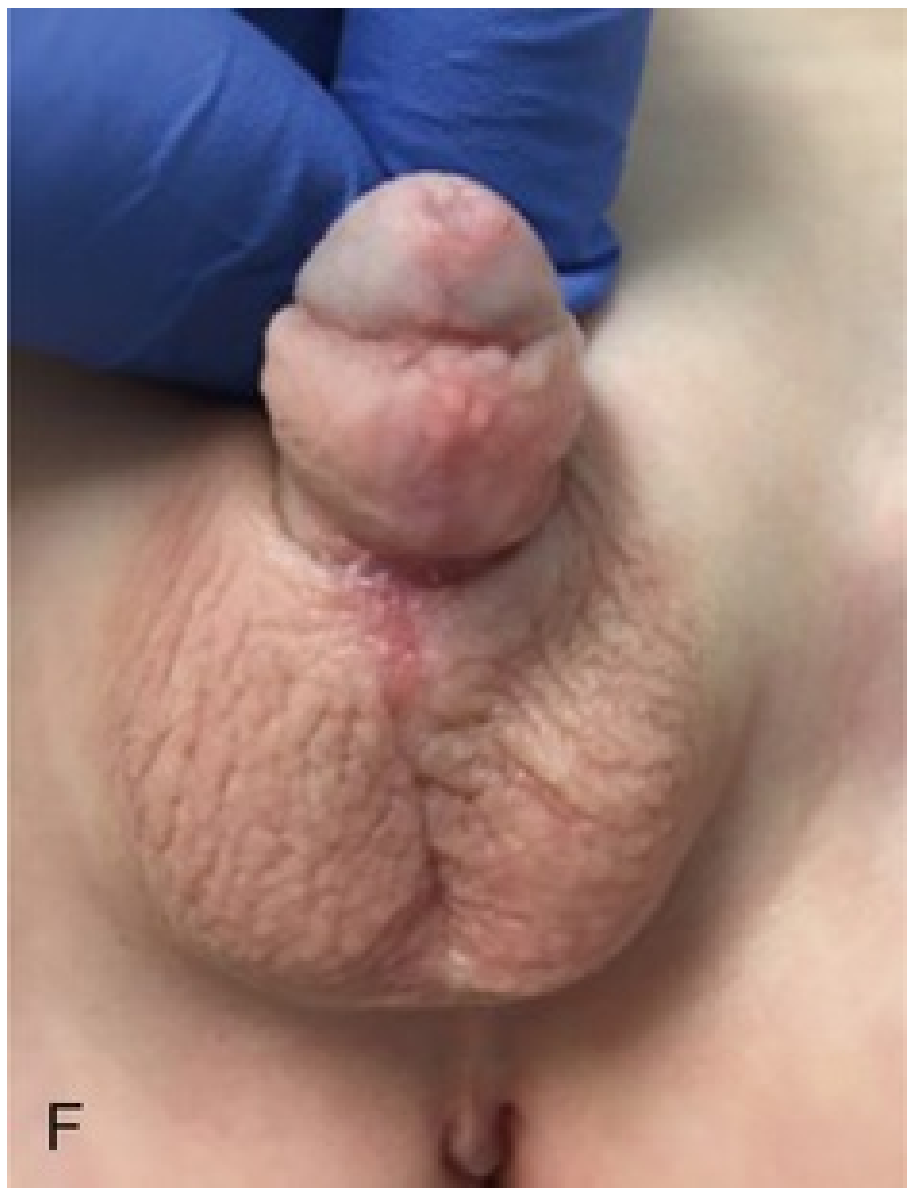

FIG. 45.31 Repair of urethrocutaneous fistula after a prior two-stage proximal hypospadias repair. (A) Distal shaft urethrocutaneous fistula *(arrow)* with an intact glans and patent meatus. The distance from the glans is a key component in the decision making for fistula management. (B) Incision is marked, first around the fistula tract and then secondarily to raise flaps for barrier coverage. (C) Incisions are made and the fistulous tract is isolated. The surrounding skin is undermined to sufficiently mobilize tissue for skin closure as well as barrier layers. (D) Fistula tract is closed in a primary fashion and dartos layers are approximated over the repair. (E) Skin is closed. (F) Six-month postoperative picture with no evidence of recurrence.

Fistulas at the coronal margin are more challenging. Although it is tempting to perform excision and primary closure, a fistula at this site can suggest a distal narrowing or poor local tissue that requires revision of the urethroplasty to achieve a satisfactory repair (●Video 45.14).

Despite a well-performed repair, fistulas recur about 20% of the time (Snyder et al., 2005a; Sunay et al., 2007). This recurrence rate may be lessened with interposition of multiple well-vascularized nonepithelialized layers between the urethral closure and the skin. Redundant dartos tissue, if present, or a scrotal-based tunica vaginalis flap may also be used (Fahmy et al., 2016; Routh et al., 2008; Shankar et al., 2002). Scrotal dartos tissue has been used in a similar fashion (Churchill et al., 1996). A de-epithelialized flap may also be used with success (Santangelo et al., 2003). In cases in which tissue is scarce, supplemental coverage can be taken from adjacent de-epithelialized shaft skin with a subsequent Cecil modification, reviewed in more detail later in the chapter (Cecil, 1946; Ehle et al., 2001; Weiss et al., 2018). There is no need to divert the urine for simple repairs, but for more complex redo repairs, we routinely divert the urine for 7 to 14 days (Holland et al., 2008; Redman, 1993; Santangelo et al., 2003).

Glans Dehiscence

Glans dehiscence is due to a combination of factors, including undue catheter tension on the repair as noted earlier, poor technique, tension on the glans closure, and vascular compromise (Fig. 45.32). If this occurs, the meatus typically regresses back to the corona or subcoronal location. **Reoperation may or may not be necessary and should be driven by the presence or absence of voiding symptoms. If repair is indicated, an interposition inlay graft may be required as an intermediary step for a staged repair to avoid tension on the glans closure** (▶Video 45.15).

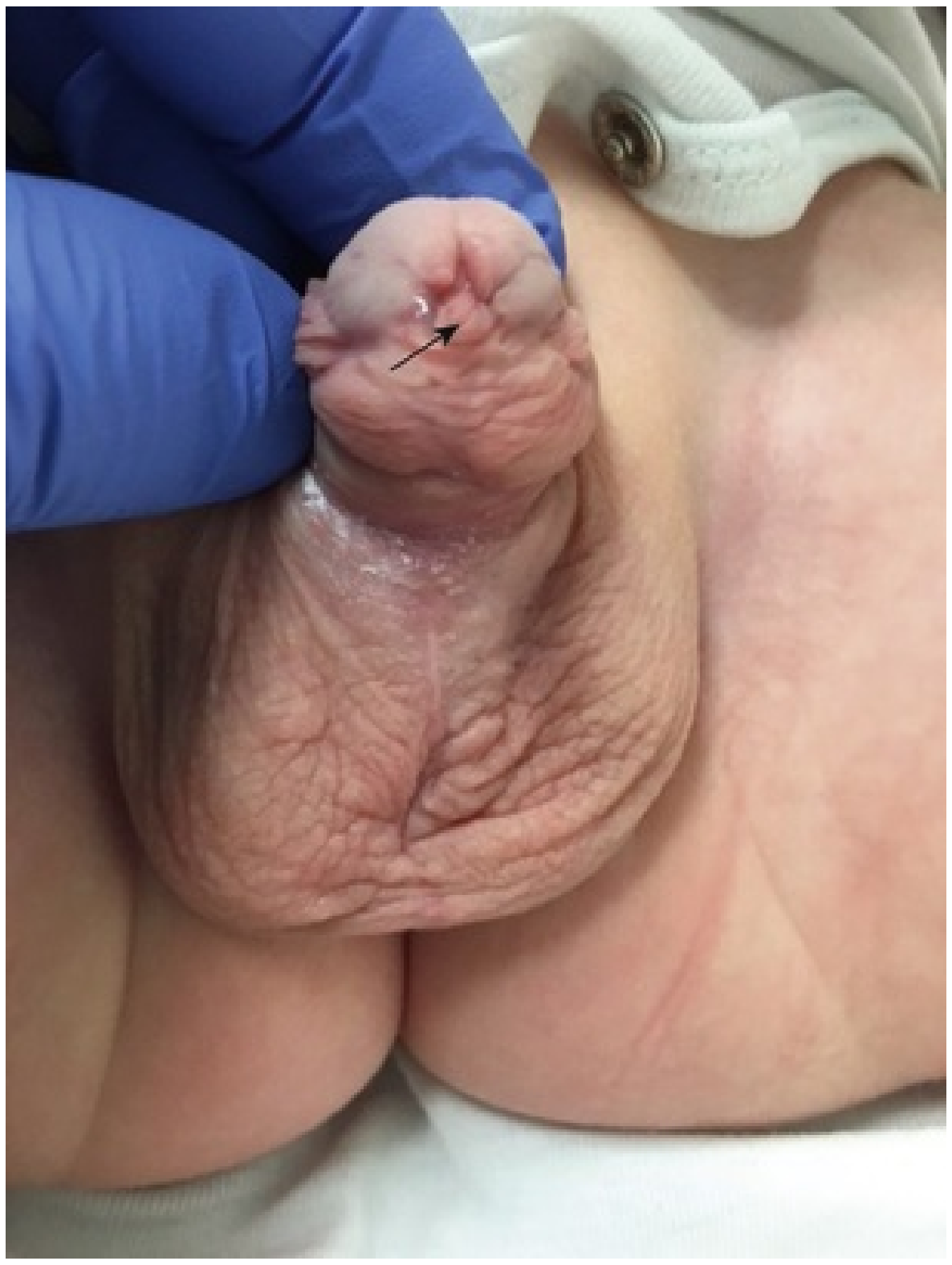

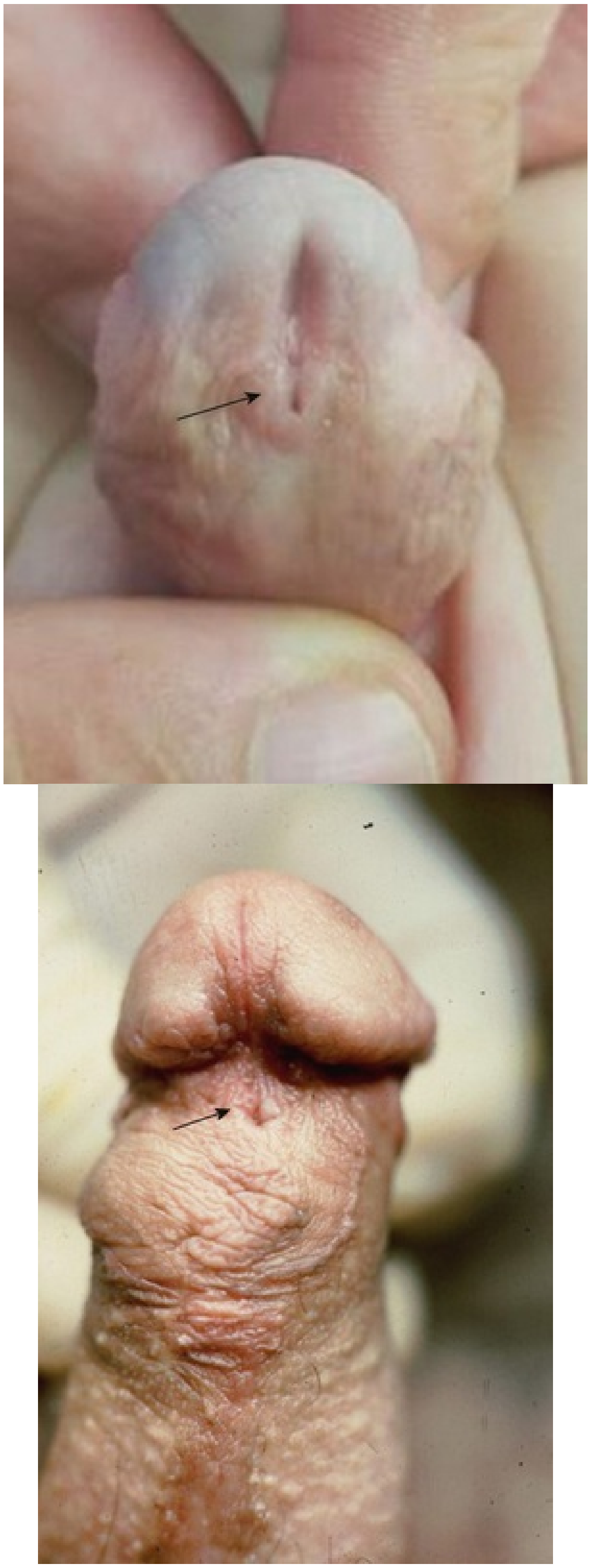

FIG. 45.32 Examples of glans dehiscence. All have a meatus below the corona *(arrows)* and lack of fusion of the glans wings in the midline.

Meatal Stenosis

Definitions for meatal stenosis vary considerably across studies (Wilkinson et al., 2012). Risk of narrowing increases if the urethra closure extends too distally or if the glans is closed with too much tension. Prolonging the time of postoperative stenting may decrease the risk of stenosis, although there are fewer data to substantiate this assumption (Daher et al., 2015). In the postoperative period the meatus should calibrate to a size no less than 8 Fr, and this should increase with age. **A narrowed meatus with symptoms of stranguria, deflected stream, poor uroflow, or urinary retention would suggest a clinically relevant stenosis that warrants repair**. Occasionally a stenotic meatus can be managed conservatively with meatal dilation with a sound and/or topical betamethasone cream (Radojicic and Perovic, 2006). Repeated dilation after hypospadias repair is not necessary as a routine practice to decrease rates of stenosis (Lorenzo and Snodgrass, 2002). It is not part of our practice but has been reportedly successful when the meatus appears narrow in the early postoperative period, and it may be diagnostic of subclinical stenosis. When the stenosis is refractory to dilation, a dorsal midline meatotomy can achieve patency in rare cases (Brannen, 1976). Otherwise a redo urethroplasty is indicated.

Meatal retrusion occurs when excessive tension on the distal urethra or the glans dehiscence has occurred (Duckett and Snyder, 1992). Meatal retrusion in part is due to improper surgical planning, resulting in an immobile or poorly vascularized urethra that retracts in the initial postoperative period because of undue tension. The consequences of this complication may be cosmetic or functional. If deflection of the stream precludes normal voiding while standing, revision of the meatus should be considered (Marte et al., 2001).

Urethral Stricture

Urethral narrowing that extends more proximally than the meatus is also a frequently reported complication of hypospadias repair, with rates varying depending on urethroplasty technique and length of urethroplasty (Duel et al., 1998; Husmann and Rathbun, 2006). These strictures tend to form at the junction of the native and neourethra, along the path of the neourethra, or within the glans. The clinical picture can vary, but complaints of a diminished urine stream force, stranguria, urinary retention, or urinary tract infection are most common.

Several factors increase the risk of postoperative stricture. Improper urethroplasty technique, tissue ischemia, trauma, or infection can result in narrowing of the lumen. When clinically apparent, it is best to characterize the stricture via cystoscopy to delineate the length, caliber, and location of the stricture.

Initial management depends upon the severity of the stricture. For short strictures causing minimal symptoms, urethral dilation or endoscopic incision can be attempted. In most cases, however, this will not provide a long-term solution. Direct visual internal urethrotomy in adult strictures has low success rates and risks worsening the stricture by generating more inflammation and scar (Santucci and Eisenberg, 2010; Tang et al., 2008). Success rates for small strictures (less than 1 cm), even when done in conjunction with intermittent catheterization, are poor: only 20% of boys exhibit a normal flow rate 2 years postincision (Husmann and Rathbun, 2006). The outcome may be better for short anastomotic strictures when endoscopic treatment is initiated 3 months after operation, although in our experience conservative management is rarely successful in these patients (Duel et al., 1998).

Strictures not responding to conservative management or those with extensive disease at diagnosis require revision urethroplasty (Gargollo et al., 2011). The surgeon must be prepared to harvest a local skin flap or buccal mucosa because there will likely be significant tissue loss at the site of stricture. This often results in a multistage repair, as discussed further in the reoperative hypospadias section.

If hair-bearing skin is used for the hypospadias repair, the patient may notice hair extending from the meatus. This complication usually occurs after multiple-stage procedures or complex reoperations in which there is a shortage of non–hair-bearing skin. Hair in the urethral lumen, if combined with urethral narrowing, acts as a nidus for stone formation or recurrent UTIs. Laser ablation may result in success in some cases (Cohen et al., 2007; Neal et al., 1999). Stone debris can be endoscopically removed in the majority of cases. In most cases in which stones, hair, and UTI coexist, the surgeon must resect the affected portion of the urethra and replace it with new tissue, such as a buccal graft, or in the unusual case in which redundant local skin is present, a local graft or flap.

Recurrent UTIs should prompt evaluation for urethral diverticulum or stricture. Occasionally, a voiding cystourethrogram or cystoscopy demonstrates an enlarged prostatic utricle, which can promote urinary stasis resulting in bacterial colonization. If no other source of infection is obvious, consideration should be given to either excision or fulguration of the utricle (Ciftci et al.,

1999).

Urethral Diverticulum

Symptoms of urethral diverticulum include weak urinary stream, postvoid dribbling, UTI, or, less commonly, hematuria. The boy or his parents may notice ballooning of the penile shaft during voiding or report the need to “milk” residual urine from the penile urethra to avoid soiling of the underwear. Diverticula occur more commonly in boys undergoing preputial flap repairs, two-stage repairs, and proximal repairs (Snyder et al., 2005b). This is in part anatomic, because of the lack of spongiosal tissue in the neourethra, which acts to reinforce the normal urethra during voiding. As mentioned earlier, the extra support of the glanular neourethra after glans closure can increase voiding pressure in the penile urethra, leading to diverticulum formation (Radojicic et al., 2004).

A small, localized saccular diverticulum can be excised and reduced, returning the urethral lumen to a uniform caliber. The more commonly encountered extensive diverticula are repaired by excising redundant diverticular tissue, urethral closure, and multilayered reinforcement before skin closure (Zaontz et al., 1989; Fig. 45.33; ▶Video 45.16). The redundant tissue of the diverticulum is well vascularized in some instances, making it an ideal candidate for repair of associated fistulas and distal strictures, if present (Radojicic et al., 2004). Various flap techniques have been employed to reconfigure redundant diverticular tissue for this purpose (Winslow et al., 1985). Urethral plication in an extraurethral fashion is an alternative technique that does not violate the urethral plane (Heaton et al., 1994).

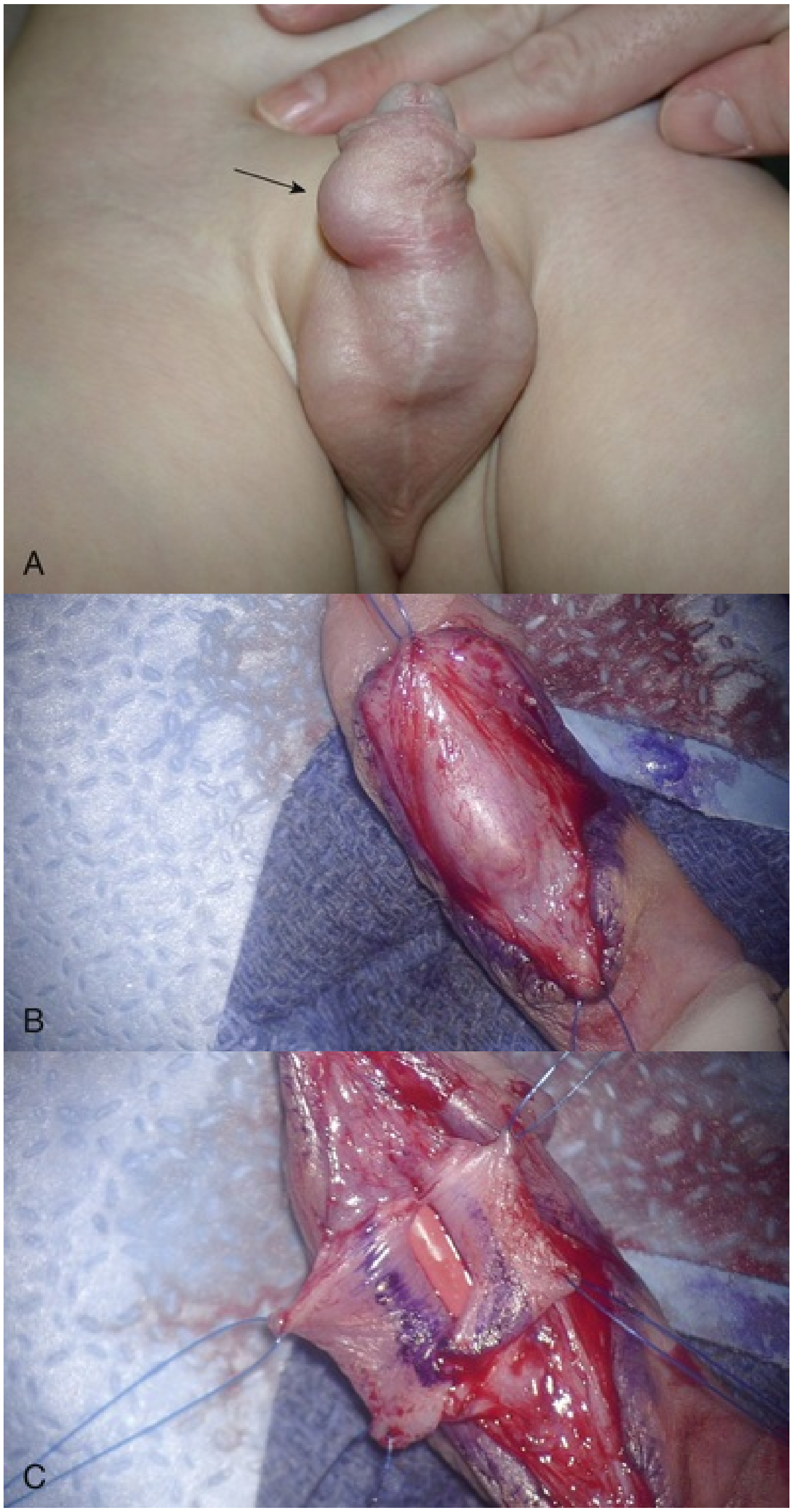
A
B
C

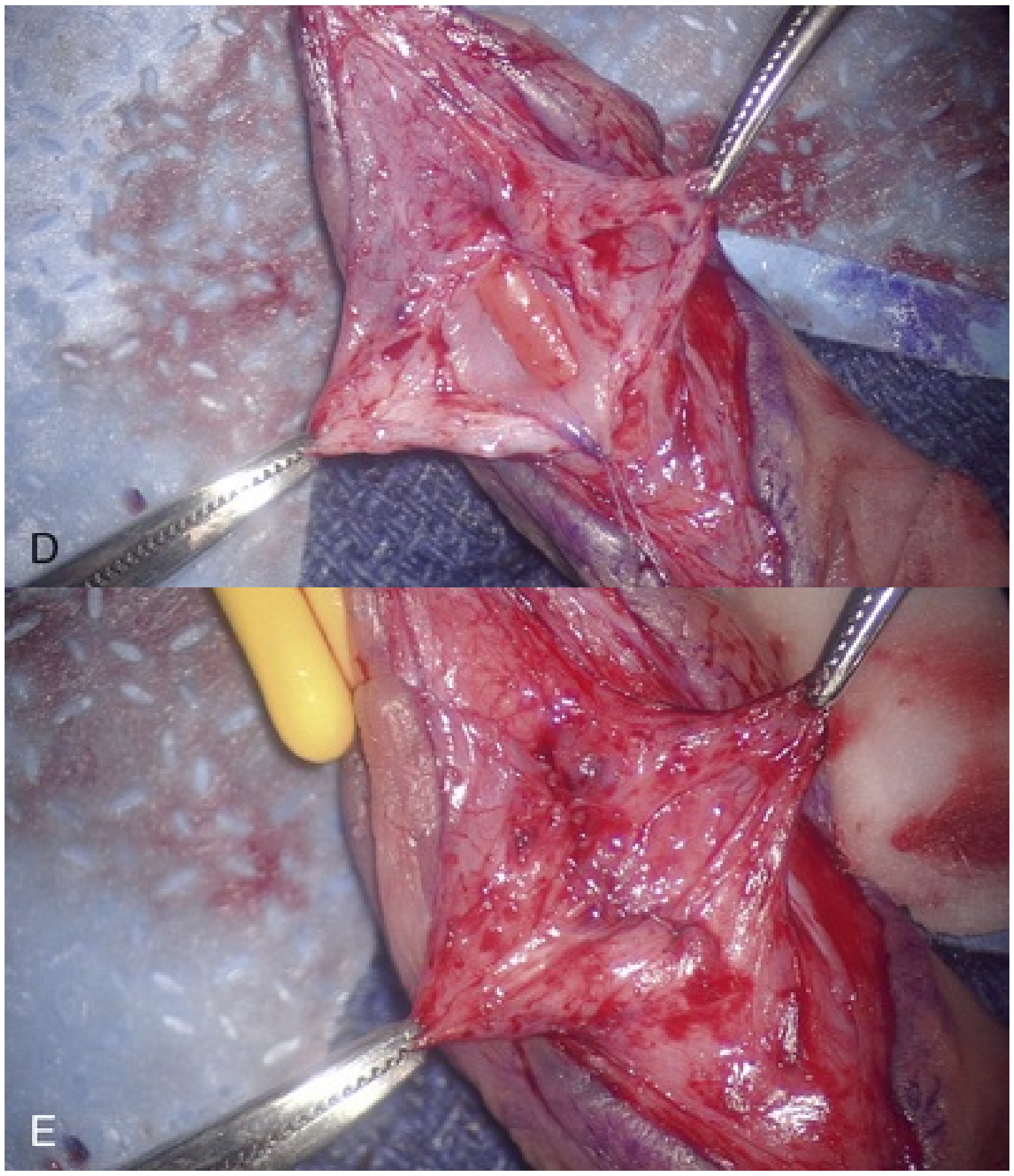

FIG. 45.33 (A) Urethral diverticulum on exam with a sacular dilation of the distal urethra *(arrow).* (B) Diverticulum is evident after ventral penile incision and partial degloving. (C) Diverticulum cavity is open and stay sutures are in place. Markings indicate the edges of urethral closure. (D) Excess epithelial tissue is excised, leaving redundant dartos tissue for extra layer closure over the urethra. (E) Urethral closure before barrier layer approximation.

Balanitis Xerotica Obliterans

Balanitis xerotica obliterans (BXO), or lichen sclerosus, is a chronic inflammatory dermatosis that can occcur in uncircumcised boys with phimosis, meatal stenosis, or progressive urethral narrowing after hypospadias repair (Fig. 45.34). Its management can prove difficult. If limited to the urethral meatus, the initial therapy is a course of topical steroids (betamethasone or clobetasol) or systemic tacrolimus (Kiss et al., 2001; Snodgrass et al., 2017). **In most cases, conservative therapy is unsuccessful and the surgeon must resect involved tissue and replace it with inner prepuce or buccal mucosa, in multistaged operations to fully reconstruct the penis** (Bracka, 2011; Dubey et al., 2005)**.**

Tissue should be sent to pathology to confirm diagnosis. These patients must be monitored closely for recurrence of BXO. Recurrence rates as high as 40% have been reported with median follow-up of 26 months (and as long as 105 months) from surgery (Snodgrass et al., 2017). **It is now recognized that BXO can and does invade buccal mucosa, further complicating treatment** (Levine et al., 2007; Snodgrass et al., 2017).

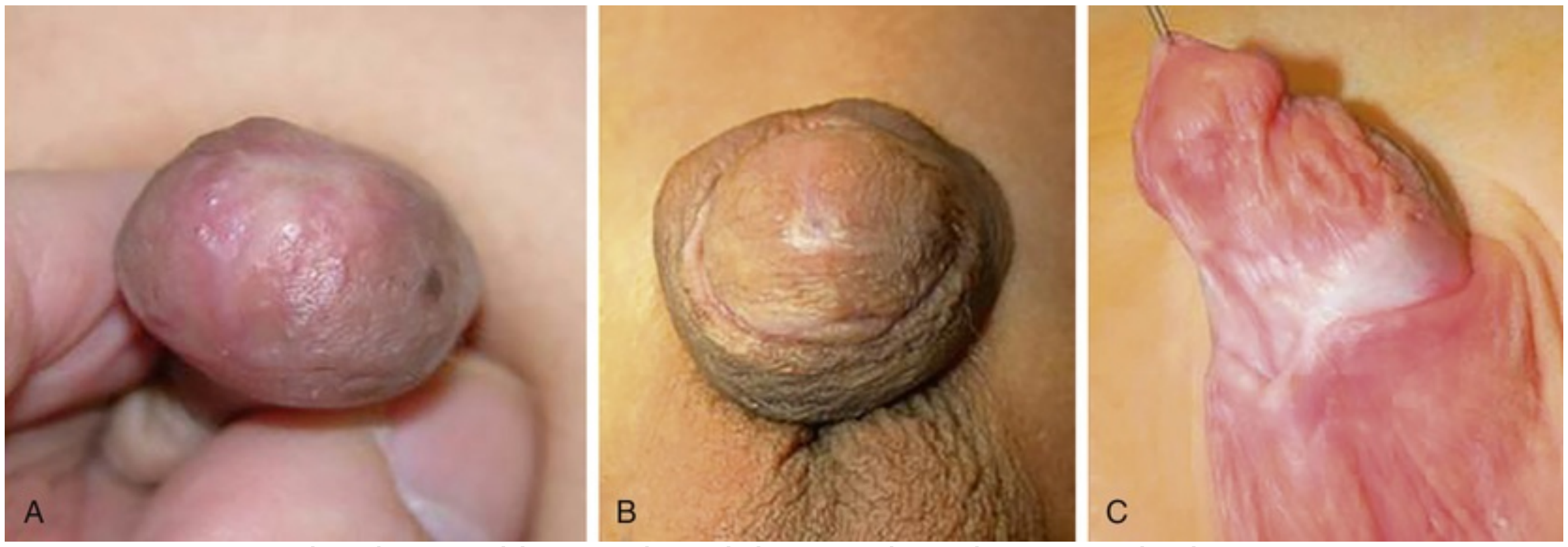

FIG. 45.34 (A,B) Balanitis xerotica obliterans (BXO) present in the meatus as evidence by the pale, white appearance to the tissue. Note the appearance on the penile shaft in C.

Recurrent Penile Curvature

Persistent penile curvature is an unfortunate complication of hypospadias repair that has severe consequences on urinary and sexual function. Residual curvature may worsen as boys advance through puberty, when penile growth surges with potentially differential growth of the dorsal and ventral portion of the corporal bodies (Barbagli et al., 2006). Persistent or recurrent curvature occurs when curvature is underestimated or is repaired incompletely (Braga et al., 2008). **If significant concern is present and intervention is indicated, the penis must be fully degloved and artificial erection performed.** Curvature may be present at the base of the penis, which can be obscured by the presence of a tourniquet. To properly assess this, artificial erection is performed with compression of the corporal bodies against the pubis. **Alternatively, prior preservation of a tethering urethral plate or ventral skin contraction can tether the penis ventrally.**

When curvature recurs, parents should be counseled that several procedures may be required (Fig. 45.35). The first stage assesses the cause of curvature, with particular attention to corporal disproportion if a dorsal plication was performed previously (Snodgrass, 2008). If a graft is used for corporoplasty, a healthy dartos layer should cover this area to act as a recipient for a buccal mucosa graft at the next stage of reconstruction. In many cases, a buccal graft to the ventral penile shaft is required for full penile reconstruction, unless a sufficient amount of skin is present to provide tension-free coverage. If shaft skin is deficient, we perform a Cecil modification during the third stage, which provides supple tissue for skin closure at the fourth stage (as outlined later) (Ehle et al., 2001).

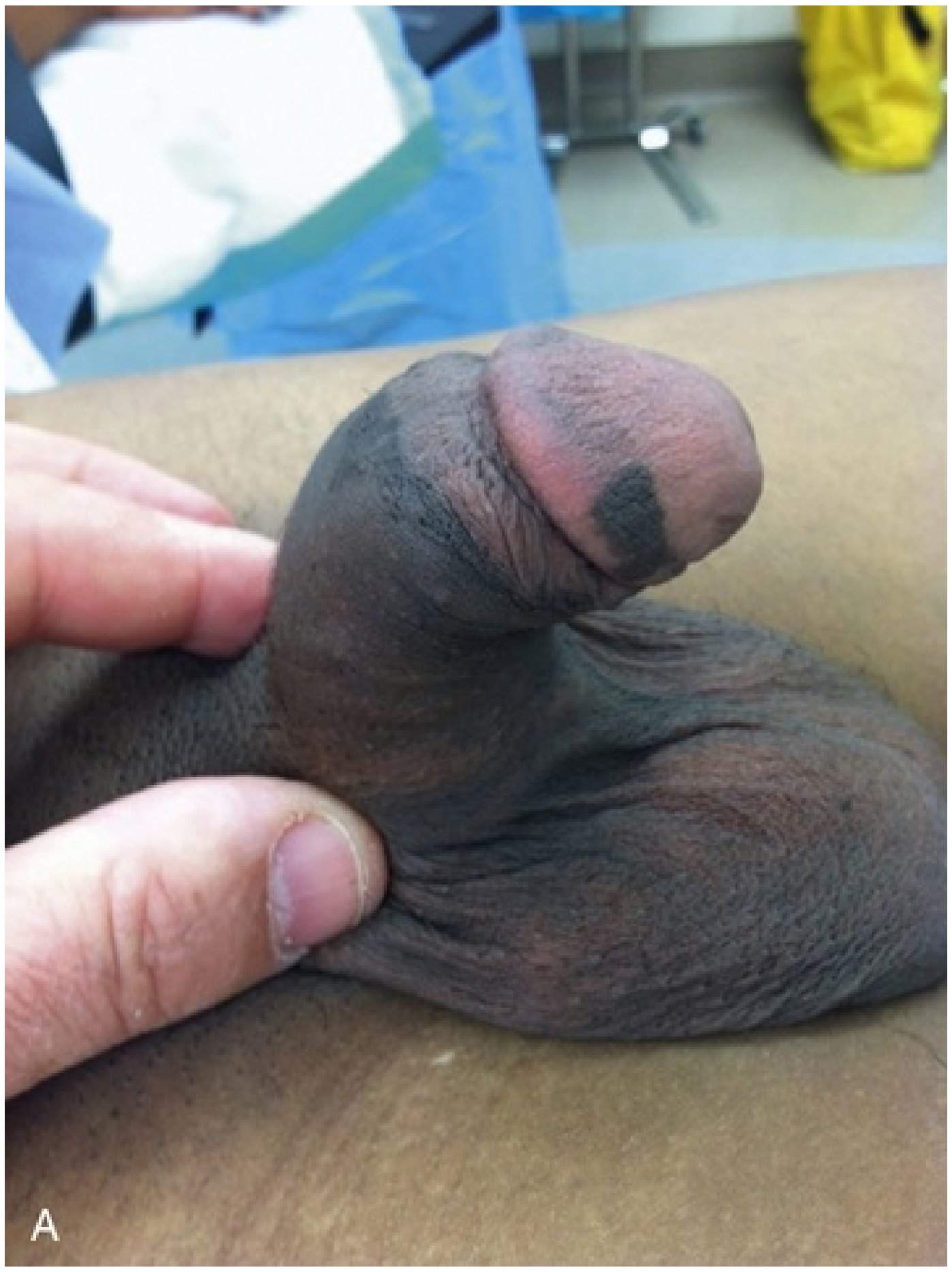

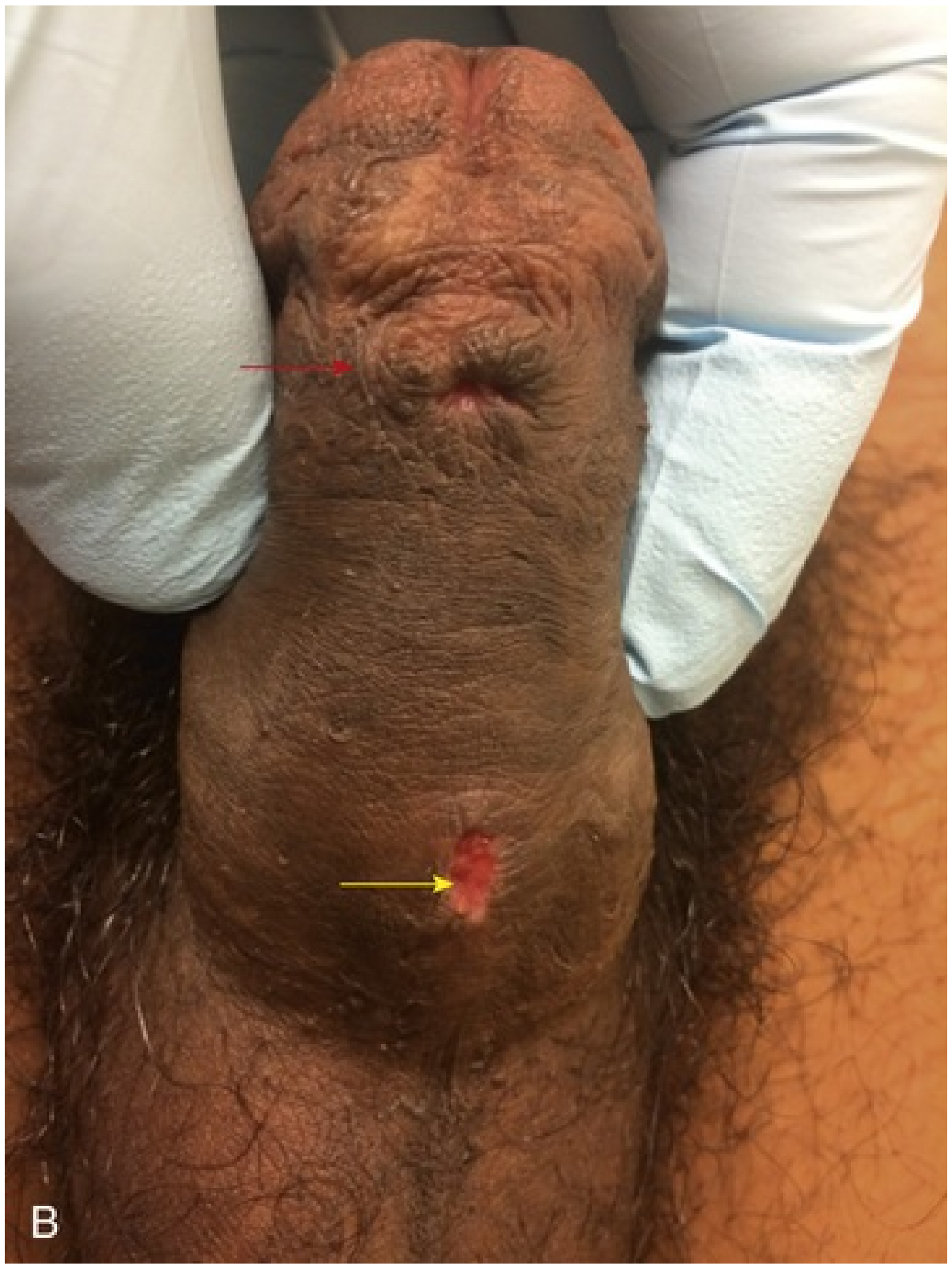

FIG. 45.35 A 14-year-old boy with a history of proximal hypospadias repair. He had undergone a single-stage hypospadias repair as an infant, including correction of his curvature with dorsal plication. He presented with significant ventral penile curvature, seen in (A). (B) Location of the urethral meatus after correction of the penile curvature in the first stage operation *(yellow arrow)*. There is a large gap between the proximal end of the distal portion of the urethra *(red arrow)* and the distal end of the proximal urethra. This boy required two additional procedures, the first of which was a buccal inlay graft with subsequent closure at the final stage.

Skin Complications

Although often perceived as minor, several skin complications may occur after primary repair. If penile concealment and poor skin fixation are present, a buried penis with shortening may occur. This condition may be avoided at the original surgery with penile shaft degloving and well-placed anchoring sutures that superficially attach Buck fascia to the corresponding dermis of the abdominal wall/shaft skin juncture. Suture sinus tracts can occur from suture reaction of the skin, particularly if thin ventral shaft skin is present or if full-thickness sutures are placed. In addition, tightly closed sutures may lead to ischemia and foster suture tracts. Patients with proximal hypospadias and/or penoscrotal transposition, penoscrotal webbing, or poor definition of the penoscrotal junction can result in an abnormal clinical appearance after repair. A scrotoplasty may be used in these settings to prevent postoperative penile concealment.

Hypospadias Outcomes

We have elected to combine the reported outcomes for distal and proximal hypospadias in a single section. **As we have mentioned throughout this chapter, there are significant concerns about the quality of the literature in its current form. Although thousands of publications can be found with a simple PubMed search, most if not all are limited to some extent by their retrospective nature, small cohort sizes, variations in technique, poorly defined outcomes, lack of independent outcome assessment, and patient loss to follow-up. This is recognized across our specialty and efforts to improve publication standards and quality collaboration across institutions are being made** (Braga et al., 2016).

In the largest and most comprehensive outcome analysis, a meta-analysis by Pfistermuller et al. in 2014 included 49 studies with 4675 boys having undergone a TIP repair (Pfistermuller et al., 2015). **They identified an overall complication rate of 10.6%, with a reoperation rate of 4.5%, at a mean follow-up of 16.1 months. Of the complications assessed, fistulae (5.7%) were most common, followed by meatal stenosis (3.6%), and urethral strictures (1.3%). The authors highlighted the high degree of variability in assessment of outcomes, limiting their ability to compare studies.** Outcomes were improved with use of an additional layer of dartos coverage, but proximal and reoperative cases had a significantly higher complication rate (Pfistermuller et al., 2015). In a similar meta-analysis comparing 1872 TIP repairs with 1496 Mathieu repairs, the overall complication rate was similar, occurring in 129 (6.9%) and 88 (6.7%) of boys (Wilkinson et al., 2012). Urethrocutaneous fistulas occurred equally in both repairs, although meatal stenosis was much more common after the TIP repair. These authors also highlighted the difficulty in comparing studies, specifically the poor quality of the data, including surgical indications, lack of follow-up, and lack of clarity in defining outcomes.

Recurrent UTIs are uncommon after hypospadias repair, occurring in 43/2249 (1.91%) of boys in a large study from the group in Toronto in the postoperative period after urethral stent removal (Wehbi et al., 2014). In this population, diagnostic imaging identified several anomalies: distal urethral narrowing in 17/43 (40%), VUR in 14/43 (33%), urethral diverticulum in 5/43 (12%), and an enlarged utricle in 5/43 (12%). Comparing boys who underwent TIP versus OIF, the TIP group was more likely to have an elevated PVR, whereas the OIF group was more likely to develop a diverticulum and/or fistula. **Based on these findings, surgeons should perform anatomic imaging for any boy with recurrent UTIs after repair.**

Prat et al. (2012) shared their findings from a single-institution study of 707 boys with distal penile to glanular hypospadias operated on over a 31-year period. Patients were included only if they had more than 1 year of follow-up. A variety of techniques were used throughout the inclusion period, including MAGPI, TIP, Mathieu flap, onlay flap, and a tubularized flap. The overall complication rate was 24% and worsened with increasing severity of the hypospadias. In a similar study of 366 distal hypospadias repairs at a median follow-up of 23 months, the reoperation rate for TIP, MAGPI, or OIF repairs was 21.3% (Spinoit et al., 2013). The complication rate was significantly higher for patients who had longer duration of follow-up and for those with a more proximal meatus.

A single-institution study of 578 patients undergoing TD distal hypospadias repair reported a complication in 17.4% of patients (Grosos et al., 2014). The median follow-up was 25.6 months, with urethrocutaneous fistula and glans dehiscence occurring more commonly in the first year, whereas urethral stricture occurred more commonly as a late complication. Successful outcomes in distal hypospadias is high, ranging from 83% to 95% (Perlmutter et al., 2006; Pfistermuller et al., 2015; Rushton and Belman, 1998).

Unfortunately, the overall complication rate for proximal hypospadias is much higher, ranging from 23% to 68% when reviewing papers that report only on proximal hypospadias and more mild forms being excluded (Castagnetti et al., 2013; Gorduza et al., 2011; Long et al., 2017; McNamara et al., 2015; Pippi Salle et al., 2016; Stanasel et al., 2015; Snodgrass and Bush, 2017a). **As with distal hypospadias repair, urethrocutaneous fistula is the most common complication, occurring in 3% to 45% of boys** (Gong and Cheng, 2017)**. This is followed by glans dehiscence and meatal stenosis. Urethral diverticula occur more frequently in the setting of a Byars flap repair or onlay procedure versus a two-stage graft repair (STAG or Bracka repair).**

Regardless of technique, the rate of recurrent penile curvature for two-stage repair of proximal hypospadias is relatively low, ranging from 0 to 10% of patients (Gong and Cheng, 2017; Long et al., 2017; McNamara et al., 2015; Pippi Salle et al., 2016; Snodgrass and Bush, 2017a; Stanasel et al., 2015). Two-stage repair with corporoplasty was associated with increased penile length and improved cosmetic results (Castagnetti et al., 2013). Penile length is an important variable, particularly with proximal hypospadias, as a survey of adult patients after infant repair reveals concerns primarily for shortened penile length (Andersson et al., 2018; Moriya et al., 2016).

The two-stage graft repair (STAG) has an overall reported complication rate of less than 25% (Ferro et al., 2002; Castagnetti et al., 2013; Snodgrass and Bush, 2017a). **The most common complication encountered was glans dehiscence and/or urethrocutaneous fistula.** The rate of recurrent penile curvature is low. Additional layers of closure and increasing the local blood supply have been shown to decrease the complication rate (Telfer et al., 1998). A comparison of four approaches to proximal hypospadias repair, including TIP, preputial island onlay, island flap tube, and a two-stage Bracka repair, found that repair approach did not affect complication rates (Castagnetti et al., 2013). Concerns for a skin graft incorporation over a corporal graft can be circumvented with dorsal plication techniques combined with proximal urethral mobilization to correct the majority of curvature (Warwick et al., 1997). Otherwise, if severe curvature persists a corporal graft should be performed and this would increase the risk for skin graft loss.

Several reports have indicated a high complication rate associated with the Byars flap two-stage repair (Long et al., 2017; McNamara et al., 2015; Pippi Salle et al., 2016; Stanasel et al., 2015)**. Complication rates ranged from 30% to 70%, with urethrocutaneous fistula representing the most common complication noted, followed by glans dehiscence.** Urethral diverticulum is also a potential complication, thought to occur as a result from a combination of a lack of spongiosum and lack of fixation of the flap onto the ventral penile shaft at the time of the urethroplasty, as mentioned previously.

The group from Texas Children's Hospital shared their 11-year experience with 56 boys with median follow-up of 34 months (Stanasel et al., 2015). The surgeons used a two-stage repair with at least 6 months between stages. Their overall complication rate, defined as any additional procedures planned beyond the initial two-stage repair, was 68%. In a similar report, the Boston Children's Hospital team reported their results over 20 years for 134 boys undergoing a staged repair for proximal hypospadias. They reported a complication rate of 49% with a median follow-up of 46 months, including fistula, diverticulum, meatal stenosis, and glans dehiscence (McNamara et al., 2015). Pippi Salle et al. (2016) from Toronto compared their experience with 3 separate techniques on 140 boys with proximal hypospadias: a long TIP, dorsal inlay graft, and a staged repair for proximal hypospadias. With mean follow-up ranging from 30 to 48 months, the complication rate was highest for a long single-stage TIP (53%) and lowest for the staged repair (32%). Our experience with proximal hypospadias repair at CHOP is similar. Of 167 consecutive boys with proximal hypospadias operated on from 2006 to 2014, 86 underwent a single-stage repair and 81 a planned two-stage repair. Median follow-up was 29 and 31 months, respectively. The complication rate was higher for the single-stage repairs compared with staged repair (62% vs. 49%, $P = .11$) (Long et al., 2017). Although mostly represented by case series, the two-stage approach incorporating distal urethra closure and correction of curvature at the first stage has reportedly favorable outcomes (Cheng et al., 2003; Dewan et al., 2004).

Castagnetti et al. (2013) sent a questionnaire as well as the penile perception score to 93 patients who underwent proximal hypospadias repair. These patients on initial exam all had ventral penile curvature that was reconstructed with an onlay island flap, onlay island flap on albuginea (a technical modification in which the onlay flap is anchored in the midline to the albuginea of the corpora cavernosa), TIP, or two-stage repair. Their significant findings include the achievement of a longer penis in the staged repair, improved cosmetic outcomes (as per the PPS) for the two-stage repair, and that the complication rate (23%) and urinary complaints were similar across all four surgical approaches.

To our knowledge no direct comparison of these three approaches mentioned earlier has been performed that would determine the ideal approach to proximal hypospadias with severe ventral penile curvature. Regardless of the approach taken, long-term outcomes data are lacking and raise concerns that more complications will be reported as these patients are followed over time (Grosos et al., 2014; Spinoit et al., 2013).

Outcome Assessment

In some cases, complications after hypospadias repair are not obvious. A urethrocutaneous fistula with multiple streams is easy to identify. However, subtle changes heralding stricture formation may be hard to appreciate. Visualization or measurement of the urinary stream in the office or on a video captured by family can be indicative of stricture. Urethral calibration in the office is not an easy task. If a high degree of concern is present for a stricture or meatal stenosis, then exam under anesthesia is warranted**. Uroflow can be performed to further characterize a slowed urinary stream, although exact definitions of a poor flow after a hypospadias repair are not well defined**

and difficult to obtain in the pre–toilet-trained population. It can also be difficult to predict which child needs surgical attention because improved flow rates with aging have been reported (Andersson et al., 2015).

Some argue that the majority of complications are identified in the first year postsurgery (Snodgrass et al., 2014c). However, longer follow-up universally yields higher complication rates with only 50% of postoperative complications noted in the first postoperative year (Grosos et al., 2014; Spinoit et al., 2013; Wood et al., 2008). **Spinoit et al.** (2013) **examined 474 primary hypospadias repairs and identified only 54 of 114 (47%) of their complications within 1 year of surgery. By 36 months of follow-up, 88 of 114 (77%) had undergone repair of complications. In a similar study, Grosos et al.** (2014) **reviewed results following the Thiersch-Duplay technique and reported that only 57% of their complications were discovered during the first year of follow-up**. The type of complication varied according to the time to presentation, with fistulas occurring more commonly in the first year, whereas urethral stricture was more common beyond this time point. These findings suggest that although a majority of boys have complications identified early in the first 3 years of surgical follow-up, there is a large number that develop later complications.

Our practice has evolved to include a minimum standard of follow-up of our surgical patients through puberty, particularly for our proximal hypospadias patients. All patients follow up after toilet training to allow an assessment of the urinary stream. Extension of follow-up through puberty allows further evaluation of the voiding velocity, curvature, and sexual function at the completion of penile development.

Patient-Reported Outcomes

Much of the discussion in the chapter has focused on surgical procedures and their outcomes as observed by the *surgeon*. Although surgeon assessment, for fistula and glans dehiscence for example, is important, without patient input, the process is incomplete. In spite of what surgeons may determine a successful repair, parental and patient perception of their outcomes may differ (Lorenzo et al., 2014; Mureau et al., 1996)**. Analyzing issues that contribute to parental decisional regret include the development of complications, parental hesitancy regarding the potential surgery, and the desire for circumcision while improved parental education and understanding of hypospadias repair decreased conflict about repair** (Lorenzo et al., 2012, 2014). Further refinement of the patient experience can help stem some of the parental and patient disappointment, which can occur even in the setting of a successful repair.

To capture PRO, several hypospadias specific scoring systems have been developed. The Hypospadias Objective Scoring Evaluation (HOSE), Pediatric Penile Perception Score (PPS), Genital perception Score (GPS), and the Hypospadias Objective Penile Evaluation (HOPE) score are scoring systems that have been generated and validated in children (Holland et al., 2001; Mureau et al., 1995; van der Toorn et al., 2013; Weber et al., 2008; Fig. 45.36 and Table 45.2). **Each instrument incorporates similar components to varying degrees, including the meatus, the presence of a fistula, the quality of the urinary stream, penile length, skin appearance, and general penile appearance. The HOPE score is unique in that a standard set of postsurgery pictures are obtained and scored by independent panels consisting of parents, patients and pediatric urologists, including reference pictures ranging from normal to severely abnormal, resulting in a high degree of interobserver reliability for surgical outcomes** (Fig. 45.37). A recent review by Sullivan et al. (2017) examines these scoring systems in depth, highlighting the lack of assessment of sexual function and psychosocial factors related to the repair. The authors also note a strong bias toward surgical outcomes, such as the location and appearance of the urethral meatus, which may prove to be less important for patient and parent satisfaction. Finally, they recognize that in spite of recognition of the need for PRO, universal incorporation into outcome analysis has been poor in the literature.

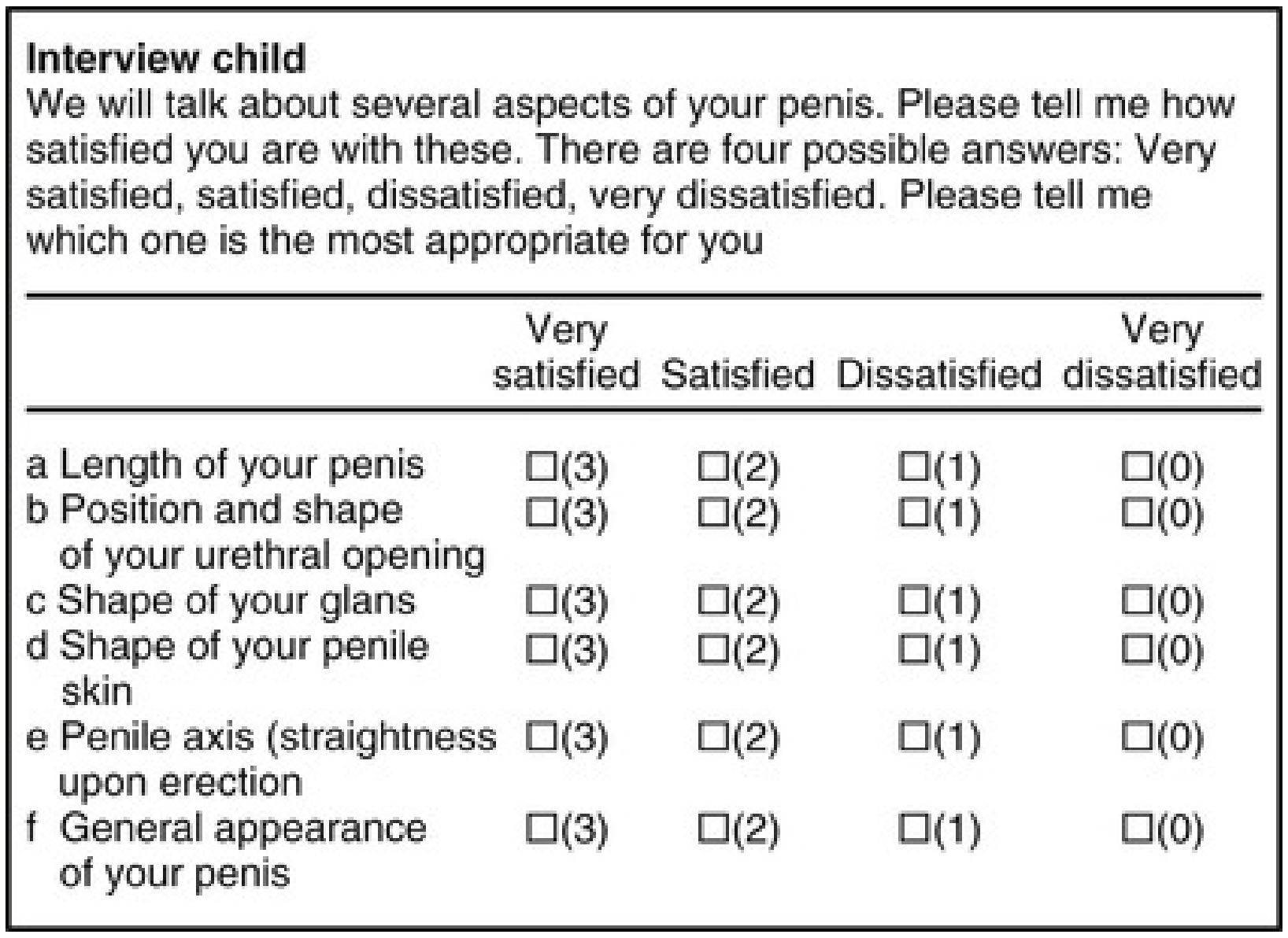

Interview child

We will talk about several aspects of your penis. Please tell me how satisfied you are with these. There are four possible answers: Very satisfied, satisfied, dissatisfied, very dissatisfied. Please tell me which one is the most appropriate for you

	Very satisfied	Satisfied	Dissatisfied	Very dissatisfied
a Length of your penis	☐(3)	☐(2)	☐(1)	☐(0)
b Position and shape of your urethral opening	☐(3)	☐(2)	☐(1)	☐(0)
c Shape of your glans	☐(3)	☐(2)	☐(1)	☐(0)
d Shape of your penile skin	☐(3)	☐(2)	☐(1)	☐(0)
e Penile axis (straightness upon erection	☐(3)	☐(2)	☐(1)	☐(0)
f General appearance of your penis	☐(3)	☐(2)	☐(1)	☐(0)

FIG. 45.36 Pediatric Penile Perception Score instrument is administered to the patient and parents for assessment after hypospadias repair. Considerations include cosmetic satisfaction with the length of the penis, meatus, glans, penile skin, and straightness of the penis. (From Weber DM, Schonbucher VB, Landolt MA, et al.: The Pediatric Penile Perception Score: an instrument for patient self-assessment and surgeon evaluation after hypospadias repair. *J Urol* 180(3):1080–1084, 2008.)

TABLE 45.2

Hypospadias Objective Penile Evaluation (HOPE) Score

1. **Position of meatus**: Assess the position of the meatus.
   See HOPE score reference pictures (see Fig. 45.37).
   ☐ Position 1 (10 points)
   ☐ Position 2 (8 points)
   ☐ Position 3 (5 points)
   ☐ Position 4 (3 points)
   ☐ Position 5 (1 point)
2. **Shape of meatus**: What is the shape of the meatus?
   See HOPE score reference pictures (see Fig. 45.37).
   ☐ Normal (10 points)
   ☐ Slightly abnormal (7 points)
   ☐ Moderately abnormal (4 points)
   ☐ Severely abnormal (1 point)
3. **Shape of glans**: What is the shape of the glans?
   See HOPE score reference pictures (see Fig. 45.37).
   ☐ Normal (10 points)

☐ Slightly abnormal (7 points)
☐ Moderately abnormal (4 points)
☐ Severely abnormal (1 point)

4. **Shape of skin**: What is the shape of the penile skin?
See HOPE score reference pictures (see Fig. 45.37).
☐ Normal (10 points)
☐ Slightly abnormal (7 points)
☐ Moderately abnormal (4 points)
☐ Severely abnormal (1 point)

5.1 **Torsion**: Is there a torsion of the penis?
See HOPE score reference pictures (see Fig. 45.37).
☐ 0–30 degrees (10 points)
☐ 30–50 degrees (7 points)
☐ 50–70 degrees (4 points)
☐ >70 degrees (1 point)

5.2 **Curvature in penile erection**: Is there a curvature of the penis in erection?
See HOPE score reference pictures (see Fig. 45.37).
☐ No erection observed (5.2 does not account for the HOPE score)
☐ 0–30 degrees (10 points)
☐ 30–50 degrees (7 points)
☐ 50–70 degrees (4 points)
☐ >70 degrees (1 point)

Hypospadias Objective Penile Evaluation (HOPE) score = mean number of points question 1–5.

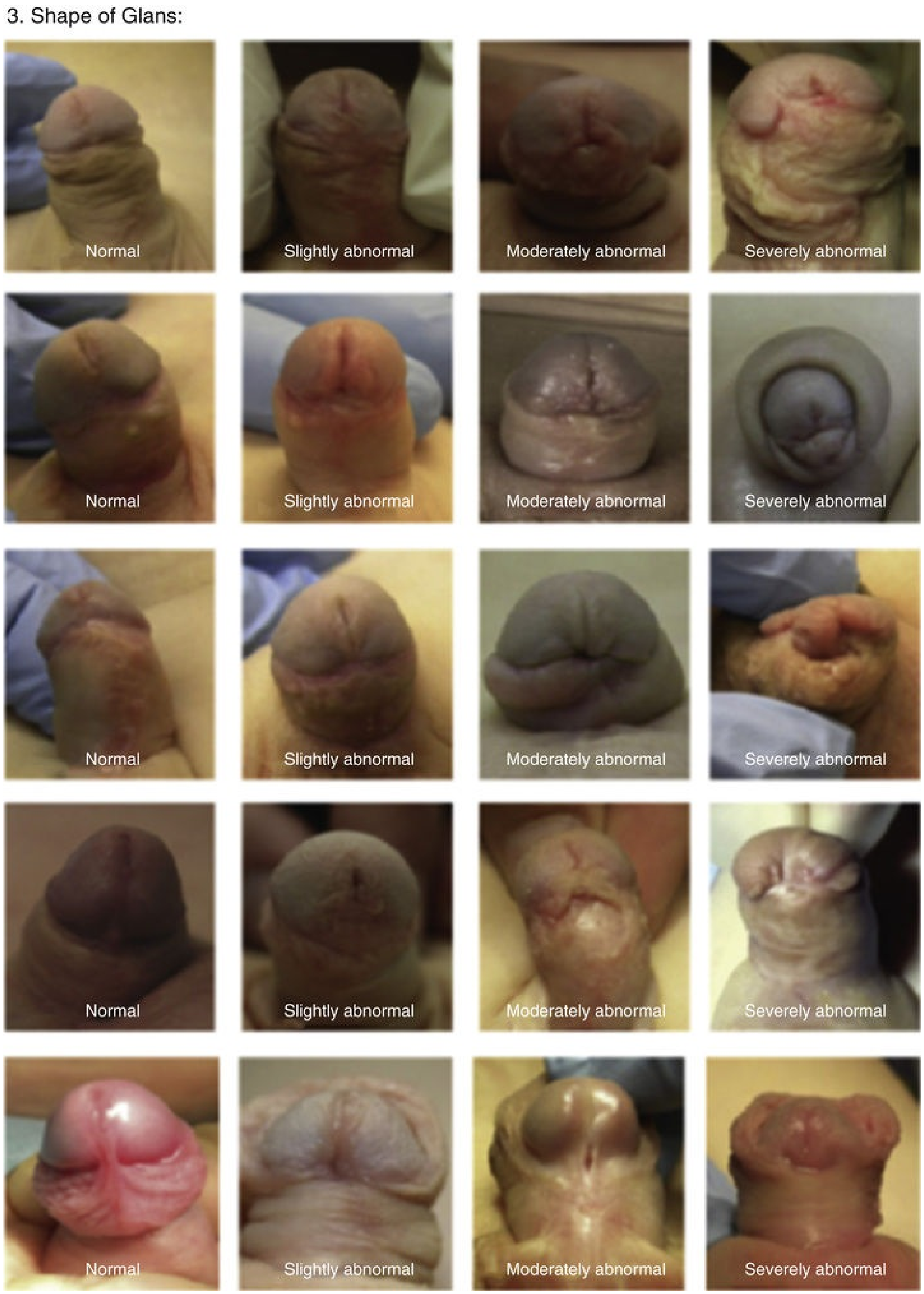
3. Shape of Glans:
Normal
Slightly abnormal
Moderately abnormal
Severely abnormal
Normal
Slightly abnormal
Moderately abnormal
Severely abnormal
Normal
Slightly abnormal
Moderately abnormal
Severely abnormal
Normal
Slightly abnormal
Moderately abnormal
Severely abnormal
Normal
Slightly abnormal
Moderately abnormal
Severely abnormal

FIG. 45.37 Reference pictures administered in conjunction with the HOPE

scoring system (see Table 45.2) depicting various degrees of appearance ranging from normal to grossly abnormal. Anatomic assessment includes the position and shape of the meatus, the shape of the glans, the penile skin, and if any penile torsion and/or curvature is present. A numerical score for each of the 5 criteria ranges from 1 to 10, with a higher score given for a more normal appearance. (From van der Toorn F, de Jong TP, de Gier RP, et al.: Introducing the HOPE [Hypospadias Objective Penile Evaluation]-score: a validation study of an objective scoring system for evaluating cosmetic appearance in hypospadias patients. *J Pediatr Urol* 9[6 Pt B]:1006–1016, 2013.)

Although PRO regarding surgical and functional status is limited, they become more evident when examining sexual and psychosocial impacts. Although there has been a recent trend toward a focus on longer-term follow-up through puberty, the majority of hypospadias patients are still lost to follow-up. Assessment of 500 previously undiagnosed men with hypospadias revealed 65 (13%) with glanular to subcoronal hypospadias and 160 (32%) with anterior (proximal glanular) displacement of the meatus (Fichtner et al., 1995). The patients with previously undiagnosed hypospadias—all mild, distal variants with no penile curvature—had minimal sexual, fertility, or voiding concerns, with a number of men unaware that they even had hypospadias. Another study identified 56 men (mean 53 years of age) with hypospadias, 9 of whom had undergone previous repair but had a persistent defect (Dodds et al., 2008). Of this group, 20 patients who had spraying or angulation to their urinary stream did not elect to pursue repair. Eighteen of 56 men were unaware they had an anomaly, 53 were sexually active without concern, and 41 of 43 attempted and fathered a child. **Both of these studies suggest that when the defect is mild, the patients readily adapt and can compensate for the defect. On the contrary, men with more severe forms of hypospadias, such as a more proximal location and ventral curvature, do report worse sexual and functional outcomes** (Schlomer et al., 2014).

In boys who have undergone surgery, some studies have identified psychological concerns. Parental survey of boys aged 6 to 10 years of age identified behavior problems and poorer school performance, which was significant when compared with normal controls but also increased in boys with more severe defects (Sandberg et al., 1989). In a series of 34 men who underwent hypospadias correction at an average age of 5 years, in spite of normal sexual development by age the men having undergone surgery were delayed in initiating their first sexual encounter and were less sexually active in their current relationships (Berg et al., 1981). **A more contemporary series**

comparing 167 men with repaired hypospadias with 169 age-matched controls found that both groups had equal reported fertility, sexual satisfaction, and age of initiation of sexual activity (Ortqvist et al., 2017)**. Subgroup analysis did reveal a lower rate of sexual satisfaction, worse fertility, and decreased sensation in patients with proximal hypospadias compared with distal variants and controls.** An analysis of 55 men (ages 14 to 25) with a history of proximal hypospadias repair found that these individuals had concern about penile growth but little issue with the location of the urethral meatus (Andersson et al., 2018). Although the majority of these men did initiate sexual activity, a significant number of them were hesitant about sexual physical contact compared with both controls and those with distal hypospadias.

In general, men with a history of hypospadias repair do not manifest major psychological problems. However, they tend to be less satisfied with penile appearance, have more inhibitions in seeking sexual contacts as a result of embarrassment, and have a more negative genital appraisal. These men tend to manifest more anxiety, hostility, and lower self-esteem, some of which may be ameliorated by operating at an earlier age (Berg and Berg, 1983)**.** What remains unclear is if the dissatisfaction with the genitalia is due to the physical appearance, the surgical procedure, development of complications, or limitations in sexual relationships. A survey of individuals unaware of hypospadias was conducted to determine their ability to identify a difference in appearance between circumcised males and variable forms of hypospadias (Ruppen-Greeff et al., 2016). They concluded that men with distal hypospadias were perceived in a similar fashion to controls, whereas those with proximal hypospadias did trend toward a perceivable difference, although this effect was minor. Several studies corroborate these findings, suggesting that the sexual and psychological effects can occur but differ only minimally from controls for distal variants but worsen with increasing severity of the defect, although large-scale studies that incorporate validated PRO that encompass all elements of the patient experience will be able to assess these outcomes (Chertin et al., 2013; Jiao et al., 2011; Rynja et al., 2011).

Key Points

- Sixty percent of urethroplasty complications occur within 1 year after surgery. Complications such as urethral stricture or penile curvature can occur in a delayed fashion. Thus boys, particularly those with proximal hypospadias, should be monitored into puberty.

- Potential risk factors for complications after urethroplasty include a proximal meatus location, glans width less than 14 mm, a lack of a barrier flap over the neourethra, and having a prior hypospadias operation.
- Urethrocutaneous fistula is the most common complication after hypospadias repair. If there is supple tissue present, a primary closure can be attempted, but if thin glans tissue is present, redo urethroplasty and glans closure should be performed.
- Meatotomy or skin flap repair of meatal stenosis most often fails in the presence of BXO, whereas excision of all tissues affected by BXO with staged buccal grafting is considered most likely to succeed without recurrent stenosis. These patients have up to a 40% failure rate; therefore they must be closely monitored.
- Long-term follow-up of patients who have had a hypospadias repair indicates that they are more likely to have ejaculatory problems, are less satisfied with sexual function, and are more likely to be dissatisfied with the appearance of their penis than controls. Patient-reported outcomes are an underrepresented component of follow-up and must be a focus of future studies.

Hypospadias Reoperations

Although some complications such as a simple fistula or skin redundancy can be managed in a single intervention, others may require a multistaged repair with a well-thought-out surgical plan. The tissue available for reconstruction is variable. Its quality decreases with each trip to the operating room. Each successive procedure leaves the penis progressively scarred, changes the established blood supply, and decreases tissue options for reconstruction, all of which result in increasing complication rates with each unplanned operation (Snodgrass and Bush, 2017b; Snodgrass et al., 2009). This can result in a boy or man who has undergone repeated unsuccessful repairs, remaining with a significant defect with poor function, a so-called hypospadias cripple.

Devine reasoned that “once complications have occurred in hypospadias repairs, the surgeon has a tendency to attempt small operations, hoping to convert failure with a minimum of effort. This generally makes matters worse. In these cases, extensive resection of scarring, major shifts of tissues and meticulous reconstruction is necessary to transform a difficult problem into a therapeutic success" (Devine, 1973). Given the complexity of reoperative hypospadias repair and its high complication rate, this quote serves as an important guide to achieve the ultimate goal of a cosmetic and functional penis (Myers et al., 2012).

The assessment begins in the office. A careful history identifies any voiding, skin, and erectile concerns. The timing of previous repairs and operative reports, if available, provide very important information such as the previous use of tunica vaginalis flaps or grafts, the method used for urethroplasty and correction of penile curvature. In the operating room the surgeon should err on the side of obtaining more information as opposed to less, having a low threshold to perform a cystoscopy to fully delineate the anatomy. The skin and available tissues must be carefully assessed for possible usage, and an artificial erection should always be performed, regardless of the type of repair performed, because if this goes undiagnosed, it will have severe long-term consequences (Nozohoor Ekmark et al., 2015; Safwat et al., 2013; Snodgrass et al., 2009). Because of the variable nature of the non-virgin tissue, there is less certainty and uniformity in the blood supply to flaps and local skin. Thus every effort should be taken to add additional layers of coverage, such as tunica vaginalis, to increase the chance of tissue survival.

Depending upon the initial approach to repair, tubularization techniques can be used to redo urethroplasty or for fistula closure. Mathieu, Thiersch Duplay, and redo TIP have been described in instances when deemed appropriate by the surgeon with a reasonable degree of success (Bar-Yosef et al., 2005; Borer et al., 2001; Nozohoor Ekmark et al., 2015; Simmons et al., 1999). Alternatively, placement of an inlay graft after incision of the urethral plate can improve outcomes in reoperative hypospadias, although surgeons must use caution when using tissue that has already failed closure in the past and now has a more variable blood supply (Kolon and Gonzales, 2000; Snodgrass et al., 2009; White and Hanna, 2018).

Salvage hypospadias for a focal issue (fistula, diverticulum) in the absence of penile curvature can be performed using local or remote skin flaps, which can be used as an onlay flap or for multilayer vascular flaps (Nozohoor Ekmark et al., 2015; Patel et al., 2005; Snodgrass et al., 2009). **We typically take this approach when redundant penile shaft skin is present from the original repair as it provides a source of non–hair-bearing skin. Our experience with**

the split onlay skin (SOS) flap is such that even a small piece of skin on a vascularized pedicle can achieve its intended effect (Fig. 45.38)**. Once harvested, the flap can be used in its entirety as an onlay to augment the urethral plate for closure or split to provide additional skin coverage for shaft skin closure or de-epithelialized for additional supplemental layers over the urethroplasty.**

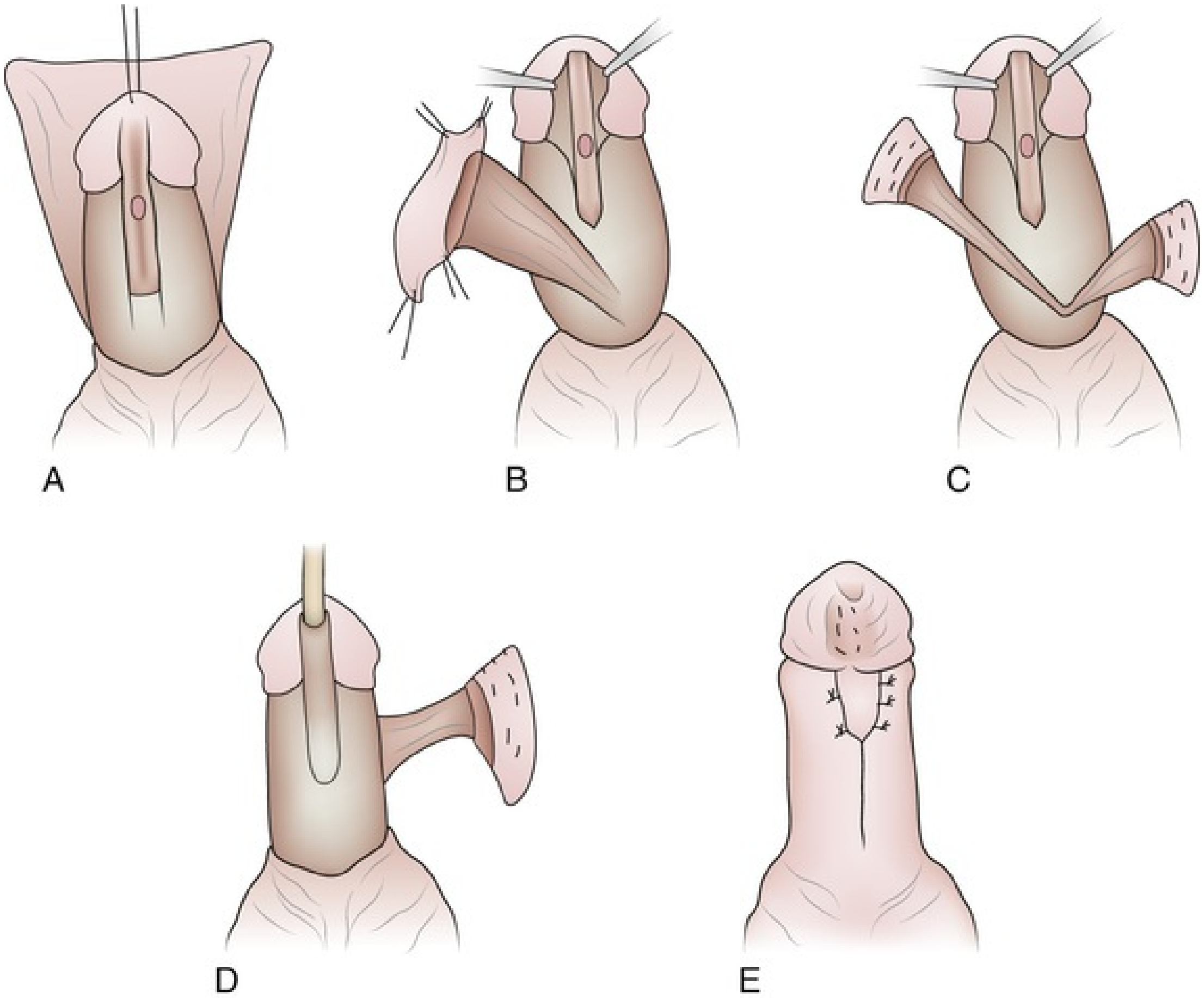

FIG. 45.38 Split onlay skin flap hypospadias repair technique. (A) A fistula is identified on the ventrum of the penis. (B) A skin flap approximately 1 cm in length is isolated and harvested, preserving its vascular pedicle. The flap can be harvested from any location with skin redundancy, either on the penile shaft or along the circumcision line. (C) Flap is divided into two segments, one to be used as an onlay for the urethral closure and the second either as a barrier layer or to facilitate skin closure. (D) Island onlay procedure is performed, closing the fistula. (E) Residual penile skin is approximated dorsally and the second half of the island flap is interposed to close the penile shaft skin. (From Patel RP, Shukla AR, Leone NT, et al: Split onlay skin flap for the salvage hypospadias repair. *J Urol* 173:1718–1720, 2005.)

Pharmacotherapy has been used to augment neovascularization or to improve local blood flow, potentially increasing flap and graft uptake. Topical nitroglycerin ointment can be applied after surgical reconstruction, typically for a period of 24 hours immediately after the repair (White and Hanna, 2018). **Nitroglycerin ointment exerts its effect on the arterial and venous systems, with a larger impact on the latter, and has been shown to increase blood flow to skin flaps as evidenced by fluorescein imaging, promoting improved survival** (Scheuer and Hanna, 1986)**. It has been used in complex hypospadias reconstruction and may provide benefit to ischemic tissues, although it has yet to be compared in a controlled, randomized fashion to determine its definitive impact** (Fam and Hanna, 2017; White and Hanna, 2018).

Hyperbaric oxygen (HO) has established clinical benefits in the setting of gas gangrene, radiation-induced necrosis, and diabetic foot ulcers, and has been proposed as a potential adjunct to promote neovascularization in the use of ischemic skin flaps and grafts (Friedman et al., 2006). HO promotes new vessel growth because of an exaggerated oxygen gradient and a reduction in tissue bacterial content (Park et al., 1992; Sander et al., 2009; Shaw et al., 2014). Its role in reoperative hypospadias is not yet established. Anecdotal reports are beginning to emerge about its potential benefits in graft take and improved vascularization (Kara et al., 2017; White and Hanna, 2018).

Subcutaneous tissue expansion allows the surgeon to augment autologous, non–hair-bearing skin for penile reconstruction in salvage procedures when scar tissue or lack of available skin threatens to compromise the reconstruction (Kajbafzadeh et al., 2007; Mir et al., 2011; Rochlin et al., 2014). A subcutaneous pocket is created under the penile shaft skin and a commercial, expandable device is inserted and inflated with saline. Additional saline is injected via a subinguinal injection port at 1- to 2-week intervals to gently dilate the tissue until sufficient tissue is developed. At the time of reconstruction, the device is removed and flaps of the expanded skin are rotated ventrally for penile shaft skin coverage or de-epithelialized to provide additional vascularized layers over the urethroplasty. One potential benefit proposed by authors is the preservation of androgen receptor–bearing shaft skin, which could prove a key factor in longitudinal growth during puberty (Celayir et al., 2007; Kajbafzadeh et al., 2007; Rochlin et al., 2014). In the largest study, Rochlin et al. (2014) operated on 42 patients with hypospadias. Although complications developed in 41%, including a 28% complication rate related specifically to the tissue expander, tissue expansion provided sufficient skin for reconstruction in 95% of these

patients.

Extragenital skin harvest is another option in the setting of salvage hypospadias repair. A graft is harvested and placed in a vascular bed on the ventrum of the penis, to augment or completely replace the urethral tissue. Several donor sites exist and have been used with variable success. **Single-stage repairs with full-thickness skin grafts have frequently failed secondary to graft shrinkage, scarring, and stricture formation, limiting their use** (Amukele et al., 2005; Webster et al., 1984).

Bladder mucosal grafts can be harvested and used to replace the urethral plate in cases where skin is damaged or scarce (Ehrlich et al., 1989; King, 1994; Memmelaar, 1947). Bladder mucosa contracts when exposed to air, which typically leads to narrowing of the neomeatus. Prolapse of the graft resulting in a cauliflower-type deformity is reported in up to 38% of patients. Meatal stenosis and stricture at the junction with the native urethra occurs frequently (Amukele et al., 2005; Hendren and Reda, 1986; Keating et al., 1990; Kinkead et al., 1994). **Although technical modifications may decrease the complication rate, extending its applicability, more recent success with buccal mucosa grafts has limited use of bladder mucosa** (Ehrlich et al., 1989).

Buccal mucosa is now the graft of choice in complex penile reconstruction (Brock, 1994; Bracka, 1995; Duckett et al., 1995). The tissue is ideally suited for urethral repair because it is well adapted to contact with fluid and air; it readily neovascularizes and is hairless; contraction is minimal; and harvest results in little damage at the donor site (Castagnetti et al., 2008). Contrary to other grafts, it retains its favorable histologic properties after placement (Mokhless et al., 2007; Soave et al., 2014). It also grows well in proportion to the phallus through puberty (Figueroa et al., 2014). Because of its elasticity and good tensile strength, buccal mucosa can be used to reconstruct the urethra in a single or multistage fashion, although a more conservative approach across two stages, allowing the graft to establish a blood supply before tubularization, is optimal (Faure et al., 2016; Ye et al., 2008). Long-term observation into puberty shows that if the graft is placed on a well-vascularized bed, the buccal graft is pliable and will not contract with age, an important aspect of management as we aim to avoid ventral penile curvature, which can result from a shortened, tethered urethra (Figueroa et al., 2014). Buccal mucosa can be harvested from the cheek, inner lip, or both. Reported local complications in men who have had buccal harvests include tightness of the mouth, transient numbness, motor deficits, scarring, and salivary duct obstruction (Wood et al., 2004).

Although single-stage buccal mucosa graft and tubularization can be performed and has been reported, the staged repair results in a higher success rate with improved graft incorporation (Hensle et al., 2002; White and Hanna, 2018). A dorsal inlay graft, in which the dorsal portion of the urethra is incised and the graft sutured in place, is a better alternative to either an onlay or a complete buccal tube, especially in the setting in redo repairs in which blood supply may be compromised (see Fig. 45.28).

Buccal mucosa taken from the upper or lower lip or tongue is thinner than that from the cheek and outcomes suggest that these grafts are better suited for urethral reconstruction, particularly in the glans. Local complications at the harvest site are no different for a lip or cheek location (Maarouf et al., 2013).

There are several important technical points when harvesting a buccal mucosa graft (Eppley et al., 1997). **The graft should be harvested 10% larger than the measured receiving bed to allow for graft contraction as it incorporates. Closure of the donor site may result in worsened postoperative pain with little objective benefit, because the sites heal by secondary intention** (Alwaal et al., 2015; Rourke et al., 2012)**. Although both are viable options for reconstruction, a labial graft appears to have fewer complications when compared with the inner cheek buccal mucosa, particularly an increased risk for glans dehiscence with cheek mucosa** (Lumen et al., 2016; Maarouf et al., 2013; Snodgrass et al., 2009). For longer defects in complex cases or in older children, buccal mucosa can be used because it allows for a larger graft size, although multiple sites can be combined to maximize tissue harvest (Morey and McAninch, 1996). **Strict attention to de-fatting and removing all nonmucosal tissue is important to maximize neovascularization.** The graft can be fenestrated with an 18- or 21-gauge needle and placed in saline until the recipient site is prepared. **Fenestration is thought to decrease hematoma formation, which can impede graft take. The recipient site is prepared by making an incision ventrally from the urethra through the glans to the site of the intended neomeatus** (Mokhless et al., 2007)**. Care should be taken to develop the recipient bed to preserve the underlying dartos, as this acts as the blood supply for graft uptake.** The graft is secured along its axis, taking care not to narrow the graft, which could lead to insufficient tissue for urethroplasty. Quilting stitches are typically placed to prevent hematoma formation. **The graft should be given at least 6 months to heal before proceeding with urethroplasty and skin closure, although it is our practice to wait 12 months before the next stage in reconstruction.** Regardless, periodic examination in the office must be performed to ensure proper graft take and to monitor for contraction. Topical steroids can be considered in the setting of some contraction in the postoperative period, waiting at least 1 month after placement. Outcomes after completion of the repair range from 30% to 75% success rate, with meatal stenosis the most common complication followed by stricture and breakdown of repair (Leslie et al., 2011; Metro et al., 2001).

The scrotum provides a rich vascular bed that can be taken advantage of in salvage hypospadias repairs. Originally described in 1946 by Cecil and modified by Culp (1951), it includes urethroplasty followed by midline scrotal incision and recession of the repair within the supple dartos bed. The penis is released at a second stage, originally reported by Cecil at 6 to 8 weeks, with the urethroplasty having parasitized the local blood supply, which aids the healing process of the urethra. **Although this repair fell out of favor with the emergence of single-stage repair and alternative techniques, it has re-emerged in the setting of difficult salvage procedures** (Fig. 45.39; Ehle et al., 2001; Fam and Hanna, 2017; Weiss et al., 2018). Concerns with this approach include the potential incorporation of hair-bearing scrotal skin on the penile shaft and the need for multiple procedures. **Weiss et al.** (2018) **have modified the approach by delaying penis release from the scrotum for a period of 9 to 12 months, increasing the transfer of secondary vascularized layers to the shaft, which in most cases eliminates the need for utilization of scrotal skin after the release of the scrotal flap**.

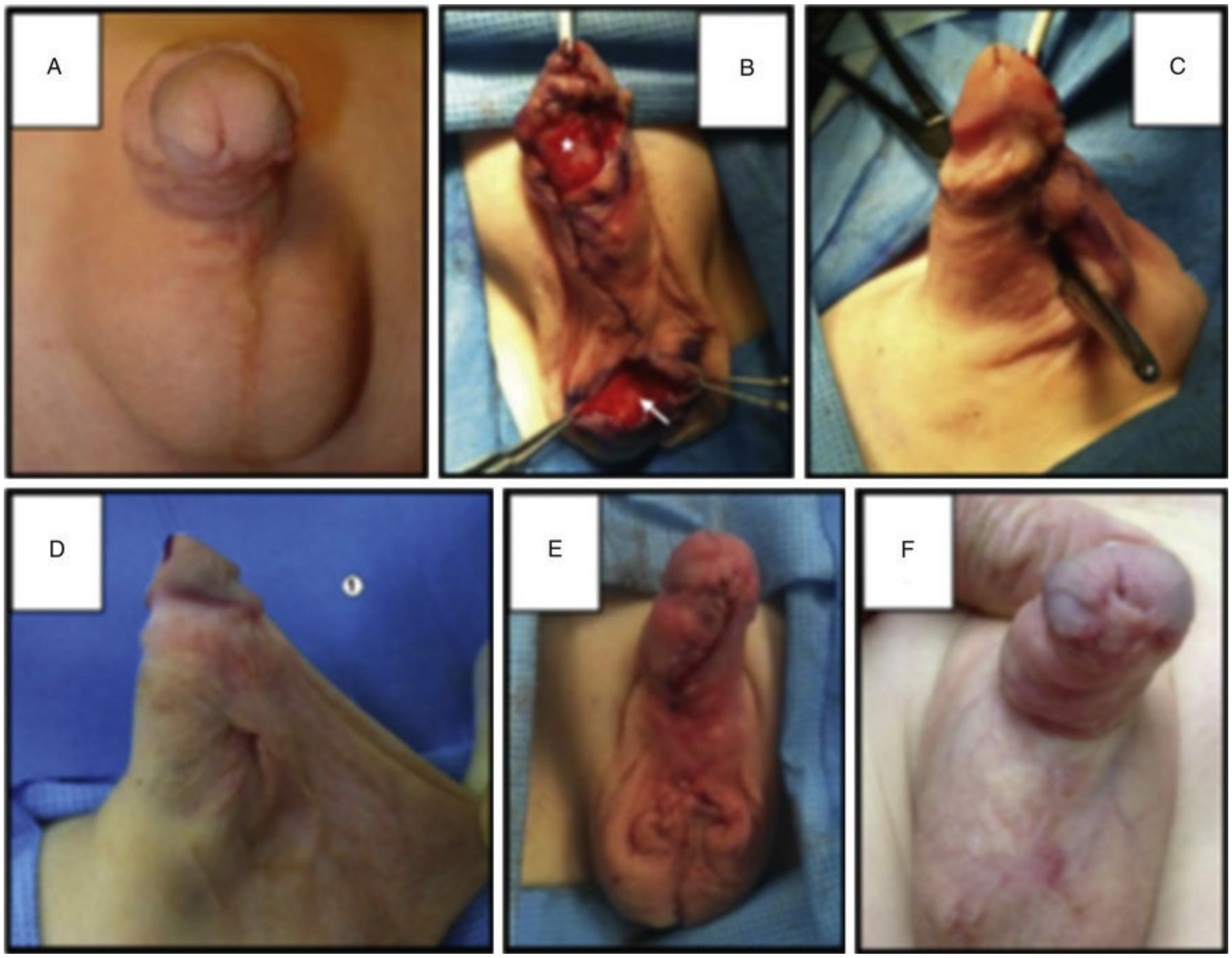

FIG. 45.39 Cecil-Culp repair for hypospadias fistula. (A) Initial appearance of a boy with a history of what was originally a penoscrotal hypospadias. He underwent a failed two-stage repair followed by buccal graft and re-ubularization. He came to us with two coronal fistulae and an irregular glans. (B) Intraoperative appearance after closure of fistulae and glans but a ventral skin defect (*) was present, precluding tension-free skin closure. A midline incision was made in the scrotum as the receiving site for the distal penile shaft anastomosis *(white arrow).* (C) Attachment of the penile shaft skin to the scrotal skin to cover the defect. (D) Approximately 1 year after Cecil-Culp placement, scar has softened and penile shaft skin has stretched. (E) Appearance after Cecil-Culp release, with midline anastomosis of penile shaft skin. (F) Three months postoperation from Cecil-Culp release. Glans is closed and there is no evidence of recurrent fistula. (From Weiss DA, Long CJ, Frazier JR, et al: Back to the future: Cecil-Culp technique for salvage penile reconstructive procedures. *J Pediatr Urol* 14[4]:328.e1–328.e7, 2018.)

Key Points

- For buccal mucosal reconstruction, lip tissue placement is preferable within the glans because it is thinner than cheek tissue and results in a lower complication rate.
- Buccal mucosa is now the graft of choice in complex penile reconstruction. The tissue is ideally suited for urethral repair because it is well adapted to contact with fluid and air, it readily neovascularizes and is hairless, contraction is minimal, and harvest results in little damage at the donor site. Contrary to other grafts, it retains its favorable histologic properties after placement.
- The Cecil modification provides an attractive alternative for skin vascularization in the setting of multiple prior repairs.

Future

As we have outlined in this chapter, there is room for improvement, the first step of which **will depend on continued honest reporting of our results. Reduction of complication rates will occur through standardization, allowing us to increase comparison across institutions with larger volume series and longer follow-up and incorporation of patient-reported outcomes.** To facilitate comparison within institutions (among surgeons) and across institutions, standardization of pre- intra-, and postoperative assessments according to exam, measurements, and outcome definitions must be agreed upon and accepted.

This should lead to establishment of multi-institutional collaborative efforts focused on identifying potential sources of complications that we are currently underpowered to assess with single-institution efforts (Joshi et al., 2018).

The fundamental aspect of this improvement process will be coaching and teamwork. **Coaching is used in athletics to maximize performance and perfection of technique, and we feel strongly that this approach can be applied to the more rare or difficult disease processes to improve our approach and outcomes, particularly for proximal hypospadias** (Borer et al., 2015; Gawande, 2011).

Much work remains to be completed in the advancement of surgical reconstruction of severe hypospadias (Long and Canning, 2016b)**. These efforts must focus on improving the relatively high complication rate, extending follow-up into adulthood, and using long-term analysis to guide patient and parental expectations of the repair.**

Clinical questions such as what is the ideal location of urethral meatus, what degree of penile curvature is cosmetically and functionally acceptable, and to what extent are boys willing to undergo painful and complicated procedures to achieve an ideal result still await an answer. This patient, with a history of proximal hypospadias repair left with a coronal meatus yet with good voiding parameters and an otherwise straight penis, has a satisfactory quality of life in spite of the meatus location (Fig. 45.40). Is that the case for all such patients? Other questions similarly await further study, such as how best to study the long-term psychological challenges of living with the birth defect and the ensuing penile reconstruction with the potential for multiple repairs. Perhaps another may be most important of all: How can we maximize our patient and parental education so that they are prepared for the road ahead?

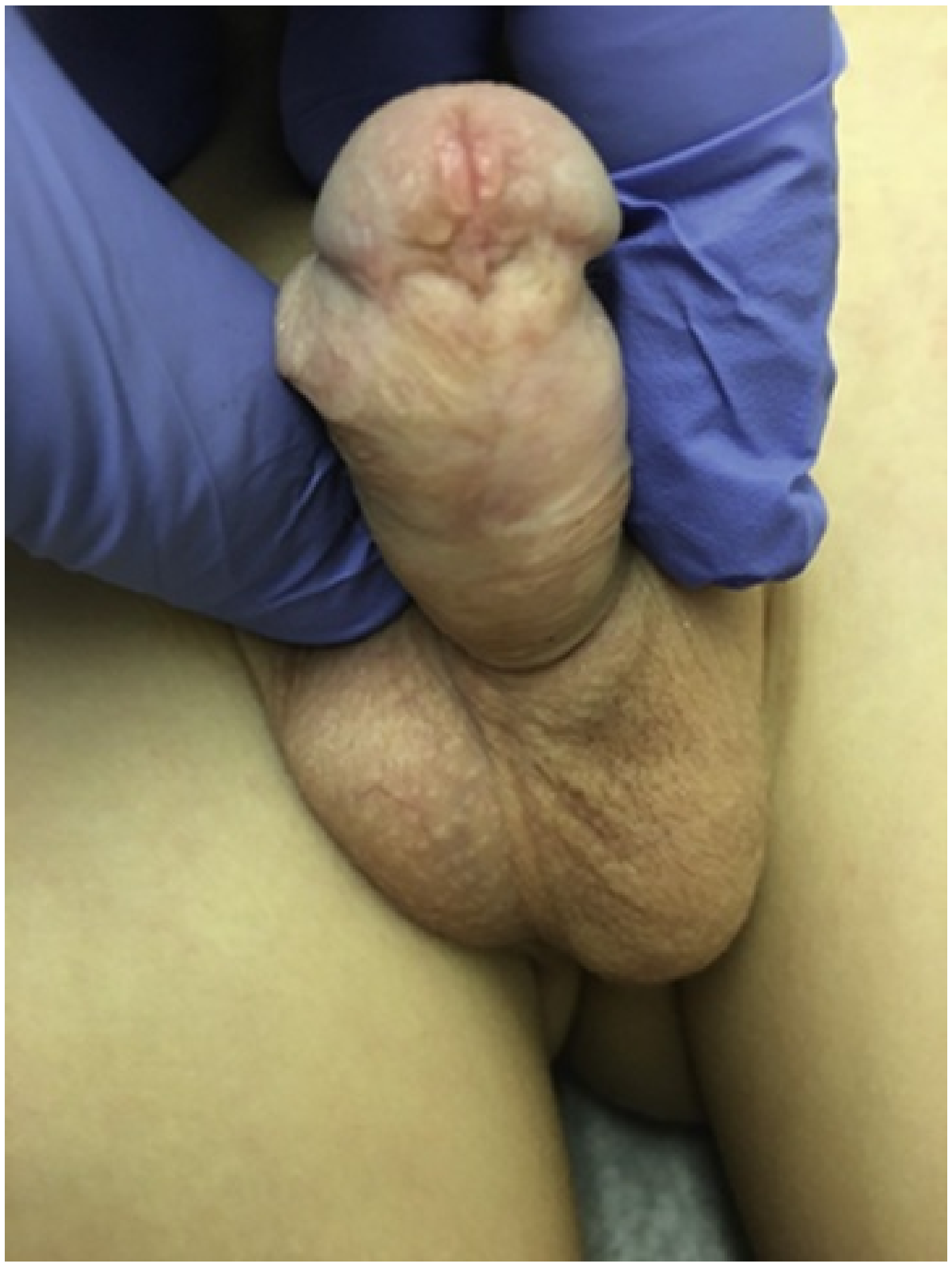

FIG. 45.40 Boy with a history of a two-stage repair resulting from a proximal hypospadias and severe ventral penile curvature. His meatus is located at the coronal margin, but his penis is straight and he voids without any spraying.

As we clamor to standardize our surgical interventions, we are limited until we can objectify our outcome measures across institutions. To this end, technology will play an increasing role. Preoperative, intraoperative, and postoperative videography with the potential for “crowd sourcing” can aid in severity assessment and long-term assessment of outcomes. Recording and cataloging of videotaped procedures, combined with artificial intelligence or machine learning, allows what was once a single surgeon's subjective assessment of a boy's outcome to be measured across thousands of patients. As personalized medicine continues to evolve and it becomes easier to perform routine genetic, proteomic, and microbiome analysis, one can imagine the potential for a refined physical and risk assessment for the boy while planning surgery. Those who take on these challenges will be the hypospadiologists of the future.

Suggested Readings

Belman AB. De-epithelialized skin flap coverage in hypospadias repair. *J Urol*. 1988;140(5 Pt 2):1273–1276.

Braga LH, Lorenzo AJ, Bagli DJ, et al. Ventral penile lengthening versus dorsal plication for severe ventral curvature in children with proximal hypospadias. *J Urol*. 2008;180(Suppl 4):1743–1747 [discussion 1747–1748].

Cox K, Kyriakou A, Amjad B, et al. Shorter anogenital and anoscrotal distances correlate with the severity of hypospadias: a prospective study. *J Pediatr Urol*. 2017;13(1):57.e51–57.e55.

Kalfa N, Paris F, Philibert P, et al. Is hypospadias associated with prenatal exposure to endocrine disruptors? A French collaborative controlled study of a cohort of 300 consecutive children without genetic defect. *Eur Urol*. 2015;68(6):1023–1030.

Kolon TF, Gonzales ET Jr. The dorsal inlay graft for hypospadias repair. *J Urol*. 2000;163(6):1941–1943.

Long CJ, Canning DA. Hypospadias: are we as good as we think when we correct proximal hypospadias? *J Pediatr Urol*. 2016.

Pfistermuller KL, McArdle AJ, Cuckow PM. Meta-analysis of complication rates of the tubularized incised plate (TIP) repair. *J Pediatr Urol*. 2015;11(2):54–59.

Snodgrass W, Bush N. Staged tubularized autograft repair for primary proximal hypospadias with 30-degree or greater ventral curvature. *J Urol*. 2017.

Snodgrass WT, Bush N, Cost N. Algorithm for comprehensive approach to hypospadias reoperation using 3 techniques. *J Urol*. 2009;182(6):2885–2891.

van der Toorn F, de Jong TP, de Gier RP, et al. Introducing the

HOPE (Hypospadias Objective Penile Evaluation)-score: a validation study of an objective scoring system for evaluating cosmetic appearance in hypospadias patients. *J Pediatr Urol*. 2013;9(6 Pt B):1006–1016.

Wong NC, Braga LH. The influence of pre-operative hormonal stimulation on hypospadias repair. *Front Pediatr*. 2015;3:31.

References

Adayener C, Akyol I. Distal hypospadias repair in adults: the results of 97 cases. *Urol Int*. 2006;76(3):247–251.

Allen TD, Spence HM. The surgical treatment of coronal hypospadias and related problems. *J Urol*. 1968;100(4):504–508.

Altarac S, Papes D, Bracka A. Two-stage hypospadias repair with inner preputial layer Wolfe graft (Aivar Bracka repair). *BJU Int*. 2012;110(3):460–473.

Alwaal A, Harris CR, Enriquez A, et al. Healing of donor-site buccal mucosa urethroplasty. *Urology*. 2015;86(3):e9–e10.

American Academy of Pediatrics. Timing of elective surgery on the genitalia of male children with particular reference to the risks, benefits, and psychological effects of surgery and anesthesia. *Pediatrics*. 1996;97(4):590–594.

Amukele SA, Stock JA, Hanna MK. Management and outcome of complex hypospadias repairs. *J Urol*. 2005;174(4 Pt 2):1540–1542 [discussion 1542–1543].

Andersson M, Doroszkiewicz M, Arfwidsson C, et al. Normalized urinary flow at puberty after tubularized incised plate urethroplasty for hypospadias in childhood. *J Urol*. 2015;194(5):1407–1413.

Andersson M, Sjostrom S, Wangqvist M, et al. Psychosocial and sexual outcome in adolescents after surgery for proximal hypospadias in childhood. *J Urol*. 2018.

Arendt LH, Ramlau-Hansen CH, Wilcox AJ, et al. Placental weight and male genital anomalies: a nationwide Danish cohort study. *Am J Epidemiol*. 2016;183(12):1122–1128.

Arlen AM, Kirsch AJ, Leong T, et al. Further analysis of the Glans-Urethral Meatus-Shaft (GMS) hypospadias score: correlation with postoperative complications. *J Pediatr Urol*.

2015;11(2):71.e1–71.e75.

Asgari SA, Safarinejad MR, Poorreza F, et al. The effect of parenteral testosterone administration prior to hypospadias surgery: a prospective, randomized and controlled study. *J Pediatr Urol*. 2015;11(3):143.e1–143.e6.

Ashcroft GS, Mills SJ. Androgen receptor-mediated inhibition of cutaneous wound healing. *J Clin Invest*. 2002;110(5):615–624.

Asklund C, Jorgensen N, Skakkebaek NE, et al. Increased frequency of reproductive health problems among fathers of boys with hypospadias. *Hum Reprod*. 2007;22(10):2639–2646.

Asopa HS, Elhence IP, Atri SP, et al. One stage correction of penile hypospadias using a foreskin tube. A preliminary report. *Int Surg*. 1971;55(6):435–440.

Baillargeon E, Duan K, Brzezinski A, et al. The role of preoperative prophylactic antibiotics in hypospadias repair. *Can Urol Assoc J*. 2014;8(7–8):236–240.

Bar-Yosef Y, Binyamini J, Matzkin H, et al. Salvage Mathieu urethroplasty: reuse of local tissue in failed hypospadias repair. *Urology*. 2005;65(6):1212–1215.

Barbagli G, De Angelis M, Palminteri E, et al. Failed hypospadias repair presenting in adults. *Eur Urol*. 2006;49(5):887–894 [discussion 895].

Bartone F, Shore N, Newland J, et al. The best suture for hypospadias? *Urology*. 1987;29(5):517–522.

Basavaraju M, Balaji DK. Choosing an ideal vascular cover for Snodgrass repair. *Urol Ann*. 2017;9(4):348–352.

Baskin LS, Ebbers MB. Hypospadias: anatomy, etiology, and technique. *J Pediatr Surg*. 2006;41(3):463–472.

Baskin LS, Erol A, Li YW, et al. Anatomical studies of hypospadias. *J Urol*. 1998;160(3 Pt 2):1108–1115 [discussion 1137].

Baskin LS, Himes K, Colborn T. Hypospadias and endocrine disruption: is there a connection? *Environ Health Perspect*. 2001;109(11):1175–1183.

Bauer SB, Bull MJ, Retik AB. Hypospadias: a familial study. *J Urol*. 1979;121(4):474–477.

Belman AB. De-epithelialized skin flap coverage in hypospadias repair. *J Urol*. 1988;140(5 Pt 2):1273–1276.

Belman AB, Kass EJ. Hypospadias repair in children less than 1 year old. *J Urol*. 1982;128(6):1273–1274.

Berg R, Berg G. Penile malformation, gender identity and sexual orientation. *Acta Psychiatr Scand*. 1983;68(3):154–166.

Berg R, Svensson J, Astrom G. Social and sexual adjustment of men operated for hypospadias during childhood: a controlled study. *J Urol*. 1981;125(3):313–317.

Bergman JE, Loane M, Vrijheid M, et al. Epidemiology of hypospadias in Europe: a registry-based study. *World J Urol*. 2015;33(12):2159–2167.

Bermudez DM, Canning DA, Liechty KW. Age and pro-inflammatory cytokine production: wound-healing implications for scar-formation and the timing of genital surgery in boys. *J Pediatr Urol*. 2011;7(3):324–331.

Bhat A, Saxena G, Abrol N. A new algorithm for management of chordee without hypospadias based on mobilization of urethra. *J Pediatr Urol*. 2008;4(1):43–50.

Borer JG, Bauer SB, Peters CA, et al. Tubularized incised plate urethroplasty: expanded use in primary and repeat surgery for hypospadias. *J Urol*. 2001;165(2):581–585.

Borer JG, Vasquez E, Canning DA, et al. An initial report of a novel multi-institutional bladder exstrophy consortium: a collaboration focused on primary surgery and subsequent care. *J Urol*. 2015;193(Suppl 5):1802–1807.

Bouty A, Ayers KL, Pask A, et al. The genetic and environmental factors underlying hypospadias. *Sex Dev*. 2015;9(5):239–259.

Bracka A. Hypospadias repair: the two-stage alternative. *Br J Urol*. 1995;76(Suppl 3):31–41.

Bracka A. Buccal mucosa: good but not perfect. *J Urol*. 2011;185(3):777–778.

Braga LH, Pippi Salle JL, Lorenzo AJ, et al. Comparative analysis of tubularized incised plate versus onlay island flap urethroplasty for penoscrotal hypospadias. *J Urol*. 2007;178(4 Pt 1):1451–1456 [discussion 1456–1457].

Braga LH, Pippi Salle JL, Dave S, et al. Outcome analysis of severe chordee correction using tunica vaginalis as a flap in boys with proximal hypospadias. *J Urol*. 2007;178(4 Pt 2):1693–1697 [discussion 1697].

Braga LH, Lorenzo AJ, Bagli DJ, et al. Ventral penile lengthening versus dorsal plication for severe ventral curvature in children with proximal hypospadias. *J Urol*. 2008;180(Suppl 4):1743–1747 [discussion 1747–1748].

Braga LH, Lorenzo AJ, Bagli DJ, et al. Application of the STROBE statement to the hypospadias literature: report of the international pediatric urology task force on hypospadias. *J Pediatr Urol*. 2016;12(6):367–380.

Braga LH, Jegatheeswaran K, McGrath M, et al. Cause and effect versus confounding—is there a true association between caudal blocks and tubularized incised plate repair complications? *J Urol*. 2017;197(3 Pt 2):845–851.

Brannen GE. Meatal reconstruction. *J Urol*. 1976;116(3):319–321.

Brock JW 3rd. Autologous buccal mucosal graft for urethral reconstruction. *Urology*. 1994;44(5):753–755.

Bush NC, DaJusta D, Snodgrass WT. Glans penis width in patients with hypospadias compared to healthy controls. *J Pediatr Urol*. 2013;9(6 Pt B):1188–1191.

Bush NC, Holzer M, Zhang S, et al. Age does not impact risk for urethroplasty complications after tubularized incised plate repair of hypospadias in prepubertal boys. *J Pediatr Urol*. 2013;9(3):252–256.

Bush NC, Villanueva C, Snodgrass W. Glans size is an independent risk factor for urethroplasty complications after hypospadias repair. *J Pediatr Urol*. 2015;11(6):355.e1–355.e5.

Byars LT. Functional restoration of hypospadias deformities; with a report of 60 completed cases. *Surg Gynecol Obstet*. 1951;92(2):149–154.

Camoglio FS, Bruno C, Zambaldo S, et al. Hypospadias anatomy: elastosonographic evaluation of the normal and hypospadic penis. *J Pediatr Urol*. 2016.

Castagnetti M, Ghirardo V, Capizzi A, et al. Donor site outcome after oral mucosa harvest for urethroplasty in children and adults. *J Urol*. 2008;180(6):2624–2628.

Castagnetti M, Zhapa E, Rigamonti W. Primary severe hypospadias: comparison of reoperation rates and parental perception of urinary symptoms and cosmetic outcomes among 4 repairs. *J Urol*. 2013;189(4):1508–1513.

Castellan M, Gosalbez R, Devendra J, et al. Ventral corporal body grafting for correcting severe penile curvature associated with single or two-stage hypospadias repair. *J Pediatr Urol*. 2011;7(3):289–293.

Cecil AB. Repair of hypospadias and urethral fistula. *J Urol*. 1946;56(2):237–242.

Celayir S, Elicevik M, Tireli G, et al. Expression of estrogen and androgen receptors in children with hypospadias: preliminary report. *Arch Androl*. 2007;53(2):83–85.

Chalmers D, Wiedel CA, Siparsky GL, et al. Discovery of hypospadias during newborn circumcision should not preclude completion of the procedure. *J Pediatr*.

2014;164(5):1171–1174 [e1171].

Chandrasekharam VV. Temporary re-catheterization as a treatment for early fistulas after hypospadias repair. *J Pediatr Urol*. 2016;12(2):129–130.

Chariatte V, Ramseyer P, Cachat F. Uroradiological screening for upper and lower urinary tract anomalies in patients with hypospadias: a systematic literature review. *Evid Based Med*. 2013;18(1):11–20.

Chatterjee US, Mandal MK, Basu S, et al. Comparative study of dartos fascia and tunica vaginalis pedicle wrap for the tubularized incised plate in primary hypospadias repair. *BJU Int*. 2004;94(7):1102–1104.

Cheng EY, Kropp BP, Pope JC 4th, et al. Proximal division of the urethral plate in staged hypospadias repair. *J Urol*. 2003;170(4 Pt 2):1580–1583 [discussion 1584].

Chertin B, Natsheh A, Ben-Zion I, et al. Objective and subjective sexual outcomes in adult patients after hypospadias repair performed in childhood. *J Urol*. 2013;190(Suppl 4):1556–1560.

Chhibber AK, Perkins FM, Rabinowitz R, et al. Penile block timing for postoperative analgesia of hypospadias repair in children. *J Urol*. 1997;158(3 Pt 2):1156–1159.

Chul Kim S, Kyoung Kwon S, Pyo Hong Y. Trends in the incidence of cryptorchidism and hypospadias of registry-based data in Korea: a comparison between industrialized areas of petrochemical estates and a non-industrialized area. *Asian J Androl*. 2011;13(5):715–718.

Churchill BM, van Savage JG, Khoury AE, et al. The dartos flap as an adjunct in preventing urethrocutaneous fistulas in repeat hypospadias surgery. *J Urol*. 1996;156(6):2047–2049.

Ciftci AO, Senocak ME, Buyukpamukcu N, et al. Abnormal prostatic utricle configuration in hypospadias and intersex patients. *Eur J Pediatr Surg*. 1999;9(3):167–172.

Cimador M, Castagnetti M, Milazzo M, et al. Suture materials: do they affect fistula and stricture rates in flap urethroplasties? *Urol Int*. 2004;73(4):320–324.

Cohen S, Livne PM, Ad-El D, et al. CO2 laser desiccation of urethral hair post-penoscrotal hypospadias repair. *J Cosmet Laser Ther*. 2007;9(4):241–243.

Cook A, Khoury AE, Neville C, et al. A multicenter evaluation of technical preferences for primary hypospadias repair. *J Urol*. 2005;174(6):2354–2357 [discussion 2357].

Cox K, Kyriakou A, Amjad B, et al. Shorter anogenital and anoscrotal distances correlate with the severity of hypospadias: a prospective study. *J Pediatr Urol*. 2017;13(1):57.e51–57.e55.

Culp OS. Early correction of congenital chordee and hypospadias. *J Urol*. 1951;65(2):264–278.

Daher P, Khoury A, Riachy E, et al. Three-week or one-week bladder catheterization for hypospadias repair? A retrospective-prospective observational study of 189 patients. *J Pediatr Surg*. 2015;50(6):1063–1066.

Darewicz B, Kudelski J, Szynaka B, et al. Ultrastructure of the tunica albuginea in congenital penile curvature. *J Urol*. 2001;166(5):1766–1768.

Daskalopoulos EI, Baskin L, Duckett JW, et al. Congenital penile curvature (chordee without hypospadias). *Urology*. 1993;42(6):708–712.

Davidson AJ, Disma N, de Graaff JC, et al. Neurodevelopmental outcome at 2 years of age after general anaesthesia and awake-regional anaesthesia in infancy (GAS): an international multicentre, randomised controlled trial. *Lancet*. 2016;387(10015):239–250.

Dean GE, Burno DK, Zaontz MR. Chordee repair utilizing a novel technique ensuring neurovascular bundle preservation. *Tech Urol*. 2000;6(1):5–8.

Decter RM. M inverted V glansplasty: a procedure for distal hypospadias. *J Urol*. 1991;146(2 Pt 2):641–643.

Devine C. Hypospadias cripples. *Plast Reconstr Surg*. 1973;389–392.

Devine CJ Jr, Horton CE. Chordee without hypospadias. *J Urol*. 1973;110(2):264–271.

Devine CJ Jr, Horton CE. Use of dermal graft to correct chordee. *J Urol*. 1975;113(1):56–58.

Devine CJ Jr, Gonzalez-Serva L, Stecker JF Jr, et al. Utricular configuration in hypospadias and intersex. *J Urol*. 1980;123(3):407–411.

Dewan PA, Erdenetsetseg G, Chiang D. Ulaanbaatar procedure for tubularization of the glans in severe hypospadias. *J Urol*. 2004;171(3):1263–1265.

DiSandro M, Palmer JM. Stricture incidence related to suture material in hypospadias surgery. *J Pediatr Surg*. 1996;31(7):881–884.

Dodds PR, Batter SJ, Shield DE, et al. Adaptation of adults to uncorrected hypospadias. *Urology*. 2008;71(4):682–685 [discussion 685].

Donnahoo KK, Cain MP, Pope JC, et al. Etiology, management and surgical complications of congenital chordee without hypospadias. *J Urol*. 1998;160(3 Pt 2):1120–1122.

Dubey D, Sehgal A, Srivastava A, et al. Buccal mucosal urethroplasty for balanitis xerotica obliterans related urethral strictures: the outcome of 1 and 2-stage techniques. *J Urol*. 2005;173(2):463–466.

Duckett JW. MAGPI (meatoplasty and glanuloplasty): a procedure for subcoronal hypospadias. *Urol Clin North Am*. 1981;8(3):513–519.

Duckett JW. The current hype in hypospadiology. *Br J Urol*. 1995;76(Suppl 3):1–7.

Duckett JW, Keating MA. Technical challenge of the megameatus intact prepuce hypospadias variant: the pyramid procedure. *J Urol*. 1989;141(6):1407–1409.

Duckett JW, Snyder HM 3rd. Meatal advancement and glanuloplasty hypospadias repair after 1,000 cases: avoidance of meatal stenosis and regression. *J Urol*. 1992;147(3):665–669.

Duckett JW, Coplen D, Ewalt D, et al. Buccal mucosal urethral replacement. *J Urol*. 1995;153(5):1660–1663.

Duckett JW Jr. Transverse preputial island flap technique for repair of severe hypospadias. *Urol Clin North Am*. 1980;7(2):423–430.

Duckett JW Jr. Hypospadias. *Pediatr Rev*. 1989;11(2):37–42.

Duel BP, Barthold JS, Gonzalez R. Management of urethral strictures after hypospadias repair. *J Urol*. 1998;160(1):170–171.

Duplay S. De I'hypospadias perineo-scrotal et de son traitement chirgucal. *Arch Gen Med*. 1874;1:613.

el-Kassaby AW, Al-Kandari AM, Elzayat T, et al. Modified tubularized incised plate urethroplasty for hypospadias repair: a long-term results of 764 patients. *Urology*. 2008;71(4):611–615.

Eardley I, Whitaker RH. Surgery for hypospadias fistula. *Br J Urol*. 1992;69(3):306–310.

Eassa W, He X, El-Sherbiny M. How much does the midline incision add to urethral diameter after tubularized incised plate urethroplasty? An experimental animal study. *J Urol*. 2011;186(Suppl 4):1625–1629.

Ehle JJ, Cooper CS, Peche WJ, et al. Application of the Cecil-Culp repair for treatment of urethrocutaneous fistulas after hypospadias surgery. *Urology*. 2001;57(2):347–350.

Ehrlich RM, Reda EF, Koyle MA, et al. Complications of bladder mucosal graft. *J Urol*. 1989;142(2 Pt 2):626–627 [discussion 631].

Eisenberg ML, Hsieh MH, Walters RC, et al. The relationship between anogenital distance, fatherhood, and fertility in adult men. *PLoS ONE*. 2011;6(5) [e18973].

Elbakry A, Shamaa M, Al-Atrash G. An axially vascularized meatal-based flap for the repair of hypospadias. *Br J Urol*. 1998;82(5):698–703.

Elliott CS, Halpern MS, Paik J, et al. Epidemiologic trends in penile anomalies and hypospadias in the state of California, 1985-2006. *J Pediatr Urol*. 2011;7(3):294–298.

Eppley BL, Keating M, Rink R. A buccal mucosal harvesting technique for urethral reconstruction. *J Urol*. 1997;157(4):1268–1270.

Faasse MA, Johnson EK, Bowen DK, et al. Is glans penis width a risk factor for complications after hypospadias repair? *J Pediatr Urol*. 2016;12(4):202.e1–202.e5.

Fahmy O, Khairul-Asri MG, Schwentner C, et al. Algorithm for optimal urethral coverage in hypospadias and fistula repair: a systematic review. *Eur Urol*. 2016;70(2):293–298.

Fam MM, Hanna MK. Resurfacing the penis of complex hypospadias repair (“Hypospadias Cripples”). *J Urol*. 2017;197(3 Pt 2):859–864.

Faure A, Bouty A, Nyo YL, et al. Two-stage graft urethroplasty for proximal and complicated hypospadias in children: a retrospective study. *J Pediatr Urol*. 2016;12(5):286.e281–286.e287.

Ferro F, Zaccara A, Spagnoli A, et al. Skin graft for 2-stage treatment of severe hypospadias: back to the future? *J Urol*. 2002;168(4 Pt 2):1730–1733 [discussion 1733].

Fichtner J, Filipas D, Mottrie AM, et al. Analysis of meatal location in 500 men: wide variation questions need for meatal advancement in all pediatric anterior hypospadias cases. *J Urol*. 1995;154(2 Pt 2):833–834.

Figueroa V, de Jesus LE, Romao RL, et al. Buccal grafts for urethroplasty in pre-pubertal boys: what happens to the neourethra after puberty? *J Pediatr Urol*. 2014;10(5):850–853.

Firlit CF. The mucosal collar in hypospadias surgery. *J Urol*. 1987;137(1):80–82.

Fredell L, Iselius L, Collins A, et al. Complex segregation analysis of hypospadias. *Hum Genet*. 2002;111(3):231–234.

Friedman HI, Fitzmaurice M, Lefaivre JF, et al. An evidence-based appraisal of the use of hyperbaric oxygen on flaps and grafts. *Plast Reconstr Surg*. 2006;117(Suppl 7):175S–190S [discussion 191S–192S].

Funke S, Flach E, Kiss I, et al. Male reproductive tract abnormalities: more common after assisted reproduction? *Early Hum Dev*. 2010;86(9):547–550.

Gargollo PC, Cai AW, Borer JG, et al. Management of recurrent urethral strictures after hypospadias repair: is there a role for repeat dilation or endoscopic incision? *J Pediatr Urol*. 2011;7(1):34–38.

Gaspari L, Sampaio DR, Paris F, et al. High prevalence of micropenis in 2710 male newborns from an intensive-use pesticide area of Northeastern Brazil. *Int J Androl*. 2012;35(3):253–264.

Gatti JM, Kirsch AJ, Troyer WA, et al. Increased incidence of hypospadias in small-for-gestational age infants in a neonatal intensive-care unit. *BJU Int*. 2001;87(6):548–550.

Gawande A. *Personal best: top athletes and singers have coaches. Should you?*. *The New Yorker*. 2011.

Gearhart JP, Jeffs RD. The use of parenteral testosterone therapy in genital reconstructive surgery. *J Urol*. 1987;138(4 Pt 2):1077–1078.

Gershbaum MD, Stock JA, Hanna MK. A case for 2-stage repair of perineoscrotal hypospadias with severe chordee. *J Urol*. 2002;168(4 Pt 2):1727–1728 [discussion 1729].

Ghirri P, Scaramuzzo RT, Bertelloni S, et al. Prevalence of hypospadias in Italy according to severity, gestational age and birthweight: an epidemiological study. *Ital J Pediatr*. 2009;35:18.

Gilliver SC, Ruckshanthi JP, Hardman MJ, et al. 5alpha-dihydrotestosterone (DHT) retards wound closure by inhibiting re-epithelialization. *J Pathol*. 2009;217(1):73–82.

Gittes RF, McLaughlin AP 3rd. Injection technique to induce penile erection. *Urology*. 1974;4(4):473–474.

Glenister TW. The origin and fate of the urethral plate in man. *J Anat*. 1954;88(3):413–425.

Gong EM, Cheng EY. Current challenges with proximal hypospadias: we have a long way to go. *J Pediatr Urol*. 2017;13(5):457–467.

Gorduza DB, Gay CL, de Mattos ESE, et al. Does androgen stimulation prior to hypospadias surgery increase the rate of healing complications? A preliminary report. *J Pediatr Urol*. 2011;7(2):158–161.

Gray LE Jr, Kelce WR. Latent effects of pesticides and toxic substances on sexual differentiation of rodents. *Toxicol Ind Health*. 1996;12(3–4):515–531.

Grosos C, Bensaid R, Gorduza DB, et al. Is it safe to solely use ventral penile tissues in hypospadias repair? Long-term outcomes of 578 Duplay urethroplasties performed in a single institution over a period of 14 years. *J Pediatr Urol*. 2014;10(6):1232–1237.

Hadidi AT. The slit-like adjusted Mathieu technique for distal hypospadias. *J Pediatr Surg*. 2012;47(3):617–623.

Hakim S, Merguerian PA, Rabinowitz R, et al. Outcome analysis of the modified Mathieu hypospadias repair: comparison of stented and unstented repairs. *J Urol*. 1996;156(2 Pt 2):836–838.

Hatch DA, Maizels M, Zaontz MR, et al. Hypospadias hidden by a complete prepuce. *Surg Gynecol Obstet*. 1989;169(3):233–234.

Hayes TB, Collins A, Lee M, et al. Hermaphroditic, demasculinized frogs after exposure to the herbicide atrazine at low ecologically relevant doses. *Proc Natl Acad Sci USA*. 2002;99(8):5476–5480.

Heaton BW, Snow BW, Cartwright PC. Repair of urethral diverticulum by plication. *Urology*. 1994;44(5):749–752.

Hendren WH, Reda EF. Bladder mucosa graft for construction of male urethra. *J Pediatr Surg*. 1986;21(3):189–192.

Hensle TW, Tennenbaum SY, Reiley EA, et al. Hypospadias repair in adults: adventures and misadventures. *J Urol*. 2001;165(1):77–79.

Hensle TW, Kearney MC, Bingham JB. Buccal mucosa grafts for hypospadias surgery: long-term results. *J Urol*. 2002;168(4 Pt 2):1734–1736 [discussion 1736–1737].

Hester AG, Kogan SJ. The prostatic utricle: an under-recognized condition resulting in significant morbidity in boys with both hypospadias and normal external genitalia. *J Pediatr Urol*. 2017;13(5):492.e491–492.e495.

Hjertkvist M, Damber JE, Bergh A. Cryptorchidism: a registry based study in Sweden on some factors of possible aetiological importance. *J Epidemiol Community Health*. 1989;43(4):324–329.

Holland AJ, Smith GH, Ross FI, et al. HOSE: an objective scoring system for evaluating the results of hypospadias surgery. *BJU Int*. 2001;88(3):255–258.

Holland AJ, Abubacker M, Smith GH, et al. Management of urethrocutaneous fistula following hypospadias repair. *Pediatr Surg Int*. 2008;24(9):1047–1051.

Horowitz M, Salzhauer E. The ‘learning curve’ in hypospadias surgery. *BJU Int*. 2006;97(3):593–596.

Hsieh MH, Wildenfels P, Gonzales ET Jr. Surgical antibiotic practices among pediatric urologists in the United States. *J Pediatr Urol*. 2011;7(2):192–197.

Hsieh MH, Eisenberg ML, Hittelman AB, et al. Caucasian male infants and boys with hypospadias exhibit reduced anogenital distance. *Hum Reprod*. 2012;27(6):1577–1580.

Hughes IA, Houk C, Ahmed SF, et al. Consensus statement on management of intersex disorders. [the; Lawson Wilkins Pediatric Endocrine Society/European Society for Paediatric Endocrinology Consensus Group] *J Pediatr Urol*. 2006;2(3):148–162.

Husmann DA, Rathbun SR. Long-term followup of visual internal urethrotomy for management of short (less than 1 cm) penile urethral strictures following hypospadias repair. *J Urol*. 2006;176(4 Pt 2):1738–1741.

Hussain N, Chaghtai A, Herndon CD, et al. Hypospadias and early gestation growth restriction in infants. *Pediatrics*. 2002;109(3):473–478.

Jain VG, Singal AK. Shorter anogenital distance correlates with undescended testis: a detailed genital anthropometric analysis in human newborns. *Hum Reprod*. 2013;28(9):2343–2349.

Jayanthi VR, Ching CB, DaJusta DG, et al. The modified Ulaanbaatar procedure: reduced complications and enhanced cosmetic outcome for the most severe cases of hypospadias. *J Pediatr Urol*. 2017;13(4):353.e351–353.e357.

Jevtovic-Todorovic V, Hartman RE, Izumi Y, et al. Early exposure to common anesthetic agents causes widespread neurodegeneration in the developing rat brain and persistent learning deficits. *J Neurosci*. 2003;23(3):876–882.

Jiao C, Wu R, Xu X, et al. Long-term outcome of penile appearance and sexual function after hypospadias repairs: situation and relation. *Int Urol Nephrol*. 2011;43(1):47–54.

John Radcliffe Hospital Cryptorchidism Study Group. Cryptorchidism: a prospective study of 7500 consecutive male births, 1984-8. *Arch Dis Child*. 1992;67(7):892–899.

Joshi RS, Shrivastava D, Grady R, et al. A model for sustained collaboration to address the unmet global burden of bladder exstrophy-epispadis complex and penopubic epispadis: the international bladder exstrophy consortium. *JAMA Surg*. 2018;153(7):618–624.

Kaefer M, Diamond D, Hendren WH, et al. The incidence of intersexuality in children with cryptorchidism and hypospadias: stratification based on gonadal palpability and meatal position. *J Urol*. 1999;162(3 Pt 2):1003–1006 [discussion 1006–1007].

Kajbafzadeh AM, Sina A, Payabvash S. Management of multiple failed repairs of the phallus using tissue expanders: long-term postpubertal results. *J Urol*. 2007;177(5):1872–1877.

Kalfa N, Philibert P, Baskin LS, et al. Hypospadias: interactions between environment and genetics. *Mol Cell Endocrinol*. 2011;335(2):89–95.

Kalfa N, Paris F, Philibert P, et al. Is hypospadias associated with prenatal exposure to endocrine disruptors? A French collaborative controlled study of a cohort of 300 consecutive children without genetic defect. *Eur Urol*. 2015;68(6):1023–1030.

Kanaroglou N, Wehbi E, Alotay A, et al. Is there a role for prophylactic antibiotics after stented hypospadias repair? *J Urol*. 2013;190(Suppl 4):1535–1539.

Kara O, Malkoç E, Dursun F, et al. The effectiveness of adjuvant hyperbaric oxygen therapy in adults who underwent hypospadias surgery. *J Clin Anal Med*. 2017;8(1):60–63.

Kaya C, Bektic J, Radmayr C, et al. The efficacy of dihydrotestosterone transdermal gel before primary hypospadias surgery: a prospective, controlled, randomized study. *J Urol*. 2008;179(2):684–688.

Keating MA, Cartwright PC, Duckett JW. Bladder mucosa in urethral reconstructions. *J Urol*. 1990;144(4):827–834.

Kendigelen P, Tutuncu AC, Emre S, et al. Pudendal versus caudal block in children undergoing hypospadias surgery: a randomized controlled trial. *Reg Anesth Pain Med*. 2016;41(5):610–615.

Khuri FJ, Hardy BE, Churchill BM. Urologic anomalies associated with hypospadias. *Urol Clin North Am*. 1981;8(3):565–571.

Kim KS, Liu W, Cunha GR, et al. Expression of the androgen receptor and 5 alpha-reductase type 2 in the developing human fetal penis and urethra. *Cell Tissue Res*. 2002;307(2):145–153.

Kim MH, Im YJ, Kil HK, et al. Impact of caudal block on postoperative complications in children undergoing tubularised incised plate urethroplasty for hypospadias repair: a retrospective cohort study. *Anaesthesia*. 2016;71(7):773–778.

King LR. Hypospadias–a one-stage repair without skin graft based on a new principle: chordee is sometimes produced by the skin alone. *J Urol*. 1970;103(5):660–662.

King LR. Bladder mucosal grafts for severe hypospadias: a successful technique. *J Urol*. 1994;152(6 Pt 2):2338–2340.

Kinkead TM, Borzi PA, Duffy PG, et al. Long-term followup of bladder mucosa graft for male urethral reconstruction. *J Urol*. 1994;151(4):1056–1058.

Kiss A, Csontai A, Pirot L, et al. The response of balanitis xerotica obliterans to local steroid application compared with placebo in children. *J Urol*. 2001;165(1):219–220.

Koff SA. Mobilization of the urethra in the surgical treatment of hypospadias. *J Urol*. 1981;125(3):394–397.

Kogan BA. Intraoperative pharmacological erection as an aid to pediatric hypospadias repair. *J Urol*. 2000;164(6):2058–2061.

Kolon TF, Gonzales ET Jr. The dorsal inlay graft for hypospadias repair. *J Urol*. 2000;163(6):1941–1943.

Kolon TF, Herndon CD, Baker LA, et al. Evaluation and treatment of cryptorchidism: AUA guideline. *J Urol*. 2014;192(2):337–345.

Kramer SA, Aydin G, Kelalis PP. Chordee without hypospadias in children. *J Urol*. 1982;128(3):559–561.

Kundra P, Yuvaraj K, Agrawal K, et al. Surgical outcome in children undergoing hypospadias repair under caudal epidural vs penile block. *Paediatr Anaesth*. 2012;22(7):707–712.

Kurzrock EA, Baskin LS, Cunha GR. Ontogeny of the male urethra: theory of endodermal differentiation. *Differentiation*. 1999;64(2):115–122.

Lane C, Boxall J, MacLellan D, et al. A population-based study of prevalence trends and geospatial analysis of hypospadias and cryptorchidism compared with non-endocrine mediated congenital anomalies. *J Pediatr Urol*. 2017;13(3):284.e281–284.e287.

Lee OT, Durbin-Johnson B, Kurzrock EA. Predictors of secondary surgery after hypospadias repair: a population based analysis of 5,000 patients. *J Urol*. 2013;190(1):251–255.

Leslie B, Lorenzo AJ, Figueroa V, et al. Critical outcome analysis of staged buccal mucosa graft urethroplasty for prior failed hypospadias repair in children. *J Urol*. 2011;185(3):1077–1082.

Levine LA, Strom KH, Lux MM. Buccal mucosa graft urethroplasty for anterior urethral stricture repair: evaluation of the impact of stricture location and lichen sclerosus on surgical outcome. *J Urol*. 2007;178(5):2011–2015.

Li Y, Sinclair A, Cao M, et al. Canalization of the urethral plate precedes fusion of the urethral folds during male penile urethral development: the double zipper hypothesis. *J Urol*.

2015;193(4):1353–1359.

Long CJ, Canning DA. Hypospadias: are we as good as we think when we correct proximal hypospadias? *J Pediatr Urol*. 2016.

Long CJ, Canning DA. Proximal hypospadias: we aren't always keeping our promises. *F1000Res*. 2016;5.

Long CJ, Chu DI, Tenney RW, et al. Intermediate-term followup of proximal hypospadias repair reveals high complication rate. *J Urol*. 2017;197(3 Pt 2):852–858.

Lorenzo AJ, Snodgrass WT. Regular dilatation is unnecessary after tubularized incised-plate hypospadias repair. *BJU Int*. 2002;89(1):94–97.

Lorenzo AJ, Braga LH, Zlateska B, et al. Analysis of decisional conflict among parents who consent to hypospadias repair: single institution prospective study of 100 couples. *J Urol*. 2012;188(2):571–575.

Lorenzo AJ, Pippi Salle JL, Zlateska B, et al. Decisional regret after distal hypospadias repair: single institution prospective analysis of factors associated with subsequent parental remorse or distress. *J Urol*. 2014;191(Suppl 5):1558–1563.

Lu W, Tao Y, Wisniewski AB, et al. Different outcomes of hypospadias surgery between North America, Europe and China: is patient age a factor? *Nephrourol Mon*. 2012;4(4):609–612.

Lumen N, Vierstraete-Verlinde S, Oosterlinck W, et al. Buccal versus lingual mucosa graft in anterior urethroplasty: a prospective comparison of surgical outcome and donor site morbidity. *J Urol*. 2016;195(1):112–117.

Lund L, Engebjerg MC, Pedersen L, et al. Prevalence of hypospadias in Danish boys: a longitudinal study, 1977-2005. *Eur Urol*. 2009;55(5):1022–1026.

Luo CC, Lin JN, Chiu CH, et al. Use of parenteral testosterone prior to hypospadias surgery. *Pediatr Surg Int*. 2003;19(1–

2):82–84.

Maarouf AM, Elsayed ER, Ragab A, et al. Buccal versus lingual mucosal graft urethroplasty for complex hypospadias repair. *J Pediatr Urol*. 2013;9(6 Pt A):754–758.

Malik RD, Liu DB. Survey of pediatric urologists on the preoperative use of testosterone in the surgical correction of hypospadias. *J Pediatr Urol*. 2014;10(5):840–843.

Manzoni G, Bracka A, Palminteri E, et al. Hypospadias surgery: when, what and by whom? *BJU Int*. 2004;94(8):1188–1195.

Marte A, Di Iorio G, De Pasquale M. MAGPI procedure in meatal regression after hypospadias repair. *Eur J Pediatr Surg*. 2001;11(4):259–262.

Mattos RM, Araujo SR, Quitzan JG, et al. Can a graft be placed over a flap in complex hypospadias surgery? An experimental study in rabbits. *Int Braz J Urol*. 2016;42(6):1228–1236.

McNamara ER, Schaeffer AJ, Logvinenko T, et al. Management of proximal hypospadias with 2-stage repair: 20-year experience. *J Urol*. 2015;194(4):1080–1085.

McQuaid JW, Johnson EK, Andrews E, et al. The efficacy of congenital penile curvature repair in preadolescent males: early outcomes. *Urology*. 2016;92:95–99.

Meir DB, Livne PM. Is prophylactic antimicrobial treatment necessary after hypospadias repair? *J Urol*. 2004;171(6 Pt 2):2621–2622.

Memmelaar J. Use of bladder mucosa in a one-stage repair of hypospadias. *J Urol*. 1947;58(1):68–73.

Menon P, Rao KLN, Handu A, et al. Outcome of urethroplasty after parenteral testosterone in children with distal hypospadias. *J Pediatr Urol*. 2017;13(3):292.e291–292.e297.

Menon V, Breyer B, Copp HL, et al. Do adult men with untreated ventral penile curvature have adverse outcomes? *J Pediatr Urol*. 2016;12(1):31.e1–31.e7.

Merriman LS, Arlen AM, Broecker BH, et al. The GMS hypospadias score: assessment of inter-observer reliability and correlation with post-operative complications. *J Pediatr Urol*. 2013;9(6 Pt A):707–712.

Metro MJ, Wu HY, Snyder HM 3rd, et al. Buccal mucosal grafts: lessons learned from an 8-year experience. *J Urol*. 2001;166(4):1459–1461.

Mir T, Simpson RL, Hanna MK. The use of tissue expanders for resurfacing of the penis for hypospadias cripples. *Urology*. 2011;78(6):1424–1429.

Miyagawa S, Matsumaru D, Murashima A, et al. The role of sonic hedgehog-Gli2 pathway in the masculinization of external genitalia. *Endocrinology*. 2011;152(7):2894–2903.

Mokhless IA, Kader MA, Fahmy N, et al. The multistage use of buccal mucosa grafts for complex hypospadias: histological changes. *J Urol*. 2007;177(4):1496–1499 [discussion 1499–1500].

Moreno-Garcia M, Miranda EB. Chromosomal anomalies in cryptorchidism and hypospadias. *J Urol*. 2002;168(5):2170–2172 [discussion 2172].

Morey AF, McAninch JW. Technique of harvesting buccal mucosa for urethral reconstruction. *J Urol*. 1996;155(5):1696–1697.

Moriya K, Nakamura M, Nishimura Y, et al. Factors affecting post-pubertal penile size in patients with hypospadias. *World J Urol*. 2016;34:1317–1321.

Morrison K, Herbst K, Corbett S, et al. Pain management practice patterns for common pediatric urology procedures. *Urology*. 2014;83(1):206–210.

Mureau MA, Slijper FM, Nijman RJ, et al. Psychosexual adjustment of children and adolescents after different types of hypospadias surgery: a norm-related study. *J Urol*. 1995;154(5):1902–1907.

Mureau MA, Slijper FM, Slob AK, et al. Satisfaction with penile appearance after hypospadias surgery: the patient and surgeon view. *J Urol*. 1996;155(2):703–706.

Mustarde JC. One-stage correction of distal hypospadias: and other people's fistulae. *Br J Plast Surg*. 1965;18(4):413–422.

Myers JB, McAninch JW, Erickson BA, et al. Treatment of adults with complications from previous hypospadias surgery. *J Urol*. 2012;188(2):459–463.

Neal DE Jr, Orihuela E, Crotty K, et al. Laser ablation of urethral hair. *Lasers Surg Med*. 1999;24(4):261–263.

Nerli RB, Koura A, Prabha V, et al. Comparison of topical versus parenteral testosterone in children with microphallic hypospadias. *Pediatr Surg Int*. 2009;25(1):57–59.

Nesbit RM. Congenital curvature of the phallus: report of three cases with description of corrective operation. *J Urol*. 1965;93:230–232.

Netto JM, Ferrarez CE, Schindler Leal AA, et al. Hormone therapy in hypospadias surgery: a systematic review. *J Pediatr Urol*. 2013;9(6 Pt B):971–979.

Nordenvall AS, Frisen L, Nordenstrom A, et al. Population based nationwide study of hypospadias in Sweden, 1973 to 2009: incidence and risk factors. *J Urol*. 2014;191(3):783–789.

Nozohoor Ekmark A, Svensson H, Arnbjornsson E, et al. Failed hypospadias repair: an algorithm for secondary reconstruction using remaining local tissue. *J Plast Reconstr Aesthet Surg*. 2015;68(11):1600–1609.

Ortqvist L, Fossum M, Andersson M, et al. Sexuality and fertility in men with hypospadias; improved outcome. *Andrology*. 2017;5(2):286–293.

Ozkuvanci U, Ziylan O, Donmez MI, et al. An unanswered question in pediatric urology: the post pubertal persistence of prepubertal congenital penile curvature correction by tunical plication. *Int Braz J Urol*. 2017;43(5):925–931.

Paiva KC, Bastos AN, Miana LP, et al. Biometry of the hypospadic penis after hormone therapy (testosterone and estrogen): a randomized, double-blind controlled trial. *J Pediatr Urol*. 2016.

Park MK, Myers RA, Marzella L. Oxygen tensions and infections: modulation of microbial growth, activity of antimicrobial agents, and immunologic responses. *Clin Infect Dis*. 1992;14(3):720–740.

Patel RP, Shukla AR, Leone NT, et al. Split onlay skin flap for the salvage hypospadias repair. *J Urol*. 2005;173(5):1718–1720.

Paulozzi LJ. International trends in rates of hypospadias and cryptorchidism. *Environ Health Perspect*. 1999;107(4):297–302.

Perlmutter AE, Morabito R, Tarry WF. Impact of patient age on distal hypospadias repair: a surgical perspective. *Urology*. 2006;68(3):648–651.

Pfistermuller KL, McArdle AJ, Cuckow PM. Meta-analysis of complication rates of the tubularized incised plate (TIP) repair. *J Pediatr Urol*. 2015;11(2):54–59.

Pinyavat T, Warner DO, Flick RP, et al. Summary of the update session on clinical neurotoxicity studies. *J Neurosurg Anesthesiol*. 2016;28(4):356–360.

Pippi Salle JL, Sayed S, Salle A, et al. Proximal hypospadias: a persistent challenge. Single institution outcome analysis of three surgical techniques over a 10-year period. *J Pediatr Urol*. 2016;12(1):28.e1–28.e7.

Prat D, Natasha A, Polak A, et al. Surgical outcome of different types of primary hypospadias repair during three decades in a single center. *Urology*. 2012;79(6):1350–1353.

Radojicic ZI, Perovic SV, Stojanoski KD. Calibration and dilatation with topical corticosteroid in the treatment of stenosis of neourethral meatus after hypospadias repair. *BJU*

Int. 2006;97(1):166–168.

Radojicic ZI, Perovic SV, Djordjevic ML, et al. ‘Pseudospongioplasty’ in the repair of a urethral diverticulum. *BJU Int*. 2004;94(1):126–130.

Rajfer J, Walsh PC. The incidence of intersexuality in patients with hypospadias and cryptorchidism. *J Urol*. 1976;116(6):769–770.

Redman JF. Results of undiverted simple closure of 51 urethrocutaneous fistulas in boys. *Urology*. 1993;41(4):369–371.

Retik AB, Bauer SB, Mandell J, et al. Management of severe hypospadias with a 2-stage repair. *J Urol*. 1994;152(2 Pt 2):749–751.

Rich MA, Keating MA, Snyder HM, et al. Hinging the urethral plate in hypospadias meatoplasty. *J Urol*. 1989;142(6):1551–1553.

Rochlin DH, Zhang K, Gearhart JP, et al. Utility of tissue expansion in pediatric phallic reconstruction: a 10-year experience. *J Pediatr Urol*. 2014;10(1):142–147.

Rohatgi M, Menon PS, Verma IC, et al. The presence of intersexuality in patients with advanced hypospadias and undescended gonads. *J Urol*. 1987;137(2):263–267.

Rourke K, McKinny S, St Martin B. Effect of wound closure on buccal mucosal graft harvest site morbidity: results of a randomized prospective trial. *Urology*. 2012;79(2):443–447.

Routh JC, Wolpert JJ, Reinberg Y. Tunneled tunica vaginalis flap for recurrent urethrocutaneous fistulae. *Adv Urol*. 2008.

Ruppen-Greeff NK, Landolt MA, Gobet R, et al. Appraisal of adult genitalia after hypospadias repair: do laypersons mind the difference? *J Pediatr Urol*. 2016;12(1):32.e1–32.e8.

Rushton HG, Belman AB. The split prepuce in situ onlay hypospadias repair. *J Urol*. 1998;160(3 Pt 2):1134–1136 [discussion 1137].

Rynja SP, de Jong TP, Bosch JL, et al. Functional, cosmetic and psychosexual results in adult men who underwent hypospadias correction in childhood. *J Pediatr Urol*. 2011;7(5):504–515.

Saavedra-Belaunde JA, Soto-Aviles O, Jorge J, et al. Can regional anesthesia have an effect on surgical outcomes in patients undergoing distal hypospadia surgery? *J Pediatr Urol*. 2017;13(1):45.e41–45.e44.

Safwat AS, Elderwy A, Hammouda HM. Which type of urethroplasty in failed hypospadias repair? An 8-year follow up. *J Pediatr Urol*. 2013;9(6 Pt B):1150–1154.

Samuel M, Hampson-Evans D, Cunnington P. Prospective to a randomized double-blind controlled trial to assess efficacy of double caudal analgesia in hypospadias repair. *J Pediatr Surg*. 2002;37(2):168–174.

Sandberg DE, Meyer-Bahlburg HF, Aranoff GS, et al. Boys with hypospadias: a survey of behavioral difficulties. *J Pediatr Psychol*. 1989;14(4):491–514.

Sander AL, Henrich D, Muth CM, et al. In vivo effect of hyperbaric oxygen on wound angiogenesis and epithelialization. *Wound Repair Regen*. 2009;17(2):179–184.

Santangelo K, Rushton HG, Belman AB. Outcome analysis of simple and complex urethrocutaneous fistula closure using a de-epithelialized or full thickness skin advancement flap for coverage. *J Urol*. 2003;170(4 Pt 2):1589–1592 [discussion 1592].

Santucci R, Eisenberg L. Urethrotomy has a much lower success rate than previously reported. *J Urol*. 2010;183(5):1859–1862.

Savanelli A, Esposito C, Settimi A. A prospective randomized comparative study on the use of ventral subcutaneous flap to prevent fistulas in the Snodgrass repair for distal hypospadias. *World J Urol*. 2007;25(6):641–645.

Scheuer S, Hanna MK. Effect of nitroglycerin ointment on penile skin flap survival in hypospadias repair. Experimental and clinical studies. *Urology*. 1986;27(5):438–440.

Schlomer B, Breyer B, Copp H, et al. Do adult men with untreated hypospadias have adverse outcomes? A pilot study using a social media advertised survey. *J Pediatr Urol*. 2014;10(4):672–679.

Schnack TH, Zdravkovic S, Myrup C, et al. Familial aggregation of hypospadias: a cohort study. *Am J Epidemiol*. 2008;167(3):251–256.

Schroder A, Campbell FA, Farhat WA, et al. Postoperative pain and analgesia administration in children after urological outpatient procedures. *J Pediatr Urol*. 2018;14(2):171.e171–171.e176.

Schultz JR, Klykylo WM, Wacksman J. Timing of elective hypospadias repair in children. *Pediatrics*. 1983;71(3):342–351.

Sekaran P, O'Toole S, Flett M, et al. Increased occurrence of disorders of sex development, prematurity and intrauterine growth restriction in children with proximal hypospadias associated with undescended testes. *J Urol*. 2013;189(5):1892–1896.

Shankar KR, Losty PD, Hopper M, et al. Outcome of hypospadias fistula repair. *BJU Int*. 2002;89(1):103–105.

Shaw JJ, Psoinos C, Emhoff TA, et al. Not just full of hot air: hyperbaric oxygen therapy increases survival in cases of necrotizing soft tissue infections. *Surg Infect (Larchmt)*. 2014;15(3):328–335.

Shen J, Overland M, Sinclair A, et al. Complex epithelial remodeling underlie the fusion event in early fetal development of the human penile urethra. *Differentiation*. 2016;92(4):169–182.

Shima H, Ikoma F, Terakawa T, et al. Developmental anomalies associated with hypospadias. *J Urol*. 1979;122(5):619–621.

Shohet I, Alagam M, Shafir R, et al. Postoperative catheterization and prophylactic antimicrobials in children with hypospadias. *Urology*. 1983;22(4):391–393.

Silver RI, Russell DW. 5alpha-reductase type 2 mutations are present in some boys with isolated hypospadias. *J Urol*. 1999;162(3 Pt 2):1142–1145.

Simmons GR, Cain MP, Casale AJ, et al. Repair of hypospadias complications using the previously utilized urethral plate. *Urology*. 1999;54(4):724–726.

Skakkebaek NE, Rajpert-De Meyts E, Main KM. Testicular dysgenesis syndrome: an increasingly common developmental disorder with environmental aspects. *Hum Reprod*. 2001;16(5):972–978.

Smith D. A de-epithelialised overlap flap technique in the repair of hypospadias. *Br J Plast Surg*. 1973;26(2):106–114.

Smith J, Patel A, Zamilpa I, et al. Analysis of preoperative antibiotic prophylaxis in stented, distal hypospadias repair. *Can J Urol*. 2017;24(2):8765–8769.

Snodgrass W. Tubularized, incised plate urethroplasty for distal hypospadias. *J Urol*. 1994;151(2):464–465.

Snodgrass W, Bush N. Tubularized incised plate proximal hypospadias repair: continued evolution and extended applications. *J Pediatr Urol*. 2011;7(1):2–9.

Snodgrass W, Bush N. Staged tubularized autograft repair for primary proximal hypospadias with 30-degree or greater ventral curvature. *J Urol*. 2017.

Snodgrass W, Bush NC. Re-operative urethroplasty after failed hypospadias repair: how prior surgery impacts risk for additional complications. *J Pediatr Urol*. 2017;13(3):289.e281–289.e286.

Snodgrass W, Yucel S. Tubularized incised plate for mid shaft and proximal hypospadias repair. *J Urol*. 2007;177(2):698–

702.

Snodgrass W, Macedo A, Hoebeke P, et al. Hypospadias dilemmas: a round table. *J Pediatr Urol*. 2011;7(2):145–157.

Snodgrass W, Villanueva C, Bush N. Primary and reoperative hypospadias repair in adults—are results different than in children? *J Urol*. 2014;192(6):1730–1733.

Snodgrass W, Villanueva C, Bush NC. Duration of follow-up to diagnose hypospadias urethroplasty complications. *J Pediatr Urol*. 2014;10(2):208–211.

Snodgrass W, Blanquel JS, Bush NC. Recurrence after management of meatal balanitis xerotica obliterans. *J Pediatr Urol*. 2017;13(2):204.e201–204.e206.

Snodgrass WT. Management of penile curvature in children. *Curr Opin Urol*. 2008;18(4):431–435.

Snodgrass WT, Khavari R. Prior circumcision does not complicate repair of hypospadias with an intact prepuce. *J Urol*. 2006;176(1):296–298.

Snodgrass WT, Lorenzo A. Tubularized incised-plate urethroplasty for proximal hypospadias. *BJU Int*. 2002;89(1):90–93.

Snodgrass WT, Bush N, Cost N. Algorithm for comprehensive approach to hypospadias reoperation using 3 techniques. *J Urol*. 2009;182(6):2885–2891.

Snodgrass WT, Granberg C, Bush NC. Urethral strictures following urethral plate and proximal urethral elevation during proximal TIP hypospadias repair. *J Pediatr Urol*. 2013;9(6 Pt B):990–994.

Snodgrass WT, Villanueva C, Granberg C, et al. Objective use of testosterone reveals androgen insensitivity in patients with proximal hypospadias. *J Pediatr Urol*. 2014;10(1):118–122.

Snow BW, Cartwright PC, Unger K. Tunica vaginalis blanket wrap to prevent urethrocutaneous fistula: an 8-year experience. *J Urol*. 1995;153(2):472–473.

Snyder CL, Evangelidis A, Hansen G, et al. Management of complications after hypospadias repair. *Urology*. 2005;65(4):782–785.

Snyder CL, Evangelidis A, Snyder RP, et al. Management of urethral diverticulum complicating hypospadias repair. *J Pediatr Urol*. 2005;1(2):81–83.

Soave A, Steurer S, Dahlem R, et al. Histopathological characteristics of buccal mucosa transplants in humans after engraftment to the urethra: a prospective study. *J Urol*. 2014;192(6):1725–1729.

Soliman MG, Ansara S, Laberge R. Caudal anaesthesia in paediatric patients. *Can Anaesth Soc J*. 1978;25(3):226–229.

Sorber M, Feitz WF, de Vries JD. Short- and mid-term outcome of different types of one-stage hypospadias corrections. *Eur Urol*. 1997;32(4):475–479.

Spinoit AF, Poelaert F, Groen LA, et al. Hypospadias repair at a tertiary care center: long-term followup is mandatory to determine the real complication rate. *J Urol*. 2013;189(6):2276–2281.

Spinoit AF, Poelaert F, Van Praet C, et al. Grade of hypospadias is the only factor predicting for re-intervention after primary hypospadias repair: a multivariate analysis from a cohort of 474 patients. *J Pediatr Urol*. 2015;11(2):70.e1–70.e6.

Springer A, Krois W, Horcher E. Trends in hypospadias surgery: results of a worldwide survey. *Eur Urol*. 2011;60(6):1184–1189.

Springer A, van den Heijkant M, Baumann S. Worldwide prevalence of hypospadias. *J Pediatr Urol*. 2015.

Stanasel I, Le HK, Bilgutay A, et al. Complications following staged hypospadias repair using transposed preputial skin flaps. *J Urol*. 2015;194(2):512–516.

Steckler RE, Zaontz MR. Stent-free Thiersch-Duplay hypospadias repair with the Snodgrass modification. *J Urol*.

1997;158(3 Pt 2):1178–1180.

Steven L, Cherian A, Yankovic F, et al. Current practice in paediatric hypospadias surgery; a specialist survey. *J Pediatr Urol*. 2013;9(6 Pt B):1126–1130.

Sugar EC, Firlit CF. Urinary prophylaxis and postoperative care of children at home with an indwelling catheter after hypospadias repair. *Urology*. 1988;32(5):418–420.

Sullivan KJ, Hunter Z, Andrioli V, et al. Assessing quality of life of patients with hypospadias: a systematic review of validated patient-reported outcome instruments. *J Pediatr Urol*. 2017;13(1):19–27.

Sun LS, Li G, Miller TL, et al. Association between a single general anesthesia exposure before age 36 months and neurocognitive outcomes in later childhood. *J Am Med Assoc*. 2016;315(21):2312–2320.

Sunay M, Dadali M, Karabulut A, et al. Our 23-year experience in urethrocutaneous fistulas developing after hypospadias surgery. *Urology*. 2007;69(2):366–368.

Swan SH, Main KM, Liu F, et al. Decrease in anogenital distance among male infants with prenatal phthalate exposure. *Environ Health Perspect*. 2005;113(8):1056–1061.

Taicher BM, Routh JC, Eck JB, et al. The association between caudal anesthesia and increased risk of postoperative surgical complications in boys undergoing hypospadias repair. *Paediatr Anaesth*. 2017;27(7):688–694.

Tang SH, Hammer CC, Doumanian L, et al. Adult urethral stricture disease after childhood hypospadias repair. *Adv Urol*. 2008.

Tang YM, Chen SJ, Huang LG, et al. Chordee without hypospadias: report of 79 Chinese prepubertal patients. *J Androl*. 2007;28(4):630–633.

Telfer JR, Quaba AA, Kwai Ben I, et al. An investigation into the role of waterproofing in a two-stage hypospadias repair.

Br J Plast Surg. 1998;51(7):542–546.

Thiersch C. Uber die Entsehungweise und operative Behandlung des Epispadie. *Arch Heilkd*. 1869;10.

Titley OG, Bracka A. A 5-year audit of trainees experience and outcomes with two-stage hypospadias surgery. *Br J Plast Surg*. 1998;51(5):370–375.

Toppari J, Larsen JC, Christiansen P, et al. Male reproductive health and environmental xenoestrogens. *Environ Health Perspect*. 1996;104(Suppl 4):741–803.

Toppari J, Virtanen HE, Main KM, et al. Cryptorchidism and hypospadias as a sign of testicular dysgenesis syndrome (TDS): environmental connection. *Birth Defects Res A Clin Mol Teratol*. 2010;88(10):910–919.

Ulman I, Erikci V, Avanoglu A, et al. The effect of suturing technique and material on complication rate following hypospadias repair. *Eur J Pediatr Surg*. 1997;7(3):156–157.

Uygur MC, Erol D, Germiyanoglu C. Lessons from 197 Mathieu hypospadias repairs performed at a single institution. *Pediatr Surg Int*. 1998;14(3):192–194.

van der Toorn F, de Jong TP, de Gier RP, et al. Introducing the HOPE (Hypospadias Objective Penile Evaluation)-score: a validation study of an objective scoring system for evaluating cosmetic appearance in hypospadias patients. *J Pediatr Urol*. 2013;9(6 Pt B):1006–1016.

Walsh TJ, Hotaling JM, Lue TF, et al. How curved is too curved? The severity of penile deformity may predict sexual disability among men with Peyronie's disease. *Int J Impot Res*. 2013;25(3):109–112.

Warwick RT, Parkhouse H, Chapple CR. Bulbar elongation anastomotic meatoplasty (BEAM) for subterminal and hypospadiac urethroplasty. *J Urol*. 1997;158(3 Pt 2):1160–1167.

Watcha MF, Jones MB, Lagueruela RG, et al. Comparison of ketorolac and morphine as adjuvants during pediatric surgery. *Anesthesiology*. 1992;76(3):368–372.

Weber DM, Schonbucher VB, Landolt MA, et al. The Pediatric Penile Perception Score: an instrument for patient self-assessment and surgeon evaluation after hypospadias repair. *J Urol*. 2008;180(3):1080–1084 [discussion 1084].

Weber DM, Schonbucher VB, Gobet R, et al. Is there an ideal age for hypospadias repair? A pilot study. *J Pediatr Urol*. 2009;5(5):345–350.

Webster GD, Brown MW, Koefoot RB Jr, et al. Suboptimal results in full thickness skin graft urethroplasty using an extrapenile skin donor site. *J Urol*. 1984;131(6):1082–1083.

Wehbi E, Patel P, Kanaroglou N, et al. Urinary tract abnormalities in boys with recurrent urinary tract infections after hypospadias repair. *BJU Int*. 2014;113(2):304–308.

Weidner IS, Moller H, Jensen TK, et al. Risk factors for cryptorchidism and hypospadias. *J Urol*. 1999;161(5):1606–1609.

Weiss DA, Long CJ, Frazier JR, et al. Back to the future: the Cecil-Culp technique for salvage penile reconstructive procedures. *J Pediatr Urol*. 2018.

Wennerholm UB, Bergh C, Hamberger L, et al. Incidence of congenital malformations in children born after ICSI. *Hum Reprod*. 2000;15(4):944–948.

White CM, Hanna MK. Salvaging the dehisced glans penis. *J Pediatr Urol*. 2018.

Wilkinson DJ, Farrelly P, Kenny SE. Outcomes in distal hypospadias: a systematic review of the Mathieu and tubularized incised plate repairs. *J Pediatr Urol*. 2012;8(3):307–312.

Wilson CA, Sommerfield D, Drake-Brockman TFE, et al. A prospective audit of pain profiles following general and urological surgery in children. *Paediatr Anaesth*.

2017;27(11):1155–1164.

Winslow BH, Vorstman B, Devine CJ Jr. Urethroplasty using diverticular tissue. *J Urol*. 1985;134(3):552–553.

Wong NC, Braga LH. The influence of pre-operative hormonal stimulation on hypospadias repair. *Front Pediatr*. 2015;3:31.

Wood DN, Allen SE, Andrich DE, et al. The morbidity of buccal mucosal graft harvest for urethroplasty and the effect of nonclosure of the graft harvest site on postoperative pain. *J Urol*. 2004;172(2):580–583.

Wood HM, Kay R, Angermeier KW, et al. Timing of the presentation of urethrocutaneous fistulas after hypospadias repair in pediatric patients. *J Urol*. 2008;180(Suppl 4):1753–1756.

Wu WH, Chuang JH, Ting YC, et al. Developmental anomalies and disabilities associated with hypospadias. *J Urol*. 2002;168(1):229–232.

Ye WJ, Ping P, Liu YD, et al. Single stage dorsal inlay buccal mucosal graft with tubularized incised urethral plate technique for hypospadias reoperations. *Asian J Androl*. 2008;10(4):682–686.

Yildiz T, Tahtali IN, Ates DC, et al. Age of patient is a risk factor for urethrocutaneous fistula in hypospadias surgery. *J Pediatr Urol*. 2013;9(6 Pt A):900–903.

Zaidi RH, Casanova NF, Haydar B, et al. Urethrocutaneous fistula following hypospadias repair: regional anesthesia and other factors. *Paediatr Anaesth*. 2015;25(11):1144–1150.

Zaontz MR. The GAP (glans approximation procedure) for glanular/coronal hypospadias. *J Urol*. 1989;141(2):359–361.

Zaontz MR, Dean GE. Glandular hypospadias repair. *Urol Clin North Am*. 2002;29(2):291–298 [v–vi].

Zaontz MR, Dean GE. Dermal patch graft correction of severe chordee secondary to penile corporal body disproportion without urethral division in boys without hypospadias. *J*

Pediatr Urol. 2016;12(4):204.

Zaontz MR, Kaplan WE, Maizels M. Surgical correction of anterior urethral diverticula after hypospadias repair in children. *Urology*. 1989;33(1):40–42.

Zeiai S, Nordenskjold A, Fossum M. Advantages of reduced prophylaxis after tubularized incised plate repair of hypospadias. *J Urol*. 2016;196(4):1244–1249.

Ziada A, Hamza A, Abdel-Rassoul M, et al. Outcomes of hypospadias repair in older children: a prospective study. *J Urol*. 2011;185(Suppl 6):2483–2485.

Etiology, Diagnosis, and Management of the Undescended Testis

Julia Spencer Barthold MD, Jennifer A. Hagerty DO

Introduction

Cryptorchidism, or undescended testis, is a common reproductive anomaly that is extensively studied yet incompletely understood. Testicular descent is a complex and prolonged event that is completed in the third trimester of gestation or soon after birth. The fetal structure that orchestrates descent of the testis, the gubernaculum, is anatomically well-characterized, but gaps in knowledge remain regarding its mechanical function during testicular descent. Genetic and/or environmental factors likely contribute to failure of testicular descent, but also these remain largely unknown. The available evidence suggests that susceptibility is complex and multifactorial, and may include both genetic factors and exposure to endocrine-disrupting chemicals (EDCs), potentially in combination. Cryptorchidism was traditionally considered a congenital anomaly identifiable at birth, but strong evidence now exists that an initial diagnosis well beyond the neonatal period is not uncommon. Clinically significant differences that affect long-term outcome, if any, between the acquired and congenital presentations of cryptorchidism remain obscure. Retractile testes may represent a milder form of the disease in some cases, conferring a higher risk for acquired cryptorchidism that is diagnosed later in childhood. Ultrasonography and other forms of imaging are rarely if ever needed for diagnosis, and hormonal therapy is no longer advocated as a first-line treatment for cryptorchidism. Present evidence supports surgery as the preferred treatment, with the specific approach depending on testicular palpability and position, size, patient age, and overall health status. Increasingly, primary scrotal and laparoscopic approaches are used and preferred. Suboptimal semen quality is common in bilateral cases, but can also occur in unilateral cryptorchidism, although paternity may be preserved. Risk for testicular germ cell tumor (TGCT) is increased in the affected, and to a lesser degree, contralateral testis but may be reduced by early surgery. Long-term outcome depends on laterality, age at treatment, and potentially, on the underlying etiology.

Definitions

As differing terminology is used to describe conditions related to normal and abnormal testicular descent and absence of a testis in the scrotum, we provide definitions for the following terms that are used throughout the chapter:

- ***Normal scrotal position*** has been defined as positioning of the midpoint of the testis at or below the midscrotum (Wohlfahrt-Veje et al., 2009). Although "high scrotal testes" are not routinely considered undescended by most clinicians, they have been included in the definition of undescended testis in some epidemiologic studies (Sijstermans et al., 2008). This is likely a heterogeneous group that includes stable descended testes that reside above the scrotal midpoint, retractile testes, and undescended "gliding" testes (Hack et al., 2007), which are not stable.
- ***Undescended testis*** or ***cryptorchidism*** is the absence of one or both testes in normal scrotal position and during initial clinical evaluation may refer to palpable or nonpalpable testes, which are either cryptorchid or absent. Testes may be arrested along the normal line of descent, or reside in an ***ectopic*** position outside the ipsilateral inguinal canal. Most absent testes are ***vanishing*** or ***vanished,*** present initially in development but lost as a result of vascular accident or torsion unilaterally ***(monorchia)*** or, very rarely, bilaterally ***(anorchia)*** (Abeyaratne et al., 1969).
- ***Agenesis*** refers to a testis that was never present, and therefore associated with ipsilateral müllerian duct persistence.
- ***Congenital cryptorchidism*** refers to a testis that is extrascrotal at birth.
- ***Acquired cryptorchidism*** is defined as a cryptorchid testis that was documented as scrotal at a previous examination.
- ***Recurrent cryptorchidism*** is defined as a cryptorchid testes that

was undescended at birth, descended spontaneously, and is subsequently extrascrotal.

- ***Secondary cryptorchidism*** and ***testicular retraction*** have been used to describe a testis that is suprascrotal after inguinal hernia repair or as a complication of orchidopexy, respectively. Testicular malposition after hernia repair could be caused by either primary maldescent or postoperative scarring.
- ***Retractile testes*** are scrotal testes that retract easily out of the scrotum but can be manually replaced in a stable scrotal position and remain there at least temporarily until there is recurrent stimulation. Testes that are significantly retractile, that is, those that rarely remain in a stable scrotal position (spontaneously or with manipulation) and/or are located at rest in the high scrotum may or may not be diagnosed as cases of acquired cryptorchidism on longitudinal examination.

Etiology

Embryology of Testicular Descent and Maldescent

Cryptorchidism represents a failure of testicular descent, which is in turn dependent on growth and hormonal function of the developing testis and its regulation of growth and function of the gubernaculum (Hutson et al., 2013, 2016; Virtanen and Toppari, 2014). Testicular descent is regulated by two Leydig cell hormones: insulin-like 3 (INSL3) via its receptor relaxin/insulin-like family peptide receptor 2 (RXFP2), and androgens (dihydrotestosterone [DHT] and testosterone) via the androgen receptor (AR). Descent also appears to require intact innervation of the gubernaculum by the genitofemoral nerve (GFN). Downstream effects and interactions, if any, between hormonal and neural pathways, are poorly defined. Altered expression or function of key molecules that participate in testicular and/or gubernacular development, as a result of genetic or environmental effects, likely contribute to cryptorchidism susceptibility.

Differentiation of the Testis

Gonadal differentiation is more complicated than the original concept of ovarian development as the default pathway. Activation of specific programs involving multiple genes is required for both male and female sex determination in mice (Capel, 2017; Rotgers et al., 2018; Sekido et al., 2013; Ungewitter and Yao, 2013). Although basic work has moved the field substantially forward in recent years, the mechanisms of cell-specific development in the testis remain incompletely understood (Svingen and Koopman, 2013). ***Sry*** **(sex-determining region on the Y chromosome) expression in the indifferent gonad triggers testicular development.** *Sry* “tips the balance” of antagonistic signaling between male and female pathways toward the male program (Capel, 2017) and is activated in part by steroidogenic factor 1 (SF1/*Nr5a1)*. In turn, SRY and SF1 proteins cooperate to promote prolonged expression of another transcription factor, *Sox9* (SRY box-containing 9), in pre-Sertoli supporting cells. SRY is important for Sertoli cell specification, but downstream testis-determining genes including *Sox9*, *Fgf9* (fibroblast growth factor 9), *Amh* (anti-Müllerian hormone), *Ptgds* (prostaglandin synthase), and likely others are required for Sertoli cell differentiation and proliferation (Kashimada and Koopman, 2010). Establishment of the Sertoli cell lineage is required for subsequent testicular cord formation. Studies in the fetal mouse indicate that patterning of the testis requires a temporal series of events that includes germ cell migration into the undiffererentiated gonad, and migration of interstitial cell precursors from the coelomic epithelium and the mesonephros (Combes et al., 2009; Cool et al., 2009; McClelland et al., 2012; Wainwright and Wilhelm, 2010).

In humans, gonads containing somatic and germ cells are first identified on the medial aspect of the urogenital ridge at 32 days postovulation (Hanley et al., 1999). At this sexually indifferent stage, the gonads and the internal and external genitalia are identical in males and females. Expression of *SRY* and *SOX9* transcripts begins at 40 days' gestation (Mamsen et al., 2017) and is followed by the histologic appearance of Sertoli cells (Ostrer et al., 2007). By 6 weeks' gestation, primordial germ cells (PGCs) migrate from the yolk sac, differentiate into gonocytes, and by 8 weeks are localized within the testicular cords (Culty, 2009). Gonocytes express c-KIT (mast/stem cell growth factor receptor Kit) beginning at 7 weeks, and their numbers increase further during the remainder of the first trimester (Ostrer et al., 2007). During the second trimester, three subpopulations of germ cells including gonocytes, intermediate spermatogonia, and prespermatogonia can be distinguished by immunostaining for specific markers (Gaskell et al., 2004). POU5F1 (POU domain class 5 homeobox 1, also known as OCT4) and c-KIT are expressed in the earlier lineages and disappear with loss of gonocytes by 20 weeks, and gain of MAGE-A4 (melanoma antigen, family A, 4) immunopositivity occurs with emergence of prespermatogonia (Culty 2009; Gaskell et al., 2004).

Two populations of Leydig cells exist in mammals, fetal and adult Leydig cells, which differ in appearance, function, and regulation (Martin, 2016; Teerds et al., 2015). Fetal Leydig cells (FLCs) arise from the coelomic epithelium and perivascular cells at the gonad-mesonephric border, which form interstitial Leydig cell progenitors (Rotgers et al., 2018). Recent evidence shows that these progenitors express AR and are regulated by androgens (Kaftanovskaya et al., 2015; Kilcoyne et al., 2014). FLC development is dependent on a wide variety of growth factors and developmental proteins and on paracrine interactions with Sertoli and peritubular myoid cells (reviewed in Martin, 2016; Rotgers et al., 2018). *Wt1* expression in mouse Sertoli cells contributes to proliferation and differentiation of peritubular myoid and Leydig cells (Wen et al., 2016). FLCs become active at 6 to 7 weeks, proliferate until about 15 weeks, and involute after 24 weeks (Codesal et al., 1990; Habert et al., 2001; O'Shaughnessy et al., 2007; Rotgers et al., 2018). Before the end of the first trimester of gestation, the external genitalia are completely masculinized, the testis cords are established, and subpopulations of both proliferating and degenerating germ cells exist. Sertoli and germ cell proliferation continues well into the second trimester (O'Shaughnessy et al., 2007).

Testicular Hormone Production

Hormonal function of the human fetal testis is critical for masculinization of the reproductive tract and testicular descent (Ivell et al., 2016). Activation of testicular hormone production occurs at discrete intervals during fetal, postnatal, and pubertal life (Fig. 46.1). In the fetus, Leydig cell development is divided into three phases: a proliferation and differentiation phase between 7 and 14 weeks, a maturation phase until 18 weeks, and an involution phase that continues until term (Svechnikov and Soder, 2008). Synthesis of testosterone by FLCs starts as early as 6 to 7 weeks and appears to be initially independent of gonadotropin stimulation. However, placental human chorionic gonadotropin (hCG) stimulates a peak in androgen production at 14 to 16 weeks, and the testis then becomes responsive to fetal luteinizing hormone (LH). Insulin-like 3 (INSL3) of Leydig cell origin is measurable in human amniotic fluid as early as 11 weeks, and production peaks at 15 to 17 weeks (Anand-Ivell et al., 2008, 2018; Bay et al., 2008; Ivell et al., 2016). Fetal Sertoli cells produce antimüllerian hormone (AMH; also called müllerian-inhibiting substance [MIS]) soon after they differentiate; the human fetal müllerian duct is responsive to AMH before 8 weeks, and the process of regression occurs between 9 and 10 weeks (Josso et al., 2006).

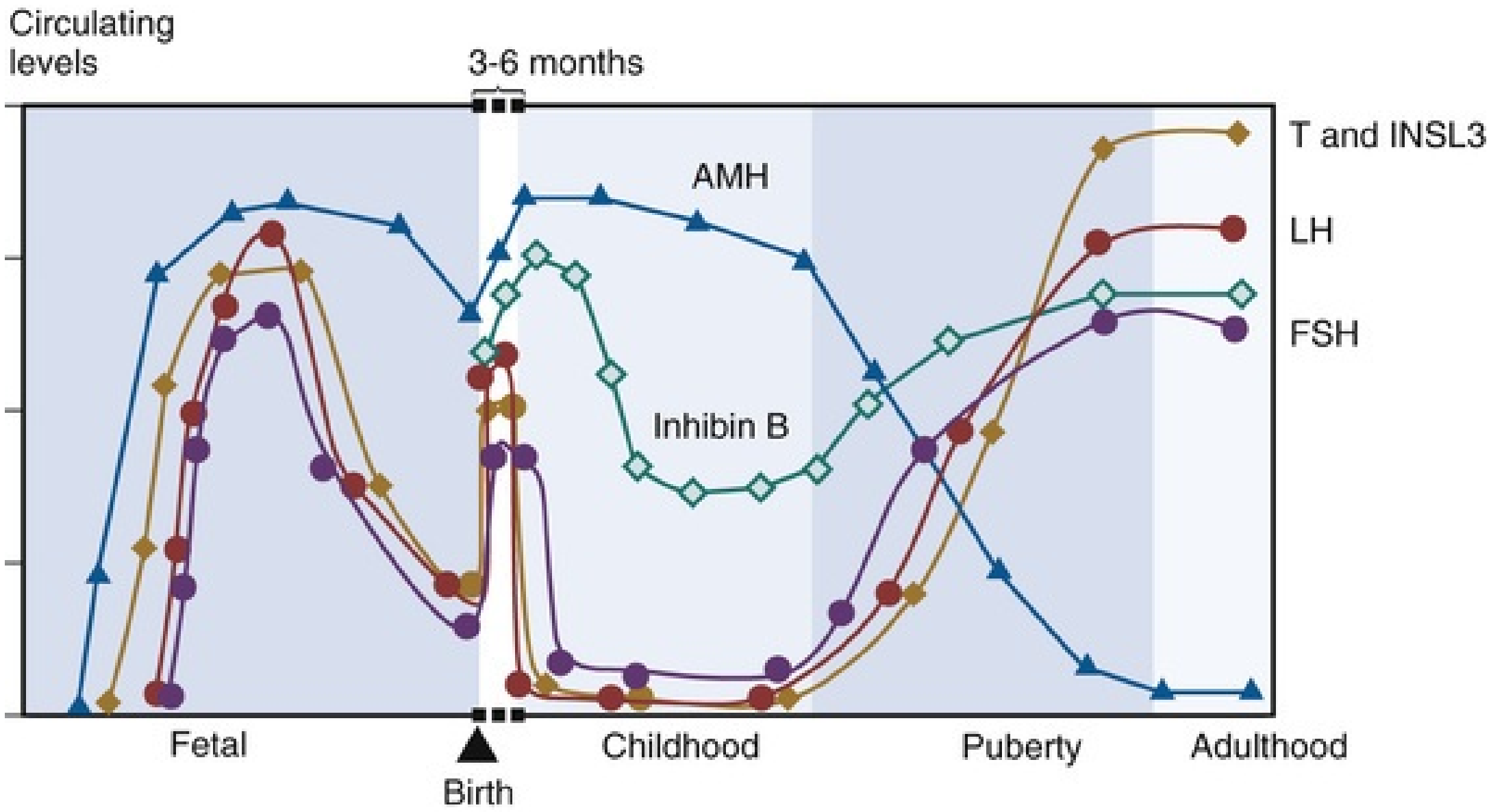

FIG. 46.1 Circulating male hypothalamic-pituitary-gonadal axis hormones from conception to puberty. Schematic view shows the rise in testosterone *(T),* insulin-like 3 *(INSL3),* luteinizing hormone *(LH),* follicle-stimulating hormone *(FSH),* and anti-Müllerian hormone *(AMH)* during early fetal life, secondary elevation of these hormones and of inhibin B soon after birth, and suppression of AMH at puberty. (From Grinspon RP, Ropelato MG, Bedecarras P, et al. Gonadotrophin secretion pattern in anorchid boys from birth to pubertal age: pathophysiological aspects and diagnostic usefulness. *Clin Endocrinol (Oxf)* 76(5):698–705, 2012b).

Steroid hormones exert their effects via sex steroid receptors in the reproductive tract and testis. AR and estrogen receptor beta (ERβ) are expressed in the undifferentiated gonad at 7 weeks, although their role in testis development is unclear (Boukari et al., 2007; Shapiro et al., 2005). AR is present primarily in peritubular myoid cells and in some Leydig and interstitial cells, but is absent in Sertoli cells during early development. Lack of AR expression in fetal and early postnatal Sertoli cells is physiologically important because its presence would allow inappropriate androgen-induced inhibition of AMH production and precocious simulation of spermatogenesis (Boukari et al., 2009; Rey et al., 2009). ERβ expression in fetal testis is observed in germ, peritubular myoid, Sertoli, and some Leydig cells, and expression of estrogen receptor alpha (ERα) is limited (Shapiro et al., 2005) or absent (Boukari et al., 2007) in human fetal testis. Concomitant expression of aromatase during the same time frame suggests that locally produced estrogen may play a role in testis development.

Reactivation of the hypothalamic pituitary gonadal axis occurs during the neonatal period, a phenomenon known as “mini-puberty” (see Fig. 46.1), with cross-sectional data suggesting that peak hormone levels occur at 1 to 3 months of age. Serum LH and follicle-stimulating hormone (FSH) levels rise postnatally, followed by increases in testosterone, AMH, and inhibin B (INHB), and INSL3 levels are high in both cord blood and at 3 months of age (Aksglaede et al., 2010; Andersson et al., 1998; Bay et al., 2007; Bergada et al., 2006). However, individual longitudinal data indicate that postnatal urinary LH, FSH, and testosterone levels peak earlier, at or before 1 month of age, and are more pronounced in preterm boys (Kuiri-Hanninen et al., 2011). Studies of the androgen insensitivity syndrome provide evidence that the postnatal hormone surge occurs as a response to maternal androgen withdrawal, resulting in secondary upregulation of hypothalamic and pituitary hormone secretion (Quigley, 2002). FLCs regress after birth followed by emergence of a neonatal Leydig cell population at 2 to 3 months of age that regresses by the end of the first year of life (Prince, 2001). As postnatal hormonal levels wane, FLCs either degenerate or regress to immature, partially differentiated Leydig/interstitial cells that are less responsive to LH.

The postnatal hormone surge is accompanied by increased testicular volume primarily caused by Sertoli and germ cell proliferation (Grumbach, 2005). Several studies show significant growth of testes during the neonatal period (Berensztein et al., 2002; Kuijper et al., 2008; Main et al., 2006a, 2006b), and increased testicular growth rate and HPG axis activation are correlated in preterm boys (Kuiri-Hanninen et al., 2011), suggesting that growth is a direct response to hormonal stimulation. Sertoli cell proliferation continues in the first year of life and is a major determinant of ultimate testicular size (Sharpe et al., 2003). Undifferentiated germ cells, called *prespermatogonia*, *prospermatogonia*, or *gonocytes* (Culty, 2013; McCarrey, 2013), migrate to the basement membrane after birth and become established as undifferentiated type A spermatogonia. In humans and primates, type adult dark (Ad) and adult pale (AP) spermatogonia include a subpopulation of spermatogonial stem cells (Griswold and Oatley, 2013; Hermann et al., 2010). Because migration occurs in a similar time frame to HPG axis activation, a relationship is presumed (Hadziselimovic et al., 1986, Hutson et al., 2012), but regulation of this important event remains poorly understood. Factors known to regulate migration of prespermatogonia/gonocytes include platelet-derived growth factor, thyroid hormone, and cell adhesion molecules (Basciani et al., 2008; Oatley et al., 2011; Orth et al., 2000; Tres and Kierszenbaum, 2005) as well as other nonhormonal factors (Barthold, 2015; Mecklenburg and Hermann, 2016), which in turn may be regulated by HPG axis hormones. However, a role, if any, for androgens in gonocyte migration and differentiation is controversial. Fetal gonocytes express AR, and androgens inhibit their proliferation, but there is no evidence that androgens affect neonatal gonocyte proliferation, migration, or differentiation (Li et al., 2015; Manku and Culty, 2015; Merlet et al., 2007). If migration fails to occur, prespermatogonia/gonoctyes may be at increased risk for apoptosis or future malignant transformation (Rajpert-de Meyts and Hoei-Hansen, 2007; Rajpert-De Meyts et al., 2016).

Gubernacular Development and Testicular Descent

The physiology of normal testicular descent and the etiology of abnormal descent in humans remain incompletely understood, and the morphologic events have been well-studied in mammals. Knowledge of the regulation of testicular descent is inferred from studies of human diseases that include cryptorchidism and/or from animal models of the disease.

The human indifferent gonad develops adjacent to and becomes suspended from the mesonephros, which has replaced the pronephros by 5 weeks (Lemeh, 1960). A rudimentary cranial mesonephric ligament connects to the diaphragm, disappearing by 13 weeks as the mesonephros regresses (Barteczko and Jacob, 2000). Recent human fetal studies confirm that there is no direct connection between the gonad and this ligament (Bouzada et al., 2017); therefore it appears that no “cranial gonadal ligament” exists in humans as noted in other species. However, like rodents, the gubernaculum is attached proximally to the epididymis, and not directly to the testis (Bouzada et al., 2017; Favorito et al., 2014). Using fixed sections, Barteczko and Jacob observed an “inner” or relative transabdominal descent of the human testis from vertebral levels C7–T8 to T9–L3 between 5 and 7 weeks, and to the sacral level by 10 weeks; using dissections, others described the testis at the level of L4 by 7 weeks (Lemeh, 1960) or always “close to the groin” (Wyndham, 1943). Other human fetal studies confirm that the testis remains close to the internal inguinal ring from 10 weeks onward (Bouzada et al., 2017; Favorito et al., 2016), suggesting that if true transabdominal descent occurs, it is unrelated to swelling or hormonal stimulation of the gubernaculum (see later). Caudal movement of the ovary is prevented by the ovarian ligament and development of the müllerian ducts.

Barteczko and Jacob (2000) described five major phases of testicular descent in the human fetus (Fig. 46.2). In **Phase 1** (5 weeks), the caudal mesonephros contacts the future gubernaculum at the internal inguinal ring. In **Phase 2**, the genitofemoral nerve (GFN) is seen to accompany the newly formed gubernaculum (abdominal, interstitial, and subcutaneous portions) and processus vaginalis (7 weeks); subsequently, growth of the gubernaculum, deepening of the processus vaginalis, and extension of cremaster muscle fibers into the interstitial gubernaculum occurs (8 to 10 weeks). In **Phase 3** (10 to 14 weeks), growth of the testis and regression of the müllerian ducts and mesonephros occurs; the gubernaculum is visible as a thin cord in both sexes and begins its swelling phase in males beginning at 12 weeks, after the testis is already located at the internal inguinal ring. In **Phase 4** (14 to 20 weeks)**,** swelling of the gubernaculum, further development of the cremaster muscle, and migration of the processus vaginalis produce widening of the inguinal canal. In **Phase 5** (20 to 28 weeks), release of the distal subcutaneous attachment of the gubernaculum and transinguinal passage of the testis occur. Further caudal movement of the testis into the scrotum up until the time of birth is accompanied by regression of the gubernaculum.

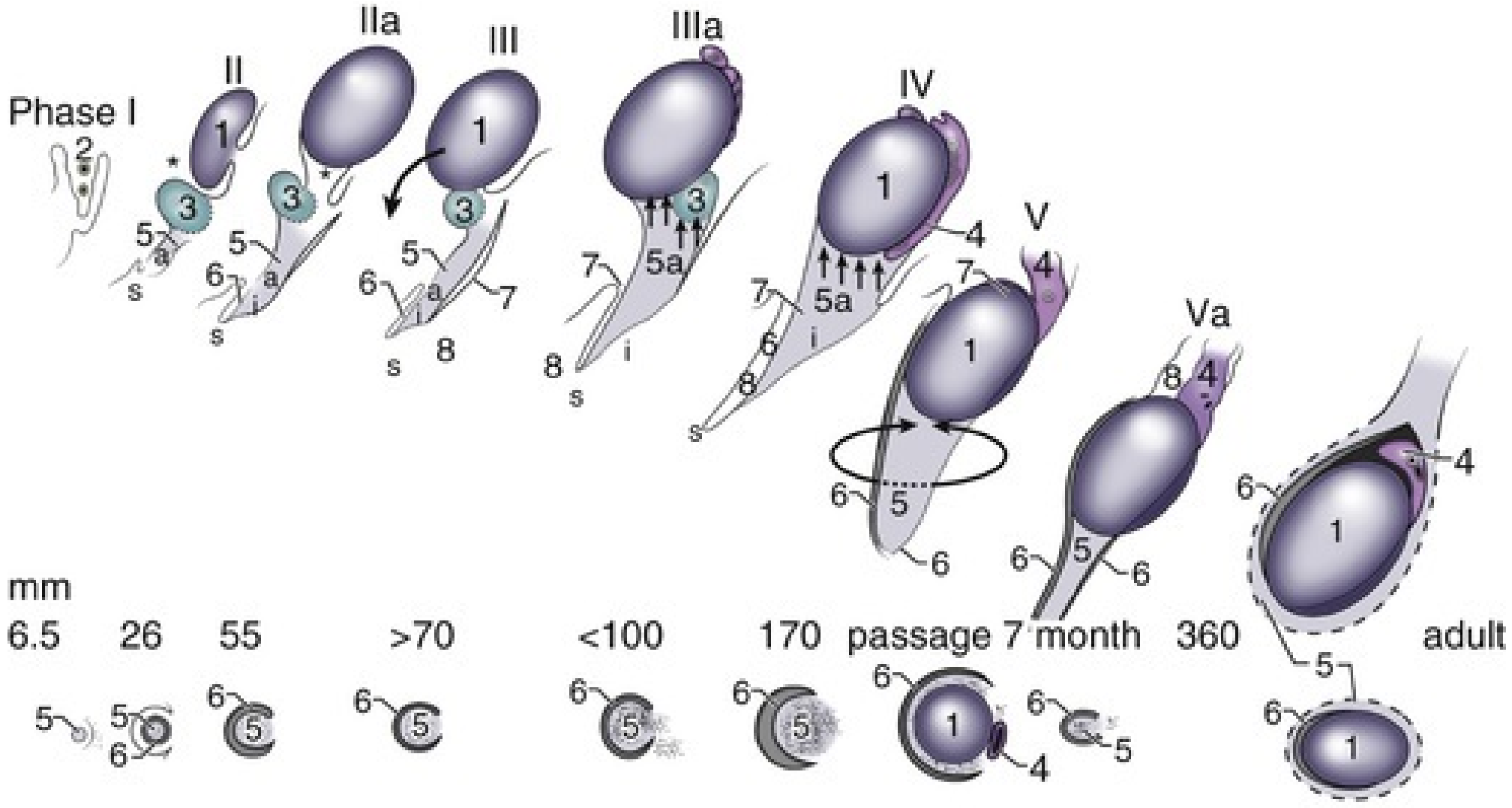

FIG. 46.2 Overview of human testicular descent. Sagittal view *(above)* and transverse sections *(below)*; *1,* gonad; *2,* mesonephros; *3,* Wolffian and müllerian ducts; *4,* vas deferens/epididymis; *5,* gubernaculum: *a,* abdominal; *i,* interstitial; *s,* subcutaneous part; *6,* processus vaginalis; *7,* internal inguinal ring; *8,* external inguinal ring. *Straight arrows* (phase I) show the ventral side; *Asterisks* (I–IIIa) show the link between the caudal pole of the testis and the dorsal mesenchyme of the genital ducts; *curved arrow* (III) shows the direction of testicular migration; *short arrows* (IIIa–IV) indicate attachment between the testis or epididymis and gubernaculum; *oval arrowline* (V) indicates no connection between the boltlike gubernaculum and neighboring structures. (Modified from Barteczko KJ,

Jacob MI. The testicular descent in human. Origin, development and fate of the gubernaculum Hunteri, processus vaginalis peritonei, and gonadal ligaments. *Adv Anat Embryol Cell Biol* 156[III–X]:1–98, 2000).

Detailed anatomic observations by Barteczko and Jacob (2000) throughout gestation help clarify some aspects of human testicular descent. For example, apparent transabdominal movement of the testis occurs before sexually dimorphic changes in the gubernaculum and is therefore not a male hormone-specific event. The subsequent male-specific swelling of the gubernaculum parallels the peak in Leydig cell secretion of testosterone (14 to 16 weeks) and INSL3 (15 to 17 weeks). The GFN precedes and accompanies the gubernaculum and developing processus vaginalis in both sexes beginning at an early stage (7 weeks), and both smooth (in the abdominal portion) and skeletal (in the interstitial and subcutaneous portion) muscle fibers are present within these three segments of the gubernaculum. Both muscle types were also observed by other (Lemeh, 1960; Wyndham, 1943) but not all (Bouzada et al., 2017; Costa et al., 2002; Heyns, 1987; Niikura et al., 2008) observers. However, studies of the in situ gubernaculum beginning at 20 weeks clearly show the presence of peripheral and centrally located striated muscle bundles (Barteczko and Jacob, 2000; Niikura et al., 2008) and infiltration of the gubernaculum by the GFN (Tayakkanonta, 1963). Controversy exists as to whether skeletal cremaster muscle fibers originate from abdominal wall musculature or from within the gubernaculum itself (Barteczko and Jacob, 2000; Niikura et al., 2008; van der Schoot, 1996), but their unique innervation and recent studies of transgenic mice (see the following) suggest the latter.

Swelling of the gubernaculum, caused by cellular proliferation and production of extracellular matrix, is required for enlargement of the inguinal canal and testicular passage (Heyns, 1987). Once the canal is created, unknown mechanical factors trigger a typically rapid transinguinal passage of the testis. The gubernaculum is unattached distally during and after transinguinal passage (Fig. 46.3), and settling of the gubernaculum and testis into the preformed scrotum is gradual. The scrotum itself develops from genital swellings that are first visible at 7 weeks and fuse by 10 to 12 weeks in response to circulating dihydrotestosterone. Passage of the testis into the inguinal canal rarely occurs before 22 weeks in the human fetus, and the majority of testes are scrotal after 27 weeks; time spent in the inguinal canal seems to be limited for the majority of human fetal testes (Heyns, 1987; Sampaio et al., 1998). The rapidity of transinguinal testicular transit, early innervation of the gubernaculum in human fetuses (Barteczko and Jacob, 2000), significance of the GFN in rodents (Hutson and Hasthorpe, 2005), and the complex anatomic distribution of cremaster muscle in and around the gubernaculum (Harnaen et al., 2007; Niikura et al., 2008) suggest that neuromuscular forces are required for testicular descent.

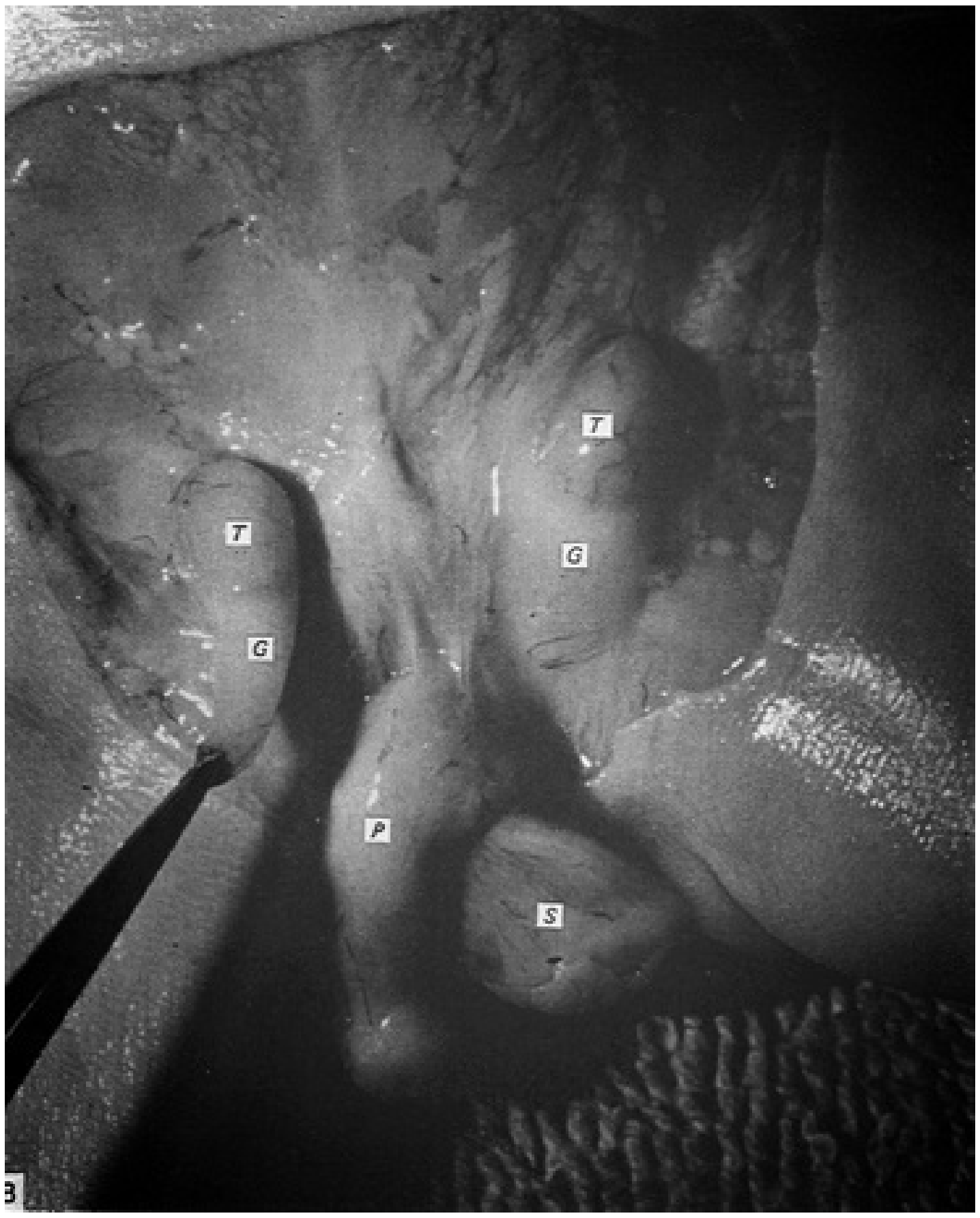

FIG. 46.3 The distally unattached human gubernaculum just before transinguinal passage. Human fetus at 25 weeks of gestation (215-mm crown-rump length) just before transinguinal testicular descent. *T,* Testis; *G,* gubernaculum; *P,* penis; *S,* scrotum. (From Heyns CF. The gubernaculum during testicular descent in the human fetus. *J Anat* 153:93–112, 1987.)

Regulation of Testicular Descent

Direct evidence for hormonal control of testicular descent is based on studies in animal models, primarily rodents. The relevance of rodent data to humans has been questioned because of anatomic differences, which in mice and rats include a less prominent interstitial gubernaculum, a cranial gonadal ligament, a well-developed intrinsic cremaster muscle located in the periphery of the gubernaculum, an absent inguinal canal, and failure of closure of the processus vaginalis (Wensing, 1988). However, the developing processus vaginalis and cremaster muscle are sufficiently anatomically similar among species to warrant translational studies using rodent models (Harnaen et al., 2007; van der Schoot, 1996), and their normal development is essential for testicular descent.

Animal models and indirect clinical evidence strongly support an essential role for the testicular hormones INSL3 and androgens in the regulation of testicular descent. Transgenic or spontaneous rodent strains with inactivation of *Insl3*, *Rxfp2*, or *Ar* are cryptorchid (Adham et al., 2000; Overbeek et al., 2001; Zimmermann et al., 1999) as are boys with abnormalities of androgen synthesis or action (Barthold et al., 2000; Foresta et al., 2008; Gaspari et al., 2011). According to a paradigm first developed by Hutson (1985), testicular descent occurs in separate transabdominal and transinguinal phases, regulated by a nonandrogenic factor (now known as INSL3) and by androgens via the GFN, respectively (Hutson, 1985; Hutson and Hasthorpe, 2005). However, animal models show that INSL3 and androgen synergistically stimulate cellular proliferation and growth of the gubernaculum (Adham et al., 2000; Emmen et al., 2000; Kubota et al., 2002) and that both INSL3 binding and AR expression are present before and during the swelling phase of the fetal rat gubernaculum (Staub et al., 2005). Moreover, INSL3 and testosterone levels peak after 12 weeks in the human fetus, concurrent with gubernacular swelling, and apparent transabdominal testicular descent, if it does occur, happens earlier, during the third month of gestation (Barteczko and Jacob, 2000; Koskimies et al., 2003; McKinnell et al., 2005). In mice, INSL3 signaling also promotes development of the processus vaginalis, and androgen signaling causes regression of the cranial gonadal ligament (Adham and Agoulnik, 2004; Adham et al., 2002; Koskimies et al., 2003), a structure that does not exist in the human fetus. Therefore, the testis remains stable as the gubernaculum swells (the “outgrowth” phase) and facilitates creation of the processus vaginalis, and then descends as the gubernaculum shrinks (the “regression” phase), as described over 30 years ago (Heyns 1987; Wensing 1988). INSL3 and androgens appear to regulate both phases of gubernacular development and descent.

Both INSL3/RXFP2 and AR also appear to directly regulate myogenic differentiation of the cremaster. Conditional deletion of *Rxfp2* or *Ar* in gubernacular mesenchymal cells, before their differentiation into muscle (Robbins et al., 2016), disrupts testicular descent (Kaftanovskaya et al., 2011, 2012). In gubernaculum-specific *Rxfp2*–/– transgenic mice, aberrant muscle cells are visible within the developing mesenchymal core of the gubernaculum, and the cremaster muscle fails to develop normally, suggesting that proliferation, migration, and patterning of muscle precursors depends on INSL3/RXFP2 signaling. Moreover, AR-positive cells are mislocalized in the gubernaculum of conditional *Rxfp2*–/– mouse fetuses, suggesting interaction between the RXFP2 and AR pathways. The defect in cremaster development is less severe with conditional deletion of *Ar* in gubernacular mesenchyme, however, muscle organization and growth are impaired, expression of muscle-specific markers is altered, and testicular descent fails to occur (Kaftanovskaya et al., 2012).

The definition of pathways and mechanisms of gubernacular development and testicular descent downstream of hormone signaling are provided by transgenic mouse models and human syndromes with phenotypes that include cryptorchidism (Barthold 2008; Foresta et al., 2008). A theme that again emerges from these studies is the importance of myogenesis in gubernacular development. In mice, transgenic inactivation of genes including *Notch1* and several involved in Wnt pathway signaling including *Ctnnb1, Sfrp1, Sfrp2, Wnt5a,* and *Ror2* results in marked disruption of fetal muscle patterning (Chawengsaksophak et al., 2012; Kaftanovskaya et al., 2011; Warr et al., 2009). Gene expression in fetal rat gubernaculum after stimulation by dihydrotestosterone (Barthold et al., 2013) or INSL3 (Johnson et al., 2010) also supports activation of Wnt pathways by both hormones and strong overlap in their transcriptional response. Transgenic deletion of either of two homeobox genes, *Hoxa10* and *Hoxa11,* is associated with isolated cryptorchidism in mice (Potter and Branford, 1998; Satokata et al., 1995), with evidence for delayed muscle development in the *Hoxa11* gubernaculum (Harisis et al., 2013). Also, the cremaster muscle is overdeveloped and associated with retractile testes in *Esr1* knockout mice (Donaldson et al., 1996). Other transgenic rodent models that include the cryptorchid phenotype provide insight into pathways required for testicular descent. These include targeted deletions of *Tgfb2* (Sanford et al., 1997), *Arid5b* (Lahoud et al., 2001), *Wt1* (Kaftanovskaya et al., 2013), *Ptgds* (Philibert et al., 2013), *Loxl1* (Wood et al., 2009), *Adamts16* (Abdul-Majeed et al., 2014), *Crkl* (Haller et al., 2017), *Lifr* (Kosfeld et al., 2017), and *Vamp7* (Tannour-Louet et al., 2014), and spontaneous mutations of *Ptch1* (Sweet et al., 1996) and *Bmp5* (Green 1968).

Based on extensive rodent studies, Hutson et al. showed that gubernacular innervation by the GFN is essential for its function, and they propose that release of calcitonin gene-related peptide (CGRP) from GFN sensory nerve endings stimulates development and function of the gubernaculum (Chan et al., 2009; Yamanaka et al., 1993). They further suggest that androgens indirectly regulate testicular descent via receptors located in mesenchymal tissue along the mammary line (reviewed in Hutson et al., 2016). This theory conflicts with data indicating that functional AR is present within the gubernaculum (reviewed in Robbins et al. in re-review). Although a role for CGRP release from the GFN in human testicular descent remains undefined, it is clear that the fetal gubernaculum contains and is surrounded by muscle and is innervated by the GFN beginning as early as 7 weeks (Barteczko and Jacob, 2000; Lemeh, 1960; Niikura et al., 2008; Tayakkanonta, 1963). Moreover, genome-wide association data suggest that *RBFOX* genes, which encode RNA-binding proteins that regulate production of CGRP, are associated with clinical cryptorchidism (Wang et al., 2018a).

In summary, the gubernaculum develops in both sexes beginning early in the second month of gestation, and the testicular hormones INSL3 and androgen stimulate development of the gubernaculum and testicular descent in the second and third trimesters. Enlargement and migration of the gubernaculum are key events that facilitate and direct caudal movement of the testis. INSL3 and androgens appear to synergistically target cellular proliferation, migration, and muscle patterning within the gubernaculum, in part via Wnt signaling. A consistent theme in experimental models of cryptorchidism is altered myogenesis of the cremaster, suggesting an important role in the process of testicular descent.

Epidemiology

Cryptorchidism is one of the most common congenital anomalies, occurring in 1% to 9% of full-term and 1% to 45% of preterm newborn males (Barthold et al., 2016b; Gurney et al., 2017b; Sijstermans et al., 2008). Although 80% to 85% of cases are isolated, or nonsyndromic (Barthold et al., 2016b), cryptorchidism is also a component of almost 500 syndromes causally linked to 387 genes within 414 loci, according to the most current data available in Online Mendelian Inheritance in Man (OMIM; https://www.ncbi.nlm.nih.gov/omim). The most common associated syndromes are reviewed elsewhere (Foresta et al., 2008; Virtanen and Toppari, 2008), but a common subset of syndromic cases is associated with hormonal defects of the hypothalamic-pituitary-gonadal (HPG) axis.

Congenital Cryptorchidism

Studies of the prevalence of isolated cryptorchidism at birth are complicated by confounding factors that include subjectivity of the examination, differences in the definition of undescended testis (inclusion/exclusion of high scrotal testes), study populations, and experimental design (Sijstermans et al., 2008). Although most studies support a prevalence at birth of 2% to 4% and at 3 months of age of 1% to 2%, this varies geographically, with frequency as high as 9% in some studies (Boisen et al., 2004; Virtanen and Toppari, 2008), supporting the possibility of an increase over time. However, other data have failed to show reproducible upward or downward trends in frequency (Abdullah et al., 2007; Barthold et al., 2016b; Bonney et al., 2009; Cortes et al., 2008; Gurney et al., 2017b; Sijstermans et al., 2008; Wagner-Mahler et al., 2011). Cryptorchidism is more common in Caucasian as compared with non-Caucasian populations (Gurney et al., 2017b).

The reported frequency of spontaneous testicular descent after birth varies among series, likely because of similar confounding factors, most notably variable inclusion of boys with high scrotal testes. In several population-based, prospective studies, the frequency of spontaneous descent by 3 months of age in boys identified as cryptorchid at birth was reported as 50% to 87% (Berkowitz et al., 1993; Ghirri et al., 2002; Mavrogenis et al., 2014; Radpour et al., 2007; van der Plas et al., 2013b; Wagner-Mahler et al., 2011;Wohlfahrt-Veje et al., 2009). In smaller cohorts, spontaneous descent occurred in significantly more Danish (68%) than Finnish (45%) boys at 3 months of age, possibly attributable to increased severity of the disease in the latter group (Suomi et al., 2006). In a group of boys followed closely from birth, spontaneous descent was common before 2 months of age (Kollin et al., 2013). Extrascrotal testes were less likely to descend by 1 year of age (50%) than high scrotal testes defined as cryptorchid at birth (87.5%) (Acerini et al., 2009). On the other hand, of 95 cryptorchid infants referred to a urology practice, spontaneous descent occurred subsequently in 16% and 0% of those presenting before and after 6 months of age, respectively (Wenzler et al., 2004). The lower rate of descent in this series could be related to exclusion of many cases of early neonatal descent, and a higher degree of cryptorchidism severity in this referral population. The long-term risk for recurrent cryptorchidism is not well defined, but in two large longitudinal series, re-ascent occurred in 10% and 22% of boys, usually between

1 and 5 years of age (Kollin et al., 2013; Wagner-Mahler et al., 2011).

Acquired Cryptorchidism

In the past, cryptorchidism was considered a congenital anomaly identifiable at birth. First reported 40 years ago (Myers and Officer, 1975), acquired cryptorchidism, or testes that are diagnosed as cryptorchid after apparent full descent at birth or in the neonatal period, is now an established clinical entity (Acerini et al., 2009; Barthold and González, 2003; Hack et al., 2012; Taghizadeh et al., 2008; Wohlfahrt-Veje et al., 2009). **Acquired cryptorchidism most likely represents a milder presentation of congenital cryptorchidism that escapes detection in infancy.** Compared with cases diagnosed at birth, these are diagnosed at an average age of 8 to 11 years, and are more likely to be in a lower position distal to the inguinal canal, and accompanied by a closed processus vaginalis and a normal epididymis. The reason for a later diagnosis remains unknown; theories include presence of a fibrous remnant of the processus vaginalis that tethers or foreshortens the cord over time, or mobility of the testis within an open sac (Keys and Heloury, 2012). However, it is most likely that the testis is incompletely descended from birth, as many are located in a lateral (ectopic) position within the superficial inguinal pouch (Barthold and González, 2003; van Brakel et al., 2011). These testes may be highly mobile and initially appear descended until somatic growth results in relative widening of the distance between testis and scrotum (Agarwal et al., 2006; Redman, 2005). Acquired cryptorchidism is more common in boys with proximal hypospadias (Itesako et al., 2011; Tasian et al., 2010) and is also associated with abnormal germ cell development (Rusnack et al., 2002) and subfertility risk (van Brakel et al., 2014).

Some boys with retractile testes are more likely to develop acquired cryptorchidism, although retractile testes are common in normal populations. In a hospital-based study of unselected boys, the testis was initially suprascrotal on examination (retractile) in up to 30% of boys at 4 years and 10% of boys 4 to 12 years of age, but it was intrascrotal in all boys older than 12 years of age (Farrington, 1968). In population-based studies of healthy boys, retractile testes were present in 11% to 15% of boys up to 11 years of age (Goede et al., 2011; Wohlfahrt-Veje et al., 2009) and 4% of boys 7 to 12 years of age (Inan et al., 2008). Both prospective and retrospective studies of the natural history of retractile testes support the concept that a subset of these becomes undescended over time (Keys and Heloury, 2012). However, a selection bias exists in studies of the risk for cryptorchidism in boys with retractile testes, as those referred for follow-up by specialists are likely those with the most severe retractility. For example, Wyllie (1984) prospectively studied a cohort of 100 boys with unilateral retractile testis and identified 64 cases in which testicular position, as documented by the distance between the pubic tubercle and mid-testis, and/or testicular size, as estimated by orchidometer, was reduced after 5 years of follow-up. Orchidopexy was performed in 45 of these cases, although specific documentation of testicular position and size as indications for surgery were not reported. Retrospective case series report that cryptorchidism is diagnosed in up to 7% to 32% of boys with retractile testes followed a mean of 2.2 to 3.8 years by the same observer(s) (Agarwal et al., 2006; La Scala and Ein, 2004; Stec et al., 2007). However, in a prospective study of 1072 boys, 520 of whom were followed from birth to latest follow up at 4.5 to 10 years of age, only 2.6% with retractile testes developed ipsilateral cryptorchidism, although an additional 13.5% developed contralateral or secondary cryptorchidism (Wohlfahrt-Veje et al., 2009).

Although these data suggest an association between retractile testes and cryptorchidism, the nature of this association may reflect either difficulty in distinguishing the two entities or an increased risk for acquired cryptorchidism in boys with testicular retractility. In patients with retractile testes, some who underwent orchidopexy for social reasons, pathologies associated with cryptorchidism were also found, suggesting a continuum between the two entities. These included reduced testicular volume (Goede et al., 2011), a higher incidence of ipsilateral patent processus vaginalis and epididymal anomalies (Anderson et al., 2016), and altered cremaster muscle innervation (Favorito et al., 2018).

The true prevalence of acquired cryptorchidism is incompletely defined, because longitudinal data that provide documentation of prior scrotal position are limited, and address only the first few years of life. In one study, 742 infants were followed with serial examinations for 2 years after birth with complete follow-up in 326 (Acerini et al., 2009). The prevalence of extrascrotal testes was 2.7% at birth (27% nonpalpable, surgical findings not reported), and 0.2%, 1.8%, 0.3%, and 0% of testes in the studied population became extrascrotal at 3, 12, 18, and 24 months, respectively. The number of suprascrotal testes diagnosed at birth in this series (10) was the same as the number diagnosed subsequently (10), although almost one-half of the boys were lost to follow-up during the study. Including high scrotal testes, a total of 5.7% were identified as cryptorchid at birth and 1% to 4% rose to a high scrotal position with each follow-up visit. In another study, 1072 boys were followed with serial examinations from birth to 4.5 to 10 years of age, with complete follow-up in 500 (Wohlfahrt-Veje et al., 2009). The prevalence of congenital cryptorchidism (including high scrotal testes) was 9% at birth but dropped to 1% at 18 months, and 8 (1.6%) acquired cases were observed during follow up, suggesting that the prevalence of persistent congenital and acquired forms of cryptorchidism is similar. Retrospective series also suggest that acquired cryptorchidism is common, but cannot reliably differentiate true acquired cases from delayed referral of congenital cases (Barthold et al., 2012; Guven and Kogan, 2008; Hack et al., 2012; Jensen et al., 2011; van der Plas et al., 2013b). Delayed intervention may have adverse effects, therefore serial physical examination is recommended to accurately determine testicular position and identify cases of acquired cryptorchidism in boys with retractile testes.

Pathogenesis

The specific cause of cryptorchidism is unknown in most cases, but indirect evidence suggests that the disease is heterogeneous and most likely the result of multiple genetic and environmental risk factors. The most consistent risk factors for cryptorchidism occurrence are prematurity and/or low birth weight for gestational age, familial factors related to the maternal environment and/or rare genetic variants, maternal diabetes, and maternal smoking (Arendt et al., 2018; Barthold et al., 2016b; Bay et al., 2011; Brouwers et al., 2012; Damgaard et al., 2008; Gurney et al., 2017b; Jensen et al., 2010b, 2012). Maternal obesity or increased BMI was associated with cryptorchidism in large population-based studies but not in a meta-analysis of primarily smaller case-control studies, implying variability among populations (Arendt et al., 2018; Kjersgaard et al., 2018; Zhang et al., 2015). Studies of isolated, or nonsyndromic cryptorchidism do not suggest strong genetic risk at large effect genomic loci, but rather a multilocus, complex pattern of genetic susceptibility. Also, available human data have identified few clear and consistent exposures associated with the disease, although animal models suggest that certain environmental EDCs, potentially in combination, may contribute to cryptorchidism risk.

Genetic Susceptibility

Family studies of cryptorchidism suggest that the disease is heritable, but that susceptibility is likely polygenic and multifactorial. Clustering of cryptorchidism has been reported in a number of families affecting multiple individuals in the same generation, but the phenotype is variable (Czeizel et al., 1981; Minehan and Touloukian, 1974; Pardo-Mindan et al., 1975; Savion et al., 1984). Extended pedigrees were not usually examined, but autosomal dominance with reduced penetrance was most often cited as the probable mode of inheritance. Population case-control studies also support genetic contribution to the disease. Familial aggregation suggesting moderate genetic risk was reported in a recent large cohort study of greater than 1 million male births in the Netherlands based on extensive hospital registry data (Schnack et al., 2008). Recurrence risk ratio was 10.1 in twins, 3.5 in brothers, and 2.3 in offspring and was significantly higher in maternal than in paternal half-brothers. Another population-based study in Denmark, using different methodology, identified greater concordance rates of cryptorchidism diagnosis in maternal (6%) than in paternal (3.4%) half-brothers and in dizygotic (24%) and monozygotic (27%) twins relative to brothers (9%) (Jensen et al., 2008). However, when the analysis was limited to cases of persistent cryptorchidism treated surgically, concordance rates were 7.5% in brothers, 17% in dizygotic twins, and 27% in monozygotic twins. These observations suggest that environmental effects and/or maternal factors contribute to the risk for cryptorchidism in Denmark. Previous smaller studies reported a 5- and 7- to 10-fold increased prevalence in fathers and brothers, respectively, of affected as compared with unaffected subjects, and some also support the possibility that maternal factor(s), or X-linked risk alleles, influence expression of the disease (Barthold et al., 2012; Czeizel et al., 1981; Elert et al., 2003; Jensen et al., 2008; Jones and Young, 1982).

The most promising gene candidates for nonsyndromic cryptorchidism based on animal studies are *INSL3* and *RXFP2*. However, DNA coding variants within these genes are rare, identified in only 0.6% to 1.8% and 1.6% to 2.9% of persistently cryptorchid males, respectively (Foresta et al., 2008). Notably, some of these variants are associated with a range of phenotypes that include unilateral/bilateral and persistent/spontaneously resolving presentations, and apparently deleterious mutations may exist in normal family members, as noted for an *INSL3* mutation showing reduced receptor activation (El Houate et al., 2007). More than 1500 cryptorchidism cases have been screened for mutations in *INSL3*, but of 10 exonic variants identified in cases but not controls, few are clearly functional (Bay et al., 2011; Ferlin et al., 2008; Foresta et al., 2008). A nonsynonymous polymorphism of the *RXFP2* gene, T222P, was considered a strong etiologic candidate for cryptorchidism based on absence in normal controls and in vitro studies showing curtailed cell membrane localization and activation of the abnormal receptor (Bogatcheva et al., 2007). However, cases and controls in other European populations show a similar frequency of the *T222P* allele (Ars et al., 2011; Nuti et al., 2008). Although these data suggest that mutations of *INSL3* and *RXFP2* are infrequent in cases of cryptorchidism, regulatory variation in noncoding regions, or copy number variants (CNVs) that alter transcript or protein expression levels may exist, but have not been studied.

Analysis of other potential candidate genes for human cryptorchidism has failed to yield consistent results across populations. Two homeobox genes are strong candidates based on findings of isolated cryptorchidism in transgenic mice (Hsieh-Li et al., 1995; Rijli et al., 1995; Satokata et al., 1995), but associations between variants in these genes, *HOXA10* and *HOXA11*, and cryptorchidism have not been consistent (Bertini et al., 2004; Chavez-Saldana et al., 2018; Cheng et al., 2017; Kolon et al., 1999; Wang et al., 2007). Studies of polymorphic trinucleotide (CAG and GGN) repeats of AR in cryptorchidism have also shown varying results, but a recent meta-analysis of 8 studies comprising 321 cases and 784 controls supports association with longer AR repeat lengths in Caucasians (Wang et al., 2018b). A specific haplotype of the gene encoding estrogen receptor alpha *(ESR1)* appears to be associated with cryptorchidism, specifically in Asians but not in Caucasians (Galan et al., 2007; Lo Giacco et al., 2011; Tang et al., 2011; Yoshida et al., 2005; Wang et al., 2008). Microdeletions of the Y chromosome have also been studied in cryptorchid children and previously cryptorchid men, with no consistent association observed (Gurbuz et al., 2008; Mamoulakis et al., 2013a). *NR5A1*, which encodes steroidogenic factor 1 (SF1), a transcription factor that regulates expression of *INSL3*, *RXFP2*, and steroidogenesis genes, was associated with cryptorchidism in 72 cryptorchid Japanese males (Wada et al., 2006), but not in a larger population of 275 European males, although a rare variant was enriched in previously cryptorchid men with severe spermatogenic impairment (Ferlin et al., 2015). An association between aryl hydrocarbon receptor–associated genes and cryptorchidism was also noted in a single study (Qin et al., 2012). No cryptorchidism-associated variants were identified in the sex hormone–binding globulin gene *(SHBG)* or in genes associated with hypogonadotropic hypogonadism (HH) (Laitinen et al., 2011; Mamoulakis et al., 2013b). Differences among series may relate to small, insufficient sample sizes (most single series include less than 100 cases), and heterogeneity may explain the lack of replication in other population groups.

Limited available data from unbiased genome-wide studies identified rare CNVs in novel genes including *VAMP7*, *OTX1*, and *CRKL* associated with cryptorchidism, which were subsequently validated in knockout mice (Haller et al., 2017; Jorgez et al., 2014; Tannour-Louet et al., 2014). In contrast, genome-wide association studies (GWAS) have failed to identify a cryptorchidism-associated single nucleotide polymorphism (SNP) that passed the threshold of genome-wide significance ($P < 5 \times 10^{-8}$) and could be validated in an independent population. Although underpowered, a study of 488 men with at least one of the four phenotypes comprising the so-called *testicular dysgenesis syndrome (TDS)* (Sharpe and Skakkebaek, 2008) including infertility, cryptorchidism ($n = 138$), hypospadias, and/or TGCT (Dalgaard et al., 2012) did not identify any SNP passing this stringent threshold. Using a systems biology approach to map less significant signals into functional pathways, the authors identified transforming growth factor beta receptor 3 *(TGFBR3)*, a gene associated with transient Leydig cell dysgenesis in knockout mice (Sarraj et al., 2010), as a potential locus associated with cryptorchidism and TGCT in both discovery and replication cohorts. The TGFBR3 protein is expressed in FLCs (Dalgaard et al., 2012) and interacts with transforming growth factor-β2 (TGF-β2) (Bilandzic and Stenvers, 2011). Incomplete testicular descent was reported in *Tgfb2* –/– mice (Sanford et al., 1997) and Leydig cell dysfunction noted in *Tgfbr3* –/– mice, but testicular descent could not be assessed in the latter strain because offspring rarely survive past birth (Sarraj et al., 2010).

In a larger GWAS, isolated (nonsyndromic) cryptorchidism was not associated with any genome-wide significant locus that could be replicated in an unrelated case-control cohort, although SNPs within or near *TGFBR3* were again identified as suggestive (Barthold et al., 2015a,b). These results are in marked contrast to hypospadias and TGCT, which are also considered polygenic, but for which multiple associations have been confirmed using GWAS methodology (Geller et al., 2014; Kanetsky et al., 2009; Litchfield et al., 2018; Wang et al., 2017). Pathway analysis of suggestive ($P < 0.001$) cryptorchidism-associated intragenic SNPs identified enrichment in cytoskeleton-, neural- and AR-related pathways, similar to results of genomic analyses of a rat strain with inherited cryptorchidism (Barthold et al., 2008, 2016a). A comparison of suggestive intragenic GWAS SNPs associated with cryptorchidism with or without TGCT identified *RBFOX* and other neurodevelopmental genes as candidates for further study (Wang et al., 2018a). Future validation of RBFOX paralogs as causal alleles would link human and animal models of cryptorchidism because RBFOX proteins regulate splicing of *CALCA*, which encodes CGRP.

Similarly, studies of animal models of inherited cryptorchidism, including swine, dogs, and rats suggest that the genetic etiology is uniformly complex (Barthold et al., 2016a; Rothschild et al., 1988; Sevillano et al., 2015; Zhao et al., 2014;). At least one-half of testes in the LE/orl rat strain reside in the superficial inguinal pouch (SIP); genetic and genomic studies of this strain suggest polygenic inheritance associated with reduced fetal testosterone production and functional variants in genes encoding AR-interacting proteins (Barthold et al., 2008, 2013, 2014, 2016a).

In summary, **studies of clinical and animal models of cryptorchidism suggest that genetic susceptibility is complex, but that specific causative alleles, other than rare variants in *INSL3, RXFP2*, or *NR5A1*, are mostly unknown at this time.** Failure to identify genetic loci associated with human cryptorchidism is likely related to confounding environmental risk factors and to limitations associated with the reported methodology, particularly insufficient sample size, geographic variability, and phenotypic variability.

Environmental Risk Factors

Population-based studies suggest that the maternal environment may contribute to the risk for cryptorchidism, but it remains unclear if risk is related to maternal exposures, characteristics, or lifestyle. The data available for maternal smoking suggest a mild to moderate increased risk for cryptorchidism in offspring, and a possible increased risk for germ cell abnormalities as compared with cryptorchid boys of maternal nonsmokers (Duarte et al., 2017; Hakonsen et al., 2014; Kjersgaard et al., 2018; Virtanen et al., 2012b; Zhang et al., 2015). Maternal alcohol consumption or binge drinking was associated with cryptorchidism in some studies but not in others (Damgaard et al., 2007; Jensen et al., 2007; Kjersgaard et al., 2018; Mongraw-Chaffin et al., 2008; Strandberg-Larsen et al., 2009; Thorup et al., 2006; Zhang et al., 2015). Several series suggest increased risk with maternal use of acetaminophen or more than one analgesic in midpregnancy or earlier (Jensen et al., 2010a, 2010b; Kristensen et al., 2011; Snijder et al., 2012) and are supported by data suggesting that analgesics can alter hormone production by the human fetal testis in culture (Mazaud-Guittot et al., 2013). However, possibly in part because of variations in type, timing, and degree of fetal exposure, recent meta-analyses concluded that the evidence for association of analgesic use with cryptorchidism in offspring is weak (Gurney et al., 2017a, 2017b; Hurtado-Gonzalez and Mitchell, 2017). Parental occupation is not consistently associated with cryptorchidism in offspring, although some data suggest increased risk in horticulture-related professions (Andersen et al., 2008; Gabel et al., 2011; Jorgensen et al., 2013, 2014; Morales-Suarez-Varela et al., 2011; Pierik et al., 2004;Weidner et al., 1998) or in areas of higher pesticide use (Garcia et al., 2017). In addition, a single study identified reduced breastfeeding and increased use of soy formula as variables associated with first diagnosis of cryptorchidism at an older age (Barthold et al., 2012).

TDS (testicular dysgenesis syndrome) refers to a constellation of reproductive abnormalities including cryptorchidism, hypospadias, infertility, and TGCT, purportedly resulting from impaired testicular function in utero (Sharpe et al., 2008; Skakkebaek 2016). The proposed etiology is a deficiency in fetal androgen production resulting from exposure to EDCs. The concern for a link between EDCs and cryptorchidism arose because of a reported increased risk for cryptorchidism after maternal exposure to diethylstilbestrol (DES) (Gill et al., 1979). In a large cohort study of 1197 men previously exposed to DES and 1038 unexposed men, the RR (risk ratio) of cryptorchidism was 1.9 (95% confidence interval [CI], 1.1 to 3.4) overall. When data were subdivided based on gestational age less than 11 weeks and exposure greater than or equal to 5 g, the RRs were 2.9 (95% CI, 1.6 to 5.2) and 3.2 (95% CI, 1.7 to 6.0), showing that early and significant exposure present the clearest risks (Palmer et al., 2009).

In recent years, concern has increased that EDC exposure is linked to multiple health issues, with the strongest support for association with neurodevelopmental, metabolic, and reproductive disorders, including cryptorchidism (Barthold et al., 2016b; Bonde et al., 2016; Hauser et al., 2015; Lymperi and Giwercman, 2018; Trasande et al., 2016; Virtanen and Adamsson, 2012; Virtanen et al., 2012a). Animal models suggest a relationship between prenatal exposure to antiandrogenic EDCs and risk for cryptorchidism and other reproductive end points, although levels of exposure are much higher than applicable clinically (Rider et al., 2009); concerns exist about the applicability of EDC animal models to humans (Habert et al., 2014); and species-specific, differential sensitivity to EDCs exists. Human testes appear insensitive to inhibition of steroidogenesis by phthalates or DES, but more sensitive to the inhibitory effects of bisphenol A (Heger et al., 2012; Lambrot et al., 2009; Mitchell et al., 2012; N'Tumba-Byn et al., 2012). Additionally, measured levels of anti-androgenic and/or estrogenic EDCs in placenta, breast milk, or cord blood, including pesticides, polychlorinated biphenyls (PCBs), dioxins, perfluorinated compounds, flame retardants (PBDEs), and organotin were not consistently higher in association with affected pregnancies (Cook et al., 2011; Damgaard et al., 2006; Fenichel et al., 2012; Main et al., 2007; Rantakokko et al., 2013; Trabert et al., 2012; Vesterholm Jensen et al., 2014; Virtanen and Adamsson, 2012). Consistent with data showing lack of inhibition of human fetal testicular steroidogenesis by phthalates, levels of individual phthalate metabolites did not show consistent correlation with occurrence of cryptorchidism or hormone levels in affected boys (Main et al., 2006a). Nevertheless, several recent studies suggest possible associations between levels of flame retardant chemicals in maternal hair (Goodyer et al., 2017), bisphenol A in placenta (Fernandez et al., 2016), and organic pollutants in adipose tissue (Koskenniemi et al., 2015), with the occurrence of clinical cryptorchidism. In animal models, recent data suggest that mixtures of antiandrogenic chemicals with different mechanisms of action can cumulatively inhibit fetal reproductive development at low levels of exposure (Conley et al., 2018; Howdeshell et al., 2017), findings that may have more relevance for human populations.

Indirect end points indicative of potential fetal exposure to EDCs include anogenital distance (AGD), a measure of prenatal androgen exposure first described in animal models, and placental weight, a measure of placental function that is associated with intrauterine growth restriction, and may correlate with hCG production during a critical window of testicular descent. Both AGD and placental weight may reflect genetic and/or environmental influences. AGD, perineal length from the posterior margin of the scrotum to the anal verge, is sexually dimorphic and correlated with newborn body weight (Sathyanarayana et al., 2010; Thankamony et al., 2016). Reduced AGD has been correlated with cryptorchidism, hypospadias, AR CAG repeat length, phthalate exposure, maternal analgesic use, reduced duration of breastfeeding, and variants in genes linked to reproductive anomalies, including *ESR1* (Dean and Sharpe, 2013; Eisenberg et al., 2013; Jain and Singal, 2013; Lind et al., 2017; Ortega-Garcia et al., 2016; Sathyanarayana et al., 2012; Thankamony et al., 2014). Placental weight is reportedly reduced in boys with cryptorchidism (Arendt et al., 2016; Ghazarian et al., 2018) and a higher risk for early gestational preeclampsia was linked to possible placental dysfunction in a large population study (Arendt et al., 2018). These observations are in keeping with the strong association between intrauterine growth restriction and cryptorchidism. However, the maternal biomarkers of placental function, hCG and alpha-fetoprotein, were not strongly or consistently associated with cryptorchidism in other studies (Boyd et al., 2006; Chedane et al., 2014; Schneuer et al., 2016a).

Further studies are needed to assess the relationship between environmental exposures and cryptorchidism susceptibility because a causal role for single chemicals or classes of EDCs may be difficult to demonstrate in view of the apparent heterogeneity of disease susceptibility, and the wide variety of EDCs to which humans are exposed may allow for synergistic effects that are difficult to measure (Toppari et al., 2016). **At present, epidemiologic data suggest potential associations with exposure to pesticides, flame retardants, bisphenol A (BPA), or organic pollutants in selected populations and raise the possibility that the cumulative effects of mixtures of multiple anti-androgenic and estrogenic chemicals may increase the risk for cryptorchidism in susceptible individuals.**

Hormonal Defects

Because testicular hormones are required for testicular descent, defective hormone production and/or action may contribute to the pathogenesis of cryptorchidism. Scant data documenting hormone production during fetal life are available in humans, although a recent report suggests that increased variance in amniotic fluid INSL3 levels exist between 13 and 16 weeks in male fetuses subsequently diagnosed with cryptorchidism or hypospadias (Anand-Ivell et al., 2018). When present, hormonal defects may also be manifest during postnatal activation of the HPG axis (see Fig. 46.1). Prospective studies of varying size and quality are available that report neonatal hormone levels in cryptorchidism, and although some data suggest that the HPG axis is abnormal, results are conflicting, and baseline levels may not directly reflect the status of germ cell development. In the first reported series of cryptorchid and control boys undergoing hormonal evaluation in the first few months of life, serum testosterone was lower in 7 of 17 (41%) persistently cryptorchid boys but comparable to control levels in 4 of 25 boys with spontaneous testicular descent (Gendrel et al., 1978). Subsequent studies have shown reduced testosterone and/or LH levels in some series (Facchinetti et al., 1983; Pierik et al., 2009; Raivio et al., 2003) but not in others (Barthold et al., 2004; De Muinck Keizer-Schrama et al., 1988; Grinspon et al., 2018). In larger series, Suomi et al. (2006) showed geographic differences in serum INHB and follicle-stimulating hormone (FSH) levels but no differences in testosterone levels in cryptorchid infants from Finland (*n* = 88, 36% spontaneous descent) or Denmark (*n* = 34, 68% spontaneous descent) as compared with 300 and 399 control boys, respectively.

In this series, INHB levels varied geographically, and when compared with respective controls, were lower in Finnish but not Danish cryptorchid boys. INSL3 levels were reduced in cord blood but not in serum obtained at 3 months of age in persistently cryptorchid males, and testosterone levels in cord blood did not differ from controls (Bay et al., 2007, Fenichel et al., 2015). Neonatal studies do, however, suggest that LH:testosterone and LH:INSL3 ratios are increased in boys with cryptorchidism, potentially indicating that subtly reduced Leydig cell function may lead to compensatory upregulation of LH levels (Bay et al., 2007; Suomi et al., 2006). A similar form of compensated Leydig cell function has also been described in adults with reduced semen quality (Jorgensen et al., 2016). Nevertheless, in the largest series to date of 225 boys with congenital cryptorchidism in whom LH, FSH, testosterone, and INHB were measured at 0 to 3 weeks, 2 months, and 6 months of age (*n* ≥57 per time point), hormone levels were not significantly different among unilateral, bilateral, and spontaneously resolving cryptorchid cases, and did not correlate with spermatogenesis (Kollin et al., 2012). In accordance with genetic studies, these varied results suggest significant heterogeneity in infants with cryptorchidism that is in part based on geography.

In older boys, hormonal defects are more difficult to identify because LH, FSH, and testosterone levels fall to low or undetectable levels as the HPG axis becomes quiescent during childhood (Grinspon and Rey, 2010). However, INHB and AMH levels remain easily measurable during childhood (see Fig. 46.1), and these Sertoli cell–specific proteins are sensitive biomarkers of testicular activity during prepuberty (Edelsztein et al., 2016; Grinspon et al., 2012a). Although levels of serum AMH and INHB in older boys also show variability, increasing evidence suggests that Sertoli cell dysfunction is present, particularly in bilateral cryptorchidism (reviewed in Grinspon et al., 2018). In a randomly generated subset of cases from an extensive database, Grinspon et al. found that AMH levels were reduced in 17% of cryptorchid boys, including 22% of bilateral (*n* = 186) and 8% of unilateral (*n* = 124) cases younger than 9 years of age (Grinspon et al., 2018). Gonadotropin levels were either normal or (rarely) elevated in these patients: of nonanorchid boys, FSH was mildly increased (>97th percentile for age) in 4 (3%) unilateral and 7 (4%) bilateral cases, and LH was mildly increased in 9 (7%) unilateral and 10 (5%) bilateral cases. In contrast, Thorup and colleagues (2015) reported that FSH was increased in 25% and 18%, while INHB was reduced in 13% and 16% of bilaterally (*n* = 69) and unilaterally (*n* = 50) cryptorchid infant boys. However, these studies used reference standards rather than control subjects for comparison. In a cohort of similar age, both AMH and INHB were also significantly reduced in cryptorchid as compared with control boys, and more severely in bilateral cases (Hamdi et al., 2017). Yet in another series of 62 older boys (mean age 7.7 years), no differences were identified in inhibin B levels, or in LH, FSH, or testosterone levels before or after hCG stimulation (Christiansen et al., 2002). These varying results may be related to differences in populations or to other confounding factors, such as maternal smoking, which was associated with reduced INHB in cryptorchid offspring (Hildorf et al., 2019). Reduced or unexpectedly low levels of prepubertal serum gonadotropins is some boys has led investigators to posit that an absolute, transient, or relative gonadotropin deficiency may be a cause of cryptorchidism and germ cell loss (Cortes et al., 2016a,b; Hamdi et al., 2017; Verkauskas and Hadziselimovic, 2016; Verkauskas et al., 2016). However, these data are difficult to interpret, the HPG axis is inactive in childhood, and gonadotropin levels may be normal, even in cases of anorchia (Grinspon et al., 2012b).

In additional studies, hormonal changes after orchidopexy suggested a potential beneficial effect of surgery. In a longitudinal study of 27 boys (mean age 4.8 years, 25 with unilateral cryptorchidism) undergoing orchidopexy, an increase in serum INHB was identified in 81% of cases 6 months postoperatively (Irkilata et al., 2004). Thorup et al. reported that INHB levels were more commonly abnormal in uncorrected (23%) as compared with corrected (11%) cryptorchidism cases (Hildorf et al., 2019; Thorup et al., 2015b). INHB levels increased postoperatively in 13% of bilateral and 32% of unilateral cases followed longitudinally by this group in other studies but normalized in less than one-half of cases and did not closely correlate with testicular histology (Thorup et al., 2012, 2015a). Elevated FSH levels, present in 25% of the bilaterally cryptorchid cases, also normalized postoperatively in 82% of these cases. However, changes in FSH and INHB levels over time in these studies are difficult to interpret, because considerable intra-individual fluctuation exists, even in normal males, in the first 2 years of life (Andersson et al., 1998).

Various hormonal defects in nonsyndromic cryptorchidism have been proposed. These include (1) a gonadal defect that is either primary or caused by the adverse effects of testicular position on Sertoli cell function (Grinspon et al., 2018), with or without hypergonadotropic hypogonadism (Cortes et al., 2016b), or (2) isolated or transient HH characterized by unexpectedly normal FSH and LH levels despite low INHB (Cortes et al., 2016b) and association of poor spermatogonial differentiation with low LH levels (Verkauskas and Hadziselimovic, 2016; Verkauskas et al., 2016) or reduced Leydig cell response to hCG (Zivkovic et al., 2007). Isolated HH as a cause of nonsyndromic cryptorchidism and rationale for adjuvant hormonal therapy remain areas of controversy (Biers and Malone, 2010; Chua et al., 2014; Rosch and Schroder, 2016; Verkauskas and Hadziselimovic, 2016; Verkauskas et al., 2016), but direct measurements of hormone levels during mini-puberty (as noted earlier) tend to suggest *increased* gonadotropin drive. Complex interplay between genetic and/or environmental factors at multiple levels of the HPG axis, with adverse effects on testicular descent, hormonal function, and testicular development may be difficult to tease out (Barthold and Ivell, 2018; Barthold et al., 2018). **Whatever the cause, these studies suggest that some cryptorchid boys have abnormalities of the HPG axis, with stronger support for primary gonadal (Sertoli and/or Leydig cell) defects and less for central hypogonadism in nonsyndromic cases.** Inconsistent findings among studies are likely based on timing and type of assays, sample size and heterogeneity based on age, severity, genetic background and/or other interindividual differences. No hormonal studies to date have been shown to precisely predict germ cell numbers or subfertility in cases of cryptorchidism. Because multiple genetic and environmental factors likely contribute to cryptorchidism, identification of risk factors for HPG axis dysfunction will require further research.

Syndromic Cryptorchidism

Undescended testes are frequently present in association with diseases characterized by a major reduction in androgen production and/or action, such as androgen biosynthetic defects, androgen insensitivity, Leydig cell agenesis, and gonadotropin deficiency disorders (Barthold et al., 2000; Foresta et al., 2008). Conditions associated with generalized failure of masculinization are considered disorders of sexual differentiation (DSD) and are not reviewed here (see Chapter 48). Persistent müllerian duct syndrome, a DSD resulting from defective AMH signaling, is also associated with cryptorchidism or transverse testicular ectopia (Josso et al., 2006; Picard et al., 2017). Gubernacular defects that are observed in these patients may be caused by hindrance of descent by retained müllerian ducts (Barteczko and Jacob, 2000) and/or via loss of direct proliferative effects of AMH on the gubernaculum (Hutson and Lopez-Marambio, 2017; Kubota et al., 2002). The frequency of Klinefelter syndrome (47,XXY) is less than 2% in large series of primarily nonsyndromic cryptorchidism but is more frequent when other anomalies, particularly hypospadias, are present (Barthold et al., 2015a; Ferlin et al., 2008; Moreno-Garcia and Miranda, 2002; Sasagawa et al., 1996). More than one-half of prepubertal patients with Klinefelter syndrome have cryptorchidism (Pacenza et al., 2012). Other genomic rearrangements and trisomies, including Down syndrome (trisomy 21), are associated with cryptorchidism (Hadziselimovic, 1983).

Certain congenital anomalies are associated with increased risk for cryptorchidism, many related to musculoskeletal, CNS, or abdominal wall/gastrointestinal defects, and some may occur together. These include all cases of classic prune belly (triad or Eagle-Barrett) syndrome; 53% to 80% of Spigelian hernia (Bilici et al., 2012; Balsara et al., 2014; Durham and Ricketts, 2006; Jones and Hutson, 2015); 25% to 54% of cerebral palsy (CP; Barthold and Ivell, 2018; Barthold et al., 2018; Cortada and Kousseff, 1984; Rundle et al., 1982); 38% of arthrogryposis (Fallat et al., 1991); 15% of myelomeningocele (Ferrara et al., 1998); 16% to 33% of omphalocele; 5% to 25% of gastroschisis (Corona-Rivera et al., 2016; Kaplan et al., 1986; Koivusalo et al., 1998; Yardley et al., 2012); 19% of imperforate anus (Cortes et al., 1995b); 12% to 17% of posterior urethral valve (Heikkila et al., 2008; Krueger et al., 1980; Wong et al., 2016); 7% to 30% of congenital diaphragmatic hernia (Azarow et al., 2015); and 6% of umbilical hernia (Kaplan et al., 1986) patients. Multisystem congenital anomalies are often associated with omphalocele (80%), prune belly syndrome (45%), and CP (19%), suggesting syndromic etiologies (Barthold and Ivell, 2018; Barthold et al., 2018; Koivusalo et al., 1998; Loder et al., 1992). Depue also reported a significant association of cryptorchidism with CNS dysfunction, particularly CP (relative risk [RR] = 34), low IQ (RR = 2.7), and hypotonia (RR = 3.6) (Depue 1988). In more recent population-based studies, additional associations with autism and other developmental abnormalities were reported (Chen et al., 2018;, Rotem et al., 2018; Rzhetsky et al., 2014; Schieve and Shapira, 2018; Schneuer et al., 2017). Cortes et al. (1998) reported associations between renal and T10–S5 spinal anomalies, considered caudal developmental field defects, and cryptorchidism, with the affected testis on the same side as the renal anomaly in 90% of cases. Similarly, cryptorchidism was ipsilateral to the side affected by CDH in all cases (Azarow et al., 2015). In addition, syndromic cryptorchidism, especially in association with CP or CNS malformations, is more commonly bilateral (Barthold and Ivell, 2018; Barthold et al., 2018; Cendron et al., 1993; Cortes et al., 1995b). These data support common origins of cryptorchidism and anomalies of urogenital ridge, abdominal wall, lumbosacral spine, and CNS development.

The occurrence of cryptorchidism with other nongenital anomalies may complicate and/or alter the timing of treatment. For example, Spigelian hernia may be difficult to diagnose, and associated absence of the gubernaculum and inguinal canal may complicate orchidopexy (Balsara et al., 2014; Bilici et al., 2012). Spontaneous testicular descent is reported in 50% to 55% of gastroschisis cases (Hill and Durham, 2011; Yardley et al., 2012), suggesting that observation is warranted.

Diagnosis

Examination

To best determine testicular position, boys should be examined in the supine and, if possible, upright cross-legged and standing positions. Abduction of the thighs contributes to inhibition of the cremasteric reflex, which is elevation of the testis that is elicited by scratching the inner thigh. The examination should include documentation of testicular palpability, position, mobility, size, and possible associated findings such as hernia, hydrocele, penile size, and urethral meatus position. Patient distraction, a warm room and hands, use of liquid soap or lubricant on the examiner's hands, and repeated examinations also help localize the testis and limit cremaster muscle activity and resultant difficulty in determining testicular position. Sustained gentle traction on the cord can help inhibit the cremaster reflex and allow a retractile testis to remain at least temporarily in stable scrotal position. Scrotal asymmetry can be a useful clinical sign as it is commonly present in boys with unilateral cryptorchidism (Fig. 46.4) (Snodgrass et al., 2011).

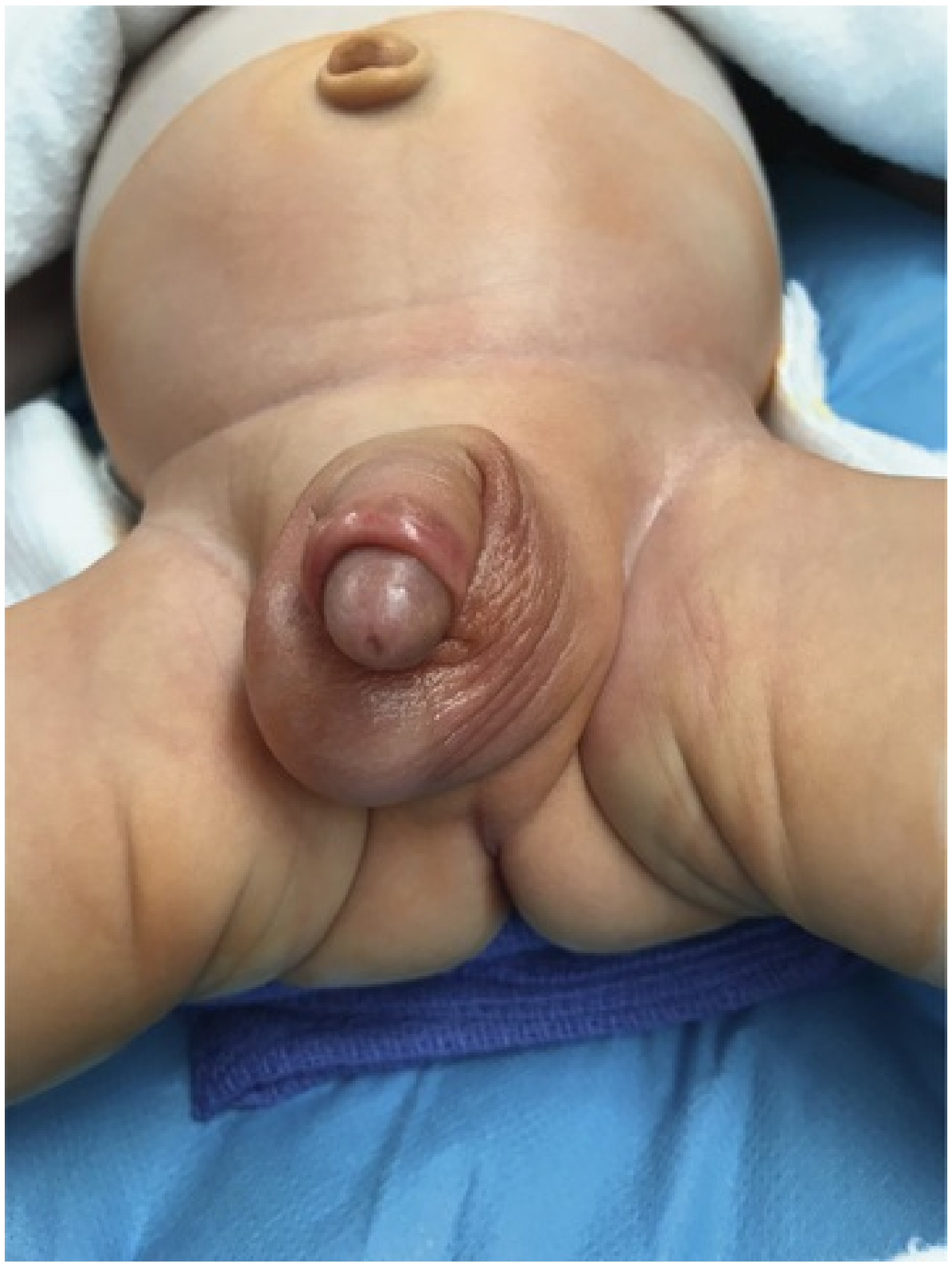

FIG. 46.4 Scrotal asymmetry in a boy with unilateral left cryptorchidism.

In large clinical series, the majority (75% to 80%) of undescended testes are palpable and 60% to 70% are unilateral; involvement of the right side is more common overall but less frequent in series of nonpalpable testes (Cendron et al., 1993; Cortes et al., 2001; Giannopoulos et al., 2001; Hadziselimovic 1983). Position of undescended testes varies markedly with the population studied, which may in part be a result of different classification techniques. In a meta-analysis of surgical patients, testes were abdominal in 34%, near the internal ring (“peeping”) in 12%, canalicular in 27%, and beyond the external ring in 27% (Docimo, 1995), and in large single-institution series, testes were abdominal in 3% to 10% of total cases, were canalicular in 16% to 27% of cases, and the majority were distal to the external ring (Cendron et al., 1993; Hadziselimovic 1983; Kraft et al., 2011; Moul and Belman, 1988). In a multi-institutional review of almost 40,000 European cryptorchid boys, 8% of testes were abdominal, 63% were canalicular, 24% were prescrotal, and 11% were SIP or ectopic. Moul and Belman classified all subinguinal testes with a lateral gubernacular attachment as ectopic (66% of their total cases).

Associated genital findings may warrant additional diagnostic studies that are best completed in the neonatal period. If neither testis is palpable, particularly if penile development is abnormal, karyotype and hormonal analyses are performed urgently to rule out congenital adrenal hyperplasia and obviate the potential adverse effects of undiagnosed salt wasting. Routine circumcision if desired should be delayed until evaluation confirms a genetically normal male. Hypospadias is associated with cryptorchidism in 12% to 24% of cases (Cendron et al., 1993; Cox et al., 2008; Moreno-Garcia and Miranda, 2002). If proximal hypospadias is present, chromosomal analysis is warranted as the frequency of abnormalities is high (32% to 47%) (Cox et al., 2008; Sekaran et al., 2013). Micropenis was reported in 46% of boys with anorchia caused by bilateral vanishing testes (Zenaty et al., 2006) (also called *testicular regression syndrome*), and small penile size in association with cryptorchidism is also observed in cases of hypogonadotropic hypogonadism. In these cases, measurement of **testosterone, LH, and FSH levels in the first few months of life during the window of opportunity afforded by the physiologic activation of the HPG axis can facilitate early identification of hormone deficiency or anorchia** (Grumbach, 2005).

Palpable Testes

Undescended testes may be located along the line of normal descent between the abdomen and scrotum or in an ectopic position that is most commonly the SIP (anterior to the rectus abdominus muscle) or, more rarely, in a perirenal, prepubic, femoral, peripenile, perineal, or contralateral scrotal position (Fig. 46.5). Careful examination of these areas is needed to correctly classify a testis as palpable or nonpalpable, a critical step that influences further diagnosis and treatment (Fig. 46.6). Every effort should be made by the examiner to determine the lowest position the testis may attain. Manual downward pressure with one hand along the ipsilateral inguinal canal from the anterior iliac spine to the scrotum and palpation with the opposite hand helps identify the lowest position of a palpable testis.

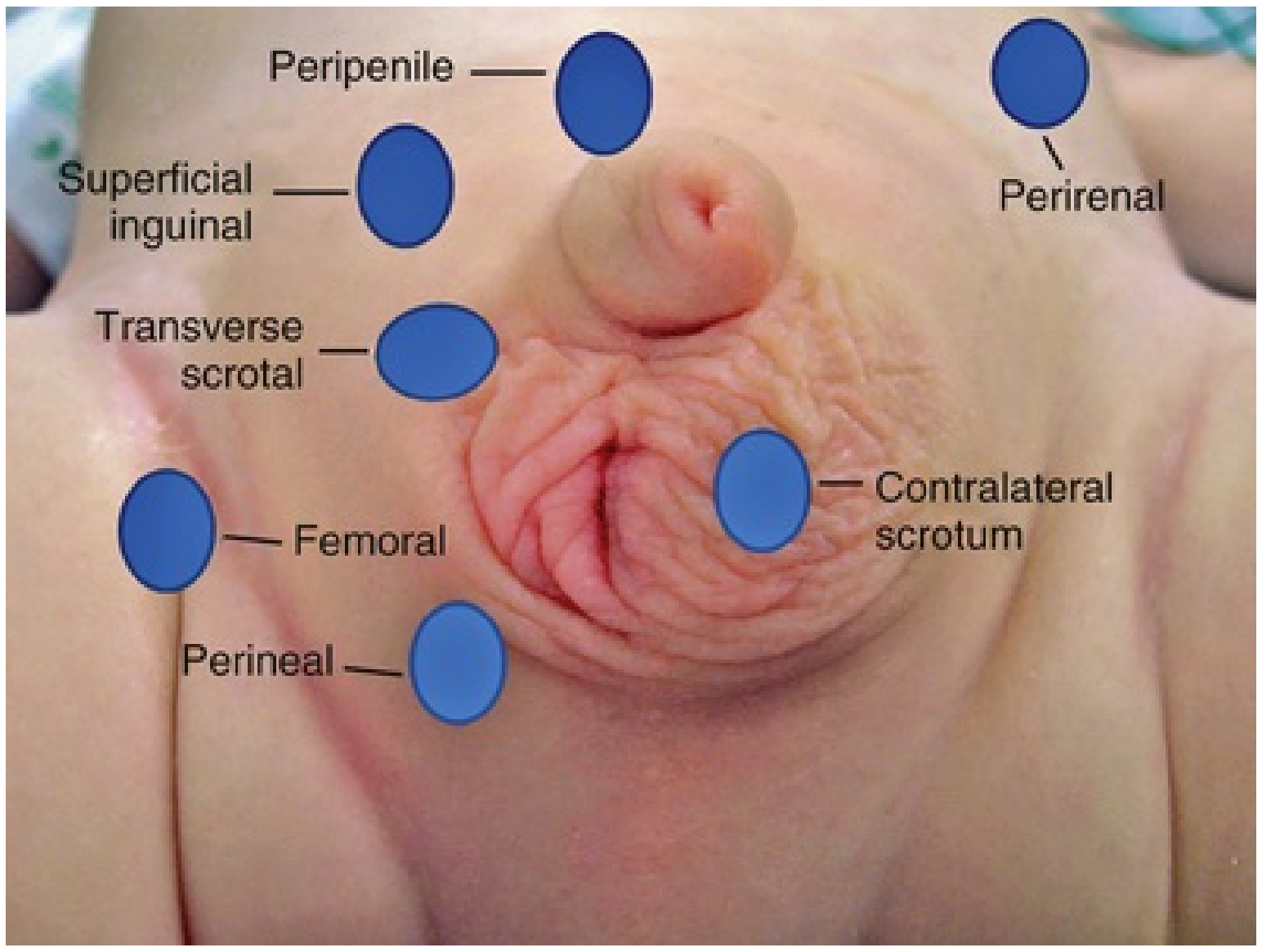
Peripenile
Perirenal
Superficial inguinal
Transverse scrotal
Contralateral scrotum
Femoral
Perineal

FIG. 46.5 Positions of the ectopic testis. The ectopic testis can be identified in various positions, as shown. The most common location is the superficial inguinal pouch.

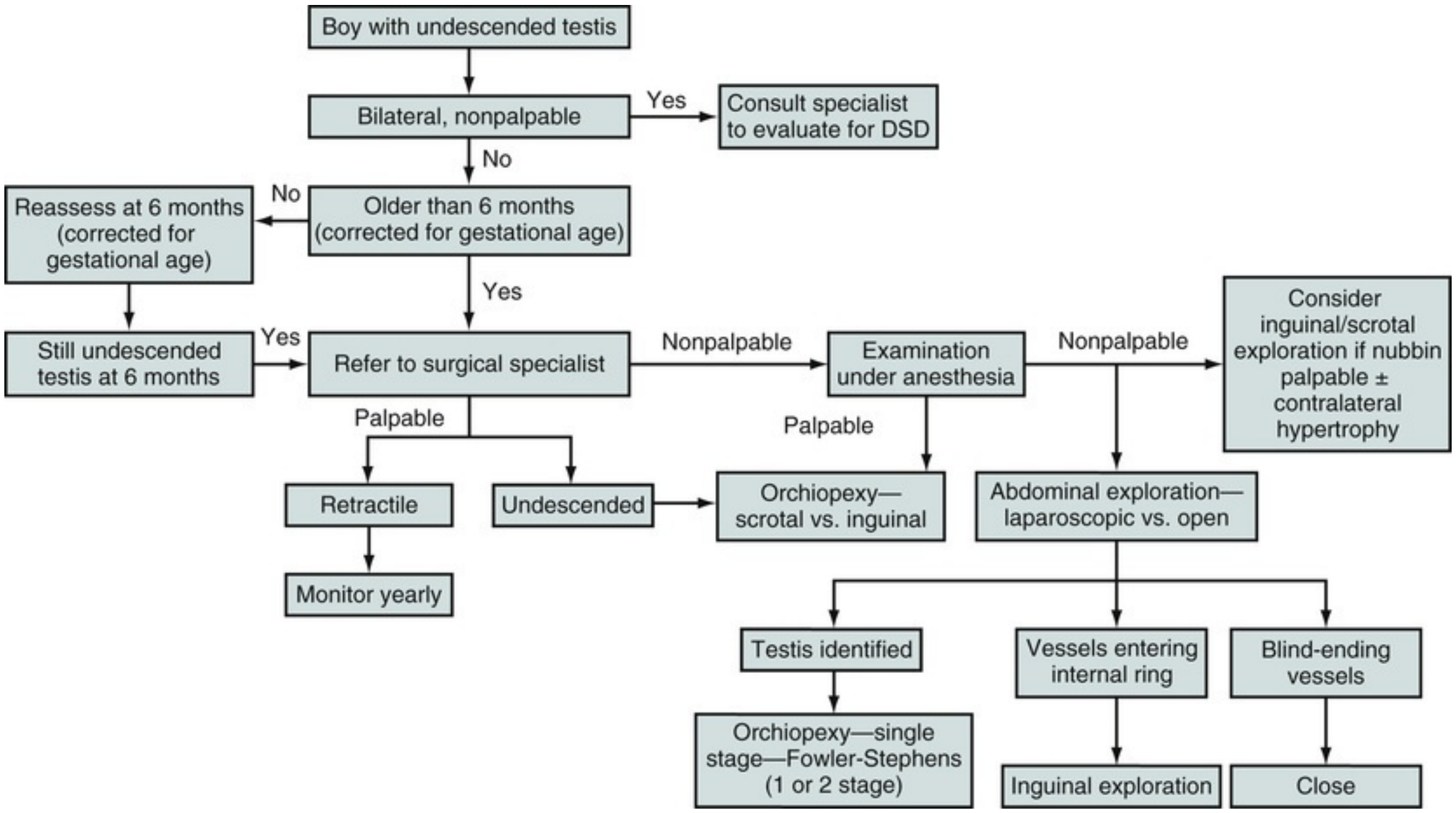
Boy with undescended testis
Bilateral, nonpalpable
Yes
Consult specialist to evaluate for DSD
No
Reassess at 6 months (corrected for gestational age)
No
Older than 6 months (corrected for gestational age)
Yes
Consider inguinal/scrotal exploration if nubbin palpable ± contralateral hypertrophy
Still undescended testis at 6 months
Yes
Refer to surgical specialist
Nonpalpable
Examination under anesthesia
Nonpalpable
Palpable
Palpable
Retractile
Undescended
Orchiopexy—scrotal vs. inguinal
Abdominal exploration—laparoscopic vs. open
Monitor yearly
Testis identified
Vessels entering internal ring
Blind-ending vessels
Orchiopexy—single stage—Fowler-Stephens (1 or 2 stage)
Inguinal exploration
Close

FIG. 46.6 Algorithm for management of the undescended testis. The American Urological Association guideline algorithm for diagnosis and treatment of palpable and nonpalpable testes in patients confirmed to have undescended testis by an experienced examiner. *DSD,* Disorder of sexual differentiation. (From American Urological Association. Evaluation and treatment of cryptorchidism (2014). Available at: http://www.auanet.org/education/guidelines/cryptorchidism.cfm.)

Difficulty in the clinical classification of cryptorchidism when the testis is palpable is related to both documentation of testicular position and differentiation of truly undescended from retractile testes, complicated by the fact that these entities may coexist. The gold standard for diagnosis remains careful examination of a child in several positions and confirmation of incomplete descent of the testis to a dependent scrotal position after induction of anesthesia. Prospective studies of intraobserver and interobserver variation show major differences in documentation of testicular position among examiners (Olsen 1989; Wit et al., 1987). Olsen noted complete agreement between two examiners on scaled measures of testicular position and mobility in only 5 (13.5%, 95% CI, 4.5% to 28.8%) of 37 boys. Cendron et al. (1993) reported that preoperative testicular position correlates poorly with intraoperative findings. Frimberger et al. also demonstrated an inability to consistently predict an absence of an intraabdominal testicle by the scrotal examinations in children with nonpalpable testicles. Of 74 children, 4 were predicted to have nubbins by an experienced surgeon and were found on laparoscopy to have a viable testicle (Frimberger et al., 2015). Variation in observed testicular position preoperatively and postoperatively may influence assessment of prognosis and outcome in boys with cryptorchidism.

Nonpalpable Testes

When a testis is nonpalpable, possible clinical findings at surgery include (1) abdominal or transinguinal “peeping” location (25% to 50%) (Fig. 46.7), (2) complete atrophy (“vanishing” testis, 15% to 40%) (Fig. 46.8), and (3) extra-abdominal location but nonpalpable because of body habitus, testicular size, and/or limited cooperation of the patient (10% to 30%) (Cendron et al., 1993; Cisek et al., 1998; Kirsch et al., 1998; Patil et al., 2005; Radmayr et al., 2003). If both testes are nonpalpable and not distal to the internal inguinal ring in a genetic male, at least 95% are abdominal, with cases of bilateral vanishing testis occurring rarely (Cendron et al., 1993; Moore et al., 1994). If neither vas nor spermatic artery is found at the time of laparoscopy, laparoscopic or surgical dissection of the perivesical area and retroperitoneum up to the level of the kidney is required to exclude the presence of a testis, as true agenesis is extremely rare. Perirenal or other abdominal testes may be associated with multicystic dysplastic or absent ipsilateral kidneys and/or nonunion of the testis and epididymis (Foley et al., 2005; Kim et al., 2005; Zaccara et al., 2004).

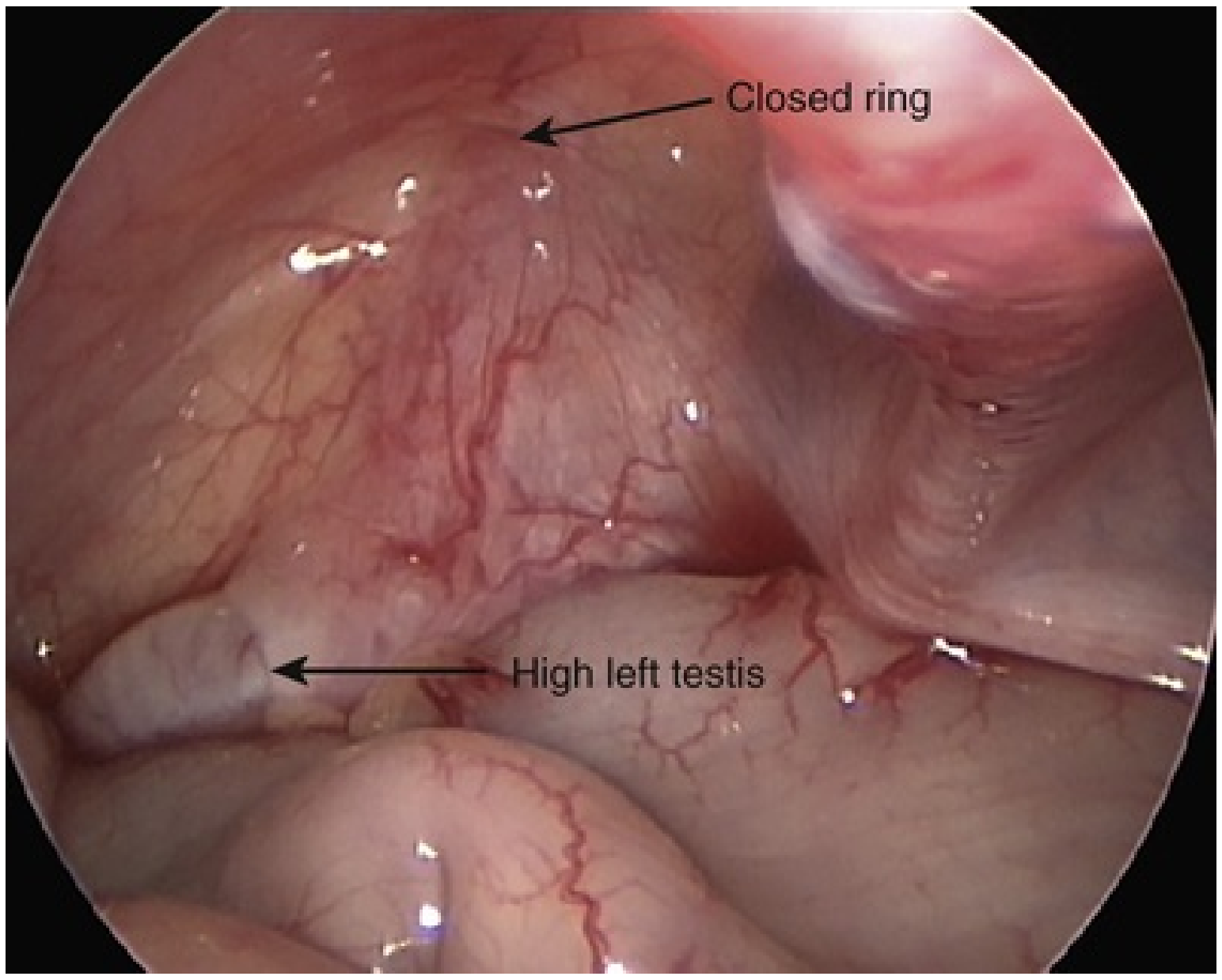
Closed ring
High left testis

FIG. 46.7 High intra-abdominal testis identified on laparoscopic evaluation. Left testis identified high in the abdomen is associated with a closed internal ring.

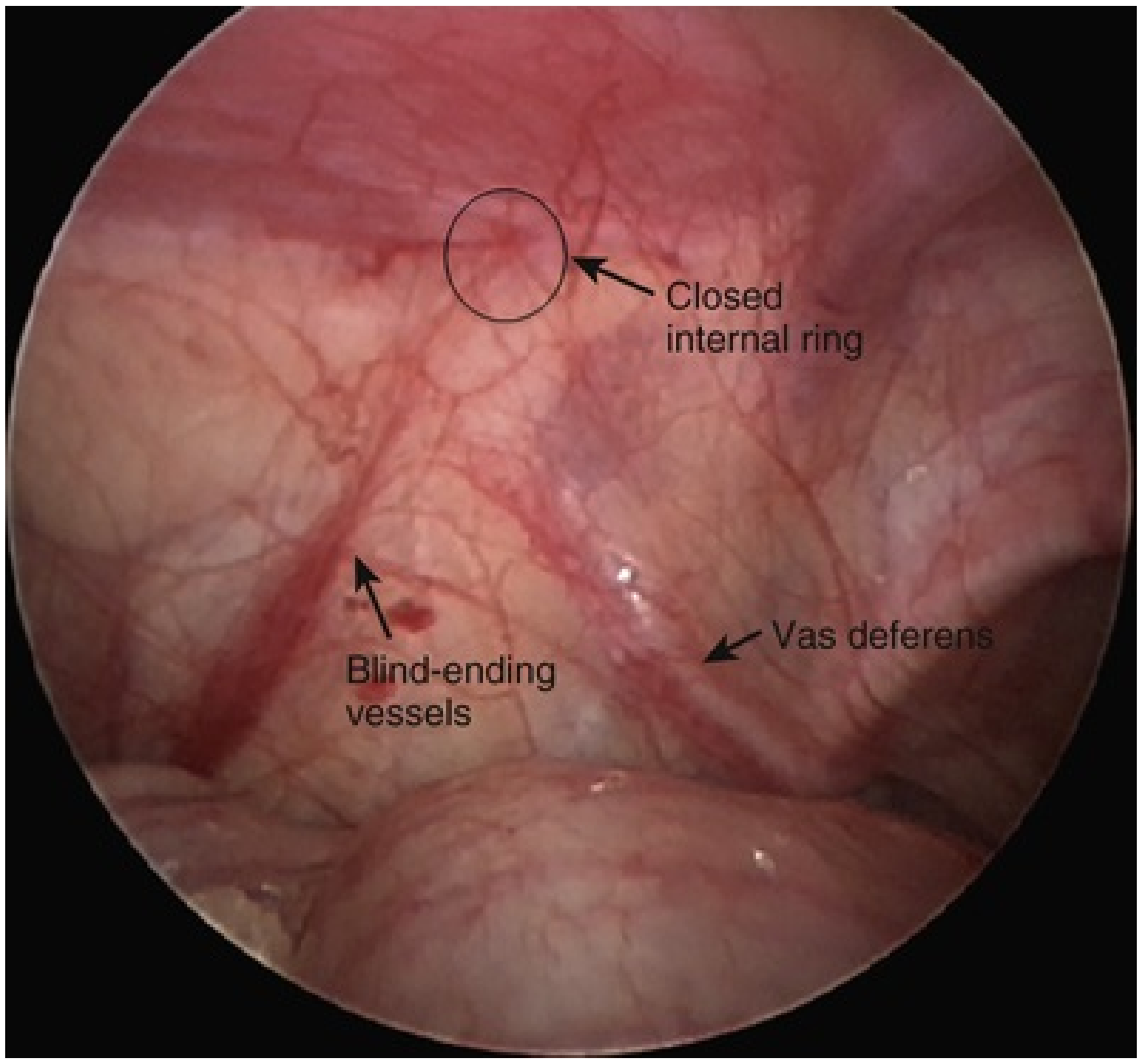
Closed internal ring
Blind-ending vessels
Vas deferens

FIG. 46.8 Vanishing testis noted on laparoscopic evaluation. Note the blind ending spermatic vessels and vas deferens.

The etiology of vanishing testis is not known but is thought to represent spermatic cord torsion or vascular accident occurring after completion of genital masculinization but before fixation of the testis in the scrotum. Evidence supporting this etiology includes the presence of hemosiderin in remnant testicular “nubbins” excised at surgery (Turek et al., 1994) and reported cases of contralateral postnatal torsion (Gong et al., 1996). An enlarged contralateral testis (Huff et al., 1992) and absence of palpable intrascrotal “appendage” tissue (processus vaginalis, Wolffian structures, or gubernaculum) are highly predictive of a vanishing testis (Mesrobian et al., 2002). In a recent review, contralateral testicular volume of greater than 2 mL was reported to have 72% sensitivity and 100% specificity (Hodhod et al., 2016) in line with prior work (Huff et al., 1992; Koff, 1991). A contralateral testicle cutoff length of 19 to 20 mm has been shown to be accurate in predicting which children will be found to have a solitary testicle (Braga et al., 2014). This information can be useful in preoperative counseling but should not negate further surgical workup. **Diagnosis of a vanishing testis requires documentation of blind-ending spermatic vessels in the abdomen, inguinal canal, or scrotum.**

Hormonal Evaluation

Endocrine evaluation in cases of suspected bilateral vanishing testes (anorchia) shows elevated basal serum gonadotropin levels and no response to hCG stimulation; however, gonadotropins may be unexpectedly low in mid-childhood (Grinspon et al., 2012b; Lee, 2000; Lustig et al., 1987). Because hCG stimulation testing is not well standardized and has the potential for side effects and inaccuracy, it is no longer the procedure of choice for documentation of anorchia (Kolon et al., 2014). In most cases, laparoscopic or surgical abdominal exploration is performed, although hormone testing can also be useful and may be sufficient for the diagnosis of anorchia, particularly when taking advantage of the window of opportunity provided by mini-puberty. In the absence of testicular tissue, FSH and LH are higher than normal in early infancy and, at any point in childhood, AMH and INHB levels are useful adjuncts in the diagnosis of anorchia (Brauner et al., 2011; Grinspon et al., 2012b; Grumbach 2005; Lee et al., 2003; Thorup et al., 2011b). Very low or undetectable AMH and INHB, together with high levels of gonadotropins (LH >5 IU/L and FSH >2 IU/L in boys 0.5 to 6 years of age or LH or FSH >5 IU/L in boys 6 to 11 years of age) are diagnostic for anorchia. Gonadotropin levels may be normal in cases of anorchia during childhood (Grinspon et al., 2012b), and in these cases laparoscopy is required to confirm the diagnosis.

Imaging

Although many children have imaging done before referral to a surgical specialist, inguinoscrotal ultrasonography and magnetic resonance imaging (MRI) are not usually helpful and are not recommended in the evaluation and management of a nonpalpable testis (Elder 2002; Kolon et al., 2014; Tasian et al., 2011). Overall, the sensitivity and specificity of ultrasonography in localizing the nonpalpable testis is 45% and 78%, respectively (Tasian et al., 2011). In a recent meta-analysis, the sensitivity and specificity of MRI in identifying cryptorchid testes was 65% and 100%, respectively, and was higher for inguinal than for abdominal testes (Krishnaswami et al., 2013). No imaging modality is reliable for diagnosing vanishing testes. Some authors advocate very selective use of imaging if recommended by the managing surgical specialist after referral; in this situation, the sensitivity of ultrasonography in identifying inguinal testes is reported to be as high as 95% to 97%, and abdominal testes are also seen in some cases (Cain et al., 1996; Nijs et al., 2007), but examination under anesthesia is likely to provide the same information (Tasian et al., 2011). Similarly, MRI can be useful in some cases to identify nonpalpable abdominal testes, but its accuracy is variable, the procedure requires sedation in younger children, and it is unlikely to change the management approach (Hartigan and Tasian, 2014; Shepard and Kraft, 2017; Siemer et al., 2000; Yeung et al., 1999). The superior accuracy of magnetic resonance angiography (MRA) in localizing and differentiating viable from vanished testes (96% of 23 nonpalpable testes in 21 boys, mean age 2.5 years) has not been replicated in a recent study of younger boys (57% of 29 testes in 26 boys, mean age 13 months) (Desireddi et al., 2008; Yeung et al., 1999). One indication for MRI may be identification of an ectopic abdominal testis not localized by laparoscopy. Despite the consensus that imaging is not indicated, it is still very commonly performed. In a large review of a Canadian data warehouse, it was found that up to 50% of referred patients had ultrasound examinations, which ultimately delayed surgical intervention by 3 months and was only accurate 54% of the time (Kanaroglou et al., 2015). **Imaging is not indicated for diagnosis of the nonpalpable testis, as it has limited accuracy and does not obviate the need for definitive surgical intervention.**

Diagnostic Laparoscopy

Diagnostic laparoscopy, followed by laparoscopic orchidopexy if an abdominal testis is present, has become the preferred approach to the nonpalpable testis for many clinicians. Laparoscopy is preceded by an examination under anesthesia, which may be a useful adjunct that helps define the appropriate course of action. Although laparoscopy does not always provide a direct diagnosis, in many cases it either provides visualization of the testis or guidance for the surgeon's next steps. Important laparoscopic observations include the size and position of the spermatic vessels and vas; testicular size, quality and position if visible; and patency of the internal inguinal ring. The combination of a closed internal ring and a blind-ending spermatic artery and vas confirms an abdominal vanishing testis (see Fig. 46.8), and a hernia is frequently but not always associated with a viable abdominal or distal testis (Elder, 1994; Moore et al., 1994). An atretic spermatic cord coursing through a closed inguinal ring is suggestive of a distal vanishing testis, but this finding may be subjective, and, conversely, normal appearing vessels may be associated with both viable and vanishing testes (Zaccara et al., 2004). Moreover, the laparoscopic view may suggest abdominal blind ending vessels despite a testis being present distally or in an ectopic abdominal position (Ellsworth and Cheuck, 2009; Kim et al., 2005; Zaccara et al., 2004). Therefore, **if laparoscopy does not unequivocally localize the testis or blind-ending spermatic artery, additional surgical exploration is needed for definitive diagnosis. This may be performed laparoscopically after the placement of additional working ports.**

The need for excision and contralateral scrotal orchidopexy in vanishing testis cases remains controversial. Germ cells and/or tubules are consistently present in 5% to 15% of excised testicular remnants (Bader et al., 2011; Cortes et al., 1995a; De Luna et al., 2003; Moore et al., 1994; Renzulli et al., 2005; Tennenbaum et al., 1994; Turek et al., 1994), but the risk for malignancy is unknown. Rozanski et al. (1996) reported a single case of carcinoma in situ in a testicular remnant. Excision is appropriate when the spermatic vessels traverse the internal inguinal ring, to provide confirmation that no viable (or atrophic) testis is present, as the laparoscopic appearance of the spermatic vessels and processus vaginalis may be deceiving and may not reliably exclude the presence of an inguinal testis (Ellsworth and Cheuck, 2009). Vanishing testes are often in or near the scrotum; therefore, initial scrotal exploration can be considered when a palpable scrotal “nubbin” and contralateral testicular hypertrophy (testicular length ≥ 1.8 cm) are present (Belman and Rushton, 2003; Snodgrass et al., 2007). However, a transscrotal search is time-consuming and unproductive when a vanishing testis is intraabdominal. Moreover, in cases of testicular-epididymal dissociation, a scrotal “nubbin” may actually be the epididymis instead of a vanishing testis; a laparoscopic approach facilitates more accurate diagnosis and subsequent management of such cases (De Luna et al., 2003; Wolffenbuttel et al., 2000). **Laparoscopy is the procedure of choice to confirm or exclude the presence of a viable or remnant abdominal testis, unless a prominent scrotal nubbin is palpable with other clinical signs of monorchism.**

Contralateral fixation of a solitary testis in cases of monorchism is advocated by some but not universally supported. The possibility that prenatal torsion is the etiology of vanishing testis (Gong et al., 1996) does not imply that the contralateral testis is likely to undergo a similar fate after the postnatal period and may not warrant the risk from surgery (Kehoe and Christman, 2017). However, some surgeons empirically recommend contralateral fixation to eliminate the risk for such a devastating complication (Rozanski et al., 1996) and/or because a contralateral bell-clapper deformity (incomplete testicular fixation to the tunica vaginalis) may be present (Al-Zahem and Shun, 2006; Bellinger 1985). However, review of the anatomy of the tunica vaginalis contralateral to vanishing testes suggests that the bell-clapper anomaly is rare and the risk for torsion of the solitary testis in these cases is minimal (Martin and Rushton, 2014).

Associated Pathology

Testicular Maldevelopment

Many observational studies of the histologic development of prepubertal normal and cryptorchid testes have been published. Over 40 years ago, Mancini et al. (1965) systematically measured germ cell counts and reported arrested development of spermatogonia with progressive loss in cryptorchid testes. Additional histologic studies of prepubertal cryptorchid testes have generally shown decreased germ cell numbers beginning after infancy, and failure to increase with age in cryptorchid, and to a lesser degree, contralateral scrotal testes (Cortes et al., 2001; Gracia et al., 1995; Hadziselimovic et al., 1986; Hedlinger 1982; Huff et al., 2001a; Kraft et al., 2011; Kollin et al., 2012; McAleer et al., 1995; Schindler et al., 1987; Tasian et al., 2009; Thorup et al., 2012, 2013). When reported, the frequency of abnormal histology in affected testes varied between studies, ranging from 38% to 98%. Some patient populations excluded individuals who responded to hormonal therapy and therefore did not undergo surgery with biopsy. Other variables include differing histologic methods and/or use of age-corrected normative values. A recent systematic review and meta-analysis defined precise age-dependent reference values from studies of normal boys (Masliukaite et al., 2016). These data show that the average (95% CI) number of spermatogonia per tubule (S/T) is 2.5 (2.3 to 3.0) at birth, 2.2 (1.8 to 2.6) at 1 year of age, 1.2 (1.0 to 1.4) at 2 to 3 years of age, 2.0 (1.7 to 2.3) at 4 years of age, and 2.5 (2.1 to 2.9) at 5 years of age, where it remains steady until early puberty (11 years of age). The drop in mean S/T values at 2 to 3 years of age to levels that are one-half of those seen at earlier and later ages would suggest a requirement to report age-specific data. In contrast, data obtained at autopsy from 69 normal boys 0 to 1.9 years of age showed a gradual reduction, with no secondary rise in the number of germ cells per tubule (Kvist et al., 2018). Of note, variability within and between biopsies from single testes has been reported (Hedlinger 1982; Schindler et al., 1987).

Despite these limitations, the available data provide strong evidence that abnormal germ cell development is often present after early infancy in cryptorchid testes and, to a lesser degree, in their descended partners. The degree of pathology reported was similar in true ectopic, superficial inguinal pouch, abdominal, and ascending testes (Herzog et al., 1992, Hutcheson et al., 2000b; Kollin et al., 2012; Rusnack et al., 2002), although some studies suggest higher severity may be associated with an abdominal location (Gracia et al., 1995; Kollin et al., 2012; Schindler et al., 1987; Tasian et al., 2009). Germ cell depletion was also present in limited samples from patients with myelomeningocele, posterior urethral valves, and prune belly syndrome (Orvis et al., 1988; Patel et al., 2008). Findings are similar in boys with secondary cryptorchidism after hernia repair, suggesting that these may in fact be cases of primary cryptorchidism (Fenig et al., 2001), although the secondary effects of malposition may also contribute to germ cell depletion (Kollin et al., 2012). In other studies, higher germ cell counts were correlated with reduced age-dependent interstitial fibrosis (Suskind et al., 2008), lower age at surgery, and increased likelihood of testicular palpability (Kraft et al., 2011; Tasian et al., 2009). In a series of 723 boys with cryptorchidism (14% bilateral), testicular volume did not predict germ cell count (Noh et al., 2000), but in a subsequent series of 1326 boys with unilateral cryptorchidism from the same institution, testis volume was positively correlated with germ cell counts in both undescended and contralateral descended testes (Kraft et al., 2011).

Detailed studies of peritubular myoid and Sertoli cells in cryptorchidism are limited, but their abnormal development or function may contribute to the observed germ cell abnormalities. The available data suggest disruption of prepubertal Sertoli cell morphology, failure of maturation at puberty, and evidence for reduced number after 4 months of age in cryptorchid testes (Lackgren and Ploen, 1984; Regadera et al., 2001; Rune et al., 1992; Zivkovic et al., 2009a). Reduced expression of type IV collagen, a product of both Sertoli and myoid cells that may function in cell-to-cell communication, was reduced in basement membranes of undescended and contralaterally descended testes (Santamaria et al., 1990). In their prospective, randomized study, Kollin et al. (2007, 2012) reported that Sertoli cell counts were significantly higher in boys who underwent orchidopexy at 9 months of age as compared with 3 years of age. They also noted that Sertoli cell number and testicular volume were significantly correlated at both time points, and remained higher at 4 years of age in the early surgery group, suggesting that a nonscrotal testis position is detrimental, even in infancy. These histologic data are congruent with recent studies showing that average levels of Sertoli cell hormones are reduced, particularly in bilateral cryptorchidism.

Impaired transformation of gonocytes to spermatogonia is reported in cryptorchid testes and may help define fertility potential. The ratio of gonocytes to spermatogonia appears to be normal in cryptorchid testes at about 1.5 months of age, but delays in the disappearance of gonocytes and in the appearance of Ad spermatogonia occur in the undescended as compared with the contralateral descended testis (Hadziselimovic et al., 1986; Huff et al., 2001a). As noted for total germ cell counts, the reported range of cryptorchid testes lacking Ad spermatogonia, 7% to 85%, is wide (Canavese et al., 2009; Thorup et al., 2013; Verkauskas et al., 2019; Zivkovic et al., 2009b) and also shows geographic variation. Reduced Ad spermatogonia number per tubule (Ad/T) can also be found in the contralateral testis of boys with unilateral cryptorchidism (Kraft et al., 2011; Verkauskas et al., 2019) and was also reported in a series of boys with acquired cryptorchidism (Promm et al., 2016), providing further evidence that these are testes that are not truly descended at birth but escape detection until later in childhood. Additionally, the appearance of primary spermatocytes at 4 to 5 years of age is delayed in cryptorchid testes (Huff et al., 1989, 2001a).

Kollin et al. studied testicular growth in undescended and scrotal testes and measured the effect in orchidopexy on testicular size using serial ultrasonography in prospective randomized studies of congenital cryptorchidism (Kollin et al., 2006, 2007, 2012, 2013). They showed that the undescended testis is smaller at birth and grows less well than the scrotal testis, even if spontaneous descent occurs. Postoperative testicular growth was superior in boys who underwent orchidopexy at 9 months of age as compared with those randomized to surgery at 3 years of age. Biopsies at the time of orchidopexy in these patients showed marked reductions in germ cell number and a less prominent reduction in Sertoli cells when orchidopexy was delayed until 3 years of age. In these studies, INHB levels correlated with testicular volume, as reported previously for neonates with normal testes, where INHB levels were interpreted to primarily reflect differences in Sertoli cell number (Main et al., 2006b; Sharpe 2006). **These well-conducted prospective studies suggest that cryptorchidism is associated with primary and secondary effects on testicular development, and that an extrascrotal position may have adverse effects, even in infancy.** Because Sertoli cells provide critical paracrine signaling during the process of spermatogonial differentiation (Manku and Culty, 2015), it is possible that the histologic abnormalities observed in cryptorchid testes are the result of functional defects in Sertoli cells, germ cells, or both.

Anomalies of the Epididymis, Processus Vaginalis, and Gubernaculum

Attachment of the epididymis to the testis may be abnormal in cryptorchid boys (Marshall and Shermeta, 1979), with a reported frequency that varies from 16% to 75% (Gill et al., 1989; Heath et al., 1984; Kraft et al., 2011; Merksz and Tóth, 1987; Mollaeian et al., 1994), in part because identification of this anomaly may be subjective. **Anatomic findings in decreasing order of frequency include partial or complete nonfusion between the caput and/or cauda epididymis and the testis, epididymal elongation and/or looping, and atresia (Fig. 46.9).** The occurrence of epididymal anomalies correlates with both the severity of cryptorchidism and the degree of closure of the processus vaginalis (Barthold and Redman, 1996; Elder 1992). Epididymal anomalies were more common in congenital (37% to 60%) than in acquired (11% to 31%) cryptorchidism (Barthold et al., 2012; van Brakel et al., 2012). Complete epididymal detachment or nonunion between the testis and epididymis/vas is rare and more likely to be associated with abdominal testes (Foley et al., 2005; Karaman et al., 2011; Sharma and Sen, 2013; Wakeman and Warner, 2010) but did not correlate with testicular histology (Kraft et al., 2011). However, the degree to which these anomalies alter sperm transport, if at all, and potentially contribute to subfertility in males with a history of cryptorchidism, remains undefined.

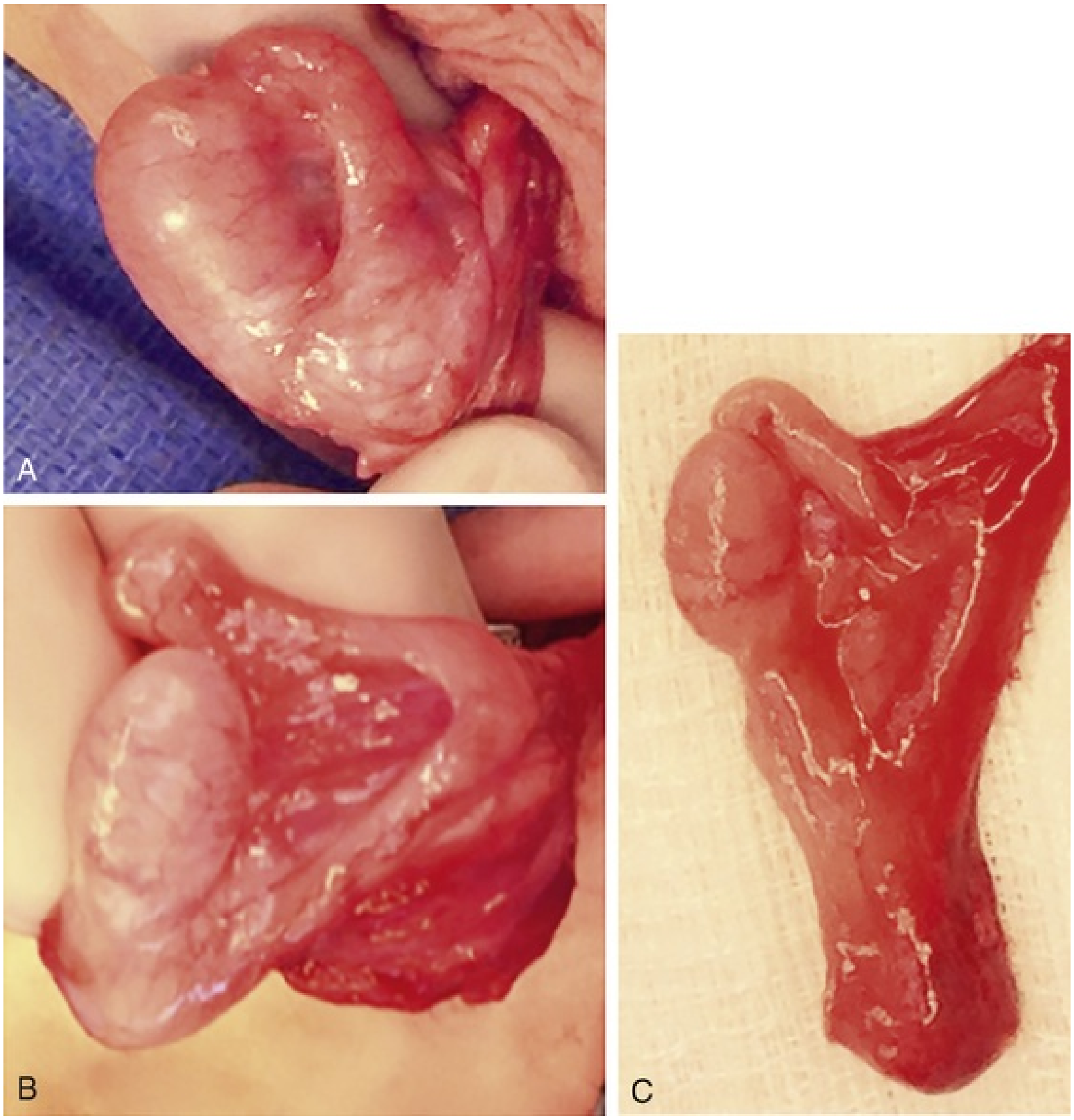

FIG. 46.9 Epididymal anomalies. (A) Normal epididymis. (B) Looped epididymis. (C) Malunion of the tail of the epididymis.

Patency of the processus vaginalis (inguinal hernia) and abnormal attachment of the gubernacular remnant are common in association with cryptorchidism. In their study of 759 patients, Cendron et al. identified a persistently patent processus vaginalis ipsilateral to 87% of unilateral and 71% of bilateral undescended testes. Specific notation of the gubernacular position available from this and another large study indicates aberrant attachment lateral to the scrotum in 66% to 75% of cases (Cendron et al., 1993; Moul and Belman, 1988). The processus is patent in 45% to 50% of boys presenting with ascending testes, possibly related to older patient age and/or reduced severity of cryptorchidism in this group (Barthold and Gozalez, 2003; Barthold et al., 2012; van Brakel et al., 2012). Inguinal hernia is also more common in family members of boys with cryptorchidism (Barthold et al., 2012). **Anomalies of the tunica and processus vaginalis in cryptorchidism predispose to development of testicular torsion or clinical hernia, respectively, in rare cases.** Torsion of an undescended testis can occur at any age (reviewed by Zilberman et al., 2006) and may be confused with an incarcerated inguinal hernia. The risk for torsion is higher in undescended testes than in scrotal testes, and it may be particularly high in children with developmental disorders. Delay in diagnosis is common, and a high index of suspicion is needed to reduce the high risk for testicular loss. A rare but significant concern is the potential risk for torsion with testicular loss in infancy, as boys are observed for spontaneous testicular descent (Singal et al., 2013).

Other Testicular Anomalies Associated With Cryptorchidism

Several rare anomalies of testicular development associated with cryptorchidism, each with 100 to 150 reported cases in the literature, include polyorchidism, splenogonadal fusion, and transverse testicular ectopia. As abdominal cryptorchidism commonly occurs in these cases, laparoscopy is useful in both diagnosis and treatment.

Polyorchidism is the presence of a supernumerary testis that is more commonly unilateral and on the left side, with rare cases of bilateral duplication or triplication reported in a comprehensive meta-analysis of pediatric and adult literature (Bergholz and Wenke, 2009). The cause is unknown, but most authors speculate that this anomaly is related to duplication or division of the genital ridge with or without the Wolffian duct (Danrad et al., 2004). Testes are reported to be scrotal, inguinal, and abdominal in 75%, 20%, and 5% of cases, respectively (Kumar et al., 2008). Affected individuals are frequently asymptomatic, and the polyorchidism is identified at the time of orchidopexy or hernia repair (present in 24% to 30% of cases); other reported associations include a scrotal or inguinal mass, pain (7%), testicular torsion (13% to 15%), persistent müllerian remnants (7% to 9%), and/or testicular tumor (Avargues et al., 2015). Various classification schemes have been proposed, with a recent trend toward categorizing testes based on epididymal and vasal configuration (Bergholz et al., 2007; Khedis et al., 2008; Kumar et al., 2008). Kumar et al. suggest a classification that differentiates between testes that are drained by a vas deferens: *Type A1*, separate epididymis and vas; *Type A2*, separate epididymis; and *Type A3*, shared epididymis and vas, from those with no vasal drainage: *Type B1*, epididymis present, and *Type B2*, no epididymis or vas. This classification can aid in management decisions that should be based not only on the anatomy of the accessory ducts but also the position, size, and attachments of the testis. Observation and periodic self-examination without surgery should be considered for sonographically normal scrotal testes and orchidopexy for testes that are undescended but with intact ductal drainage (Bergholz et al., 2007; Khedis et al., 2008; Spranger et al., 2002). Occasional cases of testicular tumor have been reported in supernumerary testes, but it is unclear if this is a risk related to polyorchidism per se or to associated cryptorchidism or persistent müllerian duct syndrome (Ghose et al., 2007; Spranger et al., 2002). Testicular torsion may also occur (Arlen et al., 2014).

Splenogonadal fusion is a defect characterized by continuous or discontinuous fibrous union between splenic tissue and the gonad, a condition much more commonly recognized in males (Khairat and Ismail, 2005) (Fig. 46.10). In the continuous form (55%), a cord connects the testis to the spleen; in the discontinuous form, the splenic tissue is attached to the gonad and not continuous with the main body of the spleen (Ferron and Arce, 2013). Approximately 30% of affected individuals have cryptorchidism, with the majority of cases abdominal and bilateral (59%), and 65% and 26% involving the left and right sides, respectively (Cortes et al., 1996). The continuous form of splenogonadal fusion is more commonly syndromic and associated with limb defects, micrognathia, microglossia, anal atresia, and pulmonary hypoplasia (Celik et al., 2016; McPherson et al., 2003) and less commonly with cardiac defects, cleft palate, imperforate anus, and myelomeningocele (Lin et al., 2010). The discontinuous form can present as a testicular mass, with distinctive ultrasound findings that include a somewhat hyperechoic mass (relative to testis) that contains multiple hypoechoic nodules and obvious vascularity (Ferron and Arce, 2013). The pathogenesis of splenogonadal fusion is unknown, but based on the constellation of defects observed is hypothesized to represent a developmental field defect with aberrant migration of spleen cells occurring at 5 to 8 weeks. Most cases present incidentally at the time of orchidopexy or inguinal hernia repair, or with scrotal swelling related to illness-associated reactive changes within the splenic tissue. Testicular malignancy is reported rarely in association with cryptorchidism and not likely related to the splenic anomaly. Treatment should focus on recognition of the defect at the time of orchidopexy and avoidance of unnecessary orchiectomy.

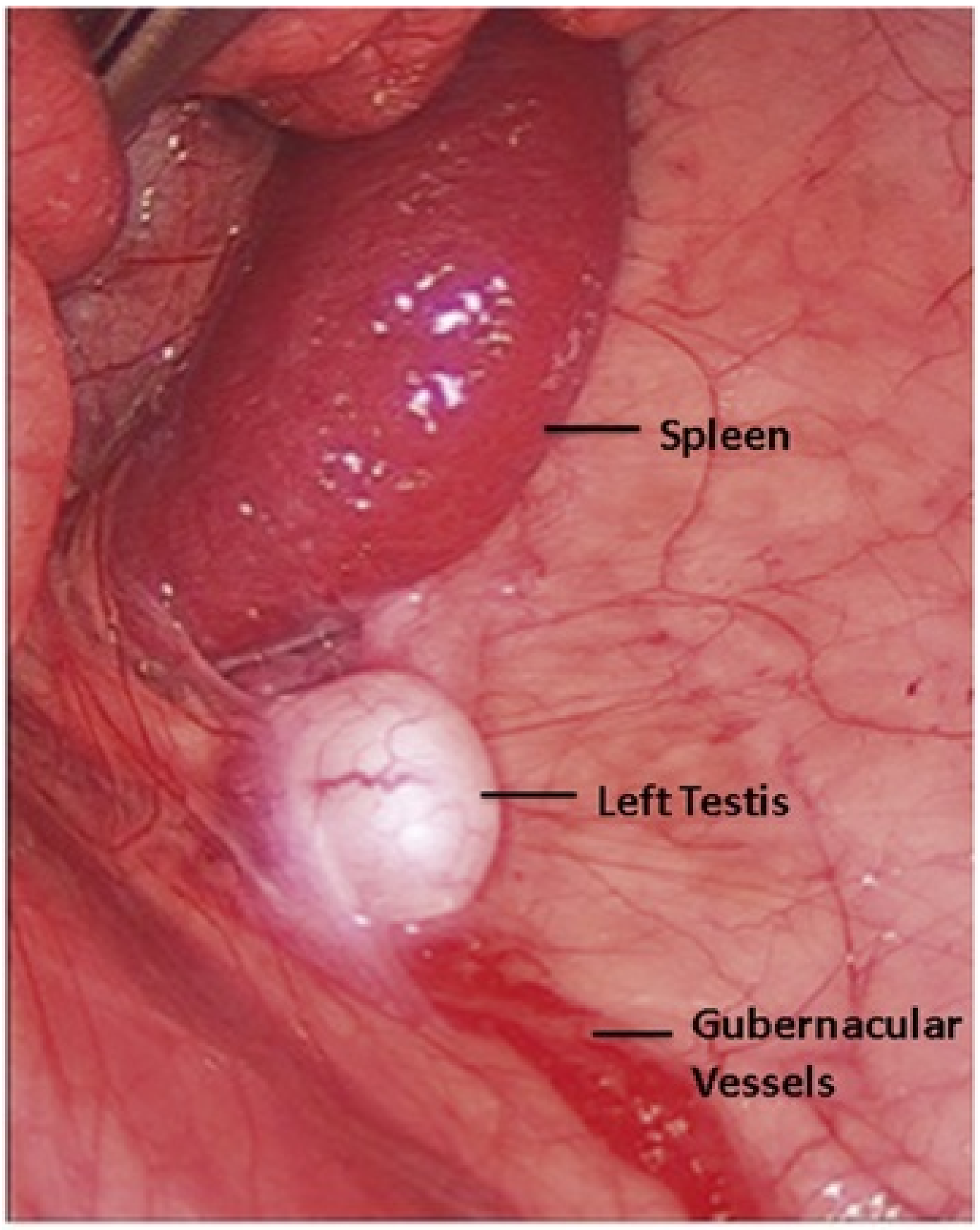

FIG. 46.10 Splenogonadal fusion. A case of continuous splenogonadal fusion in a boy with a left nonpalpable testis with fusion to the spleen as identified by laparoscopy.

Transverse testicular ectopia (TTE) may occur as an isolated anomaly in otherwise normal males with cryptorchidism or vanishing testes, or may be associated with persistent müllerian duct syndrome (PMDS) in 20% to 50% of cases (De Luna et al., 2003; Thambidorai and Khaleed, 2008; Wuerstle et al., 2007). The classic presentation is inguinal hernia with contralateral nonpalpable testis, although both testes may be palpable in the same hemiscrotum. The etiology may be related to mechanical hindrance to descent by fusion of Wolffian duct derivatives (Chacko et al., 2006) or persistent müllerian ducts, or to a primary gubernacular defect. Interestingly, in transgenic *Insl3 –/–* mice, complete loss of the gubernacular attachment, TTE, and/or torsion were observed (Nef and Parada, 1999; Sozubir et al., 2010; Zimmermann et al., 1999). In the largest series of PMDS to date, presentations included bilateral cryptorchidism (59%), unilateral cryptorchidism with contralateral hernia (hernia uteri inguinalis, 19%) or TTE (22%) (Picard et al., 2017). Mutations in *AMH* or its receptor, *AMHR1*, occur in 88% of patients, and infertility is present in at least 80% and testicular malignancy in 33% of adults.

Laparoscopy is a useful adjunct in diagnosis and treatment of TTE (Alamsahebpour et al., 2015). Orchidopexy may be performed using open surgical or laparoscopic techniques, but in cases of vasal fusion, the involved testis is mobilized ipsilaterally and a trans-septal approach is used to place the testis in the contralateral scrotum (Chacko et al., 2006; Thambidorai and Khaleed, 2008).

General Guidelines for Management

Surgical correction of cryptorchidism is indicated to optimize testicular function, reduce and/or facilitate diagnosis of testicular malignancy, provide cosmetic benefits, and prevent complications such as clinical hernia or torsion. Except in certain cases of associated complex medical illness or in the postnatal period, treatment should proceed after confirmation of the diagnosis. An algorithm has been established and published as part of the AUA Cryptorchidism guideline (Kolon et al., 2014) (see Fig. 46.6), which outlines the recommended approach to palpable and nonpalpable testes in patients confirmed to have an undescended testis by an experienced examiner. Similar guidelines have also been established by the Canadian Urologic Association and the European Association of Urology (Braga et al., 2017; Radmayr et al., 2016).

In infants, observation is indicated for the first 6 postnatal months to allow spontaneous testicular descent. If spontaneous testicular descent does not occur, surgical treatment after 6 months but preferably by 12 months of (corrected gestational) age is indicated. Support for this approach is based on the following rationale: (1) spontaneous descent is unlikely in full-term males after 2 to 6 months of age, (2) testicular growth is restored after early orchidopexy at 9 months as compared with 3 years of age, and (3) orchidopexy for abdominal testes may be easier in young infants, soon after mini-puberty. In boys with a history of prematurity, spontaneous descent may be delayed, and therefore observation should be continued for 6 months beyond the expected date of delivery or, especially if testicular position is marginal, until 1 year of age.

Despite these and prior guidelines which have progressively recommended younger ages at surgery, reports from diverse countries suggest that intervention is delayed in many children. For example, between 2001 and 2014, 20,275 boys were diagnosed with cryptorchidism in Sweden, but only 63% underwent surgery, and the median age decreased from 6.3 to 3.4 years during that interval (Bergbrant et al., 2018). The proportion having surgery in the first year of life remained low (~5%) although the total undergoing orchidopexy by 2 years of age increased from 10% to 30%. Similar reports from Australia (Schneuer et al., 2016b), the UK (Bradshaw et al., 2014), Germany (Hensel and Wirth, 2014), China (Wei et al., 2016), and multiple regions within the United States (Point et al., 2017; Savoie et al., 2017; Williams et al., 2017) found gradual reductions in the mean age at surgery yet delay beyond 2 years of age for the majority.

Although these studies could not differentiate between true delays in diagnosis (acquired cryptorchidism) and delayed treatment of congenital cases, intervention is often delayed in boys diagnosed at birth (Ellerkamp et al., 2018; Nah et al., 2014). Potential reasons for delay include lack of provider education, local resources, and/or socioeconomic factors, or likely, in some cases, recurrent cryptorchidism. Continued observation is needed after the occurrence of spontaneous testicular descent in infancy in light of the risk for testicular re-ascent.

Investigators in the Netherlands adopted an observational approach to boys with acquired cryptorchidism and reported spontaneous descent in 75 of 132 (57%) and 98 of 129 (75%) testes, respectively, most by mid-puberty (Eijsbouts et al., 2007; Sijstermans et al., 2006). The mean volume of descended testes in the study by Eijsbouts et al. was closer to those of normal contralateral testes as compared with boys who underwent orchidopexy. However, in both of these series, high scrotal testes comprised the majority of those that descended, and low scrotal "unstable" testes (likely retractile) were also included. On the other hand, Eijsbouts et al. reported that 19 of 82 unilateral cases had previous contralateral orchidopexy, and 10 boys required orchidopexy because of clinical hernia, pain, or torsion, suggesting a higher likelihood of true cryptorchidism in these cases. In follow-up studies of 391 boys with 464 acquired cryptorchid testes, 90% of high scrotal testes and 64.5% of inguinal/nonpalpable testes descended spontaneously at a mean age of 12.9 years (Hack et al., 2010). In contrast, a study from the same institution showed that testicular volumes were significantly smaller for age in 155 postpubertal patients who underwent orchidopexy at diagnosis (the majority before puberty) after a mean of 6.6 ± 3.8 years' follow-up (van der Plas et al., 2013c). Because these individuals were selected for orchidopexy and the majority (92%) had suprascrotal testes, they are likely not comparable to the group of boys treated after puberty at the same institution (Hack et al., 2010). These investigators obtained follow-up hormonal and semen analysis from 63 of 169 eligible men (49 unilateral, 14 bilateral) who underwent orchidopexy at diagnosis and 65 of 207 men who were observed for spontaneous descent (24 unilateral, 8 bilateral) or were observed initially but required surgery (51%; 26 unilateral and 7 bilateral) (van der Plas et al., 2015). Differences in the frequency of oligospermia, 27% and 38%, respectively, in operated versus observed unilateral cases, and 43% and 67%, respectively, in bilateral cases, were not statistically significant. These studies were not randomized, and many cases were lost to follow-up. Without adequate long-term paternity and malignancy outcome data, this approach cannot be recommended for cases of acquired, particularly bilateral cryptorchidism.

Medical Management

Hormonal therapy has been previously used for a variety of indications in patients with cryptorchidism, including differentiation of retractile from true undescended testes, stimulation of testicular descent, or germ cell maturation and as an adjunct to facilitate abdominal orchidopexy. In prospective series reporting the response of putative retractile testes to hCG, success rates vary from 58% to 100% and may be dependent not only on age, degree of retractility, and accuracy of diagnosis, but also on the dosage regimen used (Metin et al., 2005; Miller et al., 2003; Rajfer et al., 1986). These data suggest that hCG does not reliably distinguish retractile from cryptorchid testes, or eliminate the need for serial examinations in these patients.

Therapeutic LHRH and/or hCG

Luteinizing hormone–releasing hormone (LHRH) and/or hCG have been used as hormonal therapy to induce descent of testes for more than 70 years based on the premise that androgens promote testicular descent, but efficacy is questionable (Bu et al., 2016; Henna et al., 2004; Li et al., 2016; Pyorala et al., 1995; Thorsson et al., 2007). Although the efficacy of either hormonal treatment is about 20% and superior to placebo in randomized trials, this effect is not clearly clinically significant. Overall, the evidence from rigorous studies indicates that LHRH therapy is marginally more effective than placebo, and although not studied in randomized placebo-controlled trials because of its route of administration, hCG also shows limited efficacy. Other uses of hCG, including treatment of acquired cryptorchidism and to facilitate palpability and/or treatment of the abdominal testis (Baker et al., 2001; Bukowski et al., 2001; Polascik et al., 1996) also have limited efficacy. **Consequently, hormonal therapy to stimulate testicular descent is not currently recommended for treatment of boys with cryptorchidism** (Kolon et al., 2014; Thorsson et al., 2007).

The question of whether therapeutic hCG or LHRH protocols alter germ cell development has been addressed in several conflicting studies that are limited by small sample size, absent or suboptimal randomization, and variable availability of biopsy data (Ong et al., 2005). In small, retrospective studies, hCG treatment was associated with increased germ cell apoptosis at biopsy and lower adult testis volume (Dunkel et al., 1997), and previous hCG or LHRH therapy was associated with reduced germ cell counts in boys 1 to 3 years of age as compared with surgery alone (Cortes et al., 2000). In contrast, in a study of young boys (mean age 33 months, 21 per group) randomized to therapeutic doses of LHRH or no hormonal therapy before surgery, mean germ cell count was higher (1.05 ± 0.71) in LHRH-treated testes as compared with nontreated (0.52 ± 0.39) testes, with the effect enhanced in boys younger than 2 years of age (Schwentner et al., 2005). However, an additional recent report compared a more homogeneous group of boys who all underwent surgery before 2 years of age; 10 who had not responded to therapeutic LHRH (1.2 mg/day for 4 weeks) in a prior randomized study (De Muinck Keizer-Schrama et al., 1986) were compared with 14 who did not receive hormonal therapy (van Brakel et al., 2013). The authors found no differences in semen parameters or endocrine function between these two groups. In view of a lack of large prospective, randomized studies, it is unclear if specific types of hormone therapy for treatment of cryptorchidism are beneficial or harmful to germ cells in the short- or long-term. Future research in this area is unlikely, as this approach to treatment is no longer recommended.

Adjuvant Hormonal Therapy

Hadziselimovic et al. (1986, 1987a–c) were first to advocate the use of adjuvant or neoadjuvant LHRH agonist therapy to improve potential fertility in boys with cryptorchidism. The rationale for use of hormonal therapy to augment fertility potential is based on the premise that insufficient androgen stimulation, caused by “defective mini-puberty” or relative hypogonadotropic hypogonadism (Huff et al., 1989) is the cause of impaired transformation of gonocytes to Ad spermatogonia in neonatal cryptorchid boys and can be restored by gonadotropin stimulation later in childhood. No studies have directly tested this by hypothesis by directly correlating hormone levels in mini-puberty with spermatogonial development in control or cryptorchid individuals. However, existing data (see the Hormonal Defects section earlier in this chapter) do not confirm HPG axis defects in most cryptorchid infants. Moreover, age at scrotal placement of testes, but not LH, testosterone, FSH, or inhibin B levels, predicted higher germ and Sertoli cell counts at 9 months and 3 years of age (Kollin et al., 2012).

LHRH agonist (buserelin) therapy using a low-dose, long-term (10 or 20 mcg intranasally, every other day for 6 months) regimen to avoid HPG downregulation has been the primary approach used for stimulation of germ cell development, in conjunction with orchidopexy. In a retrospective study of nonrandomized, non–age-matched patients receiving buserelin versus surgery only, germ cell counts were significantly higher in the treated group (Hadziselimovic et al., 1987b). A subset of patients from this same cohort with the most severe testicular histology underwent re-biopsy after completion of therapy and were compared with a group of boys (8) of unknown age who required reoperative orchidopexy (Hadziselimovic et al., 1987a). A significant improvement in testicular histology was seen in the buserelin-treated group but not the surgical group. Similarly, in a smaller select group of boys treated with low doses of a related LHRH agonist, nafarelin, improved histology was observed in one or both testes at rebiopsy in 8 of 12 boys (Huff et al., 2001b). In a randomized study of clinically matched boys receiving buserelin + hCG, placebo + hCG, or surgery alone (19 to 25/group), germ cell counts were also significantly higher in those treated with buserelin (Bica and Hadziselimovic, 1992). In a nonrandomized retrospective study, buserelin-treated males, most of whom also received hCG, with a history of unilateral cryptorchidism and poor pretreatment germ cell counts had much higher sperm counts than patients who underwent surgery only (*n* = 15 per group) (Hadziselimovic, 2008). Unfortunately, these two groups were small and not clinically matched prospectively to limit other potential confounding factors, such as testicular position; and sperm counts in the surgery-only group were lower than typical for unilateral cryptorchidism.

Additional data from two randomized studies of boys with bilateral cryptorchidism were recently reported. In the first study, 10 boys (7 months to 3.5 years of age) with S/T counts 0.5 to 4.0 (normal considered 1.0, 0.65, and 0.38 at birth, 6 months, and 1 to 4 years, respectively) were included; testicular position was not stated (Thorup et al., 2018). Matched based on blinded germ cell counts, 5 received adjuvant LHRH, 200 mcg twice daily, every other day for 4 months beginning 9 months postoperatively, and 5 received no further therapy. At re-biopsy 12 months later, 2 LHRH-treated boys showed improvement in S/T counts to greater than 0.4 and 3 normalized Ad/T counts (>0.2). In the control group, 2 boys normalized both S/T and Ad/T, although mean S/T was higher in the LHRH-treated group. In the second study, 10 boys, 7 to 55 months of age at first surgery for bilateral cryptorchidism and nonblinded biopsy showing absent Ad spermatogonia, were computer-randomized to receive the adjuvant LHRH agonist (LHRHa) buserelin, 10 mcg intranasally, every other day for 6 months, followed by re-biopsy (Vincel et al., 2018). In the LHRHa group, all with inguinal testes, S/T rose after surgery and hormonal treatment to greater than or equal to 0.4 in 4 boys, and all developed measurable Ad/T values (0.005 to 0.02), although still below normal (≥0.1). In the surgery-only group, 3 with abdominal and 2 with inguinal testes, S/T rose to greater than 0.4 in 1 case, and none had visible Ad spermatogonia at the second biopsy. These pilot data suggest a potential role for adjuvant hormonal therapy in selected cases of bilateral cryptorchidism, but it is yet unclear which patients are most likely to benefit. Because Ad/T greater than 0.2 seems to be more predictive of future fertility than S/T (see later), it is also unclear whether the observed effects will translate to improved fertility in adulthood.

Recent reviews of the literature have addressed currently available data from these and other investigators, including the results of case-control (5), retrospective cohort (2), and randomized (3) studies (Biers and Malone, 2010; Chua et al., 2014). Using the Cochrane collaborative risk for bias assessment, the potential for bias was determined to be high or unclear in most domains analyzed for the randomized studies (Chua et al., 2014). The studies were highly variable with regard to patient age; sample size (range of 12 to 52 per treated group); type, dose, timing, and duration of therapy used; outcome criteria, and blinding. In some series, both hCG and either adjuvant or therapeutic doses of LHRH were used, and some patients in control groups also received hormones. Although these data suggest potential efficacy of adjuvant therapy in improving fertility potential, the methodologic limitations make interpretation difficult, and therefore adjuvant therapy is not widely in use. **Large, well-designed studies of bilateral cryptorchidism, for which this approach may be most useful, that use standardized treatment regimens, and report fertility and paternity outcome measurements, are needed.**

Surgical Management

The recommendation that surgical intervention proceed once failure of spontaneous descent is confirmed is now standard (Chan et al., 2014; Kolon et al., 2014) but is not new. Retrospective studies that address the question of whether early surgery is preferable have shown mixed results, and, particularly in view of the heterogeneity of the disease, are difficult to interpret. However, the prospective, randomized study by Kollin et al. (2007, 2012) suggests that surgery in the first year of life in cases of congenital cryptorchidism is likely to be beneficial with regard to testicular growth and histology, although long-term outcome data are not available. Despite long-standing recommendations for surgery in infancy in cases of congenital cryptorchidism, the median or average age at which orchidopexy is performed remains 1.5 to 4 years in many series (Barthold and González, 2003; Barthold et al., 2012; Bayne et al., 2011; Bradshaw et al., 2014; Kokorowski et al., 2010; Nah et al., 2014; Snodgrass et al., 2011). A review of the Pediatric Health Information System (PHIS) database by Kokorowski et al. demonstrated that only 18% of 28,204 boys who underwent surgery did so by 1 year of age. The reason for later surgery likely reflects a combination of factors, primarily delayed referral of congenital cases and new diagnoses of acquired cryptorchidism. Cases of congenital cryptorchidism may go undetected or untreated in infancy because of prematurity or other morbidity, undergo longer than necessary observation for spontaneous descent, or represent cases of undetected re-ascent after spontaneous descent in infancy. Delay may also be exacerbated by difficulty in distinguishing undescended from retractile testes.

A treatment option for **pubertal and postpubertal boys** is orchiectomy, especially if the testis is abdominal or difficult to mobilize because poor spermatogenesis and hypotrophy are usually present and the risk for carcinoma in situ and torsion exist (Chung and Lee, 2015; Rogers et al., 1998). A testicular prosthesis may be placed at the same setting if desired.

Palpable Testes

Inguinal Orchidopexy

The traditional approach to surgical treatment of palpable testes is inguinal orchidopexy (Video 46.1) with repair of an associated hernia if present (Hutcheson et al., 2000a), although a primary scrotal approach as originally described and advocated by Bianchi et al. is an increasingly popular approach (Bianchi and Squire, 1989; Iyer et al., 1995).

After induction of anesthesia, the patient is re-examined to confirm that the testis is palpable and to identify the lowest testicular position. In the standard inguinal approach, a low transverse incision in Langer's lines at or below the inguinal crease is made superolateral to the pubic tubercle. Dissection of the subcutaneous tissue should include a search for a testis within the superficial inguinal pouch. After identifying the external ring, the external oblique fascia is incised to expose the canal with care to avoid injury to the ilioinguinal nerve. Testis position is recorded relative to the inguinal canal. The spermatic cord is isolated, and the testis is dissected distally to its attachment to the gubernacular remnant. Transection of the gubernaculum distal to the sac will avoid potential injury to a long-looping vas. Longitudinal incision of the internal spermatic fascia allows free mobilization of an intact hernia sac, if present, and minimizes skeletonization of the vas and spermatic vessels. Alternatively, the sac may be opened overlying the testis and the incision extended proximally along the length of the cord. Once isolated, the sac is mobilized to the level of the internal inguinal ring and suture-ligated. Incision of the internal spermatic and transversalis fascia at the level of the ring facilitates additional retroperitoneal mobilization of the vas and vessels, if needed. Further maneuvers to provide spermatic cord length include transection of lateral fascial bands along the cord, cranial retroperitoneal dissection, medial transposition of the testis beneath the epigastric vessels (Prentiss maneuver), and, if required, cranial extension of the incision. Very rarely, the testis cannot be brought to dependent scrotal position after these maneuvers, and a two-stage procedure may be considered as an alternative to orchiectomy, which is preferentially reserved for visibly abnormal or atrophic testes, postpubertal patients, or cases associated with insufficient vasal length.

After mobilization of the spermatic cord, a transverse scrotal incision is made and a subdartos pouch created. A large clamp or a finger can be used to create a tunnel just anterior to the pubis. The testis is passed through an opening in the dartos without twisting of the spermatic cord. Existing appendages should be excised and the epididymis inspected and any anomalies recorded. Recording of testicular volume by measurement in three dimensions and similar (estimated) measurements of contralateral testicular volume can establish a baseline for postoperative assessment. Secure fixation of the testis within the pouch can be achieved by tension-free closure of the opening in the dartos around the cord, incorporating the cut edge of the tunica vaginalis. If needed, additional fixation sutures can be placed between the visceral tunica vaginalis and the dartos. Alternatively, suture fixation through the tunica albuginea to the scrotal wall may be performed. There is a theoretical risk for injury to the testis, however, via inflammatory or vascular insult with suture placement through the tunica albuginea. Closure is completed with absorbable sutures. Supplemental local or regional techniques for perioperative pain control are advisable and may include local anesthetic infiltration, ilioinguinal nerve block, or caudal anesthesia; the latter is particularly useful in younger patients undergoing bilateral inguinal or concomitant penile surgery.

Testicular biopsy has been performed routinely is some centers and has been advocated by Hadziselimovic et al. (2007) as a method to determine prognosis for fertility. This approach is controversial and has not been recommended for routine use outside of research protocols because it does not change the current approach to treatment (Beckers et al., 2008; Ritzen et al., 2007). Increasingly, however, other investigators suggest that biopsy be considered in cases of bilateral cryptorchidism as a method to identify individuals who lack Ad spermatogonia and are potential candidates for gonadotropin therapy, and to identify CIS in males older than 13 years of age, using available protein markers (Biers and Malone, 2010; Cortes et al., 2016a; Faure et al., 2016; Mechlin and Kogan, 2014; Thorup and Cortes, 2016; Thorup et al., 2018; Verkauskas and Hadziselimovic, 2016; Verkauskas et al., 2016) (see the Prognosis section later in this chapter). The risk to the cryptorchid testis from biopsy is theoretical; although long-term effects do not appear to include increased risk for microlithiasis or antisperm antibody formation (Patel et al., 2005), other more subtle effects cannot be excluded from the available data. Biopsy is indicated in cases of sexual ambiguity or if clinical evidence of testicular dysgenesis is present.

Complications of inguinal orchidopexy are uncommon; those of greatest significance include testicular retraction and atrophy. Docimo (1995) reported a comprehensive review of the orchidopexy literature in 1995, before the routine use of laparoscopic orchidopexy, and including both palpable and nonpalpable testes. He concluded that the overall risk for atrophy or nonscrotal position was approximately 15% overall in published reports, significantly higher in abdominal or peeping testes (24%) compared with those distal to the internal ring (10%) and higher in boys operated after 6 years of age. More recently, analysis of boys presenting with postoperative testis retraction over an 18-year period at a single institution composed less than 2% of 1886 primary open orchidopexies performed during that period, with a slightly higher risk for failure in older boys (McIntosh et al., 2013). However, these boys were not actively followed by the authors, so detailed clinical data were not available, and the frequency of testicular atrophy could not be defined. In another series of 418 orchidopexies in 356 boys from a single institution with a median of 1 year follow-up, the risk for atrophy was 1.9% and of nonscrotal position was 10.3% (Thorup et al., 2011a). However, in this series the risk for complications was higher when surgery was performed at a younger age, and all boys with acquired cryptorchidism had a successful result. The authors conclude that earlier orchidopexy may be more technically demanding, and support the concept that expertise of the surgeon is relevant for more challenging cases.

A minimum of 6 months' follow-up is recommended to determine postoperative testis position and size. Long-term follow-up should be considered for counseling of the patient regarding fertility issues, risk for testicular malignancy, and self-examination. Torsion of a scrotal testis after orchidopexy has been reported but is very rare, and the risk may be minimized by routine extravaginal testicular fixation in a subdartos pouch. If complete intrascrotal testicular atrophy occurs postoperatively, further intervention is not needed, but the option of testicular prosthesis placement should be offered to the patient and family (Bodiwala et al., 2007). Implantation of a testicular prosthesis should occur at least 6 months after any scrotal procedure or after puberty, and is best performed through an inguinal approach. Fixation of the prosthesis to the dartos and closure of the scrotal fascia above the implant using purse-string nonabsorbable suture is required. Risks including displacement, pain, or infection occur in less than 5% of cases. Clinical experience suggests that cryptorchid boys request prosthesis implantation less frequently than males with acute testicular loss after puberty (Bodiwala et al., 2007).

Reoperation is indicated if a testis is nonscrotal after orchidopexy. If the testis is prescrotal, a primary scrotal approach can be considered and may allow adequate mobilization of the testis. If inguinal exploration is needed to provide sufficient cord length, several approaches are available. Redman (2000) described an approach for primary or secondary orchidopexy that involves a lateral approach to the cord after mobilization of the external oblique and cremaster fasciae. This approach avoids traversal of the previously scarred layers anterior to the cord and a clearer view of the anatomy. Cartwright et al. (1993) described mobilization of the intracanicular cord with an overlying patch of external spermatic fascia. The importance of correcting a persistently patent processus vaginalis and/or of adequate retroperitoneal mobilization of the cord in cases of high recurrent cryptorchidism has been stressed (Pesce et al., 2001; Redman 2000; Ziylan et al., 2004). The results of secondary orchidopexy appear to be similar to the primary procedure, although the risk for vascular and vasal injury is theoretically higher (Pesce et al., 2001).

Transscrotal Orchidopexy (▶*Video 46.2)*

A primary scrotal approach can be considered when the testis is palpable (Bianchi and Squire, 1989; Cloutier et al., 2011; Iyer et al., 1995), although some surgeons reserve this approach for testes that are close to or can be drawn into the scrotum (Bassel et al., 2007; Rajimwale et al., 2004; Russinko et al., 2003; Takahashi et al., 2009). After induction of anesthesia, the patient is re-examined to confirm the position of the testis. An incision along the superior scrotal border is made as described by Bianchi et al. for any palpable testicles. Alternatively, a transverse low scrotal approach (Misra et al., 1997) and midline scrotal approach (Cloutier et al., 2011) have been described for those testes that can be drawn into the scrotum (Fig. 46.11). After the testis is delivered, the distal sac and overlying cremaster are mobilized proximally as far cranially as possible, “high above the inguinal canal” (Iyer et al., 1995). Some cases require conversion to an inguinal approach for ligation of the sac or to gain further length on the spermatic cord (Dayanc et al., 2007; Parsons et al., 2003). Rajimwale et al. (2004) confirmed in several cases that the hernia sac had been effectively ligated above the internal ring via the scrotal incision when a secondary inguinal incision was required for further mobilization of the testis. Fixation sutures through the tunica albuginea were used in many series of scrotal orchidopexy (Bassel et al., 2007; Dayanc et al., 2007; Jawad 1997; Russinko et al., 2003; Takahashi et al., 2009) followed by placement of the testis in a subdartos pouch. In an extensive review of the literature by Gordon et al. (2010), additional inguinal incisions were needed in 4.4% of cases, and there were early postoperative complications in 1.6% of cases. The single-institution long-term results reported by these authors included a reoperative rate of 4.9% and 0.6% incidence of testicular atrophy. In a literature review of 1558 cases in 20 series reporting 3 months to 5 years of follow-up, a hernia was present in 30% of cases, and 3.5% of cases required an inguinal incision (Novaes et al., 2013). Complications included recurrence

(0.6%), testicular atrophy or hypotrophy (0.3%), hematoma (1.4%), wound infection (0.8%), and vasal injury (1 case) with a low overall complication rate of 3%. **Scrotal incision orchidopexy is used selectively in many series, but the available evidence suggests that efficacy and complication rates are similar to standard inguinal orchidopexy.** Increasingly, the scrotal approach is advocated as a first choice for all palpable testes (Arena et al., 2016; Feng et al., 2016; Gordon et al., 2010).

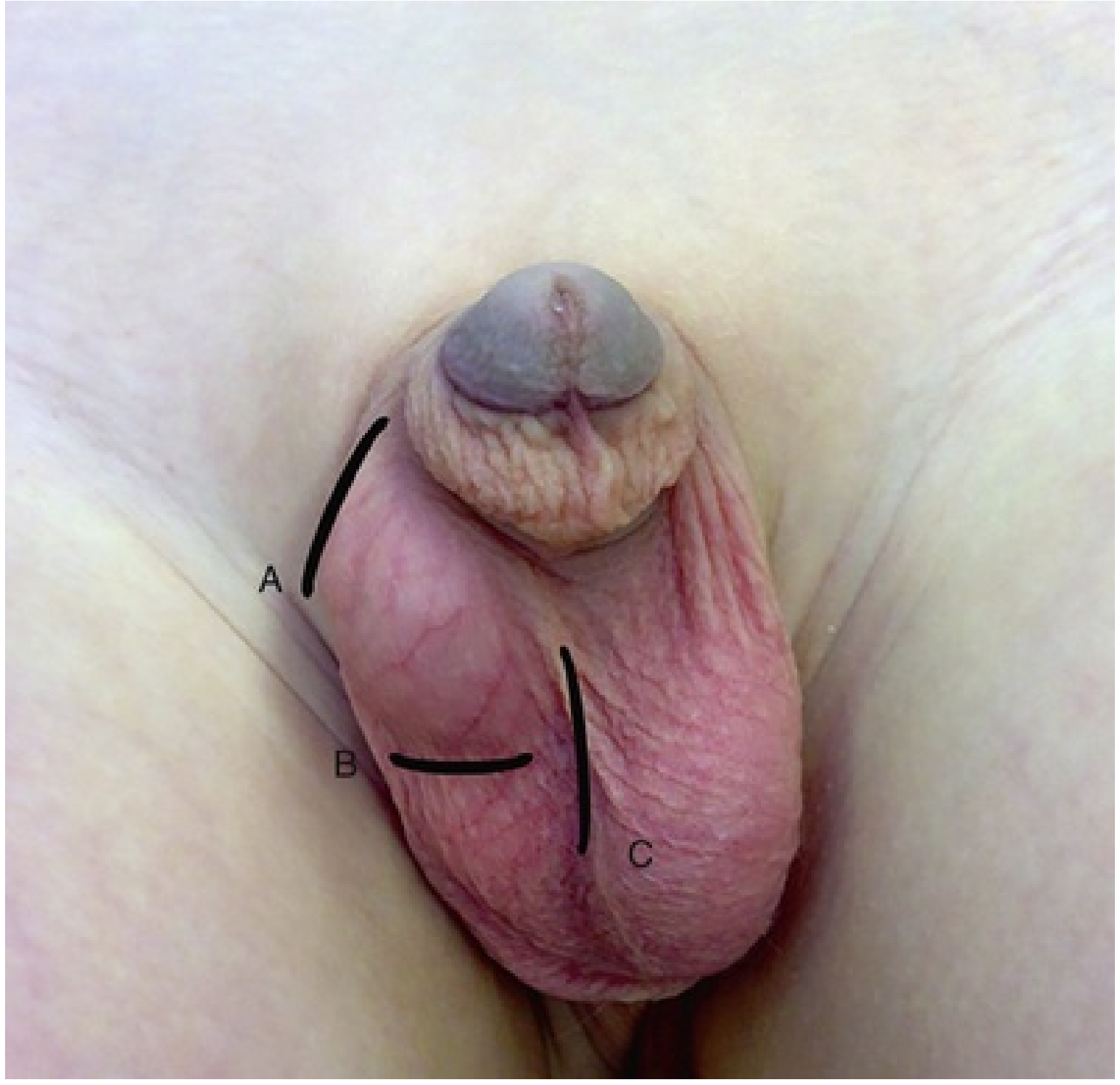

FIG. 46.11 Transscrotal orchidopexy. Various scrotal incisions that have been reported; (A) Bianchi incision (Bianchi). (B) Transverse low scrotal approach (Misra). (C) Midline scrotal approach (Cloutier).

Abdominal Testes

Once an abdominal testis has been identified, the surgeon must decide whether to proceed with an open or laparoscopic, one- or two-stage orchidopexy with possible spermatic vessel transection. Orchiectomy is appropriate for patients with testes that are poorly viable and/or at higher risk for tumor, which may include testes in postpubertal patients or very small or dysgenetic testes in postpubertal patients, and is in the opinion of these authors best performed laparoscopically.

Open Transabdominal Orchidopexy

Extensive dissection of the vas and vessels is facilitated by a longitudinal opening of the internal oblique and peritoneum through an extended inguinal incision (Kirsch et al., 1998) or via a higher incision medial to the pubic tubercle and a preperitoneal approach (Gheiler et al., 1997; Jones and Bagley, 1979). In the procedure described by Jones and Bagley, the internal ring is approached via a muscle-splitting incision, the peritoneum is opened, the testis is delivered, and the vas and vessels are freed from their peritoneal attachments. A tunnel is created to the scrotum, and the testis is secured in place as for an inguinal orchidopexy. The reported success rate for this procedure for abdominal testes was 95% (Gheiler et al., 1997).

Laparoscopic Orchidopexy and Fowler-Stephens Orchidopexy *(▶Video 46.3)*

Operative laparoscopy emerged over 25 years ago as the procedure of choice for abdominal orchidopexy (Caldamone and Amaral, 1994; Jordan et al., 1994), and the basic surgical approach and high success rates have stood the test of time. The feasibility of primary versus Fowler-Stephens orchidopexy depends on the length of vas and vessels, presence/absence of looping ductal structures, and patient age. Laparoscopy allows the surgeon to assess some of these features before choosing a specific surgical procedure, but the choice may be difficult (Shepard and Kraft, 2017; Yucel et al., 2007). Observed testicular position alone may correlate poorly with the ultimate length of the cord after mobilization.

After induction of anesthesia, a further attempt to palpate the testis is made, although a laparoscopic approach may be considered for mobilization of high canalicular testes as well. After decompression of the bladder and stomach, an infraumbilical 5-mm trocar is placed for passage of a 30-degree lens, and both internal rings are visualized. An open Hasson or Bailez technique is preferable for umbilical trocar placement in the pediatric age group to minimize the risk for injury (Franc-Guimond et al., 2003). CO_2 pneumoperitoneum to a maximum pressure of 8 to 12 mm Hg is used. The size and position of the testis within the abdomen is determined before further decision making. For single-stage laparoscopic orchidopexy, additional 2- or 3-mm trocars are placed in the right and left lower quadrants to triangulate with the umbilicus and ipsilateral internal ring, or in the midclavicular line at the level of the umbilicus bilaterally for bilateral abdominal testes. The major steps are mobilization of any structures extending distal to the internal ring, including epididymis/vas and gubernacular remnant; transection of the peritoneum lateral to the vessels and distal to the vas; and proximal mobilization of the vessels while maintaining collateral blood supply between the vas and spermatic vessels. Samadi et al. (2003) advocate initial mobilization of the gubernaculum to be used as a handle for further mobilization of the testis, and minimal use of cautery during this maneuver. Ability to mobilize the testis to the opposite internal ring has been used as a measure of adequate length for placement in the scrotum, but is not predictable in some series. Once mobilized, the testis is brought through a new hiatus medial to the epigastrics and lateral to the medial umbilical ligament or through the existing internal inguinal ring. This maneuver can be completed using a trans-scrotal clamp or an additional port passed up from the scrotum. With tension on the extra-abdominal testis, peritoneal attachments overlying the cord can be more easily transected, thus providing additional length. In some cases, the testis can only be brought into the upper scrotum; the long-term adequacy of this approach is not clear. Excessive tension on the vessels during placement of the testis should be avoided, as injury or avulsion of the spermatic vessels may occur (Esposito et al., 2002). A key strategy should be preservation of the blood supply between the vas and spermatic artery during dissection so that the Fowler-Stephens procedure can be performed if necessary.

Formal closure of the dissected internal ring is not necessary (Handa et al., 2005; Riquelme et al., 2007); indeed, previous experience with open hernia repair suggests that ligation is not needed if the internal ring is dissected (Mohta et al., 2003). No inguinal hernias were identified a mean of 41 to 50 months after laparoscopic orchidopexy in a retrospective series in which formal closure of the internal ring was performed in 54% of cases (Khairi et al., 2013). A contralateral patent processus vaginalis was identified in 9% of boys undergoing laparoscopic orchidopexy in one series, and laparoscopic repair was performed and recommended (Palmer and Rastinehad, 2008). However, the necessity for this approach in preventing clinical hernia formation is questionable based on studies of boys undergoing laparoscopic or open hernia repair (Schier, 2007).

For testes that are not near (variably defined as 2 to 4 cm above) the internal inguinal ring, transection of the spermatic vessels as originally described by Fowler and Stephens may be necessary (Fowler and Stephens, 1959); a long-looping vas facilitates but is not required for testicular mobilization to the scrotum. The Fowler-Stephens procedure is now typically performed laparoscopically with spermatic vessel clipping (Bloom 1991) followed by laparoscopic or open testicular mobilization in the same setting, or in a staged approach 6 months later. The peritoneum should be left intact over the vasal vessels, and the gubernacular vessels should be left intact if possible. Although most surgeons transect the spermatic vessels at least 1.5 to 3 cm above the testis, Koff and Sethi (1996) proposed that ligation close to the testis is preferable. This group subsequently studied the effect of low- versus high-transection of the vessels in prepubertal rats and showed a reduction in adult testicular sperm numbers that was similar in both groups (Srinivas et al., 2005). In human studies, testicular biopsies before and after spermatic vessel transection also showed a reduction in germ cell count, a finding that was significant in younger boys (Rosito et al., 2004; Thorup et al., 1999). In general, the preferred approach is avoidance of spermatic vessel transection whenever possible; the available data suggest this is possible in the majority of cases of abdominal orchidopexy. In rare cases, particularly if the testis is retrovesical, the vas is too short to allow scrotal placement of the testis, and orchiectomy is ultimately required (Perovic and Janic, 1997).

The success rates for laparoscopic procedures has been extensively reported over the past 20 years (Alagaratnam et al., 2014; Alam et al., 2017; Bagga et al., 2018; Baker et al., 2001; Bracho-Blanchet et al., 2016; Casanova et al., 2013; Chang and Franco, 2008; Denes et al., 2008; Erdoğan et al., 2017; Esposito and Garipoli, 1997; Esposito et al., 2002; Handa et al., 2005; Hay et al., 1999; Jordan et al., 1994; Kaye and Palmer, 2008; Lotan et al., 2001; Radmayr et al., 2003; Robertson et al., 2007; Samadi et al., 2003; Stedman et al., 2015; Wayne et al., 2015; Yucel et al., 2007) and still appear to compare favorably with the corresponding 74%, 63%, and 77% overall success rates for open surgical one- and two-stage Fowler-Stephens procedures, respectively, that were reported early on after the inception of laparoscopy (Docimo, 1995). The available data suggest that a primary procedure is more consistently successful (>90% in most series) as compared with a Fowler-Stephens approach (variable success of 60% to 97%). In directly comparing the results of 156 abdominal orchidopexies at a single institution, Stec et al. observed significantly more favorable results for a primary open (89% success) or laparoscopic (97%) approach as compared with one-stage (63%) or two-stage (68%) Fowler-Stephens procedure (Stec et al., 2009). Variation in reported results among series may reflect inherent selection bias resulting from differences in patient age, testicular position or quality, length of follow-up, and/or criteria used to define success, such as “intrascrotal” versus “dependent scrotal” position. In a meta-analysis, Elyas et al. (2010) calculated a slightly better pooled estimate for success of two-stage as compared with one-stage Fowler-Stephens orchidopexy, irrespective of primary (open or laparoscopic) approach, but again note that the quality of the included studies was low. More recent studies have shown no difference in atrophy rates between one- and two-stage Fowler-Stephens orchidopexy, but there may be better positioning after a two-stage approach (Alam et al., 2017; Bagga et al., 2018; Ostlie et al., 2015). **Despite their limitations, the available data seem to suggest that primary orchidopexy without transection of the spermatic vessels is preferable whenever possible.** Some authors recommend that ultrasonography be used to confirm testicular viability postoperatively (Esposito et al., 2002). Other complications of laparoscopic orchidopexy are rare and potentially include bladder or vascular injury, hypercapnia, and delayed small bowel obstruction (Esposito et al., 2003; Hsieh et al., 2009; Riquelme et al., 2015).

Laparoscopic techniques may be applicable in unusual cases, including bilateral orchidopexy, abdominal wall defects, polyorchidism, splenogonadal fusion, and transverse testicular ectopia with or without persistent müllerian ducts. Many authors recommend simultaneous bilateral abdominal orchidopexy (Kaye and Palmer, 2008), but the surgeon should consider a staged approach if both testes are very high or the viability of a testis is questioned during the course of orchidopexy as noted in their algorithm. Depending on the outcome of the first procedure at 6-month follow-up, the surgeon can choose an operative approach to the contralateral side that would appear to minimize the risk for bilateral testicular atrophy (Thorup et al., 2007). Some surgeons have considered microvascular orchidopexy to be a preferred approach to the solitary abdominal testis, particularly with historical success rates of 88% as compared with lower rates for open procedures (Docimo, 1995). At a center with substantial experience using the microvascular approach, long-term success rates of 96% for standard and 88% for laparoscopically-assisted autotransplantation were reported (Bukowski et al., 1995; Tackett et al., 2002). The advantage of this approach is preservation of the spermatic vessels, at the cost of longer operative time and requirements for an experienced microvascular surgeon and hospital stay.

Prognosis

Despite its common occurrence and voluminous literature on the subject of cryptorchidism, many gaps exist in our present understanding of the factors contributing to long-term outcome. This is likely a result of the expectation that surgical correction will be successful in most cases, and prospective studies into adulthood are difficult and not routine in otherwise healthy males. These studies would need to (1) account for multiple confounding variables, many that are incompletely defined, including severity of the disease (based on testicular position, laterality, epididymal anomalies, hormone profiles), multifactorial etiology, age at surgery, exposure to hormone therapy, and type of procedure performed, and (2) use standardized methodology based on adequate follow-up and complete documentation of complications to report results. Well-designed studies providing high-quality evidence are clearly needed.

Fertility

There is strong evidence that a history of cryptorchidism is associated with the risk for subfertility or infertility, particularly in bilateral but also in unilateral cases (Schneuer et al., 2018; Thorup and Cortes, 2016). Conversely, cryptorchidism is one of the most common antecedent factors in men evaluated for infertility, composing up to 10% to 17% of that population (Olesen et al., 2017; Paasch et al., 2004; Schneuer et al., 2018). Subfertility risk is difficult to predict in individual patients, because multiple factors likely contribute including presumably diverse etiologies, age at diagnosis and treatment, approach to treatment, and/or severity of disease. Major limitations in the interpretation of cryptorchidism outcome studies include the selection bias that occurs when follow-up includes less than one-third of eligible cases, who may self-select, and the results of a single semen analyses that may not accurately predict paternity. In a large review of retrospective studies published in the 50 previous years that did not take these limitations into consideration and did not include a statistical meta-analysis, Chilvers et al. (1986) reported that 42% and 31% of men with former bilateral, and 31% and 14% with unilateral cryptorchidism developed oligospermia and azoospermia, respectively. The limited available data comparing earlier treatment (age <9, 45% of cases) and later treatment did not show differences in the frequency of subfertility after unilateral (281 cases) or bilateral (123 cases) orchidopexy. Similarly, subset analysis failed to identify any effect of hCG treatment, which was used in 42% of patients. The observation that azoospermia occurs in unilateral cryptorchidism is consistent with data showing that germ cell development is abnormal in some contralateral descended testes. However, the frequency appears lower in studies of previously cryptorchid men (0% to 10%), as compared with subjects accrued from infertility clinic populations (11% to 28%) (Hadziselimovic et al., 2011; Rohayem et al., 2017). In contrast, Schneuer et al. (2018) demonstrated in a population-based cohort study of 7499 boys with cryptorchidism that surgery before 18 months reduced the need for assisted reproductive technologies (ARTs), but for every 6-month delay in treatment there was a 5% increase in the future need for ART.

Subsequent reports of semen parameters in large series of men who underwent orchidopexy in childhood also found differences between bilateral and unilateral cryptorchidism but less consistent overall results. In general, outcomes were not consistently related to childhood hormone therapy, adult hormone levels, prior testicular position, or age at surgery, although the mean or median age of surgery in many reported series was high, typically 6 years or older. Gracia et al. (2000) reported normal semen samples in only 57 of 171 (33%) men with previous unilateral and 10 of 55 (18%) men with a history of bilateral cryptorchidism who underwent surgery at a mean age of 6.4 years. Kraft et al. (2012) reported normal sperm counts after unilateral orchidopexy in 60% of 85 men, and after bilateral orchidopexy in 18% of 17 men with surgery performed at a mean age of 7.0 years. Cortes et al. (2003a) found very low sperm counts (<5 million/mL) in 9% of 65 unilateral and 54% of 70 bilateral cases who underwent surgery at a median age of 10.8 and 12.7 years, respectively. Of 108 patients who underwent unilateral orchidopexy between 6 and 12 years of age, 31% had a normal sperm concentration (Ponchietti and Grechi, 1986). In 91 patients with unilateral cryptorchidism who underwent orchidopexy after the onset of puberty (14 to 29 years of age), normospermia was present in only 16% (Grasso et al., 1991).

Other studies suggest more encouraging long-term results. Okuyama et al. (1989) reported normal sperm density based on 3 semen analyses in 0%, 72%, 77%, and 42% of men after bilateral orchidopexy (61), unilateral orchidopexy (149), unilateral orchiectomy (26), and no treatment (38). Puri and O'Donnell (1988) studied 142 men who underwent unilateral (119) or bilateral (23) orchidopexy at 7 years of age or older and reported normal sperm density in 84% and 50% of cases, respectively. Similarly, testicular atrophy or Sertoli cell–only histology was present in 179 of 222 (81%) adults who underwent orchiectomy for unilateral cryptorchidism, but of 97 in this series who had semen analysis, 61% and 5% had normospermia and azoospermia, respectively (Ates et al., 2016). In a small series of 51 men who had orchidopexy before 2 years of age, a normal sperm count was reported in 96% of unilateral (27) and 75% of bilateral (24) cases (Feyles et al., 2014). Hence, it appears that the quality of germ cell development in the descended testis of cases of unilateral cryptorchidism, and other unmeasured factors in cases of bilateral cryptorchidism, are major determinants of fertility potential.

Mean germ cell counts obtained at biopsy correlate with long-term fertility potential as measured by mean semen analysis parameters in some series (Cortes et al., 2003a; Engeler et al., 2000; Rusnack et al., 2003) but not in others (Hadziselimovic and Herzog, 2001; Hadziselimovic et al., 2008; Kraft et al., 2011, 2012). The wide variation in sperm concentrations reported, particularly in association with abnormal histology (Kraft et al., 2012), suggests that the utility of total germ cell counts as a predictor of fertility at the individual level is limited. More recent reports investigated the use of Ad spermatogonia number as a better predictor of semen quality in adulthood. Hadziselimovic et al. reported a strong correlation between the number of Ad spermatogonia in cryptorchid testes and sperm count in adulthood after previous unilateral or bilateral orchidopexy with or without prior hormonal therapy (Hadziselimovic and Herzog, 2001; Hadziselimovic et al., 2007, 2008). In nonhormonally treated cases, total sperm count was normal (>40 million/ejaculate) in 84% of 25 men who had Ad spermatogonia present in biopsies from both testis, and it was subnormal in all 18 men (10 of the 19 men in this series with a history of bilateral cryptorchidism) in whom biopsies were negative for Ad spermatogonia (Hadziselimovic and Hoecht, 2008). Of subjects with bilateral cryptorchidism and Ad spermatogonia in one or both testes, 55% had a normal sperm count. In a larger series of men with prior unilateral (91) or bilateral (19) cryptorchidism, Kraft et al. (2012) observed lower mean sperm counts and higher FSH levels in adulthood when bilateral biopsy at surgery showed severe loss of germ cells or abnormal Ad spermatogonia counts, but likely because of the variability of the data, group means remained within normal range and/or were not statistically significant, confirming that even analysis of Ad spermatogonia does not always predict individual fertility potential. In view of the heterogeneity of the disease and its treatment, most studies are likely underpowered to detect clear associations between histologic and phenotypic variables and fertility potential as estimated by semen analysis. **Nevertheless, both Ad spermatogonia count and germ cell absence are potentially useful measures of fertility prognosis, but may be more useful in cases of bilateral cryptorchidism.** Additional, larger prospective studies of these parameters in boys undergoing surgery in infancy are needed.

The use of semen analysis alone to define outcome and predict fertility potential has limitations. For example, a large population study of fertile and infertile men with fertile partners suggests that there is large overlap between semen parameters in men with and without proven paternity (Guzick et al., 2001). In this study, the authors established lower infertile threshold levels for density (13.5×10^6/mL), motility (>35%), and normal morphology (>9%) than had been established by World Health Organization criteria. About 3% of fertile men in this series had a sperm density less than 10×10^6/mL, and measurements between 13.4 and 48×10^6/mL were considered indeterminate. Repeated semen analyses, rarely obtained in studies of formerly cryptorchid men, were reportedly necessary to provide reliable data in normal men (Oshio et al., 2004). However, the reliability of semen analysis in adolescents is not fully known. Christman et al. (2013) recently addressed this question in Tanner stage V youths (<25 years of age) being evaluated for cryptorchidism (48) or varicocele (31). In this study, semen parameters were not highly reproducible between samples in the same individual, yet the computed intraclass correlation coefficient was considered substantially reliable, particularly for total sperm counts, suggesting that a single sample, especially when normal, may suffice in estimating fertility potential. When semen analysis results are abnormal, repeat samples should be obtained whenever possible.

Paternity status may be a more helpful measure of fertility that should be considered when determining prognosis. Limitations of this approach include paternal discrepancy, female factors, and variability in the timing and degree of interest in attempts at paternity, which may be based on age, marital status, and so on. Although of concern and not ethically retrievable, a recent review (Bellis et al., 2005) found that the median level of paternal discrepancy in 17 studies of unselected populations in Europe and the Americas is only 3.7% (interquartile range, 2% to 9.6%). Two retrospective cohort studies of men with previous cryptorchidism assessed paternity in 145 (Gilhooly et al., 1984) and 40 (Cendron et al., 1989) cases. Together, these studies identified successful paternity in 100 of 123 (81%) men with a history of unilateral and 19 of 54 (35%) men with a history of bilateral cryptorchidism. Lee et al. published a series of well-designed case-control studies of fertility in cryptorchidism (Coughlin et al., 1999; Lee and Coughlin, 2001, 2002; Lee et al., 1996, 1997, 2000, 2005). Questionnaire, hormone, semen analysis, and paternity data were analyzed for a large cohort of men who underwent orchidopexy between 1955 and 1975 and a control group of similar age who were matched for timing of unrelated surgery. For all married or cohabitating men, 32 of 88 (36%) former bilateral, 322 of 609 (53%) former unilateral, and 413 of 708 (58%) controls had fathered children. **Of those attempting paternity, 32 of 49 (65%) former bilateral, 322 of 359 (90%) former unilateral, and 413 of 443 (93%) controls were successful.** There were no significant differences between the unilateral and control groups and no differences between groups in the frequency of attempted paternity or in other lifestyle factors that may adversely affect fertility. The frequency of successful paternity did not differ between men with previous unilateral cryptorchidism who had undergone orchiectomy and the control group. The RR for infertility was increased after hCG treatment (RR 4.7, $P = 0.002$), but not with higher testicular position or age at orchidopexy. Sperm density was less than or equal to 13×10^6/mL in all 8 patients with bilateral cryptorchidism who were studied; however, 3 of these men had fathered children (Lee and Coughlin, 2001). Sperm density and motility were normal in 83% of men in the unilateral group, and morphology did not differ from control values. The authors concluded that prediction of infertility is difficult in the absence of azoospermia or severe oligospermia.

In limited series, investigators have addressed the possibility of defective spermatogenesis in adult patients with persistently retractile testes or with milder forms of acquired cryptorchidism, with or without apparent spontaneous descent of the testis at puberty. In small, retrospective outcome studies, Puri and Nixon (1977) reported 74% paternity and normal testicular volume in a series of 43 adults with untreated retractile testes in childhood. Conversely, Nistal and Paniagua (1984) and Caroppo et al. (2005) identified 23 and 34 males, respectively, from infertility clinic data and identified poor semen parameters in the majority of cases, but the duration and severity of retractility were poorly documented. Two series reported varying degrees of abnormal germ cell or Sertoli cell development in retractile testes of boys who underwent elective orchidopexy as compared with boys with descended testes; differences were qualitatively similar to findings in cryptorchid testes (Caucci et al., 1997; Hadziselimovic et al., 1987a). Han et al. (1999) compared 61 retractile with 83 cryptorchid testis biopsies and noted similar trends but did not include a control group. Methodologic limitations prevent clear differentiation of retractile from acquired undescended testes in these studies. Prospective studies of well-characterized patients are needed, but there is insufficient evidence to support an increased risk for infertility in uncomplicated cases of retractile testis.

Similarly, the outcome data for acquired cryptorchidism are difficult to interpret, because to date they are based on retrospective, nonrandomized studies that analyzed cases of both spontaneous descent at puberty and prior orchidopexy. In a retrospective series of 45 adults with spontaneous descent of bilaterally undescended testes after 10 years of age by history (without clear documentation of congenital vs. acquired classification), testicular volumes were less than 15 mL in 62%, and sperm counts were below 20 million/mL in 44% of patients (Bremholm Rasmussen et al., 1988). Investigators from the Netherlands who have followed boys with either congenital or acquired cryptorchidism reported follow-up fertility data (van Brakel et al., 2013, 2014). In prior publications from these institutions, the majority of the acquired group, particularly those with spontaneous descent at puberty, included high scrotal and low scrotal "unstable" testes (likely retractile) (Eijsbouts et al., 2007; Hack et al., 2010; Sijstermans et al., 2006). Van Brakel et al. (2013, 2014) observed no differences in semen parameters or hormone levels in small subgroups of men with a history of acquired cryptorchidism after spontaneous testicular descent (24) or orchidopexy (26) at puberty. Of 62 men with prior congenital cryptorchidism, the majority (89%) unilateral, 33% and 57% of unilateral and bilateral cases, respectively, had oligospermia, and none had azoospermia. Of 65 men with a history of acquired cryptorchidism, 39% and 8% of prior unilateral, and 71% and 7% of prior bilateral cryptorchid men had oligospermia and azoospermia, respectively. There were no significant differences in semen parameters between acquired and congenital cryptorchidism, or between observed and surgically treated subsets of the acquired group. These data provide further support for a shared etiology for congenital and acquired cryptorchidism.

The available data indicate that fertility potential is compromised in many men with a history of bilateral cryptorchidism, but abnormal semen parameters and/or abnormal spermatogonial differentiation in unilateral cases suggest an increased risk for infertility that is not supported by available paternity data. However, much of the available evidence suggests a congenital cause for subfertility that affects both testes in males with cryptorchidism that may not be abrogated by surgery alone, although early surgery is preferred and may be beneficial (Thorup and Cortes, 2016; Virtanen and Toppari, 2015). Future studies should focus on the effects of early surgery and correlate cryptorchidism etiology, once known, with long-term fertility potential.

Testicular Cancer

A history of cryptorchidism is associated with a twofold to fivefold increased risk for TGCT, or an odds ratio (OR) of 4.3 (95% CI, 3.6 to 5.1) (Banks et al., 2012; Rajpert-De Meyts et al., 2016; Schneuer, et al., 2018; Trabert et al., 2013; Wood et al., 2009). TGCT developed in 6 of 506 (1.2%) males in a cryptorchid cohort, and prior cryptorchidism is one of the most common risk factors for TGCT, composing 5% to 10% of affected individuals (Giwercman et al., 1987; Kvist et al., 2018; McGlynn and Cook, 2009). Shared risk factors include inguinal hernia, prematurity, and low birth weight (Rajpert-De Meyts et al., 2016). In a population-based study in Sweden, hypospadias (OR 2.25, 95% CI, 1.17 to 4.32), inguinal hernia (OR 1.30, 95% CI, 1.06 to 1.60), and other genital malformations (OR 1.90, 95% CI, 1.00 to 3.63) were independent risk factors for TGCT in addition to cryptorchidism (OR 3.16, 95% CI, 2.45 to 3.96) (Trabert et al., 2013). ORs were lower when cryptorchidism was diagnosed before puberty (OR 2.76, 95% CI, 2.09 to 3.65) versus after puberty (OR 4.96, 95% CI, 3.06 to 8.04), and the reverse was true for hypospadias and hernia, where associations were stronger at a younger age at presentation.

Tumors may occur in the descended testis of men with a history of unilateral cryptorchidism, as suggested by two meta-analyses showing ORs for contralateral tumor risk for 1.7 (95% CI, 1.01 to 2.98) and 1.5 (95% CI, 0.9 to 2.6) (Akre et al., 2009; Banks et al., 2012). In another meta-analysis, Walsh et al. (2007) reported an RR of 5.8 (95% CI, 1.8 to 19.3) in men undergoing orchidopexy after 10 to 11 years of age as compared with those undergoing earlier correction. Subsequent population studies have confirmed a positive correlation between age at surgery and risk, with ORs of 1.1 to 2.35 (<9 years of age), 2.9 (10 to 14 years), 5.1 (13 to 15 years), 6.2 (16 to 19 years), and 14.4 (untreated adults) (Osterballe et al., 2017). In this large series, Osterballe et al. (2017) reported the long-term outcome of a mixed population of 1403 cryptorchid males (14% syndromic) who underwent surgery at a mean age of 10.8 years, followed at a mean of 28.9 years. Among these, 16 cases of TGCT (1.1%) were identified at a mean age of 33.3 years (range 26 to 37 years of age), 8 each in cases of bilateral and unilateral cryptorchidism, with 3 arising in the contralateral scrotal testis. In the majority (81.2%) of TGCT cases, orchidopexy was performed at greater than or equal to 10 years, and 2 (12.5%) cases occurred in men with a history of syndromic cryptorchidism. In this series, 7 cases of intratubular germ cell neoplasia, unclassified (IGCNU) (0.5%) were identified prepubertally, although 4 (67%) occurred in syndromic cases, including DSD. Others have reported a prevalence of carcinoma in situ of the testis, also known as IGCNU, in 2% to 3% in previously cryptorchid men (Giwercman et al., 1989) and 0% to 0.4% of children with nonsyndromic cryptorchidism (Cortes et al., 2001; Husmann 2005). In the large population-based study of all boys born in Australia, there was also evidence of increasing risk for cancer for every 6 months delay in treatment after 18 months of age. This was similar to prior studies, although the subset of patients with cancer (27) was small (Schneuer et al., 2018).

A review of tumor pathology in treated versus untreated cryptorchidism showed that seminoma is associated with persistently cryptorchid testes (74%) and nonseminoma is present in the majority of scrotal testes (63%) (Wood et al., 2009). Both seminoma and nonseminomatous germ cell tumors (NSGCTs) arise from IGCNU. A developmental origin for TGCT, characterized by gonocytes that fail to differentiate normally and then undergo adaptive genetic and epigenetic changes to form IGCNU (Rajpert-De Meyts et al., 2016), is supported by gene expression data suggesting a common origin for the two cell types (Sonne et al., 2009). In contrast, failure of PGCs to differentiate normally may lead to infantile germ cell tumors, including teratoma/teratocarcinoma and yolk sac tumor. Although rare, these tumors have also been reported in boys with cryptorchidism before puberty (Mittal et al., 2015).

Failure of normal gonocyte differentiation in cryptorchid testes may contribute to the increased risk for IGNCU and TGCT. Markers of undifferentiated spermatogonia, including placental-like alkaline phosphatase (PLAP), octamer-binding transcription factors (OCT3/4), tyrosine kinase receptor c-KIT and its ligand, stem cell factor (SCF), homeobox nanog (NANOG), transcription factor AP2γ (TFAP2C), D2-40 receptor, and sal-like 4 (SALL4) show decreasing expression in the fetus and normally disappear after birth, but may be re-expressed in IGCNU and TGCT (Cools et al., 2005; Hoei-Hansen et al., 2005; Honecker et al., 2004; Rajpert-De Meyts et al., 2016; Stoop et al., 2008; Ulbright et al., 2014; Vigueras-Villaseñor et al., 2015) or upregulated postnatally in individuals with dysgenetic gonads at higher risk for malignancy (Rajpert-De

Meyts et al., 2004). Persistent expression of these markers beyond the first year of life in germ cells of cryptorchid testes has been reported, consistent with delayed spermatogonial maturation (Kvist et al., 2014; Thorup et al., 2013; Vigueras-Villaseñor et al., 2015). Prior evidence suggesting that expression of IGCNU markers disappears in normal testes in the first year of life (Vigueras-Villaseñor et al., 2015) was recently superseded by observations that PLAP and c-KIT expression may persist for 2 years after birth or longer, although expression of D2-40 and OCT3/4 was absent beyond 6 and 9 months, respectively (Kvist et al., 2018). Because they did not did not identify IGCNU marker expression in the majority of individuals who later developed TGCT, Osterballe et al. (2017) questioned if TGCT does in fact arise from persistent, undifferentiated gonocytes. **The persistence of gonocyte markers in cryptorchid testes is consistent with delayed spermatogonial maturation, but so far no marker can reliably predict development of IGCNU or TGCT in cryptorchidism.**

Cortes et al. (2003b) identified multinucleated spermatogonia in 13 (8%) of 163 consecutive patients undergoing biopsy at the time of orchidopexy. This occurred in younger boys and was associated with a germ cell count that was usually normal and higher than the mean for the majority of cases. Although not identified in normal boys, the relevance of this finding to tumor risk remains unknown. The risk for TGCT is higher in conditions associated with chromosomal defects or DSD (Cortes et al., 2001; Husmann, 2005). Husmann has recommended that biopsy be performed in these individuals and in boys older than 12 years of age undergoing orchidopexy, although the age cutoff and usefulness of biopsy during pubertal orchidopexy has not been clearly defined. Orchiectomy should be considered the preferred treatment of cryptorchid testes in postpubertal males up to 50 years of age (Wood et al., 2009). Swerdlow et al. (1997) reported in a retrospective cohort study that testicular biopsy at orchidopexy was associated with an increased risk for future TGCT compared with orchidopexy without biopsy (RR 6.7, 95% CI, 2.7 to 13.5), but the indications for biopsy in this series were not clearly known. A subsequent report from a large Scandinavian cohort showed that universal biopsy did not appear to increase the risk for TGCT beyond what is expected for previously cryptorchid men (Moller et al., 1998).

Testicular microlithiasis, characterized by multiple spectral calcifications within the testicular parenchyma (Fig. 46.12), is more frequently present in men with IGCNU or TGCT, but is also present in 5% to 10% of the normal population and in a similar proportion of previously cryptorchid men (Patel et al., 2005; van Casteren et al., 2009). **Although concern exists that the risk for TGCT may be higher when cryptorchidism coexists with microlithiasis in individual patients, no data exist to support this hypothesis, and the appropriate follow-up strategy remains undefined.** Even less well-defined is the significance of microlithiasis in general, which is not clearly shown to be an independent risk factor for TGCT. A population-based analysis of the prevalence of microlithiasis in a series of primarily Caucasian boys shows that the prevalence is 4.2% and increases with age (Goede et al., 2009). In about one-half of these cases, the degree of microlithiasis was limited, defined as less than 5 lesions per testis, and not considered clinically significant. The general prevalence of microlithiasis was 3.5% in boys with cryptorchidism and 6.4% in a series of 261 older boys (mean age 18.9 years) being followed up for a diagnosis of acquired cryptorchidism (Goede and Hack, 2012; van der Plas et al., 2013a). In 99 men with prior cryptorchidism, the prevalence of microlithiasis was 14% in affected testes and 19% in contralateral descended testes, with no significant difference between these groups or between cases of congenital and acquired cryptorchidism (van Brakel et al., 2015). In a recent multicenter review of over 37,000 boys, Trout et al. (2017) confirmed that a positive association exists between microlithiasis and testicular neoplasia. The prevalence of microlithiasis in this series was 2.9%. Testicular tumors were identified in 4.64% of boys with microlithiasis versus 0.33% of those without, but an association with cryptorchidism was not addressed.

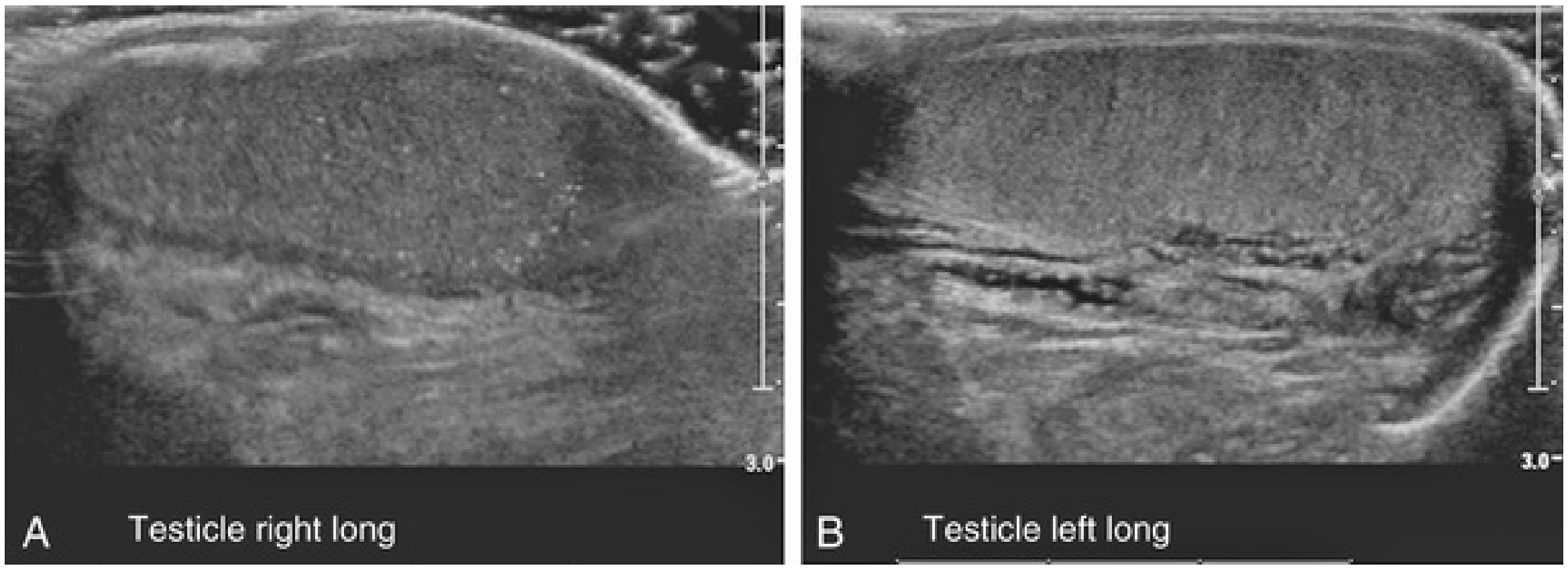

FIG. 46.12 Associated sonographic abnormalities in boys with cryptorchidism. Ultrasound images from an 11-year-old boy presenting with testicular asymmetry who underwent bilateral orchidopexies in infancy. (A) Right microlithiasis. (B) Ectasia of the left rete testis.

Other testicular abnormalities identified during ultrasound follow-up in males treated for cryptorchidism include ectasia of the rete testis (see Fig. 46.12) (Nistal et al., 1996) and intratesticular varicocele (Meij-de Vries et al., 2013). The significance of these entities in the context of cryptorchidism remains poorly defined. Routine use of ultrasonography has not been recommended.

The U.S. Preventive Services Task Force does not recommend routine testicular self-examination (TSE) in adolescents and adults, assigning it an evidence grade of “D”, in part because treatment for TGCT is highly effective, but this recommendation does not explicitly include prior cryptorchid males (http://www.uspreventiveservicestaskforce.org/uspstf10/testicular/testicuprs.htm# However, cost-benefit and other analyses suggest that recommending TSE generally is worthwhile (Aberger et al., 2014; Rovito et al., 2018). **Physicians should educate patients and their families about the risks of infertility and TGCT in cryptorchidism and provide counsel about the potential benefits of TSE.**

Key Points

- Gonadal determination involves separate genetic pathways for development of testis and ovary, and *SRY* is a master switch in males that regulates downstream testis-determining genes.
- Differentiation of gonocytes, Sertoli cells, and Leydig cells occurs between 5 and 9 weeks’ gestation, and the gubernaculum, the guide for testicular descent, appears at 7 weeks.
- Levels of the Leydig cell hormones testosterone and INSL3 peak between 14 and 17 weeks and are critical for testicular descent.
- Swelling of the gubernaculum, which starts in the second trimester, provides space for passage of the testis into the scrotum between 20 and 28 weeks.
- Cryptorchidism occurs in 1% to 4% of full-term males; both spontaneous descent (in the first few months of life, usually by 6 months) and re-ascent of testes may occur.
- The causes of cryptorchidism are largely unknown, but birth weight, gestational age, genetic factors, and environmental risk factors both likely contribute to disease risk.

- Acquired cryptorchidism is not uncommon but is likely equivalent to cases diagnosed at birth. It may occur after scrotal testes are confirmed at birth or after spontaneous descent of a cryptorchid testis and may be more common in boys with retractile testes. Yearly testicular examinations are recommended during childhood.
- About 80% of undescended testes are palpable, and 60% to 70% are unilateral.
- Epididymal anomalies and a patent processus vaginalis are common in cases of cryptorchidism.
- Subsets of boys with cryptorchidism have subtle abnormalities of the hypothalamic-pituitary-gonadal axis during mini-puberty and/or reduced levels of hormones secreted by Sertoli cells, AMH, or INHB.
- Orchidopexy is recommended for testes that remain undescended after 6 months of age; hormone therapy is not recommended.
- Laparoscopy is the procedure of choice, and imaging studies are rarely useful in the diagnosis and treatment of abdominal cryptorchidism.
- Sperm counts are reduced in at least 25% of formerly unilateral and the majority of formerly bilateral cryptorchid men, but paternity rates in the unilateral group are similar to control men.
- Ad spermatogonia counts may predict fertility potential in some males with cryptorchidism.
- TGCT risk is 2 to 5 times higher in boys with cryptorchidism and is positively correlated with age at surgery.

Suggested Readings

Baker LA, Docimo SG, Surer I, et al. A multi-institutional analysis of laparoscopic orchidopexy. *BJU Int*. 2001;87(6):484–489.

Barteczko KJ, Jacob MI. The testicular descent in human. Origin, development and fate of the gubernaculum Hunteri, processus vaginalis peritonei, and gonadal ligaments. *Adv Anat Embryol Cell Biol*. 2000;156(III–X):1–98.

Barthold JS, González R. The epidemiology of congenital cryptorchidism, testicular ascent and orchiopexy. *J Urol*. 2003;170(6 Pt 1):2396–2401.

Cortes D, Holt R, de Knegt VE. Hormonal aspects of the pathogenesis and treatment of cryptorchidism. *Eur J Pediatr Surg*. 2016;26(5):409–417.

Docimo SG. The results of surgical therapy for cryptorchidism: a literature review and analysis. *J Urol*. 1995;154(3):1148–1152.

Elyas R, Guerra LA, Pike J, et al. Is staging beneficial for Fowler-Stephens orchiopexy? A systematic review. *J Urol*. 2010;183(5):2012–2018.

Foresta C, Zuccarello D, Garolla A, et al. Role of hormones, genes, and environment in human cryptorchidism. *Endocr Rev*. 2008;29(5):560–580.

Gordon M, Cervellione RM, Morabito A, et al. 20 years of transcrotal orchidopexy for undescended testis: results and outcomes. *J Pediatr Urol*. 2010;6(5):506–512.

Gurney JK, McGlynn KA, Stanley J, et al. Risk factors for cryptorchidism. *Nat Rev Urol*. 2017;14(9):534–548.

Huff DS, Fenig DM, Canning DA, et al. Abnormal germ cell development in cryptorchidism. *Horm Res*. 2001;55(1):11–17.

Hutson JM, Southwell BR, Li R, et al. The regulation of testicular descent and the effects of cryptorchidism. *Endocr Rev*. 2013;34(5):725–752.

Ivell R, Anand-Ivell R, Morley SD. Endocrinology of the fetal testis. Simoni M, Huhtaniemi IT. *Endocrinology of the testis and male reproduction*. Springer International Publishing: Switzerland; 2016:245–272.

Kollin C, Stukenborg JB, Nurmio M, et al. Boys with undescended testes: endocrine, volumetric and morphometric studies on testicular function before and after orchidopexy at nine months or three years of age. *J Clin Endocrinol Metab*. 2012;97(12):4588–4595.

Kolon TF, Herndon CD, Baker LA, et al. American Urological Association. Evaluation and treatment of cryptorchidism: AUA guideline. *J Urol*. 2014;192(2):337–345.

Lee PA. Fertility after cryptorchidism: epidemiology and other outcome studies. *Urology*. 2005;66(2):427–431.

Marshall FF, Shermeta DW. Epididymal abnormalities associated with undescended testis. *J Urol*. 1979;121(3):341–343.

Svingen T, Koopman P. Building the mammalian testis: origins, differentiation, and assembly of the component cell populations. *Genes Dev*. 2013;27(22):2409–2426.

Tasian GE, Copp HL. Diagnostic performance of ultrasound in nonpalpable cryptorchidism: a systematic review and meta-analysis. *Pediatrics*. 2011;127(1):119–128.

Virtanen HE, Adamsson A. Cryptorchidism and endocrine disrupting chemicals. *Mol Cell Endocrinol*. 2012;355(2):208–220.

Wood HM, Elder JS. Cryptorchidism and testicular cancer: separating fact from fiction. *J Urol*. 2009;181(2):452–461.

References

Abdullah NA, Pearce MS, Parker L, et al. Birth prevalence of cryptorchidism and hypospadias in northern England, 1993–2000. *Arch Dis Child*. 2007;92(7):576–579.

Abdul-Majeed S, Mell B, Nauli SM, et al. Cryptorchidism and infertility in rats with targeted disruption of the Adamts16 locus. *PLoS ONE*. 2014;9(7):e100967.

Aberger M, Wilson B, Holzbeierlein JM, et al. Testicular self-examination and testicular cancer: a cost-utility analysis. *Cancer Med*. 2014;3(6):1629–1634.

Abeyaratne MR, Aherne WA, Scott JE. The vanishing testis. *Lancet*. 1969;2(7625):822–824.

Acerini CL, Miles HL, Dunger DB, et al. The descriptive epidemiology of congenital and acquired cryptorchidism in a UK infant cohort. *Arch Dis Child*. 2009;94(11):868–872.

Adham IM, Agoulnik AI. Insulin-like 3 signalling in testicular descent. *Int J Androl*. 2004;27(5):257–265.

Adham IM, Emmen JM, Engel W. The role of the testicular factor INSL3 in establishing the gonadal position. *Mol Cell Endocrinol*. 2000;160(1–2):11–16.

Adham IM, Steding G, Thamm T, et al. The overexpression of the insl3 in female mice causes descent of the ovaries. *Mol Endocrinol*. 2002;16(2):244–252.

Agarwal PK, Diaz M, Elder JS. Retractile testis—is it really a normal variant? *J Urol*. 2006;175(4):1496–1499.

Akre O, Pettersson A, Richiardi L. Risk of contralateral testicular cancer among men with unilaterally undescended testis: a meta analysis. *Int J Cancer*. 2009;124(3):687–689.

Aksglaede L, Sorensen K, Boas M, et al. Changes in anti-Mullerian hormone (AMH) throughout the life span: a population-based study of 1027 healthy males from birth (cord blood) to the age of 69 years. *J Clin Endocrinol Metab*. 2010;95(12):5357–5364.

Alagaratnam S, Nathaniel C, Cuckow P, et al. Testicular outcome following laparoscopic second stage Fowler-Stephens orchidopexy. *J Pediatr Urol*. 2014;10(1):186–192.

Alam A, Delto JC, Blachman-Braun R, et al. Staged Fowler-Stephens and single-stage laparoscopic orchiopexy for intra-abdominal testes: is there a difference? A single institution experience. *Urology*. 2017;101:104–110.

Alamsahebpour A, Blachman-Braun R, Gupta A, et al. Laparoscopy and transseptal orchiopexy in the management of transverse testicular ectopia. *Curr Urol Rep*. 2015;16(7):48.

Al-Zahem A, Shun A. Routine contralateral orchiopexy for children with a vanished testis. *Eur J Pediatr Surg*. 2006;16(5):334–336.

Anand-Ivell R, Ivell R, Driscoll D, et al. Insulin-like factor 3 levels in amniotic fluid of human male fetuses. *Hum Reprod*. 2008;23(5):1180–1186.

Anand-Ivell R, Cohen A, Norgaard-Pedersen B, et al. Amniotic fluid INSL3 measured during the critical time window in human pregnancy relates to cryptorchidism, hypospadias, and phthalate load: a large case-control study. *Front Physiol*. 2018;9:406.

Andersen HR, Schmidt IM, Grandjean P, et al. Impaired reproductive development in sons of women occupationally exposed to pesticides during pregnancy. *Environ Health Perspect*. 2008;116(4):566–572.

Anderson KM, Costa SF, Sampaio FJ, et al. Do retractile testes have anatomical anomalies? *Int Braz J Urol*. 2016;42(4):803–809.

Andersson AM, Toppari J, Haavisto AM, et al. Longitudinal reproductive hormone profiles in infants: peak of inhibin B levels in infant boys exceeds levels in adult men. *J Clin Endocrinol Metab*. 1998;83(2):675–681.

Arena S, Impellizzeri P, Perrone P, et al. Our experience in transcrotal orchidopexy in children affected by palpable undescended testis. *Eur J Pediatr Surg*. 2016;26(1):13–16.

Arendt LH, Ramlau-Hansen CH, Wilcox AJ, et al. Placental weight and male genital anomalies: a nationwide danish cohort study. *Am J Epidemiol*. 2016;183(12):1122–1128.

Arendt LH, Lindhard MS, Henriksen TB, et al. Maternal diabetes mellitus and genital anomalies in male offspring: a nationwide cohort study in 2 Nordic countries. *Epidemiology*. 2018;29(2):280–289.

Arlen AM, Holzman SA, Weiss AD, et al. Functional supernumerary testis in a child with testicular torsion and review of polyorchidism. *Pediatr Surg Int*. 2014;30(5):565–568.

Ars E, Lo Giacco D, Bassas L, et al. Further insights into the role of T222P variant of RXFP2 in non-syndromic cryptorchidism in two Mediterranean populations. *Int J Androl*. 2011;34(4):333–338.

Ates F, Soydan H, Okcelik S, et al. Clinical and histopathological results of the adult patients with unilateral cryptorchidism. *Turk J Urol*. 2016;42(2):74–79.

Avargues A, Rogel R, Broseta E, et al. Polyorchidism: the case in a young male and review of the literature. *Asian J Androl*. 2015;17(3):511–512.

Azarow KS, Cusick R, Wynn J, et al. The association between congenital diaphragmatic hernia and undescended testes. *J Pediatr Surg*. 2015;50(5):744–745.

Bader MI, Peeraully R, Ba'ath M, et al. The testicular regression syndrome—do remnants require routine excision? *J Pediatr Surg*. 2011;46(2):384–386.

Bagga D, Prasad A, Grover SB, et al. Evaluation of two-staged

Fowler-Stephens laparoscopic orchidopexy (FSLO) for intra-abdominal testes (IAT). *Pediatr Surg Int*. 2018;34(1):97–103.
Baker LA, Docimo SG, Surer I, et al. A multi-institutional analysis of laparoscopic orchidopexy. *BJU Int*. 2001;87(6):484–489.
Balsara ZR, Martin AE, Wiener JS, et al. Congenital spigelian hernia and ipsilateral cryptorchidism: raising awareness among urologists. *Urology*. 2014;83(2):457–459.
Banks K, Tuazon E, Berhane K, et al. Cryptorchidism and testicular germ cell tumors: comprehensive meta-analysis reveals that association between these conditions diminished over time and is modified by clinical characteristics. *Front Endocrinol (Lausanne)*. 2012;3:182.
Barteczko KJ, Jacob MI. The testicular descent in human. Origin, development and fate of the gubernaculum Hunteri, processus vaginalis peritonei, and gonadal ligaments. *Adv Anat Embryol Cell Biol*. 2000;156(III–X):1–98.
Barthold JS. What regulates neonatal gonocyte migration? *J Urol*. 2015;193(4):1087–1088.
Barthold JS, Redman JF. Association of epididymal anomalies with patent processus vaginalis in hernia, hydrocele and cryptorchidism. *J Urol*. 1996;156(6):2054–2056.
Barthold JS, González R. The epidemiology of congenital cryptorchidism, testicular ascent and orchiopexy. *J Urol*. 2003;170(6 Pt 1):2396–2401.
Barthold JS, Ivell R. Perspective: a neuro-hormonal systems approach to understanding the complexity of cryptorchidism susceptibility. *Front Endocrinol (Lausanne)*. 2018;9:401.
Barthold JS. Undescended testis: current theories of etiology. *Curr Opin Urol*. 2008;18(4):395–400.
Barthold JS, Kumasi-Rivers K, Upadhyay J, et al. Testicular position in the androgen insensitivity syndrome: implications for the role of androgens in testicular descent. *J Urol*.

2000;164(2):497–501.

Barthold JS, Manson J, Regan V, et al. Reproductive hormone levels in infants with cryptorchidism during postnatal activation of the pituitary-testicular axis. *J Urol*. 2004;172(4 Pt 2):1736–1741 [discussion 1741].

Barthold JS, McCahan SM, Singh AV, et al. Altered expression of muscle- and cytoskeleton-related genes in a rat strain with inherited cryptorchidism. *J Androl*. 2008;29(3):352–366.

Barthold JS, Hossain J, Olivant-Fisher A, et al. Altered infant feeding patterns in boys with acquired nonsyndromic cryptorchidism. *Birth Defects Res A Clin Mol Teratol*. 2012;94(11):900–907.

Barthold JS, Wang Y, Robbins A, et al. Transcriptome analysis of the dihydrotestosterone-exposed fetal rat gubernaculum identifies common androgen and insulin-like 3 targets. *Biol Reprod*. 2013;89(6):143.

Barthold JS, Robbins A, Wang Y, et al. Cryptorchidism in the orl rat is associated with muscle patterning defects in the fetal gubernaculum and altered hormonal signaling. *Biol Reprod*. 2014;91(2):41.

Barthold JS, Wang Y, Kolon TF, et al. Pathway analysis supports association of nonsyndromic cryptorchidism with genetic loci linked to cytoskeleton-dependent functions. *Hum Reprod*. 2015;30(10):2439–2451.

Barthold JS, Wang Y, Kolon TF, et al. Phenotype specific association of the TGFBR3 locus with nonsyndromic cryptorchidism. *J Urol*. 2015;193(5):1637–1645.

Basciani S, De Luca G, Dolci S, et al. Platelet-derived growth factor receptor beta-subtype regulates proliferation and migration of gonocytes. *Endocrinology*. 2008;149(12):6226–6235.

Barthold JS, Pugarelli J, MacDonald ML, et al. Polygenic inheritance of cryptorchidism susceptibility in the LE/orl rat.

Mol Hum Reprod. 2016;22(1):18–34.

Barthold JS, Reinhardt S, Thorup J. Genetic, maternal, and environmental risk factors for cryptorchidism: an update. *Eur J Pediatr Surg*. 2016;26(5):399–408.

Barthold JS, Wintner A, Hagerty JA, et al. Cryptorchidism in boys with cerebral palsy is associated with the severity of disease and with co-occurrence of other congenital anomalies. *Front Endocrinol (Lausanne)*. 2018;9:151.

Bassel YS, Scherz HC, Kirsch AJ. Scrotal incision orchiopexy for undescended testes with or without a patent processus vaginalis. *J Urol*. 2007;177(4):1516–1518.

Bay K, Virtanen HE, Hartung S, et al. Insulin-like factor 3 levels in cord blood and serum from children: effects of age, postnatal hypothalamic-pituitary-gonadal axis activation, and cryptorchidism. *J Clin Endocrinol Metab*. 2007;92(10):4020–4027.

Bay K, Cohen AS, Jørgensen FS, et al. Insulin-like factor 3 levels in second-trimester amniotic fluid. *J Clin Endocrinol Metab*. 2008;93(10):4048–4051.

Bay K, Main KM, Toppari J, et al. Testicular descent: INSL3, testosterone, genes and the intrauterine milieu. *Nat Rev Urol*. 2011;8(4):187–196.

Bayne AP, Alonzo DG, Hsieh MH, et al. Impact of anatomical and socioeconomic factors on timing of urological consultation for boys with cryptorchidism. *J Urol*. 2011;186(4 Suppl):1601–1605.

Beckers G, van der Horst E. Re: relationship between adult dark spermatogonia and secretory capacity of Leydig cells in cryptorchidism. *BJU Int*. 2008;101(4):514 [author reply 514–515].

Bellinger MF. The blind-ending vas: the fate of the contralateral testis. *J Urol*. 1985;133(4):644–645.

Bellis MA, Hughes K, Hughes S, et al. Measuring paternal discrepancy and its public health consequences. *J Epidemiol Community Health*. 2005;59(9):749–754.

Belman AB, Rushton HG. Is an empty left hemiscrotum and hypertrophied right descended testis predictive of perinatal torsion? *J Urol*. 2003;170(4 Pt 2):1674–1675 [discussion 1675–1676].

Berensztein EB, Sciara MI, Rivarola MA, et al. Apoptosis and proliferation of human testicular somatic and germ cells during prepuberty: high rate of testicular growth in newborns mediated by decreased apoptosis. *J Clin Endocrinol Metab*. 2002;87(11):5113–5118.

Bergada I, Milani C, Bedecarras P, et al. Time course of the serum gonadotropin surge, inhibins, and anti-Mullerian hormone in normal newborn males during the first month of life. *J Clin Endocrinol Metab*. 2006;91(10):4092–4098.

Bergbrant S, Omling E, Bjork J, et al. Cryptorchidism in Sweden: a nationwide study of prevalence, operative management, and complications. *J Pediatr*. 2018;194 [197.e6–203.e6].

Bergholz R, Koch B, Spieker T, et al. Polyorchidism: a case report and classification. *J Pediatr Surg*. 2007;42(11):1933–1935.

Bergholz R, Wenke K. Polyorchidism: a meta-analysis. *J Urol*. 2009;182(5):2422–2427.

Berkowitz GS, Lapinski RH, Dolgin SE, et al. Prevalence and natural history of cryptorchidism. *Pediatrics*. 1993;92(1):44–49.

Bertini V, Bertelloni S, Valetto A, et al. Homeobox HOXA10 gene analysis in cryptorchidism. *J Pediatr Endocrinol Metab*. 2004;17(1):41–45.

Bianchi A, Squire BR. Transscrotal orchidopexy: orchidopexy revised. *Pediatr Surg Int*. 1989;4(3):189–192.

Bica DT, Hadziselimovic F. Buserelin treatment of cryptorchidism: a randomized, double-blind, placebo-controlled study. *J Urol*. 1992;148(2 Pt 2):617–621.

Biers SM, Malone PS. A critical appraisal of the evidence for improved fertility indices in undescended testes after gonadotrophin-releasing hormone therapy and orchidopexy. *J Pediatr Urol*. 2010;6(3):239–246.

Bilandzic M, Stenvers KL. Betaglycan: a multifunctional accessory. *Mol Cell Endocrinol*. 2011;339(1–2):180–189.

Bilici S, Güneş M, Göksu M, et al. Undescended testis accompanying congenital Spigelian hernia: is it a reason, a result, or a new syndrome? *Eur J Pediatr Surg*. 2012;22(2):157–161.

Bloom DA. Two-step orchiopexy with pelviscopic clip ligation of the spermatic vessels. *J Urol*. 1991;145(5):1030–1033.

Bodiwala D, Summerton DJ, Terry TR. Testicular prostheses: development and modern usage. *Ann R Coll Surg Engl*. 2007;89(4):349–353.

Bogatcheva NV, Ferlin A, Feng S, et al. T222P mutation of the insulin-like 3 hormone receptor LGR8 is associated with testicular maldescent and hinders receptor expression on the cell surface membrane. *Am J Physiol Endocrinol Metab*. 2007;292(1):E138–E144.

Boisen KA, Kaleva M, Main KM, et al. Difference in prevalence of congenital cryptorchidism in infants between two Nordic countries. *Lancet*. 2004;363(9147):1264–1269.

Bonde JP, Flachs EM, Rimborg S, et al. The epidemiologic evidence linking prenatal and postnatal exposure to endocrine disrupting chemicals with male reproductive disorders: a systematic review and meta-analysis. *Hum Reprod Update*. 2016;23(1):104–125.

Bonney T, Southwell B, Donnath S, et al. Orchidopexy trends in the paediatric population of Victoria, 1999–2006. *J Pediatr Surg*. 2009;44(2):427–431.

Boukari K, Ciampi ML, Guiochon-Mantel A, et al. Human fetal testis: source of estrogen and target of estrogen action. *Hum Reprod*. 2007;22(7):1885–1892.

Boukari K, Meduri G, Brailly-Tabard S, et al. Lack of androgen receptor expression in Sertoli cells accounts for the absence of anti-Mullerian hormone repression during early human testis development. *J Clin Endocrinol Metab*. 2009;94(5):1818–1825.

Bouzada J, Vazquez T, Duran M, et al. New insights into the morphogenesis of the gubernaculum testis and the inguinal canal. *Clin Anat*. 2017;30(5):599–607.

Boyd HA, Myrup C, Wohlfahrt J, et al. Maternal serum alpha-fetoprotein level during pregnancy and isolated cryptorchidism in male offspring. *Am J Epidemiol*. 2006;164(5):478–486.

Bracho-Blanchet E, Unda-Haro S, Ordorica-Flores R, et al. Laparoscopic treatment of nonpalpable testicle. Factors predictive for diminished size. *J Pediatr Surg*. 2016;51(7):1201–1206.

Bradshaw CJ, Corbet-Burcher G, Hitchcock R. Age at orchidopexy in the UK: has new evidence changed practice? *J Pediatr Urol*. 2014;10(4):758–762.

Braga LH, Kim S, Farrokhyar F, et al. Is there an optimal contralateral testicular cut-off size that predicts monorchism in boys with nonpalpable testicles? *J Pediatr Urol*. 2014;10(4):693–698.

Braga LH, Lorenzo AJ, Romao RLP. Canadian Urological Association-Pediatric Urologists of Canada (CUA-PUC) guideline for the diagnosis, management, and followup of cryptorchidism. *Can Urol Assoc J*. 2017;11(7):E251–E260.

Brauner R, Neve M, Allali S, et al. Clinical, biological and genetic analysis of anorchia in 26 boys. *PLoS ONE*. 2011;6(8):e23292.

Bremholm Rasmussen T, Ingerslev HJ, Høstrup H. Bilateral spontaneous descent of the testis after the age of 10: subsequent effects on fertility. *Br J Surg*. 1988;75(8):820–823.

Brouwers MM, de Bruijne LM, de Gier RP, et al. Risk factors for undescended testis. *J Pediatr Urol*. 2012;8(1):59–66.

Bu Q, Pan Z, Jiang S, et al. The effectiveness of hCG and LHRH in boys with cryptorchidism: a meta-analysis of randomized controlled trials. *Horm Metab Res*. 2016;48(5):318–324.

Bukowski TP, Wacksman J, Billmire DA, et al. Testicular autotransplantation: a 17-year review of an effective approach to the management of the intra-abdominal testis. *J Urol*. 1995;154(2 Pt 1):558–561.

Bukowski TP, Sedberry S, Richardson B. Is human chorionic gonadotropin useful for identifying and treating nonpalpable testis? *J Urol*. 2001;165(1):221–223.

Cain MP, Garra B, Gibbons MD. Scrotal-inguinal ultrasonography: a technique for identifying the nonpalpable inguinal testis without laparoscopy. *J Urol*. 1996;156(2 Pt 2):791–794.

Caldamone AA, Amaral JF. Laparoscopic stage 2 Fowler-Stephens orchiopexy. *J Urol*. 1994;152(4):1253–1256.

Canavese F, Mussa A, Manenti M, et al. Sperm count of young men surgically treated for cryptorchidism in the first and second year of life: fertility is better in children treated at a younger age. *Eur J Pediatr Surg*. 2009;19(6):388–391.

Capel B. Vertebrate sex determination: evolutionary plasticity of a fundamental switch. *Nat Rev Genet*. 2017;18(11):675–689.

Caroppo E, Niederberger C, Elhanbly S, et al. Effect of cryptorchidism and retractile testes on male factor infertility: a multicenter, retrospective, chart review. *Fertil Steril*. 2005;83(5):1581–1584.

Cartwright PC, Velagapudi S, Snyder HM 3rd, et al. A surgical approach to reoperative orchiopexy. *J Urol*. 1993;149(4):817–818.

Casanova NC, Johnson EK, Bowen DK, et al. Two-step Fowler-Stephens orchiopexy for intra-abdominal testes: a 28-year single institution experience. *J Urol*. 2013;190(4):1371–1376.

Caucci M, Barbatelli G, Cinti S. The retractile testis can be a cause of adult infertility. *Fertil Steril*. 1997;68(6):1051–1058.

Celik A, Tiryaki S, Darcan S, et al. Splenogonadal fusion-limb deformity syndrome: a rare but important cause of undescended testis. *World J Pediatr*. 2016;12(2):246–248.

Cendron M, Keating MA, Huff DS, et al. Cryptorchidism, orchiopexy and infertility: a critical long-term retrospective analysis. *J Urol*. 1989;142(2 Pt 2):559–562 [discussion 572].

Cendron M, Huff DS, Keating MA, et al. Anatomical, morphological and volumetric analysis: a review of 759 cases of testicular maldescent. *J Urol*. 1993;149(3):570–573.

Chacko JK, Furness PD 3rd, Mingin GC. Presentation of fused vas deferens. *Urology*. 2006;67(5):1085 e1017–1085 e1088.

Chan E, Wayne C, Nasr A. FRCSC for Canadian Association of Pediatric Surgeon Evidence-Based Resource. Ideal timing of orchiopexy: a systematic review. *Pediatr Surg Int*. 2014;30(1):87–97.

Chan JJ, Farmer PJ, Southwell BR, et al. Calcitonin gene-related peptide is a survival factor, inhibiting apoptosis in neonatal rat gubernaculum in vitro. *J Pediatr Surg*. 2009;44(8):1497–1501.

Chang M, Franco I. Laparoscopic Fowler-Stephens orchiopexy: the Westchester Medical Center experience. *J Endourol*. 2008;22(6):1315–1319.

Chavez-Saldana M, Vigueras-Villasenor RM, Yokoyama-Rebollar E, et al. Single nucleotide polymorphisms associated with nonsyndromic cryptorchidism in Mexican patients.

Andrologia. 2018;50(1).

Chawengsaksophak K, Svingen T, Ng ET, et al. Loss of Wnt5a disrupts primordial germ cell migration and male sexual development in mice. *Biol Reprod*. 2012;86(1):1–12.

Chedane C, Puissant H, Weil D, et al. Association between altered placental human chorionic gonadotrophin (hCG) production and the occurrence of cryptorchidism: a retrospective study. *BMC Pediatr*. 2014;14:191.

Chen J, Sorensen HT, Miao M, et al. Cryptorchidism and increased risk of neurodevelopmental disorders. *J Psychiatr Res*. 2018;96:153–161.

Cheng Z, Wang M, Xu C, et al. Mutational analysis of HOXA10 gene in Chinese patients with cryptorchidism. *Andrologia*. 2017;49(1).

Chilvers C, Dudley NE, Gough MH, et al. Undescended testis: the effect of treatment on subsequent risk of subfertility and malignancy. *J Pediatr Surg*. 1986;21(8):691–696.

Christiansen P, Andersson AM, Skakkebaek NE, et al. Serum inhibin B, FSH, LH and testosterone levels before and after human chorionic gonadotropin stimulation in prepubertal boys with cryptorchidism. *Eur J Endocrinol*. 2002;147(1):95–101.

Christman MS, Kraft KH, Tasian GE, et al. Reproducibility and reliability of semen analysis in youths at risk for infertility. *J Urol*. 2013;190(2):683–688.

Chua ME, Mendoza JS, Gaston MJ, et al. Hormonal therapy using gonadotropin releasing hormone for improvement of fertility index among children with cryptorchidism: a meta-analysis and systematic review. *J Pediatr Surg*. 2014;49(11):1659–1667.

Chung JM, Lee SD. Individualized treatment guidelines for postpubertal cryptorchidism. *World J Mens Health*. 2015;33(3):161–166.

Cisek LJ, Peters CA, Atala A, et al. Current findings in diagnostic laparoscopic evaluation of the nonpalpable testis. *J Urol*. 1998;160(3 Pt 2):1145–1149 [discussion 1150].

Cloutier J, Moore K, Nadeau G, et al. Modified scrotal (Bianchi) mid raphe single incision orchiopexy for low palpable undescended testis: early outcomes. *J Urol*. 2011;185(3):1088–1092.

Codesal J, Regadera J, Nistal M, et al. Involution of human fetal Leydig cells. An immunohistochemical, ultrastructural and quantitative study. *J Anat*. 1990;172:103–114.

Combes AN, Wilhelm D, Davidson T, et al. Endothelial cell migration directs testis cord formation. *Dev Biol*. 2009;326(1):112–120.

Conley JM, Lambright CS, Evans N, et al. Mixed "antiandrogenic" chemicals at low individual doses produce reproductive tract malformations in the male rat. *Toxicol Sci*. 2018;164(1):166–178.

Cook MB, Trabert B, McGlynn KA. Organochlorine compounds and testicular dysgenesis syndrome: human data. *Int J Androl*. 2011;34(4 Pt 2):e68–e84 [discussion e84–e85].

Cool J, Capel B. Mixed signals: development of the testis. *Semin Reprod Med*. 2009;27(1):5–13.

Cools M, van Aerde K, Kersemaekers AM, et al. Morphological and immunohistochemical differences between gonadal maturation delay and early germ cell neoplasia in patients with undervirilization syndromes. *J Clin Endocrinol Metab*. 2005;90(9):5295–5303.

Corona-Rivera JR, Nieto-Garcia R, Lopez-Marure E, et al. Associated congenital anomalies in infants with isolated gastroschisis: a single-institutional experience. *Am J Med Genet A*. 2016;170A(2):316–321.

Cortada X, Kousseff BG. Cryptorchidism in mental retardation. *J Urol*. 1984;131(4):674–676.

Cortes D, Thorup JM, Lenz K, et al. Laparoscopy in 100 consecutive patients with 128 impalpable testes. *Br J Urol*. 1995;75(3):281–287.

Cortes D, Thorup JM, Nielsen OH, et al. Cryptorchidism in boys with imperforate anus. *J Pediatr Surg*. 1995;30(4):631–635.

Cortes D, Thorup JM, Visfeldt J. The pathogenesis of cryptorchidism and splenogonadal fusion: a new hypothesis. *Br J Urol*. 1996;77(2):285–290.

Cortes D, Thorup JM, Beck BL, et al. Cryptorchidism as a caudal developmental field defect. A new description of cryptorchidism associated with malformations and dysplasias of the kidneys, the ureters and the spine from T10 to S5. *APMIS*. 1998;106(10):953–958.

Cortes D, Thorup J, Visfeldt J. Hormonal treatment may harm the germ cells in 1 to 3-year-old boys with cryptorchidism. *J Urol*. 2000;163(4):1290–1292.

Cortes D, Thorup JM, Visfeldt J. Cryptorchidism: aspects of fertility and neoplasms. A study including data of 1,335 consecutive boys who underwent testicular biopsy simultaneously with surgery for cryptorchidism. *Horm Res*. 2001;55(1):21–27.

Cortes D, Thorup J, Lindenberg S, et al. Infertility despite surgery for cryptorchidism in childhood can be classified by patients with normal or elevated follicle-stimulating hormone and identified at orchidopexy. *BJU Int*. 2003;91(7):670–674.

Cortes D, Thorup J, Visfeldt J. Multinucleated spermatogonia in cryptorchid boys: a possible association with an increased risk of testicular malignancy later in life? *APMIS*. 2003;111(1):25–30 [discussion 31].

Cortes D, Kjellberg EM, Breddam M, et al. The true incidence of cryptorchidism in Denmark. *J Urol*. 2008;179(1):314–318.

Cortes D, Clasen-Linde E, Hutson JM, et al. The Sertoli cell hormones inhibin-B and anti Mullerian hormone have different patterns of secretion in prepubertal cryptorchid boys. *J Pediatr Surg*. 2016;51(3):475–480.

Cortes D, Holt R, de Knegt VE. Hormonal aspects of the pathogenesis and treatment of cryptorchidism. *Eur J Pediatr Surg*. 2016;26(5):409–417.

Costa WS, Sampaio FJ, Favorito LA, et al. Testicular migration: remodeling of connective tissue and muscle cells in human gubernaculum testis. *J Urol*. 2002;167(5):2171–2176.

Coughlin MT, Bellinger MF, Lee PA. Age at unilateral orchiopexy: effect on hormone levels and sperm count in adulthood. *J Urol*. 1999;162(3 Pt 2):986–988 [discussion 989].

Cox MJ, Coplen DE, Austin PF. The incidence of disorders of sexual differentiation and chromosomal abnormalities of cryptorchidism and hypospadias stratified by meatal location. *J Urol*. 2008;180(6):2649–2652 [discussion 2652].

Culty M. Gonocytes, the forgotten cells of the germ cell lineage. *Birth Defects Res C Embryo Today*. 2009;87(1):1–26.

Culty M. Gonocytes, from the fifties to the present: is there a reason to change the name? *Biol Reprod*. 2013;89(2):46.

Czeizel A, Erödi E, Tóth J. Genetics of undescended testis. *J Urol*. 1981;126(4):528–529.

Dalgaard MD, Weinhold N, Edsgard D, et al. A genome-wide association study of men with symptoms of testicular dysgenesis syndrome and its network biology interpretation. *J Med Genet*. 2012;49(1):58–65.

Damgaard IN, Skakkebaek NE, Toppari J, et al. Persistent pesticides in human breast milk and cryptorchidism. *Environ Health Perspect*. 2006;114(7):1133–1138.

Damgaard IN, Jensen TK, Petersen JH, et al. Cryptorchidism and maternal alcohol consumption during pregnancy. *Environ Health Perspect*. 2007;115(2):272–277.

Damgaard IN, Jensen TK. Nordic Cryptorchidism Study Group. Risk factors for congenital cryptorchidism in a prospective birth cohort study. *PLoS ONE*. 2008;3(8):e3051.

Danrad R, Ashker L, Smith W. Polyorchidism: imaging may denote reproductive potential of accessory testicle. *Pediatr Radiol*. 2004;34(6):492–494.

Dayanc M, Kibar Y, Irkilata HC, et al. Long-term outcome of scrotal incision orchiopexy for undescended testis. *Urology*. 2007;70(4):786–788 [discussion 788–789].

De Luna AM, Ortenberg J, Craver RD. Exploration for testicular remnants: implications of residual seminiferous tubules and crossed testicular ectopia. *J Urol*. 2003;169(4):1486–1489.

De Muinck Keizer-Schrama SM, Hazebroek FW, Drop SL, et al. Double-blind, placebo-controlled study of luteinising-hormone-releasing-hormone nasal spray in treatment of undescended testes. *Lancet*. 1986;327(8486):876–880.

De Muinck Keizer-Schrama SM, Hazebroek FW, Drop SL, et al. Hormonal evaluation of boys born with undescended testes during their first year of life. *J Clin Endocrinol Metab*. 1988;66(1):159–164.

Dean A, Sharpe RM. Clinical review: anogenital distance or digit length ratio as measures of fetal androgen exposure: relationship to male reproductive development and its disorders. *J Clin Endocrinol Metab*. 2013;98(6):2230–2238.

Denes FT, Saito FJ, Silva FA, et al. Laparoscopic diagnosis and treatment of nonpalpable testis. *Int Braz J Urol*. 2008;34(3):329–334 [discussion 335].

Depue RH. Cryptorchidism, and epidemiologic study with emphasis on the relationship to central nervous system dysfunction. *Teratology*. 1988;37(4):301–305.

Desireddi NV, Liu DB, Maizels M, et al. Magnetic resonance arteriography/venography is not accurate to structure management of the impalpable testis. *J Urol*. 2008;180(4 Suppl):1805–1808 [discussion 1808–1809].

Docimo SG. The results of surgical therapy for cryptorchidism: a literature review and analysis. *J Urol*. 1995;154(3):1148–1152.

Donaldson KM, Tong SY, Washburn T, et al. Morphometric study of the gubernaculum in male estrogen receptor mutant mice. *J Androl*. 1996;17(2):91–95.

Duarte A, Bessa JJ, Mrad FCC, et al. Smoking and its association with cryptorchidism in Down syndrome. *Rev Assoc Med Bras (1992)*. 2017;63(8):693–696.

Dunkel L, Taskinen S, Hovatta O, et al. Germ cell apoptosis after treatment of cryptorchidism with human chorionic gonadotropin is associated with impaired reproductive function in the adult. *J Clin Invest*. 1997;100(9):2341–2346.

Durham MM, Ricketts RR. Congenital spigelian hernias and cryptorchidism. *J Pediatr Surg*. 2006;41(11):1814–1817.

Edelsztein NY, Grinspon RP, Schteingart HF, et al. Anti-Mullerian hormone as a marker of steroid and gonadotropin action in the testis of children and adolescents with disorders of the gonadal axis. *Int J Pediatr Endocrinol*. 2016;2016:20.

Eijsbouts SW, de Muinck Keizer-Schrama SM, Hazebroek FW. Further evidence for spontaneous descent of acquired undescended testes. *J Urol*. 2007;178(4 Pt 2):1726–1729.

Eisenberg ML, Hsieh TC, Pastuszak AW, et al. The relationship between anogenital distance and the androgen receptor CAG repeat length. *Asian J Androl*. 2013;15(2):286–289.

El Houate B, Rouba H, Sibai H, et al. Novel mutations involving the INSL3 gene associated with cryptorchidism. *J Urol*. 2007;177(5):1947–1951.

Elder JS. Epididymal anomalies associated with hydrocele/hernia and cryptorchidism: implications regarding testicular descent. *J Urol*. 1992;148(2 Pt 2):624–626.

Elder JS. Laparoscopy for impalpable testes: significance of the patent processus vaginalis. *J Urol*. 1994;152(2 Pt 2):776–778.

Elder JS. Ultrasonography is unnecessary in evaluating boys with a nonpalpable testis. *Pediatrics*. 2002;110(4):748–751.

Elert A, Jahn K, Heidenreich A, et al. The familial undescended testis]. *Klin Padiatr*. 2003;215(1):40–45.

Ellerkamp V, Schmid A, Blumenstock G, et al. Guideline implementation for the treatment of undescended testes: still room for improvement. *J Pediatr Surg*. 2018;53(11):2219–2224.

Ellsworth PI, Cheuck L. The lost testis: failure of physical examination and diagnostic laparoscopy to identify inguinal undescended testis. *J Pediatr Urol*. 2009;5(4):321–323.

Elyas R, Guerra LA, Pike J, et al. Is staging beneficial for Fowler-Stephens orchiopexy? A systematic review. *J Urol*. 2010;183(5):2012–2018.

Emmen JM, McLuskey A, Adham IM, et al. Hormonal control of gubernaculum development during testis descent: gubernaculum outgrowth in vitro requires both insulin-like factor and androgen. *Endocrinology*. 2000;141(12):4720–4727.

Engeler DS, Hosli PO, John H, et al. Early orchiopexy: prepubertal intratubular germ cell neoplasia and fertility outcome. *Urology*. 2000;56(1):144–148.

Erdoğan C, Bahadir B, Taşkinlar H, et al. Laparoscopic management and its outcomes in cases with nonpalpable testis. *Turk J Urol*. 2017;43(2):196–201.

Esposito C, Garipoli V. The value of 2-step laparoscopic Fowler-Stephens orchiopexy for intra-abdominal testes. *J Urol*. 1997;158(5):1952–1954 [discussion 1954–1955].

Esposito C, Damiano R, Gonzalez Sabin MA, et al. Laparoscopy-assisted orchidopexy: an ideal treatment for children with intra-abdominal testes. *J Endourol*.

2002;16(9):659–662.

Esposito C, Lima M, Mattioli G, et al. Complications of pediatric urological laparoscopy: mistakes and risks. *J Urol*. 2003;169(4):1490–1492 [discussion 1492].

Facchinetti F, Bracci R, Sardelli S, et al. Possible testicular 3 beta-hydroxysteroid dehydrogenase deficiency in cryptorchid neonates. *Arch Androl*. 1983;10(3):253–259.

Fallat ME, Hersh JH, Hutson JM. Theories on the relationship between cryptorchidism and arthrogryposis. *Pediatr Surg Int*. 1991;7(4):271–273.

Farrington GH. The position and retractibility of the normal testis in childhood with reference to the diagnosis and treatment of cryptorchidism. *J Pediatr Surg*. 1968;3(1 Pt 1):53–59.

Faure A, Bouty A, O'Brien M, et al. Testicular biopsy in prepubertal boys: a worthwhile minor surgical procedure? *Nat Rev Urol*. 2016;13(3):141–150.

Favorito LA, Costa SF, Julio-Junior HR, et al. The importance of the gubernaculum in testicular migration during the human fetal period. *Int Braz J Urol*. 2014;40(6):722–729.

Favorito LA, Bernardo FO, Costa SF, et al. Is there a trans-abdominal testicular descent during the second gestational trimester? Study in human fetuses between 13 and 23 weeks post conception. *Int Braz J Urol*. 2016;42(3):558–563.

Favorito LA, Anderson KM, Costa SF, et al. Structural study of the cremaster muscle in patients with retractile testis. *J Pediatr Surg*. 2018;53(4):780–783.

Feng S, Yang H, Li X, et al. Single scrotal incision orchiopexy versus the inguinal approach in children with palpable undescended testis: a systematic review and meta-analysis. *Pediatr Surg Int*. 2016;32(10):989–995.

Fenichel P, Dechaux H, Harthe C, et al. Unconjugated bisphenol A cord blood levels in boys with descended or undescended testes. *Hum Reprod*. 2012;27(4):983–990.

Fenichel P, Lahlou N, Coquillard P, et al. Cord blood insulin-like peptide 3 (INSL3) but not testosterone is reduced in idiopathic cryptorchidism. *Clin Endocrinol (Oxf)*. 2015;82(2):242–247.

Fenig DM, Snyder HM 3rd, Wu HY, et al. The histopathology of iatrogenic cryptorchid testis: an insight into etiology. *J Urol*. 2001;165(4):1258–1261.

Ferlin A, Zuccarello D, Zuccarello B, et al. Genetic alterations associated with cryptorchidism. *JAMA*. 2008;300(19):2271–2276.

Ferlin A, Rocca MS, Vinanzi C, et al. Mutational screening of NR5A1 gene encoding steroidogenic factor 1 in cryptorchidism and male factor infertility and functional analysis of seven undescribed mutations. *Fertil Steril*. 2015;104(1) [163.e1–169.e1].

Fernandez MF, Arrebola JP, Jimenez-Diaz I, et al. Bisphenol A and other phenols in human placenta from children with cryptorchidism or hypospadias. *Reprod Toxicol*. 2016;59:89–95.

Ferrara P, Rossodivita A, Ruggiero A, et al. Cryptorchidism associated with meningomyelocele. *J Paediatr Child Health*. 1998;34(1):44–46.

Ferron SA, Arce JD. Discontinuous splenogonadal fusion: new sonographic findings. *Pediatr Radiol*. 2013;43(12):1652–1655.

Feyles F, Peiretti V, Mussa A, et al. Improved sperm count and motility in young men surgically treated for cryptorchidism in the first year of life. *Eur J Pediatr Surg*. 2014;24(5):376–380.

Foley PT, Sparnon AL, Lipsett J. Urogenital nonunion—the case for laparoscopy for the impalpable testis. *Pediatr Surg Int*. 2005;21(8):655–656.

Foresta C, Zuccarello D, Garolla A, et al. Role of hormones, genes, and environment in human cryptorchidism. *Endocr Rev*. 2008;29(5):560–580.

Fowler R, Stephens FD. The role of testicular vascular anatomy in the salvage of high undescended testes. *Aust N Z J Surg*. 1959;29:92–106.

Franc-Guimond J, Kryger J, Gonzalez R. Experience with the Bailez technique for laparoscopic access in children. *J Urol*. 2003;170(3):936–938.

Frimberger D, Malm-Buatsi E, Kropp BP, et al. Reliance of preoperative scrotal examination versus final operative findings in the evaluation of non-palpable testes. *J Pediatr Urol*. 2015;11(5):255.e1–255.e5.

Gabel P, Jensen MS, Andersen HR, et al. The risk of cryptorchidism among sons of women working in horticulture in Denmark: a cohort study. *Environ Health*. 2011;10:100.

Galan JJ, Guarducci E, Nuti F, et al. Molecular analysis of estrogen receptor alpha gene AGATA haplotype and SNP12 in European populations: potential protective effect for cryptorchidism and lack of association with male infertility. *Hum Reprod*. 2007;22(2):444–449.

Garcia J, Ventura MI, Requena M, et al. Association of reproductive disorders and male congenital anomalies with environmental exposure to endocrine active pesticides. *Reprod Toxicol*. 2017;71:95–100.

Gaskell TL, Esnal A, Robinson LL, et al. Immunohistochemical profiling of germ cells within the human fetal testis: identification of three subpopulations. *Biol Reprod*. 2004;71(6):2012–2021.

Gaspari L, Paris F, Philibert P, et al. “Idiopathic” partial androgen insensitivity syndrome in 28 newborn and infant males: impact of prenatal exposure to environmental endocrine disruptor chemicals? *Eur J Endocrinol*.

2011;165(4):579–587.

Geller F, Feenstra B, Carstensen L, et al. Genome-wide association analyses identify variants in developmental genes associated with hypospadias. *Nat Genet*. 2014;46(9):957–963.

Gendrel D, Job JC, Roger M. Reduced post-natal rise of testosterone in plasma of cryptorchid infants. *Acta Endocrinol (Copenh)*. 1978;89(2):372–378.

Ghazarian AA, Trabert B, Graubard BI, et al. Placental weight and risk of cryptorchidism and hypospadias in the collaborative perinatal project. *Am J Epidemiol*. 2018;187(7):1354–1361.

Gheiler EL, Barthold JS, Gonzalez R. Benefits of laparoscopy and the Jones technique for the nonpalpable testis. *J Urol*. 1997;158(5):1948–1951.

Ghirri P, Ciulli C, Vuerich M, et al. Boldrini. Incidence at birth and natural history of cryptorchidism: a study of 10,730 consecutive male infants. *J Endocrinol Invest*. 2002;25(8):709–715.

Ghose A, Rodrigues G, Izawa J. Two primary seminomas in a patient with polyorchidism. *Can Urol Assoc J*. 2007;1(3):285–287.

Giannopoulos MF, Vlachakis IG, Charissis GC. 13 Years' experience with the combined hormonal therapy of cryptorchidism. *Horm Res*. 2001;55(1):33–37.

Gilhooly PE, Meyers F, Lattimer JK. Fertility prospects for children with cryptorchidism. *Am J Dis Child*. 1984;138(10):940–943.

Gill WB, Schumacher GF, Bibbo M, et al. Association of diethylstilbestrol exposure in utero with cryptorchidism, testicular hypoplasia and semen abnormalities. *J Urol*. 1979;122(1):36–39.

Gill B, Kogan S, Starr S, et al. Significance of epididymal and ductal anomalies associated with testicular maldescent. *J Urol*. 1989;142(2 Pt 2):556–558 [discussion 572].

Giwercman A, Bruun E, Frimodt-Moller C, et al. Prevalence of carcinoma in situ and other histopathological abnormalities in testes of men with a history of cryptorchidism. *J Urol*. 1989;142(4):998–1001 [discussion 1001–1002].

Giwercman A, Grindsted J, Hansen B, et al. Testicular cancer risk in boys with maldescended testis: a cohort study. *J Urol*. 1987;138(5):1214–1216.

Goede J, Hack WW. Clinical aspects of testicular microlithiasis in boys: a review. *J Pediatr Urol*. 2012;8(5):459–469.

Goede J, Hack WW, van der Voort-Doedens LM, et al. Prevalence of testicular microlithiasis in asymptomatic males 0 to 19 years old. *J Urol*. 2009;182(4):1516–1520.

Goede J, van der Voort-Doedens LM, Sijstermans K, et al. The volume of retractile testes. *J Urol*. 2011;186(5):2050–2054.

Gong M, Geary ES, Shortliffe LM. Testicular torsion with contralateral vanishing testis. *Urology*. 1996;48(2):306–307.

Goodyer CG, Poon S, Aleksa K, et al. A case-control study of maternal polybrominated diphenyl ether (PBDE) exposure and cryptorchidism in Canadian populations. *Environ Health Perspect*. 2017;125(5):057004.

Gordon M, Cervellione RM, Morabito A, et al. 20 years of transcrotal orchidopexy for undescended testis: results and outcomes. *J Pediatr Urol*. 2010;6(5):506–512.

Gracia J, González N, Gómez ME, et al. Clinical and anatomopathological study of 2000 cryptorchid testes. *Br J Urol*. 1995;75(6):697–701.

Gracia J, Sanchez Zalabardo J, Sanchez Garcia J, et al. Clinical, physical, sperm and hormonal data in 251 adults operated on for cryptorchidism in childhood. *BJU Int*. 2000;85(9):1100–1103.

Grasso M, Buonaguidi A, Lania C, et al. Postpubertal cryptorchidism: review and evaluation of the fertility. *Eur Urol*. 1991;20(2):126–128.

Green MC. Mechanism of the pleiotropic effects of the short-ear mutant gene in the mouse. *J Exp Zool*. 1968;167(2):129–150.

Grinspon RP, Rey RA. Anti-mullerian hormone and sertoli cell function in paediatric male hypogonadism. *Horm Res Paediatr*. 2010;73(2):81–92.

Grinspon RP, Loreti N, Braslavsky D, et al. Sertoli cell markers in the diagnosis of paediatric male hypogonadism. *J Pediatr Endocrinol Metab*. 2012;25(1–2):3–11.

Grinspon RP, Ropelato MG, Bedecarras P, et al. Gonadotrophin secretion pattern in anorchid boys from birth to pubertal age: pathophysiological aspects and diagnostic usefulness. *Clin Endocrinol (Oxf)*. 2012;76(5):698–705.

Grinspon RP, Gottlieb S, Bedecarras P, et al. Anti-Mullerian hormone and testicular function in prepubertal boys with cryptorchidism. *Front Endocrinol (Lausanne)*. 2018;9:182.

Griswold MD, Oatley JM. Concise review: defining characteristics of Mammalian spermatogenic stem cells. *Stem Cells*. 2013;31(1):8–11.

Grumbach MM. A window of opportunity: the diagnosis of gonadotropin deficiency in the male infant. *J Clin Endocrinol Metab*. 2005;90(5):3122–3127.

Gurbuz N, Ozbay B, Aras B, et al. Do microdeletions in the AZF region of the Y chromosome accompany cryptorchidism in Turkish children? *Int Urol Nephrol*. 2008;40(3):577–581.

Gurney J, Richiardi L, McGlynn KA, et al. Analgesia use during pregnancy and risk of cryptorchidism: a systematic review and meta-analysis. *Hum Reprod*. 2017;32(5):1118–1129.

Gurney JK, McGlynn KA, Stanley J, et al. Risk factors for cryptorchidism. *Nat Rev Urol*. 2017;14(9):534–548.

Guven A, Kogan BA. Undescended testis in older boys: further evidence that ascending testes are common. *J Pediatr Surg*. 2008;43(9):1700–1704.

Guzick DS, Overstreet JW, Factor-Litvak P, et al. Sperm morphology, motility and concentration in fertile and infertile men. *NEJM*. 2001;345(19):1388–1393.

Habert R, Lejeune H, Saez JM. Origin, differentiation and regulation of fetal and adult Leydig cells. *Mol Cell Endocrinol*. 2001;179(1–2):47–74.

Habert R, Muczynski V, Grisin T, et al. Concerns about the widespread use of rodent models for human risk assessments of endocrine disruptors. *Reproduction*. 2014;147(4):R119–R129.

Hack WW, Sijstermans K, van der Voort-Doedens LM, et al. The high scrotal (“gliding”) testis revised. *Eur J Pediatr*. 2007;166(1):57–61.

Hack WW, van der Voort-Doedens LM, Goede J, et al. Natural history and long-term testicular growth of acquired undescended testis after spontaneous descent or pubertal orchidopexy. *BJU Int*. 2010;106(7):1052–1059.

Hack WW, Goede J, van der Voort-Doedens LM, et al. Acquired undescended testis: putting the pieces together. *Int J Androl*. 2012;35(1):41–45.

Hadziselimovic F. Examinations and clinical findings in cryptorchid boys. Hadziselimovic F. *Cryptorchidism: management and implications*. Springer-Verlag: Berlin; 1983:93–98.

Hadziselimovic F. Successful treatment of unilateral cryptorchid boys risking infertility with LH-RH analogue. *Int Braz J Urol*. 2008;34(3):319–326 [discussion 327–318].

Hadziselimovic F, Herzog B. The importance of both an early orchidopexy and germ cell maturation for fertility. *Lancet*. 2001;358(9288):1156–1157.

Hadziselimovic F, Hoecht B. Testicular histology related to fertility outcome and postpubertal hormone status in cryptorchidism. *Klin Padiatr*. 2008;220(5):302–307.

Hadziselimovic F, Thommen L, Girard J, et al. The significance of postnatal gonadotropin surge for testicular development in normal and cryptorchid testes. *J Urol*. 1986;136(1 Pt 2):274–276.

Hadziselimovic F, Herzog B, Hocht B, et al. Screening for cryptorchid boys risking sterility and results of long-term buserelin treatment after successful orchiopexy. *Eur J Pediatr*. 1987;146(Suppl 2):S59–S62.

Hadziselimovic F, Huff D, Duckett J, et al. Long-term effect of luteinizing hormone-releasing hormone analogue (buserelin) on cryptorchid testes. *J Urol*. 1987;138(4 Pt 2):1043–1045.

Hadziselimovic F, Huff D, Duckett J, et al. Treatment of cryptorchidism with low doses of buserelin over a 6-months period. *Eur J Pediatr*. 1987;146(Suppl 2):S56–S58.

Hadziselimovic F, Hocht B, Herzog B, et al. Infertility in cryptorchidism is linked to the stage of germ cell development at orchidopexy. *Horm Res*. 2007;68(1):46–52.

Hadziselimovic F, Hadziselimovic NO, Demougin P, et al. Testicular gene expression in cryptorchid boys at risk of azoospermia. *Sex Dev*. 2011;5(2):49–59.

Hakonsen LB, Ernst A, Ramlau-Hansen CH. Maternal cigarette smoking during pregnancy and reproductive health in children: a review of epidemiological studies. *Asian J Androl*. 2014;16(1):39–49.

Haller M, Mo Q, Imamoto A, et al. Murine model indicates 22q11.2 signaling adaptor CRKL is a dosage-sensitive regulator of genitourinary development. *Proc Natl Acad Sci USA*. 2017;114(19):4981–4986.

Hamdi SM, Almont T, Galinier P, et al. Altered secretion of Sertoli cells hormones in 2-year-old prepubertal cryptorchid boys: a cross-sectional study. *Andrology*. 2017;5(4):783–789.

Han SW, Lee T, Kim JH, et al. Pathological difference between retractile and cryptorchid testes. *J Urol*. 1999;162(3 Pt 1):878–880.

Handa R, Kale R, Harjai MM. Laparoscopic orchiopexy: is closure of the internal ring necessary? *J Postgrad Med*. 2005;51(4):266–267 [discussion 268].

Hanley NA, Ball SG, Clement-Jones M, et al. Expression of steroidogenic factor 1 and Wilms' tumour 1 during early human gonadal development and sex determination. *Mech Dev*. 1999;87(1–2):175–180.

Harisis GN, Lewis AG, Southwell BR, et al. Hoxa-11 maintains cell proliferation in the mouse gubernaculum to facilitate testicular descent. *J Pediatr Surg*. 2013;48(12):2431–2436.

Harnaen EJ, Na AF, Shenker NS, et al. The anatomy of the cremaster muscle during inguinoscrotal testicular descent in the rat. *J Pediatr Surg*. 2007;42(12):1982–1987.

Hartigan S, Tasian GE. Unnecessary diagnostic imaging: a review of the literature on preoperative imaging for boys with undescended testes. *Transl Androl Urol*. 2014;3(4):359–364.

Hauser R, Skakkebaek NE, Hass U, et al. Male reproductive disorders, diseases, and costs of exposure to endocrine-disrupting chemicals in the European Union. *J Clin Endocrinol Metab*. 2015;100(4):1267–1277.

Hay SA, Soliman HA, Abdel Rahman AH, et al. Laparoscopic classification and treatment of the impalpable testis. *Pediatr Surg Int*. 1999;15(8):570–572.

Heath AL, Man DW, Eckstein HB. Epididymal abnormalities associated with maldescent of the testis. *J Pediatr Surg*. 1984;19(1):47–49.

Hedlinger E. Histopathology of undescended testes. *Eur J Pediatr*. 1982;139(4):266–271.

Heger NE, Hall SJ, Sandrof MA, et al. Human fetal testis xenografts are resistant to phthalate-induced endocrine disruption. *Environ Health Perspect*. 2012;120(8):1137–1143.

Heikkila J, Taskinen S, Toppari J, et al. Posterior urethral valves are often associated with cryptorchidism and inguinal hernias. *J Urol*. 2008;180(2):715–717.

Henna MR, Del Nero RG, Sampaio CZ, et al. Hormonal cryptorchidism therapy: systematic review with metanalysis of randomized clinical trials. *Pediatr Surg Int*. 2004;20(5):357–359.

Hensel KO, Wirth S. Undescended testis guideline—is it being implemented in practice? *Dtsch Arztebl Int*. 2014;111(39):647–648.

Hermann BP, Sukhwani M, Hansel MC, et al. Spermatogonial stem cells in higher primates: are there differences from those in rodents? *Reproduction*. 2010;139(3):479–493.

Herzog B, Steigert M, Hadziselimovic F. Is a testis located at the superficial inguinal pouch (Denis Browne pouch) comparable to a true cryptorchid testis? *J Urol*. 1992;148(2 Pt 2):622–623.

Heyns CF. The gubernaculum during testicular descent in the human fetus. *J Anat*. 1987;153:93–112.

Hildorf S, Clasen-Linde E, Dong L, et al. Impaired serum inhibin-B and number of germ cells in boys with cryptorchidism following heavily gestational maternal smoking. *J Pediatr Surg*. 2019;54(4):809–814.

Hill SJ, Durham MM. Management of cryptorchidism and gastroschisis. *J Pediatr Surg*. 2011;46(9):1798–1803.

Hodhod A, Capolicchio JP, Jednak R, et al. Testicular hypertrophy as a predictor for contralateral monorchism: retrospective review of prospectively recorded data. *J Pediatr Urol*. 2016;12(1):34.e1–34.e5.

Hoei-Hansen CE, Almstrup K, Nielsen JE, et al. Stem cell pluripotency factor NANOG is expressed in human fetal gonocytes, testicular carcinoma in situ and germ cell tumours. *Histopathology*. 2005;47(1):48–56.

Honecker F, Stoop H, de Krijger RR, et al. Pathobiological implications of the expression of markers of testicular carcinoma in situ by fetal germ cells. *J Pathol*. 2004;203(3):849–857.

Howdeshell KL, Hotchkiss AK, Gray LE Jr. Cumulative effects of antiandrogenic chemical mixtures and their relevance to human health risk assessment. *Int J Hyg Environ Health*. 2017;220(2 Pt A):179–188.

Hsieh-Li HM, Witte DP, Weinstein M, et al. Hoxa 11 structure, extensive antisense transcription, and function in male and female fertility. *Development*. 1995;121(5):1373–1385.

Hsieh MH, Bayne A, Cisek LJ, et al. Bladder injuries during laparoscopic orchiopexy: incidence and lessons learned. *J Urol*. 2009;182(1):280–284 [discussion 284–285].

Huff DS, Hadziselimovic F, Snyder HM 3rd, et al. Postnatal testicular maldevelopment in unilateral cryptorchidism. *J Urol*. 1989;142(2 Pt 2):546–548 [discussion 572].

Huff DS, Snyder HM 3rd, Hadziselimovic F, et al. An absent testis is associated with contralateral testicular hypertrophy. *J Urol*. 1992;148(2 Pt 2):627–628.

Huff DS, Fenig DM, Canning DA, et al. Abnormal germ cell development in cryptorchidism. *Horm Res*. 2001;55(1):11–17.

Huff DS, Snyder HM 3rd, Rusnack SL, et al. Hormonal therapy for the subfertility of cryptorchidism. *Horm Res*. 2001;55(1):38–40.

Hurtado-Gonzalez P, Mitchell RT. Analgesic use in pregnancy and male reproductive development. *Curr Opin Endocrinol Diabetes Obes*. 2017;24(3):225–232.

Husmann DA. Cryptorchidism and its relationship to testicular neoplasia and microlithiasis. *Urology*. 2005;66(2):424–426.

Hutcheson JC, Cooper CS, Snyder HM 3rd. The anatomical approach to inguinal orchiopexy. *J Urol*. 2000;164(5):1702–1704.

Hutcheson JC, Snyder HM 3rd, Zuniga ZV, et al. Ectopic and undescended testes:2 variants of a single congenital anomaly? *J Urol*. 2000;163(3):961–963.

Hutson JM. A biphasic model for the hormonal control of testicular descent. *Lancet*. 1985;2(8452):419–421.

Hutson JM, Hasthorpe S. Abnormalities of testicular descent. *Cell Tissue Res*. 2005;322(1):155–158.

Hutson JM, Lopez-Marambio FA. The possible role of AMH in shortening the gubernacular cord in testicular descent: a reappraisal of the evidence. *J Pediatr Surg*. 2017;52(10):1656–1660.

Hutson JM, Li R, Southwell BR, et al. Germ cell development in the postnatal testis: the key to prevent malignancy in cryptorchidism? *Front Endocrinol (Lausanne)*. 2012;3:176.

Hutson JM, Southwell BR, Li R, et al. The regulation of testicular descent and the effects of cryptorchidism. *Endocr Rev*. 2013;34(5):725–752.

Hutson JM, Li R, Vikraman J, et al. What animal models of testicular descent and germ cell maturation tell us about the mechanism in humans. *Eur J Pediatr Surg*. 2016;26(5):390–398.

Inan M, Aydiner CY, Tokuc B, et al. Prevalence of cryptorchidism, retractile testis and orchiopexy in school children. *Urol Int*. 2008;80(2):166–171.

Irkilata HC, Yildirim I, Onguru O, et al. The influence of orchiopexy on serum inhibin B level: relationship with histology. *J Urol*. 2004;172(6 Pt 1):2402–2405 [discussion 2405].

Itesako T, Nara K, Matsui F, et al. Acquired undescended testes in boys with hypospadias. *J Urol*. 2011;185(6 Suppl):2440–

2443.

Ivell R, Anand-Ivell R, Morley SD. Endocrinology of the fetal testis. Simoni M, Huhtaniemi IT. *Endocrinology of the testis and male reproduction*. Springer International Publishing: Switzerland; 2016:245–272.

Iyer KR, Kumar V, Huddart SN, et al. The scrotal approach. *Pediatr Surg Int*. 1995;10(1):58–60.

Jain VG, Singal AK. Shorter anogenital distance correlates with undescended testis: a detailed genital anthropometric analysis in human newborns. *Hum Reprod*. 2013;28(9):2343–2349.

Jawad AJ. High scrotal orchidopexy for palpable maldescended testes. *Br J Urol*. 1997;80(2):331–333.

Jensen MS, Bonde JP, Olsen J. Prenatal alcohol exposure and cryptorchidism. *Acta Paediatr*. 2007;96(11):1681–1685.

Jensen MS, Rebordosa C, Thulstrup AM, et al. Maternal use of acetaminophen, ibuprofen, and acetylsalicylic acid during pregnancy and risk of cryptorchidism. *Epidemiology*. 2010;21(6):779–785.

Jensen MS, Toft G, Thulstrup AM, et al. Cryptorchidism concordance in monozygotic and dizygotic twin brothers, full brothers, and half-brothers. *Fertil Steril*. 2010;93(1):124–129.

Jensen MS, Olsen LH, Thulstrup AM, et al. Age at cryptorchidism diagnosis and orchiopexy in Denmark: a population based study of 508,964 boys born from 1995 to 2009. *J Urol*. 2011;186(4 Suppl):1595–1600.

Jensen MS, Wilcox AJ, Olsen J, et al. Cryptorchidism and hypospadias in a cohort of 934,538 Danish boys: the role of birth weight, gestational age, body dimensions, and fetal growth. *Am J Epidemiol*. 2012;175(9):917–925.

Johnson KJ, Robbins AK, Wang Y, et al. Insulin-like 3 exposure of the fetal rat gubernaculum modulates expression of genes involved in neural pathways. *Biol Reprod*. 2010;83(5):774–782.

Jones BC, Hutson JM. The syndrome of Spigelian hernia and cryptorchidism: a review of paediatric literature. *J Pediatr Surg*. 2015;50(2):325–330.

Jones IR, Young ID. Familial incidence of cryptorchidism. *J Urol*. 1982;127(3):508–509.

Jones PF, Bagley FH. An abdominal extraperitoneal approach for the difficult orchidopexy. *Br J Surg*. 1979;66(1):14–18.

Jordan GH, Winslow BH. Laparoscopic single stage and staged orchiopexy. *J Urol*. 1994;152(4):1249–1252.

Jorgensen KT, Jensen MS, Toft GV, et al. Hougaard. Risk of cryptorchidism and hypospadias among boys of maternal hairdressers—a Danish population-based cohort study. *Scand J Work Environ Health*. 2013;39(3):302–309.

Jorgensen KT, Jensen MS, Toft GV, et al. Risk of cryptorchidism among sons of horticultural workers and farmers in Denmark. *Scand J Work Environ Health*. 2014;40(3):323–330.

Jorgensen N, Joensen UN, Toppari J, et al. Compensated reduction in Leydig cell function is associated with lower semen quality variables: a study of 8182 European young men. *Hum Reprod*. 2016;31(5):947–957.

Jorgez CJ, Rosenfeld JA, Wilken NR, et al. Genitourinary defects associated with genomic deletions in 2p15 encompassing OTX1. *PLoS ONE*. 2014;9(9):e107028.

Josso N, Picard JY, Rey R, et al. Testicular anti-Mullerian hormone: history, genetics, regulation and clinical applications. *Pediatr Endocrinol Rev*. 2006;3(4):347–358.

Kaftanovskaya EM, Feng S, Huang Z, et al. Suppression of insulin-like3 receptor reveals the role of beta-catenin and Notch signaling in gubernaculum development. *Mol Endocrinol*. 2011;25(1):170–183.

Kaftanovskaya EM, Huang Z, Barbara AM, et al. Cryptorchidism in mice with an androgen receptor ablation in gubernaculum testis. *Mol Endocrinol*. 2012;26(4):598–607.

Kaftanovskaya EM, Neukirchner G, Huff V, et al. Left-sided cryptorchidism in mice with Wilms' tumour 1 gene deletion in gubernaculum testis. *J Pathol*. 2013;230(1):39–47.

Kaftanovskaya EM, Lopez C, Ferguson L, et al. Genetic ablation of androgen receptor signaling in fetal Leydig cell lineage affects Leydig cell functions in adult testis. *FASEB J*. 2015;29(6):2327–2337.

Kanaroglou N, To T, Zhu J, et al. Inappropriate use of ultrasound in management of pediatric cryptorchidism. *Pediatrics*. 2015;136(3):479–486.

Kanetsky PA, Mitra N, Vardhanabhuti S, et al. Common variation in KITLG and at 5q31.3 predisposes to testicular germ cell cancer. *Nat Genet*. 2009;41(7):811–815.

Kaplan LM, Koyle MA, Kaplan GW, et al. Association between abdominal wall defects and cryptorchidism. *J Urol*. 1986;136(3):645–647.

Karaman A, Karaman I, Yilmaz E, et al. Complete urogenital nonunion. *J Pediatr Surg*. 2011;46(12):e17–e18.

Kashimada K, Koopman P. Sry: the master switch in mammalian sex determination. *Development*. 2010;137(23):3921–3930.

Kaye JD, Palmer LS. Single setting bilateral laparoscopic orchiopexy for bilateral intra-abdominal testicles. *J Urol*. 2008;180(4 Suppl):1795–1799 [discussion 1799].

Kehoe JE, Christman MS. To 'Pex or not to 'Pex: what to do for the contralateral testis when a nubbin is discovered. *Curr Urol Rep*. 2017;18(2):9.

Keys C, Heloury Y. Retractile testes: a review of the current literature. *J Pediatr Urol*. 2012;8(1):2–6.

Khairat AB, Ismail AM. Splenogonadal fusion: case presentation and literature review. *J Pediatr Surg*. 2005;40(8):1357–1360.

Khairi A, Shehata S, El-Kholi N. Is it necessary to close the peritoneum over the deep inguinal ring during laparoscopic orchidopexy? *J Pediatr Urol*. 2013;9(2):157–160.

Khedis M, Nohra J, Dierickx L, et al. Polyorchidism: presentation of 2 cases, review of the literature and a new management strategy. *Urol Int*. 2008;80(1):98–101.

Kilcoyne KR, Smith LB, Atanassova N, et al. Fetal programming of adult Leydig cell function by androgenic effects on stem/progenitor cells. *Proc Natl Acad Sci USA*. 2014;111(18):E1924–E1932.

Kim C, Bennett N, Docimo SG. Missed testis on laparoscopy despite blind-ending vessels and closed processus vaginalis. *Urology*. 2005;65(6):1226.

Kirsch AJ, Escala J, Duckett JW, et al. Surgical management of the nonpalpable testis: the Children's Hospital of Philadelphia experience. *J Urol*. 1998;159(4):1340–1343.

Kjersgaard C, Arendt LH, Ernst A, et al. Lifestyle in pregnancy and cryptorchidism in sons: a study within two large Danish birth cohorts. *Clin Epidemiol*. 2018;10:311–322.

Koff SA. Does compensatory testicular enlargement predict monorchism? *J Urol*. 1991;146(2 Pt 2):632–633.

Koff SA, Sethi PS. Treatment of high undescended testes by low spermatic vessel ligation: an alternative to the Fowler-Stephens technique. *J Urol*. 1996;156(2 Pt 2):799–803 [discussion 803].

Koivusalo A, Taskinen S, Rintala RJ. Cryptorchidism in boys with congenital abdominal wall defects. *Pediatr Surg Int*. 1998;13(2–3):143–145.

Kokorowski PJ, Routh JC, Graham DA, et al. Variations in timing of surgery among boys who underwent orchidopexy for cryptorchidism. *Pediatrics*. 2010;126(3):e576–e582.

Kollin C, Hesser U, Ritzen EM, et al. Testicular growth from birth to two years of age, and the effect of orchidopexy at age nine months: a randomized, controlled study. *Acta Paediatr*. 2006;95(3):318–324.

Kollin C, Karpe B, Hesser U, et al. Surgical treatment of unilaterally undescended testes: testicular growth after randomization to orchiopexy at age 9 months or 3 years. *J Urol*. 2007;178(4 Pt 2):1589–1593 [discussion 1593].

Kollin C, Stukenborg JB, Nurmio M, et al. Boys with undescended testes: endocrine, volumetric and morphometric studies on testicular function before and after orchidopexy at nine months or three years of age. *J Clin Endocrinol Metab*. 2012;97(12):4588–4595.

Kollin C, Granholm T, Nordenskjold A, et al. Growth of spontaneously descended and surgically treated testes during early childhood. *Pediatrics*. 2013;131(4):e1174–e1180.

Kolon TF, Wiener JS, Lewitton M, et al. Analysis of homeobox gene HOXA10 mutations in cryptorchidism. *J Urol*. 1999;161(1):275–280.

Kolon TF, Herndon CD, Baker LA, et al. American Urological Association. Evaluation and treatment of cryptorchidism: AUA guideline. *J Urol*. 2014;192(2):337–345.

Kosfeld A, Brand F, Weiss AC, et al. Mutations in the leukemia inhibitory factor receptor (LIFR) gene and Lifr deficiency cause urinary tract malformations. *Hum Mol Genet*. 2017;26(9):1716–1731.

Koskenniemi JJ, Virtanen HE, Kiviranta H, et al. Association between levels of persistent organic pollutants in adipose tissue and cryptorchidism in early childhood: a case-control study. *Environ Health*. 2015;14:78.

Koskimies P, Suvanto M, Nokkala E, et al. Female mice carrying a ubiquitin promoter-Insl3 transgene have descended ovaries and inguinal hernias but normal fertility. *Mol Cell Endocrinol*. 2003;206(1–2):159–166.

Kraft KH, Mucksavage P, Canning DA, et al. Histological findings in patients with cryptorchidism and testis-epididymis nonfusion. *J Urol*. 2011;186(5):2045–2049.

Kraft KH, Canning DA, Snyder HM 3rd, et al. Undescended testis histology correlation with adult hormone levels and semen analysis. *J Urol*. 2012;188(4 Suppl):1429–1435.

Krishnaswami S, Fonnesbeck C, Penson D, et al. Magnetic resonance imaging for locating nonpalpable undescended testicles: a meta-analysis. *Pediatrics*. 2013;131(6):e1908–e1916.

Kristensen DM, Hass U, Lesne L, et al. Intrauterine exposure to mild analgesics is a risk factor for development of male reproductive disorders in human and rat. *Hum Reprod*. 2011;26(1):235–244.

Krueger RP, Hardy BE, Churchill BM. Cryptorchidism in boys with posterior urethral valves. *J Urol*. 1980;124(1):101–102.

Kubota Y, Temelcos C, Bathgate RA, et al. The role of insulin 3, testosterone, Mullerian inhibiting substance and relaxin in rat gubernacular growth. *Mol Hum Reprod*. 2002;8(10):900–905.

Kuijper EA, van Kooten J, Verbeke JI, et al. Ultrasonographically measured testicular volumes in 0- to 6-year-old boys. *Hum Reprod*. 2008;23(4):792–796.

Kuiri-Hanninen T, Seuri R, Tyrvainen E, et al. Increased activity of the hypothalamic-pituitary-testicular axis in infancy results in increased androgen action in premature boys. *J Clin Endocrinol Metab*. 2011;96(1):98–105.

Kumar B, Sharma C, Sinha DD. Supernumerary testis: a case report and review of literature. *J Pediatr Surg*. 2008;43(6):E9–E10.

Kvist K, Clasen-Linde E, Cortes D, et al. Adult immunohistochemical markers fail to detect intratubular germ cell neoplasia in prepubertal boys with cryptorchidism. *J Urol*. 2014;191(4):1084–1089.

Kvist K, Clasen-Linde E, Langballe O, et al. The expression of markers for intratubular germ cell neoplasia in normal infantile testes. *Front Endocrinol (Lausanne)*. 2018;9:286.

La Scala GC, Ein SH. Retractile testes: an outcome analysis on 150 patients. *J Pediatr Surg*. 2004;39(7):1014–1017.

Lackgren G, Ploen L. The morphology of the human undescended testis with special reference to the Sertoli cell and puberty. *Int J Androl*. 1984;7(1):23–38.

Lahoud MH, Ristevski S, Venter DJ, et al. Gene targeting of Desrt, a novel ARID class DNA-binding protein, causes growth retardation and abnormal development of reproductive organs. *Genome Res*. 2001;11(8):1327–1334.

Laitinen EM, Tommiska J, Virtanen HE, et al. Isolated cryptorchidism: no evidence for involvement of genes underlying isolated hypogonadotropic hypogonadism. *Mol Cell Endocrinol*. 2011;341(1–2):35–38.

Lambrot R, Muczynski V, Lecureuil C, et al. Phthalates impair germ cell development in the human fetal testis in vitro without change in testosterone production. *Environ Health Perspect*. 2009;117(1):32–37.

Lee PA. Appropriate use and interpretation of human chorionic gonadotropin stimulation in prepubertal male patients. *Endocr Pract*. 2000;6(1):112–114.

Lee PA. Fertility after cryptorchidism: epidemiology and other outcome studies. *Urology*. 2005;66(2):427–431.

Lee PA, Coughlin MT. Fertility after bilateral cryptorchidism. Evaluation by paternity, hormone, and semen data. *Horm Res*. 2001;55(1):28–32.

Lee PA, Coughlin MT. The single testis: paternity after presentation as unilateral cryptorchidism. *J Urol*. 2002;168(4 Pt 2):1680–1682 [discussion 1682–1683].

Lee PA, O'Leary LA, Songer NJ, et al. Paternity after unilateral cryptorchidism: a controlled study. *Pediatrics*. 1996;98(4 Pt 1):676–679.

Lee PA, O'Leary LA, Songer NJ, et al. Paternity after bilateral cryptorchidism. a controlled study. *Arch Pediatr Adolesc Med*. 1997;151(3):260–263.

Lee PA, Coughlin MT, Bellinger MF. Paternity and hormone levels after unilateral cryptorchidism: association with pretreatment testicular location. *J Urol*. 2000;164(5):1697–1701.

Lee MM, Misra M, Donahoe PK, et al. MIS/AMH in the assessment of cryptorchidism and intersex conditions. *Mol Cell Endocrinol*. 2003;211(1–2):91–98.

Lemeh CN. A study of the development and structural relationships of the testis and guernaculum. *Surg Gynecol Obstet*. 1960;110:164–172.

Li R, Vannitamby A, Meijer J, et al. Postnatal germ cell development during mini-puberty in the mouse does not require androgen receptor: implications for managing cryptorchidism. *J Urol*. 2015;193(4):1361–1367.

Li T, Gao L, Chen P, et al. A systematic review and meta-analysis of comparative studies assessing the efficacy of luteinizing hormone-releasing hormone therapy for children with cryptorchidism. *Int Urol Nephrol*. 2016;48(5):635–644.

Lin CS, Lazarowicz JL, Allan RW, et al. Splenogonadal fusion. *J Urol*. 2010;184(1):332–333.

Lind DV, Main KM, Kyhl HB, et al. Maternal use of mild analgesics during pregnancy associated with reduced anogenital distance in sons: a cohort study of 1027 mother-child pairs. *Hum Reprod*. 2017;32(1):223–231.

Litchfield K, Loveday C, Levy M, et al. Large-scale sequencing of testicular germ cell tumour (TGCT) cases excludes major TGCT predisposition gene. *Eur Urol*. 2018;73(6):828–831.

Lo Giacco D, Ars E, Bassas L, et al. ESR1 promoter polymorphism is not associated with nonsyndromic cryptorchidism. *Fertil Steril*. 2011;95(1):369–371 [371.e1–

371.e2].

Loder RT, Guiboux JP, Bloom DA, et al. Musculoskeletal aspects of prune-belly syndrome. Description and pathogenesis. *Am J Dis Child*. 1992;146(10):1224–1229.

Lotan G, Klin B, Efrati Y, et al. Laparoscopic evaluation and management of nonpalpable testis in children. *World J Surg*. 2001;25(12):1542–1545.

Lustig RH, Conte FA, Kogan BA, et al. Ontogeny of gonadotropin secretion in congenital anorchism: sexual dimorphism versus syndrome of gonadal dysgenesis and diagnostic considerations. *J Urol*. 1987;138(3):587–591.

Lymperi S, Giwercman A. Endocrine disruptors and testicular function. *Metabolism*. 2018;86:79–90.

Main KM, Mortensen GK, Kaleva MM, et al. Human breast milk contamination with phthalates and alterations of endogenous reproductive hormones in infants three months of age. *Environ Health Perspect*. 2006;114:270–276.

Main KM, Toppari J, Suomi AM, et al. Larger testes and higher inhibin B levels in Finnish than in Danish newborn boys. *J Clin Endocrinol Metab*. 2006;91(7):2732–2737.

Main KM, Kiviranta H, Virtanen HE, et al. Flame retardants in placenta and breast milk and cryptorchidism in newborn boys. *Environ Health Perspect*. 2007;115(10):1519–1526.

Mamoulakis C, Georgiou I, Dimitriadis F, et al. Screening for Y chromosome microdeletions in childhood: lack of evidence for a direct association with testicular maldescent. *Andrologia*. 2013;45(6):409–416.

Mamoulakis C, Sofikitis N, Tsounapi P, et al. Georgiou. The (TAAAA)n polymorphism of sex hormone-binding globulin gene is not associated with testicular maldescent. *Andrologia*. 2013;45(1):40–45.

Mamsen LS, Ernst EH, Borup R, et al. Temporal expression pattern of genes during the period of sex differentiation in human embryonic gonads. *Sci Rep*. 2017;7(1):15961.

Mancini RE, Rosemberg E, Cullen M, et al. Cryptorchid and scrotal human testes. I. cytological, cytochemical and quantitative studies. *J Clin Endocrinol Metab*. 1965;25:927–942.

Manku G, Culty M. Mammalian gonocyte and spermatogonia differentiation: recent advances and remaining challenges. *Reproduction*. 2015;149(3):R139–R157.

Marshall FF, Shermeta DW. Epididymal abnormalities associated with undescended testis. *J Urol*. 1979;121(3):341–343.

Martin AD, Rushton HG. The prevalence of bell clapper anomaly in the solitary testis in cases of prior perinatal torsion. *J Urol*. 2014;191(5 Suppl):1573–1577.

Martin LJ. Cell interactions and genetic regulation that contribute to testicular Leydig cell development and differentiation. *Mol Reprod Dev*. 2016;83(6):470–487.

Masliukaite I, Hagen JM, Jahnukainen K, et al. Establishing reference values for age-related spermatogonial quantity in prepubertal human testes: a systematic review and meta-analysis. *Fertil Steril*. 2016;106(7) [1652.e2–1657.e2].

Mavrogenis S, Urban R, Czeizel AE. Ac N s. Possible association of maternal factors with the higher risk of isolated true undescended testis: a population-based case-control study. *Congenit Anom (Kyoto)*. 2014;54(3):178–183.

Mazaud-Guittot S, Nicolaz CN, Desdoits-Lethimonier C, et al. Paracetamol, aspirin, and indomethacin induce endocrine disturbances in the human fetal testis capable of interfering with testicular descent. *J Clin Endocrinol Metab*. 2013;98(11):E1757–E1767.

McAleer IM, Packer MG, Kaplan GW, et al. Fertility index analysis in cryptorchidism. *J Urol*. 1995;153(4):1255–1258.

McCarrey JR. Toward a more precise and informative nomenclature describing fetal and neonatal male germ cells in rodents. *Biol Reprod*. 2013;89(2):47.

McClelland K, Bowles J, Koopman P. Male sex determination: insights into molecular mechanisms. *Asian J Androl*. 2012;14(1):164–171.

McGlynn KA, Cook MB. Etiologic factors in testicular germ-cell tumors. *Future Oncol*. 2009;5(9):1389–1402.

McIntosh LA, Scrimgeour D, Youngson GG, et al. The risk of failure after primary orchidopexy: an 18 year review. *J Pediatr Urol*. 2013;9(6 Pt A):759–762.

McKinnell C, Sharpe RM, Mahood K, et al. Expression of insulin-like factor 3 protein in the rat testis during fetal and postnatal development and in relation to cryptorchidism induced by in utero exposure to di (n-Butyl) phthalate. *Endocrinology*. 2005;146(10):4536–4544.

McPherson F, Frias JL, Spicer D, et al. Splenogonadal fusion-limb defect “syndrome” and associated malformations. *Am J Med Genet A*. 2003;120A(4):518–522.

Mechlin CW, Kogan BA. What lessons can be learned from testicular histology in undescended testes? *Transl Androl Urol*. 2014;3(4):365–369.

Mecklenburg JM, Hermann BP. Mechanisms regulating spermatogonial differentiation. *Results Probl Cell Differ*. 2016;58:253–287.

Meij-de Vries A, den Bakker FM, van der Wolf-de Lijster FS, et al. High prevalence of intratesticular varicocele in a post-orchidopexy cohort. *J Pediatr Urol*. 2013;9(3):328–333.

Merksz M, Tóth J. Testicular-epididymal fusion abnormality in undescended testis. *Int Urol Nephrol*. 1987;19(2):179–187.

Merlet J, Racine C, Moreau E, et al. Male fetal germ cells are targets for androgens that physiologically inhibit their proliferation. *Proc Natl Acad Sci USA*. 2007;104(9):3615–3620.

Mesrobian HG, Chassaignac JM, Laud PW. The presence or absence of an impalpable testis can be predicted from clinical observations alone. *BJU Int*. 2002;90(1):97–99.

Metin A, Kayigil O, Ahmed SI. The efficacy of human chorionic gonadotropin in retractile testis. *Neuro Endocrinol Lett*. 2005;26(1):39–42.

Miller OF, Stock JA, Cilento BG, et al. Prospective evaluation of human chorionic gonadotropin in the differentiation of undescended testes from retractile testes. *J Urol*. 2003;169(6):2328–2331.

Minehan T, Touloukian R. Letter: cryptorchidism in siblings. *Pediatrics*. 1974;53(5):770.

Misra D, Dias R, Kapila L. Scrotal fixation: a different surgical approach in the management of the low undescended testes. *Urology*. 1997;49(5):762–765.

Mitchell RT, Childs AJ, Anderson RA, et al. Do phthalates affect steroidogenesis by the human fetal testis? Exposure of human fetal testis xenografts to di-n-butyl phthalate. *J Clin Endocrinol Metab*. 2012;97(3):E341–E348.

Mittal D, Agarwala S, Yadav DK, et al. Testicular Tumors in Undescended Testes in Children Below 5 y of Age. *Indian J Pediatr*. 2015;82(6):549–552.

Mohta A, Jain N, Irniraya KP, et al. Non-ligation of the hernial sac during herniotomy: a prospective study. *Pediatr Surg Int*. 2003;19(6):451–452.

Mollaeian M, Mehrabi V, Elahi B. Significance of epididymal and ductal anomalies associated with undescended testis: study in 652 cases. *Urology*. 1994;43(6):857–860.

Moller H, Cortes D, Engholm G, et al. Risk of testicular cancer with cryptorchidism and with testicular biopsy: cohort study. *BMJ*. 1998;317(7160):729.

Mongraw-Chaffin ML, Cohn BA, Cohen RD, et al. Maternal smoking, alcohol consumption, and caffeine consumption during pregnancy in relation to a son's risk of persistent cryptorchidism: a prospective study in the Child Health and Development Studies cohort, 1959–1967. *Am J Epidemiol*. 2008;167(3):257–261.

Moore RG, Peters CA, Bauer SB, et al. Laparoscopic evaluation of the nonpalpable tests: a prospective assessment of accuracy. *J Urol*. 1994;151(3):728–731.

Morales-Suarez-Varela MM, Toft GV, Jensen MS, et al. Parental occupational exposure to endocrine disrupting chemicals and male genital malformations: a study in the Danish National Birth Cohort study. *Environ Health*. 2011;10(1):3.

Moreno-Garcia M, Miranda EB. Chromosomal anomalies in cryptorchidism and hypospadias. *J Urol*. 2002;168(5):2170–2172 [discussion 2172].

Moul JW, Belman B. A review of surgical treatment of undescended testes with emphasis on anatomical position. *J Urol*. 1988;140(1):125–128.

Myers NA, Officer CB. Undescended testis: congenital or acquired? *Aust Paediatr J*. 1975;11(2):76–80.

Nah SA, Yeo CS, How GY, et al. Undescended testis: 513 patients' characteristics, age at orchidopexy and patterns of referral. *Arch Dis Child*. 2014;99(5):401–406.

Nef S, Parada LF. Cryptorchidism in mice mutant for Insl3. *Nat Genet*. 1999;22(3):295–299.

Niikura H, Okamoto S, Nagase S, et al. Fetal development of the human gubernaculum with special reference to the fasciae and muscles around it. *Clin Anat*. 2008;21(6):547–557.

Nijs SM, Eijsbouts SW, Madern GC, et al. Nonpalpable testes: is there a relationship between ultrasonographic and operative findings? *Pediatr Radiol*. 2007;37(4):374–379.

Nistal M, Paniagua R. Infertility in adult males with retractile testes. *Fertil Steril*. 1984;41(3):395–403.

Nistal M, Mate A, Paniagua R. Cystic transformation of the rete testis. *Am J Surg Pathol*. 1996;20(10):1231–1239.

Noh PH, Cooper CS, Snyder HM 3rd, et al. Testicular volume does not predict germ cell count in patients with cryptorchidism. *J Urol*. 2000;163(2):593–596.

Novaes HF, Carneiro Neto JA, Macedo A Jr, et al. Single scrotal incision orchiopexy - a systematic review. *Int Braz J Urol*. 2013;39(3):305–311.

N'Tumba-Byn T, Moison D, Lacroix M, et al. Differential effects of bisphenol a and diethylstilbestrol on human, rat and mouse fetal leydig cell function. *PLoS ONE*. 2012;7(12):e51579.

Nuti F, Marinari E, Erdei E, et al. The leucine-rich repeat-containing G protein-coupled receptor 8 gene T222P mutation does not cause cryptorchidism. *J Clin Endocrinol Metab*. 2008;93(3):1072–1076.

Oatley MJ, Racicot KE, Oatley JM. Sertoli cells dictate spermatogonial stem cell niches in the mouse testis. *Biol Reprod*. 2011;84(4):639–645.

Okuyama A, Nonomura N, Nakamura M, et al. Surgical management of undescended testis: retrospective study of potential fertility in 274 cases. *J Urol*. 1989;142(3):749–751.

Olesen IA, Andersson AM, Aksglaede L, et al. Clinical, genetic, biochemical, and testicular biopsy findings among 1,213 men evaluated for infertility. *Fertil Steril*. 2017;107(1) [74.e7–82.e7].

Olsen LH. Inter-observer variation in assessment of undescended testis. Analysis of kappa statistics as a coefficient of reliability. *Br J Urol*. 1989;64(6):644–648.

Ong C, Hasthorpe S, Hutson JM. Germ cell development in the descended and cryptorchid testis and the effects of hormonal manipulation. *Pediatr Surg Int*. 2005;21(4):240–254.

Ortega-Garcia JA, Olano-Soler HA, Martinez-Alvarez A, et al. Breastfeeding duration and anogenital distance in 2-year-old infants. *Breastfeed Med*. 2016;11:350–355.

Orth JM, Jester WF, Li LH, et al. Gonocyte-Sertoli cell interactions during development of the neonatal rodent testis. *Curr Top Dev Biol*. 2000;50:103–124.

Orvis BR, Bottles K, Kogan BA. Testicular histology in fetuses with the prune belly syndrome and posterior urethral valves. *J Urol*. 1988;139(2):335–337.

O'Shaughnessy PJ, Baker PJ, Monteiro A, et al. Developmental changes in human fetal testicular cell numbers and messenger ribonucleic acid levels during the second trimester. *J Clin Endocrinol Metab*. 2007;92(12):4792–4801.

Oshio S, Ashizawa Y, Yotsukura M, et al. Individual variation in semen parameters of healthy young volunteers. *Arch Androl*. 2004;50(6):417–425.

Osterballe L, Clasen-Linde E, Cortes D, et al. The diagnostic impact of testicular biopsies for intratubular germ cell neoplasia in cryptorchid boys and the subsequent risk of testicular cancer in men with prepubertal surgery for syndromic or non-syndromic cryptorchidism. *J Pediatr Surg*. 2017;52(4):587–592.

Ostlie DJ, Leys CM, Fraser JD, et al. Laparoscopic orchiopexy requiring vascular division: a randomized study comparing the primary and two-stage approaches. *J Laparoendosc Adv Surg Tech A*. 2015;25(6):536–539.

Ostrer H, Huang HY, Masch RJ, et al. Acellular study of human testis development. *Sex Dev*. 2007;1(5):286–292.

Overbeek PA, Gorlov IP, Sutherland RW, et al. Atransgenic insertion causing cryptorchidism in mice. *Genesis*. 2001;30(1):26–35.

Paasch U, Thieme C, Grunewald S, et al. Electronic data base systems support the evaluation of male infertility factors, example cryptorchidism. *Urol Int*. 2004;72(2):154–161.

Pacenza N, Pasqualini T, Gottlieb S, et al. Clinical presentation of Klinefelter's syndrome: differences according to age. *Int J Endocrinol*. 2012;2012:324835.

Palmer LS, Rastinehad A. Incidence and concurrent laparoscopic repair of intra-abdominal testis and contralateral patent processus vaginalis. *Urology*. 2008;72(2):297–299 [discussion 299].

Palmer JR, Herbst AL, Noller KL, et al. Urogenital abnormalities in men exposed to diethylstilbestrol in utero: a cohort study. *Environ Health*. 2009;8:37.

Pardo-Mindan FJ, Vargas Torcal F, Garcia Julian G, et al. Letter: familial cryptorchidism. *Pediatrics*. 1975;56(4):616.

Parsons JK, Ferrer F, Docimo SG. The low scrotal approach to the ectopic or ascended testicle: prevalence of a patent processus vaginalis. *J Urol*. 2003;169(5):1832–1833 [discussion 1833].

Patel RP, Kolon TF, Huff DS, et al. Testicular microlithiasis and antisperm antibodies following testicular biopsy in boys with cryptorchidism. *J Urol*. 2005;174(5):2008–2010 [discussion 2010].

Patel RP, Kolon TF, Huff D, et al. Cryptorchid testis histopathology in myelomeningocele patients. *J Pediatr Urol*. 2008;4(6):434–437.

Patil KK, Green JS, Duffy PG. Laparoscopy for impalpable testes. *BJU Int*. 2005;95(5):704–708.

Perovic S, Janic N. A short vas deferens limiting successful laparoscopic testicular descent. *Br J Urol*. 1997;79(1):120–121.

Pesce C, d'Agostino S, Costa L, et al. Reoperative orchiopexy: surgical aspects and functional outcome. *Pediatr Surg Int*. 2001;17(1):62–64.

Philibert P, Boizet-Bonhoure B, Bashamboo A, et al. Unilateral cryptorchidism in mice mutant for Ptgds. *Hum Mutat*. 2013;34(2):278–282.

Picard JY, Cate RL, Racine C, et al. The persistent Mullerian duct syndrome: an update based upon a personal experience of 157 cases. *Sex Dev*. 2017;11(3):109–125.

Pierik FH, Burdorf A, Deddens JA, et al. Maternal and paternal risk factors for cryptorchidism and hypospadias: a case-control study in newborn boys. *Environ Health Perspect*. 2004;112(15):1570–1576.

Pierik FH, Deddens JA, Burdorf A, et al. The hypothalamus-pituitary-testis axis in boys during the first six months of life: a comparison of cryptorchidism and hypospadias cases with controls. *Int J Androl*. 2009;32(5):453–461.

Point D, Morley C, Tourchi A, et al. Rural versus urban compliance in the management of cryptorchidism: is there a difference? *Eur J Pediatr*. 2017;176(8):1067–1073.

Polascik TJ, Chan-Tack KM, Jeffs RD, et al. Reappraisal of the role of human chorionic gonadotropin in the diagnosis and treatment of the nonpalpable testis: a 10-year experience. *J Urol*. 1996;156(2 Pt 2):804–806.

Ponchietti R, Grechi G. Fertility in unilateral cryptorchidism: review of 104 cases. *Acta Eur Fertil*. 1986;17(4):277–278.

Potter SS, Branford WW. Evolutionary conservation and tissue-specific processing of Hoxa 11 antisense transcripts. *Mamm Genome*. 1998;9(10):799–806.

Prince FP. The triphasic nature of Leydig cell development in humans, and comments on nomenclature. *J Endocrinol*. 2001;168(2):213–216.

Promm M, Schroder A, Neissner C, et al. Acquired cryptorchidism: more harm than thought? *J Pediatr Urol*. 2016;12(4):236.e1–236.e6.

Puri P, Nixon HH. Bilateral retractile testes—subsequent effects on fertility. *J Pediatr Surg*. 1977;12(4):563–566.

Puri P, O'Donnell B. Semen analysis of patients who had orchidopexy at or after seven years of age. *Lancet*.

1988;2(8619):1051–1052.

Pyorala S, Huttunen NP, Uhari M. A review and meta-analysis of hormonal treatment of cryptorchidism. *J Clin Endocrinol Metab*. 1995;80(9):2795–2799.

Qin XY, Kojima Y, Mizuno K, et al. Association of variants in genes involved in environmental chemical metabolism and risk of cryptorchidism and hypospadias. *J Hum Genet*. 2012;57(7):434–441.

Quigley CA. Editorial: the postnatal gonadotropin and sex steroid surge-insights from the androgen insensitivity syndrome. *J Clin Endocrinol Metab*. 2002;87(1):24–28.

Radmayr C, Oswald J, Schwentner C, et al. Long-term outcome of laparoscopically managed nonpalpable testes. *J Urol*. 2003;170(6 Pt 1):2409–2411.

Radmayr C, Dogan HS, Hoebeke P, et al. Management of undescended testes: European Association of Urology/European Society for Paediatric Urology Guidelines. *J Pediatr Urol*. 2016;12(6):335–343.

Radpour R, Rezaee M, Tavasoly A, et al. Association of long polyglycine tracts (GGN repeats) in exon 1 of the androgen receptor gene with cryptorchidism and penile hypospadias in Iranian patients. *J Androl*. 2007;28(1):164–169.

Raivio T, Toppari J, Kaleva M, et al. Serum androgen bioactivity in cryptorchid and noncryptorchid boys during the postnatal reproductive hormone surge. *J Clin Endocrinol Metab*. 2003;88(6):2597–2599.

Rajfer J, Handelsman DJ, Swerdloff RS, et al. Hormonal therapy of cryptorchidism. Arandomized, double-blind study comparing human chorionic gonadotropin and gonadotropin-releasing hormone. *N Engl J Med*. 1986;314(8):466–470.

Rajimwale A, Brant WO, Koyle MA. High scrotal (Bianchi) single-incision orchidopexy: a “tailored” approach to the palpable undescended testis. *Pediatr Surg Int*.

2004;20(8):618–622.

Rajpert-de Meyts E, Hoei-Hansen CE. From gonocytes to testicular cancer: the role of impaired gonadal development. *Ann N Y Acad Sci*. 2007;1120:168–180.

Rajpert-De Meyts E, Hanstein R, Jorgensen N, et al. Developmental expression of POU5F1 (OCT-3/4) in normal and dysgenetic human gonads. *Hum Reprod*. 2004;19(6):1338–1344.

Rajpert-De Meyts E, McGlynn KA, Okamoto K, et al. Testicular germ cell tumours. *Lancet*. 2016;387(10029):1762–1774.

Rantakokko P, Main KM, Wohlfart-Veje C, et al. Association of placenta organotin concentrations with congenital cryptorchidism and reproductive hormone levels in 280 newborn boys from Denmark and Finland. *Hum Reprod*. 2013;28(6):1647–1660.

Redman JF. Inguinal reoperation for undescended testis and hernia: approach to the spermatic cord through the cremaster fascia. *J Urol*. 2000;164(5):1705–1707.

Redman JF. The ascending (acquired undescended) testis: a phenomenon? *BJU Int*. 2005;95(9):1165–1167.

Regadera J, Martinez-Garcia F, Gonzalez-Peramato P, et al. Androgen receptor expression in sertoli cells as a function of seminiferous tubule maturation in the human cryptorchid testis. *J Clin Endocrinol Metab*. 2001;86(1):413–421.

Renzulli JF 2nd, Shetty R, Mangray S, et al. Clinical and histological significance of the testicular remnant found on inguinal exploration after diagnostic laparoscopy in the absence of a patent processus vaginalis. *J Urol*. 2005;174(4 Pt 2):1584–1586 [discussion 1586].

Rey RA, Musse M, Venara M, et al. Ontogeny of the androgen receptor expression in the fetal and postnatal testis: its relevance on Sertoli cell maturation and the onset of adult spermatogenesis. *Microsc Res Tech*. 2009;72(11):787–795.

Rider CV, Wilson VS, Howdeshell KL, et al. Cumulative effects of in utero administration of mixtures of “antiandrogens” on male rat reproductive development. *Toxicol Pathol*. 2009;37(1):100–113.

Rijli FM, Matyas R, Pellegrini M, et al. Cryptorchidism and homeotic transformations of spinal nerves and vertebrae in Hoxa-10 mutant mice. *Proc Natl Acad Sci USA*. 1995;92(18):8185–8189.

Riquelme M, Aranda A, Rodriguez C, et al. Incidence and management of the inguinal hernia during laparoscopic orchiopexy in palpable cryptoorchidism: preliminary report. *Pediatr Surg Int*. 2007;23(4):301–304.

Riquelme M, Elizondo RA, Aranda A. Palpable undescended testes:15 years of experience and outcome in laparoscopic orchiopexy. *J Endourol*. 2015;29(9):978–982.

Ritzen EM, Bergh A, Bjerknes R, et al. Nordic consensus on treatment of undescended testes. *Acta Paediatr*. 2007;96(5):638–643.

Robbins AK, Mateson AB, Khandha A, et al. Fetal rat gubernaculum mesenchymal cells adopt myogenic and myofibroblast-like phenotypes. *J Urol*. 2016;196(1):270–278.

Robertson SA, Munro FD, Mackinlay GA. Two-stage Fowler-Stephens orchidopexy preserving the gubernacular vessels and a purely laparoscopic second stage. *J Laparoendosc Adv Surg Tech A*. 2007;17(1):101–107.

Rogers E, Teahan S, Gallagher H, et al. The role of orchiectomy in the management of postpubertal cryptorchidism. *J Urol*. 1998;159(3):851–854.

Rohayem J, Luberto A, Nieschlag E, et al. Delayed treatment of undescended testes may promote hypogonadism and infertility. *Endocrine*. 2017;55(3):914–924.

Rosch WH, Schroder A. Commentary to “Prospective study of histological and endocrine parameters of gonadal function in boys with cryptorchidism”. *J Pediatr Urol*. 2016;12(4):239.

Rosito NC, Koff WJ, da Silva Oliveira TL, et al. Volumetric and histological findings in intra-abdominal testes before and after division of spermatic vessels. *J Urol*. 2004;171(6 Pt 1):2430–2433.

Rotem RS, Chodick G, Davidovitch M, et al. Congenital abnormalities of the male reproductive system and risk of autism spectrum disorders. *Am J Epidemiol*. 2018;187(4):656–663.

Rotgers E, Jørgensen A, Yao HH. At the crossroads of fate—somatic cell lineage specification in the fetal gonad. *Endocr Rev*. 2018;39(5):739–759.

Rothschild MF, Christian LL, Blanchard W. Evidence for multigene control of cryptorchidism in swine. *J Hered*. 1988;79(4):313–314.

Rovito MJ, Leone JE, Cavayero CT. “Off-Label” usage of testicular self-examination (TSE): benefits beyond cancer detection. *Am J Mens Health*. 2018;12(3):505–513.

Rozanski TA, Wojno KJ, Bloom DA. The remnant orchiectomy. *J Urol*. 1996;155(2):712–713 [discussion 714].

Rundle JS, Primrose DA, Carachi R. Cryptorchism in cerebral palsy. *Br J Urol*. 1982;54(2):170–171.

Rune GM, Mayr J, Neugebauer H, et al. Pattern of Sertoli cell degeneration in cryptorchid prepubertal testes. *Int J Androl*. 1992;15(1):19–31.

Rusnack SL, Wu HY, Huff DS, et al. The ascending testis and the testis undescended since birth share the same histopathology. *J Urol*. 2002;168(6):2590–2591.

Rusnack SL, Wu HY, Huff DS, et al. Testis histopathology in boys with cryptorchidism correlates with future fertility potential. *J Urol*. 2003;169(2):659–662.

Russinko PJ, Siddiq FM, Tackett LD, et al. Prescrotal orchiopexy: an alternative surgical approach for the palpable undescended testis. *J Urol*. 2003;170(6 Pt 1):2436–2438.

Rzhetsky A, Bagley SC, Wang K, et al. Environmental and state-level regulatory factors affect the incidence of autism and intellectual disability. *PLoS Comput Biol*. 2014;10(3):e1003518.

Samadi AA, Palmer LS, Franco I. Laparoscopic orchiopexy: report of 203 cases with review of diagnosis, operative technique, and lessons learned. *J Endourol*. 2003;17(6):365–368.

Sampaio FJ, Favorito LA. Analysis of testicular migration during the fetal period in humans. *J Urol*. 1998;159(2):540–542.

Sanford LP, Ormsby I, Gittenberger-de Groot AC, et al. TGFbeta2 knockout mice have multiple developmental defects that are non-overlapping with other TGFbeta knockout phenotypes. *Development*. 1997;124(13):2659–2670.

Santamaria L, Martinez-Onsurbe P, Paniagua R, et al. Laminin, type IV collagen, and fibronectin in normal and cryptorchid human testes. An immunohistochemical study. *Int J Androl*. 1990;13(2):135–146.

Sarraj MA, Escalona RM, Umbers A, et al. Fetal testis dysgenesis and compromised Leydig cell function in Tgfbr3 (beta glycan) knockout mice. *Biol Reprod*. 2010;82(1):153–162.

Sasagawa I, Nakada T, Ishigooka M, et al. Chromosomal anomalies in cryptorchidism. *Int Urol Nephrol*. 1996;28(4):99–102.

Sathyanarayana S, Beard L, Zhou C, et al. Measurement and correlates of ano-genital distance in healthy, newborn infants. *Int J Androl*. 2010;33(2):317–323.

Sathyanarayana S, Swan SH, Farin FM, et al. A pilot study of the association between genetic polymorphisms involved in estrogen signaling and infant male genital phenotypes. *Asian J Androl*. 2012;14(5):766–772.

Satokata I, Benson G, Maas R. Sexually dimorphic sterility phenotypes in Hoxa10-deficient mice. *Nature*. 1995;374(6521):460–463.

Savion M, Nissenkorn I, Servadio C, et al. Familial occurrence of undescended testes. *Urology*. 1984;23(3):355–358.

Savoie KB, Bachier-Rodriguez M, Schurtz E, et al. Health disparities in the appropriate management of cryptorchidism. *J Pediatr*. 2017;185 [187.e1–192.e1].

Schier F. An open internal inguinal ring is not an inguinal hernia. *Pediatr Surg Int*. 2007;23(8):825.

Schieve LA, Shapira SK. Invited commentary: male reproductive system congenital malformations and the risk of autism spectrum disorder. *Am J Epidemiol*. 2018;187(4):664–667.

Schindler AM, Diaz P, Cuendet A, et al. Cryptorchidism: a morphological study of 670 biopsies. *Helv Paediatr Acta*. 1987;42(2–3):145–158.

Schnack TH, Zdravkovic S, Myrup C, et al. Familial aggregation of cryptorchidism—a nationwide cohort study. *Am J Epidemiol*. 2008;167(12):1453–1457.

Schneuer FJ, Bower C, Holland AJ, et al. Maternal first trimester serum levels of free-beta human chorionic gonadotrophin and male genital anomalies. *Hum Reprod*. 2016;31(8):1895–1903.

Schneuer FJ, Holland AJ, Pereira G, et al. Age at surgery and outcomes of an undescended testis. *Pediatrics*. 2016;137(2):e20152768.

Schneuer FJ, Bentley JP, Holland AJA, et al. Early childhood development of boys with genital anomalies. *Birth Defects Res*. 2017;109(8):535–542.

Schneuer FJ, Milne E, Jamieson SE, et al. Association between male genital anomalies and adult male reproductive disorders: a population-based data linkage study spanning more than 40 years. *Lancet Child Adolesc Health*. 2018 https://doi.org/10.1016/S2352-4642(18)30254-2.

Schwentner C, Oswald J, Kreczy A, et al. Neoadjuvant gonadotropin-releasing hormone therapy before surgery may improve the fertility index in undescended testes: a prospective randomized trial. *J Urol*. 2005;173(3):974–977.

Sekaran P, O'Toole S, Flett M, et al. Increased occurrence of disorders of sex development, prematurity and intrauterine growth restriction in children with proximal hypospadias associated with undescended testes. *J Urol*. 2013;189(5):1892–1896.

Sekido R, Lovell-Badge R. Genetic control of testis development. *Sex Dev*. 2013;7(1–3):21–32.

Sevillano CA, Lopes MS, Harlizius B, et al. Genome-wide association study using deregressed breeding values for cryptorchidism and scrotal/inguinal hernia in two pig lines. *Genet Sel Evol*. 2015;47:18.

Shapiro E, Huang H, Masch RJ, et al. Immunolocalization of androgen receptor and estrogen receptors alpha and beta in human fetal testis and epididymis. *J Urol*. 2005;174(4 Pt 2):1695–1698 [discussion 1698].

Sharma S, Sen A. Complete testicular epididymal dissociation in the abdominal cryptorchid testis. *J Pediatr Urol*. 2013;9(6 Pt B):1023–1027.

Sharpe RM. Perinatal determinants of adult testis size and function. *J Clin Endocrinol Metab*. 2006;91(7):2503–2505.

Sharpe RM, Skakkebaek NE. Testicular dysgenesis syndrome: mechanistic insights and potential new downstream effects. *Fertil Steril*. 2008;89(2 Suppl):e33–e38.

Sharpe RM, McKinnell C, Kivlin C, et al. Proliferation and functional maturation of Sertoli cells, and their relevance to disorders of testis function in adulthood. *Reproduction*. 2003;125(6):769–784.

Shepard CL, Kraft KH. The nonpalpable testis: a narrative review. *J Urol*. 2017;198(6):1410–1417.

Siemer S, Humke U, Uder M, et al. Diagnosis of nonpalpable testes in childhood: comparison of magnetic resonance imaging and laparoscopy in a prospective study. *Eur J Pediatr Surg*. 2000;10(2):114–118.

Sijstermans K, Hack WW, van der Voort-Doedens LM, et al. Puberty stage and spontaneous descent of acquired undescended testis: implications for therapy? *Int J Androl*. 2006;29(6):597–602.

Sijstermans K, Hack WW, Meijer RW, et al. The frequency of undescended testis from birth to adulthood: a review. *Int J Androl*. 2008;31(1):1–11.

Singal AK, Jain V, Dubey M, et al. Undescended testis and torsion: is the risk understated? *Arch Dis Child*. 2013;98(1):77–79.

Skakkebaek NE. A brief review of the link between environment and male reproductive health: lessons from studies of testicular germ cell cancer. *Horm Res Paediatr*. 2016;86(4):240–246.

Snijder CA, Kortenkamp A, Steegers EA, et al. Intrauterine exposure to mild analgesics during pregnancy and the occurrence of cryptorchidism and hypospadia in the offspring: the Generation R Study. *Hum Reprod*. 2012;27(4):1191–1201.

Snodgrass WT, Yucel S, Ziada A. Scrotal exploration for unilateral nonpalpable testis. *J Urol*. 2007;178(4 Pt 2):1718–1721.

Snodgrass W, Bush N, Holzer M, et al. Current referral patterns and means to improve accuracy in diagnosis of undescended testis. *Pediatrics*. 2011;127(2):e382–e388.

Sonne SB, Almstrup K, Dalgaard M, et al. Analysis of gene expression profiles of microdissected cell populations indicates that testicular carcinoma in situ is an arrested gonocyte. *Cancer Res*. 2009;69(12):5241–5250.

Sozubir S, Barber T, Wang Y, et al. Loss of Insl3: a potential predisposing factor for testicular torsion. *J Urol*. 2010;183(6):2373–2379.

Spranger R, Gunst M, Kühn M. Polyorchidism: a strange anomaly with unsuspected properties. *J Urol*. 2002;168(1):198.

Srinivas M, Kilmartin B, Das SN, et al. Prepubertal unilateral spermatic vessel ligation decreases haploid cell population of ipsilateral testis postpubertally in rats. *Pediatr Surg Int*. 2005;21(5):360–363.

Staub C, Rauch M, Ferriere F, et al. Expression of estrogen receptor ESR1 and its 46-kDa variant in the gubernaculum testis. *Biol Reprod*. 2005;73(4):703–712.

Stec AA, Thomas JC, DeMarco RT, et al. Incidence of testicular ascent in boys with retractile testes. *J Urol*. 2007;178(4 Pt 2):1722–1724 [discussion 1724–1725].

Stec AA, Tanaka ST, Adams MC, et al. Orchiopexy for intra-abdominal testes: factors predicting success. *J Urol*. 2009;182(4 Suppl):1917–1920.

Stedman F, Bradshaw CJ, Kufeji D. Current practice and outcomes in the management of intra-abdominal testes. *Eur J Pediatr Surg*. 2015;25(5):409–413.

Stoop H, Honecker F, van de Geijn GJ, et al. Stem cell factor as a novel diagnostic marker for early malignant germ cells. *J Pathol*. 2008;216(1):43–54.

Strandberg-Larsen K, Jensen MS, Ramlau-Hansen CH, et al. Alcohol binge drinking during pregnancy and cryptorchidism. *Hum Reprod*. 2009;24(12):3211–3219.

Suomi AM, Main KM, Kaleva M, et al. Hormonal changes in 3-month-old cryptorchid boys. *J Clin Endocrinol Metab*. 2006;91(3):953–958.

Suskind A, Hayner-Buchan A, Feustel PJ, et al. Fibrosis correlates with detailed histological analysis of human undescended testes. *BJU Int*. 2008;101(11):1441–1445.

Svechnikov K, Soder O. Ontogeny of gonadal sex steroids. *Best Pract Res Clin Endocrinol Metab*. 2008;22(1):95–106.

Svingen T, Koopman P. Building the mammalian testis: origins, differentiation, and assembly of the component cell populations. *Genes Dev*. 2013;27(22):2409–2426.

Sweet HO, Bronson RT, Donahue LR, et al. Mesenchymal dysplasia: a recessive mutation on chromosome 13 of the mouse. *J Hered*. 1996;87(2):87–95.

Swerdlow AJ, Higgins CD, Pike MC. Risk of testicular cancer in cohort of boys with cryptorchidism. *BMJ*. 1997;314(7093):1507–1511.

Tackett LD, Wacksman J, Billmire D, et al. The high intra-abdominal testis: technique and long-term success of laparoscopic testicular autotransplantation. *J Endourol*. 2002;16(6):359–361.

Taghizadeh AK, Thomas DF. Ascent of the testis revisited: fact not fiction. *BJU Int*. 2008;102(6):676–678.

Takahashi M, Kurokawa Y, Nakanishi R, et al. Low transscrotal orchidopexy is a safe and effective approach for undescended testes distal to the external inguinal ring. *Urol Int*. 2009;82(1):92–96.

Tang KF, Zheng JZ, Xing JP. Molecular analysis of SNP12 in estrogen receptor alpha gene in hypospadiac or cryptorchid patients from Northwestern China. *Urol Int*. 2011;87(3):359–362.

Tannour-Louet M, Han S, Louet JF, et al. Increased gene copy number of VAMP7 disrupts human male urogenital development through altered estrogen action. *Nat Med*. 2014;20(7):715–724.

Tasian GE, Hittelman AB, Kim GE, et al. Age at orchiopexy and testis palpability predict germ and Leydig cell loss: clinical predictors of adverse histological features of cryptorchidism. *J Urol*. 2009;182(2):704–709.

Tasian GE, Zaid H, Cabana MD, et al. Proximal hypospadias and risk of acquired cryptorchidism. *J Urol*. 2010;184(2):715–720.

Tasian GE, Copp HL, Baskin LS. Diagnostic imaging in cryptorchidism: utility, indications, and effectiveness. *J Pediatr Surg*. 2011;46(12):2406–2413.

Tayakkanonta K. The gubernaculum testis and its nerve supply. *Aust N Z J Surg*. 1963;33:61–67.

Teerds KJ, Huhtaniemi IT. Morphological and functional maturation of Leydig cells: from rodent models to primates. *Hum Reprod Update*. 2015;21(3):310–328.

Tennenbaum SY, Lerner SE, McAleer IM, et al. Preoperative laparoscopic localization of the nonpalpable testis: a critical analysis of a 10-year experience. *J Urol*. 1994;151(3):732–734.

Thambidorai CR, Khaleed A. Transverse testicular ectopia: correlation of embryology with laparoscopic findings. *Pediatr Surg Int*. 2008;24(3):371–374.

Thankamony A, Lek N, Carroll D, et al. Anogenital distance and penile length in infants with hypospadias or cryptorchidism: comparison with normative data. *Environ Health Perspect*. 2014;122(2):207–211.

Thankamony A, Pasterski V, Ong KK, et al. Anogenital distance as a marker of androgen exposure in humans. *Andrology*. 2016;4(4):616–625.

Thorsson AV, Christiansen P, Ritzen M. Efficacy and safety of hormonal treatment of cryptorchidism: current state of the art.

Acta Paediatr. 2007;96(5):628–630.

Thorup J, Cortes D. Long-term follow-up after treatment of cryptorchidism. *Eur J Pediatr Surg*. 2016;26(5):427–431.

Thorup JM, Cortes D, Visfeldt J. Germ cells may survive clipping and division of the spermatic vessels in surgery for intra-abdominal testes. *J Urol*. 1999;162(3 Pt 1):872–874.

Thorup J, Cortes D, Petersen BL. The incidence of bilateral cryptorchidism is increased and the fertility potential is reduced in sons born to mothers who have smoked during pregnancy. *J Urol*. 2006;176(2):734–737.

Thorup J, Haugen S, Kollin C, et al. Surgical treatment of undescended testes. *Acta Paediatr*. 2007;96(5):631–637.

Thorup J, Jensen CL, Langballe O, et al. The challenge of early surgery for cryptorchidism. *Scand J Urol Nephrol*. 2011;45(3):184–189.

Thorup J, Petersen BL, Kvist K, et al. Bilateral vanished testes diagnosed with a single blood sample showing very high gonadotropins (follicle-stimulating hormone and luteinizing hormone) and very low inhibin B. *Scand J Urol Nephrol*. 2011;45(6):425–431.

Thorup J, Petersen BL, Kvist K, et al. Bilateral undescended testes classified according to preoperative and postoperative status of gonadotropins and inhibin B in relation to testicular histopathology at bilateral orchiopexy in infant boys. *J Urol*. 2012;188(4 Suppl):1436–1442.

Thorup J, Kvist K, Clasen-Linde E, et al. The relation between adult dark spermatogonia and other parameters of fertility potential in cryptorchid testes. *J Urol*. 2013;190(4 Suppl):1566–1571.

Thorup J, Clasen-Linde E, Thorup SC, et al. Pre- and postoperative status of gonadotropins (FSH and LH) and inhibin-B in relation to testicular histopathology at orchiopexy in infant boys with unilateral undescended testes.

J Pediatr Urol. 2015;11(1):25.e1–25.e5.

Thorup J, Kvist K, Clasen-Linde E, et al. Serum inhibin B values in boys with unilateral vanished testis or unilateral cryptorchidism. *J Urol*. 2015;193(5):1632–1636.

Thorup J, Clasen-Linde E, Dong L, et al. Selecting infants with cryptorchidism and high risk of infertility for optional adjuvant hormonal therapy and cryopreservation of germ cells: experience from a pilot study. *Front Endocrinol (Lausanne)*. 2018;9:299.

Toppari J, Rodprasert W, Koskenniemi JJ. Exposure variation and endocrine disruption of the male reproductive system. *Horm Res Paediatr*. 2016;86(4):247–252.

Trabert B, Longnecker MP, Brock JW, et al. Maternal pregnancy levels of trans-nonachlor and oxychlordane and prevalence of cryptorchidism and hypospadias in boys. *Environ Health Perspect*. 2012;120(3):478–482.

Trabert B, Zugna D, Richiardi L, et al. Congenital malformations and testicular germ cell tumors. *Int J Cancer*. 2013;133(8):1900–1904.

Trasande L, Zoeller RT, Hass U, et al. Burden of disease and costs of exposure to endocrine disrupting chemicals in the European Union: an updated analysis. *Andrology*. 2016;4(4):565–572.

Tres LL, Kierszenbaum AL. The ADAM-integrin-tetraspanin complex in fetal and postnatal testicular cords. *Birth Defects Res C Embryo Today*. 2005;75(2):130–141.

Trout AT, Chow J, McNamara ER, et al. Association between testicular microlithiasis and testicular neoplasia: large multicenter study in a pediatric population. *Radiology*. 2017;285(2):576–583.

Turek PJ, Ewalt DH, Snyder HM 3rd, et al. The absent cryptorchid testis: surgical findings and their implications for diagnosis and etiology. *J Urol*. 1994;151(3):718–720

[discussion 720–711].

Ulbright TM, Tickoo SK, Berney DM, et al. Members of the ISUP Immunohistochemistry in Diagnostic Urologic Pathology Group. Best practices recommendations in the application of immunohistochemistry in testicular tumors: report from the International Society of Urological Pathology consensus conference. *Am J Surg Pathol*. 2014;38(8):e50–e59.

Ungewitter EK, Yao HH. How to make a gonad: cellular mechanisms governing formation of the testes and ovaries. *Sex Dev*. 2013;7(1–3):7–20.

van Brakel J, Dohle GR, De Muinck Keizer-Schrama SM, et al. Surgical findings in acquired undescended testis: an explanation for pubertal descent or non-descent? *Eur J Pediatr Surg*. 2011;21(6):351–355.

van Brakel J, Dohle GR, De Muinck Keizer-Schrama SM, et al. Different surgical findings in congenital and acquired undescended testes. *BJU Int*. 2012;110(8 Pt B):E387–E391.

van Brakel J, Kranse R, De Muinck Keizer-Schrama SM, et al. Fertility potential in men with a history of congenital undescended testes: a long-term follow-up study. *Andrology*. 2013;1(1):100–108.

van Brakel J, Kranse R, De Muinck Keizer-Schrama SM, et al. Fertility potential in a cohort of 65 men with previously acquired undescended testes. *J Pediatr Surg*. 2014;49(4):599–605.

van Brakel J, de Muinck Keizer-Schrama SM, van Casteren NJ, et al. Scrotal ultrasound findings in previously congenital and acquired unilateral undescended testes and their contralateral normally descended testis. *Andrology*. 2015;3(5):888–894.

van Casteren NJ, Looijenga LH, Dohle GR. Testicular microlithiasis and carcinoma in situ overview and proposed clinical guideline. *Int J Androl*. 2009;32(4):279–287.

van der Plas E, Meij-de Vries A, Goede J, et al. Testicular microlithiasis in acquired undescended testis after orchidopexy at diagnosis. *Andrology*. 2013;1(6):957–961.

van der Plas E, Zijp G, Froeling F, et al. Orchidopexy in late childhood often associated with previously normal testicular position. *Eur J Pediatr Surg*. 2013;23(4):276–282.

van der Plas EM, Zijp GW, Froeling FM, et al. Long-term testicular volume after orchiopexy at diagnosis of acquired undescended testis. *J Urol*. 2013;190(1):257–262.

van der Plas EM, van Brakel J, Meij-de Vries A, et al. Acquired undescended testes and fertility potential: is orchiopexy at diagnosis better than awaiting spontaneous descent? *Andrology*. 2015;3(4):677–684.

van der Schoot P. Towards a rational terminology in the study of the gubernaculum testis: arguments in support of the notion that the cremasteric sac should be considered the gubernaculum in postnatal rats and other mammals. *J Anat*. 1996;189(Pt 1):97–108.

Verkauskas G, Hadziselimovic F. Response to commentary to "Prospective study of histological and endocrine parameters of gonadal function in boys with cryptorchidism". *J Pediatr Urol*. 2016;12(4):241–242.

Verkauskas G, Malcius D, Eidukaite A, et al. Prospective study of histological and endocrine parameters of gonadal function in boys with cryptorchidism. *J Pediatr Urol*. 2016;12(4):238.e1–238.e6.

Verkauskas G, Malcius D, Dasevicius D, et al. Histopathology of unilateral cryptorchidism. *Pediatr Dev Pathol*. 2019;22(1):53–58.

Vesterholm Jensen D, Christensen J, Virtanen HE, et al. No association between exposure to perfluorinated compounds and congenital cryptorchidism: a nested case-control study among 215 boys from Denmark and Finland. *Reproduction*.

2014;147(4):411–417.

Vigueras-Villaseñor RM, Cortés-Trujillo L, Chávez-Saldaña M, et al. Analysis of POU5F1, c-Kit, PLAP, AP2gamma and SALL4 in gonocytes of patients with cryptorchidism. *Acta Histochem*. 2015;117(8):752–761.

Vincel B, Verkauskas G, Bilius V, et al. Gonadotropin-releasing hormone agonist corrects defective mini-puberty in boys with cryptorchidism: a prospective randomized study. *Biomed Res Int*. 2018;2018:4651218.

Virtanen HE, Adamsson A. Cryptorchidism and endocrine disrupting chemicals. *Mol Cell Endocrinol*. 2012;355(2):208–220.

Virtanen HE, Toppari J. Epidemiology and pathogenesis of cryptorchidism. *Hum Reprod Update*. 2008;14(1):49–58.

Virtanen HE, Toppari J. Embryology and physiology of testicular development and descent. *Pediatr Endocrinol Rev*. 2014;11(Suppl 2):206–213.

Virtanen HE, Toppari J. Cryptorchidism and Fertility. *Endocrinol Metab Clin North Am*. 2015;44(4):751–760.

Virtanen HE, Koskenniemi JJ, Sundqvist E, et al. Associations between congenital cryptorchidism in newborn boys and levels of dioxins and PCBs in placenta. *Int J Androl*. 2012;35(3):283–293.

Virtanen HE, Sadov S, Toppari J. Prenatal exposure to smoking and male reproductive health. *Curr Opin Endocrinol Diabetes Obes*. 2012;19(3):228–232.

Wada Y, Okada M, Fukami M, et al. Association of cryptorchidism with Gly146Ala polymorphism in the gene for steroidogenic factor-1. *Fertil Steril*. 2006;85(3):787–790.

Wagner-Mahler K, Kurzenne JY, Delattre I, et al. Prospective study on the prevalence and associated risk factors of cryptorchidism in 6246 newborn boys from Nice area, France. *Int J Androl*. 2011;34(5 Pt 2):e499–e510.

Wainwright EN, Wilhelm D. The game plan: cellular and molecular mechanisms of mammalian testis development. *Curr Top Dev Biol*. 2010;90:231–262.

Wakeman D, Warner BW. Urogenital nonunion—a rare anomaly associated with the undescended testis. *Am J Surg*. 2010;199(5):e59–e60.

Walsh T, Dall'Era MA, Croughan MS, et al. Prepubertal orchiopexy for cryptorchidism may be associated with lower risk of testicular cancer. *J Urol*. 2007;178(4 Pt 1):1440–1446 [discussion 1446].

Wang Y, Barthold J, Kanetsky PA, et al. Allelic variants in HOX genes in cryptorchidism. *Birth Defects Res A Clin Mol Teratol*. 2007;79(4):269–275.

Wang Y, Barthold J, Figueroa E, et al. Analysis of five single nucleotide polymorphisms in the ESR1 gene in cryptorchidism. *Birth Defects Res A Clin Mol Teratol*. 2008;82(6):482–485.

Wang Z, McGlynn KA, Rajpert-De Meyts E, et al. Testicular Cancer Consortium. Meta-analysis of five genome-wide association studies identifies multiple new loci associated with testicular germ cell tumor. *Nat Genet*. 2017;49(7):1141–1147.

Wang Y, Gray DR, Robbins AK, et al. Testicular Cancer Consortium. Subphenotype meta-analysis of testicular cancer genome-wide association study data suggests a role for RBFOX family genes in cryptorchidism susceptibility. *Hum Reprod*. 2018;33(5):967–977.

Wang Y, Wei Y, Tang X, et al. Association between androgen receptor polymorphic CAG and GGC repeat lengths and cryptorchidism: a meta-analysis of case-control studies. *J Pediatr Urol*. 2018;14(5):432.e1–432.e9.

Warr N, Siggers P, Bogani D, et al. Greenfield. Sfrp1 and Sfrp2 are required for normal male sexual development in mice.

Dev Biol. 2009;326(2):273–284.

Wayne C, Chan E, Nasr A. Canadian Association of Paediatric Surgeons Evidence-Based Resource. What is the ideal surgical approach for intra-abdominal testes? A systematic review. *Pediatr Surg Int*. 2015;31(4):327–338.

Wei Y, Wu SD, Wang YC, et al. A 22-year retrospective study: educational update and new referral pattern of age at orchidopexy. *BJU Int*. 2016;118(6):987–993.

Weidner IS, Møller H, Jensen TK, et al. Cryptorchidism and hypospadias in sons of gardeners and farmers. *Environ Health Perspect*. 1998;106(12):793–796.

Wen Q, Wang Y, Tang J, et al. Sertoli cell Wt1 regulates peritubular myoid cell and fetal leydig cell differentiation during fetal testis development. *PLoS ONE*. 2016;11(12):e0167920.

Wensing CJ. The embryology of testicular descent. *Horm Res*. 1988;30(4–5):144–152.

Wenzler DL, Abloom D, Park JM. What is the rate of spontaneous testicular descent in infants with cryptorchidism? *J Urol*. 2004;171(2 Pt 1):849–851.

Williams K, Baumann L, Shah A, et al. Age at orchiopexy for undescended testis in the United States. *J Pediatr Surg*. 2017 [pii: S0022-3468(17)30642-5].

Wit JM, Delemarre-van der Waal HA, Faber JA, et al. Intra- and inter-observer variability in the assessment of testicular descent. *Andrologia*. 1987;19(5):585–590.

Wohlfahrt-Veje C, Boisen KA, Boas M, et al. Acquired cryptorchidism is frequent in infancy and childhood. *Int J Androl*. 2009;32(4):423–428.

Wolffenbuttel KP, Kok DJ, Den Hollander JC, et al. Vanished testis: be aware of an abdominal testis. *J Urol*. 2000;163(3):957–958.

Wong J, Punwani V, Lai C, et al. Why do undescended testes and posterior urethral valve occur together? *Pediatr Surg Int*. 2016;32(5):509–514.

Wood HM, Lee UJ, Vurbic D, et al. Sexual development and fertility of Loxl1–/– male mice. *J Androl*. 2009;30(4):452–459.

Wuerstle M, Lesser T, Hurwitz R, et al. Persistent mullerian duct syndrome and transverse testicular ectopia: embryology, presentation, and management. *J Pediatr Surg*. 2007;42(12):2116–2119.

Wyllie GG. The retractile testis. *Med J Aust*. 1984;140(7):403–405.

Wyndham NR. A morphological study of testicular descent. *J Anat*. 1943;77(Pt 2):179–188 [173].

Yamanaka J, Metcalfe SA, Hutson JM, et al. Testicular descent. II Ontogeny and response to denervation of calcitonin gene-related peptide receptors in neonatal rat gubernaculum. *Endocrinology*. 1993;132(1):280–284.

Yardley IE, Bostock E, Jones MO, et al. Congenital abdominal wall defects and testicular maldescent—a 10-year single-center experience. *J Pediatr Surg*. 2012;47(6):1118–1122.

Yeung CK, Tam YH, Chan YL, et al. A new management algorithm for impalpable undescended testis with gadolinium enhanced magnetic resonance angiography. *J Urol*. 1999;162(3 Pt 2):998–1002.

Yoshida R, Fukami M, Sasagawa I, et al. Association of cryptorchidism with a specific haplotype of the estrogen receptor alpha gene: implication for the susceptibility to estrogenic environmental endocrine disruptors. *J Clin Endocrinol Metab*. 2005;90(8):4716–4721.

Yucel S, Ziada A, Harrison C, et al. Decision making during laparoscopic orchiopexy for intra-abdominal testes near the internal ring. *J Urol*. 2007;178(4 Pt 1):1447–1450 [discussion 1450].

Zaccara A, Spagnoli A, Capitanucci ML, et al. Impalpable testis and laparoscopy: when the gonad is not visualized. *JSLS*. 2004;8(1):39–42.

Zenaty D, Dijoud F, Morel Y, et al. Bilateral anorchia in infancy: occurrence of micropenis and the effect of testosterone treatment. *J Pediatr*. 2006;149(5):687–691.

Zhang L, Wang XH, Zheng XM, et al. Maternal gestational smoking, diabetes, alcohol drinking, pre-pregnancy obesity and the risk of cryptorchidism: a systematic review and meta-analysis of observational studies. *PLoS ONE*. 2015;10(3):e0119006.

Zhao X, Onteru S, Saatchi M, et al. A genome-wide association study for canine cryptorchidism in Siberian Huskies. *J Anim Breed Genet*. 2014;131(3):202–209.

Zilberman D, Inbar Y, Heyman Z, et al. Torsion of the cryptorchid testis—can it be salvaged? *J Urol*. 2006;175(6):2287–2289 [discussion 2289].

Zimmermann S, Steding G, Emmen JM, et al. Targeted disruption of the Insl3 gene causes bilateral cryptorchidism. *Mol Endocrinol*. 1999;13(5):681–691.

Zivkovic D, Bica DT, Hadziselimovic F. Relationship between adult dark spermatogonia and secretory capacity of Leydig cells in cryptorchidism. *BJU Int*. 2007;100(5):1147–1149 [discussion 1149].

Zivkovic D, Hadziselimovic F. Development of Sertoli cells during mini-puberty in normal and cryptorchid testes. *Urol Int*. 2009;82(1):89–91.

Zivkovic D, Varga J, Konstantinidis G, et al. Regional differences in maturation of germ cells of cryptorchid testes: role of environment. *Acta Paediatr*. 2009;98(8):1339–1343.

Ziylan O, Oktar T, Korgali E, et al. Failed orchiopexy. *Urol Int*. 2004;73(4):313–315.

47

Management of Abnormalities of the Genitalia in Girls

Martin Kaefer MD

As with all organ systems, genital development in the female occurs in an orderly fashion through multiple complex steps that result in an anatomically and functionally normal child in the majority of cases. However, errors in development can occur, from minor, clinically insignificant disorders to severe abnormalities that are devastating to the child and parents. The abnormalities can be seen alone or in combination with internal genital anomalies or be a part of a more global syndrome that involves many organ systems. This chapter briefly describes normal female urogenital development and then discusses anomalies that arise when abnormal development occurs. Genital ambiguity may be the initial finding in these disorders.

Female Genital Embryology

A comprehensive description of genitourinary embryology can be found in other chapters. However, to foster a deeper understanding of the complex combination of anomalies that can occur in patients with external genital/vaginal anomalies, a brief review of relevant embryologic events is presented.

The cloaca is an endoderm-lined primordial organ that is first apparent at the beginning of the second week of gestation (Grosfeld, 1996). This structure, which represents a confluence of the primitive hindgut (dorsally) and the allantois (ventrally), receives the mesonephric ductal system just before the fourth week of gestation. The urorectal septum, which first appears during the fourth week of development, separates the urogenital sinus (ventrally) from the anal canal (dorsally) (Moore and Persaud, 1995). The urorectal septum actually consists of two components. The first is the Tourneux fold, which develops along the coronal plane in the angle between the allantois and the hindgut and grows in a caudal fashion toward the cloacal membrane. As this septum nears the cloacal membrane, infoldings of the lateral walls of the cloaca form Rathke plicae, which coalesce in the coronal midline and form the urorectal septum caudally. By weeks 6 to 7 of development the urorectal septum has fused with the cloacal membrane and divided it into a ventral urogenital membrane and a dorsal anal membrane. The fibromuscular node of tissue that results from contact of the septum with the cloacal membrane serves as a critical insertion site for the perineal muscles and as the dividing point of the primitive cloacal sphincter complex into anterior (urogenital diaphragm) and posterior (external anal sphincter) components. **The common ontogeny of these two sphincter complexes explains why the pudendal nerve supplies all of these muscles.**

While the urorectal anlage is undergoing division, the developing mesonephric ducts, which have contacted the cloaca, enter the urogenital sinus near the müllerian tubercle (Churchill et al., 1978). An offshoot of the mesonephric duct, the ureteric bud, extends cranially to induce development of the metanephric blastema, the mass of cells that will form the secretory component of the kidney. The terminal branch point of the ureteral bud from the mesonephric duct is later absorbed into the wall of the urogenital sinus. Proper incorporation of this complex results in the ureters opening at the lateral aspect of the trigone.

During this critical phase of development, paired müllerian ducts, which

form from the coelomic epithelium, develop lateral to the mesonephric ducts and cross medially to fuse in the midline. The close proximity of these two ductal systems helps explain the common association of paramesonephric abnormalities and ipsilateral renal anomalies. The paired müllerian ducts then proceed caudally to join the urogenital sinus, where they produce an elevation called the *müllerian tubercle*. The caudal fusion of portions of these ducts normally leads to dissolution of the shared midline partition and the formation of a common uterovaginal canal, which, as the name implies, gives rise to the uterus, cervix, and proximal two-thirds of the vagina. Failure of septal regression can result in a number of possible müllerian duct abnormalities.

As first delineated by Koff in 1933, contact of the uterovaginal primordium with the urogenital sinus forms the müllerian tubercle, which in turn induces the formation of paired caudal endodermal outgrowths called *sinovaginal bulbs*. Evidence suggests that these outpouchings may in fact represent the terminal segments of the wolffian ducts (Bok and Drews, 1983). Regardless of origin, the cells within these sinovaginal bulbs then proliferate to form a cord of tissue that develops into a distal vaginal plate, which is later canalized in a caudal-to-cranial direction to form the distal aspect of the vagina (Fig. 47.1). The portion of the urogenital sinus distal to the müllerian tubercle subsequently undergoes exstrophy and everts to become the vestibule. As a result of this process, the urethra and vagina acquire separate openings in the vulva. The lumen of the vagina is separated from the cavity of the urogenital sinus by the hymen, an invagination of the posterior wall of the urogenital sinus. Rupture of the hymen should occur during the perinatal period.

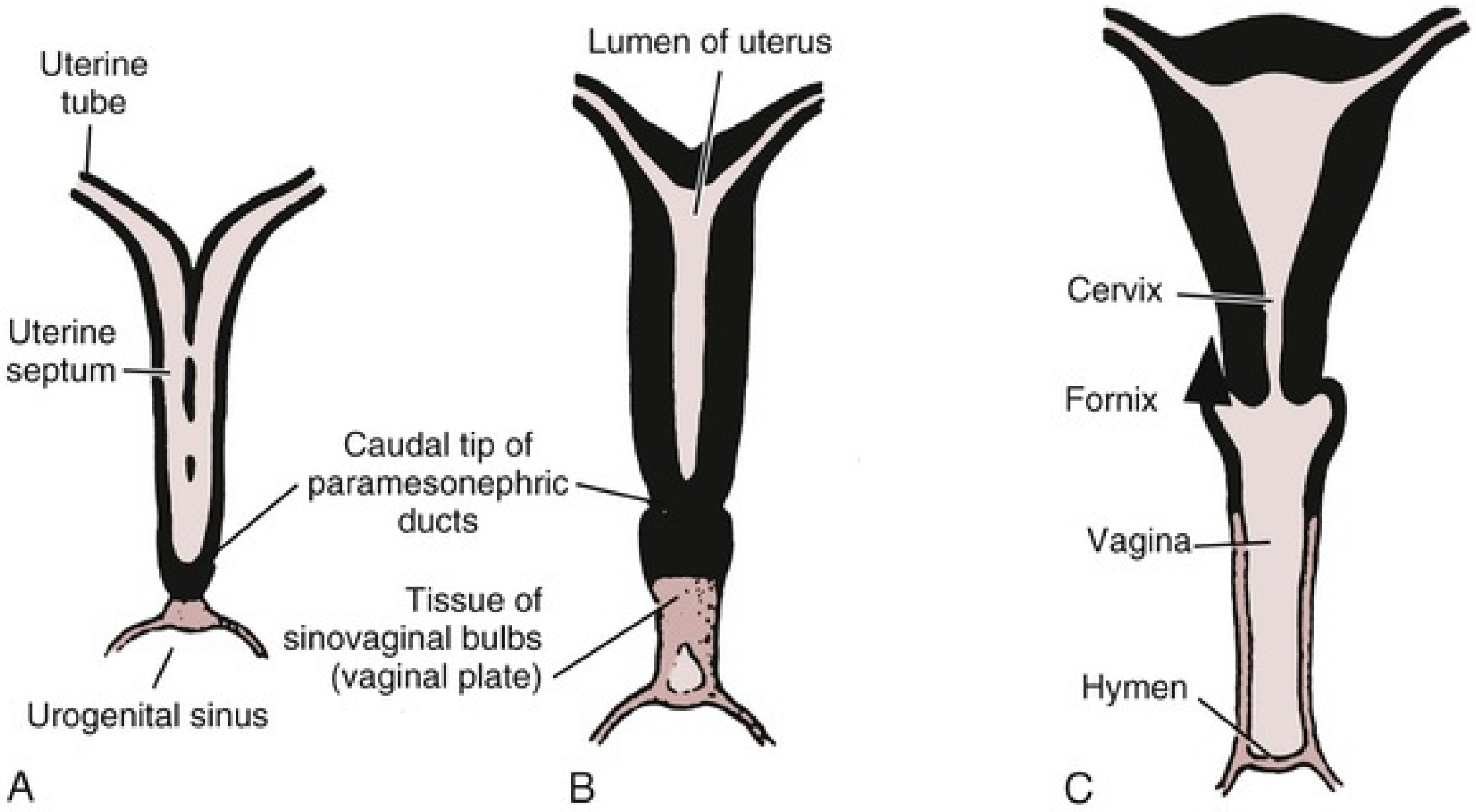

FIG. 47.1 (A to C) Formation of the vagina from the sinovaginal bulbs. (From Saler TW: *Langman's medical embryology,* ed 6, Baltimore, 1990, Williams & Wilkins.)

Various cystic structures may form along the luminal aspect of the vagina. Remnants of the prostatic ductal system and the wolffian duct give rise to the paraurethral glands of Skene and Gardner, respectively. Outgrowths from the urogenital sinus form the greater vestibular glands of Bartholin, which are homologs of the bulbourethral glands in the male.

Key events in skeletal formation occur concurrently with cloacal division and proper formation of the mesonephric and paramesonephric ductal systems (Churchill et al., 1978). The vertebrae develop in a craniocaudal direction, with the lower extremity limb buds developing from condensation of somites 25 through 29. These somites undergo critical differentiation from the fourth through the eighth weeks of development.

From the foregoing brief description of caudal embryology it should be evident that a disturbance in segmentation at the level of the caudal somites when the fetus is less than 10 mm (fourth to fifth weeks of human development) can affect many organ systems. Duhamel (1961) described the association of these “coincidentally” occurring congenital malformations and introduced the term *caudal regression syndrome*. Laboratory data with teratogens support the concept that a key event occurs between the fourth and fifth weeks of gestation that results in an error in the simultaneous development of the terminal bowel, kidney, bladder, paramesonephric ductal system, and lumbosacral spine (Mesrobian et al., 1994). The actual inciting event remains unclear, although disordered mesodermal migration, reduced cellular proliferation, and premature apoptosis have been proposed as potential mechanisms (Alles and Sulik, 1993; Kallen and Winberg, 1974). Elements of the caudal regression syndrome are seen with increased frequency in infants of mothers with diabetes, but the exact mechanism is still in question (Deuchar, 1978; Lynch et al., 1995). Specific gene deletions in the homeobox region of the mammalian genome (the region critical for proper mammalian spatial orientation and segmentation) have been shown to result in a constellation of anatomic findings, as predicted by Duhamel (Warot et al., 1997). Because differentiation of the somites progresses in a cranial-to-caudal direction, it would follow that the most complex anomalies (higher anorectal malformations) would occur as a result of aberrations at an earlier stage of development. This also helps explain the greater association of severe upper urinary tract malformations, internal genital duct abnormalities, and spinal anomalies in these patients than in those with less severe cases of imperforate anus.

Mesodermal disturbances are not limited to the caudal somites. As seen in the VATER (***V***ertebral defects, ***A***nal atresia, ***T***racheoesophageal fistula with ***E***sophageal atresia, and ***R***adial and **r**enal dysplasia) and MURCS (***MÜ***llerian duct aplasia, ***R***enal aplasia, and ***C***ervicothoracic ***S***omite **d**ysplasia) associations, mesodermally derived organs as cranial as the C1 vertebra and tracheoesophageal anlagen can be affected in association with congenital abnormalities of the mesonephric and paramesonephric ductal systems (Duncan et al., 1979; Quan and Smith, 1973).

Key Points: Female Genital Embryology

- The common ontogeny of the urogenital sphincter and the external anal sphincter explains why the pudendal nerve supplies both muscle complexes.
- The close proximity of the müllerian and wolffian ductal systems is responsible for the common association of paramesonephric abnormalities and ipsilateral renal anomalies.
- A disturbance in segmentation at the level of the caudal somites during the fourth or fifth weeks of development can result in a constellation of

malformations involving the urogenital, skeletal, and gastrointestinal systems that are commonly referred to as the *caudal regression syndrome*.

Evaluation and Classification of Female Genital Anomalies

Structural anomalies of the vulva are numerous and varied. The differential diagnosis in the neonate and young child is broad and requires a thorough understanding of the diagnostic possibilities and a systematic evaluation. The age and racial background of the patient can help narrow the differential diagnosis, but physical examination remains the most useful tool for determining the specific pathology.

The physician must be sure to specifically reassure the girl that the examination will not be painful. With the child in the frog-leg position, the physician should note the size of the clitoris, the configuration of the hymen, the location of the urethra, and the character of the interlabial mass (e.g., smooth, lobulated, hemorrhagic). **To aid in visualization, the labia majora can be gently grasped and pulled caudally and laterally to enable funneling of the introitus and vagina (often referred to as the "pull-down maneuver")** (Kaefer, 2010; Fig. 47.2). Establishing the location of expected anatomic landmarks can facilitate determining the nature of a specific mass. In certain circumstances, the relationship of the mass to the vagina and urethra can be improved by gentle placement of a lubricated cotton applicator posteriorly or placement of a small feeding tube within the suspected urethral orifice, or both. Although an otoscope, nasal speculum, or pediatric vaginal speculum can be useful in evaluating the vagina while the patient is awake, complaints of vaginal origin (i.e., vaginal discharge or bleeding) are often best investigated with a carefully performed examination and vaginoscopy under anesthesia. Renal-pelvic ultrasonography can be a useful adjunct in confirming or establishing the diagnosis in a few of these disorders.

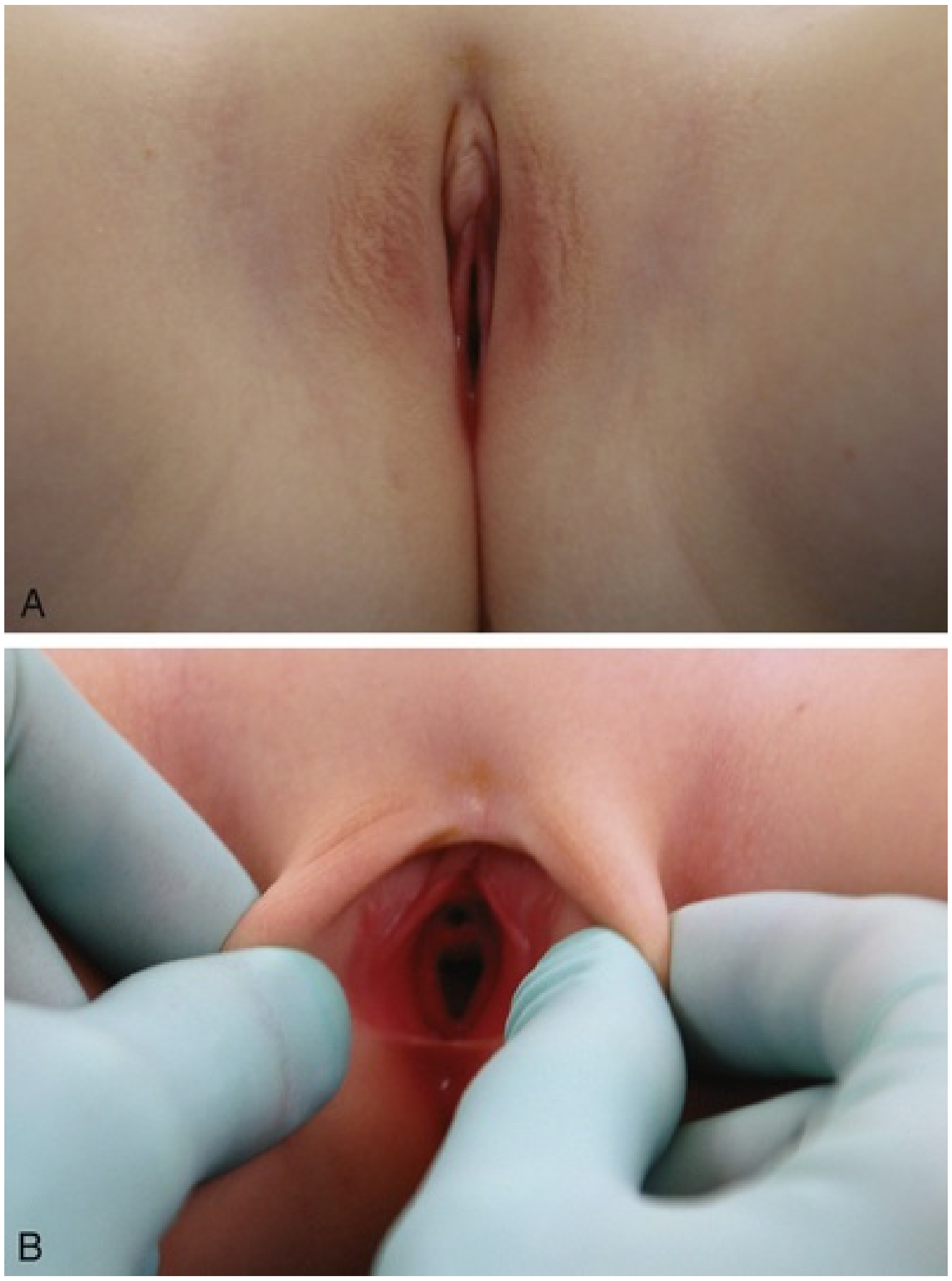

FIG. 47.2 (A and B) Photographs of the labial "pull-down maneuver." To aid in visualization of the female introitus, the labia majora are gently grasped and pulled caudally and laterally to enable funneling of the introitus and a clear view of the distal vagina.

Structural anomalies of the vagina can be grouped into three main categories: (1) those resulting from either hypoplasia or agenesis, (2) those caused by vertical fusion (canalization abnormalities resulting from abnormal contact of the müllerian structures with the urogenital sinus), and (3) those resulting from lateral fusion (duplication). The clinical manifestations, physical findings, evaluation, and subsequent therapy vary considerably among these groups. Radiographic imaging is of central importance in determining the correct diagnosis. Ultrasonography is helpful not only in identifying the genital anatomy but also in screening for associated upper urinary tract abnormalities (Fernandez et al., 1996; Rosenberg et al., 1986). Magnetic resonance imaging (MRI) is considered by many to be the gold standard for defining müllerian anatomy (Fedele et al., 1996; Lang et al., 1999; Russ et al., 1997). It is especially useful for determining the presence or absence of the cervix and the presence of functioning endometrium in complex anomalies. In complicated cases, additional information can be obtained by examination under anesthesia, vaginoscopy, hysteroscopy, and laparoscopy (Major et al., 1997). Obstructive anomalies typically require immediate intervention, but nonobstructive anomalies often do not require surgical intervention unless the patient has reached reproductive age and the condition affects intercourse or adversely affects fertility. Various systems have been proposed for the classification of these anomalies, with the system proposed by the American Society for Reproductive Medicine being the most inclusive (American Fertility Society, 1988).

Congenital Disorders of Female External Genitalia

Disorders of the Clitoris

Hypertrophied Clitoris

Clitoral hypertrophy is most commonly the result of excess androgenic metabolites arising secondary to an enzymatic defect in adrenal steroid synthesis (Fig. 47.3). The most commonly seen syndromes of congenital adrenal hyperplasia (CAH) result from a deficiency of either 21-hydroxlase or 11-hydroxylase. Some degree of clitoral enlargement can be appreciated in nearly every female patient with CAH. Although there is often concordance between the degree of clitoromegaly and the length of the common urogenital sinus, this does not always apply. Because the overwhelming majority of clitoral hypertrophy is secondary to CAH, any newborns noted to have this physical finding should undergo an evaluation of their serum electrolytes, 17-hydroxyprogesterone level, and karyotype. Replacement of glucocorticoids and mineralocorticoids will exert a negative feedback on the adrenal gland and thus eliminate further stimulation of the external genitalia from endogenously derived androgens. Medical and surgical management of this disorder is discussed elsewhere in this text.

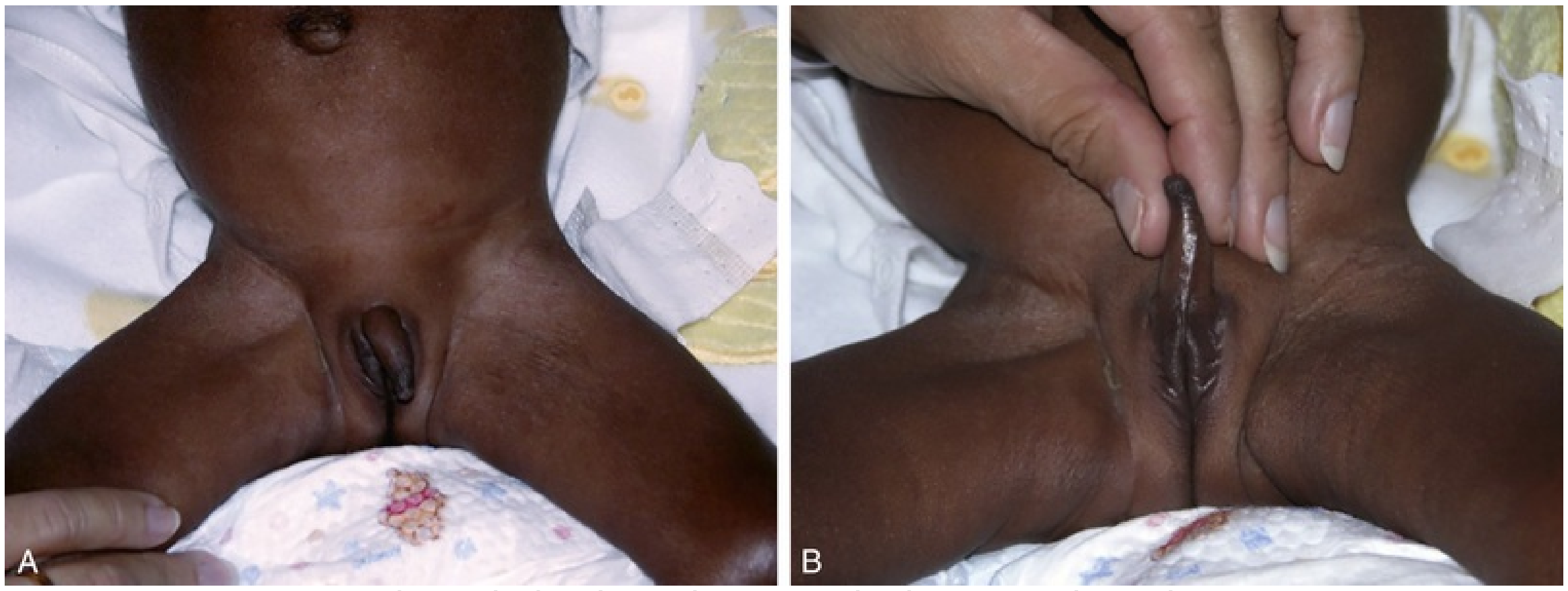

FIG. 47.3 (A and B) Clitoral hypertrophy in congenital adrenal hyperplasia.

Clitoral enlargement can result from other disorders. Endogenous androgen-producing tumors in the mother can result in stimulation of the fetal phallus. The presence of unilateral viable testicular tissue in a patient with Turner syndrome also has been reported (Haddad et al., 2003). Finally, local growth factor secretion from a neighboring plexiform neurofibroma in patients with neurofibromatosis has been reported on multiple occasions to result in clitoromegaly (Cost et al., 2009; Kaefer et al., 1997; Kearse and Ritchey, 1993; Rink and Mitchell, 1983; Yuksel et al., 2003).

Diminutive Clitoris

Small clitoral size (Fig. 47.4) is found in patients with complete androgen insensitivity syndrome (CAIS). One study evaluating 19 patients with known CAIS revealed a statistically significantly reduced mean clitoral length compared with that in controls (Crouch et al., 2011). In contrast, no difference was observed for the clitoral to urethral distance between the two groups.

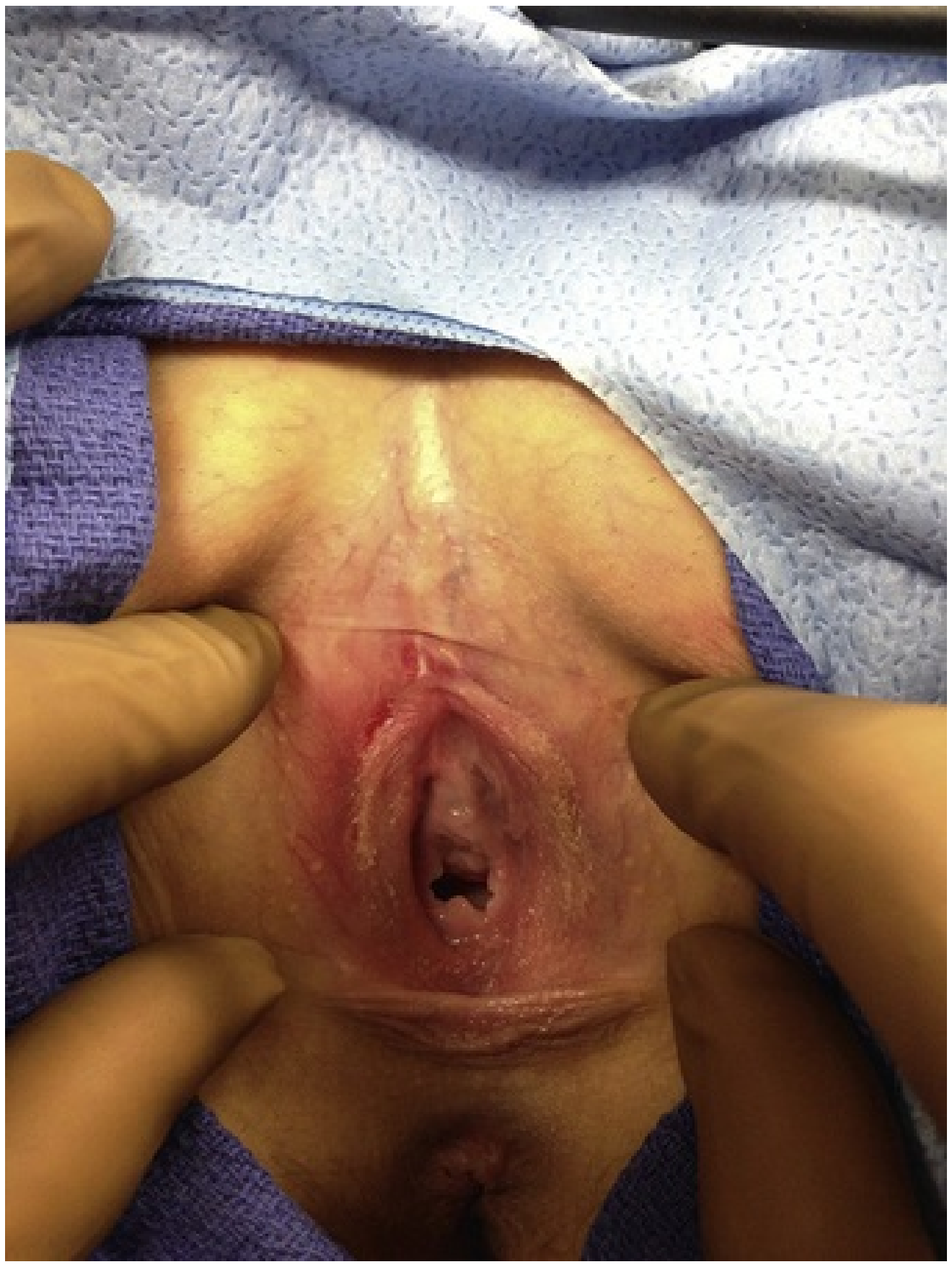

FIG. 47.4 Diminutive clitoris in complete androgen insensitivity syndrome.

Disorders of the Vestibule

Urethral Prolapse

Urethral prolapse generally involves complete circumferential eversion of the urethral mucosa at the level of the external urethral meatus (Fig. 47.5; Lowe et al., 1986). **This entity, first described by Solinger in 1732, occurs most often in prepubertal black girls and in postmenopausal white women** (Epstein and Strauss, 1937; Richardson et al., 1982). Various causes that have been proposed for urethral prolapse include hypoestrogenism (Desai and Cohen, 1997), abnormal connections between the inner longitudinal and outer circular muscle layers of the distal urethra (Lowe et al., 1986), and episodic increases in intra-abdominal pressure (Desai and Cohen, 1997; Lowe et al., 1986; Valerie et al., 1999). The most common initial complaint is bleeding from the edematous and friable mucosa, which results in blood spotting on the underwear (Chaouachi et al., 1989; Richardson et al., 1982). Urethral prolapse is easily recognized as a doughnut-shaped mass with the urethral meatus at the center. If the diagnosis can be confirmed by passing a urethral catheter, radiographic evaluation is not indicated (Nussbaum and Lebowitz, 1983). Treatment options include observation, topical corticosteroids, conjugated estrogens, and surgical excision (Fernandes et al., 1993; McCaskill et al., 2018; Redman, 1982). Sitz baths may be helpful. **Nonoperative treatment may lead to spontaneous reduction of the prolapse, but a recurrence rate of up to 67% has been noted** (Jerkins et al., 1984). Many methods of surgical repair have been described. Circumferential excision of the redundant mucosa with subsequent suturing of the normal urethra to the vestibule is the procedure of choice (Devine and Kessel, 1980). Other methods, including ligation over a transurethral catheter with subsequent sloughing and cryosurgery, should be discouraged (Klaus and Stein, 1973; Owens and Morse, 1968).

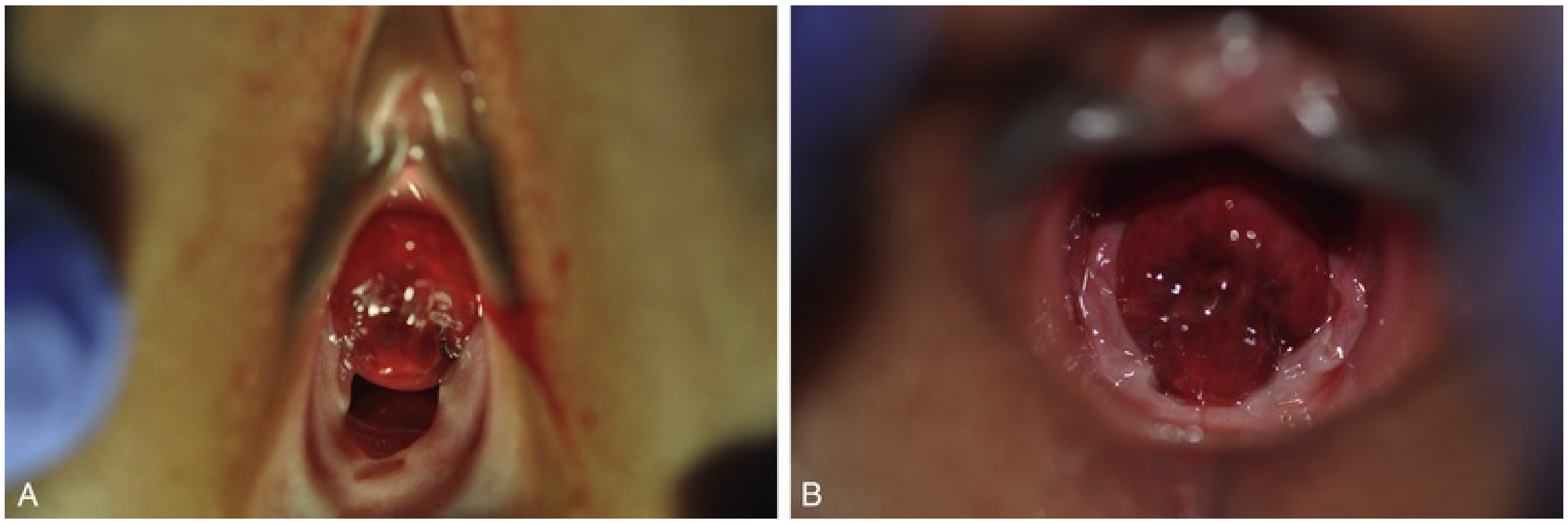

FIG. 47.5 (A and B) Urethral prolapse.

Urethral Polyp

The pediatric equivalent of a urethral caruncle, namely, a urethral polyp, is a rare lesion that can manifest as an interlabial mass (Fig. 47.6). The cause of these lesions has not been completely elucidated, but in a young child they probably represent either hamartomatous growth or a response to inflammation.

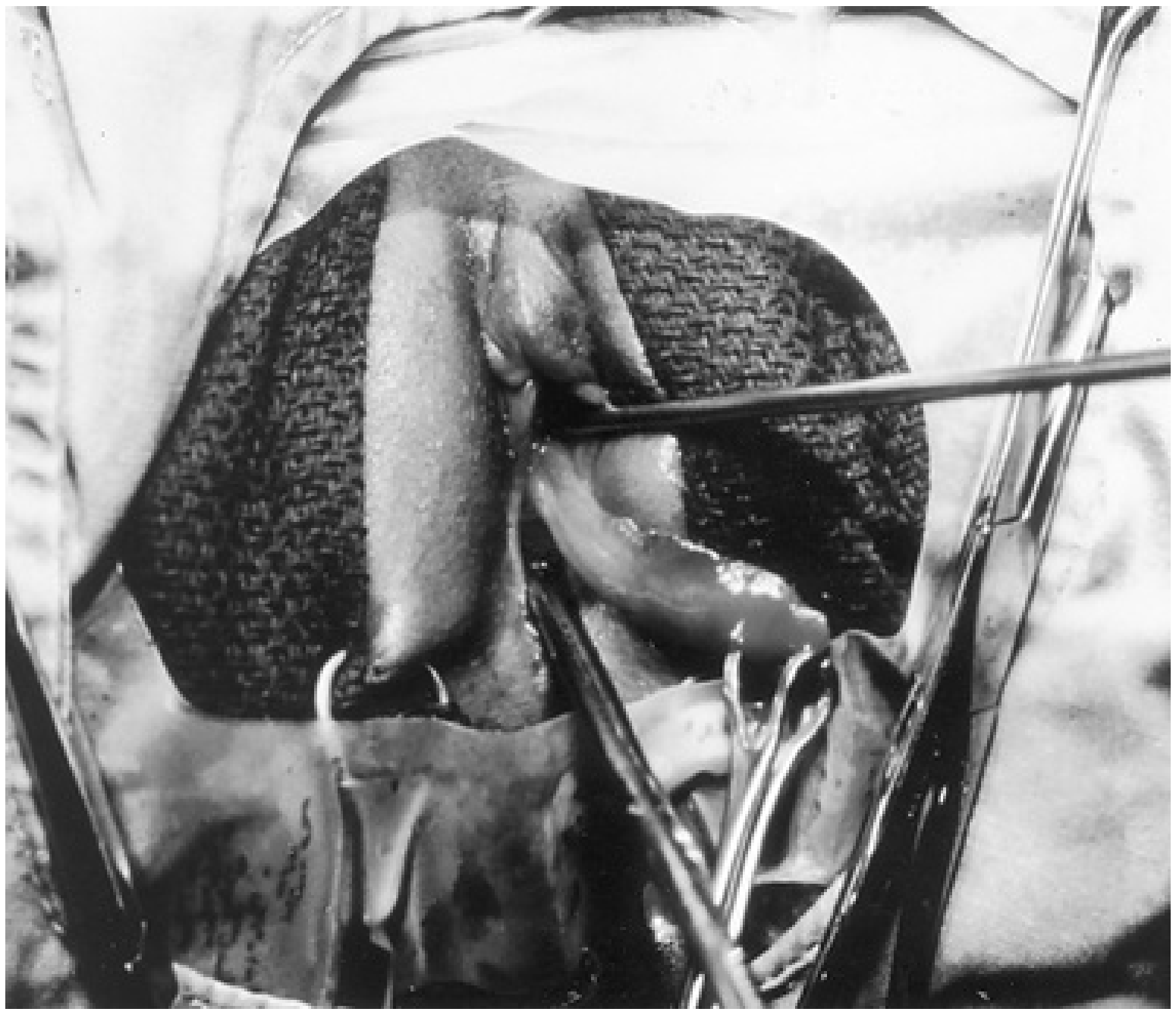

FIG. 47.6 Urethral polyp. Probe in urethra and Babcock clamp on urethral polyp.

Klee described two young girls with an interlabial mass. Histologic examination of each excised mass revealed a benign urethral polyp covered with transitional and squamous epithelium (Klee et al., 1993). Urethral polyps should be included in the differential diagnosis of an interlabial mass in young female patients.

Vestibular Cysts

Introital cysts in the newborn can represent one of three entities: paraurethral cysts (i.e., Skene duct cyst), remnants of the mesonephric ductal system (Gartner duct cyst), and a covered ectopic ureter. When the cyst is large and clearly emanating from the vaginal introitus, further investigation in the form of a renal-pelvic ultrasound evaluation is indicated to look for renal duplication.

Paraurethral cysts in a neonate represent a dilation of the periurethral glands, which are located just inside the urethral meatus (Fig. 47.7). These glands are homologs of the male prostatic glands and number between 6 and 30, with the two largest termed the *periurethral glands of Skene* (Gottesman and Sparkuhl, 1979; Skene, 1880). In a neonate the periurethral glands occasionally respond to maternal estrogen and secrete mucoid material, which can result in cyst formation. The main distinguishing feature of this condition is displacement of the urethral meatus by the mass and, consequently, an eccentric urinary stream. If the urethral meatus can be identified as being completely separate from the mass, radiographic evaluation is not needed to confirm the diagnosis (Nussbaum and Lebowitz, 1983). These cysts are frequently self-limited and often rupture spontaneously. If they are persistent, drainage by a small needle is easily achieved at the bedside.

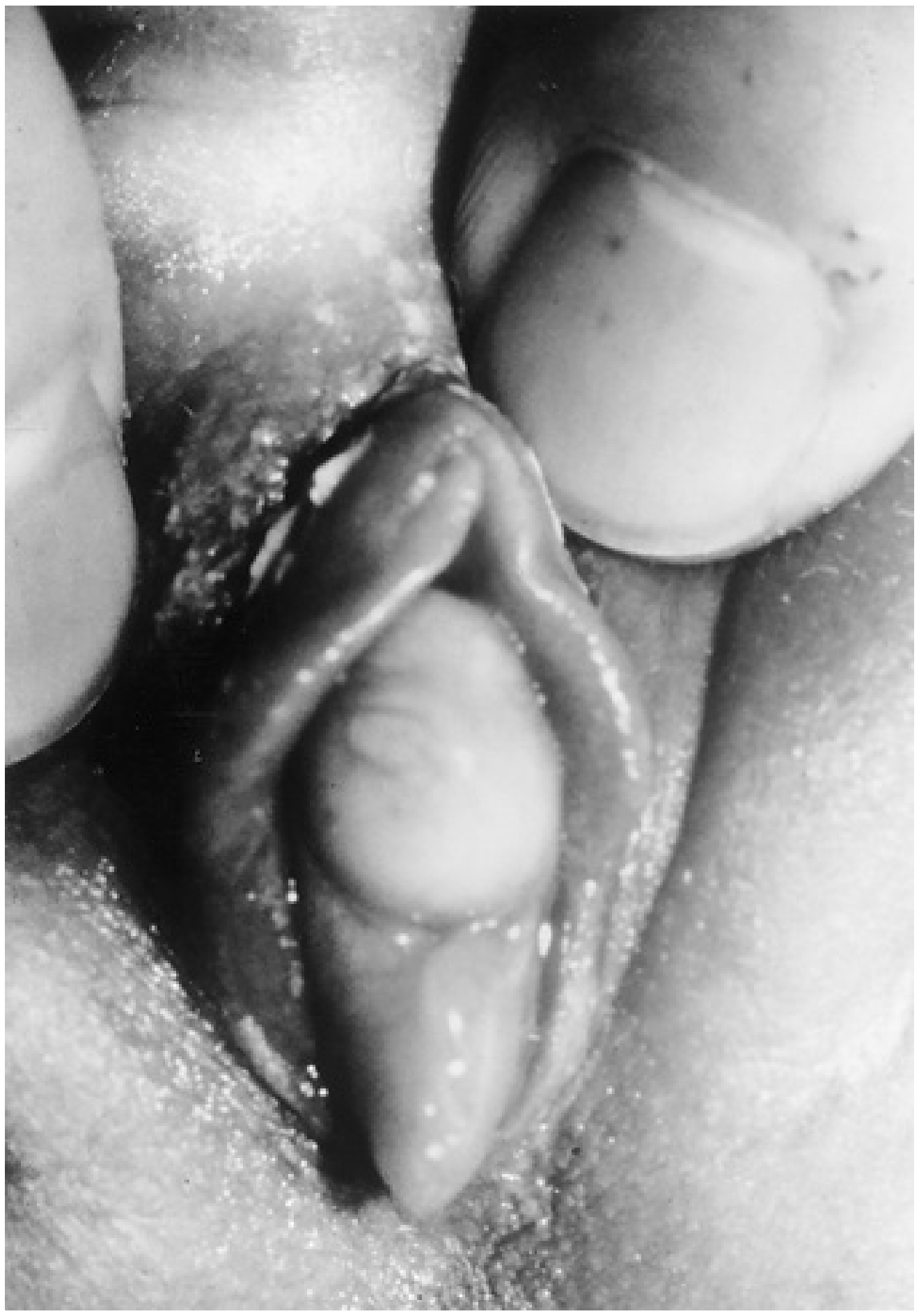

FIG. 47.7 Paraurethral cyst.

Gartner duct cysts represent incomplete regression of the wolffian duct system. They are cystic remnants that can be found along the anteromedial wall of the vagina (Pradhan and Tobon, 1986). A cystic structure related to a Gartner duct cyst is a covered ectopic ureter that enters into the vagina (Holmes et al., 1999; Rosenfeld and Lis, 1993). Embryologically, the ureter would not be expected to enter the vagina. However, an ectopically located ureter may end in a segment of the wolffian duct system, which in a female is represented by a Gartner duct cyst. In most instances this cystic structure spontaneously ruptures before delivery, thereby resulting in direct communication between the ectopic ureter and the vagina. However, if the surface epithelium fails to rupture, a covered, urine-filled cyst will exist within the vagina. Intraoperative injection of the cystic structure with radiographic contrast material may be beneficial in outlining the anatomy (Fig. 47.8). Incision of the cystic structure relieves the obstruction. As a general rule, the more ectopic the insertion of the ureter, the more dysplastic will be the segment that it drains. However, renal moieties that ectopically insert into the vagina may produce urine. Subsequent upper pole heminephrectomy may be indicated if the child has significant urine production from the segment (resulting in incontinence) or an infection develops after decompression.

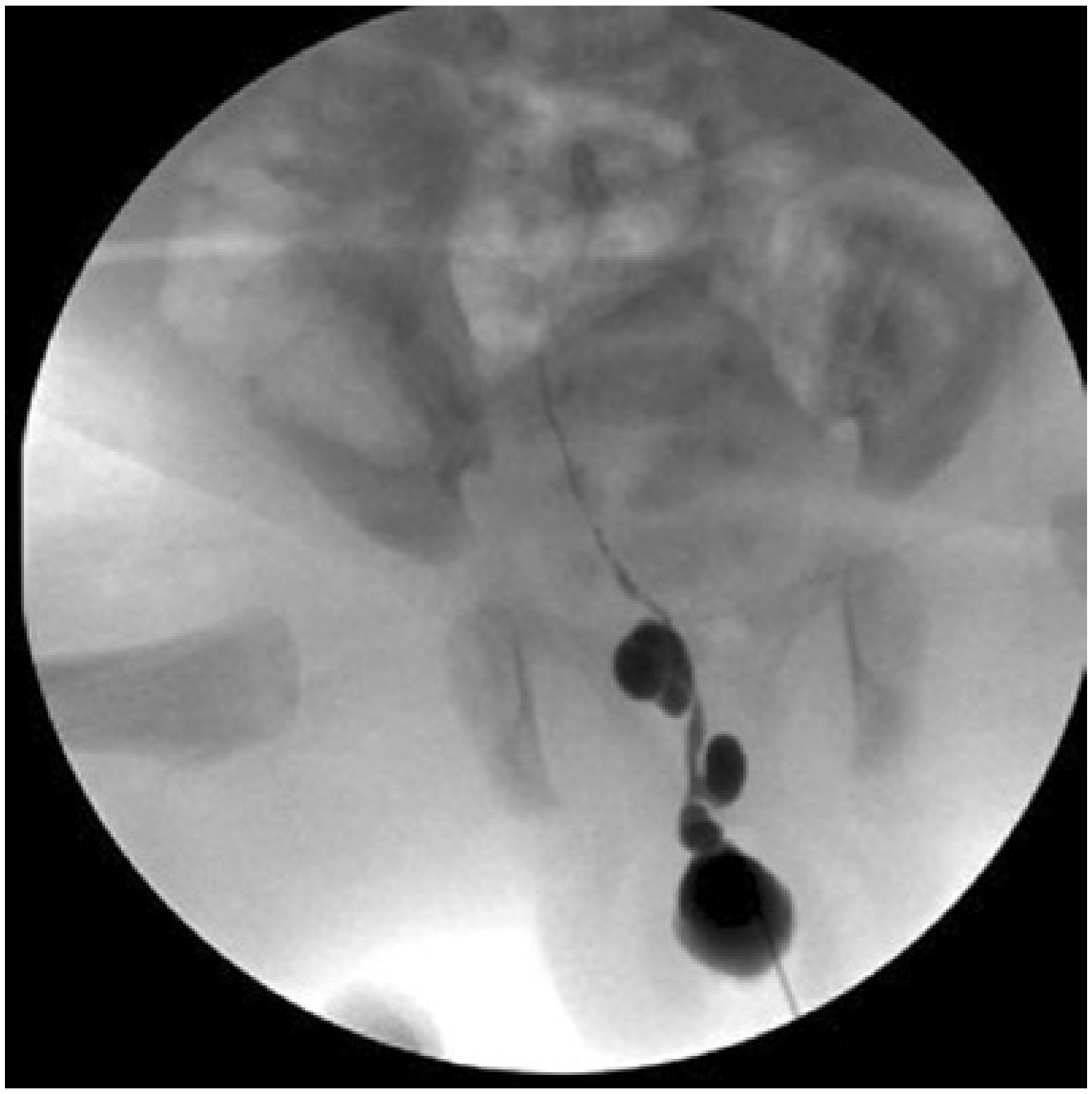

FIG. 47.8 Retrograde injection of an ectopic ureter inserting into a Gartner duct cyst. After injection of a vaginal cyst, contrast agent ascends cranially into an atretic, dysplastic ureter.

Prolapsed Ureterocele

An ectopic ureterocele is a cystic dilation of the terminal portion of the ureter that occurs predominantly in white females (Mandell et al., 1980). Approximately 90% of ectopic ureteroceles are associated with the upper pole of a duplex collecting system. Although they normally remain positioned proximal to the bladder neck, some may prolapse through the urethra during micturition, almost always in infancy, and result in urinary retention and a relative urologic emergency (Gingell et al., 1971). **Depending on the length of time that the ureterocele has been prolapsed, it may vary in color from pink to dusky purple (Fig. 47.9). If a prolapsed ureterocele is in the differential diagnosis,** bladder-renal ultrasonography should be performed to look for upper pole hydronephrosis in a duplicated collecting system (Fig. 47.10).

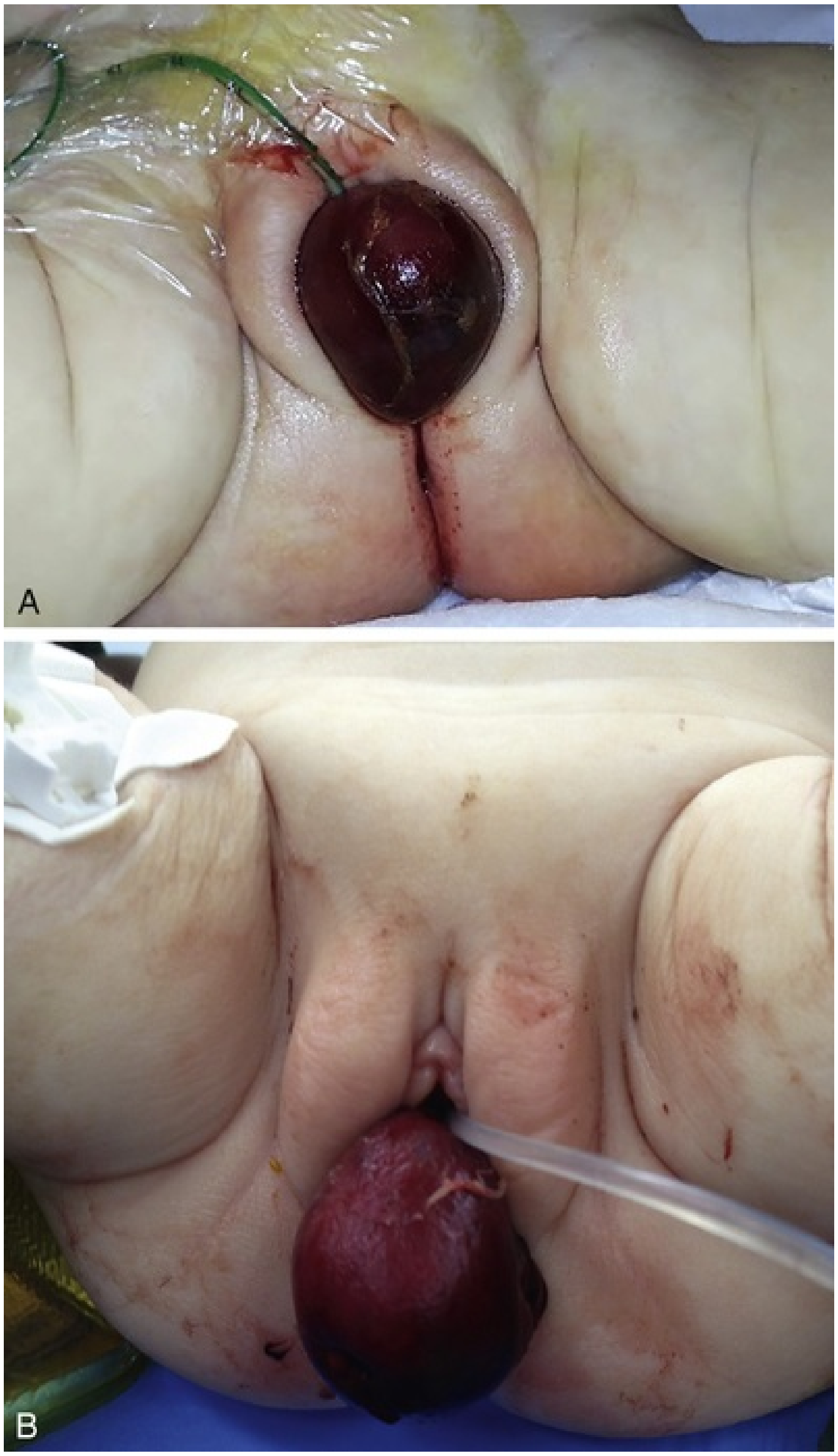

FIG. 47.9 (A) Prolapsed ureterocele. (B) Prolapsed ureterocele with catheter inserted in the urethra.

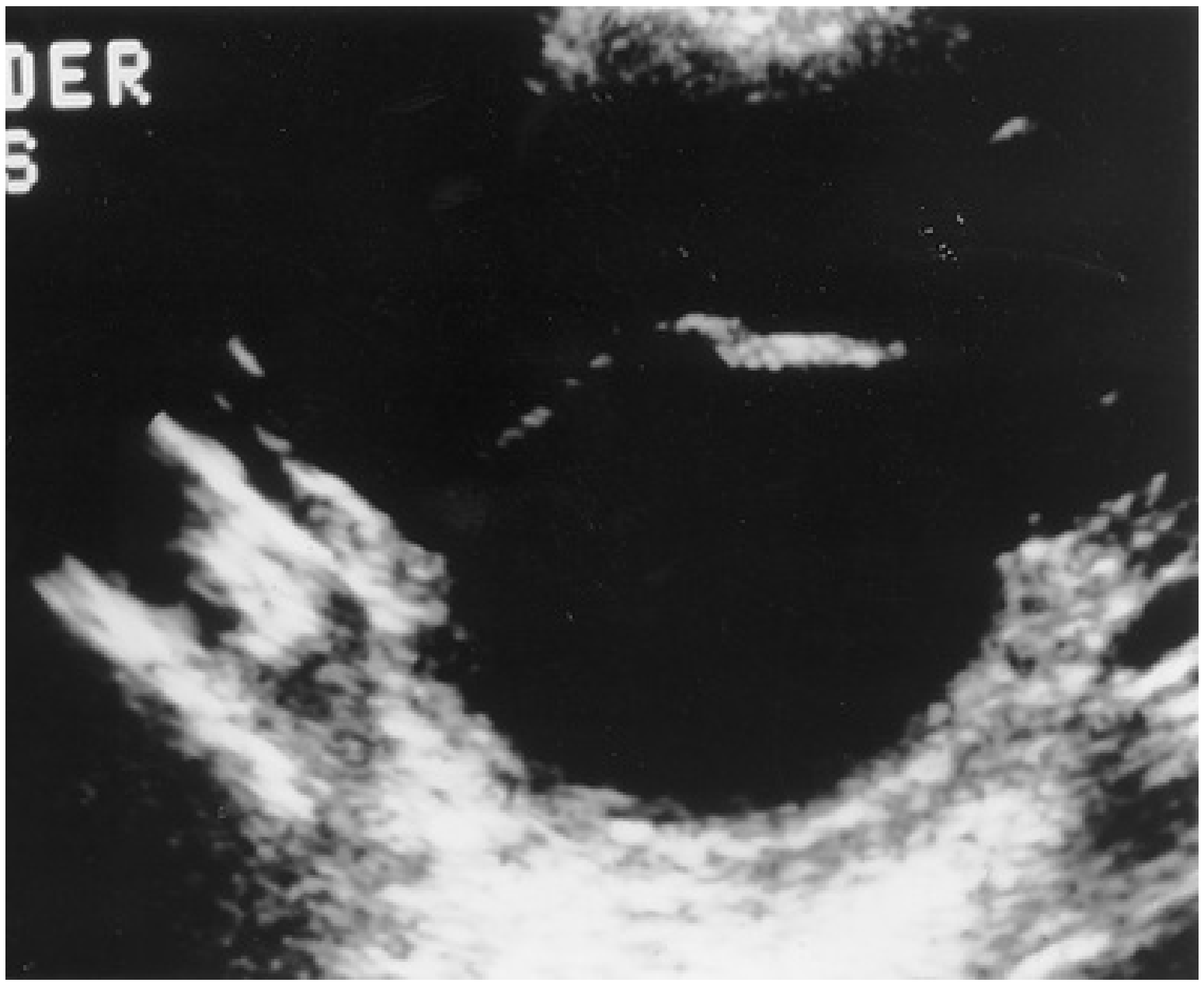

FIG. 47.10 A ureterocele evident on ultrasonography of the bladder.

Treatment of a prolapsed ureterocele consists of either needle decompression or incision and reduction and then placement of a urethral catheter. Although this occasionally can be achieved in the emergency department setting, abdominal straining by the infant may make this procedure difficult, and treatment under general anesthesia often is preferable. Injection of radiographic contrast material into the ureterocele can be helpful in identifying the relevant anatomy.

Ectopic Ureteral Insertion

In females an ectopic ureter may enter distal to the urethral sphincter. Ectopic ureters to the vestibule are typically associated with diurnal incontinence in the presence of normal voiding habits (Fig. 47.11). Most commonly the ureter subtends an upper pole of a duplex system. However, single-system ectopic ureters also may manifest in this fashion and on occasion can be associated with apparent complete absence of the kidney. A thorough search for an ectopic kidney at times may prove fruitful in identifying the cause of the patient's wetting (Borer et al., 1998).

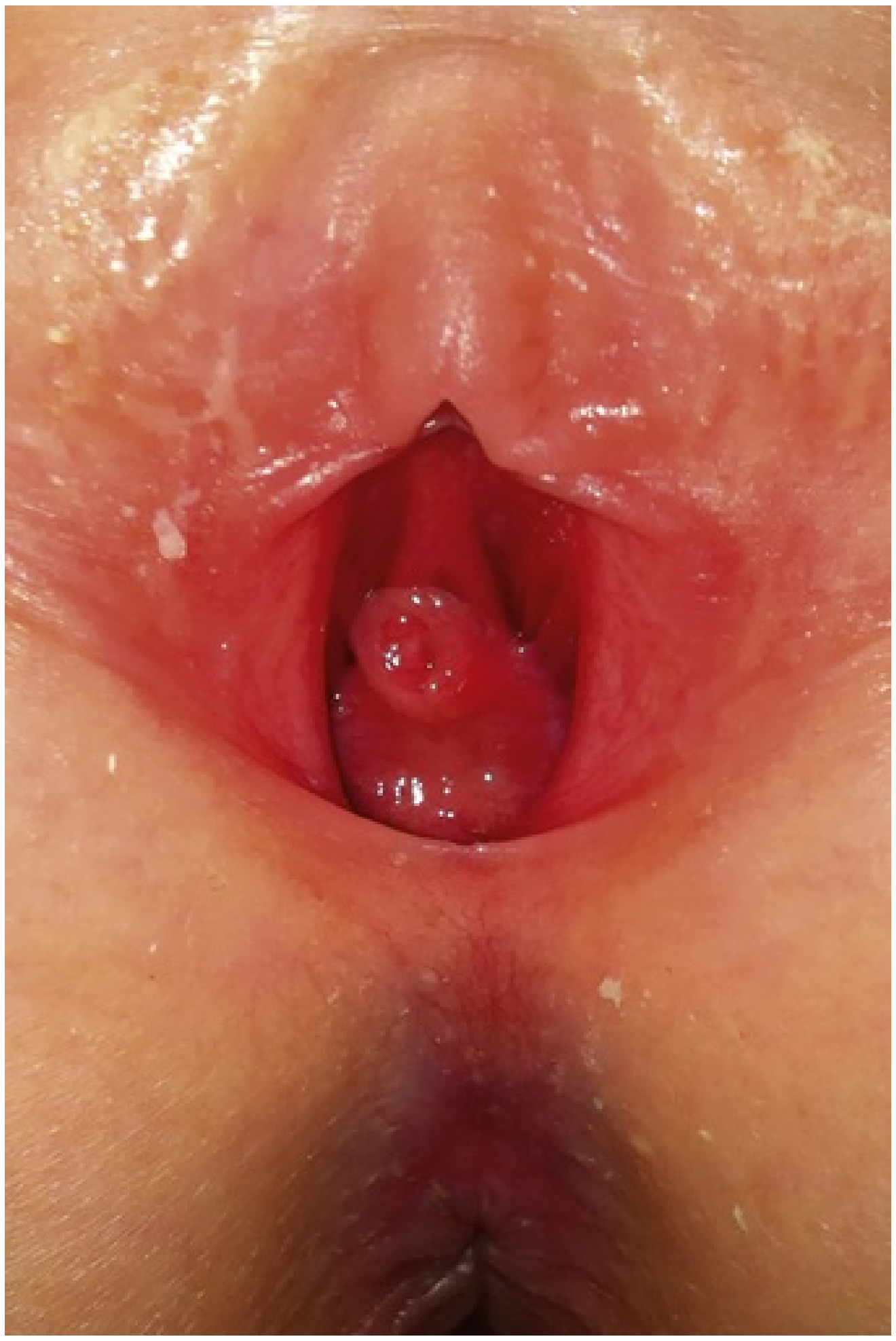

FIG. 47.11 Ectopic ureter to vestibule.

Key Points: Disorders of the Clitoris, Vestibule, and Urethra

- A diminutive clitoris is seen in patients with CAIS.
- Workup for a child with an introital (interlabial) mass that appears to be associated with the urethra always should include renal-pelvic ultrasonography.
- Urethral prolapse occurs most often in prepubertal black girls and in postmenopausal white women.

Disorders of the Vagina

Imperforate Hymen and Hymenal Skin Tags

Hymenal skin tags are almost a normal finding and are rarely symptomatic (Fig. 47.12). When symptomatic (i.e., bleeding), they should be excised to ensure that they do not represent a malignancy and to provide symptomatic relief. Congenital abnormalities of the hymen are not uncommon and range from an imperforate hymen to one with numerous small microperforations.

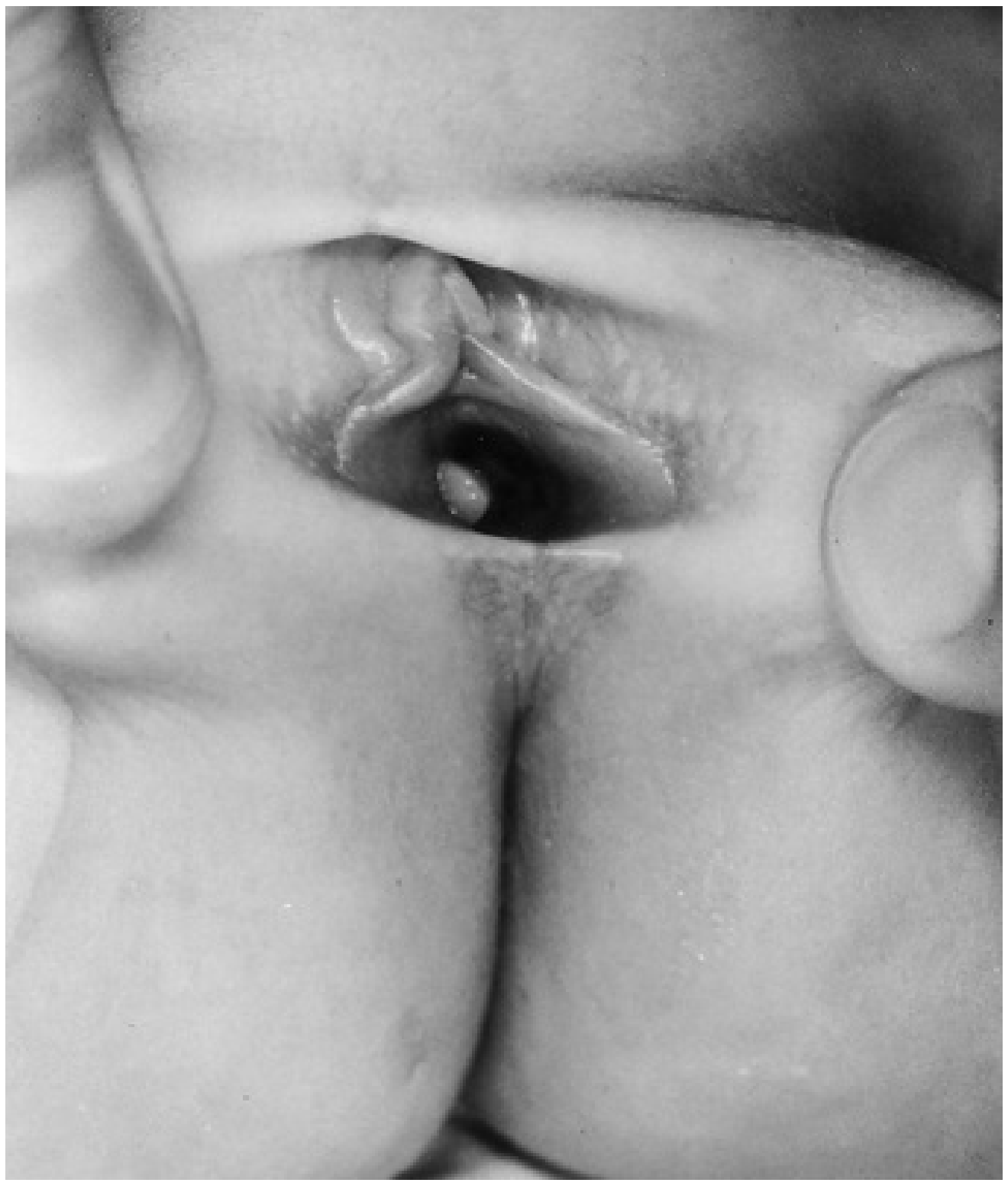

FIG. 47.12 Hymenal skin tag.

Imperforate hymen is probably the most common congenital obstructive anomaly of the female reproductive tract. The diagnosis is most frequently made at birth by noting the presence of a bulge along the posterior aspect of the introitus, which represents retained fluid within the vagina, or by palpation of a suprapubic mass from a distended vagina (Fig. 47.13). The buildup of retained vaginal secretions in the neonatal period, which imparts a whitish appearance to the bulging hymenal membrane, is caused by maternal estradiol stimulation. If the diagnosis is made after the neonatal period, the mucus often will have been reabsorbed, and a bulge in the hymenal membrane may no longer be evident. On occasion, the diagnosis is not made until the adolescent period, when the patient experiences amenorrhea and possibly cyclic abdominal pain. In these circumstances, a bluish bulging hymen may be observed on genital inspection and a mass will be appreciated on rectoabdominal palpation. In newborns, repair by incision of the hymenal tissue at the bedside is performed in the transverse direction to avoid inadvertent extension of the incision anteriorly or posteriorly (which may injure the urethra or rectal structures). Simple aspiration of the vagina without a definite drainage procedure should be discouraged because incompletely evacuated material may be prone to ascending bacterial growth. In pubertal girls, general anesthesia with excision of excess hymenal tissue may be indicated (Fig. 47.14).

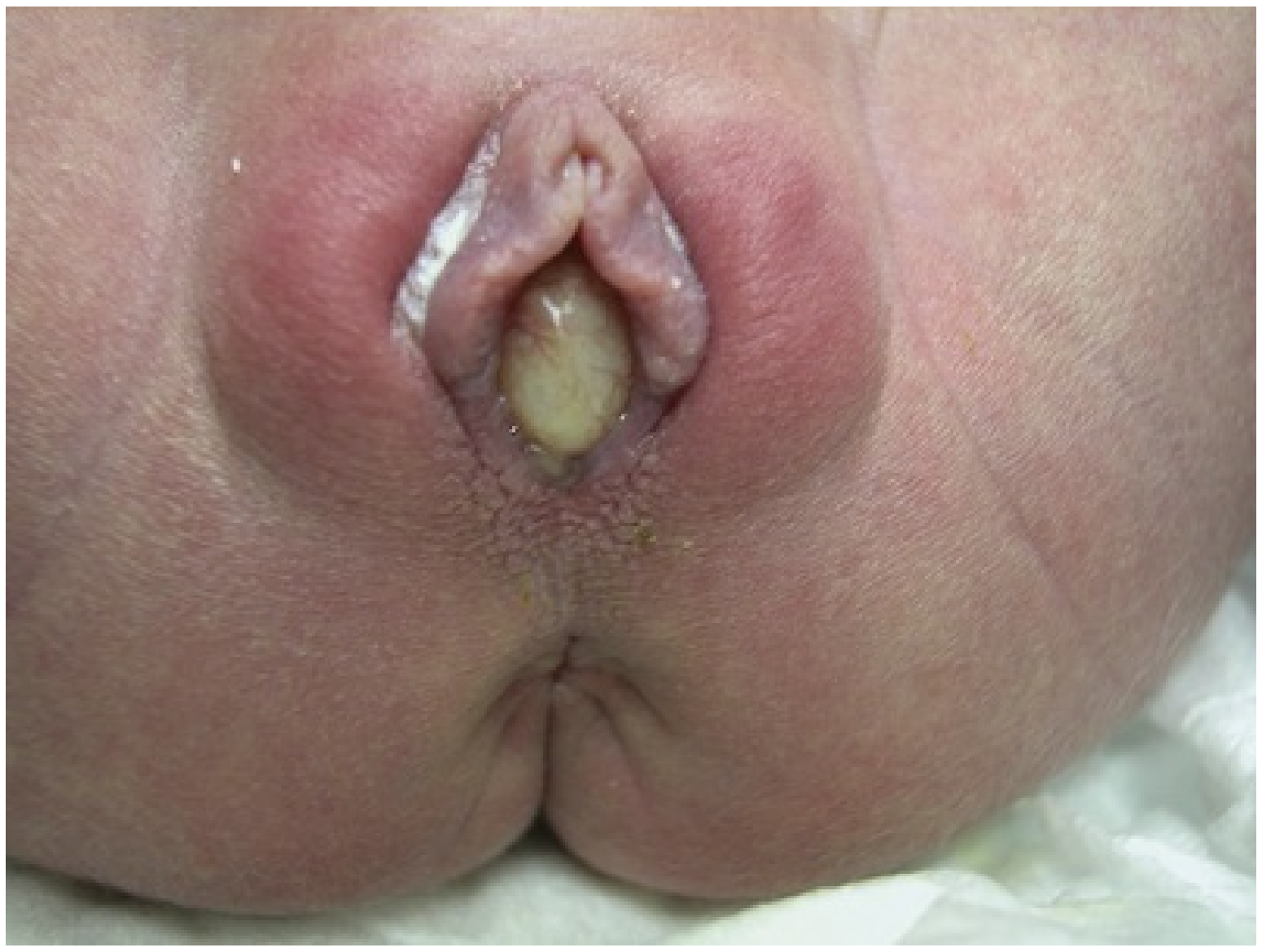

FIG. 47.13 Imperforate hymen. Note the significant distention from vaginal secretions.

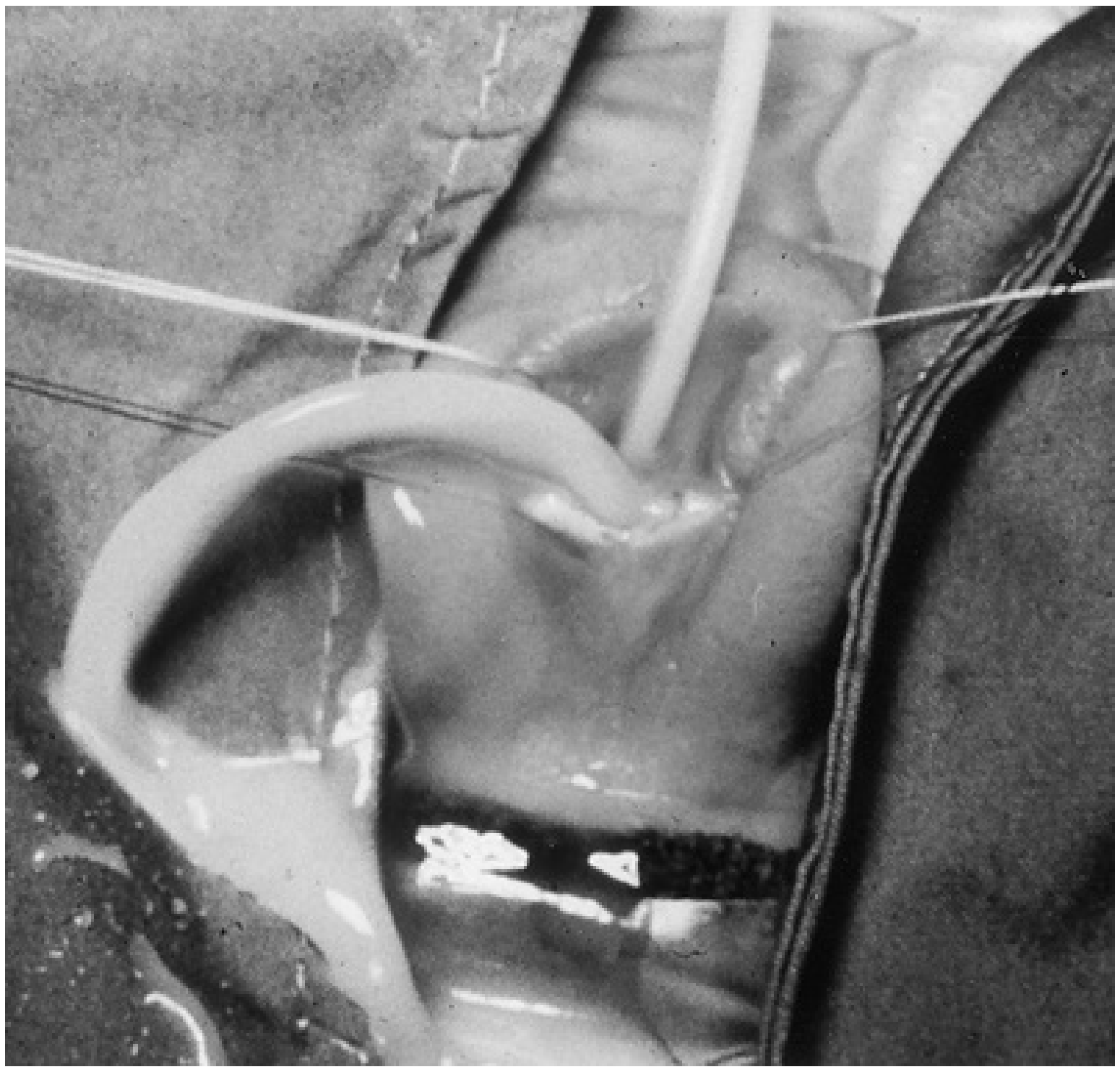

FIG. 47.14 Intraoperative photograph showing incisional drainage of an imperforate hymen. (From Yerkes EB, Rink RC: What urologists should know about pediatric gynecologic abnormalities. *Contemp Urol* 14:12, 2002.)

Acquired abnormalities of the hymenal ring usually result from sexual abuse. The associated finding of a hematoma, abrasion, or laceration in combination with hymenal transection should raise the possibility of this diagnosis. Proper examination under anesthesia and forensic swabbing of affected areas should be undertaken with the use of a standardized protocol.

Abnormalities of Vertical Fusion

General.

Patients with vertical fusion anomalies typically experience amenorrhea and abdominopelvic pain after the initiation of puberty. It is common for these patients to experience abdominal distention resembling a pregnancy. Awareness of this condition is important to avoid delay in diagnosis. A delay in diagnosis can increase the probability of retrograde menstrual flow through the fallopian tubes with resultant endometriosis (Deligeoroglou et al., 2012).

Transverse Vaginal Septum.

Transverse vaginal septa are believed to arise from a failure in fusion or canalization (or both) of the urogenital sinus and müllerian ducts. The estimated incidence of transverse vaginal septum is 1 in 70,000 females (Banerjee and Laufer, 1998). Many of the patients have amenorrhea and a distended upper vagina and experience amenorrhea. However, the condition may be incidentally recognized on imaging obtained for other reasons. **A complete transverse vaginal septum may be located at various levels in the vagina, but there is a higher frequency in the middle and upper third of the vagina. In one large series the distribution was 46% in the upper vagina, 40% in the middle vagina, and 14% in the lower vagina** (Fig. 47.15; Lodi, 1951). The septa are usually less than 1 cm thick and frequently have a small central or eccentric perforation (Suidan and Azoury, 1979). Even in cases in which a perforation is present, significant obstruction and ascending infection can occur. Transperineal, transrectal, and abdominal ultrasonography and MRI may be beneficial in establishing the diagnosis and determining the location and thickness of a transverse vaginal septum (Ammann et al., 1983; Caloia et al., 1998; Doyle, 1992; Fedele et al., 1999; Lang et al., 1999; Meyer et al., 1995). MRI can help determine whether a cervix is present so that a high septum can be differentiated from congenital absence of the cervix. Failure to differentiate between these diagnoses can result in significant patient morbidity (Casey and Laufer, 1997).

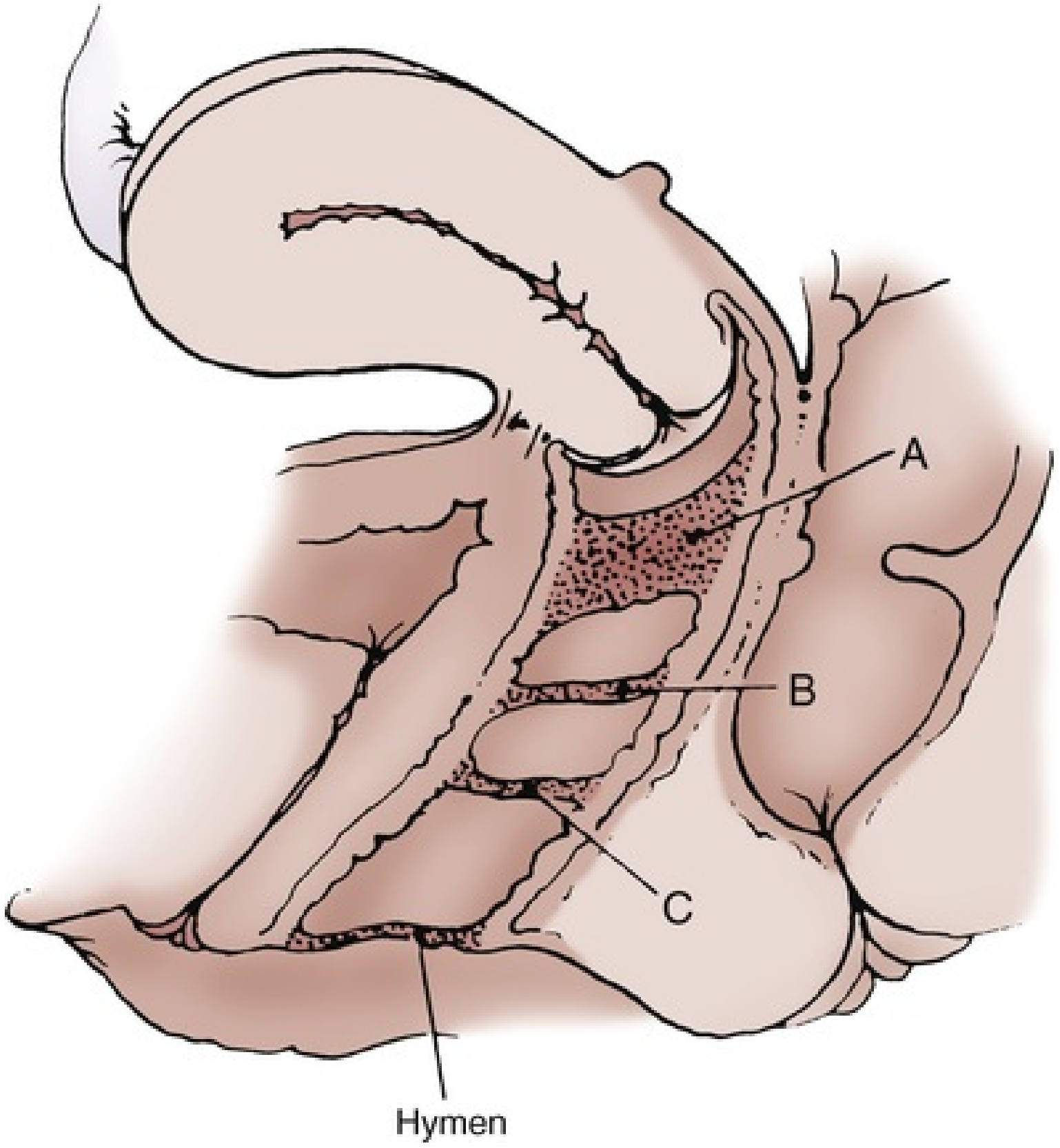

FIG. 47.15 Transverse vaginal septum. *A,* High (upper vagina); *B,* middle; *C,* low.

Several surgical treatment modalities have been developed to treat congenital transverse vaginal septa. If the patient's pain from hematocolpos is manageable, surgery may be delayed with suppression of endometrial activity by a gonadotropin-releasing hormone (GnRH) agonist or continuous oral contraceptives (Beyth et al., 2004). This may allow time for dilation of the lower vaginal segment, potentially improving the ease of surgical repair. Techniques include simple incision (Brenne et al., 1965; Buttram, 1983), surgical excision of the septum followed by approximation of the corresponding portions of the transversely cut edges of the upper and lower mucosal membranes of the septum (Rock et al., 1982), and the use of Z-plasties involving vaginal mucosa (Wierrani et al., 2003). We have described a method that improves the safety of entering the obstructed vaginal segment and subsequently excising the septum (Keenan and Kaefer, 2012). Under ultrasound guidance a 14-gauge angiocatheter is placed through the thick transverse septum. After aspiration reveals thick blood, a 0.35-mm Sensor wire (Boston Scientific, Marlborough, MA) is placed through the angiocatheter and the NephroMax (Boston Scientific) balloon dilating system is placed over the wire. The balloon is insufflated and subsequently removed, providing a generous aperture through which the remainder of the septum can be excised (Fig. 47.16). In cases in which the septum is of significant thickness, subsequent excision of the wall with a resectoscope loop can provide a more satisfactory long-term result.

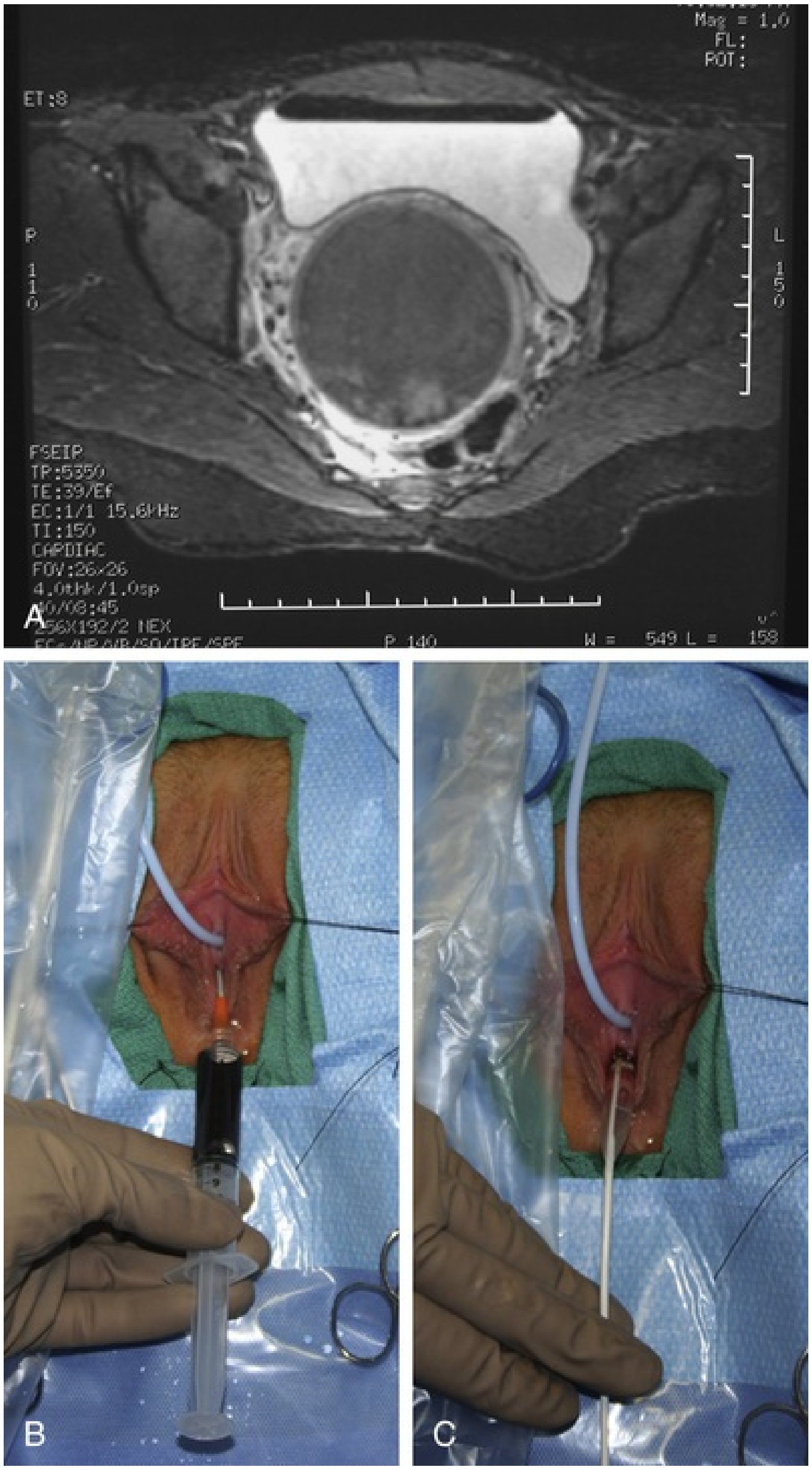
Mag = 1.0
FL:
ROT:
ET:8
P
110
L
150
FSEIR
TR:5350
TE:39/Ef
EC:1/1 15.6kHz
TI:150
CARDIAC
FOV:26x26
4.0thk/1.0sp
40/08:45
256X192/2 NEX
P 140
W = 549 L = 158
A
B
C

FIG. 47.16 Balloon-assisted division of transverse vaginal septum. (A) Hematocolpos on magnetic resonance imaging resulting from transverse vaginal septum. (B) Angiocatheter placed into transverse vaginal septum (placed under ultrasound guidance). (C) NephroMax balloon dilating the septum.

A transabdominal surgical approach for management of transverse vaginal septum has been described. The posterior wall of the distended vagina is opened in a vertical fashion to reveal the septum, which is then perforated. An inflated Foley balloon is left across the site for 2 weeks and then removed. Although this approach would seem unnecessarily cumbersome, the authors suggest this as an alternative approach when sociocultural beliefs dictate that the hymen is not violated (Gezginc et al., 2011).

Vaginal stenosis at the site of resection is the most common complication (Joki-Erkkila and Heinonen, 2003). To minimize this complication Z-plasties are often used. The primary advantage of a Z-plasty is that as the suture line contracts the incision is more likely to take on a longitudinal rather than a transverse orientation. Placement of a vaginal mold subsequent to surgery has been reported to further reduce the risk for postoperative stenosis (Bijsterveldt and Willemsen, 2009). Characteristics of molds for transverse septa are different from those used after a McIndoe vaginoplasty (see later). Whereas a solid mold may be used after a vaginoplasty skin graft (because there is no uterus), the mold used after resection of a transverse septum is ideally hollow, to allow egress of menstrual flow.

Vaginal Atresia (Distal Vagina).

Vaginal atresia occurs when the urogenital sinus fails to contribute to formation of the lower (distal) portion of the vagina. This condition differs from vaginal agenesis and testicular feminization in that the müllerian structures are not affected. As a result, the uterus, cervix, and upper portion of the vagina are normal. A very shallow dimple caudal to the urethral opening may be appreciated on physical examination. Palpation of a distended vagina on rectal examination may help distinguish this condition from testicular feminization or vaginal agenesis. Radiographic evaluation in the form of ultrasonography or MRI, or both, is mandatory to adequately define the müllerian anatomy before intervention.

Surgical correction consists of a transverse incision at the level of the hymenal ring. Dissection is carried out through the fibrous area of the absent lower vagina until the upper vagina is reached. As in treatment of a transverse vaginal septum, distention of the vagina with retained menstrual blood products can prove extremely beneficial in that it acts as a tissue expander. After the obstruction is drained and the vaginal mucosa is identified, a pull-through procedure can be performed to bring the distended vagina down to the introitus. The distance to bridge between the vagina and the perineal surface almost always can be successfully managed with perineal skin flaps or simple mobilization of the vagina (or both). Ramenofsky and Raffensperger (1971) described a combined abdominoperineal approach that can help in exposing and anastomosing the distal vagina to the perineal skin.

Vaginal Agenesis (Müllerian Aplasia).

Vaginal agenesis, which occurs at an incidence of approximately 1 in 5000 live female births, is congenital absence of the proximal portion of the vagina in an otherwise phenotypically (i.e., normal secondary sexual characteristics), chromosomally (i.e., 46,XX), and hormonally (i.e., normal levels of luteinizing hormone and follicle-stimulating hormone) intact female (Bryan et al., 1949; Griffin et al., 1976; Herlin et al., 2016). Although Renaldus Columbus is credited by some authors as the first to describe a case of vaginal agenesis, Mayer (1829) was one of the first to report vaginal agenesis in stillborn children (Lesavoy, 1985). In 1838 Rokitansky reported 19 adult autopsy cases of uterovaginal agenesis, including 3 with associated unilateral renal agenesis. In 1910 Küster recognized urologic associations, such as renal ectopy and agenesis, along with skeletal deformities. Hauser and Schreiner (1961) brought further attention to the frequent association of renal and skeletal anomalies in these patients and stressed the differences between patients with these findings and those with testicular feminization.

The Mayer-Rokitansky-Kuster-Hauser (MRKH) syndrome, as the entity of **müllerian** aplasia has come to be known, results from failure of the sinovaginal bulbs to develop and form the vaginal plate (Fig. 47.17). This may be caused by improper induction of the sinovaginal bulbs from the neighboring uterovaginal primordium. Chronologically, the uterovaginal canal develops at a point in embryogenesis during which other critical mesodermally derived organ systems are also forming, which in part explains the many associated findings. Müllerian aplasia also has been associated with maternal deficiency of galactose-1-phosphate uridyltransferase (Cramer et al., 1996). In contrast to vaginal atresia, the hymenal fringe is usually present, along with a small vaginal pouch, because they are both derived embryologically from the urogenital sinus. Most patients with MRKH syndrome are initially evaluated by the physician after the expected age of menarche because of primary amenorrhea. This syndrome is in fact second only to gonadal dysgenesis as a cause of primary amenorrhea. A minority of patients have cyclic abdominal pain caused by retention of menstrual fluid in the uterus. Physical examination reveals absence of the vagina. Inguinal hernia is less common in this disorder than in complete androgen insensitivity syndrome (Schmid-Tannwald and Hauser, 1973). The karyotype is that of a normal 46,XX woman. Radiographic evaluation is indicated to more fully delineate remnant müllerian structures and search for associated anomalies involving the renal and skeletal systems.

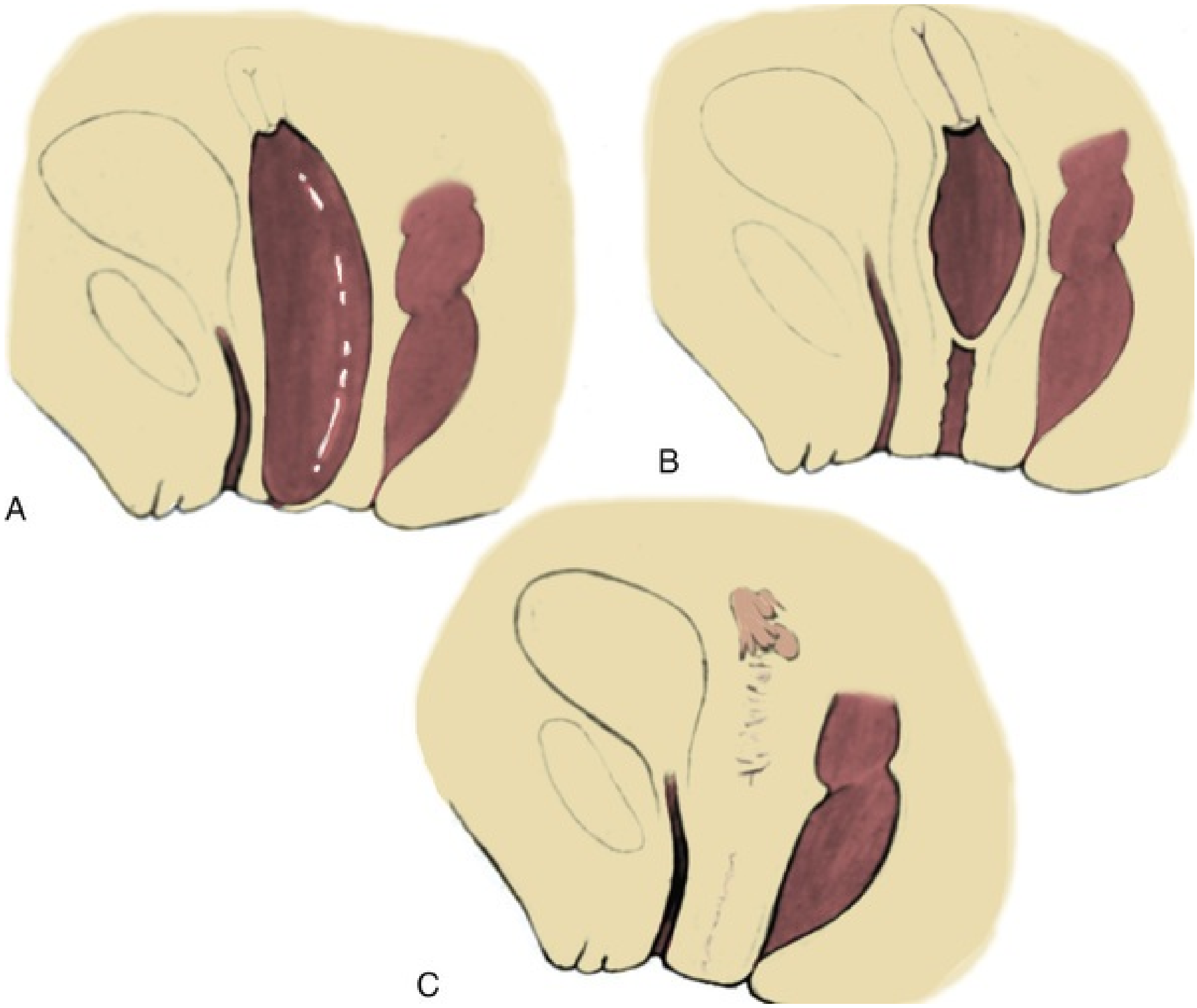

FIG. 47.17 Forms of vaginal obstruction. (A) Imperforate hymen. (B) Transverse vaginal septum. (C) Vaginal agenesis. (From Yerkes EB, Rink RC: What urologists should know about pediatric gynecologic abnormalities. *Contemp Urol* 14:12, 2002.)

Associated Findings

MRKH syndrome is associated with variable absence or hypoplasia of the cervix, uterus, and fallopian tubes. In approximately 10% of patients, a normal but obstructed uterus or rudimentary uterus with functional endometrium is present (Bates and Wiser, 1985; Murray and Gambrell, 1979; Singh and Devi, 1983). In one of the largest single series, Salvatore and Lodovicci (1978) reported that of 91 patients with vaginal agenesis, almost 25% lacked a uterus, 55% had a solid rudimentary uterus, and the remaining 30% had other abnormalities of this organ. In addition they demonstrated that, although the fallopian tubes were normal in 32% of cases, they were rudimentary in almost 50% and completely absent in 10%. Although occasionally cystic, the ovaries were always present and functional (Salvatori and Ludovicci, 1978). It was subsequently recognized, based on the morphology of the retained müllerian structures, that MRKH syndrome could be divided into the typical and atypical forms (Schmid-Tannwald and Hauser, 1977).

In the typical form of MRKH syndrome (type A) the patient has symmetrical uterine remnants and normal fallopian tubes. The atypical form (type B) is characterized by asymmetrical uterine buds and/or abnormally developed fallopian tubes. This distinction is important because the overwhelming majority of associated findings and other organ systems have been reported to be present with the atypical form, whereas in the typical form these findings are usually absent (Strubbe et al., 1992, 1993).

The prevalence of type A versus type B variants of MRKH syndrome appears to vary between different racial and ethnic groups. Although 46.2% of cases have recently been shown to be type B in a Caucasian cohort, the percentage of cases can vary between 7% and 28% among various Chinese populations (Deng et al., 2019).

The association between vaginal agenesis and developmental abnormalities of the kidney was first recognized by Rokitansky (1838). Approximately one-third of patients were found to have abnormal renal findings on intravenous pyelography or ultrasound examination (Strubbe et al., 1993). Renal anomalies are present almost exclusively in patients with the atypical subtype of vaginal agenesis (type B). In the series by Strubbe et al. (1993), 34 of 51 patients with type B anatomy had renal anomalies, but none of the 40 patients with type A anatomy demonstrated such a deformity. A meta-analysis published by Griffin et al. (1976) demonstrated that the renal anomaly consists of either unilateral renal agenesis or ectopia of one or both kidneys in 74% of those affected. The close proximity of the mesonephric and paramesonephric structures during the early phase of fetal development is thought to be the reason for this frequent association of renal anomalies. Not surprisingly, the converse is also true: the incidence of associated genital anomalies in female patients with renal anomalies ranges between 25% and 89% (Thompson and Lynn, 1966).

Associated congenital abnormalities of the skeletal system have been described in 10% to 20% of cases (Strubbe et al., 1987; Turunen, 1967; Willemsen, 1982). Congenital fusion (failure of segmentation) of the cervical vertebrae, known as the Klippel-Feil syndrome, occurs approximately once in 30,000 to 40,000 live births (Gunderson et al., 1967). The association between this abnormality of cervical somite development and vaginal agenesis was first recognized by Duncan (1977). He proposed the term *MURCS association* to describe a combination of **Mü**llerian duct aplasia, **R**enal aplasia, and **C**ervicothoracic **S**omite dysplasia, which many believe is caused by a generalized disordered development of mesodermal differentiation during the fourth week of fetal life (Duncan et al., 1979). Strubbe et al. (1992) demonstrated that the Klippel-Feil abnormality was found only in patients with the atypical form of MRKH syndrome (type B). Additional, albeit less common, skeletal abnormalities include scoliosis and abnormalities of the hands and face (Fisher et al., 2000; Willemsen, 1982). Abnormal pelvic vasculature has also been reported. Although this does not appear to occur as frequently as in other conditions that affect the female genitalia (i.e., cloaca), awareness of this possibility is important to avoid surgical misadventure (Bailey et al., 2010). Unlike müllerian anomalies that are associated with an increased incidence of abnormal cloacal septation, vaginal agenesis is not associated with an increased incidence of lumbosacral spinal disorders or occult spinal dysraphism (Gunderson et al., 1967).

Key Points: Disorders of Vagina

- Anomalies of the female reproductive system can be grouped into three main categories, those resulting from (1) hypoplasia or agenesis, (2) vertical fusion, and (3) lateral fusion.
- Transverse vaginal septa are believed to arise from a failure in fusion or

canalization (or both) of the urogenital sinus and müllerian ducts.

- Vaginal atresia occurs when the urogenital sinus fails to contribute to formation of the lower (distal) portion of the vagina.
- Vaginal agenesis is congenital absence of the proximal portion of the vagina in an otherwise phenotypically, chromosomally, and hormonally intact female.
- MRKH syndrome, as the entity of müllerian aplasia has come to be known, results from failure of the sinovaginal bulbs to develop from the vaginal plate.

Vaginal Replacement Surgery

Creation of a Skin Neovagina.

Nonoperative and operative treatment options exist for this anomaly. Regardless of the method used, it can be very helpful to have the patient speak with someone who has previously undergone treatment before a specific management strategy is initiated (Ingram, 1981). The nonoperative approach, initially popularized by Frank (1938), involves gentle pressure of graduated hard dilators against the perineal surface to create a progressive invagination of the vaginal dimple. Ingram (1981) modified this technique by using a bicycle seat mounted on a stool. The nonoperative approach has greatest success when a vaginal dimple or pouch is already present (Williams et al., 1984, 1985). Gargollo et al. (2009) recently reported their experience with 69 females (mean 17.5 years) with vaginal agenesis treated with progressive perineal dilation. Success, defined as the ability to achieve sexual intercourse, vaginal acceptance of the largest dilator without discomfort, or vaginal length of 7 cm, was achieved in 88% of patients. The authors concluded that progressive perineal dilation should be offered as first-line therapy in adolescents with congenitally absent vagina.

Modifications of the Frank technique of perineal pressure have been developed that incorporate the surgical placement of tension sutures to aid in directing pressure from a Plexiglas dilator against the vaginal dimple (Vecchietti, 1979). The mold, often referred to as an “olive,” has sutures attached to it that are guided in a cranial direction through the vesicorectal space into the peritoneal cavity and brought out through the abdominal wall (Vecchietti technique). Tension is progressively increased via the abdominal wall sutures until sufficient vaginal length has been achieved. To avoid a formal laparotomy, laparoscopic techniques have been described to assist in dissection of the tissue plane for the Vecchietti technique (Borruto, 1992; Brucker et al., 2008; Fedele et al., 1996, 1999; Gauwerky et al., 1992). In more recent series by Fedele et al. (2006), all patients were found to have healthy vaginal mucosa, with the average vaginal length being almost 8 cm at 3 months. This technique has had limited use by urologists.

If the Frank method has been unsuccessful or is not accepted as a reasonable option by the patient or parents, creation of a functional vagina can be achieved by one of several techniques (Abbé, 1898; Hendren and Atala, 1994; McIndoe and Banister, 1938). The first landmark advance in vaginal reconstruction is attributed to Abbe in 1898. He described dissecting a canal between the rectum and urethra and lining this area with split-thickness skin grafts. This procedure was later popularized by McIndoe, and the procedure that now bears his name has gained wide acceptance in the United States (McIndoe and Banister, 1938). Preoperative preparation consists of full mechanical and antibiotic bowel preparation. A split-thickness skin graft is taken from the buttocks (0.018 to 0.022 inch) and tubularized over a stent (Fig. 47.18). A transverse incision is made at the level of the perineal dimple, and the potential space between the urethra and the rectum is carefully dissected up to the level of the peritoneal reflection. The graft and mold are then inserted into the potential space, and the labia minora are sutured around the stent to prevent extrusion during the initial healing phase (McIndoe, 1950). Many types of vaginal stents have been used for this purpose, including packed gauze, wood covered with a condom, silicone foam, acrylic, various metals, and inflatable vaginal stents (Barutcu and Akguner, 1998; Chen, 1994; Concannon et al., 1993). The Foley catheter is replaced by a suprapubic catheter and postoperatively the patient is kept at strict bed rest for 1 full week. A high incidence of postoperative vaginal stenosis necessitates postoperative vaginal dilation (Ingram, 1981). Excellent patient satisfaction has been reported in most large series (Alessandrescu et al., 1996; Martinez-Mora et al., 1992; Strickland et al., 1993).

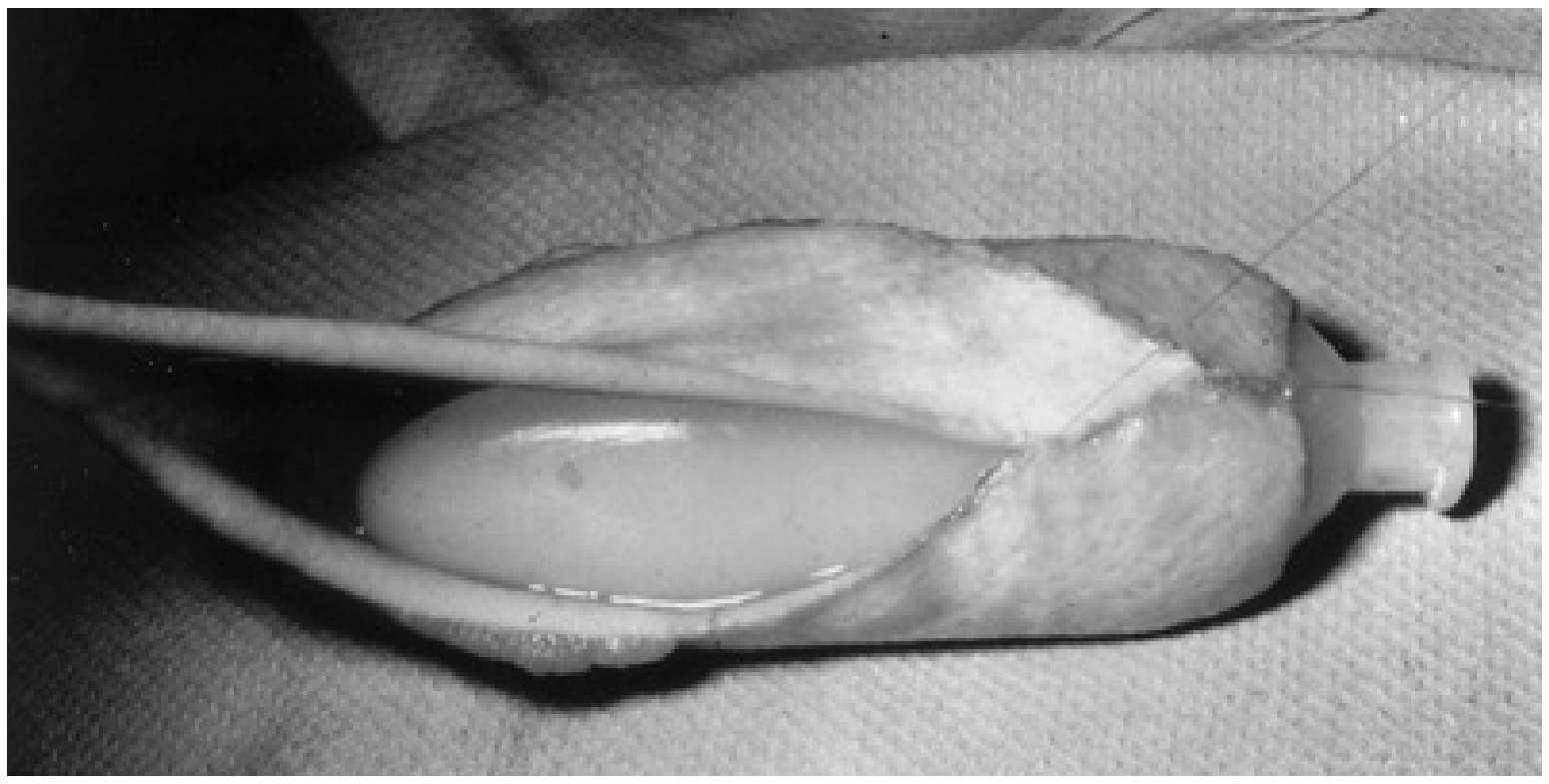

FIG. 47.18 McIndoe skin vagina sewn over vaginal stent.

Other options for creation of a neovagina with local tissues include the use of full-thickness skin graft from the buttocks or full-thickness skin flaps based on the labia majora. Those who champion the use of full-thickness skin grafts report a lower incidence of graft contracture than when split-thickness graft techniques are used (Sadove and Horton, 1988). The Williams (1964) vaginoplasty involves a creation of a vaginal pouch from the labia majora. The combination of this procedure and Frank-type dilation along the vaginal access can provide a satisfactory result. In 2014 Baker's team described the use of buccal mucosa for construction of the neovagina (Grimsby et al., 2014). Oral mucosa shares many properties similar to vaginal mucosa in that both are hairless, moist, and nonkeratinized stratified squamous epithelium. Oral mucosa possesses a dense layer of elastic fibers and a predilection for robust neovascularization resulting in excellent graft survival and function. Other authors have subsequently published favorable long-term anatomic and functional results using this versatile tissue (Li et al., 2014).

Many other surgical procedures have been developed for creation of a functional neovagina with various muscle flaps (e.g., pudendal thigh, rectus abdominis, buttock) (Dumanian and Donahoe, 1992; Joseph, 1997; Lilford et al., 1989; McCraw et al., 1976; Wang and Hadley, 1993). The pelvic peritoneum and human amnion are two other donor sites that have been used to create a neovagina (Ashworth et al., 1986; Davydov, 1977; Marquis et al., 2008; Morton and Dewhurst, 1986; Tamaya and Imai, 1991).

Between 2006 and 2013 Panici et al. performed McIndoe vaginoplasty procedures in 23 patients with MRKH syndrome using autologous cultured vaginal tissue. They reported that in all cases the vagina was of normal length and depth and that it allowed for normal and satisfying sexual intercourse (Panici et al., 2015). A subsequent quality-of-life study involving their first 39 patients revealed that 12 months after the procedure, 29 patients were engaged in regular sexual activity and had satisfactory sexual function compared with the general population (Sabatucci et al., 2018).

Creation of an Intestinal Neovagina.

Baldwin first described use of bowel for creation of the vagina in 1907. The procedure involved anastomosis of a U–shaped segment of sigmoid colon to the perineum with subsequent division of the intervening septum (Hensle and Dean, 1992). Additional experience with this technique was reported by Fall in 1940, but it did not gain widespread acceptance until the 1970s because of high patient morbidity and mortality (Fall, 1940; Pratt, 1972). Subsequent improvements in technique and postoperative care resulted in renewed enthusiasm for these techniques (Hendren and Atala, 1994; Hensle and Reiley, 1998; Tillem et al., 1998; Turner-Warwick and Kirby, 1990). Sigmoid, cecum, and small intestine have been used successfully for the creation of a functional neovagina.

The day before surgery, the patient undergoes full mechanical and antibiotic cleansing of the alimentary tract. The procedure is performed with the patient supine, the legs spread, and the knees bent (frog-leg position). In an older child, Allen stirrups can be used. For a sigmoid vaginoplasty, the intra-abdominal portion of the procedure begins by first identifying an appropriate length of distal sigmoid with a blood supply that will comfortably reach the perineum (Fig. 47.19). The distal end of the proposed segment was then divided and anastomosed to the perineum (Fig. 47.20). An intervening segment of sigmoid (approximately 3 cm) is excised to create a space between the oversewn proximal edge of the bowel vagina and the end of the sigmoid, which is anastomosed to the rectum. This maneuver prevents any overlap of suture lines and thereby has the potential advantage of limiting the incidence of fistula formation. The bowel vagina is thereafter fixed to the posterior peritoneum to prevent prolapse. Gosalbez (personal communication, 2009) described a modified Monti technique of bowel detubularization for vaginal replacement that can aid in allowing the segment to reach the perineum. By opening the colonic segment close to its mesentery along one side of the bowel and then re-tubularizing in a Heineke-Mikulicz fashion, as described by Monti, the reconfigured segment allows for the mesentery to be located at the most cranial end of the tube and allows the caudal end to extend more distally.

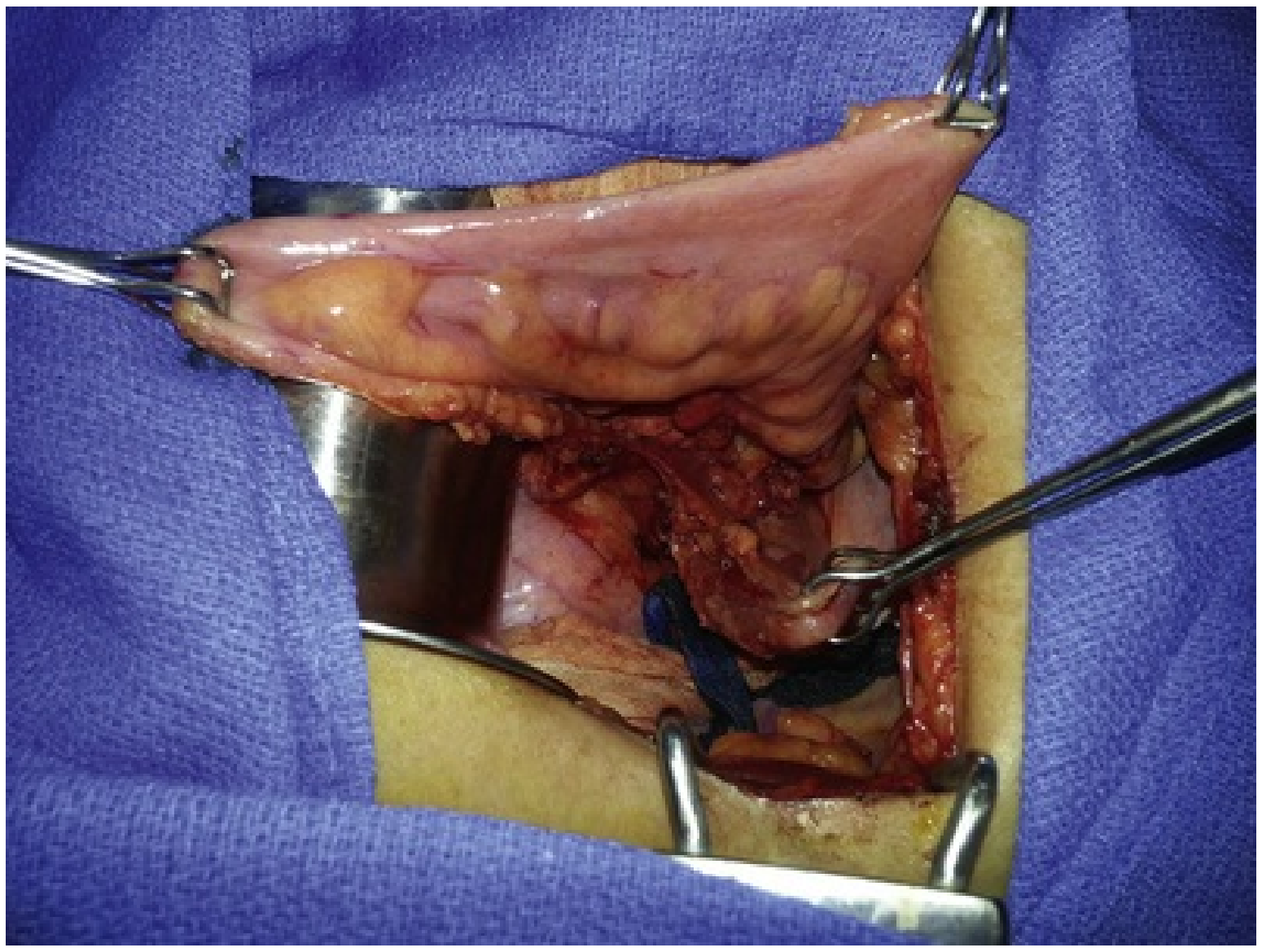

FIG. 47.19 Sigmoid segment harvested for bowel vagina. Clamp on peritoneum.

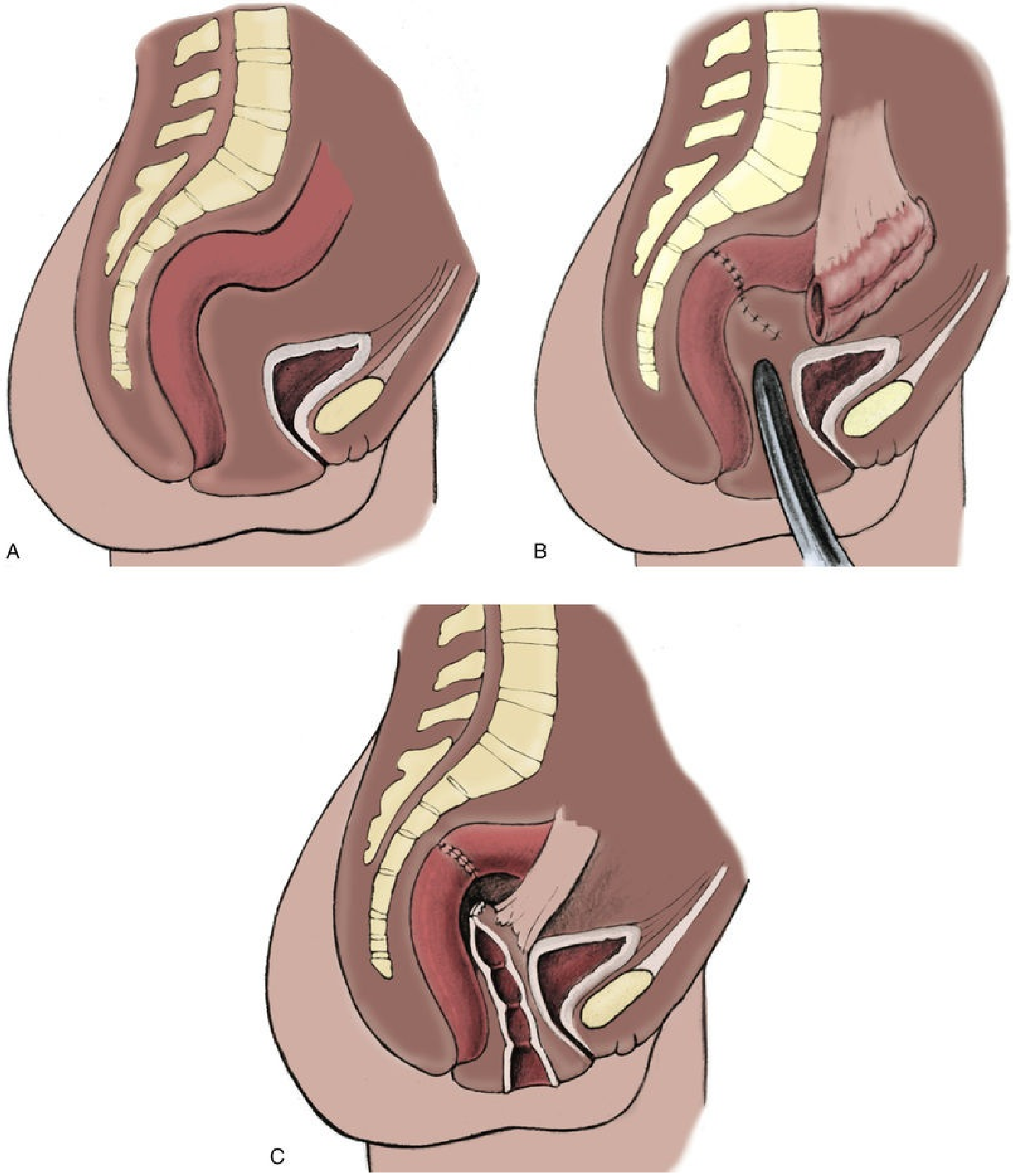

FIG. 47.20 (A) Vaginal agenesis. (B) Harvest of colonic segment and creation of vaginal space. (C) Colonic segment sewn in place.

Although we have had the most success with the sigmoid, a small bowel segment may be chosen with a vascular pedicle that is of adequate length to reach the perineum. After isolating an appropriate length of ileum and reestablishing bowel continuity, the segment is detubularized and reconfigured in a conical arrangement to provide increased internal diameter (Hendren and Atala, 1994). The segment is then brought down to the perineum and sewn in place, as for a sigmoid neovagina. To avoid a formal laparotomy, laparoscopically assisted techniques have been described for harvest and delivery of the bowel segment to the perineal location (Ota et al., 2000).

If there is a perineal dimple (i.e., the segment of vagina contributed by the urogenital sinus is present), the bowel segment should be anastomosed directly to it. When a direct perineal anastomosis is required, it is vital to create a large enough space between the rectum and bladder to avoid compromise of the intestinal blood supply. Creation of such a space can be facilitated by the use of progressively larger Hegar dilators. Gentle passage of the intestinal segment into position is facilitated by placing the segment in a large lubricated Penrose drain before transfer to the perineum.

The functional results of bowel vaginoplasty have been excellent. Of the 65 patients supported by Hendren and Atala (1994), 16 experienced mild inversion of the bowel segment, which in every case was amenable to simple trimming. Eight patients experienced mild stenosis that was later corrected by appropriate Z-plasties to increase the circumference of the mucocutaneous junction. Patient satisfaction is high, and the majority of patients who are old enough to engage in sexual relations are able to achieve adequate coitus (Hensle and Reiley, 1998).

Stenosis has been reported more frequently after the use of ileum (Hensle and Dean, 1992). This higher stenosis rate may be due not only to the more narrow ileal lumen but also to the limited mobility of the small bowel mesentery. As a result, the we and others believe that large intestine is the bowel segment of choice. Two specific indications for the use of an ileal segment for bowel vaginoplasty are previous irradiation of the deep pelvis and the absence of large intestine (i.e., cloacal exstrophy). When ileum is used, various methods of reconfiguration can be used to increase the diameter (Hendren and Atala, 1994). Advantages of a bowel vagina over the McIndoe procedure include the lubricating properties and mucus (which may help facilitate intercourse) and the decrease incidence of postoperative contracture (and hence reduced need for postoperative dilation). Disadvantages include the frequent need to wear pads because of the chronic vaginal discharge. Daily douching may be necessary to evacuate the mucus. Finally, the potential transmission of blood-borne pathogens such as hepatitis and human immunodeficiency virus may be increased (in comparison to a squamous epithelium–lined vagina) because of the poor barrier properties of the gastrointestinal tract.

All patients undergoing creation of a functional vagina with perineal skin require annual examination because of reports of condylomata acuminata and squamous cell carcinoma involving grafts (Buscema et al., 1987; Duckler, 1972; Rotmensch et al., 1983). Annual examination of the bowel vagina is also indicated because adenocarcinoma has been identified after this procedure (Andryjowicz et al., 1985).

The optimal timing of surgery remains a source of debate. The majority of surgeons who favor the McIndoe procedure for construction of a neovagina think it is better to wait until adulthood to perform the procedure because a degree of maturity is required to consistently perform daily dilations. Many surgeons who favor the use of bowel for neovaginal reconstruction do not think vaginoplasty should be deferred until the patient reaches adulthood. Hendren and Atala (1994) think that delaying creation of a neovagina until adulthood may be psychologically traumatic to a young girl. We have based our timing on the underlying diagnosis and need for a neovagina.

Special Considerations: Cervical Atresia

Cervical agenesis is an uncommon disorder associated with symptoms common to other obstructive entities of the female reproductive tract (i.e., primary amenorrhea, cyclic or chronic abdominal pain). Failure to establish the correct diagnosis and thereby choose the appropriate method of surgical intervention can be fraught with disaster and possible patient mortality. MRI is the most useful radiographic modality for establishing this diagnosis (Fig. 47.21). In many circumstances the patient is best served by hysterectomy with subsequent vaginal replacement by one of the previously described techniques (Cukier et al., 1986; Rock et al., 1982). Successful direct anastomosis of the neovagina to the uterine remnant has been reported. Deffarges et al. (2001), in describing their experience with uterovaginal anastomosis, reported a 40% pregnancy rate in patients attempting to conceive. Cerclage was performed in only one case. All deliveries were by cesarean section. Although this procedure appears to be successful in the majority of cases, absence of the normal endocervical barrier can leave the patient predisposed to development of life-threatening ascending infection (Casey and Laufer, 1997; Maciulla et al., 1978; Niver et al., 1980).

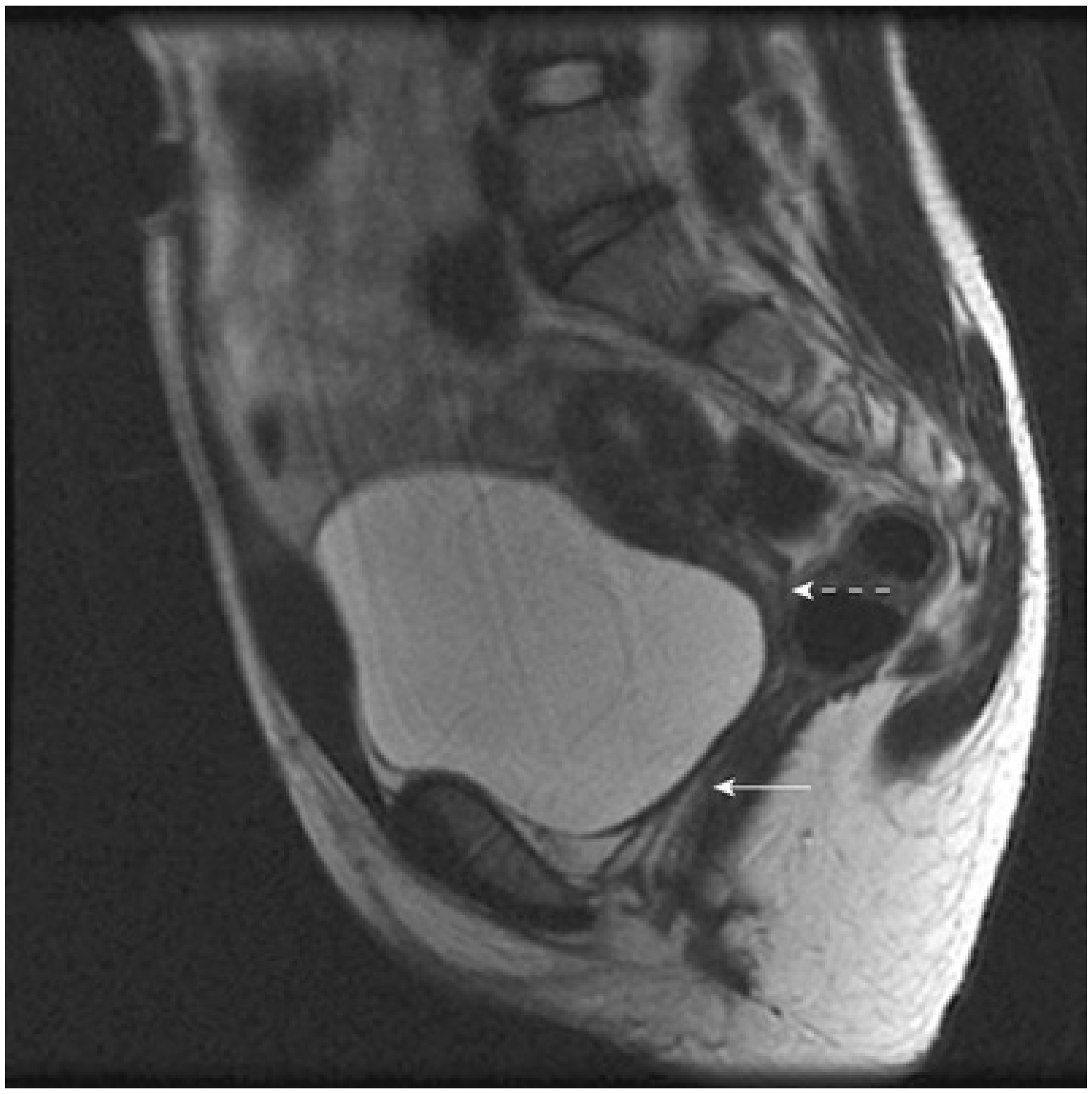

FIG. 47.21 Magnetic resonance imaging scan of the pelvis in a 12-year-old girl with Klippel-Feil syndrome and associated proximal vaginal and cervical atresia. The *solid arrow* points to the most cranial portion of the perineal vaginal pit. The *dashed arrow* point to the most inferior aspect of the uterus, where no cervical impression can be appreciated.

In cases in which it has not been possible to successfully achieve continuity between the uterus and vagina, in vitro fertilization plus transmyometrial embryo transfer has been performed, with subsequent delivery of a healthy fetus by cesarean section (Anttila et al., 1999; Lai et al., 2001). If this option is considered, hormonal blockade of the endometrium until the time at which the patient desires to initiate a pregnancy is indicated to minimize discomfort and reduce the incidence of endometriosis from retrograde menstrual flow in the fallopian tubes.

Key Points: Vaginal Replacement Surgery

- The McIndoe procedure (skin neovagina) is associated with a higher incidence of postoperative vaginal stenosis than a bowel neovagina.
- Vaginal stenosis after creation of an intestinal neovagina is more common

with ileum than large bowel.
- Vaginal reconstruction extending from the perineum to the uterus should be avoided in patients with cervical agenesis (because of the potential life-threatening complication of ascending bacterial infection).

Abnormalities of Lateral Fusion

Most abnormalities of lateral fusion have no functional significance. With the exception of those with uterus didelphys and unilateral vaginal obstruction, most patients are asymptomatic. Although an exhaustive description of the anomalies of lateral fusion is beyond the scope of this chapter, some general comments can be made (Fig. 47.22).

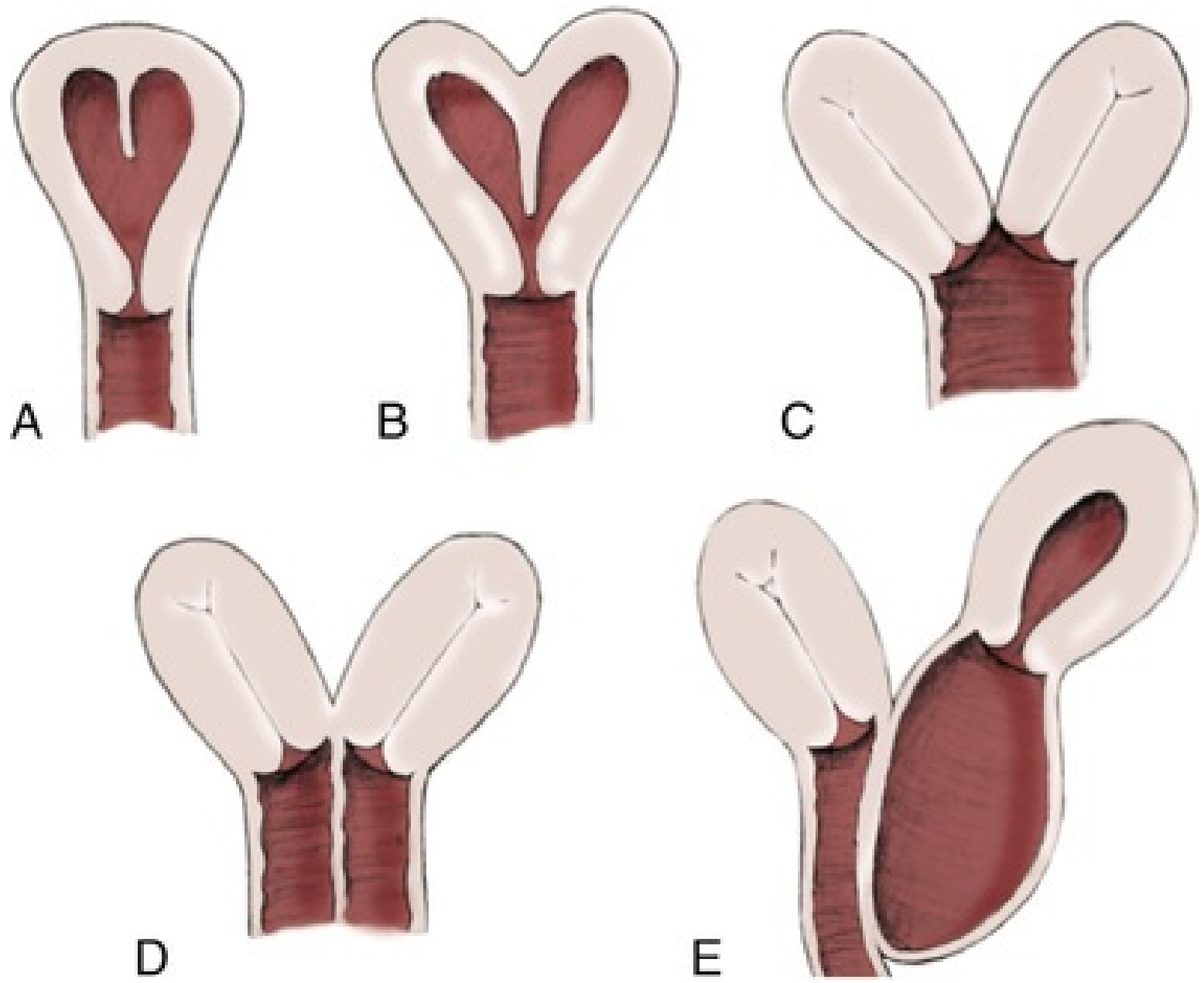

FIG. 47.22 Fusion anomalies of the müllerian system. (A) Bicornuate uterus (partial). (B) Bicornuate uterus. (C) Uterine duplication. (D) Complete uterine and vaginal duplication. (E) Duplication of the uterus and cervix with a unilateral imperforate vagina. (From Yerkes EB, Rink RC: What urologists should know about pediatric gynecologic abnormalities. *Contemp Urol* 14:12, 2002.)

True duplication of the uterus is a rare event (Fig. 47.23). This anomaly results from duplication of the müllerian ducts and subsequent doubling of the reproductive structures on one or both sides. The much more frequently encountered anomaly of uterine didelphys consists of two separate uterine cavities and cervices as a result of failed resorption of the common medial wall of the paired müllerian duct structures during development. Although up to 75% of patients also have a septate vagina, most have adequate reproductive outcomes and do not require surgical intervention. If later in life the patient experiences difficulty with intercourse, vaginal delivery, or the need to use two tampons, surgical excision of the vaginal septum should be undertaken. If only the most cranial portion of the septum remains, a bicornate uterus will result. The vagina is typically normal, and surgical incision of the uterine septum is rarely indicated except in cases of recurrent pregnancy loss (DeCherney et al., 1986).

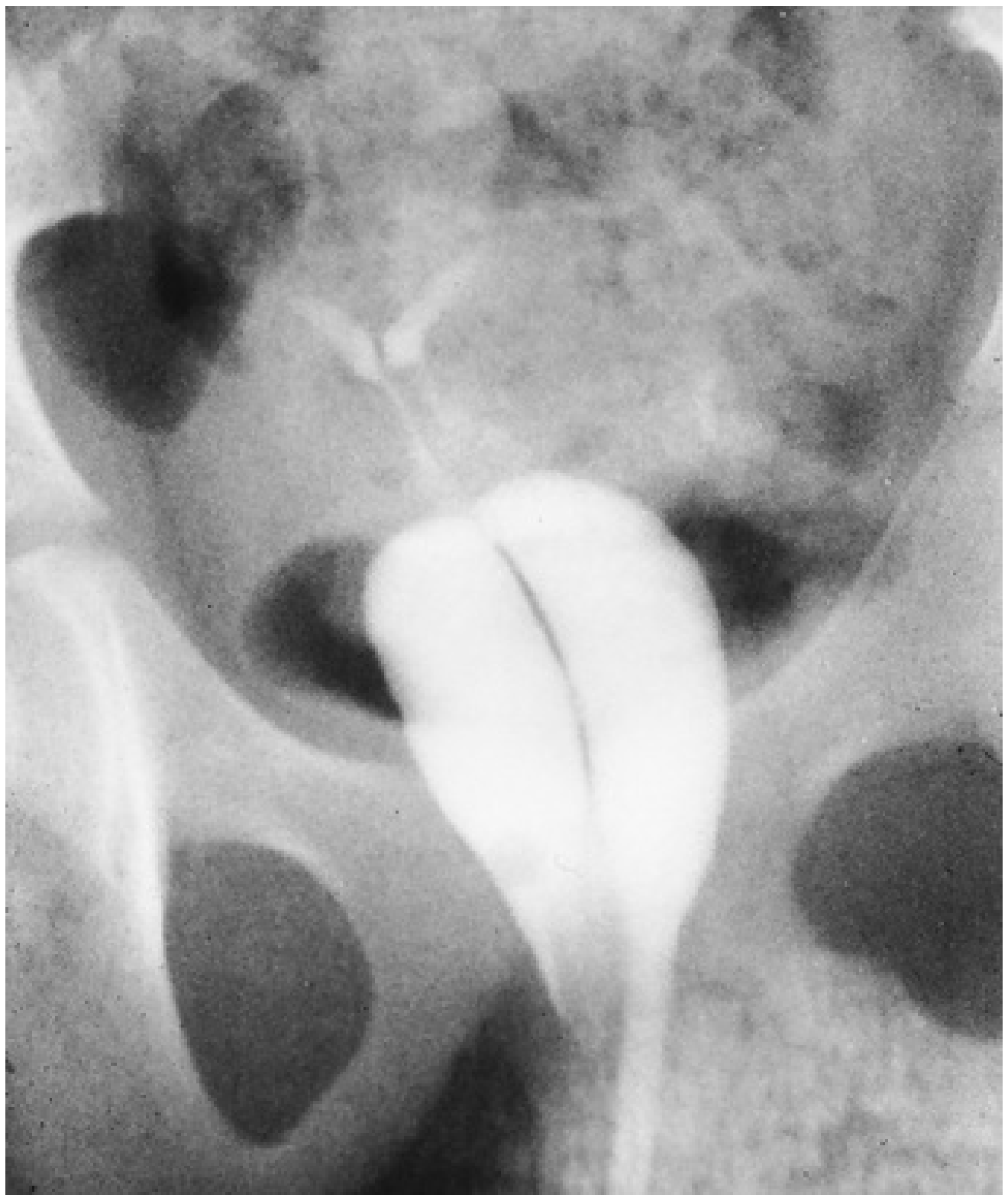

FIG. 47.23 Genitogram of complete müllerian duplication (septated vagina and separate uteri).

Duplication of the Uterus and Cervix With Unilaterally Imperforate Vagina (Herlyn-Werner-Wunderlich Syndrome).

Although the majority of obstructive lesions are caused by abnormalities of vertical fusion, occasionally an obstructive process can be encountered in the context of an abnormality of lateral fusion (Fig. 47.24). Otherwise known as the

Herlyn-Werner-Wunderlich syndrome (HWWS), more than 50 cases of uterus didelphys with unilateral imperforate vagina have been reported in the Western literature (Allan and Cowan, 1963; Burbige and Hensle, 1984; Herlyn and Werner, 1971; Wunderlich, 1976). As with other obstructive disorders, the patient may have cyclic or chronic abdominal pain. However, unlike other obstructive processes, duplication anomalies with unilateral obstruction do not result in primary amenorrhea. On physical examination, a unilateral abdominopelvic mass that terminates in a bluish bulge in the lateral vaginal wall is often appreciated (Eisenberg et al., 1982). Abdominal ultrasonography and MRI are excellent at defining the anatomy in a suspected case of unilateral noncommunicating uterine horn. Renal anomalies are frequently encountered on the side ipsilateral to the obstructed system, with renal agenesis being the most common (Eisenberg et al., 1982; Tridenti and Bruni, 1995). A prompt and accurate diagnosis is necessary to prevent injury to the genital organs as a result of chronic cryptomenorrhea and endometriosis.

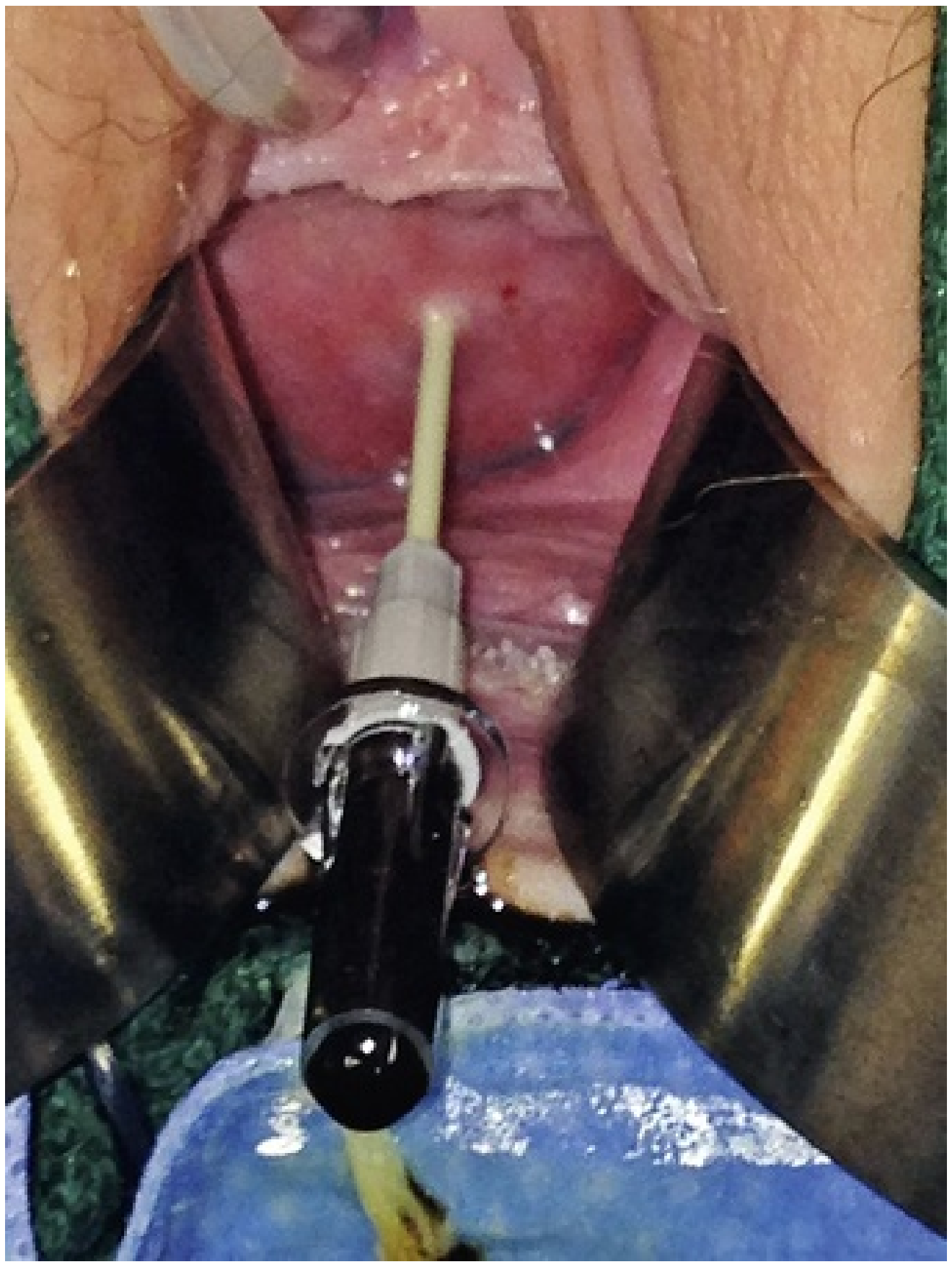

FIG. 47.24 Duplication of uterus vagina with unilateral imperforate vagina. View through vagina with angiocatheter inserted into obstructed side.

Recently, Zhu et al. (2015), in their retrospective review of 79 patients seen over a 27-year period, noted a significant number of patients with incomplete obstruction of the hemivagina and therefore proposed that patients be categorized as either Class 1 (complete obstruction) or Class 2 (incomplete obstruction with the hemivagina draining through a small perforation). The ratio of Class 1 to Class 2 was 24 : 55 with the Class 2 patients seen at a significantly later age with a lower probability of endometriosis.

Treatment of HWWS consists of wide incision of the vertical vaginal septum to release the entrapped menstrual blood.

Acquired Disorders of the Female External Genitalia

Rhabdomyosarcoma

Vaginal rhabdomyosarcoma most often manifests as a grapelike cluster of tissue emanating from the posterior aspect of the vestibule (Fig. 47.25). The mean age of patients with primary vaginal tumors is younger than 2 years (Hays et al., 1988). Of all the female genital tract primary tumors, vaginal primary tumors appear to have the best prognosis. This excellent prognosis is thought to be the result of predominance of the embryonal cell type and the relatively early detection because of symptoms of bleeding (Hays et al., 1988). Once a tissue diagnosis has been made by biopsy, proper staging with abdominal and chest computed tomography and bone marrow biopsy is critical to the optimal stratification these patients into treatment protocols (Hays et al., 1985). Advances in chemotherapy have led to a reduction in the role of surgery for this disease with each subsequent Intergroup Rhabdomyosarcoma Study (IRS) trial: IRS-I, 100%; IRS-II, 70%; IRS-III, 30%; IRS-IV, 13% (Andrassy et al., 1999). After chemotherapy, local resection may be required, but unlike other malignancies of the vagina, wide excision of the involved organ has no role except for persistent or recurrent disease (Hensley, 2000).

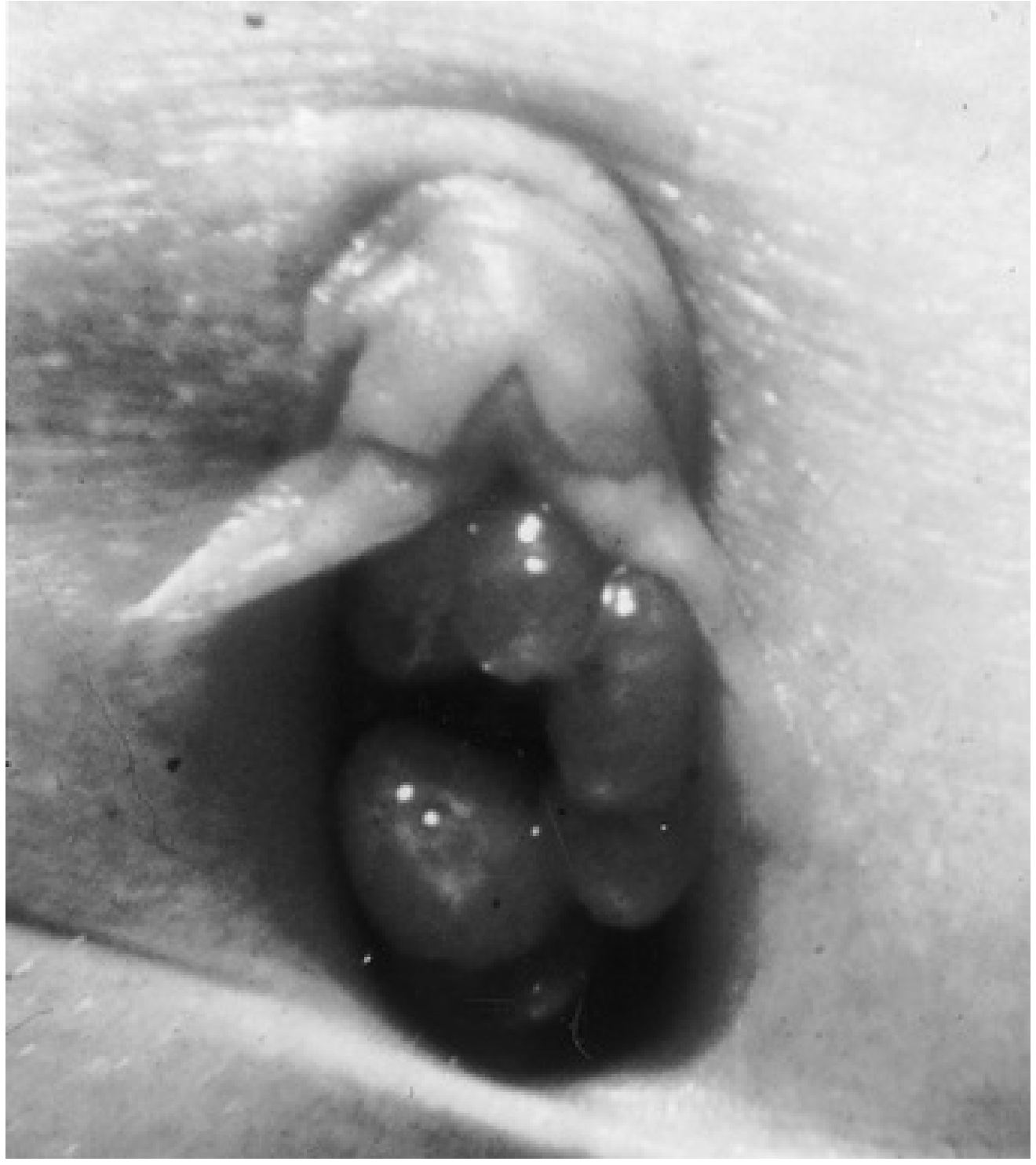
FIG. 47.25 Vaginal rhabdomyosarcoma.

Labial Adhesions

Labial adhesions, also referred to as labial agglutination and synechia vulvae, are the most common interlabial abnormality identified in children, ranging in incidence from 0.6% to 1.8% (Leung et al., 1993; Norbeck et al., 1993; Fig. 47.26). This condition occurs predominantly in the first 2 years of life, with a peak instance between 13 and 23 months. Fusion of the labia minora originates at the posterior fourchette and progresses for a variable distance toward the clitoris. It is important to differentiate this condition from the more serious entity of fusion of the labia majora, as is seen in certain disorders of sexual development. It has been hypothesized that hypoestrogenism may play a role in adhesion of the labia minora. Labial adhesions have not been reported in newborn children, presumably because of the protective effect of maternal estrogen (Leung et al., 1993). However, the etiologic role of the hypoestrogenic state has been brought into question by a number of authors (Caglar, 2007; Pulvino et al., 2008). Caglar (2007) measured circulating estradiol levels in 59 girls with labial adhesions and 60 control patients. He demonstrated no difference in the circulating level of estrogen in these 2 patient groups. It has been shown that estradiol may enhance wound re-epithelialization by promoting heparin-binding epidermal growth factor production in keratinocytes (Kanda and Watanabe, 2005). If there is a beneficial effect of topical estrogen, it may be to promote healing after the adhesions have been separated. Nonhormonal factors may play an etiologic role in the formation of labial adhesions (Papagianni and Stanhope, 2003). Local irritation and tissue trauma appear to be important inciting events in many cases. Adhesions can rarely be associated with sexual abuse; in such cases, additional physical findings are often noted, including hematoma and lacerations (McCann et al., 1988). Although labial adhesions are usually asymptomatic, urine pooling within the vagina may lead to postvoid dribbling, and perineal irritation may make it difficult to obtain an accurate urinalysis sample or perform radiographic procedures.

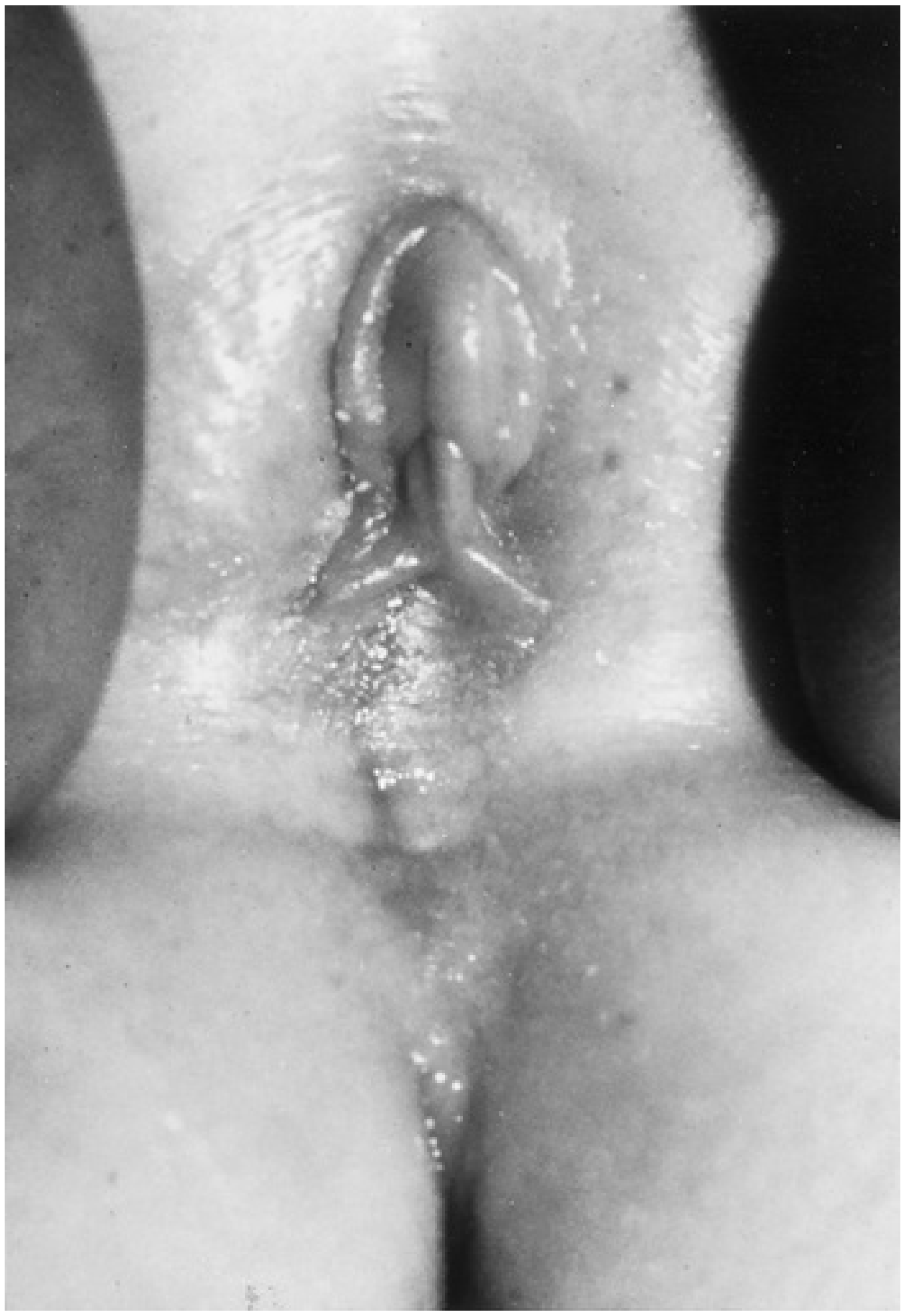

FIG. 47.26 Labial adhesions.

Most children with labial adhesions do not require treatment unless they are symptomatic. With the rate of spontaneous resolution reported to be as high as 80% within 1 year, asymptomatic labial adhesions can comfortably be observed (Pokorny, 1992). When necessary, treatment ranges from the topical application of various agents to surgical division. A recent randomized controlled trial of estradiol versus petroleum-based emollient demonstrated an increased success rate in the estradiol treatment arm (Dowlut-McElroy et al., 2019). The topical application of conjugated estrogens has been reported to be successful in separating adhesions in up to 90% of patients (Khanam et al., 1977; Leung et al., 2005). Concern over the possible side effects of breast budding and hyperpigmentation from prolonged use of conjugated estrogen led Myers et al. (2006) to treat a cohort of 19 prepubertal patients with topical betamethasone (0.05%). The authors reported success in 13 (68%) patients after administering 1 to 3 courses of twice-daily therapy for 4 to 6 weeks. It is important to have the family place the cream directly on the labia minora. In addition, it is helpful to have the family perform the labial pull-down procedure (i.e., grasping the labia majora and gently pulling in a caudal and lateral direction) a few times a day to put light stress on the midline adhesions and therefore facilitate their separation. If topical therapy is not successful, manual separation in the outpatient setting may be indicated. After the application of EMLA cream to the introitus, gentle pressure is applied to the thin connecting membrane with the aid of a lubricated probe. Rarely, in cases in which adhesions are extremely dense, surgical revision is required. Some authors advocate oversewing the separated edges with 7-0 chromic suture (Nurzia et al., 2003). We have not found this to be necessary if the family is properly educated to keep the labia separated after the procedure. Recurrence rates appear to be similar when comparing children who have undergone manual separation (16.7%) versus surgical separation (15.4%), emphasizing the importance of having family continue to separate the labia after separation has been achieved (Muram, 1999). In cases of highly recalcitrant dense adhesions, external use of an oxidized cellulose barrier has been proposed in adults but has not been used in the pediatric setting (Wyman et al., 2018).

Female Circumcision (Infibulation)

Acquired vaginal obstruction may be secondary to a number of ritual female genital mutilation (FGM) procedures that are widespread in many countries in Africa (stretching in a band from the Horn of Africa through central Africa to parts of Nigeria), the Middle East, and Muslim populations of Indonesia and Malaysia (Dorkenoo, 1996; Toubia, 1994). Although similar procedures were prescribed for use in British women during the 19th century for the treatment of ailments ranging from epilepsy to lesbianism, all forms of genital mutilation are now illegal in these Western countries. Population-based prevalence data from 30 countries estimate that approximately 200 million girls and women have been subjected to female genital cutting. An estimated 3 million African girls will be subjected annually to this practice (Unicef, 2016).

A survey of reproductive age women in Ethiopia has revealed that the prevalence of FGM is associated with ethnicity and socioeconomic status. In their study of nearly 29,000 women, Setegn et al. (2016) noted that FGM was more common among those of Muslim ethnicity and families of higher socioeconomic status. In contrast, the likelihood of experiencing FGM was inversely correlated with the level of maternal education.

The age at which this procedure is performed ranges from birth to just before marriage. However, it is typically performed on preadolescent children between the ages of 4 and 10 years, most commonly at age 7 (American Medical Association, 1995). The procedure is usually performed without anesthesia in the context of a ceremony designating the rite of passage into adult society (American Medical Association, 1995). The extent of the mutilation varies according to ritual, but the practice predates Islam and is therefore not a part of a religion (McCaffrey et al., 1995). In many countries the women have a deinfibulation procedure performed just before consummating the marriage.

The type of mutilation ranges from simple excision of the prepuce of the clitoris (termed *sunna*) to complete excision of all elements of the vulvar region (McCaffrey et al., 1995). Toubia (1994) classified the more extensive female genital mutilation procedures according to the amount of tissue destruction:

- Type I: Complete or partial removal of the clitoris
- Type II: Excision of the clitoris and a portion of the labia minora
- Type III: Excision of the entire clitoris and labia minora with incision of the labia majora along its medial aspect to create a raw surface. The anterior two-thirds of the of the labia majora are approximated to cover the urethra and introitus, with the lower third at the level of the posterior fourchette left for the passage of urine and menstrual fluid.

- Type IV: Excision of the entire clitoris and labia minora with near complete approximation of the labia majora, leaving only a pinhole opening at the posterior fourchette for the passage of urine and menstrual fluid (Fig. 47.27).

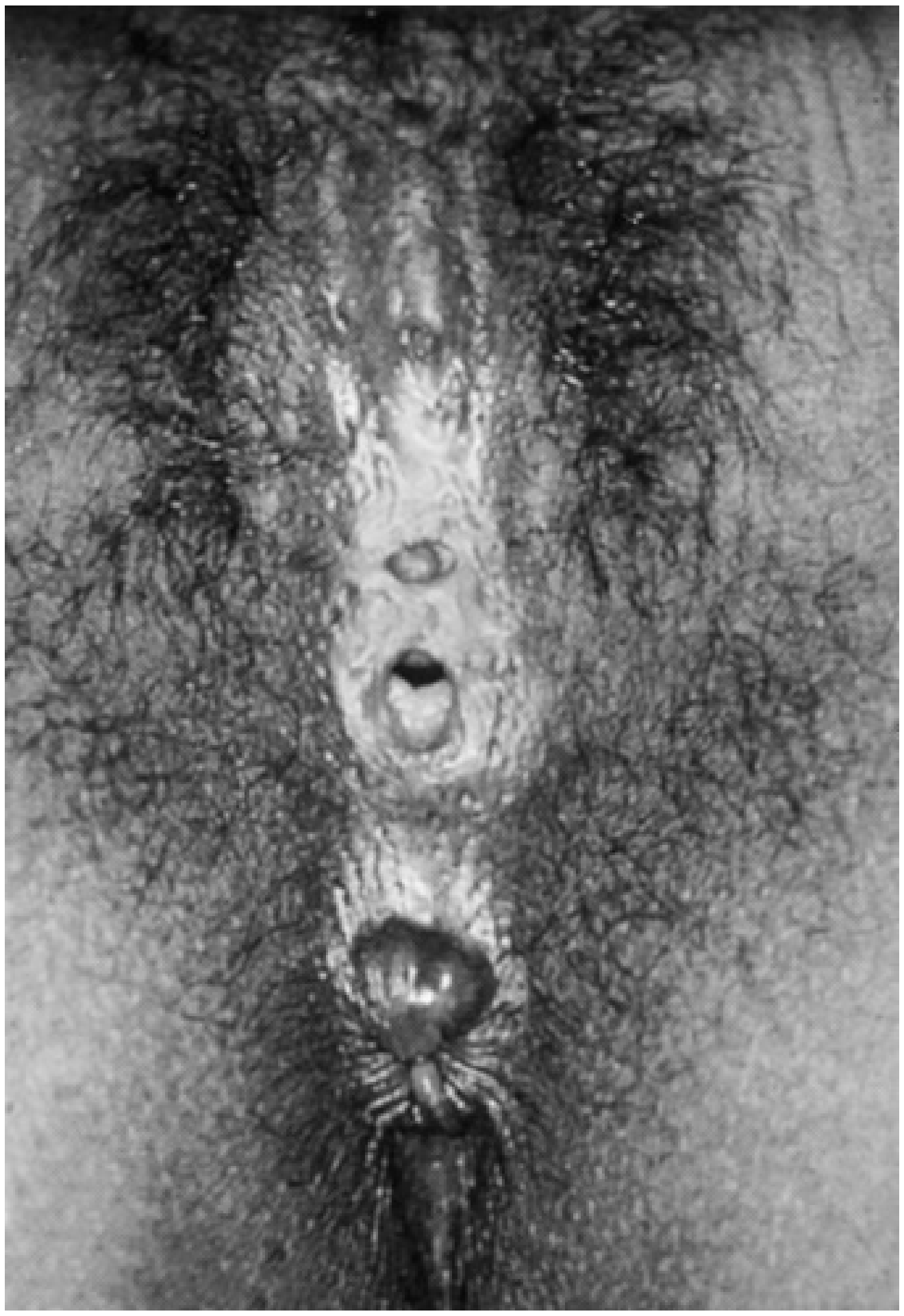

FIG. 47.27 Female infibulation. Note the scarred labia majora with only a pinhole opening for the passage of menstrual fluid and urine. (From Gonzales ET, Bauer SB, editors: *Pediatric urology practice,* Philadelphia, 1999, Lippincott Williams and Wilkins, p 599.)

- Closing of the introitus, typically referred to as infibulation or pharaonic circumcision, is performed by a variety of means, including absorbable and nonabsorbable suture materials, thorns, and twigs. The child's legs are then bound for up to 40 days to ensure secondary healing in the ventral midline (McCaffrey et al.,

1995).

The physical, psychological, and reproductive repercussions of these forms of genital mutilation are numerous and include immediate destruction and infection of local tissues (e.g., rectum, urethra). Long-term risks include chronic pain, recurrent urinary tract infection and vaginal infections, dysmenorrhea, dyspareunia, and apareunia. For individuals with the most narrowing, additional “surgeries” to revise the introital opening may be necessary for intercourse and vaginal delivery (Aziz, 1980; Toubia, 1994).

Care of the patient who has undergone infibulation must be individualized not only to provide functionality but also to respect the cultural and ritual desires of the woman. Educating the patient about the normal appearance of the external female genitalia is critical. Visual aids, including photographs or hand-drawn illustrations of the patient's anatomy and the planned revision, have been used as part of informed consent to avoid misunderstanding.

Complications resulting from infibulation are dependent on the degree of tissue destruction that results from the mutilation. A close assessment of all genital structures is required to make an accurate assessment. Complications resulting from closure of the introitus can range from urinary tract infections to retention of menstrual flow with endometriosis and even formation of calculus secondary to stagnation of urine in the vagina (Yusuf et al., 2008).

The broad spectrum of acquired anatomic anomalies secondary to FGM requires that reconstructive efforts be individualized.

Simple opening of the midline scar tissue with subcuticular closure of each edge has a high success rate. Nour et al. (2006) reported their results in 40 patients in which 92% could be reached for adequate follow-up. All of the patients who responded and their husbands were satisfied with the results, felt their appearance had improved, and were sexually satisfied.

As may be expected, more complex reconstructive efforts involving the clitoris may be less satisfying depending on the degree of injury to the glans and corpora. Foldès et al. have reported their extensive experience of nearly 3000 women with a mean age of 29 years who underwent genital reconstruction. They reported that reconstructive surgery after female genital mutilation was associated with reduced pain and restored pleasure. Of the 841 women who returned for follow-up, 51% reported that they were able to experience orgasm. The conclusions of this study are limited by the low 1-year follow-up (29%) among the cohort studied (Foldés et al., 2012).

Condyloma Acuminata

The incidence of genital warts in children has increased over the past 5 decades (Leclair et al., 2012). Although the majority are found in the perianal region, involvement of the vestibule can at times occur. The treatment of condyloma acuminatum in pediatric patients is difficult, with a wide range of treatment options that yield variable success. The decision as to which treatment is most ideal depends on patient age and location and the severity of the lesions. Although very high suspicion for sexual abuse is warranted, perinatal transmission is also a possible mechanism. De Jesus et al. (2001) reported perinatal transmission occurred in 7 of their 17 patients.

Reports of spontaneous resolution exist (Leclair et al., 2012). Allen and Siegfried (1998) reported that spontaneous resolution of pediatric condyloma occurred in more than half of their subjects. Medical therapy can be effective. Imiquimod, an immune response modifier that works through the Toll-like receptor 7 pathway, has been used extensively in adults. Leclair et al. (2012) found this to be highly effective in a young child with rapidly progressing lesions that were not amenable to surgical resection. Although carbon dioxide laser ablation of anogenital lesions is straightforward, lesions directly involving the vestibule may be more challenging. In one series of 17 patients in whom 12 were female, nearly 70% responded favorably to CO_2 ablation therapy (Johnson et al., 1997). Because the cause of condyloma acuminatum is human papilloma virus (HPV), authors emphasize the primary prevention of HPV infection through vaccination as a key component in decreasing the incidence of this disease (Thornsberry and English, 2012).

Inguinal Hernias

Hernias occur far less frequently in girls than boys, with a ratio between 1 : 5 and 1 : 10 reported in major series. Although usually an isolated event, this anatomic finding can be the manifesting symptom in a child with CAIS. Multiple authors have reported a 1% incidence of CAIS in patients with an inguinal hernia (Hurme et al., 2009; Sarpel et al., 2005). It is therefore imperative that all phenotypic females with inguinal hernia be evaluated to determine if they are a genetic male. Various methods of determining whether the patient has CAIS are available to the clinician. A karyotype, although definitive, is costly and therefore not obtained routinely by most practitioners. A pelvic sonogram to evaluate for the presence of (or absence) of a vaginal stripe can also be obtained but has the similar drawback of added cost.

Simple evaluation by way of vaginoscopy at the time of hernia repair will reveal if the cervix is present. A patient with CAIS also may have a significantly shorter vagina. While the hernia is being repaired, inguinal laparoscopy can be performed to study the contralateral gonad and evaluate for the presence of the uterus. The round ligament will be uniformly absent in genetic males.

Key Points: Acquired Disorders of the Female Genitalia

- Most children with labial adhesions do not require treatment unless they are symptomatic.
- FMG affects an estimated 200 million women worldwide.
- *Condylomata acuminata* can be acquired through perinatal transmission from the mother.
- Inguinal hernias in a female should alert the clinician to the possible diagnosis of CAIS.

Suggested Readings

Embryology

Duhamel B. From the mermaid to anal imperforation: the syndrome of caudal regression. *Arch Dis Child*. 1961;36:152.

Disorders of the Vestibule

Lowe FC, Hill GS, Jeffs RD, et al. Urethral prolapse in children: insights into etiology and management. *J Urol*. 1986;135:100–103.

Mandell J, Colodny AH, Lebowitz R, et al. Ureteroceles in infants and children. *J Urol*. 1980;123:921–926.

Nussbaum AR, Lebowitz RL. Interlabial masses in little girls: review and imaging recommendations. *AJR Am J Roentgenol*. 1983;141:65–71.

Valerie E, Gilchrist BF, Frischer J, et al. Diagnosis and treatment of urethral prolapse in children. *Urology*. 1999;54:1082–1084.

Abnormalities of Vertical MÜllerian Fusion

Bijsterveldt C, Willemsen W. Treatment of patients with a congenital transverse vaginal septum or a partial aplasia of the vagina: the vaginal pull-through versus the push-through technique. *J Pediatr Adolesc Gynecol*. 2009;22:157–161.

Duncan PA, Shapiro LR, Strangel JJ, et al. The MURCS association: müllerian duct aplasia, renal aplasia, and cervicothoracic somite dysplasia. *J Pediatr*. 1979;95:399–402.

Herlin M, Bjørn AM, Rasmussen M, et al. Prevalence and patient characteristics of Mayer-Rokitansky- Küster-Hauser syndrome: a nationwide registry-based study. *Hum Reprod*. 2016;31(10):2384–2390.

Strubbe EH, Willemsen WN, Lemmens JA, et al. Mayer-Rokitansky-Kuster-Hauser syndrome: distinction between two forms based on excretory urographic, sonographic, and laparoscopic findings. *AJR Am J Roentgenol*. 1993;160:331–334.

Vaginal Agenesis Management

Frank R. The formation of an artificial vagina without operation. *Am J Obstet Gynecol*. 1938;35:1053.

Hendren WH, Atala A. Use of bowel for vaginal reconstruction. *J Urol*. 1994;152:752–755 [discussion 756–757].

Ingram JM. The bicycle seat stool in the treatment of vaginal agenesis and stenosis: a preliminary report. *Am J Obstet Gynecol*. 1981;140:867–873.

Strickland JL, Cameron WJ, Frantz KE, et al. Long-term satisfaction of adults undergoing McIndoe vaginoplasty as adolescents. *Adolesc Pediatr Gynecol*. 1993;6:135.

Female Genital Mutilation

Foldès P, Cuzin B, Andro A. Reconstructive surgery after female genital mutilation: a prospective cohort study. *Lancet*. 2012;380:134–141.

Nour NM, Michels KB, Bryant AE. Defibulation to treat female genital cutting: effect on symptoms and sexual function. *Obstet Gynecol*. 2006;108:55–60.

Toubia N. Female circumcision as a public health issue. *N Engl J Med*. 1994;331:712–716.

References

Abbé R. New method of creating a vagina in a case of congenital absence. *Med Rec*. 1898;54:836.

Alessandrescu D, Peltecu GC, Buhimschi CS, et al. Neocolpopoiesis with split-thickness skin graft as a surgical treatment of vaginal agenesis: retrospective review of 201 cases. *Am J Obstet Gynecol*. 1996;175:131–138.

Allan N, Cowan LE. Uterus didelphys with unilateral imperforate vagina: report of 4 cases. *Obstet Gynecol*. 1963;22:422–426.

Allen AL, Siegfried EC. The natural history of condyloma in children. *J Am Acad Dermatol*. 1998;39(6):951–955.

Alles A, Sulik K. A review of caudal dysgenesis and its pathogenesis as illustrated in an animal model. *Birth Defects Orig Artic Ser*. 1993;29:83–102.

American Fertility Society. The American Fertility Society classifications of adnexal adhesions, distal tubal occlusion, tubal occlusion secondary to tubal ligation, tubal pregnancies, müllerian anomalies, and intrauterine adhesions. *Fertil Steril*. 1988;49:944–955.

American Medical Association, Council on Scientific Affairs. Female genital mutilation. *JAMA*. 1995;274:1714–1716.

Ammann AM, Brewer WH, Hurt WG. A high transverse vaginal septum: sonographic findings. *J Ultrasound Med*. 1983;2:471–472.

Andrassy RJ, Wiener ES, Raney RB, et al. Progress in the surgical management of vaginal rhabdomyosarcoma: a 25-year review from the Intergroup Rhabdomyosarcoma Study Group. *J Pediatr Surg*. 1999;34:731–734 [discussion, 734–5].

Andryjowicz E, Qizilbash AH, DePetrillo AD, et al. Adenocarcinoma in a cecal neovagina-complication of irradiation: report of a case and review of literature. *Gynecol Oncol*. 1985;21:235–239.

Anttila L, Penttila TA, Suikkari AM. Successful pregnancy after in-vitro fertilization and transmyometrial embryo transfer in a patient with congenital atresia of cervix: case report. *Hum Reprod*. 1999;14:1647–1649.

Ashworth MF, Morton KE, Dewhurst J, et al. Vaginoplasty using amnion. *Obstet Gynecol*. 1986;67:443–446.

Aziz FA. Gynecologic and obstetric complications of female circumcision. *Int J Gynecol Obstet*. 1980;17:560–563.

Bailey AP, Young JL, Nigrini E, et al. Anomalous vasculature in Mayer-Rokitansky-Kuster-Hauser syndrome. *Fertil Steril*. 2010;94(1):350–352.

Banerjee R, Laufer D. Reproductive disorders associated with pelvic pain. *Semin Pediatr Surg*. 1998;7:52.

Barutcu A, Akguner M. McIndoe vaginoplasty with the inflatable vaginal stent [letter]. *Ann Plast Surg*. 1998;41:568–569.

Bates GW, Wiser WL. A technique for uterine conservation in adolescents with vaginal agenesis and a functional uterus. *Obstet Gynecol*. 1985;66:290–294.

Beyth Y, Klein Z, Weinstein S, et al. Thick transverse vaginal septum: expectant management followed by surgery. *J Pediatr Adolesc Gynecol*. 2004;17:379–381.

Bijsterveldt C, Willemsen W. Treatment of patients with a congenital transveral vaginal septum or a partial aplasia of the vagina: the vaginal pull-through versus the push-through technique. *J Pediatr Adolesc Gynecol*. 2009;22:157–161.

Bok G, Drews U. The role of the wolffian ducts in the formation of the sinus vagina: an organ culture study. *J Embryol Exp Morphol*. 1983;73:275–295.

Borer JG, Bauer SB, Peters CA, et al. A single-system ectopic ureter draining an ectopic dysplastic kidney: delayed diagnosis in the young female with continuous urinary incontinence. *Br J Urol*. 1998;81:474–478.

Borruto F. Mayer-Rokitansky-Küster Syndrome: Vecchietti's personal series. *Clin Exp Obstet Gynecol*. 1992;19:273–274.

Brenne P, Sedlis A, Cooperman H. Complete imperforate transverse vaginal septum. *Obstet Gynecol*. 1965;25:135–138.

Brucker SY, Gegusch M, Zubke W, et al. Neovagina creation in vaginal agenesis: development of a new laparoscopic Vecchietti-based procedure and optimized instruments in a prospective comparative interventional study in 101 patients. *Fertil Steril*. 2008;1940–1952.

Bryan AL, Nigro JA, Counceller VS, et al. One hundred cases of congenital absence of the vagina. *Surg Gynecol Obstet*. 1949;88:79.

Burbige KA, Hensle TW. Uterus didelphys and vaginal duplication with unilateral obstruction presenting as a newborn abdominal mass. *J Urol*. 1984;132:1195–1198.

Buscema J, Rosenshein NB, Shah K. Condylomata acuminata arising in a neovagina. *Obstet Gynecol*. 1987;69:528–530.

Buttram VC. Müllerian anomalies and their management. *Fertil Steril*. 1983;40:159–163.

Caglar MK. Serum estradiol levels in infants with and without labial adhesions: the role of estrogen in the etiology and treatment. *Pediatr Dermatol*. 2007;24:373–375.

Caloia DV, Morris H, Rahmani MR. Congenital transverse vaginal septum: vaginal hydrosonographic diagnosis. *J Ultrasound Med*. 1998;17:261–264.

Casey A, Laufer M. Cervical agenesis: septic death after surgery. *Obstet Gynecol*. 1997;90:706–707.

Chaouachi B, Helardot PG, Ben Jalah S, et al. Urethral prolapse in 14 young female patients. *Pediatr Surg Int*. 1989;4:118.

Chen TH. Refinement of McIndoe's vaginal reconstruction with

ORFIT “S” vaginal stent. *Plast Reconstr Surg*. 1994;94:394–396.

Churchill B, Hardy B, Stephens CA. Urologic aspects of malformations and common abnormalities of the anus and rectum. *Urol Clin North Am*. 1978;5:141–154.

Concannon MJ, Croll GH, Puckett CL. An intraoperative stent for McIndoe vaginal construction. *Plast Reconstr Surg*. 1993;91:367–368.

Cost NG, Sanchez FS, Weinberg AG, et al. Neurofibromatosis presenting as painless clitoromegaly. *Urol J*. 2009;6(3):220–222.

Cramer DW, Goldstein DP, Fraer C, et al. Vaginal agenesis (Mayer-Rokitansky-Küster-Hauser syndrome) associated with the N314D mutation of galactose 1-phosphate uridyltransferase (GALT). *Mol Hum Reprod*. 1996;2:145–148.

Crouch NS, Michala L, Creighton SM, et al. Androgen-dependent measurements of female genitalia in women with complete androgen insensitivity syndrome. *BJOG*. 2011;118(1):84–87.

Cukier J, Batzofin JH, Conner JS, et al. Genital tract reconstruction in a patient with congenital absence of the vagina and hypoplasia of the cervix. *Obstet Gynecol*. 1986;68(3 Suppl):32S–36S.

Davydov SN. Experience in the field of the peritoneal colpopoiesis. Castelazo-Ayala L, MacGregor C. *Gynecology and obstetrics*. Excerpta Medica: Amsterdam; 1977:349–353.

De Jesus LE, Cirne Neto O, Meoneiro do Nascimento LM, et al. Anogenital warts in children: sexual abuse or unintentional contamination? *Cad Saude Publica*. 2001;17(6):1383–1391.

DeCherney AH, Russell JB, Graebe RA, et al. Resectoscopic management of müllerian fusion defects. *Fertil Steril*. 1986;45:726–728.

Deffarges JV, Haddad B, Musset R, et al. Utero-vaginal anastomosis in women with uterine cervix atresia: long-term follow-up and reproductive performance. A study of 18 cases. *Hum Reprod*. 2001;16:1722–1725.

Deligeoroglou E, Iavazzo C, Sofoudis C, et al. Management of hematocolpos in adolescent with transverse vaginal septum. *Arch Gynecol Obstet*. 2012;285(4):1083–1087.

Deng S, He Y, Zhu L. Spectrum of Type I and Type II syndromes and associated malformations in Chinese patients with Mayer-Rokitansky- Küster-Hauser syndrome: a retrospective analysis of 274 cases. *J Pediatr Adolesc Gynecol*. 2019;32(3):287.

Desai SR, Cohen RC. Urethral prolapse in a premenarchal girl: case report and literature review. *Aust N Z J Surg*. 1997;67:660–662.

Deuchar EM. Culture in vitro as a means of analysing the effect of maternal diabetes on embryonic development in rats. *Ciba Found Symp*. 1978;63:181–197.

Devine P, Kessel H. Surgical correction of urethral prolapse. *J Urol*. 1980;123:856–857.

Dorkenoo E. Combating female genital mutilation: an agenda for the next decade. *World Health Stat Q*. 1996;49:142–147.

Doyle M. Magnetic resonance imaging in müllerian fusion defects. *J Reprod Med*. 1992;37:33–38.

Dowlut-McElroy T, Higgins J, Williams KB, et al. Treatment of prepubertal labial adhesion: a randomized controlled trial. *J Pediatr Adolesc Gynecol*. 2019;32(3):259–263.

Duckler L. Squamous cell carcinoma developing in an artificial vagina. *Obstet Gynecol*. 1972;40:35–38.

Duhamel B. From the mermaid to anal imperforation: the syndrome of caudal regression. *Arch Dis Child*. 1961;36:152.

Dumanian GA, Donahoe PK. Bilateral rotated buttock flaps for vaginal atresia in severely masculinized females with adrenogenital syndrome. *Plast Reconstr Surg*. 1992;90:487–491.

Duncan P. Embryologic pathogenesis of renal agenesis associated with cervical vertebral anomalies (Klippel-Feil phenotype). *Birth Defects*. 1977;13:91–101.

Duncan PA, Shapiro LR, Strangel JJ, et al. The MURCS association: müllerian duct aplasia, renal aplasia, and cervicothoracic somite dysplasia. *J Pediatr*. 1979;95:399–402.

Eisenberg E, Farber M, Mitchell GW Jr, et al. Complete duplication of the uterus and cervix with a unilaterally imperforate vagina. *Obstet Gynecol*. 1982;60:259–262.

Epstein A, Strauss B. Prolapse of the female urethra with gangrene. *Am J Surg*. 1937;35:563–565.

Fall F. A simple method for making an artificial vagina. *Am J Obstet Gynecol*. 1940;40:906.

Fedele L, Bianchi S, Tozzi L, et al. A new laparoscopic procedure for creation of a neovagina in Mayer-Rokitansky-Küster-Hauser syndrome. *Fertil Steril*. 1996;66:854–857.

Fedele L, Portuese A, Bianchi S, et al. Transrectal ultrasonography in the assessment of congenital vaginal canalization defects. *Hum Reprod*. 1999;14:359–362.

Fedele L, Bianchi S, Berlanda N, et al. Neovaginal mucosa after Vecchietti's laparoscopic operation for Rokitansky syndrome: structural and ultrastructural study. *Am J Obstet Gynecol*. 2006;195:56–61.

Fernandes ET, Dekermacher S, Sabadin MA, et al. Urethral prolapse in children. *Urology*. 1993;41:240–242.

Fernandez CO, McFarland RD, Timmons C, et al. MURCS association: ultrasonographic findings and pathologic correlation. *J Ultrasound Med*. 1996;15:867–870.

Fisher K, Esham RH, Thorneycroft I. Scoliosis associated with typical Mayer-Rokitansky-Küster-Hauser syndrome. *South*

Med J. 2000;93:243–246.

Foldès P, Cuzin B, Andro A. Reconstructive surgery after female genital mutilation: a prospective cohort study. *Lancet*. 2012;380:134–141.

Frank R. The formation of an artificial vagina without operation. *Am J Obstet Gynecol*. 1938;35:1053.

Gargollo PC, Cannon GM, Diamond DA, et al. Should progressive perineal dilation be considered first line therapy for vaginal agenesis? *J Urol*. 2009;182:1882–1889.

Gauwerky JF, Wallwiener D, Bastert G. An endoscopically assisted technique for construction of a neovagina. *Arch Gynecol Obstet*. 1992;252:59–63.

Gingell JC, Gordon IR, Mitchell JP. Acute obstructive uropathy due to prolapsed ectopic ureterocele: case report. *Br J Urol*. 1971;43:305–308.

Gosalbez R: Personal communication, AAP 2009.

Gottesman JE, Sparkuhl A. Bilateral Skene duct cysts. *J Pediatr*. 1979;94:945–946.

Griffin JE, Edwards C, Madden JD, et al. Congenital absence of the vagina: the Mayer-Rokitansky-Küster-Hauser syndrome. *Ann Intern Med*. 1976;85:224–236.

Grimsby GM, Bradshaw K, Baker LA. Autologous buccal mucosa graft augmentation for foreshortened vagina. *Obstet Gynecol*. 2014;123(5):947–950.

Grosfeld J. Anorectal anomalies. Zuidema GD, Condon RE. *Shackelford's surgery of the alimentary tract*. ed 4. Saunders: Philadelphia; 1996:450.

Gunderson CH, Greenspan RH, Glaser GH, et al. The Klippel-Feil syndrome: genetic and clinical reevaluation of cervical fusion. *Medicine (Baltimore)*. 1967;46:491–512.

Haddad NG, Vance GH, Eugster EA, et al. Turner syndrome (45x) with clitoromegaly. *J Urol*. 2003;170:1355–1356.

Hauser G, Schreiner W. Mayer-Rokitansky-Küster syndrome:

rudimentary solid bipartite uterus with solid vagina. *Schweiz Med Wochenschr*. 1961;91:381–384.

Hays DM, Shimada H, Raney RB Jr, et al. Clinical staging and treatment results in rhabdomyosarcoma of the female genital tract among children and adolescents. *Cancer*. 1988;61:1893–1903.

Hays DM, Shimada H, Raney RB Jr, et al. Sarcomas of the vagina and uterus: the Intergroup Rhabdomyosarcoma Study. *J Pediatr Surg*. 1985;20:718–724.

Hendren WH, Atala A. Use of bowel for vaginal reconstruction. *J Urol*. 1994;152:752–755 [discussion 756–7].

Hensle TW, Dean GE. Vaginal replacement in children. *J Urol*. 1992;148:677–679.

Hensle TW, Reiley EA. Vaginal replacement in children and young adults. *J Urol*. 1998;159:1035–1038.

Hensley ML. Uterine/female genital sarcomas. *Curr Treat Options Oncol*. 2000;1:161–168.

Herlin M, Bjørn AM, Rasmussen M, et al. Prevalence and patient characteristics of Mayer-Rokitansky- Küster-Hauser syndrome: a nationwide registry-based study. *Hum Reprod*. 2016;31(10):2384–2390.

Herlyn U, Werner H. Simultneous occurrence of an open Gartner-duct cyst, a homolateral aplasia of the kidney and a double uterus as a typical syndrome of abnormalities. *Geburtshilfe Fraunheilkd*. 1971;31:340–347.

Holmes M, Upadhyay V, Pease P. Gartner's duct cyst with unilateral renal dysplasia presenting as an introital mass in a newborn. *Pediatr Surg Int*. 1999;15:277–279.

Hurme T, Lahdes-Vasama T, Makela E, et al. Clinical findings in prepubertal girls with inguinal hernia with special reference to the diagnosis of androgen insensitivity syndrome. *Scand J Urol Nephrol*. 2009;43(1):42–46.

Sabatucci I, Palaia I, Marches C, et al. Treatment of the Mayer-

Rokitansky-Kuster-Hauser syndrome with autologous in vitro cultured vaginal tissue: descriptive study of long-term results and patient outcomes. *BJOG*. 2018.

Ingram JM. The bicycle seat stool in the treatment of vaginal agenesis and stenosis: a preliminary report. *Am J Obstet Gynecol*. 1981;140:867–873.

Jerkins GR, Verheeck K, Noe HN. Treatment of girls with urethral prolapse. *J Urol*. 1984;132:732–733.

Johnson PJ, Mirzai TH, Bentz ML. Carbon dioxide laser ablation of anogenital condyloma acuminata in pediatric patients. *Ann Plast Surg*. 1997;39(6):578–582.

Joki-Erkkila M, Heinonen B. Presenting and long-term clinical implications and fecundity in females with obstructing vaginal malformations. *J Pediatr Adolesc Gynecol*. 2003;16:307–312.

Joseph VT. Pudendal-thigh flap vaginoplasty in the reconstruction of genital anomalies. *J Pediatr Surg*. 1997;32:62–65.

Gezginc K, Yazici F, Karatayli R, et al. A new technique for the treatment of transverse vaginal septum by Foley catheter. *J Pediatr Adolesc Gynecol*. 2011;24(5):322–325.

Kaefer M, Adams MC, Rink RC, et al. Principles in management of complex pediatric genitourinary plexiform neurofibroma. *Urology*. 1997;49(6):936–940.

Kaefer M. *The labial pull down maneuver (LPDM) increases the efficacy of estrogen cream in treating labial adhesions*. [Paper presented at the North Central Section of the American Urological Association. Chicago, Illinois; October] 2010.

Kallen B, Winberg J. Caudal mesoderm pattern of anomalies: from renal agenesis to sirenomelia. *Teratology*. 1974;9:99–111.

Kanda N, Watanabe S. 17 beta-estradiol enhances heparin-binding epidermal growth factor-like growth factor production in human keratinocytes. *Am J Physiol Cell Physiol*. 2005;288:13–23.

Kearse WS, Ritchey ML. Clitoral enlargement secondary to neurofibromatosis. *Clin Pediatr (Phila)*. 1993;32(5):303–304.

Keenan A, Kaefer M. *Novel management of transverse vaginal septum using balloon dilation*. [Paper presented at the North Central Section of the American Urological Association. Chicago, Illinois; October] 2012.

Khanam W, Chogtu L, Mir Z, et al. Adhesion of the labia minora—a study of 75 cases. *Aust N Z J Obstet Gynaecol*. 1977;17:176.

Klaus H, Stein R. Urethral prolapse in young girls. *Pediatrics*. 1973;52:645–648.

Klee LW, Rink RC, Gleason PE, et al. Urethral polyp presenting as interlabial mass in young girls. *Urology*. 1993;41:132–133.

Koff A. Development of the vagina in the human fetus. *Contemp Embryol*. 1933;24:61.

Küster H. Uterus bipartitus solidus rudimentarius cum vagina solida. *Z Geb Gyn*. 1910;67:692.

Lai TH, Wu MH, Hung KH, et al. Successful pregnancy by transmyometrial and transtubal embryo transfer after IVF in a patient with congenital cervical atresia who underwent uterovaginal canalization during caesarean section: case report. *Hum Reprod*. 2001;16:268–271.

Lang IM, Babyn P, Oliver GD. MR imaging of paediatric uterovaginal anomalies. *Pediatr Radiol*. 1999;29:163–170.

Leclair E, Black A, Fleming N. Imiquimod 5% cream treatment for rapidly progressive genital condyloma in a 3-year-old girl. *J Pediatr Adolesc Gynecol*. 2012;25(6):119–121.

Lesavoy MA. Vaginal reconstruction. *Urol Clin North Am*. 1985;12:369–379.

Leung AK, Robson WL, Kao CP, et al. Treatment of labial fusion with topical estrogen therapy. *Clin Pediatr (Phila)*. 2005;44:245–247.

Leung AK, Robson WL, Tay-Uyboco J. The incidence of labial fusion in children. *J Paediatr Child Health*. 1993;29:235–236.

Li FY, Xu YS, Zhou CD, et al. Long-term outcomes of vaginoplasty with autologous buccal micromucosa. *Obstet Gynecol*. 2014;123(5):951–956.

Lilford RJ, Johnson N, Batchelor A. A new operation for vaginal agenesis: construction of a neo-vagina from a rectus abdominis musculocutaneous flap. *Br J Obstet Gynaecol*. 1989;96:1089–1094.

Lodi A. Contributo clinico statistico sulle malformazioni della vagina osservate nella clinica osterica e ginecologica di Milano dal 1906 al 1950. *Ann Obstet Gynecol*. 1951;73:1246.

Lowe FC, Hill GS, Jeffs RD, et al. Urethral prolapse in children: insights into etiology and management. *J Urol*. 1986;135:100–103.

Lynch SA, Bond PM, Copp AJ, et al. A gene for autosomal dominant sacral agenesis maps to the holoprosencephaly region at 7q36. *Nat Genet*. 1995;11:93–95.

Maciulla G, Heine M, Christian C. Functional endometrial tissue with vaginal agenesis. *J Reprod Med*. 1978;21:373–376.

Major T, Borsos A, Bacsko G. Application of minimally invasive surgery in Mayer-Rokitansky-Küster-Hauser syndrome. *Acta Chir Hung*. 1997;36:219–220.

Mandell J, Colodny AH, Lebowitz R, et al. Ureteroceles in infants and children. *J Urol*. 1980;123:921–926.

Marquis HS, Santos FL, Lopes-Costa PV, et al. Creation of a neovagina in patients with Rokitansky syndrome using peritoneum from the pouch of Douglas: an analysis of 48 cases. *Fertil Steril*. 2008;90:827–832.

Martinez-Mora J, Isnard R, Castellvi A, et al. Neovagina in vaginal agenesis: surgical methods and long-term results. *J Pediatr Surg*. 1992;27:10–14.

Mayer C. Uber Verdoppelungen des Uterus und ihre Arten, nebst Bemerkungen uber Hasensharte und. *Wolfsrachen J Chir Auger*. 1829;13:525.

McCaffrey M, Jankowska A, Gordon H. Management of female genital mutilation: the Northwick Park Hospital experience. *Br J Obstet Gynaecol*. 1995;102:787–790.

McCann J, Voris J, Simon M. Labial adhesions and posterior fourchette injuries in childhood sexual abuse. *Am J Dis Child*. 1988;142:659–663.

McCaskill A, Inabinet CF, Tomlinson K, et al. Prepubertal genital bleeding: examination and differential diagnosis in pefiatric female patients. *J Emerg Med*. 2018;55(4):e97–e100.

McCraw JB, Massey FM, Shanklin KD, et al. Vaginal reconstruction with gracilis myocutaneous flaps. *Plast Reconstr Surg*. 1976;58:176–183.

McIndoe A, Banister J. An operation for the cure of congenital absence of the vagina. *J Obstet Gynaecol Br Commonw*. 1938;45:490.

McIndoe A. The treatment of congenital absence and obliterative conditions of the vagina. *Br J Plast Surg*. 1950;2:254–267.

Mesrobian HG, Sessions RP, Lloyd RA, et al. Cloacal and urogenital abnormalities induced by etretinate in mice. *J Urol*. 1994;152:675–678.

Meyer WR, McCoy MC, Fritz MA. Combined abdominal-perineal sonography to assist in diagnosis of transverse vaginal septum. *Obstet Gynecol*. 1995;85:882–884.

Moore K, Persaud T. *The developing human*. ed 5. Saunders: Philadelphia; 1995 [199–220].

Morton KE, Dewhurst CJ. Human amnion in the treatment of vaginal malformations. *Br J Obstet Gynaecol*. 1986;93:50–54.

Muram D. Treatment of prepubertal girls with labial adhesions. *J Pediatr Adolesc Gynecol*. 1999;12:67–70.

Murray JM, Gambrell RDJ. Complete and partial vaginal agenesis. *J Reprod Med*. 1979;22:101–105.

Myers JZB, Sorensen CM, Wisner BP, et al. Betamethasone cream for the treatment of pre-pubertal labial adhesions. *J Pediatr Adolesc Gynecol*. 2006;19:407–411.

Niver DH, Barrette G, Jewelewicz R. Congenital atresia of the uterine cervix and vagina: three cases. *Fertil Steril*. 1980;33:25–29.

Nour NM, Michels KB, Bryant AE. Defibulation to treat female genital cutting: effect on symptoms and sexual function. *Obstet Gynecol*. 2006;108:55–60.

Norbeck JC, Ritchey MR, Bloom DA. Labial fusion causing upper urinary tract obstruction. *Urology*. 1993;42:209–211.

Nurzia MJ, Eickhorst KM, Ankem MK, et al. The surgical treatment of labial adhesions in prepubertal girls. *J Pediatr Adolesc Gynecol*. 2003;16:21–23.

Nussbaum AR, Lebowitz RL. Interlabial masses in little girls: review and imaging recommendations. *Am J Roentgenol*. 1983;141:65–71.

Ota H, Tanaka J, Murakami M, et al. Laparoscopy-assisted Ruge procedure for the creation of a neovagina in a patient with Mayer-Rokitansky-Küster-Hauser syndrome. *Fertil Steril*. 2000;73:641–644.

Owens S, Morse W. Prolapse of the female urethra in children. *J Urol*. 1968;100:171–174.

Papagianni M, Stanhope R. Labial adhesions in a girl with isolated premature thelarche: the importance of estrogenization. *J Pediatr Adolesc Gynecol*. 2003;16:31–32.

Panici PB, Maffucci D, Ceccarelli S, et al. Autologous in vitro cultured vaginal tissue for vaginoplasty in women with Mayer-Rokitansky-Kuster-Hauser syndrome: anatomic and functional results. *J Minim Invasive Gynecol*. 2015;22(2):205–211.

Pokorny SF. Prepubertal vulvovaginopathies. *Obstet Gynecol Clin North Am*. 1992;19:39–58.

Pradhan S, Tobon H. Vaginal cysts: a clinicopathological study of 41 cases. *Int J Gynecol Pathol*. 1986;5:35–46.

Pratt JH. Vaginal atresia corrected by use of small and large bowel. *Clin Obstet Gynecol*. 1972;15:639–649.

Pulvino JQ, Flynn MK, Buchsbaum GM. Urinary incontinence secondary to severe labial agglutination. *Int Urogynecol J Pelvic Floor Dysfunct*. 2008;19:253–256.

Quan L, Smith DW. The VATER association: vertebral defects, anal atresia, T-E fistula with esophageal atresia, radial and renal dysplasia: a spectrum of associated defects. *J Pediatr*. 1973;82:104–107.

Ramenofsky ML, Raffensperger JG. An abdomino-perineal-vaginal pull-through for definitive treatment of hydrometrocolpos. *J Pediatr Surg*. 1971;6:381–387.

Redman J. Conservative management of urethral prolapse in female children. *Urology*. 1982;19:505–506.

Richardson DA, Hajj SN, Herbst AL. Medical treatment of urethral prolapse in children. *Obstet Gynecol*. 1982;59:69–74.

Rink RC, Mitchell ME. Genitourinary neurofibromatosis in childhood. *J Urol*. 1983;130(6):1176–1179.

Rock JA, Zacur HA, Dlugi AM, et al. Pregnancy success following surgical correction of imperforate hymen and complete transverse vaginal septum. *Obstet Gynecol*. 1982;59:448–451.

Rokitansky K. Uber die sogenannten Verdoppelungen des. *Uterus Med Jahrb Ost Staat*. 1838;26:39.

Rosenberg HK, Sherman NH, Tarry WF, et al. Mayer-Rokitansky-Küster-Hauser syndrome: US aid to diagnosis. *Radiology*. 1986;161:815–819.

Rosenfeld DL, Lis E. Gartner's duct cyst with a single vaginal ectopic ureter and associated renal dysplasia or agenesis. *J Ultrasound Med*. 1993;12:775–778.

Rotmensch J, Rosenshein N, Dillon M, et al. Carcinoma arising in the neovagina: case report and review of the literature. *Obstet Gynecol*. 1983;61:534–536.

Russ PD, Allen-Davis JT, Weingardt JP, et al. Mayer-Rokitansky-Küster-Hauser syndrome diagnosed by magnetic resonance imaging in a 15-year-old girl. *J Pediatr Adolesc Gynecol*. 1997;10:89–92.

Sadove RC, Horton CE. Utilizing full-thickness skin grafts for vaginal reconstruction. *Clin Plast Surg*. 1988;15:443–448.

Salvatore CA, Lodovicci O. Vaginal agenesis. *Acta Obstet Gynecol Scand*. 1978;57:89–94.

Sarpel U, Palmer SK, Dolgin SE. The incidence of complete androgen insensitivity in girls with inguinal hernias and assessment of screening by vaginal length measurement. *J Pediatr Surg*. 2005;4(1):133–136.

Schmid-Tannwald I, Hauser G. Syndrome of testicular feminization and the Mayer-Rokitansky-Küster syndrome: a comparison. *Geburtshilfe Frauenheilkd*. 1973;33:194–198.

Schmid-Tannwald I, Hauser GA. Atypical forms of the Mayer-Rokitansky-Kuster syndrome. *Geburtshilfe Frauenheilkd*. 1977;37:386–392.

Singh J, Devi YL. Pregnancy following surgical correction of nonfused müllerian bulbs and absent vagina. *Obstet Gynecol*. 1983;61:267–269.

Skene A. The anatomy and pathology of two important glands of the female urethra. *Am J Obstet*. 1880;13:265.

Strickland JL, Cameron WJ, Frantz KE, et al. Long-term satisfaction of adults undergoing McIndoe vaginoplasty as adolescents. *Adolesc Pediatr Gynecol*. 1993;6:135.

Strubbe EH, Lemmens JA, Thijn CJ, et al. Spinal abnormalities and the atypical form of the Mayer-Rokitansky-Küster-Hauser syndrome. *Skeletal Radiol*. 1992;21:459–462.

Strubbe EH, Thijn C, Willemsen WN, et al. Evaluation of radiographic abnormalities of the hand in patients with the Mayer-Rokitansky-Küster-Hauser syndrome. *Skeletal Radiol*. 1987;16:227–231.

Strubbe EH, Willemsen WN, Lemmens JA, et al. Mayer-Rokitansky-Kuster-Hauser syndrome: distinction between two forms based on excretory urographic, sonographic, and laparoscopic findings. *AJR Am J Roentgenol*. 1993;160:331–334.

Suidan F, Azoury R. The transverse vaginal septum: a clinicopathologic evaluation. *Obstet Gynecol*. 1979;54:278–283.

Setegn T, Lakew Y, Deribe K. Geographic variation and factors associated with female genital mutilation among reproductive age women in Ethiopia: a national population based survey. *PLoS ONE*. 2016;11(1).

Tamaya T, Imai A. The use of peritoneum for vaginoplasty in 24 patients with congenital absence of the vagina. *Arch Gynecol Obstet*. 1991;249:15–17.

Thompson DP, Lynn HB. Genital anomalies associated with solitary kidney. *Mayo Clin Proc*. 1966;41:538–548.

Thornsberry L, English JC. Evidence-based treatment and prevention of external genital warts in female pediatric and adolescent patients. *J Pediatr Adolesc Gynecol*. 2012;25(2):150–154.

Tillem SM, Stock JA, Hanna MK. Vaginal construction in children. *J Urol*. 1998;160:186–190.

Toubia N. Female circumcision as a public health issue. *N Engl*

J Med. 1994;331:712–716.

Tridenti G, Bruni V. Double uterus with a blind hemivagina and ipsilateral renal agenesis: clinical variants in three adolescent women. Case reports and literature review. *Adolesc Pediatr Gynecol*. 1995;8:201.

Turner-Warwick R, Kirby R. The construction and reconstruction of the vagina with the colocecum. *Surg Gynecol Obstet*. 1990;170:132–136.

Turunen A. Spinal changes in patients with congenital aplasia of the vagina. *Acta Obstet Gynecol Scand*. 1967;46:99–106.

UNICEF. *Female genital mutilation/cutting: a global concern*. [New York: UNICEF] 2016.

Valerie E, Gilchrist BF, Frischer J, et al. Diagnosis and treatment of urethral prolapse in children. *Urology*. 1999;54:1082–1084.

Vecchietti G. Le neo-vagin dans le syndrome de Rokitansky-Küster-Hauser. *Rev Med Suisse Romande*. 1979;99:593.

Wang Y, Hadley HR. The use of rotated vascularized pedicle flaps for complex transvaginal procedures. *J Urol*. 1993;149:590–592.

Warot X, Fromental-Ramain C, Fraulob V, et al. Gene dosage-dependent effects of the Hoxa-13 and Hoxd-13 mutations on morphogenesis of the terminal parts of the digestive and urogenital tracts. *Development*. 1997;124:4781–4791.

Wierrani F, Bodner K, Spangler B, et al. “Z”-plasty of the transverse vaginal septum using Garcia's procedure and the Grunberger modification. *Fertil Steril*. 2003;79:608–612.

Willemsen WN. Combination of the Mayer-Rokitansky-Küster and Klippel-Feil syndrome: a case report and literature review. *Eur J Obstet Gynecol Reprod Biol*. 1982;13:229–235.

Williams E. Congenital absence of the vagina: a simple operation for its relief. *J Obstet Gynaecol Br Commonw*. 1964;71:511–512.

Williams JK, Ingram JM, Welden SW. Management of noncongenital vaginal stenosis and distortion by the bicycle seat stool pressure technique. *Am J Obstet Gynecol*. 1984;150:166–167.

Williams JK, Lake M, Ingram JM. The bicycle seat stool in the treatment of vaginal agenesis and stenosis. *J Obstet Gynecol Neonatal Nurs*. 1985;14:147–150.

Wunderlich M. Unusual form of genital malformation with aplasia of the right kidney. *Zentralbl Gynakol*. 1976;98:559–562.

Wyman AM, Lafranchise E, Lynch C. External use of an oxidized regenerated cellulose agent in the treatment of labial agglutination in postmenopausal women. *BMC Pediatr*. 2018;18(1):104–106.

Yuksel H, Odabasi AR, Kafkas S, et al. Clitoromegaly in type 2 neruofibromatosis: a case report and review of the literature. *Eur J Gynaecol Oncol*. 2003;24(5):447–451.

Yusuf L, Negash S. Vaginal calculus following severe form of female genital mutilation: a case report. *Ethiop Med J*. 2008;46:185–188.

Zhu L, Chen N, Tong J, et al. New classification of Herlyn-Werner-Wunderlich Syndrome. *Chin Med J*. 2015;128(2):222–225.

48

Disorders of Sexual Development

Etiology, Evaluation, and Medical Management

Richard Nithiphaisal Yu MD, PhD, David Andrew Diamond MD

Disorders of sexual development are among the most fascinating and complex disease processes encountered by the urologist. This field has undergone a striking evolution over the past few decades. Remarkable advances in molecular biology and genetic research have provided new insight into the precise mechanisms responsible for sexual differentiation and for specific DSDs. In addition, there has been a major shift in nomenclature to promote precise communication among colleagues and respect for the sensitivity of patients by eliminating terms such as *pseudohermaphroditism,* which have been regarded as pejorative by patients. The term *intersex disorders* has been replaced by *disorders of sexual development*.

Normal Sexual Development

Under normal circumstances, sexual development is a dynamic and sequential process. According to the Jost paradigm, three steps must occur: establishment of chromosomal sex at fertilization, which determines development of the undifferentiated gonads into testes or ovaries, and subsequent differentiation of the internal ducts and external genitalia as a result of endocrine functions associated with the type of gonad present (Jost et al., 1973). Therefore, sexual development occurs as a result of different but complementary processes: genotypic effects, phenotypic events, and gender identity formation. Interference with this highly ordered process at any step can result in a disorder of sexual development.

Normal Genotypic Development

Chromosomal Sex

In 1921, Painter demonstrated cytologically that humans have X and Y chromosomes. Based on chromosomal studies of *Drosophila,* it was assumed that sex was determined by the X chromosomes possessed by the individual (Bridges, 1921). The Y chromosome was thought to impart no genetic information until karyotyping of mammalian chromosomes, developed in the 1950s, demonstrated that the Y chromosome specified development of the testis. Specifically, reports in the late 1950s describing the karyotype 47,XXY as male with Klinefelter syndrome and 45,XO as female with Turner syndrome demonstrated that the presence of a Y chromosome, independent of the number of X chromosomes, resulted in the development of a male embryo, whereas in the absence of a Y chromosome the embryo developed as a female (Ford et al., 1959; Jacobs and Strong, 1959). Therefore, the Y chromosome appeared to possess a gene or genes that determined the destiny of the bipotential gonad as a testis or ovary. **In the human, the hypothetical Y-chromosomal gene was termed the *testis-determining factor (TDF)*.**

During the following years, the search for the TDF was the focus of intense research. The observation that antibodies raised in inbred female mice transplanted with male skin grafts resulted in graft rejection, whereas female-to-male skin grafts were accepted in the same strain of mice led to the proposal that the histocompatibility-Y, or H-Y, antigen was the product of TDF (Eichwald, 1955). Assays for quantifying H-Y antigen were developed. With the use of these assays, it was discovered that the presence of a testis resulted in serologically detectable levels of H-Y antigen. This was confirmed in normal patients, patients with DSDs, and males of other species. **Therefore, it was believed that the *H-Y* gene was the TDF** (Wachtel, 1977). **This theory was considered valid for more than 10 years.**

The application of molecular techniques to evaluate Y-chromosomal sequences present in XX males and deletions of the Y chromosome in XY females led to the cloning of TDF (Lukusa et al., 1992). **Deletion maps based on the genomes of these individuals were constructed by a number of laboratories, and TDF was mapped to the most distal aspect of the Y-unique region of the short arm of the Y chromosome, adjacent to the pseudoautosomal boundary** (Fig. 48.1).

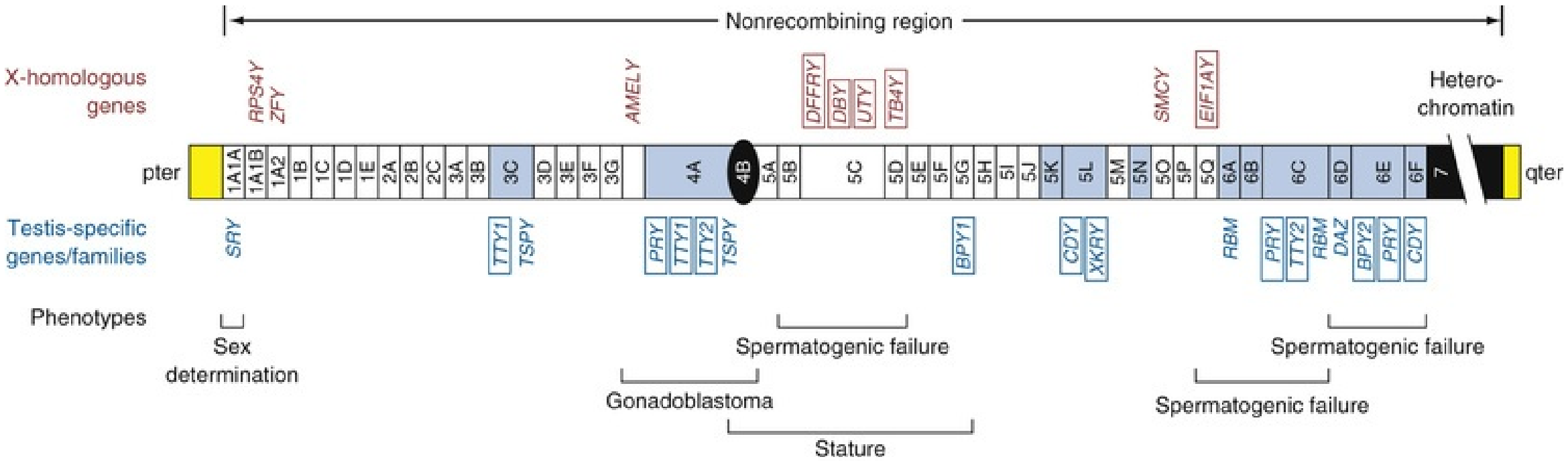
Nonrecombining region
X-homologous genes
RPS4Y
ZFY
AMELY
DFFRY
DBY
UTY
TB4Y
SMCY
EIF1AY
Hetero-chromatin
pter
1A1A
1A1B
1A2
1B
1C
1D
1E
2A
2B
2C
3A
3B
3C
3D
3E
3F
3G
4A
4B
5A
5B
5C
5D
5E
5F
5G
5H
5I
5J
5K
5L
5M
5N
5O
5P
5Q
6A
6B
6C
6D
6E
6F
7
qter
Testis-specific genes/families
SRY
TTY1
TSPY
PRY
TTY1
TTY2
TSPY
BPY1
CDY
XKRY
RBM
PRY
TTY2
RBM
DAZ
BPY2
PRY
CDY
Phenotypes
Sex determination
Spermatogenic failure
Gonadoblastoma
Stature
Spermatogenic failure
Spermatogenic failure

FIG. 48.1 Genetic map of the short arm of the human Y chromosome. The pseudoautosomal region, where genetic crossing over may occur between sex chromosomes, is highlighted in yellow. The *SRY* and *ZFY* loci are located near the pseudoautosomal boundary on the short arm of the Y chromosome at the terminal end *(pter)*. The SRY gene encodes the molecular switch that promotes gonadal sex determination. (From Lahn BT, Page DC. Functional coherence of the human Y chromosome. *Science*. 1997;278:675–680.)

SRY

The locus for TDF was ultimately narrowed down to a 35-kb region adjacent to the pseudoautosomal boundary (Fig. 48.2). Using probes from this region, Sinclair et al. (1990) discovered a single-copy male-specific sequence that was evolutionarily conserved. This gene was termed *SRY* (sex-determining region Y gene) in humans and *Sry* in mice. Analysis of the SRY protein sequence demonstrated a highly conserved, 78–amino acid region with homology to a DNA-binding motif of the high-mobility group (HMG) family of proteins (Fig. 48.3). When DNA encoding the HMG box was used to probe a genomic library, a subfamily of closely related genes was identified. Members of this family, defined as those encoding a region with 60% or greater amino acid similarity to the SRY HMG-box motif, are called *SOX* (SRY–box-related) genes (Goodfellow and Lovell-Badge, 1993).

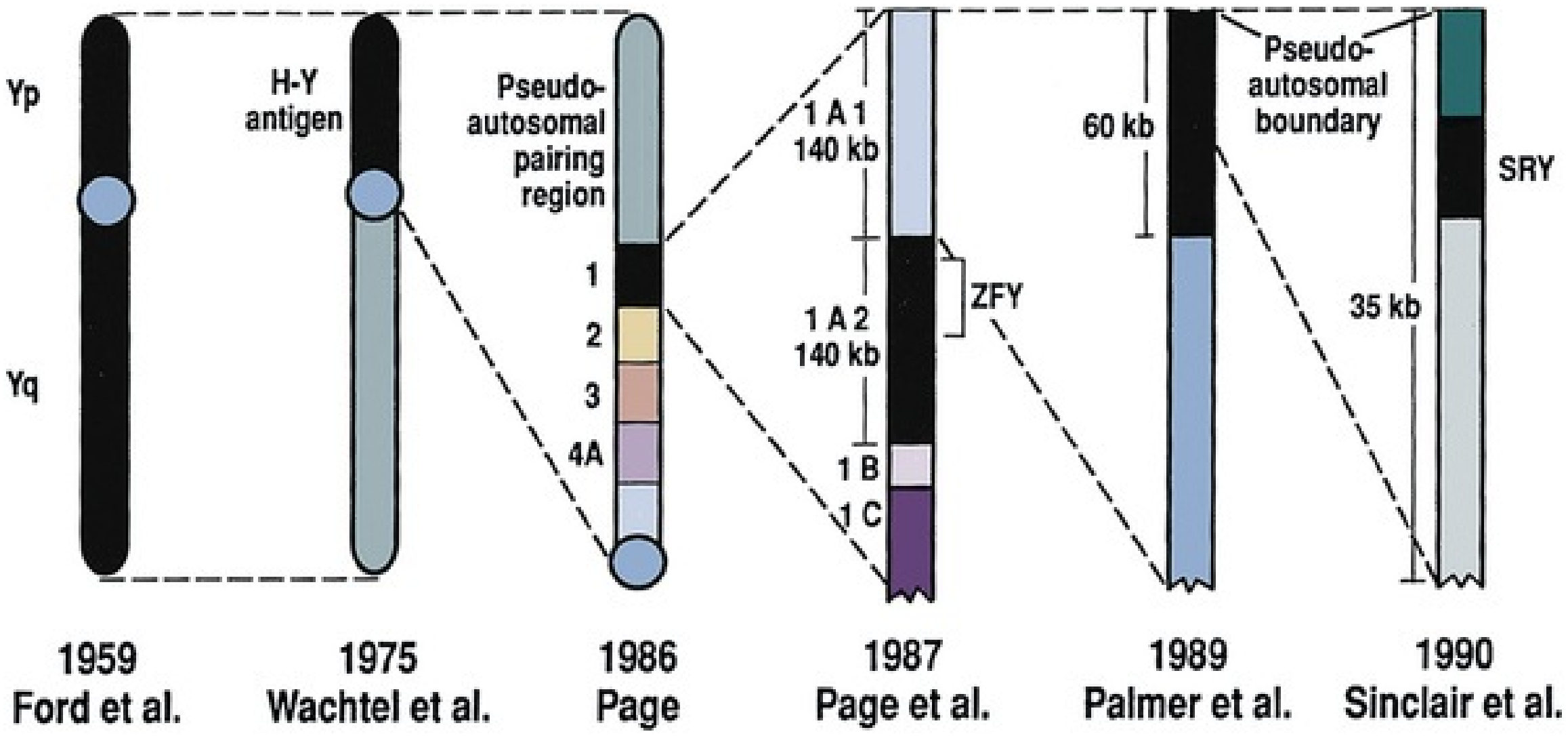
Yp
Yq
H-Y antigen
Pseudo-autosomal pairing region
1
2
3
4A
1 A 1
140 kb
1 A 2
140 kb
1 B
1 C
ZFY
60 kb
Pseudo-autosomal boundary
35 kb
SRY
1959
Ford et al.
1975
Wachtel et al.
1986
Page
1987
Page et al.
1989
Palmer et al.
1990
Sinclair et al.

FIG. 48.2 Diagrammatic representation of the historical search for the testis-determining factor (TDF). The *shaded area* on the Y chromosome is the region to which this factor has been localized. (From Grumbach MM, Conte FH. Disorders of sex differentiation. In: Wilson JD, Foster DW, eds. *Williams textbook of endocrinology.* Philadelphia, PA: WB Saunders; 1998. p. 1315.)

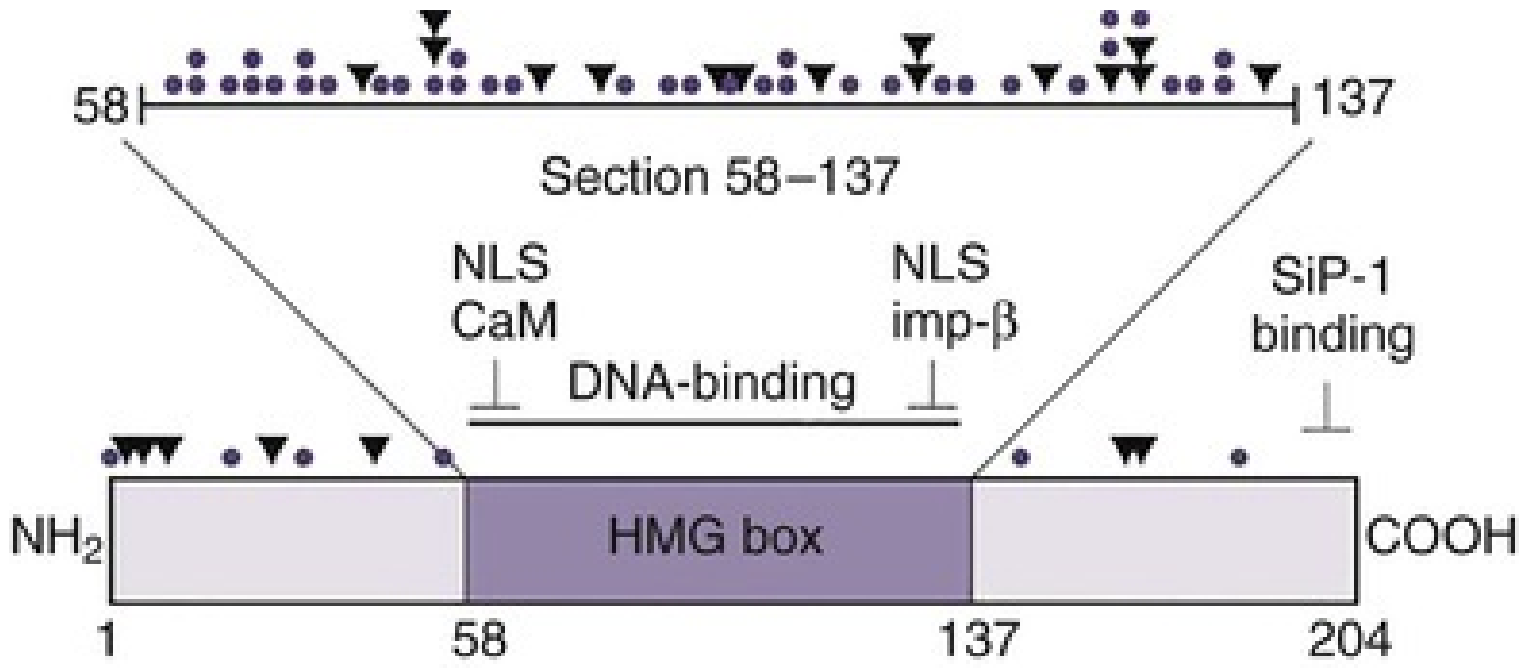
58
137
Section 58–137
NLS
CaM
NLS
imp-β
DNA-binding
SiP-1
binding
NH2
HMG box
COOH
1
58
137
204

FIG. 48.3 Diagram of the *SRY* (sex-determining region on the Y gene)

locus, with the high-mobility group (HMG)-related box, DNA binding domain. Solid circles denote missense mutations that affect testicular development. Triangles indicate nonsense and frameshift mutations. (From Achermann JC, Hughes IA. Disorders of sex development. In: Melmed S, Polonsky KS, Larsen PR, Kronenberg HM, eds. *Williams textbook of endocrinology.* Philadelphia, PA: WB Saunders; 2011. Figure 23-21.)

Considerable evidence has accumulated that *SRY* is the TDF. In the mouse, expression of *Sry* correlates with testicular determination in the gonadal ridge (Koopman et al., 1990). *SRY* is an evolutionarily conserved gene on the Y chromosome of mammals. Chromosomal fragments related to *SRY* (i.e., the *SOX* genes) are very much conserved evolutionarily, being demonstrated in various vertebrates and marsupials. ***SRY* is localized to the smallest region of the Y chromosome capable of inducing testicular differentiation in humans and in mice** (Gubbay et al., 1992). In fact, Koopman et al. (1991) introduced into XX mouse embryos a 14-kb mouse genomic DNA fragment containing *Sry* and no other Y-linked gene sequences and demonstrated that it was capable of giving rise to normal testicular development in the transgenic mice. **The *SRY* protein functions as a transcription factor that, by binding and producing bending of the DNA, promotes protein-protein interaction and is able to activate downstream gene expression.** An expectation for TDF was that mutations in its protein sequence would result in sex reversal. Examination of the *SRY* sequence in XY females has identified more than 50 mutations in the protein-coding sequence, with the majority located within the DNA-binding domain. Another prediction for TDF is that its presence can cause XX male sex reversal. The majority of XX males to date have been found to contain Y chromosome segments containing *SRY*. This suggests a causative role of *SRY* in most cases of XX sex reversal. **Therefore, genetic and molecular data have established that *SRY* can be equated to the TDF.**

Additional insights have been gained regarding *SRY* function as a molecular switch that promotes testis development. *SRY* is expressed and functions in the supporting cells of the developing male urogenital ridge. These cells participate in cord formation and ultimately develop into Sertoli cells.

Key Points: Chromosomal Sex

- Sinclair et al. (1990) discovered the testis-determining factor (TDF), a single-copy male-specific sequence that was evolutionarily conserved.
- This gene was termed *SRY* (sex-determining region Y gene) in humans and *Sry* in mice.

Additional Genes Involved in Gonadal Determination

Several additional genes involved in gonadal development have been identified and characterized. These include, but are not limited to, *WT1*, *NR5A1(SF1)*, *SOX9*, *NR0B1(DAX1)*, *WNT4*, *RSPO1*, and *FOXL2* (Fig. 48.4; Table 48.1). Newer data suggest that these factors function in defined but interrelated differentiation pathways during gonadal formation and determination.

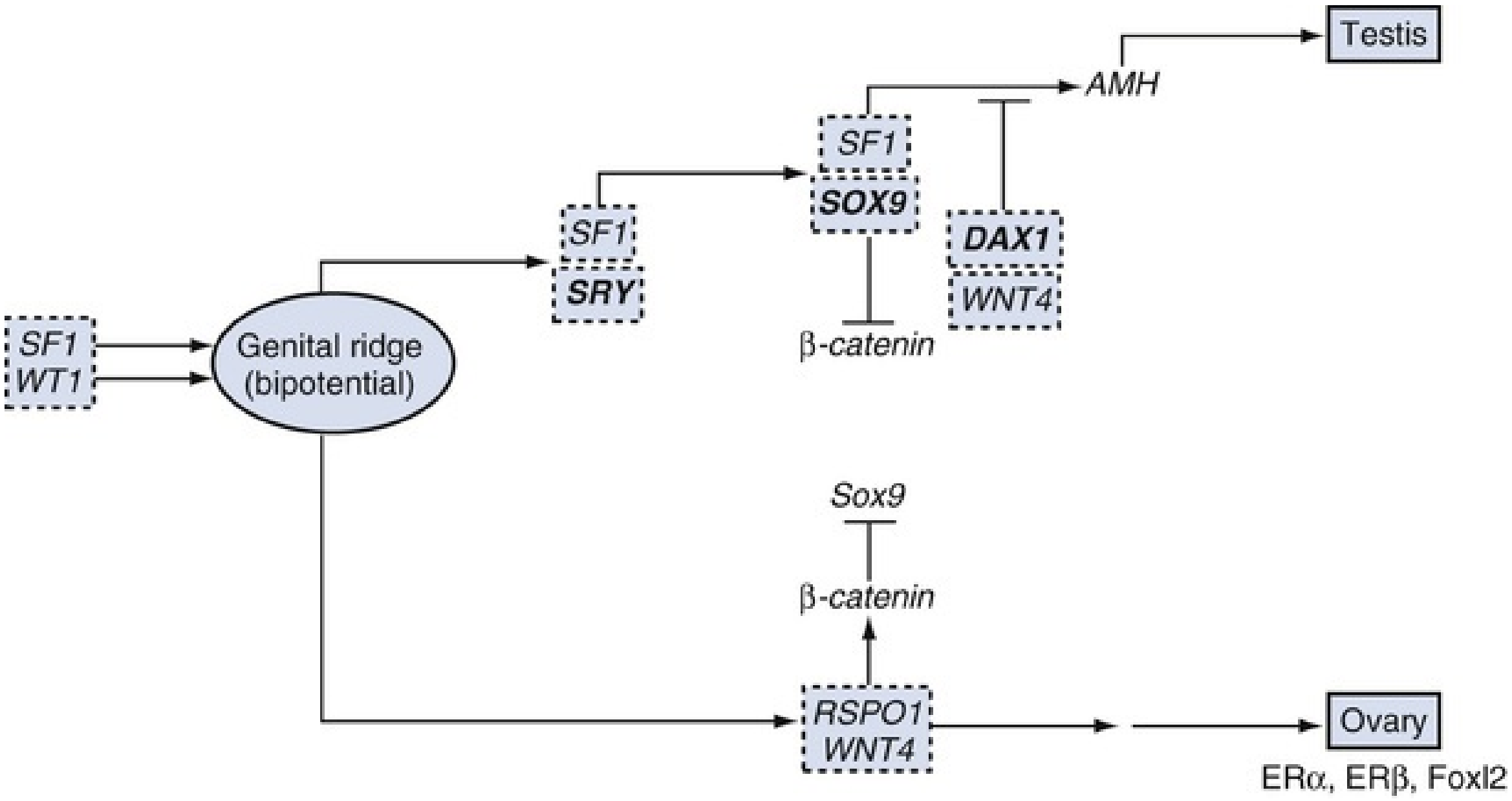

FIG. 48.4 Genes determining testis or ovarian differentiation from bipotential gonad. *SF1* and *WT1* are essential for gonadal ridge formation and development. Gonadal determination is influenced by transient expression of the testis determination factor, SRY. SOX9 upregulation by SRY leads to testis formation. Repression of SOX9, by factors such as DAX1 and WNT4/β-catenin, results in inhibition of testis formation and promotion of ovarian development. (From Hughes IA. Intersex. BJU Int 2002;90:771; and Sekido R, Lovell-Badge R. Sex determination and SRY: down to a wink and a nudge? *Trends Genet.* 2009;25[1]:19–29.)

TABLE 48.1

Loss-of-Function Phenotype (Human Data)

GENE	**CHROMOSOME**	**46,XY**	**46,XX**
SRY	Yp11.3	Female; gonadal dysgenesis (Swyer syndrome)	
SOX9	17q24.3–q25.1	Female; camptomelic dysplasia; ovaries to gonadal dysgenesis	Female; camptomelic dysplasia
WT1	11p13	Female; Wilms tumor; gonadal dysgenesis, mesangial sclerosis (Denys-Drash syndrome); streak gonads, glomerulosclerosis (Frasier syndrome)	Female; Wilms tumor; gonadal dysgenesis, mesangial sclerosis (Denys-Drash syndrome); streak gonads, glomerulosclerosis (Frasier syndrome)
NR5A1(SF1)	9q33	Female; adrenal insufficiency; gonadal dysgenesis	
NR0B1 (DAX1)	Xp21.3–p21.2	Male; gonadal dysgenesis, hypogonadotropic hypogonadism; adrenal hypoplasia	
WNT4	1p36.23–p35.1		Male; aberrant müllerian structure development; wolffian development
RSPO1	1p34.3		Male; palmoplantar keratoderma; aberrant müllerian development; ovotestis
FOXL2	3q23		Female; blepharophimosis-ptosis-epicanthus inversus syndrome (BPES); premature ovarian failure (BPES, type II)

WT1.

The *WT1* gene was originally isolated in cloning experiments that identified an oncogene on human chromosome 11 as being involved in the etiology of Wilms tumor (Call et al., 1990). This gene, originally localized by examining chromosomal deletions in children with WAGR syndrome (*W*ilms tumor, *A*niridia, *G*enitourinary abnormalities, gonadoblastoma, and mental *R*etardation), was found to be expressed primarily in the kidney and gonads of the developing human embryo (Kreidberg et al., 1993). The first reported mutations in Denys-Drash syndrome, which includes Wilms tumor, renal failure, and gonadal and genital abnormalities, were found to involve the WT1 protein (Pelletier et al., 1991a, 1991b). Indeed, mutations involving *WT1* have been found responsible for both the Frasier and Denys-Drash syndromes and manifest as a spectrum of genetically induced abnormalities involving the gonads and kidneys, owing to the earlier involvement of *WT1* in the differentiation of both structures. Frasier syndrome is characterized by both gonadal dysgenesis and renal abnormalities that result in streak gonads and a nephrotic syndrome (MacLaughlin and Donahoe, 2004). If it occurs in the XY genotype, sex reversal results. As a result of alternative splicing of the *WT1* gene, patients with Frasier syndrome are not susceptible to Wilms tumor, whereas those with Denys-Drash syndrome are (Koziell and Grundy, 1999). In addition, with the Denys-Drash syndrome, gonads differentiate more completely than with Frasier syndrome. Research on *Wt1* in the mouse suggests that it exerts its effects upstream of *Sry* and is likely to be necessary for commitment and maintenance of gonadal tissue (Lim and Hawkins, 1998).

NR5A1 (SF1).

The *NR5A1* gene encodes nuclear receptor steroidogenic factor 1 (*SF1)*, which is expressed in all steroidogenic tissues, including adrenal cortex, testis (Leydig cells), ovarian theca, granulosa cells, and corpus luteum. *SF1* is a key regulator of enzymes involved in steroid production, including the sex hormones, and contributes to the regulation of pituitary gonadotropin expression (Parker et al., 2002). In addition, *SF1* appears to play a role in early gonadal development at multiple levels of the reproductive endocrine axis (Ingraham et al., 1994; Luo et al., 1994). ***SF1* also appears to act synergistically with *WT1* in the regulation of anti-müllerian hormone (AMH), also known as müllerian-inhibiting substance (MIS),** expression (Shen et al., 1994; Imbeaud et al., 1995; Nachtigal et al., 1998) and may regulate *DAX1* (Yu et al., 1998) and *SOX9* expression (Sekido and Lovell-Badge, 2008).

Recent studies have suggested an additional role for NR5A1 in DSD. 46,XY individuals with heterozygous *NR5A1* mutations may have varying levels of undervirilization and gonadal dysgenesis (Philibert et al., 2007). There are two case reports of heterozygous mutations resulting in a more severe phenotype of 46,XY DSD associated with gonadal dysgenesis and adrenal insufficiency (Achermann et al., 1999; Orekhova et al., 2018). More recently, whole-exome sequencing of 46,XY and 46,XX DSD patients without prior genetic diagnoses has revealed a role for NR5A1, resulting in more subtle phenotypes. In addition, mutation of *NR5A1* in 46,XX individuals may lead to testicular or ovotesticular DSD as a result of decreased inhibition of the male developmental pathway (Baetens et al., 2017; Swartz et al., 2017). These findings suggest a novel role for NR5A1 in ovarian determination. Heterozygous missense mutations in NR5A1 have also been associated with male infertility because of severe impairment in spermatogenesis (Ferlin et al., 2015; Bashamboo et al., 2010).

SOX9.

The *SOX9* gene was originally identified in patients with campomelic dysplasia, a congenital disease of bone and cartilage formation that is often associated with XY sex reversal (Wagner et al., 1994). **The *SOX9* gene is structurally quite similar to *SRY*, with a 71% sequence similarity of the high-mobility group (HMG) domain to that of *SRY*.** Expression of the gene in adults is greatest in the testes. **Interestingly, *SOX9* gene activity increases immediately after SRY expression, and cell lineage analyses show that SOX9 protein is expressed in cells determined to become Sertoli cells** (Sekido and Lovell-Badge, 2009). Transgenic expression of SOX9 during urogenital ridge development in 46,XX mice results in induction of testis development in the absence of SRY expression (Vidal et al., 2001). **Therefore, the *SOX9* gene is a key downstream effector of SRY action. The activity of SRY on *SOX9* is synergistic with the activity of an additional transcription factor, steroidogenic factor 1 (SF1), which is essential for gonadal and adrenal development** (Sekido and Lovell-Badge, 2008). **The role of *SOX9* in male gonadal determination is further highlighted by data from genotypic males with *SOX9* mutations (46,XY) that exhibit ovarian development and male-to-female sex reversal** (Foster et al., 1994; Wagner et al., 1994). *SOX9* also upregulates *AMH* gene expression (MacLaughlin and Donahoe, 2004).

More recent studies have reported that mutations in the regulatory region of SOX9 can result in 46,XX DSD or 46,XY DSD. Duplication of a key regulatory region upstream of SOX9 may induce testicular differentiation in 46,XX individuals (Huang et al., 1999; Benko et al., 2011; Hyon et al., 2015). Furthermore, deletions of a different SOX9 regulatory region can result in undervirilization and gonadal dysgenesis in 46,XY individuals (Bhagavath et al., 2014; Kim et al., 2015).

NR0B1 (DAX1) and Dosage-Sensitive Sex Reversal (DSS).

The first indication that an X-specific gene was involved in human sex determination was provided in 1978 with the identification of a family with an X-linked mode of inheritance of 46,XY gonadal dysgenesis. Subsequent studies of a number of sex-reversed subjects confirmed the presence of additional X chromosomal genetic material and a normal Y chromosome (Ogata et al., 1992). **This finding suggested that duplication of an X-specific gene causes XY sex reversal by expressing a double dose of a region normally subject to X inactivation. Screening of XY females with a normal *SRY* gene detected such a submicroscopic duplication, involving a 160-kb region designated as the dosage-sensitive sex reversal (DSS) critical region** (Bardoni et al., 1994). Parallel studies examining 46,XY males with gonadal dysgenesis, hypogonadotropic hypogonadism, and congenital adrenal hypoplasia resulted in the identification of a candidate gene, *NR0B1 (DAX1)*, within the DSS critical region (Muscatelli et al., 1994; Zanaria et al., 1994). Interestingly, *DAX1* can act to suppress or promote the testis determination pathway (Yu et al., 1998; Meeks et al., 2003). Although *DAX1* was initially believed to be the primary gene involved in DSS, several sex-reversed 46,XY patients have been identified with duplication of the DSS region in the absence of *DAX1* duplication, which suggests that the gene dosage effects of this region may be associated with an additional gene or genes (Zanaria et al., 1995).

WNT4.

WNT4 on chromosome 1p34 appears to be involved in müllerian duct regression and may also function by antagonizing SRY activity (Kim et al., 2006; Bernard and Harley, 2007). Early inactivation of *Wnt4* in mice causes failure of the formation of müllerian duct derivatives in both sexes. In addition, inactivation of *Wnt4* in female mice leads to wolffian duct development without testicular tissue formation and female external genitalia. *WNT4* is implicated in development and maintenance of the female phenotype in women by regulating müllerian duct development and ovarian steroidogenesis (Biason-Lauber et al, 2004). Missense mutations of *WNT4* have been reported in 46,XX DSD with abnormal development of müllerian structures and variable degrees of virilization (Biason-Lauber et al., 2004; Biason-Lauber et al., 2007; Philibert et al., 2008; Maimoun et al., 2011).

RSPO1.

RSPO1 (R-spondin1) belongs to a family of ligands that activate the Wnt and β-catenin signaling pathways. Expression of RSPO1 overlaps that of Wnt in many tissues and can synergize with Wnt by stabilizing cytoplasmic β-catenin. This gene was identified as a candidate gene in ovarian determination by linkage analysis of a large consanguineous Italian family with cosegregation of palmoplantar hyperkeratosis (PPK) trait and XX female-to-male sex reversal (Parma et al., 2006). A single nucleotide, frameshift mutation was found in affected individuals from the consanguineous family and deletion mutations in sporadic cases of PPK and XX sex reversal.

Normal Phenotypic Development

Gonadal Stage of Differentiation

During the first 6 weeks of embryonic development, the gonadal ridge, germ cells, internal ducts, and external genitalia are bipotential in both 46,XY and 46,XX embryos. Under the genetic influences of sex determination, the bipotential gonadal ridges differentiate into either ovaries or testes, and germ cells develop into either oocytes or spermatocytes. Primordial germ cells can be recognized in the third week of gestation on the posterior wall of the secondary yolk sac. **Migration of the germ cells begins in the fifth week of gestation from the dorsal wall of the yolk sac through the mesentery to the medial ventral aspect of the urogenital ridge** (DeFilici et al., 2013) (Fig. 48.5). This process is dependent on chemoattractants and cell adhesion molecules (Hughes, 2002). Overall, a population of 1000 to 2000 primordial germ cells reaches the gonadal blastema by the sixth week of gestation.

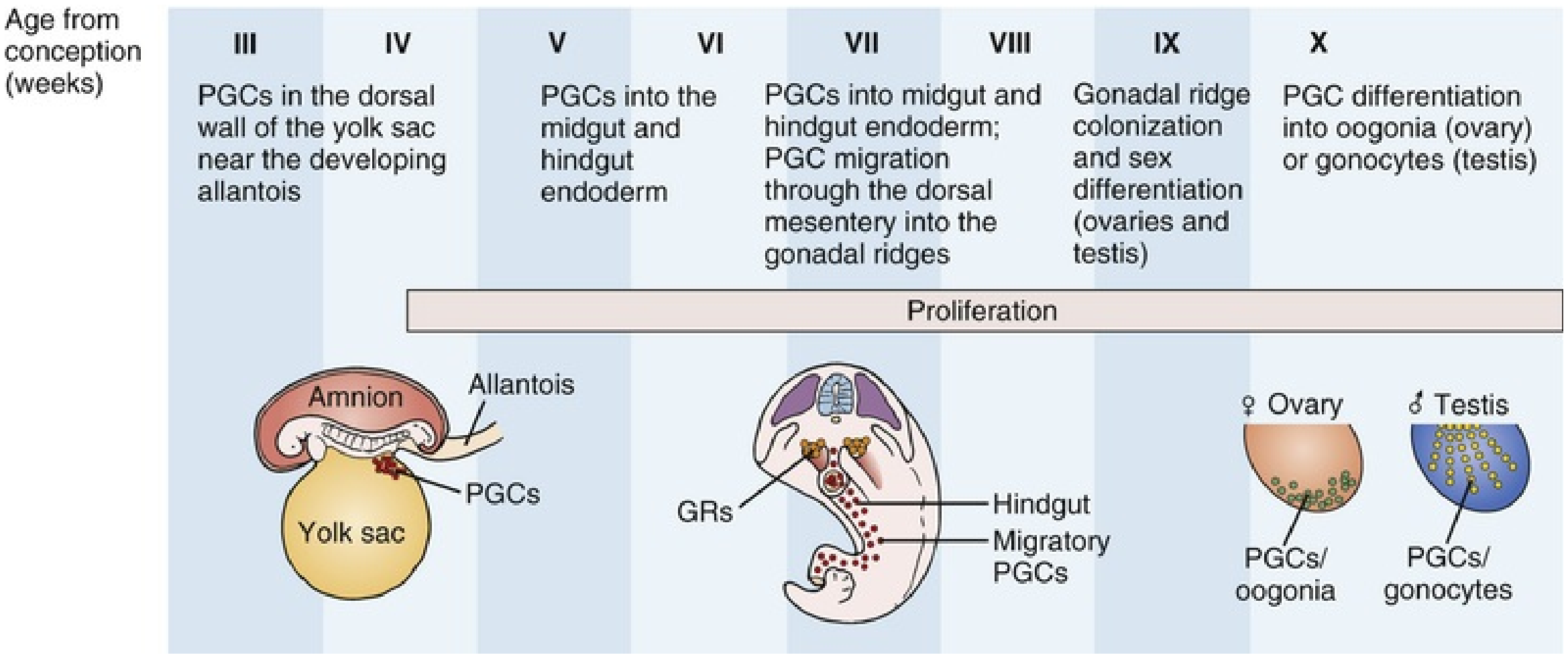
Age from conception (weeks)
III
IV
V
VI
VII
VIII
IX
X
PGCs in the dorsal wall of the yolk sac near the developing allantois
PGCs into the midgut and hindgut endoderm
PGCs into midgut and hindgut endoderm; PGC migration through the dorsal mesentery into the gonadal ridges
Gonadal ridge colonization and sex differentiation (ovaries and testis)
PGC differentiation into oogonia (ovary) or gonocytes (testis)
Proliferation
Amnion
Allantois
PGCs
Yolk sac
GRs
Hindgut
Migratory PGCs
♀ Ovary
♂ Testis
PGCs/ oogonia
PGCs/ gonocytes

FIG. 48.5 Migration of primordial germ cells. At 3 weeks, primordial germ cells are being formed and migrate along the wall of the yolk sac to reach the caudal part of the fetus. By 5 weeks, they have reached the level of the gonadal ridge. (From DeFelici M. Origin, migration, and proliferation of human primordial germ cells. In: Coticchio G, Albertini DF, DeSantis L, eds. *Oogenesis.* London: Springer-Verlag; 2013. p. 21.)

Transformation of the germ cells into spermatogonia and oogonia results from differentiation of the epithelial gonadal compartments referred to as testicular and ovarian “cords.” ***SRY* initiates the switch that induces a cascade of genes directing the indifferent gonad toward testicular organogenesis.** The precise moment at which this occurs remains unknown. Initially, differentiation of Sertoli cells is noted as testicular cords form at 6 to 7 weeks’ gestation, creating the basement membrane, or blood-testis barrier, of spermatogonia and Sertoli cells on one side and mesenchymal fibroblasts on the other. **The differentiation of Sertoli cells is associated with the production of AMH (anti-Müllerian hormone), a glycoprotein encoded by a gene on the short arm of chromosome 19** (Haqq et al., 1994). In males, a second line of primordial cells of steroidogenic mesenchyme remain among the testicular cords and represent future Leydig cells, which differentiate at 8 to 9 weeks. **In the absence of *SRY,* ovarian organogenesis results.** Little is known about the genetic control of ovarian development. To date, no genes whose products direct development of the ovary have been identified. **It does appear necessary that there be duplicate copies of at least one X chromosomal locus (which presumably explains the dysgenetic ovaries in 45,XO Turner syndrome patients).** A potential candidate may lie within the DSS critical region on Xp-21, which, when duplicated, promotes male-to-female “sex reversal” (Bardoni et al., 1994; Lopez et al., 1998).

Unlike the testis, which functions primarily as a fetal endocrine organ, the ovary has primarily exocrine activity. In embryonal ovaries, germ cells undergo intense mitotic proliferation (preceding the onset of meiotic prophase) and in the process exhaust their entire mitotic potential prenatally, reaching a maximum endowment of 20 million cells by 20 weeks' gestation. The presence of two X chromosomes appears to be responsible for differentiation of the granulosa cells into the protective mantle of the granulosa layer and "rescue" of 30% of germ cells (approximately 2 million) (Byskov and Westergaard, 1998).

Key Point: Gonadal State of Differentiation

- During the first 6 weeks of embryonic development, the gonadal ridge, germ cells, internal ducts, and external genitalia are bipotential in both 46,XY and 46,XX embryos.

Gonadal Function

Testis

The initial endocrine function of the fetal testes is the secretion of AMH by the Sertoli cells at 7 to 8 weeks' gestation. AMH, one of the two hormones necessary for male sexual differentiation, acts locally to produce müllerian regression. It is a member of the transforming growth factor-β (TGF-β) family, and the human gene has been cloned and mapped to chromosome 19 (Cate et al., 1986). Little is known about the cellular mechanism of action of AMH. Because the hallmark of AMH-mediated müllerian duct regression is the formation of a ring of connective tissue around the epithelial cells, it is likely that the mesenchyme is the primary target of AMH. **Testosterone secretion by the fetal testes is detectable shortly after the formation of Leydig cells in the interstitium at approximately 9 weeks' gestation** (Siiteri and Wilson, 1974). There is a rise in serum and testicular testosterone to a peak concentration at 13 weeks and then a decline. The rate-limiting enzyme for fetal testosterone synthesis is 3β-hydroxysteroid dehydrogenase, which is approximately 50 times more highly concentrated in the fetal testes than in the ovary. Androgens are synthesized by the Leydig cells, initially autonomously, but then dependent on placental human chorionic gonadotropin (hCG) secretion. Later in gestation, with declining hCG concentrations, androgen synthesis is controlled by luteinizing hormone (LH) secretion by the fetal pituitary gland. **Jost et al.** (1973) **clearly demonstrated that androgen is essential for virilization of wolffian duct structures, the urogenital sinus, and the genital tubercle. Testosterone, the major androgen secreted by the testes, enters target tissues by passive diffusion.** Organs such as the wolffian duct, adjacent to the fetal testis, also take up testosterone by pinocytosis. **The local source of androgen is important for wolffian duct development, which does not occur if testosterone is supplied only via the peripheral circulation. In some cells, such as those in the urogenital sinus, testosterone is converted to dihydrotestosterone (DHT) by intracellular 5α-reductase.** Testosterone or DHT then binds to a high-affinity intracellular receptor protein, and this complex enters the nucleus, where it binds to acceptor sites on DNA, resulting in new messenger RNA and protein synthesis (Fig. 48.6). The androgen receptor has been characterized as a high-affinity receptor that mediates the action of testosterone and DHT in all androgen-dependent tissues. In disorders of the androgen receptor, such as androgen insensitivity syndrome, testosterone production is normal, but the hormone is unable to reach the nucleus and interact with DNA. Various defects in the androgen receptor result in a spectrum of phenotypic abnormalities in the genetic male. Because gonadal females have androgen receptor within their tissues, exogenous androgen produces virilization. **DHT binds to the androgen receptor with greater affinity and stability than does testosterone. Therefore, in tissues equipped with 5α-reductase at the time of sexual differentiation (e.g., prostate, urogenital sinus, external genitalia), DHT is the active androgen** (George and Peterson, 1988). The 5α-reductase activity has two optimal pH values in cultured genital skin fibroblasts—one at pH 5.5 and a second one near pH 8—that correspond to two distinct enzymes (Jenkins et al., 1992). The alkaline enzyme, human steroid 5α-reductase type 1, was cloned first; however, the primary enzyme in the prostate is 5α-reductase type 2 (Andersson and Russell, 1990). A deletion in the gene coding for this enzyme has been discovered in DSD patients with 5α-reductase deficiency (Andersson et al., 1991). The gene encoding the androgen receptor has been cloned and mapped to the X chromosome at Xq11–12 (Lubahn et al., 1988).

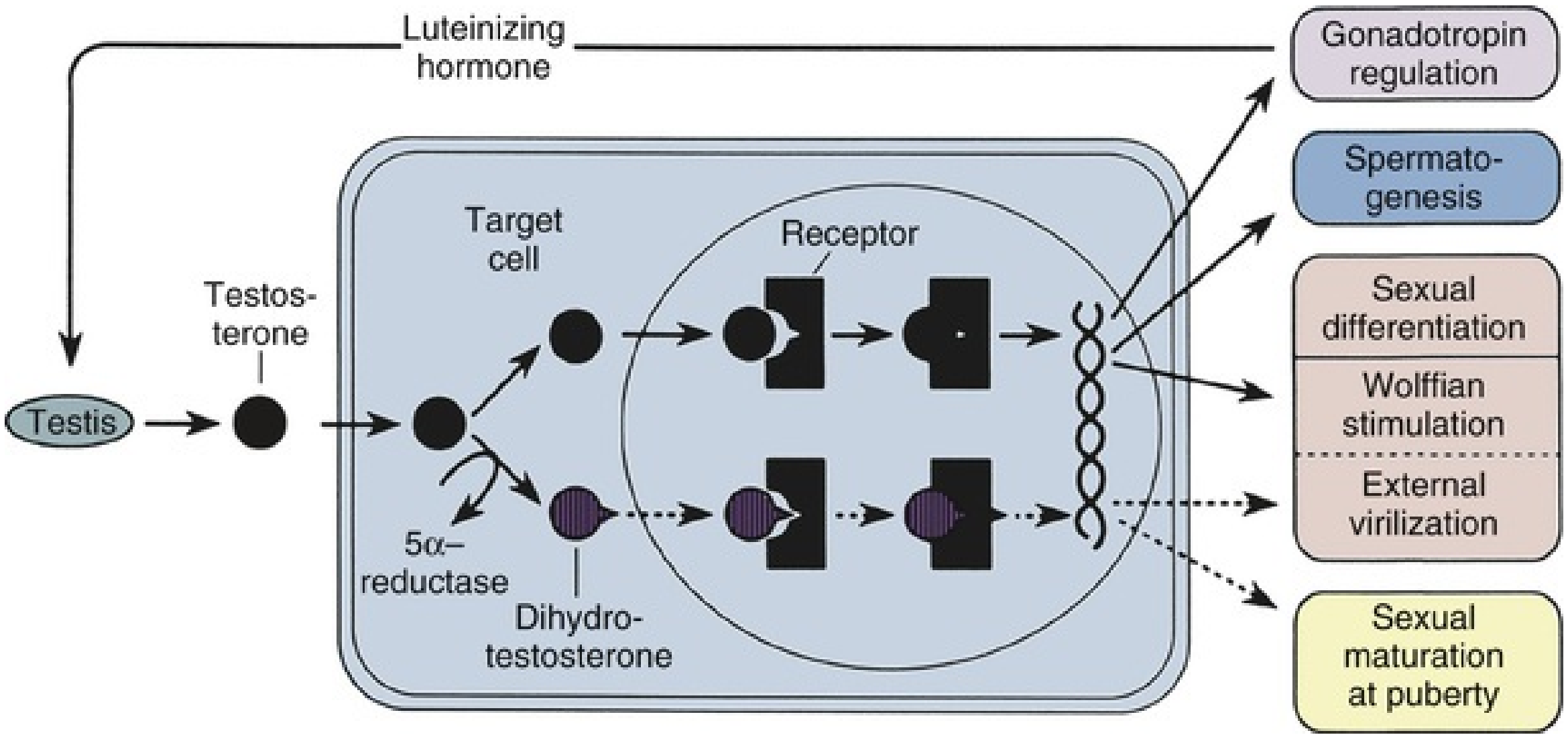
Luteinizing hormone
Gonadotropin regulation
Spermato-genesis
Target cell
Receptor
Testos-terone
Testis
Sexual differentiation
Wolffian stimulation
External virilization
5α–reductase
Dihydro-testosterone
Sexual maturation at puberty

FIG. 48.6 Schematic diagram of normal androgen physiology. The major actions of androgens are listed on the right. Testosterone enters androgen target tissues and either binds to the androgen receptor in cell nuclei or is converted by 5α-reductase to dihydrotestosterone (DHT). DHT binds to the same receptor but with greater affinity. Androgen actions mediated by testosterone are indicated by *solid arrows,* and those mediated by DHT are indicated by *dashed arrows.* (From Griffin JE, Wilson JD. Syndromes of androgen resistance. *Hosp Pract.* 1987;22:99–114.)

Key Point: Gonadal Function

- DHT binds to the androgen receptor with greater affinity and stability than does testosterone. Therefore in tissues equipped with 5α-reductase at the time of sexual differentiation (e.g., prostate, urogenital sinus, external genitalia), DHT is the active androgen.

Ovary

Estrogen synthesis is detectable in the female embryo just after 8 weeks' gestation. The rate-limiting enzyme is aromatase, which is higher in the fetal ovary than in the fetal testis. Estrogens are not required for normal female differentiation of the reproductive tract, but they can interfere with male differentiation. Estrogen can block the effect of AMH on müllerian ducts, and prenatal estrogen treatment of mothers has been associated with male reproductive tract abnormalities (Gill et al., 1979; Vigier et al., 1989).

Phenotypic Sexual Development

Before the eighth week of gestation, the urogenital tract is identical in the two sexes. Both the wolffian and the müllerian duct systems are present as anlagen of the internal accessory organs of reproduction (Fig. 48.7). In addition, at this stage, the anlagen of the external genitalia of male and female embryos are indistinguishable (Fig. 48.8). **In the male fetus, Sertoli cells produce AMH, which acts locally and unilaterally to suppress the müllerian ducts, and Leydig cells produce testosterone, which permits local development of the wolffian ducts.** By 10 weeks' gestation, degeneration of the müllerian ducts is almost complete, and the wolffian ducts have become more prominent (see Fig. 48.7). Adjacent to the testes, convolutions of the ducts organize to form the epididymis. The wolffian ducts of the epididymis join with the collecting portion of the testicular tubules (rete testes). Distally, the ducts join the urogenital sinus by about 30 days' gestation, where they develop into the seminal vesicles. In the female fetus, testosterone is not secreted by the ovaries, and therefore the wolffian ducts regress. Because the ovary does not produce AMH, the müllerian ducts are maintained and develop into the female internal reproductive tract. The cephalic ends are anlagen of the fallopian tubes, and the caudal ends fuse to form the uterus (see Fig. 48.7). Contact of the müllerian ducts with the urogenital sinus induces formation of the uterovaginal plate, which ultimately forms the lumen of the vagina. The relative contributions of the müllerian ducts and urogenital sinus to the formation of the vagina remain somewhat controversial; however, there is some agreement that the proximal two-thirds of the vagina is contributed by the müllerian ducts and the distal one-third by the urogenital sinus. Masculinization of the male fetus starts between 7 and 8 weeks' gestation (Fig. 48.9). The first sign of male phenotypic differentiation is degeneration of the müllerian ducts adjacent to the testes as a result of AMH secretion by the Sertoli cells. Whereas the effects of androgen on the wolffian ducts are related to diffusion of testosterone from the adjacent gonad, masculinization of the external genitalia results from the systemic delivery of testosterone with local conversion to dihydrotestosterone. By 10 weeks' gestation, an increase in distance between genital tubercle and anal folds can be seen. The genital tubercle thickens and elongates to become the penis, and the urethral folds fuse from posterior to anterior over the urethral groove (Fig. 48.10). Near the bladder, the urethra is surrounded by the prostate. The urogenital swellings migrate posteriorly to the genital tubercle and fuse to form the scrotum. **By 12 to 13 weeks' gestation, the**

genitalia of the male fetus are completed with closure of the elongated urogenital cleft. Under the influence of androgen secreted by the fetal testes, penile growth and testicular descent occur in the third trimester (see Fig. 48.9). In the female fetus, the absence of circulating testosterone maintains the appearance of the external genitalia at the 6-week gestational stage. The genital tubercle develops only slightly to form the clitoris. The lateral genital swellings become the labia majora, and the adjacent urethral folds become the labia minora (Fig. 48.11). Between the labia minora will develop the vaginal introitus and urethral meatus.

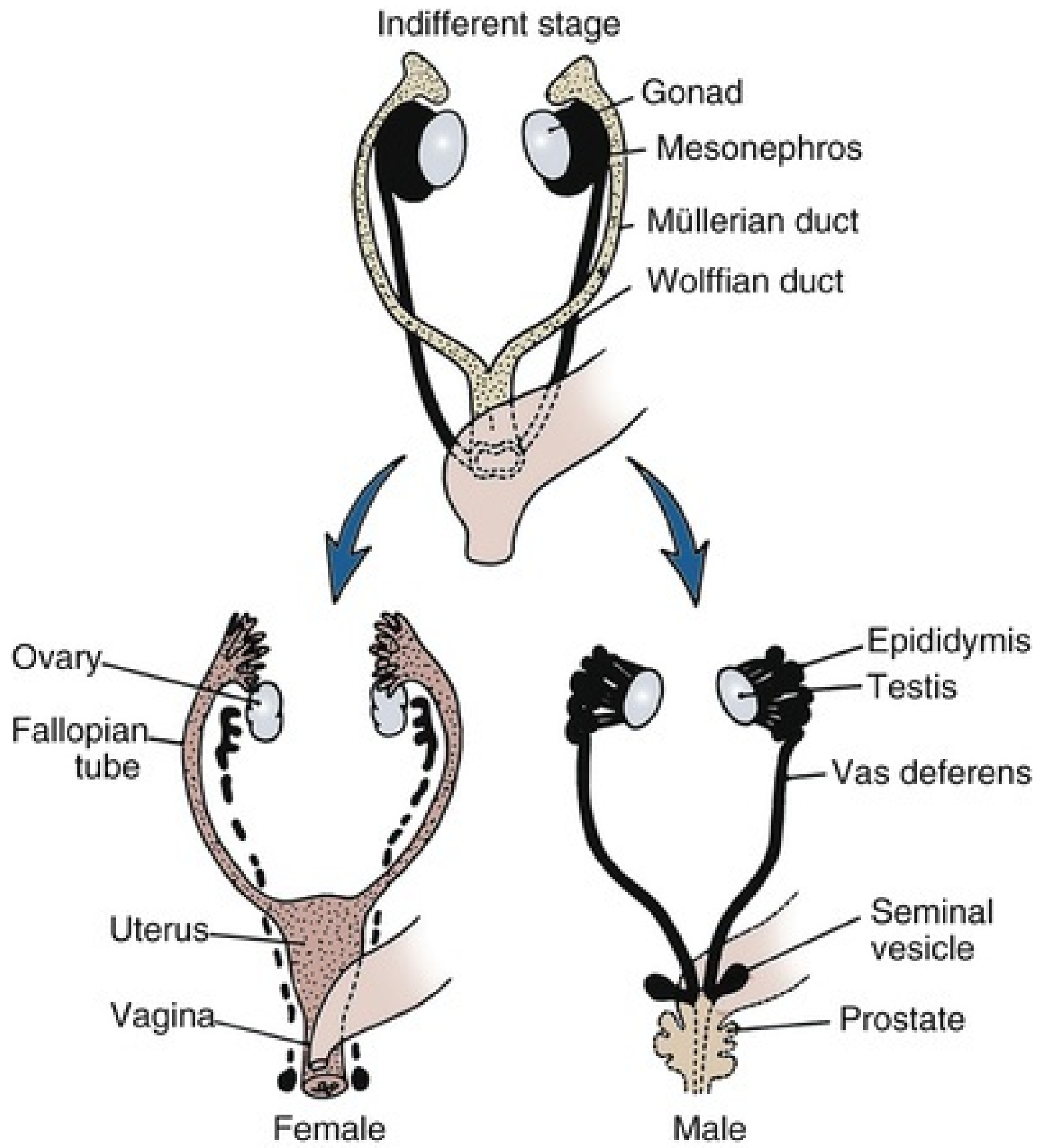
Indifferent stage
Gonad
Mesonephros
Müllerian duct
Wolffian duct
Ovary
Fallopian tube
Uterus
Vagina
Female
Epididymis
Testis
Vas deferens
Seminal vesicle
Prostate
Male

FIG. 48.7 Differentiation of the wolffian and müllerian duct and urogenital sinus in the male and female. (From Wilson JD. Embryology of the genital tract. In: Harrison HH, Gittes RF, Perlmutter AD, et al., eds. *Campbell's urology.* 4th ed. Philadelphia, PA: WB Saunders; 1979. p. 1473.)

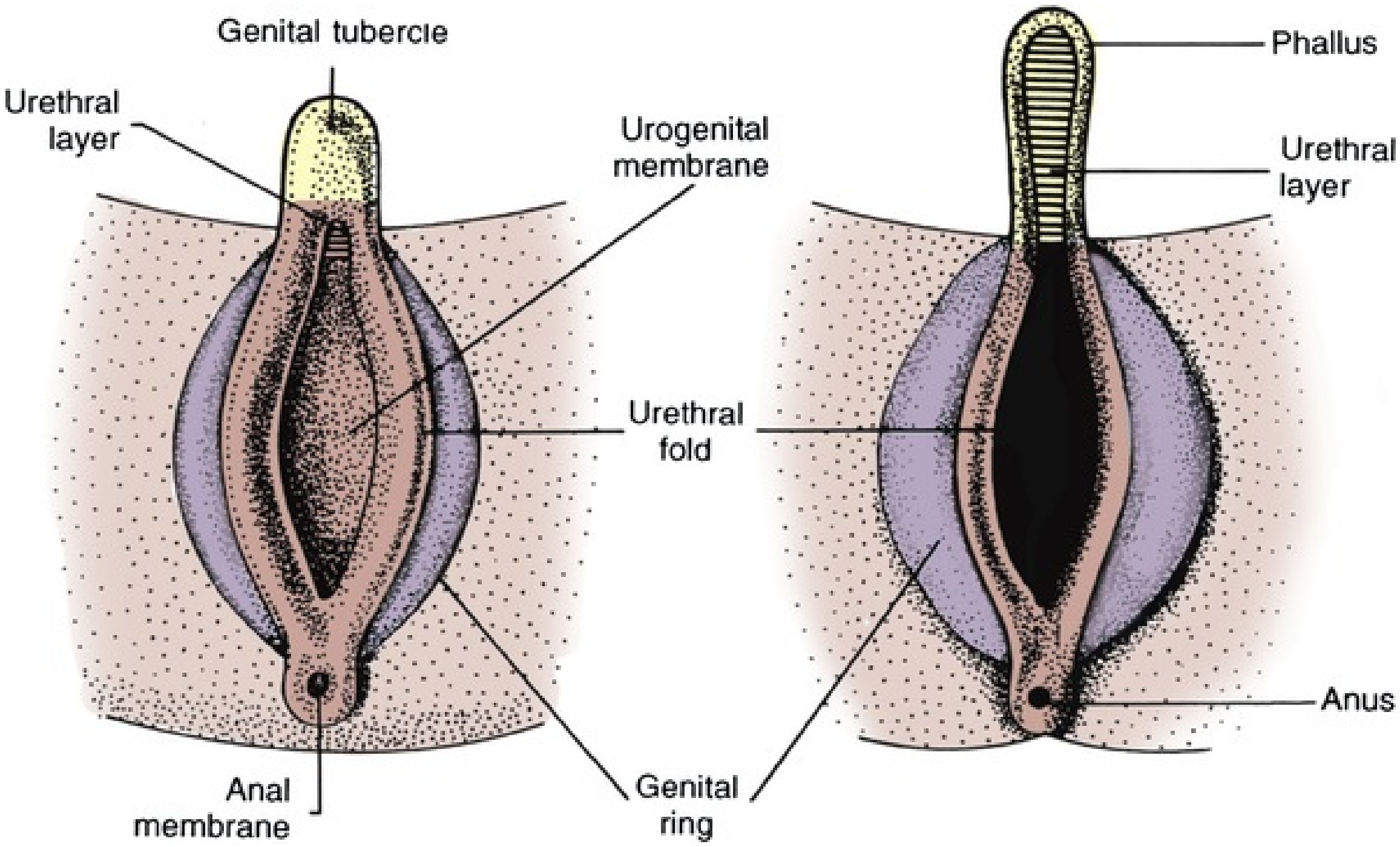
Genital tubercle
Urethral layer
Urogenital membrane
Urethral fold
Anal membrane
Genital ring
Phallus
Urethral layer
Anus

FIG. 48.8 Schematic diagram of external genitalia in the undifferentiated period. (From Martinez-Mora J. Development of the genital tract. In: Martinez-Mora J, ed. *Intersexual states: disorders of sex differentiation.* Barcelona: Ediciones Doymer; 1994. p. 52.)

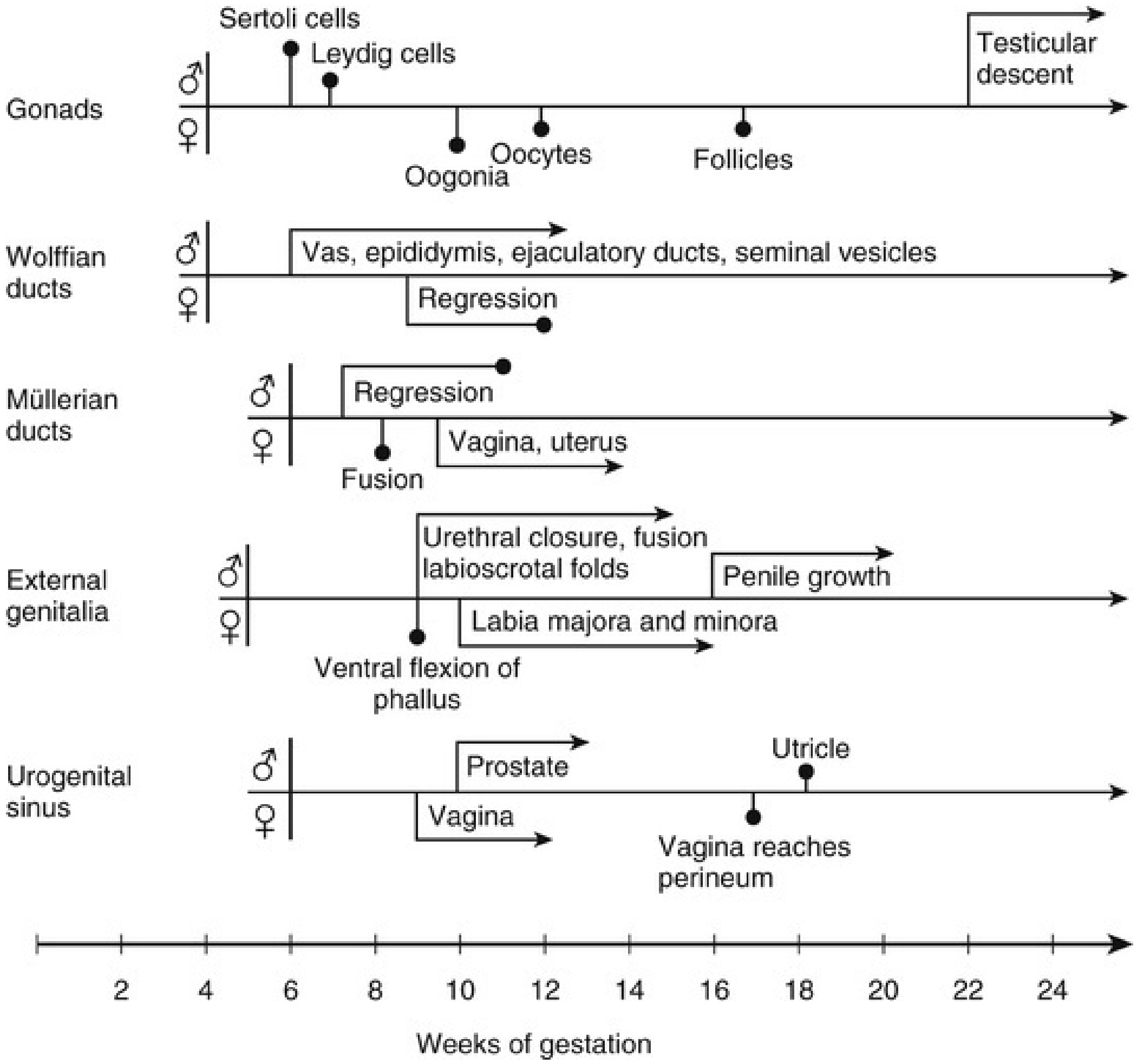
Gonads
♂
♀
Sertoli cells
Leydig cells
Testicular descent
Oogonia
Oocytes
Follicles
Wolffian ducts
Vas, epididymis, ejaculatory ducts, seminal vesicles
Regression
Müllerian ducts
Regression
Fusion
Vagina, uterus
External genitalia
Urethral closure, fusion labioscrotal folds
Penile growth
Labia majora and minora
Ventral flexion of phallus
Urogenital sinus
Prostate
Utricle
Vagina
Vagina reaches perineum
2
4
6
8
10
12
14
16
18
20
22
24
Weeks of gestation

FIG. 48.9 Timetable of normal sexual differentiation. (From White PC, Speiser PW. Congenital adrenal hyperplasia due to 21-hydroxylase deficiency. *Endocr Rev.* 2000;21(3):245–291.)

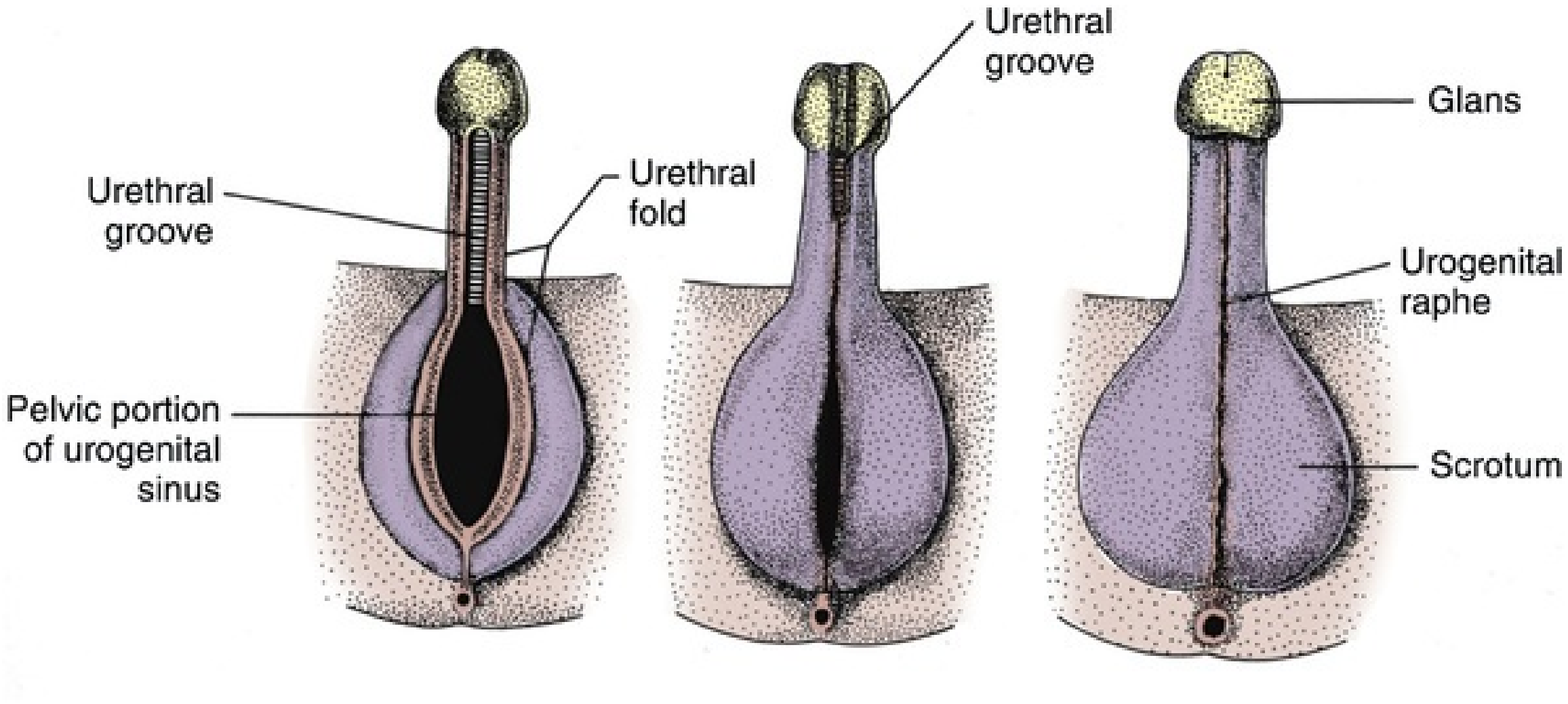
Urethral groove
Urethral groove
Urethral fold
Glans
Urogenital raphe
Pelvic portion of urogenital sinus
Scrotum

FIG. 48.10 Schematic diagram of differentiation of the male external genitalia. (From Martinez-Mora J. Development of the genital tract. In: Martinez-Mora J, ed. Intersexual states: disorders of sex differentiation. Barcelona: Ediciones Doymer; 1994. p. 53.)

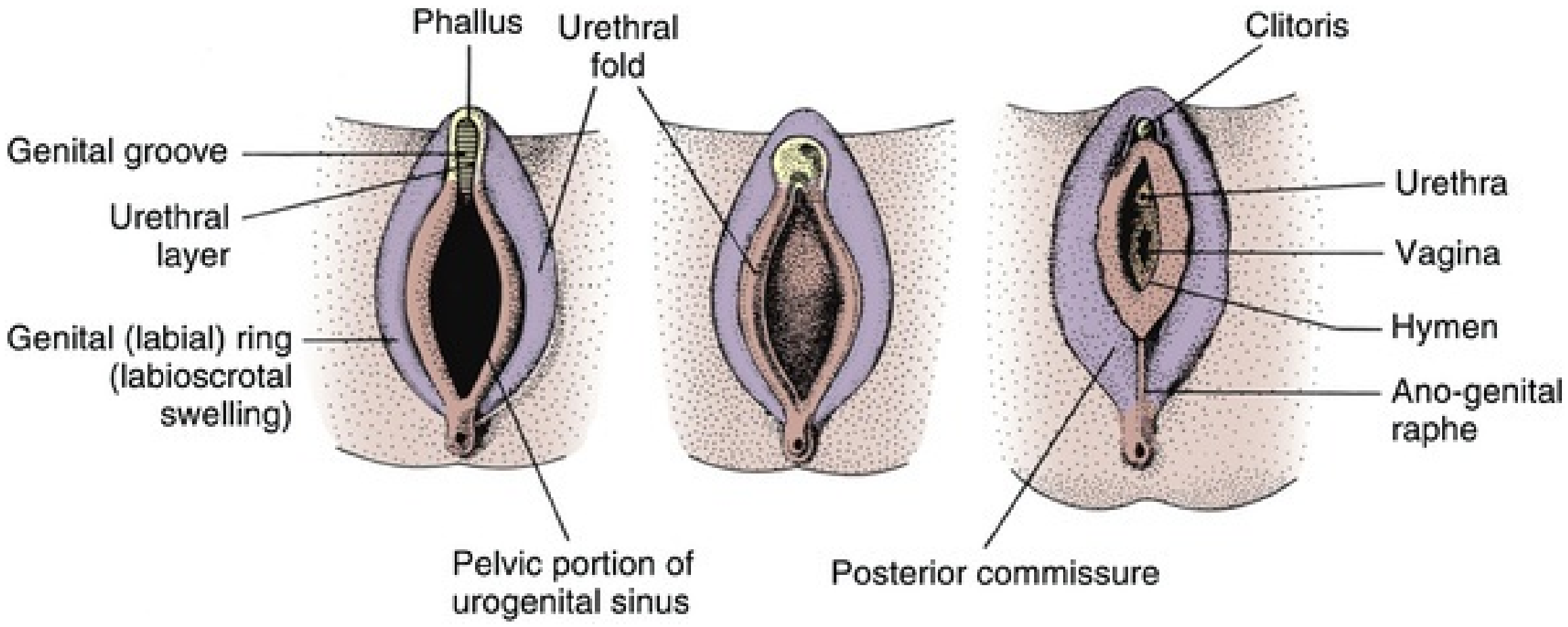
Phallus
Urethral fold
Clitoris
Genital groove
Urethral layer
Urethra
Vagina
Hymen
Genital (labial) ring (labioscrotal swelling)
Ano-genital raphe
Pelvic portion of urogenital sinus
Posterior commissure

FIG. 48.11 Schematic diagram of differentiation of the female external genitalia. (From Martinez-Mora J. Development of the genital tract. In: Martinez-Mora J, ed. *Intersexual states: disorders of sex differentiation.* Barcelona: Ediciones Doymer; 1994. p. 52.)

Gender Identity, Gender Role, and Gender Orientation

Psychosexual Development

Humans have been recognized as having sexually dimorphic behavior, which has several aspects: (1) *gender identity,* the identification of self as either male or female; (2) *gender role,* aspects of behavior in which males and females appear to differ; (3) *gender orientation,* or choice of sexual partner (heterosexual, homosexual, or bisexual); and (4) *cognitive differences* (Grumbach and Conte, 1998). Gender identity is a complex and poorly understood phenomenon in humans, and the mechanisms appear multifactorial. Experience in patients with congenital adrenal hyperplasia (CAH) who were exposed prenatally to androgen and in patients reared in a sex opposite to their chromosomal or gonadal sex have provided evidence to indicate that gender identity is not merely a function of chromosomal complement or prenatal endocrine milieu. Postnatal environmental factors and learning appear to have an important effect. However, strong evidence has accumulated for the impact of prenatal hormonal influences on sexually dimorphic behavior or gender role. For example, long-term follow-up with CAH patients has supported a greater interest in “tomboyish behavior” than in unaffected girls, although these patterns are not abnormal in relation to female behavior in Western society (Ehrhardt and Meyer-Bahlburg, 1981). Additional information regarding the influence of androgens on gender identity and gender role has arisen from one study of males with cloacal exstrophy who underwent gender reassignment within the first few months of life. A majority of these patients had behaviors and attitudes that reflected strong male-typical characteristics regardless of whether they were raised as males or females (Reiner and Gearhart, 2004). However, a subsequent British study of a similar 46,XY cloacal exstrophy cohort presented contradictory findings (Baker Towell and Towell, 2003). The previously accepted dogma that children are psychosexually neutral at birth and capable of being environmentally oriented (the blue room/pink room theory) has been seriously challenged by those who support the concept of prenatal psychosexual differentiation (Money and Ehrhardt, 1972; Diamond and Sigmundson, 1997). Support for either theory in humans is based on the assessment of a limited number of affected patients. An improved understanding of the “nature versus nurture” controversy will probably prove important in the optimal management of patients with DSDs. However, our increased awareness of physiologically normal patients with genuine “gender dysphoria” has illustrated the complexity of this process and the fluidity of gender that challenges long-held concepts of binary behavior.

Key Point: Psychosexual Development

- The previously accepted dogma that children are psychosexually neutral at birth and capable of being environmentally oriented (the blue room/pink room theory) has been seriously challenged by those who support the concept of prenatal psychosexual differentiation.

Abnormal Sexual Development

The classification of DSDs (previously “intersex disorders”) has undergone evolutionary change as understanding of the etiologic mechanisms of normal and abnormal sexual development has improved. As a result, classification systems vary. The authors have borrowed from the system used by Grumbach and Conte (1998), which incorporates the historical emphasis on classification by gonadal morphology and introduced more contemporary terminology (Hughes et al., 2006). Descriptive terms for abnormal gonadal histology have been retained, with the exception of *true hermaphroditism*, which has been replaced by *ovotesticular DSD*. But, for masculinized 46,XX females with two ovaries, *female pseudohermaphroditism* has been replaced by 46,XX DSD. And, for undermasculinized 46,XY males, the term *male pseudohermaphroditism* has been replaced by 46,XY DSD. The first category includes disorders of gonadal differentiation, the second includes ovotesticular DSD, the third includes 46,XX DSD (the masculinized female, that is, ovaries present but external genitalia exhibiting evidence of masculinization), the fourth includes 46,XY DSD (the undermasculinized male, that is, testes present but genital ducts and/or external genitalia incompletely masculinized), and the fifth category includes unclassified forms. Within each category, remarkable advances in chromosomal and biochemical information have allowed subclassification of disorders based on etiologic mechanisms, contributing to a more rational classification system (Table 48.2).

TABLE 48.2

Abnormal Sexual Differentiation

1. Disorders of Gonadal Differentiation

Seminiferous tubule dysgenesis
Klinefelter syndrome
46,XX male
Syndromes of gonadal dysgenesis
    Turner syndrome
    Pure gonadal dysgenesis
    Mixed gonadal dysgenesis
    Partial gonadal dysgenesis (dysgenetic male pseudohermaphroditism)
    Bilateral vanishing testis/testicular regression syndromes

2. Ovotesticular DSD (True Hermaphroditism)
3. 46,XX DSD (Masculinized Female)
Congenital adrenal hyperplasia (21-hydroxylase, 11β-hydroxylase, 3β-hydroxysteroid dehydrogenase deficiencies) Maternal androgens
4. 46,XY DSD (Undermasculinized Male)
Leydig cell agenesis, unresponsiveness Disorders of testosterone biosynthesis Variants of congenital adrenal hyperplasia affecting corticosteroid and testosterone synthesis StAR deficiency (congenital lipoid adrenal hyperplasia) Cytochrome P450 oxidoreductase (POR) deficiency 3β-Hydroxysteroid dehydrogenase deficiency 17β-Hydroxylase deficiency Disorders of testosterone biosynthesis 17,20-Lyase deficiency 17β-Hydroxysteroid oxidoreductase deficiency Disorders of androgen-dependent target tissue Androgen receptor and postreceptor defects Syndrome of complete (severe) androgen insensitivity Syndrome of partial androgen insensitivity Mild androgen insensitivity syndrome (MAIS) Disorders of testosterone metabolism by peripheral tissues 5α-Reductase deficiency Disorders of synthesis, secretion, or response to müllerian-inhibiting substance Persistent müllerian duct syndrome
5. Unclassified Forms
In females Mayer-Rokitansky-Küster-Hauser syndrome

Evaluation and Management of the Newborn With Ambiguous Genitalia

The evaluation and initial management of the neonate with ambiguous genitalia must be regarded as a medical and psychosocial emergency and be handled with great sensitivity toward the family. Ideally, a medical team including a pediatric urologist, an endocrinologist, a geneticist, and a psychiatrist or psychologist experienced in managing DSD patients should work closely with the family. **The team's goal should be to make a precise diagnosis of the disorder (which can be achieved in most cases) and, with the involvement of the parents, to assign a proper sex of rearing based on the diagnosis, the status of the child's anatomy, and the functional potential of the genitalia and reproductive tract.**

In obtaining the history, certain pieces of information may be particularly valuable. A history of infant death within the family might suggest the possibility of CAH, and infertility, amenorrhea, or hirsutism might also suggest possible familial patterns of DSD states. Certainly, maternal use of medications, in particular steroids or contraceptives, during the pregnancy is of great importance.

One critical finding on physical examination is the presence or absence of gonads. Bilateral nonpalpable gonads with ambiguous genitalia is suspicious for virilization of a female secondary to CAH. The ability to palpate one or two gonads effectively rules out overmasculinization of the female. Because ovaries do not descend, a distinctly palpable gonad along the pathway of descent is highly suggestive of a testis. Rarely, an ovotestis undergoes descent to the inguinal canal and may be suspected on the basis of asymmetry of tissue texture of the poles of the gonad. This suspicion may be further supported by ultrasound findings. **The patient with bilaterally impalpable testes or a unilaterally impalpable testis and hypospadias should be regarded as having a DSD until proven otherwise, whether or not the genitalia appear ambiguous.** Kaefer et al. (1999) studied the incidence of DSDs in patients with cryptorchidism and hypospadias and without ambiguous genitalia. **With both unilateral and bilateral cryptorchidism, and hypospadias, the incidence of DSD was 30% overall. The incidence was approximately 15% if an undescended testis was palpable and 50% if it was impalpable.** In addition, posterior urethral meatal position was noted to be a strong predictor of DSD in this group of patients—65%, versus 5% to 8% with a midshaft to anteriorly located hypospadiac meatus (Kaefer et al., 1999).

In addition to gonadal examination, penile size should be assessed and an accurate measure of stretched penile length recorded. The mean stretched penile length in full-term males born in the United States is 3.5 cm (± 0.04) (Lee et al., 2006). The location of the urethral meatus versus a single perineal opening should be identified and documented. Measurement of the anogenital distance (AGD) may serve as an indicator of fetal androgen exposure and has been found to correlate with testis size, sperm count, penis length, and testosterone levels in rats and humans (Dean et al, 2013). However, AGD is not widely used because of the lack of normative values. Another means to document the degree of virilization is the External Masculinization Score (EMS). Scoring is based on individual features of the external genitalia (phallus size, labioscrotal fusion, gonad location, and location of urethral meatus) (Ahmed et al., 2011). The utility of this instrument in predicting clinical outcomes has not been demonstrated thus far.

An additional important finding on physical examination is the presence of a uterus, which is noted as an anterior midline cordlike structure on rectal examination. **A more precise means of assessing müllerian anatomy is by pelvic ultrasonography, which may be performed immediately in the neonatal period.** In addition to defining müllerian anatomy and confirming the presence or absence of a uterus, the gonads and adrenal glands should be studied. Normal anatomy of an undescended gonad should be confirmed, and a cyst within the gonad, consistent with ovotestis, should be ruled out.

Within the immediate neonatal period, a karyotype should be obtained. Typically this requires 2 days to perform. Therefore, an attractive approach to obtain chromosomal data quickly is fluorescence in-situ hybridization, which rapidly identifies X and Y chromosomes. It is typically used to confirm the presence of a second X chromosome. The technique is much more rapid than karyotyping, producing results within a few hours.

Serum studies should be immediately sent to rule out a salt-wasting form of CAH. In addition to serum electrolytes, testosterone and DHT should be measured early. Migeon et al. (1994) emphasized that the androgen levels may drop quickly, necessitating early study. In addition, they suggested that serum 17-hydroxyprogesterone should not be measured until day 3 or 4 to rule out 21-hydroxylase deficiency, because the stress of delivery may result in physiologic elevation of this steroid precursor in the first 1 or 2 days of life.

In the absence of palpable testes, the presence or absence of testicular tissue should be determined by documentation of a markedly elevated LH during mini-puberty, consistent with anorchia, or by means of an hCG stimulation test, which can demonstrate normally functioning testicular tissue (Jarow et al., 1986). In addition to ruling out anorchia, the study can enable diagnosis of 5α-reductase deficiency (by virtue of an increased ratio of testosterone to DHT) and can help distinguish between impaired testosterone synthesis (deficient response to hCG) and androgen insensitivity (normal response to hCG). Serum AMH measurement has been proposed as a reliable marker of the presence of testes (Hughes, 2002).

Key Points: Evaluation and Management of DSD

- The team's goal should be to make a precise diagnosis of the disorder (which can be achieved in most cases) and, with the involvement of the parents, to assign a proper sex of rearing based on the diagnosis, the status of the child's anatomy, and the functional potential of the genitalia and reproductive tract.
- The patient with bilaterally impalpable testes or a unilaterally impalpable testis and hypospadias should be regarded as having a DSD until proven otherwise, whether or not the genitalia appear ambiguous.

Based on physical examination (largely, gonadal palpability), the presence or absence of müllerian structures on ultrasonography, 17-hydroxyprogesterone concentration, and the karyotype, a reasonable differential diagnosis may be formulated (Fig. 48.12). A precise diagnosis can virtually always be achieved for the 46,XX DSD (overvirilized female) but in less than 50% of 46,XY DSD undervirilized males (Lee et al, 2006). The presence of asymmetrical anatomy on examination and ultrasonography is an important observation and suggests mixed gonadal dysgenesis if the karyotype is XY and ovotesticular DSD if it is 46,XX (Fig. 48.13).

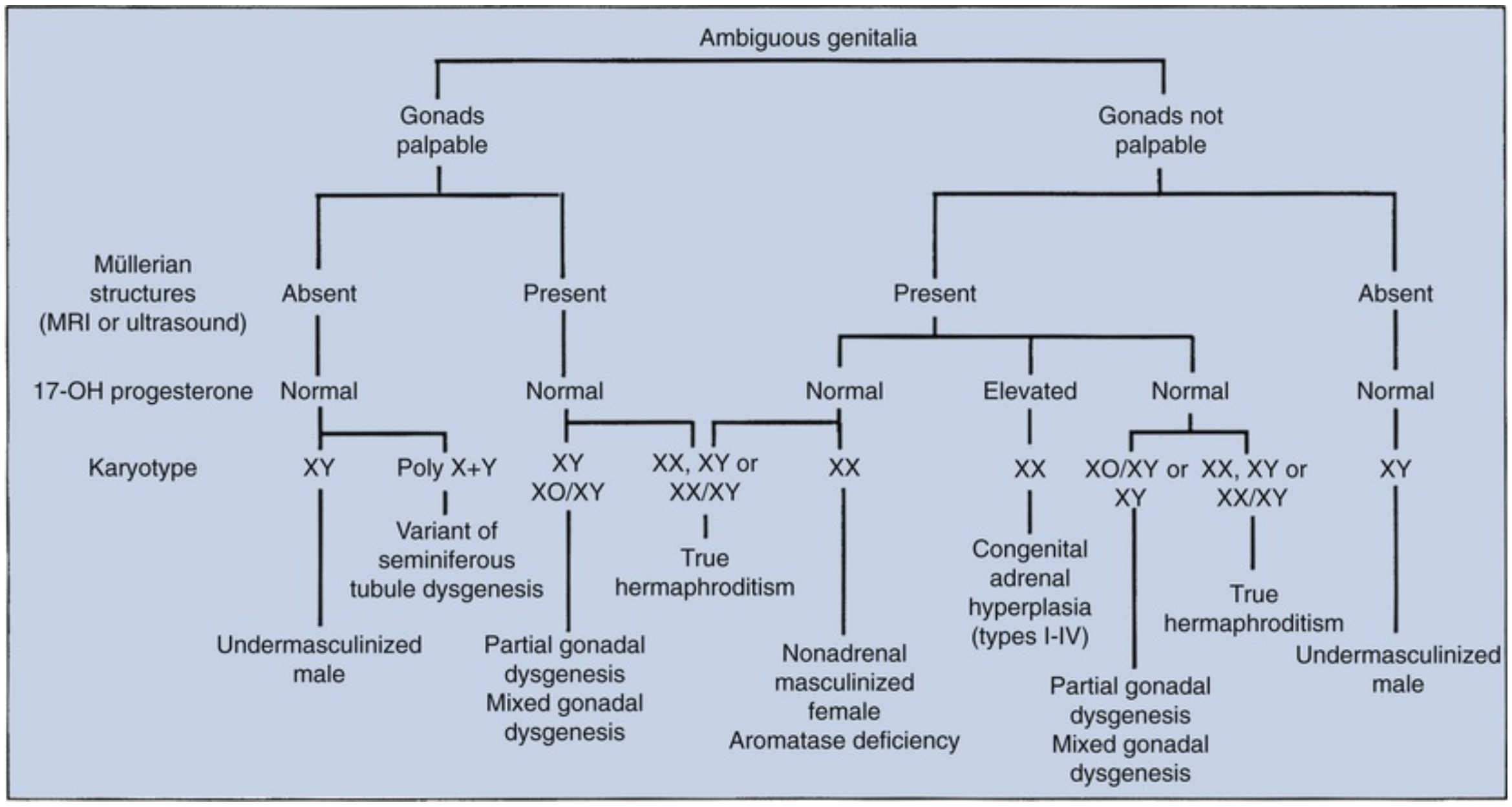
Ambiguous genitalia
Gonads palpable
Gonads not palpable
Müllerian structures (MRI or ultrasound)
Absent
Present
Present
Absent
17-OH progesterone
Normal
Normal
Normal
Elevated
Normal
Normal
Karyotype
XY
Poly X+Y
XY XO/XY
XX, XY or XX/XY
XX
XX
XO/XY or XY
XX, XY or XX/XY
XY
Variant of seminiferous tubule dysgenesis
True hermaphroditism
Congenital adrenal hyperplasia (types I-IV)
True hermaphroditism
Undermasculinized male
Partial gonadal dysgenesis Mixed gonadal dysgenesis
Nonadrenal masculinized female Aromatase deficiency
Partial gonadal dysgenesis Mixed gonadal dysgenesis
Undermasculinized male

FIG. 48.12 Diagnostic algorithm for a newborn with ambiguous genitalia based on gonadal palpability, presence or absence of müllerian structures, 17-hydroxyprogesterone concentration, and karyotype. (Modified from Grumbach MM, Conte FH. Disorders of sex differentiation. In: Wilson JD, Foster DW, eds. Williams textbook of endocrinology. Philadelphia, PA: WB Saunders; 1998. p. 1401.)

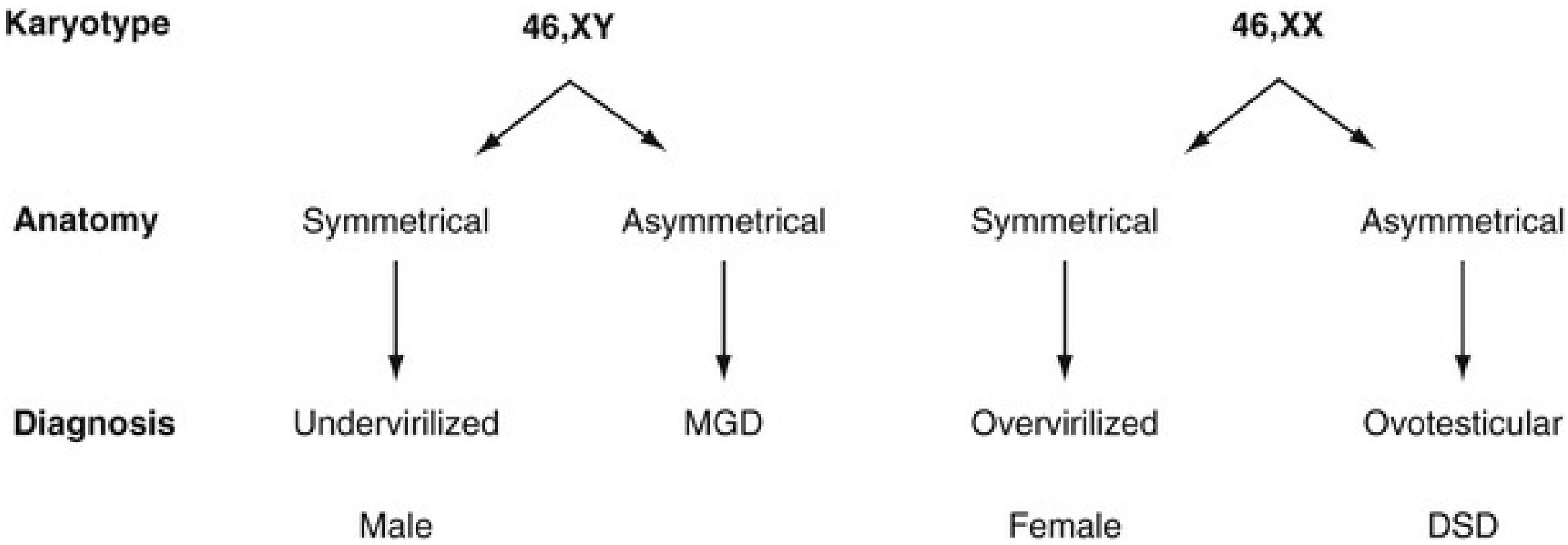
Karyotype
46,XY
46,XX
Anatomy
Symmetrical
Asymmetrical
Symmetrical
Asymmetrical
Diagnosis
Undervirilized
MGD
Overvirilized
Ovotesticular
Male
Female
DSD

FIG. 48.13 Likely diagnoses based on karyotype and anatomic symmetry. *DSD,* disorder of sex differentiation; *MGD,* mixed gonadal dysgenesis. (From Donahoe P.)

Laparotomy or laparoscopy and gonadal biopsy is usually the next definitive clinical step required when a firm diagnosis based on the aforementioned data is impossible. **Laparotomy or laparoscopy in this setting remains a diagnostic maneuver; removal of gonads or reproductive organs should be deferred**

until the final pathology report is available and a gender has been assigned. Polymerase chain reaction (PCR) characterization of the androgen receptor in venous blood DNA may define the precise genetic abnormality responsible for a given DSD, be it an abnormal androgen receptor or an enzyme abnormality. These studies should be performed in specialized laboratories where normal values are well established.

Finally, anatomic definition of the urogenital sinus and ductal structures contributes to the correct diagnosis and is necessary before any surgical intervention. The urogenital sinus is well imaged by retrograde contrast injection, which also opacifies ductal structures, defines the entry of urethra and vagina into the sinus, and outlines the cervical impression within the vagina. Endoscopy can define these relationships further but is usually not necessary until surgical reconstruction becomes imminent.

Gender Assignment

After a definitive diagnosis has been reached, a thorough and candid discussion with the family regarding gender assignment should take place. **Issues related to the diagnosis-specific potential for normal sexual functioning and fertility and the risk for gonadal malignancy should be addressed.** Parents should understand that high-quality data regarding the long-term psychosocial outcomes of gender assignment for the majority of DSDs are lacking, although longitudinal studies are being pursued. Parental involvement in the decision-making process is essential. If the diagnosis of a DSD is made prenatally, it is important to present a plan of management to the parents or risk termination of the pregnancy (Nihoul-Fekete, 2004).

In the setting of a 46,XX karyotype and masculinized female, gender assignment is usually appropriately female. In CAH, cortisol suppresses the undesired androgen; and if maternal androgen is responsible for virilization, its discontinued stimulation is corrective. In both cases, there are normal ovaries and müllerian ducts, and a normal reproductive potential exists. **If the karyotype is 46,XY, the issue is a more complex one and includes factors such as penile length and evidence of androgen insensitivity.** For example, 46,XY patients with complete (severe) androgen insensitivity are appropriately assigned a female gender, whereas those with 5α-reductase deficiency may be more appropriately assigned a male gender. The most frequent abnormal karyotype is 45,X/46,XY mosaicism, which presents a variable phenotypic spectrum. The degree of masculinization of the external genitalia appears to vary with the amount of testicular tissue present, and gender assignment depends on the functional potential of the gonadal tissue, reproductive tracts, and genitalia. The best predictor of adult gender identity is initial gender assignment (Cohen-Kettenis, 2005). Some investigators have suggested deferring the issue of gender assignment until patients reach an age at which they may declare their own gender identity. Such an approach, although rational, is difficult to implement given cultural norms and not recommended in the consensus statement (Lee et al., 2006). As Elliott (1998) states, "We treat these children the way we do (as male or female) because this is the way we see the world; most importantly it is the way that the children, themselves, are taught to see the world."

Overall, it is well to remember in the management of ambiguous genitalia the parameters of optimal gender policy outlined by Meyer-Bahlburg (1998):

- **Reproductive potential (if attainable at all)**
- **Good sexual function**
- **Minimal medical procedures**
- **An overall gender-appropriate appearance**
- **A stable gender identity**
- **Psychosocial well-being**

Disorders of Gonadal Differentiation and Development

Klinefelter Syndrome and Variants

In 1942, Klinefelter, Reifenstein, and Albright described a syndrome characterized by eunuchoidism, gynecomastia, azoospermia, increased gonadotropin levels, and small, firm testes. By 1959, these patients were noted to have a 47,XXY karyotype (Jacobs and Strong, 1959).

Klinefelter syndrome represents the most common major abnormality of sexual development. By definition, males with at least one Y chromosome and at least two X chromosomes have Klinefelter syndrome. The classic 47,XXY complement arises as a result of nondisjunction during meiosis; it occurs in 1 of 600 liveborn males (Morris et al, 2008). But the phenotype is also associated with 48,XXYY and 49,XXXYY, and an exaggerated form of the phenotype is associated with 48,XXXY and 49,XXXXY. The mosaic form 46,XY/47,XXY is associated with milder phenotypic features of classic 47,XXY Klinefelter syndrome. Perhaps as a result of phenotypic variability, Klinefelter syndrome is believed to be underdiagnosed, with a 25% diagnostic rate in one Danish study (Bojesen et al, 2003).

In 47,XXY adults, seminiferous tubules degenerate and are replaced with hyaline. As a result, testes are firm and small, less than 3.5 cm in length. Histologically, Leydig cells appear to predominate. They are seen in large clumps in certain areas of the testes, sometimes resembling Leydig cell tumors. However, the absolute volume of Leydig cells is not increased and is probably lower than normal. Serum levels of testosterone are low-normal and those of gonadotropins are elevated. Plasma estradiol levels tend to be high, with gynecomastia the result of an increased ratio of estradiol to testosterone. The vast majority of patients are azoospermic, and the presence of sperm suggests 46,XY/47,XXY mosaicism. There does appear to be a depletion of germ cells with the onset of puberty (Wikström et al., 2004). Fertility, with the benefit of testicular sperm extraction and intracytoplasmic sperm injection (ICSI), has been reported in patients with Klinefelter syndrome. A recent meta-analysis examining ICSI outcomes reported a 43% live birth rate per ICSI cycle (Corona et al., 2017). Some infertility experts advocate coupling intracytoplasmic sperm injection with preimplantation diagnosis given the lower rate of normal embryos from Klinefelter syndrome patients (54%) versus controls (77%) (Staessen et al, 2003). However, there have been over 200 normal live births reported using ICSI without preimplantation genetic analysis, which brings into question the utility of this testing in predicting outcomes (Ni et al., 2016).

The decreased androgen production may impair normal secondary sexual development. Muscle development may be poor, and the fat distribution is more typical of females than of males. Normal amounts of pubic and axillary hair may be present, but facial hair is sparse. Patients tend to be taller than average, mainly because of the disproportionate length of their legs, which is present even in childhood. Otherwise, few if any distinguishing features are present in the prepubertal child.

Gynecomastia, which can be quite marked, is a common pubertal development in patients with Klinefelter syndrome. As a result, these patients have eight times the risk for development of breast carcinoma compared with normal males (Harnden et al., 1971). In addition, they are predisposed to developing malignant neoplasms of extragonadal germ cell origin as well as Leydig and Sertoli cell tumors (Völkl et al., 2006). Routine testicular examinations for postpubertal patients with Klinefelter syndrome is recommended.

An intriguing area of research has been in the neuropsychiatric function of Klinefelter syndrome patients. Studies have demonstrated depressed verbal ability and limitations in frontal executive functioning. Neuroimaging studies have shown selective volume differences in corresponding areas of Klinefelter syndrome patients' brains versus normal subjects (Giedd et al., 2007). Other studies have demonstrated altered cerebral perfusion in Klinefelter syndrome, corresponding to impaired verbal skills (Itti et al., 2003).

Management of Klinefelter syndrome entails careful androgen supplementation in selected male patients to improve libido and reduction mammoplasty if necessary. Surveillance for testicular tumor and breast carcinoma is also appropriate. Assisted reproductive techniques now offer potential fertility to nonmosaic Klinefelter syndrome patients. Microdissection testicular sperm extraction (micro-TESE) results in sperm retrieval rates in the 40% to 50% range, with higher rates in younger men (Bryson et al., 2014). Research studies have determined that sperm retrieval rates in adolescent males are comparable to adults (Plotton et al., 2015; Nahata and Yu et al., 2016).

46,XX Males

The condition of 46,XX maleness, which occurs in 1 of 20,000 males, may be closely related to that of Klinefelter syndrome. Historically, the genetic analysis of subjects with sex reversal who had a phenotypic sex different from that anticipated based on karyotype was crucial for identification of the *SRY* gene.

XX maleness, first recognized by de la Chappelle et al. in 1964, is characterized by testicular development in subjects who have two X chromosomes and lack a normal Y chromosome. Most of these subjects have normal male external genitalia, but 10% have hypospadias, and all are infertile.

Two categories of patients with XX maleness have been identified: 80% are *SRY* positive and 20% are *SRY* negative (Andersson et al., 1986; Zenteno-Ruiz et al., 2001; Ono et al., 2013). The *SRY*-positive group rarely have genital abnormalities, but they have phenotypic features of Klinefelter syndrome, including hypogonadism, gynecomastia, azoospermia, and hyalinization of seminiferous tubules with altered hormonal levels at puberty (low testosterone, increased follicle-stimulating hormone [FSH] and LH) (Fechner et al., 1993). Often, the diagnosis is made in a pubertal male who presents for evaluation of gynecomastia. **These patients differ from those with Klinefelter syndrome in that they are shorter (mean height, 168 cm) and have normal skeletal proportions.** XX males with no detectable *SRY* more commonly have genital ambiguity.

Several mechanisms have been proposed to explain XX sex reversal. **The most common is translocation of Y chromosomal material, including *SRY,* to the X chromosome**. Clearly, this can be proven in the majority of patients. Alternatively, sex reversal could result either from the mutation of an autosomal or X chromosomal gene, permitting testicular differentiation downstream from *SRY,* or from undetected mosaicism with a Y-bearing cell line. Clinical studies have demonstrated XX sex reversal to be a genetically and phenotypically heterogeneous condition (Fechner et al., 1993). Recently, Bashamboo et al. reported on 46,XX children and adults from four families with varying degrees of testis development and suggest that heterozygous missense mutations in *NR5A1* may alter organ fate from ovary to testis (Bashamboo et al., 2016).

Treatment of XX maleness is similar to that for Klinefelter syndrome. Androgen replacement benefits selected patients, and reduction mammoplasty may be beneficial. It is likely that these patients will also be at increased risk for breast carcinoma and testis tumor. Because of their lack of germ cell elements, those classic patients presenting with infertility would not benefit from testicular biopsy for potential intracytoplasmic sperm injection.

Syndromes of Gonadal Dysgenesis

Turner Syndrome.

In 1938, Henry Turner described the combination of sexual infantilism, webbed neck, and cubitus valgus (increased carrying angle at the elbows) as a distinct entity. Subsequently, gonadal dysgenesis was recognized as part of this syndrome (Hall and Gilchrist, 1990). It was not until 1959 that Ford recognized that one missing X chromosome was the etiologic basis for the syndrome. Subsequent chromosomal studies showed that **Turner syndrome is characterized by the presence of only one normally functioning X chromosome** (Ford et al., 1959). The other sex chromosome may be absent or abnormal, or mosaicism may be present.

Turner syndrome, with a 45,X karyotype, is associated with four classic features: female phenotype, short stature, lack of secondary sexual characteristics, and a variety of somatic abnormalities. But the clinical features of Turner syndrome are quite variable, and almost any combination of physical features may be seen with any X chromosomal abnormality. The severity of phenotypic features does not necessarily correlate with karyotypic findings. The diagnosis of Turner syndrome should be considered in any infant with lymphedema or any young woman with short stature or primary amenorrhea. Deletions in the short stature homeobox *(SHOX)* gene located on the pseudoautosomal region of the X and Y chromosomes have been suggested as the basis for the short stature in this syndrome.

Turner syndrome has an incidence of 1 in 2500 live births. One-half of the patients have a 45,X karyotype in all cells; this is believed to be secondary to loss of an X chromosome through nondisjunction in gametogenesis or an error in mitosis. From 12% to 20% of patients with Turner syndrome have an isochrome X (duplication of one arm of the X chromosome with loss of the other arm). Mosaicism—the presence of two or more chromosomally different cell lines—occurs in 30% to 40% of these patients, the majority (10% to 15%) being 45,X/46,XX and 2% to 5% being 45,X/46,XY (Zinn et al, 1993). **The presence of Y chromosomal material is of critical importance in patients with Turner syndrome because it predisposes them to potential masculinization and gonadoblastoma (Fig. 48.14).**

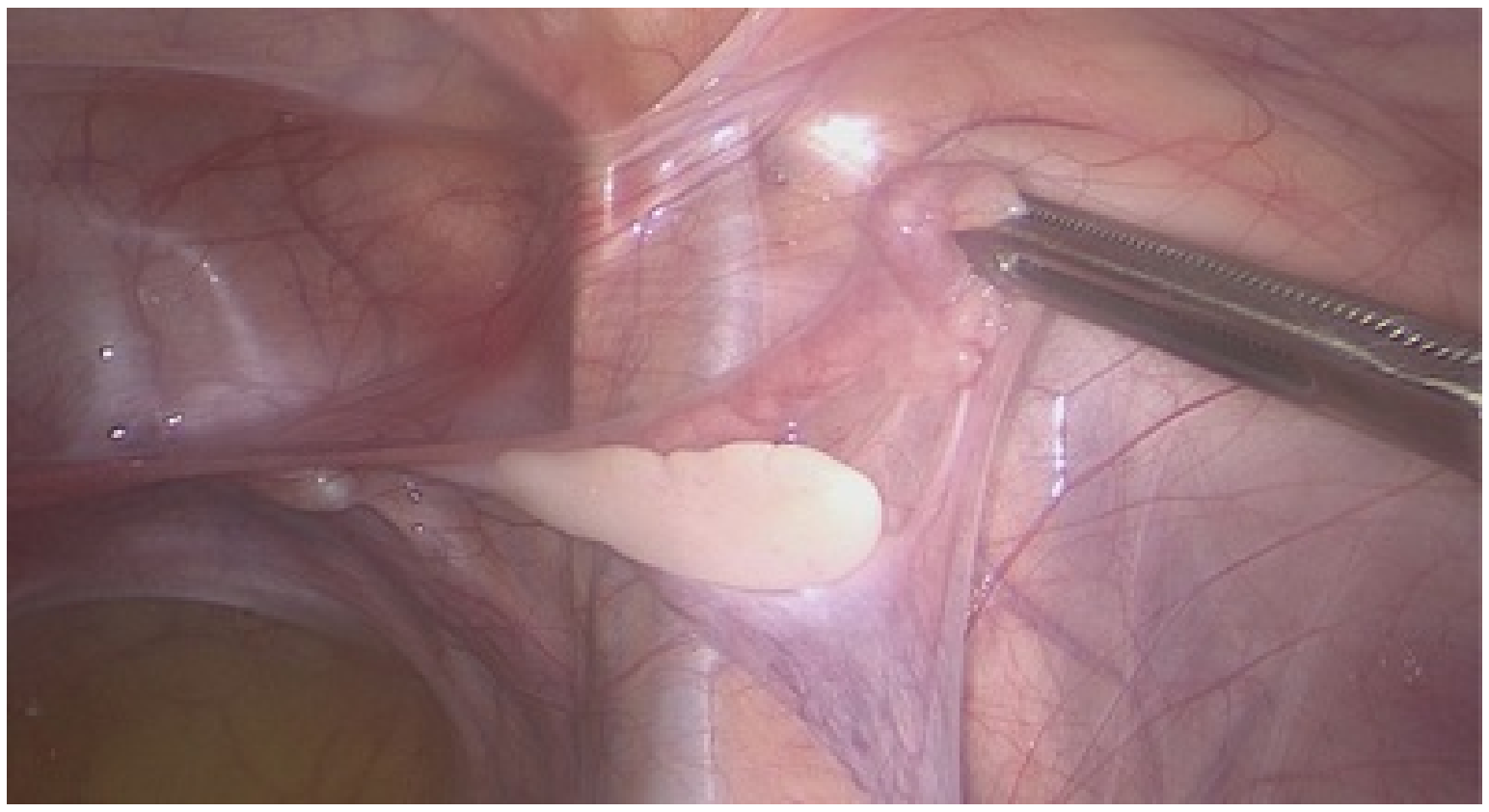

FIG. 48.14 Gross appearance of streak gonad during diagnostic laparoscopy. (Courtesy of D. Diamond, MD.)

Turner syndrome may be diagnosed prenatally on the basis of a variety of ultrasound findings (increased nuchal translucency, lymphedema, cystic hygroma, coarctation of the aorta, renal anomalies) or by abnormal results of fetal karyotyping. Affected fetuses often abort spontaneously. Whereas a 45,X fetus identified prenatally has a prognosis similar to that of a child with Turner syndrome diagnosed postnatally, approximately 90% of fetuses in whom a 45,X/46,XX or 45,X/46,XY karyotype is incidentally diagnosed prenatally will have a normal female or male phenotype at birth. This so-called *ascertainment bias* in Turner syndrome has profound implications for prenatal counseling.

It is postulated that in Turner syndrome, follicular cells that normally surround the germ cells and provide a protective mantle for the oocytes are inadequate (Stanhope et al, 1992). As a result, the rate of attrition of oocytes caused by apoptosis is so rapid that by birth few or no oocytes remain in the **ovaries, which become streaks** (Epstein, 1990). Typically, these streaks are white, fibrous structures, 2 to 3 cm long and approximately 0.5 cm wide, located in the broad ligament. Histologically, the streak possesses interlacing waves of dense fibrous stroma that is devoid of oocytes but is otherwise indistinguishable from normal ovarian stroma. Both estrogen and androgen are decreased, and levels of FSH and LH are increased. Secondary sexual development does not occur in the majority of patients. Pubic and axillary hair fails to develop in normal abundance, and the well-differentiated external genitalia, vagina and müllerian derivatives, and breasts remain small (Saenger, 1996). Turner syndrome is a common cause of primary amenorrhea, and the diagnosis is frequently made because pubertal development never occurs. Spontaneous pubertal development may occur in up to 30% of Turner syndrome patients, however.

The associated congenital anomalies that are thought typical in Turner syndrome include short stature, broad chest, widespread nipples, webbing of the neck, peripheral edema at birth, short fourth metacarpal, hypoplastic nails, multiple pigmented nevi, coarctation of the aorta, bicuspid aortic valve, and renal anomalies, but there is phenotypic variability (Fig. 48.15) (Miguel-Neto et al., 2016). The majority of the associated congenital anomalies can be explained by the presence of lymphedema at critical points in development, leading to an imbalance in growth forces. This may be secondary to failed opening of embryonic lymphatic channels (Zinn et al., 1993).

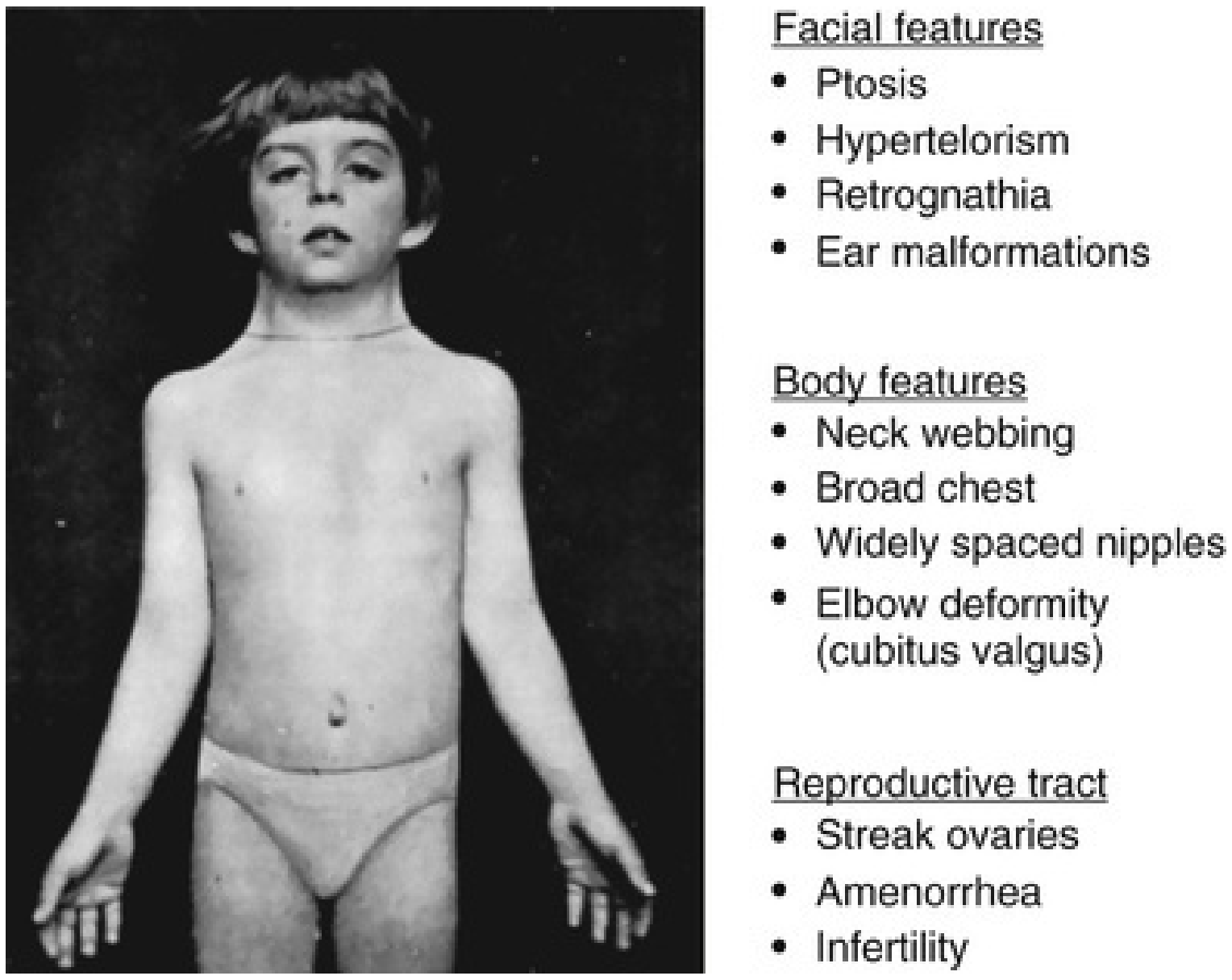
Facial features
- Ptosis
- Hypertelorism
- Retrognathia
- Ear malformations
Body features
- Neck webbing
- Broad chest
- Widely spaced nipples
- Elbow deformity (cubitus valgus)
Reproductive tract
- Streak ovaries
- Amenorrhea
- Infertility

FIG. 48.15 Patient with Turner syndrome as originally described by Ullrich in 1930. (From Ullrich O. *Über typische Kombinationsbilder multipler Abartungen.* Z Kinderheilkd 1930;49:271–276.)

Of paramount importance in the assessment of the patient with Turner syndrome is identification of Y chromosomal material or 45,X/46,XY mosaicism, whose detection has been enhanced by use of the PCR (Bianco et al, 2006). **In patients with occult Y chromosomal material, the risk for gonadoblastoma, an in-situ germ cell cancer, is 12% to 20% and is being further defined** (Kwon et al, 2017; Schoemaker et al, 2008). Gonadoblastoma is associated with dysgerminoma or other germ cell neoplasms in 18% to 35% of cases, sometimes associated with virilization (Cools et al, 2011; Zelaya et al., 2015). **Because the age of occurrence of gonadoblastoma is variable and has been reported as early as 5 months of age, timely prophylactic excision of the streak gonads in the Y mosaic Turner syndrome patient is advised** (Coyle et al., 2016). This may be well performed laparoscopically. Streak gonads confirmed to be in 45,XO patients need not be removed. In a British national cohort study, there was also an increased risk for bladder and urethral cancer in Turner syndrome patients followed into adulthood (Schoemaker et al., 2008).

Between 33% and 60% of patients with Turner syndrome have structural or positional abnormalities of the kidney; this occurs most frequently in the classic 45,XO karyotype (Hall and Gilchrist, 1990). **Horseshoe kidney accounts for 10%, duplication or renal agenesis for 20%, and malrotation for 15% of these abnormalities.** Multiple renal arteries have been noted in 90% of patients with Turner syndrome as a result of their cardiovascular evaluation (Hall and

Gilchrist, 1990).

The contemporary treatment of patients with Turner syndrome has undergone considerable advances. In the neonate, it entails a concerted search for occult Y chromosomal material, including fluorescent in-situ hybridization (FISH) or PCR and, subsequently, prophylactic gonadectomy if necessary and ultrasound screening for renal and cardiac abnormalities such as bicuspid aortic valves (Klásková et al., 2017). **In the child, human growth hormone has successfully been employed** to achieve increased adult height (Pasquino, 2004). At an appropriate age, typically between 12 and 15 years, exogenous hormonal therapy to induce puberty and then to maintain a normal female endocrine status is begun. An improved understanding of the long-term medical management of these patients, including cardiac surveillance and management of glucose intolerance, autoimmune disorders, and osteoporosis, has also resulted in considerable progress. **Finally, with the remarkable advances in assisted reproductive technology, pregnancy is a realistic possibility for patients with Turner syndrome, although spontaneous fertility is rare** (Sybert and McCauley, 2004). A spectrum of potential gonadal function has been noted in large series of patients with Turner syndrome (Kaneko et al., 1990). In one series, nonstreak gonads were reported in one-third of such patients and were more commonly noted in girls with loss of only the short arm of the X chromosome. In 2% to 5% of Turner syndrome patients, spontaneous menses will occur with a potential to achieve pregnancy independently (Saenger et al., 2001). This appears most likely in women with mosaicism for a normal 46,XX cell line, a 47,XXX cell line, or distal Xp deletion. To date, more than 160 pregnancies have been reported among spontaneously menstruating Turner syndrome patients. For the vast majority with true streak gonads, for whom egg donor implantation is used, 40% to 50% pregnancy rates have been reported by centers specializing in in-vitro fertilization (Saenger, 1993). However, among these rare pregnancies, the rates of miscarriage, stillbirth, and malformed infants is high (Abir et al., 2001). Because there is a high likelihood of premature ovarian failure, early oocyte preservation may be useful for long-term fertility preservation. Techniques for mature oocyte cryopreservation have dramatically improved, resulting in guidelines stating that the technology should no longer be considered experimental (Practice Committees of the American Society for Reproductive Medicine and the Society for Assisted Reproductive Technology, 2013). However, the risk for chromosomal abnormalities and unknown efficacy of oocyte preservation in this population require further investigation.

It is of great interest that neuroanatomic imaging studies of 45,XO Turner syndrome patients have demonstrated differences in parietal and temporal lobe anatomy and posterior fossa morphology that appear to correlate with certain established neurophysiologic and cognitive deficits (Brown et al, 2004; Rae et al, 2004).

Psychosocial care of the Turner syndrome patient throughout childhood and transition to adult care, including disclosure, has been increasingly emphasized (Amedro et al., 2017; Culen et al., 2017).

Key Point: Turner Syndrome

- In patients with Turner syndrome and occult Y chromosomal material, the risk for gonadoblastoma, an in-situ germ cell cancer, is 12% and is being further defined.
- Young women with Turner syndrome and spontaneous menses are at high risk for premature ovarian failure. However, mature oocyte cryopreservation is currently considered experimental.

46,XX “Pure” Gonadal Dysgenesis.

Patients with 46,XX “pure” gonadal dysgenesis are characterized by normal female external genitalia, normal müllerian ducts with absence of wolffian duct structures, a normal height, bilateral streak gonads, sexual infantilism, and a normal 46,XX karyotype. The streak gonads result in elevated serum gonadotropins. Because these subjects exhibit none of the somatic stigmata associated with Turner syndrome, and their condition entails gonadal dysgenesis only, it has been regarded by some authors as “pure.”

A familial incidence of 46,XX gonadal dysgenesis has been reported as an autosomal recessive trait (Espiner et al., 1970). This suggests the possibility that autosomal genes in addition to genes on the X chromosome may be involved in ovarian maintenance.

Management of patients with 46,XX “pure” gonadal dysgenesis entails proper cyclic hormone replacement with estrogen and progesterone. In contrast with Turner syndrome, growth is not abnormal with this condition, and therefore growth hormone should not be required. Because, by definition, these patients have no Y chromosomal material, gonadectomy is not required.

Mixed Gonadal Dysgenesis.

The term *mixed gonadal dysgenesis* was coined by Sohval in 1963 (Sohval, 1963). In 1975, Zah et al. reported on their series of more than 100 patients with 45,X/46,XY karyotypes, 72 of whom had mixed gonadal dysgenesis with a streak gonad on one side and a testis on the other (Zah et al., 1975).

Mixed gonadal dysgenesis is characterized by a unilateral testis, which is often intra-abdominal, a contralateral streak gonad, and persistent müllerian structures associated with varying degrees of inadequate masculinization. Most patients with mixed gonadal dysgenesis have a 45,XO/46,XY karyotype, which is probably the result of anaphase lag during mitosis. The 45,X/46,XY mosaicism is the most common form of mosaicism involving the Y chromosome.

The phenotypic spectrum of patients with XO/XY mosaicism ranges from phenotypic females with Turner syndrome, to those with ambiguous genitalia, to those with normal male genitalia (Johansen, 2012). **In the neonatal period, mixed gonadal dysgenesis is the second most common cause of ambiguous genitalia (after CAH) and must be in the differential diagnosis.** The majority of these patients present with varying degrees of phallic development, a urogenital sinus with labioscrotal fusion, and an undescended testis. In virtually all of these patients, a uterus, vagina, and fallopian tube are present. Short stature and associated somatic stigmata are variable features.

Key Point: Mixed Gonadal Dysgenesis

- In the newborn period, mixed gonadal dysgenesis is the second most common cause of ambiguous genitalia (after CAH) and must be in the differential diagnosis.

The phenotypic asymmetry of the internal ducts epitomizes the mechanism of local testosterone and AMH production on müllerian and wolffian duct regression and development. In the series of Mendez et al. (1993) comprising 16 patients, all had a fallopian tube accompanied by a streak gonad, consistent with absent AMH. **Therefore, whereas a dysgenetic or streak gonad is associated with ipsilateral müllerian derivatives (uterus, fallopian tube)** (Fig. 48.16), **a well-differentiated testis with functional Sertoli and Leydig cells will have ipsilateral wolffian but no müllerian ducts** (Davidoff and Federman, 1973). In addition, the presence of severe external genital ambiguity in many of these patients suggests that testosterone production in utero was inadequate to promote complete differentiation of the external genitalia. Yet, despite postpubertal endocrine function, it is postulated that fetal testicular endocrine function is either delayed or deficient. Martinerie et al. found that 55% of 45X/46XY males required testosterone therapy to complete puberty, and no patient was fertile (Martinerie et al., 2012). Histologically, the testes lacked germinal elements, so infertility was anticipated. However, successful sperm extraction has been reported.

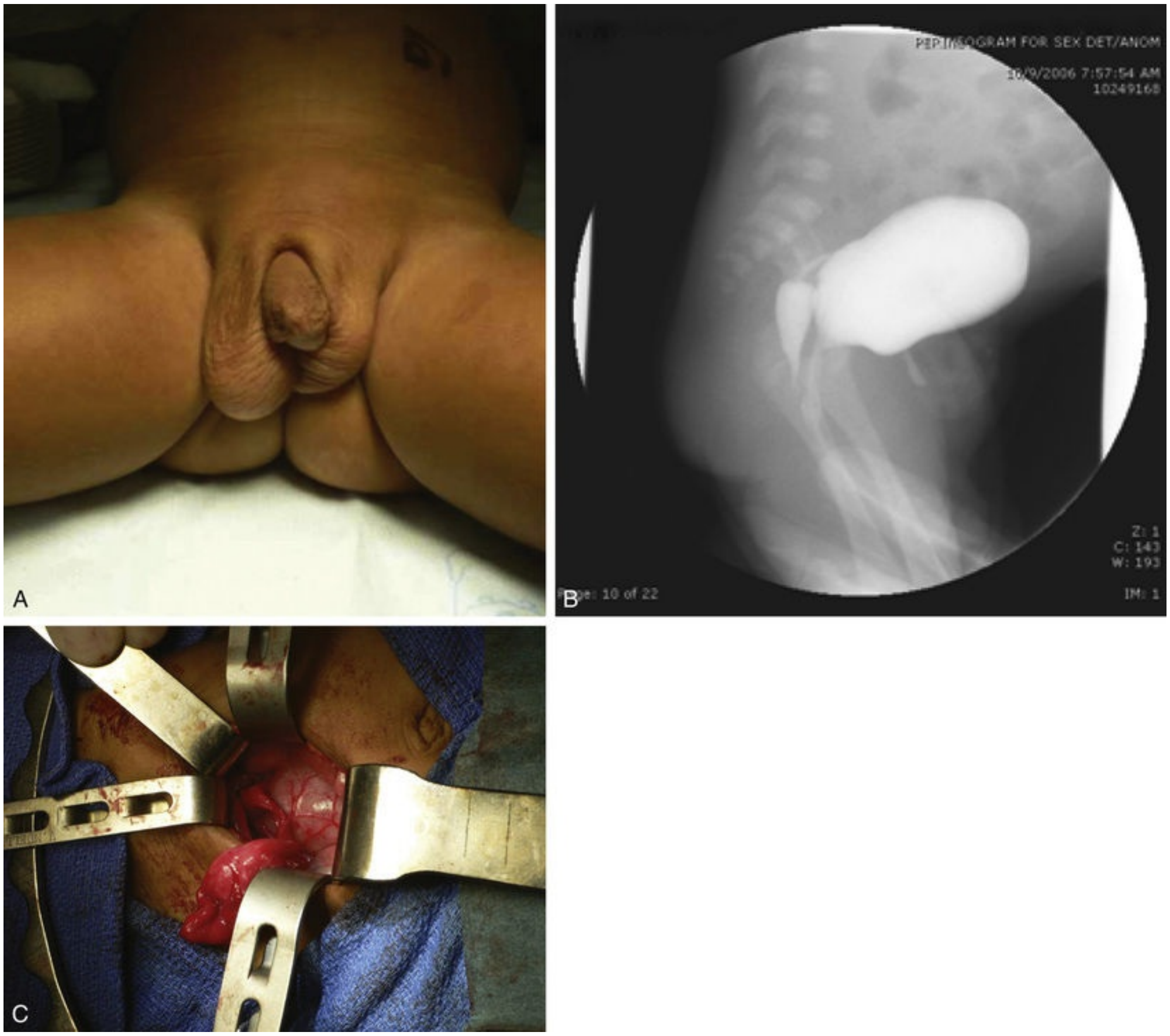

FIG. 48.16 (A) Patient with mixed gonadal dysgenesis showing asymmetrical anatomy. (B) Hemiuterus and opacified fallopian tube in left inguinal hernia. (C) Structures noted in (B) shown at surgical exploration.

The risk for developing a gonadal tumor (gonadoblastoma, dysgerminoma) is increased in mixed gonadal dysgenesis, with an estimated incidence of 15% to 35% (Robboy et al., 1982; Wallace and Levin, 1990). Gonadoblastoma, a premalignant lesion, is the most common. It was so named because it recapitulates gonadal development more completely than any other tumor (Scully, 1970). **Germ cell tumors occur both in the streak gonads and in the dysgenetic testes of individuals with 46,X/46,XY mosaicism. Cools et al. noted the greatest risk for tumor or preneoplastic lesion with streak gonads and when the phenotype was ambiguous (52%), and less risk with mild undervirilization and scrotal testes (13%)** (Cools et al, 2011).

Patients with mixed gonadal dysgenesis are also at increased risk for Wilms tumor. Rajfer (1981) reported that 50% of 10 patients with a DSD and Wilms tumor had mixed gonadal dysgenesis. He postulated that there was a genetic or teratogenic defect involving the urogenital ridge, the common embryonic anlage of both kidney and gonad. This concept was borne out by improved understanding of the Denys-Drash syndrome, now clearly associated with mutations in the Wilms tumor suppressor gene *(WT1)*. In 1967, Denys et al. described a child with XX/XY mosaicism, nephropathy, genital abnormalities, and Wilms tumor. Drash et al. (1970) reported two further examples in 1970. **The full triad of the syndrome includes nephropathy, characterized by early onset of proteinuria and hypertension, and progressive renal failure in most patients.** Renal histology demonstrates diffuse focal mesangial sclerosis. **Because incomplete forms of the syndrome may occur, the nephropathy has become regarded as the common denominator of the syndrome** (Habib et al., 1985). Wilms tumor may be diagnosed before, after, or simultaneously with presentation with nephropathy. The majority of the tumors are of favorable triphasic histology (Beckwith and Palmer, 1978). However, there is a high incidence of bilateral Wilms tumor in this syndrome. The genital abnormalities include frank ambiguity, hypospadias, and cryptorchidism. **A large number of patients with Denys-Drash syndrome have been noted to have mixed gonadal dysgenesis.** These have an increased risk for gonadal tumor of 40% (Table 48.3) (Lee et al., 2006). An interesting and relatively consistent finding with Denys-Drash syndrome is that of caliceal blunting without obstruction (Jadresic et al., 1990). The high mortality rate associated with this syndrome has prompted an aggressive treatment approach with prophylactic bilateral nephrectomy in an attempt to improve the prognosis for these children (Jadresic et al., 1990).

TABLE 48.3

Risk for Germ Cell Malignancy According to Diagnosis

RISK GROUP	DISORDER	MALIGNANCY RISK (%)
High	GD[a] (+Y)[b] intra-abdominal	15–35
	PAIS nonscrotal	50
	Frasier	60
	Denys-Drash (+Y)	40
Intermediate	Turner (+Y)	12
	17β-hydroxysteroid	28
	GD (+Y)[b] scrotal	Unknown
	PAIS scrotal gonad	Unknown
Low	CAIS	2
	Ovotesticular DSD	3
	Turner (–Y)	1

[a] Gonadal dysgenesis (including not further specified, 46,XY, 46,X/46,XY, mixed, partial, and complete).

[b] GBY region positive, including the *TSPY* (testis-specific protein Y encoded) gene.

CAIS, Complete androgen insensitivity syndrome; *PAIS,* partial androgen insensitivity syndrome.

Data from Lee PA, Houk CP, Ahmed F, et al. Consensus statement on management of intersex disorders. *Pediatrics*. 2006;118:e488–e500.

Frasier syndrome, a related disorder caused by mutations in the alternative splice donor site of exon 9 on *WT1*, presents in similar fashion to Denys-Drash syndrome but with certain important distinctions (Klamt et al., 1998). The nephropathy caused by focal segmental glomerulosclerosis occurs later in life with a more gradual progression to renal failure (Koziell et al., 1999). There is no known predisposition to Wilms tumor. Gonadoblastomas in 46,XY individuals are far more common in Frasier syndrome than in Denys-Drash syndrome with a gonadal tumor risk for 60% (see Table 48.3). These individuals typically have a female phenotype, but rarely male phenotypes will occur (Ezaki et al., 2015). Because 46,XX individuals with Frasier syndrome have normal gonadal development, they would present with renal failure. But, it is presumed that many such 46,XX individualso go undiagnosed. Frasier syndrome should be considered for girls presenting with steroid-resistant nephrotic syndrome, primary amenorrhea, and pubertal delay (Gwin et al., 2008).

The management of mixed gonadal dysgenesis entails gender assignment, appropriate gonadectomy, and proper screening for Wilms tumor. If the diagnosis is made in the neonatal period, the decision regarding sex of rearing should be based on the potential for normal function of the external genitalia and gonads. Historically, two-thirds of patients with mixed gonadal dysgenesis have been raised as female. Potential fertility is not a significant issue in this disorder, and therefore the anatomy of the reproductive tract may direct the decision making. The likelihood of significant androgen imprinting is greater in association with a better-masculinized phenotype, and this may serve as the best clinical guide. For patients with Turner syndrome stigmata and growth below the fifth percentile, growth hormone therapy may be appropriate. If the male gender is elected and the testis can be brought to the scrotum, the decision between careful screening for gonadoblastoma (with physical examination and ultrasonography) versus prophylactic gonadectomy and androgen replacement must be made. Gonadal biopsy with immunohistochemistry after 1 year of age or postpubertally may be instructive (Cools et al., 2011).

The expanded use of prenatal diagnosis has changed the understanding of 45,X/46,XY mosaicism. Studies have shown that 90% to 95% of all infants with 45,X/46,XY mosaicism have normal-appearing male genitalia (Hsu, 1989). Approximately 25% have abnormal gonadal histology (Chang et al., 1990). Because only a small proportion of those with dysgenetic gonads actually have ambiguous genitalia, the possibility exists that some males with gonadal dysfunction and infertility have 45,X/46,XY mosaicism.

Partial Gonadal Dysgenesis.

In 1967, Federman coined the term *dysgenetic male pseudohermaphroditism,* **which is a condition closely related to mixed gonadal dysgenesis in that patients with abnormal sexual development have two dysgenetic testes rather than one dysgenetic testis and a streak gonad** (Federman, 1967). Others have applied the term *partial gonadal dysgenesis* to this condition to distinguish it from mixed and complete forms of gonadal dysgenesis. As with mixed gonadal dysgenesis, these individuals typically have a 45,X/46,XY or 46,XY karyotype. They may present with a spectrum of external genital abnormalities, depending on the capability of the dysgenetic gonads to produce testosterone. Similarly, persistent müllerian structures are typically present, but to varying degrees depending on AMH secretion by the dysgenetic gonads.

Fabbri et al. noted that *NR5A1* loss-of-function mutations account for 15% of cases of partial gonadal dysgenesis (Fabbri et al., 2016). On histology, the dysgenetic testis is found to be composed of immature hypoplastic seminiferous tubules and persistent stroma resembling that seen in the streak gonad.

Patients with partial gonadal dysgenesis are at increased risk for gonadal malignancy. Manuel et al. (1976) reported that the incidence of gonadoblastoma or dysgerminoma was 46% by 40 years of age. These patients are also at risk for Denys-Drash syndrome (Borer et al., 1995).

The management of partial gonadal dysgenesis, in terms of gender assignment and surveillance for malignancy, is similar to that for patients with mixed gonadal dysgenesis.

46,XY Complete (Pure) Gonadal Dysgenesis (Swyer Syndrome).

Just as 46,XX males were of great importance in discovery of the TDF, so too have been the 46,XY females. **Patients with 46,XY complete gonadal dysgenesis are characterized by normal female genitalia, well-developed müllerian structures, bilateral streak gonads, and a nonmosaic karyotype.** Because there is complete absence of testicular determination in this condition, ambiguity of genitalia is not an issue, but sexual infantilism is the primary clinical problem.

The etiology of 46,XY complete gonadal dysgenesis may well be an abnormality of the *SRY* gene that eliminates SRY function or loss of another gene downstream from *SRY* that is necessary for SRY protein action. In either case, the absence of testicular determination would permit ovarian differentiation. To date, mutations in the *SRY* gene are the cause of 46,XY complete gonadal dysgenesis in 10% to 15% of cases (Bastian et al., 2015). Bastian et al. identified mutation in 50% of patients with 46,XY gonadal dysgenesis, including *SRY*, *WT1,* and *Fog 2/ZFPM2* and deletion of distal chromosome 9P. Mutation in the Desert hedgehog *(DHH)* gene was noted in 3 of 6 patients with 46,XY complete gonadal dysgenesis, suggesting that the genetic origin of this entity is heterogeneous and *DHH* is likely an important gene in gonadal differentiation (Canto et al., 2004). Novel *NR5A1* mutations have recently been associated with 46,XY gonadal dysgenesis (Rehkämper et al., 2017).

The majority of individuals with 46,XY complete gonadal dysgenesis present in their teens with delayed puberty and amenorrhea. Breast development is usually absent. The serum concentration of gonadotropins is abnormally elevated, which leads the clinician to the determination of karyotype and the subsequent diagnosis (Grumbach and Conte, 1998). The high concentration of serum LH in these patients is thought to be responsible for the increased androgen levels that lead to clitoromegaly in some individuals (Fig. 48.17).

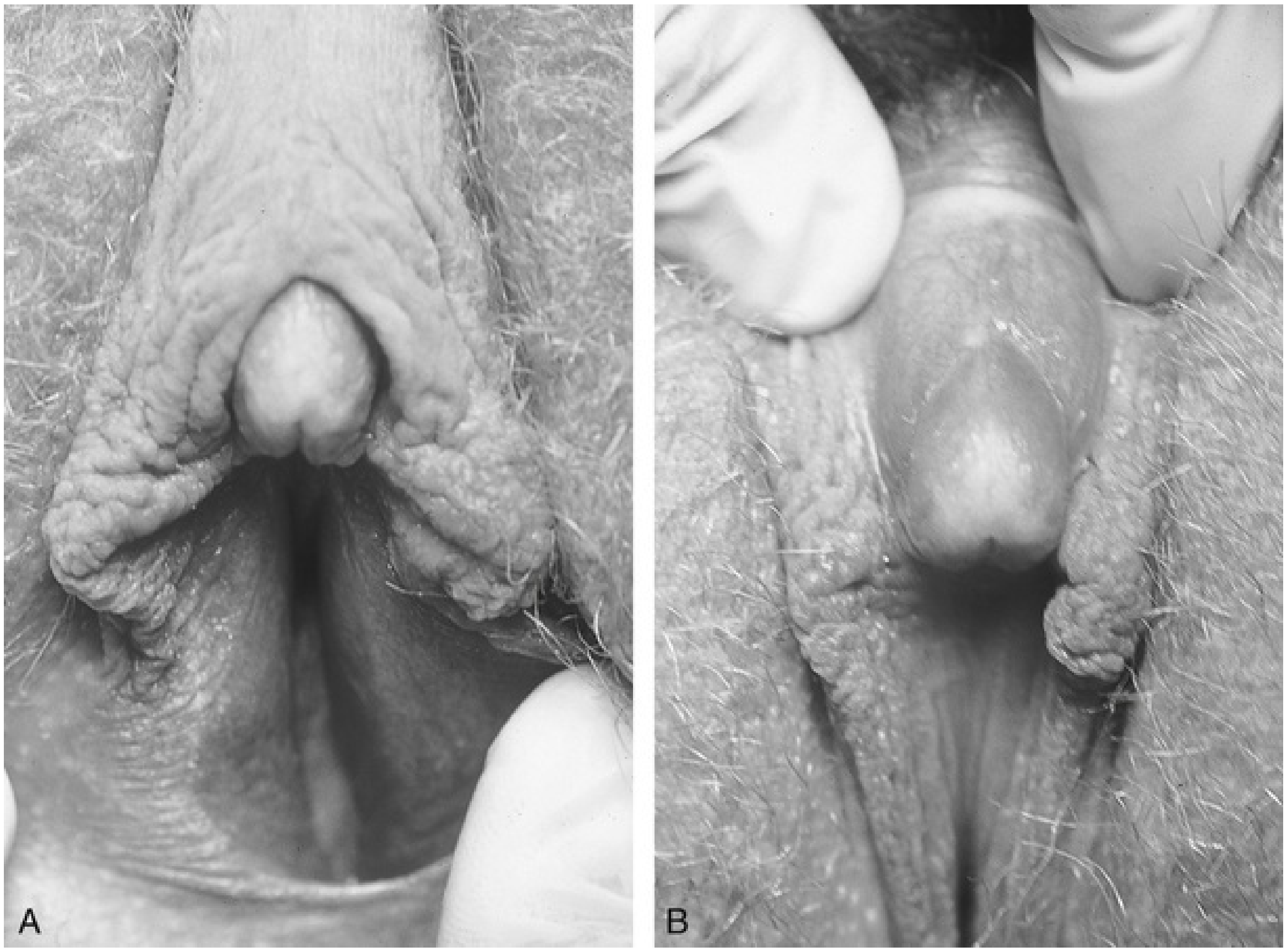

FIG. 48.17 (A and B) External genitalia of a 15-year-old female presenting with amenorrhea and hirsutism who was diagnosed with 46,XY gonadal dysgenesis, demonstrating clitoromegaly and urogenital sinus. (Courtesy of S. Bauer, MD.)

The histology of the streak gonad is similar to that of Turner syndrome, with fibrous connective tissue resembling wavy ovarian stroma but without follicles. Some histologic variability has been noted, with more proliferative-appearing stroma in some and, rarely, preservation of intact primordial follicles. This variability in ovarian histology is thought to support the hypothesis that these gonads developed as ovaries in utero (German et al., 1978). This would resemble the process that occurs in the streak gonad of Turner syndrome.

Patients with 46,XY complete or pure gonadal dysgenesis are at significant risk for germ cell tumors. There appears to be up to a 35% risk for tumor development by 30 years of age (Manuel et al, 1976**; see Table**

48.3). Gonadoblastoma is most common, and it is frequently bilateral (Fig. 48.18). Other tumors that may arise in this patient population include embryonal carcinoma, endodermal sinus tumor, choriocarcinoma, and immature teratoma. These more highly malignant tumors occur in fewer than 10% of patients with 46,XY complete gonadal dysgenesis (Scully, 1981).

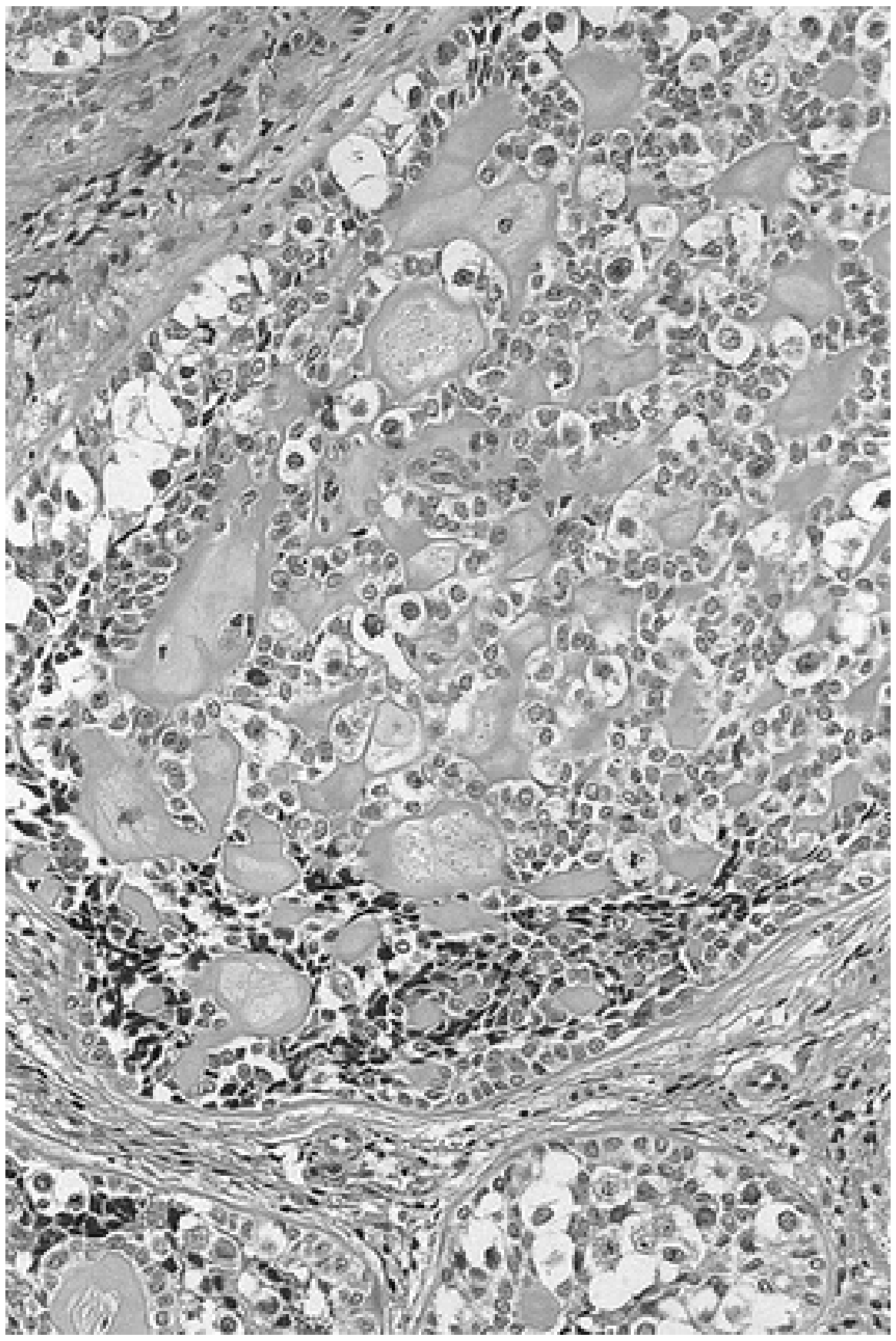

FIG. 48.18 Pathology of gonadoblastoma discovered in the patient shown in Fig. 48.17 with 46,XY gonadal dysgenesis. Encapsulated nests of gonadoblastoma comprise small sex cord–type cells arranged around rounded spaces of amorphous eosinophilic material and interspersed germ cells. (Courtesy of S. Bauer, MD.)

Management of 46,XY complete gonadal dysgenesis entails removal of both streak gonads and proper cyclic hormone replacement with estrogen and progesterone.

Embryonic Testicular Regression and Bilateral Vanishing Testes Syndromes

The syndromes of embryonic testicular regression and bilateral vanishing testes are characterized by **patients with a 46,XY karyotype and absent testes in whom there is clear evidence of testicular function at some point during embryogenesis.** The syndrome entails the presence of testes that "vanish" during embryogenesis and is distinguished from pure gonadal dysgenesis, in which there is no evidence of testicular function in utero.

These syndromes have been regarded as synonymous by some authors. Other authors, including Migeon et al. (1994), have suggested a rational stratification whereby "embryonic testicular regression" refers to loss of testicular tissue within the first trimester and is associated with ambiguity of external genitalia, whereas "bilateral vanishing testes syndrome" refers to individuals in whom male sexual differentiation of ducts and genitalia took place but loss of testicular tissue occurred subsequently in utero.

The etiology of these disorders remains unclear. **It is possible that regression of the testes in utero is caused by a genetic mutation, a teratogen, or bilateral torsion.** A genetic cause is supported by the finding of familial instances of XY agonadism that might be consistent with the rare recessive trait. Marcantonio et al. (1994) suggested the possibility that embryonic testicular regression represents a variant of 46,XY gonadal dysgenesis. They noted a group of patients with absent testes but evidence of incongruity between the extent of Leydig cell and Sertoli cell function, suggesting that gonadal tissue in these subjects was intrinsically abnormal before the testicular regression occurred. The occurrence of embryonic testicular regression in several subjects from one family in their series suggested a genetic basis for the condition, and the pattern of inheritance implicated the involvement of an X-chromosome gene. In another group of patients, these authors noted multiple congenital anomalies, suggesting either a mutation in a single gene that functions in several developmental pathways or a defect of multiple genes that might be the result of a large chromosomal deletion. A heterozygous mutation in *NR5A1* has been noted in a series of patients with bilateral vanishing testes syndrome with micropenis (Philibert et al., 2007).

Clinically, these two syndromes represent a spectrum of phenotypes ranging in severity from complete female, to varying degrees of genital ambiguity in the embryonic testicular regression syndrome, to a normal male phenotype with microphallus and empty scrotum in the bilateral vanishing testes syndrome (Edman et al, 1977). **The diagnosis can be made on the basis of a 46,XY karyotype, castrate levels of testosterone, elevated serum LH and FSH**

during “mini-puberty” from 2 to 6 months of age (Jarow et al, 1986), and undetectable AMH level (Lee et al, 2003). In the most severe form of embryonic testicular regression syndrome, agonadism is discovered in a 46,XY phenotypic female with no internal genital structures. This picture is presumed to result when the testis has elaborated AMH but vanishes at approximately day 60 to 70 of gestation, before the elaboration of androgen. Because of the absence of gonadal androgens later in fetal development and transient expression of AMH, the individual goes on to develop a sexually infantile female phenotype but lacks any internal ductal structures. At an intermediate point in the clinical spectrum is the 46,XY patient with absent gonads and internal ductal structures but with ambiguous genitalia owing to incomplete elaboration of androgen by the vanishing testes. Finally, in bilateral vanishing testes syndrome, patients may present as agonadal XY phenotypic males with fully developed wolffian structures but an empty scrotum, absent prostate, and microphallus. This represents testicular loss after complete anatomic development of the male external genitalia within the first trimester.

On surgical exploration of patients with bilateral vanishing testes syndrome, rudimentary cord structures are usually identified, and biopsy of their distal ends demonstrates no recognizable testicular tissue histologically, only hemosiderin deposits (Bergada et al., 1962). Atrophic epididymal remnants are occasionally seen.

The management of patients with embryonic testicular regression syndrome or bilateral vanishing testes syndrome is dictated by their position in the clinical spectrum of either disorder. Sexually infantile phenotypic females require estrogen supplementation at the time of expected puberty for development of secondary sexual characteristics and may require vaginal dilation or vaginoplasty. Similarly, phenotypic males require long-term androgen replacement beginning at the time of expected puberty. A study of 21 males so treated demonstrated that replacement therapy started at the correct time caused a normal pubertal growth spurt with normal secondary sex characteristics including penile growth, together with normal bone maturation (Aynsley-Green et al., 1976). In addition, these patients may benefit from placement of testicular prostheses, although optimal timing remains controversial. Patients with embryonic testicular regression syndrome and ambiguous genitalia require individualized assessment to determine the optimal gender assignment.

Ovotesticular DSD

Ovotesticular DSD describes individuals who have both testicular tissue with well-developed seminiferous tubules and ovarian tissue with primordial follicles, which may take the form of one ovary and one testis or, more commonly, one or two ovotestes.

Both the external genitalia and internal duct structures of ovotesticular DSD display gradations between male and female. **In most patients the external genitalia are ambiguous but masculinized to varying degrees, and 75% are raised as male.** Among those raised as male, hypospadias and chordee occur in approximately 80%. Among those patients raised as females, two-thirds have clitoromegaly. Virtually all patients have a urogenital sinus, and in most cases a uterus is present (see Figs. 48.16 and 48.17). The ovary is found in a normal location, more commonly on the left side. The testis or ovotestis may reside at any point along the path of testicular descent. Testes and ovotestes are more commonly located on the right side (Blyth and Duckett, 1991; Mittwoch, 2000). Sixty percent of gonads palpable in the inguinal canal or labioscrotal folds are ovotestes, which may be clinically suspected on the basis of a difference in firmness at either end of the gonad, consistent with polar segregation of ovarian and testicular tissue (Grumbach and Conte, 1998). A recent review of a large cohort of patients with ovotesticular DSD from South Africa demonstrated 56% of gonads to be ovotestes, 23% to be ovaries (more commonly left-sided), and 16% to be testes (typically right-sided) (Ganie et al., 2017). Detailed evaluation of gonads from this large cohort of patients suggests three distinct patterns of gonad development admixed (central core containing stroma and a mixture of ovarian and testicular tissue), compartmentalized (ovarian tissue in upper pole with lower pole of testicular tissue encapsulated by mantle of ovarian tissue), and bipolar (strict polar distribution of testicular and ovarian tissue) (Wiersma and Ramdial, 2009).

Approximately 60% of ovotesticular DSDs have a 46,XX karyotype; 33% are mosaics with a second cell line containing a Y chromosome (46,XX/46,XY; 46,XX/46,XXY), and 7% are 46,XY. Chimerism (mosaicism) has been thought to result from fusion of a fertilized ovum with its polar body, fusion of two nuclei, or double fertilization. It has also been suggested that ovotesticular DSD may result from hidden mosaicism with a Y cell line. Ortenberg et al. (2002) demonstrated the *SRY* gene in ovotestes of all eight cases of ovotesticular DSD studied, supporting somatic mosaicism. Other studies have demonstrated heterogeneity of Y-specific DNA regions detected in patients with ovotesticular DSD (Hadjiathanasiou et al., 1994). This supports a non–Y-chromosome–related mechanism responsible for 46,XX ovotesticular DSD, such as mutation in an autosomal or X-linked gene involved in sex determination. Recently, Bashamboo et al. and Baetens et al. noted a mutation in *NR5A1* to be responsible for ovotesticular DSD by disinhibition of the male developmental pathway, through down-regulation of female antitestis genes, tipping the balance toward testicular differentiation in 46,XX individuals (Bashamboo et al., 2016; Baetens et al., 2017). **Just as the differentiation of external genitalia is variable in ovotesticular DSD, differentiation of the internal ducts is also quite variable and is related to the function of the ipsilateral gonad.** Fallopian tubes are consistently present on the side of the ovary, and a vas deferens is always present adjacent to a testis (Berkovitz et al., 1991). The ovotestis, which comprises two-thirds of gonads in ovotesticular DSD, is associated with a fallopian tube in two-thirds of cases and with either a vas deferens only or both structures in one-third of cases.

The ovarian portion of the ovotestis is frequently normal, whereas the testicular portion is typically dysgenetic. Therefore, although ovulation and pregnancy have been reported for female 46,XX ovotesticular DSDs, male fertility has not been clearly documented.

The incidence of gonadal tumors is approximately 3% in 46,XY ovotesticular DSD and rare in 46,XX ovotesticular DSD. Both gonadoblastoma and dysgerminoma have been described (Verp and Simpson, 1987).

The most important aspect of management in ovotesticular DSD is gender assignment. Sex assignment should be based on the functional potential of external genitalia, internal ducts, and gonads according to the findings at laparoscopy or laparotomy. **Unlike patients with most other forms of gonadal dysgenesis, individuals with ovotesticular DSD have the potential for fertility if raised as female with the appropriate ductal structures.** Pregnancies have been reported in patients with ovotesticular DSD, the majority with the 46,XX karyotype (Starceski et al., 1988). If the patient is to be raised as female, all testicular and wolffian tissue should be removed. For those patients with an ovary, this is straightforward; if an ovotestis is present, surgical cleavage of the gonad with excision of the testicular portion has been performed successfully by Nihoul-Fekete et al. (1984). They recommend postoperative stimulation with human chorionic gonadotropin (hCG) to confirm that all testicular tissue has been removed. In settings in which the cleavage plane between testicular and ovarian tissues is unclear, as in admixed pathology described earlier, gonadectomy is advisable. When ovarian tissue is preserved, normal ovarian function can occur at puberty, although hormonal replacement may be necessary. Careful surveillance for potential gonadal tumors in the patient raised as female is also advisable. If a male gender is assigned, as has been most common historically, all ovarian and müllerian tissue should be removed. Consideration should be given to gonadectomy at puberty with appropriate androgen replacement in this setting, given the high risk for malignancy and unlikelihood of male fertility. At the very least, long-term gonadal surveillance ultrasound for tumor development would seem appropriate.

46,XX DSD (Masculinized Female)

46,XX DSD (masculinized female) is a disorder of phenotypic sexual development in which 46,XX individuals with ovaries have partially masculinized phenotype and ambiguous genitalia. By far the most common cause of the masculinized female is congenital adrenal hyperplasia (CAH), which is the most common cause of ambiguous genitalia in the newborn. Two very rare causes of 46,XX DSD (masculinized female) are maternal ingestion of androgens and virilizing tumors in the mother.

Congenital Adrenal Hyperplasia

The adrenogenital syndrome caused by CAH is a classic example of an inborn error of metabolism—in this case, an error involving cortisol synthesis. A defect in any one of the five enzymes involved in the cortisol biosynthetic pathway (cholesterol side-chain cleavage enzyme, 3β-hydroxysteroid dehydrogenase, 17-hydroxylase, 21-hydroxylase, and 11-hydroxylase) may result in CAH. The most commonly recognized syndromes result from a deficiency of one of the terminal two enzymes of glucocorticoid synthesis (21-hydroxylase or 11-hydroxylase) (New and Levine, 1984) (Fig. 48.19). As a result of deficiency of either terminal enzyme, formation of hydrocortisone is impaired, causing a compensatory increase in the secretion of adrenocorticotrophic hormone (ACTH). This increase enhances formation of adrenal steroids proximal to the enzymatic defect and a secondary increase in the formation of testosterone, the active androgen in CAH.

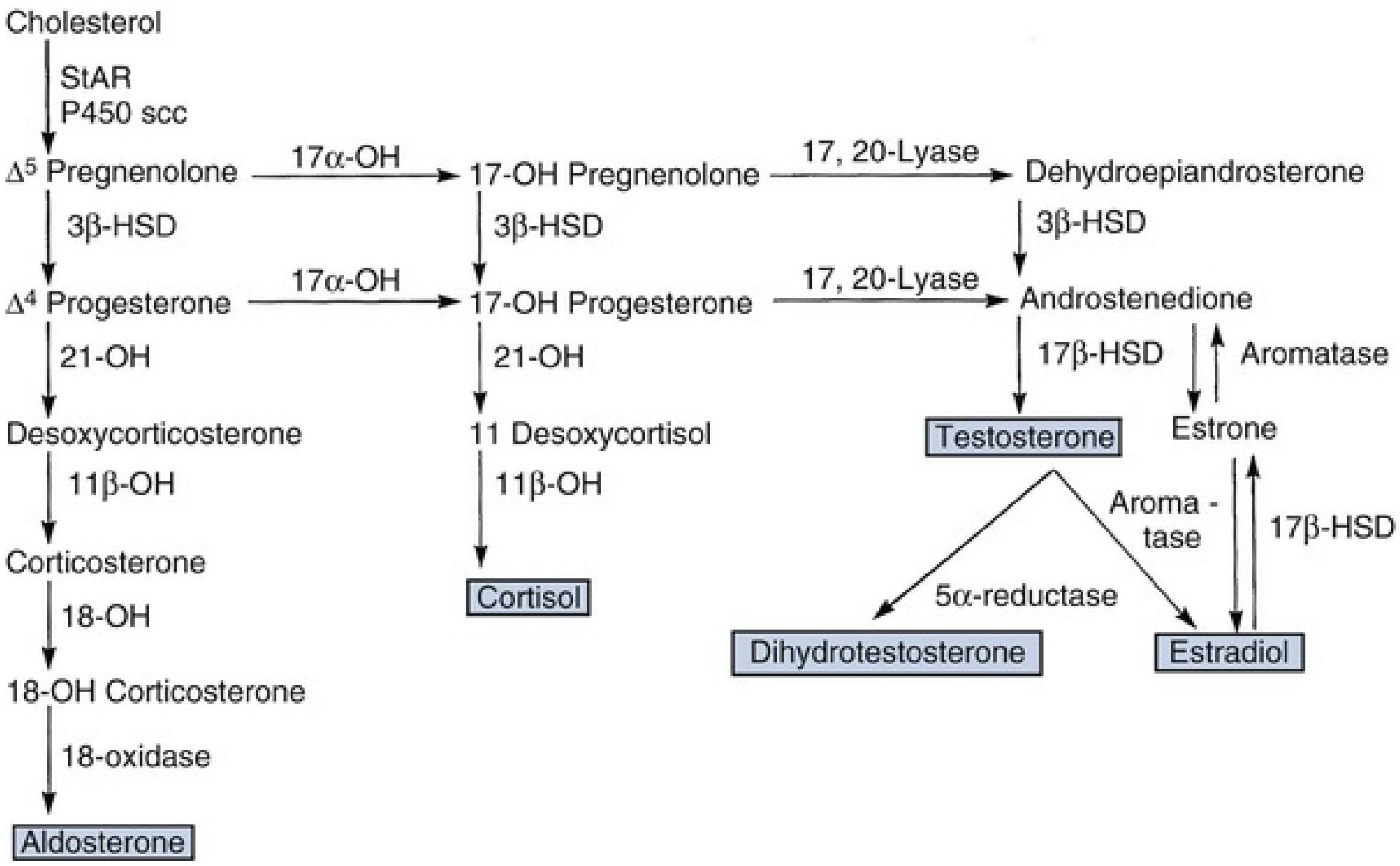
Cholesterol
StAR
P450 scc
Δ5 Pregnenolone
17α-OH
17-OH Pregnenolone
17, 20-Lyase
Dehydroepiandrosterone
3β-HSD
3β-HSD
3β-HSD
Δ4 Progesterone
17α-OH
17-OH Progesterone
17, 20-Lyase
Androstenedione
21-OH
21-OH
17β-HSD
Aromatase
Desoxycorticosterone
11 Desoxycortisol
Testosterone
Estrone
11β-OH
11β-OH
Aroma - tase
17β-HSD
Corticosterone
Cortisol
5α-reductase
18-OH
Dihydrotestosterone
Estradiol
18-OH Corticosterone
18-oxidase
Aldosterone

FIG. 48.19 Steroid biosynthetic pathway for mineralocorticoid, glucocorticoid, and sex steroid hormone production.

Key Point: Congenital Adrenal Hyperplasia

- The most commonly recognized syndromes of CAH result from a deficiency of one of the terminal two enzymes of glucocorticoid synthesis (21-hydroxylase or 11-hydroxylase).

A deficiency of steroid 21-hydroxylase is responsible for 95% of cases of CAH; it occurs with an incidence ranging from 1 in 5000 to 1 in 15,000 in the United States and Europe. The highest incidence, 1 in 490, is reported in the Yupik Alaskan Eskimo population (New et al., 1994). **Clinically, patients are divided into three categories: (1) salt wasters (patients with virilization and aldosterone deficiency), (2) simple virilizers (patients with virilization but without salt wasting), and (3) nonclassic patients (those without evidence of virilization or salt wasting).** Dramatic progress has been made in understanding the molecular basis of CAH, and 95% of the mutations that account for CAH have been identified. The wide clinical spectrum of the disease appears to represent different degrees of enzymatic compromise conferred by specific, identifiable genetic defects.

The 21-hydroxylase gene *(CYP21A2)* is located on chromosome 6p21.3 within the major human leukocyte antigen (HLA) complex and is transmitted in an autosomal recessive pattern (Wilson et al, 1995). Adjacent to the *CYP21A2* gene, separated by 30 kb, and adjacent to and alternating with *C4B* and *C4A* genes encoding the fourth component of serum complement is the CYP21 pseudogene *(CYP21PA1)*, so called because it encodes no proteins and is therefore inactive (Tusie-Luna and White, 1995). The inactive *CYP21PA1* is 98% homologous to the active gene *CYP21A2*. During meiosis, a gene conversion may occur that transfers segments from the *CYP21PA1* gene to the *CYP21A2* gene, rendering it inactive. Thus far, all mutations causing 21-hydroxylase deficiency appear to result from either a complete deletion of the genes *C4B* and *CYP21B* (a product of misalignment and unequal crossing over between chromatids during meiosis). To date, approximately 10 mutations constitute 90% to 95% of alleles and are derived from intergenic recombination of DNA sequences between the *CYP21A2* gene and the highly homologous *CYP21PA1*, whereas the remaining are spontaneous mutations (Forest, 2004). Over 200 different *CYP21* mutations have been reported (Witchel et al., 2017).

The majority of patients with CAH secondary to 21-hydroxylase deficiency exhibit one of the two classic forms of the disease: **75% present with salt wasting and 25% with simple virilization** (Kohn et al., 1995). The higher proportion of patients with the salt-wasting form of the disease recognized in more recent series has been attributed to improved diagnostic capabilities and a high level of clinical suspicion as well as to increased survival resulting from prenatal screening and proper mineralocorticoid supplementation (Fife and Rappaport, 1983). Neonatal screening programs for CAH, utilized in all 50 states and over 40 countries, have been credited with increasing the rate and shortening the time to diagnosis, particularly in males with the salt-wasting form of the disease (El-Maouche et al, 2017). This has also proven to be an important means of diagnosing the simple virilizing form in the male and the nonclassic forms in some males and females (Brosnan et al., 1999).

In the female with the classic salt-wasting and simple virilizing forms of the disorder, a masculinized female results. Because impaired steroidogenesis begins early in life—at the time of formation of the external genitalia (beginning at 10 weeks' gestation)—there is virtually always evidence of some degree of masculinization at birth. This is manifested by enlargement of the clitoris and varying degrees of labial fusion (Fig. 48.20). In addition, the vagina and urethra open into a common urogenital sinus. The enlargement of the clitoris may be so dramatic as to make it appear to be a hypospadiac penis with bilateral cryptorchidism or, rarely, a fully masculinized urethra to the tip of an apparent glans penis (Fig. 48.21). The severity of the virilization is usually greater in infants who experience salt wasting but not uniformly so. Prader (1958) classified the degrees of virilization of external genitalia in females with CAH (Fig. 48.22). The müllerian structures in these patients are typically normal. There may be an increased incidence of upper tract abnormalities (hydronephrosis, duplication) in CAH (Nabhan and Eugster, 2007).

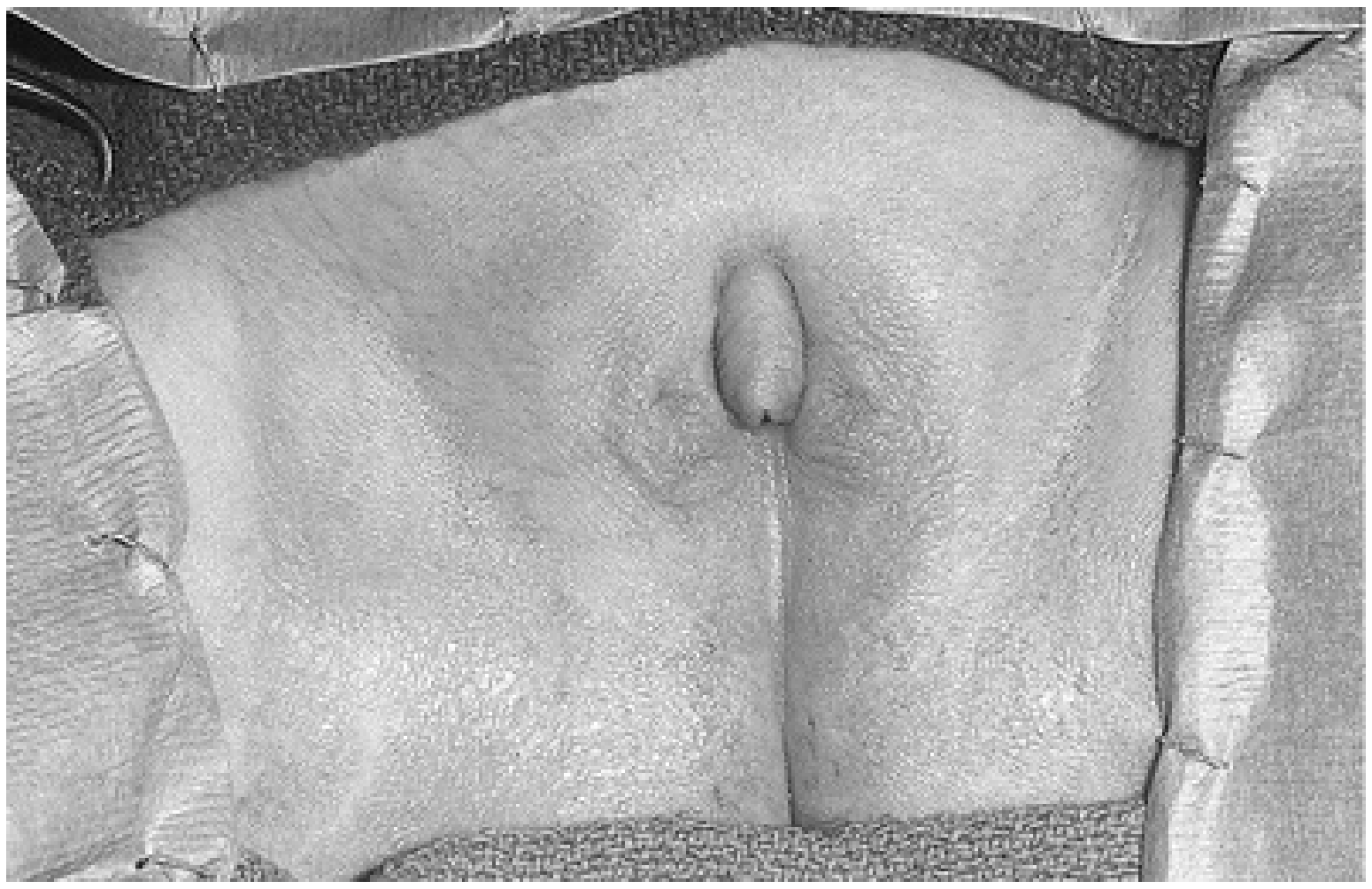

FIG. 48.20 External genitalia of a patient with congenital adrenal hyperplasia secondary to 21-hydroxylase deficiency, showing labioscrotal fusion and clitoromegaly.

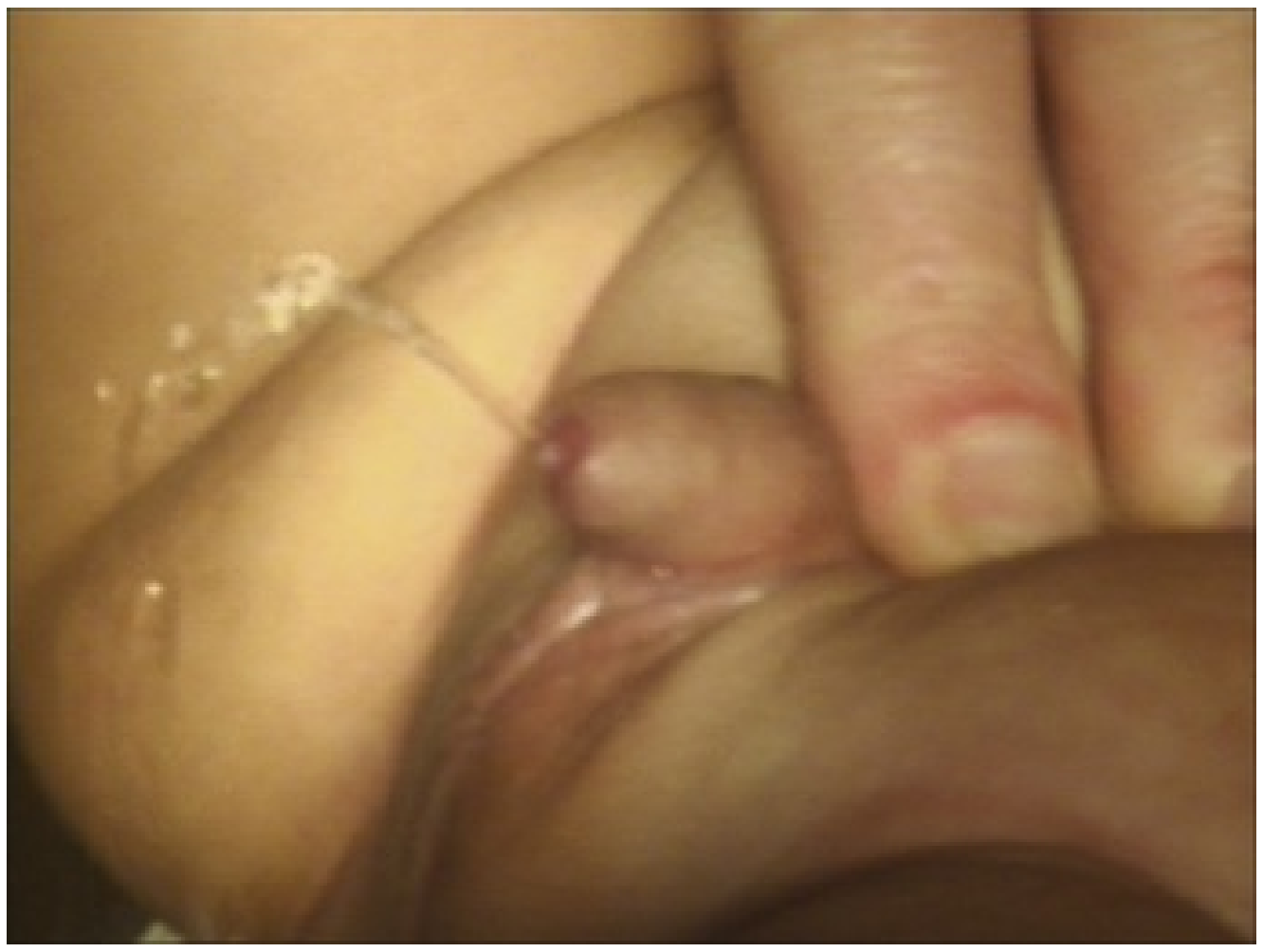

FIG. 48.21 Prader V patient with congenital adrenal hyperplasia secondary to 21-hydroxylase deficiency demonstrating complete virilization of phallus.

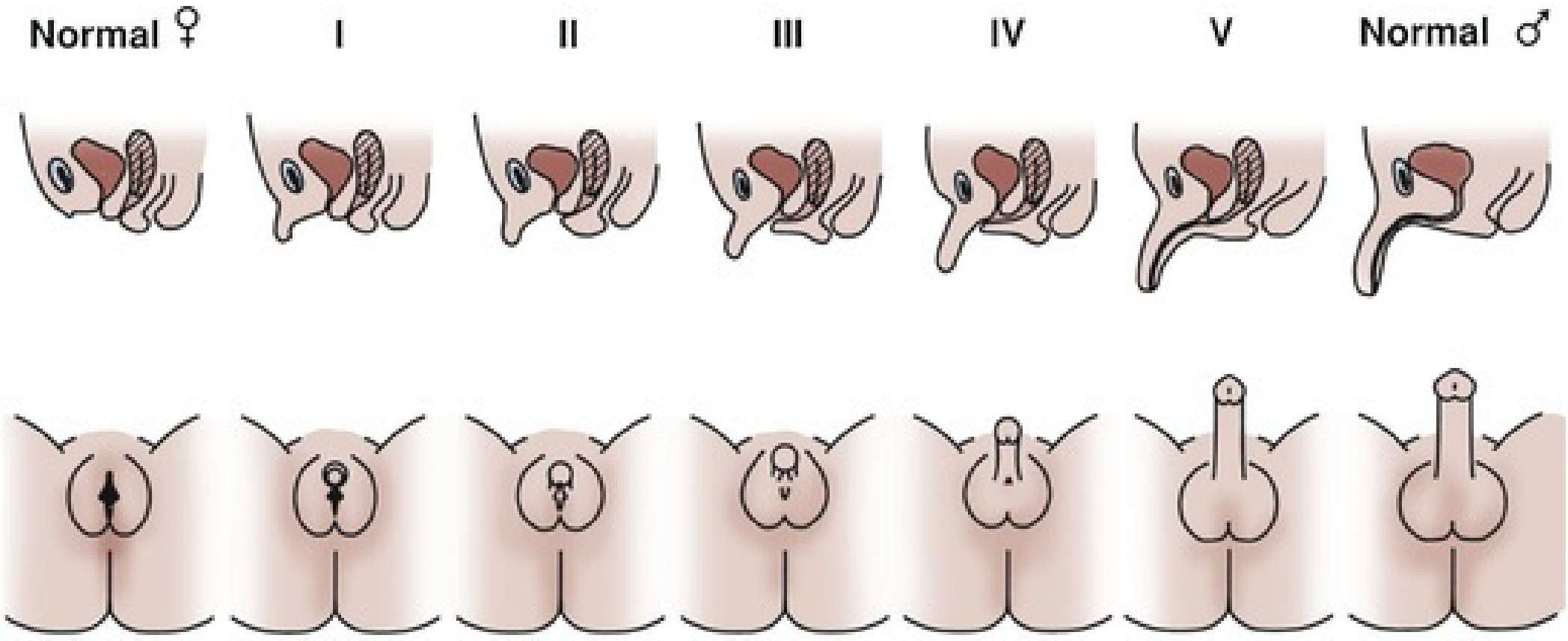

FIG. 48.22 Classification by Prader of the various degrees of masculinization of the external genitalia in females with congenital adrenal hyperplasia that has been applied by some authors to intersexual states in general. (From Prader A. Die Haufigkeit der kongenitalen androgenitalen Syndroms. *Helv Pediatr Acta.* 1958;13:426.)

In both males and females with the salt-losing variant of CAH, symptoms begin within the first few weeks after birth, with failure to regain birth weight, progressive weight loss, and dehydration. In severely affected infants, adrenal crises occur within the first 10 to 21 days of life (Grumbach and Conte, 1998)**. Vomiting is prominent and can be so extreme that a mistaken diagnosis of pyloric stenosis is made, particularly in the male.** Without therapy, death may rapidly ensue from hyperkalemia, dehydration, and shock. In the male infant, in particular, the classic fluid and electrolyte abnormalities of CAH may be mimicked by urosepsis secondary to reflux or obstructive uropathy, which should be ruled out (Mastrandrea et al., 2005). After birth, there is progression of masculinization of the untreated female; pubic and axillary hair develop prematurely, acne appears, and the voice deepens. There is rapid somatic maturation, resulting in premature epiphyseal closure and short adult stature. Although the internal genitalia are female, breast development and menstruation do not occur unless the excessive androgen production is suppressed by adequate steroid therapy.

In the male without salt wasting, the chief clinical manifestations are those of isosexual precocity. The infant appears normal at birth, but signs of sexual and somatic precocity appear within the first 2 to 3 years of life. Although the testes remain normal in size, enlargement of the penis, scrotum, and prostate occur, accompanied by the appearance of pubic hair, acne, and deepening of the voice. The musculature is well developed (prompting the descriptive term “little Hercules”), and bone age is more advanced than appropriate for the chronologic age. The syndrome often goes unrecognized in the non–salt-wasting male until signs of androgen excess, such as accelerated height and precocious pubic hair, appear later in childhood.

In the non–salt-wasting male, two major long-term implications are short stature and infertility in 20% to 40%. Premature epiphyseal closure will result unless early medical control is instituted. This emphasizes the value of neonatal screening. Infertility has been noted in 30% of CAH males, often related to the finding of testicular adrenal rest tissue (TART) most reliably diagnosed with scrotal ultrasonography. These nodules, present in 25% to 30% of males with CAH, represent hypertrophy of adrenal rests caused by ACTH stimulation and, when associated with impaired fertility, warrant periodic scrotal ultrasonography, intensified glucocorticoid suppression, and possibly testis-sparing excision (Claahsen-van der Grinten et al., 2008). Some advocate sperm cryopreservation in postpubertal males with adrenal rest tumors. In addition, poor control of the disease in boys with classic CAH has been associated with small testes and infertility with reduced sperm counts (New and Wilson, 1999). This is caused by peripheral aromatization of excess androgen to estrogen that suppresses pituitary gonadotropins.

In classic 21-hydroxylase deficiency, plasma levels of progesterone and 17-hydroxyprogesterone are markedly elevated. Urinary levels of 17-ketosteroids and pregnanetriol are elevated. **The diagnosis may be made**

biochemically with the use of radioimmunoassay of plasma 17-hydroxyprogesterone. A pelvic ultrasound study demonstrating the presence of müllerian tissues is confirmatory. Some investigators have suggested that the finding of abnormally enlarged or "cerebriform"-appearing adrenal glands on neonatal ultrasonography, available before biochemical results, may represent the earliest diagnostic tool for CAH (Hernanz-Schulman et al., 2002).

More aggressive screening for 21-hydroxylase deficiency has provided considerable benefits. In one series, despite sexual ambiguity, one-third to one-half of the affected female newborns were not diagnosed as having 21-hydroxylase deficiency until they were identified by the screening test (Pang et al., 1985).

Nonclassic 21-hydroxylase deficiency represents an attenuated, late-onset form that is variable in clinical severity because of its partial deficiency of 21-hydroxylase and timing of onset. These patients have a 30% to 50% reduction in 21-hydroxylase enzymatic activity and have hyperandrogenism. New and Wilson (1999) found the nonclassic 21-hydroxylase deficiency to be the most common autosomal recessive disorder in humans, with an incidence of 1 in 100, based on the heterogeneous population of New York City. The presenting symptoms in females are commonly hirsutism and oligomenorrhea, male pattern baldness, and polycystic ovaries. In men with the nonclassic form of 21-hydroxylase deficiency, oligospermia and subfertility have been presenting features, and reversal of infertility with glucocorticoid therapy has been reported. Typically, lower doses of glucocorticoid are required for management of the nonclassic form of CAH.

A deficiency of 11β-hydroxylase accounts for roughly 5% of cases of CAH. Both classic and mild forms have been recognized. Unlike 21-hydroxylase, 11β-hydroxylase is not linked to human leukocyte antigen. The defect results from mutations in the *CYP11B1* gene located on the long arm of chromosome 8 (Merke et al., 1998). Like 21-hydroxylase deficiency, the nonclassic variant of 11β-hydroxylase deficiency (late onset) is characterized by signs and symptoms of androgen excess in childhood or adolescence. **Hypertension is a common finding in patients with this type of CAH, and it is believed to be secondary to increased serum levels of deoxycorticosterone (DOC).** Although most patients are hypertensive, some are normotensive and others experience only intermittent hypertension. Marked virilization occurs in the severe form of the defect and may be as severe as in those patients with a 21-hydroxylase deficiency. In the late-onset form, mild virilization occurs in prepubertal and postpubertal patients.

The diagnosis of 11β-hydroxylase deficiency can be confirmed by finding increased plasma levels of 11-deoxycortisol and 11-DOC. The treatment with glucocorticoids is identical to that of patients with 21-hydroxylase deficiency.

The least common enzyme deficiency responsible for a virilizing form of CAH is 3β-hydroxysteroid dehydrogenase. This deficiency affects the early steps in steroid biosynthesis in both adrenal glands and gonads, resulting in inability to convert 3β-hydroxysteroids to 3-ketosteroids. As a result, the severe form leads to impaired synthesis of aldosterone, cortisol, and sex steroids. Affected females exhibit mild clitoromegaly and labial fusion accompanied by symptoms of aldosterone and cortisol deficiency.

Two homologous genes have been identified for 3β-hydroxysteroid dehydrogenase, both of which contain four exons (Merke et al., 1998). A number of mutations giving rise to the syndrome have been described. This defect has an autosomal recessive inheritance pattern and is heterogeneous in its biochemical and clinical appearance. A non–salt-losing form and mild- and late-onset forms have been described, although the nonclassic form appears to be exceedingly rare.

The diagnosis of 3β-hydroxysteroid dehydrogenase is based on finding increased serum levels of 17-hydroxypregnenolone and dehydroepiandrosterone (DHEA). The pelvic ultrasound evaluation, confirming presence of müllerian tissue, would be supportive. Treatment is similar to that of patients with 21-hydroxylase deficiency.

Currently, one of the most exciting aspects of CAH is the capability of diagnosing and treating the disorder prenatally. **Prenatal diagnosis of CAH in the at-risk fetus was initially made by a measurement of amniotic fluid for 17-hydroxyprogesterone at 16 to 17 weeks' gestation** (Laue and Rennert, 1995). Currently, the diagnosis is made during the first trimester by HLA genotyping or by DNA analysis of genes within the HLA complex in cells obtained by chorionic villus sampling at 9 to 11 weeks' gestation (Hughes, 2002). **Treatment of the mother is with dexamethasone, which crosses the placenta and suppresses fetal secretion of ACTH, thereby preventing virilization of the genitalia.** However, treatment should be instituted as soon as pregnancy is confirmed, and no later than 9 weeks after the last menstrual period, before initial development of the external genitalia (Nimkarn and New, 2007). There are certain complexities to this form of management. The diagnosis of CAH in the fetus may be determined on chorionic villous cells or on cells from amniotic fluid for families in which a prior member was affected. **Therefore, it is not possible to confirm the diagnosis before therapy is initiated.** Because virilization is not a concern with the male fetus and three of four female fetuses at risk are unaffected, given the autosomal recessive pattern of inheritance, seven of eight fetuses may be treated unnecessarily. Therefore, one goal in therapy has been earlier diagnosis to avoid unnecessary treatment. The incorporation of PCR analysis of free fetal DNA from circulating trophoblastic cells in the maternal circulation has allowed detection of Y chromosome, thus avoiding treatment of males (Rijnders et al., 2001).

A number of series have established the effectiveness of prenatal treatment for CAH with dexamethasone in 85% of cases (Migeon, 1990; Pang et al., 1990; Speiser et al., 1990). In some neonates, there is no evidence of masculinization, suggesting totally successful therapy. In another group, there is milder masculinization than that noted in an affected sibling. Although compliance and timing of initiation of treatment have been variable from series to series, this heterogeneity of response to therapy raises intriguing questions about the mechanisms involved in virilization of the CAH fetus. In addition, prenatal treatment with dexamethasone has raised ethical concerns. **Although there is no arguing its ability to prevent androgen effects on the genitalia and potentially the brain of affected females, the long-term effects of prenatal dexamethasone treatment on unaffected fetuses remain an important concern.** A study by Meyer-Bahlburg et al. (2004a) demonstrated no cognitive or developmental motor impairment resulting from prenatal treatment of CAH fetuses, but others have suggested potential deleterious effects on verbal working memory, self-perceived scholastic competence, and increased social anxiety (Hirvikoski et al, 2007). More recently, Meyer-Bahlburg et al. (2012) confirmed no adverse effect of short-term prenatal dexamethasone exposure on working memory. However, long-term exposure was associated with slower mental processing. Because of these potential risks, Miller (2015) has strongly advocated the use of prenatal treatment for CAH only as an experimental therapy in large centers and under institutional review board scrutiny. In contrast, Wallensteen et al. (2018) reported no differences in adaptive functioning, behavioral/emotional problems, social anxiety, or temperament between dexamethasone-treated and control children and adolescents. Furthermore, Wallensteen et al. (2018) found no significant neuropsychological deficits when they examined first-trimester dexamethasone-exposed adults as compared with controls and suggest that deficits observed during childhood may improve with time. Long-term follow-up of former dexamethasone-treated fetuses is essential.

Hughes (2002) and others have emphasized the close correlation in CAH of genotype and phenotype. Hannah-Shmouni et al. (2017) recently noted a genotype-phenotype correlation in 90% of cases (Hannah-Shmouni et al, 2017). Certain genotypes were more frequent in specific ethnic groups. This has a number of practical implications. Molecular biologists can now predict not only the risk for a couple having an affected child but also the likely clinical form of the disease. Therefore, genotypes of severe mutations would motivate prenatal treatment, whereas genotypes of less severe mutations would not. In addition, less severe genotypes in the newborn would allow for modification of corticosteroid treatment to minimize side effects.

The treatment of affected children with hydrocortisone in childhood and adolescence achieves a number of goals, as noted by Bongiovanni and Root (1963): “to supply the deficient hormone; to suppress pituitary ACTH secretion and hence adrenal androgens and clinical virilization; to forestall abnormally rapid somatic growth and osseous advance; to permit normal gonadal development; and to correct salt-water loss or hypertension in the complicated forms.” The required dose of glucocorticoid may be predicted by genotype, as noted by Hughes (2002), but should be adjusted for the individual patient based on bone age, linear growth, 24-hour excretion of ketosteroids, and clinical evidence of glucocorticoid deficiency or excess (Grumbach and Conte, 1998). The effectiveness of therapy may be assessed by measuring morning plasma 17-hydroxyprogesterone levels. Those children with the salt-losing form of the disease require increased salt intake and mineralocorticoid treatment in addition to hydrocortisone therapy. After control of electrolytes and blood pressure has been achieved in the acute setting, maintenance therapy with fludrocortisone should be instituted (Laue and Rennert, 1995; Grumbach and Conte, 1998). The administration of hydrocortisone and, when required, fludrocortisone (0.05–0.3 mg/day) is continued indefinitely in all patients (American Association of Pediatrics, 2000). Typically, patients are instructed to triple their oral dose of hydrocortisone during physically stressful events such as surgery or infection.

In significantly virilized females (who will not have been diagnosed and treated prenatally), it is appropriate to perform feminizing genitoplasty at 6–12 months of age, when a well-established course of medical therapy has been instituted, the risks of anesthesia have become minimal, and the child has grown large enough to make the procedure technically feasible (Passerini-Glazel, 1990). **Long-term fertility in males and feminization, menstruation, and fertility in females can be anticipated in the well-treated patient.** Indeed, this potential in even the most masculinized female CAH patient has provided support for feminizing genitoplasty in virtually all 46,XX CAH patients. Although female gender rearing is supported by the 2006 Consensus Statement, it has been challenged by Lee and Husmann for those patients with 46,XX CAH who appear unambiguously male for whom they recommend consideration of male gender assignment (Lee et al, 2010).

An important area of research has been the potential imprinting of the brain by elevated prenatal androgen levels. A number of studies confirm that prenatal hyperandrogenization is associated with masculinization of gender-related behavior but not masculinization of gender identity. Meyer-Bahlburg et al. (Dessens et al, 2005; Meyer-Bahlburg et al, 2004b, 2008) noted a close correlation between hormonal abnormalities as a function of severity of enzyme deficiency with sexual orientation (homosexuality, bisexuality rates). Furthermore, Berenbaum et al. (2003, 2004) noted that in females with CAH and virilized genitalia psychological development is not compromised in those who are reared as females and receive good medical care. Meyer-Bahlburg et al. (2004a) noted in 46,XX CAH girls that marked masculinization of gender-related behavior in prenatally hyperandrogenized CAH girls was not associated with masculinization of gender identity. However, this has been challenged by recent work noting increased cross-gender identification in CAH girls that appears to occur in proportion to physiologic evidence of virilization (Pasterski et al., 2015). Indeed, proper psychological support should be a component of long-term follow-up.

In an interesting finding, both male and female patients with classic CAH have been noted on magnetic resonance imaging to have smaller amygdala volumes than controls and altered amygdala function. The amygdala, regulated by glucocorticoids, is important in processing emotion (Ernst et al., 2007).

An intriguing area of surgical innovation in the management of CAH has been the experimental use of “prophylactic” adrenalectomy for selected patients. This approach is based on the premise that in certain patients it is more difficult to maintain adrenal suppression than to prevent adrenal crises. Clinically, these patients are the salt losers and extremely virilized females. For those with this most severe form of 21-hydroxylase deficiency, adequate suppression of adrenal production has required significant degrees of hypercortisolism, associated with poor growth, obesity, and infertility (in 40%).

For the 25% of CAH patients who completely lack 21-hydroxylase enzyme activity and therefore produce neither cortisol nor aldosterone, adrenalectomy may be a practical approach (VanWyk et al., 1996). In general, these patients may be identified genotypically as homozygotes or compound heterozygotes for “null alleles” of the *CYP21* gene (VanWyk et al., 1996). In a series of 18 patients with long-term follow-up, VanWyk and Ritzen (2003) noted bilateral adrenalectomy to be safe and effective in managing severe forms of CAH in which patients repeatedly escaped adrenal suppression. Most of these patients reported a better quality of life after bilateral adrenalectomy. Bilateral adrenalectomy proved more successful for those patients pursuing fertility rather than control of obesity and hyperandrogenism (Ogilvie et al., 2006).

Although these patients are rendered Addisonian by this surgery, those with the most severe form of CAH would have a poor intrinsic adrenal response to metabolic stress (Gunther et al., 1997). One theoretical disadvantage of this approach is that if gene therapy were to one day allow functional *CYP21* genes to be introduced into adrenal cortical tissue, adrenalectomized patients would not be candidates for such therapy (VanWyk et al., 1996).

Males with congenital adrenal hyperplasia must be followed for testicular adrenal rest tumors (TARTs) as a potential cause of infertility. This is ideally performed with annual screening testicular ultrasounds (Kang, 2011).

46,XX DSD (Masculinized Female) Secondary to Maternal Androgens and Progestins and Maternal Tumors

The masculinization of a female fetus as a result of maternal administration of synthetic progestational agents or androgens is a rare occurrence; lessons have been learned from prior unfortunate experiences. Historically, progestational agents were used to prevent threatened abortion. In one large series, masculinization occurred in 2% of female infants whose mothers were treated with progestins during pregnancy (Ishizura et al., 1962). In addition, danazol, a testosterone derivative used to treat endometriosis, has been associated with virilization of the female fetus. **The degree to which any androgen or progestational agent affects female fetal development is a function of the strength of the agent, its maternal dosage, and timing and duration of administration** (Bongiovanni and McFadden, 1960).

Very rarely, a maternal ovarian or adrenal tumor has virilizing effects on a female fetus. More typically, such a tumor has virilizing effects on the mother but no apparent effect on the fetus. Ovarian tumors that have resulted in masculinization of the female fetus include arrhenoblastoma, hilar cell tumor, lipoid cell tumor, ovarian stromal cell tumor, luteoma of pregnancy, and Krukenberg tumor (Calaf et al., 1994).

Rarer still are maternal adrenal tumors (adrenocortical carcinoma and adenoma), which have masculinizing effects on the female fetus.

Aromatase deficiency represents an even rarer cause of transplacental transport of excess androgens to the fetus. The cytochrome P450 aromatase enzyme catalyzes the conversion of androgens to estrogens. Normally, weak androgens produced by the fetal adrenal gland are converted to estrogens by placental aromatase and pass to the maternal circulation. Mutations of the *CYP19* aromatase gene can result in profound virilization of the female fetus and mother during pregnancy. Although maternal virilization resolves postnatally, it recurs in subsequent pregnancies.

In any case of exogenous androgen effect on a female fetus, normal endocrine status is recognized postnatally, and management is confined to external genital reconstruction, as required.

46,XY DSD (Undermasculinized Male)

The term *46,XY DSD (undermasculinized male)* refers to 46,XY individuals with differentiated testes who exhibit varying degrees of feminization phenotypically. Impaired male differentiation in these patients is secondary to inadequate secretion of testosterone by the testes at the necessary period in development, inability of target tissue to respond to androgen appropriately, or impaired production or action of AMH.

Leydig Cell Aplasia (Luteinizing Hormone Receptor Abnormality)

Leydig cell aplasia as a cause of undermasculinization of the male was first reported in 1976 by Berthezene et al. (Berthezene et al.,1976). **In its pure form, this rare disorder is characterized by a normal 46,XY male karyotype associated with a normal-appearing female phenotype. Typically, testes are palpable in the inguinal canals or labia majora.** On investigation, there are no müllerian structures, and the vagina is short. A low testosterone level is noted in conjunction with an elevated LH concentration. **The absence of a rise in serum testosterone level after hCG stimulation is characteristic of this disorder** (Brown et al., 1978). Physiologically, this disorder represents a spectrum between absent Leydig cells and Leydig cells with abnormal LH receptor (David et al., 1984). Because a number of inactivating mutations have been found in the LH receptor gene, a correlation can be made between the phenotype of patients with Leydig cell hypoplasia and the activity of their LH receptor alleles (Richter-Unruh et al., 2004). It is transmitted as an autosomal recessive trait expressed only in males. Incomplete forms of the syndrome occur, with the mildest form being expressed as primary hypogonadism with normal male external genitalia (Lee et al., 1982).

The clinical diagnosis of Leydig cell aplasia, or LH receptor abnormality, is typically made as a result of sexual infantilism and the absence of development of secondary sexual characteristics or the discovery of palpable gonads in the inguinal canal or labia on physical examination (Arnholt et al., 1985). The differential diagnosis includes androgen insensitivity syndrome or a terminal defect in androgen synthesis. The histology of the abnormal testes demonstrates absence of Leydig cells in intratubular spaces with normal Sertoli cells.

Disorders of Testosterone Biosynthesis

A defect in any of the five enzymes required for the conversion of cholesterol to testosterone can cause incomplete (or absent) virilization of the male fetus during embryogenesis. The first three enzymes (cholesterol side-chain cleavage enzyme, 3β-hydroxysteroid dehydrogenase, and 17β-hydroxylase) are present in both adrenal glands and testes. **Therefore, their deficiency results in impaired synthesis of glucocorticoids and mineralocorticoids in addition to testosterone.** For all five enzyme deficiencies, the pattern of inheritance is autosomal recessive.

Congenital Lipoid Adrenal Hyperplasia (StAR Deficiency).

The first step in gonadal and adrenal steroidogenesis is conversion of cholesterol to pregnenolone, which is mediated by a single cholesterol side-chain cleavage enzyme known as 450SCC (previously known as 20-22 desmolase). A defect in this enzyme, first described by Prader and Gurtner in 1955, was believed to result in the rare condition congenital lipoid adrenal hyperplasia, so named because the adrenal glands became large and lipid laden. **However, more recent evidence suggests that a defect in cholesterol transport is usually etiologically responsible** (Sahakitrungruang, 2015). The steroidogenic acute regulatory (StAR) protein stimulates cholesterol transport from the outer to the inner mitochondrial membrane (site of the cholesterol side-chain cleavage complex). This appears to be the rate-limiting step in acute steroid synthesis.

Over 40 StAR mutations causing lipoid adrenal hyperplasia have been found in various ethnic groups but are most commonly reported in patients of Japanese, Korean, and Palestinian origin (Bhangoo et al., 2005). Affected 46,XY individuals have female or ambiguous external genitalia with a blind-ending vaginal pouch; intra-abdominal, inguinal, or labial testes; and absence of müllerian structures, consistent with functioning Sertoli cells (Hauffa et al., 1985). Wolffian ducts are present but rudimentary. Infants often present in the first few weeks of life with severe adrenal insufficiency and salt wasting, but delayed presentation has been reported (Lekarev et al., 2012).

A diagnosis of StAR (cholesterol side-chain cleavage enzyme) deficiency should be entertained in any neonate with nonvirilized female external genitalia and evidence of cortisol and aldosterone deficiency with hyponatremia, hyperkalemia, and metabolic acidosis. Abdominal computed tomography demonstrates large, lipid-laden adrenal glands.

Management is similar to that for 21-hydroxylase deficiency. Classically, 46,XY patients with this disorder have been raised as females and have undergone gonadectomy (Laue and Rennert, 1995). Because testosterone production was never significant, brain imprinting is not a factor in gender assignment. But, phenotype can be quite variable, such that partial virilization or even normal male genitalia may result (Lekarev et al., 2012).

Cytochrome P450 Oxidoreductase Deficiency.

Cytochrome P450 oxidoreductase (POR) deficiency has been added to the causes of both 46XY and 46XX DSD. POR is a cofactor to all microsomal P450 enzymes, including 17-hydroxylase, 17,20-lyase, 21-hydroxylase, and aromatase. The condition emerged as a distinct entity through the realization that apparent combined deficiency of 17-hydroxylase and 21-hydroxylase enzymes is a single disorder caused by lack of POR, a membrane-bound flavoprotein that plays a central role in electron transfer from NADPH to P450 enzymes. It was originally characterized in patients with Antley-Bixler syndrome (a skeletal dysplasia syndrome) in whom some had ambiguous genitalia and abnormal steroidogenesis. Subsequently, it has become clear that POR deficiency can cause DSD unassociated with skeletal dysplasia and characteristics of Antley-Bixler syndrome (Hughes, 2008).

3β-Hydroxysteroid Dehydrogenase Deficiency.

3β-Hydroxysteroid dehydrogenase catalyzes the 3β-hydroxysteroids (pregnenolone, 17-hydroxypregnenolone, and DHEA) to the three ketosteroids, progesterone, 17-hydroxyprogesterone, and androstenedione. A congenital deficiency of 3β-hydroxysteroid dehydrogenase was first described by Bongiovanni in 1962.

Affected individuals present with varying degrees of incomplete masculinization resulting from a block in testosterone biosynthesis and with salt-wasting adrenal insufficiency resulting from impaired synthesis of aldosterone and cortisol. The lack of salt-retaining hormone and cortisol results in a salt-losing crisis soon after birth. However, partial deficiencies associated with severe salt wasting occur, consistent with genetic heterogeneity. Two isoenzymes, type 1 and type 2 3β-hydroxysteroid dehydrogenase, are involved in steroid biosynthesis. These enzymes are encoded by two genes, *HSD3B1* and *HSD3B2,* localized to chromosome 1 at locus p11–p13 (Chang et al., 1993). Classical 3β-hydroxysteroid dehydrogenase deficiency results from inactivating mutations, 37 of which have been identified, in the *HSD3B2* gene (Welzel et al., 2008).

Males with this deficiency usually exhibit incomplete virilization of the external genitalia, with a small phallus, hypospadias with labioscrotal fusion, a urogenital sinus, and a blind-ending vaginal pouch. Testes are often scrotal, and wolffian ducts develop normally. As with other defects in testosterone biosynthesis, in which normal Sertoli cell function is preserved, müllerian structures are absent.

The diagnosis should be considered in 46,XY males with ambiguous genitalia and signs of adrenal insufficiency. Endocrine study demonstrating increased levels of 3β-hydroxysteroids confirms the diagnosis.

Management of 3β-hydroxysteroid dehydrogenase is similar to that for patients with 21-hydroxylase deficiency. The chronic sequelae of exogenous glucocorticoid excess with reduced quality of life for these severe CAH patients has been well documented (Benkert et al., 2015).

17α-Hydroxylase Deficiency.

17α-Hydroxylase catalyzes the conversion of pregnenolone and progesterone to 17α-hydroxypregnenolone and 17-hydroxyprogesterone, respectively, in adrenal and gonadal steroidogenesis. The first case of male pseudohermaphroditism caused by this enzyme deficiency was reported in 1970 by New (1970). The gene for this enzyme has been localized to chromosome 10 (Laue and Rennert, 1995).

Affected 46,XY individuals usually have female external genitalia with absent to slight masculinization. **A deficiency in 17α-hydroxylase activity impairs cortisol production, causing ACTH hypersecretion and resulting in increased levels of DOC, corticosterone, and 18-hydroxycorticosterone in the adrenal glands. These compounds with mineralocorticoid activity produce excess salt and water retention, hypertension, and hypokalemia.**

The phenotype of affected individuals varies from female with external genitalia with a blind-ending vaginal pouch to male with perineal hypospadias and chordee. The diagnosis should be considered in an undervirilized male with hypertension. Endocrine laboratory evaluation demonstrates elevated serum progesterone, DOC, corticosterone, 18-hydroxycorticosterone, and ACTH.

Therapy with glucocorticoid replacement brings blood pressure and hypokalemia back to normal by suppressing ACTH and hence adrenal cortical stimulation. Some patients have been raised as females with gonadectomy and estrogen replacement at puberty. In partial forms, typically with reasonable phallic size, patients may be raised as male with testosterone replacement at puberty. **Fertility has not been reported in patients with testosterone biosynthetic defects, and inadequate testosterone production makes androgen imprinting a less significant issue for these patients.** Therefore, the phenotype may dictate gender assignment.

17,20-Lyase Deficiency.

The enzyme 17,20-lyase has been demonstrated to be related to 17α-hydroxylase in that the activities of both are linked to the same gene product on chromosome 10 (Laue and Rennert, 1995). However, in some patients with the genetic defect, both biologic activities are absent, but with others only the 17,20-lyase function appears deficient. Zachmann et al. first described this clinical entity in 1972.

In cases in which the deficiency primarily involves 17,20-lyase, cortisol and ACTH secretion are normal. Aldosterone is secreted normally, and hypertension does not result. **However, impaired biosynthesis of testosterone in the 46,XY individual results typically in ambiguous rather than totally female genitalia at birth.** The deficient masculinization of the external genitalia can range from severe, resulting in a female gender assignment in the neonate, to mild, resulting only in hypospadias. At puberty, the secretion of testicular androgen remains low. Zachmann et al. (1982) have postulated that there are two types of 17,20-lyase deficiency—one that is partial and another that is a complete defect.

The diagnosis may be suspected in undervirilized males with absent müllerian derivatives and no defect in glucocorticoid or mineralocorticoid synthesis. At the time of expected pubertal development, patients may present with failure to develop secondary sexual characteristics and elevated gonadotropin levels. The diagnosis may be made prepubertally using hCG and ACTH stimulation.

Management entails plastic reconstruction of the external genitalia and appropriate sex steroid replacement at puberty.

17β-Hydroxysteroid Oxidoreductase Deficiency.

This last enzyme in the testosterone biosynthetic pathway catalyzes the conversion of androstenedione to testosterone, DHEA to androstenediol, and estrone to estradiol. Male undervirilization resulting from a deficiency in 17β-hydroxysteroid oxidoreductase was first described by Saez et al. in 1971.

Clinically, this is the most interesting enzymatic defect in testosterone biosynthesis in its similarities to 5α-reductase deficiency. At birth, affected individuals appear to have a normal female phenotype, without significant evidence of virilization. Therefore, a female gender assignment is usually made. However, these individuals have well-differentiated testes located intra-abdominally, inguinally, or in the labia and no müllerian structures. Surprisingly, wolffian ducts are normally developed, which may be secondary to the action of androstenedione or minimal amounts of testosterone produced during embryogenesis (Boehmer et al., 2001). **At puberty, there is phallic growth and progressive development of male secondary sexual characteristics.** These include increased muscle mass and development of pubic, axillary, and facial and body hair with male distribution. Gynecomastia may occur, and the testes may become palpable (Saez et al., 1972). In some cases, gender reassignment to male has been reported (Imperato-McGinley et al, 1979; Rosler and Kohn, 1983).

The late onset of virilization is related to the pubertal increase in gonadotropin production, which may partially overcome the block in testosterone biosynthesis.

There is a characteristic hormonal profile in this disorder. In the prepubertal patient, plasma androstenedione and estrone levels may not be increased. At puberty, androstenedione, the immediate precursor of testosterone, is increased to 10 to 15 times the normal plasma concentration (Virdis and Saenger, 1984). Earlier precursors are within normal levels. Plasma testosterone is in the low-normal range. Serum levels of LH and FSH are markedly elevated, typically four to six times normal.

As a result of biochemical characterization and molecular cloning, 14 different 17β-hydroxysteroid dehydrogenase isozymes have been identified to date (Lukacik et al., 2006). **The type III 17β-hydroxysteroid dehydrogenase isozyme, cloned by Andersson et al. (1997), catalyzes the biosynthesis of testosterone from androstenedione. A mutation involving the *HSD17B3* gene, mapped to chromosome 9q22, is responsible for male undervirilization.** The type III isozyme is apparently expressed early in utero and is responsible for testosterone biosynthesis during the critical period of sexual development, based on the observation that male adults homozygous for 17β-hydroxysteroid dehydrogenase type III gene defects have ambiguous genitalia (Zhu et al., 1998).

The diagnosis is rarely made in the neonatal period. It may become apparent on discovery of a testis during a hernia repair in infancy or childhood. An hCG stimulation test resulting in an increased testosterone-to-androstenedione ratio would confirm the diagnosis and differentiate this condition from androgen insensitivity (Ahmed et al., 2000). **The primary management issue for patients with 17β-hydroxysteroid oxidoreductase deficiency has been gender assignment.** At this early stage, maintenance of the female sex of rearing with gonadectomy is usually elected. If the diagnosis is not made until puberty, when dramatic changes in virilization occur, certain families prefer a gender change to male. Cohen-Kettenis found gender role changes in 39% to 64% of 17β-hydroxysteroid oxidoreductase deficiency patients raised as female (Cohen-Kettenis, 2005). In an Arab cohort of 22 patients, Sobel et al. (2004) noted seven to undergo spontaneous gender role reversal to male without parental consent or psychiatric intervention. Traditionally, this decision has been strongly culturally influenced.

If a female sex of rearing is elected, gonadectomy, plastic reconstruction of the genitalia as necessary, and estrogen replacement therapy at puberty are indicated. For the patient maintained in the male gender, orchidopexy and reconstruction of the external genitalia are required. This entails hypospadias repair and chordee correction, which can be quite successful. However, phallic size remains small, and infertility is the rule. Some have suggested that childhood treatment with intramuscular testosterone may result in a larger phallus (Sobel and Imperato-McGinley, 2004). Usually endogenous androgen levels are adequate long term.

Two hypotheses have been proposed to explain the frequency of gender change from female to male with this enzyme deficiency, particularly among the cohort of Arab male pseudohermaphrodites with 17β-hydroxysteroid dehydrogenase type III deficiency. One entails the potential male imprinting of the brain in utero caused by the conversion of androstenedione to estrone; this theory is supported by studies in rats and rabbits demonstrating that administration of estrogen or androstenedione is capable of inducing male sexual behavior (Reddy et al., 1974). The second is the possibility that 17β-hydroxysteroid dehydrogenase activity is not deficient in the brain, its effect being mediated by the conversion of androstenedione to testosterone or estrogen (Imperato-McGinley et al., 1979).

Androgen Receptor and Postreceptor Defects

Disorders of androgen receptor function represent the most common definable cause of 46,XY DSD and the undervirilized male. These patients characteristically have a 46,XY karyotype and testes and present with a spectrum of phenotypic abnormalities that vary from complete external feminization (syndrome of complete androgen insensitivity), to ambiguous genitalia (partial androgen insensitivity syndrome), to the phenotypically infertile male. Although the clinical presentations vary according to the severity of the disorder, the pathophysiology is similar (Wiener et al., 1997).

Syndrome of Complete Androgen Insensitivity.

The syndrome of complete androgen insensitivity is characterized clinically by a 46,XY karyotype, bilateral testes, female-appearing external genitalia, and absence of müllerian derivatives. Wilkins first suggested in 1950 that the clinical features of this syndrome were the result of androgen resistance. This condition has an incidence of 1 in 20,000 to 1 in 60,000 males, and it is transmitted as an X-linked trait.

The androgen receptor regulates the transcription of other specific genes, once activated by testosterone or DHT. This results in new mRNA synthesis from the downstream genes and protein production. The androgen receptor has been mapped to the X chromosome at Xq11–12, spanning 90 kb and comprising eight exons (Brown et al., 1989; Hiort and Holterhus, 2003). Males have only one copy of this gene. A mutation of the gene is identified in 95% of cases of complete androgen insensitivity (Hughes et al., 2012). **The identifiable molecular alterations of the androgen receptor gene cannot predict the resulting phenotype of the affected individual unless there is total loss of the receptor, which occurs in only 1% of all patients** (Quigley et al, 1995).

Patients with complete androgen insensitivity have a normal female phenotype with the exception of diminished axillary and pubic hair. Their breast development and body habitus are feminine in character, and their external genitalia are unequivocally female, although the vagina is short and blind ending. It had previously been believed that in-utero resistance to testosterone action prevented stabilization of the wolffian ducts. Hannema et al. (2004), however, demonstrated wolffian duct derivatives in cases of complete androgen insensitivity. In 42% of patients, screening of the paratesticular area revealed well-developed epididymis and/or vasa deferentia. The mutations found in these patients entailed a single amino acid substitution in the androgen receptor ligand-binding domain, rather than frameshift mutations, premature stop codons, or mutations in the DNA-binding domain, all of which were associated with absence of well-developed wolffian duct structures. These investigators suggest that mutant receptors with residual activity in vivo stimulate wolffian duct development. As a result, they should be classified as having *severe* rather than complete androgen insensitivity. Because the fetal testes secrete AMH, müllerian structures are absent. The testes may be found in the labia, inguinal canal, or abdomen.

These patients are rarely diagnosed in the neonatal period, unless a prenatal diagnosis is made on the basis of female phenotype and 46,XY karyotype on amniocentesis. With the increase in prenatal diagnostics, this is becoming a more common occurrence (Hughes and Patterson, 1994). More typically, however, the diagnosis is made as a result of primary amenorrhea or the finding of a testis at inguinal herniorrhaphy. Fifty percent of patients with complete (severe) androgen insensitivity syndrome have an inguinal hernia (Conte and Grumbach, 1989). Conversely, 1% to 2% of apparently female infants with inguinal hernia are found to have a 46,XY karyotype and complete androgen insensitivity syndrome (Wiener et al., 1997; Barthold et al., 2000). Therefore, routine vaginoscopy to confirm the presence of a cervix or endoscopy through a hernia sac to identify an intra-abdominal testis at the time of inguinal herniorrhaphy in female patients is a prudent maneuver. Histologically, the testes exhibit incomplete or absent spermatogenesis, with normal or hyperplastic Leydig cells. They are comparable to immature, cryptorchid testes.

Endocrine evaluation in the neonatal period demonstrates normal male levels of testosterone, DHT, and gonadotropins. At puberty, gonadotropin levels rise, leading to increased levels of plasma estradiol and also peripheral aromatization of testosterone, which result in feminization, including breast development.

Several types of mutant receptor abnormality that would account for this syndrome have been described, including (1) a decreased amount of apparently normal receptor; (2) absence of receptor binding; (3) a qualitatively abnormal receptor (thermolabile, or unstable); and (4) other “receptor-positive” forms, including increased rate of dissociation of steroid receptor complex, defective upregulation of the androgen receptor, decreased affinity of ligand binding, and impaired nuclear retention of the ligand (Grumbach and Conte, 1998). In general, the severity of the defect in androgen receptor (quantity or quality) correlates with the phenotype. In addition, Hughes (2001) noted the absence of coregulator proteins, without the absence of the androgen receptor, in cases of complete androgen insensitivity, suggesting that for androgen effects to be optimal an integrated array of transcriptional factors, coregulators, and ligands is required.

The diagnosis of complete (severe) androgen insensitivity may readily be made in the postpubertal patient on the basis of clinical and hormonal findings of amenorrhea, absence of pubic hair, or inguinal hernias containing testes. It is confirmed by a 46,XY karyotype and a normal male androgen and gonadotropin profile. Pelvic ultrasound examination confirms the absence of müllerian tissue, and a vaginal examination confirms a blind-ending vagina without a cervix.

In the prepubertal child, one may use PCR to characterize the androgen receptor gene in DNA obtained from a venous blood sample to detect a genetic mutation responsible for androgen insensitivity syndrome.

Management of complete (severe) androgen insensitivity relates primarily to the optimal timing of gonadectomy. Because the testes produce estradiol, which results in the appropriate changes for the female phenotype, it is considered by many preferable to leave the testes in situ until puberty is complete. Potential exceptions to the policy of delayed gonadectomy are palpable testes or testes associated with an inguinal hernia. One important caveat in deciding to leave the testes in situ is the need to confirm with absolute certainty that complete rather than partial androgen insensitivity exists by PCR characterization of the androgen receptor gene in venous blood DNA. If an incomplete form should exist, virilization at puberty could result (Batch et al.,

1993).

A competing concern for retention of testicular tissue is the potential for malignant degeneration of the testes. In prepubertal patients with complete androgen insensitivity with a retained testis, the risk for development of a testis tumor—usually gonadoblastoma, dysgerminoma, or seminoma—is thought to be 0.8% to 2%, only slightly higher than for a cryptorchid testis (Manuel et al., 1976; Muller and Skakkebaek, 1984; Hughes, 2012). Therefore, in general, delayed gonadectomy after puberty is believed to be safe (Cools et al., 2006). Accurate figures to predict adult gonadal tumor risk in CAIS are sparse as there have been too few adult gonadectomized patients to truly assess risk. Chaudhry et al. suggested a combined premalignant and malignant histology prevalence of 6% based on a review of 133 patients in all age ranges, and Cools et al. noted an incidence of premalignant histology of 14% of 42 women with CAIS ranging from 14 to 54 years of age (Chaudhry et al, 2017; Cools et al., 2017) Because of the complexity of managing the CAIS patient, Hughes has advocated an individualized and holistic approach for each patient (Hughes, 2012).

After orchiectomy, cyclic estrogen/progestin therapy is begun. The majority of patients have successful treatment of their short vagina with progressive dilation (Ismail-Pratt et al., 2007). Some patients may benefit from vaginoplasty (Boehmer et al., 2001). **Currently, all studies of patients with complete androgen insensitivity support an unequivocal female gender identity, consistent with androgen resistance of brain tissue as well.** In one study, no statistical differences were found between the complete androgen insensitivity group and normal controls in any quality-of-life or gender-related behavior criterion (Hines et al., 2003). To date, there has been no report of a patient with complete androgen insensitivity raised as a female who needed gender reassignment to male (Meyer-Bahlburg, 1999). In any event, age-appropriate psychological counseling is an important component of management in the androgen insensitivity syndromes.

Syndrome of Partial Androgen Resistance.

The syndrome of partial androgen resistance includes syndromes that were once thought to represent separate entities: Reifenstein, Gilbert-Dreyfus, Rosewater, and Lubs syndromes (Griffin, 1992). **These are X-linked disorders** of incomplete masculinization that represent a spectrum of phenotypic abnormalities. **The major finding is ambiguity of the external genitalia to varying degrees.** The partial form of androgen insensitivity may be expressed variably, even within the same family. **The classic phenotype is that of a male with perineoscrotal hypospadias, cryptorchidism, rudimentary wolffian duct structures, gynecomastia, and infertility. However, the phenotypic spectrum can range from hypospadias and a pseudovagina to gynecomastia and azoospermia** (Wilson et al., 1974). The differential diagnosis includes 5α-reductase deficiency and 17β-hydroxysteroid dehydrogenase. The endocrine profile of partial androgen insensitivity syndrome is similar to that of the complete androgen insensitivity syndrome. At puberty, gynecomastia may develop. The phallus may enlarge slightly, but it remains small.

To date, over 800 mutations in the androgen receptor gene have been discovered (Hughes, 2012). It has been well recognized in PAIS that these mutations produce a diversity of phenotypes between and within affected families, consistent with additional factors that modulate responsiveness to androgen.

The diagnosis of PAIS can be difficult. In the neonatal period, it may be made in the setting of a 46,XY karyotype, ambiguous external genitalia, and absent müllerian structures on pelvic ultrasound. Endocrine evaluation confirms normal male levels of testosterone and gonadotropins, and a normal testosterone/DHT ratio. An hCG stimulation test and characterization of the androgen receptor gene in serum DNA by PCR should confirm the diagnosis. A family history consistent with X-linked inheritance of ambiguous genitalia is of great assistance. A course of androgen injections in early infancy is often used to assess androgen responsiveness, which can aid in gender assignment.

Management must be individualized depending on the degree of genital ambiguity. In patients assigned a female gender, gonadectomy and surgical reconstruction of the external genitalia are indicated; at puberty, estrogen/progestin replacement is instituted. The majority of PAIS patients raised as males require treatment of cryptorchidism, reduction of gynecomastia, and genital reconstruction. Phallic size remains small, however, and the effects of supraphysiologic doses of testosterone have been disappointing (Migeon et al., 1994). A study by Szafran et al. presented a novel high content analysis (HCA) approach to study androgen receptor function at a single-cell level in genital fibroblasts (Szafran et al., 2009). This could help individualize medical therapy. The risk for gonadal tumor may be somewhat lower than in complete androgen insensitivity syndrome (10%), and there is an increased risk for male breast cancer with partial androgen insensitivity syndrome (Hughes, 2006; Cools et al., 2017). Of importance in considering gender assignment in patients with partial androgen insensitivity is the recognition that the receptor defect affecting the external genitalia appears to affect brain receptors for testosterone similarly. Unfortunately, because of the distinct phenotypic variability, even within families, gender assignment of patients with partial androgen insensitivity syndrome cannot be based on the specifically identified androgen receptor gene (Boehmer et al., 2001). The study by Melo et al. (2003) of 11 patients with partial androgen insensitivity syndrome (5 raised female, 6 raised male) demonstrated gender of rearing to be consistent with adult gender role. This suggests the possibility that in the setting of inadequate androgen imprinting of the fetal brain, sex of rearing may predominate in determination of gender identity. Unfortunately, this has not consistently proven to be the case.

Unfortunately, long-term outcome data in the management of patients with partial androgen insensitivity syndrome is limited. In a study of 14 patients with partial androgen insensitivity syndrome, Migeon et al. noted that 23% were dissatisfied with neonatal gender assignment irrespective of current status as male or female (Migeon et al., 2002). Another study of 15 postpubertal males with partial androgen insensitivity syndrome documented major impairment in sexual function in all (Bouvattier et al, 2006). However, Mazur (2005) found that only 9% of patients with partial androgen insensitivity syndrome self-initiated a gender reassignment.

The current recommendation for partial androgen insensitivity syndrome is to allow virilization of the external genitalia to serve as a guide in gender assignment, in that this may be the best means of assessing androgen imprinting of the brain, for lack of a more precise marker (Sobel and Imperato-McGinley, 2004).

Mild Androgen Insensitivity Syndrome.

A relatively new classification is that of mild androgen insensitivity syndrome discovered in the course of investigations for male factor infertility. Studies have demonstrated a variety of mutations, usually quite discrete within the androgen receptor gene, to account for the infertility (Hiort and Holterhus, 2003). Men with this syndrome may be normal phenotypically or have a history of mild hypospadias repair and development of gynecomastia but are azoospermic or severely oligospermic. They have been found to have normal to elevated serum testosterone levels with normal to elevated LH levels. This suggests that infertility in otherwise normal males may be the clinical manifestation of partial androgen insensitivity, representing the far end of a variable phenotypic spectrum. Knockout experiments of the androgen receptor in mice have demonstrated a functional receptor expressed in Sertoli and Leydig cells that is essential for normal spermatogenesis (Hughes et al., 2012).

5α-Reductase Deficiency

The disorder of 5α-reductase deficiency is one of the most fascinating forms of male undervirilization. The clinical presentation of this enzyme disorder was actually predicted in 1972, before the description of such patients in 1974 by Walsh and Imperato-McGinley et al. (Wilson, 1972; Imperato-McGinley et al., 1974; Walsh et al., 1974). Extensive characterization of the disease has been achieved since that time.

5α-Reductase is a microsomal enzyme that catalyzes the conversion of testosterone to DHT. The condition is transmitted in an autosomal recessive pattern, and only homozygous males are affected. Two 5α-reductase genes have been cloned; they encode different isoenzymes. The type 1 isoenzyme, encoded on chromosome 5, is expressed in low levels in the prostate and external genitalia. The type 2 isoenzyme is encoded on chromosome 2 and is expressed in high levels in the prostate and external genitalia (Thigpen et al., 1992b). **Male undervirilization caused by 5α-reductase deficiency is secondary to mutations in the type 2 gene.** At least 68 mutations have been identified (Berra et al., 2011; Thigpen et al., 1992a; Imperato-McGinley, 2002). Identical mutations in individuals with widely different geographic and ethnic backgrounds support the concept of mutational “hot spots” on the gene.

Individuals with this disorder present as neonates with a 46,XY karyotype and a phenotype that may vary from normal female to markedly ambiguous genitalia (more common) to penoscrotal hypospadias to the rare, isolated microphallus (Maimoun, et al. 2011). Typically, the phallus is quite small, appearing as a normal or enlarged clitoris. A urogenital sinus is present, with convergence of vaginal and urethral channels, and there is labioscrotal fusion (Fig. 48.23). The vaginal pouch is short and blind ending. Testes and epididymides are located in the labia, inguinal canals, or abdomen, and the vasa terminate in the blind-ending vaginal pouch. At puberty, partial masculinization occurs with an increase in muscle mass, development of male body habitus, increase in phallic size, and onset of erections (Peterson et al., 1977). Sperm production and fertility in affected individuals have been reported (Imperato-McGinley et al., 1982; Zhu et al., 1998). Other secondary sexual characteristics, including enlargement of the prostate and hairline recession, do not develop.

Recognition of the rare 5α-reductase patient presenting as a female phenotype suggestive of CAIS has been made (Maimoun et al., 2011) (Fig. 48.24).

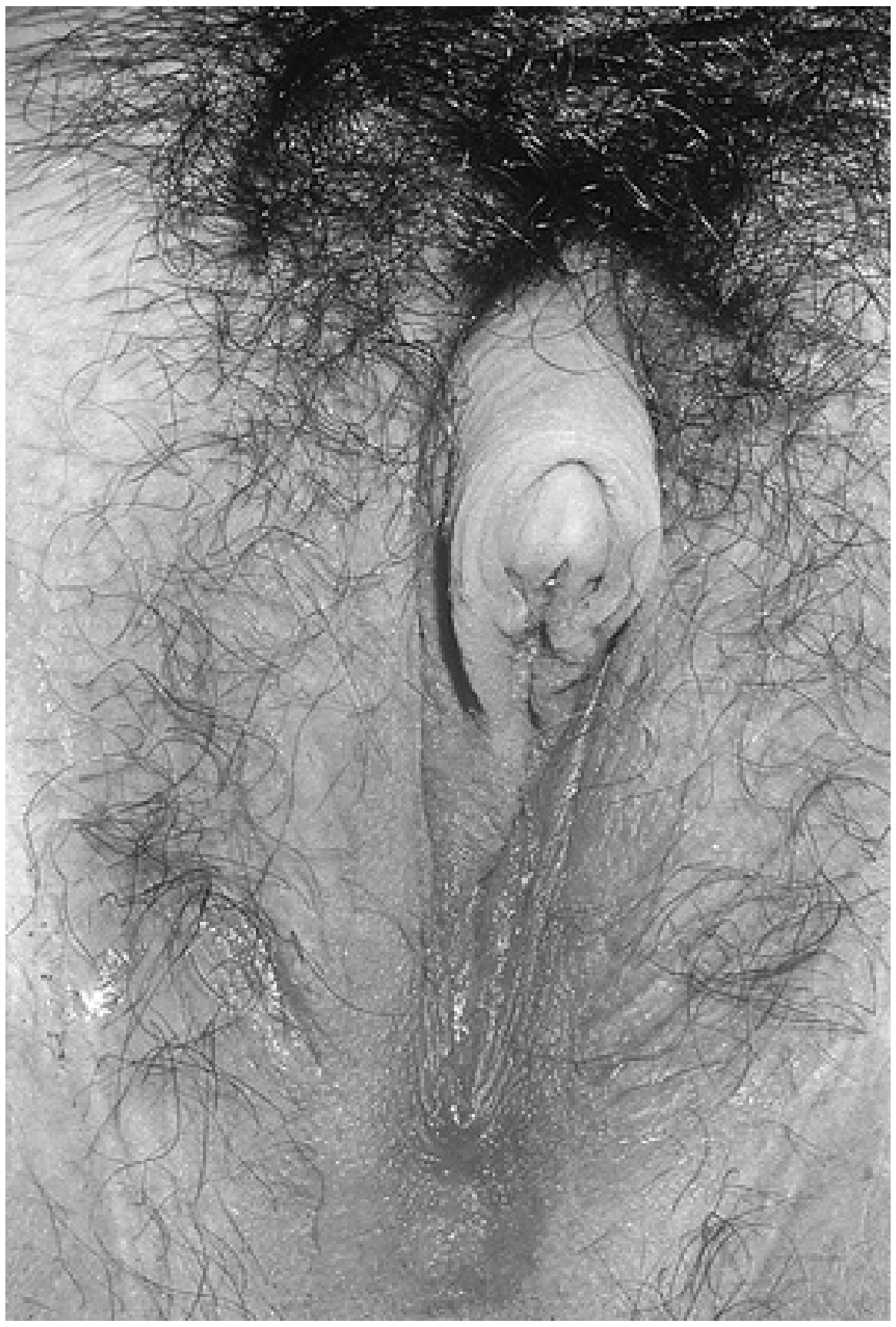

FIG. 48.23 External genitalia of patient with 5α-reductase deficiency. Note clitoromegaly with marked labioscrotal fusion and small vaginal introitus. (From Diamond D. *Intersex disorders: I and II. AUA Update Series,* vol. IX, lessons 9 and 10. Houston: American Urological Association Office of Education; 1990.)

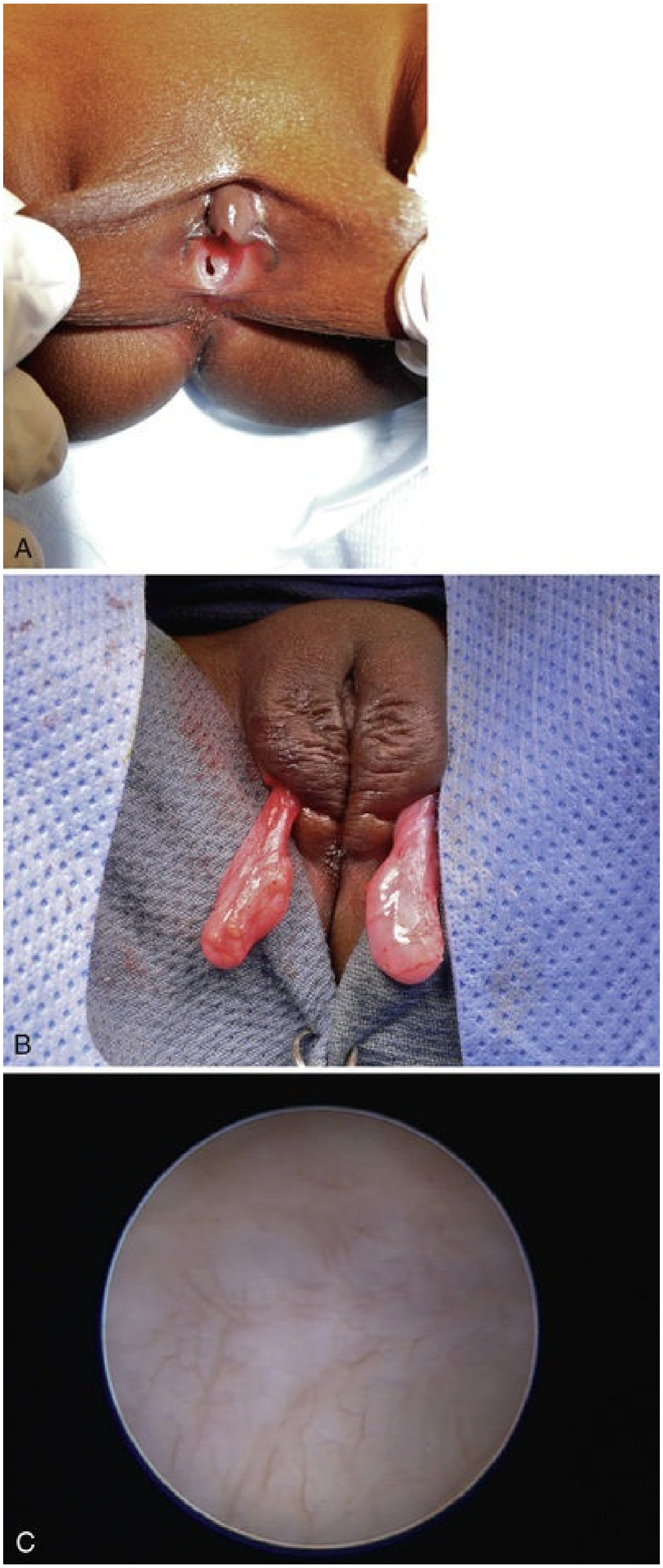
A
B
C

FIG. 48.24 (A) Unusual presentation of 5α-reductase deficiency with normal female external genitalia. (B) Bilateral scrotal testes palpable on newborn examination. (C) Absent cervix on vaginoscopy at the time of bilateral orchiectomy.

On endocrine evaluation, these individuals have elevated mean plasma testosterone but low DHT levels. After hCG stimulation, the testosterone-to-DHT ratio increases to greater than 20:1. At puberty, virilization is presumed to occur because the androgen receptor binds markedly higher levels of testosterone at low affinity or because of the normal increase at puberty in the activity of the 5α-reductase type 1 isoform, resulting in sufficient DHT for virilization (MacLaughlin and Donahoe, 2004). Indeed, the enzyme abnormalities in this disorder have been shown to be biochemically heterogeneous, ranging from reduced affinity of the enzyme for testosterone and reduced affinity for nicotinamide adenine dinucleotide phosphate (NADPH) to altered pH activity profiles (Kupfer et al., 1992). The diagnosis is confirmed by sequencing the entire 5α-reductase type 2 *(SRD5A2)* gene.

The phenotypic characteristics of this disorder have helped to clarify the roles of testosterone and DHT in normal development. **Although DHT appears to be critical for the development of normal external genitalia in utero, testosterone alone appears sufficient for wolffian duct development.**

Individuals in the pedigree studied by Imperato-McGinley et al. in the Dominican Republic underwent gender reversal at puberty and were known within the community as *guevedoces* (“penis at 12” or “testicles at 12”) (Imperato-McGinley et al., 1979). This strong tendency toward reversal of gender identity in 5α-reductase deficiency has been one of the most intriguing aspects of the disorder. It has lent support to the concept that testosterone exerts the primary male imprinting effect on the brain. However, the discovery that there are two isoenzymes for 5α-reductase, only type 2 being deficient in this syndrome, allows for the possibility that 5α-reductase type 1 has some impact on the brain (Thigpen et al., 1992b). As a result, with early diagnosis of 5α-reductase deficiency, a male gender assignment is generally favored, bearing in mind that the studies strongly supporting male gender identity in this disorder were performed in sociologically unique environments (Zhu et al., 1998). Cohen-Kettenis (2005) noted 56% to 63% of 5α-reductase deficiency patients to undergo gender reversal from female to male. The clinician must be open to familial cultural considerations regarding the value of male gender and the significance of penile size. In the setting of male gender assignment, cryptorchidism and hypospadias should be surgically corrected. Fertility is possible, particularly with the advent of intrauterine insemination (Katz et al., 1997). Exogenous DHT could be used at puberty in an attempt to promote phallic growth, but it would be likely to impair spermatogenesis. For some individuals with an unambiguously female phenotype or extremely small phallic size, female gender may be assigned. For these patients, gonadectomy should be performed as early as possible and certainly well before puberty to prevent virilization. Estrogen/progestin should be administered at the expected time of puberty. Vaginoplasty and clitoral reduction may be performed within the first year of life in those with a severe defect to provide for normal appearance of the external genitalia and to allay parental anxiety.

Persistent Müllerian Duct Syndrome

Persistent müllerian duct syndrome (PMDS),* or *hernia uteri inguinale, the term originally used by Nilson (1939), characteristically describes **a group of patients with a 46,XY karyotype and normal male external genitalia but internal müllerian duct structures. Typically, these phenotypic males have unilateral or bilateral undescended testes, bilateral fallopian tubes, a uterus, and an upper vagina draining into a prostatic utricle.** The condition is commonly diagnosed after müllerian tissue is encountered during inguinal herniorrhaphy or orchidopexy (Fig. 48.25).

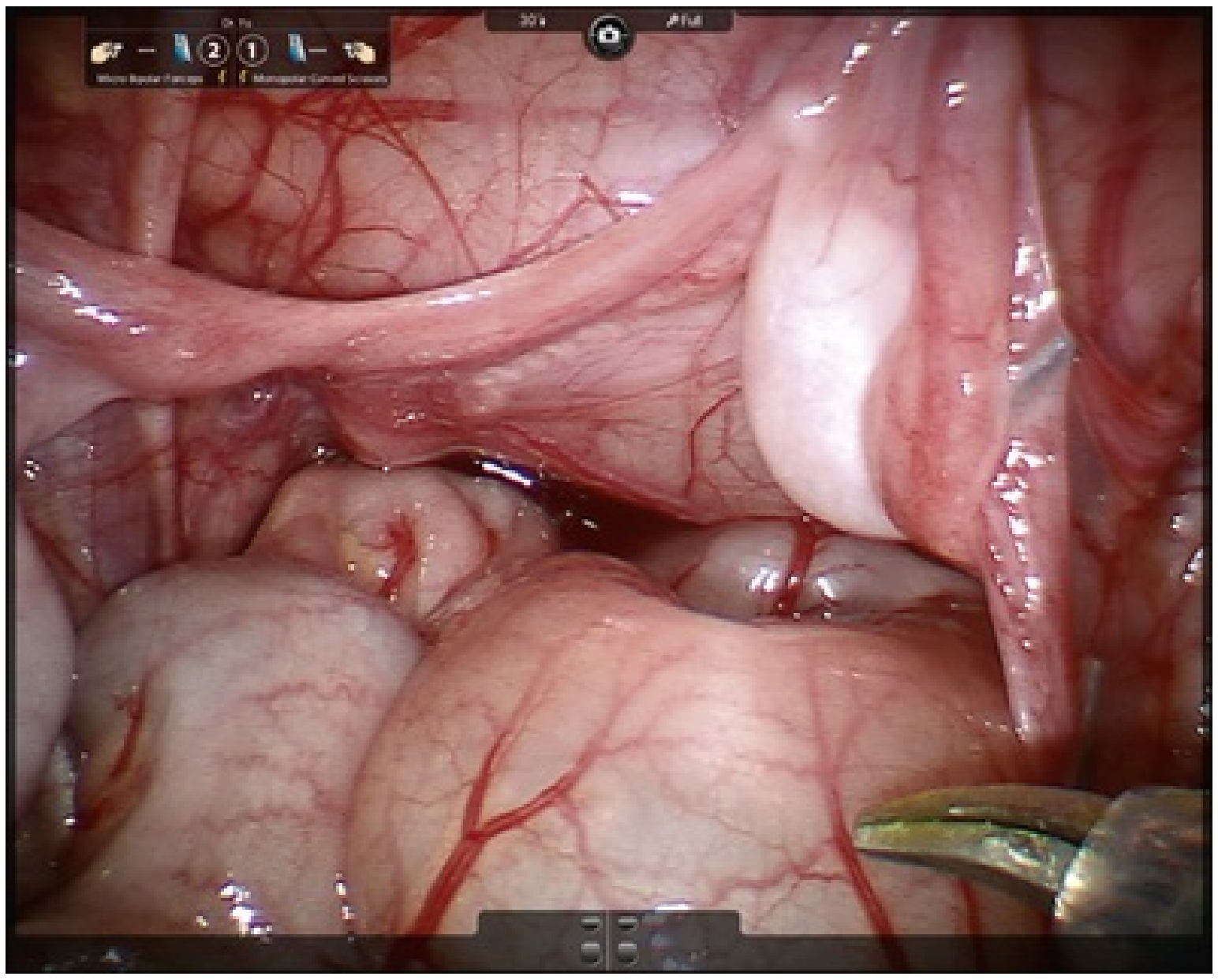

FIG. 48.25 Intraoperative view of patient with persistent müllerian duct syndrome. (Courtesy of D. Diamond, MD.)

Clarnette et al. (1997) suggested three categories for patients with PMDS: (1) the majority (60% to 70%) with bilateral intra-abdominal testes in a position analogous to ovaries; (2) a smaller group (20% to 30%) in which one testis is found in a hernia sac or scrotum in association with a contralateral inguinal hernia (the classic presentation of hernia uteri inguinale); and (3) the smallest group (10%), in which both testes are located in the same hernia sac (as a result of transverse testicular ectopia) along with the fallopian tubes and uterus (Fig. 48.26). Indeed, **PMDS is believed to be etiologically important in transverse testicular ectopia, occurring in 30% to 50% of cases** (Fujita, 1980).

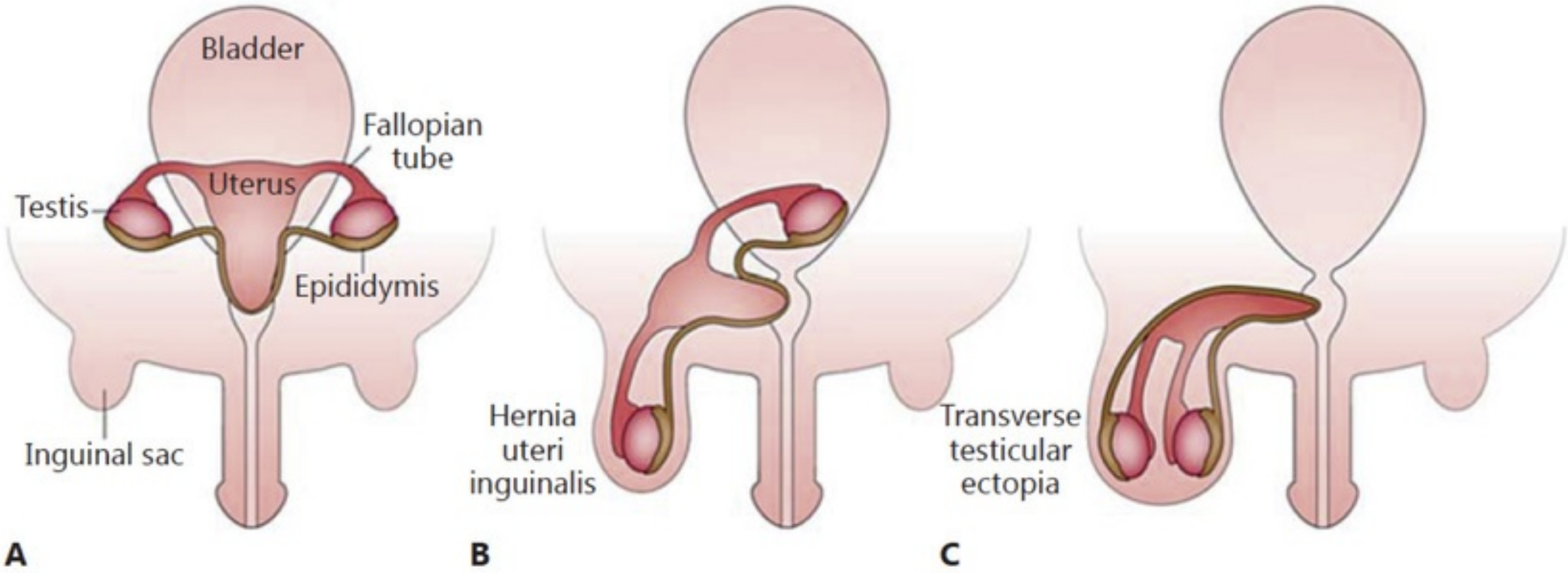
Bladder
Fallopian tube
Testis
Uterus
Epididymis
Inguinal sac
A
Hernia uteri inguinalis
B
Transverse testicular ectopia
C

FIG. 48.26 (A to C) Schematic illustration of three presentations of persistent müllerian duct syndrome. (From Hutson JM, Grover SR, O'Connell M, Pennell SD. Malformation syndromes associated with disorders of sex development. *Nat Rev Endocrinol*. 2014;10(8):476–487.)

The *AMH* gene was cloned in 1986 and localized on the short arm of chromosome 19 (Cates et al., 1986). It shows homology with the transforming growth factor-β superfamily of growth and differentiation factors (Imbeaud et al., 1995). **PMDS is thought to be a heterogeneous disorder genetically in which some subjects have a defect in the gene for AMH located on chromosome 19p13 and others have a defect in the gene for the AMH type II receptor located on chromosome 12q13** (MacLaughlin and Donahoe, 2004). Mutations of either the *AMH* or *AMH Receptor II* gene have been detected in 88% of cases; inheritance is autosomal recessive (Picard et al., 2017).

The treatment of persistent müllerian duct syndrome is relatively straightforward, in that all patients are phenotypic males who require orchidopexy. The cases of adult patients with associated testis tumor (most commonly seminoma) probably reflect the increased risk for malignancy in intra-abdominal undescended testes. One treatment caveat relates to management of the rudimentary müllerian structures. **The vasa deferentia are in close proximity to the uterus and proximal vagina, and historically preservation of the necessary müllerian structures to avoid injury to the vasa was recommended to preserve fertility** (Sloan and Walsh, 1976). Eleven malignancies have now been reported in retained müllerian remnants, consistent with a risk of 3% to 8%, supporting careful surgical excision, which can be performed laparoscopically (Farikullah et al., 2012).

Unclassified Forms: Mayer-Rokitansky-Küster-Hauser Syndrome

The Mayer-Rokitansky-Küster-Hauser (MRKH) syndrome is a rare disorder entailing congenital absence of the uterus and vagina. It occurs in approximately 1 in 4000 to 5000 female births. Patients with MRKH syndrome have a 46,XX karyotype and are normal-appearing females with normal secondary sex characteristics. The external genitalia appear normal, but only a shallow vaginal pouch is present. In the typical form of the syndrome, there is symmetrical anatomy with absence of both vagina and uterus. Normal ovaries and fallopian tubes are present, and ovarian function is normal, but only symmetrical uterine remnants are found (Griffin et al., 1976). The report of a

WNT4 mutation in a woman with a phenotype resembling MRKH suggests the importance of this gene in müllerian duct formation, but the genetic basis of the disorder remains largely unknown because of lack of a sizeable family cohort (Biason-Lauber et al., 2004).

The most common clinical presentation for MRKH syndrome is primary amenorrhea, but patients may present with infertility or dyspareunia. **Upper urinary tract anomalies occur in approximately one-third of patients and include renal agenesis, pelvic kidney, and horseshoe kidney.**

Atypical forms of MRKH syndrome have been described in up to 10% of cases, in which asymmetrical uterine remnants and/or aplasia of one or both fallopian tubes is discovered. As a result, endometrial tissue or variable development of the uterus with hematometra may be present, resulting in a clinical presentation with cyclical abdominal pain. **Urinary tract anomalies occur more commonly in patients with the atypical form of MRKH.** In a study of 100 patients with MRKH syndrome, 38 of 56 patients (68%) with the atypical form of the condition had upper urinary tract abnormalities. None of the 44 patients with the typical form of MRKH syndrome had an upper urinary tract anomaly (Strubbe et al., 1994). In addition, associated cardiac anomalies have been noted in 16% of MRKH patients (Pittock et al., 2005).

A radiologic evaluation with ultrasonography and magnetic resonance imaging may define müllerian anatomy accurately in MRKH and distinguish between typical and atypical forms of the disorder (Nussbaum-Blask et al., 1991; Reinhold et al., 1997).

Treatment entails creation of a neovagina, by means of dilation or surgically, to allow for sexual function (Ismail-Pratt et al., 2007). Given the frequent success of dilation and its comparable functional outcomes to surgery, it should be the first line of therapy as recommended by the American College of Obstetrics and Gynecology (Gargollo, 2009; Morcel, 2013). If present, a hemiuterus should be removed, whereas a midline uterine structure should be hormonally suppressed rather than connecting this structure to a reconstructed vagina.

Uterine transplantation has provided a controversial fertility option for MRKH patients. The first clinical trial by Brännström included 9 women, 2 of whom required premature graft removal (Brännström, 2014). Multiple live births were reported. Overall, 17 uterine transplants have been reported worldwide by 5 groups, with 8 grafts requiring premature removal (Flyckt et al., 2018).

Future Directions

Collaborative Networking

Conducting substantive research on DSD patients presents a challenge to most individual institutions given the relative rarity of this diagnosis at any one location. Therefore, several collaborative networks have been established over the last decade to not only consolidate efforts to address research questions but also to standardize terminology, phenotype characterization, and delivery of care. The first research collaborative was the Euro-DSD, now called the international DSD (I-DSD) registry formed in 2008. This is a Web-based registry to collate cross-sectional data (genetic, biochemical, and phenotypic) and involves 33 sites across 4 continents (Sandberg et al, 2015). In the United States, the DSD-Translational Research Network (DSD-TRN) was created in 2012 to establish an infrastructure for collaborative, interdisciplinary clinical practice and research. Currently, the network includes 10 sites linked to a central registry. The overarching goal of the DSD-TRN is to standardize diagnostic and treatment protocols, including genetic evaluation, psychosocial screening, and approaches for patient and family support (Delot et al., 2017). Guidelines for genetic evaluation are especially important given the rapid development of precision medicine and the availability of advanced genomic technologies, such as next-generation DNA sequencing.

Impact of DSD Diagnosis on Caregivers

Caregivers faced with a DSD diagnosis may experience feelings of stigma, isolation, anxiety, stress, or depression. In a recent multi-institutional study, approximately 18% of parents reported experiencing significant levels of depressive symptoms and 25% reported anxiety-related symptoms (Suorsa et al., 2015). Families should routinely be offered psychological support. Future research should take into account both societal and familial influences that may alter patient and parental perceived outcomes and explore targeted interventions to improve parental competence and experienced efficacy (Wisniewski and Sandberg, 2015). Preliminary results from a recent multi-institutional study demonstrated that both parents and surgeons report similar levels of overall satisfaction with cosmetic outcomes in children with moderate-to-severe genital atypia (Bernabé et al., 2018). In the same cohort of patients 6 months after genitoplasty, the majority of parents reported minimal levels of psychological distress (Wolfe-Christensen et al., 2017). Nevertheless, approximately 25% of parents had a range of psychological symptoms that persisted from diagnosis to after genitoplasty (Wolfe-Christensen et al., 2017). Negative patient and parental experiences with the health care system have led to the formation of advocacy groups, which have been both collaborative and confrontational. Joint collaborative efforts between the medical community and advocacy groups have led to the publication of two important handbooks: *Clinical Guidelines for Management of Disorders of Sex Development in Childhood* (Accord Alliance, 2006a) and *A Handbook for Parents* (Accord Alliance, 2006b). Continued collaborative research should incorporate patient and family perspectives to assess long-term outcomes in a systematic multidisciplinary and quantitative manner.

Ethical Considerations

In contemplating surgical reconstruction for children with DSDs and ambiguous genitalia, a central ethical dilemma is the potential conflict between respect for the fundamental right of the child for physical and emotional integrity and self-determination and the right of parents to serve as surrogate decision-makers and act in their child's best interest. Often management decisions must be made based on incomplete information before it is possible to ascertain the child's self-identified gender.

The literature suggests that adult DSD patients who underwent reconstructive surgery to address genital ambiguity in childhood generally favor early surgery rather than waiting until the age of legal consent (Meyer-Bahlburg et al., 2004). However, the uncertainty of future gender identity in the face of some diagnoses favors preservation of anatomic options, whenever possible, and an open future for the child that the adult will become (Kon, 2015).

As moral agents in the face of parental and patient suffering, urologists must do their utmost to foster the physiologic and psychological health of the child while respecting parental and family wishes and rights in pursuing what they perceive as the “best interests” of their child (Diamond, 2016).

The importance of transparency with the family and patient in management of DSDs cannot be overemphasized. Uncertainties in outcomes with different gender assignment for different disorders mandates involvement of the parents in early decision-making. In the long run, transparency is essential for a healthy physician-patient relationship as the child develops into adolescence and adulthood, affording them knowledgeable engagement in DSD management for the long term.

Ultimately, management of patients with DSDs remains a challenging and humbling process. On the one hand, physicians have at their disposal sophisticated molecular biological techniques that have enabled them to identify genetic disorders responsible for the majority of DSDs. On the other hand, the mysteries of the neurophysiology of gender in the setting of sexual ambiguity remain to be solved to optimize the long-term psychosocial outcome of gender assignment for the individual patient.

Suggested Readings

Hughes IA. Congenital adrenal hyperplasia: a continuum of disorders. *Lancet*. 1998;352:752–754.

Hughes IA. Intersex. *BJU Int*. 2002;90:769–776.

Hughes IA. Androgen resistance. *Best Pract Res Clin Endocrinol Metab*. 2006;20:577–598.

Hughes IA. Disorders of sex development: a new definition and classification. *Best Pract Res Clin Endocrinol Metab*. 2008;22:119–134.

Jost A, Vigier B, Prepin J, et al. Studies on sex differentiation in mammals. *Recent Prog Horm Res*. 1973;29:1–41.

Kaefer M, Diamond DA, Hendren WH, et al. The incidence of intersexuality in children with cryptorchidism and hypospadias: stratification based on gonadal palpability and meatal position. *J Urol*. 1999;162:1003–1007.

Lee PA, Houk CP, Ahmed SF, et al. Consensus statement on management of intersex disorders. International Consensus Conference on Intersex. *Pediatrics*. 2006;118:e488–e500.

MacLaughlin DT, Donahoe PK. Sex determination and differentiation. *N Engl J Med*. 2004;350:367–378.

Meyer-Bahlburg HF. Gender assignment and reassignment in 46,XY pseudo-hermaphroditism and related conditions. *J Clin Endocrinol Metab*. 1999;84:3455–3458.

Pang S, Pollack MS, Marshall RN, et al. Prenatal treatment of congenital adrenal hyperplasia due to 21-hydroxylase deficiency. *N Engl J Med*. 1990;322:111–115.

Saenger P. Turner's syndrome. *N Engl J Med*. 1996;335:1749–1754.

Sinclair AH, Berta P, Palmer MS, et al. A gene from the human sex determining region encodes a protein with homology to a conserved DNA-binding motif. *Nature*. 1990;346:240–244.

VanWyk JJ, Ritzen EM. The role of bilateral adrenalectomy in the treatment of congenital adrenal hyperplasia. *J Clin Endocrinol Metab*. 2003;88:2993–2998.

References

Normal Sexual Differentiation

Achermann JC, Ito M, Ito M, et al. A mutation in the gene encoding steroidogenic factor-1 causes XY sex reversal and adrenal failure in humans. *Nat Gen*. 1999;22:125–126.

Andersson S, Berman DM, Jenkins EP, et al. Deletion of steroid 5 alpha-reductase 2 gene in male pseudohermaphroditism. *Nature*. 1991;354(6349):159–161.

Andersson S, Russell DW. Structural and biochemical properties of cloned and expressed human and rat steroid 5 alpha-reductases. *Proc Natl Acad Sci USA*. 1990;87(10):3640–3644.

Baetens D, Stoop H, Peelman F, et al. *NR5A1* is a novel disease gene for 46,XX testicular and ovotesticular disorders of sex development. *Genet Med*. 2017;19(4):367–376.

Baker Towell DM, Towell AD. A preliminary investigation into quality of life, psychological distress and social competence in children with cloacal exstrophy. *J Urol*. 2003;169:1850–1853.

Bardoni B, Zanaria E, Guioli S, et al. A dosage sensitive locus at chromosome Xp21 is involved in male to female sex reversal. *Nat Genet*. 1994;7(4):497–501.

Bashamboo A, Ferraz-de-Souza B, Lourenco D, et al. Human male infertility associated with mutation in NR5A1 encoding steroidogenic factor 1. *Am J Hum Genet*. 2010;87:505–512.

Benko S, Gordon CT, Mallet D, et al. Disruption of a long distance regulatory region upstream of SOX9 in isolated disorders of sex development. *J Med Genet*. 2011;48(12):825–830.

Bernard P, Harley VR. Wnt4 action in gonadal development and sex determination. *Int J Biochem Cell Biol*. 2007;39(1):31–43.

Bhagavath B, Layman LC, Ullmann R, et al. Familial 46,XY sex reversal without campomelic dysplasia caused by a deletion upstream of the SOX9 gene. *Mol Cell Endocrinol*. 2014;393(1–2):1–7.

Biason-Lauber A, De Filippo G, Konrad D, et al. WNT4 deficiency–a clinical phenotype distinct from the classic Mayer-Rokitansky-Kuster-Hauser syndrome: a case report. *Hum Reprod*. 2007;22(1):224–229.

Biason-Lauber A, Konrad D, et al. A *WNT4* mutation associated with Müllerian-duct regression and virilization in a 46,XX woman. *N Engl J Med*. 2004;351(8):792–798.

Bridges CB. Triploid intersexes in *Drosophila melanogaster*. *Science*. 1921;54(1394):252–254.

Byskov AG, Westergaard LG. Differentiation of the ovary. Polin RA, Fox WW. *Fetal neonatal physiology*. WB Saunders: Philadelphia; 1998:2484–2491.

Call KM, Glaser T, Ito CY, et al. Isolation and characterization of a zinc finger polypeptide gene at the human chromosome 11 Wilms’ tumor locus. *Cell*. 1990;60(3):509–520.

Cate RL, Mattaliano RJ, Hession C, et al. Isolation of the bovine and human genes for Müllerian inhibiting substance and expression of the human gene in animal cells. *Cell*. 1986;45(5):685–698.

DeFilici M. Origin, migration, and proliferation of human primordial germ cells. Coticchio G, Albertini DF, DeSantis L. *Oogenesis*. Springer-Verlag: London; 2013:19–37.

Denys P, Malvaux P, Van Den Berghe H, et al. [Association of an anatomo-pathological syndrome of male pseudohermaphroditism, Wilms' tumor, parenchymatous nephropathy and XX/XY mosaicism]. *Arch Fr Pediatr*. 1967;24(7):729–739.

Diamond M, Sigmundson HK. Sex reassignment at birth: long-term review and clinical implications. *Arch Pediatr Adolesc Med*. 1997;151:298–304.

Ehrhardt AA, Meyer-Bahlburg HFL. Effects of prenatal sex hormones on gender-related behavior. *Science*. 1981;211:1312–1318.

Eichwald EJ, Silmser CR. Skin. *Transplant Bull*. 1955;2:148–149.

Ferlin A, Rocca MS, Vinanzi C, et al. Mutational screening of *NR5A1* gene encoding steroidogenic factor 1 in cryptorchidism and male factor infertility and functional analysis of seven undescribed mutations. *Fertil Steril*. 2015;104(1):163–169.

Ford CE, Jones KW, Polani P, et al. A sex-chromosome anomaly in a case of gonadal dysgenesis (Turner's syndrome). *Lancet*. 1959;1(7075):711–713.

Foster JW, Dominguez-Steglich MA, Guioli S, et al. Campomelic dysplasia and autosomal sex reversal caused by mutations in an *SRY*-related gene. *Nature*. 1994;372(6506):525–530.

George FW, Peterson KG. 5Alpha-dihydrotestosterone formation is necessary for embryogenesis of the rat prostate. *Endocrinology*. 1988;122(3):1159–1164.

Gill WB, Schumacher GF, Bibbo M, et al. Association of diethylstilbestrol exposure in utero with cryptorchidism, testicular hypoplasia and semen abnormalities. *J Urol*. 1979;122(1):36–39.

Goodfellow PN, Lovell-Badge R. SRY and sex determination in mammals. *Annu Rev Genet*. 1993;27:21–92.

Grumbach MM, Conte FA. Disorders of sex differentiation. Wilson JD, Foster DW, Kronenberg HM, et al. *Williams textbook of endocrinology*. ed 9. WB Saunders: Philadelphia; 1998:1303–1426.

Gubbay J, Vivian N, Economou A, et al. Inverted repeat structure of the *Sry* locus in mice. *Proc Natl Acad Sci USA*. 1992;89(17):7953–7957.

Haqq CM, King CY, Ukiyama E, et al. Molecular basis of mammalian sexual determination: activation of Müllerian inhibiting substance gene expression by *SRY*. *Science*. 1994;266(5190):1494–1500.

Huang B, Wang S, Ning Y, et al. Autosomal XX sex reversal caused by duplication of SOX9. *Am J Med Genet*. 1999;87(4):349–353.

Hughes IA. Intersex. *BJU Int*. 2002;90(8):769–776.

Hyon C, Chantot-Bastaraud S, Harbuz R, et al. Refining the regulatory region upstream of SOX9 associated with 46,XX testicular disorders of Sex Development (DSD). *Am J Med Genet A*. 2015;167A(8):1851–1858.

Imbeaud S, Faure E, Lamarre I, et al. Insensitivity to anti-müllerian hormone due to a mutation in the human anti-müllerian hormone receptor. *Nat Genet*. 1995;11(4):382–388.

Ingraham HA, Lala DS, Ikeda Y, et al. The nuclear receptor steroidogenic factor 1 acts at multiple levels of the reproductive axis. *Genes Dev*. 1994;8(19):2302–2312.

Jacobs PA, Strong JA. A case of human intersexuality having a possible XXY sex-determining mechanism. *Nature*. 1959;183(4657):302–303.

Jenkins EP, Andersson S, Imperato-McGinley J, et al. Genetic and pharmacological evidence for more than one human steroid 5alpha-reductase. *J Clin Invest*. 1992;89(1):293–300.

Jost A, Vigier B, Prepin J, et al. Studies on sex differentiation in mammals. *Recent Prog Horm Res*. 1973;29:1–41.

Kim GJ, Sock E, Buchberger A, et al. Copy number variation of two separate regulatory regions upstream of SOX9 causes isolated 46,XY or 46,XX disorder of sex development. *J Med Genet*. 2015;52(4):240–247.

Kim Y, Kobayashi A, Sekido R, et al. Fgf9 and Wnt4 act as antagonistic signals to regulate mammalian sex determination. *PLoS Biol*. 2006;4(6):e187.

Koopman P, Munsterberg A, Capel B, et al. Expression of a candidate sex-determining gene during mouse testis differentiation. *Nature*. 1990;348(6300):450–452.

Koopman P, Gubbay J, Vivian N, et al. Male development of chromosomally female mice transgenic for *Sry*. *Nature*. 1991;351:117–121.

Koziell A, Grundy R. Frasier and Denys-Drash syndromes: different disorders or part of a spectrum? *Arch Dis Child*. 1999;81(4):365–369.

Kreidberg JA, Sariola H, Loring JM, et al. WT-1 is required for early kidney development. *Cell*. 1993;74(4):679–691.

Lim HN, Hawkins JR. Genetic control of gonadal differentiation. *Baillieres Clin Endocrinol Metab*. 1998;12(1):1–16.

Lopez ML, Erickson RP, Belcher SR. Sex determination. Polin RA, Fox WW. *Fetal and neonatal physiology*. WB Saunders: Philadelphia; 1998:2469–2474.

Lubahn DB, Joseph DR, Sullivan PM, et al. Cloning of human androgen receptor complementary DNA and localization to the X chromosome. *Science*. 1988;240(4850):327–330.

Lukusa T, Fryns JP, van Der Berghe H. The role of the Y-chromosome in sex determination. *Genet Couns*. 1992;3(1):1–11.

Luo X, Ikeda Y, Parker KL. A cell-specific nuclear receptor is essential for adrenal and gonadal development and sexual differentiation. *Cell*. 1994;77(4):481–490.

MacLaughlin DT, Donahoe PK. Sex determination and differentiation. *N Engl J Med*. 2004;350(4):367–378.

Meeks JJ, Weiss J, Jameson JL. *Dax1* is required for testis determination. *Nat Genet*. 2003;34:32–33.

Money J, Ehrhardt AA. *Man and woman, boy and girl: the differentiation and dimorphism of gender identity from conception to maturity*. Johns Hopkins University Press: Baltimore; 1972.

Muscatelli F, Strom TM, Walker AP, et al. Mutations in the *DAX-1* gene give rise to both X-linked adrenal hypoplasia congenita and hypogonadotropic hypogonadism. *Nature*. 1994;372(6507):672–676.

Nachtigal MW, Hirokawa Y, Enyeart-VanHouten DL, et al. Wilms' tumor 1 and Dax-1 modulate the orphan nuclear receptor SF-1 in sex-specific gene expression. *Cell*. 1998;93(3):445–454.

Ogata T, Hawkins JR, Taylor A, et al. Sex reversal in a child with a 46,X, Yp+ karyotype: support for the existence of a gene(s), located in distal Xp, involved in testis formation. *J Med Genet*. 1992;29(4):226–230.

Orekhova AS, Kalinchenko N, Morozov IA, et al. A novel mutation in the critical P-box residue of steroidogenic factor-1 presenting with XY sex reversal and transient adrenal failure. *Horm Res Paediatr*. 2018;89(6):450–454.

Parker KL, Rice DA, Lala DS, et al. Steroidogenic factor 1: an essential mediator of endocrine development. *Recent Prog Horm Res*. 2002;57:19–36.

Parma P, Radi O, Vidal V, et al. R-spondin1 is essential in sex determination, skin differentiation and malignancy. *Nat Genet*. 2006;38:1304–1309.

Pelletier J, Bruening W, Kashtan CE, et al. Germline mutations in the Wilms' tumor suppressor gene are associated with abnormal urogenital development in Denys-Drash syndrome. *Cell*. 1991;67(2):437–447.

Pelletier J, Schalling M, Buckler AJ, et al. Expression of the Wilms' tumor gene *WT1* in the murine urogenital system. *Genes Dev*. 1991;5(8):1345–1356.

Philibert P, Biason-Lauber A, Rouzier R, et al. Identification and functional analysis of a new WNT4 gene mutation among 28 adolescent girls with primary amenorrhea and müllerian duct abnormalities: a French collaborative study. *J Clin Endocrinol Metab*. 2008;93(3):895–900.

Philibert P, Zenaty D, Lin L, et al. Mutational analysis of steroidogenic factor 1 (NR5a1) in 24 boys with bilateral anorchia: a French collaborative study. *Hum Reprod*. 2007;22(12):3255–3261.

Reiner WG, Gearhart JP. Discordant sexual identity in some genetic males with cloacal exstrophy assigned to female sex at birth. *N Engl J Med*. 2004;350:333–341.

Sekido R, Lovell-Badge R. Sex determination involves synergistic action of *SRY* and *SF1* on a specific Sox9 enhancer. *Nature*. 2008;453(7197):930–934.

Sekido R, Lovell-Badge R. Sex determination and *SRY:* down to a wink and a nudge? *Trends Genet*. 2009;25(1):19–29.

Shen WH, Moore CC, Ikeda Y, et al. Nuclear receptor steroidogenic factor 1 regulates the müllerian inhibiting substance gene: a link to the sex determination cascade. *Cell*. 1994;77(5):651–661.

Siiteri PK, Wilson JD. Testosterone formation and metabolism during male sexual differentiation in the human embryo. *J Clin Endocrinol Metab*. 1974;38(1):113–125.

Sinclair AH, Berta P, Palmer MS, et al. A gene from the human sex-determining region encodes a protein with homology to a conserved DNA-binding motif. *Nature*. 1990;346:240–244.

Swartz JM, Ciarlo R, Guo MH, et al. A 46,XX ovotesticular disorder of sex development likely caused by a steroidogenic factor-1 (*NR5A1*) variant. *Horm Res Paediatr*. 2017;87:191–195.

Vigier B, Forest MG, Eychenne B, et al. Anti-müllerian hormone produces endocrine sex reversal of fetal ovaries.

Proc Natl Acad Sci USA. 1989;86(10):3684–3688.

Wachtel SS. H-Y antigen and the genetics of sex determination. *Science*. 1977;198:797–799.

Wagner T, Wirth J, Meyer J, et al. Autosomal sex reversal and campomelic dysplasia are caused by mutations in and around the *SRY*-related gene *SOX9*. *Cell*. 1994;79(6):1111–1120.

Vidal VPI, Chaboissier M, deRooij DG, et al. Sox9 induces testis development in XX transgenic mice. *Nat Gen*. 2001;28:216–217.

Yu RN, Ito M, Jameson JL. The murine Dax-1 promoter is stimulated by SF-1 (steroidogenic factor-1) and inhibited by COUP-TF (chicken ovalbumin upstream promoter-transcription factor) via a composite nuclear receptor-regulatory element. *Mol Endocrinol*. 1998;12(7):1010–1022.

Zanaria E, Bardoni B, Dabovic B, et al. Xp duplications and sex reversal. *Philos Trans R Soc Lond B Biol Sci*. 1995;350(1333):291–296.

Zanaria E, Muscatelli F, Bardoni B, et al. An unusual member of the nuclear hormone receptor superfamily responsible for X-linked adrenal hypoplasia congenita. *Nature*. 1994;372(6507):635–641.

Abnormal Sexual Differentiation

Grumbach MM, Conte FA. Disorders of sex differentiation. Wilson JD, Foster DW, Kronenberg HM, et al. *Williams textbook of endocrinology*. ed 9. WB Saunders: Philadelphia; 1998:1303–1426.

Hughes IA, Houk C, Ahmed SF, et al. Consensus statement on management of intersex disorders. *J Pediatr Urol*. 2006;2:148–162.

Evaluation and Management of the Newborn

with Ambiguous Genitalia

Ahmed SF, Achermann JC, Arlt W, et al. UK guidance on the initial evaluation of an infant or an adolescent with a suspected disorder of sex development. *Clin Endocrinol*. 2011;75:12–26.

Dean A, Sharpe RM. Clinical review: anogenital distance or digit length ratio as measures of fetal androgen exposure: relationship to male reproductive development and its disorders. *J Clin Endocrinol Metab*. 2013;08:2230–2238.

Hughes IA. Intersex. *BJU Int*. 2002;90:769–776.

Jarow JP, Berkovitz GD, Migeon CJ, et al. Elevation of serum gonadotropins established the diagnosis of anorchism in prepubertal boys with bilateral cryptorchidism. *J Urol*. 1986;136:277.

Kaefer M, Diamond DA, Hendren WH, et al. The incidence of intersexuality in children with cryptorchidism and hypospadias: stratification based on gonadal palpability and meatal position. *J Urol*. 1999;162:1003–1007.

Lee PA, Houk CP, Ahmed SF, et al. Consensus statement on management of intersex disorders. International Consensus Conference on Intersex. *Pediatrics*. 2006;118:e488–e500.

Meyer-Bahlburg HFL. Gender assignment in intersexuality. *J Psychol Hum Sex*. 1998;10:1–21.

Migeon CJ, Berkovitz GD, Brown TR. Sexual differentiation and ambiguity. Kappy MS, Blizzard RN, Migeon CJ. *Wilkins: the diagnosis and treatment of endocrine disorders in childhood and adolescence*. Charles C. Thomas: Springfield (IL); 1994.

Gender Assignment

Cohen-Kettenis P. Psychological long-term outcome in intersex conditions. *Horm Res*. 2005;64(Suppl):27.

Elliott C. Why can't we go on as three? *Hastings Center Rep*. 1998;(May–June; 3):36–39.

Lee PA, Houk CP, Ahmed SF, et al. Consensus statement on management of intersex disorders. International Consensus Conference on Intersex. *Pediatrics*. 2006;118:e488–e500.

Meyer-Bahlburg HFL. Gender assignment in intersexuality. *J Psychol Hum Sex*. 1998;10:1–21.

Nihoul-Fekete C. Surgical management of the intersex patient: an overview in 2003. *J Pediatr Surg*. 2004;39:144–145.

Disorders of Gonadal Differentiation and Development

Klinefelter Syndrome and Variants

Bryson CF, Ramasamy R, Sheehan M, et al. Severe testicular atrophy does not affect the success of microdissection testicular sperm extraction. *J Urol*. 2014;191(1):175–178.

Bojesen A, Juul S, Gravholt CH. Prenatal and postnatal prevalence of Klinefelter syndrome: a national registry study. *J Clin Endocrinol Metab*. 2003;88(2):622–626.

Corona G, Pizzocaro A, Lanfranco F, Klinefelter ItaliaN Group (KING), et al. Sperm recovery and ICSI outcomes in Klinefelter syndrome: a systematic review and meta-analysis. *Hum Reprod Update*. 2017;23(3):265–275.

Giedd JN, Clasen LS, Wallace GL, et al. XXY (Klinefelter syndrome): a pediatric quantitative brain magnetic resonance imaging case-control study. *Pediatrics*. 2007;119:e232–e240.

Harnden DG, Maclean N, Langlands AO. Carcinoma of the breast and Klinefelter's syndrome. *J Med Genet*. 1971;8:460–461.

Itti E, Gonzalo ITG, Boone KB, et al. Functional neuroimaging provides evidence of anomalous cerebral laterality in adults with Klinefelter's syndrome. *Ann Neurol*. 2003;54:669–673.

Jacobs PA, Strong JA. A case of human intersexuality having a possible XXY sex-determining mechanism. *Nature*. 1959;183:302.

Morris JK, Alberman E, Scott C, et al. Is the prevalence of Klinefelter syndrome increasing? *Eur J Hum Genet*. 2008;16:163–170.

Nahata L, Yu RN, Paltiel HJ, et al. Sperm retrieval in adolescents and young adults with Klinefelter syndrome: a prospective, pilot study. *J Pediatr*. 2016;170:260–265.

Ni T, Yan J, Wang B, et al. Outcomes of 13 ICSI-PGD cycles with ejaculated spermatozoa in patients with Klinefelter syndrome. *Asian J Androl*. 2016;18:498–499.

Plotton I, Giscard d'Estaing S, Cuzin B, FERTIPRESERVE, et al. Preliminary results of a prospective study of testicular sperm extraction in young versus adult patients with nonmosaic 47, XXY Klinefelter syndrome. *J Clin Endocrinol Metab*. 2015;100(3):961–967.

Staessen C, Tournaye H, Van Assche E, et al. PGD in 47,XXY Klinefelter's syndrome patients. *Hum Reprod Update*. 2003;9:319–330.

Völkl TMK, Langer T, Aigner T, et al. Klinefelter syndrome and mediastinal germ cell tumors. *Am J Med Genet*. 2006;140A:471–481.

Wikström AM, Raivio T, Hadziselimovic F, et al. Klinefelter syndrome in adolescence: onset of puberty is associated with accelerated germ cell depletion. *J Clin Endocrinol Metab*. 2004;89:2263–2270.

46,XX Males

Andersson M, Page DC, de la Chapelle A. Chromosome Y-specific DNA is transferred to the short arm of X chromosome in human XX males. *Science*. 1986;233:786–

788.

Bashamboo A, Donohoue PA, Vilain E, et al. A recurrent p.Arg92Trp variant in steroidogenic factor-1 (NR5A1) can act as a molecular switch in human sex development. *Hum Mol Gen*. 2016;25(16):3446–3453.

de la Chappelle A, Hortling H, Niemi M, et al. Sex chromosomes in a human male: first case. *Acta Med Scand Suppl*. 1964;412:25.

Fechner PY, Marcantonio SM, Jaswaney V, et al. The role of the sex-determining region Y gene *(SRY)* in the etiology of 46XX maleness. *J Clin Endocrinol Metab*. 1993;76:690–695.

Ono M, Harley VR. Disorders of sex development: new genes, new concepts. *Nat Rev Endocrinol*. 2013;**9**:79–91.

Zenteno-Ruiz JC, Kofman-Alfaro S, Mendez JP. 46,XX sex reversal. *Arch Med Res*. 2001;32:559–566.

Syndromes of Gonadal Dysgenesis

Turner Syndrome

Abir R, Fisch B, Nahum R, et al. Turner's syndrome and fertility: current status and possible putative prospects. *Hum Reprod Update*. 2001;7:603–610.

Amedro P, Tahhan N, Bertet H, et al. Health-related quality of life among children with Turner syndrome: controlled cross-sectional study. *J Pediatr Endocrinol Metab*. 2017;30(8):863–868.

Bianco B, Vannucci M, Lipay N, et al. Detection of hidden Y mosaicism in Turner's syndrome: importance in the prevention of gonadoblastoma. *J Pediatr Endocrinol Metab*. 2006;19:1113–1118.

Brown WE, Kesler SR, Eliez S, et al. A volumetric study of parietal lobe subregions in Turner syndrome. *Dev Med Child Neurol*. 2004;46:607–609.

Cools M, Wolffenbuttel KP, Drop SL, et al. Gonadal development and tumor formation at the crossroads of male and female sex determination. *Sex Dev*. 2011;5(4):167–180.

Coyle D, Kutasy B, Han Suyin K, et al. Gonadoblastoma in patients with 45,X/46,XY mosaicism: a 16-year experience. *J Pediatr Urol*. 2016;12(5):283.e1–283.e7.

Culen C, Ertl DA, Schubert K, et al. Care of girls and women with Turner syndrome: beyond growth and hormones. *Endocr Connect*. 2017;6(4):R39–R51.

Epstein CJ. Mechanisms leading to the phenotype of Turner syndrome. Rosenfeld RG, Grumbach MM. *Turner syndrome*. Marcel Dekker: New York; 1990:13–25.

Ford CE, Jones KW, Polani P, et al. A sex-chromosome anomaly in a case of gonadal dysgenesis (Turner's syndrome). *Lancet*. 1959;1(7075):711–713.

Hall JG, Gilchrist DM. Turner syndrome and its variants. *Pediatr Clin North Am*. 1990;37:1421–1441.

Kaneko N, Kawagoe S, Hizoi M. Turner's syndrome: review of the literature with reference to a successful pregnancy outcome. *Gynecol Obstet Invest*. 1990;29:81–87.

Klásková E, Zapletalová J, Kaprálová S, et al. Increased prevalence of bicuspid aortic valve in Turner syndrome links with karyotype: the crucial importance of detailed cardiovascular screening. *J Pediatr Endocrinol Metab*. 2017;30(3):319–325.

Kwon A, Hyun SE, Jung MK, et al. Risk of gonadoblastoma development in patients with turner syndrome with cryptic Y chromosome material. *Horm Cancer*. 2017;8(3):166–173.

Miguel-Neto J, Carvalho AB, Marques-de-Faria AP, et al. New approach to phenotypic variability and karyotype-phenotype correlation in Turner syndrome. *J Pediatr Endocrinol Metab*. 2016;29(4):475–479.

Pasquino AM. Turner syndrome and GH treatment: the state of the art. *J Endocrinol Invest*. 2004;27:1072–1075.

Practice Committees of the American Society for Reproductive Medicine and the Society for Assisted Reproductive Technology. Mature oocyte cryopreservation: a guideline. *Fert Steril*. 2013;99:37–43.

Rae C, Joy P, Harasty J, et al. Enlarged temporal lobes in Turner syndrome: an X-chromosome effect? *Cerebral Cortex*. 2004;14:156–164.

Saenger P. Clinical review 48: the current status of diagnosis and therapeutic intervention in Turner's syndrome. *J Clin Endocrinol Metab*. 1993;77:297–301.

Saenger P. Turner's syndrome. *N Engl J Med*. 1996;335:1749–1754.

Saenger P, Wikland A, Conway GS, et al. Recommendations for the diagnosis and management of Turner syndrome. *J Clin Endocrinol Metab*. 2001;86:3061–3069.

Schoemaker MJ, Swerdlow AJ, Higgins CD, et al. Cancer incidence in women with Turner syndrome in Great Britain: a national cohort study. *Lancel Oncol*. 2008;9:239–246.

Stanhope RG, Massarano AA, Brook CGD: The natural history of ovarian demise in the Turner's syndrome [abstract]. Proceedings of the Third International Symposium on Turner's Syndrome, London, April 9, 1992, p 34.

Sybert VP, McCauley E. Turner's syndrome. *N Engl J Med*. 2004;351:1227–1238.

Zelaya G, López Marti JM, Marino R, et al. Gonadoblastoma in patients with Ullrich-Turner syndrome. *Pediatr Dev Pathol*. 2015;18(2):117–121.

Zinn AR, Page DC, Fisher ENC. Turner syndrome: the case of the missing sex chromosome. *Trends Genet*. 1993;9:90–93.

46,XX “Pure” Gonadal Dysgenesis

Espiner A, Veale AMD, Sands VE, et al. Familial syndrome of streak gonads and normal male karyotype in five phenotypic females. *N Engl J Med*. 1970;283:6.

Mixed Gonadal Dysgenesis

Beckwith JB, Palmer NF. Histopathology and prognosis of Wilms' tumor: results from the first national Wilms' tumor study. *Cancer*. 1978;41:1937–1948.

Chang HG, Clark RD, Bachman H. The phenotype of 45X/46XY mosaicism: an analysis of 92 prenatally diagnosed cases. *Am J Hum Genet*. 1990;46:156.

Cools M, Wolffenbuttel KP, Drop SL, et al. Gonadal development and tumor formation at the crossroads of male and female sex determination. *Sex Dev*. 2011;5(4):167–180.

Davidoff F, Federman DB. Mixed gonadal dysgenesis. *Pediatrics*. 1973;52:725–742.

Denys P, Malvaux P, van der Berghe H, et al. Association d'un syndrome anatomo-pathologique de pseudohermaphrodisme masculin, d'une tumeur de Wilms'; d'une nephropathie parenchymateuse et d'un mosaisism XX/XY. *Arch Fr Pediatr*. 1967;24:729–739.

Drash A, Sherman F, Hartmann WH, et al. A syndrome of pseudohermaphroditism, Wilms' tumor, hypertension and degenerative disease. *J Pediatr*. 1970;76:585–593.

Ezaki J, Hashimoto K, Asano T, et al. Gonadal tumor in Frasier syndrome: a review and classification. *Cancer Prev Res (Phila)*. 2015;8(4):271–276.

Gwin K, Cajaiba MM, Caminoa-Lizarralde A, et al. Expanding the clinical spectrum of Frasier syndrome. *Pediatr Devel Pathol*. 2008;11:122–127.

Habib R, Loirat C, Gubler MC, et al. The nephropathy associated with male pseudohermaphroditism and Wilms' tumor (Drash syndrome): a distinctive glomerular lesion-report of ten cases. *Clin Nephrol*. 1985;24:269–278.

Hsu LYF. Prenatal diagnosis of 45/46XY mosaicism: a review and update. *Prenat Diagn*. 1989;9:31.

Jadresic L, Leake J, Gordon I, et al. Clinico-pathologic review of 12 children with nephropathy, Wilms' tumor, genital abnormalities (Drash syndrome). *J Pediatr*. 1990;117:717–725.

Johansen ML, Hagen CP, DeMeyts ER, et al. 45,X/46XY mosaicism: phenotypic characteristics, growth, and reproductive function – A retrospective longitudinal study. *J Clin Endocrinol Metab*. 2012;97:E1540–E1549.

Klamt B, Koziell A, Poulat F, et al. Frasier syndrome is caused by defective alternative splicing of *WT1* leading to an altered ratio of *WT1/KTS* splice isoforms. *Hum Mol Genet*. 1998;7:709–714.

Koziell AB, Grundy R, Barratt TM, et al. Evidence for the genetic heterogeneity of nephropathic phenotypes associated with Denys-Drash and Frasier syndromes. *Am J Hum Genet*. 1999;64:1778–1781.

Lee PA, Houk CP, Ahmed F, et al. Consensus statement on management of intersex disorders. *Pediatrics*. 2006;118:e488–e500.

Martinerie L, Morel Y, Gay CL, et al. Impaired puberty, fertility, and final stature in 45,X/46,XY mixed gonadal dysgenetic patients raised as boys. *Eur J Endocrinol*. 2012;166(4):687–694.

Mendez JP, Ulloa-Aguirre A, Kofman-Alfaro S, et al. Mixed gonadal dysgenesis: clinical cytogenetic, endocrinological and histopathological findings in 16 patients. *Am J Med Genet*. 1993;46:263–267.

Rajfer J. Association between Wilms' tumor and gonadal dysgenesis. *J Urol*. 1981;125:388–390.

Robboy SJ, Miller T, Donahoe PK, et al. Dysgenesis of testicular and streak gonads in a syndrome of mixed gonadal dysgenesis. *Hum Pathol*. 1982;13:700.

Scully RE. Gonadoblastoma. *Cancer*. 1970;25:1340.

Sohval AR. Mixed gonadal dysgenesis: a variety of hermaphroditism. *Am J Hum Genet*. 1963;15:155.

Wallace T, Levin HS. Mixed gonadal dysgenesis. *Arch Pathol Lab Med*. 1990;114:679.

Zah W, Kalderone HE, Tucci JR. Mixed gonadal dysgenesis. *Acta Endocrinol*. 1975;79:3–39.

Partial Gonadal Dysgenesis (Dysgenetic Male Pseudohermaphroditism)

Borer JB, Nitti VW, Glassberg KI. Mixed gonadal dysgenesis and dysgenetic male pseudohermaphroditism. *J Urol*. 1995;153:1267–1273.

Fabbri HC, Ribeiro de Andrade JG, Maciel-Guerra AT, et al. NR5A1 loss-of-function mutations lead to 46,XY partial gonadal dysgenesis phenotype: report of three novel mutations. *Sex Dev*. 2016;10(4):191–199.

Federman DD. Disorders of sexual development. *N Engl J Med*. 1967;277:351.

Manuel M, Katayama KP, Jones HW Jr. The age of occurrence of gonadal tumors in intersex patients with a Y chromosome. *Am J Obstet Gynecol*. 1976;124:293.

46,XY Complete (Pure) Gonadal Dysgenesis (Swyer Syndrome)

Bastian C, Muller J, Lortat-Jacob S, et al. Genetic mutations and somatic anomalies in association with 46,XY gonadal dysgenesis. *Fertil Steril*. 2015;103:1294–1304.

Canto P, Soderlund D, Reyes E, et al. Mutations in the Desert hedgehog *(DHH)* gene in patients with 46,XY complete pure gonadal dysgenesis. *J Clin Endocrinol Metab*. 2004;89:4480–4483.

German J, Simpson JL, Chaganti RSK, et al. Genetically determined sex reversal in 46XY humans. *Science*. 1978;202:53.

Grumbach MM, Conte FA. Disorders of sexual differentiation. Wilson JD, Foster DW, Konenberg HM, et al. *Williams textbook of endocrinology*. WB Saunders: Philadelphia; 1998:1303–1425.

Manuel M, Katayama KP, Jones HW Jr. The age of occurrence of gonadal tumors in intersex patients with a Y chromosome. *Am J Obstet Gynecol*. 1976;124:293.

Rehkämper J, Tewes A, Horvath J, et al. Four novel NR5A1 mutations in 46,XY gonadal dysgenesis patients including frameshift mutations with altered subcellular SF-1 localization. *Sex Dev*. 2017;11(5–56):248–253.

Scully RE. Neoplasia associated with anomalous sexual development and abnormal sex chromosomes. Josso N. *The intersex child*. Karger: Basel; 1981:203.

Embryonic Testicular Regression and Bilateral Vanishing Testes Syndromes

Aynsley-Green AA, Zachman NM, Illig R, et al. Congenital bilateral anorchia in childhood: a clinical and endocrine and therapeutic evaluation of 21 cases. *Clin Endocrinol*. 1976;5:381–391.

Bergada C, Cleveland WW, Jones HW Jr, et al. Variants of embryonic testicular dysgenesis: bilateral anorchia and the syndrome of rudimentary testes. *Acta Endocrinol*. 1962;40:521–536.

Edman CD, Winters AJ, Porter JC, et al. Embryonic testicular regression: a clinical spectrum of XY agonadal individuals. *Obstet Gynecol*. 1977;49:208–217.

Jarow JP, Berkovitz GD, Migeon CJ, et al. Elevation of serum gonadotropins established the diagnosis of anorchism in prepubertal boys with bilateral cryptorchidism. *J Urol*. 1986;136:277.

Lee MM, Misra M, Donahoe PK, et al. MIS/AMH in the assessment of cryptorchidism and intersex conditions. *Mol Cell Endocrinol*. 2003;211:91–98.

Marcantonio SM, Fechner PY, Migeon CJ, et al. Embryonic testicular regression sequence: a part of the clinical spectrum of 46,XY gonadal dysgenesis. *Am J Med Genet*. 1994;49:1–5.

Migeon CJ, Berkovitz GD, Brown TR. Sexual differentiation and ambiguity. Kappy MS, Blizzard RN, Migeon CJ. *Wilkins: the diagnosis and treatment of endocrine disorders in childhood and adolescence*. Charles C. Thomas: Springfield (IL); 1994:573–716.

Philibert P, Zenaty D, Lin L, et al. Mutational analysis of steroidogenic factor 1 (NR5a1) in 24 boys with bilateral anorchia: a French collaborative study. *Hum Reprod*. 2007;22:3255–3261.

Ovotesticular DSD (True Hermaphroditism)

Baetens D, Stoop H, Peelman F, et al. *NR5A1* is a novel disease gene for 46,XX testicular and ovotesticular disorders of sex development. *Genet Med*. 2017;19(4):367–376.

Bashamboo A, Donohoue PA, Vilain E, et al. A recurrent p.Arg92Trp variant in steroidogenic factor-1 (NR5A1) can act as a molecular switch in human sex development. *Hum Mol Gen*. 2016;25(16):3446–3453.

Berkovitz GD, Fechner PY, Zacur HW, et al. Clinical and pathologic spectrum of 46,XY gonadal dysgenesis: its relevance to the understanding of sex determination. *Medicine (Baltimore)*. 1991;70:375.

Blyth B, Duckett JW Jr. Gonadal differentiation: a review of the physiological process and influencing factors based on recent experimental evidence. *J Urol*. 1991;145:689–694.

Ganie Y, Aldous C, Balakrishna Y, et al. The spectrum of ovotesticular disorders of sex development in South Africa: a Single-Centre experience. *Horm Res Paediatr*. 2017;87(5):307–314.

Grumbach MM, Conte FA. Disorders of sex differentiation. Wilson JD, Foster DW, Kronenberg HM, et al. *Williams' textbook of endocrinology*. ed 9. WB Saunders: Philadelphia; 1998:1303–1426.

Hadjiathanasiou CG, Brauner R, Lortat-Jacob S, et al. True hermaphroditism: genetic variants and clinical management. *J Pediatr*. 1994;125:738–744.

Mittwoch U. Genetics of sex determination: exceptions that prove the rule. *Mol Genet Metab*. 2000;71:405–410.

Nihoul-Fekete C, Lortat-Jacob S, Cachin O, et al. Preservation of gonadal function in true hermaphroditism. *J Pediatr Surg*. 1984;19:50–55.

Ortenberg J, Oddoux C, Craver R, et al. *SRY* gene expression in the ovotestes of XX true hermaphrodites. *J Urol*. 2002;167:1828–1831.

Starceski PJ, Sieber WK, Lee PA. Fertility and true hermaphroditism. *Adolesc Pediatr Gynecol*. 1988;1:55–56.

Wiersma R, Ramdial PK: The gonads of 111 South African patients with ovotesticular disorder of sex differentiation.

Verp MS, Simpson JL. Abnormal sexual differentiation and neoplasia. *Cancer*. 1987;25:191–218.

46,XX DSD (Masculinized Female)

Congenital Adrenal Hyperplasia

American Association of Pediatrics. Technical report: congenital adrenal hyperplasia. *Pediatrics*. 2000;106:1511–1518.

Berenbaum SA, Bailey JM. Effects on gender identity of prenatal androgens and genital appearance: evidence from girls with congenital adrenal hyperplasia. *J Clin Endocrinol Metab*. 2003;88:1102–1106.

Berenbaum SA, Bryk KK, Duck SC, et al. Psychological adjustment in children and adults with congenital adrenal hyperplasia. *J Pediatr*. 2004;144:741–746.

Bongiovanni AM, Root AW. The adrenogenital syndrome. *N Engl J Med*. 1963;268:1391–1399.

Brosnan PG, Brosnan CA, Kemp SF, et al. Effect of newborn screening for congenital adrenal hyperplasia. *Arch Pediatr Adolesc Med*. 1999;153:1272–1278.

Claahsen-van der Grinten HL, Otten BJ, Hermus ARMM, et al. Testicular adrenal rest tumors in patients with congenital adrenal hyperplasia can cause severe testicular damage. *Fertil Steril*. 2008;89:597–601.

Dessens AB, Slijper FME, Drop SLS. Gender dysphoria and gender change in chromosomal females with congenital adrenal hyperplasia. *Arch Sex Behav*. 2005;34:389–397.

El-Maouche D, Arlt W, Merke DP. Congenital adrenal hyperplasia. *Lancet*. 2017;390(10108):2194–2210.

Ernst M, Maheu FS, Schroth E, et al. Amygdala function in adolescents with congenital adrenal hyperplasia: a model for the study of early steroid abnormalities. *Neuropsychologia*. 2007;45:2104–2113.

Fife D, Rappaport EB. Prevalence of salt-losing among congenital adrenal hyperplasia patients. *Clin Endocrinol*. 1983;18:259.

Forest MG. Recent advances in the diagnosis and management of congenital adrenal hyperplasia due to 21-hydroxylase deficiency. *Hum Reprod Update*. 2004;10:469–485.

Grumbach MM, Conte FA. Disorders of sex differentiation. Wilson JD, Foster DW, Kronenberg HM, et al. *Williams' textbook of endocrinology*. ed 9. WB Saunders: Philadelphia; 1998:1303–1426.

Gunther DF, Bukowski TP, Ritzen EM, et al. Prophylactic adrenalectomy of a three-year-old girl with congenital adrenal hyperplasia: pre- and post-operative studies. *J Clin Endocrinol Metab*. 1997;82:3324–3327.

Hernanz-Schulman M, Brock JW, Russell W. Sonographic findings in infants with congenital adrenal hyperplasia. *Pediatr Radiol*. 2002;32:130–137.

Hannah-Shmouni F, Chen W, Merke DP. Genetics of congenital adrenal hyperplasia. *Endocrinol Metab Clin North Am*. 2017;46(2):435–458.

Hirvikoski T, Nordenström A, Lindholm T, et al. Cognitive functions in children at risk for congenital adrenal hyperplasia treated prenatally with dexamethasone. *J Clin Endocrinol Metab*. 2007;92:542–548.

Hughes IA. Congenital adrenal hyperplasia: 21-hydroxylase deficiency in the newborn and during infancy. *Semin Reprod Med*. 2002;20:229–241.

Lee PA, Houk CP, Husmann DA. Should male gender assignment be considered in the markedly virilized patient with 46, XX and congenital adrenal hyperplasia? *J Urol*. 2010;184:1786–1792.

Kang MJ, Kim JH, Lee SH, et al. The prevalence of testicular adrenal rest tumors and associated factors in postpubertal patients with congenital adrenal hyperplasia caused by 21-hydroxylase deficiency. *Endocrine J*. 2011;58:501–508.

Kohn B, Day D, Alenzadeh R, et al. Splicing mutation in *CYP-21* associated with delayed presentation of salt-wasting congenital adrenal hyperplasia. *Am J Med Genet*. 1995;57:450–454.

Laue L, Rennert OM. Congenital adrenal hyperplasia: molecular genetics and alternative approaches to treatment. *Adv Pediatr*. 1995;42:113–143.

Lee PA, Houk CP, Husmann DA. Should male gender assignment be considered in the markedly virilized patient with 46,XX and congenital adrenal hyperplasia? *J Urol*. 2010;184:1786–1792.

Mastrandrea LD, Martin DJ, Springate JE. Clinical and biochemical similarities between reflux/obstructive uropathy and salt-wasting congenital adrenal hyperplasia. *Clin Pediatr*. 2005;44:809–812.

Merke DP, Tajima T, Chhabra A, et al. Novel *CYP-11B1* mutations in congenital adrenal hyperplasia due to steroid-11 beta-hydroxylase deficiency. *J Clin Endocrinol Metab*. 1998;83:270–273.

Meyer-Bahlburg HF, Dolezal C, Baker SW, et al. Cognitive and motor development of children with and without congenital adrenal hyperplasia after early-prenatal dexamethasone. *J Clin Endocrinol Metab*. 2004;89:610–614.

Meyer-Bahlburg HFL, Dolezal C, Baker SW, et al. Prenatal androgenization affects gender-related behavior but not gender identity in 5-12-year-old girls with congenital adrenal hyperplasia. *Arch Sex Behav*. 2004;33:97–104.

Meyer-Bahlburg HFL, Dolezal C, Baker SW, et al. Sexual orientation in women with classical or non-classical congenital adrenal hyperplasia as a function of degree of prenatal androgen excess. *Arch Sex Behav*. 2008;37:85–99.

Meyer-Bahlburg HFL, Doleal C, Haggerty R, et al. Cognitive outcome of offspring from dexamethasone-treated pregnancies at risk for congenital adrenal hyperplasia due to 21-hydroxylase deficiency. *Eur J Endocrinol*.

2012;167(1):103–110.

Migeon CJ. Comments about the need for prenatal treatment of congenital adrenal hyperplasia due to 21-hydroxylase deficiency. *J Clin Endocrinol Metab*. 1990;70:836–837.

Miller WL. Fetal endocrine therapy for congenital adrenal hyperplasia should not be done. *Best Pract Res Clin Endocrinol Metab*. 2015;29(3):469–483.

Nabhan ZM, Eugster EA. Upper-tract genitourinary malformations in girls with congenital adrenal hyperplasia. *Pediatrics*. 2007;10:e304.

New MI, Levine LS. Steroid 21-hydroxylase deficiency in adrenal diseases in childhood. New MI, Levine LS. *Pediatric and adolescent endocrinology, vol 13. Adrenal disease in childhood*. Karger: Basel; 1984:1–46.

New MI, White PC, Speiser P. Congenital adrenal hyperplasia. Martinez-Mora J. *Intersexual states: disorders of sex differentiation*. Ediciones Doyma: Barcelona; 1994:162–186.

New MI, Wilson RC. Steroid disorders in children: congenital adrenal hyperplasia and apparent mineralocorticoid excess. *Proc Natl Acad Sci USA*. 1999;96:12790–12797.

Nimkarn S, New MI. Prenatal diagnosis and treatment of congenital adrenal hyperplasia owing to 21-hydroxylase deficiency. *Trends Endocrinol Metab*. 2007;3:405–413.

Ogilvie CM, Rumsby G, Kurzawinski T, et al. Outcome of bilateral adenalectomy in congenital adrenal hyperplasia: one unit's experience. *Eur J Endocrinol*. 2006;154:405–408.

Pang S, Pollack MS, Marshall RN, et al. Prenatal treatment of congenital adrenal hyperplasia due to 21-hydroxylase deficiency. *N Engl J Med*. 1990;322:111–115.

Pang S, Spence D, New MI. Newborn screening for congenital adrenal hyperplasia with special reference to screening in Alaska. *Ann N Y Acad Sci*. 1985;458:90–102.

Passerini-Glazel G. Feminizing genitoplasty [editorial]. *J Urol*.

1990;161:1592–1593.

Pasterski V, Zucker KJ, Hindmarsh PC, et al. Increased cross-gender identification independent of gender role behavior in girls with congenital adrenal hyperplasia: results from a standardized assessment of 4- to 11-year-old children. *Arch Sex Behav*. 2015;44(5):1363–1375.

Prader A. Perfect male external genital development and salt-loss syndrome in girls with congenital adrenogenital syndrome. *Helv Paediatr Acta*. 1958;13:5–14.

Rijnders RJ, van der Schoot CE, Bossers B, et al. Fetal sex determination from maternal plasma in pregnancies at risk for congenital adrenal hyperplasia. *Obstet Gynecol*. 2001;98:374–378.

Speiser PW, Laforgia N, Kato K, et al. First trimester prenatal treatment and molecular genetic diagnosis of congenital adrenal hyperplasia. *J Clin Endocrinol Metab*. 1990;70:838–848.

Tusie-Luna M, White PC. Gene conversions and unequal crossovers between *CYP-21* (steroid 21-hydroxylase gene) and *CYP-21P* involve different mechanisms. *Proc Natl Acad Sci USA*. 1995;92:10796–10800.

VanWyk JJ, Gunther DF, Ritzen EM, et al. The use of adrenalectomy as a treatment for congenital adrenal hyperplasia. *J Clin Endocrinol Metab*. 1996;81:3180–3190.

VanWyk JJ, Ritzen EM. The role of bilateral adrenalectomy in the treatment of congenital adrenal hyperplasia. *J Clin Endocrinol Metab*. 2003;88:2993–2998.

Wallensteen L, Karlsson L, Messina V, et al. Evaluation of behavioral problems after prenatal dexamethasone treatment in Swedish children and adolescents at risk of congenital adrenal hyperplasia. *Horm Behav*. 2018;98:219–224.

Wilson RC, Mercado AB, Cheng KC, et al. Steroid 21-hydroxylase deficiency: genotype may not predict phenotype.

J Clin Endocrinol Metab. 1995;80:2322–2329.

Witchel SF. Congenital adrenal hyperplasia. *J Pediatr Adolesc Gynecol*. 2017;30(5):520–534.

46,XX (Masculinized Female) Secondary to Maternal Androgens and Progestins and Maternal Tumors

Bongiovanni AM, McFadden AJ. Steroids during pregnancy and possible fetal consequences. *Fertil Steril*. 1960;11:181.

Calaf J, Prats J, Esteban-Altirriba J. Female pseudohermaphroditism caused by maternal hyperandrogenism. Martinez-Mora J. *Intersexual states: disorders of sex differentiation*. Ediciones Doyma: Barcelona; 1994:187–197.

Ishizura N, Kawashima P, Nakanish T, et al. Statistical observations on genital anomalies of newborns following the administration of progestins to their mothers. *J Jpn Obstet Gynecol Soc*. 1962;9:271.

46,XY DSD (Undermasculinized Male)

Leydig Cell Aplasia

Arnholt JP, Mendonca BB, Bloise W, et al. Male pseudohermaphroditism resulting from Leydig cell hyperplasia. *J Pediatr*. 1985;106:1057.

Berthezene F, Forest MG, Grimaud JA, et al. Leydig cell agenesis: a cause of male pseudohermaphroditism. *N Engl J Med*. 1976;295:969–972.

Brown DM, Markland C, Dehner LP. Leydig cell hyperplasia: cause of male pseudohermaphroditism. *J Clin Endocrinol Metab*. 1978;46:1–7.

David R, Yoon DJ, Landin L, et al. A syndrome of gonadotropin resistance possibly due to a luteinizing hormone receptor defect. *J Clin Endocrinol Metab*. 1984;59:156–160.

Lee PA, Rock JA, Brown TR, et al. Leydig cell hypofunction resulting in male pseudohermaphroditism. *Fertil Steril*. 1982;37:675–679.

Richter-Unruh A, Verhoef-Post M, Malak S, et al. Leydig cell hypoplasia: absent luteinizing hormone receptor cell surface expression caused by a novel homozygous mutation in the extracellular domain. *J Clin Endocrinol Metab*. 2004;89:5161–5167.

Disorders of Testosterone Biosynthesis

Ahmed SF, Iqbal A, Hughes IA. The testosterone:androstenedione ratio in male undermasculinization. *Clin Endocrinol*. 2000;53:697–702.

Andersson S, Moghrabi N. Physiology and molecular genetics of 17-beta-hydroxysteroid dehydrogenase. *Steroids*. 1997;62:143–147.

Benkert AR, Young M, Robinson D, et al. Severe salt-losing 3β-Hydroxysteroid dehydrogenase deficiency: treatment and outcomes of HSD3B2 c.35G>A homozygotes. *J Clin Endocrinol Metab*. 2015;100(8):E1105–E1115.

Bhangoo A, Gu W-X, Pavlakis S, et al. Phenotypic features associated with mutations in steroidogenic acute regulatory protein. *J Clin Endocrinol Metab*. 2005;90:6303–6309.

Boehmer ALM, Bruggenwirth H, Van Assendelft C, et al. Genotype versus phenotype in families with androgen insensitivity syndrome. *J Clin Endocrinol Metab*. 2001;86:4151–4160.

Bongiovanni AM. The adrenogenital syndrome with deficiency of 3-beta-hydroxysteroid dehydrogenase. *J Clin Invest*. 1962;41:2086–2092.

Chang YT, Kappy MS, Iwamoto K, et al. Mutations in type-2 3-beta-hydroxysteroid dehydrogenase gene in a patient with classic salt wasting 3-beta-hydroxysteroid dehydrogenase deficiency congenital adrenal hyperplasia. *Pediatr Res*. 1993;34:698–700.

Cohen-Kettenis PT. Gender change in 46,XY persons with 5α-reductase-2 deficiency and 17β-hydroxysteroid dehydrogenase-3 deficiency. *Arch Sex Behav*. 2005;34:399–410.

Hauffa BT, Miller WL, Grumbach MM, et al. Congenital adrenal hyperplasia due to deficient cholesterol side chain cleavage activity (20–22 desmolase) in a patient treated for 18 years. *Clin Endocrinol*. 1985;23:481–493.

Hughes IA. Disorders of sex development: a new definition and classification. *Best Pract Research Clin Endocrinol*. 2008;22:119–134.

Imperato-McGinley J, Peterson RE, Stoller R, et al. Male pseudohermaphroditism secondary to 17-hydroxysteroid dehydrogenase deficiency: gender role change with puberty. *J Clin Endocrinol Metab*. 1979;49:391–395.

Laue L, Rennert OM. Congenital adrenal hyperplasia: molecular genetics and alternative approaches to treatment. *Adv Pediatr*. 1995;42:113–143.

Lekarev O, Mallet D, Yuen T, et al. Congenital lipoid adrenal hyperplasia (a rare form of adrenal insufficiency and ambiguous genitalia) caused by a novel mutation of the steroidogenic acute regulatory protein gene. *Eur J Pediatr*. 2012;171:787–793.

Lukacik P, Kavanagh KL, Oppermann U. Structure and function of human 17beta-hydroxysteroid dehydrogenases. *Mol Cell Endocrinol*. 2006;248(1–2):61–71.

New MI. Male pseudohermaphrodism due to a 17-alpha-hydroxylase deficiency. *J Clin Invest*. 1970;49:1930–1941.

Prader A, Gurtner HP. Das Syndrom des Pseudohermaphroditismus masculinus bei kongenitaler nebennierenrinden Hyperplasie ohne Androgen-uberproduktion (Adrenaler pseudohermaphroditismus masculinus). *Helv Pediatra Acta*. 1955;10:397–412.

Reddy VV, Naftolin F, Ryan KJ. Conversion of androstenedione to estrone by neural tissues from fetal and neonatal rats. *Endocrinology*. 1974;94:117–121.

Rosler A, Kohn G. Male pseudohermaphroditism due to 17 beta-hydroxysteroid dehydrogenase deficiency: studies on the natural history of the defect and the effect of androgens on gender role. *J Steroid Biochem*. 1983;39:663–674.

Saez JM, DePeretti E, Morera AM, et al. Familial male pseudohermaphroditism with gynecomastia due to a testicular 17-ketosteroid reductase defect: in vivo studies. *J Clin Endocrinol Metab*. 1971;32:604–610.

Saez JM, Morera AM, DePeretti E, et al. Further in vivo studies in male pseudohermaphroditism with gynecomastia due to a testicular 17-ketosteroid reductase defect (compared to a case of testicular feminization). *J Clin Endocrinol Metab*. 1972;34:598–600.

Sahakitrungruang T. Clinical and molecular review of atypical congenital adrenal hyperplasia. *Ann Pediatr Endocrinol Metab*. 2015;20(1):1–7.

Sobel V, Imperato-McGinley J. Gender identity in XY intersexuality. *Child Adolesc Psychiatric Clin North Am*. 2004;13:609–622.

Virdis R, Saenger P. 17-Beta-hydroxysteroid dehydrogenase deficiency. New MI, Levine LS. *Pediatric and adolescent endocrinology*. Karger: Basel; 1984:110–124. *Adrenal disease in childhood*. vol 13.

Welzel M, Wustemann N, Simic-Schleicher G, et al. Carboxyl-terminal mutations in 3beta-hydroxysteroid dehydrogenase type II cause severe salt-wasting congenital adrenal hyperplasia. *J Clin Endocrinol Metab*. 2008;93:1418–1425.

Zachmann M, Vollmin JA, Hamilton W, et al. Steroid 17,20-desmolase deficiency: a new cause of male pseudohermaphroditism. *Clin Endocrinol*. 1972;1:369–385.

Zachmann M, Werder EA, Prader A. Two types of male pseudohermaphroditism due to 17,20-desmolase deficiency. *J Clin Endocrinol Metab*. 1982;55:487–490.

Zhu Y, Katz MD, Imperato-McGinley J. Natural potent androgens: lessons from human genetic models. *Baillieres Clin Endocrinol Metab*. 1998;12:83–113.

Androgen Receptor and Postreceptor Defects

Syndrome of Complete (Severe) Androgen Insensitivity

Barthold JS, Kumasi-Rivers K, Upadhyay J, et al. Testicular position in the androgen insensitivity syndrome: implications for the role of androgens in testicular descent. *J Urol*. 2000;164:497–501.

Batch JA, Davies HR, Evans BA, et al. Phenotypic variation and detection of carrier status in the partial androgen insensitivity syndrome. *Arch Dis Child*. 1993;68:453.

Boehmer AL, Brinkmann O, Bruggenwirth H, et al. Genotype versus phenotype in families with androgen insensitivity syndrome. *J Clin Endocrinol Metab*. 2001;86:4151–4160.

Brown CJ, Goss SJ, Lubahn DB, et al. Androgen receptor locus on the human X chromosome: regional localization to Xq11–12 and description of a DNA polymorphism. *Am J Hum Genet*. 1989;44:264.

Chaudhry S, Tadokoro-Cuccaro R, Hannema SE, et al. Frequency of gonadal tumours in complete androgen insensitivity syndrome (CAIS): a retrospective case-series analysis. *J Pediatr Urol*. 2017;13(5):498.e1–498.e6.

Conte FA, Grumbach MM. Pathogenesis, classification, diagnosis and treatment of anomalies of sex. Besset GM, Cahill GF Jr, Marshall JC, et al. *Endocrinology*. ed 2. WB Saunders: Philadelphia; 1989:1810–1847.

Cools M, Drop SL, Wolffenbuttel KP, et al. Germ cell tumors in the intersex gonad: old paths, new directions, moving frontiers. *Endocr Rev*. 2006;27:468.

Cools M, Wolffenbuttel KP, Hersmus R, et al. Malignant testicular germ cell tumors in postpubertal individuals with androgen insensitivity: prevalence, pathology and relevance of single nucleotide polymorphism-based susceptibility profiling. *Hum Reprod*. 2017;32(12):2561–2573.

Grumbach MM, Conte FA. Disorders of sex differentiation. Wilson JD, Foster DW, Kronenberg HM, et al. *Williams' textbook of endocrinology*. ed 9. WB Saunders: Philadelphia; 1998:1303–1426.

Hannema SE, Scott IS, Hodapp J, et al. Residual activity of mutant androgen receptors explains wolffian duct development in the complete androgen insensitivity syndrome. *J Clin Endocrinol Metab*. 2004;89:5815–5822.

Hines M, Ahmed SF, Hughes IA. Psychological outcomes and gender-related development in complete androgen insensitivity syndrome. *Arch Sex Behav*. 2003;32:93–101.

Hiort O, Holterhus P-M. Androgen insensitivity and male infertility. *Int J Androl*. 2003;26:16–20.

Hughes IA. Diversity in developmental actions of androgens. *Clin Endocrinol*. 2001;54:707–708.

Hughes IA, Patterson MN. Prenatal diagnosis of androgen insensitivity. *Clin Endocrinol*. 1994;40:295.

Hughes IA, Werner R, Bunch T, et al. Androgen insensitivity syndrome. *Semin Reprod Med*. 2012;30:432–442.

Ismail-Pratt IS, Bikoo M, Liao L-M, et al. Normalization of the vagina by dilator treatment alone in complete androgen insensitivity syndrome and Mayer-Rokitansky-Küster-Hauser syndrome. *Human Reprod*. 2007;22:2020–2024.

Manuel M, Katayama KP, Jones HW Jr. The age of occurrence of gonadal tumors in intersex patients with a Y chromosome. *Am J Obstet Gynecol*. 1976;124:293.

Meyer-Bahlburg HFL. Gender assignment and reassignment in 46XY pseudo-hermaphroditism and related conditions. *J Clin Endocrinol Metab*. 1999;84:3455–3458.

Muller J, Skakkebaek NE. Testicular carcinoma in situ in children with the androgen insensitivity (testicular feminization) syndrome. *BMJ*. 1984;288:1419.

Quigley CA, DeBellis A, Marschke KB, et al. Androgen receptor defects: historical, clinical, molecular perspectives. *Endocr Rev*. 1995;16:271.

Wiener JS, Teague JL, Roth DR, et al. Molecular biology and function of the androgen receptor in genital development. *J Urol*. 1997;157:1377–1386.

Wilkins L. *The diagnosis and treatment of endocrine disorders in childhood and adolescence*. Charles C. Thomas: Springfield (IL); 1950.

Syndrome of Partial Androgen Resistance

Boehmer ALM, Bruggenwirth H, Van Assendelft C, et al. Genotype versus phenotype in families with androgen insensitivity syndrome. *J Clin Endocrinol Metab*. 2001;86:4151–4160.

Bouvattier C, Mignot B, Lefevre H, et al. Impaired sexual activity in male adults with partial androgen insensitivity. *J Clin Endocrinol Metab*. 2006;91:3310–3315.

Cools M, Wolffenbuttel KP, Hersmus R, et al. Malignant testicular germ cell tumors in postpubertal individuals with androgen insensitivity: prevalence, pathology and relevance of single nucleotide polymorphism-based susceptibility profiling. *Hum Reprod*. 2017;32(12):2561–2573.

Griffin JE. Androgen resistance: the clinical and molecular spectrum. *N Engl J Med*. 1992;326:611–618.

Hiort O, Holterhus P-M. Androgen insensitivity and male infertility. *Int J Androl*. 2003;26:16–20.

Hughes IA. Androgen resistance. *Best Pract Res Clin Endocrinol Metab*. 2006;20:577–598.

Hughes IA, Werner R, Bunch T, et al. Androgen insensitivity syndrome. *Semin Reprod Med*. 2012;30:432–442.

Mazur T. Gender dysphoria and gender change in androgen insensitivity or micropenis. *Arch Sex Behav*. 2005;34:411–421.

Melo KFS, Mendonca BB, Billerbeck AEC, et al. Clinical, hormonal, behavioral, and genetic characteristics of androgen insensitivity syndrome in a Brazilian cohort: five novel mutations in the androgen receptor gene. *J Clin Endocrin Metab*. 2003;88:3241–3250.

Migeon CJ, Berkovitz GD, Brown TR. Sexual differentiation and ambiguity. Kappy MS, Blizzard RN, Migeon CJ. *Wilkins: the diagnosis and treatment of endocrine disorders in childhood and adolescence*. Charles C. Thomas: Springfield (IL); 1994:573–716.

Migeon CJ, Wisniewski AB, Gearhart JP, et al. Ambiguous genitalia with perineoscrotal hypospadias in 46,XY individuals: long-term medical, surgical, and psychosexual outcome. *Pediatrics*. 2002;110:e31.

Sobel V, Imperato-McGinley J. Gender identity in XY intersexuality. *Child Adolesc Psychiatr Clin N Am*. 2004;13:609–622.

Szafran AT, Hartig S, Sun H, et al. Androgen receptor mutations associated with androgen insensitivity syndrome: a high content analysis approach leading to personalized medicine.

PLoS ONE. 2009;4:e8179.

Wilson JD, Harrod MJ, Goldstein JL, et al. Familial incomplete male pseudohermaphroditism, type I. *N Engl J Med*. 1974;290:1097–1103.

5α-Reductase Deficiency

Berra M, Williams EL, Muroni B, et al. Recognition of 5α-reductase-2 deficiency in an adult female 46XY DSD clinic. *Europ J Endocrinol*. 2011;164:1019–1025.

Cohen-Kettenis PT. Gender change in 46,XY persons with 5α-reductase-2 deficiency and 17β-hydroxysteroid dehydrogenase-3 deficiency. *Arch Sex Behav*. 2005;34:399–410.

Imperato-McGinley J. 5α-Reductase-2 deficiency and complete androgen insensitivity: lessons from nature. Zderic SA, Canning DA, Carr MC, et al. *Pediatric gender assignment: a critical reappraisal*. Kluwer Academic/Plenum Publishers: New York; 2002:121–134.

Imperato-McGinley JL, Guerrero L, Gautier T, et al. Steroid 5 alpha-reductase deficiency in men: an inherited form of male pseudohermaphroditism. *Science*. 1974;186:1213.

Imperato-McGinley J, Peterson RE, Gautier T, et al. Hormonal evaluation of a large kindred with complete androgen insensitivity: evidence for secondary 5 alpha-reductase. *J Clin Endocrinol Metab*. 1982;54:931–941.

Imperato-McGinley J, Peterson RE, et al. Androgens and the evolution of male-gender identity among male pseudohermaphrodites with 5 alpha-reductase deficiency. *N Engl J Med*. 1979;300:1233–1237.

Katz MD, Kligman I, Cai L-Q, et al. Paternity by intrauterine insemination with sperm from a man with 5α-reductase-2 deficiency. *N Engl J Med*. 1997;336:994–997.

Kupfer SR, Quigley CA, French FS. Male pseudohermaphroditism. *Semin Perinatol*. 1992;16:319–331.

MacLaughlin DT, Donahoe PK. Sex determination and differentiation. *N Engl J Med*. 2004;350:367–378.

Maimoun L, Philibert P, Cammas B, et al. Phenotypical, biological, and molecular heterogeneity of 5α-reductase deficiency: an extensive international experience of 55 patients. *J Clin Endocrinol Metab*. 2011;96:296–307.

Peterson RE, Imperato-McGinley J, Gautier T, et al. Male pseudohermaphroditism due to steroid 5 alpha-reductase deficiency. *Am J Med*. 1977;62:170–191.

Thigpen AE, Davis DL, Gautier T, et al. Brief report: the molecular basis of steroid 5 alpha-reductase deficiency in a large Dominican kindred. *N Engl J Med*. 1992;327:1216–1219.

Thigpen AE, Davis DL, Milatovich A, et al. Molecular genetics of steroid 5 alpha-reductase 2 deficiency. *J Clin Invest*. 1992;90:799–809.

Walsh PC, Madden JD, Harrod MJ, et al. Familial incomplete male pseudo-hermaphroditism, type II: decreased dihydrotestosterone formation in pseudovaginal perineal scrotal hypospadias. *N Engl J Med*. 1974;291:944.

Wilson JD. Recent studies on the mechanism of action of testosterone. *N Engl J Med*. 1972;287:1284–1291.

Zhu Y, Katz MD, Imperato-McGinley J. Natural potent androgens: lessons from human genetic models. *Baillieres Clin Endocrinol Metab*. 1998;12:83–113.

Persistent Müllerian Duct Syndrome

Cates RL, Mattaliano RJ, Hession C, et al. Isolation of the bovine and human genes from müllerian-inhibiting substance and expression of the human gene in animal cells. *Cell*.

1986;45:685.

Clarnette TD, Sugita Y, Hutson JM. Genital anomalies in human and animal models reveal the mechanisms and hormones governing testicular descent. *Br J Urol*. 1997;79:99–112.

Farikullah J, Ehtisham S, Nappo S, et al. Persistent Müllerian duct syndrome: lessons learned from managing a series of eight patients over a 10-year period and review of literature regarding malignant risk from the Müllerian remnants. *Br J Urol Int*. 2012;110:e1084–e1089.

Fujita J. Transverse testicular ectopia. *Urology*. 1980;16:400–402.

Imbeaud S, Faure E, Lamarre I, et al. Insensitivity to anti-müllerian hormone due to a mutation in the human anti-müllerian hormone receptor. *Res Genet*. 1995;11:382–388.

MacLaughlin DT, Donahoe PK. Sex determination and differentiation. *N Engl J Med*. 2004;350:367–378.

Nilson O. Hernia uteri inguinalis beim Manne. *Acta Chir Scand*. 1939;83:231.

Picard JY, Cate RL, Racine C, et al. The persistent müllerian duct syndrome: an update based upon a personal experience of 157 cases. *Sex Dev*. 2017;11(3):109–125.

Sloan WR, Walsh PC. Familial persistent müllerian duct syndrome. *J Urol*. 1976;115:459–461.

Mayer-Rokitansky-Küster-Hauser Syndrome

Biason-Lauber A, Konrad D, Navratil F, et al. A *WNT4* mutation associated with müllerian-duct regression and virilization in a 46,XX woman. *N Engl J Med*. 2004;351:792–798.

Brännström M, Johannesson L, Dahm-Kähler P, et al. First clinical uterus transplantation trial: a six-month report. *Fertil Steril*. 2014;101(5):1228–1236.

Flyckt R, Davis A, Farrell R, et al. Uterine transplantation: surgical innovation in the treatment of uterine factor infertility. *J Obstet Gynaecol Can*. 2018;40(1):86–93.

Gargollo PC, Cannon GM, Diamond DA, et al. Should progressive perineal dilation be considered first line therapy for vaginal agenesis? *J Urol*. 2009;182:1882–1889.

Griffin JE, Edwards C, Madden JD, et al. Congenital absence of the vagina: the Mayer-Rokitansky-Küster-Hauser syndrome. *Ann Intern Med*. 1976;85:224–236.

Ismail-Pratt IS, Bikoo M, Liao L-M, et al. Normalization of the vagina by dilator treatment alone in complete androgen insensitivity syndrome and Mayer-Rokitansky-Küster-Hauser syndrome. *Hum Reprod*. 2007;22:2020–2024.

Morcel K, Lavoue V, Jaffre F, et al. Sexual and functional results after creation of a neovagina in women with Mayer-Rokitansky- Küster-Hauser syndrome: a comparison of nonsurgical and surgical procedures. *Euro J Obst Gynecol Reprod Biol*. 2013;169:317–320.

Nussbaum-Blask AR, Sanders RC, Rock JA. Obstructed uterovaginal anomalies: demonstration with sonography. *Radiology*. 1991;179:84–88.

Pittock ST, Babovic-Vuksanovic D, Lteif A. Mayer-Rokitansky-Küster-Hauser anomaly and its associated malformations. *Am J Med Genet*. 2005;135A:314–316.

Reinhold C, Hricak H, Forstner R, et al. Primary amenorrhea: evaluation with MR imaging. *Radiology*. 1997;203:383–390.

Strubbe EH, Cremers CWRJ, Willemsen WNP, et al. The Mayer-Rokitansky-Küster-Hauser (MRKH) syndrome without and with associated features: two separate entities? *Clin Dysmorphol*. 1994;3:192–199.

Future Directions

Networking
Delot EC, Papp JC, DSD-TRN Genetics Workgroup, et al. Genetics of Disorders of Sex Development: the DSD-TRN experience. *Endocrinol Metab Clin N Am*. 2017;46:519–535.
Sandberg DE, Callens N, Wisniewski AB. Disorders of Sex Development (DSD): networking and standardization considerations. *Horm Metab Res*. 2015;47:387–393.

Impact on Caregivers

Bernabé KJ, Nokoff NJ, Galan D, et al. Preliminary report: surgical outcomes following genitoplasty in children with moderate to severe genital atypia. *J Pediatr Urol*. 2018;14(2):157.e1–157.e8.
Consortium on the management of disorders of sex development. [Clinical Guidelines for management of disorders of sex development in childhood. Accord Alliance] 2006.
Consortium on the management of disorders of sex development. [Handbook for parents. Accord Alliance] 2006.
Suorsa KI, Mullins AJ, Tackett AP, et al. Characterizing early psychosocial functioning of parents of children with moderate to severe genital ambiguity due to disorders of sex development. *J Urol*. 2015;194:1737–1742.
Wisniewski AB, Sandberg DE. Parenting children with disorders of sex development (DSD): a developmental perspective beyond gender. *Horm Metab Res*. 2015;47:375–379.
Wolfe-Christensen C, Wisniewski AB, Mullins AJ, et al. Changes in levels of parental distress after their child with atypical genitalia undergoes genitoplasty. *J Pediat Urol*. 2017;13(1):32.e1–32.e6.

Ethical Considerations

Diamond DA. The ethics of gender in pediatric reconstructive urology. *J Urol*. 2016;196(2):305–307.

Kon AA. Ethical issues in decision-making for infants with disorders of sex development. *Horm Metab Res*. 2015;47:340–343.

Meyer-Bahlburg HF, Migeon CJ, Berkovitz GD, et al. Attitudes of adult 46,XY intersex persons to clinical management policies. *J Urol*. 2004;171(4):1615–1619.

SECTION F

Reconstruction and Trauma

OUTLINE

49 Surgical Management of Differences of Sexual Differentiation and Cloacal and Anorectal Malformations

50 Adolescent and Transitional Urology

51 Urologic Considerations in Pediatric Renal Transplantation

52 Pediatric Genitourinary Trauma

49

Surgical Management of Differences of Sexual Differentiation and Cloacal and Anorectal Malformations

Richard C. Rink MD, FAAP, FACS

The surgical management of disorders of sex development (DSDs), genital atypia, and cloacal anomalies is one of the most complex problems a pediatric urologist/surgeon will ever encounter. The vast majority of children with DSDs will be noted to have some genital ambiguity. Surgery in this group is not only one of the most controversial topic addressed in this entire textbook but is the most controversial and debated topics in all of medicine. Even the term *DSD* is controversial. The majority of congenital adrenal hyperplasia (CAH) patients and parents were found to be dissatisfied with the term *DSD* (Lin-Su et al., 2015). The complexity of this topic has led to featured presentations by nearly every major television and print media outlet. Having a child born with a DSD is very stressful for the parents, and it is therefore imperative to create a supportive medical team that can not only help the family understand the diagnosis but also help them understand all controversies and options they have for medical and surgical management. Most families have historically opted for early surgery to “normalize” their child's genitalia. The thought of “doing nothing” for their child with DSD has been noted to be stressful for families (Creighton et al., 2012). Most parents viewed surgery as obvious and necessary and something that did not involve decision making (Crissman et al., 2011). However, Lloyd et al. (2005) and Akbiyik and Kutlu (2010) have now shown tremendous variability in genital proportions of “normal” adults and children who do not have a DSD. The family should also be informed of the possible long-term psychosocial experience of the child with DSD (Krishnan and Wisniewski, 2014). What is clear is that the parents must be made aware of all pros and cons of having surgery and also of not having surgery. **No parent or child should ever be talked into having surgery.** Regardless of whether surgery or observation is elected, the multidisciplinary family-centered medical team should be supportive of the family and should make sure the parents are aware of the options for management and the advantages and disadvantages for each option. Parents should also be made aware of and have access to support groups such as the CARES Foundation (www.caresfoundation.org), Accord Alliance (accordalliance.org), Magic Foundation (magicfoundation.org), and InterACT (interactadvocates.org).

It is not so much the technical aspects of the surgery that are controversial but rather the timing of surgical management and who has the right to decide whether surgery is appropriate; the parents or the child. As pediatric urologists, we are neither for nor against surgery but for a multidisciplinary family-centered team approach to the care of each individual child in concert with the parents/family. The reader, however, must understand that the purpose of this chapter is to address the surgical options available to the patient/parents regardless of the patient's age and to address the management of this complex spectrum of anomalies with the assumption that the parents, family, and multidisciplinary team all agree on the appropriate management plan. At a minimum, the multidisciplinary team should include the patient/family, a pediatric urologist/surgeon, a pediatric endocrinologist, a geneticist, a neonatologist, a psychologist/psychiatrist, and an ethicist with the patient/family having access to all advocacy groups and, if desired, clergy.

Classification of Urogenital Sinus and Cloacal Anomalies

Because of the spectrum and complexity of urogenital sinus anomalies and the potential for other associated organ system abnormalities, evaluation and management must be meticulous. In urogenital sinus anomalies, there is a persistent communication of the vagina with the urinary tract. Communication of the vagina with the urinary tract may occur at any point from the urethral meatus to the bladder, but the majority occur within the mid- to distal portion of the urethra. The two structures join and exit on the perineum as a single common urogenital sinus channel.

A persistent urogenital sinus is **seen in four entities.** Most commonly it occurs in **genital ambiguity states,** most frequently with CAH (Fig. 49.1). It can also occur as a **pure urogenital sinus** with normal external genitalia (Fig. 49.2). In persistent **cloacal anomalies,** there is the added complexity of rectal involvement, with all three systems—genital, urinary, and intestinal—exiting as an isolated single perineal opening. **Female exstrophy** has been thought to represent a form of persistent urogenital sinus.

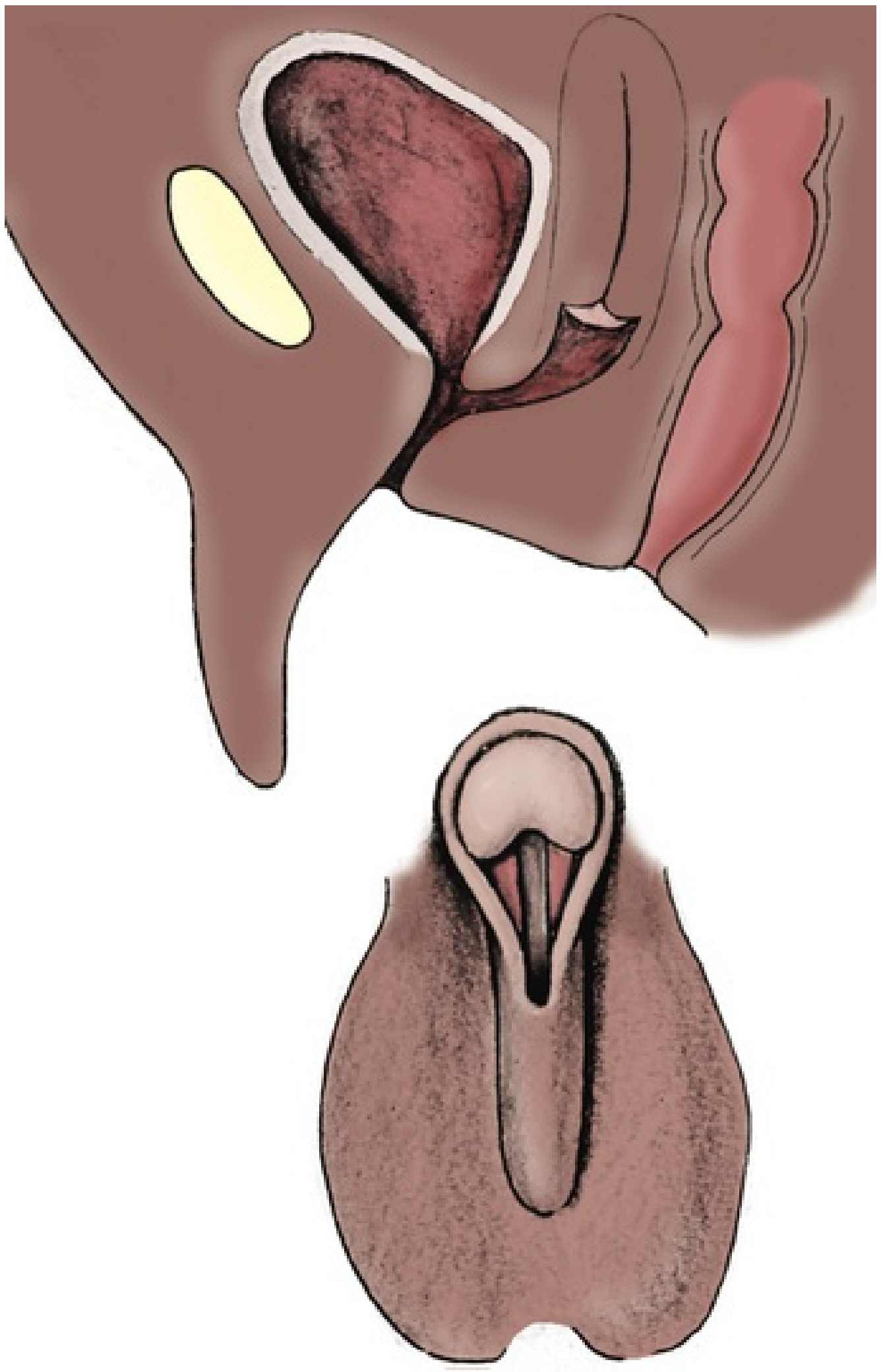

FIG. 49.1 Urogenital sinus in a patient with intersex.

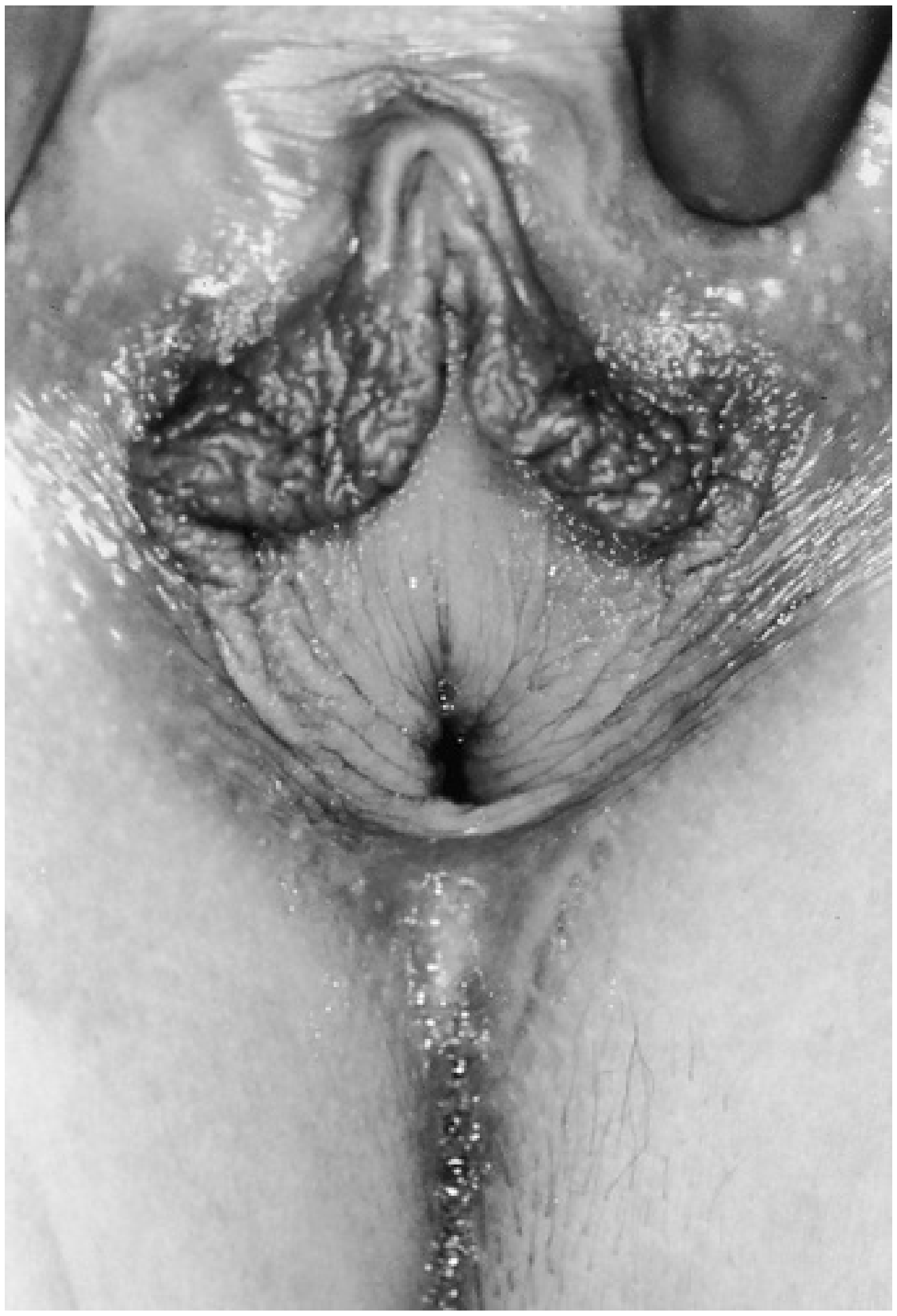

FIG. 49.2 Pure urogenital sinus abnormality.

Early descriptions of this confluence were based on previous medical training. Urologists described the vagina as entering the urethra, whereas gynecologists noted that the urethra entered the vaginal vestibule (Jones and Jones, 1954). Jaramillo et al. (1990) noted that on examination the external cloacal orifice appears vaginal in nature in some cases but in others appears more like a normal urogenital orifice (Figs. 49.3 and 49.4). **Regardless of how the confluence of the urinary and genital tracts is described, the confluence location in relation to the bladder neck is a more critical factor in surgical management than the length of the common channel** (Rink et al., 2005a).

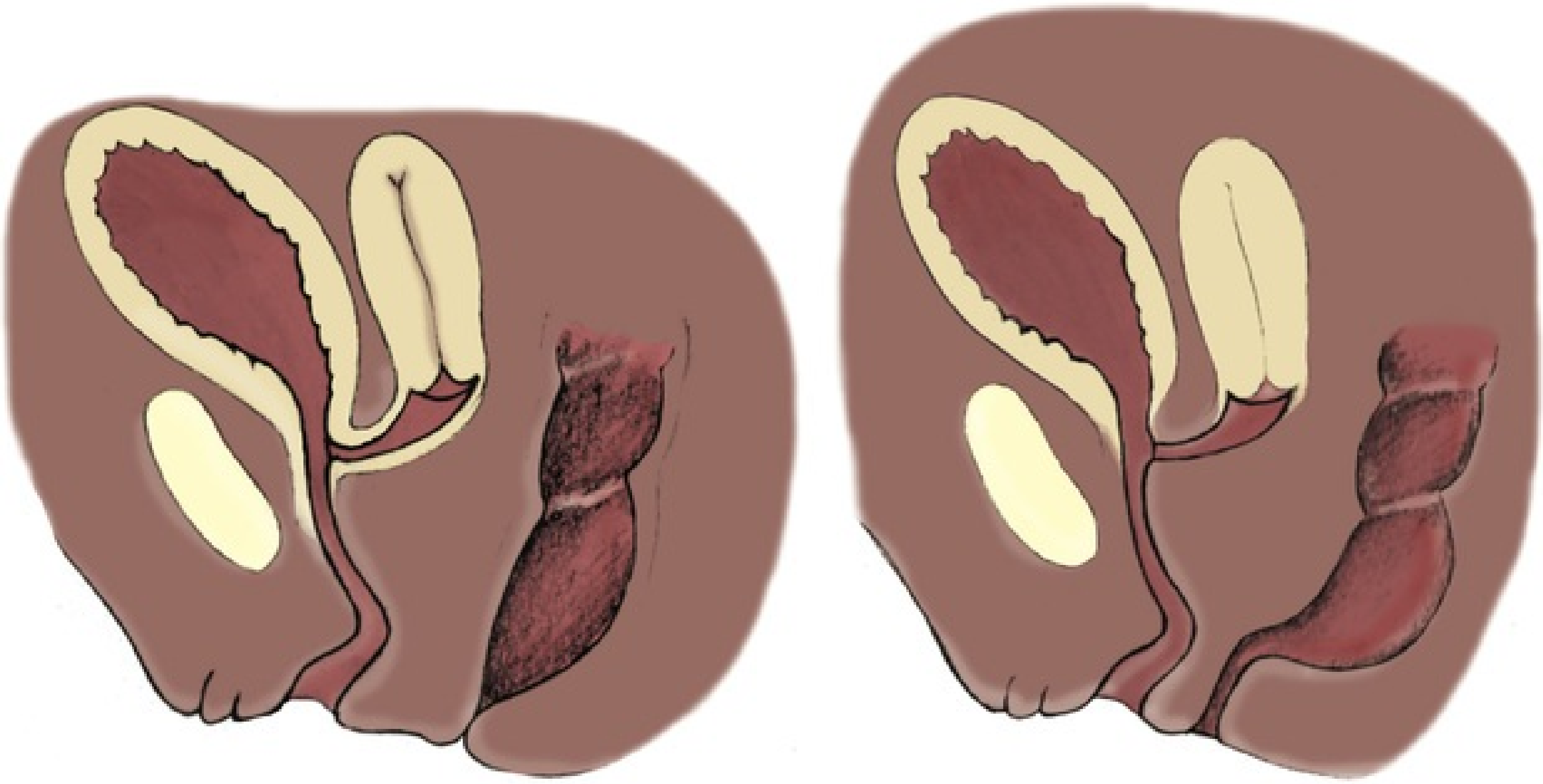

FIG. 49.3 *Left,* Urethral-type urogenital sinus. *Right,* Urethral-type urogenital sinus with an anteriorly placed rectum.

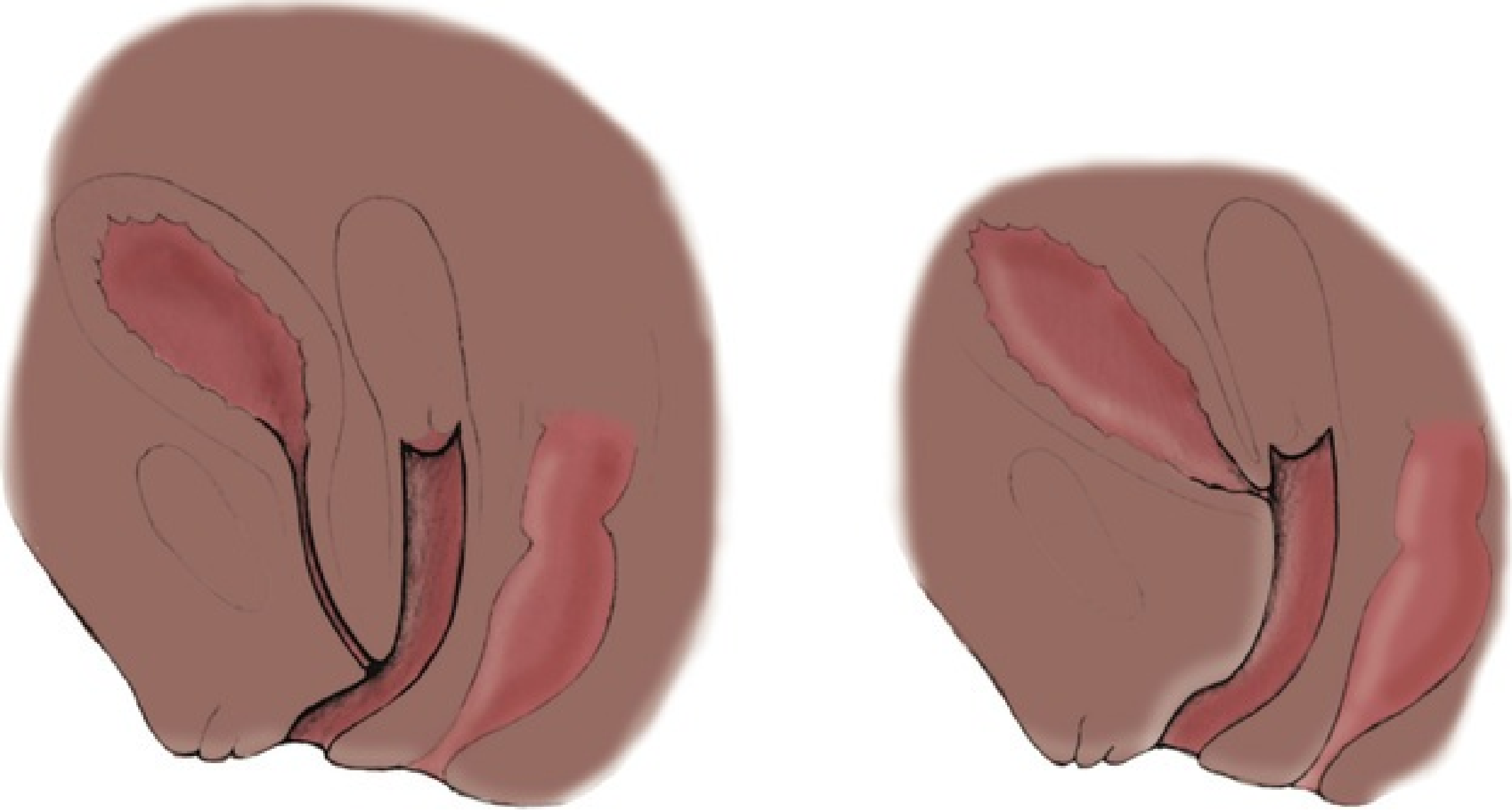

FIG. 49.4 Vaginal-type urogenital sinus showing high *(right)* and low *(left)* confluence.

Key Point: Urogenital Sinus Anomalies—General

- Urogenital sinus anomalies are found in four entities: genital ambiguity states, pure urogenital sinus, persistent cloaca with rectal involvement, and female exstrophy.

Evaluation

Urogenital sinus abnormalities are most often seen in DSD states, most commonly in association with CAH, which has been noted to have an incidence as high as 1 in 500 in the nonclassic, mild form (Hughes, 1988). CAH is a group of inherited autosomal recessive genetic abnormalities of which the most common enzymatic defect resulting in genital ambiguity is 21-hydroxylase deficiency. This occurs in approximately 1 in 15,000 to 16,000 persons (Merke and Bornstein, 2005; Speiser and White, 2003). Mutations in the 21-hydroxylase gene (the *CYP21A2* gene on the short arm of chromosome 6 in 90% to 95% of individuals) result in varying degrees of virilization corresponding to the type of mutation. CAH should be regarded as a spectrum disorder from mild anomalies to those with deep impact on life (Elmasri et al., 2018; Nordenskjöld et al., 2008). Therefore, initial management must focus on making an accurate diagnosis to allow proper management. Every effort should be made to establish the karyotype within 48 hours. Children with CAH require careful monitoring of fluid and electrolytes because 67% to 75% will have significant salt wasting resulting from lack of aldosterone secretion (Merke and Bornstein, 2005; Speiser and White, 2003). The classic findings of salt wasting in 21-hydroxylase deficiency are hyponatremia, hyperkalemia, high urinary sodium, low serum and urinary aldosterone, and elevated plasma renin activity (New et al., 2014). This may lead to dehydration, poor feeding, hypotension, and even vascular collapse, shock, and death (adrenal crisis). Evaluation should include rapid karyotyping of cultured peripheral leukocytes, measurement of serum electrolyte levels, and determination of hormonal levels for CAH. All results are shared with the multidisciplinary DSD team and patient/family as described earlier. There is a growing understanding of gender fluidity, not a simple binary male-female system. The child should not be named until the evaluation is complete and the family has met with the multidisciplinary team (Rink and Adams, 1998).

Cloacal anomalies are a much more complex problem involving multiple organ systems, but fortunately they occur in only 1 in 20,000 to 50,000 patients (Karlin et al., 1989; Rintala, 2016). They are the most challenging of the anorectal malformations (ARMs) and make up 13.6% of this group (Fleming et al., 1986). These children have a very broad spectrum of findings on examination of the external genitalia. Some may have a prominent phallic structure and also initially require evaluation for a DSD.

History and Physical Examination

Many children with urogenital sinus abnormalities are now identified by antenatal ultrasonography, with the findings of fluid-filled pelvic structures (vagina and bladder) with indeterminate genitalia. Furthermore, since 2009 newborn CAH screening programs have been carried out in all 50 states and in areas worldwide, which helps identify some affected children (New et al., 2014). However, the history and the physical examination remain extremely helpful in cases of genital ambiguity and can often lead to the diagnosis itself. It is critical to determine whether the mother ingested any medications during pregnancy, especially androgenic substances. A family history of early infant death or fluid and electrolyte abnormalities suggests CAH. Have other children had genital atypia or gender dysphoria? Notation should be made of any family members with abnormal pubertal development.

The physical examination can at times be very useful in determining the appropriate management and in helping to identify other organ systems involved. A general evaluation of the child's overall health should be completed before focusing on the genital examination. Abnormal facies or other physical findings suggesting a syndrome should be noted. **Hypertension can occur in children with genital ambiguity secondary to CAH from 11β-hydroxylase deficiency.** Therefore, blood pressure should be documented. Evidence of dehydration may also lead to a diagnosis of CAH. On abdominal examination, a mass, particularly a suprapubic mass, may be present because of a distended bladder, hydrometrocolpos, or both. **Hydrometrocolpos is frequently an initial sign and is often the only early finding in pure urogenital sinus abnormalities.**

In cloacal anomalies, abdominal distention may be severe secondary to hydrometrocolpos and bladder and intestinal distention. Hydrometrocolpos was noted commonly in early series (Chappell and Bleloch, 1973; Klugo et al., 1974); its incidence ranged from 29% of Peña's patients (1989) to 63% of those reported by Bartholomew and Gonzales (1978). It is caused most commonly by preferential flow of urine through the urogenital sinus into the vagina (or vaginas) with voiding and associated poor vaginal drainage. Maternal estrogen stimulation of the cervical glands results in mucus production, thereby further adding to the distention. Urine flow can occur into the rectum also. The distention of these pelvic structures has resulted in edematous, cyanotic legs, respiratory distress, and acidosis (Raffensperger, 1988).

The lower part of the back should be examined to identify any evidence of spinal cord abnormalities, which can be associated with urogenital sinus abnormalities and are very common with cloacal anomalies. Such abnormalities may take the form of a sacral dimple, hair patch, or area of abnormal pigmentation, but more commonly there is evidence of a bone abnormality, such as an abnormal buttock crease or flattened buttocks as a result of sacral agenesis.

Genital examination should note the size of the phallus and the consistency of the erectile bodies. Any degree of curvature should be documented. Huffman multiplied the width of the glans times the length of the phallus to determine the "clitoral index," which he noted should be less than 3.5 mm to be normal and was of concern when greater than 10 mm. The average clitoral length for a full-term girl in the United States was noted to be 4.0 ± 1.24 mm, and the average width was 3.32 ± 0.78 mm (Hughes et al., 2006). **Persistent isolated clitoral hypertrophy may be found in premature infants and is not associated with DSDs or other signs of ambiguity** (Williams et al., 2013). The location of the meatus of the urogenital sinus should be noted and may occur in a spectrum from a near-normal introital location to the tip of a well-formed glans. The gonads should be sought, and, when found, their number, location, and consistency should be noted. If both gonads are descended, it is extremely unlikely that a 46,XX chromosome makeup will be found. The labioscrotal folds should be examined for their relationship to the phallus and rectum, and for the degree of fusion. Increased pigmentation of the labioscrotal folds and areola may be seen in some cases of CAH as a result of increased levels of melanocyte-stimulating hormone.

In urogenital sinus anomalies, the location of the anus should be noted. Although it is usually in the normal location, anterior displacement is not uncommon, and this bridges the gap to cloacal anomalies (see Fig. 49.3). A gentle rectal examination is helpful in identifying a cervix.

Examination of a child with a persistent cloaca deserves special mention. There is a single perineal orifice because the rectum also enters this common channel. The appearance of the external genitalia assumes a much wider spectrum, from a nearly normal female appearance to much more bizarre appearances such as complete genital transposition or a blank-appearing (doll-like) perineum (Fig. 49.5) (Hendren, 1989). In some instances, there is an enlarged phallic structure that gives the genitalia an ambiguous appearance. The single perineal opening may exit what appears to be a normal vaginal introitus, or it may extend to the tip of a phallic structure. I and others have encountered children with a secondary accessory channel that exits the tip of the phallus (Hendren, 1989; Karlin et al., 1989; Krstic et al., 2001; Rink et al., 2005b).

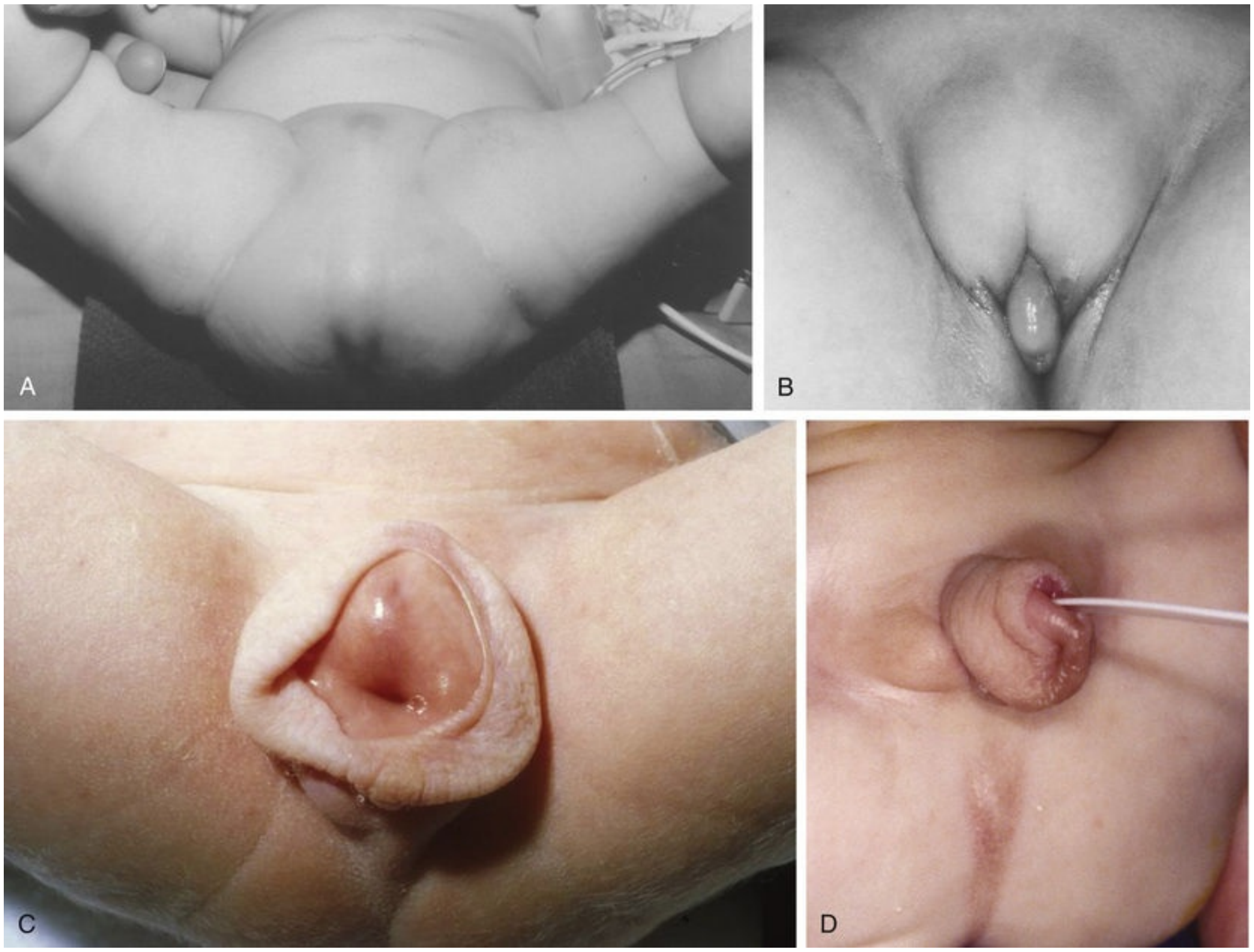

FIG. 49.5 (A) Cloaca with a blank perineal appearance. (B) Cloaca with genital transposition. (C) Cloaca, vaginal type, external appearance. (D) Cloaca, urethral type, external appearance.

Cloacal anomalies are associated with a high incidence of related anomalies in other organ systems. I have previously found 14 of 23 patients with renal anomalies, including 6 with solitary kidneys, 4 with renal dysplasia, 2 with ureteropelvic junction obstruction, 1 with duplication, and 1 with crossed fused ectopia; there were also 2 with bladder duplications (Rink et al., 2005b). Approximately 60% have some degree of septation of the vagina and uterus

(Pradhan et al., 2018; Warne et al., 2003). Kay and Tank (1977) reported that 13% of patients with cloacal anomalies have cardiovascular abnormalities, 10% have central nervous system problems, and 5% have respiratory abnormalities; vertebral, particularly sacral, anomalies are common. Many have the VACTERL association (*V*ertebral abnormalities, *A*nal atresia, *C*ardiac abnormalities, *T*racheoesophageal fistula and/or *E*sophageal atresia, *R*enal agenesis and dysplasia, and *L*imb defects), so tracheoesophageal fistula is often present (Hendren, 1986, 1988). Other gastrointestinal anomalies have been noted, including duodenal atresia and rectal duplication in 2% (Karlin et al., 1989). Gut malrotation in patients with ARM has the same frequency as in the general population, but it is more common in severe malformations. Surgeons treating these patients should address the malrotation at the time of colostomy opening if detected. The appendix should be preserved for potential future use as an appendicocecostomy for antegrade administration of enemas.

Key Points: Urogenital Sinus Anomalies—Evaluation

- Key points of the history and physical examination are findings of a family history of sudden infant death, fluid and electrolyte abnormalities, hypertension, suprapubic mass, lower extremity cyanosis, palpable gonads, hyperpigmentation, and number of perineal orifices.
- The level of the urethrovaginal confluence and the location of the rectum must be identified radiographically or endoscopically, with note made of their relationship to the bladder neck. Ultrasonography is mandatory to look for the uterus, ovaries, and kidneys.

Radiographic and Endoscopic Evaluation

Urogenital Sinus Abnormalities

Certain critical details of the anatomy, including the length of the common urogenital sinus, the location of the vaginal confluence and its proximity to the bladder neck, the size of the vagina and the number of vaginas, the presence of a cervix, and bladder and urethral anatomy, must be defined. This can be done radiographically or endoscopically. I believe that the location of the vagina in relation to the bladder neck is the critical issue in determining the type of surgery, and this distance is far more important than the length of the common channel (Ludwikowski and González, 2013; Rink et al., 2005a). This concept of the importance of the bladder neck to confluence (urethral length) has now been appreciated in cloacal anomalies and has resulted in a new treatment algorithm for surgical management of persistent cloaca (Wood et al., 2017). Vaginal confluence with the urinary tract in pure urogenital sinus and cloacal anomalies occurs in a continuum from the bladder to a nearly normal location in the perineum. **It is not simply "high" (proximal/suprasphincteric) or "low" (distal/infrasphincteric)** (Hendren and Crawford, 1969; Powell et al., 1995; Rink and Kaefer, 2002) (Fig. 49.6). I am in agreement with Ganesan et al. (2002) that the confluence of the urethra and vagina in CAH is fairly constant with a normal proximal urethra. This bladder neck to confluence distance is generally 1.5 to 2 cm in CAH infants. It is the distance from the vagina to the meatus that lengthens with increasing virilization, making some appear to be "very high." This latter distance is much more variable. Furthermore, this high confluence appearance is exacerbated in the more virilized urogenital sinus because there may be the appearance of a well-defined (malelike) external sphincter with a verumontanum appearance to the vaginal confluence just proximal to it, and the bony pelvis is more masculinized.

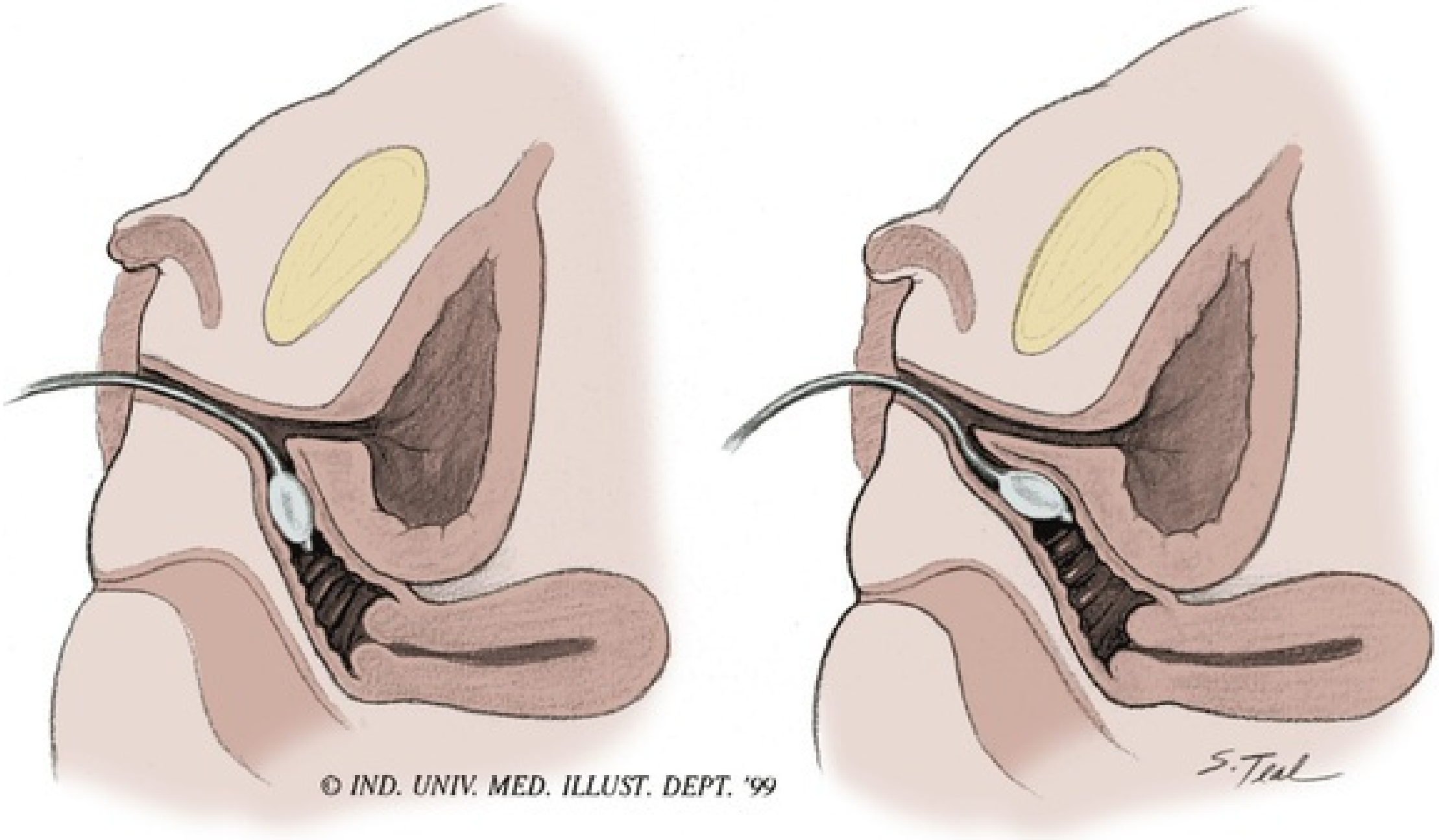

FIG. 49.6 Fogarty catheter placed in the vagina in high confluence *(left)* and in low confluence *(right)*. (© 1999, Indiana University Medical

Illustration Department.)

A urogenital sinus classification that measures the exact distance of the common channel and the distance of the bladder neck to the vagina has been devised to help delineate the exact level of the confluence and the clitoral size and appearance of the external genitalia (Rink et al., 2005a).

Ultrasonography of the urinary tract and pelvis is mandatory. The location and normalcy of the kidneys, ovaries, and uterus should be defined. Any bladder or vaginal distention should be noted. A cerebriform appearance with enlargement of the adrenal glands is indicative of CAH (Brock et al., 1998).

Filling the entire bladder, urethra, vagina, and sinus with contrast (i.e., genitography) is critical in the anatomic evaluation of many children with a urogenital sinus or cloacal anomaly (Figs. 49.7 and 49.8). Genitography is performed by placing a Foley catheter with the balloon occluding the perineal meatus and injecting a contrast agent. It is often helpful to pass a catheter into the bladder as for a voiding cystourethrogram. In some children, the vagina will only be demonstrated with voiding. A cervical impression at the vaginal dome denotes normal female internal organs. Magnetic resonance imaging (MRI) is of limited value in CAH but may be very helpful to define the anatomy in pure urogenital sinus anomalies or other DSD and cloacal conditions. In CAH patients, the internal anatomy can nearly always be defined by an endoscopy at the time of reconstruction, making genitography less useful in this group (VanderBrink et al., 2010). At our institution, the anatomy was accurately defined in CAH in only 72% of cases by genitography and it did not provide any information that could not be obtained by endoscopy, and genitography did not influence the type or timing of surgery (VanderBrink et al., 2010).

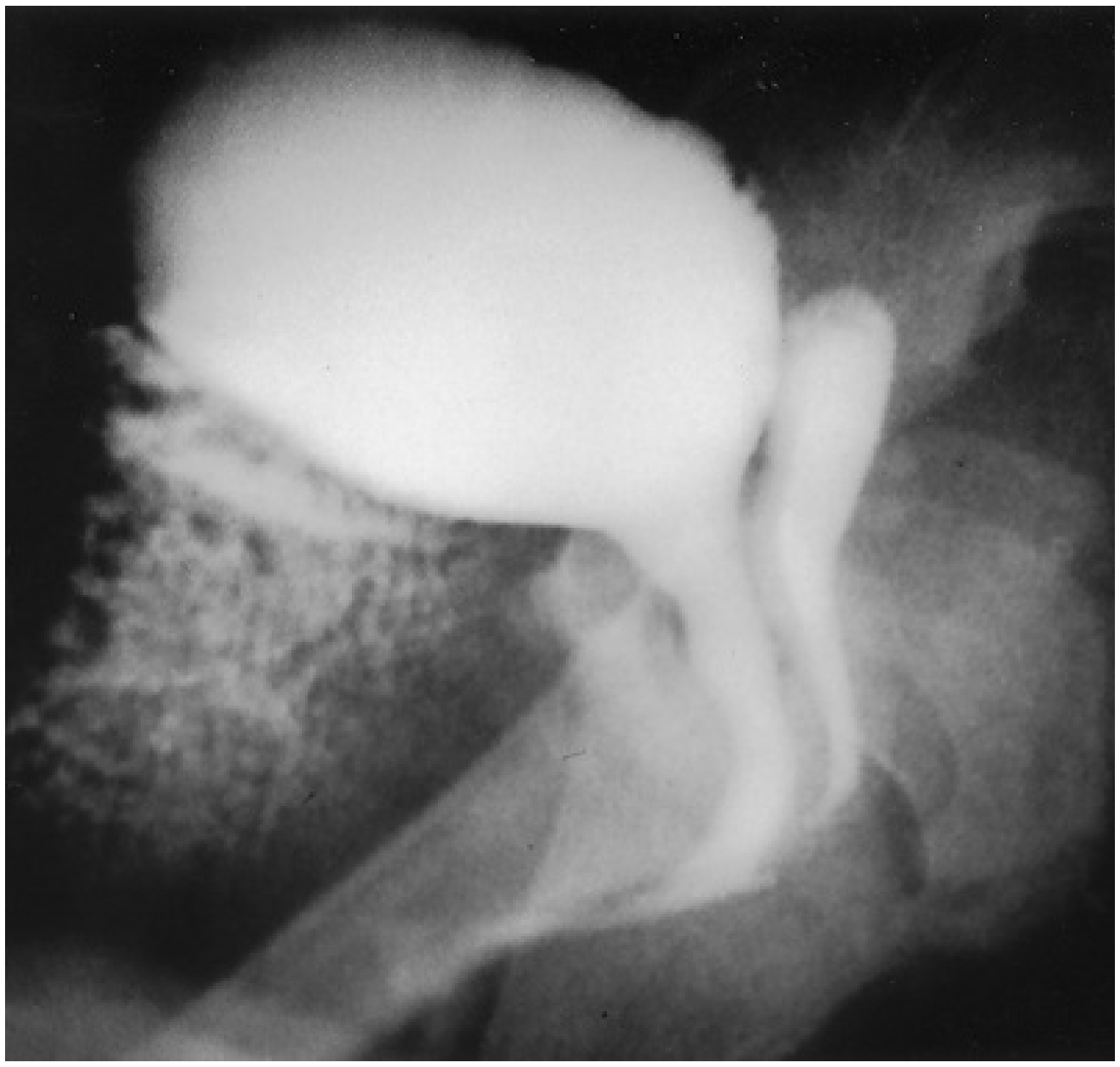

FIG. 49.7 Genitography showing low confluence of the urethra and vagina.

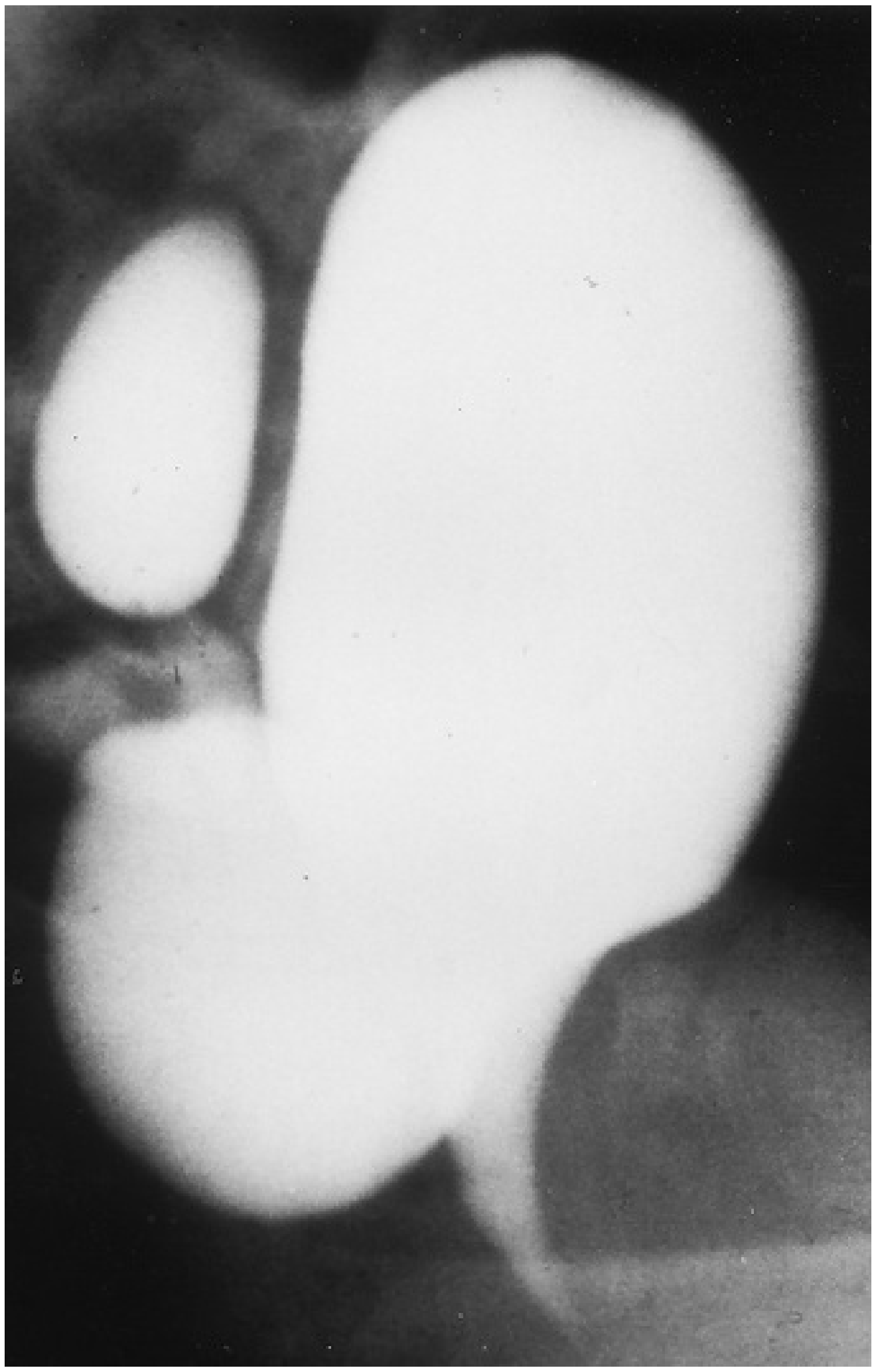

FIG. 49.8 Genitography showing high confluence of the vagina entering near the bladder neck, with flow of contrast medium into the uterus.

The most helpful diagnostic study in defining the anatomy for surgical reconstruction is endoscopy. In patients with CAH, endoscopy is usually performed at the time of reconstruction but may be necessary as a separate early procedure to help with gender identity in other DSD cases or in those with complex pure urogenital sinus anomalies or if the vagina is not identified on genitography (Rink and Kaefer, 2002). In the latter situation, multiple punctuate openings in the proximal portion of the urethra may be observed (Donahoe and Gustafson, 1994). I have found it helpful to pass a ureteral catheter into the opening and evaluate the vagina fluoroscopically in this situation (Rink and Kaefer, 2002). Again, the exact location, size, and number of the vaginas should be recorded (Fig. 49.9). Hendren has noted a malelike external sphincter in severely masculinized children, with the vagina entering proximal to it in a verumontanum-like structure (Hendren and Atala, 1995; Hendren and Crawford, 1969). In my initial experience, I thought this rarely if ever occurred (Adams and Rink, 1998), but as noted earlier, I have more recently seen several CAH children with a completely masculinized malelike urethra with an external sphincter and verumontanum-like structure.

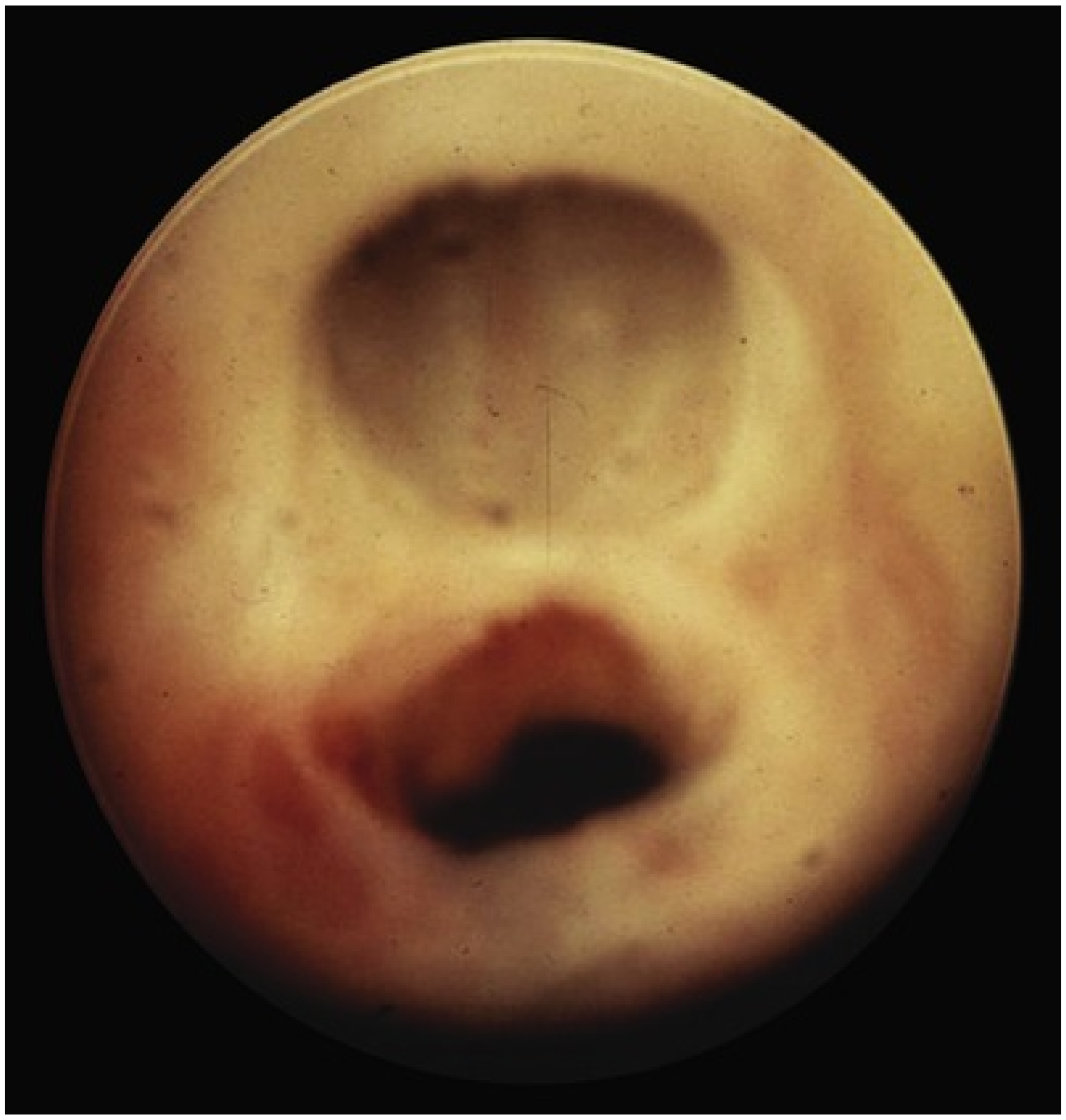

FIG. 49.9 Endoscopic view of confluence. The urethra is superior; the vagina is inferior.

Rarely, even with the evaluation described, some children with DSD require gonadal biopsy or evaluation of the internal genitalia, which has historically been done by laparotomy but in most cases can now be easily performed laparoscopically. Regardless of the means, it should be performed only when the findings would influence the gender of rearing (Rink and Adams, 1999). **If a biopsy is necessary, a deep longitudinal incision should be made in the gonad because the ovarian component of ovotestes may completely surround the testicular component or be located at the poles** (Hensle and Kennedy, 1998; Schnitzer and Donahoe, 2001). Finally, scrotal skin biopsy may at times be helpful in males with incomplete androgen insensitivity, decreased

5α-reductase activity, or decreased dihydrotestosterone binding (Griffin and Wilson, 1989). Certainly, all children with DSD should undergo chromosomal, endocrinologic, and genetic evaluation. This is well described in Chapter 48.

Cloacal Anomalies

Evaluation for cloacal anomalies begins with antenatal ultrasonography because several groups have now reported the prenatal diagnosis of persistent cloaca (Adams and Rink, 1998; Cacciaguerra et al., 1998; Cilento et al., 1994; Odibo et al., 1997; Petrikovsky et al., 1988; Shalev et al., 1986; Warne et al., 2002a). The diagnosis has been made as early as 19 weeks' gestation. **The finding of transient fetal ascites with bilobed or trilobed pelvic cystic structures, bilateral hydronephrosis, and decreased amniotic fluid is diagnostic** (Cacciaguerra et al., 1998; Warne et al., 2002b). The ascites is thought to develop via retrograde flow of urine into the uterus and out the fallopian tubes secondary to outlet obstruction from the distended vagina (Adams et al., 1998; Cacciaguerra et al., 1998).

Postnatal radiographic evaluation begins with a plain abdominal film (Jaramillo et al., 1990) **and abdominal ultrasonography.** A pelvic mass may be obvious on a kidneys, ureters, and bladder view. Retrograde flow of urine and meconium, as described earlier, may result in the classic linear calcifications or calcified meconium. More granular calcifications may be noted along the course of the rectum as a result of urine flow into the rectum that yields calcified meconium (Jaramillo et al., 1990). **Abdominal ultrasonography is very important to visualize not only the pelvic anatomy but also the kidneys because hydronephrosis is common** (Hendren, 1998). Hydronephrosis is usually related to hydrocolpos, with the distended vagina compressing the bladder neck and resulting in varying degrees of bladder outlet obstruction (Hendren, 1998). Ureteral compression may also occur; however, I have seen hydronephrosis caused by primary obstructive megaureter in patients with cloacal anomaly.

Ultrasonography may also detect other renal anomalies. **Renal anomalies such as dysplasia, fusion anomalies, ectopia, ureteropelvic junction obstruction, and duplication have been seen in 33% to 83% of children with a persistent cloaca** (Kay and Tank, 1977; Rink et al., 2005b; Warne et al., 2002a).

As opposed to some urogenital sinus abnormalities in CAH in which genitography may be avoided, both genitography and endoscopy are

mandatory to define the anatomy, which is even more complex with a cloacal anomaly.

The technique and goals of genitography and endoscopy are the same but must now include identification of the rectal and vaginal confluence. The length of the urethra and its communication with the cloaca are important for reconstructive purposes. In Hendren's patients, the urinary communication to the cloaca was urethral in 77%, but in 23% there was virtually no urethra and the communication was noted at the bladder neck level (Jaramillo et al., 1990).

Cloacal malformations may interfere with Mullerian duct fusion often leading to Mullerian anomalies (Gupta et al., 2014). Thus the vaginal anatomy may be quite complex and variable. In Hendren's report of 154 patients, 66 had one vagina, 68 had two vaginas, and the vagina was absent in 20 (Hendren, 1998). In a recent report by Pradhan et al. (2018), 63% of patients had vaginal and uterine duplications. They noted that defining this genital anatomy can be challenging, even with the use of pelvic ultrasonography, MRI, cloacogram, and vaginoscopy. They had the most success in defining the anatomy preoperatively with vaginoscopy (92%) and the least success with pelvic ultrasonography, which was accurate in only 4 of 8 (50%). In 5 of 15 patients, the cloacogram did not correlate with defined anatomy at the time of laparoscopy/laparotomy. Vaginal duplication has been seen in nearly all of my patient population (Rink and Yerkes, 2001) (Fig. 49.10). The duplication anatomy is also variable. Most authors have observed that the vaginas enter side by side with a single opening into the cloaca, but separate openings have been noted. The vaginas may be of different size, and one may enter the sidewall of the other. A cervix is usually seen at the top of each vagina. **The vaginal entrance into the cloaca again lies along a spectrum from the bladder to a location near the perineum.** Although the uterus is usually similar to the vagina (i.e., two vaginas with two uteri), the vagina may be absent with the uterus still present or the uterus may be hypoplastic. Hall et al. (1985) found a bicornuate uterus, hypoplastic uterus, or uterus didelphys in 35% of their patients with persistent cloaca.

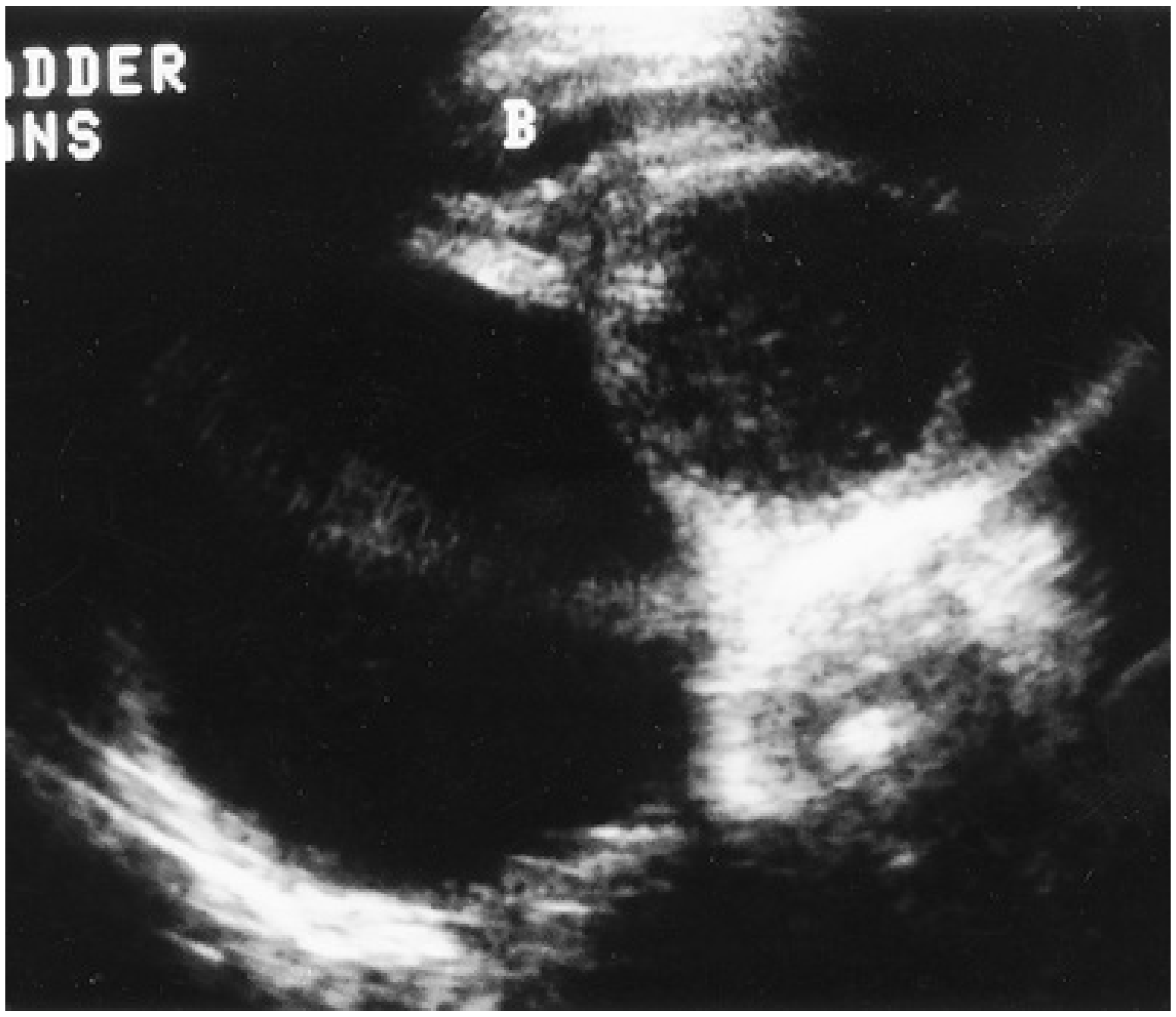

FIG. 49.10 Pelvic ultrasonography in a patient with a cloaca. Duplicate fluid-filled vaginas are seen posterior to the decompressed bladder *(B).*

The rectal confluence is equally complex, with the entrance in my experience most commonly located just at the level of the vaginal confluence. This rectal opening may be broad, or it may have a long, narrow fistulous tract. It can even enter the vagina or bladder with no communication to the common cloaca itself. The most common entrance in my experience is within the septum of a duplicated vagina, with all three joining the cloaca together (Rink and Kaefer, 2002). The rectal communication has been found to be vaginal in 68% and cloacal in 11%, with the remainder in other locations (Jaramillo et al., 1990). The length and configuration of the common cloaca should also be noted because it has important surgical and anatomic implications. At times, the common channel is narrow and appears very much like a urethra; in other instances, the channel is much larger and redundant and appears more like a vagina. The urethral appearance was found in 48% of patients and the vaginal appearance in 52% (Jaramillo et al., 1990). **I and others have noted that the urethral types result in higher outlet resistance and are more likely to lead to hydrocolpos** (Adams et al., 1998; Warne et al., 2002b).

The frequent presence of associated organ system abnormalities necessitates further radiographic evaluation. Echocardiography should always be performed. MRI is necessary for evaluating the lumbosacral spine and assessing the pelvic anatomy and musculature. Historically, it has been well recognized that sacral anomalies are common. Peña (1989) noted a normal sacrum in only 35% of his 54 patients, and Jaramillo et al. (1990) reported sacral agenesis in 40% of Hendren's 65 patients. De Filippo et al. (1999) found 10 of 21 patients with imperforate anus or cloaca to have an abnormality of the sacrum and spine. **With the use of MRI, spinal cord abnormalities have been more commonly detected, with an incidence as high as 43%** (Jaramillo et al., 1990). Hendren (1998) found that one-third of his patients had a tethered spinal cord. Skin stigmata in the lumbosacral region were absent in 8 of 10 patients with spinal cord tethering in a report by Morimoto et al. (2003). MRI has also been very helpful in defining the level of the rectal atresia and in identifying the degree of sphincteric muscle development (Sato et al., 1988).

Because of the complexity of the anatomy and the frequency of hydrometrocolpos, a child with a cloacal anomaly often needs endoscopy early as a separate procedure to decompress the vagina and bladder and to define the anatomy. As a general rule, visualization of the vagina (or vaginas) is easily accomplished, but entry into the bladder can be very difficult and even impossible at times in a neonate because it is compressed very anteriorly by the distended vagina. The vagina should always first be emptied. Identification of the rectal fistula can also be difficult at times. Once it is located, mucus and fecal material should be irrigated from the colon, which can be done by irrigation through the scope in combination with irrigation through the mucous fistula of the divided colostomy. Passage of a small catheter through the mucous fistula when present can be very help in defining the location of the rectal confluence. The length of the urethra to the vaginal and rectal confluence and the length of the common cloacal channel should be documented. The length of the common channel is helpful in cloacal patients in predicting fecal continence outcomes (Peña et al., 2004).

Surgical Reconstruction of Disorders of Sex Development and Urogenital Sinus

Initial Management, Timing, and Principles

The majority of children born with a urogenital sinus have genital ambiguity, and this should be initially evaluated by the multidisciplinary DSD team. It is extremely important that the family be made aware of all controversies surrounding the medical and surgical management of these children. Certainly, most families, physicians, and surgeons have historically made the decision to proceed with early surgical procedures to “normalize” the child to allow what was thought to be positive psychosocial adjustment (Schober, 1998). This was thought to relieve the parents’ distress and improve their outlook toward their child, although there is limited evidence for this. The thought has been that raising a child with genital ambiguity would be extremely difficult (Thomas, 2004). Creighton et al. (2012) noted that the idea of “doing nothing” can be a stressful concept for parents. Trakakis et al. (2009) stated that surgical treatment must be offered between 2 and 6 months because the tissues are maximally pliable and psychological trauma is minimized. Clearly, gender assignment when the individual's ultimate gender identity is unknown is a challenge and is at the core of this controversy (Mouriquand et al., 2014). A number of advocacy groups including InterACT, Human Rights Watch, the United Nations, three former Surgeons General, and some physician groups have questioned the wisdom of early surgery. In fact, most of these groups have supported a moratorium on surgery for genital atypia until the patients are at an age where they can express their desire for or against surgery. This exact age has yet to be defined. It is obvious that informed consent is impossible with an infant, and many believe that the decision for genital surgery is a right of the patient, not the parents. The ethical issues involving parents’ rights and responsibilities to make decisions for their child remain unresolved (Lee and Witchel, 2002). Unfortunately, the infant is the passive center of the team but ultimately has the most important voice (Yerkes and Rink, 2010). In 2002, Rangecroft noted that data on the impact of raising a child with genital ambiguity are still lacking (Rangecroft, 2002). Regardless of one's personal beliefs, all pros and cons of both surgery and observation must be presented to the parents without bias, and certainly observation with psychological and peer support must be an option (Creighton and Liao, 2004). However, this same psychological and peer support should be given to the parents who do elect to proceed with early surgical management (Rink and Szymanski, 2015).

With current operative techniques, excellent cosmetic results can be achieved with feminizing genitoplasty for the virilized female. Although anatomic appearance likely plays a role, it must be remembered that one's sexual identity is a result of many factors (Mouriquand et al., 2014). It is known that the brain is the dominant organ in sexual orientation (Woodhouse, 2004). Schober (1999) has pointed out that little is known about how adults adjust to genitoplasty, nor are there any data on what path infants undergoing genitoplasty might have chosen had the opportunity been given to them as adults. Feminizing genitoplasty is unique in that outcomes of early surgery are not known for perhaps 20 years, and the results reported at the time of this writing may be based on techniques no longer used. However, it is clear that genital surgery does not “cure” a DSD. It is known that women with CAH are less satisfied with their genitalia than control subjects whether they had undergone an operation or not (Nordenskjöld et al., 2008).

Unfortunately, a dilemma remains for DSD surgery because there is no absolute correct answer at this time. Information should **never** be withheld from the parents. Secrecy from the family or patient has no place in the care of DSD. Counseling should always be provided. At our institution, all parents meet with a clinical psychologist. Parents must be informed of all risks and options and be made aware of the current state of knowledge. They should also be given access to all major advocacy groups regardless of the group's stance on surgery. There has been a changing of attitudes regarding early reconstructive procedures particularly with regard to clitoral surgery (Lee et al., 2006). Szymanski et al. (2018) evaluated parental concerns and decision making when considering surgery in children with CAH for 16 consecutive families. The largest concerns were not surgical but on life-threatening and developmental effects of CAH and the side effects of necessary medications. One of the least prioritized issues was the child not being involved in the decision making. Our group also evaluated decisional regret (DR) in 39 CAH parents after genital surgery and noted 20.5% of parents to have some DR after genitoplasty (mild to moderate) with no parent having severe DR. This DR was less than that found in parents after hypospadias, adenotonsillectomy, or pediatric cancer treatment, and no parent preferred delayed surgery (Szymanski et al., 2017).

For the purposes of the remaining description of surgical techniques, it is assumed that all parties (parents and multidisciplinary team as described earlier) agree that surgery is warranted. The techniques described are applicable to all ages from infants to adults.

Children born with a urogenital sinus associated with genital ambiguity usually have clitoral hypertrophy, some degree of fusion and anterior displacement of the labia majora with absence of the labia minora, and a common urogenital sinus (Fig. 49.11). Furthermore, it has been shown that there is significant variability in what is considered normal clitoral, vaginal, and labial size (Akbiyik and Kutlu, 2010; Lloyd et al., 2005). **Genital reconstruction has historically addressed all of these issues and therefore has generally involved three steps: (1) clitoroplasty, (2) labioplasty, and (3) vaginoplasty.**

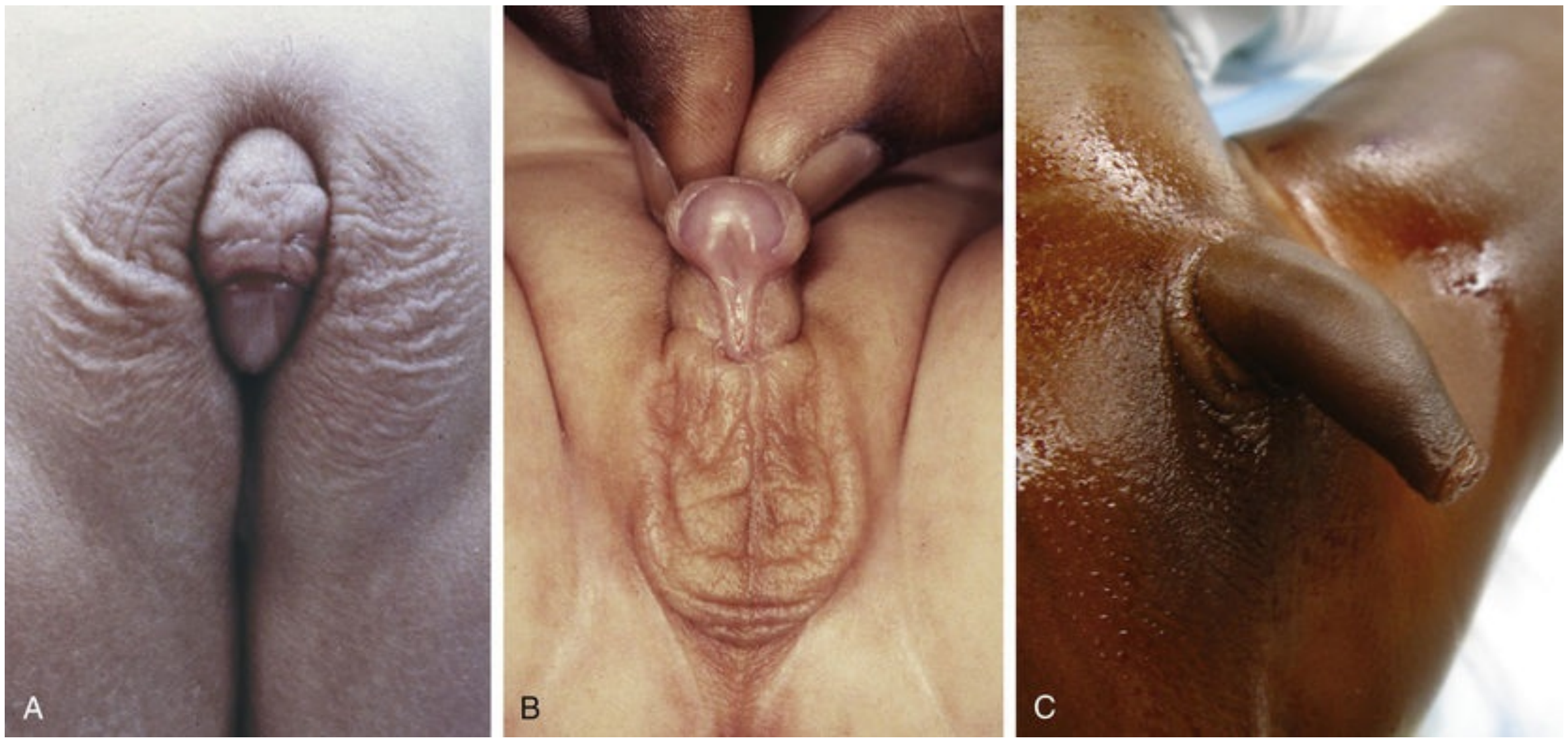

FIG. 49.11 External appearance of genitalia in congenital adrenal hyperplasia. (A) Moderately virilized with incomplete labioscrotal fusion. (B) Moderately virilized with complete labioscrotal fusion. (C) Severely virilized.

Historically, clitoroplasty has been performed early in life, but this has again been challenged by DSD advocacy groups and some physicians. In the mid-1900s, there was not thought to be an optimal timing for reconstruction (Jones and Jones, 1954; Lattimer, 1961), but more recently, clitoral reconstruction has been carried out progressively earlier. Gross et al. (1966) and Spence and Allen (1973) noted that clitoral surgery can ideally be performed when the child is 1 year of age. By the 1980s, clitoral surgery was recommended as early as the first few months of life (Snyder et al., 1983). More recently, de Jong and Boemers

(1995) reported surgical correction at 1 to 3 weeks of age. Parents are now less likely to choose surgery for minimal clitoral hypertrophy (Lee and Witchel, 2002), and a consensus document recommends surgery for only the more severe degrees of hypertrophy (Prader III to IV) (Hughes et al., 2006). In a recent review on timing, it was suggested that clitoral surgery be considered in infancy for Prader score of III or greater (Speiser et al., 2010). The most recent reports agree with early surgery for severe clitoral hypertrophy (Acimi, 2013; Braga and Salle, 2009; Escala Aguirre et al., 2009; Guarino et al., 2013; Speiser et al., 2010; Vidal et al., 2010; Willihnganz-Lawson et al., 2013). Johannsen et al. (2010) noted a higher satisfaction with clitoral function the younger the age at clitoral surgery. However, clitoral surgery, whether recession or resection, is overwhelmingly the most controversial component of the genital atypia management debate.

The optimal timing for vaginoplasty also continues to be debated. It is important to remember that the vagina serves no function in childhood. Some have based the timing partly on the level of the vaginal confluence. A consensus statement on CAH from the Lawson-Wilkins Paediatric Endocrine Society (LWPES) and the European Society for Pediatric Endocrinology (ESPE) recommends surgery in the 2- to 6-month-old range for those with a high vaginal confluence, and surgery between 12 months and adolescence is not recommended (Joint LWPES/ESPE CAH Working Group, 2002). **“There is inadequate evidence currently in relation to establishment of functional anatomy, to abandon the practice of early separation of the vagina and urethra”** (Hughes et al., 2006). In a poll of delegates at the Fourth World Congress of the International Society of Hypospadias and Disorders of Sex Development, surgery before 2 years of age was preferred by 78% of surgeons, and most suggested single-stage clitoroplasty, vaginoplasty, and labioplasty (Yankovic et al., 2013). In an effort to determine current practice in the United States, Roth et al reviewed the Pediatric Health Information System (PHIS) database, which is collaborative data collected from 43 free-standing pediatric hospitals. Using a timeframe of 2004 to 2014, they identified 4617 unique female CAH encounters with 544 undergoing surgery (Roth et al., 2018). They noted the average age of genital surgery to be 9.9 months, with 92% having vaginal surgery, 48% having clitoral surgery, and 85% having perineal surgery. Readmission for any reason was noted in 13.8%, with 4 % having an unidentified surgical complication. Several studies have noted that the overwhelming majority of CAH patients or parents are happy with their decision for early genital surgery, and those who had later surgery generally wished it had been done earlier (Binet et al., 2016; Daynor et al., 2004; Fagerholm, 2011; Marei et al., 2015; Szymanski et al., 2017; Wisniewski et al., 2004).

Simultaneous performance of clitoroplasty, vaginoplasty, and labioplasty has been the historical standard practice for a child with a low (distal) vaginal confluence. Two separate schools of thought have been put forth for a high vaginal confluence. Some believe that the high rate of vaginal stenosis warrants delay of vaginal surgery until after puberty, which also avoids any need for vaginal dilation (Alizai et al., 1999; Creighton et al., 2001; Escala Aguirre et al., 2009; Rangecroft, 2002; Snyder et al., 1983; Sotiropoulos et al., 1976; Thomas, 2004). Others have recommended that vaginoplasty for the small hypoplastic vagina (<3 cm) be delayed also (Salle et al., 2012). Others have found the incidence of vaginal stenosis to be higher in those who undergo surgery after puberty rather than during infancy (Eroglu et al., 2004). **There is some technical surgical advantage to combining vaginoplasty, regardless of the vaginal location, with clitoroplasty and labioplasty in a single-stage procedure. This allows the surgeon flexibility in using redundant phallic skin for the reconstruction, which is compromised when the skin has previously been mobilized** (de Jong and Boemers, 1995; Gonzalez and Fernandes, 1990; Hendren and Atala, 1995; Mandell et al., 1988; Passerini-Glazel, 1998; Rink et al., 1997; Vidal et al., 2010)**. Lean et al.** (2007) **found any plans for one-stage repair to give better results. Furthermore, several authors have noted that maternal estrogen stimulation of the child's genitalia results in thicker vaginal tissue that is better vascularized, thus making it easier to perform early vaginal mobilization** (Braga and Salle, 2009; de Jong and Boemers, 1995; Donahoe and Gustafson, 1994; Eroglu et al., 2004; Farkas et al., 2001; Hamza et al., 2001; Hensle and Bingham, 2002; Passerini-Glazel, 1989; Rink and Adams, 1999). Those in favor of pubertal surgery generally perform it for the high vagina and note the advantage of the patient being able to provide consent (Escala Aguirre et al., 2009; Guarino et al., 2013). As in infants, the estrogen stimulation at puberty may be advantageous. Schober (2004) has noted that estrogen has a beneficial effect on tissue healing that, along with vaginal growth and distention, may result in improved outcomes, making puberty the best opportunity for reconstruction. Still others believe that a hybrid of these two—clitoroplasty and labioplasty in infancy with vaginoplasty at puberty—is most appropriate, particularly in the setting of a high vaginal confluence (Creighton and Farhat, 2005; Escala Aguirre et al., 2009; Guarino et al., 2013). The surgery is not easier, and there is no evidence that actual healing is better at puberty (Braga and Salle, 2009). **At the time of this writing, there is no universal agreement among those caring for DSD children on optimal timing for vaginoplasty, and sadly there are no adequate data comparing early versus late surgery.**

The clitoris is a sexual organ; therefore, when performing clitoroplasty, every effort is made to not only provide excellent cosmesis but also retain normal clitoral innervation for optimal sexual gratification. Clitoral surgery has undergone significant evolution since Hugh Hampton Young's work in 1934 (Young, 1937). Initial efforts were primarily directed at not just amputating the clitoris but also completely excising all clitoral tissue to avoid any later painful erection (Gross et al., 1966; Hendren and Crawford, 1969; Jones and Jones, 1954). Clitoral amputation was based on reports by Hampson (1955) and by Money (1955), who noted that the clitoris was not necessary for normal sexual response. As recognition of the importance of the clitoris evolved, several ingenious clitoral recession techniques that preserved the innervation and all clitoral tissue were reported. Lattimer (1961) recessed the clitoris in subcutaneous fat and buried it beneath the skin. He also denuded the glans epithelium, which would not be recommended today. Kaplan (1967) reported an interesting technique of splitting the two corpora apart and performing closure in a transverse Heineke-Mikulicz fashion. Pellerin (1965) and also Randolph and Hung (1970) buried the corpora beneath the pubis. Efforts to preserve the glans based on a flap were attempted as early as the 1930s by Young, but the glans sloughed (Young, 1937). Schmid (1961) was the first to report excising corporeal tissue yet preserving the neurovascular bundle with the glans intact. Kumar et al. (1974) later noted a similar technique proposed by Kiefer the same year. Spence and Allen (1973) excised all of the clitoral shaft but left the glans intact to survive from the attached ventral urethral plate, but this technique excised all of the neurovascular bundle. **Virtually all techniques since then have been based on Schmid's preservation of the neurovascular bundle** (Barrett and Gonzales, 1980; Glassberg and Laungani, 1981; Mollard et al., 1981; Rajfer et al., 1982; Shaw, 1977). Although the glans often did well with these techniques, shrinkage and devascularization occurred at times. **Kogan et al.** (1983) **reported subtunical excision of the erectile tissue by incising laterally through the Buck fascia to resect the erectile corpus cavernosa tissue.** Clitoroplasty techniques exhibited only minor technical advances until the demonstration of the neurovascular anatomy of the clitoris by Baskin et al.

(1999). This work suggests that a ventral, rather than lateral, incision would preserve not only the main dorsal neurovascular bundle but also the neural branches that fan out laterally (Fig. 49.12). Currently, much research is under way to further evaluate clitoral neuroanatomy, and develop techniques to evaluate sexual sensitivity. I believe that the Buck fascia with its neurovascular bundle and glans should always be preserved. Pippi Salle reported a technique whereby the corporeal bodies are mobilized and disassembled and then placed in the labial fat. This has the potential option of later use for reconstruction of the phallus should the patient choose a male gender identity (Pippi Salle et al., 2007) although the results of this remain unknown.

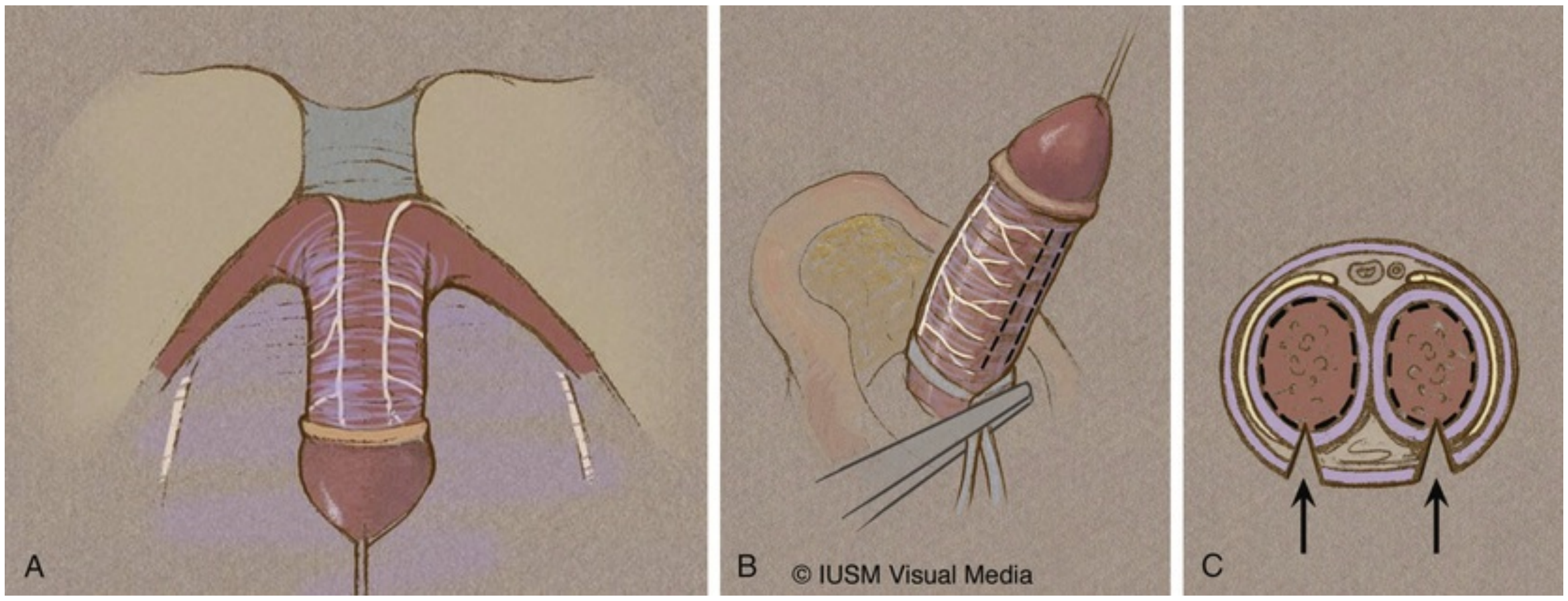

FIG. 49.12 Hypertrophied clitoris with dorsal nerves and branches. (A) Anteroposterior view. (B) Side view. (C) Cross-sectional view. (© Indiana University Medical Illustration Department.)

Vaginoplasty techniques have similarly evolved, with all repairs based on a few landmark reports. **Almost every vaginal repair today uses a posteriorly based perineal flap proposed by Lattimer and originally described by Fortunoff et al. in 1964.** This wide-based "Fortunoff flap" has been modified to a more omega-shaped flap that has resulted in improved cosmesis (Freitas-Filho et al., 2003; Jenak et al., 2001). In 1969, **Hendren and Crawford reported a "pull-through" vaginoplasty for a high vaginal confluence.** Their efforts to establish the location of the vaginal confluence as the determining factor for the type of vaginoplasty remain the basis for all vaginoplasties today. Vaginal reconstruction techniques now generally take the form of one of four types:

1. **The "cut-back" vaginoplasty is rarely used today. I and most authors**

believe it is only appropriate for simple labial fusion. However, Escala Aguirre et al. (2009) **recently reported its use in Prader I and II children.**

2. The “flap” vaginoplasty is applicable to a low (distal) vaginal confluence. In this procedure, the posterior walls of the sinus and vagina are opened, but the anterior wall of the vagina is left intact. The posterior perineal flap fits into the opened vagina. **This procedure does not change the level of confluence; it simply widely opens the introitus and urogenital sinus** (Rink and Adams, 1998). Mild degrees of female hypospadias are common with this technique. I and others believe that a flap vaginoplasty should never be used for patients with a very high vaginal confluence because it may result in a short hypospadiac urethra, vaginal voiding, infections, and even incontinence (Hendren and Atala, 1995; Rink and Adams, 1999).
3. **The “pull-through” vaginoplasty may be used for any level of confluence but is generally reserved for a very high confluence.** In this procedure, the vagina is separated from the urogenital sinus, and the sinus is used to create a urethra. The mobilized vagina may reach the perineum, but in most cases skin flaps have been required.
4. **Complete vaginal replacement can be achieved by several techniques, but this is used only for a rudimentary or absent vagina.**

Labioplasty techniques also continue to evolve. In CAH and other DSD states, the labia minora are absent and the labia majora are superior to the new vaginal introitus. Labia minora are created by using the split phallic skin as described by Marberger (1975). Both the labia majora and labia minora should be moved inferiorly by YV-plasty to create a normal cosmetic appearance of the vagina now located between the labia (Hendren and Donahoe, 1980; Rink and Adams, 1998) (Fig. 49.13).

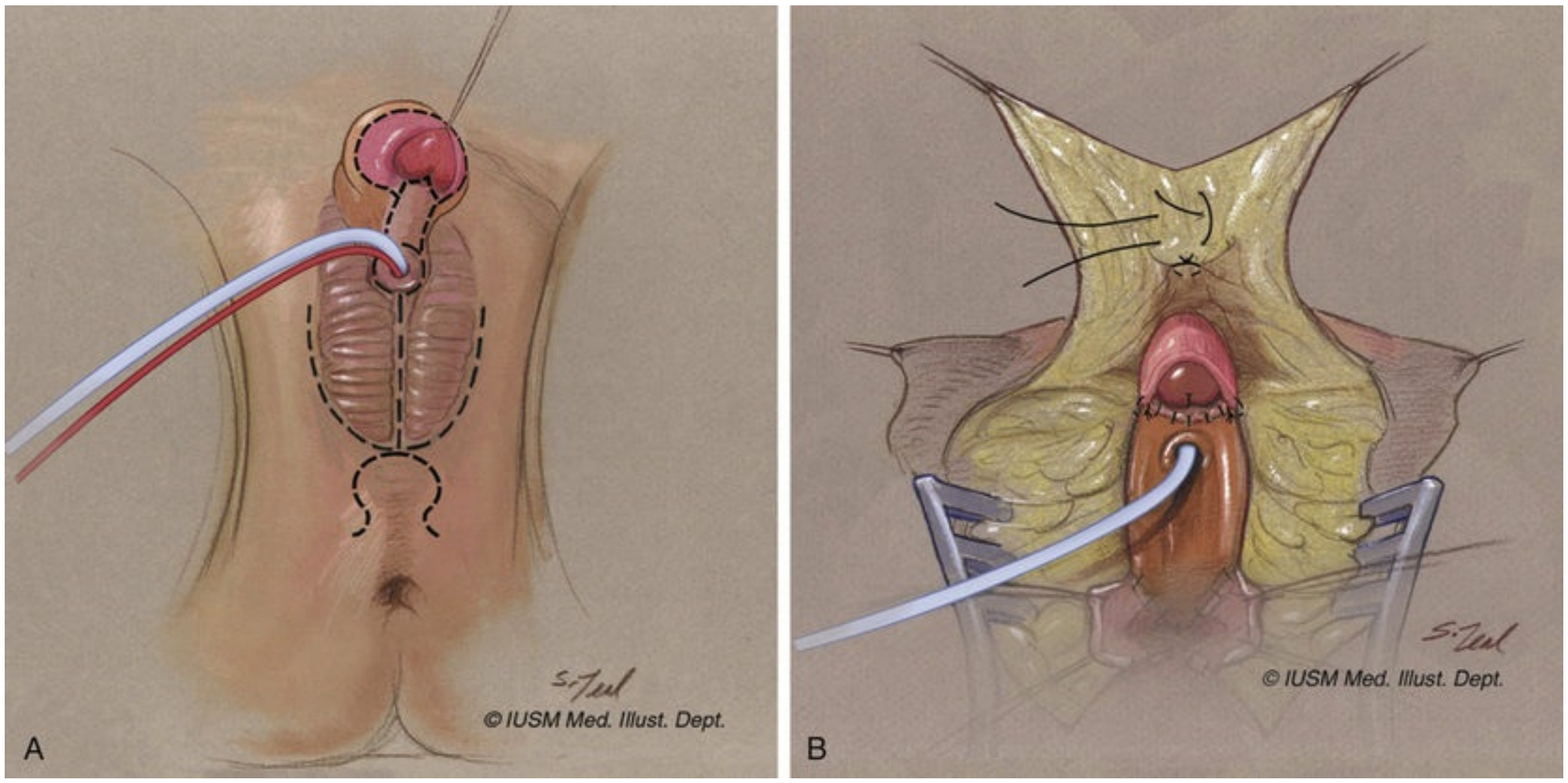

FIG. 49.13 Labioplasty. (A) Proposed incision lines for feminizing genitoplasty. Note preservation of skin cuff around glans clitoris that will be used to fashion clitoral hood. (B) After recession of the glans clitoris, the preputial skin is partially split to create the labia minora. The proximal preputial skin is plicated along its undersurface to create a "hooded" appearance to the segment of skin that will cover the glans. (© Indiana University Medical Illustration Department.)

A balanced presentation to the patient/family of all pros and cons of surgery versus no surgery is imperative, and this should be presented with the multidisciplinary team's involvement. All current data should be made available to the parents and the risks associated with each path clearly defined. The ultimate decision currently lies with the parents in concert with their multidisciplinary DSD team. These parental rights have been supported by the recent rulings of the American Medical Association's Council on Ethical and Judicial Affairs (CEJA) after 2 years of review. They rejected the idea of a moratorium on surgery. The new Endocrine Society Guidelines for CAH state that all surgical decisions remain the prerogative of families in joint decision making with experienced surgical consultants (Speiser et al., 2018). However, some advocacy groups view these parental decisions as a human rights violation for the child's rights. At the time of this writing, parental rights are currently being challenged in a number of states (California, Connecticut, Nevada, Texas), where bills have been proposed to stop any genital surgery for DSD cases if not medically necessary until the patient is of age for consent. In the following sections, the techniques described are applicable to either infants or adolescents.

Current Operative Techniques for Female Disorders of Sex Development and Urogenital Sinus Repair

Preoperatively, it is important to ensure that the patient is metabolically stable, particularly a child with CAH. Most children with CAH do not require any bowel preparation, but if there is an indication of a high confluence, complete bowel preparation with a polyethylene glycol–electrolyte solution (GoLYTELY) may be warranted. All children receive preoperative broad-spectrum antibiotics. Children with CAH must undergo “stress-dose” steroid replacement at the time of surgery. After general anesthesia, endoscopy is performed as described previously. **After passing a Fogarty catheter into the vagina, the balloon is inflated, and the catheter is clamped and left indwelling. A Foley catheter is then anchored in the bladder.** Both are kept sterile, and the child's skin is prepared with an antibiotic solution. Many surgeons prefer to place the child in lithotomy position, but I have found that this position limits vision to only the surgeon, hinders teaching, and does not allow manipulation of the child if a posterior or abdominal approach is unexpectedly needed. At the Riley Hospital for Children, all children undergo a complete lower body preparation from nipples to feet. The child's legs are wrapped, and the lower part of the body is passed through the aperture in the drapes; this facilitates access to the entire perineum and abdomen and further allows the child to be rotated either supine or prone during the procedure (Fig. 49.14). In postpubertal patients, such total body preparation may be difficult, necessitating the lithotomy position.

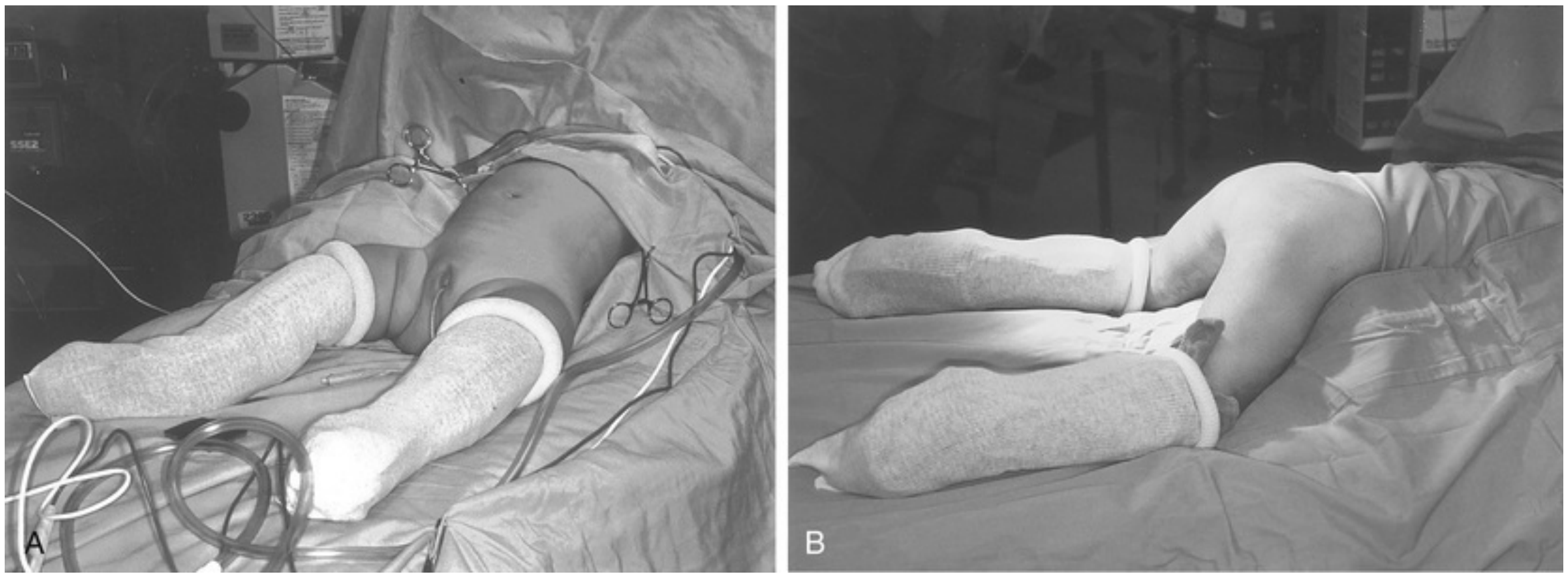

FIG. 49.14 Total lower body preparation allows both supine (A) and prone (B) approaches. (From Rink RC, Adams MC. Feminizing genitoplasty: state

of the art. *World J Urol*. 16(3):212–218, 1988.)

Key Points: Urogenital Sinus Anomalies—Reconstruction

- The three historical steps in surgical reconstruction are clitoroplasty, vaginoplasty, and labioplasty.
- As noted earlier, clitoroplasty is very controversial in infants. When performed, the glans and tunics with their neurovascular bundles must be preserved. Excision of erectile tissue, when performed, must be from the ventral aspect only.
- Vaginoplasties consist of four types: *cut-back* (generally no longer used), *flap* for a low- to mid-level confluence, *pull-through* for a high confluence, and *vaginal replacement* for a rudimentary or absent vagina. The timing of vaginoplasties is controversial.
- Labia minora are absent in urogenital sinus patients with genital ambiguity. They are reconstructed from phallic skin. The anteriorly located labia majora should be moved inferiorly.
- It is helpful to place a Fogarty catheter with the balloon inflated in the vagina. For a low confluence, an omega-shaped perineal flap provides better cosmesis. The flap is sewn into the posteriorly opened sinus, and this flap must reach to the more proximal normal-caliber vagina.
- For a high confluence, the vagina may require separation from the urinary tract at its confluence and is “pulled through” toward the perineum. The sinus opening is closed to create a urethra. With a very small, very high confluence vagina, the surgeon should strongly consider waiting until puberty for vaginoplasty.

Low Vaginal Confluence: Clitoral Hypertrophy

The vast majority of children who undergo surgery for DSD or urogenital sinus conditions have a low vaginal confluence amenable to flap vaginoplasty. They usually have clitoral hypertrophy. As noted earlier, the decision to perform clitoroplasty is very controversial in infants, but the techniques are applicable to any age. This decision should only be made after careful consideration and explanation to the patient/family of all pros, cons, risks, benefits, and controversies. Clitoroplasty and classic flap vaginoplasty are described. With the child in the supine position, a traction suture is placed through the glans, and the proposed incisions are outlined with a skin scribe. Along these lines, 0.5% lidocaine with 1 : 200,000 epinephrine is injected subcutaneously for hemostasis. The proposed incision around the glans, leaving the inner surface of the prepuce intact, is drawn along with parallel longitudinal lines on either side of the ventral mucosal strip (urethral plate equivalent) extending around the meatus. A perineal omega-shaped flap with the apex near the meatus is outlined. A Y-shaped incision line is drawn around the inferior aspect of each labia majora. The incision begins on the dorsal aspect of the clitoris, and all inner preputial skin is left intact for later construction of a clitoral hood. This skin has been shown to be second only to the glans in sensitivity (Schober and Ransley, 2002). The clitoris is degloved while keeping the ventral "urethral plate" intact with the meatus. Dissection is carried out to the level of the bifurcation of the corporeal bodies ventrally and the pubis dorsally, and care should be taken to not injure any neurovascular tissue (see Fig. 49.12). It is important to recognize that the clitoral arterial supply branches from the internal pudendal artery from Alcock's canal near the ischial tuberosity. These arteries course ventrally and are on the medial aspect of the bifurcated corpora, where they then course dorsally along the phallic shaft (Schnitzer and Donahoe, 2001). The clitoral neural bundles ascend along the ischiopubic rami and meet as paired bundles that pass along the dorsal surface and then pass largely intact into the glans (Baskin et al., 1999; O'Connell et al., 2005). My current clitoroplasty technique, regardless of patient age, is described, but, regardless of technique, the just-described clitoral innervation must not be disturbed.

A tourniquet may be placed at the base of the clitoris, or the bifurcated corpora may be compressed against the pubis with Kitner dissectors. Longitudinal incisions are then made through the Buck fascia on the ventralmost aspect of each corporeal body (Fig. 49.15); the incisions extend from the glans to the bifurcation to expose the corpora cavernosa tissue, which is dissected (often teased) from the tunics. The tunics are left undisturbed, except for the ventral incision. **No tunical tissue is excised. The dorsal neurovascular bundle should not be mobilized or disturbed in any way.** The proximal ends of the erectile tissue only are suture ligated. Other techniques involve mobilization of the neurovascular bundles from the corpora, but I believe this is more likely to injure clitoral sensitivity and vascularity. If mobilization is done, Braga and Salle

(2009) pointed out the need to dissect in the exact plane (below the second layer of the Buck fascia just beneath the tunica albuginea) to avoid neurovascular injury. Efforts to decrease the size of the glans are controversial and, if attempted, should be done with great caution. Studies by Juskiewenski et al. (1982) and Baskin et al. (1999) suggest that any glans excision should be performed ventrally near the midline (similar to hypospadias glans wings). The glans is innervated by perforating branches entering at the dorsal junction of the glans and corpora (Baskin et al., 1999). Excision of glanular epithelium to conceal the glans is to be avoided because the sensory neuropeptides are located just beneath this layer. **Remember there are no data to suggest that a large glans or clitoris is detrimental to sexual function.** The glans is now secured to the coronal stumps. In my experience, a glans sewn to the pubis results in an abnormally high prominent position (Rink and Yerkes, 2001). Pippi Salle et al. (2007) described an alternative technique whereby the corpora are dissected from the neurovascular bundle, separated, and buried beneath the labia, which allows reversibility of the clitoroplasty in those patients with later gender dysphoria.

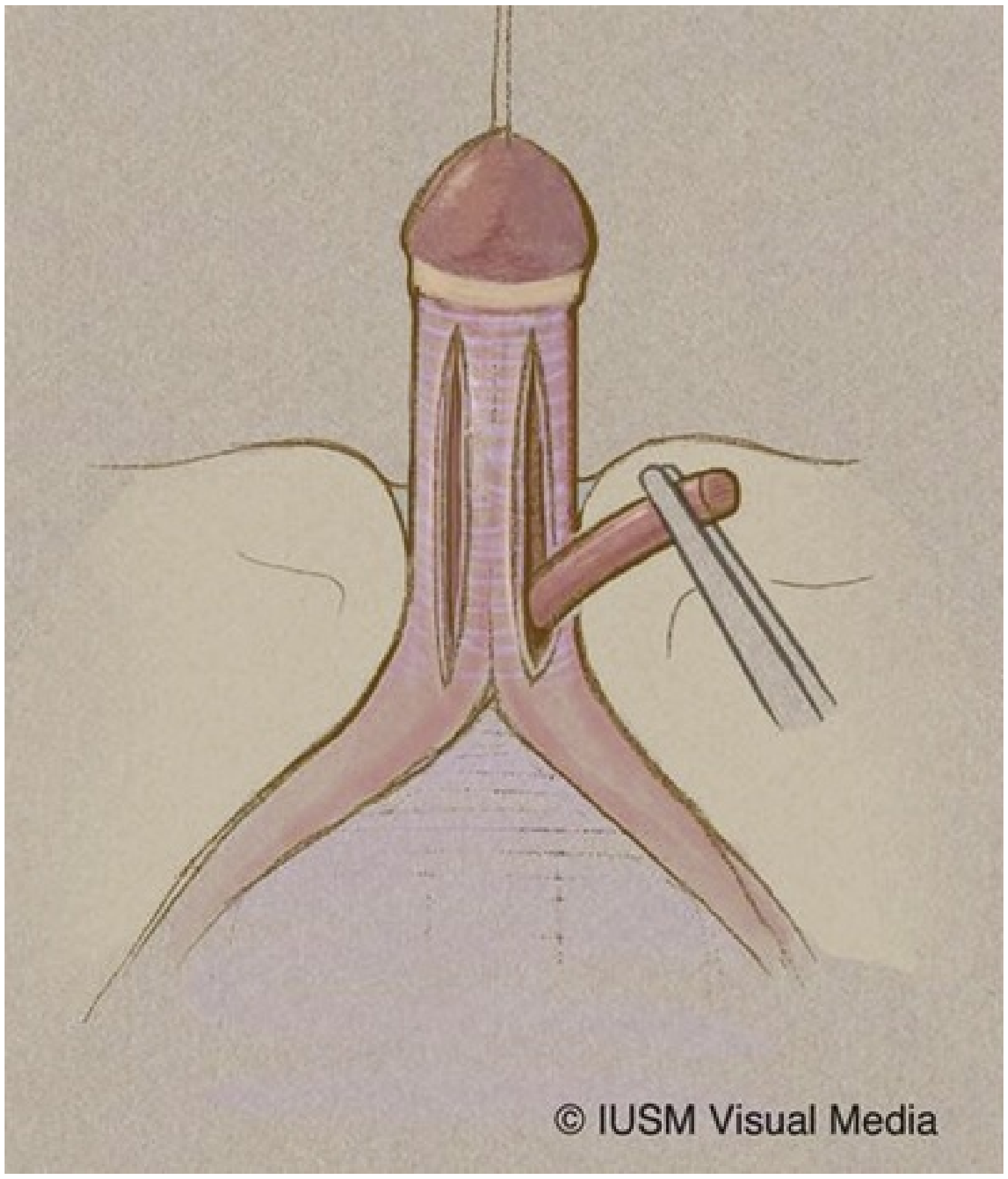

FIG. 49.15 Proposed clitoral incisions. Note the ventral location. (© Indiana University Medical Illustration Department.)

With clitoroplasty completed, the flap vaginoplasty is started. The previously outlined omega-shaped flap is incised, and the underlying fat is mobilized with the flap to expose the urogenital sinus. The flap must be made long enough to provide a tension-free anastomosis to the vagina and wide enough to provide a normal-caliber introitus without compromising the blood supply of the perineal body. It should not be redundant because this will create an obstructing mound of tissue at the introitus. The posterior wall of the sinus and vagina is now dissected free from the underlying rectum. This initial posterior step in separating the vagina from the rectum is the most difficult. With stay sutures in the meatus, the posterior wall of the sinus is opened in the midline and extended proximally into the posterior wall of the vagina. **The distal third of the vagina is usually narrowed; therefore, the posterior wall incision must be carried proximally until a normal-caliber vagina is encountered.** Sutures are placed individually through the perineal flap and then through the split posterior wall of the vagina and tied.

The mobilized phallic skin is unfurled and divided longitudinally in the midline while stopping well short of the base to allow a clitoral hood. This tissue at its base is incorporated with the preputial skin to create a clitoral hood. Labia minora are now created with this split clitoral skin, which is moved inferiorly and anastomosed to the preserved ventral plate and the lateral vaginal wall. I have found that the inferior placement of these flaps along the side of the vagina often results in an M-shaped clitoral hood, which can be overcome by plicating the dermis of the new hood to give it a more normal inverted U shape. The proposed Y-shaped incisions are now made around the inferior aspect of each labia majora. The labia are mobilized and secured inferiorly alongside the vagina as a YV-plasty. The vaginal introitus should now reside between the labia minora and majora rather than appear as an isolated hole on the perineum.

High Vaginal Confluence: With or Without Clitoral Hypertrophy

Most believe that complete separation of the vagina from the urogenital sinus with a pull-through vaginoplasty, as proposed by Hendren and Crawford (1969)**, is the best solution to a high vaginal confluence.** Braga and Salle (2009) recommend it only when the urogenital sinus is longer than 3 cm. Fortunately, this complex situation is found in only about 5% of patients with CAH (Dumanian and Donahoe, 1992). This high confluence is more commonly seen in pure urogenital sinus abnormalities. As noted earlier, I agree with Ganesan et al. (2002) that in the urogenital sinus associated with CAH, the severely virilized child may appear to have a high vaginal confluence, but it is the shared common portion of the sinus that lengthens, and there is relatively minimal shortening of the urethra. It is this lengthened common sinus in combination with the appearance of a more malelike external sphincter that gives it a high confluence appearance (Ganesan et al., 2002). Although the concept of vaginal separation and pull-through vaginoplasty was a major advance, the operation as originally described frequently resulted in an isolated vaginal opening that appeared to be separate from the remainder of the genitalia, and a mucosal lining was lacking (Passerini-Glazel, 1989). It was also technically difficult because of poor vision at the critical points (Rink et al., 1997). Several authors have addressed these issues. Passerini-Glazel (1989) used the mobilized sinus by dividing it dorsally. When tubularized with the phallic skin and folded back toward the vagina, it would create a more normal cosmetic result and provide excellent coverage in the area of the vaginal separation while helping to prevent a urethrovaginal fistula. He later used this as a flap to form the anterior vaginal wall rather than completely tubularizing it (Passerini-Glazel, 1994). Gonzalez and Fernandes (1990) used the preputial skin to construct the vaginal vestibule and anterior wall.

The critical and most technically demanding aspect of a pull-through vaginoplasty is the separation of the anterior wall of the vagina from the urethra and bladder neck. There is no obvious plane of dissection, and great care must be taken to avoid injury to the urinary tract and its sphincteric mechanism. This area is also the most difficult to visualize, and poor exposure naturally leads to poor results, with the potential for a stricture, fistula, diverticulum, or retained distal vagina (Rink and Adams, 1998). Furthermore, this is an area of significant nerve supply for the vagina and urethra. Most surgeons have positioned the patient in the supine or lithotomy position. Several authors have reported means of improving exposure for this critical area. Passerini-Glazel (1989, 1994) mobilized the vagina transtrigonally in difficult cases but later reported that this approach is seldom necessary. Similarly, the anterior sagittal transanorectal approach, or ASTRA (division of the anterior rectal wall), has provided excellent exposure for separation of the vagina and certainly should be considered for patients with a very high vaginal confluence (Di Benedetto et al., 1997; Dòmini et al., 1997; Rossi et al., 1998; Salle et al., 2012). A diverting colostomy has not been necessary with the ASTRA technique. Hendren and Atala (1995) reported lateral mobilization of the rectum but later stopped because of the difficulty of this maneuver. Rink et al. (1997) reported a midline posterior prone approach with retraction but not division of the rectum that provides excellent exposure for critical aspects of the pull-through vaginoplasty and is described here.

Endoscopy with Fogarty and Foley catheter placement and total-body preparation are as described for a flap vaginoplasty. If the child has associated clitoral hypertrophy, the clitoroplasty is performed with the child supine as described earlier for a low confluence. The child is then rotated to the prone position. In a patient with a pure urogenital sinus, the procedure is started with the patient in the prone position. Although I have found this to be very beneficial to provide improved exposure, others have not found it necessary (Ludwikowski and González, 2013).

The perineal omega-shaped flap incision is made as previously described, and then the flap is retracted posteriorly, with dissection now carried out in the midline between the posterior wall of the sinus/vagina and rectum. As dissection proceeds proximally, the rectum is easily retracted with a small Deaver retractor

(Fig. 49.16) to expose the entire urogenital sinus without the need to divide the rectum. The entire length of the sinus may be divided in the midline posteriorly to the normal caliber of the vagina. The Deaver retractor is now placed in the vagina and with upward retraction easily exposes the anterior wall of the vagina at its confluence with the sinus. This allows dissection of the vagina from the urethra under direct vision (Fig. 49.17). The tissues are quite thin in this area, and one should always err on the side of the vagina. More proximally, the dissection becomes easier. Excellent vision is also provided for tubularization of the sinus to create a urethra, which is closed in two or three layers over a Foley catheter. The anterior wall of the vagina is now mobilized inferiorly, closer to the perineum. “Pull-through” vaginoplasty is often a misnomer because frequently the separated vagina will not reach the perineum. In this situation, skin flaps have been used to reach up to the vagina (rather than the vagina “pulled through” to the perineum). Preputial skin may be sewn to the spatulated anterior vagina, as described by Gonzalez and Fernandes (1990) or as modified by Acimi (Acimi, 2013) (Fig. 49.18). When preputial skin is not available, a buttock flap or a laterally based skin flap can be used (Dumanian and Donahoe, 1992; Moriya et al., 2009; Parrott and Woodard, 1991) (Fig. 49.19). The child is returned to the supine position, and the posterior perineal flap is anastomosed to the vagina as described for the flap vaginoplasty. I believe that skin flaps are best avoided because they are more likely to stenose and may be hair bearing. The use of urogenital tissue to create the flaps is more reliable, as in the Passerini-Glazel flap.

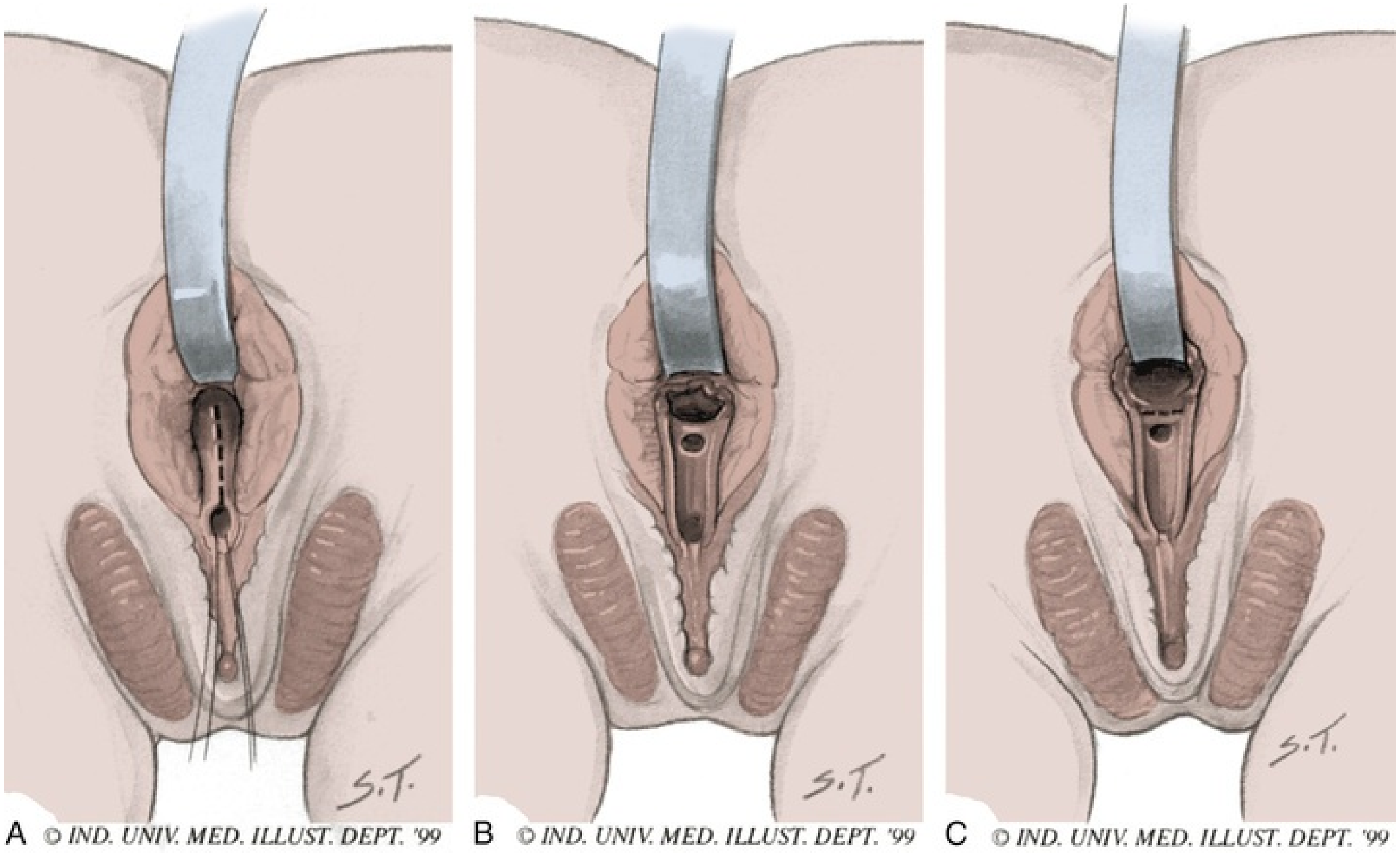
A
© IND. UNIV. MED. ILLUST. DEPT. '99
B
© IND. UNIV. MED. ILLUST. DEPT. '99
C
© IND. UNIV. MED. ILLUST. DEPT. '99

FIG. 49.16 (A) Posterior flap developed with the sinus exposed. (B) Sinus opened in the posterior midline. (C) Retractor in the vagina. (© 1999, Indiana University Medical Illustration Department.)

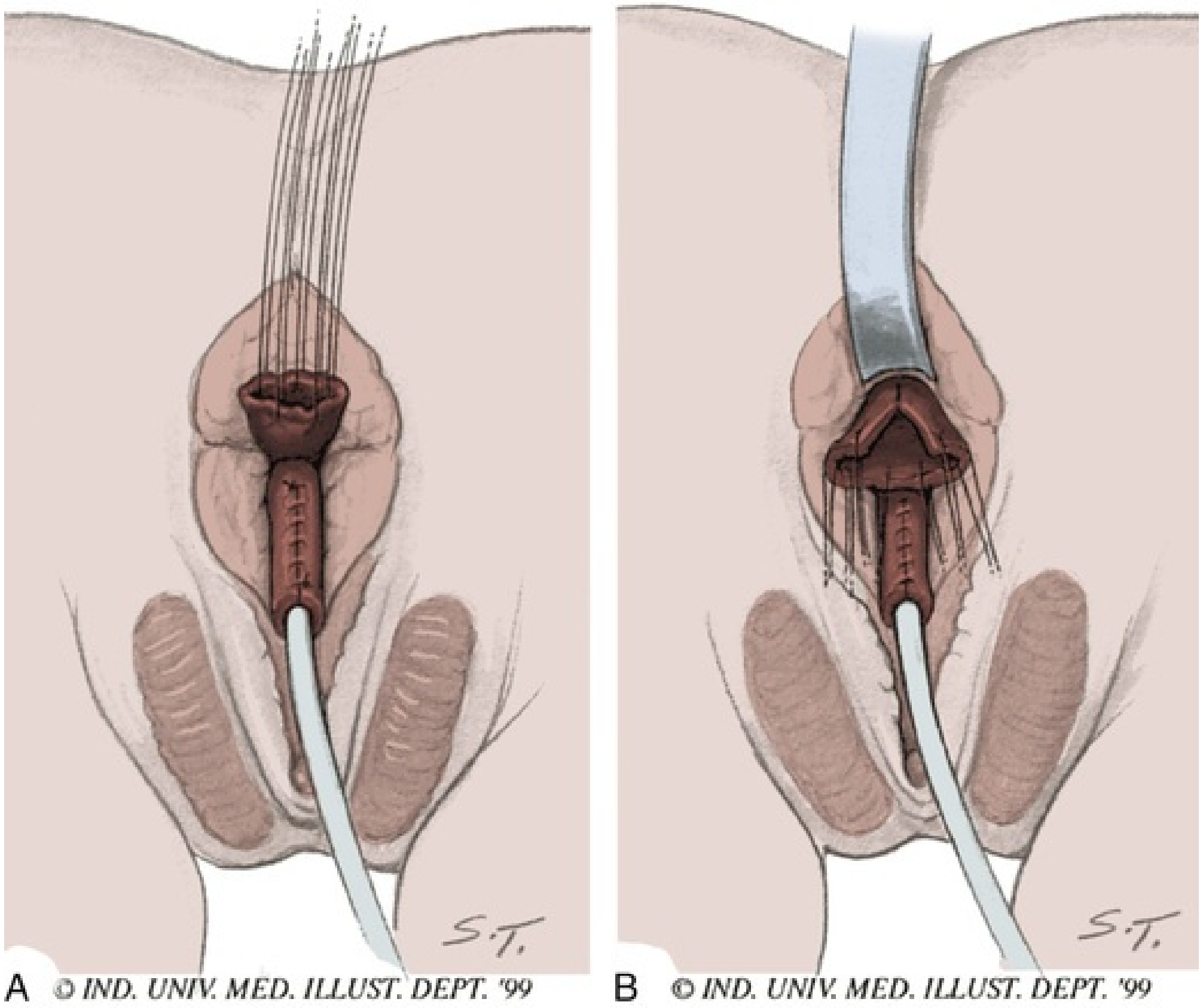
S.T.
A © IND. UNIV. MED. ILLUST. DEPT. '99
S.T.
B © IND. UNIV. MED. ILLUST. DEPT. '99

FIG. 49.17 (A) Vagina mobilized and the sinus tubularized to create a urethra. (B) Posterior vagina spatulated. (© 1999, Indiana University Medical Illustration Department.)

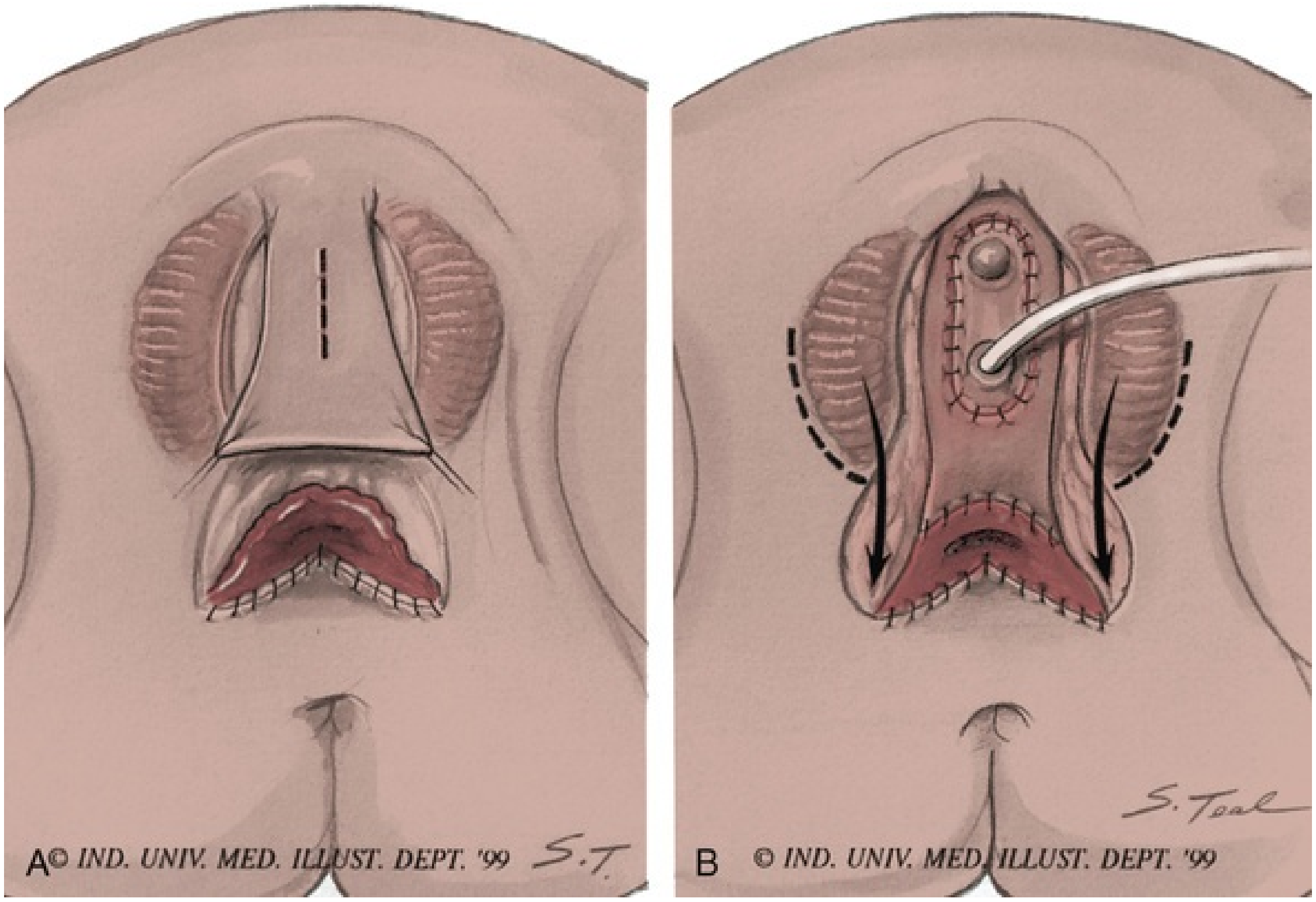
A © IND. UNIV. MED. ILLUST. DEPT. '99 S.T.
B © IND. UNIV. MED. ILLUST. DEPT. '99
S. Toal

FIG. 49.18 (A and B) Modified Gonzalez preputial flap to create an anterior vaginal wall. The posterior flap has been anastomosed to the spatulated vagina. (© 1999, Indiana University Medical Illustration Department.)

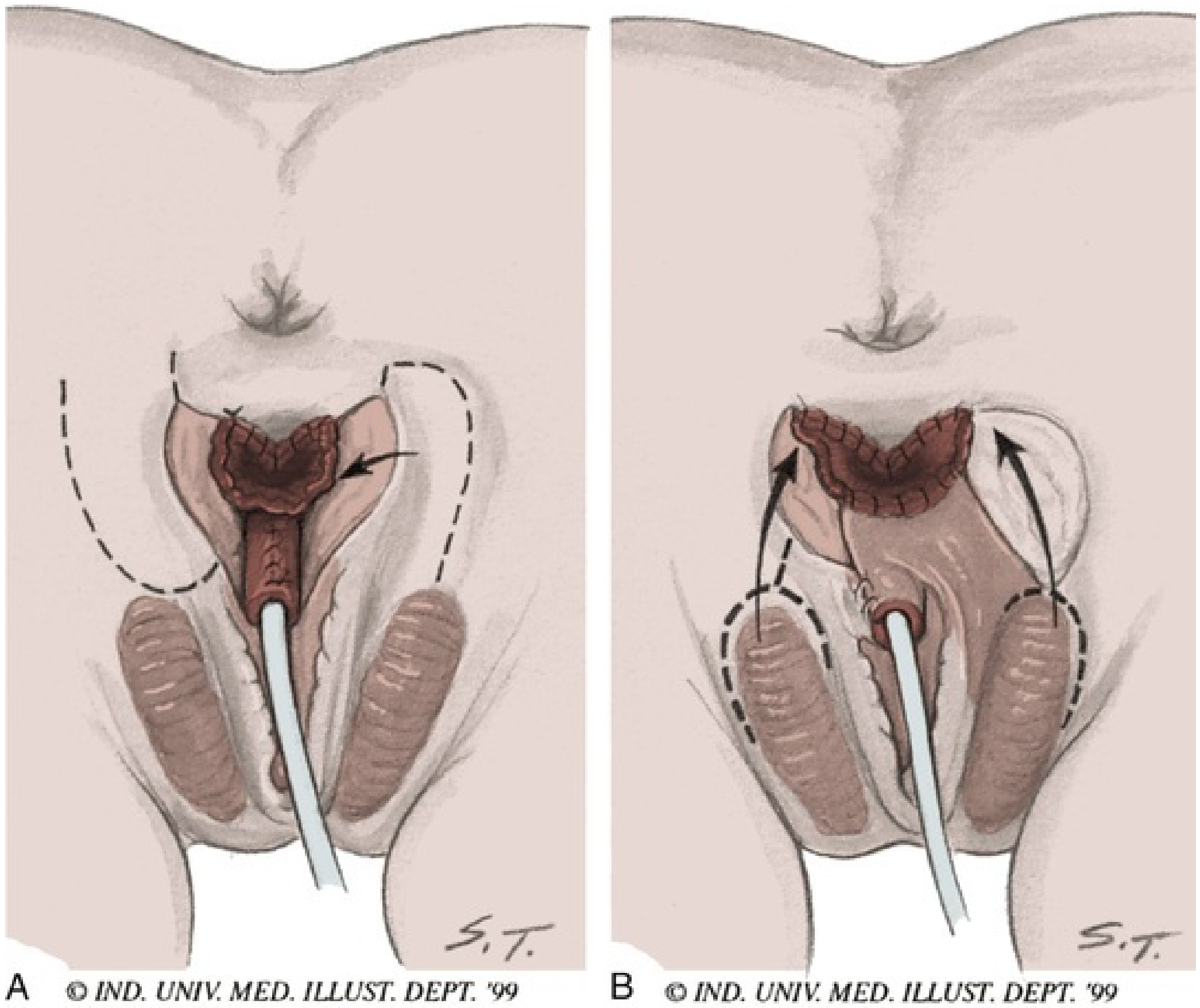
S.T.
A
© IND. UNIV. MED. ILLUST. DEPT. '99
S.T.
B
© IND. UNIV. MED. ILLUST. DEPT. '99

FIG. 49.19 (A and B) A buttocks- or labial-based flap may be used to create the anterior vaginal wall in a patient with a pure urogenital sinus. (© 1999, Indiana University Medical Illustration Department.)

Labioplasty is now completed as described earlier. If a laterally based flap is required for the anterior wall, posterior relocation of the labia majora may be performed at a later stage.

In patients with a high confluence, particularly if multiple flaps have been used, the legs are bound together loosely postoperatively to prevent tension on the flaps. Although rarely required for urogenital sinus associated with CAH, the high confluence in the pure urogenital sinus patient may benefit from the ASTRA procedure noted earlier. In this procedure, with the patient prone, the posterior wall of the rectum is divided in the midline allowing excellent exposure of the high vagina for its separation and mobilization. This does not affect rectal continence and does not require a temporary colostomy.

Total and Partial Urogenital Mobilization

In 1997, Alberto Peña proposed a maneuver called ***total urogenital mobilization***

(TUM) **as a means to complete the urogenital sinus component of a cloacal repair. In this procedure, the entire sinus is dissected circumferentially and mobilized toward the perineum.** Peña noted a decrease in operative time by 70%, a superior cosmetic result, and less risk for fistula, vaginal stenosis, or acquired vaginal atresia with TUM because vaginal separation is not usually required (Peña, 1997). Since Peña's original description, TUM has been applied to several disorders, such as urogenital sinus, female exstrophy, and penile agenesis (Kropp and Cheng, 2000; Ludwikowski et al., 1999; Rink et al., 2006). Both Peña (1997) and Ludwikowski et al. (1999) reported amputation of the mobilized sinus so that the vagina and urethra can be sewn flush to the perineum. **I have reported using the mobilized sinus to provide a mucosa-lined vestibule or a Passerini flap to cover the anterior vaginal wall when a pull-through procedure is performed** (Rink and Adams, 1999; Rink et al., 2006). Jenak et al. (2001) have since reported similar use of the mobilized sinus to create a mucosal vestibule, and Hamza et al. (2001) have noted that the sinus may be used as a Passerini-like flap. There have been two recent descriptions of use of the mobilized sinus to replace the posterior perineal-based skin flap with a sinus flap. In one, the sinus is split laterally and rotated posteriorly (Rink and Cain, 2002; Rink et al., 2006). In the other, the sinus is split in half longitudinally, and the two halves are rotated inferiorly (Gosalbez et al., 2005). At the Riley Hospital for Children, I have incorporated urogenital mobilization techniques into nearly all of our urogenital sinus repairs. **This allows a midlevel confluence to reach the perineum without requiring vaginal separation. The highest-level confluences may still need a pull-through procedure with separation of the vagina and urethra,** but it is much more easily performed after the urogenital sinus has been mobilized.

TUM is often thought of as its own type of vaginoplasty but is, in fact, a technique to allow vaginoplasty that may result in the vagina being sewn flush to the perineum; however, a flap or pull-through vaginoplasty may still be required. Only rarely do I believe the vagina should be sewn flush to the perineum because of concerns of a circumferential anastomosis becoming stenotic. As described earlier, TUM is started with endoscopy to evaluate the anatomy, to note the level of the confluence, and to place a Fogarty catheter in the vagina and a Foley catheter in the bladder. A sponge is placed in the rectum, and the proposed incisions are outlined. Subcutaneous injection of 0.5% lidocaine with 1 : 200,000 epinephrine along the lines is carried out. Clitoroplasty is performed as described earlier, with the meatus of the urogenital sinus and urethral plate being circumscribed with stay sutures to allow mobilization of the sinus from the corporeal bodies. This is initially carried out to just between the bifurcation of the corporeal bodies. The clitoroplasty is now completed as described earlier. The dissection is carried out in the midline posterior to the sinus until the peritoneal reflection is reached to allow access to the entire posterior wall of the vagina (Figs. 49.20 and 49.21). This circumferential mobilization is done directly on the urogenital sinus and continues proximally beneath the pubis. As the avascular ligaments from the pubis to the sinus are divided in this area, the entire urogenital sinus is felt to "give" and move toward the perineum (Fig. 49.22).

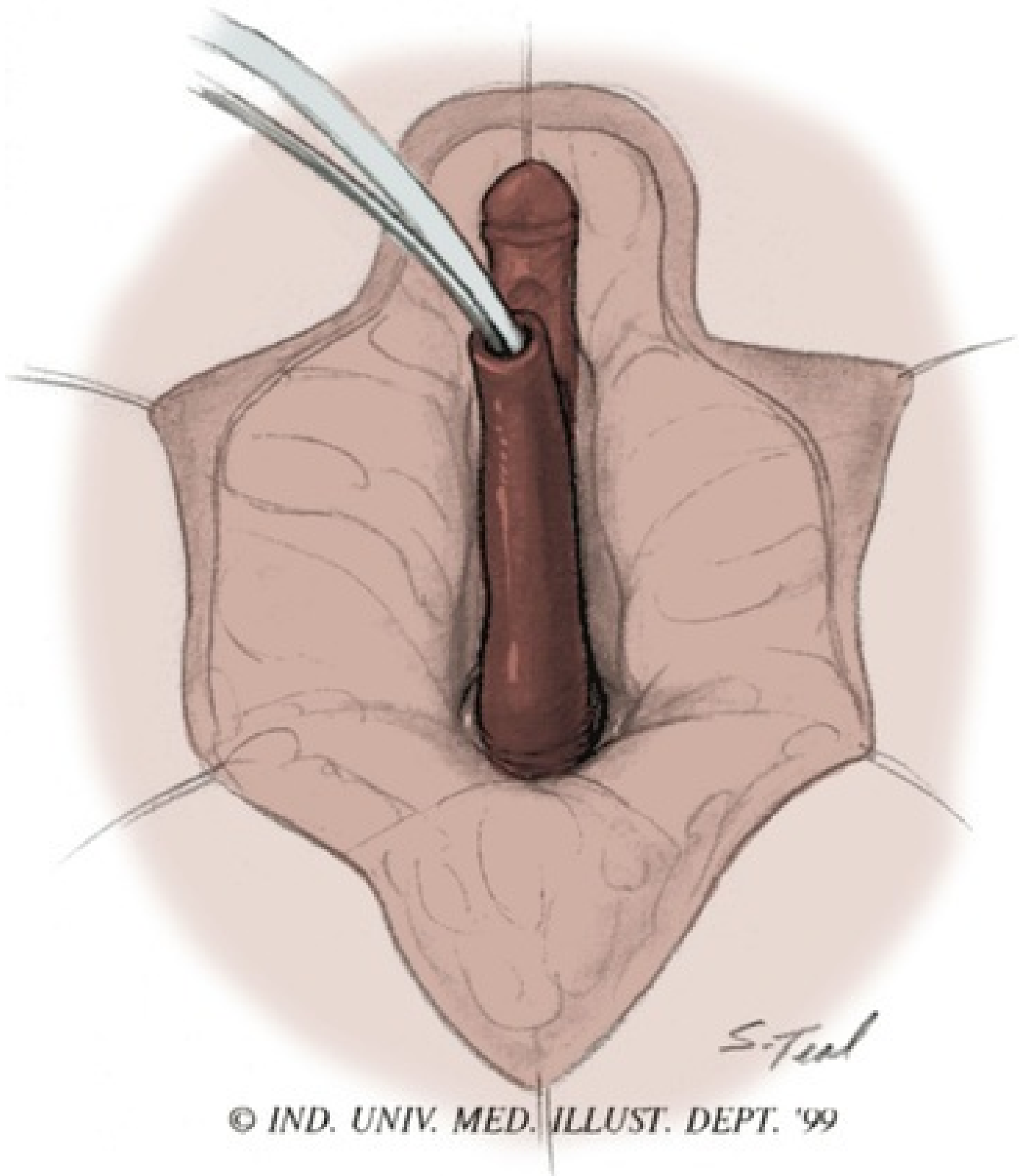

FIG. 49.20 Skin mobilized with the sinus exposed. (© 1999, Indiana University Medical Illustration Department.)

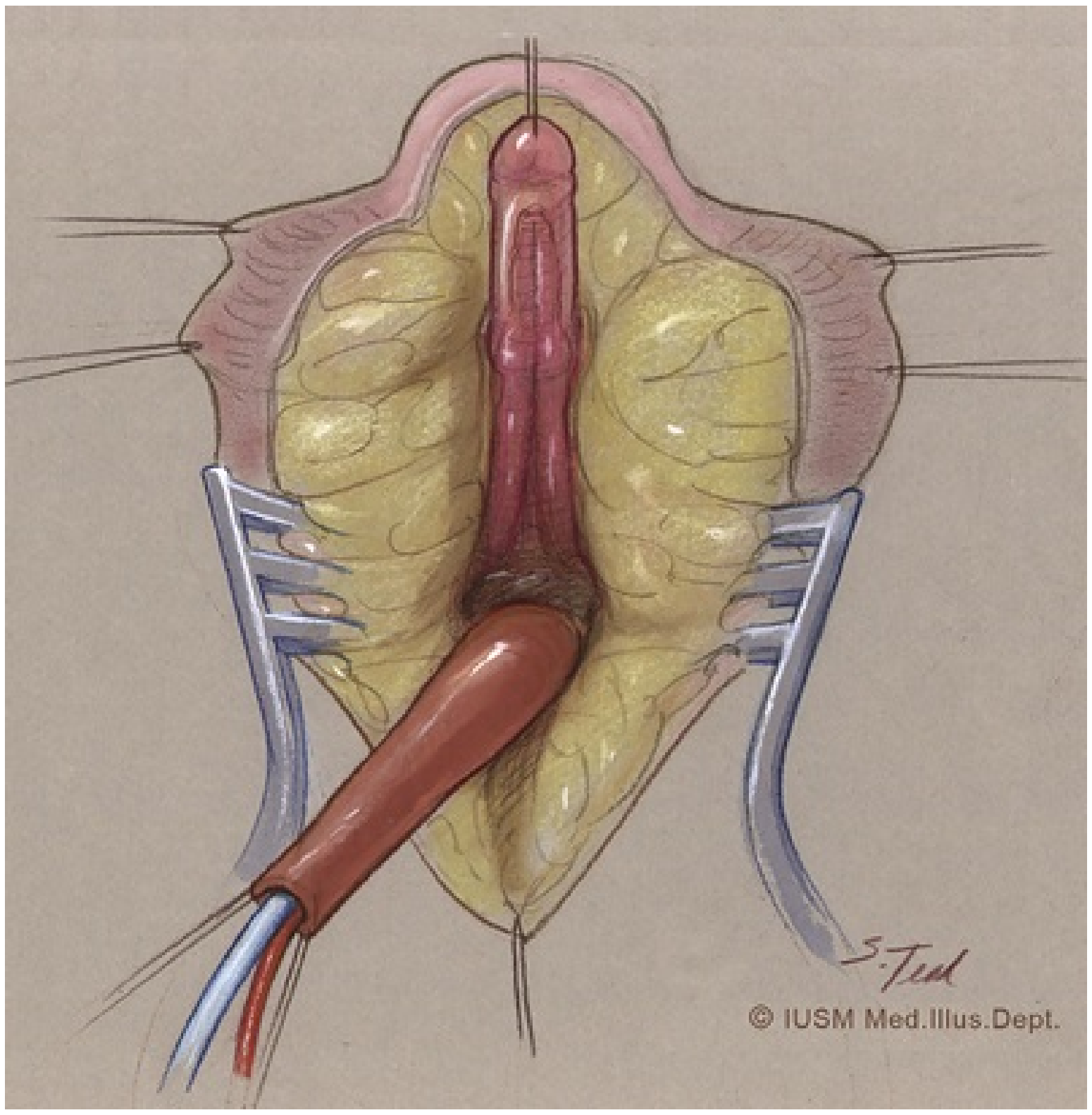
S. Teal
© IUSM Med.Illus.Dept.

FIG. 49.21 Total urogenital mobilization with the sinus mobilized. (© Indiana University Medical Illustration Department.)

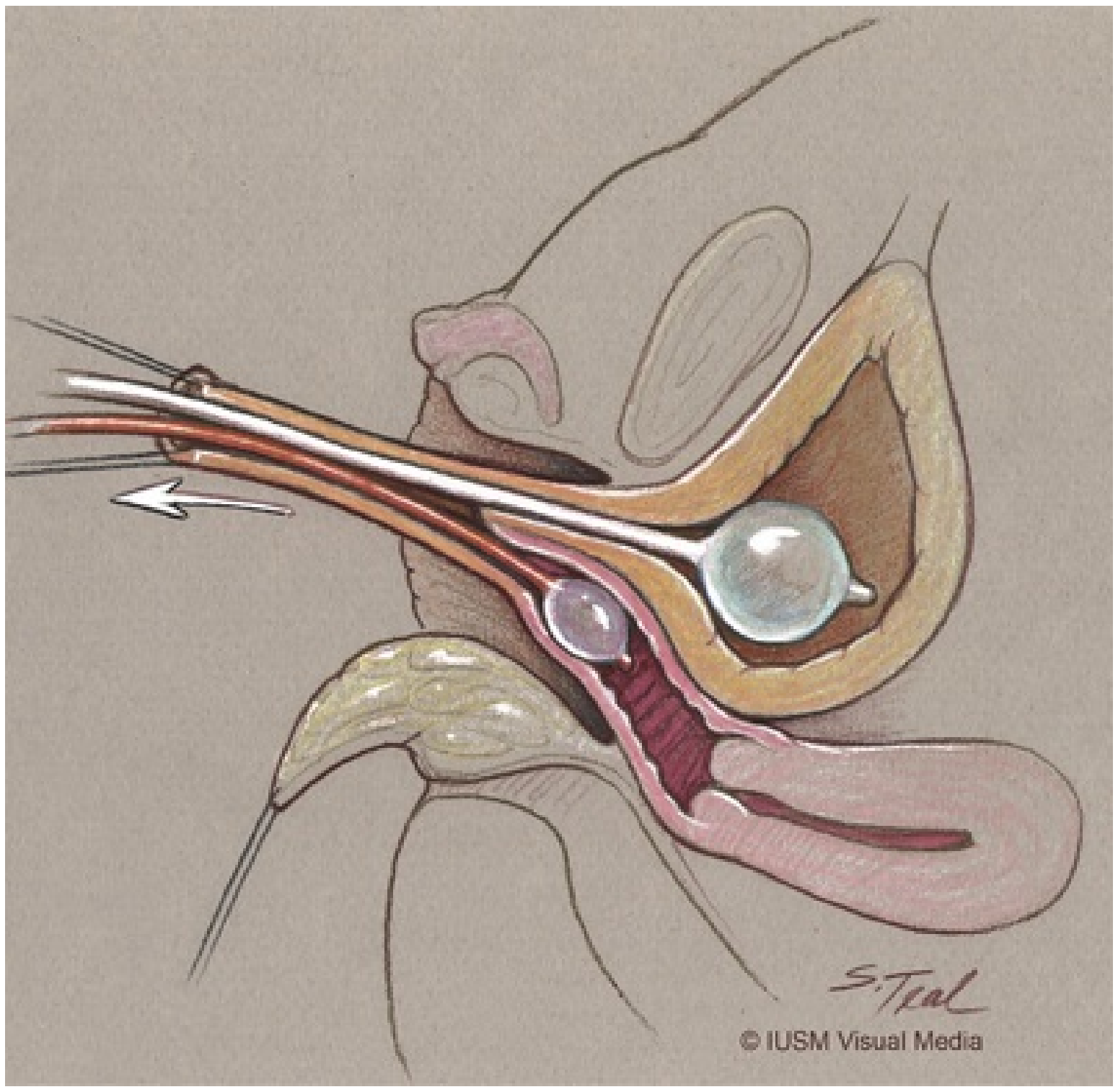

FIG. 49.22 Total urogenital mobilization. The sinus is mobilized to a position beneath the pubis. (© Indiana University Medical Illustration Department.)

The Fogarty balloon is now easily palpable in the vagina. The posterior wall of the vagina is opened between stay sutures. If the vagina is now near the perineum, it may be sewn flush to the perineum, or an omega-shaped perineal flap may be placed into the spatulated posterior wall to augment the vaginal caliber; I prefer the latter. Rather than discard the mobilized sinus, as previously reported, it is helpful to split the sinus ventrally and use it to provide a mucosa-lined vestibule (Fig. 49.23). If the vagina is still quite high, the anterior wall of the vagina should be separated from the urethra and bladder neck as in the pull-through procedure (Peña, 1997; Rink and Kaefer, 2002; Rink et al., 2006). This is most easily performed with the child in the prone position to allow direct vision. The opening in the urethra is closed in two layers. The mobilized sinus in this situation is split anteriorly and then used as a Passerini-like flap to create the anterior vagina wall (Rink and Adams, 1999; Rink et al., 2006) (Fig. 49.24). The posterior perineal flap is approximated to the spatulated posterior vaginal wall. Labioplasty is performed as previously described. TUM has achieved great popularity, and reports to date reveal excellent cosmesis and no problems with continence (Ludwikowski and González, 2013; Palmer et al., 2012). No long-term results are available.

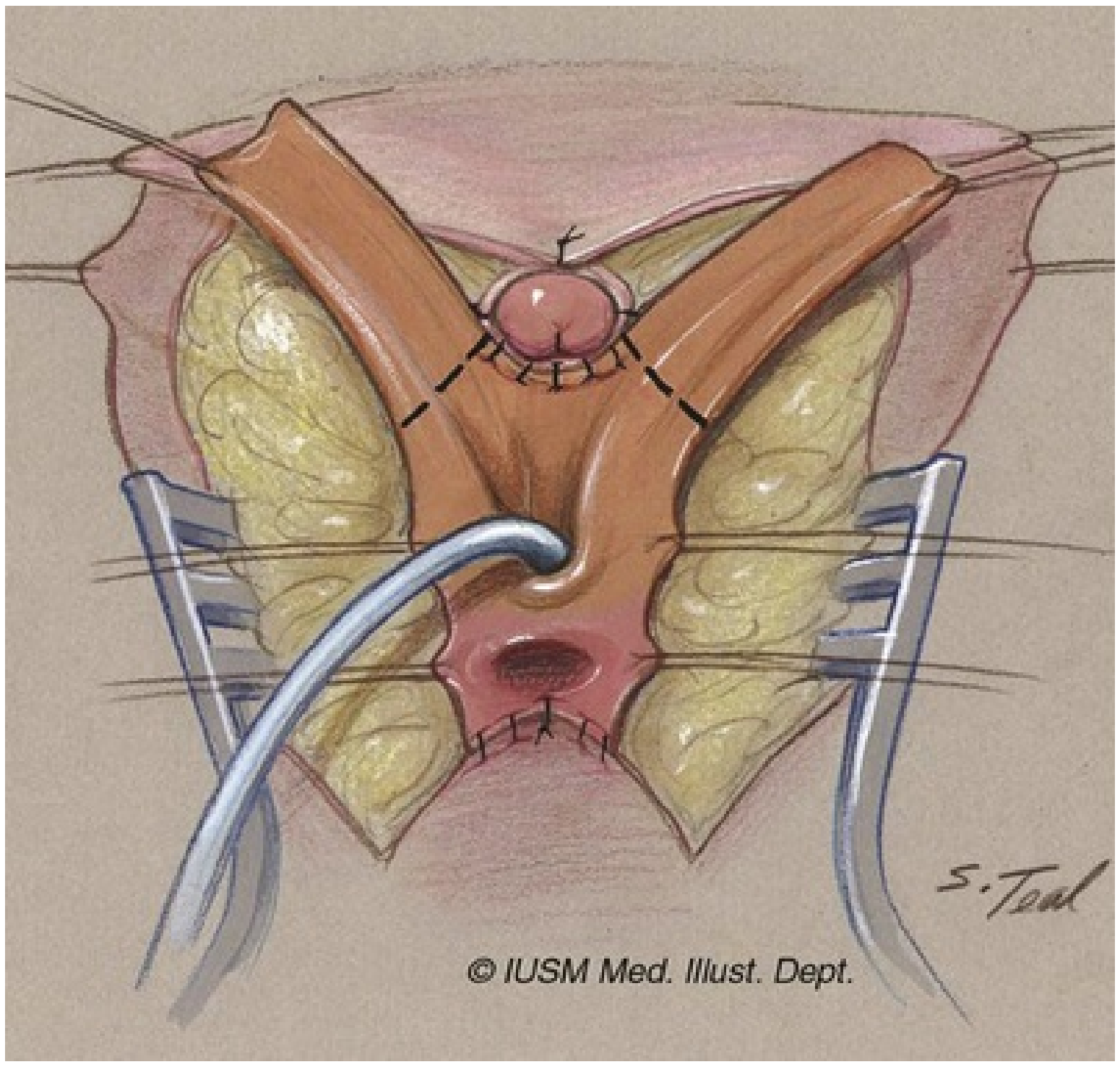
S. Teal
© IUSM Med. Illust. Dept.

FIG. 49.23 A ventral incision on the mobilized sinus allows the creation of a mucosa-lined vestibule. (© Indiana University Medical Illustration Department.)

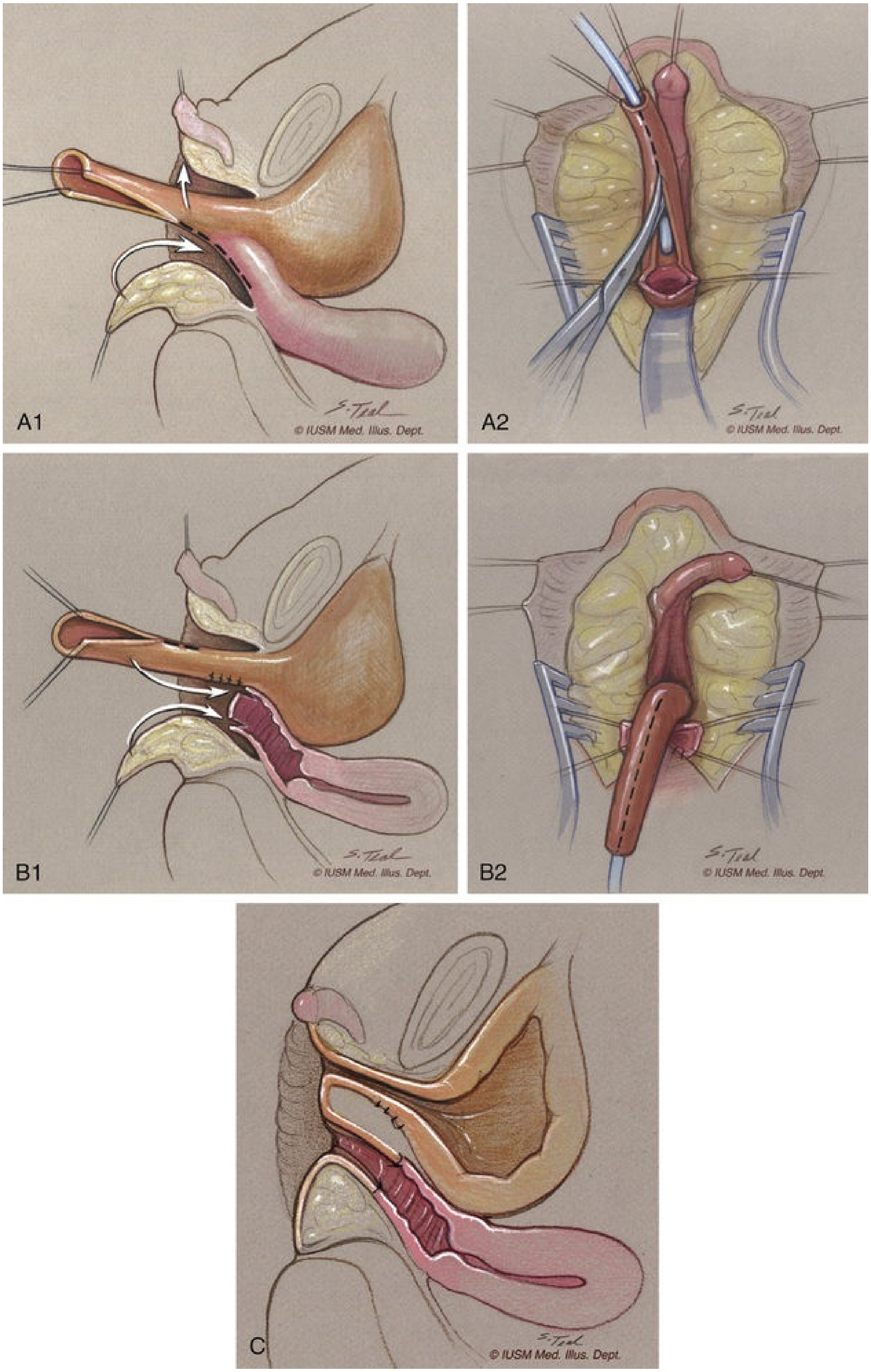
A1
S. Teal
© IUSM Med. Illus. Dept.
A2
S. Teal
© IUSM Med. Illus. Dept.
B1
S. Teal
© IUSM Med. Illus. Dept.
B2
S. Teal
© IUSM Med. Illus. Dept.
C
S. Teal
© IUSM Med. Illus. Dept.

FIG. 49.24 Total urogenital mobilization. (A1 and A2) For flap vaginoplasty, the sinus is split ventrally to create a mucosa-lined vestibule. (B1 and B2) For pull-through vaginoplasty, the sinus is split dorsally to create an anterior vaginal wall. (C) The opened sinus now becomes the anterior vaginal wall. (© Indiana University Medical Illustration Department.)

Some have expressed concern regarding the proximal circumferential dissection because of the potential risk for sphincteric musculature or nerve injury. There is concern for resultant stress incontinence or foreshortening of the vagina. **To address these concerns, Rink et al.** (2005c, 2006) **proposed *partial urogenital mobilization (PUM)*, a technique that starts with the same circumferential dissection but stops at the level of the pubourethral ligament** (Fig. 49.25). This still allows use of the mobilized sinus as described earlier to improve cosmesis, yet it avoids the aggressive retropubic and suprapubic dissection and is applicable to the majority of patients. If more mobilization is necessary for a very high vagina, TUM is easily carried out.

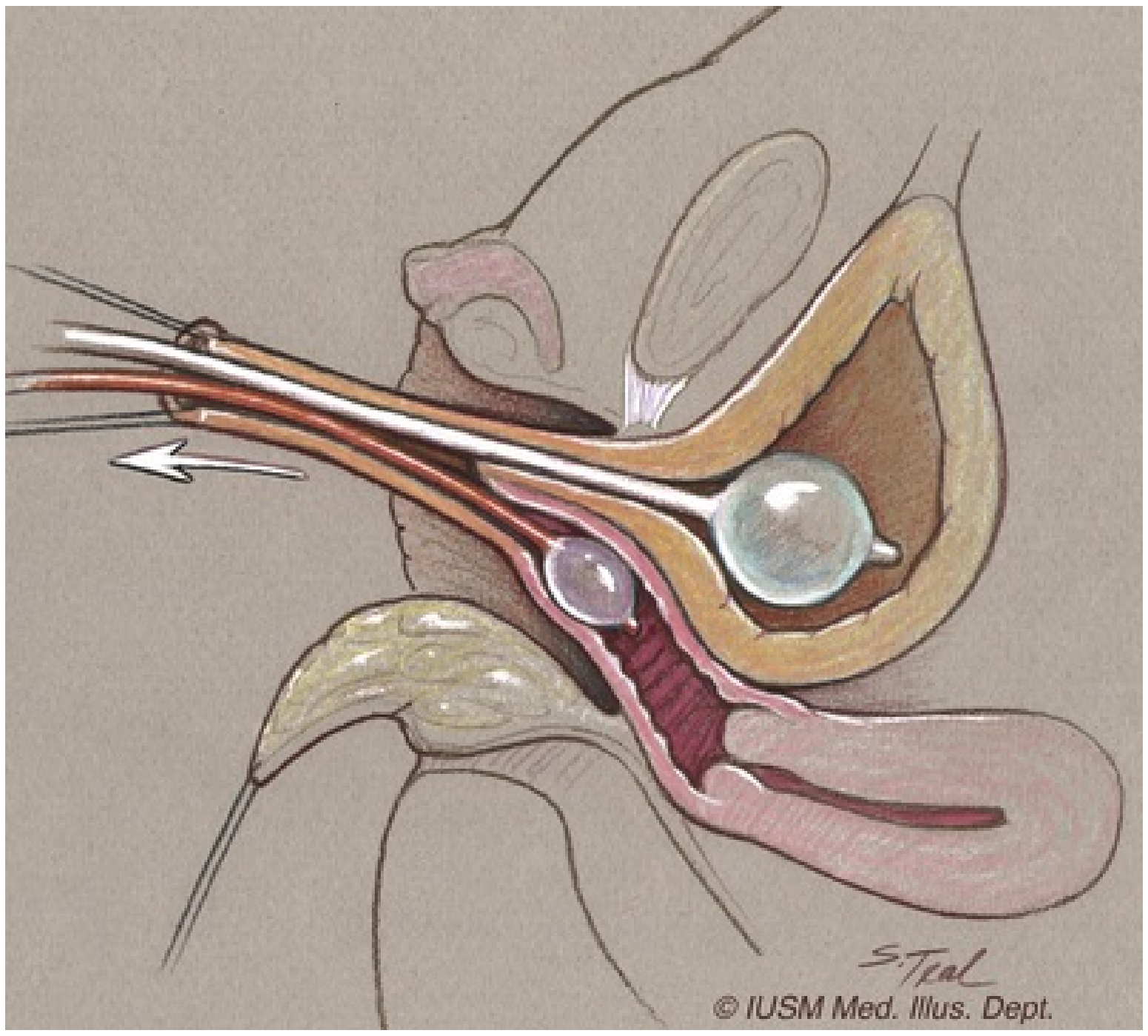

FIG. 49.25 Partial urogenital mobilization. Dissection stops at the pubourethral ligament. (© Indiana University Medical Illustration Department.)

Key Points: Urogenital Mobilization

- TUM is a technique applicable to both urogenital sinus and cloacal anomalies. The entire sinus is dissected circumferentially to above the pubis to allow the confluence to move inferiorly to the perineum.
- With the TUM or PUM technique, the mobilized sinus tissue can be used to create a mucosa-lined vestibule or an anterior or posterior vaginal wall. This sinus tissue should not be discarded.
- PUM circumferentially mobilizes the sinus to the level of the pubourethral ligament but does not extend above this level.

Results of Urogenital Sinus and Disorders of Sex Development Surgery

There are a number of significant issues when reviewing the data on surgery for DSD. The data are limited and nearly always retrospective, reviewing only small numbers of patients from a single institution, and the techniques reviewed are often outdated or not reported (Rink and Szymanski, 2015). Braga and Salle (2009) noted that available data were so poor that it was "scientifically pointless" to try to make sense of the current literature. Furthermore, most articles only look at success as an adequately open vagina with a feminized appearance. Success should include normal erotic sensation, lubrication, sexual satisfaction, orgasm, and intercourse without discomfort. These latter factors are just beginning to be studied. The psychological aspects of both early surgery without the child's consent versus raising a child with genital atypia remain largely unexplored. **Cosmetic and early functional results have uniformly been reported to be favorable. Long-term outcomes are of more concern.** Unfortunately, in these studies it is often difficult to tell what procedures were done for what degree of severity of urogenital sinus, and none of the studies include data on the quality of endocrinologic control in these patients. Looking at what data are available, Jones et al. (1976) noted that 25 of 84 patients undergoing vaginoplasty required a secondary procedure to provide a vaginal outlet satisfactory for intercourse; 5 of these 25 also required a third procedure. **The poor results were caused by failure to exteriorize the vagina initially or by scar formation. The distal vagina is always narrow. The normal-caliber**

vagina must always be reached and exteriorized with current procedures. Sotiropoulos et al. (1976) found that all patients undergoing prepubertal vaginoplasty required revision at puberty. Azziz et al. (1986) reported the results of attempted coitus in 42 women with CAH 23.6 years after vagina repair. Satisfactory coitus was noted in 62% (46% in salt wasters and 87% in those with the non–salt-losing form). There was a less favorable outcome when the initial procedure was performed before 1 year of age. Thirty secondary or tertiary procedures were needed to achieve the final results. These data are widely quoted, but almost all of these patients initially underwent a cut-back vaginoplasty ("incision of the urogenital sinus"), which is a procedure only rarely used because it does not adequately open the vagina to the proximal normal caliber; specifically, the distal end of the vagina is narrowed and thus will be stenotic. Revisions for these patients involved the performance of a flap vaginoplasty, which currently would probably have been the initial procedure. In a series from Johns Hopkins Hospital, 28 patients (32% lost to follow-up) had adequate follow-up, 22 (78.6%) of whom needed further vaginal surgery (Bailez et al., 1992). Bailez et al. (1992) noted that if secondary surgery was needed for vaginal stenosis, success rates were high when the procedure was performed near puberty, with only 8 of 18 needing a secondary procedure requiring a flap. This group also reported less favorable results in those younger than 1 year of age (Bailez et al, 1992). Nihoul-Fekete et al. (1982) noted that 30% of 43 CAH patients required secondary surgery. Hendren and Atala (1995) reported on 16 patients with high vaginal confluence and noted that 6 of 9 adults had satisfactory coitus and 2 had vaginal stenosis.

Fourteen girls with CAH, 11 to 15 years of age, who had undergone genitoplasty at a mean age of 2.5 years were assessed under anesthesia by Alizai et al. (1999), who noted that 13 of the 14 required additional vaginal surgery. Stenosis was seen in 43%, and persistent urogenital sinus with or without fibrosis in 50%. Minto et al. (2003) found that 39% of 28 patients required secondary surgery, and 11% required a third procedure. Al-Bassam and Gado (2004) noted vaginal stenosis in 16% of their patients who underwent various types of vaginoplasties (43 vaginoplasties: 26 flap, 11 pull-through, 2 cut-back, 3 sigmoid vaginal replacement, 1 abdomino-perineal pull-through). Nearly all underwent vaginal dilation. Nordenskjöld et al. (2008) noted vaginal stenosis in 37% of their operated CAH patients, with 15 of 50 noting painful intercourse. However 24 of the 41 vaginoplasties were cut-backs, with 10 flaps and 7 combinations. In a cross-sectional study of Dutch women older than 15 years of age, 7 of 13 single-stage repairs required secondary surgery, and of 20 women who had intercourse, 8 complained of dyspareunia, but only 2 had vaginal stenosis (van der Zwan et al., 2013). It is tempting to assume that postpubertal vaginal surgery may result in more favorable outcomes, but there are no data to support this assumption. Furthermore, Eroglu et al. (2004) actually noted less vaginal stenosis in those patients who underwent early single-stage repair (3.4%) than in those who underwent late vaginoplasty (42.8%). Lean et al. (2007) noted no difference whether the surgery was done before or after 2 years of age. In their series of 32 patients, they noted good cosmesis in 72%, satisfactory in 22%, and poor in 6%. They believed that the planned one-stage operation gave better results than the planned multistage procedure, with only 2 of the 32 former patients requiring further major surgery and 3 needing minor revisions. Al-Bassam and Gado (2004) also recommended a single-stage repair at 3 to 6 months of age. It may be that the level of vaginal confluence and number of procedures is far more predictive of outcome than is the timing (van der Zwan et al., 2013).

It seems clear that a single-stage early vaginoplasty will often require a secondary repair after puberty, but this should be expected because the orifice is likely to remain the size that was created given that there is no flow through the orifice in childhood. In my experience, the secondary refinements are easily performed.

Surgical techniques to reduce clitoral size have dramatically improved and are now based on our current knowledge of clitoral neuroanatomy. Even though no long-term results are available for current techniques, some long-term results are now being reported for relatively modern techniques. Alizai et al. (1999) found clitoroplasty results to be unsatisfactory in 46% of the patients they assessed. **Gearhart et al.** (1995) **looked at pudendal evoked potentials after clitoroplasty and noted that modern clitoroplasties preserve nerve conduction in the dorsal neurovascular bundle.** Barrett and Gonzales (1980) found intact sensation in all of their patients after clitoroplasty. Chase (1996) reported that even with normal evoked potentials there may be an absence of sensation and orgasm. I have not noted vascularization defects after modern clitoroplasty. It is clear that further long-term studies are necessary. Minto et al. (2003) found the clitoris to be cosmetically normal in 59% of patients who had undergone clitoral surgery, but it was excessive in 20%, large in 7%, small in 7%, and absent in 7%. This group also reported that hot, cold, and vibratory sensation was markedly altered as recorded by a genitosensory analyzer.

Sensation alone may be a poor indication of clitoral normality after surgery. Further studies to analyze the newest techniques are warranted. The erotic sensitivity and potential for orgasm should be studied. More recently, Nordenskjöld et al. (2008) compared 62 CAH patients with 62 controls. Of the 49 who underwent clitoroplasty, 16 had 1 operation, 14 had 2, 4 had 3, 4 had 4, and 11 had between 5 and 10 operative procedures. Twenty percent were not satisfied with their surgery; they thought there was decreased sensitivity. However, 50% of the nonoperated patients thought their clitoris was too large. There was no difference in the ability to achieve orgasm between the two groups. The authors noted that women with CAH were less satisfied with their genitalia whether operated or not. Nordenström et al. (2010) noted that clitoral sensitivity was affected in nearly all patients who had undergone clitoroplasty. However, those with partial clitoral resection sparing more nerve function had a more favorable outcome and did not differ from those with no surgery. Initial degree of virilization also affected clitoral sensitivity.

The results of TUM and PUM are very early. These procedures are technically easier, and the cosmetic results are superior, but whether the functional results are better is unknown. The potential for stress incontinence or denervation of the sphincteric mechanisms also is unknown. Most authors to date have not found continence to be altered by TUM (Hamza et al., 2001; Jesus et al., 2018; Kryger and Gonzales, 2004; Ludwikowski and González, 2013; Palmer et al., 2012; Rink and Adams, 1999; Rink et al., 2007). Until these results are available, these procedures should be used with caution.

Recently there has been an effort to understand sexual function and mental health after feminizing genitoplasty. Fagerholm et al. (2012) noted that quality of life and health-related quality of life studies appeared normal in most patients and that mental health was similar to or better than published data from Finland. There were 5 of 24 patients who had some poorer scores because of distressful memories of too-late surgery, the operative treatment itself, or poor sexual function. This same group also noted that intercoital relationships started later in females who underwent genital reconstruction in childhood as compared with the normal population. In addition, the patients preferred surgery to be done early in life. In a study of 62 Swedish women with CAH, Nordenström et al. (2010) reported several interesting results. Overall satisfaction with sexual function after feminizing genitoplasty was as good as controls except for patients with salt-wasting CAH, the most severely affected. The cosmetic score did not differ between those who were satisfied and those who were not, and cosmetic outcome did not contribute to sexual orientation. In this study, as in the study by Wisniewski et al. (2004), the physicians perceived the genital appearance as better than did the patients. Callens et al. (2012) noted that feminizing surgery did not seem to improve or hamper psychosexual outcome, especially in those patients with severe virilization. In a recent review of the literature, the prevalence of homosexuality and bisexuality was noted to be increased in CAH patients versus the non-CAH group and was found to be greater in salt-wasting versus non–salt-wasting patients (Gondim et al., 2018).

There has been some concern that lower urinary tract symptoms are more likely in those patients with CAH (Davies et al., 2005), but in the study by Fagerholm et al. (2013), symptoms did not seem to differ in female DSD patients versus controls. Occasional lower urinary tract symptoms were common in both patients and controls.

Timing of vaginoplasty remains quite controversial. Although the few reported long-term studies suggest that delayed vaginoplasty may be preferable, most children currently continue to undergo vaginoplasty as infants, particularly for the CAH group (Rink and Whittam, 2014; Yankovic et al., 2013). Most would recommend delaying vaginoplasty for the patient with a small (<3 cm), very high confluence vagina. They argue that the available long-term studies are based on outdated techniques and that there are tremendous surgical advantages to a single-stage repair. If early vaginoplasty is performed, it is well recognized that secondary introitoplasty may be necessary, but this is usually accomplished easily. The argument, which will not be settled soon, contrasts two approaches, both of which usually result in two procedures: (1) a simple procedure in an infant (i.e., clitorolabioplasty) with a postpubertal extensive procedure (i.e., vaginoplasty) or (2) an extensive single-stage clitorolabiovaginoplasty in an infant with a simple introitoplasty in the postpubertal period. Should a moratorium be mandated, this would never be answered. There is also controversy on the correct timing to share information with the affected child. Unfortunately, research on when to convey information is virtually nonexistent (Sandberg et al., 2012). In an effort to support guideline development for CAH by the Pediatric Endocrine Society, a meta-analysis was performed of all available outcomes data in the literature from throughout the world. (Elmasri et al., 2018). There were 29 observational (1178 patients) studies that met inclusion criteria. The mean age at surgery was 2.7 years, and average follow-up was 10.3 years. The data points were not represented in all studies, but their conclusions were that 88.7% had female gender identity. The Female Sexual Index Score was

25.3 (36 maximum), suggesting some residual difficulties. The authors noted one study reported significantly lower scores than controls, and three others noted no significant difference from controls. Most patients were sexually active and satisfied with the surgical outcomes, but only 1 in 2 reported comfortable intercourse. Vaginal stenosis was found in 27%, but fistulas, urinary incontinence, and urinary tract infections were much less common. Although these data are helpful in discussions with CAH patients and their families, they have multiple limitations and do not compare early versus later surgery.

Several studies have noted that the most important factor affecting results is whether there was a surgeon or surgical team with a special interest in feminizing genitoplasty procedures (Creighton et al., 2001; Lean et al., 2007; Nordenskjöld et al., 2008). This suggests that support for Centers of Excellence may be appropriate for the care of children with DSD. Comprehensive CAH Centers have been designated in the United States by the CARES Foundation.

Key Points: Urogenital Sinus Anomalies—Outcomes of Reconstruction

- It is clear that neonatal vaginoplasties will usually require a secondary procedure for stenosis after puberty (25% to 100%).
- Successful coitus is often reported, but further studies should note sexual satisfaction, lubrication, erotic sensitivity, and nonpainful coitus.
- Current techniques of clitoroplasty seem unlikely to injure sensation, but newer studies question whether sensitivity is an adequate indication of clitoral function. Some studies note decreased sensation with newer techniques.

Surgical Reconstruction for Cloacal Malformations

Initial Management, Timing, and Principles

The initial management of cloacal anomaly involves stabilization because the child is often quite ill with abdominal distention that at times results in respiratory compromise. As with all other anomalies, its management has evolved. Historically, after decompression of the distended organs, it was common practice to perform a rectal pull-through procedure; genitourinary reconstruction followed at a later date, if at all (Okonkwo and Crocker, 1977). Hall et al. (1985) suggested that the vaginal surgery be done after puberty, when estrogen levels are higher. Although it is tempting to perform a pull-through procedure only, it is now thought by the majority of authors that piecemeal repair of the cloaca is a disservice to the child and is absolutely contraindicated. It is optimal to repair all abnormalities (i.e., rectal, vaginal, and urethral) in a single stage (Kay and Tank, 1977; Mollitt et al., 1981). This allows the best exposure for the difficult rectal and vaginal separation. Furthermore, the tissues have not been previously violated, and the rectum does not require remobilization. Hendren (1982, 1986) pointed out that rectal pull-through should never be done as a separate procedure. Of his 154 patients with cloacal anomaly, 60 were secondary cases, many of whom had undergone a previous pull-through procedure. Definitive repair in this situation often requires repeat rectal mobilization. Raffensperger (1988) proposed neonatal complete repair but later noted that this may not be appropriate. Levitt and Peña (2005) have stated that there are three pitfalls in the management of neonates with cloacae: (1) failure to recognize and manage hydrocolpos, (2) colostomy or vesicostomy problems, and (3) clinical misdiagnosis. Recently, Kittur and Vora (2017) and Bal et al. (2017) have offered a different approach. They recommend avoiding urethrovaginal reconstruction in infancy and performing only the anorectal surgery. They opt for a Mitfanoff procedure in those requiring clean intermittent catheterization (CIC). Peripubertal vaginal reconstruction did not worsen voiding dynamics or continence and overall decreased the number of children requiring CIC. They believe that this approach lessens the significant complications of early urethrovaginal surgery they had seen. They believe that these complications, which may put the urinary and genital tract at risk and result in worsening renal function, are best avoided.

Surgical management now involves four basic steps: (1) decompression of the gastrointestinal tract, (2) decompression of the genitourinary tract, (3) correction of nephron-destructive or potentially lethal urinary anomalies, and (4) definitive repair of the cloaca.

Decompression of the Gastrointestinal Tract

Decompression of the gastrointestinal tract is done by colostomy. Although nearly all surgeons agree on the need for colostomy initially, the best anatomic location of the colostomy is debated. Hendren initially recommended a low-loop colostomy but more recently has performed a right transverse colon divided colostomy (Hendren, 1982, 1986, 1998). This change was prompted by difficulty in obtaining a bowel segment for vaginoplasty during the rectal pull-through procedure when a low colostomy has been performed. A divided transverse colostomy keeps the left colic blood supply intact (Hendren, 1992). Peña, as cited by Spitz and Coran (2006), preferred a descending colostomy because there was less surface area for resorption of urine. A divided colostomy in the descending colon just after the colon takes off from its retroperitoneal attachment is now recommended by Levitt and Peña (2005). This procedure maintains the availability of enough distal colon for future pull-through, and prolapse is less likely to occur. However, Peña did recommend leaving a long segment of sigmoid to prevent a difficult pull-through requiring abdominal exploration. Levitt and Peña (2005) noted that 24 of 361 patients had a colostomy too low that interfered with the rectal pull-through. I have favored a proximal colostomy but have at times found clinically challenging acidosis caused by urine absorption through the colonic mucosa. Masuko et al. (2005) reported successful decompression of the colon by balloon catheter drainage with irrigation of the bowel three times per day. This avoided temporary colostomy and allowed a single-stage repair. Malrotation in patients with ARM has the same frequency as in the general population but is more common in severe malformations. These should be recognized and addressed at the time of colostomy, and the appendix should be preserved for potential appendicocecostomy later.

At the time of colostomy, endoscopy may be performed to more clearly define the anatomy and to aid in decompression of the urinary tract. In my experience, as the cystoscope advances proximally through the cloacal channel, it tends to enter the vagina (or vaginas). In fact, entrance into the urethra/bladder can be extremely difficult in a neonate with a distended vagina because the vagina compresses the bladder to the anterior abdominal wall and obstructs the bladder neck. Drainage plus irrigation of the vagina (or vaginas) not only allows decompression and relief of abdominal distention but also may allow visualization of the bladder. Often, the rectal fistula is also difficult to locate; as noted earlier, it is more often found within the septum of the duplicated vaginas but can enter at almost any location. With a combination of irrigation through the fistula and through the distal limb of the colostomy, the inspissated mucus and meconium can easily be cleared. It is often helpful to leave small feeding tubes in all channels and then obtain radiographic studies to further delineate the anatomy. In my experience, this is best done in the radiology suite with fluoroscopy.

Decompression of the Genitourinary Tract

Even after decompression of all structures draining into the cloaca, at times voiding continues into the vagina (or vaginas) or the rectum (or both) and results in rapid distention of these structures with subsequent poor urinary drainage, persistent hydronephrosis, abdominal distention, urinary infection, and hyperchloremic acidosis. This can generally be managed by intermittent catheterization. The catheter often enters the vagina rather than the bladder, but it still functions to drain and decompress the genitourinary tract (Hendren, 1992). If the desired decompression is not achieved, further maneuvers are required. I agree with Hendren that, in a long urethra-like cloaca, catheterization can at times be difficult, and a cut-back procedure (opening the cloaca) may be helpful to aid catheterization (Fig. 49.26). If this approach fails, further decompression can be achieved by either vesicostomy or vaginostomy (Kay and Tank, 1977). Levitt and Peña (2005, 2010) have found vaginostomy or tube vaginostomy to be helpful, but it is my belief that CIC should be the first-line treatment because it will usually keep the vagina adequately decompressed. Only when CIC fails should vesicostomy or vaginostomy be performed. The concern of tethering the vagina to the abdominal wall with later difficulty doing a pull-through or TUM has led some to recommend vesicostomy over vaginostomy, but others have found this not to be a concern. It also necessitates an abdominal procedure. Levitt and Peña (2005) found that 25% of their cloaca patients had hydrocolpos but that in 59% of them it was either not identified or mismanaged. This resulted in significant morbidity from ureteral obstruction, urinary tract infection, acidosis, and failure to thrive. Adequate vaginal drainage resulted in resolution of these problems. Chalmers et al. (2015) recently reported that initial management with CIC was equivalent to diversion by vesicostomy or vaginostomy in protecting the urinary tract and preventing hydrocolpos.

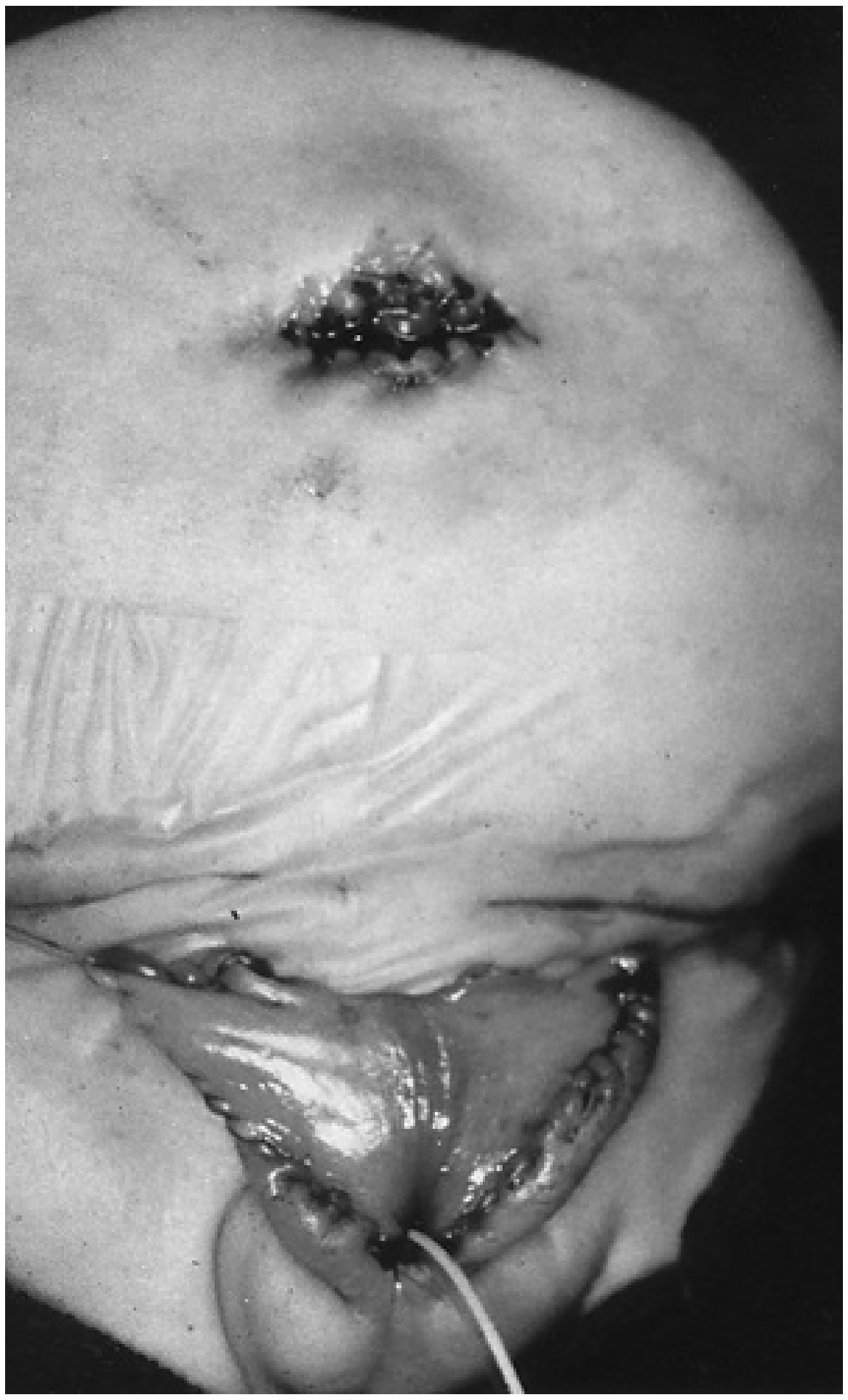

FIG. 49.26 The urethra-like cloaca is opened with a catheter in place; vesicostomy has also been performed.

Repair of Obstructive Urinary and Other Pathology

The third stage of care of a child with a cloacal anomaly is repair of any obstructive urinary tract pathologic process. Renal structural abnormalities, some of which were obstructive, have been identified in 60% to 83% of patients with persistent cloaca (Rink et al., 2005b; Warne et al., 2003). In those patients with a common channel longer than 3 cm, 91% had urologic defects (Peña et al., 2004). At times, these anomalies are ignored early on while awaiting definitive cloacal repair, but this practice should be avoided. Obstructive lesions should be treated promptly. However, vesicoureteral reflux, which is quite common, can generally be managed medically if urinary infection is prevented. Other organ system anomalies (e.g., cardiac, spinal cord) should be fully evaluated. Some may require repair during this phase.

Definitive Repair of Cloacal Malformations

Definitive repair of a cloaca is usually carried out at 6 to 12 months of age, but obviously the child must be well nourished and thriving to proceed with repair. In healthy thriving children, Peña et al. (2004) operate at 1 month of age. Definitive repair should never occur until the urinary tract has been evaluated and hydrocolpos has been ruled out. If endoscopy has not been performed previously, it may be helpful as a separate procedure before the definitive repair. Defining the anatomy can be tedious, and it is helpful to thoroughly cleanse the distal colonic segment, which usually requires irrigation from the mucous fistula, and the distal limb of the colostomy. A standard GoLYTELY bowel preparation should also be done.

Operative Technique: Cloaca

The definitive repair begins with endoscopy to reacquaint the surgeon with the anatomy. I have also found it is helpful to place a Foley catheter in the bladder and different-colored Fogarty catheters in the vagina (or vaginas) and rectum. The catheters are kept sterile during preparation. As described earlier for urogenital sinus repair, a complete lower body preparation with an antibacterial solution is done circumferentially from the level of the nipples to the toes, and the legs are wrapped sterilely. Such preparation allows prone and supine positioning for perineal and abdominal surgery.

The definitive posterior sagittal anorectovaginourethroplasty (PSARVUP) is begun with the child in the prone position and the pelvis elevated on rolls to achieve a jackknife position. An electrical stimulator is used to determine the area of maximal contraction, which is marked with a skin scribe and with stay sutures for later rectal placement. The proposed locations of the perineal body and vagina are also marked (Fig. 49.27). I agree with Hendren (1992) that it is at times helpful to have a sound in the common cloacal channel, but the Foley and Fogarty catheters usually suffice. The entire dissection is done in the midline until mobilization of the rectum and vagina is begun. The most important advances of Peña's PSARVUP procedure are that it allows identification of the external sphincter and muscle complex of the rectum and provides excellent exposure for separation of the rectum and vagina (or vaginas) from the cloaca.

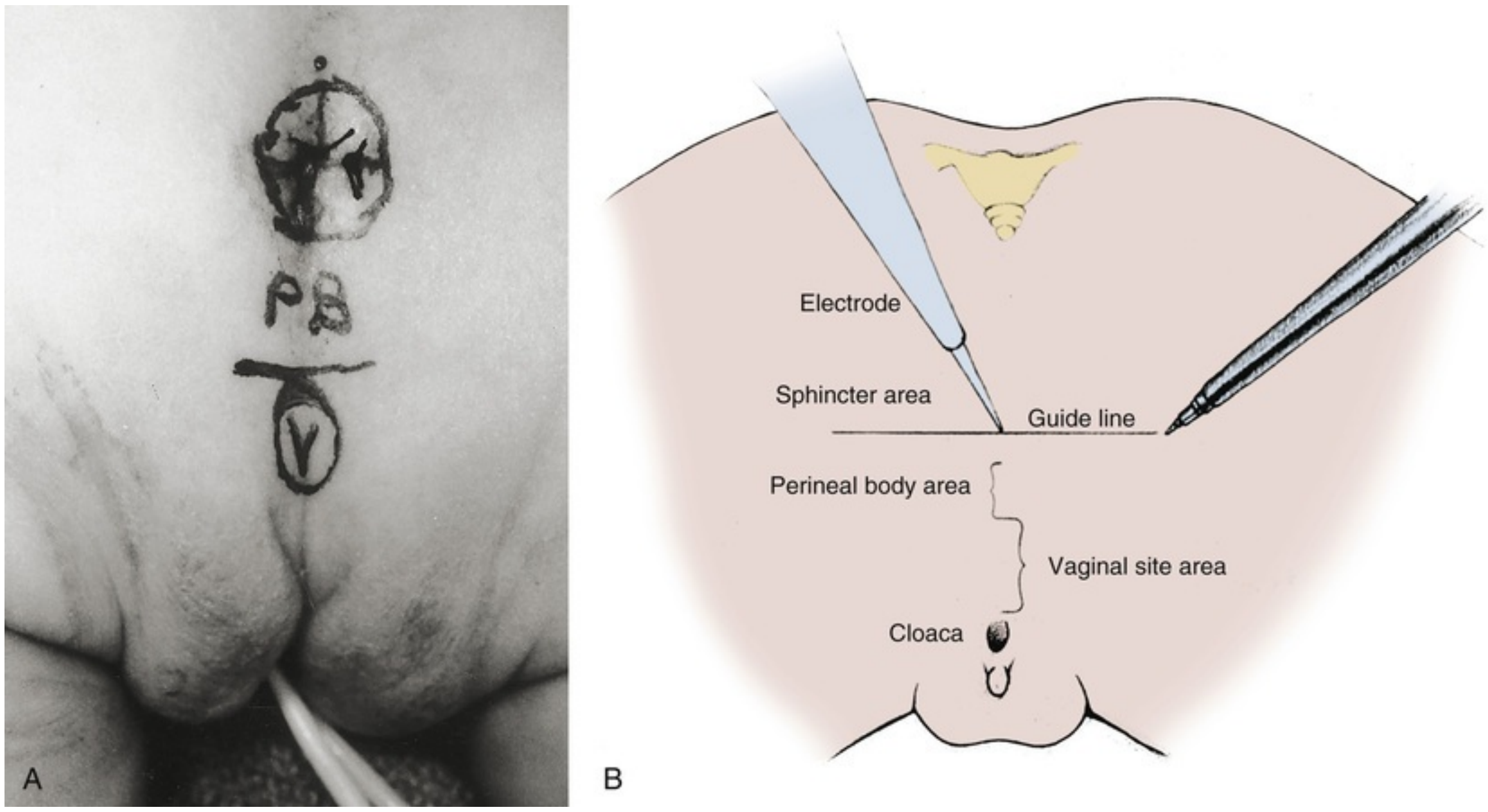

FIG. 49.27 (A) Cloaca: proposed location of the vagina (V) and perineal body (PB). (B) Rectal location is identified by electrical stimulation.

The initial incision extends from the tip of the coccyx in the midline to the posterior aspect of the cloacal orifice. Sutures mark the sphincteric muscular structures on either side as they are encountered. I have found it helpful to open the common cloaca in the midline posteriorly to the level of the confluences to allow easy identification of the rectal and vaginal insertions. With TUM, this is less appropriate because it may limit the options for use of the sinus in the reconstruction as described earlier for a urogenital sinus. When the rectal fistula is identified, it is opened posteriorly and multiple silk stay sutures are placed. These sutures are helpful in mobilizing the rectum away from the vagina (or vaginas). It is important to remember that the structures share a common wall initially, and it is better to enter the vagina than either the rectum or urethra. Circumferential dissection of the rectum to well above the sacrum may be necessary. Separation of the peritoneum can be done from this position. Rarely, a child with a very high rectal confluence needs to be turned to the supine position for abdominal exploration to free the rectum more proximally. Levitt and Peña (2010) have noted abdominal surgery to be more likely when the common channel is greater than 3 cm in length. Once adequate rectal mobilization to allow a tension-free anastomosis to the perineal skin has been achieved, the rectal stay sutures are used to retract the rectum from the genitourinary structures.

In the classic PSARVUP procedure, the vagina is now separated from the sinus. This dissection is even more tedious and difficult than the rectal separation. With TUM (described later), which has now achieved widespread acceptance for cloacal repair, the vagina may not require separation. In classic vaginal separation, as noted earlier, it is an error to enter the urinary tract during vaginal mobilization. Side-by-side vaginal duplication is most common, and the midline septum has been incised with electrocautery during the initial endoscopy. Hendren (1998) noted that 66 patients had a single vagina, 68 had two, and 20 had none. Pradhan et al. (2018) noted vaginal and uterine duplication in 63%. The Fogarty catheter (or catheters) within the vagina is easily palpable, and the posterior aspect of the vagina is opened at the level of the confluence. Again, circumferential stay sutures are very helpful in separating the vagina from the urethra and bladder. A malleable retractor inserted into the opened posterior vaginal wall exposes the anterior wall confluence for separation. Sharp dissection is less likely to injure the urinary tract than is cautery. Making dissection even more difficult is the realization that frequently the vagina almost encircles the urethra. Failure to recognize this situation can result in injury to these structures. Use of the stay suture for traction aids in further mobilization of the vagina (or vaginas). The outer wall of the vagina appears white, and identification of this color is helpful. Great care should be taken to avoid devascularization of the vagina during mobilization. Usually, vaginal mobilization allows the vagina to be “pulled through” to a position near the perineum. If after significant mobilization it still does not reach the perineum, skin flaps can be used to reach the spatulated vagina. With an extremely high vagina or the rare vaginal agenesis, it may be necessary to interpose a bowel segment to reach the perineum, which obviously requires abdominal surgery. With a very dilated vagina, a vaginal flap or vaginal “switch” can be created to reach the perineum, although care must be taken to avoid devascularization and stenosis (Hendren, 1986; Peña, 1989; Peña et al., 2004).

Before the vagina is brought to the perineum, the openings in the common cloacal channel should be closed in two to three layers with absorbable suture to create a urethra. If the cloaca is large and resembles a vagina, it needs to be opened in its entirety and tailored over the Foley catheter. The vagina is then secured to the perineum. If there is any concern about vaginal injury, the vagina should be rotated to avoid overlapping suture lines (Hendren, 1992). The Foley catheter is left indwelling for 2 weeks.

Some surgeons have more recently noted that laparoscopic-assisted PSARVUP can help in achieving a low dissection of the fistula and accurate placements of the rectal pull-through, while allowing excellent visualization of the pelvic structures (Tei et al., 2003). Single- incision laparoscopic procedures have been performed, and Ren et al. have noted single incision laparoscopic assisted anorectoplasty to be as effective as three port assisted procedures with improved cosmesis (Ren et al., 2018; Wang et al., 2016).

The perineal body is now reconstructed, and the rectum is pulled through to the perineum. Peña (1989) stressed the importance of tailoring the widened rectum. The amount of tailoring differs in each patient. The muscles must meet posterior to the rectum. The rectum is placed in the center of the sphincteric muscle mass and anastomosed to the skin. Rectal dilation is begun gradually at 2 to 3 weeks after surgery, and the colostomy is closed in 3 months if all has healed well.

Once the urethral catheter has been removed, it is imperative to monitor the urinary tract and voiding dynamics closely because poor emptying secondary to a neuropathic component is seen in almost one-third of patients. If any concern arises about the child's ability to empty, CIC should be started and continued until normal bladder dynamics are ensured. Failure to do so can ultimately result in urinary tract infection, hydronephrosis, and even loss of renal function.

Peña's TUM technique is now widely accepted for cloacal anomalies. It is a technically easier procedure that requires less time with less blood loss. The basic technique involves 360-degree mobilization of the entire urogenital sinus after the rectum has been separated. The technique at this point is not different from that described earlier for TUM for urogenital sinus abnormalities. I have found this technique to be extremely helpful. It makes the most difficult part of cloacal surgery, vaginal separation, much more easily performed when necessary. If the confluence is only 2 to 3 cm from the perineum, separation may not be even necessary. In patients with a high vaginal confluence, separation may still be necessary, but it is much more easily accomplished (Rink et al., 1997). Concerns regarding continence have been raised, but to date the results have not been different from those with standard repairs. Long-term results of the TUM procedure are needed. Our group has noted that the most important factor in urogenital sinus reconstruction is the distance of the bladder neck to vaginal confluence (true urethral length). Using this concept, the group at Nationwide Children's Hospital has recently reported this importance in cloacal anomalies and has used this urethral length to promote a new algorithm for cloacal repair (Wood et al., 2017). In their new approach, they note that if the urethra is less than 1.5 cm, doing a TUM may result in urinary leakage and should be avoided. In those with a short urethra, one should separate the vagina from the urethra/urogenital sinus, and the urethra is reconstructed or the common sinus used as a urethra. This group later reviewed urethral length in normal healthy females by VCUG and found the normal mean female urethral length to be 2.43 cm (2.50 cm for 6 to 12 months of age, 2.31 for 12 to 24 months of age, and 2.59 for 24 to 36 months of age) and that having a urethral length greater than 1.5 cm should keep the bladder neck above the urogenital diaphragm (Halleran et al., 2019).

Key Points: Cloacal Reconstruction

- Cloacal reconstruction involves four steps: (1) decompression of the gastrointestinal tract (colostomy); (2) decompression of the urinary tract (CIC, vesicostomy, vaginostomy); (3) correction of associated organ systems anomalies; and (4) cloacal repair (PSARVUP).
- TUM is now commonly used for cloacal anomalies after the rectum is separated.
- The results of cloacal repairs are often based on the presence or absence of a normal spinal cord. CIC is frequently required, as is a bowel program, to achieve urinary and fecal continence.

Results of Cloacal Surgery

Cloacal anomalies are exceedingly challenging to repair. The anatomy is complex and differs from patient to patient. The surgeon must be prepared for a long, tedious procedure, must be imaginative, and must be willing to handle the tissues with great care. One might assume from this preface that the results would be dismal. On the contrary, most patients lead a productive life. We surgeons are indebted to Drs. W. Hardy Hendren and Alberto Peña for their pioneering work on children with cloacal anomalies, and their willingness to document their results.

Results have generally been reviewed in terms of urinary continence, fecal continence, and sexual capability; in the future, results should also focus on erotic sensitivity and fertility, pain-free intercourse, and orgasm and quality of life. Early results from a urinary standpoint were dismal: Chappell and Bleloch (1973) reported that all 5 of their patients had some degree of incontinence postoperatively, and Bartholomew and Gonzales (1978) had 5 of 7 patients wet after reconstruction. **It is now clear that a high percentage of patients have a neuropathic component to their incontinence.** In a recent series reported from the Cincinnati Children's Hospital, 89% of those with a common channel greater than 3.5 cm had a neuropathic bladder, whereas only 48% of those with a common channel less than 3.5 cm did (DeFoor et al., 2015). De Filippo et al. (1999) reported urodynamic data on 26 patients with ARMs (including 6 with cloacal anomalies). In this study, 21 of the 26 had preoperative leak point pressures greater than 40 cm H_2O, and 15 had a normal MRI of the spine. This means that even those not demonstrating a neurologic abnormality may have abnormally high outlet resistance, which adds to the risk for incontinence and upper tract changes. Muller et al. (2014) showed that the type of spinal abnormality may affect continence rates, with the short spinal cord having the greatest impact. Of Hendren's 141 patients, 83 (59%) voided spontaneously with control, 40 (28%) required CIC, 4 (3%) had undergone urinary diversion, and 1 (0.7%) was continent with urinary diversion; only 5 (3.5%) were wet, and in 8 the results were too early to assess (Hendren, 1998). Peña et al. (2004) reported a review of 339 patients operated on for cloacal anomalies, 193 of whom were evaluated for urinary continence. They found that spontaneous voiding was related to length of the common channel. Overall continence with spontaneous voiding occurred in 54%. Another 46% were dry with CIC (24% with a native urethra, 22% with a Mitrofanoff channel). However, when the common channel was less than 3 cm, 28% required CIC; if greater than 3 cm, 78% required CIC. Warne et al. (2002b) achieved 80% “social continence,” but only 22% spontaneously voided, 12% performed CIC alone, and 46% required reconstructive urologic surgery to achieve continence (mean number of operations, 4.7). They likewise found that patients with a common channel longer than 3 cm were less likely to void spontaneously (12% vs. 31%). In the series by Rink et al. (2005b), 86% were dry, but only one-third were continent with spontaneous voiding. The remainder required CIC with or without lower urinary reconstruction (Table 49.1). After TUM, spontaneous voiding occurred in 43% to 66% of patients (Levitt and Peña, 2010). Warne et al. (2002b) also noted that a good bladder neck, short common channel, normal sacrum, and two normal kidneys were all good prognostic signs for continence and spontaneous voiding. I am in agreement with Peña and Levitt (2003) that voiding abnormalities are generally related to a noncontractile bladder and warrant CIC, but Warne et al. (2002b) found hyperreflexia to be the predominant pattern in those with abnormal dynamics. It is important to note that 75% of their patients had an abnormal sacrum. In a systematic review of the largest pooled cohort of patients, less than one-half voided spontaneously (22% to 54%); 42% of patients required CIC, and 22% had urinary diversion (Versteegh et al., 2013). Long-term renal function has been a major concern in those with persistent cloaca. At presentation, renal functional impairment must be identified and treated. In 44 patients reported, 19 had hydronephrosis, 19 had vesicoureteral reflux, and chronic kidney disease (CKD) was noted to be stage I to II in 30, stage III in 5, and stage IV in 1. However, DeFoor et al. (2015) showed in these patients that with aggressive diagnosis of underlying anatomic and functional urinary tract dysfunction combined with aggressive modern bladder management (i.e., CIC, diversion, augmentation), renal function can been preserved even in those with CKD.

TABLE 49.1

Continence Rates After Cloacal Surgery

REFERENCE	VOIDING SPONTANEOUSLY	DRY WITH CIC ± CONTINENT RECTUM
Hendren, 1998	0.62	0.34
Peña et al., 2004	0.54	0.46
Warne et al., 2002b	0.22	0.58
Rink et al., 2005b	0.33	0.53

CIC, Clean intermittent catheterization.

Fecal continence is directly related to neurologic status (Peña, 1989)**. Hendren** (1992) **noted that certain factors bode well for continence: good perineal raphe, well-defined anal dimple, normal spine, normal MRI, and brisk muscle reflex** (Hendren, 1992). In 105 patients, Hendren (1992) noted that 47 had normal bowel function, 27 required enemas, 7 had a colostomy, 7 had fecal soiling, and 4 with an anterior anus had normal control. Peña et al. (2004) reported that 60% of 156 patients had voluntary bowel movements, but only 28% of them never soiled. The 40% who are fecally incontinent remain "clean" with a bowel management program. The Malone antegrade continence enema (MACE) appendicovesicostomy has been very helpful in preventing constipation and achieving fecal continence in those refractory to bowel management programs. Rintala's report on long-term fecal outcomes noted voluntary bowel movements in 57%, but 33% had total fecal incontinence with many to most needing a bowel management program (Rintala, 2016). Approximately 17% had opted for fecal diversion. Fecal continence rates were thought to improve in adolescents/adults over children, and less constipation was noted in the older group. In summary, more than one-half of these patients will have major defects in urinary and anorectal function long term.

Vaginal and perineal reconstruction in cloacal anomalies has been associated with a number of complications including introital stenosis, retained vaginal septum, persistent rectovestibular fistula, persistent urogenital sinus, and inadequate perineal body (Vilanova-Sanchez et al., 2018). An inadequate perineal body was generally related to an anterior placed rectum at the time of the initial PSARVU. Fifteen of 28 patients referred to their group after reconstruction elsewhere required redo surgery, and at the time of that surgery 26% had introital stenosis, 20% had a retained vaginal septum, and 13% had a remnant rectovestibular fistula. Late vaginal stenosis and obstructed menstruation occurred in 36% to 41% of patients (Breech, 2010; Hall et al., 1985). Warne et al. (2003) noted the vagina to be adequate for intercourse in 44%. Revision vaginoplasty is often needed. Normal menstruation was noted in only 35% long term. Additional treatment was needed in 38% for obstructive hematometra (Versteegh et al., 2013). In Rintala's own patients, 19% were found to have large cystic collections related to the uteri or adnexal tubes that required surgery (Rintala, 2016). These were not related to obstruction. Although reports are limited, it appears that the majority of reconstructed patients are capable of normal sexual life. Pregnancies have been achieved spontaneously and with in-vitro fertilization in patients with reconstructed cloacal anomalies. There is an increased risk for preterm labor, and cesarean section is the preferred mode of delivery (Vilanova-Sanchez et al., 2019).

Although not a direct result of reparative surgery, renal outcomes are worrisome. Renal insufficiency was found in 50% of the patients treated at Great Ormond Street Children's Hospital, and 17% of the patients progressed to end-stage renal failure (Warne et al., 2002a). In the series of Rink et al. (2005b), 18% had an abnormally elevated serum creatinine level, and in another 26% it was borderline. Lifelong yearly urologic evaluation is warranted, and prompt recognition plus treatment of any obstructive pathologic process or urinary tract infection is imperative. Bladder dynamics must be evaluated and abnormalities addressed. Of 24 reported adult patients, 17 had coitus and 6 had borne children (five cesarean deliveries and one vaginal delivery) (Hendren, 1998).

Leclair et al. (2007) reported on cloacal repair using the TUM technique. Urethral stenosis occurred in 2 of 22 patients, and both required a Mitrofanoff catheterizable channel. One child developed a urethrovaginal fistula, and three had vaginal stenosis. Continence was noted in 15 of 17 patients older than 4 years of age. Seven patients voided spontaneously, and 8 emptied by CIC. Fecal continence was present in 12 patients, with 9 having spontaneous bowel movements and 3 requiring MACE irrigations.

Summary

Management of urogenital sinus and cloacal anomalies can be exceedingly complex. In children with DSD, prompt but very careful evaluation by an expert multidisciplinary team is mandatory. Family support and education with openness and respect for the child and family are required. Differing cultural practices must also be respected and accepted. Confidentiality must be maintained. Regardless of patient age, surgical reconstruction requires great care of tissues, meticulous attention to detail, and a lifelong commitment by the surgeon. These complex anomalies require an entire team of physicians and nurses dedicated to the care of these problems. Urogenital sinus and cloacal anomalies are very challenging reconstructive problems. Those patients at the more severe end of the spectrum should be handled only in centers with great expertise and experience.

Suggested Readings

Hendren W. Cloaca, the most severe degree of imperforate anus: experience with 195 cases. *Am Surg*. 1998;228(3):331–346.

Jaramillo D, Lebowitz RL, Hendren WH. The cloacal malformation: radiologic findings and imaging recommendations. *Radiology*. 1990;177(2):441–448.

Joint LWPES/ESPE CAH Working Group. Consensus statement on 21-hydroxylase deficiency from the Lawson Wilkins Pediatric Endocrine Society and the European Society for Paediatric Endocrinology. *J Clin Endocrinol Metab*. 2002;87(9):4048–4053.

Peña A. Total urogenital mobilization—an easier way to repair cloacas. *J Pediatr Surg*. 1997;32(2):263–267 [discussion 267–268].

Peña A, Levitt MA, Hong A, et al. Surgical management of cloacal malformations: a review of 339 patients. *J Pediatr Surg*. 2004;39(3):470–479 [discussion 470–479].

Rink RC, Herndon CD, Cain MP, et al. Upper and lower urinary tract outcomes after surgical repair of cloacal malformation: a three-decade experience. *BJU Int*. 2005;96(1):131–134.

Schober JM. Feminizing genitoplasty for intersex. Mouriquand PDE. *Pediatric surgery and urology: long term outcomes*. Saunders: London; 1998:549–558.

Speiser PW, White P. Congenital adrenal hyperplasia. *N Engl J Med*. 2003;349(8):776–788.

References

Acimi S. Vaginoplasty using the inner surface or mucosa of the prepuce in children with congenital adrenal hyperplasia. *J Pediatr Urol*. 2013;9(6 Pt B):1038–1042.

Adams MC, Rink RC. Posterior prone approach to the high vagina. *Dialogues Pediatr Urol*. 1998;21:3–4.

Adams M, Ludlow J, Brock JW 3rd, et al. Prenatal urinary ascites and persistent cloaca: risk factors for poor drainage of urine or meconium. *J Urol*. 1998;160(6 Pt 1):2179–2181.

Akbiyik F, Kutlu AO. External genital proportions in prepubertal girls: a morphometric reference for female genitoplasty. *J Urol*. 2010;184(4):1476–1481.

Al-Bassam A, Gado A. Feminizing genital reconstruction: experience with 52 cases of ambiguous genitalia. *Eur J Pediatr Surg*. 2004;14(3):172–178.

Alizai NK, Thomas DF, Lilford RJ, et al. Feminizing genitoplasty for congenital adrenal hyperplasia: what happens at puberty? *J Urol*. 1999;161(5):1588–1591.

Azziz R, Mulaikal R, Migeon CJ, et al. Congenital adrenal hyperplasia: long term results following vaginal reconstruction. *Fertil Steril*. 1986;46(6):1011–1014 [Erratum in Fertil Steril 1987;47(6):1043].

Bailez MM, Gearhart JP, Migeon C, et al. Vaginal reconstruction after initial construction of the external genitalia in girls with salt-wasting adrenal hyperplasia. *J Urol*. 1992;148(2 Pt 2):680–682 [discussion 683–684].

Bal HS, Sen S, Sam C, et al. Urogenital management in cloaca: an alternative approach. *J Indian Assoc Pediatr Surg*. 2017;22(2):108–113.

Barrett TM, Gonzales ET Jr. Reconstruction of the female external genitalia. *Urol Clin North Am*. 1980;7(2):455–463.

Bartholomew TH, Gonzales ET Jr. Urologic management in cloacal dysgenesis. *Urology*. 1978;11(6):549–557.

Baskin L, Erol A, Li YW, et al. Anatomical studies of the human clitoris. *J Urol*. 1999;162(3 Pt 2):1015–1020.

Binet A, Lardy H, Geslin D, et al. Should we question early feminizing genitoplasty for patients with congenital adrenal hyperplasia and XX karyotype? *J Pediatr Surg*. 2016;51:465–468.

Braga LH, Salle JP. Congenital adrenal hyperplasia: a critical appraisal of the evolution of feminizing genitoplasty and the controversies surrounding gender reassignment. *Eur J Pediatr Surg*. 2009;19(4):203–210.

Breech L. Gynecologic concerns in patients with anorectal malformations. *Semin Pediatr Surg*. 2010;19(2):139–145.

Brock JI, Hernanz-Schulman M, Russel W, et al. *Diagnosis of congenital adrenal hyperplasia by ultrasound in the newborn*. [Paper presented at; American Academy of Pediatrics National Conference, Urology Section; San Francisco, CA] 1998.

Cacciaguerra S, Lo Presti L, Di Leo L, et al. Prenatal diagnosis of cloacal anomaly. *Scand J Urol Nephrol*. 1998;32(1):77–80.

Callens N, van der Zwan YG, Drop SL, et al. Do surgical interventions influence psychosexual and cosmetic outcomes in women with disorders of sex development. *ISRN Endocrinol*. 2012;2012:276742.

Chalmers DJ, Rove KO, Wiedel CA. Clean intermittent catheterization as an initial management strategy provides for adequate preservation of renal function in newborns with persistent cloaca. *J Pediatr Urol*. 2015;11(4):211 [e1–211.e4].

Chappell JS, Bleloch J. Urological aspects of the cloacal type of anorectal anomaly. *S Afr Med J*. 1973;47(19):817–820.

Chase C. Re: measurement of pudendal evoked potentials during feminizing genitoplasty: technique and applications. *J*

Urol. 1996;156(3):1139–1140.

Cilento BG Jr, Benacerraf BR, Mandell J. Prenatal diagnosis of cloacal malformation. *Urology*. 1994;43(3):386–388.

Creighton SM, Farhat WA. Early versus late intervention of congenital adrenal hyperplasia. *J Pediatr Adolesc Gynecol*. 2005;18(1):63–69.

Creighton SM, Liao LM. Changing attitudes to sex assignment in intersex. *BJU Int*. 2004;93(5):659–664.

Creighton SM, Minto C, Steele SJ. Objective cosmetic and anatomical outcomes at adolescence of feminising surgery for ambiguous genitalia done in childhood. *Lancet*. 2001;358(9276):124–125.

Creighton S, Chernausek SD, Romao R, et al. Timing and nature of reconstructive surgery for disorders of sex development—introduction. *J Pediatr Urol*. 2012;8(6):602–610.

Crissman HP, Warner L, Gardner M, et al. Children with disorders of sex development: a qualitative study of early parental experience. *Int J Pediatr Endocrinol*. 2011;2011(1):10.

Davies MC, Crouch NS, Woodhouse CR, et al. Congenital adrenal hyperplasia and lower urinary tract symptoms. *BJU Int*. 2005;95(9):1263–1266.

Daynor JE, Lee PA, Hook CP. Medical treatment of intersex: parental perspectives. *J Urol*. 2004;172:176–1765.

De Filippo R, Shaul D, Harrison EA, et al. Neurogenic bladder in infants born with anorectal malformations: comparison with spinal and urologic status. *J Pediatr Surg*. 1999;34(5):825–827 [discussion 828].

de Jong TP, Boemers TM. Neonatal management of female intersex by clitorovaginoplasty. *J Urol*. 1995;154(2 Pt 2):830–832.

DeFoor WR, Bischoff A, Reddy P, et al. Chronic kidney disease stage progression in patients undergoing repair of persistent cloaca. *J Urol*. 2015;194(1):190–194.

Di Benedetto V, Gioviale M, Bagnara V, et al. The anterior sagittal transanorectal approach: a modified approach to 1-stage clitoral vaginoplasty in severely masculinized female pseudohermaphrodites—preliminary results. *J Urol*. 1997;157(1):330–332.

Dòmini R, Rossi F, Ceccarelli PL, et al. Anterior sagittal transanorectal approach to the urogenital sinus in adrenogenital syndrome: preliminary report. *J Pediatr Surg*. 1997;32(5):714–716.

Donahoe PK, Gustafson ML. Early one-stage surgical reconstruction of the extremely high vagina in patients with congenital adrenal hyperplasia. *J Pediatr Surg*. 1994;29(2):352–358.

Dumanian GA, Donahoe PK. Bilateral rotated buttock flaps for vaginal atresia in severely masculinized females with adrenogenital syndrome. *Plast Reconstr Surg*. 1992;90(3):487–491.

Elmasri J, Zaiem F, Rodriquez-Gutierrez R, et al. Genital reconstructive surgery in females with congenital adrenal hyperplasia: a systematic review and meta-analysis. *J Clin Endocrinol Metab*. 2018;103(11):4089–4096.

Eroglu E, Tekant G, Gündoğdu G, et al. Feminizing surgical management of intersex patients. *Pediatr Surg Int*. 2004;20(7):543–547.

Escala Aguirre JM, Cadena Y, López PJ, et al. Feminizing genitoplasty in adrenal congenital hyperplasia: one or two surgical steps? *Arch Esp Urol*. 2009;62(9):724–730 [in Spanish].

Fagerholm R, Mattila AK, Roine RP, et al. Mental health and quality of life after feminizing genitoplasty. *J Pediatr Surg*. 2012;4(4):747–751.

Fagerholm R, Rintala R, Taskinen S. Lower urinary tract symptoms after feminizing genitoplasty. *J Pediatr Urol*. 2013;9(1):23–26.

Fagerholm R, Santtila P, MilHinen PJ, et al. Sexual function and attitudes toward surgery after feminizing genitoplasty. *J Urol*. 2011;185:1900–1904.

Farkas A, Chertin B, Hadas-Halpren I. 1-Stage feminizing genitoplasty: 8 years of experience with 49 cases. *J Urol*. 2001;165(6 Pt 2):2341–2346.

Fleming S, Hall R, Gysler M, et al. Imperforate anus in females: frequency of genital tract involvement, incidence of associated anomalies, and functional outcome. *J Pediatr Surg*. 1986;21(2):146–150.

Fortunoff S, Lattimer J, Edson M. Vaginoplasty technique for female pseudohermaphrodites. *Surg Gynecol Obstet*. 1964;118:545–548.

Freitas-Filho L, Carnevale J, Melo CE, et al. A posterior-based omega-shaped flap vaginoplasty in girls with congenital adrenal hyperplasia caused by 21-hydroxylase deficiency. *BJU Int*. 2003;91(3):263–264.

Ganesan A, Smith G, Broome K, et al. Congenital adrenal hyperplasia: preliminary observations of the urethra in 9 cases. *J Urol*. 2002;167(1):275–278 [discussion 278–279].

Gearhart JJ, Burnett A, Owen JH. Measurement of pudendal evoked potentials during feminizing genitoplasty: technique and applications. *J Urol*. 1995;153(2):486–487.

Glassberg KI, Laungani G. Reduction clitoroplasty. *Urology*. 1981;17(6):604–605.

Gondim R, Teles F, Barroso U Jr. Sexual orientation of 46, XX patients with congenital adrenal hyperplasia: a descriptive review. *J Pediatr Urol*. 2018;14(6):486–493.

Gonzalez R, Fernandes ET. Single-stage feminization genitoplasty. *J Urol*. 1990;143(4):776–778.

Gosalbez R, Castellan M, Ibrahim E, et al. New concepts in feminizing genitoplasty—is the Fortunoff flap obsolete? *J Urol*. 2005;174(6):2350–2353 [discussion 2353].

Griffin JE, Wilson JD. The androgen resistance syndromes: 5alpha-reductase deficiency, testicular feminization, and related syndromes. Scriver CR, Beaudet AL, Sly WS, et al. *The metabolic basis of inherited disease*. 6th ed. McGraw-Hill: New York; 1989.

Gross RE, Randolph J, Crigler JF Jr. Clitorectomy for sexual abnormalities: indications and technique. *Surgery*. 1966;59(2):300–308.

Guarino N, Scommegna S, Majore S, et al. Vaginoplasty for disorders of sex development. *Front Endocrinol (Lausanne)*. 2013;4:29.

Gupta A, Bischoff A, Peña A, et al. The great divide: septation and malformation of the cloaca, and its implications for surgeons. *Pediatr Surg Int*. 2014;30(11):1089–1095.

Hall R, Fleming S, Gysler M, et al. The genital tract in female children with imperforate anus. *Surg Gynecol Obstet*. 1985;151(2):169–171.

Halleran DR, Thompson B, Fuchs M, et al. Urethral length in female infants and its relevance in the repair of cloaca. *J Pediatr Surg*. 2019;54(2):303–306.

Hampson JG. Hermaphroditic genital appearance, rearing and eroticism in hyperadrenocorticism. *Bull Johns Hopkins Hosp*. 1955;96(6):265–273.

Hamza AF, Soliman HA, Abdel Hay SA, et al. Total urogenital sinus mobilization in repair of cloacal anomalies and congenital adrenal hyperplasia. *J Pediatr Surg*. 2001;36(11):1656–1658.

Hendren WH. Further experience in reconstructive surgery for cloacal anomalies. *J Pediatr Surg*. 1982;17(6):695–717.

Hendren WH. Repair of cloacal anomalies: current techniques. *J*

Pediatr Surg. 1986;21(12):1159–1176.

Hendren WH. Urological aspects of cloacal malformations. *J Urol*. 1988;140(5 Pt 2):1207–1213.

Hendren WH. *Cloacal malformations*. Saunders: Philadelphia, PA; 1989.

Hendren WH. Cloacal malformations: experience with 105 cases. *J Pediatr Surg*. 1992;27(7):890–901.

Hendren WH. Cloacal, the most severe degree of imperforate anus: experience with 195 cases. *Am Surg*. 1998;228(3):331–346.

Hendren WH, Crawford JD. Adrenogenital syndrome: the anatomy of the anomaly and its repair. Some new concepts. *J Pediatr Surg*. 1969;4(1):49–58.

Hendren WH, Donahoe PK. Correction of congenital abnormalities of the vagina and the perineum. *J Pediatr Surg*. 1980;15(6):751–763.

Hendren WH, Atala A. Repair of the high vagina in girls with severely masculinized anatomy from the adrenogenital syndrome. *J Pediatr Surg*. 1995;30(1):91–94.

Hensle T, Bingham J. *Feminizing genitoplasty in pediatric gender assignment: a critical reappraisal*. Kluwer Academic Plenum: New York; 2002.

Hensle T, Kennedy W. *Surgical management of intersexuality*. Saunders: Philadelphia, PA; 1998.

Huffman JW. Office gynecology: some facts about the clitoris. *Postgrad Med*. 1976;60(5):245–247.

Hughes I. Congenital adrenal hyperplasia: a continuum of disorders. *Lancet*. 1988;352(9130):752–754.

Hughes IA, Houk C, Ahmed SF, LWPES Consensus Group; ESPE Consensus Group, et al. Consensus statement on management of intersex disorders. *Arch Dis Child*. 2006;91(7):554–563.

Jaramillo D, Lebowitz RL, Hendren WH. The cloacal malformation: radiologic findings and imaging recommendations. *Radiology*. 1990;177(7):441–448.

Jenak R, Ludwikowski B, Gonzalez R. Total urogenital sinus mobilization: a modified perineal approach for feminizing genitoplasty and urogenital sinus repair. *J Urol*. 2001;165(6 Pt 2):2347–2349.

Jesus VM, Buriti F, Lessa R. Total urogenital sinus mobilization for ambiguous genitalia. *J Pediatr Surg*. 2018;53(4):808–812.

Johannsen TH, Ripa CP, Carlsen E, et al. Long-term gynecological outcomes in women with congenital adrenal hyperplasia due to 21-hydroxylase deficiency. *Int J Pediatr Endocrinol*. 2010;2010:784297.

Joint LWPES/ESPE CAH Working Group. Consensus statement on 21-hydroxylase deficiency from the Lawson Wilkins Pediatric Endocrine Society and the European Society for Paediatric Endocrinology. *J Clin Endocrinol Metab*. 2002;87(9):4048–4053.

Jones HW Jr, Garcia SC, Klingensmith GJ. Secondary surgical treatment of the masculinized external genitalia of patients with virilizing adrenal hyperplasia. *Am J Obstet Gynecol*. 1976;48(1):73–75.

Jones HW Jr, Jones GE. The gynecological aspects of adrenal hyperplasia and allied disorders. *Am J Obstet Gynecol*. 1954;68(5):1330–1361.

Juskiewenski S, Vaysse P, Moscovici J, et al. A study of the arterial blood supply to the penis. *Anat Clin*. 1982;4(2):101–107.

Kaplan I. A simple technique for shortening of the clitoris without amputations. *Obstet Gynecol*. 1967;29(2):270–271.

Karlin G, Brock JI, Rich M, et al. Persistent cloacal and phallic urethra. *J Urol*. 1989;142(4):1056–1059.

Kay R, Tank ES. Principles of management of the persistent cloaca in the female newborn. *J Urol*. 1977;117(1):102–104.

Kittur DH, Vora RM. Persistent cloaca: a long-term follow-up study. *J Indian Assoc Pediatr Surg*. 2017;22(2):126–127.

Klugo R, Fisher J, Retik AB. Management of urogenital anomalies in cloacal dysgenesis. *J Urol*. 1974;112(6):832–835.

Kogan SJ, Smey P, Levitt SB. Subtunical total reduction clitoroplasty: a safe modification of existing techniques. *J Urol*. 1983;130(4):746–748.

Krishnan S, Wisniewski AB. Ambiguous genitalia in newborns. New MI, Lekarev O, Parsa A, et al. *Genetic steroid disorders*. Academic Press: New York; 2014:87–97.

Kropp BP, Cheng EY. Total urogenital complex mobilization in female patients with exstrophy. *J Urol*. 2000;164(3 Pt 2):1035–1039.

Krstic ZD, Lukac M, Lukac R, et al. Surgical treatment of cloacal anomalies. *Pediatr Surg Int*. 2001;17(4):329–333.

Kryger JV, Gonzáles R. Urinary continence is well preserved after total urogenital mobilization. *J Urol*. 2004;172(6 Pt 1):2384–2386.

Kumar H, Kiefer JH, Rosenthal IE, et al. Clitoroplasty: experience during a 19-year period. *J Urol*. 1974;111(1):81–84.

Lattimer JK. Relocation and recession of the enlarged clitoris with preservation of the glans: an alternative to amputation. *J Urol*. 1961;86:113–116.

Lean WL, Hutson JM, Deshpande AV, et al. Clitoroplasty: past, present and future. *Pediatr Surg Int*. 2007;23(4):289–293.

Leclair MD, Gundetti M, Kiely EM, et al. The surgical outcome of total urogenital mobilization for cloacal repair. *J Urol*. 2007;177(4):1492–1495.

Lee PA, Witchel SF. Genital surgery among females with congenital adrenal hyperplasia: changes over the past five decades. *J Pediatr Endocrinol Metab*. 2002;15(9):1473–

1477.

Lee PA, Houk CP, Ahmed SF, et al. Consensus statement on management of intersex disorders. International Consensus Conference on Intersex. *Pediatrics*. 2006;118(2):e488–e500.

Levitt MA, Peña A. Pitfalls in the management of newborn cloacas. *Pediatr Surg Int*. 2005;21(4):264–269.

Levitt MA, Peña A. Cloacal malformations: lessons learned from 490 cases. *Semin Pediatr Surg*. 2010;19(2):128–138.

Lin-Su K, Lekarev O, Poppas DP, et al. Congenital adrenal hyperplasia patient perception of ‘disorders of sex development’ nomenclature. *Int J Pediatr Endocrinol*. 2015;2015(1):9.

Lloyd J, Crouch NS, Minto CL, et al. Female genital appearance: “normality” unfolds. *BJOG*. 2005;112(2):643–646.

Ludwikowski BM, González R. The surgical correction of urogenital sinus in patients with DSD: 15 years after description of total urogenital mobilization in children. *Front Pediatr*. 2013;1:41.

Ludwikowski B, Oesch Hayward I, González R. Total urogenital sinus mobilization: expanded applications. *BJU Int*. 1999;83(7):820–822.

Mandell J, Haskins JM, Hammond MG. Surgical correction of external genitalia and lower genitourinary tract of markedly virilized child. *Urology*. 1988;31(3):234–236.

Marberger H: Hunterian lecture. Presented at: Royal College of Surgeons; 1975; London, England.

Marei M, Fares A, Musa N, et al. Timing and outcome concerns regarding feminizing genitoplasty from the perspective of Egyptian families of girls with virilized external genitalia. *Horm Res Paediatr*. 2015.

Masuko T, Higashimoto Y, Iwai J. Single-stage operation without temporary colostomy for persistent cloaca with a short common channel. *Pediatr Surg Int*. 2005;21(11):922–924.

Merke DP, Bornstein SR. Congenital adrenal hyperplasia. *Lancet*. 2005;365(9477):2125–2136.

Minto CL, Liaco LM, Woodhouse CR, et al. The effect of clitoral surgery on sexual outcome in individuals who have intersex conditions with ambiguous genitalia: a cross-sectional study. *Lancet*. 2003;361(9365):1252–1257.

Mollard P, Juskiewenski S, Sarkissian J. Clitoroplasty in intersex: a new technique. *Br J Urol*. 1981;53(4):371–373.

Mollitt DL, Schullinger JN, Santulli TV, et al. Complications at menarche of urogenital sinus with associated anorectal malformations. *J Pediatr Surg*. 1981;16(3):349–352.

Money J. Hermaphroditism, gender and precocity in hyperadrenocorticism: psychologic findings. *Bull Johns Hopkins Hosp*. 1955;96(6):253–264.

Morimoto K, Takemoto O, Wakayama A. A tethered cord associated with anorectal malformation. *Pediatr Neurosurg*. 2003;38(2):79–82.

Moriya K, Higashiyama H, Tanaka H, et al. Long-term outcome of vaginoplasty with the bilateral labioscrotal flap. *J Urol*. 2009;182(4 Suppl):1876–1881.

Mouriquand P, Caldmone A, Malone P, et al. ESPU/SPU standpoint on the surgical management of disorders of sex development (DSD). *J Pediatr Urol*. 2014;10(1):8–10.

Muller CO, Crétolle C, Blanc T, et al. Impact of spinal dysraphism on urinary and faecal prognosis in 25 cases of cloacal malformation. *J Pediatr Urol*. 2014;10(6):1199–1295.

New MI, Lekarev O, Parsa A, et al. *Genetic steroid disorders*. Academic Press: New York; 2014.

Nihoul-Fekete C, Philippe F, Thibaud E, et al. Continued evaluation of results of surgical management of female congenital adrenal hyperplasia: report on 48 cases (author's transl). *Arch Fr Pediatr*. 1982;39(1):13–16 [in French].

Nordenskjöld A, Holmdahl G, Frisén L, et al. Type of mutation and surgical procedure affect long-term quality of life for women with congenital adrenal hyperplasia. *J Clin Endocrinol Metab*. 2008;93(2):380–386.

Nordenström A, Frisén L, Falhammar H, et al. Sexual function and surgical outcome in women with congenital adrenal hyperplasia due to CYP21A2 deficiency: clinical perspective and the patients' perception. *J Clin Endocrinol Metab*. 2010;95(8):3633–3640.

O'Connell HE, Sanjeevan KV, Hutson JM. Anatomy of the clitoris. *J Urol*. 2005;174(4 Pt 1):1189–1195.

Odibo AO, Turner GW, Borgida AF, et al. Late prenatal ultrasound features of hydrocolpos secondary to cloacal anomaly: case reports and review of the literature. *Ultrasound Obstet Gynecol*. 1997;9(6):419–421.

Okonkwo JE, Crocker KM. Cloacal dysgenesis. *Obstet Gynecol*. 1977;50(1):97–101.

Palmer BW, Trojan B, Griffin K, et al. Total and partial urogenital mobilization: focus on urinary continence. *J Urol*. 2012;187(4):1422–1426.

Parrott TS, Woodard JR. Abdominoperitoneal approach to management of the high, short vagina in the adrenogenital syndrome. *J Urol*. 1991;146(2 Pt 2):647–648.

Passerini-Glazel G. A new 1-stage procedure for clitorovaginoplasty in severely masculinized female pseudohermaphrodites. *J Urol*. 1989;142(2 Pt 2):565–568 [discussion 572].

Passerini-Glazel G. Vaginoplasty and clitoroplasty for the adrenogenital syndrome. Hinman F Jr. *Atlas of pediatric urologic surgery*. Saunders: Philadelphia, PA; 1994:635.

Passerini-Glazel G. Vaginoplasty in severely virilized CAH females. *Dialogues Pediatr Urol*. 1998;21:2–3.

Pellerin D. La reimplantation du clitoris: refection plastique du pseudohermaphrodisme feminin. *Mem Acad Chir (Paris)*. 1965;91:965–968.

Peña A. The surgical management of persistent cloaca: results in 54 patients treated with a posterior sagittal approach. *J Pediatr Surg*. 1989;24(6):590–598.

Peña A. Total urogenital mobilization—an easier way to repair cloacas. *J Pediatr Surg*. 1997;32(2):263–267 [discussion 267–268].

Peña A, Levitt MA. Surgical management of cloacal malformations. *Semin Neonatol*. 2003;8(3):249–257.

Peña A, Levitt MA, Hong A, et al. Surgical management of cloacal malformations: a review of 339 patients. *J Pediatr Surg*. 2004;39(3):470–479 [discussion 470–479].

Petrikovsky B, Walzak MJ Jr, D'Addario PF. Fetal cloacal anomalies: prenatal sonographic findings and differential diagnosis. *Obstet Gynecol*. 1988;72(3 Pt 2):464–469.

Pippi Salle JL, Braga LP, Macedo N, et al. Corporeal sparing dismembered clitoroplasty: an alternative technique for feminizing genitoplasty. *J Urol*. 2007;178(4 Pt 2):1796–1800 [discussion 1801].

Powell DM, Newman KD, Randolph J. A proposed classification of vaginal anomalies and their surgical correction. *J Pediatr Surg*. 1995;30(2):271–275 [discussion 275–276].

Pradhan S, Vilanova-Sanchez A, McCracken KA, et al. The Mullerian Black Box: predicting and defining Mullerian anatomy in patients with cloacal abnormalities and the need for longitudinal assessment. *J Pediatr Surg*. 2018;53(11):2164–2169.

Raffensperger JG. The cloaca in the newborn. *Birth Defects Orig Artic Ser*. 1988;24(4):111–123.

Rajfer J, Ehrlich RM, Goodwin WE. Reduction clitoroplasty via ventral approach. *J Urol*. 1982;128(2):341–343.

Randolph JG, Hung W. Reduction clitoroplasty in females with hypertrophied clitoris. *J Pediatr Surg*. 1970;5(2):224–231.

Rangecroft L. Surgical management of ambiguous genitalia. *Arch Dis Child*. 2002;88:799–801.

Ren X, Xiao H, Li L, et al. Single-incision laparoscopic-assisted anorectoplasty versus three-port laparoscopy in treatment of persistent cloaca: a midterm follow-up. *J Laparoendosc Adv Surg Tech A*. 2018;28(12):1540–1547.

Rink RC, Adams MC. Feminizing genitoplasty: state of the art. *World J Urol*. 1998;16(3):212–218.

Rink RC, Adams MC. Evaluation and surgical management of the child with intersex. *Prog Paediatr Urol*. 1999;2:67–88.

Rink RC, Yerkes EB. Surgical management of female genital anomalies, intersex disorders and cloacal anomalies. Gearhart J, Rink RC, Mouriquand PDE. *Pediatric urology*. Saunders: Philadelphia, PA; 2001:659–685.

Rink RC, Cain MP. *Further uses of the mobilized sinus in total urogenital mobilization procedures*. [Paper presented at; Annual Meeting of the American Academy of Pediatrics; Boston, MA] 2002.

Rink RC, Kaefer M. Surgical management of intersexuality, cloacal malformation and other abnormalities of the genitalia in girls. Walsh P, Retik AB, Vaugh EP, et al. *Campbell's urology*. Saunders: Philadelphia, PA; 2002:2428–2467.

Rink RC, Whittam B. Treatment and outcome of congenital adrenal hyperplasia: current reconstructive surgery. New M, Lekarev O, Parsa A, et al. *Genetic steroid disorders*. Elsevier: London; 2014:279–284.

Rink RC, Szymanski KM. Disorders of sexual development: surgical management. Lima M, Manzoni G. *Pediatric urology: contemporary strategies from fetal life to adolescence*. Springer-Verlag: Milan; 2015:247–258.

Rink RC, Pope JC, Kropp BP, et al. Reconstruction of the high urogenital sinus: early perineal prone approach without division of the rectum. *J Urol*. 1997;158(3 Pt 2):1333–1337.

Rink RC, Adams MC, Misseri R. A new classification for genital ambiguity and urogenital sinus anomalies. *BJU Int*. 2005;95(4):638–642.

Rink RC, Herndon CD, Cain MP, et al. Upper and lower urinary tract outcomes after surgical repair of cloacal malformation: a three-decade experience. *BJU Int*. 2005;96(1):131–134.

Rink RC, Metcalfe PD, Cain MP, et al. *Partial urogenital mobilization: the advantages without the risks*. [Paper presented at; Annual Meeting of the European Society of Pediatric Urology and also the American Academy of Pediatrics. Uppsala (Sweden)] 2005.

Rink RC, Metcalfe PD, Cain MP, et al. Use of the mobilized sinus with total urogenital mobilization. *J Urol*. 2006;176(5):2205–2211.

Rink RC, Leslie JA, Kaefer M, et al. *Outcomes and risk factors in urogenital mobilization*. [Paper presented at; the Annual Meeting of the American Academy of Pediatrics; Oct 26–29, 2007; San Francisco, CA] 2007.

Rintala J. Congenital cloaca: Long-term follow-up results with emphasis on outcomes beyond childhood. *Semin Pediatr Surg*. 2016;25(2):11–16.

Rossi F, De Castro R, Ceccarelli PL. Dòmini R. Anterior sagittal transanorectal approach to the posterior urethra in the pediatric age group. *J Urol*. 1998;160(3 Pt 2):1773–1777.

Roth JD, Casey JT, Whittam BM. Characteristics of female genital restoration surgery for congenital adrenal hyperplasia using a large-scale administrative database. *Urology*. 2018;115:162–167.

Salle JL, Lorenzo AJ, Jesus LE, et al. Surgical treatment of high genital sinuses using the anterior sagittal transrectal approach:

a useful strategy to optimize exposure and outcomes. *J Urol*. 2012;187(3):1024–1031.

Sandberg DE, Gardner M, Cohen-Kettenis PT. Psychological aspects of the treatment of patients with disorders of sex development. *Semin Reprod Med*. 2012;30(5):443–452.

Sato Y, Pringle KC, Bergman RA, et al. Congenital anorectal anomalies: MR imaging. *Radiology*. 1988;168(1):157–162.

Schmid M. Plastic correction of the external genitalia in a male pseudohermaphrodite. *Langenbecks Arch Klin Chir Ver Dtsch Z Chir*. 1961;298:977–982 [in German].

Schnitzer JJ, Donahoe PK. Surgical treatment of congenital adrenal hyperplasia. *Endocrinol Metab Clin North Am*. 2001;30(1):137–154.

Schober JM. Feminizing genitoplasty for intersex. Mouriquand PDE. *Pediatric surgery and urology: long term outcomes*. Saunders: London; 1998:549–558.

Schober JM. Long-term outcomes and changing attitudes to intersexuality. *BJU Int*. 1999;83(Suppl 3):39–50.

Schober JM. Feminizing genitoplasty: a synopsis of issues relating to genital surgery in intersex individuals. *J Pediatr Endocrinol*. 2004;17(5):697–703.

Schober JM, Ransley PG. Anatomical description and sensitivity mapping of adult women based on the SAGASF survey [abstract 97]. *BJU Int*. 2002;89(Suppl 2):54.

Shalev E, Feldman E, Weiner E, et al. Prenatal sonographic appearance of persistent cloaca. *Acta Obstet Gynecol Scand*. 1986;65(5):517–518.

Shaw A. Subcutaneous reduction clitoroplasty. *J Pediatr Surg*. 1977;12(3):331–338.

Snyder H 3rd, Retik AB, Bauer SB, et al. Feminizing genitoplasty: a synthesis. *J Urol*. 1983;129(5):1024–1026.

Sotiropoulos A, Morishima A, Homsy Y, et al. Long-term assessment of genital reconstruction in female pseudohermaphrodites. *J Urol*. 1976;115(5):599–601.

Speiser PW, White P. Congenital adrenal hyperplasia. *N Engl J Med*. 2003;349(8):776–788.

Speiser PW, Azziz R, Baskin LS, et al. A summary of the Endocrine Society Clinical Practice Guidelines on congenital adrenal hyperplasia due to steroid 21-hydroxylase deficiency. *Int J Pediatr Endocrinol*. 2010;494173:2010.

Speiser PW, Arlt W, Auchus RJ. Congenital adrenal hyperplasia due to steroid 21-hydroxylase deficiency: an Endocrine Society Clinical Practice Guideline. *J Clin Endocrinol Metab*. 2018;103(11):4043–4088.

Spence HM, Allen TD. Genital reconstruction in the female with the adrenogenital syndrome. *Br J Urol*. 1973;45(2):126–130.

Spitz L, Coran AG. *Operative pediatric surgery*. 6th ed. Hodder Arnold: London; 2006.

Szymanski KM, Whittam B, Kaefer M. Parental decisional regret and views about optimal timing of female genital restoration surgery in congenital adrenal hyperplasia. *J Pediatr Urol*. 2017;14(2):156 [e1–156.e7].

Szymanski KM, Whittam B, Kaefer M, et al. What about my daughter's future? Parental concerns when considering female genital restoration surgery in girls with congenital adrenal hyperplasia. *J Pediatr Urol*. 2018;14(5):417 [e1–417.e5].

Tei E, Yamataka A, Segawa O, et al. Laparoscopically assisted anorectovaginoplasty for selected types of female anorectal malformations. *J Pediatr Surg*. 2003;38(12):1770–1774.

Thomas D. Gender assignment background and current controversies. *BJU Int*. 2004;93(Suppl 3):47–50.

Trakakis E, Loghis C, Kassanos D. Congenital adrenal hyperplasia because of 21-hydroxylase deficiency. A genetic disorder of interest to obstetricians and gynecologists. *Obstet Gynecol Surv*. 2009;64(3):177–189.

van der Zwan YG, Janssen EH, Callens N, et al. Dutch Study Group on DSD. Severity of virilization is associated with cosmetic appearance and sexual function in women with congenital adrenal hyperplasia: a cross-sectional study. *J Sex Med*. 2013;10(3):866–875.

VanderBrink VA, Rink RC, Cain MP, et al. Does preoperative genitography in congenital adrenal hyperplasia cases affect surgical approach to feminizing genitoplasty? *J Urol*. 2010;184(4 Suppl):1793–1798.

Versteegh HP, van Rooij IA, Levitt MA, et al. Long-term follow-up of functional outcome in patients with a cloacal malformation: a systematic review. *J Pediatr Surg*. 2013;48(11):2343–2350.

Vidal I, Gorduza DB, Haraux E, et al. Surgical options in disorders of sex development (DSD) with ambiguous genitalia. *Best Pract Res Clin Endocrinol Metab*. 2010;24(2):311–324.

Vilanova-Sanchez A, Reck CA, McCracken KA, et al. Gynecologic anatomic abnormalities following anorectal malformations repair. *J Pediatr Surg*. 2018;53(4):698–703.

Vilanova-Sanchez A, McCrack K, Halleran DR, et al. *J Pediatr Adolesc Gynecol*. 2019;32(1):7–14.

Wang C, Li L, Diao M, et al. Single-incision laparoscopic-assisted anorectoplasty for the management of persistent cloaca. *J Laparoendosc Adv Surg Tech A*. 2016;26(4):328–333.

Warne SA, Wilcox DT, Creighton S, et al. Long-term gynecological outcome of patients with persistent cloaca. *J Urol*. 2003;170(4 Pt 2):1493–1496.

Warne SA, Wilcox DT, Ledermann SE, et al. Renal outcome in patients with cloaca. *J Urol*. 2002;167(6):2548–2551 [discussion 2551].

Warne SA, Wilcox DT, Ransley PG. Long term urological outcome of patients presenting with persistent cloaca. *J Urol*. 2002;168(4 Pt 2):1859–1862 [discussion 1862].

Williams CE, Nakhal RS, Achermann JC, et al. Persistent unexplained congenital clitoromegaly in females born extremely prematurely. *Pediatr Urol*. 2013;9(6):962–965.

Willihnganz-Lawson KH, Isharwal S, Lewis JM, et al. Secondary vaginoplasty for disorders for sexual differentiation: is there a right time? Challenges with compliance and follow-up at a multidisciplinary center. *J Pediatr Urol*. 2013;9(5):627–633.

Wisniewski AB, Migeon CJ, Malouf MA, et al. Psychosexual outcome in women affected by congenital adrenal hyperplasia due to 21-hydroxylase deficiency. *J Urol*. 2004;171(6 Pt 1):2497–2501.

Wood RJ, Reck-Burneo CA, Dajusta D, et al. Cloaca reconstruction: a new algorithm which considers the role of urethral length in determining surgical planning. *J Pediatr Surg*. 2017 [piii: S0022-3468(17)30644-9].

Woodhouse CR. Intersex surgery in the adult. *BJU Int*. 2004;93(Suppl 3):57–65.

Yankovic F, Cherian A, Steven L, et al. Current practice in feminizing surgery for congenital adrenal hyperplasia; a specialist survey. *J Pediatr Urol*. 2013;9(6 Pt B):1103–1107.

Yerkes EB, Rink RC. Surgical management of female genital anomalies, disorders of sexual development, urogenital sinus, and cloacal anomalies. Gearhart JG, Rink RC, Mouriquand PDE. *Pediatric urology*. 2nd ed. Elsevier Saunders: Philadelphia, PA; 2010:476–499.

Young H. *Genital abnormalities, hermaphroditism and related adrenal diseases*. Williams & Wilkins: Baltimore; 1937.

Adolescent and Transitional Urology

Dan Wood PhD

There have been significant developments in urology and transition, but we are relatively backward when compared with other specialties. For example, oncology and rheumatology have really recognized the need for and benefits of transitional care as a means to improve lifelong care and outcomes. They appear to have a much more consistent approach (Clemente et al., 2017; Crowley et al., 2011).

This chapter will explore some of the models of transition and the reasons why lifelong care is important in some of the conditions that we treat on a regular basis.

The essence of transition is allowing a young adult to assume a central role in their own health care. The majority of the patients we deal with have a congenital anomaly discovered at birth and managed from infancy to the present day by a (largely) consistent pediatric team. For the early years, necessity dictates that parents make many decisions for the child in keeping with advice from pediatric urologists. There are a variety of views on healthy (or not) parental involvement, particularly in adolescence. **It is consistently true that children grow up, even when faced with major congenital anomalies and the major treatments (surgical or otherwise) that these will lead to. Thus the child, adolescent, and later adult need to be at the center of these decisions.** This goes without saying and is reflected in much of the practice we see; arguably the most difficult time to achieve this is during adolescence. There are a variety of reasons behind this:

1. **The developing adolescent brain does not always see the risks or consequences that may follow some behaviors.** This can translate as a young adult patient deciding not to continue (or undertake) some important elements of treatment as they attempt to exert their independence and authority in the world. This can be misguided and

dangerous, which reinforces protective behaviors in both parents and health care workers.

2. Parents are naturally protective of their child, and although some are very good at stepping back and allowing their child room to grow into their independence, others really struggle with it. Watching their child make big treatment decisions or sign consent forms for the first time while being encouraged to sit on their hands and keep their mouth shut must be incredibly difficult, especially when they have taken such a significant role in their child's health care to that point. Sympathy for the patient is further evoked by the so-called adolescent behavior outlined in number 1. In this context, we are imploring parents to step back.
3. Pediatric practitioners have developed a strong mutual bond with their patients (and parents). Handing any patient on to another team is difficult for any doctor for all sorts of reasons. Pediatric urologists are as subject to this as any other; they need to know that their patients will remain in safe hands and that they will be allowed to learn of their long-term outcomes.

The understanding that these patients need care in adulthood was a major step forward; the further leap was to understand that the “qualifications” for providing that care in adult patients were not fully covered in either a conventional pediatric or an adult urology training, and thus a hybrid practitioner was needed. The concept of an adolescent urologist and with that congenital lifelong urology has become a growing reality. It has been applied in a variety of different ways. Most importantly is the fact that major intervention in childhood is the beginning of a contract between the health care system and that child. Somehow the system has to offer a design that will treat the initial diagnosis and then provide necessary care for the rest of the patients' lives. This may be achieved in a number of different ways, none of which is absolutely right or wrong. But care in silos (pediatric and adult urology) does not deliver what these patients need; there has to be a productive interaction between both and the provision of lifelong care where it is needed (Wood, 2014).

Definitions

Transition

The American Academy of Pediatrics (AAP), American Academy of Family Physicians, American College of Physicians, and American Society of Internal Medicine have mandated that “all adolescents with special healthcare needs should have a written healthcare transition plan by the age of 14 years” (AAP et al., 1996). **The adopted definition of transition is “the purposeful, planned movement of adolescents and young adults with chronic physical and medical conditions from child centered to adult-oriented health care systems”** (Rosen et al., 2003).

Although the author understands these definitions, it is his belief that they are both lacking. Both could be interpreted as the system being active while the patient remains the passive recipient of transition. Working in an adolescent/adult environment and looking after such urologic patients “after” their pediatric care highlights the importance of pediatric teams needing to prepare patients for an active role in their health care and the understanding that they will not be in a children's hospital forever. This is in no way underestimating the challenge of this.

Greater than 90% of children with chronic conditions expect to live into adulthood. The morbidity during transfer from pediatric to adult care is high. In cystic fibrosis, there is a peak of deaths in the adolescent and young adult period.

Too often there is focus on the transfer; good preparation of a child for transition takes years.

The essence is to begin conversations with both the child at an early age (maybe 10 or 11 years) and parent(s) that begins to get the child to write down or details his or her own diagnosis and needs both in health care and, perhaps, more widely. Making children central in this and building their confidence to participate will activate them and help to reassure parents of their capability. Gradually, the child becomes more and more active in his or her health care and ultimately is ready to take full control; ideally it should be the child in conjunction with the health care team that devises the aforementioned plan. The introduction of the adolescent team can be judged (balancing the local system setup with the individual patient needs) but is an important stage in the process.

Ideally, the new team should try to meet the patient and the parents in an environment that is familiar for the patient. The move to another center can follow. At least this incorporates a familiar face or two when the patient does move.

There is a range of reasons why conversations and indeed both transition and transfer may be delayed. Most importantly is the readiness of the child and family. This may be in medical, surgical, or psychological terms. The pediatric team needs to make that judgment, but if transition becomes part of normal parlance and therefore a realistic expectation for both the patient and their family, it may have a positive impact.

The aim of a transition program should include structure and principles that bring information and readiness into a single stream (Cooley, 2013) (Table 50.1). Having information that a patient can access would be useful. Whenever and wherever they seek medical attention, they will be able to share important and relevant medical details with the local team. The most rudimentary for this would be a paper health passport that the patient could write in and retain copies of correspondence from their health care team(s) within. Web portals through the Internet or smartphone apps may become the method of the future. There are examples around, but there has not yet been widespread uptake.

TABLE 50.1

Six Core Elements of Health Care Transition

ELEMENT	DESCRIPTION
Transition policy	Written policy that can be shared with parents, patients, and staff
Patient registry	System for registering and tracking young adults through the transition process
Preparation	Process for assessing readiness for self-care management and adult care
Transition	Written plan including actions needed, medical summary, contact details, and emergency plan
Transition and transfer	Implementation of adult care model and move to adult provider
Transition completion	Explicit end to transition and an assessment of outcome

Data from Cooley WC. Adolescent health care transition in transition. *JAMA Pediatr* 167(10):897–899, 2013.

Failure of Transition

If we are to devote chapters, energy, and medical careers to the area of adolescent, lifelong care and transition, we ought to ask what it looks like and what we should do when it fails.

Transition may fail for a variety of reasons:

1. Crossing an age threshold in a pediatric center and having nowhere to go
2. A patient deciding he or she no longer wants to engage with health care
3. Changing circumstances (e.g., moving out of the area)
4. A patient deciding he or she does not want to go to the “new” center

The least ideal is number 1; in all other scenarios, patients can be given information about how to reach out to a center equipped to help them if they wish to. In all scenarios, patients can be given medical information about themselves to ensure that, when they arrive at another center, they can at least give the background information, including who the receiving team could contact for additional information if necessary.

Data from Indiana suggest a reduction in the need to attend an emergency department in patients who are engaged in transition and long-term care (Szymanski et al., 2017). We know from groups looking after oncology and diabetes patients that **health care outcomes seem to be improved with a good transition service.**

The challenge, in our own specialty, is to offer metrics that can quantify this. We all clearly understand the need to safely monitor these patients for their potential complications and, where possible, to avoid them needing to seek emergency care. But there are an increasing number of centers adopting a more formalized approach to transition in urology (Lambert, 2015).

Transition is a purposeful process that involves preparing and screening a family and patient to ensure everything is in place for a transfer event.

Transfer

Transfer is the move of care. This can be both geographic and a change in personnel. The combination of this and available options will play a key part in the model of transition that is used. The importance of this relates mainly to infrastructure and therefore deserves relatively little coverage here. The need for mention is to ensure that transfer is distinguished from transition. Transfer is often part of the process, but the two elements are distinct.

Models for Transition

As part of a recent consultation, it is apparent that, globally, there are four potential models for transition. There are no data to support one model over another, and the development of a local system will be driven by local infrastructure, practice patterns, enthusiasm, and resource.

There is no defined or optimal age for transition. **Ideally there would be an age window that allows pediatric teams to make a judgment about the right time to transition a patient to the adolescent/adult team.** Preparation and a degree of flexibility allow health care professionals to make judgments around areas such as medical fitness, surgical concerns, emotional maturity, and support from family members. It is also important to assess the understanding of the patients themselves related to their diagnosis and treatment. These are all factors that would appear to influence transition and its likely success; the idea that it should be a gradual process rather than a sudden, age-defined event seems to be accepted.

There has been very little work to examine these factors or their relationship to success. This is a problem when trying to justify a service, particularly in a resource-limited environment. Increasing the number of appointments allowing introduction of the adult team in the pediatric setting may improve engagement with transition. Those who have successfully transitioned are less likely to attend an emergency department (12% to 14% vs. 75%) (Szymanski et al., 2017).

Lifelong care from a pediatric urologist:

1. When a pediatric urologist works in a combined pediatric/adult urology department:

    This model has two potential advantages. First, the pediatric urologist offers absolute continuity, that is, there is no transfer from one unit or doctor to another. This alleviates one aspect of concern for patients and parents. It also allows a pediatric urologist to follow his or her results throughout his or her career, a very direct form of feedback, although risking personal bias. Surgically, the pediatric urologist will need to have had sufficient training in adult reconstruction; other subspecialists including stones and endourology, andrology, and oncology will be available and important. This model allows adult urologists to understand the pediatric aspects of care and vice-versa. The colocation should also facilitate joint clinic consultations and operating.

It remains a fact that the pediatric urologist's career will be shorter than the lifelong care required for the vast majority of patients. Therefore, at some point, these patients (who will have formed an enormous bond with their surgeon) will have to move to a new doctor. This may be more easily managed in later life (for the patient) as opposed to adolescence; there is no evidence that one is better than another, but it is important to consider. There is some evidence to suggest that continuing care in a purely pediatric environment is not healthy for either the specified patient or other surrounding (pediatric) patients (Jesus et al., 2014).

2. When the pediatric urologist integrates with the (separate) adult urology department:

    This model also offers continuity from the pediatric urologist and allows him or her to work collaboratively with adult urologists and transfer elements of (or all) care as appropriate. Awareness of and willingness to use surrounding expertise are important for success.

    Multidisciplinary care for these patients is essential throughout life. The pediatric urologist will need to form links with adult specialists, including nephrologists, radiologists, endocrinologists and gynecologists. This is possible and has been done but cannot be ignored.

3. Transition from the pediatric urologist to an adolescent/adult specialist with an interest in this area:

    There must be a local, interested, and appropriately trained adult urologist. It is vital that he or she has a background that includes experience with complex pediatric urology and adult urologic reconstruction. This urologist will often act not only as a doctor and surgeon to patients but will often coordinate other aspects of a patient's care with other members of the multidisciplinary team (Bower et al., 2017; Szymanski et al., 2015).

    Preparation for transition and the management of transfer are important. The pediatric team needs to prepare patients and parents for this phase of their care. There needs to be a mutual trust between teams to allow the standard of care to be maintained. A joint clinic is very helpful, and clear communication with the patient is vital. Not all agree but allowing patients to meet their new (adult) carers in the pediatric environment that is familiar to the patient may offer some benefit in terms of knowing who they will meet once transferred and agreeing on a plan (Timberlake et al., 2015; Woodhouse, 2015).

4. Direct transfer from the pediatric urologist to adult urology:

   This model may not involve a transition plan or a managed transfer. Some health care systems have been slower to recognize the need for transition, creating a risk that patients may become invisible to health care and only present with problems and emergencies. If (and sadly when) this happens, it demonstrates the need for appropriate expertise in managing these patients who can have very complex needs.

   Ironically, patients unwittingly may introduce this for themselves. As they grow, they head off to university or work in another city or country. They may not wish or be able to travel and see their original urologist, and it can be difficult to find a comparable level of expertise for them, leading them to drop out of necessary follow-up and only present if a crisis occurs (Wood et al., 2019).

Patient Population

Adolescent patients will enter a service based around adolescents and urology in four potential ways:

1. Transition and referral from pediatric service (see previous section)
2. Referral from pediatric services without transition
3. Referral with new problems arising in adolescence
4. Emergency referral having fallen out of pediatric care.

Clearly, there is room for crossover between these groups. As a matter of principal, we should aim to pass all patients with a long-term condition who will require care in adult life through transition.

Ideally, all patients would exist in groups 1 and 3; for a variety of reasons, they do not. Although there is increasing recognition that transition is important as part of continuing care, it is far from universal. In some systems, group 4 is far more prevalent; it may be much harder for patients to obtain health care once they are no longer dependent on their parents as a result of having a preexisting condition.

Group 2 is also less than ideal. Although a pediatric team has referred the patient on, the lack of transition infers a lack of joint working and cross-team engagement.

Setting Up a Service

Training

Pediatric urologists have increasingly acted as advocates on behalf of their patients. In many areas, it is they who have highlighted the need for long-term care of their older patients. The problem has been engaging adult practitioners to take the work on. As stated in the introduction, training in general adult urology or pediatric urology will not cover some aspects of this care. It requires someone who can work in adult practice (as the majority of patients will be adults). **They must understand both the pediatric diagnosis and treatment. As part of their adult role, they must have a strong reconstructive background.** As yet, there is no formal program in any system to train the adolescent/transitional urologist.

The Multidisciplinary Team

As a urologist looking after patients with congenital anomalies, the individual and those around need to shape a multidisciplinary team around them. This is a subspecialist role, and thus adolescent urologists are likely to have a focused portfolio of surgical skills. They need to work in a group of individuals who have skills that compliment their own. This will allow cross-referral and colleague involvement when necessary. These will be complex cases, so whatever surgery is done, it is not for the occasionalist.

Outside urology (nephrology, gynecology, and radiology) are vital. Colorectal surgery can be extremely valuable along with endocrinology, genetics, psychology, and a consistent anesthetist.

Patients have many concerns and, at times, needs. These include anger at their diagnosis and sometimes at their treatment; issues around normality; and concerns about aspects of function including sexual function and at times sexuality. This rather amateur (surgical) summary emphasizes the importance of a psychologist. These can be easier to involve in some areas than in others, and resistance for them may come from our paymasters as they often do not bring in additional income. In management terms, this makes them a net cost. Thus, from a clinical and patient perspective, there is a clear justification; however, financially the cost has to be argued for.

Institutional and Political Support

There is increasing understanding of the value around transition to both patients and institutions. There are many reasons why. There is now good evidence to support the personal and financial impact of failed transition. **Patients with complicated childhood medical problems are highly likely to access health care in later life.** They are more likely to attend emergency departments if they are not part of an ongoing health care program (Szymanski et al., 2017). These attendances are expensive and are more likely to signify a crisis. Robust ongoing care reduces the risk for both the crisis and the emergency department attendance.

There is a drive for multidisciplinary care across the health care sector. Patients who attend a general urology clinic where there has been no transition are unlikely to receive the desired multidisciplinary input. These patients may be medically, psychologically, and socially vulnerable. Access to all three aspects is important to maintain an effective standard of care.

The drive for a transition service will come from the clinical teams. The fact that there is widespread recognition of its importance should help with establishing a momentum. It remains unlikely that managers in any setting are going to invite you to set up a service. It is likely that you will have to justify your cause alongside any other group or service. The current discussion and political environment should help.

Barriers to Transition

Institutional

The previous section illustrates the reasons why a service is important and should be established. Health care is a resource-limited environment; therefore those trying to initiate a service will encounter challenges and resistance.

Whether a transition service makes money (or not) for an institution depends entirely on the remuneration related to your service. The health care system is largely defined for most of us. Whether we work in a fee-per-service or nationalized system, patients have similar needs.

The logistic elements of care are essential: a room to see patients in, operating theaters, and personnel. These will be harder to argue for if your service is unlikely to profit your organization. Building a team comes down to individual engagement; whoever has the idea (usually the urologist) will need to seek out and acquire the expertise needed and engage those needed.

Children and adolescents with unmet health care needs are much more likely to attend clinics and emergency rooms. Establishing a good transition program demonstrates its worth by reducing (costly) emergency admissions and the rate of in-hospital transfers. This has been shown in urology but translates from other specialties too (Okumura et al., 2014; Szymanski et al., 2017).

Professional

Pediatric care is often centralized and multidisciplinary; adult care can be more fragmented. Adult care tends to be more subspecialty focused.

As an adolescent urologist, it is reasonable that your pediatric colleagues (your referrers) have to trust you and your service. Without their referrals, you have no work. This may be difficult at times. For example, you will wish to publish your work. This is important as it will guide present and future practice. **Honest data will acknowledge the successes and recognize complications.** There will be some controversies; in order to maintain credibility, it is important to try and understand the denominator, maintain an objective view of the patient and their treatment, recognize that these patients are complex for all and there may be limits to what is achievable. If appropriate, publish in collaboration with pediatric colleagues.

Immediate colleagues in an adult department may struggle with the content of an adolescent practice. Congenital patients are often complex. Surgery may lead to complications, and the workload will appear very different to those who principally undertake primary rather than revision surgery. Others may know the diagnosis but are unlikely to understand the full implications of that diagnosis and are, for the most part, unfamiliar with the treatment a patient has undergone.

These are rare diagnoses treated in specialist centers, thus it is neither surprising nor critical that these problems occur, but they will create some difficult conversations with colleagues who do not absorb the full extent of your work. These will come to the forefront when you discuss reasons behind patients needing more bed days than others. Most doctors are used to working within a protocol or a guideline. Many have an index diagnosis or case on which to gauge their outcomes. In this field, the diagnoses are rare and treatment often complex’ this means that although a set of principles exists, the practical application will vary with each case. It is ideal to collaborate with colleagues when appropriate but also work hard to ensure that all team members understand what is happening for an individual patient.

Patients

The adolescent brain is constantly undergoing a rewiring process. The positive aspect of this is the potential to develop independence. The negative impact is an increased tendency to expose themselves to risk without considering the consequences (Arain et al., 2013).

Many of these patients will need long-term care (and if they do not, that is a specialist decision in itself). Good medical care may help patients achieve some elements of normality that are difficult and in some cases more dangerous without medical support. An important example is pregnancy and childbirth. **Ensuring a multidisciplinary team around a patient allows the safe and certain diagnosis of pregnancy** (remembering the risk for false-positive urine pregnancy tests with cytoplasm), preservation of renal function throughout the pregnancy, and a safe decision and support for the delivery of the child. Although this does medicalize a pregnancy, it does ensure that the pregnancy is both possible and safe. Even the explanation that this is possible can be valuable to patients.

This group have a completely normal desire to be normal (Wilson et al., 2004)**; even an annual visit to hospital marks them as different from their**

peers. One part of transition is the loss or change of at least some of their health care team. A patient will ask questions about their relationship with normality and what he or she can achieve. At a time when every adolescent is establishing independence, they may push against frameworks that seem to be taking control away from them; this leads to clashes. A sudden change in behavior may center around stopping important elements of care, such as medication, catheterization, or washouts. Some may withdraw from their health care altogether.

One of the aims of transition should be to support patients through this. Engagement and information are key. Trying to work with the individual patient can be difficult, so allowing them to explain themselves and making it clear that the bond is primarily with them and not their parents are important elements. There is a balance between encouraging patients to undertake the important parts of their own care, ask questions, or challenge what they are concerned about while avoiding confrontation unless completely necessary.

If this relationship breaks down (for whatever reason) patients are at risk for becoming a barrier to their own transition and therefore appropriate health care.

Expanding Numbers and Management of the Service Long-Term

The work delivered by an adolescent and adult service looking after the long-term care of pediatric patients can only expand. In service planning and modeling, this is an important factor. It is important to consider how a service works for a patient, too. In a specialist, centralized service, there will be a need for many patients to travel considerable distances to see a doctor in that center. The solution to these problems does not necessarily mean more medical staff in a central institution. Other options should be explored. For instance, the increased use of remote clinics using telephones or more advanced telemedicine may make efficient use of a medical team's time, allow an appropriate review for some patients, and reduce the need for them to travel for every visit.

If there are interested clinicians in other centers, it would be ideal to foster this interest. Other centers may not have the resources to run a full multidisciplinary team. This should not exclude clinicians from working in this area. They should be encouraged to work collaboratively, sending patients in for review when necessary and if possible following their patient so continuity is maintained.

There is necessity for lifelong review for some groups—most of those who have had major surgery or have some form of persistent renal impairment. In other groups, we may be able to be more selective in follow-up as long as patients know they have a center they can return to. The author's center had historically maintained follow-up of all adult posterior urethral valve patients. Anecdotally, this is changing. There is certainly a group of young adult men whose outcome seems to be favorable, and the approach is changing. They will be followed up through university or into their early twenties, and if all remains well they can be discharged.

There needs to be a central focus around which a multidisciplinary team is built. Although the numeric challenge may seem like a barrier, if acknowledged and managed well, it may serve to improve the service and the care of individual patients. Other centers and clinicians can contribute to this; this will expand interest in the specialty, improve access for patients, and help manage the expanding workload.

The Importance of Specialist Nurses

Good specialist nurses are invaluable to the service and patients. A well-trained, experienced specialist nurse adds a huge amount of expertise to the team. They can readily perform assessments and investigations for patients. They are generally much better than doctors at informing patients carefully of the direct implications of a planned procedure. They will take time and give an in-depth view rather than the rapid overview that a doctor will tend to give. Information for patients is better given in multiple forms in complex situations (Wong et al., 2010).

Anecdotally, nurses are not only very effective at giving information, but patients are often more ready to share information about their care with specialist nurses. In assessing the complex patient, this is very useful. For all of these reasons, they make a very valuable contribution to the multidisciplinary team. They may confirm or occasionally alter the course of a patient's management, picking up important warning signs.

Specialist nurses are vital to transition. The reasons detailed earlier apply—the giving and receipt of information. It is not common, but it is significant when issues around vulnerability and child protection arise. Our nurses have been exceptional at the recognition and management of these situations. They are a positive asset in reinforcing, informing, delivering, and coordinating care in the new environment (Ferguson, 2010).

Clinical Delivery

Geography

As described in the Models for Transition section earlier in this chapter, the location of the service is important, but no one setting defines the likelihood of success. Many confuse *transfer*, the change of team and (possibly) location, with *transition.* As defined earlier, transition relates to the assumption of the patient's role in his or her care. It is important to explain that care in an adult setting will feel different, simply because it is aimed at adults and not children. When patients and parents are faced with the reality of this, they can find it difficult to adjust. The presence of familiar faces and careful overall management are the only ways to overcome this. It does take time and can lead to some difficulties as part of overall transition.

The Clinic

The clinic needs to be regular and set in an appropriate environment. At the outset, there is value in the joint meeting among the patient, his or her pediatric team, and the “new” adult team. There needs to be a big enough room to accommodate the staff required. There should also be a balance to ensure that patients are not overwhelmed by health care professionals in the room.

Patient/Parent Preparation for Transition

It is easy to forget the fact that any patient transitions from a pediatric service to adult care is a success. We now take for granted that children with major congenital anomalies will survive into adulthood. This is a result of developments in surgery and the surrounding care. Yet the point at which the move is made to adult services can feel like bereavement. This is understandable and is the result of the strong bonds that are formed among a health care team, the patient, and the parents.

This sudden wrench surely contributes to the negative feelings that are associated with this change. Many other factors are included in this chapter, some which can be controlled; others cannot. **We cannot change the fact that for all patients, there will be a change in health care provider at some point.** There is some logic in making that change when the need for adult care arises and thus preparation is important (Bower et al., 2017).

The gradual introduction of the need for transition is the logical way to undertake this. Initially the pediatric team begins to discuss with the patient and the parents information about the diagnosis and treatment. The idea is to steadily increase the amount of independence a child has in his or her own health care. As independence increases, the idea that his or her health care will need to continue but in the adult world can be introduced. As these ideas become part of the same trajectory, the introduction of the adult team for joint meetings becomes appropriate. **The investment made by both sides is important; the fact that the pediatric team shows trust and collaboration with the adult team will help engender trust and cooperation from the patient.** The ability of patients to understand and discuss their diagnosis and treatment will empower them within this whole process and give them a genuine voice that influences their care. This will also make the process less traumatic for them because they continue to maintain control.

What Does Success Look Like?

There are published data to show that **the early years following transition appear to be a high-risk time.** Clinical issues seem to arise frequently around this time; 56% of patients with urologic issues required surgical treatment, and in the United States 50% will have issues with insurance coverage that interferes with their care (Duplisea et al., 2016).

It would be difficult to choose a clinical metric that would apply across the board in urology to measure success in transition. Quality of life measures are also a poor indicator of medical success in complex patients and lack specificity for these patients. We are left with looking at how these patients engage with health care. Do they attend? Does their attendance reduce the need for emergency admissions? There are some data from Indiana that support these principals. As previously discussed, other specialties (diabetes, rheumatology, and respiratory specialists) have suggested improved health outcomes as a result of engagement.

The evidence is thin but broadly supportive of engaging patients and their parents in transition with a focused team and ensuring that there is a credible plan for their long-term care.

The Price of Failure

Many of these patients will have abnormal parameters in some form such as anatomy, baseline renal function, fertility, or chronic pain. Medical deterioration may be gradual and subtle. It may be predictable in some but not in others. Identifying this and understanding what needs to be done requires a combination of expertise (Woodhouse et al., 2012).

Therefore, many of these patients will require multidisciplinary health care, some elements of which can only be delivered in a specialist center. It is the availability and the dialogue within that team that goes to creating the best care. It may be that some elements can be achieved off-site, but the dialogue and direct contribution to the team risks diminution (Woodhouse, 2012).

If this dialogue is lost, subtle changes may be missed and opportunities to prevent further damage delayed or lost.

Therefore, **the price of failure is (most commonly) preventable loss of function.** It would be wrong to say that a specialist team will always prevent such loss; it may not, as some will be inevitable. But appropriate transition may be able to slow loss of function, offer alternatives, and support patients when loss occurs. It is important that the patient is assured and knows that these situations arise because they were inevitable and not because expertise was lacking.

Key Points

- Transition is the development of a young adult's understanding of and independence in their health care.
- Preparation for transition can occur over a number of years.
- A multidisciplinary team is essential in both pediatric and adult care.
- There are a variety of models for delivering transition and adolescent care; these vary depending on the health care system.
- Those caring for adult patients with complex congenital anomalies must be trained in both pediatric and adult reconstructive urology.

Clinical Practice: Major Diagnoses

Functional Assessment of the Reconstructed Urinary Tract

There are few data published about how to assess the reconstructed urinary tract. Many of these patients have a range of things that move them away from a "normal" range. There are some parameters that need to be maintained, such as bladder pressures.

Other measurements are altered by a variety of factors; these include the original diagnosis, the treatment, and changes in puberty.

Video-Urodynamics

Video-urodynamics is a commonly used and vital tool that can be used in a variety of ways. With a new technique, it can be used to establish part of the outcome and safety, but it has a significant application in regular practice. The major indications are assessment of continence (or incontinence), especially in the face of change, and assessment of the urinary tract with deterioration in renal function (Fig. 50.1).

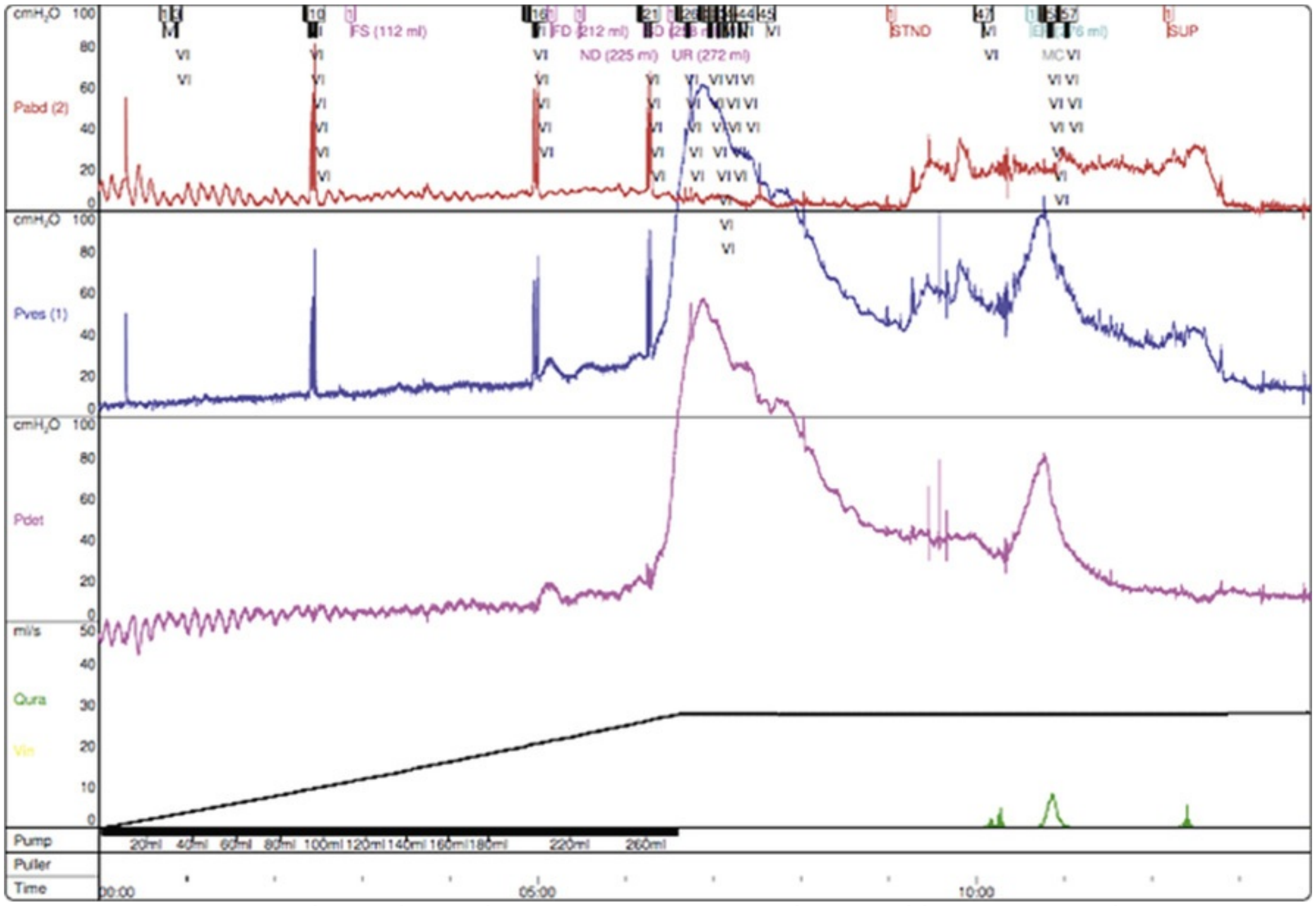

FIG. 50.1 Urodynamic tracing from a 20-year-old man with a neurogenic bladder. Note the significant detrusor overactivity after the end of filling.

Video-urodynamics is also useful in assessing the anatomy of the urinary tract. Examples include assessment of the ureters and reflux, the appearance of the bladder (can be useful with a native bladder in the presence of a diverticulum), the anatomy, and sometimes the type of bladder reconstruction. The bladder neck and (with careful views) the urethra can be assessed; this can help with assessment of a stricture, surgery, and fistula, both congenital and iatrogenic.

Flow Rates

Flow rates are a common reading that we take in any adult urology clinic. We understand what is normal in a 60-year-old male patient with lower urinary tract symptoms. There are much fewer data to tell us what is normal in a reconstructed or congenitally abnormal urethra. We know that many patients will have lower urinary tract symptoms, and there is little we have to alter those. We can attempt improvement with medical (and sometimes surgical) management, but it is common for some symptoms to persist.

Flow rates can be useful for monitoring change, including the flow itself, bladder volume, and postvoid residual. There are some published data suggesting that the flow rate is commonly low (Piplani et al., 2018; Spinoit and Hoebeke, 2015), but the individual patient will guide you much more than these on the basis of change in measured flow rate and symptoms such as pain and urinary tract infections.

Renography

Like other investigations, renography and nuclear medicine have their place. It is often something that can be used to clarify change in drainage or split function. It is rarely used as a primary follow-up investigation but is usually indicated if there is a change in measured renal function, new or progressive hydronephrosis, and/or loin pain.

Ultrasonography

This is a mainstay of long-term follow-up and often recommended for exactly that as they are noninvasive and require no radiation. Whether performed by the overseeing team themselves or a radiologist, the ultrasound operator must have an understanding of the clinical situation and anatomy. If the operator is not regularly looking after patients of this sort, your direct involvement may be necessary.

There are, of course, limitations, in particular the ability to detect stones. This is a balance. These patients will need review (usually with a scan) on an annual basis. The scan used must give good information but be balanced against any other risks to the patient (e.g., excessive ionizing radiation).

There are some useful determining factors. In the case of potential bladder stones or bladder wall lesions, asking the patient to shift position and seeing whether the “lesion” moves will differentiate between mobile debris or a stone and something that is fixed to the bladder wall. A blood supply in the lesion will rule out a diverticulum, ureterocele, or bladder wall calcification. The bladder can be assessed to ensure that it empties completely.

The upper tracts are important to assess. Looking for lesions that look like stones is important, and you must be aware that renal sinus fat can appear similar to a stone. Looking at historical scans or for an acoustic shadow are clearly important. **As with pediatric scans, it is essential to have a bladder full and empty view.** If you are not performing the scan, you will need to ask for this specifically because not all radiologists or radiographers will understand the importance of this element of the scan. When a scan has been performed and reported by someone other than you, if new or progressive hydronephrosis is a feature it is vital to determine whether the kidneys were rescanned once the bladder had been emptied. If not, the scan should be repeated with this included. If the kidneys were newly dilated with the bladder empty, then a mercaptoacetyltriglycine (MAG3) renogram and voiding cystourethrography (VCUG) will need to follow.

Blood Tests

Many patients will require annual blood tests. For those with just a neurologic, primary bladder or infravesical diagnosis, an annual renal function is all that would be needed. If patients have had a cystoplasty, neobladder, ileal conduit, or ureterosigmoidostomy, they too will need their renal function checked in addition to a full blood count and chloride, bicarbonate, and vitamin B_{12} levels.

Hypospadias

There is a strong theme in this work centering around the impact of having a congenital anomaly that requires treatment. There is little to help us understand how much of the psychological impact relates to the condition itself, its treatment, or other factors. There is a tendency to negative appraisal of genital appearance, but this does not seem to consistently correlate with a negative impact on sexual function. There are divergent data about the psychological impact (Woodhouse and Christie, 2005).

Hypospadias is principally a ventral hypoplasia. The most easily visualized feature is the meatal position, but severity may be masked with other tissues being much thinner than normal. This may only become apparent at the time of surgery. In less severe forms (usually distal), long-term follow-up may be unnecessary, however, more severe forms are likely to need further intervention beyond puberty. The need for further surgery is hard to ascertain because many publications do not quote a denominator, revision surgery rates, or long-term follow-up. If there is no immediate complication, then most cases that require revision will become apparent in later life (Barbagli et al., 2012; De Win et al., 2012; Rynja et al., 2009).

These patients are more susceptible to lower urinary tract symptoms.

These can be very troublesome for the patient. Examples include postvoid dribbling (20% to 40%), spraying (40% to 50%), and downward deflection of the urinary stream (25%) later in life. More than one-third of patients state that they are unhappy with the function of their urinary tract in adulthood. Having a baseline and being able to monitor for change (e.g., in flow rate) allows an adolescent urologist to determine whether there is an objective change and therefore the need for intervention.

There is a lack of data relating specifically to erectile function. There may be anatomic issues such as residual or recurrent chordee. This may not have been fully assessed at the original surgery, there may be a differential in growth of the hypoplastic versus the normal tissues, or it may be attributable to scar tissue. Approximately one-fourth of patients are thought to have problems with erectile function in adolescence and adulthood. The basis behind this is difficult to explain. However, the effect on ejaculatory function is easier to understand, with postoperative scarring, an abnormal spongiosum, and the potential for other problems such as urethral diverticula; this results in reported issues in 37% of patients (Higuchi et al., 2016).

Infertility may also be encountered by these patients (this is more common in patients who have other, more complex associated anomalies); in patients with isolated hypospadias, it seems to be around 13% and is probably attributable to the anatomic concerns detailed earlier (Asklund et al., 2010).

Exstrophy

Long-Term Reconstructive Outcomes

There are different concerns that arise during adolescence and adulthood.

The functional concerns are urologic, sexual (genital), and reproductive. There are a range of data to examine these; all are from small series and are therefore difficult to interpret comprehensively, but they are what we have and so are important to include. There are cosmetic concerns, and these are discussed in subsequent sections.

Where it has been examined, these patients show strong resilience. Many have experiences with bullying, although severe examples of this are relatively few. Their focus is on being as normal as possible and treated in the same way as their peers. Coping strategies centered on controlling the way they revealed information and adaptive clothing, but there were no psychiatric or defined long-term psychological findings (Wilson et al., 2004, 2007).

Urologic

Several series have looked at this aspect, and the focus has long been to look at the lower urinary tract. This is where the condition is manifest so it is logical to look at it. **Historically, regardless of technique, the principle of reconstructing the lower urinary tract in exstrophy has been the creation of bladder with a fixed outlet resistant to allow continence.** There is a considerable range of interpretation of continence. The literature needs to be read carefully. The author would define continence as the ability to retain urine without leakage and void spontaneously or catheterize urethrally. Leakage is incontinence, and if a patient is emptying by anything other than spontaneous voiding or urethral catheterization, then he or she is dry rather than continent.

The single most important variable in achieving continence was success at the primary closure. If there was need for revision or a secondary procedure, then the likelihood of spontaneous voiding was zero. The published data show that up to 77% of patients are dry (Baird et al., 2005; Chan et al., 2001); 80% have had urinary diversion at a mean age of 11 years, and 50% to 70% have had either augmentation or substitution cystoplasty (Gupta et al., 2014).

Many have had successful reconstruction of the bladder neck that protects them from urethral leakage. In this study, 50% had their bladder neck closed. Therefore, there are a percentage who have had successful bladder neck reconstruction who despite this are unable to void spontaneously or catheterize urethrally. It is not clear from published data whether urinary diversion in these patients was placed as a "back-up" option in the hope that patients would void spontaneously but may need a Mitrofanoff channel for bladder access.

Anecdotally, some adult patients have small amounts of leakage. When asked, they find this acceptable and certainly do not want further surgery to correct this. It is beyond the scope of this chapter to discuss the outcomes relating to specific forms of augmentation or diversion. These patients have usually had multiple major (mean of 8 in female patients) operations by the time they reach adulthood. In the female population, 19% suffered urinary incontinence as adults (Deans et al., 2012). They are likely to need more surgical intervention. This is not (usually) a result of their underlying disorder but the consequences of their surgery. These are not a surgical failure but are a realistic outcome of major urologic reconstruction.

Revision rates for a Mitrofanoff procedure range from 9% to 75 % of cases (Suzer et al., 1997; Veeratterapillay et al., 2013). There is no time limit on how long any one channel will last. There are some that are problematic from the start for a variety of reasons, most commonly a short skin-level stenosis. There are some that never seem to give problems.

The congenital group of patients undoubtedly have these channels for the longest of all groups and appear to have to the lowest late revision rate of all (O'Connor et al., 2019).

Those with cystoplasties or bowel of any kind in their urinary tract require careful follow-up. **Imaging will look for anatomic anomalies such as stones. They are at risk for metabolic consequences (e.g., hyperchloremic metabolic acidosis or vitamin B_{12} deficiency), stones (3% to 40%), and most commonly urinary tract infection** (Biers et al., 2012). The involvement of specialist nurses and a supportive team are very important to support patients, minimize complications, and pick up problems when they arise. They also need to be monitored for the risk for malignancy. Enterocystoplasty is probably a factor. This is especially true if they smoke or have a renal transplant (or another reason for immunosuppression) (Higuchi et al., 2010; Smeulders and Woodhouse, 2001). The risk appears greatest with a ureterosigmoidostomy. There is no value in annual cystoscopy as tumors occur in screening intervals, but changes in symptoms such as hematuria, urinary tract infections, or pain should trigger appropriate investigation (Hamid et al., 2009).

Exstrophy patients are reported as having normal kidneys (DeMaria et al., 1980; O'Kelly et al., 2018). If they develop renal problems, it can only be regarded as a consequence of the surgery they have had. These patients need to be monitored carefully for this. Annual blood tests including renal function and ultrasonography are a minimum standard. Changes in renal function or new hydronephrosis will usually require a MAG3 renogram and possibly video-urodynamics.

Key Points

- Normal values in laboratory testing or imaging may not be helpful. It is important to establish a baseline and look for changes in investigations performed.
- Long-term data for hypospadias suggest a higher complication rate than previously thought.
- Patients with hypospadias need consideration regarding erectile function

and fertility.

- Annual cystoscopy for tumors in patients with a cystoplasty is not supported by evidence, as the tumor pick rate is low; it is more important to investigate new symptoms promptly.

Male

Penile Concerns and Management

In practical terms, this is one of the most common issues to be raised in caring for men born with exstrophy. Almost all exstrophy patients will have concerns about their sexual function; it is important for those caring for them to be prepared to raise and answer these questions when appropriate.

Magnetic resonance imaging (MRI) has established that, in exstrophy, the penis is shorter in length but has a greater girth than a typical unaffected male. The total corporeal length is 60% greater in normal men (16.1 cm vs. 10.1 cm in exstrophy). Most of this deficiency is in the pendulous part of the penis (12.3 cm for normals vs. 6.9 cm for exstrophy). The posterior penis shows no difference (3.9 cm vs. 3.2 cm). The mean corporeal diameter is 1.0 cm in normal men and 1.4 cm in exstrophy men (Silver et al., 1997). The Kelly procedure is well described, and there have been a number abstracts discussed at meetings. Peer-reviewed data are needed to understand whether this offers a long-term improvement.

Dorsal chordee is common, but the severity varies. Some men will find sexual intercourse impossible, and correction is therefore necessary (Fig. 50.2). For others, there may be a need to experiment with positions, but sexual intercourse is possible. If surgery is required, there is no cross-corporal circulation, which allows disassembly and rotation of the corpora to correct a chordee (Wood and Woodhouse 2011).

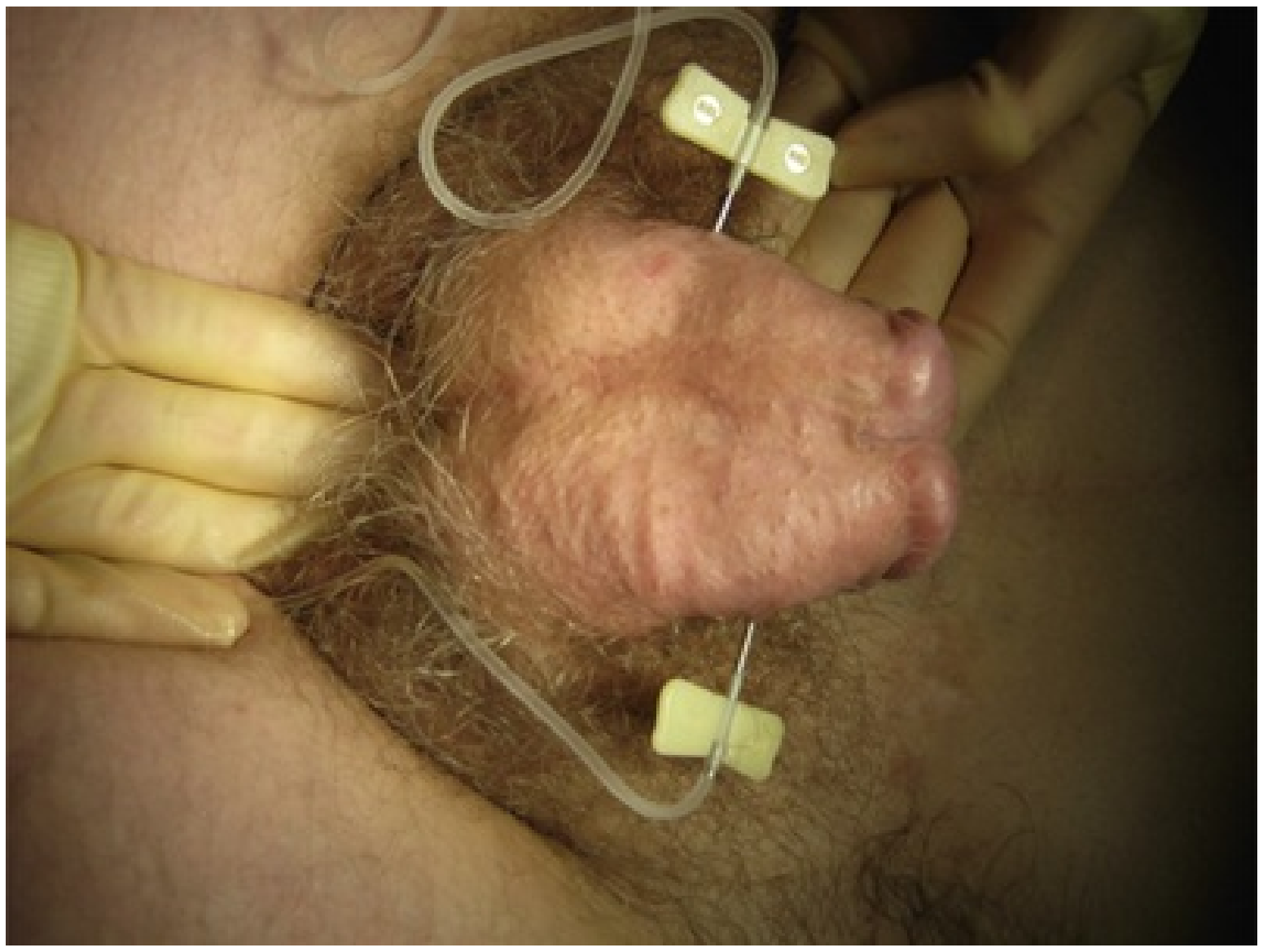

FIG. 50.2 Artificial erection demonstrating a dorsal chordee.

At birth the corpora are of equal size, but damage may occur during primary or revision reconstructive surgery (Fig. 50.3). Twenty-eight cases of complete or partial penile loss have been reported, 24 after exstrophy closure and 4 after radical penile reconstruction (Cervellione et al., 2010b).

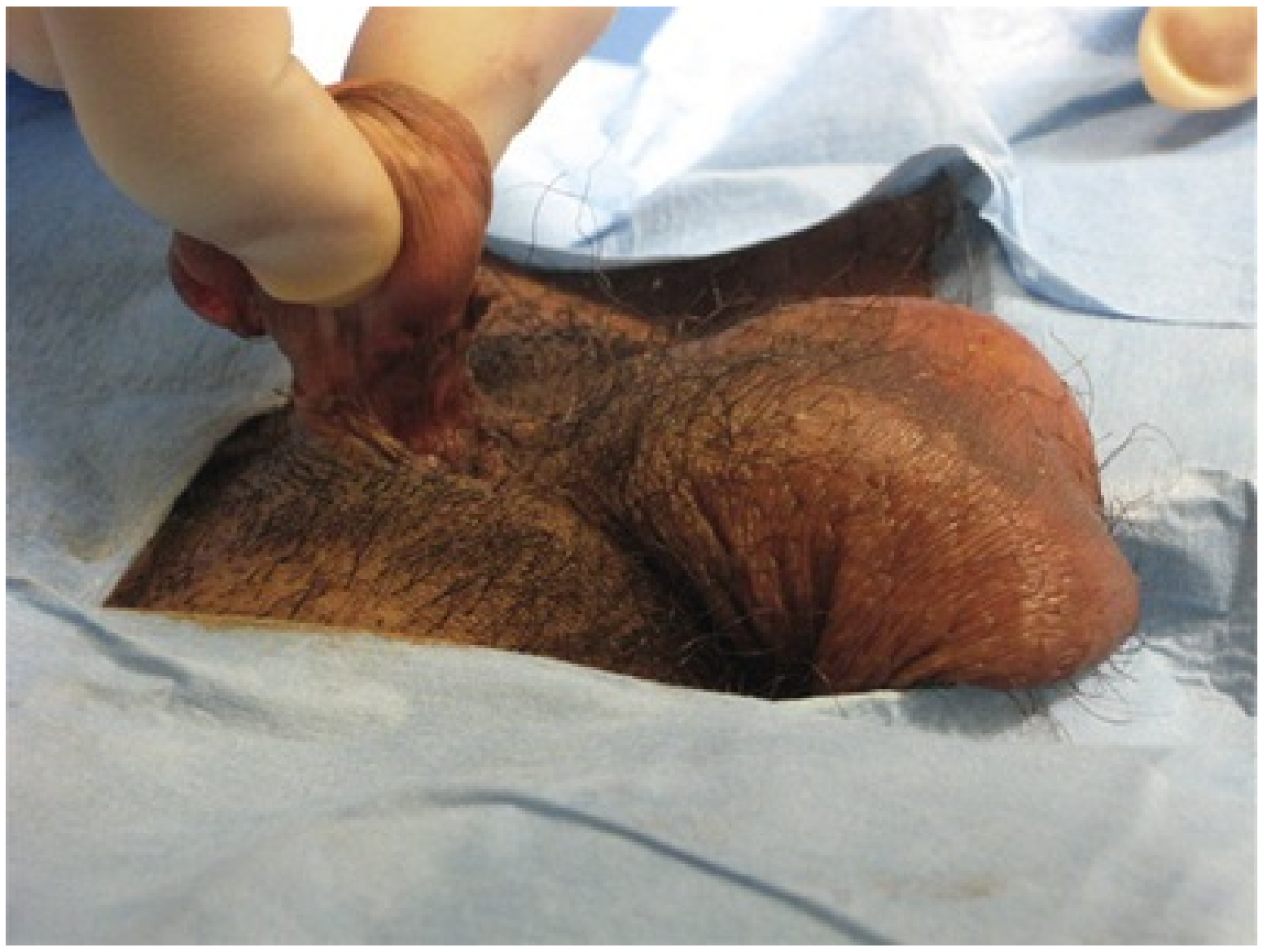

FIG. 50.3 Exstrophy penis showing severely damaged corpora.

Sexual Function

Erections can be expected to be of normal quality. However, in a comparison with normal men, 11 of 19 (58%) exstrophy patients had erectile dysfunction on the international index of erectile function-15 (IIEF-15), and the incidence in controls was 23% (Castagnetti et al., 2010). Other series report a negative impact on erectile function in up to 90% (Rubenwolf et al., 2016a).

Masturbation is virtually universal in all reported series. In a review of the literature from 1974 to 1997 including 134 men from eight series, 101 (75%) were able to ejaculate, occasionally producing as much as 5 mL. Some patients describe a more or less continuous urethral discharge of semenlike fluid (Hanna and Williams, 1972; Mesrobian et al., 1986; Silver et al., 1997).

Data from Switzerland looked at 21 male patients born between 1937 and 1968 with a mean age of 50 years at follow-up. Nineteen of 21 males were or had been sexually active, and 16 had been married. Only 56% described their intercourse as satisfactory. The main cause of dissatisfaction was the dorsal chordee (which nowadays would be corrected). Their adolescent sexual activity was similar to that of a survey of Swiss men from a later generation published in 2002 (Gobet et al., 2009). This is probably the longest available follow-up, but other groups give very similar figures, with about 75% of men cohabiting (Woodhouse, 1998).

Casual sex or the prospect of it may create considerable anxiety for adolescents with exstrophy. Boys with exstrophy are unlikely to be successful with “one night stands,” though patients reported by Ben-Chaim et al. were said to have random and short-term relationships (Ben-Chaim et al., 1996).

In a practice that focuses on transitional urology, there will be many discussions with patients about their genital anatomy. Chordee and other erectile deformities can be corrected, but there is no surgical means of producing the long, normal penis for which they hope. It is better to use knowledgeable and sympathetic counseling to help the adolescent establish a durable relationship in which normal sex takes place.

In extreme cases, phalloplasty may be an option for these patients. This was first reported in 2001 (De Fontaine et al., 2001). The native penis was incorporated within the new phallus with the glans and urethra emerging close to the base on the dorsum. A single inflatable prosthesis was inserted at a second operation. Other series have reported good satisfaction but high (50%) complication rates, particularly in relation to penile prosthetic implants (Lumen et al., 2008; Massanyi et al., 2013; Timsit et al., 2009).

Fertility

The testes are thought to be normal at birth in exstrophy. There may be an increased incidence of undescended testes, being reported in 6 of 26 neonates (23%). However, the structural integrity of the testes and epididymis suggests that the association is anatomic rather than endocrine in origin (Merksz and Tóth, 1990).

Data relating to semen parameters and fertility are sparse. In a literature review in 1998, including 66 adults who had had semen analyses for a variety of reasons, between one-third and one-half of men who were trying to father a child were successful, with only 21% having good-quality semen; 48% had azoospermia (Woodhouse, 1998). Other authors have echoed this showing poor semen parameters and low ejaculate volume (Ben-Chaim et al., 1996; Ebert et al., 2008; Rubenwolf et al., 2016a). Patients also report frequent episodes of epididymitis, which may be a description of the indurated feeling on palpation (Ebert et al., 2008).

The management of male factor infertility has been radically changed by the development of assisted fertility. Men with exstrophy can be greatly helped by these if they cannot conceive naturally (D'Hauwers et al., 2008).

Females Born With Exstrophy

Reconstruction of the Genitalia

It is important to understand the relevant anatomy for an adult female born with exstrophy. It is as if the urethra is on the abdominal wall, the vagina is just behind that, and the anus is where the vagina would be expected. Everything appears to have moved forward. They are often distressed by the dip in the region of their mons pubis and the gap in their pubic hair. **They may have a narrow introitus, which can make tampon use and penetrative sexual intercourse difficult and painful without surgical correction.**

The literature suggests that 80% of women will require genital reconstruction in puberty or early adult life (Mathews et al., 2003). The important features are to prevent introital stenosis, provide a hood for the clitoris, and fuse the anterior ends of the labia to make a fourchette. With complete soft tissue mobilization of the urogenital complex, especially if done in early childhood, it is possible to achieve a more anatomically correct outcome (Kropp and Cheng, 2000).

A narrow vaginal introitus is common in exstrophy; the vagina itself may be slightly shortened but of normal caliber and when the patient is standing the vagina is parallel to the floor. To open it, an incision is made posteriorly from the introitus until a sufficient opening has been created. It is usually possible to close the vaginal mucosa to the perineal skin directly. Cervellione et al. (2010a) describe a longitudinal incision of the vagina alone and laying in of a perineal flap. The results in all but 1 of their 29 cases were favorable regardless of the technique used, but they do not mention if any were having intercourse.

Procedentia Repair

The absence of a complete pelvic floor and the open pelvic ring makes the incidence of uterine prolapse very high in this group. Total procidentia may be seen even in nulliparous women (Woodhouse, 1999). The overall risk for prolapse sits between 38% and 52% with 85% deciding to have surgical treatment (Nakhal et al., 2012a; Rubenwolf et al., 2016b).

The restoration of a soft tissue hammock using the Kelly operation seems to show a significant reduction in prolapse. None of the nine patients who had a Kelly procedure had prolapse compared with two of three in the same series who had a different reconstruction. However, some of the patients were barely into puberty (Jarzebowski et al., 2009).

Several techniques have been reported for the repair of this difficult condition. Hohenfellner advocates fixation of the uterus to the anterior abdominal wall in childhood. This is said to prevent prolapse but still allow normal pregnancy with cesarean delivery (Stein et al., 1994). Once prolapse has occurred, anterior fixation does not appear to be an effective repair.

Although hysterectomy or partial hysterectomy has been advocated in occasional patients (Mathews et al., 2003), ideally the uterus is better preserved as it is the only “plug” that will prevent other pelvic and abdominal organs from prolapsing.

The most successful procedure is the Gor-Tex wrap. The sacral promontory is exposed. A strip of Gor-Tex is sutured or screwed to the periosteum. The end is passed around the cervix through the base of the broad ligament and brought back to the sacrum. This shows a success rate of 75% (Nakhal et al., 2012a).

Female Sexual Function

There are very few data looking specifically at this. The most recent data is the largest series (38 patients); using the Female Sexual Function Index suggested that there was little effect on overall sexual function (Rubenwolf et al., 2016b). Other earlier series cover 43 patients, but they represent only about 20% of the women recorded in the relevant institutions’ databases (Burbige et al., 1986; Mathews et al., 2003; Stein et al., 1994). Thirty-four (79%) had regular intercourse, and 10 of them had dyspareunia (29% of those having regular intercourse). The age of sexual debut is 19.9 years; 13 of 22 (59%) who were specifically asked had regular orgasms.

Fertility

Deans et al. (2012) reported that 4 of 19 patients achieved fertility naturally within 1 year, and the remainder were delayed or required fertility treatment. Rubenwolf et al. (2016) reported that the pregnancy rate after primary continence diversion was higher than after secondary diversion. Therefore, women with exstrophy do have some difficulties with conception that may be secondary to surgical reconstruction resulting in tubal damage.

Pregnancy and Delivery

Pregnancy is possible for these women. One report shows 57 pregnancies in 19 women with 21 miscarriages; this may be an overestimate as a result of false-positive pregnancy tests (associated with enterocystoplasty) (Nakhal et al., 2012b; Nethercliffe et al., 2001) but is greater than that expected in the unaffected population (Deans et al., 2012).

With modern obstetric care, pregnancy and delivery should be uncomplicated except for the risk for prolapse. Other series of patients including 43 pregnancies in 28 women were identified. Four ended in spontaneous abortion, and four ended in therapeutic abortion. There were 34 live births and 1 intrauterine death of twins (Greenwell et al., 2003; Mathews et al., 2003; Woodhouse, 1994). There is a high incidence of breech presentation at 57% compared with 4% in normal women (Greenwell et al., 2003).

The mode of delivery is clearly an obstetric decision, but a urologist should be involved in the management of the pregnancy to spot and treat urologic complications, which had an incidence of 63%. Delivery should be discussed, and emergency cesarean delivery should be avoided. This most commonly tends to lead to an elective caesarian delivery at approximately 37 weeks (Deans et al., 2012).

Spina Bifida: the Neuropathic Bladder

These are a challenging group of patients at any age. Their care needs to be multidisciplinary, and some will have complex needs. Many patients are fully mobile, and without knowing them, you would never know that they were affected by spina bifida. The spectrum of disability covers a huge range right through to those who are confined to a wheelchair with varying cognitive impairment. In caring for these patients, this becomes an important factor. These patients will have the same desires as their peers, including an education and the ability to work, form relationships, and have a family. These desires are shared by many patients with major congenital anomalies (Woodhouse et al., 2012).

In many, there is the ability to live independently and achieve these desires, however, others will need more support. Parents and family will often do an extraordinary job at this. **It can be enormously challenging to make judgements in some patients about their ability to make complex decisions.** They can be very emotionally labile and become very upset about conversations about complications. For those with impaired executive function, trying to gauge an understanding and make decisions about the right choice for a patient and the capacity for independent consent can be very difficult. Although parents may be very loving and supportive with only the best intentions, their support risks encouraging their son/daughter to undertake a procedure. Data suggest that surgery in this group is high risk, and thus the whole scenario needs to be judged very carefully. Some clinics run as a fully integrated multidisciplinary service with many agencies present. Not all institutions can or will support that way of working. Awareness in the clinician remains central to providing the best care (Szymanski et al., 2017).

Changes in Bladder Function and Continence

The bladder and outlet may change in their nature with time, particularly through puberty. It is also clear that patients themselves may well change their attitude to aspects of their care, especially during adolescence. Those who had been conscientious in performing regular self-catheterization may suddenly rebel. Their perspective is that they are “taking control.” This can be extremely dangerous, and may lead to unnecessary loss of renal function in a bladder in which pressure is a concern.

Renal and Urologic Concerns

Aggressive early bladder management combined with long-term follow-up have moved us past the time when renal failure was the primary cause of death for these patients (Malakounides et al., 2013). Great care needs to be taken as changing behavior of the bladder may damage renal function, especially through puberty and in combination with other factors such as urinary tract infections (Mundy et al., 1985; Woodhouse, 2005). Urodynamics are an important part of evaluating the urinary tract of these patients, and changes in continence or radiologic or measured changes in renal function should be assessed with video-urodynamics. These patients should be seen once per year with relevant blood tests and ultrasonography.

Proactive management continues into adulthood with the importance of regular catheterization regimes coupled with anticholinergic medication, botulinum toxin, and potentially enterocystoplasty when necessary.

Urinary continence is a major concern for these patients, and the severity of the incontinence has a significant impact on quality of life (Szymanski et al., 2018). Recent US data showed that 92.6% of adult spina bifida patients were using some form of bladder treatment; 76.8% needed to use intermittent catheterization, and up to 63% reported continence (Wiener et al., 2018).

These issues need to be raised proactively in clinic. Patients may feel embarrassed to discuss some subjects or may accept that this is the way things are going to be unless they are offered alternatives. They may choose not to take those alternatives, but they need to know their options; with the use of artificial sphincters, slings, and occasionally urinary diversion, patients do not need to be wet.

For those patients with fecal incontinence, it is important to either address this yourself or work with a colorectal colleague who can help you. Various systems exist, and the antegrade continence enema (ACE) works very well for children. Anecdotally, it is less successful in adults as the colon becomes more capacious. Per anal irrigation systems provide an excellent alternative. Occasionally a colostomy or ileostomy is necessary.

It is important to understand that operating on these patients in adult life carries a high potential morbidity. This should not prevent necessary or important surgery, but it should make all parties review very carefully whether surgery is the right option and what the alternatives may be. Up to 91.5% of adult spina bifida patients who have a laparotomy will have at least one complication; 40% will require further intervention (Clavien-Dindo 3 or 4) (Loftus et al., 2017).

Sex and Sexuality

Patients with spina bifida have normal desires to form relationships. Data suggest that although this is important to patients, it is often not discussed by health care providers. Published data have shown that this conversation is only had by physicians in one-third of cases (Bong and Rovner, 2007). Erectile function data vary widely with ranges from 40% to 75%. Those with a level below L3 seem to function normally. Above this level seems to make sensation and erectile and ejaculatory function less predictable, although erectile dysfunction is responsive to PDE5 inhibitors (Cassata et al., 2008). Some data suggest that azoospermia becomes more likely above the T10 level (Bong and Rovner, 2007; Choi et al., 2017; Palmer et al., 2000).

In females affected by spina bifida, L3 also seems to be a critical level, with those affected above that level having a significantly reduced frequency of orgasm (12.5% vs. 40%) (Cass et al., 1986).

Preparation for Pregnancy

For ladies growing up with any form of neural tube defect, it is important for a clinician to prompt a discussion around issues relating to pregnancy and preparation for it.

It is well documented that there is a higher incidence of neural tube defects in children of affected parents. This risk is halved with the use of high-dose folic acid supplements, which should be taken for 3 months before conception and throughout the first trimester (AAP, 1999). This conversation needs to take place and be documented for the sake of all parties, but most importantly the prospective mother.

If a patient has any form of bowel in his or her urinary tract, there is a 57% false-positive rate for urine pregnancy tests (Nethercliffe et al., 2001). This is probably caused by a contaminant in the mucous, but the exact mechanism has not been elucidated. The important point is that if a couple is trying to conceive and the woman has had urinary reconstruction with bowel, pregnancy should be confirmed with a serum hCG.

As with any other diagnosis, the pregnancy needs to be managed jointly between a urologist and an obstetrician. The discussion around delivery may be more weighted to a vaginal delivery if the pelvis is normal. There is a higher incidence of cesarean deliveries when compared with the unaffected population: 52.4% versus 31.9% (Shepard et al., 2018). Recent Canadian data have shown a higher incidence of morbidity to both the mother (intensive care admission, respiratory complications) and infant (hypoxia and intracranial hemorrhage) associated with pregnancy in spina bifida mothers resulting in prolonged hospital stay (Auger et al., 2019).

Posterior Urethral Valves

Posterior urethral valves causing subtrigonal obstruction affect approximately 1 in 5000 live male births. They have proven to be a significant long-term challenge (Heikkilä et al., 2011). Antenatal scanning has resulted in access to earlier diagnosis, although only 45% are diagnosed during pregnancy, and findings may be variable (Dinneen et al., 1993; Eckoldt et al., 2004). Understanding the pathophysiology explains the reason why long-term outcomes have not improved greatly despite improved diagnosis and some aggressive intervention.

The continued picture is one of approximately one-third of those born with valves needing a transplant, another one-third having chronic renal failure, and the remainder maintaining normal renal function. Those affected by renal failure appear to suffer the biggest impact on quality of life (Woodhouse et al., 2012).

Despite improved imaging and more aggressive techniques for early and even intrauterine intervention, the progression of the valve bladder and kidneys seems to be unchanged (Lambert, 2015). The valve bladder will hypertrophy and thicken, creating the classic appearance on antenatal ultrasonography with a blown-out prostatic fossa; this is a high-pressure, poorly compliant system that may ultimately decompensate and become unable to empty. The bladder pressure leads to upper tract damage and renal failure. The reason for the apparent lack of improvement in long-term outcomes may be that the kidneys are already damaged by the time the diagnosis is made, even with the in utero imaging that we have today. The child needs aggressive management, and the adolescent and adult will need long-term follow-up (Woodhouse et al., 2012).

In patients cared for by modern standards, 36.6% will progress to end-stage renal failure before they are 30 years of age. In fact, these data appear worse than previous cohorts, but this is probably because of the onset of antenatal ultrasonography and the ability to avoid fatal complications (such as sepsis) in early life with proactive early management. The data from Finland showed that 22.8% progressed to end-stage renal disease, with 32% of these patients progressing after adolescence, reinforcing the need to monitor these patients and work closely with a nephrologist to ensure optimal renal preservation (Heikkilä et al., 2011). Routine evaluation should include monitoring of renal function, blood pressure, and urine dipsticks for proteinuria (significant proteinuria is an important sign of progression of renal failure).

Data suggest that 36% of patients will continue to have issues with urinary incontinence beyond 5 years of age (Heikkilä et al., 2011). Others may have more minor but bothersome lower urinary tract symptoms. These need to be monitored and discussed during transition and continuing into adult life (Kovell et al., 2018).

Sexual Function and Fertility

It appears that erectile function and paternity rates in valve patients are not significantly different from unaffected males (Taskinen et al., 2012). The dilated prostatic fossa may result in retrograde ejaculation. Declining renal function is associated with erectile dysfunction, and this may affect some patients. Some data suggest an effect on semen parameters, such as a greater number of immotile sperm, longer liquefaction times, and intermittently reduced sperm counts (López Pereira et al., 2013; Puri et al., 2002).

Summary

In a book such as this one, adolescent urology or congenital lifelong urology will cross over with pediatric urology and elements of reconstructive urology. This chapter does not discuss every diagnosis that comes into an adolescent clinic, as much of the detail relating to these cases is found in other chapters. The aim has been to use some of the major diagnoses to highlight the principles of transition and the importance of long-term care.

Many patients who come to these clinics have had a lifelong relationship with hospitals and health care, and at times they may exhibit frustration. The ability to manage this frustration, broach subjects that others will not (as shown earlier), and understand conditions and care from pediatric practice are all essential components. Another characteristic of these patients is that, having seen doctors and nurses during their whole life, they very quickly pick up on those who are not as familiar and comfortable with their condition or care.

The increasing recognition of the need for a seamless link from pediatric care though adolescence and into adult care demonstrates the importance of this work to health care systems and, most of all, to patients. To undertake reconstructive surgery in anyone, but especially a child, creates a contract between that child and the system that provided that surgery. There will be a number of ways by which that system can provide care, but it must make provision for the lifelong care that child needs.

Key Points

- Congenital lifelong urology requires a proactive approach and an understanding of complex congenital genitourinary conditions.
- Regular follow-up examinations of renal and urinary function are essential for many patients.
- Sexual function and fertility must be proactively addressed and managed.
- Pregnancy is likely to need preparation (for some) and combined urologic and obstetric care.
- Collaboration with other specialties and urologic subspecialties is essential for safe and appropriate care.

Suggested Readings

Bower WF, Christie D, DeGennaro M, et al. The transition of young adults with lifelong urological needs from pediatric to adult services: an international children's continence society position statement. *Neurourol Urodyn*. 2017;36(3):811–819.

Higuchi T, Holmdahl G, Kaefer M, et al. International Consultation on Urological Diseases: Congenital Anomalies of the Genitalia in Adolescence. *Urology*. 2016;94:288–310.

Higuchi TT, Granberg CF, Fox JA, et al. Augmentation cystoplasty and risk of neoplasia: fact, fiction and controversy. *J Urol*. 2010;184(6):2492–2496.

Kovell RC, Skokan AJ, Wood DN. Transitional urology. *Urol Clin North Am*. 2018;45(4):601–610.

Rubenwolf P, Thomas C, Thüroff JW, et al. Sexual function, social integration and paternity of males with classic bladder exstrophy following urinary diversion. *J Urol*. 2016;195(2):465–470.

Rubenwolf P, Thomas C, Thüroff JW, et al. Sexual function and fertility of women with classic bladder exstrophy and continent urinary diversion. *J Urol*. 2016;196(1):140–145.

Rynja SP, Wouters GA, Van Schaijk M, et al. Long-term followup of hypospadias: functional and cosmetic results. *J Urol*. 2009;182(4 Suppl):1736–1743.

Szymanski KM, Misseri R, Whittam B, et al. Current opinions regarding care of the mature pediatric urology patient. *J Pediatr Urol*. 2015;11:251 [e1–e4].

Wood D, Baird A, Carmignani L, et al. Lifelong congenital urology: the challenges for patients and surgeons. *Eur Urol*. 2019;75(6):1001–1007.

Woodhouse CR, Neild GH, Yu RN, et al. Adult care of children from pediatric urology. *J Urol*. 2012;187(4):1164–1171.

References

American Academy of Pediatrics Committee on Children with Disabilities and Committee on Adolescence. Transition of care provided for adolescents with special health care needs. *Pediatrics*. 1996;98(6 Pt 1):1203–1206.

American Academy of Pediatrics. Committee on Genetics. Folic acid for the prevention of neural tube defects. *Pediatrics*. 1999;104(2 Pt 1):325–327.

Arain M, Haque M, Johal L, et al. Maturation of the adolescent brain. *Neuropsychiatr Dis Treat*. 2013;9:449–461.

Asklund C, Jensen TK, Main KM, et al. Semen quality, reproductive hormones and fertility of men operated for hypospadias. *Int J Androl*. 2010;33(1):80–87.

Auger N, Arbour L, Schnitzer ME, et al. Pregnancy outcomes of women with spina bifida. *Disabil Rehabil*. 2019;41(12):1403–1409.

Baird AD, Sponseller PD, Gearhart JP. The place of pelvic osteotomy in the modern era of bladder exstrophy reconstruction. *J Pediatr Urol*. 2005;1(1):31–36.

Barbagli G, Sansalone S, Djinovic R, et al. Surgical repair of late complications in patients having undergone primary hypospadias repair during childhood: a new perspective. *Adv Urol*. 2012;2012.

Ben-Chaim J, Jeffs RD, Reiner WG, et al. The outcome of patients with classic bladder exstrophy in adult life. *J Urol*. 1996;155(4):1251–1252.

Biers SM, Venn SN, Greenwell TJ. The past, present and future of augmentation cystoplasty. *BJU Int*. 2012;109(9):1280–1293.

Bong GW, Rovner ES. Sexual health in adult men with spina bifida. *ScientificWorldJournal*. 2007;7:1466–1469.

Bower WF, Christie D, DeGennaro M, et al. The transition of young adults with lifelong urological needs from pediatric to adult services: an international children's continence society position statement. *Neurourol Urodyn*. 2017;36(3):811–819.

Burbige KA, Hensle TW, Chambers WJ, et al. Pregnancy and sexual function in women with bladder exstrophy. *Urology*. 1986;28(1):12–14.

Cass AS, Bloom BA, Luxenberg M. Sexual function in adults with myelomeningocele. *J Urol*. 1986;136(2):425–426.

Cassata R, Iannuzzi A, Parma P, et al. Clinical, cytogenetic and molecular evaluation in a dog with bilateral cryptorchidism and hypospadias. *Cytogenet Genome Res*. 2008;120(1–2):140–143.

Castagnetti M, Tocco A, Capizzi A, et al. Sexual function in men born with classic bladder exstrophy: a norm related study. *J Urol*. 2010;183(3):1118–1122.

Cervellione RM, Phillips T, Baradaran N, et al. Vaginoplasty in the female exstrophy population: outcomes and complications. *J Pediatr Urol*. 2010;6(6):595–599.

Cervellione RM, Husmann DA, Bivalacqua TJ, et al. Penile ischemic injury in the exstrophy/epispadias spectrum: new insights and possible mechanisms. *J Pediatr Urol*. 2010;6(5):450–456.

Chan DY, Jeffs RD, Gearhart JP. Determinants of continence in the bladder exstrophy population: predictors of success? *Urology*. 2001;57(4):774–777.

Choi EK, Ji Y, Han SW. Sexual function and quality of life in young men with spina bifida: could it be neglected aspects in clinical practice? *Urology*. 2017;108:225–232.

Clemente D, Leon L, Foster H, et al. Transitional care for rheumatic conditions in Europe: current clinical practice and available resources. *Pediatr Rheumatol Online J*. 2017;15(1):49.

Cooley WC. Adolescent health care transition in transition. *JAMA Pediatr*. 2013;167(10):897–899.

Crowley R, Wolfe I, Lock K, et al. Improving the transition between paediatric and adult healthcare: a systematic review. *Arch Dis Child*. 2011;96(6):548–553.

D'Hauwers KW, Feitz WF, Kremer JA. Bladder exstrophy and male fertility: pregnancies after ICSI with ejaculated or epididymal sperm. *Fertil Steril*. 2008;89(2):387–389.

De Fontaine S, Lorea P, Wespes E, et al. Complete phalloplasty using the free radial forearm flap for correcting micropenis associated with vesical exstrophy. *J Urol*. 2001;166(2):597–599.

De Win G, Cuckow P, Hoebeke P, et al. Long-term outcomes of pediatric hypospadias and surgical intervention. *Pediatr Health Med Ther*. 2012;(3):69–77.

Deans R, Banks F, Liao LM, et al. Reproductive outcomes in women with classic bladder exstrophy: an observational cross-sectional study. *Am J Obstet Gynecol*. 2012;206(6):496 [e1–e6].

DeMaria JE, Alton DJ, Krueger RP, et al. Renal function in continent patients after surgical closure of bladder exstrophy. *J Urol*. 1980;124(1):85–88.

Dinneen MD, Dhillon HK, Ward HC, et al. Antenatal diagnosis of posterior urethral valves. *Br J Urol*. 1993;72(3):364–369.

Duplisea JJ, Romao RLP, MacLellan DL, et al. Urological follow-up in adult spina bifida patients: is there an ideal interval? *Urology*. 2016;97:269–272.

Ebert AK, Bals-Pratsch M, Seifert B, et al. Genital and reproductive function in males after functional reconstruction of the exstrophy-epispadias complex—long-term results. *Urology*. 2008;72(3):566–569 [discussion 569–570].

Eckoldt F, Heling KS, Woderich R, et al. Posterior urethral valves: prenatal diagnostic signs and outcome. *Urol Int*.

2004;73(4):296–301.

Ferguson C. Principles of transitional care for young people with longstanding continence problems. *Nurs Times*. 2010;106(47):10–12.

Gobet R, Weber D, Horst M, et al. Long-term followup 37 to 69 years in patients with bladder exstrophy treated with ureterosigmoidostomy: psychosocial and psychosexual outcomes. *J Urol*. 2009;182(4 Suppl):1819–1823.

Greenwell TJ, Venn SN, Creighton S, et al. Pregnancy after lower urinary tract reconstruction for congenital abnormalities. *BJU Int*. 2003;92(7):773–777.

Gupta AD, Goel SK, Woodhouse CRJ, et al. Examining long-term outcomes of bladder exstrophy: a 20-year follow-up. *BJU Int*. 2014;113(1):137–141.

Hamid R, Greenwell TJ, Nethercliffe JM, et al. Routine surveillance cystoscopy for patients with augmentation and substitution cystoplasty for benign urological conditions: is it necessary? *BJU Int*. 2009;104(3):392–395.

Hanna MK, Williams DI. Genital function in males with vesical exstrophy and epispadias. *Br J Urol*. 1972;44(2):169–174.

Heikkilä J, Holmberg C, Kyllönen L, et al. Long-term risk of end stage renal disease in patients with posterior urethral valves. *J Urol*. 2011;186(6):2392–2396.

Higuchi TT, Granberg CF, Fox JA, et al. Augmentation cystoplasty and risk of neoplasia: fact, fiction and controversy. *J Urol*. 2010;184(6):2492–2496.

Higuchi T, Holmdahl G, Kaefer M, et al. International Consultation on Urological Diseases: Congenital Anomalies of the Genitalia in Adolescence. *Urology*. 2016;94:288–310.

Jarzebowski AC, McMullin ND, Grover SR, et al. The Kelly technique of bladder exstrophy repair: continence, cosmesis and pelvic organ prolapse outcomes. *J Urol*. 2009;182(4 Suppl):1802–1806.

Jesus LE, Dekermacher S, Frota J, et al. Adolescents and adults in pediatric urology clinics. *J Pediatr Urol*. 2014;10(3):408–411.

Kovell RC, Skokan AJ, Wood DN. Transitional urology. *Urol Clin North Am*. 2018;45(4):601–610.

Kropp BP, Cheng EY. Total urogenital complex mobilization in female patients with exstrophy. *J Urol*. 2000;164(3 Pt 2):1035–1039.

Lambert SM. Transitional care in pediatric urology. *Semin Pediatr Surg*. 2015;24(2):73–78.

Loftus CJ, Moore DC, Cohn JA, et al. Postoperative complications of patients with spina bifida undergoing urologic laparotomy: a multi-institutional analysis. *Urology*. 2017;108:233–236.

López Pereira P, Miguel M, Martínez Urrutia MJ, et al. Long-term bladder function, fertility and sexual function in patients with posterior urethral valves treated in infancy. *J Pediatr Urol*. 2013;9(1):38–41.

Lumen N, Monstrey S, Ceulemans P, et al. Reconstructive surgery for severe penile inadequacy: phalloplasty with a free radial forearm flap or a pedicled anterolateral thigh flap. *Adv Urol*. 2008.

Malakounides G, Lee F, Murphy F, et al. Single centre experience: long term outcomes in spina bifida patients. *J Pediatr Urol*. 2013;9(5):585–589.

Massanyi EZ, Gupta A, Goel S, et al. Radial forearm free flap phalloplasty for penile inadequacy in patients with exstrophy. *J Urol*. 2013;190(4 Suppl):1577–1582.

Mathews RI, Gan M, Gearhart JP. Urogynaecological and obstetric issues in women with the exstrophy-epispadias complex. *BJU Int*. 2003;91(9):845–849.

Merksz M, Tóth J. The state of the testicle and the epididymis associated with exstrophy of the bladder in undescended testes. *Acta Chir Hung*. 1990;31(4):297–301.

Mesrobian HG, Kelalis PP, Kramer SA. Long-term followup of cosmetic appearance and genital function in boys with exstrophy: review of 53 patients. *J Urol*. 1986;136(1 Pt 2):256–258.

Mundy AR, Shah PJ, Borzyskowski M, et al. Sphincter behaviour in myelomeningocele. *Br J Urol*. 1985;57(6):647–651.

Nakhal RS, Deans R, Creighton SM, et al. Genital prolapse in adult women with classical bladder exstrophy. *Int Urogynecol J Pelvic Floor Dysfunct*. 2012;23(9):1201–1205.

Nakhal RS, Wood D, Woodhouse C, et al. False-positive pregnancy tests following enterocystoplasty. *BJOG*. 2012;119(3):366–368.

Nethercliffe J, Trewick A, Samuell C, et al. False-positive pregnancy tests in patients with enterocystoplasties. *BJU Int*. 2001;87(9):780–782.

O'Connor EM, Foley C, Taylor C, et al. Appendix or ileum—which is the best material for Mitrofanoff channel formation in adults. *J Urol*. 2019.

O'Kelly F, Keefe D, Herschorn S, et al. Contemporary issues relating to transitional care in bladder exstrophy. *Can Urol Assoc J*. 2018;12(4 Suppl 1):S15–S23.

Okumura MJ, Ong T, Dawson D, et al. Improving transition from paediatric to adult cystic fibrosis care: programme implementation and evaluation. *BMJ Qual Saf*. 2014;23(Suppl 1):i64–i72.

Palmer JS, Kaplan WE, Firlit CF. Erectile dysfunction in patients with spina bifida is a treatable condition. *J Urol*. 2000;164(3 Pt 2):958–961.

Piplani R, Aggarwal SK, Ratan SK. Role of uroflowmetry before and after hypospadias repair. *Urol Ann*. 2018;10(1):52–58.

Puri A, Gaur KK, Kumar A, et al. Semen analysis in post-pubertal patients with posterior urethral valves: a pilot study. *Pediatr Surg Int*. 2002;18(2–3):140–141.

Rosen DS, Blum RW, Britto M, et al. Transition to adult health care for adolescents and young adults with chronic conditions. *J Adolesc Health*. 2003;33(4):309–311.

Rubenwolf P, Thomas C, Thüroff JW, et al. Sexual function, social integration and paternity of males with classic bladder exstrophy following urinary diversion. *J Urol*. 2016;195(2):465–470.

Rubenwolf P, Thomas C, Thüroff JW, et al. Sexual function and fertility of women with classic bladder exstrophy and continent urinary diversion. *J Urol*. 2016;196(1):140–145.

Rynja SP, Wouters GA, Van Schaijk M, et al. Long-term followup of hypospadias: functional and cosmetic results. *J Urol*. 2009;182(4 Suppl):1736–1743.

Shepard CL, Yan PL, Hollingsworth JM, et al. Pregnancy among mothers with spina bifida. *J Pediatr Urol*. 2018;14(1):11 [e1–e6].

Silver RI, Yang A, Ben-Chaim J, et al. Penile length in adulthood after exstrophy reconstruction. *J Urol*. 1997;157(3):999–1003.

Smeulders N, Woodhouse CR. Neoplasia in adult exstrophy patients. *BJU Int*. 2001;87(7):623–628.

Spinoit AF, Hoebeke P. Urinary flow rate after TIP urethroplasty for hypospadias. *Nat Rev Urol*. 2015;12:477–478.

Stein R, Stöckle M, Fisch M, et al. The fate of the adult exstrophy patient. *J Urol*. 1994;152(5 Pt 1):1413–1416.

Suzer O, Vates TS, Freedman AL, et al. Results of the Mitrofanoff procedure in urinary tract reconstruction in children. *Br J Urol*. 1997;79(2):279–282.

Szymanski KM, Misseri R, Whittam B, et al. Current opinions regarding care of the mature pediatric urology patient. *J Pediatr Urol*. 2015;11(5):251 [e1–e4].

Szymanski KM, Cain MP, Hardacker TJ, et al. How successful is the transition to adult urology care in spina bifida? A single center 7-year experience. *J Pediatr Urol*. 2017;13(1):40 [e1–e6].

Szymanski KM, Cain MP, Whittam B, et al. Incontinence affects health-related quality of life in children and adolescents with spina bifida. *J Pediatr Urol*. 2018;14(3):279 [e1–e8].

Taskinen S, Heikkilä J, Santtila P, et al. Posterior urethral valves and adult sexual function. *BJU Int*. 2012;110(8 Pt B):E392–E396.

Timberlake MD, Corbett ST, Costabile RA, et al. Identification of adolescent and adult patients receiving pediatric urologic care and establishment of a dedicated transition clinic. *J Pediatr Urol*. 2015;11(2):62 [e1–e6].

Timsit MO, Mouriquand PE, Ruffion A, et al. Use of forearm free-flap phalloplasty in bladder exstrophy adults. *BJU Int*. 2009;103(10):1418–1421.

Veeratterapillay R, Morton H, Thorpe AC, et al. Reconstructing the lower urinary tract: the Mitrofanoff principle. *Indian J Urol*. 2013;29(4):316–321.

Wiener JS, Suson KD, Castillo J, et al. Bladder management and continence outcomes in adults with spina bifida: results from the National Spina Bifida Patient Registry, 2009 to 2015. *J Urol*. 2018;200(1):187–194.

Wilson C, Christie D, Woodhouse CR. The ambitions of adolescents born with exstrophy: a structured survey. *BJU Int*. 2004;94(4):607–612 [discussion 612].

Wilson CJ, Pistrang N, Woodhouse CR, et al. The psychosocial impact of bladder exstrophy in adolescence. *J Adolesc Health*. 2007;41(5):504–508.

Wong LH, Chan FW, Wong FY, et al. Transition care for adolescents and families with chronic illnesses. *J Adolesc Health*. 2010;47(6):540–546.

Wood D. Adolescent urology: developing lifelong care for congenital anomalies. *Nat Rev Urol*. 2014;11(5):289–296.

Wood D, Woodhouse C. Penile anomalies in adolescence. *ScientificWorldJournal*. 2011;11:614–623.

Wood D, Baird A, Carmignani L, et al. Lifelong congenital urology: the challenges for patients and surgeons. *Eur Urol*. 2019;75(6):1001–1007.

Woodhouse CR. The sexual and reproductive consequences of congenital genitourinary anomalies. *J Urol*. 1994;152(2 Pt 2):645–651.

Woodhouse CR. Sexual function in boys born with exstrophy, myelomeningocele, and micropenis. *Urology*. 1998;52(1):3–11.

Woodhouse CR. The gynaecology of exstrophy. *BJU Int*. 1999;83(Suppl 3):34–38.

Woodhouse CR. Myelomeningocele in young adults. *BJU Int*. 2005;95(2):223–230.

Woodhouse C. Platinum Opinion: adolescent urology and transitional care. *Eur Urol*. 2015;68(5):745–746.

Woodhouse CR, Christie D. Nonsurgical factors in the success of hypospadias repair. *BJU Int*. 2005;96(1):22–27.

Woodhouse CR, Neild GH, Yu RN, et al. Adult care of children from pediatric urology. *J Urol*. 2012;187(4):1164–1171.

51

Urologic Considerations in Pediatric Renal Transplantation

Craig A. Peters MD, Armando J. Lorenzo MD, MSc, FRCSC, FAAP, FACS

The child requiring renal replacement most often is a boy with an obstructive uropathy. The challenge for the pediatric urologist is to ensure that the underlying problem that led to damage to the native kidneys will not cause problems to the transplant. These patients require some of the most complex care. It is paramount to develop a therapeutic plan to provide for **several goals: (1) normal urinary drainage from the kidney into a reservoir, (2) a continent reservoir that permits low pressure storage for a socially acceptable time, (3) volitional emptying of the reservoir, (4) absence of infection, and (5) the fewest surgical procedures and patient trauma**. These goals are achievable, but until they are ensured, renal transplantation should be deferred or a plan to achieve these must be in place.

Patient and family understanding and compliance are essential for successful urologic management of the child with an abnormal urinary tract and end-stage renal disease (ESRD). Before the onset of ESRD, a management strategy should be developed to avoid more rapid deterioration of the child's chronic kidney disease and to facilitate a smooth transition into transplantation. The integration of the entire care team in this preparation is critical and demands a close working relationship between the urology team, pediatric nephrology, and the transplant team. The urologist must have a basic understanding of the needs and constraints of the nephrologists and transplant surgeons. The transplant ureteral implantation can be performed by the urologist or the transplant surgeons, but this should depend upon the state of the lower urinary tract and the comfort level of the surgical teams with the particular aspects of the surgery and their postoperative management, including any complications.

Pretransplant Assessment

Screening

A large percentage of children in need of renal replacement have some type of uropathy: congenital obstruction, vesicoureteral reflux, or neuropathic bladder dysfunction (NAPRTCS, 2008; NAPRTCS, 2014; Van Arendonk et al., 2014). Younger boys typically have obstructive uropathy, including posterior urethral valves, whereas the patients with reflux and neuropathic bladder tend to be older, including young adults. Some children have uncharacterized ESRD. It is reasonable to have all children screened for urologic issues before transplant. A detailed history, renal ultrasound, and flow rate with postvoid residual urine by ultrasound (in toilet-trained children) can effectively rule out most significant uropathies. Routine voiding cystourethrogram (VCUG) is not necessary unless there is a history of a specific urologic disease, febrile or recurrent UTI, the presence of hydronephrosis, or abnormal voiding (Ramirez et al., 2001; Singer et al., 2009; Fig. 51.1).

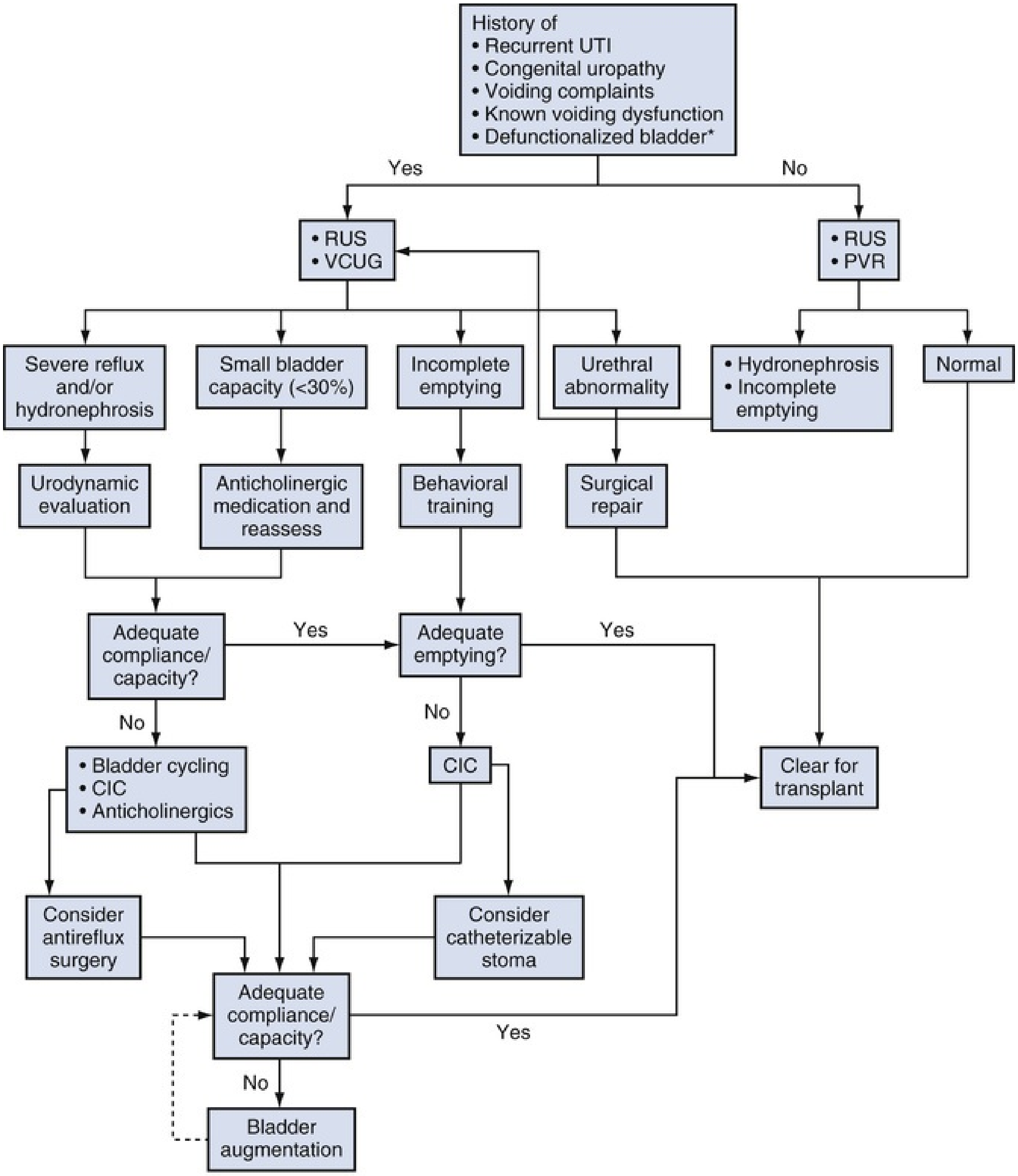
History of
• Recurrent UTI
• Congenital uropathy
• Voiding complaints
• Known voiding dysfunction
• Defunctionalized bladder*
Yes
No
• RUS
• VCUG
• RUS
• PVR
Severe reflux and/or hydronephrosis
Small bladder capacity (<30%)
Incomplete emptying
Urethral abnormality
• Hydronephrosis
• Incomplete emptying
Normal
Urodynamic evaluation
Anticholinergic medication and reassess
Behavioral training
Surgical repair
Adequate compliance/ capacity?
Yes
Adequate emptying?
Yes
No
No
• Bladder cycling
• CIC
• Anticholinergics
CIC
Clear for transplant
Consider antireflux surgery
Consider catheterizable stoma
Adequate compliance/ capacity?
Yes
No
Bladder augmentation

*If patient is anuric and has no urologic history, no further testing is essential; if there is a history of neurogenic bladder, posterior urethral valves, or complex urologic condition, consideration of bladder cycling and anticholinergics is appropriate.

FIG. 51.1 Algorithm for evaluation and management of the bladder in patients in preparation for renal transplantation. The key element is the history of urologic conditions or symptoms. *CIC,* Clean intermittent catheterization; *PVR,* post void residual; *RUS,* renal ultrasound; *VCUG,* voiding cystourethrogram.

Focused Assessment

The child with a known urologic abnormality requires a targeted pretransplant assessment directed by the underlying condition and the status of the bladder and kidneys. In most, a VCUG is useful to evaluate voiding function, the state of the urethra, and the presence and grade of reflux. When bladder dynamics are abnormal, consideration for urodynamic evaluation is also appropriate. **The indications for urodynamic testing to assess bladder capacity, compliance, contractility and emptying, as well as sphincter function include a known neuropathic bladder abnormality, bladder outlet obstruction resulting from posterior urethral valves (PUV) or a large ureterocele, and selected cases with recalcitrant voiding dysfunction, high-grade hydronephrosis, or recurrent urinary tract infections (UTIs)** (Burns et al., 1992; Riley et al., 2010; Zermann et al., 2003). The principal goals of urodynamic testing are to determine the presence of abnormal bladder dynamics, which may place the allograft at risk and establish the need for further therapy to optimize bladder function. This may include medical therapy with anticholinergics, the use of intermittent catheterization, and the potential need for bladder augmentation.

Urodynamics also provide insight into bladder emptying function, which is critical to minimize the risk of infections. Moreover, if medical therapy for a noncompliant bladder is needed, this may impair bladder emptying and necessitate clean intermittent catheterization (CIC) to permit effective emptying. In the child with a sensate or difficult-to-negotiate urethra, as well as in some patients with neuropathic bladder, the creation of a continent catheterizable stoma may be the ideal way to facilitate effective CIC. It is reasonable to make and execute these decisions before transplant. Urodynamic evaluation often is a regular monitoring evaluation in these children and a critical element in ongoing optimization of bladder function. It often is necessary to repeat the study to ensure that the therapeutic intervention has been effective and that the bladder is indeed ready for the transplant.

Key Points: Urologic Evaluation and Management

- Goals:
    - Normal urinary drainage from the kidney into a reservoir

  - A urinary reservoir that permits low pressure storage for a socially acceptable time
  - Volitional emptying of the reservoir, with continence
  - Absence of infection
  - The fewest surgical procedures and patient trauma
- A large fraction of children in need of renal replacement have some type of uropathy, either congenital obstruction, vesicoureteral reflux, or neuropathic bladder dysfunction.
- Pretransplant assessment is directed by the underlying condition and the status of the bladder and kidneys.
- Urodynamic testing aims to assess bladder capacity, compliance, and emptying, as well as sphincter function.
- Indications for urodynamics include a known neuropathic bladder, history of posterior urethral valves, and children with ongoing voiding dysfunction, high-grade hydronephrosis, or recurrent UTIs.

Pretransplant Preparation

Bladder Preparation

General Issues

The most common early bladder abnormalities associated with ESRD are low capacity, hypercontractility, and poor compliance. Although this is the typical picture in patients with PUVs, it is important to recognize that these bladders continue to evolve over time, progressing to a pattern of resolution of hypercontractility and increasing bladder capacity, up to insufficient contractility and inefficient emptying (so-called "myogenic failure") (De Gennaro et al., 2000; Holmdahl et al., 1996; Nguyen and Peters, 1999; Peters et al., 1990). Of these, hypertonicity and poor compliance are the most dangerous urodynamic patterns, because high pressures will be transmitted to the kidneys even in the absence of reflux. Failure to address these aspects of bladder dysfunction can increase graft loss (Herthelius and Oborn, 2007).

Hypertonicity and Poor Compliance

Initial management is medical, typically with anticholinergics, with augmentation cystoplasty as a second-line intervention (Greer et al., 2016; Lopez Pereira et al., 2000). Medical management requires diligence on the part of the family and follow-up to regularly assesses response to therapy. It usually requires introducing CIC in combination with anticholinergics, although some children with PUVs can learn to void by Valsalva maneuver. In some cases, alpha-blockers may also be employed to further aid with bladder emptying (Abraham et al., 2009; Austin et al., 1999). It should never be assumed that they will be able to do so, thus the need to demonstrate this by repeated low postvoid residual volumes on catheterization or ultrasound.

Because of the side effect profile, anticholinergic therapy is best titrated with increasing doses, watching for changes in catheterized volumes, incontinence, and hydronephrosis. Urodynamic evaluation can more precisely define the efficacy. Often medical therapy is introduced at the same time as CIC, although this is not essential. Compliance with CIC is often an excellent test of future patient/family compliance with the stringent requirements of renal transplant. If a family is unable to manage with CIC, their ability to manage the medical care of a transplant should be questioned. The goal of therapy is for the child to be able to store up to estimated bladder capacity for age, at low pressures (i.e., less than 30 cm H_2O), and gain social continence.

Capacity

Bladder capacity is another element of normal function and is the basis for safe storage and social continence. Bladder capacity can be improved with anticholinergic medication but may ultimately require further interventions such as bladder augmentation. There is a clear shift away from augmentation in all patients, to the extreme that augmentation is not needed in renal transplant (Alfrey et al., 1997; Salvatierra et al., 1999). A cautious, selective approach is warranted because the allograft requires a safe reservoir to avoid damage from high pressures or recurrent infections. Augmentation remains a necessary aspect of urologic management in some children with complex uropathies with ESRD. Current indications include a nonsalvageable bladder (because of exstrophy, tumor, or severe end-stage neuropathic bladder) or failure of medical and CIC therapy to achieve low-pressure storage for up to 3 hours. If pressures are only safe for a shorter period of time or regularly exceed 40 cm H_2O despite maximal medical therapy and catheterization, consideration for augmentation is appropriate.

There is no evidence, nor logic, that bladder augmentation increases the risk of complications during or after transplant, despite some reports (Alfrey et al., 1997). **Conversely, it has permitted many effective transplants into abnormal bladders** (Broniszczak et al., 2010; Djakovic et al., 2009; Koo et al., 1999, Luke et al., 2003; Sheldon et al., 1994; Taghizadeh et al., 2007). There is no single approach or timing that is ideal. Although gastric augmentation gained popularity for ESRD children in the late 1980s and early 1990s—based on the theoretical benefits of secreting acid in a patient who is typically acidotic, limiting infections, and lowering the rate of bladder stones (Traxel et al., 2011)—it currently is rarely offered. Gastric augments have been linked with severe complications (particularly in the pretransplant, anuric group) because of gastric secretion injury to the native bladder segment and the resulting hematuria-dysuria syndrome (Nguyen et al., 1993; Reinberg et al., 1992). Moreover, recent reports of malignancy, particularly in the transplant group, are worrisome (Castellan et al., 2007; Husmann and Rathbun, 2008). Caution and monitoring are essential in patients who have previously undergone reconstruction with gastric segments. Ileum and sigmoid segments are the most commonly employed and remain very useful. Selection depends upon anatomy, prior surgery, and preferences for concurrent continent catheterizable stomas.

The augmented patch rarely creates an issue during the transplant, but the presence and location of the pedicle as well as its anatomic orientation must be recognized by the transplanting team. Similarly, **continent stomas should be placed in such a location to avoid conflicting with the anticipated transplant incision(s) and nearly always must be positioned medial to these.** In most cases, the allograft will be placed in a retroperitoneal location employing a Gibson-type incision (Fig. 51.2). Thus intraperitoneal dissection and location of the stomas do not create major difficulties. However, in infants and small children (<15 kg), the vascular anastomosis may have to be fashioned at the level of the aorta and vena cava, and this may require a transperitoneal approach. In these cases, it would be unusual that an augment or catheterizable channel would be in place; however, anticipation and multidisciplinary planning is key. Coordination between the reconstructive and transplant teams remains essential in all cases.

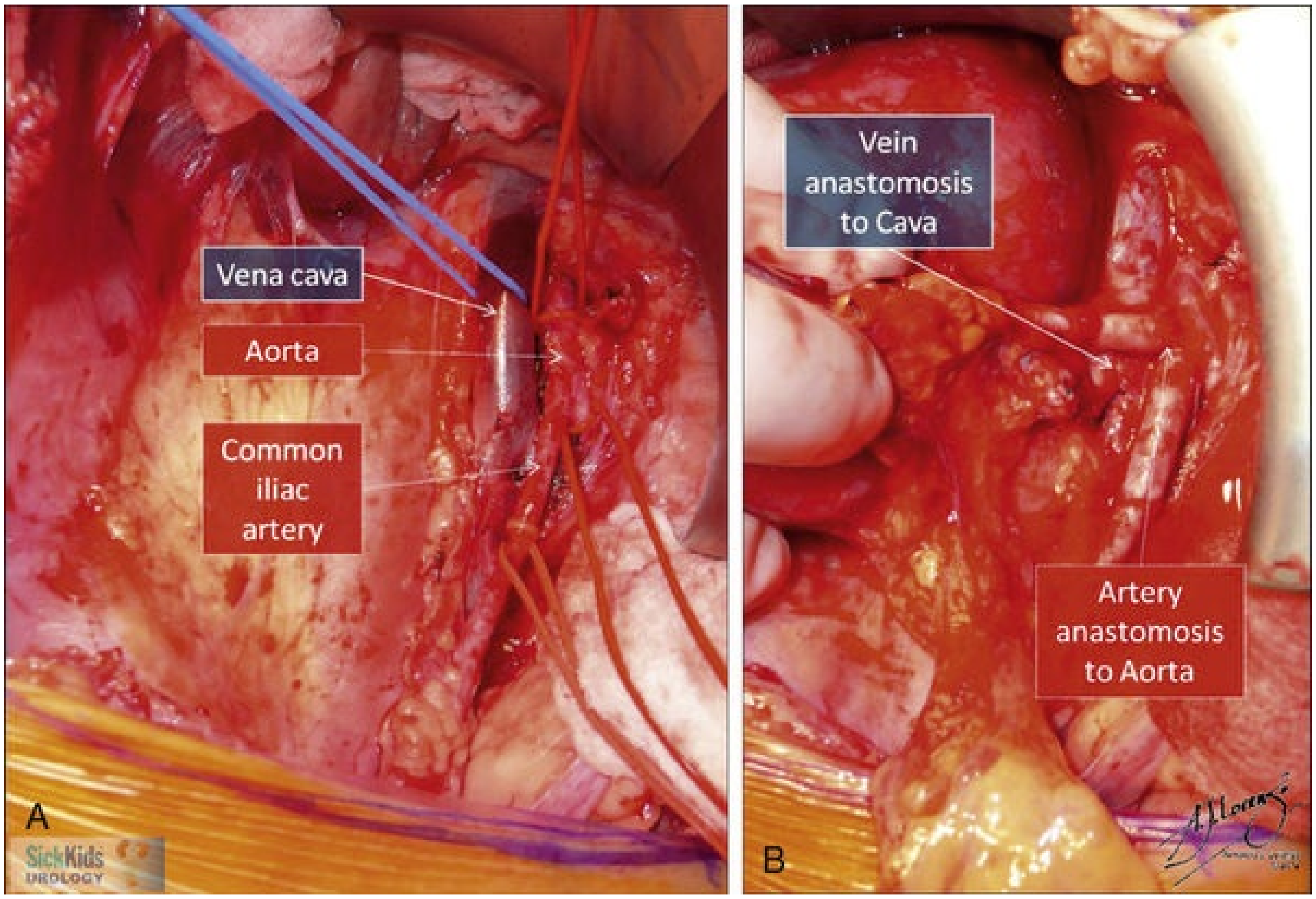

FIG. 51.2 Retroperitoneal dissection through a right Gibson incision in a

small child undergoing a living-related renal transplantation. Adequate space created for an adult-size allograft (A), allowing for a comfortable vascular anastomosis to the aorta and vena cava (B).

Infections

Many children with complex reconstruction of the urinary tract have a history of recurrent UTI, which may be associated with intermittent catheterization and the presence of an augment. This is a potential hazard for the transplant because pyelonephritis of the graft can generate significant morbidity in an immunocompromised host and can ultimately lead to graft loss (Dunn et al., 1987; Hanevold et al., 1987; Howie et al., 2002; Herthelius and Oborn, 2007; Neuhaus et al., 1997). The underlying cause of the infection is most likely urinary stasis resulting from inadequate emptying of the reservoir, either by catheterization or voiding, or urinary obstruction with hydronephrosis (Chu et al., 2013). This must be assessed and addressed in advance of the renal transplant. Strategies include double and triple voiding to avoid using CIC, or—if CIC has already been instituted—to ensure timely and complete emptying. Moreover, it is critical to differentiate true UTIs versus bacterial colonization, which is exceedingly common in patients performing CIC. In general, UTIs do not present a major threat to the renal graft as long as they are managed early and appropriately (Fallahzadeh et al., 2011; Traxel et al., 2011).

Persistent UTIs in the face of appropriate CIC technique suggests either an anatomic abnormality that has not been detected or chronic colonization. The latter sometimes responds to long-term antibiotic courses, using agents including fluoroquinolones or cephalosporins. The cause and specific therapy for this situation is uncertain. Although uncommon, specific anatomic abnormalities such as diverticula or ureteral stumps may require more specific imaging studies and may be amenable to surgical cure.

Clean Intermittent Catheterization

The **use of CIC in managing the abnormal bladder has been a truly revolutionary intervention since its introduction in the 1970s** (Bloom, 2017; Lapides et al., 1972). Although it may be a challenge to initiate, once started it is nearly always well accepted. Careful preparation, teaching, support and follow-up are critically important for long-term success.

The importance and principles of CIC must be well understood by the care providers and carefully communicated to the family, including all possible caregivers. This is a means by which to reduce infection and attain safe bladder storage and control over voiding, which is very important and yet may not be readily apparent on first pass.

The frequency of CIC must be determined by a measure of approximate urine outputs, as well as storage pressures based on urodynamic assessment or by home-catheterization opening pressure measurements (Hidas et al., 2017), and appropriately tailored to fluid intake. This permits an estimate of safe pressure-volume relationships for day-to-day life. Avoiding regular excesses of these volumes and therefore high pressures optimizes healthy kidney drainage. The typical frequency is every 3 and 4 hours. Pressures should not exceed 40 cm H_2O for any prolonged period of time.

Initiating CIC in preparation for transplantation serves an assessment purpose as well. For families for whom follow-through may be imperfect, CIC is a useful means of determining their commitment and ability to follow complex medical care plans. If CIC cannot be instituted pretransplant to manage an abnormal bladder, there is no reason to believe this ability will suddenly manifest post-transplant. **The response to CIC can predict the ability to manage the necessary transplant medication and care regimen as well.** The committed and understanding family will manage well, and this will demonstrate their readiness for transplant.

Defunctionalized Bladder

Neuropathic.

The defunctionalized neurogenic bladder is becoming scarce because of better management but will occasionally be seen clinically in a transplant patient who has not had ongoing urologic care (Firlit, 1976; Serrano et al., 1996). **It is impossible to know without testing what the potential function of the bladder may be. It is also important to recognize that a bladder that has been defunctionalized will take some time to reach its maximal functional potential. This is often best accomplished by bladder cycling to increase capacity, determine bladder wall compliance, and assess the family's ability to perform CIC.**

Some have advocated simply implanting the transplant ureter into the bladder and anticipating normal function (Salvatierra et al., 1999). Although this may occur on rare occasions, it is a highly risky approach to the chronically defunctionalized bladder. A renal allograft should not be employed to test if a bladder functions properly or not; conversely, clearance for transplantation should be granted when bladder function has been adequately assessed and optimized.

Cycling the defunctionalized bladder is best accomplished using a progressive program of catheterization with instillation of increasing volumes of saline, with a set dwell time and then catheter drainage (Alam and Sheldon, 2008). The amounts are determined empirically based on initial tolerated volumes and should increase at regular intervals, usually 10 to 15 cc per day. The response to these instillations gives useful clues regarding the utility of the bladder as a reservoir and any ability to empty spontaneously. Adjunctive anticholinergic medications are often necessary to increase bladder capacity and compliance.

The defunctionalized neurogenic bladder almost certainly requires intermittent catheterization for emptying. It is therefore reasonable to introduce this concept to the family. In the rare instance in which the child can learn to empty satisfactorily, CIC may no longer be needed. This is a major step and requires a careful study of voiding diaries, postvoid residuals, and urodynamic testing.

The target volume is expected capacity for age based on any of the available formulas (Kaeferet al., 1997; Koff, 1983). This may not be reached immediately, but if volumes increase steadily without significant leakage, further expansion is likely. Although storage capacity is important, compliance is equally critical, and this must be formally assessed with urodynamics. Only if acceptable capacity and compliance parameters can be reached should the patient be cleared for transplant. Aggressive medical management is also important in this determination. If adequate storage and compliance cannot be attained, consideration for augmentation must be entertained. This should be performed before transplant unless there are pressing reasons.

Key Points: Pretransplant Preparation

- The most common bladder abnormality associated with uropathy and ESRD is a low-capacity, hypertonic bladder with poor compliance.
- There is no evidence that bladder augmentation increases the risk of transplant.

- Recurrent pyelonephritis is a potential hazard for the transplant and is associated with graft loss.
- Initiating CIC in preparation for transplantation serves an assessment purpose as well as facilitating bladder emptying.
- Bladder re-functionalization is often best accomplished by bladder cycling to increase capacity, determine bladder wall compliance, and assess the family's ability to perform CIC.

Non-Neuropathic.

The defunctionalized bladder associated with renal insufficiency is often due to posterior urethral valves or vesicoureteral reflux. In addition, a small group of anuric patients without prior urologic problems seek transplantation. These include patients who have undergone bilateral nephrectomies, such as patients with severe proteinuria resulting from congenital nephrotic syndrome. These bladders may be more often salvaged to permit spontaneous voiding but should be initially approached as the defunctionalized neuropathic bladder, with the assumption that CIC will be needed long term. The critical factor will be safe storage capacity, and progressive cycling as described earlier can provide that assessment. At the same time, children can be asked to attempt to void after holding the instilled saline for a period of 15 or 20 minutes. A postvoid catheterization then determines the postvoid residual volume.

The ability to empty spontaneously also affects the decision regarding the need for a continent catheterizable stoma. This is more critical in boys with normal sensation who may be understandably resistant to urethral catheterization. The period of pretransplant CIC permits assessment of voiding ability and tolerance of urethral CIC. These decisions are best made concurrently with other reconstructive choices to permit an integrated strategy and a single surgical procedure, if possible.

Decision to Augment.

Although the use of bladder augmentation is declining because of concerns regarding metabolic, infectious, and neoplastic complications, enterocystoplasty remains the most effective means to provide adequate bladder storage function in neurogenic and postobstructive bladder dysfunction (Aki et al., 2006; Barnett et al., 1987; Capizzi et al., 2004; DeFoor et al., 2003; Hatch et al., 2001; Mendizabal et al., 2005; Nahas et al., 2002;

Rigamonti et al., 2005; Sheldon et al., 1994; Traxel et al., 2011). To lose a renal graft because of the same processes that contributed to native renal demise is unacceptable. The potential complications of augmentation must also be clearly recognized and anticipated, although some reports (Alfrey et al., 1997) have presented extreme examples that are not our personal experience. A strategy of aggressive intermittent catheterization with medical management becomes the best approach to identify those patients in whom augmentation is the only real option for successful renal transplantation. It is difficult to determine a meaningful incidence of the need for augmentation as the effort expended by family and health care team varies as much as the underlying pathology. With early aggressive bladder management, the need for augmentation in neuropathic and obstructive bladder dysfunction has been declining.

Broad indications for augmentation before transplantation would be the inability to develop capacity greater than 75% of expected for age with pressures below 30 cm H_2O, using catheterization that is no more frequent than every 3 hours, and using maximal anticholinergic medications. Although there has been an increase in use of botulinum toxin injection in patients with neuropathic bladder dysfunction (Greer et al., 2016), the safety and efficacy after transplantation is largely unknown. Irrespective of the anticholinergic agent, tolerance to medication obviously is an important factor. Admittedly, these thresholds remain somewhat arbitrary and lack strong clinical data to support them. It is also critical to remember the dynamic nature of bladder dysfunction, as previously described for patients with PUVs. In addition, the development of long-term complications in a time-dependent fashion (Metcalfe et al., 2006) as well as the potential added complications of performing an augmentation cystoplasty in a post-transplant (immunocompromised) setting should be taken into account. It is not an easy decision and should clearly be individualized. For example, because many patients with PUVs eventually develop myogenic failure, it seems prudent to postpone as much as possible augmentation cystoplasty in this population (Jesus, 2015), providing this delay does not accelerate progression to end stage.

The availability of a dilated ureter to permit ureterocystoplasty (Kim et al., 1996; Kurzrock et al., 2002; Landau et al., 1997) should be explored, although results have been mixed and dependent on ureteral diameter, bladder compliance, and presence of vesicoureteral reflux. It is preferable to enterocystoplasty in terms of certain issues such as mucous production, stone formation, recurrent infections, or metabolic abnormalities. In this context, efforts should be made to preserve the ureter when possible for this use, for fashioning a continent catheterizable channel, or to use as a target for allograft ureteral anastomosis (Penna et al., 2017).

Cutaneous Stomas

The defunctionalized bladder may be associated with a variety of urinary diversions, including ileal and colon conduits as well as pyelostomies or ureterostomies. In the past, transplantation has been performed with the ureters draining into the diversion (Kelly et al., 1966). This is rarely accepted today, although it remains an option in very selected cases and at the expense of higher complications, particularly UTIs (Broniszczak et al., 2010; Jesus, 2015). A functioning ileal loop diversion in the setting where augmentation is determined to be necessary can be used as the augmenting patch with bladder refunctionalization, even if the patient is anuric. If augmentation is not needed (based on response to CIC cycling) and the patient continues to produce urine, the native kidney should be implanted to refunctionalize the bladder and the loop discarded. If there is uncertainty regarding the need for augmentation, the loop may be preserved and kept available for later augmentation (including after transplant).

Reconstruction Strategies

In the setting in which bladder reconstruction will be needed, several factors must be considered in anticipation of the renal transplant. These considerations include the type of dialysis (either hemo- or peritoneal), likely placement of the graft, timing relative to initiation of dialysis (if not already begun) and transplantation, the need for bowel surgery, and the status of the native kidneys.

Dialysis Issues

If a patient is already on peritoneal dialysis (PD), any intraperitoneal surgery will likely require temporary or permanent transition to hemodialysis. Limiting this to one procedure is valuable. At times an intraperitoneal procedure can be performed at the time of PD catheter placement, but if bowel surgery is required, doing so may increase the risk of catheter infection and need for removal.

If the patient is not yet on dialysis but is approaching the need for renal replacement therapy, there may be some consideration for initiating dialysis before reconstruction to improve the metabolic status of the child. This can promote wound healing, decrease complications, and help the child tolerate the metabolic demands imposed by reabsorption of urine in cases in which bowel will be employed. At the same time, extensive intra-abdominal surgery may preclude the use of the peritoneum for dialysis. Last, for those on hemodialysis, there is a risk of catheter infection in the setting of postoperative sepsis and arteriovenous fistula injury during surgery because of low-flow states or direct pressure.

Graft Placement

Consideration should be made for the most likely future location of the graft. In the very small child, in whom the graft may be placed intraperitoneally, careful movement of any mesenteric pedicles away from the midline is advisable, as well as trying to avoid a transureteroureterostomy. Thankfully, very small children are unlikely to have prior reconstructive procedures, and most allografts can be accommodated using an extraperitoneal approach (Chinnakotla et al., 2017; Gander et al., 2017; Vitola et al., 2013). A prior psoas hitch or extensive dissection for ureteral reimplantation of the native kidney (if it is to be salvaged) can make ipsilateral iliac graft placement difficult.

The need for additional (nonurologic) procedures and challenging vascular anatomy should also be taken into consideration. In patients with primary hyperoxaluria, a concurrent or prior liver transplant places space and dissection restrictions on the right upper quadrant and flank. This makes any future surgical procedures to address problems with the right native kidney very difficult and favors placement of the renal allograft on the left side. Thrombosis of the vena cava or iliac system dictates the best location for the venous anastomosis, and avoidance of this area (as well as respecting any collateral venous drainage) will be of value. Last, the presence of an uncorrected ipsilateral undescended testicle should be addressed (eFig. 51.3). The resulting peri-allograft inflammatory reaction and fibrosis make any subsequent attempts at finding or mobilizing the testicle extremely difficult.

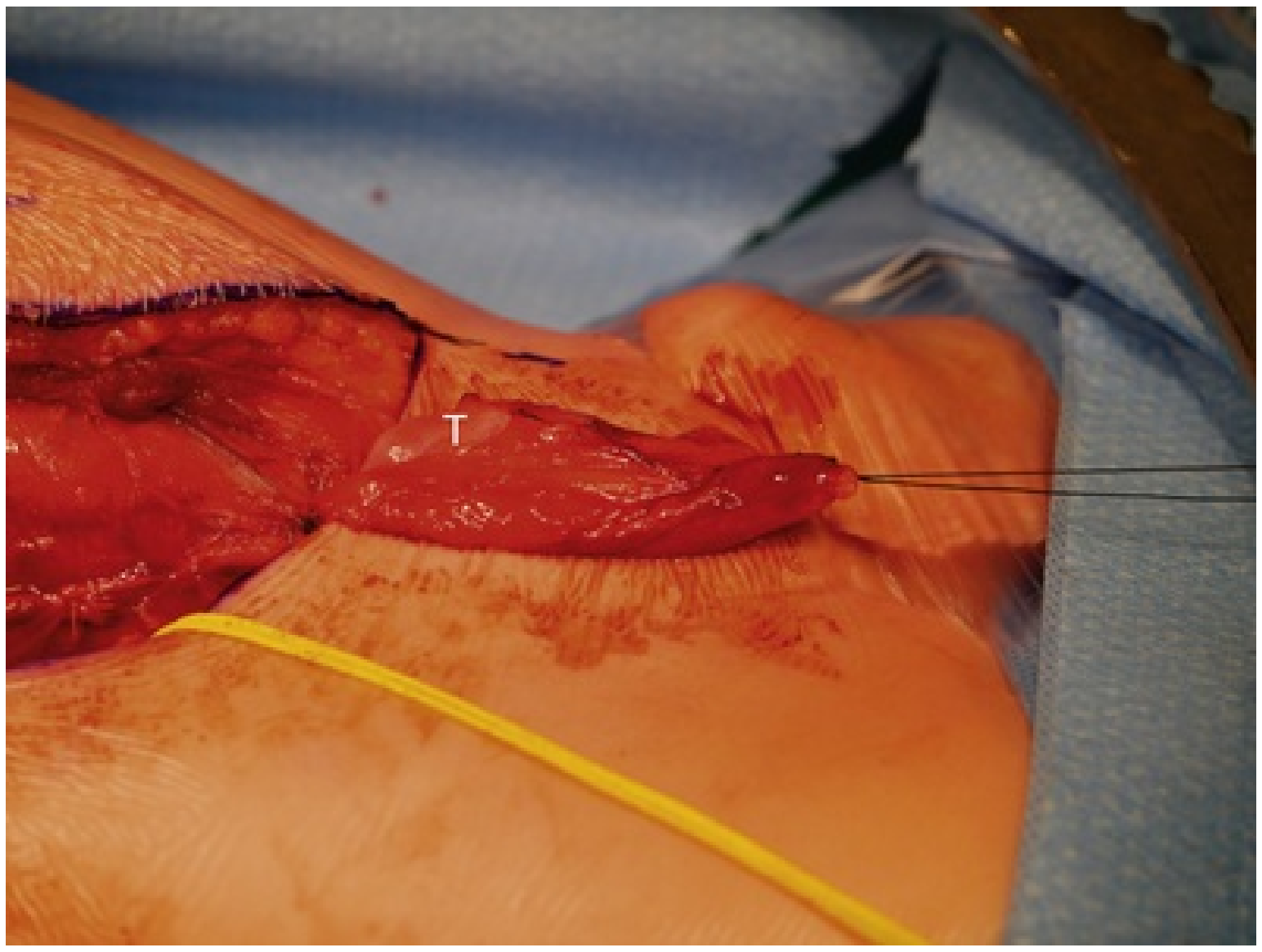

EFIG. 51.3 Dissection of intra-abdominal testicle *(T),* with orchidopexy at time of transplantation in a young child with renal failure on peritoneal dialysis. Because of possibility of hemodialysis and limited vascular access orchidopexy was previously deferred.

The urologist may have few feasible alternatives in difficult cases, and in such situations, careful documentation of the procedure and collaboration with the transplant team is essential. As with many other reconstructive procedures, a detailed operative report and a diagram of the operation are bound to be of great value to future surgeons (eFig. 51.4).

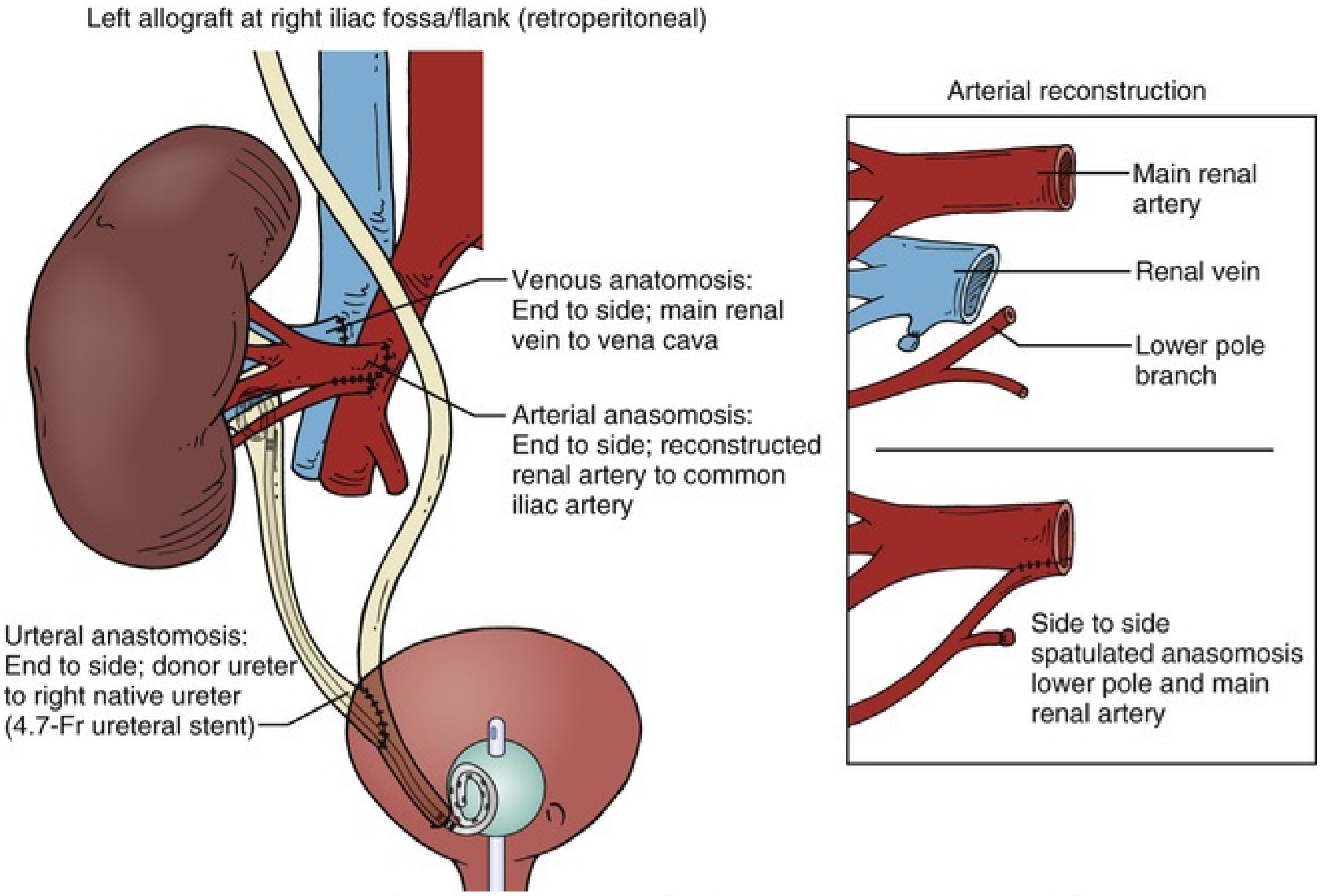
Left allograft at right iliac fossa/flank (retroperitoneal)
Venous anatomosis:
End to side; main renal
vein to vena cava
Arterial anasomosis:
End to side; reconstructed
renal artery to common
iliac artery
Urteral anastomosis:
End to side; donor ureter
to right native ureter
(4.7-Fr ureteral stent)
Arterial reconstruction
Main renal
artery
Renal vein
Lower pole
branch
Side to side
spatulated anasomosis
lower pole and main
renal artery

EFIG. 51.4 Operative diagram for pediatric renal transplant, providing anatomic details for allograft location and targets for anastomoses.

Timing

In general, it is preferable to perform any major urologic reconstruction before transplantation (Taghizadeh et al., 2007). Minor ureteral surgery may be considered at the time of transplantation, but this is unusual. After enterocystoplasty or continent diversion, at least 6 to 12 weeks are recommended for adequate healing. Unilateral native nephrectomy is reasonable at the time of transplantation. Concurrent procedures should be avoided in infants and small children because they may experience more negative outcomes with a prolonged anesthetic and hemodynamic instability. Moreover, these patients often require anticoagulants to prevent graft thrombosis (Dick et al., 2005), thus increasing the risk of postoperative bleeding.

Enterocystoplasty

Enterocystoplasty in the setting of a dialysis patient or a child approaching ESRD is feasible and, when needed, can be successfully accomplished in a manner similar to any other child (DeFoor et al., 2003; Sheldon et al., 1994;

Taghizadeh et al., 2007). The selection of bowel segment(s) and reconstructive strategy should be based on the functional anatomy and needs of the individual child. These include factors such as the need for a continent catheterizable stoma, the availability of native bladder tissue, the status of the bladder neck and continence mechanism, and bowel function. **If continent diversion is needed because of an unsalvageable bladder, there is no reason to defer this until after transplant.** The often-quoted metabolic problems with continent diversion in the setting of renal impairment are not an absolute contraindication. These patients need careful medical management after diversion, and in cases in which pre-emptive transplantation is considered, dialysis may be needed. In some cases, by improving bladder dynamics and limiting infection, the progression to ESRD may be delayed.

The use of gastric segments was considered particularly appropriate for the child approaching end-stage failure and in very selected cases may still be useful (Burns et al., 1992; DeFoor et al., 2003; Traxel et al., 2011). Because of the various complications of gastrocystoplasty, however, this approach has lost popularity. The benefit of acid excretion for the child with CKD is undeniable, but these children are still at risk for complex metabolic derangements including alkalosis. For the anuric child, the presence of gastric secretions can lead to bladder erosion and even perforation (Reinberg et al., 1992). In addition, development of dysuria and hematuria can be particularly challenging (Castellan et al., 2012). Care must be taken in those children to use proton pump inhibitors and to irrigate with bicarbonate solutions until urine output is restored.

Native Nephrectomy

The decision regarding native nephrectomy must be made as a multidisciplinary team. There is controversy in this regard and, although in general it is preferable to leave the native kidneys (Fraser et al., 2013), **there are several situations in which removal pretransplant is necessary. These include difficult-to-control hypertension, profound nephrotic syndrome with malnutrition resulting from protein losses (Kim et al., 1992), massive polyuria (Kravarusic et al., 2006), recurrent upper tract infections, large stone burden, high risk for malignancy, very large kidneys (to gain space for the allograft** [eFig. 51.5]**) or allow for dialysis** [eFig. 51.6]**), and massive vesicoureteral reflux.** The latter may be relative, but with stasis and possible infection in an immunosuppressed child, removal may be preferable and less risky than reimplantation or conservative management. The utility of leaving a native kidney that produces some urine is in making dialysis more manageable with lower fluid restrictions, which can facilitate nutritional support in the younger child. This must be balanced against the possible risks of infection and hypertension, as well as graft function.

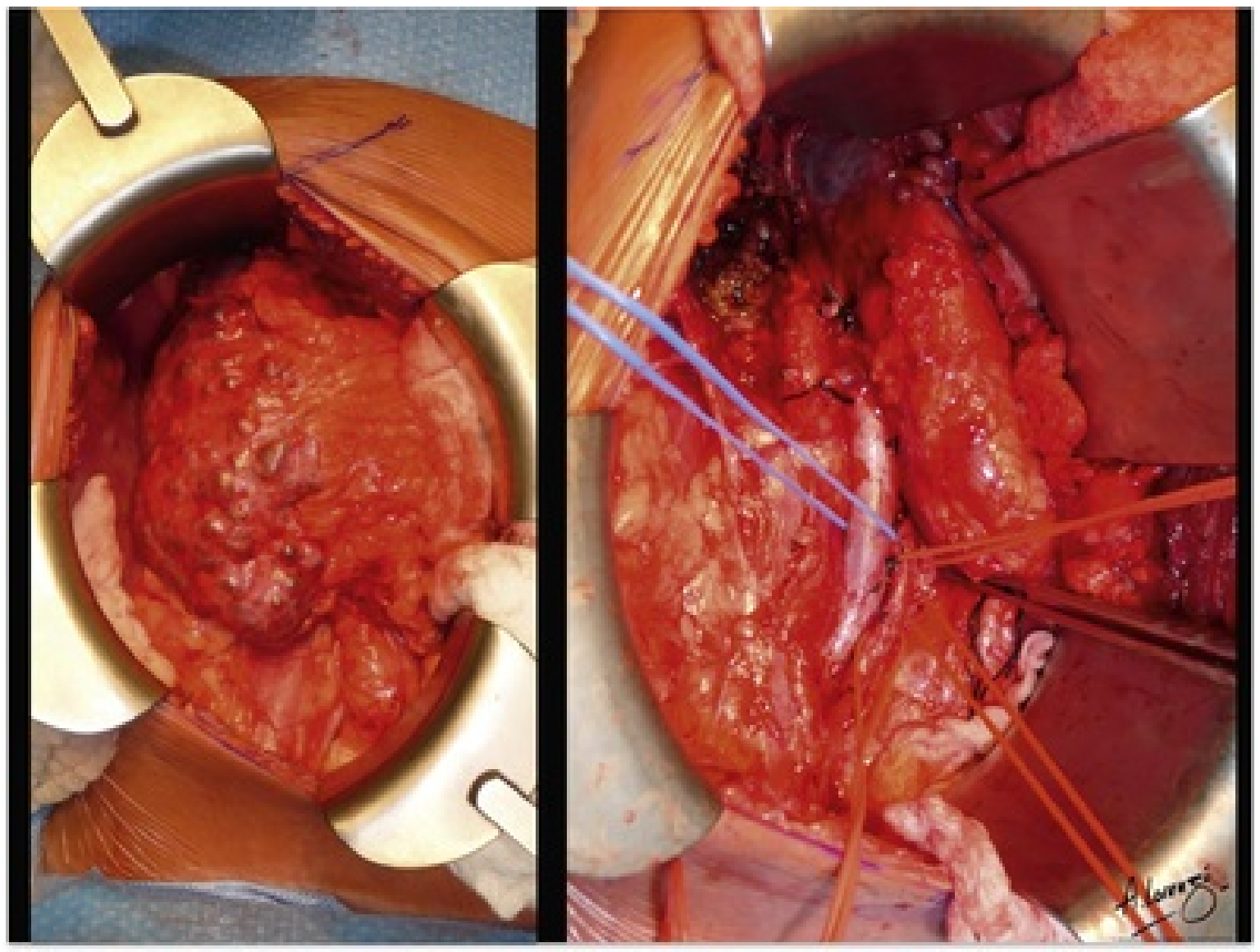

EFIG. 51.5 Native nephrectomy at the time of renal transplantation in a child with autosomal kidney disease. Note amount of spaced gained by the procedure, along with easy access to vena cava, aorta, and iliac system.

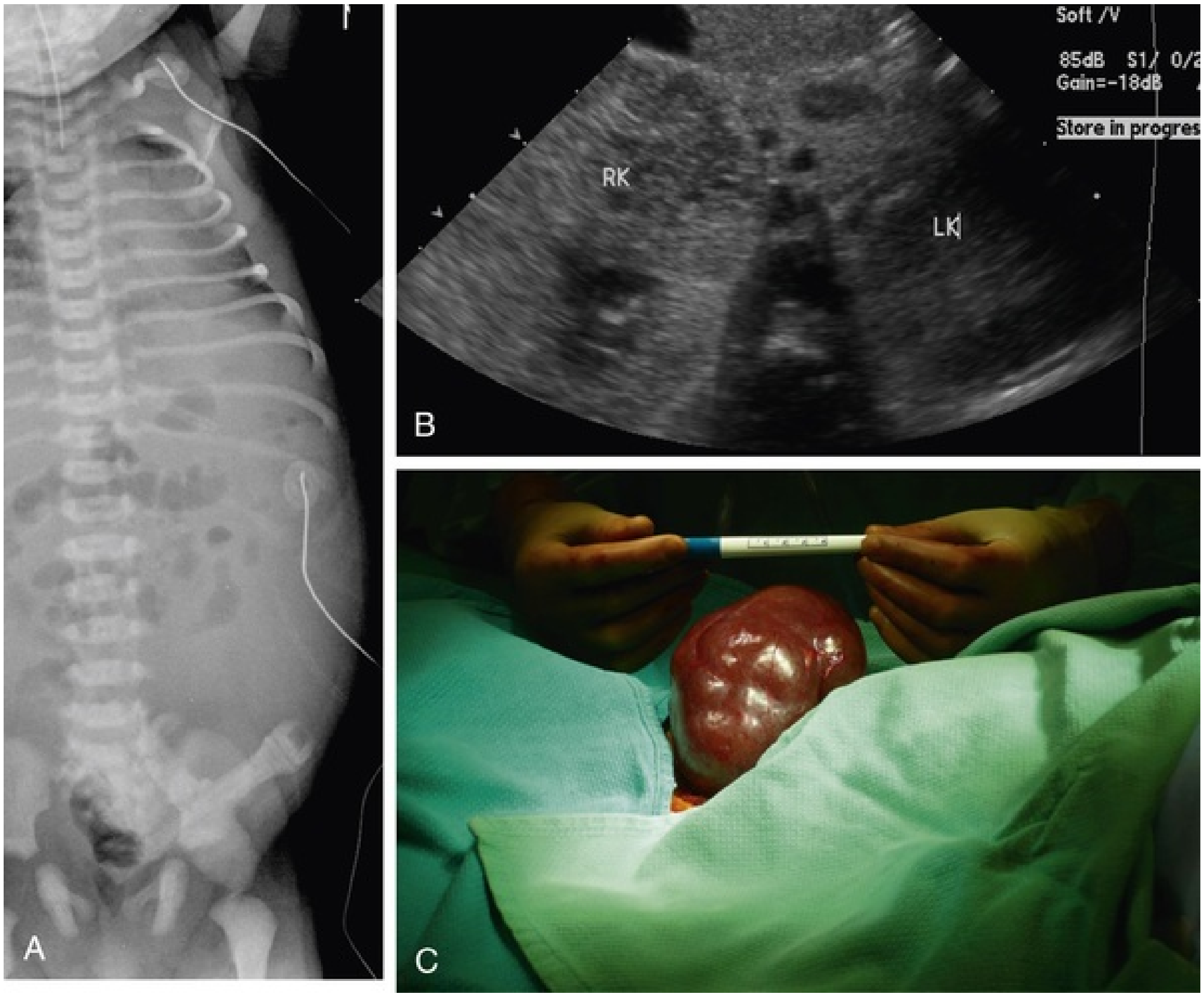

EFIG. 51.6 (A) Abdominal radiograph of a neonate with autosomal recessive polycystic kidney disease (note gas distribution and displacement of diaphragm). (B) Ultrasound showing right and left kidney (*RK* and *LK*), touching in the midline. (C) Intraoperative picture at time of nephrectomy. Note the large size of native kidney.

In a child in whom native nephrectomy is to be performed, the main factor to choose the best approach is whether the patient is on peritoneal dialysis (PD). If so, entering the peritoneal cavity (either open or laparoscopically) requires temporary hemodialysis. Moreover, open surgical procedures may trigger adhesions and scarring of the peritoneal membrane, thus making subsequent PD ineffective. Some advocate for attempts at immediate or early PD after transperitoneal surgery, but the risk of leakage and possible infection would argue against this practice. Conversely, retroperitoneal nephrectomy can be performed with immediate PD (eFig. 51.7; Gundeti et al., 2007), but leaks may still be encountered if the peritoneum is disrupted (eFig. 51.8). When bilateral nephrectomies are performed on the same setting, the prone approach offers some advantages, such as the ability to perform both procedures without repositioning (eFig. 51.9). If the kidneys are relatively small, this is the optimal approach. For children on PD with large kidneys, a posterior open nephrectomy or laparoscopic nephrectomy with morcellation are suitable options.

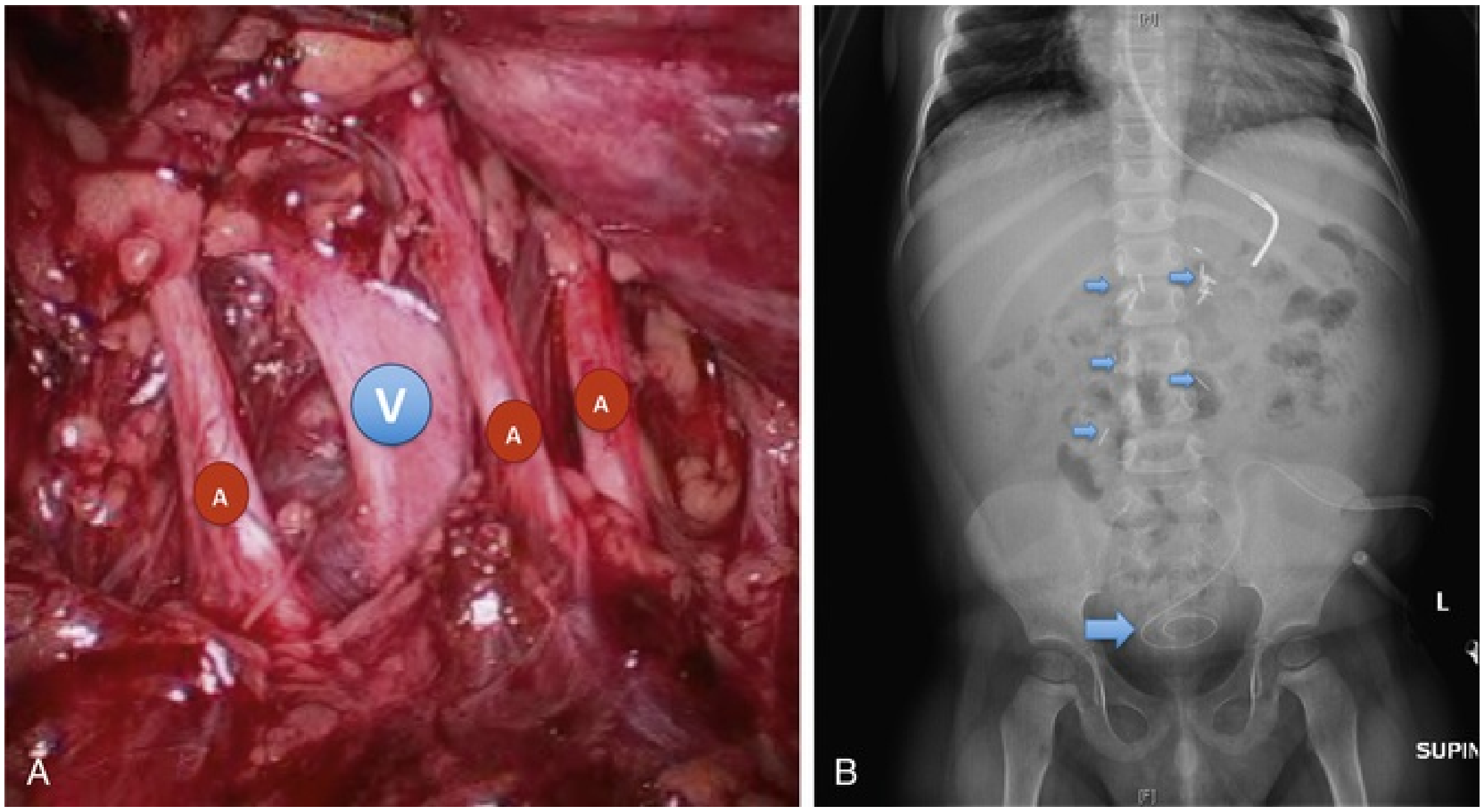

EFIG. 51.7 Exposure of renal hilum during laparoscopic retroperitoneal nephrectomy in a child on peritoneal dialysis. (A) Note the accurate identification of renal vein *(V)* and multiple renal arteries *(A).* (B) On postoperative abdominal radiograph, metal clips can be seen on the area of hilar dissection *(small arrows),* and the functioning peritoneal dialysis catheter tip coiled in the expected position *(large arrow).*

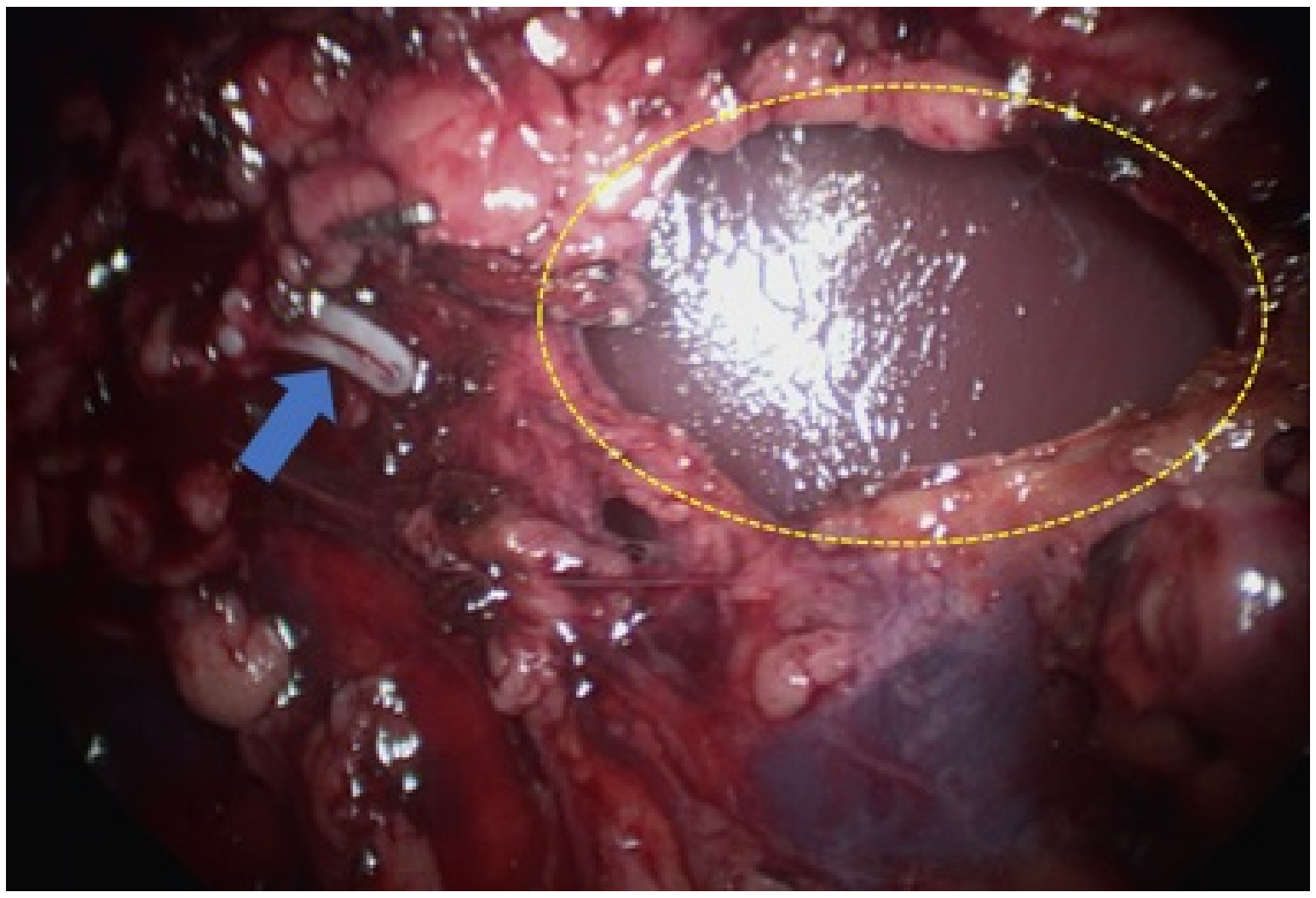

EFIG. 51.8 Peritoneal disruption during dissection of hilum during laparoscopic retroperitoneal dissection. Note clip securing the hilum *(arrow).*

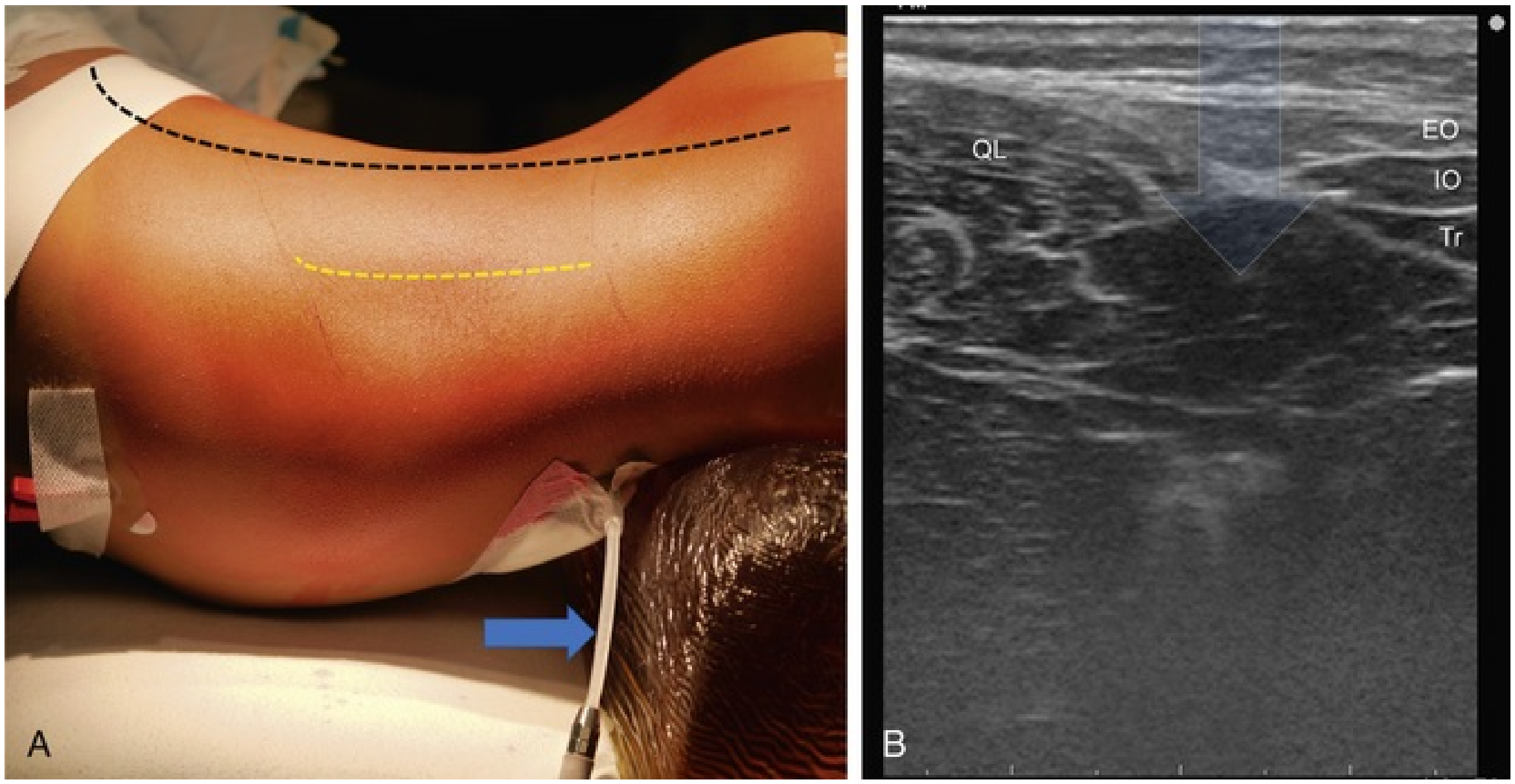

EFIG. 51.9 (A) Positioning for prone laparoscopic retroperitoneal nephrectomy. Note the placement of bolsters under the chest and pelvis creating gentle curvature *(black line)* to gain space when developing retroperitoneal space. Also, peritoneal dialysis catheter *(arrow)* is placed to gravity to check for intraperitoneal gas leaks or bleeding. The entry point can be estimated based on anatomic landmarks *(yellow line).* (B) Alternatively, intraoperative ultrasound may help define the most optimal point for entry, medial to the abdominal wall muscles (external oblique *[EO],* internal oblique *[IO],* and transversus *[Tr]*), and lateral to quadratus lumborum *(QL).*

If PD is not being performed, then any type of nephrectomy is acceptable. With laparoscopy the incidence of postoperative adhesions is limited and is unlikely to affect the future efficacy of PD. The ureter should be preserved and transected as high as possible. There is the potential impact on the ultimate transplant procedure when the distal ureter is removed, thus causing adhesions in the area of the iliac vessels. Furthermore, the native ureter may be used as a target for allograft anastomosis (Penna et al., 2017). However, if there is significant reflux or obstruction and a dilated ureter, total removal may be best to limit the risk of infection. In selected cases with high risk for complications with open or laparoscopic nephrectomy, renal embolization may be attempted as a reasonable alternative (Capozza et al., 2007).

Managing Patients With Native Kidneys

Avoiding Removal

In the absence of specific indications for nephrectomy, leaving the native kidneys in place offers the advantage of having a potential source of water excretion if the graft fails. In addition, there may be benefit in preserving the native kidneys for erythropoietin production and vitamin D metabolism, as well as avoiding the potential complications of a nephrectomy. Although this can be helpful in managing nutrition and lifestyle, it should not become a rigid goal if there are reasons to remove the kidneys. Their ultimate utility may be very limited, particularly after a period of graft function, because they often regress in size and urine output. Most allograft can be easily transplanted without removing the native kidneys, particularly if these are small or atrophic (eFig. 51.10).

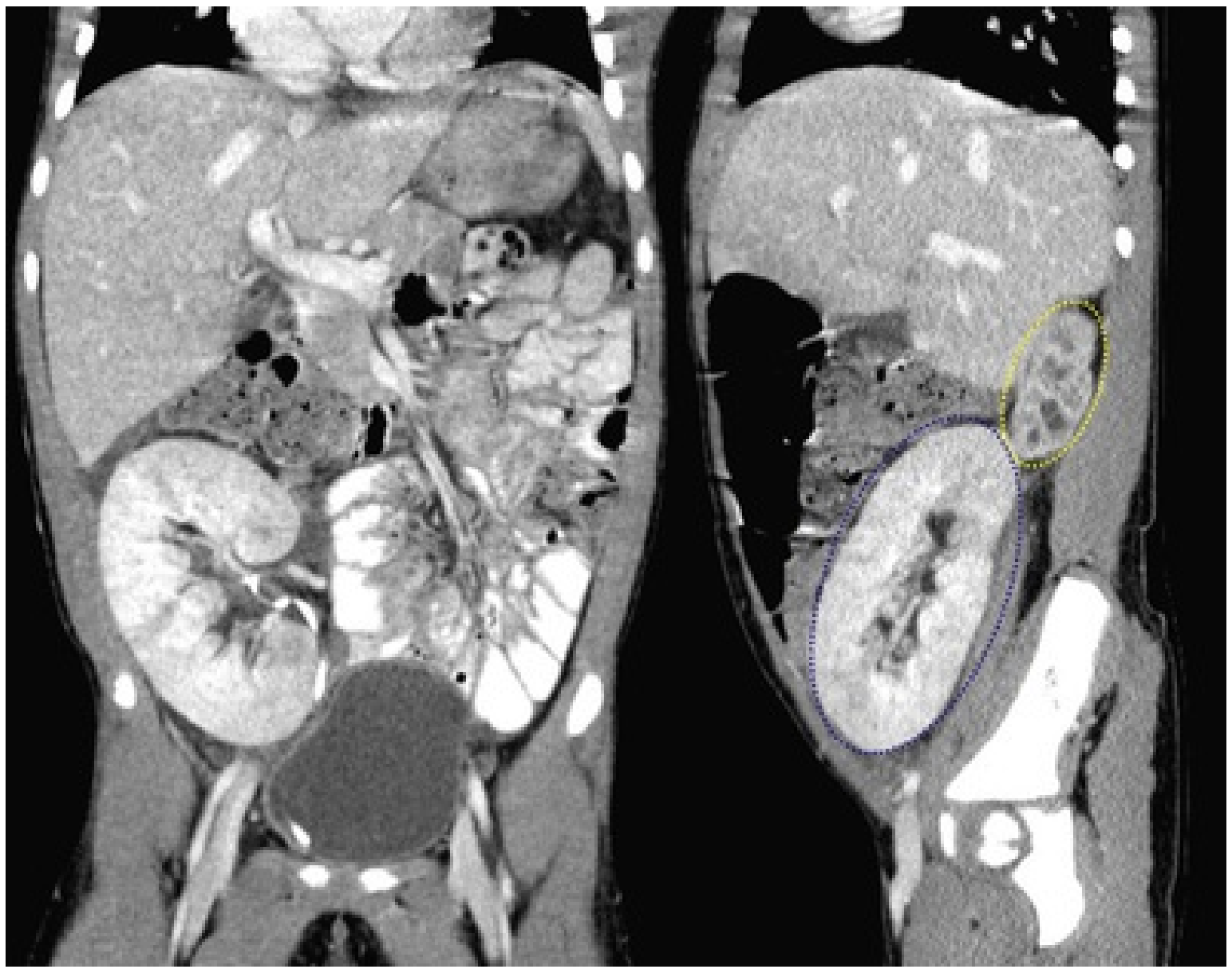

EFIG. 51.10 CT scan of patient with renal transplant on right side and native kidneys in place. Allograft encircled in blue, native kidney encircled in yellow.

Limit Risk of Infection

Urinary infection in the setting of an immunosuppressed host with a renal transplant is damaging to the child and the graft. Preventing infection in patients with known urologic issues is therefore a priority that should be acted upon proactively, rather than purely in response to an infection. The additive damage and morbidity may be critical in the long-term outcome of that child. Situations in which active prevention of infection may be useful include high-grade reflux, persisting hydronephrosis (Chu et al., 2013) with or without reflux, and children who depend on intermittent catheterization. These patients are frequently colonized with bacteria and may be more susceptible to UTI. The nondilated, nonrefluxing native kidney is unlikely to be subject to infection and can generally be maintained in the absence of other indications for removal. It is reasonable to discuss with families the protective value of circumcision in boys at risk for ESRD and consider the procedure early on (before transplantation) (Mukherjee et al., 2009; Singh-Grewal et al., 2005).

Ureteral Preservation

When nephrectomy is to be performed, ureteral preservation should be considered. If the ureter is normal, it should always be left to limit surgical dissection near the iliac vessels and to have an option for primary or salvage uretero-ureterostomy for distal ureteral stenosis (eFig. 51.11; Kockelbergh et al., 1993; Lapointe et al., 2001; Penna et al., 2017). If bladder function is abnormal and intermittent catheterization may be needed, preserving the ureter for use as a continent stoma is also advisable. This is best performed pretransplant; however, creation of the continent stoma at the time of transplant remains an option.

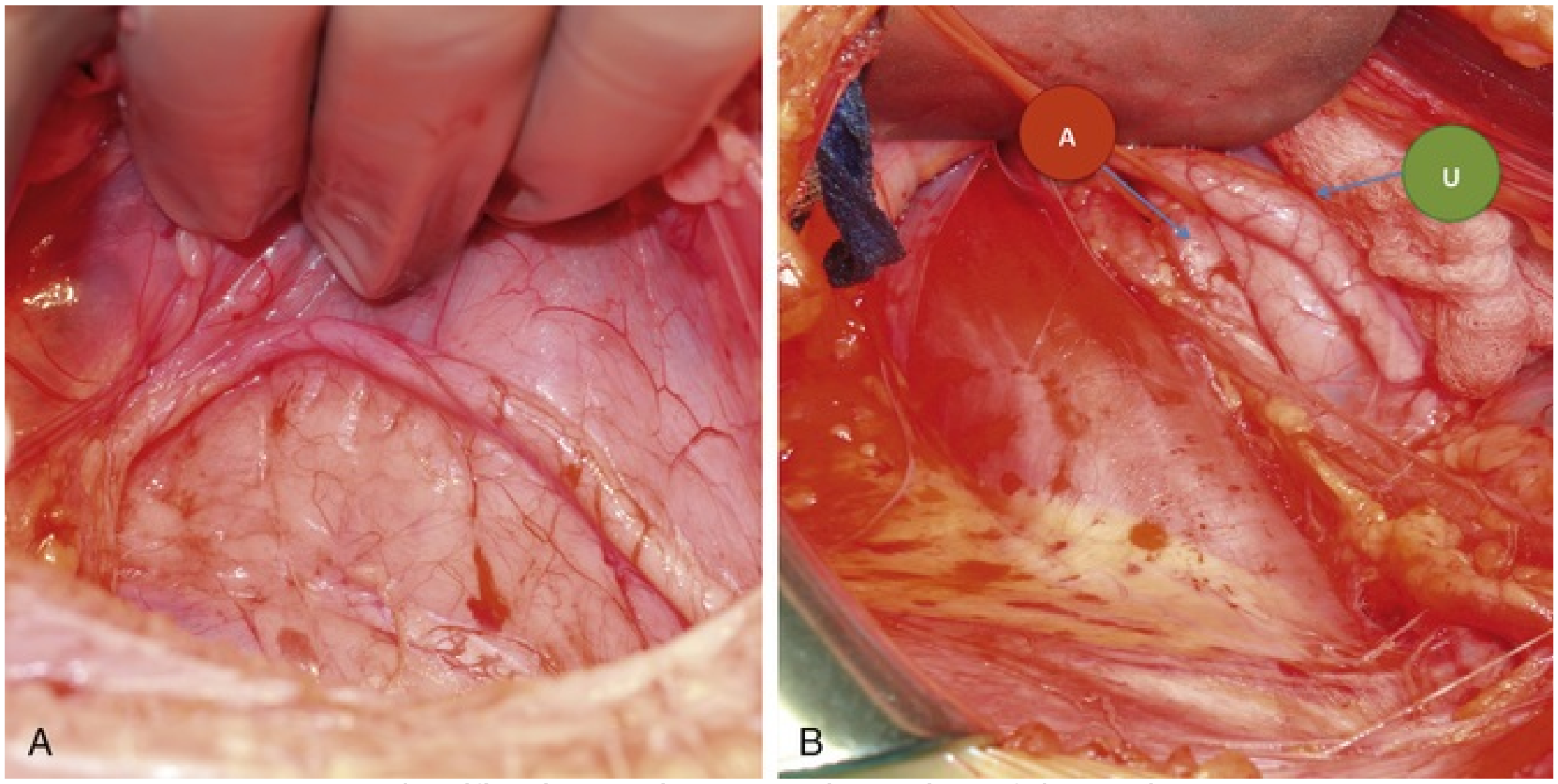

EFIG. 51.11 Identification and expected location of the native ureter during exposure for retroperitoneal placement of renal allograft. The native ureter is often encountered during medial dissection of the peritoneum (A); and the ureter *(U)* can be seen crossing on over the iliac vessels *(A)* when dissection proceeds toward the pelvis (B). This is a common location for performing a uretero-ureterostomy.

Combining Nephrectomy and Transplant

Native kidneys may be removed at the time of the renal transplantation, but this is generally avoided to limit surgical morbidity and time under anesthesia. It may be appropriate for a single ipsilateral native kidney, which may be swiftly removed through the transplant incision. In the absence of specific justification, however, this strategy is best avoided.

Key Points: Pretransplant Reconstruction

- The ability to empty spontaneously will also affect the decision regarding the need for a continent catheterizable stoma.
- Indications for augmentation before transplantation include the following:
  - Capacity less than 75% of expected for age
  - Pressures above 30 cm H_2O
  - Catheterization every 3 hours
  - Maximal anticholinergic medications
- For patients on peritoneal dialysis, intraperitoneal surgery will likely require temporary transition to hemodialysis.
- In general, any major urologic reconstruction should be undertaken well before anticipated transplantation.
- Native nephrectomy is indicated for:
  - Malignant hypertension
  - Profound nephrotic syndrome with malnutrition resulting from protein loss
  - High risk for malignancy
  - Recurrent upper tract infections
  - Massive reflux

Transplantation

The technical elements of the vascular component of renal transplantation are described in Chapter 88, and the principles remain appropriate to children.

Although pediatric urologists have different levels of involvement in this aspect of care, it is important to understand some situations that may have implications with urologic management. These include the implications of transplantation of infants or patients with prothrombotic states, which usually demands the use of anticoagulation. This has important implications in terms of bleeding risk and need for careful hemostasis during bladder surgery. Also, vascular targets are critical, and location may be driven by availability of adequate sites for arterial and venous anastomosis rather than convenience for urinary tract reconstruction (eFig. 51.12). The urologist must adapt and be able to address limits imposed by the length of the donor kidney, which may have to be addressed with creative use of the native ureter or bladder flaps. Examples include transplantation in an orthotopic location (eFig. 51.13) or an "upside down" allograft resulting from a more favorable position of the artery and vein (eFig. 51.14). Meticulous vascular dissection is imperative to avoid vessel damage, vasospasm (eFig. 51.15), or subsequent thrombosis, as well as careful ligation of lymphatics to prevent lymphoceles (eFig. 51.16). In addition, particular attention should be paid in cases with multiple renal arteries. Damage to an arterial branch creates a permanent area of ischemia (with subsequent scar and loss of parenchyma). Lack of perfusion to the lower pole heralds the additional risk of ureteral ischemia (eFig. 51.17). Thus great efforts should be expended to vascular reconstruction of lower pole vessels, even if small in caliber (eFig. 51.18).

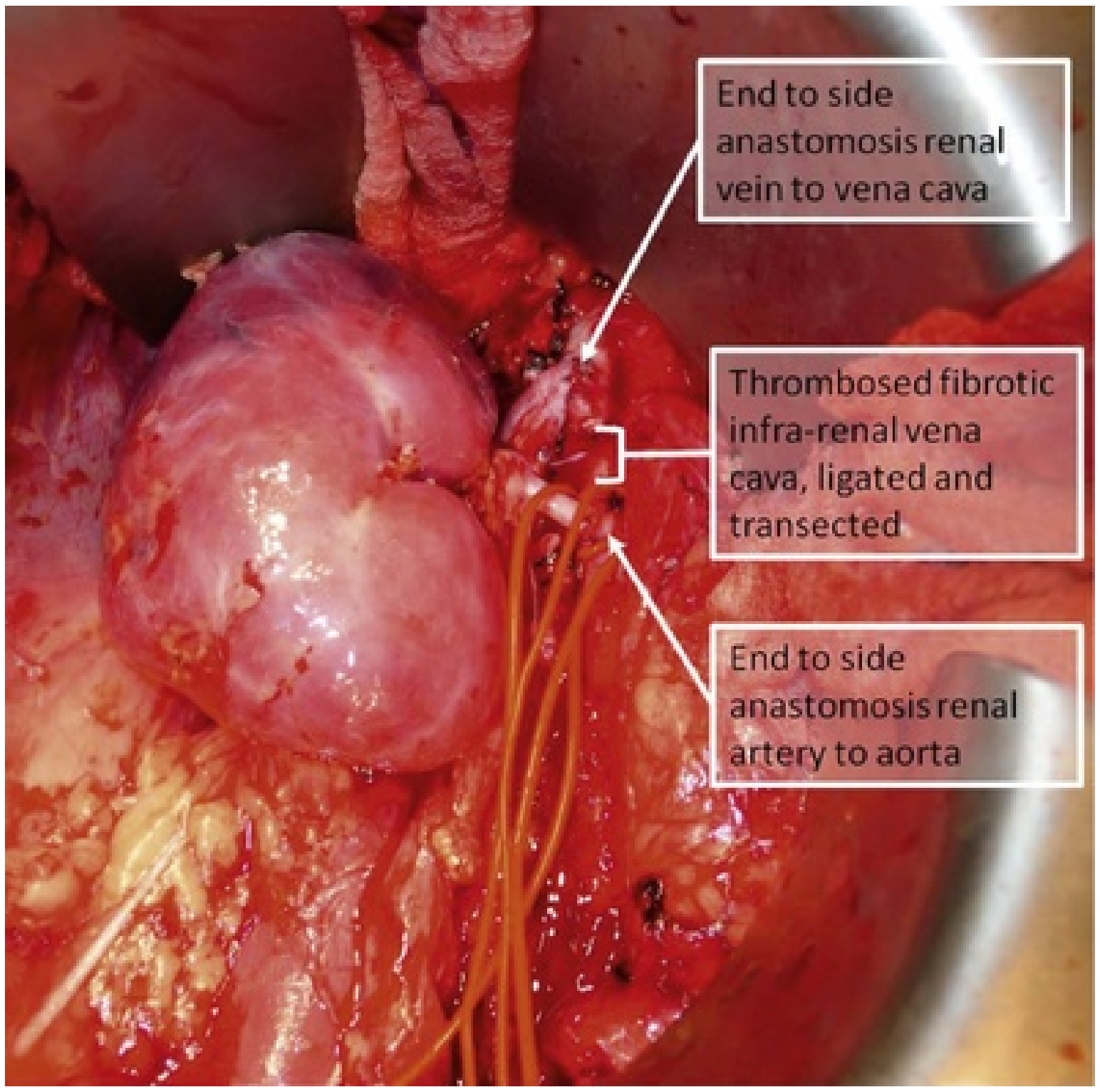
End to side anastomosis renal vein to vena cava
Thrombosed fibrotic infra-renal vena cava, ligated and transected
End to side anastomosis renal artery to aorta

EFIG. 51.12 Renal transplantation with venous anastomosis between donor and recipient renal vein to address prior infrarenal vein thrombosis. Note placement of allograft in an anatomic location, which demands appropriate strategies to reconstruct the lower urinary tract (i.e., reimplantation of a long donor ureter, ureteroureterostomy, or reimplantation on a bladder wall flap).

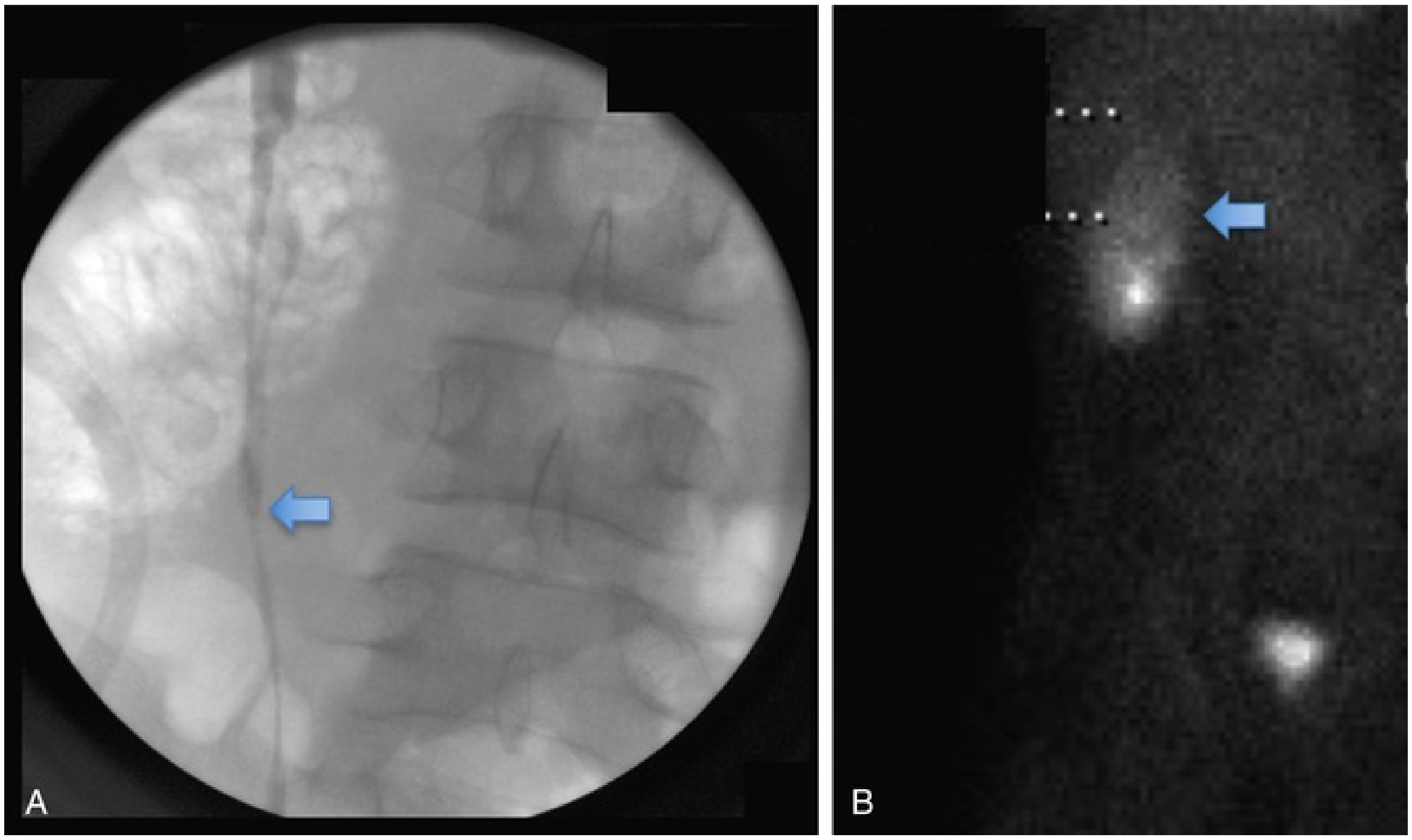

EFIG. 51.13 Orthotopic renal transplantation in a child with abnormal infrarenal vasculature. (A) Note use of the native ureter for reconstruction (retrograde pyelogram at time of stent removal), with end-to-side uretero-ureterostomy between the donor ureter and the proximal native ureter, near the renal pelvis. (B) Drainage confirmed on postoperative renal scan.

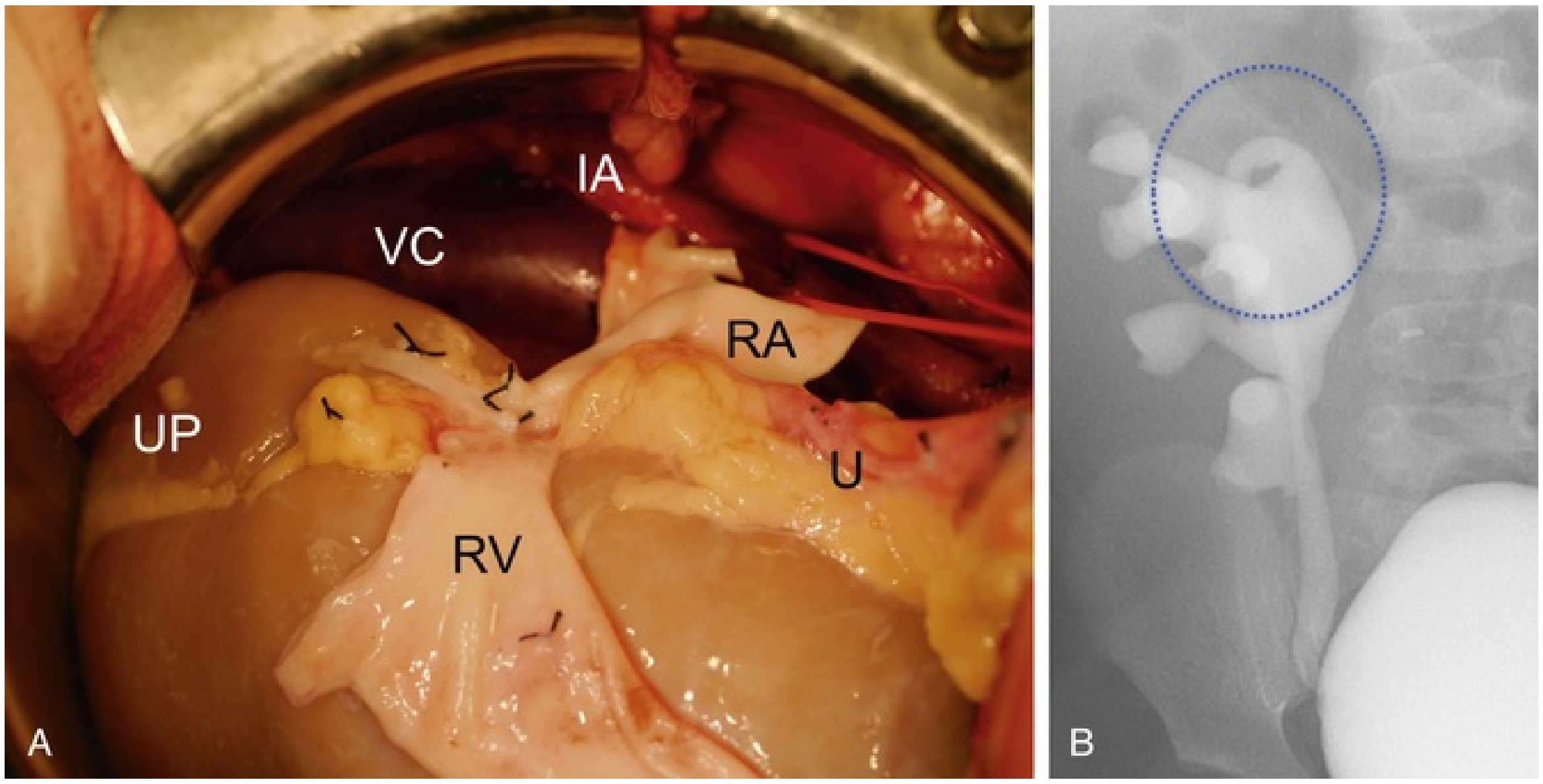

EFIG. 51.14 Retroperitoneal placement of right allograft in right flank and fossa. (A) Allograft in orthotopic orientation, with cephalad location of the upper pole *(UP)* and expected position of the donor ureter *(U).* The

anatomic configuration of the renal artery *(RA)* and renal vein *(RV)* precludes anastomosis to the vena cava *(VC)* and iliac artery *(IA)* without twisting or crisscrossing the vessels. By repositioning the allograft in an “upside-down” fashion, the anastomosis is successfully performed. (B) Postoperative voiding cystourethrogram showing reflux with the location of the ureteropelvic junction towards the upper pole. The kidney showed minimal hydronephrosis and adequate draining on postvoid images.

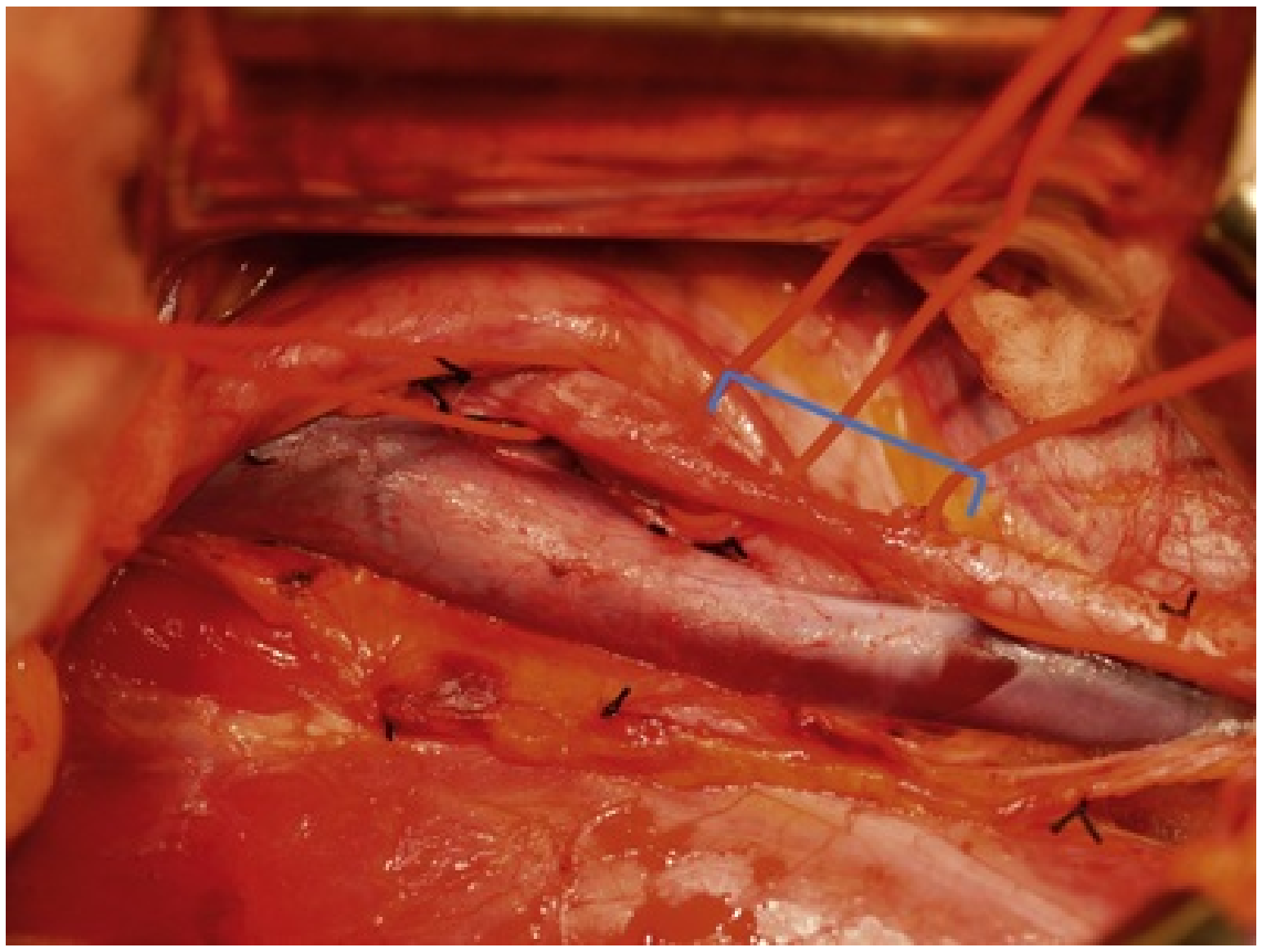

EFIG. 51.15 Spasm of the external iliac artery during mobilization *(bracket).* Without correction, anastomosis at this site may lead to poor perfusion and thrombosis of the allograft and/or lower extremity ischemia.

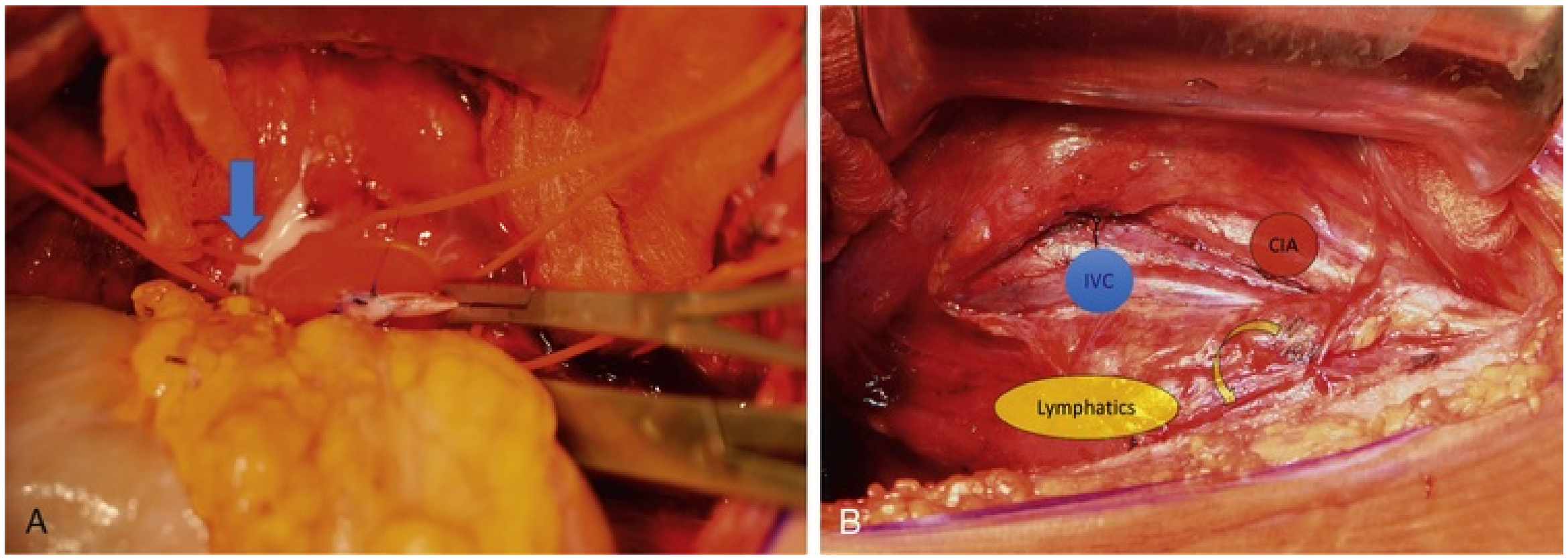

EFIG. 51.16 (A) Intra-operative evidence of lymphatic leak *(arrow)* noted during vascular anastomosis. (B) Careful dissection and ligation of lymphatics is critical to minimize this situation and avoid postoperative

lymphoceles. When prominent lymphatic channels and nodes are encountered, these may be reflected and tacked to the psoas muscle rather than dividing *(curved arrow).*

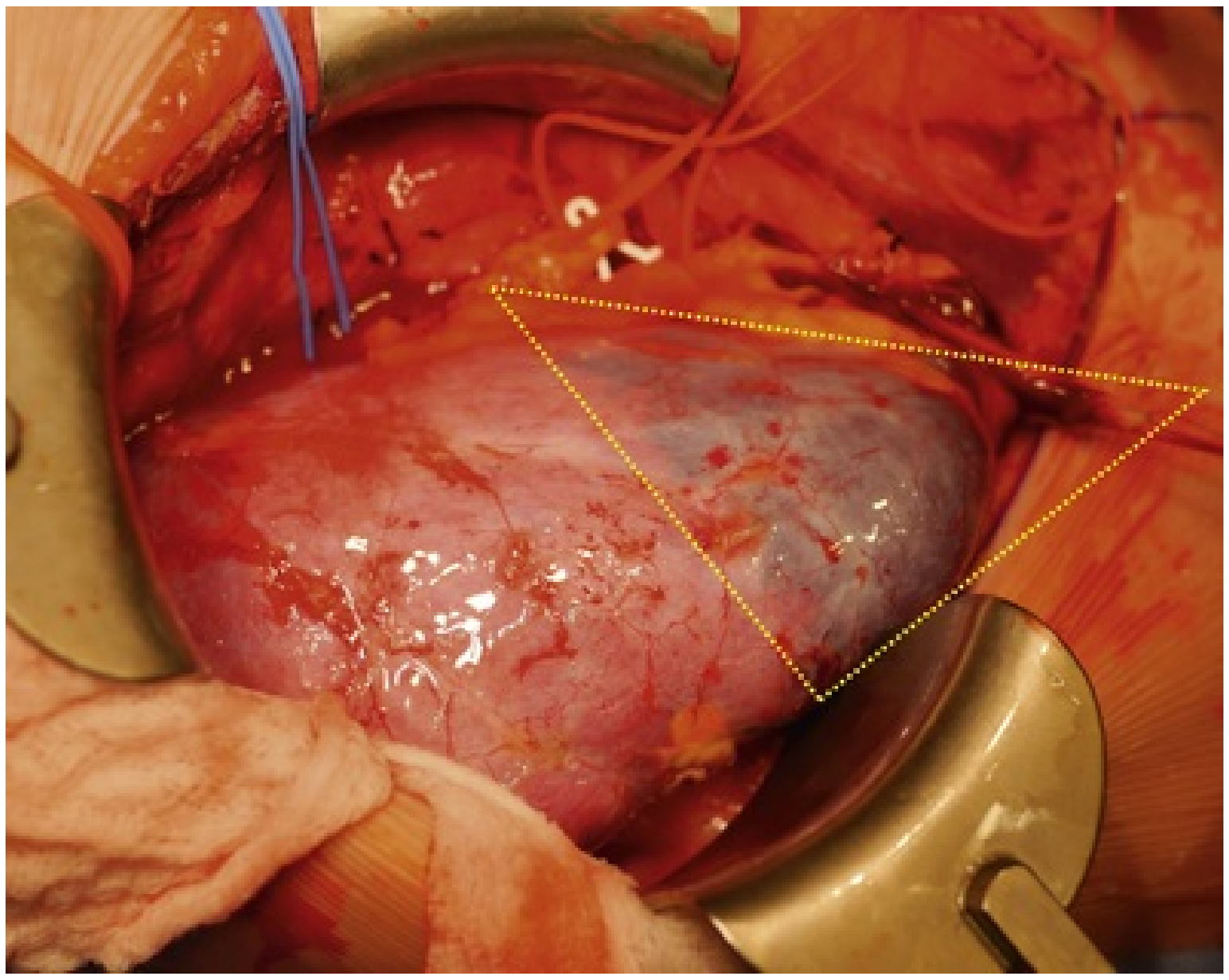

EFIG. 51.17 Lower pole ischemia after allograft reperfusion, likely resulting from damage to lower pole branch. This, along with extensive dissection in the area of the “golden triangle” (confined by ureter, kidney, and renal artery), increases the risk of ischemic ureteral complications, such as urine leak and strictures.

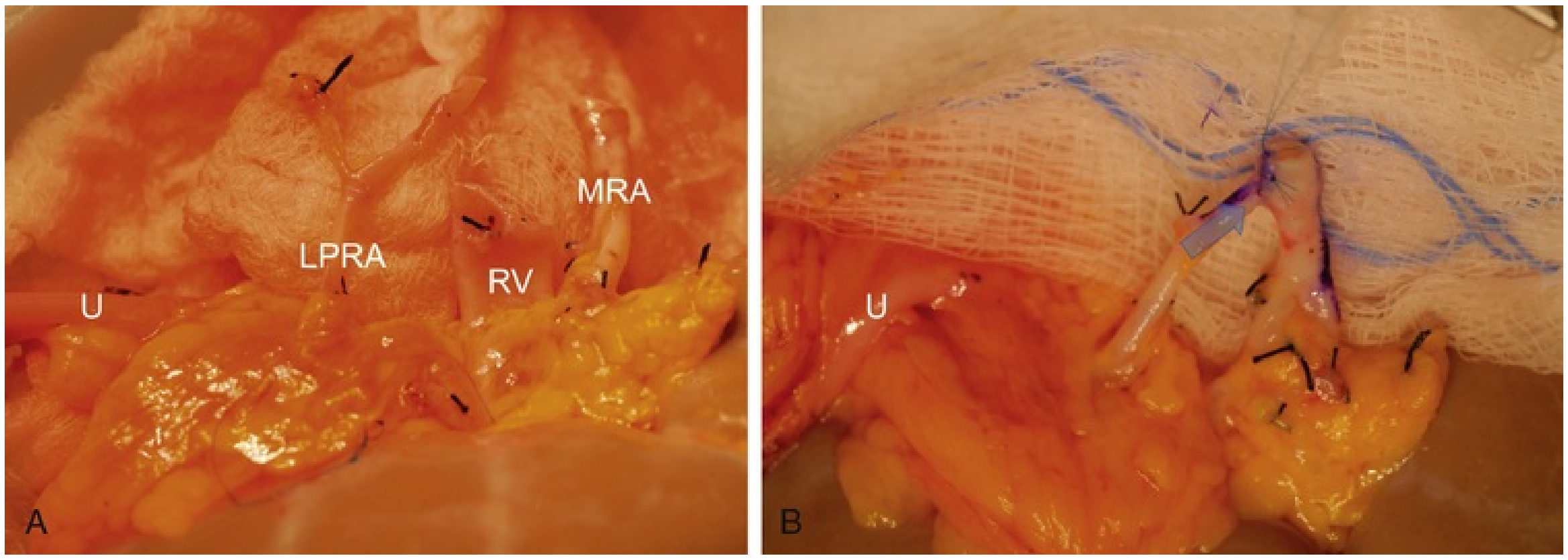

EFIG. 51.18 (A) Bench dissection of living-related renal allograft, with known lower pole renal artery *(LPRA)* noted during exposure of the main renal artery *(MRA),* renal vein *(RV)* and ureter *(U).* (B) Lower pole artery anastomosed to main renal artery *(arrow)* before transfer to surgical field

for revascularization.

For the pediatric urologist who is not involved in performing the vascular anastomosis, the lower urinary tract reconstruction becomes the focus of intraoperative attention, as well as of urologic complications.

Ureteral Anastomosis

Surgical Techniques and Options

As with ureteroneocystostomy for VUR, there are intravesical and extravesical techniques for the transplant ureteral anastomosis. We favor a nonrefluxing anastomosis in most cases in which reimplantation into the bladder is planned, although clearly this is not always essential. Careful screening can identify patients with bladder dysfunction and therefore at risk for graft reflux; however, this method to prevent reflux is simple, effective, and with minimal morbidity.

Extravesical ureteroneocystostomy is the preferred ureteral bladder anastomosis. After graft perfusion and hemostasis, the bladder is partially filled with saline or a dilute antibiotic solution. The anterolateral aspect is cleared and traction sutures are placed to mobilize the lateral aspect upward and to provide tension on the vesical wall. The ureter is sized to ensure it will reach. The detrusor is incised to the level of the mucosa for a length of about 3 to 3.5 cm in an anatomic direction, avoiding kinks in the donor ureter. Flaps of detrusor are elevated away from the mucosa, and a small disc of mucosa is excised at the distal aspect of the trough. The bladder drains, and the traction sutures keep the trough in position. The ureter is trimmed loosely to length and spatulated for 4 to 5 mm. An interrupted mucosa-to-mucosa anastomosis is performed using a fine absorbable suture. A monofilament is preferred. The detrusor flaps are then brought over the ureter. No advancement stitch is used, but two stitches are placed through the detrusor and the adventitia of the terminal ureter to prevent eversion. The detrusor is closed with interrupted absorbable sutures, mindful of not tightening too much the entry point of the ureter (eFig. 51.19). Alternatively, the widely known Barry technique (Barry, 1983; Barry and Hatch, 1985) may be used, whereby a 4-cm tunnel is created between parallel incisions through which the ureter is passed. A shorter tunnel has been used in some pediatric centers with acceptable outcomes (Vasdev et al., 2011).

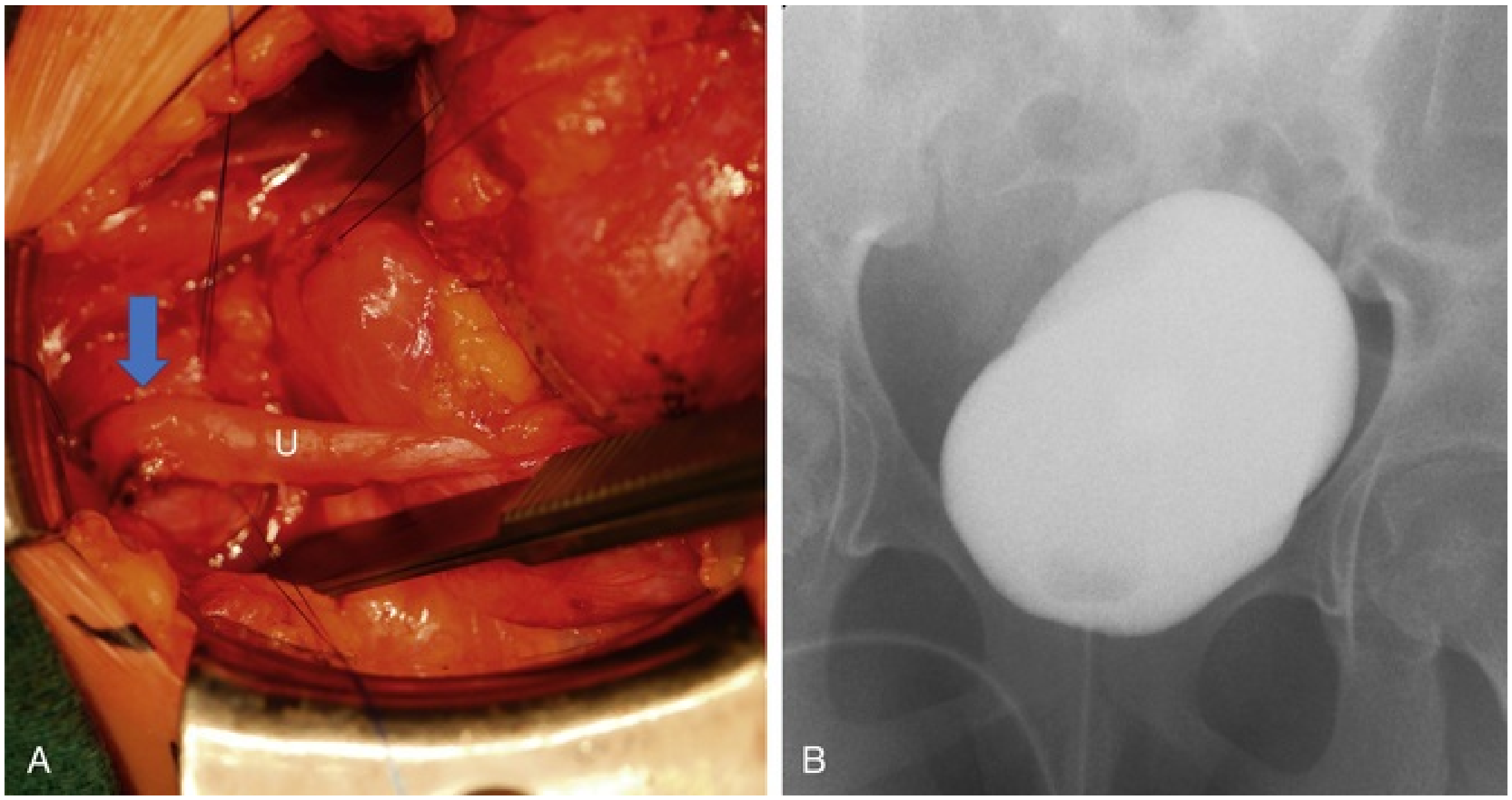

EFIG. 51.19 (A) Donor ureter nonrefluxing reimplantation, with anastomosis to bladder and approximation of detrusor flaps over the ureter *(arrow).* (B) Postoperative cystogram demonstrating absence of vesicoureteral reflux.

If the bladder wall is particularly abnormal and thick, a longer tunnel is developed and the flaps are dissected back a bit further to provide a more robust antireflux tunnel and limit the risk of obstruction, because these are typically abnormally functioning bladders. Implanting the graft ureter into an augmented bladder poses additional challenges and it is preferred to perform the ureteroneocystostomy into the detrusor. On occasion this demands an intravesical approach through the augment to reach the detrusor, which may be impossible to mobilize effectively otherwise. If there is no detrusor available, anastomosis into the bowel segment is reasonable and technically easier than into a colonic or gastric segment. It is advisable to perform a nonrefluxing ureteroneocystostomy in these settings because these patients are inevitably on intermittent catheterization and often colonized with bacteria.

Transplant to the native ureter (uretero-ureterostomy) is routinely performed in some centers with good results (Gurkan et al., 2006; Lapointe et al., 2001; Penna et al., 2017). The procedure can be performed in an end-to-side or end-to-end fashion, based on surgeon preference and the presence of a native kidney. When the native kidney is in place, some advocate ligation of the proximal ureteral segment without major complications and a low rate of subsequent nephrectomies (Timsit, et al., 2010; Torino et al., 2016). It remains unclear if this option is superior to ureteroneocystostomy but is appealing in cases with a normal, nonrefluxing native ureter, a small bladder, or a short donor ureter or when pelvic dissection is difficult because of previous surgery. Moreover, this option is available as a salvage procedure in the setting of post-transplant ureteral stenosis.

Ureteral Stenting

The role of routine ureteral stenting in pediatric transplant is highly debated, with lack of conclusive data to demonstrate its routine utility (Dharnidharka et al., 2008; French et al., 2001; Simpson et al., 2006). There are situations in which ureteral stenting is appropriate, including a difficult implant (particularly in an abnormal bladder) or when the graft ureter appears traumatized or devascularized. In adult series, stenting has been shown to be an advantage for cadaveric donors in terms of reducing the incidence of ureteral complications from 5.8% to 1.9% but at a higher risk of infection (Fayek et al., 2012). If a stent is to be used, a short double-J ureteral stent is placed and generally removed in 4 to 6 weeks, although some advocate early removal (5 days post-transplant) by securing the stent to the tip of the urethral catheter or employing an externalized stent or splint (Ter Haar et al., 2017). This strategy may decrease stent-related complication and infections (Patel et al., 2017). Removal of an internal stent requires cystoscopy and can be coordinated with other procedures, such as removal of a tunneled intravenous access or renal biopsy.

Key Points: Transplant Ureteroneocystostomy

- Extravesical ureteroneocystostomy is the preferred ureteral anastomosis.
- Transplant to native uretero-ureterostomy is an effective option.
- There are no data to support routine ureteral stenting at the time of transplantation.

Complications

The urologic complications of pediatric renal transplantation are discussed in this section. Those related to the graft directly, including vascular and rejection issues, are dealt with in Chapter 88. Table 51.1 presents a summary of selected recent reports of urologic complications in pediatric renal transplantation. The unique analysis of Khositseth et al., comparing the incidence of urologic complications in transplant recipients having a history of obstructive uropathy or reflux to those without that history, shows the increased risk of all urologic complications in patients with pre-existing uropathy (Khositseth et al., 2007). Posterior urethral valves have been associated with an increased risk of graft dysfunction in some series (Adams et al., 2004; Luke et al., 2003), yet not in others (Fine et al., 2011; Kamal et al., 2011; Nuininga et al., 2001). In nearly all series, however, obstructive uropathy is associated with a higher risk of urologic complications. Special vigilance and a lower threshold for intervention are appropriate in this population.

TABLE 51.1

Incidence of Complications After Pediatric Renal Transplantation

AUTHOR	YEAR	PATIENTS	URETERAL STENOSIS	URINARY LEAK	VUR	STONE	
Rossi (Rossi et al., 2016)	2016	117	5	3	1		Complic more co in patier with uro conditio
Almeida (Almeida et al., 2013)	2013	134	5	3			100% cadaveri
Routh (Routh et al., 2012)	2012	71	6		17		Underly GU path
		140	10		6		No GU patholog
Irtan (Irtan et al., 2010)	2010	193	10	6	25		Greater incidenc with PU

El Atat (El Atat et al., 2010)	2010	50		2	5		70% LR 13% uro complic
Ruiz (Ruiz et al., 2006)	2006	23	0	0	0	0	Patients between 10 years
El-Husseini (El-Husseini et al., 2008)	2008	292	13	12			Under 2 years: 1 urologic complic
Englesbe (Englesbe et al., 2008)	2008	147	5	4	7	0	
Khositseth (Khositseth et al., 2007)	2007	117	26	2	10	11	H/o obstruct VUR
		117	11	2	1	2	No obstruct VUR
LaPointe (LaPointe et al., 2001)	2001	166	3	7	1	1	Uretero-ureteros
Nuininga (Nuininga et al., 2001)	2001	183	7	8	0	5	183 transplan 146 pati
Shokeir (Shokeir et al., 2005)	2005	250	11	10	0	1	All livin related
Tanabe (Tanabe et al., 1998)	1998	107	2	1	1	0	
Summary		**2107**	**106 (5.0%)**	**68 (3.2%)**	**74 (3.5%)**	**20 (1.0%)**	

GU, Genitourinary; *h/o,* history of; *LRD,* living related donor; *PUV,* posterior urethral valve; *VUR,* vesicoureteral reflux.

Urine Leaks

Urine leaks are typically identified in the early postoperative period with increasing fluid from the wound drains or a perinephric collection on ultrasound. The fluid's creatinine level can determine if this is a urine leak as opposed to lymph or peritoneal fluid (if a transperitoneal approach was employed or there a peritoneal opening occurred during the procedure). At first presentation, it is critical to assess all urinary drainage tubes, particularly the indwelling bladder catheter. If the catheter is in place, it is reasonable to irrigate it and check for patency. If it has been removed, it is often best to replace it. A transplant ultrasound is performed to determine if there is hydronephrosis, although its absence does not rule out obstruction. If hydronephrosis is present, distal ureteral obstruction should be suspected and consideration for a percutaneous nephrostomy should be entertained. If a stent was employed, adequate position should be documented. The level of the leak must then be determined, and either a MAG3 scan (assuming adequate graft function) or a cystogram may be useful. The latter can identify a bladder leak at the site of the anastomosis or a leak within the pyelocaliceal system if a stent is in place and reflux of contrast is achieved (Fig. 51.20). Although a CT scan can be effective, exposure to intravenous contrast may adversely affect renal recovery.

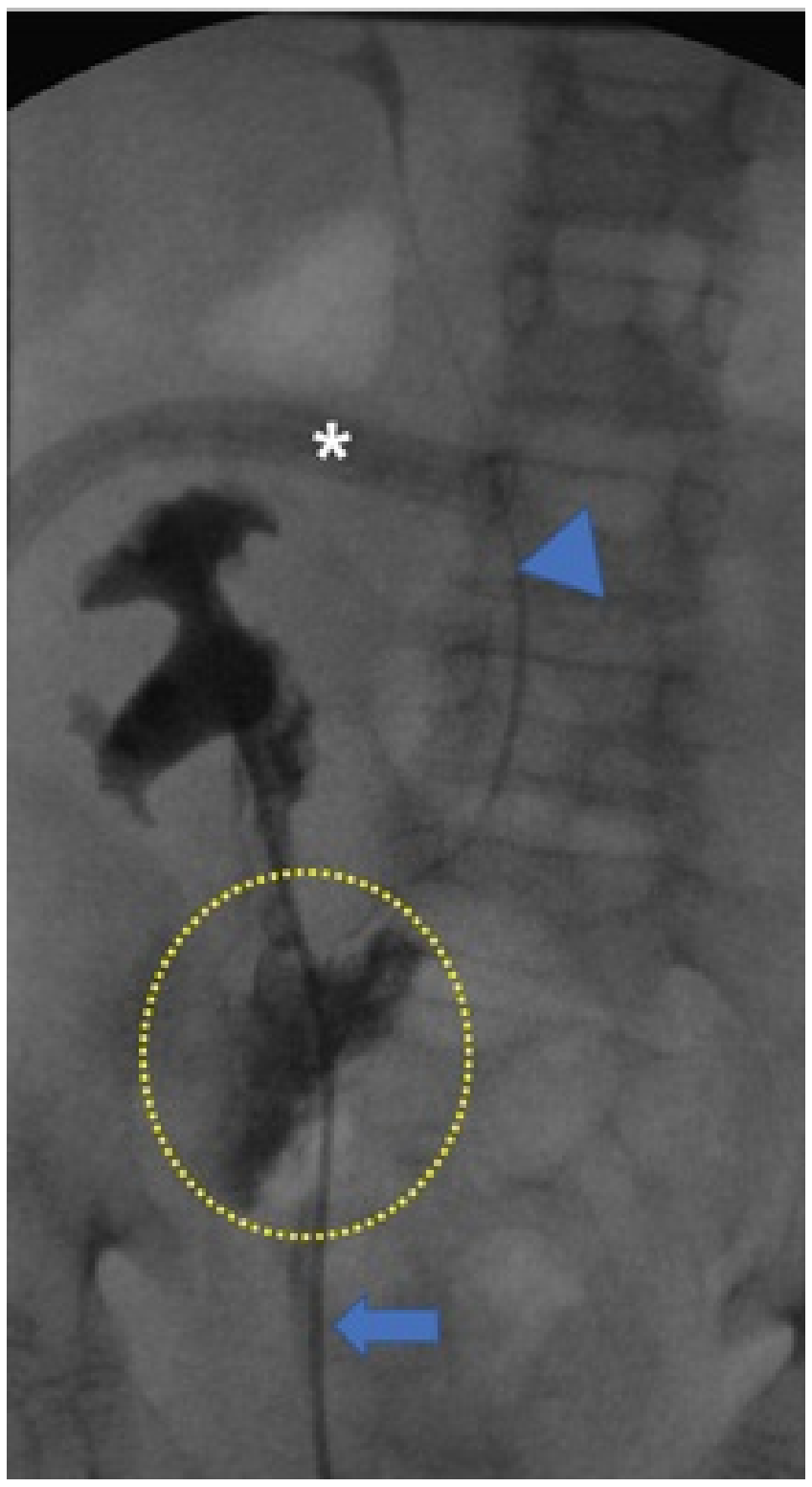

FIG. 51.20 Detection of leak at site of uretero-ureterostomy during cystogram with retrograde flow of contrast around a stent *(arrow).* Note reflux into native ureter *(arrowhead)* up to renal pelvis as well as presence of a drain (*). Leak initially detected by increase in drain output with fluid having a high creatinine concentration.

The indications for intervention are clinically based, and if the leak is limited, an observational approach is reasonable. We have seen leaks in the setting of very high post-transplant urine output in smaller children simply because of a small bladder catheter. If a larger catheter may be placed, this may facilitate resolution. If there is persistent worsening or a large urine leak despite adequate bladder drainage, percutaneous renal drainage and/or exploration may be needed.

The goal of exploration is to identify the cause, confirm the location of the leak, and provide for repair. If the leak is bladder based, revision of the anastomosis with closure of the defect and adequate drainage is effective. However, if the leak is due to distal ureteral necrosis, some means of ureteral replacement is needed. For a short segment of necrosis, bladder mobilization and reimplantation is effective. If a long segment of ureter has been lost, native ureter, either ipsilateral or even contralateral, may be useful (if available). A psoas hitch or bladder flap may be needed if the native ureter is not present.

These strategies are similar to those used for ureteral strictures. Careful stenting and drainage are essential (eFig. 51.21).

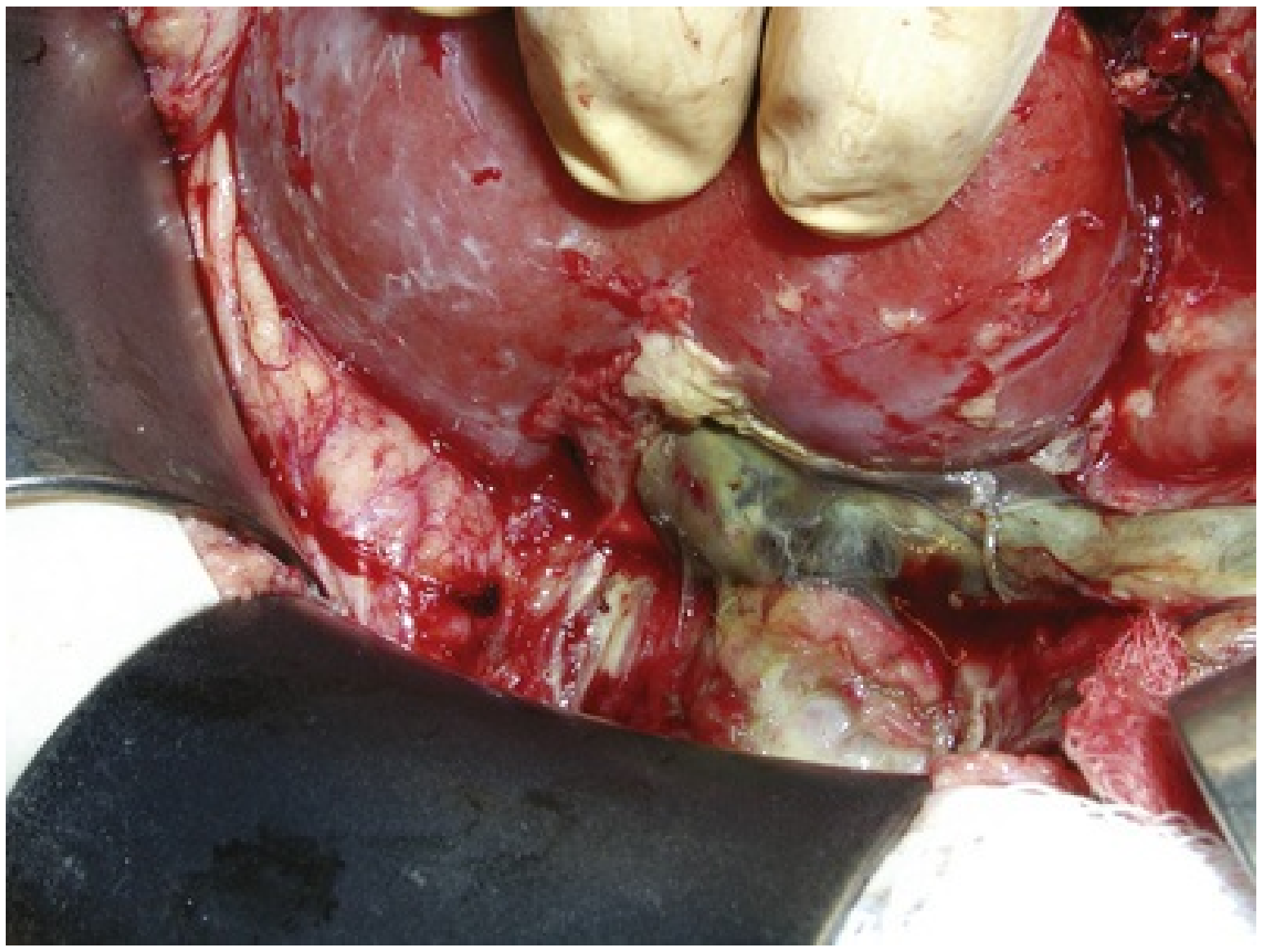

EFIG. 51.21 Ischemic loss of the entire renal pelvis and ureter in a cadaveric renal graft into a patient with a gastrocystoplasty. This presented with urine leak after a period of ATN. The graft was salvaged with an augment-bladder flap to the lower calyces of the graft.

Infection

Urinary infection is a long-term and often delayed complication that largely reflects the status of bladder function and underlying urologic causes of renal failure (Herthelius and Oborn 2007; Silva et al., 2010). The presence of hydronephrosis is often associated with pyelonephritis and worsening renal function (Chu et al., 2013). Routine assessment of bladder emptying, determining the presence of hydronephrosis, and selective use of a voiding cystourethrogram usually identify the underlying cause. If the patient is on CIC and no specific correctable cause is present, a strategy of prevention by way of prophylactic antibiotics and bladder irrigation may be effective. Aggressive management of bladder dysfunction, which should have been identified pretransplant, is essential to preserve graft function. If VUR is present into the graft and febrile infections with altered renal function are documented, surgical correction is warranted. Reflux in the absence of infection and with normal bladder function may be observed.

Reflux

Vesicoureteral reflux into the transplant kidney is entirely distinct from routine reflux into an otherwise normal renal unit based upon the fact that this is a reimplanted ureter, that the risk to renal function of an episode of pyelonephritis is greater in a transplanted kidney, and that the patient is immunosuppressed (Coulthard and Keir, 2006; DeFoor et al., 2003). Routine evaluation for reflux after renal transplant has been performed in some centers, even though not all cases require surgery. Identification of this potential risk factor is useful for clinical decision making and ongoing risk assessment. If febrile UTIs occur, a cystogram is clearly indicated as the presence of transplant reflux justifies surgical correction with an open ureteral reimplantation (Hanevold et al., 1987; Krishnan et al., 2006). The risk of subsequent episodes of allograft pyelonephritis is significant (Barrero et al., 2007; Neuhaus et al., 1997; Ranchin et al., 2000) and increases the potential for graft loss (Herthelius and Oborn, 2007; Fig. 51.22). Identification of simultaneous bladder dysfunction is equally important (Casale et al., 2005), although this may not always be correctable. In the setting of intermittent catheterization, a lower threshold for reflux correction should be exercised because these bladders will be chronically colonized. Reflux in the absence of infection and bladder dysfunction may be observed and attempts made to improve bladder and bowel function. There are no data to suggest that low-grade sterile VUR into a renal graft is harmful in children. Close observation for possible infection or deteriorating bladder function is warranted.

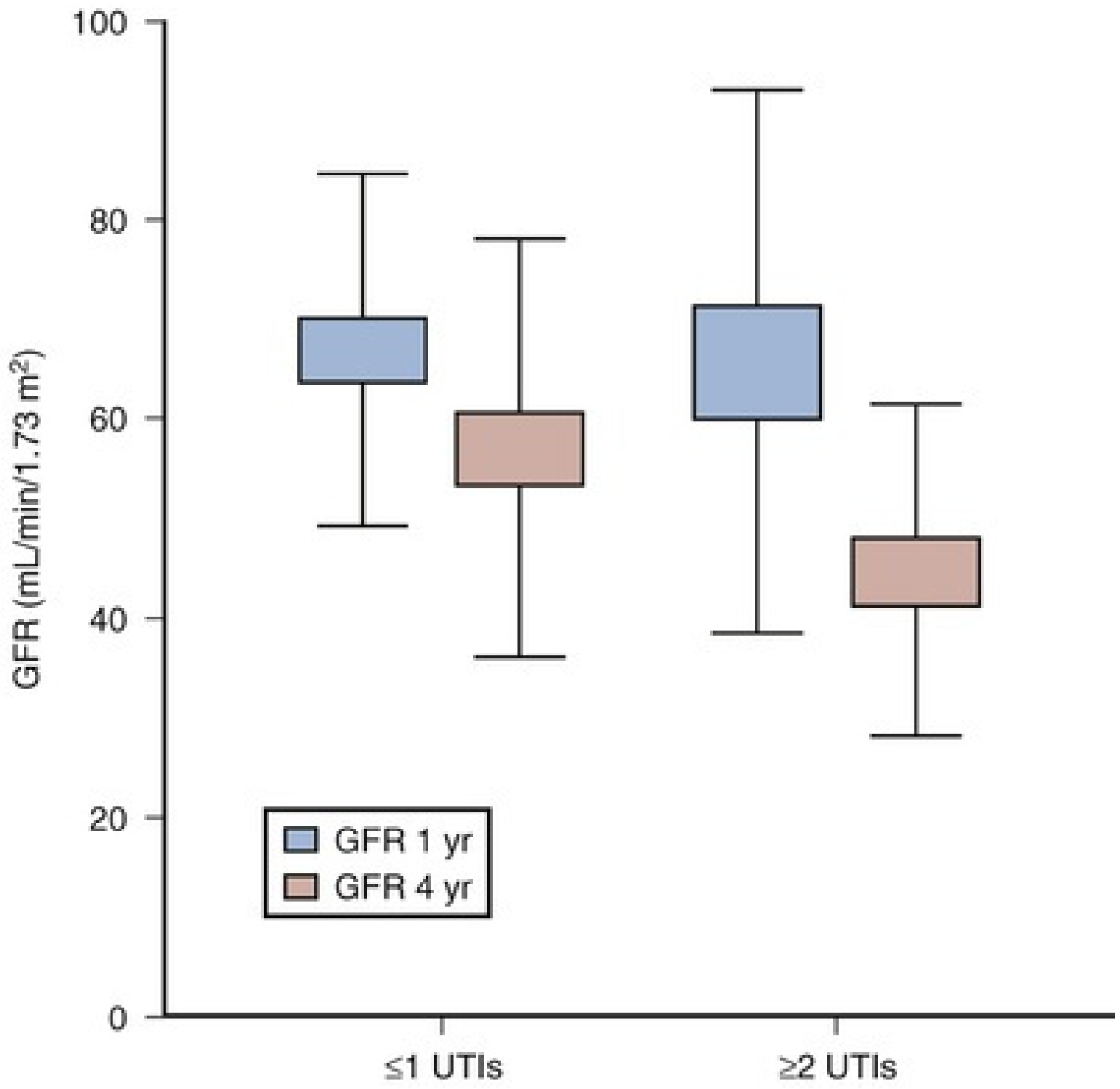

FIG. 51.22 Graft function at 1 and 4 years in children with ≤1 and ≥2 urinary tract infection. (From Herthelius M, Oborn H: Urinary tract infections and bladder dysfunction after renal transplantation in children. *J Urol* 177:1883–1886, 2007.)

Surgical management of reflux into a transplanted ureter is never routine. The role of endoscopic therapy is limited, and the few reports available suggest limited benefit, with resolution rates of 50% to 80% (Kitchens et al., 2006; Vemulakonda et al., 2010; Williams et al., 2008). This may be an option for asymptomatic reflux, but in the face of an episode of febrile UTI, a more definitive intervention is justified. There are few data regarding relative efficacy of intravesical compared with extravesical methods (Krishnan et al., 2006), but the authors' preference is intravesical, often using extravesical mobilization. A transtrigonal technique is effective if the contralateral native ureter can be avoided. Otherwise an advancement or Politano-Leadbetter technique may be used. Ureteral stenting is advisable.

If the transplant ureter was anastomosed to the ipsilateral native ureter, options are similar, yet the response to endoscopic injection and difficulty with dissection may be different and more favorable because of the preservation of the patient's ureterovesical junction.

Hydronephrosis and Obstruction

A frequent urologic complication in pediatric renal transplant is development of hydronephrosis, and intervention for ureteral obstruction may be needed in as many as 8% of transplants (Chu et al., 2013; Shokeir et al., 2005; Smith et al., 2010). The presence of hydronephrosis necessitates careful evaluation and selective management to tailor appropriate treatment to the individual. The transplant kidney appears to be particularly sensitive to obstruction, and the degree of impairment does not always correlate with the grade of hydronephrosis. In most cases, obstruction is heralded by increasing renal dysfunction with a rising creatinine. Hydronephrosis is identified on ultrasound or delayed drainage on MAG3 renal scan. **More than half of obstructions in a recent series occurred within the first 100 days post-transplant** (Smith et al., 2010). In the setting of normal prior bladder function, this pattern indicates ureteral obstruction until proven otherwise. If bladder dysfunction is known (or suspected) to be present, then both factors must be evaluated and managed, as obstruction is more frequent in patients with bladder abnormalities, particularly PUVs (Smith et al., 2010; Fig. 51.23). Placement of an indwelling catheter may be a reasonable first step because improvement in hydronephrosis and renal function may point toward a problem with bladder function.

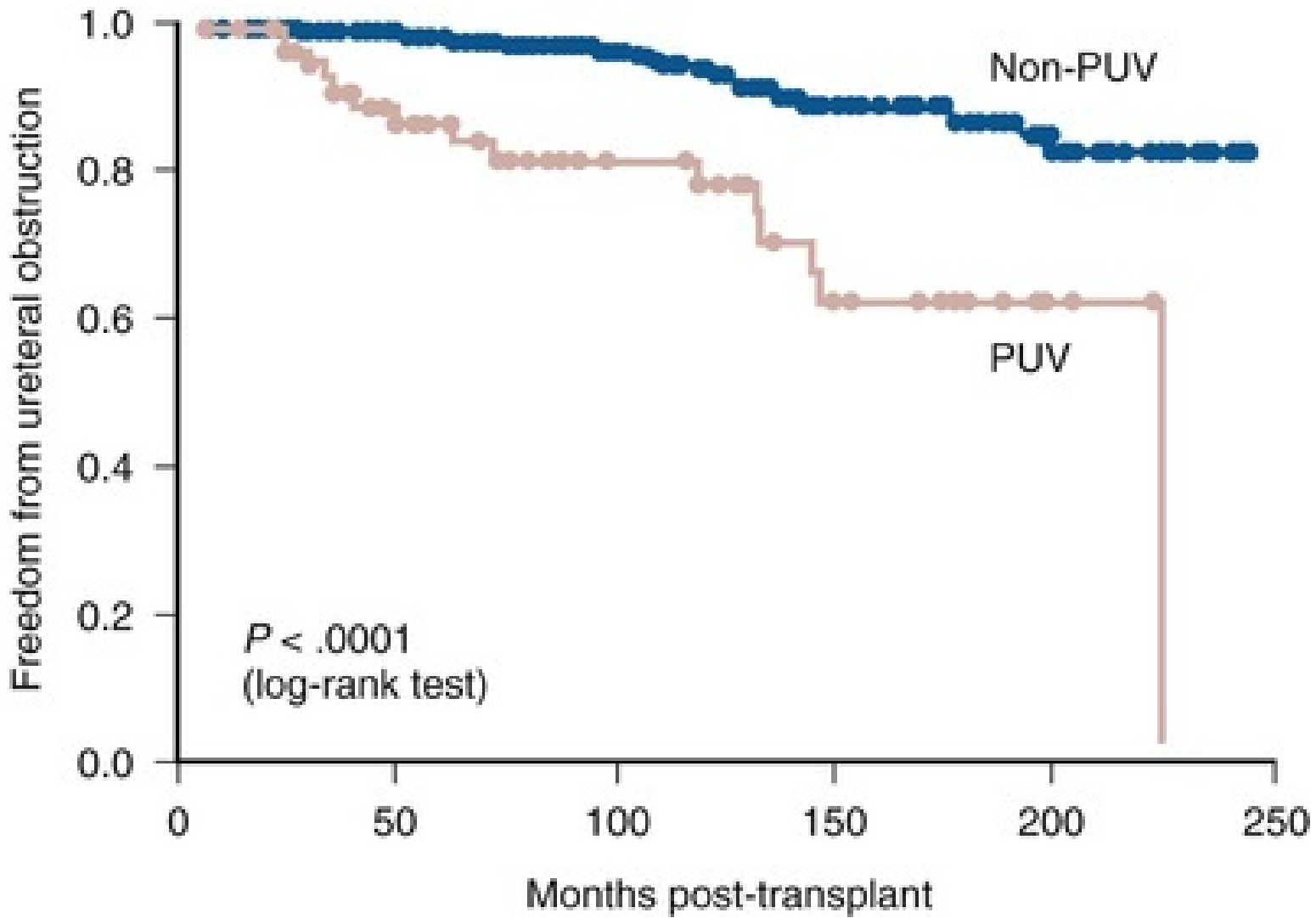

FIG. 51.23 Obstruction-free survival in pediatric renal transplant patients with and without a history of posterior urethral valves. (From Smith et al.: Risk factors and treatment success for ureteral obstruction after pediatric renal transplantation. *J Urol* 183:317–322, 2010.)

In the setting of a rising creatinine and hydronephrosis, obstruction and rejection may be intermingled. If the hydronephrosis is mild and there are other signs of rejection, the most efficient first step is biopsy (Khater and Khauli, 2012). If there is no clinical suggestion of rejection and dilation does not improve with bladder drainage, ureteral stenting (with or without a biopsy) is a reasonable next step. Although vesicoureteral reflux is unlikely to cause progressive hydronephrosis and worsening renal function, it is reasonable to verify that reflux is not present. Diagnostic studies for obstruction in the transplant setting are not completely reliable, and given the associated risks it is warranted to have a low threshold for stenting to assess the impact on renal function. It has been in this setting, albeit rarely, that an acutely failing transplant will show subsequent improvement in function, even in the absence of rejection. The more common situation is with moderate hydronephrosis and a rising creatinine with some rejection on biopsy. If the graft is not failing rapidly, initial medical treatment of the rejection is justified, with stenting being reserved for lack of improvement. If negotiating a stent in a retrograde fashion is not successful, percutaneous drainage is justified. Subsequent antegrade studies will show the location of the obstruction, and a stent can be advanced in the same setting.

The cause of ureteral obstruction is usually in the distal ureter with stenosis at the reimplantation site (Martino et al., 2013), but may be anywhere along the ureter and include an element of ischemia (particularly toward the distal aspect of the donor ureter). In a recent analysis, neither ureteral implant method nor use of stents was a contributing factor to obstruction. Bladder abnormalities, particularly because of posterior urethral valves, however, represent a risk factor of post-transplant obstruction (Smith et al., 2010). Extrinsic compression from a lymphocele (Fig. 51.24) or mass effect from post-transplant lymphoproliferative disease (PTLD; Fig. 51.25) are also possible causes (Buell et al., 2006; Dharnidharka et al., 2001).

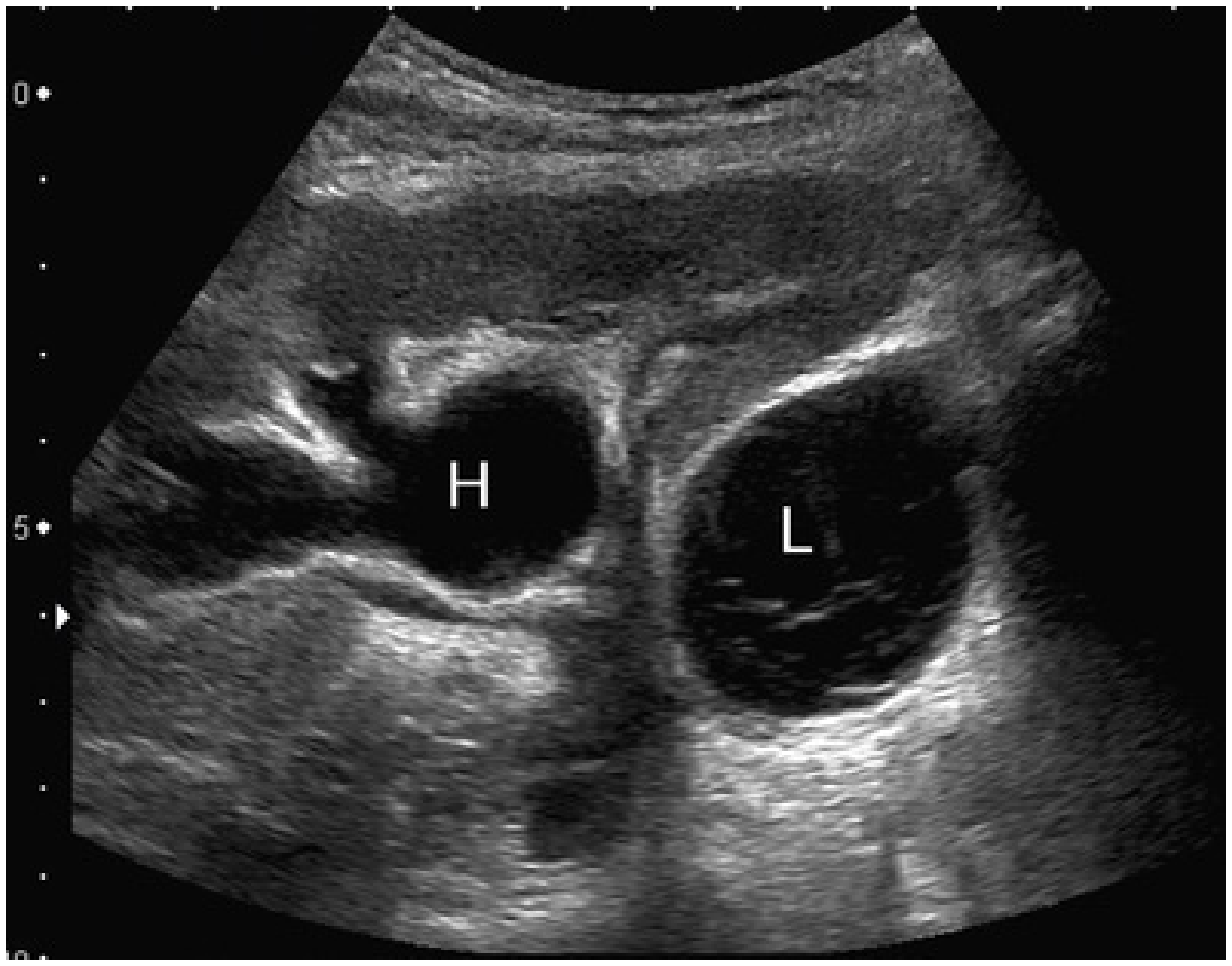

FIG. 51.24 Ultrasound image of renal allograft demonstrating hydronephrosis *(H)* secondary to extrinsic compression resulting from a septated fluid collection (lymphocele; *L*).

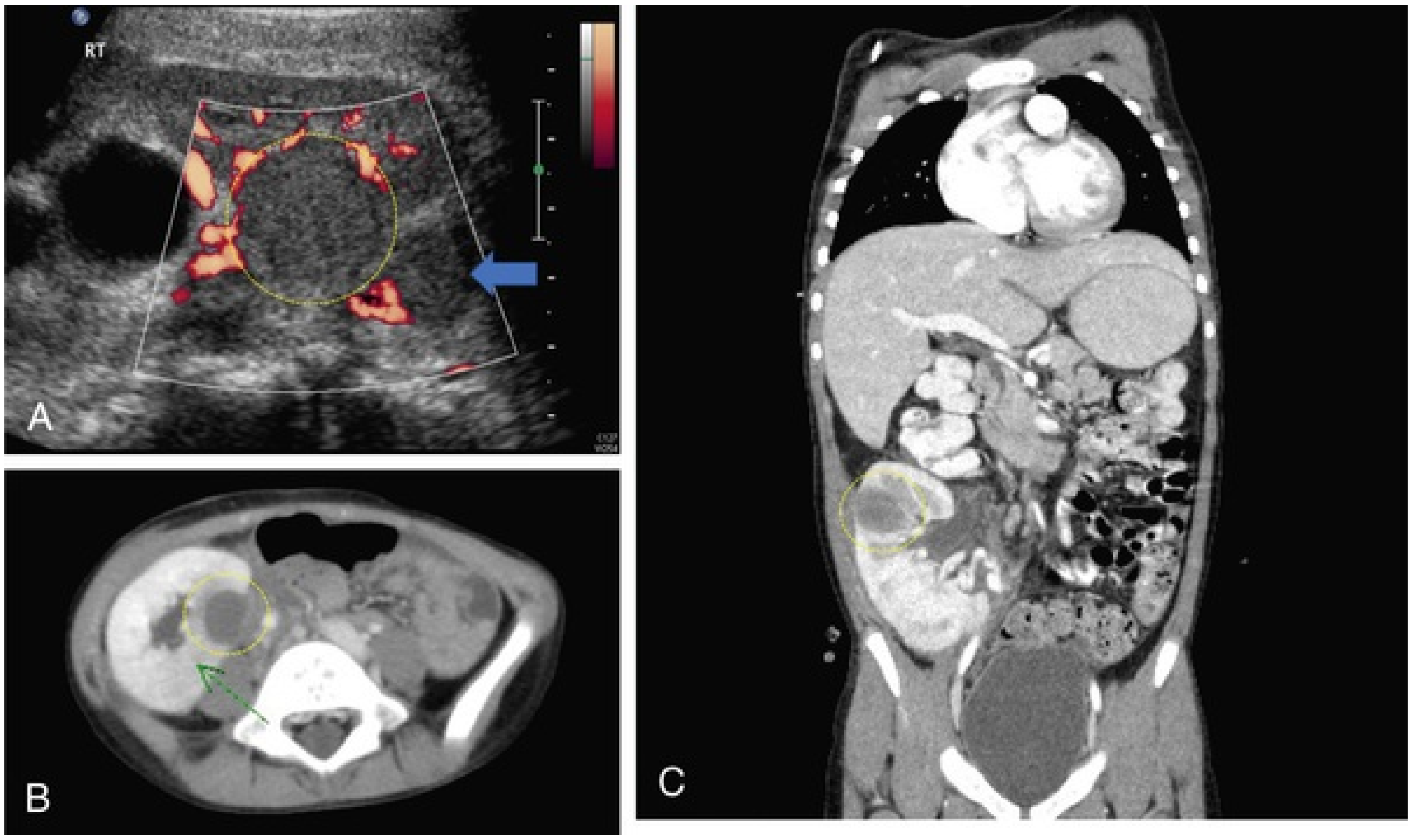

FIG. 51.25 Imaging studies with examples of post-transplant lymphoproliferative disease (PTLD). (A) Intrarenal mass with associated lymphadenopathy *(arrow)*. (B and C) CT scan images depicting PTLD lesions. An allograft mass after transplant should be considered PTLD until proven otherwise.

Definitive therapy is determined by the most likely cause. Focal ureteral narrowing on retrograde imaging may be effectively treated with balloon dilation and stenting for 4 to 6 weeks. Long-term stenting has been used in adult series with thermolabile nitinol stents, but it is uncertain if this would be a satisfactory approach in children (Bach et al., 2013). Recognizing the risk posed to the graft resulting from obstruction, open definitive repair should not be delayed excessively (Smith et al., 2010). As previously mentioned, these procedures entail complex reconstruction using native ureter or bladder flaps (Kockelbergh et al., 1993). Avoiding use of nonurothelial segments, such as appendix (Corbetta et al., 2012), is advisable, although any of these methods may be needed. Pyeloureteral anastomosis can be an option if the native ureter remains in place and is healthy (Sandhu et al., 2012). All of the principles of reoperative reconstruction must be followed to preserve well-vascularized functional tissues.

Bladder Dysfunction

Bladder dysfunction may increase the risk of infections but may also create an obstructive process that impairs renal graft function (Herthelius and Oborn, 2006; Herthelius and Oborn, 2007, Nahas et al., 2008; Van der Weide et al., 2006). Discriminating this from ureteral obstruction may not be simple and, on occasion, has necessitated sequential diagnostic drainage steps. If a bladder catheter can be placed easily, then continuous drainage for 1 to 2 weeks with reassessment of creatinine can usually identify bladder dysfunction as the cause of graft dysfunction if the creatinine declines. If not, then combined stent and bladder drainage followed by a re-check of the creatinine is needed. Elements of bladder and ureteral dysfunction may contribute to graft failure. Both may have to be addressed. Treating bladder dysfunction involves measures to increase compliance using anticholinergics as well as instituting or enhancing an intermittent catheterization program. Bladder augmentation may also be needed, although only after aggressive medical management has been tried. When intermittent catheterization per urethra is difficult, creation of a continent stoma may be needed. As discussed in the beginning of the chapter, identification of these potential risks to graft function is best accomplished before the transplant whenever possible.

Stones

Nephrolithiasis in a pediatric renal transplant is uncommon, occurring in up to 5% of patients (Khositseth et al., 2004), but more likely to be less than 1% (Stravodimos et al., 2012), yet potentially dangerous for long-term graft survival. With appropriate management, stones were not seen to increase the risk of graft loss but were associated with more UTIs (Khositseth et al., 2004). Previous reports have suggested a high incidence of bladder stones, yet many of these were due to retained suture material in the bladder (Lipke et al., 2004). Detection of an asymptomatic stone on routine surveillance should prompt attempts at removal as well as a search for an underlying predisposing factor. Stones associated with renal graft dysfunction resulting from obstruction or infection should be managed with urgent intervention to ensure drainage and prompt removal. All conventional means of stone management are appropriate in a renal graft but should be modulated by recognition of the potential balance of risk to the graft as well as relative efficacy of the various modalities. Selection of modality that will have the highest likelihood of success with a single intervention is likely to be the best option in the long term, even if this incurs more complexity. A lower pole stone may be best managed with a percutaneous approach or ureteroscopic removal rather than extracorporeal shock wave lithotripsy, given the lower success of clearance of lower pole stones. These decisions should be individualized based upon clinical presentation, location and size of the stone, and renal functional status.

Key Points: Complications

- Common urologic complications for pediatric renal transplant include ureteral stenosis (6%), urinary leaks (3%), stones (2%), and clinically significant reflux (2%).
- Urine leaks are typically identified in the early postoperative period with increasing fluid from the wound drains.
- Urinary infection is a long-term and often delayed complication that largely reflects the status of bladder function.
- Vesicoureteral reflux into the transplant is entirely distinct from routine reflux as the risk to renal function of acute pyelonephritis is greater.
- In the setting of a rising creatinine and hydronephrosis, obstruction and rejection may be both present.

- The cause of ureteral obstruction is usually in the distal ureter with stenosis at the reimplantation site.
- Bladder dysfunction may produce infection but may also create an obstructive process that impairs renal graft function.
- Nephrolithiasis is uncommon but may occur in up to 5% of patients.

Summary

Preparation and management of the pediatric transplant patient, particularly with an underlying urologic condition, requires a thorough understanding of the patterns of bladder dysfunction and clear strategies for evaluation and treatment before transplant. Anticipating the needs and constraints of the transplant procedure and being involved in all cases permits a smoother procedure and ongoing continuity of care by the pediatric urologist. Post-transplant monitoring should be diligent to identify pathological processes before they have damaged renal graft function irreversibly. This takes a high index of suspicion and a clear sense of which patients are at high risk for these outcomes. A multidisciplinary collaboration between pediatric nephrology, urology, and the transplant surgical team is critical to maximize patient and graft survival.

Suggested Readings

Alam S, Sheldon C. Urological issues in pediatric renal transplantation. *Curr Opin Urol*. 2008;18:413–418.

Barrero R, Fijo J, Fernandez-Hurtado M, et al. Vesicoureteral reflux after kidney transplantation in children. *Pediatr Transplant*. 2007;11:498–503.

Chinnakotla S, Verghese P, Chavers B, et al. Pediatric transplant program: outcomes and risk factors for graft loss: lessons learned from 1,056 pediatric kidney transplants at the University of Minnesota. *J Am Coll Surg*. 2017;224(4):473–486.

Chu L, Jacobs BL, Schwen Z, et al. Hydronephrosis in pediatric kidney transplant: clinical relevance to graft outcome. *J Pediatr Urol*. 2013;9(2):217–222.

Coulthard MG, Keir MJ. Reflux nephropathy in kidney transplants, demonstrated by dimercaptosuccinic acid scanning. *Transplantation*. 2006;82:205–210.

Englesbe MJ, Lynch RJ, Heidt DG, et al. Early urologic complications after pediatric renal transplant: a single-center experience. *Transplantation*. 2008;86:1560–1564.

Fine MS, Smith KM, Shrivastava D, et al. Posterior urethral valve treatments and outcomes in children receiving kidney transplants. *J Urol*. 2011;185(6 Suppl):2507–2511.

Gander R, Asensio M, Royo GF, et al. Kidney transplantation in children weighing 15 kg or less is challenging but associated with good outcome. *J Pediatr Urol*. 2017;13(3):279 e271–279 e277.

Herthelius M, Oborn H. Bladder dysfunction in children and adolescents after renal transplantation. *Pediatr Nephrol*. 2006;21:725–728.

Jesus LE, Pippi Salle JL. Pre-transplant management of valve bladder: a critical literature review. *J Pediatr Urol*. 2015;11(1):5–11; 10.1016/j.jpurol.2014.12.001.

Khositseth S, Askiti V, Nevins TE, et al. Increased urologic complications in children after kidney transplants for obstructive and reflux uropathy. *Am J Transplant*. 2007;7:2152–2157.

Lopez Pereira P, Jaureguizar E, Martinez Urrutia MJ, et al. Does treatment of bladder dysfunction prior to renal transplant improve outcome in patients with posterior urethral valves? *Pediatr Transplant*. 2000;4:118–122.

Luke PP, Herz DB, Bellinger MF, et al. Long-term results of pediatric renal transplantation into a dysfunctional lower urinary tract. *Transplantation*. 2003;76(11):1578–1582.

Ramirez SP, Lebowitz RL, Harmon WE, et al. Predictors for abnormal voiding cystourethrography in pediatric patients undergoing renal transplant evaluation. *Pediatr Transplant*. 2001;5:99–104.

Smith KM, Windsperger A, Alanee S, et al. Risk factors and treatment success for ureteral obstruction after pediatric renal transplantation. *J Urol*. 2010;183:317–322.

Traxel E, DeFoor W, Minevich E, et al. Low incidence of urinary tract infections following renal transplantation in children with bladder augmentation. *J Urol*. 2011;186(2):667–671.

References

Abraham MK, Nasir AR, Sudarsanan B, et al. Role of alpha adrenergic blocker in the management of posterior urethral valves. *Pediatr Surg Int*. 2009;25(12):1113–1115.

Adams J, Mehls O, Wiesel M. Pediatric renal transplantation and the dysfunctional bladder. *Transpl Int*. 2004;17(10):596–602.

Aki FT, Besbas N, Ozcan O, et al. Renal transplantation in children with augmentation enterocystoplasty. *Transplant Proc*. 2006;38(2):554–555.

Alam S, Sheldon C. Urological issues in pediatric renal transplantation. *Curr Opin Urol*. 2008;18(4):413–418.

Alfrey EJ, Conley SB, Tanney DC, et al. Use of an augmented urinary bladder can be catastrophic in renal transplantation. *Transplant Proc*. 1997;29(1–2):154–155.

Alfrey EJ, Salvatierra O Jr, Tanney DC, et al. Bladder augmentation can be problematic with renal failure and transplantation. *Pediatr Nephrol*. 1997;11(6):672–675.

Almeida F, Branco F, Cavadas V, et al. Urological complications after 134 pediatric kidney transplants: a single-center study. *Transplant Proc*. 2013;45(3):1096–1098.

Austin PF, Homsy YL, Masel JL, et al. Alpha-Adrenergic blockade in children with neuropathic and nonneuropathic voiding dysfunction. *J Urol*. 1999;162(3 Pt 2):1064–1067.

Bach C, Kabir MN, Goyal A, et al. A self-expanding thermolabile nitinol stent as a minimally invasive treatment alternative for ureteral strictures in renal transplant patients. *J Endourol*. 2013;27(12):1543–1545.

Barnett MG, Bruskewitz RC, Belzer FO, et al. Ileocecocystoplasty bladder augmentation and renal transplantation. *J Urol*. 1987;138(4):855–858.

Barrero R, Fijo J, Fernandez-Hurtado M, et al. Vesicoureteral reflux after kidney transplantation in children. *Pediatr Transplant*. 2007;11(5):498–503.

Barry JM. Unstented extravesical ureteroneocystostomy in kidney transplantation. *J Urol*. 1983;129(5):918–919.

Barry JM, Hatch DA. Parallel incision, unstented extravesical ureteroneocystostomy: followup of 203 kidney transplants. *J Urol*. 1985;134(2):249–251.

Bloom DA. The retrograde idea of Jack Lapides: clean intermittent catheterization. *J Urol*. 2017;197(2S):S125–S126.

Broniszczak D, Ismail H, Nachulewicz P, et al. Kidney transplantation in children with bladder augmentation or ileal conduit diversion. *Eur J Pediatr Surg*. 2010;20(1):5–10.

Buell JF, Gross TG, Thomas MJ, et al. Malignancy in pediatric transplant recipients. *Semin Pediatr Surg*. 2006;15(3):179–187.

Burns MW, Watkins SL, Mitchell ME, et al. Treatment of bladder dysfunction in children with end-stage renal disease. *J Pediatr Surg*. 1992;27(2):170–174.

Capizzi A, Zanon GF, Zacchello G, et al. Kidney transplantation in children with reconstructed bladder. *Transplantation*. 2004;77(7):1113–1116.

Capozza N, Collura G, Falappa P, et al. Renal embolization as an alternative to surgical nephrectomy in children. *Transplant Proc*. 2007;39(6):1782–1784.

Casale P, Grady RW, Mitchell ME, et al. Recurrent urinary tract infection in the post-transplant reflux nephropathy patient: is reflux in the native ureter the culprit? *Pediatr Transplant*. 2005;9(3):324–327.

Castellan M, Gosalbez R, Bar-Yosef Y, et al. Complications after use of gastric segments for lower urinary tract reconstruction. *J Urol*. 2012;187(5):1823–1827.

Castellan M, Gosalbez R, Perez-Brayfield M, et al. Tumor in bladder reservoir after gastrocystoplasty. *J Urol*. 2007;178(4 Pt 2):1771–1774 [discussion 1774].

Chinnakotla S, Verghese P, Chavers B, et al. Outcomes and risk factors for graft loss: lessons learned from 1,056 pediatric kidney transplants at the University of Minnesota. *J Am Coll Surg*. 2017;224(4):473–486.

Chu L, Jacobs BL, Schwen Z, et al. Hydronephrosis in pediatric kidney transplant: clinical relevance to graft outcome. *J Pediatr Urol*. 2013;9(2):217–222.

Corbetta JP, Weller S, Bortagaray JI, et al. Ureteral replacement with appendix in pediatric renal transplantation. *Pediatr Transplant*. 2012;16(3):235–238.

Coulthard MG, Keir MJ. Reflux nephropathy in kidney transplants, demonstrated by dimercaptosuccinic acid scanning. *Transplantation*. 2006;82(2):205–210.

De Gennaro M, Capitanucci ML, Mosiello G, et al. The changing urodynamic pattern from infancy to adolescence in boys with posterior urethral valves. *BJU Int*. 2000;85(9):1104–1108.

DeFoor W, Minevich E, McEnery P, et al. Lower urinary tract reconstruction is safe and effective in children with end stage renal disease. *J Urol*. 2003;170(4 Pt 2):1497–1500 [discussion 1500].

Dharnidharka VR, Araya CE, Wadsworth CS, et al. Assessing the value of ureteral stent placement in pediatric kidney transplant recipients. *Transplantation*. 2008;85(7):986–991.

Dharnidharka VR, Sullivan EK, Stablein DM, et al. Risk factors for posttransplant lymphoproliferative disorder (PTLD) in pediatric kidney transplantation: a report of the North American pediatric Renal Transplant Cooperative Study (NAPRTCS). *Transplantation*. 2001;71(8):1065–1068.

Dick AA, Lerner SM, Boissy AR, et al. Excellent outcome in infants and small children with thrombophilias undergoing kidney transplantation. *Pediatr Transplant*. 2005;9(1):39–42.

Djakovic N, Wagener N, Adams J, et al. Intestinal reconstruction of the lower urinary tract as a prerequisite for renal transplantation. *BJU Int*. 2009;103(11):1555–1560.

Dunn SP, Vinocur CD, Hanevold C, et al. Pyelonephritis following pediatric renal transplant: increased incidence with vesicoureteral reflux. *J Pediatr Surg*. 1987;22(12):1095–1099.

El Atat R, Derouiche A, Guellouz S, et al. Surgical complications in pediatric and adolescent renal transplantation. *Saudi J Kidney Dis Transpl*. 2010;21(2):251–257.

El-Husseini AA, Sobh MA, Ghoneim MA. Complications of pediatric live-donor kidney transplantation: a single center's experience in Egypt. *Pediatr Nephrol*. 2008;23(11):2067–2073.

Englesbe MJ, Lynch RJ, Heidt DG, et al. Early urologic complications after pediatric renal transplant: a single-center experience. *Transplantation*. 2008;86(11):1560–1564.

Fallahzadeh MK, Fallahzadeh MH, Derakhshan A, et al. Urinary tract infection after kidney transplantation in children and adolescents. *Iran J Kidney Dis*. 2011;5(6):416–419.

Fayek SA, Keenan J, Haririan A, et al. Ureteral stents are associated with reduced risk of ureteral complications after kidney transplantation: a large single center experience. *Transplantation*. 2012;93(3):304–308.

Fine MS, Smith KM, Shrivastava D, et al. Posterior urethral valve treatments and outcomes in children receiving kidney transplants. *J Urol*. 2011;185(6 Suppl):2507–2511.

Firlit CF. Use of defunctionalized bladders in pediatric renal transplantation. *J Urol*. 1976;116(5):634–637.

Fraser N, Lyon PC, Williams AR, et al. Native nephrectomy in pediatric transplantation–less is more!. *J Pediatr Urol*. 2013;9(1):84–89.

French CG, Acott PD, Crocker JF, et al. Extravesical ureteroneocystostomy with and without internalized ureteric stents in pediatric renal transplantation. *Pediatr Transplant*. 2001;5(1):21–26.

Gander R, Asensio M, Royo GF, et al. Kidney transplantation in children weighing 15 kg or less is challenging but associated with good outcome. *J Pediatr Urol*. 2017;13(3):279 e271–279 e277.

Greer T, Abbott J, Breytenbach W, et al. Ten years of experience with intravesical and intrasphincteric onabotulinumtoxinA in children. *J Pediatr Urol*. 2016;12(2):94 e91–94 e96.

Gundeti MS, Taghizaedh A, Mushtaq I. Bilateral synchronous posterior prone retroperitoneoscopic nephrectomy with simultaneous peritoneal dialysis: a new management for end-stage renal disease in children. *BJU Int*. 2007;99(4):904–906.

Gurkan A, Yakupoglu YK, Dinckan A, et al. Comparing two ureter reimplantation techniques in kidney transplant recipients. *Transpl Int*. 2006;19(10):802–806.

Hanevold CD, Kaiser BA, Palmer J, et al. Vesicoureteral reflux and urinary tract infections in renal transplant recipients. *Am J Dis Child*. 1987;141(9):982–984.

Hatch DA, Koyle MA, Baskin LS, et al. Kidney transplantation in children with urinary diversion or bladder augmentation. *J Urol*. 2001;165(6 Pt 2):2265–2268.

Herthelius M, Oborn H. Bladder dysfunction in children and adolescents after renal transplantation. *Pediatr Nephrol*. 2006;21(5):725–728.

Herthelius M, Oborn H. Urinary tract infections and bladder dysfunction after renal transplantation in children. *J Urol*. 2007;177(5):1883–1886.

Hidas G, Soltani T, Billimek J, et al. Home urodynamic pressures and volume measurement for the neurogenic bladder: initial validation study. *J Urol*. 2017;198(6):1424–1429.

Holmdahl G, Sillen U, Hanson E, et al. Bladder dysfunction in boys with posterior urethral valves before and after puberty. *J Urol*. 1996;155(2):694–698.

Howie AJ, Buist LJ, Coulthard MG. Reflux nephropathy in transplants. *Pediatr Nephrol*. 2002;17(7):485–490.

Husmann DA, Rathbun SR. Long-term follow up of enteric bladder augmentations: the risk for malignancy. *J Pediatr Urol*. 2008;4(5):381–385 [discussion 386].

Irtan S, Maisin A, Baudouin V, et al. Renal transplantation in children: critical analysis of age related surgical complications. *Pediatr Transplant*. 2010;14(4):512–519.

Jesus LE, Pippi Salle JL. Pre-transplant management of valve bladder: a critical literature review. *J Pediatr Urol*. 2015;11(1):5–11.

Kaefer M, Zurakowski D, Bauer SB, et al. Estimating normal bladder capacity in children. *J Urol*. 1997;158(6):2261–2264.

Kamal MM, El-Hefnawy AS, Soliman S, et al. Impact of posterior urethral valves on pediatric renal transplantation: a single-center comparative study of 297 cases. *Pediatr Transplant*. 2011;15(5):482–487.

Kelly WD, Merkel FK, Markland C. Ileal urinary diversion in conjunction with renal homotransplantation. *Lancet*. 1966;1(7431):222–226.

Khater N, Khauli R. Pseudorejection and true rejection after kidney transplantation: classification and clinical significance. *Urol Int*. 2012;90(4):373–380.

Khositseth S, Askiti V, Nevins TE, et al. Increased urologic complications in children after kidney transplants for obstructive and reflux uropathy. *Am J Transplant*.

2007;7(9):2152–2157.

Khositseth S, Gillingham KJ, Cook ME, et al. Urolithiasis after kidney transplantation in pediatric recipients: a single center report. *Transplantation*. 2004;78(9):1319–1323.

Kim CO Jr, Gosalbez R Jr, Burke GW 3rd. Simultaneous ureterocystoplasty and living related renal transplantation. *Clin Transplant*. 1996;10(4):333–336.

Kim MS, Primack W, Harmon WE. Congenital nephrotic syndrome: preemptive bilateral nephrectomy and dialysis before renal transplantation. *J Am Soc Nephrol*. 1992;3(2):260–263.

Kitchens D, Minevich E, DeFoor W, et al. Endoscopic injection of dextranomer/hyaluronic acid copolymer to correct vesicoureteral reflux following failed ureteroneocystostomy. *J Urol*. 2006;176(4 Pt 2):1861–1863.

Kockelbergh RC, Millar RJ, Walker RG, et al. Pyeloureterostomy in the management of renal allograft ureteral complications: an alternative technique. *J Urol*. 1993;149(2):366–368.

Koff SA. Estimating bladder capacity in children. *Urology*. 1983;21(3):248.

Koo HP, Bunchman TE, Flynn JT, et al. Renal transplantation in children with severe lower urinary tract dysfunction. *J Urol*. 1999;161(1):240–245.

Kravarusic D, Sigalet DL, Hamiwka LA, et al. Persistent post-transplant polyuria managed by bilateral native-kidney laparoscopic nephrectomy. *Pediatr Nephrol*. 2006;21(6):880–882.

Krishnan A, Swana H, Mathias R, et al. Redo ureteroneocystostomy using an extravesical approach in pediatric renal transplant patients with reflux: a retrospective analysis and description of technique. *J Urol*. 2006;176(4 Pt 1):1582–1587 [discussion 1587].

Kurzrock EA, Butani L, Kakker SP, et al. Ureterocystoplasty (bladder augmentation) with a solitary kidney. *Pediatr Transplant*. 2002;6(3):240–243.

Landau EH V, Jayanthi R, McLorie GA, et al. Renal transplantation in children following augmentation ureterocystoplasty. *Urology*. 1997;50(2):260–262.

Lapides J, Diokno AC, Silber SJ, et al. Clean, intermittent self-catheterization in the treatment of urinary tract disease. *J Urol*. 1972;107(3):458–461.

Lapointe SP, Charbit M, Jan D, et al. Urological complications after renal transplantation using ureteroureteral anastomosis in children. *J Urol*. 2001;166(3):1046–1048.

Lipke M, Schulsinger D, Sheynkin Y, et al. Endoscopic treatment of bladder calculi in post-renal transplant patients: a 10-year experience. *J Endourol*. 2004;18(8):787–790.

Lopez Pereira P, Jaureguizar E, Martinez Urrutia MJ, et al. Does treatment of bladder dysfunction prior to renal transplant improve outcome in patients with posterior urethral valves? *Pediatr Transplant*. 2000;4(2):118–122.

Luke PP, Herz DB, Bellinger MF, et al. Long-term results of pediatric renal transplantation into a dysfunctional lower urinary tract. *Transplantation*. 2003;76(11):1578–1582.

Martino P, Impedovo SV, Palazzo S, et al. Ureteral strictures after kidney transplantation: risk factors. *Arch Ital Urol Androl*. 2013;84(4):287–290.

Mendizabal S, Estornell F, Zamora I, et al. Renal transplantation in children with severe bladder dysfunction. *J Urol*. 2005;173(1):226–229.

Metcalfe PD, Cain MP, Kaefer M, et al. What is the need for additional bladder surgery after bladder augmentation in childhood? *J Urol*. 2006;176(4 Pt 2):1801–1805 [discussion 1805].

Mukherjee S, Joshi A, Carroll D, et al. What is the effect of circumcision on risk of urinary tract infection in boys with posterior urethral valves? *J Pediatr Surg*. 2009;44(2):417–421.

Nahas WC, Mazzucchi E, Arap MA, et al. Augmentation cystoplasty in renal transplantation: a good and safe option–experience with 25 cases. *Urology*. 2002;60(5):770–774.

Nahas WC I, Antonopoulos M, Piovesan AC, et al. Comparison of renal transplantation outcomes in children with and without bladder dysfunction. A customized approach equals the difference. *J Urol*. 2008;179(2):712–716.

NAPRTCS. *NAPRTCS Annual Report*. https://web.emmes.com/study/ped/annlrept/annualrept2014.p 2014.

NAPRTCS. *NAPTRTCS Annual Report*. https://web.emmes.com/study/ped/annlrept/Annual Report -2008.pdf; 2008.

Neuhaus TJ, Schwobel M, Schlumpf R, et al. Pyelonephritis and vesicoureteral reflux after renal transplantation in young children. *J Urol*. 1997;157(4):1400–1403.

Nguyen DH, Bain MA, Salmonson KL, et al. The syndrome of dysuria and hematuria in pediatric urinary reconstruction with stomach. *J Urol*. 1993;150(2 Pt 2):707–709.

Nguyen HT, Peters CA. The long-term complications of posterior urethral valves. *BJU Int*. 1999;83(Suppl 3):23–28.

Nuininga JE, Feitz WF, van Dael KC, et al. Urological complications in pediatric renal transplantation. *Eur Urol*. 2001;39(5):598–602.

Patel P, Rebollo-Mesa I, Ryan E, et al. Prophylactic ureteric stents in renal transplant recipients: a multicenter randomized controlled trial of early versus late removal. *Am J Transplant*. 2017;17(8):2129–2138.

Penna FJ, Lorenzo AJ, Farhat WA, et al. Ureteroureterostomy: an alternative to ureteroneocystostomy in select cases of pediatric renal transplantation. *J Urol*. 2017;197(3 Pt 2):920–924.

Peters CA, Bolkier M, Bauer SB, et al. The urodynamic consequences of posterior urethral valves. *J Urol*. 1990;144(1):122–126.

Ramirez SP, Lebowitz RL, Harmon WE, et al. Predictors for abnormal voiding cystourethrography in pediatric patients undergoing renal transplant evaluation. *Pediatr Transplant*. 2001;5(2):99–104.

Ranchin B, Chapuis F, Dawhara M, et al. Vesicoureteral reflux after kidney transplantation in children. *Nephrol Dial Transplant*. 2000;15(11):1852–1858.

Reinberg Y, Manivel JC, Froemming C, et al. Perforation of the gastric segment of an augmented bladder secondary to peptic ulcer disease. *J Urol*. 1992;148(2 Pt 1):369–371.

Rigamonti W, Capizzi A, Zacchello G, et al. Kidney transplantation into bladder augmentation or urinary diversion: long-term results. *Transplantation*. 2005;80(10):1435–1440.

Riley P, Marks SD, Desai DY, et al. Challenges facing renal transplantation in pediatric patients with lower urinary tract dysfunction. *Transplantation*. 2010;89(11):1299–1307.

Rossi V, Torino G, Gerocarni Nappo S, et al. Urological complications following kidney transplantation in pediatric age: a single-center experience. *Pediatr Transplant*. 2016;20(4):485–491.

Routh JC, Yu RN, Kozinn SI, et al. Urological complications and vesicoureteral reflux following pediatric kidney transplantation. *J Urol*. 2012;189(3):1071–1076.

Ruiz E, Cateriano JE, Lobos P, et al. Kidney transplantation in small children with live related donors: 20 years of experience. *J Pediatr Urol*. 2006;2(4):373–379.

Salvatierra O Jr, Sarwal M, Alexander S, et al. A new, unique and simple method for ureteral implantation in kidney recipients with small, defunctionalized bladders. *Transplantation*. 1999;68(6):731–738.

Sandhu K, Masters J, Ehrlich Y. Ureteropyelostomy using the native ureter for the management of ureteric obstruction or symptomatic reflux following renal transplantation. *Urology*. 2012;79(4):929–932.

Serrano DP, Flechner SM, Modlin CS, et al. Transplantation into the long-term defunctionalized bladder. *J Urol*. 1996;156(3):885–888.

Sheldon CA, Gonzalez R, Burns MW, et al. Renal transplantation into the dysfunctional bladder: the role of adjunctive bladder reconstruction. *J Urol*. 1994;152(3):972–975.

Shokeir AA, Osman Y, Ali-El-Dein B, et al. Surgical complications in live-donor pediatric and adolescent renal transplantation: study of risk factors. *Pediatr Transplant*. 2005;9(1):33–38.

Silva A, Rodig N, Passerotti CP, et al. Risk factors for urinary tract infection after renal transplantation and its impact on graft function in children and young adults. *J Urol*. 2010;184(4):1462–1467.

Simpson CM, Sterne JA, Walker RG, et al. Stent-related ureteric obstruction in paediatric renal transplantation. *Pediatr Nephrol*. 2006;21(1):79–85.

Singer JS, Zaid U, Gritsch HA, et al. Selective use of voiding cystourethrography in children undergoing renal transplant evaluation. *J Urol*. 2009;182(3):1158–1162.

Singh-Grewal D, Macdessi J, Craig J. Circumcision for the prevention of urinary tract infection in boys: a systematic review of randomised trials and observational studies. *Arch Dis Child*. 2005;90(8):853–858.

Smith KM, Windsperger A, Alanee S, et al. Risk factors and treatment success for ureteral obstruction after pediatric renal transplantation. *J Urol*. 2010;183(1):317–322.

Stravodimos KG, Adamis S, Tyritzis S, et al. Renal transplant lithiasis: analysis of our series and review of the literature. *J Endourol*. 2012;26(1):38–44.

Taghizadeh AK, Desai D, Ledermann SE, et al. Renal transplantation or bladder augmentation first? A comparison of complications and outcomes in children. *BJU Int*. 2007;100(6):1365–1370.

Tanabe K, Takahashi K, Kawaguchi H, et al. Surgical complications of pediatric kidney transplantation: a single center experience with the extraperitoneal technique. *J Urol*. 1998;160(3 Pt 2):1212–1215.

Ter Haar AS, Parekh RS, Leunissen RWJ, et al. *How to stent the ureter after kidney transplantation in children?-A comparison of two methods of urinary drainage*. Pediatr Transplant. 2017.

Timsit MO, Lalloue F, Bayramov A, et al. Should routine pyeloureterostomy be advocated in adult kidney transplantation? A prospective study of 283 recipients. *J Urol*. 2010;184(5):2043–2048.

Torino G, Innocenzi M, Mele E, et al. Comparison of native ureteral ligation and open nephrectomy for pediatric renal transplantation. *J Urol*. 2016;196(3):875–880.

Traxel E, DeFoor W, Minevich E, et al. Low incidence of urinary tract infections following renal transplantation in children with bladder augmentation. *J Urol*. 2011;186(2):667–671.

Van Arendonk KJ, Boyarsky BJ, Orandi BJ, et al. National trends over 25 years in pediatric kidney transplant outcomes. *Pediatrics*. 2014;133(4):594–601.

Van der Weide MJ, Cornelissen EA, Van Achterberg T, et al. Dysfunction of lower urinary tract in renal transplant children with nephrologic disease. *Urology*. 2006;67(5):1060–1065 [discussion 1065].

Vasdev N, Coulthard MG, Lambert H, et al. The modified Barry technique to prevent vesicoureteric reflux in paediatric renal transplant recipients: initial recipient outcomes. *J Pediatr Urol*. 2011;8(1):97–102.

Vemulakonda VM, Koyle MA, Lendvay TS, et al. Endoscopic treatment of symptomatic refluxing renal transplant ureteroneocystostomies in children. *Pediatr Transplant*. 2010;14(2):212–215.

Vitola SP, Gnatta D, Garcia VD, et al. Kidney transplantation in children weighing less than 15 kg: extraperitoneal surgical access-experience with 62 cases. *Pediatr Transplant*. 2013;17(5):445–453.

Williams MA, Giel DW, Colleen Hastings M. Endoscopic Deflux injection for pediatric transplant reflux: a feasible alternative to open ureteral reimplant. *J Pediatr Urol*. 2008;4(5):341–344.

Zermann DH, Loffler U, Reichelt O, et al. Bladder dysfunction and end stage renal disease. *Int Urol Nephrol*. 2003;35(1):93–97.

52

Pediatric Genitourinary Trauma

Bruce J. Schlomer MD, Micah A. Jacobs MD, MPH

Renal Injuries

Epidemiology

Renal injuries are the most common form of pediatric genitourinary trauma. The pediatric kidney is thought to be more susceptible to trauma when compared with the adult kidney for several reasons. The pediatric kidney is protected by less perirenal fat and less developed abdominal wall muscles. The pediatric kidney also sits lower so is less protected by the rib cage. In addition, the pediatric vertebral column may be more pliable, leading to more stretch injuries on the ureters. However, it is unclear whether children are more susceptible to genitourinary trauma when compared with adults (Brown et al., 1998; Chopra et al., 2002; Heyns, 2004; McAleer et al., 2002). Approximately 5% to 20% of pediatric patients with blunt trauma will have renal trauma (Fraser et al., 2009).

In a review of the US National Trauma Data Bank, approximately 25% of all renal injuries were in patients younger than 19 years of age (Grimsby et al., 2014). Of these, 90% were blunt trauma injuries, with almost 80% grade 1 to 3 injuries. The mean age for pediatric renal trauma is 14 years, with only 6% younger than 5 years of age and only 2% younger than 1 year of age. Around 20% of patients with grade 4 injuries underwent an open operation, and 50% of those with grade 5 injuries underwent open surgery. Minimally invasive treatments such as angioembolization or ureteral stents were seen in about 5% of all cases with 10% to 15% for grade 4 to 5 injuries. **Nephrectomy for pediatric renal trauma is rare, occurring in around 5% of admissions.** Even though nephrectomy is rare, it may be more common when children are managed in adult trauma units when compared with pediatric trauma units (Grimsby et al., 2014). The most common causes of pediatric renal trauma are motor vehicle collisions, falls, bicycle accidents, and sports-related injuries. All-terrain vehicle accidents as a cause of trauma may be increasing over time (Dangle et al., 2016). **Congenital anomalies such as hydronephrosis or ureteropelvic junction (UPJ) obstruction are three to five times more common in children screened by computed tomography (CT) for trauma than in adults** (Brown et al., 1998; Chopra et al., 2002; Heyns, 2004; McAleer et al., 2002). It is unclear if a congenital anomaly increases the risk for renal injury, and most patients with congenital anomalies such as UPJ obstruction who sustain a renal injury will have lower grade injury (Al-Qudah and Santucci, 2006; Chopra et al., 2002; McAleer et al., 2002).

Presentation

Blunt trauma is the most common cause of pediatric renal trauma with motor vehicle collision, falls, sports injuries, pedestrian versus vehicle, all-terrain vehicle, and motorcycle collisions being some of the most common causes (Ishida et al., 2017; Margenthaler et al., 2002; Nance et al., 2004). **Other organ system injuries are present in about 50% of cases of pediatric blunt renal trauma including liver, spleen, head, or orthopedic injuries** (Ishida et al., 2017; Margenthaler et al., 2002; Nance et al., 2004). History of rapid deceleration, such as from a motor vehicle accident or a fall from height, is associated with renal injuries.

On physical examination, flank tenderness or ecchymosis can be seen in severe renal injuries. Fractured ribs can be found as well. Tachycardia and hypotension can be seen with significant blood loss. **However, in children, sympathetic tone may sustain normal blood pressure longer than in adults, even with significant blood loss, making hypotension a less reliable sign for significant blood loss in renal trauma** (Quinlan and Gearhart, 1990).

Gross or microscopic hematuria can be seen in renal trauma, but the absence of hematuria alone does not rule out significant renal trauma in children (Buckley and McAninch, 2004, 2006; Morey et al., 1996). In many if not most cases of pediatric renal trauma, a urologist is not involved with the decision to obtain imaging or not. Most often, the urologist is called after the diagnosis of renal trauma is made by emergency department or trauma physicians.

Indications for Renal Imaging

In adult patients, the presence of gross hematuria or the presence of microscopic hematuria with hypotension (systolic blood pressure <90 mm Hg) were classically used as indications for evaluation for traumatic genitourinary injury. In adults, these two criteria have a sensitivity of 98% for blunt trauma and 90% for penetrating trauma (Heyns, 2004; Mee et al., 1989; Santucci et al., 2004). However, the specificity of these findings in adults is lower, with only 30% of patients with gross hematuria having an identifiable genitourinary injury and 10% of the patients with microscopic hematuria and shock having an identifiable injury (Heyns, 2004; Mee et al., 1989; Santucci et al., 2004).

In children, the presence of hematuria may be a less sensitive indicator of renal injury. Some studies have found that up to two-thirds of children sustaining a grade 2 or higher renal injury will have a normal urine analysis (Buckley and McAninch, 2004, 2006; Morey et al., 1996). As mentioned earlier, children may maintain their blood pressure with blood loss longer than adults, which would make hypotension a less reliable indicator of significant blood loss from a renal injury (Quinlan and Gearhart, 1990). **Mechanism of injury is an important predictor of renal trauma in children.** A significant deceleration or high-velocity injury such as a fall from greater than 10 feet, motor vehicle collision at high speed, or injury to the abdomen or flank with a foreign object are indications for evaluation of genitourinary injury in children. In addition, associated injuries to thoracic organs or intra-abdominal organs and orthopedic fractures of the ribs, spine, femur, or pelvis are associated with genitourinary trauma in children. When these four criteria (hematuria, hypotension, associated injuries, and mechanism of injury) are used in children as the indications for genitourinary imaging for trauma, they have more than a 98% sensitivity of identifying significant genitourinary injuries (Bartley and Santucci, 2012; Bernard, 2009; Buckley and McAninch, 2011; Herschorn et al., 1991). **Gunshot wounds to the abdomen require evaluation for genitourinary trauma.** In addition, stab wounds to areas near the kidney such as the flank, upper abdomen, or lower chest require imaging to evaluate renal trauma.

In light of the previous information, the American Urological Association (AUA) urotrauma guidelines and the European Association of Urology (EAU) urogenital trauma guidelines recommend obtaining imaging to evaluate for blunt renal trauma if there is gross hematuria, microscopic

hematuria, systolic blood pressure <90 mm Hg, a rapid deceleration injury, a significant blow to the flank injury, or if there are suspicious associated injuries or examination findings (rib fracture, flank ecchymosis, associated abdominal injuries, penetrating injury to abdomen) (Table 52.1) (Kitrey et al., 2018; Morey et al., 2014).

TABLE 52.1

Indications for Imaging for Renal Trauma

Stable blunt trauma patients with gross hematuria
Stable blunt trauma patients with microscopic hematuria and systolic blood pressure <90 mmHg
Mechanism of injury concerning for renal injury (rapid deceleration, significant blow to flank, rib fracture, flank ecchymosis)
Penetrating injury of abdomen, flank, or lower chest

Modified from Morey AF, Brandes S, Dugi DD 3rd, et al. Urotrauma: AUA guideline. *J Urol.* 2014;192(2):327–335.

Imaging Studies for Diagnosis

As Low as Reasonably Achievable

The use of CT for evaluation of blunt abdominal trauma is ubiquitous, and several authors have suggested that it is overused for mild trauma in children (Bregstein et al., 2014; Gaither et al., 2018; Streck et al., 2012; Streck et al., 2017). The dose of ionizing radiation from a CT scan is associated with a very small absolute increased risk for subsequent cancers such as leukemia and brain tumors, and the risk increases the younger the age of patient at the time of CT scan (Berrington de Gonzalez et al., 2017; Mathews et al., 2013; Pearce et al., 2012). **Therefore, ALARA (as low as reasonably achievable) is a concept that should be emphasized in pediatric trauma imaging evaluation and follow-up strategies.**

Focused Assessment With Sonography for Trauma

Ultrasonography is an attractive method for evaluating for renal injury because of its wide availability and lack of radiation exposure. The focused assessment with sonography for trauma (FAST) examination has been evaluated as a method for diagnosing renal trauma. Unfortunately, the reported sensitivity is quite variable, with published results ranging from 22% to 96% (Bent et al., 2008; Jang et al., 2004; Lee et al., 2007; McGahan et al., 1999; Nural et al., 2005; Sirlin et al., 2004; Stengel et al., 2015; Suthers et al., 2004; Tsui et al., 2012). When the FAST examination is combined with serial physical examinations for a 24-hour period, a normal FAST examination and normal physical examinations over 24 hours is very good at ruling out any clinically significant renal or intra-abdominal injuries (Bent et al., 2008; Jang et al., 2004; Lee et al., 2007; McGahan et al., 1999; Nural et al., 2005; Sirlin et al., 2004; Suthers et al., 2004; Tsui et al., 2012). **The FAST examination has low sensitivity in diagnosing renal trauma injuries because it is performed in the emergency department, often by emergency department providers, and is usually utilized to look for free fluid in dependent regions of the abdomen and does not specifically evaluate for organ injuries.** None of these studies were done in a pediatric-specific population.

Dedicated Renal Ultrasonography

The comparison of a dedicated renal ultrasonography to CT to diagnose and rule out renal trauma has not been studied extensively in children or adults. In a 2004 prospective study comparing ultrasonography to CT in hemodynamically stable children, ultrasonography missed 2 of 19 (11%) of the renal injuries (Tas et al., 2004). However, the grade or clinical implications of the missed injuries was not given (Tas et al., 2004). In a 2015 study in which 38 patients underwent a focused renal ultrasonography with color Doppler, 35 of 38 patients had a renal injury diagnosed by the ultrasonography. The three patients who were missed had grade 1 renal injuries of likely no clinical significance (Amerstorfer et al., 2015). Given the increasingly nonoperative management of renal trauma and continued focus on limiting radiation exposure in children, more study is needed to define the role of dedicated ultrasonography to diagnose and rule out clinically significant renal trauma. **Because of the lack of studies, the AUA urotrauma guidelines state that ultrasonography can be used for the initial evaluation of renal trauma in children, but CT is preferred** (Morey et al., 2014)**. The EAU pediatric urology guidelines state that ultrasonography can be used as a screening tool for renal injury but that CT scan is the best imaging modality for diagnosis and staging** (Radmayr et al., 2018).

Computed Tomography

For hemodynamically stable patients, CT is currently the most sensitive and specific radiologic test to diagnose and rule out genitourinary trauma. The AUA and EAU trauma guidelines recommend obtaining an IV contrast-enhanced abdominal and pelvic CT scan with immediate and delayed images for the evaluation of renal injury (Kitrey et al., 2018; Morey et al., 2014). In children, a single contrast phase abdominal and pelvic CT scan is often obtained to limit radiation exposure or because of a lack of knowledge about recommended imaging (Fuchs et al., 2018). The obvious limitation of this is that the accuracy in diagnosing urine extravasation and isolated ureteral injuries is decreased, especially in patients with a urinoma or with deep or multiple lacerations (Hardee et al., 2013b). However, in the current era of nonoperative management, some question exists whether obtaining a routine delayed-phase CT in children affects outcomes (Fuchs et al., 2018). In our experience, the radiologist can do a delayed CT phase in real time if there are findings on the nephrogram phase concerning for urine leak (e.g., perinephric fluid collection or deep/multiple renal lacerations), which may avoid unnecessary radiation exposure for the delayed phase (Fuchs et al., 2018; Hardee et al., 2013b; Santucci et al., 2004). **The EAU urogenital trauma guidelines acknowledge that practically, the initial CT scan is often a single phase, and additional phases can be obtained if renal injury is not characterized well enough** (Kitrey et al., 2018).

Classification and Grading of Renal Injuries

AAST Grading System

The American Association for the Surgery of Trauma (AAST) renal organ injury scale (OIS) was created in 1989 and is the most widely used grading system, but a proposed revision was published in 2011 (Table 52.2) (Buckley and McAninch, 2011; Moore et al., 1989). The proposed revision was created to help clarify and classify high-grade renal injuries (grade 4 to 5). The kidney with multiple lacerations into the collecting system (shattered kidney) was moved from a grade 5 classification to a grade 4 classification. In the 2011 proposed revision, only main renal artery or vein laceration or avulsion and main renal artery or vein thromboses are included as grade 5 injuries. Renal pelvic laceration or UPJ disruption injuries were classified in the 2011 revision as grade 4 injuries. The 1989 AAST OIS and the 2011 revised renal injury grading system are shown in Table 52.2. Examples of these injuries are shown in Figs. 52.1 to 52.3. **The AAST OIS grade of injury is associated with need for intervention and risk for developing complications in adults and in children** (Buckley and McAninch, 2011; Grimsby et al., 2014; Margenthaler et al., 2002; Nance et al., 2004; Shariat et al., 2007). As the risk for intervention, complications, and subsequent loss of kidney function is negligible for grade 1 to 3 injuries, some have categorized these as low-grade renal injuries and grade 4 to 5 as high-grade injuries (Au et al., 2016; Dugi et al., 2010; Hardee et al., 2013a; Nerli et al., 2011; Okur et al., 2017; van der Wilden et al., 2013).

TABLE 52.2

Renal Injury: 1989 American Association for the Surgery of Trauma Organ Injury Scale and 2011 Revised Injury Staging Classification

GRADE OF RENAL INJURY	1989 AMERICAN ASSOCIATION FOR THE SURGERY OF TRAUMA ORGAN INJURY SCALE	2011 PROPOSED REVISION
1	Subcapsular hematoma that is nonexpanding without	Subcapsular hematoma and/or contusion

	laceration Microscopic or gross hematuria with normal urologic studies	No collecting system injury
2	Nonexpanding perirenal hematoma confined to renal retroperitoneum Laceration <1 cm in depth into cortex without urinary extravasation	Laceration <1 cm in depth and into cortex, small hematoma contained within Gerota fascia No collecting system injury
3	Laceration >1 cm into parenchyma without collecting system rupture or urinary extravasation	Laceration >1 cm in depth and into medulla, hematoma contained within Gerota fascia No collecting system injury
4	Parenchymal laceration extending through the renal cortex, medulla, and collecting system Main renal artery or vein injury with contained hemorrhage	One or more lacerations through the parenchyma into the urinary collecting system with urinary extravasation Vascular segmental vein or artery injury Renal pelvis laceration and/or complete ureteropelvic junction disruption
5	Completely shattered kidney Avulsion of renal hilum, which vascularizes kidney	Main renal artery or vein laceration or avulsion Main renal artery or vein thrombosis

Modified from Moore EE, Shackford SR, Pachter HL, et al. Organ injury scaling: spleen, liver, and kidney. *J Trauma.* 1989;29(12):1664–1666; Buckley JC, McAninch JW. Revision of current American Association for the Surgery of Trauma Renal Injury grading system. *J Trauma*. 2011;70(1):35–37.

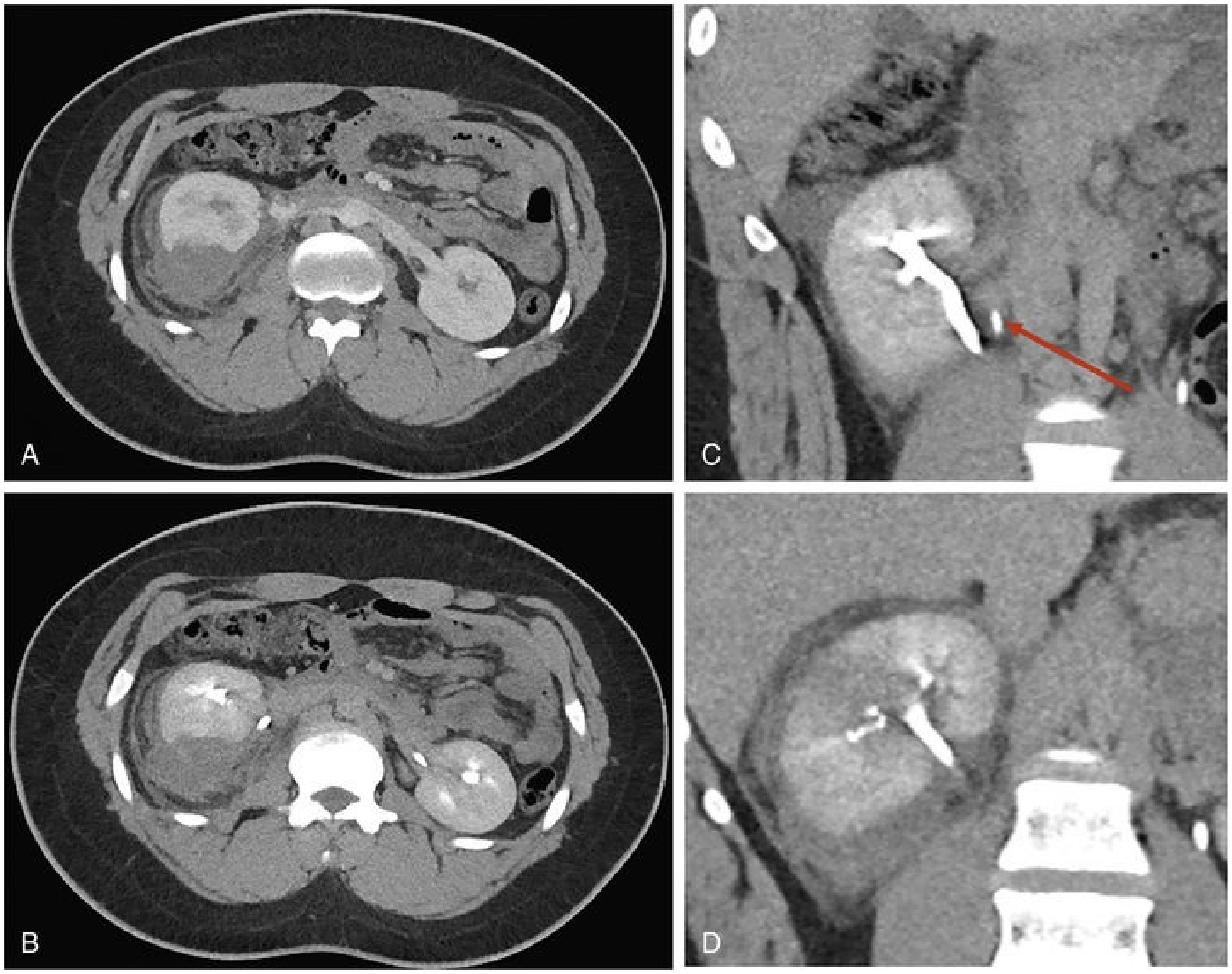

FIG. 52.1 Grade 2 right renal laceration with perirenal hematoma. Immediate phase (A) and delayed phase (B). Note bifid collecting system with lower pole (C) with upper pole ureter *(red arrow)* and upper pole (D).

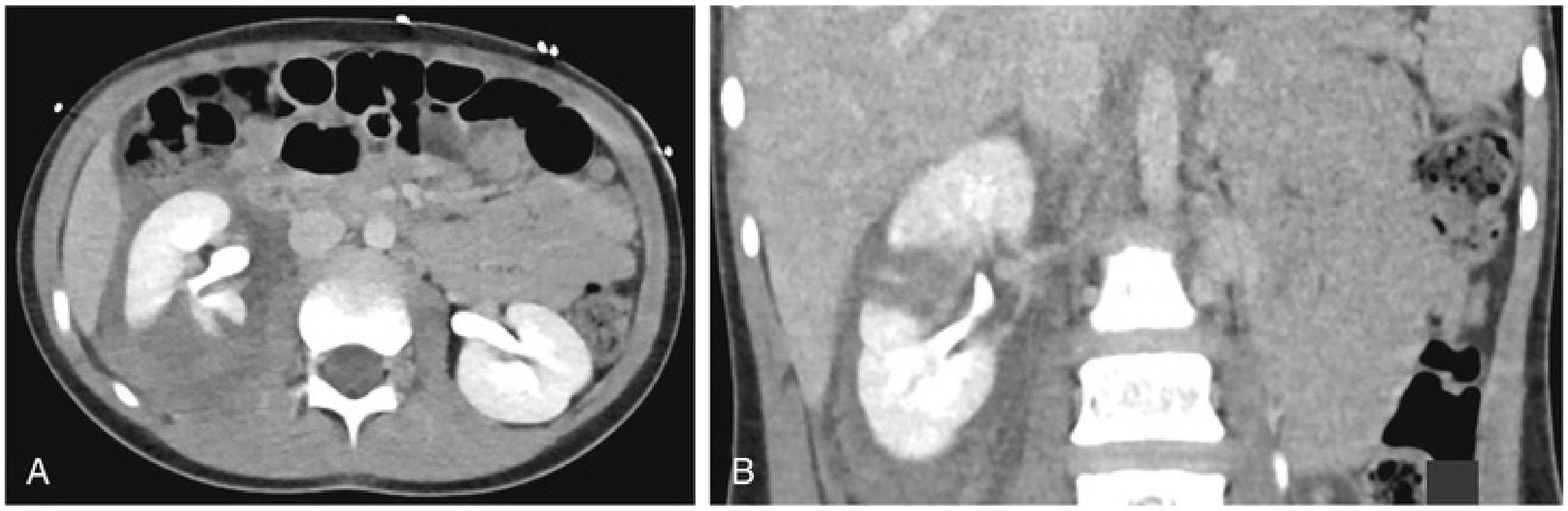

FIG. 52.2 (A) Grade 3 right renal laceration on delayed phases. (B) Laceration greater than 1 cm in depth but no extravasation of contrast on delayed phase.

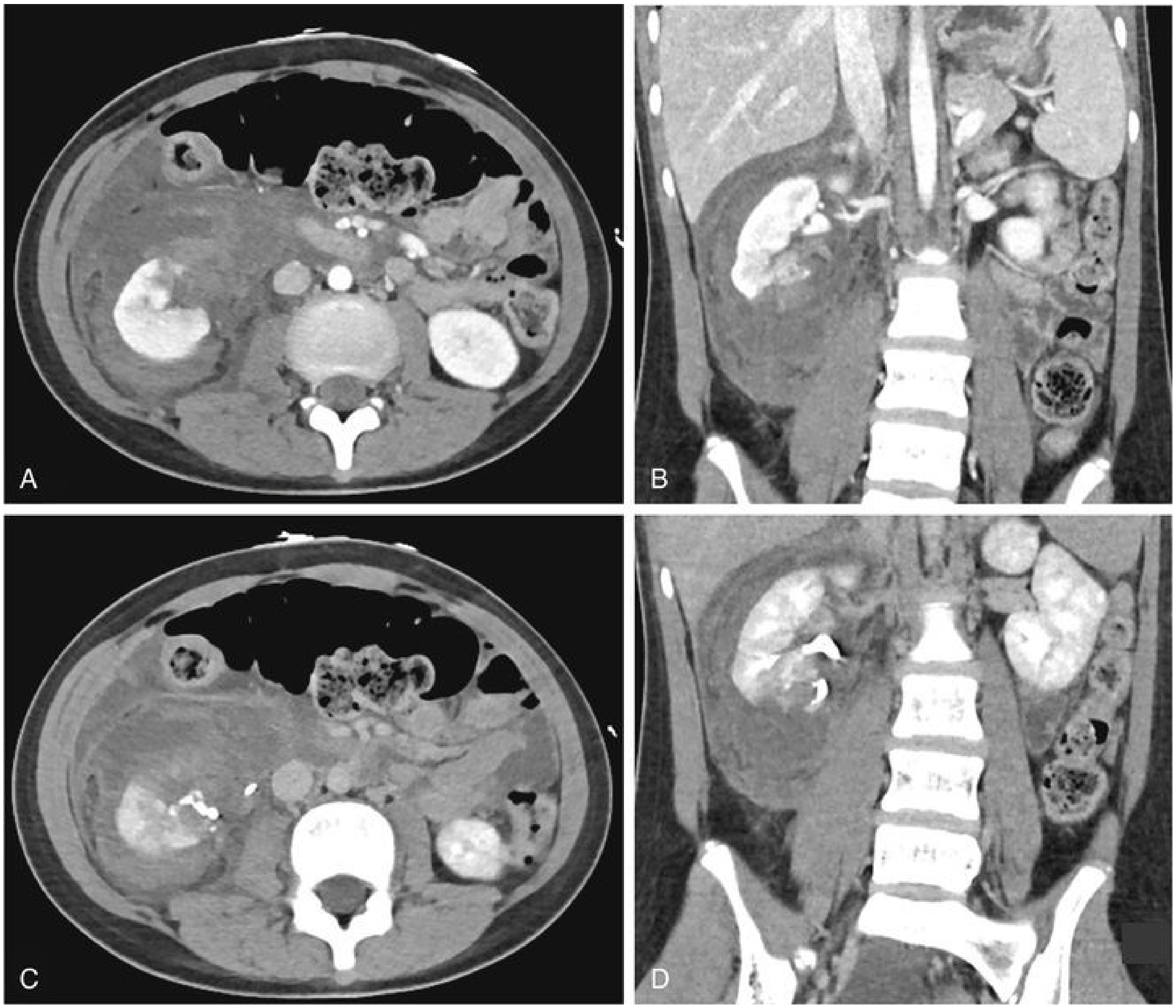

FIG. 52.3 Grade 4 right renal laceration. Immediate contrast phases show laceration (A and B) with delayed phases showing extravasation of contrast from collecting system (C and D).

High-Risk Criteria

Some specific findings for grade 4 to 5 injuries on CT scan are associated with subsequent intervention. **Medial extravasation of contrast is worrisome for possible ureteropelvic junction disruption and is associated with intervention** (Al-Qudah and Santucci, 2006; Bartley and Santucci, 2012; Kawashima et al., 1997)**. Lack of contrast seen in the ureter in the setting of grade 4 injury is associated with subsequent intervention for urine leak in pediatric series** (Au et al., 2016; Cannon et al., 2008)**. If greater than 25% of renal parenchyma is devitalized, this has been associated with a significantly higher rate of angioembolization and open surgery** (Long et al., 2013). A large perirenal hematoma (>3.5 cm), vascular contrast extravasation, and medial renal laceration have been associated with undergoing procedure for bleeding such as angioembolization (Charbit et al., 2011; Dugi et al., 2010; Figler et al., 2013; Hardee et al., 2013a; Lin et al., 2013; Nuss et al., 2009). The risk for intervention has been associated with the number of these risk factors present (perirenal hematoma greater than 3.5 cm, vascular extravasation, and medial laceration), with 1 or fewer risk factors having less than 10% intervention risk and two to three risk factors having greater than 50% risk for intervention (Dugi et al., 2010; Figler et al., 2013; Hardee et al., 2013a). These high-risk criteria have also been associated with intervention in children and with perirenal hematoma greater than 2.2 cm associated with intervention (Lee et al., 2016). These high-risk criteria are important predictors of intervention in high-grade renal trauma, and many leaders in the field recommend revision of the AAST OIS to reflect these findings (Chiron et al., 2016; Dugi et al., 2010; Figler et al., 2013; Hardee et al., 2013a). Reported high-risk criteria are shown in Table 52.3, and examples of these findings on CT imaging are shown in Fig. 52.4.

TABLE 52.3

High-Risk Criteria for Intervention in Grades 4 to 5 Renal Injuries

Large perirenal hematoma (>3.5 cm for adults, >2.2 cm for children)
Vascular contrast extravasation
Medial renal laceration
>25% of renal parenchyma devitalized
Medial extravasation of urine during excretory phase
Urine extravasation and lack of contrast seen in distal ureter during excretory phase

Modified from Au JK, Tan X, Sidani M, et al. Imaging characteristics associated with failure of nonoperative management in high-grade pediatric blunt renal trauma. *J Pediatr Urol*. 2016;12(5):294.e1–294.e6; Canon S, Recicar J, Head B, et al. The utility of initial and follow-up ultrasound reevaluation for blunt renal trauma in children and adolescents. *J Pediatr Urol*. 2014;10(5):815–818; Dugi DD 3rd, Morey AF, Gupta A, et al. American Association for the Surgery of Trauma grade 4 renal injury substratification into grades 4a (low risk) and 4b (high risk). *J Urol*. 2010;183(2):592–597; Figler BD, Malaeb BS, Voelzke B, et al. External validation of a substratification of the American Association for the Surgery of Trauma renal injury scale for grade 4 injuries. *J Am Coll Surg*. 2013;217(5):924–928; Hardee MJ, Lowrance W, Brant WO, et al. High grade renal injuries: application of Parkland Hospital predictors of intervention for renal hemorrhage. *J Urol*. 2013a;189(5):1771–1776; Long JA, Fiard G, Descotes JL, et al. High-grade renal injury: non-operative management of urinary extravasation and prediction of long-term outcomes. *BJU Int*.

2013;111(4 Pt B):E249–E255.

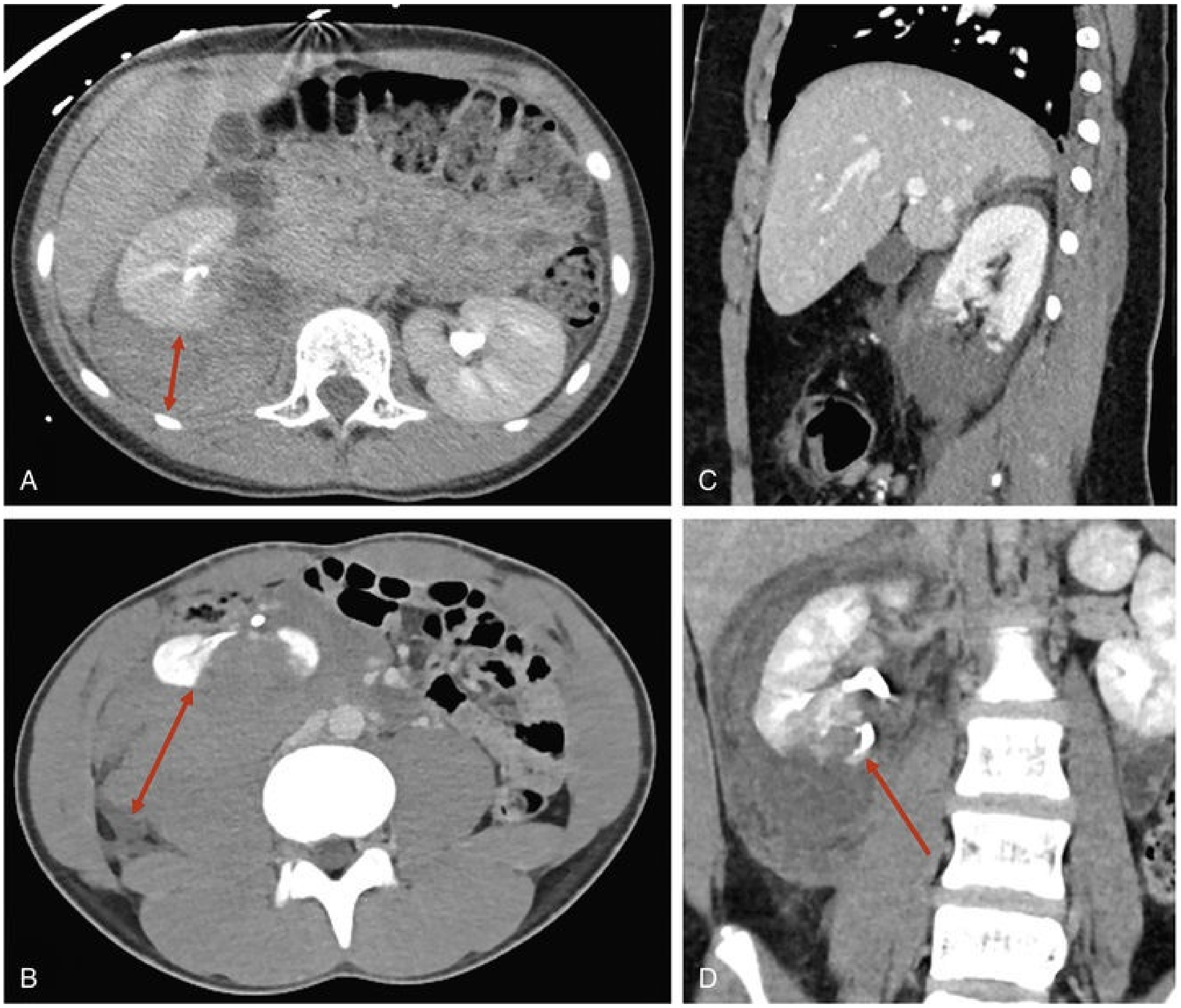

FIG. 52.4 Examples of high-risk criteria for intervention. Large perirenal hematomas (A and B). *Arrows* indicate the size of the perirenal hematoma. Significant amount of devascularized parenchyma (C). Medial extravasation of contrast on delayed phase (D). The *arrow* indicates medial extravasation of contrast.

Blunt Versus Penetrating

The distinction between blunt and penetrating genitourinary trauma affects the decision to obtain imaging and pursue surgical exploration. **In general, any significant penetrating injury to the abdomen, flank, or lower chest should lead to an evaluation for genitourinary trauma** (Kitrey et al., 2018; Morey et al., 2014). This applies to patients with penetrating abdominal injury who are hemodynamically stable and without hematuria (Kitrey et al., 2018; Morey et al., 2014). If a patient with penetrating abdominal trauma is unstable or has other injuries that require repair and an exploratory laparotomy is performed, the retroperitoneum and ureters should be inspected, and surgeons should have a high index of suspicion for renal or ureteral injury, especially with high-velocity gunshot wounds.

Management

The majority of pediatric renal trauma is managed nonoperatively, and this is a strong recommendation by the EAU pediatric urology guidelines (Ishida et al., 2017; LeeVan et al., 2016; Margenthaler et al., 2002; Nance et al., 2004; Radmayr et al., 2018). The vast majority of grade 1 to 3 injuries do not require any intervention, let alone open surgery (Buckley and McAninch, 2011; Grimsby et al., 2014; Ishida et al., 2017; LeeVan et al., 2016; Margenthaler et al., 2002; Nance et al., 2004; van der Wilden et al., 2013). Grade 4 and 5 injury patients have a higher risk for undergoing an intervention (Au et al., 2016; Buckley and McAninch, 2011; Eassa et al., 2010; Grimsby et al., 2014; Richards et al., 2017; van der Wilden et al., 2013). **The interventions most often required are endoscopic or percutaneous, such as percutaneous nephrostomy tube, ureteral stent, percutaneous drain placement, and angioembolization** (Au et al., 2016; Buckley and McAninch, 2011; Eassa et al., 2010; Grimsby et al., 2014; Ishida et al., 2017; Margenthaler et al., 2002; Nance et al., 2004; Richards et al., 2017; van der Wilden et al., 2013).

Nonoperative

In addition to numerous publications in adults supporting nonoperative management of renal trauma, several publications have confirmed the safety and efficacy of nonoperative management for renal trauma in children (Broghammer et al., 2006; Henderson et al., 2007; Ishida et al., 2017; LeeVan et al., 2016; Margenthaler et al., 2002; Nance et al., 2004; Richards et al., 2017; Tsui et al., 2012). **The nephrectomy rate has been reported to be higher with surgical exploration than with nonoperative management in multiple series in adults and one series in children** (Jacobs et al., 2012). For a patient to be eligible for a nonoperative management protocol, they must either be hemodynamically stable or able to be resuscitated adequately and remain stable after resuscitation. **The**

ideal candidate for a nonoperative management protocol is a patient with a grade 1 to 3 injury from blunt trauma who has no other associated injuries that require surgery and is hemodynamically stable. However, even children with grade 4 to 5 injuries have been successfully managed nonoperatively with series reported from several centers (Au et al., 2016; Eassa et al., 2010; Henderson et al., 2007; LeeVan et al., 2016; Nerli et al., 2011; Okur et al., 2017; Umbreit et al., 2009). In addition, nonoperative management of penetrating renal trauma has favorable outcomes (Bjurlin et al., 2011; Moolman et al., 2012; Wessells et al., 1997).

Nonoperative Management Protocol

The first steps in nonoperative management are to confirm lack of hemodynamic instability and grade the renal injury. The AUA and EAU guidelines state that in children a dedicated renal ultrasonography is an option, but a contrast-enhanced CT scan of the abdomen and pelvis with immediate and delayed phases is preferred (Kitrey et al., 2018; Morey et al., 2014; Radmayr et al., 2018). However, perhaps in the future, dedicated renal ultrasonography will be enough to confirm the absence of a significant retroperitoneal hematoma, deep laceration, or urinoma and thereby avoid CT in certain stable patients with grade 1 to 3 renal injuries (Amerstorfer et al., 2015; Tas et al., 2004). At our institution, the patient is placed on bed rest, serial hemoglobin/hematocrit measurements are obtained, and an abdominal examination is performed. Bed rest is typically continued until gross hematuria has resolved and blood counts have remained stable. The duration of bed rest and intensity of observation varies by injury severity. A grade 1 to 2 renal injury without gross hematuria and no decline in hemoglobin/hematocrit may require only a 23-hour observation with two serial blood tests. At the other end of the spectrum, a grade 4 renal injury with a large perirenal hematoma with vascular contrast extravasation on CT scan and ongoing gross hematuria may require Intensive Care Unit admission, blood draws every 4 to 6 hours, potential blood transfusions, and most likely angioembolization.

Early Repeat Imaging

The AUA urotrauma guidelines recommend a repeat contrast-enhanced CT scan of the abdomen and pelvis 48 hours after injury for grade 4 to 5 injuries, but the

EAU urogenital trauma guidelines state that repeat imaging can be omitted for grade 1 to 4 injuries as long as there are no clinical concerns for missed complication (Kitrey et al., 2018; Morey et al., 2014). In children, there is more attention on avoiding unnecessary radiation from CT scans and adhering to the ALARA concept. If the patient is stable and doing well on nonoperative management, it is unclear what utility a repeat CT scan has over dedicated renal ultrasonography (Canon et al., 2014; Eeg et al., 2009; Gaither et al., 2018). At our institution, we typically obtain follow-up renal ultrasonography in 48 to 72 hours for a high-grade injury instead of repeat abdominal CT, and we only obtain a repeat abdominal CT scan if the renal ultrasound scan does not provide enough information to guide clinical management. However, even the utility of routine repeat ultrasonography in 48 hours in grade 4 to 5 injuries has been called into question if the patient is stable and doing well on nonoperative management without apparent complications (Canon et al., 2014).

Outcomes of Nonoperative Management

Several series in the adult literature and one series in children have shown a lower nephrectomy rate with nonoperative management compared with the operative approach (Broghammer et al., 2007; Cass and Ireland, 1973; Cass et al., 1987; Hammer and Santucci, 2003; Jacobs et al., 2012; Kristjansson and Pedersen, 1993). In children, several series have also shown that the vast majority of renal trauma cases can be managed nonoperatively (Broghammer et al., 2006; Henderson et al., 2007; Ishida et al., 2017; LeeVan et al., 2016; Margenthaler et al., 2002; Nance et al., 2004; Richards et al., 2017; Tsui et al., 2012). **The risk for intervention is significantly higher in grade 4 to 5 injuries and penetrating injuries, but these patients can be managed successfully nonoperatively in the majority of patients who are hemodynamically stable** (Bjurlin et al., 2011; Buckley and McAninch, 2011; Eassa et al., 2010; Grimsby et al., 2014; Henderson et al., 2007; Kansas et al., 2004; Moolman et al., 2012; Nerli et al., 2011; Okur et al., 2017; van der Wilden et al., 2013; Wessells et al., 1997).

Management of Complications in Nonoperative Patients

Patients on a nonoperative management protocol may develop complications, and urologists need to be aware of the management issues. The risk for complications increases with grade of injury and is close to 0% for grade 1 to 2 injuries and for grade 3 injuries without devitalized segments. Hemodynamically stable patients with grade 3 injuries with devitalized segments to grade 5 injuries have around a 25% risk for bleeding requiring angioembolization and a 15% risk for urinoma requiring intervention. **Only around 5% of patients will undergo open surgical exploration for a complication that cannot be managed nonoperatively or with percutaneous/endoscopic intervention** (Cannon et al., 2008; Dangle et al., 2016; Eassa et al., 2010; Hammer and Santucci, 2003; Henderson et al., 2007; Ishida et al., 2017; LeeVan et al., 2016; Nance et al., 2004; Nerli et al., 2011; Okur et al., 2017; Richards et al., 2017; Santucci et al., 2004; Tsui et al., 2012; Umbreit et al., 2009; van der Wilden et al., 2013).

Persistent Urine Leak

By definition, grade 1 to 3 injuries do not have a laceration into the collecting system, and grade 4 to 5 injuries can have urine leaks. The most common location for a urine leak is at a renal laceration site, but it can be seen from a renal pelvis rupture, ureteral injury, or UPJ disruption. **The AUA urotrauma and EAU urogenital trauma guidelines state that renal injuries with a urine leak can be managed nonoperatively** (Kitrey et al., 2018; Morey et al., 2014). In patients with urine leak, it is important to evaluate the renal pelvis and ureter for UPJ disruption injury and renal pelvis rupture. This can be done by CT scan with delayed images or by retrograde pyelography.

Although most urine leaks from renal lacerations can be managed without intervention, some will require percutaneous drainage of the urinoma or diversion of the urine away from the urine leak with either percutaneous nephrostomy tube and/or ureteral stent. It is estimated that up to 85% of urine leaks will resolve spontaneously and not have an intervention (Alsikafi et al., 2006; Henderson et al., 2007; Umbreit et al., 2009). It is unclear if a Foley catheter improves the chances or speed of urine leak resolution, but is often placed to facilitate bladder drainage for 2 to 3 days initially after the trauma. In addition, the use of IV antibiotics (typically IV cefazolin) is commonly used when there is a urine leak, but there is no published data showing that this practice decreases infectious complications.

Indications for Intervention for Urine Leak or

Urinoma

The classic triad of a symptomatic persistent urinoma after renal trauma is ipsilateral flank pain, ileus, and low-grade fever. Clearly, some urinomas are more symptomatic than others, and we recommend use of shared decision making with patients and families rather than a strict algorithm when deciding whether to intervene or continue observation for symptomatic urinomas. A very large, symptomatic urinoma may be best managed by early intervention, and a small, mildly symptomatic urinoma can be observed longer and potentially avoid intervention.

Another indication for evaluation and potential intervention is urine leak with no contrast seen in the distal ureter on the urogram phase of CT. This could be a UPJ disruption or significant injury to the renal pelvis, which may need immediate repair or at least urine drainage (Au et al., 2016; Kawashima et al., 1997). Therefore, a cystoscopy with retrograde pyelography is recommended for evaluation (Fig. 52.5). If the retrograde pyelogram does not show UPJ disruption or renal pelvis laceration, some recommend ureteral stent placement in this situation. This recommendation is based on the observation that patients with urine leak after renal trauma and no contrast seen in ipsilateral ureter at time of initial CT scan are at higher risk for developing symptomatic urinoma if they do not have a ureteral stent placed (Au et al., 2016; Cannon et al., 2008).

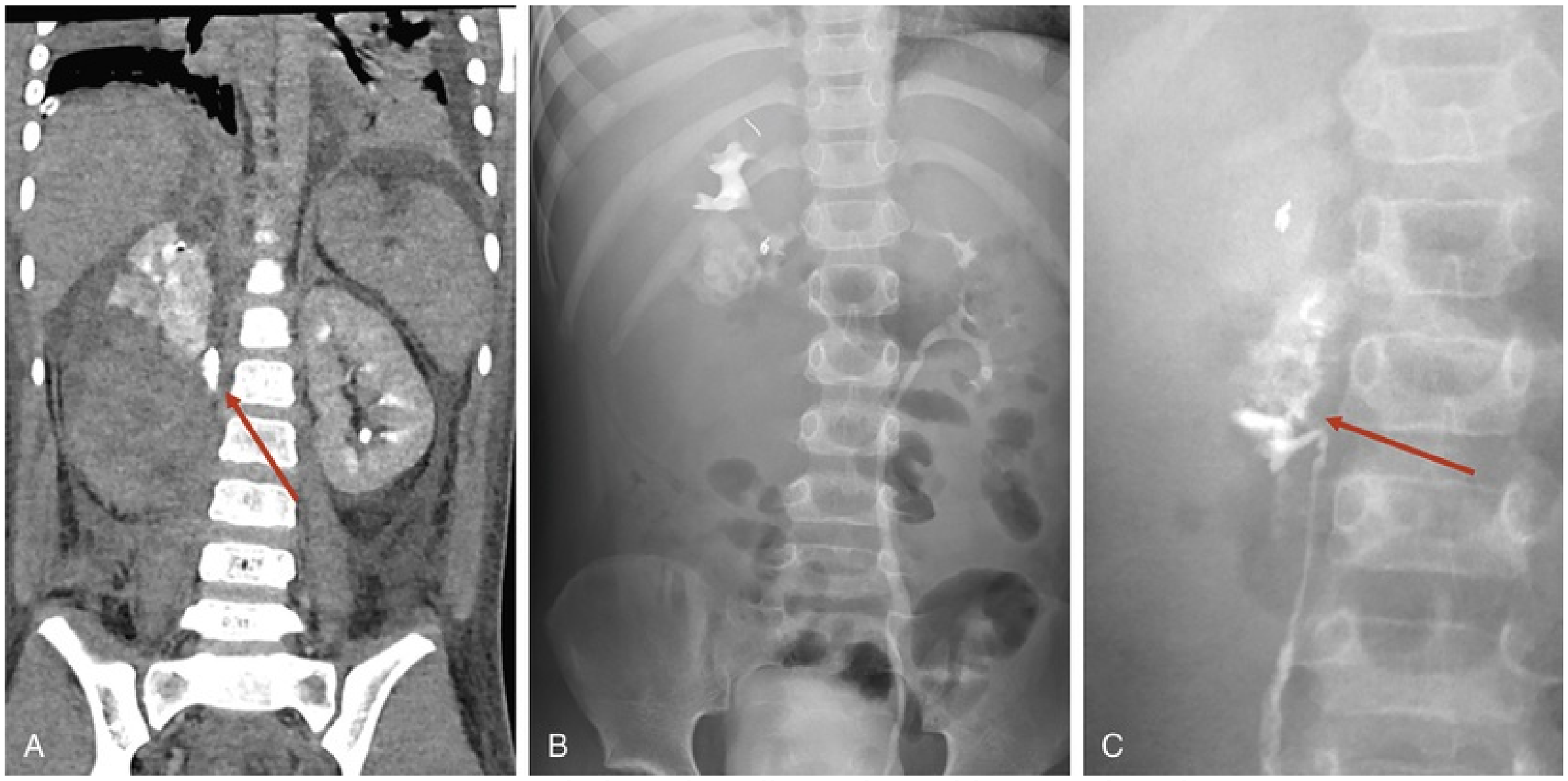

FIG. 52.5 Ureteropelvic junction disruption with associated renal parenchymal injury. There is medial extravasation of contrast *(red arrow)* and significant amount of devitalized parenchyma on the right lower pole

(A). An intravenous pyelogram failed to show any contrast in the right ureter (B); note the coil from selective angioembolization is also visible. Retrograde pyelogram confirmed ureteropelvic junction disruption *(red arrow)* (C).

Ureteral Stent

Based on expert opinion, the AUA urotrauma guidelines recommend starting with a ureteral stent if the intervention is performed for a urine leak or urinoma and augmenting urine drainage with percutaneous drainage if needed (Morey et al., 2014). **The EAU guidelines state that ureteral stent placement and/or percutaneous drainage often leads to resolution of urinary extravasation** (Kitrey et al., 2018). Placement of a ureteral stent and Foley catheter has been reported to resolve 90% of symptomatic urinomas (Alsikafi et al., 2006; Au et al., 2016; Reese et al., 2014; Umbreit et al., 2009). We typically leave the Foley catheter for 1 to 2 days after symptoms from urinoma have resolved, evaluate urinoma size with renal ultrasonography, remove the Foley catheter, and observe for at least another day for recurrent symptoms. Although the Foley catheter is in place, IV Ancef is often given, but this is not based on any good guidance from literature. The ureteral stent is then removed 4 to 6 weeks later, with consideration given to renal ultrasonography before removal. We often use prophylactic antibiotics while the ureteral stent is in place, but it is unclear if this is necessary.

The advantages of using ureteral stents include their minimally invasive nature and the lack of any external drainage tubes or devices that can be dislodged, which can be an issue in the pediatric population. The disadvantages of ureteral stents are the need for anesthesia for placement and removal in the pediatric population; symptoms from indwelling double-*J* ureteral stents can be quite bothersome, especially to pubertal patients; there is a potential for clogging or blockage; and it can be more difficult to determine if a urine leak has resolved compared to a percutaneous drain.

Percutaneous Drain

Placement of a percutaneous drain into the urinoma is another intervention for symptomatic urinomas. This is often used if a ureteral stent does not lead to resolution of symptoms from a urinoma, especially a very large urinoma.

However, it can be used as the first intervention for a urinoma (Russell et al., 2001; Umbreit et al., 2009). Fig. 52.6 shows a case of a symptomatic urinoma treated by percutaneous drain placement without Foley catheter placement that led to resolution in 3 days. The drain was then removed without anesthesia. If the family elects to proceed with percutaneous drain placement initially, we discuss Foley catheter placement as a method to potentially facilitate drainage as well. Drain output is followed, and the drain is removed once output is minimal and renal ultrasonography shows resolution of urinoma. The need for repeat renal ultrasonography to ensure urinoma resolution if symptoms have resolved is unclear but is typically obtained.

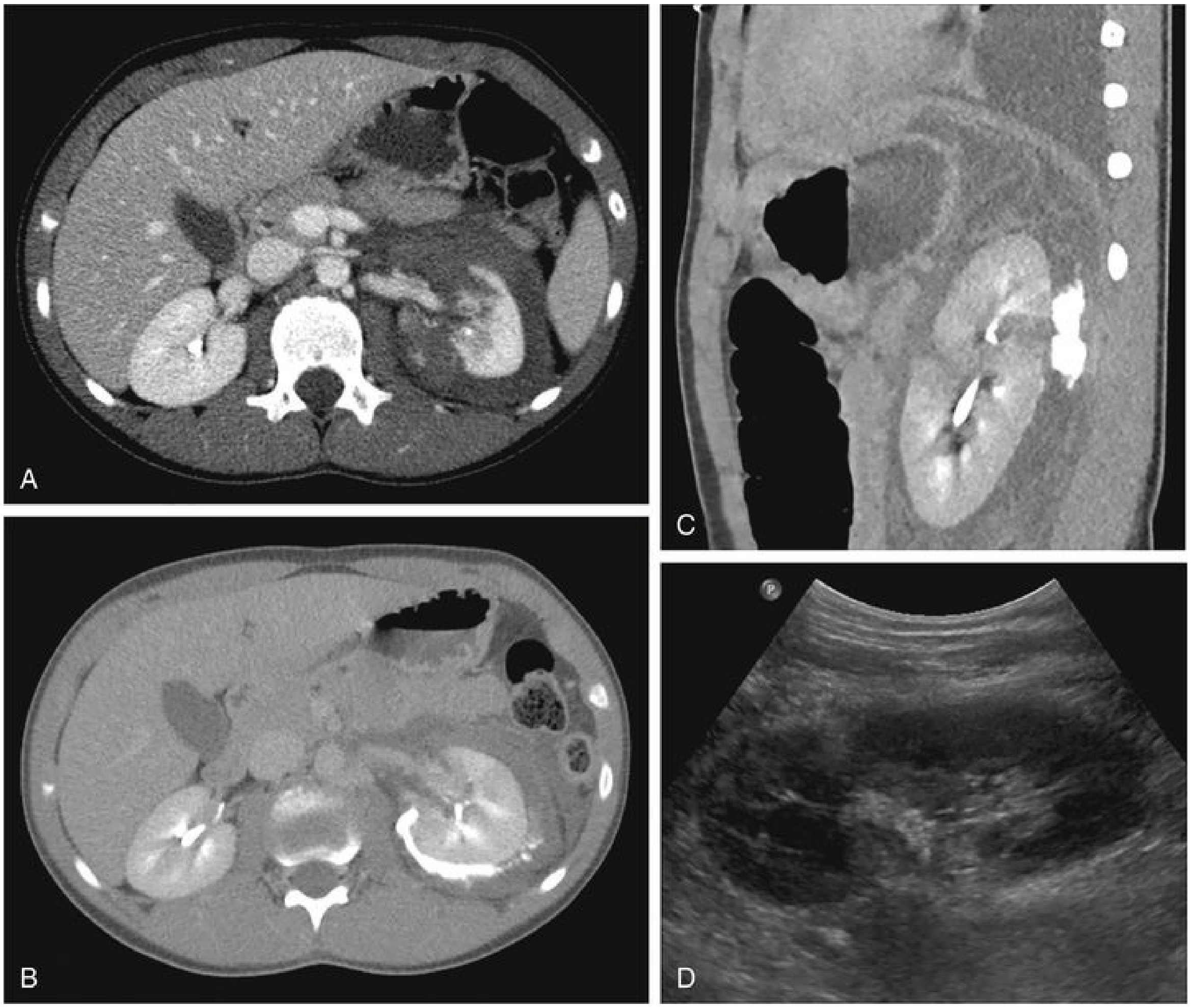

FIG. 52.6 Grade 4 renal laceration managed with percutaneous drain into urinoma only. Initial CT scan day of injury showing contrast extravasation (A and B). Repeat CT scan 2 days later obtained because of fever and worsening abdominal pain showing atelectasis in left lung and persistent extravasation of contrast (C). Percutaneous drain placed and removed 3

days later with follow-up ultrasonography 2 months in future (D).

The advantages of percutaneous drain placement are rapid resolution of symptoms from the urinoma, ability to monitor output from the drain, and ability to remove the drain without the need for anesthesia. The disadvantages of percutaneous drain placement include the need for anesthesia and interventional radiology for placement, the possibility of dislodgement, and the possible need for a ureteral stent.

Nephrostomy Tube

Nephrostomy tube placement is another method for diverting urine away from a urine leak. We favor ureteral stent placement or percutaneous drain into a urinoma initially over nephrostomy tube placement because of the risk for kidney injury and bleeding with nephrostomy tube placement. **Nephrostomy tube placement alone is rarely used for symptomatic urinoma and urine leak.** Nephrostomy tube placement combined with antegrade ureteral stent placement has a high resolution rate for symptomatic urinomas (Al-Qudah and Santucci, 2006; Umbreit et al., 2009). In a patient with persistent urine leak after ureteral stent placement and percutaneous drain placement into a urinoma, we consider nephrostomy tube placement. Also, in a patient who cannot be placed in the lithotomy position because of other injuries, a nephrostomy tube with antegrade ureteral stent placement is an option.

Angioembolization of Isolated Renal Segment

In persistent urine leaks from an isolated renal parenchymal segment not in continuity with the rest of the collecting system that fails to resolve with ureteral stent placement, nephrostomy, and percutaneous urinoma drain, angioembolization of the isolated renal segment is a useful option. This is a very rare situation to encounter, but some have reported success with this technique (Akbari et al., 2016; Pinto and Chimeno, 1998).

Renal Exploration With Repair of Urine Leak

The need for renal exploration to repair a urine leak from a renal laceration is thankfully quite rare as most resolve with observation or minimally invasive procedures, however, it has been reported (Henderson et al., 2007; Lee et al., 2016; Long et al., 2013; Reese et al., 2014). **Open repair would only be considered after a significant period of observation for the urine leak and multiple minimally invasive procedures.** Principles of repair would be to debride any devitalized tissue, close the collecting system with absorbable sutures, repair the renal parenchyma over a bolster, and adequately drain with a ureteral stent and perinephric drain. The risk for renal loss or nephrectomy should be discussed with the patient and family.

Persistent or Delayed Bleeding

Indications for Angioembolization

Around 25% of grade 3 to 5 renal injuries managed nonoperatively will have persistent bleeding or develop a delayed bleed that requires an intervention (Al-Qudah and Santucci, 2006; Kansas et al., 2004; LeeVan et al., 2016). As stated earlier, high-risk criteria such as perirenal hematoma size, vascular contrast extravasation, and medial renal laceration are risk factors for needing angioembolization in high-grade renal injuries (Dugi et al., 2010; Figler et al., 2013; Hardee et al., 2013a). Persistent bleeding after injury is typically caused by the injured blood vessels failing to tamponade. Delayed bleeding can be caused by the development of an arteriovenous fistula or a pseudoaneurysm in an injured artery that ruptures after a period. Some theorize that resolution or liquification of the hematoma that was tamponading the arteriovenous fistula or pseudoaneurysm leads to the delayed bleed. **Delayed bleeds typically develop 1 to 2 weeks postinjury but can occur up to 1 month postinjury.**

For persistent bleeding in a hemodynamically stable patient, we typically allow a patient to receive two to three blood transfusions before recommending angioembolization. However, if a patient is having trouble maintaining stable blood pressure, is transiently hemodynamically unstable from active bleeding, or we are concerned about rapid bleeding, more urgent angioembolization is undertaken. In some series, most cases of delayed bleeding require intervention to resolve (Goffette and Laterre, 2002). Therefore, when a patient presents with a delayed bleed after renal trauma, we are more likely to recommend early angioembolization unless the bleeding is mild and stopped spontaneously.

Superselective angioembolization has a high success rate for resolution of persistent and delayed bleeding, with most series reporting over 80% success in adults and children (Au et al., 2016; Breyer et al., 2008; Eassa et al., 2010; Henderson et al., 2007; LeeVan et al., 2016; Mohsen et al., 2008; Nance et al., 2004; Reese et al., 2014; Umbreit et al., 2009)**. Even if initial angioembolization is not successful, a repeat angioembolization can be performed with success** (Hotaling et al., 2011; Mohsen et al., 2008). The procedure is typically performed by interventional radiologists, and the goal is to embolize the smallest amount of viable parenchyma and still stop bleeding. Even with superselective embolization, some functional renal parenchyma will likely be lost (Mohsen et al., 2008). The amount of preserved renal function lost depends on the degree of initial injury and the embolization procedure, but the retained differential renal function after grade 4 injuries has been reported at 35% to 45% and after grade 5 injuries at 10% to 30% (Fiard et al., 2012; Keller et al., 2004; Tasian et al., 2010).

Complications of renal angioembolization include postembolization syndrome, persistent bleeding, and postembolization abscess. **Postembolization syndrome is a self-limited condition, which includes flank pain, fever, and possible ileus and occurs in less than 10% of these patients. The symptoms typically resolve within 3 to 4 days** (Breyer et al., 2008)**. If the fever persists, evaluation for postembolization abscess is indicated.** Repeat CT is usually the best way to evaluate for postembolization abscess, and placement of a drain into any concerning fluid collection could then be performed. Persistent or recurrent bleeding can be seen in a minority of cases after angioembolization (Breyer et al., 2008). Repeat angioembolization is usually successful, and this is what we recommend if the patient is hemodynamically stable (Hotaling et al., 2011; Mohsen et al., 2008). However, if bleeding persists after repeat angioembolization, the need for renal exploration should be considered.

Renal Exploration

Renal exploration for persistent or delayed bleeding during initial nonoperative management of a renal injury occurs in a small percentage of cases (LeeVan et al., 2016; Umbreit et al., 2009; van der Wilden et al., 2013). The goals of exploration at this time are similar to the goals of renal exploration for unstable patients at the time of initial presentation, but patients are typically more stable. **The goals include isolation and control of renal vasculature, complete exposure of the area of injury, debridement of any devitalized tissue, closure of collecting system defects, closure of renal parenchyma over a bolster, and adequate drainage of the area.**

Key Points: Nonoperative Management and Complications During Nonoperative Management

- The majority of renal trauma can be managed nonoperatively. Grade 4 to 5 injuries can be managed nonoperatively but have higher risk for intervention.

- Around 25% of patients with grade 3 to 5 injuries being managed nonoperatively will have persistent or delayed bleeding. Superselective angioembolization of bleeding vessels is very successful and is the preferred method for management. Repeat angioembolization can also be successful if the initial attempt fails.
- Approximately 15% of patients with a urine leak being managed nonoperatively will have an indication for intervention such as ureteral stent placement and/or percutaneous drain placement.
- Repeat CT imaging 48 to 72 hours after injury is not needed for patients with grade 1 to 3 injuries who are recovering without complication. Repeat CT imaging in 48 to 72 hours may be obtained in patients with grade 4 to 5 injuries but is of unclear utility if the patient is recovering without apparent complication.

Operative

Indications

The primary indication for renal exploration is persistent hemodynamic instability caused by renal bleeding. If, at the time of surgical exploration of an unstable patient without prior imaging, a pulsatile and expanding retroperitoneal hematoma is found, that kidney should be explored due to evidence of persistent renal bleeding leading to the hemodynamic instability (Kitrey et al., 2018). **Another indication for operative intervention is a patient with known renal bleeding that cannot be controlled by selective angioembolization.** In an unstable patient with an inadequately staged renal trauma or a renal trauma with known devitalized segments at the time of exploration who is found to have a nonpulsatile retroperitoneal hematoma, the decision to explore that kidney is less clear. In the past, some have advocated for renal exploration for those with a nonpulsatile hematoma at time of exploratory laparotomy in the setting of penetrating trauma or when there are known devitalized segments in grade 3 to 5 injuries (Kansas et al., 2004; Santucci et al., 2004). Most recent reports recommend not proceeding with renal exploration in the setting of a stable hematoma even in the setting of gunshot wounds as the nephrectomy rate may be lower (Bjurlin et al., 2011; Rostas et al., 2016). In addition, more recent reports have indicated that higher grade injuries in children can be managed nonoperatively (Eassa et al., 2010; Henderson et al., 2007; LeeVan et al., 2016; Nerli et al., 2011; Okur et al., 2017). The AUA urotrauma and EAU urogenital trauma guidelines do not specifically offer recommendations for these scenarios (Kitrey et al., 2018; Morey et al., 2014). If there is an obvious injury to another organ leading to blood loss and hemodynamic instability in a patient with a nonpulsatile retroperitoneal hematoma who has not had a prior CT scan, it would seem prudent to avoid renal exploration.

One-Shot intraoperative Intravenous Pyelography or Ultrasonography

If the presence of a contralateral kidney has not been confirmed by preoperative imaging, this information can be obtained by one-shot intraoperative intravenous pyelography (IVP) (Heyns, 2004; Santucci et al., 2004). Classically, one-shot IVP involves 2 mL/kg intravenous bolus of contrast followed by a radiograph taken 10 to 15 minutes later. The IVP may only inform the surgeon whether or not there is a contralateral kidney present and will not grade any injury accurately. This information may help guide decision making in the situation in which renal exploration with nephrectomy versus attempts at renal reconstruction is being considered intraoperatively. Intraoperative renal ultrasonography with Doppler may be another option to confirm a contralateral kidney with good blood flow but has not been reported on or recommended as frequently as one-shot IVP.

Control of Renal Vasculature

When renal exploration for trauma was more common, the method and timing of control of the renal vessels was a topic of interest. Some advocated for early control of vessels through an incision in the mesentery medial to the inferior mesenteric vein to identify the aorta and renal vessels as a way to decrease nephrectomy risk (Carroll et al., 1989, 1994; McAninch et al., 1991). In addition, retrospective series with early vascular control seemed to have lower nephrectomy rates than series without early vascular control (Atala et al., 1991; Carroll et al., 1989, 1994; Corriere et al., 1991; McAninch et al., 1991). One randomized trial between early vascular control and no early vascular control did not show a difference in nephrectomy rates, and the early vascular control group had longer operative times (Gonzalez et al., 1999). Early control of vessels would seem wise for a hemodynamically unstable patient with an expanding retroperitoneal hematoma; however, the AUA urotrauma and EUA urogenital trauma guidelines do not address this topic (Kitrey et al., 2018; Morey et al., 2014). For early control of vessels, an incision in the posterior mesentery medial to the inferior mesenteric vein over the aorta is made, and vessel loops are applied around the renal vessels and tightened if needed.

Reconstruction Versus Nephrectomy

In addition to stopping life-threatening hemorrhage, one goal of renal exploration should be to save and reconstruct the kidney whenever feasible and safe for the patient (Kitrey et al., 2018). If the presence of a contralateral kidney has not been confirmed by CT imaging, on-table IVP or ultrasonography can be used to do this before renal exploration. After opening up Gerota fascia, vascular control of the main renal arteries and veins should be obtained if this has not been done. The kidney should be freed up so the entire area of injury is exposed, which may require exposure of the entire kidney. Any devitalized tissue should be debrided. Any bleeding parenchymal vessels should be oversewn with absorbable suture and any holes in the collecting system closed with absorbable suture. Small renal defects can be closed by placing large absorbable sutures through the renal capsule. Larger renal defects are typically closed after packing the defect with hemostatic bolsters or omentum. For closure of larger defects, we like to use bolsters of hemostatic agents and to close the defect over the bolster using the sliding clip technique; however, many different techniques for renorrhaphy are available (Benway et al., 2010). If the renal injury is too severe to repair or would leave a very small portion of remaining kidney, nephrectomy should be performed. In addition, if the patient is unstable and it is safest to expedite surgery with nephrectomy to save the life of the patient because of hypothermia, coagulopathy, or ongoing blood loss, nephrectomy should be performed. In a penetrating injury, especially high-velocity gunshot wounds, it is important to inspect the ipsilateral ureter for any injury and repair if found.

Renal Arterial Laceration

Because the kidney does not have good collateral arterial flow, whatever renal segments that are devitalized by an arterial injury typically are not salvageable. If the main renal artery is avulsed or injured and bleeding significantly, the surviving patient will be hemodynamically unstable and should be explored with an anticipated nephrectomy. In fact, attempts to repair these types of injuries are associated with poorer outcomes (Knudson et al., 2000; Turner et al., 1983). In a patient with a solitary kidney or bilateral renal arterial injuries, consideration should be given to an attempt at renal artery injury repair (Kitrey et al., 2018). Vascular surgery consultation should be obtained if available for these rare situations.

Renal Arterial Occlusion

Another type of renal artery injury is complete or partial occlusion of renal arterial flow after blunt trauma caused by renal artery embolism or an intimal flap. This type of injury has been observed successfully, but a postinfarction syndrome with fever and flank pain may be expected, and these patients should be followed for the development of hypertension (Jawas and Abu-Zidan, 2008; Xu et al., 2017). Exploration with nephrectomy may be considered for uncontrolled pain or infection in a patent who is being observed. In more than 50 reported cases, percutaneous renal artery revascularization by interventional radiologists with angioplasty and/or endovascular stenting has been reported to successfully salvage some kidneys with completely occluded or partially occluded renal arteries after blunt trauma (Jahangiri et al., 2017).

Ureteropelvic Junction Disruption

Ureteropelvic junction disruption is a rare renal injury but is important not to miss (Murphy et al., 2017)**. This injury is associated with high-velocity acceleration/deceleration injuries and hyperextension of torso** (Palmer and Drago, 1981; Pesenti et al., 2016; Slobogean et al., 2007). A rapid change in position of the more mobile kidney away from the more fixed proximal ureter is thought to be the pathophysiology. Because of the severity of the mechanism of injury, we and others have seen patients with UPJ disruption having Chance fractures (flexion/extension crush injury to the anterior part of the vertebra and transverse fracture through the posterior part of vertebra) and other significant injuries to intra-abdominal organs such as the aorta and duodenum (Brandes et al., 2004; Dar et al., 2017; Palmer and Drago, 1981; Pereira et al., 2010; Pesenti et al., 2016; Slobogean et al., 2007). Many patients with a UPJ disruption injury will have significant enough associated injuries that an exploratory laparotomy is performed, often without preoperative imaging (Al-Qudah and Santucci, 2006; Chopra et al., 2002; McAleer et al., 2002). The urine analysis usually shows some degree of hematuria, but a significant minority of cases do not demonstrate hematuria (Al-Qudah and Santucci, 2006; Brandes et al., 2004; Chopra et al., 2002; Dar et al., 2017; McAleer et al., 2002). **Because of these factors, the diagnosis of UPJ disruption is often delayed, which can lead to complications that could lead to significant morbidity and mortality such as retroperitoneal abscess, fistula, or infected urinoma** (Boone et al., 1993; Brandes et al., 2004; Pereira et al., 2010). Persistent postoperative fever, ileus, flank pain, urine leaking from intra-abdominal drains, or increasing urinoma will lead to repeat CT scan and subsequent diagnosis of UPJ disruption.

The classic findings suggestive of UPJ disruption on CT scan include medial extravasation of contrast near the ureteropelvic junction, lack of contrast in the distal ureter, and lack of renal parenchymal laceration (Al-

Qudah and Santucci, 2006; Boone et al., 1993; Chopra et al., 2002; Dar et al., 2017; McAleer et al., 2002; Pesenti et al., 2016; Slobogean et al., 2007). Fig. 52.7 shows an example of bilateral UPJ disruption with minimal parenchymal laceration. Renal parenchymal lacerations can be seen in our experience, and the presence of a laceration does not exclude UPJ disruption (see Fig. 52.5). If there is any suspicion for UPJ disruption, retrograde pyelography should be performed.

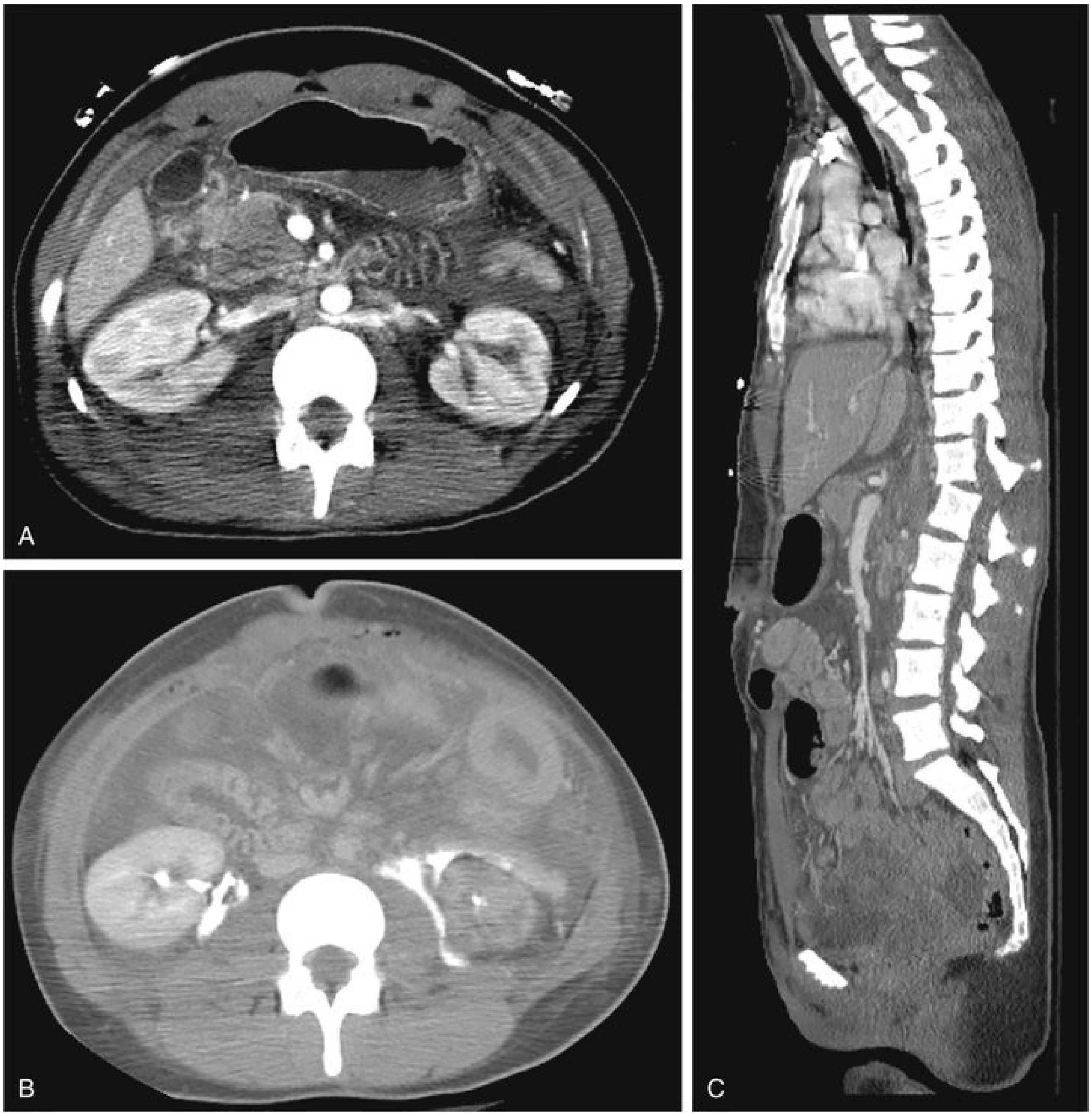

FIG. 52.7 Bilateral ureteropelvic junction disruption injury after a high-velocity motor vehicle collision. Nephrogram phase of CT scan showed only minimal lacerations (A). Delayed phase of CT showed medial

extravasation of urine bilaterally (B). Associated Chance type fracture at T12–L1 with malalignment of vertebral bodies in this area (C).

The management of UPJ disruption depends on the clinical stability of the patient and timing of diagnosis. In a clinically stable patient in whom the diagnosis is made within a few days of the injury, immediate exploration with repair of the UPJ disruption may be preferred (Boone et al., 1993; Brandes et al., 2004; Dar et al., 2017; Pereira et al., 2010)**. Immediate repair of ureteral injuries in stable patients at time of laparotomy is recommended by the AUA urotrauma and EAU urogenital trauma guidelines** (Kitrey et al., 2018; Morey et al., 2014). This surgery is difficult as the renal pelvis is typically not dilated, and good exposure is essential. Debridement of any nonviable ureter and renal pelvis should be performed followed by a spatulated, tension-free anastomosis of the ureter to the renal pelvis. Mobilization of the kidney downward may be needed for a tension-free anastomosis. We recommend doing the repair over a double-*J* ureteral stent left in place for 4 to 6 weeks and over a retroperitoneal drain left in place for several days. A nephrostomy tube could also be considered based on surgeon preference or if repair was tenuous. In a clinically unstable patient, a patient who cannot be positioned for surgery because of orthopedic injuries, or when the diagnosis is delayed more than 1 week, placement of a nephrostomy tube and retroperitoneal drain with delayed repair of the UPJ disruption is recommended by most and is suggested by AUA urotrauma guidelines for delayed ureteral injuries (Morey et al., 2014). Although there is little guidance from literature, we would recommend delayed repair about 2 to 3 months after drain placement. The delayed surgery follows the same principles as the immediate surgery, but scar tissue in the area of the renal pelvis and proximal ureter may make the surgery more difficult. Nephrectomy should always be mentioned to families as a possibility if a repair is not possible.

Renal Pelvis Rupture

Renal pelvis rupture is a rare finding after renal trauma (Ashebu et al., 2004; Hall and Carpinito, 1994; Li et al., 2007; Murawski et al., 2008; Taken et al., 2015). It may be more common in patients with pre-existing hydronephrosis and UPJ obstruction, but this is unclear given how rarely renal pelvis rupture occurs (Ashebu et al., 2004; Hall and Carpinito, 1994; Li et al., 2007). Cases have been managed successfully with an indwelling ureteral stent, and others have undergone operative repair (Ashebu et al., 2004; Hall and Carpinito, 1994; Li et al., 2007; Murawski et al., 2008; Taken et al., 2015). Some cases with pre-existing UPJ obstruction have been managed by delayed pyeloplasty after healing of the urine leak (Ashebu et al., 2004; Hall and Carpinito, 1994; Li et al., 2007). Fig. 52.8 shows a case of renal pelvis rupture managed by ureteral stent, percutaneous drain into urinoma, and delayed robotic-assisted laparoscopic pyeloplasty.

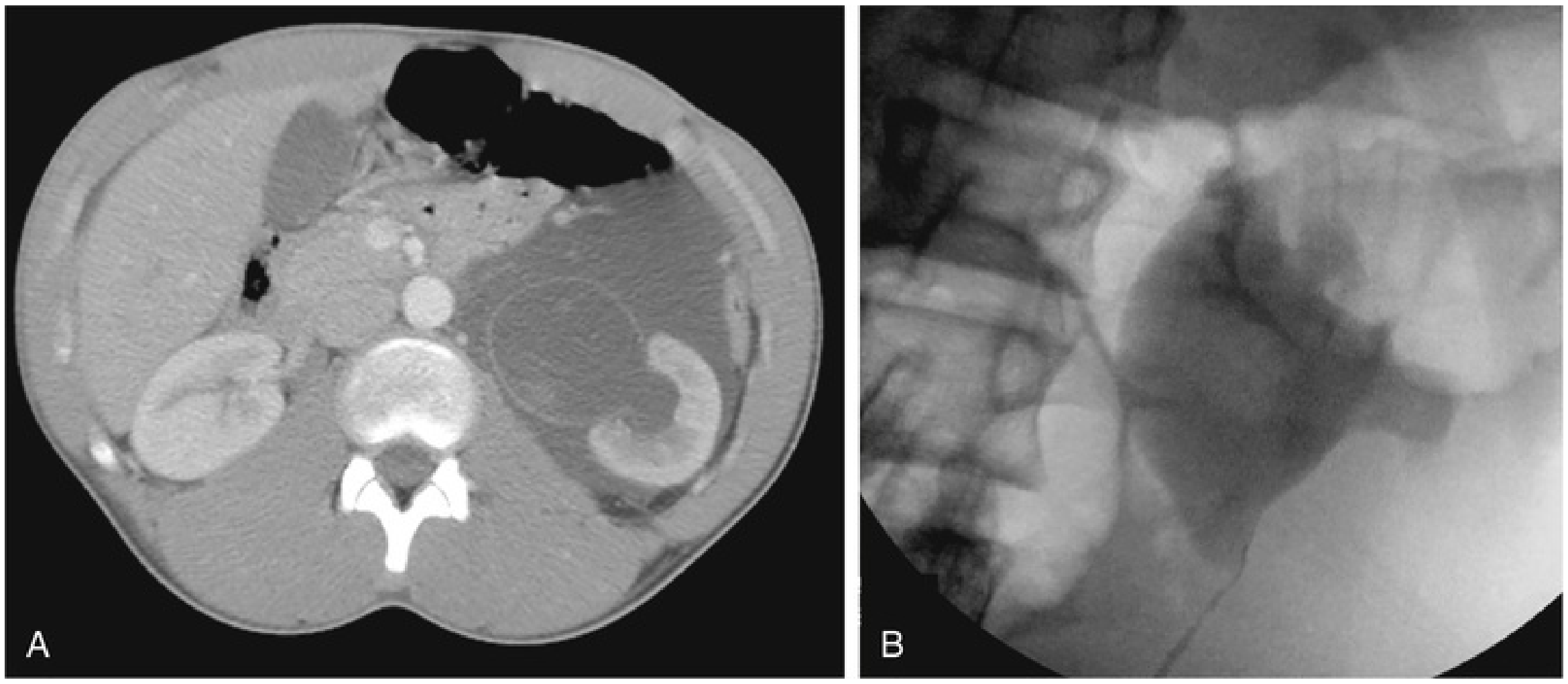

FIG. 52.8 Urine leak from renal pelvis laceration or rupture. Large fluid collection around dilated renal pelvis led to ureteral stent placement and percutaneous drain into urinoma (A). Percutaneous drain fluid consistent with urine and removed after drainage was minimal. Retrograde pyelogram at time of ureteral stent removal showing no extravasation (B).

Key Points: Operative Intervention Including Ureteropelvic Junction Disruption and Renal Pelvis Rupture

- Indications for operative intervention include hemodynamic instability caused by renal bleeding, pulsatile or expanding retroperitoneal hematoma at time of laparotomy without prior renal imaging, and failure of angioembolization to control renal bleeding.
- Control of renal vasculature should be performed immediately after opening Gerota fascia or before opening Gerota fascia.
- Operative intervention should include attempt to salvage the kidney if

possible.

- UPJ disruptions should be repaired in the acute phase if the patient is stable; otherwise drainage with a nephrostomy tube and possible percutaneous perirenal drainage with delayed repair should be performed.
- Renal pelvis rupture may require operative intervention but has been managed successfully with endoscopic and percutaneous urinary drainage.

Congenital Anomalies and Renal Injuries

Congenital anomalies such as duplex kidneys, fusion anomalies, hydronephrosis, hydroureter, and UPJ obstructions are occasionally seen at the time of renal injury (Onen et al., 2002). **In general, the risk for renal injury is not thought to be higher in patients with hydronephrosis or UPJ obstructions, but this is controversial** (Al-Qudah and Santucci, 2006; Chopra et al., 2002; McAleer et al., 2002; Schmidlin et al., 1998).

Ureteropelvic Junction Obstruction

A patient with a renal injury and UPJ obstruction can lead to interesting management decisions. **Although the most common injuries are still grade 1 to 2 renal injuries, urine leaks may require more aggressive management because of delayed drainage of urine through the UPJ.** A urine leak is most likely going to be a grade 4 injury through thinned renal parenchyma, but consideration for renal pelvis laceration or UPJ disruption should be given (Al-Qudah and Santucci, 2006; Ashebu et al., 2004; Chopra et al., 2002; Hall and Carpinito, 1994; Li et al., 2007; McAleer et al., 2002). If contrast is not seen in the ureter on excretory phase, retrograde pyelography should be performed to evaluate for UPJ disruption or renal pelvis laceration. UPJ disruption should be managed as described earlier. For patients with renal pelvic laceration and what appears to be a UPJ obstruction, we typically move quickly with ureteral stent placement and possible temporary perinephric drain placement. Nephrostomy tube placement with or without ureteral stent placement is also an option if the urine leak persists and exploration may be necessary (see Fig. 52.8). After the patient recovers from the injury, options include removal of the ureteral stent followed by pyeloplasty several weeks later or pyeloplasty with an indwelling ureteral stent. In our experience, removal of the ureteral stent followed by delayed robotic-assisted laparoscopic pyeloplasty 8 to 12 weeks later has worked well with minimal periureteral inflammation and scarring. However, given concern for infection in a poorly draining kidney after ureteral stent removal, a pyeloplasty with an indwelling ureteral stent in place can be performed.

Duplex Kidney

Duplication anomalies can make management of urine leaks more complicated, and urologists need to keep in mind that approximately 1% to 2% of the population have complete duplications of the renal collecting system, and partial duplications such as bifid pelvis are more common (Privett et al., 1976; Whitten and Wilcox, 2001). For example, if a ureteral stent is placed for a urine leak into the upper pole ureter when the urine leak is coming from the lower pole of the kidney, this obviously would not help the urine leak.

Fusion Anomalies and Ectopic Kidney

In general, renal injuries to kidneys with fusion anomalies or ectopic kidneys are managed similarly to kidneys without fusion or position anomalies. Horseshoe kidneys and ectopic kidneys are more likely to have hydronephrosis and UPJ obstructions and typically have anomalous vasculature, which may make management more complex (Gleason et al., 1994). Fig. 52.9 shows a case of horseshoe kidney with a grade 4 laceration to the left side with chronic UPJ obstruction that was managed with ureteral stenting and delayed pyeloplasty.

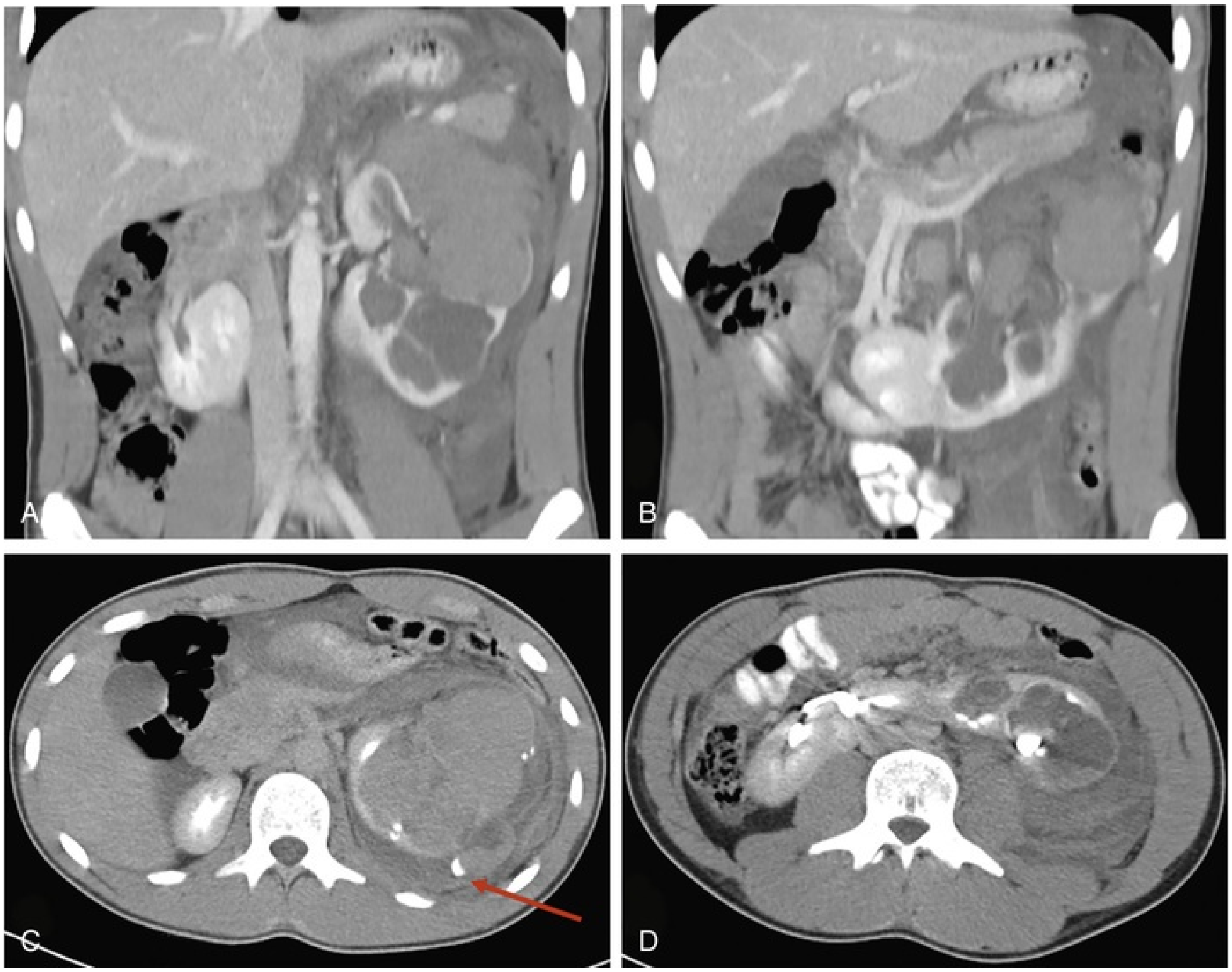

FIG. 52.9 Grade 4 injury to left-sided moiety with chronic ureteropelvic junction obstruction of a horseshoe kidney. Immediate contrast phases showing chronic-appearing hydronephrosis with hematoma in collecting system and perirenal hematoma (A and B). Delayed phases showing urine leak *(red arrow)* (C) and isthmus (D) of horseshoe kidney.

Follow-Up and Long-Term Issues

Once a patient has recovered from his or her traumatic injuries, several issues should be addressed with the patient and family. These issues include follow-up imaging, need for assessment of remaining renal function in the injured kidney, long-term risks of hypertension and chronic kidney disease, and physical activity limitations.

Late Repeat Imaging and Assessment of Renal Function

One issue that comes up at time of discharge is what follow-up imaging pediatric renal trauma patients should have. **The risk for renal scarring is likely negligible after a grade 1 to 2 injury, and repeat imaging is not recommended by the AUA urotrauma guidelines** (Dunfee et al., 2008; Morey et al., 2014; Surana et al., 1995)**. The risk for renal scarring is approximately 60% for grade 3 injures and closer to 100% for grade 4 to 5 injuries, with some decline in differential function** (Dunfee et al., 2008; El-Sherbiny et al., 2004; Tasian et al., 2010). Some have recommended a follow-up CT scan at 3 months in grade 3 to 5 injuries, and others have advocated for follow-up ultrasonography. DMSA or MAG3 renal scans can be obtained to evaluate renal function after recovery from injury, but it is unclear if they change management in the majority of cases. **Typically renal scans are obtained if there is concern about significant loss of function and/or if hypertension is present in follow-up.** Keeping with the ALARA concept, at our institution we obtain a renal ultrasonography 2 to 4 months after a grade 3 to 5 injury in children. If there is concern about significant loss of renal function, especially in the setting of hypertension, a DMSA scan would be discussed with the family. In patients with a very abnormal renal ultrasound scan or in those who underwent angioembolization, we would also consider a DMSA scan after discussing the option with family. **The EUA urogenital trauma guidelines recommend an individualized radiologic evaluation during follow-up for renal trauma** (Kitrey et al., 2018).

Hypertension

Hypertension that develops or persists 30 days after renal injury should raise the possibility of renal trauma–related hypertension. The risk for renal trauma–related hypertension is uncommon in grade 1 to 2 injuries. **In adults after a grade 3 or higher injury, the risk for developing hypertension is likely 5% to 15%** (Osterberg et al., 2018). Renal vascular hypertension is thought to arise from renal parenchymal ischemia leading to increased renin levels, renal parenchymal compression leading to increases in renin (Page type kidney), trauma-induced vascular anomaly such as arteriovenous fistula or pseudoaneurysm, or significant renal scarring from injury. Most pediatric series report between a 0% and 5% incidence of hypertension (LeeVan et al., 2016).

Evaluation of renal vascular hypertension typically includes nephrology referral, renal ultrasonography, assessment of function and scarring by renal scan, and evaluation for vascular malformation such as arteriovenous fistula by magnetic resonance imaging (MRI) or CT if there is a concern for this. Because the hypertension is thought to be mediated by elevated renin levels, angiotensin-converting enzyme (ACE) inhibitors or angiotensin receptor blockers (ARBs) are often used to medically control the hypertension. In a patient with hypertension and a poorly functioning, scarred kidney after a grade 4 to 5 injury or one that required angioembolization, consideration for nephrectomy should be given in consultation with nephrology. **A Page type kidney in which a subcapsular fluid collection is compressing renal parenchyma leading to renin-mediated hypertension is rarely seen** (Moriarty et al., 1997; Sokhal et al., 2018). Drainage of the compressing hematoma/fluid collection or nephrectomy have been reported to be successful in resolving hypertension, but long-term outcomes are unclear (Moriarty et al., 1997; Sokhal et al., 2018).

Chronic Flank Pain

Chronic flank pain after renal injury is uncommon and is not addressed in pediatric series (Al-Qudah and Santucci, 2006; LeeVan et al., 2016). Evaluations may include urine analysis and urine culture, renal ultrasonography, CT, MRI, and renogram to exclude an obvious renal etiology for the pain such as nephrolithiasis or UPJ obstruction. Consideration for musculoskeletal causes of pain or other causes of flank pain should be given. We recommend pain management referral for evaluation for medical management or nerve blocks before considering nephrectomy, even in patients with a poorly functioning kidney, as flank pain may persist after nephrectomy.

Chronic Kidney Disease

The risk for chronic kidney disease is mainly a concern for parents of a child who either required a nephrectomy for renal injury, had bilateral renal injuries, or who had almost complete loss of function in one kidney because of renal injury. We inform families that hypertension and diabetes are the most common causes of chronic kidney disease in people with a solitary kidney and that healthy lifestyles should be promoted (Ibrahim et al., 2016). If there is concern for developing hypertension or diabetes in the future (e.g., a child with obesity), appropriate referrals are made. We recommend that families pay attention to yearly blood pressure evaluation for patients with a solitary kidney or a history of grade 3 to 5 renal injury. **The loss of a kidney resulting from renal trauma is thought to play a role in the development of end-stage renal disease in 0.5% of patients based on a review of the National Trauma Data Bank and other national datasets** (Dozier et al., 2013)**. In patients who have a solitary kidney from donation, there may be a slightly increased risk for hypertension, but it is unknown if this increases the risk for chronic kidney disease** (Boudville et al., 2006; Sanchez et al., 2018)**. We offer referral to a nephrologist if a family is concerned and wants yearly monitoring for a solitary kidney.**

Follow-Up and Activities With a Solitary Kidney

The risk for renal injury with organized sports is lower than from motor vehicle accidents, and the grades of injury are lower than what is seen in motorized sports activities, such as all-terrain vehicles or dirt bikes (Gerstenbluth et al., 2002; Wu and Gaines, 2007). However, renal injury from sports is more likely to be an isolated injury (Patel et al., 2015). **The American Association of Pediatrics states that children with normal solitary kidneys can participate with sports and should use flank protection if participating in contact sports such as hockey or football** (Rice and American Academy of Pediatrics Council on Sports Medicine and Fitness, 2008)**. Higher risk activities include dirt-bike riding, cycling, and riding all-terrain vehicles** (Brown et al., 2002; Gerstenbluth et al., 2002; Wu and Gaines, 2007). If the patient wants to participate in these activities, the patient and family need to be aware of the increased risk for renal injury and that protective equipment should be worn. We typically clear patients with a normal solitary kidney for participation in organized sports and recommend protective gear for contact sports. We remind families that contact sports such as football, rugby, and hockey are associated with a higher risk for head injuries (Pfister et al., 2016).

Key Points: Follow-Up and Long-Term Issues

- The risk for renal scarring is negligible in grade 1 to 2 injuries, approximately 50% in grade 3 injuries, and 100% in grade 4 to 5 injuries.
- Follow-up imaging for grade 3 to 5 injuries should be considered. Starting with renal ultrasonography and obtaining CT, MRI, or DMSA scans if

necessary is a common approach.

- Hypertension is a rare occurrence after renal trauma in children and typically is only seen after grade 3 to 5 injuries.
- The development of chronic kidney disease or end-stage renal disease is very rare after renal trauma, even when nephrectomy is performed.
- Patients with a normal solitary kidney can participate in sports, but protective equipment is recommended for contact sports. High-risk activities include dirt-bike riding, cycling, and all-terrain vehicle riding.

Ureteral Trauma

Epidemiology

Traumatic ureteral injuries are quite rare. In adult series, they occur in less than 5% of penetrating trauma cases and are very rare in blunt trauma cases (Marekovic et al., 1997; Medina et al., 1998; Paquette, 2007; Siram et al., 2010). **A ureteral injury should be considered as a possibility in patients with penetrating trauma near the ureter or with a trajectory toward the ureter, in patients with multivisceral abdominal injuries or vertebral injuries, and in patients with rapid deceleration injuries** (Elliott and McAninch, 2003; Siram et al., 2010). There is a high risk for associated kidney, vascular, bowel, and other solid organ injuries with penetrating trauma and a high risk for associated pelvic fracture with blunt trauma (Elliott and McAninch, 2003; Siram et al., 2010). **Because of the severity of associated injuries, there is a high mortality rate in patients who sustain a ureteral injury from trauma, reported to be around 10%** (Best et al., 2005; Siram et al., 2010). Renal injuries have been reported in about 20% of those with ureteral injury (Elliott and McAninch, 2003). Ureteral injuries are important to diagnose as a delayed or missed diagnosis is associated with increased likelihood of nephrectomy and prolonged hospital stay (Elliott and McAninch, 2003; Kunkle et al., 2006).

Ureteral injuries can occur during open or laparoscopic surgical procedures typically involving the rectum, colon, urologic structures, or gynecologic structures. Intraoperative injuries can include suture ligation, crush injury, partial or complete transection, devascularization, and injury from electrocautery. In addition, significant ureteral injuries can rarely occur during ureteroscopy (de la Rosette et al., 2014). The epidemiology of iatrogenic ureter injuries has been reported in adults with gynecologic or colorectal surgery (around 1%) having the highest incidence, but limited to case reports or small series in children (Goodno et al., 1995; Marcelissen et al., 2016; Park et al., 2012; Routh et al., 2009).

Presentation

As stated earlier, blunt trauma patients with ureteral injuries often have other injuries including pelvic fractures caused by high-velocity injuries. With penetrating trauma, the entrance is often near the area of the ureter or with a trajectory toward the ureter. In many cases, there is gross or microscopic hematuria, but a lack of hematuria is seen in around 25% to 50% of cases (Elliott and McAninch, 2003; Medina et al., 1998). The majority of patients with penetrating trauma will have traumatic ureteral injuries diagnosed intraoperatively (Best et al., 2005; Elliott and McAninch, 2003). **Even with laparotomy at the time of injury, around 10% of ureteral injuries will be missed at laparotomy and have a delayed diagnosis** (Kunkle et al., 2006)**.**

High-velocity (>610 m/sec) gunshot wounds can cause tissue injury well beyond the path of the projectile. In addition, the projectile can tumble or have significant course changes that will result in damage to organs. Examples of high-velocity guns include military assault rifles and AR-15–style rifles. In cases of high-velocity gunshot wounds, it has been reported that at the time of initial laparotomy the renal pelvis, ureter, and bladder may appear uninjured or slightly contused only to develop necrosis several days later with urine extravasation (al-Ali and Haddad, 1996; Cetti, 1983; Stutzman, 1977). **Ureteral stent and drain placement around urinary structures is recommended after laparotomy for high-velocity gunshot wounds if there is any suspicion of a urine leak developing so the leak can be readily identified and managed.**

In cases of intraoperative ureteral injury, this can be identified immediately, but diagnosis can be delayed in 50% to 60% of patients until they present with urine output from surgical drain, urinary ascites, ileus, fever, or sepsis (Blackwell et al., 2018).

Imaging Findings

A delayed-contrast phase of CT is typically the imaging study used to diagnose ureteral injury and is recommended by the AUA urotrauma guidelines (Morey et al., 2014). Findings will include lack of contrast in the ureter distal to the injury with extravasation in complete ureteral transections or possibly some contrast in the ureter distal to the injury with extravasation in partial ureteral injuries. Other imaging studies that can be used to confirm or diagnose ureteral injury include retrograde pyelography or IVP.

American Association for the Surgery of Trauma Classification

The AAST OIS classification for ureteral injury is shown in Table 52.4 and correlated with complexity of repair and associated injuries by one study (Best et al., 2005; Moore et al., 1992). Grade 1 injuries may not require any intervention. Grade 2 to 3 injuries will require at least an endoscopic intervention and potentially an open or laparoscopic repair. Grade 4 to 5 injuries will require an open or laparoscopic repair either at time of diagnosis or in a delayed fashion. The management of complete and partial transections is also affected by location of injury as discussed in the following sections.

TABLE 52.4

Ureteral Injury: American Association for the Surgery of Trauma Organ Injury Scale

Contusion or hematoma without devascularization
<50% transection
>50% transection
Complete transection with <2 cm devascularization
Avulsion with >2 cm devascularization

Modified from Moore EE, Cogbill TH, Jurkovich GJ, et al. Organ injury scaling. III: Chest wall, abdominal vascular, ureter, bladder, and urethra. *J Trauma*. 1992;33(3):337–339.

Management of Traumatic Ureteral Injury

Immediate Diagnosis

Penetrating or blunt trauma, if a partial or complete ureteral transection injury is diagnosed intraoperatively and the patient is stable, should be repaired intraoperatively under the same anesthetic (Kitrey et al., 2018; Morey et al., 2014). Intraoperative injuries should be repaired under the same anesthetic if diagnosed at that time. The type of repair used depends on length of ureteral injury and location. For ureteral contusions, ureteral stent or excision with repair can be performed depending on the clinical scenario (Kitrey et al., 2018; Morey et al., 2014).

If a trauma patient is unstable, urinary diversion with delayed repair may be necessary (Kitrey et al., 2018; Morey et al., 2014). In these damage-control situations, the ureter can be tied off followed by nephrostomy tube placement, the ureter can be brought to the skin, a ureteral stent can be placed and brought to the skin, or, if there is no time, a large drain can be left near the ureteral injury.

Delayed Diagnosis

For ureteral injuries diagnosed within the first week of injury, immediate surgical repair is an option (Morey et al., 2014). If a ureteral injury diagnosis is delayed more than 5 to 7 days after injury, classically these patients have been managed with urinary diversion with nephrostomy tube and possible drain or ureteral stent with planned delayed repair. The optimal length of time one should wait until delayed repair is unknown, but recommendations between 6 and 12 weeks are common. Some authors have challenged this idea and recommend an attempt at placement of a ureteral stent. If a ureteral stent can be placed across the injury, authors have reported ureteral injuries including partial and complete ureteral transections healed without the need for open intervention from 15% to 75% (Chung et al., 2017; Koukouras et al., 2010; Liatsikos et al., 2006; Liu et al., 2014; Morrow et al., 2017). The AUA guidelines recommend attempts at ureteral stent placement for partial ureteral injuries that are diagnosed in a delayed fashion, but this has been reported as an option for complete transections as well (Liu et al., 2014; Morey et al., 2014). The EAU urogenital trauma guidelines state that endourologic management is the initial approach in most cases of delayed diagnosis of ureteral injury, and open repair is needed in failures (Kitrey et al., 2018).

Proximal or Mid-Ureteral Injury Surgical Repair

A very proximal ureteral injury can be managed similar to a UPJ disruption (see the Ureteropelvic Junction Disruption section earlier in this chapter) with a tension free spatulated anastomosis of ureter to renal pelvis. A partial transection of the mid- to upper- ureter can be repaired surgically either by ureteroureterostomy with a spatulated, tension-free anastomosis or closure of the partial transection without narrowing the ureteral lumen. A transureteroureterostomy may be less desirable in children given longer life span and potentially putting the other kidney at risk. A Boari flap can reach the mid- to proximal ureter if the distal ureter is not available. Typically, a ureteral stent is left in place for 4 to 6 weeks, but the optimal duration is unknown. Series specific to the pediatric population are limited, but favorable outcomes have been reported in mid- to proximal ureteral injuries (Routh et al., 2009).

Distal Ureteral Injury Surgical Repair

There are several options for surgical repair of distal ureteral injuries. Ureteroureterostomy and ureteral reimplant with or without psoas hitch with ureteral stenting are used for most repairs. Series in the pediatric population are limited, but results indicate favorable outcomes with these methods (Routh et al., 2009).

Lengthy Ureteral Injuries

Lengthy ureteral injuries are thankfully very rare. **Options to restore drainage of the kidney to the bladder include long Boari flap, ileal ureter, and autotransplantation** (Brandes and McAninch, 1999; Kastelan et al., 2004; Sevinc et al., 2016). The management of these cases is highly individualized. Nephrectomy is also an option, especially for a poorly functioning kidney with a normal contralateral kidney.

Follow-Up Imaging

Follow-up imaging after any ureteral injury is recommended. Once the ureteral stent is removed, renal ultrasonography is obtained in 4 to 6 weeks. If there is no hydronephrosis, we recommend at least yearly ultrasound examinations for 2 to 3 years. If there is any concerning hydronephrosis with or without flank pain, a MAG3 diuretic renogram can be obtained to assess function and drainage. If there is concern for postinjury ureteral stricture, antegrade and retrograde pyelography is helpful in determining length and location. If a postinjury ureteral stricture occurs, some advocate for endoscopic management with dilation or incision of the stricture, but a significant minority will have recurrent strictures (Erdogru et al., 2005; Richter et al., 2000; Seseke et al., 2002).

Key Points: Ureteral Injuries

- Ureteral injuries are rare in any trauma but are more commonly seen with penetrating trauma.
- Contrast-enhanced CT with delayed phase or retrograde pyelography are the preferred methods used to diagnose a ureteral injury.
- Ureteral injuries are often associated with other organ injuries in trauma cases, and ureteral injuries can be missed at initial laparotomy for trauma.
- If a ureteral injury is diagnosed less than 1 week from injury, immediate repair can be performed and may be preferable if the patient is stable.
- If a ureteral injury is diagnosed more than 1 week from injury, an attempt at ureteral stent placement can be made, but often a nephrostomy tube with delayed open repair is needed.
- Ureteral injuries in children are repaired similar to adults.

Bladder Injuries

Presentation

Although injuries such as gunshot wounds and other penetrating injury do occur in the pediatric bladder, this is less common than seen in the adult population. **In children, the mechanism for injury to the bladder and urethra is blunt trauma in more than 80% of cases** (Deibert et al., 2012). Isolated bladder trauma is rare in children; however it is more common than in the adult population. This is possibly due, in part, to the fact that more of the bladder is intraperitoneal in children (Brereton et al., 1980). **Severity scoring mirrors that used in adults are shown in Table 52.5, and the critical differentiation is whether the injury is intraperitoneal or extraperitoneal, as in the adult population.**

TABLE 52.5

Bladder Injury: American Association for the Surgery of Trauma Organ Injury Scale

Contusion, intramural hematoma, or partial-thickness laceration
Extraperitoneal bladder wall laceration <2 cm
Extraperitoneal (>2 cm) or intraperitoneal (<2 cm) bladder wall laceration
Intraperitoneal bladder wall laceration >2 cm
Intraperitoneal or extraperitoneal bladder wall laceration extending into the bladder neck or ureteral orifice (trigone)

Modified from Moore EE, Cogbill TH, Jurkovich GJ, et al. Organ injury scaling. III: Chest wall, abdominal vascular, ureter, bladder, and urethra. *J Trauma*. 1992;33(3):337–339.

Pelvic Fracture

In a review of the National Trauma Data Bank from 2002 to 2008, Deibert et al. reported on 816 children that were found to have bladder trauma (Deibert et al., 2012). Most of these patients were also noted to have a pelvic fracture, which was the likely cause. As expected, the injury is typically found because of hematuria or because the mechanism of injury prompts a study to rule out involvement of the urinary tract.

Pelvic fractures occur less commonly in children and are associated with more severe intra-abdominal injuries. In fact, children may be only one-half as likely to have a pelvic fracture. This is likely because the bony pelvis in a child is more pliable, and therefore more force is required to generate a fracture (Chia et al., 2004; Demetriades et al., 2003). Because of this, it has been hypothesized that this may lead to more severe intra-abdominal injuries in children when a pelvic fracture has occurred, but this is not always borne out in the literature (Demetriades et al., 2003). **About one-half of children with a bladder injury might be expected to have a pelvic fracture** (Sivit et al., 1995), demonstrating that even without a bony pelvis injury the bladder is still at risk in the pediatric patient. In addition, injuries to the bony pelvis in smaller children differ from those in adolescents and adults, which also may play a role in differing patterns of injury to surrounding pelvic organs. These changes probably occur during the early teenage years (Silber and Flynn, 2002).

Imaging

In determining the need to obtain radiographic or cystoscopic evaluation in the presence of pelvic trauma, the presence of gross hematuria or urinary retention is paramount. According to the AUA urotrauma and EAU urogenital trauma guidelines, evaluation for a bladder injury with cystography (either plain radiography or CT) should be done in patients with pelvic fracture and gross hematuria, in patients with gross hematuria and mechanism concerning for bladder injury, and in patients with pelvic fracture and clinical signs of bladder rupture (Kitrey et al., 2018; Morey et al., 2014).

The presence of hematuria in the trauma patient warrants radiographic workup for injury to the upper urinary tract as described earlier, however a retrograde contrast-based study (CT or standard cystography) is recommended to evaluate the lower urinary tract when there is concern for possible bladder or urethral injury. This is particularly true in the case of hematuria with concomitant pelvic fractures, given that about one-half of these patients will be found to have a bladder rupture (Hochberg and Stone, 1993). Delayed imaging on CT is critical to evaluate renal and ureteral injury but may not be sensitive enough to elucidate bladder involvement (Haas et al., 1999). Cystography can also obviate the need for intravenous contrast if a catheter is in place or can be placed. A retrograde urethrogram can be obtained at the same time if there is concern for urethral injury as described later.

Management

The management of isolated bladder injury depends largely on the location of the injury. Injuries in the pediatric population can be categorized by intraperitoneal and extraperitoneal location in addition to bladder neck injuries as in the adult population. These distinctions largely dictate the type of intervention. As in adults, extraperitoneal injury can be managed without repair in most cases. Exceptions arise when there is concern for boney fragments protruding into the bladder that are exposed to urine, thus raising the risk for complex infections in the bony pelvis. In addition, if an orthopedic procedure requires hardware in the pelvis, closure is necessary to prevent seeding of the hardware with infected urine. **AUA and EAU guidelines give intraperitoneal location of a bladder injury as an absolute indication for surgical repair along with extraperitoneal location that involves exposed bone, concomitant rectal or vaginal laceration, or need for internal fixation or abdominal** surgery (Kitrey et al., 2018; Morey et al., 2014).

Closure of an extraperitoneal bladder injury is typically performed at the time of other operative intervention such as orthopedic fixation of the pelvis. This can be done through a midline incision, particularly if a laparotomy needs to be performed for evaluation and treatment of intra-abdominal solid organ injury. We perform a two-layer closure with running absorbable suture. A Foley catheter is left for 1 to 2 weeks, and a drain can be left in the perivesical space at the surgeon's discretion. A cystogram is obtained at the time of catheter removal.

Injury to the bladder neck is more common in children and can be particularly difficult to manage (Boone et al., 1992; Husmann et al., 1990; Koraitim, 2015). If a tear extends through the bladder neck, a formal repair is necessary. The outcome of the repair may depend on the severity of the injury with complete avulsion having poorer rates of postrepair continence, particularly in female patients who likely depend more on the bladder neck mechanism for continence than male patients (Black et al., 2006). **Regardless, urinary continence in this group of injuries is notoriously poor, with many requiring secondary**

procedures and even bladder neck closure and diversion to achieve complete dryness (Routh and Husmann, 2007).

Although an extraperitoneal bladder rupture can often be observed, intraperitoneal ones are repaired as a rule because of the potential for an uncontained peritoneal urinoma and associated morbidity and even mortality. There is evidence that a select group of intraperitoneal ruptures can be managed without operative intervention, but this is controversial. If observed, the patient with an intraperitoneal injury requires continuous drainage of the bladder and potential abdominal urinoma, raising the question of whether a repair of the defect is less morbid (Osman et al., 2005). Therefore, intraperitoneal injuries are typically managed by laparotomy either at the time of exploration of concomitant injury or on their own. A catheter is typically left in place for approximately 1 to 2 weeks depending on the nature of the trauma and is removed with follow-up cystography.

Urethral Injuries

Categorization of urethral injury in children parallels the adult system of posterior and anterior injuries and adult severity scoring (Table 52.6). In addition, the Goldman classification is frequently used because of its clinical utility (Table 52.7) (Goldman et al., 1997). Posterior injuries, including those that incorporate the bladder neck, occur most frequently with straddle injury and pelvic fracture as in adults (Helmy et al., 2014). As described earlier, the differences in occurrence lie in the fact that pelvic fracture in children requires a higher energy mechanism so that when there is a pelvic fracture, the likelihood of concomitant injury of surrounding structures such as the urethra is substantially higher (Delaney et al., 2016). In addition, children are more likely to have injuries of the supraprostatic and prostatic urethra itself than adult men who more often have injuries at the bulbomembranous junction (Boone et al., 1992; Onen et al., 2002). Injuries of the anterior urethra including those of the pendulous urethra are described later in the Penile Injury section.

TABLE 52.6

Urethral Injury: American Association for the Surgery of Trauma Organ Injury Scale

Blood at urethral meatus; retrograde urethrography normal (contusion)

Elongation of urethra without extravasation on urethrography (stretch injury)
Extravasation of urethrography contrast at injury site with visualization in the bladder (partial disruption)
Extravasation of urethrography contrast at injury site without visualization in the bladder; <2 cm of urethral separation (complete disruption)
Complete transaction with >2 cm urethral separation or extension into the prostate or vagina (complete disruption)

Modified from Moore EE, Cogbill TH, Jurkovich GJ, et al. Organ injury scaling. III: Chest wall, abdominal vascular, ureter, bladder, and urethra. *J Trauma*. 1992;33(3):337–339.

TABLE 52.7

Urethral Injury: Goldman Classification for Blunt Urethral Trauma

Posterior urethra stretched but intact
Urethral rupture above intact urogenital diaphragm
Injury extends through the urogenital diaphragm; involves proximal bulbous urethra
Extraperitoneal bladder rupture with extension into proximal urethra
Anterior urethral injury

Modified from Goldman SM, Sandler CM, Corriere JN Jr, McGuire EJ. Blunt urethral trauma: a unified, anatomical mechanical classification. *J Urol*. 1997;157(1):85–89.

Evaluation

Urethrography should be performed when the mechanism of injury is concerning for pelvic trauma (e.g., straddle injury, motor vehicle accident with pelvic fracture). Typically a history of urinary retention or gross hematuria is elicited. Examination findings such as blood per urethra or from the vagina and perineal hematoma are also concerning for urethral injury and should prompt radiographic and/or cystoscopic workup. Oftentimes, by the time the urologist is at the bedside, other imaging in the form of a CT scan or plain radiograph has been obtained and can be used to confirm or rule out the presence of concomitant pelvic bony or organ injury. **AUA urotrauma guidelines advise retrograde urethrography in all cases with blood at the meatus in the setting of pelvic trauma** (Morey et al., 2014).

Management

The severity of the urethral defect plays a large role in how the treatment is addressed at the outset. If a catheter has not already been placed, we favor retrograde urethrography before attempted placement when there is concern for injury. Although this can be more difficult in children, particularly when awake, it is critical in evaluating the extent of injury, particularly to determine whether there is a complete versus partial disruption of the urethra. If a catheter has already been placed, retrograde urethrography can be performed around the catheter or voiding cystourethrography can be performed if the patient can void with the catheter in place. Ultimately, an examination under anesthesia with cystourethroscopy may be necessary if other studies are inconclusive.

If a catheter has been placed before evaluation, this suggests that the injury is not likely to be a complete disruption. This can be confirmed by retrograde urethrography as described earlier. In these cases, it is recommended to manage the injury with catheter drainage and reassess in several weeks. Although resultant strictures can be treated endoscopically with urethrotomy, about one-half of these recur, and repeated attempts at endoscopic management should be avoided (Hsiao et al., 2003).

When unable to achieve urethral drainage in the acute setting, a suprapubic tube must be placed. Initial management options for the urethra include an attempt at primary realignment performed under cystoscopic and fluoroscopic guidance, open primary realignment, and delayed repair in several weeks to months. In children, when there has been complete disruption of the urethra or avulsion from the bladder, there is some evidence to suggest that primary realignment performed endoscopically can have good results (Herschorn et al., 1992; Onen et al., 2005a, 2005b). Others advocate against this because of high rates of stricture and subsequent need for further intervention (Husmann et al., 1990). However, primary alignment may not be advisable for several reasons. In the case of endoscopic alignment, it may simply be too difficult to identify the bladder neck and access the bladder. In the attempt to do so, irrigation is infused into the pelvis, potentially complicating a simple hematoma and expanding the space between the bladder and the pelvic floor. It is also argued that prior endoscopic attempts at realignment can negatively impact the success of a delayed open repair when necessary (Culty and Boccon-Gibod, 2007; Singh et al., 2010). Therefore, in the stable patient an attempt can be made to pass a catheter endoscopically, but prolonged attempts should be avoided.

Open realignment in the acute setting often requires further endoscopic treatment or open revision making the benefit of attempting this questionable (Nerli et al., 2008). In addition, once the pelvic space is violated, a hematoma, once controlled by tamponade, may no longer be contained and is free to bleed. A once-stable patient with a contained pelvic bleed can rapidly deteriorate. Poor visualization in the operative field may also lead to excessive debridement, which may be why erectile dysfunction and incontinence rates have been shown to be higher when immediate open repair is attempted (Brandes, 2006; Koraitim, 1996). **These considerations led the EUA to recommend against attempts at immediate urethroplasty** (Kitrey et al., 2018). This is despite the findings by some that the results can be quite similar to delayed repair (Husmann et al., 1990). One more clear indication for immediate repair is with an associated bladder neck injury. It has been shown to be beneficial to repair the injury up-front largely as a result of concern for resultant urinoma and infection rather than long-term benefit of the early repair (Routh and Husmann, 2007).

If a catheter cannot be placed easily, a suprapubic catheter can be left in place and allowed to drain until a repair can be performed at a later date (Trachta et al., 2016). For a delayed urethral repair, we typically wait several months from the date of injury to let the scar mature. If there is a pelvic hematoma that has elevated the bladder up off the pelvic floor, common in the case of a complete urethral disruption, it will resolve over this period, allowing the bladder to descend back into the pelvis, facilitating the repair. This evolution of the scar can change a defect that appeared rather large in the acute setting into a relatively small one later on**. For this reason, it is recommended to reevaluate any patient needing a delayed formal repair with imaging and cystourethroscopy closer to the date of the repair.** In these cases, a suprapubic catheter was inevitably placed at the time of the initial presentation. This access helps in determining the size of the gap between bladder neck and patent urethra. This can be easily assessed by cystography and retrograde urethrography or a combination of radiologic imaging with cystoscopy from below and/or above through the suprapubic cystotomy site. Fig. 52.10 shows an example of pelvic fracture with urethral disruption injury.

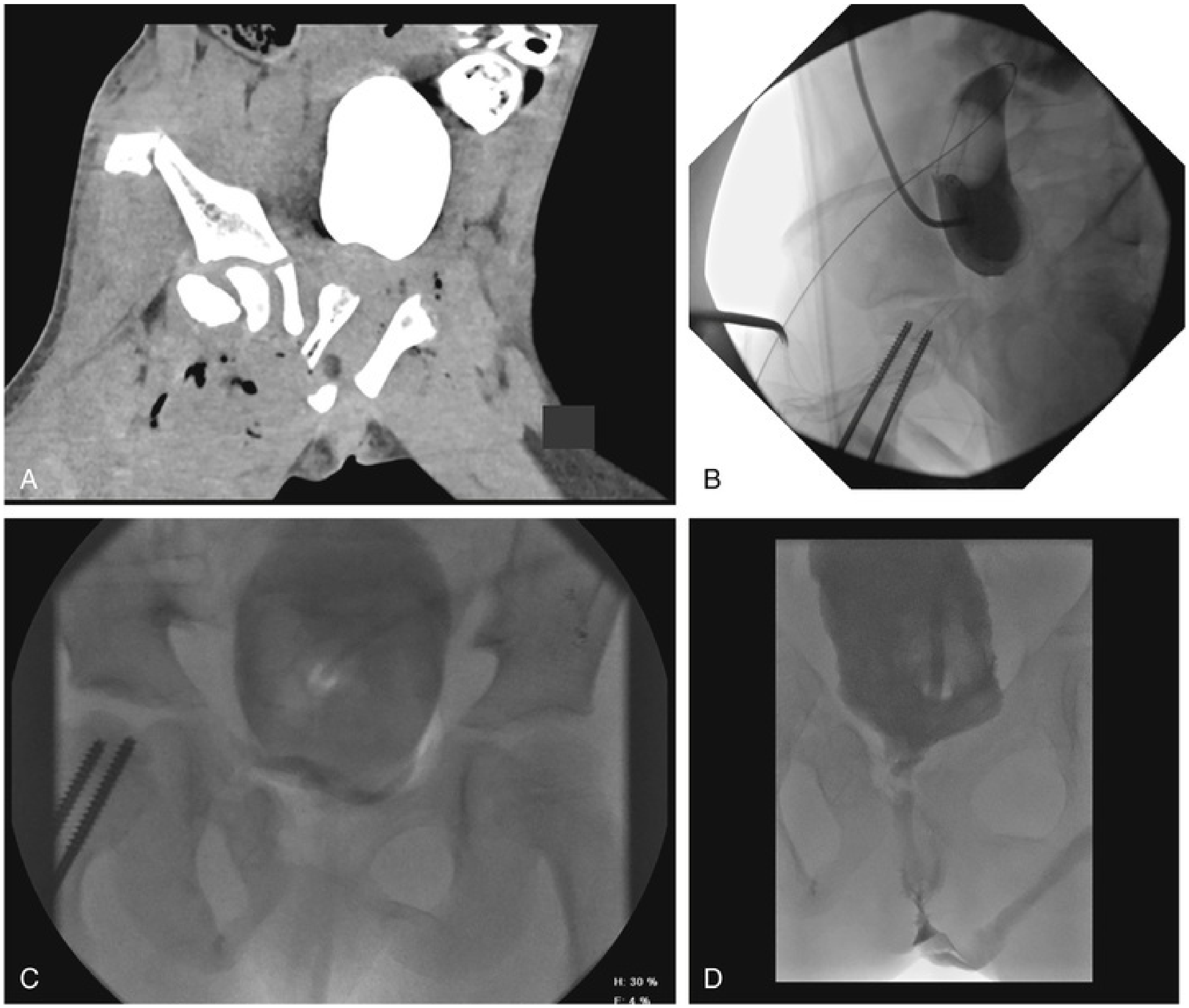

FIG. 52.10 Pelvic fracture with urethral disruption injury in a 6-year-old female patient. CT scan at presentation and initial cystogram demonstrating elevation of bladder off of shattered pelvis (A and B). Cystogram after resolution of hematoma with descent of bladder back into pelvis before reconstruction (C). Voiding cystourethrogram after reconstruction (D).

In children, even with the most severe injuries, excision of the scar with primary anastomosis is typically feasible to perform without concern about tension on the anastomosis (Helmy et al., 2014). We perform this through a perineal approach with the child in the lithotomy position, making sure to prepare the lower abdomen in case the bladder needs to be mobilized from above. A midline incision is made on the perineum, and the urethra is mobilized and circumscribed. This can be dissected distally to the glans if necessary. Proximal dissection is performed to the scar and, assuming a primary repair is being performed, the urethra is transected through the scar. The bladder neck can be difficult to identify depending on the extent of the scar. This is facilitated by the passage of a sound through the suprapubic site into the bladder neck. An incision through the scar onto the sound then provides a more direct entry into the bladder neck. The scar is then excised aggressively from both the distal and proximal portions of the urethra until only soft tissue with good blood supply is present. The urethra is then spatulated and the anastomosis is performed with interrupted dissolving suture over a Foley catheter. If there is tension on the anastomosis after mobilization of the urethra, more length can be obtained first by partial pubectomy and then by mobilization of the bladder from above through an abdominal incision. The catheter is left in place for approximately 2 to 3 weeks. The suprapubic tube is removed after a voiding trial and cystogram. A similar technique can also be performed through a posterior sagittal transanorectal approach (Onofre et al., 2011).

If the gap is too large for excision and primary anastomosis, several options are available for reconstruction. Skin or buccal inlays can be used as grafts or flaps. Interposition with appendix, bowel, and ureter has also been described for larger defects. Defects less than 5 cm in length, however, are typically amenable to excision and primary anastomosis. This is the case in almost all initial repairs, however in the situation of reoperation, the defects can be longer (Aggarwal et al., 2002; Sunay et al., 2011).

Postoperative outcomes in children are generally favorable. Complications can include urinary retention (either caused by atony or recurrent stricture), incontinence, penile shortening, and erectile dysfunction as in adults, however the rates are lower (Trachta et al., 2016). **AUA urotrauma guidelines recommend that follow-up be continued for at least 1 year after the repair** (Morey et al., 2014).

Recurrent stricture occurs in about 10% of pediatric patients, at which point internal urethrotomy can be attempted, although failure rates are high. As expected, this is more successful with shorter (<1 cm) postoperative strictures, and a repeat urethroplasty may be necessary if it fails (Aggarwal et al., 2002; El-Sheikh et al., 2008; Helmy et al., 2014; Onofre et al., 2011). Redo urethroplasty is understandably more likely to result in recurrent stricture due in part to the more complicated original lesion (Aggarwal et al., 2002).

Urinary incontinence can occur in as many as 20% of children and appears to relate to the type and extent of injury. It is more commonly associated with more proximal injuries such as those to the bladder neck or prostatic urethra (Boone et al., 1992; Onofre et al., 2011; Podesta and Podesta, 2015). In the case of urethral injuries that extend up into the bladder neck, continence rates are notoriously unfavorable regardless of the timing or type of repair (Routh and Husmann, 2007).

Postoperative erectile dysfunction seems to correlate with preoperative dysfunction with potential long-term recovery (Aggarwal et al., 2002; Podesta and Podesta, 2015). In addition, certain characteristics of the injury such as the severity of the fracture and length of the defect) can predict greater likelihood of dysfunction (Hemal et al., 2000; Husmann et al., 1990). This can occur in up to one-half of children and appears to occur more commonly in patients treated with acute open realignment, possibly providing a rationale to avoid attempts at immediate realignment (Boone et al., 1992; Koraitim, 2014). Other associated findings in patients with resultant erectile dysfunction are lateral prostatic displacement at time of injury and urethral gap larger than 2.5 cm (Koraitim, 2014).

Urethral Disruption in Females

Female urethral injury requiring intervention is rare. This happens almost exclusively in the presence of pelvic fracture and most often presents as a complete disruption below the bladder neck. The overall incidence of urethral injury in female pelvic fracture is about 5% (Black et al., 2006; Hosseini et al., 2009; Podesta and Jordan, 2001) but should be ruled out when hematuria, urinary retention, or injury to the vagina or rectum is present (Hemal et al., 2000; Perry and Husmann, 1992; Venn et al., 1999). Common etiologies include crush injuries, motor vehicle accidents, and falls involving pelvic fracture. As described earlier, management relies on suprapubic drainage initially with delayed repair several months after the trauma. Because the external sphincter is typically preserved, the reconstruction is performed as an excision of the scar with primary anastomosis. We perform this with the patient in the lithotomy position as we do in male patients, with the abdomen prepared in case bladder mobilization is necessary. Published continence results are favorable when the bladder neck is not involved (Hosseini et al., 2009; Podesta and Jordan, 2001), however incontinence, recurrent stricture, and fistula do occur (Hemal et al., 2000; Huang et al., 2003; Venn et al., 1999).

Key Points: Bladder and Urethral Injury

- A history of pelvic trauma with gross hematuria or inability to void and pelvic fracture necessitate urologic evaluation with retrograde urethrography and/or cystography.
- Indications to repair an extraperitoneal bladder rupture include need for placement of orthopedic hardware in the field, bony pelvis fragments protruding into the bladder, involvement of the bladder neck in the injury, and concurrent abdominal surgery.
- Intraperitoneal bladder ruptures are managed with surgical repair.
- Bladder neck injuries are more common in children and best served with early repair.

Genital Injury in the Pediatric Population

Although most genital injuries in children are accidental, it is critical to assess whether trauma to the penis or scrotum in boys, or the vagina in girls, is the result of abuse. About 1 in 7 boys and 1 in 3 girls will be sexually abused in childhood. In most of these cases, the abuse is penetrative (Briere and Elliott, 2003). This is not always obvious, and if there is any suspicion, ancillary services such as social services can be helpful in determining the safety of the child in his or her home environment on discharge from the hospital. In addition, when abuse is suspected, it is imperative to ensure that no other harm has been done. Often concomitant injuries go unnoticed, particularly to the anus and rectum.

Penile Injury

In larger series, most penile injury in children happens inadvertently from a number of causes. These include circumcision, hair tourniquet strangulation, motor vehicle accidents, animal bites, zippers, and burns or scalds, with circumcision making up the majority of the injuries. (El-Bahnasawy et al., 2002). Severity and type of injury directs evaluation and treatment (Table 52.8).

TABLE 52.8

Penile Injury: American Association for the Surgery of Trauma Organ Injury Scale

Cutaneous laceration/contusion
Buck fascia (cavernosum) laceration without tissue loss
Cutaneous avulsion, laceration through the glans/meatus, or cavernosal/urethral defect <2 cm
Partial penectomy or cavernosal/urethral defect >2 cm
Total penectomy

Modified from Goldman SM, Sandler CM, Corriere JN Jr, McGuire EJ. Blunt urethral trauma: a unified, anatomical mechanical classification. *J Urol.* 1997;157(1):85–89.

Amputation of the penis can occur with circumcision and strangulation injury, such as with a hair tourniquet. Depending on the technique and the training of the practitioner, newborn circumcision has been shown to have variable rates of complication and injury (Ceylan et al., 2007; Okeke et al., 2006). Minor injury involves the removal of excess skin, and severe injuries of partial or complete amputation of the glans penis can occur. **Typically these more profound injuries occur when performed without appropriate training. Injuries are less common in the hospital and clinic settings and are more often seen when a Mogen-type device is utilized.** This can be attributed to the lack of protective bell for the glans penis. Careful lysis of preputial adhesions can probably prevent the vast majority of these complications, even with use of a Mogen clamp (Pippi Salle et al., 2013). Hair or thread strangulation results in partial or circumferential damage with urethral injury or even penile loss. The damage is typically slow in onset and may not cause significant pain. In addition, the offending hair or thread may be too small to see. All of these factors can lead to late recognition and potentially greater harm (El-Bahnasawy et al., 2002).

When amputation occurs, whether caused by a complication of circumcision or caused by strangulation injury, careful repair often results in a good cosmetic outcome. This is the case with or without attempt at microvascular reanastomosis of the glans penis or penile shaft. A catheter is left in place for 1 to 2 weeks when a urethral anastomosis is used in the repair of the amputation. With a hair tourniquet injury, the injury may be less severe and can be managed conservatively. When surgical repair is necessary, outcomes have been favorable (Badawy et al., 2010).

Fistulae can also result from causes such as hair tourniquet strangulation or circumcision. Often a fistula caused by a hair tourniquet is on the proximal shaft. In these cases, a multilayer closure is usually performed if the fistula does not heal with an attempt at conservative management with catheter drainage. The outcomes for repair are quite favorable with occasional resultant urethral stricture or recurrent/persistent fistula (Badawy et al., 2010). In contrast, fistula from circumcision is often in a subcoronal position and may require splitting the glans and treating the injury in the manner of a hypospadias repair (Baskin et al., 1997).

Although blunt trauma to the penis in children is rare, Glass et al. reported relatively high numbers of patients presenting to emergency departments in the

United States with toilet seat crush injuries, with more than 9000 occurring from 2002 to 2010, reported through a consumer database (Glass et al., 2013). Usually this occurs in toilet training boys and most of these injuries are minor, typically managed conservatively and treated as an outpatient.

Burns to the genitalia are rare in children but occur more commonly than in the adult population. Most of these are caused by scalds. They are usually not isolated to the genitalia and can result in significant skin loss (Abel et al., 2012). This may require transposition of skin by either graft or flap technique. In our practice, we typically harvest from sites expected to bear less hair in the postpubertal male. We use full-thickness and unmeshed grafts to cover the penile shaft. This provides more natural-looking skin that moves more freely over the underlying corporal bodies. A bolster dressing is left in place for 5 to 7 days, and activity is limited. Excessive skin removal at the time of circumcision, however, can typically be managed conservatively with dressing changes, allowing the wound to heal by secondary intention with good cosmetic outcomes (Banihani et al., 2014; El-Bahnasawy et al., 2002).

In the case of animal bites, debridement and copious irrigation must accompany any treatment. If there is no obvious sign of infection, wounds can be reapproximated, usually, however, they are best left to heal by secondary intention (Gomes et al., 2001).

Scrotal Injury

Epidemiology

Testis trauma in children is rare. Of all surgical cases for acute scrotum, these make up less than 5% of trips to the operating room (Pogorelic et al., 2016). Penetrating trauma to the scrotum can include superficial injury to the skin and dartos or deeper injury into the tunica vaginalis (Table 52.9). Blunt trauma to the testis ranges from minor hematoma to testicular rupture, with extrusion of seminiferous tubules as described by the AAST severity scoring for testicular trauma shown in Table 52.10.

TABLE 52.9

Scrotal Injury: American Association for the Surgery of Trauma Organ Injury Scale

Contusion

Laceration <25% of scrotal diameter
Laceration >25% of scrotal diameter
Avulsion <50%
Avulsion >50%

Modified from Moore EE, Cogbill TH, Jurkovich GJ, et al. Organ injury scaling. III: Chest wall, abdominal vascular, ureter, bladder, and urethra. *J Trauma*. 1992;33(3):337–339.

TABLE 52.10

Testicular Injury: American Association for the Surgery of Trauma Organ Injury Scale

Contusion/hematoma
Subclinical laceration of tunica albuginea
Laceration of tunica albuginea with <50% parenchymal loss
Major laceration of tunica albuginea with >50% parenchymal loss
Total testicular destruction or avulsion

Modified from Moore EE, Cogbill TH, Jurkovich GJ, et al. Organ injury scaling. III: Chest wall, abdominal vascular, ureter, bladder, and urethra. *J Trauma*. 1992;33(3):337–339.

Imaging

As with suspicion for testicular torsion, often a good history or examination warrants immediate operative intervention, and no imaging is necessary. However, for a child with scrotal trauma, scrotal imaging in the form of ultrasonography can be helpful in determining whether there is a rupture of the testis. **Ultrasonographic signs of rupture include discontinuity of the tunica albuginea, hematocele, and loss of Doppler signal to part of or the entire testis.** Fig. 52.11 shows an example of testis rupture case.

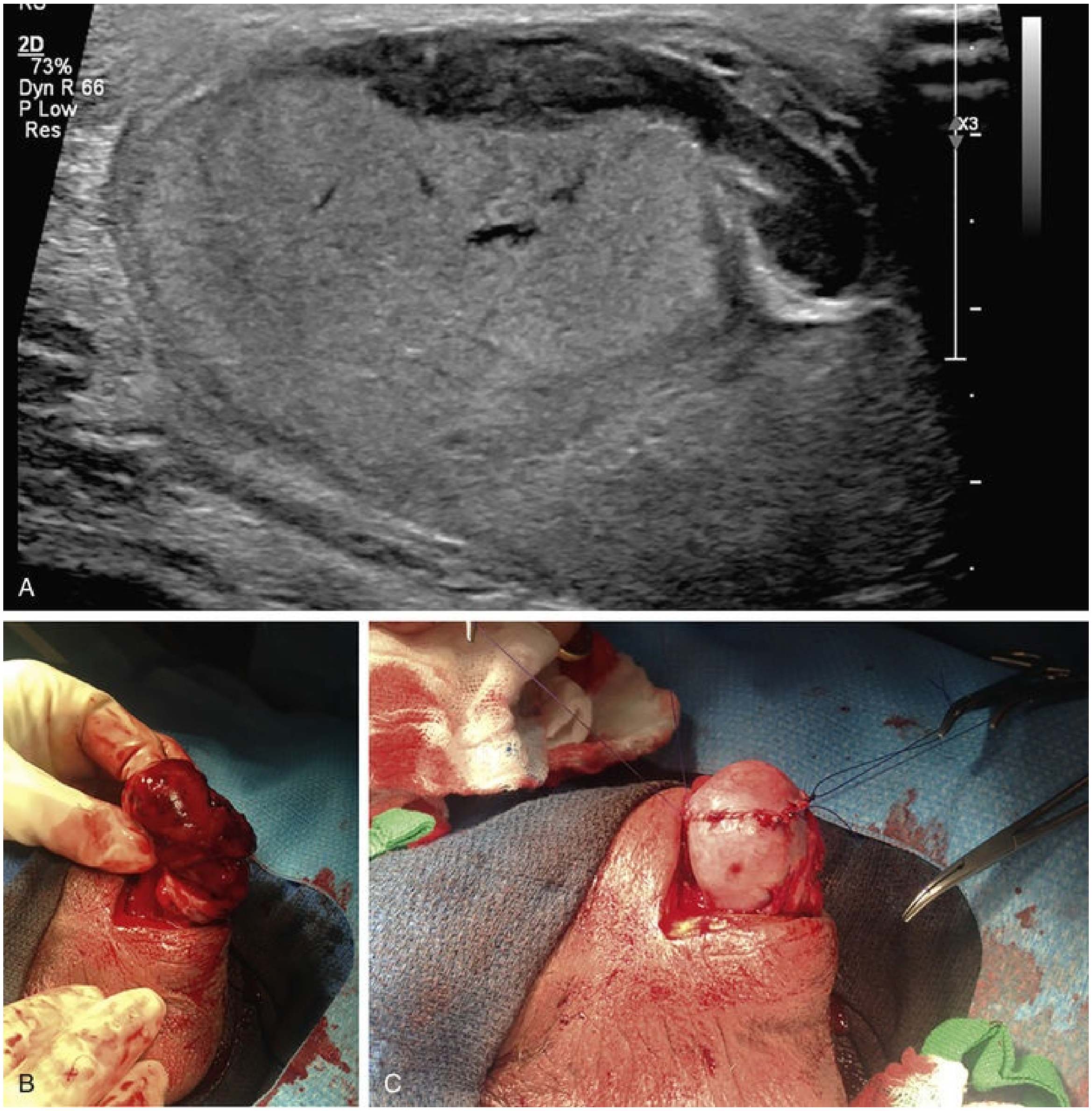

FIG. 52.11 Testis rupture with preoperative ultrasound (A) and intraoperative images before and after repair (B and C).

Management

As in adults, penetrating scrotal lacerations can be managed simply with washout and closure given that the tunica vaginalis is not violated. In children, this can often be performed in the emergency department with local anesthetic and minimal sedation if any. If there is concern about entry into the tunica vaginalis or if there is extrusion of the testicle, a more formal debridement and washout in the operating room is indicated. Depending on the nature of the injury, a drain might be left for several days.

Management of blunt trauma to the scrotum is dependent on whether there is a concern about testicular rupture. In the case in which the tunica albuginea does not appear intact on the ultrasonography or there is an apparent hematocele, testicular rupture is suspected, and exploration is typically recommended.. **In the case of rupture, most literature advocates for debridement and repair of the tunica albuginea in the operating room in the acute setting, and this is supported by AUA urotrauma and EAU urogenital trauma guidelines** (Kitrey et al., 2018; Morey et al., 2014). Some authors, however, have advocated for conservative management even when a rupture is confirmed. In a recent series, atrophy rates in this setting were less than 20% (Redmond et al., 2018).

Loss of scrotal skin often can be managed by coverage with surrounding skin with an advancement flap. This is the case, even with significant skin loss after scrotal debridement. If needed, however, skin can be harvested from the abdomen or thigh and used as a split-thickness and meshed graft.

We arrange office follow-up in most of our acute scrotal trauma patients about 6 weeks after initial presentation for an examination and ultrasonography. This allows us to ensure that any symptoms are improving and visualize the testis once the acute pathology is resolved. This is particularly true if there was no operative intervention to ensure that there is no other underlying testicular pathology masked by hematoma or testicular injury.

Vaginal Injury

Vaginal injuries in female patients are relatively uncommon and can generally be divided into two categories—straddle injuries and penetrative injuries. Although there is an AAST scoring system for both vaginal and vulvar injury (Tables 52.11 and 52.12), this is not often cited, and no other scoring systems that have been proposed are widely used (Onen et al., 2005a, 2005b).

TABLE 52.11

Vaginal Injury: American Association for the Surgery of Trauma Organ Injury Scale

Contusion or hematoma
Laceration, superficial (mucosa only)
Laceration, deep (into fat or muscle)

Laceration, complex, into cervix or peritoneum
Injury into adjacent organs (anus, rectum, urethra, bladder)

Modified from Moore EE, Cogbill TH, Jurkovich GJ, et al. Organ injury scaling. III: Chest wall, abdominal vascular, ureter, bladder, and urethra. *J Trauma*. 1992;33(3):337–339.

TABLE 52.12

Vulvar Injury: American Association for the Surgery of Trauma Organ Injury Scale

Contusion or hematoma
Laceration, superficial (skin only)
Laceration, deep (into fat or muscle)
Avulsion; skin, fat, or muscle
Injury into adjacent organs (anus, rectum, urethra, bladder)

Modified from Moore EE, Cogbill TH, Jurkovich GJ, et al. Organ injury scaling. III: Chest wall, abdominal vascular, ureter, bladder, and urethra. *J Trauma*. 1992;33(3):337–339.

Straddle injury is by far the most common etiology of vaginal trauma, accounting for about 80% of all injuries, and penetrating injuries make up about 5% (Dowd et al., 1994; Spitzer et al., 2008). Straddle injuries do not ordinarily result in perianal, hymen, or vaginal trauma (Saxena et al., 2014). These injuries are suggestive of a penetrating mechanism, intentional or not (Dowd et al., 1994).

Any history or sign of penetrating vaginal injury must raise suspicion of abuse and should prompt careful assessment of the etiology of the trauma. Signs of penetrative injury are associated with injury to neighboring anatomy (such as the bladder, urethra, anus, or rectum), internal vaginal injury, or hymenal injury. Hymenal injury in particular has been strongly correlated with sexual abuse (Bond et al., 1995; Heppenstall-Heger et al., 2003) and, when present, suggests abuse unless the event precipitating the injury was witnessed to be unintentional.

Injuries can be associated with boney pelvis fracture and concomitant injury to the urethra, bladder, and rectum. In these circumstances, examination under general anesthesia is indicated so that cystoscopy and vaginoscopy might be performed along with anoscopy by a general surgeon.

Management

Straddle injuries typically result in minor trauma to the labia minora, with most not requiring surgical intervention or a trip to the operating room. Minor injuries of the labia minora that are managed conservatively typically heal well without substantial scarring. Older patients that present acutely with larger injuries, particularly those involving the hymen, are more likely to require operative intervention particularly if associated with perineal bleeding, hematoma, or swelling (Scheidler et al., 2000; Spitzer et al., 2008).

In children, outward appearance of the genitalia may not necessarily reflect the underlying severity of the trauma or, in fact, that any trauma has even occurred (Heger et al., 2002). In a prospective study over 10 years, 94 children (81 females) were followed for anogenital trauma. Of the 81 females, more than one-half had injuries as a result of abuse. Only 15% of these had significant anatomic evidence of injury when examined later, suggesting that most heal without obvious scar. They did recommend repair of the posterior forchette in the acute setting to improve later healing of the vaginal introitus (Heppenstall-Heger et al., 2003). Injury to the urethra, bladder, anus, and rectum can be missed, and consideration to performing an examination under anesthesia should be given if there is a high suspicion for abuse (Okur et al., 1996).

Two papers described healing of hymenal and nonhymenal injuries in females who were of adolescent age and younger (McCann et al., 2007a, 2007b). In 239 nonhymenal injuries (113 of which were in prepubertal girls), most were secondary to abuse. Not surprisingly, superficial injuries such as abrasions, contusions, and superficial lacerations healed rapidly, and deep lacerations took several weeks. Hymenal injuries healed rapidly without evidence of scar, and most had no evidence of injury once healed. Thus, importantly, the lack of outward evidence of trauma does not preclude the possibility of a history of sexual abuse (Adams et al., 1994).

Key Points: Genital Injury

- Genital injury in children should raise suspicion for abuse.
- If abuse is suspected, concomitant injury to the rectum and anus should be ruled out.
- Most circumcision injuries can probably be avoided by ensuring that adhesions are properly reduced at the beginning of the procedure.
- Findings on ultrasonography consistent with testicular rupture should prompt strong consideration of surgical exploration.
- Straddle injuries make up the majority of vaginal injuries. Injuries to bladder, urethra, anus, rectum, hymen, and internal vaginal structures are suggestive of penetrative injury and should prompt evaluation for abuse.

References

Abel NJ, Klaassen Z, Mansour EH, et al. Clinical outcome analysis of male and female genital burn injuries: a 15-year experience at a level-1 burn center. *Int J Urol*. 2012;19(4):351–358.

Adams JA, Harper K, Knudson S, et al. Examination findings in legally confirmed child sexual abuse: it's normal to be normal. *Pediatrics*. 1994;94(3):310–317.

Aggarwal SK, Goel D, Gupta CR, et al. The use of pedicled appendix graft for substitution of urethra in recurrent urethral stricture. *J Pediatr Surg*. 2002;37(2):246–250.

Akbari A, Heran MK, Afshar K. Concurrent use of endourological and radiologic methods in the management of high-grade renal trauma. *Can Urol Assoc J*. 2016;10(9–10):E312–E315.

al-Ali M, Haddad LF. The late treatment of 63 overlooked or complicated ureteral missile injuries: the promise of nephrostomy and role of autotransplantation. *J Urol*. 1996;156(6):1918–1921.

Al-Qudah HS, Santucci RA. Complications of renal trauma. *Urol Clin North Am*. 2006;33(1):41–53 [vi].

Alsikafi NF, McAninch JW, Elliott SP, et al. Nonoperative management outcomes of isolated urinary extravasation following renal lacerations due to external trauma. *J Urol*. 2006;176(6 Pt 1):2494–2497.

Amerstorfer EE, Haberlik A, Riccabona M. Imaging assessment of renal injuries in children and adolescents: CT or ultrasound. *J Pediatr Surg*. 2015;50(3):448–455.

Ashebu SD, Dahniya MH, Aduh P, et al. Rupture of the renal pelvis of a ureteropelvic junction hydronephrosis after blunt abdominal trauma. *Australas Radiol*. 2004;48(2):256–258.

Atala A, Miller FB, Richardson JD, et al. Preliminary vascular control for renal trauma. *Surg Gynecol Obstet*. 1991;172(5):386–390.

Au JK, Tan X, Sidani M, et al. Imaging characteristics associated with failure of nonoperative management in high-grade pediatric blunt renal trauma. *J Pediatr Urol*. 2016;12(5):294 [e1–294.e6].

Badawy H, Soliman A, Ouf A, et al. Progressive hair coil penile tourniquet syndrome: multicenter experience with 25 cases. *J Pediatr Surg*. 2010;45(7):1514–1518.

Banihani OI, Fox JA, Gander BH, et al. Complete penile amputation during ritual neonatal circumcision and successful replantation using postoperative leech therapy. *Urology*. 2014;84(2):472–474.

Bartley JM, Santucci RA. Computed tomography findings in patients with pediatric blunt renal trauma in whom expectant (nonoperative) management failed. *Urology*. 2012;80(6):1338–1343.

Baskin LS, Canning DA, Snyder HM 3rd, et al. Surgical repair of urethral circumcision injuries. *J Urol*. 1997;158(6):2269–2271.

Bent C, Iyngkaran T, Power N, et al. Urological injuries following trauma. *Clin Radiol*. 2008;63(12):1361–1371.

Benway BM, Cabello JM, Figenshau RS, et al. Sliding-clip renorrhaphy provides superior closing tension during robot-assisted partial nephrectomy. *J Endourol*. 2010;24(4):605–608.

Bernard JJ. Renal trauma: evaluation, management, and return to play. *Curr Sports Med Rep*. 2009;8(2):98–103.

Berrington de Gonzalez A, Journy N, Lee C, et al. No association between radiation dose from pediatric CT scans and risk of subsequent Hodgkin lymphoma. *Cancer Epidemiol Biomarkers Prev*. 2017;26(5):804–806.

Best CD, Petrone P, Buscarini M, et al. Traumatic ureteral injuries: a single institution experience validating the American Association for the Surgery of Trauma-Organ Injury Scale grading scale. *J Urol*. 2005;173(4):1202–1205.

Bjurlin MA, Jeng EI, Goble SM, et al. Comparison of nonoperative management with renorrhaphy and nephrectomy in penetrating renal injuries. *J Trauma*. 2011;71(3):554–558.

Black PC, Miller EA, Porter JR, et al. Urethral and bladder neck injury associated with pelvic fracture in 25 female patients. *J Urol*. 2006;175(6):2140–2144 [discussion 2144].

Blackwell RH, Kirshenbaum EJ, Shah AS, et al. Complications of recognized and unrecognized iatrogenic ureteral injury at time of hysterectomy: a population based analysis. *J Urol*. 2018;199(6):1540–1545.

Bond GR, Dowd MD, Landsman I, et al. Unintentional perineal injury in prepubescent girls: a multicenter, prospective report of 56 girls. *Pediatrics*. 1995;95(5):628–631.

Boone TB, Gilling PJ, Husmann DA. Ureteropelvic junction disruption following blunt abdominal trauma. *J Urol*. 1993;150(1):33–36.

Boone TB, Wilson WT, Husmann DA. Postpubertal genitourinary function following posterior urethral disruptions in children. *J Urol*. 1992;148(4):1232–1234.

Boudville N, Prasad GV, Knoll G, et al. Meta-analysis: risk for hypertension in living kidney donors. *Ann Intern Med*. 2006;145(3):185–196.

Brandes S. Initial management of anterior and posterior urethral injuries. *Urol Clin North Am*. 2006;33(1):87–95 [vii].

Brandes S, Coburn M, Armenakas N, et al. Diagnosis and management of ureteric injury: an evidence-based analysis. *BJU Int*. 2004;94(3):277–289.

Brandes SB, McAninch JW. Reconstructive surgery for trauma of the upper urinary tract. *Urol Clin North Am*. 1999;26(1):183–199 [x].

Bregstein JS, Lubell TR, Ruscica AM, et al. Nuking the radiation: minimizing radiation exposure in the evaluation of pediatric blunt trauma. *Curr Opin Pediatr*. 2014;26(3):272–278.

Brereton RJ, Philp N, Buyukpamukcu N. Rupture of the urinary bladder in children. The importance of the double lesion. *Br J Urol*. 1980;52(1):15–20.

Breyer BN, McAninch JW, Elliott SP, et al. Minimally invasive endovascular techniques to treat acute renal hemorrhage. *J Urol*. 2008;179(6):2248–2252 [discussion 2253].

Briere J, Elliott DM. Prevalence and psychological sequelae of self-reported childhood physical and sexual abuse in a general population sample of men and women. *Child Abuse Negl*. 2003;27(10):1205–1222.

Broghammer JA, Fisher MB, Santucci RA. Conservative management of renal trauma: a review. *Urology*. 2007;70(4):623–629.

Broghammer JA, Langenburg SE, Smith SJ, et al. Pediatric blunt renal trauma: its conservative management and patterns of associated injuries. *Urology*. 2006;67(4):823–827.

Brown RL, Koepplinger ME, Mehlman CT, et al. All-terrain vehicle and bicycle crashes in children: epidemiology and comparison of injury severity. *J Pediatr Surg*. 2002;37(3):375–380.

Brown SL, Elder JS, Spirnak JP. Are pediatric patients more susceptible to major renal injury from blunt trauma? A comparative study. *J Urol*. 1998;160(1):138–140.

Buckley JC, McAninch JW. The diagnosis, management, and outcomes of pediatric renal injuries. *Urol Clin North Am*. 2006;33(1):33–40 [vi].

Buckley JC, McAninch JW. Revision of current American

Association for the Surgery of Trauma Renal Injury grading system. *J Trauma*. 2011;70(1):35–37.

Buckley JC, McAninch JW. Pediatric renal injuries: management guidelines from a 25-year experience. *J Urol*. 2004;172(2):687–690 [discussion 690].

Cannon GM Jr, Polsky EG, Smaldone MC, et al. Computerized tomography findings in pediatric renal trauma—indications for early intervention? *J Urol*. 2008;179(4):1529–1532 [discussion 1532–1523].

Canon S, Recicar J, Head B, et al. The utility of initial and follow-up ultrasound reevaluation for blunt renal trauma in children and adolescents. *J Pediatr Urol*. 2014;10(5):815–818.

Carroll PR, Klosterman P, McAninch JW. Early vascular control for renal trauma: a critical review. *J Urol*. 1989;141(4):826–829.

Carroll PR, McAninch JW, Wong A, et al. Outcome after temporary vascular occlusion for the management of renal trauma. *J Urol*. 1994;151(5):1171–1173.

Cass AS, Ireland GW. Comparison of the conservative and surgical management of the more severe degrees of renal trauma in multiple injured patients. *J Urol*. 1973;109(1):8–10.

Cass AS, Luxenberg M, Gleich P, et al. Long-term results of conservative and surgical management of blunt renal lacerations. *Br J Urol*. 1987;59(1):17–20.

Cetti NE. Delayed urinary fistula from high velocity missile injury to the ureter. *Ann R Coll Surg Engl*. 1983;65(5):286–288.

Ceylan K, Burhan K, Yilmaz Y, et al. Severe complications of circumcision: an analysis of 48 cases. *J Pediatr Urol*. 2007;3(1):32–35.

Charbit J, Manzanera J, Millet I, et al. What are the specific computed tomography scan criteria that can predict or exclude the need for renal angioembolization after high-grade renal trauma in a conservative management strategy? *J Trauma*. 2011;70(5):1219–1227 [discussion 1227–1218].

Chia JP, Holland AJ, Little D, et al. Pelvic fractures and associated injuries in children. *J Trauma*. 2004;56(1):83–88.

Chiron P, Hornez E, Boddaert G, et al. Grade IV renal trauma management. A revision of the AAST renal injury grading scale is mandatory. *Eur J Trauma Emerg Surg*. 2016;42(2):237–241.

Chopra P, St-Vil D, Yazbeck S. Blunt renal trauma—blessing in disguise? *J Pediatr Surg*. 2002;37(5):779–782.

Chung D, Briggs J, Turney BW, et al. Management of iatrogenic ureteric injury with retrograde ureteric stenting: an analysis of factors affecting technical success and long-term outcome. *Acta Radiol*. 2017;58(2):170–175.

Corriere JN Jr, McAndrew JD, Benson GS. Intraoperative decision-making in renal trauma surgery. *J Trauma*. 1991;31(10):1390–1392.

Culty T, Boccon-Gibod L. Anastomotic urethroplasty for posttraumatic urethral stricture: previous urethral manipulation has a negative impact on the final outcome. *J Urol*. 2007;177(4):1374–1377.

Dangle PP, Fuller TW, Gaines B, et al. Evolving mechanisms of injury and management of pediatric blunt renal trauma—20 years of experience. *Urology*. 2016;90:159–163.

Dar TI, Rather MH, Khawaja AR, et al. Post traumatic isolated ureteropelvic junction avulsion in a child. *Curr Urol*. 2017;10(3):160–162.

de la Rosette J, Denstedt J, Geavlete P, et al. The clinical research office of the endourological society ureteroscopy global study: indications, complications, and outcomes in 11,885 patients. *J Endourol*. 2014;28(2):131–139.

Deibert CM, Glassberg KI, Spencer BA. Repair of pediatric bladder rupture improves survival: results from the National Trauma Data Bank. *J Pediatr Surg*. 2012;47(9):1677–1681.

Delaney KM, Reddy SH, Dayama A, et al. Risk factors associated with bladder and urethral injuries in female children with pelvic fractures: an analysis of the National Trauma Data Bank. *J Trauma Acute Care Surg*. 2016;80(3):472–476.

Demetriades D, Karaiskakis M, Velmahos GC, et al. Pelvic fractures in pediatric and adult trauma patients: are they different injuries? *J Trauma*. 2003;54(6):1146–1151 [discussion 1151].

Dowd MD, Fitzmaurice L, Knapp JF, et al. The interpretation of urogenital findings in children with straddle injuries. *J Pediatr Surg*. 1994;29(1):7–10.

Dozier KC, Yeung LY, Miranda MA Jr, et al. Death or dialysis? The risk of dialysis-dependent chronic renal failure after trauma nephrectomy. *Am Surg*. 2013;79(1):96–100.

Dugi DD 3rd, Morey AF, Gupta A, et al. American Association for the Surgery of Trauma grade 4 renal injury substratification into grades 4a (low risk) and 4b (high risk). *J Urol*. 2010;183(2):592–597.

Dunfee BL, Lucey BC, Soto JA. Development of renal scars on CT after abdominal trauma: does grade of injury matter. *AJR Am J Roentgenol*. 2008;190(5):1174–1179.

Eassa W, El-Ghar MA, Jednak R, et al. Nonoperative management of grade 5 renal injury in children: does it have a place? *Eur Urol*. 2010;57(1):154–161.

Eeg KR, Khoury AE, Halachmi S, et al. Single center experience with application of the ALARA concept to serial imaging studies after blunt renal trauma in children—is ultrasound enough? *J Urol*. 2009;181(4):1834–1840 [discussion 1840].

El-Bahnasawy MS, El-Sherbiny MT. Paediatric penile trauma.

BJU Int. 2002;90(1):92–96.

El-Sheikh MG, Ziada AM, Sadek SZ, et al. Pediatric and adolescent transperineal anastomotic urethroplasty. *J Pediatr Urol*. 2008;4(5):333–336.

El-Sherbiny MT, Aboul-Ghar ME, Hafez AT, et al. Late renal functional and morphological evaluation after non-operative treatment of high-grade renal injuries in children. *BJU Int*. 2004;93(7):1053–1056.

Elliott SP, McAninch JW. Ureteral injuries from external violence: the 25-year experience at San Francisco General Hospital. *J Urol*. 2003;170(4 Pt 1):1213–1216.

Erdogru T, Kutlu O, Koksal T, et al. Endoscopic treatment of ureteric strictures: acucise, cold-knife endoureterotomy and wall stents as a salvage approach. *Urol Int*. 2005;74(2):140–146.

Fiard G, Rambeaud JJ, Descotes JL, et al. Long-term renal function assessment with dimercapto-succinic acid scintigraphy after conservative treatment of major renal trauma. *J Urol*. 2012;187(4):1306–1309.

Figler BD, Malaeb BS, Voelzke B, et al. External validation of a substratification of the American Association for the Surgery of Trauma renal injury scale for grade 4 injuries. *J Am Coll Surg*. 2013;217(5):924–928.

Fraser JD, Aguayo P, Ostlie DJ, et al. Review of the evidence on the management of blunt renal trauma in pediatric patients. *Pediatr Surg Int*. 2009;25(2):125–132.

Fuchs ME, Beecroft N, Dajusta DG, et al. Is delayed phase computed tomography imaging necessary after blunt renal trauma in children? *Urology*. 2018;113:187–191.

Gaither TW, Awad MA, Leva NV, et al. Missed opportunities to decrease radiation exposure in children with renal trauma. *J Urol*. 2018;199(2):552–557.

Gerstenbluth RE, Spirnak JP, Elder JS. Sports participation and high grade renal injuries in children. *J Urol*. 2002;168(6):2575–2578.

Glass AS, Bagga HS, Tasian GE, et al. No small slam: increasing incidents of genitourinary injury from toilets and toilet seats. *BJU Int*. 2013;112(3):398–403.

Gleason PE, Kelalis PP, Husmann DA, et al. Hydronephrosis in renal ectopia: incidence, etiology and significance. *J Urol*. 1994;151(6):1660–1661.

Goffette PP, Laterre PF. Traumatic injuries: imaging and intervention in post-traumatic complications (delayed intervention). *Eur Radiol*. 2002;12(5):994–1021.

Goldman SM, Sandler CM, Corriere JN Jr, et al. Blunt urethral trauma: a unified, anatomical mechanical classification. *J Urol*. 1997;157(1):85–89.

Gomes CM, Ribeiro-Filho L, Giron AM, et al. Genital trauma due to animal bites. *J Urol*. 2001;165(1):80–83.

Gonzalez RP, Falimirski M, Holevar MR, et al. Surgical management of renal trauma: is vascular control necessary? *J Trauma*. 1999;47(6):1039–1042 [discussion 1042–1034].

Goodno JA Jr, Powers TW, Harris VD. Ureteral injury in gynecologic surgery: a ten-year review in a community hospital. *Am J Obstet Gynecol*. 1995;172(6):1817–1820 [discussion 1820–1812].

Grimsby GM, Voelzke B, Hotaling J, et al. Demographics of pediatric renal trauma. *J Urol*. 2014;192(5):1498–1502.

Haas CA, Brown SL, Spirnak JP. Limitations of routine spiral computerized tomography in the evaluation of bladder trauma. *J Urol*. 1999;162(1):51–52.

Hall SJ, Carpinito GA. Traumatic rupture of a renal pelvis obstructed at the ureteropelvic junction: case report. *J Trauma*. 1994;37(5):850–852.

Hammer CC, Santucci RA. Effect of an institutional policy of nonoperative treatment of grades I to IV renal injuries. *J*

Urol. 2003;169(5):1751–1753.

Hardee MJ, Lowrance W, Brant WO, et al. High grade renal injuries: application of Parkland Hospital predictors of intervention for renal hemorrhage. *J Urol*. 2013;189(5):1771–1776.

Hardee MJ, Lowrance W, Stevens MH, et al. Process improvement in trauma: compliance with recommended imaging evaluation in the diagnosis of high-grade renal injuries. *J Trauma Acute Care Surg*. 2013;74(2):558–562.

Heger A, Ticson L, Velasquez O, et al. Children referred for possible sexual abuse: medical findings in 2384 children. *Child Abuse Negl*. 2002;26(6–7):645–659.

Helmy TE, Sarhan O, Hafez AT, et al. Perineal anastomotic urethroplasty in a pediatric cohort with posterior urethral strictures: critical analysis of outcomes in a contemporary series. *Urology*. 2014;83(5):1145–1148.

Hemal AK, Dorairajan LN, Gupta NP. Posttraumatic complete and partial loss of urethra with pelvic fracture in girls: an appraisal of management. *J Urol*. 2000;163(1):282–287.

Henderson CG, Sedberry-Ross S, Pickard R, et al. Management of high grade renal trauma: 20-year experience at a pediatric level I trauma center. *J Urol*. 2007;178(1):246–250 [discussion 250].

Heppenstall-Heger A, McConnell G, Ticson L, et al. Healing patterns in anogenital injuries: a longitudinal study of injuries associated with sexual abuse, accidental injuries, or genital surgery in the preadolescent child. *Pediatrics*. 2003;112(4):829–837.

Herschorn S, Radomski SB, Shoskes DA, et al. Evaluation and treatment of blunt renal trauma. *J Urol*. 1991;146(2):274–276 [discussion 276–277].

Herschorn S, Thijssen A, Radomski SB. The value of immediate or early catheterization of the traumatized posterior urethra. *J Urol*. 1992;148(5):1428–1431.

Heyns CF. Renal trauma: indications for imaging and surgical exploration. *BJU Int*. 2004;93(8):1165–1170.

Hochberg E, Stone NN. Bladder rupture associated with pelvic fracture due to blunt trauma. *Urology*. 1993;41(6):531–533.

Hosseini J, Tavakkoli Tabassi K, Razi A. Delayed retropubic urethroplasty of completely transected urethra associated with pelvic fracture in girls. *Urol J*. 2009;6(4):272–275.

Hotaling JM, Sorensen MD, Smith TG 3rd, et al. Analysis of diagnostic angiography and angioembolization in the acute management of renal trauma using a national data set. *J Urol*. 2011;185(4):1316–1320.

Hsiao KC, Baez-Trinidad L, Lendvay T, et al. Direct vision internal urethrotomy for the treatment of pediatric urethral strictures: analysis of 50 patients. *J Urol*. 2003;170(3):952–955.

Huang CR, Sun N, Wei-ping, et al. The management of old urethral injury in young girls: analysis of 44 cases. *J Pediatr Surg*. 2003;38(9):1329–1332.

Husmann DA, Wilson WT, Boone TB, et al. Prostatomembranous urethral disruptions: management by suprapubic cystostomy and delayed urethroplasty. *J Urol*. 1990;144(1):76–78.

Ibrahim HN, Foley RN, Reule SA, et al. Renal function profile in white kidney donors: the first 4 decades. *J Am Soc Nephrol*. 2016;27(9):2885–2893.

Ishida Y, Tyroch AH, Emami N, et al. Characteristics and management of blunt renal injury in children. *J Emerg Trauma Shock*. 2017;10(3):140–145.

Jacobs MA, Hotaling JM, Mueller BA, et al. Conservative management vs early surgery for high grade pediatric renal trauma—do nephrectomy rates differ? *J Urol*. 2012;187(5):1817–1822.

Jahangiri Y, Ashwell Z, Farsad K. Percutaneous renal artery revascularization after prolonged ischemia secondary to blunt trauma: pooled cohort analysis. *Diagn Interv Radiol*. 2017;23(5):371–378.

Jang T, Sineff S, Naunheim R, et al. Residents should not independently perform focused abdominal sonography for trauma after 10 training examinations. *J Ultrasound Med*. 2004;23(6):793–797.

Jawas A, Abu-Zidan FM. Management algorithm for complete blunt renal artery occlusion in multiple trauma patients: case series. *Int J Surg*. 2008;6(4):317–322.

Kansas BT, Eddy MJ, Mydlo JH, et al. Incidence and management of penetrating renal trauma in patients with multiorgan injury: extended experience at an inner city trauma center. *J Urol*. 2004;172(4 Pt 1):1355–1360.

Kastelan Z, Derezic D, Pasini J, et al. Renal autotransplantation in management of bilateral ureteral mortar shell injuries: a case report. *Mil Med*. 2004;169(11):894–895.

Kawashima A, Sandler CM, Corriere JN Jr, et al. Ureteropelvic junction injuries secondary to blunt abdominal trauma. *Radiology*. 1997;205(2):487–492.

Keller MS, Eric Coln C, Garza JJ, et al. Functional outcome of nonoperatively managed renal injuries in children. *J Trauma*. 2004;57(1):108–110 [discussion 110].

Kitrey ND, Djakovic N, Kuehhas FE, et al. *European Association of Urology guidelines on urological trauma*. [Available at] http://uroweb.org/guideline/urological-trauma/; 2018.

Knudson MM, Harrison PB, Hoyt DB, et al. Outcome after major renovascular injuries: a Western trauma association multicenter report. *J Trauma*. 2000;49(6):1116–1122.

Koraitim MM. Bladder neck incompetence at posterior urethroplasty. *Arab J Urol*. 2015;13(1):64–67.

Koraitim MM. Pelvic fracture urethral injuries: evaluation of various methods of management. *J Urol*. 1996;156(4):1288–1291.

Koraitim MM. Predicting risk of erectile dysfunction after pelvic fracture urethral injury in children. *J Urol*. 2014;192(2):519–523.

Koukouras D, Petsas T, Liatsikos E, et al. Percutaneous minimally invasive management of iatrogenic ureteral injuries. *J Endourol*. 2010;24(12):1921–1927.

Kristjansson A, Pedersen J. Management of blunt renal trauma. *Br J Urol*. 1993;72(5 Pt 2):692–696.

Kunkle DA, Kansas BT, Pathak A, et al. Delayed diagnosis of traumatic ureteral injuries. *J Urol*. 2006;176(6 Pt 1):2503–2507.

Lee JN, Lim JK, Woo MJ, et al. Predictive factors for conservative treatment failure in grade IV pediatric blunt renal trauma. *J Pediatr Urol*. 2016;12(2):93 [e1–93.e7].

Lee YJ, Oh SN, Rha SE, et al. Renal trauma. *Radiol Clin North Am*. 2007;45(3):581–592 [ix].

LeeVan E, Zmora O, Cazzulino F, et al. Management of pediatric blunt renal trauma: a systematic review. *J Trauma Acute Care Surg*. 2016;80(3):519–528.

Li WM, Liu CC, Wu WJ, et al. Rupture of renal pelvis in an adult with congenital ureteropelvic junction obstruction after blunt abdominal trauma. *Kaohsiung J Med Sci*. 2007;23(3):142–146.

Liatsikos EN, Karnabatidis D, Katsanos K, et al. Ureteral injuries during gynecologic surgery: treatment with a minimally invasive approach. *J Endourol*. 2006;20(12):1062–1067.

Lin WC, Lin CH, Chen JH, et al. Computed tomographic imaging in determining the need of embolization for high-grade blunt renal injury. *J Trauma Acute Care Surg*.

2013;74(1):230–235.

Liu C, Zhang X, Xue D, et al. Endoscopic realignment in the management of complete transected ureter. *Int Urol Nephrol*. 2014;46(2):335–340.

Long JA, Fiard G, Descotes JL, et al. High-grade renal injury: non-operative management of urinary extravasation and prediction of long-term outcomes. *BJU Int*. 2013;111(4 Pt B):E249–E255.

Marcelissen TA, Den Hollander PP, Tuytten TR, et al. Incidence of iatrogenic ureteral injury during open and laparoscopic colorectal surgery: a single center experience and review of the literature. *Surg Laparosc Endosc Percutan Tech*. 2016;26(6):513–515.

Marekovic Z, Derezic D, Krhen I, et al. Urogenital war injuries. *Mil Med*. 1997;162(5):346–348.

Margenthaler JA, Weber TR, Keller MS. Blunt renal trauma in children: experience with conservative management at a pediatric trauma center. *J Trauma*. 2002;52(5):928–932.

Mathews JD, Forsythe AV, Brady Z, et al. Cancer risk in 680,000 people exposed to computed tomography scans in childhood or adolescence: data linkage study of 11 million Australians. *BMJ*. 2013;346:f2360.

McAleer IM, Kaplan GW, LoSasso BE. Congenital urinary tract anomalies in pediatric renal trauma patients. *J Urol*. 2002;168(4 Pt 2):1808–1810 [discussion 1810].

McAninch JW, Carroll PR, Klosterman PW, et al. Renal reconstruction after injury. *J Urol*. 1991;145(5):932–937.

McCann J, Miyamoto S, Boyle C, et al. Healing of hymenal injuries in prepubertal and adolescent girls: a descriptive study. *Pediatrics*. 2007;119(5):e1094–e1106.

McCann J, Miyamoto S, Boyle C, et al. Healing of nonhymenal genital injuries in prepubertal and adolescent girls: a descriptive study. *Pediatrics*. 2007;120(5):1000–1011.

McGahan JP, Richards JR, Jones CD, et al. Use of ultrasonography in the patient with acute renal trauma. *J Ultrasound Med*. 1999;18(3):207–213 [quiz 215–206].

Medina D, Lavery R, Ross SE, et al. Ureteral trauma: preoperative studies neither predict injury nor prevent missed injuries. *J Am Coll Surg*. 1998;186(6):641–644.

Mee SL, McAninch JW, Robinson AL, et al. Radiographic assessment of renal trauma: a 10-year prospective study of patient selection. *J Urol*. 1989;141(5):1095–1098.

Mohsen T, El-Assmy A, El-Diasty T. Long-term functional and morphological effects of transcatheter arterial embolization of traumatic renal vascular injury. *BJU Int*. 2008;101(4):473–477.

Moolman C, Navsaria PH, Lazarus J, et al. Nonoperative management of penetrating kidney injuries: a prospective audit. *J Urol*. 2012;188(1):169–173.

Moore EE, Cogbill TH, Jurkovich GJ, et al. Organ injury scaling. III: Chest wall, abdominal vascular, ureter, bladder, and urethra. *J Trauma*. 1992;33(3):337–339.

Moore EE, Shackford SR, Pachter HL, et al. Organ injury scaling: spleen, liver, and kidney. *J Trauma*. 1989;29(12):1664–1666.

Morey AF, Brandes S, Dugi DD 3rd, et al. Urotrauma: AUA guideline. *J Urol*. 2014;192(2):327–335.

Morey AF, Bruce JE, McAninch JW. Efficacy of radiographic imaging in pediatric blunt renal trauma. *J Urol*. 1996;156(6):2014–2018.

Moriarty KP, Lipkowitz GS, Germain MJ. Capsulectomy: a cure for the page kidney. *J Pediatr Surg*. 1997;32(6):831–833.

Morrow J, Curry D, Dooher M, et al. Minimally invasive management of delayed recognition iatrogenic ureteric injury. *Ulster Med J*. 2017;86(3):181–184.

Murawski M, Golebiewski A, Komasara L, et al. Rupture of the normal renal pelvis after blunt abdominal trauma. *J Pediatr Surg*. 2008;43(9):e31–e33.

Murphy GP, Gaither TW, Awad MA, et al. Management of pediatric grade iv renal trauma. *Curr Urol Rep*. 2017;18(3):23.

Nance ML, Lutz N, Carr MC, et al. Blunt renal injuries in children can be managed nonoperatively: outcome in a consecutive series of patients. *J Trauma*. 2004;57(3):474–478 [discussion 478].

Nerli RB, Koura AC, Ravish IR, et al. Posterior urethral injury in male children: long-term follow up. *J Pediatr Urol*. 2008;4(2):154–159.

Nerli RB, Metgud T, Patil S, et al. Severe renal injuries in children following blunt abdominal trauma: selective management and outcome. *Pediatr Surg Int*. 2011;27(11):1213–1216.

Nural MS, Yardan T, Guven H, et al. Diagnostic value of ultrasonography in the evaluation of blunt abdominal trauma. *Diagn Interv Radiol*. 2005;11(1):41–44.

Nuss GR, Morey AF, Jenkins AC, et al. Radiographic predictors of need for angiographic embolization after traumatic renal injury. *J Trauma*. 2009;67(3):578–582 [discussion 582].

Okeke LI, Asinobi AA, Ikuerowo OS. Epidemiology of complications of male circumcision in Ibadan, Nigeria. *BMC Urol*. 2006;6:21.

Okur H, Kucikaydin M, Kazez A, et al. Genitourinary tract injuries in girls. *Br J Urol*. 1996;78(3):446–449.

Okur MH, Arslan S, Aydogdu B, et al. Management of high-grade renal injury in children. *Eur J Trauma Emerg Surg*. 2017;43(1):99–104.

Onen A, Kaya M, Cigdem MK, et al. Blunt renal trauma in children with previously undiagnosed pre-existing renal lesions and guidelines for effective initial management of kidney injury. *BJU Int*. 2002;89(9):936–941.

Onen A, Ozturk H, Kaya M, et al. Long-term outcome of posterior urethral rupture in boys: a comparison of different surgical modalities. *Urology*. 2005;65(6):1202–1207.

Onen A, Ozturk H, Yayla M, et al. Genital trauma in children: classification and management. *Urology*. 2005;65(5):986–990.

Onofre LS, Leao JQ, Gomes AL, et al. Pelvic fracture urethral distraction defects in children managed by anterior sagittal trans anorectal approach: a facilitating and safe access. *J Pediatr Urol*. 2011;7(3):349–355.

Osman Y, El-Tabey N, Mohsen T, et al. Nonoperative treatment of isolated posttraumatic intraperitoneal bladder rupture in children-is it justified? *J Urol*. 2005;173(3):955–957.

Osterberg EC, Awad MA, Murphy GP, et al. Renal trauma increases risk of future hypertension. *Urology*. 2018;116:198–204.

Palmer JM, Drago JR. Ureteral avulsion from non-penetrating trauma. *J Urol*. 1981;125(1):108–111.

Paquette EL. Genitourinary trauma at a combat support hospital during Operation Iraqi Freedom: the impact of body armor. *J Urol*. 2007;177(6):2196–2199 [discussion 2199].

Park JH, Park JW, Song K, et al. Ureteral injury in gynecologic surgery: a 5-year review in a community hospital. *Korean J Urol*. 2012;53(2):120–125.

Patel DP, Redshaw JD, Breyer BN, et al. High-grade renal injuries are often isolated in sports-related trauma. *Injury*. 2015;46(7):1245–1249.

Pearce MS, Salotti JA, Little MP, et al. Radiation exposure from CT scans in childhood and subsequent risk of leukaemia and brain tumours: a retrospective cohort study. *Lancet*. 2012;380(9840):499–505.

Pereira BM, Ogilvie MP, Gomez-Rodriguez JC, et al. A review of ureteral injuries after external trauma. *Scand J Trauma Resusc Emerg Med*. 2010;18(1):6.

Perry MO, Husmann DA. Urethral injuries in female subjects following pelvic fractures. *J Urol*. 1992;147(1):139–143.

Pesenti S, Blondel B, Faure A, et al. Small bowel entrapment and ureteropelvic junction disruption associated with L3 Chance fracture-dislocation. *World J Clin Cases*. 2016;4(9):264–268.

Pfister T, Pfister K, Hagel B, et al. The incidence of concussion in youth sports: a systematic review and meta-analysis. *Br J Sports Med*. 2016;50(5):292–297.

Pinto IT, Chimeno PC. Treatment of a urinoma and a post-traumatic pseudoaneurysm using selective arterial embolization. *Cardiovasc Intervent Radiol*. 1998;21(6):506–508.

Pippi Salle JL, Jesus LE, Lorenzo AJ, et al. Glans amputation during routine neonatal circumcision: mechanism of injury and strategy for prevention. *J Pediatr Urol*. 2013;9(6 Pt A):763–768.

Podesta M, Podesta M Jr. Delayed surgical repair of posttraumatic posterior urethral distraction defects in children and adolescents: long-term results. *J Pediatr Urol*. 2015;11(2):67 [e1–67.e6].

Podesta ML, Jordan GH. Pelvic fracture urethral injuries in girls. *J Urol*. 2001;165(5):1660–1665.

Pogorelic Z, Mustapic K, Jukic M, et al. Management of acute scrotum in children: a 25-year single center experience on 558 pediatric patients. *Can J Urol*. 2016;23(6):8594–8601.

Privett JT, Jeans WD, Roylance J. The incidence and importance of renal duplication. *Clin Radiol*. 1976;27(4):521–530.

Quinlan DM, Gearhart JP. Blunt renal trauma in childhood. Features indicating severe injury. *Br J Urol*. 1990;66(5):526–

531.

Radmayr C, Bogaert G, Dogan HS, et al. *European Association of Urology guidelines on paediatric urology*. [Available at] https://uroweb.org/guideline/paediatric-urology/; 2018.

Redmond EJ, Mac Namara FT, Giri SK, et al. Blunt testicular trauma—is surgical exploration necessary? *Ir J Med Sci*. 2018;187(4):1109–1113.

Reese JN, Fox JA, Cannon GM Jr, et al. Timing and predictors for urinary drainage in children with expectantly managed grade IV renal trauma. *J Urol*. 2014;192(2):512–517.

Rice SG, American Academy of Pediatrics Council on Sports Medicine and Fitness. Medical conditions affecting sports participation. *Pediatrics*. 2008;121(4):841–848.

Richards CR, Clark ME, Sutherland RS, et al. Retrospective review of pediatric blunt renal trauma: a single institution's five year experience. *Hawaii J Med Public Health*. 2017;76(5):119–122.

Richter F, Irwin RJ, Watson RA, et al. Endourologic management of benign ureteral strictures with and without compromised vascular supply. *Urology*. 2000;55(5):652–657.

Rostas J, Simmons JD, Frotan MA, et al. Intraoperative management of renal gunshot injuries: is mandatory exploration of Gerota's fascia necessary. *Am J Surg*. 2016;211(4):783–786.

Routh JC, Husmann DA. Long-term continence outcomes after immediate repair of pediatric bladder neck lacerations extending into the urethra. *J Urol*. 2007;178(4 Pt 2):1816–1818 [discussion 1818].

Routh JC, Tollefson MK, Ashley RA, et al. Iatrogenic ureteral injury: can adult repair techniques be used on children? *J Pediatr Urol*. 2009;5(1):53–55.

Russell RS, Gomelsky A, McMahon DR, et al. Management of grade IV renal injury in children. *J Urol*. 2001;166(3):1049–

1050.

Sanchez OA, Ferrara LK, Rein S, et al. Hypertension after kidney donation: incidence, predictors, and correlates. *Am J Transplant*. 2018;18(10):2534–2543.

Santucci RA, Langenburg SE, Zachareas MJ. Traumatic hematuria in children can be evaluated as in adults. *J Urol*. 2004;171(2 Pt 1):822–825.

Santucci RA, Wessells H, Bartsch G, et al. Evaluation and management of renal injuries: consensus statement of the renal trauma subcommittee. *BJU Int*. 2004;93(7):937–954.

Saxena AK, Steiner M, Hollwarth ME. Straddle injuries in female children and adolescents: 10-year accident and management analysis. *Indian J Pediatr*. 2014;81(8):766–769.

Scheidler MG, Schultz BL, Schall L, et al. Mechanisms of blunt perineal injury in female pediatric patients. *J Pediatr Surg*. 2000;35(9):1317–1319.

Schmidlin FR, Iselin CE, Naimi A, et al. The higher injury risk of abnormal kidneys in blunt renal trauma. *Scand J Urol Nephrol*. 1998;32(6):388–392.

Seseke F, Heuser M, Zoller G, et al. Treatment of iatrogenic postoperative ureteral strictures with Acucise endoureterotomy. *Eur Urol*. 2002;42(4):370–375.

Sevinc C, Balaban M, Ozkaptan O, et al. The management of total avulsion of the ureter from both ends: our experience and literature review. *Arch Ital Urol Androl*. 2016;88(2):97–100.

Shariat SF, Roehrborn CG, Karakiewicz PI, et al. Evidence-based validation of the predictive value of the American Association for the Surgery of Trauma kidney injury scale. *J Trauma*. 2007;62(4):933–939.

Silber JS, Flynn JM. Changing patterns of pediatric pelvic fractures with skeletal maturation: implications for classification and management. *J Pediatr Orthop*.

2002;22(1):22–26.

Singh BP, Andankar MG, Swain SK, et al. Impact of prior urethral manipulation on outcome of anastomotic urethroplasty for post-traumatic urethral stricture. *Urology*. 2010;75(1):179–182.

Siram SM, Gerald SZ, Greene WR, et al. Ureteral trauma: patterns and mechanisms of injury of an uncommon condition. *Am J Surg*. 2010;199(4):566–570.

Sirlin CB, Brown MA, Andrade-Barreto OA, et al. Blunt abdominal trauma: clinical value of negative screening US scans. *Radiology*. 2004;230(3):661–668.

Sivit CJ, Cutting JP, Eichelberger MR. CT diagnosis and localization of rupture of the bladder in children with blunt abdominal trauma: significance of contrast material extravasation in the pelvis. *AJR Am J Roentgenol*. 1995;164(5):1243–1246.

Slobogean GP, Tredwell SJ, Masterson JS. Ureteropelvic junction disruption and distal ureter injury associated with a Chance fracture following a traffic accident: a case report. *J Orthop Surg (Hong Kong)*. 2007;15(2):248–250.

Sokhal AK, Prakash G, Saini DK, et al. Page kidney: a rare but surgically treatable cause of hypertension. *Saudi J Kidney Dis Transpl*. 2018;29(1):193–197.

Spitzer RF, Kives S, Caccia N, et al. Retrospective review of unintentional female genital trauma at a pediatric referral center. *Pediatr Emerg Care*. 2008;24(12):831–835.

Stengel D, Rademacher G, Ekkernkamp A, et al. Emergency ultrasound-based algorithms for diagnosing blunt abdominal trauma. *Cochrane Database Syst Rev*. 2015;(9) [CD004446].

Streck CJ, Vogel AM, Zhang J, et al. Identifying children at very low risk for blunt intra-abdominal injury in whom CT of the abdomen can be avoided safely. *J Am Coll Surg*. 2017;224(4):449–458 [e3].

Streck CJ Jr, Jewett BM, Wahlquist AH, et al. Evaluation for intra-abdominal injury in children after blunt torso trauma: can we reduce unnecessary abdominal computed tomography by utilizing a clinical prediction model? *J Trauma Acute Care Surg*. 2012;73(2):371–376 [discussion 376].

Stutzman RE. Ballistics and the management of ureteral injuries from high velocity missiles. *J Urol*. 1977;118(6):947–949.

Sunay M, Karabulut A, Dadali M, et al. Single-institution outcomes of open reconstruction techniques for management of pediatric and adolescent post-traumatic urethral strictures. *Urology*. 2011;77(3):706–710.

Surana R, Khan A, Fitzgerald RJ. Scarring following renal trauma in children. *Br J Urol*. 1995;75(5):663–665.

Suthers SE, Albrecht R, Foley D, et al. Surgeon-directed ultrasound for trauma is a predictor of intra-abdominal injury in children. *Am Surg*. 2004;70(2):164–167 [discussion 167–168].

Taken K, Oncu MR, Ergun M, et al. Isolated renal pelvis rupture secondary to blunt trauma: case report. *Int J Surg Case Rep*. 2015;9:82–84.

Tas F, Ceran C, Atalar MH, et al. The efficacy of ultrasonography in hemodynamically stable children with blunt abdominal trauma: a prospective comparison with computed tomography. *Eur J Radiol*. 2004;51(1):91–96.

Tasian GE, Aaronson DS, McAninch JW. Evaluation of renal function after major renal injury: correlation with the American Association for the Surgery of Trauma Injury Scale. *J Urol*. 2010;183(1):196–200.

Trachta J, Moravek J, Kriz J, et al. Pediatric bulbar and posterior urethral injuries: operative outcomes and long-term follow-up. *Eur J Pediatr Surg*. 2016;26(1):86–90.

Tsui A, Lazarus J, Sebastian van As AB. Non-operative management of renal trauma in very young children:

experiences from a dedicated South African paediatric trauma unit. *Injury*. 2012;43(9):1476–1481.

Turner WW Jr, Snyder WH 3rd, Fry WJ. Mortality and renal salvage after renovascular trauma. A review of 94 patients treated in a 20 year period. *Am J Surg*. 1983;146(6):848–851.

Umbreit EC, Routh JC, Husmann DA. Nonoperative management of nonvascular grade IV blunt renal trauma in children: meta-analysis and systematic review. *Urology*. 2009;74(3):579–582.

van der Wilden GM, Velmahos GC, Joseph DK, et al. Successful nonoperative management of the most severe blunt renal injuries: a multicenter study of the research consortium of New England Centers for Trauma. *JAMA Surg*. 2013;148(10):924–931.

Venn SN, Greenwell TJ, Mundy AR. Pelvic fracture injuries of the female urethra. *BJU Int*. 1999;83(6):626–630.

Wessells H, McAninch JW, Meyer A, et al. Criteria for nonoperative treatment of significant penetrating renal lacerations. *J Urol*. 1997;157(1):24–27.

Whitten SM, Wilcox DT. Duplex systems. *Prenat Diagn*. 2001;21(11):952–957.

Wu HY, Gaines BA. Dirt bikes and all terrain vehicles: the real threat to pediatric kidneys. *J Urol*. 2007;178(4 Pt 2):1672–1674.

Xu G, He L, Fang X, et al. Management of renal artery occlusion related to multiple trauma in children: two case reports. *Urology*. 2017;101:154–157.

SECTION G

Oncology

OUTLINE

53 Pediatric Urologic Oncology Renal and Adrenal
54 Pediatric Urologic Oncology Bladder and Testis

53

Pediatric Urologic Oncology

Renal and Adrenal

Michael L. Ritchey MD, Nicholas G. Cost MD, Robert C. Shamberger MD

Neuroblastoma

Neuroblastoma is the most common extracranial solid tumor of childhood. Unfortunately, more than half of the children are seen initially with metastatic disease. Neuroblastoma is known to arise from cells of the neural crest that form the adrenal medulla and sympathetic ganglia. Tumors may occur anywhere along the sympathetic chain within the neck, thorax, retroperitoneum, or pelvis or in the adrenal gland: 75% arise in the retroperitoneum, 50% in the adrenal, and 25% in the paravertebral ganglia. The variety of locations where these tumors arise and the spectrum of their differentiation result in a wide range of clinical presentations and behaviors (Brodeur, 1991). These tumors can undergo spontaneous regression (Brodeur, 1991), differentiate to benign neoplasms, or exhibit extremely malignant behavior. Biologic factors have been defined that predict and explain much of the variance in behavior between tumors.

Epidemiology and Genetics

Incidence

Neuroblastoma accounts for 8% to 10% of all childhood cancers. In the United States, the annual incidence is 10 cases per 1 million live births. It is the most common malignant tumor of infancy. A review of 3666 children enrolled in the cooperative group trials of the Pediatric Oncology Group and the Children's Cancer Group showed a median age at diagnosis of 19 months (Brodeur and Maris, 2006): 36% were infants, 89% were younger than 5 years, and 98% were diagnosed by 10 years of age.

Genetics

There have been a number of familial cases reported that are postulated to represent an autosomal dominant pattern of inheritance (Knudson and Strong, 1972; Robertson et al., 1991). Although the median age at diagnosis of neuroblastoma is 19 months, in familial cases it is 9 months (Kushner et al., 1986). At least 20% of patients with familial neuroblastoma have bilateral adrenal or multifocal primary tumors, which are unusual in spontaneous cases. The risk for development of neuroblastoma in a sibling or offspring of a patient with neuroblastoma is less than 6% (Kushner et al., 1986). Linkage analysis in seven families with two or more first-degree relatives affected with neuroblastoma identified a single interval at chromosome 16p12-13 with consistent linkage (Maris et al., 2002). This suggested that a hereditary neuroblastoma predisposition gene may be located at this site and may explain the familial cases. Subsequent studies in these familial cases, which account for less than 1% of patients with neuroblastoma, have identified *PHOX2B* and *ALK* as hereditary predisposition genes (Mosse et al., 2004, 2008).

Constitutional Chromosome Abnormalities

Numerous karyotypic abnormalities have been found in neuroblastoma, and these are recognized to have prognostic significance. These changes occur in the form of chromosomal deletions, translocations, and cytogenetic evidence of gene amplification. Aneuploidy of the tumor DNA, an abnormal number of copies of the normal 23 chromosomes, occurs in a significant number of cases (55%) and is a favorable prognostic indicator when compared with tumors that have a normal or tetraploid number (Kaneko et al., 1987). **Amplification of the *MYCN* oncogene at 2p24 defined as greater than 10 copies of this gene is seen in roughly 20% to 25% of primary tumors and is an adverse prognostic indicator** (Look et al., 1991; Muraji et al., 1993). It is present in 40% of patients with advanced stage disease but in only 5% to 10% of children with low-stage disease (Brodeur et al., 1984). It is associated with rapid tumor progression and poor outcome from treatment. These findings have been so striking that neuroblastoma was the first tumor in which the intensity of chemotherapy for a patient was determined not only by the stage and histology of the tumor but also by its "biologic markers," which were primarily chromosomal (Matthay et al., 1998).

Deletion of the short arm of chromosome 1 (1p) is found in 25% to 35% of neuroblastomas and is an adverse prognostic marker (Brodeur et al., 1992; Caron et al., 1996). The deletions are of various lengths, but, in a series of eight cases, a consensus deletion included the segment 1p36.1-2, suggesting that a tumor suppressor may be present in this region; although the involved genes have not been identified conclusively, *CHD5* is a strong candidate for this role (Fujita et al., 2008; Maris et al., 2007; Weith et al., 1989). This deletion is present in 70% of advanced stage neuroblastoma, and it has been demonstrated to be an independent prognostic factor (Attiyeh et al., 2005). There have been reports of constitutional abnormalities involving the short arm of chromosome 1 (Laureys et al., 1990). It has been demonstrated that loss of heterozygosity (LOH) at 1p36 and Unb11q is independently associated with a worse outcome in patients with neuroblastoma (Attiyeh et al., 2005). (Unbalanced LOH implies LOH at markers on 11q with retention of 11p material, in contrast with “whole-chromosome” 11 LOH, where there is LOH at every marker along the chromosome.) Although the 1p deletions are seen in conjunction with advanced stage and *MYCN* amplification, the 11q deletions are rarely seen in tumors with *MYCN* amplification but are associated with other high-risk features and are predictive of poor outcomes in the subset of patients with low-stage disease without *MYCN* amplification (Spitz et al., 2006). An additional genetic abnormality, gain of one to three copies of 17q, often the result of translocation with chromosomes 1 or 11, has been demonstrated to correlate with more aggressive tumors (Bown et al., 1999). The break points vary, but the addition of a region from 17q22-qter is common, suggesting that genes replicated in this region provide an advantage (Schleiermacher et al., 2004). In multivariate analysis, gain of 17q was the most powerful prognostic factor, followed by the presence of stage IV disease and deletion of 1p.

Embryology and Spontaneous Regression

In 1963 Beckwith and Perrin coined the term *in situ neuroblastoma* for small nodules of neuroblasts found incidentally within the adrenal gland that are histologically indistinguishable from neuroblastoma. In situ neuroblastoma was found during postmortem examination in 1 of 224 infants younger than 3 months. This represents an incidence of approximately 40 to 45 times greater than that of clinical tumors, suggesting that these small tumors regress spontaneously in most cases. Subsequent studies have shown that these nodules of neuroblasts are found in all fetuses studied and generally regress (Ikeda et al., 1981). Neuroblastoma identified by prenatal ultrasonography (US) has also been shown to have a clinically favorable course (Ho et al., 1993).

The concept of in situ neuroblastoma has been used to support the argument that many neuroblastomas arise and regress spontaneously. This concept has been further supported by population-based studies in Quebec province and in Japan, where prospective screening of infants for neuroblastoma has been performed based on urinary catecholamine excretion. An increased number of children were identified with low-stage neuroblastoma, a higher frequency than present clinically, but resection of those tumors did not result in a decrease in the incidence of advanced-stage tumors seen at an older age (Hayashi et al., 1995;

Woods et al., 1996). A subsequent German Neuroblastoma Screening Study postponed screening until 10 to 19 months of age. Fewer early stage cases were identified, and a greater frequency of patients with unfavorable clinical and biologic features were identified, but there was no decrease in the mortality of these patients (Schilling et al., 2002). Evaluation of adrenal tumors resected in the neonatal period, whether cystic or solid, showed that in most, the “biologic markers” were favorable (Kozakewich et al., 1998). The highly favorable outcome of infants diagnosed with neuroblastoma in the population screening studies led to attempts at expectant observation. These trials demonstrated a high rate of spontaneous resolution (Yamamoto et al., 1998; Yoneda et al., 2001). Spontaneous regression of these perinatally identified lesions also has been demonstrated radiographically (Holgerson et al., 1996). These findings led to a prospective study by the Children's Oncology Group (COG) evaluating treatment of infants with adrenal masses identified in the perinatal or neonatal period in which expectant observation for infants with small lesions with favorable catecholamine ratios was encouraged and is discussed later.

Pathology

Neuroblastoma, ganglioneuroblastoma, and ganglioneuroma display a spectrum of histologic maturation and differentiation (Fig. 53.1). A grading classification of neuroblastoma, introduced in 1984 by Shimada and subsequently modified by him and others as the International Neuroblastoma Pathology Classification in 1999, has helped to define risk-based subtypes of ganglioneuroblastoma and neuroblastoma (Shimada et al., 1984, 1999a, 1999b). This revised system has been demonstrated to add independent prognostic information beyond the contribution of age that is one of the factors contained in the system (Sano et al., 2006). Ganglioneuroma is a histologically benign, fully differentiated counterpart of neuroblastoma. It is unclear whether ganglioneuroma arises de novo or by maturation of a preexisting neuroblastoma or ganglioneuroblastoma. Metastatic lesions from neuroblastoma have been observed to develop the histology of mature ganglioneuroma, supporting the latter theory (Hayes et al., 1989).

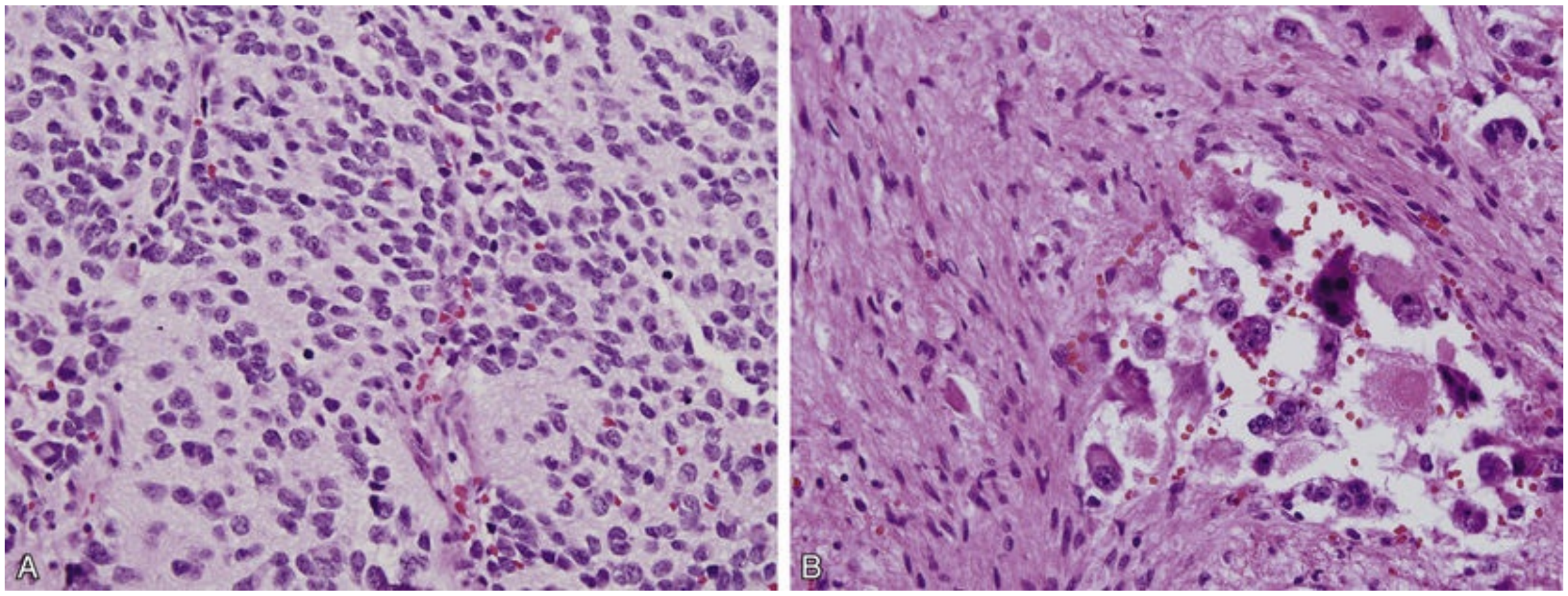

FIG. 53.1 (A) Poorly differentiated neuroblastoma with a minimal to moderate amount of neuropil. (B) Ganglioneuroblastoma with more than 50% of surface area occupied by Schwannian stroma on left. Lobule contains ganglion cells, immature ganglion cells, and poorly differentiated neuroblasts; only minimal neuropil is present within lobule. (Photo courtesy Dr. Harry Kozakewich.)

The Shimada classification is an age-linked histopathologic classification. One of its important aspects is determining whether the tumor is stroma poor or stroma rich. Patients with stroma-poor tumors with unfavorable histopathologic features have a very poor prognosis (less than 10% survival) (Shimada et al., 1984). Stroma-rich tumors can be separated into three subgroups: nodular, intermixed, and well differentiated. Tumors in the latter two categories more closely resemble ganglioneuroblastoma or immature ganglioneuroma and carry a higher rate of survival. The stroma-poor tumors can be divided into favorable and unfavorable subgroups based on the patient's age at diagnosis, the degree of histologic maturation, and the mitotic rate. When compared with other clinical features, these histologic patterns were independently predictive of outcome (Shimada et al., 1984).

In contrast to neuroblastomas, ganglioneuromas are most often diagnosed in older children and are usually located in the posterior mediastinum and retroperitoneum, with only a small number arising in the adrenal glands (Enzinger and Weiss, 1988). Ganglioneuromas often grow to a very large size before they cause symptoms as a result of compression of adjacent structures or extension into the spinal canal (Benjamin et al., 1972; Fig. 53.2). Because survival is not influenced by extent of resection, it should be used only in those patients in whom significant symptoms are present, and aggressive attempts at resection should be avoided (DeBernardi et al., 2008).

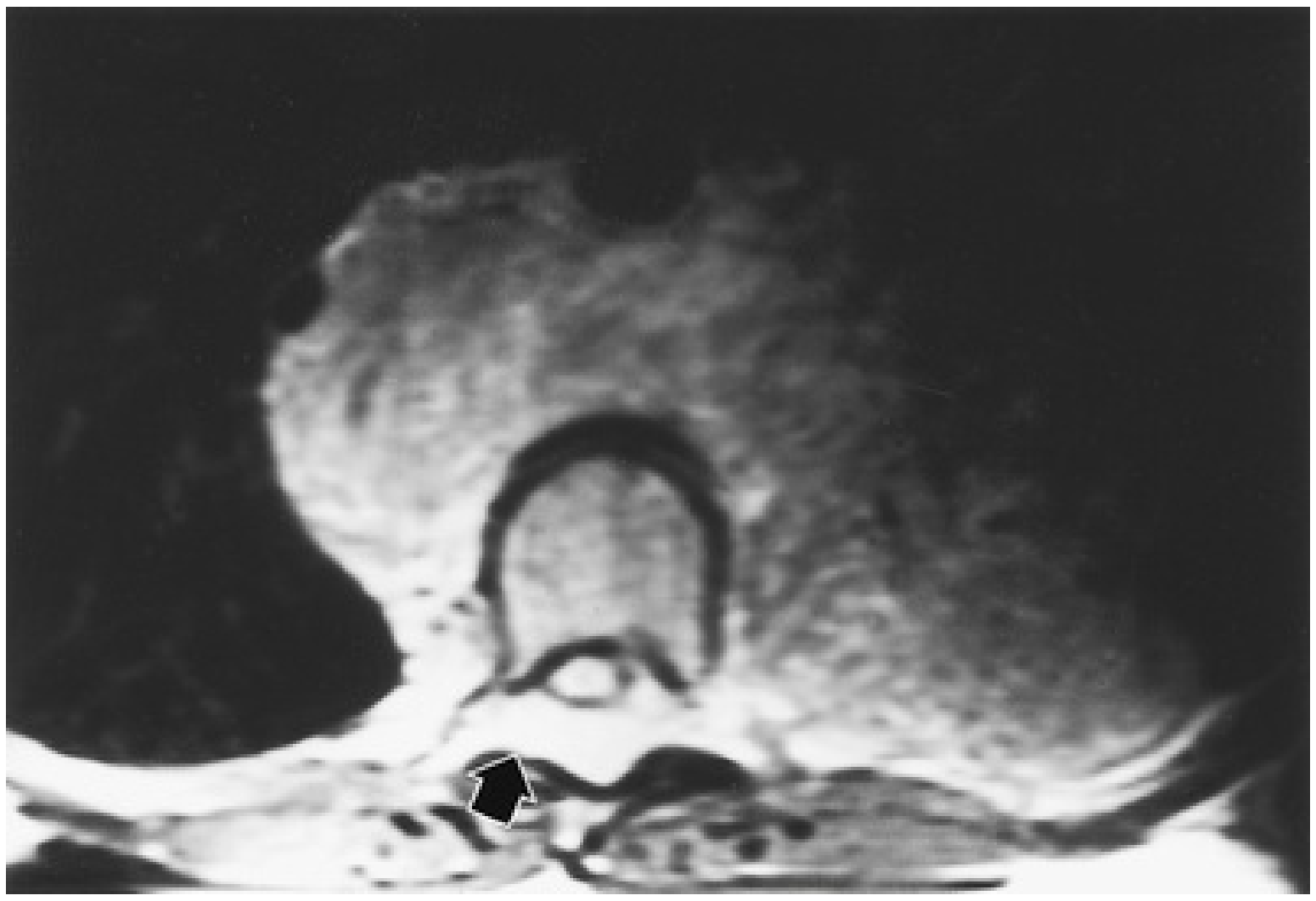

FIG. 53.2 MRI of child with thoracic ganglioneuroma extending into the spinal canal *(solid arrow)*.

Clinical Presentation and Pattern of Spread

The clinical manifestations of neuroblastoma vary widely. Most children have abdominal pain or a palpable mass, but others are identified as a result of manifestations of their metastatic disease, including bone or joint pain and periorbital ecchymosis. Thoracic lesions may produce respiratory symptoms of cough or dyspnea. Direct extension of the tumor into the spinal canal may produce neurologic deficits as a result of cord compression.

Most primary tumors arise within the abdomen (65%); the frequency of adrenal tumors is slightly higher in children than in infants. Physical examination often reveals a fixed, hard abdominal mass. Pelvic neuroblastoma arising from the organ of Zuckerkandl accounts for 4% of tumors (Haase et al., 1995). Extrinsic compression of the bowel and bladder can produce symptoms of urinary retention and constipation (Fig. 53.3).

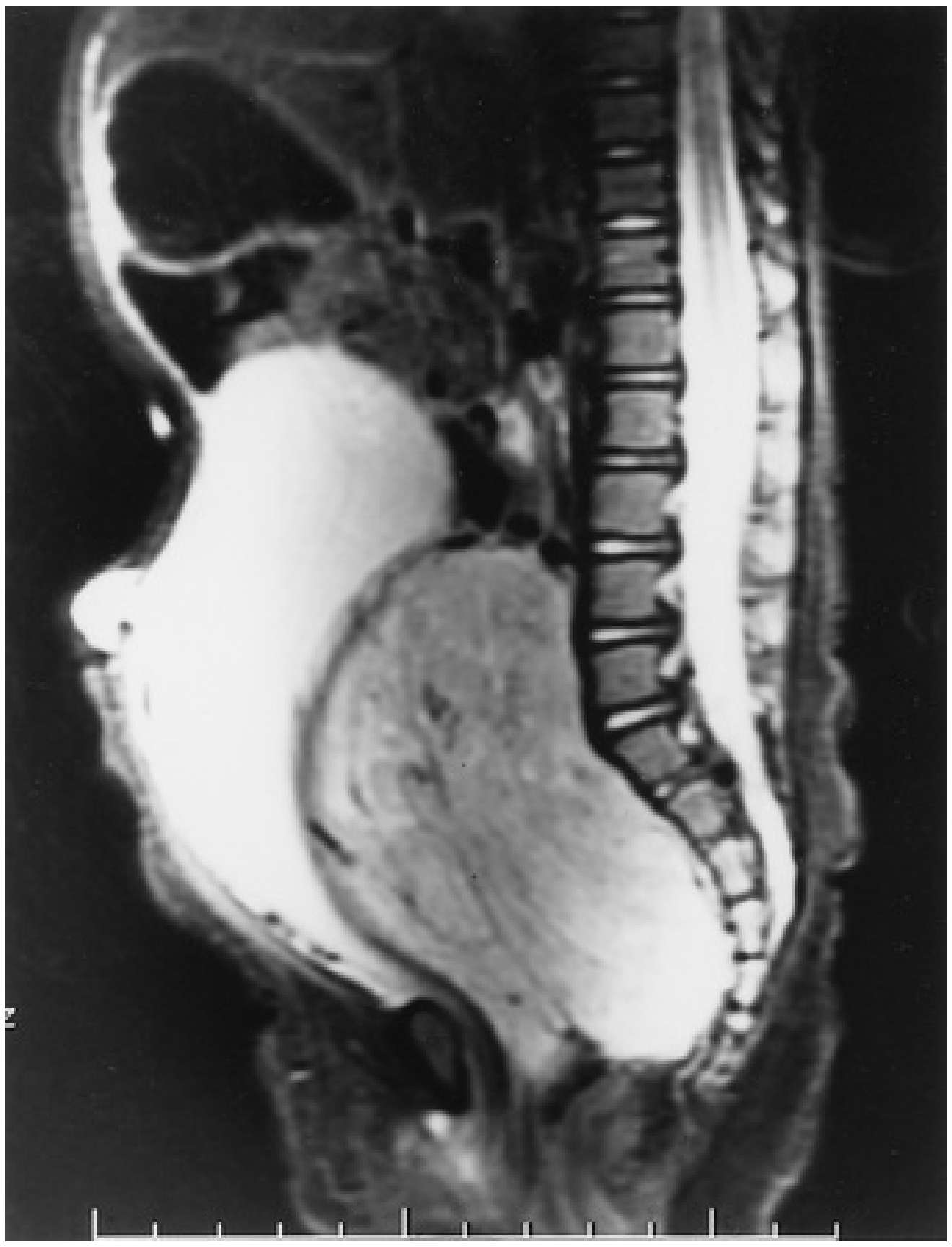

FIG. 53.3 MRI demonstrating compression of bowel and bladder by a pelvic neuroblastoma.

Metastases are present in 70% of patients with neuroblastoma at diagnosis and can be responsible for a variety of the clinical signs and symptoms at presentation. A number of unique paraneoplastic syndromes have been associated with localized and disseminated neuroblastoma. Symptoms produced by catecholamine release may mimic those seen in pheochromocytoma: paroxysmal hypertension, palpitations, flushing, and headache. Secretion of vasoactive intestinal peptide (VIP) by the tumor can produce severe watery diarrhea and hypokalemia (Cooney et al., 1982). Another unusual presentation of neuroblastoma is acute myoclonic encephalopathy, in which patients develop myoclonus, rapid multidirectional eye movements (opsoclonus), and ataxia. It is thought to result from an interaction of antibodies produced against the neuroblastoma to normal neural tissues (Connolly et al., 1997; Farrelly et al, 1984). Although this syndrome is associated with a favorable outcome from an oncologic perspective (Altman and Baehner, 1976), prolonged neurologic impairment, including learning disabilities and developmental delay, is the rule in 70% to 80% of these children, and symptomatic therapy is often required (Mitchell et al., 2002; Rudnick et al., 2001; Russo et al., 1997). Adrenocorticotropic hormone (ACTH) or steroids are the basis of most therapy, but other treatments include high-dose intravenous gamma globulin and cyclophosphamide. A recently completed protocol of the Children's Oncology Group evaluated the efficacy of cyclophosphamide plus steroids randomized to receive intravenous gamma globulin or not. The addition of IVIG to prednisone and risk-adapted chemotherapy improved opsoclonus/myoclonus response (de Alarcon et al., 2018).

Diagnosis

Laboratory Evaluation

When sensitive techniques are used, increased levels of urinary metabolites of catecholamines, vanillylmandelic acid (VMA) and homovanillic acid (HVA), are found in 90% to 95% of patients (Williams and Greer, 1963). Therapy with various modalities produces a reduction in catecholamine metabolite excretion in most patients (Gerson and Koop, 1974). These metabolites can be monitored to detect tumor relapse and response to therapy.

Anemia is noted in children with widespread bone marrow involvement. Studies suggest that marrow biopsies add substantially to the detection of marrow involvement by tumor, compared with marrow aspirates alone (Franklin and Pritchard, 1983). It is recommended that two marrow aspirates and two biopsies be performed for staging at presentation. In the future, neuroblastoma-specific immunocytology of marrow aspirates may obviate the need for marrow biopsies in most patients (Hsiao et al., 1990).

Imaging

Imaging studies play an important role in the evaluation of a child with neuroblastoma. **Plain radiographs may demonstrate a calcified abdominal or posterior mediastinal mass.** Computed tomography (CT) and magnetic resonance imaging (MRI) provide more information about the local extent of the primary tumors and vascular involvement. Invasion of the renal parenchyma is not common, but it can be detected radiographically by CT (Albregts et al., 1994). MRI has advantages over CT in the evaluation of intraspinal tumor extension, which is common in the paravertebral lesions (see Fig. 53.2), and in demonstrating the relationship between the major vessels and the tumor

(Azizkhan and Haase, 1993; Fig. 53.4). **The finding of intratumoral calcifications, vascular encasement, or both on preoperative CT may help distinguish neuroblastoma from Wilms tumor** (Dickson et al., 2008). Current Children's Oncology Group protocols require a radionuclide meta-iodobenzylguanidine (MIBG) scan for staging but no longer require the classic skeletal survey or bone scans. MIBG scans use ^{123}I-MIBG (Geatti et al., 1985), which is taken up by the adrenergic secretory vesicles of the tumor cells in primary and metastatic sites. MIBG scintigraphy can determine the extent of disease and detect tumor recurrence after completion of therapy (Geatti et al., 1985). ^{123}I-MIBG has been shown to be more sensitive than either ^{131}I-MIBG or bone scans in detecting tumor relapse (Kushner et al., 2009). For patients who have non-MIBG avid tumors, positron emission tomography (PET) scans are used. Osseous metastatic lesions occur most commonly in the long bones and skull.

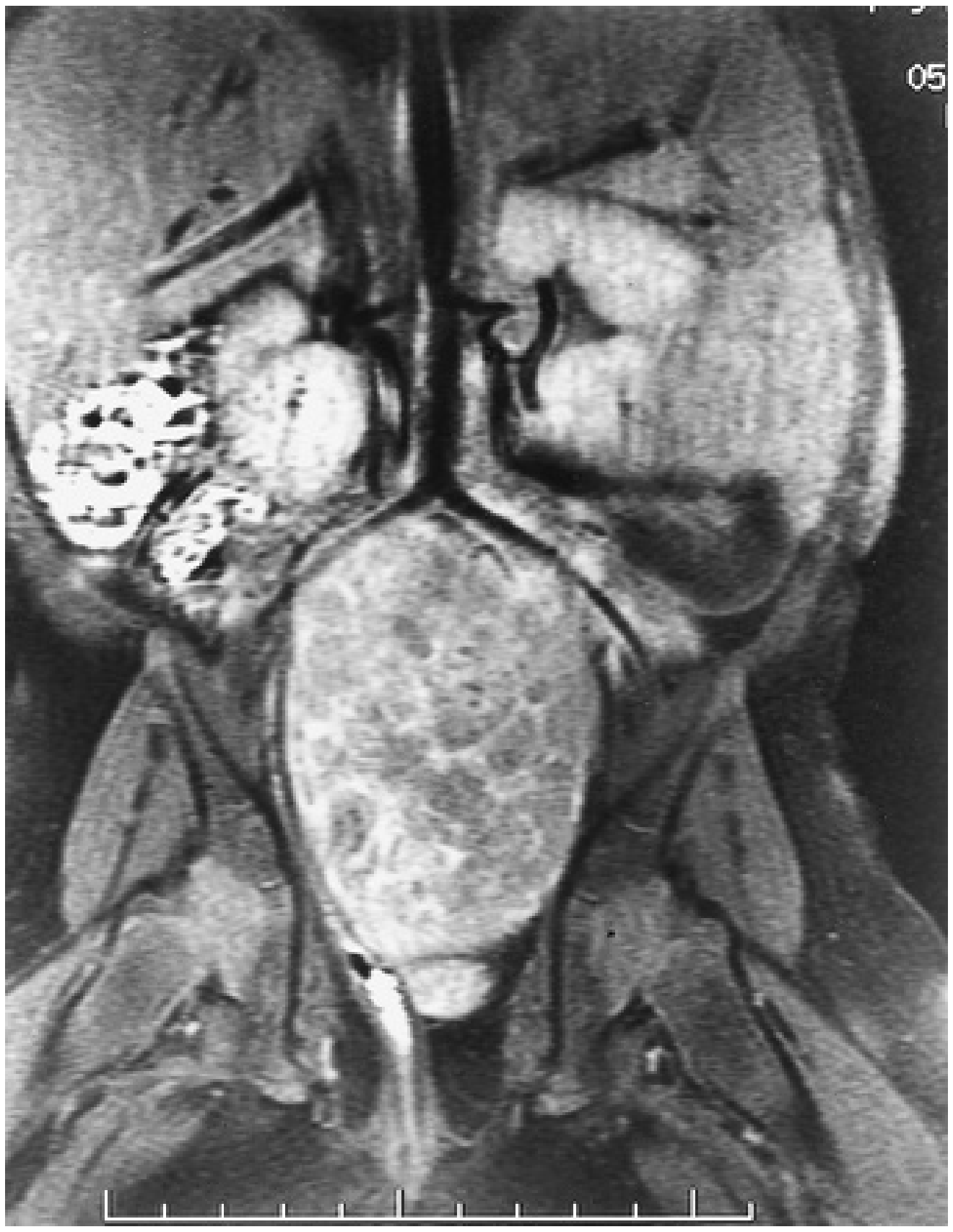

FIG. 53.4 MRI of pelvic neuroblastoma. The bifurcation of the aorta and iliac vessels are well delineated, showing the relationship to the mass.

Screening

Mass population screening for neuroblastoma has been widely used in Japan for more than 20 years (Nishi et al., 1987). The goal of screening programs is to detect disease at an earlier stage and to decrease the number of older children with advanced-stage disease, thereby improving survival. In fact, the children diagnosed as a result of screening studies have had almost uniformly favorable survival (>97%) (Suita, 2002). An increased number of infants younger than 1 year of age have been diagnosed through the mass screening program (Ishimoto et al., 1990), and most of these patients have lower-stage tumors (Sawada, 1992). Before mass screening, 20% of neuroblastoma cases were diagnosed before 1 year of age, compared with 55% after its implementation. However, the number of children older than 1 year of age diagnosed with advanced-stage disease has not decreased. These results suggest that the aggressive advanced-stage tumors in older children did not arise from the low-risk tumors seen in the infants less than 1 year of age.

There are biologic differences between tumors diagnosed by screening and those detected clinically (Hayashi et al., 1992). In one review of 48 cases discovered by screening, no tumors were observed to have amplified *MYCN* oncogene expression (Ishimoto et al., 1991), and in a second review of 20 infants, only one who did poorly had amplification (Hase et al., 2002). Furthermore, 80% had a diploid chromosome pattern, which is also associated with a favorable prognosis. On follow-up, all 48 patients were still alive without tumor. In another series of 357 patients whose tumors were diagnosed by mass screening, the overall survival rate was 97% (Sawada, 1992). Given the favorable biologic characteristics of tumors discovered by screening, it is possible that many would spontaneously resolve without therapy, particularly given the increased incidence of neuroblastomas seen in the screened population.

Two large prospective population-based studies were conducted in the Province of Quebec and in Germany. These studies demonstrated that urine screening at various ages was successful in identification of neuroblastoma, but there was no decrease in the occurrence of neuroblastoma in older children and its subsequent mortality (Schilling et al., 2002; Woods et al., 2002).

Staging

Staging of neuroblastoma is an important aspect of management. **The stage of the disease is a significant prognostic variable that determines adjuvant**

therapy in the cooperative group trials. The International Neuroblastoma Staging System (INSS) is based on clinical, radiographic, and surgical evaluation of children with neuroblastoma (Brodeur et al., 1993; Table 53.1). Earlier staging systems provided generally comparable results in terms of distinguishing low-stage, good-prognosis disease from high-stage, poor-prognosis disease. Use of a uniform international system, however, makes comparison of results from various studies much easier. The biggest differences arise when the various systems are applied to those with intermediate-stage disease.

TABLE 53.1

International Neuroblastoma Staging System

STAGE	DEFINITION
1	Localized tumor with complete gross excision with or without microscopic residual disease; representative ipsilateral lymph nodes negative for tumor microscopically (nodes attached to and removed with the primary tumor may be positive).
2A	Localized tumor with incomplete gross excision; representative ipsilateral nonadherent lymph nodes negative for tumor microscopically.
2B	Localized tumor with or without complete gross excision, with ipsilateral nonadherent lymph nodes positive for tumor. Enlarged contralateral lymph nodes must be negative microscopically.
3	Unresectable unilateral tumor infiltrating across the midline[a], with or without regional lymph node involvement; or localized unilateral tumor with contralateral regional lymph node involvement; or midline tumor with bilateral extension by infiltration (unresectable) or by lymph node involvement.
4	Any primary tumor with dissemination to distant lymph nodes, bone, bone marrow, liver, skin and/or other organs.
4S	Localized primary tumor (as defined for stage I, IIA, or IIB), with dissemination limited to skin, liver, and/or bone marrow (less than 10% tumor) in infants < 1 year of age.

[a] The midline is defined as the vertebral column. Tumors originating on one side and crossing the midline must infiltrate to or beyond the opposite side of the vertebral column.

An effort has been made to identify, preoperatively, those tumors that are resectable without significant surgical risks. The Localized Neuroblastoma European Study Group (LNESG) defined the radiographic criteria associated with higher surgical morbidity. They validated that the criteria's presence was associated with a lower rate of complete resection and a greater risk of surgical complications (Cecchetto et al., 2005). This finding has been confirmed by others (Simon et al., 2008). The International Neuroblastoma Risk Group (INRG) Task Force proposed a staging system based on tumor imaging rather than the extent of surgical resection to address this problem (Monclair et al., 2009). In this system, localized tumors are graded as L1 or L2 based on the absence or presence of 1 or more of 20 image-defined risk factors (IDRFs), which are related primarily to encasement of vessels or nerves. Metastatic tumors are termed stage M, and MS refers to INSS stage IV-(S) in children younger than 18 months of age, whereas in INSS the age cutoff was 12 months. These factors were found to be prognostic, and in 661 patients, those with L1 disease had a greater 5-year event-free survival (EFS) (90 ± 3%) compared with those with L2 disease (78 ± 4%, $P = 0.001$). A further description of these guidelines has been reported by this group (Brisse et al., 2011). Although a close correlation between presence of IDRFs and resectability of the tumor has been reported, others have not supported this finding (Günther et al., 2011; Rich et al., 2011). A follow-up from the LNESG of patients with localized disease demonstrated that the presence of IDRFs is associated with worse survival rates and higher rates of operative complications (Monclair et al., 2015). A SIOPEN study of children with unresectable neuroblastoma demonstrated that the IDRFs remained unchanged in 50% of patients receiving chemotherapy and that in fact 20% suffered the appearance of new IDRFs (Avanzini et al., 2017). They also identified that children with midline perivascular IDRFs had an increased incidence of operative complications but also lower EFS and overall survival (OS).

The International Neuroblastoma Risk Group Pretreatment Classification uses the Risk Group Classification (INRGSS), pathological findings, stage, age, and several of the biologic markers to best define the child's risk for progressive disease (Table 53.2; Cohn et al., 2009). Although the classification appears complex, it provides the most accurate assessment of how intense the chemotherapy and radiotherapy must be to cure the child. The challenge with any staging system that uses extent of resection as a component, however, is that a more aggressive approach to a tumor at one institution may result in a different stage for the child than if treated at another.

TABLE 53.2

International Neuroblastoma Risk Group (INRG) Classification System

INRG STAGE	AGE (MONTHS)	HISTOLOGIC CATEGORY	GRADE OF TUMOR DIFFERENTIATION	*MYC*
L1/L2		GN maturing		
		GNB intermixed		
L1		Any, except the above		NA
				Amp
L2	<18	Any, except the above	NA	No
				Yes
	≥18	GNB nodular neuroblastoma	Differen	NA
			Poorly differen or undifferen	NA
				Amp
M	<18			NA
	<12			NA
	12 to <18			NA
	<18			Amp
	≥18			
MS	<18			NA
				NA
				Amp

Blank field = any; Diploid – DNA index ≤ 1.0; Hyperdiploid – DNA index > 1.0 and includes near-triploid and near-tetraploid; very-low–risk 5-year EFS >85%; low-risk 5-year EFS >75% to ≤85%; intermediate-risk 5-year EFS ≥50% to ≤75%; high-risk 5-year EFS <50%; L1 localized tumor confined to one body compartment and with absence of image-defined risk factors (IDRFs); L2 locoregional tumor with presence of one or more IDRFs; M distant metastatic disease except stage MS; MS metastatic disease confined to skin, liver, and/or bone marrow in children <18 months of age.

Amp, Amplified; *Differen,* differentiating; *GN,* ganglioneuroma; *GNB,* ganglioneuroblastoma; *NA,* not amplified; *Undifferen,* undifferentiating.

Prognostic Factors

Many variables affect the prognosis of neuroblastoma. In addition to the clinical features, there are now many biologic factors that can be used to stratify patients for treatment.

Clinical Variables

Age remains an important indicator of outcome, as originally reported by Breslow (Breslow and McCann, 1971). **Children age 1 year or younger have been recognized historically to have a better survival than older children**

(Nitschke et al., 1988)**. This may be attributed to the presence of favorable biologic parameters in tumors diagnosed at this age.** Retrospective reviews have suggested that age is a more “continuous” prognostic variable and that a cutoff of 460 days maximized the outcome difference between the younger and older patients (London et al., 2005). More recent data from the INRG suggest that an age at diagnosis cutoff of greater than 18 months is associated with a higher risk of disease recurrence (Moroz et al., 2011). Teenagers and adults with neuroblastoma have a particularly indolent and relentless disease (Gaspar et al., 2003; Kushner et al., 2003). **The site of origin is also of significance, with better survival noted for nonadrenal primary tumors** (Haase et al., 1995). Most children with thoracic neuroblastoma are seen at a younger age with localized disease and have improved survival even when corrected for age and stage (Adams et al., 1993). Tumors at this site are less likely to have *MYCN* amplification and more likely to have a DNA index greater than 1.0, both favorable prognostic indicators (Morris et al., 1995).

Stage of the disease is a powerful independent prognostic indicator. All stage I patients with complete resection of the primary tumor survive. Stage II patients also have a favorable survival prospect, even though there may be incomplete excision (Matthay et al., 1989). Children with advanced regional disease, stages III or IV, fare less well and require more intensive treatment. The proportion of patients with localized, regional, or metastatic disease is age dependent (Nitschke et al., 1988). The OS for stages I, II, or IV-S was a range of 75% to 90%, whereas those children with stage IV disease had a historical 2-year disease-free survival range of 19% to 30% despite intensive therapy, including bone marrow transplantation. The outcome for infants younger than 1 year of age is substantially better than for older patients with the same stage of disease.

Stage IV-S (S meaning special) is a distinct category referring to infants with small primary tumors and liver, skin, and bone marrow metastases without radiographic evidence of bone metastases. This group of patients has a good prognosis, with OS ranging from 80% to 88%. The INSS criteria later restricted this stage to children with less than 10% bone marrow involvement (Brodeur et al., 1993). This stage accounts for 7% to 10% of all cases of neuroblastoma. Many of these tumors undergo spontaneous regression (Evans et al., 1987; Haas et al., 1990). In general, the tumors in infants with stage IV-S neuroblastoma have favorable prognostic findings not typically seen in children with stage IV disease (Hachitanda et al., 1991; Nickerson et al., 2000). Poor outcome in stage IV-S patients is associated with elevated serum neuron-specific enolase (>100 nmol/mL), ferritin (>280 ng/mL), urinary dopamine levels (>2500 nmol/mmol creatinine), as well as *MYCN* amplification and chromosome 1p deletion (Schleiermacher et al., 2003). Most deaths in this group are in infants under 2 months of age with extensive abdominal involvement and respiratory compromise or disseminated intravascular coagulation (Nickerson et al., 2000).

Biologic Variables

The presence of homogeneously staining regions and double-minute chromosomes was noted in approximately one-third of neuroblastoma tumors. These abnormalities are cytogenetic manifestations of gene amplification, and it was subsequently found that the *MYCN* oncogene was mapped to these regions. The association of *MYCN* amplification with the pathogenesis of neuroblastoma is unclear, but *MYCN* amplification is almost always present at the time of diagnosis (Brodeur, 1991). Seeger et al. (1985, 1988) showed that ***MYCN* amplification is associated with rapid tumor progression and a poor prognosis. Amplification is found in 5% to 10% of patients with low-stage or stage IV-S** (Hachitanda et al., 1991) **but in 30 to 40% of those with advanced-stage disease** (Brodeur, 1990; Brodeur and Fong, 1989). **The poor prognosis associated with *MYCN* amplification is independent of patient age or stage of disease at presentatio**n (Iehara et al., 2006). However, not all patients with a poor outcome have *MYCN* amplification. Many advanced-stage tumors lack *MYCN* at diagnosis, and recurrence or progression of disease develops in most of these patients.

DNA content of tumor cells and ploidy number has been reported to have prognostic value in patients with neuroblastoma (Cohn et al., 1990). Studies of DNA content measured by flow cytometry showed that a “hyperdiploid” karyotype (or increased DNA content) was associated with a favorable outcome (Kusafuka et al., 1994; Look et al., 1984). DNA diploidy and tetraploidy were associated with decreased survival. A review of 2660 children with localized neuroblastoma registered with the International Neuroblastoma Risk Group database evaluated tumor ploidy in children with *MYCN*–amplified tumors (Bagatell et al., 2009). They reported an improved prognosis in children with hyperdiploid tumors compared with diploid tumors. This could be used to identify children for reduction in the intensity of their therapy. A full INRG analytic cohort of 8800 patients from North America, Europe, and Japan provided an extensive analysis of the survival implications of multiple genetic characteristics (Cohn et al., 2009). Again, *MYCN* status was the most powerful predictor of EFS and OS along with ploidy, 11q and 1p status, and to a lesser extent 17q gain.

Deletions of the short arm of chromosome 1 have been found in 70% to 80% of the near-diploid tumors that have been karyotyped (Brodeur, 1990; Brodeur and Fong, 1989). Preliminary studies suggest a correlation between 1p deletion and poor survival (Brodeur and Fong, 1989; Hayashi et al., 1989). Children currently treated on protocols of the COG are assigned to a risk group that is determined by age, stage of disease, *MYCN* status, histologic grade, and DNA ploidy (Katzenstein et al., 1998). Other factors that have been demonstrated to have prognostic significance, although they are often associated with these genetic abnormalities, include expression of the gene encoding the high-affinity nerve growth factor receptor (termed *TRKA* proto-oncogene) and the low-affinity nerve growth factor receptor (Tanaka et al., 1995). Both are favorable prognostic predictors and are inversely related to amplification of *MYCN* oncogene (Nakagawara et al., 1993). Lack of expression of CD44 glycoprotein on the tumor cell surface and increased levels of serum ferritin, serum neuron-specific enolase, and serum lactate dehydrogenase are adverse prognostic factors (Chan et al., 1991; Silber et al., 1991). They have not, however, been shown by multivariate analysis to be independently predictive from age, stage, ploidy, and *MYCN* status. Telomere length has also been described as a significant prognostic parameter, and in a cohort of high-risk patients, it was the sole significant parameter that identified a group of patients with a favorable prognosis (Ohali et al., 2006).

Treatment

The treatment modalities primarily used in the management of neuroblastoma are surgery, chemotherapy, and radiation therapy. The role of each in individual patients varies depending on tumor stage, age, and biologic prognostic factors. These can be used to stratify patients into favorable and unfavorable categories by risk group (see Table 53.2).

Surgery

The goals of surgery are to establish the diagnosis, stage the tumor, excise the tumor (if localized), and provide tissue for biologic studies. Resectability of the primary tumor should take into consideration tumor location,

mobility, relationship to major vessels and nerves (IDRFs), and overall prognosis of the patient. Neoadjuvant chemotherapy, given the efficacy of modern agents, is successful in reducing the size of primary tumors and enhancing their resectability. Sacrifice of vital structures to achieve resection at diagnosis should be avoided, particularly in young children in whom prognosis is excellent.

Low-Risk Disease (Stages I, II, and IV-S).

Children with stage I neuroblastoma have a disease-free survival rate of greater than 90% with surgical excision alone (DeBernardi et al., 1995; Nitschke et al., 1988; O'Neill et al., 1985). **Chemotherapy is indicated only in the event of recurrence unless the child has *MYCN* amplification and unfavorable histology.** The Pediatric Oncology Group reviewed 101 children with localized neuroblastoma who had complete gross excision of the primary tumor (Nitschke et al., 1988). Nine patients experienced relapse, but 6 were salvaged with chemotherapy. Radiation therapy has no role in this subset of patients. With current use of the risk factor grading, those children with recurrence in the past may be identified now as the small number with adverse biologic markers. In a comparable study from the Children's Cancer Group, 374 stage I and II patients were treated primarily by resection (Perez et al., 2000). EFS and OS for stage I patients were 93 ± 3% and 99 ± 1%, respectively, compared with 81 ± 4% and 98 ± 2% for stage II patients, respectively. Supplemental treatment was required in only 10% of stage I and 20% of stage II patients, and excellent OS was achieved in the stage II patients. *MYCN* amplification, unfavorable histology, age greater than 2 years, and positive lymph nodes predicted a lower OS. The Children's Oncology Group (COG) conducted a trial of asymptomatic INSS stages 2a and 2b patients treated with surgery alone (Strother et al., 2012). Chemotherapy on this study was reserved for patients with symptomatic disease or in those considered at risk for its development, or those with less than 50% resection with unresectable progressive disease after surgery. For all 915 enrolled patients, the 5-year EFS and OS were 89% ± 1% and 97 ± 1%. In the cohort with IIb disease, the EFS and OS were significantly lower for those with unfavorable histology or diploid tumors, and OS was significantly lower for those 18 months and older. The 5-year OS for patients with stage I and IV-S were 99% ± 1% and 91% ± 1%, respectively; 11.1% of patients observed after surgery experienced recurrence or progressive disease.

Radical resection resulting in removal of normal organs, particularly the kidney, is not justified in this group of patients. Radiation of the local tumor bed has been advocated for treatment of residual disease in stage II cases. However, a review of 156 patients with stage II neuroblastoma found a 90%, 6-year, progression-free survival rate regardless of whether radiation therapy was used (Matthay et al., 1989). Therefore radiation should be reserved for those relapsed patients who fail to respond to either primary or secondary chemotherapy. In stage III disease, or in stage II with extensive tumor around the kidney and renal vessels, preoperative treatment with chemotherapy significantly decreases the risk of nephrectomy as a result of resection of the tumor (Shamberger et al., 1998; Fig. 53.5). **The generally favorable behavior of IV-S disease has been explained by our current knowledge of the significance of biologic markers. The majority of these infants have tumors with entirely favorable markers, explaining their favorable behavior. However, a small fraction have adverse markers; these children have progressive disease that often is fatal.** Resection of the primary tumor is not mandatory (Evans et al., 1987; Nickerson et al., 1985). Although excellent survival has been reported after surgery (Martinez et al., 1992), information regarding histologic prognostic factors was not available for all of these patients. In a review of 110 infants with stage IV-S disease, the entire cohort had an estimated 3-year survival rate of 85% ± 4% (Katzenstein et al., 1998). This rate was significantly decreased to 68% ± 12% for infants whose tumors were diploid; to 44% ± 33% for those with *MYCN* amplification; and to 33% ± 19% for those with unfavorable histology. There was no statistical difference in survival rate for infants who underwent complete resection of their primary tumor compared with those who had partial resection or only biopsy (Katzenstein et al., 1998; Nickerson et al., 2000; von Schweinitz et al., 2002). Patients with extensive metastatic disease and *MYCN* amplification represent a high-risk group (Martinez et al., 1992). These patients should be considered for a more intensive treatment with multimodal therapy, according to the risk group classification (see Table 53.2) (Schleiermacher et al., 2003). Those with favorable biologic markers and no symptoms can be followed with supportive care and limited chemotherapy. Intensive chemotherapy is reserved for those with adverse markers, although these infants do poorly even with therapy.

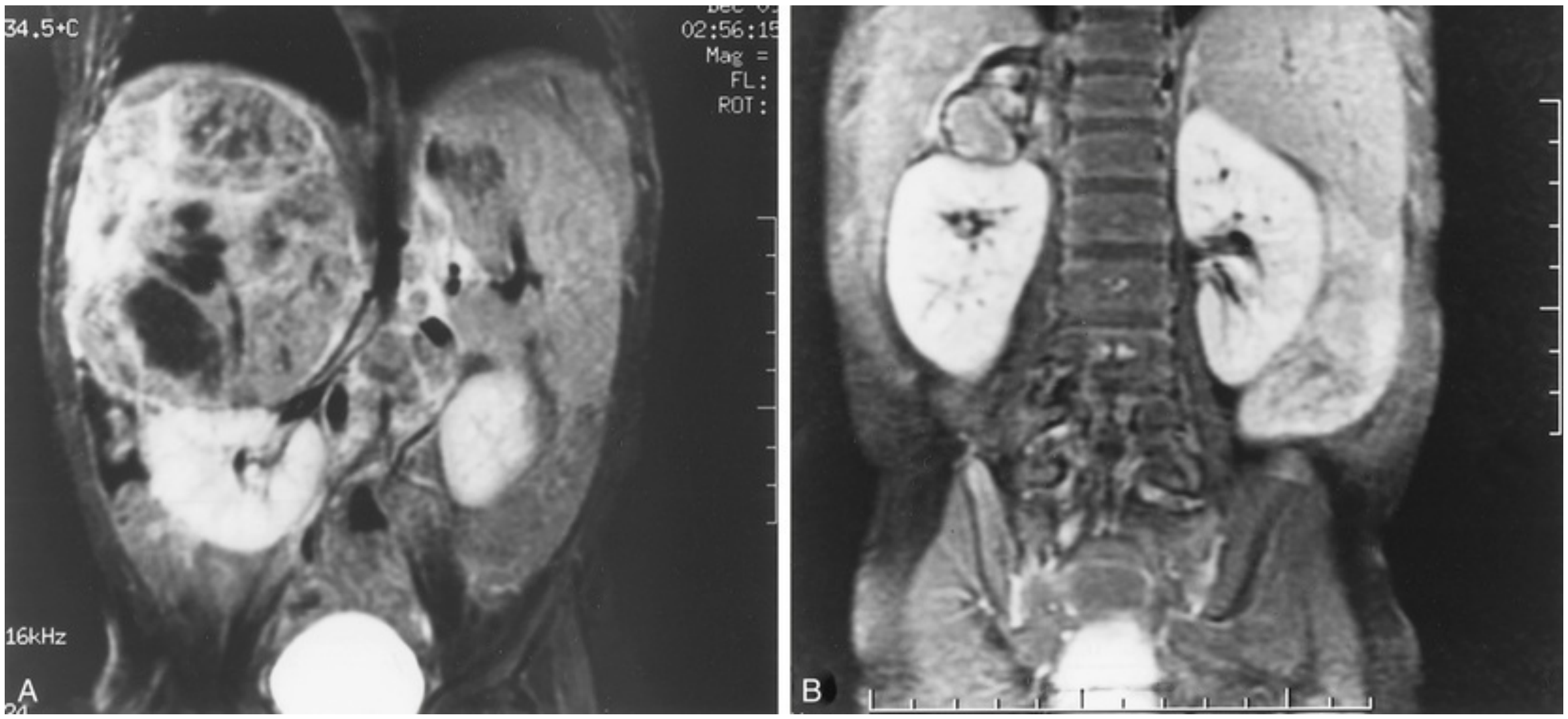

FIG. 53.5 MRI before and after chemotherapy showing marked reduction in size of right suprarenal neuroblastoma. (A) Before chemotherapy. (B) After chemotherapy.

Perinatal Neuroblastoma.

Based on the favorable outcomes of infants identified with neuroblastoma from the screening studies discussed earlier and the favorable biology of these tumors, a prospective study was performed by the COG to assess the outcome of expectant observation for neuroblastoma in young infants. Infants were enrolled who were under 6 months of age with small adrenal masses (≤16 mL in volume if solid or ≤65 mL if the mass was at least 25% cystic) and no evidence of spread beyond the primary tumor (Nuchtern et al., 2012) was found. Serial abdominal sonograms and urinary catecholamine levels were obtained during a 90-week interval. A 50% increase in the volume of the mass, urine catecholamine values, or the homovanillic acid–to–vanillylmandelic acid ratio greater than 2 were referred for surgical resection: 87 infants were enrolled, 83 families elected observation, and 4 chose immediate surgery. Sixteen infants on the observation arm ultimately had surgery; 8 had INSS stage I neuroblastoma, 2 had higher-stage neuroblastoma (IIB and IV-S), 2 had a low-grade adrenocortical neoplasm, 2 had adrenal hemorrhage, and 2 had extralobar pulmonary sequestration. The 2 adrenal cortical tumors were resected because of a greater than 50% increase in tumor volume. The 3-year EFS for a neuroblastoma event was 97.7% ± 2.2% within the entire cohort of infants. The 3-year OS was 100% with a median follow-up of 3.2 years. Following this protocol, 81% of the infants avoided resection, supporting the role of expectant observation in this selected population. Based on the success of the first trial with fairly restrictive entry criteria, a follow-up study was developed in which infants can be enrolled who are under 12 months of age at presentation with suspected lesions at any site that are under 5 cm in greatest diameter. For non-adrenal primary tumors, MIBG update in the tumor or elevated catecholamine levels must be present. Similar indications for surgical intervention are used from the initial study. Until this approach is established as safe, infants should be managed in this manner only if enrolled in a therapeutic study.

Intermediate and High-Risk Disease (Stages III and IV).

There is debate regarding the extent of surgical resection required for stage III lesions. A report from the Children's Cancer Group of 58 patients with stage III disease found that 8 of 12 patients with initial complete excision, and 12 of 14 with subsequent resection of the primary tumor, were long-term survivors (Haase et al., 1989). This result contrasts with only 9 of 32 survivors among patients in whom complete tumor excision could not be accomplished. Significant morbidity was reported in association with the surgical procedures, including 21 major complications. The Italian Cooperative Group for Neuroblastoma found that complete resection after chemotherapy of extensive unresectable neuroblastoma was associated with improved survival, compared with partial resection only (Garaventa et al., 1993). Similar results have been noted by others (Fischer et al., 2017; LeTourneau et al., 1985; O'Neill et al., 1985; Powis et al., 1996). It has been suggested by some that even children with stage III disease do not need cytotoxic therapy if the biologic marker *MYCN* amplification is not present (Kushner et al., 1996). These results are not widely accepted, however, and confirmatory studies are required before this policy can be widely adopted.

Children with bulky pelvic tumors generally do well even with limited residual disease (LeClair et al., 2004). Extensive surgery at this site has been associated with long-term neurologic sequelae; thus the extent of resection must be balanced against this morbidity (Cruccetti et al., 2000).

A study from the COG of intermediate-risk patients attempted to decrease the intensity of therapy while maintaining outcomes (Baker et al., 2010). Criteria for enrollment into this study included intermediate-risk neuroblastoma without *MYCN* amplification, including infants younger than 365 days of age with stage III or IV disease, children older than 365 days of age who had stage III tumors with favorable histopathological features, and infants who had stage IV-S disease with a diploid DNA index or unfavorable histopathological features. Children received four active agents in this study: cyclophosphamide, doxorubicin, carboplatin, and etoposide. They received 4 cycles if they had favorable biology or 8 cycles if they had unfavorable biology. Radiotherapy was used only for progressive disease or in patients with an unresectable primary tumor with unfavorable prognostic features. The 3-year estimate of OS for the entire group was 96% ± 1%; 98% ± 1% for those with favorable biologic features, and 93% ± 2% for those with unfavorable biologic features. These findings supported the reduction in therapy for this cohort of patients. Complete data regarding surgical intervention were available in 235 patients. Gross total resection was achieved in 89 patients, near total resection (>90% of the tumor) in 51, major resection (>50% of the tumor) in 26, and limited resection (≤50% of the tumor) in 54. **No significant difference was demonstrated in OS according to the extent of resection (complete vs. incomplete; *P* = 0.37); 28% of patients had one or more complications.**

A report from Memorial Sloan Kettering Cancer Center of children with stage III, non-*MYCN*–amplified disease with gross residual disease after initial surgery demonstrated that these patients could be safely observed and maintained excellent OS without use of cytotoxic therapy (Kushner et al., 1996). Similar results were found in the German neuroblastoma 97 study, in which infants with stage II or III *MYCN* non-amplified tumors who had incomplete resections were observed after surgery without chemotherapy. Regression of the residual masses without additional treatment was seen in 32 of 55 patients. Tumors that recurred or progressed were responsive to therapy with a 3-year OS rate of 98% (Hero et al., 2008).

Unfortunately, more than half of all newly diagnosed patients with neuroblastoma have high-risk disease. There is conflicting evidence regarding the benefit of extensive resection in children with stage IV disease between studies that support (Adkins et al., 2004; Chamberlain et al., 1995; DeCou et al., 1995; Haase et al., 1991; Koh et al., 2005; Kuroda et al., 2003; LaQuaglia et al., 1994, 2004; LeTourneau et al., 1985; McGregor et al., 2005; Tsuchida et al., 1992; Vollmer et al., 2017; von Allmen et al., 2005; Yokoyama et al., 1995) and those that refute that approach (Adams et al., 1993; Castel et al., 2002; Kaneko et al., 1997; Kiely, 1994; Losty et al., 1993; Matsumura et al., 1988; McGregor et al., 2005; Simon et al., 2013; Sitarz et al., 1983; von Schweinitz et al., 2002). In a retrospective review, Kiely (1994) compared the results of radical tumor resection with those of more conventional surgery in patients with stages III and

IV disease. He found no difference in survival between 46 patients treated with radical surgical procedures and 34 patients treated with more conventional surgery. Shorter et al. (1995) also did not find any evidence that the extent of surgical resection had an impact on the survival of stage IV patients. Simon et al. (2013) reported the results of the German cooperative trial NB97 that evaluated the role of surgery (upfront and post-neoadjuvant therapy) in patients older than 18 months with stage IV disease: 278 patients were evaluated. Their data suggested that neither upfront surgery nor operations performed post neoadjuvant therapy produced a positive impact on EFS, local progression-free survival, or OS. In contrast, von Allmen et al. (2005) reported on the local control of 76 patients treated at two institutions with the same treatment protocol and a consistent surgical approach. They found that aggressive surgery followed by local radiotherapy provided excellent local tumor control with no isolated local relapse in patients who had greater than 90% resection (60 of 76 children).

Subsequently, von Allmen et al. (2017) reviewed 220 patients treated on the COG study A3973 with high-risk neuroblastoma. In this cohort the blinded radiographic central imaging review for completeness of resection was compared with the surgeon's assessment. Concordance between surgeon's assessments and the radiographic assessment was low, 63%. Nonetheless, the clinical assessment of resection extent of greater than or equal to 90% (in 154 patients) compared with resection of less than 90% (in 66 patients) after adjustment for *MYCN* amplification or diploidy was associated with longer EFS and lower clinical incidence of local progression but had no effect on OS. In these nonrandomized studies, it has been difficult to determine whether improved survival in those with complete resection has been due to the more favorable intrinsic biology of the tumor, allowing resection or truly because of the completeness of resection. LaQuaglia has assessed the results in 33 non-redundant studies, which provided adequate surgical data for analysis of survival (LaQuaglia et al., 2014). The analysis included 2599 patients for the survival analysis and 412 in the analysis of local progression. Meta-analysis revealed that the relative risk of mortality for stage III and IV patients who had more than 90% resection was 0.67 (95% CI 0.59–0.77) compared with those with a lesser resection. For stage IV patients alone the relative risk was 0.75 (95% CI 0.62–0.92). The relative risk of local recurrence or progression in patients with stage IV disease was 0.38 (95% CI 0.27–0.53) for those undergoing extensive primary resection compared with those who did not.

As the intensity of the therapy increases (including the use of autologous bone marrow transplantation) and control of distant metastasis improves, the impact of maximal local control may become apparent. The combination of gross total resection and external beam irradiation has achieved local control in 84% to 90% of children (Kushner et al., 2001; Wolden et al., 2000). In another series of reports, intensive chemotherapy followed by double autologous bone marrow transplantation, aggressive surgical resection, and radiotherapy has achieved an OS of 56% and a local recurrence rate of only 2.6% (Marcus et al., 2003; von Allmen et al., 2005).

Usually the safest approach for advanced tumors is to defer resection until after initial chemotherapy (Berthold et al., 1989; Black et al., 1996; LaQuaglia et al., 1994; Shamberger et al., 1991; Shochat, 1992). **The tumors are smaller and firmer, with less risk of rupture and hemorrhage after chemotherapy, resulting in a decreased rate of complications, particularly nephrectomy** (Shamberger et al., 1998; see Fig. 53.5). One specific complication encountered after resection of extensive tumor surrounding the celiac axis and the superior mesenteric artery is diarrhea (Kiely, 1994). It is thought to result from resection of the autonomic nerves to the gut found anterior to the aorta at the base of the superior mesenteric artery and the celiac axis (Rees et al., 1998). The second frequent complication after extensive resection is chylous ascities resulting from resection of the involved retroperitoneal lymph nodes. This is generally a self-limited problem, but initial extensive abdominal distention may require intervention (Qureshi et al., 2016). Preoperative chemotherapy does appear to increase the proportion of children able to achieve a complete resection (Adkins et al., 2004).

Surgery usually is performed 13 to 18 weeks after initiation of chemotherapy, allowing three to four courses of treatment (Azizkhan and Haase, 1993). Some tumors remain inoperable even after chemotherapy.

Infants under 1 year of age with extensive local disease or stage IV disease make up a special subset of patients. They have historically fared much better than children older than 1 year of age with comparable disease, but not as well as infants with stage IV-S disease. It is now recognized that biologic markers can be used to identify which infants have high-risk disease and require intensive therapy and which will have intermediate-risk disease requiring less intensive therapy. The SIOPEN Infant Neuroblastoma European Study reported 120 infants with localized tumors and no *MYCN* amplification who were deemed unresectable based on IDRFs (Rubie et al., 2011). These infants were treated with low-dose cyclophosphamide and vincristine (VCR) repeated once to three times every 2 weeks until surgical excision could be safely performed. Infants with either one threatening symptom or an insufficient response were given carboplatin and etoposide (CaE) sometimes followed by vincristine, cyclophosphamide, and doxorubicin. Seventy-nine received the two-drug therapy with VCR and 49 received CaE because of insufficient response. Thirty-two infants had threatening symptoms and of these 30 received CaE. Anthracyclines were used in 46 infants. Surgery was performed in 102 infants leading to gross surgical excision in 93. Relapse occurred in 12 patients (9 local and 3 distant). The 5-year OS and EFS were 99% ± 1% and 90% ± 3%, respectively. The low-dose chemotherapy without an anthracycline was effective in 62% of these infants with an unresectable tumor and no *MYCN* amplification.

In a large cohort (134 infants), *MYCN* amplification, serum ferritin, Shimada histopathologic classification, and bone marrow involvement by immunocytology were analyzed. Although each factor had prognostic significance by univariate analysis, only *MYCN* amplification was significant by multivariate analysis; the EFS for infants without *MYCN* amplification was 93% ± 4% versus 10% ± 7% in those with amplification despite intensive therapy (Schmidt et al., 2000).

Clinical trials in Europe evaluated these infants without *MYCN* amplification and achieved excellent survival (OS of 97.6% at 2 years) without chemotherapy in those with primaries extending across the midline or a positive skeletal survey (DeBernardi et al., 2009). Infants with overt metastases to the skeleton, lung, and central nervous system (CNS) were treated with a minimum of four chemotherapy courses and achieved a 2-year OS of 95.6%.

Chemotherapy

A variety of multiagent treatment regimens have been developed to treat high-risk patients with neuroblastoma that use a combination of intensive induction therapy, myeloablative consolidation therapy with stem cell support, and biologic therapy to control minimal residual disease. The goal of this treatment intensification in a sequence of protocols is better disease control, and 5-year survival rates have gone from less than 15% to 30% to 40% (Philip et al., 1997). Although initial response rates are improving, with a prolonged time to progression of disease, relapse continues to be a major problem. A meta-analysis of 44 trials showed a correlation between dose intensity and treatment efficacy including improved response and survival (Cheung et al., 1991).

An induction regimen developed at Memorial Sloan-Kettering Cancer Center has been widely used in subsequent protocols. It used cycles of cyclophosphamide, vincristine, and doxorubicin alternating with cycles of cisplatin and etoposide. In their single institution study Kushner et al. (1994) reported complete response rate of 63% and a complete plus very good partial response rate of 87% in 24 patients. The dose intensification of chemotherapy required for local tumor control results in significant myelosuppression, limiting the amount of therapy that can be given. This has prompted the use of autologous bone marrow transplantation after sublethal chemotherapy or total-body irradiation. The use of marrow-ablative chemoradiotherapy followed by autologous marrow reinfusion has resulted in complete remission in up to 50% of patients with stage IV disease (Dinndorf et al., 1992; Grupp et al., 2000; Matthay et al., 1995; Moss et al., 1987; Mugishima et al., 1994; Seeger et al., 1991). However, a significant problem is the risk for late relapse. The randomized clinical trial of the German Society of Paediatric Oncology and Hematology of high-risk neuroblastoma showed improved EFS at 3 years with myeloablative therapy and autologous stem cell rescue compared with maintenance chemotherapy (Berthold et al., 2005). These results were similar to those of the COG study (Matthay et al., 1999). Unfortunately, the OS rates were not statistically different in either study at initial report. An update of the latter study, however, reveals that the 5-year OS of the patients receiving the autologous bone marrow transplant was improved (Matthay et al., 2009).

A subsequent study by the COG addressed the issue of the need for “purging” of the bone marrow before return to the patient to remove any potential remaining neuroblastoma cells (Kreissman et al., 2013). This study was terminated when interim analysis showed no difference in outcome between the two groups. A further study addressed the benefit between a single versus a paired autologous transplant to see if additional intensification would improve outcome. It was demonstrated that tandem versus single myeloablative therapy improves 3-year EFS in children with high-risk neuroblastoma (Park et al., 2016).

Recent trials in COG have piloted a strategy of using non–cross-resistant chemotherapy to further improve induction response rates. Topotecan, a topoisomerase-1 inhibitor has shown activity against neuroblastoma in phase I and II trials. In a COG feasibility trial high-dose topotecan was added to the Memorial Sloan-Kettering induction backbone (Park et al., 2011). Thirty-one patients were enrolled and the combination was well tolerated without unexpected toxicity. Fifteen of 31 patients (48%) achieved a complete or very good partial response. This regimen was added in a non-randomized fashion in the large phase III trial between single and tandem transplantation.

The presence of osseous disease has long been recognized as an adverse prognostic finding, particularly after induction therapy. A multivariate analysis of 549 patients with high-risk neuroblastoma in the European Bone Marrow Transplantation Solid Tumor Registry demonstrated that persistent cortical bone lesions ($P = 0.004$) and bone marrow involvement ($P = 0.03$) were the only independent adverse prognostic factors (Ladenstein et al., 1998). More recent retrospective studies of patients treated on COG A3973 assessed a "semiquantitative" MIBG score using the Curie scoring system. Patients who had a Curie score greater than 2 at the end of induction (n = 52) had a significantly decreased EFS compared with patients who had Curie scores of 2 or less (3-year EFS 15.4% ± 5.3% vs. 44.9% ± 3,8%, $P < 0.001$) (Yanik et al., 2013). This finding was particularly stark for patients with *MYCN* amplification (6 patients), in whom 3-year EFS was 0.

The presence of bulky disease results in increased failure. Tumor debulking with surgery or radiation therapy is warranted before autologous bone marrow transplantation. There are many questions yet to be resolved about this modality of treatment. Toxicity of bone marrow transplantation can be lethal, and the long-term complications in patients with successful transplantation are unknown. However, these risks are acceptable given that long-term survival is difficult to achieve without such intensive therapy.

Additional new agents in phase I and II trials for relapsed neuroblastoma include temozolomide and irinotecan (Kushner et al., 2006; Rubie et al., 2006; Simon et al., 2007). As efficacy is established, they will be advanced into clinical trials for high-risk tumors with a goal to improve the overall outcome.

New Innovative Biologic Therapies

Double autologous bone marrow transplantation has allowed the use of myeloablative therapies, but the maximum benefit to that approach has been reached. 13-cis-retinoic acid produces differentiation of neuroblastoma in cell cultures including cultures of recurrent tumors. It was given for a 6-month period after cytotoxic therapy in children with advanced-stage disease and significantly decreased the frequency of relapse (Matthay et al., 1999). Long-term follow-up has shown that the 5-year OS was improved (Matthay et al., 2009). Antibody therapy against the GD2 disialoganglioside cell surface marker uniformly expressed in neuroblastoma has been shown to be an effective adjuvant therapy in combination with granulocyte-macrophage colony-stimulating factor and interleukin-2 along with 13-cis-retinoic acid after autologous bone marrow transplant compared with 13-cis-retinoic acid alone (Yu et al., 2010). More recent studies have combined antibody therapy with a "backbone" of irinotecan and temozolomide, a pair of newer agents not included in front-line therapy. In one study these agents were combined with either antibody to GD2 or temsirolimus, an mTOR inhibitor that has a role in regulation of protein synthesis and cell proliferation (Mody et al., 2017). In this randomized study of relapsed patients the combination with the antibody to GD2 was effective but the mTOR inhibitor had a very low response rate. Newer "humanized" antibodies are also being tested to see if they are more effective and if they can minimize the pain produced by the current antibody, which can limit the extent of treatment. Studies are also in preparation to evaluate the use of the GD2 antibody in front-line therapy.

A new synthetic retinoid, fenretinide, which has produced apoptosis rather than differentiation in neuroblastoma cell lines, is also in clinical trials for maintenance therapy. It has been shown to be effective against some neuroblastoma cell lines that are resistant to 13-cis-retinoic acid.

Other avenues of treatment in current phase I and phase II trials include vaccine and antiangiogenic therapy. Vaccines have been developed against the GD2 antigen, but they are in early stages of testing. Inhibition of angiogenesis is another appealing avenue of therapy in this very vascular tumor, particularly once there is minimal residual disease, although efficacy has not yet been established in phase 1 or 2 studies.

Another modality in the treatment of metastatic neuroblastoma is the use of ^{131}I-MIBG (Hutchinson et al., 1992). The finding that the primary tumor and metastatic areas take up this radiotracer suggested the possibility that therapeutic doses can be delivered to the tumor. Preliminary analysis indicates that objective responses do occur in terms of reduction of tumor volume, even in previously heavily treated patients (Howard et al., 2005; Matthay et al., 2007). Significant myelosuppression is seen with dose escalation, however, and stem cell support is required. It has not yet been tested as an "up-front" therapy.

Radiotherapy

Radiotherapy is effective for local control in neuroblastoma, and risk of local relapse can be correlated with the biologic markers. Although irradiation has not provided a benefit in low-stage tumors, it has increased local control in children with advanced stage IV or bulky stage III tumors (Castleberry et al., 1991; Evans et al., 1996; Matthay et al., 1989). A randomized control trial to evaluate the efficacy of local control between radiotherapy alone and surgery has not been performed. Doses of external beam irradiation used have ranged between 15 and 30 Gy, depending on the patient's age, location of the tumor, and extent of residual disease.

Intraoperative radiation therapy has been used for patients with unresectable disease. This technique has the advantage of delivering a higher dose of radiation to the operative field while sparing normal adjacent tissues (Leavey et al., 1997). Although its use has been promoted, it has not been convincingly demonstrated to improve control when compared with external beam irradiation (Haas-Kogan et al., 2000).

Spinal Cord Compression

Extension of tumor into the spinal canal produces symptoms of spinal cord compression in up to 5% of patients presenting with neuroblastoma (DeBernardi et al., 2001), whereas up to 13% of patients have radiographic evidence of extension into the spinal canal (Plantaz et al., 1996). These children have been treated by decompressive laminectomy, radiotherapy, or chemotherapy. Neurologic outcome has been similar by all modalities and, unfortunately, patients presenting with severe motor deficits generally recover little function (DeBernardi et al., 2001; Katzenstein et al., 2001). Because of the delayed complications of scoliosis after laminectomy, current recommendations are to initiate treatment with chemotherapy and reserve laminectomy for children with progressive neurologic deterioration (Katzenstein et al., 2001). Radiotherapy is now generally avoided, because of its adverse effect on growth of the spine.

Key Points: Neuroblastoma

- Neuroblastoma is the most common extracranial solid neoplasm in children.
- Children 18 months of age or younger have a better survival rate than older children. This may be attributed to more favorable biologic parameters in tumors diagnosed at this age.
- Complete surgical resection is curative for low-stage disease.
- *MYCN* amplification, found in 20% of patients with primary tumors, is

associated with tumor progression. This poor prognosis is independent of patient age and tumor stage. Additional biologic markers of poor prognosis have been defined and treatment protocols are currently based on these factors.

Wilms Tumor

Wilms tumor, or nephroblastoma, is the most common primary malignant renal tumor of childhood. It is an embryonal tumor that develops from remnants of immature kidney. Treatment of patients with nephroblastoma has been extensively investigated in a number of large randomized clinical trials in North America and Europe. The focus of the most recently completed trials was on reducing the morbidity of treatment for low-risk patients, reserving more intensive treatment for high-risk patients for whom survival remains poor. This section outlines current recommendations for treatment and reviews the latest developments in the biology of Wilms tumor.

Epidemiology

Wilms tumor accounts for approximately 6% to 7% of all childhood cancers. It is the most common renal tumor of childhood, accounting for 95% of all kidney cancers in children under the age of 15 in the United States (Ali et al., 2012; Howlader et al., 2013). According to the Surveillance, Epidemiology, and End Results (SEER) registry, the average annual age-adjusted incidence rate of Wilms tumor is 8.0 per million (Bernstein et al., 1999; Breslow et al., 1993). More than 80% of cases are diagnosed before 5 years of age, with a median age of 3.5 years. Nevertheless, older children and occasionally even adults can be affected (Ali et al., 2012; Arrigo et al., 1990; Kalapurakal et al., 2004a). The median age at diagnosis is lower in children with bilateral Wilms tumor (Breslow et al., 1993) and those with a syndromic predisposition to Wilms tumor (Kalish et al., 2017). Wilms tumor presents at an earlier age among males with both unilateral and bilateral tumors.

In North America, Wilms tumor is slightly more frequent in females than in males. With regard to ethnicity, the incidence of Wilms tumor is lower in East Asian populations and higher in black populations compared with the incidence reported for North American and European Caucasians (Axt et al., 2011; Breslow et al., 1994; Fukuzawa et al., 2004). The fact that such variations exist more closely associated with race than geography suggests that environmental risk factors likely play a minor etiologic role, certainly in comparison with adult epithelial cancers (Breslow et al., 1993). Black children often have a more advanced stage of disease at presentation, but it is not clear if this is related to tumor biology or reflects delays in diagnosis resulting from impaired access to health care (Axt et al., 2011). Data also exist on the very poor survival outcomes of children in Africa with Wilms tumor; however, as with the data on black children in North America it is still unclear what contribution tumor biology plays relative to other known barriers to care (Paintsil et al., 2015). Several epidemiologic studies have investigated occupational, environmental, and lifestyle factors as risk factors for Wilms tumor. Although some studies have suggested that a number of parental and prenatal exposures may be associated with an increased risk of Wilms tumor, very few have been established conclusively (Breslow et al., 1993; Shrestha et al., 2014).

Biology/Genetics

Children with Wilms tumor have been extensively studied to determine the role of genetic alterations in tumor development (Gadd et al., 2012). We now recognize that the majority of Wilms tumors arise from somatic mutations restricted to tumor tissue and a much smaller percentage originate from germline mutations (Dome and Huff, 2016; Ruteshouser et al., 2008; Scott et al., 2012). It is apparent that several genetic events result in Wilms tumorigenesis and that the Knudson two-hit model of cancer formation does not explain most cases (Knudson and Strong, 1972). In 10% to 15% of individuals with Wilms tumor, the cause is considered to be a germline pathogenic variant or an epigenetic alteration occurring early during embryogenesis (see 11p15-Related Wilms Tumor). These may or may not be associated with a known congenital malformation syndrome or hereditary cancer syndrome. Approximately 1% to 2% of individuals with Wilms tumor have at least one relative also diagnosed with Wilms tumor (familial Wilms tumor); however, although germline variants that are likely pathogenic have been identified in some families, they are still not known for the majority of individuals. The most commonly reported germline genetic and epigenetic variants in individuals with Wilms tumor involve WT1 and the 11p15.5 locus. A growing number of variants in other genes have been reported. In some cases, the estimated of risk of Wilms tumor with these variants is high, but the variant or syndrome is so rare in the general population that only a handful of individuals with Wilms tumor have ever been reported (Dome and Huff, 2016). A number of genes have been identified that play a role in the development of Wilms tumor (Table 53.3).

TABLE 53.3

Gene Mutations in Wilms Tumors

GENE (CHROMOSOME)	FREQUENCY	SOMATIC OR GERMLINE
IGF2 (11p15)	70%	Both
WTX (Xq11)	20%	Somatic only
WT1 (11p13)	20%	Both
CTNNB1 (3p21)	15%	Somatic only
TP53 (17p13)	4% all tumors	Both
	70% anaplastic	

WT1

The first gene mutation described in Wilms tumor was *WT1* with somatic and germ-line mutations noted. **The identification and subsequent cloning of *WT1* resulted from cytogenetic observations of gross deletions at chromosome 11p13 in patients with the WAGR (Wilms tumor, Aniridia, Genital anomalies, mental Retardation) syndrome.** These children were shown to have heterozygous germline deletions at 11p13 (Riccardi et al., 1978). Subsequent molecular analysis of the DNA mapping of this specific region led to the identification of the *WT1* in 1990 (Bonetta et al., 1990; Call et al., 1990). *WT1* mutations are often associated with β-catenin (*CTNNB1*) mutations, defining a specific genetic subset of Wilms tumor (Li et al., 2004; Royer-Pokora et al., 2008). This subset has been called the ideal type I Wilms tumor (Breslow et al., 2006). It is characterized by a stromal predominant favorable histology, intralobar nephrogenic rests, early onset of Wilms tumor, and genitourinary abnormalities in males. Wilms tumors from patients with Wilms tumor-aniridia-urogenital abnormalities-mental retardation (WAGR) and Denys–Drash syndrome (DDS) belong to this subtype of tumors.

Aniridia, found in 1.1% of Wilms tumor patients, arises from deletion of *PAX6*, which lies within approximately 0.6 Mb of *WT1* (Vasilyeva et al., 2017). Aniridia patients with visible (microscopic) chromosomal deletions that include *WT1* were noted to be prone to the development of Wilms tumor (Muto et al., 2002). FISH analysis of aniridia patients has been used to identify submicroscopic deletions of *WT1* and is also a useful predictor of Wilms tumor development (van Heyningen et al., 2007). Wilms tumor will develop in approximately 40% to 70% of aniridia patients with deletions of *WT1*.

Conversely, aniridia patients with normal *WT1* do not develop Wilms tumor (Grenskov et al., 2001; van Heyningen et al., 2007).

The *WT1* gene is important for normal kidney and gonadal development. *WT1* encodes a zinc finger transcription regulating mesenchymal to epithelial transition in kidney development (Dressler, 1995; Pritchard-Jones, 1990). *WT1* is necessary for ureteric bud outgrowth and is also important in nephrogenesis. Targeted mutation of the *WT1* gene in mice results in failure of kidney and gonadal development (Kreidberg et al., 1997). **The Denys-Drash syndrome (DDS) is the specific association of male pseudohermaphroditism, renal mesangial sclerosis, and nephroblastoma** (Drash et al., 1970). The syndrome is caused by point mutations in the zinc-finger DNA binding region of *WT1* (Coppes et al., 1993). More than 90% of DDS patients harbor germline point mutations in only one *WT1* allele (Coppes et al., 1992; Pelletier et al., 1991). Therefore the *WT1* mutation acts dominantly with respect to genitourinary abnormalities. The fact that the phenotype resulting from these heterozygous mutations is far more severe than that resulting from constitutional deletion of one *WT1* allele (i.e., WAGR patients) suggests that the Denys-Drash mutations do not result in inactivation of the WT1 protein, but rather in the production of a dysfunctional *WT1* protein. It is postulated that this abnormally expressed protein alters regulation of transcription and urogenital development. The majority of these patients progress to end-stage renal disease. Nephropathy usually occurs early in life and renal biopsy demonstrates mesangial sclerosis. Some *WT1* mutations can lead to an incomplete DDS phenotype, with varying degrees of genitourinary anomalies, renal pathologies, and penetrance of Wilms tumor (McTaggart et al., 2001). Although XY individuals have been reported most often, the DDS has been reported in genotypic/phenotypic females. WAGR and DDS patients are more likely to have bilateral tumors and are diagnosed at a younger age (Breslow et al., 2003, 2006).

This risk for renal insufficiency in DDS is shared by children with WAGR and children with genitourinary abnormalities, all associated with a *WT1* mutation (Diller et al., 1998). **WAGR patients and those with genitourinary abnormalities have an increased risk of renal failure if they survive into puberty** (Breslow et al., 2000, 2005). Genitourinary anomalies (renal fusion anomalies, cryptorchidism, hypospadias) are present in 4.5% of patients with Wilms tumor (Breslow et al., 1993). The incidence of *WT1* mutations in patients with Wilms tumor not associated with any genitourinary abnormality is approximately 2% (Little et al., 2004). Studies of non-tumoral renal tissue in children with WAGR and DDS have demonstrated smaller glomerular diameters than controls (Dahan et al., 2007). This suggests a specific defect of WT1 function during renal development that leads to subsequent deterioration in renal function with age.

WT1 was originally considered to be a classic tumor suppressor gene, and the loss of both copies or mutations of this gene would lead to Wilms tumor development (Rauscher, 1993). Although this may be the case for some tumors, only 20% of patients with Wilms tumor have a mutation in the germline or in tumor tissue (Diller et al., 1998; Ruteshouser et al., 2008). It is well established that most constitutional cancer syndrome mutations, including *WT1*, are associated with younger age of onset. The median age of onset in children with somatic *WT1* mutations was 14 months. It is postulated that *WT1* mutations are associated with a more rapid progression to Wilms tumor than other molecular abnormalities (Scott et al., 2012).

WTX

Another tumor suppressor gene, *WTX*, is targeted by somatic mutations in up to 30% of cases of Wilms tumor, the most common type of pediatric kidney cancer (Rivera et al., 2007). Most tumors have deletions of the entire WTX gene, but one-third of WTX-mutated Wilms tumors carry truncating mutations or missense mutations. The functional importance of the missense alterations is unclear, because the missense alteration can be present in normal tissue from the same patient, whereas the deletion and truncation mutations are always specific to the tumor. The location of WTX on the X chromosome is of particular interest because it is inactivated by a monoallelic, or “single-hit” event rather than by the classical biallelic inactivation of autosomal tumor suppressor genes. It targets the single X chromosome in males and the active X chromosome in females with tumors and occurs at comparable frequencies in males and females alike. Initially it was reported that tumors caused by *WTX* mutations lack *WT1* mutations. Subsequently, it has been observed that *WTX* mutations occur with equivalent frequency in tumors with or without mutations in *WT1* and *CTNNB1* (Ruteshouser et al., 2008). *WTX*, like *WT1*, appears to play a role in the Wnt/beta-catenin signaling pathway. Mutations in *WT1*, *WTX*, and *CTNNB1* provide the genetic basis for about one-third of Wilms tumors (Bahrami et al., 2018).

11p15

Additional molecular alterations are observed at the chromosome 11p15 locus, which contains a cluster of imprinted genes (Koufos et al., 1989; Mannens et al., 1990). LOH or loss of imprinting (LOI) on 11p15 occurs in up to 70% of tumors (Scott et al., 2012). A WT2 locus has been postulated in 11p15, but so far, the respective gene has not been identified. **This region is known to harbor genes for the Beckwith-Wiedemann syndrome (BWS) and other syndromes with overgrowth features** (Koufos et al., 1989). **These include hemihypertrophy, which may occur alone or as part of the BWS, Perlman, Soto, and the Simpson-Golabi-Behmel syndromes** (Neri et al., 1998; Perlman et al., 1975). Most cases of BWS are sporadic, but up to 15% exhibit heritable characteristics with apparent autosomal dominant inheritance. The BWS critical region on 11p15 includes two domains of imprinted genes located in proximity in band 11p15. Imprinting center region 1 (ICR1) regulates the expression of *IGF2* and *H19*; and center 2 (ICR2), which regulates the *CDKN1C*, *KCNQ10T1*, and *KCNQ1*. These imprinting centers are differentially methylated on the paternal and maternal allele, leading to expression of only one parent-specific allele (Choufani et al., 2013).

Wilms tumor associated with epigenetic alterations in the 11p15 region has been termed the ideal type II Wilms tumor (Breslow et al., 2006). A type II Wilms tumor is characterized by a limited nephrogenic differentiation and a mostly blastemal or epithelial-type histology; patients develop tumors at a later age and have a heavier birth weight. **The risk of nephroblastoma in children with BWS and hemihypertrophy is estimated to be 4% to 10%; 21% of children have bilateral disease** (Beckwith, 1996; Debaun and Tucker, 1998; Porteus et al., 2000). The mean age at diagnosis of Wilms tumor in BWS and hemihypertrophy patients is similar to that of the general Wilms tumor population (Breslow et al., 1993). Adrenocortical neoplasms and hepatoblastoma also occur with increased frequency in BWS. Children with BWS found to have nephromegaly (kidneys greater than or equal to the 95th percentile of age adjusted renal length) are at the greatest risk for the development of Wilms tumor (Debaun et al., 1998). Investigators have been able to correlate genetic changes to identify which BWS patients are at risk for Wilms tumor development (Bliek et al., 2004; Brioude et al., 2013; DeBaun et al., 2002). An increased Wilms tumor risk is observed only in BWS patients with ICR1 gain of methylation and 11p15 uniparental disomy. In contrast, the tumor risk is lower in BWS with ICR2 loss of methylation and CDKN1C mutations.

Familial Wilms Tumor

As noted earlier, 1% to 2% of Wilms tumor patients have a family history of Wilms tumor (Breslow et al., 1996; Ruteshouser and Huff, 2004). Familial cases have an earlier age of onset and an increased frequency of bilateral disease. Two familial Wilms tumor genes have been localized (Ruteshouser and Huff, 2004). FWT1 is located at 17q12-q21 and FWT2 at 19q13.4 (McDonald et al., 1998; Rahman et al., 1996). Penetrance of these genes appears to be moderate, and these genes do not follow the typical tumor suppressor gene pattern of loss of heterozygosity (Strong, 2003).

Other Chromosomal Abnormalities

Mutations of the tumor suppressor gene *TP53* are frequently encountered genetic events in human cancer (Hollstein et al., 1991). *TP53* mutations are detected in 50% to 75% of patients with anaplastic histology Wilms tumor (Bardeesy et al., 1994, Ooms et al., 2016). It has been suggested that a favorable histology tumor may progress to an anaplastic tumor by acquiring a disruption of *TP53* function in a group of selected cells (Natrajan et al., 2007). The *TP53* mutations also have been correlated with advanced stage disease (Malkin et al., 1990; Sredni et al., 2001). A recent report from COG on *TP53* mutations in diffuse anaplastic Wilms tumor noted improved relapse-free survival in those with advanced stage disease who had wild-type *TP53* (Ooms et al., 2016).

Loss of the long arm of chromosome 16 has been found in approximately 20% of Wilms tumors (Maw et al., 1992), suggesting the presence of a gene at 16q involved in the biology of Wilms tumor. Similarly, loss of the short arm of chromosome 1p has been found in approximately 10% of cases (Grundy et al., 1994). **LOH at 1p and 16q are associated with an increased risk of tumor relapse and death** (Grundy et al., 1994, 2005; Wittman et al., 2007). Confirming the utility of LOH of 16q and 1p to predict outcome was one of the major objectives of the fifth National Wilms Tumor Study (NWTS) (see discussion later). LOH of chromosome 11q is noted in approximately 20% of tumors. LOH of 11q is 3 to 4 times more frequent in anaplastic tumors (Wittman et al., 2007). There is a correlation with tumor recurrence and death but only for tumors that lost the entire long arm of chromosome 11. Combined LOH (at 1p and 16q) was used to risk-stratify patients with favorable-histology Wilms tumor (FHWT) on the most recently completed COG renal tumor studies. COG Study AREN 0533 intensified therapy for those stage III and IV FHWT and demonstrated that therapeutic intensification improved EFS and OS (Dix et al., 2015; Fernandez et al., 2018). However, this is of limited clinical importance because only approximately 5% of all FHWT patients have combined LOH.

Gain of 1q has also been identified to be another genetic change associated with outcome (Gratias et al., 2013, 2016; Segers et al., 2013). 1q gain has the potential to be a more clinically significant factor because it is consistently noted in one-fourth of FHWTs. It is important to note that 1q gain and LOH at 1p and 16q are not independent events. LOH at 1p and 16q often arises through chromosomal translocations that also result in 1q gain. After stratification for stage of disease, 1q gain was associated with a significantly increased risk of disease recurrence and worse OS (Gratias et al., 2016). Future studies will likely investigate the ability of 1q gain to be used to risk-stratify patients for therapeutic intensification.

COG investigators have evaluated a large cohort of FHWTs for global gene expression patterns; *WT1*, *CTTNNB1*, and *WTX* mutation; and 11p15 copy number and methylation patterns. They identified five subsets of tumors showing distinct differences in their clinical and pathological features. One unique subset was epithelial Wilms tumor in infants that lacked *WT1*, *CTTNNB1*, and *WTX* mutations and nephrogenic rests, and none had recurrence of tumor. COG investigators hope to use this type of information to develop specific treatment strategies for different subsets of patients based on biology (Gadd et al., 2012; Sredni et al., 2009).

Screening

Screening with serial renal sonograms has been recommended in children at high risk for development of Wilms tumor. Review of most studies suggests that 3 to 4 months is the appropriate screening interval. The frequency of screening does not change as the patient ages; the rate of tumor growth is expected to be the same in older children. Tumors detected by screening will usually be at a lower stage (Choyke et al., 1999; Green et al., 1993; Kalish et al., 2017). No studies have demonstrated that early detection has improved patient survival. Early detection can provide an opportunity for nephron-sparing surgery, because these children are at an increased risk for bilateral disease. The smaller tumors found on screening studies are more amenable to renal-sparing surgery (Romao et al., 2012; Fig. 53.6). A recent report from the American Association for Cancer Research Childhood Cancer Predisposition Workshop recommended that screening be performed when a condition has a Wilms tumor incidence of greater than 1% (Table 53.4; Kalish et al., 2017). Others have recommended screening when the Wilms tumor incidence is greater than 5% (Scott et al., 2006a,b). Although there is emerging evidence of different cancer risks based on genetic or epigenetic subgroups for certain syndromes, and several European countries now use subgroup-specific recommendations for WT screening particularly in BWS, these practices have not yet been adopted in North America (Mussa et al., 2016). Ultrasound surveillance is recommended until 7 years of age. For patients with BWS/IHH, trisomy 18, and SGBS, screening for hepatoblastoma is also required. They need full abdominal ultrasound and simultaneous serum AFP screening every 3 months starting at birth (or at the time of diagnosis) and continuing through the child's fourth birthday.

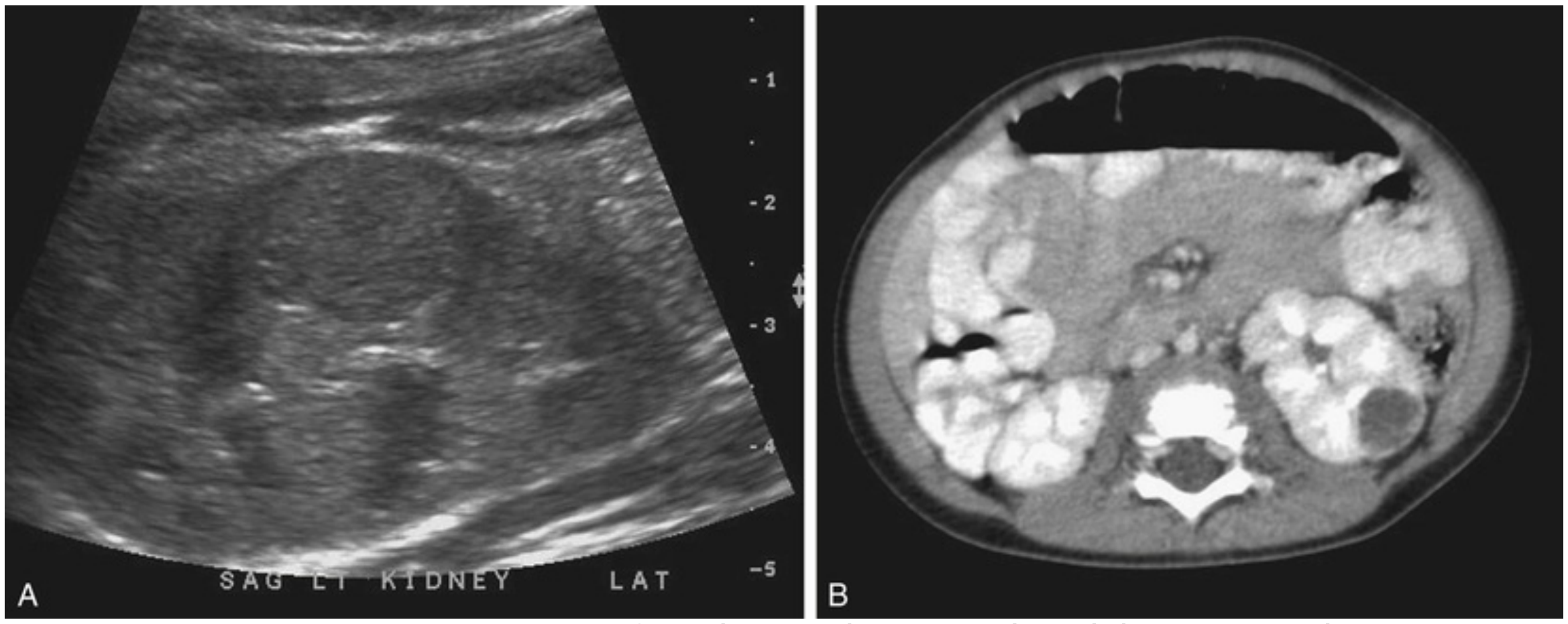

FIG. 53.6 Small renal tumor found on serial screening. (A) Ultrasound shows solid lesion just pushing out from the cortex. (B) CT demonstrates that lesion is amenable to renal-sparing surgery.

TABLE 53.4

Syndromes Associated With Development of Wilms Tumor

SYNDROME	GENES	LOCUS	WILMS TUMOR RISK
HIGH RISK			
WAGR	*WT1*	11p13	50%
Denys-Drash	*WT1*	11p13	50%
Fanconi anemia D1	*BRCA2*	13q12.3	>20%
Perlman	Unknown		>20%
Mosaic variegated aneuploidy	*BUB1B*	15q15	>20%

MODERATE RISK			
Beckwith-Wiedemann	*WT2*	IGF2, H19	5%–10%
Hemihypertrophy	*WT2*	IGF2, H19	5%
Frasier	*WT1*	11p13'	5%–10%
Simpson-Golabi-Behmel	*GPC3*	Xq26	10% (in males)
LOW RISK			
Li-Fraumeni	*p53*	17p13	Low
Neurofibromatosis	*NF1*	17q11	Low
Sotos	*NSD1*	5q35	Low
Trisomy 18	Unknown	18	Low
Bloom	*BLM*	15q26	Low

Screening of the contralateral kidney after nephrectomy for unilateral Wilms tumor is also recommended (D'Angio et al., 1993). Infants younger than 12 months found to have nephrogenic rests (NRs) in the resected kidney are at the greatest risk for metachronous tumors (Coppes et al., 1999). Ultrasound surveillance is performed from time of diagnosis until 5 years of age, with a frequency of every 3 to 4 months.

CT or MRI should be performed if ultrasonography demonstrates a suspicious lesion. Nonmalignant renal lesions—for example, renal cysts—do occur at an increased rate in children with BWS, and recognition of these is important to avoid unnecessary nephrectomy when new lesions are identified on screening ultrasonography (Borer et al., 1999; Choyke et al., 1999).

Pathology

Pathologists have made important contributions to the study of the clinical behavior and biology of Wilms tumor (Beckwith and Palmer, 1978; Gadd et al., 2012, 2017; Perlman et al., 2011; Ravenel et al., 2001; Schmidt and Beckwith, 1995; Vujanic et al., 2002, 2010; Weeks et al., 1987; Zuppan et al., 1991). Wilms tumor is characterized by wide histologic diversity, and thus the classification of these childhood tumors can be difficult. As noted in the discussion earlier, correlation of the pathologic findings with genetic events is improving our understanding of the development of Wilms tumor.

Favorable Histology Wilms Tumor

Wilms tumor usually compresses the adjacent normal renal parenchyma, forming a pseudocapsule composed of compressed, atrophic renal tissues. This intrarenal pseudocapsule can be helpful to distinguish Wilms tumor from NRs and other renal tumors. The texture of the tumors varies depending on the predominant histologic pattern. Many are soft and friable with necrotic or hemorrhagic areas frequently noted. This consistency increases the risk of intraoperative tumor rupture during primary nephrectomy. Most Wilms tumors are unicentric, but 12% are multicentric unilateral tumors (Breslow et al., 1988a). Extrarenal Wilms tumor arising in the retroperitoneum and elsewhere are rare and are thought to arise from displaced metanephric elements or mesonephric remnants. Wilms tumor is derived from primitive metanephric blastema (Beckwith and Palmer, 1978). In addition to expressing a variety of cell types found in a normal developing kidney, Wilms tumor often contains tissues such as skeletal muscle, cartilage, and squamous epithelium. These heterotopic cell types likely reflect the primitive developmental potential of metanephric blastema that is not expressed in normal nephrogenesis. **"Classic" Wilms tumor is characterized by islands of compact undifferentiated *blastema* and the presence of variable *epithelial* differentiation in the form of embryonic tubules, rosettes, and glomeruloid structures separated by a significant *stromal* component** (Fig. 53.7). The proportion of each of these components varies from infrequent to abundant within and among individual tumors. However, some Wilms tumors are not triphasic but have only biphasic or even monomorphous patterns, and the latter can present diagnostic difficulty (Schmidt and Beckwith, 1995). **Wilms tumors with predominantly epithelial differentiation have a low degree of aggressiveness, and the majority are stage I tumors** (Beckwith et al., 1996; Gadd et al., 2012; Vujanic and Sandstedt, 2010)**. However, these tumors may be more resistant to therapy if they are seen initially as advanced stage disease.**

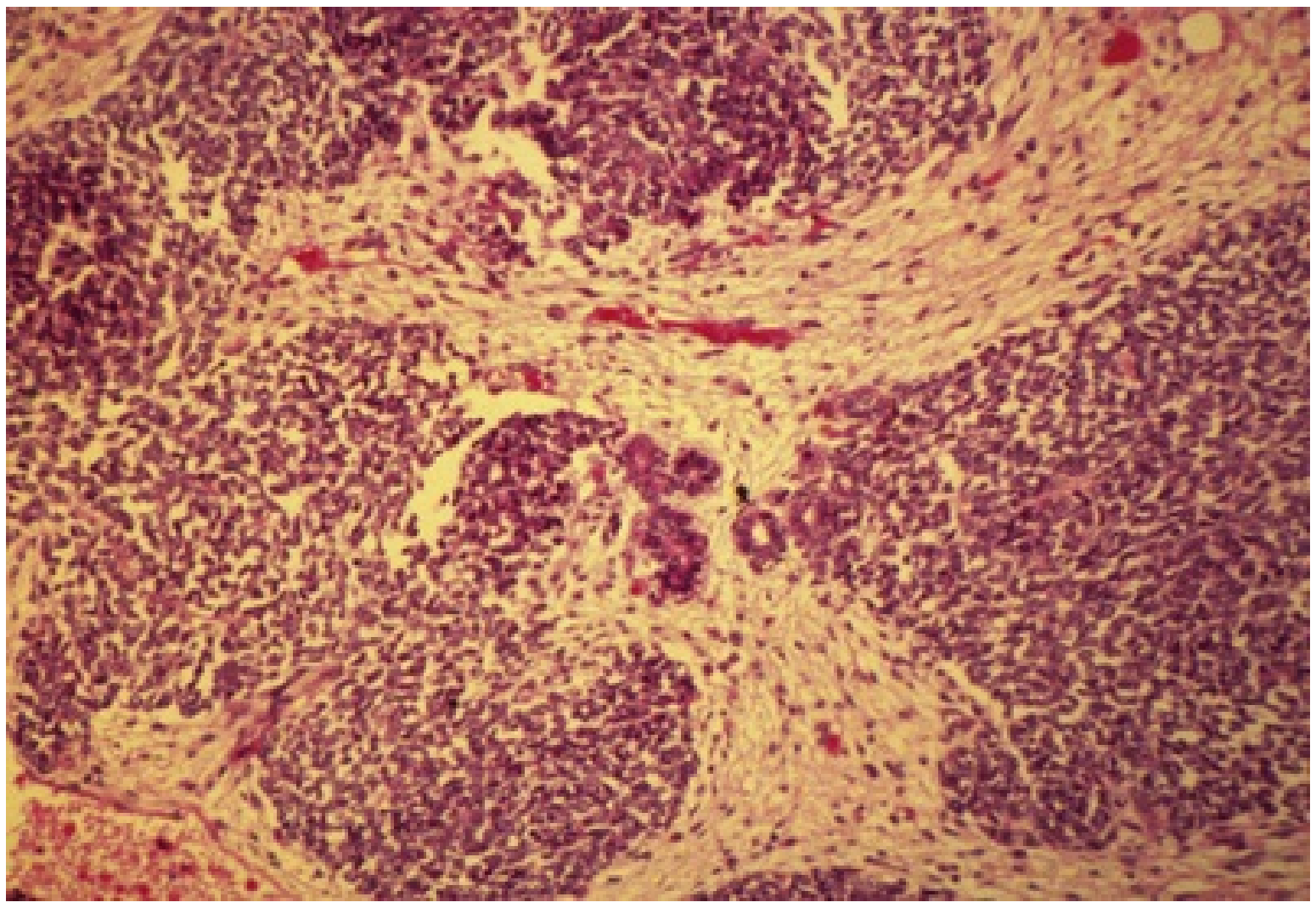

FIG. 53.7 Typical Wilms tumor with blastemal, epithelial, and stromal components.

Anaplastic Wilms Tumor

Identification of tumors with unfavorable histologic features such as anaplasia was an important milestone accomplished by the inclusion of the central pathological review of the National Wilms Tumor Study Group protocols (Beckwith and Palmer, 1978; Bonadio et al., 1985; Zuppan et al., 1991). It has allowed progressive use of adjuvant therapies in the sequential studies based on the risk and response of the various pathological tumor types. Anaplasia is characterized by the presence of three abnormalities: nuclear enlargement to three or more times the diameter of the adjacent cells, hyperchromasia of enlarged nuclei, and abnormal mitotic figures. Anaplasia is rarely seen in tumors of patients younger than 2 years of age at diagnosis (incidence about 2%), but its presence increases to a relatively stable incidence of about 13% in those older than 5 years of age (Bonadio et al., 1985; Green et al., 1994). **Anaplasia is associated with resistance to chemotherapy**. **The presence of anaplasia has clearly been demonstrated to carry a poor prognosis even when the tumor is apparently confined to the kidney, stage I** (Dome et al., 2006). Anaplasia has been further divided into focal and diffuse patterns to reflect further the different prognosis of anaplasia that is present throughout the kidney or in an extrarenal location (Faria et al., 1996). The later age at diagnosis and the general absence of anaplasia from nephrogenic rests suggests that anaplasia develops from Wilms tumor cells that acquire additional genetic lesions (Williams et al., 2011). As mentioned earlier, approximately 50% of anaplastic Wilms tumors harbor *TP53* mutations.

Pathology After Preoperative Chemotherapy

The International Society of Paediatric Oncology (SIOP) studies have made some important observations on the histology of Wilms tumor after preoperative chemotherapy. They have performed an assessment of the tumor response after preoperative chemotherapy in terms of tumor volume and histology. The relative proportions of histologic subtypes of WT differ following preoperative chemotherapy when compared with those reported after primary surgical resection (Weirich et al., 2001). **Stromal and epithelial predominant tumors are found more often after chemotherapy. These histologic subtypes may demonstrate a poor clinical response to therapy but have an excellent prognosis if the tumor is completely excised** (Verschuur et al., 2010). The proportion of blastemal predominant tumors is decreased after chemotherapy, indicating some response of this tumor type to the preoperative chemotherapy. **However, patients with blastemal predominant tumors after chemotherapy have a high rate of relapse** (Reinhard et al., 2004b). Tumor progression during therapy occurred in 5% of patients enrolled in SIOP 93-01 (Ora et al., 2007). These patients were documented to have decreased OS.

As an embryonal tumor, nephroblastoma may differentiate into more mature mesenchymal tissue types, such as skeletal muscle, after chemotherapy. Chemotherapy and radiation may induce cytodifferentiation of Wilms tumor cells or select for the survival of less mitotically active cells. In follow-up biopsies, the presence of rhabdomyomatous differentiation can confound the histologic diagnosis. Furthermore, these differentiated tumors appear to be more resistant to chemotherapy, thus surgical excision is considered the treatment of choice (Seifert et al., 2012).

SIOP classifies tumors with complete tumor necrosis after preoperative chemotherapy as “low risk.” **The blastemal element commonly responds very dramatically to chemotherapy. The degree of tumor necrosis after chemotherapy has a positive correlation with the proportion of blastemal component and a negative correlation with proportion of epithelial component in pre-chemotherapy biopsy samples** (Taskinen et al., 2017)**. Unfortunately, if not responsive to therapy and there is blastemal predominance in residual tumor specimens after pre-surgical chemotherapy, this predicts worse survival outcomes** (Reinhard et al., 2004b). Children with stage I “low-risk” tumors after post-chemotherapy nephrectomy receive no further chemotherapy (Boccon-Gibod et al., 2000). Tumors with diffuse anaplasia and blastemal predominance after chemotherapy are classified as “high risk.” SIOP “intermediate risk” tumors comprise all other histologies.

Nephrogenic Rests

More than one-third of kidneys resected for Wilms tumor (regardless of those receiving preoperative chemotherapy or not) contain precursor lesions known as NRs (Beckwith, 1993; Beckwith et al., 1990; Vujanić et al., 2017). Nephrogenic rests have a varied natural history and most do not form Wilms tumor. A rest can undergo maturation, sclerosis, involution, or complete disappearance. NRs have also been detected in 1% of kidneys in infants on postmortem examination; a much higher incidence than that of Wilms tumor. Therefore most apparently undergo involution (Beckwith, 1998). It has been recently postulated that epigenetic changes and relative methylation affect Wilms tumor evolution from its precursor NRs, which may be useful to differentiate between these tissues and potentially predict which NRs will become Wilms tumors (Charlton et al., 2015).

NRs can be separated into two fundamentally distinct categories, *perilobar nephrogenic rests* (PLNRs) and *intralobar nephrogenic rests* (ILNRs) (Beckwith et al., 1990). These two types of NRs are distinguished by their location within the renal lobe. Relative position within the lobe is a direct reflection of the chronology of the embryologic development of the kidney. **PLNRs are found only in the lobar periphery, which is elaborated late in embryogenesis, whereas ILNRs are found anywhere within the lobe, as well as the renal sinus and the wall of the pelvicaliceal system.** Therefore ILNRs are generally believed to be the result of earlier gestational aberrations (Beckwith, 1998). ILNRs are commonly stroma rich and intermingle with the adjacent renal parenchyma. PLNRs are usually subcortical, sharply demarcated, and contain predominantly blastema and tubules. Of particular interest is the observation that PLNRs are usually found in children with BWS, linked to 11p15, whereas ILNRs are typically seen in children with aniridia, WAGR, and DDS or other features associated with *WT1*. The age at diagnosis is lower for Wilms tumor associated with *WT1* mutations and those arising in association with ILNR. These tumors have a stromal-predominant histology with varying degrees of rhabdomyogenesis (Fukuzawa et al., 2008).

Multiple rests in one kidney usually implies that NRs are present in the other kidney (Beckwith et al. 1990). **Children younger than 12 months of age diagnosed with Wilms tumor who also have NRs, in particular PLNRs, have**

a markedly increased risk of developing contralateral disease and require frequent and regular surveillance for several years (Coppes et al., 1999). Surveillance is also recommended for those diagnosed after 12 months of age who have NRs (D'Angio et al., 1993). The occurrence of metachronous Wilms tumor in patients previously treated with conventional chemotherapeutic regimens suggests that nephrogenic rests are not always eradicated.

NRs display a spectrum of appearances. Hyperplastic NRs can produce a renal mass that can be mistaken for a small Wilms tumor (Beckwith, 1998). Incisional biopsy of a hyperplastic rest is of little value in distinguishing this lesion from a Wilms tumor, unless the interface between the rest and normal kidney is included. Wilms tumor has a pseudocapsule at the interface with the normal parenchyma compressing the normal elements. The appearance of the lesion can provide some help in distinguishing between NR and Wilms tumor. The Wilms tumor will have a spheric shape, whereas hyperplasic rests retain the appearance of the original rest and are more elliptical or lenticular in shape. MRI may be of some value in distinguishing between the two lesions, but this must be confirmed prospectively in large numbers of patients (Hoffer, 2005; Rohrschneider et al., 1998).

Nephroblastomatosis refers to the presence of multiple nephrogenic rests. Diffuse overgrowth of PLNRs may produce a thick rind that enlarges the kidney but preserves its original shape (Fig. 53.8). Patients with nephroblastomatosis are prone to Wilms tumor development, and bilateral lesions are common. Perlman et al. (2005) have reviewed 52 cases of diffuse hyperplastic perilobar nephrogenic rests reported to the National Wilms Tumor Study Group (NWTSG) pathology center. Wilms tumor developed in 23 patients at a median of 30 months. Of children receiving adjuvant therapy at diagnosis, 17/33 (52%) developed a Wilms tumor. There was an increased incidence of anaplasia noted in tumors that developed after chemotherapy in patients with nephroblastomatosis (Perlman et al., 2005).

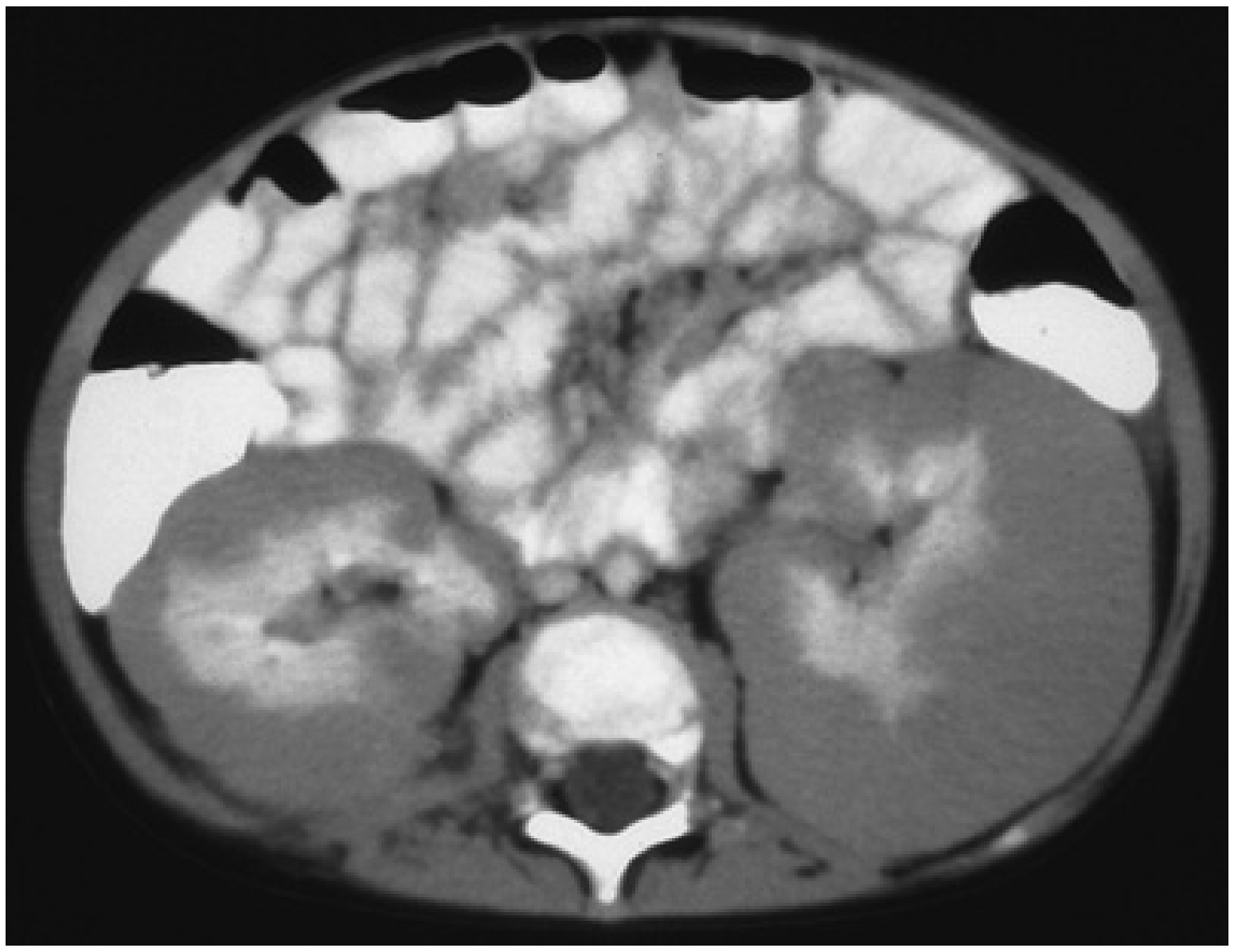

FIG. 53.8 Typical appearance of diffuse hyperplastic perilobar nephrogenic rest with thick rind compressing the normal renal tissue centrally.

Preoperative Evaluation and Staging

The majority of children (>85%) are symptomatic at presentation with either an abdominal mass, abdominal pain or hematuria (Pritchard-Jones et al., 2016). Less commonly an asymptomatic abdominal mass is discovered incidentally by a family member or primary care physician. A small percentage of tumors are diagnosed by screening. A higher proportion of stage I and II tumors (72.7%) are noted in those who are asymptomatic at diagnosis compared with those who are symptomatic (52.9%).

The mass may be extremely large relative to the size of the child and is not necessarily confined to one side. Approximately 20% of children with Wilms tumor have hematuria at diagnosis, and 25% will have hypertension at diagnosis that can be caused by elevated plasma renin levels (Maas et al., 2007). Gross hematuria warrants further evaluation including a cystoscopy and retrograde pyelogram at the time of nephrectomy to rule out tumor extension into the collecting system (Ritchey et al., 2008). Other symptoms include fever, anorexia, and weight loss in 10% of patients. Rarely, children may have acute abdominal pain from tumor rupture into the peritoneal cavity or bleeding within the tumor. There is limited evidence that patterns of diagnosis may differ by medical specialty and that delays in diagnosis can adversely affect survival outcomes

(Pritchard-Jones et al., 2016).

Compression or invasion of adjacent structures may result in an atypical presentation. A persistent varicocele in the supine position or hepatomegaly may be reflective of inferior vena cava (IVC) obstruction from tumor thrombus. Atrial thrombus may manifest as hypertension or congestive heart failure. Such symptoms are found in less than 10% of patients with intracaval or atrial tumor extension (Ritchey et al., 1988; Shamberger et al., 2001). During the physical examination, it is important to assess for signs of associated Wilms tumor syndromes such as aniridia, hemihypertrophy, and genitourinary anomalies.

Emergent operation is not necessary unless there is evidence of active bleeding or tumor rupture. The preoperative laboratory evaluation of a child with an abdominal mass should include a complete blood count, liver enzymes, and serum electrolytes, including blood urea nitrogen, creatinine, and calcium. Because as many as 8% of newly diagnosed patients with Wilms tumor will have acquired von Willebrand disease, coagulation studies should be considered (Baxter et al., 2009). This includes prothrombin time and partial thromboplastin time, which may be normal in the presence of von Willebrand disease. This defect can generally be corrected preoperatively with the administration of 1-desamino-8-d-arginine-vasopressin (DDAVP) but may require IVIG or plasmapheresis (Callaghan et al., 2013). Generally, this acquired defect and coagulopathy will be reversed with surgical removal of the tumor or with preoperative chemotherapy (Baxter et al., 2009; Blanchette and Coppes 2009).

Imaging

All solid renal tumors of childhood have some common radiographic features (Miniati et al., 2008; Smets and de Kraker, 2010). Therefore Wilms tumors cannot be reliably distinguished from other renal tumors (e.g., renal cell carcinoma [RCC], or clear cell sarcoma of the kidney [CCSK]). In the SIOP-9 study, 5.4% of patients in whom preoperative chemotherapy for Wilms tumor was commenced before diagnostic biopsy were found on nephrectomy to have renal malignancies other than Wilms tumor or benign renal conditions (Tournade et al., 2001). In the United Kingdom Children's Cancer Study Group (UKCCSG), 12% of renal tumors clinically and radiographically consistent with Wilms tumor were found to have some other diagnosis on biopsy (Vujanic et al., 2003). Other clinical parameters can provide some clues to the diagnosis. The development of a renal tumor in a child known to have aniridia, hemihypertrophy, or other syndromes associated with an increased incidence of nephroblastoma is most likely to be a Wilms tumor. Bilateral or multicentric tumors are more typical of Wilms tumor, but renal lymphoma can manifest in this fashion. Congenital mesoblastic nephroma (CMN) is the most likely diagnosis in a neonate with a renal mass. However, favorable-histology (FH) Wilms tumor and rhabdoid tumor of the kidney (RTK) can also manifest in the first few months of life (LeClair et al., 2005; Ritchey et al., 1995). The renal origin of the mass is usually apparent on CT, but it can be mistaken for neuroblastoma.

The clinical presentation—that is, as abdominal pain with tumor rupture—can create confusion regarding the preoperative diagnosis. In 2.5% of NWTS-3 patients, there was an erroneous diagnosis before surgical exploration (Ritchey et al., 1992). Most of these children did not have any preoperative imaging studies performed, and this group of patients had an increased incidence of surgical complications. This emphasizes that defining the exact histology is not as important as establishing that the child has a solid renal tumor, allowing the surgeon to plan for a major cancer operation. These events are now rare with modern imaging and the almost universal use of CT and MRI for preoperative evaluation.

Ultrasonography is recommended as first-line imaging in children with an abdominal mass. This demonstrates the solid nature of the lesion, and it can also help triage appropriate subsequent imaging such as chest CT at the same time as abdominal cross-sectional imaging and avoid unnecessary scans such as a noncontrasted CT abdomen. Doppler ultrasonography may be able to exclude intracaval tumor extension that occurs in 4% of Wilms tumor patients (Ritchey et al., 1988; Shamberger et al., 2001). However, properly phased CT has been shown to more reliably identify all clinically significant extension of tumor into the IVC when compared with ultrasonography (Khanna et al., 2012).

All patients should undergo either CT of the abdomen and pelvis with oral and intravenous contrast or MRI of the abdomen and pelvis with gadolinium. MRI avoids radiation but typically requires anesthesia or sedation in young children. These imaging modalities can further define the extent of the lesion (Fig. 53.9; Hoffer, 2005; McDonald et al., 2012; Schenk et al., 2008). This allows improved preoperative planning by evaluating for extrarenal spread of disease, the relationship of the tumor to adjacent visceral structures, and the presence of synchronous tumors in the contralateral kidney. **Routine exploration of the contralateral kidney at the time of nephrectomy is not necessary when preoperative imaging with CT or MRI demonstrates a**

normal contralateral kidney (Ritchey et al., 2005).

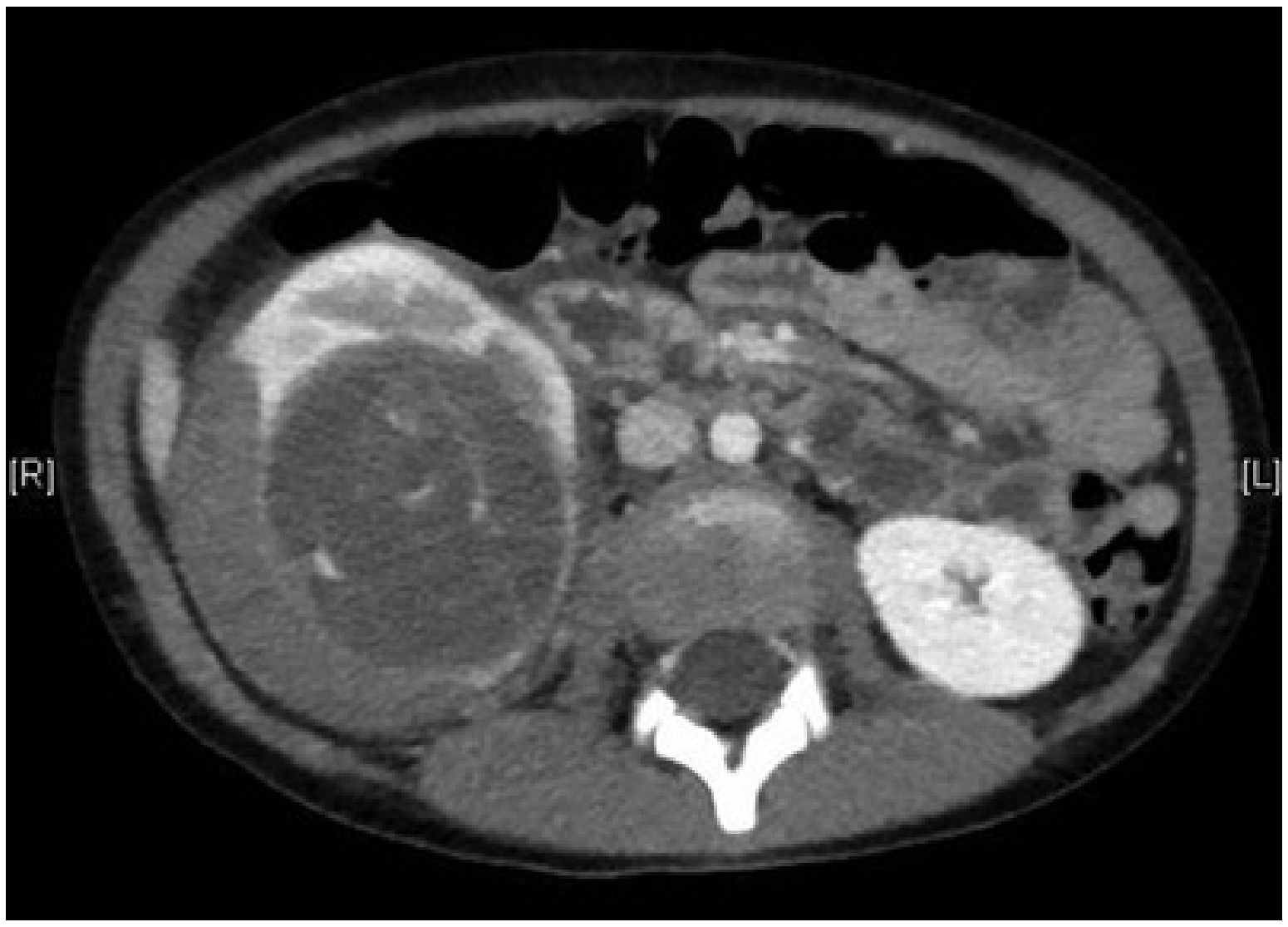

FIG. 53.9 CT scan of a Wilms tumor that demonstrates preoperative rupture with perirenal hemorrhage.

The role of imaging studies in renal tumor staging continues to be defined. The COG found that CT has moderate specificity but poor sensitivity in the detection of preoperative tumor rupture (Khanna et al., 2013). Ascites beyond the cul-de-sac was most strongly associated with tumor rupture. If the preoperative imaging could accurately detect local extension of tumor beyond the renal capsule or into regional lymph nodes, it would obviate concerns regarding staging in patients treated with preoperative therapy. The local tumor burden (e.g., regional lymph node involvement) determines the intensity of the chemotherapy regimen and whether a child receives abdominal irradiation. Regional adenopathy can be identified on CT or MRI, but enlarged retroperitoneal benign lymph nodes are common in children, and correlation between pathologic findings and lymph node evaluation at surgical exploration in Wilms tumor patients has found significant false-positive and false-negative error rates (Lubahn et al., 2012; Othersen et al., 1990). Positron emission tomography (PET) has not been shown to have any advantages over conventional imaging modalities in preoperative assessment of Wilms tumor (Misch et al., 2008). Detection of extrarenal tumor extension into the perirenal fat and into adjacent structures is also problematic. Therefore determination of inoperability should be made at surgical exploration.

The lung is the most common site of distant metastasis in children with

Wilms tumor. Preoperative chest CT with or without contrast is performed to rule out pulmonary metastases. The clinical significance of lung nodules detected on CT scan alone is controversial (Green, 2016; Grundy et al., 2012; Meisel et al., 1999; Owens et al., 2002; Smets et al., 2012). CT will clearly detect more lesions than a standard chest radiograph, but not all of these lesions represent metastases (Ehrlich et al., 2006). Some reports have suggested that treatment of such patients with dactinomycin (actinomycin D [AMD]) and vincristine (VCR) is sufficient without the need for DOX or pulmonary radiation (Grundy et al., 2012; Smets et al., 2012). Others have found an increased risk of pulmonary relapse if more intensive treatment is not given (Owens et al., 2002). The most recent round of renal tumor studies from COG prospectively investigated this issue and found no statistical significant decrease in EFS or OS in children with favorable histology Wilms tumor who lacked LOH at 1p and 16q and who had complete resolution of their lung nodules after 6 weeks of VCR, AMD, and doxorubicin and thus then omitted lung radiation (Dix et al., 2014).

Imaging surveillance after treatment of the primary tumor is recommended to detect tumor recurrence. COG studies advocate for periodic chest CT and either CT or MRI of the abdomen. However, some have begun to question the value of these studies and whether they will detect relapse early enough to improve survival (McHugh and Roebuck, 2014). Many patients will have clinical symptoms related to relapse before imaging detection. Omitting even the pelvic portion of the abdominal CT can significantly reduce the radiation exposure without compromising detection of relapse (Kaste et al., 2013; Mirza et al., 2015).

CCSK and rhabdoid tumor of the kidney (RTK) have a propensity to metastasize to the skeleton (D'Angio et al., 1993; Seibel et al., 2018). Bone scans are recommended after the histologic diagnosis is confirmed (Feusner et al., 1990). Cranial CT or MRI is performed on all children with CCSK or with RTK, because both are associated with intracranial metastases (Gooskens et al., 2014; Tomlinson et al., 2005; Weeks et al., 1989).

Staging

The most important determinants of outcome in children with Wilms tumor are the histopathology and tumor stage. Accurate staging of Wilms tumor allows treatment results to be evaluated and enables universal comparisons of outcomes. The current staging system used by the COG (Table 53.5) is based primarily on the surgical and histopathological findings. Examination for extension through the capsule, residual disease, vascular involvement, and lymph node involvement are essential to properly assess the extent of the tumor at presentation.

TABLE 53.5

Staging System of the Childrens Oncology Group

STAGE	
I	Tumor confined to the kidney and completely resected. The renal capsule is intact and the tumor was not ruptured prior to removal. No renal sinus extension. There is no residual tumor.
II	Extracapsular penetration but is completely resected. Renal sinus extension or extrarenal vessels may contain tumor thrombus or be infiltrated by tumor.
III	Residual nonhematogenous tumor confined to the abdomen: lymph node involvement, any tumor spillage, peritoneal implants, tumor beyond surgical margin either grossly or microscopically, or tumor not completely removed.
IV	Hematogenous metastases to lung, liver, bone, brain, etc.
V	Bilateral renal involvement at diagnosis.

Stage I tumors are limited to the kidney and completely resected. However, evidence for tumor extension can be subtle. Tumor invasion of blood and lymphatic vessels in the renal sinus is the first sign of spread outside the kidney in stage II tumors (Weeks et al., 1987). Penetration through the renal capsule is the next most common finding of extrarenal spread. Clear demonstration of tumor cells in the perirenal fat is required to document capsular penetration. **Any tumor spill leads to a stage III designation because of the increased risk for local tumor recurrence** (Ehrlich et al., 2013; Shamberger et al., 1999). On the COG biology and banking study AREN 03B2, the distribution by stage for patients with FHWT tumors was stage I, 19%; stage II, 20%; stage III, 35%; stage IV, 18%; and stage V, 8% (Mullen et al., 2014). Patients with anaplastic tumors are more likely to present with stage III or IV disease than those with FHWT tumors (Dome et al., 2006).

Prognostic Factors

As the treatment regimens for children with Wilms tumor have become more effective, the ability of retrospectively determined prognostic factors to predict outcomes is diminished. Traditional staging factors (e.g., tumor size, histology, and lymph node metastases) relied upon in the past to predict risk for tumor progression or relapse are now less able to stratify FH patients for treatment. Clinical cancer trials incorporate biologic factors that predict tumor behavior to stratify patients for treatment.

Chromosomal Abnormalities.

As noted earlier, LOH for a portion of chromosome 16q and/or 1p has been noted in 20% of Wilms tumors. This is associated with an increased risk for relapse (Grundy et al., 1994, 2005; Messahel et al., 2009; Wittman et al., 2007). This difference in outcome is independent of histology and stage. NWTS-5 patients with stage I or II FH tumors with LOH of either 1p or 16q had an increased risk of relapse and death in comparison with patients lacking LOH at either locus (Grundy et al., 2005). The risks of relapse and death for patients with stage III or IV FH tumors were increased only with LOH for both regions.

Patients enrolled in the recently published COG renal tumor protocols were selected for more intensive treatment if the tumor demonstrated LOH for 1p and 16q. Compared with historical controls, they found that intensification of treatment improved EFS for stage III FHWT displaying LOH of 16q and 1p (Dix et al., 2015). Treatment was likewise intensified for stage I and II patients, with DOX added to VCR/ACT-D, although this did not significantly affect outcome.

As mentioned earlier, gain of 1q has also been identified to be a related genetic change associated with oncologic outcome (Gratias et al., 2013, 2016; Segers et al., 2013). Future studies will likely expand the investigative thread from the prior generation of COG renal tumor studies to look at treatment intensification for those with FHWT and gain of 1q because only approximately 5% of FHWT will have combined LOH, whereas at least 25% will have gain of 1q.

A number of other markers have been evaluated to predict tumor recurrence including several immunohistochemical markers. It appears that most of the markers that are predictive of tumor progression are found in the blastemal component of the tumor (Ghanem et al., 2013; Routh et al., 2013). These markers will have to be evaluated in larger numbers of patients to determine their usefulness for risk stratification.

Treatment

Surgical Considerations

The initial therapy for most children with Wilms tumor is radical nephrectomy. Nephrectomy is generally performed via a transperitoneal approach. The surgeon is responsible for determining the extent of tumor. Accurate staging is essential for the subsequent determination of the need for radiation therapy and the appropriate chemotherapy regimen. Thorough exploration of the abdominal cavity is necessary to exclude local tumor extension, liver and nodal metastases, or peritoneal seeding. Exploration of the contralateral kidney is no longer mandated before nephrectomy if the preoperative CT or MRI demonstrates a normal kidney (Ritchey et al., 2005). The renal vein and IVC are palpated to exclude intravascular tumor extension before vessel ligation. Wilms tumor extends into the IVC in approximately 6% of cases and may be clinically asymptomatic in more than 50% (Ritchey et al., 1988; Shamberger et al., 2001). The adrenal gland can be spared without increasing the risk for tumor spill or recurrence if it is not in proximity to the tumor (Kieran et al., 2013a). **Selective sampling of regional lymph nodes is an essential component of local tumor staging. Formal retroperitoneal lymph node dissection is not mandated** (Othersen et al., 1990; Shamberger et al., 1999). En bloc resection yields a lower rate of positive lymph nodes compared with separate sampling (Stewart and Bruny, 2015). In a review of NWTS-4 and -5 patients, 12.5% of patients did not have lymph node sampling performed (Kieran et al., 2012). The likelihood of having a positive lymph nodes is greater when more lymph nodes were sampled, emphasizing the importance of the surgeon and surgical quality in accurately staging Wilms tumor (Kieran et al., 2012; Saltzman et al., 2018). Future studies will likely mandate more specific nodal sampling patterns to standardize surgical staging across institutions and individual surgeons.

The other major responsibility when performing a nephrectomy for Wilms tumor is complete removal of the tumor without contamination of the operative field. Gentle handling of the tumor throughout the procedure is mandatory to avoid tumor spillage. A COG study reported intraoperative tumor spillage in 9.7% of patients undergoing primary nephrectomy (Gow et al., 2013). Multivariate analysis demonstrated that spillage was more common with right-sided tumors and larger tumors. Avoiding tumor spillage has a real impact on patient outcomes because these patients have an increase in local abdominal relapse (Shamberger et al., 1999). **Shamberger et al.** (1999) **identified risk factors for local tumor recurrence as tumor spillage, unfavorable histology, incomplete tumor removal, and absence of any lymph node sampling**. This study included stage II and III disease. The risk of recurrence was highest in those patients with stage II disease. More recent COG studies have treated all spill patients as stage III. Review of these patients shows that the greatest risk of recurrence in stage III patients are positive lymph nodes, combined LOH, or residual disease (Ehrlich et al., 2013; Fernandez et al., 2018). Tumor spillage was not predictive of recurrence likely resulting from the increased therapy currently given to these patients.

There have been several reports of laparoscopic or robotic nephrectomy for Wilms tumor. This is usually done in conjunction with preoperative chemotherapy and is likely more feasible after the tumor is reduced in size (Duarte et al., 2014; Romao et al., 2014; Varlet et al., 2014; Warmann et al., 2014). Experience with open nephrectomy after chemotherapy has shown that these tumors are less prone to tumor spillage (Powis et al., 2013). Although pre-chemotherapy laparoscopic nephrectomy has been reported, many more cases will have to be performed to determine if there is an increased risk of tumor spillage, residual disease, or surgical complications (Barber et al., 2009; Cost et al., 2015).

Removing a large renal tumor in a small child is associated with some morbidity. NWTS-4 patients undergoing primary nephrectomy had an 11% incidence of surgical complications (Ritchey et al., 1999). The most common complications encountered are hemorrhage and small bowel obstruction (Ritchey et al., 1992, 1993a, 1999). Factors that have been associated with an increased risk for surgical complications are higher tumor stage, tumor size greater than 10 cm, incorrect preoperative diagnosis, thoracoabdominal incision, intracaval tumor extension, and resection of other visceral organs.

Preoperative chemotherapy may influence surgical complication rates by producing tumor shrinkage. A report from the UKCCSG compared the complication rate for patients undergoing immediate nephrectomy compared with delayed nephrectomy performed after 6 weeks of chemotherapy (Powis et al., 2013). They found significantly fewer complications in those undergoing delayed nephrectomy (1% vs. 5.8%). They also noted a much higher rate of tumor rupture/spill in those undergoing immediate nephrectomy (14.6% vs. 0). This is similar to the rate of intraoperative tumor spill after immediate nephrectomy reported by the COG (Gow et al., 2013).

Cooperative Group Trials

Multiple randomized clinical trials have been conducted by the NWTSG, COG, SIOP, and the UKCCSG to determine the appropriate role for each of the therapeutic modalities available. Patients are stratified into different treatment groups based on stage and pathology. The goals of these trials are to decrease the intensity of therapy for most patients in an effort to prevent late sequelae of treatment while maintaining excellent OS.

National Wilms Tumor Study Group.

The NWTSG was formed in 1969 to study Wilms tumor. The early NWTSG studies, NWTS-1 (1969–1973) and NWTS-2 (1974–1978), showed that the combination of VCR and AMD was more effective than the use of either drug alone. The addition of doxorubicin (DOX) was found to improve survival for stage III and IV patients, and postoperative flank irradiation was unnecessary for stage I patients (D'Angio et al., 1976, 1981). **A major achievement of the early trials was identification of prognostic factors that allowed stratification of patients into high-risk and low-risk treatment groups. Patients with positive lymph nodes and diffuse tumor spill were found to be at increased risk of abdominal relapse and therefore considered stage III and given postoperative irradiation. One of the most important findings was the identification of the unfavorable histologic features that have a very adverse impact on survival.**

NWTS-3 (1979–1986) demonstrated that stage I and II patients could be treated with 18 weeks of AMD and VCR without irradiation (D'Angio et al., 1989). For stage III FH patients, 10.8 Gy of abdominal irradiation was shown to be as effective as 20 Gy in preventing abdominal relapse if DOX was added to VCR and AMD. NWTS-4 (1987–1994) proved that treatment durations of 6 months produced comparable outcomes to 15 months of therapy for patients with stages II to IV/FH tumors (Green et al., 1998). The NWTSG has assessed the impact of postoperative irradiation on flank recurrence and survival (Breslow et al., 2006; Green et al., 2014; Kalapurakal et al., 2010). The investigators found that abdominal recurrence rates after tumor spillage were significantly higher among patients treated with two- or three-drug chemotherapy without RT. Irradiation with 10 Gy appeared to be successful in reducing tumor recurrence rates after tumor spillage, and 20 Gy even more so. Although radiation did decrease the incidence of flank recurrence, there was only an increase in OS for stage II patients with tumor spillage. This was attributed to a lower post-recurrence mortality in unirradiated patients. The overall risk for relapse is low in stage II FH with spillage; the risks of late effects of intensified treatment must be weighed against benefit of decreased relapse (Green et al., 2014).

NWTS-5 (1995–2003) was a single-arm therapeutic trial. One of the major aims of the trial was to confirm the utility of LOH for chromosomes 16q and 1p to predict increased risk of tumor relapse and death (Grundy et al., 2005). Another objective was to evaluate the efficacy of treatment regimens for anaplastic histology Wilms tumor. Stage I patients with anaplastic tumors were treated with AMD and VCR, but this resulted in a low 4-year EFS of 69.5% (Dome et al., 2006). A new intensified chemotherapy regimen used for patients with stage II to IV diffuse anaplasia did not result in an improved survival.

In NWTS-5, children less than 2 years of age with stage I FH tumors weighing less than 550 g were defined as very low-risk Wilms tumors (VLRWT) did not receive chemotherapy after nephrectomy. This portion of the study was closed early when the number of tumor relapses exceeded the limit allowed by the design of the study (Green et al., 2001a). A long-term review of this cohort was completed comparing the outcomes to similar patients treated with postoperative AMD and VCR (Shamberger et al., 2010). The 5-year EFS for surgery alone was 84% compared with 97% for the treated group, but the 5-year OS was equivalent between the two groups at 98% and 99%, respectively ($P = 0.70$). There is a trade-off between more intensive therapy and its potential long-term sequelae required for the 16% of children who relapse versus the avoidance of any postoperative chemotherapy in the majority. As noted earlier, COG investigators hope to use biologic prognostic factors to select patients who do not require adjuvant therapy. All VLRWT registered on NWTS-5 who did not receive adjuvant chemotherapy were analyzed for LOH at 11p15 and for *WT1* mutation. LOH, as determined by 11p15 methylation analysis, was significantly associated with relapse in VLRWT as were *WT1* abnormalities (Perlman et al., 2011). If these results are validated in an independent cohort of patients, it would be worthwhile to conduct a clinical trial that uses molecular genetic factors rather than the arbitrarily defined clinical factors of patient age and tumor weight to identify patients with stage I FHWT who do not require adjuvant therapy. It is anticipated that such a trial would expand the number of patients who would be candidates to be treated with surgery only.

Children's Oncology Group.

The first generation of COG studies (2006–2013) grouped patients by risk for recurrence (very low, low, standard, and high). The COG again examined the role of surgery-only treatment for patients with stage I FHWT in which the tumor and kidney weighed less than 550 g and patient's age was less than 2 years. This further demonstrated the success in a surgery-only approach for those with very low risk FHWT. The 4-year EFS was 89.7% and OS was 100% (Fernandez et al., 2017). This will likely prompt future study of expanding those approaches offered surgery-only.

Children with stage I or II FHWT and LOH of 1p and 16q were treated with VCR, AMD, and DOX without radiotherapy. Patients with stage III FHWT disease without LOH of 1p and 16q were treated with VCR, AMD, and DOX and irradiation of the flank or abdomen. These risk-stratified stage III patients enjoyed an excellent outcome with 4-year EFS of 88% and OS of 97% (Fernandez et al., 2018). The COG evaluated a response-based approach for management of children with pulmonary metastases. Those with resolution of the pulmonary lesions on chest CT after 6 weeks of chemotherapy were continued on treatment with VCR, AMD, and DOX. These patients who were termed “rapid complete responders” had a 4-year EFS of 79.5% and OS of 96.1% that was not statistically inferior to historical standards; this suggests that these risk-adapted patients may be able to avoid lung radiation (Dix et al., 2018). Patients who did not have resolution of the pulmonary lesions by week 6 received more intensive chemotherapy and pulmonary irradiation. These patients were termed “slow incomplete responders” and intensification to regimen M led to an improved outcome with 4-year EFS of 88.5% and OS of 95.4% (Dix et al., 2018).

A specific study was focused on those with “high-risk” renal tumors. Children with stage I to III focal anaplastic histology Wilms tumor (AHWT) and stage I diffuse AHWT were treated with AMD, VCR, DOX, and abdominal irradiation. Patients with stage II, III, or IV (no measurable disease) diffuse AHWT, stage IV focal AHWT, stage IV clear cell sarcoma, and stage I to III malignant rhabdoid tumor were treated with a new chemotherapy regimen to try to improve OS. Publication of these trial data is still pending.

International Society of Paediatric Oncology.

In the randomized clinical trials conducted by SIOP, preoperative therapy is given before surgery. This approach usually results in tumor shrinkage (Fig. 53.10), reducing the risk of intraoperative rupture or spill (Lemerle et al., 1976). A greater number of patients have “post-chemotherapy stage I” tumors resulting from disappearance of micrometastases after neoadjuvant therapy. This was thought to be a significant advantage in terms of decreasing morbidity of treatment, particularly the late effects of radiotherapy.

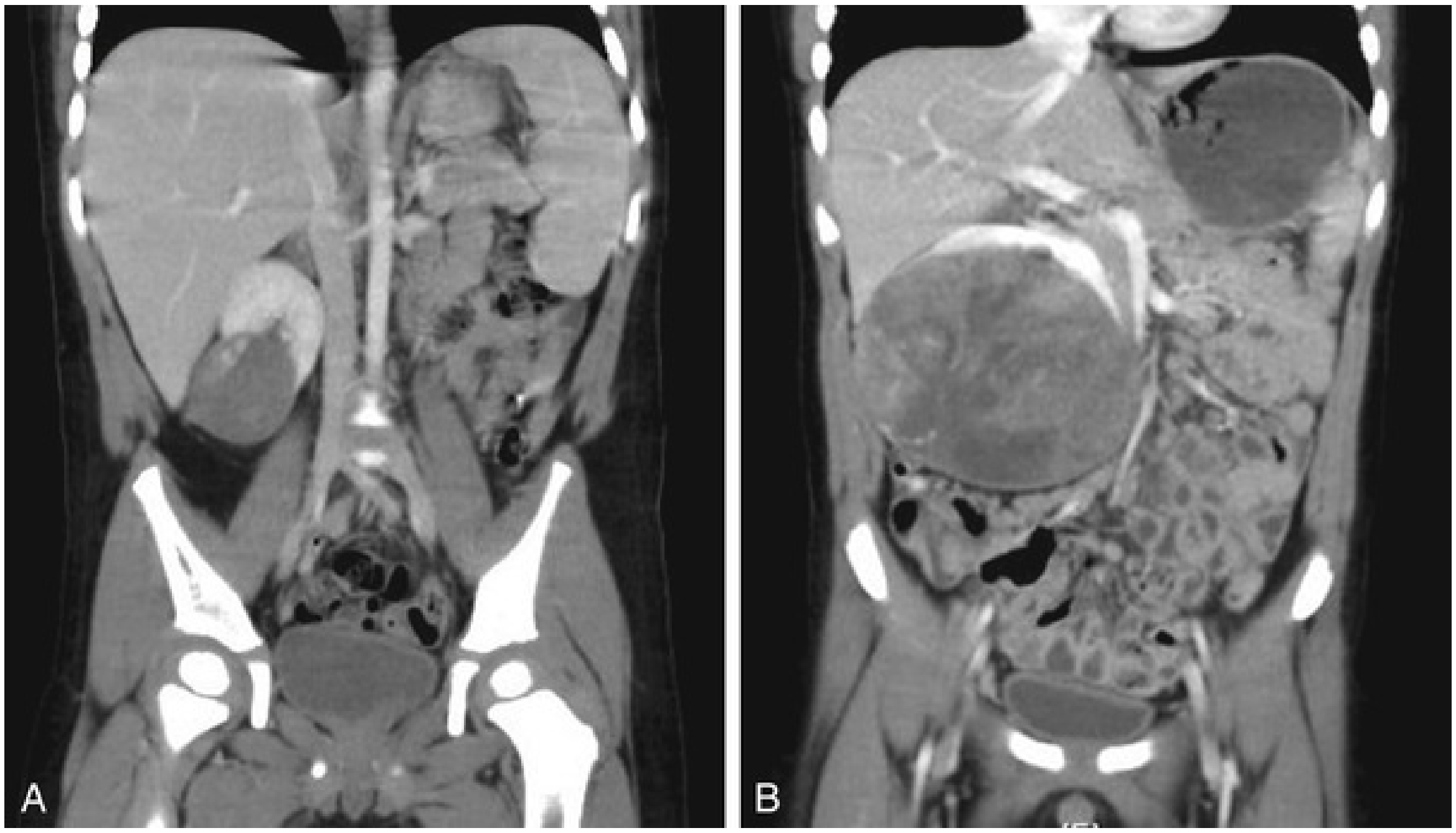

FIG. 53.10 (A) CT of a Wilms tumor that was pretreated with chemotherapy. (B) After 6 weeks of chemotherapy, the tumor is much smaller in size.

Early SIOP studies evaluated pre-nephrectomy XRT (Lemerle et al., 1976)**. SIOP-5 (1976–1980) showed that 4 weeks of AMD and VCR were as effective as pre-nephrectomy XRT in avoiding surgical tumor rupture and increasing the proportion of patients with low stage disease** (Lemerle et al., 1983)**. SIOP-6 (1980–1987) demonstrated that patients with "post-chemotherapy stage I" disease can safely be treated with 18 weeks of AMD and VCR** (Tournade et al., 1993)**. However, patients with "post-chemotherapy stage II" tumors and negative lymph nodes were found to have a higher rate of abdominal relapse if postoperative irradiation was omitted** (Tournade et al., 1993). An anthracycline was subsequently added for treatment of these children. SIOP-6 confirmed the need for a three-drug chemotherapy regimen after nephrectomy for patients with "post-chemotherapy stage II" lymph node positive and stage III tumors. SIOP-9 (1987–1993) demonstrated that the relapse rate for stage II patients with negative lymph nodes without radiation therapy was reduced with epirubicin (Tournade et al., 2001). This study also demonstrated that treatment with VCR and AMD for 4 weeks versus 8 weeks had comparable rates of stage distribution and tumor shrinkage in patients with stage I and III disease. The majority of tumor shrinkage was noted in the first 4 weeks of therapy. Radiotherapy was limited to patients with stage II node-positive and III disease resulting in 18% of patients being irradiated (Graf et al., 2000). There were 59 children with stage I to IV tumors who had complete tumor necrosis induced by chemotherapy, and 98% of these children had no evidence of disease at 5 years (Boccon-Gibod et al., 2000).

The SIOP 93-01 study (1993–2001), evaluated a reduction in postoperative therapy for patients with stage I intermediate risk and anaplastic Wilms tumor (deKraker et al., 2004; Reinhard et al., 2004b). Patients were randomized to receive either 4 or 18 weeks of postoperative chemotherapy with AMD and VCR. Two-year EFS was 91.4% after 4 weeks and 88.8% after 18 weeks of therapy, demonstrating that survival can be maintained while shortening the duration of post-nephrectomy therapy. Patients with stage II or III with low- or intermediate-risk histology received 4 weeks of dactinomycin and VCR before surgery (Graf et al., 2012). Postoperative chemotherapy consisted of dactinomycin, VCR, and epirubicin/doxorubicin for 27 weeks. Flank or whole-abdomen irradiation was given for stage III. With a median follow-up of 8 years, 5-year EFS was 90% and OS 95%. Patients with blastemal type histology had a worse prognosis with 62% EFS at 5 years. They made up only 10% of patients but contributed to one-third of the relapses and deaths. The other important prognostic factors were a large tumor volume at surgery and stage III disease.

The SIOP 2001 study asked the question whether patients with stage II and III intermediate-risk histology Wilms tumors could be safely treated without an anthracycline. Data from SIOP 93-01 had suggested that survival was not adversely affected when nonviable tumor was identified in the renal sinus and/or perirenal fat after preoperative chemotherapy (Vujanic et al., 2009). Between 2001 and 2009, 583 patients were randomized (Pritchard-Jones et al., 2015). For stage II or stage III intermediate-risk histology Wilms tumor, 2-year EFS was 92.6% for patients treated with DOX and 88.2% for treatment excluding DOX. OS was 96.5% and 95.8%, respectively. The SIOP group uses the response of the tumor to preoperative chemotherapy in their risk stratification (Vujanic et al., 2002). This includes not only percentage of necrosis but also on the predominant cell type in the residual viable tumor component. Patients with high-risk blastemal tumors continue to receive treatment with DOX, including stage I tumors (van den Heuvel-Eibrink et al., 2015). The intensified treatment for the latter patients yielded improved OS in SIOP 2001 with EFS of 96% (OS 100%)

compared with EFS of 71% (OS 90%) in SIOP 93-01.

United Kingdom Children's Cancer Study Group.

The UKCCSG has conducted several trials using prenephrectomy chemotherapy but, unlike SIOP, they perform biopsy before treatment (Mitchell et al., 2000; Pritchard et al., 1995; Pritchard-Jones et al., 2003). This is done to avoid giving chemotherapy to infants and children with benign tumors, which accounts for 1% of lesions thought to be Wilms tumor on imaging studies (Tournade et al., 2001). The other reason to perform biopsy is to avoid giving inappropriate chemotherapy to non–Wilms tumors, which often require more intensive therapy. The UKW3 trial noted a 12% incidence of non–Wilms tumors in patients with the typical features of Wilms tumor on imaging study (Vujanic et al., 2003). The UKW1 and UKW2 studies evaluated the single-agent VCR for treatment of stage I FH tumors (Mitchell et al., 2000; Pritchard et al., 1995). The OS of 96% compares well with two-drug chemotherapy, but age greater than 4 years was considered an adverse prognostic factor (Pritchard-Jones et al., 2003).

The UKW3 trial randomly assigned patients to either immediate surgery or to 6 weeks preoperative chemotherapy and then delayed surgery (Mitchell et al., 2006). EFS and OS at 5 years were similar in the two groups. Around 20% of survivors avoided treatment with doxorubicin or radiotherapy because of favorable stage distribution after preoperative therapy. They concluded, like the SIOP group, that all children with non-metastatic Wilms tumor should receive chemotherapy before tumor resection.

Adult Wilms Tumor

Wilms tumor occasionally occurs in adults. Earlier reports suggested that the outcome for adults with Wilms tumor was poor and that they require more intensive therapy (Arrigo et al., 1990). More recent reviews of adult patients with FH Wilms tumor have found improved survival compared with prior reports (Ali et al., 2012; Kalapurakal et al., 2004a; Reinhard et al., 2004a). The recommendation is that adult patients receive stage-appropriate combined modality therapy.

Relapse

A uniform approach for the treatment of tumor relapse was used in NWTS-5. Patients with relapsed Wilms tumor may be divided into risk groups according to

OS rates after salvage therapy (Spreafico et al., 2009). Children with non-anaplastic Wilms tumor who relapse after therapy with only VCR and/or AMD are considered standard risk and have survival rates in the 70% to 80% range (Green et al., 2007). Patients with non-anaplastic Wilms tumor who relapse after therapy with three or more agents are called high risk and have survival rates in the 40% to 50% range (Malagolowkin et al., 2008). The very high-risk group includes recurrent anaplastic or blastemal-type Wilms tumor and have survival rates in the 10% range (Reinhard et al., 2008). Further studies are needed to determine the optimal treatment strategies for the “high risk” and “very high-risk” groups and to define the role of high-dose myeloablative chemotherapy and stem cell rescue (Ha et al., 2013).

Preoperative Chemotherapy (COG Recommendations)

On the COG renal tumor protocols, treatment is dependent on surgical and pathological staging after immediate nephrectomy. There are, however, some situations in which preoperative chemotherapy is recommended. These include children for whom renal-sparing surgery is planned (Blute et al., 1987), tumors inoperable at surgical exploration (Ritchey et al., 1994), and tumor extension into the IVC above the hepatic veins (Ritchey et al., 1993b; Shamberger et al., 2001; Szavay et al., 2004). The last two conditions are associated with an increased risk for surgical complications if primary nephrectomy is performed (Ritchey et al., 1992).

Inoperable Tumors.

The surgeon, not the oncologist or radiotherapist, must make the determination that a tumor is inoperable. This decision should not be based on preoperative imaging studies, which can overestimate local tumor extension. As noted earlier, not all renal masses in children represent Wilms tumor (Vujanic et al., 2003). If the tumor is found to be unresectable, pretreatment with chemotherapy almost always reduces the bulk of the tumor and renders it resectable (Grundy et al., 2004; Ritchey et al., 1994). Patients who are staged with imaging studies alone and receive preoperative chemotherapy before nephrectomy are also at risk for understaging (Tournade et al., 1993). **Patients enrolled in COG studies determined to have an inoperable tumor are treated as stage III disease** (Dome et al., 2015). The number of patients in North America treated with preoperative chemotherapy has increased over time. On NWTS-3, only 5.4% of patients were treated as inoperable (Ritchey et al., 1994). For the recently completed COG AREN0532 and AREN0533 studies, approximately 20% of patients with overall stage III disease and 40% of patients with overall stage IV disease underwent delayed nephrectomy (Dome et al., 2015).

Repeat imaging is performed after 6 weeks of chemotherapy. Experience in SIOP has shown that the majority of reduction (48%) in tumor volume occurs in the first 4 weeks of therapy (Tournade et al., 2001) but that reduction extends out through 8 weeks (62%). After there has been adequate shrinkage of the tumor, definitive resection can usually be completed. A clinically good response (by imaging) is usually associated with a pathologically good response in terms of regressive histologic changes (Weirich et al., 2001; Zuppan et al., 1991). The converse is not always true. The distribution of histologic subtypes is different after preoperative chemotherapy compared with primary surgery, with differentiation of the tumor occurring after chemotherapy. Stromal- and epithelial-predominant tumors are found more often after treatment with preoperative chemotherapy. These histologic subtypes may demonstrate a poor clinical response to therapy but have an excellent prognosis if the tumor is completely excised. Patients with progressive disease have a poor prognosis, and these patients require treatment with a more intensive chemotherapeutic regimen (Ora et al., 2007; Ritchey et al., 1994).

Bilateral Wilms Tumors.

Synchronous bilateral Wilms tumors occur in 5% to 7% of children with Wilms tumor (Blute et al., 1987; Coppes et al., 1989; Montgomery et al., 1991)**. Children with bilateral tumors should not undergo initial radical nephrectomy.** These children should receive preoperative chemotherapy with the goal of tumor shrinkage and renal-sparing surgery (Blute et al., 1987; Coppes et al., 1989; Hamilton et al., 2011; Kumar et al., 1998). Preservation of renal tissue is important to decrease the incidence of renal failure, which approaches 15%, at 15 years after treatment in patients with bilateral Wilms tumor (Breslow et al., 2005; Ritchey et al., 1996). The most common cause for renal failure was the need for bilateral nephrectomy for persistent or recurrent tumor in the remaining kidney after initial nephrectomy. Complete nephrectomy can be avoided in the majority of patients if a careful protocol is followed and the surgery is performed by surgeons experienced in renal-sparing techniques (Davidoff et al., 2008; Fuchs et al., 2011).

The recently completed COG protocol (AREN0534) recommended that patients with bilateral Wilms tumor receive 6 weeks of chemotherapy before surgery. Biopsy was not required if the radiographic picture was consistent with Wilms tumor. Tumor response was assessed after 6 weeks with CT or MRI to determine the reduction in tumor volume and feasibility of partial resection. Patients with tumors amenable to renal-sparing procedures were allowed to proceed with surgery. **Tumors not responding to therapy required bilateral open biopsy to determine histology. Open biopsies are recommended because they are more accurate than percutaneous needle biopsies when assessing for anaplasia, and bilateral biopsies are recommend because anaplasia is found to be discordant between the two kidneys in 83% of children** (Hamilton et al., 2006). Biopsy is necessary because imaging cannot predict the histology of the tumor based on changes in volume of the tumor after chemotherapy (Olsen et al., 2004; Weirich et al., 2001). Failure to achieve a reduction in volume is likely a result of tumor differentiation (Fig. 53.11) (Anderson et al., 2002; Shamberger et al., 2006; Weirich et al., 2001). Differentiated tumors may show a poor clinical response to therapy, but they have an excellent prognosis if the tumor is completely excised. If renal-sparing surgery is not feasible, additional chemotherapy is then given based on the biopsy findings, but all patients were recommended to undergo surgical resection within 12 weeks of starting therapy. Continuing treatment beyond 12 weeks will not likely provide any additional reduction in tumor burden.

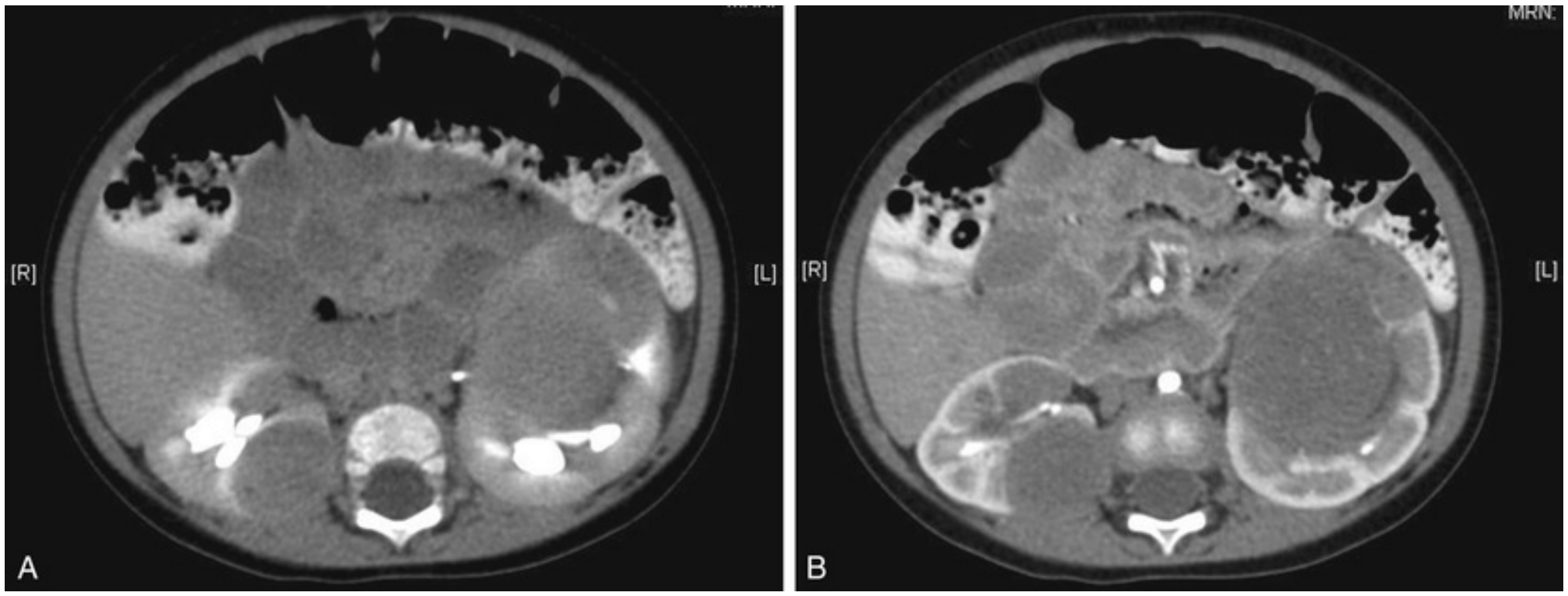

FIG. 53.11 Patient with bilateral tumors who was treated with chemotherapy. (A) CT before treatment. (B) CT after 12 weeks of chemotherapy, revealing only minimal decrease in the size of the tumors. Bilateral partial nephrectomies were performed, revealing mature tumor elements with rhabdomyoblastic differentiation.

At the time of second-look surgery, partial nephrectomy or wedge excision of the tumor is preferred with an attempt to achieve negative margins. Radical nephrectomy may be needed in a kidney with extensive tumor involvement. The kidney with the lower tumor burden is addressed first. Tumor enucleation may be considered in lieu of a formal partial nephrectomy. This is often needed for large centrally located tumors when removal of a margin of renal tissue would compromise the vascular supply to the kidney (Cozzi et al., 1996; Horwitz et al., 1996). The concern is that enucleation will be more likely to result in positive surgical margins. For FH tumors, adjuvant therapy may still achieve a good outcome (Cozzi et al., 1996; Davidoff et al., 2008; Horwitz et al., 1996). However, if there is anaplasia in the resected specimen, a positive margin will adversely affect survival and requires additional resection. Even when large bilateral masses remain after initial chemotherapy, a high percentage of children can be successfully managed with renal-sparing surgery (Davidoff et al., 2008). It is easy to underestimate the amount of renal parenchyma that can be salvaged as a result of compression by the tumor; therefore nephron-sparing surgery should be considered in all patients (Fig. 53.12). One concern regarding enucleation of large centrally located tumors is the potential for positive surgical margins. Kieran et al. (2013b) reported a 23% incidence of positive surgical margins in a cohort of 21 patients with bilateral Wilms tumor undergoing renal-sparing surgery. They did not demonstrate an increased risk of local recurrence, but this was a small number of patients, with all receiving 10.5-Gy flank radiation.

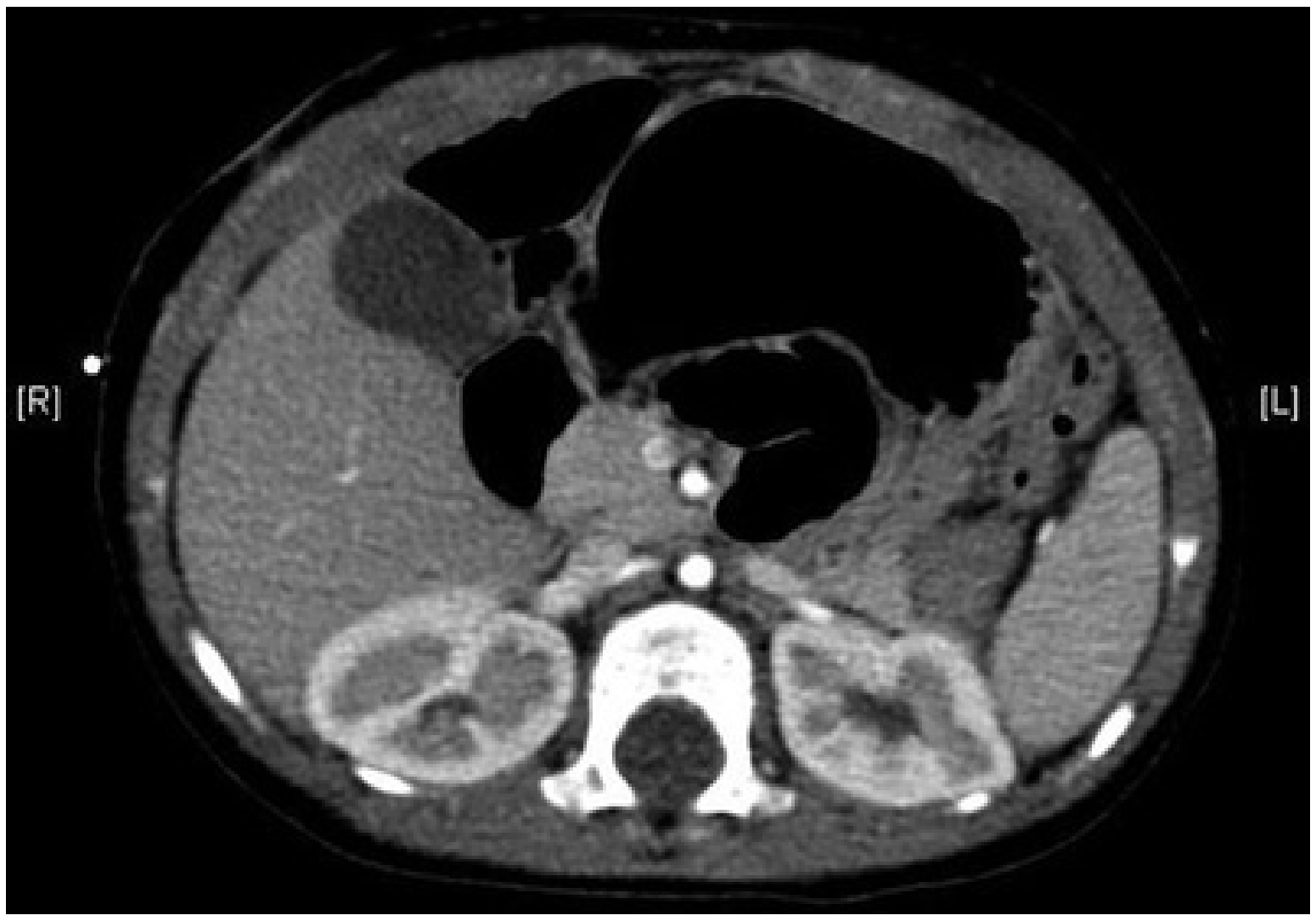

FIG. 53.12 Postoperative image from patient shown in Fig. 53.11.

Demonstrates that the kidneys have pretty near normal volume after resection of the bilateral tumors.

The COG AREN0534 study enrolled 195 patients with bilateral Wilms tumor (Ehrlich et al., 2017). Of the 189 evaluable patients, 84.0% underwent definitive surgical treatment (partial or complete nephrectomy or wedge resection in at least one kidney) by 12 weeks after initiation of chemotherapy. Thirty percent of those patients who achieved definitive surgical resection within the 12-week specified aim did so by the 6-week evaluation point. Surgical approaches included unilateral total nephrectomy with contralateral partial nephrectomy (48%), bilateral partial nephrectomy (35%), unilateral total nephrectomy (10.5%), unilateral partial nephrectomy (4%), and bilateral total nephrectomies (2.5%). The 4-year EFS and OS were 82.1% and 94.9%, respectively. This is compared with 4-year EFS and OS of 56% and 80.8% on NWTS-5.

Bilateral nephrectomies and dialysis are rarely required when the tumors fail to respond to chemotherapy and radiation therapy. This is the most common cause of renal failure in patients with bilateral Wilms tumor (Ritchey et al., 1996). Fortunately, anephric patients can still be administered chemotherapy with some modifications (Feusner et al., 2008). The recommended interval between successful completion of treatment of the Wilms tumor and renal transplantation varies (Kist-van Holthe et al., 2005; Penn, 1979). Some advocate a waiting period of 2 years to ensure that the patient does not develop metastatic disease; others have found that a 1-year interval is sufficient (Gregoriev et al., 2012). Patients who develop renal failure after renal-sparing surgery should have removal of the remaining renal tissue before transplant to prevent tumor recurrence after starting immunosuppression (Kubiak et al., 2004).

All patients treated for bilateral Wilms tumor require close long-term follow-up. SIOP investigators noted that late relapses have occurred in patients with bilateral Wilms tumor more than 4 years after treatment and recommended long-term follow-up (Coppes et al., 1989). These patients should also have frequent assessment of renal function, urine protein, and blood pressure.

Partial Nephrectomy for Unilateral Tumors.

There have been a number of papers examining the role of parenchymal-sparing procedures in children with unilateral Wilms tumors (Cost et al., 2012; Haecker et al., 2003; McLorie et al., 1991; Wilde et al., 2014; Zani et al., 2005). The primary motivation for this approach is concern about late occurrence of renal dysfunction after unilateral nephrectomy. However, **the incidence of renal**

failure after nephrectomy for most children with unilateral Wilms tumor is low, 0.6% at 20 years after treatment (Breslow et al., 2005; Lange et al., 2011). **The risk of renal failure is higher for patients with genitourinary anomalies, DDS, and WAGR.** As noted earlier, this is a result of mutation of *WT1,* which is necessary for normal renal development. Syndromic patients are more likely to have smaller tumors identified on screening studies that are more amenable to renal-sparing surgery (Romao et al., 2012; Scalabre et al., 2016).

Most Wilms tumors are too large at diagnosis to allow partial nephrectomy. After preoperative chemotherapy, partial nephrectomy can be performed in 10% to 15% of patients. However, this higher percentage is only achieved if the clinician is more aggressive in proceeding with nephron sparing surgery (NSS). The SIOP 2001 study restricted NSS for polar or peripherally non-infiltrating tumors (Wilde et al., 2014). They reported that 3% of tumors met the criteria for NSS. Only the occasional case of Wilms tumor will involve a lesion small enough to allow partial nephrectomy at diagnosis—for example, tumors detected on screening studies for Beckwith-Wiedemann syndrome and aniridia (see Fig. 53.6). Even in the young children with very-low–risk stage I tumors, it is estimated that less than 10% of children would be amenable to partial nephrectomy (Ferrer et al., 2013). As noted earlier, there are concerns regarding staging after chemotherapy, requiring some patients to receive added therapy to prevent local recurrence. Another concern is the increased risk for local recurrence after partial nephrectomy (Haecker et al., 2003; Horwitz et al., 1996; Wilde et al., 2014). Patients who develop intra-abdominal relapse have a markedly decreased survival (Shamberger et al., 1999).

The COG AREN0534 study also included a renal-sparing protocol for select patients with unilateral Wilms tumors known to be at risk for bilateral disease or at increased risk for renal failure. These patients were managed with a strict surgical protocol to minimize risk for residual disease (Cozzi et al., 2004). The protocol required that the lesion be completely excised with a margin of normal renal parenchyma. These patients should not undergo partial nephrectomy if the tumor cannot be removed at stage I. Patients with high-risk histologic patterns such as anaplasia or persistent blastemal-predominant tumor after chemotherapy should be treated with complete nephrectomy because these tumors have resistance to chemotherapy (Reinhard et al., 2004b). Results of AREN0534 for patients with unilateral tumors have not been published.

Late Effects of Treatment

The 5-year survival rate for childhood cancers has increased over the past decades to more than 80%. Achieving these high cure rates requires exposure of normal healthy tissue to potential harm with many organ systems subject to the late sequelae of anticancer therapy. These survivors are at increased risk for numerous chronic health conditions, hospitalizations, and reduced productivity because of health problems (Phillips et al., 2015). Clinicians must be aware of the spectrum of problems that face children as they grow into adulthood. Our understanding of late effects in Wilms tumor survivors has been advanced through several large studies. The NWTSG Late Effects Study followed patients treated in NWTS-1 to NWTS-5. The original Childhood Cancer Survivor Study (CCSS) was a retrospectively ascertained cohort of childhood cancer survivors diagnosed from 1970 to 1986. More than 14,000 survivors were surveyed and followed for long-term health outcomes. Because of the significant changes in therapy for children with cancer over the past 30 years, a second group of about 10,000 survivors diagnosed between 1987 and 1999 were also recruited for the study. Similar efforts are also conducted in other countries, some of which are population-based cohort studies (Wong et al., 2016).

The CCSS reported a cumulative incidence of 65% for all chronic health conditions in Wilms tumor survivors at 25 years after completion of therapy (Termuhlen et al., 2011). These rates continue to increase with longer periods of follow-up (Phillips et al., 2015). The cumulative incidence of severe (grades 3 or 4) chronic health conditions was 24% (Termuhlen et al., 2011).

Mortality

The NWTSG Late Effects Study showed that survivors remain at elevated risk for death compared with the general population for many years after their original diagnosis (Cotton et al., 2009). A more recent report from the CCSS has shown that mortality for survivors of childhood cancer has decreased for those patients treated in the 1990s compared with the early 1970s (Armstrong et al., 2016). This is attributed to changes in therapy (e.g., reduction the number of patients exposed to radiotherapy or anthracyclines).

Fertility and Pregnancy

Gonadal radiation can produce hypogonadism and temporary azoospermia in boys (Kinsella et al., 1989). The severity of damage is radiation dose dependent.

The Leydig cells are more radioresistant than the germ cells, but higher doses can produce damage, resulting in inadequate production of testosterone. This can result in delayed sexual maturation. Chemotherapeutic agents can also adversely affect testicular function (Mustieles et al., 1995). Pelvic irradiation and exposure to alkylating agents are risk factors for ovarian failure and premature menopause in female Wilms tumor survivors (Green et al., 2009). Very few pregnancies have been reported in patients who received whole abdominal radiation therapy (Green et al., 2010). Pregnancy complications were evaluated extensively through the NWTSG. The offspring of irradiated female patients are at risk for low birth weights and premature birth. Radiation portals that include the pelvis and doses exceeding 20 Gy increase the risk of miscarriage (Kalapurakal et al., 2004b). Wilms tumor survivors treated with abdominal radiotherapy are also at increased risk of hypertension complicating pregnancy (Reulen et al., 2017).

Second Malignancies

An increased incidence of second malignant neoplasms has been noted in children treated for Wilms tumor. There is a 1% cumulative incidence at 10 years postdiagnosis, and a rising incidence thereafter (Breslow et al., 1988b, 2010; Taylor et al., 2008). One of the greatest risk factors is prior irradiation, and most tumors occur in the radiation field (Bassal et al., 2006; Breslow et al., 1988b; Taylor et al., 2008). The incidence of leukemia is highest during the first 5 years after Wilms tumor treatment. The incidence of solid tumors increases with longer periods of follow-up (Lee et al., 2015).

Cardiac Effects

The risk of cardiotoxicity in Wilms tumor survivors has been carefully studied. In a review of patients entered in NWTS-1, NWTS-2, NWTS-3, and NWTS-4, the frequency of congestive heart failure was 4.4% among DOX-treated patients who received this drug as part of their initial chemotherapy regimen (Green et al., 2001b). The risk was increased if the patient received whole-lung or left-flank irradiation. Only one patient with congestive heart failure received a DOX cumulative dose below 150 mg/m^2, which is used in contemporary North American treatment regimens. However, subclinical cardiotoxicity was not assessed, and it is possible that clinical effects with modern regimens will become apparent with longer follow-up. The British CCSS has found that cardiac problems were the second most common cause of mortality more than 30 years after Wilms tumor diagnosis (Wong et al., 2016).

Other Renal Tumors

Clear Cell Sarcoma of the Kidney

CCSK accounts for 3% of renal tumors reported to the NWTSG. The tumor derives its name from the clear cytoplasm of the predominant cell type (Schmidt and Beckwith, 1995). **Important predictors of improved survival are lower stage, younger age at diagnosis, treatment with DOX, and absence of tumor necrosis** (Argani et al., 2000). **The addition of doxorubicin improved OS and relapse-free survival** (Argani et al., 2000; D'Angio et al., 1989; Seibel et al., 2004). Patients with stage I tumors (using the current criteria of absence of renal sinus invasion) had a 98% survival rate. Unlike anaplastic Wilms tumor, even stage I CCSK lesions are associated with increased rates of relapse and require postoperative irradiation. Long-term follow-up of CCSK patients is needed because 30% of relapses occurred more than 3 years after diagnosis and some as late as 10 years. Unlike Wilms tumor, **CCSK is associated with bone and brain metastases.** Bilateral involvement has thus far not been reported, nor has the presence of Wilms tumor associated congenital anomalies such as aniridia or hemihypertrophy. Patients with CCSK were treated on NWTS-5 with a regimen combining VCR, DOX, cyclophosphamide, and etoposide in an attempt to further improve the survival of this high-risk group. However, outcomes for patients with CCSK treated on NWTS-5 were similar to that seen on NWTS-4 (5-year RFS and OS of 79% and 89%, respectively) (Seibel et al., 2018). Stage was found to be highly predictive of outcome; 5-year RFS rates for stages I, II, III, and IV on NWTS-5 were 100%, 88%, 73%, and 29%, respectively. Similar outcomes have been reported by SIOP investigators (Furtwangler et al., 2013).

Rhabdoid Tumor of the Kidney

RTK is the most aggressive and lethal childhood renal tumor that accounts for 2% of renal tumors. RTK and CCSK occur in renal and extrarenal locations, suggesting an origin from a non–organ-specific mesenchymal cell. These tumors are characterized by loss of function of the *SMARCB1/INI1/SNF5/BAF47* gene in chromosome band 22q11.2 (Biegel et al., 1999). Consistent with its role as a tumor suppressor gene, tumors arise after inactivation of both alleles of *SMARCB1*. Germ-line alterations of the *SMARCB1* gene are found in one-third of the patients (Eaton et al., 2011). Germ-line mutations of *INI1* have been identified in renal rhabdoid tumors. Staining for the products of the *INI1* gene can be useful because rhabdoid tumor of the kidney is consistently negative (Hoot et al., 2004).

Typical clinical features include early age of diagnosis (median age <16 months), advanced stage, resistance to chemotherapy, and high mortality (Amar et al., 2001; Tomlinson et al., 2005). Younger age at diagnosis is an adverse prognostic factor. **RTK is distinguished by its propensity to metastasize to the brain** (D'Angio et al., 1993). There is no standard therapy for RTK. Intensification of therapy with high-dose chemotherapy and autologous stem-cell transplantation have not yielded improved survival (Furtwangler et al., 2018).

Congenital Mesoblastic Nephroma

CMN is the most common renal tumor in infants with a mean age at diagnosis of 3½ months (Howell et al., 1982; van den Heuvel-Eibrink et al., 2008). **This is the most common renal tumor diagnosed on antenatal ultrasound (LeClair et al., 2005).** Congenital mesoblastic nephroma is a very firm tumor on gross examination, and the cut surface has the yellowish-gray trabeculated appearance of a leiomyoma. There are three histologic subtypes: classic, cellular, and mixed (showing areas of classical and cellular). The classic subtype, characterized by interlacing sheets of bland spindle cells, resembles infantile fibromatosis. The cellular variant, with a solid sheet-like growth pattern and frequent mitoses, is virtually identical histologically to congenital fibrosarcoma (Beckwith, 1986; Gormley et al., 1989; Joshi et al., 1986). Both tumors have a similar translocation that fuses the *ETV6* (TEL) gene from 12p13 with the 15q25 neurotrophin-3 receptor gene, *NTRK3* (Argani et al., 1998; Vokuhl et al., 2017). A SIOP/GPOH showed that patients with cellular type CMN who have translocation-positive tumors had a significantly superior RFS (5-year RFS: 100% vs. 73%). In CMN, tumor induction is postulated to occur at a time when the multipotent blastema is predominately stromagenic (Snyder et al., 1981; Tomlinson et al., 1992). WT1 is not expressed in CMN (Tomlinson et al., 1992).

The most important aspect of CMN is the usually excellent outcome with radical surgery only (Howell et al., 1982). The tumor can extend into the hilar or perirenal soft tissue; therefore complete surgical resection is important (Beckwith, 1986). Local recurrence and metastasis can occur particularly with the cellular variant of CMN (Fitchey et al., 2003; Gormley et al., 1989; Joshi et al., 1986). The risk of recurrence is thought to be less in children under 3 months of age at diagnosis, but metastases have been reported in a few infants (Heidelberger et al., 1993). Neither chemotherapy nor radiation therapy is routinely recommended (Howell et al., 1982), but consideration for adjuvant treatment should be given to patients with cellular variants that are incompletely resected (Gormley et al., 1989). There are reports demonstrating response of inoperable and recurrent tumors to chemotherapy (Loeb et al., 2002; McCahon et al., 2003).

Solitary Multilocular Cyst and Cystic Partially Differentiated Nephroblastoma

Solitary multilocular cyst, or multilocular cystic nephroma, is an uncommon, benign renal tumor. Fifty percent of multilocular cysts are found in young children, usually boys. The second peak incidence occurs in young adult women (Eble and Bonsib, 1998; Luithle et al., 2007). Although the majority of cases of multilocular cystic renal disease have been unilateral, there are rare reports of bilateral cases (Ferrer and McKenna, 1994). The gross appearance of the tumor is its most distinguishing feature. The cut surfaces reveal a well-encapsulated multilocular tumor composed of various-size cysts compressing the surrounding renal parenchyma. This tumor is distinguished by the finding of only mature cell types within the septa of the cyst wall. Multilocular cystic nephroma is cured by nephrectomy, but recurrence has occurred after incomplete excision by partial nephrectomy. If partial nephrectomy is considered, frozen section is indicated to exclude cystic partially differentiated nephroblastoma (CPDN) or clear cell sarcoma, which can occasionally have a similar appearance.

Another entity reported in the literature with similar features is CPDN. The majority of these lesions occur in the first 2 years of life (Blakely et al., 2003; Joshi and Beckwith, 1989; Luithle et al., 2007). Eble and Bonsib (1998) recommend that multilocular cystic nephroma and CPDN be considered the same entity. They are indistinguishable radiographically. Histologic examination reveals that blastemal cells or nephrogenic rests may be found in the septa of both tumors. Surgery is curative in almost all patients with recurrence being the result of incomplete resection (Blakely et al., 2003; Eble and Bonsib, 1998). In a review of 21 children with cystic partially differentiated nephroblastoma (CPDN) reported to the NWTSG, there was 100% survival. Eight were treated with surgery alone (Blakely et al., 2003). Thirteen patients received postoperative chemotherapy, including two patients with stage II disease.

Metanephric Adenofibroma

Another tumor with prominent stromal features that can resemble CMN is metanephric adenofibroma (Arroyo et al., 2000). The epithelial component of these tumors can range from inactive metanephric adenoma to Wilms tumor. Other lesions contain areas morphologically identical to papillary renal cell carcinoma. This uncommon entity may be derived from ILNR (Arroyo et al., 2000). Metanephric adenofibromas with a composite Wilms tumor component occur at a young age (mean of 12 months) similar to other ILNR-related Wilms tumors that develop in patients with DDS and aniridia. None of these tumors have recurred after nephrectomy, but all have been treated with Wilms tumor chemotherapy.

Renal Cell Carcinoma

Renal cell carcinoma (RCC) is the most common renal malignancy in the second decade of life. Only 5% of RCCs occur in children (Broecker, 1991; Geller et al., 2015; Hartman et al., 1982). An abdominal mass is the most common presentation, but hematuria is more common than in Wilms tumor (Broecker, 1991). Imaging studies cannot differentiate RCC from other solid renal tumors. **There is a higher incidence of papillary RCC in children** (Renshaw et al., 1999; Selle et al., 2006). However, the most common histology of RCC in children and adolescents, at approximately 50%, is translocation-associated RCC (Geller et al., 2015). **These tumors, typically seen in adolescence or young adults, are genetically unique in that they have chromosome translocations involving a common breakpoint in the *TFE3* gene located at Xp11.2** (Bruder et al., 2004). These tumors differ from adult RCC in that immunoreactivity for epithelial markers is reduced or absent. There is also an increased risk of lymph node involvement (40%–50%), and presentation is at a higher stage than adult RCC (Geller et al., 2015).

Another type of RCC more often seen in children is renal medullary carcinoma found in patients with sickle cell hemoglobinopathy (Swartz et al., 2002). The median age at presentation is 13 years, but it can be found in much younger children. It is a highly lethal tumor. A recent report from COG noted that 22 of 25 patients (88%) with renal medullary carcinoma in their Biology and Banking Study (AREN03B2) were diagnosed with stage IV disease at diagnosis (Sandberg et al., 2017).

Complete tumor resection is the most important determinant of outcome in RCC. Raney et al. (1983) found that all children with stage I lesions survived, and others have reported 64% to 80% survival for stage I and II tumors (Aronson et al., 1996; Castellanos et al., 1974; Dehner et al., 1970). Partial nephrectomy has been used in pediatric patients with RCC, but outcome data are limited (Cook et al., 2006). Younger age at diagnosis is a favorable prognostic factor (Raney et al., 1983). Regional lymph node involvement does not portend the same poor prognosis as adult renal cell carcinoma (Geller and Dome, 2004). Geller et al. (2008) reported that patients with TFE+ translocation and positive nodes were found to have 93% survival at a median follow-up of 4.3 years. However, others have noted higher rates of relapse (Perlman, 2010). Like RCC in adults, these tumors are generally not responsive to chemotherapy or radiation therapy, although case reports of successful adjuvant treatment have been published (Chowdhury et al., 2013).

Angiomyolipoma

Renal angiomyolipoma is a hamartomatous lesion that is only rarely seen in childhood. The majority of adult patients have sporadic angiomyolipomas. In children, they are most commonly detected in patients with the tuberous sclerosis complex (TSC), and presentation is more often bilateral in these patients (Bissler et al., 2016; Ewalt et al., 1998; Warncke et al., 2017). Angiomyolipoma develops in 50% to 80% of patients with TSC. The lesions progressively enlarge through childhood with an apparent growth spurt in teenagers and young adults. Warncke et al. (2017) noted increase annual growth in those TSC patients older than 11 years and those with AMLs smaller than 2 cm in size. Annual ultrasounds are recommended with consideration of MRI for those older than 11 years and having lesions smaller than 2 cm. Other renal lesions found in the TSC include simple cysts, polycystic kidney disease, and RCC. Renal cysts occur in up to 30% of patients with TSC. Mutations of one of two genes on chromosome 9 *(TSC1)* and chromosome 16 *(TSC2)* are found in 85% of TSC patients (Crino et al., 2006). It has been postulated that these genes act as tumor suppressor genes and that the LOH of *TSC1* or *TSC2* may explain the progressive growth pattern of renal lesions seen in these patients (Henske, 2004).

Patients with angiomyolipomas resulting from tuberous sclerosis are at risk for hemorrhage and impaired renal function (Bissler et al., 2016). For many years, the threshold diameter for intervention has been more than 4 cm. Recent data in adult patients with sporadic angiomyolipoma suggest that intervention can be delayed until the diameter exceeds 6 cm (Kuusk et al., 2015). The International TSC Consensus Group recommends intervention for lesions larger than 3 cm in diameter (Kingswood et al., 2016). Lesions in TSC patients that are larger than 3 cm and enlarging appear to be at greatest risk for bleeding. **The first-line treatment for children with growing lesions** (Fig. 53.13) **is with mTOR inhibitor, and embolization or surgery are second-line treatments.**

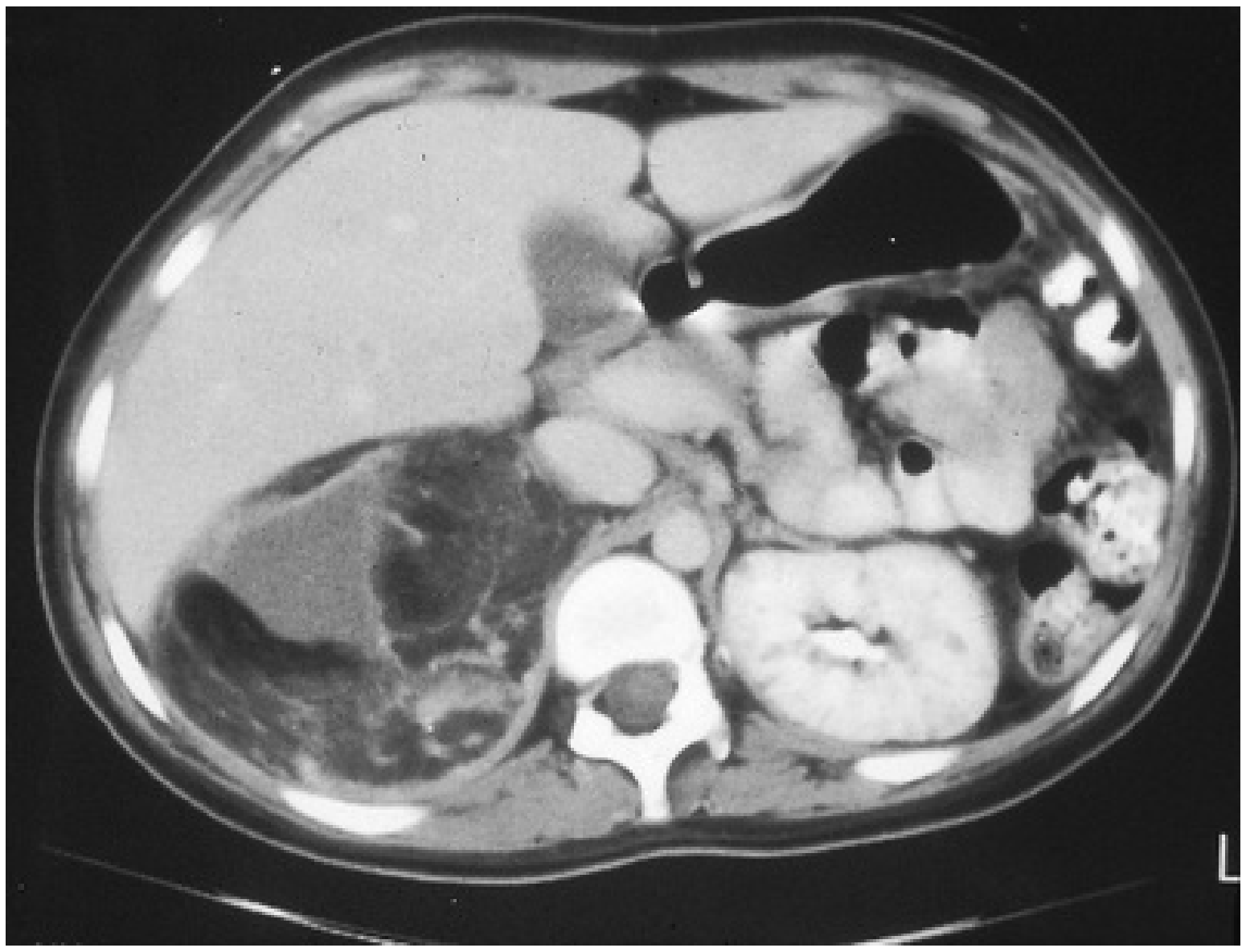

FIG. 53.13 Angiomyolipoma of the right kidney in a patient with tuberous sclerosis.

The main problems with embolization are risks of damage to infarction of normal adjacent renal parenchyma and risk of short-term complications and that it will not prevent other smaller lesions from progressing. Repeat intervention is required in 35% of patients undergoing embolization (Kuusk et al., 2015). Embolization is reserved for patients with active bleeding.

TSC1 or *TSC2* mutations in patients with TSC give rise to hyperactivation of the mTOR pathway. The first mTOR inhibitor studied for TSC patients was sirolimus. The renal studies all showed that sirolimus was very effective at preventing enlargement of the lesions and also significantly reducing their size, while the medication was taken continuously. When discontinued after 12 months, the angiomyolipomata started to enlarge again, demonstrating that the mTOR inhibitors must be continued (Bissler and Kingwood, 2016).

A randomized placebo-controlled trial (EXIST-1) reported that 42% of patients had at least a 50% reduction in total volume of angiomyolipoma after treatment with everolimus compared with 0 of placebo (Bissler et al., 2013). The patients were all age 18 years or older. An extended follow-up study (EXIST-2) has shown that 14% of patients will experience some progression of the angiomyolipomas (Bissler et al., 2017). No renal bleeding or nephrectomies were reported.

Some lesions are fat poor, and differentiation from other renal tumors—for example, RCC—on imaging studies can be difficult (Hindman et al., 2012). In some cases, biopsy of the lesion may be needed to confirm diagnosis of angiomyolipoma before proceeding with treatment. Nephron-sparing approaches are recommended in children with TSC because of the presence of multiple, bilateral lesions and the risk of development of new lesions.

Key Points: Renal Tumors

- Deletions of *WT1*, located on chromosome 11p, are found in patients with aniridia and Wilms tumor. Mutations of *WT1* occur in DDS.
- Local recurrence is increased in Wilms tumor patients with local tumor spillage, and this is not classified stage III disease. The 2-year survival rate after local recurrence is 43%.
- Patients with bilateral Wilms tumor should be treated with preoperative chemotherapy. This will allow more patients to undergo renal-sparing surgery in an attempt to decrease the risk of renal failure.
- CMN is the most common renal tumor in infants.

References

Neuroblastoma

Adams GA, Shochat SJ, Smith EI, et al. Thoracic neuroblastoma: a Pediatric Oncology Group study. *J Pediatr Surg*. 1993;28:372–377.

Adkins ES, Sawan R, Gerbing RB, et al. Efficacy of complete resection for high-risk neuroblastoma: a Children's Oncology Group Study. *J Pediatr Surg*. 2004;39:931–936.

Albregts AE, Cohen MD, Galliani CA. Neuroblastoma invading the kidney. *J Pediatr Surg*. 1994;29:930–933.

Altman AJ, Baehner RL. Favorable prognosis for survival in children with coincident opsomyoclonus and neuroblastoma. *Cancer*. 1976;37:846.

Attiyeh EF, London WB, Mossé YP, et al. Chromosome 1p and 11q deletions and outcome in neuroblastoma. *N Engl J Med*. 2005;353:2243–2253.

Avanzini S, Pio L, Erminio G, et al. Image-defined risk factors in unresectrable neuroblastoma: SIOPEN study on incidence, chemotherapy-induced variation, and impact on surgical outcomes. *Pediatr Blood Cancer*. 2017;64:e26605.

Azizkhan RG, Haase GM. Current biologic and therapeutic implications in the surgery of neuroblastoma. *Semin Surg Oncol*. 1993;9:493–501.

Bagatell R, Beck-Popovic M, London WB, et al. Significance of MYCN amplification in international neuroblastoma staging system stage 1 and 2 neuroblastoma: a report from the International Neuroblastoma Risk Group. *J Clin Oncol*. 2009;20:365–370.

Baker DL, Schmidt ML, Cohn WL, et al. Outcome after reduced chemotherapy for intermediate-risk neuroblastoma.

N Engl J Med. 2010;363:1313–1323.

Beckwith JB, Perrin EV. In situ neuroblastomas: a contribution to the natural history of neural crest tumors. *Am J Pathol*. 1963;43:1089–1104.

Benjamin SP, McCormack LJ, Effler DB, et al. Primary tumors of the mediastinum. *Chest*. 1972;62:297–303.

Berthold F, Boos J, Burdach S, et al. Myeloablative megatherapy with autologous stem-cell rescue versus oral maintenance chemotherapy as consolidation treatment in patients with high-risk neuroblastoma: a randomized controlled trial. *Lancet*. 2005;6:649–658.

Berthold F, Utsch S, Holschneider AM. The impact of preoperative chemotherapy on resectability of primary tumour and complication rate in metastatic neuroblastoma. *Z Kinderchir*. 1989;44:21–24.

Black CT, Haase GM, Azizkham RG, et al. Optimal timing of primary resection in high risk neuroblastoma. *Med Pediatr Oncol*. 1996;27:220.

Bown N, Cotterill BA, Lastowska M, et al. Gain of chromosome arm 17q and adverse outcome in patients with neuroblastoma. *N Engl J Med*. 1999;340:1954–1961.

Breslow N, McCann B. Statistical estimation of prognosis for children with neuroblastoma. *Cancer Res*. 1971;31:2098–2103.

Brisse HJ, McCarville MB, Granata C, et al. Guidelines for imaging and staging of neuroblastic tumors: consensus report from the International Neuroblastoma Risk Group Project. *Radiology*. 2011;261:243–257.

Brodeur GM. Neuroblastoma: clinical applications of molecular parameters. *Brain Pathol*. 1990;1:47.

Brodeur GM. Neuroblastoma and other peripheral neuroectodermal tumors. Fernbach DJ, Vietti TJ. *Clinical pediatric oncology*. 4th ed. Mosby-Year Book: St Louis;

1991:337.

Brodeur GM, Azar C, Brother M, et al. Neuroblastoma: effect of genetic factors on prognosis and treatment. *Cancer Suppl*. 1992;70:1685–1694.

Brodeur GM, Fong CT. Molecular biology and genetics of human neuroblastoma. *Cancer Genet Cytogenet*. 1989;41:153–174.

Brodeur GM, Maris JM. Neuroblastoma. Pizzo PA, Poplack DG. *Principles and practice of pediatric oncology*. 5th ed. Lippincott-Raven: Philadelphia; 2006:933–970.

Brodeur GM, Pritchard J, Berthold F, et al. Revisions of the international criteria for neuroblastoma diagnosis, staging, and response to treatment. *J Clin Oncol*. 1993;11:1466–1477.

Brodeur GM, Seeger RC, Schwab M, et al. Amplification of N-myc in untreated human neuroblastoma correlates with advanced disease stage. *Science*. 1984;224:1121–1124.

Caron H, VanSluis P, DeKraker J, et al. Allelic loss of chromosome 1p as a predictor of unfavorable outcome in patients with neuroblastoma. *N Engl J Med*. 1996;334:225–230.

Castel V, Tovar JA, Costa E, et al. The role of surgery in stage IV neuroblastoma. *J Pediatr Surg*. 2002;37:1574–1578.

Castleberry RP, Kun LE, Shuster JJ, et al. Radiotherapy improves the outlook for patients older than 1 year with Pediatric Oncology Group stage C neuroblastoma. *J Clin Oncol*. 1991;9:789–795.

Cecchetto G, Mosseri V, DeBernardi B, et al. Surgical risk factors in primary surgery for localized neuroblastoma: the LNESG1 study of the European International Society of Pediatric Oncology Neuroblastoma Group. *J Clin Oncol*. 2005;23:8483–8489.

Chamberlain RS, Quinones R, Dinndorf P, et al. Complete surgical resection combined with aggressive adjuvant chemotherapy and bone marrow transplantation prolongs survival in children with advanced neuroblastoma. *Ann Surg*. 1995;2:93–100.

Chan HSL, Haddad G, Thorner PS, et al. P-Glycoprotein expression as a predictor of the outcome of therapy for neuroblastoma. *N Engl J Med*. 1991;325:1608–1614.

Cheung NK, Heller G, Kushner BH, et al. Stage IV neuroblastoma more than 1 year of age at diagnosis: major response to chemotherapy and survival durations correlated strongly with dose intensity. *Prog Clin Biol Res*. 1991;366:567–573.

Cohn SL, Pearson ADJ, London W, et al. The International Neuroblastoma Risk Group (INRG) classification system: an INRG task force report. *J Clin Oncol*. 2009;27:289–297.

Cohn SL, Rademaker AW, Salwen HR, et al. Analysis of DNA ploidy and proliferative activity in relation to histology and N-myc amplification in neuroblastoma. *Am J Pathol*. 1990;136:1043–1052.

Connolly A, Pestronk A, Mehta S, et al. Serum autoantibodies in childhood opsoclonus-myoclonus syndrome: an analysis of antigenic targets in neural tissues. *J Pediatr*. 1997;130:878–884.

Cooney DR, Voorhess ML, Fisher JE, et al. Vasoactive intestinal peptide producing neuroblastoma. *J Pediatr Surg*. 1982;17:821–825.

Cruccetti A, Kiely EM, Spitz L, et al. Pelvic neuroblastoma: low mortality and high morbidity. *J Pediatr Surg*. 2000;35:724–728.

de Alarcon PA, Matthay KK, London WB, et al. Intravenous immunoglobulin with prednisone and risk-adapted chemotherapy for children with opsoclonus myoclonus ataxia syndrome associated with neuroblastoma (ANBL00P3): a randomised, open-label, phase 3 trial. *Lancet Child Adolesc*

Health. 2018;2:25–34.

DeBernardi B, Conte M, Mancini A, et al. Localized resectable neuroblastoma: results of the second study of the Italian Cooperative Group for neuroblastoma. *J Clin Oncol*. 1995;13:884–893.

DeBernardi B, Gambini C, Haupt R, et al. Retrospective study of childhood ganglioneuroma. *J Clin Oncol*. 2008;26:1710–1716.

DeBernardi B, Gerrard M, Boni L, et al. Excellent outcome with reduced treatment for infants with disseminated neuroblastoma without MYCN gene amplification. *J Clin Oncol*. 2009;27:1034–1040.

DeBernardi B, Pianca C, Pistamiglio P, et al. Neuroblastoma with symptomatic spinal cord compression at diagnosis: treatment and results with 76 cases. *J Clin Oncol*. 2001;19:183–190.

DeCou JM, Bowman LC, Rao BN, et al. Infants with metastatic neuroblastoma have improved survival with resection of the primary tumor. *J Pediatr Surg*. 1995;30:937–941.

Dickson PV, Sims TL, Streck CJ, et al. Avoiding misdiagnosing neuroblastoma as Wilms tumor. *J Pediatr Surg*. 2008;43:1159–1163.

Dinndorf P, Johnson L, Gaynon P, et al. Outcome of autologous (auto) vs. allogeneic (allo) bone marrow transplantation in 25 children with neuroblastoma (nb) and unfavorable features (UPF) [Abstract]. *J Cell Biochem*. 1992;16A(Suppl):201.

Enzinger FM, Weiss SW. *Soft tissue tumors*. CV Mosby: St Louis; 1988:828–831.

Evans AE, D'Angio GJ, Propert K, et al. Prognostic factors in neuroblastoma. *Cancer*. 1987;59:1853–1859.

Evans AE, Silver JH, Shpilsky A, et al. Successful management of low-stage neuroblastoma without adjuvant therapies: a comparison of two decades, 1972 through 1981 and 1982 through 1992, in a single institution. *J Clin Oncol*. 1996;14:2504–2510.

Farrelly C, Daneman A, Chan HSL, et al. Occult neuroblastoma presenting with opsomyoclonus: utility of computed tomography. *Am J Roentgenol*. 1984;142:807–810.

Fischer J, Pohl A, Volland R, et al. Complete surgical resection improves outcome in INRG high-risk patients with localized neuroblastoma older than 18 months. *BMC Cancer*. 2017;17:520.

Franklin IM, Pritchard J. Detection of bone marrow invasion by neuroblastoma is improved by sampling at two sites with both aspirates and trephine biopsies. *J Clin Pathol*. 1983;36:1215.

Fujita T, Igarashi J, Okawa ER, et al. CHD5, a tumor suppressor gene delted from 1p36.31 in neuroblastomas. *J Natl Cancer Inst*. 2008;100:940–949.

Garaventa A, DeBernardi B, Pianca C, et al. Localized but unresectable neuroblastoma: treatment and outcome of 145 cases. *J Clin Oncol*. 1993;11:1770–1779.

Gaspar N, Hartmann O, Munzer C, et al. Neuroblastoma in adolescents. *Cancer*. 2003;98:349–355.

Geatti OK, Shapiro B, Sisson J, et al. Iodine-131 metaiodobenzylguanidine scintigraphy for the location of neuroblastoma: preliminary experience in ten cases. *J Nucl Med*. 1985;26:736–742.

Gerson JM, Koop CE. Neuroblastoma. *Semin Oncol*. 1974;11:35–46.

Grupp SA, Stern JW, Ross AA, et al. Tandem high dose therapy in rapid sequence for children with high-risk neuroblastoma. *J Clin Oncol*. 2000;13:2567–2575.

Günther P, Holland-Cunz S, Schupp CJ, et al. Significance of image-define risk factors for surgical complications in patients with abdominal neuroblastoma. *Eur J Pediatr Surg*.

2011;21:314–317.

Haas D, Ablin AR, Miller C, et al. Complete pathologic maturation and regression on stage IV-S neuroblastoma without treatment. *Cancer*. 1990;62:2572–2575.

Haas-Kogan DA, Fisch BM, Wara WM, et al. Intraoperative radiation therapy for high-risk pediatric neuroblastoma. *Int J Radiat Oncol Biol Phys*. 2000;47:985–992.

Haase GM, O'Leary MC, Ramsay N, et al. Aggressive surgery combined with intensive chemotherapy improves survival in poor risk neuroblastoma. *J Pediatr Surg*. 1991;26:1119–11123.

Haase GM, O'Leary MC, Stram DO, et al. Pelvic neuroblastoma: implications for a new favorable subgroup. A Children's Cancer Group experience. *Ann Surg Oncol*. 1995;2:516–523.

Haase GM, Wong KY, DeLorimier AA, et al. Improvement in survival after excision of primary tumor in stage III neuroblastoma. *J Pediatr Surg*. 1989;24:194–200.

Hachitanda Y, Ishimoto K, Shimada H. Stage IVS neuroblastoma: histopathology of 27 cases compared with conventional neuroblastomas. *Lab Invest*. 1991;64(26):5P.

Hase T, Ohta S, Tani T, et al. Outcome of infants with neuroblastoma detected by mass screening and surgically treated in Shiga Prefecture, Japan: what is the role of surgery? *Pediatr Surg Int*. 2002;18:289–294.

Hayashi Y, Hanada R, Yamamoto K. Biology of neuroblastomas in Japan found by screening. *Am J Pediatr Hematol Oncol*. 1992;14:342–347.

Hayashi Y, Kanda N, Inaba T, et al. Cytogenetic findings and prognosis in neuroblastoma with emphasis on marker chromosome 1. *Cancer*. 1989;63:126–132.

Hayashi Y, Ohi R, Yaoita S, et al. Problems of neuroblastoma screening for 6 month olds and results of second screening for 18 month olds. *J Pediatr Surg*. 1995;30:467–470.

Hayes FA, Green AA, Rao BN. Clinical manifestations of ganglioneuroma. *Cancer*. 1989;63:1211–1214.

Hero B, Simon T, Spitz R, et al. Localized infant neuroblastomas often show spontaneous regression: results of the prospective trials NB95-S and NB97. *J Clin Oncol*. 2008;26:1504–1510.

Ho PTC, Estroff JA, Kozakewich H, et al. Prenatal detection of neuroblastoma: a ten-year experience from the Dana-Farber Cancer Institute and Children's Hospital. *Pediatrics*. 1993;92:358–364.

Holgerson LO, Subramanian S, Kirpekar M, et al. Spontaneous resolution of antenatally diagnosed adrenal masses. *J Pediatr Surg*. 1996;31:153–155.

Howard JP, Maris JM, Kersun LS, et al. Tumor response and toxicity with multiple infusions of high dose ^{131}I-MIBG for refractory neuroblastoma. *Pediatr Blood Cancer*. 2005;44:232–239.

Hsiao RJ, Seeger RC, Yu AL, et al. Chromogranin A in children with neuroblastoma. *J Clin Invest*. 1990;85:1555.

Hutchinson RJ, Sisson JC, Shapiro B, et al. I-131-metaiodobenzylguanidine treatment in patients with refractory advanced neuroblastoma. *Am J Clin Oncol*. 1992;15:226–232.

Iehara T, Hosoi H, Akazawa K, et al. MYCN gene amplification is a powerful prognostic factor even in infantile neuroblastoma detected by mass screening. *Br J Cancer*. 2006;94:1510–1515.

Ikeda Y, Lister J, Bouton JM, et al. Congenital neuroblastoma, neuroblastoma in situ, and the normal fetal development of the adrenal. *J Pediatr Surg*. 1981;16:636.

Ishimoto K, Kiyokawa N, Fujita H, et al. Problems of mass screening for neuroblastoma: analysis of false-negative cases.

J Pediatr Surg. 1990;25:398–401.

Ishimoto K, Kiyokawa N, Fujita H, et al. Biological analysis of neuroblastoma in mass screened negative cases. Evans AE, D'Angio G, Brodeur G, et al. *Advances in neuroblastoma research 3*. Alan R Liss: New York; 1991:602–608.

Kaneko M, Ohakawa H, Iwakawa M. Is extensive surgery required for treatment of advanced neuroblastoma? *J Pediatr Surg*. 1997;32:1616–1619.

Kaneko Y, Kanda N, Maseki N, et al. Different karyotypic patterns in early and advanced stage neuroblastomas. *Cancer Res*. 1987;47:311–318.

Katzenstein HM, Bowman LC, Brodeur GM, et al. Prognostic significance of age MYCN oncogene amplification, tumor cell ploidy, and histology in 110 infants with stage D(S) neuroblastoma: the Pediatric Oncology Group Experience. A Pediatric Oncology Group Study. *J Clin Oncol*. 1998;16:2007–2017.

Katzenstein HM, Kent PM, London WB, et al. Treatment and outcome of 83 children with intraspinal neuroblastoma: the Pediatric Oncology Group Experience. *J Clin Oncol*. 2001;4:1047–1055.

Kiely EM. The surgical challenge of neuroblastoma. *J Pediatr Surg*. 1994;29:128–133.

Knudson AG Jr, Strong LC. Mutation and cancer: neuroblastoma and pheochromocytoma. *Man J Hum Genet*. 1972;24:514–532.

Koh CC, Sheu JC, Liang DC, et al. Complete surgical resection plus chemotherapy prolongs survival in children with stage 4 neuroblastoma. *Pediatr Surg Int*. 2005;21:69–72.

Kozakewich HPW, Perez-Atayde AR, Donovan MJ, et al. Cystic neuroblastoma: emphasis on gene expression, morphology, and pathogenesis. *Pediatr Dev Pathol*. 1998;1:17–28.

Kreissman SG, Seeger RC, Mathay KK, et al. Purged versus non-purged peripheral blood stem-cell tansplantation for high-risk neuroblastoma (COG A3973): a randomize phase 3 trial. *Lancet Oncol*. 2013;14:999–1008.

Kuroda T, Saeki M, Honna T, et al. Clinical significance of intensive surgery with intraperative radiation for advanced neuroblastoma: does it really make sense? *J Pediatr Surg*. 2003;38:1735–1738.

Kusafuka T, Fukuzawa M, Oue T, et al. DNA flow cytometric analysis of neuroblastoma: distinction of tetraploidy subset. *J Pediatr Surg*. 1994;29:543–547.

Kushner BH, Cheung NKV, LaQuaglia MP, et al. Survival from locally invasive or widespread neuroblastoma without cytotoxic therapy. *J Clin Oncol*. 1996;14:373–381.

Kushner BH, Gilbert F, Helson L. Familial neuroblastoma: case reports, literature review and etiologic considerations. *Cancer*. 1986;57:1887–1893.

Kushner BH, Kramer K, LaQuaglia MP, et al. Neuroblastoma in adolescents and adults: the Memorial Sloan-Kettering Experience. *Med Pediatr Oncol*. 2003;41:508–515.

Kushner BH, Kramer K, Modak S, et al. Irinotecan plus temozolomide for relapsed or refractory neuroblastoma. *J Clin Oncol*. 2006;33:5271–5276.

Kushner BH, Kramer K, Modak S, et al. Sensitivity of surveillance studies for detecting asymptomatic and unsuspected relapse of high-risk neuroblastoma. *J Clin Oncol*. 2009;27:1041–1046.

Kushner BH, LaQuaglia MP, Bonilla MA, et al. Highly effective induction therapy for stage 4 neuroblastoma in children over 1 year of age. *J Clin Oncol*. 1994;12:2607–2613.

Kushner BH, Wolden S, LaQuaglia MP, et al. Hyperfractionated low-dose radiotherapy for high-risk neuroblastoma after intensive chemotherapy and surgery. *J Clin Oncol*. 2001;19:2821–2828.

Ladenstein R, Philip T, Lasset C, et al. Multivariate analysis of risk factors in stage 4 neuroblastoma patients over the age of one year treated with megatherapy and stem-cell transplantation: a report from the European Bone Marrow Transplantation Solid Tumor Registry. *J Clin Oncol*. 1998;16:953–965.

LaQuaglia MP, Kushner BH, Heller G, et al. Stage 4 neuroblastoma diagnosed at more than 1 year of age: gross total resection and clinical outcome. *J Pediatr Surg*. 1994;29:1162–1166.

LaQuaglia MP, Kushner BH, Su W, et al. The impact of gross total resection on local control and survival in high-risk neuroblastoma. *J Pediatr Surg*. 2004;39:412–417.

LaQuaglia MP. State of the art in oncology: high risk neuroblastoma, alveolar rhabdomyosarcoma, desmoplastic small round cell tumor, and POST-TEXT 3 and 4 hepatoblastoma. *J Pediatr Surg*. 2014;49:233–240.

Laureys G, Speleman F, Opdenakker G, et al. Constitutional translocation t(1;17)(p36; q12–21) in a patient with neuroblastoma. *Genes Chromosomes Cancer*. 1990;2:252–254.

Leavey PJ, Odom LF, Poole M, et al. Intra-operative radiation therapy in pediatric neuroblastoma. *Med Pediatr Oncol*. 1997;28:424–428.

LeClair MD, Hartmann O, Heloury Y, et al. Localized pelvic neuroblastoma: excellent surgical and low morbidity with tailored therapy—the 10-year experience of the French Society of Pediatric Oncology. *J Clin Oncol*. 2004;22:1689–1695.

LeTourneau JN, Bernard JL, Hendren WH, et al. Evaluation of the role of surgery in 130 patients with neuroblastoma. *J*

Pediatr Surg. 1985;20:244–249.

London WB, Castleberry RP, Matthay KK, et al. Evidence for an age cutoff greater than 365 days for neuroblastoma risk group stratification in the Children's Oncology Group. *J Clin Oncol*. 2005;27:6459–64564.

Look AT, Hayes FA, Nitschke R, et al. Cellular DNA content as a predictor of response to chemotherapy in infants with unresectable neuroblastoma. *N Engl J Med*. 1984;311:231–235.

Look AT, Hayes FA, Shuster J, et al. Clinical relevance of tumor cell ploidy and N-myc gene amplification in childhood neuroblastoma: a Pediatric Oncology Group study. *J Clin Oncol*. 1991;9:581–591.

Losty P, Quinn F, Breatnach F, et al. Neuroblastoma—a surgical perspective. *Eur J Surg Oncol*. 1993;19:23–26.

Marcus KJ, Shamberger RC, Litman H, et al. Primary tumor control in padtients with stage 3–4 unfavorable neuroblastoma treated with tandem double autologous stem cell transplants. *J Pediatr Hematol Oncol*. 2003;25:934–940.

Maris JM, Hogarty MD, Bagatell R, et al. Neuroblastoma. *Lancet*. 2007;369:2106–2115.

Maris JM, Weiss MJ, Mosse Y, et al. Evidence for a hereditary neuroblastoma predisposition locus at chromosome 16p12–13. *Cancer Res*. 2002;62:6651–6658.

Martinez DA, King DR, Ginn-Pease ME, et al. Resection of the primary tumor is appropriate for children with stage IV-S neuroblastoma: an analysis of 37 patients. *J Pediatr Surg*. 1992;27:1016–1021.

Matsumura M, Atkinson JB, Hays DM, et al. An evaluation of the role of surgery in metastatic neuroblastoma. *J Pediatr Surg*. 1988;23:448–453.

Matthay KK, O'Leary MC, Ramsay NK, et al. Role of myeloablative therapy in improved outcome for high risk neuroblastoma: review of recent Children's Cancer Group results. *Eur J Cancer*. 1995;31A:572–575.

Matthay KK, Perez C, Seeger RC, et al. Successful treatment of stage III neuroblastoma based on prospective biologic staging: a Children's Cancer Group Study. *J Clin Oncol*. 1998;16:1256–1264.

Matthay KK, Reynolds CP, Seeger RC, et al. Long-term results for children with high-risk neuroblastoma treated on a randomized trial of myeloblative therapy followed by 13-*cis* retinoic acid: a Children's Oncology Group Study. *J Clin Oncol*. 2009;27:1007–1013.

Matthay KK, Sather HM, Seeger RC, et al. Excellent outcome of stage II neuroblastoma is independent of residual disease and radiation therapy. *J Clin Oncol*. 1989;7:236–244.

Matthay KK, Villablanca JG, Seeger RC, et al. Treatment of high-risk neuroblastoma with intensive chemotherapy, radiotherapy, autologous bone marrow transplantation, and 13-cis-retinoic acid. *N Engl J Med*. 1999;341:1165–1173.

Matthay KK, Yanik G, Messina J, et al. Phase II study on the effect of disease sites, age, and prior therapy on response to iodine-131-metaiodobenzylguanidine therapy in refractory neuroblastoma. *J Clin Oncol*. 2007;25:1054–1060.

McGregor LM, Rao BN, Davidoff AM, et al. The impact of early resection of primary neuroblastoma on the survival of children older than 1 year of age with Stage 4 disease. *Cancer*. 2005;104:2837–2846.

Mitchell WG, Davalos-Gonzalez Y, Brumm VL, et al. Opsoclonus-Ataxia caused by childhood neuroblastoma: developmental and neurologic sequelae. *Pediatrics*. 2002;109:86–98.

Mody R, Naranjo A, Van Ryn C, et al. Irinotecan-temozolomide with temsirolimus or dinutuximab in children with refractory or relapsed neuroblastoma (COG ANBL1221): an open-label, randomized, phase 2 trial. *Lancet Oncol*. 2017;18:946–957.

Monclair T, Brodeur GM, Ambros PF, et al. The international neuroblastoma risk group (INRG) staging system: an INRG Task Force Report. *J Clin Oncol*. 2009;27:298–303.

Monclair T, Mosseri V, Cecchetto G, et al. Influence of Image-Defined RiskFactors on the outcome of patients with localized neuroblastoma. A report from the LNESG1 study of the European International Society of Paediatric Oncology Neuroblastoma Group. *Pediatr Blood Cancer*. 2015;62:1536–1542.

Moroz V, Machin D, Faldum A, et al. Changes over three decades in outcome and the prognostic influence of age-at-diagnosis in young patients with neuroblastoma. A report from the International Neuroblastoma Risk Group Project. *Eur J Cancer*. 2011;47:561–571.

Morris JA, Shochat SJ, Smith EI, et al. Biological variables in thoracic neuroblastoma: a Pediatric Oncology Group study. *J Pediatr Surg*. 1995;30:296–303.

Moss TJ, Fonkalssrud EW, Feig SA, et al. Delayed surgery and bone marrow transplantation for widespread neuroblastoma. *Ann Surg*. 1987;206:514–520.

Mosse YP, Laudenslager M, Khazi D, et al. Germline *PHOX2B* Mutation in hereditary neuroblastoma. *Am J Hum Genet*. 2004;75:727–730.

Mosse YP, Laudenslager M, Longo L, et al. Identification of *ALK* as a major familial neuroblastoma predisposition gene. *Nature*. 2008;455:930–936.

Mugishima H, Iwata M, Okabe I, et al. Autologous bone marrow transplantation in children with advanced neuroblastoma. *Cancer*. 1994;74:972–977.

Muraji T, Okamoto E, Fujimoto J, et al. Combined determination of N-myc oncogene amplification and DNA ploidy in neuroblastoma. *Cancer*. 1993;72:2763–2768.

Nakagawara A, Arima-Nakagawara M, Scavarda NJ, et al. Association between high levels of expression of the TRK gene and favorable outcome in human neuroblastoma. *N Engl J Med*. 1993;328:847–854.

Nickerson HJ, Matthay KK, Seeger RC, et al. Favorable biology and outcome of stage IV-S neuroblastoma with supportive care or minimal therapy: a Children's Cancer Group Study. *J Clin Oncol*. 2000;18:477–486.

Nickerson HJ, Nesbit ME, Grosfeld JL, et al. Comparison of stage IV and IV-S neuroblastoma in the first year of life. *Med Pediatr Oncol*. 1985;13:261–268.

Nishi M, Miyake H, Takeda T, et al. Effects of the mass screening of neuroblastoma in Sapporo City. *Cancer*. 1987;60:433–436.

Nitschke R, Smith EI, Shochat S, et al. Localized neuroblastoma treated by surgery: a Pediatric Oncology Group Study. *J Clin Oncol*. 1988;6:1271–1279.

Nuchtern JG, London WB, Barnewolt CE, et al. A prospective study of expectant observation as primary therapy for neuroblastoma in young infants: a Children's Oncology Group Study. *Ann Surg*. 2012;256:573–580.

Ohali A, Avigad S, Ash S, et al. Telomere length is a prognostic factor in neuroblastoma. *Cancer*. 2006;107:1391–1399.

O'Neill JA, Littman P, Blitzer P, et al. The role of surgery in localized neuroblastoma. *J Pediatr Surg*. 1985;20:708–712.

Park JR, Kreissman SG, London WB, et al. A phase III randomized clinical trial (RCT) of tandem myeloablative autologous stem cell transplant (ASCT) using peripheral blood stem cell (PBSC) as consolidation therapy for high-risk neuroblastoma (HR-NB): a Children's Oncology Group (COG) study. *J Clin Oncol*. 2016;34(18_suppl) [LBA3-LBA3].

Park JR, Scott JR, Stewart CF, et al. Pilot induction regimen incorporating pharmacokinetically guided topotecan for treatment of newly diagnosed high-risk neuroblastoma: a Children's Oncology Group study. *J Clin Oncol*. 2011;29:4351–4357.

Perez CA, Matthay KK, Atkinson JB, et al. Biologic variables in the outcome of stages I and II neuroblastoma treated with surgery as primary therapy: a Children's Cancer Group Study. *J Clin Oncol*. 2000;18:18–26.

Philip T, Ladenstein R, Lasset C, et al. 1070 myeloablative megatherapy procedures followed by stem cell rescue for neuroblastoma: 17 years of European experience and conclusions. European Group for Blood and Marrow Transplant Registry Solid Tumour Working Party. *Eur J Cancer*. 1997;33:2130–2135.

Plantaz D, Rubie H, Michon J, et al. The treatment of neuroblastoma with intraspinal extension with chemotherapy followed by surgical removal of residual disease. *Cancer*. 1996;78:311–319.

Powis MR, Imeson JD, Holmes SJK. The effect of complete excision on stage III neuroblastoma: a report of the European Neuroblastoma Study Group. *J Pediatr Surg*. 1996;31:516–519.

Qureshi SS, Rent EG, Bhagat M, et al. Chyle leak following surgery for abdominal neuroblastoma. *J Pediatr Surg*. 2016;51:1557–1560.

Rees H, Markley MA, Kiely EM, et al. Diarrhea after resection of advanced abdominal neuroblastoma: a common management problem. *Surgery*. 1998;123:568–572.

Rich BS, McEvoy MP, Kelly NE, et al. Resectibility and operative morbidity after chemotherapy in neuroblastoma patients with encasement of major visceral arteries. *J Pediatr Surg*. 2011;46:103–107.

Robertson CM, Tyrrell JC, Pritchard J. Familial neural crest tumours. *Eur J Pediatr*. 1991;150:789–792.

Rubie H, Chisholm J, Defachelles AS, et al. Phase II study of Temozolomide in relapsed or refractory high-risk neuroblastoma: a joint Société Française des Cancers de l'Enfant and United Kingdom Children Cancer Study Group-New Agents Group Study. *J Clin Oncol*. 2006;24:5259–5264.

Rubie H, DeBernardi B, Gerrard M, et al. Excellent outcome with reduced treatment in infants with nonmetastatic and unresectable neuroblastoma without *MYCN* amplification: results of the prospective INES 99.1. *J Clin Oncol*. 2011;29:449–455.

Rudnick E, Khakoo Y, Antunes NL, et al. Opsoclonus-myoclonus-ataxia syndrome in neuroblastoma: clinical outcome and antineuronal antibodies: a report from the Children's Cancer Group Study. *Med Pediatr Oncol*. 2001;36:612–622.

Russo C, Cohn SL, Petruzzi MJ, et al. Long-term neurologic outcome in children with opsoclonus-myoclonus associated with neuroblastoma: a report from the Pediatric Oncology Group. *Med Pediatr Oncol*. 1997;29:284–288.

Sano J, Bonadio J, Gerbing RB, et al. International neuroblastoma pathology classification adds independent prognostic information beyond the prognostic contribution of age. *Eur J Cancer*. 2006;42:1113–1119.

Sawada T. Past and future of neuroblastoma screening in Japan. *Am J Pediatr Hematol Oncol*. 1992;14:320–326.

Schilling FH, Spix C, Berthold F, et al. Neuroblastoma screening at one year of age. *N Engl J Med*. 2002;346:1047–1053.

Schleiermacher G, Raynal V, Janoueix-Lerosey I, et al. Variety and complexity of chromosome 17 translocations in neuroblastoma. *Genes Chromosomes Cancer*. 2004;39:143–150.

Schleiermacher G, Rubie H, Hartmann O, et al. Treatment of stage 4s neuroblastoma—report of 10 years' experience of the French Society of Paediatric Oncology (SFOP). *Br J Cancer*. 2003;89:470–476.

Schmidt ML, Lukens JN, Seeger RC, et al. Biologic factors determine prognosis in infants with stage IV neuroblastoma: a prospective Children's Cancer Group Study. *J Pediatr Surg*. 2000;18:1260–1268.

Seeger RC, Brodeur GM, Sather H, et al. Association of multiple copies of the N-myc oncogene with rapid progression of neuroblastomas. *N Engl J Med*. 1985;313:1111–1116.

Seeger RC, Villablanca JG, Matthay KK, et al. Intensive chemoradiotherapy and autologous bone marrow transplantation for poor prognosis neuroblastoma. *Prog Clin Biol Res*. 1991;366:527–534.

Seeger RC, Wada R, Brodeur GM, et al. Expression of N-myc by neuroblastomas with one or multiple copies of the oncogene. *Prog Clin Biol Res*. 1988;271:41–49.

Shamberger RC, Allarde-Segundo A, Kozakewich HPW, et al. Surgical management of stage III and IV neuroblastoma: resection before or after chemotherapy? *J Pediatr Surg*. 1991;26:1113–1118.

Shamberger RC, Smith EI, Joshi VV, et al. The risk of nephrectomy during local control in abdominal neuroblastoma. *J Pediatr Surg*. 1998;33:161–164.

Shimada H, Ambros IM, Dehner LP, et al. Terminology and morphologic criteria of neuroblastic tumors: recommendations by the International Neuroblastoma Pathology Committee. *Cancer*. 1999;86:349–363.

Shimada H, Ambros IM, Dehner LP, et al. The International Neuroblastoma Pathology Classification (the Shimada system). *Cancer*. 1999;86:364–372.

Shimada H, Chatten J, Newton WA Jr, et al. Histopathologic prognostic factors in neuroblastic tumors: definition of subtypes of ganglioneuroblastoma and an age-linked classification of neuroblastomas. *J Natl Cancer Inst*. 1984;73:405–416.

Shochat SJ. Update on solid tumor management. *Surg Clin North Am*. 1992;72:1417–1428.

Shorter NA, Davidoff AM, Evans AE, et al. The role of surgery in the management of stage IV neuroblastoma: a single institution study. *Med Pediatr Oncol*. 1995;24:287–291.

Silber JH, Evans AE, Fridman M. Models to predict outcome from childhood neuroblastoma: the role of serum ferritin and tumor histology. *Cancer Res*. 1991;51:1426–1433.

Simon T, Häberle B, Hero B, et al. Role of surgery in the treatment of patients with Stage 4 neuroblastoma age 18 months or older at diagnosis. *J Clin Oncol*. 2013;31:752–758.

Simon T, Hero B, Benz-Bohm G, et al. Review of image defined risk factors in localized neuroblastoma patients: results of the GPOH NB 97 Trial. *Pediatr Blood Cancer*. 2008;50:965–969.

Simon T, Längler A, Berthold F, et al. Topotecan and etoposide in the treatment of relapsed high-risk neuroblastoma. Results of Phase 2 trial. *J Pediatr Hematol Oncol*. 2007;29:101–106.

Sitarz A, Finklestein J, Grosfeld J, et al. An evaluation of the role of surgery in disseminated neuroblastoma: a report from the Children's Cancer Study Group. *J Pediatr Surg*. 1983;18:147–151.

Spitz R, Hero B, Simon T, et al. Loss in chromosome 11q identifies tumors with increased risk for metastatic relapsed in localized and 4S neuroblastoma. *Clin Cancer Res*. 2006;12:3368–3373.

Strother DR, London WB, Schmidt ML, et al. Outcome after surgery alone or with restricted use of chemotherapy for patients with low-risk neuroblastoma: results of Children's Oncology Group Study P9641. *J Clin Oncol*. 2012;15:1842–1848.

Suita S. Mass screening for neuroblastoma in Japan: lessons learned and future directions. *J Pediatr Surg*. 2002;37:949–954.

Tanaka T, Hiyama E, Sugimoto T, et al. trk A gene expression in neuroblastoma: the clinical significance of an immunohistochemical study. *Cancer*. 1995;76:1086–1095.

Tsuchida Y, Yokoyama J, Kaneko M, et al. Therapeutic significance of surgery in advanced neuroblastoma: a report from the Study Group of Japan. *J Pediatr Surg*. 1992;27:616–622.

Vollmer K, Gfroerer S, Theilen TM, et al. Radical surgery improves survival in patients with stage 4 neuroblastoma. *World J Surg*. 2017.

von Allmen D, Davidoff AM, London WB, et al. Impact of extent of resection on local control and survival in patients from the COG A3973 study with high-risk neuroblastoma. *J Clin Oncol*. 2017;35:208–216.

von Allmen D, Grupp S, Diller L, et al. Aggressive surgical therapy and radiotherapy for patients with high-risk neuroblastoma treated with rapid sequence tandem transplant. *J Pediatr Surg*. 2005;40:936–941.

von Schweinitz D, Hero B, Berthold F. The impact of surgical radicality on outcome in childhood neuroblastoma. *Eur J Surg*. 2002;12:402–409.

Weith A, Martinsson T, Cziepluch C, et al. Neuroblastoma consensus deletion maps to I p36.1–2. *Genes Chromosomes Cancer*. 1989;1:159–166.

Williams CM, Greer M. Homovanillic acid and vanillylmandelic acid in diagnosis of neuroblastoma. *JAMA*. 1963;183:836–840.

Wolden SL, Gollamudi SV, Kushner BH, et al. Local control with multimodality therapy for stage 4 neuroblastoma. *Int J Radiat Oncol Biol Phys*. 2000;46:969–974.

Woods W, Gao RN, Shuster JJ, et al. Screening of infants and mortality due to neuroblastoma. *N Engl J Med*. 2002;346:1041–1046.

Woods WG, Tuchman M, Robison LL, et al. A population-based study of the usefulness of screening for neuroblastoma. *Lancet*. 1996;348:1682–1687.

Yamamoto K, Hanada R, Kikchi A, et al. Spontaneous regression of neuroblastoma detected by mass screening. *J Clin Oncol*. 1998;16:1265–1269.

Yanik GA, Parisi MT, Shulkin BL, et al. Semiquantitative mIBG scoring as a prognostic indicator in patients with stage 4 neuroblastoma: a report from the Children's Oncology Group. *J Nucl Med*. 2013;54:541–548.

Yokoyama J, Ikawa J, Endow M, et al. The role of surgery in advanced neuroblastoma. *Eur J Pediatr Surg*. 1995;5:23–26.

Yoneda A, Oue T, Imura K, et al. Observation of untreated patients with neuroblastoma detected by mass screening: a “wait and see” pilot study. *Med Pediatr Oncol*. 2001;36:160–162.

Yu AL, Gilman AL, Ozkaynak F, et al. Anti-GD2 antibody with GM-CSF, Interleukin-2, and isotretinoin for neuroblastoma. *N Engl J Med*. 2010;363:1324–1334.

Nephroblastoma

Ali AN, Diaz R, Shu HK, et al. A Surveillance, epidemiology and end results (SEER) comparison of adult and pediatric Wilms tumor. *Cancer*. 2012;118:2541–2551.

Amar AM, Tomlinson G, Green DM, et al. Clinical presentation of rhabdoid tumor of the kidney. *J Pediatr Hematol Oncol*.

2001;23:105–108.

Anderson J, Slater O, McHugh K, et al. Response without shrinkage in bilateral Wilms tumor: significance of rhabdomyomatous histology. *J Pediatr Hematol Oncol*. 2002;24:31–34.

Argani P, Fritsch M, Kadkol SS, et al. ETV6-NTRK3 Gene fusions and trisomy 11 establish a histogenetic link between mesoblastic nephroma and congenital fibrosarcoma. *Cancer Res*. 1998;58:5046–5048.

Argani P, Perlman EJ, Breslow NE, et al. Clear cell sarcoma of the kidney: a review of 351 cases from the National Wilms Tumor Study Group Pathology Center. *Amer J Surg Pathol*. 2000;24:4–18.

Armstrong GT, Yan Chen MM, Yasui Y, et al. Reduction in late mortality among 5-year survivors of childhood cancer. *NEJM*. 2016;374:833–842.

Aronson DC, Medary I, Finlay JL, et al. Renal cell carcinoma in childhood and adolescence: a retrospective survey for prognostic factors in 22 cases. *J Pediatr Surg*. 1996;31:183–186.

Arrigo S, Beckwith JB, Sharples K, et al. Better survival after combined modality care for adults with Wilms' tumor. A report from the National Wilms' Tumor Study. *Cancer*. 1990;66:827–830.

Arroyo M, Green D, Breslow N, et al. Metanephric adenofibroma and related lesions. Clinicopathologic study of 24 cases. *Mod Pathol*. 2000;13:1P.

Axt J, Murphy AJ, Seeley EH, et al. Race disparities in Wilms tumor incidence and biology. *J Surg Res*. 2011;170:112–119.

Bahrami A, Joodi M, Maftooh M, et al. The genetic factors contributing to the development of Wilm's tumor and their clinical utility in its diagnosis and prognosis. *J Cell Physiol*. 2018;233:2882–2888.

Barber TD, Wickiser JE, Wilcox DT, et al. Prechemotherapy laparoscopic nephrectomy for Wilms' tumor. *J Pediatr Urol*. 2009;5:416–419.

Bardeesy N, Falkoff D, Petruzzi MJ, et al. Anaplastic Wilms' tumour, a subtype displaying poor prognosis, harbours p53 gene mutations. *Nat Genet*. 1994;7:91–97.

Bassal M, Mertens AC, Taylor L, et al. Risk of selected subsequent carcinomas in survivors of childhood cancer: a report from the Childhood Cancer Survivor Study. *J Clin Oncol*. 2006;24:476–483.

Baxter PA, Nuchtern JG, Guillerman RP, et al. Acquired von Willebrand syndrome and Wilms tumor: not always benign. *Pediatr Blood Cancer*. 2009;52:392–394.

Beckwith JB, Palmer NF. Histopathology and prognosis of Wilms tumor. Results from the National Wilms Tumor Study. *Cancer*. 1978;41:1937–1948.

Beckwith JB. Congenital mesoblastic nephroma. When should we worry? *Arch Pathol Lab Med*. 1986;110:98–99.

Beckwith JB, Kiviat NB, Bonadio JF. Nephrogenic rests, nephroblastomatosis, and the pathogenesis of Wilms' tumor. *Pediatr Pathol*. 1990;10:1–36.

Beckwith JB. Precursor lesions of Wilms tumor: clinical and biological implications. *Med Pediatr Oncol*. 1993;21:158–168.

Beckwith JB. Certain conditions have an increased incidence of Wilms' tumor. *AJR Am J Roentgenol*. 1996;164:1294–1295.

Beckwith JB, Zuppan CE, Browning NG, et al. Histological analysis of aggressiveness and responsiveness in Wilms tumor. *Med Pediatr Oncol*. 1996;27:422–428.

Beckwith JB. Nephrogenic rests and the pathogenesis of Wilms tumor: developmental and clinical considerations. *Am J Med Genet*. 1998;79:268–273.

Bernstein L, Linet M, Smith MA, et al. Renal tumors. Ries

LAG, Smith MA, Gurney JG, et al. *Cancer incidence and survival among children and adolescents: United States SEER program 1975–1995, National Cancer Institute, SEER Program*. National Institutes of Health: Bethesda (MD); 1999:79–90 [Pub. No. 99–4649].

Biegel JA, Zhou JY, Rorke LB, et al. Germ-line and acquired mutations of INI1 in atypical teratoid and rhabdoid tumors. *Cancer Res*. 1999;59:74–79.

Bissler J, Kingswood C, Radzikowska E, et al. Everolimus for angiomyolipoma associated with tuberous sclerosis complex or sporadic lymphanioleiomyomatosis (EXIST-2): a multicenter, randomized, double-blind placebo-controlled trial. *Lancet*. 2013;381:817–824.

Bissler JJ, Kingswood JC. Optimal treatment of tuberous sclerosis complex associated renal angiomyolipomata: a systematic review. *Ther Adv Urol*. 2016;8:279–290.

Bissler JJ, Cappell K, Charles H, et al. Long-term clinical morbidity in patients with renal angiomyolipoma associated with tuberous sclerosis complex. *Urology*. 2016;95:80–87.

Bissler JJ, Kingswood JC, Radzikowska E, et al. Everolimus long-term use in patients with tuberous sclerosis complex: four-year update of the EXIST-2 study. *PLoS ONE*. 2017;12:e0180939.

Blakely ML, Shamberger RC, Norkool P, et al. Outcome of children with cystic partially differentiated nephroblastoma treated with or without chemotherapy. *J Pediatr Surg*. 2003;38:897–900.

Blanchette V, Coppes MJ. Routine bleeding history and laboratory tests in children presenting with a renal mass. *Pediatr Blood Cancer*. 2009;52:314–315.

Bliek J, Gicquel C, Maas S, et al. Epigenotyping as a tool for the prediction of tumor risk and tumor type in patients with Beckwith-Wiedemann syndrome (BWS). *J Pediatr*.

2004;145:796–799.

Blute ML, Kelalis PP, Offord KP, et al. Bilateral Wilms' tumor. *J Urol*. 1987;138:968–973.

Boccon-Gibod L, Rey A, Sandstedt B, et al. Complete necrosis induced by preoperative chemotherapy in Wilms tumor as an indicator of low risk: report of the International Society of Paediatric Oncology (SIOP) Nephroblastoma Trial and Study 9. *Med Pediatr Oncol*. 2000;34:183–190.

Bonadio JF, Storer B, Norkool P, et al. Anaplastic Wilms' tumor: clinical and pathological studies. *J Clin Oncol*. 1985;3:513–520.

Bonetta L, Kuehn SE, Huang A, et al. Wilms tumor locus on 11p13 defined by multiple CpG island-associated transcripts. *Science*. 1990;250:994–997.

Borer JG, Kaefer M, Barnewolt CE, et al. Renal findings on radiological follow-up of patients with Beckwith-Wiedemann syndrome. *J Urol*. 1999;161:235–239.

Breslow N, Beckwith JB, Ciol M, et al. Age distribution of Wilms tumor: report from the National Wilms Tumor Study. *Cancer Res*. 1988;48:1653–1657.

Breslow NE, Norkool PA, Olshan A, et al. Second malignant neoplasm in survivors of Wilms' tumor: a report from the National Wilms' Tumor Study. *J Natl Cancer Inst*. 1988;80:592–595.

Breslow N, Olshan A, Beckwith JB, et al. Epidemiology of Wilms' tumor. *Med Pediatr Oncol*. 1993;21:172–181.

Breslow N, Olshan A, Beckwith JB, et al. Ethnic variation in the incidence, diagnosis, prognosis and follow-up of children with Wilms' tumor. *J Natl Cancer Inst*. 1994;86:49–51.

Breslow NE, Olson J, Moksness J, et al. Familial Wilms tumor: a descriptive study. *Med Pediatr Oncol*. 1996;27:398–403.

Breslow NE, Takashima J, Ritchey ML, et al. Renal failure in the Denys-Drash and Wilms tumor aniridia syndromes.

Cancer Res. 2000;60:4030–4032.

Breslow NE, Norris R, Norkool P, et al. Characteristics and outcomes of children with the Wilms tumor-aniridia syndrome: a report from the National Wilms Tumor Study Group. *J Clin Oncol*. 2003;21:4579–4585.

Breslow NE, Collins AJ, Ritchey ML, et al. End stage renal disease in patients with Wilms tumor: results from the National Wilms Tumor Study Group and the United States Renal Data System. *J Urol*. 2005;174:1972–1975.

Breslow NE, Beckwith JB, Haase GM, et al. Radiation therapy for favorable histology Wilms t umor: prevention of flank recurrence did not improve survival on National Wilms Tumor Studies 3 and 4. *Int J Radiat Oncol Biol Phys*. 2006;65:203–209.

Breslow NE, Beckwith JB, Perlman EJ, et al. Age distributions, birth weights, nephrogenic rests, and heterogeneity in the pathogenesis of Wilms tumor. *Pediatr Bood Cancer*. 2006;47:260–267.

Breslow NE, Lange JM, Freidman DL, et al. Secondary malignant neoplasms after Wilms tumor: an international collaborative study. *Int J Cancer*. 2010;127:657–666.

Brioude F, Lacoste A, Netchine I, et al. Beckwith-Wiedemann syndrome: growth pattern and tumor risk according to molecular mechanism, and guidelines for tumor surveillance. *Horm Res Paediatr*. 2013;80:457–465.

Broecker B. Renal cell carcinoma in children. *Urology*. 1991;38:54–56.

Bruder E, Passera O, Harms D, et al. Morphologic and molecular characterization of renal cell carcinoma in children and young adults. *Am J Surg Pathol*. 2004;28:1117–1132.

Call KM, Glaser T, Ito CY, et al. Isolation and characterization of a zinc finger polypeptide gene at the human chromosome 11 Wilms' tumor locus. *Cell*. 1990;60:509–520.

Callaghan MU, Wong TE. Federic AB. Treatment of acquired von Willebrand syndrome in childhood. *Blood*. 2013;122:2019–2022.

Castellanos RD, Aron BS, Evans AT. Renal adenocarcinoma in children: incidence, therapy and prognosis. *J Urol*. 1974;111:534–537.

Charlton J, Williams RD, Sebire NJ, et al. Comparative methylome analysis identifies new tumour subtypes and biomarkers for transformation of nephrogenic rests into Wilms tumour. *Genome Med*. 2015;7:11.

Choufani S, Shuman C, Weksberg R. Molecular findings in Beckwith-Wiedemann syndrome. *Am J Med Genet C Semin Med Genet*. 2013;163C:131–140.

Chowdhury T, Prichard-Jones K, Sebire N, et al. Persistent complete response after single agent Sunitinib treatment in a case of TFE translocation positive relapsed metastatic pediatric renal cell carcinoma. *J Pediatr Hematol Oncol*. 2013;35:e1–e3.

Choyke PL, Siegel MJ, Craft AW, et al. Screening for Wilms tumor in children with Beckwith-Wiedemann syndrome or idiopathic hemihypertrophy. *Med Pediatr Oncol*. 1999;32:196–200.

Cook A, Lorenzo AJ, Pippi Salle JL, et al. Pediatric renal cell carcinoma: single institution 25-year case series and intial experience with partial nephrectomy. *J Urol*. 2006;175:1456–1460.

Coppes MJ, deKraker J, vanKijken PJ, et al. Bilateral Wilms' tumor: long-term survival and some epidemiological features. *J Clin Oncol*. 1989;7:310–315.

Coppes MJ, Liefers GJ, Higuchi M, et al. Inherited WT1 mutations in Denys-Drash syndrome. *Cancer Res*. 1992;52:6125–6128.

Coppes MJ, Huff V, Pelletier J. Denys-Drash syndrome: relating a clinical disorder to genetic alterations in the tumor suppressor gene WT1. *J Pediatr*. 1993;123:673–678.

Coppes MJ, Arnold M, Beckwith JB, et al. Factors affecting the risk of contralateral Wilms tumor development. *Cancer*. 1999;85:1616–1625.

Cost NG, Lubahn JD, Granberg CF, et al. Oncologic outcomes of partial versus radical nephrectomy for unilateral Wilms tumor. *Pediatr Blood Cancer*. 2012;58:898–904.

Cost NG, Liss ZJ, Bean CM, et al. Prechemotherapy robotic-assisted laparoscopic radical nephrectomy for an adolescent with Wilms tumor. *J Pediatr Hematol Oncol*. 2015;37:e125–e127.

Cotton CA, Peterson S, Norkool PA, et al. Early and late mortality after diagnosis of Wilms tumor. *J Clin Oncol*. 2009;27:1304–1309.

Cozzi F, Schiavetti A, Bonanni M, et al. Enucleative surgery for stage I nephroblastoma with a normal contralateral kidney. *J Urol*. 1996;156:1788–1791.

Cozzi F, Schiavetti A, Cozzi DA, et al. Conservative management of hyperplastic and multicentric nephroblastomatosis. *J Urol*. 2004;172:1066–1070.

Crino PB, Nathanson KL, Henske EP. The tuberous sclerosis complex. *NEJM*. 2006;355:1345–1356.

Dahan K, Kamal M, Noel LH, et al. Small glomeruli in WAGR (Wilms tumor, aniridia, genitourinary anomalies and mental retardation) syndrome. *Am J Kidney Dis*. 2007;49:793–800.

D'Angio GJ, Evans AE, Breslow N, et al. The treatment of Wilms’ tumor: results of the National Wilms’ Tumor Study. *Cancer*. 1976;38:633–646.

D'Angio GJ, Evans A, Breslow N, et al. The treatment of Wilms’ tumor: results of the Second National Wilms’ Tumor Study. *Cancer*. 1981;47:2302–2311.

D'Angio GJ, Breslow N, Beckwith JB, et al. Treatment of

Wilms' tumor: results of the Third National Wilms' Tumor Study. *Cancer*. 1989;64:349–360.

D'Angio GJ, Rosenberg H, Sharples K, et al. Position paper: imaging methods for primary renal tumors of childhood: cost versus benefits. *Med Pediatr Oncol*. 1993;21:205–212.

Davidoff AM, Giel DW, Jones DP, et al. The feasibility and outcome of nephron-sparing surgery for children with bilateral Wilms tumor. The St Jude Children's Research Hospital experience: 1999-2006. *Cancer*. 2008;112:1877–1878.

Debaun MR, Tucker MA. Risk of cancer during the first four years of life in children from the Beckwith-Wiedemann syndrome registry. *J Pediatr*. 1998;132:377–379.

Debaun MR, Siegel MJ, Choyke PL. Nephromegaly in infancy and early childhood: a risk factor for Wilms tumor in Beckwith-Wiedemann syndrome. *J Pediatr*. 1998;132:401–404.

DeBaun MR, Niemitz EL, McNeil DE, et al. Epigenetic alterations of *H19* and *LIT1* distinguish patients with Beckwith-Wiedemann syndrome with cancer and birth defects. *Am J Hum Genet*. 2002;70:604–611.

Dehner LP, Leestma JE, Price EB Jr. Renal cell carcinoma in children: a clinicopathologic study of 15 cases and review of the literature. *J Pediatr*. 1970;76:358–368.

deKraker J, Graf N, van Tinteren H, et al. Reduction of postoperative chemotherapy in children with stage I intermediate-risk and anaplastic Wilms' tumour (SIOP 93-01 trial): a randomised controlled trial. *Lancet*. 2004;364:1229–1235.

Diller L, Ghhremani M, Morgan J, et al. Constitutional WT1 mutations in Wilms tumor patients. *J Clin Oncol*. 1998;16:3634–3640.

Dix DB, Gratias EJ, Seibel N, et al. Treatment of stage IV favorable histology Wilms tumor with incomplete lung metastasis response after chemotherapy: a report from Children's Oncology Group study AREN0533. *J Clin Oncol*. 2014;32 [5s (suppl; abstr 10001)].

Dix DB, Fernandez CV, Chi Y-Y, et al. Augmentation of therapy for favorable histology Wilms tumor combined with loss of heterozygosity of chromosomes 1p and 16q: a report from the Children's Oncology Group studies AREN0532 and AREN0533. *J Clin Oncol*. 2015;33(Suppl) [abstr 10009.].

Dix DB, Seibel N, Chi YY, et al. Treatment of stage IV favorable histology Wilms tumor with lung metastases: a report from Children's Oncology Group AREN0533 study. *J Clin Oncol*. 2018;36:1564–1570.

Dome JS, Cotton CA, Perlman EJ, et al. Treatment of anaplastic histology Wilms tumor: results from the fifth National Wilms Tumor Study. *J Clin Oncol*. 2006;24:2352–2358.

Dome JS, Graf N, Geller JI, et al. Advances in Wilms tumor treatment and biology: progress through international collaboration. *J Clin Oncol*. 2015;33:2999–3007.

Dome JS, Huff V. Wilms tumor predisposition. Adam MP, Ardinger HH, Pagon RA, et al. *GeneReviews® [internet]*. University of Washington, Seattle: Seattle (WA); 2016 [1993-2018. Updated; Oct 20].

Drash A, Sherman F, Hartmann WH, et al. A syndrome of pseudohermaphroditism, Wilms tumor, hypertension and degenerative renal disease. *J Pediatr*. 1970;76:585–593.

Dressler GR. Transcription factors in renal development: the WT1 and Pax-2 story. *Semin Nephrol*. 1995;15:263–271.

Duarte RJ, Cristofani LM, Denes FT, et al. Wilms tumor: a retrospective study of 32 patients using videolaparoscopic and open approaches. *Urology*. 2014;84:191–195.

Eaton KW, Toole LS, Wainwright LM, et al. Spectrum of SMARCB1 /INI1 mutations in familial and sporadic rhabdoid tumors. *Pediatr Blood Cancer*. 2011;56:7–15.

Eble JN, Bonsib SM. Extensively cystic renal neoplasms: cystic nephroma, cystic partially differentiated nephroblastoma, multilocular cystic renal cell carcinoma, and cystic hamartoma of renal pelvis. *Semin Diag Pathol*. 1998;15:2–20.

Ehrlich PF, Hamilton TE, Grundy P, et al. The value of surgery in directing therapy for patients with Wilms' tumor with pulmonary disease. A report from the National Wilms' Tumor Study Group (National Wilms' Tumor Study 5). *J Pediatr Surg*. 2006;41:162–167.

Ehrlich PF, Anderson JR, Ritchey ML, et al. Clinicopathologic findings predictive of relapse in children with stage III favorable-histology Wilms tumor. *J Clin Oncol*. 2013;31:1196–1201.

Ehrlich PF, Chi YY, Chintagumpala MM, et al. Results of the first prospective multi-institutional study in children with bilateral Wilms tumor (AREN0534): a report from the Children's Oncology Group. *Ann Surg*. 2017;266:470–478.

Ewalt DH, Sheffield E, Sparagana SP, et al. Renal lesion growth in children with tuberous sclerosis complex. *J Urol*. 1998;160:141–145.

Faria P, Beckwith JB, Mishra K, et al. Focal versus diffuse anaplasia in Wilms tumor—new definitions with prognostic significance: a report from the National Wilms Tumor Study Group. *Am J Surg Pathol*. 1996;20:909–920.

Fernandez CV, Perlman EJ, Mullen EA, et al. Clinical outcome and biological predictors of relapse after nephrectomy only for very low-risk Wilms tumor: a report from Children's Oncology Group AREN0532. *Ann Surg*. 2017;265:835–840.

Fernandez CV, Mullen EA, Chi YY, et al. Outcome and prognostic factors in stage III favorable-histology wilms tumor: a report from the Children's Oncology Group Study

AREN0532. *J Clin Oncol*. 2018;36:254–261.

Ferrer FA, McKenna PH. Partial nephrectomy in a metachronous multilocular cyst of the kidney (cystic nephroma). *J Urol*. 1994;151:1358–1360.

Ferrer FA, Rosen N, Herbst CV, et al. Image based feasibility of renal sparing surgery for very low risk unilateral Wilms tumors: a report from the Children's Oncology Group. *J Urol*. 2013;190:1846–1851.

Feusner JH, Beckwith JB, D'Angio GJ. Clear cell sarcoma of the kidney: accuracy of imaging methods for detecting bone metastases. Report from the National Wilms' Tumor Study. *Med Pediatr Oncol*. 1990;18:225–227.

Feusner JH, Ritchey ML, Norkool PA, et al. Renal failure does not preclude cure in children receiving chemotherapy for Wilms tumor: a report from the National Wilms Tumor Study Group. *Pediatr Blood Cancer*. 2008;50:242–245.

Fitchey P, Beckwith JB, Perlman EJ. Congenital mesoblastic nephroma: prognosis and outcome. *Lab Investig*. 2003;83:2P.

Fuchs J, Szavay P, Seitz G, et al. Nephron sparing surgery for synchronous bilateral nephroblastoma involving the renal hilus. *J Urol*. 2011;186:1430–1436.

Fukuzawa R, Breslow NE, Morison IM, et al. Epigenetic differences between Wilms tumours in white and east Asian children. *Lancet*. 2004;363:446–451.

Fukuzawa R, Anaka MR, Heathcott RW, et al. Wilms tumour histology is determined by distinct types of precursor lesions and not epigenetic changes. *J Pathol*. 2008;215:377–387.

Furtwangler R, Gooskens SL, van Tintern H, et al. Clear cell sarcomas of the kidney registered on International Society of Pediatric Oncology (SIOP) 93-01 and SIOP 2001 protocols: a report of the SIOP renal tumour study group. *Eur J Cancer*. 2013;49:3497–3506.

Furtwangler R, Kager L, Melchior P, et al. High-dose treatment for malignant rhabdoid tumor of the kidney: no evidence for improved survival – the Gesellachaft fur Padiatrische Onkolgie und Hamatolgie (GPOH) experience. *Pediatr Blood Cancer*. 2018;65.

Gadd S, Huff V, Huang CC, et al. Clinically relevant subsets identified by gene expression patterns support a revised ontogenic model of Wilms tumor: a Children's Oncology Group Study. *Neoplasia*. 2012;14:742–756.

Gadd S, Huff V, Walz AL, et al. A Children's Oncology Group and TARGET initiative exploring the genetic landscape of Wilms tumor. *Nat Genet*. 2017;49:1487–1494.

Geller J, Dome JL. Local lymph node involvement does not predict poor outcome in pediatric renal cell carcinoma. *Cancer*. 2004;101:1575–1583.

Geller JI, Argani P, Adeniran A, et al. Translocation renal cell carcinoma. Lack of negative impact due to lymph node spread. *Cancer*. 2008;112:1607–1616.

Geller JI, Ehrlich PF, Cost NG, et al. Characterization of adolescent and pediatric renal cell carcinoma: a report from the Children's Oncology Group study AREN03B2. *Cancer*. 2015;121:2457–2464.

Ghanem MA, van der Kwast TH, Molenaar WM, et al. The predictive value of immunohistochemical markers in untreated Wilms’ tumour: are they useful? *World J Urol*. 2013;31:811–816.

Gormley TS, Skoog SJ, Jones RV, et al. Cellular congenital mesoblastic nephroma: what are the options? *J Urol*. 1989;142:479–483.

Gooskens SL, Furtwangler R, Spreafico F, et al. Treatment and outcome of patients with relapsed clear cell sarcoma of the kidney: a combined SIOP and AIEOP study. *Br J Cancer*. 2014;111:227–233.

Gow KW, Barnhat DC, Hamilton TE, et al. Primary nephrectomy and intraoperative tumor spill: report from the Childrens Oncology Group renal tumors committee. *J Pediatr Surg*. 2013;48:34–38.

Graf N, Tournade MF, deKraker J. The role of preoperative chemotherapy in the management of Wilms' tumor. *Urol Clin North Am*. 2000;27:443–454.

Graf N, van Tintern H, Bergeron C, et al. Characteristics and outcome of stage II and III non-anaplastic Wilms' tumor treated according to SIOP trial and study 93-01. *Eur J Cancer*. 2012;17:3240–3248.

Gratias EJ, Jennings LJ, Anderson JA, et al. Gain of 1q is associated with associated with inferior event-free and overall survival in patients with favorable histology Wilms tumor. *Cancer*. 2013;119:2887–2894.

Gratias EJ, Dome JS, Jennings LJ, et al. Association of chromosome 1q gain with inferior survival in favorable-histology Wilms tumor: a report from the Children's Oncology Group. *J Clin Oncol*. 2016;34:3189–3194.

Green DM, Breslow NE, Beckwith JB, et al. Screening of children with hemihypertrophy, aniridia, and Beckwith-Wiedemann syndrome in patients with Wilms' tumor: a report from the National Wilms Tumor Study. *Med Pediatr Oncol*. 1993;21:188–192.

Green DM, Beckwith JB, Breslow NB, et al. The treatment of children with Stage II-IV anaplastic Wilms tumor. A report from the National Wilms Tumor Study. *J Clin Oncol*. 1994;12:2126–2131.

Green DM, Breslow NE, Beckwith JB, et al. Effect of duration of treatment on treatment outcomes and cost of treatment for Wilms' tumor: a report from the National Wilms Tumor Study Group. *J Clin Oncol*. 1998;16:3744–3751.

Green DM, Breslow NE, Beckwith JB, et al. Treatment with nephrectomy only for small, stage I/favorable histology

Wilms’ tumor: a report from the National Wilms’ Tumor Study Group. *J Clin Oncol*. 2001;19:3719–3724.

Green DM, Grigoriev YA, Nan B, et al. Congestive failure after treatment for Wilms tumor. A report from the National Wilms Tumor Study Group. *J Clin Oncol*. 2001;19:1026–1034.

Green DM, Cotton CA, Malagolowkin M, et al. Treatment of Wilms tumor relapsing after initial treatment with vincristine and actinomycin D: a report from the National Wilms Tumor Study Group. *Pediatr Blood Cancer*. 2007;48:493–499.

Green DM, Sklar CA, Boice JD, et al. Ovarian failure and reproductive outcomes after childhood cancer treatment: results from the Childhood Cancer Survivor Study. *J Clin Oncol*. 2009;27:2374–2381.

Green DM, Lange JM, Peabody EM, et al. Pregnancy outcome after treatment for Wilms tumor: a report from the national Wilms tumor long-term follow-up study. *J Clin Oncol*. 2010;28:2824–2830.

Green DM, Breslow NE, D'Angio G, et al. Outcome of patients with stage II favorable histology Wilms tumor with and without local tumor spill: a report from the National Wilms tumor Study Group. *Pediatr Blood Cancer*. 2014;61:134–139.

Green DM. Considerations in the diagnosis and management of pediatric patients with favorable histology Wilms tumor who present with only pulmonary nodules. *Pediatr Blood Cancer*. 2016;63:589–592.

Gregoriev Y, Lange J, Peterson S, et al. Treatment and outcomes for end-stage renal disease following Wilms tumor. *Pediatr Nephrol*. 2012;27:1325–1333.

Grenskov K, Olsen JH, Sand A, et al. Population-based risk estimates of Wilms tumor in sporadic aniridia. A comprehensive mutation screening procedure of PAX6 identifies 80% of mutations in aniridia. *Hum Genet*.

2001;109:11–18.

Grundy PE, Telzerow PE, Breslow N, et al. Loss of heterozygosity for chromosomes 16q and 1p in Wilms tumor predicts an adverse outcome. *Cancer Res*. 1994;54:2331–2333.

Grundy PE, Breslow NE, Li S, et al. Loss of heterozygosity for chromosomes 1p and 16q is an adverse prognostic factor in favorable histology Wilms tumor. A Report from the National Wilms Tumor Study Group. *J Clin Oncol*. 2005;23:7312–7321.

Grundy RG, Hutton C, Middleton H, et al. Outcome of patients with stage III or inoperable WT treated on the second United Kingdom WT protocol (UKWT2); a United Kingdom Children's Cancer Study Group (UKCCSG) study. *Pediatr Blood Cancer*. 2004;42:311–319.

Grundy PE, Green DM, Dirks AC, et al. Clinical Significance of pulmonary nodules detected by CT and not CXR in patients treated for favorable histology Wilms tumor on National Wilms Tumor Studies-4 and -5: a report from the Children's Oncology Group. *Pediatr Blood Cancer*. 2012;59:631–635.

Ha TC, Spreafico F, Graf N, et al. An international strategy to determine the role of high dose therapy in recurrent Wilms tumor. *Eur J Cancer*. 2013;49:194–210.

Haecker FM, vonSchweinitz D, Harms D, et al. Partial nephrectomy for unilateral Wilms tumor: result of study SIOP 93-01/GPOH. *J Urol*. 2003;170:939–944.

Hamilton TE, Greet D, Perlman E, et al. Bilateral Wilms’ tumor with anaplasia. Lessons learned from the National Wilms Tumor Study Group. *J Pediatr Surg*. 2006;41:1641–1644.

Hamilton TE, Ritchey ML, Haase GM, et al. The management of synchronous bilateral Wilms tumor: a report from the National Wilms Tumor Study Group. *Ann Surg*. 2011;253:1004–1010.

Hartman D, Davis C, Madewell J, et al. Primary malignant tumors in the second decade of life: Wilms tumor versus renal cell carcinoma. *J Urol*. 1982;127:888–891.

Heidelberger KP, Ritchey ML, Dauser RC, et al. Congenital mesoblastic nephroma metastatic to the brain. *Cancer*. 1993;72:2499–2502.

Henske EP. The genetic basis of kidney cancer: why is tuberous sclerosis complex often overlooked? *Curr Mol Med*. 2004;4:825–831.

Hindman N, Ngo L, Genega EM, et al. Angiomyolipoma with minimal fat: can it be differentiated from clear cell renal cell carcinoma by using standard MR techniques? *Radiology*. 2012;265:468–477.

Hoffer FA. Magnetic resonance imaging of abdominal masses in the pediatric patient. *Semin Ultrasound CT MR*. 2005;26:212–223.

Hollstein M, Sidransky D, Vogestein B, et al. *p53* mutations in human cancers. *Science*. 1991;253:49–53.

Hoot AC, Russo P, Judkins AR, et al. Immunohistochemical analysis of hSNF5/INI1 distinguishes renal and extra-renal malignant rhabdoid tumors from other pediatric soft tissue tumors. *Am J Surg Pathol*. 2004;28:1485–1491.

Horwitz J, Ritchey ML, Moksness J, et al. Renal salvage procedures in patients with synchronous bilateral Wilms tumors: a report of the NWTSG. *J Pediatr Surg*. 1996;31:1020–1025.

Howell CJ, Othersen HB, Kiviat NE, et al. Therapy and outcome in 51 children with mesoblastic nephroma: a report of the National Wilms' Tumor Study. *J Pediatr Surg*. 1982;17:826–830.

Howlader N, Noone AM, Krapcho M, et al. *SEER Cancer Statistics Review, 1975-2010*. [National Cancer Institute. Bethesda, MD; Available from:]

http://seer.cancer.gov/csr/1975_2010/; 2013 [based on November 2012 SEER data submission, posted to the SEER web site, April].

Joshi VV, Kasznica J, Walters TR. Atypical mesoblastic nephroma. Pathologic characterization of a potentially aggressive variant of conventional congenital mesoblastic nephroma. *Arch Pathol Lab Med*. 1986;110:100–106.

Joshi VV, Beckwith JB. Multilocular cyst of the kidney (cystic nephroma) and cystic, partially differentiated nephroblastoma. Terminology and criteria for diagnosis. *Cancer*. 1989;64:466–479.

Kalapurakal JA, Peterson S, Peabody EM, et al. Pregnancy outcomes after abdominal irradiation that included or excluded the pelvis in childhood Wilms tumor survivors: a report from the National Wilms Tumor Study. *Int J Radiat Oncol Biol Phys*. 2004;58:1364–1368.

Kalapurakal JA, Nan B, Norkool P, et al. Treatment outcomes in adults with favorable histologic type Wilms tumor – an update from the National Wilms Tumor Study Group. *Int J Radiat Oncol Biol Phys*. 2004;60:1379–1384.

Kalapurakal JA, Li SM, Breslow NE, et al. Intraoperative spillage of favorable histology Wilms tumor cells: influence of irradiation and chemotherapy regimens on abdominal recurrence: a report from the NWTSG. *Int J Radiat Oncol Biol Phys*. 2010;76:201–206.

Kalish JM, Doros L, Helman LJ, et al. Surveillance recommendations for children with overgrowth syndromes and predisposition to Wilms tumors and hepatoblastoma. *Clin Cancer Res*. 2017;23:e115–e122.

Kaste SC, Brady SL, Yee B, et al. Is routine pelvic surveillance imaging necessary in patients with Wilms tumor? *Cancer*. 2013;119:182–188.

Khanna G, Rosen N, Anderson JR, et al. Evaluation of diagnostic performance of CT for detection of tumor thrombus in children with Wilms tumor: a report from the Children's Oncology Group. *Pediatr Blood Cancer*. 2012;58:551–555.

Khanna G, Naranjo A, Hoffer F, et al. Detection of preoperative Wilms tumor rupture with CT: a report from the Children's Oncology Group. *Radiology*. 2013;266:610–617.

Kieran K, Anderson JR, Dome JS, et al. Lymph node involvement in Wilms tumor: results from the National Wilms Tumor Studies 4 and 5. *J Pediatr Surg*. 2012;47:700–706.

Kieran K, Anderson JR, Dome JS, et al. Is adrenalectomy necessary during unilateral nephrectomy for Wilms tumor: a report from the Children's Oncology Group. *J Pediatr Surg*. 2013;48:1598–1603.

Kieran K, Williams MA, Dome JS, et al. Margin status and tumor recurrence after nephron sparing surgery for bilateral Wilms tumor. *J Pediatr Surg*. 2013;48:1481–1485.

Kingswood JC, Bissler JJ, Budde K, et al. Review of the tuberous sclerosis renal guidelines from the 2012 consensus conference: current data and future study. *Nephron*. 2016;134:51–58.

Kinsella TJ, Trivette G, Rowland J, et al. Long-term follow-up of testicular function following radiation for early-stage Hodgkin's disease. *J Clin Oncol*. 1989;7:718–724.

Kist-van Holthe JE, Ho PL, et al. Outcome of renal transplantation for Wilms’ tumor and Denys-Drash syndrome: a report of the North American Pediatric Renal Transplant Cooperative Study. *Pediatr Transplant*. 2005;9:305–310.

Knudson AG, Strong LC. Mutation and cancer: a model for Wilms’ tumor of the kidney. *J Natl Cancer Inst*. 1972;48:313–324.

Koufos A, Grundy P, Morgan K, et al. Familial Wiedemann-

Beckwith syndrome and a second Wilms tumor locus both map to 11p15.5. *Am J Human Genet*. 1989;44:711–719.

Kreidberg JA, Sariola H, Loring JM, et al. WT-1 is required for early kidney development. *Cell*. 1997;74:679–691.

Kubiak R, Gundeti M, Duffy PG, et al. Renal function and outcome following salvage surgery for bilateral Wilms tumor. *J Pediatr Surg*. 2004;39:1667–1672.

Kumar R, Fitzgerald R, Breatnach F. Conservative surgical management of bilateral Wilms tumor: results of the United Kingdom Children's Cancer Study Group. *J Urol*. 1998;160:1450–1453.

Kuusk T, Biancari F, Lane B, et al. Treatment of renal angiomyolipoma: pooled analysis of individual patient data. *BMC Urol*. 2015;15:123–129.

Lange J, Peterson SM, Takashima JR, et al. Risk factors for end-stage renal disease in non WT-1 syndromic Wilms tumor. *J Urol*. 2011;186:378–386.

LeClair M, El-Ghoneime A, Audry G, et al. The outcome of prenatally diagnosed renal tumors. *J Urol*. 2005;173:186–189.

Lee JS, Padilla B, Dubois SG, et al. Second malignant neoplasms among children, adolescents and young adults with Wilms tumor. *Pediatr Blood Cancer*. 2015;65:1259–1264.

Lemerle J, Voute PA, Tournade MF, et al. Preoperative versus postoperative radiotherapy, single versus multiple courses of actinomycin D, in the treatment of Wilms’ tumor: preliminary results of a controlled clinical trial conducted by the International Society of Paediatric Oncology (SIOP). *Cancer*. 1976;38:647–654.

Lemerle J, Voute PA, Tournade MF, et al. Effectiveness of preoperative chemotherapy in Wilms’ tumor: results of an International Society of Paediatric Oncology (SIOP) clinical trial. *J Clin Oncol*. 1983;1:604–609.

Li CM, Kim CE, Margolin AA, et al. CTNNB1 mutations and overexpression of Wnt/beta-catenin target genes in WT1-mutant Wilms tumors. *Am J Pathol*. 2004;165:1943–1953.

Little SE, Hanks SP, King-Underwood L, et al. Frequency and heritability of WT1 mutations in nonsyndromic Wilms tumor patients: a UK Children's Cancer Study Group Study. *J Clin Oncol*. 2004;22:4140–4146.

Loeb DM, Hill DA, Dome JS. Complete response of recurrent cellular congenital mesoblastic nephroma to chemotherapy. *J Pediatr Hematol Oncol*. 2002;24:478–481.

Lubahn JD, Cost NG, Kwon J, et al. Correlation between preoperative staging computerized tomography and pathological findings after nodal sampling in children with Wilms tumor. *J Urol*. 2012;188:1500–1504.

Luithle T, Szavay P, Furtwangler R, et al. Treatment of cystic nephroma and cystic partially differentiated nephroblastoma—a report from the SIOP/GPOH Study Group. *J Urol*. 2007;177:294–296.

Maas MH, Cransberg K, van Grotel M, et al. Renin-induced hypertension in Wilms tumor patients. *Pediatr Blood Cancer*. 2007;48:500–503.

Malagolowkin M, Cotton CA, Green DM, et al. Treatment of Wilms tumor relapsing after initial treatment with vincristine and actinomycin D and doxorubicin: a report from the National Wilms Tumor Study Group. *Pediatr Blood Cancer*. 2008;50:236–241.

Malkin D, Li FP, Strong LC, et al. Germ line p53 mutations in a familial sydrome of breast cancer, sarcomas, and other neoplasms. *Science*. 1990;250:1233–1238.

Mannens M, Devilee P, Bliek J, et al. Loss of heterozygosity in Wilms' tumors, studied for six putative tumor suppressor regions, is limited to chromosome 11. *Cancer Res*.

1990;50:3279–3283.

Maw MA, Grundy PE, Millow LJ, et al. A third Wilms’ tumor locus on chromosome 16q. *Cancer Res*. 1992;52:3094–3098.

McCahon E, Sorensen PH, Davis JH, et al. Non-resectable congenital tumors with the ETV6-NTRK3 gene fusion are highly responsive to chemotherapy. *Med Pediatr Oncol*. 2003;40:288–292.

McDonald JM, Douglass EC, Fisher R, et al. Linkage of familial Wilms’ tumor predisposition to chromosome 19 and a two-locus model for the etiology of familial tumors. *Cancer Res*. 1998;58:1387–1390.

McDonald K, Duffy P, Chowdhury T, et al. Added value of abdominal cross-sectional imaging (CT or MRI) in staging of Wilms’ tumours. *Clin Radiol*. 2012;68:16–20.

McHugh K, Roebuck DJ. Pediatric oncology surveillance imaging: two recommendations. Abandon CT scanning, and randomize to imaging or solely clinical follow-up. *Pediatr Blood Cancer*. 2014;61:3–6.

McLorie GA, McKenna PH, Greenburg M, et al. Reduction in tumor burden allowing partial nephrectomy following preoperative chemotherapy in biopsy proved Wilms’ tumor. *J Urol*. 1991;146:509–513.

McTaggart SJ, Algar E, Chow CW, et al. Clinical spectrum of Denys-Drash and Frasier syndrome. *Pediatr Nephrol*. 2001;16:335–339.

Meisel JA, Guthrie KA, Breslow N, et al. Significance and management of computed tomography detected pulmonary nodules: a report from the National Wilms Tumor Study Group. *Int J Rad Oncol*. 1999;44:579–585.

Messahel B, Williams R, Ridolfi A, et al. Allele loss at 16q defines poorer prognosis Wilms tumor irrespective of treatment approach in the UKW1-3 clinical trials: a Children's Cancer and Leukaemia Group (CCLG) Study. *Eur*

J Cancer. 2009;45:819–826.

Miniati D, Gay AN, Parks KV, et al. Imaging accuracy and incidence of Wilms' and non-Wilms' tumors in children. *J Pediatr Surg*. 2008;43:1301–1307.

Mirza W, McHugh K, Aslam M, et al. CT pelvis in children; should we routinely scan pelvis for Wilms tumor and hepatoblastoma? Implications for imaging protocol development. *J Coll Physicians Surg Pak*. 2015;25:768–770.

Misch D, Steffen IG, Schonberger S, et al. Use of positron emission tomography for staging, preoperative response assessment and posttherapeutic evaluation in children with Wilms tumour. *Eur J Nucl Med Mol Imaging*. 2008;35:1642–1650.

Mitchell C, Jones PM, Kelsey A, et al. The treatment of Wilms tumour: results of the United Kingdom Children's Cancer Study Group (UKCCSG) second Wilms tumour study. *Br J Cancer*. 2000;83:602–608.

Mitchell C, Pritchard-Jones K, Shannon R, et al. Immediate nephrectomy versus preoperative chemotherapy in the management of non-metastatic Wilms' tumour: results of a randomised trial (UKW3) by the UK Children's Cancer Study Group. *Eur J Cancer*. 2006;42:2554–2562.

Mullen EA, Geller JI, Gratias EJ, et al. Real-time central review: a report of the first 3,000 patients enrolled on the Children's Oncology Group Renal Tumor Biology and Risk Stratification protocol AREN03B2. *J Clin Oncol*. 2014;32(15 Suppl).

Montgomery BT, Kelalis PP, Blute ML, et al. Extended follow-up of bilateral Wilms' tumor: results of the National Wilms Tumor Study. *J Urol*. 1991;146:514–518.

Mussa A, Molinatto C, Baldassarre G, et al. Cancer risk in Beckwith-Wiedemann syndrome: a systematic review and meta-analysis outlining a novel (epi)genotype specific histotype targeted screening protocol. *J Pediatr*. 2016;176:142–149.

Mustieles C, Munoz A, Alonso M, et al. Male gonadal function after chemotherapy in survivors of childhood malignancies. *Med Pediatr Oncol*. 1995;24:347–351.

Muto R, Yamamori S, Ohashi H, et al. Prediction of FISH analysis of the occurrence of Wilms tumor in aniridia patients. *Am J Med Genet*. 2002;108:285–289.

Natrajan R, Little SE, Sodha N, et al. Analysis by array CGH of genomic changes associated with the progression or relapse of Wilms’ tumour. *J Pathol*. 2007;211:52–59.

Neri G, Gurrieri F, Zanni G, et al. Clinical and molecular aspects of the Simpson-Golabi-Behmel syndrome. *Am J Med Genet*. 1998;79:279–283.

Olsen OE, Jeanes AC, Sebire NJ, et al. Changes in computed tomography features following preoperative chemotherapy for nephroblastoma: relation to histopathological classification. *Eur Radiol*. 2004;14:990–994.

Ooms AH, Gadd S, Gerhard DS, et al. Significance of TP53 Mutation in Wilms tumors with diffuse anaplasia: a report from the Children's Oncology Group. *Clin Cancer Res*. 2016;22:5582–5591.

Ora I, van Tinteren H, Bergeron C, et al. Progression of localised Wilms’ tumour during preoperative chemotherapy is an independent prognostic factor: a report from the SIOP 93-01 nephroblastoma trial and study. *Eur J Cancer*. 2007;43:131–136.

Othersen HB Jr, DeLorimer A, Hrabovsky E, et al. Surgical evaluation of lymph node metastases in Wilms’ tumor. *J Pediatr Surg*. 1990;25(3):1–2.

Owens CM, Veys PA, Pritchard J, et al. Role of chest computed tomography at diagnosis in the management of Wilms’ tumor: a study by the United Kingdom Children's Cancer Study

Group. *J Clin Oncol*. 2002;20:2768–2773.

Paintsil V, David H, Kambugu J, et al. The Collaborative Wilms Tumour Africa Project: baseline evaluation of Wilms tumour treatment and outcome in eight institutes in sub-Saharan Africa. *Eur J Cancer*. 2015;51:84–91.

Pelletier J, Bruening W, Kashtan CE, et al. Germline mutations in the Wilms’ tumor suppressor gene are associated with abnormal urogenital development in Denys-Drash syndrome. *Cell*. 1991;67:437–447.

Penn I. Renal transplantation for Wilms’ tumor: report of 20 cases. *J Urol*. 1979;122:793–794.

Perlman M, Levin M, Wittels B. Syndrome of fetal gigantism, renal hamartomas, and nephroblastomatosis with Wilms’ tumor. *Cancer*. 1975;35:1212–1217.

Perlman EJ. Pediatric renal cell carcinoma. *Surg Pathol Clin*. 2010;3:641–651.

Perlman EJ, Faria P, Soares A, et al. Hyperplastic perilobar nephroblastomatosis. Long term survival in 52 patients. *Pediatr Blood Cancer*. 2005;46:203–221.

Perlman EJ, Grundy PE, Anderson JR, et al. WT1 mutation and 11P15 loss of heterozygosity predict relapse in very low-risk wilms tumors treated with surgery alone: a children's oncology group study. *J Clin Oncol*. 2011;29:698–703.

Phillips SM, Padgett LS, Lesisenring WM, et al. Survivors of childhood cancer in the United States: prevalence and burden of morbidity. *Cancer Epidemiol Biomarkers Prev*. 2015;24:653–663.

Porteus MH, Norkool P, Neuberg D, et al. Characteristics and outcome of children with Beckwith-Weidemann syndrome and Wilms’ tumor: a report from the National Wilms Tumor Study Group. *J Clin Oncol*. 2000;18:2026–2031.

Powis M, Messahel B, Hobson R, et al. Surgical complications after immediate nephrectomy versus preoperative chemotherapy in non-metastatic Wilms’ tumor: findings from the 1991-2001 United Kingdom Children's Cancer Study Group UKW3 trial. *J Pediatr Surg*. 2013;48:2181–2186.

Pritchard J, Imeson J, Barnes J, et al. Results of the United Kingdom Children's cancer Study Group (UKCCSG) first Wilms tumour study (UKW1). *J Clin Oncol*. 1995;13:124–133.

Pritchard-Jones K, Fleming S, et al. The candidate Wilms’ tumour gene is involved in genitourinary development. *Nature*. 1990;346:194–197.

Pritchard-Jones K, Kelsey A, Vujanic G, et al. Older age is an adverse prognostic factor in stage I, favorable histology Wilms tumor treated with vincristine monochemotherapy: a study by the United Kingdom Children's Cancer Study Group, Wilms tumor working group. *J Clin Oncol*. 2003;21:3269–3275.

Pritchard-Jones K, Bergeron C, de Camrgo B, et al. Omission of doxorubicin from the treatment of stage II-III intermediate-risk Wilms tumour (SIOP WT 2001): an open-label, non-inferiorty, randomized clinical trial. *Lancet*. 2015;386:1156–1164.

Pritchard-Jones K, Graf N, van Tinteren H, et al. Evidence for a delay in diagnosis of Wilms’ tumour in the UK compared with Germany: implications for primary care for children. *Arch Dis Child*. 2016;101:417–420.

Rahman N, Arbour L, Tonin P, et al. Evidence for a familial Wilms tumour gene (FWT1) on chromosome 17q12-q21. *Nat Genet*. 1996;13:461–463.

Raney RB Jr, Palmer N, Sutow WW, et al. Renal cell carcinoma in children. *Med Pediatr Oncol*. 1983;11:91–98.

Rauscher IIIFJ. The WT1 Wilms tumor gene product: a developmentally regulated transcription factor in the kidney that functions as a tumor suppressor. *FASEB J*. 1993;7:896–

903.

Ravenel JD, Broman KW, Perlman EJ, et al. Loss of imprinting of insulin-like growth factor-II (IGF2) gene in distinguishing specific biologic subtypes of Wilms tumor. *J Natl Cancer Inst*. 2001;93:1698–1703.

Reinhard H, Aliani S, Ruebe C, et al. Wilms tumor in adults: results of the Society of Pediatric Oncology (SIOP) 93-01/Society for Pediatric Oncology and hematology (GPOH) study. *J Clin Oncol*. 2004;22:4500–4506.

Reinhard H, Semler O, Burger D, et al. Results of the SIOP 93-01/GPOH trial and study for the treatment of patients with unilateral nonmetastatic Wilms Tumor. *Klin Pediatr*. 2004;216:132–140.

Reinhard H, Schmidt A, Furtwangler R, et al. Outcome of relapses of nephroblastoma in patients registered in the SIOP/GPOH trials and studies. *Oncol Rep*. 2008;20:463–467.

Renshaw AA, Granter SR, Fletcher JA, et al. Renal cell carcinoma in children and young adults: increased incidence of papillary architecture and unique subtypes. *Am J Surg Pathol*. 1999;23:795–802.

Reulen RC, Bright CJ, Winter DL, et al. Pregnancy and labor complications in female survivors of childhood cancer: the British Childhood Cancer Survivor study. *J Natl Cancer Inst*. 2017;109:1–10.

Riccardi VM, Sujansky E, Smith AC, et al. Chromosomal imbalance in the aniridia-Wilms’ tumor association: 11p interstitial deletion. *Pediatrics*. 1978;61:604–610.

Ritchey ML, Kelalis PP, Breslow N, et al. Intracaval and atrial involvement with nephroblastoma: review of National Wilms’ Tumor Study-3. *J Urol*. 1988;140:1113–1118.

Ritchey ML, Kelalis PP, Breslow N, et al. Surgical complications following nephrectomy for Wilms’ tumor: a report of National Wilms’ Tumor Study-3. *Surg Gynecol*

Obstet. 1992;175:507–514.

Ritchey ML, Kelalis PP, Haase GM, et al. Preoperative therapy for intracaval and atrial extension of Wilms' tumor. *Cancer*. 1993;71 [41-4-4110].

Ritchey ML, Kelalis P, Breslow N, et al. Small bowel obstruction following nephrectomy for Wilms' tumor. *Ann Surg*. 1993;218:654–659.

Ritchey ML, Pringle K, Breslow N, et al. Management and outcome of inoperable Wilms tumor. A report of National Wilms' Tumor Study. *Ann Surg*. 1994;220:683–690.

Ritchey ML, Azizhkan R, Beckwith JB, et al. Neonatal Wilms tumors. *J Pediatr Surg*. 1995;30:856–859.

Ritchey ML, Green DM, Thomas P, et al. Renal failure in Wilms tumor patients: a report of the NWTSG. *Med Pediatr Oncol*. 1996;26:75–80.

Ritchey ML, Shamberger RC, Haase G, et al. Surgical complications after nephrectomy for Wilms tumor: report from the National Wilms Tumor Study Group. *Pediatrics*. 1999;104:816–817.

Ritchey ML, Shamberger RC, Hamilton T, et al. Fate of bilateral lesions missed on preoperative imaging: a report of the National Wilms Tumor Study Group. *J Urol*. 2005;174:1519–1521.

Ritchey ML, Daley S, Shamberger R, et al. Ureteral extension in childhood renal tumors: a report from the National Wilms Tumor Study Group (NWTSG). *J Pediatr Surg*. 2008;43:1625–1629.

Rivera MN, Kim WJ, Wells J, et al. An X chromosome gene, WTX, is commonly inactivated in Wilms tumor. *Science*. 2007;315:642–645.

Rohrschneider WK, Weirich A, Rieden K, et al. US, CT and MR imaging characteristics of nephroblastomatosis. *Pediatr Radiol*. 1998;28:435–443.

Romao RL, Pippi Salle JL, Shuman C, et al. Nephron sparing surgery for unilateral Wilms tumor in children with predisposing syndromes: a single center experience over 10 years. *J Urol*. 2012;188:1493–1498.

Romao RL, Weber B, Gerstle JT, et al. Comparison between laparoscopic and open radical nephrectomy for the treatment of primary renal tumors in children: single-center experience over a 5-year period. *J Pediatr Urol*. 2014;10:488–494.

Routh JC, Grundy PE, Anderson JR, et al. B7-H1 as a biomarker for therapy failure in patients with favorable histology Wilms Tumor. *J Urol*. 2013;189:1487–1492.

Royer-Pokora B, Weirich A, Schumacher V, et al. Clinical relevance of mutations in the Wilms tumor suppressor 1 gene WT1 and the cadherin-associated protein **β**1 gene CTNNB1 for patients with Wilms umors. *Cancer*. 2008;113:1080–1089.

Ruteshouser EC, Huff V. Familial Wilms tumor. *Am J Med Genet C Semin Med Genet*. 2004;129:29–34.

Ruteshouser EC, Robinson SM, Huff V. Wilms tumor genetics: mutations in WT1, WTX and CTNNB1 account for only about one-third of tumors. *Genes Chromosomes Cancer*. 2008;47:461–470.

Saltzman AF, Carrasco A Jr, Maccini MA, et al. Patterns of lymph node sampling and the impact of lymph node density in favorable histology Wilms tumor: an analysis of the national cancer database. *J Pediatr Urol*. 2018;14:E161.e1–E161.e8.

Sandberg JK, Mullen EA, Cajaiba MM, et al. Imaging of renal medullary carcinoma in children and young adults: a report from the Children's Oncology Group. *Pediatr Radiol*. 2017;47:1615–1621.

Scalabre A, Bergeron C, Brioude F, et al. Is nephron sparing surgery justified in Wilms tumor with Beckwith-Wiedemann syndrome or isolated hemihypertrophy. *Pediatr Blood Cancer*. 2016;63:1571–1577.

Schenk JP, Graf N, Gunther P, et al. Role of MRI in the management of patients with nephroblastoma. *Eur Radiol*. 2008;18:683–691.

Schmidt D, Beckwith JB. Histopathology of childhood renal tumors. *Hematol Oncol Clin North Am*. 1995;9:1179–1200.

Scott RH, Walker L, Olsen OE, et al. Surveillance for Wilms tumour in at-risk children: pragmatic recommendations for best practice. *Arch Dis Child*. 2006;91:995–999.

Scott RH, Stiller CA, Walker L, et al. Syndromes and constitutional chromosomal abnormalities associated with Wilms tumour. *J Med Genet*. 2006;43:705–715.

Scott RH, Murray A, Baskcomb L, et al. Stratification of Wilms tumor by genetic and epigenetic analysis. *Oncotarget*. 2012;3:327–335.

Segers H, van den Heuvel-Eibrink MM, Williams RD, et al. Gain of 1q is a marker of poor prognosis in Wilms' tumors. *Genes Chrom Cancer*. 2013;52:1065–1074.

Seibel NL, Li S, Breslow NE, et al. Effect of duration of treatment on treatment outcome for patients with clear-cell sarcoma of the kidney: a report from the National Wilms' Tumor Study Group. *J Clin Oncol*. 2004;22:468–473.

Seibel NL, Chi YY, Perlman EJ, et al. Impact of cyclophosphamide and etoposide on outcome of clear cell sarcoma of the kidney treated on the National Wilms Tumor Study-5 (NWTS-5). *Pediatr Blood Cancer*. 2018 [(in press)].

Seifert RP, McNab P, Sexton WJ, et al. Rhabdomyomatous differentiation in Wilms tumor pulmonary metastases: a case report and literature review. *Ann Clin Lab Sci*. 2012;42:409–416.

Selle B, Furtwangler R, Graf N, et al. Population-based study of renal cell carcinoma in children in Germany, 1980-2005:

more frequently localized tumors and underlying disorders compared with adult counterparts. *Cancer*. 2006;107:2906–2914.

Shamberger RC, Guthrie KA, Ritchey ML, et al. Surgery-related factors and local recurrence of Wilms tumor in National Wilms Tumor Study 4. *Ann Surg*. 1999;229:292–297.

Shamberger RC, Ritchey ML, Haase GM, et al. Intravascular extension of Wilms tumor. *Ann Surg*. 2001;234:116–121.

Shamberger RC, Haase GM, Argani P, et al. Bilateral Wilms' tumors with progressive or nonresponsive disease. *J Pediatr Surg*. 2006;41:652–657.

Shamberger RC, Anderson JR, Breslow NE, et al. Long-term outcomes of infants with very low risk Wilms tumor treated with surgery alone on National Wilms Tumor Study-5. *Ann Surg*. 2010;251:555–558.

Shrestha A, Ritz B, Wilhelm M, et al. Prenatal exposure to air toxics and risk of Wilms' tumor in 0-5year old children. *J Occup Environ Med*. 2014;56:573–578.

Smets AM, de Kraker J. Malignant tumours of the kidney: imaging strategy. *Pediatr Radiol*. 2010;40:1010–1018.

Smets AM, van Tinteren H, Bergeron C, et al. The contribution of chest CT-scan at diagnosis in children with unilateral Wilms' tumour. Results of the SIOP 2001 study. *Eur J Cancer*. 2012;48:1060–1065.

Snyder HM III, Lack EE, Chetty-Baktovizian A, et al. Congenital mesoblastic nephroma. Relationship to other renal tumors of infancy. *J Urol*. 1981;126:513–516.

Spreafico F, Pritchard-Jones K, Bergeron C, et al. Value and difficulties of a common European strategy for recurrent Wilms' tumor. *Expert Rev Anticancer Ther*. 2009;9:693–696.

Sredni ST, de Camargo B, Lopes LF, et al. Immunohistochemical detection of p53 protein expression as a prognostic indicator in Wilms tumor. *Med Pediatr Oncol*. 2001;37:455–458.

Sredni ST, Gadd S, Huang CC, et al. Subsets of very low risk Wilms tumor show distinctive gene expression, histologic, and clinical features. *Clin Cancer Res*. 2009;15:6800–6809.

Saltzman AF, Carrasco A Jr, Maccini MA, et al. Patterns of lymph node sampling and the impact of lymph node density in favorable histology Wilms tumor: an analysis of the national cancer database. *J Pediatr Urol*. 2017;14(2):161.e1–161.e8.

Stewart CL, Bruny JL. Maximizing lymph node retrieval during surgical resection of Wilms tumor. *Eur J Pediatr Surg*. 2015;25:109–112.

Strong LC. The two-hit model for Wilms' tumor: where are we 30 years later? *Genes Chromosomes Cancer*. 2003;38:294–299.

Swartz MA, Karth J, Schneider DT, et al. Renal medullary carcinoma: clinical, pathologic, immunohistochemical, and genetic analysis with pathogenetic implications. *Urology*. 2002;60:1083–1089.

Szavay P, Luithle T, Semler O, et al. Surgery of cavoatrial tumor thrombus in nephroblastoma: a report of the SIOP/GPOH study. *Pediatr Blood Cancer*. 2004;43:40–45.

Taskinen S, Lohi J, Koskenvuo M, et al. Evaluation of effect of preoperative chemotherapy on Wilms' tumor histopathology. *J Pediatr Surg*. 2017 [epub].

Taylor AJ, Winter DL, Pritchard-Jones K, et al. Second primary neoplasms in survivors of Wilms' tumour–a population-based cohort study from the British Childhood Cancer Survivor Study. *Int J Cancer*. 2008;122:2085–2093.

Termuhlen AM, Tersak JM, Liu Q, et al. Twenty-Five year follow-up of childhood Wilms tumor: a report from the childhood cancer survivor study. *Pediatr Blood Cancer*.

2011;57:1210–1216.

Tomlinson GE, Argyle JC, Velasco S, et al. Molecular characterization of congenital mesoblastic nephroma and its distinction from Wilms tumor. *Cancer*. 1992;70:2358–2361.

Tomlinson GE, Breslow NE, Dome J, et al. Rhabdoid tumor of the kidney in the National Wilms' Tumor Study: age at diagnosis as a prognostic factor. *J Clin Oncol*. 2005;23:7641–7645.

Tournade MF, Com-Nougue C, Voute PA, et al. Results of the sixth International Society of Pediatric Oncology Wilms' tumor trial and study: a risk-adapted therapeutic approach in Wilms' tumor. *J Clin Oncol*. 1993;11:1014–1023.

Tournade MF, Com-Nogoue C, deKraker J, et al. Optimal duration of preoperative chemotherapy in unilateral and nonmetastatic Wilms' tumor in children over 6 months of age: result of the 9th SIOP Wilms' tumor trial and study. *J Clin Oncol*. 2001;19:488–500.

van den Heuvel-Eibrink MM, Grundy P, Graf N, et al. Characteristics and survival of 750 children diagnosed with a renal tumor in the first seven months of life: a collaborative study by the SIOP/GPOH/SFOP, NWTSG, and UKCCSG Wilms tumor study groups. *Pediatr Blood Cancer*. 2008;50:1130–1134.

van den Heuvel-Eibrink MM, van Tinteren H, Bergeron C, et al. Outcome of localised blastemal-type Wilms tumour patients treated according to intensified treatment in the SIOP WT 2001 protocol, a report of the SIOP Renal Tumour Study Group (SIOP-RTSG). *Eur J Cancer*. 2015;51:498–506.

van Heyningen V, Hoovers JM, de Kraker J, et al. Raised risk of Wilms tumour in patients with aniridia and submicroscopic WT1 deletion. *J Med Genet*. 2007;44:787–790.

Varlet F, Petit T, Leclair MD, et al. Laparoscopic treatment of renal cancer in children: a multicentric study and review of oncologic and surgical complications. *J Pediatr Urol*. 2014;10:500–505.

Vasilyeva TA, Voskresenskaya AA, Käsmann-Kellner B, et al. Molecular analysis of patients with aniridia in Russian Federation broadens the spectrum of PAX6 mutations. *Clin Genet*. 2017;92:639–644.

Verschuur AC, Vujanic GM, Tinteren HV, et al. Stromal and epithelial predominant tumours have an excellent outcome: the SIOP 93 experience. *Pediatr Blood Cancer*. 2010;55:233–238.

Vokuhl C, NourkamiTutdibi N, Furtwangler R, et al. ETV6-NTRK3 in congenital mesoblastic nephroma: a report of the SIOP/GPOH nephroblastoma study. *Pediatr Blood Cancer*. 2017 [epub].

Vujanic GM, Sanstedt B, Harms D, et al. Revised International Society of Paediatric Oncology (SIOP) working classification of renal tumors of childhood. *Med Pediatr Oncol*. 2002;38:79–82.

Vujanic GM, Kelsey A, Mitchell C, et al. The role of biopsy in the diagnosis of renal tumors of childhood: results of the UKCCSG Wilms tumor study 3. *Med Pediatr Oncol*. 2003;40:18–22.

Vujanic GM, Harms D, Bohoslavsky R, et al. Non-viable tumor tissue should not upstage Wilms’ tumor from stage I to stage I—a report from the SIOP 93-01 nephroblastoma trial and study. *Pediatr Dev Pathol*. 2009;12:111–115.

Vujanic GM, Sandstedt B. The pathology of Wilms tumor (nephroblastoma): the International Society of Paediatric Oncology approach. *J Clin Pathol*. 2010;63:102–109.

Vujanić GM, Apps JR, Moroz V, et al. Nephrogenic rests in Wilms tumors treated with preoperative chemotherapy: the UK SIOP Wilms Tumor 2001 Trial experience. *Pediatr Blood Cancer*. 2017;64 [epub].

Warmann SW, Godzinski J, van Tinteren H, et al. Minimally invasive nephrectomy for Wilms tumors in children - data from SIOP 2001. *J Pediatr Surg*. 2014;49:1544–1548.

Warncke JC, Brodie KE, Grantham EC, et al. Pediatric renal angiomyolipomas in tuberous sclerosis complex. *J Urol*. 2017;197:500–506.

Weeks DA, Beckwith JB. Relapse-associated variables in stage I, favorable histology Wilms' tumor. *Cancer*. 1987;60:1204–1212.

Weeks DA, Beckwith JB, Mierau G, et al. Rhabdoid tumor of kidney. A report of 111 cases from the National Wilms' Tumor Study Pathology Center. *Am J Surg Pathol*. 1989;13:439–458.

Weirich A, Leuschner I, Harms D, et al. Clinical impact of histologic subtypes in localized non-anaplastic nephroblastoma treated according to the trial and study SIOP-9/GPOH. *Ann Oncol*. 2001;12:311–319.

Wilde JC, Aronson DC, Sznajder B, et al. Nephron sparing surgery (NSS) for unilateral wilms tumor (UWT): the SIOP 2001 experience. *Pediatr Blood Cancer*. 2014;61:2175–2179.

Williams RD, Al-Saadi R, Natrajan R, et al. Molecular profiling reveals frequent gain of MYCN and anaplasia specific loss of 4q and 14q in Wilms tumor. *Genes Chrom Cancer*. 2011;50:982–995.

Wittman S, Zirn B, Alkassar M, et al. Loss of 11q and16q in Wilms tumors is associated with anaplasia, tumor recurrence and poor prognosis. *Genes Chromosomes Cancer*. 2007;46:163–170.

Wong KF, Reulen RC, Winter DL, et al. Risk of adverse health and social outcomes up to 50 years after Wilms tumor: the British Childhood Cancer Survivor Study. *J Clin Oncol*. 2016;34:1772–1779.

Zani A, Schiavetti A, Gambino M, et al. Long-term outcome of nephron sparing surgery and simple nephrectomy for unilateral localized Wilms tumor. *J Urol*. 2005;173:946–948.

Zuppan CW, Beckwith JB, Weeks DA, et al. The effect of preoperative therapy on the histologic features of Wilms' tumor. An analysis of cases from the Third National Wilms' Tumor Study. *Cancer*. 1991;68:385–394.

54

Pediatric Urologic Oncology

Bladder and Testis

Fernando A. Ferrer MD, FACS, FAAP

Since the first Intergroup Rhabdomyosarcoma Study (IRS-I 1972–1978), treatment strategies for patients with bladder prostate rhabdomyosarcoma (B/P RMS) have changed dramatically. Primary anterior exoneration (Ferrer et al., 2006; Horn and Enterline, 1958) has been replaced by organ preservation strategies. In IRS-IV (1993–1997) the bladder preservation rate among 88 analyzed patients was approximately 62%, significantly improved from that of IRS-I (23%) (Arndt et al., 2004). More recent studies from the European groups have demonstrated even higher rates of bladder preservation. Detailed long-term evaluation of bladder function remains lacking; thus the true efficacy of this approach remains somewhat uncertain. The relative roles of surgery versus radiotherapy in local control remain a subject of debate. Progress in the molecular/genomic characterization of rhabdomyosarcoma (RMS) has changed risk stratification and provided new insights into molecular mechanistic drivers, proving to be the most significant advances in RMS.

Epidemiology and Syndromic Associations

Approximately 350 cases of RMS are diagnosed annually in the United States; of these 15% to 20% arise from the genitourinary system (Crist et al., 2001; Maurer et al., 1988)**. RMS is the most common soft tissue sarcoma in children and is the third most common pediatric solid tumor, representing 5% to 15% of all childhood solid tumors.** B/P RMS demonstrates a bimodal age distribution with incidence peaking from ages 0 to 2 years and then again in adolescence. Males are preferentially affected. Causality remains unclear. Reports have suggested a higher risk of RMS in children with poor prenatal care or those conceived with assisted reproductive techniques, but overall, as with other childhood cancers, genetic factors are considered more important in pathogenesis than environmental factors (Shrestha et al., 2013; Williams et al., 2013).

Most cases of RMS are considered to be sporadic; however, a genetic basis is inferred from the association of RMS with certain syndromic conditions. These include Li-Fraumeni syndrome, basal cell nevus syndrome, Costello syndrome, Noonan syndrome, and multiple endocrine neoplasm type 2A (MEN 2A).

Li-Fraumeni syndrome results from germline mutations of the p53 tumor suppressor gene. Patients are predisposed to sarcomas, breast cancer, brain tumors, adrenal carcinoma, and leukemia. The overall cancer risk in affected individuals may be as high as 50% by age 30. Soft-tissue sarcomas, typically seen by age 10, account for 15% to 20% of tumors in these patients (Diller et al., 1995; Malkin et al., 1990). Neurofibromatosis is an autosomal dominant disorder. Deregulation of Ras protein function predisposes patients to malignancy (Oguzkan et al., 2006). In IRS-IV the incidence of neurofibromatosis-1 (NF-1) among enrollees was noted to be 20 times greater than in the normal population. **The lifetime risk of RMS has been estimated at 10% among NF-1 patients** (Sung et al., 2004) **who have a particular predilection for B/P RMS, prompting some to recommend surveillance** (Sung et al., 2004). Basal cell nevus, or Gorlin syndrome, confers constitutive activation of the hedgehog-signaling pathway as a result of defects in the *PTCH* gene (Hahn et al., 1996; Johnson et al., 1996). These abnormalities cause tumor cell resistance to apoptosis (Kappler et al., 2003). This syndrome is characterized by overgrowth features, skeletal abnormalities, and benign and malignant tumors. Patients are at particular risk for basal cell carcinoma, medulloblastoma, and RMS. Noonan syndrome is distinguished by facial abnormalities, short stature, and cardiac abnormalities. Hematologic and solid tumors result from PTPN11 abnormalities affecting the Ras-MAPK signaling pathways (Jongmans et al., 2011). Costello syndrome is an autosomal dominant disorder, which manifests clinically as mental retardation, unusual facial features, heart abnormalities, and short stature (Quezada and Gripp, 2007). **In Costello syndrome, permanent activation of *HRAS* results in unchecked cell division** (Rauen, 2007)**. Cancer may eventually occur in 15% of affected individuals. In one report of 200 patients, 13 (6.5%) eventually developed pelvic RMS, prompting a recommendation for screening ultrasounds every 3 to 6 months** (Gripp et al., 2002). MEN 2A is associated with medullary thyroid carcinoma, pheochromocytoma, and hyperparathyroidism. It is inherited in an autosomal dominant fashion and results in activating mutations of the *RET* proto-oncogene. Alveolar RMS (ARMS) has been reported in these patients, and some have recommended screening (Jones et al., 2010).

Pathology and Molecular Biology

The RMS histologic classification system was originally developed by Horne and Enterline (1958) and included four subtypes: embryonal, alveolar, pleomorphic, and undifferentiated. **Recognition that pleomorphic tumors were in fact anaplastic variants of embryonal (ERMS) or ARMS led to consolidation of the original system into the three histologic categories used today: embryonal, alveolar, and undifferentiated** (Kodet et al., 1993)**. Histology is an independent prognostic indicator. Recently molecular staging has been formally introduced into Childrens Oncology Group (COG) protocols.**

ERMS is the most common form of RMS and the predominant bladder histology. Two variants of ERMS account for up to two-thirds of all genitourinary RMS: sarcoma botryoides and spindle cell. These tumors are most common in young children and have a survival rate of 85% to 90% (Ferrer and Ritchey, 2006). The “botryoid” variant is a polypoid tumor, often appearing as a “cluster of grapes.” Botryoides arise within a hollow viscus. Spindle cell variants are commonly found in the paratesticular region.

Histologically, ERMS resembles fetal striated muscle correlating to a gestational age of 7 to 10 weeks. Cells are spindle shaped with minimal cytoplasm, associated with larger cells harboring abundant eosinophilic cytoplasm or alternatively small, dark ovoid cells. Some cells may demonstrate characteristic cross striations (Fig. 54.1; Ferrer and Ritchey, 2006; Horn and Enterline, 1958). ARMS is the second most common histologic type of RMS. It occurs most frequently in adolescents and young adults in the extremities and trunk. Histologic appearance correlates with striated muscle of 10 to 21 weeks’ gestational age. Small, round tumor cells form irregular nests that give the appearance of alveolar spaces (see Fig. 54.1; Horn and Enterline, 1958). ARMS expresses myogenin, a fetal myogenic regulatory gene, which serves as a useful immunohistochemical marker for ARMS (Dias et al., 2000). Myogenin staining is absent or weak in ERMS. Compared with ERMS, ARMS metastasizes more frequently and has a worse prognosis (Crist et al., 2001; Stevens et al., 2005). Undifferentiated tumors are the least common form of RMS and carry a poor prognosis. Histologically, they appear as primitive round cells with scant cytoplasm and lack common antigenic markers (Dodd et al., 1989; Parham et al., 1991).

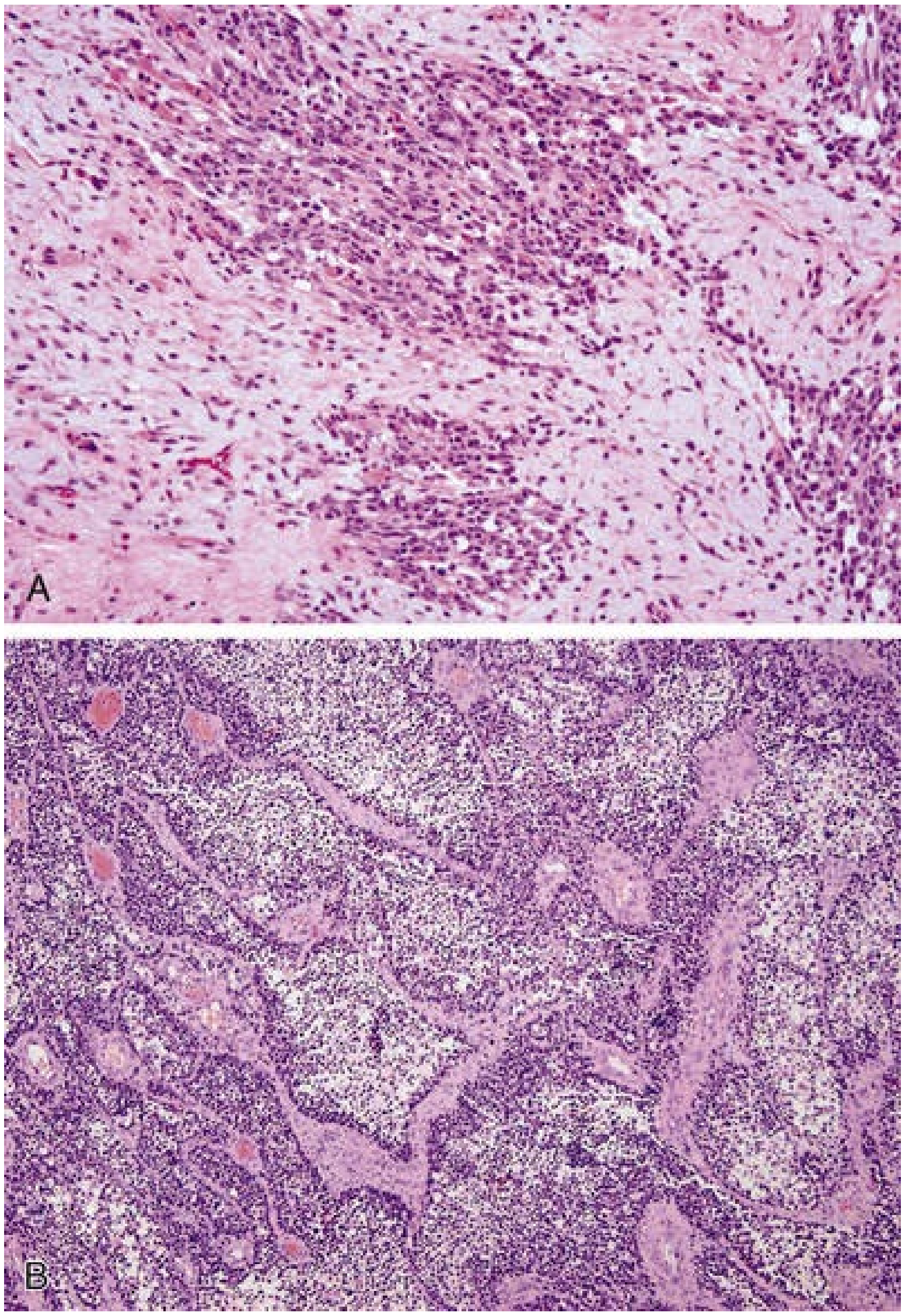

FIG. 54.1 Histologic images of common rhabdomyosarcoma variants. (A) Embryonal rhabdomyosarcoma (hematoxylin and eosin, ×200). (B) Alveolar rhabdomyosarcoma (hematoxylin and eosin, ×100). (Courtesy Cheryl Coffin, Vanderbilt University Medical Center.)

Histologic diagnosis is determined through standard immunohistochemistry and ultrastructural examination. Myogenic markers such as desmin, muscle-specific actin, myosin, and myoglobin are routinely used. As mentioned earlier, nuclear transcription factors that initiate myogenesis, MyoD and myogenin, are also being used (Cessna et al., 2001; Morotti et al., 2006; Parham and Barr, 2013).

The most significant recent development in RMS research is the discovery of oncogenic fusion proteins produced by chromosomal translocations. Histologic and clinical differences between ERMS and ARMS have long been recognized.

Only recently has molecular genetic analysis been able to distinguish two distinct subtypes of ARMS: fusion positive and fusion negative. Translocations between chromosomes 2;13 or 1;13 result in disruption of specific genes in 2q35 or 1p30 and 13q14. Rejoining these segments leads to the formation of fusion genes. The involved genes on chromosomes 2 and 1 are *Pax3* and *Pax7*. These genes are members of the paired-box family of transcription factors (Barr et al., 1993; Davis et al., 1994). The chromosome 13 fusion partner is *FOXO1*, which encodes transcription factors from the forkhead family (Davis et al., 1994; Galili et al., 1993). **The resulting fusion genes *Pax3-FOXO1* and *Pax7-FOXO1* are believed to encode proteins involved in ARMS pathogenesis and confer more aggressive phenotype** (Parham and Barr, 2013)**. It appears that roughly 80% of ARMS are fusion positive.**

The clinical relevance of these molecular features has been highlighted in a report from the COG sarcoma committee in a survival analysis; patients with intermediate-risk RMS, *Pax3-FOXO1*$^+$ ARMS (n = 85), *Pax7*-FOXO1$^+$ ARMS (n = 23), translocation-negative ARMS (n = 21), and 305 patients with ERMS were evaluated for event-free survival (EFS) and overall survival (OS). As expected, EFS and OS were worse at 5 years for those with ARMS compared with those with ERMS. ***Pax3/ Pax7-FOXO1*$^+$ fusion-positive patients had inferior EFS compared with those with fusion-negative ARMS and ERMS** (Fig. 54.2). In addition, OS proved worse for those with *Pax3* fusion compared with those with *Pax7* fusion (Skapek et al., 2013). These findings provide insight into the 20% of ARMS patients who enjoy favorable outcomes more consistent with ERMS; 20% of ARMS patients are fusion negative. A recent re-review of patients originally enrolled in the RMS study group D9602 focused on the outcomes of patients with ARMS that were fusion negative. The authors concluded that patients with low-risk features who were fusion positive should be treated on the intermediate-risk protocol, whereas those with fusion-negative features may be treated with lower intensity therapy (Arnold et al., 2016). In the current study ARST1431, patients with fusion-negative ARMS will be eligible for reduced therapy.

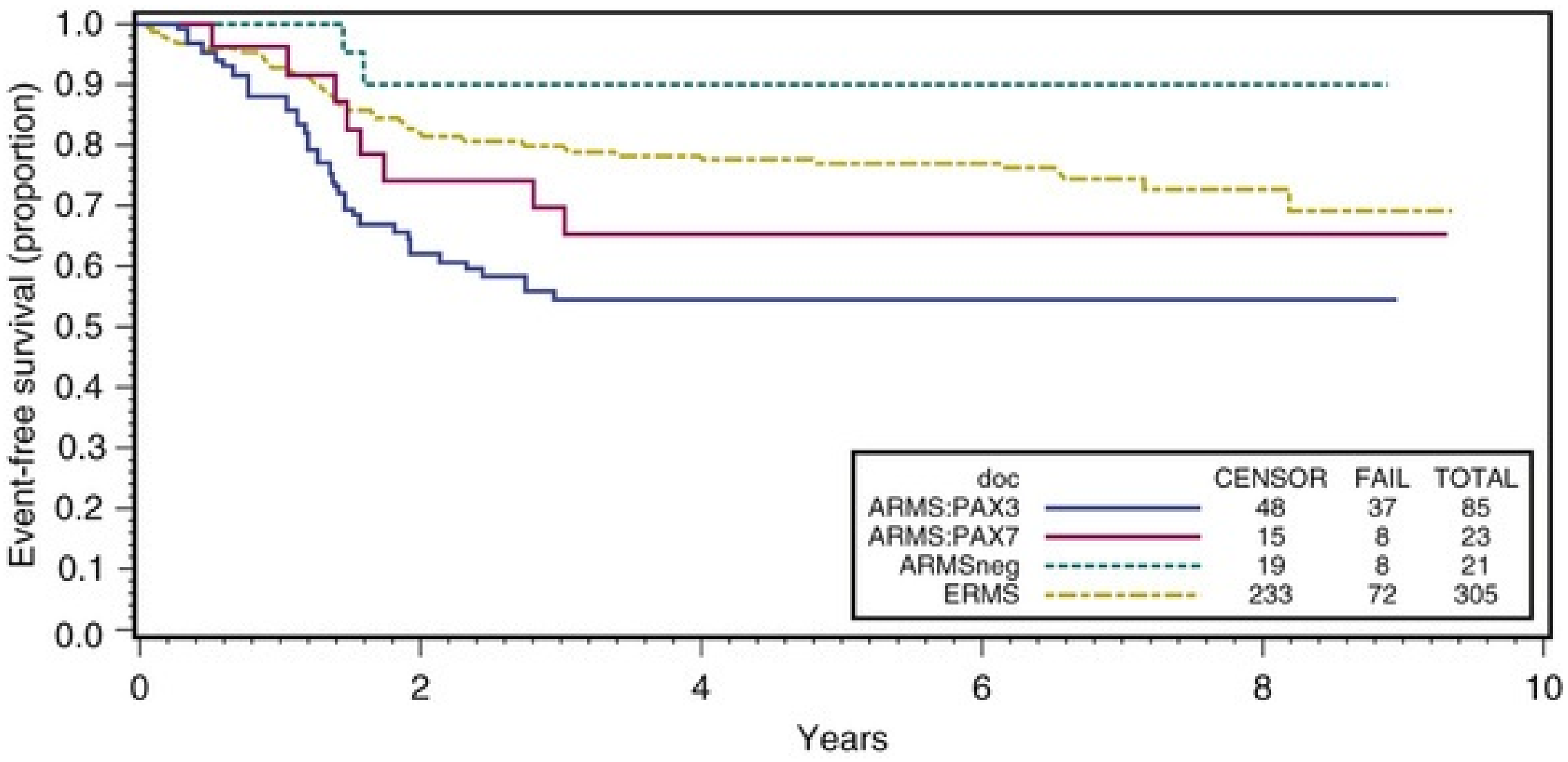

FIG. 54.2 Event-free survival of patients with alveolar rhabdomyosarcoma (ARMS) based on *PAX-FOXO1* fusion status compared with an embryonal RMS (ERMS) cohort. (Data from Skapek SX, Anderson J, Barr FG, et al.: *PAX-FOXO1* fusion status drives unfavorable outcome for children with rhabdomyosarcoma: a Children's Oncology Group report. *Pediatr Blood Cancer* 60:1411–1417, 2013.)

Studies are underway to understand the oncologic drivers downstream of these translocation proteins. Preliminary studies using genome-wide ChIP sequencing have identified transcriptional targets of *Pax3-FOXO1* protein such as fibroblast growth factor receptor 4 (FGFR4), which enhances proliferation and cell survival in ARMS; the insulin-like growth factor receptor 1 (IGF1R), known to stimulate myoblast growth; as well as another growth promoting gene, the c-Met receptor (c-Met) (Cao et al., 2010; Crose et al., 2012; Engert et al., 1996; Epstein et al., 1996; Ginsberg et al., 1998; Keller and Guttridge, 2013; Lagha et al., 2008). Finally, it appears that *Pax-FOXO1* fusion proteins can also disrupt the function of MyoD-regulated genes such as myogenin, p21, and muscle creatine kinase (Calhabeu et al., 2013).

Key Points

- Embryonal is the most common histology for bladder and prostate lesions.
- Alveolar histology is uncommon in the bladder or prostate.
- New studies indicated two distinct types of ARMS: PAX-FOXO1 fusion positive and negative; fusion-positive tumors carry a worse prognosis.

Presentation, Initial Evaluation and Management, Staging

Presenting Symptoms and Examination

It is estimated that 5% to 10% of all RMSs occur in the bladder or the prostate. The majority of these tumors are localized at presentation. Presenting symptoms commonly include urinary obstruction, urinary retention, urgency, frequency, and incontinence. Gross or microscopic hematuria occurs when the tumor breaks through the mucosal layer (Ferrer, 2010; Ferrer et al., 2006). On examination, a mass corresponding with a distended bladder or tumor may be palpated. Tumors within the bladder tend to grow intraluminally and are frequently botryoid in appearance. Rarely, tumors may prolapse into the urethra and be visible externally. Tumors of prostatic origin tend to be solid masses at presentation. Rarely are patients seen initially with evidence of systemic disease. Nodal drainage is to the pelvic nodes; thus they are typically not palpable (see Table 54.1).

TABLE 54.1

Nodal Drainage Patterns for Genitourinary Rhabdomyosarcoma

PRIMARY TUMOR SITE	NODAL DRAINAGE
Bladder/prostate	Pelvic and retroperitoneal nodes at or below renal arteries
Uterus/cervix	Pelvic and retroperitoneal nodes at or below level of renal arteries
Paratesticular	Pelvic and retroperitoneal nodes at or below level of renal arteries (inguinal nodes if scrotal skin is involved)
Vagina	Pelvic and retroperitoneal nodes at or below level of renal arteries
Vulva	Inguinal nodes
Retroperitoneum/pelvis	Pelvic and retroperitoneal nodes
Perianal/perineal	Inguinal and pelvic nodes; may cross midline

Data from Scarpato KR, Ferrer FA, Rodeberg DA, et al.: Genitourinary rhabdomyosarcoma in children. *AUA Update Series* volume 32, lesson 9, 2013.

Key Point

- Bladder/prostate tumors typically are accompanied by symptoms of obstruction, retention, or hematuria.

Evaluation

Abdominal/pelvic ultrasonography (US) is commonly the first study in children with hematuria or obstructive symptoms. When a mass lesion is suspected, definitive imaging with computed tomography (CT) or magnetic resonance imaging (MRI) is indicated. The site of origin, prostate versus bladder, can be difficult to ascertain. The pelvic nodal basin of the bladder/prostate tumors should be assessed using fine-cut CT or MRI. CT of the chest is required to exclude pulmonary metastasis (the most common site). Bone scan, bone marrow biopsy, and aspirates are also indicated; however, recently, a reduction in staging investigations for patients with translocation-negative disease has been recommended by the COG.

A recent analysis of ERMS and ARMS patients demonstrated that patients with ERMS who have tumors that are less than 5 cm and noninvasive (T1), without nodal disease, had a 0 chance of having bone or bone marrow metastases. Thus patients with ERMS without nodal or lung metastases do not require bone scans or bone marrow evaluations (Weiss et al., 2013). Any metastatic sites must be identified for appropriate treatment selection. Growing evidence suggests a role for positron emission tomography CT (PET-CT) in staging and monitoring disease response. Tateishi et al. have suggested that TNM stage and post-treatment restaging were more accurately described by PET-CT than by conventional imaging (Federico et al., 2013; Tateishi et al., 2009). The current intermediate-risk protocol evaluates the role of fluorodeoxyglucose (FDG)-positron emission tomography (PET) imaging in RMS patients.

Biopsy Techniques and Management of Obstruction

Biopsy for definitive diagnosis can be challenging. The limited size of pediatric resectoscopes and narrow width of hot loupes make adequate endoscopic biopsy difficult. Circumscribing a section of a polypoid tumor using cutting current and then subsequently removing the section intact with biopsy forceps can aid in obtaining an adequate sample (Snyder, 2005). Excessive use of cautery can lead to cautery artifact, which may mimic spindle cells. Coordination with an experienced onsite pathologist is essential to evaluate frozen sections. **If adequate tissue for diagnoses cannot be obtained endoscopically, COG protocols recommend open transvesical biopsy with pelvic and para-aortic lymph node sampling.**

Patients may require management of lower or upper urinary tract obstruction at presentation. **Early and effective management of obstruction is essential in these patients to maximize renal function, which will be taxed by systemic therapy.** As a general rule I prefer placement of a urethral catheter above a suprapubic tube for bladder outlet obstruction. In my experience, response to therapy may be rapid, and the catheter can be removed in a few weeks. Ureteral obstruction is best managed using indwelling ureteral catheters. If these cannot be placed in a retrograde fashion, percutaneous nephrostomy tube placement with conversion to internal catheters may be considered (Meir et al., 2004).

Staging and Childrens Oncology Group Risk Group Assignment

Staging patients with RMS is complex and involves the use of a pretreatment TNM staging system, a post-biopsy or resection surgical-pathological group system, and finally, risk group stratification (low, intermediate, high), which is derived from the TNM and surgical-pathological group systems (see Tables 54.2 through 54.4). The pretreatment TNM system sorts patients into favorable and unfavorable sites. Favorable sites for genitourinary (GU) RMS include para-testicular, vulvar-vaginal, and uterine tumors. Bladder/prostate (B/P) tumors arise from an unfavorable site (see Table 54.2). Local stage, tumor size, histology, nodal status, and metastasis are also considered in the pretreatment stage. The surgical-pathological group score is affected by the presence of residual disease. With the advent of organ preservation strategies, more patients undergo initial biopsy in lieu of resection, which has shifted the majority of B/P RMS patients from group I to group III (see Table 54.3). Patients are then stratified into low-, intermediate-, and high-risk groups. B/P RMS patients are commonly intermediate risk (see Table 54.4). Patient age is another independent prognostic factor: patients younger than 1 year and older than 10 years have inferior survival rates (Joshi et al., 2004; Meza et al., 2006). **The ARST1431 study will be the first sarcoma study to use FOXO1 fusion status rather than histology for study eligibility, because it is more predictive of outcome**

as demonstrated by several independent analyses (Furlong et al., 2001; Skapek et al., 2013).

TABLE 54.2

Intergroup Rhabdomyosarcoma Study Group Pretreatment TNM Clinical Staging

Stage 1: Favorable site, nonmetastatic Stage 2: Unfavorable site, small tumor, negative nodes, nonmetastatic Stage 3: Unfavorable site, larger or positive nodes, nonmetastatic Stage 4: Any site, metastatic
TUMOR
T1: Confined to site of origin ≤5 cm 5 cm T2: Fixation to surrounding tissues ≤5 cm >5 cm
SITE
Favorable: Orbit, nonparameningeal head and neck sites, male (paratesticular) or female (vagina, vulva, cervix, or uterus) genital tracts ***Unfavorable:*** All other locations (e.g., bladder and prostate)
REGIONAL LYMPH NODES
N0: Regional lymph nodes not clinically involved N1: Regional lymph nodes clinically involved
METASTASES
M0: No distant metastases M1: Metastases present

TABLE 54.3

Postoperative Clinical Group Assignments

GROUP I
Localized disease, completely resected
GROUP II
Grossly resected tumor with microscopic residual disease Regional disease with involved nodes, completely resected with no microscopic residual Regional disease with involved nodes, grossly resected, but with evidence of microscopic residual and/or histologic involvement of the most distal regional node (from the primary site) in the dissection

GROUP III
Incomplete resection or biopsy with gross residual mass
GROUP IV
Distant metastasis

Data from Scarpato KR, Ferrer FA, Rodeberg DA, et al.: Genitourinary rhabdomyosarcoma in children. *AUA Update Series* volume 32, lesson 9, 2013.

TABLE 54.4

Rhabdomyosarcoma Risk Stratification

HISTOLOGY	CLINICAL GROUP	STAGE	AGE	RISK GROUP
Embryonal, with variants	I, II, III	1	All	Low
Embryonal, with variants	I, II	2, 3	All	Low
Embryonal, with variants	III	2, 3	All	Intermediate
Embryonal, with variants	IV	4	<10 yr	Intermediate
Embryonal, with variants	IV	4	≥10 yr	High
Alveolar	I, II, III	1, 2, 3	All	Intermediate
Alveolar	IV	4	All	High

Treatment and Outcomes

Evolution of Multimodal Treatment

Advances in the treatment of RMS have been facilitated by collaborative groups, including the COG (encompassing the Intergroup Rhabdomyosarcoma Study [IRS]), the International Society for Pediatric Oncology (SIOP), the Italian Cooperative Group (ICG), and the German sarcoma study group, Cooperativen Weichteilsarkom Studie (CWS). At the initiation of IRS-I (1972–1978), treatment of B/P RMS involved radical surgery (Ferrer et al., 2006; Horn and Enterline, 1958). The combination of upfront surgery with adjuvant chemotherapy resulted in an OS of 78% with significant associated morbidity related to extirpative surgical procedures (Ferrer and Ritchey, 2006; Raney et al., 1993).

IRS-II (1979–1984) and SIOP RMS 75 were the first to use neoadjuvant chemotherapy and radiation and focus on bladder preservation. Ten percent of patients achieved relapse-free survival with chemotherapy alone. OS was 80%, but the functional bladder preservation rate was still only 25% (Crist et al., 1995; Raney et al., 2001). In IRS-III (1985–1992) the use of doxorubicin, cisplatin, and etoposide coupled with radiotherapy saw OS for BP/RMS rise to 83% and bladder preservation rates go up to 60% (Crist et al., 1995; Hays et al., 1995, Lobe et al., 1996; Raney et al., 2001). In IRS-IV (1993–1997) pretreatment TNM staging and a regimen of vincristine, dactinomycin, and cyclophosphamide were used. Arndt et al. (2004) reported on the IRS-IV outcomes for patients with B/P RMS. At 6.1 years EFS was 77% and OS was 82% (Arndt et al., 2004), but only 36 (40%) of the original 88 patients are failure free with “normal” bladder function.

IRS-V was the first protocol to use risk stratification. The 3-year failure-free survival rate was 88% for low risk, 76% for intermediate risk, and less than 30% for high-risk patients (Alexander et al., 2012; Ferrer and Ritchey, 2006; Ferrer et al., 2006). Little change has occurred in survival in subsequent studies.

Current Multi-Model Approaches: Children's Oncology Group

The majority of B/P patients have tumors that are unresectable at presentation and therefore undergo diagnostic biopsy, as opposed to an upfront primary excision that could compromise organ function. If resection is attempted as a primary procedure (e.g., a bladder dome lesion), or later in the patient's course as a secondary procedure (rare), surgeons should mark any area outside the bladder lumen, suspicious for residual disease with titanium clips, because frozen section margins may be unreliable. Patients undergo imaging of the appropriate nodal drainage pathways (see Table 54.1). Pathological confirmation of any radiographically positive nodes should be performed to avoid unnecessary radiotherapy. If a patient has suspicious nodes, open bladder and concomitant pelvic and para-aortic nodal biopsy may be preferred.

COG protocols advise that complete response to nonoperative therapy (chemo/radiation) may not be rapid and that radical surgery should be avoided. A residual mass does not always represent viable tumor. Tumors cells may involute, leaving a mass that consists primarily of surrounding stroma. They may also differentiate into mature rhabdomyoblasts that do not require radical resection (Wu and Snyder 2004; Wu et al., 2009). **Further, residual mass does not correlate with outcome.** IRS-III highlighted this fact, showing that 36% of patients without radiologic response to nonoperative treatment were in complete remission based on pathological assessment of resection specimens (Hays et al., 1995; Raney et al., 2001).

After diagnostic biopsy patients proceed to the appropriate risk-stratified treatment regimen, which, in the current study involves chemotherapy, surgery, and radiation therapy. The only open COG study as of this writing is the intermediate-risk study, which is most relevant to B/P RMS patients. The objectives of the current COG intermediate-risk study ARST1431 are to

1. Compare EFS and OS of patients treated with surgery, radiotherapy, and vincristine, adriamycin, and cyclophosphamide (VAC), alternating with vincristine and irinotecan (VI) to that of patients in which temsirolimus (mTOR inhibitor) has been as added to the treatment regimen.
2. Compare survival of patients based on their FOXO1 fusion gene partner (*PAX3* vs. *PAX7*).
3. Assess response at 9 weeks of therapy using FDG-PET as a predictor of outcome.
4. Estimate the frequency of patients with circulating tumor DNA at diagnosis and subsequent therapeutic time points.

Specifics regarding local control measures in this study are delineated in the local control section that follows. Study protocols are available through each participating institution's principal investigator and have detailed surgical guidelines.

Key Points

- Organ preservation is a principal goal of treatment; therefore most patients treated in COG protocols undergo endoscopic/open biopsy as the initial step.
- Pretreatment TNM staging and a surgical-pathological group classification contribute to the patients’ final risk group assignment, which, in turn, determines therapy.
- New to the current study is the use of fusion status for therapeutic group assignment.
- Bladder/prostate tumors arise from an unfavorable site and gross residual tumor usually remains after biopsy; therefore most patients are assigned to the intermediate-risk group.
- A residual mass after chemotherapy and radiotherapy does not necessarily

mean viable tumor remains.

- Rhabdomyoblasts are differentiated tumor cells that do not require further treatment.

Current Multi-Model Approaches: European Cooperative Groups

SIOP's philosophical approach to B/P RMS has varied from that of IRS and later COG. Although both groups have focused on bladder preservation, the SIOP MMT 84, 89, and 95 (1984–2003) studies have taken a fundamentally different view on local control, avoiding radiation. Patients are treated with chemotherapy and assessed for response (Flamant et al., 1985; Oberlin et al., 2012; Stevens et al., 2005). Patients enrolled in MMT 89 also received ifosfamide, vincristine, and dactinomycin (IVA) as primary therapy, and in MMT 95 patients were randomized to receive either IVA or a 6-drug regimen consisting of ifosfamide, vincristine, actinomycin D, carboplatin, epirubicin, and etoposide. Tumor response is evaluated radiographically and endoscopically. Patients not exhibiting complete response are considered for conservative surgery (tumorectomy, partial cystectomy, or prostatectomy). Radiotherapy is used only in cases in which a cure is not achieved by chemotherapy and surgery. If necessary, radical surgery is considered, as opposed to external beam radiotherapy (ERT), to avoid the late consequences of ERT (Flamant et al., 1985; Oberlin et al., 2012; Stevens et al., 2005).

Using this approach SIOP recently reported the combined results for MMT 84, 89, and 95 (Jenney et al., 2014). In all, 175 patients were eligible for analysis. Key outcomes included EFS and OS, which were 63% and 77%, respectively. Although the 5-year OS was similar to that of other international groups, the EFS was lower than that reported by COG. It is assumed that the lower EFS is related to the diminished use of radiotherapy in these trials. The similar OS may reflect the ability to “recover” some of these patients with second-line therapy. The percentage of preserved bladders increased from 69% to 73%, and most recently in MMT 95, to 76% (Jenney et al., 2014). Similar to SIOP protocols, the reported Italian Cooperative Group (ICG) studies ICG-79 and ICG-88 focus on upfront 3-drug chemotherapy and attempted to avoid radiotherapy. EFS and OS results were not significantly different from those observed in SIOP studies (Rodeberg et al., 2011).

Results from the CWS study, CWS-96, were reported in 2011 (Seitz et al., 2011). Patients were biopsied and then went on to receive neoadjuvant chemotherapy with 3 drugs. Radiologic response after 9 weeks determined local therapy. Patients with complete response did not receive radiotherapy, those with more than two-thirds response received 32 Gy, and those with less than two-thirds response received 45 Gy. Primary resection was discouraged unless it would not affect bladder function. Secondary surgery was performed only if residual disease remained after radiotherapy. A total of 63 patients were analyzed. Radiation was given to 60.3%; 51 underwent upfront biopsy, and only 12 had primary resection. Secondary resection was performed in 45 patients. The 5-year OS for the entire group (all stages) was 76.3%. Patients having only chemoradiotherapy had an OS of 87.5%. Patients who had chemotherapy and surgery had an OS of 84% as compared with those undergoing chemo-radiation followed by tumor resection in 87.8%. Those undergoing incomplete resection with follow-up radiotherapy and chemotherapy had an OS of only 39% (Seitz et al., 2011). The follow-up study to CWS-96 was the CWS 2002P trial, for which results were reported in 2016. The treatment protocol was similar to CWS-96; 42 B/P RMS patients were evaluable, the 5-year OS was 84.5%, and EFS was 79.9%. The bladder preservation rate was 80.9%. Although not statistically different, the results are somewhat improved from CWS-96, presumably because of fewer protocol violations and lower use of radiation. Patients with large tumors greater than 10 cm had a poor 5-year EFS (50%). The 5-year OS for 6 patients with local relapse was only 33% (Seitz et al., 2016a,b).

In summary, all of the cooperative groups have focused on bladder preservation. Overall survival results between the two different approaches are similar. Protocols avoiding radiotherapy appear to have lower EFS but comparable OS, suggesting that children who fail can be rescued with intensified chemotherapy. Survival for B/P RMS has not changed substantially in two decades. It is likely that novel therapies or an enhanced understanding of risk stratification, perhaps based on genomic analysis, will be required before we see further improvement (Rodeberg et al., 2011).

Local Control

How to best attain local control in RMS patients has been a subject of intense discussion. Approaches have involved surgery, radiation therapy, or the combination of both. Both modalities have the potential for significant side effects. The concern regarding radiation late effects has prompted our European colleagues to use XRT very selectively (Dantonello et al., 2009). In study D9803 radiation dosage was based on the size of the residual mass at 12 weeks: the minimum dose was 36 Gy and the maximum dose was 50.4 Gy. For patients with group III disease the local recurrence rate was 19%, for those with bladder prostate lesions specifically, that number was 14%. The only clear predictor of local recurrence was initial tumor size exceeding 5 cm (25% vs. 10% for those under 5 cm).

The current COG intermediate-risk study (ARST1431) addresses local control with 2 approaches. The first delayed primary excision (DPE) allows for patients to undergo resection at 12 weeks post-initiation of chemotherapy when appropriate (debulking operations or procedures that would compromise organ functionality are not indicated). Patients who had a gross total resection may qualify for reduced-dose radiation. The second strategy involves increasing radiation for tumors exceeding 5 cm at presentation. Specifically, in the current study a total dose of radiation of 59.4 Gy is recommended for primary tumors exceeding 5 cm for those patients who will not undergo DPE.

Treatment of Very Young Children

Because of their increased susceptibility to treatment-related morbidity, management of infants with B/P RMS is a significant challenge, and age less than 1 year remains an adverse prognostic factor (Crist et al., 2001; Joshi et al., 2004; Malempati et al., 2011). Various collaborative groups have demonstrated significantly lower failure-free survival in infants (Ferrari et al., 2003; Joshi et al., 2004; Malempati et al., 2011). Because there is no clear evidence that the biology of RMS is different in young children, it is thought that reduction in prescribed therapy is responsible. Specifically, studies by Ragab et al. (1986) and Malempati et al. (2011) have demonstrated higher local failure rates for infants treated in IRS studies. These higher local failure rates have been associated with a reduction in recommended radiation therapy (Ferrari et al., 2003; Malempati et al., 2011). Puri et al. (2006) evaluated a population of 20 infants and toddlers receiving external beam radiotherapy, 7 of 20 experienced long-term morbidity, including altered ambulation, recurrent infections, and second malignant neoplasms. COG protocol allows the treating institution to deviate from protocol-prescribed radiation therapy for children younger than 24 months of age who are FOXO1 fusion negative. The issue of appropriate therapy for very young children remains unresolved.

Timing of Surgical Reconstruction

Although bladder preservation rates have risen, some cases still require extirpative surgery. In these instances, the appropriate timing for reconstruction is a central question. Several authors have suggested that it is feasible to perform reconstruction concomitantly with cystectomy or cystoprostatectomy. Lander et al. (1992) described performing immediate “le bag” neobladder reconstruction on 3 children undergoing cystectomy for RMS. The reconstructive procedures themselves were successful and initial frozen sections of margins were negative. However, viable tumor was present on permanent sections, mandating further chemotherapy and radiotherapy to the reconstructed pelvis (Lander et al., 1992). Similarly, Merguerian et al. (1998) noted that frozen section proved unreliable in predicting residual disease. Hensle and Cheng (2000) observed that, although early reconstruction is feasible, it should be considered carefully and avoided if further local therapy is a possibility. The group from Padua, Italy, published their experience with continent orthotopic reconstruction using the “VIP” bladder (Castagnetti et al., 2013). Of 9 patients undergoing urethral preservation, 2 experienced local recurrence despite negative intraoperative frozen section and permanent section evaluation. Contrasting this experience is that of the Mainz group (Stein et al., 2013). Their preference is to perform continent reconstruction at the time of cystectomy. From a group of 25 patients, 11 underwent continent cutaneous diversion and 2 underwent a urethral ileocecal pouch. All of these patients are reported to be continent, and none appear to have had local recurrence (Stein et al., 2013).

The difficulty in predicting local recurrence and concerns related to irradiating the recently reconstructed GU tract has prompted some to advocate for delayed reconstruction. Duel et al. (1996) performed initial urinary diversion followed by delayed reconstruction in those patients obtaining long-term cure. They used colonic segments to create a temporary conduit, avoiding the previously irradiated ileum. These segments were later reconfigured into the cutaneous continent reconstructions. Experience with delayed orthotopic reconstruction is limited. Recently the group from Padua described their disappointing continence results in 2 patients in which this approach was attempted (Castagnetti et al., 2013). **In conclusion, early reconstruction is feasible; however, the inaccuracy of intraoperative margin analysis increases the likelihood of positive margins, local tumor recurrence, and further local therapy in a reconstructed pelvis.**

Outcomes

In the most current large report the outcomes of patients from IRS/COG, SIOP, ICG, and CWS are reviewed collectively and comparatively (Rodeberg et al., 2011). In all, the outcomes of 379 patients were evaluated. Patients aged birth to 5 years made up 74% of the cohort; 87% were younger than age 10; 82% were male. Analysis of pathology revealed that 322 of 379 (85%) had localized embryonal tumors. Metastases were observed in only 7% of patients with ERMS. Thirty patients (8%) had nonembryonal pathology (alveolar or other). The site of origin was recorded as bladder 59%, prostate 29%, or bladder or prostate 12% (Rodeberg et al., 2011). Prognostic features included local tumor invasion, tumor size, and histology. In evaluation of the treatment of localized B/P RMS patients, 48% of SIOP/ICG received radiotherapy versus 85% of patients enrolled in IRS/CWS.

The collective outcomes demonstrated a 5-year failure-free survival of approximately 75% for patients with localized tumors. The 5-year OS was 84%. The majority of failures (88%) occurred within 3 years. The location of failures was local 60%, regional nodes with or without local disease 9%, and 25% with distant failure with or without local disease (Rodeberg et al., 2011). **Comparative outcomes analysis of collaborative group protocols revealed no statistically significant difference between the groups in FFS or OS when correcting for tumor invasion and tumor size between the groups** (Rodeberg et al., 2011).

The last fully reported IRS/COG results come from IRS-IV. Eighty-eight patients were included in the analysis. The OS at 6 years was 82%, the EFS was 77%. Fifty-five patients retained their bladders, but only 36 (40%) reported normal bladder function (Arndt et al., 2004). Functional bladder evaluation was limited in this study. In 2006 an international workgroup reported on continence of 62 patients, age 6 or older who did not undergo cystectomy. Forty-three (69%) were reported to be continent, 16 had nocturnal incontinence, and 9 had diurnal incontinence. Patients undergoing partial cystectomy had a continence rate of 73%. Of the entire group only 11 underwent formal urodynamic study (Raney et al., 2006). The oft-cited series by Yeung et al. (1994) reports on 11 patients undergoing complete urodynamic evaluation after cure for pelvic RMS. In this report only children who did not receive RT had normal bladder function. Similarly, Hays et al. (1995) observed that patients receiving radiation were more likely to have adverse bladder functional sequela and that a dose effect was present; those receiving 40 Gy or higher had more complications.

Another important question remains: What is the outcome of children who require salvage surgery? The question was addressed in a recent report from the 28-year Italian experience. Of the 108 patients enrolled in their protocols, 33 (30.6%) underwent “salvage” surgery, of whom 26 patients had more than 5 years of follow-up. For these patients the authors found that the most significant predictor of EFS was tumor differentiation within the resected specimen. Undifferentiated tumors had a statistically significant poorer outcome as measured by progression-free survival at 5 years. Undifferentiated histology increased the odds of failure 28 times. Interestingly, positive tumor margins did not correlate with outcomes in this study (Angelini et al., 2016).

In summary, OS continues to be relatively unchanged for more than 2 decades in patients with B/P RMS. Molecular staging will hopefully lead to more appropriate staging and appropriate treatment burdens. The true long-term success of bladder preservations strategies remains somewhat unclear.

Late Effects

The treatment of RMS at any pelvic site is associated with potential short- and long-term morbidity. Relative to fertility and sexual function, Raney et al. (2006) analyzed the urologic complications of 164 patients treated for B/P RMS from an international cohort. Unfortunately, data were available for only 35 (21%) of the patients. After treatment for B/P RMS 25 men were potent and 2 were impotent. Sixteen had preserved ejaculation and 4 suffered from anejaculation. Two of 7 females with available data had abnormal menses (Raney et al., 2006). Mansky et al. (2007) used a questionnaire and serum analysis to evaluate survivors of pediatric sarcoma. Of 13 female participants, 7 (47%) became pregnant, 6 remained premenopausal, and 7 experienced premature menopause. With regard to male fertility, only 4 of 17 (24%) fathered children. Among those who did not father children, 9 consented to semen analysis for the study. Six of these were azoospermic, 2 had oligospermia, and 1 was normal; thus only 29% were fertile based on history or semen evaluation. All 3 males who received pelvic XRT were infertile (Mansky et al., 2007). Frees et al. (2016) reported on 13 males undergoing RMS treatment between 1975 and 2014. Patients were studied using the erection hardness score (EHS) and the self-estimation index of erectile function–no sexual intercourse (SIEF-NS). Three patients demonstrated no impairment; none of these patients had undergone radiotherapy; radical cystoprostatectomy had been performed in 2 before age 3. The rest of the patients had erectile dysfunction. Patients who failed oral PDE-5 therapy were successfully treated with alprostadil (Frees et al., 2016). Spunt et al. (2005) reviewed the 20-year late effects of female survivors of pelvic RMS. Delayed morbidity was found in 24 of 26 patients. Of the whole group, 77% had endocrinologic/ovarian dysfunction, and 58% experienced gynecologic dysfunction, including absence of a uterus, ovaries, or vaginal stenosis. **Although large detailed studies are lacking, it is clear that significant reproductive and sexual functional consequences occur with current treatments** (Armstrong et al., 2014).

Bladder function may be impaired as a result of surgery, chemotherapy, or radiation. **Arndt's review of outcomes from patients in IRS-IV suggests that despite bladder preservation strategies, more than 60% of patients have some degree of bladder dysfunction.** Only 3 studies have used the “gold standard,” urodynamics, to evaluate treatment. Yeung et al. (1994) evaluated 11 children treated for pelvic sarcoma. Seven patients received ERT or brachytherapy, and all of them experienced decreased bladder capacity and irritative symptoms. Soler et al. (2005) evaluated 8 children undergoing multimodal therapy. Five of them experienced dysuria, urgency, frequency, and diminished capacity. More recently, Martelli et al. (2016) evaluated 11 children post-treatment with urinary dysfunction; the most common finding was detrusor sphincter dyssynergia.

An increased risk of second malignant neoplasm is associated with radiotherapy and chemotherapy. Studies of pelvic RMS survivors suggest that they develop secondary malignant disease at 6 times the normal rate (Cohen et al., 2005). Mansky et al. (2007) reported second malignancies including osteosarcoma, Ewing sarcoma, and T-cell lymphoma in 9% of patients treated for pelvic sarcoma. Osteosarcoma, colon adenocarcinoma, and cervical squamous cell carcinoma were among the second malignancies experienced in Spunt's series of 26 survivors (Spunt et al., 2005). International cooperative groups have validated these findings (Bisogno et al., 2012). **Long-term monitoring of B/P RMS patients in specialized survivorship clinics is recommended.**

Oncofertility

Just under 16,000 children were diagnosed with cancer in 2016. As survival rates have increased, so have long-term effects of treatment (CureSearch Institute, NC). Future fertility is adversely affected in males and females by cancer treatment. The risk of infertility increases with the cumulative dose of alkylating agents and radiation affecting the gonads (Ginsberg, 2011). Males are vulnerable to gonadotoxicity from chemotherapy at all ages; females, on the other hand, are relatively protected in the prepubertal period. Radiotherapy affects male and female fertility. In prepubertal males 6 grays (Gy) is enough to result in permanent azoospermia; the threshold drops to 2.5 Gy in postpubertal males. In prepubertal females threshold doses for infertility are more than 15 Gy and more than 10 Gy in postpubertal girls. Females undergoing cranial or spinal radiation are also at risk because of the scatter effect on the ovaries. Patients undergoing myeloablative therapy and subsequent bone marrow transplant are also at high risk (CureSearch; Green et al., 2014a,b).

Despite the fact that multiple societies have released guidelines regarding fertility preservation in prepubertal children and adolescents, many patients are not adequately counseled before treatment, and studies have shown racial and other demographic bias can affect access (Practice Committee of American Society for Reproductive Medicine, 2013). In postpubertal males semen cryopreservation is an accepted modality for preservation of fertility. Although there are potential psychological and physical barriers involved, it is a technique that is well understood and widely available. The overall success rate of sperm banking is unclear. A multicentric study from a sperm-banking cooperative in France demonstrated that more than 4300 young cancer patients visited a fertility clinic, and 93% were able to provide a sample; 3616 (83%) provided enough material to allow sperm to be cryopreserved. Conversely, a UK study (180 patients) yielded less optimistic results, with only 66% of the patients being able to bank sperm; azoospermia was found in 13% (Daudin et al., 2015; Keene et al., 2012).

For prepubertal boys limited options exist: tissue retrieval at this time is unlikely to generate cells that can be used for assisted reproduction techniques. The counterarguments are that these patients will not be interested in fathering children for decades and that novel techniques are evolving. In fact, Yokonishi et al. (2014) have reported successful pregnancy in a murine model using neonatal testicular tissue with in vitro induction of spermatogenesis. Viable offspring were produced, and they, in turn, were able to produce progeny of their own. Options to preserve female fertility include radiation shielding, ovarian transposition, oocyte cryopreservation, embryo cryopreservation, and ovarian tissue cryopreservation. Gonadotropin-releasing hormone analogues have not proven effective in pediatric patients (Burns et al., 2018).

In postpubertal females, embryo cryopreservation and oocyte cryopreservation is standard of care as per the American Society for Reproductive Medicine. Both techniques involve ovarian stimulation follicular monitoring using ultrasound and subsequent transvaginal oocyte retrieval under sedation or anesthesia (Practice Committee of American Society for Reproductive Medicine, 2013). The only preservation option for prepubertal females is ovarian tissue cryopreservation (OTC). In this technique ovarian tissue or the complete ovary is harvested laparoscopically. The tissue is evaluated to exclude malignant tissue, and the ovarian cortex is harvested and cryopreserved. Clinical pregnancy rates in excess of 50% have been reported with this technique (Burns et al., 2018). Finally, ovarian tissue transplantation (OTT) involves thawing and then transplanting orthotopically or heterotopically ovarian cortex to patients. This is the only technique that can restore hormonal function to women and has been reported to be successful in some patients who were prepubertal at harvest (Demeestere et al., 2015).

Other Bladder Tumors

Transitional Cell Carcinoma

Transitional cell carcinoma (TCC) of the bladder is an uncommon lesion in children and adolescents. In a review of 10,000 cases of bladder epithelial tumors performed by Javadpour and Mostofi (1969) only 38 cases of TCC occurred in patients younger than 20 years of age. A more recent review indicated that there are about 125 cases reported in patients younger than age 20, only 20 of which are in patients younger than 10 years old (Lerena et al., 2010). A male-to-female preponderance of 3-9 : 1 exists (Hoenig et al., 1996; Lerena et al., 2010). Unlike adult tumors, which have been associated with environmental exposures and smoking, the cause in children remains unclear. Familial history or genetic conditions have not been associated with pediatric cases (Lerena et al., 2010). Cyclophosphamide treatment and more recently chronic exposure to dantrolene have been cited as possible causes (Dowling et al., 2007; Hoenig et al., 1996).

The most common presenting symptom is gross hematuria, although symptoms of bladder irritation and UTI have been noted. The diagnosis is frequently delayed in children and is often discovered when US detects a lesion. It has been postulated that US approaches 100% sensitivity and is the preferred method for surveillance (Hoenig et al., 1996; Serrano-Durba et al., 1999). Voiding cystourethrogram is less sensitive because dye density may obscure the tumor (Lerena et al., 2010). The definitive diagnosis is made by cystoscopy and biopsy. The majority of lesions (75%) occur in the trigone and are unifocal, although multifocal lesions have been reported (Hoenig et al., 1996; Khasidy et al., 1990; Quillin and McAlister, 1991; Serrano-Durba et al., 1999). The overwhelming majority of lesions (80%) are superficial, low-grade lesions. A small portion of lesions are high grade. A recent study suggests that higher-grade lesions are associated with increasing age (Caione et al., 2017). A single case of invasive disease leading to death has been reported (Hoenig et al., 1996; Paduano and Chiella, 1988; Scott et al., 1989). Pediatric TCC is best treated with transurethral resection; intravesical therapy has had no defined role.

Typically pediatric bladder TCC does not involve the upper tracts; therefore no recommendations for routine upper tract surveillance exist (Vikram et al., 2009). Recurrence appears to be rare, even when higher-grade lesions have been reported (Lerena et al., 2010). Periodic surveillance with ultrasound is recommended, because it is sensitive in this scenario, obviating the need for serial cystoscopy. I perform US every 3 months for 1 year, every 6 months for the second year, and annually thereafter. No guidance exists regarding timing for discontinuing evaluation.

Cancer in the Augmented Bladder

Concern that patients undergoing urinary diversion were at risk for cancer began with the ureterosigmoidostomy experience (Husmann and Spence, 1990). It was assumed that by separating urinary and fecal streams, augmentation could avoid these complications; however, reports of cancer in patients with augmented bladders raised concerns anew (Filmer and Spencer, 1990; Gittes, 1986; Golomb et al., 1989; Nurse and Mundy, 1989). Recommendations for annual endoscopic screening for patients beginning 5 to 10 years after reconstruction followed. **These recommendations have recently been critically re-evaluated in light of 2 observations:**

1. **The majority of reported cases come from a patient pool biased toward infectious causes; few data on risk in patients augmented for noninfectious causes are available** (Filmer and Spencer, 1990; Golomb et al., 1989; Kamyshan et al., 2000).
2. **Patients with congenital bladder abnormalities related to exstrophy complex and spina bifida have a higher basal incidence of cancer than the normal population** (Austin et al., 2007; Barrington et al., 1997; Beare et al., 1956).

Husmann and Rathbun (2008) studied augmented patients compiled within a registry using the following criteria:

1. Minimum follow-up interval was 10 years.
2. No patient ever had a form of urinary diversion in which a mixture of feces and urine had occurred.
3. Patients with a history of bladder exstrophy/epispadias complex could be included only if they had undergone bladder closure within the first 2 weeks of life.
4. Only patients augmented secondary to neurogenic bladder or

exstrophy/epispadias complex or as a consequence of PUV were included.

Of the patients enrolled, 7/153 (4.5%) developed cancer; the median time to development of a tumor was 32 years. Bacteriuria did not correlate with the development of tumor. Incidence between ileal and colonic augments was not markedly different. Two patients augmented for neurogenic bladder developed multifocal TCC in their native bladder, but both had prolonged tobacco exposure. Twelve percent of patients augmented for PUV developed adenocarcinoma of the augmented bladder. Notably, all had ESRD, had undergone transplant, and were immunosuppressed. **The authors commented that patients with a smoking history after augmentation or those with ESRD, transplantation, and immunosuppression appear to be at greatest risk** (Husmann and Rathbun, 2008).

Higuchi et al. (2010) compared 153 patients who had undergone ileal/colonic augmentation with age- and disease-matched controls without augmentation to determine if an increased cancer risk was present. The authors documented no statistically significant increase in bladder cancers in augmented vs. nonaugmented patients (4.6% vs. 2.6%). Their data suggested that patients with neurogenic bladder have a baseline increase in cancer rates. They also supported the concept that exstrophy-epispadias patients are also at an increased risk. Again, an increase risk of cancer was present in immunosuppressed patients with a history of opportunistic viral infection (Higuchi et al., 2010).

Regarding surveillance, Higuchi et al. (2011) evaluated the utility of annual cytology and endoscopy. The authors found cytology was not helpful because of a significant false-positive rate. The authors also noted that only 4 of 250 surveillance cystoscopies revealed suspicious lesions, none of which proved cancerous. Based on the current estimated rate of malignant transformation of 1.5% to 2.8% the authors concluded that more than 980 cystoscopies would have to be performed over a decade to diagnose 1 tumor. Endoscopy was recommended only in the following circumstances (Higuchi et al., 2011):

1. Four or more symptomatic urinary tract infections (UTIs) occur per year.
2. A history of gross hematuria and/or urinalysis with greater than 50 RBCs/hpf is present.
3. Chronic perineal, pelvic, or bladder pain occurs.
4. Abnormal radiographic screening studies are seen.

5. Patients with colon augments turn age 50 years or older, consistent with recommendations for colonoscopy.

Similarly, using Markov model analysis, Kokorowski et al. (2011) concluded that annual cytology and endoscopy were not cost effective and questioned their effectiveness overall. A recent literature review suggests that no survival difference exists between spina bifida patients with bladder cancer based on whether they have been augmented (Rove et al., 2017).

In summary, it appears that the risk of cancer after augmentation may have been overstated. Augmented patients who are immunosuppressed after transplantation or perhaps those with a tobacco history may be in a higher risk group. The efficacy of annual cystoscopy and cytology appears questionable.

Urachal Carcinoma

Urachal adenocarcinomas in children are exceedingly rare (Rankin et al., 1993). A retrospective review of medical records from the Mayo Clinic from 1951 to 2005 identified no malignancies among urachal remnants in children (Ashley et al., 2007). Recently, a mucinous carcinoma of the urachus was reported. The lesion was managed by complete surgical excision (Gupta et al., 2014).

Adenocarcinoma and Squamous Cell Carcinoma

Patients with bladder exstrophy are considered to be at increased risk for adenocarcinoma. In a recent review of augmented patients 3 of 38 (8%) developed adenocarcinoma involving the bladder and an augment bowl segment. The site of origin could not be determined, and all patients fared poorly. These findings are consistent with prior publications, suggesting an increased risk of adenocarcinoma, squamous carcinoma, or tumors of mixed cell types in extrophy patients (Beare et al., 1956; Sahai et al., 2004; Smeulders and Woodhouse, 2001; Woodhouse et al., 2006). The belief that early closure may diminish the rate of malignancy in exstrophy patients does not appear to have held up: all 3 exstrophy patients within Hussmann's series had early closure (Husmann and Rathbun, 2008). Squamous cell carcinoma (SCC) has also been reported in exstrophy patients (Patil et al., 2012). It appears that the most common scenario is that of tumors occurring in patients with exposed bladders.

In the absence of exstrophy or schistosomiasis, SCC in the pediatric population is exceedingly rare: the youngest reported patient was a 16-year-old with a history of bladder calculus (Sung and Koyle, 2000).

Benign Bladder Tumors

Inflammatory myofibroblastic tumor (IMT) is a locally invasive lesion that can mimic RMS in children and young adults. The diagnosis can be made endoscopically; however, in my experience, open biopsy is commonly needed to exclude RMS. The tumor consists of spindle cells with myofibroblastic differentiation in a collagen stroma with an inflammatory cell infiltrate. Abnormalities of the anaplastic lymphoma kinase gene *(ALK)* and the rain binding protein (RANBP2) have been reported. IMTs with these rearrangements are termed IMT-RAs and have a higher risk of local recurrence and metastasis (Li et al.. 2013). Tumors without rearrangement have been treated with celecoxib with or without surgery with some success (Berger et al., 2007; Chavez and Hoffman, 2013; Li et al., 2013).

Bladder hemangiomas or venous malformations of the bladder in children typically are accompanied by gross hematuria and can be difficult to distinguish from malignant lesions. An association between bladder hemangiomas and proteus syndrome (a rare hamartomatous disorder) has been documented in two patients (Lopez-Gutierrez and Jaureguizar, 2010). These lesions can be treated by partial cystectomy or laser ablation (Ashley and Figueroa, 2010; March Villalba, 2012; Takemoto et al., 2011).

Nephrogenic adenoma (NA) is a benign papillary lesion of the bladder that is associated with recurrent infections, radiation, bladder surgery, including bladder augmentation and other forms of bladder injury. It has been rarely reported in children with congenital anomalies involving the bladder (Broecker et al., 2011). NA has also been associated with renal transplantation (Mazal et al., 2002). Histologically, tumors have a polyploid or papillary pattern consisting of layers of cuboidal cells, which frequently organize themselves into tubular patterns (Heidenreich et al., 1999). Patients may have symptoms such as hematuria, dysuria, frequency, recurrent UTI, and bladder instability. Cystoscopy and biopsy are required for diagnosis. Treatment consists of minimizing or eliminating inflammatory stimuli (antibiotic prophylaxis or improvement in voiding function). Transurethral resection or fulguration has been used effectively. Recurrence is common, so long-term follow-up is warranted.

Malignant transformation is rare (Hartmann et al., 2006).

Female Genital Tract

Tumors of the Vulva and Clitoris

True vulvar tumors, as opposed to lesions originating from the vagina, are exceedingly rare. Primary sarcoma of the vulva represents only 1% to 3% of all vulvar malignancies. The most common pathology appears to be leiomyosarcoma, with RMS seen less frequently. Rhabdomyosarcoma of the vulva is therefore uncommon: the total number of patients enrolled in IRS-I to IRS-IV with vulvar sarcoma was 20. The age distribution was 12 patients younger than age 10 and 7 patients between the ages 10 and 20. Compared with patients with cancer of other female genital sites, a larger percentage of these patients have alveolar/undifferentiated histology, 9 of 20 (45%). However, because these tumors are typically localized at presentation, the prevailing theory is that patients have a favorable prognosis (Andrassy et al., 1995; Martelli et al., 1999). The usual presenting symptom is a labial/vulvar mass. Clinicians should be aware that tumors may also be seen as a clitoral or preclitoral mass (Bond et al., 1994; Ghushe and Drugas, 2007). Treatment may include upfront excision or biopsy followed by chemotherapy and local therapy per COG protocols; brachytherapy for treatment of vulvar lesions is also reported (Magne and Haie-Meder, 2007; Magne et al., 2008).

In a recent review from 1996 to 2016 at The Royal Children's Hospital of Melbourne, 17 cases of female GU RMS were identified, of which 2 presented with a vulvar mass and 1 with vulvar inflammation. In the group with perineal/vulvar mass, the ages of these patients were younger than 3 years of age or, in 1 case, age 13, demonstrating a typical bimodal distribution. The most common secondary symptom was inguinal adenopathy. The current COG protocol ARST1431 acknowledges that primary resection is often not feasible for vulvar lesions without significant disfigurement. In these cases, biopsy with primary chemotherapy should be performed because tumor response to chemotherapy can be significant.

In a review of 38 girls with nonmetastatic GU RMS treated with multimodal therapy, 4 presented with vulvar lesions, 2 had alveolar histology, and 2 were embryonal. Both patients with alveolar histology expired after relapse. In general IRS and European studies have reported favorable outcomes for patients with vulvar or vaginal lesions (Flamant et al., 1979; Heij et al., 1993; Raney et al., 1990). Primary yolk sac tumors (YSTs, endodermal sinus tumors) of the vulva have been reported in women and children as young as 22 months of age, although typically they are seen in the second to third decade of life. They are very rare and appear to be more aggressive than YSTs arising from the ovary or vagina. Serum alpha-fetoprotein (AFP) is a useful biomarker for monitoring therapy and recurrence. Excision or biopsy with regional node dissection followed by chemo/radiotherapy has been recommended. Recurrence and metastasis are common (Mochizuki et al., 2012).

Vaginal Rhabdomyosarcoma

The vagina is the most common location for RMS of the female genital tract. An analysis of IRS-I through IRS-IV identified 151 patients suffering from female genital tract RMS (vulva, vagina, cervix, uterine), of which 84 (54%) originated from the vagina. Most, 86%, were clinical group III, and 95% had botryoid/embryonal histology. Presenting complaints included vaginal bleeding, discharge, or a protruding mass (see Fig. 54.3; Andrassy et al., 1995, 1999). The management of vaginal RMS has changed dramatically since IRS-I. Each subsequent iteration of protocols has demonstrated a decreased need for surgical resection (IRS-I, 100%; IRS-II, 70%; IRS-III, 30%; IRS-IV, 13%) and excellent disease-free survival (Andrassy et al., 1995, 1999; Arndt et al., 2001). Overall survival in IRS-III was approximately 83% (20/24). Most patients today undergo upfront biopsy followed by chemotherapy with or without local control measures (Andrassy et al., 1995, 1999; Arndt et al., 2001). Between 1997 and 2008, COG conducted two consecutive low-risk RMS studies (D9602: 1997–2004 and ARST0331: 2004–2008); initially these studies limited or omitted radiotherapy for vaginal tumors and at times used lower doses of cyclophosphamide. Higher-than-expected local failure rates prompted COG investigators to recommend that radiation therapy (RT) should not be omitted. Despite these local failures OS was excellent in this series (Walterhouse et al., 2011). European studies have advocated brachytherapy, documenting excellent results with survival rates of 91% (Magne and Haie-Meder, 2007; Magne et al., 2008). In a recent study published by the 4 cooperative groups (US and European), patients with vaginal/uterine RMS had an OS at 10 years of 92%. More than one-half of the patients were cured without RT or radical surgery. About 70% of patients with vaginal RMS achieved local control with primary therapy. COG study ARST0331 recently reported an increased failure rate if the cyclophosphamide dose was diminished and radiation was omitted in certain low-risk group patients (group III vaginal/uterine RMS); for these patients 3-year EFS dropped to 57%, suggesting undertreatment for these patients. This cooperative group report also concluded that brachytherapy (BT) was preferable to external beam RT because of increased dose potential to the tumor site while diminishing off-target exposure. Using this approach, they were able to salvage patients with vaginal RMS who previously needed radical therapy (Minard-Colin et al., 2018).

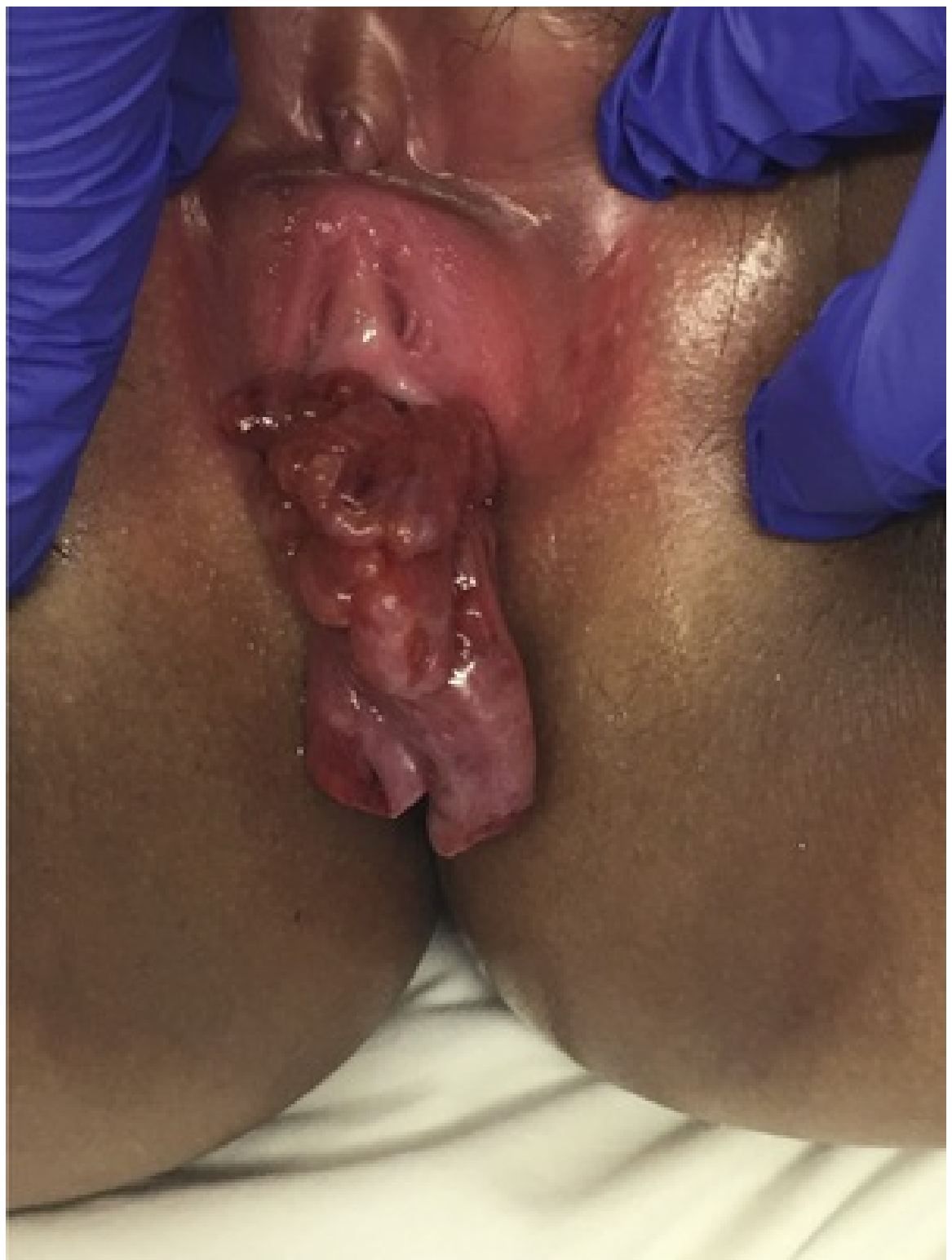

FIG. 54.3 Botryoid vaginal rhabdomyosarcoma emanating from the introitus of a young girl.

Cervical or Uterine Rhabdomyosarcoma

Cervical or uterine RMS is the second most common site of female genital RMS. A recent review using the SEER database described 26 cases from 1973 to 2006 (Kirsch et al., 2014). Of 151 patients with female GU sarcoma in IRS-I through IRS-IV, 49 had tumors of the cervix or uterine body (Arndt et al., 2001). Patients typically experience vaginal bleeding or an abdominal mass (the latter more common with uterine body tumors.) As with vaginal RMS, radical surgery has given way to organ-sparing approaches. Corpron et al. (1995) published the IRS-III and IRS-IV pilot experience, which included 14 patients ages 4 months to 17 years, the mean age of this group was 5.5 years old. Thirteen patients had embryonal pathology, 1 had an alveolar tumor. Of 8 patients with group III disease, 5 expired, but 4 of these succumbed because of sepsis and chemotherapy-related complications. All patients with group I disease, and even those with metastatic disease at presentation, survived (Corpron et al., 1995). A SIOP report using organ-sparing therapy reported survival of 10 of 11 patients with cervical/uterine RMS. The 2018 combined cooperative group report highlighted the differences between patients with cervical and uterine body RMS. The local control rate was 86% for patients with cervical lesions but only 70% for patients with uterine lesions. Lesion location has significant predictive value on the need for radical surgery. Patients with uterine lesions had approximately a 50% rate of requiring hysterectomy, whereas only 12% of cervical lesions required radical surgery. In addition, the cure rate for uterine relapses was lower than that of cervical relapse (Martelli et al., 1999). Organ-sparing procedures, such as trachelectomy, have been applied to select patients with cervical RMS (Kayton et al., 2009).

Ovarian Lesions

Pediatric urologists frequently become aware of patients with ovarian or adnexal masses, which occur as an incidental finding on imaging or during the workup of a symptomatic complaint, which is in fact related to an ovarian lesion. For these reasons, pediatric urologists should be familiar with these lesions.

Cystic Lesions

It is estimated that up to 98% of female newborns have small cysts visible on US. Cysts that would be clinically significant in newborns are uncommon, estimated at 1 in 2500 births. Of children up to age 8, 2% to 3% demonstrate an incidental cystic lesion (Brandt and Helmrath, 2005). Cysts present in the newborn period are usually related to maternal hormone levels, which drop after birth. Levels may rise again driven by the immaturity of the hypothalamic-pituitary-ovarian axis, which resolves around 2 to 3 years of life when patients settle into typical prepubertal hormone levels. A significant percentage of cystic lesions in newborns therefore involute spontaneously. When appropriate, evaluation of these lesions involves complete blood count (CBC), human chorionic gonadotropin (HCG), alfa-feto protein (AFP), lactate dehydrogenase (LDH), cancer antigen-125 (CA 125), US, and MRI (Templeman and Fallat, 2005). Intervention is typically indicated when lesions are indeterminate or symptomatic. Lesions that are benign, for example, simple cysts, are managed with organ-sparing approaches. Malignant cystic lesions in infants are rare, and even complex cysts in this age group are often observed (Brandt and Helmrath, 2005). Similarly, in prepubertal children up to 89% of cystic lesions are benign. These lesions should be observed only if (1) the cyst is clearly of ovarian origin, (2) the cyst is not complex, (3) AFP and HCG are normal, and (4) the patient is asymptomatic. Indications for surgery in prepubertal girls include persistence of the cyst, concern for malignancy, or any symptom, including changes induced by hormonally active cysts. **In adolescents ovarian cysts are usually the result of dysfunctional ovulation; treatment focuses on ovarian preservation.** Hormonal manipulation is frequently used; surgery is reserved for cysts that fail to resolve, persistent symptoms, or concern for malignancy.

Ovarian Malignancies

Ovarian tumors represent about 1% of childhood cancers. These tumors, similar to gonadal tumors in boys, are classified histologically as germ cell tumors, sex cord stromal tumors, or epithelial in origin. Tumors of epithelial origin are very rare before puberty (You et al., 2005). Germ cell tumors in girls arise from the primordial germ cells of the ovary and include teratoma (mature and immature), gonadoblastomas, and yolk sac (endodermal sinus) tumors. As in boys, gonadoblastomas occur in the setting of dysgenetic gonads and rarely metastasize. Sex cord stromal tumors in girls include theco-fibromas, Sertoli cell tumors, Leydig cell tumors, and granulosa cell tumors (GCTs). These tumors are hormonally active and may occur with precocious puberty. Their course is typically benign (Schultz et al., 2006).

The incidence of an ovarian mass in prepubertal girls is approximately 2.6 in 100,000; of these 50% are malignant and the other half are benign. Of the malignant tumors, the large majority (85%) are germ cell tumors, 8% are epithelial malignancies, and 5% are sex cord tumors.

Germ Cell Tumors

GCTs of the ovary exhibit a bimodal age incidence with a group at less than

1 year of age and another group between the ages of 15 and 19. Presentation varies and can include abdominal pain, distention, or a mass. Other symptoms include acute abdomen, ovarian torsion, and precocious puberty. GCTs are of varied histologic origin. They may be divided into 2 broad groups: seminomas (dysgerminomas) and nonseminomas (YST, teratomas, embryonal carcinomas, and choriocarcinomas). Teratoma is the most common subtype, and they can be benign or malignant. Mature teratomas (dermoid cysts) are typically benign and treated by resection. Immature teratomas and yolk sac tumors can exhibit aggressive behavior and are staged and treated along COG protocols. Dysgerminomas are most commonly found in adolescents and are composed of undifferentiated germ cells. YSTs comprise all 3 germ cell layers and can be aggressive. Tumor markers (AFP, B-HCG, and LDH) can be useful diagnostically; YSTs along with rare embryonal carcinomas and choriocarcinomas produce serum markers, which play a role in treatment and follow-up. Prognosis for these tumors is generally very good. COG protocol 9048 treated these tumors with resection and platinum-based multiagent chemotherapy and demonstrated an overall 6-year survival of 95% and 93% for stage I and stage II tumors, respectively (Rogers et al., 2004). Reports of excellent outcomes for children with stage III disease are also available. More recently observation alone for patients with stage I tumors has been studied. Although EFS decreased, the overwhelming majority of patients were effectively treated by chemotherapy upon recurrence (Billmire et al., 2014). Fertility preservation approaches are pursued when appropriate.

Sex Cord Tumors

Juvenile granulosa cell tumors (JGCTs) and Sertoli-Leydig tumors are exceedingly rare ovarian malignancies. JGCTs often occur with precocious puberty because of estrogen production. Early stage lesions can be treated with surgery alone, whereas more advanced stages require chemotherapy. Sertoli-Leydig cell tumors frequently produce androgens, so they may be seen with virilization, abdominal pain, or a mass. Again low-stage lesions may be treated with surgery alone, whereas higher stages may require multimodal therapy. In general, prognosis for these lesions is favorable (Schultz et al., 2005, 2006).

Epithelial Tumors

Cystadenomas can be benign or malignant and are most commonly seen in older patients but have been reported in children. Small cell carcinoma in children is extremely rare but has also been reported in the pediatric population (Schultz et al., 2005, 2006).

Key Points

- Vaginal RMS is the most common female genital site.
- The majority of embryonal histology and organ preservation strategies have resulted in excellent OS.
- Ovarian tumors make up 1% of all childhood cancers. Ovarian tumors are histologically classified as germ cell, sex cord, or epithelial tumors.

Testicular Tumors

Prepubertal testicular tumors differ markedly from those of postpubertal males in that benign lesions are more common and malignant tumors have a more favorable course. Estimates suggest that testicular tumors account for roughly 1% of pediatric solid tumors, with an incidence of 0.5 to 2 per 100,000 children. Much of our information regarding these tumors comes from the Pediatric Testis Tumor Registry (PTTR), established by the Urology Section of the American Academy of Pediatrics, or from large single- or multi-institutional series. Conflicting data regarding the most frequent pathologic variant have raised questions about enrollment bias in the PTTR. Fortunately, these discrepancies do not affect clinical management, allowing for clear and simple algorithms.

Epidemiology

The PTTR suggests that the most common pathological diagnosis in children with a testicular mass is a YST, followed by teratoma (Ross et al., 2002). Similarly, a recent study from the National Cancer Database reported YSTs as the most common pathology; however, this registry does not record benign lesions such as teratoma (Maizlin, 2018). A large single-center series from Turkey also found that YSTs were most common (Ciftci et al., 2001), but these findings are reversed in most single- or multi-institutional series (Agarwal and Palmer, 2006; Metcalfe et al., 2003; Shukla et al., 2004). A review on the subject from 4 large pediatric hospitals that included 98 patients younger than age 12 found that teratoma was present in 48% of children, YST in 15%, epidermoid cyst in 14%, JGCT in 5%, Leydig cell in 4%, Sertoli cell in 3%, and mixed gonadal stromal in 1%. The remaining 9% included diagnoses such as gonadoblastoma, lymphoma, cystic dysplasia, and IMT (Pohl et al., 2004). Based on this analysis more than 74% of prepubertal testis tumors are benign in nature. **This topic was reviewed in detail by Agawarl and Palmer, who acknowledge the discrepancy and conclude simply that teratoma and YST are the most common cause of a testicular mass** (Agarwal and Palmer, 2006). Tumor incidence peaks near age 2, and a second rise in incidence is seen in the peripubertal period (Haas and Schmidt, 1995; Haas et al., 1995; Li and Fraumeni 1972). Karmazyn et al. (2018) recently looked specifically at children ages 5 to

12 years with testicular lesions and found that none of the lesions were malignant. This report is limited by the fact it is retrospective and a single-institution experience. Tumors are more frequent in whites than in non-whites (Walsh et al., 2008). Incidence appears to vary with geographic location. When considering all males, (pre- and postpubertal) some suggest that the incidence of testicular GCTs has been rising; however, it appears that postpubertal, not prepubertal, tumors account for this increase (Reuter, 2005).

Pathogenesis and Molecular Biology

GCTs comprise a heterogeneous group of neoplasms that derive primarily from the gonads but may arise from extragonadal sites along the migration route of the primordial germ cells to the genital ridge (midline mediastinum, peritoneum, and sacrum) (Looijenga and Oosterhuis, 1999; Oosterhuis and Looijenga, 2003; Slowikowska-Hilczer et al., 2003). As a group, testicular GCTs make up 98% of malignant testicular tumors and are the most common cancer in men ages 15 to 35 (Bosl and Motzer, 1997). High levels of maternal estrogens, low and high birth weights, neonatal jaundice, and disorders of sexual development (DSD) have been associated with the development of GCT. Many of these factors support the concept that initiating events occur in the pre- or perinatal period (Depue et al., 1983; Ekbom and Akre, 1998; Reuter, 2005; Richiardi et al., 2002).

The most widely accepted association with GCT is cryptorchidism, with 10% of cases linked to a history of undescended testis (Halme, Kellokumpu-Lehtinen et al. 1989a,b; Schottenfeld et al., 1980). Patients with cryptorchidism have a fourfold higher lifetime risk of developing GCT. It does not appear that this risk completely returns to baseline after surgical correction (Giwercman et al., 1987; Halme et al., 1989a,b; Schottenfeld et al., 1980). Finally, as is discussed in subsequent sections, patients with DSD are known to be at risk for the development of GCT (Collins et al., 1993; Rutgers and Scully, 1987, 1991; Skakkebaek et al., 2003). Patients with hypovirilization and gonadal dysgenesis are at highest risk.

Much remains unknown regarding the molecular pathogenesis of GCT. Intratubular germ cell neoplasia (IGCN) is considered by many to be a precursor lesion to GCT. Two theories predominate regarding the development of IGCN. The first suggests that aberrant chromatid exchange events lead to a chromosome 12p copy number increase. This in turn allows zygote-pachytene spermatocytes to avoid the apoptotic effects of p53 and become cancerous (Chaganti and Houldsworth, 1998, 2000). The second theory maintains that fetal gonocytes undergo abnormal cell division because of environmental factors and give rise to IGCN. Polyploidization thus precedes chromosome 12p abnormalities. These cells become vulnerable to postnatal or postpubertal development of invasive cancer (Chaganti and Houldsworth, 1998; Looijenga et al.; 1999; Skotheim and Lothe, 2003). Pediatric cases are mostly diploid, with the exception of YSTs, which may be nondiploid. GCTs in children have been characterized by deletions of 1p, loss of chromosome 6q, and abnormalities of chromosome 2 and 3p (Jenderny et al., 1996; Schneider et al., 2001; Silver et al. 1994).

The COG conducted the largest study evaluating family history of cancer and subsequent development of malignant GCT (Poynter et al., 2010). The study enrolled 278 cases and 423 controls. No association was observed between a family history of cancer and GCT in the group as a whole. The study did observe an increased risk of GCT in males, when a relative was diagnosed with cancer before the age of 40 years (OR = 2.56, 95% CI 1.02–6.44). Recently, Poynter et al. (2012) evaluated several susceptibility loci that had been identified in adult GCTs in a cohort of pediatric GCTs. Fifty-two cases from patients age birth to 21 were evaluated. The majority of patients were female and the tumors were predominantly teratomas and yolk sac tumors. The SNP for *SPRY4* was significantly associated with an increased risk of GCT in boys and in adolescent males. *BAKI* was associated with gonadal tumors in both sexes. Prior studies had identified similarities in chromosomal abnormalities present in adolescent males and adult males with GCTs. These included losses on chromosomes 11, 13, and 18 and gains on 7, 8, and X (Bussey et al., 1999).

Presentation, Evaluation, and Staging

Testicular tumors most commonly occur as a painless mass. Alternatively, the lesion may be incidentally discovered by US of the scrotum to rule out torsion or investigate scrotal pain. A hydrocele is present in 15% to 20% of cases. The differential includes other intrascrotal processes such as paratesticular tumors, epididymitis, benign epididymal lesions, hernias, and hydroceles. Patients with hormonally active tumors may be referred for precocious puberty. Patients with undescended testis may present when a testicular mass predisposes to intrabdominal torsion (Agarwal and Palmer, 2006).

Ultrasonography

Although the sensitivity of US approaches 100% for detection, it is important to recognize that US cannot reliably distinguish benign from malignant testicular lesions. Common sonographic features of benign and malignant testicular masses are summarized in Fig. 54.4 and discussed later.

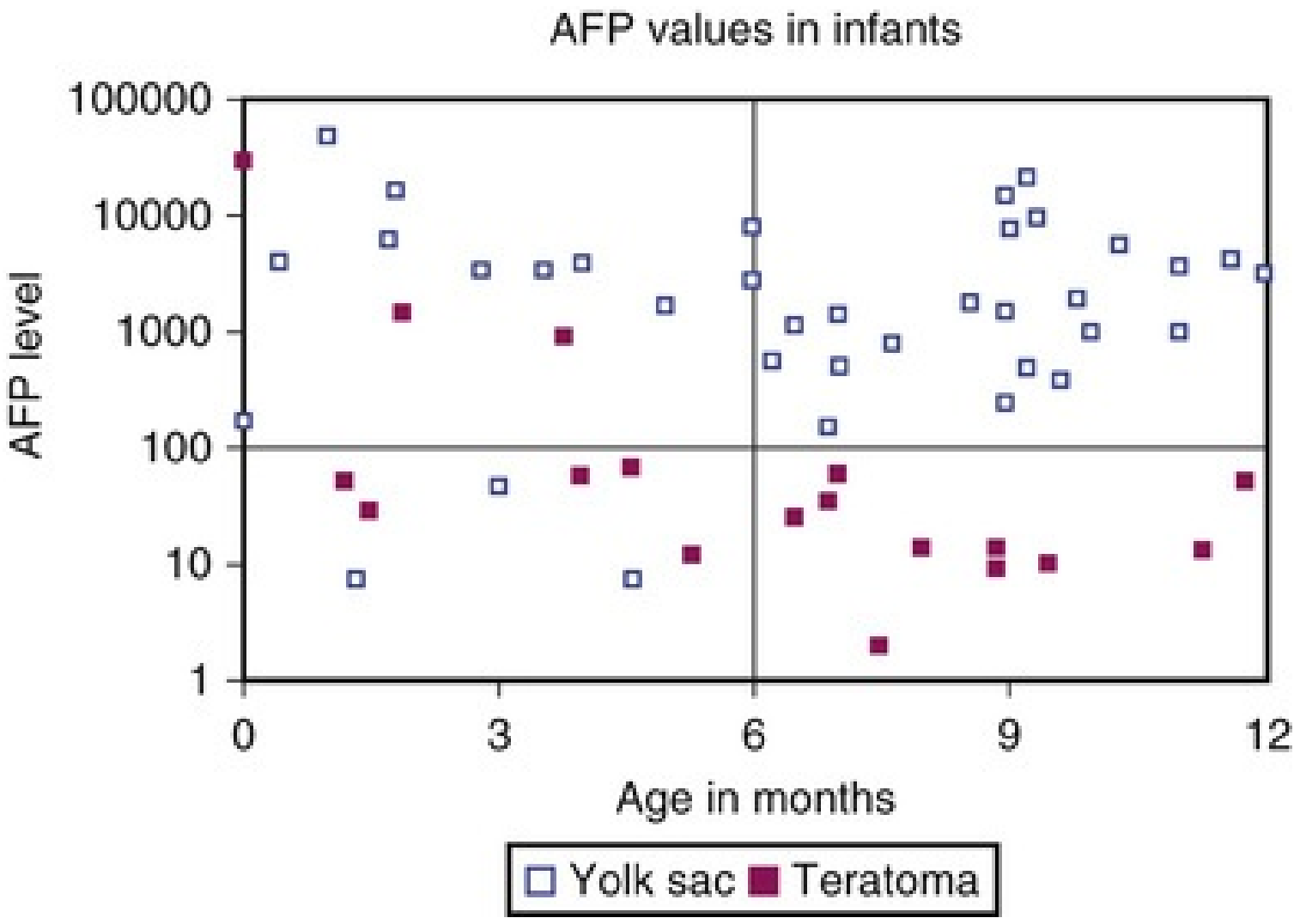

FIG. 54.4 α-Fetoprotein (AFP) levels in infants with yolk sac tumor and teratoma (ng/mL). (From Ross JH: Prepubertal testicular tumors. *Urology* 74:94–99, 2009.)

Teratomas appear as heterogenous complex lesions on US, reflective of their composition, which typically includes three germ cell layers. They may contain cystic and solid components. Bony elements appear as calcifications with shadowing. Adipose tissue appears as echogenic areas without shadowing. Epidermoid cysts represent a monolayer teratoma and have a characteristic appearance described as "onion skin," made up of concentric rings of alternating hypo-/hyperechoic lesions. YSTs are typically well circumscribed and heterogenous in appearance. These tumors may be hypervascular in appearance and may have areas of hemorrhage and necrosis. Sertoli and Leydig cell tumors are similar in appearance and commonly occur as a well-circumscribed hypoechoic mass. GCTs may contain cystic and solid components. Gonadoblastomas are solid, hypoechoic lesions and unlike other testicular lesions, may occur bilaterally.

Interpretation of Biomarkers in Children

Serum biomarkers play an important role in the diagnosis and management of pediatric testicular lesions. Human chorionic gonadotropin-B (b-HCG) is rarely elevated in prepubertal tumors. AFP is normally produced by the fetal yolk sac, liver, and gastrointestinal tract. **Serum AFP is elevated in YST; measurement of AFP levels is valuable for diagnosis, staging, and management of patients with YST. As a result of the physiologically persistent elevation in children younger than 1 year of age, interpretation of AFP levels in young children undergoing evaluation for testis mass must be performed with caution.** Although the accepted half-life of AFP is 5 days, levels may be particularly high after birth, and a normal T1/2 may not occur for up to 4 months. AFP levels frequently do not come down to basal levels until 6 to 8 months of age, and in some patients elevated levels may persist until 12 months. Several features of AFP level analysis bear mention. In YST, AFP is elevated (>10 ng/mL) in 92% of cases. **If a child older than 1 year of age has a testicular mass and an elevated AFP, it is likely the patient harbors a YST, and an organ-sparing procedure should not be entertained. Conversely, a normal AFP provides considerable assurance that the mass under evaluation is benign** (Ross et al., 2002). Ross et al. have made other nuanced observations that may help clinicians:

1. In children younger than age 1 with YST, the median AFP levels are higher than children with teratoma.
2. In children older than 6 months with teratoma, AFP levels rarely exceed 100 ng/mL (see Fig. 54.4).

Staging

Careful physical examination is indicated, with particular focus on any evidence of precocious puberty, suggesting a hormonally active tumor. Disseminated disease is rare in children. After ultrasonography and serum tumors marker analysis, if concern exists that a lesion is malignant (elevated AFP), CT of the abdomen and retroperitoneum should be performed. The most common site of metastatic disease is the lung, which may be assessed by CT or radiograph. The COG staging system is a postsurgical system based on assessment after primary orchiectomy and imaging (see Table 54.5).

TABLE 54.5

Children's Oncology Group Staging System for Testicular Germ Cell

Tumors

STAGE	EXTENT OF DISEASE
I	Tumor is limited to testis, completely resected by high inguinal orchiectomy. No clinical, radiographic, or histologic evidence of disease beyond the testes. If scrotal orchiectomy has been performed, all margins are negative after resection of proximal cord structures to the level of the internal inguinal ring. Tumor markers are negative after appropriate half-life decline. Patients with normal or unknown tumor markers at diagnosis must have a negative ipsilateral retroperitoneal node sampling to confirm stage I disease, if radiographic studies demonstrate lymph nodes >2 cm.
II	Microscopic residual disease is present in the scrotum or high in spermatic cord (<5 cm from proximal end). Tumor markers remain elevated after appropriate half-life interval. Tumor rupture or scrotal biopsy before complete orchiectomy.
III	Retroperitoneal lymph node involvement. Lymph nodes >4 cm by CT are considered metastases. Biopsy needed to document nodal metastases in lymph nodes >2 cm and <4 cm.
IV	Distant metastatic deposits

CT, Computed tomography.

Tumors Associated With Disorders of Sexual Development

Patients with DSD and dysgenetic testis or hypovirilization have an increased incidence of testicular tumors. Patients harboring Y chromosomal material in their karyotype are at highest risk. The noninvasive precursors of GCTs (primarily seminoma/nonseminoma and dysgerminoma/nondysgerminoma) in these patients are presumed to be carcinoma in situ and gonadoblastoma (CIS and GB, respectively) (Cools et al., 2006; Skakkebaek, 1972). Both arise from fetal germ cells. Immunohistochemical, mRNA analysis, and the resemblance of subsequent tumors suggest a common origin for carcinoma-in-situ (CIS) and gonadoblastoma (GB) (Gillis et al., 2007; Looijenga et al., 2007; Pleskacova et al., 2010). The pathogenesis of tumors in patients with DSD involves the transformation of immature germ cells. Several key factors in this transformation have been identified. OCT3/4, a transcription factor that has antiapoptotic functions in primordial germ cells (PGC) and can be used to identify early fetal germ cells, is one such factor (Cheng et al., 2007). Another crucial element appears to be the expression of testis-specific protein Y-encoded (TSPY) in the germ cells of DSD gonads (Oram et al., 2006). TSPY is the most likely candidate for the gonadoblastoma locus on the Y chromosome (GBY) and defines the section of the Y chromosome that appears to confer risk for the development of GCT (Lau et al., 2009). It has been proposed that double staining for OCT3/4 and TSPY can help identify dysplastic cells early in DSD patients (Kersemaekers et al., 2005). In addition, recent studies have identified that stem cell factor (SCF) is also a potentially useful CIS/GB marker (Stoop et al., 2008). Combined analysis on biopsy specimens could help identify those at risk (Pleskacova et al., 2010). A consensus statement on the risk associated with various DSD diagnoses and recommended management was released in 2007 and provides guidance for the counseling and management of these patients (see Table 54.6; Looijenga et al., 2007; Pleskacova et al., 2010).

TABLE 54.6

Testis Tumor Risk Associated With Specific Disorders of Sex Development and Recommended Management

RISK GROUP	DISORDER	MALIGNANCY RISK (%)	RECOMMENDED ACTION	STUDIES (N)	PATIEN (N)
High	GD[a] (+Y)[b] intra-abdominal	15–35	Gonadectomy[c]	12	>350
	PAIS nonscrotal	50	Gonadectomy[c]	2	24
	Frasier	60	Gonadectomy[c]	1	15
	Denys-Drash (+Y)	40	Gonadectomy[c]	1	5
Intermediate	Turner (+Y)	12	Gonadectomy[c]	11	43
	17β-HSD	28	Monitor	2	7
	GD (+Y)[b]	Unknown	Biopsy[d] and irradiation (?)[e]	0	0
	PAIS scrotal gonad	Unknown	Biopsy[d] and irradiation (?)	0	0
Low	CAIS	2	Biopsy[d] and ???	2	55
	Ovotestis DSD	3	Testis tissue removal (?)	3	426
	Turner (−Y)	1	None	11	557
No (?)	5α-	0	Unresolved	1	3

	Reductase				
	Leydig cell hypoplasia	0	Unresolved	2	

[a] Gonadal dysgenesis (including not further specified, 46,XY, 46,X/46,XY, mixed, partial, complete).

[b] GBY region positive, including *TSPY* gene.

[c] At time of diagnosis.

[d] At puberty, allowing investigation of at least 30 seminiferous tubules, with diagnosis preferably based on OCT3/4 immunohistochemistry.

[e] Question marks indicate that there was a lack of clear recommendation on how to proceed.

CAIS, Complete androgen insensitivity syndrome; *DSD,* disorders of sex development; *17β-HSD,* 17β-hydroxysteroid dehydrogenase deficiency; *PAIS,* partial androgen insensitivity syndrome.

Data from Looijenga LH, Hersmus R, Oosterhuis JW, et al.: Tumor risk in disorders of sex development (DSD). *Best Pract Res Clin Endocrinol Metab* 21:480–495, 2007.

Germ Cell Tumors

Teratomas are, according to some series, the most common testicular tumor in children and consist of variable combinations of the 3 primitive embryologic germ cell layers (Metcalfe et al., 2003; Pohl et al., 2004; Shukla et al., 2004). They pose a characteristic ultrasound appearance (described earlier) and do not express AFP. Unlike adult males, the majority of prepubertal lesions are benign, consisting of mature elements only (Gobel et al., 1998). Rare reports of teratomas harboring immature elements and metastasizing are present in the literature (De Backer et al., 2008; Gobel et al., 1998, 2006). The combination of AFP measurements and characteristic US appearance can suggest to the surgeon the presence of teratoma. **The preferred treatment for suspected teratomas is partial orchiectomy (see description of technique later)** (Makari et al., 2010; Ross, 2009; Ross and Kay, 2004, Shukla et al., 2004).

Epidermoid cysts are benign lesions in prepubertal males and may account for more than 15% of prepubertal testis lesions (Pohl et al., 2004). They consist of cysts lined with keratin-producing epithelium. They demonstrate a mixed appearance (hypo- and hyperechoic) on ultrasound and AFP levels are normal. They are managed by testis-sparing surgery. No surveillance is required after treatment (Ahmed et al., 2010; Walsh and Rushton, 2000).

YST has been variably reported to be the first or second most common testicular tumor in prepubescent males. It is the most common malignant prepubertal tumor. YSTs have also been referred to as endodermal sinus tumor or juvenile embryonal carcinoma. They are typically well-demarcated, heterogenous masses, which may have hemorrhage or necrosis on US. On gross appearance they are solid and gray-yellow in color. YSTs express positive stain for periodic acid–Schiff and AFP. **Schiller-Duval bodies consist of a central blood vessel surrounded by two layers of tumor cells and are pathopneumonic for YST (see Fig. 54.5). AFP levels are elevated in about 90% of patients and represent a reliable marker for follow-up studies.** The majority of prepubertal cases (>85%) are stage I at diagnosis (Grady, 2000; Grady et al., 1995). When metastases occur, YST often exhibit hematogenous spread to the lungs (~20%), without retroperitoneal disease. For these reasons **retroperitoneal lymph node dissection (RPLND) plays very little role in prepubertal YST. RPLND is used exclusively for patients with a residual retroperitoneal mass or persistently elevated AFP after chemotherapy and orchiectomy** (Ahmed et al., 2010). About 20% of stage I tumors recur after orchiectomy alone. Post-orchiectomy stage I patients undergo a rigorous surveillance protocol, which includes chest and retroperitoneal imaging and tumor marker assessment (Connolly and Gearhart, 1993). An inguinal incision should be used in all patients with a testicular mass. When a patient with a YST has undergone a trans-scrotal orchiectomy, if the pathological margins are negative, the patient may be treated as stage I, so long as the cord is resected to the inguinal ring. If a prior transscrotal biopsy has been performed, the patient should undergo complete orchiectomy and is considered stage II (Rogers et al., 2004). Hemiscrotectomy is not required in these cases. If enlarged nodes are present on imaging, biopsy is indicated. Patients with adenopathy and elevated AFP are treated as stage III. **Treatment protocols that use multiagent chemotherapy are recommended by the North American, English, and European groups. Survival, even for patients with metastasis, approaches 100%** (Haas et al., 1999; Lo Curto et al., 2003; Mann et al., 1989, 2000; Schlatter et al., 2003).

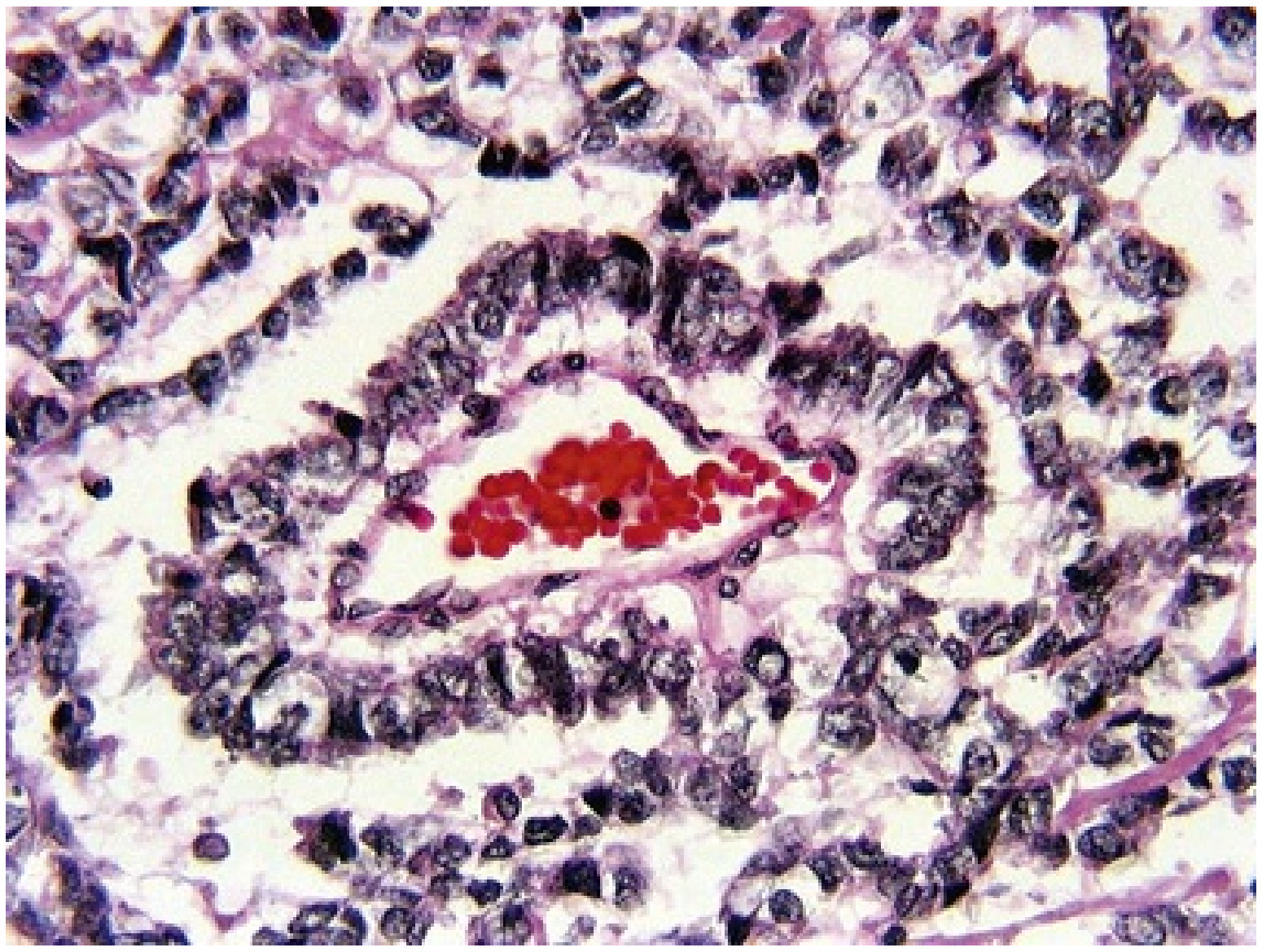

FIG. 54.5 Schiller-Duval body. (From Department of Pathology, University of Pittsburgh, http://path.upmc.edu/cases/index.html.)

Gonadal Stromal Tumors

JGCTs are described to be the most common testicular tumors affecting neonates. They are easily differentiated from YSTs, because they stain negatively for AFP and stain positively for markers such as inhibin alpha. They have been reported in patients with ambiguous genitalia (Cortez and Kaplan, 1993; Shukla et al., 2004). These lesions are benign and are treated with a testis-sparing approach.

Leydig cell tumors (LCTs) are hormonally active and are associated with precocious puberty. LCTs are responsible for about 10% of all cases of precocious puberty. Other causes of precocious puberty include pituitary lesions, Leydig cell hyperplasia, large-cell Sertoli cell tumors, and hyperplastic nodules in congenital adrenal hyperplasia (CAH) patients. If the practitioner is confused, they can exclude pituitary lesions by demonstrating an increased testosterone level with age-appropriate LH and FSH. Leydig cell hyperplasia patients have normal urinary 17-ketosteroids. Boys commonly are seen between the ages of 5 and 10 years with virilization, although a small percentage appear with gynecomastia (Cortez and Kaplan, 1993). **The tumors may be small and appear as yellow-brown nodules; histologically they contain diffuse layers of polygonal cells and about 40% demonstrate Reinke crystals. Reinke crystals contain lipofuscin pigment and are rod-shaped, crystal-like structures 3 to 20 µm in diameter** (see Fig. 54.6). Their purpose is unknown but they are unique to Leydig cell tumors. Elevated testosterone levels are commonly found, and these may drop after resection, but the virilizing features may persist. Because of the small size of the lesions intraoperative localization may be difficult. The lesions are managed with an organ-sparing approach; recurrence is very uncommon (Wegner et al., 1997).

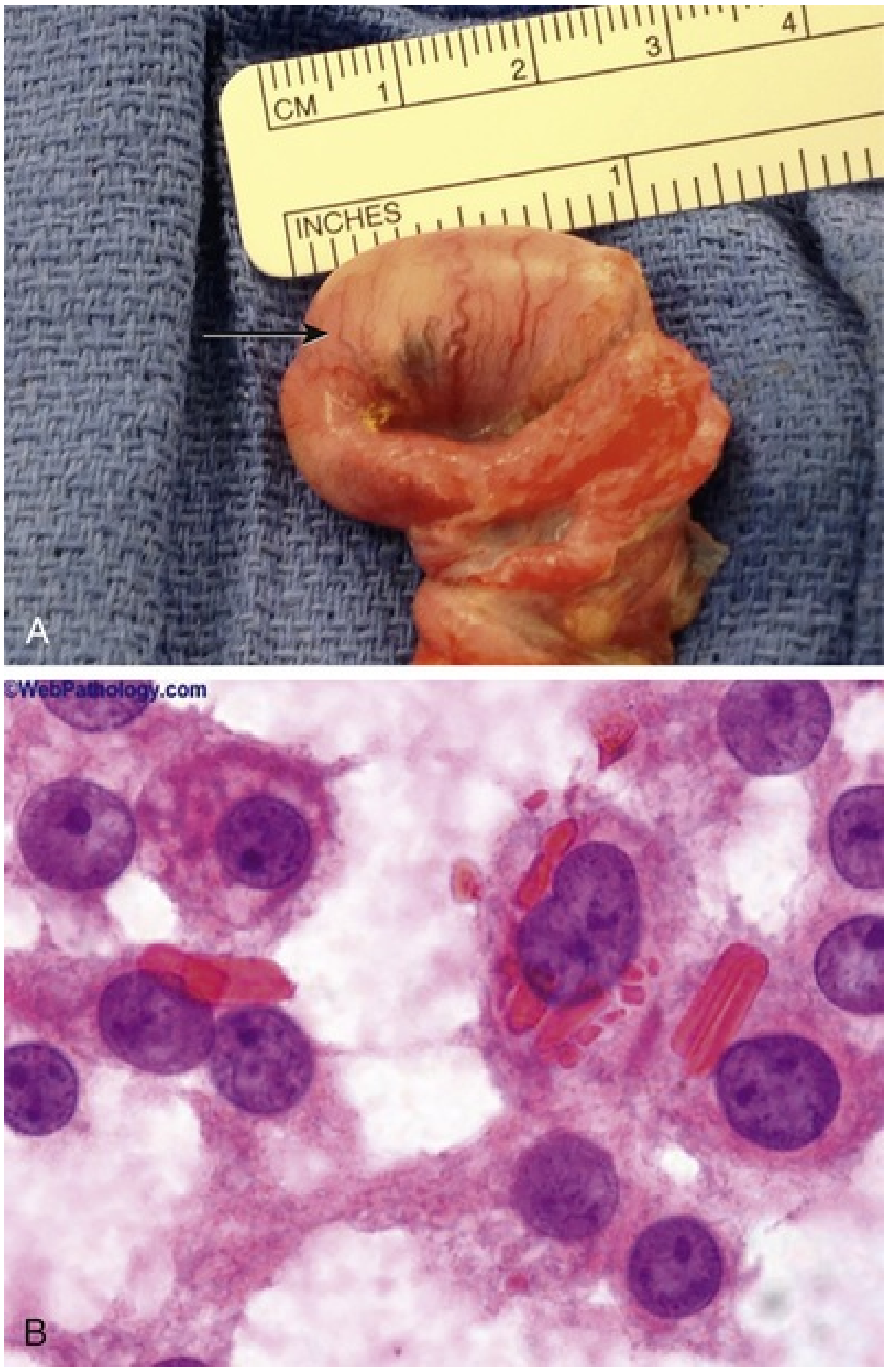

FIG. 54.6 (A) Leydig cell tumor demonstrating characteristic brown appearance related to abundant lipofuscin pigmentation. (B) Reinke crystals. (*A,* Courtesy Fernando Ferrer, MD; *B,* from http://www.webpathology.com.)

Sertoli cell tumors typically occur at an earlier age than Leydig tumors (mean age 52 months) and have been reported in children from age 4 months to age 10 (Thomas et al., 2001). The usual presentation is a painless mass. They have been associated with endocrinologic and genetic syndromes such as Peutz-Jeghers and Carney syndromes. Ten percent of these tumors are hormonally active, and patients may have virilization or feminization (Gabrilove et al., 1980; Thomas et al., 2001). The tumors are usually firm, well-circumscribed, and tan-gray in gross appearance. They may contain areas of hemorrhage or cysts. For infants and children up to age 5, orchiectomy is usually sufficient treatment unless the tumor demonstrates the following features: large size (>5 cm), vascular invasion, necrosis, cellular atypia, or increased mitotic activity. Tumors with these features or those occurring in children older than age 5 merit a full staging evaluation. Children with retroperitoneal metastasis may be candidates for RPLND, chemotherapy, and radiation. Large-cell calcifying Sertoli cell tumors are a distinct entity seen in prepubertal children and adolescents; they can be managed by simple orchiectomy.

Leukemia and Lymphoma

The most common cancers metastatic to the testis are leukemia and lymphoma. Up to 20% of patients with bulky disease may have gonadal disease or relapse in the testis (Askin et al., 1981). Because of the high success rates of systemic chemotherapy and whole-body irradiation, routine testis biopsy is no longer required in these patients (Trigg et al., 2000). Burkitt lymphoma may occasionally occur as a testicular lesion, and follicular lymphomas may occur primarily in the testis (Finn et al., 1999; Lamm and Kaplan, 1974).

Testicular Microlithiasis

The incidence of testicular microlithiasis in asymptomatic males age 0 to 19 has been reported to be 2.4% (Goede et al., 2009). A concern that these lesions are harbingers of testicular cancer has prompted some to recommend surveillance with US (Furness et al., 1998; Leenen and Riebel, 2002). However, more recent studies have determined that screening US is not required for patients without risk factors such as infertility associated with atrophic testis and microlithiasis or testis cancer and contralateral microlithiasis (Hoei-Hansen et al., 2005; Holm et al., 2003). Controversy on this subject continues: some publications have called into question if an association between microlithiasis and GCT exists at all in children, whereas others continue to cite a strong association between microlithiasis and primary testicular tumors (Trout et al., 2017; Volokhina et al., 2014). Routine self-examination is the current recommendation followed by many.

Management Algorithms

With the recognition that the majority of these tumors are benign, management of prepubertal testis tumors has evolved from radical orchiectomy. This evolution began in the 1980s, facilitated by improvements in ultrasonography and the ability for frozen section analysis to accurately distinguish benign from malignant lesions. Today patients are preferentially treated with excisional biopsy, intraoperative frozen section analysis, followed by an organ-preserving procedure. The exception is when preoperative AFP or intraoperative biopsy suggests malignancy. Ross et al. (2002) published their recommended approach after reviewing the results from the prepubertal testis tumor registry of the urology section of the American Academy of Pediatrics (see Fig. 54.7). A recent review by Woo and Ross (2016) discusses the evolving thought on partial orchiectomy in adolescent males. European guidelines have allowed for consideration of partial orchiectomy for synchronous and metachronous bilateral lesions an in the case of a solitary testis. This is an evolving area: these patients have been managed primarily according to adult protocols.

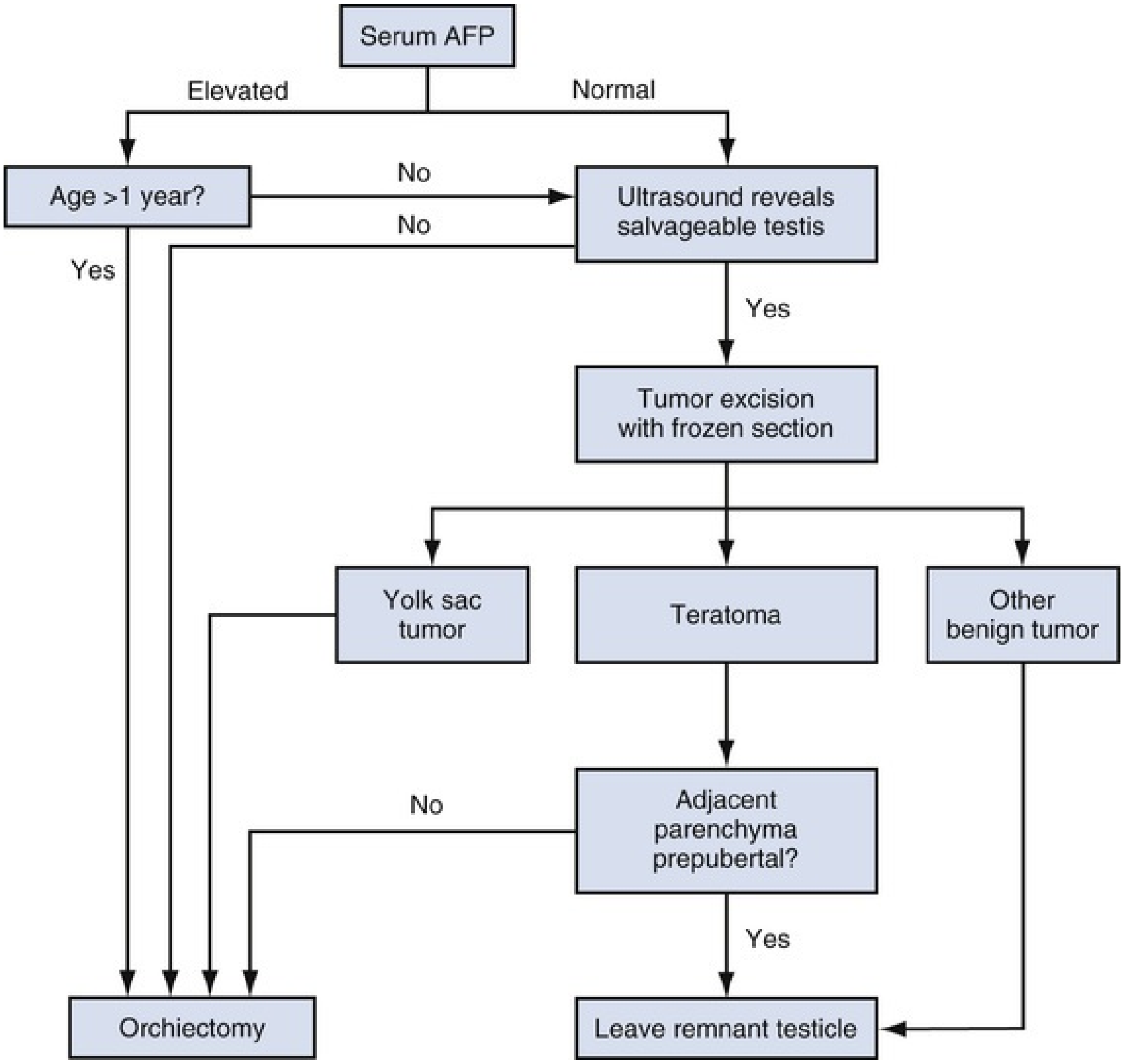
Serum AFP
Elevated
Normal
Age >1 year?
No
No
Ultrasound reveals salvageable testis
Yes
Yes
Tumor excision with frozen section
Yolk sac tumor
Teratoma
Other benign tumor
No
Adjacent parenchyma prepubertal?
Yes
Orchiectomy
Leave remnant testicle

FIG. 54.7 Algorithm for the management of prepubertal testis tumors. *AFP,* α-fetoprotein. (From Ross JH, Rybicki L, Kay R: Clinical behavior and a contemporary management algorithm for prepubertal testis tumors: a summary of the Prepubertal Testis Tumor Registry. *J Urol* 168[4 Pt. 2]:1675–1678, 2002.)

Key Points

- A large percentage of prepubertal testis tumors are benign; therefore testicular preservation approaches are often indicated.
- Ultrasonography cannot reliably distinguish benign from malignant lesions.
- AFP is the relevant biomarker in prepubertal testis tumors, and elevation is associated with YSTs.

- AFP levels must be interpreted with caution because physiologic elevation above normal values is common in children younger than age 1.

Testis-Sparing Surgery Technique

Patients undergoing testis-sparing surgery should be counseled regarding the potential need for radical orchiectomy. Preoperative coordination of intraoperative frozen section is required. If the tumor is not palpable, intraoperative sonography should be available. The testicle is approached through an inguinal incision, and early vascular control of the spermatic cord is achieved with a vessel loop or Penrose drain. The gonad is delivered through the inguinal incision, and the tunica vaginalis is incised to expose the testicle. With lesions involving or immediately adjacent to the tunica albuginea, an elliptical incision beyond the tumor margins should be made in the tunica albuginea. In patients with nonpalpable lesions, I have used intraoperative sonography for localization. Ice may be applied to reduce warm ischemia time. While awaiting intraoperative frozen pathology, the surgeon may reapproximate tunica albuginea with 5-0 running interlocked polydioxanone suture. Intraoperative considerations for testis-sparing surgery include the presence of sufficient normal parenchyma to facilitate closure of the testis. If intraoperative frozen pathology reveals malignancy, a radical orchiectomy is completed. To my knowledge, no reports document a malignant diagnosis on final pathology when intraoperative frozen pathology revealed a benign diagnosis.

Paratesticular Rhabdomyosarcoma

Paratesticular RMS arises from the testicular tunics, epididymis, or the spermatic cord. Up to 40% of paratesticular lesions are due to RMS (Shapiro and Strother, 1992)**. The tumor may invade locally and/or involve the scrotal wall. These tumors represent 7% to 10% of all GU RMS. Peak incidence occurs between ages 1 and 5, a bimodal age distribution has been reported by some, with peaks at less than 1 year of age and at 16** (Ahmed et al., 2010). In general, patients with paratesticular RMS do better than those with tumors arising at other sites because (1) the overwhelming majority of these tumors are stage I at diagnosis (up to 80%), unlike RMS in general, in which only 13% of tumors are stage I; (2) more than 90% of patients have embryonal histology; and (3) those patients with more aggressive histology, alveolar, appear to do better than patients with alveolar histology at other locations (Anderson et al., 2004; Ferrari et al., 2002, 2004; Wiener et al., 1994, 2001). A recent report from Germany looked at paratesticular RMS patients enrolled in studies between 1990 and 2013; all patients' pathology and molecular characteristics were re-evaluated. Seven patients were analyzed at a median follow-up of 7 years; all patients were alive. Four patients demonstrated areas consistent with alveolar histology on pathological review; all 7 patients were fusion negative, further supporting a biologic difference, which likely explains the improved outcomes of these patients (Seitz et al., 2016a,b).

Presentation and Staging

Patients have a unilateral, firm, painless scrotal mass. The lesion may or may not be distinct from the gonad. Ultrasound, typically the first interrogation, reveals a hyperechoic, heterogenous, solid mass. Evaluation of these patients involves assessment of testicular tumors markers, liver function tests, and evaluation of the chest for metastasis using CT. Complete retroperitoneal imaging using double-contrast, thin-cut CT (<10 years old = 5 mm and >10 years old = 7 mm) up to the level of the ipsilateral hilum is essential, because this is the primary lymphatic landing site, and nodes are positive in up to 20% of patients.

Treatment

Patients with suspected paratesticular tumors should undergo inguinal exploration and radical orchiectomy with resection of the spermatic cord up to the internal ring inguinal and marking of the stump site. Biopsy should be avoided because it may lead to contamination of the operative field. In cases in which biopsy is considered essential, isolation of the gonad and the application of an atraumatic tourniquet is required. If frozen section biopsy is consistent with tumor, the cord should be transected above the tourniquet and the specimen kept in isolation. Any unprotected spill results in upstaging. For patients referred after trans-scrotal biopsy or resection, standard recommendations have included pretreatment re-excision of the surrounding scrotal skin. Recent data from the German and Italian cooperative group question the necessity for this (Dall'Igna et al., 2003; Stewart et al., 2003).

The appropriate management of regional lymph nodes is essential in patients with paratesticular rhabdomyosarcoma. **Patients younger than 10 years old who are considered to be in clinical group 1 (total gross resection with negative margins) who have a negative retroperitoneal CT scan do not require further surgical treatment** (Wiener et al., 2001). Patients younger than 10 years old who have evidence of positive nodes on CT scan should undergo staging ipsilateral (SI) RPLND; if all tumor is removed the patients are classified as clinical stage II. A nerve-sparing ipsilateral technique is recommended by COG protocols and, in the hands of experienced surgeons, a laparoscopic approach is acceptable (Cost et al., 2012; Tomaszewski et al., 2010). Patients who have grossly positive lymph nodes on staging CT scan can be managed simply by confirmatory biopsy and are considered to be stage III. **As opposed to children younger than age 10, children older than 10 should always undergo SIRPLND.** Paratesticular tumors rarely involve inguinal lymph nodes. However, when scrotal involvement occurs, inguinal node sampling should be performed. These are not considered “regional nodes,” and patients with positive nodes are classified as clinical group IV.

Role of Retroperitoneal Lymph Node Dissection

Original protocols, which frequently used non–nerve-sparing bilateral RPLND for patients with paratesticular RMS, resulted in significant morbidity, such as intestinal obstruction (10%), ejaculatory dysfunction (8%), and lower extremity edema (5%). The IRS-III analysis of 121 patients undergoing RPLND for paratesticular RMS compared CT evaluation of lymph nodes (LN) with the pathologic results of RPLND (mostly unilateral). Eighty-one percent of the 121 patients had CT-negative LN status; of these 14% had positive nodes on pathological examination. Patients with negative nodes had a much higher 5-year EFS, 96% versus 69% (Wiener et al., 1994). After IRS-III, strategy shifted and patients enrolled in IRS-IV did not undergo RPLND if they had negative nodes on imaging (Crist et al., 2001). Further comparison between the two studies demonstrated a stage shift in patients categorized as group I, such that 68% of IRS-III patients were group I versus 82% in IRS-IV. This change was reflective of the reliance of CT only for staging in IRS-IV. Comparative analysis between these studies demonstrated that adolescents (>10 years old) were much more likely to have retroperitoneal disease and fared worse than children younger than 10 (Wiener et al., 2001). As a result of these findings, COG recommendations shifted back so that all children older than 10 should undergo SIRPLND.

The Italian and German groups compared the accuracy of CT versus pathological assessment of the retroperitoneum and found that only 1 of 72 patients with a negative CT had positive retroperitoneal lymph nodes. SIOP studies MMT 84 and 89 treated patients with nonmetastatic, paratesticular RMS without RPLND (Stewart et al., 2003). A total of 96 patients were enrolled; 25 of these patients were 10 or older. Only 1 patient underwent lymphadenectomy as initial therapy. Five-year OS was 92% and EFS was 82%. Relapse occurred in 16 patients, 14 in the retroperitoneum. Eight were salvaged with second-line chemotherapy, radiation, and in some cases, lymphadenectomy. Although the authors recognize that these sixteen patients may have been understaged, they point out that OS is comparable with that of IRS (Stewart et al., 2003). Older age and primary tumors greater than 5 cm predisposed to poor outcome. A recent SEER-based study identified 225 cases of paratesticular RMS. Among 173 patients older than 10 years of age, LN dissection was found to improve the 5-year OS rate from 64% to 86% ($P < 0.01$). Conversely, patients aged younger than 10 years fared well regardless of LN dissection status; the 5-year OS rate was 100% and 97%, respectively (Dang et al., 2013). Seitz reported the cumulative results of CWS-86, -91, -96, and -2002P, which included a total of 147 patients. The 5-year OS was 95.5% and EFS was 89.8%. Contrary to COG protocols the authors recommend that initially positive LNs be re-imaged after 7 to 10 weeks; those with evidence of persistent LN enlargement (particularly those >10) should have RT or RPLND. They suggest that patients with adenopathy may be observed based on the finding that few patients actually had positive nodes after chemotherapy (Seitz et al., 2016a,b).

In summary, although some European collaborative groups have avoided RPLND, COG recommends RPLND for all children older than 10 hoping to avoid failure in the retroperitoneum and the burden of second-line therapy. Despite data supporting these recommendations, an analysis of the SEER database recently published showed that one-third of adolescents still do not undergo RPLND, despite a distinct survival advantage (OS at 5 years 92% vs. 64%) (Hamilton et al., 2018). Recently, the utility of PET-CT for detecting nodal involvement in RMS has been reported; it is possible that will be a useful adjunct for retroperitoneal staging (Burnette et al., 2013).

Outcomes

Before the advent of multimodal therapy, surgery alone provided for a 2-year EFS of 50% (Sutow et al., 1970). In most recently reported studies from the SIOP and MMT 84 and 89, the 5-year OS was 92% and the EFS at 5 years was 82% (Stewart et al., 2003). These studies identified age older than 10 and a primary tumor larger than 5 cm as adverse prognostic factors. The Italian and German cooperative groups jointly reported on 216 patients who had excellent 5-year OS and EFS of 94.6% and 90.7%, respectively (Ferrari et al., 2002). Patients with metastatic disease had a 5-year survival of only 22%. Like SIOP this group has also transitioned away from RPLND. Three-year overall survival in IRS-III was 96% and in IRS-IV was 92% (Crist et al., 1995, 2001).

A unique feature of paratesticular RMS is the good outcome of patients with alveolar histology now known to be related to fusion-negative status (Anderson et al., 2004; Ferrari et al., 2004).

Key Points

- Paratesticular rhabdomyosarcoma arises from the testicular tunics, epididymis, or the spermatic cord.
- In general, patients with paratesticular rhabdomyosarcoma enjoy a favorable prognosis in part because of the following: more than 80% are stage I at presentation, more than 90% are embryonal histology, and there are better-

than-expected outcomes for patients with alveolar histology.

- Patients suspected of having a paratesticular tumor should always be explored with an inguinal incision.
- Tumors in children greater than age 10 years require staging RPLND in COG protocols because of a higher retroperitoneal failure rate.

Perineal Rhabdomyosarcoma

RMS of the perineum (Fig. 54.8) and perianal region (PRMS) is very rare and constitutes fewer than 2% of all RMS cases. The initial lesion may be misdiagnosed as a perineal or perirectal abscess, so a high index of suspicion should be maintained (Hill et al., 2002; Raney et al., 1981). Alveolar histology is more common in this location, and these patients more frequently have regional nodes and metastasis (Raney et al., 1990). PRMS patients in general have experienced poor outcomes. IRS-I through IRS-IV trials demonstrated a 5-year OS of 49% with multimodal therapy (Crist et al., 1995).

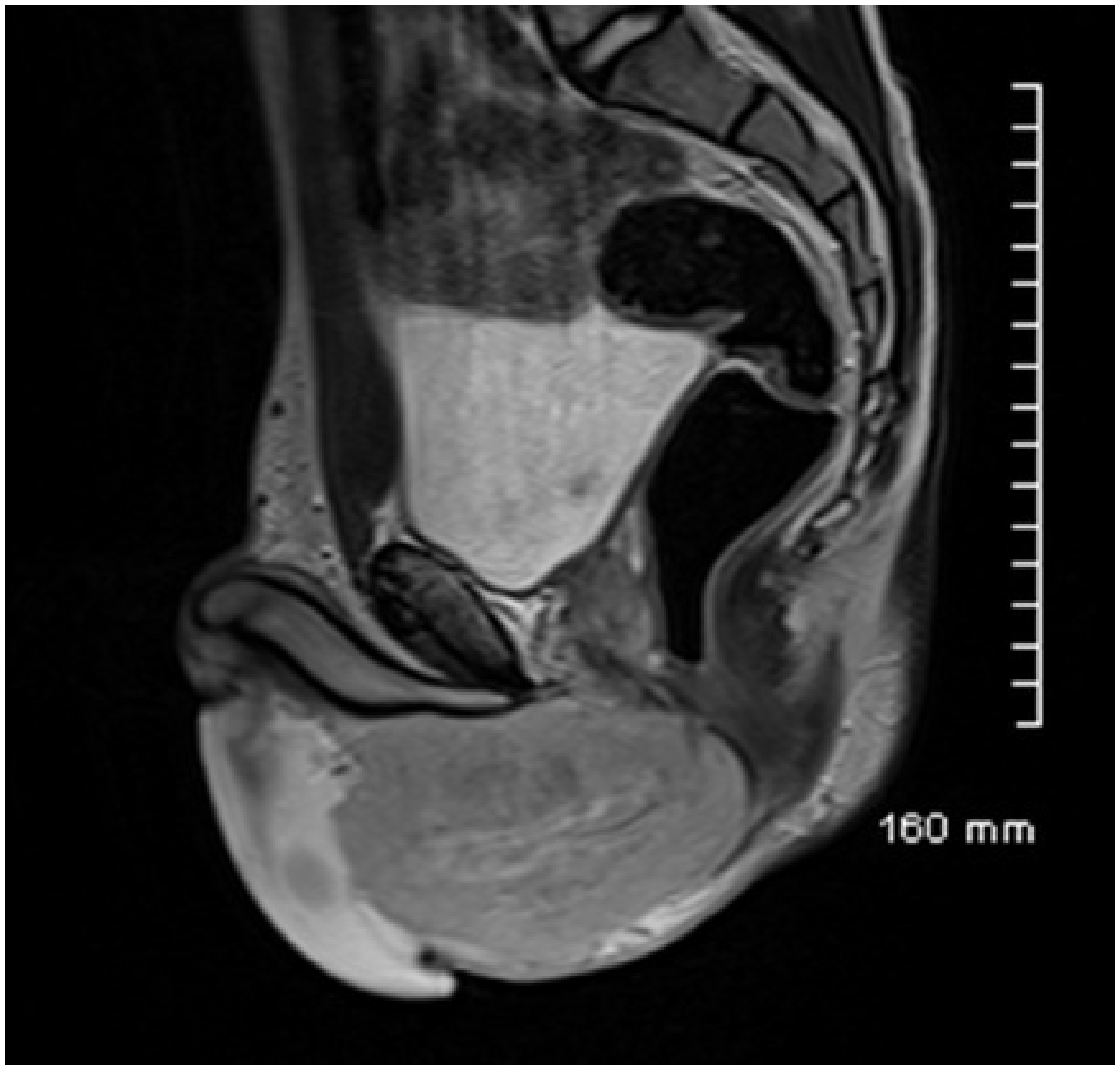

FIG. 54.8 Male patient with large perineal rhabdomyosarcoma. (Courtesy Angela J. Beavers, MD.)

A recent study retrospectively reviewed the outcomes of the Cooperative Soft Tissue Sarcoma Studies between 1986 and 2008 (eligible patients *n* = 32) (Fuchs et al., 2014). All patients received multiagent chemotherapy; for those treated after biopsy, subsequent treatment was decided based on response at 9 weeks.

Local control was then attempted using radiation, surgery, or both. Initial surgery consisted of biopsy (open, needle, punch, or image-guided) in 24 patients; of these 8 had lymph nodes sampled, all of which were positive. Eight patients had primary resection followed by chemotherapy. Consistent with prior reports, the OS and EFS rates were 47%. Positive predictive factors included age younger than 10, tumor size smaller than 5 cm, negative local regional nodes, low IRS group, and embryonal histology.

Suggested Readings

Agarwal PK, Palmer JS. Testicular and paratesticular neoplasms in prepubertal males. *J Urol*. 2006;176(3):875–881.

Andrassy RJ, Wiener ES, Raney RB, et al. Progress in the surgical management of vaginal rhabdomyosarcoma: a 25-year review from the Intergroup Rhabdomyosarcoma Study Group. *J Pediatr Surg*. 1999;34(5):731–734 [discussion 734–5].

Arndt C, Rodeberg D, Breitfeld PP, et al. Does bladder preservation (as a surgical principle) lead to retaining bladder function in bladder/prostate rhabdomyosarcoma? Results from the Intergroup Rhabdomyosarcoma Study Group IV. *J Urol*. 2004;171:2396–2403.

Crist WM, Anderson JR, Meza JL, et al. Intergroup rhabdomyosarcoma study-IV: results for patients with nonmetastatic disease. *J Clin Oncol*. 2001;19(12):3091–3102.

Dang ND, Dang PT, Samuelian J, et al. Lymph node management in patients with paratesticular rhabdomyosarcoma: a population-based analysis. *Cancer*. 2013;119(17):3228–3233.

Ferrer FA, Isakoff M, Koyle MA. Bladder/prostate rhabdomyosarcoma: past, present and future. *J Urol*. 2006;176(4 Pt 1):1283–1291.

Higuchi TT, Granberg CF, Fox JA, et al. Augmentation cystoplasty and risk of neoplasia: fact, fiction and controversy. *J Urol*. 2010;184(6):2492–2496.

Higuchi TT, Fox JA, Husmann DA. Annual endoscopy and urine cytology for the surveillance of bladder tumors after enterocystoplasty for congenital bladder anomalies. *J Urol*. 2011;186(5):1791–1795.

Lerena J, Krauel L, Garcia-Aparicio L, et al. Transitional cell carcinoma of the bladder in children and adolescents: six-case series and review of the literature. *J Pediatr Urol*. 2010;6(5):481–485.

Looijenga LH, Hersmus R, Oosterhuis W, et al. Tumor risk in disorders of sex development (DSD). *Best Pract Res Clin Endocrinol Metab*. 2007;21(3):480–495.

Malempati S, Rodeberg DA, Donaldson SS, et al. Rhabdomyosarcoma in infants younger than 1 year: a report from the Children's Oncology Group. *Cancer*. 2011;117(15):3493–3501.

Pohl HG, Shukla AR, Metcalf PD, et al. Prepubertal testis tumors: actual prevalence rate of histological types. *J Urol*. 2004;172(6 Pt 1):2370–2372.

Rogers PC, Olson TA, Cullen JW, et al. Treatment of children and adolescents with stage II testicular and stages I and II ovarian malignant germ cell tumors: a Pediatric Intergroup Study–Pediatric Oncology Group 9048 and Children's Cancer Group 8891. *J Clin Oncol*. 2004;22:3563–3569.

Rogers PC, Olson TA, Cullen JW, et al. Treatment of children and adolescents with stage II testicular and stages I and II ovarian malignant germ cell tumors: a Pediatric Intergroup Study–Pediatric Oncology Group 9048 and Children's Cancer Group 8891. *J Clin Oncol*. 2004;22(17):3563–3569.

Ross JH, Rybicki L, Kay R. Clinical behavior and a contemporary management algorithm for prepubertal testis tumors: a summary of the Prepubertal Testis Tumor Registry. *J Urol*. 2002;168(4 Pt 2):1675–1678 [discussion 1678–9].

Rushton G, Belman AB, Sesterhenn I, et al. Testicular sparing surgery for prepubertal teratoma of the testis: a clinical and pathological study. *J Urol*. 1990;144:726–730.

Skapek SX, Anderson J, Barr FG, et al. PAX-FOXO1 fusion status drives unfavorable outcome for children with rhabdomyosarcoma: a children's oncology group report.

Pediatr Blood Cancer. 2013;60(9):1411–1417.

Spunt SL, Sweeney TA, Judson MM, et al. Late effects of pelvic rhabdomyosarcoma and its treatment in female survivors. *J Clin Oncol*. 2005;23:7143–7151.

Walterhouse DO, Meza JL, Breneman JC, et al. Local control and outcome in children with localized vaginal rhabdomyosarcoma: a report from the Soft Tissue Sarcoma committee of the Children's Oncology Group. *Pediatr Blood Cancer*. 2011;57(1):76–83.

Wiener ES, et al. Controversies in the management of paratesticular rhabdomyosarcoma: is staging retroperitoneal lymph node dissection necessary for adolescents with resected paratesticular rhabdomyosarcoma? *Semin Pediatr Surg*. 2001;10(3):146–152.

References

Agarwal PK, Palmer JS. Testicular and paratesticular neoplasms in prepubertal males. *J Urol*. 2006;176(3):875–881.

Ahmed HU, Arya M, Muneer A, et al. Testicular and paratesticular tumours in the prepubertal population. *Lancet Oncol*. 2010;11(5):476–483.

Alexander N, Lane S, Hitchcock R. What is the evidence for radical surgery in the management of localized embryonal bladder/prostate rhabdomyosarcoma? *Pediatr Blood Cancer*. 2012;58(6):833–835.

Anderson JR, Meyer WH, Wiener ES. Favorable outcome for children with paratesticular alveolar history rhabdomysosarcoma. *Pediatr Blood Cancer*. 2004;43(2):180.

Andrassy RJ, Hays DM, Raney RB, et al. Conservative surgical management of vaginal and vulvar pediatric rhabdomyosarcoma: a report from the Intergroup Rhabdomyosarcoma Study III. *J Pediatr Surg*. 1995;30(7):1034–1036 [discussion 1036–1037].

Andrassy RJ, Wiener ES, Raney RB, et al. Progress in the surgical management of vaginal rhabdomyosarcoma: a 25-year review from the Intergroup Rhabdomyosarcoma Study Group. *J Pediatr Surg*. 1999;34(5):731–734 [discussion 734–735].

Angelini L, Bisogno G, Alaggio R, et al. Prognostic factors in children undergoing salvage surgery for bladder/prostate rhabdomyosarcoma. *J Pediatr Urol*. 2016;12(4):265.e1–265.e8.

Armstrong GT, Kawashima T, Leisenring W, et al. Aging and risk of severe, disabling, life-threatening, and fatal events in the childhood cancer survivor study. *J Clin Oncol*. 2014;32(12):1218–1227.

Arndt C, Rodeberg D, Breitfeld PP, et al. Does bladder preservation (as a surgical principle) lead to retaining bladder function in bladder/prostate rhabdomyosarcoma? Results from intergroup rhabdomyosarcoma study IV. *J Urol*. 2004;171(6 Pt 1):2396–2403.

Arndt CA, Donaldson SS, Anderson JR, et al. What constitutes optimal therapy for patients with rhabdomyosarcoma of the female genital tract? *Cancer*. 2001;91(12):2454–2468.

Arnold MA, Anderson JR, Gastier-Foster JM, et al. Histology, fusion status, and outcome in alveolar rhabdomyosarcoma with low-risk clinical features: a report from the Children's Oncology Group. *Pediatr Blood Cancer*. 2016;63(4):634–639.

Ashley RA, Figueroa TE. Gross hematuria in a 3-year-old girl caused by a large isolated bladder hemangioma. *Urology*. 2010;76(4):952–954.

Ashley RA, Inman BA, Routh JC, et al. Urachal anomalies: a longitudinal study of urachal remnants in children and adults. *J Urol*. 2007;178(4 Pt 2):1615–1618.

Askin FB, Land VJ, Sullivan MP, et al. Occult testicular leukemia: testicular biopsy at three years continuous complete remission of childhood leukemia: a Southwest Oncology Group Study. *Cancer*. 1981;47(3):470–475.

Austin JC, Elliott S, Cooper CS. Patients with spina bifida and bladder cancer: atypical presentation, advanced stage and poor survival. *J Urol*. 2007;178(3 Pt 1):798–801.

Barr FG, Galili N, Holick J, et al. Rearrangement of the PAX3 paired box gene in the paediatric solid tumour alveolar rhabdomyosarcoma. *Nat Genet*. 1993;3(2):113–117.

Barrington JW, Jones A, James D, et al. Antioxidant deficiency following clam enterocystoplasty. *Br J Urol*. 1997;80(2):238–242.

Beare JB, Tormey AR Jr, Wattenberg CA. Exstrophy of the urinary bladder complicated by adenocarcinoma. *J Urol*. 1956;76(5):583–594.

Berger A, Kim C, Hagstrom N, et al. Successful preoperative treatment of pediatric bladder inflammatory myofibroblastic tumor with anti-inflammatory therapy. *Urology*. 2007;70(2):372.e13–372.e15.

Billmire DF, Cullen JW, Rescorla FJ, et al. Surveillance after initial surgery for pediatric and adolescent girls with stage I ovarian germ cell tumors: report from the Children's Oncology Group. *J Clin Oncol*. 2014.

Bisogno G, Pastore G, Perilongo G, et al. Long-term results in childhood rhabdomyosarcoma: a report from the Italian Cooperative Study RMS 79. *Pediatr Blood Cancer*. 2012;58(6):872–876.

Bond SJ, Seibel N, Kapur S, et al. Rhabdomyosarcoma of the clitoris. *Cancer*. 1994;73(7):1984–1986.

Bosl GJ, Motzer RJ. Testicular germ-cell cancer. *N Engl J Med*. 1997;337(4):242–253.

Brandt ML, Helmrath MA. Ovarian cysts in infants and children. *Semin Pediatr Surg*. 2005;14(2):78–85.

Broecker JS, Steelman CK, Broecker BH, et al. Nephrogenic adenoma of the bladder in a prune belly syndrome patient: case report and review of the literature. *Fetal Pediatr Pathol*. 2011;30(5):296–300.

Burnette JO, Klaassen Z, Hatley RM, et al. Staging paratesticular rhabdomyosarcoma in the “as low as reasonably achievable” age: the case for PET-CT. *Urology*. 2013;82(1):220–223.

Burns KC, Hoefgen H, Strine A, et al. Fertility preservation options in pediatric and adolescent patients with cancer. *Cancer*. 2018;124(9):1867–1876.

Bussey KJ, Lawce HJ, Olson SB, et al. Chromosome abnormalities of eighty-one pediatric germ cell tumors: sex-, age-, site-, and histopathology-related differences–a Children's Cancer Group study. *Genes Chromosomes Cancer*. 1999;25(2):134–146.

Caione P, Patruno G, Pagliarulo V, et al. Nonmuscular invasive urothelial carcinoma of the bladder in pediatric and young adult patients: age-related outcomes. *Urology*. 2017;99:215–220.

Calhabeu F, Hayashi S, Morgan JE, et al. Alveolar rhabdomyosarcoma-associated proteins PAX3/FOXO1A and PAX7/FOXO1A suppress the transcriptional activity of MyoD-target genes in muscle stem cells. *Oncogene*. 2013;32(5):651–662.

Cao L, Yu Y, Bilke S, et al. Genome-wide identification of PAX3-FKHR binding sites in rhabdomyosarcoma reveals candidate target genes important for development and cancer. *Cancer Res*. 2010;70(16):6497–6508.

Castagnetti M, Angelini L, Alaggio R, et al. Oncological outcome and urinary function after radical cystectomy for rhabdomyosarcoma in children: role of the orthotopic ileal neo-bladder based on a 15-year experience at a single centre. *J Urol*. 2013.

Cessna MH, Zhou H, Perkins SL, et al. Are myogenin and myoD1 expression specific for rhabdomyosarcoma? A study of 150 cases, with emphasis on spindle cell mimics. *Am J Surg Pathol*. 2001;25(9):1150–1157.

Chaganti RS, Houldsworth J. The cytogenetic theory of the pathogenesis of human adult male germ cell tumors. Review article. *APMIS*. 1998;106(1):80–83 [discussion 83–84].

Chaganti RS, Houldsworth J. Genetics and biology of adult human male germ cell tumors. *Cancer Res*. 2000;60(6):1475–1482.

Chavez C, Hoffman MA. Complete remission of ALK-negative plasma cell granuloma (inflammatory myofibroblastic tumor) of the lung induced by celecoxib: a case report and review of the literature. *Oncol Lett*. 2013;5(5):1672–1676.

Cheng L, Sung MT, Cossu-Rocca P, et al. OCT4: biological functions and clinical applications as a marker of germ cell neoplasia. *J Pathol*. 2007;211(1):1–9.

Ciftci AO, Bingol-Kologlu M, Senocak ME, et al. Testicular tumors in children. *J Pediatr Surg*. 2001;36(12):1796–1801.

Cohen RJ, Curtis RE, Inskip PD, et al. The risk of developing second cancers among survivors of childhood soft tissue sarcoma. *Cancer*. 2005;103(11):2391–2396.

Collins GM, Kim DU, Logrono R, et al. Pure seminoma arising in androgen insensitivity syndrome (testicular feminization syndrome): a case report and review of the literature. *Mod Pathol*. 1993;6(1):89–93.

Connolly JA, Gearhart JP. Management of yolk sac tumors in children. *Urol Clin North Am*. 1993;20(1):7–14.

Cools M, Stoop H, Kersemaekers AM, et al. Gonadoblastoma arising in undifferentiated gonadal tissue within dysgenetic gonads. *J Clin Endocrinol Metab*. 2006;91(6):2404–2413.

Corpron CA, Andrassy RJ, Hays DM, et al. Conservative management of uterine pediatric rhabdomyosarcoma: a report from the Intergroup Rhabdomyosarcoma Study III and IV pilot. *J Pediatr Surg*. 1995;30(7):942–944.

Cortez JC, Kaplan GW. Gonadal stromal tumors, gonadoblastomas, epidermoid cysts, and secondary tumors of the testis in children. *Urol Clin North Am*. 1993;20(1):15–26.

Cost NG, DaJusta DG, Granberg CF, et al. Robot-assisted laparoscopic retroperitoneal lymph node dissection in an adolescent population. *J Endourol*. 2012;26(6):635–640.

Crist W, Gehan EA, Ragab AH, et al. The third intergroup rhabdomyosarcoma study. *J Clin Oncol*. 1995;13(3):610–630.

Crist WM, Anderson JR, Meza JL, et al. Intergroup rhabdomyosarcoma study-IV: results for patients with nonmetastatic disease. *J Clin Oncol*. 2001;19(12):3091–3102.

Crose LE, Etheridge KT, Chen C, et al. FGFR4 blockade exerts distinct antitumorigenic effects in human embryonal versus alveolar rhabdomyosarcoma. *Clin Cancer Res*. 2012;18(14):3780–3790.

CureSearch: Childhood Childhood-Cancer-Statistics.

Dall'Igna P, Bisogno G, Ferrari A, et al. Primary transcrotal excision for paratesticular rhabdomyosarcoma: is hemiscrotectomy really mandatory? *Cancer*. 2003;97(8):1981–1984.

Dang ND, Dang PT, Samuelian J, et al. Lymph node management in patients with paratesticular rhabdomyosarcoma: a population-based analysis. *Cancer*. 2013;119(17):3228–3233.

Dantonello TM, Int-Veen C, Harms D, et al. Cooperative trial CWS-91 for localized soft tissue sarcoma in children, adolescents, and young adults. *J Clin Oncol*. 2009;27(9):1446–1455.

Daudin M, Rives N, Walschaerts M, et al. Sperm cryopreservation in adolescents and young adults with cancer: results of the French national sperm banking network (CECOS). *Fertil Steril*. 2015;103(2):478–486.e1.

Davis RJ, D'Cruz CM, Lovell MA, et al. Fusion of PAX7 to FKHR by the variant t(1;13)(p36;q14) translocation in alveolar rhabdomyosarcoma. *Cancer Res*. 1994;54(11):2869–2872.

De Backer A, Madern GC, Pieters R, et al. Influence of tumor site and histology on long-term survival in 193 children with extracranial germ cell tumors. *Eur J Pediatr Surg*. 2008;18(1):1–6.

Demeestere I, Simon P, Dedeken L, et al. Live birth after autograft of ovarian tissue cryopreserved during childhood. *Hum Reprod*. 2015;30(9):2107–2109.

Depue RH, Pike MC, Henderson BE. Estrogen exposure during gestation and risk of testicular cancer. *J Natl Cancer Inst*. 1983;71(6):1151–1155.

Dias P, Chen B, Dilday B, et al. Strong immunostaining for myogenin in rhabdomyosarcoma is significantly associated with tumors of the alveolar subclass. *Am J Pathol*. 2000;156(2):399–408.

Diller L, Sexsmith E, Gottlieb A, et al. Germline p53 mutations are frequently detected in young children with rhabdomyosarcoma. *J Clin Invest*. 1995;95(4):1606–1611.

Dodd S, Malone M, McCulloch W. Rhabdomyosarcoma in children: a histological and immunohistochemical study of 59 cases. *J Pathol*. 1989;158(1):13–18.

Dowling CR, Reddihough D, Smith P, et al. Transitional cell carcinoma in the paediatric population: be aware of unusual aetiologies. *J Paediatr Child Health*. 2007;43(11):773–775.

Duel BP, Hendren WH, Bauer SB, et al. Reconstructive options in genitourinary rhabdomyosarcoma. *J Urol*. 1996;156(5):1798–1804.

Ekbom A, Akre O. Increasing incidence of testicular cancer–birth cohort effects. *APMIS*. 1998;106(1):225–229 [discussion 229–231].

Engert JC, Berglund EB, Rosenthal N. Proliferation precedes differentiation in IGF-I-stimulated myogenesis. *J Cell Biol*. 1996;135(2):431–440.

Epstein JA, Shapiro DN, Cheng J, et al. Pax3 modulates expression of the c-Met receptor during limb muscle development. *Proc Natl Acad Sci USA*. 1996;93(9):4213–4218.

Federico SM, Spunt SL, Krasin MJ, et al. Comparison of PET-CT and conventional imaging in staging pediatric rhabdomyosarcoma. *Pediatr Blood Cancer*. 2013;60(7):1128–1134.

Ferrari A, Bisogno G, Casanova M, et al. Is alveolar histotype a prognostic factor in paratesticular rhabdomyosarcoma? The experience of Italian and German Soft Tissue Sarcoma Cooperative Group. *Pediatr Blood Cancer*. 2004;42(2):134–138.

Ferrari A, Bisogno G, Casanova M, et al. Paratesticular rhabdomyosarcoma: report from the Italian and German Cooperative Group. *J Clin Oncol*. 2002;20(2):449–455.

Ferrari A, Casanova M, Bisogno G, et al. What chemotherapy should alveolar paratesticular rhabdomyosarcoma receive? *Pediatr Blood Cancer*. 2004;43(3):295.

Ferrari A, Casanova M, Bisogno G, Italian Cooperative Group, et al. Rhabdomyosarcoma in infants younger than one year old: a report from the Italian Cooperative Group. *Cancer*. 2003;97(10):2597–2604.

Ferrer FA. Bladder and prostate rhabdomyosarcoma. *Dialogues Pediatr Urol*. 2010;31(4):1–5.

Ferrer FA, Isakoff M, Koyle MA. Bladder/prostate rhabdomyosarcoma: past, present and future. *J Urol*. 2006;176(4 Pt 1):1283–1291.

Ferrer FA, Ritchey M. Pediatric bladder tumors. Lerner SP, Schoenberg M, Sternberg C. *Textbook of bladder cancer*. Bota Raton, FL: CRC Press; 2006:735–748.

Filmer RB, Spencer JR. Malignancies in bladder augmentations and intestinal conduits. *J Urol*. 1990;143(4):671–678.

Finn LS, Viswanatha DS, Belasco JB, et al. Primary follicular lymphoma of the testis in childhood. *Cancer*. 1999;85(7):1626–1635.

Flamant F, Chassagne D, Cosset JM, et al. Embryonal rhabdomyosarcoma of the vagina in children: conservative treatment with curietherapy and chemotherapy. *Eur J Cancer*. 1979;15(4):527–532.

Flamant F, Rodary C, Voute PA, et al. Primary chemotherapy in the treatment of rhabdomyosarcoma in children: trial of the International Society of Pediatric Oncology (SIOP) preliminary results. *Radiother Oncol*. 1985;3(3):227–236.

Frees S, Rubenwolf P, Ziesel C, et al. Erectile function after treatment for rhabdomyosarcoma of prostate and bladder. *J Pediatr Urol*. 2016;12(6):404.e1–404.e6.

Fuchs J, Dantonello TM, Blumenstock G, et al. Treatment and outcome of patients suffering from perineal/perianal rhabdomyosarcoma: results from the CWS trials–retrospective clinical study. *Ann Surg*. 2014;259(6):1166–1172.

Furlong MA, Mentzel T, Fanburg-Smith JC. Pleomorphic rhabdomyosarcoma in adults: a clinicopathologic study of 38 cases with emphasis on morphologic variants and recent skeletal muscle-specific markers. *Mod Pathol*. 2001;14(6):595–603.

Furness PD 3rd, Husmann DA, Brock JW 3rd, et al. Multi-institutional study of testicular microlithiasis in childhood: a benign or premalignant condition? *J Urol*. 1998;160(3 Pt 2):1151–1154 [discussion 1178].

Gabrilove JL, Freiberg EK, Leiter E, et al. Feminizing and non-feminizing Sertoli cell tumors. *J Urol*. 1980;124(6):757–767.

Galili N, Davis RJ, Fredericks WJ, et al. Fusion of a fork head domain gene to PAX3 in the solid tumour alveolar rhabdomyosarcoma. *Nat Genet*. 1993;5(3):230–235.

Ghushe ND, Drugas GT. Rhabdomyosarcoma of the clitoris. *Pediatr Radiol*. 2007;37(11):1179.

Gillis AJ, Stoop HJ, Hersmus R, et al. High-throughput microRNAome analysis in human germ cell tumours. *J Pathol*. 2007;213(3):319–328.

Ginsberg JP. New advances in fertility preservation for pediatric cancer patients. *Curr Opin Pediatr*. 2011;23(1):9–13.

Ginsberg JP, Davis RJ, Bennicelli JL, et al. Up-regulation of

MET but not neural cell adhesion molecule expression by the PAX3-FKHR fusion protein in alveolar rhabdomyosarcoma. *Cancer Res*. 1998;58(16):3542–3546.

Gittes RF. Carcinogenesis in ureterosigmoidostomy. *Urol Clin North Am*. 1986;13(2):201–205.

Giwercman A, Grindsted J, Hansen B, et al. Testicular cancer risk in boys with maldescended testis: a cohort study. *J Urol*. 1987;138(5):1214–1216.

Gobel U, Calaminus G, Engert J, et al. Teratomas in infancy and childhood. *Med Pediatr Oncol*. 1998;31(1):8–15.

Gobel U, Calaminus G, Schneider DT, et al. The malignant potential of teratomas in infancy and childhood: the MAKEI experiences in non-testicular teratoma and implications for a new protocol. *Klin Padiatr*. 2006;218(6):309–314.

Goede J, Hack WW, van der Voort-Doedens LM, et al. Prevalence of testicular microlithiasis in asymptomatic males 0 to 19 years old. *J Urol*. 2009;182(4):1516–1520.

Golomb J, Klutke CG, Lewin KJ, et al. Bladder neoplasms associated with augmentation cystoplasty: report of 2 cases and literature review. *J Urol*. 1989;142(2 Pt 1):377–380.

Grady RW. Current management of prepubertal yolk sac tumors of the testis. *Urol Clin North Am*. 2000;27(3):503–508 [ix].

Grady RW, Ross JH, Kay R. Patterns of metastatic spread in prepubertal yolk sac tumor of the testis. *J Urol*. 1995;153(4):1259–1261.

Green DM, Liu W, Kutteh WH, et al. Cumulative alkylating agent exposure and semen parameters in adult survivors of childhood cancer: a report from the St Jude Lifetime Cohort Study. *Lancet Oncol*. 2014;15(11):1215–1223.

Green DM, Nolan VG, Goodman PJ, et al. The cyclophosphamide equivalent dose as an approach for quantifying alkylating agent exposure: a report from the Childhood Cancer Survivor Study. *Pediatr Blood Cancer*.

2014;61(1):53–67.

Gripp KW, Scott CI Jr, Nicholson L, et al. Five additional Costello syndrome patients with rhabdomyosarcoma: proposal for a tumor screening protocol. *Am J Med Genet*. 2002;108(1):80–87.

Gupta S, Bhaijee F, Harmon EP. Mucinous neoplasm arising in a urachal cyst: a first in the pediatric population. *Urology*. 2014;83(2):455–456.

Haas RJ, Schmidt P. Testicular germ-cell tumors in childhood and adolescence. *World J Urol*. 1995;13(4):203–208.

Haas RJ, Schmidt P, Gobel U, et al. Testicular germ cell tumors. Results of the GPO MAHO studies -82, -88, -92. *Klin Padiatr*. 1995;207(4):145–150.

Haas RJ, Schmidt P, Gobel U, et al. Testicular germ cell tumors, an update. Results of the German cooperative studies 1982-1997. *Klin Padiatr*. 1999;211(4):300–304.

Hahn H, Wicking C, Zaphiropoulous PG, et al. Mutations of the human homolog of Drosophila patched in the nevoid basal cell carcinoma syndrome. *Cell*. 1996;85(6):841–851.

Halme A, Kellokumpu-Lehtinen P, Lehtonen T. Trends in incidence and results of treatment of testicular germ cell tumours in Finland 1972-1983. *Acta Oncol*. 1989;28(6):777–783.

Halme A, Kellokumpu-Lehtinen P, Lehtonen T, et al. Morphology of testicular germ cell tumours in treated and untreated cryptorchidism. *Br J Urol*. 1989;64(1):78–83.

Hamilton EC, Miller CC 3rd, Joseph M, et al. Retroperitoneal lymph node staging in paratesticular rhabdomyosarcoma—are we meeting expectations? *J Surg Res*. 2018;224:44–49.

Hartmann A, Junker K, Dietmaier W, et al. Molecular evidence for progression of nephrogenic metaplasia of the urinary bladder to clear cell adenocarcinoma. *Hum Pathol*. 2006;37(1):117–120.

Hays DM, Raney RB, Wharam MD, et al. Children with vesical rhabdomyosarcoma (RMS) treated by partial cystectomy with neoadjuvant or adjuvant chemotherapy, with or without radiotherapy. A report from the Intergroup Rhabdomyosarcoma Study (IRS) Committee. *J Pediatr Hematol Oncol*. 1995;17(1):46–52.

Heidenreich A, Zirbes TK, Wolter S, et al. Nephrogenic adenoma: a rare bladder tumor in children. *Eur Urol*. 1999;36(4):348–353.

Heij HA, Vos A, de Kraker J, et al. Urogenital rhabdomyosarcoma in children: is a conservative surgical approach justified? *J Urol*. 1993;150(1):165–168.

Hensle TW, Chang DT. Reconstructive surgery for children with pelvic rhabdomyosarcoma. *Urol Clin North Am*. 2000;27(3):489–502 [ix].

Higuchi TT, Fox JA, Husmann DA. Annual endoscopy and urine cytology for the surveillance of bladder tumors after enterocystoplasty for congenital bladder anomalies. *J Urol*. 2011;186(5):1791–1795.

Higuchi TT, Granberg CF, Fox JA, et al. Augmentation cystoplasty and risk of neoplasia: fact, fiction and controversy. *J Urol*. 2010;184(6):2492–2496.

Hill DA, Dehner LP, Gow KW, et al. Perianal rhabdomyosarcoma presenting as a perirectal abscess: a report of 11 cases. *J Pediatr Surg*. 2002;37(4):576–581.

Hoei-Hansen CE, Sommer P, Meyts ER, et al. A rare diagnosis: testicular dysgenesis with carcinoma in situ detected in a patient with ultrasonic microlithiasis. *Asian J Androl*. 2005;7(4):445–447.

Hoenig DM, McRae S, Chen SC, et al. Transitional cell carcinoma of the bladder in the pediatric patient. *J Urol*. 1996;156(1):203–205.

Holm M, Hoei-Hansen CE, Rajpert-De Meyts E, et al. Increased risk of carcinoma in situ in patients with testicular germ cell cancer with ultrasonic microlithiasis in the contralateral testicle. *J Urol*. 2003;170(4 Pt 1):1163–1167.

Horn RC Jr, Enterline HT. Rhabdomyosarcoma: a clinicopathological study and classification of 39 cases. *Cancer*. 1958;11(1):181–199.

Husmann DA, Rathbun SR. Long-term follow up of enteric bladder augmentations: the risk for malignancy. *J Pediatr Urol*. 2008;4(5):381–385 [discussion 386].

Husmann DA, Spence HM. Current status of tumor of the bowel following ureterosigmoidostomy: a review. *J Urol*. 1990;144(3):607–610.

Institute NC. *Cancer in children and adolescents*. [From] https://www.cancer.gov/types/childhood-cancers/child-adolescent.

Javadpour N, Mostofi FK. Primary epithelial tumors of the bladder in the first two decades of life. *J Urol*. 1969;101(5):706–710.

Jenderny J, Koster E, Borchers O, et al. Interphase cytogenetics on paraffin sections of paediatric extragonadal yolk sac tumours. *Virchows Arch*. 1996;428(1):53–57.

Jenney M, Oberlin O, Audry G, et al. Conservative approach in localised rhabdomyosarcoma of the bladder and prostate: results from International Society of Paediatric Oncology (SIOP) studies: malignant mesenchymal tumour (MMT) 84, 89 and 95. *Pediatr Blood Cancer*. 2014;61(2):217–222.

Johnson RL, Rothman AL, Xie J, et al. Human homolog of patched, a candidate gene for the basal cell nevus syndrome. *Science*. 1996;272(5268):1668–1671.

Jones AE, Albano EA, Lovell MA, et al. Metastatic alveolar rhabdomyosarcoma in multiple endocrine neoplasia type 2A. *Pediatr Blood Cancer*. 2010;55(6):1213–1216.

Jongmans MC, van der Burgt I, Hoogerbrugge PM, et al.

Cancer risk in patients with Noonan syndrome carrying a PTPN11 mutation. *Eur J Hum Genet*. 2011;19(8):870–874.

Joshi D, Anderson JR, Paidas C, Soft Tissue Sarcoma Committee of the Children's Oncology Group, et al. Age is an independent prognostic factor in rhabdomyosarcoma: a report from the Soft Tissue Sarcoma Committee of the Children's Oncology Group. *Pediatr Blood Cancer*. 2004;42(1):64–73.

Kamyshan IS, Klimenko IA, Kirichenko SA. Urinary bladder cancer in patients with tuberculous and post-tuberculous cystitis. *Urologiia*. 2000;2:21–24.

Kappler R, Calzada-Wack J, Schnitzbauer U, et al. Molecular characterization of Patched-associated rhabdomyosarcoma. *J Pathol*. 2003;200(3):348–356.

Karmazyn B, Weatherly DL, Lehnert SJ, et al. Characteristics of testicular tumors in prepubertal children (age 5-12 years). *J Pediatr Urol*. 2018;14(3):259.e1–259.e6.

Kayton ML, Wexler LH, Lewin SN, et al. Pediatric radical abdominal trachelectomy for anaplastic embryonal rhabdomyosarcoma of the uterine cervix: an alternative to radical hysterectomy. *J Pediatr Surg*. 2009;44(4):862–867.

Keene DJ, Sajjad Y, Makin G, et al. Sperm banking in the United Kingdom is feasible in patients 13 years old or older with cancer. *J Urol*. 2012;188(2):594–597.

Keller C, Guttridge DC. Mechanisms of impaired differentiation in rhabdomyosarcoma. *FEBS J*. 2013;280(17):4323–4334.

Kersemaekers AM, Honecker F, Stoop H, et al. Identification of germ cells at risk for neoplastic transformation in gonadoblastoma: an immunohistochemical study for OCT3/4 and TSPY. *Hum Pathol*. 2005;36(5):512–521.

Khasidy LR, Khashu B, Mallett EC, et al. Transitional cell carcinoma of bladder in children. *Urology*. 1990;35(2):142–144.

Kirsch CH, Goodman M, Esiashvili N. Outcome of female pediatric patients diagnosed with genital tract rhabdomyosarcoma based on analysis of cases registered in SEER database between 1973 and 2006. *Am J Clin Oncol*. 2014;37(1):47–50.

Kodet R, Newton WA Jr, Hamoudi AB, et al. Childhood rhabdomyosarcoma with anaplastic (pleomorphic) features. A report of the Intergroup Rhabdomyosarcoma Study. *Am J Surg Pathol*. 1993;17(5):443–453.

Kokorowski PJ, Routh JC, Borer JG, et al. Screening for malignancy after augmentation cystoplasty in children with spina bifida: a decision analysis. *J Urol*. 2011;186(4):1437–1443.

Lagha M, Kormish JD, Rocancourt D, et al. Pax3 regulation of FGF signaling affects the progression of embryonic progenitor cells into the myogenic program. *Genes Dev*. 2008;22(13):1828–1837.

Lamm DL, Kaplan GW. Urological manifestations of Burkitt's lymphoma. *J Urol*. 1974;112(3):402–405.

Lander EB, Shanberg AM, Tansey LA, et al. The use of continent diversion in the management of rhabdomyosarcoma of the prostate in childhood. *J Urol*. 1992;147(6):1602–1605.

Lau YF, Li Y, Kido T. Gonadoblastoma locus and the TSPY gene on the human Y chromosome. *Birth Defects Res C Embryo Today*. 2009;87(1):114–122.

Leenen AS, Riebel TW. Testicular microlithiasis in children: sonographic features and clinical implications. *Pediatr Radiol*. 2002;32(8):575–579.

Lerena J, Krauel L, Garcia-Aparicio L, et al. Transitional cell carcinoma of the bladder in children and adolescents: six-case series and review of the literature. *J Pediatr Urol*. 2010;6(5):481–485.

Li FP, Fraumeni JF. Testicular cancers in children: epidemiologic characteristics. *J Natl Cancer Inst*.

1972;48(6):1575–1581.

Li J, Yin WH, Takeuchi K, et al. Inflammatory myofibroblastic tumor with RANBP2 and ALK gene rearrangement: a report of two cases and literature review. *Diagn Pathol*. 2013;8:147.

Lo Curto M, Lumia F, Alaggio R, et al. Malignant germ cell tumors in childhood: results of the first Italian cooperative study “TCG 91. *Med Pediatr Oncol*. 2003;41(5):417–425.

Lobe TE, Wiener E, Andrassy RJ, et al. The argument for conservative, delayed surgery in the management of prostatic rhabdomyosarcoma. *J Pediatr Surg*. 1996;31(8):1084–1087.

Looijenga LH, de Munnik H, Oosterhuis JW. A molecular model for the development of germ cell cancer. *Int J Cancer*. 1999;83(6):809–814.

Looijenga LH, Hersmus R, Oosterhuis JW, et al. Tumor risk in disorders of sex development (DSD). *Best Pract Res Clin Endocrinol Metab*. 2007;21(3):480–495.

Looijenga LH, Oosterhuis JW. Pathogenesis of testicular germ cell tumours. *Rev Reprod*. 1999;4(2):90–100.

Lopez-Gutierrez JC, Jaureguizar E. Bladder vascular anomalies. *J Pediatr Urol*. 2010;6(5):530–531.

Magne N, Haie-Meder C. Brachytherapy for genital-tract rhabdomyosarcomas in girls: technical aspects, reports, and perspectives. *Lancet Oncol*. 2007;8(8):725–729.

Magne N, Oberlin O, Martelli H, et al. Vulval and vaginal rhabdomyosarcoma in children: update and reappraisal of Institut Gustave Roussy brachytherapy experience. *Int J Radiat Oncol Biol Phys*. 2008;72(3):878–883.

Maizlin II, Dellinger M, Gow KW, et al. Testicular tumors in prepubescent patients. *J Pediatr Surg*. 2018;53(9):1748–1752.

Makari JH, Ramachandra P, Ferrer FA Jr. Pediatric urologic oncology: organ-sparing surgery in kidney and testis. *Urol Clin North Am*. 2010;37(2):287–298.

Malempati S, Rodeberg DA, Donaldson SS, et al. Rhabdomyosarcoma in infants younger than 1 year: a report from the Children's Oncology Group. *Cancer*. 2011;117(15):3493–3501.

Malkin D, Li FP, Strong LC, et al. Germ line p53 mutations in a familial syndrome of breast cancer, sarcomas, and other neoplasms. *Science*. 1990;250(4985):1233–1238.

Mann JR, Pearson D, Barrett A, et al. Results of the United Kingdom Children's Cancer Study Group's malignant germ cell tumor studies. *Cancer*. 1989;63(9):1657–1667.

Mann JR, Raafat F, Robinson K, et al. The United Kingdom Children's Cancer Study Group's second germ cell tumor study: carboplatin, etoposide, and bleomycin are effective treatment for children with malignant extracranial germ cell tumors, with acceptable toxicity. *J Clin Oncol*. 2000;18(22):3809–3818.

Mansky P, Arai A, Stratton P, et al. Treatment late effects in long-term survivors of pediatric sarcoma. *Pediatr Blood Cancer*. 2007;48(2):192–199.

March Villalba JA. Editorial comment to a case of large bladder hemangioma successfully treated with endoscopic yttrium aluminium garnet laser irradiation. *Int J Urol*. 2012;19(1):85.

Martelli H, Borrego P, Guerin F, et al. Quality of life and functional outcome of male patients with bladder-prostate rhabdomyosarcoma treated with conservative surgery and brachytherapy during childhood. *Brachytherapy*. 2016;15(3):306–311.

Martelli H, Oberlin O, Rey A, et al. Conservative treatment for girls with nonmetastatic rhabdomyosarcoma of the genital tract: a report from the Study Committee of the International Society of Pediatric Oncology. *J Clin Oncol*. 1999;17(7):2117–2122.

Maurer HM, Beltangady M, Gehan EA, et al. The Intergroup

Rhabdomyosarcoma Study-I. A final report. *Cancer*. 1988;61(2):209–220.

Mazal PR, Schaufler R, Altenhuber-Muller R, et al. Derivation of nephrogenic adenomas from renal tubular cells in kidney-transplant recipients. *N Engl J Med*. 2002;347(9):653–659.

Meir DB, Inoue M, Gur U, et al. Urinary diversion in children with pelvic tumors. *J Pediatr Surg*. 2004;39(12):1787–1790.

Merguerian PA, Agarwal S, Greenberg M, et al. Outcome analysis of rhabdomyosarcoma of the lower urinary tract. *J Urol*. 1998;160(3 Pt 2):1191–1194 [discussion 1216].

Metcalfe PD, Farivar-Mohseni H, Farhat W, et al. Pediatric testicular tumors: contemporary incidence and efficacy of testicular preserving surgery. *J Urol*. 2003;170(6 Pt 1):2412–2415 [discussion 2415–2416].

Meza JL, Anderson J, Pappo AS, Children's Oncology Group, et al. Analysis of prognostic factors in patients with nonmetastatic rhabdomyosarcoma treated on intergroup rhabdomyosarcoma studies III and IV: the Children's Oncology Group. *J Clin Oncol*. 2006;24(24):3844–3851.

Minard-Colin V, Walterhouse D, Bisogno G, International Society of Pediatric Oncology Sarcoma Committee, the Children's Oncology Group, the Italian Cooperative Soft Tissue Sarcoma Group, and the European pediatric Soft tissue sarcoma Study Group, et al. Localized vaginal/uterine rhabdomyosarcoma-results of a pooled analysis from four international cooperative groups. *Pediatr Blood Cancer*. 2018;65(9).

Mochizuki K, Obatake M, Taura Y, et al. Yolk sac tumor of the vulva: a case report with recurrence after long-term follow-up. *Pediatr Surg Int*. 2012;28(9):931–934.

Morotti RA, Nicol KK, Parham DM, Children's Oncology Group, et al. An immunohistochemical algorithm to facilitate diagnosis and subtyping of rhabdomyosarcoma: the

Children's Oncology Group experience. *Am J Surg Pathol*. 2006;30(8):962–968.

Nurse DE, Mundy AR. Assessment of the malignant potential of cystoplasty. *Br J Urol*. 1989;64(5):489–492.

Oberlin O, Rey A, Sanchez de Toledo J, et al. Randomized comparison of intensified six-drug versus standard three-drug chemotherapy for high-risk nonmetastatic rhabdomyosarcoma and other chemotherapy-sensitive childhood soft tissue sarcomas: long-term results from the International Society of Pediatric Oncology MMT95 study. *J Clin Oncol*. 2012;30(20):2457–2465.

Oguzkan S, Terzi YK, Cinbis M, et al. Molecular genetic analyses in neurofibromatosis type 1 patients with tumors. *Cancer Genet Cytogenet*. 2006;165(2):167–171.

Oosterhuis JW, Looijenga LH. Current views on the pathogenesis of testicular germ cell tumours and perspectives for future research: highlights of the 5th Copenhagen Workshop on Carcinoma in situ and Cancer of the Testis. *APMIS*. 2003;111(1):280–289.

Oram SW, Liu XX, Lee TL, et al. TSPY potentiates cell proliferation and tumorigenesis by promoting cell cycle progression in HeLa and NIH3T3 cells. *BMC Cancer*. 2006;6:154.

Paduano L, Chiella E. Primary epithelial tumors of the bladder in children. *J Urol*. 1988;139(4):794–795.

Parham DM, Barr FG. Classification of rhabdomyosarcoma and its molecular basis. *Adv Anat Pathol*. 2013;20(6):387–397.

Parham DM, Webber B, Holt H, et al. Immunohistochemical study of childhood rhabdomyosarcomas and related neoplasms. Results of an Intergroup Rhabdomyosarcoma study project. *Cancer*. 1991;67(12):3072–3080.

Patil S, Jain SK, Kaza R, et al. Squamous cell carcinoma in bladder exstrophy: a rare entity. *Singapore Med J*.

2012;53(12):e254–e257.

Pleskacova J, Hersmus R, Oosterhuis JW, et al. Tumor risk in disorders of sex development. *Sex Dev*. 2010;4(4–5):259–269.

Pohl HG, Shukla AR, Metcalf PD, et al. Prepubertal testis tumors: actual prevalence rate of histological types. *J Urol*. 2004;172(6 Pt 1):2370–2372.

Poynter JN, Hooten AJ, Frazier AL, et al. Associations between variants in KITLG, SPRY4, BAK1, and DMRT1 and pediatric germ cell tumors. *Genes Chromosomes Cancer*. 2012;51(3):266–271.

Poynter JN, Radzom AH, Spector LG, et al. Family history of cancer and malignant germ cell tumors in children: a report from the Children's Oncology Group. *Cancer Causes Control*. 2010;21(2):181–189.

Practice Committee of American Society for Reproductive Medicine. Fertility preservation in patients undergoing gonadotoxic therapy or gonadectomy: a committee opinion. *Fertil Steril*. 2013;100(5):1214–1223.

Puri DR, Wexler LH, Meyers PA, et al. The challenging role of radiation therapy for very young children with rhabdomyosarcoma. *Int J Radiat Oncol Biol Phys*. 2006;65(4):1177–1184.

Quezada E, Gripp KW. Costello syndrome and related disorders. *Curr Opin Pediatr*. 2007;19(6):636–644.

Quillin SP, McAlister WH. Transitional cell carcinoma of the bladder in children: radiologic appearance and differential diagnosis. *Urol Radiol*. 1991;13(2):107–109.

Ragab AH, Heyn R, Tefft M, et al. Infants younger than 1 year of age with rhabdomyosarcoma. *Cancer*. 1986;58(12):2606–2610.

Raney B, Anderson J, Jenney M, et al. Late effects in 164 patients with rhabdomyosarcoma of the bladder/prostate region: a report from the international workshop. *J Urol*. 2006;176(5):2190–2194 [discussion 2194–2195].

Raney B Jr, Heyn R, Hays DM, et al. Sequelae of treatment in 109 patients followed for 5 to 15 years after diagnosis of sarcoma of the bladder and prostate. A report from the Intergroup Rhabdomyosarcoma Study Committee. *Cancer*. 1993;71(7):2387–2394.

Raney RB Jr, Crist W, Hays D, et al. Soft tissue sarcoma of the perineal region in childhood. A report from the Intergroup Rhabdomyosarcoma Studies I and II, 1972 through 1984. *Cancer*. 1990;65(12):2787–2792.

Raney RB Jr, Donaldson MH, Sutow WW, et al. Special considerations related to primary site in rhabdomyosarcoma: experience of the Intergroup Rhabdomyosarcoma Study, 1972–76. *Natl Cancer Inst Monogr*. 1981;56:69–74.

Raney RB Jr, Gehan EA, Hays DM, et al. Primary chemotherapy with or without radiation therapy and/or surgery for children with localized sarcoma of the bladder, prostate, vagina, uterus, and cervix. A comparison of the results in Intergroup Rhabdomyosarcoma Studies I and II. *Cancer*. 1990;66(10):2072–2081.

Raney RB, Maurer HM, Anderson JR, et al. The Intergroup Rhabdomyosarcoma Study Group (IRSG): major lessons from the IRS-I through IRS-IV studies as background for the current IRS-V treatment protocols. *Sarcoma*. 2001;5(1):9–15.

Rankin LF, Allen GD, Yuppa FR, et al. Carcinoma of the urachus in an adolescent: a case report. *J Urol*. 1993;150(5 Pt 1):1472–1473.

Rauen KA. HRAS and the Costello syndrome. *Clin Genet*. 2007;71(2):101–108.

Reuter VE. Origins and molecular biology of testicular germ cell tumors. *Mod Pathol*. 2005;18(Suppl 2):S51–S60.

Richiardi L, Akre O, Bellocco R, et al. Perinatal determinants of germ-cell testicular cancer in relation to histological subtypes. *Br J Cancer*. 2002;87(5):545–550.

Rodeberg DA, Anderson JR, Arndt CA, et al. Comparison of outcomes based on treatment algorithms for rhabdomyosarcoma of the bladder/prostate: combined results from the Children's Oncology Group, German Cooperative Soft Tissue Sarcoma Study, Italian Cooperative Group, and International Society of Pediatric Oncology Malignant Mesenchymal Tumors Committee. *Int J Cancer*. 2011;128(5):1232–1239.

Rogers PC, Olson TA, Cullen JW, Pediatric Oncology Group 9048, Children's Cancer Group 8891, et al. Treatment of children and adolescents with stage II testicular and stages I and II ovarian malignant germ cell tumors: a pediatric intergroup Study–Pediatric Oncology Group 9048 and Children's Cancer Group 8891. *J Clin Oncol*. 2004;22(17):3563–3569.

Ross JH. Prepubertal testicular tumors. *Urology*. 2009;74(1):94–99.

Ross JH, Kay R. Prepubertal testis tumors. *Rev Urol*. 2004;6(1):11–18.

Ross JH, Rybicki L, Kay R. Clinical behavior and a contemporary management algorithm for prepubertal testis tumors: a summary of the Prepubertal Testis Tumor Registry. *J Urol*. 2002;168(4 Pt 2):1675–1678 [discussion 1678–1679].

Rove KO, Husmann DA, Wilcox DT, et al. Systematic review of bladder cancer outcomes in patients with spina bifida. *J Pediatr Urol*. 2017;13(5):456.e1–456.e9.

Rutgers JL, Scully RE. Pathology of the testis in intersex syndromes. *Semin Diagn Pathol*. 1987;4(4):275–291.

Rutgers JL, Scully RE. The androgen insensitivity syndrome (testicular feminization): a clinicopathologic study of 43 cases. *Int J Gynecol Pathol*. 1991;10(2):126–144.

Sahai A, Rosenblatt GS, Parra RO. Squamous cell carcinoma arising in an augmented bladder in a patient with bladder exstrophy. *J Urol*. 2004;172(6 Pt 1):2187–2188.

Schlatter M, Rescorla F, Giller R, Children's Cancer Group, Pediatric Oncology Group, et al. Excellent outcome in patients with stage I germ cell tumors of the testes: a study of the Children's Cancer Group/Pediatric Oncology Group. *J Pediatr Surg*. 2003;38(3):319–324 [discussion 319–324].

Schneider DT, Schuster AE, Fritsch MK, et al. Genetic analysis of childhood germ cell tumors with comparative genomic hybridization. *Klin Padiatr*. 2001;213(4):204–211.

Schottenfeld D, Warshauer ME, Sherlock S, et al. The epidemiology of testicular cancer in young adults. *Am J Epidemiol*. 1980;112(2):232–246.

Schultz KA, Ness KK, Nagarajan R, et al. Adnexal masses in infancy and childhood. *Clin Obstet Gynecol*. 2006;49(3):464–479.

Schultz KA, Sencer SF, Messinger Y, et al. Pediatric ovarian tumors: a review of 67 cases. *Pediatr Blood Cancer*. 2005;44(2):167–173.

Scott AA, Stanley W, Worsham GF, et al. Aggressive bladder carcinoma in an adolescent. Report of a case with immunohistochemical, cytogenetic, and flow cytometric characterization. *Am J Surg Pathol*. 1989;13(12):1057–1063.

Seitz G, Dantonello TM, Int-Veen C, et al. Treatment efficiency, outcome and surgical treatment problems in patients suffering from localized embryonal bladder/prostate rhabdomyosarcoma: a report from the Cooperative Soft Tissue Sarcoma trial CWS-96. *Pediatr Blood Cancer*. 2011;56(5):718–724.

Seitz G, Fuchs J, Martus P, Cooperative Weichteilsarkom Studiengruppe (CWS), et al. Outcome, treatment, and treatment failures in patients suffering localized embryonal paratesticular rhabdomyosarcoma: results from the “Cooperative Weichteilsarkom Studiengruppe” trials CWS-86, -91, -96, and -2002P. *Ann Surg*. 2016;264(6):1148–1155.

Seitz G, Fuchs J, Sparber-Sauer M, et al. Improvements in the treatment of patients suffering from bladder-prostate rhabdomyosarcoma: a report from the CWS-2002P trial. *Ann Surg Oncol*. 2016;23(12):4067–4072.

Serrano-Durba A, Dominguez-Hinarejos C, Reig-Ruiz C, et al. Transitional cell carcinoma of the bladder in children. *Scand J Urol Nephrol*. 1999;33(1):73–76.

Shapiro E, Strother D. Pediatric genitourinary rhabdomyosarcoma. *J Urol*. 1992;148(6):1761–1768.

Shrestha A, Ritz B, Ognjanovic S, et al. Early life factors and risk of childhood rhabdomyosarcoma. *Front Public Health*. 2013;1:17.

Shukla AR, Huff DS, Canning DA, et al. Juvenile granulosa cell tumor of the testis: contemporary clinical management and pathological diagnosis. *J Urol*. 2004;171(5):1900–1902.

Shukla AR, Woodard C, Carr MC, et al. Experience with testis sparing surgery for testicular teratoma. *J Urol*. 2004;171(1):161–163.

Silver SA, Wiley JM, Perlman EJ. DNA ploidy analysis of pediatric germ cell tumors. *Mod Pathol*. 1994;7(9):951–956.

Skakkebaek NE. Possible carcinoma-in-situ of the testis. *Lancet*. 1972;2(7776):516–517.

Skakkebaek NE, Holm M, Hoei-Hansen C, et al. Association between testicular dysgenesis syndrome (TDS) and testicular neoplasia: evidence from 20 adult patients with signs of maldevelopment of the testis. *APMIS*. 2003;111(1):1–9 [discussion 9–11].

Skapek SX, Anderson J, Barr FG, et al. PAX-FOXO1 fusion status drives unfavorable outcome for children with rhabdomyosarcoma: a children's oncology group report.

Pediatr Blood Cancer. 2013;60(9):1411–1417.

Skotheim RI, Lothe RA. The testicular germ cell tumour genome. *APMIS*. 2003;111(1):136–150 [discussion 150–131].

Slowikowska-Hilczer J, Romer TE, Kula K. Neoplastic potential of germ cells in relation to disturbances of gonadal organogenesis and changes in karyotype. *J Androl*. 2003;24(2):270–278.

Smeulders N, Woodhouse CR. Neoplasia in adult exstrophy patients. *BJU Int*. 2001;87(7):623–628.

Snyder HM: Personal communication, 2005.

Soler R, Macedo A Jr, Bruschini H, et al. Does the less aggressive multimodal approach of treating bladder-prostate rhabdomyosarcoma preserve bladder function? *J Urol*. 2005;174(6):2343–2344.

Spunt SL, Sweeney TA, Hudson MM, et al. Late effects of pelvic rhabdomyosarcoma and its treatment in female survivors. *J Clin Oncol*. 2005;23(28):7143–7151.

Stein R, Frees S, Schroder A, et al. Radical surgery and different types of urinary diversion in patients with rhabdomyosarcoma of bladder or prostate–a single institution experience. *J Pediatr Urol*. 2013;9(6 Pt A):932–939.

Stevens MC, Rey A, Bouvet N, et al. Treatment of nonmetastatic rhabdomyosarcoma in childhood and adolescence: third study of the International Society of Paediatric Oncology–SIOP Malignant Mesenchymal Tumor 89. *J Clin Oncol*. 2005;23(12):2618–2628.

Stewart RJ, Martelli H, Oberlin O, International Society of Pediatric Oncology, et al. Treatment of children with nonmetastatic paratesticular rhabdomyosarcoma: results of the Malignant Mesenchymal Tumors Studies (MMT 84 and MMT 89) of the International Society of Pediatric Oncology. *J Clin Oncol*. 2003;21(5):793–798.

Stoop H, Honecker F, van de Geijn GJ, et al. Stem cell factor as a novel diagnostic marker for early malignant germ cells. *J Pathol*. 2008;216(1):43–54.

Sung JD, Koyle MA. Squamous cell carcinoma of the bladder in a pediatric patient. *J Pediatr Surg*. 2000;35(12):1838–1839.

Sung L, Anderson JR, Arndt C, et al. Neurofibromatosis in children with rhabdomyosarcoma: a report from the Intergroup Rhabdomyosarcoma study IV. *J Pediatr*. 2004;144(5):666–668.

Sutow WW, Sullivan MP, Ried HL, et al. Prognosis in childhood rhabdomyosarcoma. *Cancer*. 1970;25(6):1384–1390.

Takemoto J, Yamazaki Y, Sakai K. A case of large bladder hemangioma successfully treated with endoscopic yttrium aluminium garnet laser irradiation. *Int J Urol*. 2011;18(12):854–856.

Tateishi U, Hosono A, Makimoto A, et al. Comparative study of FDG PET/CT and conventional imaging in the staging of rhabdomyosarcoma. *Ann Nucl Med*. 2009;23(2):155–161.

Templeman CL, Fallat ME. Benign ovarian masses. *Semin Pediatr Surg*. 2005;14(2):93–99.

Thomas JC, Ross JH, Kay R. Stromal testis tumors in children: a report from the prepubertal testis tumor registry. *J Urol*. 2001;166(6):2338–2340.

Tomaszewski JJ, Sweeney DD, Kavoussi LR, et al. Laparoscopic retroperitoneal lymph node dissection for high-risk pediatric patients with paratesticular rhabdomyosarcoma. *J Endourol*. 2010;24(1):31–34.

Trigg ME, Steinherz PG, Chappell R, et al. Early testicular biopsy in males with acute lymphoblastic leukemia: lack of impact on subsequent event-free survival. *J Pediatr Hematol Oncol*. 2000;22(1):27–33.

Trout AT, Chow J, McNamara ER, et al. Association between testicular microlithiasis and testicular neoplasia: large multicenter study in a pediatric population. *Radiology*. 2017;285(2):576–583.

Vikram R, Sandler CM, Ng CS. Imaging and staging of transitional cell carcinoma: part 1, lower urinary tract. *AJR Am J Roentgenol*. 2009;192(6):1481–1487.

Volokhina YV, Oyoyo UE, Miller JH. Ultrasound demonstration of testicular microlithiasis in pediatric patients: is there an association with testicular germ cell tumors? *Pediatr Radiol*. 2014;44(1):50–55.

Walsh C, Rushton HG. Diagnosis and management of teratomas and epidermoid cysts. *Urol Clin North Am*. 2000;27(3):509–518.

Walsh TJ, Davies BJ, Croughan MS, et al. Racial differences among boys with testicular germ cell tumors in the United States. *J Urol*. 2008;179(5):1961–1965.

Walterhouse DO, Meza JL, Breneman JC, et al. Local control and outcome in children with localized vaginal rhabdomyosarcoma: a report from the Soft Tissue Sarcoma committee of the Children's Oncology Group. *Pediatr Blood Cancer*. 2011;57(1):76–83.

Wegner HE, Dieckmann KP, Herbst H, et al. Leydig cell tumor–comparison of results of radical and testis-sparing surgery in a single center. *Urol Int*. 1997;59(3):170–173.

Weiss AR, Lyden ER, Anderson JR, et al. Histologic and clinical characteristics can guide staging evaluations for children and adolescents with rhabdomyosarcoma: a report from the Children's Oncology Group Soft Tissue Sarcoma Committee. *J Clin Oncol*. 2013;31(26):3226–3232.

Wiener ES, Anderson JR, Ojimba JI, et al. Controversies in the management of paratesticular rhabdomyosarcoma: is staging retroperitoneal lymph node dissection necessary for adolescents with resected paratesticular rhabdomyosarcoma?

Semin Pediatr Surg. 2001;10(3):146–152.

Wiener ES, Lawrence W, Hays D, et al. Retroperitoneal node biopsy in paratesticular rhabdomyosarcoma. *J Pediatr Surg*. 1994;29(2):171–177 [discussion 178].

Williams CL, Bunch KJ, Stiller CA, et al. Cancer risk among children born after assisted conception. *N Engl J Med*. 2013;369(19):1819–1827.

Woo LL, Ross JH. The role of testis-sparing surgery in children and adolescents with testicular tumors. *Urol Oncol*. 2016;34(2):76–83.

Woodhouse CR, North AC, Gearhart JP. Standing the test of time: long-term outcome of reconstruction of the exstrophy bladder. *World J Urol*. 2006;24(3):244–249.

Wu HY, Snyder HM 3rd. Pediatric urologic oncology: bladder, prostate, testis. *Urol Clin North Am*. 2004;31(3):619–627 [xi].

Wu HY, Snyder HM 3rd, Womer RB. Genitourinary rhabdomyosarcoma: which treatment, how much, and when? *J Pediatr Urol*. 2009;5(6):501–506.

Yeung CK, Ward HC, Ransley PG, et al. Bladder and kidney function after cure of pelvic rhabdomyosarcoma in childhood. *Br J Cancer*. 1994;70(5):1000–1003.

Yokonishi T, Sato T, Komeya M, et al. Offspring production with sperm grown in vitro from cryopreserved testis tissues. *Nat Commun*. 2014;5:4320.

You W, Dainty LA, Rose GS, et al. Gynecologic malignancies in women aged less than 25 years. *Obstet Gynecol*. 2005;105(6):1405–1409.

Volume II

OUTLINE

Part IV Infections and Inflammation
Part V Molecular and Cellular Biology
Part VI Reproductive and Sexual Function
Part VII Male Genitalia
Part VIII Renal Physiology and Pathophysiology
Part IX Upper Urinary Tract Obstruction and Trauma
Part X Urinary Lithiasis and Endourology
Part XI Neoplasms of the Upper Urinary Tract

PART IV
Infections and Inflammation

OUTLINE

55 Infections of the Urinary Tract
56 Inflammatory and Pain Conditions of the Male Genitourinary Tract Prostatitis and Related Pain Conditions, Orchitis, and Epididymitis
57 Interstitial Cystitis/Bladder Pain Syndrome and Related Disorders
58 Sexually Transmitted Diseases*
59 Cutaneous Diseases of the External Genitalia
60 Tuberculosis and Parasitic Infections of the Genitourinary Tract

55

Infections of the Urinary Tract

Kimberly L. Cooper MD, Gina M. Badalato MD, Matthew P. Rutman MD

Urinary tract infections (UTIs) are common, affect men and women of all ages, vary dramatically in their presentation and sequelae, and are one of the most frequent reasons for prescribing antibiotics. The overwhelming majority of UTIs contribute to varying levels of morbidity yet rarely progress to life-threatening emergencies. In certain populations, however, UTIs can contribute to significant mortality if undiagnosed and untreated. When bacterial virulence increases or host defense mechanisms decrease, bacterial inoculation, colonization, and infection of the urinary tract occur. Careful diagnosis and treatment result in successful resolution of infections in most instances. A better understanding of the pathogenesis of UTIs and the role of host and bacterial factors has improved the ability to identify patients at risk and prevent or minimize sequelae. Recent evidence has proven that urine is not sterile; indeed, in many cases bacteriuria is protective against the development of UTIs. In this era of widespread multidrug-resistant (MDR) bacteria it is crucial that we do not overdiagnose UTIs and expose patients to unnecessary antibiotics. The appropriate management of UTIs includes implementation of antibiotic stewardship, which undoubtedly will have a beneficial impact on global public health. Clinical presentation, in conjunction with analysis of urine samples that are collected in a proper fashion, must be critically determined before recommending antibiotics for bacteriuria and UTIs. Guidelines should be incorporated into clinical practice to improve the use of antibiotics in terms of choice of and duration of therapy. Education of practitioners and patients regarding best practices related to bacteriuria and UTIs is paramount.

Definitions

UTI is an inflammatory response of the urothelium to bacterial invasion that is usually associated with bacteriuria and pyuria.

***Bacteriuria* is the presence of bacteria in the urine.** It has been assumed to be a valid indicator of either bacterial colonization or infection of the urinary tract. Although this is usually true, studies in animals (Hultgren et al., 1985; Mulvey et al., 1998) and humans (Elliott et al., 1985) have indicated that bacteria may be in the urothelium in the absence of bacteriuria. Alternatively, bacteriuria may represent bacterial contamination of an abacteriuric specimen during collection.

***Pyuria*, the presence of white blood cells (WBCs) in the urine, is generally indicative of infection and/or an inflammatory response of the urothelium to bacteria, stones, an indwelling foreign body, or other conditions that can contribute to pyuria. Bacteriuria without pyuria is generally indicative of bacterial colonization without overt infection of the urinary tract. Pyuria without bacteriuria, or sterile pyuria, warrants further evaluation (see the discussion of pyuria in the section on urinalysis).**

Infections are often defined clinically by their presumed site of origin. ***Cystitis* describes a clinical syndrome of dysuria, frequency, urgency, and occasionally suprapubic pain**. These symptoms, although generally indicative of bacterial cystitis, may also be associated with infection of the urethra or vagina or noninfectious conditions such as interstitial cystitis/ painful bladder syndrome, bladder carcinoma, or calculi.

***Acute pyelonephritis* is a clinical syndrome of chills, fever, and flank pain that is accompanied by bacteriuria and pyuria, a combination that is reasonably specific for an acute bacterial infection of the kidney.** Often there are no associated lower urinary symptoms. The term should not be used if flank pain is absent. It may have no morphologic or functional components detectable by routine clinical modalities. There may be significant difficulties in diagnosing spinal cord–injured and elderly patients who may be unable to localize the site of their discomfort.

Chronic pyelonephritis describes a shrunken, fibrosed kidney, diagnosed by morphologic, radiologic, or functional evidence of renal disease that may be postinfectious but is frequently not associated with current (active) UTI. Bacterial infection of the kidney may cause a *focal*, *coarse scar* in the renal cortex overlying a calyx, almost always accompanied by some calyceal distortion (Fig. 55.1), which can be detected radiographically or by gross examination of the kidney. These radiographic changes are identical to those that may be produced by vesicoureteral reflux (VUR) or calyceal stone disease. Less commonly, renal scarring from infection can result in atrophic pyelonephritis or generalized thinning of the renal cortex, with a small kidney appearing radiographically similar to one with postobstructive atrophy (Fig. 55.2). Xanthogranulomatous pyelonephritis (XGP) is a rare form of chronic pyelonephritis often associated with stone disease and characterized by destructive replacement of normal renal parenchyma with granulomatous inflammation; it is associated with ipsilateral loss of renal function (see the section on XGP).

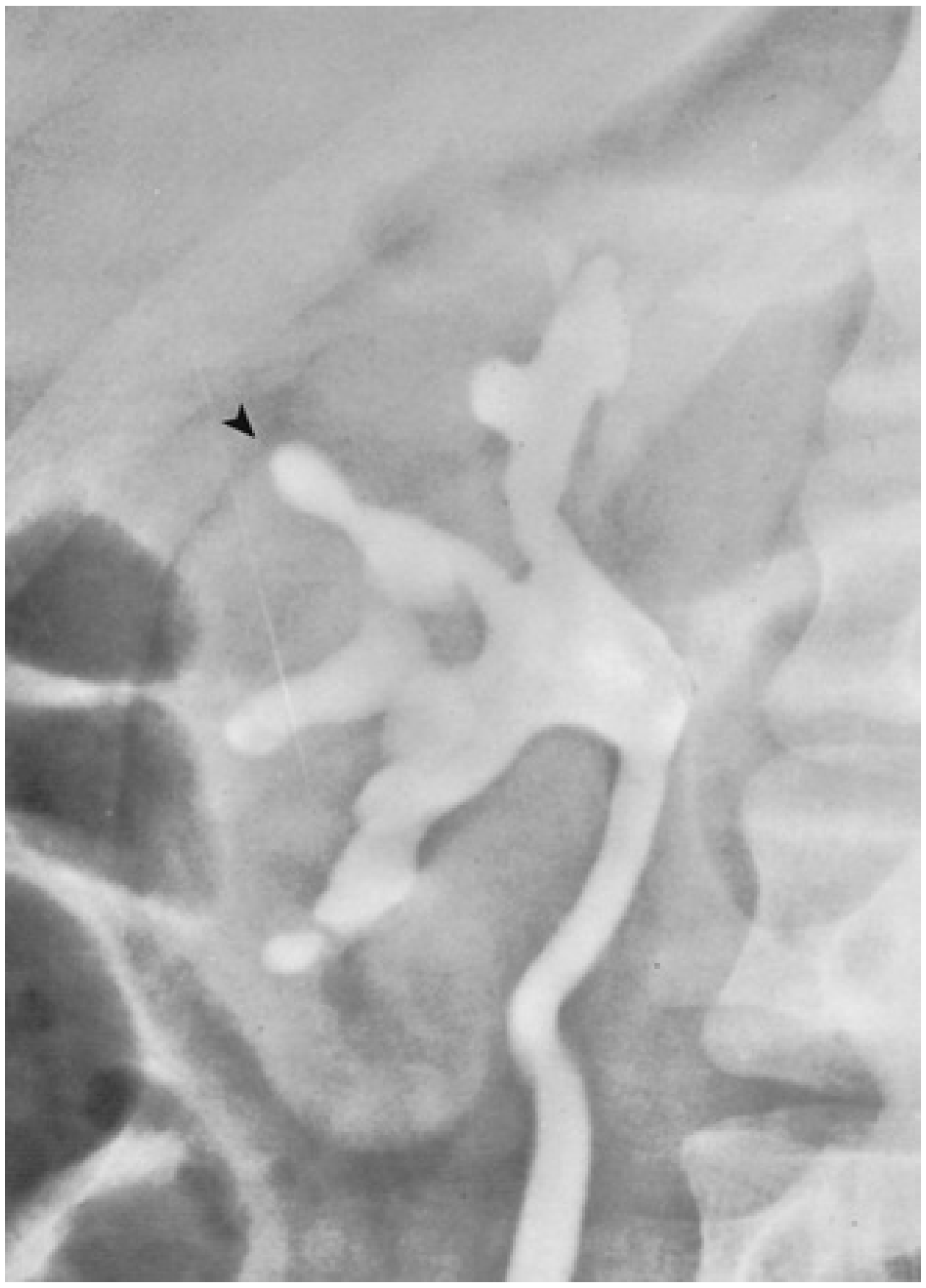

FIG. 55.1 Excretory urogram demonstrates focal, coarse scarring in the right kidney of an 18-year-old girl with a history of many recurrent fevers between 2 months and 2 years of age. A cystogram when the patient was 2 years old established an atrophic left kidney with marked reflux up to the left kidney and slight reflux up to the right kidney. Excretory urography at

the age of 6 years established severe atrophy of the left kidney. She had no infections between the ages of 6 and 15 years. Several reinfections occurred at the age of 15 years, and they ceased with prophylactic therapy. Her blood pressure has remained normal, and her serum creatinine level was 0.9 mg/dL at the age of 18 years. At 21 years of age she stopped antimicrobial prophylaxis for 18 months without infections or introital colonization with Enterobacteriaceae. Note that all calyces are blunted and that one extends to the capsule *(arrowhead)* because of atrophy of the overlying cortex.

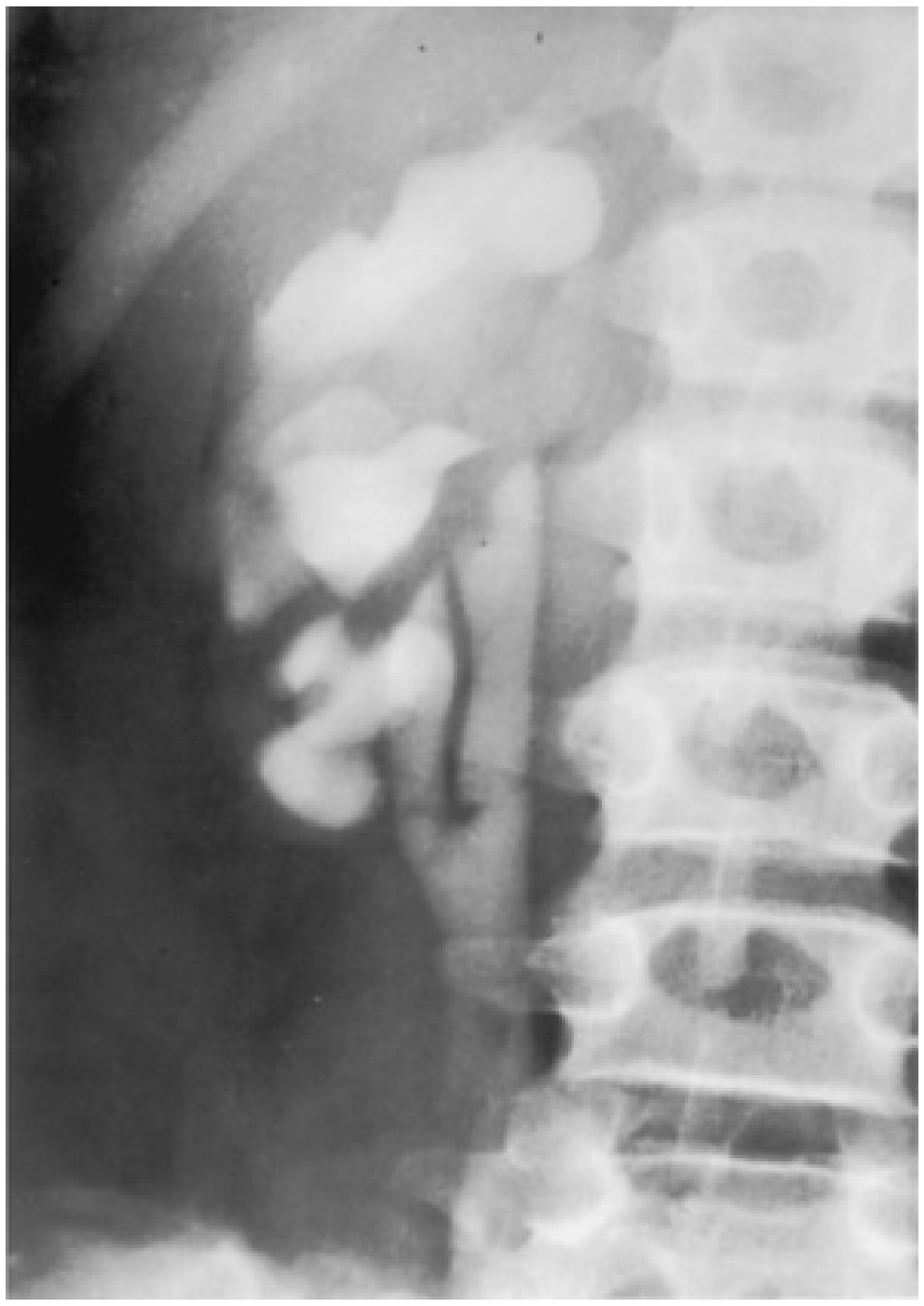

FIG. 55.2 Pyelonephritic atrophy, suggestive of postobstructive atrophy, in a 20-year-old woman with spina bifida, neurogenic bladder, and many episodes of fever and bacteriuria in early childhood. Observe the uniform, regular atrophy of the renal cortex that suggests reflux of bacteria simultaneously into virtually all nephrons. This type of pyelonephritic atrophy is uncommon and is characteristic of obstruction with superimposed infection.

UTIs may also be described in terms of the anatomic or functional status of the urinary tract and the health of the host.

Uncomplicated **describes an infection in a healthy patient with a structurally and functionally normal urinary tract; this often specifically**

refers to the absence of obstruction to any part of the urinary tract. The majority of these patients are women with isolated or recurrent bacterial cystitis or acute pyelonephritis, and the infecting pathogens are usually susceptible to and eradicated by a short course of oral antimicrobial therapy.

A *complicated* infection is associated with factors that increase the chance of acquiring bacteria and decrease the efficacy of therapy (Box 55.1). **The urinary tract is structurally or functionally abnormal, the host is compromised, and/or the bacteria have increased virulence or antimicrobial resistance.**

Box 55.1

Factors That Suggest a Complicated Urinary Tract Infection

- Functional or anatomic abnormality of urinary tract
- Male gender
- Pregnancy
- Elderly patient
- Diabetes
- Immunosuppression
- Childhood urinary tract infection
- Recent antimicrobial agent use
- Indwelling urinary catheter
- Urinary tract instrumentation
- Hospital-acquired infection
- Symptoms for more than 7 days at presentation

Data from Schaeffer AJ: Urinary tract infections. In Gillenwater JY, Grayhack JT, Howards SS, et al., editors: *Adult and pediatric urology*, Philadelphia, 2002, Lippincott Williams & Wilkins, p 212.

Renal diseases that reduce the concentrating ability of the kidney or voiding dysfunction that alter bladder-emptying capabilities are commonly encountered functional abnormalities. Examples of renal diseases, which mainly affect the tubulointerstitial compartment, include postobstructive nephropathy, sickle cell nephropathy, lithium nephropathy, chronic tubulointerstitial nephritis, and inherited diseases such as medullary cystic kidney disease. Examples of anatomic abnormalities include enlargement of the prostate or congenital or acquired sites of residual urine, such as calyceal or urethral or bladder diverticula. Bladder outlet obstruction, neurogenic bladder, and detrusor underactivity also contribute to functional abnormalities. A complicated infection is frequently caused by multidrug-resistant bacteria.

***Chronic*, although implying long time frames,** is a poor term that should be avoided in the context of UTIs, except for chronic pyelonephritis or bacterial prostatitis, because the duration of the infection is not defined.

UTIs may also be defined by their relationship to other UTIs:

- A ***first*** or ***isolated*** infection is one that occurs in an individual who has never had a UTI or has one remote infection from a previous UTI.
- An ***unresolved*** infection is one that has not responded to antimicrobial therapy and is documented to be the same organism with a similar resistance profile.
- A ***recurrent*** infection is one that occurs after documented, successful resolution of an antecedent infection. Consider these two different types of recurrent infection:
    1. *Reinfection* describes a new event associated with reintroduction of bacteria into the urinary tract.
    2. *Bacterial persistence* refers to a recurrent UTI caused by the same bacteria reemerging from a focus within the urinary tract, such as an infectious stone or the prostate. *Relapse* is frequently used interchangeably. These definitions require careful clinical and bacteriologic assessment and are important because they influence the type and extent of the patient's evaluation and treatment.

***Antimicrobial prophylaxis* (AP) is the attempted prevention of reinfections of the urinary tract by the administration of antimicrobial drugs.** If the term is used correctly in reference to the urinary tract, it can be assumed that bacteria have been eliminated before prophylaxis is begun. **Surgical AP entails**

administration of an antimicrobial agent before and for a *limited* time after a procedure to prevent local or systemic postprocedural infections (see the later section on American Urological Association (AUA) guidelines for prophylaxis).

***Antimicrobial suppression* is the attempted prevention of growth of a focus of bacterial persistence that cannot be eradicated.**

Domiciliary* or *outpatient UTIs occur in patients who are not hospitalized or institutionalized at the time they become infected.

***Nosocomial* or *health care–associated UTIs* occur in patients who are hospitalized or institutionalized**.

Catheter-associated UTIs (CAUTIs) occur within that population of patients with indwelling bladder drainage catheters. They are cumulatively the most common cause of secondary bacteremia and are associated with increased morbidity and mortality (Flores-Mireles et al., 2015). Prolonged catheterization, female gender, advanced age, and diabetes represent risk factors for developing a CAUTI (Chenoweth et al., 2014) (see the later section on CAUTIs).

Key Points: Definitions

- Bacteriuria and pyuria are not synonymous with a UTI.
- UTIs are classified based on their presumed site of origin.
- UTIs can be uncomplicated (occurring in healthy patients with normal urinary tracts) or complicated (associated with factors that increase the likelihood of bacteriuria and decrease the efficacy of therapy).

Incidence and Epidemiology

UTI-related complaints are among the most common primary diagnoses for women visiting the emergency department in the United States (Foxman, 2014; Niska et al., 2010). **In 2007 in the United States alone, there were an estimated 10.5 million office visits for UTI-related complaints (accounting for a total of 0.9% of all ambulatory visits), and 2 to 3 million visits to the emergency room** (Schappert, 2011). **Nearly 30% of women have had a symptomatic UTI requiring antimicrobial therapy by age 24, and almost half of all women experience a UTI during their lifetime** (Foxman, 2002). Moreover, 11% of women over the age of 18 have one UTI annually.

Given the frequency of this problem, the associated **financial impact is staggering.** In the United States the direct and indirect costs for the treatment of UTIs annually was estimated to be $2.3 billion in 2010 (Foxman, 2010). For each of these infections, the cost in treating an antimicrobial-resistant organism is greater than treating susceptible bacterial counterparts (Neidell et al., 2012). Furthermore, as it pertains to acute pyelonephritis, the direct and indirect costs were estimated at $2.14 billion in 2000, which is projected to be $2.9 billion in 2013 (Brown et al., 2005).

The incidence of bacteriuria increases with institutionalization or hospitalization and concurrent conditions (Sourander et al., 1966). **CAUTIs are the most common nosocomial infection,** constituting more than 80% of nosocomial UTIs (Foxman, 2002; Sedor, 1999). **The incidence of UTIs is also elevated during pregnancy and in patients with spinal cord injury (SCI), diabetes, multiple sclerosis, organ transplant recipients, and human immunodeficiency virus (HIV) infection/acquired immunodeficiency syndrome (AIDS).**

Once a patient has an infection, he or she is likely to develop subsequent infections. In fact, historical data by Mabeck originally established that the probability of recurrent UTIs increases with the number of previous infections (Mabeck, 1972). More recent cohort analyses have verified this trend among diverse populations (Foxman, 2014). First, the risk of recurrence is particularly high among young, sexually active women. In a prospective trial following 285 college women after their first UTI, the risk of a second infection was 24% within the 6-month follow-up period (Foxman et al., 2000). In another study examining a group of 796 women starting a new method of contraception, subset analysis showed that those women with a history of 2 or more previous UTIs had 2 to 5 times the risk of recurrence at 1 year compared with counterparts who only had 1 or no previous infections (Hooton et al., 1996). Postmenopausal women with a history of UTIs are similarly at increased risk of recurrence. A 2012 double-bind, non-inferiority study by Beerepoot et al. compared daily trimethoprim-sulfamethoxazole (TMP-SMX) versus lactobacilli prophylaxis among 252 postmenopausal women with approximately 7 symptomatic UTIs in the preceding year. At 12 months, a total of 69.3% recurred in the antibiotic arm compared with 79.1% in the probiotics group, with the mean number of recurrences in the 12-month follow-up period being 2.9 and 3.3, respectively (Beerepoot et al., 2012). Last, among men treated in an ambulatory setting for a UTI within the Veteran Affairs system, the risk of recurrence at 30 days was 4.1% in one retrospective study (Drekonja et al., 2013). Overall, these data examining different demographic groupings underscore the finding that populations with a track record of UTIs do have predisposition to recur.

When women with recurrent bacteriuria were observed after treatment, about one-sixth (37 of 219) had a very high recurrence rate (2.6 infections per year), whereas the remaining women had a recurrence rate of only 0.32 per year (Mabeck, 1972). Similar separation was seen in a prospective study, in which only 28.6% of 60 women who experienced their first symptomatic UTI had recurrent infections over the first 18 months of observation, as opposed to recurrences in 82.5% of 106 women who had had previous UTIs (Harrison, 1974). **Other investigators also have found that the probability of recurrent UTIs increases with the number of previous infections and decreases in inverse proportion to the elapsed time between the first and the second infections** (Mabeck, 1972). Of these recurrent infections, 71% to 73% are caused by reinfection with different organisms, rather than recurrence with the same organism (Guttmann, 1973; Mabeck, 1972).

The sequelae of complicated UTIs are substantial. It is well established in the presence of obstruction, infection stones, diabetes mellitus, and other risk factors that UTIs in adults can lead to progressive renal damage (Freedman, 1975). **The long-term effects of uncomplicated recurrent UTIs are not completely known, but, so far, no association between recurrent infections and renal scarring, hypertension, or progressive renal azotemia has been established** (Asscher et al., 1973; Freedman, 1975).

Key Points: Incidence and Epidemiology

- UTIs are the most common bacterial infection and, as such, make a significant impact on health care costs.
- The incidence of bacteriuria increases with institutionalization/hospitalization as well as with pregnancy and certain comorbidities that alter lower urinary tract function or cause immunosuppression.
- No clear association has been described between recurrent uncomplicated UTIs and renal sequelae such as scarring, hypertension, or progressive renal insufficiency.

Pathogenesis

UTIs occur as a result of interactions between the uropathogen and the host. Successful infection of the urinary tract is determined in part by the virulence factors of the bacteria, the inoculum size, and the inadequacy of host defense mechanisms. These factors also play a role in determining the ultimate level of colonization and damage to the urinary tract. Whereas increased bacterial virulence appears to be necessary to overcome strong host resistance, bacteria with minimal virulence factors are able to infect patients who are significantly compromised.

Routes of Infection

Ascending Route

Most bacteria enter the urinary tract from the bowel and skin reservoir via ascent through the urethra into the bladder. Adherence of pathogens to the introital and urothelial mucosa plays a significant role in ascending infections. This route is further enhanced in individuals with significant soilage of the perineum with feces, women who use spermicidal agents (Foxman, 2002; Handley et al., 2002; Hooton et al., 1996), and patients with intermittent or indwelling catheters.

Most episodes of pyelonephritis are caused by retrograde ascent of bacteria from the bladder through the ureter to the renal pelvis and parenchyma. Although reflux of urine is probably not required for ascending infections, edema associated with cystitis may cause sufficient changes in the ureterovesical junction to permit reflux (Fig. 55.3). Once the bacteria are introduced into the ureter, they may ascend to the kidney unaided. **However, this ascent would be greatly increased by any process that interferes with the normal ureteral peristaltic function. Gram-negative bacteria and their endotoxins, as well as pregnancy, ureteral obstruction, and high lower tract pressures have a significant antiperistaltic effect.**

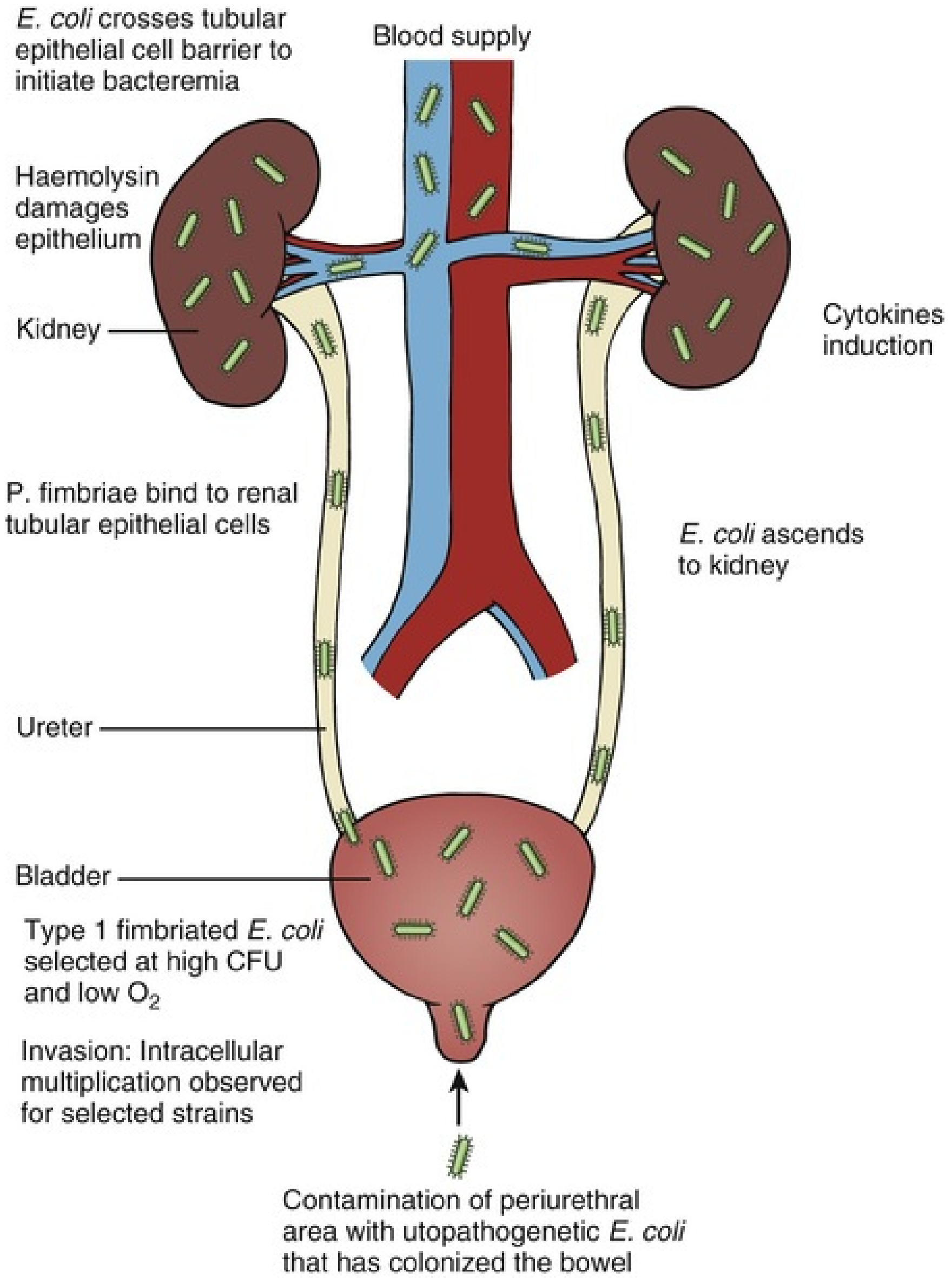
E. coli crosses tubular epithelial cell barrier to initiate bacteremia
Blood supply
Haemolysin damages epithelium
Kidney
Cytokines induction
P. fimbriae bind to renal tubular epithelial cells
E. coli ascends to kidney
Ureter
Bladder
Type 1 fimbriated *E. coli* selected at high CFU and low O_2
Invasion: Intracellular multiplication observed for selected strains
Contamination of periurethral area with utopathogenetic *E. coli* that has colonized the bowel

FIG. 55.3 Bacterial adherence in ascending urinary tract infections. (Modified from Glover M, Moreira CG, Sperandio V, et al.: Recurrent urinary tract infections in healthy and nonpregnant women. *Urological Sci* 25:1, 2014, pp 1–8.)

Bacteria that reach the renal pelvis can enter the renal parenchyma by means of the collecting ducts at the papillary tips and then ascend upward within the collecting tubules. This process is hastened and exacerbated by increased intrapelvic pressure from ureteral obstruction or VUR, particularly when it is associated with intrarenal reflux.

Hematogenous Route

Infection of the kidney by the hematogenous route is uncommon in normal individuals. However, the kidney is occasionally secondarily infected in patients with *Staphylococcus aureus* bacteremia originating from oral sites or with *Candida fungemia*. Experimental data indicate that infection is enhanced when the kidney is obstructed (Smellie et al., 1975).

Lymphatic Route

Direct extension of bacteria from the adjacent organs via lymphatics may occur in unusual circumstances, such as a severe bowel infection or retroperitoneal abscesses. There is little evidence that lymphatic routes play a significant role in the majority of UTIs.

Urinary Pathogens

Most UTIs are caused by facultative anaerobes usually originating from the bowel flora. Uropathogens such as *Staphylococcus epidermidis* and *Candida albicans* originate from the flora of the vagina or perineal skin (Fig. 55.4).

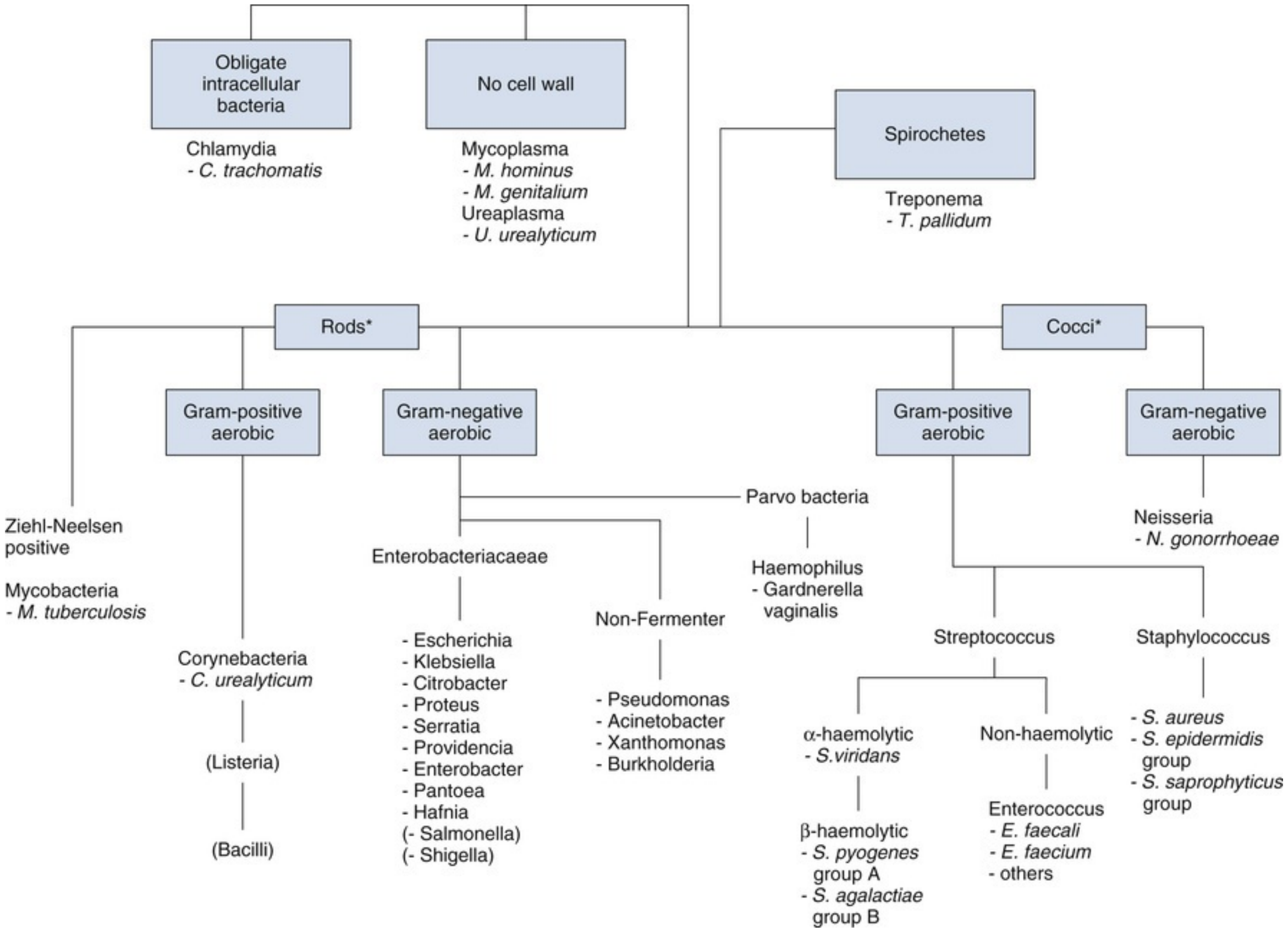
Obligate intracellular bacteria
Chlamydia
- C. trachomatis
No cell wall
Mycoplasma
- M. hominus
- M. genitalium
Ureaplasma
- U. urealyticum
Spirochetes
Treponema
- T. pallidum
Rods*
Cocci*
Gram-positive aerobic
Gram-negative aerobic
Gram-positive aerobic
Gram-negative aerobic
Ziehl-Neelsen positive
Mycobacteria
- M. tuberculosis
Corynebacteria
- C. urealyticum
(Listeria)
(Bacilli)
Enterobacteriacaeae
- Escherichia
- Klebsiella
- Citrobacter
- Proteus
- Serratia
- Providencia
- Enterobacter
- Pantoea
- Hafnia
(- Salmonella)
(- Shigella)
Non-Fermenter
- Pseudomonas
- Acinetobacter
- Xanthomonas
- Burkholderia
Parvo bacteria
Haemophilus
- Gardnerella vaginalis
Neisseria
- N. gonorrhoeae
Streptococcus
α-haemolytic
- S.viridans
β-haemolytic
- S. pyogenes group A
- S. agalactiae group B
Non-haemolytic
Enterococcus
- E. faecali
- E. faecium
- others
Staphylococcus
- S. aureus
- S. epidermidis group
- S. saprophyticus group

FIG. 55.4 Relevant bacteria for urological infections. *Anaerobic bacteria not considered (see Grabe et al., 2015, p. 60 for clarification). (From Grabe M, Bartoletti R, Bjerklund Johansen TE, et al: *Guidelines on urological infections*, 2015 (website): https://uroweb.org/wp-content/uploads/19-Urological-infections_LR2.pdf.)

***E. coli* is by far the most common cause of UTIs, accounting for 85% of community-acquired and 50% of hospital-acquired infections.** Other gram-negative Enterobacteriaceae, including *Proteus* and *Klebsiella*, and gram-positive *Enterococcus faecalis* and *Staphylococcus saprophyticus* are responsible for the remainder of most community-acquired infections. **Nosocomial infections** are caused by *E. coli, Klebsiella, Enterobacter, Citrobacter, Serratia, Pseudomonas aeruginosa, Providencia, E. faecalis,* and *Staphylococcus epidermidis* (Kennedy et al., 1965). Less common organisms such as *Gardnerella vaginalis, Mycoplasma* species, and *Ureaplasma urealyticum* may infect patients, some of whom have intermittent or indwelling catheters (Fairley, 1989; Josephson et al., 1988). *U. urealyticum* and *M. hominis* have been identified in the urine of women with chronic urinary symptoms but negative standard urine cultures; antibiotic treatment targeted at these organisms has resulted in improvement in symptoms (Baka et al., 2009; Potts et al., 2000). Within the intensive care unit, where virtually all patients who develop a UTI have indwelling catheters, the most frequent pathogens include *Escherichia coli, Pseudomonas aeruginosa*, enterococci, and *Candida albicans*, with species distribution and resistance patterns differing considerably among institutions and regions (Bagshaw, 2006).

With the development of more sophisticated urine culture techniques and the identification of the urinary microbiome (see the section on microbiome), several emerging uropathogens have been identified. Although some may suggest these organisms are part of the microbiome, patients who have these emerging pathogens may be symptomatic and require treatment. *Aerococcus urinae* is a rare pathogen that causes UTIs in older adults with significant comorbidities, including some urologic malignancies (Higgins, 2017). *A. urinae* is often mistaken for *Staphylococcus, Streptococcus*, and *Enterococcus* spp. Another emerging pathogen, *Raoultella planticola*, is a gram-negative rod that has been associated with UTIs in immunocompromised patients (Skelton et al., 2017). *Myroides odoratimimus,* a gram-negative rod commonly found in environmental sources such as soil, has been identified as the causative agent in UTIs in immunocompromised patients and is particularly dangerous because of its extensive drug resistance (Licker et al., 2018).

E. coli strains mediating extraintestinal infections are typically grouped into broad phylogenetic classes by multiplex polymerase chain reaction (Clermont et al., 2000), where 70% of uropathogenic *E. coli* (UPEC) isolates fall into the B2 group (Johnson et al., 2001). More recent studies have used multilocus sequence typing to further define and characterize *E. coli* strains mediating UTI and other infections at the level of “sequence type.” ***E. coli*** **sequence type ST131 (serotype O25b:H4) merits special attention as a rapidly emerging cause of multidrug-resistant infections, including UTI** (Johnson et al., 2010; Kudinha et al., 2013). Although first noted for extended-spectrum β-lactamases (ESBLs), fluoroquinolone resistance is a hallmark phenotype among ST131 isolates. **The prevalence of infecting organisms is influenced by the patient's age.** For example, *S. saprophyticus* is recognized as causing approximately 10% of symptomatic lower UTIs in young, sexually active females (Latham et al., 1983), whereas it rarely causes infection in males and elderly individuals.

Fastidious Organisms

Anaerobes in the Urinary Tract

Symptomatic anaerobic infections of the urinary tract are uncommon. However, the distal urethra, perineum, and vagina are normally colonized by anaerobes. Whereas 1% to 10% of voided urine specimens are positive for anaerobic organisms (Finegold, 1977), anaerobic organisms found in suprapubic aspirates are much more unusual (Gorbach and Bartlett, 1974). Clinically symptomatic UTIs in which only anaerobic organisms are cultured are rare, although they may frequently be a contaminant in midstream urine cultures (Hooton et al., 2013). Nevertheless, **these organisms must be suspected as causative when a patient with persistent bladder irritative symptoms has cocci or gram-negative rods seen on microscopic examination of the centrifuged urine** (catheterized, suprapubic aspirated, or voided midstream urine) **and routine quantitative aerobic cultures fail to grow organisms** (Ribot et al., 1981).

Anaerobic organisms are frequently found in cases of enteric fistualization with the urinary tract or in **suppurative infections** of the genitourinary (GU) system. In one study of suppurative GU infections in males, 88% of scrotal, prostatic, and perinephric abscesses included anaerobes among the infecting organisms (Bartlett and Gorbach, 1981). The organisms found are usually *Bacteroides* species, including *B. fragilis*, *Fusobacterium* species, anaerobic cocci, and *Clostridium perfringens* (Finegold, 1977). The growth of clostridia may be associated with cystitis emphysematosa (Bromberg et al., 1982).

Mycobacterium tuberculosis and Other Nontuberculous Mycobacteria

Mycobacterium tuberculosis and other nontuberculous mycobacteria may be found in the urinary tract (Brooker and Aufderheide, 1980; Thomas et al., 1980). Urinary tuberculosis (UTB) most commonly occurs with hematuria (either gross hematuria, microhematuria, and/or sterile pyuria), storage symptoms, and/or dysuria, with or without systemic symptoms such as fever and weakness. Diagnosis and subsequent treatment are often delayed because of nonspecific symptoms, potentially contributing to impaired renal function and eventual renal failure. Polymerase chain reaction for *M. tuberculosis* has replaced acid-fast staining as the ideal method of diagnosis (Altiparmak et al., 2015; Figueiredo and Lucon, 2008; Ghaleb et al., 2013).

Chlamydia

Chlamydiae are not routinely grown in aerobic culture but have been implicated in GU infections.

Bacterial Virulence Factors

Virulence characteristics play a role in determining if an organism will invade the urinary tract and the subsequent level of infection within the urinary tract. It is generally believed that uropathogenic strains resident in the bowel flora, such as UPEC, can infect the urinary tract not only by chance but also by the expression of virulence factors that enable them to adhere to and colonize the perineum and urethra and migrate to the urinary tract, where they establish an inflammatory response in the urothelium (Moreno et al., 2008; Schaeffer et al., 1981; Schlager et al., 2002; Yamamoto et al., 1997). The same virulence factors can be found on bacterial strains that cause recurrent UTI in patients (Foxman et al., 1995). Some of these virulence determinants are located on 1 of approximately 20 UPEC-specific pathogenicity-associated islands (PAIs) ranging in size from 30 to 170 kb. These PAIs collectively increase the size of the pathogen genome by about 20% over a commensal strain. UPEC phylogroups (A, B1, B2, and D) have been defined based on the presence of genomic PAIs and the expression of associated virulence factors such as adhesions, toxins, surface polysaccharides, flagella, and iron-acquisition systems (Bien et al., 2012).

Early Events in Uropathogenic *E. coli* Pathogenesis

The steps of UPEC pathogenesis include (1) UPEC colonization of the periurethral and vaginal tissue as well as the urethra; (2) ascending infection into the bladder lumen and within the urine; (3) adherence to the surface urothelium and interaction with the bladder epithelial cell defense mechanism; (4) biofilm elaboration; (5) invasion and replication by forming bladder Intracellular Bacterial Communities (IBCs), in which quiescent intracellular reservoirs (QIRs) can form and stay dormant in the underlying urothelium; (6) and, in some cases, renal colonization and host tissue damage with high risk for sepsis (Terlizzi et al., 2017; Fig. 55.5).

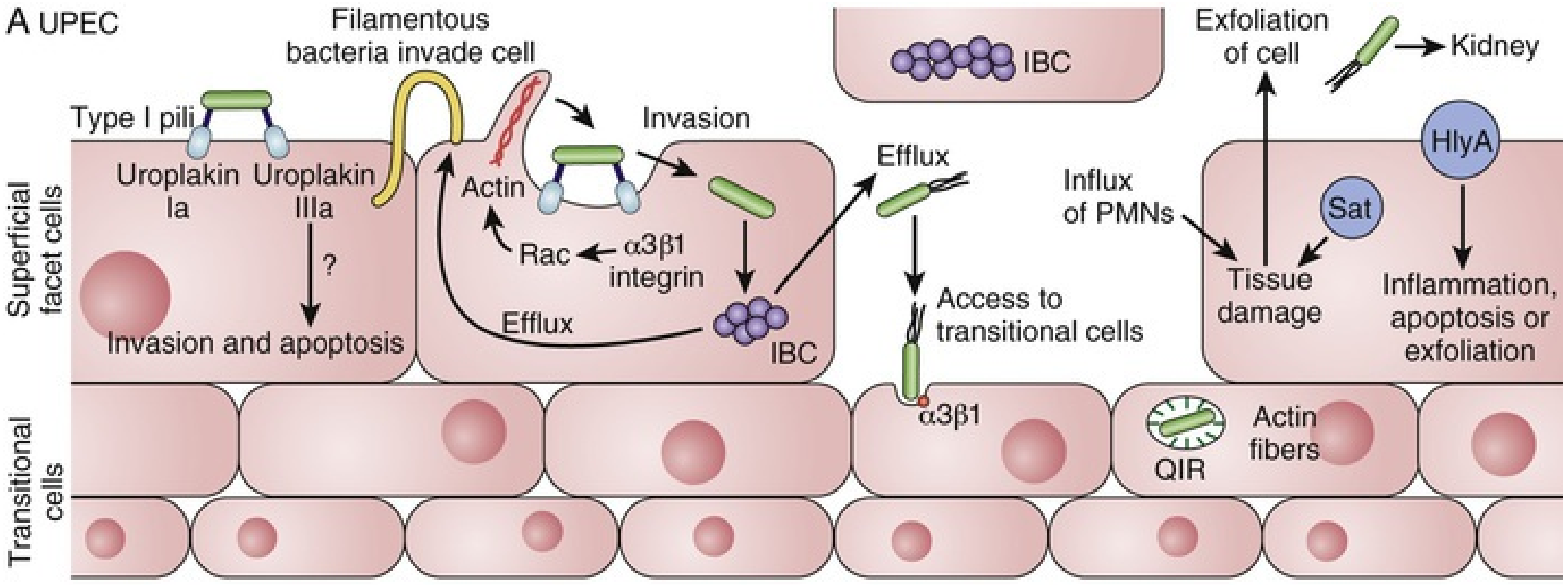
A UPEC
Filamentous bacteria invade cell
IBC
Exfoliation of cell
Kidney
Type I pili
Invasion
Uroplakin Ia
Uroplakin IIIa
Actin
Efflux
Influx of PMNs
HlyA
Sat
?
Rac
α3β1 integrin
Tissue damage
Access to transitional cells
Inflammation, apoptosis or exfoliation
Invasion and apoptosis
Efflux
IBC
Superficial facet cells
α3β1
Actin fibers
QIR
Transitional cells

FIG. 55.5 Uropathogenic *E. coli* (UPEC). UPEC attaches to the uroepithelium through type 1 pili, which bind the receptors uroplakin Ia and IIIa; this binding stimulates unknown signalling pathways (indicated by the question mark) that mediate invasion and apoptosis. Binding of type 1 pili to α3β1 integrins also mediates internalization of the bacteria into superficial facet cells to form intracellular bacterial communities (IBCs) or pods. Exfoliation of the uroepithelium exposes the underlying transition cells for further UPEC invasion, and the bacteria can reside in these cells as quiescent intracellular reservoirs (QIRs) that may be involved in recurrent infections. (Modified from Croxen MA, Finlay BB. Molecular mechanisms of *Escherichia coli* pathogenicity. *Nat Rev Microbiol* 8:26–38, 2010.)

Bacterial Adherence

Bacterial adherence to vaginal and urothelial epithelial cells is an essential step in the initiation of UTIs. This interaction is influenced by the adhesive characteristics of the bacteria, the receptive characteristics of the epithelial surface, and the fluid bathing both surfaces. Bacterial adherence is a specific interaction that plays a role in determining the organism, the host, and the site of infection. Portions of this section on bacterial adherence have been published elsewhere (Schaeffer et al., 1981).

Bacterial Adhesins.

UPEC expresses a number of adhesins that allow it to attach to urinary tract tissues (Mulvey, 2002). These adhesins are classified as either **fimbrial** or **afimbrial,** depending on whether the adhesin is displayed as part of a rigid fimbria or pilus. Bacteria may produce a number of antigenically and functionally different pili on the same cell; others produce a single type; in some, no pili are seen (Klemm, 1985). A typical piliated cell may contain 100 to 400 pili. The pilus is usually 5 to 10 nm in diameter, is up to 2 µm long, and appears to be composed primarily of subunits known as *pilin* (Klemm, 1985). Pili are defined functionally by their ability to mediate hemagglutination of specific types of erythrocytes. The most well-described pili are types 1, P, and S.

Type 1 (Mannose-Sensitive) Pili.

Type 1 pili are commonly expressed on nonpathogenic and pathogenic *E. coli.* Type 1 pili consist of a helical rod composed of repeating FimA subunits joined to a 3-nm–wide distal tip structure containing the adhesin FimH (Jones et al., 1995). These pili mediate hemagglutination of guinea pig erythrocytes (Duguid et al., 1966). The reaction is inhibited by the addition of mannose; thus type 1 pili are termed *mannose-sensitive hemagglutination* (MSHA) (Reid and Sobel, 1987; Svenson et al., 1984).

The role of type 1 pili as a virulence factor in UTIs has been established. This evidence has been obtained (1) from the analysis of bacteria isolated from the urine of patients with UTIs, which were found to express mannose-sensitive (MS) adhesins (Ljungh and Wadstrom, 1983); (2) from studies with animal models (Fader and Davis, 1982, Hagberg et al., 1983a,b; Hultgren et al., 1985; Iwahi et al., 1983) in which inoculation of type 1 piliated organisms into the bladder resulted in significantly more colonization of the urinary tract than inoculation of nonpiliated organisms; and (3) from the observation that anti–type 1 pili antibodies and competitive inhibitors such as methyl-α-D-mannopyranoside protected mice from contracting UTIs (Aronson et al., 1979; Hultgren et al., 1985). **Studies have demonstrated that interactions between FimH and receptors expressed on the luminal surface of the bladder epithelium are critical for the ability of many UPEC strains to colonize the bladder and cause disease** (Connell et al., 1996; Langermann et al., 1997; Mulvey et al., 1998; Thankavel et al., 1997).

P (Mannose-Resistant) Pili.

P pili confer tropism to the kidney; the designation "P" stands for pyelonephritis (Mulvey, 2002). P pili, which are found in most pyelonephritogenic strains of UPEC, mediate hemagglutination of human erythrocytes that is not altered by mannose and is thus termed *mannose-resistant hemagglutination* (MRHA) (Kallenius et al., 1979). The adhesin PapG, at the tip of the pilus, recognizes the α-D-galactopyranosyl-(1-4)-β-D-galactopyranoside moiety present in the globoseries of glycolipids (Kallenius et al., 1980; Leffler and Svanborg-Eden, 1980), which are found on P blood group antigens and on uroepithelium (Svenson et al., 1983). The *fm* operon of UPEC encodes the type 1 pili and the *pap* operon encodes the P- or Pap-pili. Clinical isolates of UPEC have demonstrated that the fm operon is constitutive and the pap component is part of a PAI that contains other virulence factors (Terlizzi et al., 2017).

Svanborg-Eden and Svennerholm (1978) were the first to report a correlation between bacterial adherence and severity of UTIs. They showed that UPEC strains from girls with acute pyelonephritis had high adhesive ability, whereas strains causing asymptomatic bacteriuria or from the feces of healthy girls had low bacterial adherence. Between 70% and 80% of the pyelonephritic strains, but only 10% of the bowel isolates, had adhesive capacity. Furthermore, P pili were present in 91% of urinary strains causing pyelonephritis, 19% of strains causing cystitis, and 14% of strains causing asymptomatic bacteriuria but only 7% of bowel isolates from healthy children, highlighting the correlation between bacterial adherence and UTIs (Kallenius et al., 1981).

Whereas P pili are strongly associated with pyelonephritis, these virulence factors are not associated with renal scarring and reflux caused by bacterial infection (Vaisanen et al., 1981). Studies suggest minimal correlation between P-piliated *E. coli* strains and recurrent pyelonephritis with gross reflux in girls

(Lomberg et al., 1983). Thus it would appear that P pili in acute pyelonephritis are important mainly in nonrefluxing or minimally refluxing children.

Other Adhesins.

Although pili are important in the initial attachment of UPEC to urothelium, UPEC also expresses a group of afimbrial adhesins (AFA) that are responsible for maintaining this connection (Vigil et al., 2011). One common adhesion TosA was found to be expressed during UTI and was found in 30% of urinary tract samples. Another example includes the iron-regulated adhesion Iha, which mediated adherence to bladder epithelial cells (Johnson et al., 2005).

Catch Bonds.

Not surprisingly, UPEC adhesins have evolved to meet the physical dynamics of the urinary tract, and this is best understood for FimH. Using hemagglutination assays and flow cell approaches, **the affinity of *E. coli* expressing specific FimH alleles for erythrocytes was found to be enhanced by shear stress,** and mutations that abolished FimH-erythrocyte interactions in static conditions did not affect dynamic affinities (Thomas et al., 2002). Conversely, static conditions reduced FimH-erythrocyte interactions. Known as *catch bonds*, this fingertrap-like mechanism is mediated by shear-altered interactions between the FimH pili and mannose-binding domains that result in force-induced tightening of the mannose-binding pocket (Le Trong et al., 2010). Similar shear-enhanced binding now appears widespread in biology and includes *E. coli* P-fimbriae (reviewed in Sokurenko et al., 2008). The implications of catch bonds for UPEC adherence and UTI pathogenesis are obvious. **Enhanced adherence in the presence of shear would promote UPEC retention in the urethra and bladder during voiding and in the ureters against peristalsis. In the absence of shear, reduced FimH affinity would facilitate diffusion and thereby promote ascending infection.**

Phase Variation of Bacterial Pili in vivo

Assessment of pili production by clinical *E. coli* isolates demonstrates that environmental growth conditions can produce rapid changes in pilus expression (Duguid et al., 1966; Goransson and Uhlin, 1984; Hultgren et al., 1986), wherein cells switch back and forth between piliated and nonpiliated phases (Eisenstein, 1981). For example, some bacteria grown in a broth medium express pili, whereas the same strain grown on the same medium in a solid state will cease production of pili. **This process, called *phase variation*, can also occur in vivo and has obvious biologic and clinical implications.** For example, the presence of type 1 pili may be advantageous to the bacteria for adhering to and colonizing the bladder mucosa but disadvantageous because the pili enhance phagocytosis and killing by neutrophils (Silverblatt et al., 1979).

Studies in humans using indirect immunofluorescence of fresh urine bacteria have confirmed in vivo expression and phase variation of pili. Analysis of the urine of adults with lower UTI detected type 1 pili in 31 of 41 specimens and P pili in 6 of 18 specimens (Kisielius et al., 1989). The piliation status of the bacterial population in the urine was heterogeneous, varying from predominantly piliated to a mixture of piliated and nonpiliated cells (eFig. 55.6). Strains isolated from different sites in the urogenital tract showed variation in the state of piliation.

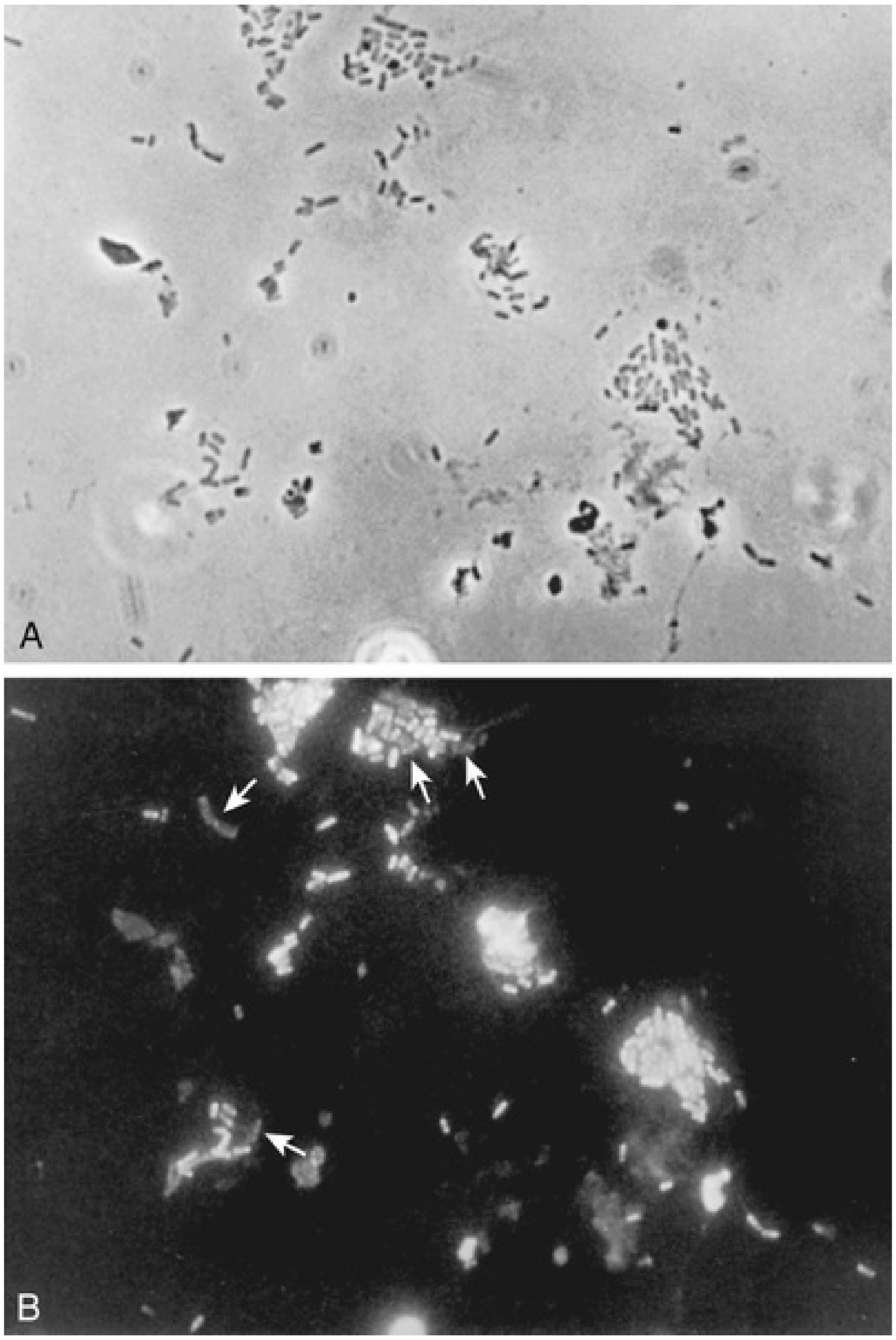

EFIG. 55.6 Phase-contrast micrograph (A) and immunofluorescence micrograph (B) of a sample stained with antiserum to type 1 pili of strain I-49 and with fluorescein isothiocyanate–conjugated second antibody against nonadherent *Escherichia coli* in the urine of a patient with acute urinary tract infection show a mixture of piliated and nonpiliated (*arrows* in B) cells. (From Kisielius PV, Schwan WR, Amundsen SK, et al.: In vivo expression and variation of *Escherichia coli* type 1 and P pili in the urine of adults with acute urinary tract infections. *Infect Immun* 57:1656–1662, 1989.)

This process of phase variation has obvious biologic and clinical implications. For example, the presence of type 1 pili may be advantageous to the bacteria for initially adhering to and colonizing the bladder mucosa. Subsequently, type 1 pili may be unnecessary for strains in suspension in urine and in fact detrimental because they enhance apoptosis, phagocytosis, and killing by neutrophils (Mulvey et al., 1998; Silverblatt et al., 1979). In the kidney, P pili may then take over as the primary mediator of bacterial attachment via their binding to the glycolipid receptors (Stapleton et al., 1995).

Epithelial Cell Receptivity

Vaginal Cells

The significance of epithelial cell receptivity in the pathogenesis of ascending UTI has been studied initially by examining adherence of *E. coli* to vaginal epithelial cells and uroepithelial cells collected from voided urine specimens. Fowler et al. (1977) established that certain indigenous microorganisms (e.g., lactobacilli, *S. epidermidis*) avidly attached themselves to washed epithelial cells in large numbers. When vaginal epithelial cells were collected from patients susceptible to reinfection and compared with such cells obtained from controls resistant to UTI, the *E. coli* strains that cause cystitis adhered much more avidly to the epithelial cells from the susceptible women. **These studies established increased adherence of pathogenic bacteria to vaginal epithelial cells as the first demonstrable biologic difference that could be shown in women susceptible to UTI.**

Subsequently, Schaeffer et al. (1981) **confirmed these vaginal differences in women, but in addition they observed that the increased bacterial adherence was also characteristic of buccal epithelial cells.** As can be seen in Fig. 55.7, there is a striking similarity in the ability of both cell types to bind to the same *E. coli* strain. In addition, there was a significant relationship between vaginal cell and buccal cell receptivity. Seventy-seven different *E. coli* strains were tested for their ability to bind to vaginal and buccal epithelial cells. A direct nonlinear relationship between buccal and vaginal adherence in controls and patients was confirmed for urinary, vaginal, and anal isolates. Thus high vaginal cell receptivity was associated with high buccal cell receptivity.

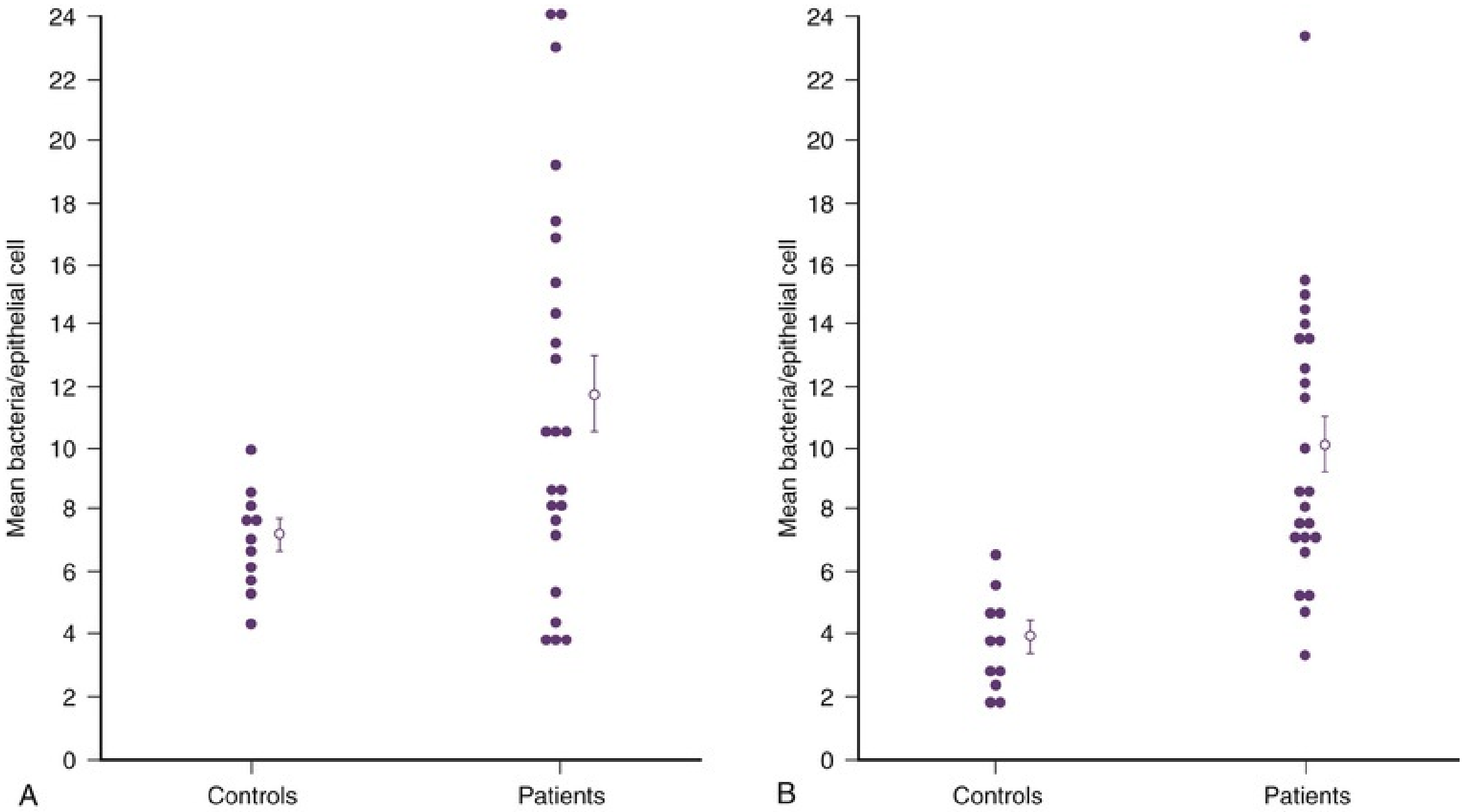

FIG. 55.7 In vitro adherence of *Escherichia coli* to vaginal (A) and buccal (B) cells from healthy controls and patients with recurrent urinary tract infections. Values represent an average of 14 (A) and 11 (B) determinations in each individual. The *open circles* and *bars* represent the means + standard error of the mean. (Data from Schaeffer AJ, Jones JM, Dunn JK: Association of in vitro *Escherichia coli* adherence to vaginal and buccal epithelial cells with susceptibility of women to recurrent urinary tract infections. *N Engl J Med* 304:1062–1066, 1981.)

These observations emphasize that the increase in receptor sites for UPEC on epithelial cells from women with recurrent UTIs is not limited to the vagina and thus suggest that a genotypic trait for epithelial cell receptivity may be a major susceptibility factor in UTIs. This concept was extended by examining the human leukocyte antigens (HLAs), which are the major histocompatibility complex in humans and have been associated statistically with many diseases (Schaeffer et al., 1994). The A3 antigen was identified in 12 (34%) of the patients, which is significantly higher than the 8% frequency observed in healthy controls. Thus HLA-A3 may be associated with increased risk of recurrent UTIs.

Variation in Receptivity.

A small variation in vaginal cell and buccal cell receptivity may be observed from day to day in healthy controls. Adherence ranges from 1 to 17 bacteria per cell and appears to be cyclic and repetitive. When adherence was correlated with the days of a woman's menstrual cycle, higher values were noted in the early phase, diminishing shortly after the time of expected ovulation (day 14). The number of bacteria per epithelial cell often correlated with the value obtained on the same day of the menstrual cycle 1 or 2 months previously. Premenopausal women are particularly susceptible to attachment of UPEC and nonpathogenic lactobacilli at certain times during the menstrual cycle and to *E. coli* during the early stages of pregnancy. **The importance of such hormones as estrogens in the pathogenesis of UTI is therefore a matter of great interest, especially because the clinical urologist may see women who have recurrent cystitis at regular intervals, possibly in response to these hormonal changes.**

Reid and Sobel (1987) found that uropathogens attached in larger numbers to uroepithelial cells from women older than 65 years of age than to cells from premenopausal women 18 to 40 years of age. Raz and Stamm (1993) noted that **susceptibility to recurrent UTI was increased by the lowered estrogen levels found in the postmenopausal women and that estrogen replacement decreased uropathogenic bacterial colonization and the incidence of UTI.**

Blood group antigens and carbohydrate structures bound to membrane lipids or proteins also constitute an important part of the uroepithelial cell membrane. The **presence or absence of blood group determinants on the surface of uroepithelial cells may influence an individual's susceptibility to a UTI**. Sheinfeld et al. (1989) determined the blood group phenotypes in women with recurrent UTI and compared them with those of age-matched women controls. There is a higher frequency of Lewis nonsecretor Le(a+b−) and recessive Le(a−b−) phenotypes among women with recurrent UTIs. The nonsecretor status has also been associated with female acute uncomplicated pyelonephritis, especially in premenopausal women (Ishitoya et al., 2002). Stapleton et al. (1995) have shown that unique *E. coli*–binding glycerides are found in vaginal epithelial cells from nonsecretors but not from secretors. **These studies individually and collectively support the concept that there is an increased epithelial receptivity for *E. coli* on the introital, urethral, and buccal mucosa that is characteristic of women susceptible to recurrent UTIs and may be a genotypic trait.**

The possibility that vaginal mucus may influence bacterial receptivity was investigated by Schaeffer et al. (1994). Type 1 piliated *E. coli* bound to all of the vaginal fluid specimens (Venegas et al., 1995). The binding capacity of vaginal fluid from women colonized with *E. coli* in vivo was greater than that from noncolonized women (Schaeffer and Stuppy, 1999). The importance of vaginal fluid in bacteria/epithelial cell interactions was investigated in an in vitro model that measured the effect of vaginal fluid on the binding of bacteria to an epithelial cell line (Gaffney et al., 1995). Vaginal fluid from colonized women enhanced binding of bacteria to epithelial cells. Conversely, vaginal fluid from noncolonized women inhibited adherence. Thus the **vaginal fluid appears to influence adherence to cells** and, presumably, vaginal mucosal colonization. Subsequent studies demonstrated that secretory IgA is the primary glycoprotein responsible for vaginal fluid receptivity (Rajan et al., 1999).

Bladder Cells

FimH binds mannosylated residues on the uroplakin molecules covering bladder superficial epithelial cells. The luminal surface of the bladder is lined by umbrella cells. The apical surfaces of umbrella cells appear as a quasi-crystalline array of hexagonal complexes composed of four integral membrane proteins known as *uroplakins* (Sun, 1996). In vitro binding assays have shown that two of the uroplakins, UPIa and UPIb, can specifically bind UPEC expressing type 1 pili (Wu et al., 1996). High-resolution freeze-fracture electron microscopy has shown that the tips of these pili, including the adhesins, are buried in the central cavity of the uroplakin hexameric rings (Mulvey et al., 2000; Fig. 55.8). **Thus FimH-mediated binding to the bladder epithelium is the initial step in the intricate cascade of events leading to UTIs.** Immediate urothelial responses to UPEC may be triggered by uroplakins because FimH binding to UPIb was shown to result in phosphorylation of UPIII and subsequent UPIII-mediated increases in intracellular calcium (Thumbikat et al., 2009).

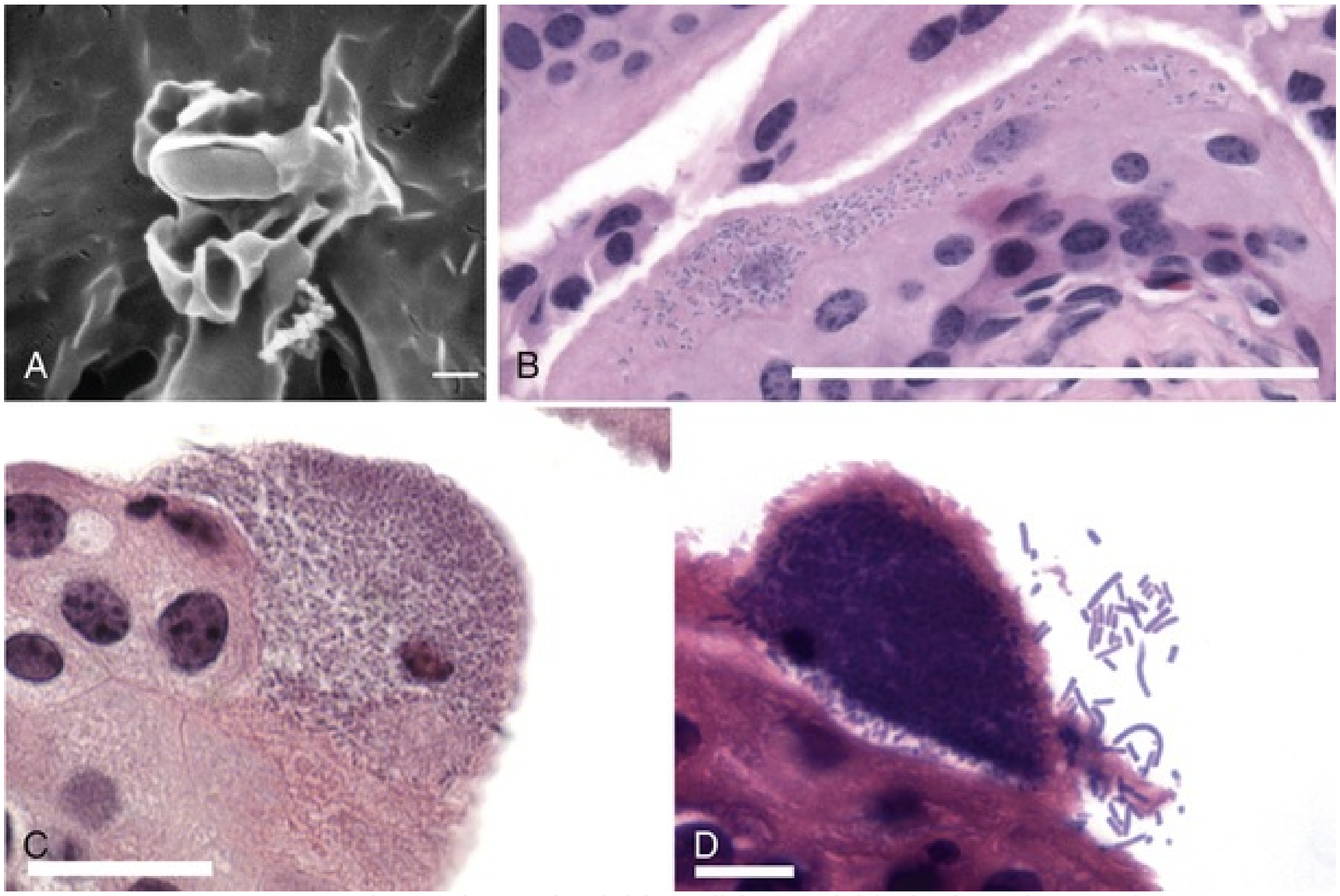

FIG. 55.8 Uropathogenic *Escherichia coli* (UPEC) binds, invades, and multiplies inside the superficial cells of the bladder epithelium. (A) Scanning electron microscopy shows a single UPEC bound to the surface of a bladder cell. Type 1 pilus–mediated contact between bacterium and host cell initiates signaling cascades in the bladder cell, leading to localized actin rearrangements and membrane protrusions around the bacterium. Scale bar, 0.5 µm. (B) Once inside the bladder superficial cells, UPEC rapidly multiplies to form disordered bacterial clusters in the host cell cytoplasm, called an early intracellular bacterial community (IBC). Bacteria are visible as dark-staining rods inside the cell in this hematoxylin and eosin (H&E)-stained thin bladder section. Scale bar, 100 µm. (C) H&E-stained thin bladder section reveals a middle IBC, wherein the constituent bacteria have organized themselves into a biofilm-like state within the bladder cell. Scale bar, 20 µm. (D) A late IBC, visible by H&E staining, is typified by detachment of peripheral bacteria and fluxing of these organisms into the bladder lumen. Scale bar, 10 µm. (From Anderson GG, Martin SM, Hultgren SJ: Host subversion by formation of intracellular bacterial communities in the urinary tract. *Microbes Infect* 6:1094–1101, 2004.)

Uropathogenic *E. coli* Persistence in the Bladder.

Soon after attachment to the epithelium, UPEC is quickly internalized into the bladder superficial cells (Anderson et al., 2004a,b; Martinez and Hultgren, 2002; Fig. 55.9). Invasion into the superficial epithelium of the bladder allows UPEC to establish a new niche in an effort to protect itself from the host innate immune response (Anderson et al., 2004a,b).

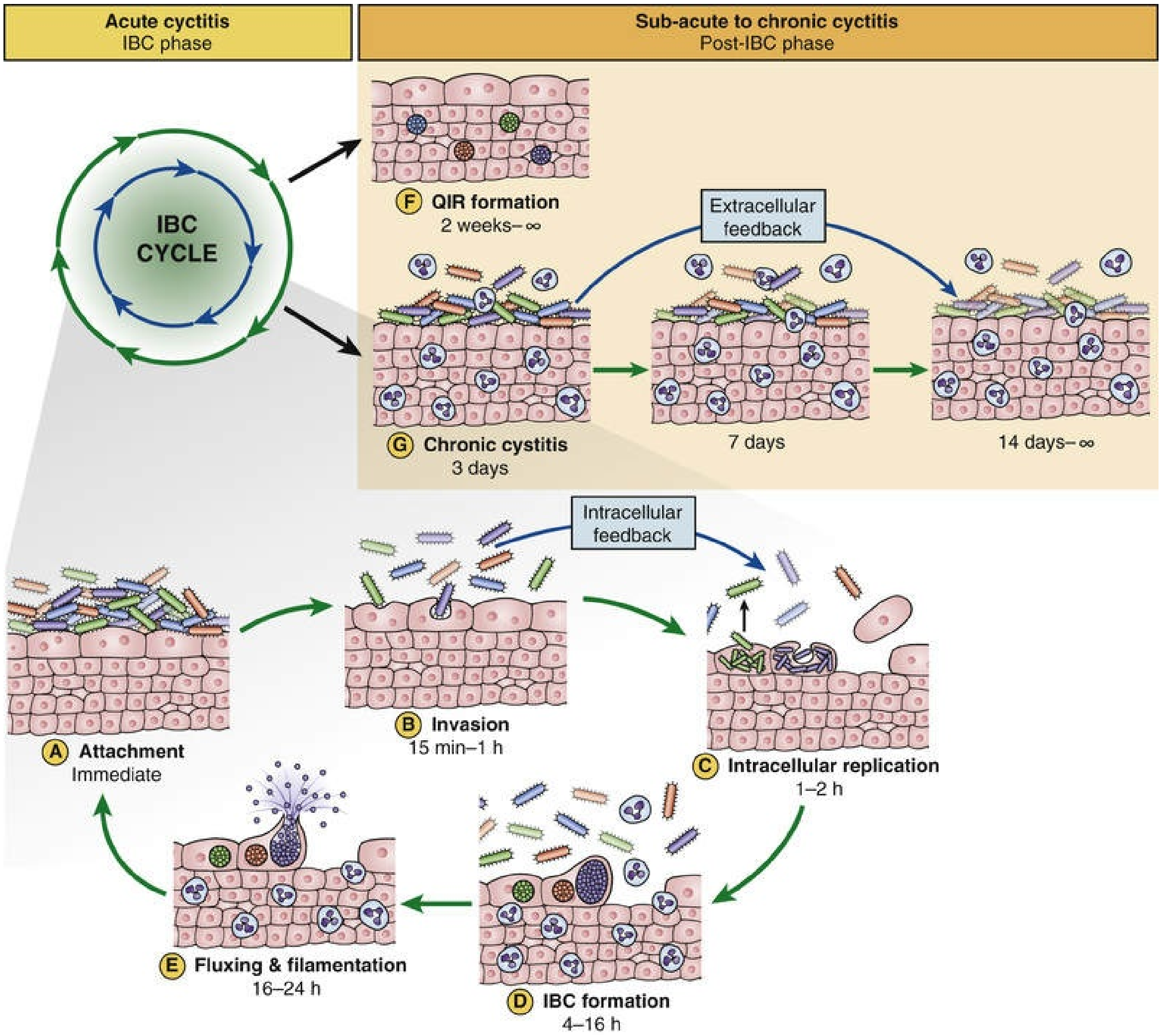
Acute cyctitis
IBC phase
Sub-acute to chronic cyctitis
Post-IBC phase
IBC CYCLE
F QIR formation
2 weeks–∞
Extracellular feedback
G Chronic cystitis
3 days
7 days
14 days–∞
Intracellular feedback
A Attachment
Immediate
B Invasion
15 min–1 h
C Intracellular replication
1–2 h
D IBC formation
4–16 h
E Fluxing & filamentation
16–24 h

FIG. 55.9 Uropathogenic *Escherichia coli* model for acute cystitis, chronic cystitis, and quiescent intracellular reservoir formation: intracellular bacterial community (IBC) formation starts when bacteria attach onto the apical transitional epithelium of the bladder via type 1 pili. These bacteria are then enveloped and invade the epithelium, replicating and forming IBCs. As a host response to infection, the urothelium typically exfoliates, resulting in IBC liberation and IBC recreation in a clonal fashion. IBCs may also progress to quiescent intracellular reservoirs, which are not metabolically active and do not produce a measurable inflammatory response. (Modified from Hannan TJ, Totsika M, Mansfield KJ, et al.: Host-pathogen checkpoints and population bottlenecks in persistent and intracellular uropathogenic *Escherichia coli* bladder infection. *FEMS Microbiol Rev* 3:616e48, 2012.)

Once intracellular, the UPEC organisms rapidly grow and divide within the cell cytosol, forming small clusters of bacteria termed *early intracellular bacterial communities* (IBCs) (Anderson et al., 2004a,b; Justice et al., 2004). As they grow, the bacteria maintain their typical rod shape of approximately 3 µm and form a loosely organized cluster, with microorganisms randomly oriented in the cell cytoplasm. Between 6 and 8 hours after inoculation, early IBCs show a drop in bacterial growth rate, resulting in doubling times greater than 60 minutes, a significant shortening of the bacterial morphology to an average of 0.7 µm, and a phenotypic switch into a biofilm-like community (Justice et al., 2004) Similar bacteria-engorged urothelial cells have been identified in 22% of voided urine specimens from patients with UTI with *E. coli* (Rosen et al., 2007). Importantly, **UPEC isolated from the human IBC-like cells were capable of infecting mice and recapitulating IBCs** (Garofalo et al., 2007).

Biofilms shield bacteria from environmental challenges such as antimicrobial agents and the host immune response (Donlan and Costerton, 2002)**. Characteristics of the biofilm that increase protection include the slower growth rate of the bacteria with associated physiologic changes, expression of factors that inhibit antimicrobial activity, and the inability of the antimicrobial agent to penetrate the biofilm matrix** (Anderson et al., 2004a,b). The biofilm also protects the bacteria from neutrophils because they are unable to effectively penetrate the IBC and engulf the bacteria. In animal models, bacteria on the edge of IBCs eventually detach, differentiate to typical rod morphology, become motile, and then escape the host cell into the bladder lumen in a process called *fluxing* (Mulvey et al., 2001). These bacteria may become highly filamentous, reaching up to 70 µm or greater in length. This process occurs by approximately 24 hours after inoculation (Justice et al., 2004). It is possible that the filaments may help the bacteria evade the immunologic response. Moreover, a large majority of UPEC isolated from women with acute, asymptomatic, or recurrent UTIs have shown the presence of flagellum-mediated movement, which may play an important role in adherence and dispersal during biofilm elaboration (Nakamura et al., 2016; Wright et al., 2005).

The escaped bacteria re-adhere and reinvade superficial cells to lead to second IBC formation. In subsequent rounds, further IBC formation occurs. After a few days, the invasive bacteria become more quiescent. In animal models, the bacteria can persist in this dormant reservoir state for some time before reemerging to cause recurrent UTIs (Anderson et al., 2004a,b). Indeed, in murine UTI, individuals with sterile urine nonetheless may contain thousands of viable UPEC within bladder tissue (Mulvey et al., 2001), suggesting that IBCs may be a transient intermediate in the establishment of stable UPEC reservoirs within the bladder. Exfoliation of superficial urothelial cells (see later) exposes underlying transitional cells. In contrast to the cytosolic UPEC aggregates characteristic of IBCs, UPEC invasion of transitional cells results in membrane-bound bacteria limited to two to four bacteria per cell (Justice et al., 2004). These intracellular UPEC remain quiescent, and thus such transitional cells are referred to as *quiescent intracellular reservoirs* (QIRs) (Mysorekar and Hultgren, 2006). However, chemically perturbing the urothelium to evoke urothelial differentiation caused reemergence of UPEC from QIR marked by significant bacterial proliferation. **Together, these findings suggest that bladder reservoirs of intracellular UPEC may contribute to recurrent UTI in susceptible individuals as the transitional cells undergo differentiation.**

Natural Defenses of the Urinary Tract

Periurethral and Urethral Region

The normal flora of the vaginal introitus, the periurethral area, and the urethra usually contain microorganisms such as lactobacilli, coagulase-negative staphylococci, corynebacteria, and streptococci that form a barrier against uropathogenic colonization (Fair et al., 1970; Marrie et al., 1978; Pfau and Sacks, 1977). Changes in the vaginal environment related to estrogen, cervical IgA (Stamey et al., 1978), and low vaginal pH (Stamey and Timothy, 1975) may alter the ability of these bacteria to colonize. More commonly, however, acute changes in colonization have been associated with use of antimicrobial agents and spermicidal agents that alter the normal flora and increase the receptivity of the epithelium for uropathogens.

Little is known about the factors that predispose patients to urethral colonization with uropathogens. The proximity of the urethral meatus to the vulvar and perianal areas suggests that contamination occurs frequently. The nature of urethral defense mechanisms other than flow of urine is largely unknown. Bacterial multiplication in the normal urethra may be inhibited by the indigenous flora (Chan et al., 1984). Although colonization of the periurethral and urethral regions is prerequisite to most infections, the ability of the organisms to overcome the normal defense mechanisms of the urine and the bladder is clearly pivotal.

Urine

In general, fastidious organisms that normally colonize the urethra will not multiply in urine and rarely cause UTIs (Cattell et al., 1973). In contrast, urine usually supports the growth of nonfastidious bacteria (Asscher, et al. 1973). **Urine from normal individuals may be inhibitory, especially when the inoculum is small** (Kaye, 1968)**. The most inhibitory factors are the osmolality, urea concentration, organic acid concentration, and pH. Bacterial growth is inhibited by either very dilute urine or a high osmolality when associated with a low pH.** Much of the antimicrobial activity of urine is related to a high urea and organic acid content (Solomon et al., 1983). From a clinical perspective, however, these conditions do not appear to significantly distinguish between patients who are susceptible or resistant to infection.

Uromodulin (Tamm-Horsfall protein), a kidney-derived mannosylated protein that is present in an extraordinarily high concentration in the urine (>100 mg/mL), **may play a defensive role by saturating all the mannose-binding sites of the type 1 pili, thus potentially blocking bacterial binding to the uroplakin receptors of the urothelium** (Duncan, 1988; Kumar and Muchmore, 1990).

Bladder

Bacteria presumably make their way into the bladder frequently. Whether small inocula of bacteria persist, multiply, and infect the host depends in part on the ability of the bladder to empty (Cox and Hinman, 1961). Additional factors responsible for defense involve innate and adaptive immunity and exfoliation of epithelial cells.

Immune Response

Pathogen Recognition.

The host recognition of the pathogen is mediated by a series of pathogen-associated molecular pattern receptors (PAMPs), such as Toll-like receptors (TLRs) (Anderson et al., 2004a,b), which provide the link between recognition of invading organisms and development of the innate immune response. TLRs recognize molecular patterns that are conserved among many species of pathogens, such as lipopolysaccharide (LPS) and peptidoglycan (PG), and activate signaling pathways that initiate immune and inflammatory responses to kill pathogens. Superficial bladder epithelial cells express TLR4 on their membranes, which, along with CD14, recognize LPS from the bacteria and activate the innate immune response (Anderson et al., 2004a,b). The newly identified TLR11, which recognizes UPEC and protects the kidneys from ascending infection, is also expressed on uroepithelial cells, as well as renal cells (Zhang et al., 2004).

The innate system response to an infection in the bladder or kidneys is primarily local inflammation. **The innate immune response occurs more rapidly than the adaptive response and involves a variety of cell types, including polymorphonuclear leukocytes, neutrophils, macrophages, eosinophils, natural killer cells, mast cells, and dendritic cells.** In addition, increased transcription of inducible nitric oxide synthase by polymorphonuclear leukocytes results in high levels of nitric oxide and related breakdown products that also have toxic effects on the bacteria (Poljakovic and Persson 2003; Poljakovic et al., 2001). Adaptive immunity involves the specific recognition of pathogens by T and B lymphocytes and production of high-affinity antibodies, a process that occurs 7 to 10 days after infection.

The urinary tract is part of the secretory immune system. In pyelonephritis, IgG and SIgA appear in the urine and may become evident before antibodies are detected in the serum. These antibodies are synthesized locally within the kidney and may enhance bacterial opsonization and ingestion by local phagocytic cells. These antibodies may have further protective function. Svanborg-Eden and Svennerholm (1978) showed that IgG and SIgA derived from the urine of patients with acute pyelonephritis reduced in vitro adherence of the same strain of *E. coli* to uroepithelial cells. Similarly, immunization with *E. coli* P pili resulted in immunoglobulin production in experimental animals that prevented ascending pyelonephritis by reducing the adhesive capacity of the invading autologous uropathogenic *E. coli* (O'Hanley et al., 1983; Roberts and Phillips, 1979).

Toll-Like Receptor Signaling.

Because TLR signaling triggers innate immune responses and mediates innate-adaptive interactions, diverse pathogens target TLR signaling. Consistent with this, TLR modulation has been identified in UPEC. UPEC was found to modulate urothelial inflammatory responses at the levels of nuclear factor-κB (NF-κB) activation and cytokine suppression, and this inflammatory suppression is widespread among clinical *E. coli* strains (Billips et al., 2007; Hunstad et al., 2005; Klumpp et al., 2001). In contrast to bacteria that modulate inflammatory responses through the action of secreted virulence factors, UPEC genetic screens identified genes associated with modification of TLR ligands (Billips et al., 2008; Hunstad et al., 2005). Some UPEC strains even encode direct inhibitors of TLR signaling (Cirl et al., 2008). Together, these findings suggest that **UPEC enhances virulence by modulating inflammatory responses at the level of TLR recognition, thereby extending a "window of opportunity"** to establish infection by evading innate surveillance mechanisms.

Induced Exfoliation.

Mulvey et al. (1998) **demonstrated that exfoliation and excretion of infected and damaged superficial cells is mediated by type 1 piliated bacteria that induce programmed cell death.** By using an in vivo mouse model, it has been demonstrated that mice exhibiting a strong exfoliation response to UPEC infiltration are unlikely to form IBCs (Anderson et al., 2004a,b). However, mice with a much milder exfoliation response tend to form biofilms, which become sequestered in the bladder and presumably could lead to recurrent UTIs. **It has also been shown that many uropathogenic bacteria can suppress NF-κB, increase apoptosis, and decrease the inflammatory responses** (Klumpp et al., 2001)**, a process that could lead to subsequent bacterial invasion into deeper tissues. Indeed, a key reason for the high rate of recurrence of infections in the bladder and resistance to antibiotics is associated with the formation of subepithelial QIRs. Thus in some instances apoptosis may be a bacterial offense maneuver rather than a host defense** (Leatham-Jensen et al., 2016).

Alterations in Host Defense Mechanisms

Obstruction

Obstruction to urine flow at all anatomic levels, whether secondary to anatomic abnormalities or elevated storage pressure, is a key factor in increasing host susceptibility to UTI. Obstruction inhibits the normal flow of urine, and the resulting stasis compromises bladder and renal defense mechanisms. **Stasis also contributes to the growth of bacteria in the urine and their ability to adhere to the urothelial cells.** In the animal model of experimental hematogenous pyelonephritis, the kidney is relatively resistant to infection unless a ureter is ligated. Under these circumstances, only the obstructed kidney becomes infected (Beeson and Guze, 1956). Clinical observations support the role of obstruction in pathogenesis of UTI and in increasing severity of infection. **Minimal episodes of cystitis or pyelonephritis can become life threatening when obstruction to urine flow becomes present.** Although obstruction clearly increases the severity of infection, it need not be a predisposing factor. For example, men with large residual urine may remain uninfected for years.

Vesicoureteral Reflux

Hodson and Edwards (1960) first described the association of VUR, UTI, and renal clubbing and scarring. **Children with high-grade reflux and UTIs usually develop progressive renal damage manifested by renal scarring, proteinuria, and renal failure. Those with a lesser degree of reflux usually improve or completely recover spontaneously or after treatment of the UTI. In adults, the presence of reflux does not appear to decrease renal function unless there is high storage pressure or stasis and concurrent UTIs.**

Underlying Disease

There is a high incidence of renal scarring in patients with underlying conditions that cause chronic interstitial nephritis, almost all of which produce primary renal papillary damage. These conditions include diabetes mellitus, sickle cell disorders, adult nephrocalcinosis, hyperphosphatemia, hypokalemia, analgesic abuse, sulfonamide nephropathy, gout, heavy-metal poisoning, and aging (Freedman, 1979).

Diabetes Mellitus

An increased incidence of asymptomatic bacteriuria and symptomatic UTIs appears to occur in women with diabetes mellitus, but there is no substantial increase among men with diabetes (Forland et al., 1977; Meiland et al., 2002; Ooi et al., 1974; Vejlsgaard, 1973). Some contributory factors to the increased incidence include incomplete bladder emptying, poor glucose control, and impaired immune response (Boyko et al., 2005)

Diabetes appears to predispose the patient to more severe infections. Frequent courses of antibiotics for asymptomatic bacteriuria and symptomatic UTIs in patients with diabetes result in a higher incidence of resistant pathogens (ESBL-positive Enterobacteriaceae, carbapenem-resistant Enterobacteriaceae, and vancomycin-resistant enterococci [VRE]). Multiple studies have investigated the relationship between risk of UTI and glycosuria, but there is no evidence to support this relationship (Johnsson et al., 2013; Rizzi and Trevisan, 2016). One study using antibody-coated bacteria techniques to localize the site of infection showed the upper urinary tract to be involved in nearly 80% of patients with diabetes and UTIs (Forland et al., 1977). This evidence of increasing immunologic response in patients with diabetes who acquire bacteriuria suggests renal parenchymal involvement and a potential increase in morbidity.

Infections are frequently caused by atypical organisms such as yeast and result in upper tract infections and significant sequelae such as emphysematous pyelonephritis, papillary necrosis, perinephric abscess, or metastatic infection (Stapleton, 2002; Wheat, 1980).

Renal Papillary Necrosis

The role of infection in the development and progression of renal papillary necrosis (RPN) is controversial. **Multiple predisposing conditions have been associated with the development of RPN, particularly diabetes, analgesic abuse, sickle cell hemoglobinopathy, and obstruction** (Box 55.2).

Box 55.2

Conditions Associated With Renal Papillary Necrosis

Diabetes mellitus
Pyelonephritis
Urinary tract obstruction
Analgesic abuse
Sickle cell hemoglobinopathies
Renal transplant rejection
Cirrhosis of the liver
Dehydration, hypoxia, and jaundice of infants
Miscellaneous: renal vein thrombosis, cryoglobulinemia, renal candidiasis, contrast media injection, amyloidosis, calyceal arteritis, necrotizing angiitis, rapidly progressive glomerulonephritis, hypotensive shock, acute pancreatitis

Data from Eknoyan G, Qunibi WY, Grissom RT, et al.: Renal papillary necrosis: an update. *Medicine* 61:55, 1982.

Clinically, RPN is a spectrum of disease. Patients may have an acute fulminating illness with rapid progression or may have a chronic disease that is incidentally discovered. Some patients may chronically pass necrotic tissue in their urine (Hernandez et al., 1975), whereas some may never experience papilla loss in the urine (Lindvall, 1978). Retained necrotic papillae may calcify, especially in association with infection. Furthermore, this necrotic tissue may form the nidus for chronic infection. Opportunistic fungal infections have been reported (Juhasz et al., 1980; Madge and Lombardias, 1973; Tomashefski and Abramowsky, 1981; Vordermark et al., 1980). Renal sonography may be useful to diagnose RPN (Buonocore et al., 1980; Hoffman et al., 1982).

The early diagnosis of RPN is important to improve prognosis and reduce morbidity. In addition to chronic infection, patients with analgesic abuse–associated papillary necrosis may have an increased incidence of urothelial tumors; routine urinary cytologic examinations may be helpful to diagnose these tumors early (Jackson et al., 1978). In patients who have analgesic abuse–induced RPN, the disease stabilizes if the analgesic intake is stopped (Gower, 1976). Furthermore, adequate antimicrobial therapy to control infection and early recognition and treatment of ureteral obstruction caused by sloughed necrotic tissue can minimize a decline in renal function. **A patient who suffers from an acute ureteral obstruction caused by a sloughed papilla and who has a concomitant UTI has a urologic emergency.** In this case, immediate removal of the obstructing papilla by stone basket (Jameson and Heal, 1973) or acute drainage of the kidney by ureteral catheter or percutaneous nephrostomy is necessary.

In the case of sickle cell disease, it is particularly important that patients engage with nephrology early to prevent the progression of sickle cell nephropathy, which includes glomerular disease in addition to papillary necrosis. Preventive measures include ensuring adequate fluid intake, blood pressure control, and the use of angiotensin-converting enzyme (ACE) inhibitors or angiotensin II receptor blockers (ARBs) in patients who have microalbuminuria and/or proteinuria (Gebreselassie et al., 2015).

Other conditions that may increase the susceptibility of the kidney to infection include hypertension and vascular obstruction (Freedman, 1979). The association of renal infection with several other renal diseases, including glomerulonephritis, atherosclerosis, and tubular necrosis, which are not associated with papillary necrosis, does not lead to pyelonephritis and scarring.

Human Immunodeficiency Virus

UTIs are fivefold more prevalent in HIV-positive individuals than in control subjects (Schonwald et al., 1999). The pathologic bacteria include higher rates of *Acinetobacter* and *Salmonella* species in HIV-positive patients. Patients with AIDS (defined by either an AIDS-defining illness and/or CD4 count <200 cells/mm^3) are at higher risk for atypical infections including fungal (*Candida* spp., *Aspergillus* spp., *Cryptococcus neoformans*, and other endemic fungi such as *Histoplasma*), mycobacterial (tuberculosis and nontuberculous mycobacteria), and viral (cytomegalovirus and adenoviruses) infections. Patients with a CD4 count below 200 cells/mm^3 are typically placed on *Pneumocystis* pneumonia prophylaxis; often TMP-SMX (which decreases UTI risk), unless the patient has a sulfa allergy or G6PD deficiency.

Other Conditions That Increase Risk of Urinary Tract Infections

Renal Transplantation

UTIs are among the most common infection sustained by renal transplant recipients, with more than one-third of renal transplant recipients sustaining at least one infection after surgery; they also remain a potential risk factor for poorer graft outcomes (Golebiewska et al., 2011). Transplant recipients are noted to have a higher incidence of infections with bacteria-harboring antibiotic resistance capability and are prone to recurrent episodes of symptomatic infection, likely related to colonization within their urinary tract (Hollyer and Ison, 2017). Exposure to intensified immunosuppression resulting from acute rejection episodes, female gender, advanced age of the recipients, long catheter duration, and cadaveric donor remains the risk factor for recurrent UTIs (Wu et al., 2016).

Menopause

UTIs among women increase in frequency after menopause; the rationale and treatment strategies for this are discussed in subsequent sections.

Pregnancy

See the section entitled *Bacteriuria in Pregnancy* for a complete discussion of this topic.

Spinal Cord Injury With High-Pressure Bladders

Of all patients with bacteriuria, no group compares in severity and morbidity with those who have SCI. Nearly all these patients require catheterization early after their injuries because of bladder overactivity or flaccidity, and significant numbers develop ureterectasis, hydronephrosis, reflux, and renal calculi. Bacteriologic and urodynamic advances in the management of these patients have greatly reduced their morbidity and mortality. Special problems associated with SCI are presented in a later section.

Key Points: Pathogenesis

- Most UTIs are caused by bacteria, usually originating from the bowel and skin flora.
- Bacterial virulence factors, including adhesin, play a role in determining which bacteria invade and the extent of infection.
- Increased epithelial cell receptivity predisposes patients to recurrent UTIs and is a genotypic trait.
- Obstruction to urine flow is a key factor in increasing host susceptibility to UTIs.

Evaluation

Diagnosis of a UTI must involve a thorough history with a specific focus on signs and symptoms of the urinary complaints as well as investigating risk factors for infection. Physical exam, although necessary, is often unrevealing. Diagnosis of UTI is dependent on a properly collected urine sample. Additional testing is sometimes warranted, depending on the history.

Signs and Symptoms

Cystitis is typically associated with symptoms of dysuria, frequency, and/or urgency. Suprapubic pain, hematuria, and fever may also be present. Pyelonephritis is classically associated with fever, chills, flank pain, and costovertebral-angle tenderness. Nausea, vomiting, and malaise may be present. Urinary symptoms may or may not be present. Complicated UTIs can occur with other signs and symptoms. If patients complain of pneumaturia or fecaluria, a vesicoenteric or vesicovaginal fistula should be suspected. Renal or perirenal abscess may cause indolent fever and flank mass and tenderness. Patients with indwelling catheters often have asymptomatic bacteriuria, but fever associated with bacteremia may occur rapidly and become life threatening. Diagnosing a UTI in the geriatric population presents unique challenges (see the section on UTIs in the elderly).

In addition to focusing on presenting symptoms, other relevant information that must be ascertained includes recent infections (urologic and nonurologic) and/or antibiotic use, significant comorbidities that may predispose to infections, recent hospitalizations, presence of pediatric voiding dysfunction, sexual and reproductive history, known urologic anatomic abnormalities, prior surgery of the urinary tract, reproductive organs or spine, family history, and current medications (Box 55.3).

Box 55.3

Important Information in Evaluation of Urinary Tract Infection

- Recent infections/antibiotic use
- Recent hospitalizations
- Comorbidities
- History of pediatric voiding dysfunction
- Sexual and reproductive history
- Anatomic urologic abnormalities
- Prior surgery of genitourinary tract, reproductive organs, spine
- Family history
- Current medications

In the differential diagnosis of UTIs clinicians should consider voiding dysfunction that is not secondary to bacterial factors and will not improve with antibiotics targeted at a UTI (see chapters on interstitial cystitis/painful bladder syndrome, hematuria evaluation, STDs, VUR). For example, the symptoms associated with painful bladder syndrome may mimic a UTI, and, unfortunately, many patients who suffer from this syndrome are often treated with many courses of antibiotics despite the absence of documented positive cultures.

Furthermore, vaginitis is characterized by irritative voiding associated with vaginal irritation and is subacute in onset. A history of vaginal discharge or odor and multiple or new sexual partners is common. Frequency, urgency, hematuria, and suprapubic pain are not present. Physical examination reveals a vaginal discharge, and examination of vaginal fluid demonstrates inflammatory cells. Differential diagnosis includes herpes simplex virus, gonorrhea, *Chlamydia,* trichomoniasis, yeast, and bacterial vaginosis.

Last, urethritis causes dysuria that is usually subacute in onset and is associated with a history of discharge and new or multiple sexual partners. Frequency and urgency of urination may be present but are less pronounced than in patients with cystitis, and fever and chills are absent. Urethral discharge with inflammatory cells or initial pyuria in the male is characteristic. The common causes of urethritis include *Neisseria gonorrhoeae, Chlamydia,* herpes simplex virus, and trichomoniasis. Appropriate cultures and immunologic tests are indicated. Urethral injury associated with sexual intercourse, chemical irritants, or allergy may also cause dysuria. A history of trauma or exposure to irritants and a lack of discharge or pyuria are characteristic.

As a general rule, **painless gross hematuria, or microhematuria in the**

absence of a positive culture, should always raise the suspicion for urologic malignancy, and a hematuria evaluation must be initiated.

Physical examination should focus on the abdominal and pelvic regions. On examination of the suprapubic area, bladder distention may be palpated, often an indicator of an elevated postvoid residual. The presence or absence of costovertebral-angle tenderness should be assessed, particularly if the suspicion for pyelonephritis is high. During pelvic examination in a woman the presence of vaginal discharge should be noted. Inspection and palpation of the urethral area may identify the presence of a urethral diverticulum or Skene gland infection. If either of these are present, a cystic-appearing structure may be palpable or visualized. Fluid may be expressed on palpation of the area and tenderness may be elicited when palpating the cystic structure directly. In postmenopausal women careful attention should be focused on assessing the quality of the vaginal epithelium, specifically noting the degree of vaginal atrophy; atrophic vaginal tissue is an indicator of a hypoestrogenic state, which is a known risk factor for the development of UTIs. Pelvic organ prolapse may be identified as well; prolapse can contribute to incomplete emptying, which can be associated with a UTI. In men a rectal exam should be performed to assess the prostate. A focused neurologic exam on the pelvic area should be performed to assess whether sensation is intact.

Diagnosis by Urine Testing

Urine Collection

The diagnosis of a UTI is dependent on obtaining a properly collected urine sample with subsequent analysis of urine (urinalysis) and urine culture. Diagnostic accuracy and decreased rates of false-positive urinalysis and culture can be improved by reducing bacterial contamination during collection. Although studies have not demonstrated a clear benefit to cleansing the meatus before giving a midstream voided sample, it is a commonly accepted practice that is endorsed universally.

Before sample collection in circumcised men, the glans should be cleansed with a 2% castile soap towelette. For those uncircumcised, the foreskin should be retracted and the glans cleansed with the towelette before specimen collection. A midstream specimen should be obtained by collecting it in a sterile cup.

In women, contamination of a midstream urine specimen with introital bacteria and WBCs is common, particularly when the woman has difficulty maintaining separation of the labia. Women should therefore be instructed to spread the labia, wash and cleanse the periurethral area with a 2% castile soap towelette, and then collect a midstream urine specimen. The voided specimen is contaminated if it shows evidence of vaginal epithelial cells and lactobacilli on urinalysis. **Increased BMI, significant vaginal atrophy, decreased manual dexterity, and the inability to bear weight are factors that contribute to difficulty obtaining an adequate clean-catch midstream sample in women. The presence of an intravaginal pessary also increases the likelihood of obtaining a contaminated sample; if a woman has an indwelling pessary, analysis of a catheterized sample is preferable** (Box 55.4).

Box 55.4

Factors That Affect Ability to Provide Adequate Midstream Clean-Catch Sample

- Increased body mass index
- Vaginal atrophy
- Poor manual dexterity
- Inability to bear weight
- Intravaginal pessary
- Nonsterile collection receptacle

The collection receptacle also can affect the reliability of the sample. In some cases, voided urine samples, not collected via a midstream clean-catch sample, are collected from a bedpan or a nonsterile paper cup, rather than a sterile cup. This may occur in an emergency room setting or when a urine sample is requested during a well visit with a general practitioner or gynecologist. Analysis of these samples should be disregarded, but unfortunately patients are often treated based on abnormal findings in such erroneous samples, irrespective of symptoms. **If a patient has an indwelling Foley catheter and there is suspicion of a UTI, the catheter should be removed and a new catheter should be placed under sterile conditions to obtain a sample that reflects microbes in the urine, as opposed to microbes that may be colonizing the catheter or drainage bag**. Likewise, samples should not be taken from an ostomy appliance; rather they should be obtained via intubation of the stoma.

Catheterization with collection of a mid-catheterized specimen is more accurate than a voided specimen; however, because of its invasive nature it is only used in certain circumstances. Situations in which a catheterized sample should be considered include when the voided sample shows clear evidence of contamination (i.e., many squamous epithelial cells), a patient has a pessary, the patient is unable to provide an adequate clean-catch sample, or the patient cannot provide any sample at all. Although time intensive, the risk of iatrogenic infection is low and catheterization is critical to obtain the best quality samples, particularly if the symptoms of a UTI are equivocal. Indeed, a recent study evaluating the utility of catheterized samples in patients with symptoms not strongly suggestive of a UTI revealed obtaining a catheterized sample decreased the percent of patients who would have been treated with an antibiotic based on a positive voided sample by slightly more than 50% (Aisen et al., 2018).

Suprapubic aspiration is highly accurate, but because it is associated with some morbidity, there is limited clinical usefulness except for a patient who cannot urinate on command, such as patients with SCI. However, even in those populations, catheterized samples are preferred over suprapubic aspiration. A single aspirated specimen reveals the bacteriologic status of the bladder urine without introducing urethral bacteria.

Much of the evidence surrounding the efficacy of suprapubic aspiration for urine specimen collection comes from the pediatric literature regarding the diagnosis of a UTI in infants and young children. In 1999 the American Academy of Pediatrics published their Practice Parameter; in this guideline, they recommended that if an infant were ill enough to begin empiric antibiotic treatment, it was strongly recommended that a urine culture be obtained via suprapubic aspiration or catheterization. Given the high false-positive rate of urine culture obtained by bag collection, the Academy advised that suprapubic aspiration of urine for culture was the “gold standard.” Similar practice principles were set forth in the WHO guidelines for obtaining urine specimens in children (Long and Vince, 2007). These conclusions regarding the relative value of suprapubic aspiration may be extrapolated to the management of UTIs in adults, particularly in patients who cannot provide a midstream specimen nor are readily straight catheterized.

Further studies regarding the relative value of suprapubic aspirate specimens were done with the characterization of the urinary microbiome. In one of these early DNA sequencing studies by Wolfe et al. (2012), the goal was to obtain urine from the female urinary bladder in subjects without a known UTI that was not contaminated by any other sources (such as the vagina, gut, or skin) (Wolfe et al., 2012). To control for possible contamination, samples obtained by suprapubic aspiration were compared with control swabs of the sample site, samples from suprapubic needles that punctured the skin but did not penetrate the bladder, clean-catch midstream samples, and those specimens obtained by urethral catheterization. The microbiota obtained from suprapubic aspirate closely resembled that obtained by transurethral catheterization; in contrast, voided specimens contained organisms that more closely resembled vaginal swabs. This work not only established the presence of nonpathogenic bacteria in urine as part of the microbiome but also found that transurethral catheterization was akin to suprapubic aspirates in studying bladder microbiota. Because of this latter finding, suprapubic aspiration remains a viable option for the acquisition of "non-contaminated" urine samples, although the provider should assess individual patient circumstances to determine if this approach is to be used instead of straight catheterization.

Key Issues in Analysis of Urine Samples.

Certain components of a urine sample are highly suggestive of a UTI. Leukocyte esterase is produced by the breakdown of WBCs in the urine. Its presence is an indication of pyuria, but not bacteria specifically. As mentioned previously, the presence of WBCs and therefore leukocyte esterase is not uncommon in women with vaginal contamination. Nitrites are present when bacteria reduce dietary nitrates, via bacterial nitrate reductase activity. Not all bacteria produce nitrites, though, so the absence of nitrites does not mean bacteria are not present. **All Enterobacteriaceae produce nitrites, including *E. coli, Klebsiella, Enterobacter, Proteus, Citrobacter, Morganella,* and *Salmonella* spp. Non–nitrite-producing bacteria include all gram positives and Pseudomonads (e.g., Pseudomonas and Acinetobacter).** In addition, patients who adhere to low-nitrate diets may have false-negative results. The presence of nitrites has a high specificity but much lower sensitivity. The presence of leukocyte esterase and nitrites is more reliable when bacterial counts are more than 100,000 colony-forming units (CFUs) per milliliter. Cloudy urine may occur because of pyuria but it can also occur because of precipitated phosphate crystals in alkaline or concentrated urine.

Ideally a sample is analyzed in proximity to the time at which it was received. If a sample is left standing too long, it may become alkaline and subsequently may contain bacteria or lysed red cells. If the sample will not be analyzed within a few hours, it must be refrigerated, especially if not in a specimen cup that contains preservatives. Hydration can also dilute the concentration of certain constituents.

Urine Dipsticks.

Dipsticks, or chemically impregnated reagent strips, are often used in urgicares or medical clinics, or by patients at home when they develop symptoms of a UTI. **Although dipsticks are most helpful in ruling out a UTI, each parameter has false positives and negatives, which make it less reliable in determining whether a patient has a UTI.** However, in a patient who has symptoms strongly suggestive of a UTI, a positive dipstick can be helpful in determining whether to initiate antibiotics. A positive nitrite is the independent variable most likely to rule in a UTI, when analyzed in conjunction with symptoms (Meister et al., 2013). Analysis of several of the components of a dipstick increases the diagnostic abilities compared with just one component. **Positive nitrites or positive leukocyte esterase and blood on a dipstick most accurately diagnose a UTI** (Little et al., 2009; Marques et al., 2017).

However, the borderline sensitivity of dipsticks, especially among patients with less characteristic symptoms of UTIs, does not allow these inexpensive tests to replace careful microscopic urinalysis in symptomatic patients (Semeniuk and Church, 1999). In addition, results of a dipstick can be inaccurate if the test strips are expired or improperly stored. Some of the dipstick reagents, like nitrites, are sensitive to air exposure, so if a container of strips is not closed as soon as one is used, the other strips are more likely to give false-positive results in the future. The leukocyte reaction takes up to 5 minutes to occur, so if a strip is not observed for the appropriate duration, a patient may display a false-negative result.

Urinalysis.

Automated urinalysis allows for more sensitive detection of hematuria and bacteria in the urine as compared with dipsticks. Preferred collection tubes for urinalysis are those that have non-mercuric preservatives, such as a combination of chlorhexidine, ethylparaben, and sodium propionate. Such preservatives ensure the quality of the sample for up to 72 hours without refrigeration, therefore preventing bacterial overgrowth. Approximately 6 to 8 mL of urine is centrifuged at 1800 to 2000 RPM for 4 minutes, then examined. Microscopic analysis reports on the number of RBCs, WBCs, squamous epithelial cells, bacteria, crystals, and casts. The number of squamous cells is an indicator of the sample quality.

Abnormal results of any one urinary constituent is usually not pathognomonic of a UTI; thus several constituents must be evaluated together. **Multiple aspects of the urinalysis may indicate an acute inflammatory response, particularly pyuria (the presence of at least 5 to 10 leukocytes per high-power field) and hematuria. This information is valuable in conjunction with culture results given that bacteriuria may represent chronic colonization** versus acute infection. In addition, cultures typically require 48 to 72 hours to result; thus urinalysis provides for quick analysis. Ideally a sample is sent for analysis soon after the sample is given, with attention paid to proper sample collection. The strongest predictors of a UTI, in the correct clinical context, include moderate bacteriuria, moderate pyuria, and nitrites (Meister et al., 2013).

Pyuria can be found in several conditions other than UTIs, so the mere presence of WBCs in the urine is not diagnostic. Increasing numbers of WBCs present in a symptomatic patient, however, do support a UTI diagnosis. Indeed, it has been suggested that moderate pyuria, defined as WBC count greater than 50, in conjunction with symptoms suggestive of a UTI, justifies treatment with antibiotics (Meister et al., 2013). Other conditions known to cause pyuria include GU tuberculosis, urolithiasis, injury to the urothelium (including chlamydial urethritis), and interstitial nephritis. Depending on the level of hydration, the intensity of the tissue reaction producing the cells, and the method of urine collection, any number of WBCs can be seen in the microscopic sediment in the presence of an uninfected urinary tract. **The absence of pyuria should cause the diagnosis of UTI to be questioned until urine culture results are available. If a culture is positive yet no pyuria is demonstrated on urinalysis, clinicians should consider obtaining a catheterized sample.**

Bacteria may be present on initial urinalysis even though the final culture is negative, thus rendering the bacteria found on urinalysis a false-positive result. This is most likely to occur when vaginal bacteria, such as lactobacilli and corynebacteria, are present in a voided sample from a female patient.

Automated urinalysis can reliably rule out a UTI and preclude the need to order a urine culture (Kayalp et al., 2013). However, ruling in a UTI based on a urinalysis is not as straightforward, because urinalyses may have abnormal parameters even in healthy, asymptomatic women, using preferred collection techniques (Frazee et al., 2015). Thus **relying on results of urinalyses alone**

can lead to overdiagnosis of UTIs. It is critically important that results of urinalyses are interpreted in conjunction with the clinical presentation and eventually correlation with a urine culture.

Urine Culture.

Standard urine culture is the gold standard for identifying the presence of bacteriuria, which supports a diagnosis of UTI in the symptomatic patient. The technique was originally described in the 1950s. Ideally, urine is collected via a midstream clean-catch sample or catheterized sample and is placed in a vacutainer tube that contains freeze-dried preservatives, which practically eliminate false-positive results. The sample is then placed on blood agar and MacConkey culture plates.

Historically, a colony count of at least 10^5 CFU/mL of urine was used to diagnose a UTI. Initially, this colony count confirmed a diagnosis of pyelonephritis (Kass, 1956) but has subsequently been employed to make a diagnosis of cystitis as well. However, many studies have demonstrated that women with dysuria may have lower bacterial colony counts. Indeed, 20% to 40% of women with symptomatic UTIs have bacteria counts of 10^2 to 10^4 CFU/mL of urine (Kraft and Stamey, 1977; Kunz et al., 1975; Stamey et al., 1965), probably because of the slow doubling time of bacteria in urine (every 30 to 45 minutes) combined with frequent bladder emptying (every 15 to 30 minutes) from irritation. **Thus, in dysuric patients, an appropriate threshold value for defining significant bacteriuria is 10^2 CFU/mL of a known pathogen** (Stamm and Hooton, 1993).

Urine culture results are reported as negative, commensal flora, or positive. Commensal flora includes coagulase-negative staphylococci, alpha and non-hemolytic streptococci, diphtheroids, non-pathogenic *Neisseria* spp., and yeasts. Results of positive urine cultures are reported with antibiotic sensitivities for each pathogen: S (sensitive), I (indeterminate), and R (resistant), with the minimum inhibitory concentration (MIC) following the sensitivities. **The MIC is the lowest concentration of an antibiotic that inhibits growth of an organism.** If an antibiotic is listed as sensitive, it suggests that growth of an organism is inhibited by the serum concentration of the medication that is achieved using the recommended dose. If listed as indeterminate, the antibiotic still may be effective in locations where the medication is physiologically concentrated or a higher-than-recommended dose can be used. Resistant organisms are those that are resistant to standard achievable serum drug levels

(Fig. 55.10). **Efficacy of the antimicrobial therapy is critically dependent on the antimicrobial levels in the urine and the duration that this level remains above the minimal inhibitory concentration of the infecting organism** (Hooton and Stamm, 1991). **Resolution of infection is closely associated with the susceptibility of the bacteria to the concentration of the antimicrobial agent achieved in the urine** (McCabe and Jackson, 1965; Stamey et al., 1965, 1974). The concentration of useful antimicrobial agents in the serum and urine of healthy adults is shown in eTable 55.1, which demonstrates that the **urinary levels are often several hundred times greater than the serum levels. Inhibitory concentrations in urine are achieved after oral administration of all commonly used antimicrobial agents, except for the macrolides (erythromycin).**

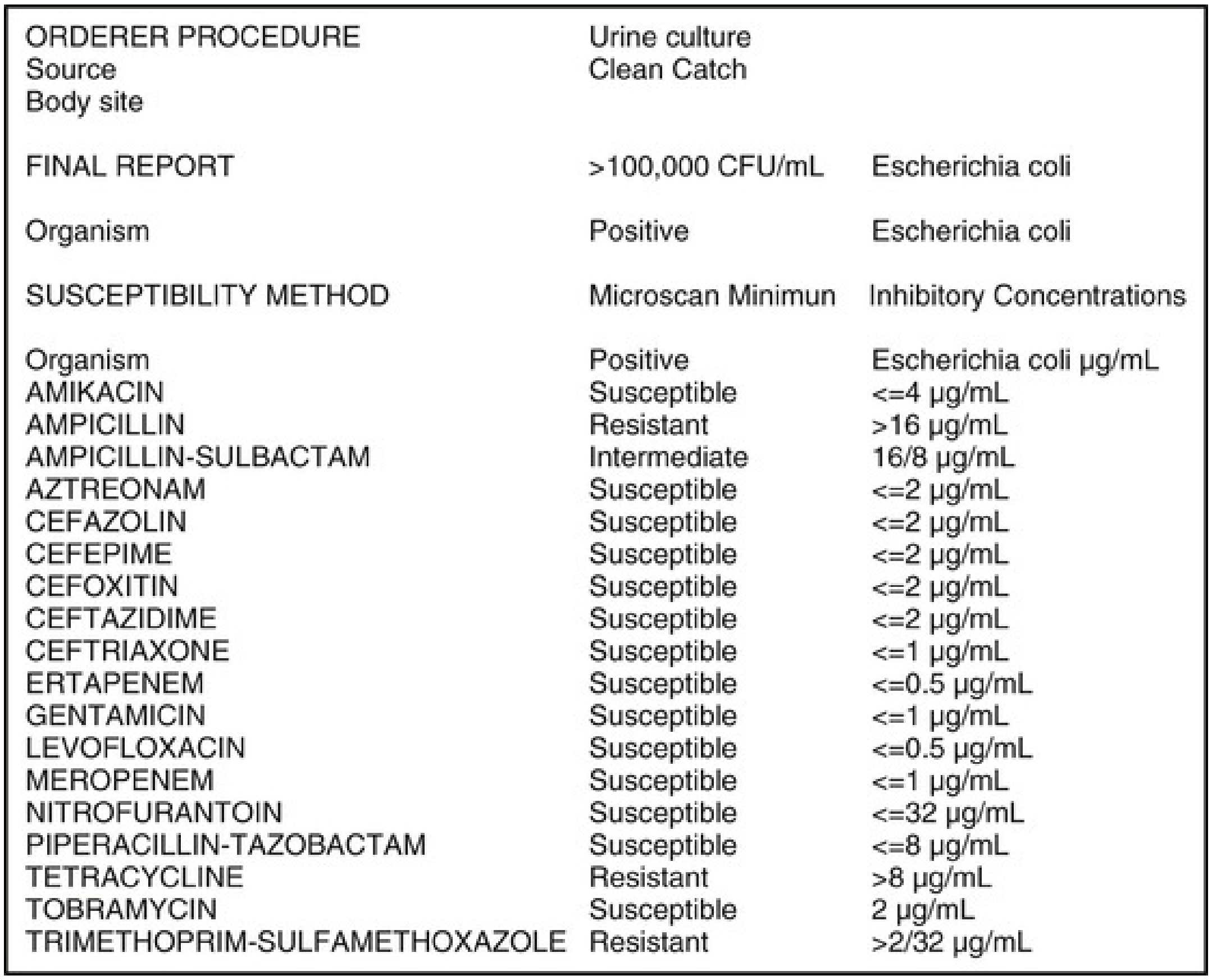

ORDERER PROCEDURE	Urine culture	
Source	Clean Catch	
Body site		
FINAL REPORT	>100,000 CFU/mL	Escherichia coli
Organism	Positive	Escherichia coli
SUSCEPTIBILITY METHOD	Microscan Minimun	Inhibitory Concentrations
Organism	Positive	Escherichia coli μg/mL
AMIKACIN	Susceptible	<=4 μg/mL
AMPICILLIN	Resistant	>16 μg/mL
AMPICILLIN-SULBACTAM	Intermediate	16/8 μg/mL
AZTREONAM	Susceptible	<=2 μg/mL
CEFAZOLIN	Susceptible	<=2 μg/mL
CEFEPIME	Susceptible	<=2 μg/mL
CEFOXITIN	Susceptible	<=2 μg/mL
CEFTAZIDIME	Susceptible	<=2 μg/mL
CEFTRIAXONE	Susceptible	<=1 μg/mL
ERTAPENEM	Susceptible	<=0.5 μg/mL
GENTAMICIN	Susceptible	<=1 μg/mL
LEVOFLOXACIN	Susceptible	<=0.5 μg/mL
MEROPENEM	Susceptible	<=1 μg/mL
NITROFURANTOIN	Susceptible	<=32 μg/mL
PIPERACILLIN-TAZOBACTAM	Susceptible	<=8 μg/mL
TETRACYCLINE	Resistant	>8 μg/mL
TOBRAMYCIN	Susceptible	2 μg/mL
TRIMETHOPRIM-SULFAMETHOXAZOLE	Resistant	>2/32 μg/mL

FIG. 55.10 Minimum inhibitory concentration for *E. coli* urinary tract infection, demonstrating sensitivity to most antibiotics except ampicillin, ampicillin-sulbactam, tetracycline, and trimethoprim-sulfamethoxazole.

eTABLE 55.1

Clinical Examples of Ureteral Catheterization Studies in Localizing the Site of Bacteriuria

SOURCE OF RENAL INFECTION	BLADDER INFECTION (BACTERIA/mL)	LEFT RENAL INFECTION (BACTERIA/mL)	RIGHT RENAL INFECTION (BACTERIA/mL)	BILATER (BACTERI
CB	$>10^5$	5000	$>10^5$	4000
WB	900	300	1000	20
LK$_1$	20	2000	20	400
LK$_2$	0	2200	0	350
LK$_3$	0	2500	0	500
LK$_4$	0	2200	0	400
RK$_1$	10	0	10,000	260
RK$_2$	0	0	10,000	220
RK$_3$	0	0	8000	300
RK$_4$	0	0	12,000	250

CB, Catheterized patient, cystoscopic specimen; *LK$_1$, LK$_2$, etc.,* serial cultures of urine from the left kidney; *RK$_1$, RK$_2$, etc.,* serial cultures of urine from the right kidney; *WB,* controlled, “wash bladder” specimen collected after copious irrigation of the bladder.

Data from Stamey T: *Pathogenesis and treatment of urinary tract infections*, Baltimore, 1980, Williams & Wilkins.

Factors other than the MIC should be taken into account when selecting an antibiotic, such as anatomic location of the infection and fluid type that is harboring infection (i.e., urine vs. blood). The lowest MIC is not always the most effective option. Route of administration should also be considered when determining which antibiotic to choose. This is particularly important in the outpatient setting when patients demonstrate the presence of multidrug-resistant organisms.

The specific pathogen identified in the culture is also a critical factor in evaluating the need to proceed with treatment, particularly if symptoms are equivocal. Although there is consensus regarding the benefit of treating a symptomatic patient who has gram-negative rods in the urine, the significance of gram-positive organisms in women is more controversial. In many cases a gram-positive organism may represent a periurethral contaminant. In a study comparing the presence of uropathogens in voided samples versus catheterized samples in symptomatic premenopausal women, the presence of *E. coli* in midstream samples had a high positive predictive value (93%) of bladder bacteriuria, even at low colony counts, whereas the presence of enterococci and group B streptococci were not predictive of bladder bacteriuria at any colony count (Hooton et al., 2013). In women who grew enterococci and/or group B streptococci in a voided sample, *E coli* grew from a catheterized sample in 61% of these subjects. The authors concluded that gram-positive organisms rarely cause acute cystitis in isolation.

In some cases, despite symptoms and a UA that are suggestive of a UTI, a standard urine culture may be negative. In this scenario a culture should be sent specifically looking for atypical organisms such as *Ureaplasma urealyticum* or *Mycoplasma hominis.*

Recently, more sensitive culture techniques have been described, known as the Expanded Quantitative Urine Culture (EQUC) (see the section on microbiome). Although the EQUC is not widely used yet, its ability to detect more organisms in the urine challenges traditional thinking about cutoff thresholds for the diagnosis of UTIs as well as the concept that polymicrobial presence should be discounted as a contaminant. Some have argued that the standard urine culture should no longer be considered the gold standard for detecting uropathogens (Price et al., 2018). **With more sophisticated techniques available to detect microbes, clinical judgment is paramount to prevent overtreatment of bacteriuria.**

Key Points: Evaluation

- Clinical presentation is critical in considering diagnosis; results of urine testing cannot be analyzed without knowledge of signs and symptoms.
- Urine must be collected in a manner that minimizes contamination.
- Formal urinalysis is preferred over dipstick testing.
- Urine culture results provide information regarding bacterial sensitivities.

Localization

Ureteral Catheterization

In cases of bacterial persistence it is useful to try to identify the source. Ureteral catheterization allows separation of not only bacterial persistence into upper and lower urinary tracts but also the infection between one kidney and the other, and even localization of infection to ectopic ureters or to nonrefluxing ureteral stumps (by using saline solution irrigation) (Stamey, 1980). Attempts to identify one or both kidneys as a source of infection are particularly important in patients with fever, flank pain, and/or costovertebral angle tenderness. This modality of diagnostics is also particularly important for the patient with renal transplant in determining if the native kidneys are harboring infection contributing to a UTI (see eTable 55.1).

Stone Cultures

It is clinically useful to culture stones removed from the urinary tract to identify the bacteria—and their sensitivities—that reside within their interstices. Urinary and stone cultures must be analyzed separately because results may be discordant. UTIs are the most common complication after stone removal procedures. Manipulation of infected stones, and possible release of endotoxins into the bloodstream, can lead to systemic inflammatory response syndrome (SIRS) or potentially fatal urosepsis. Studies have shown that stone cultures, rather than periprocedure urine cultures, are a better predictor of postoperative sepsis and SIRS (Korets et al., 2011; Mariappan et al., 2005).

Imaging

Imaging studies are not required in most cases of UTI because clinical and laboratory findings are sufficient for correct diagnosis, initiation of treatment, and adequate management of most patients. However, infections in most men, compromised hosts, febrile infections, signs or symptoms of urinary tract obstruction, failure to respond to appropriate therapy, and a pattern of recurrent infections suggesting bacterial persistence within the urinary tract warrant imaging for identification of underlying abnormalities that require modification of medical management or percutaneous or surgical intervention (Box 55.5).

Box 55.5

Indications for Radiologic Investigation in Acute Clinical Pyelonephritis

Potential ureteral obstruction (e.g., caused by stone, ureteral stricture, tumor)
History of calculi, especially infection (struvite) stones
Potential papillary necrosis (e.g., patients with sickle cell anemia, severe diabetes mellitus, analgesic abuse)
History of genitourinary surgery that predisposes to obstruction, such as ureteral reimplantation or ureteral diversion
Poor response to appropriate antimicrobial agents after 5 to 6 days of treatment
Diabetes mellitus
Polycystic kidneys in patients in dialysis or with severe renal insufficiency
Neuropathic bladder
Unusual infecting organisms, such as tuberculosis, fungus, or urea-splitting organisms (e.g., *Proteus*)

A UTI associated with possible urinary tract obstruction must be urgently evaluated. This refers to patients with calculi, especially infection (struvite) stones; ureteral tumors; ureteral strictures; congenital obstructions; or previous

GU surgery, such as ureteral reimplantation or urinary diversion procedures that may have caused obstruction. Patients with **diabetes mellitus** can develop special complications from UTIs; they may acquire emphysematous pyelonephritis or papillary necrosis. **Impacted necrotic papillae** may cause acute ureteral obstruction. Patients with **polycystic kidney disease who are on dialysis** are particularly prone to developing perinephric abscesses.

Urologic imaging is indicated in patients whose symptoms of acute clinical pyelonephritis persist after several days of appropriate antimicrobial therapy; they may manifest perinephric or renal abscesses. In addition, **patients with unusual organisms,** including urea-splitting organisms (e.g., *Proteus* species), should be examined for abnormalities within the urinary tract, such as obstructing stones, strictures, or fungus aggregates.

The second reason for radiologic evaluation is to diagnose a focus of bacterial persistence. **In patients whose bacteriuria fails to resolve after appropriate antimicrobial therapy or who have rapid recurrence of infection, abnormalities that allow bacterial persistence should be sought.** Although uncommon, it is important to identify causes of persistence because they may represent surgically correctable urologic abnormalities. Acquired or congenital urologic abnormalities that can cause unresolved or recurrent UTIs are listed in Box 55.6.

Box 55.6

Correctable Urologic Abnormalities That Cause Bacterial Persistence

- Infection stones
- Chronic bacterial prostatitis
- Unilateral infected atrophic kidneys
- Ureteral duplication and ectopic ureters
- Foreign bodies
- Urethral diverticula and infected periurethral glands
- Unilateral medullary sponge kidneys
- Nonrefluxing, normal-appearing, infected ureteral stumps after nephrectomy
- Infected urachal cysts

- Infected communicating cysts of the renal calyces
- Papillary necrosis
- Perivesical abscess with fistula to bladder

Ultrasonography

Renal and bladder ultrasound (RBUS) is an important imaging technique because it is noninvasive, easy and rapid to perform, and offers no radiation or contrast agent risk to the patient. Ultrasound is particularly useful in identifying calculi and hydronephrosis, pyonephrosis, and perirenal abscesses. Although with the known pitfalls of limited sensitivity, a single radiograph for calculi could accompany ultrasonography. Ultrasonography is also useful for diagnosing postvoid residual urine. A disadvantage is that the study is dependent on the interpretative and performance skills of the examiner. Furthermore, the study may be technically poor in patients who are obese or have other anatomic challenges, or who have dressings, drainage tubes, or open wounds overlying the area of interest. **The sensitivity of ultrasound for demonstrating renal parenchymal abnormalities in acute pyelonephritis is lower than that of CT and MRI; it is lower than that of CT for detecting small renal stones and most ureteral stones and is less accurate than CT in detecting ureteral obstruction.**

Computed Tomography and Magnetic Resonance Imaging

The radiologic modalities that offer the best anatomic detail for evaluation of UTI are CT and MRI. These studies are more sensitive than excretory urography or ultrasonography in the diagnosis of acute focal bacterial nephritis, renal and perirenal abscesses, and radiolucent calculi (Kuhn and Berger, 1981; Mauro et al., 1982; Soler et al., 1997; Soulen et al., 1989; Wadsworth et al., 1982). When used to localize renal and perirenal abscesses, CT improves the approach to surgical drainage and permits percutaneous approaches. MRI has not supplanted CT in the evaluation of renal inflammation, but it has provided some advantages in delineating extrarenal extension of inflammation. Pelvic MRI is the most useful imaging modality for detecting a urethral diverticulum.

Voiding Cystourethrogram

The voiding cystourethrogram is an important examination in assessing VUR. In women with a history of febrile UTIs, known VUR as a child, or recurrent pyelonephritis as an adult, a voiding cystourethrogram (VCUG) should be performed. VCUG should also be considered in patients with a history of recurrent UTIs and hydronephrosis detected on upper tract imaging. Historically VCUG with a double-balloon catheter was recommended if there was suspicion of a urethral diverticulum; however, the current standard of care used is pelvic MRI.

Radionuclide Studies

Although such radiologic evaluations are rarely employed in current practice, hippuran I-131 and technetium-99m (^{99m}Tc) glucoheptonate and dimercaptosuccinic acid scans may be used to detect focal parenchymal damage, renal function impairment, and decreased renal perfusion in acute renal infections (McAfee, 1979). Gallium-67 scanning has also been reported to be useful in the diagnosis of pyelonephritis and renal abscess; it is uncommonly required and may be positive even with in noninfectious entities. Indium-111–labeled WBC studies may have limited efficacy in establishing the presence of an inflammatory focus, particularly when the patient's clinical presentation does not suggest an infectious process.

Microbiome

Contrary to traditional thought, urine is not sterile. In recent years, 16S ribosomal RNA sequencing analysis has been used to help determine that many bacterial species inhabit the urinary tract of healthy men and women who do not have symptoms of a UTI (Lewis et al., 2013; Nelson et al., 2010; Wolfe et al., 2012). Standard culture techniques readily identify fast-growing bacteria that thrive in an oxygen-rich environment. However, many bacteria require special nutrients or are anaerobic and thus will not grow in standard culture preparations. This initial work involving the urinary microbiome has since revolutionized our thought process when it comes to identifying bacteria in the urinary tract. Although bacteria in the urine were traditionally thought of as categorically pathological, it is now established that bacteria are present in the urine of symptomatic as well as asymptomatic men and women.

Once the female urinary microbiome was identified, researchers started investigating whether modifying standard culture techniques would enable detection of bacteria that previously would have been missed. Indeed, using an expanded quantitative urine culture (EQUC) protocol, many bacteria were identified that would have been missed using standard culture preparations (Hilt et al., 2014). The EQUC specifically analyzed a larger volume of urine, which was subject to different atmospheric conditions and longer incubation times. Hilt et al. then compared standard culture protocols to the EQUC protocol in 65 samples from patients with or without overactive bladder symptoms. They found that 52/65 samples grew bacteria in the EQUC protocol group, yet 48 of these 52 were negative in standard culture cohort. Beyond typical bacteria often cultured in urine, 35 different genera and 85 different species were identified. This discovery further supported the notion that the female urinary microbiome exists and contains many different nonpathogenic microbiota (Table 55.2).

TABLE 55.2

List of Bacterial Species Cultured in Different Conditions

ORGANISM	AEROBIC 35°	AEROBIC 30°	CO_2 35°	ANAEROBIC 35°	CAMPY (6% O_2, 10% CO_2) 35°

Actinobaculum schaalii (7)	+		+	+	+
Actinobaculum urinale (1)				+	
Actinomyces europaeus (2)			+		
Actinomyces graevenitzii (1)					+
Actinomyces naeslundii (1)		+			
Actinomyces neuii (5)	+		+	+	
Actinomyces odontolyticus (2)	+		+	+	
Actinomyces oris (1)			+		
Actinomyces turicensis (3)	+	+	+	+	
Actinomyces urogenitalis (3)	+	+			
Aerococcus sanguinicola (3)	HD	HD	+		
Aerococcus urinae (9)	+	+	+	+	+
Aerococcus viridans (1)			+		
Alloscardovia omnicolens (4)	+		+	+	
Arthrobacter cumminsii (4)	+	+	+	+	
Bacillus subtilis (1)	HD	+			
Bifidobacterium bifidum (1)			+	+	
Bifidobacterium breve (6)			+	+	+
Bifidobacterium dentum (1)			+	+	
Bifidobacterium longum (1)				+	
Brevibacterium ravenspurgense (2)			+	+	
Campylobacter ureolyticus (1)	HD			+	
Candida glabrata (2)	+		+	+	
Corynebacterium	+			+	

afermentans (2)					
Corynebacterium amycolatum (3)		+	+	+	+
Corynebacterium aurimucosum (3)	+	+	+	+	
Corynebacterium coyleae (7)	+	+	+	+	+
Corynebacterium freneyi (2)	+		+	+	
Corynebacterium imitans (2)	+	+	+		
Corynebacterium lipophile-group F1 (4)	+	+	+	+	+
Corynebacteirum matruchotii (1)			+		
Corynebacterium minutissium (1)		+		+	
Corynebacterium riegelii (4)	+	+	+	+	
Corynebacterium tuberculostearicum (2)	+				
Corynebacterium tuscaniense (3)	+		+		
Corynebacterium urealyticum (3)	+		+		
Enterobacter aerogenes (1)	+	+	+	+	+
Enterococcus faecalis (7)	+	+	+	+	+
Escherichia coli (3)	+	+	+	+	+
Facklamia hominis (5)	+	+		+	
Fingoldia magna (1)	HD			+	
Fusobacterium nucleatum (1)	HD			+	
Gardnerella vaginalis (10)	+	+	+	+	
Gardnerella sp. *(3)*	+		+	+	+
Gemella haemolysans (1)		+			
Gemella sanguinis (1)		+			
Klebsiella pneumoniae (1)	+	+	+	+	+
Kocuria rhizophila (1)		+			

Lactobacillus crispatus (6)			+	+	
Lactobacillus delbrueckii (1)			+	+	
Lactobacillus fermentum (1)					+
Lactobacillus gasseri (12)	+	+	+	+	+
Lactobacillus iners (6)	+		+	+	+
Lactobacillus jensenii (10)	+		+	+	+
Lactobacillus johnsonii (1)			+		
Lactobacillus rhamnosus (2)			+	+	
Micrococcus luteus (9)	+	+	+		+
Micrococcus lylae (1)	+		+		
Neisseria perflava (1)			+		
Oligella urethralis (5)					+
Peptoniphilus harei (3)				+	
Prevotella bivia (1)				+	+
Propionibacterium avidum (1)				+	
Propionimicrobium lymphophilum (1)				+	
Pseudomonas aeruginosa (1)			+		
Rothia dentocariosa (1)	+		+		
Rothia mucilaginosa (2)	+		+		+
Slackia exigua (1)				+	
Staphylococcus capitis (1)	+		+	+	
Staphylococcus epidermidis (7)	+	+	+	+	+
Staphylococcus haemolyticus (2)	+		+		
Staphylococcus hominis (2)	+		+		
Staphylococcus lugdunesis (2)	+	+	+	+	+
Staphylococcus simulans	+			+	+

(2)					
Staphylococcus warneri (2)	+				+
Streptococcus agalactiae (1)	+	+		+	+
Streptococcus anginosus (15)	+	+	+	+	+
Streptococcus gallolyticus (1)	+	+	+	+	+
Streptococcus gordonii (1)		+	+	+	
Streptococcus parasanguinis (1)	+				
Streptococcus pneumonia/mitis/oralis (6)	+	+	+	+	+
Streptococcus salivarius (3)				+	
Streptococcus sanguinis (2)			+		
Streptococcus vestibularis (1)	HD		+	+	
Trueperella bernardiae (3)	+		+		
Unclassified#1 (1)	+	+			
Unclassified#2 (1)	+	+			+
Unclassified#3 (1)			+		
Unclassified#4 (1)	+	+			
Unclassified#5 (1)				+	
Unclassified#6 (1)	+		+		
Unclassified#7 (1)	+				
Unclassified#8 (1)	+		+	+	

The “+” symbol designates the environmental conditions from which the organism was isolated and identified. The “HD” symbol indicates that only high-dilution (1 µL) urine was plated for that condition and that no growth was observed. A blank space designates no growth in that condition for that particular organism using a low-dilution (100 µL) inoculum. The (#) next to the organism name designates the number of times the organism has been isolated.

Data from Hilt EE, McKinley K, Pearce MM, et al.: Urine is not sterile: use of enhanced urine culture techniques to detect resident bacterial flora in the adult female bladder. *J Clin Microbiol.* 52(3):871–876, 2014.

Now that we are aware of the existence of the female urinary microbiome,

we face the "challenge of interpretation": we must determine when and how to treat bacteria in the urinary tract with the acknowledgment that we will never, nor should we strive to, eradicate all bacteria (Brubaker and Wolfe, 2017). Indeed, many bacteria within the microbiome are considered protective (Brubaker et al., 2014; Pearce et al., 2014). Ongoing research seeks to determine if disruptions in the established microbiota are seen in certain forms of lower urinary tract pathology, focusing particularly on determining whether the microbiome differs in women with conditions such as urge incontinence or painful bladder syndrome (Nickel et al., 2016; Thomas-White et al., 2016).

In line with this understanding of a dynamic urinary microbiome that affects bladder physiology, emerging scientific theories continue to develop and explore the concept that urine has a role beyond purely functioning as a vehicle for excretory waste. First, the Urinology Think Tank, a group supported by the National Institute of Diabetes and Digestive and Kidney Disease, is investigating the notion that properties intrinsic to urine, including the microbiotia, exfoliated cells, exosomes, pH, metabolites, protein, and specific gravity, may interact with the urothelium to influence bladder function and homeostasis (Urinology Think Tank Writing, 2018). Furthermore, emerging basic science work continues to explore the possibility that the constituents of urine, including donor-derived urine stem cells, can be used for human cell therapy and autologous repair (Pavathuparambil Abdul Manaph et al., 2018).

Key Points: Microbiome

- Urine is not sterile.
- The female urinary microbiome has been identified using RNA sequencing techniques, and knowledge of these microbiota should inform UTI management and interpretation of novel culture techniques such as the EQUC protocol.

Asymptomatic Bacteriuria

The management of asymptomatic bacteriuria has evolved with time, even before the identification of the urinary microbiome, which essentially renders the term “asymptomatic bacteriuria” obsolete. Nonetheless, for the purposes of this chapter, we will continue to use this term and review its significance.

The term *asymptomatic bacteriuria* is appropriately used when a person has no signs or symptoms of a UTI, yet bacteria are identified in a noncontaminated urine sample. In women, the term *asymptomatic bacteriuria* is used when the same bacteria is identified in quantitative counts of greater than or equal to 100,000 CFUs in two consecutive voided samples that are obtained in a fashion that minimizes contamination. In men, only one clean-catch voided sample that identifies one bacterial species in quantitative counts greater than or equal to 100,000 CFUs is necessary to use the term *asymptomatic bacteriuria* appropriately. Alternatively, in men or women, one catheterized sample that identifies a single bacterial species in a quantitative count of greater than or equal to 100 can make the diagnosis of asymptomatic bacteriuria (Nicolle, et al., 2005; Box 55.7).

Box 55.7

Diagnosis of Asymptomatic Bacteriuria

- Lack of signs and symptoms of UTI
- Diagnosis based on urine specimen collected in a manner that minimizes contamination
- For asymptomatic women: 2 consecutive voided urine specimens with isolation of same bacterial strain in quantitative counts ≥100,000 CFUs/mL
- For asymptomatic men: single voided urine specimen with one bacterial species isolated in quantitative count ≥100,000 CFUs/mL
- For women or men: single catheterized urine specimen with one bacterial species isolated quantitative count ≥100 CFUs/mL

CFUs, Colony-forming units; *UTI*, urinary tract infection.

Data from Nicolle LE, Bradley S, Colgan R, et al.: Infectious Diseases Society of America guidelines for the diagnosis and treatment of asymptomatic bacteriuria in adults. *Clin Infect Dis* 40(5):643–654, 2005. Based on ISDA guidelines.

The prevalence of asymptomatic bacteriuria varies based on age, sex, and comorbid conditions. First, the prevalence of asymptomatic bacteriuria increases with age: it has been identified in approximately 1% of school-age girls but is present in greater than 20% of healthy women older than 80 years of age who are community dwellers (Nicolle, 2003). It also correlates with sexual activity; in fact population studies have identified a prevalence in premenopausal, married women of 4.6%, whereas in age-matched nuns the prevalence is only 0.7% (Kunin and McCormack, 1968). Menopause is also a risk factor for asymptomatic bacteriuria with a prevalence estimated as 1% to 5% in healthy premenopausal women and 2.8% to 8.6% in postmenopausal women between the ages of 50 and 70 (Nicolle, 2003). In younger men, asymptomatic bacteriuria is uncommon (Lipsky, 1989). As men age, the prevalence increases; in elderly (>75 years old) community dwellers it has been quoted as 6% to 15% (Nicolle, 2003). The overall prevalence is increased in both sexes living in long-term care facilities: it has been reported in 25% to 50% of women and 15% to 40% of men in facilities (Nicolle, 1997). Asymptomatic bacteriuria is more common in female patients with diabetes as compared with males (9%–27% vs. 0.7%–11%) (Zhanel et al., 1991a,b). The presence of asymptomatic bacteriuria is also strongly associated with duration of disease as well as comorbidities associated with poorly controlled diabetes (Zhanel et al., 1995). In patients with SCI who perform clean intermittent catheterization (CIC), the prevalence is 23% to 89% (Bakke and Digranes, 1991). Finally, the prevalence in patients with long-term indwelling catheters is 100% (Warren et al., 1982). **As demonstrated by all of these statistics, risk factors for asymptomatic bacteriuria include advanced age, female gender, institutionalization, comorbid conditions such as diabetes, and catheterization/presence of an indwelling Foley catheter** (Colgan et al., 2006; Table 55.3).

TABLE 55.3

Prevalence of Asymptomatic Bacteriuria in Selected Populations

POPULATION	PREVALENCE (%)	REFERENCE
Healthy, premenopausal women	1.0–5.0	Nicolle, 2003
Pregnant women	1.9–9.5	Nicolle, 2003
Postmenopausal women aged 50–70 years	2.8–8.6	Nicolle, 2003
Patients with diabetes		
Women	9.0–27	Zhanel et al., 1991a
Men	0.7–11	Zhanel et al., 1991a
Elderly persons in the community		
Women	10.8–16	Nicolle, 2003
Men	3.6–19	Nicolle, 2003
Elderly persons in a long-term care facility		
Women	25–50	Nicolle, 1997
Men	14–50	Nicolle, 1997
Patients with spinal cord injuries		
Intermittent catheter use	23–89	Bakke and Digranes, 1991
Sphincterotomy and condom catheter in place	57	Waites et al., 1993b
Patients undergoing hemodialysis	28	Chaudhry, 1993
Patients with indwelling catheter use		
Short-term	9–23	Stamm, 1991
Long-term	100	Warren, 1982

Data from Nicolle LE, Bradley S, Colgan R, et al.: Infectious Diseases Society of America guidelines for the diagnosis and treatment of asymptomatic bacteriuria in adults. *Clin Infect Dis* 40:643–654, 2005.

In older women living in the community, *E. coli* is the predominant pathogen isolated in asymptomatic women; it was found in 51.4% of samples in one study. Other species of bacteria were found in fewer than 10% of samples and included *Klebsiella pneumoniae*, *Proteus mirabilis*, and *Enterococcus faecalis* (Linhares et al., 2013). The *E. coli* strains identified in women with asymptomatic bacteriuria have less virulence factors than other strains that cause symptomatic urinary infections (Svanborg, 1997). Molecular studies have shown that some *E. coli* strains are actually commensal strains, whereas others may have initially been virulent but transitioned into commensal strains (Klemm et al., 2007; Zdziarski et al., 2008). In men, gram-negative bacilli, enterococci, and coagulase-negative staphylococci are common pathogens identified in the urine (Lipsky et al., 1984; Mims et al., 1990). The bacterial isolates vary in institutionalized patients or those with indwelling catheters, as compared with community dwellers. In this former population, polymicrobial bacteriuria is frequent; common bacteria found in these populations include *Pseudomonas aeruginosa*, *Morganella morganii*, and *Providencia stuartii* (Nicolle, 1993, Nicolle et al., 2005).

Historically there was concern that untreated asymptomatic bacteriuria may be a risk factor for recurrent UTIs and long-term sequelae such as hypertension, renal insufficiency, or development of urinary tract cancer. However, studies have shown that this is not the case (Bengtsson et al., 1998; Tencer, 1988). **On the contrary, more recent work establishes that treating asymptomatic bacteriuria in all groups is potentially deleterious** (Cai et al., 2012, 2015). Indeed, treatment can lead to an increased risk of subsequent symptomatic UTIs, increased costs associated with treatment of bacteriuria, and potential adverse effects of antibiotics.

To promote a universal approach to the diagnosis and management of asymptomatic bacteriuria in adult populations greater than 18 years old, the **Infectious Disease Society of America (IDSA) published guidelines in 2005 (that are endorsed by the AUA)** (Nicolle et al., 2005). **These guidelines clearly stipulate that, in the majority of patients, asymptomatic bacteriuria should not be treated. Specifically, it should not be treated in the following populations: premenopausal, non-pregnant women; women with diabetes; older community dwellers; elderly institutionalized patients; patients with SCI; and patients with indwelling catheters. On the contrary, it should always be treated in pregnant women and in patients who are undergoing procedures in which transmucosal bleeding is anticipated.** Pyuria, which in isolation often triggers many practitioners to recommend antimicrobial therapy, is not an indication to treat even if it is found in conjunction with asymptomatic bacteriuria. No recommendation was made for whether to treat asymptomatic bacteriuria in renal transplant patients or other immunocompromised hosts (Box 55.8). The IDSA published an update to this guideline in 2019. This update included populations not addressed in the 2005 guideline, specifically children and patients with solid organ transplants or neutropenia (Nicolle et al., 2019).

Box 55.8

Treat or Not Treat Asymptomatic Bacteriuria

Do Not Treat: premenopausal, non-pregnant women, women with diabetes, older community dwellers, elderly institutionalized patients, patients with spinal cord injury, patients with indwelling catheters, pyuria with asymptomatic bacteriuria

Treat: pregnant women, patients undergoing procedures in which transmucosal bleeding is anticipated

---

Data from Nicolle LE, Bradley S, Colgan R, et al.: Infectious Diseases Society of America guidelines for the diagnosis and treatment of asymptomatic bacteriuria in adults. *Clin Infect Dis* 40(5):643–654, 2005. Based on ISDA guidelines.

The US Preventive Services Task Force (USPSTF) concurred with the IDSA, and in 2008 published a statement urging people not to indiscriminately screen for asymptomatic bacteriuria (Lin et al., 2008). This task force looked at several different types of studies that included pregnant and non-pregnant women as well as men. The Taskforce concluded that women who are pregnant are the only group who should be screened for asymptomatic bacteriuria.

Likewise, a Cochrane review published in 2015 also concluded that treatment of asymptomatic bacteriuria is not recommended (Zalmanovici Trestioreanu et al., 2015). This review included nine randomized or “quasi” randomized controlled studies, which included a total of 1614 subjects. Studies were not included in this review if they contained any of the following subjects: pregnant women, subjects who either had indwelling catheters or performed CIC, subjects who had indwelling stents or nephrostomy tubes, transplant recipients, subjects who had bacteriuria related to recent urologic procedures, patients with SCI, or hospitalized patients. The review found that symptomatic UTI, complications, and death were similar between the subjects who were treated with antibiotics and those who were not. Although bacteriuria was eradicated more often in those treated, more adverse effects were also noted in this population. No decline in renal function was identified in those not treated.

One of the studies included in the Cochrane review looked at young sexually active women who were seen in a sexually transmitted disease clinic in Italy for recurrent UTIs between 2005 and 2009 (Cai et al., 2012). Subjects were included in the study if they had at least one symptomatic UTI in the 12 months before enrollment and had documented asymptomatic bacteriuria at the onset of the study. The participants were then randomized into two groups: in group A, asymptomatic bacteriuria was observed, whereas in group B, it was treated. At periodic intervals (3, 6, 12 months), their urine samples were analyzed for the presence of bacteriuria. A total of 673 women between the ages of 18 and 40 were studied. The data showed that those in group B had a higher rate of symptomatic UTI over 1 year, as compared with the untreated women in group A. Multivariate analysis showed that antibiotic use was an independent risk factor ($P < 0.001$; hazard ratio, 3.09; 95% CI) for the development of a symptomatic UTI. The majority of subjects who had not had a symptomatic UTI did have asymptomatic *E. faecalis* present in their urine with late follow-up. The investigators concluded that treatment of asymptomatic bacteriuria may remove the protective benefit of an asymptomatic strain.

With extended follow-up of this study population (albeit a smaller total population of 550 subjects because of dropout during extended follow-up), the difference in recurrence rates for symptomatic UTIs was statistically significant ($P < 0.001$) at a mean of 38.8 months (Cai et al., 2015). In group A, 97 (37.7%) subjects recurred, while in group B, 204 (69.6%) recurred. In addition to demonstrating higher recurrence rates in the treated group, the *E. coli* isolated in group B showed higher resistance to several antibiotics, including amoxicillin-clavulanic acid, TMP-SMX, and ciprofloxacin as compared with *E. coli* isolates from group A. The increased resistance rates were not seen until at least 2 years of follow-up. The authors concluded that use of antibiotics in women with asymptomatic bacteriuria and a history of recurrent UTIs must be discouraged. These findings overall further corroborate the IDSA guidelines.

Despite the extensive data available that argue against treating asymptomatic bacteriuria, unfortunately inappropriate antibiotic treatment is still a widespread problem. Ferroni et al. cite several translational barriers to the adoption of IDSA principles among all practitioners; these include a lack of awareness, confusion regarding the guidelines, and continued fear about adverse outcomes associated with not prescribing an antibiotic (Ferroni and Taylor, 2015; James et al., 1998; Wolfe et al., 2004). Indeed a study by Ditkoff et al. (2018) showed that more than 50% of practitioners from a variety of specialties including family practice, internal medicine, gynecology, urology, and emergency medicine were not aware of IDSA guidelines for management of asymptomatic bacteriuria or acute cystitis. Cumulatively, these data suggest that there is more work to be done to normalize the standards of care, because the sequelae of in appropriate antibiotic use remains a growing concern from the standpoint of individual patient care and from a public health perspective.

Interestingly, although many providers ignore the recommendations not to treat, some are actually using asymptomatic bacteriuria as a prophylactic strategy against the development of UTIs (Nicolle, 2015). Known as bacterial interference, this therapy involves establishing the presence of avirulent bacteria in the urinary tract to essentially "block" virulent organisms from invading the urinary tract. Preliminary studies have not been conclusive in terms of efficacy and study design and interpretation of results have been complicated. Nonetheless, this concept of bacterial interference merits further investigation in the future.

The management of asymptomatic bacteriuria before nonurologic surgery is another topic that lacks a universal approach. Perhaps this question has best been studied as it pertains to the management of asymptomatic bacteriuria before joint replacement surgery. Recent data challenge the traditional dogma that asymptomatic bacteriuria should be treated before joint surgery to reduce the risk of developing a septic joint. One multicenter, multinational study by Sousa et al. (2014) specifically looked at the incidence of postoperative joint infections in 2497 patients with and without asymptomatic bacteriuria who underwent knee or hip arthroplasties. A total of 12.1% (n = 303) of these patients had asymptomatic bacteriuria preoperatively, and 154 patients in this cohort were pretreated before surgery. The postoperative joint infection rate within the entire population was 1.7%. In patients with asymptomatic bacteriuria, the joint infection rate was significantly higher than in the group who were not bacteriuric (4.3% vs. 1.4%; OR 3.23; 95% CI). However, treatment of asymptomatic bacteriuria did not significantly affect the development of postoperative joint infections. In those treated, which was a decision made by the individual physician and was not randomized, the rate of infections was 3.9%, whereas in the untreated group it was 4.7%, which was not a statistically significant difference. Interestingly, although the bacteriuric patients had a higher incidence of gram-negative prosthetic infections, the organism cultured from the urine was not the same as the organism cultured from the joint. The authors concluded that the presence of asymptomatic bacteriuria is a surrogate marker for increased risk of infection overall, but preoperative treatment of the bacteriuria did not modulate the likelihood of remaining infection free in the joint. Therefore **treatment of asymptomatic bacteriuria before orthopedic surgery is not recommended.**

A more recent study by Lamb et al. (2017) concluded that obtaining preoperative urine cultures before joint replacement surgery is not necessary because the presence of asymptomatic bacteriuria does not correlate with the incidence of prosthetic joint infections. They compared the incidence of joint infections during a period when preoperative urine cultures were routinely obtained to the incidence after the adoption of a policy that eliminated urine cultures from preoperative order sets. Although the joint infection rate was no different, the financial impact to the health care system was drastic: without the cost of processing urine cultures the savings were approximately $20,000 per year. This study thus introduces another added consideration, in the form of cost savings, when advocating for restraint in the screening and treatment of asymptomatic bacteriuria.

Key Points: Asymptomatic Bacteriuria

- The prevalence of asymptomatic bacteriuria varies with age, sex, and comorbid conditions.
- Untreated asymptomatic bacteriuria is not associated with hypertension or renal insufficiency.
- Several guidelines recommend not screening for or treating asymptomatic bacteriuria except in specific patient populations.
- Asymptomatic bacteriuria should be screened for and treated in pregnant women and in patients who are undergoing urologic procedures in which mucosal bleeding is anticipated.
- Treatment of asymptomatic bacteriuria contributes to development of multidrug-resistant symptomatic UTIs.

Principles of Antimicrobial Therapy

Antibiotics have been the mainstay of therapy for UTIs. A decision regarding the antimicrobial selection and the duration of therapy must consider the spectrum of activity of the drug against the known pathogen or the most probable pathogen based on the presumed source of acquisition of infection, whether the infection is judged to be uncomplicated or complicated, potential adverse effects, and cost. The concentration of the antimicrobial agent achieved in blood is not important in treatment of uncomplicated UTIs. However, blood levels are critical in patients with bacteremia and febrile urinary infections consistent with parenchymal involvement of the kidney and prostate.

In patients with renal insufficiency, dosage modifications are necessary for agents that are cleared primarily by the kidneys and cannot be cleared by another mechanism. In renal failure, the kidneys may not be able to concentrate an antimicrobial agent in the urine; therefore difficulty in eradicating bacteria may occur. Urinary tract obstruction may also reduce concentration of antimicrobial agents within the urine.

An often underemphasized but important characteristic is the drug's impact on the bowel and vaginal flora and the hospital bacterial environment. Bacterial susceptibility varies dramatically in patients exposed to antimicrobial agents and in individuals in inpatient and outpatient settings. Each clinician must keep abreast of changes that affect antimicrobial use and susceptibility patterns.

Most important, the decision to initiate antibiotic therapy should not be based on treating a positive urine culture alone; rather clinical presentation, in conjunction with urine testing, should be considered, and we must assess the likelihood that the patient will benefit from or be harmed by antibiosis. As stated by Thomas Hooton in 2012, **“Acute uncomplicated cystitis rarely progresses to severe disease, even if untreated; thus, the primary goal of treatment is to ameliorate symptoms.”** In an era when we are witnessing the increasing resistance of bacterial strains as well as managing the sequelae of inappropriate antibiotic use, decisive clinical judgment and antibiotic stewardship are imperative. As Thomas Finucane wrote, **“Clinicians considering intervention should not ask whether the individual has a real ‘UTI’ but should ask instead whether there is evidence that antibiotic treatment directed at standard bacteriuria is more likely to benefit than harm this individual”**

(Finucane, 2017). It is the firm belief of the authors that these considerations should guide management of UTIs in the contemporary era.

Urinary analgesics are an invaluable adjunct to antibiotic management and may not only reduce symptoms but also shorten the course of antibiotics (Finucane, 2017). In fact a randomized trial involving 500 women younger than 65 years of age compared immediate fosfomycin treatment to ibuprofen alone for the treatment of acute cystitis (Gagyor et al., 2015). At 28 days, the fosfomycin group had received 283 total courses of antibiotics as compared with 94 in the ibuprofen group, corresponding to a significant incidence in the reduction of antibiotic use by 66.5%. An effective urinary analgesic may thus be an important advance in curtailing antibiotic use.

Ecologic Impact and Collateral Damage

Collateral damage refers to the ecologic adverse events associated with antibiotics such as bacterial resistance and selection and/or colonization with multidrug-resistant organisms, which have been associated with the use of broad-spectrum cephalosporins and quinolones (Gupta et al., 2011; Paterson, 2004; Ramphal and Ambrose, 2006). **It is particularly important to consider the collateral impact of antibiotics with respect to uncomplicated cystitis, because (1) there is minimal risk of progression to tissue invasion and sepsis, and (2) this problem is one of the most common sources of antibiotic exposure in otherwise healthy populations, thus potentially magnifying the impact of adverse events when they do occur** (Gupta et al., 2001a,b)**. In the past several years, the frequency and spectrum of antimicrobial-resistant UTIs have increased in the hospital and community.** The increasing frequency of drug resistance has been attributed to combinations of microbial characteristics, bacterial selection pressure caused by antimicrobial use, and societal and technologic changes that enhance the transmission of drug resistance (Shepherd and Pottinger, 2013). Resistance patterns have been shown to vary by geographic location (Manges et al., 2001).

Bacterial resistance may occur because of intrinsic chromosomal-mediated resistance or by acquired chromosomal- or extrachromosomal (plasmid)-mediated resistance caused by exposure of an organism to antimicrobial agents.

Intrinsic chromosomal resistance exists in a bacterial species because of the absence of the proper mechanism on which the antimicrobial agent can act.

Acquired chromosomal resistance occurs during therapy for UTIs. The bacteria susceptible to the administered antimicrobial agent will be eradicated by therapy, but within 24 to 48 hours a repeat urine culture will show high bacterial counts of some resistant mutants. In essence, the antimicrobial therapy has selected the resistant mutant. This phenomenon is most likely to occur when the antimicrobial level in the urine is close to or below the minimal inhibitory concentration of the drug. **Selection of resistant clones in the course of therapy for a previously sensitive bacteriuric population occurs between 5% and 10% of the time, clearly not an insignificant factor.** Underdosing and noncompliance, as well as diuresis induced by increased fluid intake, can contribute to this process. Therefore, when the decision is made that a patient would benefit from antibiotics, the clinician should select an antimicrobial agent with a urinary concentration that exceeds the minimal inhibitory concentration, avoid underdosing, and emphasize patient compliance.

Extrachromosomal-mediated resistance may be acquired and transferable via plasmids, which contain the genetic material for the resistance. **This mechanism of resistance occurs in the bowel flora and is much more common than selection of preexisting mutants in the urinary tract. All antimicrobial classes are capable of causing plasmid-mediated resistance**. In addition, the plasmids carrying the resistant genetic material are transferable within species and across genera. Thus, for example, a patient receiving tetracycline may harbor several bowel strains that are resistant to tetracycline, ampicillin, sulfonamides, and TMP. Because the bowel flora is the major reservoir for bacteria that ultimately colonize the urinary tract, infections that occur after antimicrobial therapy and that can cause plasmid-mediated resistance are commonly caused by organisms with multidrug resistance.

Several bacteria have evolved to develop specific resistance genes to different classes of antibiotics. In 1983 the first report of plasmid-mediated β-lactamases capable of hydrolyzing extended-spectrum cephalosporins was made. They have since been characterized as extended-spectrum β-lactamases (ESBLs) and confer resistance to most β-lactam antibiotics, including third-generation cephalosporins; also, ESBL *E. coli* can have co-resistance to other classes of antibiotics, including fluoroquinolones and aminoglycosides (Pitout and Laupland, 2008; Prakash et al., 2009). In a similar vein, AmpC β-lactamases are cephalosporinases encoded on chromosomes of many Enterobacteriaceae and a few other organisms that confer resistance to broad-spectrum cephalosporins; transmissible plasmids with the AmpC enzyme genes can now appear in bacteria such as *E. coli* that had poor chromosomal expression of this gene (Jacoby, 2009). In 2001 the first *K. pneumoniae* carbapenemase (KPC)–producing bacteria, a group of highly drug-resistant gram-negative bacilli, was isolated. It has since become the most prevalent mechanism of carbapenem resistance in the United States at the time of this writing (Lee et al., 2009). Although *K. pneumoniae* remains the most relevant bacterial species carrying KPCs, the enzyme has been identified in other gram-negative bacilli (Kitchel et al., 2009).

Antimicrobial resistance is influenced by the duration and amount of antimicrobial agent used. For example, documented increased use of fluoroquinolones in the hospital setting has been directly associated with increased resistance of bacteria (particularly *Pseudomonas* spp.) to the fluoroquinolones. Resistance tends to increase the longer the agent is used. Conversely, reduction in duration of therapy and in the amount of the drug used may lead to reemergence of more susceptible strains.

The inappropriate and excessive use of fluoroquinolones for UTIs and other infections has contributed to the growing problem of quinolone resistance among uropathogens (Chen et al., 2012). According to the European Center for Disease Prevention and Control 2015 report, fluroquinolone resistance was noted among 22.8% of *E. coli* strains and 29.7% *K. pneumoniae* isolates (European Centre for Disease Prevention and Control, 2017.)

In institutionalized settings, such as intensive care units or nursing homes, extended-spectrum β-lactamase–producing *E. coli* and *K. pneumoniae* isolates have a reported 40% to 45% resistance rate to quinolones (Itokazu, et al., 1996; Wiener et al., 1999). Furthermore, specific to a transplant unit, where fluoroquinolones are commonly administered prophylactically, *E. coli* resistance can be up to 80%. **Previous use of fluoroquinolones and the presence of underlying urologic diseases were the strongest determinants for UTIs caused by resistant strains** (Ena et al., 1995)**. Last, fluoroquinolone resistance is associated with more frequent multidrug-resistant bacterial strains** and may thus serve as a harbinger of increased individual risk of resistance to first-line antibiotics (Karlowsky et al., 2006).

In fact, many of the adverse events related to antibiotics are also related to a perturbation in commensal microbiomes, such as in the gut and vagina (MacDonald et al., 1993; Vollaard and Clasener, 1994). Antibiotic-related disruption to the intestinal microbiota has been associated with the development of *Clostridium difficile* and colonization with vancomycin-resistant bacteria (Khoruts et al., 2010; Ubeda et al., 2010). Studies in animal models have demonstrated that changes to the intestinal flora after antibiotics can then result in an increased susceptibility to subsequent enteric infection (Sekirov et al., 2008). As far as the implications for the vaginal microbiome, there is a clear association between the risk for vaginal candidiasis and previous treatment with antibiotics (MacDonald et al., 1993). The likelihood of vaginal candidiasis appears directly related to the duration of antibacterial use, particularly with broad-spectrum agents, as well as those who have had repeated episodes of *Candida* infection (Spinillo et al., 1999). Narrowing the spectrum of antibiotic choice and limiting treatment course, particularly in cases of uncomplicated UTIs, are thus instrumental measures in mitigating the systemic implications of treatment.

Antimicrobial Formulary

The mechanism of action, reliable coverage, and common adverse reactions, precautions, and contraindications for antimicrobial agents used in the treatment of UTIs are indicated in Tables 55.4 through 55.7. Bactericidal antibiotics refer to those that cause irreversible death of bacteria, whereas bacteriostatic agents inhibit bacterial replication without killing the organisms (i.e., reversible stoppage).

TABLE 55.4

Bacteriostatic Versus Bactericidal Agents

BACTERIOSTATIC	BACTERICIDIAL
Chloramphenicol	Aminoglycosides
Clindamycin	Quinolones
Macrolides (e.g., azithromycin, erythromycin)	β-lactams
Sulfonamides	Vancomycin
Tetracycline	
Trimethoprim	

Nitrofurantoin is generally bacteriostatic, but it can be bactericidal in high doses and against certain organisms.

TABLE 55.5

Mechanism of Action of Common Antimicrobials Used in the Treatment of Urinary Tract Infections

DRUG OR DRUG CLASS	MECHANISM OF ACTION	MECHANISMS OF DRUG RESISTANCE
β-Lactams (penicillins, cephalosporins, aztreonam)	Inhibition of bacterial cell wall synthesis	Production of β-lactamase Alteration in binding site of penicillin-binding protein Changes in cell wall porin size (decreased penetration)
Aminoglycosides	Inhibition of ribosomal protein synthesis	Downregulation of drug uptake into bacteria Bacterial production of aminoglycoside-modifying enzymes
Quinolones	Inhibition of bacterial DNA gyrase	Mutation in DNA gyrase-binding site Changes in cell wall porin size (decreased penetration) Active efflux
Fosfomycin	Inhibition of bacterial cell wall synthesis	Novel amino acid substitutions or the loss of function of transporters
Nitrofurantoin	Inhibition of several bacterial enzyme systems	Not fully elucidated—develops slowly with prolonged exposure
Trimethoprim-sulfamethoxazole	Antagonism of bacterial folate metabolism	Draws folate from environment (enterococci)
Vancomycin	Inhibition of bacterial cell wall synthesis (at β-lactams)	Enzymatic alteration of peptidoglycan at different point than target

TABLE 55.6

Reliable Coverage of Antimicrobials Used in the Treatment of Urinary Tract Infections of Commonly Encountered Pathogens[a]

ANTIMICROBIAL AGENT OR CLASS	GRAM-POSITIVE PATHOGENS	GRAM-NEGATIVE PATHOGENS
Amoxicillin or ampicillin	*Streptococcus* Enterococci	*Proteus mirabilis*
Amoxicillin with clavulanate	*Streptococcus* Enterococci	*P. mirabilis* *Klebsiella* species
Ampicillin with sulbactam	*Staphylococcus* (not MRSA)	*P. mirabilis* *Haemophilus influenzae,*

	Enterococci	*Klebsiella* species
Antistaphylococcal penicillins	*Streptococcus* *Staphylococcus* (not MRSA)	None
Antipseudomonal penicillins	*Streptococcus* Enterococci	Most, including *Pseudomonas aeruginosa*
First-generation cephalosporins	*Streptococcus* *Staphylococcus* (not MRSA)	*Escherichia coli* *P. mirabilis* *Klebsiella* species
Second-generation cephalosporins (cefamandole, cefuroxime, cefaclor)	*Streptococcus* *Staphylococcus* (not MRSA)	*E. coli, P. mirabilis* *H. influenzae, Klebsiella* species
Second-generation cephalosporins (cefoxitin, cefotetan)	*Streptococcus*	*E. coli, Proteus* species (including indole-positive) *H. influenzae, Klebsiella* species
Third-generation cephalosporins (ceftriaxone)	*Streptococcus* *Staphylococcus* (not MRSA)	Most, excluding *P. aeruginosa*
Third-generation cephalosporins (ceftazidime)	*Streptococcus*	Most, including *P. aeruginosa*
Aztreonam	None	Most, including *P. aeruginosa*
Aminoglycosides	*Staphylococcus* (urine)	Most, including *P. aeruginosa*
Fluoroquinolones	*Streptococcus*[a]	Most, including *P. aeruginosa*
Nitrofurantoin	*Staphylococcus* (not MRSA) Enterococci	Many Enterobacteriaceae (not *Providencia, Serratia, Acinetobacter*) *Klebsiella* species
Fosfomycin	Enterococci	Most Enterobacteriaceae (not *P. aeruginosa*)
Pivmecillinam	None	Most, excluding *P. aeruginosa*
Trimethoprim-sulfamethoxazole	*Streptococcus* *Staphylococcus*	Most Enterobacteriaceae (not *P. aeruginosa*)
Vancomycin	All, including MRSA	None

[a] Depends on the antimicrobial agent.

MRSA, Methicillin-resistant *Staphylococcus aureus*.

TABLE 55.7

Common Adverse Reactions, Precautions, and Contraindications for

Antimicrobial Agents Used in Treatment of Urinary Tract Infection

DRUG OR DRUG CLASS	**COMMON ADVERSE REACTIONS**	**PRECAUTIONS AND CONTRAINDICATIONS**
Amoxicillin or ampicillin	Hypersensitivity (immediate or delayed) Diarrhea (especially with ampicillin), GI upset AAPMC Maculopapular rash (not hypersensitivity) Decreased platelet aggregation	Increased risk of rash with concomitant viral disease, allopurinol therapy
Amoxicillin with clavulanic acid	Increased diarrhea, GI upset with amoxicillin/clavulanic acid	
Ampicillin with sulbactam	Same as with amoxicillin/ampicillin	
Antistaphylococcal penicillins	Same as with amoxicillin/ampicillin GI upset (with oral agents) Acute interstitial nephritis (especially with methicillin)	
Antipseudomonal penicillins	Same as with amoxicillin/ampicillin Hypernatremia (these drugs are given as sodium salt; especially carbenicillin, ticarcillin) Local injection site reactions	Use with caution in patients very sensitive to sodium loading.
Cephalosporins	Hypersensitivity (less than with penicillins) GI upset (with oral agents) Local injection site reactions AAPMC	Should not be used in patients with immediate hypersensitivity to penicillins; may use with caution in patients with delayed hypersensitivity reactions

	Positive Coombs test Decreased platelet aggregation (especially with cefotetan, cefamandole, cefoperazone)	
Aztreonam	Hypersensitivity (less than with penicillins)	Less than 1% incidence of cross-reactivity in penicillin- or cephalosporin-allergic patients; may be used with caution in these patients
Aminoglycosides	Ototoxicity: vestibular and auditory components Nephrotoxicity: nonoliguric azotemia Neuromuscular blockade with high levels	Avoid in pregnant patients, except in pyelonephritis. Avoid if possible in patients with severely impaired renal function, diabetes, or hepatic failure. Use with caution in myasthenia gravis patients (because of potential for neuromuscular blockade). Use with caution with other potentially ototoxic and nephrotoxic drugs.
Fluoroquinolones	Mild GI effects; dizziness, lightheadedness; photosensitivity Central nervous system effects, including dizziness, tremors, confusion, mood disorder, hallucinations Tendon rupture	Avoid in children or pregnant patients because of arthropathic effects. Concomitant antacid, iron, zinc, or sucralfate use dramatically decreases oral absorption; use another antimicrobial agent or discontinue sucralfate use while taking quinolones. Space administration of quinolones from antacids, iron, or zinc products by at least 2 h to ensure adequate absorption. Ensure adequate patient hydration. These agents can significantly increase theophylline plasma levels (ciprofloxacin and enoxacin seem to have a greater effect than norfloxacin or

		ofloxacin); avoid quinolones or monitor theophylline levels closely. These agents can lower seizure threshold; avoid in patients with epilepsy and in patients with other risk factors (medications or illness) that may lower the seizure threshold. Monitor glucose levels in patients taking antidiabetic agents because hypoglycemia and hyperglycemia have been reported in patients treated concurrently with fluoroquinolones and antidiabetic agents. These agents can enhance warfarin effects; closely monitor coagulation tests.
Fosfomycin	Headache GI upset Vaginitis	Hypersensitivity to fosfomycin or any component of the formulation
Pivmecillinam	Rash GI upset	Use with caution in patients with penicillin hypersensitivity.
Nitrofurantoin	GI upset Peripheral polyneuropathy (especially in patients with impaired renal function, anemia, diabetes, electrolyte imbalance, vitamin B deficiency, and debilitated) Hemolysis in patients with G6PD deficiency Pulmonary hypersensitivity reactions can range from acute to chronic and include cough, dyspnea, fever, and	Do not use in patients with low creatinine clearance (<50 mL/min) because adequate urine concentrations will not be achieved. Monitor long-term patients closely. Avoid concomitant probenecid use, which blocks renal excretion of nitrofurantoin. Avoid concomitant magnesium or quinolones, which are antagonistic to nitrofurantoin.

	interstitial changes.	
Trimethoprim-sulfamethoxazole	Hypersensitivity, rash GI upset Photosensitivity Hematologic toxicity (AIDS patients)	Higher incidence of all adverse reactions occurs in AIDS patients and in the elderly. Avoid in pregnant patients. Avoid in patients receiving warfarin; concomitant use can significantly elevate prothrombin time.
Vancomycin	"Red-man syndrome": flushing, fever, chills, rash, hypotension (histaminic effect) Nephrotoxicity and/or ototoxicity when combined with other nephrotoxic and/or ototoxic drugs Local injection site reactions	Use with caution with other potentially ototoxic and nephrotoxic drugs.

AAPMC, Antimicrobial-associated pseudomembranous colitis; *AIDS,* acquired immunodeficiency syndrome; *GI,* gastrointestinal; *G6PD,* glucose-6-phosphate dehydrogenase.

Data from McEvoy GK, editor: *American Hospital Formulary Service drug information,* Bethesda, MD, 1995, American Society of Health-System Pharmacists.

Nitrofurantoin

Nitrofurantoin is effective against most common uropathogens. It is rapidly excreted from the urine but does not obtain therapeutic levels in most body tissues, including the gastrointestinal (GI) tract. Therefore it is not useful for upper tract, complicated infections, or blood-borne infections (Wilhelm and Edson, 1987)**. It has minimal effects on the resident bowel and vaginal flora.** Acquired bacterial resistance to this drug is exceedingly low. Nitrofurantoin can cause GI upset and rare pulmonary issues, such as pulmonary fibrosis, when used chronically. Nitrofurantoin should also be avoided in patients with suspicion of or known glucose-6-phosphate dehydrogenase (G6PD) deficiency because it can lead to hemolytic anemia. It had always been recommended that nitrofurantoin be avoided in patients with chronic renal insufficiency, defined as a CrCl less than 60 mL/min, because of lack of efficacy from poor renal concentrating ability. However, in the 2015 American Geriatric

Society Beers Criteria, this threshold was reduced to 30 mL/min because of new data regarding its effectiveness in certain populations with renal impairment. Despite this revision, it remains prudent to use nitrofurantoin with caution in patients with significant renal impairment, particularly for long courses. In fact, Geerts, et al. (2013) found that in a cohort of 21,317 women treated with 3 to 10 days of nitrofurantoin for UTI, renal impairment (defined as CrCl 30–50 mL/min) was not significantly associated with treatment ineffectiveness; nevertheless, a significant association was noted between renal impairment (CrCl < 50 mL/min) and pulmonary adverse events leading to hospitalization.

The Beers Criteria strongly recommend against the *long-term* use of nitrofurantoin for the purposes of antibiotic suppression, founded on the potential adverse events described earlier; nevertheless, **there is no specific recommendation against the *short-term* use of these agents within a carefully selected geriatric population, specifically those with normal renal function.** It is the authors' shared opinion that this agent can still remain a first-line treatment option for the acute management of uncomplicated cystitis within select elderly populations, although the categorical recommendation against long-term usage has created insurance coverage barriers to prescribing nitrofurantoin even for limited courses in these patients.

Trimethoprim-Sulfamethoxazole

The combination of TMP-SMX has been one of the most widely used antimicrobial agents for the treatment of acute UTIs. TMP-SMX attains therapeutic levels in most tissues and is effective against most common uropathogens, with the notable exception of *Enterococcus* and *Pseudomonas* spp. TMP-SMX is inexpensive and has minimal adverse effects on the bowel flora. Disadvantages are relatively common adverse effects, consisting primarily of rashes and GI complaints (Cockerill and Edson, 1991). Stevens-Johnson syndrome and toxic epidermal necrolysis are rare and potentially life-threatening, blistering skin reactions that have been associated with TMP-SMX. In fact, one contemporary Canadian retrospective review analyzing the inciting agent for the 64 documented cases seen at their regional hospital between 2001 and 2011 identified TMP-SMX as the antibiotic most often associated with this reaction; it was implicated in 4 of the 64 patients reviewed (6%) (Miliszewski et al., 2016).

Fosfomycin

Fosfomycin, an oral bactericidal antimicrobial agent similar to phosphonic acid in chemical structure, is active against most uropathogens. Its major benefit is its limited cross-resistance between most other common antibacterial agents, as well as its efficacy against the majority of gram-negative organisms and vancomycin-resistant *Enterococcus* (VRE). Further, it has been shown to be effective as a single-dose agent when used as an empirical treatment for uncomplicated cystitis. It is an excellent oral option for MDR bacteria that would otherwise necessitate treatment with intravenous antibiotics. It is generally well tolerated with low incidences of GI upset and headache and very rare adverse events seen in multiple trials (Patel et al., 1997). Fosfomycin should not be used in the setting of urosepsis/blood-borne infections. Currently, in the United States a 3-g sachet of fosfomycin costs $70 to $90 or more, depending on the insurance coverage; this expense may preclude its use in some patients.

Fluoroquinolones

Fluoroquinolones share a common predecessor in nalidixic acid and inhibit DNA gyrase, a bacterial enzyme integral to replication. The fluoroquinolones have a broad spectrum of activity that makes them ideal for the empirical treatment of UTIs. **They are effective against Enterobacteriaceae and *P. aeruginosa*. Activity is also high against *S. aureus* and *S. saprophyticus*, but, in general, antistreptococcal coverage is marginal.** Most anaerobic bacteria are resistant to these drugs; therefore the normal vaginal and bowel flora are not altered (Wright et al., 1993). **Bacterial resistance initially appeared to be uncommon but has increased because of indiscriminate use of these agents** (Vromen et al., 1999; Wright et al., 1993).

These drugs are not nephrotoxic, but renal insufficiency prolongs the serum half-life, requiring adjusted dosing in patients with creatinine clearances of less than 30 mL/min. Among the adverse reactions reported for fluoroquinolones, GI disturbances are the most common, and this is likely related to the collateral damage to commensal microbiota in the gut (Stewardson et al., 2015). Hypersensitivity, skin reactions, central and peripheral nervous system reactions, and even acute renal failure have been reported (Hootkins et al., 1989). In addition, serious central nervous system side effects, anxiety/depression, hallucinations, confusion, and suicidal thoughts have been cited (FDA Drug Safety Communication, 2016).

In 2008 the US Food and Drug Administration (FDA) announced a black box warning of tendon ruptures associated with fluoroquinolones. In 2013 it

added a risk of irreversible nerve damage to the warning. In 2015 the FDA acknowledged the existence of fluoroquinolone-associated disability (FQAD) in 178 patients, with chronic pain reported as the most common symptom. Although it does not affect the majority of patients, FQAD may be "underappreciated" (Tennyson and Averch, 2017). Some have speculated that mitochondrial damage is responsible for the serious adverse effects, but there is no consensus about this theory (Marchant, 2018).

Achilles tendon disorders, including rupture, have been estimated to occur in 20 cases per 100,000 and therefore fluoroquinolone use should be discontinued at the first sign of tendon pain (Greene, 2002). Drug-induced tendinopathy is listed as a class effect of fluoroquinolones; indeed, there is a 3.8-fold increased risk of Achilles tendinopathy compared with use of other antibiotics (Chhajed et al., 2002). A recent study determined that factors that contribute to an increased risk of sustaining an Achilles tendon disorder while taking a fluoroquinolone include advanced age, chronic renal failure, male gender, normal body mass index (BMI), and concurrent use of corticosteroids (Godoy-Santos et al., 2018). The mechanism of tendon rupture is unclear, but ciprofloxacin stimulates matrix-degrading protease activity from fibroblasts and exerts an inhibitory effect on fibroblast metabolism and synthesis of matrix ground substance, factors that may contribute to tendinopathy (Williams, et al., 2000). Other soft tissue and peripheral nervous system side effects reported with fluoroquinolones include paresthesias, myalgias, and arthralgias (2016). Administration of the fluoroquinolones to immature animals has caused damage to the developing cartilage; therefore they are currently contraindicated in children, adolescents, and pregnant or nursing women (Christ et al., 1988). More research is needed to better characterize side effects associated with fluoroquinolone usage and understand why certain people are susceptible to these adverse results (Marchant, 2018).

Because of the disabling and potentially irreversible side effects of these drugs on soft tissue and the nervous system, in 2016 the FDA revised the boxed warning on these products to reflect the fact these agents should be prescribed sparingly. According to this warning, "fluoroquinolones should be reserved for use in patients who have no other treatment options for… uncomplicated urinary tract infections because the risk of these serious side effects generally outweighs the benefits in these patients." A new FDA warning issued in 2018 warns against the development of mental health side effects, specifically agitation, disorientation, delirium, memory impairment,

nervousness, and problems with attention. In addition, the FDA expressed concerns about blood sugar disturbances associated with fluoroquinolone use (FDA, 2018b). Later in 2018 the FDA issued a warning about an increased risk of aortic dissection associated with fluoroquinolone use (FDA, 2018a).

There are important drug interactions associated with the fluoroquinolones. The World Health Organization (WHO) warns of rare increases in the anticoagulant effects of Coumadin when taken with fluoroquinolones. Antacids containing magnesium or aluminum interfere with absorption of fluoroquinolones (Davies et al., 1972). Certain fluoroquinolones (enoxacin and ciprofloxacin) elevate plasma levels of theophylline and prolong its half-life (Wright et al., 1993).

Cephalosporins

Three generations of cephalosporins have been used for the treatment of acute UTIs (Wilhelm and Edson, 1987). In general, as a group, activity is high against Enterobacteriaceae and poor against enterococci. First-generation cephalosporins have greater activity against gram-positive organisms, as well as common uropathogens such as *E. coli* and *K. pneumoniae,* whereas second-generation cephalosporins have activity against anaerobes. Third-generation cephalosporins are more reliably active against community-acquired and nosocomial gram-negative organisms than other β-lactam antimicrobials. First-generation cephalosporins such as cephalexin can be prescribed in doses that range from 500 mg twice daily to three or four times daily for 3 to 7 days for uncomplicated cystitis; dosing is highly variable depending on the source. Fourth- and fifth-generation cephalosporins can be used for complicated UTIs.

Aminopenicillins

Ampicillin and amoxicillin have been used often in the past for the treatment of UTIs, but the emergence of resistance in 40% to 60% of common urinary isolates has lessened the usefulness of these drugs (Gupta et al., 2011; Hooton and Stamm, 1991). The effects of these agents on the normal bowel and vaginal flora can predispose patients to reinfection with resistant strains and often lead to candidal vaginitis (Iravani, 1991). The addition of the β-lactamase inhibitor clavulanate to amoxicillin greatly improves activity against β-lactamase–producing bacteria resistant to amoxicillin alone. However, its high cost and frequent GI side effects limit its usefulness. The extended-spectrum penicillin derivatives (e.g., pivmecillinam, piperacillin, mezlocillin, azlocillin) retain ampicillin's activity against enterococci and offer activity against many ampicillin-resistant gram-negative bacilli. **This makes them attractive agents for use in patients with nosocomially acquired UTIs and as the initial parenteral treatment of acute uncomplicated pyelonephritis acquired outside of the hospital, although less-expensive agents are equally effective.**

Aminoglycosides

When combined with TMP-SMX or ampicillin, aminoglycosides are the first drugs of choice for febrile UTIs. Their nephrotoxicity and ototoxicity are well recognized; therefore careful monitoring of patients for renal and auditory impairment associated with infection is indicated. Once-daily aminoglycoside regimens have been instituted to maximize bacterial killing by optimizing the peak concentration-to-minimal inhibitory concentration ratio and reduce the potential for toxicity (Fig. 55.11; Nicolau et al., 1995). Administering an aminoglycoside as a single daily dose can take advantage not only of its concentration-dependent killing ability but also of two other important characteristics: time-dependent toxicity and a more prolonged postantimicrobial effect (Gilbert, 1991; Zhanel et al., 1991a,b). The regimen consists of a fixed 5 to 7-mg/kg dose of gentamicin or 5 to 7 mg/kg tobramycin. Subsequent interval adjustments are made by using a single concentration in serum and a nomogram designed for monitoring of once-daily therapy (Fig. 55.12). Antimicrobial doses are given at the interval determined by the drug concentration of a sample obtained after the start of the initial infusion. For example, if the serum concentration was 7 mg/mL 10 hours after the start of the infusion, subsequent 7-mg/kg doses would be given every 36 hours. This regimen is clinically effective, reduces the incidence of nephrotoxicity, and provides a cost-effective method for administering aminoglycosides by reducing ancillary service times and serum aminoglycoside determinations.

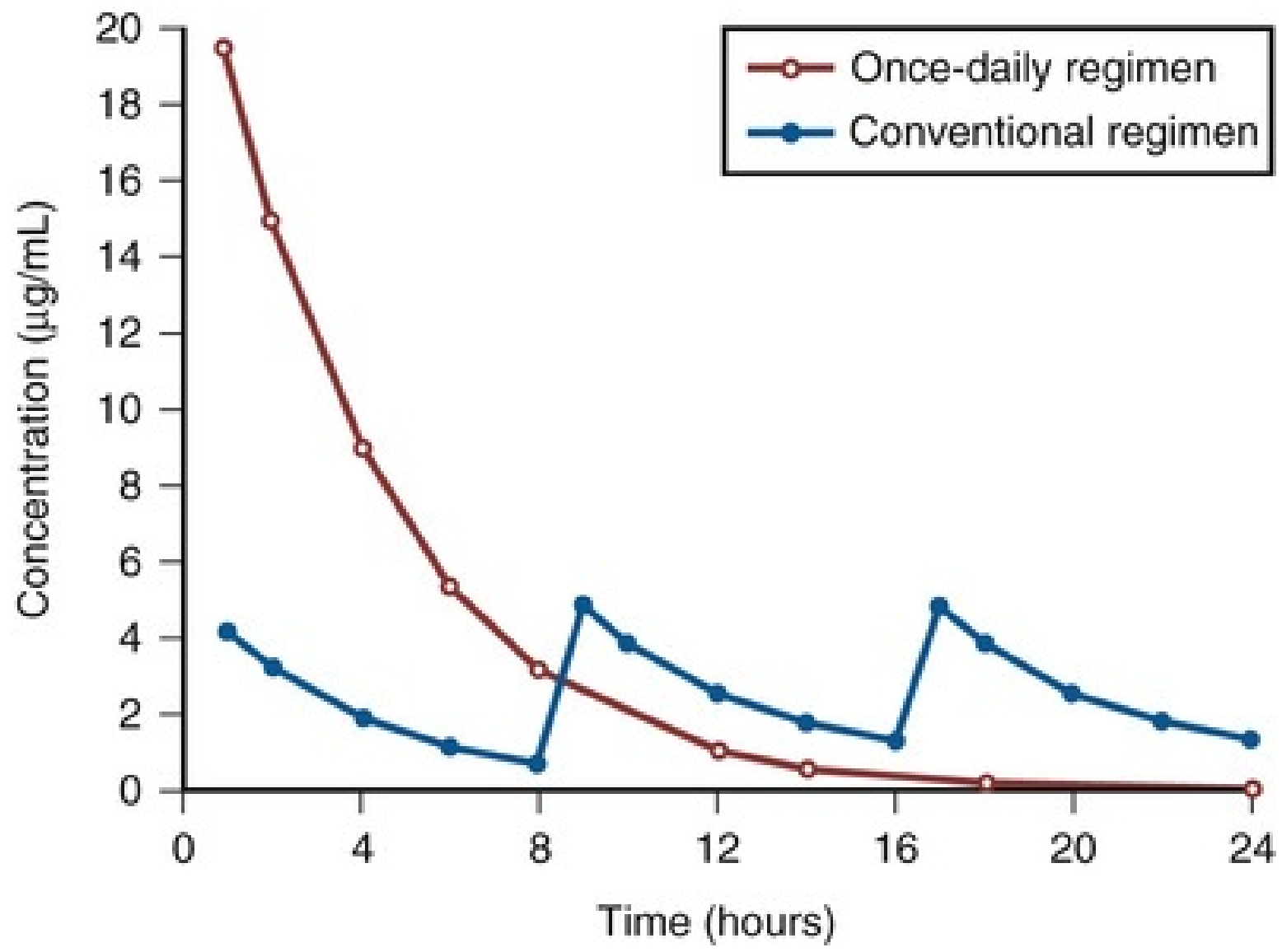

FIG. 55.11 Simulated concentration-versus-time profile of once-daily (7 mg/kg/24 h) and conventional (1.5 mg/kg/8 h) regimens for patients with normal renal function. (From Nicolau DP, Freeman CD, Belliveau PP, et al.: Experience with a once-daily aminoglycoside program administered to 2,184 adult patients. *Antimicrob Agents Chemother* 39:650–655, 1995.)

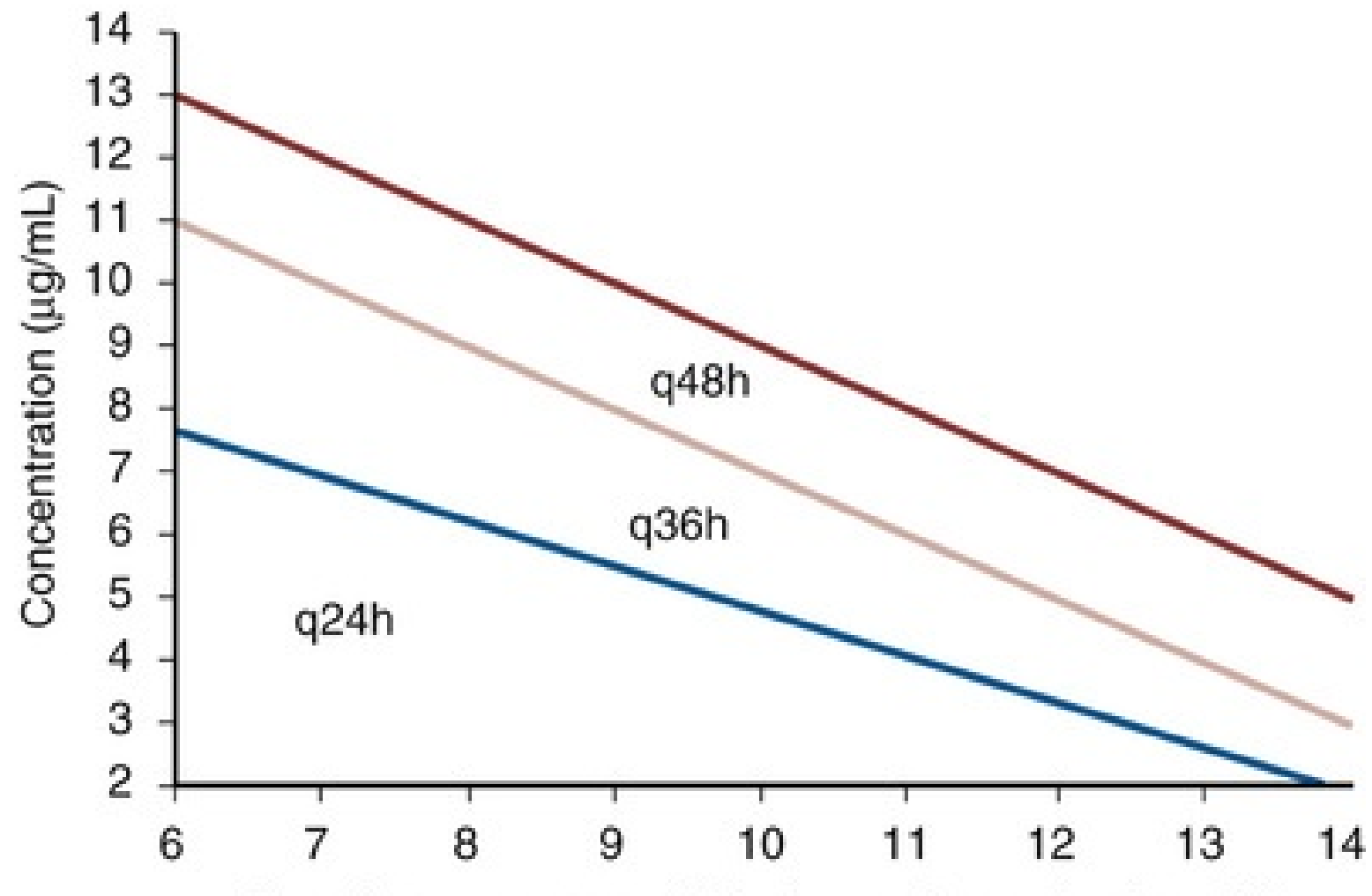

FIG. 55.12 Once-daily aminoglycoside nomogram for gentamicin and tobramycin at 7 mg/kg. (From Nicolau DP, Freeman CD, Belliveau PP, et al.: Experience with a once-daily aminoglycoside program administered to 2,184 adult patients. *Antimicrob Agents Chemother* 39:650–655, 1995.)

Aztreonam

Aztreonam has a similar spectrum of activity as the aminoglycosides, and as with all β-lactams, it is not nephrotoxic. However, its spectrum of activity is less broad than the third-generation cephalosporins. **It should be used primarily in patients who have penicillin allergies.**

Pivmecillinam

Pivmecillinam is a penicillin-like β-lactam antibiotic that is the prodrug of mecillinam. It has high activity against gram-negative organisms and is primarily used in Nordic countries for empirical treatment of uncomplicated cystitis. **It is not currently available in the United States,** but it has been shown to have low resistance patterns (roughly 2% of *E. coli*) as well as being safe and effective (Grainger et al., 1982).

Choice of Antimicrobial Agents

Many antimicrobial agents have been shown to be effective in the treatment of UTIs. **Factors important in aiding selection of empirical therapy include whether the infection is complicated or uncomplicated; the spectrum of activity of the drug against the probable pathogen; a history of hypersensitivity; potential side effects, including renal and hepatic toxicity; the ecologic impact of antibiotic choice; and cost.** The bacterial susceptibility and cost of the drug vary dramatically among inpatient and outpatient settings throughout the country. Therefore it is imperative that each clinician keep abreast of changes in bacterial susceptibility via regional antibiograms as well as cost patterns and use current information when choosing antimicrobial agents.

As mentioned earlier, antibiotic-related disruption to the intestinal microbiota can result in GI side effects, specifically diarrhea. *C. difficile* infections (CDIs) are particularly concerning. In recent years CDIs have become more common and more resistant to treatment. In 2011 453,000 CDIs were diagnosed, resulting in 29,000 deaths in the United States (Lessa et al., 2015). Antibiotics most likely to cause CDI include cephalosporins, clindamycin, carbapenems, trimethoprim/sulfamethoxazole, fluoroquinolones, and penicillin combinations. Macrolides, tetracyclines, and aminoglycosides are not associated with CDI (Slimings, 2014). The diagnosis of CDI requires the presence of diarrhea (diagnosed as greater than or equal to 3 unformed stools in 24 hours) or radiologic evidence of ileus or toxic megacolon and a stool test that is positive for toxigenic *C. difficile* or its toxins or histopathologic or colonoscopic evidence of pseudomembranous colitis. Treatment of CDI should be guided by the severity of illness and the risk of recurrence or complications. Metronidazole and vancomycin are the treatment of choice for CDI; recent data reveal higher treatment failure rates associated with metronidazole with increasing disease severity. Thus, with more mild cases metronidazole is the preferred treatment of choice, whereas with more severe cases vancomycin is recommended (Bagdasarian et al., 2015).

Duration of Therapy

The duration of therapy needed to cure a UTI appears to be related to a number of variables, including the extent and duration of tissue invasion, the bacterial concentration in urine, the achievable urine concentration of the antimicrobial agent, and risk factors (see later) **that impair the host and natural defense mechanisms.**

Key Points: Principles of Antimicrobial Therapy

- Antimicrobial resistance is increasing because of excessive use.
- Antimicrobial selection should be influenced by efficacy, safety, cost, and compliance.
- The choice of the agent as well as the duration of therapy are critical in preventing the perpetuation of antimicrobial resistance as well as adverse events related to treatment.

Bladder Infections

Uncomplicated Cystitis

The overwhelming majority of infections encountered in urology are acute uncomplicated cystitis. Often these infections are treated by practitioners other than urologists. **Most cases of uncomplicated cystitis occur in women. Each year, approximately 10% of women report having had a UTI, and more than 50% of all women have at least one such infection in their lifetime** (Foxman et al., 2000). Uncomplicated cystitis occasionally occurs in prepubertal girls, but it increases greatly in incidence in late adolescence and during the second and fourth decades of life. Twenty-five to 30 percent of women 20 to 40 years of age have a history of UTIs (Kunin, 1961). **Although it is much less common, young men may also experience acute cystitis without underlying structural or functional abnormalities of the urinary tract** (Krieger et al., 1993). Risk factors (Box 55.9) include sexual intercourse and use of spermicides (Foxman, 2002; Handley et al., 2002; Hooton et al., 1996). Sexual transmission of uropathogens has been suggested by demonstrating identical *E. coli* in the bowel and urinary flora of sex partners (Johnson and Stamm, 1989).

Box 55.9

Risk Factors for Urinary Tract Infections

Reduced Urine Flow

- Outflow obstruction, prostatic hyperplasia, prostatic carcinoma, urethral stricture, foreign body (calculus)
- Neurogenic bladder
- Inadequate fluid uptake (dehydration)

Promote Colonization

- Sexual activity—increased inoculation
- Spermicide—increased binding
- Estrogen depletion—increased binding

Antimicrobial agents—decreased indigenous flora

Facilitate Ascent

Catheterization
Urinary incontinence
Fecal incontinence
Residual urine with ischemia of bladder wall

***E. coli* is the causative organism in 75% to 90% of cases of acute cystitis in young women** (Latham et al., 1985; Ronald, 2002)**. *S. saprophyticus*, a commensal organism of the skin, is the second most common cause of acute cystitis in young women, accounting for 10% to 20% of these infections** (Jordan et al., 1980). **Other organisms less commonly involved include *Klebsiella, Proteus,* and *Enterococcus* spp. In men, *E. coli* and other Enterobacteriaceae are the most commonly identified organisms.**

Clinical Presentation

The validated UTI Symptom Assessment questionnaire includes seven symptoms that are most likely reported in association with a UTI: frequency, urgency, painful urination, incomplete emptying, suprapubic pain/pressure, low back pain, and hematuria. In addition to identifying the presence or absence of individual patient-reported symptoms, the degree of severity and bother are also assessed with this questionnaire (Clayson et al., 2005). Cystitis is a superficial infection of the bladder mucosa, so fever, chills, and other signs of dissemination are usually not present.

Although many patients complain of foul-smelling or cloudy urine when requesting treatment for a UTI, studies have not identified these symptoms as reliable indicators of the presence of a UTI, particularly in the absence of specific urinary symptoms. If patients have one or both of these symptoms, yet none of the earlier-mentioned classic symptoms, they should be encouraged to hydrate vigorously and then reassess.

Studies suggest that having more than one symptom raises the likelihood of being diagnosed with a UTI. However, dysuria alone is the most reliable indicator of UTI; when present it contributes to higher severity and bother scores compared with other typical UTI symptoms (Dune et al., 2017). Diagnosis of a UTI can be challenging because many patients complain of symptoms such as frequency, urgency, or incontinence at baseline associated with other lower urinary tract pathology. Thus, when critically evaluating a patient with symptoms suggestive of UTI, clinicians must establish whether the symptoms are different from their baseline voiding dysfunction symptoms. In addition, patients often complain of “burning,” which may be burning associated with urination (dysuria), or burning in the vaginal or pelvic area that is present irrespective of voiding. If patients complain of “burning,” it is important to have them articulate their complaint beyond just “burning.”

A review of nine studies (published between 1965 and 2001) investigating the accuracy of history and physical examination in properly detecting acute uncomplicated UTI determined that **in the absence of vaginal discharge or irritation, the combination of symptoms of dysuria and frequency can predict the presence of a UTI in more than 90%. Overall, the probability of having a UTI is increased when a patient experiences frequency, dysuria, hematuria, and back pain, along with demonstrating CVAT on exam** (Bent et al., 2002).

Similarly, a recent meta-analysis compiled 16 studies encompassing 3711 patients in an effort to ascertain the diagnostic accuracy of individual symptoms by correlating them to urine culture results. In this investigation, the presence of frequency, dysuria, hematuria, nocturia, and urgency increased the probability of having a UTI, whereas the presence of vaginal discharge decreased the likelihood of having a UTI. When hematuria was associated with nitrites on a dipstick, the probability of having a UTI was at least 90% (Giesen et al., 2010).

Overall, acute onset of dysuria and acute change in baseline voiding symptoms are most consistent with a diagnosis of acute uncomplicated cystitis.

Laboratory Diagnosis

See prior discussion of urine testing in the evaluation section.

Management

Antimicrobial Selection.

Oral antimicrobial agents for treatment of acute uncomplicated cystitis are outlined in Fig. 55.13. The recommendations set forth for the management of uncomplicated cystitis in women, described herein, are based on the IDSA and European Society of Microbiology and Infectious Diseases guidelines statement (Gupta et al., 2011). **In general, these treatment algorithms should inform** management, and the ultimate choice of agent should be individualized based on allergy status, projected compliance, local antibiograms/ practice patterns, availability, and cost.

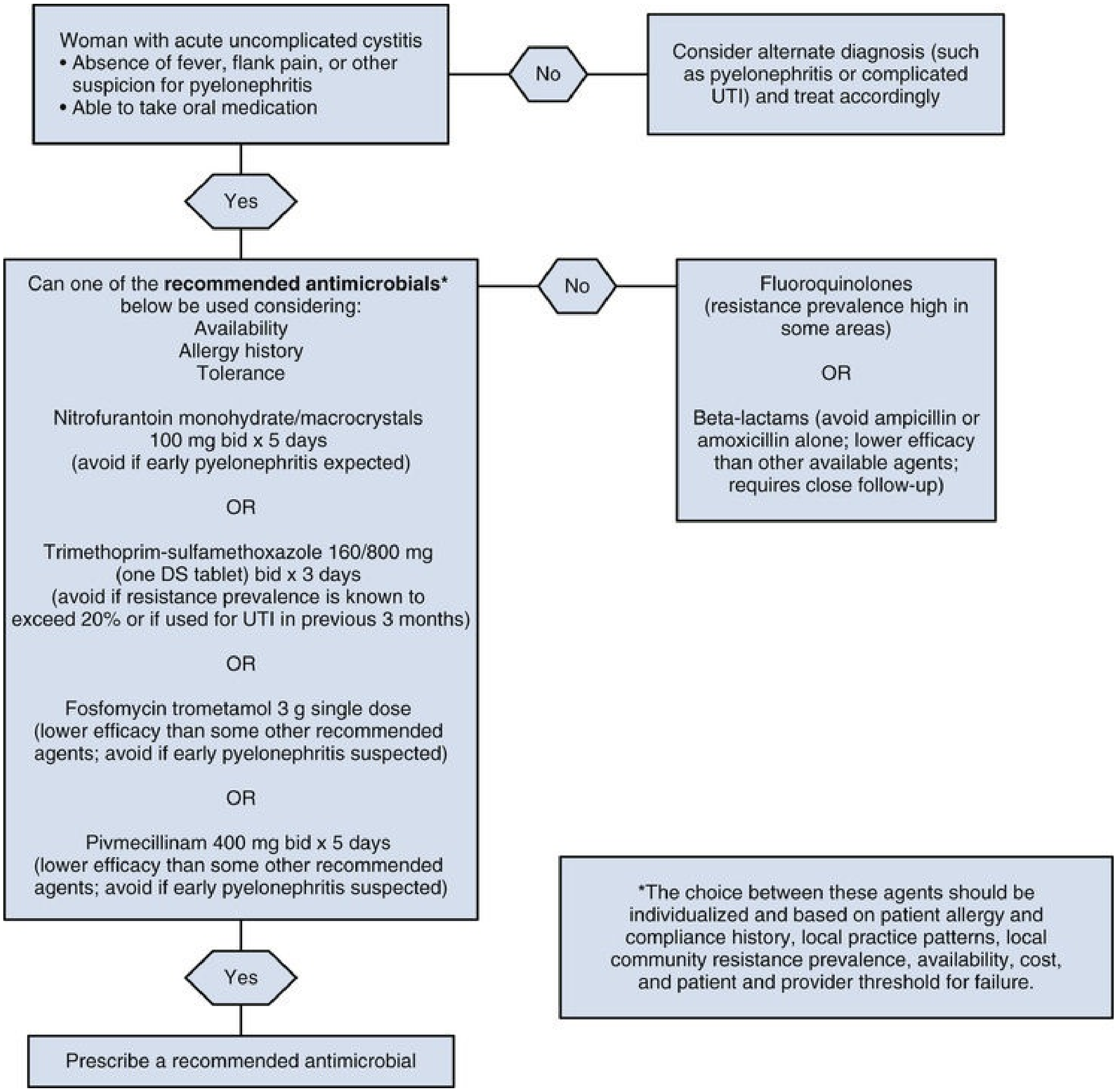
Woman with acute uncomplicated cystitis
• Absence of fever, flank pain, or other suspicion for pyelonephritis
• Able to take oral medication
No
Consider alternate diagnosis (such as pyelonephritis or complicated UTI) and treat accordingly
Yes
Can one of the **recommended antimicrobials*** below be used considering:
Availability
Allergy history
Tolerance
Nitrofurantoin monohydrate/macrocrystals 100 mg bid x 5 days (avoid if early pyelonephritis expected)
OR
Trimethoprim-sulfamethoxazole 160/800 mg (one DS tablet) bid x 3 days (avoid if resistance prevalence is known to exceed 20% or if used for UTI in previous 3 months)
OR
Fosfomycin trometamol 3 g single dose (lower efficacy than some other recommended agents; avoid if early pyelonephritis suspected)
OR
Pivmecillinam 400 mg bid x 5 days (lower efficacy than some other recommended agents; avoid if early pyelonephritis suspected)
No
Fluoroquinolones (resistance prevalence high in some areas)
OR
Beta-lactams (avoid ampicillin or amoxicillin alone; lower efficacy than other available agents; requires close follow-up)
*The choice between these agents should be individualized and based on patient allergy and compliance history, local practice patterns, local community resistance prevalence, availability, cost, and patient and provider threshold for failure.
Yes
Prescribe a recommended antimicrobial

FIG. 55.13 IDSA-recommended treatment of acute uncomplicated cystitis.

Nitrofurantoin has maintained an excellent level of activity over 4 decades and is well tolerated. Nitrofurantoin (100 mg twice daily for 5 days) is an appropriate choice for first-line therapy because of minimal resistance and propensity for ecologic adverse side effects; its efficacy is comparable with 3 days of TMP-SMX.

TMP and TMP-SMX (DS twice daily for 3 days) are effective and

inexpensive agents for empirical therapy, resulting in bacteriologic cure (i.e., eradication of the pathogen from the urine) within 7 days after the start of treatment in approximately 94% of women (Warren et al., 1999). **They are recommended in areas where the prevalence of resistance to these drugs among *E. coli* strains causing cystitis is less than 20%** (Gupta et al., 2011). When used alone, TMP is as efficacious as TMP-SMX and is associated with fewer side effects, presumably because of the absence of the sulfa component (Harbord and Gruneberg, 1981). It can be prescribed to patients who are allergic to sulfa. However, TMP can cause hypersensitivity and rashes that may be erroneously attributed to sulfa (Alonso et al., 1992).

Fosfomycin trometamol (3 g in a single dose) is an appropriate choice for therapy where it is available because of minimal resistance and propensity for collateral damage, but it may have inferior efficacy compared with standard short-course regimens according to data submitted to the FDA and summarized in the Medical Letter (1997; Gupta et al., 2011).

Pivmecillinam (400 mg twice daily for 3 to 7 days) is an appropriate choice for therapy in regions where it is available (availability limited to some European countries; not licensed and/or available for use in North America) because of minimal resistance and propensity for collateral damage, but it may have inferior efficacy compared with other available therapies (A-I; Gupta et al., 2011).

The **fluoroquinolones** have been used in the management of uncomplicated cystitis in the past, and they are effective in 3-day regimens (Gupta et al., 2011). **They have a high propensity for collateral damage (i.e., ecological adverse effects, such as drug resistance) and should be reserved as antimicrobials of last resort for acute cystitis; indeed this is in agreement with the FDA warning mentioned in an earlier section** (2016; Gupta et al., 2011).

β-lactam agents (such as amoxicillin-clavulanate, cefdinir, cefaclor, and cefpodoxime-proxetil) remain second-line treatment options for uncomplicated cystitis and can be used in 3- to 7-day regimens (Gupta et al., 2011).

Duration of Therapy.

Three-day therapy is the preferred regimen for uncomplicated cystitis in women (Norrby, 1990; Warren et al., 1999). In an excellent review of more than 300 separate clinical trials of single-dose, 3-day, or 7-day treatment with TMP, TMP-SMX, fluoroquinolones, and β-lactam antimicrobial therapies, it was concluded that, irrespective of the antimicrobial used, 3-day therapy is more effective than single-dose therapy. Three-day therapy with TMP-SMX and TMP has been associated with cure rates similar to longer courses of therapy and an incidence of adverse effects about as low as that seen with single-dose therapy and lower than seen with longer courses of therapy (Charlton et al., 1976; Kunin, 1985; McCue, 1986; Warren et al., 1999). Because 7-day therapy often causes more adverse effects, it is recommended only for women with symptoms of 1 week or more, men, and individuals with possible complicating factors. Other durational variations include nitrofurantoin 5-day therapy and fosfomycin single-dose therapy.

Seven-day therapy is the preferred regimen for cystitis in men.

Cost of Therapy.

The cost of treating a UTI involves not only the initial evaluation and cost of the drug but also what occurs subsequently. The most important prediction of high cost-effectiveness is high efficacy against the most common urinary pathogen, *E. coli*. The lower the effectiveness against this bacterium, the greater the number of revisits, cases of progression to pyelonephritis, and follow-up costs. Antimicrobial cost is a poor prediction of cost-effectiveness (Rosenberg, 1999).

Follow-Up

Approximately 90% of women are asymptomatic within 72 hours after initiating antimicrobial therapy (Fihn et al., 1985)**. A follow-up visit or culture is not required in women who are asymptomatic after therapy. Further urologic evaluation is unnecessary in women who respond to therapy** (Abarbanel et al., 2003; Lipsky, 1989). **However, UTIs in most men should be considered complicated until proven otherwise.** Andrews et al. (2002) showed that approximately 50% of men with UTIs have a significant abnormality. Furthermore, if a patient does not respond to therapy, appropriate microbiologic urologic evaluations should be undertaken for the causes of unresolved and complicated UTIs.

Compliance With Recommended Agents.

Despite the compelling argument for the purposeful and selective use of antibiotic therapy with respect to the treatment of uncomplicated cystitis, practice patterns within the prescribing community as a whole have yet to change. In a recent questionnaire distributed to physicians, including non-urologists, more than half of the 260 respondents were not familiar with the

IDSA guidelines, and 30% did not recommend a first-line agent for the treatment of uncomplicated cystitis (Ditkoff et al., 2017). This suggests that further education and outreach efforts are critical to ensure all practitioners managing patients with uncomplicated cystitis are practicing the standard of care; only this way can the negative ecologic impact of inappropriate antibiotic use be mitigated on a population level.

Complicated Urinary Tract Infections

Complicated UTIs are those that occur in a patient with a compromised urinary tract or that are caused by a very resistant pathogen (Table 55.8). **These complicating factors may be readily apparent from the severity of the presenting illness or the past medical history. However, they may not be obvious at first and may only become evident from subsequent failure of the patient to respond to appropriate therapy** (see later discussion on unresolved or recurrent UTIs).

TABLE 55.8

Host Factors Classifying a Urinary Tract Infection as Complicated

COMPLICATION	EXAMPLES
Anatomic abnormality	Cystocele, fistula, diverticulum
Iatrogenic	Nosocomial infection, surgery, indwelling catheter
Urinary tract obstruction	Bladder outlet obstruction, ureteropelvic junction obstruction, ureteral stricture
Voiding dysfunction	Neurologic disease, pelvic floor dysfunction, vesicoureteral reflux, incontinence, high postvoid residual
Other	Pregnancy, urolithiasis, diabetes, other immunosuppression

Data from Dason S, Dason J, Kappor A, et al.: Guidelines for the diagnosis and management of recurrent urinary tract infections in women. *Can Urol Assoc J* 5(5):316–322, 2011.

The clinical spectrum ranges from mild cystitis to life-threatening kidney infections and urosepsis (kidney infections and urosepsis are discussed subsequently). These infections can be caused by a broad range of bacteria with resistance to multiple antimicrobial agents. Therefore urine cultures are mandatory to identify the bacteria and its antimicrobial susceptibility.

Because of the wide range of host conditions and pathogens and a lack of adequate controlled trials, guidelines for empirical therapy are limited. For patients with mild to moderate illness who can be treated as an outpatient with oral therapy, 10 to 14 days of fluoroquinolones have traditionally been recommended because of their concentration in the urine and good tissue penetration (Stamm and Hooton, 1993); however, emerging resistance patterns to this class of antibiotics as well as concerns about side effects will likely change prior practice patterns.

For patients requiring hospitalization, IV antimicrobials should be administered based on the susceptibility patterns of the known uropathogens at that institution.

Because therapy will be compromised without addressing complicating factors, every effort should be made to correct any underlying urinary tract abnormalities, such as obstruction, and treat host factors that exacerbate the infection.

Therapy is usually continued for 10 to 14 days on culture-specific antibiotics and switched from parenteral to oral therapy when the patient is afebrile and clinically stable. Repeat urine cultures should be performed if the patient fails to respond to therapy.

Emphysematous Cystitis

Emphysematous cystitis is a rare and potentially life-threatening form of complicated cystitis that is associated with a mortality rate of up to 7% (Amano and Shimizu, 2014). Early medical therapy is important in achieving a favorable outcome and avoiding the need for surgical intervention. The pathognomonic finding of this disease process is gas noted within the wall on cross-sectional imaging. Emphysematous cystitis is typically observed in elderly women (60–70 years of age) with poorly controlled diabetes; additional risk factors include any condition that may predispose to incomplete emptying and lower urinary stasis, such as neurogenic bladder and bladder outlet obstruction. Although various microorganisms have been associated with this disease process, *E. coli* (60%) and *K. pneumoniae* (10%–20%) are most commonly implicated (Amano and Shimizu, 2014).

Clinical Presentation.

The clinical signs and symptoms are variable, ranging from asymptomatic (reported in up to 7%) to overt sepsis (Kuo et al., 2009; Wortmann and Fleckenstein, 1998). The most common symptom in these patients is abdominal pain (80%) (Grupper et al., 2007) followed by gross hematuria (60%), and obstructive urinary symptoms (10%) (Yoshida et al., 2010). The presence of fever is variable and has been reported in 30% to 50% of these patients (Amano and Shimizu, 2014).

Radiologic Findings.

The characteristic feature on plain radiograph involves curvilinear areas of increased radiolucency delineating the bladder wall and separate from the rectal gas posteriorly; the distribution of the air has been described as a cobblestoned or "beaded necklace" appearance, reflecting the irregular submucosal blebs (Grayson et al., 2002). A CT scan of the pelvis will also show air pocketed diffusely within the bladder wall, and possibly intraluminally; a CT scan is necessary to make the diagnosis and exclude other sources of pelvic air such as a fistula, trauma, or gangrene of adjacent structures (Amano and Shimizu, 2014; Fig. 55.14).

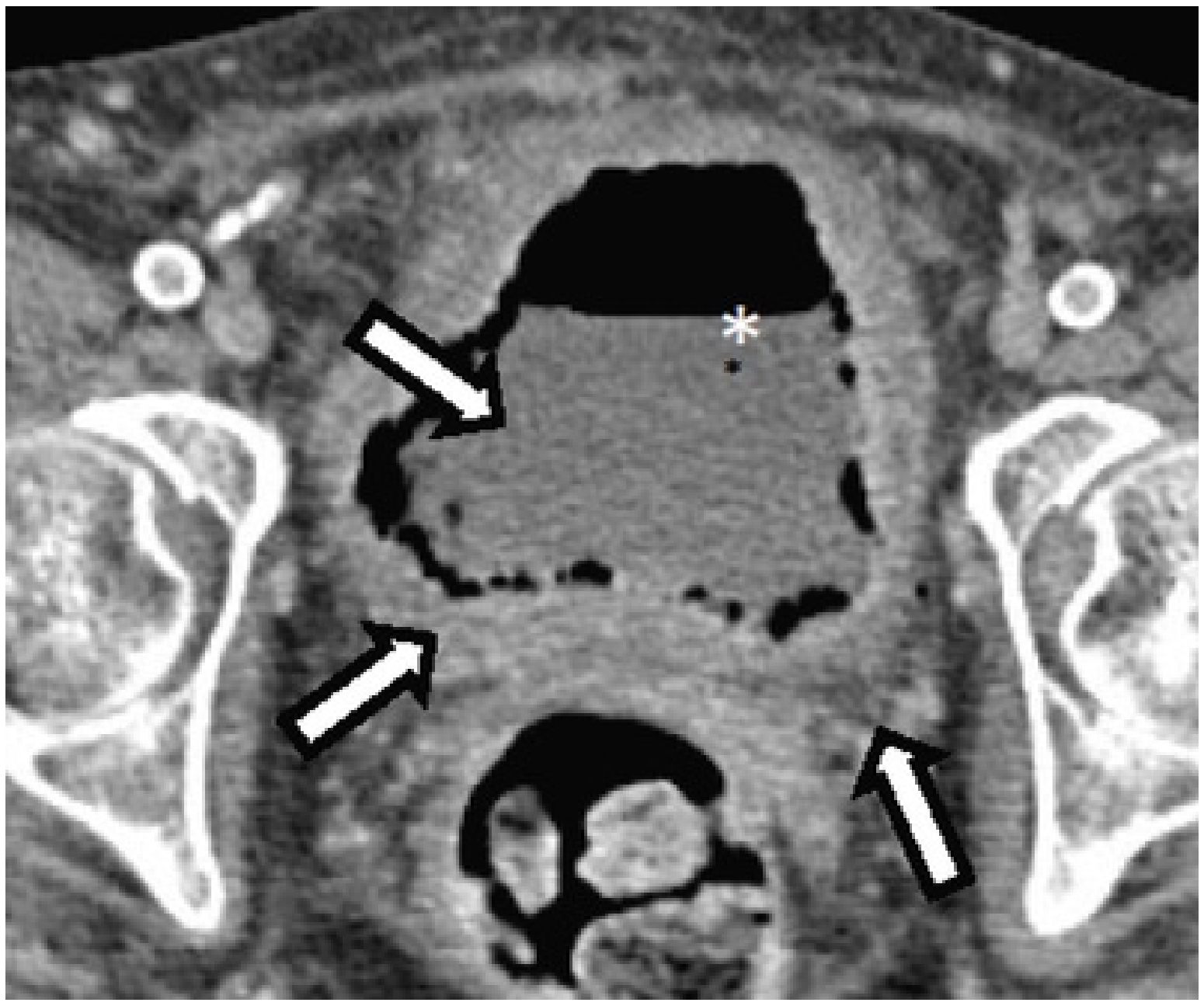

FIG. 55.14 Computed tomography of emphysematous cystitis. *Arrows* indicate intramural gas; there is also air in the bladder lumen (*).

Management.

The majority (90%) of these patients are treated with medical therapy alone, which consists of antibiotics (often parenteral), bladder drainage, and treatment of comorbid conditions such as poorly controlled diabetes (Amano and Shimizu, 2014). Antibiotic treatment regimens include agents that offer broad gram-negative coverage that can then be narrowed based on culture sensitivities and clinical response; if an initial Gram stain identifies gram-positive cocci, ampicillin or amoxicillin should be incorporated into the treatment regimen for better enterococcal coverage. The need for surgical intervention is rare and is reserved for those cases that respond poorly to initial medical management or severe necrotizing infections. The severity of the condition determines the nature of the surgical intervention, but case reports have described debridement, partial cystectomy, and total cystectomy in advanced cases (Thomas et al., 2007).

Unresolved Urinary Tract Infections

Clinical Presentation

Unresolved infection indicates that initial therapy has been inadequate in eliminating symptoms and/or pathologic bacterial growth in the urinary tract. If the symptoms of UTI do not resolve by the end of treatment or if symptoms recur shortly after therapy, a urinalysis and urine culture with susceptibility testing should be obtained. If the patient's symptoms are significant and cannot be alleviated with urinary analgesics, broad-spectrum antibiotics may be initiated as empirical therapy pending the availability of the culture and susceptibility testing.

The causes of unresolved bacteriuria during antimicrobial therapy are shown in Box 55.10. **Most commonly, the bacteria are resistant to the antimicrobial agent selected to treat the infection.** Typically, the patient has received the antimicrobial therapy in the recent past and developed bowel colonization with resistant bacteria. β-lactams, tetracycline, and sulfonamides are notorious for causing plasmid-mediated R factors that simultaneously carry resistance to multiple antimicrobial agents. **The second most common cause is development of resistance in a previously susceptible population of bacteria during the course of treatment of UTIs. This problem occurs in approximately 5% of the patients receiving antimicrobial therapy. It is easy to recognize clinically because the culture on therapy shows that the previous susceptible population has been replaced by resistant bacteria of the same species.** It can be shown that resistant organisms were actually present before contact with the initial antimicrobial agent, but they were present in such low numbers that it was impossible to detect by in vitro susceptibility studies before therapy. When the antimicrobial concentration in the urine is insufficient to kill all the bacteria present, the more resistant forms will emerge. This characteristically is seen in patients who are underdosed or who are poorly compliant and hence have inadequate dose regimens. **The third cause is the presence of an unsuspected, second pathogen that was present initially and is resistant to the antimicrobial therapy chosen.** Treatment of the dominant organism unmasks the presence of the second strain. **The fourth cause is rapid reintroduction of a new resistant species while the patient is undergoing initial therapy.** Rapid reinfection that mimics unresolved bacteriuria should alert the clinician to the possibility of an enterovesical fistula.

Box 55.10

Causes of Unresolved Bacteriuria, in Descending Order of Importance

Bacterial resistance to the drug selected for treatment
Development of resistance from initially susceptible bacteria
Bacteriuria caused by two different bacterial species with mutually exclusive susceptibilities
Rapid reinfection with a new, resistant species during initial therapy for the original susceptible organism
Azotemia
Papillary necrosis from analgesic abuse
Giant staghorn calculi in which the “critical mass” of susceptible bacteria is too great for antimicrobial inhibition
Self-inflicted infections or deception in taking antimicrobial drugs (a variant of Munchausen syndrome)

If the culture obtained on therapy shows that the initial species is still present and susceptible to the antimicrobial chosen to treat the infection, the unresolved infection must be caused by inability to deliver an adequate concentration of antimicrobial agents into the urinary tract, an excessive number of bacteria that “override” the antimicrobial activity, or noncompliance with the regimen. In patients with azotemia, a determination of urinary antimicrobial concentrations usually shows that the level of the drug is below the minimal inhibitory concentration of the infecting organism.

In patients with papillary necrosis, severe defects in the medullary concentrating ability dilute the antimicrobial agent. A large mass of bacteria within the urinary tract is most commonly associated with a giant staghorn calculus. Even though adequate urinary levels of bactericidal drugs are present, the concentration is inadequate to sterilize the urine. This occurs because even susceptible bacteria cannot be inhibited once they reach a certain critical density, particularly if attached to a foreign body.

The last cause of unresolved bacteriuria occurs in those patients who have variants of Munchausen syndrome. These patients secretly inoculate their bladders with uropathogens or omit their oral antimicrobial agents while steadfastly asserting that they never miss a dose. The patient with Munchausen syndrome has an inconsistent clinical history and invariably a normal urinary tract on urologic imaging. Careful bacteriologic observations usually indicate the implausibility of the clinical picture.

Laboratory Diagnosis

Urinalysis and urine culture are mandatory to determine the cause of unresolved bacteriuria. The first four causes associated with resistant bacteria require no further evaluation. However, if reculture shows that the bacteria are sensitive to the antimicrobial agent the patient is taking, renal function and radiologic evaluation should be performed to identify renal or urinary tract abnormalities.

Management

If the patient's symptoms are significant, initial broad-spectrum empirical antimicrobial treatment may be initiated, and selection should be based on the assumption that the bacteria are resistant. Therefore an antimicrobial agent different from the original agent should be selected.

Recurrent Urinary Tract Infections

A recurrent UTI is defined as two UTIs in a 6-month period or three or more UTIs in a 12-month period. Recurrent UTIs are common in otherwise healthy women. Indeed, in healthy college-age women, 20% had at least one culture-documented UTI within 6 months of an index UTI (Foxman et al., 2000). Other studies have reported a 20% to 30% recurrence rate in women (Albert et al., 2004; Gupta et al., 2001a,b). It is well established that one of the most significant risk factors for development of a UTI is a prior recent UTI. Recurrent infections are hypothesized to be secondary to either bacterial persistence within the urinary tract or, more commonly, novel reinfection. Persistence, caused by the same bacterial strain, usually leads to recurrent infections in a short time frame, whereas reinfections generally occur over a more remote period. Reinfections are caused by either the same organism more than 2 weeks after treatment or a different organism. Reinfection is likely secondary to ascent of uropathogens from fecal flora into the urinary tract or from reemergence of bacteria from uroepithelial intracellular colonies. In men, reinfections raise suspicion for the presence of anatomic abnormalities.

Evaluation

In evaluation of a woman with recurrent UTIs, the clinical focus should be on preventing recurrence by identifying risk factors for, and altering behaviors that contribute to, recurrent infections. The history and physical exam should eliminate overt external anatomic or obvious functional abnormalities of the urinary tract that predispose to recurrent UTIs. If any of these factors are identified, the UTIs are classified as complicated.

Obtaining a thorough medical history is imperative. Emphasis should be on ascertaining the prior number of infections and their frequency, culture results, associated symptoms, and identifiable triggers or risk factors. Symptoms such as pneumaturia, fecaluria, obstipation, as well as prior history of diverticulitis, prior pelvic surgery, or radiation should raise suspicion for vesicoenteric or vesicovaginal fistula. Description of any concomitant bowel symptoms, such as chronic constipation, diarrhea, and fecal incontinence may provide additional information to identify reversible contributing factors. Prior treatment strategies and patient response should be carefully investigated. **Significant risk factors for recurrence in women include sexual activity, a new sexual partner within the past year, menopause, spermicidal use, family history of UTI in a first-degree female relative, and recent antimicrobial use** (Dielubanza and Schaeffer, 2011; Hooton et al., 1996; Scholes et al., 2000, 2010). **In postmenopausal women, risk factors for recurrent UTIs include incontinence, elevated postvoid residual, and presence of a cystocele. A history of a UTI before menopause has also been identified as a risk factor** (Raz et al., 2000) (Box 55.11).

Box 55.11

Risk Factors for Recurrent Urinary Tract Infections

- Sexual activity
- New sexual partner within past year
- Family history of urinary tract infection (UTI) in first-degree female relative
- Recent antimicrobial use
- Spermicide use
- History of UTI before menopause
- Menopause
- Incontinence, elevated postvoid residual, cystocele (in postmenopausal women)

On physical examination, palpating the suprapubic area and performing a pelvic examination are important. One may identify a distended bladder; a significant postvoid residual contributes to bacteriuria. On pelvic examination the appearance of vaginal epithelium, particularly in postmenopausal women, should be characterized. The presence of pelvic organ prolapse or a urethral diverticulum could help establish the cause of recurrent UTIs.

Obtaining laboratory data, specifically urinalysis and urine culture, is imperative in patients with recurrent UTIs. Many of these patients are treated based on symptoms that overlap significantly with irritative storage symptoms and may in fact be inappropriately treated for UTIs. It is important in this population to establish that their symptoms are secondary to bacteriuria. In addition, quantification of the bacterial burden, species, and degree of resistance, if present, is also important information. Obtaining a urine culture in women with uncomplicated recurrent UTIs resulted in decreased hospitalization for treatment of UTI and decreased intravenous antibiotic usage (Suskind et al., 2016).

In many patients obtaining a postvoid residual and uroflow measurement provides important information. **In patients with emptying symptoms or a distended bladder on physical examination, documentation of a postvoid residual is critical.** In postmenopausal women with recurrent UTIs, higher postvoid residual and decreased urine flow were associated with uncomplicated recurrent UTIs (Raz et al., 2000). In fact, elevated PVR or decreased flow rates are often considered parameters that contribute to complicated UTIs; thus identification of abnormal values is important if the suspicion is high.

Imaging and cystoscopic evaluation are not warranted in all women with recurrent UTIs. Indeed, the yield of imaging in women without suspected complicated UTI is low and is not recommended by the American College of Radiology, the Canadian Urological Association Guidelines, or the European Association of Urology (EAU) Guidelines (Dason et al., 2011; EAU Guidelines, 2015; Segal et al., 2000). However, **in women with risk factors for a complicated UTI the evaluation should include imaging and cystoscopy.** These diagnostic tests may reveal kidney or bladder stones, neoplasms, fistulae, anatomic renal anomalies including scarring or papillary necrosis, or many other possible abnormalities (Table 55.9). Preferred imaging includes renal and bladder ultrasound with possible plain radiograph of the abdomen. In some cases, a CT scan is recommended as well, especially if there is a high index of suspicion for a complicated infection with no abnormality demonstrated on prior imaging. In patients with stones or obstruction, a CT scan is particularly useful in providing structural detail. In premenopausal women with a functional uterus, it is imperative to ask whether they may be pregnant; if they are uncertain, a pregnancy test should be obtained before any imaging that confers radiation (Fairchild et al., 1982).

TABLE 55.9

Indications for Further Investigation of Recurrent Urinary Tract Infection

Previous urinary tract trauma or surgery
Previous bladder or renal calculi
Gross hematuria after resolution of infection
Obstructive symptoms, low uroflowmetry, or high postvoid residual
Urea-splitting bacteria on culture
Previous abdominopelvic malignancy
Bacterial persistence after sensitivity-based therapy
Diabetes or other immune compromise
Pneumaturia, fecaluria, anaerobic bacteria, or history of diverticulitis
Repeated pyelonephritis
Asymptomatic microhematuria after resolution of infection should be evaluated

Data from Dason S, Dason J, Kappor A, et al.: Guidelines for the diagnosis and management of recurrent urinary tract infections in women. *Can Urol Assoc J* 5(5):316–322, 2011.

Many providers perform cystoscopy for the evaluation of all women with recurrent UTIs; however, several studies substantiate the fact that cystoscopy does not confer any added value beyond imaging, particularly in uncomplicated UTIs (Lawrentschuk et al., 2006; Pagano et al., 2017; van Haarst et al., 2001). These data demonstrate that, if imaging has been performed, an invasive diagnostic procedure should not be considered in the uncomplicated setting. There is utility for cystoscopic evaluation in patients with complicated UTIs.

Bacterial Persistence

For culture-documented infections with acute symptoms, if patients fail to respond to an appropriate course of antibiotics, then bacterial persistence may be present. **The incidence of bacterial persistence in the recurrent UTI population is very small, but, when present, it is critical to diagnose the source of persistence. In such cases of bacterial persistence, cystoscopic evaluation and imaging studies are necessary.** With persistence there are usually correctable urologic abnormalities that may be reversible (see Box 55.6). Such abnormalities create persistence often immune from treatment because of the inability of antibiotics to penetrate or eliminate the nidus of infection. In select instances, surgical removal of the source of infection has been shown to eradicate the infections (Stamey, 1980).

Proper evaluation for bacterial persistence includes endoscopic evaluation of the urinary tract as well as radiologic studies. Cystoscopy, ultrasonography, and CT scan may be useful in identifying the source. VCUG is useful when there is suspicion of VUR or the presence of a nonrefluxing ureteral stump. Pelvic MRI is standard of care to identify a urethral diverticulum. Retrograde urethrogram should be considered in men with suspected urethral stricture disease.

One of the most common causes of bacterial persistence are struvite renal calculi. Urea-splitting organisms, such as *P. mirabilis*, contribute to such infection stones (see Chapter 91, Table 91.3). Urease-splitting organisms cause alkalinization of urine with precipitation of calcium, magnesium, ammonium, and phosphate salts. These minerals contribute to formation of branched struvite stones. The bacteria in these stones often persist despite antibiotic treatment; urine cultures may show no growth after treatment, but this is misleading because the bacteria remain sheltered within these stones. Oxalate and apatite stones that become secondarily colonized also may contribute to bacterial persistence. Risk factors for the development of infection stones include chronic indwelling catheters, urinary diversions, or other urinary tract abnormalities that affect stasis. To eradicate bacteriuria thought to be related to stone disease, surgical treatment of the infection stones is recommended in all patients safe for intervention, per the AUA Guidelines: Medical Management of Kidney Stones (American Urological Association, 2014). In those patients with residual or recurrent struvite stones who are not surgical candidates, acetohydroxamic acid in conjunction with antibiotic suppression may be offered (American Urological Association, 2014).

Management of nonobstructing stones in recurrent UTIs is controversial. One study identified certain patient characteristics that increase the likelihood of recurrent UTIs despite complete stone extraction, including type 2 diabetes mellitus, hypertension, and black ethnicity (Omar et al., 2015). In this cohort of 120 patients 50% remained infection free 1 year after surgical extraction of the stone. Further research is necessary to determine whether eradicating small, nonobstructing stones has a beneficial effect on reducing the incidence of recurrent UTIs.

Management

The majority of women with recurrent infections do not have identifiable and/or correctible anatomic abnormalities. Options for minimizing recurrent infections include behavioral modifications, use of non-antibiotic therapies, and, as a last resort, antibiotic treatment and prophylaxis.

In this era of widespread antibiotic overuse and the prevalence of alarming numbers of multidrug-resistant bacteria, judicious use of antibiotics is imperative.

The development of multidrug-resistant bacteria is associated with increased and prolonged hospitalization rates and significant adverse effects, including death. The Centers for Disease Control and Prevention (CDC) has reported that antibiotic resistance is one of the most serious health threats we encounter. More than 2 million people annually are infected with an antibiotic-resistant infection, which results in more than 20,000 deaths (CDC, 2014).

To minimize overuse of antibiotics and preserve their effectiveness, antibiotic stewardship programs have been developed. These programs have been efficacious at improving antibiotic prescribing patterns, improving patient outcomes, decreasing adverse effects, and improving rates of susceptibilities to particular agents (Barlam et al., 2016)**. Indeed, a recent Cochrane review demonstrated that stewardship programs have**

improved compliance with antibiotic guideline recommendations and have helped decrease the duration of antibiotic courses (Davey et al., 2017). The management of UTIs must adhere to antibiotic stewardship efforts (Fig. 55.15).

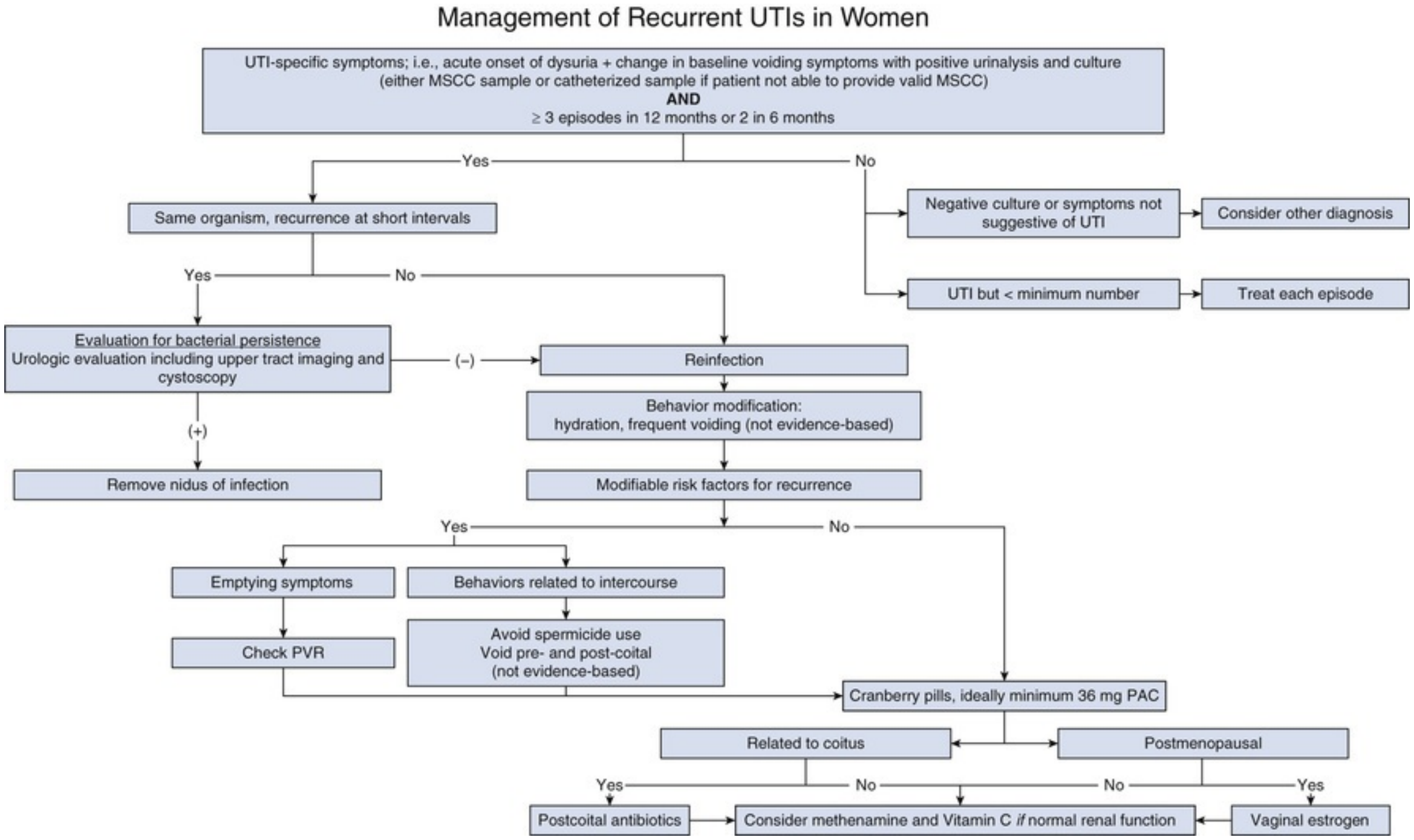
Management of Recurrent UTIs in Women
UTI-specific symptoms; i.e., acute onset of dysuria + change in baseline voiding symptoms with positive urinalysis and culture (either MSCC sample or catheterized sample if patient not able to provide valid MSCC) AND ≥ 3 episodes in 12 months or 2 in 6 months
Yes
No
Same organism, recurrence at short intervals
Negative culture or symptoms not suggestive of UTI
Consider other diagnosis
Yes
No
UTI but < minimum number
Treat each episode
Evaluation for bacterial persistence
Urologic evaluation including upper tract imaging and cystoscopy
(–)
Reinfection
Behavior modification: hydration, frequent voiding (not evidence-based)
(+)
Remove nidus of infection
Modifiable risk factors for recurrence
Yes
No
Emptying symptoms
Behaviors related to intercourse
Check PVR
Avoid spermicide use
Void pre- and post-coital
(not evidence-based)
Cranberry pills, ideally minimum 36 mg PAC
Related to coitus
Postmenopausal
Yes
No
No
Yes
Postcoital antibiotics
Consider methenamine and Vitamin C *if* normal renal function
Vaginal estrogen

FIG. 55.15 Algorithm for management of recurrent urinary tract infections. *MSCC,* Midstream clean-catch sample; *PAC,* proanthocyanidin; *PVR,* postvoid residual; *UTI,* urinary tract infection.

Behavioral Modification.

It is a clinically accepted principle that employing behavioral modification is a reasonable strategy to minimize recurrent UTIs, despite the lack of scientific evidence in support of several aspects of this approach. Such behavioral modifications carry minimal to no risks and enhance overall bladder health. Many women prone to UTIs acknowledge that they drink insufficient quantities of water and/or have a tendency to hold urine for extended periods despite feeling urges to void. Hydration is recommended to augment innate immunity by sloughing of urothelial cells and flushing of adherent bacteria. A recent study found that in premenopausal women with a history of recurrent UTIs, increasing water intake by 1.5 L daily led to a significant decrease in the number of cystitis episodes (Hooton et al., 2018). Likewise, frequent voiding helps to continually empty the bladder, which is particularly important if women have a tendency to hold urine for extended periods or do not empty their bladders adequately when they do void. Sexual activity is a known risk factor for UTIs because it transiently increases bacteriuria. Therefore emptying the bladder after intercourse should help minimize the likelihood that the transient bacteriuria will progress to clinical symptomatology of a UTI. By this same logic that has been favored for managing patients with a history of UTIs, voiding pre-intercourse, when possible, may also be beneficial. Spermicides (nonoxynol-9) have been associated with an increased risk of developing a UTI because they contribute to decreased population of normal vaginal flora and subsequently alter the vaginal pH, making the environment more hospitable for uropathogenic bacteria to thrive (Fihn et al., 1985,1996; Handley et al., 2002). Clinicians have speculated that shaving pubic hair and wearing thong underwear may contribute to recurrent UTIs; however, scientific data confirming this do not exist.

Self-Start Therapy.

One widespread practice that has been favored for managing patients who suspect they have a UTI involves allowing reliable patients to start antimicrobial therapy with onset of their typical UTI symptoms, sometimes without providing a urine sample or consulting their health care provider. Although this practice empowers the appropriate patient with the ability to self-diagnose and allows for instant access to antibiotics, it countermands the principles of antibiotic stewardship and the meaningful use of culture-specific antibiotics described in previous sections. Historical literature provided justification of this practice, with older studies suggesting patients have excellent diagnostic skills and will appropriately treat only when necessary (Gupta et al., 2001a,b; Schaeffer and Stuppy, 1999). Initially this approach depended on patients providing urine samples and following up for culture results after initiating antimicrobial therapy. With time, however, the expectation of providing samples has dissipated, and, in the current era, most patients begin antibiotics without making an effort to confirm the presence of a UTI, much less the causative organism and sensitivities.

Historically, patients were encouraged to rely on broad-spectrum antibiotics to treat their symptoms, and fluoroquinolones were considered “ideal” agents for self-start therapy. However, although this approach is endorsed by many practitioners, partially because of ease of patient management, this strategy only perpetuates antibiotic overuse by relying on self-diagnosis. Many patients with a history of UTIs have anxiety because of fear of when the next UTI will appear. These patients may prematurely and incorrectly initiate treatment if they notice any change in their typical urinary habits; often patients are quick to assume they have another UTI if they have a slight increase in urgency, or mild discomfort with urination. **Our anecdotal clinical experience suggests that patients are not always adequate diagnosticians when it comes to UTIs, and the risks outweigh the benefits of self-start therapy. A practice that allows patients to self-medicate, often with extended courses of broad-spectrum antibiotics, is not a sustainable strategy.**

In the management algorithm for recurrent infections, many experienced clinicians encourage patients to medicate with urinary analgesics with the onset of symptoms to provide some relief, provide a urine sample, and continue observation unless they display significant symptoms. For persistent issues despite analgesics, prescription of IDSA-recommended antibiotics, in consultation with local antibiograms, may be administered and tailored once culture results are available. In many cases patient symptoms are transient and unrelated to bacterial infection and thus are self-limiting; this approach spares a course of unnecessary antibiotics.

Low-Dose Continuous Prophylaxis.

Another widely advocated management option for recurrent UTIs is daily prophylaxis with low-dose antibiotics. Conceptually, this strategy has been promoted because particular antimicrobial agents eradicate pathogenic bacteria from introital and bowel reservoirs without fostering bacterial resistance. Many papers were published in the late 20th century endorsing the use of TMP-SMX, TMP alone, nitrofurantoin, cephalexin (low dose) and fluoroquinolones, as well as several other antibiotics no longer in use (Bailey et al., 1971; Martinez et al., 1985; Nicolle, et al., 1989; Raz and Boger, 1991; Stamm et al., 1980a). In these studies, some of which were placebo controlled, patients who received daily prophylaxis, generally for 6 months to a year, demonstrated lower rates of UTIs (compared with placebo or with the patients’ prior experiences as controls). Although these studies concluded that daily antibiotic use was safe and effective, some did mention an increased incidence of non-*E.coli* UTIs after such prophylaxis.

A 2004 Cochrane review of AP against recurrent UTIs in non-pregnant women concluded that women with uncomplicated recurrent UTIs are less likely to have an infection if they take prophylactic antibiotics for 6 to 12

months (Albert et al., 2004). This review included 19 randomized controlled studies, involving 1120 women. Study designs of these 19 studies included comparing antibiotics with placebo, the same antibiotic with different regimens (i.e., daily vs. weekly vs. monthly vs. postcoital), different antibiotics, or antibiotics versus non-antibiotic pharmacologic interventions. The majority of these studies evaluated 6 months of prophylaxis; only one studied subjects for 1 year of treatment. The most recently published study included was published in 1995. The studies reported on the number of recurrences while subjects were on prophylaxis as well as after prophylaxis was discontinued. Adverse effects of antibiotic use were also investigated. The authors concluded that continuous antibiotic use did decrease the clinical and microbiologic recurrence rate; however, there were more adverse effects attributed to the antibiotics.

Only two studies performed follow-up 6 months beyond the prophylactic period (Schaeffer et al., 1982; Stamm et al., 1980). In these two studies, once prophylaxis was discontinued, the recurrence rate was comparable between those treated and the placebo group. Therefore, **although prophylaxis was deemed an effective strategy in the short term, in the long term patients who were treated prophylactically demonstrated the same risk of recurrence as those not treated.** Two of the studies assessed postcoital antibiotic use; one compared it with placebo, the other compared it with daily antibiotics use. Both studies found that postcoital antibiotic use, in women with recurrent UTIs secondary to intercourse, is an effective strategy and is preferable to daily antibiotic use.

Although many practitioners advocate prophylactic antibiotics, at least in part because of the conclusions of this Cochrane review, several points must be emphasized. The authors of the Cochrane review questioned the quality of the clinical trials reviewed, specifically citing concerns regarding inconsistent definitions of recurrent UTIs, outcomes analyzed, analysis of antibiotic side effects, and follow-up of subjects. Although continuous antibiotics were effective, no consensus existed related to how long to continue suppression. The studies analyzed in this review are several decades old, performed at a time when antibiotic resistance rates were much lower than those encountered today. Clearly long-term suppressive antibiotics pose a major risk to society because this practice undoubtedly will contribute to perpetuation of multidrug-resistant organisms. **Because of the risk of adverse effects of exposure to antibiotics, long-term treatment with daily prophylaxis is not an appropriate contemporary approach. Indeed, the European Association of Urology (EAU) guidelines for urologic infections state that recent concerns highlight**

the “need for reconsidering long-term antibiotic prophylaxis in recurrent UTI and assess in each individual case effective alternative preventive measures” (Grabe et al., 2015). If patients desire indefinite daily prophylaxis they should be educated that no long-term data exist in support of this strategy and that they are exposing themselves to potentially severe side effects and development of multidrug-resistant organisms.

Postcoital antibiotic use is an acceptable strategy in patients with a clear-cut causal relationship between intercourse and onset of UTIs when other management options have not been effective. Ideally, prior cultures with sensitivities should be taken into consideration when choosing an antibiotic, in addition to a patient's allergies as well as local resistance patterns and ecologic effects of the chosen agent.

Nitrofurantoin remains a popular choice for prophylaxis because it concentrates in urine, is efficacious against many uropathogens, and does not promote widespread resistance. However, nitrofurantoin is associated with significant adverse effects, particularly with long-term use. Unfortunately, providers do not routinely address the risk of pulmonary fibrosis or renal and neurotoxicity, and many patients are encouraged to take it daily, indefinitely, lacking appropriate counseling detailing the potential harm they may encounter in the future. A recent systematic review and meta-analysis of common antibiotics used for prophylaxis in women concluded that nitrofurantoin was equally as effective, in terms of clinical and microbiologic cure, as norfloxacin, trimethoprim, sulfamethoxazole/trimethoprim, cefaclor, estriol, or methenamine hippurate. However, it was also associated with increased risk of adverse effects, mostly related to the GI tract (Price et al., 2016).

Non-Antibiotic Management.

Although it has been historically acceptable to recommend AP, a review of the literature from the last 10 years suggests that the majority of recent research has focused on non-antibiotic strategies to prevent UTIs. Contemporary research corroborates that, although AP may be effective, increasing rates of antibiotic resistance and subsequent adverse ecologic effects associated with AP make this strategy less desirable. **It is imperative that we develop alternatives to antibiotics for minimizing UTIs without further contributing to the alarming rates of antibiotic resistance; as stated earlier more than two million illnesses and more than 20,000 deaths occur yearly because of antibiotic resistance.**

Recent articles have reviewed several forms of non-AP; one included a systematic review and meta-analysis of available randomized controlled trials (RCTs). The authors found that the oral immunostimulant OM-89, the vaginal vaccine Urovac, vaginal estrogen, cranberry, and acupuncture had varying degrees of success in lowering the risk of recurrent UTIs; however, oral estrogens and lactobacilli were not effective (Beerepoot et al., 2013). Another review article examined the efficacy of vitamin C, cranberry, estrogen, lactobacilli, methenamine, OM-89, and Urovac (Geerlings et al., 2014). Use of vitamin C was not deemed effective in reducing the incidence of UTIs, whereas the others had varying degrees of success. Researchers acknowledge that further studies must be undertaken, particularly comparisons between specific products and the gold-standard AP, before strong recommendations can be made in support of non-antibiotic strategies. In addition, standardized doses and products should be used in all studies to make the conclusions more powerful.

Cranberry.

Cranberry products for UTI prophylaxis have been investigated for years in the scientific and lay press. **One of the active ingredients in cranberry is the polyphenol type A proanthocyanidin (PAC), which prevents the P fimbriae of *E. coli* from adhering to uroepithelial cells** (Howell et al., 2010). Studies have investigated various formulations of cranberry, including juice/concentrate, capsules, tablets and extract, in comparison with placebo or no treatment (Barbosa-Cesnik et al., 2011; Kontiokari et al., 2001; Stothers, 2002). Other studies have examined the efficacy of cranberry versus AP (Beerepoot et al., 2011; McMurdo et al., 2009).

Some of the earlier studies were analyzed in a **Cochrane review from 2008** (Jepson and Craig, 2008). This review included 10 studies (1049 subjects) that investigated cranberry supplementation in patients with recurrent UTIs. Most of these studies (seven) evaluated use of juice, whereas tablet formulations were evaluated in four studies. One study investigated juice and tablets. Investigators concluded that cranberry was effective in reducing the incidence of recurrent UTIs in women as compared with older men or women, or people who required catheterization (either indwelling catheters or who performed CIC). Indeed, **in women with recurrent UTIs cranberry significantly reduced the incidence of UTIs at 1 year** (RR 0.65; 95% CI 0.46–0.90). As discussed by investigators who conducted this review, an obstacle in drawing conclusions about the efficacy of cranberry is that there was significant heterogeneity of products available and routes of administration, thus making the dosage of cranberry in each study population variable. Although side effects were minimal, there was a large dropout rate, particularly in those who ingested the juice.

A more recent Cochrane review added 14 more studies to the original review; thus a total of 24 studies (4473 subjects) were included (Jepson et al., 2012). In these investigations various cranberry formulations were evaluated and compared with placebo, water, antibiotics, methenamine, lactobacillus, or no treatment. In contrast to the earlier meta-analysis, these data reported that cranberry supplementation did not significantly reduce the symptomatic UTI rate overall, in comparison with water, placebo, or no treatment (RR 0.86; 95% CI 0.71–1.04). **In subgroup analysis, cranberry did not significantly reduce the recurrence rate of UTIs in any group, including in women with a history of recurrent UTIs (RR 0.74; 95% CI 0.42–1.31), a contradictory finding compared with the prior Cochrane review**. Interestingly, two of the studies compared cranberry capsules or syrup with AP in women with recurrent UTIs and found that cranberry was equally as effective as antibiotic in reducing the risk of recurrent UTIs (RR 1.31; 95% CI 0.85–2.02).

Although GI adverse effects were no higher in those who took cranberry products compared with placebo or no treatment, many studies did report low compliance rates/high dropout rates, which were attributed to tolerability of the products, particularly juice intake. **The authors of the review did acknowledge that most studies did not report on how much active ingredient, or PAC, the products had, and thus the products may not have been potent enough to achieve desired results**. **Based on this more recent review, cranberry juice cannot be recommended for prevention of recurrent UTIs; however, the efficacy of other cranberry products must be further examined and must include standardization of the preparation and confirmation of the presence of active ingredient. Based on prior research, 36 mg of PAC equivalents/day has been shown to be effective, but 72 mg may be even more effective** (Howell et al., 2010; Fig. 55.16). In addition, because the anti-adhesion effect is not long acting, the product should be taken twice a day.

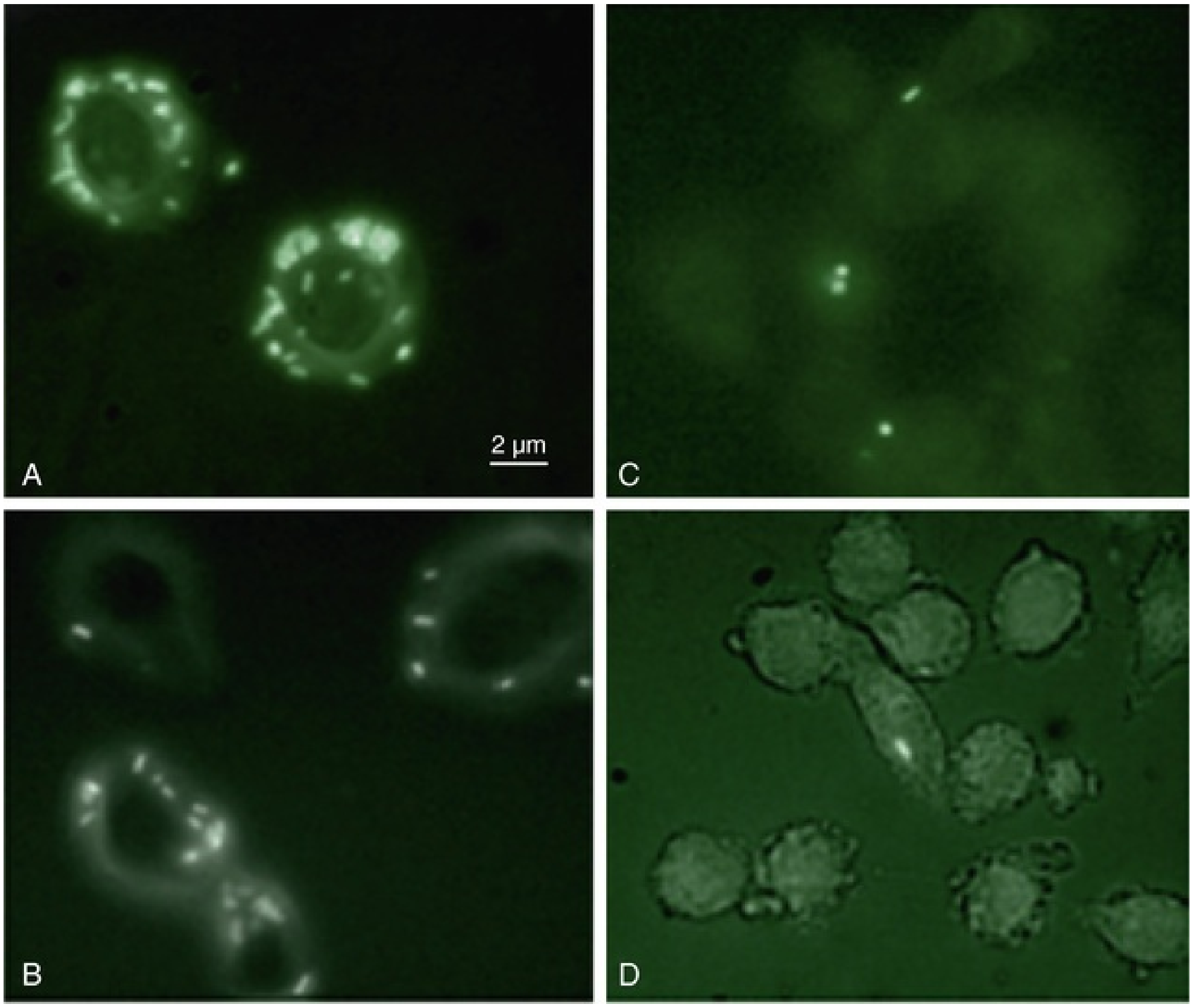

FIG. 55.16 *Escherichia coli* and effect of proanthocyanidin (PAC). (A) *E. coli* cultured in urines collected after placebo consumption. (B) *E. coli* cultured in urines collected 6 hours after consumption of cranberry powder containing 18-mg PAC. (C) *E. coli* cultured in urines collected 6 hours after consumption of cranberry powder containing 36-mg PAC. (D) *E. coli* cultured in urines collected 6 hours after consumption of cranberry powder containing 72-mg PAC.

Administering 72 mg of PAC daily to women in nursing homes was ineffective in decreasing the rates of bacteriuria plus pyuria, or of developing a symptomatic UTI, over a 1-year period (Juthani-Mehta et al., 2016). However, the majority of these women did not have bacteriuria plus pyuria or recurrent symptomatic UTIs before the study period, so the benefit of PAC may not have been as apparent as it may have been in a different cohort, namely those who were prone to UTIs. In addition, samples were obtained via midstream clean-catch samples, rather than catheterized samples, despite that these women were most likely atrophic and may have had comorbidities that made providing appropriate voided samples more challenging. Furthermore, postvoid residual volumes or degree of incontinence were not characterized; these are two known risk factors for bacteriuria in the elderly population. Although this study had significant limitations, some argued that these data confirm that “it is time to move on from cranberries” (Nicolle, 2016). However, challenging the efficacy of cranberry in preventing recurrent UTIs in all women based on results from a nursing home cohort does not seem wise.

The most recent systematic review and meta-analysis of cranberry products included 28 studies (4947 subjects) and concluded that ingestion of cranberry products confer a significant reduction in the risk of recurrent UTIs (Luis et al., 2017). A subgroup analysis determined that subjects with a history of recurrent UTIs and those who had undergone gynecologic surgery benefitted the most from cranberry products.

Although research has determined that a minimum quantity of 36 mg of PAC is most important in achieving efficacy against recurrent UTIs, few products report on the PAC content. In addition the cost of those products that report on PAC dosage may make them prohibitively expensive for some.

A pre-existing FDA warning to avoid cranberries and cranberry products when taking warfarin was removed in 2011. The concern about adverse interactions, specifically that cranberry elevates the INR and thus increases bleeding diathesis, has not been substantiated in scientific studies (Ansell et al., 2009; Mellen et al., 2010; Zikria et al., 2010). **Practitioners should feel comfortable recommending cranberry products even if their patient is taking warfarin.**

As evidenced by the contradictory conclusions of the Cochrane reviews, as well as various other articles reviewed, the efficacy of cranberry supplements in minimizing recurrent UTIs is controversial at best and remains an area ripe for more investigation. The authors do recommend cranberry supplements, ideally those with a minimum of 36 mg of PAC, based on our successful anecdotal experience.

Estrogen.

Postmenopausal women may have frequent reinfections (Hooton and Stamm, 1991; Raz and Stamm, 1993). Such infections are **sometimes attributable to residual urine** after voiding, which is often associated with bladder or uterine prolapse. **In addition,** decreased estrogen levels contribute to the transformation to atrophic vaginal epithelium and increased vaginal pH, which creates a more hospitable environment for bacteria to thrive. Indeed, **the lack of estrogen**

causes marked changes in the vaginal microflora, including a loss of lactobacilli and increased colonization by *E. coli* (Raz and Stamm, 1993). An early placebo-controlled study with 93 women showed that the use of vaginal estriol reduced the number of UTIs as compared with placebo (RR 0.25; 95% CI 0.13–0.50) (Raz, 1993). The UTI rate was significantly lower in the group that received the vaginal estriol (0.5 vs. 5.9 episodes per patient-year, $P < 0.001$) (Fig. 55.17). The efficacy was attributed to the reemergence of vaginal lactobacilli and the decrease in vaginal pH in those who received vaginal estrogen. Adverse effects were minimal, although there was a 28% dropout rate in the estrogen group as compared with 17% in the placebo group; the most common reason for dropout was bothersome local adverse reactions to estriol including vaginal burning, itching, or irritation. Another study compared the use of an estradiol-releasing vaginal ring to no estrogen administration and found that the use of vaginal estrogen lowered the likelihood of developing a UTI in postmenopausal women with a history of recurrent UTIs (RR 0.64; 95% CI 0.47–0.86; Eriksen, 1999).

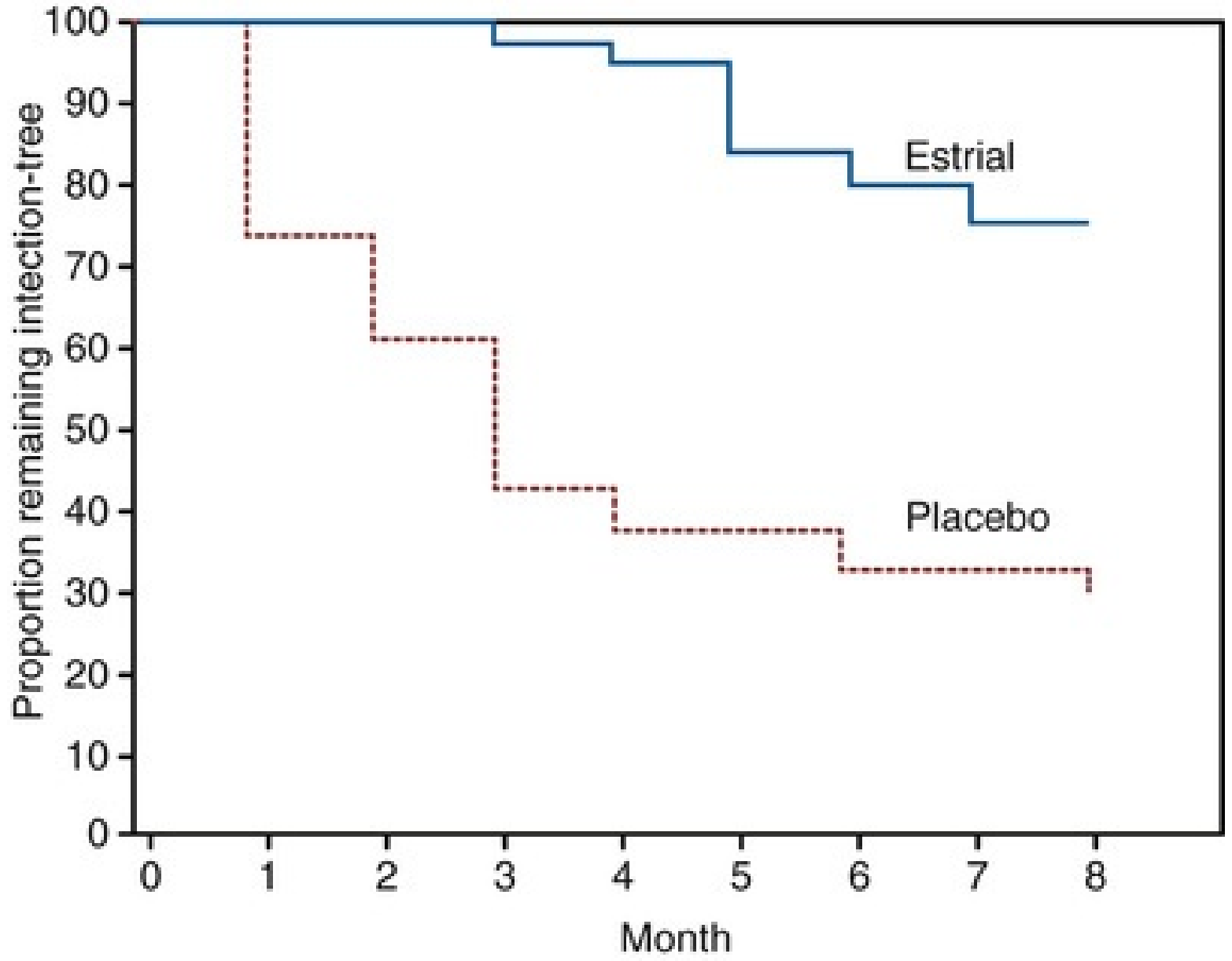

FIG. 55.17 Kaplan-Meier analysis showing the cumulative proportions of women remaining free of urinary tract infections in the Estriol and placebo groups ($P < 0.001$ by the Log-Rank Test). (Data from Raz R, Stamm WE: A controlled trial of intravaginal estriol in postmenopausal women with recurrent urinary tract infections, *N Engl J Med* 329(11):753–756, 1993.)

This literature was included in a **Cochrane review** that investigated the efficacy of oral and vaginal estrogen in preventing recurrent UTIs in postmenopausal women (Perrotta et al., 2008). A total of nine studies that included 3345 women were analyzed. Oral estrogens compared with placebo, analyzed in four studies, were not effective in preventing a UTI. Some of the studies comparing oral antibiotics to vaginal estrogen showed significant heterogeneity and results could not be pooled. Based on the two studies discussed earlier, the authors concluded that **vaginal estrogen is effective in preventing recurrent UTIs in postmenopausal women. The beneficial effect from vaginal estrogen use can take at least 12 weeks to manifest.** Adverse effects included breast tenderness, nonphysiologic discharge, and vaginal bleeding/spotting, irritation, itching and burning. Investigators encouraged the performance of future studies that investigated the optimal administration of vaginal estrogen.

A recent review of various forms of vaginal estrogen was performed and found that all forms (estrogen cream, tablets, and ring) improved symptoms of vaginal atrophy, but the impact on UTIs specifically was not analyzed (Lethaby et al., 2016).

Package inserts for vaginal estrogen preparations include warnings about potential systemic effects of estrogen administration, which likely contributes to some patients’ reluctance to initiate vaginal estrogen therapy. However, the boxed warnings refer to all forms of estrogen administration, regardless of route of administration, and concerns about the risks of *vaginal* estrogen have not been supported by scientific studies. Although estrogen is detectable in plasma after vaginal administration, the levels are lower compared with those achieved with oral administration of low-dose conjugated estrogens. Daily administration of low-dose vaginal estrogen resulted in steady-state estrogen concentrations that were noted to be within or slightly above the normal reference range for postmenopausal women (Dorr et al., 2010). Indeed, all low-dose vaginal estrogen preparations result in minimal systemic absorption that results in levels that do not exceed normal postmenopausal levels (Santen, 2015).

RCTs of vaginal estrogen use have not been designed to analyze outcomes such as cancer or cardiovascular disease. However, observational studies have found no increased risk of fracture or breast cancer in women who used vaginal estrogen (Lyytinen et al., 2006; Michaelsson et al., 2002). Analysis of data from subjects in the Women's Health Initiative Observational Study confirmed that vaginal estrogen preparations do not confer an increased risk of cancer or cardiovascular disease (Crandall et al., 2018).

Vaginal estrogen use in breast cancer survivors has been studied. An increased risk of breast cancer recurrence was not demonstrated (Dew et al., 2003; Le Ray et al., 2012), including in those who were taking tamoxifen. The safety of vaginal estrogen use in survivors who are taking aromatase inhibitors has not been clearly demonstrated (Wills et al., 2012). All of these studies focused on vaginal estrogen use for amelioration of symptoms secondary to vulvovaginal atrophy. Despite the lack of data demonstrating an increased risk of recurrence, vaginal estrogen use is generally discouraged in this population (Santen et al., 2017). However, for these women who are suffering from recurrent UTIs vaginal estrogen can be prescribed after endorsement from their oncologist. As discussed, data *do not* demonstrate an increased risk of cancer recurrence but *do* demonstrate a decreased risk of recurrent UTIs.

Laser therapy to treat symptoms associated with vulvovaginal atrophy has become popular in recent years as an alternative to hormonal therapies. The MonaLisa Touch laser is a fractional CO_2 laser designed for the vaginal mucosa. It stimulates the production of new collagen. Scientific data supporting this modality to decrease the risk of recurrent UTIs do not exist.

Probiotics.

Certain strains of lactobacilli can interfere with the presence of uropathogenic bacteria in the urogenital epithelium. The maintenance of normal urogenital flora may be enhanced by strains that produce antibacterial substances such as hydrogen peroxide (Falagas et al., 2006). Initial studies evaluated various strains for prevention of recurrent UTIs, including a *Lactobacillus* GC drink and the vaginal suppository *L. casei v rhamnosus* (Baerheim et al., 1994; Kontiokari et al., 2001). However, neither product proved effective in reducing the UTI recurrence rates. More recent studies using *L. crispatus* vaginal suppositories and *L. rhamnosus GR-1* and *L. reuteri RC-14* oral capsules showed more promising results (Beerepoot et al., 2012; Stapleton et al., 2011).

A Cochrane review published in 2015 examined the efficacy of probiotic use in women and children (Schwenger et al., 2015). This review included 9 studies; study design compared probiotics with placebo, no treatment, or antibiotics. Many forms and dosages of probiotics and duration of treatment were used in the studies reviewed. This review concluded that **probiotics cannot be recommended as an effective strategy for prevention of recurrent UTIs.** However, the authors acknowledge the studies reviewed were small and had design flaws. More investigation into the efficacy of probiotics is necessary before they become part of the urologist's treatment algorithm.

Methenamine.

Methenamine salts, which have been used for urinary indications for approximately 100 years, are 70% to 90% renally excreted and are converted to ammonia and formaldehyde in an acidic environment ($pH < 6$) (Lo et al., 2014). Formaldehyde is either bactericidal or bacteriostatic in urine depending on its concentration. To achieve acidification of the urine when these oral tablets are taken, high doses of ascorbic acid (vitamin C) (1–4 g) can be ingested in conjunction with the methenamine (recommended dose is 1 g twice daily). Two formulations of methenamine are FDA approved, methenamine hippurate and methenamine mandelate. Two early randomized placebo-controlled trials conducted in otherwise healthy women demonstrated a 56% to 75% reduction in recurrent UTIs with the use of methenamine mandelate 500 mg four times daily with ascorbic acid 500 mg four times daily, and methenamine hippurate 1 g twice daily without the addition of vitamin C (Cronberg et al., 1987; Harding, 1974). The acid salts, mandelate and hippurate, have nonspecific bacteriostatic properties and are therefore not effective against urease-producing bacteria. Methenamine is contraindicated if the creatinine clearance is less than 50 cc/min or in patients with severe liver disease or hypersensitivity to the drug or its components. It must also be avoided in patients who are also taking sulfonamides, antacids, and carbonic anhydrase inhibitors (Table 55.10).

TABLE 55.10

Methenamine Drug Interactions

Antacids: may diminish therapeutic effect
Carbonic anhydrase inhibitors: may diminish therapeutic effect
Sodium picosulfate: therapeutic effect may be diminished by concomitant methenamine use
Foods/diets that alkanize urine ($pH > 5.5$)[a]: may diminish therapeutic effect

[a] Almonds; chestnuts; flax, pumpkin, and sunflower seeds; berries; cherries; grapes; citrus; cantaloupe; figs; kiwi.

Data from Lo TS, Hammer KD, Zegarra M, Cho WC: Methenamine: a forgotten drug for preventing recurrent urinary tract infection in a multidrug resistance era. *Expert Rev Anti Infect Ther* 12(5):549–554, 2014.

A Cochrane Review published in 2012 included 13 studies (2032 subjects) of methenamine hippurate (Lee et al., 2012). Various doses were investigated in these studies, ranging from 1 to 4 g per day. Acidification agents were combined with methenamine in only two of the studies. Researchers concluded that there was significant heterogeneity in the studies reviewed; thus definitive conclusions could not be made. However, methenamine showed some benefit in patients with normal urinary tracts (symptomatic UTI: RR 0.24; 95% CI 0.07–0.89; bacteriuria: RR 0.56; 95% CI 0.37–0.83), but not in patients with anatomic abnormalities (symptomatic UTI: RR 1.54; 95% CI 0.38–6.20; bacteriuria: RR 1.29; 95% CI 0.54–3.07). **In patients who had normal urinary tracts and did not have indwelling catheters, short-term (≤7 days) therapy contributed to a significant reduction in symptomatic infections (RR 0.14; 95% CI 0.05–0.38).** Methenamine hippurate was not effective in patients with known urinary tract abnormalities. Adverse effects were infrequent; nausea and diarrhea were most frequently encountered.

Concern has been raised about the use of a product that gets converted to formaldehyde, which is listed as a carcinogen in the 2011 National Toxicology Program Report on Carcinogens. However, in this report, formaldehyde has been associated with nasopharyngeal cancer, sinonasal cancer, and lymphohematopoietic cancers. Formaldehyde was not listed as being associated with urothelial cancers. The risk of developing bladder cancer secondary to the use of methenamine thus appears to be theoretical (Geerlings et al., 2014).

D-Mannose.

D-mannose is a simple sugar that has shown some promise recently in preventing bacterial adhesion to the urothelium. It binds and blocks Fim H, an adhesin protein located at the tip of type 1 pili of enteric bacteria, therefore functioning as a competitive inhibitor of bacterial adhesion mechanisms. Historically it has been used for treating UTIs in some animals (Altarac and Papes, 2014). Recent studies have found that D-mannose was equally as efficacious as nitrofurantoin in reducing the risk of recurrent UTIs and demonstrated a significantly lower risk of adverse effects. D-mannose was also effective in reducing symptoms associated with acute cystitis as well as preventing recurrent UTIs (Domenici et al., 2016; Kranjcec et al., 2014). More studies must be performed to draw more definitive conclusions about the efficacy of D-mannose. Optimal dosing for D-mannose formulations remains unknown.

Immunoactive Prophylaxis.

Bacterial extracts have been investigated as potential prophylactic agents against UTIs. Oral and vaginal products exist and have been studied.

The oral immunostimulant OM-89 (Uro-Vaxum) is an extract that contains 18 serotypes of heat-killed uropathogenic *E. coli*. The different serotypes increase neutrophils and macrophage phagocytosis, thereby stimulating the host immune system to target uropathogenic *E. coli*. Several studies have investigated the efficacy of OM-89 in women with recurrent UTIs (Bauer et al., 2005; Magasi et al., 1994; Schulman et al., 1993; Tammen, 1990). A meta-analysis of these studies included 891 patients who took 1 capsule a day of OM-89 or placebo (Beerepoot et al., 2013). In the treated group the risk ratio of developing at least one UTI was significantly lower in the OM-89–treated group (RR 0.61; 95% CI 0.48–0.78). The mean number of UTIs was also about 50% lower in the treated group, as compared with placebo. Adverse effects were equally common in the treated and placebo groups, with headaches and GI complaints reported most frequently. The manufacturer of OM-89 funded some of the studies, so results must account for potential funding bias. A more recently conducted meta-analysis of existing studies of OM-89 identified 15 double-blind randomized controlled studies but only included 5 in their analysis because of methodologic flaws with the other 10 studies (Taha Neto et al., 2016). Although analysis of the literature demonstrated a benefit in favor of OM-89, the authors concluded that the studies were of variable quality, demonstrated potential reporting bias, and had short follow-up. They emphasized the need for future high-quality studies with longer follow-up before endorsement of OM-89 for use in prophylaxis is justified.

A vaginal vaccine (Urovac) that works via stimulating IgA and IgG in the urinary tract and subsequently decreasing potential colonization of uropathogens has also been studied (Hopkins et al., 2007). The vaccine contains 10 heat-killed uropathogenic bacterial species, including six serotypes of uropathogenic *E. coli, Proteus vulgaris, K. pneumoniae, Morganella morganii*, and *E. faecalis*. Three trials that included 220 women total were conducted by the same group of investigators. In one trial, primary immunization (three vaginal vaccine suppositories at weekly intervals) was compared with placebo (Uehling et al., 1997); in the other two trials booster immunizations (three additional suppositories at monthly intervals) followed initial primary immunization (Hopkins et al., 2007; Uehling et al., 2003). Women who received the boosters were less likely to develop a UTI. A meta-analysis of these three studies concluded that Urovac slightly reduced recurrent UTI rates (RR 0.81; 95% CI

0.68–0.96) (Beerepoot et al., 2013). More studies with much larger numbers of subjects must be conducted before robust conclusions can be made about Urovac.

In 2019 the AUA released a guideline on evaluation and management of recurrent uncomplicated UTIs in women (American Urological Association, 2019).

Key Points: Recurrent Urinary Tract Infections

- Obtaining a thorough history is critical, with emphasis on prior symptoms, urinalysis and culture results, and triggers for infections.
- Sources of possible bacterial persistence must be identified and eradicated.
- Imaging and cystoscopy are NOT recommended for recurrent uncomplicated UTIs.
- Prevention of recurrence should focus on nonantibiotic interventions.

Kidney Infections

Renal Infection (Bacterial Nephritis)

Although renal infection is less prevalent than bladder infection, it often is a more difficult problem for the patient and his or her physician because of its often varied and morbid presentation and course, the difficulty in establishing a firm microbiologic and pathologic diagnosis, and its potential for significantly impairing renal function. **Although the classic symptoms of acute onset of fever, chills, and flank pain are usually indicative of renal infection, some patients with these symptoms do not have renal infection. Conversely, significant renal infection may be associated with an insidious onset of nonspecific local or systemic symptoms, or it may be entirely asymptomatic.** Therefore a high clinical index of suspicion and appropriate radiologic and laboratory studies are required to establish the diagnosis of renal infection.

Unfortunately, **the relationship between laboratory findings and the presence of renal infection often is poor. Bacteriuria and pyuria, the hallmarks of UTI, are not predictive of renal infection. Conversely, patients with significant renal infection may have sterile urine if the ureter draining the kidney is obstructed or the infection is outside of the collecting system.**

The pathologic and radiologic criteria for diagnosing renal infection may also be misleading. Interstitial renal inflammation, once thought to be caused predominantly by bacterial infection, is now recognized as a nonspecific histopathologic change associated with a variety of immunologic, congenital, or chemical lesions that usually develop in the absence of bacterial infection. Infectious granulomatous diseases of the kidney often have either radiologic or pathologic characteristics that mimic renal cystic disease, neoplasia, or other renal inflammatory disease.

The effect of renal infection on renal function is varied. Acute or chronic pyelonephritis may transiently or permanently alter renal function, but nonobstructive pyelonephritis is no longer recognized as a major cause of renal failure (Baldassarre and Kaye, 1991; Fraser et al., 1995). However, pyelonephritis, when associated with urinary tract obstruction or granulomatous renal infection, may lead rapidly to significant inflammatory complications, renal failure, or even death.

Pathology

The opportunity for pathologic confirmation of **acute bacterial nephritis** is rare. The kidney may be edematous. Focal acute suppurative bacterial nephritis caused by hematogenous dissemination of bacteria to the renal cortex is characterized by multiple focal areas of suppuration on the surface of the kidney (Fig. 55.18). Histologic examination of the renal cortex shows focal suppurative destruction of glomeruli and tubules. Adjacent cortical structures and the medulla are not involved in the inflammatory reaction. **Acute ascending pyelonephritis** is characterized by linear bands of inflammation extending from the medulla to the renal capsule (Fig. 55.19). Histologic examination usually reveals a focal wedge-shaped area of acute interstitial inflammation with the apex of the wedge in the renal medulla. Polymorphonuclear leukocytes or a predominantly lymphocytic and plasma cell response are seen. Bacteria also may be present.

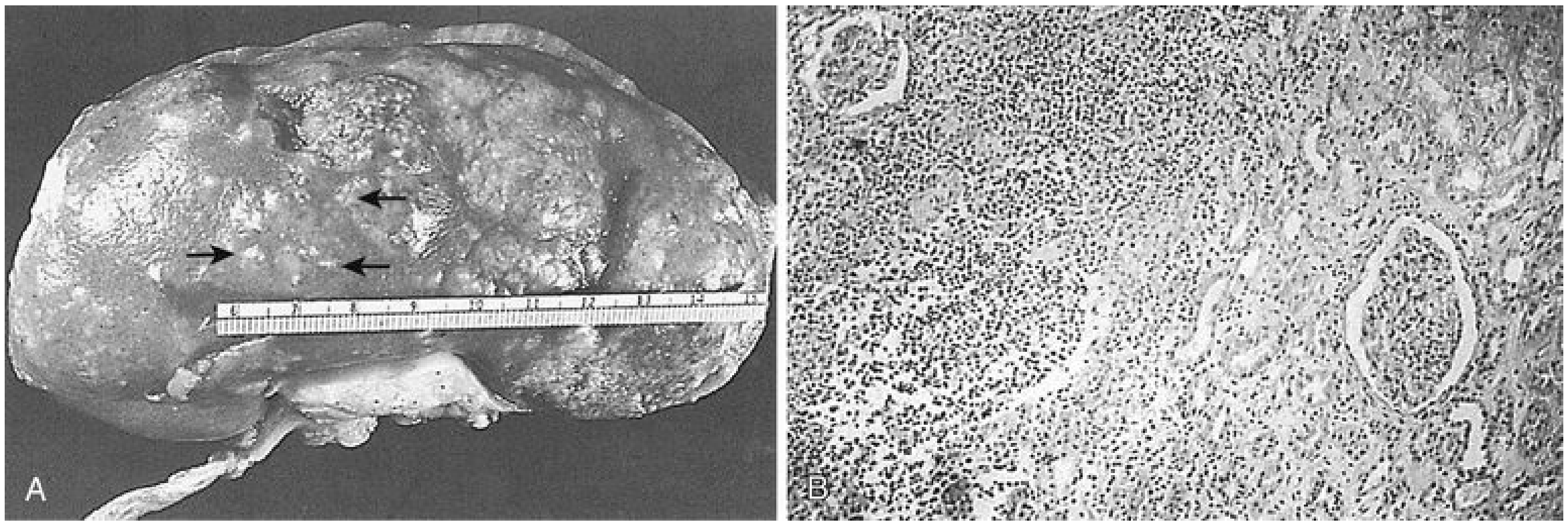

FIG. 55.18 Acute focal suppurative bacterial nephritis. (A) Surface of kidney. *Arrows* indicate focal areas of suppuration. (B) Renal cortex showing focal suppuration destruction of glomeruli and tubules. (From Schaeffer AJ: Urinary tract infections. In Gillenwater JY, Grayhack JT, Howards SS, et al., editors: *Adult and pediatric urology*, Philadelphia, 2002, Lippincott Williams & Wilkins, pp 211–272.)

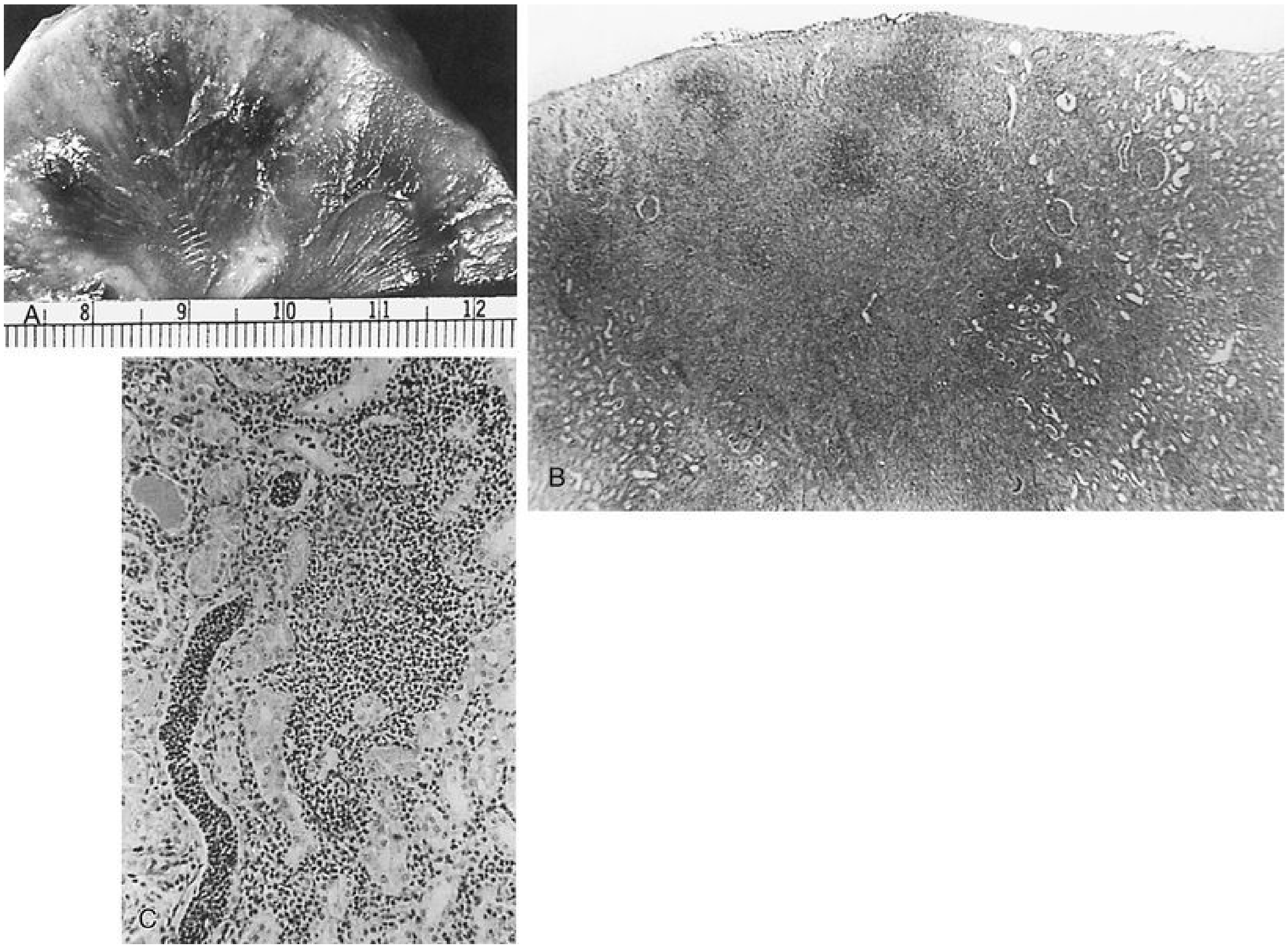

FIG. 55.19 Acute ascending pyelonephritis. (A) Cortical structures, tubules, and collecting ducts diffusely infiltrated with inflammatory cells. (B) Section of the renal cortex showing wedge-shaped destruction of renocortical structures as a result of ascending infiltration with inflammatory cells. (C) Thickened and inflamed tissue surrounding the collecting ducts in the medulla. A polymorphonuclear cast of segmented neutrophils is clearly visible. (From Schaeffer AJ: Urinary tract infections. In Gillenwater JY, Grayhack JT, Howards SS, et al., editors: *Adult and pediatric urology,* Philadelphia, 2002, Lippincott Williams & Wilkins, pp 211–272.)

The changes that appear to be most specific for **chronic pyelonephritis** are evident on careful gross examination of the kidney and consist of a cortical scar associated with retraction of the corresponding renal papilla (Freedman, 1979; Heptinstall, 1974; Hodson, 1965; Hodson and Wilson, 1965). The kidney shows evidence of patchy involvement with numerous chronic inflammatory foci mainly confined to the cortex but also involving the medulla (Fig. 55.20).

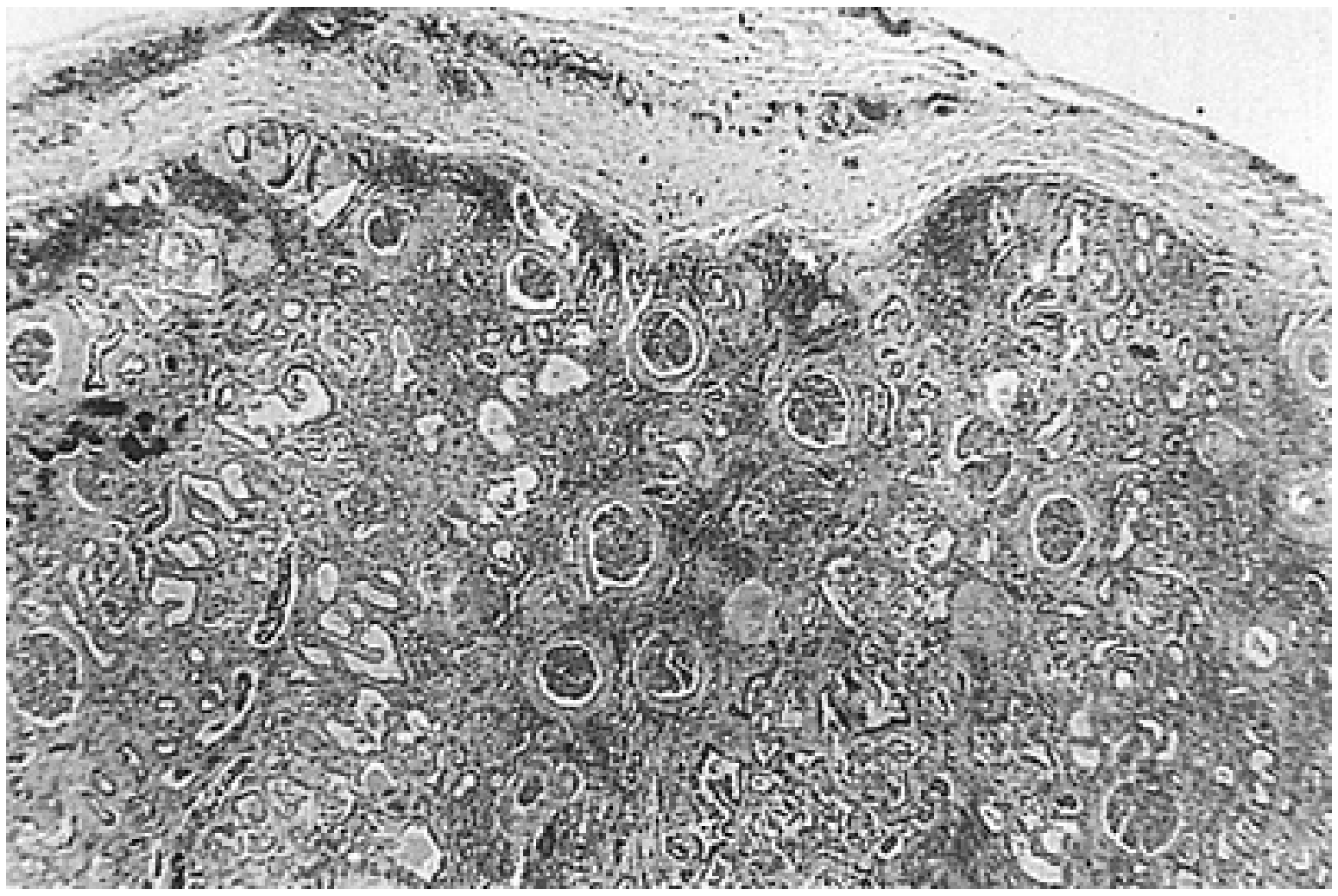

FIG. 55.20 Chronic pyelonephritis. The renal cortex shows thickened fibrous capsule and focal retracted scar on surface of kidney. Focal destruction of tubules in center of picture is accompanied by periglomerular fibrosis and scarring. (From Schaeffer AJ: Urinary tract infections. In Gillenwater JY, Grayhack JT, Howards SS, et al., editors: *Adult and pediatric urology,* Philadelphia, 2002, Lippincott Williams & Wilkins, pp 211–272.)

The scars may be separated by intervening zones of normal parenchyma, causing a grossly irregular renal outline. The microscopic appearance, as with most chronic interstitial disease, includes the presence of lymphocytes and plasma cells. Although glomeruli within scars may be surrounded by a cuff of fibrosis or be partially or completely hyalinized, glomeruli outside these severely scarred zones are relatively normal. Vascular involvement is variable, but in patients with hypertension, nephrosclerosis may be found. Papillary abnormalities include deformity, sclerosis, and sometimes necrosis. Studies in animals have clearly indicated the critical role of the papilla in the initiation of pyelonephritis (Freedman and Beeson, 1958). However, these changes are not necessarily specific for bacterial infection and may occur in the absence of infection as a result of other disorders such as analgesic abuse, diabetes, and sickle cell disease.

Acute Pyelonephritis

Although pyelonephritis is defined as inflammation of the kidney and renal pelvis, the diagnosis is clinical. True infection of the "upper urinary tract" can be proved by catheterization tests (ureteral catheterization or bladder washout) as described in this chapter, but these are impractical and unnecessary in most patients with acute pyelonephritis. None of the noninvasive tests that have been developed to determine infection in the kidney or bladder are totally reliable.

Clinical Presentation.

The clinical spectrum ranges from gram-negative sepsis to cystitis with mild flank pain (Stamm and Hooton, 1993)**. The classic presentation is an abrupt onset of chills, fever (100.3°F or greater), and unilateral or bilateral flank or costovertebral angle pain and/or tenderness. These so-called upper tract signs are sometimes accompanied by dysuria, increased urinary frequency, and urgency, but in many cases lower urinary symptoms are not present.**

Although some authors regard loin pain and fever in combination with significant bacteriuria as diagnostic of acute pyelonephritis, it is clear from localization studies using ureteral catheterization (Stamey and Pfau, 1963) or the bladder washout technique (Fairley et al., 1967) that **clinical symptoms correlate poorly with the site of infection** (Eykyn et al., 1972; Fairley, 1972; Smeets and Gower, 1973; Stamey et al., 1965).

On physical examination, there often is tenderness to deep palpation in the costovertebral angle. Variations of this clinical presentation have been recognized. Acute pyelonephritis may also simulate GI tract abnormalities with abdominal pain, nausea, vomiting, and diarrhea. Asymptomatic progression of acute pyelonephritis to chronic pyelonephritis, particularly in compromised hosts, may occur in the absence of overt symptoms. Acute renal failure may be present in the rare case (Olsson et al., 1980; Richet and Mayaud, 1978).

Laboratory Diagnosis.

The patient may have leukocytosis with a predominance of neutrophils. **Urinalysis usually reveals numerous WBCs, often in clumps, and bacterial rods or chains of cocci. The presence of large amounts of granular or leukocyte casts in the urinary sediment is suggestive of acute pyelonephritis.** A specific type of urinary cast characterized by the presence of bacteria in its matrix has been demonstrated in the urine of patients who have had acute pyelonephritis (Fig. 55.21; Lindner et al., 1980). Blood tests may show leukocytosis with a predominance of neutrophils, increased erythrocyte sedimentation rate, elevated C-reactive protein levels, and elevated creatinine levels if renal failure is present. In addition, creatinine clearance may be decreased. Blood cultures may be positive.

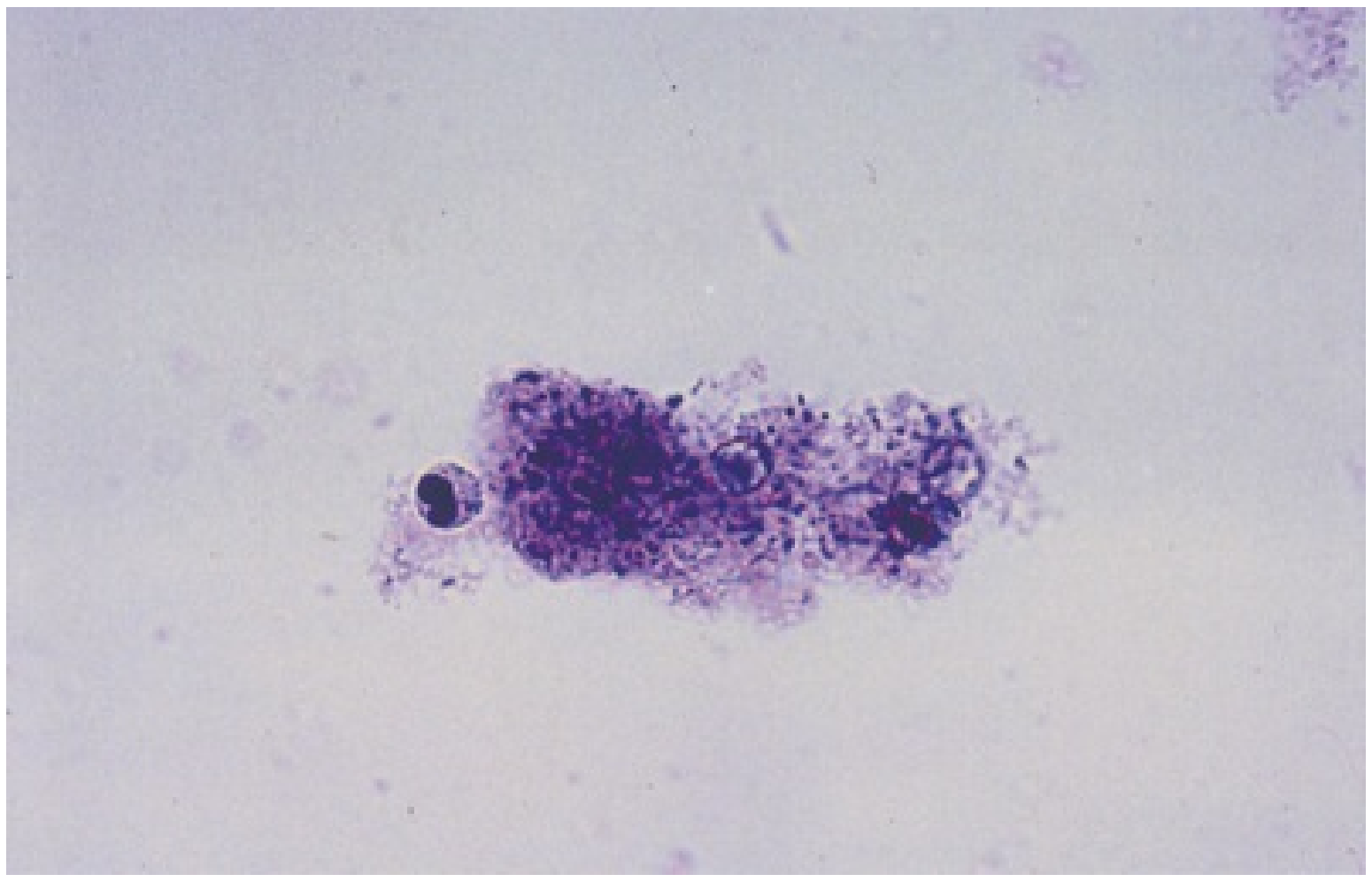

FIG. 55.21 Brightfield micrograph of a mixed bacterial leukocyte cast from patient with acute pyelonephritis. Only the bacteria and the nucleus of a leukocyte stain strongly. Many bacteria are clearly demonstrated by through-focusing (toluidine blue O stain, magnification ×640). (Modified from Lindner LE, Jones RN, Haber MH: A specific urinary cast in acute pyelonephritis. *Am J Clin Pathol* 73:809–811, 1980.)

Bacteriology.

Urine cultures are positive, but about 20% of patients have urine cultures with fewer than 10^5 CFU/mL and therefore negative results on Gram staining of the urine (Rubin et al., 1992).

***E. coli*, which constitutes a unique subgroup that possesses special virulence factors, accounts for 80% of cases.** If VUR is absent, a patient bearing the P blood group phenotype may have special susceptibility to recurrent pyelonephritis caused by *E. coli* that have P pili and bind to the P blood group antigen receptors (Lomberg et al., 1983). Bacterial K antigens and endotoxins also may contribute to pathogenicity (Kaijser et al., 1977). Many cases of community-acquired pyelonephritis are caused by a limited number of multiantimicrobial-resistant clonal groups (Manges et al., 2004).

More resistant species, such as *Proteus, Klebsiella, Pseudomonas, Serratia, Enterobacter,* or *Citrobacter,* should be suspected in patients who have recurrent UTIs, are hospitalized, or have indwelling catheters, as well as in those who required recent urinary tract instrumentation. Except for *E. faecalis, S. epidermidis,* and *S. aureus,* gram-positive bacteria rarely cause pyelonephritis.

Blood cultures are positive in about 25% of cases of uncomplicated pyelonephritis in women, and the majority replicate the urine culture and

do not influence decisions regarding therapy. Therefore blood cultures should not be routinely obtained for the evaluation of uncomplicated pyelonephritis in women. **However, they should be performed in men and women with systemic toxicity or in those requiring hospitalization or with risk factors such as pregnancy** (Velasco et al., 2003).

Renal Ultrasonography, Computed Tomography, and Magnetic Resonance Imaging.

Ultrasound may show focal parenchymal swelling and regions of increased or decreased echogenicity (Fig. 55.22). CT and MRI also may show focal swelling and diminished and inhomogeneous parenchymal contrast enhancement (Fig. 55.23). Without contrast, CT may show diminished density of affected areas and MRI may show regions of restricted diffusion. Acute pyelonephritis may cause chronic renal scarring; however, radiographic changes usually resolve; therefore future renal imaging will show a normal-appearing kidney.

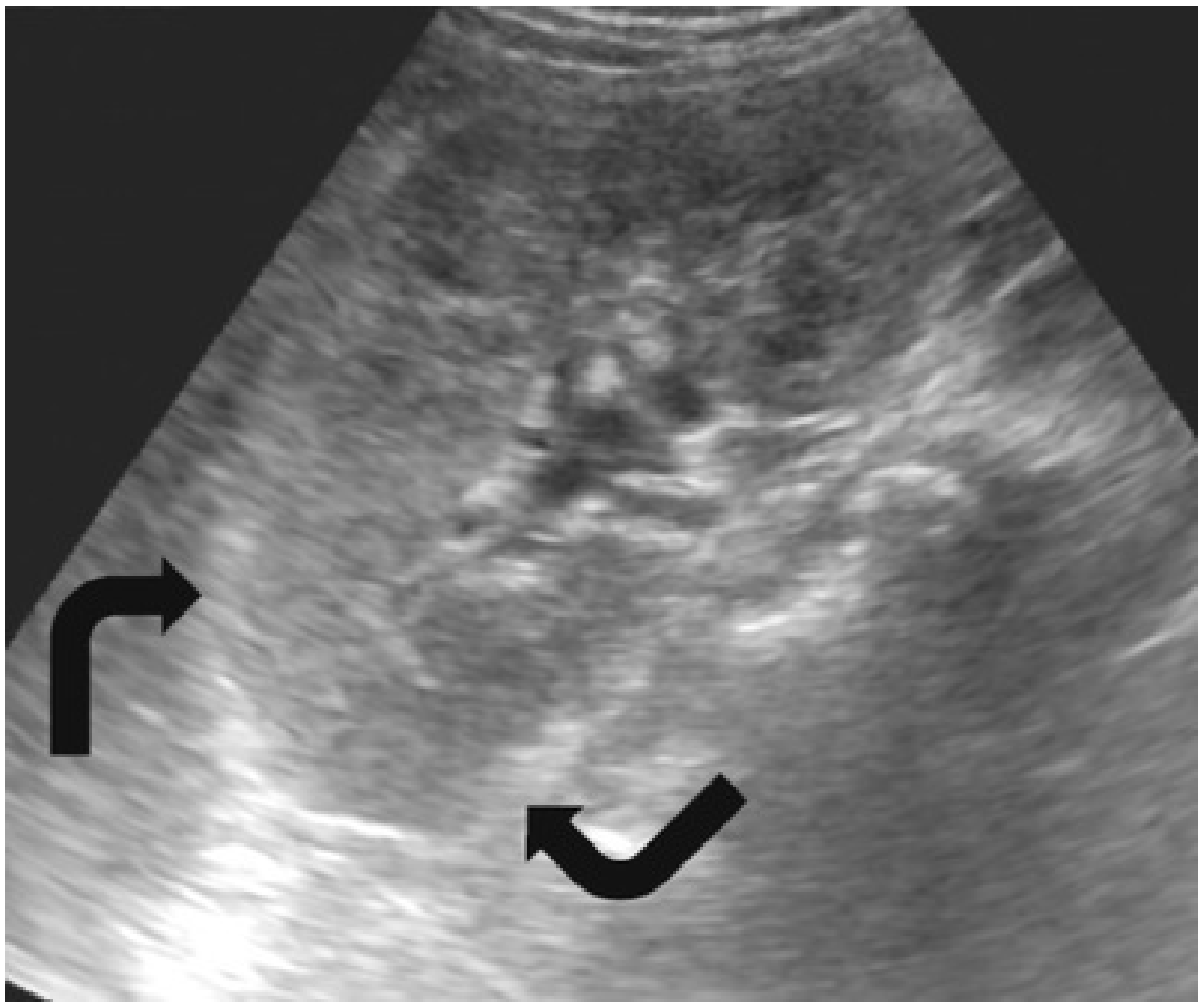

FIG. 55.22 Ultrasound of acute pyelonephritis. *Arrows* show abnormally echogenic and swollen upper pole.

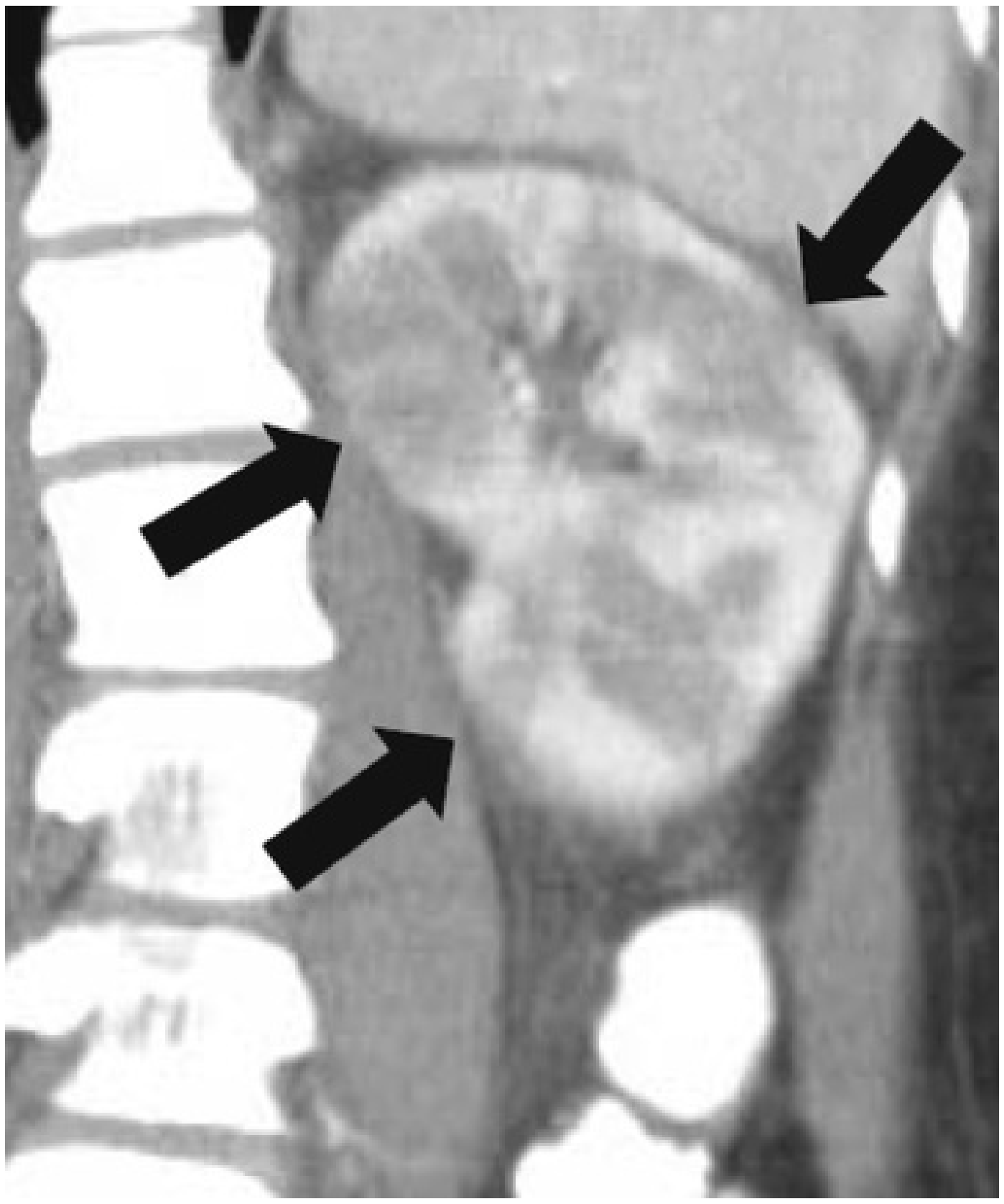

FIG. 55.23 Computed tomography of focal pyelonephritis. *Arrows* show patchy regions of diminished heterogeneous enhancement and swelling.

Differential Diagnosis.

Acute appendicitis, diverticulitis, and pancreatitis can cause a similar degree of pain, but the location of the pain often is different. Results of the urine examination are usually normal. Herpes zoster can cause superficial pain in the region of the kidney but is not associated with symptoms of UTI; the diagnosis will be apparent when shingles appear.

Management

Initial Management.

Infection in patients with acute pyelonephritis can be subdivided into (1) uncomplicated infection that does not warrant hospitalization, (2) uncomplicated infection in patients with normal urinary tracts who are ill enough to warrant hospitalization for parenteral therapy, and (3) complicated infection associated with hospitalization, catheterization, urologic surgery, or urinary tract abnormalities (Fig. 55.24).

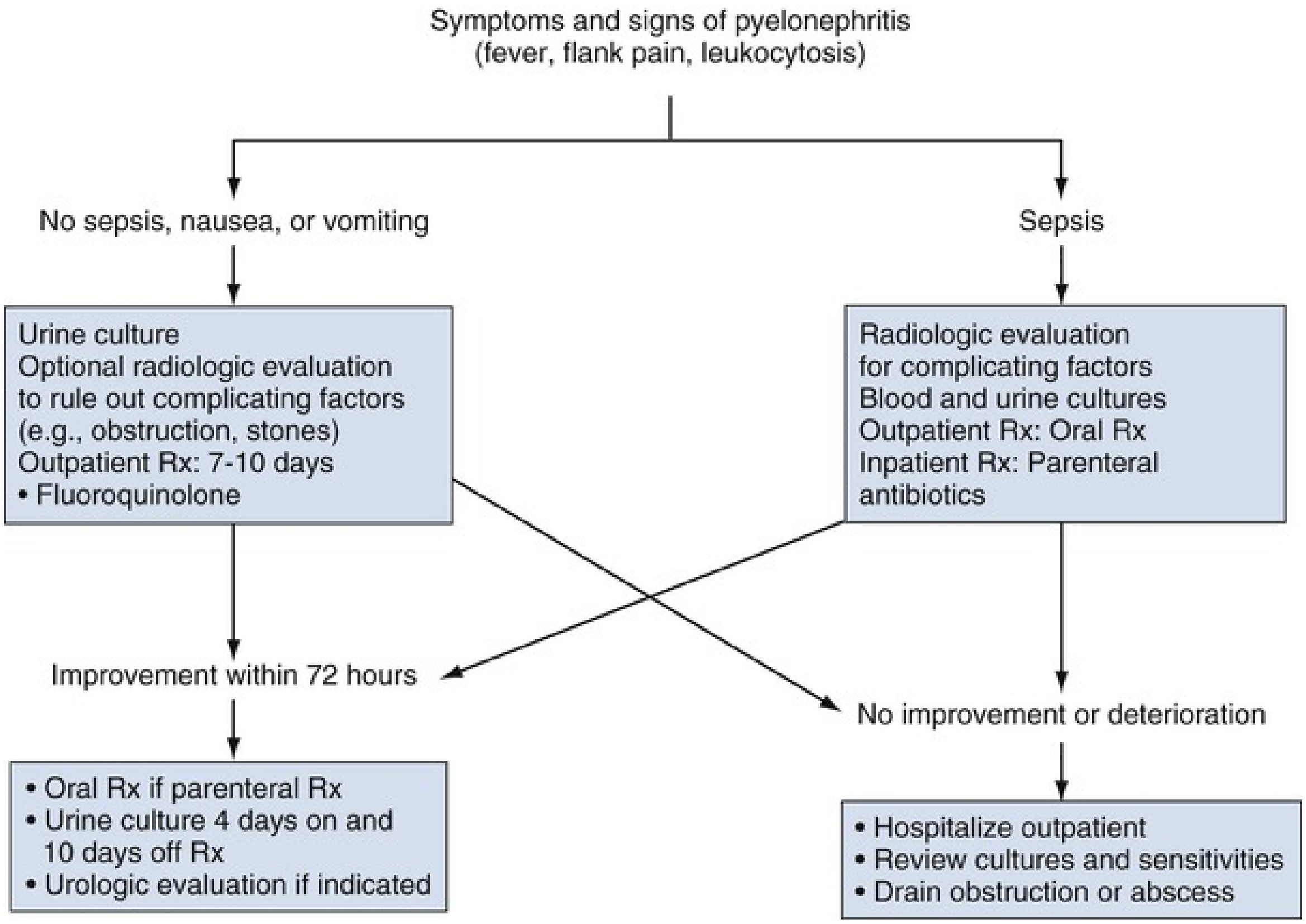
Symptoms and signs of pyelonephritis
(fever, flank pain, leukocytosis)
No sepsis, nausea, or vomiting
Sepsis
Urine culture
Optional radiologic evaluation
to rule out complicating factors
(e.g., obstruction, stones)
Outpatient Rx: 7-10 days
• Fluoroquinolone
Radiologic evaluation
for complicating factors
Blood and urine cultures
Outpatient Rx: Oral Rx
Inpatient Rx: Parenteral
antibiotics
Improvement within 72 hours
No improvement or deterioration
• Oral Rx if parenteral Rx
• Urine culture 4 days on and
10 days off Rx
• Urologic evaluation if indicated
• Hospitalize outpatient
• Review cultures and sensitivities
• Drain obstruction or abscess

FIG. 55.24 Management of acute pyelonephritis.

It is critical to determine whether the patient has an uncomplicated or complicated UTI because significant abnormalities have been found in 16% of patients with acute pyelonephritis (Shen and Brown, 2004). In patients with presumed uncomplicated pyelonephritis who will be managed as outpatients, initial radiologic evaluation can usually be deferred. **However, if there is any reason to suspect a problem or if the patient will not have reasonable access to imaging if there should be no change in condition, we prefer renal ultrasonography to rule out stones or obstruction.** In patients with known or suspected complicated pyelonephritis, CT provides excellent assessment of the status of the urinary tract and the severity and extent of the infection.

Oral ciprofloxacin (500 mg twice daily) for 7 days is an appropriate first-line therapy in patients not requiring hospitalization where the prevalence of uropathogen resistance to quinolones in the community does not exceed 10%, as per the IDSA guidelines on management of acute pyelonephritis (Gupta et al., 2011). If an initial one-time parenteral dose of antibiosis is chosen, a long-acting agent such as 1 g of ceftriaxone or a consolidated 24-hour dose of an aminoglycoside can be used as an alternative to an intravenous fluoroquinolone (Gupta et al., 2011). Once-daily oral fluoroquinolones, such as ciprofloxacin 1000 mg extended release for 7 days or levofloxacin 750 mg for 5 days, are also reasonable alternatives in non-hospitalized patients in whom resistance patterns in the community are low (Gupta et al., 2011). Oral TMP-SMX (160/800 mg [1 double-strength tablet] twice daily for 14 days) is an appropriate agent if the organism is known to be sensitive; if the susceptibility is unknown, an initial intravenous dose of a long-acting parenteral antibiotic, such as 1 g ceftriaxone or a consolidated 24-hour dose of an aminoglycoside is recommended (Gupta et al., 2011; Talan et al., 2000) (Table 55.11). As mentioned in previous sections, with the emerging resistance and potential for collateral damage associated with quinolones, future guidelines will likely need to address the role of cephalosporins for outpatient treatment of pyelonephritis.

TABLE 55.11

Treatment Regimens for Acute Complicated and Uncomplicated Pyelonephritis in Women

CIRCUMSTANCES	ROUTE	DRUG	DOSAGE[e]	FREQUENCY PER DOSE	DURAT (DAYS)
Outpatient—moderately ill, no nausea or vomiting	Oral[a]	TMP-SMX DS[b]	160–800 mg	q12h	14
		Ciprofloxacin[c]	500 mg	q12h	7
		Ciprofloxacin[c] (extended release)	1000 mg	q24h	7
		Levofloxacin[c]	750 mg	q24h	5
Inpatient—severely ill, possible sepsis	Parenteral[d]	Ampicillin and gentamicin	1–2 g	q6h	10–14
			1–1.5 mg/kg	q8h	
		Levofloxacin[c]	500–750 mg	q24h	10–14
		Ceftriaxone	1 g	q24h	10–14
		Carbapenem	(dosage varies)		10–14
Pregnant	Parenteral[d]	Ampicillin	1–2 g	q6h	10–14

		and gentamicin			
			1–1.5 mg/kg	q8h	
		Aztreonam	1 g	q8h	10–14
	Oral	Cephalexin	500 mg	q6h	

[a] May be given with an initial 1-time intravenous dose of a long-acting parenteral antimicrobial such as 1 g of ceftriaxone or a consolidated 24-hour dose of an aminoglycoside. See IDSA recommendations.

[b] Appropriate choice if uropathogen is known to be susceptible. If susceptibility is unknown, an initial dose of long-acting parenteral antimicrobial such as 1 g of ceftriaxone or a consolidated 24-hour dose of an aminoglycoside is recommended.

[c] May be used in areas where the prevalence of resistance of community uropathogens to fluoroquinolones is not known to exceed 10%.

[d] For parenteral agents, take until afebrile then transition to oral agents according to sensitivities.

[e] All dosages should be adjusted for renal function.

DS, Double strength; *TMP-SMX,* trimethoprim-sulfamethoxazole.

If a patient has an uncomplicated infection but is sufficiently ill to require hospitalization (high fever, high WBC count, vomiting, dehydration, evidence of sepsis), has complicated pyelonephritis, or fails to improve during the initial outpatient treatment period, a parenteral antibiotic is recommended. In women with pyelonephritis requiring hospital admission, recent IDSA guidelines recommend an intravenous regimen such as a fluoroquinolone, an aminoglycoside with or without ampicillin, an extended-spectrum cephalosporin with or without an aminoglycoside, or a carbapenem (Gupta et al., 2011; Warren et al., 1999). If gram-positive cocci are causative, ampicillin/sulbactam with or without an aminoglycoside is recommended.

Hospitalization, IV fluids, and antipyretics are required.

Overall kidney function is not affected in the presence of unilateral obstruction. **However, a solitary obstructed kidney causes acute renal failure; antimicrobial agents are dosed based on the GFR. Any substantial obstruction must be relieved expediently by the safest and simplest means, such as ureteral stent or percutaneous nephrostomy tube placement.**

A Gram stain of the urine sediment is helpful to guide the selection of the initial empirical antimicrobial therapy. In all cases, antimicrobial therapy should be active against potential uropathogens and achieve antimicrobial levels in renal tissue and urine.

Subsequent Management.

Even though the urine usually becomes sterile within a few hours of starting antimicrobial therapy, patients with acute uncomplicated pyelonephritis may continue to have fever, chills, and flank pain for several more days after initiation of successful antimicrobial therapy (Behr et al., 1996). They should be observed.

Alterations in antimicrobial therapy may be made depending on the patient's clinical response and the results of the culture and susceptibility tests. Susceptibility tests should also be used to replace potentially toxic drugs, such as aminoglycosides, with less toxic drugs, such as aztreonam and cephalosporins.

Patients with complicated pyelonephritis and positive blood cultures should be treated with parenteral therapy until clinically stable. If blood cultures are negative, 2- to 3-day parenteral therapy is sufficient. After parenteral therapy, an appropriate oral antimicrobial drug (fluoroquinolone, TMP, TMP-SMX, or amoxicillin or amoxicillin/clavulanic acid for gram-positive organisms) should be continued in full dosage for an additional 10 to 14 days.

Unfavorable Response to Therapy.

When the response to therapy is slow or the urine continues to show infection, an immediate reevaluation is mandatory. Urine and blood cultures must be repeated and appropriate alterations in antimicrobial therapy made on the basis of susceptibility testing. CT is indicated to attempt to identify unsuspected obstructive uropathy, abscess formation, urolithiasis, or underlying anatomic abnormalities that may have predisposed the patient to infection, prevented a rapid therapeutic response, or caused complications of the infectious process, such as renal or perinephric abscess. **In patients with fever lasting longer than 72 hours, CT is most helpful for ruling out obstruction and identifying renal and perirenal infections** (Soulen et al., 1989). Radionuclide imaging may be useful to demonstrate functional changes associated with acute pyelonephritis (decrease in renal blood flow, delay in peak function, and delay in excretion of the radionuclide) (Fischman and Roberts, 1982) and cortical defects associated with VUR.

Follow-Up.

Depending on the clinical presentation and response and initial urologic evaluation, some patients may require additional evaluation (e.g., VCUG, cystoscopy, bacterial localization studies) and correction of an underlying abnormality of the urinary tract. Raz et al. (2003) evaluated the long-term impact of acute pyelonephritis in women. Scanning with ^{99m}Tc-dimercaptosuccinic acid (^{99m}Tc-DMSA) 10 to 20 years after acute pyelonephritis revealed scars in approximately 50% of the patients, but changes in renal function were minimal and not associated with renal scarring.

Acute Focal or Multifocal Bacterial Nephritis

Acute focal or multifocal bacterial nephritis is an uncommon, severe form of acute renal infection in which a heavy leukocyte infiltrate is confined to a single renal lobe (focal) or multiple lobes (multifocal).

Clinical Presentation.

The clinical presentation of patients with acute bacterial nephritis is similar to that of patients with acute pyelonephritis but usually is more severe. About half of the patients are diabetic, and sepsis is common. Generally, leukocytosis and UTI resulting from gram-negative organisms are found; more than 50% of the patients are bacteremic (Wicks and Thornbury, 1979). There is growing evidence that acute focal bacterial nephritis (AFBN) represents a midpoint on the spectrum between pyelonephritis and renal abscess.

Radiologic Findings.

The diagnosis must be made by radiologic examination. The mass has slightly less nephrographic density than the surrounding normal renal parenchyma.

Ultrasonography and CT establish the diagnosis. On ultrasonography, the lesion is typically poorly marginated and relatively sonolucent with occasional low-amplitude echoes that disrupt the cortical medullary junction (Corriere and Sandler, 1982; eFig. 55.25A). **Enhancement with a contrast agent is necessary with CT studies because the lesion is difficult to visualize on the unenhanced study** (eFig. 55.25B). **Wedge-shaped areas of decreased enhancement are seen.** No definite wall is evident, and frank liquefaction is absent. Conversely, abscesses tend to have liquid centers, are usually round, and are present before and after contrast medium enhancement. More chronic abscesses may also show a ring-shaped area of increased enhancement surrounding the lesion (Corriere and Sandler, 1982). Gallium scanning reveals uptake that is in the region of and larger than the previously demonstrated mass (Rosenfield et al., 1979). In patients with multifocal disease, the findings are similar but multiple lobes are involved.

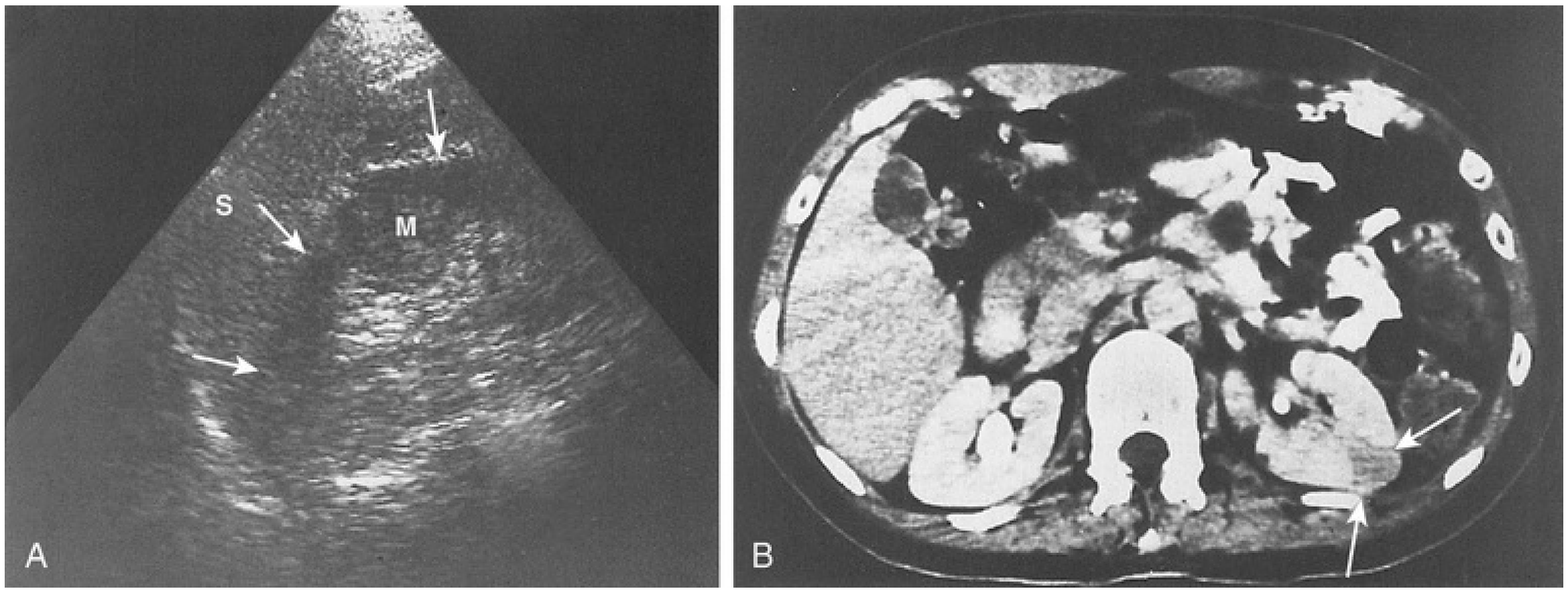

EFIG. 55.25 Acute focal bacterial nephritis. (A) Ultrasound image; longitudinal view of the left kidney demonstrates spleen *(S)* and left kidney *(arrows).* Note irregular midpole mass *(M)* of slightly higher echo texture than surrounding normal renal parenchyma. (B) Contrast medium–enhanced computed tomography scan demonstrates a wedge-shaped area of low density *(arrows)* in the middle portion of the left kidney. The findings resolved after antimicrobial therapy. (From Schaeffer AJ: Urinary tract infections. In Gillenwater JY, Grayhack JT, Howards SS, et al., editors: *Adult and pediatric urology,* Philadelphia, 2002, Lippincott Williams & Wilkins, pp 211–272.)

Management.

Acute bacterial nephritis probably represents a relatively early phase of frank abscess formation. In a series of cases reported by Lee et al. (1980), a patient with acute focal bacterial nephritis progressed to abscess formation. McCoy et al. (1985) reported radiographically proven progression from acute nephritis to an abscess despite appropriate medical management. Shimizu et al. (2005) presented a case of a 16-year-old female with CT imaging consistent with AFBN and no evidence of drainable fluid collection, which progressed by hospital day 13 to a hypodense large abscess in the area previously seen to be nephritis while being treated. **Treatment includes hydration and IV antimicrobial agents for at least 7 days, followed by 7 days of oral antimicrobial therapy.** Patients with bacterial nephritis typically respond to medical therapy, and follow-up studies will show resolution of the wedge-shaped zones of diminished attenuation. **Failure to respond to antimicrobial therapy is an indication for appropriate studies to rule out obstructive uropathy, renal or perirenal**

abscess, renal carcinoma, or acute renal vein thrombosis. Long-term follow-up studies performed in a few patients with multifocal disease have demonstrated a decrease in renal size and focal calyceal deformities suggestive of papillary necrosis (Davidson and Talner, 1978).

Emphysematous Pyelonephritis

Emphysematous pyelonephritis is a urologic emergency characterized by an acute necrotizing parenchymal and perirenal infection caused by gas-forming uropathogens. The pathogenesis is poorly understood. **Because the condition usually occurs in patients with diabetes, it has been postulated that the high tissue glucose levels provide the substrate for microorganisms such as *E. coli,* which are able to produce carbon dioxide by the fermentation of sugar** (Schainuck et al., 1968). Although glucose fermentation may be a factor, the explanation does not account for the rarity of emphysematous pyelonephritis despite the high frequency of gram-negative UTI in patients with diabetes, nor does it explain the rare occurrence of the condition in nondiabetic patients.

In addition to diabetes, many patients have urinary tract obstruction associated with urinary calculi or papillary necrosis and significant renal functional impairment. The overall mortality rate has been reported to be between 19% (Huang and Tseng, 2000) and 43% (Freiha et al., 1979).

Clinical Presentation.

Nearly all of the documented cases of emphysematous pyelonephritis have occurred in adults (Hawes et al., 1983). Juvenile patients with diabetes do not appear to be at risk. Women are affected more often than men.

The usual clinical presentation is severe, acute pyelonephritis, although in some instances a chronic infection precedes the acute attack. **Almost all patients display the classic triad of fever, vomiting, and flank pain** (Schainuck et al., 1968). Emphysematous pyelonephritis affects predominantly female patients with diabetes and can occur in insulin-dependent and non–insulin-dependent patients in the absence of ureteral obstruction. Patients without diabetes can also develop this form of pyelonephritis but often have ureteric obstruction and do not seem to develop extensive disease (Pontin and Barnes, 2009). Pneumaturia is absent unless the infection involves the collecting system. Results of urine cultures are invariably positive. *E. coli* is most commonly identified. *Klebsiella* and *Proteus* spp. are less common.

Radiologic Findings.

The diagnosis is established radiographically. Tissue gas that is distributed in the parenchyma may appear on abdominal radiographs as mottled gas shadows over the involved kidney (Fig. 55.26). This finding is often mistaken for bowel gas. A crescentic collection of gas over the upper pole of the kidney is more distinctive. As the infection progresses, gas extends to the perinephric space and retroperitoneum. This distribution of gas should not be confused with cases of emphysematous pyelitis in which air is in the collecting system of the kidney. Emphysematous pyelitis is secondary to a gas-forming bacterial UTI, often occurs in patients without diabetes, is less serious, and usually responds to antimicrobial therapy.

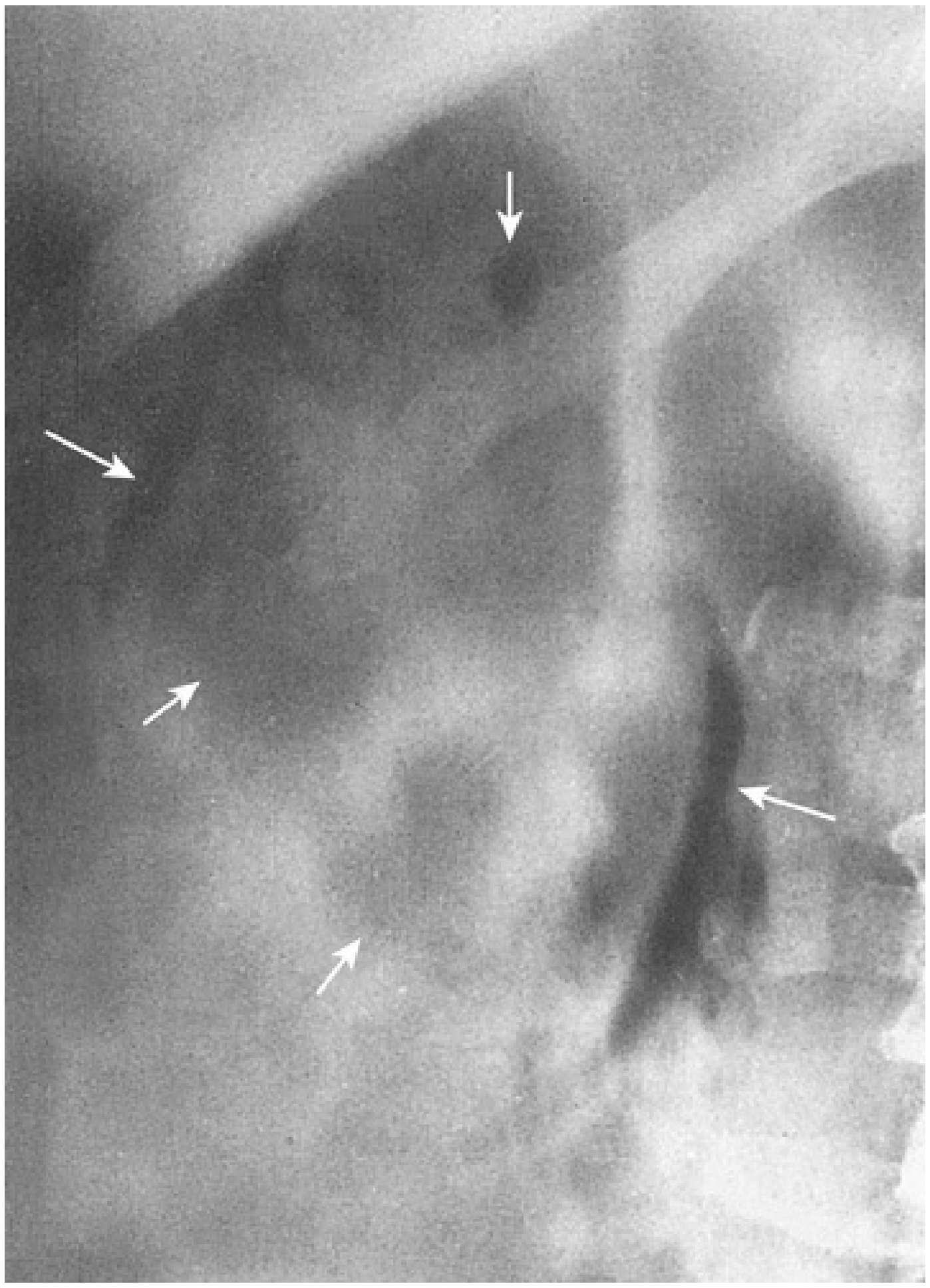

FIG. 55.26 Emphysematous pyelonephritis; plain film. Extensive perinephric *(long arrows)* and intraparenchymal *(short arrows)* gas secondary to acute bacterial pyelonephritis. (From Schaeffer AJ: Urinary tract infections. In Gillenwater JY, Grayhack JT, Howards SS, et al., editors:

Adult and pediatric urology, Philadelphia, 2002, Lippincott William & Wilkins, pp 211–272.)

Ultrasonography usually demonstrates strong focal echoes suggesting the presence of intraparenchymal gas (Brenbridge et al., 1979; Conrad et al., 1979). **CT is the imaging procedure of choice in defining the extent of the emphysematous process and guiding management** (Fig. 55.27). **An absence of fluid in CT images or the presence of streaky or mottled gas with or without bubbly and loculated gas appears to be associated with rapid destruction of renal parenchyma and a 50% to 60% mortality rate** (Best et al., 1999; Wan et al., 1996). The presence of renal or perirenal fluid, the presence of bubbly or loculated gas or gas in the collecting system, and the absence of streaky or mottled gas patterns are associated with a less than 20% mortality rate.

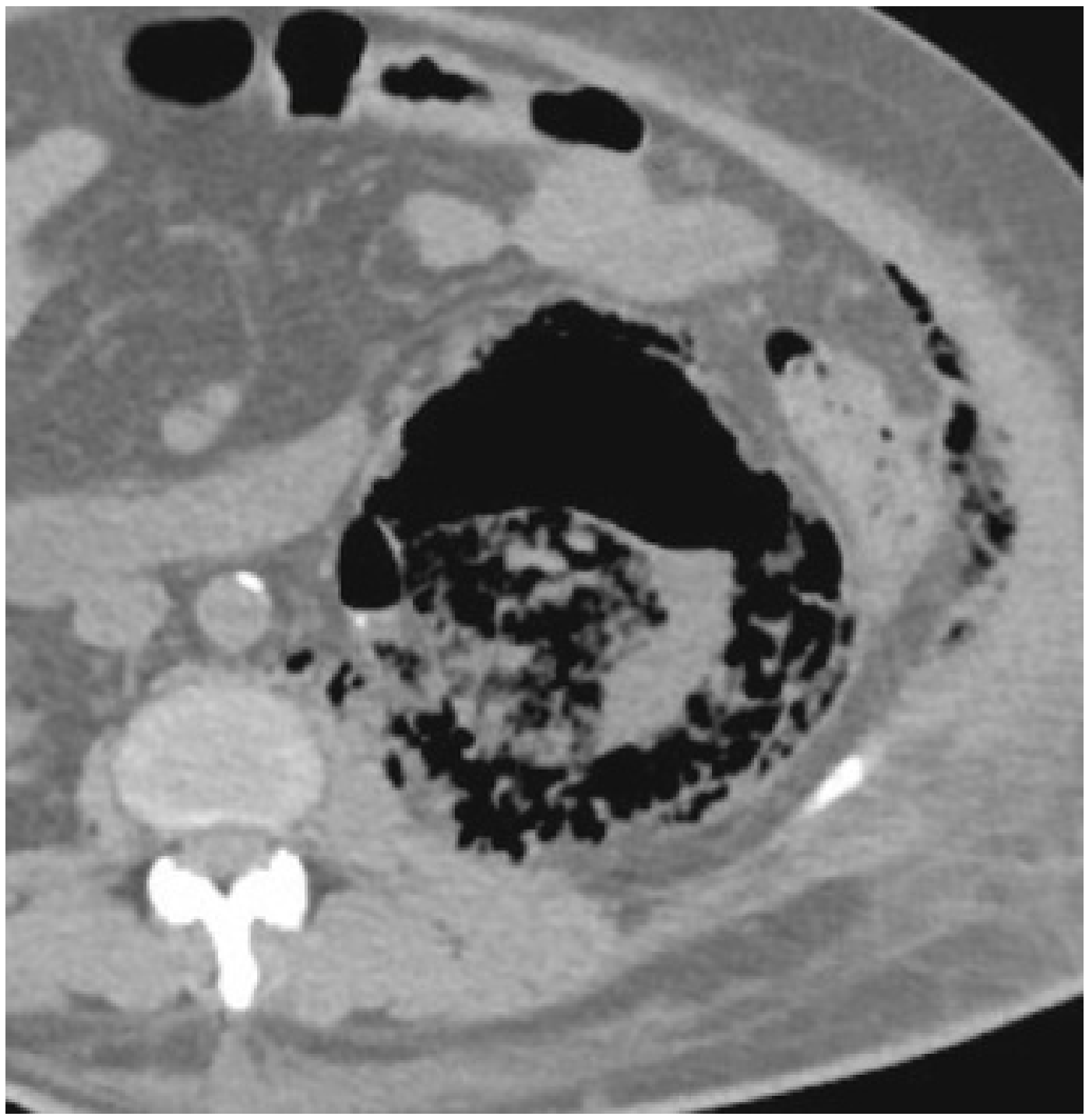

FIG. 55.27 Computed tomography of emphysematous pyelonephritis. There is air within and surrounding the left kidney.

In line with these observations, in 2000, Huang and Tseng developed a radiologic classification system based on the extent of gas involvement in the renal tissue on CT scan that has been used to help guide management; the system uses a four-category system that grades progressively more gas involvement with the renal and adjacent renal tissue with ascension through the classes (Huang, 2000).

Obstruction is demonstrated in approximately 25% of the cases. A nuclear renal scan should be performed to assess the degree of renal function impairment in the involved kidney and the status of the contralateral kidney.

Management.

Emphysematous pyelonephritis is a urologic emergency. Most patients are septic, and fluid resuscitation, glucose and electrolyte management, and broad-spectrum antimicrobial therapy are essential. Ureteral obstruction, if present, is alleviated by a percutaneous nephrostomy tube or a stent (Pontin and Barnes, 2009). Hypoalbuminemia, shock at initial presentation, bacteremia, indications for hemodialysis, thrombocytopenia, altered mental status, and polymicrobial infection are among various prognostic risk factors that have been associated with increased mortality in different outcomes studies involving emphysematous pyelonephritis patients (Huang and Tseng, 2000; Lu et al., 2014). Treatment has evolved over the years from nephrectomy to more conservative management with percutaneous catheter drainage or the use of a double-J ureteral stent depending on the severity of presentation. Until the late 1980s, management involved emergency nephrectomy with or without open surgical drainage and antibiosis, although this management was still associated with a mortality rate of 40% to 50% (Ahlering et al., 1985; Michaeli et al., 1984). Since this time, the overall mortality rate has decreased with advancements in medicine, and **definitive management is by percutaneous drainage, except in cases of extensive diffuse gas with renal destruction; in this latter scenario, nephrectomy is advised** (Huang and Tseng, 2000; Pontin and Barnes, 2009). Early diagnosis and treatment of patients with diabetes and urinary infection is important to potentially avoid progression of this disease process and in turn nephrectomy (Pontin and Barnes, 2009).

Renal Abscess

Renal abscess or carbuncle is a collection of purulent material confined to the renal parenchyma. Before the antimicrobial era, 80% of renal abscesses were attributed to hematogenous seeding by staphylococci (Campbell, 1930). In addition, historically, patients with abscesses were young men with no prior renal disease. Although experimental and clinical data document the facility for abscess formation in normal kidneys after hematogenous inoculation with staphylococci, widespread use of antimicrobial agents since about 1950 appears to have diminished the propensity for gram-positive abscess formation (Cotran, 1969; DeNavasquez, 1950). The current index patient typically has a history of renal disease or obstruction, no gender predominance, and no laterality, and the infection is typically with a gram-negative organism.

Since about 1970, gram-negative organisms have been implicated in the majority of adults with renal abscesses. The most common organisms include *E. coli, Klebsiella, Proteus,* and *Pseudomonas* spp. (Fowler and Perkins, 1994; Shu et al., 2004). Hematogenous renal seeding by gram-negative organisms may occur, but this is not likely to be the primary pathway for gram-negative abscess formation. Clinically, there is no evidence that gram-negative septicemia antedates most lesions. Further, gram-negative hematogenous pyelonephritis is almost impossible to produce in animals unless the kidney is traumatized or completely obstructed (Cotran, 1969; Timmons and Perlmutter, 1976). Like the normal kidney, the partially obstructed kidney rejects blood-borne gram-negative inocula. Thus ascending infection associated with tubular obstruction from prior infections or calculi appears to be the primary pathway for the establishment of gram-negative abscesses. Two-thirds of gram-negative abscesses in adults are associated with renal calculi or damaged kidneys (Salvatierra et al., 1967; Siegel et al., 1996). Although the association of pyelonephritis with VUR is well established, the association of renal abscess with VUR has been infrequently noted (Segura and Kelalis, 1973). Case reports in the pediatric literature exist, but literature within the adult population is sparse. More recent observations, however, indicate that reflux is frequently associated with renal abscesses and persists long after sterilization of the urinary tract (Anderson and McAninch, 1980; Timmons and Perlmutter, 1976). Renal abscesses are also associated with IV drug abuse.

Clinical Presentation.

The patient may present with fever, chills, abdominal or flank pain, and occasionally weight loss and malaise. Symptoms of cystitis may occur. Occasionally, these symptoms may be vague and delay diagnosis until surgical exploration or, in more severe cases, autopsy (Anderson and McAninch, 1980). **A thorough history may reveal a gram-positive source of infection 1 to 8 weeks before the onset of urinary tract symptoms or symptoms consistent with UTI or pyelonephritis in the weeks prior** (Hung et al., 2007)**. The infection may have occurred in any area of the body.** Multiple skin carbuncles and IV drug abuse introduce gram-positive organisms into the bloodstream. Other common sites are the mouth, lungs, and bladder (Lyons et al., 1972). Complicated UTIs associated with stasis, calculi, pregnancy, neurogenic bladder, and diabetes mellitus also appear to predispose the patient to abscess formation (Anderson and McAninch, 1980).

Shu et al. (2004) published their experience with 26 cases of renal/perirenal abscesses with anatomically normal GU tracts, and no stones or prior urologic manipulation. In 24 of the 26 cases, the patients had at least 1 predisposing factor (diabetes mellitus, HIV, steroid use, IV drug abuse, liver disease, UTI, pregnancy). Diabetes mellitus is noted to be a very significant risk factor for development of renal abscesses, as is increased length of hospitalization (Ko et al., 2011, 2013).

Laboratory Diagnosis.

The patient typically has marked leukocytosis. In a series by Siegel et al. (1996) of 52 patients, blood cultures were positive 28% of the time, whereas Yen et al. (1999) published a series of 78 patients, 25 of which (32%) had positive blood cultures. In comparison of positive cultures in all three types of fluids (abscess, blood, urine) only 1 patient of the 78 had identical isolates in all three. Urine and abscess culture had a 15% identical culture rate, whereas blood and abscess had a 13% identical culture rate (Yen et al., 1999). Pyuria and bacteriuria may not be evident unless the abscess communicates with the collecting system. **Because gram-positive organisms are most commonly blood-borne, urine cultures in these cases typically show no growth or a microorganism different from that isolated from the abscess.** Another study showed not only a bacteremia rate of 26% but also that positive urine cultures were only present in roughly 30% of patients (Shu et al., 2004).

Ultrasonography and CT distinguish abscess from other inflammatory renal diseases. **Ultrasonography is the quickest and least expensive method to demonstrate a renal abscess. An echo-free or low-echodensity space-occupying lesion with increased transmission is found on the ultrasound image** (Fig. 55.28). The margins of an abscess are indistinguishable in the acute phase, but the structure contains a few echoes and the surrounding renal parenchyma is edematous (Fiegler, 1983). Subsequently, the appearance tends to be that of a well-defined mass. The internal appearance, however, may vary from a virtually solid lucent mass to one with large numbers of low-level internal echoes (Schneider et al., 1976). The number of echoes depends on the amount of cellular debris within the abscess. The presence of air results in a strong echo with a shadow. Differentiation between an abscess and a tumor is impossible in many cases. Arteriography is used infrequently to demonstrate abscesses. The center of the mass tends to be hypervascular or avascular, with increased vascularity at the cortical margins and lack of vascular displacement and neovascularity.

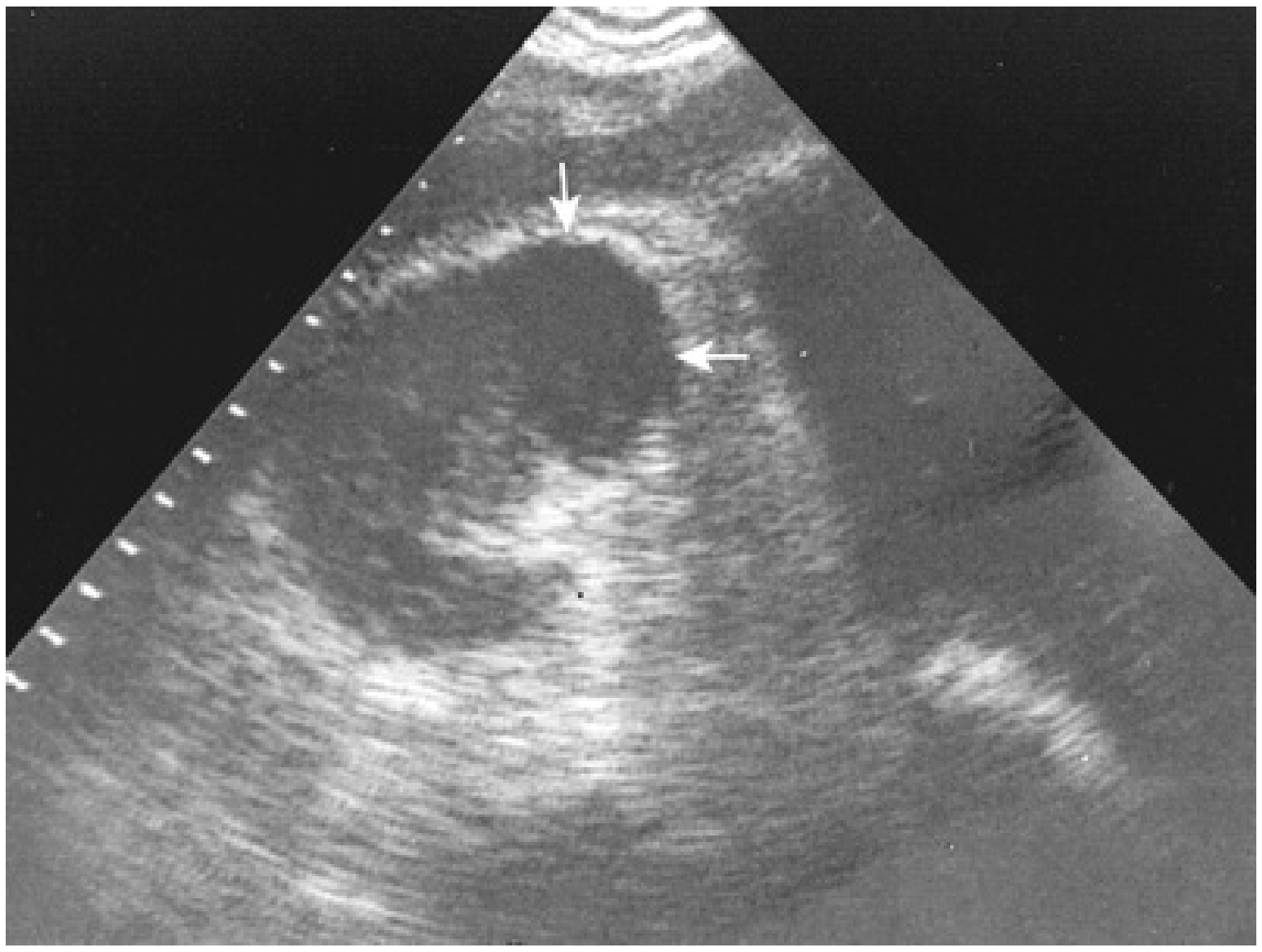

FIG. 55.28 Acute renal abscess. Transverse ultrasound image of the right kidney demonstrates a poorly marginated rounded focal hypoechoic mass *(arrows)* in the anterior portion of the kidney.

CT appears to be the diagnostic procedure of choice for renal abscesses because it provides excellent delineation of the tissue. On CT, abscesses are characteristically well defined before and after contrast agent enhancement. The findings depend in part on the age and severity of the abscess (Baumgarten and Baumgartner, 1997). Initially, CT shows renal enlargement and focal, rounded areas of decreased attenuation (Fig. 55.29). After several days of the onset of the infection, a thick fibrotic wall begins to form around the abscess. An echo-free or slightly echogenic mass caused by the presence of necrotic debris is seen. CT of a chronic abscess shows obliteration of adjacent tissue planes, thickening of the Gerota fascia, a round or oval parenchymal mass of low attenuation, and a surrounding inflammatory wall of slightly higher attenuation that forms a ring when the scan is enhanced with contrast material (Fig. 55.30). The ring sign is caused by the increased vascularity of the abscess wall (Callen, 1979; Gerzof and Gale, 1982).

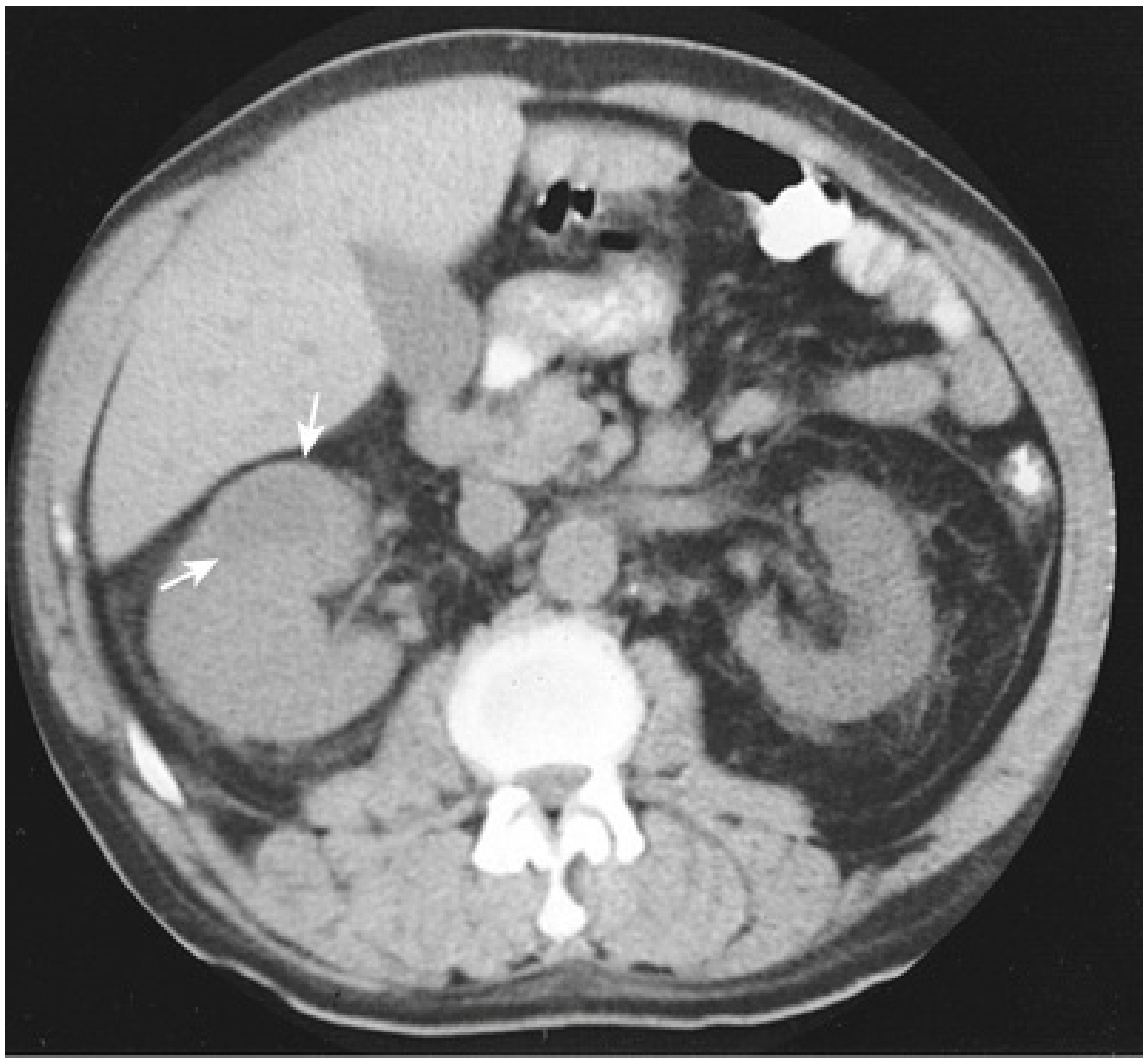

FIG. 55.29 Acute renal abscess. Nonenhanced computed tomography scan through the mid pole of the right kidney demonstrates right renal enlargement and an area of decreased attenuation *(arrows)*. After antimicrobial therapy, a follow-up scan showed complete regression of these findings.

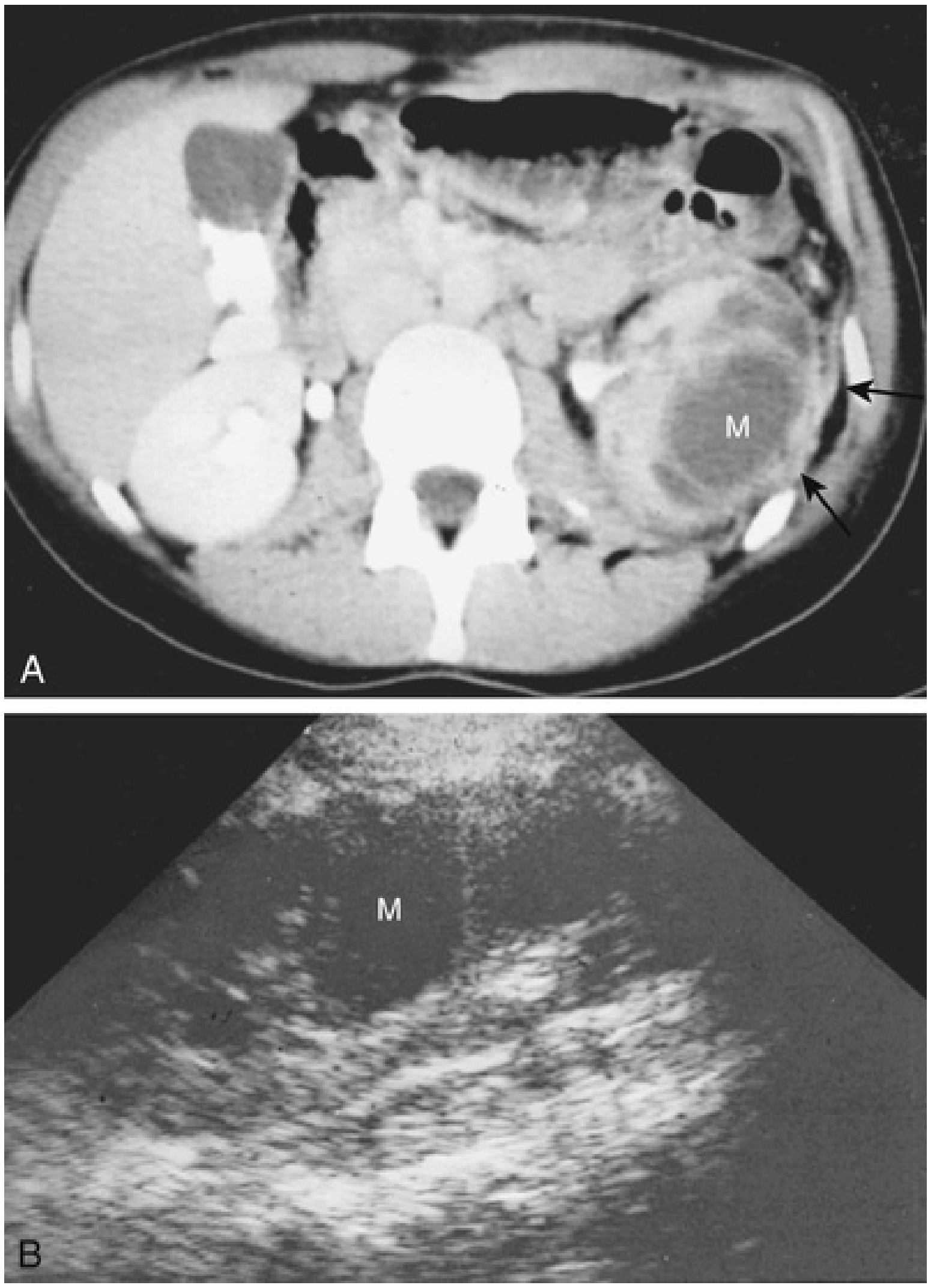

FIG. 55.30 Chronic renal abscess. (A) Enhanced computed tomography scan shows an irregular septated low-density mass *(M)* extensively involving the left kidney. Note thickening of perinephric fascia *(arrows)* and extensive compression of the renal collecting system. Findings are typical of renal abscess. (B) Ultrasound longitudinal image demonstrates a septated hypoechoic mass *(M)* occupying much of the renal parenchymal volume.

Radionuclide imaging with gallium or indium is sometimes useful in evaluating patients with renal abscesses (see previous sections).

Management.

Although the classic treatment for an abscess has been percutaneous or open incision and drainage, there is good evidence that use of IV antimicrobial agents and careful observation of a small abscess less than 3 cm or even 5 cm in a clinically stable patient is appropriate. Antibiotics, if

begun early enough in the course of the process, may obviate surgical procedures (Hoverman et al., 1980; Levin et al., 1984; Shu et al., 2004). **CT- or ultrasound-guided needle aspiration may be necessary to differentiate an abscess from a hypervascular tumor.** Aspirated material should be cultured and appropriate antimicrobial therapy instituted on the basis of the findings.

All patients should be immediately started on IV antibiotic therapy. The selection of empirical antimicrobial therapy is dependent on the presumed source of the infection and the resistance patterns within the hospital. When hematogenous dissemination is suspected, the pathogenic organism most frequently is penicillin-resistant *Staphylococcus,* and the antimicrobial of choice therefore is a penicillinase-resistant penicillin (Schiff et al., 1977). If a history of penicillin hypersensitivity is present, the recommended drug is vancomycin. Cortical abscesses that occur in the abnormal urinary tract are associated with more typical gram-negative pathogens secondary to ascending infection and should be treated empirically with IV third-generation cephalosporins, antipseudomonal penicillins, or aminoglycosides until specific therapy can be instituted. Patients should have serial examinations with ultrasonography or CT until the abscess resolves. The radiographic evolution or resolution of the abscesses typically further dictates clinical management. The suspicion of misdiagnosis or an uncontrolled infection with the development of perinephric abscess or infection with an organism resistant to the antimicrobial agents used in therapy should be suspected with worsening clinical picture.

After patients are started on IV antibiotic therapy and there is radiographic confirmation of abscess, the size of the abscess typically dictates management. Abscesses 3 cm or less can be managed with antibiotics alone (Lee et al., 2010; Shu et al., 2004; Siegel et al., 1996). In a series from South Korea of 49 patients with normal urinary tracts and abscesses smaller than 5 cm, there was 100% resolution of abscesses confirmed with CT scan with antibiotics alone (Lee et al., 2010).

Although fewer data exist for patients with obstruction or anomalous urinary tracts, **abscesses 3 to 5 cm in diameter should be conservatively managed initially in the setting of stable clinical parameters.** We suggest following the clinical course and size of the abscess radiographically to assess for improvement. Should the patient progress, percutaneous drainage should be considered. Abscesses of all sizes in immunocompromised hosts or those that do not respond to antimicrobial therapy should be drained percutaneously (Fernandez et al., 1985; Fowler and Perkins, 1994; Siegel et al., 1996).

However, percutaneous drainage remains the first-line procedure of choice for most renal abscesses larger than 5 cm in diameter. Typically, abscesses of this size require multiple drains, multiple drain manipulations, or eventual surgical washout and potential nephrectomy (Siegel et al., 1996).

Infected Hydronephrosis and Pyonephrosis

***Infected hydronephrosis* is bacterial infection in a hydronephrotic kidney. The term *pyonephrosis* refers to infected hydronephrosis associated with suppurative destruction of the parenchyma of the kidney, in which there is total or nearly total loss of renal function** (Fig. 55.31). Where infected hydronephrosis ends and pyonephrosis begins is difficult to determine clinically. Rapid diagnosis and treatment of pyonephrosis are essential to avoid permanent loss of renal function and to prevent sepsis.

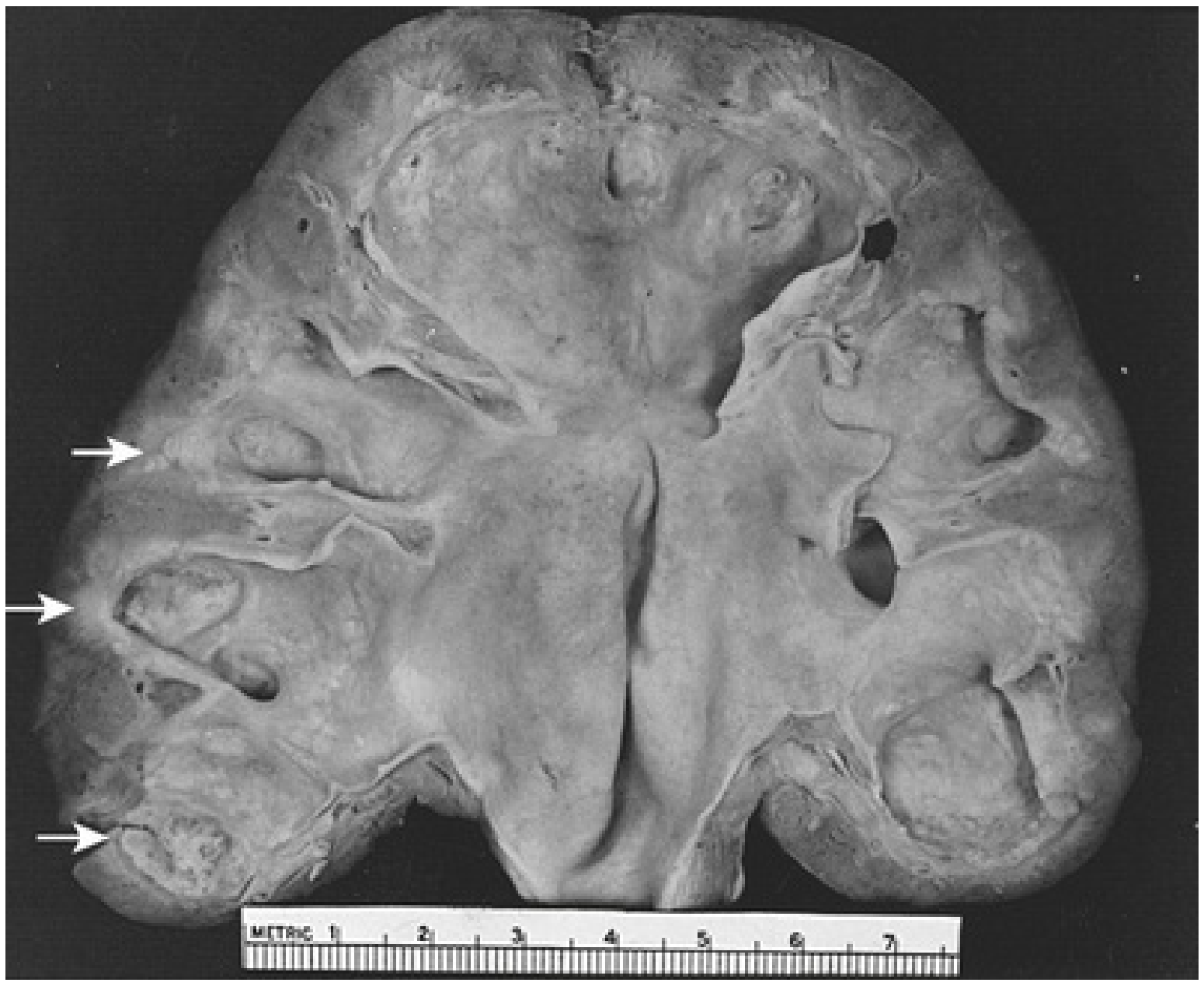

FIG. 55.31 Pyonephrosis: gross specimen. The kidney shows marked thinning of the renal cortex and medulla, suppurative destruction of the parenchyma *(arrows),* and distention of the pelvis and calyces. Previous incision released a large quantity of purulent material. The ureter showed obstruction distal to the point of section.

Clinical Presentation.

The patient is usually very ill, with high fever, chills, flank pain, and

tenderness. Occasionally, however, a patient may have only an elevated temperature and a complaint of vague gastrointestinal discomfort. A previous history of urinary tract calculi, infection, or surgery is common. **Bacteriuria may not be present if the ureter is completely obstructed.**

Radiologic Findings.

The ultrasonographic diagnosis of infected hydronephrosis depends on demonstration of internal echoes within the dependent portion of a dilated pyelocalyceal system. CT is nonspecific but may show thickening of the renal pelvis, stranding of the perirenal fat, and a striated nephrogram. Ultrasonography demonstrates hydronephrosis and fluid debris levels within the dilated collecting system (Corriere and Sandler, 1982; Fig. 55.32A). The diagnosis of pyonephrosis is suggested if focal areas of decreased echogenicity are seen within the hydronephrotic parenchyma.

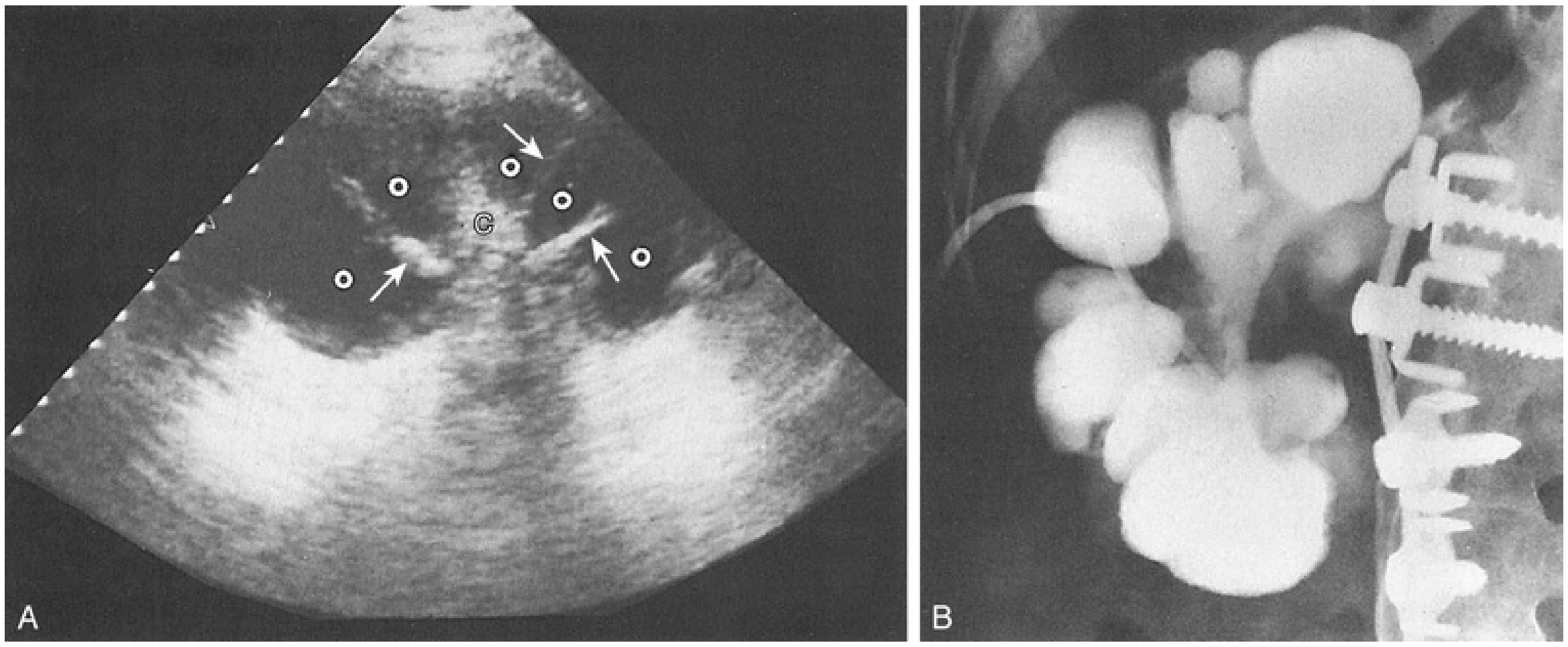

FIG. 55.32 Pyonephrosis. (A) Longitudinal ultrasound image of the right kidney demonstrates echogenic central collecting complex (C) with radiating echogenic septa *(arrows)* and thinned hypoechoic parenchyma. Multiple dilated calyces *(o)* with diffuse low-level echoes are seen. (B) Antegrade pyelogram performed through a percutaneous nephrostomy catheter correlates well with the ultrasound image. Dilated pus-filled calyces are demonstrated. The renal pelvis is obliterated by chronic scarring and stone disease. The kidney did not regain function. (From Schaeffer AJ: Urinary tract infections. In Gillenwater JY, et al., editors: *Adult and pediatric urology,* Philadelphia, 2002, Lippincott Williams & Wilkins, pp 211–272.)

Management.

Once the diagnosis of pyonephrosis is made, the treatment is initiated with appropriate antimicrobial drugs and drainage of the infected pelvis. A ureteral catheter can be passed to drain the kidney, but if the obstruction prevents this, a percutaneous nephrostomy tube should be placed (Camunez et al., 1989; Fig. 55.32B). When the patient becomes hemodynamically stable, other procedures are usually needed to identify and treat the source of the obstruction.

Perinephric Abscess

A perinephric abscess extends beyond the renal capsule but is contained by Gerota fascia and **usually results from rupture of an acute cortical abscess into the perinephric space,** extravasated infected urine from obstruction**, or from hematogenous seeding from sites of infection.** Patients with pyonephrosis, particularly when a calculus is present in the kidney, are susceptible to perinephric abscess formation. **Diabetes mellitus is present in approximately one-third of patients with perinephric abscess** (Edelstein and McCabe, 1988; Meng et al., 2002). **In about one-third of the cases, perinephric abscess is caused by hematogenous spread, usually from sites of skin infection** (Gardiner et al., 2011). A perirenal hematoma can become secondarily infected by the hematogenous route or by direct extension of a primary renal infection. When a perinephric infection ruptures through the Gerota fascia into the pararenal space, the abscess becomes paranephric. Paranephric abscesses may also result from infectious disorders of the bowel, pancreas, or pleural cavity. Conversely, perinephric or psoas abscess may be the result of bowel perforation, Crohn disease, or spread of osteomyelitis from the thoracolumbar spine. *E. coli, Proteus,* and *S. aureus* account for most infections.

Clinical Presentation.

The onset of symptoms is typically insidious. Symptoms are present for more than 5 days in most patients with perinephric abscess compared with only about 10% of patients with pyelonephritis. The clinical presentation may be similar to that of pyelonephritis; however, more than one-third of patients may be afebrile. An abdominal or flank mass can be felt in about half of the cases; costovertebral angle tenderness is typically present. Psoas abscess should be suspected if the patient has a limp and flexion and external rotation of the ipsilateral hip. Laboratory features include leukocytosis, elevated levels of serum creatinine, and pyuria in more than 75% of cases. Edelstein (1988) showed that results of urine cultures predicted perinephric abscess isolates in only 37% of cases; a blood culture, particularly with multiple organisms, was often indicative of perinephric abscess but identified all organisms in only 42% of cases. Meng et al. (2002) showed that roughly 75% of patients had a positive culture. Urine was statistically significantly more sensitive than blood and abscess fluid collection in their study. **Therefore caution should be exercised when choosing therapy based on the results of urine and blood cultures because data may sometimes be inadequate. Pyelonephritis usually responds within 4 to 5 days of appropriate antimicrobial therapy; perinephric abscess does not. Thus perinephric abscess should be suspected in a patient with UTI and abdominal or flank mass or persistent fever after 4 days of antimicrobial therapy. Perinephric abscesses are commonly seen concomitantly with renal abscesses.**

CT is particularly valuable for demonstrating the primary abscess. In some cases, the abscess is confined to the perinephric space; however, extension to the flank or psoas muscle may occur (Fig. 55.33). CT is able to show with exquisite anatomic detail the route of spread of infection into the surrounding tissues and will demonstrate any obstruction that may be present (Fig. 55.34). This information may be helpful in planning the approach for surgical drainage. Ultrasonography demonstrates a diverse appearance ranging from a nearly anechoic mass displacing the kidney to an echogenic collection that tends to blend with normally echogenic fat within the Gerota fascia (Corriere, 1982). Occasionally, a retroperitoneal or subdiaphragmatic infection may spread to the paranephric fat that is outside this fascia. The clinical symptoms of insidious onset of fever, flank mass, and tenderness are indistinguishable from those associated with perinephric abscess. UTI, however, is absent. Ultrasonography and CT can usually delineate the abscess outside the Gerota fascia.

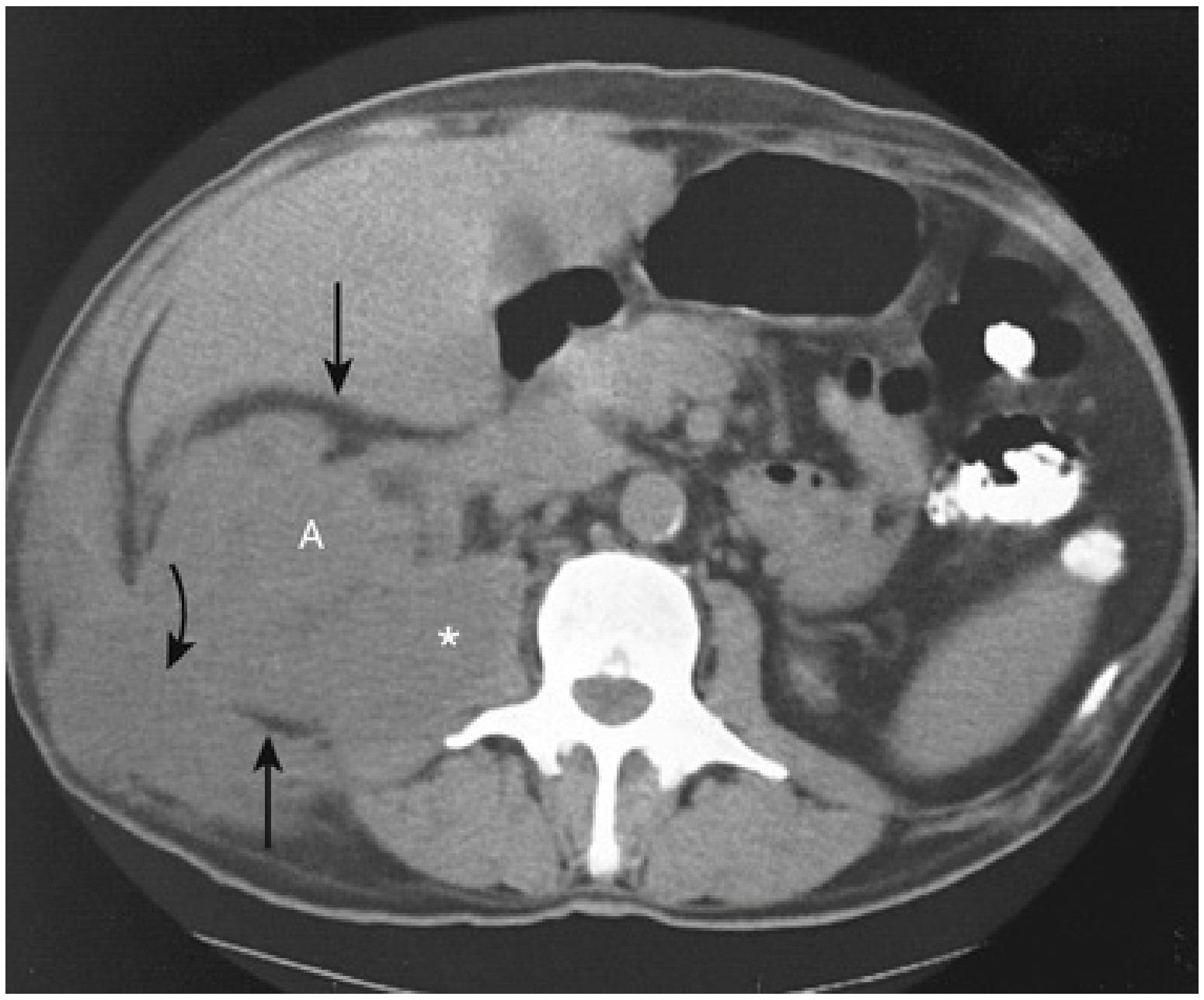

FIG. 55.33 Nonenhanced computed tomography scan through the lower pole of the right kidney (previous left nephrectomy) shows extensive perinephric abscess. Extensive abscess (A) distorts and enlarges the renal contour, infiltrates perinephric fat *(straight arrows),* and extends into the psoas muscle *(asterisk)* and the soft tissues of the flank *(curved arrow).* Also note that normal renal collecting system fat has been obliterated by the process.

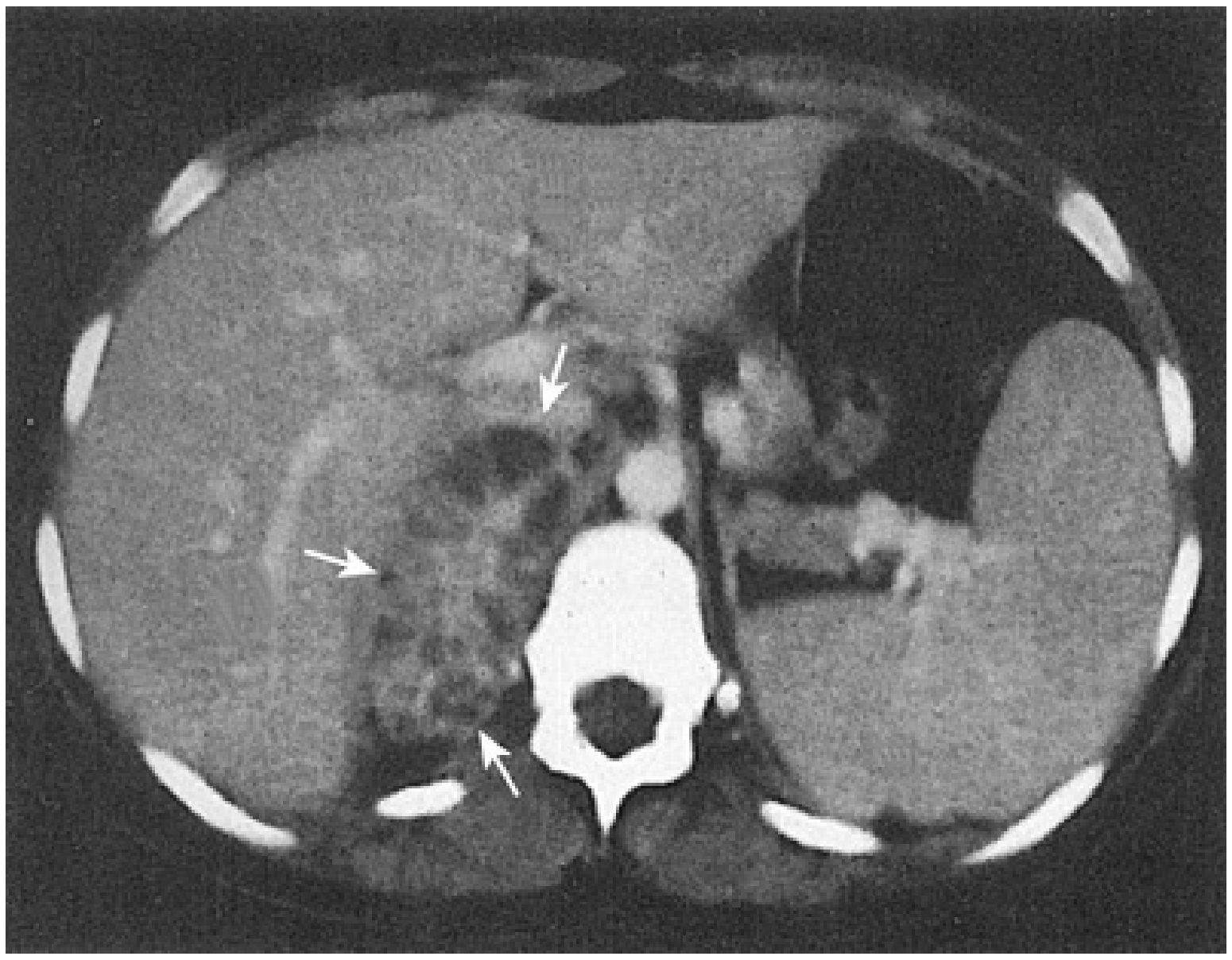

FIG. 55.34 Perinephric abscess involving the right adrenal gland. Computed tomography scan shows large right pararenal mass *(arrows)* with multiple low-density areas within. At surgery, a large pararenal

abscess with extensive involvement of the right adrenal was found. (From Schaeffer AJ: Urinary tract infections. In Gillenwater JY, Grayhack JT, Howards SS, et al., editors: *Adult and pediatric urology,* Philadelphia, 2002, Lippincott Williams & Wilkins, pp 211–272.)

Improved imaging techniques have decreased the mortality rate of 40% to 50% in early series to roughly 12%, but there is still an average of 3.4 days' lag time before appropriate diagnosis in a contemporary series (Meng et al., 2002). Only 35% of patients were correctly diagnosed on presentation in the Meng series, and this lag time contributed to mortality in nearly all patients in that series. Having an appropriate threshold for imaging will continue to improve the rate of correct diagnoses.

Management.

Antimicrobial agents should be immediately started upon diagnosis of perinephric abscess. Gram stain identifies the pathogenesis and guides antimicrobial therapy. An aminoglycoside together with an antistaphylococcal agent, such as methicillin or oxacillin, should be started immediately. If the patient has a penicillin hypersensitivity, cephalothin or vancomycin may be used.

In addition to controlling sepsis and preventing further spread of infection, Meng et al.'s series of 25 patients suggests that, for small perinephric abscesses (<3 cm), antibiotics alone can appropriately treat immune-competent patients (Meng et al., 2002)**. Eight out of the 10 patients treated with antibiotics alone had full resolution after a mean of 10 days in the hospital. The average size of abscess treated was 1.8 cm. Siegel et al.** (1996) **also showed good resolution of perinephric abscesses less than 3 cm, with cure seen in all five patients in their series.**

For larger collections or those not responsive to initial antibiotic therapy, intervention is the next step in treatment. **Surgical drainage, or nephrectomy if the kidney is nonfunctioning or severely infected, was the classic treatment for perinephric abscesses. However, with the advent of the field of interventional radiology and improvements in percutaneous drainage techniques, renal ultrasonography and CT- or ultrasound-guided percutaneous aspiration and drainage of perirenal collections is now a good option for therapy.** In Meng's study, 11 of the 25 patients had percutaneous drainage in addition to antibiotics (Meng et al., 2002). The mean abscess size was 11 cm and the mean time to resolution was 25 days. Four of these patients eventually required open surgical exploration and drainage. All removed kidneys demonstrated hallmarks of minimal function. **Unlike in renal abscesses, early drainage of abscesses greater than 3 cm in diameter is recommended.**

Once the perinephric abscess has been drained, the underlying problem must be addressed. Some conditions such as renal cortical abscess or enteric communication require prompt attention. Nephrectomy for pyonephrosis may be performed concurrent with drainage of the perinephric abscess if the patient's condition is good. In other instances it is best to drain the perinephric abscess first and correct the underlying problem or perform a nephrectomy when the patient's condition has improved. Meng's series of 11 patients with abscesses greater than 11 cm had a roughly 33% need for nephrectomy (Meng et al., 2002). Although this is a high number in patients who are likely diabetic, whereas the nephron-sparing approach is ideal, it is decidedly lower than the historical nephrectomy rate, likely secondary to more successful percutaneous drainage rates. In three of their patients with small perinephric abscesses and hydronephrosis, antibiotics and drainage of the obstructed urinary system led to cure.

Perinephric Abscess Versus Acute Pyelonephritis.

Once again, the greatest obstacle to the treatment of perinephric abscess is the delay in diagnosis. **In the series by Thorley et al. (1974), a common misdiagnosis was acute pyelonephritis; Meng's study showed a similar delay of roughly 3 to 4 days in appropriate diagnosis in a modern study** (Meng et al., 2002). **Thorley's study found that two factors differentiated perinephric abscess and acute pyelonephritis: (1) most patients with uncomplicated pyelonephritis were symptomatic for less than 5 days before hospitalization, whereas most with perinephric abscesses were symptomatic for longer than 5 days; and (2) no patient with acute pyelonephritis remained febrile for longer than 4 days once appropriate antimicrobial agents were started. All patients with perinephric abscesses had a fever for at least 5 days, with a median of 7 days. Similar results were noted by Fowler and Perkins (1994).**

Patients with polycystic renal disease who undergo hemodialysis may be particularly susceptible to the progression from acute UTIs to perinephric abscess. Of 445 patients undergoing chronic hemodialysis at the Regional Kidney Disease Program in Minneapolis, 5.4% had polycystic kidney disease and 33.3% developed symptomatic UTIs (Sweet and Keane, 1979). Eight (62.5%) developed perinephric abscesses, and three of these patients died. According to the investigators, all UTIs, even those that progressed to perinephric abscesses, were promptly treated with appropriate antimicrobial agents, and all patients in this group became afebrile and asymptomatic when the agents were stopped. However, later, after various times, symptoms attributable to perinephric abscess developed in eight of the patients. The mechanism of this process is not clear, but the limited bioavailability of some antimicrobial agents in cysts is variable and could contribute to the progression of renal infection.

Chronic Pyelonephritis

In patients without underlying renal or urinary tract disease, chronic pyelonephritis secondary to UTI is a rare disease and an even more rare cause of chronic renal failure. In patients with underlying functional or structural urinary tract abnormalities, however, chronic renal infection can cause significant renal impairment. Thus it is essential that appropriate studies be used to diagnose, localize, and treat chronic renal infection.

The prevalence of chronic pyelonephritis has also been assessed in patients undergoing dialysis for end-stage renal disease. Despite a 2% to 5% prevalence of bacteriuria in women, pyelonephritis uncomplicated by obstruction or urinary tract malformation does not cause end-stage renal disease. Schechter et al. (1971) analyzed the cause for renal failure in 170 patients referred to them for dialysis. Chronic pyelonephritis was the primary cause of end-stage renal disease in 22 (13%) but was usually associated with an underlying structural defect. Unequivocal nonobstructive chronic pyelonephritis was not found. Symptomatic infections tended to occur before the onset of azotemia in most patients with chronic pyelonephritis. Similarly, Huland and Busch (1982) evaluated 161 patients with end-stage renal disease and found that 42 had chronic pyelonephritis. However, in addition to a history of UTIs, these 42 patients had complicating defects, such as VUR, analgesic abuse, nephrolithiasis, or obstruction. Nonobstructive uncomplicated UTI alone was never found to be the cause of renal insufficiency. Thus, using end-stage renal disease seen at autopsy or at the dialysis clinic as an indicator, the occurrence of uncomplicated chronic bacterial pyelonephritis is rare.

In addition, the role of bacterial infection in development of chronic renal disease can be assessed in patients with renal interstitial and tubular damage similar to that which has classically been called chronic pyelonephritis. The frequency with which various potential causes of interstitial damage are operative in patients with interstitial nephritis was assessed by Murray and Goldberg (1975). These investigators not only concluded that UTI is rarely the sole cause of chronic renal disease in the adult but also observed that 89% of their azotemic patients had a readily identifiable primary cause of their interstitial nephritis. Thus, when patients with a clinical diagnosis of chronic interstitial nephritis are selected as the starting point, it is easy to associate many factors with this disease, but UTI does not seem to be one of them.

Clinical Presentation.

There are no symptoms of chronic pyelonephritis until it produces renal insufficiency, and then the symptoms are similar to those of any other form of chronic renal failure. If a patient's chronic pyelonephritis is thought to be a result of many episodes of acute pyelonephritis, a history of intermittent symptoms of fever, flank pain, and dysuria may be elicited. Similarly, urinary findings and the presence of renal infection correlate poorly. Bacteriuria and pyuria, the hallmarks of UTI, are not predictive of renal infection. Conversely, patients with significant renal infection may have sterile urine if the ureter draining the kidney is obstructed or the infection is outside of the collecting system.

The pathologic and radiologic criteria for diagnosing renal infection may also be misleading. Asscher (1980) has tabulated eight long-term follow-up studies from the literature on kidneys of adults with UTIs. The data from these reports on 901 patients show that bacteriuria present in otherwise healthy adults for long periods may be associated with nonexistent or extremely minimal evidence of kidney damage. Conversely, patients who have chronic pyelonephritis may have negative urine cultures.

Radiologic Findings.

The diagnosis of chronic pyelonephritis can be made with the greatest confidence on the basis of pyelographic findings. The essential features are asymmetry and irregularity of the kidney outlines, blunting and dilation of one or more calyces, and cortical scars at the corresponding site (Fig. 55.35). In addition to stones, obstruction, tuberculosis, and analgesic nephritis with papillary necrosis (which can be readily excluded by history), chronic pyelonephritis can also produce a localized scar over a deformed calyx. In advanced pyelonephritis, calyceal distortion and irregularity together with cortical scars complete the picture. Calyceal stones and reflux nephropathy may produce a scarred kidney that is indistinguishable from post-pyelonephritis findings. Regardless of the cause of chronic pyelonephritis, CT findings will be consistent with atrophy, cortical/parenchymal thinning, calyceal clubbing, and possible hypertrophy of residual normal tissue and asymmetry (Craig et al., 2008). Fig. 55.36 (D'Souza et al., 1995) showed a linear relationship between renal parenchymal volume loss and function decline as assessed by DMSA scan. Hodson and Wilson (1965) pointed out that renal infarction, an extremely rare condition, may closely resemble pyelonephritic scars but that the renal pyramid remains with renal infarction in contradistinction to pyelonephritis.

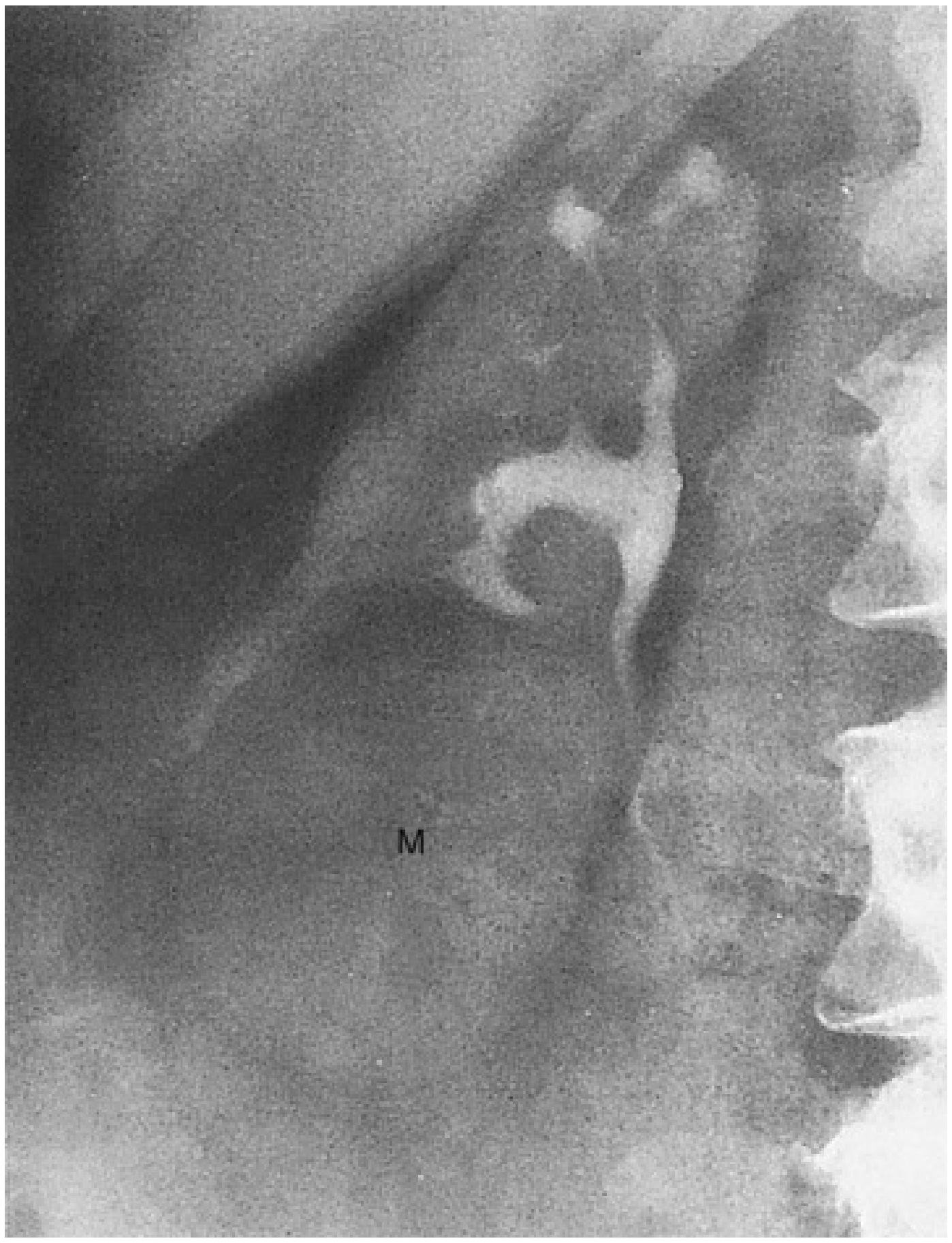

FIG. 55.35 Chronic pyelonephritis. Ten-minute excretory urogram demonstrates irregular renal outline with upper pole parenchymal atrophy. Note significant loss of renal cortical thickness over blunted and dilated calyces. Lower pole mass *(M)* is a simple cyst. (From Schaeffer AJ: Urinary tract infections. In Gillenwater JY, Grayhack JT, Howards SS, et al., editors: *Adult and pediatric urology,* Philadelphia, 2002, Lippincott Williams & Wilkins, pp 211–272.)

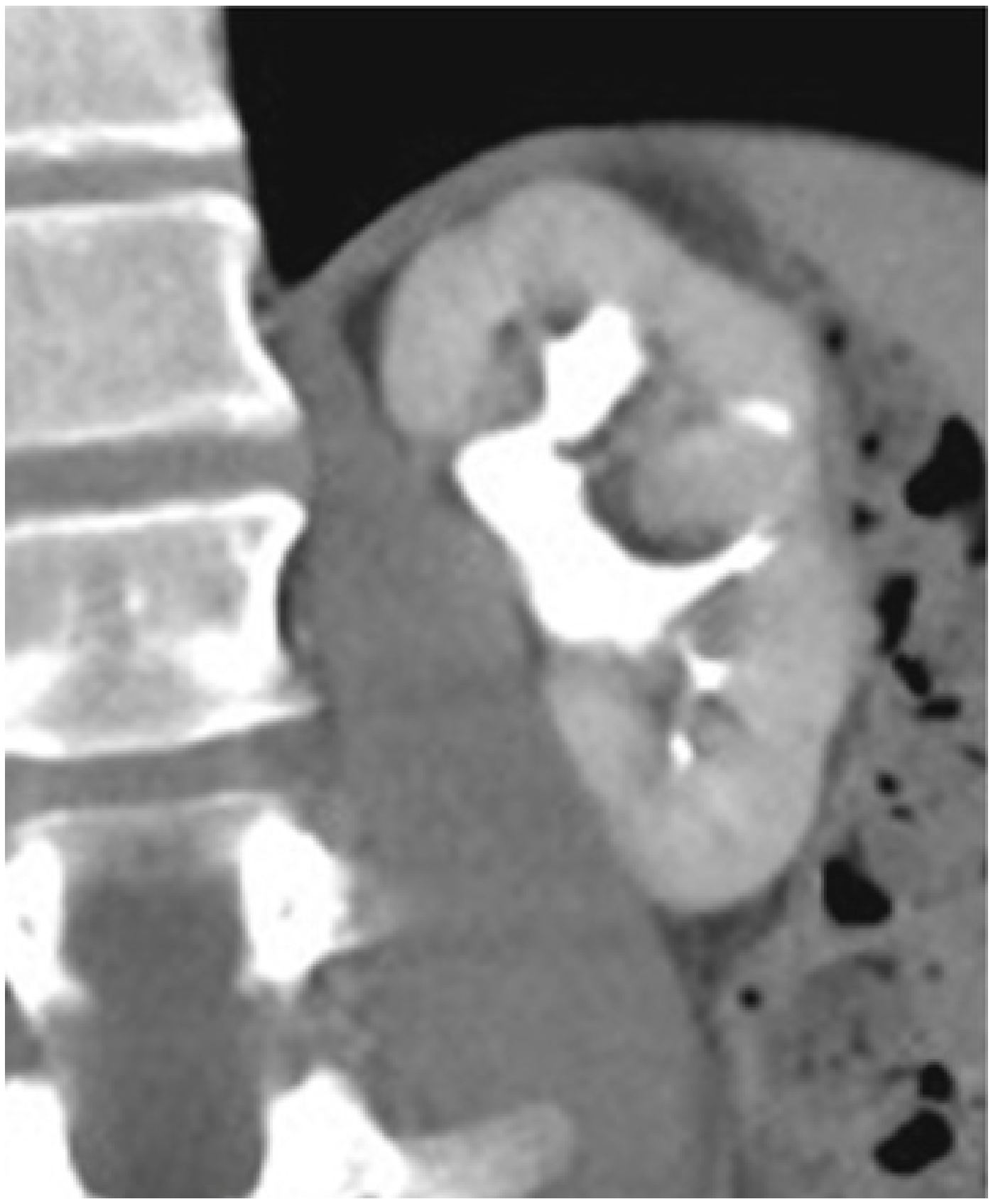

FIG. 55.36 Computed tomography of chronic pyelonephritis. There are cortical scars and blunted calyces.

Pathology.

In chronic pyelonephritis, the gross kidney is often diffusely contracted, scarred, and pitted. The scars are Y-shaped, flat, broad-based depressions with red-brown granular bases. The scarring is often polar with underlying calyceal blunting. The parenchyma is thin, and the corticomedullary demarcation is lost. **Histologic changes are patchy.** There is usually an interstitial infiltrate of lymphocytes, plasma cells, and occasional polymorphonuclear cells. Portions of the parenchyma may be replaced by fibrosis, and, although glomeruli may be preserved, periglomerular fibrosis is often seen. In some affected areas, glomeruli may be completely fibrosed and tubules atrophied. Leukocyte and hyaline casts are sometimes present in the tubules; the latter may cause resemblance to the thyroid colloid, hence the description *renal thyroidization* (Braude, 1973). In general, the changes are nonspecific; they also may be seen in toxic exposures, postobstructive atrophy, hematologic disorders, postirradiation nephritis, ischemic renal disease, and nephrosclerosis. **The pathology of stone-**

induced scars and reflux-induced scars may be identical.

Management.

Management of radiographic evidence of pyelonephritis should be directed at treating infection if present, preventing future infections, and monitoring and preserving renal function. The treatment of existing infection must be based on careful antimicrobial susceptibility tests and selection of drugs that can achieve bactericidal concentrations in the urine and yet are not nephrotoxic. Achievement of acceptable bactericidal levels of a drug in the urine of a patient with chronic pyelonephritis may be difficult because the diminished concentrating ability of pyelonephritis may impair excretion and concentration of the antimicrobial agent. The duration of antimicrobial therapy is often prolonged to maximize the chance of cure. With patients in whom renal damage develops or progresses in the presence of UTI, the working hypothesis should be that there is an underlying renal, usually papillary, lesion or underlying urologic condition, such as obstruction or calculus, which has increased susceptibility to renal damage. Appropriate nephrologic and urologic evaluation should be undertaken to identify and, if possible, correct these abnormalities.

Bacterial “Relapse” From a Normal Kidney

The concept that bacteria persist in the renal parenchyma between bacteriuric episodes and cause “relapsing” UTIs was based on a study by Turck et al. (1968) that suggested that bacterial persistence could be recognized by simply identifying two consecutive recurrent infections with the same organism. Unfortunately, this study did not indicate whether the urine was cultured during therapy to ensure that the original infection had actually been eradicated. It is possible that some of these so-called relapses were in fact unresolved initial infections and that ureteral edema associated with catheterization may have impeded clearance of the initial infecting strain.

Subsequent studies summarized by Stamey (1980) **and Forland et al.** (1977) **have shown that, in a normal urinary tract, recurrent infections are not caused by relapse from bacterial persistence in the kidney.** With ureteral catheterization techniques Cattell et al. (1973) localized the site of bacteriuria in 42 patients who had follow-up for 6 months after therapy. He analyzed the response to antimicrobial therapy of 2 weeks’ duration. Of the 26 patients who were cured of their initial infection, 16 had recurrence with the same organism, 8 had upper tract infections, and 8 had bladder bacteriuria.

Most of the changes of chronic pyelonephritis seem to occur in infancy, probably because the growing kidney is most susceptible to scarring. A review that examined the long-term effect of UTIs in adults concluded that renal damage is rare in nonobstructive UTIs (Stamey, 1980), but it does occur (Bailey et al., 1969; Davidson and Talner, 1978; Davies et al., 1972; Feldberg, 1982).

The association between hypertension and the pyelonephritic kidney has been addressed by Pfau and Rosenmann (1978), who concluded that the association of chronic pyelonephritis and hypertension is usually coincidental. Their conclusion agrees with that of a study by Parker and Kunin (1973) that examined 74 women who had been admitted to the hospital 10 to 20 years previously for pyelonephritis. Only 14.5% of these women had hypertension, a rate similar to that found in a random female population of the same age.

Infectious Granulomatous Nephritis

Xanthogranulomatous Pyelonephritis

Xanthogranulomatous pyelonephritis (XGP) is a rare, severe, chronic renal infection typically resulting in diffuse renal destruction. Most cases are unilateral and result in a nonfunctioning, enlarged kidney associated with obstructive uropathy secondary to nephrolithiasis. XGP is characterized by accumulation of lipid-laden foamy macrophages. It begins within the pelvis and calyces and subsequently extends into and destroys renal parenchymal and adjacent tissues. It has been known to imitate almost every other inflammatory disease of the kidney, as well as renal cell carcinoma, on radiographic examination (Malek and Elder, 1978; Tolia et al., 1980). In addition, the microscopic appearance of XGP has been confused with clear cell adenocarcinoma of the kidney on frozen section and has led to radical nephrectomy (Anhalt et al., 1971; Flynn et al., 1979; Lorentzen and Nielsen, 1980; Malek and Elder, 1978; Tolia et al., 1980). The entity is uncommon and is found in only about 0.6% (Malek et al., 1972) to 1.4% (Ghosh, 1955) of patients with renal inflammation who are evaluated pathologically.

Pathogenesis.

The primary factors involved in the pathogenesis of XGP are nephrolithiasis, obstruction, and infection (Gregg et al., 1999). Nephrolithiasis has been noted in as many as 83% of the patients in various series;

approximately half of the renal stones have been of the staghorn type (Chuang et al., 1992; Nataluk et al., 1995; Parsons et al., 1983). It has been proposed clinically and demonstrated experimentally that primary obstruction followed by infection with *E. coli* can lead to tissue destruction and collections of lipid material by macrophages (Povysil and Konickova, 1972). These macrophages (xanthoma cells) are distributed in sheets around parenchymal abscesses and calyces and are intermixed with lymphocytes, giant cells, and plasma cells. The bacteria appear to be of low virulence because spontaneous bacteremia has rarely been described. Other possible interrelated factors include venous occlusion and hemorrhage, abnormal lipid metabolism, lymphatic blockage, failure of antimicrobial therapy in UTI, altered immunologic competence, and renal ischemia (Friedenberg and Spjut, 1963; Goodman et al., 1979; McDonald, 1981; Mering et al., 1973; Tolia et al., 1981). The concept that XGP is related to incomplete bacterial degradation and altered host response has received mixed support (Khalyl-Mawad et al., 1982; Nielsen and Lorentzen, 1981). Thus it appears that there is probably no single factor instrumental in the pathogenesis of this disease. Rather, there is an inadequate host acute inflammatory response within an obstructed, ischemic, or necrotic kidney.

Pathology.

The kidney is usually massively enlarged and has a normal contour. XGP may be diffuse, as in approximately 80% of the patients, or segmental. In the diffuse form of the disease, the entire kidney is involved, whereas in segmental XGP, only the parenchyma surrounding one or more calyces or one pole of a duplicated collecting system is involved. On sectioning, the kidney usually demonstrates nephrolithiasis and peripelvic fibrosis. The calyces are dilated and filled with purulent material, but fibrosis surrounding the pelvis usually prevents dilation. The papillae are often destroyed by papillary necrosis (Goodman et al., 1979). In advanced stages of the disease, multiple parenchymal abscesses are filled with viscous pus and lined by yellowish tissue (Fig. 55.37A). The cortex is often thin and replaced by xanthogranulomatous tissue. The capsule is often thickened, and extension of the inflammatory process into the perinephric or paranephric space is common (Goodman et al., 1979; Gregg et al., 1999; McDonald, 1981).

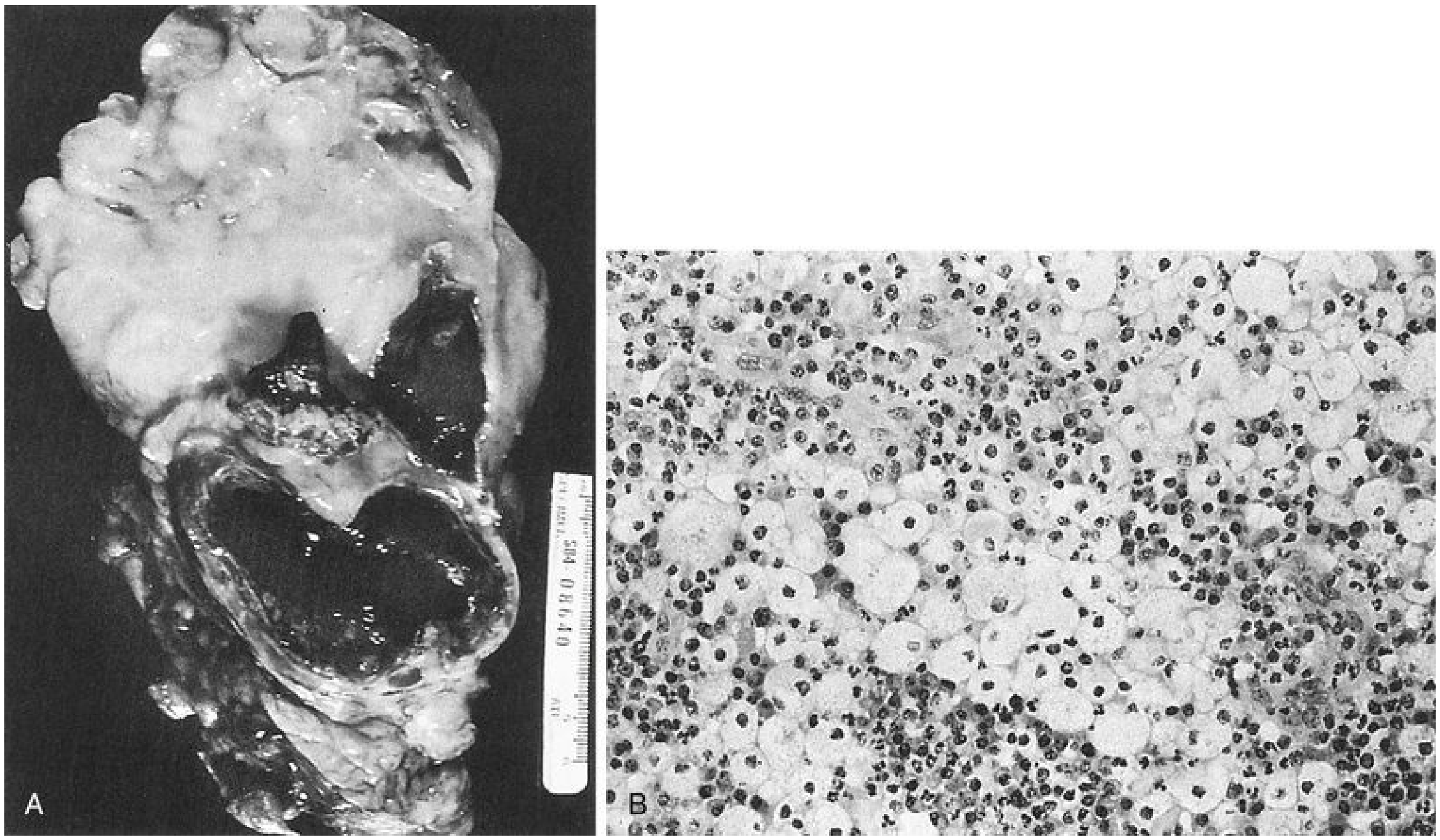

FIG. 55.37 Xanthogranulomatous pyelonephritis. (A) Gross specimen. Kidney is massively enlarged, measuring 23 × 12 cm; the normal architecture is replaced by a shaggy yellow upper pole mass corresponding to xanthogranulomatous inflammation and numerous distorted and dilated calyces. (B) Microscopically, the shaggy yellow tissue is composed primarily of lipid-laden histiocytes mixed with other inflammatory cells. (From Schaeffer AJ: Urinary tract infections. In Gillenwater JY, Grayhack JT, Howards SS, et al., editors: *Adult and pediatric urology*, Philadelphia, 2002, Lippincott Williams & Wilkins, pp 211–272.)

On microscopic examination, the yellowish nodules that line the calyces and surround the parenchymal abscesses contain dark sheets of lipid-laden macrophages (foamy histiocytes with small, dark nuclei and clear cytoplasm) intermixed with lymphocytes, giant cells, and plasma cells (Fig. 55.37B). Xanthogranulomatous cells are not specific to XGP but may be present anywhere inflammation or obstruction coexists. The origin of the fatty substance is disputed. Cholesterol esters that make up a part of the lipid may be derived from lysis of erythrocytes after hemorrhage (Saeed and Fine, 1963).

Clinical Presentation.

XGP should be suspected in patients with UTIs and a unilateral enlarged nonfunctioning or poorly functioning kidney with a stone or a mass lesion indistinguishable from malignant tumor. Most patients experience flank pain (69%), fever and chills (69%), and persistent bacteriuria (46%) (Malek and Elder, 1978). **Additional vague symptoms, such as malaise, may be**

present. On physical examination, 62% of the patients had a flank mass and 35% had previous calculi (Malek and Elder, 1978). Less commonly, hypertension, hematuria, or hepatomegaly is the presenting complaint. The medical history is often positive for UTIs and urologic instrumentation (Eastham et al., 1994; Flynn et al., 1979; Goodman et al., 1979; Grainger et al., 1982; Malek and Elder, 1978; Nataluk et al., 1995; Petronic et al., 1989; Yazaki et al., 1982). People with diabetes also appear to be at greater risk of developing the disease (Eastham et al., 1994). Although it may occur at any age, the peak incidence of XGP is in the fifth to the seventh decade. Women are more commonly affected than men. There is no predilection for either kidney.

Bacteriology and Laboratory Diagnosis.

Although review of the literature shows *Proteus* to be the most common organism involved with XGP (Anhalt et al., 1971; Tolia et al., 1981), *E. coli* is also common. The prevalence of *Proteus* organisms may reflect their association with stone formation and subsequent chronic obstruction and irritation. Malek and Elder (1978), in their analysis of 26 cases, found that renal tissue cultures grew bacteria in 22 of 23 cases. Anaerobes also have been cultured (Malek and Elder, 1978).

Approximately 10% of patients have mixed cultures. About one-third of patients have no growth in their urine, probably because many patients have recently taken or are taking antimicrobial agents when cultures are obtained. The infecting organism may be revealed only by tissue cultures obtained during surgery. Urinalysis usually shows pus and protein. In addition, blood tests often reveal anemia and may show hepatic dysfunction in up to 50% of the patients (Malek and Elder, 1978).

XGP is almost always unilateral; therefore azotemia or frank renal failure is uncommon (Goodman, et al. 1979; Gregg et al., 1999).

CT is probably the most useful radiologic technique in evaluating patients with XGP (Fig. 55.38). Fifty to eighty percent of patients show the classic triad of unilateral renal enlargement with little or no function and a large calculus in the renal pelvis (Elder, 1984)**. CT usually demonstrates a large, reniform mass with the renal pelvis tightly surrounding a central calcification but without pelvic dilatation** (Goldman et al., 1984; Hartman, 1985; Solomon et al., 1983). Renal parenchyma is replaced by multiple water-density masses representing dilated calyces and abscess cavities filled with varied amounts of pus and debris. On enhanced scans, the walls of these cavities demonstrate a prominent blush because of the abundant vascularity within the granulation tissue. The cavities themselves, however, fail to enhance, whereas tumors and other inflammatory lesions usually do. The CT scan is particularly helpful in demonstrating the extent of renal involvement and may indicate whether adjacent organs or the abdominal wall are involved by XGP (Eastham et al., 1994; Kaplan et al., 1997).

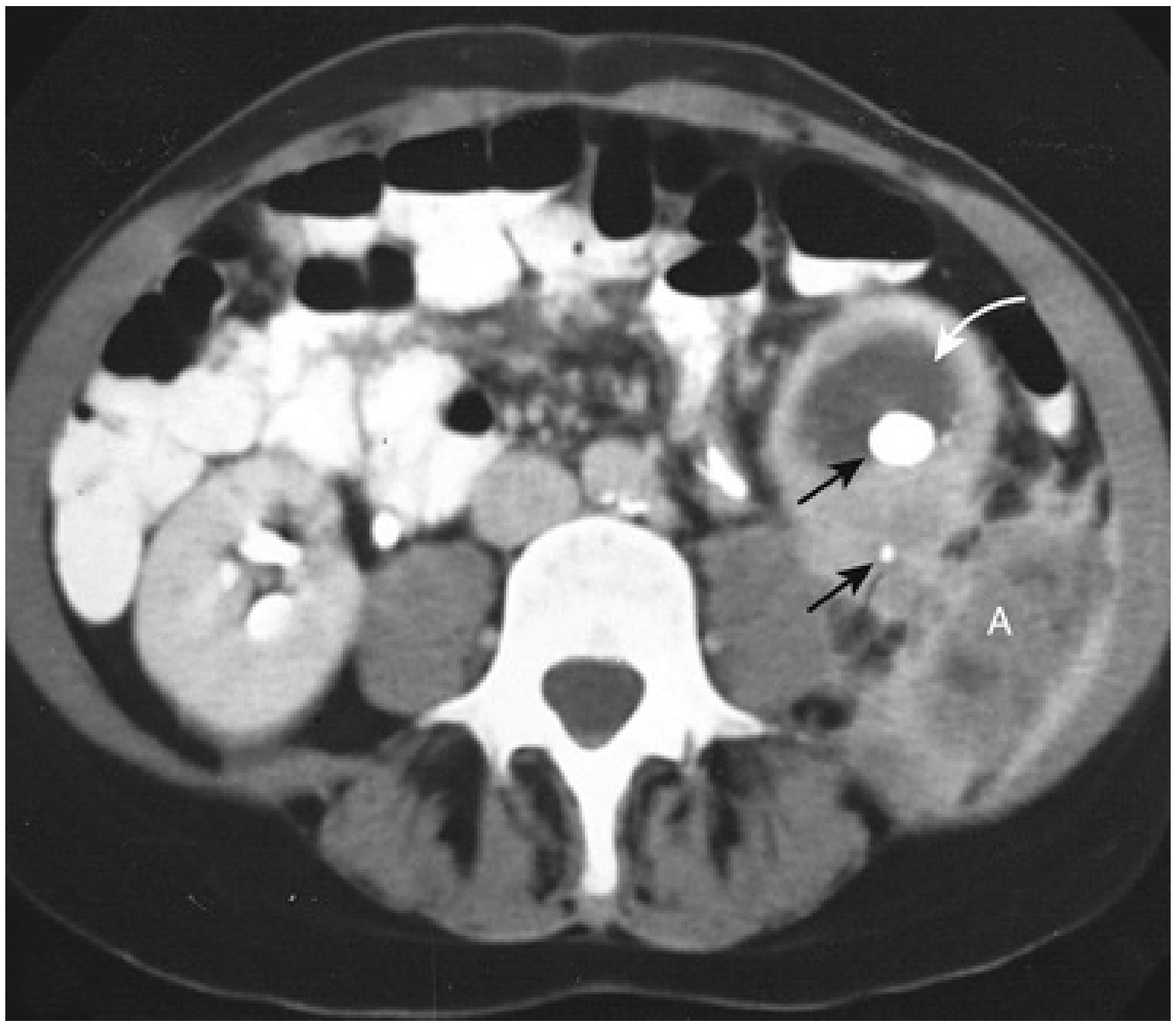

FIG. 55.38 Xanthogranulomatous pyelonephritis. Enhanced computed tomography scan shows collecting system and parenchymal calculi *(straight black arrows)* with lower pole pyonephrosis *(curved white arrow)* and an irregular, predominantly low-density perinephric abscess *(A)* extending into the soft tissues of the flank.

Ultrasonography usually demonstrates global enlargement of the kidney (Merenich and Popky, 1991). The normal renal architecture is replaced by multiple hypoechoic fluid-filled masses that correspond to debris-filled, dilated calyces or foci of parenchymal destruction (Fagerholm, 1983; Hartman et al., 1984). With focal involvement, a solid mass involving a segment of the kidney is sometimes called tumefactive xanthogranulomatous pyelonephritis. There may or may not be an associated calculus in the collecting system or ureter. Renal cell carcinoma and other solid renal lesions must be considered in the differential diagnosis (Elder, 1984).

Radionuclide renal scanning using ^{99m}Tc-DMSA is used to confirm and quantify the differential lack of function in the involved kidney (Gregg et al., 1999). MRI has not yet superseded CT in the evaluation of renal inflammation, but it provides some advantages in delineating extrarenal extension of inflammation (Soler et al., 1997). Lesions of XGP may appear as cystic foci of intermediate intensity signal on T1-weighted images and hyperintensity on T2-weighted images. Arteriography shows hypervascular areas, but there may be some hypovascular areas (Malek and Elder, 1978, Tolia et al., 1981; Van Kirk et al., 1980). Therefore radiologic studies, although distinctive, often cannot be used to differentiate between XGP and renal cell carcinoma.

Differential Diagnosis.

Diagnosis of segmental XGP without calculi may be difficult. XGP in association with massive pelvic dilation cannot be distinguished from pyonephrosis. When XGP occurs within a small contracted kidney, the radiographic findings are nonspecific and nondiagnostic. Renal parenchymal malacoplakia may show renal enlargement and multiple inflammatory masses replacing the normal renal parenchyma, but calculi are usually not present. Renal lymphoma may be associated with multiple hypoechoic masses surrounding the contracted, nondilated pelvis, but lymphoma is usually clinically obvious, and renal involvement is usually bilateral and not associated with calculi (Hartman et al., 1984).

Management.

The primary obstacle to the correct treatment of XGP is incorrect diagnosis. Today with CT technology, the diagnosis of XGP is made preoperatively nearly 90% of the time (Eastham et al., 1994; Nataluk et al., 1995). Antimicrobial therapy may be necessary to stabilize the patient preoperatively, and, **occasionally, long-term antimicrobial therapy will eradicate the infection and restore renal function** (Mollier et al., 1995). Because the renal abnormality may be diagnosed preoperatively as a renal tumor and/or is diffuse, **nephrectomy is usually performed.** If localized XGP is diagnosed preoperatively or at exploration, it is amenable to partial nephrectomy (Malek and Elder, 1978; Osca et al., 1997; Tolia et al., 1980).

The lipid-laden macrophages associated with XGP, however, closely resemble clear cell adenocarcinoma and may be difficult to distinguish solely on the basis of frozen section. Furthermore, XGP has been associated with renal cell carcinoma, papillary transitional cell carcinoma of the pelvis

or bladder, and infiltrating squamous cell carcinoma of the pelvis (Pitts et al., 1981; Schoborg et al., 1980; Tolia et al., 1981); thus, if malignant renal tumor cannot be excluded, nephrectomy should be performed. When diffuse and extensive disease into the retroperitoneum exists, removal of the kidney and perinephric fat may be needed. Under these circumstances, the surgery may be difficult and may involve dissection of granulomatous tissue from the diaphragm, great vessels, and bowel (Flynn et al., 1979; Malek and Elder, 1978). It is important to remove the entire inflammatory mass because in nearly three-fourths of patients, xanthogranulomatous tissue is infected. If incision and drainage alone are performed rather than nephrectomy, the patient may continue to suffer from protracted debilitating illness and may develop a renal cutaneous fistula; an even more difficult nephrectomy will then be necessary. One early case-matched series of laparoscopic nephrectomies performed for XGP concluded that the benefits of laparoscopic surgery do not extend to the treatment of this disease (Bercowsky et al., 1999); however, a larger review of a modern XGP experience suggests that laparoscopic nephrectomy is a reasonable treatment approach (Guzzo et al., 2009; Kapoor et al., 2006; Vanderbrink et al., 2007). Some studies suggest a retroperitoneal approach laparoscopically and, if transperitoneal, the use of a hand-assist port (Tobias-Machado et al., 2005). Although feasible, removal of an XGP kidney is difficult, and high conversion rates were seen across multiple studies (Korkes et al., 2008).

Malacoplakia

Malacoplakia, from the Greek word meaning “soft plaque,” is an unusual inflammatory disease originally described to affect the bladder but has been found to affect the GU and GI tracts, skin, lungs, bones, and mesenteric lymph nodes. It is an inflammatory lesion described originally by Michaelis and Gutmann (1902). It was characterized by von Hansemann (1903) as soft, yellow-brown plaques with granulomatous lesions in which the histiocytes contain distinct basophilic lysosomal inclusion bodies or Michaelis-Gutmann bodies. Although its exact pathogenesis is unknown, malacoplakia probably results from abnormal macrophage function in response to a bacterial infection, which is most often *E. coli*.

Pathogenesis.

The pathogenesis is unknown, but several theories are popular. In 93 patients who had cultures of urine, diseased tissue, or blood, 89.4% had coliform infections (Stanton and Maxted, 1981). Moreover, 40% of the patients in this review had an immunodeficiency syndrome, autoimmune disease, carcinoma, or another systemic disorder. **This association of coliform infections and compromised health status in patients with malacoplakia is well recognized.**

It is hypothesized that bacteria or bacterial fragments form the nidus for the calcium phosphate crystals that laminate the Michaelis-Gutmann bodies. Most investigations into the pathogenesis of this disease support theories that a defect in intraphagosomal bacterial digestion accounts for the unusual immunologic response that causes malacoplakia.

Pathology.

The diagnosis is made by biopsy. The lesion is characterized by large histiocytes, known as *von Hansemann cells*, and small basophilic, extracytoplasmic, or intracytoplasmic calculospherules called *Michaelis-Gutmann bodies*, which are pathognomonic (Fig. 55.39). Electron microscopy has revealed intact coliform bacteria and bacterial fragments within phagolysosomes of the foamy-appearing malacoplakic histiocytes (Lewin et al., 1976; Stanton and Maxted, 1981). In their review of the subject, Stanton and Maxted (1981) and Esparza et al. (1989) emphasized that, although pathognomonic for the disease, Michaelis-Gutmann bodies may be absent in early malacoplakia and are not necessary for the diagnosis.

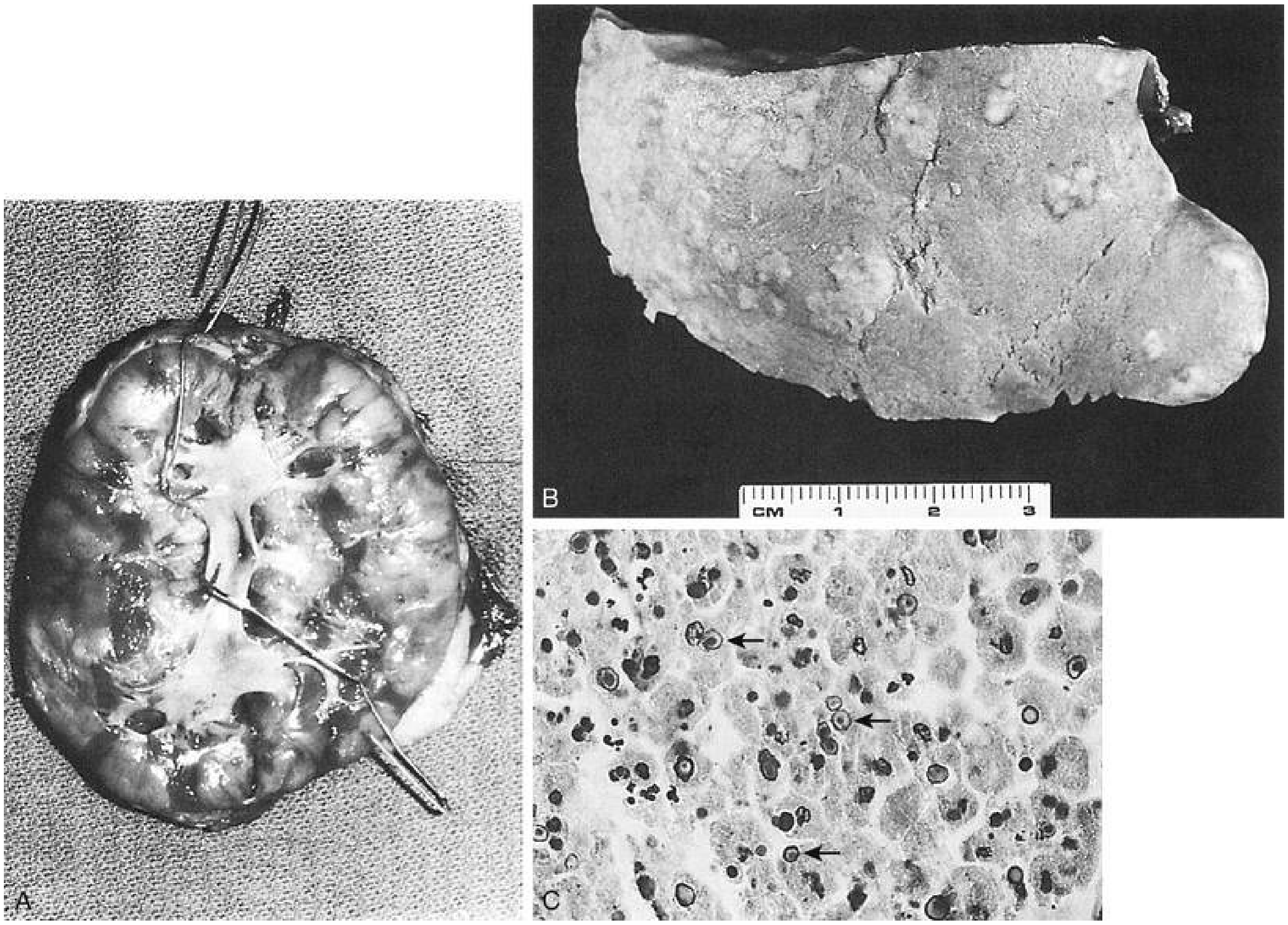

FIG. 55.39 Renal parenchymal malacoplakia. (A) Cut surface demonstrates extensive cortical and upper medullary replacement by multifocal, confluent, tumorlike masses. (B) Cortical surface exhibits multiple, firm, plaquelike lesions. (C) Hallmark of malacoplakia is demonstration of the Michaelis-Gutmann body *(arrows),* which represents incompletely destroyed bacteria surrounded by lipoprotein membrane (hematoxylin and eosin stain). (From Hartman DS: Radiologic pathologic correlation of the infectious granulomatous diseases of the kidney: I and II. *Monogr Urol* 6:3, 1985.)

It has been shown that macrophages in malacoplakia involving the kidney and bladder contain large amounts of immunoreactive α_1-antitrypsin (Callea et al., 1982). The amount of α_1-antitrypsin remains unchanged during the morphogenetic stages of the pathologic process. Macrophages from other pathologic processes, closely resembling malacoplakia but without Michaelis-Gutmann bodies, do not contain α_1-antitrypsin except for a few macrophages in tuberculosis and XGP. **Therefore immunohistochemical staining for α_1-antitrypsin may be a useful test for an early and accurate differential diagnosis of malacoplakia.**

Clinical Presentation.

Most patients are older than 50 years. **The ratio of females to males with malacoplakia within the urinary tract is 4:1, but this disparity does not occur in other body tissues** (Stanton and Maxted, 1981). **The patients often are debilitated and immunosuppressed and have other chronic diseases. In fact, malakoplakia is increasingly described after solid organ transplantation, particularly renal transplant recipients** (Nieto-Rios et al., 2017). The symptoms of bladder malacoplakia are bladder irritability and hematuria. Cystoscopy reveals mucosal plaques or nodules. As these lesions progress, they may become fungating, firm, sessile masses that cause filling defects of the bladder, ureter, or pelvis on excretory urograms. The distal ureter may become strictured or stenotic and cause subsequent renal obstruction or nonfunction (Sexton et al., 1982). A typical patient with renal parenchymal disease may have one or more radiographic masses and chronic *E. coli* infections. Renal parenchymal malacoplakia may be complicated by renal vein thrombosis and inferior vena cava thrombosis (McClure, 1983). When malacoplakia involves the testis, epididymo-orchitis is present. Malacoplakia of the prostate is rare, but, when it occurs, it may be confused with carcinoma clinically (Shimizu et al., 2005). Mortality can exceed 50%, and the morbidity can be substantial (Stanton and Maxted, 1981).

Radiologic Findings.

Multifocal malacoplakia on excretory urography typically is seen as enlarged kidneys with multiple filling defects. Renal calcification, lithiasis, and hydronephrosis are absent. The multifocal nature is best appreciated by using ultrasonography, CT, or arteriography. Ultrasound examination may demonstrate renal enlargement and distortion of the central echo complex. The masses are often confluent, resulting in an overall increase in the echogenicity of the renal parenchyma (Hartman et al., 1980). On CT, the foci of malacoplakia are less dense than the surrounding enhanced parenchyma (Hartman, 1985). Arteriography typically reveals a hypovascular mass without peripheral neovascularity (Cavins and Goldstein, 1977; Trillo et al., 1977).

Unifocal malacoplakia on excretory urography appears as a noncalcified mass that is indistinguishable from other inflammatory or neoplastic lesions. Ultrasonography and CT may demonstrate a solid or cystic structure, depending on the degree of internal necrosis. Angiography may demonstrate neovascularity (Trillo et al., 1977). Extension beyond the kidney, which can occur with either multifocal or uniform malacoplakia, is best demonstrated by

CT.

Differential Diagnosis.

The differential diagnosis includes renal cystic disease, neoplasia, and renal inflammatory disease (Hartman, 1985). **Malacoplakia should be considered when one or more renal masses are observed, particularly in female patients with recurrent UTIs with *E. coli*, altered immune response syndromes, or cystoscopic evidence of malacoplakia or filling defects in the collecting system** (Charboneau, 1980)**. Malacoplakia should also be suspected when these radiographic findings occur in a renal transplant patient who has persistent UTI despite appropriate antimicrobial therapy.** Cystic disease generally can be excluded by careful sonographic and CT evaluations. Renal involvement with metastatic disease or lymphomas usually occurs late in the course of the disease, which is well established. Multifocal renal cell carcinoma is most often seen in the context of von Hippel-Lindau disease with its other clinical manifestations. Patients with XGP usually have signs and symptoms of UTI. As with malacoplakia, the involved kidney is enlarged but renal calculi and obstruction are common. Multiple renal abscesses are often associated with hematogenous dissemination resulting from cardiac disease.

Management.

Management of malacoplakia should be directed at control of the UTIs, which should stabilize the disease process. This subject is well reviewed by Stanton and Maxted (1981). Although multiple long-term antimicrobial agents, including many antituberculosis agents, have been used, the sulfonamides, rifampin, doxycycline, and TMP are thought to be especially useful because of their intracellular bactericidal activity (Maderazo et al., 1979). Fluoroquinolones are taken up by macrophages directly and have also proven effective in the management of malacoplakia (Vallorosi et al., 1999). Other investigators have used ascorbic acid and cholinergic agents such as bethanechol in conjunction with antimicrobial therapy and have reported good results (Abdou et al., 1977; Stanton et al., 1983; Zornow et al., 1979). Both agents are thought to increase intracellular cyclic guanosine monophosphate levels, which have been postulated as the biologic defect causing macrophage dysfunction. Surgical intervention, however, may be necessary if the disease progresses in spite of antimicrobial treatment. Nephrectomy is usually performed for the treatment of symptomatic unilateral renal lesions.

The long-term prognosis appears to be related to the extent of the disease. When parenchymal renal malacoplakia is bilateral or occurs in the transplanted kidney, death usually occurs within 6 months (Bowers and Cathey, 1971; Deridder et al., 1977). Patients with unilateral disease usually have a long-term survival after nephrectomy.

Renal Echinococcosis

Echinococcosis is a parasitic infection caused by the larval stage of the tapeworm *Echinococcus granulosus.* The disease is prevalent in dogs, sheep, cattle, and humans in South Africa, Australia, New Zealand, Mediterranean countries (especially Greece), and some parts of the former Soviet Union. In the United States, the disease is rare, but it is found in immigrants from Eastern Europe or other foreign endemic areas or as an indigenous infection among American Indians in the Southwest and in Eskimos (Plorde, 1977).

Pathogenesis and Pathology.

Echinococcosis is produced by the larval form of the tapeworm, which in its adult form resides in the intestine of the dog, the definitive host. The adult worm is 3 to 9 mm long. The ova in the feces of the dog contaminate grass and farmlands and are ingested by sheep, pigs, or humans, the intermediate hosts. Larvae hatch, penetrate venules in the wall of the duodenum, and are carried by the bloodstream to the liver. Those larvae that escape the liver are next filtered by the lungs. Approximately 3% of the organisms that escape entrapment in the liver and lungs may then enter the systemic circulation and infect the kidneys. The larvae undergo vesiculation, and the resultant hydatid cyst gradually develops at a rate of about 1 cm/yr. Thus the cyst may take 5 to 10 years to reach pathologic size.

Echinococcosis cysts of the kidney are usually single and located in the cortex (Nabizadeh et al., 1983). The wall of the hydatid cyst has three zones: a peripheral zone of fibroblasts derived from tissues of the host becomes the adventitia and may calcify; an intermediate laminated layer becomes hyalinized; and a single inner layer is composed of nucleated epithelium and is called the *germinal layer.* The germinal layer gives rise to brood capsules that increase in number, become vacuolated, and remain attached to the germinal membrane by a pedicle. New larvae (scoleces) develop in large numbers from the germinal layer within the brood capsule (eFig. 55.40). The hydatid cyst is also filled with fluid. When brood capsules detach, they enlarge and move freely in the fluid and are then called daughter cysts. Hydatid sand is composed of free larvae and daughter cysts.

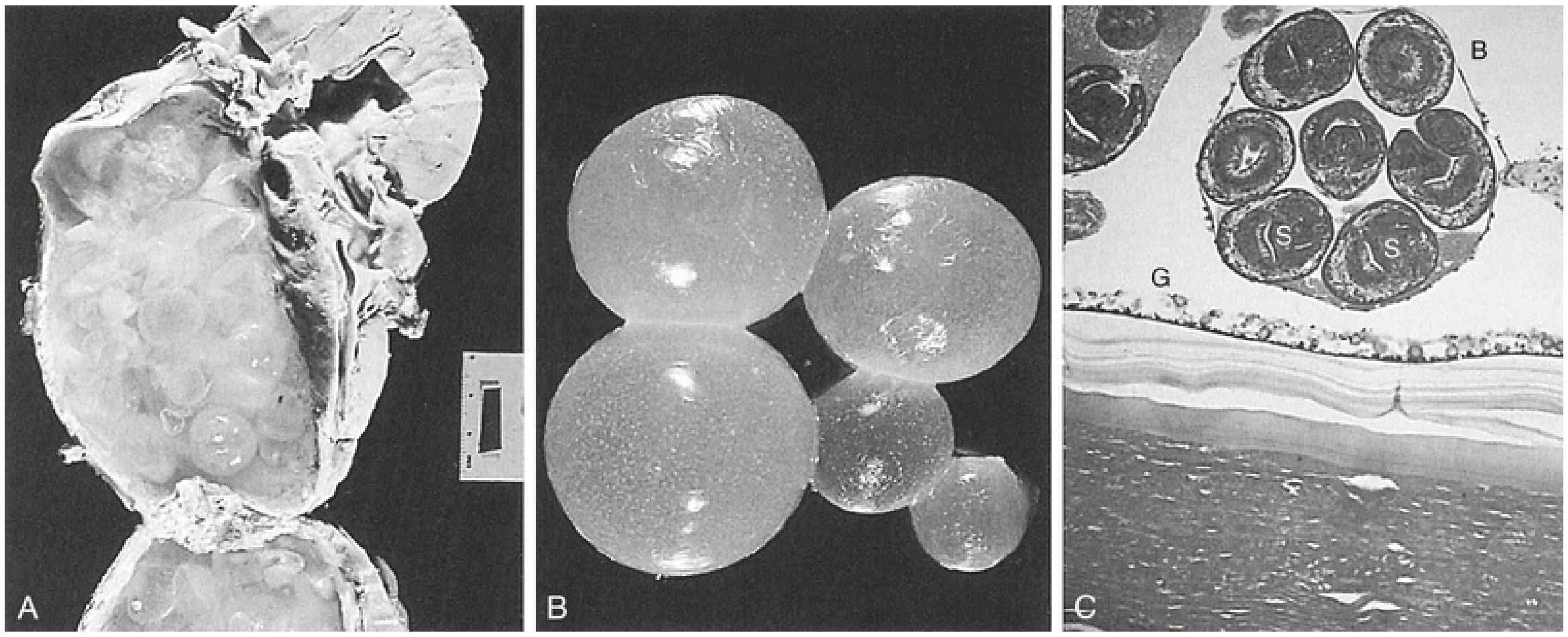

EFIG. 55.40 Echinococcosis. (A) Gross specimen. A cystic mass measuring 7 × 11 cm in lower pole. Smaller daughter cysts are identified within the larger cystic mass. (B) Gross specimen. Daughter cysts represent brood capsules that have detached and move freely. (C) Photomicrograph. Brood capsules *(B)* arising from the germinal layer *(G)* contain viable and degenerating scoleces *(S).* (From Hartman DS: Radiologic pathologic correlation of the infectious granulomatous diseases of the kidney: III and IV. *Monogr Urol* 6:26, 1985.)

Clinical Presentation.

The symptoms of echinococcosis are those of a slow-growing tumor. Most patients are asymptomatic or have a flank mass, dull pain, or hematuria (Gilsanz et al., 1980; Nabizadeh et al., 1983). Because the cyst is focal, it rarely affects renal function. Rarely, the cyst ruptures into the collecting system, and the patient may experience severe colic and passage of debris resembling grape skins in the urine (hydatiduria). The cyst may also rupture into an adjacent viscus or the peritoneal cavity. The fluid is extremely antigenic (Hartman, 1985).

Laboratory Diagnosis.

If cyst rupture occurs, the definitive diagnosis can be established by identifying daughter cysts in the urine or by identifying the laminated wall of the cyst (Sparks et al., 1976). Fewer than half of the patients have eosinophilia. The most reliable diagnostic test uses partially purified hydatid arc 5 antigens in a double-diffusion test (Coltorti and Varela-Diaz, 1978).

Complement fixation, hemagglutination, and the Casoni intradermal skin tests are less reliable but, when combined, are positive in about 90% of patients (Sparks et al., 1976).

Radiologic Findings.

Excretory urography typically shows a thick-walled cystic mass, occasionally calcified (Buckley et al., 1985). If the cyst ruptures into the collecting system, daughter cysts may be outlined in the pelvis as an irregular mass or as multiple solitary lesions (Gilsanz et al., 1980). Occasionally, direct filling of the cyst with contrast medium occurs.

Ultrasonography and CT are useful in characterizing the mass. Ultrasonography usually demonstrates a multicystic or multiloculated mass. A sudden change in position may demonstrate bright falling echoes corresponding to hydatid sand, which can be observed during real-time evaluation of hydatid cysts (Saint Martin, 1984).

On CT, several patterns of renal echinococcosis may be recognized. The most specific is a cystic mass with discrete, round daughter cysts and a well-defined enhancing membrane (Martorana et al., 1981). The less specific pattern is that of a thick-walled multiloculated cystic mass (Gilsanz et al., 1980). The presence of daughter cysts within the mother cyst differentiates the lesion from a simple renal cyst and from renal abscesses, infected cysts, and necrotic neoplasm.

CT and ultrasonography are useful in evaluating the liver. Angiography is seldom required. **Diagnostic aspiration should not be performed because of the danger of rupture and spillage of the highly antigenic cyst contents and risk of fatal anaphylaxis.** Nevertheless, Baijal et al. (1995) described a percutaneous management of renal hydatidosis as a minimally invasive diagnostic and therapeutic option.

Management.

The prognosis of echinococcosis is good but depends on the site and size of the cysts. Medical treatment with benzimidazole compounds such as mebendazole or albendazole has shown limited success with significant side effects (Nabizadeh et al., 1983).

Surgery remains the mainstay of treatment of renal echinococcosis (Poulios, 1991)**. The cyst should be removed without rupture to reduce the chance of seeding, antigen reaction, and recurrence.** If the cyst wall is calcified, the larvae are probably dead and the risk of seeding is low, although a daughter cyst may be viable. **If the cyst ruptures or cannot be removed and marsupialization is required, the contents of the cyst initially should be aspirated and filled with a scolicidal agent** such as 30% sodium chloride, 0.5% silver nitrate, 2% formalin, or 1% iodine for approximately 5 minutes to kill the germinal portion (Nabizadeh et al., 1983; Shetty et al., 1992; Sparks et al., 1976).

Key Points: Kidney Infections

- Acute pyelonephritis classically is seen as the abrupt onset of chills, fever, and flank or costovertebral angle tenderness but can involve symptoms as mild as cystitis or as severe as sepsis.
- Emphysematous pyelonephritis is a life-threatening infection diagnosed radiographically by the presence of gas in the parenchyma or collecting system and can be managed via percutaneous drainage or surgically.
- Renal abscesses are well delineated by CT and are classically managed with IV antimicrobial agents and drainage. Smaller abscesses may be amenable to conservative treatment with medical management.
- Pyonephrosis is a bacterial infection in a hydronephrotic kidney. Prompt diagnosis is critical; treatment entails intravenous antimicrobial agents and drainage of the obstructed renal unit.
- XGP is a chronic renal infection that is often found in poorly functioning renal units obstructed secondary to nephrolithiasis. XGP can be mistaken for renal tumors.
- Malacoplakia is an unusual inflammatory disease thought to result from abnormal macrophage function. Michaelis-Gutmann bodies are lysosomal inclusion bodies that characterize this disease microscopically.

Other Infections

Fournier Gangrene

Fournier gangrene is a potentially life-threatening form of necrotizing fasciitis involving the male genitalia. It is also known as idiopathic gangrene of the scrotum, streptococcal scrotal gangrene, perineal phlegmon, and spontaneous fulminant gangrene of the scrotum (Fournier, 1883, 1884). As originally reported by Baurienne in 1764, then by Fournier in 1883, it was characterized by an abrupt onset of a rapidly fulminating genital gangrene of idiopathic origin in previously healthy young patients that resulted in gangrenous destruction of the genitalia. The disease now differs from these descriptions in that it involves a broader age range, including older patients (Bejanga, 1979; Wolach et al., 1989), follows a more indolent course, and has a less abrupt onset; and, in approximately 95% of the cases, a source can now be identified (Burpee and Edwards, 1972; Jamieson et al., 1984; Kearney and Carling, 1983; Macrea, 1945; Spirnak et al., 1984).

Infection most commonly arises from the skin, urethra, or rectal regions. An association between urethral obstruction associated with strictures and extravasation and instrumentation has been well documented. **Predisposing factors include diabetes mellitus, local trauma, paraphimosis, periurethral extravasation of urine, perirectal or perianal infections, and surgery such as circumcision or herniorrhaphy. In cases originating in the genitalia, specifically as a result of urethral obstruction, the infecting bacteria probably pass through Buck fascia of the penis and spread along the Dartos fascia of the scrotum and penis, Colles fascia of the perineum, and Scarpa fascia of the anterior abdominal wall.** In view of the typical foul odor associated with this condition, a major role for anaerobic bacteria is likely. **Wound cultures generally yield multiple organisms, implicating anaerobic-aerobic synergy** (Cohen, 1986; Meleney, 1933; Miller, 1983). Mixed cultures containing facultative organisms (*E. coli*, *Klebsiella*, enterococci) along with anaerobes (*Bacteroides*, *Fusobacterium*, *Clostridium*, microaerophilic streptococci) have been obtained from the lesions.

Clinical Presentation

Patients frequently have a history of recent perineal trauma,

instrumentation, urethral stricture associated with sexually transmitted disease, or urethral cutaneous fistula. Pain, rectal bleeding, and a history of anal fissures suggest a rectal source of infection. Dermal sources are suggested by history of acute and chronic infections of the scrotum and spreading recurrent hidradenitis suppurativa or balanitis.

The infection commonly starts as cellulitis adjacent to the portal of entry. Early on, the involved area is swollen, erythematous, and tender as the infection begins to involve the deep fascia. Pain is prominent, and fever and systemic toxicity are marked (Paty and Smith, 1992). The swelling and crepitus of the scrotum quickly increase, and dark purple areas develop and progress to extensive gangrene. If the abdominal wall becomes involved in an obese patient with diabetes, the process can spread very rapidly. Specific GU symptoms associated with the condition include dysuria, urethral discharge, and obstructed voiding. Alterations in mental status, tachypnea, tachycardia, and temperature greater than 38.3°C (101°F) or less than 35.6°C (96°F) suggest gram-negative sepsis.

Laboratory Diagnosis and Radiologic Findings

Anemia occurs secondary to a decreased functioning erythrocyte mass caused by thrombosis and ecchymosis coupled with decreased production secondary to sepsis (Miller, 1983). Elevated serum creatinine levels, hyponatremia, and hypocalcemia are common. Hypocalcemia is believed to be secondary to bacterial lipases that destroy triglycerides and release free fatty acids that chelate calcium in its ionized form.

Because crepitus (subcutaneous gas) is often an early finding, a plain film of the abdomen may be helpful in identifying air. Scrotal ultrasonography is also useful in this regard. Biopsy of the base of an ulcer is characterized by superficially intact epidermis, dermal necrosis, vascular thrombosis, and polymorphonuclear leukocyte invasion with subcutaneous tissue necrosis. Stamenkovic and Lew (1984) noted that the use of frozen sections within 21 hours after the onset of symptoms could confirm a diagnosis earlier and lead to early institution of appropriate treatment.

Management

Prompt diagnosis is critical because of the rapidity with which the process can progress. The clinical differentiation of necrotizing fasciitis from cellulitis may be difficult because the initial signs including pain, edema, and erythema are not distinctive. However, **the presence of marked systemic toxicity out of proportion to the local finding should alert the clinician.** Intravenous hydration and antimicrobial therapy are indicated in preparation for surgical debridement. Antimicrobial regimens include broad-spectrum antibiotics (β-lactam plus β-lactamase inhibitor) such as piperacillin-tazobactam (especially if *Pseudomonas* is suspected), ampicillin plus sulbactam, or vancomycin or carbapenems plus clindamycin or metronidazole (Morpurgo and Galandiuk, 2002).

Immediate debridement is essential. In the patient in whom diagnosis is clearly suspected on clinical grounds (deep pain with patchy areas of surface hypoesthesia or crepitation, or bullae and skin necrosis), direct operative intervention is indicated. **Extensive incision should be made through the skin and subcutaneous tissues, going beyond the areas of involvement until normal fascia is found. Necrotic fat and fascia should be excised, and the wound should be left open. A second procedure 24 to 48 hours later is indicated if there is any question about the adequacy of initial debridement**. **Orchiectomy is almost never required** because the testes have their own blood supply independent of the compromised fascial and cutaneous circulation to the scrotum. **Suprapubic diversion should be performed in cases in which urethral trauma or extravasation is suspected. Colostomy should be performed if there is colonic or rectal perforation.** Hyperbaric oxygen therapy has shown some promise in shortening hospital stays, increasing wound healing, and decreasing the gangrenous spread when used in conjunction with debridement and antimicrobials (Paty and Smith, 1992). Once wound healing is complete, reconstruction (e.g., using myocutaneous flaps) improves cosmetic results.

Outcome

The mortality rate averages approximately 20% (Baskin et al., 1990; Clayton et al., 1990; Cohen, 1986) but ranges from 7% to 75%. Higher mortality rates are found in patients with diabetes, alcoholics, and those with colorectal sources of infection who often have a less typical presentation, greater delay in diagnosis, and more widespread extension. Regardless of the presentation, **Fournier gangrene is a true urologic emergency that demands early recognition, aggressive treatment with antimicrobial agents, and surgical debridement to reduce morbidity and mortality.**

Periurethral Abscess

Periurethral abscess is a life-threatening infection of the male urethra and periurethral tissues. Initially, the area of involvement can be small and localized by Buck fascia. However, when Buck fascia is penetrated, there can be extensive necrosis of the subcutaneous tissue and fascia. Fasciitis can spread as far as the buttocks posteriorly and the clavicle superiorly. Rapid diagnosis and treatment are essential to reduce the morbidity and high mortality historically associated with this disease.

Pathogenesis

Periurethral abscess is frequently a sequela of gonorrhea, urethral stricture disease, or urethral catheterization. Frequent instrumentation is also associated with periurethral abscess formation. The source of the infecting organism is the urine. Gram-negative rods, enterococci, and anaerobes are most frequently identified. The presence of multiple organisms is common. Anaerobes, normal residents of the male urethra, are also frequently found in wound cultures.

Clinical Presentation

Presenting signs and symptoms include scrotal swelling in 94% of patients, fever (70%), acute urinary retention (19%), spontaneously drained abscess (11%), and dysuria or urethral discharge (5% to 8%). The average interval between initial symptoms and presentation is 21 days. Urinalysis of the first glass specimen reveals pyuria and bacteriuria.

Management

Treatment consists of immediate suprapubic urinary drainage and wide debridement. Antimicrobial therapy with an aminoglycoside and a cephalosporin is usually adequate for empirical coverage. More selective antimicrobial therapy can be instituted when the antimicrobial susceptibility of the organisms is available. Perineal urethrostomy or chronic suprapubic diversion occasionally has been helpful to prevent recurrences, and it should be considered in patients with diffuse stricture disease. The presence of a malignancy is unusual, but biopsy is important.

Key Points: Other Infections

- Fournier gangrene is necrotizing fasciitis arising from the perineal skin, scrotum, urethra, or rectum.
- Emergent surgical debridement and broad-spectrum antimicrobial agents are the essentials of treatment of Fournier gangrene.
- Periurethral abscess can occur secondarily to urethral stricture or catheterization; treatment entails surgical debridement, suprapubic urinary drainage, and antimicrobial agents.

Bacteremia, Sepsis, and Septic Shock

Sepsis is a clinical syndrome characterized by extremes of body temperature, heart rate, respiratory rate, and WBC count that occurs in response to an infection. A detailed list of potential characteristics can be found in Box 55.12. Severe sepsis and septic shock are extensions of the sepsis spectrum and involve acute organ dysfunction and life-threatening hypotension not responsive to fluid resuscitation (Dellinger et al., 2008). A typical host response to infection involves localized containment and elimination of bacteria and repair of damaged tissue. This process is facilitated by macrophages and dendritic cells and orchestrated by $CD4^+$ T helper cells via the release of proinflammatory and anti-inflammatory molecules (cytokines, chemokines, interferons). Sepsis occurs when a local infectious process becomes an uncontrolled systemic blood-borne inflammatory response resulting in damage to tissues or organs remote from the initial site of infection or injury. The extremes of the spectrum are lethal in one in four patients, and there are an estimated 750,000 cases (3 cases per 1000 population) of sepsis or septic shock in the United States each year (Dellinger et al., 2008; Rivers et al., 2001). Much like other medical emergencies, including polytrauma, acute myocardial infarction, and stroke, early recognition and appropriate treatment significantly influence outcome; these are commonly known as "the golden hours."

Box 55.12

Potential Characteristics of Sepsis Spectrum

General

Fever (core temperature >38.3°C)
Hypothermia (core temperature <36°C)
Heart rate >90 min, 1 or 2 SD above the normal value for age
Tachypnea
Altered mental status
Significant edema or positive fluid balance (20 mL/kg/24 h)
Hyperglycemia (plasma glucose >120 mg/dL or 7.7 mmol/L) in the

absence of diabetes

Inflammatory

Leukocytosis (WBC count >12,000/µL)
Leukopenia (WBC count <4000/µL)
Normal WBC count with >10% immature forms

Organ Dysfunction

Arterial hypoxemia ($\mathrm{PaO_2/FIO_2} > 300$)
Acute oliguria (urine output 0.5 mL/kg in 1 h for at least 2 h)
Creatinine increase of 0.5 mg/dL
Coagulation abnormalities (INR 1.5 or aPTT >60 sec)
Ileus (absent bowel sounds)
Thrombocytopenia (platelet count <100,000/µL)
Hyperbilirubinemia (plasma total bilirubin >4 mg/dL or 70 mmol/L)

Tissue Perfusion

Hyperlactatemia (>1 mmol/L)
Decreased capillary refill or mottling

aPTT, Activated partial thromboplastin time; *INR,* international normalized ratio; *SD,* standard deviation; *WBC,* white blood cell.

Data from Levy MM, Fink MP, Marshall JC, et al.: 2001 SCCM/ESICM/ACCP/ATS/SIS International Sepsis Definitions Conference. *Crit Care Med* 31:1250–1256, 2003.

Definitions

- **Bacteremia:** the presence of viable bacteria in the blood
- **Systemic inflammatory response syndrome (SIRS):** a clinical syndrome characterized by the 2001 International Sepsis Definitions Conference (Levy et al., 2003) as extremes of body

temperature, heart rate, ventilation, and immune response. **SIRS can occur in response to multiple insults, including systemic infection, trauma, thermal injury, or a sterile inflammation.**

- **Sepsis:** SIRS and infection either documented or strongly suspected
- **Severe sepsis: sepsis plus sepsis-induced organ dysfunction or tissue hypoperfusion, typically systolic blood pressure (SBP) less than 90 mm Hg or mean arterial pressure (MAP) less than 70 mm Hg**
- **Septic shock:** an extreme form of sepsis with sepsis-induced hypotension persisting despite adequate fluid resuscitation; findings may include elevated lactic acid or oliguria

Pathophysiology

Initial studies of pathophysiologic features of septic shock concentrated on the interactions of lipopolysaccharides (LPS) from the gram-negative bacterial cell wall with various innate immune system pathways. More recent investigations now focus on understanding the activation and regulation of the innate and acquired immune systems and the array of cytokines that are released during localized and systemic inflammatory responses.

Bacterial Cell Wall Components in Septic Shock

The exotoxins produced by some bacteria (e.g., exotoxin A produced by *P. aeruginosa*) can initiate septic shock. **However, the bacteria themselves, and in particular their cell wall components, are primarily responsible for the development of septic shock. These components activate numerous innate immunologic pathways, including macrophages, neutrophils, and dendritic cells and the complement system. The prime initiator of gram-negative bacterial septic shock is endotoxin, an LPS component of the bacterial outer membrane.** Endotoxin can directly activate the coagulation, complement, and fibrinolytic systems, leading to the release of small molecules that cause vasodilation and increased endothelial permeability (Tapper and Herwald, 2000).

Cytokine Network

Monocytic cells appear to have a pivotal role in mediation of the biologic effects of SIRS and septic shock. Monocytes can remove and detoxify LPS and be beneficial to the host. However, LPS-stimulated monocytes produce cytokines such as tumor necrosis factor (TNF) and interleukin (IL)-1. The intravascular activation of inflammatory systems involved in septic shock is mainly the consequence of an overproduction of these and other cytokines. Production of these cytokines is modulated by $CD4^+$ T helper cells. Type I $CD4^+$ T helper cells release proinflammatory cytokines including TNF-α, interferon-γ, and IL-2. These cytokines are also produced by macrophages, endothelial cells, and other cells stimulated by microbial products. The systemic release of large amounts of the cytokine TNF is associated with death from septic shock in humans (Calandra et al., 1988; Girardin et al., 1988; Waage, 1987). However, despite the fact that TNF is classically regarded as a central mediator of pathophysiologic changes associated with sepsis, the role of attenuation of this and other proinflammatory cytokines remains unclear. For example, in one animal model of peritonitis, survival was worsened by the administration of antibodies blocking TNF (Eskandari et al., 1992). Also, patients suffering from rheumatoid arthritis treated with TNF-α agents remain susceptible to the development of septic shock. Last, a meta-analysis of clinical trials using anti-inflammatory agents in sepsis suggested these agents were generally harmful in all but a small subset of patients (Hotchkiss and Karl, 2003). More recently, anti-inflammatory cytokines, including IL-4 and IL-10, released by type II $CD4^+$ T helper cells, have also been noted to be elevated in sepsis, further illustrating the complex regulation of proinflammatory and anti-inflammatory cytokines in a septic patient. In summary, proinflammatory and anti-inflammatory cytokines are elements of early sepsis; however, the role of cytokine modulation in the treatment of sepsis remains unclear.

Clinical Presentation and Diagnosis

Early signs of systemic inflammatory response syndrome include temperature extremes (>38°C [100.4°F] or <36°C [96.8°F]), tachycardia (heart rate >90 beats/min), tachypnea, and altered mental status. The classic bedside findings differentiating septic shock from other types of shock include a warm patient, brisk capillary refill, and a bounding pulse reflecting pyrexia, peripheral vasodilation, and decreased systemic vascular resistance. Other diagnostic criteria include evidence of organ dysfunction

such as hypotension, oliguria, or ileus and **laboratory abnormalities** including leukocytosis or leukopenia, hyperbilirubinemia, hyperlactatemia, hyperglycemia, coagulation abnormalities, and elevated C-reactive protein and procalcitonin (see Box 55.12). The classic clinical presentation of fever and chills followed by hypotension is manifest only in about 30% of patients with gram-negative bacteremia (McClure, 1983). Even before temperature extremes and the onset of chills, bacteremic patients often begin to hyperventilate. Thus the **earliest metabolic change in septicemia is a resultant respiratory alkalosis.** In critically ill patients, the sudden onset of hyperventilation should lead to blood drawing for culture and careful evaluation of the patient. **Changes in mental status can also be important clinical clues.** Although the most common pattern is lethargy or obtundation, an occasional patient may become excited, agitated, or combative. Cutaneous manifestations such as the bull's-eye lesion associated with *P. aeruginosa* may be identified.

Metastatic infections secondary to GU tract bacteremia have been described (Siroky et al., 1976). In this review of 137 patients who developed metastatic infections from bacteremia with a GU source, 79% had undergone prior urologic instrumentation, 59% developed skeletal infections, mainly of the spine, and 29% developed endocarditis, most commonly caused by *E. faecalis*.

Bacteriology

In classic studies of sepsis syndrome and septic shock, gram-negative bacteria were predominant organisms isolated in 30% to 80% of cases and gram-positive bacteria in 5% to 24% (Bone, 1991; Calandra et al., 1988; Ispahani et al., 1987). Although *E. coli* is the most common organism causing gram-negative bacteremia, many nosocomial catheter-associated infections are caused by highly resistant gram-negative organisms: *P. aeruginosa*, *Proteus*, *Providencia*, and *Serratia* spp. *Acinetobacter* and *Enterobacter* spp. are also emerging as important nosocomial pathogens. In a large series, *E. coli* caused about one-third of the cases; the *Klebsiella-Enterobacter-Serratia* family, approximately 20%; and *Pseudomonas*, *Proteus*, *Providencia*, and anaerobic species, approximately 10% each (Kreger et al., 1980). Anaerobic organisms may cause bacteremia when the source is a postsurgical intra-abdominal abscess or transrectal prostatic biopsy. **More recent studies suggest the incidence of sepsis caused by gram-positive bacterial and fungal organisms is increasing** (Martin et al., 2003) **and reinforce the need for initial broad-spectrum**

antimicrobial coverage.

Management

The principles of management of sepsis include resuscitation, supportive care, monitoring, administration of broad-spectrum antimicrobial agents, and drainage or elimination of infection (Dellinger et al., 2008; Sessler et al., 2004). Although the identification and early intervention of sepsis by the urologist is important, the use of expert consultants is also recommended because management of sepsis and the critically ill patient is complex and always evolving. Early goal-directed therapy remains the standard approach since it was shown to be significantly beneficial in a 263-patient study by Rivers et al. (2001).

Principles of resuscitation include support of the airway and breathing and optimization of perfusion with the use of invasive pressure monitoring with central access (Rivers et al., 2001). Intubation and mechanical ventilation may be required in patients who are obtunded and unable to protect their airway. Supplemental oxygen may be instituted, but supranormal oxygen delivery is no longer considered a goal of therapy (Dellinger et al., 2008). **Tissue perfusion should first be optimized** with fluid resuscitation to restore mean circulating filling pressures; this may include crystalloid and or colloid/blood products. If additional blood pressure support is needed, vasoactive agents including phenylephrine, norepinephrine, vasopressin, and dopamine can be instituted; however, low-dose dopamine administration for renal protection is no longer recommended by critical care experts. Other principles of resuscitation and supportive care include optimization of oxygen delivery, correction of coagulopathies if clinically significant, maintenance of blood glucose levels below 110 mg/dL with intensive insulin therapy (van den Berghe et al., 2001), and implementation of hemofiltration as needed (Schiffl et al., 2002). The use of hydrocortisone therapy in septic shock patients did not show a survival or disease-specific benefit in patients in a large study (Sprung et al., 2008).

Identification of the presumptive source of infection and cultures from corresponding fluids and blood should be obtained before the initiation of antimicrobial therapy. Multiple blood cultures for aerobic and anaerobic organisms should be obtained. In addition, all potential sources of bacteremia must be cultured (i.e., urine, sputum, and wounds). Careful attempts to identify the source of infection should be made because the choice of appropriate antimicrobial coverage depends on the organisms that are thought most likely to cause the infection. The severity of the underlying disease and the possibility of synergistic interactions are also important considerations. **If the urinary tract is the most likely portal of entry, a broad-spectrum antimicrobial either alone or in combination with an aminoglycoside should be administered. Three clinical factors have been predictive of the subsequent isolation of a resistant pathogen: (1) the use of an antimicrobial drug in the last month, (2) advanced age, and (3) male sex** (Leibovici et al., 1992). If the infection is hospital acquired, or if the patient has had multiple infections or is immunocompromised or severely ill, an aminoglycoside and anti-*Pseudomonas* β-lactam or a third-generation cephalosporin should be used. When identification and drug susceptibilities of the offending organism are known, antimicrobial therapy should be changed to use the lowest cost, least toxic antimicrobial with the narrowest antimicrobial coverage. Antimicrobial treatment should be continued until the patient has been afebrile for 3 to 4 days and is clinically stable. Local infections that may have provided the focus for the bacteremia should be treated individually as appropriate. The surviving sepsis campaign suggests the initiation of broad-spectrum antibiotics within 1 hour of diagnosis of septic shock (Dellinger et al., 2008).

Key Points: Bacteremia, Sepsis, and Septic Shock

- Sepsis is a clinical syndrome characterized by extremes of body temperature, heart rate, respiratory rate, and WBC count that occurs in response to an infection.
- The principles of management of sepsis include resuscitation, supportive care, monitoring, administration of broad-spectrum antimicrobial agents, and drainage or elimination of infection.
- The surviving sepsis campaign and early goal-directed therapy have been shown to improve outcomes in critically ill patients.

Bacteriuria in Pregnancy

Pregnancy

The prevalence of bacteriuria in pregnant women varies from 4% to 7%,

and the incidence of acute clinical pyelonephritis ranges from 25% to 35% in untreated bacteriuric women (Stamey, 1980). This is probably the result of dilation of the ureters and pelvis of the kidney secondary to pregnancy-related hormonal alterations. In addition, urine obtained from a pregnant woman at any gestational stage exhibits a more suitable pH for growth of *E. coli* (Asscher et al., 1973). **It is not surprising that untreated bacteriuria in the first trimester is accompanied by a substantial increase in the incidence of acute pyelonephritis because half of these women have upper tract bacteriuria** (Fairley et al., 1966).

Untreated bacteriuria involving these dilated upper tracts could be expected to cause a significant number of abnormalities that should be radiologically apparent. Kincaid-Smith and Bullen (1965) performed a culture on 4000 women at their first antenatal visit. Out of 240 bacteriuric women, 148 returned for excretory urography 6 weeks after delivery. Approximately 40% of these patients had radiologic abnormalities consistent with pyelonephritis or analgesic nephritis. Brumfitt et al. (1967) showed that the incidence of radiologic abnormalities in bacteriuria of pregnancy was proportional to the difficulty in clearing the infection. Patients who responded promptly to a single course of therapy had a 23% incidence of radiologic abnormalities, but those who remained bacteriuric despite repeated therapeutic efforts had a 65% incidence of radiologic changes. Thus prolonged bacteriuria and pyelonephritis of pregnancy appear to be **associated** with significant radiologic abnormalities. However, there is little evidence to suggest that bacteriuria of pregnancy or acute pyelonephritis of pregnancy **causes** these renal radiologic abnormalities.

Recurrent UTIs are common in pregnant women and can result in preterm labor and low-birth-weight babies. All pregnant women should routinely be screened for bacteriuria. Aggressive management of the bacteriuria is necessary: as stated earlier, pregnant women are one of the few categories of patients who require treatment of asymptomatic bacteriuria, per the IDSA guidelines. **Screening with urine culture is recommended at the initial visit by the American College of Obstetricians and Gynecologists (ACOG). Treatment of asymptomatic bacteriuria has been shown to reduce morbidity and complications. Asymptomatic bacteriuria is one of the most common infectious issues encountered during pregnancy. The prevalence of asymptomatic bacteriuria does not change with the occurrence of pregnancy and ranges from 2% to 7%** (Hooton et al., 2000). The risk of acquiring bacteriuria during pregnancy increases with lower socioeconomic class, multiparity, and sickle cell traits (Patterson and Andriole, 1987; Stenqvist et al., 1989).

The site of bacteriuria in pregnant female patients probably also reflects the situation before conception. In two studies that localized the origin of the bacteriuria, one using the Stamey ureteral catheterization technique and the other the Fairley bladder washout, upper tract infections were found in 44% and 24.5% of pregnant female patients, respectively (Fairley et al., 1966; Heineman and Lee, 1973). In non-pregnant females with recurrent bacteriuria, Stamey (1980) has reported about a 50% probability that the origin is in the upper tract. With other techniques, which may reflect the severity of tissue infection rather than the location of infection, the results are similar; approximately 50% of women with screening bacteriuria of pregnancy are fluorescent antibody-positive (Fa^+) and thus have evidence of upper tract infection (Harrison et al., 1974). Fairley and his group (1973) found that the site of infection is unrelated to the likelihood that pyelonephritis will develop during pregnancy.

Spontaneous resolution of bacteriuria detected by standard urine culture in pregnant women is unlikely unless it is treated. Non-pregnant patients often clear their asymptomatic bacteriuria (Hooton et al., 2000)**, but pregnant women become symptomatic more frequently and tend to remain bacteriuric** (Elder et al., 1971).

Pyelonephritis develops in 1% to 4% of all pregnant women (Sweet, 1977) **and in 15% to 45% of pregnant women with untreated bacteriuria** (Pedler and Bint, 1987; Wright et al., 1993). **Of the women who develop pyelonephritis during pregnancy, 60% to 75% acquire it during the third trimester** (Cunningham et al., 1973), **when hydronephrosis and stasis in the urinary tract are most pronounced. As many as 10% to 20% of pregnant women who get pyelonephritis develop it again before or just after delivery** (Cunningham et al., 1973; Gilstrap et al., 1981). Moreover, a third of pregnant women who develop pyelonephritis have a documented prior history of pyelonephritis (Gilstrap et al., 1981). **The increased likelihood that bacteriuria may progress to acute pyelonephritis during pregnancy alters the morbidity of bacteriuria for this group. Treatment of screening bacteriuria of pregnancy decreases the incidence of acute pyelonephritis during pregnancy from a range of 13.5% to 65% to a range of 0 to 5.3%** (Sweet, 1977).

Pathogenesis

The anatomic and physiologic changes induced by the gravid state significantly alter the natural history of bacteriuria (Patterson and Andriole, 1987). **These changes may cause pregnant women to be more susceptible to pyelonephritis and may require alteration of therapy.** These changes have been well summarized in several reviews (Davidson and Talner, 1978; Waltzer, 1981).

Anatomic and Physiologic Changes During Pregnancy

Increase in Renal Size

Renal length increases approximately 1 cm during normal pregnancy. It is thought that this does not represent true hypertrophy but is the result of increased renal vascular and interstitial volume. No histologic changes have been identified in renal biopsies (Waltzer, 1981).

Smooth Muscle Atony of the Collecting System and Bladder

The collecting system, especially the ureters, undergoes decreased peristalsis during pregnancy, and most women in their third trimester show significant ureteral dilation (Davison and Lindheimer, 1978; Kincaid-Smith, 1978; Waltzer, 1981; Fig. 55.41). **This hydroureter has been attributed to the muscle-relaxing effects of increased progesterone during pregnancy and to mechanical obstruction of the ureters by the enlarging uterus at the pelvic brim.** Progesterone-induced smooth muscle relaxation also may cause an increased bladder capacity (Waltzer, 1981). Later in pregnancy, the dilation may be the result of the obstructive effect of the enlarging uterus (Poole and Thorsen, 1999).

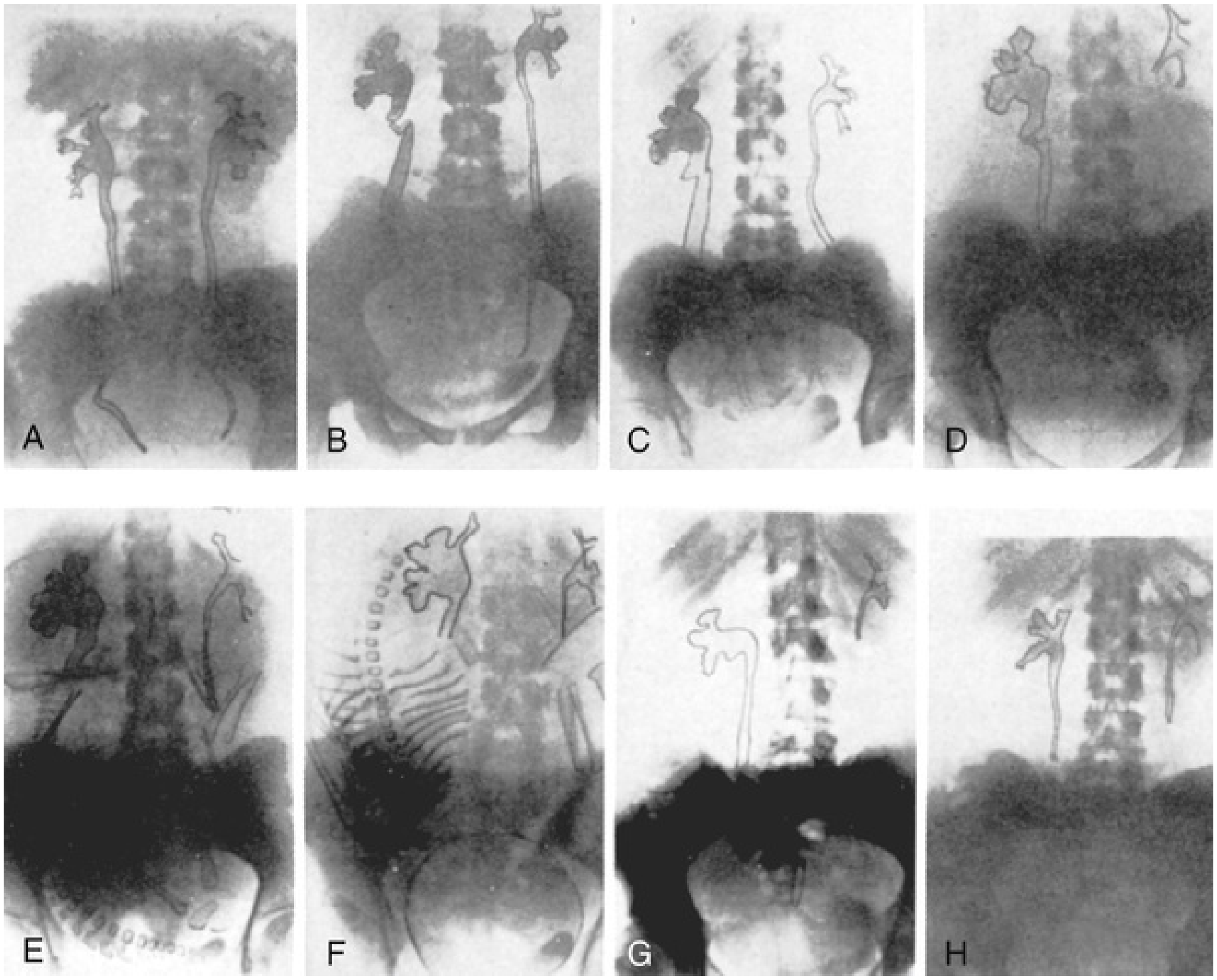

FIG. 55.41 Progressive hydroureter and hydronephrosis observed on intravenous pyelogram during a normal pregnancy. (A) 15 weeks; (B) 18 weeks; (C) 22 weeks; (D) 26 weeks; (E) 34 weeks; (F) 39 weeks; (G) 1 week postpartum; (H) 6 weeks postpartum. Bilateral hydroureter and hydronephrosis are shown as early as 15 weeks (A). (B to H) Successive urograms are from one patient during a normal pregnancy. Dilation occurs mainly on the right side, and both urinary tracts are normal by 6 weeks after delivery. (From Hundley JM, Walton HJ, Hibbits JT, et al.: Physiologic changes occurring in the urinary tract during pregnancy. *Am J Obstet Gynecol* 30:625–649, 1935.)

Bladder Changes

The enlarging uterus displaces the bladder superiorly and anteriorly. The bladder becomes hyperemic and may appear congested when viewed endoscopically (Waltzer, 1981). Estrogen stimulation probably causes bladder hypertrophy, as well as squamous changes of the urethra (Waltzer, 1981).

Augmented Renal Function

The transient increases in glomerular filtration rate and renal plasma flow during pregnancy have been well summarized by several authors, and are probably secondary to the increase in cardiac output (Davison and Lindheimer, 1978; Kincaid-Smith, 1978; Waltzer, 1981; Zacur and Mitch, 1977). **Glomerular filtration increases by 30% to 50%, and urinary protein excretion increases. The significance of these physiologic changes is apparent when the normal serum creatinine and urea nitrogen values for pregnant women are surveyed** (Table 55.12)**. Values considered normal in non-pregnant women may represent renal insufficiency during pregnancy.**

TABLE 55.12

Average Values for Serum Creatinine and Urea Nitrogen

	NON-PREGNANT FEMALES (mg/dL)	PREGNANT FEMALES (mg/dL)
Serum creatinine	0.7	0.5
Urea nitrogen	13.0	9.0

Data from Davison JM, Lindheimer MD: Renal disease in pregnant women. *Clin Obstet Gynecol* 21:411, 1978.

Davison and Lindheimer (1978) recommend that pregnant patients with serum creatinine levels greater than 0.8 mg/dL or urea nitrogen levels greater than 13 mg/dL undergo further evaluation of renal function. Similarly, **urinary protein in pregnancy is not considered abnormal until more than 300 mg of protein in 24 hours is excreted.**

These significant physiologic changes in pregnancy, which may develop as early as the first trimester, lead to urinary stasis and mild hydroureteronephrosis, and contribute to development of pyelonephritis.

Recent studies of *E. coli* adhesins and their respective specific tissue receptors have established an adhesin-based mechanism for pyelonephritis-induced preterm birth and low birth weight in mice (Kaul et al., 1999). There is a higher incidence of *E. coli*–bearing Dr adhesins during the third trimester of pregnancy in women with gestational pyelonephritis (Nowicki et al., 1994) and an upregulation of Dr adhesin in the kidney, endometrium, and placenta during the third trimester of pregnancy (Martens et al., 1993). When infected intravesically with *E. coli*–bearing Dr adhesin, nearly 90% of mice that were hyporesponsive to bacterial lipopolysaccharide and that had a deficient immune response delivered pre-term. However, only 10% of mice infected with *E. coli* without Dr adhesion delivered pre-term. Also, there was a significant reduction in fetal birth weight in the Dr adhesin–infected group. Bacterial tissue culture showed systemic spread of the *E. coli*–bearing Dr adhesins to the placentae and fetuses.

Complications Associated With Bacteriuria During Pregnancy

Prematurity and Prenatal Mortality

In the pre-antimicrobial era, pregnant women with symptomatic UTIs and bacterial pyelonephritis were reported to have a high incidence of prematurity, low birth weight, and death (Gilstrap et al., 1981). The relationship between asymptomatic bacteriuria and prematurity is less clear. Gilstrap et al. (1981) found no difference in prematurity rates between pregnant patients treated for asymptomatic bacteriuria and non-bacteriuric controls. However, Cunnington's review suggests that ascending GU tract infections may contribute to up to 50% of premature deliveries, especially when they occur before 30 weeks' gestation (Cunnington et al., 2013). **Pregnant women with asymptomatic bacteriuria are at higher risk for developing symptomatic UTIs that result in adverse fetal outcomes, pyelonephritis, and possible maternal sequelae such as sepsis. Therefore all pregnant women with asymptomatic bacteriuria should be treated** (Smaill, 2001).

Maternal Anemia

Although several studies suggest that bacteriuria untreated during pregnancy is associated with maternal anemia, not all studies support this. Some difficulties in interpreting the results of these surveys have been caused by inadequate documentation of bacteriuria. In one survey in which urine cultures were obtained by suprapubic aspiration, the data suggest that pregnant patients requiring three or more treatments for bacteriuria have lower levels of serum hemoglobin and folate than controls (McFadyen et al., 1973). In another study from England, investigators showed a statistically significant difference in the incidence of anemia between 410 bacteriuric pregnant women and 409 control pregnant women (Williams et al., 1973). In this survey, 14.6% of bacteriuric women and 10% of control women were anemic at the first prenatal visit. This separation increased during the third trimester (32 weeks), when 25% of women treated with placebo alone had anemia, but only 16.8% of those women treated with antimicrobial agents had anemia. Furthermore, in the 31 untreated (placebo-treated) bacteriuric women who subsequently developed pyelonephritis, the incidence of anemia was 45.2%. These investigators concluded that “untreated bacteriuria increases the likelihood of developing anemia during pregnancy and that this risk is enhanced by the development of acute pyelonephritis, even if it is treated promptly” (Williams et al., 1973).

Laboratory Diagnosis

Significant false-negative rates occur if screening is conducted by urinalysis or reagent strip testing (McNair et al., 2000; Preston et al., 1999)**. Therefore an initial screening culture should be performed in all pregnant women during the first trimester** (Stenqvist et al., 1989). The US Preventive Services Task Force (USPSTF) recommends screening for asymptomatic bacteriuria with urine culture in pregnant women at 12 to 16 weeks’ gestation or at the first prenatal visit, if later (Lin et al., 2008). If the culture shows no growth, repeat cultures are generally unnecessary because **patients who have no growth in their urine early in their pregnancy are unlikely to develop bacteriuria later** (McFadyen et al., 1973; Norden and Kass, 1968). Pregnant women with a history of recurrent UTI or VUR may benefit from AP (Bukowski et al., 1998).

Management

Selection of an antimicrobial agent to treat the bacteriuria must be made, however, with special considerations given to maternal and fetal toxicity. The physiologic changes of pregnancy such as maternal expanded fluid volume, the distribution of the drug to the fetus, increased renal blood flow, and increased glomerular filtration may decrease the serum drug concentration. **If the culture is positive, special consideration must be given to the selection of antimicrobial agents chosen to treat infection and prevent fetal toxicity. The pathogens are similar to those seen in non-pregnant women** (MacDonald et al., 1983). Table 55.13 lists the antimicrobial agents and dosing for use in pregnancy. The **aminopenicillins and cephalosporins are considered safe and generally effective throughout pregnancy. In patients with penicillin allergy, nitrofurantoin is a reasonable alternative. It may be used safely during the first two trimesters in patients without glucose-6-phosphate dehydrogenase deficiency.** Nitrofurantoin is often used **because fluoroquinolones and TMP-**

SMX are contraindicated in pregnancy. If nitrofurantoin is used, however, this is discontinued at 35 weeks of gestation because of an increased risk of hemolytic anemia in the neonate. If a pregnant woman has a single episode of pyelonephritis or two episodes of cystitis, daily suppression with either nitrofurantoin or cephalexin should be considered until delivery. It is prudent to prescribe a full 3- to 7-day course of therapy in pregnant women.

TABLE 55.13

Oral Antimicrobial Agents Used in Pregnancy

DRUG	DOSAGE	COMMENTS
AGENTS CONSIDERED SAFE		
Penicillins		
Ampicillin	500 mg four times daily	Extensively used
Amoxicillin	250 mg three times daily	Safe and effective
Penicillin V	500 mg four times daily	Used less frequently but achieves excellent urinary levels
Cephalosporins		
Cephalexin	500 mg four times daily	Extensively used
Cefaclor	500 mg four times daily	Somewhat more effective against gram-negative organisms
Nitrofurantoin	100 mg four times daily	May be used during the first two trimesters; may result in hemolytic anemia in patients with G6PD deficiency
AGENTS THAT SHOULD BE AVOIDED		
Fluoroquinolones		Possible damage to immature cartilage
Chloramphenicol		Associated with “gray baby” syndrome
Trimethoprim		Inhibits folic acid metabolism and is thus teratogenic especially with respect to neural tube defects
Erythromycin		Associated with maternal cholestatic jaundice
Tetracyclines		May cause acute liver decompensation in the mother and inhibition of new bone growth in the fetus

G6PD, Glucose-6-phosphate dehydrogenase.

Modified from Schaeffer AJ: Urinary tract infections. In Gillenwater JY, Grayhack JT, Howards SS, et al., editors: *Adult and pediatric urology,* Philadelphia, 2002, Lippincott Williams & Wilkins, pp 211–272.

In 2011 a Cochrane Review completed by Widmer et al. showed that antibiotic treatment of asymptomatic bacteriuria in pregnant women significantly decreases the risk of pyelonephritis and preterm delivery. However, there was not adequate evidence at that time to suggest that a single-dose treatment was as effective as standard conventional treatment (Widmer et al., 2011). A more recent Cochrane review published in 2015 looked at the duration of treatment for asymptomatic bacteriuria (Widmer et al., 2015). The authors looked at 13 studies that included 1622 women and compared single-dose treatment with 4- to 7-day course (short) treatment. The review found that a 7-day regimen was more effective than a 1-day course, especially for preventing a low-birth-weight outcome, but this was based on only one study. There were no differences for other review outcomes such as pyelonephritis and preterm birth. The authors concluded by saying although more trials were needed, women with asymptomatic bacteriuria in pregnancy should be treated with a standard time regimen of antibiotics.

Follow-up cultures should be obtained to document absence of infection. If the culture is positive, the cause of bacteriuria must be determined to be lack of resolution, bacterial persistence, or reinfection. If the infection is unresolved, proper selection and administration of another drug will likely solve the problem. If the problem is bacterial persistence or rapid reinfection, antimicrobial suppression of infection or prophylaxis (Pfau and Sacks, 1992) throughout the remainder of the pregnancy should be considered.

Pregnant women with acute pyelonephritis should be hospitalized and initially treated with parenteral antimicrobial agents until clinical improvement is noted. There is no strong evidence to recommend a specific treatment regimen in pregnant women. β-Lactam antibiotics are commonly used because they are considered relatively safe for the fetus. Carbapenems are generally used in select severe cases including those caused by multidrug-resistant bacteria (Matuszkiewicz-Rowinska et al., 2015). However, older series reported that more than 95% of these patients respond within 24 hours using ampicillin and an aminoglycoside (Cunningham et al., 1973) or cephalosporins (Sanchez-Ramos et al., 1995). Despite known toxicities, a recent study concluded that aminoglycosides, specifically gentamicin, are still used often in pregnant women with UTIs, thus subjecting them unnecessarily to ototoxicity (Kushner et al., 2016). Parenteral treatment should be tailored on the basis of culture sensitivities before transitioning to oral antibiotics. If improvement is not seen within 72 hours of the commencement of antibiotics, a renal ultrasound should be performed to assess for stone, obstruction, or abscess. If there is a strong suspicion of a urologic stone that cannot be seen with ultrasound, a plain radiograph of the abdomen or a low-dose spiral CT should be considered in urgent cases.

A Cochrane review published in 2015 looked at interventions for preventing recurrent UTI during pregnancy. The authors concluded that close surveillance alone was as effective as a daily dose of nitrofurantoin and close surveillance together to prevent recurrent UTIs, although the evidence was low quality. They also found there was a significant reduction in asymptomatic bacteriuria in women who had a high clinic attendance rate and had received nitrofurantoin and close surveillance (Schneeberger et al., 2015).

Medications that are relatively contraindicated during pregnancy include the fluoroquinolones, TMP, chloramphenicol, erythromycin, tetracycline, sulfonamides, and sometimes nitrofurantoin (Nicolle, 1987). Fluoroquinolones are contraindicated because of their effects on immature cartilage. TMP may have teratogenic effects and should be avoided, especially in the first trimester. The “gray baby” syndrome is a toxic effect of chloramphenicol on neonates resulting from the inability of the infant to metabolize or excrete the drug. Erythromycin may cause cholestatic jaundice in the mother. Tetracycline may cause fetal malformations and maternal liver decompensation. Sulfonamides may cause kernicterus and neonatal hyperbilirubinemia and should be avoided in the third trimester. As mentioned earlier, nitrofurantoin can cause hemolytic anemia in mother and child when glucose-6-phosphate dehydrogenase deficiency is present (Nicolle, 1987).

Pregnancy in Women With Renal Insufficiency

With current management of recurrent UTIs, infections alone are not contraindications to pregnancy. In patients who have renal insufficiency with or without UTIs, Davison and Lindheimer (1978) emphasize that renal function should be carefully evaluated through serum creatinine levels and creatinine clearance before a woman is counseled about conceiving or continuing a pregnancy. Although little is known about the outcome of pregnancies with differing degrees of renal insufficiency, it is known that **normal pregnancy is**

rare if the preconception serum creatinine level exceeds 3 mg/dL (about 30 mL/min clearance).

The degree of renal function impairment is the major determinant for pregnancy outcome. **In pregnant women with mild or moderate renal disease (serum creatinine <1.4 mg/dL and from 1.4 mg/dL to 2.4 to 2.8 mg/dL, respectively) the fetal survival rate is only slightly diminished, and irreversible deterioration of maternal renal function is uncommon.** However, the perinatal mortality is approximately four times higher with severe disease. The rate of perinatal morbidity associated with low birth weight or prematurity doubles with mild to moderate maternal renal disease; in moderate to severe disease it doubles once again (Vidaeff et al., 2008).

Key Points: Bacteriuria in Pregnancy

- Screening for bacteriuria via urine culture should be performed in all pregnant women during the first trimester.
- The prevalence of bacteriuria does not change with the occurrence of pregnancy; however, unlike in non-pregnant women, spontaneous resolution of bacteriuria in pregnant women is unlikely.
- All pregnant women with bacteriuria should be treated.
- Bacteriuria more commonly progresses to acute pyelonephritis during pregnancy.

Bacteriuria and Urinary Tract Infections in the Elderly

As the average life expectancy increases, the diagnosis, treatment, and morbidity and mortality of UTIs in the geriatric population will continue to be of utmost importance. In 2012 there were 43.1 million Americans older than 65 years of age (Ortman et al., 2014). By the year 2050, however, the population aged 65 and over in the United States is projected to be 83.7 million. Certainly, this trajectory in population dynamics within the US alone highlights the public health issue inherent to this topic.

Epidemiology

At least 20% of women and 10% of men older than 65 years have bacteriuria that is detected by standard urine culture (Boscia and Kaye, 1987)**. In contrast to young adults, in whom bacteriuria is 30 times more prevalent in women than in men, this ratio in the elderly progressively decreases to 2:1. Most elderly patients with bacteriuria are asymptomatic.**

The prevalence of bacteriuria in the elderly increases with age (Brocklehurst et al., 1968; Sourander, 1966) and concurrent disease and may exceed 50% in selective groups (Boscia and Kaye, 1987; Schaeffer, 1991). Bacteriuria is present in greater than 20% of healthy community-dwelling women older than 80 years of age and in 6% to 15% of community-dwelling men who are older than 75 years of age (Nicolle, 2003). Estimates of bacteriuria in those living in long-term care facilities range from 25% to 50% of women and 15% to 40% of men (Nicolle, 1997). Risk factors can be compounded. In a study of 373 women and 150 men older than 68 years of age, 24% of functionally impaired nursing home residents had bacteriuria compared with 12% of healthy domiciliary subjects (Boscia et al., 1986).

Screening for Bacteriuria

Screening for asymptomatic bacteriuria in elderly residents in the community or long-term care facilities is not recommended (Abrutyn et al., 1994; Boscia et al., 1987; Nicolle et al., 1983, 2005; Nordenstam et al., 1986)**.**

There is no documented relationship between asymptomatic bacteriuria and uncomplicated UTIs and worsening renal function. The treatment of asymptomatic bacteriuria to improve incontinence has not been justified (Baldassarre and Kaye, 1991; Ouslander et al., 1995). Although studies have demonstrated decreased survival in bacteriuric patients compared with non-bacteriuric control subjects, it is unclear whether increased mortality rates and bacteriuria are causally related (Abrutyn et al., 1994; Baldassarre and Kaye, 1991).

Pathogenesis

The pathophysiology of increased susceptibility to bacteriuria/UTIs is multifactorial and poorly understood. **Age-related changes include a decline in cell-mediated immunity, incomplete bladder emptying, neurogenic bladder dysfunction, increased perineal soiling as a result of fecal and urinary incontinence, increased incidence of urethral catheter placement, and, in women, changes in the vaginal environment associated with estrogen depletion** (Arnold et al., 2016; Raz and Stamm, 1993; Schaeffer, 1991).

Bacteriologic characteristics of infection in the elderly differ from those in younger patients (Baldassarre and Kaye, 1991). ***E. coli* remains the most common uropathogen overall, causing 50% to 75% of these infections** (Nicolle, 2001). However, there is a **significant increase in the incidence of *Proteus, Klebsiella, Enterobacter, Serratia,* and *Pseudomonas* spp., as well as enterococci.** One study found that in community-dwelling older women, organisms responsible for asymptomatic bacteriuria include *E. coli* (51.4%), *K. pneumoniae* (4.1%), *Proteus mirabilis* (3.3%), and *Enterococcus faecalis* (2.5%) (Linhares et al., 2013). Enterococci in the elderly tend to resolve without treatment; this is felt to represent colonization (Das et al., 2009). Bacteriuria caused by gram-positive bacteria is much more common in elderly men than in elderly women (Jackson et al., 1962); however, *S. saprophyticus* is not seen in this population. Polymicrobial bacteriuria is also more common among the geriatric population (Nicolle et al., 1987). Cumulatively, the shift in the pattern of uropathogens, the high frequency of polymicrobial infections, and antimicrobial resistance in the elderly are due in large part to an increase in institutionalization and hospitalization, catheterization, and overall antimicrobial usage (Routh et al., 2009).

Diagnosis

In the elderly, UTI symptoms may be more subtle, such as generalized abdominal discomfort or delirium. **Even severe upper tract infections may not be associated with fever or leukocytosis** (Baldassarre and Kaye, 1991). **However, new signs or symptoms localized to the lower urinary tract, specifically dysuria, remain the most important UTI criteria, even in the elderly.** Traditionally, altered mental status has often been attributed to a UTI in the elderly. However, because bacteriuria is more common with age, the mere presence of a positive urine culture in a patient with altered mental status is not tantamount with a UTI. This dilemma makes diagnosing a UTI, particularly in a patient who cannot reliably report symptoms, challenging. **Although it has been common practice to treat elderly bacteriuric patients with antibiotics because of confusion, no data demonstrate treatment improves a patient's condition** (Finucane, 2017).

Because new signs or symptoms localized to the GU tract are most important even in the geriatric population, dizziness and confusion, in the absence of urinary symptoms, should not be attributed to a UTI. Therefore it is not recommended to send urine cultures on patients for nonspecific symptoms or chronic urinary symptoms such as incontinence and frequency, nor for asymptomatic patients (Mody and Juthani-Mehta, 2014; Nicolle, 2002). Sending urine studies in patients with dementia or other impaired mental status (when defining dysuria is difficult) may be of clinical benefit when not responsive to other interventions (i.e., hydration). **If elderly patients experience mental status changes yet no urinary complaints, they should be hydrated then reassessed. If altered mental status and/or change in character of urine persists despite fluid resuscitation, then urine testing should be considered** (see figure at https://www.ncbi.nlm.nih.gov/pmc/articles/PMC4194886/) (Mody and Juthani-Mehta, 2014). Finally, obtaining a culture to document clearance of bacteria is never recommended (Mody and Juthani-Mehta, 2014).

A high index of suspicion is warranted when evaluating geriatric patients; therefore diagnosis should rely on the results of a carefully obtained urinalysis and culture. **The presence of greater than 10^5 CFU/mL of urine remains the standard for diagnosis** in patients with clinical signs and symptoms of UTI. However, **counts of 10^2 or more bacteria are clinically significant in catheterized specimens** (Kunin, 1987; Nicolle et al., 2005).

The use of laboratory testing in the diagnosis of UTI in the elderly also poses some challenges. Urinary dipstick testing for leukocyte esterase, nitrites, or both has a different specificity and sensitivity depending on the clinical population. Sensitivity and specificity for a positive dipstick test in older adults is 82% (95% CI 74%–92%) and 71% (95% CI 55%–71%), making the urine dipstick a more valuable test to rule out UTI than diagnosing its presence (Deville et al., 2004; Kunin, 1994). These data are linked to the fact that, unlike in younger adults, pyuria and in turn the presence of leukocyte esterase, has been shown to be an inaccurate predictor of bacteriuria in the elderly. **Pyuria is common in elderly patients, and pyuria alone is not a good predictor of bacteriuria nor an indication for antimicrobial treatment in the elderly population** (Nicolle et al., 2005; Ouslander et al., 1996). Accordingly, Boscia et al. (1989) reported that more than 60% of women with pyuria of 10 WBCs/mm^3 or greater (noted in midstream specimens) did not have a concurrent bacteriuria. However, **the absence of pyuria was a good predictor of the absence of bacteriuria**, and this accounts for the high specificity associated with dipstick testing.

Finally, declining functional and mental status in elderly adults, as well as a potentially difficult body habitus, often makes obtaining a true midstream clean-catch urine specimen extremely challenging. In institutionalized elderly patients and those with limited dexterity, a catheterized specimen may be the only way to obtain an uncontaminated urine specimen (Nicolle, 2002; Nicolle et al., 2005).

Because urinary tract abnormalities can predispose to and complicate the management and sequela of bacteriuria in the elderly, a thorough urologic evaluation is warranted. Renal dysfunction, calculi, hydronephrosis, urinary retention, neurogenic bladder dysfunction, and other abnormalities should be identified by serum creatinine measurement, CT, ultrasonography, urodynamics (UDS), and/or cystoscopy. The timing and sequence of these tests should be dictated by the clinical setting.

Bacteriuria that leads to UTIs in elderly subjects in the presence of underlying structural urinary tract abnormalities (e.g., obstruction with hydronephrosis) or systemic conditions (e.g., severe diabetes mellitus) are clinically significant, can lead to renal failure, and require prompt therapy. In addition, UTIs caused by urea-splitting bacteria, such as *Proteus* or *Klebsiella* species that cause formation of infection stones, may also lead to severe renal damage.

Sepsis and its sequelae (sepsis syndrome and septic shock) are increasingly common in the elderly. Risk factors include the aggressive use of catheters (Kunin et al., 1992) and other invasive equipment, implantation of prosthetic devices, and the administration of chemotherapy to cancer patients or corticosteroids in other immunosuppressed patients. In addition, modern medical care has given longer life spans to the elderly and other populations of patients with metabolic, neoplastic, or immunodeficiency disorders who remain at increased risk for infection.

Management

Prospective randomized comparative trials of antimicrobial or no therapy in elderly male and female nursing home residents with asymptomatic bacteriuria consistently document no benefit of antimicrobial therapy. On the contrary, treatment with antimicrobial therapy increases the occurrence of adverse drug effects and reinfection with resistant organisms and increases the cost of treatment. **Therefore asymptomatic bacteriuria in elderly residents of long-term care facilities should not be treated with antimicrobial agents.**

The McGeer infection surveillance definitions provide standardized criteria for infections that commonly occur in residents of aged-care homes. The criteria to be diagnosed with a UTI include a combination of clinical signs and microbiology (Stone et al., 2012)**. The criteria required vary, depending on whether the patient has an indwelling catheter or not. Critics of the McGeer criteria point out that the ability to interpret the clinical signs in those who are cognitively impaired is limited (**Ryan et al., 2018; **Table 55.14).**

TABLE 55.14

Surveillance Definitions for Urinary Tract Infections

CRITERIA
A. For residents without an indwelling catheter (both criteria 1 and 2 must be present)
1. At least 1 of the following sign or symptom subcriteria
a. Acute dysuria or acute pain, swelling, or tenderness of the testes, epididymis, or prostrate
b. Fever or leukocytosis and at least 1 of the following localizing urinary tract subcriteria
i. Acute costovertebral angle pain or tenderness
ii. Suprapubic pain
iii. Gross hematuria
iv. New or marked increase in incontinence, urgency, or frequency
c. In the absence of fever or leukocytosis, then 2 or more of the following

localizing urinary tract subcriteria
        - i. Suprapubic pain
        - ii. Gross hematuria
        - iii. New or marked increase in incontinence
        - iv. New or marked increase in urgency
        - v. New or marked increase in frequency
    2. One of the following microbiologic subcriteria
        - a. At least 10^5 CFU/mL of no more than 2 species of microorganisms in a voided urine sample
        - b. At least 10^2 CFU/mL of any number of organisms in a specimen collected by in-and-out catheter[5]

B. For residents with an indwelling catheter (both criteria 1 and 2 must be present)
    1. At least 1 of the following sign or symptom subcriteria
        - a. Fever, rigors, or new-onset hypotension, with no alternate site of infection
        - b. Either acute change in mental status or acute functional decline, with no alternate diagnosis and leukocytosis
        - c. New-onset suprapubic pain or costovertebral angle pain or tenderness
        - d. Purulent discharge from around the catheter or acute pain, swelling or tenderness of the testes, epididymis, or prostate
    2. Urinary catheter specimen culture with at least 10^5 CFU/mL of any organism(s)

Comment: A diagnosis of UTI can be made without localizing symptoms if a blood culture isolate is the same as the organism isolated from the urine and there is no alternate site of infection.

From McGeer Criteria, p68, Ryan, Gillespie et al. 2018.

From Stone ND et al.: Surveillance definitions of infections in long-term care facilities: revisiting the McGeer criteria. *Infect Control Hosp Epidemiol* 33(10):965–977, 2012. Reprinted with permission © Cambridge University Press & The Society for Healthcare Epidemiology of America.

If patients have lower tract symptoms and symptoms are mild, it is prudent to wait for urine culture before treatment. For those elderly patients who require immediate treatment, empirical antibiotics should be started. Traditionally, 7 days of therapy has been recommended. However, a recent Cochrane review of the antibiotic duration for treating uncomplicated symptomatic UTIs in the elderly included 15 studies totaling 1644 women and showed no difference in short-term clinical failure between short-course (3–6 days) and long-course (7–14 days) oral antibiotic regimens. The rate of persistent UTI was lower with short-term therapy compared with single-dose (Lutters and Vogt-Ferrier, 2008). For individuals with fever or more severe systemic infection, 10 to 14 days of therapy was recommended. The goal in this population was to eliminate symptoms but not sterilize the urine (McMurdo and Gillespie, 2000).

The elderly population is more susceptible than young patients to the

toxic and adverse effects of antimicrobial agents (Boscia et al., 1986; Carty et al., 1981; Grieco, 1980). The metabolism and excretion of antimicrobial agents may be impaired, and the resulting increased serum levels can further damage renal function. Interactions with other medications can occur (Stahlmann and Lode, 2003). The safety margin between therapeutic and toxic doses is significantly narrowed. Therefore antimicrobial agents must be used judiciously, and dosing and drug levels should be carefully monitored. **The recent black box warning pertaining to fluoroquinolones urges caution in patients older than 60, in whom the risk of tendon rupture is greatest.** See the Management section for further discussion of antibiotic prescribing regimens/considerations for complicated and uncomplicated infections.

Key Points: Bacteriuria in the Elderly

- Screening for bacteriuria is not recommended in elderly patients because there is no relationship between asymptomatic bacteriuria and uncomplicated UTIs and deteriorating renal function; asymptomatic bacteriuria should not be treated.
- Infections of the urinary tract may present as subtle signs, and a high index of suspicion is often required for diagnosis.
- Treatment of symptomatic UTI requires modifications for physiologic and pathophysiologic conditions of the elderly.
- Obtaining a urine culture to document clearance of bacteriuria is not recommended.

Catheter-Associated Urinary Tract Infection

Guidelines from the CDC define a CAUTI as a UTI after placement of an indwelling urinary catheter for more than 2 days (Centers for Disease Control and Prevention: Urinary Tract Infection, 2015). To be diagnosed with a CAUTI, patients must have one symptom of a UTI (suprapubic tenderness, CVA tenderness, urinary frequency/urgency/dysuria, or fever >100.4°F) and a urine culture with a single organism more than 100,000 CFU/mL.

Catheter-associated bacteriuria is widely recognized as the most common hospital-acquired infection. The development of bacteriuria in the presence of an indwelling catheter is inevitable and occurs at an incidence of approximately 10% per day of catheterization. Sterile and clean intermittent catheterization has been associated with rates of bacteriuria ranging from 1% to 3% per catheterization (Warren, 1997)**. The most important risk factors associated with increased likelihood of developing catheter-associated bacteriuria are duration of catheterization, female gender, absence of systemic antimicrobial agents, and catheter-care violations** (Stamm, 1991). **Most patients with catheter-associated bacteriuria are asymptomatic.** In patients with short-term catheter placement, only 10% to 30% of bacteriuric episodes produce typical symptoms of acute infection (Haley et al., 1981; Hartstein et al., 1981). Similarly, although patients with long-term catheters are bacteriuric, the incidence of febrile episodes occurs at a rate of only 1 per 100 days of catheterization (Warren, 1991).

Each CAUTI is estimated to cost between $589 and $758 (Anderson et al., 2007; Tambyah et al., 2002). In patients requiring intensive care, the cost is roughly $2000 per nosocomial UTI (Chen et al., 2009). The nosocomial costs for *E. coli* infections with relatively susceptible strains are considerably lower than for those caused by resistant gram-negative bacteria, which often require expensive parenteral antimicrobial therapy (Tambyah et al., 2002).

In 2008 the Center for Medicare and Medicaid Services (CMS) announced that it will no longer reimburse hospitals for the extra costs resulting from CAUTIs. Judicious use of indwelling Foley catheters in perioperative patients helps to prevent CAUTI. Current recommendations for perioperative use of an indwelling urinary catheter include intraoperative urine output monitoring, prolonged surgeries, and urologic surgeries (Gould, 2009). Limiting the duration of indwelling catheters in these patients is critical. Large nationwide hospital initiatives have helped to reduce the CAUTI rates. The Mayo Clinic reported a 70% decrease in their CAUTI rate over 1 year. They described their protocol as the bundled 6-C CAUTI approach: consider (appropriate placement and daily need for indwelling catheter), connect, clean (catheter care), closed (maintain closed system), call (irrigation when necessary) and culture (only for indication) (Sampathkumar et al., 2016).

Pathogenesis

Bacteria enter the urinary tract of a catheterized patient by several routes. **Bacteria can be introduced at the time of initial catheter placement** by either mechanical inoculation of urethral bacteria or contamination from poor technique. **Subsequently, the bacteria most commonly gain access via a periurethral or intraluminal route** (Stamm, 1991). In women, periurethral entry is the most prevalent. Daifuku and Stamm (1984) found that among 18 women who developed catheter-associated bacteriuria, 12 had antecedent urethral colonization with the infecting strain. **Bacteria may also enter the drainage bag and follow the intraluminal route to the bladder.** This route is particularly common in patients who are clustered among other patients with indwelling catheters (Maizels and Schaeffer, 1980; Tambyah et al., 1999).

The urinary catheter system provides a unique environment that allows for two distinct populations of bacteria: those that grow within the urine and those that grow on the catheter surface. A bacterial **biofilm** represents a microbial environment of microorganisms embedded in an extracellular matrix of bacterial products and host components that often lead to catheter encrustation (Bonadio et al., 2001; Stamm, 1991). The bacterial biofilm prevents antibiotic contact with the bacteria and can result in CAUTI and antibiotic resistance (Chenoweth and Saint, 2016). Certain bacteria, particularly of the *Pseudomonas* and *Proteus* species, are adept at biofilm growth, which may explain their higher incidence in this clinical setting (Mobley and Warren, 1987). The uropathogens isolated from the catheterized urinary tract often differ from those found in uncatheterized ambulatory patients. *E. coli* is still the most common organism isolated, but *Pseudomonas*, *Proteus*, and *Enterococcus* spp. are prevalent (Warren, 1991). In patients with long-term catheterization (more than 30 days), the bacteriuria is usually polymicrobial, and the presence of four or five pathogens is not uncommon (Warren et al., 1982). Although certain species may persist for long periods, the bacterial populations in these patients tend to be dynamic.

Clinical Presentation

Most patients are asymptomatic. Suprapubic discomfort and development of fever, chills, or flank pain may indicate a symptomatic UTI.

Laboratory Diagnosis

Significant bacteriuria in patients with catheters is present when greater than 100 CFU/mL is present, because even this low level progresses to greater than 10^5 CFU/mL in almost all patients (Maizels and Schaeffer, 1980; Stark and Maki, 1984). Pyuria is not a discriminate indicator of infection in this population.

Management

Careful aseptic insertion of the catheter and maintenance of a closed dependent drainage system are essential to minimize development of bacteriuria. The catheter-meatal junction should be cleaned daily with water, but antimicrobial agents should be avoided because they lead to colonization with resistant pathogens, such as *Pseudomonas*.

Incorporation of silver oxide (Schaeffer et al., 1988) or silver alloy (Saint et al., 1998) into the catheter and hydrogen peroxide into the drainage bag has been reported to decrease the incidence of bacteriuria in some studies (Schaeffer et al., 1988), but not in other populations (Stamm, 1991). **The major benefit of silver alloy is that it decreases the likelihood of bacteriuria in hospitalized adults catheterized for the short term** (Brosnahan et al., 2004; Newton et al., 2002; Saint et al., 2000).

If an asymptomatic catheterized patient has had an indwelling catheter for 3 or more days and will have the catheter removed, a dipstick test can be used to rule out bacteriuria (Tissot et al., 2001). **Concurrent administration of systemic antimicrobial agents transiently decreases the incidence of bacteriuria associated with short-term catheterization, but after 3 to 4 days the incidence of bacteriuria is similar to the rate in catheterized patients not**

taking systemic antimicrobials agents, and the prevalence of resistant bacteria and side effects is substantial. Therefore this practice is not recommended. The concept of instilling nonvirulent bacteria into the bladder to completely block colonization and infection by pathogens has been tested in patients with SCI (Hull et al., 2000). Patients successfully colonized with the nonvirulent strain had reduced symptomatic UTI and a subjective improvement in quality of life.

Patients with indwelling catheters should be treated only if they become symptomatic (e.g., febrile). Urine cultures should be performed before initiating antimicrobial therapy. The antimicrobial agent should be discontinued within 48 hours of resolution of the infection. Because the catheter has been indwelling, encrustation may shelter bacteria from the antimicrobial agent; therefore the catheter should be changed.

Key Points: Catheter-Associated Bacteriuria

- Careful aseptic insertion of the catheter and maintenance of a closed, dependent drainage system are essential to minimize development of bacteriuria.
- The development of catheter-associated bacteriuria is inevitable.
- Only symptomatic CAUTIs require treatment.

Management of Urinary Tract Infections in Patients With Spinal Cord Injury

Patients with SCI have unique characteristics that affect the risk, diagnosis, and management of UTIs, all of which are considered complicated. **Of all patients with bacteriuria, no group compares in severity and morbidity with those who have SCI.** Nearly all these patients require catheterization early after their injuries because of bladder overactivity or flaccidity, and significant numbers develop ureterectasis, hydronephrosis, VUR, and renal calculi. Bacteriologic and urodynamic advances in the management of these patients have greatly reduced their morbidity and mortality.

Epidemiology

Before the advent of CIC and modern antibiotics, UTI and renal failure accounted for the great majority of deaths in the SCI population (Barber and Cross, 1952). The National Spinal Cord Injury Statistical Center published a report in 2012 stating that GU infections account for only 3% of deaths in the SCI population, the 11th most common cause of deaths; the advent of CIC and antibiotics has clearly decreased the morbidity attributed to UTIs and renal failure, as compared with mid–20th century statistics.

UTIs are among the most common urologic complications of SCI. It has been estimated that approximately 33% of patients with SCI have bacteriuria at any time (Stover et al., 1989) and that eventually almost all patients with SCI will become bacteriuric; many will suffer significant morbidity and mortality. One prospective study of patients on intermittent catheterization or condom catheterization reported an incidence of significant bacteriuria (18 episodes per person per year) and an annual incidence of febrile UTIs of 1.8 per person per year (Waites et al., 1993a). In addition, **UTI is the most common cause of fever in the patient with SCI** (Beraldo et al., 1993). **The 1992 National Institute on Disability and Rehabilitation Research Consensus Conference examined the problems associated with UTIs in patients with SCI** (National Institute on Disability and Rehabilitation Research, 1993)**. Among the risk factors identified were impaired voiding, overdistention of the bladder, elevated intravesical pressure, increased risk of urinary obstruction, VUR, urinary**

tract instrumentation, and presence of stones. Other factors that have been implicated are decreased fluid intake, poor hygiene, perineal colonization, decubiti, and other evidence of local tissue trauma, as well as reduced host defense associated with chronic illness (Gilmore et al., 1992; Waites et al., 1993a).

Pathogenesis

The method of bladder management has a profound impact on the incidence of UTI. The National Institute on Disability and Rehabilitation Research Consensus Conference noted that indwelling catheters were most likely to lead to UTI and that the majority of patients with an indwelling catheter for 30 days are bacteriuric (National Institute on Disability and Rehabilitation Research, 1993). Suprapubic catheters and indwelling urethral catheters eventually have an equivalent infection rate (Biering-Sorensen, 2002; Kunin et al., 1987; Tambyah and Maki, 2000). However, the onset of bacteriuria may be delayed using a suprapubic catheter compared with a urethral catheter. During a 2-year period, 170 patients with SCI were evaluated regarding type of urinary drainage and infection (Warren et al., 1982). In patients using indwelling urethral catheters, all urine cultures were positive. The corresponding values for the suprapubic catheter group were 44%. Condom drainage systems are also associated with an incidence of bacteriuria from 63% (Dukes, 1928) to almost 100% (Pyrah et al., 1955).

Since its introduction by Lapides et al. (1972), clean (but not sterile) intermittent catheterization (CIC) has dramatically changed the management of patients with SCI. **Although never rigorously compared with indwelling urethral catheterization, CIC has been shown to decrease lower urinary tract complications by maintaining low intravesical pressure and by reducing the incidence of stones** (Stover et al., 1989). CIC also appears to reduce complications associated with an indwelling catheter, such as UTI, fever, bacteremia, and local infections such as epididymitis and prostatitis. Weld and Dmochowski (2000) followed 316 patients with SCI (who had received different bladder management) for a mean of 18.3 years and recorded all complications. The CIC group had statistically significantly lower complication rates compared with the urethral catheterization group and no significantly higher complication rates relative to all other management methods for each type of complication studied. Thus it is generally agreed that **CIC places patients with SCI at the**

lowest risk for significant long-term urinary tract complications (Stamm, 1975).

There is conflicting evidence over the value of sterile versus nonsterile or "no touch" methods of CIC. Some studies have reported a lower incidence of infection in patients treated with sterile techniques (Foley, 1929), whereas others have not (Nyren et al., 1981; Pyrah et al., 1955). Bennett et al. (1997) reported on a sterile method of CIC that uses an introducer tip to bypass the distal 1.5 cm of the urethra and showed a significant decrease in UTI. Different types of catheters have been used for CIC. The low-friction catheters may be less traumatic for the urethra (Casewell and Phillips, 1977; Garibaldi et al., 1980), but their impact on bacteriuria and UTI has yet to be proven. Cardenas et al. (2011) looked at the time to first UTI in SCI patients using hydrophilic catheters compared with standard non-hydrophilic catheters. They reported that half of each group experienced symptomatic UTI within a 20-day period, although the hydrophilic group had a longer time before UTI.

Clinical Presentation

The majority of patients with SCI with bacteriuria are asymptomatic. Many are managed with CIC, suprapubic catheters, and indwelling Foley catheters, which can lead to asymptomatic bacteriuria. Asymptomatic bacteriuria should not be treated in the patient with SCI (Nicolle et al., 2005; Vigil and Hickling, 2016)**. Furthermore, asymptomatic patients with SCI who use indwelling, condom, or intermittent catheters should not be screened with urinalysis or urine culture. There is no standard definition for UTI in patients with SCI. Because of a loss of sensation, patients usually do not experience frequency, urgency, or dysuria, making the diagnosis of UTI a challenge in this population. More often, they complain of flank, back, or abdominal discomfort, leakage between catheterizations, increased spasticity, malaise, lethargy, and/or cloudy, malodorous urine. As noted earlier, UTI is the most common cause of fever in this population.**

Bacteriology and Laboratory Diagnosis

Urinalysis will show bacteriuria and pyuria. Pyuria is not diagnostic of infections because it may occur from the irritative effects of the catheter. The National Institute on Disability and Rehabilitation Research Consensus Statement recommended criteria for the diagnosis of significant bacteriuria in spinal cord–injured patients (National Institute on Disability and Rehabilitation Research, 1993). Any detectable bacteria from indwelling or suprapubic catheter aspirates was considered significant because the majority of patients with an indwelling catheter and low-level bacteriuria showed an increase to greater than 10^5 CFU/mL within a short period of time (Cardenas and Hooton, 1995). For patients on CIC, greater than or equal to 10^2 CFU/mL was considered significant. For catheter-free males, a clean voided specimen showing greater than or equal to 10^4 CFU/mL was considered significant.

Bacteriuria in patients with SCI differs from that in patients with intact spinal cords with regard to cause, complexity, and antimicrobial susceptibility and is influenced by the type and duration of catheterization. *E. coli* is isolated in approximately 20% of patients. Enterococci, *P. mirabilis*, and *Pseudomonas* spp. are more common in patients with SCI than in patients with intact spinal cords. Other common organisms are *Klebsiella* spp., *Serratia* spp., *Staphylococcus*, and *Candida* spp. Most bacteriuria in short-term catheterization is single-organism, whereas patients catheterized for longer than a month usually demonstrate a polymicrobial flora caused by a wide range of gram-negative and gram-positive bacterial species (Edwards et al., 1983).

Management

As a result of the diverse flora and high probability of bacterial resistance, a urine culture must be obtained before initiating empirical therapy. For afebrile patients, β-lactams, TMP-SMX, and nitrofurantoin can be used while awaiting culture results. **An oral fluoroquinolone may considered as second-line option, given the concerns about resistance patterns and side effects with this class of antibiotics** (Cardenas and Hooton, 1995). An indwelling catheter should be changed to ensure maximal drainage and eliminate bacterial foci in catheter encrustations. **Patients with SCI and fever or chills are usually admitted and treated with a parenteral aminoglycoside and either a penicillin or a third-generation cephalosporin** (Cardenas and Hooton, 1995). In this patient population consultation with a physician with expertise in antimicrobial management may be necessary, especially in a patient with recurrent infections.

If clinical improvement does not occur within 24 to 48 hours, repeat culture and adjustment of antimicrobial therapy based on the initial culture and susceptibility should be performed. Imaging studies should be obtained to rule out obstruction, stones, and abscess. Post-therapy cultures are usually not necessary because asymptomatic recolonization is common and not clinically significant. However, if a urea-splitting bacterium is identified, a follow-up culture should be obtained to ensure its eradication. Bladder irrigation with saline or antibiotic solutions (Waites et al., 2006) has not traditionally been recommended because the rates of catheter-associated bacteriuria and UTI were not reduced with such methods. However, Cox et al. reported in 2017 on 22 patients (cause of NGB was 63.6% SCI) who underwent gentamicin bladder installations. Patients had fewer symptomatic UTIs and underwent fewer courses of oral antibiotics after initiating gentamicin irrigations. In addition, the proportion of multidrug-resistant organisms in urine cultures decreased (Cox et al., 2017).

AP is not supported for patients who have neurogenic bladder caused by SCI (Morton et al., 2002; Vigil and Hickling, 2016). AP did not significantly decrease symptomatic UTIs and resulted in an approximately twofold increase in antimicrobial-resistant bacteria (Nicolle et al., 2019).

Patients with SCI with recurrent symptomatic UTIs should undergo urinary tract imaging and urodynamic testing and a review of their bladder management program. Particular attention should be given to catheter drainage, intermittent catheterization techniques, and frequency of intermittent catheterization or voiding schedule (Cardenas and Hooton, 1995). **Recurrent UTIs may be associated with high storage pressures, and intervention to lower storage pressure may decrease the incidence of symptomatic UTI. Evidence from studies in patients with SCI suggests that bladder catheterization for longer than 10 years is associated with an increased risk of carcinoma of the bladder.** West et al. (1999) examined two databases with more than 33,000 patients with SCI, and over a 5-year period identified 130 patients with bladder cancer (0.4%). Several risk factors for bladder cancer have been proposed. Vereczky et al. (cited in Weyrauch and Bassett, 1951) tested different risk factors based on the outcome of 153 patients with SCI, of which 7 were diagnosed with bladder cancer. Upon identification of 31 possible predictors, only duration of catheterization was significant. **Chronic infection and inflammation of the bladder mucosa could be the carcinogenic stimulus in these patients** (Pyrah et al., 1955)**. Nitrosamines produced in infected urine have also been implicated** (Najenson et al., 1969).

Key Points: Management of Urinary Tract Infection in Patients With Spinal Cord Injury

- The majority of patients with SCI with bacteriuria are asymptomatic. Only symptomatic patients require therapy.
- Patients with SCI and UTI commonly experience fever; flank, back, or abdominal discomfort; leakage between catheterizations; increased spasticity; malaise; lethargy; and/or cloudy, malodorous urine.
- Urine culture before the initiation of empirical therapy is essential because patients with SCI often have evidence of diverse flora with a high probability of bacterial resistance.
- CIC places patients with SCI at the lowest risk for significant long-term urinary tract complications.
- Chronic infection can be carcinogenic.

Kidney Transplant Recipients

There is no current consensus on the role of antibiotics in renal transplant patients with asymptomatic bacteriuria. The IDSA guideline published in 2005 made no recommendation because of insufficient evidence (Nicolle et al., 2005). In the update to this guideline published in 2019, the recommendation is not to screen or treat asymptomatic bacteriuria if the transplant occured more than 1 month prior (Nicolle et al., 2019). In 2013 The American Society of Transplantation Infectious Diseases Community of Practice recommended not treating asymptomatic bacteriuria after 3 months post-transplantation, except in those patients who had a rise in serum creatinine. If the kidney donor has asymptomatic bacteriuria at the time of transplantation, the recipient should be treated. Also, transplant recipients usually receive TMP-SMX for PCP prophylaxis, which can reduce the chance of UTIs (Parasuraman et al., 2013).

In 2018 a Cochrane Review looked at antibiotics for asymptomatic bacteriuria in kidney transplant recipients (Coussement et al., 2018). Asymptomatic bacteriuria occurs in 17% to 51% of kidney transplant recipients and is thought to increase the risk for eventual UTI. The data only included two studies, totaling 212 patients, and excluded those patients with indwelling urethral catheters or ureteral stents. Because of the limited data in the Cochrane Review, the authors concluded there was insufficient evidence to support routine antibiotic treatment of asymptomatic bacteriuria in renal transplant patients. Furthermore, they stated it is unclear if screening for asymptomatic bacteriuria with urine cultures should be performed.

Whether to treat asymptomatic bacteriuria in renal transplant patients remains controversial.

Because of the immunosuppressed state of a kidney transplant recipient, particularly early in the first few months, recognition and treatment of UTI in this population is paramount and may be critical for graft survival. **Transplant recipients are at higher risk for VUR. Risk factors for infection include female gender, diabetes, cadaveric graft, two episodes of asymptomatic bacteriuria, and prolonged hemodialysis before transplantation** (Castaneda et al., 2013). Treatment duration, particularly in the early post-transplantation period (6 months), is usually 14 days for uncomplicated UTIs and 21 to 28 days for complicated UTIs (Säemann and Hörl, 2008).

Antimicrobial Prophylaxis for Common Urologic Procedures

Principles of Surgical Antimicrobial Prophylaxis

The prior urologic best practice statement (BPS) was written in 2008 and validated in 2011. There has been a great deal of effort placed on examining AP over the last decade and the latest BPS published in 2019 should update the practicing urologist. Surgical AP entails treatment with an antimicrobial agent before and for a *limited* time after a procedure to prevent local or systemic postprocedural infections. This is in contrast to antimicrobial treatment, which uses an antimicrobial agent to eradicate a suspected or documented infection.

The 2019 BPS recommends consideration of periprocedural AP for all urologic procedures in which a tissue barrier break will occur. For most procedures, prophylaxis should be initiated within 60 minutes of the procedure (Bratzler et al., 2004). When used as AP, vancomycin and fluoroquinolones should be initiated within 120 minutes of the procedure. Single-dose AP is most appropriate in the majority of uncomplicated urologic surgery. **Efficacious levels should be maintained for the duration of the procedure and, in only special circumstances, a limited time (24 hours, at most) after the procedure** (Bratzler and Houck, 2004). Although prospective studies addressing prophylaxis for urologic procedures exist, most focus on only a narrow spectrum of procedures. However, application of the principles of these studies with additional consideration of the patient and the type of procedure provides a framework for determining when and what type of AP may be indicated. The AP agent chosen should target the likely local organisms and be supported by sensitivities reflected in local antibiograms; cost and safety should be part of the decision-making process. An additional, nontraditional type of prophylaxis in urology entails periprocedural treatment of the urinary tract with an antimicrobial agent to prevent local or systemic sequelae from the manipulation of colonized hardware such as stents or urethral catheters.

A wide array of patients undergo invasive procedures in urology. Two important considerations when assessing the need for AP are the ability of a

host to respond to bacteriuria or bacteremia and the sequelae of a possible infection. Additional considerations include the likelihood of bacterial invasion at the surgical site and possible sequelae. Factors that affect the host's ability to respond to infection include advanced age, anatomic anomalies, poor nutritional status, smoking, chronic corticosteroid use, other concurrent medication use, and immunodeficiency, such as untreated HIV infection (Box 55.13). In addition, chronic indwelling hardware, infected endogenous material such as stones, distant infectious sites, and prolonged hospitalizations also increase the risk of infectious complications, by increasing the local bacterial concentration and/or altering the spectrum of bacterial flora.

Box 55.13

Host Factors That Increase the Risk of Infection

Advanced age
Anatomic anomalies
Poor nutritional status
Smoking
Chronic corticosteroid use
Immunodeficiency
Chronic indwelling hardware
Infected endogenous/exogenous material
Distant coexistent infection
Prolonged hospitalization

Data from Cruse PJ: Surgical wound infection. In Wonsiewicz MJ, editor: *Infectious disease,* Philadelphia, 1992, WB Saunders, pp 758–764; Mangram AJ, Horan TC, Pearson ML, et al.: Guideline for prevention of surgical site infection, 1999. Hospital Infection Control Practices Advisory Committee. *Infect Control Hosp Epidemiol* 20:250–278; quiz 279–280, 1999.

The type of procedure will also help direct the timing, duration, and spectrum of AP needed (see Table 55.15 for a summary of AP recommendations). Consideration should be given to the extent of the local tissue injury incurred and the anticipated type of flora at the site. The choice of AP agent should consider the patient's comorbidities, allergies, and the specific AP risk. As stated earlier in the chapter, the FDA issued a black box warning for quinolones because of serious side effects and specifically discouraged their use in treating uncomplicated cystitis; this must be kept in mind while considering use of fluoroquinolones for AP.

TABLE 55.15

Recommended Antimicrobial Prophylaxis for Urologic Procedures

---

PROCEDURE	LIKELY ORGANISMS	PROPHYLAXIS INDICATED	ANTIMICROBIAL(S) OF CHOICE	ALTE ANTI IF RE
LOWER TRACT INSTRUMENTATION				
Cystourethroscopy with minor manipulation, break in mucosal barriers, biopsy, fulguration, etc.; clean-contaminated	GNR, rarely enterococci[†]	Uncertain[§]; consider host-related risk factors. Increasing invasiveness increases risk of SSI	TMP-SMX, Amoxicillin/Clavulanate	1st/2nd Cephal Amino (Aztre Ampic
Transurethral cases: e.g. TURP, TURBT, laser enucleative and ablative procedures, etc.; clean-contaminated[‖]	GNR, rarely enterococci	All cases	Cefazolin, TMP-SMX	Amoxi Amino (Aztre Ampic
Prostate brachytherapy or cryotherapy; clean-contaminated	*S. aureus*, skin; GNR	All cases	Cefazolin	Clinda
Transrectal prostate biopsy; contaminated	GNR, anaerobes[††]; consider MDR coverage, if risks of systemic antibiotics within 6	All cases	Fluoroquinolone, 1st/2nd/3rd gen. Cephalosporin (ceftriaxone commonly used) + Aminoglycoside	Az Ma ID

	months, international travel, healthcare worker			
UPPER TRACT INSTRUMENTATION				
Percutaneous renal surgery; e.g. PCNL; clean-contaminated	GNR, rarely enterococci, and skin[‡‡], *S. aureus*	All cases	1st/2nd gen. Cephalosporin, Aminoglycoside (Aztreonam[¥]) + Metronidazole, or Clindamycin	Ampic
Ureteroscopy, all indications; clean-contaminated	GNR, rarely enterococci	All cases; of undetermined benefit for uncomplicated diagnostic only procedures	TMP-SMX, 1st/2nd gen. Cephalosporin	Amino (Aztre Ampic Cephal Amoxi
OPEN, LAPAROSCOPIC OR ROBOTIC SURGERY				
Without entering urinary tract, e.g. adrenalectomy, lymphadenectomy, retroperitoneal or pelvic; clean	*S. aureus*, skin	Consider in all cases; may not be required	Cefazolin	Clinda
Penile surgery, e.g. circumcision, penile biopsy, etc.; clean-contaminated	*S. aureus*	Likely not required		
Urethroplasty; reconstruction anterior urethra, stricture repair, including urethrectomy; clean; contaminated; controlled entry into the urinary tract	GNR, rarely enterococci, *S. aureus*	Likely required	Cefazolin	Ce Ce An
Involving	GNR *(E. coli)*,	All cases	Cefazolin, TMP-SMX	Ampic

controlled entry into urinary tract e.g. renal surgery, nephrectomy, partial or otherwise, ureterectomy pyeloplasty, radical prostatectomy; partial cystectomy, etc.; clean-contaminated	rarely enterococci			Amino (Aztre Metro Clinda
Involving small bowel (i.e. urinary diversions), cystectomy with small bowel conduit, other GU procedures; uretero-pelvic junction repair, partial cystectomy, etc.; clean-contaminated	Skin, *S. aureus*, GNR, rarely enterococci	All cases	Cefazolin	Clinda amino Cefuro genera cephal Amino combi lactam Metro
Involving large bowel[§§]; colon conduits; clean-contaminated	GNR, anaerobes	All cases	Cefazolin + Metronidazole, Cefoxitin, Cefotetan, or Ceftriaxone + Metronidazole, Ertapenem NB: these IV agents are used along with mechanical bowel preparation and oral antimicrobial (neomycin sulfate + erythromycin base or neomycin sulfate + metronidazole)	Ampic Ticarc Piperc
Implanted	GNR, *S.*	All cases	Aminoglycoside	Amino

prosthetic devices: AUS, IPP, sacral neuromodulators; clean	*aureus*, with increasing reports of anaerobic, and fungal organisms		(Aztreonam[¥]) + 1st/2nd gen. Cephalosporin or Vancomycin[χ]	lactam includi Ampic Ticarci Tazoba
Inguinal and scrotal cases; e.g. radical orchiectomy, vasectomy, reversals, varicocelectomy, hydrocelectomy, etc.; clean	GNR, *S. aureus*	Of increased risk; all cases	Cefazolin	Ampic
Vaginal surgery, female incontinence, e.g. urethral sling procedures, fistulae repair, urethral diverticulectomy, etc.; clean-contaminated	*S. aureus*, streptococci, enterococci, vaginal anaerobes; skin	All	2nd gen. Cephalosporin (Cefoxitin, Cefotetan) provides better anaerobic coverage than 1st gen. cephaloporins; however, Cefazolin is equivalent coverage for the vaginal anaerobes in sling procedures	Ampic Amino Aztreo Metron Clinda
OTHER				
Shock-wave lithotripsy; clean	GNR, rarely enterococci; GU pathogens	Only if risk factors	If risks, consider TMP-SMX, 1st gen. Cephalosporin (Cefazolin), 2nd gen. Cephalosporin (Cefuroxime), Aminopenicillin combined with a β-lactamase inhibitor + Metronidazole	1st/2nd Amoxi Ampic Amino (Aztre Clinda

[†] GU GNR: Common urinary tract organisms are *E. coli*, *Proteus* spp, *Klebsiella* spp, and GPC *Enterococcus*.

[§] If urine culture shows no growth prior to the procedure, antimicrobial prophylaxis is not necessary.

[¶] Or full course of culture-directed antimicrobials for documented infection (which is treatment, not prophylaxis).

[¥]Aztreonam can be substituted for aminoglycosides in patients with renal insufficiency.

[‖]Includes transurethral resection of bladder tumor and prostate, and any biopsy, resection, fulguration, foreign body removal, urethral dilation or urethrotomy, or ureteral instrumentation including catheterization or stent placement/removal.

[**]Clindamycin, or aminoglycoside + metronidazole or clindamycin, are general alternatives to penicillins and cephalosporins in patients with penicillin allergy, even when not specifically listed.

[††]Intestine: Common intestinal organisms include aerobes and anaerobes: *E. coli*, *Klebsiella* spp, *Enterobacter*, *Serratia* spp, *Proteus* spp, *Enterococcus*, and *Anaerobes*.

[‡‡]Skin: Common skin organisms are *S. aureus*, coagulase negative *Staphylococcus* spp, Group A *Streptococcus* spp.

[§§]For surgery involving the colorectum, bowel preparation with oral neomycin plus either erythromycin base or metronidazole are added to systemic agents.

[χ]Routine administration of vancomycin for AP is not recommended.[43] The antimicrobial spectrum of Vancomycin is less effective against methicillin-sensitive strains of *S. aureus*.

From Lightner DJ, Wymer K, Sanchez J, et al: *Urologic procedures and antimicrobial prophylaxis,* 2019 (website):
https://www.auanet.org/Documents/Guidelines/PDF/Antimicrobial%20Prophylaxis%20Table%20V.

AP is not without morbidity because drug reactions and allergic complications, although rare, may result in minor reactions such as rashes or gastric disturbances, or significant sequelae such as allergic nephritis, or anaphylaxis.

The new BPS on Urologic Procedures and Antimicrobial Prophylaxis includes some key updated recommendations, specifically regarding asymptomatic bacteriuria and funguria. Asymptomatic bacteriuria and asymptomatic funguria do not require treatment before a surgical procedure that does not violate the urothelium. The orthopedic literature has shown that there is no benefit to treating asymptomatic bacteriuria even in the setting of a total knee or hip prosthetic replacement (Sousa et al., 2014). The same is true of patients undergoing open heart surgeries (Soltanzadeh and Ebadi, 2013). Repeat urinalysis to demonstrate clearing of asymptomatic bacteriuria is also not recommended (Ramos et al., 2016).

The EAU infection guidelines published in 2017 concluded that before urologic surgery, in diagnostic and therapeutic procedures not entering the urinary tract, asymptomatic bacteriuria is not generally considered a risk factor, and screening and treatment are not considered necessary. However, the EAU guideline states that in procedures entering the urinary tract and breaching the mucosa, particularly in endoscopic urologic surgery, bacteriuria is a definite risk factor. In these patients, a urine culture must be taken before interventions and in case of asymptomatic bacteriuria, preoperative treatment is recommended (Bonkat et al., 2019). The EAU guideline also reports the treatment of asymptomatic bacteriuria is not recommended before arthroplasty surgery.

In addition, low-risk patients with asymptomatic bacteriuria and/or funguria may not require prophylaxis before a urologic surgical procedure that does not violate the urothelium with the exception of pregnant females. However, the statement does recommend single-dose antifungal prophylaxis for patients undergoing endoscopic, robotic, or open surgery on the urinary tract.

The IDSA 2016 clinical practice guidelines for management of candidiasis strongly recommended all patients with candiduria who are undergoing any urologic procedure be treated with either oral fluconazole or intravenous amphotericin B for several days before and after intervention (Pappas et al., 2016). The AUA BPS disagrees with this recommendation and states that antifungal prophylaxis should be used in patients undergoing specific endoscopic procedures in which high pressure irrigants are used (transurethral resection of bladder tumor [TURBT], transurethral resection of the prostate (TURP), ablative outlet procedures, therapeutic URS, and entry into urinary tract). Full antifungal treatment is recommended for patients with symptomatic fungal UTIs at the time of stent or drainage tube change. Neutropenic patients with funguria and a urinary tract obstruction require a longer course of periprocedural antifungal treatment. Those patients undergoing treatment of fungal balls (mycetoma) should have preoperative fungal cultures and periprocedural antifungal treatment for 5 to 7 days.

The panel recommended considering AP at the time of select procedures, including voiding trials, and catheter, drain, stent, or nephrostomy tube removals, particularly if other risk factors are present. A recent meta-analysis published in 2013 revealed a significantly lower prevalence of symptomatic UTIs with AP at the time of catheter removal in surgical and medical patients (Marschall et al., 2013).

The BPS specifically looked at the use of single-dose AP for each category of skin incision. The statement suggests that single-dose AP is not necessary in Class 1/Clean Procedures (uninfected, no GU or GI tract entry) except in groin or perineal incisions. The BPS recommends AP for those patients undergoing Class II/clean-contaminated GU procedures, which includes prostate biopsy. For transurethral procedures and therapeutic upper endoscopic procedures, single-dose AP (including first- or second-generation cephalosporins or trimethoprim/sulfamethoxazole) covering enterococci and gram-negative pathogens is recommended. For patients undergoing Class III/contaminated procedures, AP is strongly recommended because the risk of a surgical site infection (SSI) or systemic infection is high. The BPS recommends coverage of aerobic and anaerobic organisms for those undergoing colorectal surgical procedures (first-generation cephalosporin and metronidazole). The BPS does not discuss GU prosthetic antimicrobial coverage. However, it does comment that generally, AP that covers skin flora (coagulase-negative staphylococci and gram-negative bacilli) is recommended. Finally, class IV wounds are infected, and empirical antibiotics are initiated until final culture results are available.

Urethral Catheterization and Removal

The indications for the routine use of prophylactic antimicrobial agents before urethral catheterization vary and depend on the health, sex, and specific living circumstances of the individual patient, as well as the indication for catheterization (Schaeffer, 2006)**. The risk of infection after one-time urethral catheterization is 1% to 2% in healthy domiciliary women; however, this risk rises significantly in hospitalized patients** (Thiel and Spuhler, 1965; Turck et al., 1962). Thus, for patients with risk factors for infection (see Box 55.13), AP with an oral agent such as TMP-SMX should decrease the risk of postprocedural infection (see Table 55.15).

A recent Cochrane review published in 2013 looking at AP for short-term catheter (defined as ≤14 days) bladder drainage in adults found that surgical patients who received AP (3-day duration postop or from postop day 2 to catheter removal) had a reduced rate of bacteriuria and other signs of infection, including pyuria, fevers, and gram-negative urine cultures (Lusardi et al., 2013). Importantly, the authors did conclude that because of the limited evidence and allergic reactions or side effects from the AP, the results should be interpreted with caution. Patients who require long-term intermittent catheterization should not be on routine prophylaxis, because the rates of UTI are comparable and the overall risk of infection is low (Clarke et al., 2005; Duffy et al., 1995).

Prolonged use of an indwelling urethral catheter is common in hospitalized patients and is associated with an increased risk of bacterial colonization, with a 5% to 10% incidence of bacteriuria per catheter day for each day the catheter is in place (Saint and Lipsky, 1999; Sedor and Mulholland 1999; van der Wall et al., 1992). **Prophylactic administration of antimicrobial agents during**

catheterization is not generally recommended because bacterial resistance can develop rapidly and complicate subsequent necessary antimicrobial treatment (Clarke et al., 2005). This is supported by the Cochrane Database of Systematic Reviews that concluded that antimicrobials given postprocedurally until catheter removal or for the first 3 postoperative days did not reduce rates of bacteriuria or infection (Niël-weise and van den Broek, 2005).

The natural history of bacteriuria after catheter removal has not been comprehensively studied. Harding et al. (1991) reported that in asymptomatic bacteriuric women who had been catheterized for 4 to 6 days, 25% developed a UTI within 14 days of catheter removal. In this study, 1-day treatment with TMP-SMX was as effective as a 10-day course in resolving infections. Similar studies on the natural history of post-catheterization bacteriuria have not been performed in male patients.

Data from Polastri et al. (1990) suggest that AP for chronic indwelling catheter changes is not indicated. In their study of 46 catheter changes, bacteremia occurred 4% of the time and, when noted, was associated with very low concentrations of bacteria in the cultures. Systemic sequelae were not noted.

Urodynamics

Urodynamics (UDS), like cystoscopy, is a minimally traumatic procedure with limited urothelial injury that poses a small risk of local infection in hosts with normal anatomy and immune response. Several recent studies support this notion. According to the AUA Best Practice Policy on Urologic Surgery Antimicrobial Prophylaxis, prophylactic antibiotics are not indicated before UDS for patients without UTI risk factors ("index patients") (Wolf et al., 2008).

A large systematic review published in 2008 including 8 RCTs with 995 (mostly female) patients undergoing UDS compared prophylactic antibiotics with placebo or no treatment. The authors concluded there was a 40% reduction in the risk of bacteriuria and that 13 patients would need to be given prophylactic antibiotics to prevent one episode of bacteriuria (Latthe et al., 2008). This review did not assess the occurrence of symptomatic UTI, but it has been estimated that only 8% of women develop a symptomatic UTI within 1 week of a diagnosis of asymptomatic bacteriuria (Hooton et al., 2000). **In 2012 a Cochrane review evaluated the role of prophylactic antibiotics to reduce the risk of UTIs after UDS** (Foon et al., 2012). The review included 9 RCTs with 973 patients (76%

female). Patients receiving prophylaxis had fewer UTIs (20% vs. 28%), but there was no statistically significant difference. **The authors concluded there was not enough evidence that prophylaxis reduced symptomatic UTIs.**

In 2017 the Society of Urodynamics, Female Pelvic Medicine, and Urogenital Reconstruction (SUFU) published a Best Practice Policy Statement on UDS AP in the non-index patient (Cameron et al., 2017)**. The statement recommends that all patients be screened for symptoms of UTI and undergo dipstick urinalysis. If the provider suspects a UTI, the UDS should be postponed until the UTI has been treated. Patients undergoing UDS who do NOT require AP include those with no known GU anomalies, patients with diabetes, those with prior GU surgery or a history of prior UTI, postmenopausal women, recently hospitalized patients, and patients with cardiac valvular disease, nutritional deficiencies, or obesity. The panel does recommend periprocedural antibiotics in those patients with increased risk factors for UTI after UDS: relevant neurogenic LUT dysfunction, elevated postvoid residual, asymptomatic bacteriuria, immunosuppression (including renal transplant patients), age over 70, and an indwelling catheter, external collection device, or intermittent catheterization. The majority of these recommendations are based on Level IV (low level) evidence because of the lack of well-done studies. As always, clinical judgment of each individual scenario should supersede these recommendations, which, as stated, are not based on high-level evidence.** The authors strongly recommend careful and judicious use of AP until better evidence reveals the true need. Finally, the panel did recommend AP for patients undergoing UDS who have had an orthopedic total joint implant within the prior 2 years or who are considered at increased risk of developing joint infections from bacteremia (see Table 3 of Cameron et al. 2017, p 924). The first choice for prophylaxis is a single oral dose of TMP-SMX before UDS. Acceptable alternatives include first- and second-generation cephalosporins, amoxicillin/clavulanate, fluoroquinolones, and parenteral aminoglycoside plus ampicillin. The panel only found one study that used a 1-day AP course of nitrofurantoin in patients undergoing UDS and cystoscopy. They demonstrated no improvement in bacteriuria with nitrofurantoin AP (Cundiff et al., 1999). In light of the black box warning on quinolones and the lack of well-done studies, the authors currently use nitrofurantoin as an alternative to TMP-SMX.

Transrectal Ultrasound-Guided Prostate Biopsy

Infectious complications after prostate biopsy have increased in recent years, with reported rates from 0.1% to 7.0% and sepsis rates from 0.3% to 3.1% (Loeb et al., 2011; Nam et al., 2010)**. The most common cause for infection after transrectal prostate biopsy is fluoroquinolone-resistant *E. coli*** (Liss et al., 2015)**. The most common risk factor is exposure to antimicrobials within 6 months of the biopsy. The use of prophylactic antimicrobials for transrectal ultrasound-guided prostate biopsy (TRUS-Bx) reduces postprocedural fever and UTI in most studies.** The class and duration of antimicrobial treatment are more varied and controversial. AP with fluoroquinolones has been shown to significantly reduce the rate of infectious complications compared with placebo (8% vs. 25%) (Kapoor et al., 1998; Shandera et al., 1998; Sieber et al., 1997; Tal et al., 2003; Taylor and Bingham, 1997a,b; Zani et al., 2011).

However, **several recent studies have highlighted an increasing trend of infectious complications caused by fluoroquinolone-resistant organisms** among men undergoing TRUS-Bx (Binsaleh et al., 2004; Feliciano et al., 2008; Han et al., 2005; Lange et al., 2009; Ng and Chan, 2008; Young et al., 2009; Zaytoun et al., 2011). Prevalence rates for colonization with fluoroquinolone-resistant organisms in this patient population have been reported to be as high as 22% (Liss et al., 2011). Nevertheless, more than 90% of urologists continue to use fluoroquinolones empirically for AP before TRUS-Bx (Antsupova et al., 2014; Shandera et al., 1998). The increasing prevalence of infectious complications with fluoroquinolone-resistant bacteria in men undergoing TRUS-Bx suggests that this approach may not be judicious for some patients (Taylor et al., 2012). Indeed, of fluoroquinolone-resistant strains obtained (by rectal swabs) from men before prostate biopsy, 70% had an enhanced virulence profile (Liss et al., 2013).

Empirical augmented prophylaxis with a typical combination of aminoglycosides and fluoroquinolones has been effective in recent studies (Ho et al., 2009; Kehinde et al., 2013). A recent meta-analysis of 3 RCTs showed the superiority of augmented prophylaxis in reducing UTIs and hospitalizations after prostate biopsy (Yang et al., 2015); however, it is inevitable that bacterial resistance will evolve to challenge even these regimens.

Rectal swab culture obtained before TRUS-Bx allows for the isolation and identification of fluoroquinolone-resistant organisms from a patient's native

intestinal flora. Targeted prophylaxis has been extensively studied. A meta-analysis published in 2014 included 8 studies comparing targeted prophylaxis with empirical fluoroquinolone prophylaxis. The study reported that targeted prophylaxis was more efficacious in reducing infectious complications (Roberts et al., 2014). A more recent study by Liss et al. (2015) found no significant difference (between empirical and targeted prophylaxis) in sepsis rates in 5355 patients at Kaiser Permanente centers in the United States. In a study using targeted prophylaxis based on bacterial sensitivities of rectal swabs before TRUS-Bx, 19.6% of men had fluoroquinolone-resistant organisms. There were no infectious complications in the men who received targeted prophylaxis, whereas there were infectious complications, including sepsis, in 2.6% on empirical prophylaxis (Taylor et al., 2012). Cost-effectiveness analysis revealed that targeted prophylaxis yielded a cost savings of $4499 per post–TRUS-Bx infectious complication averted. Per estimation, 38 men would need to undergo rectal swab before TRUS-Bx to prevent 1 infectious complication. **Thus screening before TRUS-Bx and targeted prophylaxis should be considered as a thoughtful, predictable alternative to empirical prophylaxis. That being said, there are a number of issues related to the actual process of targeted prophylaxis including costs, time of extra visits, special culture media, and lab requirements.** There have been recent data to suggest that fosfomycin is as effective as fluoroquinolone in UTIs after TRUS-Bx (Noreikaite et al., 2018; Ongun et al., 2012; Roberts et al., 2018).

Recent studies suggest that a single-dose/day of fluoroquinolones is as effective as 3 days of treatment (Sabbagh et al., 2004). Together these data suggest that a minimum of 1 day of an antimicrobial agent is indicated for transrectal ultrasound-guided prostate biopsies**. In 2017 an Update of the AUA White Paper on the prevention and treatment of the more common complications related to prostate biopsy was published** (Liss et al., 2017)**. The authors made several key recommendations including preoperative assessment of risk factors for resistant bacteria, and urine culture and treatment of infections in men with lower urinary tract symptoms. The White Paper recommends fluoroquinolone AP within 1 hour of the prostate biopsy. If a rectal swab culture is done, culture-specific antibiotics should be administered (gentamicin and ceftriaxone are most common agents). Local antibiograms can help identify resistance patterns and the authors advocate alternative antibiotics if *E. coli* has more than 20% fluoroquinolone resistance. The EAU guideline recommends the use of AP in men before**

transrectal prostate biopsy as well as rectal cleansing with povidone-iodine in men before transrectal prostate biopsy.

Shock-Wave Lithotripsy

The AUA Guidelines on Surgical Management of Stones suggest that noninvasive procedures such as shock-wave lithotripsy do not require AP if the preoperative urine microscopy is benign (Assimos et al., 2016). A meta-analysis of nine RCTs examined the efficacy of AP for shock-wave lithotripsy and demonstrated no statistically significant benefit in reducing postoperative bacteriuria, fevers, or UTIs (Lu et al., 2012). In addition, a prospective study published in 2013 evaluating 526 shock-wave patients, of whom just 10 received AP, revealed very low rates of asymptomatic bacteriuria (0.8%) and UTI (0.2%) (Honey et al., 2013). **Prophylaxis for shock-wave lithotripsy is not recommended based on the low rates of bacteriuria and UTI; however, a history of a recent UTI or of infection stones should warrant a full treatment course of antimicrobial agents before shock-wave lithotripsy.**

Endoscopic Procedures: Lower Urinary Tract

Simple Cystoscopy (Without Manipulation)

Cystoscopy is a minimally traumatic procedure with limited urothelial injury performed on a diverse spectrum of patients, including young healthy women and older men. Several prospective trials (Burke et al., 2002; Clark and Higgs, 1990; Manson, 1988) of patients with preprocedure sterile urine report culture-proven rates of UTI between 2.2% and 7.8% after cystoscopy without AP. In Clark's report the risk of infection was higher in patients with a previous history of UTI. In a similarly designed study, Rane et al. (2001) reported a significantly higher postprocedure culture-proven infection rate of 21% without AP. Johnson et al. (2007) reported results of a randomized controlled trial of more than 2000 patients demonstrating reductions in bacteriuria with administration of single-dose trimethoprim or ciprofloxacin. In all the studies, single doses of antimicrobial agents reduced infections to between 1% and 5%. None of these studies had significant systemic infections reported after the cystoscopic procedures.

More recently, several studies have concluded that AP is not necessary before diagnostic cystoscopy. A retrospective review of more than 2000 patients who did not receive AP reported that only 1.9% of subjects developed a febrile UTI less than 30 days after a cystoscopy and all of the UTIs responded quickly to oral antibiotics; no patients required hospitalization for sepsis (Herr, 2014). This cohort included patients who had negative cultures before the cystoscopy (76%) as well as patients with asymptomatic bacteriuria (24%). A recent systematic review and meta-analysis published in 2015 showed no significant differences in post-cystoscopy UTIs when comparing patients who received AP with those who did not (Garcia-Perdomo et al., 2015). Arrabal-Polo et al. (2017) recently looked at the effect of AP in patients undergoing flexible cystoscopy and concluded that the use of ciprofloxacin or fosfomycin as prophylaxis does not appear to be indicated in flexible cystoscopy. Recent antibiotic use or hospitalization have been identified as risk factors that increase the likelihood of developing a UTI post-cystoscopy (Gregg JR et al., 2015). In a subsequent study these same investigators found that incorporating infection risks in conjunction with analysis of an antibiogram decreased the use of AP before cystoscopy without increasing the rate of post-procedure UTIs (Gregg et al., 2018).

Based on recent evidence, AP is not necessary for the overwhelming majority of diagnostic cystourethroscopy procedures. The EAU 2017 guideline on infections states “given the low absolute risk of post-procedural UTI in well-resourced countries, the high number of procedures being performed, and the high risk of contributing to increasing antimicrobial resistance the panel consensus was to strongly recommend not to use antibiotic prophylaxis in patients undergoing urethrocystocopy (flexible or rigid)” (Bonkat et al., 2019).

Transurethral Resection of the Prostate and Bladder (Cystourethroscopy With Manipulation)

Therapeutic transurethral lower urinary tract procedures increase the risk of localized infections compared with simple diagnostic cystoscopy. Although not delineated in any prospective studies, several risk factors likely increase infectious complications, including trauma to the mucosa, increased duration and/or degree of difficulty of the procedure, pressurized irrigants, and manipulation or resection of infected material. The most well-studied lower urinary tract procedure is **transurethral resection of the prostate (TURP).** In a meta-analysis of 32 studies comprising 4260 patients, a risk reduction was noted in bacteriuria from 26% to 9.1% on postoperative urine cultures obtained 2 to 5 days after the procedure for patients treated with prophylactic antimicrobial agents (Berry and Barratt, 2002). Similarly, septicemia (defined as rigors, persistently elevated temperature [>38.5°C], and an elevated C-reactive protein level) decreased from 4.4% to 0.7% with AP. The most effective antimicrobial classes included fluoroquinolones, aminoglycosides, cephalosporins, and TMP-SMX. **Single doses of antimicrobial agents did lower the relative risk of bacteriuria, but not as significantly as antimicrobial agents administered for short courses (2 to 5 days) while the urethral catheter remained in place.** Although continuation of antimicrobial therapy while the catheter is in place is not truly prophylaxis, continuation of the initial prophylactic antimicrobial agent for an anticipated short period of time (with catheter in place) does not increase the risk of developing antimicrobial-resistant organisms. In a randomized controlled trial of 243 patients undergoing transurethral resection of bladder tumors (TURBTs), three perioperative doses of cephadrine (compared with no antimicrobial) reduced the rate of bacteriuria (MacDermott et al., 1988). No recent trials have otherwise investigated prophylaxis for **TURBT;** however**, evidence from TURP procedures suggests that prophylaxis would reduce bacteriuria in these procedures. However, the EAU guidelines based on a systematic review of two RCTs found no benefit for AP in patients undergoing TURBT and recommends AP prophylaxis to reduce infectious complications in only high-risk patients undergoing transurethral resection of the bladder.**

Other cystoscopic procedures with manipulation (e.g., laser prostatectomy, bladder biopsies) have not been well studied. However, the similarity in terms of tissue trauma and invasiveness would suggest that the data regarding TURP and TURBT can be extrapolated. Nevertheless, a recent publication looked at the utility of preoperative antibiotics before bladder biopsy and showed that there was no difference in the rate of UTI or febrile UTI in those patients undergoing bladder biopsy in the office setting (without prophylaxis) versus the operating room (with prophylaxis) (Lipsky et al., 2017)**. This is a challenge as the current Center for Medicare and Medicaid Services (CMS) mandates require AP before cystoscopy and biopsy in the OR. IDSA and the AUA guidelines concur with the CMS mandate. The IDSA guidelines on surgical prophylaxis in urology recommend AP with a fluoroquinolone, trimethoprim-sulfamethoxazole, or cefazolin for lower tract instrumentation in patients with risk factors for infection. However, although CMS and the IDSA and AUA guidelines**

recommend AP before bladder biopsy, the recent study lends support to the notion that AP in all patients undergoing biopsy may not be necessary.

Patient risk factors associated with increased infectious risk include obesity, diabetes, smoking, immunosuppression, and malnutrition (Bratzler et al., 2013)**. In addition, the authors mention urologic-specific risk factors, including urinary tract anatomic anomalies, urinary obstruction, stones, and indwelling or externalized catheters. In 2009 Yokoyama et al. evaluated the possibility of discarding AP in patients undergoing TURBT. Their prospective study of 162 patients concluded that AP in patients undergoing TURBT did not provide benefit (symptomatic UTI rate of 3.4% in control group vs. 2.3% in the prophylaxis group, as well as no sepsis episodes in either)** (Yokoyama et al., 2009).

Patients who are known preoperatively to have UTIs should have the infections eradicated before the procedure is started; therefore, in these patients, preoperative antimicrobial agents are therapeutic and not prophylactic. Failure to eradicate bacteriuria results in bacteremia in 50% of patients (Morris et al., 1976).

Diagnostic and therapeutic upper tract studies that are performed with pressurized irrigants may induce urothelial injury. Prophylaxis with antimicrobial agents that cover uropathogens is indicated.

Endoscopic Procedures: Upper Urinary Tract

Ureteroscopy

Diagnostic and therapeutic upper tract endoscopic procedures have an increased risk of localized infections compared with simple diagnostic cystoscopy because of several factors, including increased trauma to the mucosa, increased duration and/or degree of difficulty of most ureteroscopic procedures, increased pressure of irrigants, and (when applicable) manipulation or resection of infected material. **The use of AP is supported** by a randomized trial involving 113 patients undergoing ureteroscopy in which prophylactic fluoroquinolone administration significantly reduced postprocedure bacteriuria (13% vs. 2%) in a healthy population of individuals with ureteral stones and uninfected preoperative urine (Knopf et al., 2003). If an infection or infectious material is suspected, culture and a full treatment course of an appropriate antimicrobial are recommended before the procedure. Some urologists advocate for medical diuresis with furosemide during the procedure.

A recent systematic review and meta-analysis looked at a total of 11 studies with more than 4500 patients undergoing ureteroscopic lithotripsy. Deng et al. (2018) found no significant difference in risk of postoperative febrile urinary tract infections between those patients with and those without AP. However, those patients receiving a single dose of preoperative antibiotics had a significantly lower risk of bacteriuria and pyuria (Deng et al., 2018). The authors concluded by recommending a single dose of oral preoperative AP for patients undergoing ureteroscopic lithotripsy.

Ureteral Stenting

AP should be administered at the time of stent removal. If the patient has significant risk factors, stent culture should be performed at this time to help direct potential antimicrobial treatment if infection occurs. The rates of colonization of the urine range from 0 to 29% without the use of AP (Kehinde et al., 2004; Lojanapiwat, 2006; Riedl et al., 1999). Rates of stent colonization in the same series were significantly higher, ranging from 42% to 70%. Dwell time of the stent was the most significant factor influencing stent colonization, and this was not reduced by prophylaxis. Urine culture correctly identified the colonizing organism (stent culture) in only 15% of the cases.

Percutaneous Renal Surgery (Prophylaxis Indicated in All Patients)

Percutaneous renal surgery is commonly performed for large renal stones, ureteropelvic junction obstruction, and transitional cell carcinoma surveillance. Pyrexia and bacteremia occur frequently and likely stem from a combination of renal parenchymal injury, pressurized irrigation, and, in some cases, manipulation of infectious stones. There are no RCTs confirming the need for prophylaxis, but several studies demonstrated a relationship between the risk of postoperative infectious complications (including bacteriuria and sepsis) and the duration of the procedure, and amount of irrigant used (Dogan et al., 2002). **If preoperative urine cultures are positive, treatment of the infection should occur before surgery. Conversely, if preoperative cultures are negative, AP covering common urinary pathogens should be instituted** (Wolf et al., 2008) (see Table 55.6).

Open, Laparoscopic, and Robotic Surgery

Open surgical procedures can be classified as clean, clean contaminated, contaminated, and dirty (Table 55.16). **AP is indicated for clean-contaminated and contaminated wounds, whereas antimicrobial treatment with an appropriate agent should be instituted for dirty-infected wounds.** No large studies have evaluated the risk of surgical site infections for different laparoscopic urologic procedures. However, data in the general surgery literature suggest that the laparoscopic approach lowers the risk of surgical site infections (Kluytmans, 1997). Clean surgeries in urology include radical nephrectomy if the urinary tract is not entered. **All urologic procedures in which the urinary tract is opened electively are considered clean-contaminated procedures (Class II), whereas entry into an infected urinary tract is considered a contaminated procedure (Class III)** and carries a higher rate of surgical site infection (Cruse, 1992). **Antimicrobial agents should be active against the most likely infecting organism, should be administered within 1 hour of the procedure, and discontinued 24 hours after,** because several studies have failed to demonstrate beneficial effects of long courses of prophylaxis (Conte et al., 1972; Goldmann et al., 1977).

TABLE 55.16

Wound Classifications

Class I/clean	Uninfected operative wound without entry into pulmonary, GI or GU systems	Inguinal and scrotal procedures for noninfectious indications, RPLND.
Class II/clean-contaminated	Entry into pulmonary, GI or GU under controlled conditions; no other contamination	Opening into urinary tract, as in nephrectomy, cystectomy, prostatectomy, endoscopic procedures.
Class III/contaminated	Infected stone procedures, use of bowel segments	PCNL on struvite stones, infected stones. TRUS prostate biopsy.
Class IV/dirty	Open trauma, abscesses	Debridement; implication that the offending organisms were present prior to the index procedure.
Prosthesis Implantation	IPP, AUS	Antibiotic prophylaxis should cover likely skin organisms; increasing resistance, MRSA colonization has led many surgeons to use vancomycin perioperatively.

AUS, Artificial genitourinary sphincter; *GI,* gastrointestinal; *GU,* genitourinary; *IPP,* implantable penile prosthesis; *MRSA,* methicillin-resistant *Staphylococcus aureus*; *PCNL,* percutaneous nephrolithotomy; *RPLND,* retroperitoneal lymph node dissection; *TRUS,* transrectal ultrasound guided.

Modified from Mangram, AJ, Horan, TC, Pearson, ML, et al: Guideline for prevention of surgical site infection. *Am J Infect Control* 27:97, 1999.

In the United States, first-generation cephalosporins are commonly used for prophylaxis of clean-contaminated procedures because they have low incidences of allergic reactions, long half-lives, and low cost. For patients with a β-lactam allergy, the 2004 National Surgical Infection Prevention Project (NSIPP) guidelines recommend either vancomycin or clindamycin. Prophylaxis for urinary reconstruction with intestine requires increased anaerobic coverage, so the use of first-generation cephalosporins and anaerobic coverage with metronidazole is recommended. When use of the colon or appendix is anticipated for urologic reconstruction, the 2004 NSIPP and WHO recommendations include orally administered antimicrobial bowel preparation (neomycin plus erythromycin or neomycin plus metronidazole) 18 to 24 hours before surgery, and parenteral cefotetan or cefoxitin 30 to 60 minutes before incision (Bratzler and Houck, 2004). Recommendations for patients with a β-lactam allergy include clindamycin plus gentamicin, aztreonam, or ciprofloxacin. Dirty wounds in urology include all abscesses and traumatic perforations of the GU tract. Treatment of a dirty wound should begin with broad coverage of anticipated organisms and intraoperative wound cultures. Subsequent therapy and treatment duration depends on the sensitivities of the cultured organism.

Skin Preparation for Surgery

Although AP plays an important role in minimizing the risk of a surgical site infection, additional considerations are important to lessen the risk of introducing pathogens into the operative site. Pre-hospital bathing, mechanical bowel prep, hair removal, and perioperative skin preparation play a role in preventing infections. See AUA BPS for more information.

Vaginal Surgery

RCTs have not been reported for vaginal urologic surgery, but there is a large body of evidence for vaginal hysterectomy. An old meta-analysis demonstrated a dramatic decrease in incidence of pelvic infections when AP was used (Duff and Park, 1980). Chang et al. (2005) reported the results of a RCT showing that a course of antimicrobials of less than 24 hours was as effective as a long course in patients undergoing laparoscopic assisted vaginal hysterectomy. The AUA AP BPS recommended AP for all vaginal procedures including midurethral sling (MUS) surgery in 2010 and again in 2019. This recommendation is based on expert opinion. Several studies have looked to see if AP is necessary in MUS surgery. One study looked at 174 patients undergoing MUS without AP. The lack of AP was not found to lead to any higher risk of infections, although there was no control arm in this study (Harmanli et al., 2012). An RCT with and without prophylactic antibiotics for MUS was ended early because of lower-than-predicted infectious complications in both groups (Harmanli et al., 2011). Shepherd et al. (2014) performed a decision analysis looking at the necessity of AP before MUS surgery for SUI and concluded that since infectious complications are rare, AP may not be necessary.

Special Considerations

Patients With Risk of Endocarditis

The risk of infectious endocarditis (IE) after urologic procedures is low. Previous guidelines from the American Heart Association (AHA) had recommended routine prophylaxis, but the current recommendation is that the use of prophylactic antibiotics solely to prevent IE is **not recommended** (Wilson et al., 2007). However, these guidelines do acknowledge that instrumentation of the GU tract may result in transient enterococcal bacteremia. Since 2007 the AHA recommends that AP during GU procedures is not an effective strategy for the sole prevention of IE (Wilson et al., 2007).

The latest American College of Cardiology (ACC)/AHA guidelines state that administration of antibiotics is not beneficial for patients undergoing urologic procedures (Nishimura et al., 2017)**. The guideline states that IE is more likely to result from random bacteremia than from a GU procedure and that prophylaxis may prevent a very small number of cases, if any. The AHA does not recommend antimicrobial treatment even for high-risk patients (prosthetic cardiac valves, previous infectious endocarditis, or cardiac transplant patients with valve disease) undergoing instrumentation of the GU tract.**

Regardless, the guidelines do state that for patients with certain concomitant conditions (prosthetic cardiac valve, previous IE, congenital heart disease, cardiac transplantation) and an active infection or

colonization who are to undergo GU tract manipulation, including elective cystoscopy, antibiotic therapy to sterilize the urine may be reasonable (Class IIb evidence). Amoxicillin or ampicillin is suggested as a first-line agent for enterococci, vancomycin for those who cannot tolerate ampicillin, or culture-directed agents when possible (Wilson et al., 2007).

Patients With Indwelling Orthopedic Hardware

In 2003 a joint commission of the AUA, American Academy of Orthopedic Surgeons (AAOS), and infectious disease specialists released an advisory statement on AP for urologic patients with total joint replacement. The commission did not advise AP for urologic patients with joint replacements, pins, plates, or screws that were at least 2 years old. However, if the prosthetic joint or implant was inserted within 2 years, prophylaxis was recommended with either an oral quinolone or 2 g of ampicillin intravenously and 1.5 mg/kg of gentamicin (vancomycin if ampicillin allergy) intravenously 30 to 60 minutes before the procedure. The AAOS's most recent statement in 2009 recommends that clinicians consider AP for all total joint replacements prior to any invasive procedure that may cause bacteremia. The impetus for this recommendation was the combination of the significant cost of treating infected joint replacements and the potential adverse outcomes. In addition, the recent AUA BPS statement from 2019 does recommend AP for the prevention of prosthetic hip or knee prostheses, particularly for urologic procedures at high risk of bacteremia, those patients within 2 years of joint replacement, and high-risk patient populations. Although the risk for infection with urologic procedures is weak, the panel recommended AP because of the potential of catastrophic harm with a joint infection (Table 55.17).

TABLE 55.17

Antimicrobial Regimens for Patients With Indwelling Orthopedic Hardware

PATIENT TYPE	ANTIMICROBIAL RECOMMENDATION
Total joint inserted >2 yr ago, pins, plates, screws + no host risk factors	Not recommended empirically
Total joint inserted <2 yr ago or aberrant host factor(s)	Oral quinolone or ampicillin, 2 g IV + gentamicin, 1.5 mg/kg IV, 30–60 min before procedure Substitute vancomycin, 1 g IV, over 1–2 h before procedure if ampicillin allergy

---

From American Urological Association and American Academy of Orthopaedic Surgeons: Antibiotic prophylaxis for urological patients with total joint replacements. *J Urol* 169:1796–1797, 2003.

Prophylaxis on the basis of potential seeding of a prosthetic joint should be instituted for procedures including stone manipulation, transmural incision of the urinary tract, upper tract endoscopic procedures, procedures involving bowel segments, and transrectal prostate biopsy. In addition, patients with recent prosthetic joints or compromised host factors and urinary diversions, indwelling stents or catheters, a recent history of urinary retention, or UTIs should receive AP before urinary tract procedures.

Key Points: Antimicrobial Prophylaxis for Common Urologic Procedures

- AP entails treatment with an antimicrobial agent before and for a limited time after a procedure to prevent local or systemic postprocedural infections.
- The type of procedure and competency of the host defenses determine the need for AP.
- Special considerations for AP include patients undergoing TRUS-Bx, those with a risk of endocarditis and bacteriuria, and patients with indwelling orthopedic hardware.

Acknowledgments

The authors thank Justin Matulay, MD, and Michael Lipsky, MD, for their assistance with the compilation of references and creation of a new flow sheet for management of rUTIs, and they also thank Jeffrey Newhouse, MD, for his expert review of radiologic information and for providing images for the chapter.

References

Abarbanel J, Engelstein D, Lask D, et al. Urinary tract infection in men younger than 45 years of age: is there a need for urologic investigation? *Urology*. 2003;62:27–29.

Abdou NI, NaPombejara C, Sagawa A, et al. Malakoplakia: evidence for monocyte lysosomal abnormality correctable by cholinergic agonist in vitro and in vivo. *N Engl J Med*. 1977;297(26):1413–1419.

Abrutyn E, Mossey J, Berlin JA, et al. Does asymptomatic bacteriuria predict mortality and does antimicrobial treatment reduce mortality in elderly ambulatory women? *Ann Intern Med*. 1994;120:827–833.

Ahlering TE, Boyd SD, Hamilton CL, et al. Emphysematous pyelonephritis: a 5-year experience with 13 patients. *J Urol*. 1985;134(6):1086–1088.

Aisen CM, Ditkoff E, RoyChoudhury A, et al. Utility of catheterized specimens in reducing overdiagnosis of urinary tract infections in women. *Neurourol Urodyn*. 2018;37(6):1996–2001.

Albert X, Huertas I, Pereiro II, et al. Antibiotics for preventing recurrent urinary tract infection in non-pregnant women. *Cochrane Database Syst Rev*. 2004;(3) [CD001209].

Alonso MD, Marcos C, Davila I, et al. Hypersensitivity to trimethoprim. *Allergy*. 1992;47(4 Pt 1):340–342.

Altarac S, Papes D. Use of D-mannose in prophylaxis of recurrent urinary tract infections (UTIs) in women. *BJU Int*. 2014;113(1):9–10.

Altiparmak MR, Trabulus S, Balkan II, et al. Urinary tuberculosis: a cohort of 79 adult cases. *Ren Fail*. 2015;37(7):1157–1163.

Amano M, Shimizu T. Emphysematous cystitis: a review of the literature. *Intern Med*. 2014;53(2):79–82.

American Academy of Pediatrics. Practice parameter: the diagnosis, treatment, and evaluation of the initial urinary tract infection in febrile infants and young children. American Academy of Pediatrics. Committee on Quality Improvement. Subcommittee on Urinary Tract Infection. *Pediatrics*. 1999;103(4 Pt 1):843–852.

American Geriatrics Society 2015 Updated Beers Criteria for potentially inappropriate medication use in older adults. *J Am Geriatr Soc*. 2015;63(11):2227–2246.

American Urological Association. *Medical management of kidney stones*. [website] https://www.auanet.org/guidelines/kidney-stones-medical-mangement-guideline; 2014.

American Urological Association. *Recurrent uncomplicated urinary tract infections in women: AUA/CUA/SUFU guideline*. [(website):] https://www.auanet.org/guidelines/recurrent-uti; 2019.

American Urological Association and American Academy of Orthopaedic Surgeons. Antibiotic prophylaxis for urological patients with total joint replacements. *J Urol*. 2003;169:1796–1797.

Anderson DJ, Kirkland KB, Kaye KS, et al. Underresourced hospital infection control and prevention programs: penny wise, pound foolish? *Infect Control Hosp Epidemiol*. 2007;28:767–773.

Anderson G, Dodson K, Hooton T, et al. Intracellular bacterial communities of uropathogenic *Escherichia coli* in urinary tract pathogenesis. *Trends Microbiol*. 2004;12:424–430.

Anderson GG, Martin SM, Hultgren SJ. Host subversion by formation of intracellular bacterial communities in the urinary tract. *Microbes Infect*. 2004;6(12):1094–1101.

Anderson KA, McAninch JW. Renal abscesses: classification and review of 40 cases. *Urology*. 1980;16(4):333–338.

Andrews SJ, Brooks PT, Hanbury DC, et al. Ultrasonography and abdominal radiography versus intravenous urography in investigation of urinary tract infection in men: prospective incident cohort study. *BMJ*. 2002;324(7335):454–456.

Anhalt MA, Cawood CD, Scott R Jr. Xanthogranulomatous pyelonephritis: a comprehensive review with report of 4 additional cases. *J Urol*. 1971;105(1):10–17.

Ansell J, McDonough M, Zhao Y, et al. The absence of an interaction between warfarin and cranberry juice: a randomized, double-blind trial. *J Clin Pharmacol*. 2009;49(7):824–830.

Antsupova V, Norgaard N, Bisbjerg R, et al. Antibiotic prophylaxis for transrectal prostate biopsy—a new strategy. *J Antimicrob Chemother*. 2014;69(12):3372–3378.

Arnold JJ, Hehn LE, Klein DA. Common questions about recurrent urinary tract infections in women. *Am Fam Physician*. 2016;93(7):560–569.

Aronson M, Medalia O, Schori L, et al. Prevention of colonization of the urinary tract of mice with Escherichia coli by blocking of bacterial adherence with methyl alpha-D-mannopyranoside. *J Infect Dis*. 1979;139(3):329–332.

Arrabal-Polo MA, Cano-Garcia MDC, Arrabal-Martin M, et al. The effect of antibiotic prophylaxis on post-operative infection in patients undergone flexible cystos-copy. *Urol J*. 2017;14(3):3050–3053.

Asscher A, Chick S, Radford N, et al. Natural history of bacteriuria in asymptomatic nonpregnant women. Brumfitt W, Asscher A. *Urinary tract infection*. University Press: London; 1973:51.

Asscher AW. *The challenge of urinary tract infection*. Academy Press: New York; 1980.

Asscher AW, McLachlan MS, Jones RV, et al. Screening for asymptomatic urinary-tract infection in schoolgirls. A two-centre feasibility study. *Lancet*. 1973;2(7819):1–4.

Assimos D, Krambeck A, Miller NL, et al. Surgical management of stones: American Urological Association/Endourological Society guideline, PART I. *J Urol*. 2016;196(4):1153–1160.

Assimos D, Krambeck A, Miller NL, et al. Surgical management of stones: American Urological Association/Endourological Society guideline, PART II. *J Urol*. 2016;196(4):1161–1169.

Baerheim A, Larsen E, Digranes A. Vaginal application of lactobacilli in the prophylaxis of recurrent lower urinary tract infection in women. *Scand J Prim Health Care*. 1994;12(4):239–243.

Bagdasarian N, Rao K, Malani PN. Diagnosis and treatment of Clostridium difficile in adults: a systematic review. *J Am Med Assoc*. 2015;313(4):398–408.

Bagshaw SM, Laupland KB. Epidemiology of intensive care unit-acquired urinary tract infections. *Curr Opin Infect Dis*. 2006;19(1):67–71.

Baijal SS, Basarge N, Srinadh ES, et al. Percutaneous management of renal hydatidosis: a minimally invasive therapeutic option. *J Urol*. 1995;153(4):1199–1201.

Bailey RR, Little PJ, Rolleston GL. Renal damage after acute pyelonephritis. *Br Med J*. 1969;1(5643):550–551.

Bailey RR, Roberts AP, Gower PE, et al. Prevention of urinary-tract infection with low-dose nitrofurantoin. *Lancet*. 1971;2(7734):1112–1114.

Baka S, Kouskouni E, Antonopoulou S, et al. Prevalence of Ureaplasma urealyticum and Mycoplasma hominis in women with chronic urinary symptoms. *Urology*. 2009;74(1):62–66.

Bakke A, Digranes A. Bacteriuria in patients treated with clean intermittent catheterization. *Scand J Infect Dis*.

1991;23(5):577–582.

Baldassarre JS, Kaye D. Special problems of urinary tract infection in the elderly. *Med Clin North Am*. 1991;75(2):375–390.

Barber KE, Cross RR Jr. The urinary tract as a cause of death in paraplegia. *J Urol*. 1952;67(4):494–502.

Barbosa-Cesnik C, Brown MB, Buxton M, et al. Cranberry juice fails to prevent recurrent urinary tract infection: results from a randomized placebo-controlled trial. *Clin Infect Dis*. 2011;52(1):23–30.

Barlam TF, Cosgrove SE, Abbo LM, et al. Executive summary: implementing an antibiotic stewardship program: guidelines by the Infectious Diseases Society of America and the Society for Healthcare Epidemiology of America. *Clin Infect Dis*. 2016;62(10):1197–1202.

Bartlett JG, Gorbach SL. Anaerobic bacteria in suppurative infections of the male genitourinary system. *J Urol*. 1981;125(3):376–378.

Baskin LS, Carroll PR, Cattolica EV, et al. Necrotising soft tissue infections of the perineum and genitalia. Bacteriology, treatment and risk assessment. *Br J Urol*. 1990;65:524–529.

Bauer HW, Alloussi S, Egger G, et al. A long-term, multicenter, double-blind study of an Escherichia coli extract (OM-89) in female patients with recurrent urinary tract infections. *Eur Urol*. 2005;47(4):542–548 [discussion 548].

Baumgarten DA, Baumgartner BR. Imaging and radiologic management of upper urinary tract infections. *Urol Clin North Am*. 1997;24(3):545–569.

Beerepoot MA, Geerlings SE, van Haarst EP, et al. Nonantibiotic prophylaxis for recurrent urinary tract infections: a systematic review and meta-analysis of randomized controlled trials. *J Urol*. 2013;190(6):1981–1989.

Beerepoot MA, ter Riet G, Nys S, et al. Cranberries vs antibiotics to prevent urinary tract infections: a randomized double-blind noninferiority trial in premenopausal women. *Arch Intern Med*. 2011;171(14):1270–1278.

Beerepoot MA, ter Riet G, Nys S, et al. Lactobacilli vs antibiotics to prevent urinary tract infections: a randomized, double-blind, noninferiority trial in postmenopausal women. *Arch Intern Med*. 2012;172(9):704–712.

Beeson PB, Guze LB. Experimental pyelonephritis. I. Effect of ureteral ligation on the course of bacterial infection in the kidney of the rat. *J Exp Med*. 1956;104(6):803–815.

Behr MA, Drummond R, Libman MD, et al. Fever duration in hospitalized acute pyelonephritis patients. *Am J Med*. 1996;101(3):277–280.

Bejanga BI. Fournier's gangrene. *Br J Urol*. 1979;51:312–316.

Bengtsson C, Bengtsson U, Bjorkelund C, et al. Bacteriuria in a population sample of women: 24-year follow-up study. Results from the prospective population-based study of women in Gothenburg, Sweden. *Scand J Urol Nephrol*. 1998;32(4):284–289.

Bennett CJ, Young MN, Razi SS, et al. The effect of urethral introducer tip catheters on the incidence of urinary tract infection outcomes in spinal cord injured patients. *J Urol*. 1997;158:519–521.

Bent S, Nallamothu BK, Simel DL, et al. Does this woman have an acute uncomplicated urinary tract infection? *J Am Med Assoc*. 2002;287(20):2701–2710.

Beraldo PS, Neves EG, Alves CM, et al. Pyrexia in hospitalised spinal cord injury patients. *Paraplegia*. 1993;31:186–191.

Bercowsky E, Shalhav AL, Portis A, et al. Is the laparoscopic approach justified in patients with xanthogranulomatous pyelonephritis? *Urology*. 1999;54(3):437–442 [discussion 442–443].

Berry A, Barratt A. Prophylactic antibiotic use in transurethral prostatic resection: a meta-analysis. *J Urol*. 2002;167(2 Pt 1):571–577.

Best CD, Terris MK, Tacker JR, et al. Clinical and radiological findings in patients with gas forming renal abscess treated conservatively. *J Urol*. 1999;162(4):1273–1276.

Bien J, Sokolova O, Bozko P. Role of uropathogenic escherichia coli virulence factors in development of urinary tract infection and kidney damage. *Int J Nephrol*. 2012;2012:681473.

Biering-Sorensen F. Urinary tract infection in individuals with spinal cord lesion. *Curr Opin Urol*. 2002;12:45–49.

Billips BK, Forrestal SG, Rycyk MT, et al. Modulation of host innate immune response in the bladder by uropathogenic Escherichia coli. *Infect Immun*. 2007;75(11):5353–5360.

Billips BK, Schaeffer AJ, Klumpp DJ. Molecular basis of uropathogenic Escherichia coli evasion of the innate immune response in the bladder. *Infect Immun*. 2008;76(9):3891–3900.

Binsaleh S, Al-Assiri M, Aronson S, et al. Septic shock after transrectal ultrasound guided prostate biopsy. Is ciprofloxacin prophylaxis always protecting? *Can J Urol*. 2004;11:2352–2353.

Bonadio M, Meini M, Spitaleri P, et al. Current microbiological and clinical aspects of urinary tract infections. *Eur Urol*. 2001;40:439–445.

Bone RC. Sepsis, the sepsis syndrome, multi-organ failure: a plea for comparable definitions. *Ann Intern Med*. 1991;114(4):332–333.

Bonkat G, Pickard R, Barlotetti R, et al. *Urological Infections Guidelines*. [website] http://uroweb.org/guideline/urological-infections/#3_14; 2019.

Boscia JA, Abrutyn E, Levison ME, et al. Pyuria and asymptomatic bacteriuria in elderly ambulatory women. *Ann*

Intern Med. 1989;110:404–405.

Boscia JA, Kaye D. Asymptomatic bacteriuria in the elderly. *Infect Dis Clin North Am*. 1987;1:893–905.

Boscia JA, Kobasa WD, Knight RA, et al. Epidemiology of bacteriuria in an elderly ambulatory population. *Am J Med*. 1986;80:208–214.

Boscia JA, Kobasa WD, Knight RA, et al. Therapy vs no therapy for bacteriuria in elderly ambulatory nonhospitalized women. *J Am Med Assoc*. 1987;257:1067–1071.

Bowers JH, Cathey WJ. Malakoplakia of the kidney with renal failure. *Am J Clin Pathol*. 1971;55(6):765–769.

Boyko EJ, Fihn SD, Scholes D, et al. Risk of urinary tract infection and asymptomatic bacteriuria among diabetic and nondiabetic postmenopausal women. *Am J Epidemiol*. 2005;161(6):557–564.

Bratzler DW, Dellinger EP, Olsen KM, et al. Clinical practice guidelines for antimicrobial prophylaxis in surgery. *Surg Infect (Larchmt)*. 2013;14(1):73–156.

Bratzler DW, Houck PM, Surgical Infection Prevention Guidelines Writers Workgroup, et al. Antimicrobial prophylaxis for surgery: an advisory statement from the National Surgical Infection Prevention Project. *Clin Infect Dis*. 2004;38(12):1706–1715.

Braude AI. Current concepts of pyelonephritis. *Medicine (Baltimore)*. 1973;52(4):257–264.

Brenbridge AN, Buschi AJ, Cochrane JA, et al. Renal emphysema of the tranplanted kidney: sonographic appearance. *AJR Am J Roentgenol*. 1979;132(4):656–658.

Brocklehurst JC, Dillane JB, Griffiths L, et al. The prevalence and symptomatology of urinary infection in an aged population. *Gerontol Clin (Basel)*. 1968;10:242–253.

Bromberg K, Gleich S, Ginsberg MB. Clostridia in urinary tract infections. *South Med J*. 1982;75(10):1298–1300.

Brooker WJ, Aufderheide AC. Genitourinary tract infections due to atypical mycobacteria. *J Urol*. 1980;124(2):242–244.

Brosnahan J, Jull A, Tracy C. Types of urethral catheters for management of short-term voiding problems in hospitalised adults. *Cochrane Database Syst Rev*. 2004;(2) [CD004013].

Brown P, Ki M, Foxman B. Acute pyelonephritis among adults: cost of illness and considerations for the economic evaluation of therapy. *Pharmacoeconomics*. 2005;23(11):1123–1142.

Brubaker L, Nager CW, Richter HE, et al. Urinary bacteria in adult women with urgency urinary incontinence. *Int Urogynecol J*. 2014;25(9):1179–1184.

Brubaker L, Wolfe AJ. The female urinary microbiota/microbiome: clinical and research implications. *Rambam Maimonides Med J*. 2017;8(2).

Brumfitt W, Gruneberg R, Leigh D. Bacteriuria in pregnancy, with reference to prematurity and long-term effects on the mother. *Symposium on pyelonephritis*. E&S Livingstone: Edinburgh; 1967.

Buckley RJ, Smith S, Herschorn S, et al. Echinococcal disease of the kidney presenting as a renal filling defect. *J Urol*. 1985;133(4):660–661.

Bukowski TP, Betrus GG, Aquilina JW, et al. Urinary tract infections and pregnancy in women who underwent antireflux surgery in childhood. *J Urol*. 1998;159:1286–1289.

Buonocore E, Vidt DG, Montie JE. Ultrasonography in the diagnosis of obstructive uropathy caused by papillary necrosis. *Cleve Clin Q*. 1980;47(2):109–114.

Burke DM, Shackley DC, O'Reilly PH. The community-based morbidity of flexible cystoscopy. *BJU Int*. 2002;89:347–349.

Burpee JF, Edwards P. Fournier's gangrene. *J Urol*. 1972;107:812–814.

Cai T, Mazzoli S, Mondaini N, et al. The role of asymptomatic bacteriuria in young women with recurrent urinary tract infections: to treat or not to treat? *Clin Infect Dis*. 2012;55(6):771–777.

Cai T, Nesi G, Mazzoli S, et al. Asymptomatic bacteriuria treatment is associated with a higher prevalence of antibiotic resistant strains in women with urinary tract infections. *Clin Infect Dis*. 2015;61(11):1655–1661.

Calandra T, Glauser MP, Schellekens J, et al. Treatment of gram-negative septic shock with human IgG antibody to Escherichia coli J5: a prospective, double-blind, randomized trial. *J Infect Dis*. 1988;158(2):312–319.

Callea F, Van Damme B, Desmet VJ. Alpha-1-antitrypsin in malakoplakia. *Virchows Arch A Pathol Anat Histol*. 1982;395(1):1–9.

Callen PW. Computed tomographic evaluation of abdominal and pelvic abscesses. *Radiology*. 1979;131(1):171–175.

Cameron AP, Campeau L, Brucker BM, et al. Best practice policy statement on urodynamic antibiotic prophylaxis in the non-index patient. *Neurourol Urodyn*. 2017;36(4):915–926.

Campbell M. Perinephric abscess. *Surg Gynecol Obstet*. 1930;51:654.

Camunez F, Echenagusia A, Prieto ML, et al. Percutaneous nephrostomy in pyonephrosis. *Urol Radiol*. 1989;11(2):77–81.

Cardenas DD, Hooton TM. Urinary tract infection in persons with spinal cord injury. *Arch Phys Med Rehabil*. 1995;76:272–280.

Cardenas DD, Moore KN, Dannels-McClure A, et al. Intermittent catheterization with a hydrophilic-coated catheter delays urinary tract infections in acute spinal cord injury: a prospective, randomized, multicenter trial. *PM R*. 2011;3(5):408–417.

Carty M, Brocklehurst JC, Carty J. Bacteriuria and its correlates in old age. *Gerontology*. 1981;27:72–75.

Casewell M, Phillips I. Hands as route of transmission for *Klebsiella* species. *Br Med J*. 1977;2:1315–1317.

Castaneda DA, Leon K, Martin R, et al. Urinary tract infection and kidney transplantation: a review of diagnosis, causes, and current clinical approach. *Transplant Proc*. 2013;45(4):1590–1592.

Cattell WR, Charleton CAC, McSherry A, et al. The localization of urinary tract infection and its relationship to relapse, reinfection and treatment. Brumfitt W, Asscher AW. *Urinary tract infection*. Oxford University Press: London; 1973:206–214.

Cavins JA, Goldstein AM. Renal malacoplakia. *Urology*. 1977;10(2):155–158.

CDC. *Report to the president on combating antibiotic resistance*. [(website):] https://www.cdc.gov/drugresistance/pdf/report-to-the-president-on-combating-antibiotic-resistance.pdf; 2014.

Chan RC, Bruce AW, Reid G. Adherence of cervical, vaginal and distal urethral normal microbial flora to human uroepithelial cells and the inhibition of adherence of gram-negative uropathogens by competitive exclusion. *J Urol*. 1984;131(3):596–601.

Chang WC, Hung YC, Li TC, et al. Short course of prophylactic antibiotics in laparoscopically assisted vaginal hysterectomy. *J Reprod Med*. 2005;50(7):524–528.

Charboneau J. Malakoplakia of the urinary tract with renal parenchymal involvement. *Urol Radiol*. 1980;2:89.

Charlton CA, Crowther A, Davies JG, et al. Three-day and ten-day chemotherapy for urinary tract infections in general practice. *Br Med J*. 1976;1(6002):124–126.

Chaudhry A, Stone WJ, Breyer JA. Occurrence of pyuria and bacteriuria in asymptomatic hemodialysis patients. *Am J Kidney Dis*. 1993;21:180–183.

Chen YH, Ko WC, Hsueh PR. The role of fluoroquinolones in the management of urinary tract infections in areas with high rates of fluoroquinolone-resistant uropathogens. *Eur J Clin Microbiol Infect Dis*. 2012;31(8):1699–1704.

Chen YY, Wang FD, Liu CY, et al. Incidence rate and variable cost of nosocomial infections in different types of intensive care units. *Infect Control Hosp Epidemiol*. 2009;30:39–46.

Chenoweth CE, Gould CV, Saint S. Diagnosis, management, and prevention of catheter-associated urinary tract infections. *Infect Dis Clin North Am*. 2014;28(1):105–119.

Chenoweth CE, Saint S. Urinary tract infections. *Infect Dis Clin North Am*. 2016;30(4):869–885.

Chhajed PN, Plit ML, Hopkins PM, et al. Achilles tendon disease in lung transplant recipients: association with ciprofloxacin. *Eur Respir J*. 2002;19(3):469–471.

Christ W, Lehnert T, Ulbrich B. Specific toxicologic aspects of the quinolones. *Rev Infect Dis*. 1988;10(Suppl 1):S141–S146.

Chuang CK, Lai MK, Chang PL, et al. Xanthogranulomatous pyelonephritis: experience in 36 cases. *J Urol*. 1992;147(2):333–336.

Cirl C, Wieser A, Yadav M, et al. Subversion of Toll-like receptor signaling by a unique family of bacterial Toll/interleukin-1 receptor domain-containing proteins. *Nat Med*. 2008;14(4):399–406.

Clark KR, Higgs MJ. Urinary infection following out-patient flexible cystoscopy. *Br J Urol*. 1990;66:503–505.

Clarke SA, Samuel M, Boddy SA. Are prophylactic antibiotics necessary with clean intermittent catheterization? A randomized controlled trial. *J Pediatr Surg*. 2005;40(3):568–571.

Clayson D, Wild D, Doll H, et al. Validation of a patient-administered questionnaire to measure the severity and bothersomeness of lower urinary tract symptoms in uncomplicated urinary tract infection (UTI): the UTI Symptom Assessment questionnaire. *BJU Int*. 2005;96(3):350–359.

Clayton MD, Fowler JE Jr, Sharifi R, et al. Causes, presentation and survival of fifty-seven patients with necrotizing fasciitis of the male genitalia. *Surg Gynecol Obstet*. 1990;170:49–55.

Clermont O, Bonacorsi S, Bingen E. Rapid and simple determination of the Escherichia coli phylogenetic group. *Appl Environ Microbiol*. 2000;66(10):4555–4558.

Cockerill FR, Edson RS. Trimethoprim-sulfamethoxazole. *Mayo Clin Proc*. 1991;66(12):1260–1269.

Cohen M. Fournier's gangrene. *AUA Update*. 1986;5:6.

Colgan R, Nicolle LE, McGlone A, et al. Asymptomatic bacteriuria in adults. *Am Fam Physician*. 2006;74(6):985–990.

Coltorti EA, Varela-Diaz VM. Detection of antibodies against Echinococcus granulosus arc 5 antigens by double diffusion test. *Trans R Soc Trop Med Hyg*. 1978;72(3):226–229.

Connell I, Agace W, Klemm P, et al. Type 1 fimbrial expression enhances Escherichia coli virulence for the urinary tract. *Proc Natl Acad Sci USA*. 1996;93(18):9827–9832.

Conrad MR, Bregman R, Kilman WJ. Ultrasonic recognition of parenchymal gas. *AJR Am J Roentgenol*. 1979;132(3):395–399.

Conte JE Jr, Cohen SN, Roe BB, et al. Antibiotic prophylaxis and cardiac surgery. A prospective double-blind comparison of single-dose versus multiple-dose regimens. *Ann Intern Med*. 1972;76:943–949.

Corriere JN Jr, Sandler CM. The diagnosis and immediate therapy of acute renal and perirenal infections. *Urol Clin North Am*. 1982;9(2):219–228.

Cotran R. Experimental pyelonephritis. Rouiller C, Muller A. *The kidney: morphology, biochemistry, physiology*. Academic

Press: New York; 1969:269–361.

Coussement J, Scemla A, Abramowicz D, et al. Antibiotics for asymptomatic bacteriuria in kidney transplant recipients. *Cochrane Database Syst Rev*. 2018;(2) [CD011357].

Cox CE, Hinman F Jr. Experiments with induced bacteriuria, vesical emptying and bacterial growth on the mechanism of bladder defense to infection. *J Urol*. 1961;86:739–748.

Cox L, He C, Bevins J, et al. Gentamicin bladder instillations decrease symptomatic urinary tract infections in neurogenic bladder patients on intermittent catheterization. *Can Urol Assoc J*. 2017;11(9):E350–E354.

Craig WD, Wagner BJ, Travis MD. Pyelonephritis: radiologic-pathologic review. *Radiographics*. 2008;28(1):255–277 [quiz 327–328].

Crandall CJ, Hovey KM, Andrews CA, et al. Breast cancer, endometrial cancer, and cardiovascular events in participants who used vaginal estrogen in the Women's Health Initiative Observational Study. *Menopause*. 2018;25(1):11–20.

Cronberg S, Welin CO, Henriksson L, et al. Prevention of recurrent acute cystitis by methenamine hippurate: double blind controlled crossover long term study. *Br Med J (Clin Res Ed)*. 1987;294(6586):1507–1508.

Cruse P. Surgical wound infection. Wonsiewicz M. *Infectious disease*. Saunders: Philadelphia; 1992:758–764.

Cundiff GW, McLennan MT, Bent AE. Randomized trial of antibiotic prophylaxis for combined urodynamics and cystourethroscopy. *Obstet Gynecol*. 1999;93(5 Pt 1):749–752.

Cunningham FG, Morris GB, Mickal A. Acute pyelonephritis of pregnancy: a clinical review. *Obstet Gynecol*. 1973;42:112–117.

Cunnington M, Kortsalioudaki C, Heath P. Genitourinary pathogens and preterm birth. *Curr Opin Infect Dis*. 2013;26:219–230.

Daifuku R, Stamm WE. Association of rectal and urethral colonization with urinary tract infection in patients with indwelling catheters. *J Am Med Assoc*. 1984;252:2028–2030.

Das R, Perrelli E, Towle V, et al. Antimicrobial susceptibility of bacteria isolated from urine samples obtained from nursing home residents. *Infect Control Hosp Epidemiol*. 2009;30(11):1116–1119.

Dason S, Dason JT, Kapoor A. Guidelines for the diagnosis and management of recurrent urinary tract infection in women. *Can Urol Assoc J*. 2011;5(5):316–322.

Davey P, Marwick CA, Scott CL, et al. Interventions to improve antibiotic prescribing practices for hospital inpatients. *Cochrane Database Syst Rev*. 2017;(2) [CD003543].

Davidson AJ, Talner LB. Late sequelae of adult-onset acute bacterial nephritis. *Radiology*. 1978;127:367–371.

Davies AG, McLachlan MS, Asscher AW. Progressive kidney damage after non-obstructive urinary tract infection. *Br Med J*. 1972;4(5837):406–407.

Davison JM, Lindheimer MD. Renal disease in pregnant women. *Clin Obstet Gynecol*. 1978;21:411–427.

Dellinger RP, Levy MM, Carlet JM, et al. Surviving Sepsis Campaign: international guidelines for management of severe sepsis and septic shock: 2008. *Intensive Care Med*. 2008;34(1):17–60.

DeNavasquez S. Experimental pyelonephritis in the rabbit produced by staphylococcal infection. *J Pathol Bacteriol*. 1950;62:429–436.

Deng T, Liu B, Duan X, et al. Antibiotic prophylaxis in ureteroscopic lithotripsy: a systematic review and meta-analysis of comparative studies. *BJU Int*. 2018;122(1):29–39.

Deridder PA, Koff SA, Gikas PW, et al. Renal malacoplakia. *J Urol*. 1977;117(4):428–432.

Deville W, Yzermans J, van Duijn N, et al. The urine dipstick test useful to rule out infections. *BMC Urol*. 2004;4:4.

Dew JE, Wren BG, Eden JA. A cohort study of topical vaginal estrogen therapy in women previously treated for breast cancer. *Climacteric*. 2003;6(1):45–52.

Dielubanza EJ, Schaeffer AJ. Urinary tract infections in women. *Med Clin North Am*. 2011;95(1):27–41.

Ditkoff EL, Mlynarczyk C, Kowalik C, et al. *Assessment of physicians' practices in screening and treating women with bacteriuria*. [AUA 2017] 2017 [Boston, MA].

Ditkoff EL, Theofanides M, Aisen CM, et al. Assessment of practices in screening and treating women with bacteriuria. *Can J Urol*. 2018;25(5):9486–9496.

Dogan HS, Sahin A, Cetinkaya Y, et al. Antibiotic prophylaxis in percutaneous nephrolithotomy: prospective study in 81 patients. *J Endourol*. 2002;16:649–653.

Domenici L, Monti M, Bracchi C, et al. D-mannose: a promising support for acute urinary tract infections in women. A pilot study. *Eur Rev Med Pharmacol Sci*. 2016;20(13):2920–2925.

Donlan RM, Costerton JW. Biofilms: survival mechanisms of clinically relevant microorganisms. *Clin Microbiol Rev*. 2002;15(2):167–193.

Dorr MB, Nelson AL, Mayer PR, et al. Plasma estrogen concentrations after oral and vaginal estrogen administration in women with atrophic vaginitis. *Fertil Steril*. 2010;94(6):2365–2368.

Drekonja DM, Rector TS, Cutting A, et al. Urinary tract infection in male veterans: treatment patterns and outcomes. *JAMA Intern Med*. 2013;173(1):62–68.

D'Souza RC, Kotre CJ, Owen JP, et al. Computed tomography evaluation of renal parenchymal volume in patients with chronic pyelonephritis and its relationship to glomerular filtration rate. *Br J Radiol*. 1995;68(806):130–133.

Duff P, Park RC. Antibiotic prophylaxis in vaginal hysterectomy: a review. *Obstet Gynecol*. 1980;55(5 Suppl):193S–202S.

Duffy LM, Cleary J, Ahern S, et al. Clean intermittent catheterization: safe, cost-effective bladder management for male residents of VA nursing homes. *J Am Geriatr Soc*. 1995;43(8):865–870.

Duguid JP, Anderson ES, Campbell I. Fimbriae and adhesive properties in Salmonellae. *J Pathol Bacteriol*. 1966;92(1):107–138.

Dukes C. Urinary infections after excision of the rectum: their cause and prevention. *Proc R Soc Med*. 1928;22:259–269.

Duncan JL. Differential effect of Tamm-Horsfall protein on adherence of Escherichia coli to transitional epithelial cells. *J Infect Dis*. 1988;158(6):1379–1382.

Dune TJ, Price TK, Hilt EE, et al. Urinary symptoms and their associations with urinary tract infections in urogynecologic patients. *Obstet Gynecol*. 2017;130(4):718–725.

Eastham J, Ahlering T, Skinner E. Xanthogranulomatous pyelonephritis: clinical findings and surgical considerations. *Urology*. 1994;43(3):295–299.

Edelstein H, McCabe RE. Perinephric abscess. Modern diagnosis and treatment in 47 cases. *Medicine (Baltimore)*. 1988;67(2):118–131.

Edwards LE, Lock R, Powell C, et al. Post-catheterisation urethral strictures. A clinical and experimental study. *Br J Urol*. 1983;55:53–56.

Eisenstein BI. Phase variation of type 1 fimbriae in *Escherichia coli* is under transcriptional control. *Science*. 1981;214:337–339.

Elder HA, Santamarina BA, Smith S, et al. The natural history of asymptomatic bacteriuria during pregnancy: the effect of tetracycline on the clinical course and the outcome of pregnancy. *Am J Obstet Gynecol*. 1971;111:441–462.

Elder J. Xanthogranulomatous pyelonephritis and gas forming infections of the urinary tract. *AUA Update*. 1984;III(2) [lesson 31].

Elliott TS, Reed L, Slack RC, et al. Bacteriology and ultrastructure of the bladder in patients with urinary tract infections. *J Infect*. 1985;11(3):191–199.

Ena J, Amador C, Martinez C, et al. Risk factors for acquisition of urinary tract infections caused by ciprofloxacin resistant *Escherichia coli*. *J Urol*. 1995;153:117–120.

Eriksen B. A randomized, open, parallel-group study on the preventive effect of an estradiol-releasing vaginal ring (Estring) on recurrent urinary tract infections in postmenopausal women. *Am J Obstet Gynecol*. 1999;180(5):1072–1079.

Eskandari MK, Bolgos G, Miller C, et al. Anti-tumor necrosis factor antibody therapy fails to prevent lethality after cecal ligation and puncture or endotoxemia. *J Immunol*. 1992;148:2724–2730.

Esparza AR, McKay DB, Cronan JJ, et al. Renal parenchymal malakoplakia. Histologic spectrum and its relationship to megalocytic interstitial nephritis and xanthogranulomatous pyelonephritis. *Am J Surg Pathol*. 1989;13(3):225–236.

European Centre for Disease Prevention and Control. *Antimicrobial resistance surveillance in Europe 2015*. [Annual Report of the European Antimicrobial Resistance Surveillance Network (EARS-Net). Stockholm] 2017 [ECDC].

Eykyn S, Lloyd-Davies RW, Shuttleworth KE, et al. The localization of urinary tract infection by ureteric catheterization. *Invest Urol*. 1972;9(4):271–275.

Fader RC, Davis CP. *Klebsiella pneumoniae*-induced experimental pyelitis: the effect of piliation on infectivity. *J*

Urol. 1982;128:197–201.

Fagerholm M. Case of the autumn season. *Semin Ultrasound*. 1983;4:145.

Fair WR, Timothy MM, Millar MA, et al. Bacteriologic and hormonal observations of the urethra and vaginal vestibule in normal, premenopausal women. *J Urol*. 1970;104(3):426–431.

Fairchild TN, Shuman W, Berger RE. Radiographic studies for women with recurrent urinary tract infections. *J Urol*. 1982;128(2):344–345.

Fairley K, Bond A, Adey F. The site of infection in pregnancy bacteriuria. *Lancet*. 1966;1:939–941.

Fairley K. The routine determination of the site of infection in the investigation of patients with urinary tract infection. Kincaid-Smith P, Fairley K. *Renal infection and renal scarring*. Mercedes: Melbourne; 1972.

Fairley KF, Birch DF. Detection of bladder bacteriuria in patients with acute urinary symptoms. *J Infect Dis*. 1989;159(2):226–231.

Fairley KF, Bond AG, Brown RB, et al. Simple test to determine the site of urinary-tract infection. *Lancet*. 1967;2(7513):427–428.

Fairley KF, Whitworth JA, Radford NJ, et al. Pregnancy bacteriuria: the significance of site of infection. *Med J Aust*. 1973;2:424–427.

Falagas ME, Betsi GI, Tokas T, et al. Probiotics for prevention of recurrent urinary tract infections in women: a review of the evidence from microbiological and clinical studies. *Drugs*. 2006;66(9):1253–1261.

FDA. *FDA In Brief: FDA warns that fluoroquinolone antibiotics can cause aortic aneurysm in certain patients*. [(website):] https://www.fda.gov/news-events/fda-brief/fda-brief-fda-warns-fluoroquinolone-antibiotics-can-cause-aortic-aneurysm-certain-patients; 2018.

FDA. *FDA updates warnings for fluoroquinolone antibiotics on risks of mental health and low blood sugar adverse reactions*. [(website):] https://www.fda.gov/news-events/press-announcements/fda-updates-warnings-fluoroquinolone-antibiotics-risks-mental-health-and-low-blood-sugar-adverse; 2018.

FDA Drug Safety Communication. *FDA updates warnings for oral and injectable fluoroquinolone antibiotics due to disabling side effects*. 2016.

Feldberg MA. Bilateral adult-onset acute bacterial pyelonephritis and its late unusual sequelae. A case report. *Diagn Imaging*. 1982;51(6):296–300.

Feliciano J, Teper E, Ferrandino M, et al. The incidence of fluoroquinolone resistant infections after prostate biopsy—are fluoroquinolones still effective prophylaxis? *J Urol*. 2008;179:952–955.

Fernandez JA, Miles BJ, Buck AS, et al. Renal carbuncle: comparison between surgical open drainage and closed percutaneous drainage. *Urology*. 1985;25:142–144.

Ferroni M, Taylor AK. Asymptomatic bacteriuria in noncatheterized adults. *Urol Clin North Am*. 2015;42(4):537–545.

Fiegler W. Ultrasound in acute renal inflammatory lesions. *Eur J Radiol*. 1983;3(4):354–357.

Figueiredo AA, Lucon AM. Urogenital tuberculosis: update and review of 8961 cases from the world literature. *Rev Urol*. 2008;10(3):207–217.

Fihn SD, Boyko EJ, Normand EH, et al. Association between use of spermicide-coated condoms and Escherichia coli urinary tract infection in young women. *Am J Epidemiol*. 1996;144(5):512–520.

Fihn SD, Latham RH, Roberts P, et al. Association between diaphragm use and urinary tract infection. *J Am Med Assoc*. 1985;254(2):240–245.

Finegold S. Urinary tract infections. Finegold S. *Anaerobic bacteria in human disease*. Academic Press: New York; 1977:311–349.

Finucane TE. “Urinary tract infection”-requiem for a heavyweight. *J Am Geriatr Soc*. 2017;65(8):1650–1655.

Fischman NH, Roberts JA. Clinical studies in acute pyelonephritis: is there a place for renal quantitative camera study? *J Urol*. 1982;128(3):452–455.

Flores-Mireles AL, Walker JN, Caparon M, et al. Urinary tract infections: epidemiology, mechanisms of infection and treatment options. *Nat Rev Microbiol*. 2015;13(5):269–284.

Flynn JT, Molland EA, Paris AM, et al. The underestimated hazards of xanthogranulomatous pyelonephritis. *Br J Urol*. 1979;51(6):443–444.

Foley F. Cystoscopic prostatectomy: a new procedure and instrument; preliminary report. *J Urol*. 1929;21:289–306.

Foon R, Toozs-Hobson P, Latthe P. Prophylactic antibiotics to reduce the risk of urinary tract infections after urodynamic studies. *Cochrane Database Syst Rev*. 2012;(10) [CD008224].

Forland M, Thomas V, Shelokov A. Urinary tract infections in patients with diabetes mellitus. Studies on antibody coating of bacteria. *J Am Med Assoc*. 1977;238(18):1924–1926.

Fosfomycin for urinary tract infections. *Med Lett Drugs Ther*. 1997;39:66–68.

Fournier J. Etude clinique de la gangrene foudroyante de la verge. *Semin Med*. 1884;4:64.

Fournier J. Gangrene foudroyante de la verge. *Semin Med*. 1883;3:345.

Fowler JE Jr, Latta R, Stamey TA. Studies of introital colonization in women with recurrent urinary infections.

VIII. The role of bacterial interference. *J Urol*. 1977;118(2):296–298.

Fowler JE Jr, Perkins T. Presentation, diagnosis and treatment of renal abscesses: 1972-1988. *J Urol*. 1994;151(4):847–851.

Foxman B, Barlow R, D'Arcy H, et al. Urinary tract infection: self-reported incidence and associated costs. *Ann Epidemiol*. 2000;10:509–515.

Foxman B, Gillespie B, Koopman J, et al. Risk factors for second urinary tract infection among college women. *Am J Epidemiol*. 2000;151(12):1194–1205.

Foxman B, Zhang L, Tallman P, et al. Virulence characteristics of Escherichia coli causing first urinary tract infection predict risk of second infection. *J Infect Dis*. 1995;172(6):1536–1541.

Foxman B. Epidemiology of urinary tract infections: incidence, morbidity, and economic costs. *Am J Med*. 2002;113(Suppl 1A):5S–13S.

Foxman B. The epidemiology of urinary tract infection. *Nat Rev Urol*. 2010;7(12):653–660.

Foxman B. Urinary tract infection syndromes: occurrence, recurrence, bacteriology, risk factors, and disease burden. *Infect Dis Clin North Am*. 2014;28(1):1–13.

Fraser IR, Birch D, Fairley KF, et al. A prospective study of cortical scarring in acute febrile pyelonephritis in adults: clinical and bacteriological characteristics. *Clin Nephrol*. 1995;43:159–164.

Frazee BW, Enriquez K, Ng V, et al. Abnormal urinalysis results are common, regardless of specimen collection technique, in women without urinary tract infections. *J Emerg Med*. 2015;48(6):706–711.

Freedman L. Interstitial renal inflammation, including pyelonephritis and urinary tract infection. Early L, Gottschalk C. *Strauss and Welt's diseases of the kidney*. Little, Brown:

Boston; 1979.

Freedman LR, Beeson PB. Experimental pyelonephritis. IV. Observations on infections resulting from direct inoculation of bacteria in different zones of the kidney. *Yale J Biol Med*. 1958;30(6):406–414.

Freedman LR. Natural history of urinary infection in adults. *Kidney Int Suppl*. 1975;4:S96–S100.

Freiha F, Messing E, Gross D. Emphysematous pyelonephritis. *J Contin Ed Urol*. 1979;18:9–19.

Friedenberg MJ, Spjut HJ. Xanthogranulomatous pyelonephritis. *Am J Roentgenol Radium Ther Nucl Med*. 1963;90:97–108.

Gaffney RA, Venegas MF, Kanerva C, et al. Effect of vaginal fluid on adherence of type 1 piliated Escherichia coli to epithelial cells. *J Infect Dis*. 1995;172(6):1528–1535.

Gagyor I, Bleidorn J, Kochen MM, et al. Ibuprofen versus fosfomycin for uncomplicated urinary tract infection in women: randomised controlled trial. *BMJ*. 2015;351 [h6544].

Garcia-Perdomo HA, Jimenez-Mejias E, Lopez-Ramos H. Efficacy of antibiotic prophylaxis in cystoscopy to prevent urinary tract infection: a systematic review and meta-analysis. *Int Braz J Urol*. 2015;41(3):412–424 [discussion 424].

Gardiner RA, Gwynne RA, Roberts SA. Perinephric abscess. *BJU Int*. 2011;107(Suppl 3):20–23.

Garibaldi RA, Burke JP, Britt MR, et al. Meatal colonization and catheter-associated bacteriuria. *N Engl J Med*. 1980;303:316–318.

Garofalo CK, Hooton TM, Martin SM, et al. *Escherichia coli* from urine of female patients with urinary tract infections is competent for intracellular bacterial community formation. *Infect Immun*. 2007;75:52–60.

Gebreselassie S, Simmons MN, Montague DK. Genitourinary manifestations of sickle cell disease. *Cleve Clin J Med*.

2015;82(10):679–683.

Geerlings SE, Beerepoot MA, Prins JM. Prevention of recurrent urinary tract infections in women: antimicrobial and nonantimicrobial strategies. *Infect Dis Clin North Am*. 2014;28(1):135–147.

Geerts AF, Eppenga WL, Heerdink R, et al. Ineffectiveness and adverse events of nitrofurantoin in women with urinary tract infection and renal impairment in primary care. *Eur J Clin Pharmacol*. 2013;69(9):1701–1707.

Gerzof SG, Gale ME. Computed tomography and ultrasonography for diagnosis and treatment of renal and retroperitoneal abscesses. *Urol Clin North Am*. 1982;9(1):185–193.

Ghaleb K, Afifi M, El-Gohary M. Assessment of diagnostic techniques of urinary tuberculosis. *Mediterr J Hematol Infect Dis*. 2013;5(1) [e2013034].

Ghosh H. Chronic pyelonephritis with xanthogranulomatous change; report of 3 cases. *Am J Clin Pathol*. 1955;25(9):1043–1049.

Giesen LG, Cousins G, Dimitrov BD, et al. Predicting acute uncomplicated urinary tract infection in women: a systematic review of the diagnostic accuracy of symptoms and signs. *BMC Fam Pract*. 2010;11:78.

Gilbert DN. Once-daily aminoglycoside therapy. *Antimicrob Agents Chemother*. 1991;35:399–405.

Gilmore DS, Schick DG, Young MN, et al. Effect of external urinary collection system on colonization and urinary tract infections with *Pseudomonas* and *Klebsiella* in men with spinal cord injury. *J Am Paraplegia Soc*. 1992;15:155–157.

Gilsanz V, Lozano G, Jimenez J. Renal hydatid cysts: communicating with collecting system. *AJR Am J Roentgenol*. 1980;135(2):357–361.

Gilstrap LC, Leveno KJ, Cunningham FG, et al. Renal infection and pregnancy outcome. *Am J Obstet Gynecol*. 1981;141:709–716.

Girardin E, Grau GE, Dayer JM, et al. Tumor necrosis factor and interleukin-1 in the serum of children with severe infectious purpura. *N Engl J Med*. 1988;319:397–400.

Godoy-Santos AL, Bruschini H, Cury J, et al. Fluoroquinolones and the risk of Achilles tendon disorders: update on a neglected complication. *Urology*. 2018;113:20–25.

Goldman SM, Hartman DS, Fishman EK, et al. CT of xanthogranulomatous pyelonephritis: radiologic-pathologic correlation. *AJR Am J Roentgenol*. 1984;142(5):963–969.

Goldmann DA, Hopkins CC, Karchmer AW, et al. Cephalothin prophylaxis in cardiac valve surgery. A prospective, double-blind comparison of two-day and six-day regimens. *J Thorac Cardiovasc Surg*. 1977;73:470–479.

Golebiewska J, Debska-Slizien A, Komarnicka J, et al. Urinary tract infections in renal transplant recipients. *Transplant Proc*. 2011;43(8):2985–2990.

Goodman M, Curry T, Russell T. Xanthogranulomatous pyelonephritis (XGP): a local disease with systemic manifestations. Report of 23 patients and review of the literature. *Medicine (Baltimore)*. 1979;58(2):171–181.

Goransson M, Uhlin BE. Environmental temperature regulates transcription of a virulence pili operon in *E. coli*. *EMBO J*. 1984;3:2885–2888.

Gorbach SL, Bartlett JG. Anaerobic infections (second of three parts). *N Engl J Med*. 1974;290(22):1237–1245.

Gould IM. Controversies in infection: infection control or antibiotic stewardship to control healthcare-acquired infection? *J Hosp Infect*. 2009;73(4):386–391.

Gower PE. A prospective study of patients with radiological pyelonephritis, papillary necrosis and obstructive atrophy. *Q J Med*. 1976;45(178):315–349.

Grabe M, Bartoletti R, Bjerklund Johansen TE, et al. *Guidelines on urological infections*. [(website):] https://uroweb.org/wp-content/uploads/19-Urological-infections_LR2.pdf; 2015.

Grainger RG, Longstaff AJ, Parsons MA. Xanthogranulomatous pyelonephritis: a reappraisal. *Lancet*. 1982;1(8286):1398–1401.

Grayson DE, Abbott RM, Levy AD, et al. Emphysematous infections of the abdomen and pelvis: a pictorial review. *Radiographics*. 2002;22(3):543–561.

Greene BL. Physical therapist management of fluoroquinolone-induced Achilles tendinopathy. *Phys Ther*. 2002;82(12):1224–1231.

Gregg CR, Rogers TE, Munford RS. Xanthogranulomatous pyelonephritis. *Curr Clin Top Infect Dis*. 1999;19:287–304.

Gregg JR, et al. Recent antibiotic treatment increases the risk of urinary tract infection after outpatient cystoscopy. *Urol Pract*. 2015;3:90.

Gregg JR, Bhalla RG, Cook JP, et al. An evidence-based protocol for antibiotic use prior to cystoscopy decreases antibiotic use without impacting post-procedural symptomatic urinary tract infection rates. *J Urol*. 2018;199(4):1004–1010.

Grieco MH. Use of antibiotics in the elderly. *Bull N Y Acad Med*. 1980;56:197–208.

Grupper M, Kravtsov A, Potasman I. Emphysematous cystitis: illustrative case report and review of the literature. *Medicine (Baltimore)*. 2007;86(1):47–53.

Gupta K, Hooton TM, Naber KG, et al. International clinical practice guidelines for the treatment of acute uncomplicated cystitis and pyelonephritis in women: a 2010 update by the Infectious Diseases Society of America and the European Society for Microbiology and Infectious Diseases. *Clin Infect Dis*. 2011;52(5):e103–e120.

Gupta K, Hooton TM, Roberts PL, et al. Patient-initiated treatment of uncomplicated recurrent urinary tract infections in young women. *Ann Intern Med*. 2001;135(1):9–16.

Gupta K, Hooton TM, Stamm WE. Increasing antimicrobial resistance and the management of uncomplicated community-acquired urinary tract infections. *Ann Intern Med*. 2001;135(1):41–50.

Guttmann D. Follow-up of urinary tract infection in domiciliary patients. Brumfitt W, Asscher A. *Urinary tract infection*. Oxford University Press: London; 1973:62.

Guzzo TJ, Bivalacqua TJ, Pierorazio PM, et al. Xanthogranulomatous pyelonephritis: presentation and management in the era of laparoscopy. *BJU Int*. 2009;104(9):1265–1268.

Hagberg L, Engberg I, Freter R, et al. Ascending, unobstructed urinary tract infection in mice caused by pyelonephritogenic *Escherichia coli* of human origin. *Infect Immun*. 1983;40:273–283.

Hagberg L, Hull R, Hull S, et al. Contribution of adhesion to bacterial persistence in the mouse urinary tract. *Infect Immun*. 1983;40(1):265–272.

Haley RW, Hooton TM, Culver DH, et al. Nosocomial infections in U.S. hospitals, 1975-1976: estimated frequency by selected characteristics of patients. *Am J Med*. 1981;70:947–959.

Han XY, Andrade RA. *Brevundimonas diminuta* infections and its resistance to fluoroquinolones. *J Antimicrob Chemother*. 2005;55:853–859.

Handley MA, Reingold AL, Shiboski S, et al. Incidence of acute urinary tract infection in young women and use of male condoms with and without nonoxynol-9 spermicides. *Epidemiology*. 2002;13(4):431–436.

Harbord RB, Gruneberg RN. Treatment of urinary tract infection with a single dose of amoxycillin, co-trimoxazole, or trimethoprim. *Br Med J (Clin Res Ed)*. 1981;283(6302):1301–1302.

Harding GK, Nicolle LE, Ronald AR, et al. How long should catheter-acquired urinary tract infection in women be treated? A randomized controlled study. *Ann Intern Med*. 1991;114:713–719.

Harding GK, Ronald AR. A controlled study of antimicrobial prophylaxis of recurrent urinary infection in women. *N Engl J Med*. 1974;291(12):597–601.

Harmanli O, Boyer RL, Metz S, et al. Double-blinded randomized trial of preoperative antibiotics in midurethral sling procedures and review of the literature. *Int Urogynecol J*. 2011;22(10):1249–1253.

Harmanli O, Hong EK, Rubin R, et al. Is antibiotic prophylaxis necessary for midurethral sling procedures? A series of 174 cases without preoperative antibiotics. *Int Urogynecol J*. 2012;23(5):621–623.

Harrison WO, Holmes KK, Belding ME. A prospective evaluation of recurrent urinary tract infection in women. *Clin Res*. 1974;22:125A.

Hartman DS, Davis CJ Jr, Goldman SM, et al. Xanthogranulomatous pyelonephritis: sonographic–pathologic correlation of 16 cases. *J Ultrasound Med*. 1984;3(11):481–488.

Hartman DS, Davis CJ Jr, Lichtenstein JE, et al. Renal parenchymal malacoplakia. *Radiology*. 1980;136(1):33–42.

Hartman DS. Radiologic pathologic correlation of the infectious granulomatous diseases of the kidney. III and IV. *Monogr Urol*. 1985;6:26.

Hartstein AI, Garber SB, Ward TT, et al. Nosocomial urinary tract infection: a prospective evaluation of 108 catheterized patients. *Infect Control*. 1981;2:380–386.

Hawes S, Whigham T, Ehrmann S, et al. Emphysematous pyelonephritis. *Infect Surg*. 1983;2:191.

Heineman HS, Lee JH. Bacteriuria in pregnancy. A heterogeneous entity. *Obstet Gynecol*. 1973;41:22–26.

Heptinstall R. *Pathology of the kidney*. Little, Brown.: Boston; 1974.

Hernandez GV, King AS, Needle MA. Nephrosis and papillary necrosis after pyelonephritis. *N Engl J Med*. 1975;293(26):1347–1349.

Herr HW. Should antibiotics be given prior to outpatient cystoscopy? A plea to urologists to practice antibiotic stewardship. *Eur Urol*. 2014;65(4):839–842.

Higgins A, Garg T. Aerococcus urinae: an emerging cause of urinary tract infection in older adults with multimorbidity and urologic cancer. *Urol Case Rep*. 2017;13:24–25.

Hilt EE, McKinley K, Pearce MM, et al. Urine is not sterile: use of enhanced urine culture techniques to detect resident bacterial flora in the adult female bladder. *J Clin Microbiol*. 2014;52(3):871–876.

Ho HS, Ng LG, Tan YH, et al. Intramuscular gentamicin improves the efficacy of ciprofloxacin as an antibiotic prophylaxis for transrectal prostate biopsy. *Ann Acad Med Singapore*. 2009;38:212–216.

Hodson CJ, Edwards D. Chronic pyelonephritis and vesico-ureteric reflex. *Clin Radiol*. 1960;11:219–231.

Hodson CJ, Wilson S. Natural history of chronic pyelonephritic scarring. *Br Med J*. 1965;2(5455):191–194.

Hodson CJ. Coarse pyelonephritic scarring or ‘atrophic pyelonephritis’. *Proc R Soc Med*. 1965;58(10):785–788.

Hoffman JC, Schnur MJ, Koenigsberg M. Demonstration of renal papillary necrosis by sonography. *Radiology*. 1982;145(3):785–787.

Hollyer I, Ison MG. The challenge of urinary tract infections in renal transplant recipients. *Transpl Infect Dis*. 2017.

Honey RJ, Ordon M, Ghiculete D, et al. A prospective study examining the incidence of bacteriuria and urinary tract infection after shock wave lithotripsy with targeted antibiotic prophylaxis. *J Urol*. 2013;189(6):2112–2117.

Hootkins R, Fenves AZ, Stephens MK. Acute renal failure secondary to oral ciprofloxacin therapy: a presentation of three cases and a review of the literature. *Clin Nephrol*. 1989;32(2):75–78.

Hooton TM, Roberts PL, Cox ME, et al. Voided midstream urine culture and acute cystitis in premenopausal women. *N Engl J Med*. 2013;369(20):1883–1891.

Hooton TM, Scholes D, Hughes JP, et al. A prospective study of risk factors for symptomatic urinary tract infection in young women. *N Engl J Med*. 1996;335(7):468–474.

Hooton TM, Scholes D, Stapleton AE, et al. A prospective study of asymptomatic bacteriuria in sexually active young women. *N Engl J Med*. 2000;343(14):992–997.

Hooton TM, Stamm WE. Management of acute uncomplicated urinary tract infection in adults. *Med Clin North Am*. 1991;75:339–357.

Hooton TM, Vecchio M, Iroz A, et al. Effect of increased daily water intake in premenopausal women with recurrent urinary tract infections: a randomized clinical trial. *JAMA Intern Med*. 2018;178(11):1509–1515.

Hooton TM, Winter C, Tiu F, et al. Association of acute cystitis with the stage of the menstrual cycle in young women. *Clin Infect Dis*. 1996;23(3):635–636.

Hooton TM. Clinical practice. Uncomplicated urinary tract infection. *N Engl J Med*. 2012;366(11):1028–1037.

Hopkins WJ, Elkahwaji J, Beierle LM, et al. Vaginal mucosal vaccine for recurrent urinary tract infections in women: results of a phase 2 clinical trial. *J Urol*. 2007;177(4):1349–

1353 [quiz 1591].

Hotchkiss RS, Karl IE. The pathophysiology and treatment of sepsis. *N Engl J Med*. 2003;348(2):138–150.

Hoverman IV, Gentry LO, Jones DW, et al. Intrarenal abscess. Report of 14 cases. *Arch Intern Med*. 1980;140:914–916.

Howell AB, Botto H, Combescure C, et al. Dosage effect on uropathogenic Escherichia coli anti-adhesion activity in urine following consumption of cranberry powder standardized for proanthocyanidin content: a multicentric randomized double blind study. *BMC Infect Dis*. 2010;10:94.

Huang JJ, Tseng CC. Emphysematous pyelonephritis: clinicoradiological classification, management, prognosis, and pathogenesis. *Arch Intern Med*. 2000;160:797–805.

Huland H, Busch R. Chronic pyelonephritis as a cause of end stage renal disease. *J Urol*. 1982;127:642–643.

Hull R, Rudy D, Donovan W, et al. Urinary tract infection prophylaxis using *Escherichia coli* 83972 in spinal cord injured patients. *J Urol*. 2000;163:872–877.

Hultgren SJ, Porter TN, Schaeffer AJ, et al. Role of type 1 pili and effects of phase variation on lower urinary tract infections produced by *Escherichia coli*. *Infect Immun*. 1985;50:370–377.

Hultgren SJ, Schwan WR, Schaeffer AJ, et al. Regulation of production of type 1 pili among urinary tract isolates of Escherichia coli. *Infect Immun*. 1986;54(3):613–620.

Hung CH, Liou JD, Yan MY, et al. Immediate percutaneous drainage compared with surgical drainage of renal abscess. *Int Urol Nephrol*. 2007;39(1):51–55.

Hunstad DA, Justice SS, Hung CS, et al. Suppression of bladder epithelial cytokine responses by uropathogenic Escherichia coli. *Infect Immun*. 2005;73(7):3999–4006.

Iravani A. Advances in the understanding and treatment of urinary tract infections in young women. *Urology*.

1991;37(6):503–511.

Ishitoya S, Yamamoto S, Mitsumori K, et al. Non-secretor status is associated with female acute uncomplicated pyelonephritis. *BJU Int*. 2002;89(9):851–854.

Ispahani P, Pearson NJ, Greenwood D. An analysis of community and hospital-acquired bacteraemia in a large teaching hospital in the United Kingdom. *Q J Med*. 1987;63(241):427–440.

Itokazu GS, Quinn JP, Bell-Dixon C, et al. Antimicrobial resistance rates among aerobic gram-negative bacilli recovered from patients in intensive care units: evaluation of a national postmarketing surveillance program. *Clin Infect Dis*. 1996;23(4):779–784.

Iwahi T, Abe Y, Nakao M, et al. Role of type 1 fimbriae in the pathogenesis of ascending urinary tract infection induced by escherichia coli in mice. *Infect Immun*. 1983;39(3):1307–1315.

Jackson B, Kirkland JA, Lawrence JR, et al. Urine cytology findings in analgesic nephropathy. *J Urol*. 1978;120:145–147.

Jackson G, Arana-Sialer J, Andersen BR, et al. Profiles of pyelonephritis. *Arch Intern Med*. 1962;110:63–75.

Jacoby GA. AmpC beta-lactamases. *Clin Microbiol Rev*. 2009;22(1):161–182 [Table of Contents].

James PA, Cowan TM, Graham RP. Patient-centered clinical decisions and their impact on physician adherence to clinical guidelines. *J Fam Pract*. 1998;46(4):311–318.

Jameson RM, Heal MR. The surgical management of acute renal papillary necrosis. *Br J Surg*. 1973;60:428–430.

Jamieson NV, Everett WG, Bullock KN. Delayed recognition of an intersphincteric abscess as the underlying cause of Fournier's scrotal gangrene. *Ann R Coll Surg Engl*. 1984;66:434–435.

Jepson RG, Craig JC. Cranberries for preventing urinary tract infections. *Cochrane Database Syst Rev*. 2008;(1) [CD001321].

Jepson RG, Williams G, Craig JC. Cranberries for preventing urinary tract infections. *Cochrane Database Syst Rev*. 2012;(10) [CD001321].

Johnson JR, Jelacic S, Schoening LM, et al. The IrgA homologue adhesin Iha is an Escherichia coli virulence factor in murine urinary tract infection. *Infect Immun*. 2005;73(2):965–971.

Johnson JR, Johnston B, Clabots C, et al. *Escherichia coli* sequence type ST131 as the major cause of serious multidrug-resistant *E. coli* infections in the United States. *Clin Infect Dis*. 2010;51:286–294.

Johnson JR, O'Bryan TT, Delavari P, et al. Clonal relationships and extended virulence genotypes among *Escherichia coli* isolates from women with a first or recurrent episode of cystitis. *J Infect Dis*. 2001;183:1508–1517.

Johnson JR, Stamm WE. Urinary tract infections in women: diagnosis and treatment. *Ann Intern Med*. 1989;111(11):906–917.

Johnson JR, Weissman SJ, Stell AL, et al. Clonal and pathotypic analysis of archetypal Escherichia coli cystitis isolate NU14. *J Infect Dis*. 2001;184(12):1556–1565.

Johnson MI, Merrilees D, Robson WA, et al. Oral ciprofloxacin or trimethoprim reduces bacteriuria after flexible cystoscopy. *BJU Int*. 2007;100:826–829.

Johnsson KM, Ptaszynska A, Schmitz B, et al. Urinary tract infections in patients with diabetes treated with dapagliflozin. *J Diabetes Complications*. 2013;27(5):473–478.

Jones CH, Pinkner JS, Roth R, et al. FimH adhesin of type 1 pili is assembled into a fibrillar tip structure in the Enterobacteriaceae. *Proc Natl Acad Sci USA*. 1995;92:2081–2085.

Jordan PA, Iravani A, Richard GA, et al. Urinary tract infection caused by *Staphylococcus saprophyticus*. *J Infect Dis*. 1980;142:510–515.

Josephson S, Thomason J, Sturino K, et al. Gardnerella vaginalis in the urinary tract: incidence and significance in a hospital population. *Obstet Gynecol*. 1988;71(2):245–250.

Juhasz J, Galambos J, Surjan L Jr. Renal actinomycosis associated with bilateral necrosing renal papillitis. *Int Urol Nephrol*. 1980;12:199–203.

Justice SS, Hung C, Theriot JA, et al. Differentiation and developmental pathways of uropathogenic *Escherichia coli* in urinary tract pathogenesis. *Proc Natl Acad Sci USA*. 2004;101:1333–1338.

Juthani-Mehta M, Van Ness PH, Bianco L, et al. Effect of cranberry capsules on bacteriuria plus pyuria among older women in nursing homes: a randomized clinical trial. *J Am Med Assoc*. 2016;316(18):1879–1887.

Kaijser B, Hanson LA, Jodal U, et al. Frequency of *E. coli* K antigens in urinary-tract infections in children. *Lancet*. 1977;1:663–666.

Kallenius G, Mollby R, Svenson S. Adhesion of *Escherichia coli* to human periurethral cells correlated to mannose-resistant agglutination of human erythrocytes. *FEMS Microbiol Lett*. 1979;5:295–299.

Kallenius G, Mollby R, Svenson S. The Pk antigen as receptor for the haemagglutinin of pyelonephritic *Escherichia coli*. *FEMS Microbiol Lett*. 1980;7:297.

Kallenius G, Mollby R, Svenson SB, et al. Occurrence of P-fimbriated *Escherichia coli* in urinary tract infections. *Lancet*. 1981;2(8260–61):1369–1372.

Kaplan DM, Rosenfield AT, Smith RC. Advances in the imaging of renal infection. Helical CT and modern coordinated imaging. *Infect Dis Clin North Am*. 1997;11:681–

705.

Kapoor DA, Klimberg IW, Malek GH, et al. Single-dose oral ciprofloxacin versus placebo for prophylaxis during transrectal prostate biopsy. *Urology*. 1998;52:552–558.

Kapoor R, Vijjan V, Singh K, et al. Is laparoscopic nephrectomy the preferred approach in xanthogranulomatous pyelonephritis? *Urology*. 2006;68(5):952–955.

Karlowsky JA, Hoban DJ, Decorby MR, et al. Fluoroquinolone-resistant urinary isolates of *Escherichia coli* from outpatients are frequently multidrug resistant: results from the North American Urinary Tract Infection Collaborative Alliance-Quinolone Resistance study. *Antimicrob Agents Chemother*. 2006;50:2251–2254.

Kass EH. Asymptomatic infections of the urinary tract. *Trans Assoc Am Physicians*. 1956;69:56–64.

Kaul AK, Khan S, Martens MG, et al. Experimental gestational pyelonephritis induces preterm births and low birth weights in C3H/HeJ mice. *Infect Immun*. 1999;67:5958–5966.

Kayalp D, Dogan K, Ceylan G, et al. Can routine automated urinalysis reduce culture requests? *Clin Biochem*. 2013;46(13–14):1285–1289.

Kaye D. Antibacterial activity of human urine. *J Clin Invest*. 1968;47(10):2374–2390.

Kearney GP, Carling PC. Fournier's gangrene: an approach to its management. *J Urol*. 1983;130:695–698.

Kehinde EO, Al-Maghrebi M, Sheikh M, et al. Combined ciprofloxacin and amikacin prophylaxis in the prevention of septicemia after transrectal ultrasound guided biopsy of the prostate. *J Urol*. 2013;189:911–915.

Kehinde EO, Rotimi VO, Al-Hunayan A, et al. Bacteriology of urinary tract infection associated with indwelling J ureteral stents. *J Endourol*. 2004;18(9):891–896.

Kennedy RP, Plorde JJ, Petersdorf RG. Studies on the epidemiology of *Escherichia coli* infections. IV. Evidence for a nosocomial flora. *J Clin Invest*. 1965;44:193–201.

Khalyl-Mawad J, Greco MA, Schinella RA. Ultrastructural demonstration of intracellular bacteria in xanthogranulomatous pyelonephritis. *Hum Pathol*. 1982;13:41–47.

Khoruts A, Dicksved J, Jansson JK, et al. Changes in the composition of the human fecal microbiome after bacteriotherapy for recurrent Clostridium difficile-associated diarrhea. *J Clin Gastroenterol*. 2010;44(5):354–360.

Kincaid-Smith P, Bullen M. Bacteriuria in pregnancy. *Lancet*. 1965;1:395–399.

Kincaid-Smith P. Management of renal and urinary tract disorders during pregnancy. Harrison J, Gittes R, Pearlmutter A, et al. *Campbell's urology*. Saunders: Philadelphia; 1978:25–28.

Kisielius PV, Schwan WR, Amundsen SK, et al. In vivo expression and variation of *Escherichia coli* type 1 and P pili in the urine of adults with acute urinary tract infections. *Infect Immun*. 1989;57:1656–1662.

Kitchel B, Rasheed JK, Patel JB, et al. Molecular epidemiology of KPC-producing Klebsiella pneumoniae isolates in the United States: clonal expansion of multilocus sequence type 258. *Antimicrob Agents Chemother*. 2009;53(8):3365–3370.

Klemm P, Hancock V, Schembri MA. Mellowing out: adaptation to commensalism by Escherichia coli asymptomatic bacteriuria strain 83972. *Infect Immun*. 2007;75(8):3688–3695.

Klemm P. Fimbrial adhesions of *Escherichia coli*. *Rev Infect Dis*. 1985;7:321–340.

Klumpp DJ, Weiser AC, Sengupta S, et al. Uropathogenic *Escherichia coli* potentiates type 1 pilus-induced apoptosis by suppressing NF-kappaB. *Infect Immun*. 2001;69:6689–6695.

Kluytmans J. Surgical infections including burns. Wenzel R. *Prevention and control of nosocomial infections*. 3rd ed. Williams & Wilkins: Baltimore; 1997:841–865.

Knopf HJ, Graff HJ, Schulze H. Perioperative antibiotic prophylaxis in ureteroscopic stone removal. *Eur Urol*. 2003;44:115–118.

Ko MC, Chiu AW, Liu CC, et al. Effect of diabetes on mortality and length of hospital stay in patients with renal or perinephric abscess. *Clinics (Sao Paulo)*. 2013;68(8):1109–1114.

Ko MC, Liu CC, Liu CK, et al. Incidence of renal and perinephric abscess in diabetic patients: a population-based national study. *Epidemiol Infect*. 2011;139(2):229–235.

Kontiokari T, Sundqvist K, Nuutinen M, et al. Randomised trial of cranberry-lingonberry juice and *Lactobacillus* GG drink for the prevention of urinary tract infections in women. *BMJ*. 2001;322:1571.

Korets R, Graversen JA, Kates M, et al. Post-percutaneous nephrolithotomy systemic inflammatory response: a prospective analysis of preoperative urine, renal pelvic urine and stone cultures. *J Urol*. 2011;186(5):1899–1903.

Korkes F, Favoretto RL, Broglio M, et al. Xanthogranulomatous pyelonephritis: clinical experience with 41 cases. *Urology*. 2008;71:178–180.

Kraft JK, Stamey TA. The natural history of symptomatic recurrent bacteriuria in women. *Medicine (Baltimore)*. 1977;56:55–60.

Kranjcec B, Papes D, Altarac S. D-mannose powder for prophylaxis of recurrent urinary tract infections in women: a randomized clinical trial. *World J Urol*. 2014;32(1):79–84.

Kreger BE, Craven DE, Carling PC, et al. Gram-negative bacteremia. III. Reassessment of etiology, epidemiology and ecology in 612 patients. *Am J Med*. 1980;68:332–343.

Krieger JN, Ross SO, Simonsen JM. Urinary tract infections in healthy university men. *J Urol*. 1993;149(5):1046–1048.

Kudinha T, Johnson JR, Andrew SD, et al. *Escherichia coli* sequence type 131 as a prominent cause of antibiotic resistance among urinary *Escherichia coli* isolates from reproductive-age women. *J Clin Microbiol*. 2013;51:3270–3276.

Kuhn JP, Berger PE. Computed tomography of the kidney in infancy and childhood. *Radiol Clin North Am*. 1981;19:445–461.

Kumar S, Muchmore A. Tamm-Horsfall protein—uromodulin (1950-1990). *Kidney Int*. 1990;37:1395–1401.

Kunin CM, Chin QF, Chambers S. Morbidity and mortality associated with indwelling urinary catheters in elderly patients in a nursing home—confounding due to the presence of associated diseases. *J Am Geriatr Soc*. 1987;35:1001–1006.

Kunin CM, Douthitt S, Dancing J, et al. The association between the use of urinary catheters and morbidity and mortality among elderly patients in nursing homes. *Am J Epidemiol*. 1992;135:291–301.

Kunin CM, McCormack RC. An epidemiologic study of bacteriuria and blood pressure among nuns and working women. *N Engl J Med*. 1968;278(12):635–642.

Kunin CM. *Detection, prevention and management of urinary tract infections*. 4th ed. Lea & Febiger: Philadelphia; 1987.

Kunin CM. The quantitative significance of bacteria visualized in the unstained urinary sediment. *N Engl J Med*. 1961;265:589–590.

Kunin CM. Use of antimicrobial agents in treating urinary tract infection. *Adv Nephrol Necker Hosp*. 1985;14:39–65.

Kunin CM. Urinary tract infections in females. *Clin Infect Dis*. 1994;18(1):1–10 [quiz 11–12].

Kunz HH, Sieberth HG, Freiberg J, et al. The value of suprapubic bladder aspiration in the diagnosis of bacteriuria (author's transl). *Dtsch Med Wochenschr*. 1975;100:2252–2256 [2261–2264].

Kuo CY, Lin CY, Chen TC, et al. Clinical features and prognostic factors of emphysematous urinary tract infection. *J Microbiol Immunol Infect*. 2009;42(5):393–400.

Kushner B, Allen PD, Crane BT. Frequency and demographics of gentamicin use. *Otol Neurotol*. 2016;37(2):190–195.

Lamb MJ, Baillie L, Pajak D, et al. Elimination of screening urine cultures prior to elective joint arthroplasty. *Clin Infect Dis*. 2017;64(6):806–809.

Lange D, Zappavigna C, Hamidizadeh R, et al. Bacterial sepsis after prostate biopsy—a new perspective. *Urology*. 2009;74:1200–1205.

Langermann S, Palaszynski S, Barnhart M, et al. Prevention of mucosal *Escherichia coli* infection by FimH-adhesin-based systemic vaccination. *Science*. 1997;276:607–611.

Lapides J, Diokno AC, Silber SJ, et al. Clean, intermittent self-catheterization in the treatment of urinary tract disease. *J Urol*. 1972;107:458–461.

Latham RH, Running K, Stamm WE. Urinary tract infections in young adult women caused by *Staphylococcus saprophyticus*. *JAMA*. 1983;250:3063–3066.

Latham RH, Wong ES, Larson A, et al. Laboratory diagnosis of urinary tract infection in ambulatory women. *J Am Med Assoc*. 1985;254:3333–3336.

Latthe PM, Foon R, Toozs-Hobson P. Prophylactic antibiotics in urodynamics: a systematic review of effectiveness and safety. *Neurourol Urodyn*. 2008;27(3):167–173.

Lawrentschuk N, Ooi J, Pang A, et al. Cystoscopy in women with recurrent urinary tract infection. *Int J Urol*. 2006;13(4):350–353.

Le Ray I, Dell'Aniello S, Bonnetain F, et al. Local estrogen therapy and risk of breast cancer recurrence among hormone-treated patients: a nested case-control study. *Breast Cancer Res Treat*. 2012;135(2):603–609.

Le Trong I, Aprikian P, Kidd BA, et al. Structural basis for mechanical force regulation of the adhesin FimH via finger trap-like beta sheet twisting. *Cell*. 2010;141:645–655.

Leatham-Jensen MP, Mokszycki ME, Rowley DC, et al. Uropathogenic Escherichia coli metabolite-dependent quiescence and persistence may explain antibiotic tolerance during urinary tract infection. *mSphere*. 2016;1(1).

Lee BS, Bhuta T, Simpson JM, et al. Methenamine hippurate for preventing urinary tract infections. *Cochrane Database Syst Rev*. 2012;(10) [CD003265].

Lee J, Patel G, Huprikar S, et al. Decreased susceptibility to polymyxin B during treatment for carbapenem-resistant Klebsiella pneumoniae infection. *J Clin Microbiol*. 2009;47(5):1611–1612.

Lee JK, McClennan BL, Melson GL, et al. Acute focal bacterial nephritis: emphasis on gray scale sonography and computed tomography. *AJR Am J Roentgenol*. 1980;135:87–92.

Lee SH, Jung HJ, Mah SY, et al. Renal abscesses measuring 5 cm or less: outcome of medical treatment without therapeutic drainage. *Yonsei Med J*. 2010;51:569–573.

Leffler H, Svanborg-Eden C. Chemical identification of glycosphingolipid receptor for *Escherichia coli* attaching to human urinary tract epithelial cells and agglutinating erythrocytes. *FEMS Microbiol Lett*. 1980;8:127–134.

Leibovici L, Greenshtain S, Cohen O, et al. Toward improved empiric management of moderate to severe urinary tract infections. *Arch Intern Med*. 1992;152:2481–2486.

Lessa FC, Mu Y, Bamberg WM, et al. Burden of Clostridium difficile infection in the United States. *N Engl J Med*.

2015;372(9):825–834.

Lethaby A, Ayeleke RO, Roberts H. Local oestrogen for vaginal atrophy in postmenopausal women. *Cochrane Database Syst Rev*. 2016;(8) [CD001500].

Levin R, Burbige KA, Abramson S, et al. The diagnosis and management of renal inflammatory processes in children. *J Urol*. 1984;132:718–721.

Levy MM, Fink MP, Marshall JC, et al. 2001 SCCM/ESICM/ACCP/ATS/SIS International Sepsis Definitions Conference. *Crit Care Med*. 2003;31:1250–1256.

Lewin KJ, Fair WR, Steigbigel RT, et al. Clinical and laboratory studies into the pathogenesis of malacoplakia. *J Clin Pathol*. 1976;29(4):354–363.

Lewis DA, Brown R, Williams J, et al. The human urinary microbiome; bacterial DNA in voided urine of asymptomatic adults. *Front Cell Infect Microbiol*. 2013;3:41.

Licker M, Sorescu T, Rus M, et al. Extensively drug-resistant Myroides odoratimimus - a case series of urinary tract infections in immunocompromised patients. *Infect Drug Resist*. 2018;11:743–749.

Lin K, Fajardo K, U.S. Preventive Services Task Force. Screening for asymptomatic bacteriuria in adults: evidence for the U.S. Preventive Services Task Force reaffirmation recommendation statement. *Ann Intern Med*. 2008;149(1):W20–W24.

Lindner LE, Jones RN, Haber MH. A specific urinary cast in acute pyelonephritis. *Am J Clin Pathol*. 1980;73:809–811.

Lindvall N. Radiological changes of renal papillary necrosis. *Kidney Int*. 1978;13:93–106.

Linhares I, Raposo T, Rodrigues A, et al. Frequency and antimicrobial resistance patterns of bacteria implicated in community urinary tract infections: a ten-year surveillance study (2000-2009). *BMC Infect Dis*. 2013;13:19.

Lipsky BA, Inui TS, Plorde JJ, et al. Is the clean-catch midstream void procedure necessary for obtaining urine culture specimens from men? *Am J Med*. 1984;76(2):257–262.

Lipsky BA. Urinary tract infections in men. Epidemiology, pathophysiology, diagnosis, and treatment. *Ann Intern Med*. 1989;110:138–150.

Lipsky MJ, Sayegh C, Theofanides MC, et al. Preoperative antibiotics before bladder biopsy: are they necessary? *Urology*. 2017;110:121–126.

Liss MA, Chang A, Santos R, et al. Prevalence and significance of fluoroquinolone resistant *Escherichia coli* in patients undergoing transrectal ultrasound guided prostate needle biopsy. *J Urol*. 2011;185:1283–1288.

Liss MA, Ehdaie B, Loeb S, et al. An update of the American Urological Association White Paper on the Prevention and Treatment of the More Common Complications Related to Prostate Biopsy. *J Urol*. 2017;198(2):329–334.

Liss MA, Johnson JR, Porter SB, et al. Clinical and microbiological determinants of infection after transrectal prostate biopsy. *Clin Infect Dis*. 2015;60(7):979–987.

Liss MA, Kim W, Moskowitz D, et al. Comparative effectiveness of targeted vs empirical antibiotic prophylaxis to prevent sepsis from transrectal prostate biopsy: a retrospective analysis. *J Urol*. 2015;194(2):397–402.

Liss MA, Peterson EM, Johnston B, et al. Prevalence of ST131 among fluoroquinolone-resistant *Escherichia coli* obtained from rectal swabs before transrectal prostate biopsy. *Urology*. 2013;81:548–555.

Little P, Turner S, Rumsby K, et al. Dipsticks and diagnostic algorithms in urinary tract infection: development and validation, randomised trial, economic analysis, observational cohort and qualitative study. *Health Technol Assess*.

2009;13(19):iii–iv [ix–xi, 1–73].

Ljungh A, Wadstrom T. Fimbriation of Escherichia coli in urinary tract infections: comparisons between bacteria in the urine and subcultured bacterial isolates. *Current Microbiol*. 1983;8:263.

Lo TS, Hammer KD, Zegarra M, et al. Methenamine: a forgotten drug for preventing recurrent urinary tract infection in a multidrug resistance era. *Expert Rev Anti Infect Ther*. 2014;12(5):549–554.

Loeb S, Carter HB, Berndt SI, et al. Complications after prostate biopsy: data from SEER-Medicare. *J Urol*. 2011;186(5):1830–1834.

Lojanapiwat B. Colonization of internal ureteral stent and bacteriuria. *World J Urol*. 2006;24(6):681–683.

Lomberg H, Hanson LA, Jacobsson B, et al. Correlation of P blood group, vesicoureteral reflux, and bacterial attachment in patients with recurrent pyelonephritis. *N Engl J Med*. 1983;308:1189–1192.

Long E, Vince J. Evidence behind the WHO guidelines: hospital care for children: what are appropriate methods of urine collection in UTI? *J Trop Pediatr*. 2007;53(4):221–224.

Lorentzen M, Nielsen HO. Xanthogranulomatous pyelonephritis. *Scand J Urol Nephrol*. 1980;14:193–200.

Lu Y, Tianyong F, Ping H, et al. Antibiotic prophylaxis for shock wave lithotripsy in patients with sterile urine before treatment may be unnecessary: a systematic review and meta-analysis. *J Urol*. 2012;188(2):441–448.

Lu YC, Chiang BJ, Pong YH, et al. Emphysematous pyelonephritis: clinical characteristics and prognostic factors. *Int J Urol*. 2014;21(3):277–282.

Luis A, Domingues F, Pereira L. Can cranberries contribute to reduce the incidence of urinary tract infections? A systematic review with meta-analysis and trial sequential analysis of clinical trials. *J Urol*. 2017;198(3):614–621.

Lusardi G, Lipp A, Shaw C. Antibiotic prophylaxis for short-term catheter bladder drainage in adults. *Cochrane Database Syst Rev*. 2013;(7) [CD005428].

Lutters M, Vogt-Ferrier NB. Antibiotic duration for treating uncomplicated, symptomatic lower urinary tract infections in elderly women. *Cochrane Database Syst Rev*. 2008;(3) [CD001535].

Lyons RW, Long JM, Lytton B, et al. Arteriography and antibiotic therapy of a renal carbuncle. *J Urol*. 1972;107:524–526.

Lyytinen H, Pukkala E, Ylikorkala O. Breast cancer risk in postmenopausal women using estrogen-only therapy. *Obstet Gynecol*. 2006;108(6):1354–1360.

Mabeck CE. Treatment of uncomplicated urinary tract infection in non-pregnant women. *Postgrad Med J*. 1972;48:69–75.

MacDermott JP, Ewing RE, Somerville JF, et al. Cephradine prophylaxis in transurethral procedures for carcinoma of the bladder. *Br J Urol*. 1988;62(2):136–139.

MacDonald P, Alexander D, Catz C, et al. Summary of a workshop on maternal genitourinary infections and the outcome of pregnancy. *J Infect Dis*. 1983;147:596–605.

MacDonald TM, Beardon PH, McGilchrist MM, et al. The risks of symptomatic vaginal candidiasis after oral antibiotic therapy. *Q J Med*. 1993;86(7):419–424.

Macrea LE. Fulminant gangrene of the penis. *Clinic*. 1945;4:796–829.

Maderazo EG, Berlin BB, Morhardt C. Treatment of malakoplakia with trimethoprim-sulfamethoxazole. *Urology*. 1979;13:70–73.

Madge GE, Lombardias S. Chronic liver disease and renal papillary necrosis with *Aspergillus*. *South Med J*. 1973;66:486–488.

Magasi P, Panovics J, Illes A, et al. Uro-Vaxom and the management of recurrent urinary tract infection in adults: a randomized multicenter double-blind trial. *Eur Urol*. 1994;26(2):137–140.

Maizels M, Schaeffer AJ. Decreased incidence of bacteriuria associated with periodic instillations of hydrogen peroxide into the urethral catheter drainage bag. *J Urol*. 1980;123:841–845.

Malek RS, Elder JS. Xanthogranulomatous pyelonephritis: a critical analysis of 26 cases and review of the literature. *J Urol*. 1978;119:589–593.

Malek RS, Greene LF, DeWeerd JH, et al. Xanthogranulomatous pyelonephritis. *Br J Urol*. 1972;44:296–308.

Manges AR, Dietrich PS, Riley LW. Multidrug-resistant *Escherichia coli* clonal groups causing community-acquired pyelonephritis. *Clin Infect Dis*. 2004;38:329–334.

Manges AR, Johnson JR, Foxman B, et al. Widespread distribution of urinary tract infections caused by a multidrug-resistant *Escherichia coli* clonal group. *N Engl J Med*. 2001;345:1007–1013.

Manson AL. Is antibiotic administration indicated after outpatient cystoscopy. *J Urol*. 1988;140:316–317.

Marchant J. When antibiotics turn toxic. *Nature*. 2018;555:431–433.

Mariappan P, Smith G, Bariol SV, et al. Stone and pelvic urine culture and sensitivity are better than bladder urine as predictors of urosepsis following percutaneous nephrolithotomy: a prospective clinical study. *J Urol*. 2005;173(5):1610–1614.

Marques AG, Doi AM, Pasternak J, et al. Performance of the dipstick screening test as a predictor of negative urine culture. *Einstein (Sao Paulo)*. 2017;15(1):34–39.

Marrie TJ, Harding GK, Ronald AR. Anaerobic and aerobic urethral flora in healthy females. *J Clin Microbiol*. 1978;8:67–72.

Marschall J, Carpenter CR, Fowler S, CDC Prevention Epicenters Program, et al. Antibiotic prophylaxis for urinary tract infections after removal of urinary catheter: meta-analysis. *BMJ*. 2013;346 [f3147].

Martens M, Kaul A, Nowicki S, et al. *Presence of receptors for Dr-hemagglutinin of uropathogenic* E. coli *in the uterus of pregnant rats*. [In: Third World Congress for Infectious Diseases in OB/GYN. Acapulco, Mexico] 1993.

Martin GS, Mannino DM, Eaton S, et al. The epidemiology of sepsis in the United States from 1979 through 2000. *N Engl J Med*. 2003;348:1546–1554.

Martinez F, Kindrachuk R, Thomas E, et al. Effect of prophylactic, low dose cephalexin on fecal and vaginal bacteria. *J Urol*. 1985;133:994–996.

Martinez JJ, Hultgren SJ. Requirement of Rho-family GTPases in the invasion of Type 1-piliated uropathogenic *Escherichia coli*. *Cell Microbiol*. 2002;4(1):19–28.

Martorana G, Giberti C, Pescatore D. Giant echinococcal cyst of the kidney associated with hypertension evaluated by computerized tomography. *J Urol*. 1981;126:99–100.

Matuszkiewicz-Rowinska J, Malyszko J, Wieliczko M. Urinary tract infections in pregnancy: old and new unresolved diagnostic and therapeutic problems. *Arch Med Sci*. 2015;11(1):67–77.

Mauro MA, Balfe DM, Stanley RJ, et al. Computed tomography in the diagnosis and management of the renal mass. *J Am Med Assoc*. 1982;248:2894–2896.

McAfee JG. Radionuclide imaging in the assessment of primary chronic pyelonephritis. *Radiology*. 1979;133:203–206.

McCabe WR, Jackson GG. Treatment of pyelonephritis:

bacterial, drug and host factors in success or failure among 252 patients. *N Engl J Med*. 1965;272:137–144.

McClure J. Malakoplakia. *J Pathol*. 1983;140:275–330.

McCoy RI, Kurtz AC, Rifkin MD, et al. Ultrasound detection of focal bacterial nephritis (lobar nephronia) and its evolution into a renal abscess. *Urol Radiol*. 1985;7:109–111.

McCue JD. Urinary tract infection and dysuria. Cost-conscious evaluation and antibiotic therapy. *Postgrad Med*. 1986;80:133–134 [139–142].

McDonald GS. Xanthogranulomatous pyelonephritis. *J Pathol*. 1981;133:203–213.

McFadyen IR, Eykyn SJ, Gardner NH, et al. Bacteriuria in pregnancy. *J Obstet Gynaecol Br Commonw*. 1973;80:385–405.

McMurdo ME, Argo I, Phillips G, et al. Cranberry or trimethoprim for the prevention of recurrent urinary tract infections? A randomized controlled trial in older women. *J Antimicrob Chemother*. 2009;63:389–395.

McMurdo ME, Gillespie ND. Urinary tract infection in old age: over-diagnosed and over-treated. *Age Ageing*. 2000;29:297–298.

McNair R, MacDonald S, Dooley S, et al. Evaluation of the centrifuged and Gram-stained smear, urinalysis, and reagent strip testing to detect asymptomatic bacteriuria in obstetric patients. *Am J Obstet Gynecol*. 2000;182:1076–1079.

Meiland R, Geerlings SE, Hoepelman AI. Management of bacterial urinary tract infections in adult patients with diabetes mellitus. *Drugs*. 2002;62:1859–1868.

Meister L, Morley EJ, Scheer D, et al. History and physical examination plus laboratory testing for the diagnosis of adult female urinary tract infection. *Acad Emerg Med*. 2013;20(7):631–645.

Meleney F. A differential diagnosis between certain types of infectious gangrene of the skin: with particular reference to hemolytic streptococcal gangrene and bacterial synergistic gangrene. *Surg Gynecol Obstet*. 1933;56:847–867.

Mellen CK, Ford M, Rindone JP. Effect of high-dose cranberry juice on the pharmacodynamics of warfarin in patients. *Br J Clin Pharmacol*. 2010;70(1):139–142.

Meng MV, Mario LA, McAninch JW. Current treatment and outcomes of perinephric abscesses. *J Urol*. 2002;168:1337–1340.

Merenich WM, Popky GL. Radiology of renal infection. *Med Clin North Am*. 1991;75:425–469.

Mering JH, Kaplan GW, McLaughlin AP 3rd. Xanthogranulomatous pyelonephritis. Unusual clinical presentations. *Urology*. 1973;1:338–342.

Michaeli J, Mogle P, Perlberg S, et al. Emphysematous pyelonephritis. *J Urol*. 1984;131(2):203–208.

Michaelis L, Gutmann C. Über Einschlüsse in Blasentumoren. *Z Klin Med*. 1902;47:208–215.

Michaelsson K, Baron JA, Farahmand BY, et al. Use of low potency estrogens does not reduce the risk of hip fracture. *Bone*. 2002;30(4):613–618.

Miliszewski MA, Kirchhof MG, Sikora S, et al. Stevens-Johnson Syndrome and toxic epidermal necrolysis: an analysis of triggers and implications for improving prevention. *Am J Med*. 2016;129(11):1221–1225.

Miller JD. The importance of early diagnosis and surgical treatment of necrotizing fasciitis. *Surg Gynecol Obstet*. 1983;157:197–200.

Mims AD, Norman DC, Yamamura RH, et al. Clinically inapparent (asymptomatic) bacteriuria in ambulatory elderly men: epidemiological, clinical, and microbiological findings. *J Am Geriatr Soc*. 1990;38(11):1209–1214.

Mobley HL, Warren JW. Urease-positive bacteriuria and obstruction of long-term urinary catheters. *J Clin Microbiol*. 1987;25:2216–2217.

Mody L, Juthani-Mehta M. Urinary tract infections in older women: a clinical review. *J Am Med Assoc*. 2014;311(8):844–854.

Mollier S, Descotes JL, Pasquier D, et al. Pseudoneoplastic xanthogranulomatous pyelonephritis. A typical clinical presentation but unusual diagnosis and treatment. *Eur Urol*. 1995;27:170–173.

Moreno E, Andreu A, Pigrau C, et al. Relationship between *Escherichia coli* strains causing acute cystitis in women and the fecal *E. coli* population of the host. *J Clin Microbiol*. 2008;46:2529–2534.

Morpurgo E, Galandiuk S. Fournier's gangrene. *Surg Clin North Am*. 2002;82:1213–1224.

Morris MJ, Golovsky D, Guinness MD, et al. The value of prophylactic antibiotics in transurethral prostatic resection: a controlled trial, with observations on the origin of postoperative infection. *Br J Urol*. 1976;48:479–484.

Morton SC, Shekelle PG, Adams JL, et al. Antimicrobial prophylaxis for urinary tract infection in persons with spinal cord dysfunction. *Arch Phys Med Rehabil*. 2002;83:129–138.

Mulvey MA, Lopez-Boado YS, Wilson CL, et al. Induction and evasion of host defenses by type 1-piliated uropathogenic *Escherichia coli*. *Science*. 1998;282:1494–1497.

Mulvey MA, Schilling JD, Hultgren SJ. Establishment of a persistent *Escherichia coli* reservoir during the acute phase of a bladder infection. *Infect Immun*. 2001;69:4572–4579.

Mulvey MA, Schilling JD, Martinez JJ, et al. Bad bugs and beleaguered bladders: interplay between uropathogenic *Escherichia coli* and innate host defenses. *Proc Natl Acad Sci USA*. 2000;97:8829–8835.

Mulvey MA. Adhesion and entry of uropathogenic *Escherichia* *coli*. *Cell Microbiol*. 2002;4:257–271.

Murray T, Goldberg M. Chronic interstitial nephritis: etiologic factors. *Ann Intern Med*. 1975;82:453–459.

Mysorekar IU, Hultgren SJ. Mechanisms of uropathogenic *Escherichia coli* persistence and eradication from the urinary tract. *Proc Natl Acad Sci USA*. 2006;103:14170–14175.

Nabizadeh I, Morehouse HT, Freed SZ. Hydatid disease of kidney. *Urology*. 1983;22:176–178.

Najenson T, Mendelson L, Sabransky H, et al. Upper urinary tract in patients after traumatic spinal cord injury. *Paraplegia*. 1969;7:85–96.

Nakamura Y, Yamamoto N, Kino Y, et al. Establishment of a multi-species biofilm model and metatranscriptomic analysis of biofilm and planktonic cell communities. *Appl Microbiol Biotechnol*. 2016;100(16):7263–7279.

Nam RK, Saskin R, Lee Y, et al. Increasing hospital admission rates for urological complications after transrectal ultrasound guided prostate biopsy. *J Urol*. 2010;183(3):963–968.

Nataluk EA, McCullough DL, Scharling EO. Xanthogranulomatous pyelonephritis, the gatekeeper's dilemma: a contemporary look at an old problem. *Urology*. 1995;45:377–380.

National Institute on Disability and Rehabilitation Research. The prevention and management of urinary tract infections among people with spinal cord injuries. National Institute on Disability and Rehabilitation Research consensus statement. January 27-29, 1992. *SCI Nurs*. 1993;10:49–61.

Neidell MJ, Cohen B, Furuya Y, et al. Costs of healthcare- and community-associated infections with antimicrobial-resistant versus antimicrobial-susceptible organisms. *Clin Infect Dis*. 2012;55(6):807–815.

Nelson DE, Van Der Pol B, Dong Q, et al. Characteristic male urine microbiomes associate with asymptomatic sexually transmitted infection. *PLoS ONE*. 2010;5(11) [e14116].

Newton T, Still JM, Law E. A comparison of the effect of early insertion of standard latex and silver-impregnated latex Foley catheters on urinary tract infections in burn patients. *Infect Control Hosp Epidemiol*. 2002;23:217–218.

Ng CF, Chan SY. Re: the incidence of fluoroquinolone resistant infections after prostate biopsy—are fluoroquinolones still effective prophylaxis? J. Feliciano, E. Teper, M. Ferrandino, R. J. Macchia, W. Blank, I. Grunberger and I. Colon. J urol 2008; 179:952-955. *J Urol*. 2008;180:1570–1571.

Nickel JC, Stephens A, Landis JR, et al. Assessment of the lower urinary tract microbiota during symptom flare in women with urologic chronic pelvic pain syndrome: a MAPP Network study. *J Urol*. 2016;195(2):356–362.

Nicolau D, Freeman C, Belliveau P, et al. Experience with a once-daily aminoglycoside program administered to 2,184 adult patients. *Antimicrob Agents Chemother*. 1995;39:650–655.

Nicolle LE, Bjornson J, Harding GK, et al. Bacteriuria in elderly institutionalized men. *N Engl J Med*. 1983;309:1420–1425.

Nicolle LE, Bradley S, Colgan R, et al. Infectious Diseases Society of America guidelines for the diagnosis and treatment of asymptomatic bacteriuria in adults. *Clin Infect Dis*. 2005;40:643–654.

Nicolle LE, Gupta K, Bradley SF, et al. Clinical practice guideline for the management of asymptomatic bacteriuria: 2019 update by the Infectious Diseases Society of America. *Clin Infect Dis*. 2019;68(10):e83–e110.

Nicolle LE, Harding GK, Thompson M, et al. Prospective, randomized, placebo-controlled trial of norfloxacin for the prophylaxis of recurrent urinary tract infection in women. *Antimicrob Agents Chemother*. 1989;33:1032–1035.

Nicolle LE, Mayhew WJ, Bryan L. Prospective randomized comparison of therapy and no therapy for asymptomatic bacteriuria in institutionalized elderly women. *Am J Med*. 1987;83:27–33.

Nicolle LE. Asymptomatic bacteriuria in the elderly. *Infect Dis Clin North Am*. 1997;11:647–662.

Nicolle LE. Asymptomatic bacteriuria: when to screen and when to treat. *Infect Dis Clin North Am*. 2003;17:367–394.

Nicolle LE. Use of antimicrobials during pregnancy. *Can Fam Physician*. 1987;33:1247–1251.

Nicolle LE. Asymptomatic bacteriuria and bacterial interference. *Microbiol Spectr*. 2015;3(5).

Nicolle LE. Cranberry for prevention of urinary tract infection?: Time to move on. *J Am Med Assoc*. 2016;316(18):1873–1874.

Nicolle LE. Urinary tract infection in geriatric and institutionalized patients. *Curr Opin Urol*. 2002;12(1):51–55.

Nicolle LE. Urinary tract infections in long-term care facilities. *Infect Control Hosp Epidemiol*. 1993;14(4):220–225.

Nicolle LE. Urinary tract pathogens in complicated infection and in elderly individuals. *J Infect Dis*. 2001;183(Suppl 1):S5–S8.

Nielsen HO, Lorentzen M. Xanthogranulomatous pyelonephritis. An immunohistochemical and ultrastructural study on the occurrence of bacteria and bacterial antigen. *Urol Int*. 1981;36:335–340.

Niël-weise BS, van den Broek PJ. Antibiotic policies for short-term catheter bladder drainage in adults. *Cochrane Database Syst Rev*. 2005;(3) [CD005428].

Nieto-Rios JF, Ramirez I, Zuluaga-Quintero M, et al. Malakoplakia after kidney transplantation: case report and literature review. *Transpl Infect Dis*. 2017;19(5).

Nishimura RA, Otto CM, Bonow RO, et al. 2017 AHA/ACC focused update of the 2014 AHA/ACC guideline for the management of patients with valvular heart disease: a report of the American College of Cardiology/American Heart Association Task Force on Clinical Practice Guidelines. *Circulation*. 2017;135(25):e1159–e1195.

Niska R, Bhuiya F, Xu J. National Hospital Ambulatory Medical Care Survey: 2007 emergency department summary. *Natl Health Stat Report*. 2010;26:1–31.

Norden CW, Kass EH. Bacteriuria of pregnancy—a critical appraisal. *Annu Rev Med*. 1968;19:431–470.

Nordenstam GR, Brandberg CA, Oden AS, et al. Bacteriuria and mortality in an elderly population. *N Engl J Med*. 1986;314:1152–1156.

Noreikaite J, Jones P, Fitzpatrick J, et al. Fosfomycin vs. quinolone-based antibiotic prophylaxis for transrectal ultrasound-guided biopsy of the prostate: a systematic review and meta-analysis. *Prostate Cancer Prostatic Dis*. 2018.

Norrby SR. Short-term treatment of uncomplicated lower urinary tract infections in women. *Rev Infect Dis*. 1990;12:458–467.

Nowicki B, Martens M, Hart A, et al. Gestational age-dependent distribution of *Escherichia coli* fimbriae in pregnant patients with pyelonephritis. *Ann N Y Acad Sci*. 1994;730:290–291.

Nyren P, Runeberg L, Kostiala AI, et al. Prophylactic methenamine hippurate or nitrofurantoin in patients with an indwelling urinary catheter. *Ann Clin Res*. 1981;13:16–21.

O'Hanley P, Lark D, Falkow S, et al. A globoside binding *E. coli* pilus vaccine prevents pyelonephritis (abstract). *Clin Res*. 1983;31:372A.

Olsson PJ, Black JR, Gaffney E, et al. Reversible acute renal failure secondary to acute pyelonephritis. *South Med J*. 1980;73:374–376.

Omar M, Abdulwahab-Ahmed A, Chaparala H, et al. Does stone removal help patients with recurrent urinary tract infections? *J Urol*. 2015;194(4):997–1001.

Ongun S, Aslan G, Avkan-Oguz V. The effectiveness of single-dose fosfomycin as antimicrobial prophylaxis for patients undergoing transrectal ultrasound-guided biopsy of the prostate. *Urol Int*. 2012;89(4):439–444.

Ooi BS, Chen BT, Yu M. Prevalence and site of bacteriuria in diabetes mellitus. *Postgrad Med J*. 1974;50:497–499.

Ortman JM, Velkoff VA, Hogan H. *An Aging Nation: The older population in the United States*. [(website):] https://www.census.gov/prod/2014pubs/p25-1140.pdf; 2014.

Osca JM, Peiro MJ, Rodrigo M, et al. Focal xanthogranulomatous pyelonephritis: partial nephrectomy as definitive treatment. *Eur Urol*. 1997;32:375–379.

Ouslander JG, Schapira M, Schnelle JF, et al. Does eradicating bacteriuria affect the severity of chronic urinary incontinence in nursing home residents? *Ann Intern Med*. 1995;122:749–754.

Ouslander JG, Schapira M, Schnelle JF, et al. Pyuria among chronically incontinent but otherwise asymptomatic nursing home residents. *J Am Geriatr Soc*. 1996;44:420–423.

Pagano MJ, Barbalat Y, Theofanides MC, et al. Diagnostic yield of cystoscopy in the evaluation of recurrent urinary tract infection in women. *Neurourol Urodyn*. 2017;36(3):692–696.

Pappas PG, Kauffman CA, Andes DR, et al. Clinical Practice Guideline for the Management of Candidiasis: 2016 Update by the Infectious Diseases Society of America. *Clin Infect Dis*. 2016;62(4):e1–e50.

Parasuraman R, Julian K, AST Infectious Diseases Community of Practice. Urinary tract infections in solid organ transplantation. *Am J Transplant*. 2013;13(Suppl 4):327–336.

Parker J, Kunin C. Pyelonephritis in young women: a 10- to 20-

year follow-up. *J Am Med Assoc*. 1973;224:585–590.

Parsons MA, Harris SC, Longstaff AJ, et al. Xanthogranulomatous pyelonephritis: a pathological, clinical and aetiological analysis of 87 cases. *Diagn Histopathol*. 1983;6:203–219.

Patel SS, Balfour JA, Bryson HM. Fosfomycin tromethamine. A review of its antibacterial activity, pharmacokinetic properties and therapeutic efficacy as a single-dose oral treatment for acute uncomplicated lower urinary tract infections. *Drugs*. 1997;53:637–656.

Paterson DL. “Collateral damage” from cephalosporin or quinolone antibiotic therapy. *Clin Infect Dis*. 2004;38(Suppl 4):S341–S345.

Patterson TF, Andriole VT. Bacteriuria in pregnancy. *Infect Dis Clin North Am*. 1987;1:807–822.

Paty R, Smith AD. Gangrene and Fournier's gangrene. *Urol Clin North Am*. 1992;19:149–162.

Pavathuparambil Abdul Manaph N, Al-Hawwas M, Bobrovskaya L, et al. Urine-derived cells for human cell therapy. *Stem Cell Res Ther*. 2018;9(1):189.

Pearce MM, Hilt EE, Rosenfeld AB, et al. The female urinary microbiome: a comparison of women with and without urgency urinary incontinence. *MBio*. 2014;5(4) [e01283-01214].

Pedler SJ, Bint AJ. Management of bacteriuria in pregnancy. *Drugs*. 1987;33:413–421.

Perrotta C, Aznar M, Mejia R, et al. Oestrogens for preventing recurrent urinary tract infection in postmenopausal women. *Cochrane Database Syst Rev*. 2008;(2) [CD005131].

Petronic V, Buturovic J, Isvaneski M. Xanthogranulomatous pyelonephritis. *Br J Urol*. 1989;64:336–338.

Pfau A, Rosenmann E. Unilateral chronic pyelonephritis and hypertension: coincidental or causal relationship? *Am J Med*.

1978;65:499–506.

Pfau A, Sacks T. The bacterial flora of the vaginal vestibule, urethra and vagina in the normal premenopausal woman. *J Urol*. 1977;118:292–295.

Pfau A, Sacks TG. Effective prophylaxis for recurrent urinary tract infections during pregnancy. *Clin Infect Dis*. 1992;14:810–814.

Pitout JD, Laupland KB. Extended-spectrum beta-lactamase-producing Enterobacteriaceae: an emerging public-health concern. *Lancet Infect Dis*. 2008;8(3):159–166.

Pitts JC, Peterson NE, Conley MC. Calcified functionless kidney in a 51-year-old man. *J Urol*. 1981;125:398–441.

Plorde L. Echinococciasis. Thorn G. *Harrison's principles of internal medicine*. McGraw-Hill: New York; 1977:117–118.

Polastri F, Auckenthaler R, Loew F, et al. Absence of significant bacteremia during urinary catheter manipulation in patients with chronic indwelling catheters. *J Am Geriatr Soc*. 1990;38:1203–1208.

Poljakovic M, Persson K. Urinary tract infection in iNOS-deficient mice with focus on bacterial sensitivity to nitric oxide. *Am J Physiol Renal Physiol*. 2003;284:F22–F31.

Poljakovic M, Svensson ML, Svanborg C, et al. *Escherichia coli*-induced inducible nitric oxide synthase and cyclooxygenase expression in the mouse bladder and kidney. *Kidney Int*. 2001;59:893–904.

Pontin AR, Barnes RD. Current management of emphysematous pyelonephritis. *Nat Rev Urol*. 2009;6(5):272–279.

Poole JH, Thorsen MS. Acute renal failure in pregnancy. *MCN Am J Matern Child Nurs*. 1999;24:66–73.

Potts JM, Ward AM, Rackley RR. Association of chronic urinary symptoms in women and Ureaplasma urealyticum. *Urology*. 2000;55(4):486–489.

Poulios C. Echinococcal disease of the urinary tract: review of the management of 7 cases. *J Urol*. 1991;145:924–927.

Povysil C, Konickova L. Experimental xanthogranulomatous pyelonephritis. *Invest Urol*. 1972;9:313–318.

Prakash V, Lewis JS 2nd, Herrera ML, et al. Oral and parenteral therapeutic options for outpatient urinary infections caused by enterobacteriaceae producing CTX-M extended-spectrum beta-lactamases. *Antimicrob Agents Chemother*. 2009;53(3):1278–1280.

Preston A, O'Donnell T, Phillips CA. Screening for urinary tract infections in a gynaecological setting: validity and cost-effectiveness of reagent strips. *Br J Biomed Sci*. 1999;56:253–257.

Price JR, Guran LA, Gregory WT, et al. Nitrofurantoin vs other prophylactic agents in reducing recurrent urinary tract infections in adult women: a systematic review and meta-analysis. *Am J Obstet Gynecol*. 2016;215(5):548–560.

Price TK, Hilt EE, Dune TJ, et al. Urine trouble: should we think differently about UTI? *Int Urogynecol J*. 2018;29(2):205–210.

Pyrah LN, Goldie W, Parsons FM, et al. Control of *Pseudomonas pyocyanea* infection in a urological ward. *Lancet*. 1955;269:314–317.

Rajan N, Cao Q, Anderson BE, et al. Roles of glycoproteins and oligosaccharides found in human vaginal fluid in bacterial adherence. *Infect Immun*. 1999;67:5027–5032.

Ramos JA, Salinas DF, Osorio J, et al. Antibiotic prophylaxis and its appropriate timing for urological surgical procedures in patients with asymptomatic bacteriuria: a systematic review. *Arab J Urol*. 2016;14(3):234–239.

Ramphal R, Ambrose PG. Extended-spectrum beta-lactamases and clinical outcomes: current data. *Clin Infect Dis*. 2006;42(Suppl 4):S164–S172.

Rane A, Cahill D, Saleemi A, et al. The issue of prophylactic antibiotics prior to flexible cystoscopy. *Eur Urol*. 2001;39:212–214.

Raz R, Boger S. Long-term prophylaxis with norfloxacin versus nitrofurantoin in women with recurrent urinary tract infection. *Antimicrob Agents Chemother*. 1991;35:1241–1242.

Raz R, Gennesin Y, Wasser J, et al. Recurrent urinary tract infections in postmenopausal women. *Clin Infect Dis*. 2000;30(1):152–156.

Raz R, Sakran W, Chazan B, et al. Long-term follow-up of women hospitalized for acute pyelonephritis. *Clin Infect Dis*. 2003;37:1014–1020.

Raz R, Stamm WE. A controlled trial of intravaginal estriol in postmenopausal women with recurrent urinary tract infections. *N Engl J Med*. 1993;329:753–756.

Reid G, Sobel JD. Bacterial adherence in the pathogenesis of urinary tract infection: a review. *Rev Infect Dis*. 1987;9:470–487.

Ribot S, Gal K, Goldblat MV, et al. The role of anaerobic bacteria in the pathogenesis of urinary tract infections. *J Urol*. 1981;126:852–853.

Richet G, Mayaud C. The course of acute renal failure in pyelonephritis and other types of interstitial nephritis. *Nephron*. 1978;22:124–127.

Riedl CR, Plas E, Hubner WA, et al. Bacterial colonization of ureteral stents. *Eur Urol*. 1999;36(1):53–59.

Rivers E, Nguyen B, Havstad S, et al. Early goal-directed therapy in the treatment of severe sepsis and septic shock. *N Engl J Med*. 2001;345:1368–1377.

Rizzi M, Trevisan R. Genitourinary infections in diabetic patients in the new era of diabetes therapy with sodium-glucose cotransporter-2 inhibitors. *Nutr Metab Cardiovasc*

Dis. 2016;26(11):963–970.

Roberts AP, Phillips R. Bacteria causing symptomatic urinary tract infection or asymptomatic bacteriuria. *J Clin Pathol*. 1979;32:492–496.

Roberts MJ, Scott S, Harris PN, et al. Comparison of fosfomycin against fluoroquinolones for transrectal prostate biopsy prophylaxis: an individual patient-data meta-analysis. *World J Urol*. 2018;36(3):323–330.

Roberts MJ, Williamson DA, Hadway P, et al. Baseline prevalence of antimicrobial resistance and subsequent infection following prostate biopsy using empirical or altered prophylaxis: a bias-adjusted meta-analysis. *Int J Antimicrob Agents*. 2014;43(4):301–309.

Ronald A. The etiology of urinary tract infection: traditional and emerging pathogens. *Am J Med*. 2002;113(Suppl 1A):14S–19S.

Rosen DA, Hooton TM, Stamm WE, et al. Detection of intracellular bacterial communities in human urinary tract infection. *PLoS Med*. 2007;4:e329.

Rosenberg M. Pharmacoeconomics of treating uncomplicated urinary tract infections. *Int J Antimicrob Agents*. 1999;11:247–251 [discussion 261–264].

Rosenfield AT, Glickman MG, Taylor KJ, et al. Acute focal bacterial nephritis (acute lobar nephronia). *Radiology*. 1979;132:553–561.

Routh JC, Alt AL, Ashley RA, et al. Increasing prevalence and associated risk factors for methicillin resistant Staphylococcus aureus bacteriuria. *J Urol*. 2009;181(4):1694–1698.

Rubin RH, Beam TR Jr, Stamm WE. An approach to evaluating antibacterial agents in the treatment of urinary tract infection. *Clin Infect Dis*. 1992;14(Suppl 2):S246–S251 [discussion S253–S254].

Ryan S, Gillespie E, Stuart RL. Urinary tract infection surveillance in residential aged care. *Am J Infect Control*. 2018;46(1):67–72.

Sabbagh R, McCormack M, Peloquin F, et al. A prospective randomized trial of 1-day versus 3-day antibiotic prophylaxis for transrectal ultrasound guided prostate biopsy. *Can J Urol*. 2004;11:2216–2219.

Saeed SM, Fine G. Xanthogranulomatous pyelonephritis. *Am J Clin Pathol*. 1963;39:616–625.

Säemann M, Hörl WH. Urinary tract infection in renal transplant recipients. *Eur J Clin Invest*. 2008;38(Suppl 2):58–65.

Saint Martin G, Chiesa JC. “Falling snowflakes,” an ultrasound sign of hydatid sand. *J Ultrasound Med*. 1984;3(6):257–260.

Saint S, Elmore JG, Sullivan SD, et al. The efficacy of silver alloy-coated urinary catheters in preventing urinary tract infection: a meta-analysis. *Am J Med*. 1998;105:236–241.

Saint S, Lipsky BA. Preventing catheter-related bacteriuria: should we? Can we? How? *Arch Intern Med*. 1999;159(8):800–808.

Saint S, Veenstra DL, Sullivan SD, et al. The potential clinical and economic benefits of silver alloy urinary catheters in preventing urinary tract infection. *Arch Intern Med*. 2000;160:2670–2675.

Salvatierra O Jr, Bucklew WB, Morrow JW. Perinephric abscess: a report of 71 cases. *J Urol*. 1967;98:296–302.

Sampathkumar P, Barth JW, Johnson M, et al. Mayo clinic reduces catheter-associated urinary tract infections through a bundled 6-C approach. *Jt Comm J Qual Patient Saf*. 2016;42(6):254–261.

Sanchez-Ramos L, McAlpine KJ, Adair CD, et al. Pyelonephritis in pregnancy: once-a-day ceftriaxone versus multiple doses of cefazolin. A randomized, double-blind trial.

Am J Obstet Gynecol. 1995;172:129–133.

Santen RJ, Stuenkel CA, Davis SR, et al. Managing menopausal symptoms and associated clinical issues in breast cancer survivors. *J Clin Endocrinol Metab*. 2017;102(10):3647–3661.

Santen RJ. Vaginal administration of estradiol: effects of dose, preparation and timing on plasma estradiol levels. *Climacteric*. 2015;18(2):121–134.

Schaeffer A, Story K, Johnson S. Effect of silver oxide/trichloroisocyanuric acid antimicrobial urinary drainage system on catheter-associated bacteriuria. *J Urol*. 1988;139:69–73.

Schaeffer A. Urinary tract infections in the elderly. *Eur Urol*. 1991;19(Suppl 1):2–6.

Schaeffer AJ, Jones JM, Dunn JK. Association of in vitro Escherichia coli adherence to vaginal and buccal epithelial cells with susceptibility of women to recurrent urinary-tract infections. *N Engl J Med*. 1981;304(18):1062–1066.

Schaeffer AJ, Jones JM, Flynn SS. Prophylactic efficacy of cinoxacin in recurrent urinary tract infection: biologic effects on the vaginal and fecal flora. *J Urol*. 1982;127(6):1128–1131.

Schaeffer AJ, Navas EL, Venegas MF, et al. Variation of blood group antigen expression on vaginal cells and mucus in secretor and nonsecretor women. *J Urol*. 1994;152(3):859–864.

Schaeffer AJ, Stuppy BA. Efficacy and safety of self-start therapy in women with recurrent urinary tract infections. *J Urol*. 1999;161(1):207–211.

Schaeffer EM. Prophylactic use of antimicrobials in commonly performed outpatient urologic procedures. *Nat Clin Pract Urol*. 2006;3:24–31.

Schainuck LI, Fouty R, Cutler RE. Emphysematous pyelonephritis. A new case and review of previous observations. *Am J Med*. 1968;44:134–139.

Schappert SM, Rechtsteiner EA. Ambulatory medical care utilization estimates for 2007. *Vital Health Stat 13*. 2011;169:1–38.

Schechter H, Leonard CD, Scribner BH. Chronic pyelonephritis as a cause of renal failure in dialysis candidates. Analysis of 173 patients. *J Am Med Assoc*. 1971;216:514–517.

Schiff M Jr, Glickman M, Weiss RM, et al. Antibiotic treatment of renal carbuncle. *Ann Intern Med*. 1977;87:305–308.

Schiffl H, Lang SM, Fischer R. Daily hemodialysis and the outcome of acute renal failure. *N Engl J Med*. 2002;346:305–310.

Schlager TA, Hendley JO, Bell AL, et al. Clonal diversity of Escherichia coli colonizing stools and urinary tracts of young girls. *Infect Immun*. 2002;70(3):1225–1229.

Schneeberger C, Geerlings SE, Middleton P, et al. Interventions for preventing recurrent urinary tract infection during pregnancy. *Cochrane Database Syst Rev*. 2015;(7)[CD009279].

Schneider M, Becker JA, Staiano S, et al. Sonographic-radiographic correlations of renal and perirenal infections. *AJR Am J Roentgenol*. 1976;127:1007–1014.

Schoborg TW, Saffos RO, Urdaneta L, et al. Xanthogranulomatous pyelonephritis associated with renal carcinoma. *J Urol*. 1980;124:125–127.

Scholes D, Hawn TR, Roberts PL, et al. Family history and risk of recurrent cystitis and pyelonephritis in women. *J Urol*. 2010;184(2):564–569.

Scholes D, Hooton TM, Roberts PL, et al. Risk factors for recurrent urinary tract infection in young women. *J Infect Dis*. 2000;182(4):1177–1182.

Schonwald S, Begovac J, Skerk V. Urinary tract infections in

HIV disease. *Int J Antimicrob Agents*. 1999;11:309–311.

Schulman CC, Corbusier A, Michiels H, et al. Oral immunotherapy of recurrent urinary tract infections: a double-blind placebo-controlled multicenter study. *J Urol*. 1993;150(3):917–921.

Schwenger EM, Tejani AM, Loewen PS. Probiotics for preventing urinary tract infections in adults and children. *Cochrane Database Syst Rev*. 2015;(12) [CD008772].

Sedor J, Mulholland SG. Hospital-acquired urinary tract infections associated with the indwelling catheter. *Urol Clin North Am*. 1999;26:821–828.

Segal AJ, Amis ES Jr, Bigongiari LR, et al. Recurrent lower urinary tract infections in women. American College of Radiology. ACR Appropriateness Criteria. *Radiology*. 2000;215(Suppl):671–676.

Segura JW, Kelalis PP. Localized renal parenchymal infections in children. *J Urol*. 1973;109:1029–1032.

Sekirov I, Tam NM, Jogova M, et al. Antibiotic-induced perturbations of the intestinal microbiota alter host susceptibility to enteric infection. *Infect Immun*. 2008;76(10):4726–4736.

Semeniuk H, Church D. Evaluation of the leukocyte esterase and nitrite urine dipstick screening tests for detection of bacteriuria in women with suspected uncomplicated urinary tract infections. *J Clin Microbiol*. 1999;37:3051–3052.

Sessler CN, Perry JC, Varney KL. Management of severe sepsis and septic shock. *Curr Opin Crit Care*. 2004;10:354–363.

Sexton CC, Lowman RM, Nyongo AO, et al. Malacoplakia presenting as complete unilateral ureteral obstruction. *J Urol*. 1982;128:139–141.

Shandera KC, Thibault GP, Deshon GE Jr. Efficacy of one dose fluoroquinolone before prostate biopsy. *Urology*. 1998;52:641–643.

Sheinfeld J, Schaeffer AJ, Cordon-Cardo C, et al. Association of the Lewis blood-group phenotype with recurrent urinary tract infections in women. *N Engl J Med*. 1989;320:773–777.

Shen Y, Brown MA. Renal imaging in pyelonephritis. *Nephrology (Carlton)*. 2004;9:22–25.

Shepherd AK, Pottinger PS. Management of urinary tract infections in the era of increasing antimicrobial resistance. *Med Clin North Am*. 2013;97:737–757 [xii].

Shepherd JP, Jones KA, Harmanli O. Is antibiotic prophylaxis necessary before midurethral sling procedures for female stress incontinence? A decision analysis. *Int Urogynecol J*. 2014;25(2):227–233.

Shetty SD, al-Saigh A, Ibrahim AI, et al. Management of hydatid cysts of the urinary tract. *Br J Urol*. 1992;70:258–261.

Shimizu M, Katayama K, Kato E, et al. Evolution of acute focal bacterial nephritis into a renal abscess. *Pediatr Nephrol*. 2005;20:93–95.

Shu T, Green JM, Orihuela E. Renal and perirenal abscesses in patients with otherwise anatomically normal urinary tracts. *J Urol*. 2004;172:148–150.

Sieber PR, Rommel FM, Agusta VE, et al. Antibiotic prophylaxis in ultrasound guided transrectal prostate biopsy. *J Urol*. 1997;157:2199–2200.

Siegel J, Smith A, Moldwin R. Minimally invasive treatment of renal abscess. *J Urol*. 1996;155:52–55.

Silverblatt FJ, Dreyer JS, Schauer S. Effect of pili on susceptibility of *Escherichia coli* to phagocytosis. *Infect Immun*. 1979;24:218–223.

Siroky MB, Moylan R, Austen G Jr, et al. Metastatic infection secondary to genitourinary tract sepsis. *Am J Med*. 1976;61:351–360.

Skelton WP 4th, Taylor Z, Hsu J. A rare case of Raoultella planticola urinary tract infection in an immunocompromised patient with multiple myeloma. *IDCases*. 2017;8:9–11.

Slimings C, Riley TV. Antibiotics and hospital-acquired Clostridium difficile infection: update of systematic review and meta-analysis. *J Antimicrob Chemother*. 2014;69(4):881–891.

Smaill F. Antibiotics for asymptomatic bacteriuria in preganancy. *Cochrane Database Syst Rev*. 2001;(2) [CD000490].

Smeets F, Gower PE. The site of infection in 133 patients with bacteriuria. *Clin Nephrol*. 1973;1:290–296.

Smellie J, Edwards D, Hunter N, et al. Vesico-ureteric reflux and renal scarring. *Kidney Int Suppl*. 1975;4:S65–S72.

Sokurenko EV, Vogel V, Thomas WE. Catch-bond mechanism of force-enhanced adhesion: counterintuitive, elusive, but widespread? *Cell Host Microbe*. 2008;4:314–323.

Soler R, Pombo F, Gayol A, et al. Focal xanthogranulomatous pyelonephritis in a teenager: MR and CT findings. *Eur J Radiol*. 1997;24:77–79.

Solomon A, Braf Z, Papo J, et al. Computerized tomography in xanthogranulomatous pyelonephritis. *J Urol*. 1983;130:323–325.

Soltanzadeh M, Ebadi A. Is presence of bacteria in preoperative microscopic urinalysis of the patients scheduled for cardiac surgery a reason for cancellation of elective operation? *Anesth Pain Med*. 2013;2(4):174–177.

Soulen MC, Fishman EK, Goldman SM, et al. Bacterial renal infection: role of CT. *Radiology*. 1989;171:703–707.

Sourander L. Urinary tract infections in the aged: an epidemiological study. *Ann Med Intern Fenn*. 1966;55:7–55.

Sourander P, Hansson HA, Olsson Y, et al. Experimental studies on the pathogenesis of leucodystrophies. II. The effect of sphingolipids on various cell types in cultures from the nervous system. *Acta Neuropathol*. 1966;6(3):231–242.

Sousa R, Munoz-Mahamud E, Quayle J, et al. Is asymptomatic bacteriuria a risk factor for prosthetic joint infection? *Clin Infect Dis*. 2014;59(1):41–47.

Sparks A, Connor D, Neafie R. Echinococcosis. Binford C, Connor D. *Pathology of tropical and extraordinary diseases*. Armed Forces Institute of Pathology: Washington (DC); 1976:530–533.

Spinillo A, Capuzzo E, Acciano S, et al. Effect of antibiotic use on the prevalence of symptomatic vulvovaginal candidiasis. *Am J Obstet Gynecol*. 1999;180(1 Pt 1):14–17.

Spirnak JP, Resnick MI, Hampel N, et al. Fournier's gangrene: report of 20 patients. *J Urol*. 1984;131:289–291.

Sprung CL, Annane D, Keh D, et al. Hydrocortisone therapy for patients with septic shock. *N Engl J Med*. 2008;358:111–124.

Stahlmann R, Lode H. Fluoroquinolones in the elderly: safety considerations. *Drugs Aging*. 2003;20:289–302.

Stamenkovic I, Lew PD. Early recognition of potentially fatal necrotizing fasciitis: the use of frozen-section biopsy. *N Engl J Med*. 1984;310:1689–1693.

Stamey T. *Pathogenesis and treatment of urinary tract infections*. Williams & Wilkins: Baltimore; 1980.

Stamey TA, Fair WR, Timothy MM, et al. Serum versus urinary antimicrobial concentrations in cure of urinary-tract infections. *N Engl J Med*. 1974;291(22):1159–1163.

Stamey TA, Govan DE, Palmer JM. The localization and treatment of urinary tract infections: the role of bactericidal urine levels as opposed to serum levels. *Medicine (Baltimore)*. 1965;44:1–36.

Stamey TA, Pfau A. Some functional, pathologic, bacteriologic, and chemotherapeutic characteristics of unilateral pyelonephritis in man. II. Bacteriologic and chemotherapeutic characteristics. *Invest Urol*. 1963;1:162–172.

Stamey TA, Timothy MM. Studies of introital colonization in women with recurrent urinary infections. I. The role of vaginal pH. *J Urol*. 1975;114:261–263.

Stamey TA, Timothy MM. Studies of introital colonization in women with recurrent urinary infections. III. Vaginal glycogen concentrations. *J Urol*. 1975;114(2):268–270.

Stamey TA, Wehner N, Mihara G, et al. The immunologic basis of recurrent bacteriuria: role of cervicovaginal antibody in enterobacterial colonization of the introital mucosa. *Medicine (Baltimore)*. 1978;57:47–56.

Stamm WE, Counts GW, Wagner KF, et al. Antimicrobial prophylaxis of recurrent urinary tract infections: a double-blind, placebo-controlled trial. *Ann Intern Med*. 1980;92:770–775.

Stamm WE, Hooton TM. Management of urinary tract infections in adults. *N Engl J Med*. 1993;329:1328–1334.

Stamm WE, Wagner KF, Amsel R, et al. Causes of the acute urethral syndrome in women. *N Engl J Med*. 1980;303:409–415.

Stamm WE. Catheter-associated urinary tract infections: epidemiology, pathogenesis, and prevention. *Am J Med*. 1991;91:65S–71S.

Stamm WE. Guidelines for prevention of catheter-associated urinary tract infections. *Ann Intern Med*. 1975;82:386–390.

Stanton MJ, Lynch JH, Maxted WC, et al. Malacoplakia of the bladder: a case report of resolution with bethanechol, trimethoprim-sulfamethoxazole and ascorbic acid. *J Urol*. 1983;130:1174–1175.

Stanton MJ, Maxted W. Malacoplakia: a study of the literature and current concepts of pathogenesis, diagnosis and treatment. *J Urol*. 1981;125:139–146.

Stapleton A, Hooton TM, Fennell C, et al. Effect of secretor status on vaginal and rectal colonization with fimbriated

Escherichia coli in women with and without recurrent urinary tract infection. *J Infect Dis*. 1995;171:717–720.

Stapleton A. Urinary tract infections in patients with diabetes. *Am J Med*. 2002;113(Suppl 1A):80S–84S.

Stapleton AE, Au-Yeung M, Hooton TM, et al. Randomized, placebo-controlled phase 2 trial of a Lactobacillus crispatus probiotic given intravaginally for prevention of recurrent urinary tract infection. *Clin Infect Dis*. 2011;52(10):1212–1217.

Stark RP, Maki DG. Bacteriuria in the catheterized patient. What quantitative level of bacteriuria is relevant? *N Engl J Med*. 1984;311:560–564.

Stenqvist K, Dahlen-Nilsson I, Lidin-Janson G, et al. Bacteriuria in pregnancy. Frequency and risk of acquisition. *Am J Epidemiol*. 1989;129:372–379.

Stewardson AJ, Gaia N, Francois P, et al. Collateral damage from oral ciprofloxacin versus nitrofurantoin in outpatients with urinary tract infections: a culture-free analysis of gut microbiota. *Clin Microbiol Infect*. 2015;21(4):344.e1–344.e11.

Stone ND, Ashraf MS, Calder J, et al. Surveillance definitions of infections in long-term care facilities: revisiting the McGeer criteria. *Infect Control Hosp Epidemiol*. 2012;33(10):965–977.

Stothers L. A randomized trial to evaluate effectiveness and cost effectiveness of naturopathic cranberry products as prophylaxis against urinary tract infection in women. *Can J Urol*. 2002;9:1558–1562.

Stover SL, Lloyd LK, Waites KB, et al. Urinary tract infection in spinal cord injury. *Arch Phys Med Rehabil*. 1989;70:47–54.

Sun TT. Epithelial growth and differentiation: an overview. *Mol Biol Rep*. 1996;23:1–2.

Suskind AM, Saigal CS, Hanley JM, et al. Incidence and management of uncomplicated recurrent urinary tract infections in a national sample of women in the United States. *Urology*. 2016;90:50–55.

Svanborg C, Godaly G. Bacterial virulence in urinary tract infection. *Infect Dis Clin North Am*. 1997;11:513–529.

Svanborg-Eden C, Svennerholm AM. Secretory immunoglobulin A and G antibodies prevent adhesion of *Escherichia coli* to human urinary tract epithelial cells. *Infect Immun*. 1978;22:790–797.

Svenson SB, Hultberg H, Kallenius G, et al. P-fimbriae of pyelonephritogenic *Escherichia coli*: identification and chemical characterization of receptors. *Infection*. 1983;11:61–67.

Svenson SB, Kallenius G, Korhonen TK, et al. Initiation of clinical pyelonephritis–the role of P-fimbriae-mediated bacterial adhesion. *Contrib Nephrol*. 1984;39:252–272.

Sweet R, Keane WF. Perinephric abscess in patients with polycystic kidney disease undergoing chronic hemodialysis. *Nephron*. 1979;23:237–240.

Sweet R. Bacteriuria and pyelonephritis during pregnancy. *Semin Perinatol*. 1977;1:25–40.

Taha Neto KA, Nogueira Castilho L, Reis LO. Oral vaccine (OM-89) in the recurrent urinary tract infection prophylaxis: a realistic systematic review with meta-analysis. *Actas Urol Esp*. 2016;40(4):203–208.

Tal R, Livne PM, Lask DM, et al. Empirical management of urinary tract infections complicating transrectal ultrasound guided prostate biopsy. *J Urol*. 2003;169:1762–1765.

Talan DA, Stamm WE, Hooton TM, et al. Comparison of ciprofloxacin (7 days) and trimethoprim-sulfamethoxazole (14 days) for acute uncomplicated pyelonephritis in women: a randomized trial. *J Am Med Assoc*. 2000;283:1583–1590.

Tambyah PA, Halvorson KT, Maki DG. A prospective study of pathogenesis of catheter-associated urinary tract infections. *Mayo Clin Proc*. 1999;74:131–136.

Tambyah PA, Knasinski V, Maki DG. The direct costs of nosocomial catheter-associated urinary tract infection in the era of managed care. *Infect Control Hosp Epidemiol*. 2002;23:27–31.

Tambyah PA, Maki DG. Catheter-associated urinary tract infection is rarely symptomatic: a prospective study of 1,497 catheterized patients. *Arch Intern Med*. 2000;160:678–682.

Tammen H. Immunobiotherapy with Uro-Vaxom in recurrent urinary tract infection. The German Urinary Tract Infection Study Group. *Br J Urol*. 1990;65(1):6–9.

Tapper H, Herwald H. Modulation of hemostatic mechanisms in bacterial infectious diseases. *Blood*. 2000;96:2329–2337.

Taylor AK, Zembower TR, Nadler RB, et al. Targeted antimicrobial prophylaxis using rectal swab cultures in men undergoing transrectal ultrasound guided prostate biopsy is associated with reduced incidence of postoperative infectious complications and cost of care. *J Urol*. 2012;187:1275–1279.

Taylor HM, Bingham JB. Antibiotic prophylaxis for transrectal prostate biopsy. *J Antimicrob Chemother*. 1997;39:115–117.

Taylor HM, Bingham JB. The use of prophylactic antibiotics in ultrasound-guided transrectal prostate biopsy. *Clin Radiol*. 1997;52:787–790.

Tencer J. Asymptomatic bacteriuria–a long-term study. *Scand J Urol Nephrol*. 1988;22(1):31–34.

Tennyson LE, Averch TD. An update on fluoroquinolones: the emegence of a multisystem toxicity syndrome. *Urol Pract*. 2017;4:383–387.

Terlizzi ME, Gribaudo G, Maffei ME. UroPathogenic Escherichia coli (UPEC) infections: virulence factors, bladder responses, antibiotic, and non-antibiotic antimicrobial strategies. *Front Microbiol*. 2017;8:1566.

Thankavel K, Madison B, Ikeda T, et al. Localization of a domain in the FimH adhesin of *Escherichia coli* type 1 fimbriae capable of receptor recognition and use of a domain-specific antibody to confer protection against experimental urinary tract infection. *J Clin Invest*. 1997;100:1123–1136.

Thiel G, Spuhler O. Catheter infection and so-called infectious (episomal) resistance. *Schweiz Med Wochenschr*. 1965;95:1155–1157.

Thomas AA, Lane BR, Thomas AZ, et al. Emphysematous cystitis: a review of 135 cases. *BJU Int*. 2007;100(1):17–20.

Thomas E, Hillman BJ, Stanisic T. Urinary tract infection with atypical mycobacteria. *J Urol*. 1980;124:748–750.

Thomas WE, Trintchina E, Forero M, et al. Bacterial adhesion to target cells enhanced by shear force. *Cell*. 2002;109:913–923.

Thomas-White KJ, Hilt EE, Fok C, et al. Incontinence medication response relates to the female urinary microbiota. *Int Urogynecol J*. 2016;27(5):723–733.

Thorley JD, Jones SR, Sanford JP. Perinephric abscess. *Medicine (Baltimore)*. 1974;53:441–451.

Thumbikat P, Berry RE, Schaeffer AJ, et al. Differentiation-induced uroplakin III expression promotes urothelial cell death in response to uropathogenic *E. coli*. *Microbes Infect*. 2009;11:57–65.

Thumbikat P, Berry RE, Zhou G, et al. Bacteria-induced uroplakin signaling mediates bladder response to infection. *PLoS Pathog*. 2009;5 [e1000415].

Timmons JW, Perlmutter AD. Renal abscess: a changing concept. *J Urol*. 1976;115:299–301.

Tissot E, Woronoff-Lemsi MC, Cornette C, et al. Cost-effectiveness of urinary dipsticks to screen asymptomatic catheter-associated urinary infections in an intensive care unit. *Intensive Care Med*. 2001;27:1842–1847.

Tobias-Machado M, Lasmar MT, Batista LT, et al. Laparoscopic nephrectomy in inflammatory renal disease: proposal for a staged approach. *Int Braz J Urol*. 2005;31:22–28.

Tolia BM, Iloreta A, Freed SZ, et al. Xanthogranulomatous pyelonephritis: detailed analysis of 29 cases and a brief discussion of atypical presentations. *J Urol*. 1981;126:437–442.

Tolia BM, Newman HR, Fruchtman B, et al. Xanthogranulomatous pyelonephritis: segmental or generalized disease. *J Urol*. 1980;124:122–124.

Tomashefski JF Jr, Abramowsky CR. Candida-associated renal papillary necrosis. *Am J Clin Pathol*. 1981;75:190–194.

Trillo A, Lorentz WB, Whitley NO. Malakoplakia of kidney simulating renal neoplasm. *Urology*. 1977;10:472–477.

Turck M, Goffe B, Petersdorf RG. The urethral catheter and urinary tract infection. *J Urol*. 1962;88:834–837.

Turck M, Ronald AR, Petersdorf RG. Relapse and reinfection in chronic bacteriuria. II. The correlation between site of infection and pattern of recurrence in chronic bacteriuria. *N Engl J Med*. 1968;278:422–427.

Ubeda C, Taur Y, Jenq RR, et al. Vancomycin-resistant Enterococcus domination of intestinal microbiota is enabled by antibiotic treatment in mice and precedes bloodstream invasion in humans. *J Clin Invest*. 2010;120(12):4332–4341.

Uehling DT, Hopkins WJ, Balish E, et al. Vaginal mucosal immunization for recurrent urinary tract infection: phase II clinical trial. *J Urol*. 1997;157(6):2049–2052.

Uehling DT, Hopkins WJ, Elkahwaji JE, et al. Phase 2 clinical trial of a vaginal mucosal vaccine for urinary tract infections. *J Urol*. 2003;170(3):867–869.

Urinology Think Tank Writing Group. Urine: waste product or biologically active tissue? *Neurourol Urodyn*. 2018;37(3):1162–1168.

Vaisanen V, Elo J, Tallgren LG, et al. Mannose-resistant haemagglutination and P antigen recognition are characteristic of *Escherichia coli* causing primary pyelonephritis. *Lancet*. 1981;2:1366–1369.

Vallorosi CJ, Putzi MJ, Wolf JS Jr. Renal malacoplakia. *Tech Urol*. 1999;5:43–44.

Van den Berghe G, Wouters P, Weekers F, et al. Intensive insulin therapy in critically ill patients. *N Engl J Med*. 2001;345:1359–1367.

van der Wall E, Verkooyen RP, Mintjes-de Groot J, et al. Prophylactic ciprofloxacin for catheter-associated urinary-tract infection. *Lancet*. 1992;339(8799):946–951.

van Haarst EP, van Andel G, Heldeweg EA, et al. Evaluation of the diagnostic workup in young women referred for recurrent lower urinary tract infections. *Urology*. 2001;57(6):1068–1072.

Van Kirk OC, Go RT, Wedel VJ. Sonographic features of xanthogranulomatous pyelonephritis. *AJR Am J Roentgenol*. 1980;134:1035–1039.

Vanderbrink BA, Ost MC, Rastinehad A, et al. Laparoscopic versus open radical nephrectomy for xanthogranulomatous pyelonephritis: contemporary outcomes analysis. *J Endourol*. 2007;21(1):65–70.

Vejlsgaard R. Studies on urinary infections in diabetics. IV. Significant bacteriuria in pregnancy in relation to age of onset, duration of diabetes, angiopathy and urological symptoms. *Acta Med Scand*. 1973;193:343–346.

Velasco M, Martinez JA, Moreno-Martinez A, et al. Blood cultures for women with uncomplicated acute pyelonephritis: are they necessary? *Clin Infect Dis*. 2003;37:1127–1130.

Venegas MF, Navas EL, Gaffney RA, et al. Binding of type 1-piliated *Escherichia coli* to vaginal mucus. *Infect Immun*. 1995;63:416–422.

Vidaeff AC, Yeomans ER, Ramin SM. Pregnancy in women with renal disease. Part 1: general principles. *Am J Perinatol*. 2008;25:385–397.

Vigil HR, Hickling DR. Urinary tract infection in the neurogenic bladder. *Transl Androl Urol*. 2016;5(1):72–87.

Vigil PD, Stapleton AE, Johnson JR, et al. Presence of putative repeat-in-toxin gene tosA in Escherichia coli predicts successful colonization of the urinary tract. *MBio*. 2011;2(3) [e00066-00011].

Vollaard EJ, Clasener HA. Colonization resistance. *Antimicrob Agents Chemother*. 1994;38(3):409–414.

von Hansemann D. Über Malakoplakie der Harnblase. *Arch Pathol Anat*. 1903;173:302–308.

Vordermark JS 2nd, Modarelli RO, Buck AS. *Torulopsis* pyelonephritis associated with papillary necrosis: a case report. *J Urol*. 1980;123:96–97.

Vromen M, van der Ven AJ, Knols A, et al. Antimicrobial resistance patterns in urinary isolates from nursing home residents: fifteen years of data reviewed. *J Antimicrob Chemother*. 1999;44:113–116.

Waage A. Production and clearance of tumor necrosis factor in rats exposed to endotoxin and dexamethasone. *Clin Immunol Immunopathol*. 1987;45(3):348–355.

Wadsworth DE, McClennan BL, Stanley RJ. CT of the renal mass. *Urol Radiol*. 1982;4:85–94.

Waites KB, Canupp KC, DeVivo MJ. Epidemiology and risk factors for urinary tract infection following spinal cord injury. *Arch Phys Med Rehabil*. 1993;74:691–695.

Waites KB, Canupp KC, DeVivo MJ. Eradication of urinary tract infection following spinal cord injury. *Paraplegia*. 1993;31:645–652.

Waites KB, Canupp KC, Roper JF, et al. Evaluation of 3 methods of bladder irrigation to treat bacteriuria in persons with neurogenic bladder. *J Spinal Cord Med*. 2006;29(3):217–226.

Waltzer WC. The urinary tract in pregnancy. *J Urol*. 1981;125:271–276.

Wan YL, Lee TY, Bullard MJ, et al. Acute gas-producing bacterial renal infection: correlation between imaging findings and clinical outcome. *Radiology*. 1996;198:433–438.

Warren JW, Abrutyn E, Hebel JR, et al. Guidelines for antimicrobial treatment of uncomplicated acute bacterial cystitis and acute pyelonephritis in women. Infectious Diseases Society of America (IDSA). *Clin Infect Dis*. 1999;29:745–758.

Warren JW, Tenney JH, Hoopes JM, et al. A prospective microbiologic study of bacteriuria in patients with chronic indwelling urethral catheters. *J Infect Dis*. 1982;146:719–723.

Warren JW. Catheter-associated urinary tract infections. *Infect Dis Clin North Am*. 1997;11:609–622.

Warren JW. The catheter and urinary tract infection. *Med Clin North Am*. 1991;75:481–493.

Weld KJ, Dmochowski RR. Effect of bladder management on urological complications in spinal cord injured patients. *J Urol*. 2000;163:768–772.

West DA, Cummings JM, Longo WE, et al. Role of chronic catheterization in the development of bladder cancer in patients with spinal cord injury. *Urology*. 1999;53:292–297.

Weyrauch HM, Bassett JB. Ascending infection in an artificial urinary tract. An experimental study. *Stanford Med Bull*. 1951;9:25–29.

Wheat LJ. Infection and diabetes mellitus. *Diabetes Care*. 1980;3:187–197.

Wicks JD, Thornbury JR. Acute renal infections in adults. *Radiol Clin North Am*. 1979;17:245–260.

Widmer M, Gulmezoglu AM, Mignini L, et al. Duration of treatment for asymptomatic bacteriuria during pregnancy. *Cochrane Database Syst Rev*. 2011;(12) [CD000491].

Widmer M, Lopez I, Gülmezoglu AM, et al. Duration of treatment for asymptomatic bacteriuria during pregnancy. *Cochrane Database Syst Rev*. 2015;(11) [CD000491].

Wiener J, Quinn JP, Bradford PA, et al. Multiple antibiotic-resistant Klebsiella and Escherichia coli in nursing homes. *J Am Med Assoc*. 1999;281(6):517–523.

Wilhelm M, Edson R. Antimicrobial agents in urinary tract infections. *Mayo Clin Proc*. 1987;62:1025–1031.

Williams J, Reeves D, Brumfitt W. The effects of bacteriuria in pregnancy on maternal health. Brumfitt W, Asscher A. *Urinary tract infection*. Oxford University Press: London; 1973:103–107.

Williams RJ 3rd, Attia E, Wickiewicz TL, et al. The effect of ciprofloxacin on tendon, paratenon, and capsular fibroblast metabolism. *Am J Sports Med*. 2000;28(3):364–369.

Wills S, Ravipati A, Venuturumilli P, et al. Effects of vaginal estrogens on serum estradiol levels in postmenopausal breast cancer survivors and women at risk of breast cancer taking an aromatase inhibitor or a selective estrogen receptor modulator. *J Oncol Pract*. 2012;8(3):144–148.

Wilson W, Taubert K, Gewitz M, et al. Prevention of Infective Endocarditis: guidelines from the American Heart Association: a guideline from the American Heart Association Rheumatic Fever, Endocarditis, and Kawasaki Disease Committee, Council on Cardiovascular Disease in the Young, and the Council on Clinical Cardiology, Council on Cardiovascular Surgery and Anesthesia, and the Quality of Care and Outcomes Research Interdisciplinary Working Group. *Circulation*. 2007;116:1736–1754.

Wolach MD, MacDermott JP, Stone AR, et al. Treatment and complications of Fournier's gangrene. *Br J Urol*. 1989;64:310–314.

Wolf JS Jr, Bennett CJ, Dmochowski RR, et al. Best practice policy statement on urologic surgery antimicrobial prophylaxis. *J Urol*. 2008;179:1379–1390.

Wolfe AJ, Toh E, Shibata N, et al. Evidence of uncultivated bacteria in the adult female bladder. *J Clin Microbiol*. 2012;50:1376–1383.

Wolfe RM, Sharp LK, Wang RM. Family physicians’ opinions and attitudes to three clinical practice guidelines. *J Am Board Fam Pract*. 2004;17(2):150–157.

Wortmann G, Fleckenstein J. Incidental discovery of emphysematous cystitis. *South Med J*. 1998;91(8):785–786.

Wright A, Walker R, Barrett D. The fluoroquinolones and their appropriate use in treatment of genitourinary tract infections. Ball T, Novicki D. *AUA update series*. American Urologic Association: Houston; 1993.

Wright KJ, Seed PC, Hultgren SJ. Uropathogenic Escherichia coli flagella aid in efficient urinary tract colonization. *Infect Immun*. 2005;73(11):7657–7668.

Wu X, Dong Y, Liu Y, et al. The prevalence and predictive factors of urinary tract infection in patients undergoing renal transplantation: a meta-analysis. *Am J Infect Control*. 2016;44(11):1261–1268.

Wu XR, Sun TT, Medina JJ. In vitro binding of type 1-fimbriated *Escherichia coli* to uroplakins Ia and Ib: relation to urinary tract infections. *Proc Natl Acad Sci USA*. 1996;93:9630–9635.

Yamamoto S, Tsukamoto T, Terai A, et al. Genetic evidence supporting the fecal-perineal-urethral hypothesis in cystitis caused by *Escherichia coli*. *J Urol*. 1997;157:1127–1129.

Yang L, Gao L, Chen Y, et al. Prophylactic antibiotics in prostate biopsy: a meta-analysis based on randomized controlled trials. *Surg Infect (Larchmt)*. 2015;16(6):733–747.

Yazaki T, Ishikawa S, Ogawa Y, et al. Xanthogranulomatous pyelonephritis in childhood: case report and review of English and Japanese literature. *J Urol*. 1982;127:80–83.

Yen DH, Hu SC, Tsai J, et al. Renal abscess: early diagnosis and treatment. *Am J Emerg Med*. 1999;17:192–197.

Yokoyama M, Fujii Y, Yoshida S, et al. Discarding antimicrobial prophylaxis for transurethral resection of bladder tumor: a feasibility study. *Int J Urol*. 2009;16(1):61–63.

Yoshida K, Murao K, Fukuda N, et al. Emphysematous cystitis with diabetic neurogenic bladder. *Intern Med*. 2010;49(17):1879–1883.

Young JL, Liss MA, Szabo RJ. Sepsis due to fluoroquinolone-resistant *Escherichia coli* after transrectal ultrasound-guided prostate needle biopsy. *Urology*. 2009;74:332–338.

Zacur HA, Mitch WE. Renal disease in pregnancy. *Med Clin North Am*. 1977;61:89–109.

Zalmanovici Trestioreanu A, Lador A, Sauerbrun-Cutler MT, et al. Antibiotics for asymptomatic bacteriuria. *Cochrane Database Syst Rev*. 2015;(4) [CD009534].

Zani EL, Clark OA, Rodrigues Netto N Jr. Antibiotic prophylaxis for transrectal prostate biopsy. *Cochrane Database Syst Rev*. 2011;(5) [CD006576].

Zaytoun OM, Vargo EH, Rajan R, et al. Emergence of fluoroquinolone-resistant *Escherichia coli* as cause of postprostate biopsy infection: implications for prophylaxis and treatment. *Urology*. 2011;77:1035–1041.

Zdziarski J, Svanborg C, Wullt B, et al. Molecular basis of commensalism in the urinary tract: low virulence or virulence attenuation? *Infect Immun*. 2008;76(2):695–703.

Zhanel GG, Harding GK, Nicolle LE. Asymptomatic bacteriuria in patients with diabetes mellitus. *Rev Infect Dis*.

1991;13(1):150–154.

Zhanel GG, Hoban DJ, Harding GK. The postantibiotic effect: a review of in vitro and in vivo data. *DICP*. 1991;25(2):153–163.

Zhanel GG, Nicolle LE, Harding GK. Prevalence of asymptomatic bacteriuria and associated host factors in women with diabetes mellitus. The Manitoba Diabetic Urinary Infection Study Group. *Clin Infect Dis*. 1995;21(2):316–322.

Zhang D, Zhang G, Hayden MS, et al. A toll-like receptor that prevents infection by uropathogenic bacteria. *Science*. 2004;303:1522–1526.

Zikria J, Goldman R, Ansell J. Cranberry juice and warfarin: when bad publicity trumps science. *Am J Med*. 2010;123(5):384–392.

Zornow DH, Landes RR, Morganstern SL, et al. Malacoplakia of the bladder: efficacy of bethanechol chloride therapy. *J Urol*. 1979;122:703–704.

Inflammatory and Pain Conditions of the Male Genitourinary Tract

---

Prostatitis and Related Pain Conditions, Orchitis, and Epididymitis

Michel Pontari MD

Prostatitis

Historical Perspective

In a presentation to the 1929 American Urological Association held in Seattle, Dr. Franklin Farman of Los Angeles gave a brief history of prostatitis and proposed a classification. He noted that knowledge of the prostate dates back to mentions by Herophilus in 350 BCE, and that Nicola Massa, a Venetian physician living the 16th century, is accredited with discovering and describing the prostate. The first description of prostatitis dates to 1838 by Verdies. Treatment by prostate massage was described by Posner of Berlin in 1893. Before this therapy, diseases of the prostate were treated by “applications to the perineum in the form of counter-irritation, heat, cupping, leeches and the like.” He proposed a classification of prostatitis divided into two groups based on bacterial cause: the specific or gonorrheal type and the nonspecific or secondary focal type. The gonococcal was divided into three types: simple catarrhal or follicular prostatitis from acute infection and spread from the posterior urethra, true chronic parenchymous prostatitis from repeated infections, and a final category of atrophic or atonic prostatitis. This latter category, he asserted, also includes symptoms of premature ejaculation and impotency but has other causative factors, “a discussion of which involves the field of neuro and psycho-pathology.” The second category of prostatitis was thought to come about from hematologic seeding from other infections.

The clinical course of infectious prostatitis was changed significantly with the development of antibiotics (Nickel, 2000). Krieger and Weidner (2003) contend that the contemporary history of prostatitis began with a letter to the editor published in the *Journal of Urology* in 1978 by George Drach et al. (1978). This is described as the first scientific recommendations for a systematic classification of patients with symptoms of prostatitis. The diagnosis was based on the microscopic examination and quantitative cultures of segmented urogenital tract specimens described by Meares and Stamey (1968) and four categories presented: (1) acute bacterial prostatitis with acute infection, (2) chronic bacterial prostatitis with recurrent episodes of bacteriuria by the same organism, (3) chronic bacterial prostatitis in which patients had symptoms of prostatitis, negative cultures, and inflammatory cells, and (4) prostatodynia, with symptoms of prostatitis including “prostatic discomfort” but no recognizable infection or inflammation.

Current Classification of Prostatitis

The current classification of prostatitis was developed at consensus conferences in 1995 and 1998; the National Institutes of Health (NIH) classification was published in 1999 (Krieger et al., 1999).

NIH Classification

I. Acute bacterial prostatitis
II. Chronic bacterial prostatitis
IIIA. Chronic prostatitis/pelvic pain syndrome, inflammatory
IIIB. Chronic prostatitis/pelvic pain syndrome, noninflammatory
IV. Asymptomatic inflammatory prostatitis

Categories I and II are similar to the Drach classification (Drach et al., 1978). Bacterial prostatitis accounts for 5% to 10% of cases. The categories of nonbacterial prostatitis and prostatodynia were transformed into category III chronic prostatitis/chronic pelvic pain syndrome (CP/CPPS). Category III is subdivided as category IIIA, inflammatory, with the presence of white blood cells in expressed prostatic secretions (EPS), post–prostate massage urine (VB3) or seminal plasma, or category IIIB, noninflammatory, without the inflammatory cells. This mirrors the distinction between nonbacterial prostatitis and prostatodynia. There have been no clinically significant differences demonstrated between these two subclasses.

The term *prostatitis* for category III may be confusing. Historically, the pain was thought to come from the prostate, from infection, or from inflammation. However, we now recognize that the prostate may not be the source of the pelvic pain in these men, and the term *chronic pelvic pain syndrome* was adopted to reflect this understanding. Although categorized as prostatitis, the pain of CP/CPPS may have nothing to do with inflammation or the prostate in some men. Type IV is asymptomatic inflammatory prostatitis and is diagnosed in men with no genitourinary pain complaints. Thus type IV is most commonly found in the evaluation of other genitourinary tract issues, such as in biopsy looking for prostate cancer or on semen analysis for evaluation for infertility.

The NIH definition of category III CP/CPPS as adopted by the Chronic

Prostatitis Research Network is that of symptoms of pain or discomfort in the pelvis for at least 3 of the previous 6 months (Schaeffer et al., 2002b). Several exclusion criteria are also included, such as demonstration of uropathogenic bacteria detected by standard microbiologic methods, urogenital cancer, prior radiation or chemotherapy, urethral stricture, or neurologic disease affecting the bladder (Schaeffer et al., 2002b). Similar inclusion and exclusion criteria are being used in the ongoing NIH study on the multidisciplinary approach to pelvic pain (MAPP) (Landis et al., 2014).

Histopathology

Histology

The term *prostatitis* can refer to the presence of inflammation on a histology examination of the prostate or is also used to describe clinical syndromes manifest by genitourinary discomfort or pain described in the NIH classification. The relationship is certainly not completely clear, and use of the terms can be confusing. The classification also contains category IV, which is prostatic inflammation, including prostate-specific specimens such as EPS, VB3, seminal plasma, and biopsies. Asymptomatic in this classification is the absence of pain. Histologic inflammation is commonly found in specimens resected for benign prostatic hyperplasia (BPH) (Nickel et al., 1999) and in biopsies done looking for prostate cancer. In a study by McNeal, prostatic inflammation was found in 44% of sampled adult prostates (McNeal, 1968). More contemporary series have found that more than 70% of men at autopsy to have chronic inflammation (Zlotta et al., 2014). Increased numbers of intraepithelial lymphocytes in areas of category IV prostatitis compared with areas of normal prostate suggest that it may be immune or autoimmune in origin (Dikov et al., 2015).

A classification system proposed by Nickel et al. recommended reporting inflammation in prostatitis by its anatomic location in the prostate, either glandular (within a duct/gland epithelium or lumen), periglandular (lies within stroma but centered around ducts and glands and approaches 50 µm or less), or stromal (in the stroma and >50 µm from a gland). Extent of inflammation is defined as focal (<10%), multifocal (10%–50%), or diffuse (> 50%). Grade is 1, or mild (individual inflammatory cells separated by distinct spaces, <100 cells); 2, or moderate (confluent sheets of cell with no tissue destruction or lymphoid follicles, 100–300 cells); and 3, or severe (confluent sheets of inflammatory cells with tissue destruction or nodule formation, 100–500 cells) (Nickel et al., 2001).

Fig. 56.1 shows a representative section illustrating the three locations of prostatic inflammation.

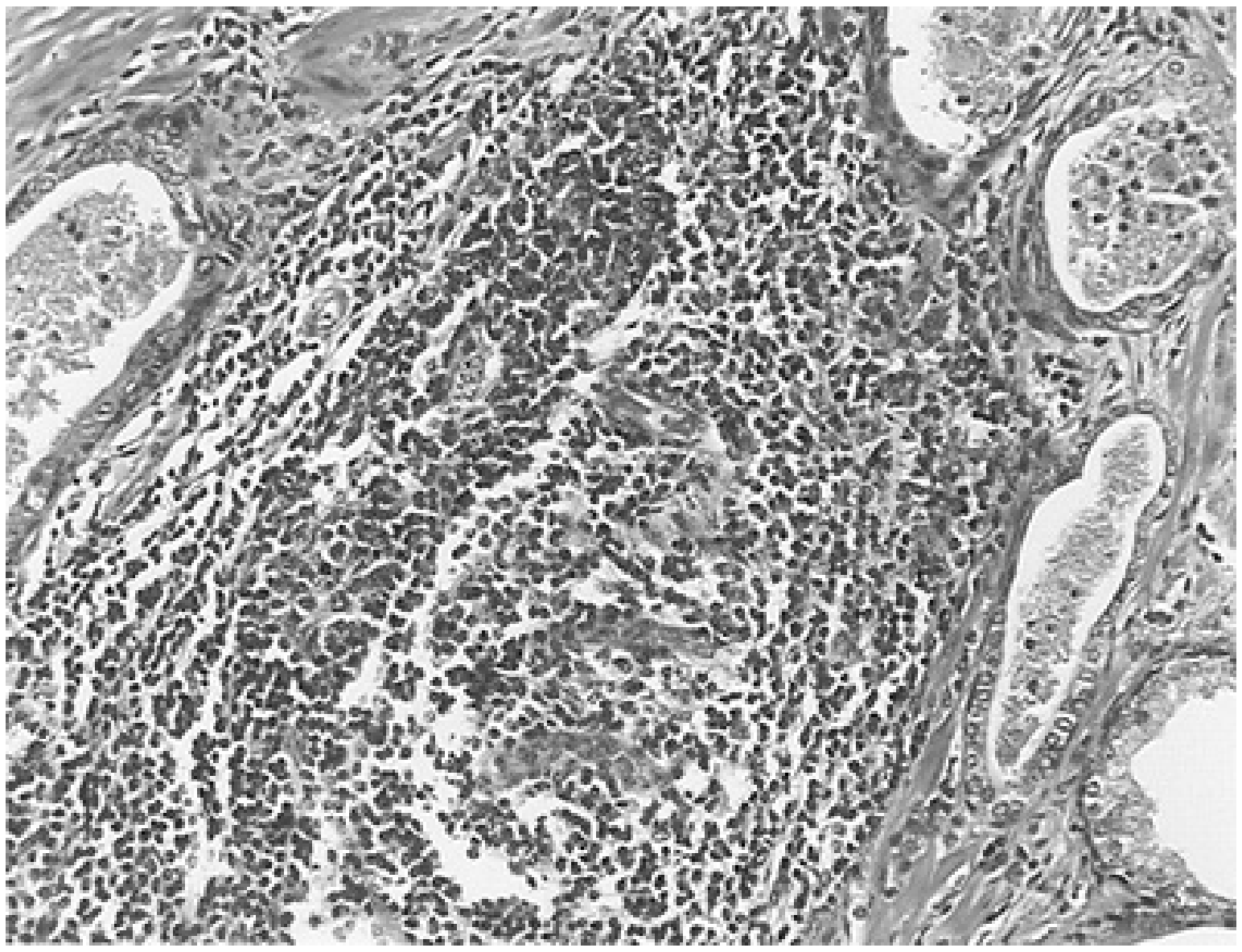

FIG. 56.1 Histologic preparation of a prostate specimen demonstrating areas of glandular, periglandular, and stromal inflammation (×400). (Courtesy Dr. Alexander Boag.)

Associated entities include corpora amylacea, which form from the deposition of prostatic secretions around sloughed epithelial cells; they do not usually cause inflammation unless they cause obstruction (Morales et al., 2005). Prostate calculi may contribute to inflammation by causing local obstruction or by providing a nidus for bacterial growth. The chemical composition of many stones suggest they may be caused by chronic infection (Dessombz et al., 2012). The presence of stones has been correlated to the symptoms of men with CP/CPPS (Shoskes et al., 2007). Occasionally they grow large enough to cause urethral obstruction and warrant surgical removal (Goyal et al., 2013).

Specific Cases of Prostatic Inflammation

Granulomatous Prostatitis

Granulomatous prostatitis is diagnosed by the histologic finding of epithelioid granulomas with or without other inflammatory cells (Uzoh et al., 2007). It is commonly found on specimens from transurethral resections and prostate biopsies. The most widely accepted grading system categorizes granulomatous prostatitis as specific, nonspecific, after transurethral resection of the prostate (TURP), and allergic granulomatous prostatitis (Epstein and Hutchins, 1984). It is commonly seen after intravesical Bacillus Calmette-Guerin (BCG) therapy for bladder cancer and can cause transient elevated levels of prostate-specific antigen (PSA) (Leibovici et al., 2000). Tuberculosis can also cause granulomatous prostatitis (Kulchavenya et al., 2012).

Immunoglobulin G Subclass 4 (IgG4)

Prostatitis has been described from IgG4-related disease (IgG4-RD). IgG4-RD is a recently described fibroinflammatory disease with multiorgan involvement. The first case of histologically confirmed IgG4 prostatitis was in 2006 (Yoshimura et al., 2006). IgG4-related disease is a fibroinflammatory condition characterized by several features: tendency to form tumorlike lesions at multiple sites, dense infiltrate of lymphocytes and IgG4 +plasma cells, characteristic pattern of fibrosis, and often, but not always, elevated levels of serum IgG4 (Deshpande et al., 2012). First described in autoimmune pancreatitis, multiple previously described disorders including Ormond disease (retroperitoneal fibrosis) are now considered to fall within this category (Stone et al., 2012). One of the characteristics of IgG4 disease is a dramatic response to corticosteroids. Patients with lower urinary tract symptoms from IgG4 disease have responded to corticosteroids with improvement in symptoms (Hart et al., 2013). There is as yet no characteristic presentation that would allow for identification of men with IgG4 prostatitis to allow for selection for treatment with steroids instead of surgery or standard BPH medications (Pontari, 2014). An obvious but perhaps small group is those men with concomitant autoimmune pancreatitis or sclerosing cholangitis and lower urinary tract symptoms (LUTS; Buijs et al., 2014). The diagnosis could be considered if histologic findings at the time of prostate biopsy for elevated PSA or a nodule suggest the diagnosis.

Category I Prostatitis: Acute Bacterial Prostatitis

Acute bacterial prostatitis (ABP) generally affects men age 20 to 40 years but also has a second peak of in cadence in men over the age of 60 (Krieger et al., 2011; Roberts et al., 1998). The causes of acute bacterial prostatitis are many. One is from ascending urethral infection. Characterization of virulence factors in the bacteria of men diagnosed with acute prostatitis indicated similar organisms in the urine specimens and rectal swab of the patient or sexual partner as the causative organism of the prostatitis in 6 of 9 men tested, indicating an ascending route of infection (Terai et al., 2000). Direct seeding from a prostate biopsy is a common cause. Other causes include intraprostatic reflux of infected urine that enters the ejaculatory and prostatic ducts of the posterior prostatic urethra and rarely spreads from the rectum via the lymphatic system. Hematogenous dissemination in the setting of bacterial sepsis or other blood-borne infections such as tuberculosis can occur (Brede and Shoskes, 2011).

Risk factors for the development of acute prostatitis include unprotected sexual intercourse, specifically insertive anal intercourse, phimosis, condom catheter use, indwelling urethral catheters, and urinary tract instrumentation, including endoscopic procedures and prostate biopsy (Dielubanza et al., 2014). Dysfunctional voiding and disorders causing urinary stasis, including distal urethral stricture and BPH, also put men at risk of developing prostatitis (Heyns, 2012). Acute prostatitis can occur after an episode of bacterial cystitis or epididymo-orchitis (Brede and Shoskes, 2011). A review of complications of clean intermittent catheterization showed that prostatitis occurs in up to 33% of these patients (Wyndaele, 2002).

The presentation of category I prostatitis is acute symptoms of a urinary tract infection (UTI), characteristically including urinary frequency and dysuria. Some patients have symptoms suggestive of systemic infection, such as malaise, fever, and myalgias (Krieger et al., 1999). Because of the UTI, pain can also be present in the lower abdomen and perineum. Urinary retention may be present because of acute swelling of the prostate, pain, or spasm of the bladder neck. In severe cases, patients can experience symptoms of sepsis: high fevers and chills, cardiovascular instability, and mental status changes (Brede and Shoskes, 2011). The presentation can vary by the cause of the prostatitis. As compared with spontaneous acute prostatitis as seen in younger men, patients who develop acute prostatitis after lower urinary tract manipulation or biopsy tend to be older and have a greater likelihood of septicemia (Kim et al., 2015; Millan-Rodriguez et al., 2006). Patients with Extended spectrum beta–lactamase (ESBL) positive bacteria also have significantly higher rates of septicemia (Kim et al., 2015). **Acute prostatitis should be considered in any man who presents with a febrile UTI. Febrile UTI in men can be from pyelonephritis, acute cystitis, or prostatitis. In a prospective study of 70 men with febrile UTI** (Ulleryd et al., 1999)**, more than 90% had increases in PSA and/or prostate volume**. In this cohort one-third had flank pain. This indicates that the prostate is likely involved even if the patient has signs of pyelonephritis.

Microbiology.

The most common causative organism is *Escherichia coli*, implicated in 65% to 80% of cases (Millan-Rodriguez et al., 2006). Other common gram-negative organisms include *Pseudomonas aeruginosa*, *Proteus mirabilis*, and *Klebsiella* and *Serratia* spp. (Etienne et al., 2008; Kim et al., 2014; Yoon et al., 2012). *Enterococcus* spp. account for up to 10% of cases of acute prostatitis (Kravchick et al., 2004; Schneider et al., 2003a). *Neisseria gonorrhoeae* should be considered as a possible cause in sexually active young men. Rare causes of bacterial prostatitis include obligate anaerobes and gram-positive bacteria other than *Enterococcus* spp. *Mycobacterium tuberculosis* is a rare cause of prostatitis and is usually associated with immunodeficiency. Prostate involvement is seen in approximately 10% of cases of genitourinary tuberculosis (TB). Common symptoms in these patients include perineal pain and dysuria (Kulchavenya, 2013; Kulchavenya et al., 2013). In tuberculous prostatitis, abscess cavities can form in the prostate, which can connect with sinuses to the perineum and result in fistula formation. In patients with impaired immunity such as HIV, other infecting organisms can cause prostatitis, including *Staphylococcus aureus*, *Klebsiella pneumonia*, *Pseudomonas aeruginosa*, *Serratia marcescens*, *Salmonella typhi*, *M. tuberculosis*, and *Mycobacterium avium intracellulare* (Weinberger et al., 1988).

There are multiple virulence factors associated with the bacteria found in men with acute prostatitis. A contemporary study of previously healthy men aged 17 to 40 years old with acute prostatitis demonstrated 26 virulence genes from the cultured *E. coli* representing 5 virulence factors, including adhesins, toxins, and siderophores in addition to the expression of α-hemolysin, aerobactin, cytotoxic necrotizing factor-1 (CNF1), cytolethal distending toxin type 1 (CDT-1), and colicins. The isolates averaged 12.5 virulence genes (Krieger et al., 2011). URIs are uncommon in young healthy men, and this study demonstrates that bacterial virulence has a significant contribution to the development of acute prostatitis in this population (Krieger and Thumbikat, 2016). Another virulence factor that occurs in the bacteria causing acute prostatitis is the production of biofilms. Biofilms are a group of bacteria together in one area protected by a polysaccharide matrix. This makes the penetration of antibiotics more difficult. In a study of uropathogenic *E. coli* causing infection, biofilm formation was found more often in bacteria recovered from men with acute prostatitis (63%) as compared with cystitis (43%) and pyelonephritis (40%) (Soto et al., 2007), consistent with other studies (Kanamaru et al., 2006).

An important concept that has emerged is the difference in bacterial cause of prostatitis and antibiotic susceptibility depending on the cause. There are differences in organisms, depending on whether the acute prostatitis developed in the community or was nosocomial. A review indicated that community-acquired infections were three times more common than nosocomial infections. *E. coli* was the predominant organism, but nosocomial cases were more often caused by *P. aeruginosa*, enterococci, or *S. aureus* and had greater antimicrobial resistance and clinical failures (Etienne et al., 2008). Further distinctions are noted, depending on whether the acute prostatitis is spontaneous or occurs after lower urinary tract instrumentation or prostate biopsy. Patients with spontaneous acute prostatitis have predominantly *E. coli* (Millan-Rodriguez et al., 2006). Patients with acute prostatitis after manipulation also have predominantly *E. coli* but have a much higher prevalence of *Pseudomonas* spp. (20%) and have a higher risk of prostate abscess (Ha et al., 2008). Acute prostatitis after transrectal biopsy also has predominantly *E. coli*, but these bacteria are more resistant to fluoroquinolones (Kim et al., 2014), more likely to have ESBL-producing bacteria, and more likely to have positive blood cultures (Kim et al., 2015). **Thus the antibiotic selection for acute prostatitis must take into consideration the route of infection.**

Evaluation.

Patient history is important given the differences in the cause of the infection. The determination should be made if the patient has spontaneous acute prostatitis or has had lower urinary tract manipulation or a recent transrectal prostate biopsy. LUTS such as frequency urgency and dysuria are common. Associated signs of bacteremia and sepsis can be present, including fever, chills, and sweats (Brede and Shoskes, 2011). The history should assess for possible complicating factors such as diabetes, HIV, neurologic disease, and recent antibiotic use (Dielubanza et al., 2014). A palpable bladder may indicate urinary retention. **Acute prostatitis is the one situation in which one may palpate a truly "boggy" prostate from edema from inflammation. The prostate is tender and swollen in 60% to 90% of cases (**Etienne et al., 2008; Millan-Rodriguez et al., 2006**). Caution should be used to avoid aggressive palpation that could lead to bacterial dissemination and sepsis.**

Laboratory tests include a CBC, urinalysis, and midstream urine culture. Urine culture is positive in 60% to 85% of cases (Etienne et al., 2010). In a series of 347 patients with acute prostatitis, positive blood cultures were associated with a fever of more than 101.1°F, and although they generally grew organisms similar to the urine culture, contributed to the microbiologic diagnosis in 5% of cases (Etienne et al., 2010). Blood cultures should be drawn for patients with fever or chills before fever who have not yet received antibiotics. Prostate massage for prostate fluid should not be performed in the acute setting. Urinalysis can show white and red blood cells consistent with an infection. If the patient has a urethral discharge, urine can be sent for nuclear amplification tests for gonorrhea or chlamydia, but the prevalence of sexually transmitted infections in the setting of acute bacterial prostatitis is approximately 2% (Etienne et al., 2008). Renal function should be assessed to help guide antibiotic therapy. An assessment of postvoid residual urine should be made to rule out urinary retention, preferably noninvasively with an ultrasound. PSA testing is not recommended because the level is expected to be high during the acute phase (Game et al., 2003) and must be followed to ensure resolution back to normal levels. This may take up to 6 months to normalize and must be followed if elevated to make sure there is no elevation from an underlying prostate cancer (Zackrisson et al., 2003). Imaging studies are generally not indicated unless a prostate abscess is suspected. A transrectal ultrasound or CT scan can be used in this setting (Horcajada et al., 2003). There is no role for prostate biopsy for acute prostatitis.

Treatment.

It is important to fully treat acute prostatitis not only for the sake of the acute illness but also to prevent progression to a chronic infection as category II prostatitis (10.2%) or category III (9.6%) (Yoon et al., 2012). Infection with ESBL bacteria after a transrectal prostate biopsy is also a risk factor for progression to chronic prostatitis, reported as 25% of those with ESBL bacteria (Oh et al., 2013). Patients with systemic signs of infection need admission for IV antibiotics, hydration, and monitoring of laboratory studies. Some patients can be treated as an outpatient if they have no signs of systemic illness, can tolerate oral intake, and do not have urinary retention (Brede and Shoskes, 2011).

Antibiotics are the mainstay of therapy for acute bacterial prostatitis. The most recent European Association of Urology (EAU) guidelines on treating UTIs recommend the parenteral administration of high-dose bactericidal antibiotics such as a broad-spectrum penicillin, third-generation cephalosporin, or a fluoroquinolone. In initial therapy, any of these can be combined with an aminoglycoside (Grabe et al., 2015). One problem with this recommendation is the issue of men presenting with acute prostatitis after transrectal prostate biopsy. **Given the rates of resistance to quinolones and the incidence of ESBL bacteria seen in these cases, a strong argument can be made to use a carbapenem antibiotic in men presenting with fever and prostatitis after a transrectal prostate biopsy** (Dielubanza et al., 2014)**. This concern is reflected in the Update of the American Urological Association White Paper on the prevention and treatment of complications after prostate biopsy** (Liss et al., 2017)**, which states patients who have a fever after prostate biopsy should:**

- Not be offered fluoroquinolones or trimethoprim-sulfamethoxazole (TMP-SMX)
- Be managed with aggressive resuscitation and broad-spectrum antibiotic coverage: carbapenems, amikacin, or second- and third-generation cephalosporins (after urine and blood cultures)

Once the fever has subsided, or as initial treatment in patients who can be safely discharged, an oral fluoroquinolone, provided the bacteria is susceptible, is a good choice of therapy. Ciprofloxacin 500 mg twice daily or levofloxacin 500 mg daily can be used (Brede and Shoskes, 2011). It is recommended to reculture the urine after 1 week to make sure the bacteria has been cleared (Dielubanza et al., 2014). The traditional recommendation for antibiotic therapy for acute prostatitis to prevent chronic infection has been 4 weeks. However, 2 weeks of ciprofloxacin in men with a febrile UTI has been shown to produce a similar bacterial cure rate compared with 4 weeks of therapy (89% vs. 97%) and clinical cure rates at 1 year (72% vs. 82%). Thus 2 weeks is likely sufficient for duration of oral antibiotics (Ulleryd and Sandberg, 2003). Treatment for tuberculous prostatitis is with anti-TB chemotherapy for at least 6 months (Kulchavenya et al., 2016).

Adjuncts to Antibiotic Therapy.

The use of nonsteroidal anti-inflammatory medications can help with pain and inflammation. Patients may also benefit from the use of alpha-blockers if they have LUTS. For patients in urinary retention requiring drainage, traditional thinking has been to place a suprapubic catheter to avoid irritation of the prostate and possible bacteremia. For short-term care, straight catheterization or a brief period of urethral catheterization may be attempted (Brede and Shoskes, 2011).

Not every author agrees with this, however (Dielubanza et al., 2014), but for long-term bladder drainage, a suprapubic catheter is recommended.

Prostatic Abscess

Prostatic abscess should be suspected in men with high fever or a history of immunosuppression such as diabetes or HIV or who do not respond to initial therapy after 48 hours (Ha et al., 2008). Risk factors for development of abscess include history of prior catheter use, history of genitourinary surgery, increasing age and increased medical co-morbidities, indwelling catheter, instrumentation of the lower urinary tract, bladder outlet obstruction, acute and chronic bacterial prostatitis, chronic renal failure, hemodialysis, biopsy of the prostate, diabetes, cirrhosis, and HIV (Abdelmoteleb et al., 2017; Weinberger et al., 1988).

Imaging should be performed to look for a prostatic abscess. Methods recommended are transrectal ultrasound or CT scan. Ultrasound will show a hypoechoic area. CT offers the advantage of clarity of location and preoperative planning, as well as identification of any spread beyond the prostate (Vaccaro et al., 1986). Smaller lesions less than 1 to 2 cm may be treated conservatively with antibiotics (Abdelmoteleb et al., 2017). In a recent series, patients with an abscess smaller than 2 cm could be cured by medical therapy alone, but those who underwent surgical drainage required a shorter duration of antibiotic treatment than those treated conservatively (Lee et al., 2016). In men with progression of symptoms, treatment is indicated. Localized lesions, or those that are very peripheral, can be treated by percutaneous drainage under ultrasound guidance (Varkarakis et al., 2004). The recurrence rate after aspiration ranges from 15% to 33% (Ackerman et al., 2018). Lesions that do not respond to initial percutaneous drainage or lesions too large to adequately drain percutaneously should be taken for TURP to unroof the abscess (Fig. 56.2). A maneuver that has proven helpful is palpation and massage of the prostate after unroofing to help fully drain the abscess cavity. Rare cases of abscess that extend beyond the prostate may require open surgical treatment (Ludwig et al., 1999).

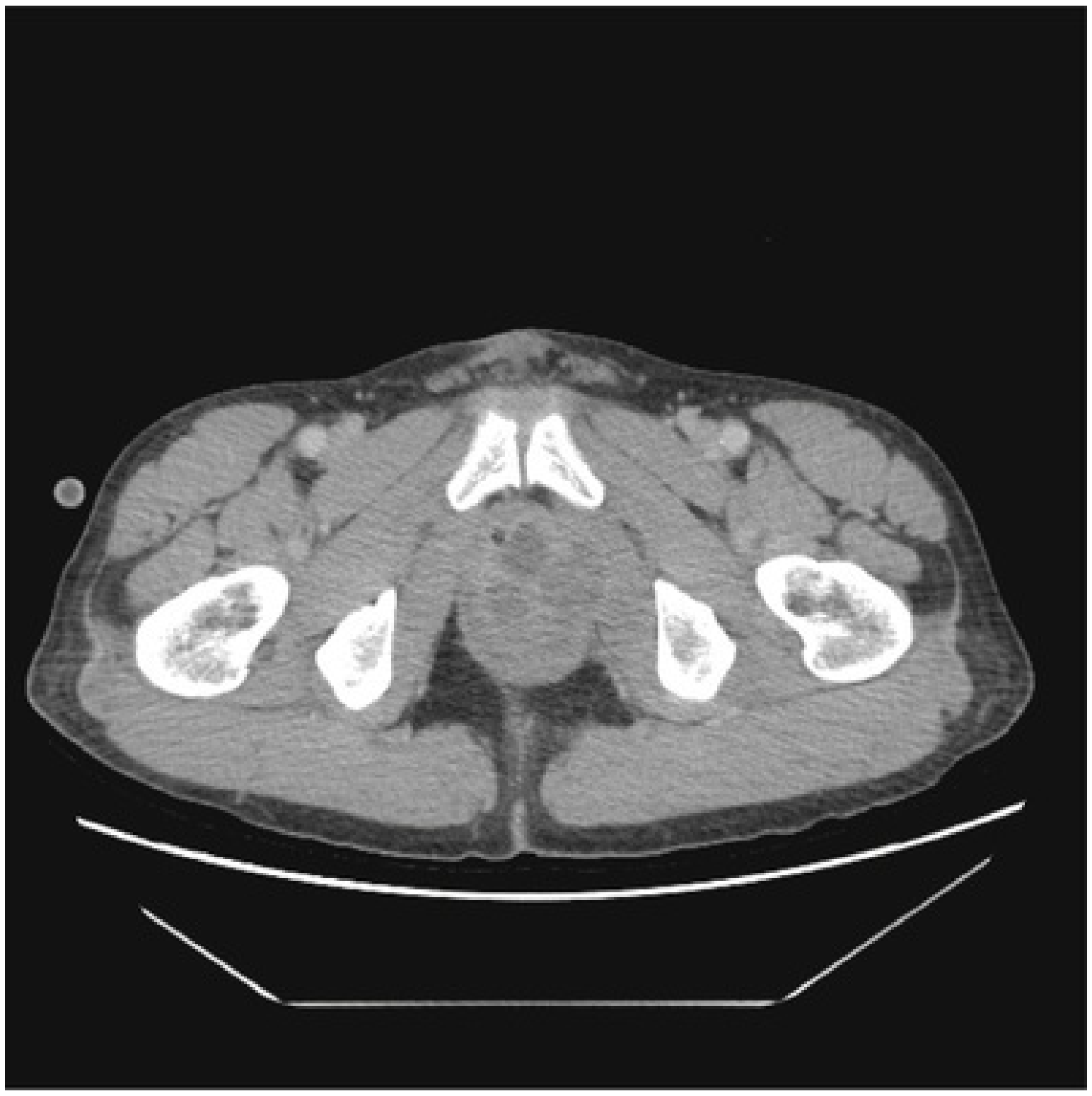

FIG. 56.2 Large prostate abscess in patient with dysuria and fever. Abscess was treated by transurethral unroofing.

Key Points

- Men with category I acute prostatitis experience acute symptoms of dysuria, frequency, and possibly fever.
- The most common causative organism is *E. coli*.
- Types of bacteria and antibiotic sensitivities differ by cause: spontaneous, after transurethral procedure, or after transrectal biopsy.
- Men with acute prostatitis after transrectal biopsy should be treated with carbapenems, amikacin, or second- and third-generation cephalosporins.
- A suprapubic tube should be used if long-term drainage is needed.
- Failure to respond to therapy should prompt imaging to look for a prostatic abscess.

Category II: Chronic Bacterial Prostatitis

Chronic bacterial prostatitis is characterized by recurrent urinary tract infections with the same organism (Krieger et al., 1999). This suggests a persistent prostatic source. This category accounts for 5% to 10% of cases of prostatitis (Krieger and Egan, 1991). **The symptoms of dysuria and pain generally respond to antibiotic treatment, and, unlike men with category III CP/CPPS, they are then relatively asymptomatic between episodes.**

Bacteria-Causing Category II Prostatitis.

Causative organisms for causing acute bacterial prostatitis, in most cases, are *E. coli, Pseudomonas, Proteus, Klebsiella*, and *Enterobacter* spp. (Gill and Shoskes, 2016). The role of enterococcus in causing chronic bacterial prostatitis is generally accepted. Of 6211 patients attending an Italian prostatitis clinic between 1997 and 2008, *Enterococcus faecalis* was found in 2745, or 44% (Cai et al., 2011). The significance of other gram-positive bacteria such as staphylococci and streptococci is debated. Microorganisms also considered to be of debatable significance include *Corynebacterium, Ureaplasma urealyticum*, and *Mycoplasma hominis*. Fastidious organisms that may require different culture techniques include *Mycoplasma tuberculosis* and *Candida* spp. (Schneider et al., 2003b). Similar to bacteria causing category I prostatitis, bacteria causing chronic bacterial prostatitis also are likely to form biofilms, which make them less likely to respond to treatment (Bartoletti et al., 2014).

Role of *Chlamydia* in Prostatitis?

The role of chlamydia as a cause of chronic bacterial prostatitis is still controversial. *Chlamydia* is an obligate intracellular gram-negative bacterium. It is surrounded by a rigid cell wall and needs other living cells to multiply because it cannot synthesize some essential nutrients (Mackern-Oberti et al., 2013). *Chlamydia* spp. can cause prostatic infection by an ascending route after urethral inoculation in animal models (Pal et al., 2004). The main argument is the difficulty of attributing the findings of *Chlamydia* spp. in the expressed prostatic secretions or semen to prostate infection alone given the possibility of urethral contamination, as *Chlamydia* spp. are a common cause of urethritis (Weidner et al., 2002). Studies of prostate tissue show *Chlamydia* spp. in 3% to 30%; however, the possibility of contamination from the prostatic urethra exists in tissue from TURP, transrectal biopsies, or open surgery and is eliminated only by perineal biopsy from the lateral lobes. Two studies of biopsies from the lateral lobes of the prostate have not detected *Chlamydia* spp. (Doble et al., 1989b;

Weidner et al., 1991b).

However, a growing body of literature on the possible role of *Chlamydia* spp. in prostate infection suggests some involvement. In a study looking for *Chlamydia* spp. in men with prostatitis compared with controls, *Chlamydia* spp. were identified by plasmid DNA found in the ejaculate of 35 of 78 patients but in none of 20 controls. Antichlamydial mucosal IgA was found in 69.2% of patients, with none found in the controls. The IgA levels correlated with symptoms and levels of IL-8 (Mazzoli et al., 2007). The presence of *Chlamydia* spp. has been linked to premature ejaculation (PE). In men with chronic prostatitis attributed to *Chlamydia* spp., 118 of 317 had PE (37.2%) as compared with 73 of 639 (11.5%) men with chronic prostatitis from common uropathogenic bacteria ($P < 0.0002$) (Cai et al., 2014). More compelling evidence was the report of a reduction in serum PSA in men with EPS or VB3 positive for *Chlamydia* spp. but negative VB1 treated with 4 weeks of a combination of levofloxacin and azithromycin; the resultant eradication of *Chlamydia* spp. and PSA response was also accompanied by a decrease in symptoms. This strongly suggests prostate involvement. Despite ongoing concerns (Benelli et al., 2017), some evidence supports a causative role for *Chlamydia* spp. in chronic bacterial prostatitis.

Diagnosis and Evaluation.

The diagnosis is currently made by the pre-massage and post-massage test (or two-glass test). The VB3 specimen gives information as to a persistent prostatic source of bacteria. The patient provides a midstream pre-massage urine specimen and a urine specimen (initial 10 mL) after prostatic massage to obtain expressed prostatic secretions (EPS) (Nickel et al., 2006). These specimens are then sent for culture. The previous method was the “four-glass test” as described by Meares and Stamey, which includes the first voided urine looking for urethral bacteria (VB1), the midstream urine (VB2), post-massage urine for EPS (VB3), and collection of the prostate fluid itself for culture (Meares and Stamey, 1968). The two-glass pre-massage and post-massage test is a simpler method and yields similar results. A study from the NIH Chronic Prostatitis Collaborative Research Network (CPCRN) examined a cohort of 353 men with CP/CPPS with complete four-glass data and noted that the two-glass test predicted a positive four-glass result with clinically acceptable accuracy (more than 95% of men would have had the same diagnosis if the four-glass test were performed) (Nickel et al., 2006). In men with human immunodeficiency virus (HIV), cultures should be sent not only for the usual bacteria but also for more atypical organisms, including anaerobes, anaerobes, fungi, and TB (Heyns and Fisher, 2005). There are no recommended diagnostic cutoff points for bacterial counts between the two specimens obtained, but some clinics use a 10-fold increase in the post-massage urine as being diagnostic of CP II (Benelli et al., 2017). Semen cultures are not recommended because of limited detection of causative bacteria (Weidner and Anderson, 2008) and decreased specificity resulting from skin contamination (Gill and Shoskes, 2016).

Urine should be assessed for hematuria. If present in the setting of infection, it should be rechecked 4 to 6 weeks after resolution of infection to look for resolution of the hematuria. Persistent hematuria should prompt an evaluation. Physical examination should evaluate for fever. Abdominal examination is necessary to rule out other causes of abdominal/suprapubic pain. Scrotal examination is needed to evaluate for any associated areas of inflammation and possible infection such as the epididymis and testis. A digital rectal examination is indicated to look for prostate size and any abnormalities to suggest prostate cancer. It is important to assess for bladder outlet obstruction and urinary retention. Retention of urine may predispose to recurrent urinary tract infection. A postvoid residual urine of more than 180 mL has been correlated with increased risk of infection (Truzzi et al., 2008). Urinary retention also increases the pathogenicity of bacteria (Johnson et al., 1993).

Not all patients with chronic bacterial prostatitis need imaging. In men younger than 45 years old with a first event of acute UTI, imaging showed no abnormalities. It is recommended, however, in this group to rule out urethral stricture. Men with a flow rate of more than 15 mL/min should be further evaluated (Abarbanel et al., 2003). Urethral strictures can occur with a UTI in up to 41% of cases (Santucci et al., 2007). Imaging is recommended for men with a UTI and history of diabetes, chronic kidney disease, stones, voiding difficulties, neurologic disease, poor response to antibiotics, infection with urea-splitting bacteria, or hematuria more than 1 month after the infection (Heyns, 2012).

Treatment of Chronic Bacterial Prostatitis (Category II).

The treatment of category II prostatitis is limited to antibiotics that can penetrate the prostate and achieve therapeutic levels. The prostate capillary bed lacks active transport mechanisms for antibiotics (Stamey et al., 1970). Penetration into the prostate, therefore, is dependent on passive transport, and the factors that influence this transport are drug concentration, lipid solubility, degree of ionization or charge, degree of protein binding, and size and shape of the molecule (Wagenlehner et al., 2013). Quinolones have excellent prostate penetration because of their configuration, including positively and negatively charged groups, also called a zwitterion. The fluid of chronic bacterial prostatitis is alkaline and contributes to concentration of the quinolones (Wagenlehner et al., 2005). These molecules also have high lipid solubility (Perletti et al., 2009). Other antimicrobial agents that have good to excellent penetration into prostatic fluid and tissue include tetracyclines because of their lipid solubility, macrolides because of their pKa values, and trimethoprim, which is a lipid-soluble base with a favorable pKa (Charalabopoulos et al., 2003b).

There are no American Urological Association (AUA) guidelines for antibiotic treatment of chronic bacterial prostatitis/category II, but the EAU has guidelines for this condition (Grabe et al., 2015). Fluoroquinolones such as ciprofloxacin and levofloxacin are the antibiotics of choice not only because of their tissue penetration but also because of their spectrum of coverage, which includes gram-negatives, including *Pseudomonas*, gram-positives, and atypical pathogens such as *Chlamydia* spp. and genital *Mycoplasma* spp. Duration of treatment is based on expert opinion; the recommendation is 4 to 6 weeks. This is in agreement with recent guidelines published by the Prostatitis Expert Reference Group from the UK (Rees et al., 2015b). Because of their ability to penetrate biofilms, the addition of a macrolide may be beneficial. In a trial by Magri et al., the combination of azithromycin 500 mg three times per week added to ciprofloxacin 750 mg per day for 4 weeks increased bacterial eradication rates compared with azithromycin and ciprofloxacin at the more standard regimen of 500 mg per day for 6 weeks (Magri et al., 2011).

Overall it is estimated that 60% to 80% of patients with *E. coli* and other gram-negative Enterobacteriaceae can be cured by the quinolone regimen (Wagenlehner et al., 2013). This is in comparison with only 30% to 50% with a 12-week course of Bactrim (timethoprim-sulfamethoxazole [TMP-SMX]) (Kurzer and Kaplan, 2002). However, in cases in which the bacteria are resistant to fluoroquinolones but susceptible to TMP-SMX, a 3-month course of TMP-SMX can be given. There are no evidence-based recommendations for treatment if the bacteria are resistant to both agents. A 2013 Cochrane review examined the treatment of chronic prostatitis (Perletti et al., 2013). For traditional bacterial prostatitis, there was no difference among the oral fluoroquinolones. No conclusion could be drawn regarding the optimal treatment duration; treatment ranged from 4 to 12 weeks. For chlamydial prostatitis, azithromycin was superior to Cipro and equivalent to clarithromycin.

CP II in HIV/Immunocompromised Patients.

In men with HIV, consideration should be made for low antimicrobial suppression for some time to reduce the risk of recurrence (Santillo and Lowe, 2006). In patients who are already treated with highly active antiretroviral therapy (HAART) and are still persistently immunocompromised, lifetime suppressive antimicrobials have been recommended to risk progression to prostatic abscess (Lee et al., 2001).

Beyond Quinolones.

In the setting of increasing quinolone resistance and trimethoprim resistance, other alternatives are needed. Alternatives that have data for use in chronic bacterial prostatitis include netilmicin, an aminoglycoside (no longer available in the US; Magri et al., 2016) and cefoxitin (Demonchy et al., 2018). Piperacillin-tazobactam achieves prostatic levels that would be adequate to treat infections from *E. coli*, *Klebsiella*, and *Proteus* but not adequate levels to treat *Pseudomonas* (Kobayashi et al., 2015). Fosfomycin has in vitro activity against *E. coli* with antimicrobial resistance, including ESBL strains (Karlowsky et al., 2014). It also has good penetration into the prostate (Gardiner et al., 2014). A dosage of 3 g every 48 to 72 hours was used in 15 patients with bacterial eradication in 8 and clinical cure in 7 (Los-Arcos et al., 2015).

Adjunct treatments for refractory chronic bacterial prostatitis include alternate regimens of antibiotics and surgery. When antibiotic therapy fails to eradicate infection, the patient can be started on a daily dose of an antibiotic targeting an identified bacterial isolate. Duration is approximately 6 months, after which it should to be titrated down to maintain the lowest dose that results in symptom relief (Dielubanza et al., 2014). A trial of the medicine near 6 months may also be advisable to see if the antibiotic is still necessary. In self-start therapies, men send urine cultures when they have a recurrence of symptoms and start the antimicrobials at the start of symptoms (Dielubanza et al., 2014). For patients whose symptoms are refractory to medical therapy, TURP has been used with results of 52% to 67% of patients responding to TURP down to the surgical capsule (Barnes et al., 1982; Decaestecker and Oosterlinck, 2015).

Key Points

- Chronic bacterial prostatitis is characterized by recurrent urinary tract infections with the same organism.
- Unlike men with category III prostatitis/chronic pelvic pain syndrome, men with category II are relatively asymptomatic between episodes.
- Urinary retention as a cause of recurrent UTI must be ruled out.
- Men younger than 45 years old do not need imaging but need assessment for a urethral stricture.
- Treatment is with antibiotics that achieve adequate prostate concentrations.
- For refractory cases daily suppressive antibiotics or TURP can be used.

Etiology

Despite a concerted research effort in the past 20 years, the cause and much of the pathogenesis of CP/CPPS remain unknown. However, there is evidence to support a possible role for infection, neurologic causes, and inflammatory/autoimmune, endocrine, and psychological factors. It is likely the interplay between all of these that contributes to the creation and continuation of pelvic pain (Pontari, 2013). One hypothesis is that an insult such as infection, stress, or trauma in a genetically susceptible individual leads to neurogenic inflammation, which is maintained by these other factors (Fig. 56.3).

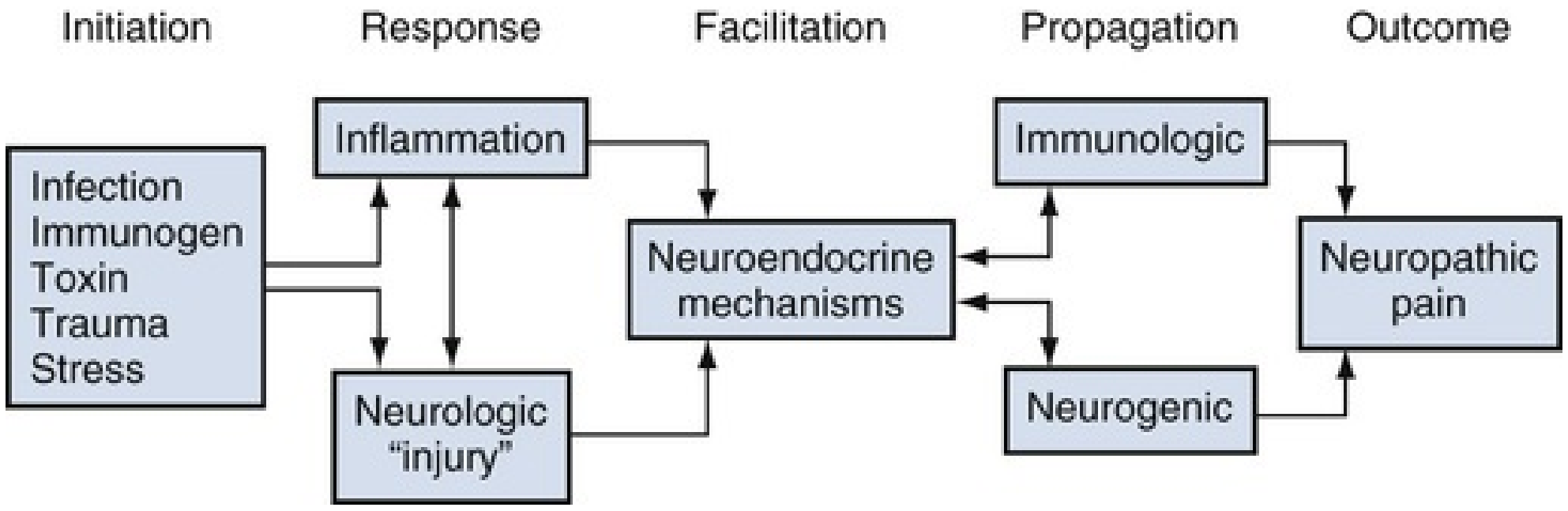
Initiation
Response
Facilitation
Propagation
Outcome
Infection
Immunogen
Toxin
Trauma
Stress
Inflammation
Neurologic "injury"
Neuroendocrine mechanisms
Immunologic
Neurogenic
Neuropathic pain

FIG. 56.3 Proposed cascade of initiation of chronic prostatitis and chronic pelvic pain syndrome (CPPS). Initial insult such as infection, immune response, toxin, trauma, or stress in genetically susceptible host leads to neurogenic inflammatory response. This is then facilitated and propagated by psychological, immune, neurologic, and endocrine mechanisms to produce the final outcome of the phenotype of CPPS.

Infection

The symptoms of CP/CPPS are similar to that of a true prostatic infection. Therefore infection has been commonly assumed by patients and clinicians to be the cause of the symptoms. A history of prior sexually transmitted disease (STD) increases the odds of prostatitis by 1.8 times (Collins et al., 2002). Although a history of STD seems to lead to greater risk of CP/CPPS, there is no evidence of an active STD in these men (Weidner et al., 1991a). There is no difference in the routine cultures of men with CP/CPPS and asymptomatic controls from urine, prostatic fluid, and post-prostate massage urine or seminal plasma (Nickel et al., 2003). Eight percent of men had uropathogenic bacteria, and roughly 70% had some form of bacteria in each group. This indicates that some asymptomatic men appear to routinely have bacteria in the prostate but may not by themselves produce disease or symptoms.

Molecular techniques that can identify bacteria without culture include polymerase chain reaction, which has failed to show a clear organism emerging as the source of CP/CPPS (Badalyan, 2003; Hochreiter et al., 2000; Krieger et al., 2000; Leskinen et al., 2003; Riley et al., 1998; Shoskes and Shahed, 2000; Takahashi et al., 2003; Xiao et al., 2013). A newer technique involves using a specific set of primers that amplifies bacterial DNA, and then algorithms can match the resultant sequences to specific organisms. This technique can identify all bacterial species present at more than 1% to 3% of the biome (Ecker et al., 2008). Using this technique, Nickel et al. reported the only significant difference was found in the initial stream (VB1) samples, with the organism *Burkholderia cenocepacia* overrepresented in the CP/CPPS patients ($P = 0.002$) compared with controls (Nickel et al., 2015). This organism is an opportunistic pathogen in patients with cystic fibrosis and is known to be able to form biofilms (Fazli et al., 2014; Ganesan and Sajjan, 2011). Organisms of this genus have been described in acute prostatitis (Arzola et al., 2007). In an animal model, a strain of bacteria called CP1, isolated from a man with CP/CPPS, induced and sustained chronic pelvic pain that persisted after bacterial clearance from the genitourinary tract (Rudick et al., 2011). Thus possibly certain bacteria produce pelvic pain. Recent studies also have found alterations in the microbiome of men with CP/CPPS compared with controls. Men with CP/CPPS have increased diversity of bacteria in the urinary tract at the phylogenic level that exhibit more varied clustering than men without symptoms (Shoskes et al., 2016). A parallel study showed less diversity in the gut microbiome in the CP/CPPS patients compared with controls (Shoskes et al., 2016).

Inflammation

The term *prostatitis* implies inflammation of the prostate gland. However only about one-third of men with clinical CPPS have been found to have prostatic inflammation on biopsy (True et al., 1999). **In those with inflammation in VB3, EPS, or seminal plasma, the degree of inflammation does not correlate with symptoms** (Schaeffer et al., 2002a). Data looking at individual cytokines vary widely and are not conclusive. The possibility of an autoimmune response in some men is supported by reports that some men with CP/CPPS have an increased lymphoproliferative response to prostate antigens (Motrich et al., 2007) compared with controls. These include a region of the prostatic acid phosphatase molecule, PSA (Kouiavskaia et al., 2009), and human seminal vesicle secretory protein 2 (SVS2) (Hou et al., 2012). Levels of the chemokines monocyte chemoattractant protein-1 and macrophage inflammatory protein-1-α are significantly elevated in patients with CP/CPPS compared with those without urologic disease or BPH, and elevated MIP-1-α levels showed positive correlation with not only absolute NIH-CPSI scores, but with pain components of the NIH-CPSI as well (Desireddi et al., 2008). Levels of IL-17 are elevated in men with CP/CPPS and correlate with patient symptoms (Murphy et al., 2015).

Neurologic Causes

The cardinal symptom in CP/CPPS is pain, which is mediated through the nervous system. In addition to the increased self-report of neurologic disease in men with CP/CPPS compared with controls (Pontari et al., 2005), there is evidence for differences in the autonomic nerve function of men with CP/CPPS. **There is evidence for central sensitization in the afferent and efferent nervous system in men with CP/CPPS** (Yang et al., 2003; Yilmaz U et al., 2007). Central sensitization is characterized by continued nerve activity in the absence of stimulation or which requires a very low level of nociceptive stimulation to continue (Woolf, 1983). There are no differences in sensory perception thresholds in these patients, indicating that there is no peripheral neuropathy (Yilmaz et al., 2010). Changes in brain structure and function have been seen on neuroimaging. Farmer et al. (2011) studied spontaneous pelvic pain, with men lying in the fMRI scanner for 10 minutes and rating their fluctuations in brain activity in the absence of any external stimulus. Pain perception was localized to the anterior insula and correlated with the intensity of self-reported pain (Fig. 56.4). There were also differences in the relationship of gray and white matter in men with CPPS compared with controls (Farmer et al., 2011). The findings in men with CPPS differ from those in other pain conditions, including low back pain (Baliki et al., 2011). Other imaging studies have indicated UCCPS patients have lower white matter tract density in areas of perception, integration of sensory information and pain modulation (Woodworth et al., 2015). Men with CP/CPPS have decreased connectivity between motor areas involved in pelvic floor control and the right posterior insula, an area involved in pain processing and sympathetic autonomic control. The greater pain was associated with less connectivity between the areas (Kutch et al., 2015).

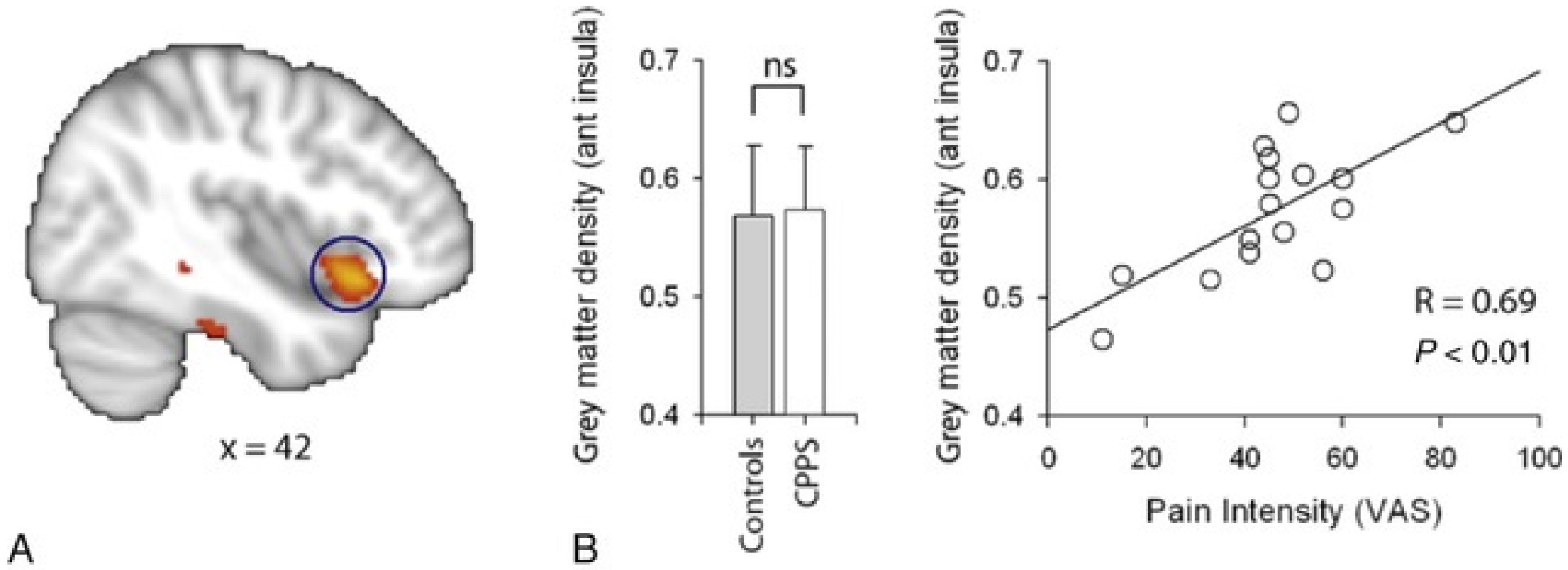

FIG. 56.4 Anterior insula activity is related to chronic prostatitis and chronic pelvic pain syndrome (CP/CPPS) pain intensity. (A) Peak activity from anterior insula *(blue circle)* identified from pain. The visual contrast shows significantly larger activity in pain task versus visual task *(bar graph),* and shows significant positive relationship between activity and CP/CPPS pain intensity (each symbol is individual subject in scatterplot). (B) Correlation of peak activity from anterior insula with clinical parameters of CP/CPPS. In addition to spontaneous pain intensity MPQ exhibited significant correlation with insular activity. (From Farmer MA: Brain functional and anatomical changes in chronic prostatitis/chronic pelvic pain syndrome. *J Urol.* 186[1]:117–124, Fig 3.)

Pelvic Floor Dysfunction

Neurologic abnormalities are postulated to also cause spasm in the pelvic floor. Patients with CP/CPPS have pathological tenderness of the striated pelvic floor muscle and poor to absent function in ability to relax the pelvic floor efficiently with a single or repetitive effort (Zermann et al., 1999). An electromyogram (EMG) study of the pelvic floor in these patients showed that compared with controls, men with CP/CPPS had (1) greater preliminary resting hypertonicity and instability and (2) lowered voluntary endurance contraction amplitude (Hetrick et al., 2006). A study by the CPCRN found that on physical examination, 14% of patients with CP/CPPS had tenderness of the internal pelvic floor, 13% had external pelvic floor tenderness, and neither was found in controls (Shoskes et al., 2008). On transabdominal ultrasound measurement of pelvic floor muscle mobility, compared with controls, men with CPPS have on average lower pelvic floor mobility resulting from increased tension (Khorasani et al., 2012).

Psychosocial Factors

Greater perceived stress is associated with greater pain intensity ($P = 0.03$) and disability ($P = 0.003$) in men with CP/CPPS (Ullrich et al., 2005). **Helplessness and catastrophizing predict overall pain along with urinary symptoms and depression** (Tripp et al., 2006). This was confirmed by a systematic review of 69 research articles looking at psychosocial influences (Riegel et al., 2014) that found an association of pain intensity with catastrophizing, perceived stress, and low satisfaction with relationships including sexual functioning. In the Boston Area Community Health (BACH) Survey, men who reported experiencing sexual, emotional, or physical abuse were at increased risk for symptoms of CP/CPPS (OR 1.7–3.3; Hu et al., 2007).

Endocrine Abnormalities

One of the common findings in chronic pain conditions is alterations of the hypothalamic-pituitary-adrenal axis; similar findings have been reported in CP/CPPS. On awakening, serum cortisol levels rise; there is a significantly greater cortisol rise in men with CPPS compared with controls. **Men with CPPS also have a lower baseline adrenocorticotropic hormone (ACTH) level and blunted ACTH rise in response to stress than men without symptoms** (Anderson et al., 2008).

Genetics

A twin study from the University of Washington compared self-reported lifetime physician diagnosis of CP/CPPS with so-called chronic overlapping pain conditions (COPC), including fibromyalgia, chronic fatigue syndrome, irritable bowel syndrome (IBS), temporomandibular disorder, tension headaches, and migraine headaches. Compared with their non-CP/CPPS twin, those with CP/CPPS were 6 to 30 times more likely to report a COPC. The conclusion is that familial factors, either shared environmental factors or genetic factors, play a large role in the relationship between CP/CPPS and COPC (Gasperi et al., 2017).

Biomarkers

There have been few biomarkers that correlate with symptoms in CP/CPPS. One of these markers is nerve growth factor (NGF), a neuropeptide that plays a role in nociception (Miller et al., 2002). NGF is reported to also decrease in men with CPPS who respond to treatment but not in those who do not respond (Watanabe et al., 2011). In the MAPP study, in men with UCCPS, pain severity was significantly positively associated with concentrations of matrix metallopeptidase 9 (MMP-9) and MMP-9/NGAL (neutrophil gelatinase-associated lipocalin) complex, and urinary severity was significantly positively associated with MMP-9, MMP-9/NGAL complex, and VEGF-R1 (vascular endothelial growth factor receptor 1) (Dagher et al., 2017). VEGF and MMP-9 are known to play a role in neuropathic pain (Ji et al., 2009; Selvaraj et al., 2015), although MMP/NGAL may be a marker of infection or inflammation (Chen et al., 2007).

Abnormal Sensory Processing

One of the hallmarks of patients with centralized chronic pain is generalized or global abnormality of sensory processing (Jensen et al., 2009; Kosek et al., 1996). In the MAPP study, this was tested using quantitative sensory testing (QST), in which a quantifiable pain stimulus, a computer-controlled pressure stimulus, is applied to the thumbnail. Patients with UCCPS (49% male) had significantly increased pain sensitivity compared with healthy controls (41% males). However, they were less sensitive to a mixed pain comparison group of patients with fibromyalgia, chronic fatigue syndrome, and irritable bowel syndrome (Clemens et al., 2018).

Key Points

- Men with CP/CPPS have amounts of bacteria in urine, prostate fluid, and seminal plasma equal to that in men without pain.

- There is evidence of central sensitization of the central nervous system (CNS) in afferent and efferent nerves.
- In those with inflammation in VB3, EPS, or seminal plasma, the degree of inflammation does not correlate with symptoms.
- Helplessness and catastrophizing predict overall pain along with urinary symptoms and depression.
- Men with CPPS also have a lower baseline ACTH level and blunted ACTH rise in response to stress than men without symptoms.
- Men with CP/CPPS have increased pain sensitivity compared with controls.

Symptoms in Chronic Prostatitis and Chronic Pelvic Pain Syndrome

The symptom that distinguishes category III prostatitis CP/CPPS from other conditions such as BPH is pain. One of the early attempts to catalog the symptoms of CP/CPPS was an Internet survey by Alexander and Tressel that surveyed of 163 men with prostatitis and reported that the most frequently reported and most severe symptom was pain in the pelvic region, followed by urinary frequency and obstructive voiding symptoms. The most frequent site of pain was the perineum (Alexander and Trissel, 1996).

In 1999 the NIH set out to develop a symptom score that could be used as an outcome measure for clinical trials (Litwin et al., 1999). It also has proved useful to help categorize the symptoms of CPPS. The development included focus groups of patients judged to have CP/CPPS, generally pelvic pain in the absence of infection. The resulting index included three domains: pain, urinary symptoms, and quality of life. Pain domains include pain in the perineum, lower abdomen/suprapubic area, testes, penis, pain with ejaculation, and dysuria. The other two sections include voiding symptoms and interference/quality of life. It has been validated (Litwin, 2002), and the pain and quality of life subscales are sensitive to change (Propert et al., 2006).

Prevalence of Individual Symptoms in Men With Chronic Prostatitis and Chronic Pelvic Pain Syndrome

A large study of 1563 men with CP/CPPS in Europe and North America looked at symptoms reported on the NIH-CPSI (Wagenlehner et al., 2013). The mean

NIH-CPSI score in the group was 20.4. The most common location of pain was in the perineum 63.3%, testicular 57.6%, tip of penis 32.4%, suprapubic area 42.3%, dysuria 43.3%, and pain with ejaculation 47.7%. Patients with dysuria were significantly more likely to have ejaculatory pain (*P* < 0.001). Patients with a greater number of pain locations also had greater severity of pain, voiding symptoms, and worse quality-of-life scores. Frequency and intensity of pain had the highest impact on overall quality of life; urinary symptoms did not correlate with changes in quality of life. Overall, using the total pain domain score as a measure, 32% had mild pain, 52% moderate pain, and 16% severe pain.

Summary of Findings From the Multidisciplinary Approach to Pelvic Pain Study

The NIH-sponsored MAPP study recruited men as part of a large phenotyping study. A large battery of urologic and psychological questions was administered. Some of the important findings to date are the following:

1. Patients who have pain beyond the pelvis have more severe symptoms than those with pelvic pain only.

   The MAPP project used a whole body map to record sites of pain (Lai et al., 2017). Forty-five sites are designated on the body map divided into seven zones. The severity of the nonpelvic pain increased with the number of regions reported. Patients with a greater number of pain sites also reported significantly greater sleep disturbance, depression and anxiety, psychological stress, somatic symptom burden, and negative affect. They also had more symptoms consistent with IBS, fibromyalgia, and migraine headaches.
2. Men with COPC have more severe symptoms than those with only urologic symptoms.

   In the MAPP study, 31% of men with pelvic pain enrolled have one or more of these so-called COPCs, the most common being IBS; patients with COPC also report more severe urologic symptoms and more frequent depression and anxiety compared with those without COPC (Krieger et al., 2015).
3. Patients with bladder-focused symptoms (bladder pain with filling and painful urgency) report more severe symptoms than those who do not have bladder symptoms.

Of 191 men enrolled in the first MAPP study, 75% were found to have either painful urgency (i.e., urgency to urinate because of pain pressure or discomfort and not because of fear of leaking) or pain that was made worse with bladder filling (Lai et al., 2015). Compared with men with pelvic pain only, men with painful urgency or bladder pain had more flares and higher levels of catastrophizing and more frequently reported having IBS. They also had more severe symptoms of pain, frequency, and urgency. These symptoms are usually thought to be associated with interstitial cystitis/bladder pain syndrome, in which older studies have reported a 10 : 1 female-to-male ratio (Clemens, 2015; Hanno et al., 2011; Lai et al., 2015). In the RAND Interstitial Cystitis Epidemiology male study, there was a 17% overlap between men who met the high specificity IC/BPS definition and the case definition for CP/CPPS (Suskind et al., 2013). Thus there is considerable symptom overlap between CP/CPPS and IC/BPS as currently defined.

4. Pain and urinary symptoms should not be measured together as part of a composite score.

Principal components and exploratory factor analysis were used to examine questionnaire items that had been administered to participants in the MAPP study (Griffith et al., 2016). Exploratory factor analysis is used to identify a small number of factors that can explain a correlation matrix among a set of questionnaire items. The analysis suggested that two separate factors drove the correlations for the questionnaires, the first being pelvic pain and the second urinary symptoms. An association with depression was predicted by pain but not by urinary symptoms, indicating these symptoms vary in their impact on patients. The conclusion of this study was that it is important to assess pain and urinary symptoms separately rather than combined as in the present symptom questionnaires, the NIH-CPSI (Litwin et al., 1999) and the GUPI (Clemens et al., 2009). The implication for treatment trials is that if they used a combined score, as has been done for the majority of trials in CP/CPPS since 1999, then there may be significant effects on either pain or urinary symptoms that were not seen because the overall change in score was not clinically significant.

Fluctuations in Symptom Severity

In the MAPP study of 424 participants with urologic pelvic pain syndrome, of whom 191 were male, symptoms were assessed every 2 weeks for 1 year (Stephens-Shields et al., 2016). The percentage of patients who improved was 24.8% for pain symptoms and 15% for urinary symptoms. The percentages for those whose symptoms became worse were 9.4% for the pain and 6.1% for the urinary symptoms. Factors that were predictive of worsening symptoms at 1 year were the extent of widespread pain, the presence of nonurologic symptoms (COPC), and poorer overall health. Pain catastrophizing and self-reported stress were predictive of just worsening pain scores. There was no contribution of anxiety, depression, and general mental health to symptom worsening (Naliboff et al., 2017).

Significant exacerbations of symptoms have been termed *flares* (Sutcliffe et al., 2012). Many factors have been postulated to cause flares. In a case crossover study from the MAPP network, 79 reported no flare at baseline or at any time thereafter in the 1 year follow-up. In a group of 292 (69%) patients with at least one flare, 116 were men. Only recent sexual activity and UTI-like symptoms were predictive of flare. Issues that did not predict a flare included diet, physical activity or sedentary behavior, stress, and constipation (Sutcliffe et al., 2018).

Sexual Dysfunction

The prevalence of ED in men with CP/CPPS is reported at 15% to 40% (Tran and Shoskes, 2013). In addition, a case control study of a large Taiwanese health database showed that men with a diagnosis of ED were more likely to have been previously diagnosed with CP/CPPS, 8.6%, compared with 2.5% of randomly selected controls ($P < 0.001$) (Chung et al., 2012). Other symptoms of sexual dysfunction are ejaculatory dysfunction/pain and premature ejaculation. From the CPCRN cohort, 74% of the men had ejaculatory pain at some point (Shoskes et al., 2004). Similar levels of premature ejaculation have been reported (Tran and Shoskes, 2013).

Anxiety and Depression

In the original CPCRN cohort study, men with CP/CPPS were twice as likely to report anxiety and depression as age-matched controls (Pontari et al., 2005). Similar findings were reported in the subsequent MAPP study, as compared with age- and education-matched controls, males with pelvic pain showed greater levels of current and lifetime stress, poor illness coping, and increased self-report of cognitive deficits (Naliboff et al., 2015). A large database study from Taiwan found that men with CP/CPPS were significantly more likely to have a diagnosis of anxiety disorder than men without the diagnosis. The odds ratio (OR) was 2.10 (95% confidence interval [CI] 1.92–2.29, P <0.001). The association held for all age groups and was particularly strong in men aged 40 to 59 years old in which the OR was 2.53 (Chung and Lin, 2013).

Association With Other Medical Diseases

Cardiovascular Disease.

In the CPCRN study that compared cases with age-matched controls, men with CP/CPPS were six times more likely to self-report a history of cardiovascular disease, most commonly hypertension. A follow-up study by Shoskes et al. found greater arterial stiffness in men with CPPS compared with controls (Shoskes et al., 2011). The association of hypertension and CP/CPPS was also examined in the Health Professionals follow-up study, which found no association on multivariate analysis with hypertension overall, but there was in men with a BPH/LUTS history (OR 1.36) (Zhang et al., 2015). Other studies have been mixed, reporting no correlation for hypertension as part of metabolic syndrome in men with CP/CPPS (Wang et al., 2013) or a significantly higher rate of hypertension in men with CP/CPPS than controls (Chung and Lin, 2013).

Neurologic Disease.

Men with CP/CPPS were 5 times more likely to self-report a history of nervous system disease compared with asymptomatic age-matched controls in the CPCRN study (Pontari et al., 2005). In the NIH cohort, the symptom that most contributed to the difference in neurologic disease was numbness and tingling in the limbs. Also significant was a history of vertebral disk disease/surgery. Migraine headaches were common in the cases, but they were not significantly different than controls.

Phenotypic Approach to Symptoms and Symptom Clustering: UPOINT

The phenotype of patients meeting the criteria for CP/CPPS is variable and can include multiple different types of symptoms. This has been well outlined by Shoskes et al. in the UPOINT classification (Shoskes et al., 2009). This includes the categories of urinary, psychosocial, organ-specific, infection, neurologic/systemic, and tenderness of skeletal muscle (Fig. 56.5). The impetus for the classification was in part the recognition of the failure of monotherapies in clinical trials in men with CP/CPPS (Nickel et al., 2004). With this classification, therapy can be targeted to specific domains of symptoms. The clinical description of the UPOINT classification includes several factors under each domain, and descriptions of the compilation of symptoms have been published (Nickel and Shoskes, 2010). The percentage of men who fall in to each domain has been strikingly similar across multiple studies; the largest domain has been organ-specific and urinary, and the smallest domain has been the infectious category. Men with CP/CPPS generally are characterized by multiple domains. In an early description, only one in five men were positive for only one domain, one-third of men were characterized by two domains, and the rest by three or more domains (Shoskes et al., 2009). There is a strong correlation between the number of domains of UPOINT and severity of symptoms (Shoskes et al., 2009; Shoskes et al., 2010; Shoskes and Nickel, 2013).

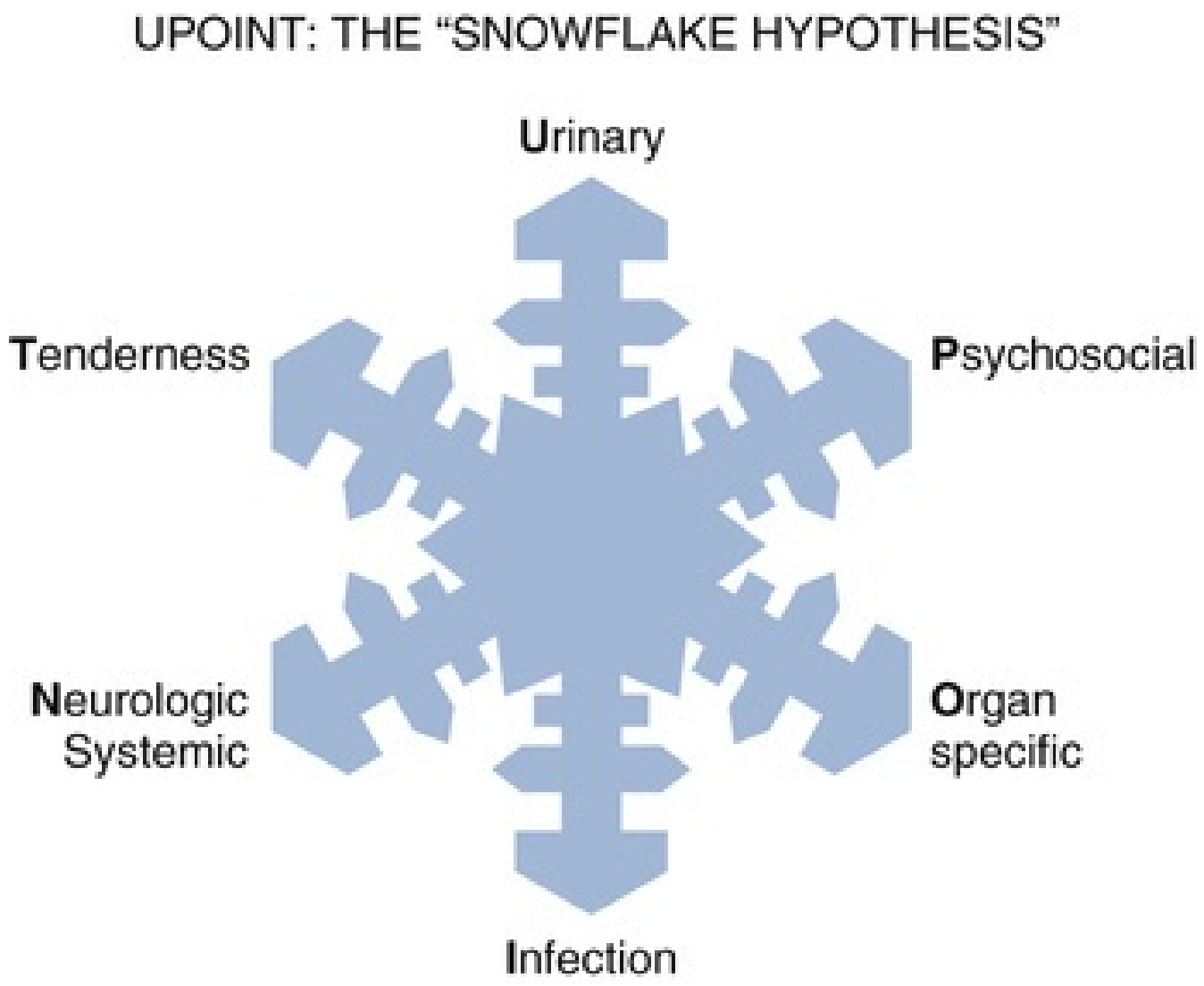

FIG. 56.5 The UPOINT classification has six clinically defined domains: urinary, psychological, organ-specific, infection, neurologic/systemic, and tenderness. Each individual patient has a unique phenotype, thus the idea of the "snowflake hypothesis." (Data from M. Pontari: *Common features*

and dissimilarities of urologic and other chronic pain syndromes: CP/CPPS, NIH meeting on phenotyping patients with pelvic pain, Baltimore, MD, June 2008.)

Evaluation of Chronic Prostatitis and Chronic Pelvic Pain Syndrome

CP/CPPS is a diagnosis of exclusion, and the evaluation must rule out identifiable causes of pelvic pain. To meet the NIH consensus definition, patients should not have active urethritis, urogenital cancer, urinary tract disease, functionally significant urethral stricture, or neurologic disease affecting the bladder (Krieger et al., 1999). A list of inclusion and exclusion and deferral criteria for diagnosis of CP/CPPS that have been used in NIH studies and trials were published by the CPCRN research network (Schaeffer et al., 2002).

Many other medical problems may be present in men with CPPS. One challenge for the urologist is that these include areas outside of the usual scope of urology, including neurologic, immunologic, and psychological factors that influence the disease process.

Two recent guidelines from the UK Prostatitis Expert Reference group (Rees et al., 2015a) and the International Consultation on Urologic Disease (Nickel et al., 2013) have published a description and recommendations for evaluation. The recommendations of these reports are incorporated into this description of the evaluation of CP/CPPS.

History

Given the wide variety of possible causes of CP/CPPS, information on possible cause can be obtained by a detailed history of the circumstances at the onset. Patients with onset associated with significant stress or psychological trauma may be more likely to have pelvic floor dysfunction. A history of trauma could indicate problems based on neurologic damage or musculoskeletal abnormalities. Some patients seek medical attention after a urinary tract infection or STD and should be assessed for persistence of infection.

Assessment

Pain.

The National Institutes of Health Chronic Prostatitis Symptom Index (NIH-CPSI) includes sections on pain including location, frequency and severity of pain, voiding symptoms, and interference/quality of life (Litwin et al., 1999). One limitation of the NIH-CPSI is that it does not have questions about pain thought to be related to the bladder. In the NIH-sponsored MAPP study, 42% of males enrolled at baseline met criteria for a diagnosis of IC/PBS (Krieger et al., 2015). A modification of the NIH-CPSI called the Genitourinary Pain Index (GUPI) (Fig. 56.6) contains two questions related to pain with bladder filling or emptying and better captures bladder symptoms (Clemens et al., 2009). The clinical importance is to remember to assess for symptoms of bladder pain in men with pelvic pain because this can prompt using bladder-specific treatments that are not useful in men with no bladder pain.

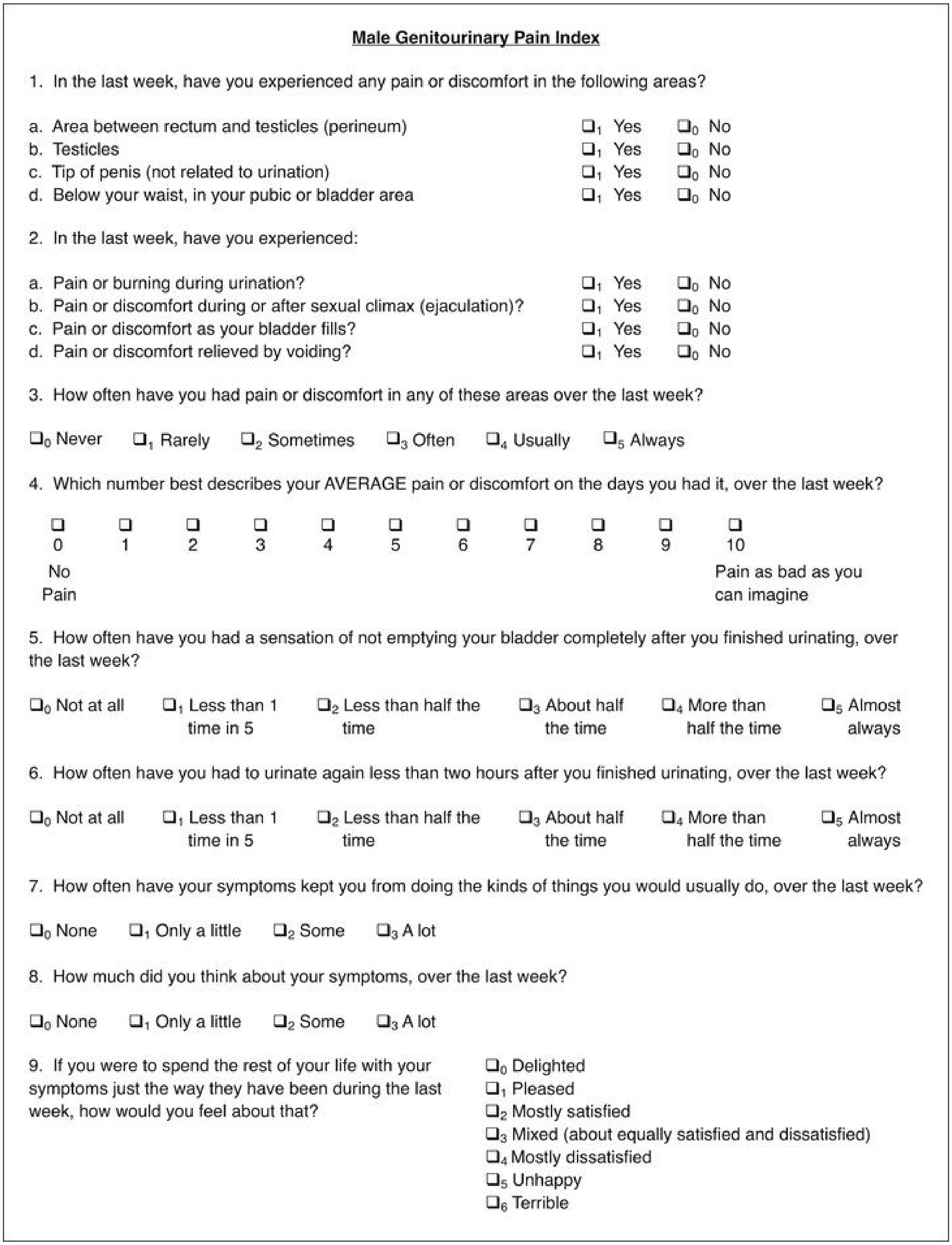

Male Genitourinary Pain Index

1. In the last week, have you experienced any pain or discomfort in the following areas?

a. Area between rectum and testicles (perineum)	☐$_1$ Yes	☐$_0$ No
b. Testicles	☐$_1$ Yes	☐$_0$ No
c. Tip of penis (not related to urination)	☐$_1$ Yes	☐$_0$ No
d. Below your waist, in your pubic or bladder area	☐$_1$ Yes	☐$_0$ No

2. In the last week, have you experienced:

a. Pain or burning during urination?	☐$_1$ Yes	☐$_0$ No
b. Pain or discomfort during or after sexual climax (ejaculation)?	☐$_1$ Yes	☐$_0$ No
c. Pain or discomfort as your bladder fills?	☐$_1$ Yes	☐$_0$ No
d. Pain or discomfort relieved by voiding?	☐$_1$ Yes	☐$_0$ No

3. How often have you had pain or discomfort in any of these areas over the last week?

☐$_0$ Never ☐$_1$ Rarely ☐$_2$ Sometimes ☐$_3$ Often ☐$_4$ Usually ☐$_5$ Always

4. Which number best describes your AVERAGE pain or discomfort on the days you had it, over the last week?

☐	☐	☐	☐	☐	☐	☐	☐	☐	☐	☐
0	1	2	3	4	5	6	7	8	9	10
No Pain										Pain as bad as you can imagine

5. How often have you had a sensation of not emptying your bladder completely after you finished urinating, over the last week?

☐$_0$ Not at all ☐$_1$ Less than 1 time in 5 ☐$_2$ Less than half the time ☐$_3$ About half the time ☐$_4$ More than half the time ☐$_5$ Almost always

6. How often have you had to urinate again less than two hours after you finished urinating, over the last week?

☐$_0$ Not at all ☐$_1$ Less than 1 time in 5 ☐$_2$ Less than half the time ☐$_3$ About half the time ☐$_4$ More than half the time ☐$_5$ Almost always

7. How often have your symptoms kept you from doing the kinds of things you would usually do, over the last week?

☐$_0$ None ☐$_1$ Only a little ☐$_2$ Some ☐$_3$ A lot

8. How much did you think about your symptoms, over the last week?

☐$_0$ None ☐$_1$ Only a little ☐$_2$ Some ☐$_3$ A lot

9. If you were to spend the rest of your life with your symptoms just the way they have been during the last week, how would you feel about that?

☐$_0$ Delighted
☐$_1$ Pleased
☐$_2$ Mostly satisfied
☐$_3$ Mixed (about equally satisfied and dissatisfied)
☐$_4$ Mostly dissatisfied
☐$_5$ Unhappy
☐$_6$ Terrible

FIG. 56.6 Genitourinary Problem Index (GUPI): Modification of the National Institutes of Health Chronic Prostatitis Symptom Index with addition of questions on bladder pain (with permission from Validation of a modified National Institutes of Health chronic prostatitis symptom index to

assess genitourinary pain in men and women. (From Clemens JQ; Calhoun EA; Litwin MS; McNaughton-Collins M; Kusek JW; Crowley EM; Landis JR; Urologic Pelvic Pain Collaborative Research Network. *Urology*. 74[5]:983–987, quiz 987.e1-3, 2009 Nov.)

Other Urologic Symptoms

Voiding: The NIH-CPSI and GUPI list only two questions on voiding dysfunction. The AUA symptom index can be useful to assess these other voiding symptoms (Barry et al., 1992).

Sexual function: The history should include an assessment including a history of erectile dysfunction, libido, and ejaculatory problems. The Sexual Health Inventory for Men (SHIM) instrument can be used to quantify the erectile dysfunction-reference (Cappelleri and Rosen, 2005). This is a shortened version of the International Index of Erectile Function (IIEF) (Rosen et al., 2002).

Review of Symptoms

Neurologic: Given the prevalence of neurologic disease in men in the CPCRN cohort, patients should be evaluated for concomitant neurologic disease (Pontari et al., 2005). A complaint of back pain with numbness or pain radiating down the legs should suggest lumbar-sacral disk disease. A history of migraine headache should be obtained. Changes in vision in a young male could suggest multiple sclerosis. Sensitivity to auditory, visual, or olfactory stimuli could also indicate underlying neurologic disease (Geisser et al., 2008).

GI: Men with CP/CPPS are more likely to have IBS (Rodriguez et al., 2009). There is overlapping innervation of the bowel and bladder such that irritation of the colon in experimental models results in inflammation of the bladder (Christianson et al., 2007). Irritation of one organ in experimental models results in inflammation of the other (Pezzone et al., 2005). The evaluation therefore of men with CP/CPPS must assess problems such as constipation, diarrhea, and the relation of discomfort to bowel movements. In the MAPP study, 31% of men had an associated chronic overlapping pain condition, the vast majority of which were IBS (Krieger et al., 2015). Men with GI symptoms can benefit from referral to a gastroenterologist, preferably one experienced in treating IBS. Thus asking about symptoms of IBS such as constipation, diarrhea, or both is important to help direct the patient to a GI specialist for treatment.

Rheumatologic: Men with CP/CPPS are at higher risk for systemic chronic pain syndromes such as fibromyalgia and chronic fatigue syndrome, although not nearly as increased a risk as IBS (Krieger et al., 2015). Fibromyalgia manifests as pain in many areas of the body. Pain with significant fatigue may indicate chronic fatigue syndrome. These conditions should be further evaluated by a rheumatologist.

Psychological symptoms: There are no published criteria for the psychological evaluation of men with CP/CPPS. However, men should be queried about significant anxiety, depression, and symptoms of obsessive compulsive behavior. Given the association of panic attacks with thyroid disease and interstitial cystitis, an assessment for panic attacks can be helpful (Weissman et al., 2004). A questionnaire that may be useful is the pain catastrophizing scale (Osman et al., 1997). Guidelines from the UK (Rees et al., 2015a) suggest using the Patient Health Questionnaire-9 (PHQ-9) (Moriarty et al., 2015) or a shortened version called the PHQ-2 and/or the Generalized Anxiety Disorder Screener-7 (GAD-7) (Lowe et al., 2008). They also offer several simple questions for initial assessment:

> **Anxiety:** In the past month, how often have you been bothered by feeling nervous, anxious, or on edge, or by not being able to stop or control worrying?
>
> **Depression:** In the last month, how often have you been bothered by feeling down, depressed, or hopeless? Having little interest or pleasure in doing things?

Physical Examination

Neurologic examination: Screening examination for abnormalities

Abdominal examination: To look for other causes of abdominal and/or suprapubic pain

Genitourinary examination: An examination for hernia, hydrocele, testicular masses, penile lesions, or other findings of the genitalia should be performed. A rectal and prostate examination should be performed. Rectal masses or hemorrhoids should be assessed. On rectal examination the prostate is tender in less than half of men (Shoskes et al., 2008); severe tenderness suggests acute prostatitis. Nodularity should not be attributed to inflammation and should prompt a consideration of prostate cancer.

Muscle tenderness: During rectal examination, palpation of the muscles lateral to the prostate and extending to the coccyx can identify myofascial trigger points and identify patients that may benefit from pelvic floor physical therapy and relaxation techniques (Berger et al., 2007). During palpation of the pelvic floor, having the patient abduct the leg on either side can make it easier to examine the muscles. An extended genitourinary pelvic floor examination has been evaluated with the MAPP study and detected pelvic floor tenderness in 47% of men with CP/CPPS compared with 6% of healthy controls. Prostatic tenderness was found in 22 of the cases and none of the controls (Yang et al., 2018). The importance of an extended examination is to maximize detection of pelvic floor tenderness, which can be amenable to pelvic floor physical therapy and targeted muscle relaxation treatments. The examination includes the perineal body, levator, obturator, and urogenital diaphragm muscles. The perineum was palpated midway between the anus and inferior edge of the scrotum. The pelvic floor muscles were palpated through the rectum: the urogenital diaphragm muscles were palpated anteriorly at the prostate apex; the obturator muscles were palpated anteriorly and laterally; the levator muscles were palpated posteriorly. The figure from the study is helpful as a roadmap to examination (Fig. 56.7).

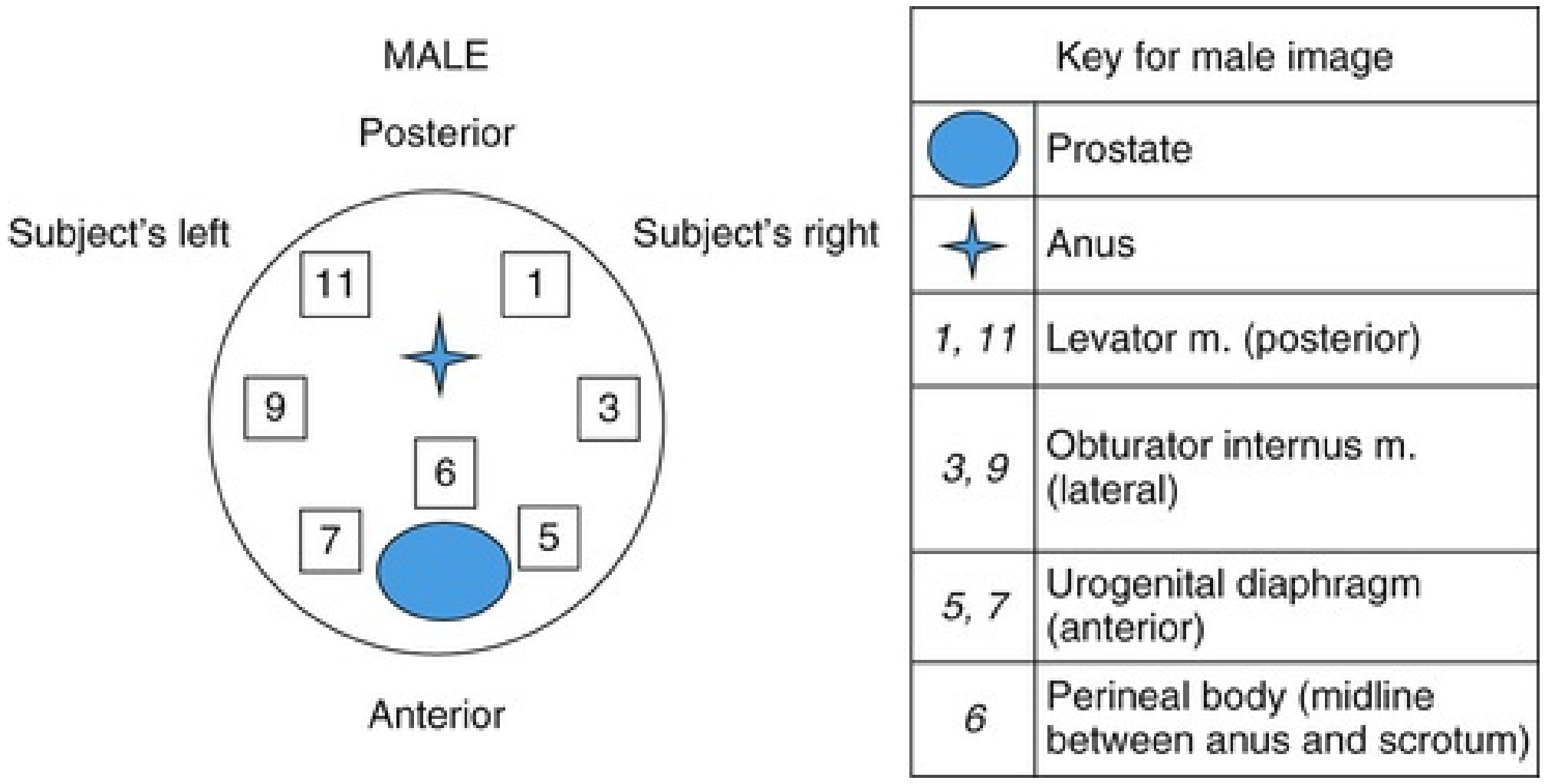
MALE
Posterior
Subject's left
Subject's right
11
1
9
3
6
7
5
Anterior
Key for male image
Prostate
Anus
1, 11 Levator m. (posterior)
3, 9 Obturator internus m. (lateral)
5, 7 Urogenital diaphragm (anterior)
6 Perineal body (midline between anus and scrotum)

FIG. 56.7 Diagram for male pelvic muscle examination. Sites of palpation, performed through the rectum, with subject's anterior surface facing down relative to examiner. Numbers correspond to clock-face positions. (From Yang CC et al.: Physical examination for men and women with urological chronic pelvic pain syndromes: a MAPP network study. *Urology.* 116:23–29, 2018.)

Laboratory/Office Studies

Urinalysis: Men should have a urinalysis to look for unevaluated hematuria. A positive urine dip must be confirmed by finding 3 or more RBC per high-power field on a microscopic evaluation of the urine (Davis et al., 2012). Microscopy of the post-prostate massage urine (VB3) or expressed prostatic secretions have been used in the past to categorize men as category IIIA or IIIB; however, given the absence of clinical utility in making this distinction, this is not recommended.

Assessment for infection: A midstream urine sample for culture is recommended. If there is no documentation of culture results available, then a urinalysis and culture should be obtained at the time of symptom recurrence (Schaeffer, 2006). Optional in the UK guidelines but recommended by the International Consultation on Urological Diseases (ICUD) is the two-glass test, using the VB2 and VB3 specimens (Nickel et al., 2006). This is a standard diagnostic method in men with recurrent UTIs. Those men with a positive midstream urine culture, however, would be diagnosed with category II prostatitis, chronic bacterial and not category III CP/CPPS. The significance of a positive VB3 with a negative VB2 is unclear. This previously was considered to be a diagnosis of chronic bacterial prostatitis in older classification systems (Nickel and Moon, 2005). Asymptomatic men with no pelvic pain can be found to have positive localization cultures (Nickel et al., 2003). A positive VB3 has been used to classify as infectious in the UPOINT classification (Shoskes et al., 2009) and can be an indication for treatment with antibiotics (Shoskes et al., 2010).

Urine assessment for nontraditional organisms: It is not recommended to routinely send urine for culture for atypical organisms. However, in men who have a concomitant urethral discharge, nuclear amplification test should be performed for gonorrhea and chlamydia.

Semen cultures are not recommended.

Urine cytology: This is optional but indicated in men with irritative voiding symptoms such as frequency, dysuria, or hematuria. Carcinoma in situ of the bladder has been diagnosed in men presenting for evaluation of CP/CPPS, and hematuria is not always present (Nickel et al., 2002).

Postvoid residual: This should be checked by catheterization or ultrasound to rule out urinary retention as a cause of symptoms.

Blood tests: APSA test is not indicated. If, however, a PSA is measured and found to be elevated, the elevation should not be ascribed to CP/CPPS but should be further evaluated as in any patient (Nadler et al., 2006).

Imaging studies are optional and may be appropriate in some patients:

- **CT scan of abdomen and pelvis:** Patients with concomitant abdominal pain may require imaging with CT to exclude an intra-abdominal process such as chronic appendicitis or diverticulitis.
- **Scrotal ultrasound:** Testicular pain should be evaluated with a scrotal ultrasound.
- **Prostate ultrasound:** Transrectal ultrasound has limited utility in men with CP/CPPS (Nickel et al., 2013).
- **MRI of lumbar and sacral spine:** Patients with signs and symptoms of lumbar radiculopathy should be considered for MRI.
- **Uroflowmetry:** This is an optional study in the evaluation of CP/CPPS. It may be helpful in a young male with complaints of decreased force of stream as an investigation into stricture disease.

Urodynamics and cystoscopy: Urodynamics are optional studies used in men with CPPS. They should be used in those who fail medical therapy and have significant voiding symptoms, decreased uroflowmetry, and or elevated postvoid residual urine (Hruz et al., 2003). In addition to bladder outlet obstruction, urodynamics can also diagnose men with pseudodyssynergy, which is retained electrical activity of the external sphincter during voiding in the absence of abdominal straining; brief and intermittent closing of the membranous urethra during voiding detected by electromyography; or fluoroscopy in videourodynamics (Gonzalez and Te, 2006). These men are considered to have pelvic floor dysfunction.

Cystoscopy can be used in men with decreased uroflow and/or elevated postvoid residual urine to evaluate for urethral stricture. Cystocopy should also be used in men who give a history of pain with bladder emptying and/or relieved by bladder emptying, suggestive of IC/BPS because in a small set of these patients a Hunner's ulcer is present, which responds to fulguration or intralesional injections (Gonzalez and Te, 2006; Hanno et al., 2011).

Prostate biopsy is not recommended for the diagnosis of CP/CPPS alone.

Clinical phenotyping tool: UPOINT

The phenotype of patients meeting the criteria for CPPS is variable and can include several different types of symptoms. This has been well outlined by Shoskes et al. in the UPOINT classification (Shoskes et al., 2009). This includes the categories of urinary, psychosocial, organ-specific, infection, neurologic/systemic, and tenderness of skeletal muscle. This classification is a convenient way to remember the assessment and is also available online. The UK guidelines (Rees et al., 2015a) and ICUD summary (Nickel et al., 2013) recommend the use of UPOINT (or equivalent) as a means to phenotype symptoms and ultimately aid in directing therapy.

An outline of recommended tests sorted into mandatory, recommended, and optional categories is provided in Box 56.1.

Box 56.1

Evaluation for Men With Chronic Pain and Chronic Pelvic Pain Syndrome

Mandatory

History

- Pelvic pain: pain in penis, testes, suprapubic area, perineum; pain with bladder filling and/or relieved by bladder emptying; pain with ejaculation, dysuria, voiding symptoms
- Review of symptoms
    - Neurologic problems: changes in vision, back pain, numbness in legs or pelvis/perineum, migraine
    - GI problems: constipation or diarrhea, pain relieved by bowel movement
    - Rheumatologic: excessive fatigue, pain in many areas throughout body
    - Psychological: significant anxiety, depression, history of traumatic experience, pain worse with stress

Physical Examination

- GU examination for hernia, hydrocele, penile lesions
- Prostate nodules or tenderness
- Pelvic floor examination
- Abdominal examination for other sources of pain

Laboratory Studies

- Urinalysis to rule out hematuria reflex to formal urinalysis
- Urine culture

Recommended

- Symptom inventory: Use NIH-CPSI or GUPI
- Sexual function assessment
- Two-glass urine VB2 and VB3
- Flow rate
- Urine cytology for dysuria or gross hematuria
- Bladder ultrasound for postvoid residual urine

Not Recommended for Initial Evaluation in All Patients; Optional in Select Patients

- Evaluation for STD with nuclear amplification (urine)
- **Imaging studies**
    - Scrotal US for testicular pain or lesions
    - CT of abdomen/pelvis for abdominal pain
    - Transrectal ultrasound
    - MRI of lumbar/sacral spine for symptoms suggestive of disk herniation
- Other
- Urodynamics/flow rate and cystoscopy: for refractory voiding symptoms, elevated residual urine volume
- PSA: for prostate cancer screening

GI, Gastrointestinal; *GU*, genitourinary; *GUPI*, Genitourinary Pain Index; *PSA*, prostate-specific antigen; *STD*, sexually transmitted disease; *US*, ultrasound; *VB2*, midstream urine; *VB3*, post-massage urine.

Key Points

- CP/CPPS is a diagnosis of exclusion and should be made only after a thorough search for other causes of pelvic pain.
- CP/CPPS has potential issues outside of the pelvis (and usual scope of urology) such as psychological issues and neurologic problems.
- Patients with CP/CPPS must be assessed for other chronic pain syndrome such as irritable bowel syndrome, fibromyalgia, and chronic fatigue syndrome.
- Patients with tenderness on pelvis examination may benefit from pelvic floor physical therapy/myofascial release.
- Therapy for CPPS is best done in a multimodal fashion; the symptom classification UPOINT can be helpful in directing evaluation and subsequently therapy.

Treatment of Chronic Prostatitis and Chronic Pelvic Pain Syndrome

Pharmacologic Treatment

Antibiotic Treatment.

Small, uncontrolled studies have lent credence to the efficacy of antibiotic therapy in ameliorating patients' symptoms, but large randomized, placebo-controlled studies have failed to consistently show meaningful benefit. Studies without a placebo control that have shown a benefit include 500 mg of tetracycline combined with a nutraceutical and an ethylenediaminetetraacetic acid suppository for 3 months (Shoskes et al., 2005); 90 days of therapy with 200 mg levofloxacin or 200 mg levofloxacin plus 0.2 mg of tamsulosin in a study of 105 men with CP/CPPS (Ye et al., 2008); 6 weeks of levofloxacin 100 mg twice daily and combination with doxazosin 4 mg at bedtime (Jeong et al., 2008); the combination of ciprofloxacin 500 mg twice daily plus tamsulosin 0.2 mg (Kim et al., 2008); and a 6-week course of levofloxacin 200 mg twice per day or in combination with terazosin 2 mg before sleep (Wang et al., 2016).

There are relatively few placebo-controlled studies of antibiotics in the treatment of CP/CPPS. Only one of these showed a benefit. A randomized trial of levofloxacin 500 mg daily in 80 men with a diagnosis consistent with CP/CPPS found that NIH-CPSI symptom scores were not significantly improved after 6 weeks of therapy (Nickel et al., 2003). An NIH-sponsored trial randomized men with CP/CPPS and an NIH-CPSI score of at least 15 to ciprofloxacin 500 mg twice daily or placebo. The trial found that NIH-CPSI symptom scores were not significantly improved after 6 weeks of therapy (change in symptom score from baseline −5.4 versus −3.9 with placebo); additional changes 6 weeks later were minimal (Alexander et al., 2004). A third trial that showed a benefit looked at tetracycline HCL 500 mg orally per day combined with 0.4 g/day of vitamin C and 0.2 g/day of co-vitamin B compared with vitamin B used as a placebo. The premise of the trial was that the antibiotic plus vitamins would be effective against nanobacterial infection (Zhou, 2008).

Several questions arise in the use of antibiotics in CP/CPPS. One is whether there is a difference based on duration of a patient's symptoms and/or prior antibiotic exposure. Trials of antibiotics in men with shorter duration of symptoms have shown greater symptom benefit (Nickel and Xiang, 2008) than those in men with longer duration of symptoms (Alexander et al., 2004). Another question with using antibiotics in men with a clinical diagnosis of CP/CPPS is why they would work in this group of patients in whom the diagnosis requires UTI to be excluded by definition. Several factors have been proposed. One is that antibiotics, especially fluoroquinolones, have anti-inflammatory properties. Ciprofloxacin decreases IL-6 and tumor necrosis factor-alpha (TNF-α) production in cell lines, animal models, and in semen and postmasturbation urine samples in men with CP/CPPS (Ogino et al., 2009; Stancik et al., 2008). Another factor could be the effect of antibiotics on bacteria that are localized to the prostate fluid (VB3 or EPS) but not resulting in a positive midstream urine culture. These men are currently classified as category III; in older classifications such as the 1978 classification of Drach et al. they would have been classified as category II or chronic bacterial prostatitis (Nickel and Moon, 2005).

Several meta-analysis and systemic review studies have been published on the treatment of men with CP/CPPS. The data indicated that the greatest decrease in symptom score was seen in the combination of antibiotics and alpha-blockers, with a decrease in total NIH-CPSI of 13.8 points compared with placebo (Anothaisintawee et al., 2011). A follow-up analysis by the same group included some of the studies that used a comparator but not a lone placebo and reached a similar conclusion (Thakkinstian et al., 2012). Another meta-analysis included only the two controlled trials using fluoroquinolone antibiotics (Alexander et al., 2004; Nickel et al., 2003) and concluded that antibiotics failed to show statistically significant or clinically significant reduction in NIH-CPSI scores (Cohen et al., 2012). A meta-analysis that included all the trials listed above use a random effects model to account for the heterogeneity of the studies and concluded that antibiotics are not effective in the treatment of CP/CPPS (Zhu et al., 2014).

Fluoroquinolones have been the most widely studies antibiotics for this condition. The rationale for their use is originally based on their spectrum of activity as well as their pharmacokinetic properties allowing for high prostatic concentration (Charalabopoulos et al., 2003a). In patients with fluoroquinolone-resistant bacteria, trimethoprim alone (TMP), or in combination with sulfamethoxazole can be used. Other second-line agents include tetracycline, doxycycline, and macrolides (Nickel and Moon, 2005; Perletti et al., 2013).

Summary of Treatment Recommendations.

At the time of this writing, there were no AUA guidelines on the treatment of CP/CPPS. There are recommendations from the European Association of Urology (Engeler et al., 2013), which were antimicrobial therapy (quinolones or tetracyclines) over a minimum of 6 weeks in treatment-naïve patients with a duration of CPPS less than 1 year. The group convened by Prostate Cancer UK (Rees et al., 2015a) adds that a repeated course of antibiotic therapy (4 to 6 weeks) should be offered if a bacterial source is confirmed or if there is a partial response to the first course. Repeated courses of antibiotics in the absence of a positive urine culture is not accepted therapy.

Alpha-Blocker Treatment.

Alpha-blockers have long been used for treating CP/CPPS. The rationale includes the idea that some cases of CP/CPPS come from dysfunctional voiding (Lee et al., 2007). The α receptors in the central nervous system have also been shown to be active in long-term pain syndromes (Teasell and Arnold, 2004). Earlier randomized trials of alpha-blockers in men with CP/CPPS showed positive results, including those that used the NIH-CPSI score and those that predated its use. These include studies of terazosin (Cheah et al., 2003; Gul et al., 2001), doxazosin (Evliyaoglu and Burgut, 2002; Tugcu et al., 2007), alfuzosin (Mehik et al., 2003), tamsulosin (Chen et al., 2011; Nickel et al., 2004), and silodosin (Nickel et al., 2011).

Two large NIH-sponsored trials failed to show a benefit for alpha-blockers. Alexander found no benefit with tamsulosin in men who were treated for 6 weeks compared with placebo (Alexander et al., 2004). Men in this study were not necessarily alpha-blocker naive. A study of alfuzosin in men with shorter duration of symptoms and who were alpha-blocker naive did not show any benefit compared with placebo after 12 weeks (Nickel et al., 2008). Several meta-analyses have been published examining the use of treatments including alpha-blockers to show that there is no benefit (Cohen et al., 2012) or likely a benefit to using alpha-blockers, and the best results were in combination with antibiotics (Anothaisintawee et al., 2011) or with antibiotics and anti-inflammatory medications (Thakkinstian et al., 2012). **The ICUD study recommends alpha-blockers for newly diagnosed, alpha-blocker–naive patients who have voiding symptoms** (Nickel et al., 2013)**.The EAU guidelines recommend use of alpha-blockers for patients with a duration of PPS less than 1 year** (Engeler et al., 2013)**.**

Anti-Inflammatory Therapy.

The term *prostatitis* implies inflammation although only one-third of men with symptoms of CP/CPPS have inflammation on prostate biopsy (True et al., 1999). A randomized placebo trial of a cyclooxygenase (COX)-2 inhibitor, rofecoxib, which is no longer available because of cardiac side effects, showed the total and subscale NIH-CPSI scores significantly decreased from baseline in all groups, and no statistically significant difference was found. Patient global assessment of pain, a secondary outcome, favored rofecoxib over placebo (Nickel et al., 2003). A study of another COX-2 inhibitor, celecoxib, in a study of men with IIIA prostatitis showed significant reduction in total NIH-CPSI score, pain, and quality-of-life subscores, but not the urinary subscore (Zhao et al., 2009).

Other forms of anti-inflammatory medication have been tried. A small trial of 17 patients compared a leukotriene inhibitor, zafirlukast, to placebo in a study in which all patients also received doxycycline and found no difference (Goldmeier et al., 2005). A trial similar in size compared placebo with a 4-week course of prednisone with a dose reduction from 20 mg to 5 mg once per day over a 4-week period. No significant change in symptom scores was seen (Bates et al., 2007). A different approach to anti-inflammatory treatment was investigated in an observational study of beclomethasone diproprionate suppositories, a rectal form of corticosteroid. Clinically significant improvement in pain and voiding symptoms were seen in 162 of the 180 patients. No significant adverse effects were reported (Bozzini et al., 2016).

Results from meta-analyses indicate that anti-inflammatory medications are considered to have beneficial effects for some patients (Thakkinstian et al., 2012). They are likely ineffective if used alone but useful in combination therapy with an alpha-blocker and a muscle relaxant that also has anti-inflammatory properties (Cohen et al., 2012). The pooled RR for studies of anti-inflammatory medications for CP/CPPS was 1.8 (95% CI 1.2–2.6) compared with placebo (Anothaisintawee et al., 2011). **In conclusion, anti-inflammatory monotherapy is not recommended but can be used as part of multimodal therapy** (Nickel et al., 2013)**, but long-term side effects have to be considered** (Engeler et al., 2013).

Reductase Inhibitors.

A significant improvement with finasteride compared with placebo in the Prostatitis Symptom Severity Scale, a precursor to the NIH-CPSI, but not in pain was seen demonstrated in a small 12-month pilot study from Finland (Leskinen et al., 1999). A 6-month trial comparing finasteride with placebo in patients with category IIIA (defined as any inflammation in the EPS or VB3 specimen) at 4 academic centers showed improvement in symptoms compared with placebo but did not reach statistical significance (Nickel JC et al., 2004). Dutasteride at 0.5 mg was studied in the REDUCE trial, a 4-year, randomized, double-blind, placebo-controlled study of prostate cancer risk reduction. The NIH-CPSI survey was used to measure baseline and change in symptom severity. After 48 months, the dutasteride group noted a significant decrease of 6 points or greater in CPSI total score compared with placebo (49% vs. 37%, $P = 0.0033$) (Nickel et al., 2011).

Overall, 5α-reductase inhibitor (5ARI) medications appear to be effective in some patients. This is demonstrated when the previous trials are subjected to a meta-analysis, with significant reduction in NIH-CPSI scores compared with placebo (−4.6, 95% CI −8.7 to −0.5) (Anothaisintawee et al., 2011). The decision in whom to use 5ARI medications must also be made in the context of side effects, including reduced volume of ejaculate, erectile dysfunction, and decrease in libido (Thompson et al., 2003). This indicates that they may be best used in older patients with CP/CPPS who also have voiding symptoms from BPH (Rees et al., 2015a).

Medications for Neuropathic Pain.

Given the data to support a possible neuropathic basis for CP/CPPS, it is logical that medications used to treat neuropathic pain are commonly used for treatment. A randomized placebo-controlled trial of the anticonvulsant pregabalin in men with CPPS showed an effect that approached significance but did not reach the primary endpoint ($P = 0.07$) (Pontari et al., 2010). However, several secondary endpoints were significantly improved. This suggests that in a subset of men with CPPS, pregabalin may be effective (Berger, 2011). Patients with suspected neuropathic pain are commonly started on tricyclic antidepressants. Non–placebo-controlled studies have shown a beneficial effect of duloxetine when combined with tamsulosin and saw palmetto (Giannantoni et al., 2014) or with the alpha-blocker doxazosin (Zhang et al., 2017). Amitriptyline has been widely used in women with interstitial cystitis, but data in men with CPPS are lacking. In the IC/PBS studies, a better response was seen if the dose was increased up to 50 mg (Foster et al., 2010).

A phase IIa proof of concept clinical trial using tenazumab, a monoclonal antibody against nerve growth factor, in men with CPPS showed at week 6 there was marginal improvement in average daily pain and urgency frequency compared with placebo, with no difference in overall NIH-CPSI score (Nickel et al., 2012). A trial of an inhibitor of fatty acid amide hydrolase (FAAH), a synaptic membrane enzyme responsible for the breakdown of endogenous cannabinoids (eCBs), showed no improvement in pain reduction compared with placebo. However, there was greater improvement in voiding frequency compared with placebo in all groups tested (Wagenlehner et al., 2017).

Phototherapy.

Wagenlehner et al. compared treatment with the pollen extract Cernilton for 12 weeks to placebo and found significant improvement in total NIH-CPSI scores, as well as pain and quality-of-life domains (Wagenlehner et al., 2009). Similar results in a controlled trial were reported using another pollen extract product for 6 months, showing significant reduction in pain, voiding symptoms, and sexual function in the treatment group (Elist, 2006). The mechanism of action of pollen extract is unknown but is thought to induce smooth muscle relaxation and anti-inflammatory effects (Wagenlehner et al., 2011). Quercetin, a plant-derived bioflavonoid, showed a significant improvement in symptoms after 4 weeks compared with placebo in a small trial and also has been used in IC/PBS (Shoskes et al., 1999).

Bladder Specific: Pentosan Polysulfate.

Pentosan polysulfate (PPS) is a medication used to treat symptoms of interstitial cystitis, thought to work by augmenting the bladder's layer of glycosaminoglycans, which acts as a protective barrier. Use of PPS in men with CP/CPPS has shown modest improvement compared with placebo, with no significant changes in Clinical Global Improvement (CGI) scores but significant improvement in the NIH-CPSI quality-of-life scores (Nickel et al., 2005). It is recommended by the EAU guidelines but with a strength rating of weak (Engeler et al., 2013). For men with painful bladder filling relieved by emptying, consideration should be made to use treatments outlined in the AUA guidelines for treating interstitial cystitis (Hanno et al., 2011).

Other Medications

Allopurinol.

It was theorized that the intraprostatic ductal reflux of urine increases the concentration of metabolites containing purine and pyrimidine bases in the prostatic ducts, causing inflammation (Persson and Ronquist, 1996). Therefore allopurinol was compared with placebo in a randomized, double-blind controlled study in 54 men. The allopurinol groups had lower levels of serum urate, urine urate, and EPS urate and xanthine (Persson et al., 1996). However, re-review of the data and statistical methods showed that the changes in the urine and prostatic secretion of purine and pyrimidine bases resulted in significant amelioration of symptoms (Nickel et al., 1996). A follow-up randomized clinical trial further showed no advantage of allopurinol compared with placebo (Ziaee et al., 2006).

Mepartricin.

This is a mediation that reduces serum estrogen levels and prostatic estrogen receptors in animal models. One small trial indicated beneficial effects on total NIH-CPSI scores in men with CP/CPPS (De Rose et al., 2004).

PDE5 Inhibitors.

PDE5 inhibitors are useful to treat erectile dysfunction in men with CPPS at any age. Tadalafil can treat lower urinary tract symptoms, erectile dysfunction, and possibly the symptoms of CP/CPPS (Grimsley et al., 2007; Oelke et al., 2012). This may be of benefit in men with concomitant erectile dysfunction.

Other Treatments for Chronic Prostatitis and Chronic Pelvic Pain Syndrome

Conservative

Lifestyle Changes: Diet and Exercise.

In a survey of 62 patients with CPPS, 47% reported having sensitivity to some foods. The most common were spicy foods, coffee, tea, chili, and alcoholic beverages. Items that improved symptoms included docusate, psyllium (dietary fiber), water, herbal teas, and polycarbophil (fiber laxative) (Herati and Moldwin, 2013). There are no specific dietary recommendations for all patients with CP/CPPS, and they should be individualized based on the patient's food sensitivities. A study in men with CPPS demonstrated significant improvement in pain scores, quality of life, and overall NIH-CPSI scores in men in an aerobic exercise group compared with placebo/stretching after 18 weeks (Giubilei et al., 2007).

Stress Management/Psychological Treatments.

Of 134 men with chronic prostatitis treated with stress reduction alone, 110 (86%) reported that they were better, much better, or “cured” (Miller, 1988). Options for our patients with these psychological factors include traditional therapy with a psychologist or psychiatrist. A feasibility trial of cognitive therapy showed significant reduction in pain, disability, and catastrophizing in a small cohort of patients who completed an 8-week program (Tripp et al., 2011). Although not yet widely available, these types of program provide a promising future method of treatment, including using these treatments via the Internet (Perry et al., 2017).

Acupuncture.

The mechanism of the improvement in CPPS symptoms after acupuncture is unknown but can be postulated to have an ameliorating effect on neuropathic pain. Acupuncture for CP/CPPS is typically performed using 4 to 6 needle points (Herati and Moldwin, 2013). Controlled trials using sham needles placed at sites away from the true acupuncture sites have also shown a significant improvement over sham including increase in β-endorphin and leucine encephalin levels (Lee et al., 2011). The use of electrical stimulation in addition to needle placement has been used and shown to be superior to sham and advice and exercise alone in men with CPPS (Lee and Lee, 2009). A systematic review of trials of acupuncture in the treatment of CPPS identified 9 clinical trials involving 890 patients that met criteria for inclusion and concluded that the evidence for the efficacy of acupuncture for treating CPPS was encouraging, but the quantity and quality of the available evidence precluded making firm conclusions in favor of acupuncture (Posadzki et al., 2012). In clinical practice, given the relatively few side effects of acupuncture, it can be suggested to individuals who do not respond to first-line medical therapy or to those who would prefer to not take medications for their discomfort.

Minimally Invasive Therapies

Pelvic Floor Physical Therapy and Skeletal Muscle Relaxants.

Studies of noninvasive techniques to treat pelvic floor dysfunction include biofeedback and pelvic floor retraining, or learning to selectively contract and then relax the pelvic muscles. Reports of small series of this technique have shown significant improvement (Clemens et al., 2000; Cornel et al., 2005; Nadler, 2002). Results of pretreatment urodynamics and sphincter EMG were not predictive of outcomes (Clemens et al., 2000). Biofeedback and pelvic floor therapy are also effective in patients who have pseudodyssynergy on urodynamics (Kaplan et al., 1997).

A series of uncontrolled studies from Stanford have reproducibly shown a benefit to combining myofascial trigger point release and paradoxic relaxation training, essentially biofeedback training (Anderson et al., 2005). In addition to pain and urinary symptoms, improvements in sexual function including ejaculatory pain, decreased libido, or erectile dysfunction are also noted (Anderson et al., 2005; Anderson et al., 2006). A shorter 6-day course of myofascial release and trigger point manipulation has been described and produced a 6-point or greater decrease in total NIH-CPSI score at 6 months in 70 of 116 patients (60%) completing the course (Anderson et al., 2011).

One of the difficulties in assessing the effects of pelvic floor physical therapy (PT) is how to control the study. A study from the NIH-sponsored Urological Pelvic Pain Collaborative Research Network (UPPCRN) group showed the feasibility of using global massage as a control for patients undergoing myofascial physical therapy (Fitzgerald et al., 2013). Although not powered or designed to be a definitive outcome study, patients undergoing myofascial therapy had a significantly greater response on global assessment response than the therapeutic massage group, 57% to 21% ($P = 0.03$). **Referral to a physical therapist who is familiar with pelvic floor PT techniques, if possible, is recommended as the improvement after pelvic floor PT appears to be better after therapy received from specialized centers** (Polackwich et al., 2015b)**.**

Adjuncts to Pelvic Floor Physical Therapy.

For refractory cases of pelvic floor spasm, needling of the area, either as dry needling or with the injection of local anesthesia, can be used (Moldwin and Fariello, 2013). The use of perineal injection of *Botulinum* toxin has also been reported to relax tender muscle/trigger points (Gottsch et al., 2011). Other described methods to relax the pelvic floor include the use of extracorporeal shock wave therapy (ESWT). Early studies appeared promising (Zimmermann et al., 2008; Zimmermann et al., 2009), but a study looking at long-term results of ESWT in CP/CPPS patients demonstrated no benefit compared with sham control at 24 weeks as a follow-up to the same patient cohort that showed significant results at 12 weeks (Moayedinia et al., 2014).

Prostate Massage.

Prostate massage may help break up areas of ductal obstruction and help with flow and antibiotic penetrance into the prostate. Given the transrectal approach, it could also potentially have some effect on the pelvic floor. Uncontrolled studies (Nickel et al., 1999; Shoskes and Zeitlin, 1999) found clinical benefits in one-third to two-thirds of patients treated with repetitive prostatic massage (2 to 3 times per week) for 4 to 6 weeks along with antibiotic therapy. Other studies did not show a benefit when combined with antibiotics, in patients with either category II or III prostatitis (Ateya et al., 2006). **A subsequent systematic review of the literature concluded that evidence for a role of repetitive prostatic massage as an adjunct in the management of CP is, at most, "soft" but that the practice could be considered as part of multimodal therapy in selected patients** (Mishra et al., 2008).

Circumcision.

A study looked at the additive effect of circumcision to a regimen of antibiotic, anti-inflammatory, and alpha-blocker medications. A control group received medication only. A total of 774 men were randomized, and 713 completed the trial. At the end of 3 months, the percentage of men in each group with at least a 4-point drop in the NIH-CPSI score was 84.6% in the circumcision group and

68.5% in the control group ($P < 0.001$). Significant changes were seen in all three domains of the NIH-CPSI compared with the control group ($P < 0.001$) (Zhao et al., 2015). These data must be replicated, and the therapy is obviously limited to men who are not already circumcised but present an interesting adjunct to therapy.

Prostate-Specific Treatments

Local Hyperthermia and Needle Ablation.

In a series of 105 patients, those treated with transrectal radiofrequency hyperthermia with or without antibiotics for 6 weeks had a significant improvement in the domains of the NIH-CPSI compared with patients treated with antibiotics alone (Gao et al., 2012). Older studies have used microwave thermotherapy for CP/CPPS (Kastner et al., 2004; Michielsen et al., 1995; Suzuki et al., 1995). Few controlled trials are reported. Nickel and Sorensen reported that, at 3 months' follow-up, the transurethral microwave thermotherapy–treated patients had significantly improved symptom scores compared with sham-treated patients; 7 of 10 men treated with transurethral microwave thermotherapy had a favorable result compared with 1 of 10 men treated with a sham therapy (Nickel and Sorensen, 1996). Thermotherapy is not currently recommended for CP/CPPS but could be used in men with concomitant BPH. Transurethral need ablation (TUNA) has been used in men with CP/CPPS with mixed results (Chiang and Chiang, 2004; Chiang et al., 1997; Leskinen et al., 2002) and is not recommended for treatment.

Intraprostatic Injection of Onabotulinumtoxin A.

Recent studies have reported on intraprostatic injection of onabotulinumtoxin A (Botox). This has been used in the past for BPH. One small, uncontrolled study indicated that Botox worked better via a transrectal route than transurethral and in smaller glands (El-enen et al., 2015). Two controlled studies used the transurethral route. At a dose of 100 to 200 U there was significant benefit to the Botox injection compared with saline (Falahatkar et al., 2015) or cystoscopy without injection (Abdel-Maguid et al., 2018). Side effects included exacerbation of dysuria in almost half of patients, hematuria in 3% to 17%, and hematospermia in 7% to 14% (El-enen et al., 2015; Falahatkar et al., 2015).

Surgical Therapy for Chronic Prostatitis and Chronic Pelvic Pain

Syndrome

Surgical Therapy for Bladder Neck Hypertrophy.

Based on the possibility of centralization and lack of evidence of the prostate as a primary pain source in men with CPPS, transurethral resection is not expected to improve pain. One entity that may be important in a subset of patients is bladder neck hypertrophy. There are no pathognomonic diagnostic criteria. This should be suspected in men with chronic pelvic pain who also have significant obstructive voiding symptoms. Pressure flow urodynamics are expected to show increased voiding pressure and decreased flow, with a relative narrowing of the bladder neck (Hruz et al., 2003). It is important to rule out pseudodyssynergy, which would show inappropriate relaxation of the external urethral sphincter on EMG (Huckabay and Nitti, 2005). Te and Kaplan reported significant improvement in 31 of 32 men with bladder neck hypertrophy and symptoms of chronic prostatitis treated with bladder neck incision (Kaplan et al., 1994).

Neurostimulation.

Sacral nerve stimulation (SNS) and percutaneous tibial nerve stimulation (PTNS) are FDA approved for urinary symptoms but not specifically for pelvic pain. Most studies have looked at SNS in patients with interstitial cystitis/bladder pain syndrome and are case series. The implantation rate after test stimulation (>50% reduction in symptoms) ranges from 56% to 68%; of those implanted and followed for up to 5 years, 64% to 72% can achieve a durable, significant improvement (Yang, 2013). In a study of 89 patients with CP/CPPS randomized to PTNS or sham, there was significant reduction in pain, urgency, and NIH-CPSI score in the treatment group compared with the sham at 12 weeks (Kabay et al., 2009). An open trial of transcutaneous electrical nerve stimulation (TENS) was successful after 12 weeks of treatment in 29 (48%) patients, and a positive effect was sustained during a mean follow-up of 43.6 months in 21 patients (Schneider et al., 2013). At this time, it appears reasonable to offer PTNS as therapy in patients with CPPS and SNS in those with pelvic pain who also have urinary frequency and urgency.

Electromagnetic Stimulation.

In an open-label trial of electromagnetic stimulation, patients sat on a chair with electromagnetic energy for 30 minutes twice weekly for 6 weeks; 22 of 37 men demonstrated a greater than 6-point drop in NIH-CPSI compared with baseline at 24 weeks. Mean total and pain subscales were significantly improved at 24 weeks compared with baseline. International Prostate Symptom Score (IPSS) scores were also significantly improved compared with baseline (Kim et al., 2013). A previous study by Rowe showed a significant improvement in mean symptoms scores at 3 months and 1 year compared with the sham control group ($P < 0.05$) at 1 year (Rowe et al., 2005).

Cystoscopy and Fulguration of Hunner's Ulcer.

Men with pain thought to be of bladder origin (i.e., pain with bladder filling and/or relieved by bladder emptying) should have a cystoscopy to look for a Hunner ulcer. Although not commonly found, fulguration of these areas can provide symptom relief (Gonzalez and Te, 2006; Hanno et al., 2011).

Not Recommended: Radical Prostatectomy.

Not recommended is surgical removal of painful structures in the setting of pain elsewhere in the pelvis. Certainly **radical prostatectomy is not recommended in the absence of treatment for prostate carcinoma** (McLoughlin et al., 2014). A concern for pain relief is the possibility of neural centralization and that the prostate is not the isolated source of pain in these patients

Cochrane Review of Nonpharmacological Interventions for Treating Chronic Prostatitis and Chronic Pelvic Pain Syndrome

A 2018 Cochrane Database review examined the evidence for acupuncture, circumcision, electromagnetic chair, lifestyle modifications, physical activity, prostate massage, extracorporeal shockwave lithotripsy, and transrectal thermotherapy (compared with medical therapy). They did not find adequate information on psychological therapy or prostatic surgery. Their conclusion was that “some of the interventions can decrease prostatitis symptoms in an appreciable number without a greater incidence of adverse events. The quality of evidence was mostly low.” They encouraged future clinical trials with more detailed report of the methods, including sample size, masking, and outcomes including adverse events (Franco et al., 2018).

Treatment: Summary and Approach

A significant limitation to treatment of CP/CPPS is that there are no positive clinical trials for monotherapy in men with CP/CPPS (Nickel et al., 2013). Certainly therapy should start with the most conservative treatments possible, including lifestyle changes. Further therapy is best directed at simultaneous multimodal therapy based on the patient's individual phenotype (Shoskes et al., 2010). The UPOINT classification offers a convenient framework in which to plan treatment(s) and is recommended in current guidelines for treatment by the EAU (Engeler et al., 2013) and ICUD (Nickel et al., 2013). Finally, many if not most patients need to see more than one type of specialist. This often involves neurology, gastroenterology, psychiatry/psychology, physical medicine, and rehabilitation in addition to urology. Referral to a pain clinic, especially one with a multimodal approach may also be helpful (Baranowski et al., 2013). A referral to pain management specialists is also recommended if a patient requires the use of opioids.

Key Points

- Repeated courses of antibiotics in the absence of a positive urine culture are not indicated.
- The best treatment combination from meta-analyses is antibiotics plus alpha-blockers.
- Men with bladder pain should be considered for bladder-specific therapies.
- Men with tenderness on pelvic floor examination should be referred for pelvic floor physical therapy.
- Sacral neuromodulation can be used in men with pain who also have frequency and urgency.
- Treatment is best undertaken as simultaneous multimodal therapy addressing all aspects of the patients symptoms.

Acute and Chronic Orchitis and Orchialgia

Acute Orchitis

The incidence of acute orchitis is not known. In a recent review of 669 cases of acute scrotum in an emergency room over a 10-month period, patients were diagnosed with orchitis in 10.3% of cases and orchid-epididymitis in 28.7%; isolated epididymitis was diagnosed in 28.4% of the patients. The mean age of those in the orchitis group was 44.6 years old and for those in the orchidoepididymitis group, the mean age was 46.5 years old (Lorenzo et al., 2016).

Etiology

Acute orchitis can be divided into specific orchitis and viral orchitis. Specific orchitis can be caused by a wide variety of infectious diseases including by a hematogenous route. In a large series examining evaluation of the acute scrotum, men with orchitis and epipidymo-orchitis over the age of 35 most commonly have bacterial infection with predominantly gram-negative bacteria, *E. coli* and *Pseudomonas*, similar to the distribution of age and infection in acute epididymitis (Kaver et al., 1990). Other reported infectious agents include *Treponema pallidum* (Chu et al., 2016), *M. tuberculosis* (Yadav et al., 2017), and many others that are not common in the United States, including *Brucella* (Savasci et al., 2014) and *Filariasis* spp. (Richens, 2004). Candiduria can lead to epididymo-orchitis (Kauffman et al., 2011).

Viral orchitis is most commonly caused by the mumps virus (Ludwig, 2008). Despite vaccination that almost eliminated this disease by 2001, sporadic outbreaks have occurred since, involving a high percentage of persons with a history of vaccination (Cortese et al., 2011; Dayan and Rubin, 2008).The usual clinical scenario in Mumps is a prodrome of headache, malaise, and myalgias followed by parotitis developing 2 to 3 weeks after exposure and lasting for 2 or 3 days (Rubin et al., 2015). Orchitis is usually associated with epididymitis and fever, resolving within 1 week. Atrophy of the testis occurs in half the cases and can be associated with oligospermia and decreased fertility but usually not complete infertility (Dejucq and Jegou, 2001). Another virus that is associated with orchitis is the human immunodeficiency virus type 1 (HIV-1). This is the result of direct infection of the virus in the testis and as a consequence of immunosuppression from the infection (De Paepe et al., 1989). Orchitis is a symptom of infectious mononucleosis, indicating that the Epstein-Barr virus may have a direct effect on the testes (Cheung et al., 1993; Dejucq and Jegou, 2001). HSV-2 has been detected in the testes (DeTure et al., 1976). Many other viruses have been reported to infect the testes including dengue, smallpox, and chickenpox (Riggs and Sanford, 1962).

Autoimmune orchitis is defined as an autoimmune aggression of the testes characterized by the presence of anti-sperm antibodies (ASA). Conditions that produce symptomatic orchitis are classified as secondary autoimmune orchitis, as opposed to primary autoimmune orchitis, which is characterized by the presence of ASA, no associated systemic disease, and they are asymptomatic (Silva et al., 2014). Primary autoimmune orchitis is primarily a problem in the evaluation of male infertility. The main causes of secondary autoimmune orchitis are usually associated with a primary vasculitis, particularly Behçet's disease, polyarteritis nodosa, and Schönlein-Henloch purpura (Pannek and Haupt, 1997). The testis is an immune-privileged site, but in autoimmune orchitis the blood testis barrier is altered by a T cell–mediated inflammatory response with an increased production of proinflammatory cytokines such as IFN-g, IL-1, IL-6, IL-12, IL-17, and IL-23 and the resultant production of anti-sperm antibodies (Jacobo et al., 2011a; Jacobo et al., 2011b).

Evaluation

Medical history should include circumstances of onset, including sexual history, recent instrumentation or surgery, and prior episodes. A history of trauma should be elicited. The duration of pain is important given that one of the prime differential diagnoses is testicular torsion. A history of symptoms of upper respiratory symptoms and/or parotitis consistent with mumps should be established. Fever, sweats, headache, and back pain are common in infection with brucellosis (Street et al., 2017). Inquiry should also be made about a history of the multiple conditions that can cause secondary autoimmune orchitis. Physical examination should include assessment for signs of systemic involvement including fever and tachycardia. Examination of the scrotum usually reveals a tender testis and spermatic cord.

Urine culture should be obtained in all patients. Urine culture has been reported to be positive in 38.5% of patients diagnosed with isolated orchitis and

37.5% of those diagnosed with orchidoepididymitis (Lorenzo et al., 2016). In sexually active patients, especially with epididymal involvement, testing for STD should be performed. Imaging with scrotal US can help to distinguish testicular torsion from orchitis and identify testicular tumors and abscess (Altinkilic et al., 2013).

Treatment

In patients with signs of infectious orchitis, antibiotics to treat gram-negative uropathogens should be started and treatment adjusted based on the result of urine culture. In patients with suspicion of STD, especially younger patients with concomitant epididymitis, treatment for STD should be started (Centers for Disease Control and Prevention, 2015). Mumps orchitis can be treated by interferon but does not always prevent testicular atrophy (Ku et al., 1999). Secondary autoimmune orchitis may be treated with systemic medications, including corticosteroids, immunosuppressive medications such as azathioprine, or IV cyclophosphamide, and intravenous immunoglobulin (Silva et al., 2014). In men with HIV, treatment requires initial antibiotic treatment followed by a period of maintenance suppression, particularly if salmonella is identified as the causative organism (Shindel et al., 2011). Patients with orchitis need to be followed up, especially those whose symptoms do not resolve to rule out missed torsion or testicular tumor. Patients should also be counseled that, although the acute pain can resolve in 1 to 3 days, the ensuing inflammation can last 2 to 4 weeks before completely resolving (Trojian et al., 2009).

Chronic Scrotal Pain Syndrome: Orchialgia

Orchialgia is defined as scrotal pain, intermittent or constant, lasting at least 3 months, and can be unilateral or bilateral (Kavoussi and Costabile, 2013). **One of the first considerations in assessing orchialgia is to determine if the pain is limited to the testis/scrotum or if it is part of a larger pelvic pain problem including other pain sites consistent with CP/CPPS** (Clemens JQ et al., 2009; Litwin et al., 1999).

Epidemiology

In Europe, orchialgia accounts for 2.5% to 4.8% of clinic visits (Ciftci et al., 2010; Strebel et al., 2005). The prevalence in the United States is not known, but Zermann et al. reported in one series that almost 40% of chronic pelvic pain localizes to the scrotum (1999). Approximately 100,000 cases per year are estimated in the United States. The breakdown of known causes reported are 6% to 12% after vasectomy, 18% after inguinal hernia repair, up to 5% after scrotal surgery, and 1% to 2% after abdominal or groin surgery (Parekattil et al., 2013). The most common age for presentation is 20 to 30 years old (Calixte et al., 2017).

Cause of Chronic Orchialgia

There are multiple identifiable causes of chronic scrotal pain. Short-term scrotal pain, which lasts a few weeks, can occur in 30% of men undergoing a vasectomy, whereas developing into long-term chronic pain that causes men to seek treatment is reported in anywhere from 1 in 1000 men (up to 15%) (Kavoussi and Costabile, 2013; Tandon and Sabanegh, 2008). Other causes include iatrogenic injury after hernia repair in up to 14% of cases or laparoscopic surgery, and inguinal hernia repair in 18% of patients, with a greater risk in patients who undergo surgery for a recurrent hernia or in which mesh was used (Dickinson et al., 2008; Massaron et al., 2007). Orchialgia can also occur after varicocele or varicocele surgery, referred pain from a mid or distal ureteral stone, indirect hernia, aortic or iliac artery aneurysm, trauma, and/or perineural fibrosis (Sigalos and Pastuszak, 2017). Another more recent finding has been that of pelvic floor dysfunction. In a series of men with chronic orchialgia, 93% had at least one symptom of pelvic floor dysfunction, and 88% were found to have increased resting pelvic floor muscle tone (Planken et al., 2010). Approximately 18% to 25% of chronic orchialgia is considered idiopathic (Quallich and Arslanian-Engoren, 2013).

The importance of alterations in nerve function may be very important in the pathophysiology and subsequent management of chronic orchalgia. Parekattil et al. (2013) reported on the finding of Wallerian degeneration (WD) on nerve biopsy in a significantly greater proportion of patients with pain (84%) than controls (20%) (*P* = 0.0008). Also, the degeneration appeared to be in reproducible patterns, involving the cremasteric muscle layer, perivasal tissues, and posterior periarterial/lipotamous tissues, the so-called “trifecta nerve complex.” WD is a well-coordinated response of a nerve to injury, including proliferation of Schwann cells, changes in the local extracellular matrix, and recruitment of neurotrophin and cytokines, to facilitate axonal regeneration (Dubovy, 2011). The subsequent neuroinflammation can also lead to neuropathic pain. However, because 20% of the asymptomatic control group also had degeneration, this is not always the case (Parekattil et al., 2013). Staining with calcitonin gene-related peptide (CGRP), which is a marker of sensory nociceptors (Greco et al., 2008), has found increased levels of CGRP-positive nerves in spermatic cords of patients with pain compared with those with no testicular pain (Oka et al., 2016).

Granulomatous orchitis is marked by the presence of granulomatous inflammation in the testis and has multiple causes, including tuberculosis, brucellosis, actinomycosis, syphilis, leprosy, and sarcoidosis (Akinci et al., 2006; Roy et al., 2011). Idiopathic granulomatous orchitis is a rare inflammatory condition of unknown cause characterized by nonspecific granulomatous inflammation with multinucleated giants cells without caseation (Roy et al., 2011). Diagnosis is usually made after orchiectomy for suspected malignancy as the presentation is similar on ultrasound. Patients may have chronic pain but may also present with painless testicular enlargement (Dhand and Casalino, 2011). Just as has been described in the prostate, IG4-related inflammation has emerged as the cause of scrotal content pain, affecting the testis cells (de Buy Wenniger et al., 2013) and perivasal tissue-causing fibrosis (Najari et al., 2014). IG4-positive cells have also been reported in specimens of idiopathic granulomatous orchitis in men with no history of systemic IG4 disease (Karram et al., 2014). Another inflammatory condition that can cause orchitis is malakoplakia. The distinction from granulomatous orchitis is a dense infiltrate of histiocytes, and pathognomonic Michaelis-Gutmann bodies (Roy et al., 2011).

Evaluation

The diagnosis is directed at ruling out the other causes of chronic orchalgia. A history should evaluate for signs and symptoms of intermittent torsion and for infection with history of prior testicular or epididymal infection. On review of systems, the presence of symptoms of bowel dysfunction with constipation or diarrhea that may be indicative of IBS should be asked (Ciftci et al., 2010). Also important are symptoms of lower back pain and vertebral disk disease, because orchalgia can be referred pain from back problems (Rowell and Rylander, 2012). LUTS could indicate a history of voiding dysfunction, which could lead to UTIs. Cui and Terlecki reported that on screening for low testosterone or B12 levels in men with chronic orchialgia, 125 of 154 were found to be deficient in either or both compounds (Cui and Terlecki, 2016). A thorough examination of the genitalia including testes, epididymis, prostate, and pelvic floor is mandatory. Inguinal hernias should be ruled out. Laboratory studies include a urinalysis**. A**

duplex Doppler ultrasound should be performed to assess for anatomic or congenital abnormality, or mass (Costabile et al., 1991b). If a ureteral stone is suspected, a CT scan can be performed.

Therapy for Idiopathic Orchialgia and Chronic Scrotal Pain Syndrome

Medical Therapies.

Much like CP/CPPS, antibiotics are commonly used but rarely indicated (Strebel et al., 2005). Doxycycline and quinolones are recommended because of their penetration into the scrotal structures and because they can be used for up to 4 weeks (Levine, 2010). Anti-inflammatory medications are commonly used for the analgesic effects. There is little supporting evidence however for a specific therapeutic target (Starke and Costible, 2017). Given that CSPS is a chronic pain condition, medications used for neuropathic pain are prescribed. These include tricyclic antidepressants and gabapentin (Costabile et al., 1991a).

Spermatic Cord Block.

When the initial evaluation does not show a discrete treatable cause and conservative medical management does not improve symptoms, a reasonable next step is spermatic cord block with bupivacaine. If positive, this can help confirm the diagnosis of orchialgia (Sigalos and Pastuszak, 2017). It may also help predict if spermatic cord denervation will be effective as a treatment. In a series of 74 patients, a positive response to a spermatic cord block with more than 50% temporary reduction in pain was an independent predictor of pain response to microsurgical denervation of the spermatic cord (MDSC) (Benson et al., 2013).

Surgical therapy: see the following for nonpharmacologic treatment of chronic scrotal pain.

Acute and Chronic Epididymitis (Epididymalgia)

Acute Epididymitis.

Acute epididymitis is defined as pain, swelling, and inflammation of the epididymis that lasts more than 6 weeks. Epididymitis is a common condition. The incidence rates range from 25 to 65 per 10,000 person years and accounts for up to 600,000 cases per year in the outpatient setting in the United States (Cek et al., 2017). The average age of acute epididymitis is variable and affects pediatric and adult populations.

Etiology.

The widely accepted route of infection is the ascent of microorganisms from the urethra, as reported by Campbell in 1927 in cases of gonococcal urethritis and subsequent epididymitis (Centers for Disease Control and Prevention, 2015). This was confirmed in later studies that compared isolates from the urine/urethra and simultaneously epididymitis and identified concurrence between the areas of approximately 80% (Berger et al., 1987; Doble et al., 1989a; Melekos and Asbach, 1987).

The causative organisms depend on the age of the patient. The classic teaching has been that men over the age of 35, as well as in children, the organisms are similar to those causing a urinary tract infection, such as *E. coli*. In men under 35 who are sexually active, *Chlamydia trachomatis* and *Neisseria gonorrhoeae* are more common (Holmes et al., 1979). Risk factors in the older men without sexually transmitted epididymitis include history of prostate infections or UTIs, recent surgical intervention in the urinary tract, bladder outlet obstruction such as BPH or stricture, uncircumcised penis or congenital deformity of the urinary tract, and immunosuppression (Ryan et al., 2018).

An updated examination of the causes of epididymitis was recently undertaken by a German group, using updated diagnostic methods for bacteria and viruses (Pilatz et al., 2015). A bacterial pathogen was found in 130/150 patients (87%), the most common was *Escherichia* (56%). The most common sexually transmitted infection was *Chlamydia* followed by *Mycoplasma* and *N. gonorrhoeae*. The sexual history did not always match the diagnosis, and men under 35 had enteric organisms in 42% of cases. **The conclusions from this very well-executed study are the following:**

1. **The age cutoffs of younger than 35 for a sexually transmitted infection (STI) as cause of acute epididymitis and older than age 35 to have an enteric bacterial pathogen are not strict rules.**
2. **A sexual history suggests that STI is not predictive of STI and that men with STI may not have a convincing history. Therefore all sexually active men with acute epididymitis should be screened for an STI.**

3. **Viruses were not a significant contributing factor to acute epididymitis, and mumps were not detected.**
4. **13% of cases still had no identifiable microbial cause.**

Clinical Evaluation.

The signs and symptoms of acute epididymitis include pain and swelling. Swelling usually starts at the cauda of the epididymis and then ascends to reach the rest of the epididymis and then to the testis. Presentation is unilateral in 96% of cases (Cek et al., 2017). In the large series of Pilatz et al., 26% of patients presented with a fever defined as greater than 38°C, whereas 6.7% presented with an epididymal abscess (Pilatz et al., 2015). Dysuria is reported in one-third of patients (Kaver et al., 1990; Pearson et al., 1988).

Medical history should include circumstances of onset, including sexual history, recent instrumentation or surgery, and prior episodes. Physical examination should include assessment for signs of systemic involvement, including fever and tachycardia. Examination of the scrotum usually reveals a tender epididymis and spermatic cord. Induration of the cauda or whole epididymis is frequently present, and orchitis is noted in half of cases (Kaver et al., 1990).

Diagnostic evaluation should include laboratory studies to assess for white blood cell count, urine for routine urine culture and susceptibility, assessment of inflammation by leukocyte esterase on first-void urine or microscopic examination of sediment from a spun first-void urine (Centers for Disease Control and Prevention, 2015). In older men with acute epididymitis, an assessment of postvoid residual urine should be made to rule out urinary retention as a cause of UTI and subsequent epididymitis.

The differential diagnosis of acute scrotal pain such as seen with acute epididymitis includes testicular torsion, torsion of the appendix testis, inguinal hernia, testicular carcinoma, pain from varicocele, scrotal or testicular abscess, acute orchitis, and/or testicular trauma (Cek et al., 2017). Imaging studies include scrotal ultrasound. Common ultrasound features include hydrocele, epididymal enlargement, hyperperfusion, and testicular involvement (Pilatz et al., 2013). This is an important tool to confirm the diagnosis and to rule out testicular torsion as a cause of the acute scrotal pain (Altinkilic et al., 2013).

Treatment.

For symptom relief, the traditional recommendations are bed rest, elevation of the scrotum, and local cooling. Nonsteroidal anti-inflammatory medications can also be useful. Most patients can be managed on an outpatient basis, but those with elevated white blood cell counts and fever should likely be admitted. Antimicrobial therapy depends on the most likely pathogen. The CDC guidelines divide this into three groups: acute epididymitis likely caused by STD, likely caused by STD and enteric organism (men who practice insertive anal sex), and likely only caused by enteric organisms. For the first group, the recommendation is ceftriaxone 250 mg in single IM dose plus doxycycline 100 mg orally twice per day for 10 days; for the second group levofloxacin 500 mg PO daily (or ofloxacin 300 mg PO twice per day) for 10 days is substituted for doxycycline, and for the third group levofloxacin (or ofloxacin) alone is recommended. Men with confirmed chlamydia or gonorrhea should also be tested for other STDs including HIV, and their sex partners should also be referred for evaluation and presumptive treatment (Centers for Disease Control and Prevention, 2015).

Follow-Up.

It is recommended that men whose symptoms do not resolve within 72 hours be re-evaluated. Follow-up ultrasound may be needed in patients who are not clinically responding to rule out progression of an infection to an abscess or testicular infarction, which would require surgical treatment. Close follow-up of urine cultures for susceptibility is also important given the increasing rates of fluoroquinolone-resistant bacteria (Ryan et al., 2018).

Chronic Epididymitis.

The definition of chronic epididymitis is similar to that for orchalgia (i.e., symptoms of discomfort and/or pain for at least 3 months' duration), localized to 1 or both epididymis (Nickel et al., 2002). In a survey of Canadian urologists over a 2-week period, of 6037 male patients seen, 57 or 0.9% had chronic epididymitis with a mean duration of 2.5 years and an average age of 41.1 years (Nickel et al., 2002).

Etiology.

Nickel et al. recommended a classification of chronic epididymitis as being one of three categories: inflammatory, postobstructive, and chronic epididymyalgia, implying no clear cause (Nickel et al., 2002). Causes in the inflammatory group include infective from chlamydia, postinfective after acute bacterial epididymitis, granulomatous from tuberculosis, drug-induced from amiodarone, and idiopathic inflammatory. Patients with AIDS are also prone to develop tuberculous epididymitis (Heyns et al., 2009). The postobstructive group includes pain associated with congenital, acquired, or iatrogenic obstruction, such as postinfective or postsurgical, including postvasectomy.

Evaluation.

Medical history should include any history of treatment for acute epididymitis. A Chronic Epididymitis Symptom Index has been published (Nickel et al., 2002). In the Canadian classification of epididymitis, the inflammatory chronic epididymitis is associated with abnormal swelling or induration. The obstructive may have induration, and in the idiopathic group or epididymalgia, the epididymis is palpably normal (Nickel et al., 2002). Patients may also experience testicular pain. Specific to tuberculous epididymitis, the onset is described as subacute, with swelling of the epididymis that may not be painful. Systemic signs of TB, along with scrotal thickening and a characteristic fistula, may be present. A scrotal mass may be present. Although TB often commonly involves the testis, the epididymis is solely infected in 45% of cases (Yadav et al., 2017). Laboratory tests include a urinalysis and midstream urine for culture. Patients with a urethral discharge should be evaluated with testing for an STD. Imaging studies including scrotal ultrasound are helpful to look for epididymal and testicular tumors. Patients should be assessed for neurologic problems that contribute to the pain, especially back pain indicating disk disease (Calixte et al., 2018).

Treatment.

Conservative measures are recommended to start. Ruling out a malignancy allows for counseling the patient on the benign nature of the condition and observation if symptoms are mild. Scrotal support and warm compresses may be beneficial. Medical treatments lack evidence-based studies. Many types of medications have been used including antibiotics, anti-inflammatories, phytotherapy, and anxiolytics (Cek et al., 2017). Approximately one-quarter of patients receive pain medications (Nickel, 2003).

Tubercular Epididymitis

The EAU has published guidelines for the treatment of genitourinary TB (Kulchavenya et al., 2016). Medical treatment is with anti-TB regimens of antibiotics. The usual regimen is 4 anti-TB drugs simultaneously for a minimum of 6 months. Five different regimens of chemotherapy are used depending on the form of urogenital TB. Surgery to drain an abscess may be needed, or removal of a chronically infected epididymis or testis may be necessary. All surgical procedures should be performed while on anti-TB medications. The treatment duration is then judged based on the histology of the removed tissue. **An indication for surgery is failure of a scrotal mass to respond or increases in size after 3 weeks of antitubercular chemotherapy; the mass should be explored by an inguinal incision to rule out testicular or epididymal malignancy** (Cek et al., 2005).

Nonmedical Therapy for Chronic Scrotal Pain: Chronic Orchitis (Orchalgia) and Chronic Epididymitis (Epididymalgia)

Minimally Invasive Treatments

Pelvic Floor Physical Therapy.

Given the results of a study of 41 men with chronic testicular pain showing increased resting pelvic floor tone (Planken et al., 2010), **pelvic floor PT should be considered in men with orchlgia and abnormal tone on digital rectal examination.** A series of 30 patients with chronic orchalgia treated with pelvic floor physical therapy reported that after 12 sessions, pain improved in 50% of men, and complete resolution of pain occurred in 13% (Farrell et al., 2016).

Botox.

Local cord denervation with onabotulinumtoxin A (Botox) has been used for chronic scrotal pain. Khambatil et al. reported on 18 patients with chronic scrotal pain with a cord injection of Botox. All patients had experienced temporary relief from a cord block of 0.5% Marcaine and 2% xylocaine. One hundred units of Botox were injected 1 to 2 cm distal to the external ring, targeting the branches of the genitofemoral and ilioinguinal nerves. At 1 month follow-up pain was reduced in 72% of patients, and at 3 months in 56%. Most men had return of pain and tenderness by 6 months (Khambati et al., 2014).

Pulsed Radiofrequency of the Spermatic Cord.

Pulsed radiofrequency has been performed for chronic back pain and sciatica, as well as for chronic visceral pelvic pain. Five patients with chronic scrotal pain (one bilateral) who responded to local anesthetic cord block were treated with pulsed radiofrequency (PRF) denervation of the spermatic cord. The treatment time was 3 minutes at 42 °C. At a mean follow-up of 25 weeks, the mean visual analog scores for pain decreased from 9 to 1. No complications such as testicular atrophy or decreased sensation of the scrotal or penile skin were reported (Basal et al., 2012). There are no long-term results available with this technique.

Nonradical Surgical Treatments

Neuromodulation

A sacral nerve stimulation trial that entered the caudal epidural space resulted in an 80% decrease in pain at 4 months in a male with recurrent epididymitis (McJunkin et al., 2009). Although the stimulator works on the S2-S4 area, the result with the testis was attributed to recent re-evaluation of dermatomes that reports that dermatomes are larger than described in most textbooks (Lee et al., 2008) and that based on cadaver studies, 25% of pudendal nerves receive a contribution from S1 (Shafik et al., 1995). Spinal cord stimulation in the epidural space to the level of T10 and T11 has been reported to help chronic scrotal pain (Nouri and Brish, 2011) as has cutaneous stimulation of the cutaneous branch of the ilioinguinal and genital branch of the genitofemoral nerves (Rosendal et al., 2013).

Surgical Therapy

Surgical Therapy for Orchalgia in Patients With Identifiable Intrascrotal Lesions

Patients can present with pain that appears to be localized to specific lesions (i.e., a varicocele or spermatocele). Patients can also have surgery for intermittent torsion. The results of surgery for pain resulting from hydrocelectomy, spermatocelectomy, and orchidopexy for intermittent torsion are reported as 100%, 94%, and 89%, respectively (Gray et al., 2001). The most common surgery for a specific target is spermatic vein ligation for treatment of a painful varicocele with a complete resolution rate of 85% by primary microsurgical and 72% for nonmicrosurgical repair; for laparoscopic repair the mean complete resolution rate is 81% with a recurrence rate of 6.8%

(Shridharani et al., 2012). Percutaneous embolization can be effective for painful varicocele, but recurrence rates are generally higher than for microsurgical repair. The rate of success for microsurgical repair as a salvage procedure for recurrent or persistent varicocele after varicocelectomy has been reported at 90% (Chawla et al., 2005). Predictors of response to varicocelectomy include greater number of veins ligated (>7), greater preoperative pain score (>6), and longer duration of pain (>9 months) (Chen, 2012).

Vasovasostomy or Vasoepididymostomy for Treatment of Postvasectomy Pain

An option unique to patients with postvasectomy pain syndrome is to reverse the vasectomy and restore patency of the vas. Complete response rates are 34% to 50%, and overall improvement is 82% to 93% (Horovitz et al., 2012; Lee et al., 2014; Myers et al., 1997; Nangia et al., 2000; Polackwich et al., 2015a). A 20% reoperation rate from 1 to 9 years was reported by Polackwich et al. (2015a). Pain relief may take 3 months or more after the procedure, an important point in counseling patients and managing expectations (Horovitz et al., 2012). Given the relatively minimal morbidity, this is an attractive option for patients who have persistent long-term pain after vasectomy in the absence of other identifiable causes.

Microsurgical Denervation of the Spermatic Cord

Microsurgical denervation of the spermatic cord (MDSC) was first described by Devine and Schellhammer in two patients in 1978 (Devine and Schellhammer, 1978). This procedure involves transecting the nerves in the spermatic cord, while preserving the blood supply and lymphatics to prevent formation of a hydrocele (Tan and Levine, 2016). The internal spermatic veins are ligated, and the cremaster muscle and spermatic cord fascia are preserved (Strom and Levine, 2008). **Three areas identified by Parekatil et al. that had the highest areas of WD were the cremasteric muscle fibers, the perivasal sheath, and the posterior lipomatous tissue; these areas were called the trifecta nerve complex, which is thought to form the anatomic basis for relief from the denervation procedure** (Parekattil et al., 2013). This approach has led to a more targeted MDSC approach in which the inner spermatic sheath is completely spared and only 5% to 10% of the spermatic cord is ligated, minimizing risk to the testicular and vasal arteries. A biowrap is also placed around the cord to minimize scarring and neuroma formation (Calixte et al., 2018).

Numerous studies on the efficacy of MDSC have been published (Benson et al., 2013; Larsen et al., 2013; Oomen et al., 2014; Parekattil et al., 2013; Strom and Levine, 2008) and report cure rates of 50% to 70%. By far the largest series is from Calixte et al., who report on 860 cases of robot-assisted microsurgical denervation. At a median follow-up of 24 months, complete resolution of pain was achieved by 49% of their patients, and 34% had a greater than 50% reduction in pain. The improvement in pain continued to progress with higher rates reported at 4 years than 6 months postoperatively (Calixte et al., 2018). Two studies have reported on specifically the results in men with postvasectomy pain syndrome, one from 1997 in which 13 of 17 reported complete relief of pain at the first follow-up visit and the other 4 had improvement (Ahmed et al., 1997). A much more recent report of overall success was achieved in 20/27 units. Patients with involvement of multiple structures in the scrotum (i.e., testis, epididymis, spermatic cord) had a success rate of 81% and were more likely to have a successful surgery ($P < 0.001$) (Tan et al., 2018). Men who have had a prior attempt at surgical repair at pain relief respond in a similar fashion to men who have not had any prior attempts at surgical therapy for chronic scrotal pain (Larsen et al., 2013; Tan et al., 2018).

Positive response to spermatic cord block predicts success with MSDC. The amount of pain relief obtained after cord block correlates with pain relief after undergoing MSDC, and those with a good response are likely to have durable and complete resolution of their pain (Benson et al., 2013). Some men may experience more pain relief with MSDC than cord block. The recommendation by Jonas et al. is to consider MSDC in men who have at least a 50% reduction in pain on spermatic cord block with 20 mL of 0.25% bupivacaine injected at the level of the pubic tubercle (Benson et al., 2013). Discussion of the risks and benefits are important because although the majority of results are good and there are few reported complications, one of those complications is testicular atrophy (Strom and Levine, 2008).

Epididymectomy for Chronic Pain

In the series of Davis of 10 patients who underwent epididymectomy, only 1 had significant pain relief and 9 subsequently underwent subsequent orchiectomy as definitive treatment (Davis et al., 1990). However, other series have reported better results. These range from 32% cure rate (Sweeney et al., 2008) up to 100% (Selikowitz and Schned, 1985). Most series report complete improvement in 50% to 75% of patients and improvement in another 15% to 21% (Chen and Ball, 1991; Hori et al., 2009; Lee et al., 2014; Padmore et al., 1996; Siu et al., 2007). Results are better in patients with a palpable area of tenderness, area of abnormality on ultrasound, or a cyst (Calleary et al., 2009; Padmore et al., 1996). Results for specifically postvasectomy pain are mixed and range from 12% to 80% cure rates (Hori et al., 2009; Lee et al., 2011; Lee et al., 2014; Siu et al., 2007; Sweeney et al., 2008). **Better rates are reported in cases with incorporation of the distal portion of the vasectomy site with the epididymectomy specimen** (Hori et al., 2009). This removes perineural inflammation, sperm extravasation, and fibrosis that may contribute to ongoing pain (Nariculam et al., 2007a). The rate for progression to orchiectomy after epididymectomy resulting from persistent pain is reported at 22% (Sweeney et al., 2008) up to 90% (Davis et al., 1990).

Orchiectomy for Chronic Scrotal Pain

The results for orchiectomy for chronic scrotal pain vary from 0 to 75% pain relief and partial improvement in 20% to 43% (Costabile et al., 1991b; Davis et al., 1990; Nariculam et al., 2007b; Yamamoto et al., 1995). Better results for an inguinal approach were noted by Davis than using a scrotal approach, 75% versus 55% complete response (Davis et al., 1990). In 17 patients after inguinal hernia repair, 65% were pain free at an average follow-up of 7 years. Of these, 6 patients were operated on for testicular ischemia. Patients operated on for nociceptive pain resulting from testicular injury such as ischemia have a better response than those operated for neuropathic pain from testicular nerve injury (Ronka et al., 2015).

Orchiectomy performed for persistent pain an average of 13.8 months after microsurgical resulted in a complete pain response in 70% and 30% still on pain medications. Men with bilateral scrotal content pain were at higher risk to develop pain after MDSC (Lipscomb and Williams IV, 2016). Although orchiectomy may be considered the last resort for treatment of scrotal pain, pain may persist, called a phantom pain (Puhse et al., 2010). Treatment of pain that persists after orchiectomy is handled in a manner similar to that described for treating persistent testicular pain after inguinal hernia repair. The genital branch of the genitofemoral nerve at the external ring is identified and neuroma is resected, and the proximal end of the nerve is placed in the pelvis. This has resulted in excellent relief in 8 out of 10 men treated for residual pain after prior orchiectomy at a mean of 17.5 months’ follow-up. The remaining two men reported a good result (Dellon et al., 2014).

An algorithm for the progression of surgical therapy in men with chronic scrotal pain is shown in Fig. 56.8.

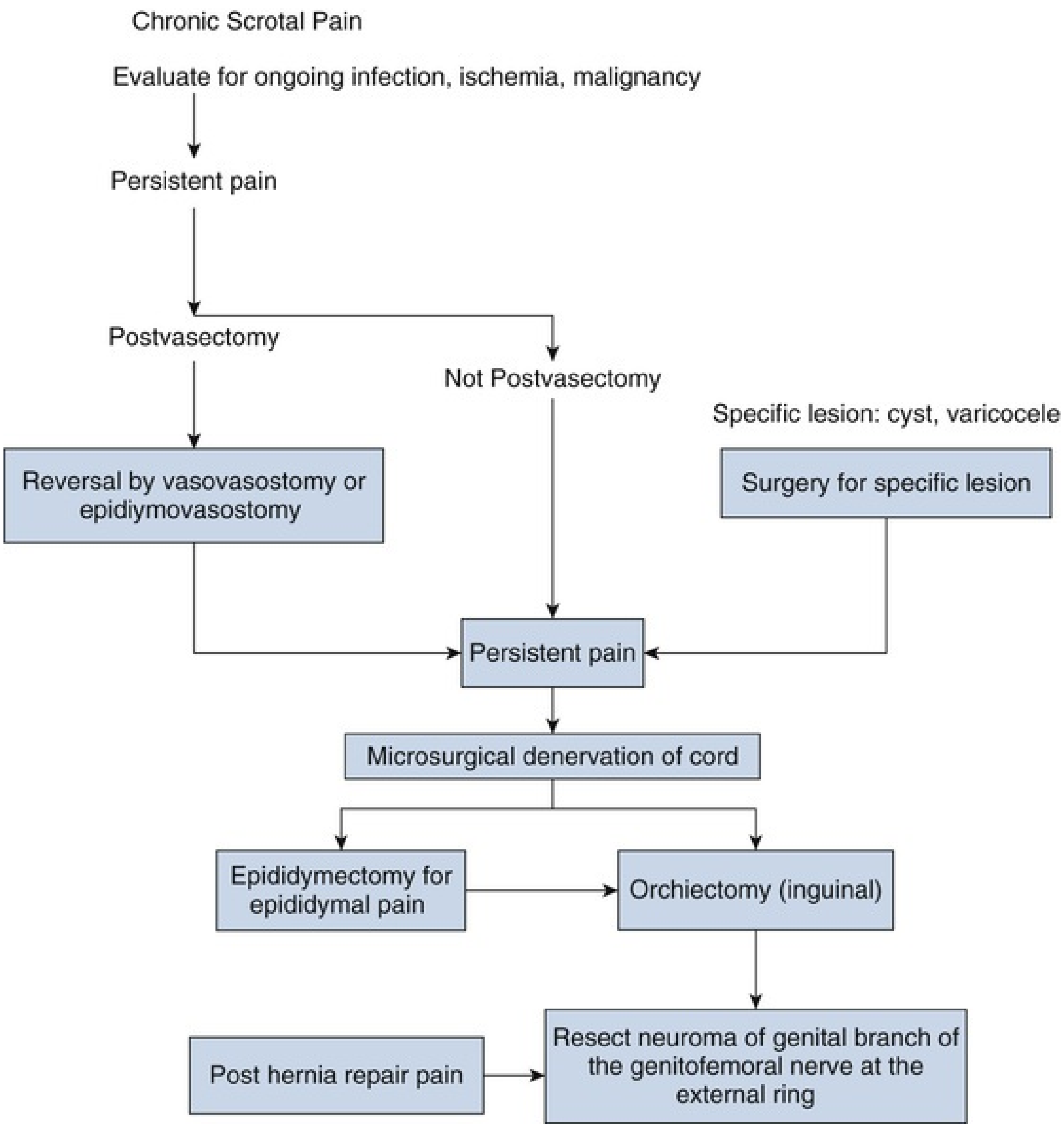
Chronic Scrotal Pain
Evaluate for ongoing infection, ischemia, malignancy
Persistent pain
Postvasectomy
Not Postvasectomy
Specific lesion: cyst, varicocele
Reversal by vasovasostomy or epidiymovasostomy
Surgery for specific lesion
Persistent pain
Microsurgical denervation of cord
Epididymectomy for epididymal pain
Orchiectomy (inguinal)
Post hernia repair pain
Resect neuroma of genital branch of the genitofemoral nerve at the external ring

FIG. 56.8 Algorithm for progression of surgical therapy for men with chronic scrotal pain.

Key Points

- Viral orchitis is most commonly caused by the mumps virus.

- For scrotal pain a duplex Doppler ultrasound should be performed to assess for anatomic or congenital abnormality, torsion, or mass.
- Pelvic floor physical therapy should be considered in men with orchalgia and abnormal tone on digital rectal examination.
- Acute epididymitis is more commonly caused by an STD in men younger than 35 and enteric organism in men older than 35.
- For MDSC, three areas that should be addressed are the cremasteric muscle fibers, the perivasal sheath, and the posterior lipomatous tissue.
- The distal vas deferens should be incorporated into the surgical specimen during an epididymectomy for postvasectomy pain syndrome.

References

Abarbanel J, Engelstein D, Lask D, et al. Urinary tract infection in men younger than 45 years of age: is there a need for urologic investigation? *Urology*. 2003;62:27–29.

Abdel-Maguid TA, Mosli HA, Alsayyad A, et al. Treatment of refractory category III nonbacterial prostatitis/chronic pelvic pain syndrome with intraprostatic injection of onabotulinumtoxinA: a prospective controlled study. *Can J Urol*. 2018;25:9273–9280.

Abdelmoteleb H, Rashed F, Hawary A. Management of prostate abscess in the absence of guidelines. *Int Braz J Urol*. 2017;43:835–840.

Ackerman AL, Parameshwar PS, Anger JT. Diagnosis and treatment of patients with prostatic abscess in the post-antibiotic era. *Int J Urol*. 2018;25:103–110.

Ahmed I, Rasheed S, White C, et al. The incidence of post-vasectomy chronic testicular pain and the role of nerve stripping (denervation) of the spermatic cord in its management. *Br J Urol*. 1997;79:269–270.

Akinci E, Bodur H, Cevik MA, et al. A complication of brucellosis: epididymoorchitis. *Int J Infect Dis*. 2006;10:171–177.

Alexander RB, Propert KJ, Schaeffer AJ, et al. Ciprofloxacin or tamsulosin in men with chronic prostatitis/chronic pelvic pain syndrome: a randomized, double-blind trial. *Ann Intern Med*. 2004;141:581–589.

Alexander RB, Trissel D. Chronic prostatitis: results of an Internet survey. *Urology*. 1996;48:568–574.

Altinkilic B, Pilatz A, Weidner W. Detection of normal intratesticular perfusion using color coded duplex sonography obviates need for scrotal exploration in patients with suspected testicular torsion. *J Urol*. 2013;189:1853–1858.

Anderson RU, Orenberg EK, Chan CA, et al. Psychometric profiles and hypothalamic-pituitary-adrenal axis function in men with chronic prostatitis/chronic pelvic pain syndrome. *J Urol*. 2008;179:956–960.

Anderson RU, Wise D, Sawyer T, et al. Integration of myofascial trigger point release and paradoxical relaxation training treatment of chronic pelvic pain in men. *J Urol*. 2005;174:155–160.

Anderson RU, Wise D, Sawyer T, et al. Sexual dysfunction in men with chronic prostatitis/chronic pelvic pain syndrome: improvement after trigger point release and paradoxical relaxation training. *J Urol*. 2006;176:1534–1538.

Anderson RU, Wise D, Sawyer T, et al. 6-day intensive treatment protocol for refractory chronic prostatitis/chronic pelvic pain syndrome using myofascial release and paradoxical relaxation training. *J Urol*. 2011;185:1294–1299.

Anothaisintawee T, Attia J, Nickel JC, et al. Management of chronic prostatitis/chronic pelvic pain syndrome: a systematic review and network meta-analysis. *J Am Med Assoc*. 2011;305:78–86.

Arzola JM, Hawley JS, Oakman C, et al. A case of prostatitis due to Burkholderia pseudomallei. *Nat Clin Pract Urol*. 2007;4:111–114.

Ateya A, Fayez A, Hani R, et al. Evaluation of prostatic massage in treatment of chronic prostatitis. *Urology*. 2006;67:674–678.

Badalyan RR, Fanarjyan SV, Aghajanyan IG. Chlamydial and ureaplasmal infections in patients with nonbacterial chronic prostatitis. *Andrologia*. 2003;35:263–265.

Baliki MN, Schnitzer TJ, Bauer WR, et al. Brain morphological signatures for chronic pain. *PLoS One*. 2011;6:e26010.

Baranowski AP, Mandeville AL, Edwards S, et al. Male chronic pelvic pain syndrome and the role of interdisciplinary pain management. *World J Urol*. 2013;31:779–784.

Barnes RW, Hadley HL, O'Donoghue EP. Transurethral resection of the prostate for chronic bacterial prostatitis. *Prostate*. 1982;3:215–219.

Barry MJ, Fowler FJ Jr, O'Leary MP, et al. The American Urological Association symptom index for benign prostatic hyperplasia. The Measurement Committee of the American Urological Association. *J Urol*. 1992;148:1549–1557.

Bartoletti R, Cai T, Nesi G, et al. The impact of biofilm-producing bacteria on chronic bacterial prostatitis treatment: results from a longitudinal cohort study. *World J Urol*. 2014;32:737–742.

Basal S, Ergin A, Yildirim I, et al. A novel treatment of chronic orchialgia. *J Androl*. 2012;33:22–26.

Bates SM, Hill VA, Anderson JB, et al. A prospective, randomized, double-blind trial to evaluate the role of a short reducing course of oral corticosteroid therapy in the treatment of chronic prostatitis/chronic pelvic pain syndrome. *BJU Int*. 2007;99:355–359.

Benelli A, Hossain H, Pilatz A, et al. Prostatitis and its management. *Eur Urol*. 2017;16:132–137.

Benson JS, Abern MR, Larsen S, et al. Does a positive response to spermatic cord block predict response to microdenervation of the spermatic cord for chronic scrotal content pain? *J Sex Med*. 2013;10:876–882.

Berger RE, Ciol MA, Rothman I, et al. Pelvic tenderness is not limited to the prostate in chronic prostatitis/chronic pelvic pain syndrome (CPPS) type IIIA and IIIB: comparison of men with and without CP/CPPS. *BMC Urol*. 2007;7:17.

Berger RE, Kessler D, Holmes KK. Etiology and manifestations of epididymitis in young men: correlations with sexual orientation. *J Infect Dis*. 1987;155:1341–1343.

Berger RE. Re: Pregabalin for the treatment of men with chronic prostatitis/chronic pelvic pain syndrome: a randomized controlled trial. *J Urol*. 2011;185:1302–1303.

Bozzini G, Provenzano M, Buffi N, et al. An observational study of the use of beclomethasone dipropionate suppositories in the treatment of lower urinary tract inflammation in men. *BMC Urol*. 2016;16:25.

Brede CM, Shoskes DA. The etiology and management of acute prostatitis. *Nat Rev Urol*. 2011;8:207–212.

Buijs J, Maillette de Buy Wenniger L, van Leenders G, et al. Immunoglobulin G4-related prostatitis: a case-control study focusing on clinical and pathologic characteristics. *Urology*. 2014;83:521–526.

Cai T, Mazzoli S, Meacci F, et al. Epidemiological features and resistance pattern in uropathogens isolated from chronic bacterial prostatitis. *J Microbiol*. 2011;49:448–454.

Cai T, Pisano F, Magri V, et al. Chlamydia trachomatis infection is related to premature ejaculation in chronic prostatitis patients: results from a cross-sectional study. *J Sex Med*. 2014;11:3085–3092.

Calixte N, Brahmbhatt J, Parekattil SJ. Genital pain: algorithm for management. *Trans Andol Urol*. 2017;6:252–257.

Calixte N, Tojuola B, Kartel I, et al. Targeted robot assisted microscurgical denervation of the spermatic cord for the treatment of chronic orchalgia or groin pain: a single center large series review. *J Urol*. 2018;199:1015–1022.

Calleary JG, Masood J, Hill JT. Chronic epididymitis: is epididymectomy a valid surgical treatment? *Int J Androl*. 2009;32:468–472.

Cappelleri JC, Rosen RC. The Sexual Health Inventory for Men (SHIM): a 5-year review of research and clinical experience. *Int J Impotence Res*. 2005;17:307–319.

Cek M, Lenk S, Naber KG, et al. EAU guidelines for the management of genitourinary tuberculosis. *Eur Urol*. 2005;48:353–362.

Cek M, Sturdza L, Pilatz A. Acute and chronic epididymitis. *Eur Urol*. 2017;16:124–131.

Centers for Disease Control and Prevention (CDC). Sexually Transmitted Diseases Treatment Guidelines, 2015. *MMWR Morb Mortal Wkly Rep*. 2015;64:1–137.

Charalabopoulos K, Karachalios G, Baltogiannis D, et al. Penetration of antimicrobial agents into the prostate. *Chemotherapy*. 2003;49:269–279.

Charalabopoulos K, Karachalios G, Baltogiannis D, et al. Penetration of antimicrobial agents into the prostate. *Chemotherapy*. 2003;49:269–279.

Chawla A, Kulkarni G, Kamal K, et al. Microsurgical varicocelectomy for recurrent or persistent varicoceles associated with orchalgia. *Urology*. 2005;66:1072–1074.

Cheah PY, Liong ML, Yuen KH, et al. Terazosin therapy for chronic prostatitis/chronic pelvic pain syndrome: a randomized, placebo controlled trial. *J Urol*. 2003;169:592–596.

Chen MC, Keshavan P, Gregory GD, et al. RANTES mediates TNF-dependent lamina propria mast cell accumulation and barrier dysfunction in neurogenic cystitis. *Am J Physiol Renal Physiol*. 2007;292:F1372–F1379.

Chen S. Factors predicting symptomatic relief by varicocelectomy in patients with normospermia and painful varicocele nonresponsive to conservative treatment. *Urology*. 2012;80:585–589.

Chen TF, Ball RY. Epididymectomy for post-vasectomy pain: histological review. *Br J Urol*. 1991;68:407–413.

Chen Y, Wu X, Liu J, et al. Effects of a 6-month course of tamsulosin for chronic prostatitis/chronic pelvic pain syndrome: a multicenter, randomized trial. *World J Urol*.

2011;29:381–385.

Cheung WY, Chan AC, Loke SL, et al. Latent sites of Epstein-Barr virus infection. *Am J Clin Pathol*. 1993;100:502–506.

Chiang PH, Chiang CP. Therapeutic effect of transurethral needle ablation in non-bacterial prostatitis: chronic pelvic pain syndrome type IIIa. *Int J Urol*. 2004;11:97–102.

Chiang PH, Tsai EM, Chiang CP. Pilot study of transurethral needle ablation (TUNA) in treatment of nonbacterial prostatitis. *J Endourol*. 1997;11:367–370.

Christianson JA, Liang R, Ustinova EE, et al. Convergence of bladder and colon sensory innervation occurs at the primary afferent level. *Pain*. 2007;128:235–243.

Chu C, Chen W, Yeh S, et al. Syphilitic orchitis mimicking a testicular tumor in a clinically occult HIV-infected young man: a case report with emphasis on a challenging pathological diagnosis. *Diagn Pathol*. 2016;11:4.

Chung SD, Lin HC. Association between chronic prostatitis/chronic pelvic pain syndrome and anxiety disorder: a population-based study. *PLoS One*. 2013;8:e64630.

Chung SD, Keller JJ, Lin HC. A case-control study on the association between chronic prostatitis/chronic pelvic pain syndrome and erectile dysfunction. *BJU Int*. 2012;110:726–730.

Ciftci H, Savas M, Yeni E, et al. Chronic orchalgia and ssociated diseases. *Curr Urol*. 2010;4:67–70.

Clemens JQ, Calhoun EA, Litwin MS, et al. Validation of a modified National Institutes of Health chronic prostatitis symptom index to assess genitourinary pain in both men and women. *Urology*. 2009;74:983 [No-987].

Clemens JQ, Clauw DJ, Kreder K, et al. Comparison of baseline urological symptoms in men and women in the MAPP research cohort. *J Urol*. 2015;193:1554–1558.

Clemens JQ, Mullins C, Ackerman AL, et al. A new undertanding of Urologic Chronic Pelvic Pain Syndrome: Findings from the MAPP reserach network. *Nat Rev Urol*. 2018 [in press].

Clemens JQ, Nadler RB, Schaeffer AJ, et al. Biofeedback, pelvic floor re-education, and bladder training for male chronic pelvic pain syndrome. *Urology*. 2000;56:951–955.

Cohen JM, Fagin AP, Hariton E, et al. Therapeutic intervention for chronic prostatitis/chronic pelvic pain syndrome (CP/CPPS): a systematic review and meta-analysis. *PLoS One*. 2012;7:e41941.

Collins MM, Meigs JB, Barry MJ, et al. Prevalence and correlates of prostatitis in the health professionals follow-up study cohort. *J Urol*. 2002;167:1363–1366.

Cornel EB, van Haarst EP, Schaarsberg RWMB, et al. The effect of biofeedback physical therapy in men with Chronic Pelvic Pain Syndrome Type III. *Eur Urol*. 2005;47:607–611.

Cortese MM, Barskey AE, Tegtmeier GE, et al. Mumps antibody levels among students before a mumps outbreak: in search of a correlate of immunity. *J Infect Dis*. 2011;204:1413–1422.

Costabile RA, Hahn M, McLeod DG. Chronic orchialgia in the pain prone patient: the clinical perspective. *J Urol*. 1991;146:1571–1574.

Costabile RA, Hahn M, McLeod DG. Chronic orchialgia in the pain prone patient: the clinical perspective. *J Urol*. 1991;146:1571–1574.

Cui T, Terlecki R. Prevalence of relative deficiencies in testosterone and vitamin B12 among patients referred for chronic orchialgia: implications for management. *Am J Mens Health*. 2016;1–4.

Dagher A, Curatolo A, Sachdev M, et al. Identification of novel non-invasive biomarkers of urinary chronic pelvic pain syndrome: findings from the Multidisciplinary Approach to the Study of Chronic Pelvic Pain (MAPP) Research Network. *BJU Int*. 2017;120:130–142.

Davis BE, Noble MJ, Weigel JW, et al. Analysis and management of chronic testicular pain. *J Urol*. 1990;143:936–939.

Davis R, Jones JS, Barocas DA, et al. Diagnosis, evaluation and follow-up of asymptomatic microhematuria (AMH) in adults: AUA guideline. *J Urol*. 2012;188:2473–2481.

Dayan GH, Rubin S. Mumps outbreaks in vaccinated populations: are available mumps vaccines effective enough to prevent outbreaks? *Clin Infect Dis*. 2008;47:1458–1467.

de Buy Wenniger LM, Scheltema JM, Verheij J, et al. Testicular inflammation as a new manifestation of IgG4-associated disease. *Urology*. 2013;82:e15–e16.

De Paepe ME, Vuletin JC, Lee MH, et al. Testicular atrophy in homosexual AIDS patients: an immune-mediated phenomenon? *Hum Pathol*. 1989;20:572–578.

De Rose AF, Gallo F, Giglio M, et al. Role of mepartricin in category III chronic nonbacterial prostatitis/chronic pelvic pain syndrome: a randomized prospective placebo-controlled trial. *Urology*. 2004;63:13–16.

Decaestecker K, Oosterlinck W. Transurethral resection of the prostate in recurrent acute bacterial prostatitis. *Urol Int*. 2015;94:442–444.

Dejucq N, Jegou B. Viruses in the mammalian male genital tract and their effects on the reproductive system. *Microbiol Mol Biol Rev*. 2001;65.

Dellon AL, Hashemi SS, Tollstrupt TH. Orchialgia after orchiectomy. *Plast Reconstr Surg*. 2014;134:998e–999e.

Demonchy E, Courjon J, Ughetto E, et al. Cefoxitin-based antibiotic therapy for ESBL producing Enterobacteriacae prostatitis: a prospective pilot study. *Int J Antimicrob Agents*. 2018;51(6):836–841.

Deshpande V, Zen Y, Chan JK, et al. Consensus statement on the pathology of IgG4-related disease. *Mod Pathol*. 2012;25:1181–1192.

Desireddi NV, Campbell PL, Stern JA, et al. Monocyte chemoattractant protein-1 and macrophage inflammatory protein-1alpha as possible biomarkers for the chronic pelvic pain syndrome. *J Urol*. 2008;179:1857–1861.

Dessombz A, Meria P, Bazin D, et al. Prostatic stones: evidence of a specific chemistry related to infection and presence of bacterial imprints. *PLoS One*. 2012;7:e51691.

DeTure FA, Drylie DM, Kaufman HE, et al. Herpesvirus type 2: isolation from seminal vesicle and testes. *Urology*. 1976;7:541–544.

Devine CJJ, Schellhammer PF. The use of microsurgical denervation of the spermatic cord for orchalgia. *Trans Am Assoc Genitourin Surg*. 1978;70:149–151.

Dhand S, Casalino DD. Idiopathic granulomatous orchitis. *J Urol*. 2011;186:1477–1478.

Dickinson KJ, Thomas M, Fawole AS, et al. Predicting chronic post-operative pain following laparoscopic inguinal hernia repair. *Hernia*. 2008;12:597–601.

Dielubanza EJ, Mazur DJ, Schaeffer AJ. Management of non-catheter-associated complicated urinary tract infection. *Infect Dis Clin North Am*. 2014;28:121–134.

Dikov D, Bachurska S, Staikov D, et al. Intraepithelial lymphocytes in relation to NIH category IV prostatitis in autopsy prostate. *Prostate*. 2015;75:1074–1084.

Doble A, Taylor-Robinson D, Thomas BJ, et al. Acute epididymitis: a microbiological and ultrasonographic study. *Br J Urol*. 1989;63:90–94.

Doble A, Thomas BJ, Walker MM, et al. The role of Chlamydia trachomatis in chronic abacterial prostatitis: a study using ultrasound guided biopsy. *J Urol*. 1989;141:332–333.

Drach GW, Fair WR, Meares EM, et al. Classification of benign diseases associated with prostatic pain: prostatitis or prostatodynia? *J Urol*. 1978;120:266.

Dubovy P. Wallerian degeneration and peripheral nerve conditions for both axonal regeneration and neuropathic pain induction. *Ann Anat*. 2011;193:267–275.

Ecker DJ, Sampath R, Massire C, et al. Ibis T5000: a universal biosensor approach for microbiology. *Nat Rev Microbiol*. 2008;6:553–558.

El-enen MA, Abou-Farha M, El-Abd A, et al. Intraprostatic injection of botulinum toxin-A in patients with refractory chronic pelvic pain syndrome: the transurethral vs. transrectal approach. *Arab J Urol*. 2015;13:94–99.

Elist J. Effects of pollen extract preparation Prostat/Poltit on lower urinary tract symptoms in patients with chronic nonbacterial prostatitis/chronic pelvic pain syndrome: a randomized, double-blind, placebo-controlled study. *Urology*. 2006;67:60–63.

Engeler DS, Baranowski AP, Dinis-Oliveira P, et al. The 2013 EAU guidelines on chronic pelvic pain: is management of chronic pelvic pain a habit, a philosophy, or a science? 10 years of development. *Eur Urol*. 2013;64:431–439.

Epstein JI, Hutchins GM. Granulomatous prostatitis: distinction among allergic, nonspecific, and post-transurethral resection lesions. *Hum Pathol*. 1984;15:818–825.

Etienne M, Chavanet P, Sibert L, et al. Acute bacterial prostatitis: heterogeneity in diagnostic criteria and management. Retrospective multicentric analysis of 371 patients diagnosed with acute prostatitis. *BMC Infect Dis*. 2008;8:12.

Etienne M, Pestel-Caron M, Chapuzet C, et al. Should blood cultures be performed for patients with acute prostatitis? *J Clin Microbiol*. 2010;48:1935–1938.

Evliyaoglu Y, Burgut R. Lower urinary tract symptoms, pain and quality of life assessment in chronic non-bacterial prostatitis patients treated with alpha-blocking agent doxazosin; versus placebo. *Int Urol Nephrol*. 2002;34:351–356.

Falahatkar S, Shahab E, Gholamjani Moghaddam K, et al. Transurethral intraprostatic injection of botulinum neurotoxin type A for the treatment of chronic prostatitis/chronic pelvic pain syndrome: results of a prospective pilot double-blind and randomized placebo-controlled study. *BJU Int*. 2015;116:641–649.

Farmer MA, Chanda ML, Parks EL, et al. Brain functional and anatomical changes in chronic prostatitis/chronic pelvic pain syndrome. *J Urol*. 2011;186:117–124.

Farrell MR, Dugan SA, Levine LA. Physical therapy for chronic scrotal content pain with associated pelvic floor pain on digital rectal exam. *Can J Urol*. 2016;23:8546–8550.

Fazli M, Almblad H, Rybtke ML, et al. Regulation of biofilm formation in Pseudomonas and Burkholderia species. *Environ Microbiol*. 2014;16:1961–1981.

Fitzgerald MP, Anderson RU, Potts J, et al. Randomized multicenter feasibility trial of myofascial physical therapy for the treatment of urological chronic pelvic pain syndromes. *J Urol*. 2013;189:S75–S85.

Foster HE Jr, Hanno PM, Nickel JC, et al. Effect of amitriptyline on symptoms in treatment naive patients with interstitial cystitis/painful bladder syndrome. *J Urol*. 2010;183:1853–1858.

Franco JVA, Turk T, Jung JH, et al. Non-pharmacological interventions for treating chronic prostatitis/chronic pelvic pain synrome (review). *Cochrane Database Syst Rev*. 2018;(5) [CD012551].

Game X, Vincendeau S, Palascak R, et al. Total and free serum prostate specific antigen levels during the first month of acute prostatitis. *Eur Urol*. 2003;43:702–705.

Ganesan S, Sajjan US. Host evasion by Burkholderia cenocepacia. *Front Cell Infect Microbiol*. 2011;1:25.

Gao M, Ding H, Zhong G, et al. The effects of transrectal radiofrequency hyperthermia on patients with chronic prostatitis and the changes of MDA, NO, SOD, and Zn levels in pretreatment and posttreatment. *Urology*. 2012;79:391–396.

Gardiner BJ, Mahony AA, Ellis AG, et al. Is fosfomycin a potential treatment alternative for multidrug-resistant gram-negative prostatitis? *Clin Infect Dis*. 2014;58:e101–e105.

Gasperi M, Krieger JN, Forsberg C, et al. Chronic prostatitis and comorbid non-urological overlapping pain conditions: a co-twin control study. *J Psychosom Res*. 2017;102:29–33.

Geisser ME, Glass JM, Rajcevska LD, et al. A psychophysical study of auditory and pressure sensitivity in patients with fibromyalgia and healthy controls. *J Pain*. 2008;9:417–422.

Giannantoni A, Porena M, Gubbiotti M, et al. The efficacy and safety of duloxetine in a multidrug regimen for chronic prostatitis/chronic pelvic pain syndrome. *Urology*. 2014;83:400–405.

Gill BC, Shoskes DA. Bacterial prostatitis. *Curr Opin Infect Dis*. 2016;29:86–91.

Giubilei G, Mondaini N, Minervini A, et al. Physical activity of men with chronic prostatitis/chronic pelvic pain syndrome not satisfied with conventional treatments–could it represent a valid option? The physical activity and male pelvic pain trial: a double-blind, randomized study. *J Urol*. 2007;177:159–165.

Goldmeier D, Madden P, McKenna M, et al. Treatment of category III A prostatitis with zafirlukast: a randomized controlled feasibility study. *Int J STD AIDS*. 2005;16:196–200.

Gonzalez RR, Te AE. Is there a role for urodynamics in chronic nonbacterial prostatitis? *Curr Urol Rep*. 2006;7:335–338.

Gottsch HP, Yang CC, Berger RE. A pilot study of botulinum toxin A for male chronic pelvic pain syndrome. *Scand J Urol Nephrol*. 2011;45:72–76.

Goyal NK, Goel A, Sankhwar S. Transurethral holmium-YAG laser lithotripsy for large symptomatic prostatic calculi: initial experience. *Urolithiasis*. 2013;41:355–359.

Grabe M, Bartoletti R, Bjerklund Johansen TE, et al. *EAU guidelines on urological infections*. European Association of Urology. 2015:237–257 [(website)] https://uroweb.org/wp-content/uploads/18-Urological-Infections_LR.pdf.

Gray CL, Powell CR, Amling CL. Outcomes for surgical management of orchalgia in patients with identifiable intrascrotal lesions. *Eur Urol*. 2001;39:455–459.

Greco R, Tassorelli C, Sandrini G, et al. Role of calcitonin gene-related peptide and substance P in different models of pain. *Cephalalgia*. 2008;28:114–126.

Griffith JW, Stephens-Shields AJ, Hou X, et al. Pain and urinary symptoms should not be combined into a single score: psychometric findings from the MAPP Research Network. *J Urol*. 2016;195:949–954.

Grimsley SJ, Khan MH, Jones GE. Mechanism of Phosphodiesterase 5 inhibitor relief of prostatitis symptoms. *Med Hypotheses*. 2007;69:25–26.

Gul O, Eroglu M, Ozok U. Use of terazosine in patients with chronic pelvic pain syndrome and evaluation by prostatitis symptom score index. *Int Urol Nephrol*. 2001;32:433–436.

Ha U, Kim ME, Kim CS, et al. Acute bacterial prostatitis in Korea: clinical outcome, including symptoms, management, microbiology and course of disease. *Int J Antimicrob Agents*. 2008;31:S96–S101.

Hanno PM, Burks DA, Clemens JQ, et al. Interstitial Cystitis

Guidelines Panel of the American Urological Association Education and Research,Inc. AUA guideline for the diagnosis and treatment of interstitial cystitis/bladder pain syndrome. *J Urol*. 2011;185:2162–2170.

Hart PA, Smyrk TC, Chari ST. IgG4-related prostatitis: a rare cause of steroid-responsive obstructive urinary symptoms. *Int J Urol*. 2013;20:132–134.

Herati AS, Moldwin RM. Alternative therapies in the management of chronic prostatitis/chronic pelvic pain syndrome. *World J Urol*. 2013;31:761–766.

Hetrick DC, Glazer H, Liu YW, et al. Pelvic floor electromyography in men with chronic pelvic pain syndrome: a case-control study. *Neurourol Urodyn*. 2006;25:46–49.

Heyns CF, Fisher M. The urological management of the patient with acquired immunodeficiency syndrome. *BJU Int*. 2005;95:709–716.

Heyns CF, Groeneveld AE, Sigarroa NB. Urologic complications of HIV and AIDS. *Nat Clin Pract Urol*. 2009;6:32–43.

Heyns CF. Urinary tract infection associated with conditions causing urinary tract obstruction and stasis, excluding urolithiasis and neuropathic bladder. *World J Urol*. 2012;30:77–83.

Hochreiter WW, Duncan JL, Schaeffer AJ. Evaluation of the bacterial flora of the prostate using a 16S rRNA gene based polymerase chain reaction. *J Urol*. 2000;163:127–130.

Holmes KK, Berger RE, Alexander ER. Acute epididymitis: etiology and therapy. *Arch Androl*. 1979;3:309–316.

Horcajada JP, Vilana R, Moreno-Martinez A, et al. Transrectal prostatic ultrasonography in acute bacterial prostatitis: findings and clinical implications. *Scand J Infect Dis*. 2003;35:114–120.

Hori S, Sengupta A, Shukla CJ, et al. Long-term outcome of epididymectomy for the management of chronic epididymal pain. *J Urol*. 2009;182:1407–1412.

Horovitz D, Tjong V, Domes T, et al. Vasectomy reversal provides long-term pain relief for men with the post-vasectomy pain syndrome. *J Urol*. 2012;187:613–617.

Hou DS, Long WM, Shen J, et al. Characterisation of the bacterial community in expressed prostatic secretions from patients with chronic prostatitis/chronic pelvic pain syndrome and infertile men: a preliminary investigation. *Asian J Androl*. 2012;14:566–573.

Hruz P, Danuser H, Studer UE, et al. Non-inflammatory chronic pelvic pain syndrome can be caused by bladder neck hypertrophy. *Eur Urol*. 2003;44:106–110.

Hu JC, Link CL, McNaughton-Collins M, et al. The association of abuse and symptoms suggestive of chronic prostatitis/chronic pelvic pain syndrome: results from the Boston Area Community Health survey. *J Gen Intern Med*. 2007;22:1532–1537.

Huckabay C, Nitti VW. Diagnosis and treatment of primary bladder neck obstruction in men. *Curr Urol Rep*. 2005;6:271–275.

Jacobo P, Guazzone VA, Theas MS, et al. Testicular autoimmunity. *Autoimmun Rev*. 2011;10:201–204.

Jacobo P, Perez CV, Theas MS, et al. CD4+ and CD8+ T cells producing Th1 and Th17 cytokines are involved in the pathogenesis of autoimmune orchitis. *Reproduction*. 2011;141:249–258.

Jensen KB, Kosek E, Petzke F, et al. Evidence of dysfunctional pain inhibition in fibromyalgia reflected in rACC during provoked pain. *Pain*. 2009;144:95–100.

Jeong CW, Lim DJ, Son H, et al. Treatment for chronic prostatitis/chronic pelvic pain syndrome: levofloxacin, doxazosin and their combination. *Urol Int*. 2008;80:157–161.

Ji RR, Xu ZZ, Wang X, et al. Matrix metalloprotease regulation of neuropathic pain. *Trends Pharmacol Sci*. 2009;30:336–340.

Johnson DE, Russell RG, Lockatell CV, et al. Urethral obstruction of 6 hours or less causes bacteriuria, bacteremia, and pyelonephritis in mice challenged with “nonuropathogenic” Escherichia coli. *Infect Immun*. 1993;61:3422–3428.

Kabay S, Kabay SC, Yucel M, et al. Efficiency of posterior tibial nerve stimulation in category IIIB chronic prostatitis/chronic pelvic pain: a sham-controlled comparative study. *Urol Int*. 2009;83:33–38.

Kanamaru S, Kurazono H, Terai A, et al. Increased biofilm formation in *Escherichia coli* isolated from acute prostatitis. *Int J Antimicrob Agents*. 2006;28:S21–S25.

Kaplan SA, Santarosa RP, D'Alisera PM, et al. Pseudodyssynergia (contraction of the external sphincter during voiding) misdiagnosed as chronic nonbacterial prostatitis and the role of biofeedback as a therapeutic option. *J Urol*. 1997;157:2234–2237.

Kaplan SA, Te AE, Jacobs BZ. Urodynamic evidence of vesical neck obstruction in men with misdiagnosed chronic nonbacterial prostatitis and the therapeutic role of endoscopic incision of the bladder neck. *J Urol*. 1994;152:2063.

Karlowsky JA, Denisuik AJ, Lagace-Wiens PRS, et al. In Vitro activity of fosfomycin against Escherichia coli isolated from patients with urinary tract infections in Canada as part of the CANWARD surveillance study. *Antimicrob Agents Chemother*. 2014;58:1252–1256.

Karram S, Kao C, Osunkoya AO, et al. Idiopathic granulomatous orchitis: morphology and evaluation of its relationship to IgG4 related disease. *Hum Pathol*. 2014;45:844–850.

Kastner C, Hochreiter W, Huidobro C, et al. Cooled transurethral microwave thermotherapy for intractable chronic prostatitis–results of a pilot study after 1 year. *Urology*. 2004;64:1149–1154.

Kauffman CA, Fisher JF, Sobel JD, et al. Candida urinary tract infections–diagnosis. *Clin Infect Dis*. 2011;52:S452–S456.

Kaver I, Matzkin H, Braf ZF. Epididymo-orchitis: a retrospective study of 121 patients. *J Fam Pract*. 1990;30:548–552.

Kavoussi PK, Costabile RA. Orchialgia and the chronic pelvic pain syndrome. *World J Urol*. 2013;31:773–778.

Khambati A, Lau S, Gordon A, et al. OnabotulinumtoxinA (Botox) nerve blocks provide durable pain relief for men with chronic scrotal pain: a pilot open-label trial. *J Sex Med*. 2014;11:3072–3077.

Khorasani B, Arab AM, Sedighi Gilani MA, et al. Transabdominal ultrasound measurement of pelvic floor muscle mobility in men with and without chronic prostatitis/chronic pelvic pain syndrome. *Urology*. 2012;80:673–677.

Kim JW, Oh MM, Bae JH, et al. Clinical and microbiological characteristics of spontaneous acute prostatitis and transrectal prostate biopsy-related acute prostatitis: Is transrectal prostate biopsy-related acute prostatitis a distinct acute prostatitis category? *J Infect Chemother*. 2015;21:434–437.

Kim SH, Ha US, Yoon BI, et al. Microbiological and clinical characteristics in acute bacterial prostatitis according to lower urinary tract manipulation procedure. *J Infect Chemother*. 2014;20:38–42.

Kim TH, Han DH, Cho WJ, et al. The efficacy of extracorporeal magnetic stimulation for treatment of chronic prostatitis/chronic pelvic pain syndrome patients who do not respond to pharmacotherapy. *Urology*. 2013;82:894–898.

Kim TH, Lee KS, Kim JH, et al. Tamsulosin monotherapy versus combination therapy with antibiotics or anti-inflammatory agents in the treatment of chronic pelvic pain syndrome. *Int Neurourol J*. 2008;15:92–96.

Kobayashi I, Ikawa K, Nakamura K, et al. Penetration of piperacillin-tazobactam into human prostate tissue and dosing considerations for prostatitis based on site-specific pharmacokinetics and pharmacodynamics. *J Infect Chemother*. 2015;21:575–580.

Kosek E, Ekholm J, Hansson P. Sensory dysfunction in fibromyalgia patients with implications for pathogenic mechanisms. *Pain*. 1996;68:375–383.

Kouiavskaia DV, Southwood S, Berard CA, et al. T-cell recognition of prostatic peptides in men with chronic prostatitis/chronic pelvic pain syndrome. *J Urol*. 2009;182:2483–2489.

Kravchick S, Cytron S, Agulansky L, et al. Acute prostatitis in middle-aged men: a prospective study. *BJU Int*. 2004;93:93–96.

Krieger JN, Dobrindt U, Riley DE, et al. Acute Escherichia coli prostatitis in previously health young men: bacterial virulence factors, antimicrobial resistance, and clinical outcomes. *Urology*. 2011;77:1420–1425.

Krieger JN, Egan KJ. Comprehensive evaluation and treatment of 75 men referred to chronic prostatitis clinic. *Urology*. 1991;38:11–19.

Krieger JN, Nyberg L Jr, Nickel JC. NIH consensus definition and classification of prostatitis. *J Am Med Assoc*. 1999;282:236–237.

Krieger JN, Riley DE, Vesella RL, et al. Bacterial dna sequences in prostate tissue from patients with prostate cancer and chronic prostatitis. *J Urol*. 2000;164:1221–1228.

Krieger JN, Stephens AJ, Landis JR, et al. Relationship between chronic nonurological associated somatic syndromes and symptom severity in urological chronic pelvic pain syndromes: baseline evaluation of the MAPP study. *J Urol*. 2015;193:1254–1262.

Krieger JN, Thumbikat P. Bacterial prostatitis: bacterial virulence, clinical outcomes, and new directions. *Microbiol Spectr*. 2016;4.

Krieger JN, Weidner W. Prostatitis: ancient history and new horizons. *World J Urol*. 2003;21:51–53.

Ku JH, Kim YH, Jeon YS, et al. The preventive effect of systemic treatment with interferon-alpha2B for infertility from mumps orchitis. *BJU Int*. 1999;84:839–842.

Kulchavenya E, Kim C, Bulanova O, et al. Male genital tuberculosis: epidemiology and diagnostic. *World J Urol*. 2012;30:15–21.

Kulchavenya E, Naber K, Bjerklund Johansen TE. Urogenital tuberculosis: classification, diagnosis and treatment. *Eur Urol*. 2016;15(Suppl):112–121.

Kulchavenya E, Zhukova I, Kholtobin D. Spectrum of urogenital tuberculosis. *J Infect Chemother*. 2013;19:880–883.

Kulchavenya E. Epidemiology of urogenital tuberculosis in Siberia. *Am J Infect Control*. 2013;41:945–946.

Kurzer E, Kaplan S. Cost effectiveness model comparing trimethoprim sulfamethoxazole and ciprofloxacin for the treatment of chronic bacterial prostatitis. *Eur Urol*. 2002;42:163–166.

Kutch JJ, Yani MS, Asavasopon S, et al. Altered resting state neuromotor connectivity in men with chronic prostatitis/chronic pelvic pain syndrome: a MAPP: Research Network Neuroimaging Study. *NeuroImage Clin*. 2015;8:493–502.

Lai HH, Jemielta T, Sutcliffe S, et al. Characteization of whole body pain in Urological Chronic Pelvic Pain Syndrome at baseline: a MAPP research network study. *J Urol*. 2017;198:622–631.

Lai HH, Krieger JN, Pontari MA, et al. Painful bladder filling and painful urgency are distinct characteristics in men and women with urological chronic pelvic pain syndromes: a MAPP Research Network Study. *J Urol*. 2015;194:1634–1641.

Landis JR, Williams DA, Lucia MS, et al. The MAPP research network: design, patient characterization and operations. *BMC Urol*. 2014;14:58.

Larsen SM, Benson JS, Levine LA. Microdenervation of the spermatic cord for chronic scrotal content pain: single institution review analyzing success rate after prior attempts at surgical correction. *J Urol*. 2013;189:554–558.

Lee DS, Choe H, Kim HY, et al. Acute bacterial prostatitis and abscess formation. *BMC Urol*. 2016;16:38.

Lee JY, Cho KS, Lee SH, et al. A comparison of epididymectomy with vasectomy reversal for the surgical treatment of postvasectomy pain syndrome. *Int Urol Nephrol*. 2014;46:531–537.

Lee JY, Lee TY, Park HY, et al. Efficacy of epididymectomy in treatment of chronic epididymal pain: a comparison of patients with and without a history of vasectomy. *Urology*. 2011;77:177–182.

Lee LK, Dinneen MD, Ahmad S. The urologist and the patient infected with human immunodeficiency virus or with acquired immunodeficiency syndrome. *BJU Int*. 2001;88:500–510.

Lee MWL, McPhee RW, Stringer MD. An evidence-based approach to human dermatomes. *Clin Anat*. 2008;21:363–373.

Lee SH, Lee BC. Electroacupuncture relieves pain in men with chronic prostatitis/chronic pelvic pain syndrome: three-arm randomized trial. *Urology*. 2009;73:1036–1041.

Lee SW, Liong ML, Yuen KH, et al. Validation of a sham acupuncture procedure in a randomised, controlled clinical trial of chronic pelvic pain treatment. *Acupunct Med*. 2011;29:40–46.

Lee SWH, Liong ML, Yuen KH, et al. Chronic prostatitis/chronic pelvic pain syndrome: role of alpha blocker therapy. *Urol Int*. 2007;78:97–105.

Leibovici D, Zisman A, Chen-Levyi Z, et al. Elevated prostate specific antigen serum levels after intravesical instillation of bacillus Calmette-Guerin. *J Urol*. 2000;164:1546–1549.

Leskinen M, Lukkarinen O, Marttila T. Effects of finasteride in patients with inflammatory chronic pelvic pain syndrome: a double-blind, placebo-controlled, pilot study. *Urology*. 1999;53:502–505.

Leskinen MJ, Kilponen A, Lukkarinen O, et al. Transurethral needle ablation for the treatment of chronic pelvic pain syndrome (category III prostatitis): a randomized, sham-controlled study. *Urology*. 2002;60:300–304.

Leskinen MJ, Rantakokko-Jalava K, Manninen R, et al. Negative bacterial polymerase chain reaction (PCR) findings in prostate tissue from patients with symptoms of chronic pelvic pain syndrome (CPPS) and localized prostate cancer. *Prostate*. 2003;55:105–110.

Levine L. Chronic orchialgia: evaluation and discussion of treatment options. *Ther Adv Urol*. 2010;2:209–214.

Lipscomb K, Williams D IV. Orchiectomy following microsurgical denervation of the spermatic cord: single institution review. *J Urol*. 2016;195:e1059.

Liss MA, Ehdaie B, Loeb S, et al. An update of the American Urological Association White Paper on the prevention and treatment of the more common complications related to prostate biopsy. *J Urol*. 2017;198:329–334.

Litwin MS, McNaughton-Collins M, Fowler FJ Jr, et al. The National Institutes of Health chronic prostatitis symptom index: development and validation of a new outcome measure. Chronic Prostatitis Collaborative Research Network. *J Urol*. 1999;162:369–375.

Litwin MS. A review of the development and validation of the National Institutes of Health Chronic Prostatitis Symptom Index. *Urology*. 2002;60:14–18.

Lorenzo L, Rogel R, Sanchez-Gonzalez JV, et al. Evaluation of adult acute scrotum in the emergency room: clinical characteristics, diagnosis, management, and costs. *Urology*. 2016;94:36–41.

Los-Arcos I, Pigrau C, Rodriguez-Pardo D, et al. Long-term fosfomycin-tromethamine oral therapy for difficult-to-treat chronic bacterial prostatitis. *Antimicrob Agents Chemother*. 2015;60:1854–1858.

Lowe B, Decker O, Muller S, et al. Validation and standardization of the Generalized Anxiety Disorder Screener (GAD-7) in the general population. *Med Care*. 2008;46:266–274.

Ludwig M, Schroeder-Printzen I, Schiefer HG, et al. Diagnosis and therapeutic management of 18 patients with prostatic abscess. *Urology*. 1999;53:340–345.

Ludwig M. Diagnosis and therapy of acute prostatitis, epididymitis and orchitis. *Andrologia*. 2008;40:76–80.

Mackern-Oberti JP, Motrich RD, Breser ML, et al. Chlamydia trachomatis infection of the male genital tract: an update. *J Reprod Immunol*. 2013;100:37–53.

Magri V, Montanari E, Marras E, et al. Aminoglycoside antibiotics for NIH category II chronic bacterial prostatitis: a single-cohort study with one-year followup. *Exper Therapeut Med*. 2016;12:2585–2593.

Magri V, Montanari E, Skerk V, et al. Fluoroquinolone-macrolide combination therapy for chronic bacterial prostatitis: retrospective analysis of pathogen eradication rates, inflammatory findings and sexual dysfunction. *Asian J Androl*. 2011;13:819–827.

Massaron S, Bona S, Fumagalli U, et al. Analysis of post-surgical pain after inguinal hernia repair: a prospective study of 1,440 operations. *Hernia*. 2007;11:517–525.

Mazzoli S, Cai T, Rupealta V, et al. Interleukin 8 and anti-chlamydia trachomatis mucosal IgA as urogenital immunologic markers in patients with C. trachomatis prostatic infection. *Eur Urol*. 2007;51:1385–1393.

McJunkin TL, Wuollet AL, Lynch PJ. Sacral nerve stimulation as a treatment modality for intractable neuropathic testicular pain. *Pain Physician*. 2009;12:991–995.

McLoughlin LC, McDermott TED, Thornhill JA. Radical prostatectomy in the presence of ongoing refractory ESBL Escherichia coli bacterial prostatitis. *BMJ Case Rep*. 2014;2014.

McNeal JE. Regional morphology and pathology of the prostate. *Am J Clin Pathol*. 1968;49:347–357.

Meares EM, Stamey TA. Bacteriologic localization patterns in bacterial prostatitis and urethritis. *Invest Urol*. 1968;5:492–518.

Mehik A, Alas P, Nickel JC, et al. Alfuzosin treatment for chronic prostatitis/chronic pelvic pain syndrome: a prospective, randomized, double-blind, placebo-controlled, pilot study. *Urology*. 2003;62:425–429.

Melekos MD, Asbach HW. Epididymitis: aspects concerning etiology and treatment. *J Urol*. 1987;138:83–86.

Michielsen D, Van Camp K, Wyndaele JJ, et al. Transurethral microwave thermotherapy in the treatment of chronic abacterial prostatitis: a 2 years follow-up. *Acta Urol Belg*.

1995;63:1–4.

Millan-Rodriguez F, Palou J, Bujons-Tur A, et al. Acute bacterial prostatitis: two different sub-categories according to a previous manipulation of the lower urinary tract. *World J Urol*. 2006;24:45–50.

Miller HC. Stress prostatitis. *Urology*. 1988;32:507–510.

Miller LJ, Fischer KA, Goralnick SJ, et al. Nerve growth factor and chronic prostatitis/chronic pelvic pain syndrome. *Urology*. 2002;59:603–608.

Mishra VC, Browne J, Emberton M. Role of repeated prostatic massage in chronic prostatitis: a systematic review of the literature. *Urology*. 2008;72:731–735.

Moayedinia A, Haghdani S, Khosrawi S, et al. Long-term effect of extracorporeal shock wave therapy on the treatment of chronic pelvic pain syndrome due to non bacterial prostatitis. *J Res Med Sci*. 2014;19:293–296.

Moldwin RM, Fariello JY. Myofascial trigger points of the pelvic floor: associations with urological pain syndromes and treatment strategies including injection therapy. *Curr Urol Rep*. 2013;14:409–417.

Morales E, Polo LA, Pastor LM, et al. Characterization of corpora amylacea glycoconjugates in normal and hyperplastic glands of human prostate. *J Mol Histol*. 2005;36:235–242.

Moriarty AS, Gilbody S, McMillan D, et al. Screening and case finding for major depressive disorder using the Patient Health Questionnaire (PHQ-9): a meta-analysis. *Gen Hosp Psychiatry*. 2015;37:567–576.

Motrich RD, Maccioni M, Riera CM, et al. Autoimmune prostatitis: state of the art. *Scand J Immunol*. 2007;66:217–227.

Murphy SF, Schaeffer AJ, Done J, et al. IL17 Mediates pelvic pain in experimental autoimmune prostatitis (EAP). *PLoS One*. 2015;10:e0125623.

Myers SA, Mershon CE, Fuchs EF. Vasectomy reversal for treatment of the post-vasectomy pain syndrome. *J Urol*. 1997;157:518–520.

Nadler RB, Collins MM, Propert KJ, et al. Prostate-specific antigen test in diagnostic evaluation of chronic prostatitis/chronic pelvic pain syndrome. *Urology*. 2006;67:337–342.

Nadler RB. Bladder training biofeedback and pelvic floor myalgia. *Urology*. 2002;60:42–43.

Najari BB, Robinson BD, Paget SA, et al. Clinical, radiographic, and pathologic description of IgG4-related perivasal fibrosis: a previously undescribed etiology of chronic orchialgia. *Urology*. 2014;84:748–750.

Naliboff BD, Stephens AJ, Afari N, et al. Widespread psychosocial difficulties in men and women with urologic chronic pelvic pain syndromes: case-control findings from the multidisciplinary approach to the study of chronic pelvic pain research network. *Urology*. 2015;85:1319–1327.

Naliboff BD, Stephens AJ, Lai HH, et al. Clinical and psychosocial predictors of urological chronic pelvic pain symptom change in 1 year: a prospective study from the MAPP research network. *J Urol*. 2017;198:848–857.

Nangia AK, Myles JL, Thomas AJ JR. Vasectomy reversal for the post-vasectomy pain syndrome: a clinical and histological evaluation. *J Urol*. 2000;164:1939–1942.

Nariculam J, Minhas S, Adeniyi A, et al. A review of the efficacy of surgical treatment for and pathological changes in patients with chronic scrotal pain. *BJU Int*. 2007;99:1091–1093.

Nariculam J, Minhas S, Adeniyi A, et al. A review of the efficacy of surgical treatment for and pathological changes in patients with chronic scrotal pain. *BJU Int*. 2007;99:1091–1093.

Nickel J, Wagenlehner F, Pontari M, et al. Male chronic pelvic pain syndrome (CPPS). Chapple CaAP. *Male lower urinary tract symptoms (LUTS); an International Consultation on Male LUTS*. Societe Internationale d'Urologie (SIU): Montreal, Canada; 2013.

Nickel J, Wagenlehner F, Pontari M. Male chronic pelvic pain syndrome (CPPS). Chapple C. *Male lower urinary tract symptoms (LUTS): an international consultation on male LUTS*. Societe Internationale d'Urologie (SIU): Montreal, Canada; 2013.

Nickel JC, Alexander RB, Schaeffer AJ, et al. Leukocytes and bacteria in men with chronic prostatitis/chronic pelvic pain syndrome compared to asymptomatic controls. *J Urol*. 2003;170:818–822.

Nickel JC, Ardern D, Downey J. Cytologic evaluation of urine is important in evaluation of chronic prostatitis. *Urology*. 2002;60:225–227.

Nickel JC, Atkinson G, Krieger JN, et al. Preliminary assessment of safety and efficacy in proof-of-concept, randomized clinical trial of tanezumab for chronic prostatitis/chronic pelvic pain syndrome. *Urology*. 2012;80:1105–1110.

Nickel JC, Downey J, Ardern D, et al. Failure of a monotherapy strategy for difficult chronic prostatitis/chronic pelvic pain syndrome. *J Urol*. 2004;172:551–554.

Nickel JC, Downey J, Clark J, et al. Levofloxacin for chronic prostatitis/chronic pelvic pain syndrome in men: a randomized placebo-controlled multicenter trial. *Urology*. 2003;62:614–617.

Nickel JC, Downey J, Feliciano AEJ, et al. Repetitive prostatic massage therapy for chronic refractory prostatitis: the Philippine experience. *Tech Urol*. 1999;5:146–151.

Nickel JC, Downey J, Pontari MA, et al. A randomized placebo-controlled multicentre study to evaluate the safety and efficacy of finasteride for male chronic pelvic pain syndrome (category IIIA chronic nonbacterial prostatitis). *BJU Int*. 2004;93:991–995.

Nickel JC, Downey J, Young I, et al. Asymptomatic inflammation and/or infection in benign prostatic hyperplasia. *BJU Int*. 1999;84:976–981.

Nickel JC, Forrest JB, Tomera K, et al. Pentosan polysulfate sodium therapy for men with chronic pelvic pain syndrome: a multicenter, randomized, placebo controlled study. *J Urol*. 2005;173:1252–1255.

Nickel JC, Krieger JN, McNaughton-Collins M, et al. Alfuzosin and symptoms of chronic prostatitis-chronic pelvic pain syndrome. *N Engl J Med*. 2008;359:2663–2673.

Nickel JC, Moon T. Chronic bacterial prostatitis: an evolving clinical enigma. *Urology*. 2005;66:2–8.

Nickel JC, Narayan P, McKay J, et al. Treatment of chronic prostatitis/chronic pelvic pain syndrome with tamsulosin: a randomized double blind trial. *J Urol*. 2004;171:1594–1597.

Nickel JC, O'Leary MP, Lepor H, et al. Silodosin for men with chronic prostatitis/chronic pelvic pain syndrome: results of a phase II multicenter, double-blind, placebo controlled study. *J Urol*. 2011;186:125–131.

Nickel JC, Pontari M, Moon T, et al. A randomized, placebo controlled, multicenter study to evaluate the safety and efficacy of rofecoxib in the treatment of chronic nonbacterial prostatitis. *J Urol*. 2003;169:1401–1405.

Nickel JC, Roehrborn C, Montorsi F, et al. Dutasteride reduces prostatitis symptoms compared with placebo in men enrolled in the REDUCE study. *J Urol*. 2011;186:1313–1318.

Nickel JC, Shoskes D, Wang Y, et al. How does the pre-massage and post-massage 2-glass test compare to the Meares-Stamey 4-glass test in men with chronic prostatitis/chronic pelvic pain syndrome? *J Urol*. 2006;176:119–124.

Nickel JC, Shoskes DA, Wagenlehner FM. Management of chronic prostatitis/chronic pelvic pain syndrome (CP/CPPS): the studies, the evidence, and the impact. *World J Urol*. 2013;31:747–753.

Nickel JC, Shoskes DA. Phenotypic approach to the management of the chronic prostatitis/chronic pelvic pain syndrome. *BJU Int*. 2010;106:1252–1263.

Nickel JC, Siemens DR, Lundie MJ. Allopurinol for prostatitis: where is the evidence? *Lancet*. 1996;347:1711–1712.

Nickel JC, Siemens DR, Nickel KR, et al. The patient with chronic epididymitis: characterization of an enigmatic syndrome. *J Urol*. 2002;167:1701–1704.

Nickel JC, Sorensen R. Transurethral microwave thermotherapy for nonbacterial prostatitis: a randomized double-blind sham controlled study using new prostatitis specific assessment questionnaires. *J Urol*. 1996;155:1950–1954.

Nickel JC, Stephens A, Landis JR, et al. Search for microorganisms in men with urologic chronic pelvic pain syndrome: a culture-independent analysis in the MAPP Research Network. *J Urol*. 2015;194:127–135.

Nickel JC, True LD, Krieger JN, et al. Consensus development of a histopathological classification system for chronic prostatic inflammation. *BJU Int*. 2001;87:797–805.

Nickel JC, Xiang J. Clinical significance of nontraditional bacterial uropathogens in the management of chronic prostatitis. *J Urol*. 2008;179:1391–1395.

Nickel JC. Chronic epididymitis: a practical approach to understanding and managing a difficult urologic enigma. *Rev Urol*. 2003;5:209–215.

Nickel JC. Prostatitis: lessons from the 20th century. *BJU Int*. 2000;85:179–185.

Nouri KH, Brish EL. Spinal cord stimulation for testicular pain.

Pain Med. 2011;12:1435–1438.

Oelke M, Giuliano F, Mirone V, et al. Monotherapy with tadalafil or tamsulosin similarly improved lower urinary tract symptoms suggestive of benign prostatic hyperplasia in an international, randomised, parallel, placebo-controlled clinical trial. *Eur Urol*. 2012;61:917–925.

Ogino H, Fujii M, Ono M, et al. In vivo and in vitro effects of fluoroquinolones on lipopolysaccharide-induced pro-inflammatory cytokine production. *J Infect Chemother*. 2009;15:168–173.

Oh MM, Chae JY, Kim JW, et al. Positive culture for extended-spectrum beta-lactamase during acute prostatitis after prostate biopsy is a risk factor for progression to chronic prostatitis. *Urology*. 2013;81:1209–1212.

Oka S, Shiraishi K, Matsuyama H. Microsurgical anatomy of the spermatic cord and spermatic fascia: distribution of lymphatics, and sensory and autonomic nerves. *J Urol*. 2016;195:1841–1847.

Oomen RJA, Witjens AC, van Wijck AJM, et al. Prospective double-blind preoperative pain clinic screening before microsurgical denervation of the spermatic cord in patients with testicular pain syndrome. *Pain*. 2014;155:1720–1726.

Osman A, Barrios FX, Kopper BA, et al. Factor structure, reliability, and validity of the Pain Catastrophizing Scale. *J Behav Med*. 1997;20:589–605.

Padmore DE, Norman RW, Millard OH. Analyses of indications for and outcomes of epididymectomy. *J Urol*. 1996;156:95–96.

Pal S, Peterson EM, de la Maza LM. New murine model for the study of Chlamydia trachomatis genitourinary tract infections in males. *Infect Immun*. 2004;72:4210–4216.

Pannek J, Haupt G. Orchitis due to vasculitis in autoimmune diseases. *Scand J Rheumatol*. 1997;26:151–154.

Parekattil SJ, Gudeloglu A, Brahmbhatt J, et al. Trifecta nerve complex- potential anatomic basis for microsurgical denervation of the spermatic cord for chronic orchalgia. *J Urol*. 2013;188:xx.

Pearson RC, Baumber CD, McGhie D, et al. The relevance of Chlamydia trachomatis in acute epididymitis in young men. *Br J Urol*. 1988;62:72–75.

Perletti G, Marras E, Wagenlehner FM, et al. Antimicrobial therapy for chronic bacterial prostatitis. *Cochrane Database Syst Rev*. 2013;(8) [CD00907].

Perletti G, Wagenlehner FME, Naber KG, et al. Enhanced distribution of fourth-generation fluoroquinolones in prostatic tissue. *Int J Antimicrob Agents*. 2009;33:206–210.

Perry J, VanDenKerkhof EG, Wilson R, et al. Guided Internet-based psycho-educational intervention using cognitive behavioral therapy and self-management for individuals with chronic pain: a feasibility study. *Pain Manag Nurs*. 2017;18:179–189.

Persson BE, Ronquist G, Ekblom M. Ameliorative effect of allopurinol on nonbacterial prostatitis: a parallel double-blind controlled study. *J Urol*. 1996;155:961–964.

Persson BE, Ronquist G. Evidence for a mechanistic association between nonbacterial prostatitis and levels of urate and creatinine in expressed prostatic secretion. *J Urol*. 1996;155:958–960.

Pezzone MA, Liang R, Fraser MO. A model of neural cross-talk and irritation in the pelvis: implications for the overlap of chronic pelvic pain disorders. *Gastroenterology*. 2005;128:1953–1964.

Pilatz A, Hossain H, Kaiser R, et al. Acute epididymitis revisited: impact of molecular diagnostics on etiology and contemporary guideline recommendations. *Eur Urol*. 2015;68:428–435.

Pilatz A, Wagenlehner F, Bschleipfer T, et al. Acute epididymitis in ultrasound: results of a prospective study with baseline and follow-up investigations in 134 patients. *Eur J Radiol*. 2013;82:e762–e768.

Planken E, Voorham-van der Zalm PJ, Lycklama A Nijeholt AA, et al. Chronic testicular pain as a symptom of pelvic floor dysfunction. *J Urol*. 2010;183:177–181.

Polackwich AS, Li J, Shoskes DA. Patients with pelvic floor muscle spasm have a superior response to pelvic floor physical therapy at specialized centers. *J Urol*. 2015;194:1002–1006.

Polackwich AS, Tadros NN, Ostrowski KA, et al. Vasectomy reversal for postvasectomy pain syndrome: a study and literature review. *Urology*. 2015;86:269–272.

Pontari MA, Krieger JN, Litwin MS, et al. Pregabalin for the treatment of men with chronic prostatitis/chronic pelvic pain syndrome: a randomized controlled trial. *Arch Intern Med*. 2010;170:1586–1593.

Pontari MA, McNaughton-Collins M, O'leary MP, et al. A case-control study of risk factors in men with chronic pelvic pain syndrome. *BJU Int*. 2005;96:559–565.

Pontari MA. Editorial comment. *Urology*. 2014;83:526–527.

Pontari MA. Etiology of chronic prostatitis/chronic pelvic pain syndrome: psychoimmunoneurendocrine dysfunction (PINE syndrome) or just a really bad infection? *World J Urol*. 2013;31:725–732.

Posadzki P, Zhang J, Lee MS, et al. Acupuncture for chronic nonbacterial prostatitis/chronic pelvic pain syndrome: a systematic review. *J Androl*. 2012;33:15–21.

Propert KJ, Litwin MS, Wang Y, et al. Responsiveness of the National Institutes of Health Chronic Prostatitis Symptom Index (NIH-CPSI). *Qual Life Res*. 2006;15:299–305.

Puhse G, Wachsmuth JU, Kemper S, et al. Phantom testis syndrome: prevalence, phenomenology and putative mechanisms. *Int J Androl*. 2010;33:e216–e220.

Quallich SA, Arslanian-Engoren C. Chronic testicular pain in adult men: an integrative literature review. *Am J Mens Health*. 2013;7:402–413.

Rees J, Abrahams M, Doble A, et al. Prostatitis Expert Reference Group (PERG). Diagnosis and treatment of chronic bacterial prostatitis and chronic prostatitis/chronic pelvic pain syndrome: a consensus guideline. *BJU Int*. 2015;116:509–525.

Rees J, Abrahams M, Doble A, et al. Prostatitis Expert Reference Group (PERG). Diagnosis and treatment of chronic bacterial prostatitis and chronic prostatitis/chronic pelvic pain syndrome: a consensus guideline. *BJU Int*. 2015;116:509–525.

Richens J. Genital manifestations of tropical diseases. *Sex Transm Infect*. 2004;80:12–17.

Riegel B, Bruenahl CA, Ahyai S, et al. Assessing psychological factors, social aspects and psychiatric co-morbidity associated with Chronic Prostatitis/Chronic Pelvic Pain Syndrome (CP/CPPS) in men – a systematic review. *J Psychosom Res*. 2014;77:333–350.

Riggs S, Sanford JP. Viral orchitis. *N Engl J Med*. 1962;266:990–993.

Riley DE, Berger RE, Miner DC, et al. Diverse and related 16S rRNA-encoding DNA sequences in prostate tissues of men with chronic prostatitis. *J Clin Microbiol*. 1998;36:1646–1652.

Roberts RO, Lieber MM, Rhodes T, et al. Prevalence of a physician-assigned diagnosis of prostatitis: the Olmsted County study of urinary symptoms and health status among men. *Urology*. 1998;51:578–584.

Rodriguez MA, Afari N, Buchwald DS. National Institute of

Diabetes and Digestive and Kidney Diseases Working Group on Urological Chronic Pelvic Pain. Evidence for overlap between urological and nonurological unexplained clinical conditions. *J Urol*. 2009;182:2123–2131.

Ronka K, Vironen J, Kokki H, et al. Role of orchiectomy in severe testicular pain after inguinal hernia surgery: audit of the Finnish Patient Insurance Centre. *Hernia*. 2015;19:53–59.

Rosen RC, Cappelleri JC, Gendrano N 3rd. The International Index of Erectile Function (IIEF): a state-of-the-science review. *Int J Impot Res*. 2002;14:226–244.

Rosendal F, Moir L, de Pennington N, et al. Successful treatment of testicular pain with peripheral nerve stimulation of the cutaneous branch of the ilioinguinal and genital branch of the genitofemoral nerves. *Neuromodulation*. 2013;16:121–124.

Rowe E, Smith C, Laverick L, et al. A prospective, randomized, placebo controlled, double-blind study of pelvic electromagnetic therapy for the treatment of chronic pelvic pain syndrome with 1 year of followup. *J Urol*. 2005;173:2044–2047.

Rowell RM, Rylander SJ. Low-back pain, leg pain, and chronic idiopathic testicular pain treated with chiropractic care. *J Altern Complement Med*. 2012;18:420–422.

Roy S, Hooda S, Parwani AV. Idiopathic granulomatous orchitis. *Pathol Res Pract*. 2011;207:275–278.

Rubin S, Eckhaus M, Rennick LJ, et al. Molecular biology, pathogenesis and pathology of mumps virus. *J Pathol*. 2015;235:242–252.

Rudick CN, Berry RE, Johnson JR, et al. Uropathogenic Escherichia coli induces chronic pelvic pain. *Infect Immun*. 2011;79:628–635.

Ryan L, Daly P, Cullen I, et al. Epididymo-orchitis caused by enteric organisms in men> 35 years old: beyond fluroquinolones. *Eur J Clin Microbiol Infect Dis*. 2018 [epub].

Santillo VM, Lowe FC. The management of chronic prostatitis in men with HIV. *Curr Urol Rep*. 2006;7:313–319.

Santucci RA, Joyce GF, Wise M. Male urethral stricture disease. *J Urol*. 2007;177:1667–1674.

Savasci U, Zor M, Karakas A, et al. Brucellar epididymo-orchitis: a retrospective multicenter study of 28 cases and review of the literature. *Travel Med Infect Dis*. 2014;12:667–672.

Schaeffer AJ, Datta NS, Fowler JE Jr, et al. Overview summary statement. Diagnosis and management of chronic prostatitis/chronic pelvic pain syndrome (CP/CPPS). *Urology*. 2002;60:1–4.

Schaeffer AJ, Knauss JS, Landis JR, et al. Leukocyte and bacterial counts do not correlate with severity of symptoms in men with chronic prostatitis: the National Institutes of Health Chronic Prostatitis Cohort Study. *J Urol*. 2002;168:1048–1053.

Schaeffer AJ, Landis JR, Knauss JS, et al. Demographic and clinical characteristics of men with chronic prostatitis: the National Institutes of Health chronic prostatitis cohort study. *J Urol*. 2002;168:593–598.

Schaeffer AJ. Clinical practice. Chronic prostatitis and the chronic pelvic pain syndrome. *N Engl J Med*. 2006;355:1690–1698.

Schneider H, Ludwig M, Hossain HM, et al. The 2001 Giessen Cohort Study on patients with prostatitis syndrome—an evaluation of inflammatory status and search for microorganisms 10 years after a first analysis. *Andrologia*. 2003;35:258–262.

Schneider H, Ludwig M, Hossain HM, et al. The 2001 Giessen Cohort Study on patients with prostatitis syndrome–an evaluation of inflammatory status and search for microorganisms 10 years after a first analysis. *Andrologia*. 2003;35:258–262.

Schneider MP, Tellenbach M, Mordasini L, et al. Refractory chronic pelvic pain syndrome in men: can transcutaneous electrical nerve stimulation help? *BJU Int*. 2013;112:E159–E163.

Selikowitz SM, Schned AR. A late post-vasectomy syndrome. *J Urol*. 1985;134:494–497.

Selvaraj D, Gangadharan V, Michalski CW, et al. A functional role for VEGFR1 expressed in peripheral sensory neurons in cancer pain. *Cancer Cell*. 2015;27:780–796.

Shafik A, el Sherif M, Youssef A, et al. Surgical anatomy of the pudendal nerve and its clinical implications. *Clin Anat*. 1995;8:110–115.

Shindel AW, Akhavan A, Sharlip ID. Urologic aspects of HIV infection. *Med Clin North Am*. 2011;95:129–151.

Shoskes DA, Altemus J, Polackwich AS, et al. The urinary microbiome differs significantly between patients with chronic prostatitis/chronic pelvic pain syndrome and controls as well as between patients with different clinical phenotypes. *Urology*. 2016;92:26–32.

Shoskes DA, Berger R, Elmi A, et al. Muscle tenderness in men with chronic prostatitis/chronic pelvic pain syndrome: the chronic prostatitis cohort study. *J Urol*. 2008;179:556–560.

Shoskes DA, Landis JR, Wang Y, et al. Impact of post-ejaculatory pain in men with category III chronic prostatitis/chronic pelvic pain syndrome. *J Urol*. 2004;172:542–547.

Shoskes DA, Lee C, Murphy D, et al. Incidence and significance of prostatic stones in men with chronic prostatitis/chronic pelvic pain syndrome. *Urology*. 2007;70:235–238.

Shoskes DA, Nickel JC, Dolinga R, et al. Clinical phenotyping of patients with chronic prostatitis/chronic pelvic pain syndrome and correlation with symptom severity. *Urology*. 2009;73:538–542.

Shoskes DA, Nickel JC, Kattan MW. Phenotypically directed multimodal therapy for chronic prostatitis/chronic pelvic pain syndrome: a prospective study using UPOINT. *Urology*. 2010;75:1249–1253.

Shoskes DA, Nickel JC, Rackley RR, et al. Clinical phenotyping in chronic prostatitis/chronic pelvic pain syndrome and interstitial cystitis: a management strategy for urologic chronic pelvic pain syndromes. *Prostate Cancer Prostatic Dis*. 2009;12:177–183.

Shoskes DA, Nickel JC. Classification and treatment of men with chronic prostatitis/chronic pelvic pain syndrome using the UPOINT system. *World J Urol*. 2013;31:755–760.

Shoskes DA, Prots D, Karns J, et al. Greater endothelial dysfunction and arterial stiffness in men with chronic prostatitis/chronic pelvic pain syndrome–a possible link to cardiovascular disease. *J Urol*. 2011;186:907–910.

Shoskes DA, Shahed AR. Detection of bacterial signal by 16S rRNA polymerase chain reaction in expressed prostatic secretions predicts response to antibiotic therapy in men with chronic pelvic pain syndrome. *Tech Urol*. 2000;6:240–242.

Shoskes DA, Thomas KD, Gomez E. Anti-nanobacterial therapy for men with chronic prostatitis/chronic pelvic pain syndrome and prostatic stones: preliminary experience. *J Urol*. 2005;173:474–477.

Shoskes DA, Wang H, Polackwich AS, et al. Analysis of gut microbiome reveals significant differences between men with chronic prostatitis/chronic pelvic pain syndrome and controls. *J Urol*. 2016;196:435–441.

Shoskes DA, Zeitlin SI, Shahed A, et al. Quercetin in men with category III chronic prostatitis: a preliminary prospective, double-blind, placebo-controlled trial. *Urology*. 1999;54:960–963.

Shoskes DA, Zeitlin SI. Use of prostatic massage in combination with antibiotics in the treatment of chronic prostatitis. *Prostate Cancer Prostatic Dis*. 1999;2:159–162.

Shridharani A, Lockwood G, Sandlow J. Varicocelectomy in the treatment of testicular pain: a review. *Curr Opin Urol*. 2012;22:499–506.

Sigalos JT, Pastuszak AW. Chronic orchalgia: epidemiology, diagnosis and evaluation. *Trans Andol Urol*. 2017;6:S37–S43.

Silva CA, Cocuzza M, Carvalho JF, et al. Diagnosis and classification of autoimmune orchitis. *Autoimmun Rev*. 2014;13:431–434.

Siu W, Ohl DA, Schuster TG. Long-term follow-up after epididymectomy for chronic epididymal pain. *Urology*. 2007;70:333–335.

Soto SM, Smithson A, Martinez JA, et al. Biofilm formation in uropathogenic Escherichia coli strains: relationship with prostatitis, urovirulence factors and antimicrobial resistance. *J Urol*. 2007;177:365–368.

Stamey TA, Meares EMJ, Winningham DG. Chronic bacterial prostatitis and the diffusion of drugs into prostatic fluid. *J Urol*. 1970;103:187–194.

Stancik I, Plas E, Juza J, et al. Effect of antibiotic therapy on interleukin-6 in fresh semen and postmasturbation urine samples of patients with chronic prostatitis/chronic pelvic pain syndrome. *Urology*. 2008;72:336–339.

Starke NR, Costible RA. Medical management of chronic orchalgia. *Transl Urol Androl*. 2017;6:S48–S50.

Stephens-Shields AJ, Clemens JQ, Jemielta T, et al. Symptom variability and early symptom regression in the MAPP study: a prospective study of urological chronic pelvic pain syndrome. *J Urol*. 2016;196:1450–1455.

Stone JH, Zen Y, Deshpande V. IgG4-related disease. *N Engl J Med*. 2012;366:539–551.

Strebel RT, Leippold T, Luginbuehl T, et al. Chronic scrotal pain syndrome: management among urologists in Switzerland. *Eur Urol*. 2005;47:812–816.

Street EJ, Justice ED, Kopa Z, et al. The 2016 European guideline on the management of epididymo-orchitis. *Int J STD AIDS*. 2017;28:744–749.

Strom KH, Levine LA. Microsurgical denervation of the spermatic cord for chronic orchialgia: long-term results from a single center. *J Urol*. 2008;180:949–953.

Suskind AM, Berry SH, Ewing BA, et al. The prevalence and overlap of interstitial cystitis/bladder pain syndrome and chronic prostatitis/chronic pelvic pain syndrome in men: results of the RAND Interstitial Cystitis Epidemiology male study. *J Urol*. 2013;189:141–145.

Sutcliffe S, Colditz G, Pakpahan R, et al. Frequency and duration spectrum of urologic chronic pelvic pain symptom flares. *J Urol*. 2012;187:114.

Sutcliffe S, Jemielta T, Lai HH, et al. A case-crossover study of urological chronic pelvic pain syndrome flare triggers in the MAPP research network. *J Urol*. 2018;199:1245–1251.

Suzuki T, Kurokawa K, Suzuki K, et al. Transurethral balloon laser hyperthermia for chronic non-bacterial prostatitis: a clinical trial. *Int J Urol*. 1995;2:29–32.

Sweeney CA, Oades GM, Fraser M, et al. Does surgery have a role in management of chronic intrascrotal pain? *Urology*. 2008;71:1099–1102.

Takahashi S, Riley DE, Krieger JN. Application of real-time polymerase chain reaction technology to detect prostatic bacteria in patients with chronic prostatitis/chronic pelvic pain syndrome. *World J Urol*. 2003;21:100–104.

Tan WP, Levine LA. An overview of the management of post-vasectomy pain syndrome. *Asian J Androl*. 2016;18:332–337.

Tan WP, Tsambarlis PN, Levine LA. Microdenervation of the spermatic cord for post vasectomy pai syndrome. *BJU Int*. 2018;121:667–673.

Tandon S, Sabanegh EJ. Chronic pain after vasectomy: a diagnostic and treatment dilemma. *BJU Int*. 2008;102:166–169.

Teasell RW, Arnold JMO. Alpha-1 adrenoceptor hyperresponsiveness in three neuropathic pain states: complex regional pain syndrome 1, diabetic peripheral neuropathic pain and central pain states following spinal cord injury. *Pain Res Manag*. 2004;9:89–97.

Terai A, Ishitoya S, Mitsumori K, et al. Molecular epidemiological evidence for ascending urethral infection in acute bacterial prostatitis. *J Urol*. 2000;164:1945–1947.

Thakkinstian A, Attia J, Anothaisintawee T, et al. Alpha-blockers, antibiotics and anti-inflammatories have a role in the management of chronic prostatitis/chronic pelvic pain syndrome. *BJU Int*. 2012;110:1014–1022.

Thompson IM, Goodman PJ, Tangen CM, et al. The influence of finasteride on the development of prostate cancer. *N Engl J Med*. 2003;349:215–224.

Tran CN, Shoskes DA. Sexual dysfunction in chronic prostatitis/chronic pelvic pain syndrome. *World J Urol*. 2013;31:741–746.

Tripp DA, Nickel JC, Katz L. A feasibility trial of a cognitive behavioural symptom management program for chronic pelvic pain for men with refractory chronic prostatitis/chronic pelvic pain syndrome. *Can Urol Assoc J*. 2011;5:328–332.

Tripp DA, Nickel JC, Wang Y, et al. National Institutes of Health-Chronic Prostatitis Collaborative Research Network (NIH-CPCRN) Study Group. Catastrophizing and pain-contingent rest predict patient adjustment in men with chronic prostatitis/chronic pelvic pain syndrome. *J Pain*. 2006;7:697–708.

Trojian TH, Lishnak TS, Heiman D. Epididymitis and orchitis: an overview. *Am Fam Physician*. 2009;79:583–587.

True LD, Berger RE, Rothman I, et al. Prostate histopathology and the chronic prostatitis/chronic pelvic pain syndrome: a prospective biopsy study. *J Urol*. 1999;162:2014–2018.

Truzzi JCI, Almeida FMR, Nunes EC, et al. Residual urinary volume and urinary tract infection–when are they linked? *J Urol*. 2008;180:182–185.

Tugcu V, Tasci AI, Fazlioglu A, et al. A placebo-controlled comparison of the efficiency of triple- and monotherapy in category III B chronic pelvic pain syndrome (CPPS). *Eur Urol*. 2007;51:1113–1117.

Ulleryd P, Sandberg T. Ciprofloxacin for 2 or 4 weeks in the treatment of febrile urinary tract infection in men: a randomized trial with a 1 year follow-up. *Scand J Infect Dis*. 2003;35:34–39.

Ulleryd P, Zackrisson B, Aus G, et al. Prostatic involvement in men with febrile urinary tract infection as measured by serum prostate-specific antigen and transrectal ultrasonography. *BJU Int*. 1999;84:470–474.

Ullrich PM, Turner JA, Ciol M, et al. Stress is associated with subsequent pain and disability among men with nonbacterial prostatitis/pelvic pain. *Ann Behav Med*. 2005;30:112–118.

Uzoh CC, Uff JS, Okeke AA. Granulomatous prostatitis. *BJU Int*. 2007;99:510–512.

Vaccaro JA, Belville WD, Kiesling VJJ, et al. Prostatic abscess: computerized tomography scanning as an aid to diagnosis and treatment. *J Urol*. 1986;136:1318–1319.

Varkarakis J, Sebe P, Pinggera G, et al. Three-dimensional ultrasound guidance for percutaneous drainage of prostatic abscesses. *Urology*. 2004;63:1017–1020.

Wagenlehner FM, Pilatz A, Bschleipfer T, et al. Bacterial prostatitis. *World J Urol*. 2013;31:711–716.

Wagenlehner FM, Schneider H, Ludwig M, et al. A pollen extract (Cernilton) in patients with inflammatory chronic prostatitis-chronic pelvic pain syndrome: a multicentre, randomised, prospective, double-blind, placebo-controlled phase 3 study. *Eur Urol*. 2009;56:544–551.

Wagenlehner FM, Weidner W, Sorgel F, et al. The role of antibiotics in chronic bacterial prostatitis. *Int J Antimicrob Agents*. 2005;26:1–7.

Wagenlehner FME, Bschleipfer T, Pilatz A, et al. Pollen extract for chronic prostatitis-chronic pelvic pain syndrome. *Urol Clin North Am*. 2011;38:285–292.

Wagenlehner FME, van Till JWO, Houbiers JGA, et al. Fatty acid amide hydrolase inhibitor treatment in men with chronic prostatitis/chronic pelvic pain syndrome: an adaptive double-blind, randomized controlled trial. *Urology*. 2017;103:191–197.

Wagenlehner FME, van Till JWO, Magri V, et al. National Institutes of Health Chronic Prostatitis Symptom Index (NIH-CPSI) symptom evaluation in multinational cohorts of patients with chronic prostatitis/chronic pelvic pain syndrome. *Eur Urol*. 2013;63:953–959.

Wang J, Yan D, Liang K, et al. A randomized controlled trial of levofloxacin, terazosin, and combination therapy in patients with category III chronic prostatitis/chronic pelvic pain syndrome. *Int Urol Nephrol*. 2016;48:13–18.

Wang Y, He L, Zhou Z, et al. The association between metabolic syndrome and the National Institutes of Health Chronic Prostatitis Symptom Index: results from 1673 men in China. *Urology*. 2013;82:1103–1107.

Watanabe T, Inoue M, Sasaki K, et al. Nerve growth factor level in the prostatic fluid of patients with chronic prostatitis/chronic pelvic pain syndrome is correlated with symptom severity and response to treatment. *BJU Int*. 2011;108:248–251.

Weidner W, Anderson RU. Evaluation of acute and chronic bacterial prostatitis and diagnostic management of chronic prostatitis/chronic pelvic pain syndrome with special reference to infection/inflammation. *Int J Antimicrob Agents*. 2008;31:S91–S95.

Weidner W, Diemer T, Huwe P, et al. The role of *Chlamydia trachomatis* in prostatitis. *Int J Antimicrob Agents*. 2002;19:466–470.

Weidner W, Schiefer HG, Krauss H, et al. Chronic prostatitis: a thorough search for etiologically involved microorganisms in 1,461 patients. *Infection*. 1991;19:S119–S125.

Weidner W, Schiefer HG, Krauss H, et al. Chronic prostatitis: a thorough search for etiologically involved microorganisms in 1,461 patients. *Infection*. 1991;19:S119–S125.

Weinberger M, Cytron S, Servadio C, et al. Prostatic abscess in the antibiotic era. *Rev Infect Dis*. 1988;10:239–249.

Weissman MM, Gross R, Fyer A, et al. Interstitial cystitis and panic disorder: a potential genetic syndrome. *Arch Gen Psychiatry*. 2004;61:273–279.

Woodworth D, Mayer E, Leu K, et al. Unique microstructural changes in the brain associated with urological chronic pelvic pain syndrome (UCPPS) revealed by diffusion tensor mri, super-resolution track density imaging, and statistical parameter mapping: a MAPP Network Neuroimaging Study. *PLoS One*. 2015;10:e0140250.

Woolf CJ. Evidence for a central component of post-injury pain hypersensitivity. *Nature*. 1983;306:686–688.

Wyndaele JJ. Complications of intermittent catheterization: their prevention and treatment. *Spinal Cord*. 2002;40:536–

541.

Xiao J, Ren L, Lv H, et al. Atypical microorganisms in expressed prostatic secretion from patients with chronic prostatitis/chronic pelvic pain syndrome: microbiological results from a case-control study. *Urol Int*. 2013;91:410–416.

Yadav S, Singh P, Hemal A, et al. Genital tuberculosis: current status of diagnosis and management. *Trans Andol Urol*. 2017;6:222–233.

Yamamoto M, Hibi H, Katsuno S, et al. Management of chronic orchialgia of unknown etiology. *Int J Urol*. 1995;2:47–49.

Yang CC, Lee JC, Kromm BG, et al. Pain sensitization in male chronic pelvic pain syndrome: why are symptoms so difficult to treat? *J Urol*. 2003;170:823–826.

Yang CC, Miller JL, Omidpanah A, et al. Physical examination for men and women with urological chronic pelvic pain syndromes: a MAPP study. *Urology*. 2018;116:23–29.

Yang CC. Neuromodulation in male chronic pelvic pain syndrome: rationale and practice. *World J Urol*. 2013;31:767–772.

Ye ZQ, Lan RZ, Yang WM, et al. Tamsulosin treatment of chronic non-bacterial prostatitis. *J Int Med Res*. 2008;36:244–252.

Yilmaz U, Ciol MA, Berger RE, et al. Sensory perception thresholds in men with chronic pelvic pain syndrome. *Urology*. 2010;75:34–37.

Yilmaz U, Liu YW, Berger RE, et al. Autonomic nervous system changes in men with chronic pelvic pain syndrome. *J Urol*. 2007;177:2170–2174.

Yoon BI, Kim S, Han DS, et al. Acute bacterial prostatitis: how to prevent and manage chronic infection? *J Infect Chemother*. 2012;18:444–450.

Yoshimura Y, Takeda S, Ieki Y, et al. IgG4-associated prostatitis complicating autoimmune pancreatitis. *Intern Med*.

2006;45:897–901.

Zackrisson B, Ulleryd P, Aus G, et al. Evolution of free, complexed, and total serum prostate-specific antigen and their ratios during 1 year of follow-up of men with febrile urinary tract infection. *Urology*. 2003;62:278–281.

Zermann DH, Ishigooka M, Doggweiler R, et al. Neurourological insights into the etiology of genitourinary pain in men. *J Urol*. 1999;161:903–908.

Zhang M, Li H, Ji Z, et al. Clinical study of duloxetine hydrochloride combined with doxazosin for the treatment of pain disorder in chronic prostatitis/chronic pelvic pain syndrome: an observational study. *Medicine (Baltimore)*. 2017;96:e6243.

Zhang R, Sutcliffe S, Giovannucci E, et al. Lifestyle and risk of chronic prostatitis/chronic pelvic pain syndrome in a cohort of United States Male Health Professionals. *J Urol*. 2015;194:1295–1300.

Zhao WP, Zhang ZG, Li XD, et al. Celecoxib reduces symptoms in men with difficult chronic pelvic pain syndrome (Category IIIA). *Braz J Med Biol Res*. 2009;42:963–967.

Zhao Y, Zhao W, Lang G, et al. Circumcision plus antibiotic, anti-inflammatory, and alpha-blocker therapy for the treatment for chronic prostatitis/chronic pelvic pain syndrome: a prospective, randomized, multicenter trial. *World J Urol*. 2015;33:617–622.

Zhou Z, Hong L, Shen X, et al. Detection of nanobacteria infection in type III prostatitis. *Urology*. 2008;71:1091–1095.

Zhu Y, Wang C, Pang X, et al. Antibiotics are not beneficial in the management of category III prostatitis: a meta analysis. *Urol J*. 2014;11:1377–1385.

Ziaee AM, Akhavizadegan H, Karbakhsh M. Effect of allopurinol in chronic nonbacterial prostatitis: a double blind randomized clinical trial. *Int Braz J Urol*. 2006;32:181–186.

Zimmermann R, Cumpanas A, Hoeltl L, et al. Extracorporeal shock-wave therapy for treating chronic pelvic pain syndrome: a feasibility study and the first clinical results. *BJU Int*. 2008;102:976–980.

Zimmermann R, Cumpanas A, Miclea F, et al. Extracorporeal shock wave therapy for the treatment of chronic pelvic pain syndrome in males: a randomised, double-blind, placebo-controlled study. *Eur Urol*. 2009;56:418–424.

Zlotta AR, Egawa S, Pushkar D, et al. Prevalence of inflammation and benign prostatic hyperplasia on autopsy in Asian and Caucasian men. *Eur Urol*. 2014;66:619–622.

57

Interstitial Cystitis/Bladder Pain Syndrome and Related Disorders

Robert M. Moldwin MD, Philip M. Hanno MD, MPH

A Brief History and Overview

Our current understanding of interstitial cystitis/bladder pain syndrome (IC/BPS) has evolved much from 1876, when Dr. Samuel Gross coined the term *interstitial cystitis*, describing a condition of chronic bladder inflammation of unknown etiology (Gross, 1876). In 1918, Dr. Guy Hunner extended this work in his report of "classical" interstitial cystitis; rare patients presented with bladder pain on filling and the cystoscopic finding of inflamed areas of the bladder wall (Hunner, 1915, 1918). This was later termed *Hunner lesions (HLs)*. Clinical experience over the next 50 years revealed that the vast majority of patients who presented with bladder pain had no evidence of bladder wall abnormality on routine cystoscopic examination. A 1987 National Institutes of Health/National Institute of Diabetes and Digestive and Kidney Diseases (NIH/NIDDK) meeting of "experts" produced a definition of IC with the objective to provide a homogenous population of patients for clinical trials (Gillenwater and Wein, 1988). Many clinicians incorporated these criteria into their practices only to find that they excluded approximately 60% of individuals who would otherwise have been clinically diagnosed with the condition (Hanno et al., 1999). Clearly, our definition needed to broaden, and this needed to be reflected in its nomenclature. Although controversy remains, the term *bladder pain syndrome (BPS)* is currently most commonly used and was selected to meet standards of medical pain taxonomy (Baranowski, et al., 2008). Today, **IC/BPS may be defined clinically as "an unpleasant sensation (pain, pressure, discomfort) perceived to be related to the urinary bladder, associated with lower urinary tract symptoms (LUTS) of more than six weeks duration, in the absence of infection or other identifiable causes"** (Hanno and Dmochowski, 2009). This definition is based on what we now believe to be a heterogeneous syndrome, a form of chronic pelvic pain that spans the gamut of patients to include not only those who present with gross inflammatory disease of the bladder wall but also those who have no visible inflammation but endorse bladder pain and often have multiple nonurologic complaints of pain (Nickel and Moldwin, 2018; Tripp et al., 2012) (Fig. 57.1).

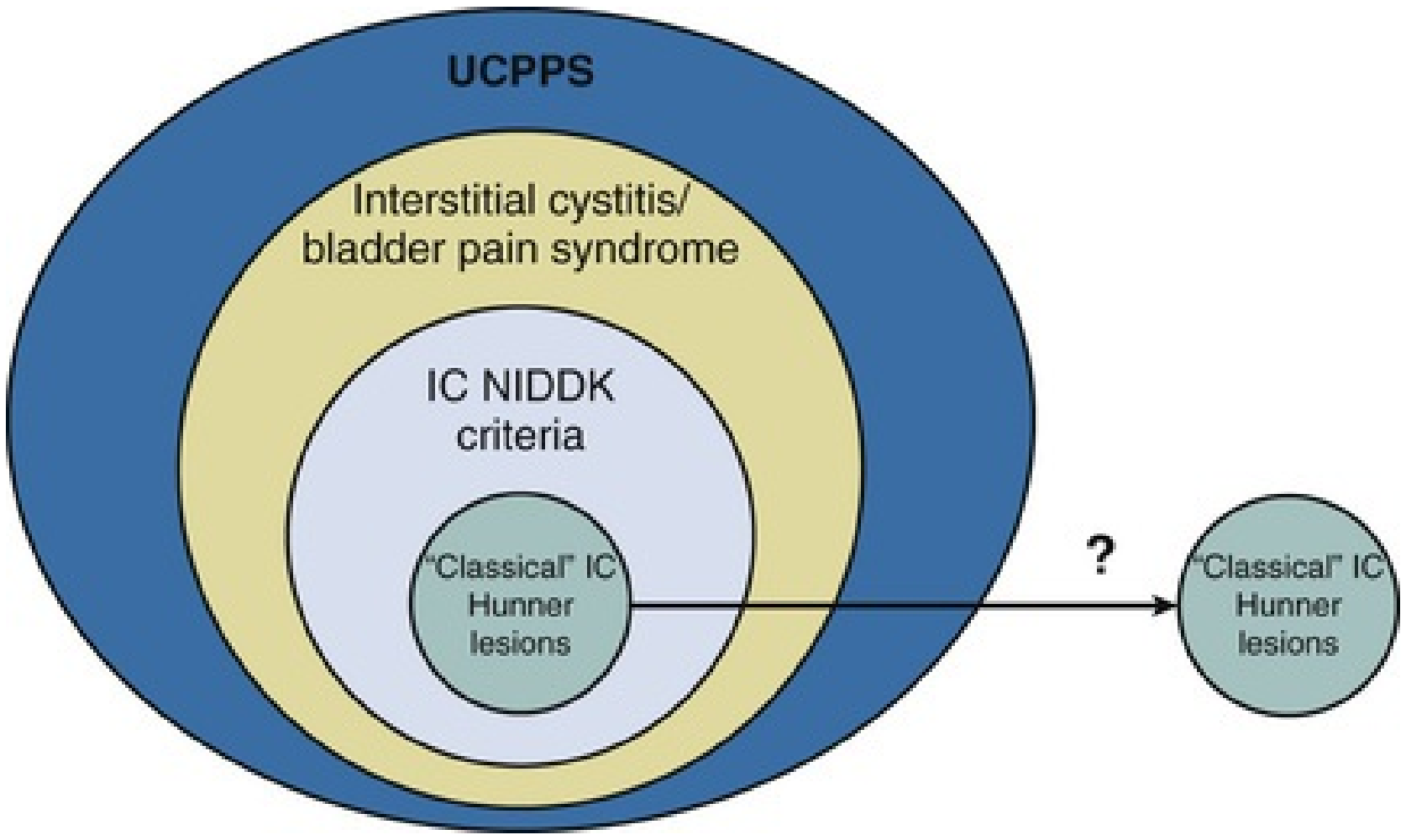
UCPPS
Interstitial cystitis/
bladder pain syndrome
IC NIDDK
criteria
"Classical" IC
Hunner
lesions
?
"Classical" IC
Hunner
lesions

FIG. 57.1 Evolving nomenclature/taxonomy and definitions are associated with a larger and more diverse patient population, all with a similar clinical presentation. The "?" denotes mounting interest to separate "classical IC" (as a disease typified by easily identifiable bladder wall inflammation) from the remainder of "syndromic" patients. *UCPPS,* Urologic chronic pelvic pain syndrome. (Modified from Nickel JC, Moldwin R. FDA BRUDAC 2018 Criteria for Interstitial Cystitis/Bladder Pain Syndrome Clinical Trials: Future Direction for Research. *J Urol* 200[1]:39–42, 2018.)

Difficulties encountered with the development of treatment strategies may be confounded by this heterogeneity, prompting many investigators to suggest that better phenotyping of the patient population may result in better clinical outcomes (Nickel and Moldwin, 2018). As our definition of the condition has broadened, prevalence estimates have increased dramatically. Current population-based studies conservatively estimate 2.1 million men (Suskind, et al., 2013) and 3.3 million women (Berry et al., 2011) in the United States having symptoms consistent with IC/BPS.

Definition, Nomenclature, and Taxonomy

“The beginning of wisdom is the definition of terms.” —Socrates (Nails, 2018)

How we define and what we name a medical condition may have an enormous impact on its diagnosis, its epidemiology, the protocol of clinical trials, recognition by the medical community, the names of patient support groups, and (in many countries) patient insurance coverage and physician reimbursement. Even subtle changes in definition, whether it be the character of pain, the location, its association with voiding or not, or its duration may have a profound effect on many of these parameters. A simple example is that of the International Continence Society's definition of *painful bladder syndrome (PBS)* as “the complaint of suprapubic pain related to bladder filling, accompanied by other symptoms such as increased daytime and night-time frequency, in the absence of proven urinary infection or other obvious pathology” (Abrams et al., 2002). Simply requiring pain to be suprapubic and linked to bladder filling eliminated 34% of patients who were clinically diagnosed with IC/PBS (Warren et al., 2006). Another example is the study by Berry et al. in which a minor change in definition (high sensitivity vs. high specificity definitions) resulted in a difference of 4.3 million estimated to have symptoms suggestive of the condition (Berry et al. 2011)!

The reader may note that current literature is replete with varied terms including *hypersensitive bladder* (Homma et al., 2009), *painful bladder syndrome/interstitial cystitis (PBS/IC)* (Hanno et al., 2005a), *interstitial cystitis/painful bladder syndrome (IC/PBS)* (Hanno et al., 2005b), and *bladder pain syndrome/interstitial cystitis (BPS/IC)* (Fall et al., 2010). **For purposes of clarity and in accordance with the guidelines of the American Urological Association (AUA), this chapter will default to the terminology of the International Consultation on Incontinence (ICI)—*bladder pain syndrome*—but keeps the term *interstitial cystitis* to facilitate recognition and understanding.**

Mounting evidence suggests that BPS is indeed a syndrome and distinct from those patients presenting with HLs (Abrams et al., 2018; Akiyama et al., 2018; Fall and Peeker, 2013; Han et al., 2018; Hanno et al., 2011, 2013) (see Fig.

57.1). This was a topic highlighted at a recent U.S. Food and Drug Administration (FDA) Bone, Reproductive, and Urologic Drugs Advisory Committee (BRUDAC) meeting. The primary question discussed was whether patients with IC and BPS should be combined in future clinical trials. The question itself implied that IC and BPS are two clinically and pathologically separate conditions. Ultimately by unanimous decision, the committee chose to study the two conditions together primarily *based on symptoms* that are indistinguishable from one another (Nickel and Moldwin, 2018).

Interstitial Cystitis/Bladder Pain Syndrome Research Criteria and Their Influence on Clinical Practice

In an effort to define IC so that patients in different geographic areas and under the care of different physicians could be compared, the NIDDK held a workshop in August 1987 at which consensus criteria were established for the diagnosis of IC (Gillenwater and Wein, 1988). **These criteria were not meant to define the disease, but rather to ensure that groups of patients included in basic and clinical research studies would be relatively comparable.** After pilot studies were carried out to test the criteria, they were revised at another NIDDK workshop 1 year later (Wein et al., 1990) (Box 57.1).

Box 57.1

National Institute of Diabetes and Digestive and Kidney Diseases Diagnostic Criteria for Interstitial Cystitis

To be diagnosed with interstitial cystitis, patients must have either glomerulations on cystoscopic examination or a classic Hunner ulcer, and they must have either pain associated with the bladder or urinary urgency. An examination for glomerulations should be undertaken after distention of the bladder under anesthesia to 80 to 100 cm H_2O for 1 to 2 minutes. The bladder may be distended up to two times before evaluation. The glomerulations must be diffuse—present in at least three quadrants of the bladder—and there must be at least 10 glomerulations per quadrant. The glomerulations must not be along the path of the cystoscope (to eliminate artifact from contact instrumentation). The presence of any one of the following excludes a diagnosis of interstitial cystitis:

1. Bladder capacity of greater than 350 mL on awake cystometry using either a gas or liquid filling medium
2. Absence of an intense urge to void with the bladder filled to 100 mL of gas or 150 mL of liquid filling medium
3. The demonstration of phasic involuntary bladder contractions on cystometry using the fill rate just described
4. Duration of symptoms less than 9 months
5. Absence of nocturia
6. Symptoms relieved by antimicrobial agents, urinary antiseptic agents, anticholinergic agents, or antispasmodic agents
7. A frequency of urination while awake of fewer than eight times per day
8. A diagnosis of bacterial cystitis or prostatitis within a 3-month period
9. Bladder or ureteral calculi
10. Active genital herpes
11. Uterine, cervical, vaginal, or urethral cancer
12. Urethral diverticulum
13. Cyclophosphamide or any type of chemical cystitis
14. Tuberculous cystitis
15. Radiation cystitis
16. Benign or malignant bladder tumors
17. Vaginitis
18. Age younger than 18 years

From Wein AJ, Hanno PM, Gillenwater JY. Interstitial cystitis: an introduction to the problem. In: Hanno PM, Staskin DR, Krane RJ, et al., eds. *Interstitial cystitis*. London: Springer-Verlag; 1990:13–15.

Historical Perspective of Interstitial Cystitis/Bladder Pain Syndrome: Early 1800S to 1970S

IC was recognized as a pathologic entity during the 19th century (Parsons and Parsons, 2004; Meijlink, 2018). Joseph Parrish, a Philadelphia surgeon, described three patients with severe lower urinary tract symptoms (LUTS) in the absence of a bladder stone in an 1836 text and termed the disorder *tic douloureux of the bladder* (Parrish, 1836). Teichman argued that this may represent the first description of IC (Teichman et al., 2000). In 1876, Dr. Samuel Gross, of Jefferson Medical College in Philadelphia used the term *interstitial cystitis* to describe inflammation of the bladder "when all the coats are implicated" (Gross, 1876). Several years later, Dr. Alexander Skene used the term *interstitial cystitis* to describe an inflammation that had "destroyed the mucous membrane partly or wholly and extended to the muscular parietes" (Skene, 1887).

Early in the 20th century, at a New England Section meeting of the AUA, Guy Leroy Hunner, a gynecologist at Johns Hopkins University, reported on eight women with a history of suprapubic pain, frequency, nocturia, and urgency lasting an average of 17 years (Hunner, 1915, 1918). He drew attention to the disease, and the red, bleeding areas he described on the bladder wall came to be called *Hunner ulcers*. As Walsh (1978) observed, this has proved to be unfortunate. In the early part of the 20th century, the very best cystoscopes available gave a poorly defined and ill-lit view of the fundus of the bladder. It is not surprising that when Hunner saw red and bleeding areas high on the bladder wall, he thought they were ulcers. For the next 60 years, urologists would look for ulcers and fail to make the diagnosis in their absence. The disease was thought to be focal, rather than a pancystitis.

Hand (1949) authored the first comprehensive review about the disease, reporting on 223 patients. He noted "small, discrete, submucosal hemorrhages, showing variations in form … dot-like bleeding points … little or no restriction to bladder capacity." Walsh (1978) later coined the term ***glomerulations*** to denote the petechial hemorrhages that Hand had described. Messing and Stamey (1978) took this a step further, declaring that in the correct clinical setting, glomerulations should be considered the "hallmark" of the disease. They felt that

Hunner's ulcers represented a different stage of the condition, implying that a spectrum of disease severity exists that is defined by physical findings.

Unexpectedly, the medical community began to use the NIDDK research criteria to establish a diagnosis in their clinical practice, leading to concerns of underdiagnosing the condition. The specificity of the finding of bladder glomerulations before or after distention came into question (Erickson, 1995; Tomaszewski et al., 2001; Waxman et al., 1998). Many patients who presented with IC symptoms had no evidence of glomerulations under anesthesia (Al Hadithi et al., 2002; Awad et al., 1992). Even the consistency of finding glomerulations at varying time points had been called to question (Shear and Mayer, 2006).

The multicenter Interstitial Cystitis Data Base (ICDB) study conducted through the NIDDK accumulated data on 424 patients with IC, enrolling patients from May 1993 to December 1995. Entry criteria were much more symptom driven than those promulgated for research studies (Simon et al., 1997). Notably, no evidence of HLs or glomerulations was needed for study participation. In an analysis of the defining criteria (Hanno et al., 1999), it appeared the NIDDK research criteria fulfilled their mission. **Fully 90% of expert clinicians agreed that patients diagnosed with IC by those criteria in the ICDB indeed had the disorder. However, 60% of patients deemed to have IC by these experienced clinicians would not have met NIDDK research criteria.** With this dilemma in mind, the European Society for the Study of Interstitial Cystitis (ESSIC) (recently renamed the International Society for the Study of BPS) developed a definition by which patients would be required to meet less stringent criteria: pelvic pain for longer than 6 months; pressure or discomfort perceived to be related to the urinary bladder accompanied by at least one other urinary symptom such as persistent urge to void or frequency; and the exclusion of confusable diseases as the cause of the symptoms (van de Merwe et al., 2008). The broader definition facilitated the diagnosis and treatment in many patients who would otherwise remain undiagnosed (Proaño et al., 2013). Although not mandated, cystoscopy with hydrodistention (CHD) and biopsy was suggested to allow subtyping.

IC/BPS is now viewed not only through the paradigm of a chronic pain syndrome that manifests through bladder-related symptoms, but as a syndrome that may not be a true disease of the bladder alone in many patients (Hanno, 2008). This paradigm is reflected in the ongoing Multi-Disciplinary Approach to the Study of Chronic Pelvic Pain (MAPP) Research Network (https://www.mappnetwork.org/), where the breadth of pelvic pain studied extends to IC/BPS and men afflicted with chronic prostatitis/chronic pelvic pain syndrome, collectively termed *urologic chronic pelvic pain syndrome (UCPPS)*. UCPPS is characterized by chronic pain in the pelvic region or genitalia, often accompanied by urinary frequency and urgency (Clemens et al., 2019; Landis et al., 2014).

Key Points: Bladder Pain Syndrome and Interstitial Cystitis

- *Bladder pain syndrome* is a term developed to meet current standards of pain taxonomy. BPS encompasses patients with pain perceived to be bladder-based associated with urinary urgency or frequency in the absence of other identified causes of symptoms. BPS includes subgroups such as those meeting NIDDK criteria and the smaller subgroup of patients with “classical disease” (HLs).
- The term *interstitial cystitis* is currently wrapped in controversy, as it is not a modern histologic description of the condition, even for those patients who manifest gross inflammatory disease of the bladder. Nevertheless, the term remains beside BPS (as IC/BPS) to facilitate patient care and to acknowledge patient support groups such as the Interstitial Cystitis Association (ICA; www.ichelp.org). Whether the older term *interstitial cystitis* should refer to a distinct subgroup of BPS (i.e., those with HLs) is, as yet, unclear.
- The HL (formerly termed *Hunner ulcer*) is the pathognomonic finding for the “classical form” of IC and represents a minority of the IC/BPS population. HLs are easily identified during office cystoscopy, although bladder distention beyond functional capacity and other imaging strategies have been used to enhance identification (Ueda et al., 2008). There is a lack of consensus as to which pathologic findings, if any, are required for, or even suggestive of, a tissue diagnosis (Hanno et al., 2005a; Tomaszewski et al., 1999, 2001).

Voiding Symptoms and Interstitial Cystitis/Bladder Pain Syndrome

Although bladder pain is the central symptom of IC/BPS and the most frequent reason for seeking health care (Clemens et al., 2018), urinary urgency is also commonly described. The ICS definition of urgency as “a *sudden* compelling desire to pass urine, which is difficult to defer” (Abrams et al., 2002) has been useful for the diagnosis of overactive bladder (OAB), and its presence in the IC/BPS patient has prompted suggestions that IC/BPS and OAB syndrome may represent a spectrum of bladder hypersensitivity (Homma, 2008; Lai et al., 2014). Nevertheless, qualitative differences in urgency usually exist between OAB and IC/BPS. **As compared with the OAB patient who fears urine loss, IC/BPS patients often describe a compelling need to void centered on mounting (not sudden) pain, pressure, or pelvic discomfort that occurs with filling.**

Urgency is not a symptom that defines IC/BPS. It is a term often poorly defined and comprehended by patients and cannot be used to clearly discriminate between IC/BPS and OAB (Clemens et al., 2011). Studies through the MAPP Network also demonstrate that descriptions of urgency vary independently from pain (Lai et al., 2015), suggesting that these symptoms should be monitored separately. Making matters more complex, the diagnosis of IC/BPS does not preclude coexisting detrusor overactivity (DO). In studies through the NIDDK database, Nigro et al. (1997a) found a 14% incidence of urodynamic DO in the IC/BPS patients, a prevalence probably close to what one might expect in the general population if studied urodynamically (Salavatore et al., 2003).

The downstream effect of urinary urgency would, of course, be low-volume urinary frequency (Abrams, 2005). **Although BPS patients may have significantly higher voiding frequencies, smaller voided volumes, and narrower ranges of voided volume compared with OAB patients** (Kim et al., 2014)**, one cannot distinguish between the two syndromes based on a voiding diary.**

High-tone pelvic floor dysfunction (HTPFD; often termed *hypertonicity of the pelvic floor musculature, nonrelaxing pelvic floor dysfunction, pelvic floor spasm*, or *myalgia of the pelvic floor*) may produce irritative and/or obstructive voiding symptoms and/or pelvic pain (Kuo et al., 2015). **HTPFD has been identified in 70% to 94% of IC/BPS patients either on the basis of urodynamically proven voiding dysfunction** (Butrick et al., 2009) **or reproduction of pelvic pain on examination of the pelvic floor musculature** (Peters et al., 2007, 2008). The clinical diagnostic dilemmas generated by the presence of HTPFD include its ability to generate pain alone or in association with IC/BPS, and the overlap of symptoms between these conditions. The associated irritative symptoms may be confused for OAB. HTPFD may also be responsible for complaints associated with other pain syndromes such as chronic prostatitis/chronic pelvic pain syndrome (CP/CPPS) (Shoskes et al., 2008) and vulvodynia (Bornstein et al., 2016) (Fig. 57.2).

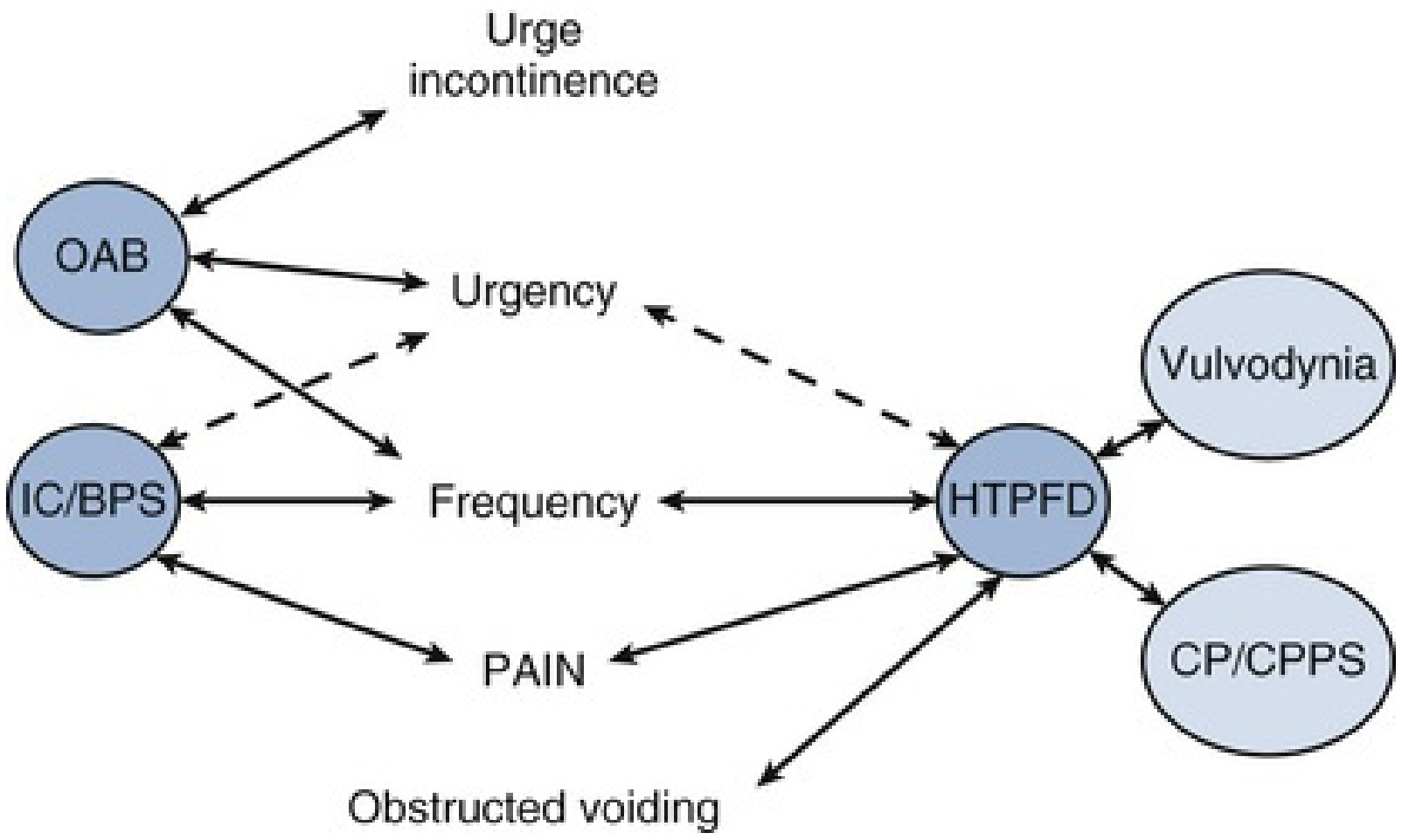

FIG. 57.2 Urinary complaints shared by commonly encountered urological conditions, adding to the complexity of diagnosis. Note that the varied constellation of symptoms associated with pelvic floor dysfunction/spasm may be remarkably similar to those of IC/BPS and OAB. HTPFD may also be associated with other pain syndromes that have been associated with IC/BPS. *CP/CPPS*, Chronic prostatitis/chronic pelvic pain syndrome; *HTPFD,* high-tone pelvic floor dysfunction; *IC/BPS,* interstitial cystitis/bladder pain syndrome; *OAB,* overactive bladder. (Modified from Abrams P, Hanno P, Wein A. Overactive bladder and painful bladder syndrome: there need not be confusion. *Neurourol Urodyn* 24[2]:149–150, 2005.)

Key Points: Lower Urinary Tract Symptoms and the Patient With Interstitial Cystitis/Bladder Pain

Syndrome

- Urgency has been defined as the complaint of a sudden compelling desire to pass urine that is difficult to defer. Fear of incontinence is more consistent with OAB, whereas pressure, pain, or discomfort suggests IC/BPS.
- As compared with the relatively uncommon finding of OAB, HTPFD is present in the majority of IC/BPS patients. This functional disorder may pose a diagnostic challenge as associated LUTS and pelvic pain overlap with IC/BPS.

Epidemiology of Interstitial Cystitis/Bladder Pain Syndrome

Since initial population-based studies of the 1970s to early 1990s, we have seen a significant increase in IC/BPS prevalence estimates, likely a result of a more liberalized definition, one without any specific physical findings needed or biochemical markers available (Nickel, 2018) (Table 57.1). Methodologic differences may also account for much of the variability in prevalence noted among investigations.

TABLE 57.1

Population-Based Prevalence Studies for Interstitial Cystitis/Bladder Pain Syndrome

AUTHOR	DATE OF PUBLICATION	COUNTRY	STUDY DESIGN	IC/BPS PREVALENCE (PER 100,000) F/M
Oravisto	1975	Finland	Physician Dx	18.1/–
Held et al.	1990	USA	Physician Dx	30.0/–
Bade et al.	1995	Netherlands	Physician Dx	8–16/–
Jones/Nyberg	1997	USA	Patient report	865/–
Curhan et al. (NHS I/II)	1999	USA	Physician Dx Patient report	52/– (I) 67/– (II)
Ito et al.	2000	Japan	Physician Dx	4.5/–
Parsons et al.	2002a	USA	Questionnaire	20,000/–
Leppilahti et al.	2002 2005	Finland Finland	Questionnaire Questionnaire	450/– 300–680/–
Roberts et al.	2003	USA (Olmstead County, MN)	Physician Dx	114/69.7
Parsons and Tatsis	2004	USA	Questionnaire	20,000/–
Clemens et al.	2005	USA (Kaiser)	Physician Dx	197/41
Temml et al.	2007	Austria	Questionnaire	306/–
Inoue et al.	2009	Japan	Questionnaire	265/–
Song et al.	2009	China	Questionnaire	100/–

Choe et al.	2011	S Korea	Questionnaire	261/–
Berry et al.	2011	USA	Questionnaire	2700–6300/–
Suskind et al.	2013	USA	Questionnaire	–/2000–4200

Dx, Diagnosis; *F/M,* female/male; *IC/BPS,* interstitial cystitis/bladder pain syndrome.

The relatively low prevalence of IC/BPS reported by Bade et al. (1995) of 8 to 16 of 100,000 might be expected as data were derived from questionnaires completed by urologists, 80% of whom used elevated mast cell counts on bladder biopsy to make the diagnosis. Two symptom-based questionnaire studies by Parsons et al. (2002a) demonstrated the other side of the prevalence spectrum. One survey queried female health care professionals or their spouses attending a lecture by the author, and the other focused on third-year American female medical students (Parsons and Tatsis, 2004). Both studies suggested that IC/BPS prevalence might be as high as 20,000 per 100,000 of the female population. Assessment of male IC/BPS prevalence has been particularly challenging because of clinical similarities between IC/BPS and CP/CPPS (Arora and Shoskes, 2015).

The most sophisticated large-scale, population-based IC/BPS prevalence study to date was conducted by the RAND Corporation and termed the RICE (RAND Interstitial Cystitis Epidemiology) study. With use of a case definition with an 83% specificity, a random sample of 146,231 households was contacted by telephone, and 12,752 women completed the questionnaire; 2.7% met the high-specificity definition of BPS. **The figures correspond to 3.3 million women in the United States 18 years of age or older with symptoms compatible with the diagnosis** (Berry et al., 2011). Prevalence increased with age from 2.21% for 18 to 29 years of age to a high of 3.41% for 50 to 59 years of age and then decreased to 1.70% for 70 to 75 years of age. Of note is that less than 10% of these women had a clinical diagnosis of IC/BPS. When the same methodology was applied to men, the **findings suggested that 1.9% (2.1 million) of adult US males have symptoms of IC/BPS,** higher than the weighted prevalence of chronic prostatitis and CPPS (Suskind et al., 2013). Although these prevalence studies suggest that a high percentage of IC/BPS patients are male, one must note that they were based on symptoms rather than diagnoses. **Investigations based on diagnoses in clinical practice suggest a female-to-male ratio of 5 : 1** (Clemens et al., 2005).

Interstitial Cystitis/Bladder Pain Syndrome in

Children

No studies exist that detail the prevalence of IC/BPS in childhood; however, the condition is considered to be uncommon. On the other hand, children with voiding dysfunction, often associated with disturbances of bowel and pelvic floor behavior, are commonly evaluated in pediatric urology practices (Aguiar and Franco, 2018; Santos et al., 2017). Many of these patients present with varied complaints of pelvic and/or urethral pain that easily can be confused with those of IC/BPS. A recall-based study suggested that adult female IC/BPS patients have a higher prevalence of urinary urgency and recurrent urinary tract infections during childhood than an asymptomatic cohort (Peters et al., 2009). In a recent recall survey, Doiron et al. (2017) also detected a link back to childhood bladder and bowel dysfunction. They found that IC/BPS patients with irritable bowel syndrome (IBS)–like symptoms frequently complained of the need to push for a bowel movement, voided only once or twice daily, and had painful urination during childhood. This coupled with the known high prevalence of HTPFD in the IC/BPS population merits concerns that adult IC/BPS patients may have linked bladder-bowel-pelvic floor dysfunction dating back to childhood (Costantini et al., 2018).

There is a small cohort of children with chronic symptoms of bladder pain, urinary frequency, and sensory urgency in the absence of infection who have been evaluated with urodynamics, cystoscopy, and bladder distention and have findings consistent with the diagnosis of IC/BPS. In a review of 20 such children by Close et al., the median age of **onset was younger than 5 years, and the vast majority of patients had long-term remissions with bladder distention** (Close et al., 1996). This group also emphasized the need to differentiate these patients from those with dysfunctional voiding.

The Epidemiology of Hunner Lesions

One might expect epidemiologic studies related to the classical form of IC/BPS to be straightforward, given that this is a diagnosis primarily based on physical findings. Unfortunately, this has not been the case. The relative rarity of these lesions has hampered patient accrual for the development of longitudinal data. Medical coding strategies often do not distinguish HL patients from those without lesions, thus making even retrospective studies difficult to perform. Most patient populations related to HLs have been derived from tertiary care centers and are, therefore, unlikely to truly reflect general population demographics. Despite these limitations, common epidemiologic threads among studies do exist.

Data regarding the prevalence of HLs in practice range from 3.5% to 56% (Table 57.2), generating an average prevalence among studies of approximately 20%. The vast majority of these data come from clinical practices within tertiary care centers. This selection bias and other concerns, previously detailed, suggest that extrapolation of prevalence data to the general IC/BPS population should be done with caution.

TABLE 57.2

Percentage of Hunner Lesion Patients Within Varied IC/BPS Studies

YEAR	AUTHOR	HL PREVALENCE/TOTAL NUMBER OF IC/BPS PATIENTS
1949	Hand	13%/223
1987a	Holm-Bentzen et al.	3.5%/115
1987	Parsons and Mulholland	28%/75
1993	Koziol et al.	20%/374
1996	Koziol et al.	19.6%/565
1997a	Nigro et al.[a]	11.3%/113
1997	Simon et al.[a]	10.5%/190
1997	Messing et al.[a]	11.3%/150
2001	Forrest et al.[b]	10%/52
2002	Peeker and Fall	56%/231
2004	Forrest and Schmidt[b]	10%/92

2008	Braunstein, et al.	39%/223
2011	Peters et al.	17%/214
2012	Logadottir et al.	55%/393
2013	Killinger et al.	17%/214

[a] Interstitial Cystitis Data Base data. HL prevalence varied from 5.3% to 33.3% between referral centers.

[b] Forrest et al. evaluated only male patients.

HL, Hunner lesion; *IC/BPS,* interstitial cystitis/bladder pain syndrome.

Patients with HLs tend to be older than those without HLs (Table 57.3). This finding was first identified by Hand (1949), who evaluated 223 IC/BPS patients and found that 13% had grade 3 lesions, a description that is consistent with most current HL definitions. He found that these patients were older at symptom onset than those without lesions (average age 41 years vs. 35.5 years, respectively). Female HL patients had a longer interval between symptom onset and diagnosis than non-HL patients (11.5 years vs. 7.5 years, respectively).

TABLE 57.3

Age Difference: Hunner Lesion (HL) Patients Versus Non-HL Patients

		HL		NON-HL		
YEAR	**AUTHOR**	**MEAN AGE OF SYMPTOM ONSET**	**MEAN AGE OF DIAGNOSIS OR AT TIME OF STUDY***	**MEAN AGE OF SYMPTOM ONSET**	**MEAN AGE OF DIAGNOSIS OR AT TIME OF STUDY[a]**	**COMM**
1949	Hand	41	53.5	35.5	43	No males noted to HL
1977	DeJuana and Everett		58[a]			Female predomi HL was inclusion criteria f study
1993	Koziol	43.6	57.1[a]	42	52[a]	
1996	Koziol	46.9		40.9		
2002	Peeker	55	62	30	38	

	and Fall					
2008	Braunstein et al.		60[a]		47[a]	Female predomi in HL an non-HL patients
2011	Peters et al.		62[a]		55[a]	
2012	Logadottir et al.		62		42	Female predomi in HL an non-HL patients
2013	Killinger et al.		62[a]		55[a]	

[a] Study did not report the age at diagnosis; rather it only supplied information about the ages of patients at the time of the study.

Koziol et al. (1993) evaluated 374 IC/BPS patients and found that 20.1% had HLs. HL patients had similar age of symptom onset, age of diagnosis, and duration of symptoms to non-HL patients. A subsequent study by the same lead author (1996) evaluating 565 IC/BPS patients (111 with and 454 without HL), however, found the average age of symptom onset to be older in the HL group (46.9 years) than in the non-HL group (40.9 years).

Peeker et al. (2000b) compared 130 HL patients to 101 non-HL patients. They found that HL patients had a higher mean age at symptom onset (55 vs. 30 years of age) and at the time diagnosis (62 vs. 38 years of age).

Rais-Bahrami et al. (2012) analyzed patient demographics, disease characteristics, and symptoms of 268 patients with IC/BPS seen at a tertiary care center between 1990 and 2008 across three age cohorts (<30 years of age, 30 to 60 years of age, and >60 years of age. They found HL in all cohorts, however, there were more HL patients in the older age cohorts (12.0%, 42.0%, and 39.8%, respectively).

The prevalence of HL in young IC/BPS patients is not well established. Hammett et al. (2013) published a case study of a 13-year-old girl with documented HL.

Heredity and Interstitial Cystitis/Bladder Pain

Syndrome

In a pioneering study, Warren et al. (2004) suggested a hereditary aspect to incidence. They found that **adult female first-degree relatives of patients with IC/BPS may have a prevalence of IC/BPS 17 times that found in the general population.** This, together with previously reported evidence showing a greater concordance of IC/BPS among monozygotic than dizygotic twins, suggests but does not prove a genetic susceptibility to IC/BPS that could partially explain the discord in prevalence rates in different populations (Warren et al., 2001, 2004). A recent study using genetic linkage analysis suggested that a genetic variant on chromosome 3 and possibly on chromosomes 1, 4, 9, and 14 contribute to an IC/BPS predisposition (Allen-Brady et al., 2018). The same group examined familial clustering of IC/BPS with 21 associated medical conditions. Diagnoses of myalgia and myositis/unspecified (fibromyalgia syndrome [FMS]) and constipation were found in significant excess in the IC/BPS patients and their first-degree and second-degree relatives. Although environmental factors may account for some of this effect, the excess clustering in more distant relatives suggests that shared genetic factors may account for the coexistence of these conditions (Allen-Brady et al., 2015). Familial clustering has also been reported between IC/BPS and CP/CPPS (Dimitrakov, 2001), a finding not surprising given the clinical overlap between these conditions (Arora and Shoskes, 2015; Moldwin, 2002).

Key Point: Prevalence of Interstitial Cystitis/Bladder Pain Syndrome

- Prevalence studies for IC/BPS show wide variation with a general upsurge over time likely related to a more “liberalized” definition of the condition.
- IC/BPS is uncommon in children, but when present may occur with or without HLs.
- Dysfunctional voiding with bowel and pelvic floor dysfunction may give rise to symptoms similar to IC/BPS and should be considered in the differential diagnosis.
- HL may be identified in approximately 20% of IC/BPS patients in clinical practice.

- Patients with HL are generally older than those without HL.
- Studies, although limited in number, suggest genetic transmission of IC/BPS in some patients.

Natural History, Effects on Quality of Life, and Economic Burden

The natural history of IC/BPS has primarily been assessed through patient recall. Rais-Bahrami et al. found that patients diagnosed at the youngest ages experienced significantly more urinary urgency, frequency, dysuria, dyspareunia, and genital pain. Older patients had a higher incidence of nocturia, urinary incontinence, and HLs (Rais-Bahrami et al., 2012). Patients with mild symptoms at onset appear to show symptom stability at 3 years, whereas those with concomitant chronic fatigue syndrome at symptom onset tend to show symptom progression of IC/BPS over time (Warren et al., 2013). **Prodromal symptoms related to pelvic pain and irritative voiding are often experienced decades before a formal diagnosis.** Urinary frequency without pain was identified in 42% of those patients with prodromal symptoms (Warren et al., 2018). These patients are more likely to have nonbladder syndromes (e.g., FMS) and a poorer prognosis. These findings are consistent with the previously discussed increase in childhood voiding complaints recalled by adult female IC/BPS patients.

Longitudinal studies will often show symptom improvement over the first few weeks simply based on a regression to the mean and an intervention effect (improvement based on the increased follow-up and care) (Propert et al., 2000). This phenomenon was also described by the MAPP Network with the most significant symptom reduction identified between baseline and week 2. A smaller reduction was noted between weeks 2 and 4. This phenomenon reinforces the need for randomized controlled trials (RCTs) and a possible pre-enrollment interval (Stephens-Shields et al., 2016).

Two distinct pain phenotypes have been identified in the IC/BPS patient: those with pelvic pain only and those with "pelvic pain and beyond." Nickel et al. (2015) found that 81% of female IC/BPS patients were afflicted with pain beyond the pelvis and had notably higher levels of sensory type pain, a poorer physical QoL, greater somatic depression, and more sleep disturbance than those with the sole complaint of pelvic pain. Pelvic pain and beyond was also identified in approximately 75% of the MAPP Network's UCPPS patients, a population that also included male CPPS and IC/BPS patients (Clemens et al., 2019). Krieger et al. (2015) reported that 38% of UCPPS patients had at least one nonurologic-associated somatic syndrome (IBS, chronic fatigue syndrome, or FMS). This cohort had more severe symptoms, symptoms of longer duration, and higher rates of depression and anxiety than those with UCPPS only. Collectively, these studies suggest that a significant proportion of IC/BPS patients may have widespread and possibly "centralized" pain that may not respond adequately when only local therapies are applied. The findings also support a role for phenotyping strategies such as UPOINT (Urinary, Psychosocial, Organ specific, Infection, Neurologic/Systemic, Tenderness) for clinical and future research (Nickel et al., 2009b).

Information detailing symptom remission is difficult to capture as the lack of complaints usually obviates the need for office evaluation. The IC database study detailed 35% of IC/BPS patients as having at least one occurrence of symptom remission for greater than 3 months, with 38% of that group having remission for at least 6 months (Simon et al., 1997). **A MAPP Network two-site study found that symptom "flares" occurred in 98% of female UCPPS patients (100% who met IC/BPS criteria).** Flares varied widely in terms of duration (seconds to months), frequency (multiple times per day to once per year or less), symptom type (pain vs. urinary symptoms), and intensity. The most common length of flare was multiple days (87%), with increasing duration of flare associated with greater pelvic pain, urologic symptoms, disruption to participants' activities, and bother (Sutcliffe et al., 2014). A subsequent case-crossover study found sexual activity to be the only consistent factor associated with flare onset. Subpopulations appeared to be triggered by various dietary factors and abdominal exercises (Sutcliffe et al., 2018). These findings support the role to intervene if a trigger for flares is identified, but a rigid plan for flare prevention is not recommended.

As with all forms of chronic pain, IC/BPS is often associated with a decline in mental and physical quality of life (QoL), poor coping skills, anxiety, and depression (Hanno et al., 2005a; Michael et al., 2000; Rothrock et al., 2002, 2003; Vasudevan and Moldwin, 2017). Symptom severity in female IC/BPS patients was an independent predictor of a poorer QoL (body pain, general health, and mental health). A "married" status was associated with both lower symptom severity and improvement in multiple QoL domains (El Khoudary et al., 2009). Furthermore, spousal distraction techniques appear to blunt the effect of pain on the mental QoL.

Sexual dysfunction in female IC/BPS patients may have a profound effect on their physical and mental QoL, underscoring the importance of identifying and ultimately treating this problem when present (Nickel et al., 2007). Catastrophic thinking (defined as believing that the worst may happen and the individual would not be able to tolerate it) was common and associated with greater impairments in various domains, including depressive symptoms, general mental health, social functioning, vitality, and pain (Rothrock et al., 2003). Disability may be partially explained by the impact of negative affect and catastrophizing (Katz et al., 2013). Cognitive behavior therapy approaches that address catastrophizing and mood may serve an important role (Muere et al., 2018).

The symptoms of IC/BPS may affect the patient's ability to adequately function or to function at all in the workplace. IC/BPS patients are six times more likely than individuals in the general population to cut down on work time because of health problems but only half as likely to do so as patients with arthritis (Shea-O'Malley and Sant, 1999). Data collected from the RICE study demonstrated that the *impact* of bladder symptoms on life activities was the most consistent predictor of work outcomes. This suggests an important role for behavioral therapies devoted to improve coping skills and self-management strategies (Beckett et al., 2014).

Abuse and Symptoms

The Boston Area Community Health Survey (BACH) found emotional, sexual, and physical abuse to be a risk factors for symptoms suggestive of IC/BPS (Link and Lutfey, 2007), and this has been borne out in other studies. A Michigan study compared a control group of 464 women with 215 IC/BPS patients and found that 22% of the control group had experienced abuse versus 37% of the patient group (Peters et al., 2007b). A study performed through the Kaiser Permanente database found a 3.8% prevalence of child abuse versus 0.4% in a control population (Clemens et al., 2008b). Those with a history of sexual abuse may have more pain and fewer voiding symptoms (Seth and Teichman, 2008). How reliable these data are is not clear, and it would be wrong to jump to any conclusions about abuse in an individual patient. However, practitioners need to have sensitivity to the possibility of an abusive relationship history in all pain patients, and BPS patients in particular. When patients are found to have multiple diagnoses, the rate of previous abuse also increases, and these patients may need referral for further counseling at a traumatic stress center (Fenton et al., 2008).

Medical Costs

Costs of the disorder are not insignificant and can range from $4000 to $7000 per year, not including lost wages, costs preceding diagnosis, costs of alternative therapies, and costs attributable to misdiagnosis (Clemens et al., 2008a, 2009b). A recent large-scale US-based study was conducted to describe and compare health care utilization, direct costs, and comorbidities for patients with and without IC/BPS during the first year after diagnosis. A diagnosis of IC/BPS was associated with $7223 higher total health care costs than not having IC/BPS, with outpatient costs contributing to 71% of the difference. HL patients used more health care resources as reflected by total health care costs $6895 higher than patients without HL (Tung et al., 2017).

Key Points: Natural History, Effects on Quality of Life, and Economic Burden

- Symptoms tend to fluctuate, with the majority of patients showing no long-term deterioration.
- Two distinct pain phenotypes have been identified in the IC/BPS patient: those with pelvic pain only and those with "pelvic pain and beyond," with the latter group representing over 75% of patients.
- Symptom flares are common and are most commonly experienced for several days. Triggers for flares vary widely among patients.
- Prodromal symptoms related to pelvic pain and irritative voiding are often experienced decades before a formal diagnosis.
- QoL in almost all domains is significantly affected.
- The ability to function effectively or at all in the workplace is affected to a significant degree by coping skills.

Associated Disorders

Multiple medical ailments are associated with IC/BPS. Many of these conditions such as FMS, chronic fatigue syndrome, temporomandibular disorder, and irritable bowel syndrome (IBS) are functional pain disorders that may account for some portion of the 75% to 80% of IC/BPS patients who endorse pain beyond the bladder. Other pain disorders of the pelvis such as HTPFD and vulvodynia are often associated with IC/BPS. Symptoms produced by these other "pain generators" may overlap with those of the bladder, further worsen pain, and complicate management strategies. The association of IC/BPS and other disorders may give clues to underlying etiology and aid in the development of phenotyping strategies.

Based on data developed by the Interstitial Cystitis Association (ICA), a large-scale survey of 6783 individuals diagnosed by their physicians as having IC/BPS studied the prevalence of associated diseases (Alagiri et al., 1997). Data from this group was combined with two smaller studies evaluating the presence of autoimmune disease. These data are compared with a more recent albeit smaller multi-institutional study (205 IC/BPS and 117 age-matched controls) (Nickel et al., 2010b) and presented in Table 57.4. Of note, among studies is the high prevalence of pain syndromes that are believed to have a centralized pain component, that is, FMS, chronic fatigue syndrome, and IBS. **IBS was the most commonly identified associated condition, afflicting over 30% of IC/BPS patients and having the highest prevalence relative to the general population of any functional somatic pain syndrome.** Altered visceral sensation has been implicated in IBS in that these patients experience intestinal pain at intestinal gas volumes that are lower than those that cause pain in healthy persons (Lynn and Friedman, 1993), strikingly similar to the pain on bladder distention in IC. Visceral organ crosstalk presumably mediated through the convergence of sensory neural pathways in the dorsal root ganglion, spinal cord, and/or brain could be responsible for some of this association (Greenwood-Van Meerveld et al., 2015).

TABLE 57.4

Diagnoses Frequently Reported in Interstitial Cystitis/Bladder Pain Syndrome (IC/BPS) Patients

	Van de Merwe, 2003, 2007 Alagiri et al., 1997 Peeker et al., 2003		Nickel et al., 2010
DIAGNOSIS	**PREVALENCE BASED UPON SYMPTOMS (%)**	**PREVALENCE OF CONDITION IN IC/BPS/PREVALENCE OF CONDITION IN GENERAL**	**SELF-REPORTED DIAGNOSIS (%) IC/BPS VS. CONTROL SIGNIFICANT**

		POPULATION	STATISTICAL DIFFERENCES IDENTIFIED FOR ALL DIAGNOSES
Allergy	44	2	
Irritable bowel syndrome	34.3	12	38.6/5.2
Sensitive skin	26.5	2.4	
Vulvodynia	25	3.1[a]	17/0.9
Fibromyalgia	25	7.8	17.7/2.6
Chronic fatigue syndrome	13	1.5	9.5/1.7
Migraine	22.4	1	29.9/11.2
Asthma	9.8	1.6	
Inflammatory bowel disease	8.2	117	
Systemic lupus erythematosus	2.3	46	
Rheumatoid arthritis	4–13	10	
Sjögren syndrome	8.0	15	
Temporomandibular disorder			12/5.2
Low back pain			46.6/18.8

[a] Estimated prevalence for vulvodynia in the general population at the time of study was 15%. A current prevalence estimate is 8% (Harlow et al., 2014). Ratio shown is consistent with updated information.

FMS was also overrepresented in the IC/BPS population**.** This is a painful nonarticular condition predominantly involving muscles; it is the most common cause of chronic, widespread musculoskeletal pain. FMS is typically associated with persistent fatigue, nonrefreshing sleep, and generalized stiffness. Females were once thought to be afflicted ten times more commonly than men (Jacobsen et al., 1993). Paralleling the path of IC/BPS, current epidemiologic findings for FMS suggest that males compose 60% of the population (Wolfe et al., 2018). The association between FMS and IC/BPS is intriguing because both conditions have similar demographic features, modulating factors, associated symptoms, and response to tricyclic compounds (Chelimsky et al., 2012; Clauw et al., 1997).

Sexual pain and dysfunction are commonly encountered in the female IC/BPS patient (Bogart et al., 2011; Rubin and Malphrus, 2018). Some of this pain may be related to **vulvodynia,** a condition defined as vulvar pain of at least 3 months duration without clear identifiable cause, which may have potential associated factors (Bornstein et al., 2016). Studies of vulvodynia prevalence in the IC/BPS patient vary widely from 17% (Nickel et al., 2010b) to almost all patients being affected (Gardella et al., 2011). Furthermore, vulvodynia and IC/BPS share common comorbid conditions including IBS, FMS, and orofacial pain (Nguyen et al., 2013; Reed et al., 2012). The concordance of these noninfectious inflammatory syndromes involving the tissues derived from the embryonic urogenital sinus and the overlap of coexisting functional syndromes argue for a common cause (Fariello and Moldwin, 2015; Fitzpatrick et al., 1993).

Well-defined inflammatory diseases such as Crohn disease, **systemic lupus erythematosus (SLE), Sjögren syndrome (SS),** and rheumatoid arthritis are infrequently seen in the IC/BPS patient, but their relative occurrence (in the few studies available) in this population is astoundingly high. The most frequently encountered of these conditions is IBS/Crohn disease in which prevalence in the IC/BPS population varies between 104 and 117 higher than in the general population (Alagiri et al., 1997). This finding has not been corroborated yet by other investigators.

Several publications have noted an association between IC/BPS and SLE (Boye et al., 1979; de la Serna and Alarcon-Segovia, 1981; Fister, 1938; Meulders et al., 1992; Weisman et al., 1981). Alagiri et al. (1997) suggested a 34 to 46 times higher prevalence of SLE in IC/BPS patients compared with the general population. Complicating studies is the common presentation of bladder symptoms predating an SLE diagnosis (Liberski et al., 2018). The question has always been whether the bladder symptoms represent an association of these two disease processes or rather are a manifestation of lupus involvement of the bladder (Yukawa et al., 2008). This is an important distinction to make as unlike IC/BPS, lupus cystitis may have a much more virulent clinical course with the development of gross inflammatory changes, bladder wall fibrosis, and hydroureteronephrosis (Abelha-Aleixo et al., 2015). Bladder symptoms may also be a consequence of myelopathy with involvement of the sacral cord in a small group of these patients (Sakakibara et al., 2003).

An association has been reported between IC/BPS and SS, an autoimmune exocrinopathy with a female preponderance manifested by dry eyes, dry mouth, and arthritis, but which can also include fever, dryness, and gastrointestinal and lung problems. Van de Merwe et al. (1993) investigated 10 IC patients for the presence of SS. Two patients had both keratoconjunctivitis sicca and focal lymphocytic sialoadenitis, allowing a primary diagnosis of SS. Only two patients had neither finding. He later reported an incidence of 28% of SS in patients with IC (van de Merwe et al., 2003). The incidence of symptoms of IC/BPS in patients with SS has been estimated to be up to 5% (Leppilahti et al., 2003). Patients with SS may have bladder symptoms from DO, and each patient requires careful individual evaluation before a diagnosis of IC/BPS is made (Lee et al., 2011).

HTPFD as identified by tender and hypertonic pelvic floor and associated musculature can be found in approximately 80% of IC/BPS patients (Bassaly et al., 2011). Its clinical importance stems from symptoms that may extensively overlap with IC/BPS, making diagnosis of both conditions more challenging (see Fig. 57.2). The etiology of HTPFD is unknown, but may date back to childhood voiding dysfunction (Doiron et al., 2017). Other etiologic considerations include its development as guarding behavior related to bladder pain. Some authors suggest that cross-talk through viscerosomatic and viscerovisceral neural pathways may play a bidirectional role in the development of IC/BPS and HTPFD (Pezzone et al., 2005). Interestingly, resting state functional MRI demonstrated altered activity and connectivity of pelvic floor sensorimotor cortical control regions in women with IC/BPS (Kilpatrick et al., 2014).

Nickel et al. (2010b) proposed that distinct phenotypes begin to emerge when one examines the epidemiology of IC/BPS and associated medical conditions (Fig. 57.3). The smallest group comprises individuals who only endorse bladder symptoms. Other groups comprise individuals in whom pain is derived from either regional or widespread pain syndromes. More complexity is added, as multiple forms of regional and widespread pain may be present in the IC/BPS patient. Data derived from prior prevalence studies suggest that autoimmune and/or immune-mediated pain may represent another distinct group associated with IC/BPS. Further epidemiologic studies are warranted, because the epidemiology of this disorder may ultimately yield as many clues into cause and treatment as other avenues of research. The heterogeneity of causes and symptoms of IC/BPS suggests that proper clinical phenotyping could foster the development of better treatments for individual phenotypes and more successful treatments for all affected patients (Baranowski et al., 2008; Shoskes et al., 2009).

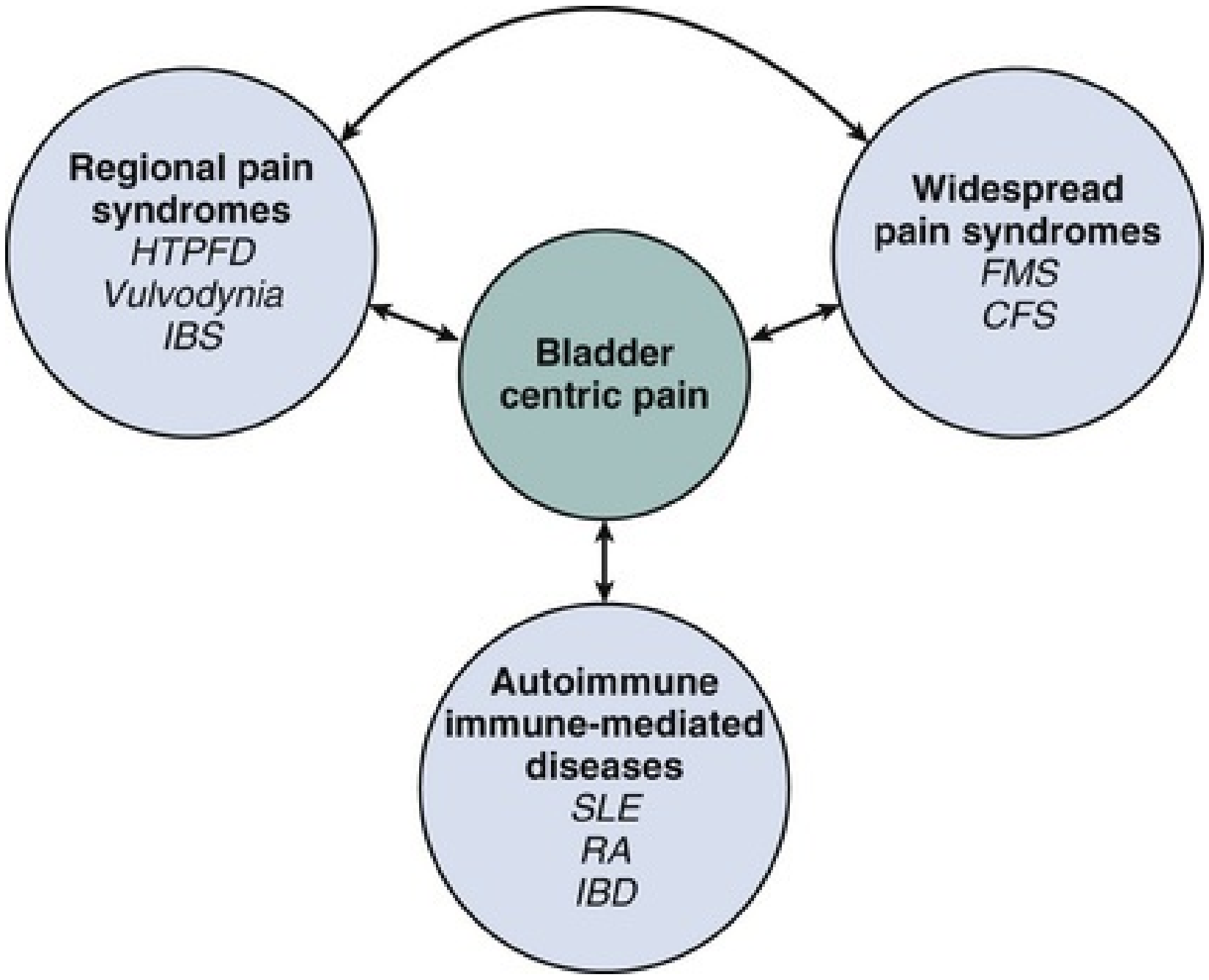
Regional pain syndromes
HTPFD
Vulvodynia
IBS
Widespread pain syndromes
FMS
CFS
Bladder centric pain
Autoimmune immune-mediated diseases
SLE
RA
IBD

FIG. 57.3 Broad categories of illnesses associated with interstitial cystitis/bladder pain syndrome. *CFS,* Chronic fatigue syndrome; *FMS,* fibromyalgia syndrome; *HTPFD,* high-tone pelvic floor dysfunction; *IBD,* inflammatory bowel disease; *IBS,* irritable bowel syndrome; *RA,* rheumatoid arthritis; *SLE,* systemic lupus erythematosus. (Modified from Nickel JC, Tripp DA, Pontari M, et al. Interstitial cystitis/painful bladder syndrome and associated medical conditions with an emphasis on irritable bowel syndrome, fibromyalgia and chronic fatigue syndrome. *J Urol* 184(4):1358–1363, 2010b.)

Key Points: Associated Disorders

- The bladder-centric patient with IC/BPS is uncommon.
- Regional pain syndromes such as HTPFD, vulvodynia, and IBS may worsen pain. They may also complicate diagnosis because of overlapping symptoms.
- The presence of distinct groups of medical conditions associated with IC/BPS underscores the heterogeneity of the condition, but also suggests that individualized strategies of care will ultimately benefit patients.

Etiology

It is likely that IC/BPS has a multifactorial cause that may act predominantly through one or more pathways, resulting in the typical symptoms (Clemens et al., 2019, Hanno et al., 2013; Nordling et al., 2017; Patnaik et al., 2017) (Fig. 57.4). There is an abundance of theories regarding its pathogenesis, but confirmatory evidence gleaned from clinical practice has proven sparse. Among numerous proposals that have been explored are “leaky epithelium,” mast cell activation, and neurogenic inflammation, or some combination of these and other factors leading to a self-perpetuating process resulting in chronic bladder pain and voiding dysfunction (Elbadawi, 1997). IBS, FMS, chronic fatigue syndrome, and various other chronic pain disorders may precede or follow the development of IC/BPS in some patients (Kim and Chang, 2012), but development of associated syndromes is not inevitable by any means, and their relationship to the cause is currently unknown (Warren et al., 2009). It has been postulated that neural cross-talk in the dorsal root ganglia, in the spinal cord, and at the level of the brain might play a role in the development of chronic pain disorders and their clinical associations through central sensitization (Furuta et al., 2012). This phenomenon may explain the lack of physical findings in many IC/BPS patients and their non-response to local therapies.

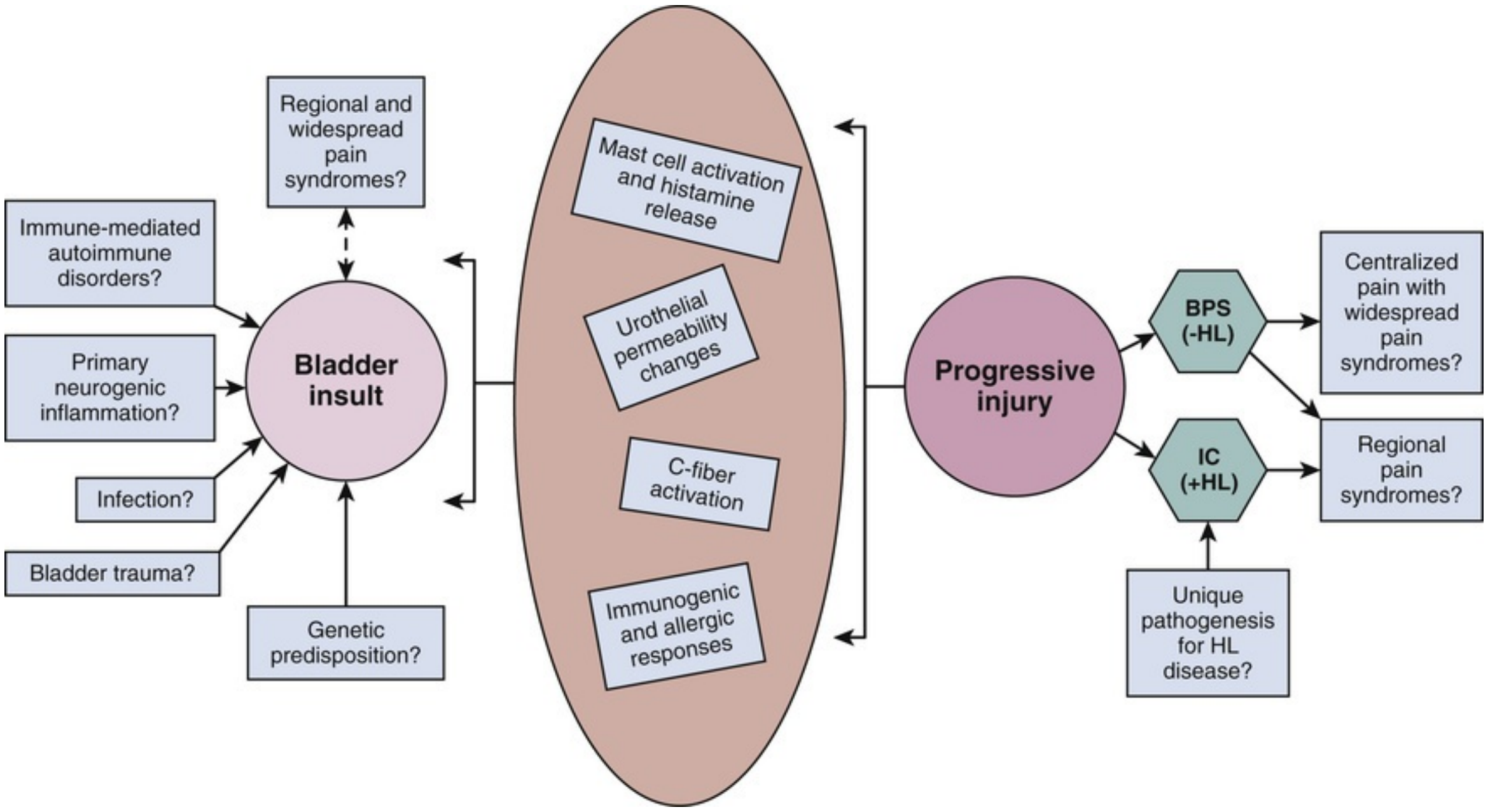
Regional and widespread pain syndromes?
Immune-mediated autoimmune disorders?
Primary neurogenic inflammation?
Infection?
Bladder trauma?
Genetic predisposition?
Bladder insult
Mast cell activation and histamine release
Urothelial permeability changes
C-fiber activation
Immunogenic and allergic responses
Progressive injury
BPS (-HL)
IC (+HL)
Unique pathogenesis for HL disease?
Centralized pain with widespread pain syndromes?
Regional pain syndromes?

FIG. 57.4 Multiple etiologic factors may play a role in the development of interstitial cystitis *(IC)*/bladder pain syndrome *(BPS)* symptoms. Current concepts of pathogenesis include its common association with pain beyond the bladder, (regional and widespread). Note the proposed distinction between patients with Hunner lesions (+HL), designated as *IC*, and those without Hunner lesions (–HL), designated as *BPS.*

Animal Models

Until recently, lacking an easily available animal model of the naturally occurring disease, researchers have had to devise animal models to study isolated symptoms of IC/BPS, hoping to uncover the root causes of the symptomatology (Ruggieri et al., 1990). Although animal models can yield clues to cause, all theories must ultimately be tested in humans with the disease. Comparative and translational studies are required if the full potential of findings obtained with animal models is to be realized (Bjorling et al., 2011).

Bullock et al. (1992) reported a mouse model in which bladder inflammation could be induced by the injection of syngeneic bladder antigen. The model demonstrated that a component in the Balb/cAn mouse is capable of inducing a bladder-specific, adoptively transferable, cell-mediated autoimmune response that exhibits many characteristics of clinical IC/BPS, but was difficult to reproduce (Klutke et al., 1997). In another mouse model, immunization of mice with recombinant mouse uroplakin II provoked an autoimmune response sufficient to induce an autoimmune cystitis (Altuntas et al., 2012). Injecting the Bartha strain of pseudorabies virus in the tail of mice causes female gender–specific pelvic pain (Rudick et al., 2012). In a pilot study, a mouse model using a synthetic APF intravesically has yielded histopathologic changes in the mouse similar to findings of IC/BPS patient biopsy specimens (Keay et al., 2012). Vascular endothelial growth factor (VEGF) instillation into the mouse bladder promotes a significant increase in peripheral nerve density with alterations in bladder function and visceral sensitivity (Malykhina et al., 2012).

In a guinea pig model, the instillation of a solution containing a protein to which the animal had been previously immunized resulted in bladder inflammation (Christensen et al., 1990; Kim et al., 1992), as did a rat model of allergic cystitis using a local challenge of ovalbumin in previously sensitized rats (Ahluwalia et al., 1998). Changes in the rat model were dependent on mast cell degranulation and activation of sensory C fibers. Induction of urinary symptoms after 7 days of repeated variate stress has been reported in a rat model (Merrill et

al., 2013).

Ghoniem et al. (1995) studied four female African green monkeys challenged with intravesical acetone (Ghoniem et al., 1995). Not surprisingly, they exhibited symptoms of IC/BPS. Rivas et al. (1997) performed similar experiments using dilute hydrochloric acid in a rat model. A rat model for neurogenic cystitis using pseudorabies virus demonstrated that inflammatory changes in the spinal cord can result in dramatic, neurogenically mediated changes in the bladder (Doggweiler et al., 1998).

The problem with all of these animal models relates to whether or not they mirror the human disease to any great extent. Buffington (2011) has described what appears to be a naturally occurring animal model of IC/BPS. Two-thirds of cats with lower urinary tract disease have sterile urine and no evidence of other urinary tract disorders (Kruger et al., 1991). A portion of these cats experience frequency and urgency of urination, pain, and bladder inflammation (Houpt, 1991). Glomerulations have been observed in the bladders of these animals. GP-51, a glycosaminoglycan (GAG) commonly found in the surface mucin covering the mucosa of the normal human bladder and decreased in IC/BPS, shows a decreased expression in cats with this symptom complex (Press et al., 1995), originally termed *feline urologic syndrome*. Bladder Aδ afferents in these cats are more sensitive to pressure changes than are afferents in normal cats (Roppolo et al., 2005). They also demonstrate an increase in baseline nitric oxide production in smooth muscle and mucosal strips when compared with healthy cats, with evidence of altered mucosal barrier function (Birder et al., 2005).

Buffington et al. (1999) now refers to this disorder as *feline interstitial cystitis (FIC)*. It is associated with urinary urgency, frequency, and pain with sterile urine, bladder mastocytosis, increased histamine excretion, increased bladder permeability, decreased urinary GAG excretion (Buffington et al., 1996), and increased plasma norepinephrine concentrations (Buffington and Pacak, 2001).

Infection

Often, a diagnosis of IC/BPS is made only after a patient has been seen by a number of physicians and treated with antibiotics for presumed urinary tract infection without resolution of symptoms (Held et al., 1990). The symptom complex looks to the patient and physician like an infectious process (Porru et al., 2004). The epidemiology of urinary tract infection and its predominance in women mirror the IC/BPS data (Warren, 1994a). The acute to subacute onset in many patients has fascinated clinicians who often associate an insidious onset with a chronic condition such as IC/BPS.

Reverse logic led some to suspect that antibiotics may be instrumental in causing IC/BPS (Holm-Bentzen et al., 1990). Most patients have been treated with antibiotics once or several times before the diagnosis is made. Numerous antibiotics, primarily in the penicillin family, can induce cystitis (Bracis et al., 1977; Chudwin et al., 1979; Cook et al., 1979; Marx and Alpert, 1984; Møller, 1978), but no evidence has ever been documented that these antibiotics or the supposedly "surface active" nitrofurantoins or tetracyclines have any involvement in pathogenesis (Levin et al., 1988; Ruggieri et al., 1987).

To determine whether there is an infectious cause of IC/BPS, certain procedures are necessary (Warren, 1994b). Not just urine, but bladder epithelium as well must be cultured for appropriate microorganisms, including bacteria, viruses, and fungi. Because some organisms might be culturable yet fastidious, special culture techniques should be used. Because some organisms in urine or tissue might be viable but nonculturable, specific nonculture techniques for discovery and identification should be employed. Most important, the same procedures must be carried out in a control population.

Attempts to show an infectious cause go back to the dawn of the disease, but **the case has never been a strong one** (Duncan and Schaeffer, 1997). Hunner (1915) originally proposed that IC/BPS resulted from chronic bacterial infection of the bladder wall secondary to hematogenous dissemination. Harn proposed a relationship between IC/BPS and streptococcal and poststreptococcal inflammation (Harn et al., 1973). He produced a progressive chronic inflammation in rabbit bladders by injecting small numbers of *Streptococcus pyogenes* in the bladder wall. Studies of *Helicobacter pylori* have failed to demonstrate an association with IC/BPS (Agarwal and Dixon, 2003; Atug et al., 2004; English et al., 1998; Haq et al., 2004). Wilkins found bacteria in catheterized urine specimens and/or bladder biopsy samples in 12 of 20 patients with IC/BPS (Wilkins et al., 1989). However, 8 of the isolates were fastidious bacteria—*Gardnerella vaginalis* and *Lactobacillus* species—and no controls were included in the study. Polyomaviruses have been reported to cause an IC/BPS-like syndrome that responds to cidofovir treatment (Eisen et al., 2009). These viruses are excreted intermittently in the urine of healthy, asymptomatic adults, making diagnosis of a true infection problematic.

Negative studies far outnumber positive ones. Hanash and Pool (1970) performed viral, bacterial, and fungal studies on 30 IC/BPS patients and failed to substantiate an infectious cause. Hedelin et al. (1983) found only 3 of 19 IC/BPS patients to have urine cultures positive for *Ureaplasma urealyticum*, and indirect hemagglutination antibodies to *Mycoplasma hominis* to be no greater than in controls. Potts et al. (2000) cultured *U. urealyticum* in 22 of 48 patients with "chronic urinary symptoms" and had great success in these patients (none of whom had established IC/BPS) with short courses of commonly prescribed antibiotics. Given the history of empirical antibiotics in the vast majority of IC/BPS patients, it is doubtful if this group represents even a small percentage of the IC/BPS-diagnosed population. Nevertheless, it illustrates that IC/BPS is a diagnosis of exclusion; urine culture is critical, and an empirical short course of antibiotics is certainly reasonable if the patient has not already been treated for presumed infection. Empirical doxycycline has been successfully used in this manner (Burkhard et al., 2004).

The development of highly sensitive, rapid, and specific molecular methods of identifying infectious agents by the direct detection of DNA or RNA sequences unique to a particular organism (Naber, 1994) resulted in a flurry of activity into the search for a responsible virus or microorganism. Hampson could find no evidence of mycobacterial involvement in eight cases of IC/BPS with the use of DNA probes (Hampson et al., 1993). Haarala et al. (1996) confirmed an absence of bacterial DNA in the bladder of 11 IC/BPS patients with no documented history of urinary tract infection. Hukkanen et al. (1996) reported an absence of adenovirus and BK virus genomes in urinary bladder biopsy specimens of IC/BPS patients. Domingue et al.'s (1995) provocative findings of the presence of bacterial 16S rRNA genes in bladder biopsy specimens from 29% of IC/BPS patients but not from control bladders and his discovery of 0.22-µm filterable forms in culture of biopsy tissue from 14 of 14 IC/BPS patients and 0 of 15 controls have never been confirmed or repeated.

A preliminary study found a statistically significant increase in urine polymerase chain reaction (PCR) to *Chlamydia pneumoniae* major outer membrane protein gene in patients with IC/BPS as compared with controls (Franke et al., 1999). Other studies have shown that similar percentages of both IC/BPS and control patient populations have nonculturable bacteria in the bladder on the basis of PCR studies of bladder biopsy specimens (Heritz et al., 1997; Keay et al., 1998a). The spirochete *Borrelia burgdorferi* has been found in bladder biopsy specimens and urine of patients with Lyme disease and can cause frequency, urgency, and nocturia. DNA studies have failed to show a role for *Borrelia* in IC/BPS (Haarala et al., 2000). A study using high-throughput sequencing analysis of urine microbiota in IC/BPS patients compared with healthy females showed a reduced microbial diversity and richness accompanied by a higher abundance of the bacterial genus *Lactobacillus* in the IC/BPS group (Siddiqui et al., 2012).

The role of infection in the pathogenesis of IC/BPS remains a mystery. **At this time, there are few data to support the role of an infectious cause,** but investigators keep returning to an infectious theory. Insights into the mechanisms by which bacteria adhere, grow, and persist in association with host tissue and form intracellular pods capable of subverting host defense mechanisms and allowing replication within epithelial cells lay the foundation for a possible role of infection in initiating the IC/BPS pathologic cascade (Kau et al., 2005). The University of Maryland group proposed a model of IC/BPS in which bladder epithelial damage such as that caused by bacterial cystitis may be the first step leading to a low-level inflammatory response (Keay and Warren, 1998). Domingue wrote, “It is logical to suggest that even if organisms are not causative agents, their presence may lead to immune and host-cell responses that could initiate or exacerbate an inflammatory state” (Domingue et al., 1997). In a case-control study, premenopausal women with a history of recurrent urinary tract infections had significantly greater urinary frequency, lower average voided volume, and a lower threshold of bladder sensitivity than controls (Arya et al., 2012).

If infection does play a role, it would be predicted that appropriate treatments to minimize microbial presence in the tissue would significantly improve the morbidity associated with IC/BPS. Durier's (1992) incredible series purporting to cure 27 of 27 IC/BPS patients with the use of up to five sequential antibiotics covering the anaerobic spectrum has never been duplicated. Warren et al.’s (2000) prospective, double-blind, placebo-controlled, randomized trial of 50 patients may well prove the end of long-term empirical antibiotic treatment in established IC/BPS. Eighteen weeks of placebo or antibiotics (sequential doxycycline, erythromycin, metronidazole, clindamycin, amoxicillin, and ciprofloxacin for 3 weeks each) were administered. Most patients guessed the arm to which they were assigned. Of the 25 patients in the active arm, 80% had new nonurinary symptoms perceived as side effects. There was minimal improvement in some patients associated with the active arm, but the conclusion that intensive antibiotics do not represent a major advance in therapy for IC/BPS seems well justified.

Although the concept that a urinary tract infection may trigger IC/BPS in some patients is appealing (Elbadawi, 1997; Elgavish et al., 1995), **it is unlikely that active infection is involved in the ongoing pathologic process or that antibiotics have a role in treatment.**

Autoimmunity and Inflammation

Immune and neuroimmune mechanisms may have an important role in the pathogenesis of IC/BPS. Excessive release of sensory nerve neurotransmitters and mast cell inflammatory mediators is thought by some to be responsible for the development and propagation of symptoms (Luo, 2005). Inflammation results in altered nerve growth factor content of the bladder and morphologic changes in sensory and motor neurons innervating the bladder. Inhibition of nerve growth factor with a monoclonal antibody showed preliminary efficacy in amelioration of IC/BPS symptoms in phase II studies (Evans et al., 2011). Neuroplasticity may be a possible explanation for the association of bladder inflammation with long-term symptoms and pain after inflammation has subsided (Dupont et al., 2001). Up to one-third of IC/BPS patients may have an acute urinary tract infection that immediately precedes the onset of chronic symptoms (Warren et al., 2008). However, abnormal differentiation in the urothelium with a loss of barrier function markers and altered differentiation markers may be independent and occur independently of inflammation (Hauser et al., 2008).

The role of inflammation may stem from inflammation originating in organs other than the bladder. Pain syndromes such as IBS and IC/BPS, which are associated with visceral hyperalgesia, are often comorbid with endometriosis and chronic pelvic pain. Tirlapur concluded that in women with chronic pelvic pain, the mean prevalence of IC/BPS is 61%, the mean prevalence of endometriosis is 70%, and the two problems coexist in 48% of this population (Tirlapur et al., 2013a). One of the possible explanations for this phenomenon is viscerovisceral cross-sensitization, in which increased nociceptive input from an inflamed pelvic organ sensitizes neurons that receive convergent input to the same dorsal root ganglion from an unaffected visceral organ. Visceral sensory integration in the dorsal root ganglia has been demonstrated in a rodent model and may underlie the observed comorbidity of female pelvic pain syndromes (Li et al., 2008).

For many years, the possibility that IC/BPS may represent some type of autoimmune disorder has been considered. Narrowly defined, autoimmune diseases are clinical syndromes caused by the activation of T cells, B cells, or both, in the absence of an ongoing infection or other discernible cause (Davidson and Diamond, 2001). To establish a disease as autoimmune, three types of evidence can be marshaled: (1) direct evidence from transfer of pathogenic antibody or pathogenic T cells; (2) indirect evidence based on reproduction of the autoimmune disease in experimental animals; and (3) circumstantial evidence from clinical clues (Rose and Bona, 1993). Circumstantial evidence would include (1) association with other autoimmune diseases in the same individual or same family; (2) lymphocytic infiltration of a target organ; (3) statistical association with a particular major histocompatibility complex haplotype; and (4) favorable response to immunosuppression.

Circumstantial evidence by itself cannot define an autoimmune disease, and **at this point the case for autoimmunity in IC/BPS is far from clear.** Three different possibilities exist: (1) IC/BPS is caused by a direct autoimmune attack on the bladder; (2) some of the autoimmune symptoms and pathology of IC/BPS arise indirectly as a result of tissue destruction and inflammation from other causes; and (3) autoimmune phenomena in IC/BPS patients are coincident and unrelated to the disease (Ochs, 1997).

Silk found bladder antibodies in 9 of 20 IC/BPS patients and none in 35 pathologic or normal control patients (Silk, 1970). Gordon found antibladder antibodies present in biopsy specimens from 6 of 8 IC/BPS patients and in 3 of 5 control patients (Gordon et al., 1973). No control patient demonstrated antibodies in the muscle, whereas 3 of 5 IC/BPS patients with muscle in the biopsy specimen did. Jokinen looked at sera from 33 IC/BPS patients and found 28 with an antinuclear antibody (ANA) titer of 1 : 10 or greater, but no bladder-specific antibodies were detected with immunofluorescence. There was poor correlation between ANA titers and symptom severity (Jokinen et al., 1972). He noted that elevated antibody titers against cell nuclei and crude kidney homogenate decreased within 12 months after cystectomy in three IC/BPS patients (Jokinen et al., 1973). All of this provided hints that IC/BPS could fall into the autoimmune group of diseases.

Oravisto (1980) summarized the world literature on this idea in 1980, concluding that the chronic course of disease, the absence of infection, the pathologic findings, the occurrence of ANAs, and the reported responses to steroids at that time provided strong circumstantial evidence of autoimmunity. He discounted the paucity of activated lymphocytes, which speaks against an autoimmune process. Studies on autoantibodies in IC/BPS have shown that these mainly consist of ANAs (Jokinen et al., 1972), similar to the autoantibody profiles in some systemic diseases such as SS, well known to be of autoimmune origin (Leppilahti et al., 2003; Tan, 1989). Mattila (1982) presented evidence of immune deposits in the bladder vascular walls in 33 of 47 IC/BPS patients. Studying sera from 41 patients with IC/BPS, he concluded that the classical pathway activation of the complement system was involved, supporting the possibility that a chronic local immunologic process was indeed occurring (Mattila et al., 1983). The autoantibodies tested were found to be directed against cytoskeletal intermediate filaments. As the autoantibodies have to gain access to intracellular structures to cause in vivo deposits, primary tissue injury of unknown cause has to be postulated (Mattila and Linder, 1984).

Anderson et al. (1989) studied 26 patients with IC/BPS and compared them with a control group of similar age and sex with other urologic complaints. They performed a standard autoimmune profile and looked for specific antibodies to normal human bladder in the serum. In this study, 65% of IC/BPS patients and 36% of controls demonstrated non–organ-specific antibodies; 40% of IC/BPS patients had ANAs; and 75% of IC/BPS patients and 40% of controls had antibladder antibodies present in the serum. There was no increase in immunoglobulin deposition in the bladder epithelium in IC/BPS patients versus controls. Although IC/BPS patients demonstrated a nonspecific increase in antibody formation, this was not significantly different from a similar group of other urologic patients. The lack of specificity indicates the immunologic findings are likely secondary to inflammation rather than a primary cause.

In a study looking for active immune cellular deposition in IC/BPS patients, no statistically significant difference between controls and IC/BPS patients was identified (Harrington et al., 1990). In contrast, the IC/BPS with HL group had focal sheets of plasma cells, aggregates of T cells, B-cell nodules, a decreased or normal helper-to-suppressor cell ratio, and suppressor cytotoxic cells in germinal centers. Flow cytometry analysis of peripheral blood lymphocyte subsets showed an increased number of secretory Ig-positive B cells and activated lymphocytes in the non-HL group, and increased numbers of secretory Ig-positive cells and activated lymphocytes in the HL group. These results may suggest a partial role for an immune mechanism in IC/BPS. Gamper et al. (2013) found elevated urinary antibody concentrations in patients with HLs. Erickson et al. (1997a) noted a major difference in inflammatory cell types and clinical features in IC/BPS patients with severe inflammation, suggesting two different patient groups with two different underlying pathophysiologies.

Christmas (1994) reported increased numbers of CD4+ and CD8+ T cells in bladder biopsy specimens from patients with IC/BPS and bacterial cystitis as compared with controls. These T cells were present in the urothelium and submucosa but not in the detrusor. Control bladder tissue demonstrated only CD8 cells in the urothelium and both CD4+ and CD8+ cells in the submucosa. The number of plasma cells was significantly greater in IC patients than in normal controls and controls with bacterial cystitis.

MacDermott et al. (1991b) found a normal distribution of peripheral blood lymphocytes in IC/BPS patients, a finding not supportive of an autoimmune mechanism in the disease (MacDermott et al., 1991b). The lamina propria showed a predominance of CD4 lymphocytes (helper T cells) over CD8 cells in both IC/BPS and other cystitis patients. The same pattern was seen in the epithelium of patients with bacterial or mechanical cystitis, but patients with IC/BPS had a predominance of CD8 lymphocytes in the urothelium—identical to controls. The findings suggest that the urothelium is not involved in the inflammatory reaction, as is the lamina propria, making the urothelium an unlikely source for the initiating factor.

Miller et al. (1992) investigated the function of peripheral blood lymphocytes from non-HL IC/BPS patients, testing the proliferative response and cytokine production of T cells to nonspecific mitogenic stimulation and the proliferative response of T cells to urine components. Proliferation and cytokine production after mitogen stimulation were the same for controls and IC/BPS patients. Moreover, no immunologic response to IC/BPS urine by autologous peripheral blood lymphocytes in vitro assays was observed. These findings cast doubt on theories, suggesting that IC/BPS is an autoimmune disease.

Numerous inflammatory mediators have been studied with regard to their relation to IC/BPS (Elgebaly et al., 1992; Felsen et al., 1994; Lotz et al., 1994; Steinert et al., 1994; Zuraw et al., 1994). There is a significant elevation of cytokines in IC/BPS bladder tissue when compared with controls (Corcoran et al., 2013) and an increase in urinary nerve growth factor (Liu and Kuo, 2012). The overexpression of genes related to immune and inflammatory responses, including T helper type 1–related chemokines and cytokines such as CXCR3-binding chemokines, may produce potential biomarkers of the disease (Ogawa et al., 2010). Urine sediment may be a substrate for gene expression analysis (Blalock et al., 2012).

Patients with IC/BPS exhibit varying degrees of inflammation that can separate them into clusters (Green et al., 2004; Tomaszewski et al., 2001). Bladder inflammation in IC/BPS is categorized by elevated urinary interleukin-6

(Erickson et al., 1997a) and activation of the kallikrein-kinin system (Rosamilia et al., 1999b). The absence of urinary interleukin-1β in IC/BPS argues against an immunologic or autoimmune cause of the disorder (Martins et al., 1994). Neurogenic inflammation may play a role in the cause, as long-term exposure of afferent nerve terminals to inflammatory mediators can alter ion channels and result in bladder hyperalgesia (Buffington and Wolfe, 1998; Yoshimura and de Groat, 1999). Substance P itself does not seem to be the single initiator of inflammation in the bladder, and its blockade does not protect the bladder from inflammatory responses in animal models (Luber-Narod et al., 1997). Urinary nitric oxide synthase (NOS) activity is known to be elevated in patients with urinary infection and is thought to play a role in the bladder's response to infection and in the inflammatory process that follows infection. The finding that urinary NOS activity is decreased in IC/BPS patients has puzzled researchers but could explain the reduction in functional bladder capacity associated with the disorder (Foster et al., 1997; Smith and Christmas, 1996). However, patients with HLs have high levels of nitric oxide in the bladder. The production of nitric oxide in this entity may occur in different tissue compartments, because there is strong immunoreactivity for both inducible nitric oxide synthase (iNOS) in the urothelium and within the inflammatory infiltrates in the lamina propria of these patients (Logadottir et al., 2013).

Urothelial cell activation in IC/BPS may result in aberrant immune responses and immune activation within the bladder wall (Liebert et al., 1993) that could relate to pathogenesis of the disease but might not reflect the initiating cause (Ochs et al., 1994). It has been proposed that inflammatory and/or immune responses in IC/BPS could be exacerbated by persistent activation of nuclear factor-κB (NF-κB) (Abdel-Mageed, 2003; Abdel-Mageed and Ghoniem, 1998). Angiogenic factors such as platelet-derived endothelial cell growth factor/thymidine phosphorylase and transforming growth factor-β may be involved in the inflammatory process to induce painful symptoms in patients with IC/BPS or bladder carcinoma (Ueda et al., 2002).

The exact role of autoimmunity in IC/BPS remains controversial (Ochs, 1997). Suplatast tosilate, an immunoregulator, has shown efficacy in a small, uncontrolled IC/BPS study in which improvements in symptoms and bladder capacity were correlated with changes in autoimmune parameters (Ueda et al., 2000). **Although the immune system remains a target for therapy, no clear indication of a primary role for autoimmunity as the cause of IC/BPS has been observed** (Liebert and Sant, 1997).

Key Points: Autoimmunity and Inflammation

- Neuroplasticity may be a possible explanation for the association of bladder inflammation with long-term symptoms and pain after inflammation has subsided.
- Abnormal differentiation in the urothelium with a loss of barrier markers and altered differentiation markers may be independent and may occur independently of inflammation.
- Visceral sensory integration may result in inflammation originating in organs other than the bladder causing symptoms identified with IC/BPS.

Mast Cell Involvement

Although mast cells are thought of primarily in the context of allergic disorders and certain acute inflammatory responses, these cells have also been implicated in biologic responses as diverse as angiogenesis and wound healing, bone remodeling, peptic ulcer disease, atherosclerosis, and reactions to neoplasms (Galli, 1993). Mast cells remain one of the most enigmatic cells in the body. They secrete significant amounts of numerous proinflammatory mediators that contribute to a number of chronic inflammatory conditions, including stress-induced intestinal ulceration, rheumatoid arthritis, scleroderma, and Crohn disease. They have been described even among the lowest order of animals, having been discovered in the frog mesentery over 100 years ago. Their raison d'être may be the initiation and coordination of the host's inflammatory and immune responses against microbial pathogens (Abraham and Malaviya, 1997). They have been implicated in a range of neuroinflammatory diseases, especially those worsened by stress (Theoharides, 2004; Theoharides and Cochrane, 2004). These include multiple sclerosis, migraines, inflammatory arthritis, atopic dermatitis, coronary inflammation, IBS, and IC/BPS. They may be activated through their Fc receptors by immunoglobulins other than IgE, and by anaphylatoxins, neuropeptides, and cytokines, to secrete mediators selectively without overt degranulation.

Mast cells have frequently been reported to be associated with IC/BPS, both as a pathogenetic mechanism and as a pathognomonic marker (Bhone et al., 1962; Hofmeister et al., 1997; Larsen et al., 1982; Simmons, 1961; Smith and Dehner, 1972). The association of bladder mastocytosis, IC/BPS, and IBS

(Pang et al., 1996) and chronic urticaria (Sant et al., 1997) is intriguing. Evidence of their importance is mounting, suggesting that **they may serve as the final common pathway through which the symptomatic condition is expressed. Mast cells produce, among other compounds, histamine. Histamine release in tissue causes pain, hyperemia, and fibrosis, all notable features of IC/BPS.**

Simmons was first to suggest mast cells as a cause of IC/BPS (Simmons, 1961). Contribution of mast cells to the cellular infiltrate in IC/BPS has been shown to vary from about 20% in non-HL IC/BPS patients to 65% in HL patients (Enerback et al., 1989; Sant et al., 1988). Mast cells participate in allergic reactions (hypersensitivity—type I) during which IgE antibody is synthesized in response to specific antigens. IgE binds to mast cell receptors, and antigen binds to the IgE, leading to degranulation (Lagunoff et al., 1983). Other triggers of mast cell secretion include acetylcholine, anaphylatoxins, cationic peptides such as substance P, chemicals, contrast, cytokines, opioids, antihistamines, exercise, hormones, viruses, and bacterial toxins (Sant and Theoharides, 1994). Mast cells promote infiltration of neutrophils, T and B lymphocytes, monocytes, and eosinophils. T lymphocytes secrete substances capable of activating mast cells, thus perpetuating the cycle of inflammation (Kaplan et al., 1985).

Since the presence of mast cells within the bladder wall was first recognized (Simmons and Bunce, 1958), numerous investigators have tried to determine whether there is an increase in the number of mast cells in the bladder of patients with IC/BPS, or differences in their location or functional state (Christmas and Rode, 1991; Fall et al., 1987; Feltis et al., 1987; Kastrup et al., 1983; Larsen et al., 1982; Lynes et al., 1987). An increase in urothelial mast cells appears to be part of the generalized inflammatory cell reaction regardless of cause, and not a specific feature of IC/BPS, whereas the presence of increased numbers of mast cells in the detrusor is more specific for IC/BPS. However, one study did report detrusor mastocytosis in 64% of IC/BPS patients and 80% of a control group with other urologic disease, with no statistically significant difference between the mean number of detrusor mast cells in the two groups (Hanno et al., 1990).

Aldenborg reported that mast cells are found predominantly in the detrusor muscle in patients with classic IC/BPS (Aldenborg et al., 1986), but there is also a secondary population of mast cells in the lamina propria and the bladder epithelium, with staining characteristics distinct from those in the detrusor. None of these epithelial mast cells were found in controls. These findings were interpreted to indicate a transepithelial migration of mast cells in patients with IC/BPS. This second population of mast cells does not appear to be involved in the non-HL type of IC/BPS (Aldenborg et al., 1989). This mucosal population of mast cells can also differ from the mast cells found in deeper tissues in physiologic responses and release of secretory products (Sant, 1991). The “mucosal mast cells” are susceptible to aldehyde fixation and require special fixation and staining techniques for proper demonstration. Detrusor mast cells are not susceptible to fixation techniques. Recent studies have shown that although all human mast cells contain the proteinase tryptase, there is a population of mast cells that also contain the proteinase chymase. The mast cell expansion in IC/BPS involves both types (Yamada et al., 2000). Mast cell activation is far more pronounced in the ulcerative form, which in addition displays prominent inflammation, in contrast with non HL IC/BPS, in which it is sparse. Thus, the basic pathologic processes may differ (Peeker et al., 2000b). Because activated mast cells lose their histologically identifiable granules once degranulation has occurred, estimates of mast cell density using standard histologic techniques may underestimate mast cell numbers (Sant and Theoharides, 1994).

Electron microscopy has confirmed that mast cells in IC/BPS are more likely to be degranulated or activated than those found in other conditions (Larsen et al., 1982; Theoharides and Sant, 1991; Theoharides et al., 1995). In at least a subpopulation of IC/BPS patients, this may be explained by increased stimulation of mast cells by stem cell factor (Pang et al., 1998). Chronic exposure of detrusor muscle to histamine in IC/BPS patients is suggested by the finding that there is an impairment of the direct contractile response to histamine in detrusor muscle affected by IC/BPS in comparison with control detrusor, suggesting a receptor desensitization (Palea et al., 1993). The clinical relationship between an increased number of mast cells and symptoms of IC/BPS has not been definitively established. Some studies have found no correlation (Dondore et al., 1996; Holm-Bentzen et al., 1987a; Lynes et al., 1987). Although mast cell infiltration in intestinal segments used for augmentation has been associated with pain and failure of the procedure (Kisman et al., 1991), other researchers have shown that mast cell infiltration in intestine used in the urinary tract is the norm and not pathologic (MacDermott et al., 1990).

Many of the substances that have been shown to induce mast cell secretion are released from neurons that innervate the organ containing the mast cells

(Christmas et al., 1990). The capsaicin-sensitive sensory neurons that innervate the bladder are thought to have a dual “sensory-efferent” function, in which an axon reflex-induced release of neuropeptides results in local inflammation (Barbanti et al., 1993; Foreman, 1987). Hand (1949) reported an increase in the submucosal nerve density in IC/BPS, a phenomenon confirmed by Christmas et al. (1990), who showed an increase in nerve fiber proliferation in patients with IC/BPS but not in patients with bacterial or lupus cystitis. Increased innervation by nerves releasing substances affecting mast cells could lead to increased mast cell secretion. Among these substances is acetylcholine. Mast cells can be stimulated by cholinergic agonists to secrete serotonin (Theoharides and Sant, 1991). Substance P–containing fibers have been found to be increased in bladders from IC/BPS patients and are found adjacent to mast cells (Pang et al., 1995b). In mice, mast cells modulate the inflammatory response of the bladder to substance P and to *Escherichia coli* lipopolysaccharide (Bjorling et al., 1999).

An increase in adrenergic but not cholinergic nerves in IC/BPS patients as compared with controls has been reported (Hohenfellner et al., 1992). Hohenfellner et al. also found increased numbers of neurons staining for vasoactive intestinal polypeptide and neuropeptide Y (NPY), both of which are associated with sympathetic nerves. Studies in rats have revealed that psychological stress can activate bladder mast cells via the action of sensory neuropeptides (Alexacos et al., 1999; Spanos et al., 1997). Diurnal cortical variations have been associated with symptom levels in IC/BPS (Lutgendorf et al., 2002), and the mast cell may represent a pathway for stress to be reflected in bladder symptomatology.

Mast cells can alter their environment by regulating tissue gene expression (Saban et al., 2001). The finding of increased synthesis of urinary leukotriene E_4 in patients with IC/BPS and detrusor mastocytosis when compared with healthy controls suggests that cysteinyl-containing leukotrienes are involved in the inflammatory reaction observed in the urinary bladder of patients with IC/BPS and may be produced from tissue mast cells in the bladder wall, or macrophages (Bouchelouche et al., 2001a).

Could mast cell products be useful in diagnosing IC/BPS? They are not specific for IC/BPS and are increased in bladder carcinoma (Serel et al., 2004). Elevated histamine levels have been found in bladder biopsy specimens from IC/BPS patients (Enerback et al., 1989; Kastrup et al., 1983; Lynes et al., 1987) and from bladder washings (Lundeberg et al., 1993). Holm-Bentzen et al. (1987b) reported a significantly elevated urinary excretion of 1,4-

methylimidazole acetic acid, the major metabolite of histamine. Others have found no differences between IC/BPS and controls in random spot tests of urinary histamine (Yun et al., 1992). Levels were elevated after hydrodistention in IC/BPS patients but not in controls—a possible consequence of hydrodistention and resultant mast cell degranulation. El Mansoury et al. (1994) found increased methylhistamine, a histamine metabolite, in spot and 24-hour urine samples from IC/BPS patients as compared with controls. Although such an increase could still be interpreted as indicating a systemic rather than a bladder syndrome, subsequent findings of elevated mast cell tryptase in the urine of IC/BPS patients could come only from the bladder (Boucher et al., 1995). Erickson et al. (2004) reported that urine methylhistamine is not useful as an objective marker of response to bladder distention or as a predictor of response to distention or as a substitute for bladder biopsy to determine mast cell counts.

The realization that mast cells are associated with the syndrome of IC/BPS by no means diminishes the other multiple theories of causation. The poor clinical results with antihistamine therapy would argue against their being a primary factor. Their very presence could be related to injury from any of the proposed etiologic theories, and degranulation could likewise reflect a final common pathway resulting in pain and frequency from multiple causes. Rickard and Lagunoff (1995) proposed, based on results with mast cell granules and epithelial cells in tissue culture, that mast cells could contribute to failure of epithelialization of the bladder surface by two potential mechanisms after injury: (1) inhibition of epithelial cell replication, and (2) interference with epithelial cell spreading, thus resulting in the “leaky epithelium” found in some patients. Mast cell activation has been correlated significantly with the apoptotic cell number in IC/BPS bladder tissue (Shie and Kuo, 2011). Mast cells may actually be the mediator through which female hormones play a role, accounting for the 10 : 1 female-to-male preponderance of the disease (Bjorling and Wang, 2001; Pang et al., 1995a; Patra et al., 1995; Vliagoftis et al., 1992). Estradiol augments the secretion of mast cell histamine in response to substance P. It has been proposed that the symptoms of IC/BPS may depend on an imbalance between the relative number of estrogen receptors and progesterone receptors on bladder mast cells (Letourneau et al., 1996).

To summarize, much important IC/BPS research has centered on the mast cell. These cells are strategically localized in the urinary bladder close to blood vessels, lymphatics, nerves, and detrusor smooth muscle (Saban et al., 1997). **Studies to date strongly suggest that IC/BPS is a syndrome with neural,**

immune, and endocrine components in which activated mast cells play a central, although not primary, pathogenetic role in many patients (Elbadawi and Light, 1996; Filippou et al., 1999). Studies in a mast cell–deficient mouse model demonstrate that mast cells promote cystitis pain and bladder pathophysiology through the separable actions of histamine and tumor necrosis factor (TNF), respectively, suggesting that pain is independent of pathology and inflammation, and histamine receptors may represent direct therapeutic targets for pain in IC/BPS (Rudick et al., 2008).

Key Points: Mast Cells and Histamine

- Mast cells may be a pathognomonic marker for IC/BPS and also represent a pathogenetic mechanism of the syndrome. They could serve as a final common pathway through which the symptomatic condition is expressed.
- Histamine, produced by mast cells, may cause pain, hyperemia, and fibrosis, all notable features of IC/BPS.

Bladder Glycosaminoglycan Layer and Epithelial Permeability

Until the early 1970s, most investigators thought that the major barrier to free flow of urinary constituents was at the level of the epithelial cells. Tight junctions between urothelial cells, specialized “umbrella cells” lining the surface, and direct bactericidal activity of the vesical mucosa were thought to be capable of defense of the internal milieu from bacteria, molecules, and ions in the urine (Ratliff et al., 1994). Staehelin et al. (1972) proposed that lipid and other hydrophobically bonded materials were important in any barrier to permeability in the luminal membrane because permeants leaked through the interplaque regions if the particles alone limited transport. It has been shown that inflammation of the underlying muscle and lamina propria can disrupt the bladder permeability barrier by damaging tight junctions and apical membranes and causing sloughing of epithelial cells. Leakage of urinary constituents through the damaged epithelium may then exacerbate the inflammation in the underlying tissues (Lavelle et al., 1998, 2000). Early investigators, attempting to find a urothelial defect responsible for symptoms, found remarkable similarities of epithelial cell and glycocalyx ultrastructure between IC/BPS and control specimens (Collan et al., 1976; Dixon et al., 1986). Anderstrom et al. (1989) saw no surface characteristics specific for IC/BPS, but believed that the mucin layer covering the urothelial cells seemed reduced in IC/BPS compared with controls, a fact disputed by Nickel et al. (1993) in a very elegant paper. Elbadawi and Light (1996) observed ultrastructural changes sufficiently distinctive to be diagnostic in specimens submitted for pathologic confirmation of IC/BPS-HL. Marked edema of various tissue elements and cells appeared to be a common denominator of many observed changes. The wide-ranging discussion of the etiology of IC/BPS in this paper is fascinating, but the pathologic findings are potentially marred by the methodology, in that specimens were obtained after diagnostic hydrodistention (Elbadawi,1997).

It was Parsons who hypothesized and popularized the **concept that IC/BPS in a subset of patients is the result of some defect in the epithelial permeability barrier of the bladder surface GAGs** (Parsons and Hurst, 1990). The major classes of GAGs include hyaluronic acid, heparin sulfate, heparin, chondroitin 4-sulfate and chondroitin 6-sulfate, dermatan sulfate, and keratan sulfate. These carbohydrate chains, coupled to protein cores, produce a diverse class of macromolecules, the proteoglycans (Trelstad, 1985). GAGs exist as a continuous layer on the bladder urothelium (Cornish et al., 1990; Dixon et al., 1986). Except heparin, all the other types of GAGs have been found on the bladder surface (Ruoslahti, 1988). **The GAG layer functions as a permeability and antiadherence barrier. When impaired, its functions can be duplicated by exogenous GAG** (Hanno et al., 1978a, 1978b). In the absence of this protective layer in the urinary bladder, its susceptibility to infection would increase, and the production of nitric oxide in the urothelial cells and of substance P in the intraepithelial afferent C-fiber terminals increases. Consequently, the permeability of both the urothelium and the blood vessels in the mucous membrane increases, and the blood flow slows as a result of vasodilatation (Hohlbrugger, 1999).

Parsons and Hurst reported a lower excretion of urinary uronic acid and GAGs in IC/BPS patients than in normal volunteers and hypothesized that a leaky transitional epithelium might be absorbing these substances to its surface (Parsons and Hurst, 1990). The data are interesting in that one might expect urinary GAG to increase with injury to the bladder and decrease with resolution (Uehling et al., 1988). Buzzega et al. (2012) noted a significant increase in total urinary hexosamines and in particular in glucosamine belonging to urinary heparin sulfate in IC/BPS patients compared with controls. The San Diego group (Lilly and Parsons, 1990; Parsons et al., 1990) went on to show experimentally that one can damage the GAG layer with protamine sulfate with resultant back-diffusion of urea through the bladder lumen, and that this urea loss can be prevented with a bladder instillation of exogenous GAG (heparin). By placing a solution of concentrated urea into the bladder of IC/BPS patients and measuring absorption versus controls, Parsons found support for his theory in patients with IC/BPS (Parsons et al., 1991). The rationale of the epithelial permeability school has been nicely summarized in four publications (Hohlbrugger and Riedl, 2000; Hurst et al., 1997; Parsons, 1993, 1994) and provides a comprehensive, if somewhat imperfect, theory of the disorder.

Support for an epithelial abnormality from a different perspective has come from Bushman, who found aneuploid DNA profiles on barbotage specimens from IC/BPS patients that may signal an underlying abnormality of the epithelial cell population in some patients with IC/BPS (Bushman et al., 1994). Wilson et al. (1995) identified a loss of type IV collagen in the urothelial basement membrane in 5 of 11 IC/BPS patients. Hurst et al. (1996) studied bladder biopsy specimens of IC/BPS patients and controls and concluded that there is a deficit of bladder luminal and basal proteoglycans associated with the disorder. The basal abnormality may reflect an altered urothelial differentiation program. In a later study, IC/BPS bladder biopsy specimens showed abnormalities in 24 of 27 patients when examined by immunohistochemical assessment of E-cadherin, ZO-1, uroplakin, and chondroitin sulfate (Slobodov et al., 2004). Erickson et al. (1996) measured a glycoprotein (epitectin) in the urine of IC/BPS patients and found a decrease compared with a control population, although a significant overlap was detected. Buffington and Woodworth (1997) gave 6 IC/BPS patients and 6 controls oral fluorescein dye. IC/BPS patients had higher levels of fluorescein in their plasma and lower urinary excretion of the dye, suggesting altered membrane permeability and increased fluorescein reabsorption in the bladder wall of IC/BPS patients. Erickson et al. (1998) compared urinary levels of hyaluronic acid in IC/BPS patients and controls, reporting higher urinary hyaluronic acid in the patient group, possibly accounted for by leakage of this GAG across the epithelium.

In FIC, the only naturally occurring animal model of the disorder, the urothelium has been shown to have decreased transepithelial resistance and increased water and urea permeability compared with controls in response to hydrodistention (Lavelle et al., 2000). This indicates that barrier function is compromised, which could lead to the sensitization of sensory nerves by irritants from urine crossing into the muscle layer. Bladder strip studies have shown that FIC bladders have significantly more spontaneous Ca^{2+} transients in the mucosal layer than control bladders. Coupled with increased sensitivity of muscarinic receptors in the mucosal layer, these bladders may manifest enhanced smooth muscle spontaneous contractions. This finding could play a contribution in the symptoms of IC/BPS (Ikeda et al., 2009). In fact, human cell culture studies comparing IC/BPS and normal bladder urothelial cells have shown greater sensitivity of IC/BPS bladder urothelial cells to carbachol, suggesting that IC/BPS pathobiology may also include alterations in muscarinic signaling (Gupta et al., 2009). Neuhaus et al. (2012) showed significantly upregulated M_2 (muscarinic), $P2X_1$ and $P2X_2$ (purinergic), and H_1 and H_2 (histaminergic) receptors in the tissue of IC/BPS patients.

Further data for an abnormal surface mucin came from Moskowitz et al. (1994), who studied biopsy specimens from 23 IC patients with regard to the presence of a glycoprotein component of the surface mucin referred to as *GP1* and compared the results with 11 normal controls. Qualitative GP1 changes in a majority of IC/BPS patients were identified. GP1 reactivity was noted in all controls but was absent in 35% of IC/BPS patients and diminished in 61%. This study may provide evidence of an abnormal bladder urothelium, but the effects of bladder distention in the IC/BPS group are unknown and may have contributed to the results. There were no pathologic controls used, and no attempt was made to correlate GP1 reactivity with IC/BPS symptoms (Messing, 1994). Castration in female rabbits is associated with bladder mucosal changes resulting in increased mucosal permeability (Parekh et al., 2004). Birder et al. (2005) showed that FIC results in increased baseline production of nitric oxide as a result of iNOS. These changes in transmitter release may have a role in altering mucosal barrier properties.

VEGF plays a key role in bladder inflammation and is closely associated with the vascular alterations observed in patients with IC/BPS. VEGF and coreceptors (neuropilins [NRPs]) are strongly expressed in human bladder urothelium. NRP-2 and VEGFR-1 are significantly downregulated in IC/BPS when compared with control subjects (Saban et al., 2008). GAG modification of NRPs plays a critical role in modulating VEGF/NRP signaling (Shintani et al., 2006), suggesting another possible mechanism whereby a GAG deficiency could act by interfering with the functionality of this signaling system.

Some have cited the “potassium sensitivity test” as providing strong evidence for a population with mucosal leak (Parsons et al., 1994b). Parsons placed water or 0.4-M potassium chloride (KCl) intravesically into normal volunteers and IC/BPS patients. Water did not provoke pain in either group, but KCl provoked the symptom in 4.5% of normal subjects and 70% of IC/BPS patients. Symptomatic responses were reduced in patients on heparinoid therapy. Similar findings occured in patients with radiation cystitis (100%) (Parsons et al., 1994b), urinary infection (100%) (Parsons et al., 1998), detrusor instability (25%) (Parsons et al., 1998), and “urethral syndrome” (55%) (Parsons et al., 2001b) and in more than 80% of women with endometriosis, vulvodynia, and pelvic pain (Parsons et al., 2001a). Up to 33% of unselected Turkish women may test positive (Sahinkanat et al., 2008). Eighty-four percent of men with prostatitis also have a positive test result (Parsons and Albo, 2002). **The poor specificity of the potassium test** suggests that it does not provide unequivocal evidence of a permeability dysfunction. **Because it is known that the normal bladder epithelium can never be absolutely tight and that there is always some leak, however small** (Hohlbrugger and Sant, 1997)**, it is conceivable that the findings of pain with KCl are related to a hypersensitivity of the sensory nerves in this condition rather than to pathologic epithelial permeability, at least in some patients.** In fact, KCl administered intravesically to cats with FIC seems to *inhibit* afferent firing of peripheral Aδ fibers. Heightened sensitivity of afferent nerve fibers can explain KCl results without necessarily evoking increased permeability (Lutgendorf and Kreder, 2005; Roppolo et al., 2005). Intravesical administration of KCl has since been proposed as a diagnostic test for IC/BPS (Parsons et al., 1998) (see later).

How central abnormal epithelial permeability is to IC/BPS is, however, by no means clear. Tamm-Horsfall protein (THP), a high-molecular-weight glycoprotein synthesized exclusively by the ascending loop of Henle and the distal tubule of the kidney, has been studied as a potential marker of urothelial permeability. Fowler provided graphic data that the urothelium might be leaky in IC/BPS. With immunohistochemical techniques, his group assayed the bladder biopsy specimens of 14 IC/BPS patients and 10 normal controls for intraurothelial THP to assess indirectly the in vivo permeability of the urothelium. Eight pathologic controls were also assessed. Ten of 14 IC/BPS patients versus 1 of 18 controls demonstrated intraurothelial THP (Fowler et al., 1988). Serum THP autoantibody is higher in IC/BPS patients versus controls (Neal et al., 1991). It is known that excretion rates of THP vary widely, even in repeat samples taken from the same individual (Reinhart et al., 1990).

Subsequent studies in IC/BPS have failed to show differences in the presence of intraurothelial THP in the IC/BPS population versus controls, and in antibody reactivity to THP (Stein et al., 1993; Stone et al., 1992). Parsons reported that the THP protein is qualitatively different in patients with IC/BPS than in controls, even if the urinary concentration of the protein is the same (Argade et al., 2013; Parsons et al., 2007, 2011). Bade et al. (1996) failed to find THP in bladder tissue from 10 IC/BPS patients. Others have suggested that when THP is seen in bladder tissue, it is an incidental finding of no clinical significance. The finding of intraurothelial THP has not been shown to be a harbinger of IC/BPS or any other bladder disorder (Truong et al., 1994).

Finally, we must look at a body of literature that has failed to find GAG abnormality or hyperpermeability. Ultrastructural, biochemical, and functional studies of bladder GAG have not supported this theory (Collan et al., 1976; Dixon et al., 1986; Johansson and Fall, 1990; Ruggieri et al., 1991). Nickel et al. (1993) reported on use of sophisticated electron micrography with a specific antimucus, antisera stabilization technique to study the ultrastructural morphologic appearance of the GAG layer. No significant difference in the morphologic appearance of the mucus or GAG layer was noted in IC/BPS versus controls. Urinary chondroitin sulfates, heparan sulfate, and total sulfated GAGs normalized to creatinine are not altered in IC/BPS (Erickson et al., 1997b). Although an increased ratio of total GAGs to sulfated GAGs in IC/BPS may indicate an altered GAG layer, whether it reflects a cause or is a result of the primary pathologic process(s) is unknown (Wei et al., 2000). This leaves one to postulate an as-yet-unknown functional abnormality, rather than GAG deficiency, to account for any increase in permeability.

Chelsky et al. (1994) measured bladder permeability in IC/BPS using direct measurement by transvesical absorption of technetium-99m diethylenetriaminepentaacetic acid (^{99m}Tc-DTPA). Although some IC/BPS patients had a more permeable bladder than others, the same was true for normal volunteers. Increased permeability in the IC/BPS group could not be demonstrated. However, 3 IC/BPS patients had marked absorption of DTPA and may represent a subpopulation of patients with increased epithelial permeability. Intravesical instillation of 10% and 20% ethanol in rabbits was reported to be a reliable quantitative measure of bladder hyperpermeability by the San Diego group (Monga et al., 2001) and subsequently failed to demonstrate bladder permeability in humans with IC/BPS (Gordon et al., 2003).

Overall, it does seem that there is a population of IC/BPS patients with

increased epithelial permeability, but the issue is far from closed. Increased mucosal permeability is nonspecific and a consequence of bladder inflammation, and also occurs with cyclophosphamide-induced bladder injury, bacterial infection, and cystitis following intravesical challenge with antigen after sensitization (Engelmann et al., 1982; Kim et al., 1992)**. It may also be a consequence of aging itself** (Jacob et al., 1978)**. Whether this represents a primary cause of IC/BPS or merely reflects the result of an as-yet-unidentified source of inflammation is unclear.** Treatments that tend to damage GAG, including transurethral resection and laser of ulcerated areas, bladder distention, silver nitrate administration, Clorpactin administration, and administration of the organic solvent dimethyl sulfoxide (DMSO) have all been used with varying results to treat IC/BPS.

One does not need increased permeability of the mucosa as a foundation for the many potential causes or contributing factors to IC/BPS. Enhanced adenosine triphosphate (ATP) release from the urothelium of patients with IC/BPS has been described (Kumar et al., 2007). This non-neuronal ATP may act as a sensory neurotransmitter. Increased purinergic activity thus may lead to a condition in which the bladder is oversensitive to distention. Increased permeability and epithelial dysfunction must be only a part of the story.

Key Points: Epithelial Permeability

- There is a population of IC/BPS patients with increased epithelial permeability.
- Increased mucosal permeability is nonspecific and a consequence of bladder inflammation. It also occurs with cyclophosphamide-induced bladder injury, bacterial infection, and cystitis following intravesical challenge with antigen after sensitization.
- It is unclear if this represents a primary cause of IC/BPS or merely reflects the result of an as-yet-unidentified source of inflammation.

Inhibition of Uroepithelial Cell Proliferation: Antiproliferative Factor

The finding that cells from the bladder lining of normal controls grow

significantly more rapidly in culture than cells from IC/BPS patients led Keay et al. (1996) **at the University of Maryland to the discovery of an APF produced by the urothelium of IC/BPS patients.** Normal bladder cells were cultured in the presence of urine from patients with IC/BPS, asymptomatic controls, bacterial cystitis, and vulvovaginitis. Only urine from IC/BPS patients inhibited bladder cell proliferation (Keay et al., 1998b). **The presence of APF was found to be a sensitive and specific biomarker for IC/BPS patients who met NIDDK criteria (Keay et al., 2001a).** It was found in bladder urine but not in renal pelvic urine of IC/BPS patients, indicating **production by the bladder urothelial cells** (Keay et al., 1999). Subsequent studies indicated **that APF is associated with decreased production of heparin-binding epidermal growth factor–like growth factor (HB-EGF)** (Keay et al., 2000)**. APF activity was related to increased production of epidermal growth factor (EGF), insulin-like growth factor-1, and insulin-like growth factor binding protein-3** by the bladder cells from IC/BPS patients but not by the cells from healthy bladders. Studies of IC/BPS patients and asymptomatic controls showed **urine levels of APF, HB-EGF, and EGF to reliably separate IC/BPS from controls** (Erickson et al., 2002; Keay et al., 2001b).

APF levels in the urine were found to discriminate between men with IC/BPS versus those with CPPS or nonbacterial prostatitis (Keay et al., 2004a). APF activity dropped significantly in IC/BPS patients within 2 hours after hydrodistention (Chai et al., 2000b) and after 5 days of sacral neuromodulation (SNM) (Chai et al., 2000a). Cell culture studies showed that APF actually caused a decrease in HB-EGF and an increase in EGF, mirroring the differences in urine levels of these growth factors between IC/BPS patients and controls and suggesting that APF is the primary abnormality (Keay et al., 2000).

Whereas APF may prove to be a useful marker for IC/BPS, it may also unlock the cause of the syndrome. **It has been hypothesized by Keay et al.** (2003) **that IC/BPS may result from an inhibition of bladder epithelial cell proliferation caused by APF, which is mediated by its regulation of growth factor production from bladder cells. Conceivably, any of a variety of injuries to the bladder (infection, trauma, and overdistention) in a susceptible individual may result in IC/BPS if APF is present and suppresses production of HB-EGF** (Keay and Warren, 1998). Theoretically, if production of APF could be “turned off” by genetic techniques or its effects were nullified by an APF antagonist (Keay et al., 2011) or exogenous HB-EGF, the clinical syndrome might be prevented (Yang et al., 2012a). HB-EGF functionally antagonizes APF activity via a mitogen-activated protein kinase pathway activation (Kim et al., 2009).

APF has been purified and proved to be a **frizzled 8 protein that belongs to a newly discovered family of proteins that seem to be important in the development of nerve tissues, skin, and the lining of organs** (Keay et al., 2004b). The frizzled family of receptors is critically involved in embryogenesis, and there is substantial evidence that members of this family also regulate tissue homeostasis in many different organs in the adult (Schulte and Bryja, 2007).

It appears that the cell cycle regulatory protein p53 is an important mediator of APF-induced effects on bladder epithelial cells (Kim et al., 2007). APF treatment suppresses cell proliferation by cell cycle arrest of human bladder urothelial cells. Evidence shows that p53 levels increase significantly after APF stimulation; p53 downregulation enhances the suppressive effect of APF on cell growth; and overexpression of p53 induces cell cycle arrest in the absence of APF. APF upregulates cellular p53 levels via functional attenuation of the USP2a-MDM2 pathway, resulting in p53 accumulation and growth arrest (Kim et al., 2012). It is possible that targeting of p53 could be a means of abrogating the pathologic effects of urinary APF and lead to new options for clinical therapy.

Studies are ongoing to confirm the research by Keay et al. and expand on its significance in diagnosis and development of a rational treatment approach (Rashid et al., 2004). The development of animal models with specific signaling abnormalities found in IC/BPS epithelial, endothelial, smooth muscle, neuronal, or immune cells to determine whether these animals develop a disease similar to the human disorder would be an extremely useful and potentially very productive pathway to learn more about potential therapeutic pathways (Keay, 2008).

Key Points: Antiproliferative Factor

- The frizzled 8 protein termed *antiproliferative factor (APF)* has been proposed as a marker to identify patients with IC/BPS.
- It is secreted by bladder epithelial cells of IC/BPS patients and inhibits bladder epithelial cell proliferation through mediation of growth factor production. Thus, it could be a proximal cause of the syndrome in many

patients.

Neurobiology

Nonadrenergic noncholinergic mechanisms play significant roles in mediating direct functional effects and indirect effects by affecting inflammation (Vesela et al., 2012).

Neuropeptides present in primary afferents and the dorsal horn of the spinal cord have an important role in the mediation of nociceptive input under normal conditions. Under pathologic conditions, such as during chronic inflammation or after peripheral nerve injury, the production of peptides and peptide receptors is dramatically altered, leading to a number of functional consequences (Wiesenfeld-Hallin and Xu, 2001). Inflammatory painful stimuli, especially if repeated, can chronically alter innervation, central pain-processing mechanisms, and tissue responses (Steers et al., 1997). It has been known for some time that the sensory nervous system can generate some of the manifestations of inflammation (Dimitriadou et al., 1991, 1992; Foreman, 1987). Activation of capsaicin-sensitive afferent neurons locally and centrally may be involved in stress-related pathologic changes in the rat bladder (Ercan et al., 2001). **Activation of sensory nerves, specifically pain fibers, is known to trigger neurogenic inflammation through release of neuropeptides such as substance P, neurokinin A, and calcitonin gene–related peptide (CGRP), and subsequent increase in vascular permeability, with leukocyte adhesion and tissue edema. The neuropeptide mediators have been shown to also cause degranulation of mast cells with release of additional potent mediators of inflammation and to lead to injury and increased permeability of epithelial surfaces** (Elbadawi and Light, 1996). An increase in nerve fibers within the suburothelium and detrusor muscle in ulcerative IC/BPS has been noted (Lundeberg et al., 1993). A correlation was found between the number of nerve fibers and numbers of mast cells and between the number of nerve fibers and the amount of histamine. **Consolidating the leaky urothelium theory and mast cell activation, neurogenic inflammation is an attractive proposal for the cause and can readily accommodate infectious, immunologic, and autoimmunologic mechanisms as factors** (Elbadawi and Light, 1996).

Harrison proposed that small-diameter sensory nerves in the bladder wall may have a role in the transmission of the sensation of pain and in the triggering of inflammatory reactions rather than forming the afferent limb of the micturition reflex (Harrison et al., 1990). Abelli demonstrated in the rat urethra that mechanical irritation alone can cause neuropeptide release from peripheral capsaicin-sensitive primary afferent neurons, resulting in neurogenic inflammation (Abelli et al., 1991). Extracellular ATP can act through the purinergic receptor subtype $P2X_3$ to transmit a pain signal to the central nervous system. These subunits expressed by cultured IC/BPS bladder urothelial cells are upregulated during in vitro stretch and may phenotypically mimic sensory neurons (Sun and Chai, 2004). Purinergic receptor antagonists that are orally bioavailable may provide an avenue for a potential therapeutic strategy (Burnstock, 2012).

Several pieces of additional information support a theory of neurogenic inflammation. Levels of nerve growth factor are elevated in bladder biopsy specimens from IC/BPS patients (Lowe et al., 1997), providing another potential therapeutic target (Ochodnicky et al., 2011). Studies in rats using pseudorabies virus clearly show that bladder inflammation can be induced from a somatic structure through a neural mechanism and that central nervous system dysfunction can bring about a peripheral inflammation (Doggweiler et al., 1998). Pelvic nerve stimulation in the rat increases urothelial permeability, which is antagonized by capsaicin, indicating both an efferent effect of afferent nerves and afferent-mediated neuroepithelial interaction (Lavelle et al., 1999). Ca^{2+}/calmodulin-dependent protein kinase II has been implicated in the neurogenic cystitis pelvic pain induced in a mouse model with pseudorabies virus infection (Yang et al., 2012b).

Numerous studies indicate increased sympathetic activity in IC/BPS. Hohenfellner et al. (1992) suggested that IC/BPS is associated with increased sympathetic outflow into the bladder and altered metabolism of vasoactive intestinal polypeptide and NPY. NPY inhibits bladder afferents and therefore may be involved in autonomic disturbances affecting the bladder. Elevation of urinary catecholamines in IC/BPS patients and plasma catecholamines in cats with FIC has been observed (Buffington and Pacak, 2001; Stein et al., 1999), as has an increased density and number of nerve fibers immunoreactive for tyrosine hydroxylase in IC/BPS patients (Peeker et al., 2000a). Whether these changes reflect a cause of IC/BPS or are merely the result of long-standing intense pain and a severely pathologic voiding pattern is unknown.

Galloway proposed that the changes in IC/BPS may be explained by an increase in sympathetic discharge, analogous to that seen in reflex sympathetic dystrophy (RSD) (now termed complex regional pain syndrome) of limbs

(Galloway et al., 1991). The pathology in RSD is the development of abnormal synaptic activity between sensory afferent and sympathetic efferent neurons. Nerve cells in the spinal cord become hypersensitive to sensory input, and this sustains abnormal sympathetic outflow and corresponding vasomotor dysregulation. The excess sympathetic outflow leads to constriction of blood vessels and tissue ischemia, setting up further sensory changes and perpetuating the cycle. In RSD, there is usually a trigger event leading to these changes. With the acute phase of RSD, regional signs of inflammation are evident in the affected extremity. One school of thought believes an inflammatory response to an injury initiates RSD. Increased capillary permeability is a direct result (Goris and Jan, 1998). Perhaps a urinary infection could trigger such a pathologic cycle in some IC/BPS patients.

Herbst produced bladder lesions in a dog resembling the ulceration of IC/BPS by ligating the blood vessels to the posterior bladder wall and infecting the area with *Streptococcus viridans* (Herbst et al., 1937). Studies using laser Doppler flowmetry have shown that when the bladder is distended under anesthesia, blood flow increases in control patients to a statistically significant degree as compared with IC/BPS patients (Irwin and Galloway, 1993; Pontari et al., 1999). Another study has purported to show that topical heparin therapy can normalize urothelial permeability and vesical blood flow in IC/BPS (Hohlbrugger et al., 1998). Decreased microvascular density has been described in the suburothelium but not in the deeper mucosa in bladder biopsy specimens from women with IC/BPS (Rosamilia et al., 1999a). Hyperbaric oxygen has been suggested to have a limited effectiveness for the treatment of IC/BPS (Gallego-Vilar et al., 2013; Loran et al., 2011; Tanaka et al., 2007, 2011; van Ophoven et al., 2004b, 2006) and radiation-induced cystitis (Weiss and Neville, 1989). The mechanism of action has been postulated to be related to the overexpression of hypoxia-inducible factor-1 and VEGF in IC/BPS bladders (Lee and Lee, 2011).

If lumbar sympathetic blocks can decrease the pain of IC/BPS, a role of the sympathetic nervous system in IC/BPS pathogenesis is a reasonable supposition (Doi et al., 2001; Irwin et al., 1993). Buffington demonstrated an increase in sympathetic activity in cats with FIC (Buffington and Pacak, 2001; Buffington et al., 2002). Similar findings were reported in a small study of IC/BPS patients (Dimitrakov et al., 2001), and sympathetic activity may be an underlying common denominator in many disorders associated with IC/BPS (Buffington, 2004).

Nevertheless, **no studies performed to date indicate that any case of**

IC/BPS is related to the syndrome of RSD (complex regional pain syndrome) (Ratliff et al., 1994). No single test can be used to exclude sympathetically maintained pain, and there are no clear symptoms that predict sympathetically mediated pain (Baron, 2000). In the animal model, bladder ischemia is associated with DO or impaired detrusor contraction, not sensory urgency (Azadzoi et al., 1999). Patients with RSD who have voiding symptoms rarely have a picture that would be confused with IC/BPS (Chancellor et al., 1996).

Before leaving the neurogenic causative theory, it is important to note that the nervous system itself almost surely contributes to the chronic nature of this pain syndrome, regardless of initiating cause (Vrinten et al., 2001). Repetitious stimulation of a peripheral nerve at sufficient intensity to activate C fibers results in a progressive buildup of the magnitude of the electrical response recorded in the second-order dorsal horn neurons. This “windup” phenomenon is central to the concept of chronic pain. Biochemically it is dependent on activation of *N*-methyl-D-aspartate (NMDA) receptors in the spinal cord (Bennett, 1999). With persistent NMDA receptor activation, spinal cord cells undergo trophic changes, and the pain resulting from subsequent stimulation becomes exaggerated and prolonged. This “pain memory” in the spinal cord may be what causes IC/BPS patients to become refractory to different therapies (Brookoff and Sant, 1997). NMDA-receptor–driven formation of new connections in the spinal cord may account for the expansion of the pain field.

Upregulation of the central nervous system and augmented sensory processing have been referred to as non-nociceptive pain (NNP) (Bennett, 1999). Chronic neuropathic pain may continue after the resolution of tissue damage and persist on the basis of a maladaptive mechanism (Urban et al., 2002).

Sun et al. followed up on Burnstock's observation that ATP has a role in mechanosensory transduction by the epithelial lining of hollow viscus organs such as bladder (Burnstock, 1999; Sun et al., 2001). Stretched epithelial cells lining hollow organs release ATP, which acts on purinergic nociceptive receptors on subepithelial sensory nerve terminals. Sun et al. (2001) found that ATP was significantly elevated in the urine of IC/BPS patients, and the stretch-activated release of ATP was augmented in IC/BPS urothelium.

Neurogenic inflammation may be the cause of some cases of IC/BPS or may be the result of other initiating causative events. It is not incompatible with the central role of the mast cell, or with the leaky epithelium theory. It conceivably could result in the appearance of autoimmune phenomena or result from an episode of infection. The central nervous system may also be implicated in dysregulation of the pelvic floor resulting in chronic pelvic pain and contributing to IC/BPS (Zermann et al., 1999), and perhaps in the rare cases of IC/BPS that chronologically seem to relate to trauma or pelvic surgery (Zermann et al., 1998). It is an etiologic theory that provides fertile ground for new treatment possibilities.

Key Points: Neurogenic Inflammation

- Numerous studies indicate increased sympathetic activity in IC/BPS. Activation of sensory pain fibers is known to trigger neurogenic inflammation through release of neuropeptides such as substance P, neurokinin A, and calcitonin gene–related peptide.
- Neurogenic inflammation may be the cause of some cases of IC/BPS. Chronic neuropathic pain may continue after the resolution of tissue damage and persist on the basis of a maladaptive mechanism.

Pelvic Organ Cross-Sensitization

Clinical observations of viscerovisceral referred pain in patients with gastrointestinal and genitourinary disorders suggest an overlap of neurohumoral mechanisms underlying both bowel and urinary bladder dysfunction. Close proximity of visceral organs within the abdominal cavity complicates identification of the exact source of chronic pelvic pain, where it originates, and how it relocates with time. Cross-sensitization among pelvic structures may contribute to chronic pelvic pain of unknown cause and involves convergent neural pathways of noxious stimulus transmission from two or more organs**. Inflammation, nerve injury, ischemia, peripheral hyperalgesia, metabolic disorders, and other pathologic conditions can dramatically alter the function of directly affected pelvic structures and organs located next to a damaged domain** (Malykhina, 2007). It has been demonstrated in a rat model that acute colitis can sensitize lumbosacral spinal neurons receiving input from the urinary bladder (Qin et al., 2008). Acute colitis and acute cystitis in the rat model can each cross-sensitize the bladder and colon, respectively (Pezzone et al., 2005).

It is thought that chronic widespread pain in chronic fatigue syndrome and

FMS (disorders associated with IC/BPS in many patients) can be a consequence of central sensitization. Central sensitization is an increased central neuronal responsiveness and causes hyperalgesia, allodynia, and referred pain and hyperalgesia across multiple spinal segments, leading to chronic widespread pain. Triggers include windup or temporal summation, dysregulated descending inhibitory pathways, and upregulated facilitatory modulation. Windup or temporal summation is the result of repetitive noxious stimuli, leading to an increase in electrical discharges in the dorsal horn. Inhibitory modulation can be impaired by abnormalities in the central nervous system, and the facilitatory pain pathways can be stimulated by certain behavioral and cognitive factors (Meeus and Nijs, 2007).

It is possible that a combination of central sensitization and pelvic cross-talk may account for the association of IC/BPS with bowel symptoms in some patients, and the use of dietary alterations for managing the severity of IC/BPS symptoms. Relatively minor gut stimuli that otherwise cause no symptoms could exacerbate established, bladder-driven pelvic pain, because even slight increases of inputs from a second site such as the gut might lead to a sum of inputs that is considerably elevated above a threshold necessary to induce pain (Klumpp and Rudick, 2008; Rudick et al., 2007). Central pain amplification might also account for the increased startle responses described in female IC/BPS patients in the context of a threat of abdominal pain (Twiss et al., 2009).

Key Points: Sensitization of Neural Pathways

- Cross-sensitization among pelvic structures may contribute to CPPS.
- Neural pathways from two or more organs, one or both of which are carrying noxious stimuli transmissions, may converge. Theoretically, this could lead to alteration of the function of not only the directly affected pelvic structures, but organs located nearby as well.

Nitric Oxide Metabolism

Regulation of urinary NOS activity has been proposed to be of importance for immunologic responses in IC/BPS. The oral administration of L-arginine, the substrate for nitric oxide production (Moncada and Higgs, 1993), has been shown to increase nitric oxide–related enzymes and metabolites in the urine of patients with IC/BPS (Smith et al., 1996). It has been reported that differences in nitric oxide evaporation between ulcerative and non-HL IC/BPS allows for subtyping of cases meeting the NIDDK criteria. This could potentially replace cystoscopy as a tool for identifying ulcerative IC/BPS (Logadottir et al., 2004). Increased levels of endogenously formed nitric oxide correspond to increased iNOS in mRNA expression and protein levels in IC/BPS patients. iNOS has been found to be localized to the urothelium and also has been found in macrophages in the bladder mucosa. Whether high levels of endogenously formed nitric oxide are a part of the pathogenesis in IC/BPS and whether it has a protective or damaging role remains to be elucidated (Koskela et al., 2008).

Urine Abnormalities

In general, current theories of pathogenesis involve access of a component of urine to the interstices of the bladder wall, resulting in an inflammatory response induced by toxic, allergic, or immunologic means. The substance in the urine may be a naturally occurring one—a substance that acts as an initiator only in particularly susceptible individuals—or may act like a true toxin, gaining access to the urine by a variety of mechanisms or metabolic pathways (Wein and Broderick, 1994). Clemmensen noted that 8 of 11 IC/BPS patients had positive skin reactions to patch tests with their own urine (Clemmensen et al., 1988). Immediate reactions were not observed, and the histology suggested a toxic rather than an allergic reaction. Lynes was unable to find a urinary myotropic substance unique to IC/BPS patients (Lynes et al., 1990b). The San Diego group found IC/BPS urine to result in higher cell death of cultured transitional cells than normal urine, suggesting a toxic compound in the urine of some IC/BPS patients (Parsons and Stein, 1990). They identified heat-labile, cationic components of low molecular weight that bind to heparin and that, when separated from the bulk of urinary wastes, are cytotoxic to urothelial cells and underlying smooth muscle cells (Parsons et al., 2000). They reported a 12% increase in 72-kDa stress protein in cells treated with urine from IC/BPS patients compared with controls (Ito et al., 1998).

Others have not been able to demonstrate in vitro cytotoxicity (Beier-Holgersen et al., 1994) or immunohistochemical changes in the nociceptive centers in the spinal cord or bladder wall when IC/BPS urine was compared with control urine (Baykara et al., 2003). Efforts to induce an IC/BPS-like picture in the rabbit bladder from exposure to urine of IC/BPS patients have failed to demonstrate conclusive changes (Kohn et al., 1998; Perzin et al., 1991; Ruggieri et al., 1993). Increased levels of soluble mediators associated with activation of sensory neurons and/or mast cells have been found in the urine of both IC/BPS and bladder cancer patients (Okragly et al., 1999).

Circumstantial evidence for the toxicity of IC/BPS urine is suggested by the failure of substitution cystoplasty and continent diversions in some of these patients because of the development of pain or contraction of the bowel segment over time (Baskin and Tanagho, 1992; Lotenfoe et al., 1995; Nielsen et al., 1990; Trinka et al., 1993), and by the histologic findings similar to IC/BPS found to occur in bowel used to augment the small-capacity IC/BPS bladder (McGuire et al., 1973; Singh and Thomas, 1996). Intestinal mucosa in contact with urine undergoes progressive changes for as long as 3 years after surgery, and the significance of the histologic IC/BPS-like changes has been questioned (Davidsson et al., 1996; MacDermott et al., 1990).

Role of Genetics in Bladder Pain Syndrome

Warren et al. (2001) reported findings from a small cohort of twins in which a greater concordance of IC/BPS was demonstrated among monozygotic than among dizygotic twins. This finding suggested that there could be a genetic susceptibility to IC/BPS. A later study by the same research group suggested that adult female first-degree relatives of patients with IC/BPS may have a prevalence of IC/BPS 17 times that found in the general population (Warren et al., 2004). This, coupled with the previously reported twin data, suggests but does not prove that a genetic component adds to the susceptibility to IC/BPS. Looking at an identical twin model with 246 twin sisters, Tunitsky et al. (2012) found that 9% were identified as having a moderate or high risk for IC/BPS, with 5 twin sets in which both twins met the criteria. They concluded that IC/BPS symptom scores within twin pairs were moderately correlated, implying some genetic component.

A Swedish study that included more than 25,000 twins born from 1959 to 1985 compared monozygotic and dizygotic twins with symptoms of IC/BPS. Overall IC/BPS prevalence was 1.1% of men and 2.4% of women. In women, genetic factors contributed less than one-third of the total variation in susceptibility to IC/BPS. Lower male prevalence prevented determinations of genetic contribution. The authors concluded that the influence of environmental factors in the development of IC/BPS in women is substantial, whereas genetic influences are of only modest importance (Altman et al., 2011).

The report by Weissman et al. (2004) of the increased frequency of IC/BPS in patients and their first-degree relatives with panic disorder and other seemingly disparate disorders suggests that there is a familial syndrome consisting of IC/BPS and other disorders of possible autonomic or neuromuscular dysfunction. A more recent case-control study by the same group suggested that this syndrome might include other anxiety disorders as well, and that families with and without this collection of symptoms were genetically distinguishable on chromosome 13 (Talati et al., 2008).

Gene-expression profiles in cultured IC/BPS cells have been investigated and compared with controls (Erickson et al., 2008a). Few differences were appreciated, indicating that, rather than being genetically based, the abnormal urothelium in IC/BPS may be caused by post-translational changes and/or to the bladder environment. It has been suggested that epigenetic reprogramming mechanisms in the bladder may provide an explanation for uroepithelial cell, mast cell, and nerve cell abnormalities in IC/BPS, and propagation of this altered state in the absence of the signal that may have triggered it (Elgavish, 2009). Viewing medically unexplained symptoms from the perspective of underlying developmental influences involving epigenetic modulation of gene expression that affect function of a variety of organs based on familial predispositions rather than from the traditional viewpoint of isolated organ-originating diseases may open up new areas of investigation for this class of “functional” disorders (Buffington, 2009).

Other Potential Causes

Various other etiologic theories have been proposed (Ratliff et al., 1994), but none has received much scientific support. Voiding almost hourly, always having to be aware of how far the nearest restroom facilities are, and suffering constant pain would be expected to lead to psychological stress. However, could there be individual differences in the propensity to develop IC/BPS that result from a dysregulation of anxiety and mood (Bodden-Heidrich, 2004; Nesse, 1999)? Childhood sexual trauma has been implicated as a causative factor for the disease (Mayson and Teichman, 2009; Nickel et al., 2011; Tietjen et al., 2010). **There are no data currently to suggest that stress itself *initiates* the chronic syndrome of IC/BPS, although it certainly can increase symptom severity** (Lutgendorf et al., 2000). Cats restricted to indoor living are five times more likely to have urinary problems than cats allowed outdoors (Buffington et al., 2002). Female patients with IC/BPS have been shown to have increased heart rate at baseline and throughout a laboratory mental stress challenge, but did not demonstrate greater autonomic reactivity to stress (Lutgendorf et al., 2004). Until stress can be shown to produce IC/BPS de novo in humans, it is just as reasonable to speculate that the stress is a result of the syndrome as a primary cause of it.

Speculation that abnormality in or obstruction of lymphatics or vascular structures is causative has never been borne out. The fact that some of these patients have had a hysterectomy probably relates more to the attempt of the physician to treat chronic pelvic pain than to postsurgical change as a cause of IC/BPS (Chung, 2004).

The knowledge that there is at least a 5 : 1 female-to-male preponderance immediately makes the role of the hormonal milieu potentially important (Bjorling and Wang, 2001). Paradoxically, it is known that estrogens can control hematuria in hemorrhagic cystitis, perhaps by decreasing the fragility of the mucosal microvasculature of the bladder (Liu et al., 1990). Estradiol augments whereas the estrogen receptor blocker tamoxifen inhibits mast cell secretion (Vliagoftis et al., 1992). Bladder mast cells express high-affinity estrogen receptors, and there is a higher number of such cells present in patients with IC/BPS compared with controls. Although this may help explain why IC/BPS is so common in women, the hormonal role can only account for the propensity of IC/BPS to occur in females, not the ultimate cause.

HTPFD has been associated with IC/BPS for many years (Schmidt and Vapnek, 1991), and trials suggest that treatment of the pelvic floor can be effective in ameliorating symptoms (Doggweiler-Wiygul et al., 2001, 2002; FitzGerald et al., 2012; Holzberg et al., 2001; Lilius et al., 1973; Oyama et al., 2004; Weiss, 2001). Speculation that abnormalities of the pelvic floor muscular function may contribute to the cause of some cases of CPPS in men is well accepted (Segura et al., 1979; Schmidt and Vapnek, 1991; Zermann et al., 1999), and a similar case might be made for patients with IC/BPS, though scientific support for a direct causative relationship is lacking.

One can understand the complexity of IC/BPS by looking at the myriad theories of etiology and the associated disorders that have been described. Complex functional disorders with patterns of comorbidity, in which there is overlap of what had once been regarded as independent syndromes, appear to fall outside the biomedical framework. It has been said that they “fully escape the profession's divided and divisive grip. By their mere existence, they challenge the medical community's view of the body, their understanding of what it is to be human and question whether present approaches to obtaining knowledge are adequate for helping people who suffer” (Kirkengen and Ulvestad, 2007).

Key Point: Etiology

- Both stress and HTPFD can contribute to IC/BPS symptom severity and may be targets for treatment. Whether they can be contributing initiators of the syndrome complex is unclear at this time. The 5 : 1 female preponderance suggests hormonal involvement in the cause, but if recent data suggest that male prevalence is close to female prevalence, this conventional wisdom will need revision (Suskind et al., 2013).

Pathology

There is no histology pathognomonic of IC/BPS. This is not surprising given a medical condition that is primarily based on the complaint of visceral pain; and this reinforces the need for accurate phenotyping. Other factors that may obfuscate histologic studies include: duration of disease, recent trauma (e.g., hydrodistention), history of bacterial cystitis, and even the location or type of biopsy. These factors align with the great variation in the reported histologic appearance of biopsy specimens from IC/BPS patients, and even the microscopic variation among biopsies taken from the same patients over time (Gillenwater and Wein, 1988).

Histologic features of IC/BPS can be remarkably bland. On the other hand, inflammatory features can be seen in 24% to 76% of patients without a visible HL (Erickson et al., 2008b). Rosamilia presented data comparing light microscopic changes of IC/BPS bladder biopsies to controls (Hanno et al., 2005a; Rosamilia et al., 2003). Although epithelial denudation, submucosal edema, congestion and ectasia, and inflammatory infiltrate were increased in the IC/BPS group, histologic parameters were normal and indistinguishable from control subjects in 55% of IC/BPS specimens. Method of biopsy can be important in interpreting findings, because transurethral resection biopsy specimens tend to show mucosal ruptures, submucosal hemorrhage, and mild inflammation (Johansson and Fall, 1990), whereas histology is normal approximately half the time with cold-cup forceps biopsy specimens (Lynes et al., 1990a; Mattila, 1982; Rosamilia et al., 2003.

Striking differences in histopathology, primarily based on severity of inflammatory events, distinguish IC/BPS with HLs (IC/BPS+HL) and IC/BPS without HLs (IC/BPS-HL). This point, along with little data to support transition from IC/BPS-HL to IC/BPS+HL (Fall et al., 1987)**, argues that these conditions may be completely separate disorders.** Johansson and Fall (1990) evaluated 64 patients with IC/BPS+HL and 44 with IC/BPS–HL. The former group had mucosal ulceration and hemorrhage, granulation tissue, intense inflammatory infiltrate (predominantly plasma cells and lymphocytes), elevated mast cell counts, and perineural infiltrates. The IC/BPS–HL group, despite having the same severe symptoms, had a relatively unaltered mucosa with a sparse inflammatory response, the main feature being multiple, small mucosal ruptures and suburothelial hemorrhages that were noted in a high proportion of patients. As these specimens were almost all taken immediately after hydrodistention, how much of the admittedly minimal findings in the IC/BPS–HL group was purely iatrogenic is a matter of speculation. The same group later reported the frequent finding of completely normal biopsy specimens in IC/BPS–HL patients (Johansson and Fall, 1994). Furthering these results, Maeda et al. (2015) found a severe lymphoplasmocytic infiltrate in 93% of IC/BPS+HL biopsies versus only 8% of IC/BPS–HL biopsies. They identified epithelial denudation to be a distinct feature of IC/BPS+HL that is not confined to the HL, and suggests a fieldlike change to the bladder surface. Although most studies report few inflammatory events associated with IC/BPS–HL (Akiyama et al., 2019), a recent study described more severe bladder wall fibrosis and increased mast cell infiltration in these patients (Kim et al., 2017). Several studies have suggested that a severely abnormal pathology may be associated with a poor prognosis (McDougald and Landon, 2003; Nordling et al., 2004); this is not necessarily the case (MacDermott et al., 1991a).

Mast cell proliferation, activation, and degranulation may play a role in the pathogenesis of IC/BPS (Theoharides and Stewart, 2017). Mast cells trigger inflammation that is associated with local pain, but the mechanisms mediating pain are unclear. In a murine model of neurogenic cystitis, Rudick et al. (2008) demonstrated that mast cells promote cystitis pain and bladder pathophysiology through the separable actions of histamine and TNF, respectively. Mast cell density has been repeatedly studied as a potential marker for IC/BPS, but results have been disparate (Gamper et al., 2015; Holm-Bentzen et al., 1987a; Larsen et al., 2008; Moore et al., 1992; Regauer et al., 2017) partially because of methodologic differences. A recent study employing immunohistochemical localization of mast cells with anti–mast cell tryptase found increased subepithelial and detrusor mast cell density in patients with IC/BPS+HL, but this finding was of low predictive value. Furthermore, there were no differences in mast cell density between IC/BPS–HL and specimens from patients with OAB (Gamper et al., 2015). Another study using digital quantitative analysis detailed the similarities of mast cell density between IC/BPS+HL and specimens with “chronic cystitis” and between IC/BPS–HL and normal controls. As one might expect, mast cell density correlated to general lymphoplasmocytic cell density (Akiyama et al., 2017). **Collectively, these findings suggest that mast cell counts, although perhaps relevant to pathogenesis, have no role in the diagnosis of IC/BPS.**

Specialized preparation of specimens may yield insights into pathophysiology and aid in diagnosis. Immunohistochemical staining techniques were used to identify nerve fibers, B-lymphocytes, the NGF receptor ($p75^{NTR}$), and mast cells performed on biopsy specimens from IC/BPS–HL, IC/BPS+HL, OAB, and normal control individuals. Sensory hyperinnervation, basal urothelial $p75^{NTR}$ staining, and an assessment of B-lymphocyte and tissue integrity enabled the differentiation of both IC/BPS+HL and IC/BPS–HL from OAB and normal control specimens (Regauer et al., 2017).

At this time, the role of histopathology in the diagnosis of IC/BPS is limited to those patients with HLs in whom one must rule out carcinoma and carcinoma in situ, eosinophilic cystitis, tuberculous cystitis, and any other entities with a specific tissue diagnosis (Hellstrom et al., 1979; Johansson and Fall, 1990; Tsiriopoulos et al., 2006).

Key Points: Pathology

- The role of histopathology is primarily to exclude other possible diagnoses that might be responsible for the symptoms.
- There is no histology pathognomonic of IC/BPS, and one cannot make the diagnosis on pathology alone in the absence of the cardinal symptoms.
- Completely normal-appearing bladder biopsy specimens in symptomatic patients are common.

Diagnosis

Current diagnostic strategies for IC/BPS are primarily based on its definition rather than strict research criteria established about 30 years ago. The definition —chronic pain, pressure, or discomfort associated with the bladder, usually accompanied by urinary frequency in the absence of any other identifiable cause (Hanno et al., 2005a, 2005b)—has been carefully crafted to incorporate noxious terms beyond “pain” that are commonly voiced by patients. The definition incorporates “urinary frequency” (that is often driven by the pain) but intentionally omits “urgency,” a term that is poorly understood by patients and clinicians alike and generally aligns with a diagnosis of OAB syndrome.

Perhaps the most challenging aspect to accurately diagnose IC/BPS is excluding other identifiable causes of symptoms. In the authors’ experience,

failure to diagnose other causes of pelvic pain that may occur with or without IC/BPS is one of the most common reasons for therapeutic failure.

Table 57.5 summarizes confusable diseases related to IC/BPS and their mode of exclusion based on diagnostic proposals and procedures modified from the ESSIC group (van de Merwe et al., 2008). **It is of utmost importance for the clinician to identify and treat all pelvic pain generators (usually in a stepwise fashion) for optimal success, and this is stressed in a suggested diagnostic algorithm modified from AUA guidelines (Fig. 57.5).**

TABLE 57.5

Disorders That May Be Mistaken for IC/BPS

CONFUSABLE DISORDER	EXCLUDED OR DIAGNOSED BY
Carcinoma and carcinoma in situ	Cystoscopy, biopsy
Infection with:	
Common intestinal bacteria	Routine bacterial culture
Chlamydia trachomatis, Ureaplasma urealyticum, Mycoplasma hominis, Mycoplasma genitalium, Corynebacterium urealyticum, Candida species, Mycobacterium tuberculosis	Special cultures Dipstick; if “sterile” pyuria, culture for *M. tuberculosis*
Herpes simplex, herpes zoster	Medical history, physical examination
Radiation	Medical history
Chemotherapy, including immunotherapy with cyclophosphamide	Medical history
Anti-inflammatory therapy with tiaprofenic acid	Medical history
Ketamine cystitis	Medical history
Bladder neck obstruction and neurogenic outlet obstruction	Medical history, urodynamic evaluation
Bladder stone; lower ureteral stone	Imaging or cystoscopy, CT
Urethral diverticulum	Medical history, physical examination, MRI
Colon cancer, diverticulitis, irritable bowel syndrome; inflammatory bowel disease	Medical history, physical examination, colonoscopy
Urogenital prolapse	Medical history, physical examination
Endometriosis, adenomyosis	Medical history, physical examination, imaging studies (i.e., MRI/pelvic

	ultrasonography) as appropriate
Pelvic congestion syndrome	Medical history, pelvic ultrasonography
Vaginal candidiasis	Medical history, physical examination, vaginal cultures as appropriate
Cervical, uterine, and ovarian cancer	Physical examination, pelvic ultrasonography
Vulvodynia	Medical history and physical examination
Incomplete bladder emptying (retention)	Postvoid residual urine volume measured by ultrasound evaluation
Overactive bladder	Medical history; urodynamic evaluation as appropriate
Prostate cancer	Physical examination, serum PSA
Benign prostatic obstruction	Medical history, physical examination, uroflowmetry and pressure-flow studies in selected cases
Chronic bacterial prostatitis	Medical history, physical examination, culture
Chronic nonbacterial prostatitis	Medical history, physical examination, culture
Pudendal nerve entrapment	Medical history, physical examination, nerve block may prove diagnosis
Abdominal wall hernia	Medical history, physical examination
Pelvic floor muscle–related pain	Medical history, physical examination

CT, Computed tomography; *MRI,* magnetic resonance imaging; *PSA,* prostate-specific antigen.

Modified from van de Merwe JP, Nordling J, Bouchelouche P, et al. Diagnostic criteria, classification, and nomenclature for painful bladder syndrome/interstitial cystitis: an ESSIC proposal. *Eur Urol* 53(1):60–67, 2008.

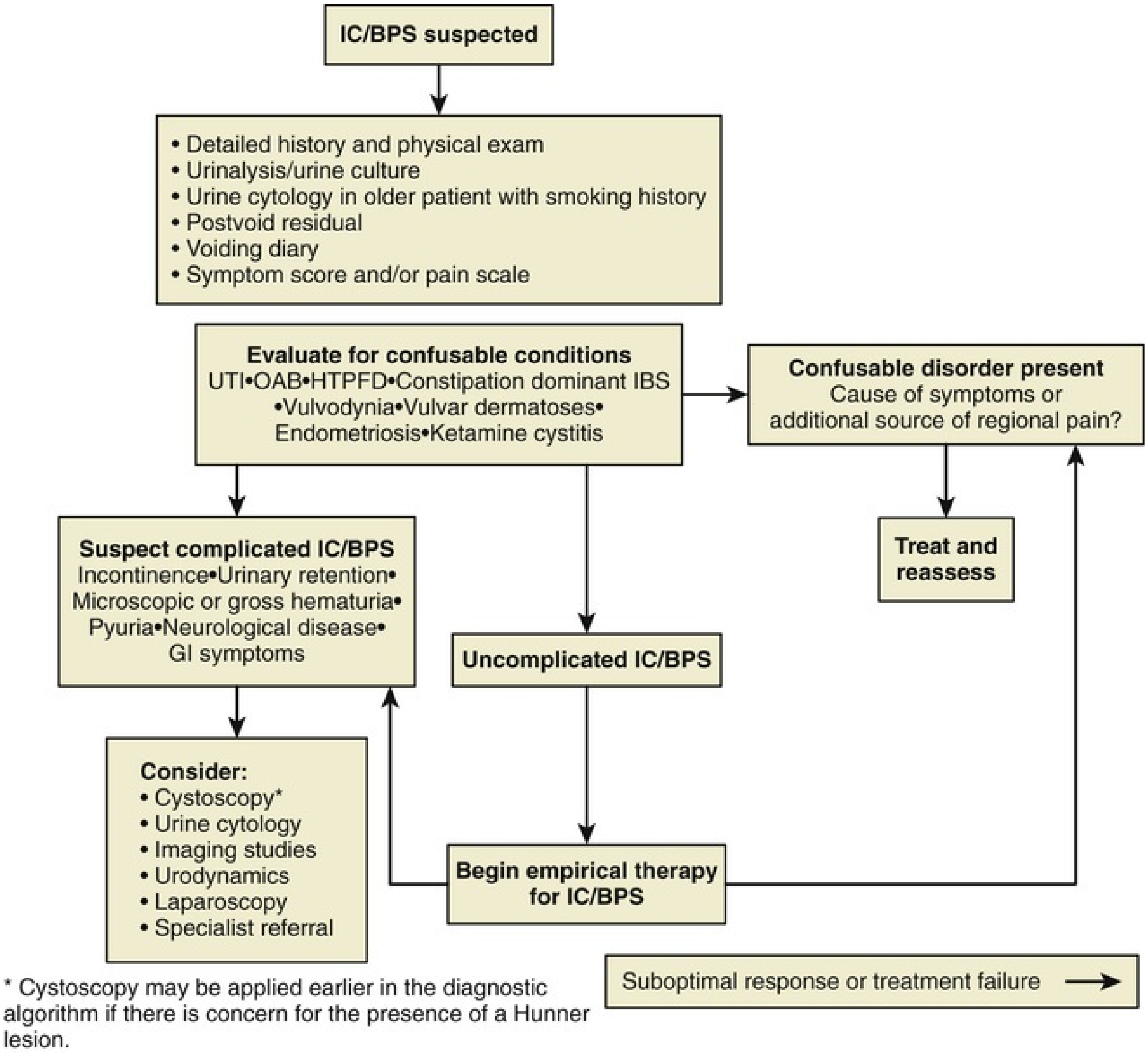
IC/BPS suspected
• Detailed history and physical exam
• Urinalysis/urine culture
• Urine cytology in older patient with smoking history
• Postvoid residual
• Voiding diary
• Symptom score and/or pain scale
Evaluate for confusable conditions
UTI•OAB•HTPFD•Constipation dominant IBS
•Vulvodynia•Vulvar dermatoses•
Endometriosis•Ketamine cystitis
Confusable disorder present
Cause of symptoms or
additional source of regional pain?
Treat and reassess
Suspect complicated IC/BPS
Incontinence•Urinary retention•
Microscopic or gross hematuria•
Pyuria•Neurological disease•
GI symptoms
Uncomplicated IC/BPS
Consider:
• Cystoscopy*
• Urine cytology
• Imaging studies
• Urodynamics
• Laparoscopy
• Specialist referral
Begin empirical therapy for IC/BPS
Suboptimal response or treatment failure
* Cystoscopy may be applied earlier in the diagnostic algorithm if there is concern for the presence of a Hunner lesion.

FIG. 57.5 Proposed diagnostic algorithm for evaluation of interstitial cystitis/bladder pain syndrome (IC/BPS). *GI,* Gastrointestinal; *HTPFD,* high-tone pelvic floor dysfunction; *IBS,* irritable bowel syndrome; *OAB,* overactive bladder; *UTI,* urinary tract infection. Modified from Hanno PM, Burks DA, Clemens JQ, et al. AUA guideline for the diagnosis and treatment of interstitial cystitis/bladder pain syndrome. *J Urol* 185(6):2162–2170, 2011.

A detailed history, physical examination, and urine studies will, in almost all circumstances, give the clinician enough clues to exclude common well-described sources of pelvic pain that might be confused with IC/BPS (Box 57.2). As described in guidelines suggested by the American Urological Association, basic urine studies including a urinalysis and urine culture are needed. The urine culture is suggested to exclude low counts of bacteria that might produce symptoms in the face of a negative urinalysis (Duldulao et al., 1997; Hanno et al., 2011). The value of urine cytology needs to be weighed against the emotional distress that could result from the frequently encountered false-positive result (Davis et al., 2012). Nevertheless, the examination should be considered in the face of clinical factors such as smoking history, age over 40 years, and irritative voiding symptoms.

Box 57.2

Highlights of Clinical Evaluation for the Pelvic Pain Patient

History

General thorough medical history emphasizing the following:

1. Location of pelvic pain and relationship to bladder filling and emptying
2. Presence/absence of initiating event for pain
3. Duration, quality, and radiation of pain
4. Presence/absence of regional pain (i.e., penile, urethral [dysuria?], vulvar, perineal, perianal, testicular, inguinal, coccygeal)
5. Presence or absence of voiding and/or bowel dysfunction
6. Relationship of pain to menstrual cycle
7. Presence/absence of sexual pain (i.e., pain associated with ejaculation, orgasm, entry, and/or deep dyspareunia)
8. Factors that trigger or decrease pain
9. Response to previous therapies
10. History of urologic/gastroenterologic, gynecologic/neurologic/rheumatic disease
11. Previous bladder/pelvic surgery
12. Previous urinary tract infection
13. Previous pelvic irradiation
14. Autoimmune diseases
15. Associated syndromes (irritable bowel, fibromyalgia, chronic fatigue)

Physical Examination

Physical examination emphasizing the following:

1. Abdominal examination: identification of tender anterior abdominal wall musculature, hernias, abdominal distention (tympany), bladder distention, suprapubic tenderness
2. Females: vaginal examination with inspection for abnormal discharge, vulvar dermatoses (i.e., introital mucosal atrophy, lichen sclerosus); pain mapping of vulvar region with Q-tip; one-digit vaginal palpation to identify tenderness or other abnormalities of the bladder, bladder neck, and/or urethra; evaluation for tenderness, hypertonicity, or trigger points of pelvic floor and obturator internus muscles

Males: digital rectal examination with pain mapping of the scrotal-anal region; evaluation for tenderness, hypertonicity, or trigger points of anal sphincter, pelvic floor, and obturator internus muscles

Laboratory Testing

1. Urinalysis
2. Urine culture
3. Urine cytology in risk groups

Symptom Evaluation

1. Voiding diary
2. Visual analog scale for pain
3. Symptom score (i.e., O'Leary-Sant symptom and problem index, University of Wisconsin IC Scale, Pelvic Pain and Urgency/Frequency questionnaire [PUF], Genitourinary Pain Index [GUPI], male or female version, Bladder Pain/Interstitial Cystitis Symptom Score [BPIC-SS])

Other Evaluations

1. Urodynamics (optional)
2. Cystoscopy with or without hydrodistention under anesthesia (Optional. The value of hydrodistention is controversial as indicated in the text.)
3. Bladder biopsy if bladder lesion identified

Modified from Hanno P, Lin AT, Nordling J, et al. Bladder pain syndrome. In: Abrams P, Cardozo L, Khoury S, et al., eds. *Incontinence*. Paris: Health

Publications Limited; 2009:1459–1518.

Difficulties of diagnosis are multiplied by the overlap of other visceral pain syndromes such as male CPPS (Forrest and Schmidt, 2004; Hakenberg and Wirth, 2002). As mentioned earlier in this chapter, similarities between these groups of patients are so striking that they are currently being studied collectively under the rubric of UCPPS by the MAPP Network (Clemens et al., 2015).

Although a table of common confusable disorders is provided (see Table 57.5), two confusable conditions bear special mention as they are likely to be encountered more frequently by the urologic community over the next several years.

Ketamine Cystitis

Ketamine, an NMDA receptor antagonist, is an anesthetic agent and newly popularized treatment for depression that when used recreationally may produce a clinical picture indistinguishable from IC/BPS (Chen et al., 2018; Gauney et al., 2016). Ketamine's rise in popularity as a recreational “club” drug (with street names including “special K,” “super K,” “super acid,” “kate,” “cat valium,” “ket,” ‘ ‘keller,” and “vitamin K”) includes its rapid onset and short duration of action **(**Smith et al., 2002). Ketamine also produces a “dissociative anesthesia” that may be characterized as an unconscious, trancelike state with profound analgesia (Sinner and Graf, 2008). Although ketamine's recreational use appears to have initially blossomed in Asia, abuse has since spread internationally. In 2015, an estimated 2.3 million people in the United States older than 12 years of age were reported to have abused ketamine, with 200,000 having used it within the previous year (National Institute on Drug Abuse, 2015). In a survey of 1900 New York City club-frequenting adults 18 to 29 years of age, 21% admitted to ketamine use, with slightly higher usage by men (Kelly et al., 2006). Mounting evidence suggests ketamine and/or its urine metabolites (e.g., hydroquinone), may be responsible for many of the pathologic and clinical manifestations of this condition (Baker et al., 2016; Misra, 2018). Specific pathologies that have been identified include bladder barrier dysfunction, neurogenic inflammation, immunoglobulin-E–mediated inflammation, overexpression of carcinogenic genes, enhanced apoptosis, and nitric oxide synthase–mediated inflammation (Jhang et al., 2015). The severity of ketamine cystitis’ inflammatory effects appear to be related to the duration of abuse (Gauney et al., 2016; Mak et al., 2011). Early presentation may manifest as only LUTS. Progression of disease is typified by additional complaints including dysuria, worsening frequency, gross hematuria, and pelvic pain. Further ketamine use may produce gross inflammatory changes similar in appearance but usually more widespread than HLs. These inflammatory changes, left unchecked, may result in irreversible bladder wall fibrosis, upper urinary tract changes, and renal dysfunction (Chen et al., 2011; Middela and Pearce, 2011). Successful management of ketamine cystitis begins with early identification and the cessation of ketamine abuse, the latter being the most important and challenging part of care. Hence, we cannot stress enough the importance of rehabilitation in this patient population. **Although ketamine abuse may be seen at any age, the clinician should be especially wary of the young patient who presents with a clinical picture of IC/BPS with visible inflammation of the bladder wall.**

High-Tone Pelvic Floor Dysfunction

HTPFD is commonly identified in patients with urologic, gynecologic, and colorectal pain syndromes (Kuo et al., 2015). Symptoms associated with HTPFD often include pelvic pressure, persistent urgency, the sensation of incomplete bladder emptying (in severe cases, poor bladder emptying is identified), urinary hesitancy, constipation, dyspareunia (pain often experienced the next day), and perineal, penile, and ejaculatory pain (Srinivasan et al., 2007). Although not essential for diagnosis, video-urodynamic evaluation suggests that poor relaxation of the external sphincter is common in IC/BPS (Kuo and Kuo, 2018). Examination of the pelvic floor has identified a myofascial trigger point in approximately 78% of IC/BPS patients, with multiple trigger points identified in 68% of individuals (Bassaly et al., 2011).

HTPFD often magnifies the pain of IC/BPS, or it may be the sole cause of symptoms. In either case, it has been our observation that failure to diagnose HTPFD in the presumed IC/BPS patient will commonly lead to a suboptimal response, as treatment strategies differ between the two conditions. **Hallmarks of HTPFD include the presence of hypertonic pelvic and nearby accessory musculature, muscle banding, and myofascial trigger points, the latter being described as tender "knots" in taut muscle band that produce pain** (Bron and Dommerholt, 2012). One should be particularly concerned about the presence of HTPFD in the patient who endorses a history of dysfunctional voiding, bowel disturbances, and sexual pain; the bowel and bladder disturbances often date back to childhood (Doiron et al., 2017). Physical examination should include a detailed palpation of the pelvic floor musculature and adjacent musculature. If HTPFD is suspected, physical therapy evaluation by a pelvic floor specialist is suggested (Polackwich et al., 2015). A multimodal program consisting of physical therapy, behavior modification (avoidance of straining maneuvers, “reverse Kegels,” stress reduction), topical heat application, skeletal muscle relaxants, control of constipation, and even anesthetic or botulinum neurotoxin type A (BTX-A) injections (myofascial trigger point injections) to affected muscles may be helpful to ameliorate symptoms (Moldwin and Fariello, 2013; Halder et al., 2017).

Beyond the History, Physical Examination, and Urine Studies

The Voiding Diary

Baseline information regarding urinary frequency and volumes voided are helpful for diagnostic purposes and to follow patient progress. One 24-hour period with time of void and volume is usually all that is needed (Mazurick and Landis, 2000). Mounting pelvic discomfort with filling typically drives *low-volume urinary frequency*. The voiding pattern may be indistinguishable from other conditions including OAB or other forms of voiding dysfunction. On the other hand, the finding of frequent but high-volume voids that solely occur during the daytime may suggest other diagnoses.

Symptom Scales for Clinical Assessment and Research

A numerical pain rating scale ranging from 0 (no pain) to 10 (worst pain imaginable) is suggested during initial assessment and can be rechecked along the course of therapy. Baseline information including the characteristics of pain/discomfort and voiding difficulties may be captured using a variety of “short form” instruments (eBox 57.3): O'Leary-Sant symptom and problem index (OSSI/OSPI) (O'Leary and Sant, 1997); Genitourinary (male and female version) Pain Index (GUPI) (Clemens et al., 2009a); Bladder Pain/Interstitial Cystitis Symptom Score (BPIC-SS) (Humphrey et al., 2012); Pelvic Pain and Urgency/Frequency questionnaire (PUF) (Parsons et al., 2002a); University of Wisconsin IC Scale (Goin et al., 1998; Keller et al., 1994). From a clinical perspective, each instrument to varying degrees may provide the clinician with a gestalt of the patient's overall clinical condition. For example, the GUPI provides information regarding location of pain, the presence of sexual pain, and effects on QoL. Although no questionnaire has been shown to be of value in definitive diagnosis (Kushner and Moldwin, 2006; Moldwin and Kushner, 2004), more recent instruments such as the GUPI and BPIC-SS have shown enhanced ability to distinguish IC/BPS from other urologic conditions.

eBox 57.3

Clinical Symptom Scales

University of Wisconsin IC Scale (Goin et al., 1998; Keller et al., 1994): Includes seven IC/BPS symptom items. It has not been validated for the diagnosis of IC/BPS but captures severity of symptom expression. This scale addresses some quality-of-life issues, and this is an advantage when such issues are the subject of investigation. Its most attractive aspects are its clinically apparent face validity and its ease of implementation. It is rarely used in current literature.

O'Leary-Sant Symptom and Problem Indices (OSSI/OSPI) (O'Leary and Sant, 1997; O'Leary et al., 1997): Questionnaire that was originally developed by focus groups, subjected to test-retest reliability analysis, and validated by administration to IC patients and asymptomatic controls. The more commonly used OSSI has three questions related to urgency and frequency and one on bladder-associated pain. Its primary utility has been to assess clinical change over time (Lubeck et al., 2001). Although these problem indices may differentiate between IC/BPS and controls, the instrument was not developed to be used as a screening tool. Additionally, all questions pertain to symptoms “during the past month,” raising concerns of recall bias.

Pelvic Pain and Urgency/Frequency questionnaire (PUF) (Parsons et al., 2002a): The PUF was specifically designed to include questions that directly reflect a wide variety of the symptoms experienced by afflicted patients. One-third of the questions address pelvic pain, including pain anywhere in the pelvis: the vagina, labia, lower abdomen, urethra, perineum, testes, penis, or scrotum. The PUF score has been indexed to the results of a potassium sensitivity test (assessment of irritative symptoms and/or pain suggestive of IC/BPS, after intravesical instillation of a dilute KCl solution). A large study using the PUF has concluded that up to 23% of female Americans have IC/BPS (Parsons et al., 2002a). This makes one wary as to the usefulness and face-validity of the PUF for diagnosis (Ito et al., 2003). Irrespective of its role in diagnosis, the PUF does focus on many clinical parameters that affect patients.

Genitourinary Pain Index (GUPI), male and female versions (Clemens et al., 2009a): This validated 9-question instrument (including a numerical pain scale) discriminated between men with chronic prostatitis or interstitial cystitis, those with other symptomatic conditions (dysuria, frequency, chronic cystitis), and those with none of these diagnoses. The GUPI includes clinically relevant questions regarding the location and other characteristics of pain, voiding symptoms, and effects on QoL. GUPI questions relate to symptoms from the past week (rather the past month), thus limiting recall bias.

Bladder Pain/Interstitial Cystitis Symptom Score (BPIC-SS) (Humphrey et al., 2012): This 8-question instrument (one question is a numerical pain rating scale) was validated to better identify moderate to severe IC/BPS patients (as compared with controls and OAB patients) for clinical trials with strong sensitivity (0.72) and specificity (0.86). Its ability to differentiate from OAB is likely because 5 of 8 questions center on pain or pressure. Like the GUPI, this instrument draws on the recollection of symptoms over the past week.

Global Response Assessment (GRA): The GRA has no place in the initial evaluation of the IC/BPS patient. Rather, this tool is a balanced patient self-report on overall response to therapy, developed for NIDDK-sponsored multicenter therapeutic trials (Sant et al., 2003). A one-category change in GRA correlates with a 1.2-point change in the O'Leary-Sant and a 3.1-point change in the University of Wisconsin instruments (Propert et al., 2006).

Urodynamic Evaluation

The primary value of urodynamic studies in the evaluation of IC/BPS is limited to the identification of other functional bladder pathology(ies) that may confound diagnosis and hinder therapeutic progress.

Cystometry in IC/BPS patients typically demonstrates normal detrusor function but a decreased bladder capacity and hypersensitivity. Bladder compliance is normal, as hypersensitivity would prevent the bladder from filling to the point of noncompliance (Siroky, 1994). Pain on bladder filling that reproduces the patient's symptoms is very suggestive of the diagnosis.

Many dispute the need for urodynamic study noting that most patients can be treated successfully based on the clinical presentation. Bladder outlet obstruction is a common occurrence in the female IC/BPS patient, presumably related to pelvic floor dysfunction (Cameron and Gajewski, 2009). The authors suggested that typical symptoms of voiding dysfunction should prompt a course of dedicated therapy and that urodynamic evaluation adds little information to change the course of care.

DO and IC/BPS may coexist in 15% to 19% of patients (Gajewski et al., 1997, Kirkemo et al., 1997). The case for urodynamics to exclude concomitant DO as a cause for irritative voiding symptoms (not pain) is debatable, as empirical therapy can easily be justified as a first-line maneuver. Additionally, medications such as amitriptyline, often used early in the course of care, have anticholinergic properties, which may resolve the issue. Of course, urodynamic evaluation would likely provide useful information for those patients who fail empirical therapy or those who present with a confusing clinical picture (e.g., pain, urgency frequency, and urinary retention). Complex cases may benefit from full video-urodynamic studies (Carlson et al., 2001).

Office Cystoscopy

Current guidelines established by the American Urological Association do not require cystoscopic evaluation in the *routine* management of IC/BPS as visual findings are generally unrevealing. We favor early endoscopy as the finding of a Hunner lesion would direct management in a different (usually more aggressive) direction. **Although the extent of HLs has been correlated to symptom severity and bladder capacity** (Akiyama et al., 2018)**, they cannot be reliably identified on the basis of clinical presentation or urine studies** (Braunstein et al., 2008; Doiron et al., 2016). Experimental data suggest that measurement of increased nitric oxide levels in the bladder can accurately identify those with inflammatory disease, but this has not folded over to routine clinical care (Logadottir et al., 2004). Flexible cystoscopy in the office setting can be accomplished with minimal discomfort and often provides the patient with immediate relief from concerns of bladder cancer. HLs can be identified (Fig. 57.6). Narrow-band imaging may enhance the identification of subtle lesions during the office procedure (Kajiwara et al., 2014). Although perhaps not as sophisticated as standard urodynamic evaluation, bladder filling during the examination allows an assessment of bladder capacity (best obtained with the voiding diary) and reproduction of pain with bladder filling. Specific sites of hyperalgesia such as the bladder neck can also be identified using the tip of the cystoscope as an examining finger. On a final note, office cystoscopy offers an opportunity to drain the bladder, then to introduce an anesthetic (i.e., alkalinized) lidocaine. Significant relief of pain after this “anesthetic challenge” suggests a bladder origin to pain. Lack of response does not exclude a diagnosis of IC/BPS (Cox et al., 2016).

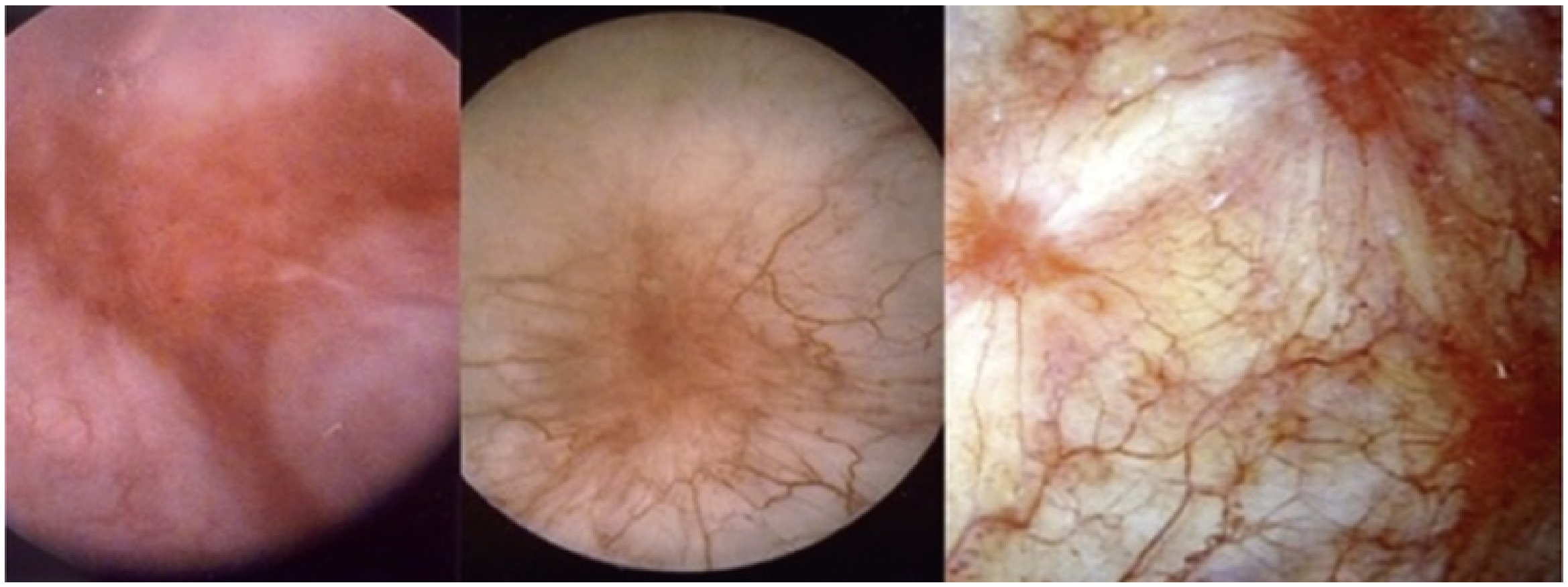

FIG. 57.6 Varied appearances of Hunner lesions identified on routine cystoscopic examination. Note the stellate appearance. Bleeding and disruption of the lesions usually occurs centrally with bladder distention. Fibrous bridging between lesions may occur, which further restricts bladder capacity.

Cystoscopy With Hydrodistention and Biopsy

Long before it was considered a diagnostic tool, cystoscopy with hydrodistention (CHD) was used as a therapeutic modality for IC/BPS (Bumpus, 1930). **CHD under anesthesia allows for sufficient distention of the bladder to afford visualization of submucosal pinpoint petechial hemorrhages, termed *glomerulations* (Fig. 57.7). After filling to 80 cm of water pressure for 1 to 2 minutes, the bladder is drained and refilled. The terminal portion of the effluent is often blood-tinged. Reinspection will reveal the glomerulations that develop throughout the bladder after distention and** are not usually seen during examination without anesthesia (Nigro et al., 1997b).

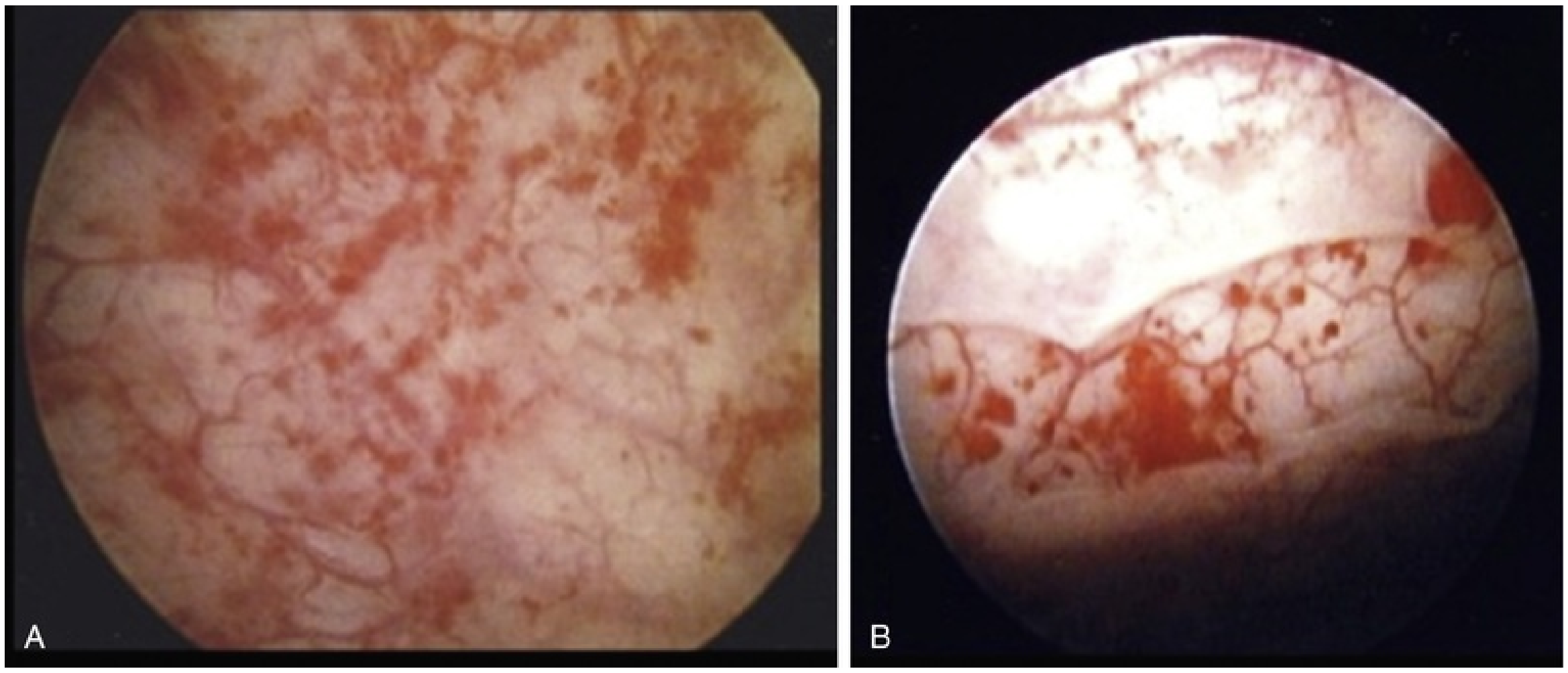

FIG. 57.7 (A) Typical appearance of glomerulations after bladder distention in a patient with interstitial cystitis/bladder pain syndrome without a Hunner lesion. (B) Mucosal tears that frequently develop during hydrodistention, often near the bladder neck (note the submucosal glomerulations).

Glomerulations are not specific for IC/BPS (Erickson, 1995; Waxman et al., 1998), and only when seen in conjunction with the clinical criteria of pain and frequency can the finding of glomerulations be viewed as potentially significant. **Glomerulations can be seen after radiation therapy, in patients with carcinoma, after exposure to toxic chemicals or chemotherapeutic agents, and often in patients on dialysis or after urinary diversion when the bladder has not filled for prolonged periods.** They have been reported in the majority of men with prostate pain syndromes, begging the question as to whether CPPS in men is closely linked with IC (Berger et al., 1998). They are observed in up to 20% of men undergoing transurethral prostatectomy for LUTS (Furuya et al., 2007). We have speculated that they may simply reflect the response of the bladder to distention after a prolonged period of chronic underfilling because of sensory urgency, rather than resulting from a primary pathologic process.

Further confusion arises when the patient demonstrates the symptoms of IC/BPS but the cystoscopic findings under anesthesia are completely normal. This occurred in 8.7% of patients undergoing CHD entered into the IC database (Messing et al., 1997). Awad et al. recognized this entity soon after the NIDDK research criteria had been described. They reported on a series of patients in whom the symptomatology, urodynamic evaluation findings, histology, and response to therapy were identical to IC/BPS but in whom findings on CHD were normal. It was termed *idiopathic reduced bladder storage* (Awad et al., 1992). Clinical, urodynamic, and cystoscopic data strongly suggest that the presence of glomerulations is not selecting out a meaningful difference in patients with symptoms of IC/BPS (Al Hadithi et al., 2002; Wennevik et al., 2016).

The presence of glomerulations on cystoscopy with hydrodistention may identify a group of patients with worse daytime frequency and nocturia, lower mean voiding volumes, and lower bladder capacity under anesthesia, but does not have any relationship to biopsy findings, bladder pain, or urgency (Boudry et al., 2013; Erickson et al., 2005). **A low bladder capacity at the time of hydrodistention (anesthetic bladder capacity) may represent a distinct clinical phenotype, having higher symptom scores and fewer reports of depression and IBS, essentially a more bladder-centric patient picture** (Walker et al., 2017).

Although hydrodistention has been commonly employed to provoke the appearance of an HL, this practice has been recently questioned (Nickel and Moldwin, 2018). As noted in the preceding section, office cystoscopy can easily identify these lesions. Furthermore, the finding of a focal bladder lesion that can only be identified on the basis of distention of the bladder well beyond its normal functional capacity suggests that this group may represent a different place in the spectrum of disease or a different phenotype altogether.

Despite a possible role to phenotype patients, the value of cystoscopy with hydrodistention for diagnosis appears to be clinically limited. Bladder biopsy is indicated only if necessary to rule out other disorders that might be suggested by the cystoscopic appearance. One common indication for biopsy is to differentiate an HL from carcinoma in situ.

The Search for a Marker

Development of a specific marker for a symptom complex that may coexist with other regional or widespread pain syndromes is daunting and probably unrealistic. Rather, we hope that biomarker development will help stratify patients into phenotypic subgroups that may share similar pathology and response to therapy. The markers themselves may also represent therapeutic targets for future drug development. Markers that have been studied fall into groups including: inflammatory mediators, proteoglycans, urinary hexosamines and GAG, proliferative factors, nitric oxide, urothelial proinflammatory gene expression, and viruses (Grigorescu et al., 2016).

One of the earliest studied markers for diagnosis of IC/BPS was the mast cell count. Biopsies were routinely obtained (at the time of hydrodistention) and analyzed in a standardized fashion with greater than 27 mast cells per cubic millimeter being indicative of mastocytosis (Larsen et al., 2008). Studies regarding the mast cell count's role for IC/BPS diagnosis were conflicting, and no study to date has associated mast cell counts with response to therapy (e.g., antihistamines). Given these factors, the use of mast cell criteria is not recommended outside the realm of research (Christmas and Rode, 1991; Dundore et al., 1996; Feltis et al., 1987; Hanno et al., 1991; Holm-Bentzen et al., 1987a; Kastrup et al., 1983; Lynes et al., 1987; Moore et al., 1992). Methylhistamine, a histamine metabolite found in the urine and thought to reflect mast cell activation, was not associated with symptom scores, response to bladder distention, cystoscopic findings, or bladder biopsy features including mast cell determination by tryptase staining (Erickson et al., 2004).

Multiple urinary markers have been investigated (Erickson, 2001, Erickson et al., 2002), including eosinophil cationic protein (Lose et al., 1987), GAG excretion (Hurst et al., 1993), and urinary histamine and methylhistamine (El Mansoury et al., 1994). Proposals for measuring smooth muscle isoactin expression (Rivas et al., 1997) and urinary levels of neurotrophin-3, nerve growth factor, glial cell line–derived neurotrophic factor, and tryptase (Okragly et al., 1999) have been suggested. Low levels of GP51, a urinary glycoprotein with a molecular weight of 5 kDa, have been documented in IC patients compared with normal controls and patients with other urinary tract disease (Byrne et al., 1999), suggesting surface mucin aberrations.

The measurement of elevated nitric oxide levels in air instilled and incubated in the bladder has been proposed for office screening (Ehrén et al., 1999; Lundberg et al., 1996). Increased levels of endogenously formed nitric oxide in patients with IC correspond to increased iNOS mRNA expression and protein levels in these patients. Furthermore, iNOS was found to be localized to the urothelium, but it was also found in macrophages in the bladder mucosa (Koskela et al., 2008). The simple technique allows for discrimination of ulcer from non-HL disease (Logadottir et al., 2004) and may provide an objective measure of treatment response (Hosseini et al., 2004).

Urinary macrophage inhibitory factor (MIF) levels in female patients with IC/BPS and HLs are approximately fivefold higher than MIF levels in female non-IC/BPS patients or IC/BPS patients without HLs. Urinary MIF was also elevated in males with other forms of bladder inflammation (bacterial and radiation cystitis), indicating that, although a good marker to detect inflammation, MIF was not specific for the presence of IC/BPS with HLs. Nevertheless, the assay may better select out those patients who would benefit from early cystoscopic evaluation, and it may pose as a target for future therapies for IC/BPS and other inflammation-based bladder diseases (Vera et al., 2018).

Patients with HLs were found to have a 5-fold to 20-fold increase in the chemokines CXCL-10 and CXCL-1, interleukin-6, and nerve growth factor when compared with BPS patients without HLs (Tyagi et al., 2012). Different expression patterns of the genes involved in pronociceptive inflammatory reactions suggest distinct pathophysiologies for HL patients compared with patients with IC/BPS without HLs (Homma et al., 2013).

Of all biomarkers analyzed for the diagnosis of IC/BPS to date, none has shown higher sensitivity (95%) and specificity (95%) to differentiate IC/BPS from healthy controls than urinary antiproliferative factor (APF), a “frizzled 8 protein” that belongs to a family of proteins that appear to have a role in the development of nerve tissues, skin, and the lining of organs (Keay et al., 2004b). APF is known to inhibit the proliferation of urothelial cells in vitro and is associated with decreased production of heparin-binding epidermal growth factor–like growth factor (HB-EGF) (Keay et al., 2000). APF activity was related to increased production of epidermal growth factor (EGF), insulin-like growth factor-1, and insulin-like growth factor–binding protein-3 by the bladder cells from IC/BPS patients but not by the cells from healthy bladders. Studies of IC/BPS patients and asymptomatic controls showed **urine levels of APF, HB-EGF, and EGF to reliably separate IC/BPS from controls** (Erickson et al., 2002; Keay et al., 2001b). Despite current concepts of overlapping pathologies between men with IC/BPS and CP/CPPS, APF levels in the urine were found to discriminate between men with IC/BPS versus those with CPPS or nonbacterial prostatitis (Keay et al., 2004a). Data regarding the reproducibility of APF and any practical clinical uses are lacking.

Uroplakin III-delta 4 is a potential marker for identifying IC/BPS with HLs (Zeng et al., 2007). The feasibility of diagnosing IC/BPS in humans and domestic cats from the spectra of dried serum films (DSFs) using infrared microspectroscopy has been reported (Rubio-Diaz et al., 2009).

Recent studies through the MAPP Network have shown female IC/BPS patients to exhibit a heightened inflammatory response compared with healthy controls as identified through stimulation of Toll-like receptor 2 (TLR2) and

TLR4 in patient-derived peripheral blood mononuclear cells (PBMCs). A TLR4 inflammation score correlated strongest for pain frequency and intensity (Schrepf et al., 2014). A one standard deviation increase in TLR4 inflammatory response was associated with a 1.59 greater likelihood of extrapelvic pain. Furthermore, patients with comorbid syndromes had higher inflammatory responses to TLR4 stimulation in PBMCs. The TLR4 response was also associated with low-pressure pain thresholds (Schrepf et al., 2015). TLR7 is associated with SLE and SS, two inflammatory conditions that are more frequently identified in the IC/BPS population. Ichihara et al. identified increased *TLR7* gene expression and TLR7 immunoreactive cells in the bladder biopsies of IC/BPS patients with HLs compared with control specimens, further suggesting that these conditions may represent two different pathologic states (Ichihara et al., 2017). Differentiation of IC/BPS with HLs from other forms of cystitis is crucial for future investigations.

Potassium Chloride Test

The intravesical KCl challenge has been described as an aid to diagnose IC/BPS (Parsons et al., 1998). The test essentially compares the sensory nerve provocative ability of sodium versus potassium using a 0.4-M KCl solution. Pain and provocation of symptoms constitutes a positive test result. Whether the results indicate abnormal epithelial permeability in the subgroup of positive patients or hypersensitivity of the sensory nerves is unclear. When first described, the KCl test was thought to help identify the IC/BPS patient without the need for cystoscopy and hydrodistention under anesthesia. Of course, as our diagnostic paradigm has shifted to one that is symptom-based, the need for a provocative test, one that can result in a great deal of patient discomfort, has waned. Accordingly, **used as a diagnostic test for IC/BPS, the KCl test is not recommended.** Interestingly, a negative KCl test will be seen in up to 25% of patients meeting strict NIDDK research criteria (suggesting a lack of sensitivity in a group of patients that would more likely respond). Specificity has also been of concern as a 36% false-positive rate was identified in asymptomatic men (Yilmaz et al., 2004) and a 33% positive rate in a fixed population of Turkish textile workers (Sahinkanat et al., 2008). Sensitivity to the KCl solution may also be present in 25% of patients with OAB. Virtually all patients with irritative symptoms from radiation cystitis and urinary tract infection test positive (Parsons et al., 1994b, 1998). The results with chronic prostatitis and CPPS in men are variable, but 50% to 84% of men have been reported to test positive (Parsons and Albo, 2002; Parsons et al., 2005; Yilmaz et al., 2004). In women with pelvic pain, the results are similar (Parsons et al., 2002b), and, based on these findings, Parsons has expressed the view that IC/BPS may affect over 20% of the female population of the United States (Parsons et al., 2002a). Another way to interpret the findings would be that the KCl test is very nonspecific, missing a significant number of IC/BPS patients and overdiagnosing much of the population.

Key Points: Diagnosis

- IC/BPS remains a diagnosis of exclusion in patients who meet the symptomatic criteria for diagnosis.
- The identification of confusable conditions that may mimic bladder-based pain or present as additional pain generators (e.g., HTPFD) is essential for a successful therapeutic outcome.
- Although cystoscopy is not mandatory for diagnosis, a flexible office cystoscopy may be considered early in the course of care to exclude the presence of HLs.
- Cystoscopy and upper tract imaging are mandatory in patients with hematuria who have not been previously evaluated for this finding.
- Urodynamics are optional and usually reserved for complex cases.
- There are no commonly available laboratory markers that substantially contribute to diagnosis.

Treatment of Interstitial Cystitis/Bladder Pain Syndrome

Before embarking on therapy for the IC/BPS patient, the clinician must first be cognizant that there is no "home run" therapy available that will apply to all patients, most certainly a result of heterogeneity of the population. This leaves a trial-and-error approach to treatment that can quickly breed frustration for the patient. Much of this frustration and perhaps secondary depression can be mitigated to a significant degree by establishing treatment goals and realistic expectations, moving forward as partners in management.

As in all disciplines of medicine, improved outcomes are often derived from factors that cannot be acquired from medical textbooks or videos. This is particularly apropos to IC/BPS, where management remains somewhat of an art form. (See Box 57.4, an algorithm with six tiers of therapeutic intervention.) This may sound straightforward, but can you use therapies of different tiers together? If so, which would be the best ones, and for which patients? Why should you choose one therapy over another? And what about those other pain generators? The answers to these questions are as diverse as the IC/BPS population. They are honed from routinely caring for afflicted patients; performing detailed, unhurried evaluations; making educated decisions regarding therapy based on multiple clinical factors (as diverse as difficulties with transportation to poor sleep quality to sexual dysfunction) along with known benefits and risks of the interventions; and then simply observing the therapeutic responses, good or bad.

Box 57.4

Tiered Therapy for IC/BPS per AUA Guidelines[a]

First-Line Treatments

- General relaxation/stress management
- Patient education
- Self-care/behavior modification

- Pain management

Second-Line Treatments

- Specialized manual physical therapy
- Oral agents: amitriptyline, hydroxyzine, cimetidine, PPS
- Intravesical therapy: DMSO, heparin, lidocaine
- Pain management

Third-Line Treatments

- Cystoscopy under anesthesia with hydrodistention
- Treatment of Hunner lesions, if found
- Pain management

Fourth-Line Treatments

- Intradetrusor botulinum A toxin
- Neuromodulation
- Pain management

Fifth-Line Treatments

- Cyclosporine A
- Pain management

Sixth-Line Treatments

- Urinary diversion (with or without cystectomy)
- Substitution cystoplasty
- Pain management

---

[a] Note exceptions for sequential management in text.

Modified from Hanno PM, Erickson D, Moldwin R, et al. Diagnosis and treatment of interstitial cystitis/bladder pain syndrome: AUA Guideline Amendment. *J Urol* 193(5):1545–1553, 2015.

General Principles of Therapy

As a general medical principle, conservative treatment strategies are recommended with progression to more aggressive care in the setting of poor symptom control and an unacceptable QoL (see Box 57.4). Re-evaluation to identify other sources of pain should also be considered in those patients who are not improving. Initial aggressive (higher-tier) care may be indicated for patients who present with severe symptomatology that, in the clinician's opinion, is unlikely to have an adequate response to more conservative measures. Although not formally studied, clinical experience suggests that concomitant treatments may yield the benefit of addressing different aspects of the patient's symptom profile and may reduce the need for higher-tier care. Placebo effect and regression to the mean is common in this population and needs to be taken into consideration during the first 3 to 4 weeks of therapy (Stephens-Shields et al., 2016). Clinicians and patients should discuss discontinuance (if only on a temporary basis) of longstanding therapy that has been of questionable benefit.

IC/BPS is a multifaceted condition that may require the talents of other practitioners to achieve an adequate reduction in symptoms. For example, cognitive behavior therapy applied by experienced mental health professionals may be helpful to address often-encountered catastrophic thinking (Tripp et al., 2017). If pudendal neuralgia is thought to be present, pudendal nerve blocks applied by trained clinicians may be helpful therapy and can also aid in diagnosis (Gupta et al., 2015; Singh et al., 2017). Anesthetic or BTX-A (non-FDA approved for this purpose) trigger-point injections to the pelvic floor musculature may reduce pain associated with HTPFD when more conservative methods such as directed physical therapy have reached a therapeutic plateau (Moldwin and Fariello, 2013). Chronic opioid therapy, with its well-known and recently highly publicized risks, is not routinely recommended for the IC/BPS patient (Engeler et al., 2013). Nevertheless, benefit may be had for carefully selected patients treated by pain management specialists familiar with “universal precautions” (Atkinson and Fudin, 2017). Gynecologic, gastroenterologic, and rheumatologic consultation, among others, should be sought early on in care, as appropriate.

Conservative Therapies

Stress reduction, exercise, warm tub baths, and efforts by the patient to maintain a normal lifestyle all contribute to overall QoL (Whitmore, 1994). In a large patient survey, dietary changes, application of heat or cold, and stress reduction all had positive response rates in more than 80% of responders (O'Hare et al., 2013). In a controlled study of 45 IC/BPS patients and 31 healthy controls, higher levels of stress were related to greater pain and urgency in patients with IC but not in the control group (Rothrock et al., 2001). Maladaptive strategies for coping with stress may adversely affect symptoms (Rothrock et al., 2003). Catastrophic thinking, the irrational, consuming fear of a disastrous outcome, appears to enhance the perception of pain, but may be modified with cognitive behavior therapy (Tripp et al., 2017).

Biofeedback, soft-tissue massage, and other physical therapies may aid in muscle relaxation of the pelvic floor (Holzberg et al., 2001; Lukban, et al., 2001; Markwell, 2001; Meadows, 1999; Mendelowitz et al., 1997). This is a reasonable intervention, given the strong association of HTPFD and IC/BPS (Bassaly et al., 2011; Peters et al., 2007a). A preliminary NIDDK trial demonstrated the feasibility of such a study and strongly suggested the efficacy of physical therapy when compared with global therapeutic massage (FitzGerald et al., 2009). This was confirmed in an RCT comparing 10 scheduled treatments of myofascial physical therapy versus global therapeutic massage at 11 North American clinical centers. The Global Response Assessment (GRA) response rate was 26% in the global therapeutic massage group and 59% in the myofascial physical therapy group ($P = .0012$) (FitzGerald et al., 2012).

Mendelowitz et al. had a 69% success rate in 16 patients treated with electromyographic biofeedback (Mendelowitz et al., 1997), but treatment response did not correlate to changes in muscle identification, and the placebo effect may have been considerable. **Acupuncture** has been used for IC/BPS and many other chronic pain syndromes. IC/BPS results with acupuncture have been disappointing, with most studies showing it to be no more effective than placebo, sham acupuncture, or standard care (Ezzo et al., 2000; Geirsson et al., 1993). Conversely, a more recent albeit open-label study showed significant improvement in multiple clinical parameters after 5 weeks of treatment (two sessions per week) that lasted 3 months. A progressive worsening of symptoms back to baseline was identified at 1-year follow-up. No doubt, further sham or placebo-controlled trials with perhaps standardization of methodology for needle placement are needed (Sönmez and Kozanhan, 2017).

Diet

Dietary triggers are endorsed by an estimated 53% to 93% of IC/BPS patients, based on patient surveys (Interstitial Cystitis Association, 2005; Koziol et al., 1993; Shorter et al., 2007). All are hampered by methodologic difficulties; however, they are remarkably consistent with regard to the specific items that are felt to trigger symptoms. Often these include caffeine, alcohol, artificial sweeteners, hot peppers, and acidic beverages such as cranberry juice (Shorter et al., 2007).

One placebo-controlled dietary study, although small, failed to demonstrate a relationship between diet and symptoms (Fisher et al., 1993). Contrary to that study, a recent controlled clinical trial from Japan investigated the effect of “intensive dietary manipulation” on 40 IC/BPS patients (30 receiving intensive and 10 receiving nonintensive manipulation) using parameters including O'Leary-Sant Symptom and Problem indices, urgency visual analog scale score, bladder or pelvic pain visual analog scale score, and numerical patient-reported QoL index. Foods/beverages that were removed or restricted included tomatoes, tomato products, soybean, tofu, spices, excessive potassium, citrus, high-acidity–inducing substances, and others. Statistically significant improvement was identified in the “intensive” group versus the “nonintensive” group at all time points up to 1 year (Oh-oka, 2017).

Urine pH has been thought to be a factor that might trigger symptoms. Indeed, several acid-sensing ion channel subunits are expressed in human bladder, and the upregulation of some of these channels in IC/BPS patients suggests involvement in increased pain and hyperalgesia (Sanchez-Freire et al., 2011). This hypothesis was somewhat dispelled by Nguan et al., who performed a prospective, double-blind, crossover study consisting of crossover instillations of urine at physiologic pH (5.0) and neutral buffered pH (7.5) (Nguan et al., 2005). There was no statistically significant difference in subjective pain scores, suggesting that adjusting urine pH with diet or dietary supplements may have little influence on symptomatology. Orange and grapefruit juices, rich in potassium and citrate, tend to *increase* urinary pH (Wabner and Pak, 1993) but are avoided by many IC patients based on “IC diet” recommendations and their personal experience with food-related flares. The discrepancy between patients’ descriptions of symptom flares based on the ingestion of acidic products and these research findings suggests that either there is very frequent misinterpretation of these agents as triggers or that some other process(es) (e.g., bladder bowel cross-talk) might be involved. Alkalinizing the urine may still be worth trying, but supporting studies are lacking. Some patients have had benefit with calcium glycerophosphate, an over-the-counter food acid–reducing agent (Hill et al., 2008; O'Hare et al., 2013), but, once again, controlled trials are lacking.

A stepwise method to determine dietary sensitivities such as an elimination diet may play an important role in patient management. This strategy requires patients to keep diaries of food intake, voiding, and pain. They begin with a bland diet using foods and beverages often chosen from food lists compiled by prior questionnaire-based studies (Box 57.5). They then slowly add potentially "offensive" items back into their diet and record results. The value of this approach rests with its ability to detect and avoid foods that appear to trigger symptoms. It also prevents patients from eliminating more foods than necessary, so that they continue to meet their nutritional requirements (Friedlander et al., 2012). Baseline data regarding diet sensitivities may be collected on a short, validated questionnaire (Shorter et al., 2014).

Box 57.5

Foods/Beverages Identified as Most and Least Bothersome to Patients With Interstitial Cystitis/Bladder Pain Syndrome

Most Bothersome

Coffee (caffeinated)
Coffee (decaffeinated)
Tea (caffeinated)
Cola carbonated beverage
Non-cola carbonated beverage
Diet carbonated beverage
Caffeine-free carbonated beverage
Beer
Red wine
White wine

Champagne
Grapefruit
Lemon
Orange
Pineapple
Cranberry juice
Grapefruit juice
Orange juice
Pineapple juice
Tomato
Tomato products
Hot peppers
Spicy foods
Chili
Horseradish
Vinegar
Monosodium glutamate
NutraSweet
Sweet'N Low
Equal (sweetener)
Saccharin
Mexican food
Thai food
Indian food

Least Bothersome

Water
Milk, low-fat
Milk, whole
Bananas
Blueberries
Honeydew melon
Pears
Raisins
Watermelon
Broccoli

Brussels sprouts
Cabbage
Carrots
Cauliflower
Celery
Cucumber
Mushrooms
Peas
Radishes
Squash
Zucchini
White potatoes
Sweet potatoes/yams
Eggs
Turkey
Beef
Pork
Lamb
Shrimp
Tuna fish
Salmon
Chicken
Oats
Rice
Pretzels
Popcorn

Modified from Friedlander JI, Shorter B, Moldwin RM. Diet and its role in interstitial cystitis/bladder pain syndrome (IC/BPS) and comorbid conditions. *BJU Int* 109(11):1584–1591, 2012.

In a large National Institutes of Health study, patients with newly diagnosed IC/BPS were treated with a focus on four targeted areas: (1) controlling or managing symptoms, (2) controlling fluid intake, (3) changing the diet to one that might improve symptoms, and (4) bladder training and urge suppression. A behavioral approach to stress and pain management was also used to help patients learn skills to reduce stress in their lives. Of 135 patients randomized to this approach without additional medication, 45% were moderately or markedly improved at the 12-week end point (Foster et al., 2010). In another trial, hydrodistention followed by bladder training produced a statistically significant better response at 24 weeks postprocedure than hydrodistention alone (Hsieh et al., 2012).

The Role of Patient Support Groups

Several support groups exist to serve IC/BPS patients, providing up-to-date education and on-line support. The Interstitial Cystitis Association (ICA) (www.ichelp.org), a not-for-profit organization, has been in existence for 34 years, providing educational services for physicians and patients, sponsoring national patient symposia and charity walks, promoting research in the field, and even running their own pilot research program for young investigators. Other excellent resources for patients include the Interstitial Cystitis Network (ICN) (www.ic-network.com) and another not-for-profit group, The International Painful Bladder Foundation (IBPF) (painful-bladder.org).

Oral Therapies (Table 57.6)

Amitriptyline

Amitriptyline, a tricyclic antidepressant (TCA), has become a staple of oral treatment for IC/BPS. The tricyclics possess varying degrees of at least three major pharmacologic actions: (1) They have central and peripheral anticholinergic actions at some but not all sites, (2) they block the active transport system in the presynaptic nerve ending that is responsible for the reuptake of the released amine neurotransmitters serotonin and noradrenaline, and (3) they are sedatives, an action that occurs presumably on a central basis but perhaps is related to their antihistaminic properties. Amitriptyline, in fact, is one of the most potent tricyclic antidepressants in terms of blocking H_1-histaminergic receptors (Baldessarini, 1985). It may also stimulate β-adrenergic receptors in bladder body smooth musculature, an action that would further facilitate urine storage by decreasing the excitability of smooth muscle in that area (Barrett et al., 1987).

TABLE 57.6

Grade and Level of Evidence According to Oxford System for Oral

and Intravesical Therapies

TREATMENT	ICI[a]	EAU[b]	GIANNANTONI[c]
Oral Therapies			
Amitriptyline	B: 2	A: 1	A: 1
Analgesics	C: 4	C: 2	
Hydroxyzine	D: 1	A: 1	
PPS	D: 1	A: 1	C: 1
Cyclosporine	C: 3	A: 1	A: 1
l-Arginine	−A: 1		A: 1
Antibiotics regimens	D: 4		
Azathioprine	D: 4		
Benzydamine	D: 3		
Chloroquine derivatives	D: 4		
Cimetidine	C: 3		
Doxycycline	D: 4		
Duloxetine	−C: 4		
Gabapentin	C: 4		
Methotrexate	D: 4		
Misoprostol	D: 4		
Montelukast	D: 4		
Nalmefene	−A: 1		
Nifedipine	D: 4		
Quercetin	D: 4		
Tanezumab	D: 1		
Suplatast tosilate	D: 3		
Vitamin E	D: 4		
Intravesical Therapies			
Lidocaine	C: 2		
DMSO	B: 2	A: 1	
Heparin	C: 3		
Hyaluronic acid	D: 1	B: 2	
Chondroitin sulfate	D: 4	B: 2	A: 1
PPS	D: 4	A: 1	
Oxybutynin	D: 4		
BTX (intramural)	A: 1		A: 1

[a] Hanno P, Dinis P, Lin A, et al. Bladder pain syndrome. In: Abrams P, Cardozo L, Khoury S, et al., eds. *Incontinence*. Paris: International Consultation on Urological Diseases/European Association of Urology; 2013:1583–1649.

[b] Fall M, Baranowski AP, Elneil S, et al. EAU guidelines on chronic pelvic pain. *Eur Urol* 57(1):35–

48, 2010.

[c]Giannantoni A, Bini V, Dmochowski R, et al. Contemporary management of the painful bladder: a systematic review. *Eur Urol* 61:29–53, 2012.

BTX, Botulinum toxin; *DMSO,* dimethyl sulfoxide; *EAU,* European Association of Urology; *ICI,* International Consultation on Incontinence; *PPS,* pentosan polysulfate.

From Committee on Bladder Pain Syndrome. *Fifth International Consultation on Incontinence*. Paris, France; 2012.

Hanno and Wein first reported a therapeutic response in IC/BPS after noting a “serendipitous” response to amitriptyline in one of their patients concurrently being treated for depression (Hanno and Wein, 1987). Reasoning that a drug used successfully at relatively low doses for many types of chronic pain syndromes, that would also have anticholinergic properties, β-adrenergic bladder effects, sedative characteristics, and strong H_1-antihistaminic activity, would seem to be ideal for IC, the first clinical trials with doses ranging from 25 to 75 mg were carried out with promising results (Hanno, 1994; Hanno et al., 1989); however, drop-out rates were high. Sedation was the most common complaint. Other uncontrolled studies followed, all demonstrating success (Kirkemo et al., 1990; Pranikoff and Constantino, 1998) along with another TCA, desipramine (Renshaw, 1988).

In a 4-month intent-to-treat, placebo-controlled, double-blind trial of 50 patients, 63% on amitriptyline at doses of 25 to 75 mg (dose as tolerated) before bed reported good or excellent satisfaction versus 4% on placebo (van Ophoven et al., 2004a). At 19-month follow-up, there was little tachyphylaxis, and good response rates were observed in the entire spectrum of IC/BPS symptoms (van Ophoven and Hertle, 2005).

The large, double-blind, RCT by the NIDDK comparing education and behavioral modification with and without oral amitriptyline showed no significant differences in symptom improvement between the groups at 12 weeks. However, reanalysis of these data selecting out patients who could tolerate doses of 50 mg or higher, did show efficacy beyond control, 77% versus 53%, respectively (Foster et al., 2010).

Amitriptyline appears to have efficacy that is unrelated to the presence or absence of an HL, and cystoscopy shows no predictive value for treatment outcome (Sun et al., 2014). It may also be beneficial in the treatment of other pain disorders that often accompany IC/BPS, (e.g., vulvodynia) (Ventolini, 2013).

Amitriptyline has proven analgesic efficacy with a **median preferred dose of**

50 mg in a range of 25 to 150 mg daily. Patients should be cautioned about fatigue, constipation, dry mouth, increased appetite (with weight gain), and dizziness. **Slowly titrating the dose on a weekly basis, beginning at 10 mg in the evening and increasing by 10 mg weekly to a maximum tolerated dose of 50 mg before bed seems to minimize side effects.** Despite the findings of research trials, long-term clinical benefits may be seen at doses lower than 50 mg. The clinician should be cautious when contemplating amitriptyline's use in the IC/BPS patient who complains of obstructive voiding symptoms or those patients who suffer from chronic constipation as the drug can easily worsen these conditions. Delayed ejaculation, anorgasmia, and decreased libido are common side effects of all TCAs (Shankar, 2015).

Tricyclic antidepressants are contraindicated in patients with long QT syndrome or significant conduction system disease (bifascicular or trifascicular block) after recent myocardial infarction (within 6 months), unstable angina, congestive heart failure, frequent premature ventricular contractions, or a history of sustained ventricular arrhythmias. They should be used with caution in patients with orthostatic hypotension (Low and Dotson, 1998). Doses greater than 100 mg are associated with increased relative risk for sudden cardiac death (Ray et al., 2004).

Antihistamines

Theoharides postulated that the unique piperazine H_1-receptor antagonist ***hydroxyzine,*** a first-generation antihistamine, would block neuronal activation of mast cells, and thereby mitigate IC/BPS symptoms (Minogiannis et al., 1998; Simons, 2004; Theoharides, 1994). In 40 patients treated with 25 mg before bed increasing over 2 weeks (if sedation was not a problem) to 50 mg at night and 25 mg in the morning, virtually every symptom evaluated improved by 30%. Only three patients had absolutely no response. As with many IC drug reports, these responses were evaluated subjectively and without blinding or placebo control. A subsequent study suggested improved efficacy in patients with documented allergies and/or evidence of bladder mast cell activation (Theoharides and Sant, 1997; Theoharides et al., 1997). **No significant response to hydroxyzine was found in an NIDDK placebo-controlled trial** (Sant et al., 2003)**. Nevertheless, a good safety profile along with its ability to improve sleep (often in conjunction with amitriptyline) and commonly reported allergy symptoms, makes hydroxyzine a useful medication in selected patients.**

Why an H_2-antagonist would be effective is unclear, but uncontrolled studies show improvement of symptoms in two-thirds of patients taking cimetidine in divided doses totaling 600 mg (Lewi, 1996; Seshadri et al., 1994). It proved effective in a double-blind, placebo-controlled trial with 400-mg twice-daily dosing (Thilagarajah et al., 2001), but histologic studies show the bladder mucosa to be unchanged before and after treatment, and the mechanism of any efficacy remains unexplained (Dasgupta et al., 2001). Cimetidine is a common treatment in the United Kingdom, where over one-third of patients reported having used it (Tincello and Walker, 2005).

Montelukast

Mast cell triggering releases two types of proinflammatory mediators, including granule stored preformed types such as heparin and histamine and newly synthesized prostaglandins and leukotrienes B_4 and C_4. Classic antagonists, such as montelukast, zafirlukast, and pranlukast, block cysteinyl leukotriene-1 receptors. In a pilot study, 10 women with IC and detrusor mastocytosis received 10 mg of montelukast daily for 2 months (Bouchelouche et al., 2001b). Frequency, nocturia, and pain improved dramatically in 8 of the patients. Further study would seem to be warranted, especially in patients with detrusor mastocytosis, defined as more than $28/\text{mm}^2$ (Traut et al., 2011).

Pentosan Polysulfate Sodium

Pentosan polysulfate (PPS; brand name Elmiron) was approved in the United States for the “relief of bladder pain or discomfort associated with interstitial cystitis” in 1996 under the FDA's orphan products program. It remains the only FDA oral medication approved for this indication. PPS is a synthetic sulfated polysaccharide, similar in structure to glycosaminoglycans (GAG) of the bladder surface. Taken orally, 3% to 6% of PPS is excreted into the urine (Barrington and Stephenson, 1997) and purportedly improves symptoms by correction of GAG defects that produce a dysfunctional, “leaky” bladder epithelium. Another hypothesis proposed by Parsons is the drug's ability to sequester “toxic cations” (Parsons, 2017).

Initial studies reported encouraging results (Parsons et al., 1983). Fourteen subsequent trials have been disparate. Trials have been plagued with methodologic differences and problems inherent to all IC/BPS clinical trials, the heterogeneity of the population (Moldwin, 2017). Small studies suggest that it may be of value in the management of radiation cystitis (Hampson and Woodhouse, 1994; Parsons, 1986) and cyclophosphamide cystitis (Toren and Norman, 2005).

An industry-sponsored trial showed no dose-related efficacy response in the range of 300 to 900 mg daily; however, adverse events *were* dose related (Nickel et al., 2005). A phase IV, randomized, double-blind, placebo-controlled trial evaluating the efficacy of PPS for IC/BPS found no statistically significant difference for the primary end point, defined as a 30% or greater reduction from the baseline Interstitial Cystitis Symptom Index (ICSI) total score between two different doses of PPS (100 mg once a day and 100 mg three times a day) and a placebo group. In this well-constructed study that included intent-to-treat analysis, the investigators used a less rigorous definition of IC/BPS for enrollment (although sub-stratification for patients meeting NIDDK criteria was also performed). They did not exclude patients with comorbid conditions such as IBS, pelvic floor dysfunction, or depression. Likewise, patients were not excluded if they had already used PPS in their clinical care. Hence, these and other factors (such as drop-out for reasons other than nonresponse to therapy and adverse events) may have had an effect on outcome (Nickel et al., 2015).

Adverse events with PPS occurred in less than 4% of patients at the dose of 100 mg three times daily and included reversible alopecia, diarrhea, nausea, and rash (Hanno, 1997). Rare bleeding problems have been reported (Rice et al., 1998). Of recent concern is a report of a **pigmentary maculopathy,** manifest by "difficulty reading," developing in 6 patients after long-term PPS use (Pearce et al., 2018). This finding merits follow-up investigation. Caution has been suggested when using PPS in groups with high risk for breast cancer and premenopausal women as the drug promotes cellular proliferation in vitro in the MCF-7 breast cancer cell line (Zaslau et al., 2004).

Despite efficacy and safety concerns, clinical practice suggests that PPS can produce clinical responses in a subset of patients (Al-Zahrani and Gajewski, 2011), and tachyphylaxis seems to be uncommon in these individuals. Hence, along with amitriptyline, hydroxyzine, and cimetidine, this agent has been recommended as a second-tier agent for IC/BPS (Hanno et al., 2015). Clinical usefulness is hampered by the inability to select patients most likely to benefit. This is magnified by high cost and a clinical response that may take 3 months (and on rare occasions, up to 6 months) to occur. Its use remains controversial among practicing clinicians.

Immunomodulator Drugs

Cyclosporine A.

Cyclosporine A (CyA), a widely used immunosuppressive drug in organ transplantation, was the subject of a novel IC/BPS trial (Forsell et al., 1996). Eleven patients received cyclosporine for 3 to 6 months at an initial dose of 2.5 to 5 mg/kg daily and a maintenance dose of 1.5 to 3 mg/kg daily. Micturition frequency decreased, and mean and maximum voided volumes increased significantly. Bladder pain decreased or disappeared in 10 patients. After cessation of treatment, symptoms recurred in the majority of patients.

In a longer-term follow-up study, 20 of 23 refractory IC patients on CyA followed for a mean of 60.8 months became free from bladder pain. Bladder capacity more than doubled. Eleven patients subsequently stopped therapy, and in 9, symptoms recurred within months but responded to reinitiating CyA (Sairanen et al., 2004). Sairanen et al. (2005) further found that cyclosporine A was far superior to sodium PPS in all clinical outcome parameters measured at 6 months. Patients who responded to cyclosporine A had a significant reduction of urinary levels of EGF (Sairanen et al., 2008). Retrospective data from three centers in the United States reported success in 23 of 34 patients with HLs, but in only 3 of 10 patients without HLs (Forrest et al., 2012), suggesting that the HL phenotype might be the best group to target with CyA therapy. A 3- to 4-month trial was suggested to gauge treatment success. Similar results were seen in a recent open-label study of patients who failed at least two prior therapies (Crescenze et al., 2017).

Measurement of luminal nitric oxide has correlated lower levels with treatment response to cyclosporine (Ehrén et al., 2013). A case report highlighted success in a patient with primary SS and IC/BPS (Emmungil et al., 2012). **CyA is a recommended fifth-tier therapy as its side effects do not warrant early use in most patients.** Its association with renal dysfunction, hypertension, heightened risk for infection and lymphoma, development of gum hyperplasia, alopecia, tremor, among others, along with multiple drug and food interactions make this a medication that requires close initial and subsequent patient follow-up. Doses that have been described are usually 1 to 3 mg/kg/day, lower than those used in the setting of renal transplant (Crescenze et al., 2017; Forrest et al., 2012; Forsell et al., 1996; Sairanen et al., 2004). Protocols for follow-up vary among centers, all focusing on monitoring for hypertension and serum studies (including estimated glomerular filtration rate [eGFR]). Crescenze et al. (2017)

found a CyA serum level drawn 2 hours after dose administration to be helpful for monitoring and allowed for dose reduction in about 40% of patients.

Other Immunoregulating Agents.

Soucy and Grégoire studied the value of **prednisone** (25 mg/day, followed by dose tapering) in patients with refractory ulcerative IC, noting a 22% reduction in symptom scores and a 69% improvement in pain (Soucy and Grégoire, 2005). **With a lack of follow-up trials and concerns for long-term safety, chronic steroid therapy is not currently recommended in the treatment algorithm.** In a single report in 1976, Oravisto et al. used **azathioprine or chloroquine derivatives** for IC/BPS patients not responding to other treatments (Oravisto and Alfthan, 1976). About 50% of patients responded. Low-dose oral **methotrexate** significantly improved bladder pain in four of nine women with IC/BPS but did not change urinary frequency, maximum voided volume, or mean voided volume (Moran et al., 1999). No placebo-controlled RCT has been done with this agent. Immunoregulating medications that have been studied but failed to show efficacy for IC/BPS include suplatast tosilate (Ueda, 2000), mycophenolate mofetil (Yang et al., 2011), and adalimumab (Bosch, 2014).

Miscellaneous Agents

l-Arginine.

Foster and Weiss were the original proponents of L-arginine in the therapy of IC (Foster et al., 1997). Eight patients with IC were given 500 mg of L-arginine three times daily. After 1 month, urinary NOS activity increased eightfold, and 7 of the 8 patients noticed improvement in symptoms. An open-label study of 11 patients showed improvement in all 10 of the patients who remained on L-arginine for 6 months (Smith et al., 1997). Further open-label studies (Ehrén et al., 1998) and RCTs (Cartledge et al., 2000; Korting et al., 1999) have shown no clinically significant improvement for IC/BPS. L-Arginine is therefore not a recommended therapy.

Quercetin.

Quercetin, a bioflavonoid available in many over-the-counter products, may have the anti-inflammatory effects of other members of this class of compounds found in fruits, vegetables, and some spices. Katske et al. (2001) administered 500 mg twice daily to 22 IC/BPS patients for 4 weeks. All but one patient had some improvement in the O'Leary-Sant symptom and problem scores and in a global assessment score. Further larger studies with placebo controls are necessary to determine efficacy.

Antibiotics.

Exclusion of a urinary tract infection is part and parcel of the IC/BPS diagnosis. No study to date has identified any organism by any technology that can be consistently identified as the cause for symptoms. Nevertheless, some studies indirectly suggest that the topic may need further study. Warren et al. (2000) randomized 50 patients to receive 18 weeks of placebo or antibiotics including rifampin plus a sequence of doxycycline, erythromycin, metronidazole, clindamycin, amoxicillin, and ciprofloxacin for 3 weeks each. Intent-to-treat analysis demonstrated that 12 of 25 patients in the antibiotic group and 6 of 25 patients in the placebo group reported overall improvement, whereas 10 and 5 patients, respectively, noticed improvement in pain and urgency. The study was complicated by the fact that 16 of the patients in the antibiotic group underwent new IC/BPS therapy during the study, as did 13 of the placebo patients. There was no statistical significance reached. What was statistically significant was the occurrence of adverse events in 80% of participants who received antibiotics compared with 40% in the placebo group. Nausea and/or vomiting and diarrhea were the predominant side effects. Most patients on antibiotics correctly guessed what treatment arm they were in, and those who guessed correctly were significantly more likely to note improvement after the study. No duration in improvement after completion of the trial of antibiotics was reported.

Burkhard et al. (2004) recorded a 71% success rate in 103 women with a history of urinary urgency and frequency and chronic urethral and/or pelvic pain often associated with dyspareunia and/or a history of recurrent urinary tract infection. This was a large, inclusive group and one that is probably broader than the IC/BPS on which we are focusing. Nevertheless, Burkhard recommended empirical doxycycline in this group. The overwhelming majority of IC/BPS patients have been treated with empirical antibiotics before diagnosis.

At this time, there is no evidence to suggest that antibiotics have a place in the therapy of IC/BPS in the absence of a culture-documented infection (Maskell, 1995). It is unlikely that the baseline symptoms of IC/BPS will respond to the incidental finding of bacteriuria without the presence of a symptom flare (Nickel et al., 2010a). Nevertheless, it would not be unreasonable to treat patients with *one* empirical course of antibiotic, if they have never been on an antibiotic for their urinary symptoms. In the event of a symptom flare thought to be caused by infection, a urinalysis and urine culture would be mandatory. An additional practical note: Some IC/BPS patients will develop recurring, uncomplicated bacterial cystitis. These episodes may trigger significant symptom flares that last for extended intervals. In these instances, the clinician should consider the use of antibiotic prophylactic protocols to "side table" these events.

Nifedipine.

The calcium channel antagonist nifedipine inhibits smooth muscle contraction and cell-mediated immunity. In a pilot study, 30 mg of an extended-release preparation was administered to 10 female patients and titrated to 60 mg daily in 4 of the patients who did not get symptom relief (Fleischmann, 1994). Within 4 months, 5 patients showed at least a 50% decrease in symptom scores, and 3 of the 5 were asymptomatic. No further studies have been reported.

Misoprostol.

The oral prostaglandin analogue misoprostol was studied in 25 patients at a dose of 600 µg daily (Kelly et al., 1998). At 3 months 14 patients were significantly improved, and at 6 months 12 patients still had a response. A cytoprotective action in the urinary bladder was postulated.

Dextroamphetamine.

A single anecdotal series of six patients reported benefit from use of 30 mg of dextroamphetamine sulfate daily, with return of symptoms on discontinuation of medication (Check et al., 2013).

Phosphodiesterase Inhibitors.

The use of phosphodiesterase type 5 inhibitors (PDE5Is) for IC/BPS has long been considered. PDE5Is are hypothesized to relax smooth muscle or structures involved in afferent signaling and suppress smooth muscle spontaneous activity (Chen et al., 2014; Hanna-Mitchell and Birder, 2011; Truss et al., 2001). Trials using them for BPS are underway.

Gabapentin.

Gabapentin, introduced in 1994 as an anticonvulsant, has found efficacy in neuropathic pain disorders including diabetic neuropathy (Backonja et al., 1998) and postherpetic neuralgia (Rowbotham et al., 1998). It demonstrates synergism with morphine in neuropathic pain (Gilron et al., 2005). It may give some benefit in CPPS and IC/BPS (Sasaki et al., 2001). Pregabalin is also reported to be effective for neuropathic pain and the pain of FMS (Agarwal and Elsi Sy, 2017; Arnold et al., 2008; Freynhagen et al., 2005).

Key Points: Oral Therapies

- Few of the oral therapies commonly used for the treatment of IC/BPS have unequivocal evidence of efficacy in large, multicenter, clinical RCTs.
- There is little evidence that any of these therapies change the natural history of the disease, although many seem effective in individual patients.
- Consider “drug holidays” to periodically check drug effectiveness.
- Consider multidrug therapy as needed to maximize clinical improvement and avoid adverse events of single high-dose medications.

Intravesical Therapies

Intravesical therapy (see Table 57.6) has the appeal of treating the bladder directly and may be an excellent choice for the patient with limited tolerance to oral agents or simply to further treat symptoms when the effects of oral medications and other conservative measures appear to have plateaued. The downside of therapy is that pain produced centrally or from other pelvic pain generators will be left untreated. Furthermore, response to an intravesical agent may be limited by poor adherence and/or poor absorption through the urothelial surface. Caustic medications that have been described as treatment options (e.g., silver nitrate, oxychlorosene sodium [Clorpactin]) are rarely used today. Many of the current commonly used agents can be self-instilled, thus enhancing patient empowerment and limiting their need for frequent trips to the medical office. Intravesical instillation therapy is suggested to be used as second-line treatment in the management of IC/BPS by the AUA (Hanno et al., 2011).

Silver Nitrate

Although the evidence for treating IC/BPS using intravesical preparations is limited and the potential for meta-analysis reduced by variation in the outcome measures used (Dawson and Jamison, 2007), intravesical lavage with one of a variety of preparations has remained a mainstay of treatment in the therapeutic armamentarium of IC/BPS. Perhaps the oldest of the intravesical therapies is silver nitrate. The use of silver nitrate has been attributed to Mercier, who reported in 1855 that excellent results with bladder instillations had been obtained in patients with symptoms compatible with IC (Pool and Rives, 1944). Dodson advocated the use of solutions of silver nitrate in increasing strengths as the treatment of choice for this condition (Dodson, 1926). Pool and Rives (1944) reported on 74 patients with IC treated with intravesical silver nitrate. The treatment was carried out as follows:

A urethral catheter is inserted and the contents of the bladder are evacuated. The bladder is then irrigated with a saturated solution of boric acid. Then 30 to 60 cc of a 1 : 5000 solution of silver nitrate is instilled into the bladder and permitted to remain there for 3 or 4 minutes if it does not cause intolerable irritation. At the end of this period, the solution is permitted to run out through the catheter, which is then withdrawn. The patient usually experiences some dysuria and vesical irritability for 2 or 3 hours. Treatments are repeated every other day. At subsequent treatments, the concentration of silver nitrate in the solution is increased to 1 : 2500, 1 : 1000, 1 : 750, 1 : 500, 1 : 400, 1 : 200, and finally 1 : 100. If at any time the reaction is too severe, the concentration is increased more slowly.

Although the initial treatments are performed with the patient under general anesthesia, later treatments are given on an outpatient basis. Ureteral reflux would be a contraindication, and it goes without saying that bladder biopsy would be contraindicated just before instillation for fear of extravasation. Twenty-three years later, Pool wrote that he still considered this treatment regimen the most efficacious form of treatment (Pool, 1967). Pool reported excellent results in 70% of patients with a mean response of 7.6 months. Burford and Burford (1958) reported a 14% cure rate and 79% improved figure. DeJuana and Everett (1977) had a 50% response rate in 102 patients.

Although **silver nitrate is not used in the current treatment of IC/BPS,** an animal study showing that intravesical administration of nanocrystalline silver (1%) decreased urine histamine, bladder TNF-α, and mast cell activation in an experimental inflammation model without any toxic effect, may re-stimulate interest in silver compounds (Boucher et al., 2008).

Clorpactin

O'Connor reported on the use of intravesical Clorpactin WCS 90 (O'Connor, 1955). *Clorpactin* is a term for closely related, highly reactive chemical compositions having a modified derivative of hypochlorous acid in a buffered base. Its activity is dependent on the liberation of hypochlorous acid and its resulting oxidizing effects, wetting and penetrating properties, and detergency. Wishard treated 20 patients with 0.2% Clorpactin gently lavaged in the bladder for 3 to 5 minutes without anesthesia; 14 patients reported subjective improvement (Wishard et al., 1957). Murnaghan noted improvement in 14 of 17 patients, although 10 required further treatment during the average 2-year follow-up (Murnaghan et al., 1970). Most commonly, the treatments are given as described by Messing and Stamey (1978), using 0.4% solution administered at 10 cm water pressure under anesthesia. Multiple instillations can be given, with a 1-month pause after the first two instillations to await a therapeutic response. Their success rate was 72%, with an average 6-month duration of response. LaRock and Sant (1995) noted a 50% to 55% meaningful improvement rate occurring within 4 to 6 weeks of treatment. A case of ureteral fibrosis complicating the treatment prompted the recommendation that vesicoureteral reflux be considered a contraindication to the procedure (Messing and Freiha, 1979).

Clorpactin is rarely used at the present time, and there is no current literature on this therapy. It is not a part of any guideline algorithm and has fallen out of favor.

Dimethyl Sulfoxide

A mainstay for the treatment of IC/BPS is the intravesical instillation of 50% dimethyl sulfoxide (DMSO) (Sant, 1987). DMSO is sometimes administered in a solution with sodium bicarbonate, heparin, and/or steroid, but its only FDA-approved use is as a stand-alone treatment (Gafni-Kane et al., 2013; Stav et al., 2012). DMSO is a byproduct of the wood pulp industry and a derivative of lignin. It has exceptional solvent properties and is freely miscible with water, lipids, and organic agents. One must be cognizant of systemic absorption of coadministered agents. Pharmacologic properties include membrane penetration, enhanced drug absorption, anti-inflammatory action (Kim et al., 2011), analgesic effects, collagen dissolution, muscle relaxation, and mast cell histamine release. In vitro effects on bladder function belie its positive effects in vivo (Freedman et al., 1989), where histamine release has not been demonstrated after treatment (Stout et al., 1995). It has been suggested that DMSO actually desensitizes nociceptive pathways in the lower urinary tract (Birder et al., 1997). Tests for DMSO for treatment of human illness began in the 1960s in the areas of musculoskeletal inflammation and the cutaneous manifestations of scleroderma.

Stewart et al. are credited for popularizing intravesical DMSO for IC/BPS (Stewart et al., 1967). Further reports by this group confirmed safety and efficacy (Shirley et al., 1978; Stewart and Shirley, 1976; Stewart et al., 1971, 1972) with symptom-free intervals of 1 to 3 months in 73% of patients. Ek et al. (1978) reported a 70% success rate but found that most patients ultimately required retreatment or further therapy with other modalities. Prospective series of Fowler (1981) and Barker et al. (1987) revealed symptomatic success rates higher than 80%, although relapse was not uncommon. Fowler noted only minimal improvements in functional bladder capacity and attributed the beneficial effects of DMSO to a direct effect on the sensory nerves of the bladder. Perez-Marrero et al. (1988) compared DMSO with saline and showed a 93% objective improvement and 53% subjective improvement compared with 35% and 18%, respectively, for saline. Patients with bladder instability do not respond (Emerson and Feltis, 1986). Stav et al. (2012) and Hung et al. (2012) reported 60% success rates and recommended it be considered a first-line therapy. Tomoe (2015) reported better efficacy in patients with HLs.

With its ease of administration (Biggers, 1986)**, low morbidity, and reasonable efficacy, DMSO certainly merits its place as a useful treatment for IC/BPS.** In vivo studies on rat bladder strips exposed to various concentrations of DMSO for 7 minutes showed absence of electrical field stimulation contraction at 40% concentration and diminished compliance at 30% concentration (Melchior et al., 2003). Concentrations of 25% or less had negligible effects in this model. How it relates to use of DMSO in humans is unknown. A rare case of eosinophilic cystitis has been reported after DMSO instillation (Abramov et al., 2004). Patients should be informed that they might experience severe urgency and frequency with the first several instillations. Patients will typically have a garlic-like odor to their breath caused by partial pulmonary excretion, making blinded clinical trials impossible to carry out.

DMSO is often administered as part of an “intravesical cocktail” (50 mL Rimso-50 + 10 mg triamcinolone + 44 mEq sodium bicarbonate + 20,000 to 40,000 units intravesical heparin) weekly for 6 weeks. If there is a good clinical response, maintenance therapy consisting of administration of the cocktail monthly for 6 months has been employed. Other combinations of agents used in DMSO cocktails have been described, but none has shown clear superiority

(Rawls, et al., 2017).

Glycosaminoglycans

Exogenous glycosaminoglycans (GAGs) have been shown to be effective in providing an epithelial permeability barrier in bladders in which the epithelium has been injured with protamine (Nickel et al., 1998). Heparin, which can mimic the activity of the bladder's own mucopolysaccharide lining (Hanno et al., 1978b), has anti-inflammatory effects and actions that inhibit fibroblast proliferation, angiogenesis, and smooth muscle cell proliferation. Given intravesically, there is virtually no systemic absorption, even in an inflamed bladder (Caulfield et al., 1995). Ten thousand units can be administered intravesically in sterile water either alone or with DMSO at varying intervals with favorable results reported (Parsons et al., 1994a; Perez-Marrero et al., 1993). Kuo reported a 50% or greater improvement in the International Prostate Symptom Score in 29 of 40 women with IC treated with 25,000 units intravesically twice weekly for 3 months (Kuo, 2001).

Parsons used daily intravesical doses of 40,000 units of heparin in 20 mL of sterile water administered by the patient daily and held for 30 to 60 minutes. “Reasonable improvement of symptoms” can be expected between 6 months and 2 years after initiation of therapy (Parsons, 2000). Adding alkalinized lidocaine to the heparin instillation provides better pain relief (Parsons, 2005). The addition of 8 mL of 2% lidocaine and 4 mL of 8.4% sodium bicarbonate may improve results (Welk and Teichman, 2008). In fact, a combination of 200 mg of lidocaine alkalinized with the sequential instillation of 8.4% sodium bicarbonate (10 mL total solution) *without* heparin showed a 30% response rate 3 days after completion of daily intravesical administration for 5 days and was statistically superior to a placebo cocktail (Nickel et al., 2009b). A Japanese study reported high success rates with weekly intravesical instillation of 20,000 units of heparin with 5 mL of 4% lidocaine and 25 mL of 7% sodium bicarbonate for 12 weeks (Nomiya et al., 2013). Intravesical administration of a solution of lidocaine and heparin has been proposed as a treatment for symptom flare (Parsons et al., 2012).

Another GAG analogue, pentosan polysulfate sodium (PPS), administered intravesically (300 mg twice weekly in 50 mL of normal saline) showed some modest benefit in a small trial (Bade et al., 1997). A 41-patient trial comparing oral PPS with oral and intravesical administration showed that the 24% reduction in O'Leary-Sant scores with oral therapy alone rose to a 46% reduction in the group that also received intravesical PPS (Davis et al., 2008).

The nonsulfated GAG hyaluronic acid has also been used intravesically. Trials using 40 mg dissolved in 46 mL of normal saline weekly for 4 to 6 weeks and then monthly treatments thereafter have had response rates varying from 71% (Morales et al., 1996) to 30% (Porru et al., 1997). In the summer of 2003, Bioniche Life Sciences and in the spring of 2004 Seikagaku Corporation reported double-blind, placebo-controlled, multicenter clinical studies of their hyaluronic acid preparations (40 mg or 200 mg/mL, respectively), and neither showed significant efficacy of sodium hyaluronate compared with placebo. These negative studies have not been published in peer-reviewed literature. Neither preparation has been approved for use for IC/BPS in the United States. An Austrian open-label study showed that 13 of 27 patients with IC/BPS and a positive potassium test result responded to intravesical hyaluronic acid 40 mg weekly for 10 weeks, though initial nonresponders at 5 weeks also were treated with intravesical PPS 200 mg three times weekly for the remaining 5 weeks (Daha et al., 2008). The best results for hyaluronic acid come from Riedl, who studied 126 patients with a positive modified potassium test result who could hold the solution for 2 hours, using 40 mg weekly for a minimum 10 weeks; 84% had significant improvement (Riedl et al., 2008). Treatment-resistant cases have been managed with a combination of sequential bladder distention under anesthesia accompanied by a hyaluronic acid instillation every 1 to 3 months depending on response, with a 74% success rate in 23 patients (Ahmad et al., 2008). Although hyaluronic acid has been seemingly efficacious in uncontrolled trials (Engelhardt et al., 2011; Figueiredo et al., 2011; Lai et al., 2013; Lv et al., 2012; Van Agt et al., 2011), **the efficacy of hyaluronic acid for IC/BPS remains unproven in controlled and blinded trials** (Iavazzo et al., 2007). It remains unapproved for IC/BPS in the United States.

Chondroitin sulfate plays an important role for bladder barrier function (Janssen et al., 2013). Hurst showed by immunohistochemistry a deficit of chondroitin sulfate from the luminal bladder surface in IC patients (Hurst, 2003). Intravesical chondroitin sulfate inhibited recruitment of inflammatory cells in an experimental “leaky bladder” model of cystitis (Engles et al., 2012). Small, uncontrolled studies using intravesical chondroitin sulfate showed success rates of 33% to 75% (Sorensen, 2003; Steinhoff et al., 2002; Tornero et al., 2013). A multicenter, open-label study using a 2% solution of sodium chondroitin sulfate weekly for 6 weeks and then monthly for 4 months had a 60% response rate with no safety issues (Nickel et al., 2009a). A larger follow-up study failed to demonstrate significant efficacy (Nickel et al., 2012; Thakkinstian and Nickel, 2013). A large open-label experience using the device for all forms of "chronic cystitis" concluded that it was effective in improving urgency, voided volumes, and nocturia, and well tolerated when administered weekly for a maximum of eight instillations (Nordling and van Ophoven, 2008).

The GAGs have been combined for instillation with favorable results reported in uncontrolled studies (Cervigni, 2015; Cervigni et al., 2008, 2012; Giberti et al., 2013; Porru et al., 2012). A recent study of combined hyaluronic acid and chondroitin sulfate demonstrated similar pain reduction and fewer associated adverse events compared with 50% DMSO when the intent-to-treat population was examined (Cervigni et al., 2016).

A large analysis of GAG layer replenishment therapy with intravesical GAGs concluded that despite the fact that GAG intravesical therapy has been in use for over two decades, most of the studies have been uncontrolled, have been poorly done, and have had a small number of patients. Large-scale RCTs are urgently needed to underline the benefit of this type of therapy. Distinct patient groups (well phenotyped) need to be confirmed by definite diagnostic findings (Madersbacher et al., 2013).

Other Intravesical Therapies

Sodium Channel Blocking Anesthetics (Lidocaine).

Intravesical instillations of anesthetics agents (most commonly used with other medications in cocktail solutions) have the advantage of observing almost immediate results, making this form of care potentially helpful for symptom flares or for maintenance therapy. Its value also rests with its ability to help discern the source of pain, with many centers using a positive response to alkalinized lidocaine preparations as evidence for a bladder-centric phenotype (Henry et al., 2015). The most common agent used has been lidocaine, a sodium channel blocker that also has anti-inflammatory and antimicrobial properties (Cassuto et al., 2006). Lidocaine has a short half-life in serum and is not absorbed to a significant degree through the urothelial surface unless in an alkaline environment. Hence, most instillations are buffered in a sodium bicarbonate. Nickel et al. (2009) explored the role of alkalinized intravesical lidocaine in an RCT that showed moderate or marked improvement 3 days after completing the 5-day course of treatment (30% and 9.6%, respectively, for patients treated with lidocaine and placebo; $P = 0.012$). The 30% response for lidocaine underscores the high percentage of patients whose pain may be derived from extravesical sources. Long-acting local anesthetics such as bupivacaine have been suggested in combination with or replacing lidocaine; however, no controlled trails have been performed for assessment. The clinician should note that lidocaine and similar preparations are associated with a tachyphylaxis. As such, patients should be monitored for decreasing efficacy of therapy over time.

Key Points: Intravesical Therapies

- The potential for high efficacy combined with safety and a low side-effect profile that is gained by applying a treatment directly to the bladder lining has made research into new methods of intravesical therapy a high priority of researchers and pharmaceutical companies.
- Patients in whom pain and other symptoms are not related directly to bladder pathology would not be expected to respond well to this type of organ-directed therapy.
- Although intravesical therapy may be helpful to control symptoms of IC/BPS, the frequency and duration of therapy and the value of maintenance therapy have not been well studied.

Intradetrusor Therapy

Onabotulinum Toxin-A (BTX-A).

Intradetrusor BTX-A is approved by the FDA for the treatment of refractory neurogenic bladder and OAB. BTX-A has been used effectively for years in different conditions associated with muscular hypercontractions and has been described for treatment of HTPFD and other associated pain syndromes (e.g., vulvodynia) with promising results (Bertolasi et al., 2009; Moldwin and Fariello, 2013; Morrissey et al., 2015). The drug is not FDA approved for use in IC/BPS, and, although results between studies have been inconsistent (Rahnama’i et al., 2018), mounting evidence suggests efficacy and low risk in selected cases and has prompted the suggestion that BTX-A be considered as fourth line therapy for IC/BPS (Hanno et al., 2015). Consideration for earlier-stage management may occur when dosing and templates for injection become more refined. As with intravesical instillations, this therapy is probably best suited to patients with what the clinician believes to be a bladder-centric phenotype.

The therapeutic potential of BTX-A for IC/BPS is related to factors beyond its known ability to temporarily inhibit the release of acetylcholine and other neurotransmitters. BTX-A also has analgesic properties (Rajkumar and Conn, 2004). Initially this effect was thought to be a result of relief of muscle spasm. However, botulinum has been shown to reduce peripheral sensitization by inhibiting the release of several neuronal signaling markers, including glutamate and substance P, and reducing *c-Fos* gene expression. It may affect the sensory feedback loop to the central nervous system by decreased input from the muscle tissue, possibly by inhibiting acetylcholine release from gamma motor neurons innervating intrafusal fibers of the muscle spindle (Rosales et al., 1996). It inhibits the release of sensory neurotransmitters from isolated bladder preparations in rat bladder models of both acute injury and chronic inflammation (Lucioni et al., 2008). Chronic inflammation and apoptosis is significantly reduced after repeated BTX-A injections in patients with IC/BPS (Shie et al., 2013). Intravesical BTX-A administration blocks the acetic acid–induced calcitonin gene–related peptide (CGRP) release from afferent nerve terminals in the bladder mucosal layer in rats (Chuang et al., 2004). In an animal model of bladder permeability barrier disruption, intravesical BTX-A minimized bladder irritability and restored afferent neural responses to baseline levels (Vemulakonda et al., 2005).

Two early RCTs showed no significant improvement from BTX-A above placebo; however, these results may have been related to injection sites that differ from other groups (e.g., periurethral) (Gottsch et al., 2010) or were performed with abobotulinum toxin A rather than onobotulinum toxin A in conjunction with therapies that have known potential benefit (e.g., bladder hydrodistention) (Manning et al., 2014). These studies were included in a meta-analysis of five RCTs, ultimately demonstrating a statistically significant improvement in subjective indices including visual analog scores for pain (Shim et al., 2016). A 1-year follow-up in 15 patients treated with 200 units of BTX-A in 20 mL of normal saline showed that the success rate fell from 86.6% at 3 months to 26.6% at 5 months and was 0 at 12 months (Giannantoni et al., 2008). Bladder biopsy 2 weeks after BTX-A intradetrusor injection showed that nerve growth factor production levels fell to those of controls in patients who responded (Liu et al., 2009).

Pinto et al. (2010) championed limiting injections to 100 units divided into 10 injection sites, all in the trigone. More than 50% of patients experienced efficacy with a duration of 9 months, and no voiding dysfunction was noted. There appears to be little tachyphylaxis associated with the treatment. Repeated injections at regular intervals, or when symptoms recur, remain effective (Kuo, 2013; Pinto et al., 2013). A recent RCT using 100 units trigonal BTX-A injections versus saline demonstrated a greater than 50% reduction in pain in 60% of BTX-A patients, versus 22% for placebo (Pinto et al., 2018). One downside of BTX-A is its inability to traverse the urothelial surface; hence the need for injection-based therapy. An innovative approach using instillation of liposome-encapsulated BTX-A to enhance its surface effect unfortunately did not show benefit above placebo (Chuang and Kuo, 2017). **Intradetrusor injection of onabotulinum toxin A appears to be a reasonable treatment for IC/BPS that is refractory to standard conservative, oral, and intravesical treatment** (Mangera et al., 2011; Yokoyama et al., 2012)**, meriting its incorporation to AUA guidelines as a fourth-line consideration** (Hanno et al., 2015). When injected into the trigone in 10-unit aliquots (100 units total), the risk for impaired bladder emptying seems to be minimized. Nevertheless, BTX-A should be used with caution in patients who present with symptoms and/or signs of incomplete bladder emptying.

Neuromodulation

The International Neuromodulation Society defines therapeutic neuromodulation as “the alteration of nerve activity through targeted delivery of a stimulus, such as electrical stimulation or chemical agents, to specific neurological sites in the body” (https://www.neuromodulation.com). This has appeal in the field of pelvic pain by its possible effect on transport or perception of pain-related information. Furthermore, its effects on pelvic floor behavior may mitigate symptoms from associated HTPFD.

Perhaps the simplest form of neuromodulation is **transcutaneous electrical nerve stimulation (TENS),** a simple and safe cutaneous method for pain relief of a variety of painful conditions (Fall, 1987). The mechanism by which conventional TENS presumably lessens pain is through the selective activation of large-diameter non-noxious afferents (Aβ fibers), thus affecting pain gate control. Another described mechanism is the release of endorphins and their precursors into the cerebrospinal fluid (Coutaux, 2017). As a secondary effect, urinary frequency may also be reduced.

Fall et al. (1980) were first to use electrical stimulation in IC/BPS, reporting on 14 women treated successfully with long-term intravaginal nerve stimulation or TENS. Subsequently, McGuire et al. (1983) noted improvement in 5 of 6 patients treated with electrical stimulation. In the most complete review of the subject (Fall and Lindstrom, 1994), 33 patients with IC/BPS with HLs and 27 patients without HLs were treated by means of suprapubic TENS. Favorable results or remission was described in 26% of patients without HLs and a surprising 54% of patients with HLs. Fall and Lindstrom (1994) caution that the experience is based on open studies, relatively few patients, and the knowledge of a significant placebo effect with peripheral pain stimulation. One of the major values of TENS is that it can easily be applied by patients in conjunction with other conservative management strategies. Further study with RCTs will be needed to determine efficacy. The best locations for electrode placement and stimulation settings still need to be determined (Fall, 2017).

Acupuncture's controversial role in the treatment of IC/BPS is discussed in the Conservative Therapies section earlier in this chapter.

Posterior tibial nerve stimulation (PTNS) was successful in 60% of 37 patients with symptoms of bladder overactivity in an uncontrolled Dutch study (van Balken et al., 2001). An Australian double-blind placebo-controlled study of transdermal posterior tibial nerve laser therapy showed no benefit in 56 patients when comparing active with placebo arms, but the placebo effect was remarkably strong, indicating the importance of such trials in evaluation of invasive therapies (O'Reilly et al., 2004). A Chinese study of PTNS twice weekly for 5 weeks in IC/BPS patients failed to show improvement in pain scores, and none of the 18 patients thought the treatment had a significant effect (Zhao et al., 2008). A more recent study of PTNS in 20 female IC/BPS patients with 12-weekly sessions found no clinically relevant improvements (Ragab et al., 2015). Taken as a whole, **there is little evidence to recommend PTNS for the pain associated with IC/BPS. An exception would be the patient who presents with symptoms of DO.**

Sacral neuromodulation (SNM) for IC/BPS, usually entailing electrical stimulation of the S3 sacral nerve, was developed through the basic and clinical research of Fandel and Tanagho (2005) and Schmidt (1993). Its current FDA-approved use in urology is for the treatment of nonobstructive urinary retention and the symptoms of OAB, including urinary urge incontinence and significant symptoms of urgency-frequency alone or in combination, in patients who have failed or could not tolerate more conservative treatments. SNM has also received FDA approval for the treatment of fecal incontinence. The device is not FDA approved for the treatment of IC/BPS; however, treatment results in this population have been encouraging (Peters, 2017). Treatment benefits for IC/BPS may be related to effects on pain gate regulation at the spinal segmental and higher levels, endorphin release, and modulation of pelvic floor muscle behavior (Rahnama'i, et al., 2018). In fact, many have observed that patients who do best with this treatment are those who have identifiable pain *and* HTPFD (Aboseif et al., 2002; Everaert et al., 2001; Siegel et al., 2001). Patients reporting pelvic pain in the absence of demonstrable pelvic floor dysfunction and levator tenderness did poorly (Schmidt, 2001). Decreases in urinary chemokines (most notably MCP-1) have been associated with favorable treatment responses (Peters et al., 2015). A successful test stimulation produced a decrease in antiproliferative activity and normalization of HB-EGF levels (Chai et al., 2000a).

A staged approach to device implantation (usually 1 to 4 weeks), as compared with a 3- to 4-day temporary electrode placement appears to improve final implantation rates (Baxter and Kim, 2010; Peters et al., 2003). Long-term efficacy related to these differences in technique is unknown.

Studies on the therapeutic potential of electrical stimulation for IC/BPS began in the late 1990s (van Kerrebroeck, 1999) followed by the use of SNM for intractable pelvic pain in 10 patients. This study showed improvement in 6 patients at a median of 19 months (Siegel et al., 2001). Peters et al. (2003) reported success in two-thirds of IC/BPS patients with sacral nerve stimulation. A single-blind, randomized crossover trial of sacral versus pudendal nerve stimulation suggested that direct stimulation of the pudendal nerve might achieve higher success rates (Peters et al., 2007). **Several studies, albeit largely uncontrolled, now attest to the benefits of sacral neuromodulation for IC/BPS** (Comiter, 2003; Ghazwani et al., 2011; Lavano et al., 2006; Marinkovic et al., 2011; Tirlapur et al., 2013b; Vaarala et al., 2011). Evaluation of long term outcomes show a mean reduction of visual analog pain scores varying from 41% to 63% (Elhilali et al., 2005; Gajewski et al., 2011; Ghazwani et al., 2011; Marinkovic et al., 2011; Powell and Kreder, 2010; Rahnama'i et al., 2018). **These reports and expert opinion have placed SNM as suggested fourth-line therapy in AUA guidelines, now recommended alongside BTX-A and pain management interventions.**

Unilateral stimulation should be performed before bilateral sacral stimulation is considered (Oerlemans and van Kerrebroeck, 2008). A bilateral test stimulation could be indicated when a unilateral test fails (Steinberg et al., 2007). The only prospective randomized crossover trial to compare the unilateral with bilateral sacral nerve stimulation found no significant differences comparing the results (Scheepens et al., 2002). The presence of pain is a predictor of adverse events (White et al., 2009), and although sacral neuromodulation is effective in 56% of patients with urgency and frequency, when pain is the major complaint, caution is indicated.

Although sacral neuromodulation can significantly decrease opioid requirements in refractory IC/BPS, the majority of patients taking chronic opioids for pain will likely continue to use them for pain relief even after implantation (Peters and Konstandt, 2004). Treatment results do not appear to be age dependent (Peters et al., 2013). Sexual functioning in women may improve as well (Yih et al., 2013). The presence of urgency may be a positive predictor of long-term success (Gajewski and Al-Zahrani, 2011). When used for IC/BPS symptoms, frequent reprogramming is often required (Maxwell et al., 2008). Dorsal root ganglion, spinal cord, and deep brain stimulation are procedures that may have a role in the treatment of pelvic pain syndromes in the future. Literature is scarce and mainly limited to case studies of pelvic pain unrelated to IC/BPS (Roy et al., 2018).

Key Points: Neuromodulation

- Multiple forms of neuromodulation may improve symptoms of IC/BPS. TENS is probably underutilized by practitioners and may serve a role as conservative self-therapy.
- Although PTNS has shown efficacy for LUTS, its role in the management of pelvic pain is questionable.
- BTX-A and SNM are recommended as fourth-line options for IC/BPS. The clinician might favor SNM over BTX-A in those patients with obstructive voiding symptoms and/or pain related to HTPFD.

Surgical Therapy

Hydrodistention

Hydrodistention of the bladder under anesthesia has been used as a treatment for IC/BPS since its original description in 1922 by Frontz. Since that time, varied methods have been explored with a technical focus on duration of distention and intravesical pressure applied. Reports of hydrodistention with systolic pressures as end points and durations of up to 3 hours showed good symptomatic results but unacceptable adverse events such as bladder rupture (Dunn et al., 1977). A more recent similar study using a balloon distention technique had equivalent results (Glemain et al., 2002). These initial observations made clinicians keenly aware that the bladder in IC patients can be very thin. **The possibility of perforation or rupture during any hydrodistention must always be kept in mind and discussed with the patient** (Badenoch, 1971; Hamer et al., 1992). Further observations suggested that **prolonged distention probably has little or no benefit over a short-term distention measured in minutes** (McCahy and Styles, 1995; Taub and Stein, 1994)**. AUA guidelines suggest that short-duration (1- to 3-minute), low-pressure (60- to 80-cm H_2O) bladder hydrodistention be considered as a third-line treatment option** (Hanno et al., 2015).

Our method is to perform an initial cystoscopic examination (the findings of which are usually unremarkable), and distend the bladder for 1 to 2 minutes at a pressure of 80 cm H_2O. The bladder should be inspected throughout the procedure as tears of the mucosa or deeper can occur rapidly. Digital compression of the urethra against the cystoscope may be needed if urine leakage occurs during filling. The bladder is emptied and then refilled to allow observation for glomerulations. A therapeutic hydraulic distention follows for another several minutes. Biopsy is rarely necessary in the setting of therapeutic hydrodistention, but, if needed, it should be done *after* the hydrodistention is completed to avoid perforation. Patients should be counseled that a postprocedural flare in symptoms is a common occurrence often necessitating short-course therapy using agents as varied as urinary anesthetics and opioids. Placement of an intravesical anesthetic may improve postprocedural discomfort. Hoke et al. (2016) retrospectively reviewed their experience using a transvaginal trigonal nerve block to improve the response to hydrodistention. Although the block did not appear to have any effect as compared with hydrodistention patients not receiving the block, the postoperative improvements in pain were impressive, with a 51% to 64% reduction in pain scores 1 month after the procedure. Therapeutic responses in patients with a bladder capacity under anesthesia of less than 600 mL showed 26% with excellent results and 29% with fair results compared with 12% with excellent results and 43% with fair results in patients with larger bladder capacities (Hanno and Wein, 1991). Most favorable responses were extremely brief. The rare patient experiencing long-term improvement (>6 months) would be a candidate for repeat therapeutic distention. Favorable results were reported combining hydrodistention and BTX-A for IC/BPS (Kuo and Chancellor, 2009), ketamine cystitis (Zeng et al., 2017), and GAG therapy (Shao et al., 2010).

Hydrodistention has no benefits for patients with DO (McCahy and Styles, 1995; Taub and Stein, 1994). Over one-half of men with “prostate pain” and without bacteriuria may have glomerulations. Symptoms in this group have been reported to improve with hydrodistention (Berger et al., 1998), yet another example of the pathophysiologic crossover between these conditions.

A review of cystodistention by Olson et al. (2018) was condemning, citing that the “quality of available evidence falls below the level that would be expected of a new intervention before widespread usage, particularly in the context of evidence-based medicine.” They advocated for its use to be restricted to those enrolled in an RCT or as part of a standardized national/international protocol with uniform technique and PROMs. Despite these admonitions, acute hydrodistention does not appear to result in any long-term bladder dysfunction (Kang et al., 1992; Lasanen et al., 1992) or decrease in capacity (Kirk et al., 2018), and clinical experience has been generally favorable. Nevertheless, further RCTs assessing the efficacy of hydrodistention are needed if the procedure is to remain as a viable third-line option.

Surgical Considerations

Nowhere in the treatment of IC/BPS does the caveat *primum non nocere* bear more relevance than when considering surgical options. **Although the high success rate/low complication rate for cystoscopy with fulguration of HLs merits its place as a third-line treatment option, major reconstructive procedures (sixth-line care) should be entertained only when all trials of conservative treatment have failed.** One worst-case scenario is the patient who develops significant postoperative complications and is still in pain, a situation that highlights the difficulties entailed with patient selection. Conversely, suicides have been attributed to unremitting pain where more aggressive intervention was withheld. When moving forward with a major surgical procedure, the clinician must feel that the patient has realistic expectations regarding risks and outcomes. If this is not felt to be the case, further counseling will be needed. Surgery should be reserved for the motivated and well-informed patient who falls into the category of having extremely severe, unresponsive disease, a group that comprises less than 10% of patients (Irwin and Galloway, 1994; Parsons, 2000).

Historical Procedures

Many surgical approaches have been employed for IC, and it is worth mentioning a few for historical perspective alone. Sympathectomy and intraspinal alcohol injections have been used to treat pelvic pain (Greenhill, 1947). Differential sacral neurotomy was reported in three patients with favorable results (Meirowsky, 1969), but like most deinnervation procedures never gained popularity because of subsequent poor results. Transvesical infiltration of the pelvic plexuses with phenol failed in 5 of 5 patients with IC (Blackford et al., 1984). With a significant complication rate of 17% (McInerney et al., 1991), it is rarely if ever currently used for sensory urgency disorders or detrusor hyperreflexia. There are several reports on cystolysis going back to Richer in 1929 (Bourque, 1951). Worth and Turner-Warwick reported some short-term benefit, but unpredictable long-term results (Worth, 1980; Worth and Turner-Warwick, 1973). Freiha and Stamey (1979) used cystolysis in six IC patients with favorable results in four. Albers and Geyer (1988) reported long-term follow-up in 11 IC patients and only 1 success. Denervation procedures have a notoriously high late-failure rate, and the procedure is not justified for IC/BPS (Stone, 1991; Walsh, 1985). In fact, Rogers (2003) concluded that there are no convincing clinical studies to recommend surgical procedures to interrupt visceral nerve pathways in women with any type of chronic pelvic pain.

Surgery for Hunner Lesion

Transurethral resection of an HL as initially reported by Kerr (1971), can provide symptomatic relief. Fall resected ulcerated lesions in 30 patients, resulting in initial disappearance of pain in all and a decrease in urinary frequency in 21 (Fall, 1985). Similar results have been attained with the neodymium: yttrium-aluminum-garnet (YAG) laser (Rofeim et al., 2001; Shanberg et al., 1985, 1989). Extreme caution is critical with use of a laser in the IC/BPS bladder, because forward scatter through these thin bladders with resulting bowel injury is an ever-present danger. As fulguration appears to be a relatively safe and effective technique, there would seem to be little justification to use laser for the treatment of HLs. Applying energy of any sort to glomerulations or to tissue having normal appearance is unlikely to benefit the patient (Shanberg et al., 1997).

Fulguration with low energy settings usually entails the use of a rollerball or bugbee electrode. Rapid development of surrounding hyperemia and edema is a hallmark finding seen during HL fulguration; these effects likely secondary to release of vasoactive substances from the inflamed tissue. The majority of patients require repeat fulguration as recurrence of the lesions and symptoms is to be expected over ensuing months to years (Hillelsohn et al., 2012). The use of an injectable steroid has the theoretical advantage of treating a focal inflammatory disease (although field changes have been noted) and preventing the development of bladder wall fibrosis and decrease in bladder capacity. Submucosal injection of 10 mL of 40 mg/mL **triamcinolone acetonide** injected in 0.5-mL aliquots was used for the treatment of HLs in 30 patients (Cox et al., 2009). Seventy percent of patients were very much improved, and duration of improvement was estimated to be 7 to 12 months. Similar benefits were derived from lower (66 mg) triamcinolone dosing (Funaro et al., 2018). The surgeon should be aware that injection of an HL is not as benign a process as BTX-A injection in the office. These are vascular lesions that often bleed when injected, often necessitating some fulguration.

Major Surgical Procedures

Proper patient selection and education is crucial when contemplating a major surgical procedure for the IC/BPS patient as risks include potentially devastating surgical complications and the suboptimal control of pain. On the other hand, every practitioner in this field knows the pure joy expressed by the patient whose chronic, life-altering symptoms are no longer present. As one might imagine, the patient most likely to respond to urinary diversion/substitution with or without cystectomy is one whose symptoms are generated solely or at least primarily by the bladder. It is therefore of great importance to identify and treat any other pain generators of the pelvis that might be present. As noted earlier in this chapter, HTPFD is the most common finding, but it is important to keep in mind that myalgia of the pelvic floor may be a consequence of bladder pain. Other factors that often clue the clinician to a bladder source of pain are the reproduction of the pain with bladder filling/palpation and urinary frequency that is driven by that pain. A profound reduction in bladder pain with the intravesical instillation of an anesthetic may also reflect a bladder source of pain. Brookoff and Sant (1997) proposed trying a differential spinal anesthetic block before considering cystectomy. If the patient continues to perceive bladder pain after a spinal anesthetic at the T10 level, it can be taken as an indicator that the pain signal is being generated at a higher level in the spinal cord and that surgery on the bladder will not result in pain relief. Some patients with intractable urinary frequency will opt for simple conduit urinary diversion alone, feeling that their QoL will be improved independent of the pain piece of the puzzle. Of course, treatment outcomes would be much more predictable in the patient with a poor QoL in the setting of HLs and a small, contracted, “end-stage” bladder unresponsive to conservative measures.

“Less Is More”

Bladder diversion, replacement, or augmentation is an attractive alternative to the standard ileal conduit and cystectomy for the young, otherwise healthy patient. Apart from carrying higher immediate and delayed postoperative risks, many can produce further difficulties for the patient, including pain, that will be discussed later. These factors must be kept in mind when considering anything but the simplest form of diversion possible.

Urinary diversion with or without cystourethrectomy is the ultimate surgical answer to the dilemma of IC/BPS, akin to cutting the “Gordian knot.” Most patients will have relief from pain with or without simple cystectomy, suggesting that it is bladder distention or the contact with agents in urine that drive the pain (Nordling and Blaivas, 2014; Redmond and Flood, 2017). Leaving the bladder in situ is clearly associated with lower morbidity, but the potential for future problems including pyocystis, hemorrhage, severe pain, and unremitting feelings of incomplete emptying and spasm (Adeyoju et al., 1996; Eigner and Freiha 1990). Bladder carcinoma has also been reported after urinary diversion but is not specifically associated with IC/BPS (Hanno and Tomaszewski, 1982). Theoretically, conduit diversion seems to be reasonable if one is concerned about disease occurring in any continent storage type of reconstruction. Although the simplest approach, urinary diversion is not without risk. A Finnish group noted failure in 2 of 4 patients treated with cystectomy and conduit diversion because of persistent pain (Lilius et al., 1973). Baskin and Tanagho (1992) also cautioned about persistence of pelvic pain after cystectomy and continent diversion, discussing three such patients, and this has been the basis for discussion of HTPFD as a confusable source of pelvic pain. A similar report followed (Irwin and Galloway, 1992).

Supratrigonal cystectomy and the formation of an enterovesical anastomosis with bowel segments (substitution cystoplasty) has been a popular surgical procedure for intractable IC/BPS. The diseased bladder is resected in its entirety, sparing only a 1-cm cuff around the trigone to which the bowel segment is anastomosed (Irwin and Galloway, 1994; Worth et al., 1972). Although it is not always clear in the literature how much bladder has been resected, the results reported using these procedures for IC/BPS have been mixed at best. Badenoch operated on 9 patients, with 4 becoming much worse and 3 ultimately undergoing urinary diversion (Badenoch, 1971). Flood et al. (1995) reviewed 122 augmentation procedures, 21 of which were done for IC/BPS. Patients with IC/BPS had the most unfavorable results of any group, with only 10 having an “excellent” outcome. Wallack et al. (1975) reported 2 successes; Seddon et al. (1977) had success in 7 of 9 patients; and Freiha et al. (1980) ended up performing formal urinary diversion in 2 of 6 patients treated with augmentation cecocystoplasty. Weiss et al. (1984) had success in 3 of 7 patients treated with sigmoidocystoplasty, and Lunghi et al. (1984) had no excellent results in 2 patients with IC/BPS. Webster and Maggio (1989) reviewed their data in 19 patients and concluded that only patients with bladder capacities under anesthesia less than 350 mL should undergo substitution cystoplasty. Hughes et al. (1995) lowered the threshold to less than 250 mL.

More recent series on subtotal cystectomy plus augmentation have been somewhat more positive (Chesa et al., 2001; Costello et al., 2000). Peeker et al. (1998) had favorable results in all 10 patients with ulcerative IC/BPS but unfavorable results in the 3 patients operated on without HLs. He no longer performs the procedure in the latter group. Linn et al. (1998) had success in 20 of 23 patients (only 2 with IC/BPS with HLs) treated with subtotal cystectomy and orthotopic bladder substitution with an ileocecal pouch. He recommends a supratrigonal cystectomy. A Spanish series reported success in 13 of 17 procedures with a mean follow-up of 94 months (Rodriguez Villamil et al., 1999). The University of Alabama group reported long-term success in 1 of 4 patients with orthotopic neobladders and 1 of 3 with augmentation cystoplasty (Lloyd, 1999). A German report on substitution cystoplasty sparing the trigone was quite enthusiastic, detailing a 78% pain-free rate in 18 patients treated with ileocecal augmentation (10) or ileal substitution (8) at a mean follow-up of 57 months (van Ophoven et al., 2002). Two patients failed to get any pain relief, and 4 required either long-term intermittent catheterization or suprapubic drainage to empty the neobladder. The results of standard bladder augmentation are significantly worse than seen with supratrigonal resection and bowel augmentation. Enterocystoplasty performed for 7 IC/BPS patients showed failure in all patients, and 67 of 69 patients treated for other benign diagnoses were either cured or improved (Blaivas et al., 2005).

From a purely conceptual perspective, a **supratrigonal cystectomy with augmentation cystoplasty** would seem to be the perfect procedure: one that can remove the pain-producing tissue, maintain urethral voiding, and avoid “the bag.” Unfortunately, even in patients with HLs, any remnant of tissue left above the trigone may become inflamed and produce further pain. Patients with preexisting urethral pain would be poor candidates for this approach, as upwards of 30% of patients will need to self-catheterize because of poor emptying. Many will also need to perform intermittent bladder irrigations to remove collected mucus. These factors along with the previously described reports of suboptimal benefit need to be considered when choosing this approach.

Bejany and Politano reported excellent results in 5 patients treated with total bladder replacement and recommended **neobladder reconstruction** (Bejany and Politano, 1995). A Thai experience using cystectomy and ileal neobladder in women in whom conservative therapy failed reported favorable results in all 35 patients treated (Kochakarn et al., 2007). Spontaneous voiding with minimal residual urine was found in 33 patients, and the remaining 2 patients had spontaneous voiding with residual urine requiring clean intermittent catheterization.

Keselman et al. (1995) had 2 failures in 11 patients treated with **continent diversion** and attributed this to surgical complications. Webster et al. (1992) had 10 failures in 14 patients treated with urinary diversion and cystectourethrectomy. Ten patients had persistent pelvic pain, and 4 of them also complained of pouch pain with only 2 patients noting symptom resolution. An English study of 27 patients who underwent cystectomy and bladder replacement with a Kock pouch noted successful treatment of pain in all patients, but follow-up was limited (Christmas et al., 1996). Parsons (2000) suggests that pouch pain will occur in 40% to 50% of patients within 6 to 36 months of surgery. In the event of neobladder pain after subtotal cystectomy and enterocystoplasty or continent diversion, it appears safe to retubularize a previously used bowel segment to form a urinary conduit for a straightforward urinary diversion without significant risk for conduit pain (Elzawahri et al., 2004).

Rössberger et al. (2007) shared their experience with 47 IC/BPS patients subjected to reconstructive or extirpative surgery, 34 of whom had classic HLs. Surgeries for the entire group included 23 substitution cystoplasties, 12 conduit diversions, and 10 Kock pouches. Twenty-eight of these 34 patients with HLs had complete symptom resolution from the initial surgical procedure. Four of the remaining 6 required urinary diversion, cystectomy, or HL resection in a trigonal remnant, but ultimately did well. Only 3 of 13 patients with non-Hunner IC/BPS had successful symptom resolution after reconstructive surgery, 2 of whom required conduit diversion. These results make one wonder whether an ileal conduit with cystectomy would have been a better initial approach for many of these patients.

Key Points: Surgical Therapy

- Major surgery for IC/BPS is a reasonable alternative for patients with severe symptoms in whom standard attempts at treatment have failed and when the disease course suggests that spontaneous remission of symptoms is unlikely.
- Patients with a small bladder capacity under anesthesia are less likely to respond to conservative attempts at therapy.
- Patients with HLs may have the best results with major surgery.
- Although pain is usually the dominant feature of IC/BPS, unremitting urinary frequency refractory to conservative therapies may be an indication to proceed with urinary diversion.
- Diversion, and even cystectomy with diversion, cannot guarantee a pain-free result, and it is critical for the patient to factor this into the decision about this often irrevocable step.
- A simple ileal conduit or continent diversion without cystectomy can be an acceptable treatment choice with favorable clinical results.
- Subtotal cystectomy with bladder augmentation may fail to give pain relief in more than one-third of patients (Andersen et al., 2012).

Final Thoughts

While a urology fellow, I (RM) listened to Phil Hanno lecturing about IC (as nomenclature directed at that time), likening the condition to a hole in the air…a vagueness that was hard to see or grasp from every clinical direction. Now, more than ever before, this metaphor holds true for a condition defined by a set of symptoms. The well-known heterogeneity of IC/BPS has confounded all clinical research, and, unfortunately, no animal model to date can reproduce the complexities of the IC/BPS universe.

What is essential moving forward is further work in the realm of phenotyping, both on a clinical and bench-top level. One major development stressed in this chapter is the growing acceptance of IC/BPS with HLs as a group that distinguishes itself demographically, pathologically, and, most importantly, in terms of clinical response to varied therapies from those without these lesions. Could patients with HLs represent a group with enough pathologic consistency to be ideal for future therapeutic trials? Work underway by the MAPP Network has already begun to find clusters of patients that may have differential responses to therapies. In the end, the development of biomarkers may not be helpful at defining the IC/BPS patient. Rather, the hope is that they will help guide the clinician toward therapies that will be of most benefit. Clinical phenotyping strategies have already been scrutinized to help clinicians establish the source(s) of pelvic pain in rapid fashion and to help foster better therapeutic outcomes.

A phenotypic approach to patient care is all well and good, and we are getting there, but the look of concern and fearfulness that we see from so many of our patients needs to be addressed by taking time to listen, to educate, and to work with them as partners in care. I am certain that these simple “human things” that clinicians do can improve the quality of a patient's life more than many of the therapies discussed in our chapter.

Suggested Readings

Berry SH, Elliott MN, Suttorp M, et al. Prevalence of symptoms of bladder pain syndrome/interstitial cystitis among adult females in the United States. *J Urol*. 2011;186(2):540–544.

Clemens JQ, Mullins C, Ackerman AL, et al. Urologic chronic pelvic pain syndrome: insights from the MAPP Research Network. *Nat Rev Urol*. 2019;16(3):187–200.

FitzGerald MP, Payne CK, Lukacz ES, et al. Randomized multicenter clinical trial of myofascial physical therapy in women with interstitial cystitis/painful bladder syndrome and pelvic floor tenderness. *J Urol*. 2012;187(6):2113–2118.

Grigorescu B, Powers K, Lazarou G. Update on urinary tract markers in interstitial cystitis/bladder pain syndrome. *Female Pelvic Med Reconstr Surg*. 2016;22(1):16–23.

Hanno PM, Burks DA, Clemens JQ, et al. AUA guideline for the diagnosis and treatment of interstitial cystitis/bladder pain syndrome. *J Urol*. 2011;185(6):2162–2170.

Hanno PM, Erickson D, Moldwin R, et al. Diagnosis and treatment of interstitial cystitis/bladder pain syndrome: AUA Guideline Amendment. *J Urol*. 2015;193(5):1545–1553.

Henry RA, Morales A, Cahill CM. Female urology beyond a simple anesthetic effect: lidocaine in the diagnosis and treatment of interstitial cystitis/bladder pain syndrome. *Urology*. 2015;85(5):1025–1033.

Kuo TL, Ng LG, Chapple CR. Pelvic floor spasm as a cause of voiding dysfunction. *Curr Opin Urol*. 2015;25(4):311–316.

Lai HH, Krieger JN, Pontari MA, et al. Painful bladder filling and painful urgency are distinct characteristics in men and women with urological chronic pelvic pain syndromes: a MAPP Research Network Study. *J Urol*. 2015;194(6):1634–1641.

Nickel JC, Moldwin R. FDA BRUDAC 2018 criteria for interstitial cystitis/bladder pain syndrome clinical trials: future direction for research. *J Urol*. 2018;200(1):39–42.

Nickel JC, Tripp DA, Pontari M, et al. Interstitial cystitis/painful bladder syndrome and associated medical conditions with an emphasis on irritable bowel syndrome, fibromyalgia and chronic fatigue syndrome. *J Urol*. 2010;184(4):1358–1363.

Nordling J, Anjum FH, Bade JJ, et al. Primary evaluation of patients suspected of having interstitial cystitis (IC). *Eur Urol*. 2004;45(5):662–669.

Norus T, Fode M, Nordling J. Ileal conduit without cystectomy may be an appropriate option in the treatment of intractable bladder pain syndrome/interstitial cystitis. *Scand J Urol*. 2014;48(2):210–215.

Parsons JK, Parsons CL. The historical origins of interstitial cystitis. *J Urol*. 2004;171(1):20–22.

Sairanen J, Forsell T, Ruutu M. Long-term outcome of patients with interstitial cystitis treated with low dose cyclosporine A. *J Urol*. 2004;171:2138–2141.

Suskind AM, Berry SH, Ewing BA, et al. The prevalence and overlap of interstitial cystitis/bladder pain syndrome and chronic prostatitis/chronic pelvic pain syndrome in men: results of the RAND Interstitial Cystitis Epidemiology male study. *J Urol*. 2013;189(1):141–145.

Tam J, Loeb C, Grajower D, et al. Neuromodulation for chronic pelvic pain. *Curr Urol Rep*. 2018;19(5):32.

Tung A, Hepp Z, Bansal A, et al. Characterizing health care utilization, direct costs, and comorbidities associated with interstitial cystitis: a retrospective claims analysis. *J Manag Care Spec Pharm*. 2017;23(4):474–482.

References

Abdel-Mageed AB. NF-kappaB-dependent gene expression of proinflammatory cytokines in T24 cells: possible role in interstitial cystitis. *Urol Res*. 2003;31(5):300–305.

Abdel-Mageed AB, Ghoniem GM. Potential role of rel/nuclear factor-kappaB in the pathogenesis of interstitial cystitis. *J Urol*. 1998;160(6 Pt 1):2000–2003.

Abelli L, Conte B, Somma V, et al. Mechanical irritation induces neurogenic inflammation in the rat urethra. *J Urol*. 1991;146(6):1624–1626.

Aboseif S, Tamaddon K, Vhalfin S, et al. Sacral neuromodulation as an effective treatment for refractory pelvic floor dysfunction. *Urology*. 2002;60(1):52–56.

Abraham SN, Malaviya R. Mast cells in infection and immunity. *Infect Immun*. 1997;65:3501–3508.

Abramov Y, Goldberg RP, McGuire M, et al. Eosinophilic cystitis after bladder instillation with dimethyl sulfoxide. *Urology*. 2004;63(6):1182–1183.

Abrams P. Urgency: the key to defining the overactive bladder. *BJU Int*. 2005;96(1):1–3.

Abrams PH, Cardozo L, Fall M, et al. The standardisation of terminology of lower urinary tract function: report from the standardisation sub-committee of the International Continence Society. *Neurourol Urodyn*. 2002;21(2):167–178.

Abrams P, Andersson KE, Apostolidis A, et al. 6th International Consultation on Incontinence. Recommendations of the International Scientific Committee: evaluation and treatment of urinary incontinence, pelvic organ prolapse and faecal incontinence. *Neurourol Urodyn*. 2018;37(7):2271–2272.

Abelha-Aleixo J, Moura M, Bernardo A, et al. Lupus cystitis and repercussions of delayed diagnosis. *Acta Reumatol Port*.

2015;40(3):294–298.

Adeyoju AB, Thornhill J, Lynch T, et al. The fate of the defunctioned bladder following supravesical urinary diversion. *Br J Urol*. 1996;78(1):80–83.

Agarwal M, Dixon RA. A study to detect *Helicobacter pylori* in fresh and archival specimens from patients with interstitial cystitis, using amplification methods. *BJU Int*. 2003;91(9):814–816.

Agarwal MM, Elsi Sy M. Gabapentenoids in pain management in urological chronic pelvic pain syndrome: gabapentin or pregabalin? *Neurourol Urodyn*. 2017;36(8):2028–2033.

Aguiar LM, Franco I. Bladder bowel dysfunction. *Urol Clin North Am*. 2018;45(4):633–640.

Akiyama Y, Maeda D, Morikawa T, et al. Digital quantitative analysis of mast cell infiltration in interstitial cystitis. *Neurourol Urodyn*. 2017;37(2):650–657.

Akiyama Y, Niimi A, Nomiya A, et al. Extent of Hunner lesions: the relationships with symptom severity and clinical parameters in Hunner type interstitial cystitis patients. *Neurourol Urodyn*. 2018;37(4):1441–1447.

Akiyama Y, Homma Y, Maeda D. Pathology and terminology of interstitial cystitis/bladder pain syndrome: a review. *Histol Histopathol*. 2019;34(1):25–32.

Ahluwalia A, Giuliani S, Scotland R, et al. Ovalbumin-induced neurogenic inflammation in the bladder of sensitized rats. *Br J Pharmacol*. 1998;124(1):190–196.

Ahmad I, Sarath KN, Meddings RN. Sequential hydrodistension and intravesical instillation of hyaluronic acid under general anaesthesia for treatment of refractory interstitial cystitis: a pilot study. *Int Urogynecol J Pelvic Floor Dysfunct*. 2008;19(4):543–546.

Alagiri M, Chottiner S, Ratner V, et al. Interstitial cystitis: unexplained associations with other chronic disease and pain syndromes. *Urology*. 1997;49(5A Suppl):52–57.

Albers DD, Geyer JR. Long-term results of cystolysis (supratrigonal denervation) of the bladder for intractable interstitial cystitis. *J Urol*. 1988;139(6):1205–1206.

Aldenborg F, Fall M, Enerback L. Proliferation and transepithelial migration of mucosal mast cells in interstitial cystitis. *Immunology*. 1986;58(3):411–416.

Aldenborg F, Fall M, Enerback L. Mast cells in interstitial cystitis. *Ann Urol (Paris)*. 1989;23(2):165–166.

Alexacos N, Pang X, Boucher W, et al. Neurotensin mediates rat bladder mast cell degranulation triggered by acute psychological stress. *Urology*. 1999;53(5):1035–1040.

Al Hadithi H, Tincello DG, Vince GS, et al. Leukocyte populations in interstitial cystitis and idiopathic reduced bladder storage. *Urology*. 2002;59(6):851–855.

Allen-Brady K, Norton PA, Cannon-Albright L. Risk of associated conditions in relatives of subjects with interstitial cystitis. *Female Pelvic Med Reconstr Surg*. 2015;21(2):93–98.

Allen-Brady K, Rowe K, Cessna M, et al. Significant linkage evidence for interstitial cystitis/painful bladder syndrome on chromosome 3. *J Urol*. 2018;199(1):172–177.

Altman D, Lundholm C, Milsom I, et al. The genetic and environmental contribution to the occurrence of bladder pain syndrome: an empirical approach in a nationwide population sample. *Eur Urol*. 2011;59(2):280–285.

Altuntas CZ, Daneshgari F, Sakalar C, et al. Autoimmunity to uroplakin II causes cystitis in mice: a novel model of interstitial cystitis. *Eur Urol*. 2012;61(1):193–200.

Al-Zahrani AA, Gajewski JB. Long-term efficacy and tolerability of pentosan polysulphate sodium in the treatment of bladder pain syndrome. *Can Urol Assoc J*. 2011;5(2):113–118.

Andersen AV, Granlund P, Schultz A, et al. Long-term experience with surgical treatment of selected patients with bladder pain syndrome/interstitial cystitis. *Scand J Urol Nephrol*. 2012;46(4):284–289.

Anderson JB, Parivar F, Lee G, et al. The enigma of interstitial cystitis—an autoimmune disease? *Br J Urol*. 1989;63(1):58–63.

Anderstrom CR, Fall M, Johansson SL. Scanning electron microscopic findings in interstitial cystitis. *Br J Urol*. 1989;63(3):270–275.

Argade S, Shaw T, Su Y, et al. Tamm-Horsfall protein-associated nucleotides in patients with interstitial cystitis. *BJU Int*. 2013;111(5):811–819.

Arnold LM, Russell IJ, Diri EW, et al. A 14-week, randomized, double-blinded, placebo-controlled monotherapy trial of pregabalin in patients with fibromyalgia. *J Pain*. 2008;9(9):792–805.

Arora HC, Shoskes DA. The enigma of men with interstitial cystitis/bladder pain syndrome. *Transl Androl Urol*. 2015;4(6):668–676.

Arya LA, Northington GM, Asfaw T, et al. Evidence of bladder oversensitivity in the absence of an infection in premenopausal women with a history of recurrent urinary tract infections. *BJU Int*. 2012;110(2):247–251.

Atkinson TJ, Fudin J. Opioids and related medications. Springer International Publishing: Cham; 2017:165–190. *Urological and gynaecological chronic pelvic pain*. vol 10.

Atug F, Turkeri L, Atug O, et al. Detection of *Helicobacter pylori* in bladder biopsy specimens of patients with interstitial cystitis by polymerase chain reaction. *Urol Res*. 2004;32(5):346–349.

Awad SA, MacDiarmid S, Gajewski JB, et al. Idiopathic reduced bladder storage versus interstitial cystitis. *J Urol*.

1992;148(5):1409–1412.

Azadzoi KM, Tarcan T, Kozlowski R, et al. Overactivity and structural changes in the chronically ischemic bladder. *J Urol*. 1999;162:1768–1778.

Backonja M, Beydoun A, Edwards KR, et al. Gabapentin for the symptomatic treatment of painful neuropathy in patients with diabetes mellitus. *JAMA*. 1998;280(21):1831–1836.

Bade JJ, Rijcken B, Mensink HJ. Interstitial cystitis in the Netherlands: prevalence, diagnostic criteria and therapeutic preferences. *J Urol*. 1995;154(6):2035–2037.

Bade JJ, Marrink J, Karrenbeld A, et al. Increased urinary levels of Tamm-Horsfall glycoprotein suggest a systemic etiology of interstitial cystitis. *J Urol*. 1996;156(3):943–946.

Bade JJ, Laseur M, Nieuwenburg A, et al. A placebo-controlled study of intravesical pentosanpolysulphate for the treatment of interstitial cystitis. *Br J Urol*. 1997;79(2):168–171.

Badenoch AW. Chronic interstitial cystitis. *Br J Urol*. 1971;43(6):718–721.

Baker SC, Shabir S, Georgopoulos NT, et al. Ketamine-induced apoptosis in normal human urothelial cells: a direct, N-methyl-d-Aspartate receptor-independent pathway characterized by mitochondrial stress. *Am J Pathol*. 2016;186(5):1267–1277.

Baldessarini RJ. Drugs and the treatment of psychiatric disorders. *The pharmacological basis of therapeutics*. Macmillan: New York, NY; 1985:387–445.

Baranowski AP, Abrams P, Berger RE, et al. Urogenital pain—time to accept a new approach to phenotyping and, as a consequence, management. *Eur Urol*. 2008;53(1):33–36.

Barbanti G, Maggi CA, Beneforti P, et al. Relief of pain following intravesical capsaicin in patients with hypersensitive disorders of the lower urinary tract. *Br J Urol*. 1993;71(6):686–691.

Barker SB, Matthews PN, Philip PF, et al. Prospective study of intravesical dimethyl sulfoxide in the treatment of chronic inflammatory bladder disease. *Br J Urol*. 1987;59:142–144.

Baron R. Peripheral neuropathic pain: from mechanisms to symptoms. *Clin J Pain*. 2000;16(2 Suppl):S12–S20.

Barrett DM, Wein AJ. Voiding dysfunction: diagnosis, classification, and management. Gillenwater JY, Grayhack JT, Howards SS, et al. *Adult and pediatric urology*. Year Book: Chicago, IL; 1987:863–892.

Barrington JW, Stephenson TP. Pentosanpolysulphate for interstitial cystitis. *Int Urogynecol J Pelvic Floor Dysfunct*. 1997;8(5):293–295.

Baskin LS, Tanagho EA. Pelvic pain without pelvic organs. *J Urol*. 1992;147(3):683–686.

Bassaly R, Tidwell N, Bertolino S, et al. Myofascial pain and pelvic floor dysfunction in patients with interstitial cystitis. *Int Urogynecol J*. 2011;22(4):413–418.

Baxter C, Kim J-H. Contrasting the percutaneous nerve evaluation versus staged implantation in sacral neuromodulation. *Curr Urol Rep*. 2010;11(5):310–314.

Baykara M, Erdogru T, Gulkesen KH, et al. Does interstitial cystitis urine include possible factors effecting the nociceptive system of the spinal cord? *Urol Int*. 2003;71(1):66–72.

Beckett MK, Elliott MN, Clemens JQ, et al. Consequences of interstitial cystitis/bladder pain symptoms on women's work participation and income: results from a national household sample. *J Urol*. 2014;191(1):83–88.

Beier-Holgersen R, Hermann GG, Mortensen SO, et al. The in vitro cytotoxicity of urine from patients with interstitial cystitis. *J Urol*. 1994;151(1):206–207.

Bejany DE, Politano VA. Ileocolic neobladder in the woman with interstitial cystitis and a small contracted bladder. *J*

Urol. 1995;153(1):42–43.

Bennett RM. Emerging concepts in the neurobiology of chronic pain: evidence of abnormal sensory processing in fibromyalgia. *Mayo Clin Proc*. 1999;74(4):385–398.

Berger RE, Miller JE, Rothman I, et al. Bladder petechiae after cystoscopy and hydrodistension in men diagnosed with prostate pain. *J Urol*. 1998;159(1):83–85.

Berry SH, Elliott MN, Suttorp M, et al. Prevalence of symptoms of bladder pain syndrome/interstitial cystitis among adult females in the United States. *J Urol*. 2011;186(2):540–544.

Bertolasi L, Frasson E, Cappelletti JY, et al. Botulinum neurotoxin type A injections for vaginismus secondary to vulvar vestibulitis syndrome. *Obstet Gynecol*. 2009;114(5):1008–1016.

Bhone AW, Hodson JM, Rebuck JW, et al. An abnormal leukocyte response in interstitial cystitis. *J Urol*. 1962;88:387–391.

Biggers RD. Self-administration of dimethyl sulfoxide (DMSO) for interstitial cystitis. *Urology*. 1986;28(1):10–11.

Birder LA, Kanai AJ, de Groat WC. DMSO: effect on bladder afferent neurons and nitric oxide release. *J Urol*. 1997;158(5):1989–1995.

Birder LA, Wolf-Johnston A, Buffington CA, et al. Altered inducible nitric oxide synthase expression and nitric oxide production in the bladder of cats with feline interstitial cystitis. *J Urol*. 2005;173(2):625–629.

Bjorling DE, Wang ZY. Estrogen and neuroinflammation. *Urology*. 2001;57(6 Suppl 1):40–46.

Bjorling DE, Jerde TJ, Zine MJ, et al. Mast cells mediate the severity of experimental cystitis in mice. *J Urol*. 1999;162(1):231–236.

Bjorling DE, Wang ZY, Bushman W. Models of inflammation of the lower urinary tract. *Neurourol Urodyn*.

2011;30(5):673–682.

Blackford HN, Murray K, Stephenson TP, et al. Results of transvesical infiltration of the pelvic plexuses with phenol in 116 patients. *Br J Urol*. 1984;56(6):647–649.

Blaivas JG, Weiss JP, Desai P, et al. Long-term follow-up of augmentation enterocystoplasty and continent diversion in patients with benign disease. *J Urol*. 2005;173(5):1631–1634.

Blalock EM, Korrect GS, Stromberg AJ, et al. Gene expression analysis of urine sediment: evaluation for potential noninvasive markers of interstitial cystitis/bladder pain syndrome. *J Urol*. 2012;187(2):725–732.

Bodden-Heidrich R. Psychosomatic aspects of urogynaecology: model considerations on the pathogenesis, diagnosis and therapy. *Zentralbl Gynakol*. 2004;126(4):237–243.

Bogart LM, Suttorp MJ, Elliott MN, et al. Prevalence and correlates of sexual dysfunction among women with bladder pain syndrome/interstitial cystitis. *Urology*. 2011;77(3):576–580.

Bornstein J, Goldstein AT, Stockdale CK, et al. 2015 ISSVD, ISSWSH and IPPS consensus terminology and classification of persistent vulvar pain and vulvodynia. *Obstet Gynecol*. 2016;127(4):745–751.

Bosch PC. A randomized, double-blind, placebo controlled trial of adalimumab in the treatment of interstitial cystitis/bladder pain syndrome. *J Urol*. 2014;191(1):77–82.

Bouchelouche K, Kristensen B, Nordling J, et al. Increased urinary excretion of leukotriene E(4) in patients with interstitial cystitis. *Urology*. 2001;57(6 Suppl 1):128.

Bouchelouche K, Nordling J, Hald T, et al. Treatment of interstitial cystitis with montelukast, a leukotriene D(4) receptor antagonist. *Urology*. 2001;57(6 Suppl 1):118.

Boucher W, El Mansoury M, Pang X, et al. Elevated mast cell tryptase in the urine of patients with interstitial cystitis. *Br J*

Urol. 1995;76(1):94–100.

Boucher W, Stern JM, Kotsinyan V, et al. Intravesical nanocrystalline silver decreases experimental bladder inflammation. *J Urol*. 2008;179(4):1598–1602.

Boudry G, Labat JJ, Riant T, et al. Validation of voiding diary for stratification of bladder pain syndrome according to the presence/absence of cystoscopic abnormalities: a two-centre prospective study. *BJU Int*. 2013;112(2):E164–E168.

Bourque JP. Surgical management of the painful bladder. *J Urol*. 1951;65:25–34.

Boye E, Morse M, Huttner I, et al. Immune complex-mediated interstitial cystitis as a major manifestation of systemic lupus erythematosus. *Clin Immunol Immunopathol*. 1979;13(1):67–76.

Bracis R, Sanders CV, Gilbert DN. Methicillin hemorrhagic cystitis. *Antimicrob Agents Chemother*. 1977;12:438–439.

Braunstein R, Shapiro E, Kaye J, et al. The role of cystoscopy in the diagnosis of Hunner's ulcer disease. *J Urol*. 2008;180(4):1383–1386.

Bron C, Dommerholt JD. Etiology of myofascial trigger points. *Curr Pain Headache Rep*. 2012;16(5):439–444.

Brookoff D, Sant GR. The causes and treatment of pain in interstitial cystitis. Sant GR. *Interstitial cystitis*. Lippincott-Raven: Philadelphia, PA; 1997:177–192.

Buffington CA. Comorbidity of interstitial cystitis with other unexplained clinical conditions. *J Urol*. 2004;172(4 Pt 1):1242–1248.

Buffington CA. Developmental influences on medically unexplained symptoms. *Psychother Psychosom*. 2009;78(3):139–144.

Buffington CA. Idiopathic cystitis in domestic cats—beyond the lower urinary tract. *J Vet Intern Med*. 2011;25(4):784–796.

Buffington CA, Woodworth BE. Excretion of fluorescein in the urine of women with interstitial cystitis. *J Urol*. 1997;158(3 Pt 1):786–789.

Buffington CA, Wolfe SA Jr. High affinity binding sites for [3H]substance P in urinary bladders of cats with interstitial cystitis. *J Urol*. 1998;160:605–611.

Buffington CA, Pacak K. Increased plasma norepinephrine concentration in cats with interstitial cystitis. *J Urol*. 2001;165(6 Pt 1):2051–2054.

Buffington CA, Chew DJ, DiBartola SP. Interstitial cystitis in cats. *Vet Clin North Am Small Anim Pract*. 1996;26(2):317–326.

Buffington CA, Chew DJ, DiBartola SP. On the definition of feline interstitial cystitis. *J Am Vet Med Assoc*. 1999;215(2):186–188.

Buffington CA, Teng B, Somogyi GT. Norepinephrine content and adrenoceptor function in the bladder of cats with feline interstitial cystitis. *J Urol*. 2002;167(4):1876–1880.

Bullock AD, Becich MJ, Klutke CG, et al. Experimental autoimmune cystitis: a potential murine model for ulcerative interstitial cystitis. *J Urol*. 1992;148(6):1951–1956.

Bumpus HC. Interstitial cystitis: its treatment by overdistention of the bladder. *Med Clin North Am*. 1930;13:1495–1498.

Burford EH, Burford CE. Hunner ulcer of the bladder: a report of 187 cases. *J Urol*. 1958;79(6):952–955.

Burkhard FC, Blick N, Hochreiter WW, et al. Urinary urgency and frequency, and chronic urethral and/or pelvic pain in females. Can doxycycline help? *J Urol*. 2004;172(1):232–235.

Burnstock G. Release of vasoactive substances from endothelial cells by shear stress and purinergic mechanosensory transduction. *J Anat*. 1999;194(Pt 3):335–342.

Burnstock G. Targeting the visceral purinergic system for pain control. *Curr Opin Pharmacol*. 2012;12(1):80–86.

Bushman W, Goolsby C, Grayhack JT, et al. Abnormal flow cytometry profiles in patients with interstitial cystitis. *J Urol*. 1994;152(6 Pt 2):2262–2266.

Butrick CW, Sanford D, Hou Q, et al. Chronic pelvic pain syndromes: clinical, urodynamic, and urothelial observations. *Int Urogynecol J Pelvic Floor Dysfunct*. 2009;20(9):1047–1053.

Buzzega D, Maccari F, Galeotti F, et al. Determination of urinary hexosamines for diagnosis of bladder pain syndrome. *Int Urogynecol J*. 2012;23(10):1367–1372.

Byrne DS, Sedor JF, Estojak J, et al. The urinary glycoprotein GP51 as a clinical marker for interstitial cystitis. *J Urol*. 1999;161(6):1786–1790.

Cameron AP, Gajewski JB. Bladder outlet obstruction in painful bladder syndrome/interstitial cystitis. *Neurourol Urodyn*. 2009;28(8):944–948.

Carlson KV, Rome S, Nitti VW. Dysfunctional voiding in women. *J Urol*. 2001;165(1):143–147 [discussion 147–148].

Cartledge JJ, Davies AM, Eardley I. A randomized double-blind placebo-controlled crossover trial of the efficacy of l-arginine in the treatment of interstitial cystitis. *BJU Int*. 2000;85(4):421–426.

Cassuto J, Sinclair R, Bonderovic M. Anti-inflammatory properties of local anesthetics and their present and potential clinical implications. *Acta Anaesthesiol Scand*. 2006;50(3):265–282.

Caulfield J, Phillips R, Steinhardt G. Intravesical heparin instillation: is there systemic absorption? *J Urol*. 1995;153:289A.

Cervigni M. Interstitial cystitis/bladder pain syndrome and glycosaminoglycans replacement therapy. *Transl Androl Urol*. 2015;4(6):638–642.

Cervigni M, Natale F, Nasta L, et al. A combined intravesical therapy with hyaluronic acid and chondroitin for refractory painful bladder syndrome/interstitial cystitis. *Int Urogynecol J Pelvic Floor Dysfunct*. 2008;19(7):943–947.

Cervigni M, Natale F, Nasta L, et al. Intravesical hyaluronic acid and chondroitin sulphate for bladder pain syndrome/interstitial cystitis: long-term treatment results. *Int Urogynecol J*. 2012;23(9):1187–1192.

Cervigni M, Sommariva M, Tenaglia R, et al. A randomized, open-label, multicenter study of the efficacy and safety of intravesical hyaluronic acid and chondroitin sulfate versus dimethyl sulfoxide in women with bladder pain syndrome/interstitial cystitis. *Neurourol Urodyn*. 2016;36(4):1178–1186.

Chai TC, Zhang C, Warren JW, et al. Percutaneous sacral third nerve root neurostimulation improves symptoms and normalizes urinary HB-EGF levels and antiproliferative activity in patients with interstitial cystitis. *Urology*. 2000;55(5):643–646.

Chai TC, Zhang CO, Shoenfelt JL, et al. Bladder stretch alters urinary heparin-binding epidermal growth factor and antiproliferative factor in patients with interstitial cystitis. *J Urol*. 2000;163(5):1440–1444.

Chancellor MB, Shenot PJ, Rivas DA, et al. Urological symptomatology in patients with reflex sympathetic dystrophy. *J Urol*. 1996;155:634–637.

Check JH, Cohen G, Cohen R, et al. Sympathomimetic amines effectively control pain for interstitial cystitis that had not responded to other therapies. *Clin Exp Obstet Gynecol*. 2013;40(2):227–228.

Chelimsky G, Heller E, Buffington CA, et al. Co-morbidities of interstitial cystitis. *Front Neurosci*. 2012;6:114.

Chelsky MJ, Rosen SI, Knight LC, et al. Bladder permeability in interstitial cystitis is similar to that of normal volunteers:

direct measurement by transvesical absorption of 99mtechnetium-diethylenetriaminepentaacetic acid. *J Urol*. 1994;151(2):346–349.

Chen CH, Lee MH, Chen YC, et al. Ketamine-snorting associated cystitis. *J Formos Med Assoc*. 2011;110(12):787–791.

Chen H, Wang F, Chen W, et al. Efficacy of daily low-dose sildenafil for treating interstitial cystitis: results of a randomized, double-blind, placebo-controlled trial—treatment of interstitial cystitis/painful bladder syndrome with low-dose sildenafil. *Urology*. 2014;84(1):51–56.

Chen MH, Li CT, Lin WC, et al. Cognitive function of patients with treatment-resistant depression after a single low dose of ketamine infusion. *J Affect Disord*. 2018;241:1–7.

Chesa PN, Armas MJ, Artiles Hernandez JL, et al. Enterocystoplasty in the treatment of interstitial cystitis. *Actas Urol Esp*. 2001;25(7):489–492.

Choe JH, Son H, Song YS, et al. Prevalence of painful bladder syndrome/interstitial cystitis-like symptoms in women: a population-based study in Korea. *World J Urol*. 2011;29(1):103–108.

Christensen MM, Keith I, Rhodes PR, et al. A guinea pig model for study of bladder mast cell function: histamine release and smooth muscle contraction. *J Urol*. 1990;144(5):1293–1300.

Christmas TJ. Lymphocyte sub-populations in the bladder wall in normal bladder, bacterial cystitis and interstitial cystitis. *Br J Urol*. 1994;73(5):508–515.

Christmas TJ, Rode J. Characteristics of mast cells in normal bladder, bacterial cystitis and interstitial cystitis. *Br J Urol*. 1991;68(5):473–478.

Christmas TJ, Rode J, Chapple CR, et al. Nerve fibre proliferation in interstitial cystitis. *Virchows Arch A Pathol Anat Histopathol*. 1990;416(5):447–451.

Christmas TJ, Holmes SA, Hendry WF. Bladder replacement by ileocystoplasty: the final treatment for interstitial cystitis. *Br J Urol*. 1996;78(1):69–73.

Chuang YC, Kuo HC. A prospective, multicenter, double-blind, randomized trial of bladder instillation of liposome formulation onabotulinumtoxina for interstitial cystitis/bladder pain syndrome. *J Urol*. 2017;198(2):376–382.

Chuang YC, Yoshimura N, Huang CC, et al. Intravesical botulinum toxin A administration produces analgesia against acetic acid induced bladder pain responses in rats. *J Urol*. 2004;172(4 Pt 1):1529–1532.

Chudwin DS, Chesney PJ, Mischler EH, et al. Hematuria associated with carbenicillin and other semisynthetic penicillins (letter). *Am J Dis Child*. 1979;133:98–99.

Chung MK. Interstitial cystitis in persistent posthysterectomy chronic pelvic pain. *JSLS*. 2004;8(4):329–333.

Clauw DJ, Schmidt M, Radulovic D, et al. The relationship between fibromyalgia and interstitial cystitis. *J Psychiatr Res*. 1997;31(1):125–131.

Clemens JQ, Meenan RT, O'Keeffe Rosetti MC, et al. Prevalence of interstitial cystitis symptoms in a managed care population. *J Urol*. 2005;174(2):576–580.

Clemens JQ, Brown SO, Calhoun EA. Mental health diagnoses in patients with interstitial cystitis/painful bladder syndrome and chronic prostatitis/chronic pelvic pain syndrome: a case/control study. *J Urol*. 2008;180(4):1378–1382.

Clemens JQ, Meenan RT, O'Keeffe Rosetti MC, et al. Case-control study of medical comorbidities in women with interstitial cystitis. *J Urol*. 2008;179(6):2222–2225.

Clemens JQ, Calhoun EA, Litwin MS, et al. Validation of a modified National Institutes of Health chronic prostatitis symptom index to assess genitourinary pain in both men and women. *Urology*. 2009;74(5):983–987.

Clemens JQ, Markossian T, Calhoun EA. Comparison of economic impact of chronic prostatitis/chronic pelvic pain syndrome and interstitial cystitis/painful bladder syndrome. *Urology*. 2009;73(4):743–746.

Clemens JQ, Bogart LM, Liu K, et al. Perceptions of “urgency” in women with interstitial cystitis/bladder pain syndrome or overactive bladder. *Neurourol Urodyn*. 2011;30(3):402–405.

Clemens JQ, Clauw DJ, Kreder K, et al. Comparison of baseline urological symptoms in men and women in the MAPP research cohort. *J Urol*. 2015;193(5):1554–1558.

Clemens JQ, Stephens-Shields A, Naliboff BD, et al. Correlates of health care seeking activities in patients with urological chronic pelvic pain syndromes: findings from the MAPP cohort. *J Urol*. 2018;200(1):136–140.

Clemens JQ, Mullins C, Ackerman AL, et al. Urologic chronic pelvic pain syndrome: insights from the MAPP Research Network. *Nat Rev Urol*. 2019;16(3):187–200.

Clemmensen OJ, Lose G, Holm-Bentzen M, et al. Skin reactions to urine in patients with interstitial cystitis. *Urology*. 1988;32(1):17–20.

Close CE, Carr MC, Burns MW, et al. Interstitial cystitis in children. *J Urol*. 1996;156(2 Pt 2):860–862.

Collan Y, Alfthan O, Kivilaakso E, et al. Electron microscopic and histological findings on urinary bladder epithelium in interstitial cystitis. *Eur Urol*. 1976;2(5):242–247.

Comiter CV. Sacral neuromodulation for the symptomatic treatment of refractory interstitial cystitis: a prospective study. *J Urol*. 2003;169(4):1369–1373.

Cook FV, Farrar WE Jr, Kreutner A. Hemorrhagic cystitis and ureteritis, and interstitial nephritis associated with administration of penicillin G. *J Urol*. 1979;122(1):110–111.

Corcoran AT, Yoshimura N, Tyagi V, et al. Mapping the cytokine profile of painful bladder syndrome/interstitial cystitis in human bladder and urine specimens. *World J Urol*. 2013;31(1):241–246.

Cornish J, Nickel JC, Vanderwee M, et al. Ultrastructural visualization of human bladder mucus. *Urol Res*. 1990;18:263–264.

Costantini E, Illiano E, Giannitsas K, et al. Urological dysfunction in young women: an inheritance of childhood? *BJU Int*. 2018;121(3):453–457.

Costello AJ, Crowe H, Agarwal D. Supratrigonal cystectomy and ileocystoplasty in management of interstitial cystitis. *Aust N Z J Surg*. 2000;70(1):34–38.

Coutaux A. Non-pharmacological treatments for pain relief: TENS and acupuncture. *Joint Bone Spine*. 2017;84(6):657–661.

Cox M, Klutke JJ, Klutke CG. Assessment of patient outcomes following submucosal injection of triamcinolone for treatment of Hunner's ulcer subtype interstitial cystitis. *Can J Urol*. 2009;16(2):4536–4540.

Cox A, Golda N, Nadeau G, et al. CUA guideline: diagnosis and treatment of interstitial cystitis/ bladder pain syndrome. *Can Urol Assoc J*. 2016;10(5–6):136–155.

Crescenze IM, Tucky B, Li J, et al. Efficacy, side effects, and monitoring of oral cyclosporine in interstitial cystitis-bladder pain syndrome. *Urology*. 2017;107:49–54.

Curhan GC, Speizer FE, Hunter DJ, et al. Epidemiology of interstitial cystitis: a population based study. *J Urol*. 1999;161(2):549–552.

Daha LK, Riedl CR, Lazar D, et al. Effect of intravesical glycosaminoglycan substitution therapy on bladder pain syndrome/interstitial cystitis, bladder capacity and potassium sensitivity. *Scand J Urol Nephrol*. 2008;42(4):369–372.

Dasgupta P, Sharma SD, Womack C, et al. Cimetidine in painful bladder syndrome: a histopathological study. *BJU Int*.

2001;88(3):183–186.

Davidson A, Diamond B. Autoimmune diseases. *N Engl J Med*. 2001;345(5):340–350.

Davidsson T, Carlen B, Bak-Jensen E, et al. Morphologic changes in intestinal mucosa with urinary contact—effects of urine or disuse. *J Urol*. 1996;156(1):226–232.

Davis EL, El Khoudary SR, Talbott EO, et al. Safety and efficacy of the use of intravesical and oral pentosan polysulfate sodium for interstitial cystitis: a randomized double-blind clinical trial. *J Urol*. 2008;179(1):177–185.

Davis R, Jones JS, Barocas DA, et al. Diagnosis, evaluation and follow-up of asymptomatic microhematuria (AMH) in adults: AUA Guideline. *J Urol*. 2012;188(6 Suppl):2473–2481.

Dawson TE, Jamison J. Intravesical treatments for painful bladder syndrome/interstitial cystitis. *Cochrane Database Syst Rev*. 2007;(4) [CD006113].

DeJuana CP, Everett JC Jr. Interstitial cystitis: experience and review of recent literature. *Urology*. 1977;10(4):325–329.

de la Serna AR, Alarcon-Segovia D. Chronic interstitial cystitis as an initial major manifestation of systemic lupus erythematosus. *J Rheumatol*. 1981;8(5):808–810.

Dimitrakov JD. A case of familial clustering of interstitial cystitis and chronic pelvic pain syndrome. *Urology*. 2001;58(2):281.

Dimitrakov J, Tchitalov J, Zlatanov T, et al. Corticotropin-releasing hormone perturbations in interstitial cystitis patients: evidence for abnormal sympathetic activity. *Urology*. 2001;57(6 Suppl 1):128.

Dimitriadou V, Buzzi MG, Moskowitz MA, et al. Trigeminal sensory fiber stimulation induces morphological changes reflecting secretion in rat dura mater mast cells. *Neuroscience*. 1991;44:97–112.

Dimitriadou V, Buzzi MG, Theoharides TC, et al.

Ultrastructural evidence for neurogenically mediated changes in blood vessels of the rat dura mater and tongue following antidromic trigeminal stimulation. *Neuroscience*. 1992;48(1):187–203.

Dixon JS, Holm-Bentzen M, Gilpin CJ, et al. Electron microscopic investigation of the bladder urothelium and glycocalyx in patients with interstitial cystitis. *J Urol*. 1986;135(3):621–625.

Dodson AI. Hunner's ulcer of the bladder; a report of ten cases. *Va Med Mon (1918)*. 1926;53:305–310.

Doggweiler R, Jasmin L, Schmidt RA. Neurogenically mediated cystitis in rats: an animal model. *J Urol*. 1998;160(4):1551–1556.

Doggweiler-Wiygul R, Blankenship J, MacDiarmid SA. Review on chronic pelvic pain from a urological point of view. *World J Urol*. 2001;19(3):160–165.

Doggweiler-Wiygul R, Wiygul JP. Interstitial cystitis, pelvic pain, and the relationship to myofascial pain and dysfunction: a report on four patients. *World J Urol*. 2002;20(5):310–314.

Doi K, Saito Y, Nikai T, et al. Lumbar sympathetic block for pain relief in two patients with interstitial cystitis. *Reg Anesth Pain Med*. 2001;26(3):271–273.

Doiron RC, Tolls V, Irvine-Bird K, et al. Clinical phenotyping does not differentiate hunner lesion subtype of interstitial cystitis/bladder pain syndrome: a relook at the role of cystoscopy. *J Urol*. 2016;196(4):1136–1140.

Doiron RC, Kogan BA, Tolls V, et al. Childhood bladder and bowel dysfunction predicts irritable bowel syndrome phenotype in adult interstitial cystitis/bladder pain syndrome patients. *Can Urol Assoc J*. 2017;11(8):255–259.

Domingue GJ, Ghoniem GM, Bost KL, et al. Dormant microbes in interstitial cystitis. *J Urol*. 1995;153(4):1321–1326.

Domingue GJ, Ghoniem GM, Sant GR. Occult infection in interstitial cystitis. Sant GR. *Interstitial cystitis*. Lippincott-Raven: Philadelphia, PA; 1997:77–86.

Dondore PA, Schwartz AM, Semerjian H. Mast cell counts are not useful in the diagnosis of nonulcerative interstitial cystitis. *J Urol*. 1996;155(3):885–887.

Duldulao KE, Diokno AC, Mitchell B. Value of urinary cytology in women presenting with urge incontinence and/or irritative voiding symptoms. *J Urol*. 1997;157(1):113–116.

Duncan JL, Schaeffer AJ. Do infectious agents cause interstitial cystitis? *Urology*. 1997;49(5A Suppl):48–51.

Dundore PA, Schwartz AM, Semerjian H. Mast cell counts are not useful in the diagnosis of nonulcerative interstitial cystitis. *J Urol*. 1996;155(3):885–887.

Dunn M, Ramsden PD, Roberts JB, et al. Interstitial cystitis, treated by prolonged bladder distension. *Br J Urol*. 1977;49(7):641–645.

Dupont MC, Spitsbergen JM, Kim KB, et al. Histological and neurotrophic changes triggered by varying models of bladder inflammation. *J Urol*. 2001;166(3):1111–1118.

Durier JL. The application of anti-anaerobic antibiotics to the treatment of female bladder dysfunctions. *Neurourol Urodyn*. 1992;11:418.

Ehrén I, Lundberg JO, Adolfsson J, et al. Effects of l-arginine treatment on symptoms and bladder nitric oxide levels in patients with interstitial cystitis. *Urology*. 1998;52(6):1026–1029.

Ehrén I, Hosseini A, Herulf M, et al. Measurement of luminal nitric oxide in bladder inflammation using a silicon balloon catheter: a novel minimally invasive method. *Urology*. 1999;54(2):264–267.

Ehrén I, Hallén Grufman K, Vrba M, et al. Nitric oxide as a marker for evaluation of treatment effect of cyclosporine A in patients with bladder pain syndrome/interstitial cystitis type

3C. *Scand J Urol*. 2013;47(6):503–508.

Eigner EB, Freiha FS. The fate of the remaining bladder following supravesical diversion. *J Urol*. 1990;144(1):31–33.

Eisen DP, Fraser IR, Sung LM, et al. Decreased viral load and symptoms of polyomavirus-associated chronic interstitial cystitis after intravesical cidofovir treatment. *Clin Infect Dis*. 2009;48(9):e86–e88.

Ek A, Engberg A, Frodin L, et al. The use of dimethyl-sulfoxide (DMSO) in the treatment of interstitial cystitis. *Scand J Urol Nephrol*. 1978;12(2):129–131.

Elbadawi A. Interstitial cystitis: a critique of current concepts with a new proposal for pathologic diagnosis and pathogenesis. *Urology*. 1997;49(5A Suppl):14–40.

Elbadawi AE, Light JK. Distinctive ultrastructural pathology of nonulcerative interstitial cystitis: new observations and their potential significance in pathogenesis. *Urol Int*. 1996;56(3):137–162.

Elgavish A. Epigenetic reprogramming: a possible etiological factor in bladder pain syndrome/interstitial cystitis? *J Urol*. 2009;181(3):980–984.

Elgavish A, Robert B, Lloyd K, et al. Evidence for a mechanism of bacterial toxin action that may lead to the onset of urothelial injury in the interstitial cystitis bladder (abstract). *J Urol*. 1995;153:329A.

Elgebaly SA, Allam ME, Walzak MP Jr, et al. Urinary neutrophil chemotactic factors in interstitial cystitis patients and a rabbit model of bladder inflammation. *J Urol*. 1992;147(5):1382–1387.

Elhilali MM, Khaled SM, Kashiwabara T, et al. Sacral neuromodulation: long-term experience of one center. *Urology*. 2005;65(6):1114–1117.

El Khoudary SR, Talbott EO, Bromberger JT, et al. Severity of interstitial cystitis symptoms and quality of life in female patients. *J Womens Health*. 2009;18(9):1361–1368.

El Mansoury M, Boucher W, Sant GR, et al. Increased urine histamine and methylhistamine in interstitial cystitis. *J Urol*. 1994;152(2 Pt 1):350–353.

Elzawahri A, Bissada NK, Herchorn S, et al. Urinary conduit formation using a retubularized bowel from continent urinary diversion or intestinal augmentations: II. Does it have a role in patients with interstitial cystitis? *J Urol*. 2004;171(4):1559–1562.

Emerson LE, Feltis JT. Urodynamic factors affecting response to DMSO in the treatment of interstitial cystitis. *J Urol*. 1986;135:188A.

Emmungil H, Kalfa M, Zihni FY, et al. Interstitial cystitis: a rare manifestation of primary Sjögren's syndrome, successfully treated with low dose cyclosporine. *Rheumatol Int*. 2012;32(5):1215–1218.

Enerback L, Fall M, Aldenborg F. Histamine and mucosal mast cells in interstitial cystitis. *J Neuroimmunol*. 1989;27:113–116.

Engeler DS, Baranowski AP, Dinis-Oliveira P, et al. The 2013 EAU guidelines on chronic pelvic pain: is management of chronic pelvic pain a habit, a philosophy, or a science? 10 years of development. *Eur Urol*. 2013;64(3):431–439.

Engelhardt PF, Morakis N, Daha LK, et al. Long-term results of intravesical hyaluronan therapy in bladder pain syndrome/interstitial cystitis. *Int Urogynecol J*. 2011;22(4):401–405.

Engelmann U, Bürger R, Jacobi G. Experimental investigations on the absorption of intravesically instilled mitomycin-C in the urinary bladder of the rat. *Eur Urol*. 1982;8(3):176–181.

Engles CD, Hauser PJ, Abdullah SN, et al. Intravesical chondroitin sulfate inhibits recruitment of inflammatory cells in an acute acid damage “leaky bladder” model of cystitis.

Urology. 2012;79(2):483.e13–483.e17.

English SF, Liebert M, Cross CA, et al. The incidence of *Helicobacter pylori* in patients with interstitial cystitis. *J Urol*. 1998;159(3):772–773.

Ercan F, Oktay S, Erin N. Role of afferent neurons in stress induced degenerative changes of the bladder. *J Urol*. 2001;165:235–239.

Erickson DR. Glomerulations in women with urethral sphincter deficiency: report of 2 cases [corrected]. *J Urol*. 1995;153(3 Pt 1):728–729.

Erickson DR. Urine markers of interstitial cystitis. *Urology*. 2001;57(6 Suppl 1):15–21.

Erickson DR, Mast S, Ordille S, et al. Urinary epitectin (MUC-1 glycoprotein) in the menstrual cycle and interstitial cystitis. *J Urol*. 1996;156(3):938–942.

Erickson DR, Belchis DA, Dabbs DJ. Inflammatory cell types and clinical features of interstitial cystitis. *J Urol*. 1997;158(3 Pt 1):790–793.

Erickson DR, Ordille S, Martin A, et al. Urinary chondroitin sulfates, heparan sulfate and total sulfated glycosaminoglycans in interstitial cystitis. *J Urol*. 1997;157(1):61–64.

Erickson DR, Sheykhnazari M, Ordille S, et al. Increased urinary hyaluronic acid and interstitial cystitis. *J Urol*. 1998;160(4):1282–1284.

Erickson DR, Xie SX, Bhavanandan VP, et al. A comparison of multiple urine markers for interstitial cystitis. *J Urol*. 2002;167(6):2461–2649.

Erickson DR, Kunselman AR, Bentley CM, et al. Is urine methylhistamine a useful marker for interstitial cystitis? *J Urol*. 2004;172(6 Part 1 of 2):2256–2260.

Erickson DR, Tomaszewski JE, Kunselman AR, et al. Do the National Institute of Diabetes and Digestive and Kidney

Diseases cystoscopic criteria associate with other clinical and objective features of interstitial cystitis? *J Urol*. 2005;173(1):93–97.

Erickson DR, Schwarze SR, Dixon JK, et al. Differentiation associated changes in gene expression profiles of interstitial cystitis and control urothelial cells. *J Urol*. 2008;180(6):2681–2687.

Erickson DR, Tomaszewski JE, Kunselman AR, et al. Urine markers do not predict biopsy findings or presence of bladder ulcers in interstitial cystitis/painful bladder syndrome. *J Urol*. 2008;179(5):1850–1856.

Evans RJ, Moldwin RM, Cossons N, et al. Proof of concept trial of tanezumab for the treatment of symptoms associated with interstitial cystitis. *J Urol*. 2011;185(5):1716–1721.

Everaert K, Devulder J, De Muynck M, et al. The pain cycle: implications for the diagnosis and treatment of pelvic pain syndromes. *Int Urogynecol J*. 2001;12(1):9–14.

Ezzo J, Berman B, Hadhazy VA, et al. Is acupuncture effective for the treatment of chronic pain? A systematic review. *Pain*. 2000;86(3):217–225.

Fall M. Conservative management of chronic interstitial cystitis: transcutaneous electrical nerve stimulation and transurethral resection. *J Urol*. 1985;133(5):774–778.

Fall M. Transcutaneous electrical nerve stimulation in interstitial cystitis. Update on clinical experience. *Urology*. 1987;29(4 Suppl):40–42.

Fall M. Use of transcutaneous electrical nerve stimulation in the management of bladder pain syndrome. Springer International Publishing: Cham; 2017:127–129. *Bladder pain syndrome – an evolution*. vol 133.

Fall M, Lindstrom S. Transcutaneous electrical nerve stimulation in classic and nonulcer interstitial cystitis. *Urol Clin North Am*. 1994;21(1):131–139.

Fall M, Peeker R. Methods and incentives for the early diagnosis of bladder pain syndrome/interstitial cystitis. *Expert Opin Med Diagn*. 2013;7(1):17–24.

Fall M, Carlsson CA, Erlandson BE. Electrical stimulation in interstitial cystitis. *J Urol*. 1980;123(2):192–195.

Fall M, Johansson SL, Aldenborg F. Chronic interstitial cystitis: a heterogeneous syndrome. *J Urol*. 1987;137(1):35–38.

Fall M, Baranowski AP, Elneil S, et al. EAU guidelines on chronic pelvic pain. *Eur Urol*. 2010;57(1):35–48.

Fandel T, Tanagho EA. Neuromodulation in voiding dysfunction: a historical overview of neurostimulation and its application. *Urol Clin North Am*. 2005;32(1):1–10.

Fariello JY, Moldwin R. Similarities between interstitial cystitis/bladder pain syndrome and vulvodynia: implications for patient management. *Transl Androl Urol*. 2015;4(6):643–652.

Felsen D, Frye S, Trimble LA, et al. Inflammatory mediator profile in urine and bladder wash fluid of patients with interstitial cystitis. *J Urol*. 1994;152(2 Pt 1):355–361.

Feltis JT, Perez-Marrero R, Emerson LE. Increased mast cells of the bladder in suspected cases of interstitial cystitis: a possible disease marker. *J Urol*. 1987;138(1):42–43.

Fenton BW, Durner C, Fanning J. Frequency and distribution of multiple diagnoses in chronic pelvic pain related to previous abuse or drug-seeking behavior. *Gynecol Obstet Invest*. 2008;65(4):247–251.

Figueiredo AB, Palma P, Riccetto C, et al. Clinical and urodynamic experience with intravesical hyaluronic acid in painful bladder syndrome associated with interstitial cystitis. *Actas Urol Esp*. 2011;35(3):184–187.

Filippou AS, Sant GR, Theoharides TC. Mast cell in interstitial cystitis. *Urol Integr Invest*. 1999;4(4):315–323.

Fisher BP, Bavendam TG, Roberts BW, et al. *Blinded placebo* *controlled evaluation on the ingestion of acidic foods and their effect on urinary pH and the symptomatology of interstitial cystitis*. [Presented at the Interstitial Cystitis Association's Research Symposium on Interstitial Cystitis; October 18–21, 1993; Orlando, Florida] 1993:53.

Fister GM. Similarity of interstitial cystitis (Hunner ulcer) to lupus erythematosus. *J Urol*. 1938;40:37–51.

FitzGerald MP, Anderson RU, Potts J, et al. Randomized multicenter feasibility trial of myofascial physical therapy for the treatment of urological chronic pelvic pain syndromes. *J Urol*. 2009;182(2):570–580.

FitzGerald MP, Payne CK, Lukacz ES, et al. Randomized multicenter clinical trial of myofascial physical therapy in women with interstitial cystitis/painful bladder syndrome and pelvic floor tenderness. *J Urol*. 2012;187(6):2113–2118.

Fitzpatrick CC, DeLancey JO, Elkins TE, et al. Vulvar vestibulitis and interstitial cystitis: a disorder of urogenital sinus-derived epithelium? *Obstet Gynecol*. 1993;81(5 Pt 2):860–862.

Fleischmann J. Calcium channel antagonists in the treatment of interstitial cystitis. *Urol Clin North Am*. 1994;21(1):107–111.

Flood HD, Malhotra SJ, O'Connell HE, et al. Long-term results and complications using augmentation cystoplasty in reconstructive urology. *Neurourol Urodyn*. 1995;14(4):297–309.

Foreman JC. Peptides and neurogenic inflammation. *Br Med Bull*. 1987;43(2):386–400.

Forrest JB, Vo Q. Observations on the presentation, diagnosis, and treatment of interstitial cystitis in men. *Urology*. 2001;57(6 Suppl 1):26–29.

Forrest JB, Schmidt S. Interstitial cystitis, chronic nonbacterial prostatitis and chronic pelvic pain syndrome in men: a common and frequently identical clinical entity. *J Urol*.

2004;172(6 Pt 2):2561–2562.

Forrest JB, Payne CK, Erickson DR. Cyclosporine A for refractory interstitial cystitis/bladder pain syndrome: experience of 3 tertiary centers. *J Urol*. 2012;188(4):1186–1191.

Forsell T, Ruutu M, Isoniemi H, et al. Cyclosporine in severe interstitial cystitis. *J Urol*. 1996;155(5):1591–1593.

Foster HE, Smith S, Wheeler M, et al. Nitric oxide and interstitial cystitis. *Adv Urol*. 1997;10:1–25.

Foster HE Jr, Hanno PM, Nickel JC, et al. Effect of amitriptyline on symptoms in treatment I patients with interstitial cystitis/painful bladder syndrome. *J Urol*. 2010;183(5):1853–1858.

Fowler JE Jr. Prospective study of intravesical dimethyl sulfoxide in treatment of suspected early interstitial cystitis. *Urology*. 1981;18(1):21–26.

Fowler JE Jr, Lynes WL, Lau JL, et al. Interstitial cystitis is associated with intraurothelial Tamm-Horsfall protein. *J Urol*. 1988;140(6):1385–1389.

Franke JJ, Stratton CW, Mitchell WM. Chlamydia pneumoniae in patients with interstitial cystitis. *J Urol*. 1999;161:29.

Freedman AI, Wein AJ, Whitmore K, et al. In vitro effects of intravesical dimethyl sulfoxide. *Neurourol Urodyn*. 1989;8:277–283.

Freiha FS, Stamey TA. Cystolysis: a procedure for the selective denervation of the bladder. *Trans Am Assoc Genitourin Surg*. 1979;71:50–54.

Freiha FS, Faysal MH, Stamey TA. The surgical treatment of intractable interstitial cystitis. *J Urol*. 1980;123(5):632–634.

Freynhagen R, Strojek K, Griesing T, et al. Efficacy of pregabalin in neuropathic pain evaluated in a 12-week, randomised, double-blind, multicentre, placebo-controlled trial of flexible- and fixed-dose regimens. *Pain*.

2005;115(3):254–263.

Friedlander JI, Shorter B, Moldwin RM. Diet and its role in interstitial cystitis/bladder pain syndrome (IC/BPS) and comorbid conditions. *BJU Int*. 2012;109(11):1584–1591.

Funaro MG, King AN, Stern JNH, et al. Endoscopic injection of low dose triamcinolone: a simple, minimally invasive, and effective therapy for interstitial cystitis with Hunner lesions. *Urology*. 2018;118:25–29.

Furuta A, Suzuki Y, Hayashi N, et al. Transient receptor potential A1 receptor-mediated neural cross-talk and afferent sensitization induced by oxidative stress: implication for the pathogenesis of interstitial cystitis/bladder pain syndrome. *Int J Urol*. 2012;19(5):429–436.

Furuya R, Masumori N, Furuya S, et al. Glomerulation observed during transurethral resection of the prostate for patients with lower urinary tract symptoms suggestive of benign prostatic hyperplasia is a common finding but no predictor of clinical outcome. *Urology*. 2007;70(5):922–926.

Gafni-Kane A, Botros SM, Du H, et al. Measuring the success of combined intravesical dimethyl sulfoxide and triamcinolone for treatment of bladder pain syndrome/interstitial cystitis. *Int Urogynecol J*. 2013;24(2):303–311.

Gajewski JB, Al-Zahrani AA. The long-term efficacy of sacral neuromodulation in the management of intractable cases of bladder pain syndrome: 14 years of experience in one centre. *BJU Int*. 2011;107(8):1258–1264.

Gajewski JB, Awad SA, Sant GR. Urodynamic evaluation in interstitial cystitis. Sant GR. *Interstitial cystitis*. Lippincott-Raven: Philadelphia, PA; 1997:169–172.

Gallego-Vilar D, García-Fadrique G, Povo-Martin I, et al. Maintenance of the response to dimethyl sulfoxide treatment using hyperbaric oxygen in interstitial cystitis/painful bladder syndrome: a prospective, randomized, comparative study. *Urol Int*. 2013;90(4):411–416.

Galli SJ. New concepts about the mast cell. *N Engl J Med*. 1993;328(4):257–265.

Galloway NT, Gabale DR, Irwin PP. Interstitial cystitis or reflex sympathetic dystrophy of the bladder? *Semin Urol*. 1991;9(2):148–153.

Gamper M, Viereck V, Eberhard J, et al. Local immune response in bladder pain syndrome/interstitial cystitis ESSIC type 3C. *Int Urogynecol J*. 2013;24(12):2049–2057.

Gamper M, Regauer S, Welter J, et al. Are mast cells still good biomarkers for bladder pain syndrome/interstitial cystitis? *J Urol*. 2015;193(6):1994–2000.

Gardella B, Porru D, Nappi RE, et al. Interstitial cystitis is associated with vulvodynia and sexual dysfunction—a case-control study. *J Sex Med*. 2011;8(6):1726–1734.

Gauney G, Lufti F, Moldwin R. Ketamine: its use and abuse in urological practice. *AUA Update Series*. 2016;35(28):287–296.

Geirsson G, Wang YH, Lindstrom S, et al. Traditional acupuncture and electrical stimulation of the posterior tibial nerve. A trial in chronic interstitial cystitis. *Scand J Urol Nephrol*. 1993;27(1):67–70.

Ghazwani YQ, Elkelini MS, Hassouna MM. Efficacy of sacral neuromodulation in treatment of bladder pain syndrome: long-term follow-up. *Neurourol Urodyn*. 2011;30(7):1271–1275.

Ghoniem GM, Shaaban AM, Clarke MR. Irritable bladder syndrome in an animal model: a continuous monitoring study. *Neurourol Urodyn*. 1995;14(6):657–665.

Giannantoni A, Porena M, Costantini E, et al. Botulinum A toxin intravesical injection in patients with painful bladder syndrome: 1-year followup. *J Urol*. 2008;179(3):1031–1034.

Giberti C, Gallo F, Cortese P, et al. Combined intravesical sodium hyaluronate/chondroitin sulfate therapy for interstitial cystitis/bladder pain syndrome: a prospective study. *Ther Adv Urol*. 2013;5(4):175–179.

Gillenwater JY, Wein AJ. Summary of the national institute of arthritis, diabetes, digestive and kidney diseases workshop on interstitial cystitis, national institutes of health, Bethesda, Maryland, August 28–29, 1987. *J Urol*. 1988;140(1):203–206.

Gilron I, Bailey JM, Tu D, et al. Morphine, gabapentin, or their combination for neuropathic pain. *N Engl J Med*. 2005;352(13):1324–1334.

Glemain P, Riviere C, Lenormand L, et al. Prolonged hydrodistention of the bladder for symptomatic treatment of interstitial cystitis: efficacy at 6 months and 1 year. *Eur Urol*. 2002;41(1):79–84.

Goin JE, Olaleye D, Peters KM, et al. Psychometric analysis of the University of Wisconsin Interstitial Cystitis Scale: implications for use in randomized clinical trials. *J Urol*. 1998;159(3):1085–1090.

Gordon HL, Rossen RD, Hersh EM, et al. Immunologic aspects of interstitial cystitis. *J Urol*. 1973;109(2):228–233.

Gordon Z, Parsons CL, Monga M. Intravesical ethanol test: an ineffective measure of bladder hyperpermeability. *Urology*. 2003;61(3):555–557.

Goris A, Jan R. Reflex sympathetic dystrophy: model of a severe regional inflammatory response syndrome. *World J Surg*. 1998;22(2):197–202.

Gottsch HP, Miller JL, Yang CC, et al. A pilot study of botulinum toxin for interstitial cystitis/painful bladder syndrome. *Neurourol Urodyn*. 2010;30(1):93–96.

Green M, Filippou A, Sant G, et al. Expression of intercellular adhesion molecules in the bladder of patients with interstitial cystitis. *Urology*. 2004;63(4):688–693.

Greenhill JP. Sympathectomy and intraspinal alcohol injections for relief of pelvic pain. *Br Med J*. 1947;2:859–862.

Greenwood-Van Meerveld B, Mohammadi E, Tyler K, et al. Investigative urology mechanisms of visceral organ crosstalk: importance of alterations in permeability in rodent models. *J Urol*. 2015;194(3):804–811.

Grigorescu B, Powers K, Lazarou G. Update on urinary tract markers in interstitial cystitis/bladder pain syndrome. *Female Pelvic Med Reconstr Surg*. 2016;22(1):16–23.

Gross SD. *A Practical Treatise on the Diseases, Injuries and Malformations of the Urinary Bladder*. [*the Prostate Gland, and the Urethra*] 1876.

Gupta GN, Lu SG, Gold MS, et al. Bladder urothelial cells from patients with interstitial cystitis have an increased sensitivity to carbachol. *Neurourol Urodyn*. 2009;28(8):1022–1027.

Gupta P, Gaines N, Sirls LT, et al. A multidisciplinary approach to the evaluation and management of interstitial cystitis/bladder pain syndrome: an ideal model of care. *Transl Androl Urol*. 2015;4(6):611–619.

Haarala M, Jalava J, Laato M, et al. Absence of bacterial DNA in the bladder of patients with interstitial cystitis. *J Urol*. 1996;156(5):1843–1845.

Haarala M, Kiiholma P, Nurmi M, et al. The role of *Borrelia burgdorferi* in interstitial cystitis. *Eur Urol*. 2000;37(4):395–399.

Hakenberg OW, Wirth MP. Chronic pelvic pain in men. *Urol Int*. 2002;68:138–143.

Halder GE, Scott L, Wyman A, et al. Botox combined with myofascial release physical therapy as a treatment for myofascial pelvic pain. *Investig Clin Urol*. 2017;58(2):134–139.

Hamer AJ, Nicholson S, Padfield CJ. Spontaneous rupture of the bladder in interstitial cystitis. *Br J Urol*. 1992;69(1):102.

Hammett J, Krupski TL, Corbett ST. Adolescent pelvic pain: interstitial cystitis. *J Pediatr Urol*. 2013;9(3):e134–e137.

Hampson SJ, Woodhouse CR. Sodium pentosanpolysulphate in the management of haemorrhagic cystitis: experience with 14 patients. *Eur Urol*. 1994;25(1):40–42.

Hampson SJ, Christmas TJ, Moss MT. Search for mycobacteria in interstitial cystitis using mycobacteria-specific DNA probes with signal amplification by polymerase chain reaction. *Br J Urol*. 1993;72(3):303–306.

Han E, Nguyen L, Sirls L, et al. Current best practice management of interstitial cystitis/bladder pain syndrome. *Ther Adv Urol*. 2018;10(7):197–211.

Hanash KA, Pool TL. Interstitial and hemorrhagic cystitis: viral, bacterial and fungal studies. *J Urol*. 1970;104(5):705–706.

Hand JR. Interstitial cystitis: report of 223 cases (204 women and 19 men). *J Urol*. 1949;61(2):291–310.

Hanna-Mitchell AT, Birder LA. New insights into the pharmacology of the bladder. *Curr Opin Urol*. 2011;18(4):347–352.

Hanno PM. Amitriptyline in the treatment of interstitial cystitis. *Urol Clin North Am*. 1994;21(1):89–91.

Hanno PM. Analysis of long-term Elmiron therapy for interstitial cystitis. *Urology*. 1997;49(5A Suppl):93–99.

Hanno PM. Interstitial cystitis/painful bladder syndrome/bladder pain syndrome: the evolution of a new paradigm. *Proceedings of the International Consultation on Interstitial Cystitis*. Comfortable Urology Network: Japan; 2008:2–9.

Hanno P, Dmochowski R. Status of international consensus on interstitial cystitis/bladder pain syndrome/painful bladder syndrome: 2008 snapshot. *Neurourol Urodyn*. 2009;28(4):274–286.

Hanno PM, Tomaszewski JE. Bladder carcinoma after urinary diversion. *JAMA*. 1982;248(21):2885–2886.

Hanno PM, Wein AJ. Medical treatment of interstitial cystitis (other than Rimso-50/Elmiron). *Urology*. 1987;29(4 Suppl):22–26.

Hanno PM, Wein AJ. Conservative therapy of interstitial cystitis. *Semin Urol*. 1991;9(2):143–147.

Hanno PM, Fritz R, Wein AJ. Heparin as an antibacterial agent in rabbit bladder. *Urology*. 1978;12(4):411–415.

Hanno PM, Parsons CL, Shrom SH, et al. The protective effect of heparin in experimental bladder infection. *J Surg Res*. 1978;25(4):324–326.

Hanno PM, Buehler J, Wein AJ. Use of amitriptyline in the treatment of interstitial cystitis. *J Urol*. 1989;141(4):846–848.

Hanno PM, Landis JR, Matthews-Cook Y, et al. The diagnosis of interstitial cystitis revisited: lessons learned from the National Institutes of Health Interstitial Cystitis Data Base study. *J Urol*. 1999;161(2):553–557.

Hanno P, Levin RM, Monson FC, et al. Diagnosis of interstitial cystitis. *J Urol*. 1990;143(2):278–281.

Hanno P, Baranowski A, Fall M, et al. Painful bladder syndrome (including interstitial cystitis). Abrams PH, Wein AJ, Cardozo L. *Incontinence*. 3rd ed. Health Publications Limited: Paris; 2005:1456–1520.

Hanno P, Keay S, Moldwin R, et al. International Consultation on IC, Rome, September 2004/Forging an International Consensus: progress in painful bladder syndrome/interstitial cystitis. Report and abstracts. *Int Urogynecol J Pelvic Floor Dysfunct*. 2005;16(Suppl 1):S2–S34.

Hanno PM, Burks DA, Clemens JQ, et al. AUA guideline for the diagnosis and treatment of interstitial cystitis/bladder pain syndrome. *J Urol*. 2011;185(6):2162–2170.

Hanno P, Dinis P, Lin A, et al. Bladder pain syndrome. Abrams

P, Cardozo L, Khoury S, et al. *Incontinence*. International Consultation on Urological Diseases/European Association of Urology: Paris; 2013:1583–1649.

Hanno PM, Erickson D, Moldwin R, et al. Diagnosis and treatment of interstitial cystitis/bladder pain syndrome: AUA guideline amendment. *J Urol*. 2015;193(5):1545–1553.

Haq A, Morsy M, Webb RJ. A study to detect *Helicobacter pylori* in fresh and archival specimens from patients with interstitial cystitis, using amplification methods. *BJU Int*. 2004;93(3):423.

Harlow BL, Kunitz CG, Nguyen RH, et al. Prevalence of symptoms consistent with a diagnosis of vulvodynia: population-based estimates from 2 geographic regions. *Am J Obstet Gynecol*. 2014;210(1):40.e1–40.e8.

Harn SD, Keutel HJ, Weaver RG. Immunologic and histologic evaluation of the urinary bladder wall after group A streptococcal infection. *Invest Urol*. 1973;11(1):55–64.

Harrington DS, Fall M, Johansson SL. Interstitial cystitis: bladder mucosa lymphocyte immunophenotyping and peripheral blood flow cytometry analysis. *J Urol*. 1990;144(4):868–871.

Harrison SCW, Ferguson DR, Hanley MR. Effect of capsaicin on the rabbit urinary bladder. What is the function of sensory nerves that contain substance P? *Br J Urol*. 1990;66(2):155–161.

Hauser PJ, Dozmorov MG, Bane BL, et al. Abnormal expression of differentiation related proteins and proteoglycan core proteins in the urothelium of patients with interstitial cystitis. *J Urol*. 2008;179(2):764–769.

Hedelin HH, Mardh PA, Brorson JE, et al. Mycoplasma hominis and interstitial cystitis. *Sex Transm Dis*. 1983;10(4 Suppl):327–330.

Held PJ, Hanno PM, Wein J, et al. Epidemiology of interstitial cystitis. Hanno PM, Staskin DR, Krane RJ, et al. *Interstitial cystitis*. Springer-Verlag: New York, NY; 1990:29–48.

Hellstrom HR, Davis BK, Shonnard JW. Eosinophilic cystitis. A study of 16 cases. *Am J Clin Pathol*. 1979;72(5):777–784.

Henry RA, Morales A, Cahill CM. Female urology beyond a simple anesthetic effect: lidocaine in the diagnosis and treatment of interstitial cystitis/bladder pain syndrome. *Urology*. 2015;85(5):1025–1033.

Herbst RH, Baumrucker GO, German KL. Elusive ulcer (Hunner) of the bladder with an experimental study of the etiology. *Am J Surg*. 1937;38(1):152–167.

Heritz DM, Lacroix JM, Batra SD, et al. Detection of eubacteria in interstitial cystitis by 16S rDNA amplification. *J Urol*. 1997;158(6):2291–2295.

Hill JR, Isom-Batz G, Panagopoulos G, et al. Patient perceived outcomes of treatments used for interstitial cystitis. *Urology*. 2008;71(1):62–66.

Hillelsohn JH, Rais-Bahrami S, Friedlander JI, et al. Fulguration for Hunner ulcers: long-term clinical outcomes. *J Urol*. 2012;188(6):2238–2241.

Hofmeister MA, He F, Ratliff TL, et al. Mast cells and nerve fibers in interstitial cystitis (IC): an algorithm for histologic diagnosis via quantitative image analysis and morphometry (QIAM). *Urology*. 1997;49(5A Suppl):41–47.

Hohenfellner M, Nunes L, Schmidt RA, et al. Interstitial cystitis: increased sympathetic innervation and related neuropeptide synthesis. *J Urol*. 1992;147(3):587–591.

Hohlbrugger G. Urinary potassium and the overactive bladder. *BJU Int*. 1999;83(Suppl 2):22–28.

Hohlbrugger G, Sant GR. Disintegrity of the vesical blood-urine barrier in interstitial cystitis: a vicious circle. Sant GR. *Interstitial cystitis*. Lippincott-Raven: Philadelphia; 1997:87–92.

Hohlbrugger G, Frauscher F, Strasser H, et al. Topical heparin therapy normalizes urothelial permeability and vesical blood flow in urgency/frequency syndrome, urge incontinence and reversible interstitial cystitis. *Eur Urol*. 1998;33(S1):A38.

Hohlbrugger G, Riedl C. Non-bacterial cystitis. *Curr Opin Urol*. 2000;10(5):371–380.

Hoke TP, Goldstein H, Saks EK, et al. Hydrodistention of the bladder for the treatment of bladder pain syndrome/interstitial cystitis (BPS/IC). *Neurourol Urodyn*. 2016;36(3):784–786.

Holm-Bentzen M, Jacobsen F, Nerstrom B, et al. Painful bladder disease: clinical and pathoanatomical differences in 115 patients. *J Urol*. 1987;138(3):500–502.

Holm-Bentzen M, Sondergaard I, Hald T. Urinary excretion of a metabolite of histamine (1,4-methyl-imidazole-acetic-acid) in painful bladder disease. *Br J Urol*. 1987;59(3):230–233.

Holm-Bentzen M, Nordling J, Hald T, et al. Etiology: etiologic and pathogenetic theories in interstitial cystitis. Hanno PM, Staskin DR, Krane RJ. *Interstitial cystitis*. Springer-Verlag: London; 1990:63–77.

Holzberg A, Kellog-Spadt S, Lukban J, et al. Evaluation of transvaginal Theile massage as a therapeutic intervention for women with interstitial cystitis. *Urology*. 2001;57(6 Suppl 1):120.

Homma Y. Lower urinary tract symptomatology: its definition and confusion. *Int J Urol*. 2008;15(1):35–43.

Homma Y, Ueda T, Tomoe H, et al. Interstitial cystitis guideline committee. Clinical guidelines for interstitial cystitis and hypersensitive bladder syndrome. *Int J Urol*. 2009;16(7):597–615.

Homma Y, Nomiya A, Tagaya M, et al. Increased mRNA expression of genes involved in pronociceptive inflammatory reactions in bladder tissue of interstitial cystitis. *J Urol*. 2013;190(5):1925–1931.

Hosseini A, Ehrén I, Wiklund NP. Nitric oxide as an objective marker for evaluation of treatment response in patients with classic interstitial cystitis. *J Urol*. 2004;172(6 Pt 1):2261–2265.

Houpt KA. House soiling: treatment of a common feline problem. *Vet Med*. 1991;86:1000–1006.

Hsieh CH, Chang WC, Huang MC, et al. Hydrodistention plus bladder training versus hydrodistention for the treatment of interstitial cystitis. *Taiwan J Obstet Gynecol*. 2012;51(4):591–595.

Hughes OD, Kynaston HG, Jenkins BJ, et al. Substitution cystoplasty for intractable interstitial cystitis. *Br J Urol*. 1995;76(2):172–174.

Hukkanen V, Haarala M, Nurmi M, et al. Viruses and interstitial cystitis: adenovirus genomes cannot be demonstrated in urinary bladder biopsies. *Urol Res*. 1996;24(4):235–238.

Humphrey L, Arbuckle R, Moldwin R, et al. The bladder pain/interstitial cystitis symptom score: development, validation, and identification of a cut score. *Eur Urol*. 2012;61(2):271–279.

Hung MJ, Chen YT, Shen PS, et al. Risk factors that affect the treatment of interstitial cystitis using intravesical therapy with a dimethyl sulfoxide cocktail. *Int Urogynecol J*. 2012;23(11):1533–1539.

Hunner GL. A rare type of bladder ulcer in women; report of cases. *Boston Med Surg J*. 1915;172:660–664.

Hunner GL. A rare type of bladder ulcer. Further notes, with a report of eighteen cases. *JAMA*. 1918;70(4):203–212.

Hurst RE. A deficit of proteoglycans on the bladder uroepithelium in interstitial cystitis. *Eur Urol*. 2003;(Suppl 2):10–13.

Hurst RE, Parsons CL, Roy JB, et al. Urinary glycosaminoglycan excretion as a laboratory marker in the diagnosis of interstitial cystitis. *J Urol*. 1993;149(1):31–35.

Hurst RE, Roy JB, Min KW, et al. A deficit of chondroitin sulfate proteoglycans on the bladder uroepithelium in interstitial cystitis. *Urology*. 1996;48(5):817–821.

Hurst RE, Roy JB, Parsons CL, et al. The role of glycosaminoglycans in normal bladder physiology and the pathophysiology of interstitial cystitis. Sant GR. *Interstitial cystitis*. Lippincott-Raven: Philadelphia, PA; 1997:93–100.

Iavazzo C, Athanasiou S, Pitsouni E, et al. Hyaluronic acid: an effective alternative treatment of interstitial cystitis, recurrent urinary tract infections, and hemorrhagic cystitis? *Eur Urol*. 2007;51(6):1534–1540.

Ichihara K, Aizawa N, Akiyama Y, et al. Toll-like receptor 7 is overexpressed in the bladder of Hunner-type interstitial cystitis, and its activation in the mouse bladder can induce cystitis and bladder pain. *Pain*. 2017;158(8):1538–1545.

Ikeda Y, Birder L, Buffington C, et al. Mucosal muscarinic receptors enhance bladder activity in cats with feline interstitial cystitis. *J Urol*. 2009;181(3):1415–1422.

Inoue Y, Mita K, Kakehashi M, et al. Prevalence of painful bladder syndrome (PBS) symptoms in adult women in the general population in Japan. *Neurourol Urodyn*. 2009;28(3):214–218.

Interstitial Cystitis Association. *ICA patient surveys*. [website] https://www.ichelp.org/research/ica-patient-surveys/; 2005.

Irwin P, Galloway NT. Re: pelvic pain without pelvic organs (letter). *J Urol*. 1992;148(4):1265–1266.

Irwin P, Galloway NT. Impaired bladder perfusion in interstitial cystitis: a study of blood supply using laser Doppler flowmetry. *J Urol*. 1993;149(4):890–892.

Irwin PP, Galloway NT. Surgical management of interstitial cystitis. *Urol Clin North Am*. 1994;21(1):145–151.

Irwin PP, Hammonds WD, Galloway NT. Lumbar epidural blockade for management of pain in interstitial cystitis. *Br J Urol*. 1993;71(4):413–416.

Ito T, Stein PC, Parsons CL, et al. Elevated stress protein in transitional cells exposed to urine from interstitial cystitis patients. *Int J Urol*. 1998;5(5):444–448.

Ito T, Miki M, Yamada T. Interstitial cystitis in Japan. *BJU Int*. 2000;86(6):634–637.

Ito T, Tomoe H, Ueda T, et al. Clinical symptoms scale for interstitial cystitis for diagnosis and for following the course of the disease. *Int J Urol*. 2003;10(Suppl):S24–S26.

Jacob J, Ludgate CM, Forde J, et al. Recent observations on the ultrastructure of human urothelium. 1. Normal bladder of elderly subjects. *Cell Tissue Res*. 1978;193:543–560.

Jacobsen S, Danneskiold-Samsoe B, Lund B. Consensus document on fibromyalgia: the Copenhagen declaration. *J Musculoskelet Pain*. 1993;1(3–4):295–312.

Janssen DA, van Wijk XM, Jansen KC, et al. The distribution and function of chondroitin sulfate and other sulfated glycosaminoglycans in the human bladder and their contribution to the protective bladder barrier. *J Urol*. 2013;189(1):336–342.

Jhang JF, Hsu YH, Kuo HC. Possible pathophysiology of ketamine-related cystitis and associated treatment strategies. *Int J Urol*. 2015;22(9):816–825.

Johansson SL, Fall M. Clinical features and spectrum of light microscopic changes in interstitial cystitis. *J Urol*. 1990;143(6):1118–1124.

Johansson SL, Fall M. Pathology of interstitial cystitis. *Urol Clin North Am*. 1994;21(1):55–62.

Jokinen EJ, Alfthan OS, Oravisto KJ. Antitissue antibodies in interstitial cystitis. *Clin Exp Immunol*. 1972;11(3):333–339.

Jokinen EJ, Oravisto KJ, Alfthan OS. The effect of cystectomy on antitissue antibodies in interstitial cystitis. *Clin Exp*

Immunol. 1973;15(3):457–460.

Jones CA, Nyberg L. Epidemiology of interstitial cystitis. *Urology*. 1997;49(5A Suppl):2–9.

Kajiwara M, Inoue S, Kobayashi K, et al. Therapeutic efficacy of narrow band imaging-assisted transurethral electrocoagulation for ulcer-type interstitial cystitis/painful bladder syndrome. *Int J Urol*. 2014;21(Suppl 1):57–60.

Kang J, Wein AJ, Levin RM. Bladder functional recovery following acute overdistention. *Neurourol Urodyn*. 1992;11(3):253–260.

Kaplan AP, Haak-Frendscho M, Fuci A, et al. A histamine-releasing factor from activated human mononuclear cells. *J Immunol*. 1985;135(3):2027–2032.

Kastrup J, Hald T, Larsen S, et al. Histamine content and mast cell count of detrusor muscle in patients with interstitial cystitis and other types of chronic cystitis. *Br J Urol*. 1983;55(5):495–500.

Katske F, Shoskes DA, Sender M, et al. Treatment of interstitial cystitis with a quercetin supplement. *Tech Urol*. 2001;7(1):44–46.

Katz L, Tripp DA, Nickel JC, et al. Disability in women suffering from interstitial cystitis/bladder pain syndrome. *BJU Int*. 2013;111(1):114–121.

Kau AL, Hunstad DA, Hultgren SJ. Interaction of uropathogenic *Escherichia coli* with host uroepithelium. *Curr Opin Microbiol*. 2005;8(1):54–59.

Keay S. Cell signaling in interstitial cystitis/painful bladder syndrome. *Cell Signal*. 2008;20(12):2174–2179.

Keay S, Warren JW. A hypothesis for the etiology of interstitial cystitis based upon inhibition of bladder epithelial repair. *Med Hypotheses*. 1998;51(1):79–83.

Keay S, Zhang CO, Trifillis AL, et al. Decreased 3H-thymidine incorporation by human bladder epithelial cells following exposure to urine from interstitial cystitis patients. *J Urol*. 1996;156(6):2073–2078.

Keay S, Zhang CO, Baldwin BR, et al. Polymerase chain reaction amplification of bacterial 16S rRNA genes in interstitial cystitis and control patient bladder biopsies. *J Urol*. 1998;159(1):280–283.

Keay S, Zhang CO, Hise MK, et al. A diagnostic in vitro urine assay for interstitial cystitis. *Urology*. 1998;52(6):974–978.

Keay S, Warren JW, Zhang CO, et al. Antiproliferative activity is present in bladder but not renal pelvic urine from interstitial cystitis patients. *J Urol*. 1999;162(4):1487–1489.

Keay S, Kleinberg M, Zhang CO, et al. Bladder epithelial cells from patients with interstitial cystitis produce an inhibitor of heparin-binding epidermal growth factor-like growth factor production. *J Urol*. 2000;164(6):2112–2118.

Keay S, Zhang CO, Marvel R, et al. Antiproliferative factor, heparin-binding epidermal growth factor–like growth factor, and epidermal growth factor: sensitive and specific urine markers for interstitial cystitis. *Urology*. 2001;57(6 Suppl 1):104.

Keay SK, Zhang CO, Shoenfelt J, et al. Sensitivity and specificity of antiproliferative factor, heparin-binding epidermal growth factor-like growth factor, and epidermal growth factor as urine markers for interstitial cystitis. *Urology*. 2001;57(6 Suppl 1):9–14.

Keay S, Zhang CO, Shoenfelt JL, et al. Decreased in vitro proliferation of bladder epithelial cells from patients with interstitial cystitis. *Urology*. 2003;61(6):1278–1284.

Keay S, Zhang CO, Chai T, et al. Antiproliferative factor, heparin-binding epidermal growth factor–like growth factor, and epidermal growth factor in men with interstitial cystitis versus chronic pelvic pain syndrome. *Urology*. 2004;63(1):22–26.

Keay SK, Szekely Z, Conrads TP, et al. An antiproliferative factor from interstitial cystitis patients is a frizzled 8 protein-related sialoglycopeptide. *Proc Natl Acad Sci USA*. 2004;101(32):11803–11808.

Keay S, Kaczmarek P, Zhang CO, et al. Normalization of proliferation and tight junction formation in bladder epithelial cells from patients with interstitial cystitis/painful bladder syndrome by d-proline and d-pipecolic acid derivatives of antiproliferative factor. *Chem Biol Drug Des*. 2011;77(6):421–430.

Keay S, Leitzell S, Ochrzcin A, et al. A mouse model for interstitial cystitis/painful bladder syndrome based on APF inhibition of bladder epithelial repair: a pilot study. *BMC Urol*. 2012;12(1):17.

Keller ML, McCarthy DO, Neider RS. Measurement of symptoms of interstitial cystitis. A pilot study. *Urol Clin North Am*. 1994;21(1):67–71.

Kelly JD, Young MR, Johnston SR, et al. Clinical response to an oral prostaglandin analogue in patients with interstitial cystitis. *Eur Urol*. 1998;34(1):53–56.

Kelly BC, Parsons JT, Wells BE. Prevalence and predictors of club drug use among club-going young adults in New York City. *J Urban Health*. 2006;83(5):884–895.

Kerr WS Jr. Interstitial cystitis: treatment by transurethral resection. *J Urol*. 1971;105(5):664–666.

Keselman I, Austin P, Anderson J, et al. Cystectomy and urethrectomy for disabling interstitial cystitis: a long term followup. *J Urol*. 1995;153:290A.

Killinger KA, Boura JA, Peters KM. Pain in interstitial cystitis/bladder pain syndrome: do characteristics differ in ulcerative and non-ulcerative subtypes? *Int Urogynecol J*. 2013;24(8):1295–1301.

Kilpatrick LA, Kutch JJ, Tillisch K, et al. Alterations in resting state oscillations and connectivity in sensory and motor networks in women with interstitial cystitis/painful bladder syndrome. *J Urol*. 2014;192(3):947–955.

Kim SE, Chang L. Overlap between functional GI disorders and other functional syndromes: what are the underlying mechanisms? *Neurogastroenterol Motil*. 2012;24(10):895–913.

Kim YS, Levin RM, Wein AJ, et al. Effects of sensitization on the permeability of urothelium in guinea pig urinary bladder. *J Urol*. 1992;147(1):270–273.

Kim J, Keay SK, Dimitrakov JD, et al. p53 mediates interstitial cystitis antiproliferative factor (APF)–induced growth inhibition of human urothelial cells. *FEBS Lett*. 2007;581(20):3795–3799.

Kim J, Keay SK, Freeman MR. Heparin-binding epidermal growth factor–like growth factor functionally antagonizes interstitial cystitis antiproliferative factor via mitogen-activated protein kinase pathway activation. *BJU Int*. 2009;103(4):541–546.

Kim R, Liu W, Chen X, et al. Intravesical dimethyl sulfoxide inhibits acute and chronic bladder inflammation in transgenic experimental autoimmune cystitis models. *J Biomed Biotechnol*. 2011;2011:937061.

Kim J, Keay SK, You S, et al. A synthetic form of frizzled 8-associated antiproliferative factor enhances p53 stability through USP2a and MDM2. *PLoS ONE*. 2012;7(12):e50392.

Kim SH, Oh SA, Oh SJ. Voiding diary might serve as a useful tool to understand differences between bladder pain syndrome/interstitial cystitis and overactive bladder. *Int J Urol*. 2014;21(2):179–183.

Kim A, Han JY, Ryu CM, et al. Histopathological characteristics of interstitial cystitis/bladder pain syndrome without Hunner lesion. *Histopathology*. 2017;71(3):415–424.

Kirk PS, Santiago-Lastra Y, Qin Y, et al. The effects of cystoscopy and hydrodistention on symptoms and bladder capacity in interstitial cystitis/bladder pain syndrome. *Neurourol Urodyn*. 2018;37(6):2002–2007.

Kirkemo AK, Miles BJ, Peters JM. Use of amitriptyline in the treatment of interstitial cystitis. *J Urol*. 1990;143:279A.

Kirkemo A, Peabody M, Diokno AC, et al. Associations among urodynamic findings and symptoms in women enrolled in the Interstitial Cystitis Data Base (ICDB) study. *Urology*. 1997;49(5A Suppl):76–80.

Kirkengen AL, Ulvestad E. Heavy burdens and complex disease—an integrated perspective. *Tidsskr Nor Laegeforen*. 2007;127(24):3228–3231.

Kisman OK, Nijeholt AA, van Krieken JH. Mast cell infiltration in intestine used for bladder augmentation in interstitial cystitis. *J Urol*. 1991;146(4):1113–1114.

Klumpp DJ, Rudick CN. Summation model of pelvic pain in interstitial cystitis. *Nat Clin Pract Urol*. 2008;5(9):494–500.

Klutke CG, Bullock AD, Ratliff TL, et al. Experimental autoimmune cystitis (EAC): an autoimmune model for interstitial cystitis. Sant GR. *Interstitial cystitis*. Lippincott-Raven: Philadelphia, PA; 1997:33–46.

Kochakarn W, Lertsithichai P, Pummangura W. Bladder substitution by ileal neobladder for women with interstitial cystitis. *Int Braz J Urol*. 2007;33(4):486–492.

Kohn IJ, Filer-Maerten S, Whitmore KE, et al. Lack of effect following repeated in vivo exposure of the rabbit urinary bladder to urine from interstitial cystitis patients at low infusion volumes. *Neurourol Urodyn*. 1998;17(2):147–152.

Korting GE, Smith SD, Wheeler MA, et al. A randomized double-blind trial of oral l-arginine for treatment of interstitial cystitis. *J Urol*. 1999;161(2):558–565.

Koskela LR, Thiel T, Ehrén I, et al. Localization and expression of inducible nitric oxide synthase in biopsies from patients with interstitial cystitis. *J Urol*. 2008;180(2):737–741.

Koziol JA. Epidemiology of interstitial cystitis. *Urol Clin North Am*. 1994;21(1):7–20.

Koziol JA, Clark DC, Gittes RF, et al. The natural history of interstitial cystitis: a survey of 374 patients. *J Urol*. 1993;149(3):465–469.

Koziol JA, Adams HP, Frutos A. Discrimination between the ulcerous and the nonulcerous forms of interstitial cystitis by noninvasive findings. *J Urol*. 1996;155(1):87–90.

Krieger JN, Stephens AJ, Clemens JQ, et al. Relationship between chronic nonurological associated somatic syndromes and symptom severity in urological chronic pelvic pain syndromes: baseline evaluation of the MAPP study. *J Urol*. 2015;193(4):1254–1262.

Kruger JM, Osborne CA, Goyal SM, et al. Clinical evaluation of cats with lower urinary tract disease. *J Am Vet Med Assoc*. 1991;199(2):211–216.

Kumar V, Chapple CR, Surprenant AM, et al. Enhanced adenosine triphosphate release from the urothelium of patients with painful bladder syndrome: a possible pathophysiological explanation. *J Urol*. 2007;178(4 Pt 1):1533–1536.

Kuo HC. Urodynamic results of intravesical heparin therapy for women with frequency urgency syndrome and interstitial cystitis. *J Formos Med Assoc*. 2001;100(5):309–314.

Kuo HC. Repeated onabotulinumtoxin-a injections provide better results than single injection in treatment of painful bladder syndrome. *Pain Physician*. 2013;16(1):E15–E23.

Kuo HC, Chancellor MB. Comparison of intravesical botulinum toxin type A injections plus hydrodistention with hydrodistention alone for the treatment of refractory interstitial cystitis/painful bladder syndrome. *BJU Int*.

2009;104(5):657–661.

Kuo YC, Kuo HC. Videourodynamic characteristics of interstitial cystitis/bladder pain syndrome—The role of bladder outlet dysfunction in the pathophysiology. *Neurourol Urodyn*. 2018;37(6):1971–1977.

Kuo TL, Ng LG, Chapple CR. Pelvic floor spasm as a cause of voiding dysfunction. *Curr Opin Urol*. 2015;25(4):311–316.

Kushner L, Moldwin RM. Efficiency of questionnaires used to screen for interstitial cystitis. *J Urol*. 2006;176(2):587–592.

Lagunoff FD, Martin TW, Read G. Agents that release histamine from mast cells. *Annu Rev Pharmacol Toxicol*. 1983;23:331–351.

Lai MC, Kuo YC, Kuo HC. Intravesical hyaluronic acid for interstitial cystitis/painful bladder syndrome: a comparative randomized assessment of different regimens. *Int J Urol*. 2013;20(2):203–207.

Lai HH, Vetter J, Jain S, et al. The overlap and distinction of self-reported symptoms between interstitial cystitis/bladder pain syndrome and overactive bladder: a questionnaire based analysis. *J Urol*. 2014;192(6):1679–1686.

Lai HH, Krieger JN, Pontari MA, et al. Painful bladder filling and painful urgency are distinct characteristics in men and women with urological chronic pelvic pain syndromes: a MAPP research network study. *J Urol*. 2015;194(6):1634–1641.

Landis JR, Williams DA, Lucia MS, et al. The MAPP research network: design, patient characterization and operations. *BMC Urol*. 2014;14:58.

LaRock DR, Sant GR. Intravesical Clorpactin for refractory interstitial cystitis. *Infect Urol*. 1995;151–157.

Larsen S, Thompson SA, Hald T, et al. Mast cells in interstitial cystitis. *Br J Urol*. 1982;54(3):283–286.

Larsen MS, Mortensen S, Nordling J, et al. Quantifying mast cells in bladder pain syndrome by immunohistochemical analysis. *BJU Int*. 2008;102(2):204–207.

Lasanen LT, Tammela TL, Kallioinen M, et al. Effect of acute distension on cholinergic innervation of the rat urinary bladder. *Urol Res*. 1992;20(1):59–62.

Lavano A, Volpentesta G, Piragine G, et al. Sacral nerve stimulation with percutaneous dorsal transforamenal approach in treatment of isolated pelvic pain syndromes. *Neuromodulation*. 2006;9(3):229–233.

Lavelle JP, Apodaca G, Meyers SA, et al. Disruption of guinea pig urinary bladder permeability barrier in noninfectious cystitis. *Am J Physiol*. 1998;274:F205–F214.

Lavelle JP, Yoshiyama M, Doty DA, et al. Capsaicin antagonizes elevated urothelial permeability in rat bladder induced by pelvic nerve stimulation. *J Urol*. 1999;161(4S):25.

Lavelle JP, Meyers SA, Ruiz WG, et al. Urothelial pathophysiological changes in feline interstitial cystitis: a human model. *Am J Physiol Renal Physiol*. 2000;278(4):F540–F553.

Lee JD, Lee MH. Increased expression of hypoxia-inducible factor-1alpha and vascular endothelial growth factor associated with glomerulation formation in patients with interstitial cystitis. *Urology*. 2011;78(4):971–975.

Lee KL, Dong CS, Chen MY, et al. Multifactorial causes of irritating bladder symptoms in patients with Sjögren's syndrome. *Neurourol Urodyn*. 2011;30(1):97–101.

Leppilahti M, Tammela TL, Huhtala H, et al. Prevalence of symptoms related to interstitial cystitis in women: a population based study in Finland. *J Urol*. 2002;168(1):139–143.

Leppilahti M, Tammela TL, Huhtala H, et al. Interstitial cystitis–like urinary symptoms among patients with Sjögren's syndrome: a population-based study in Finland. *Am J Med*. 2003;115(1):62–65.

Leppilahti M, Sairanen J, Tammela TL, et al. Prevalence of clinically confirmed interstitial cystitis in women: a population based study in Finland. *J Urol*. 2005;174(2):581–583.

Letourneau R, Pang X, Sant GR, et al. Intragranular activation of bladder mast cells and their association with nerve processes in interstitial cystitis. *Br J Urol*. 1996;77(1):41–54.

Levin RM, Lavkar RM, Monson FC, et al. Effect of chronic nitrofurantoin on the rabbit urinary bladder. *J Urol*. 1988;139(2):400–404.

Lewi HJ. Cimetidine in the treatment of interstitial cystitis. *Br J Urol*. 1996;77(Suppl 1):28.

Li J, Micevych P, McDonald J, et al. Inflammation in the uterus induces phosphorylated extracellular signal-regulated kinase and substance P immunoreactivity in dorsal root ganglia neurons innervating both uterus and colon in rats. *J Neurosci Res*. 2008;86(12):2746–2752.

Liberski S, Marczak D, Mazur E, et al. Systemic lupus erythematosus of the urinary tract: focus on lupus cystitis. *Reumatologia*. 2018;56(4):255–258.

Liebert M, Sant GR. Bladder cell activation and mucosal immunity in interstitial cystitis. Sant GR. *Interstitial cystitis*. Lippincott-Raven: Philadelphia, PA; 1997:117–122.

Liebert M, Wedemeyer G, Stein JA, et al. Evidence for urothelial cell activation in interstitial cystitis. *J Urol*. 1993;149(3):470–475.

Lilius HG, Oravisto KJ, Valtonen EJ. Origin of pain in interstitial cystitis. Effect of ultrasound treatment on the concomitant levator ani spasm syndrome. *Scand J Urol Nephrol*. 1973;7(2):150–152.

Lilly JD, Parsons CL. Bladder surface glycosaminoglycans is a human epithelial permeability barrier. *Surg Gynecol Obstet*. 1990;171:493–496.

Link CL, Lutfey KE. Is abuse causally related to urologic symptoms? Results from the Boston Area Community Health Survey. *Eur Urol*. 2007;52(2):397–406.

Linn JF, Hohenfellner M, Roth S, et al. Treatment of interstitial cystitis: comparison of subtrigonal and supratrigonal cystectomy combined with orthotopic bladder substitution. *J Urol*. 1998;159(3):774–778.

Liu HT, Kuo HC. Increased urine and serum nerve growth factor levels in interstitial cystitis suggest chronic inflammation is involved in the pathogenesis of disease. *PLoS ONE*. 2012;7(9):e44687.

Liu YK, Harty JI, Steinbock GS, et al. Treatment of radiation or cyclophosphamide induced hemorrhagic cystitis using conjugated estrogen. *J Urol*. 1990;144(1):41–43.

Liu HT, Tyagi P, Chancellor MB, et al. Urinary nerve growth factor level is increased in patients with interstitial cystitis/bladder pain syndrome and decreased in responders to treatment. *BJU Int*. 2009;104(10):1476–1481.

Lloyd LK. *Surgical treatment of interstitial cystitis*. [AUA News October:12] 1999.

Logadottir YR, Ehren I, Fall M, et al. Intravesical nitric oxide production discriminates between classic and nonulcer interstitial cystitis. *J Urol*. 2004;171(3):1148–1150.

Logadottir Y, Fall M, Kåbjörn-Gustafsson C, et al. Clinical characteristics differ considerably between phenotypes of bladder pain syndrome/interstitial cystitis. *Scand J Urol Nephrol*. 2012;46(5):365–370.

Logadottir Y, Hallsberg L, Fall M, et al. Bladder pain syndrome/interstitial cystitis ESSIC type 3C: high expression of inducible nitric oxide synthase in inflammatory cells. *Scand J Urol*. 2013;47(1):52–56.

Loran OB, Siniakova LA, Seregin AV, et al. Hyperbaric oxygenation in the treatment of patients with interstitial cystitis: clinical and morphological rationale. *Urologiia*. 2011;3:3–5.

Lose G, Frandsen B, Holm-Bentzen M, et al. Urine eosinophil cationic protein in painful bladder disease. *Br J Urol*. 1987;60(1):39–42.

Lotenfoe RR, Christie J, Parsons A, et al. Absence of neuropathic pelvic pain and favorable psychological profile in the surgical selection of patients with disabling interstitial cystitis. *J Urol*. 1995;154(6):2039–2042.

Lotz M, Villiger P, Hugli T, et al. Interleukin-6 and interstitial cystitis. *J Urol*. 1994;152(3):869–873.

Low PA, Dotson RM. Symptomatic treatment of painful neuropathy. *JAMA*. 1998;280(21):1863–1864.

Lowe EM, Anand P, Terenghi G, et al. Increased nerve growth factor levels in the urinary bladder of women with idiopathic sensory urgency and interstitial cystitis. *Br J Urol*. 1997;79(4):572–577.

Lubeck DP, Whitmore K, Sant GR, et al. Psychometric validation of the O'Leary-Sant interstitial cystitis symptom index in a clinical trial of pentosan polysulfate sodium. *Urology*. 2001;57(6 Suppl 1):62–66.

Luber-Narod J, Austin-Ritchie T, Hollins C 3rd, et al. Role of substance P in several models of bladder inflammation. *Urol Res*. 1997;25(6):395–399.

Lucioni A, Bales GT, Lotan TL, et al. Botulinum toxin type A inhibits sensory neuropeptide release in rat bladder models of acute injury and chronic inflammation. *BJU Int*. 2008;101(3):366–370.

Lukban J, Whitmore K, Kellogg-Spadt S, et al. The effect of manual physical therapy in patients diagnosed with interstitial cystitis, high-tone pelvic floor dysfunction, and sacroiliac dysfunction. *Urology*. 2001;57(6 Suppl 1):121–122.

Lundberg JO, Ehrén I, Jansson O, et al. Elevated nitric oxide in the urinary bladder in infectious and noninfectious cystitis. *Urology*. 1996;48(5):700–702.

Lundeberg T, Liedberg H, Nordling L, et al. Interstitial cystitis: correlation with nerve fibres, mast cells and histamine. *Br J Urol*. 1993;71(4):427–429.

Lunghi F, Nicita G, Selli C, et al. Clinical aspects of augmentation enterocystoplasties. *Eur Urol*. 1984;10(3):159–163.

Luo Y. A potential modality for interstitial cystitis: intravesical use of anti-inflammatory peptide RDP58. *J Urol*. 2005;173(2):340.

Lutgendorf SK, Kreder KJ. Central and peripheral mechanisms in interstitial symptoms. *J Urol*. 2005;173(3):682.

Lutgendorf SK, Kreder KJ, Rothrock NE, et al. Stress and symptomatology in patients with interstitial cystitis: a laboratory stress model. *J Urol*. 2000;164(4):1265–1269.

Lutgendorf SK, Kreder KJ, Rothrock NE, et al. Diurnal cortisol variations and symptoms in patients with interstitial cystitis. *J Urol*. 2002;167(3):1338–1343.

Lutgendorf SK, Latini JM, Rothrock N, et al. Autonomic response to stress in interstitial cystitis. *J Urol*. 2004;172(1):227–231.

Lv YS, Zhou HL, Mao HP, et al. Intravesical hyaluronic acid and alkalinized lidocaine for the treatment of severe painful bladder syndrome/interstitial cystitis. *Int Urogynecol J*. 2012;23(12):1715–1720.

Lynes WL, Flynn SD, Shortliffe LD, et al. Mast cell involvement in interstitial cystitis. *J Urol*. 1987;138(4):746–752.

Lynes WL, Flynn SD, Shortliffe LD, et al. The histology of interstitial cystitis. *Am J Surg Pathol*. 1990;14(10):969–976.

Lynes WL, Shortliffe LD, Stamey TA. Urinary myotropic substances in interstitial cystitis. *J Urol*. 1990;143:373A.

Lynn RB, Friedman LS. Irritable bowel syndrome. *N Engl J Med*. 1993;329(26):1940–1945.

MacDermott JP, Charpied GL, Tesluk H, et al. Recurrent interstitial cystitis following cystoplasty: fact or fiction? *J Urol*. 1990;144(1):37–40.

MacDermott JP, Charpied GC, Tesluk H, et al. Can histological assessment predict the outcome in interstitial cystitis? *Br J Urol*. 1991;67(1):44–47.

MacDermott JP, Miller CH, Levy N, et al. Cellular immunity in interstitial cystitis. *J Urol*. 1991;145(2):274–278.

Madersbacher H, van Ophoven A, van Kerrebroeck PE. GAG layer replenishment therapy for chronic forms of cystitis with intravesical glycosaminoglycans—a review. *Neurourol Urodyn*. 2013;32(1):9–18.

Maeda D, Akiyama Y, Morikawa T, et al. Hunner-type (classic) interstitial cystitis: a distinct inflammatory disorder characterized by pancystitis, with frequent expansion of clonal B-cells and epithelial denudation. *PLoS ONE*. 2015;10(11):e0143316.

Mak SK, Chan MT, Bower WF, et al. Lower urinary tract changes in young adults using ketamine. *J Urol*. 2011;186(2):610–614.

Malykhina AP. Neural mechanisms of pelvic organ cross-sensitization. *Neuroscience*. 2007;149(3):660–672.

Malykhina AP, Lei Q, Erickson CS, et al. VEGF induces sensory and motor peripheral plasticity, alters bladder function, and promotes visceral sensitivity. *BMC Physiol*. 2012;12:15.

Mangera A, Andersson KE, Apostolidis A, et al. Contemporary management of lower urinary tract disease with botulinum toxin A: a systematic review of botox (onabotulinumtoxinA) and dysport (abobotulinumtoxinA). *Eur Urol*. 2011;60(4):784–795.

Manning J, Dwyer P, Rosamilia A, et al. A multicentre, prospective, randomised, double-blind study to measure the treatment effectiveness of abobotulinum A (AboBTXA) among women with refractory interstitial cystitis/bladder pain syndrome. *Int Urogynecol J*. 2014;25(5):593–599.

Marinkovic SP, Gillen LM, Marinkovic CM. Minimum 6-year outcomes for interstitial cystitis treated with sacral neuromodulation. *Int Urogynecol J*. 2011;22(4):407–412.

Markwell SJ. Physical therapy of pelvi/perineal and perianal syndromes. *World J Urol*. 2001;19:194–199.

Martins SM, Darlin DJ, Lad PM, et al. Interleukin-1B: a clinically relevant urinary marker. *J Urol*. 1994;151(5):1198–1201.

Marx CM, Alpert SE. Ticarcillin-induced cystitis. *Am J Dis Child*. 1984;138(7):670–672.

Maskell R. Broadening the concept of urinary tract infection. *Br J Urol*. 1995;76(1):2–7 [discussion 7–8].

Mattila J. Vascular immunopathology in interstitial cystitis. *Clin Immunol Immunopathol*. 1982;23(3):648–655.

Mattila J, Linder E. Immunoglobulin deposits in bladder epithelium and vessels in interstitial cystitis: possible relationship to circulating anti-intermediate filament autoantibodies. *Clin Immunol Immunopathol*. 1984;32(1):81–89.

Mattila J, Harmoinen A, Hallstrom O. Serum immunoglobulin and complement alterations in interstitial cystitis. *Eur Urol*. 1983;9(6):350–352.

Maxwell KM, Clemens JQ, Mazzenga L, et al. Reprogramming requirements after sacral nerve stimulator implantation: correlation with preoperative indication. *J Urol*. 2008;179(2):549–551.

Mayson BE, Teichman JM. The relationship between sexual abuse and interstitial cystitis/painful bladder syndrome. *Curr Urol Rep*. 2009;10(6):441–447.

Mazurick CA, Landis JR. Evaluation of repeat daily voiding measures in the National Interstitial Cystitis Data Base Study. *J Urol*. 2000;163(4):1208–1211.

McCahy PJ, Styles RA. Prolonged bladder distension: experience in the treatment of detrusor overactivity and interstitial cystitis. *Eur Urol*. 1995;28(4):325–327.

McDougald M, Landon CR. The diagnosis of interstitial cystitis: is histology helpful? *Int Urogynecol J Pelvic Floor Dysfunct*. 2003;14(Suppl 1):S40–S41.

McGuire EJ, Lytton B, Cornog JL Jr. Interstitial cystitis following colocystoplasty. *Urology*. 1973;2(1):28–29.

McGuire EJ, Shi-chun Z, Horwinski ER, et al. Treatment of motor and sensory detrusor instability by electrical stimulation. *J Urol*. 1983;129(1):78–79.

McInerney PD, Vanner TF, Matenhelia S, et al. Assessment of the long-term results of subtrigonal phenolisation. *Br J Urol*. 1991;67(6):586–587.

Meadows E. Treatments for patients with pelvic pain. *Urol Nurs*. 1999;19(1):33–35.

Meeus M, Nijs J. Central sensitization: a biopsychological explanation for chronic widespread pain in patients with fibromyalgia and chronic fatigue syndrome. *Clin Rheumatol*. 2007;26(4):465–473.

Meijlink J. Historical perspectives. Hanno PM, Nordling J, Staskin DR, et al. *Bladder pain syndrome—an evolution*. 2nd ed. 2018:3–10.

Meirowsky AM. The management of chronic interstitial cystitis by differential sacral neurotomy. *J Neurosurg*. 1969;30(5):604–607.

Melchior D, Packer CS, Johnson TC, et al. Dimethyl sulfoxide:

does it change the functional properties of the bladder wall? *J Urol*. 2003;170(1):253–258.

Mendelowitz F, Moldwin R, Sant GR. Complementary approaches in the management of interstitial cystitis. Sant GR. *Interstitial cystitis*. Lippincott-Raven: Philadelphia, PA; 1997:235–240.

Merrill L, Malley SE, Vizzard MA. Repeated variate stress in male rats induces increased voiding frequency, somatic sensitivity and urinary bladder nerve growth factor expression. *Am J Physiol Regul Integr Comp Physiol*. 2013;305(2):R147–R156.

Messing EM. Interstitial cystitis. *J Urol*. 1994;151(2):355–356.

Messing EM, Stamey TA. Interstitial cystitis: early diagnosis, pathology, and treatment. *Urology*. 1978;12(4):381–392.

Messing EM, Freiha FS. Complication of Clorpactin WCS90 therapy for interstitial cystitis. *Urology*. 1979;13(4):389–392.

Messing E, Pauk D, Schaeffer A, et al. Associations among cystoscopic findings and symptoms and physical examination findings in women enrolled in the Interstitial Cystitis Data Base (ICDB) study. *Urology*. 1997;49(5A Suppl):81–85.

Meulders Q, Michel C, Marteau P, et al. Association of chronic interstitial cystitis, protein-losing enteropathy and paralytic ileus with seronegative systemic lupus erythematosus: case report and review of the literature. *Clin Nephrol*. 1992;37(5):239–244.

Michael YL, Kawachi I, Stampfer MJ, et al. Quality of life among women with interstitial cystitis. *J Urol*. 2000;164(2):423–427.

Middela S, Pearce I. Ketamine-induced vesicopathy: a literature review. *Int J Clin Pract*. 2011;65(1):27–30.

Miller CH, MacDermott JP, Quattrocchi KB, et al. Lymphocyte function in patients with interstitial cystitis. *J Urol*. 1992;147(3):592–595.

Minogiannis P, El Mansoury M, Betances JA, et al. Hydroxyzine inhibits neurogenic bladder mast cell activation. *Int J Immunopharmacol*. 1998;20(10):553–563.

Misra S. Ketamine-associated bladder dysfunction—a review of the literature. *Curr Bladder Dysfunct Rep*. 2018;13:145–152.

Moldwin RM. Similarities between interstitial cystitis and male chronic pelvic pain syndrome. *Curr Urol Rep*. 2002;3(4):313–318.

Moldwin RM. The use of pentosan polysulfate in the management of interstitial cystitis. Springer International Publishing: Cham; 2017:115–119. *Bladder pain syndrome—an evolution*. vol 130.

Moldwin R, Kushner L. The diagnostic value of interstitial cystitis questionnaires. *J Urol*. 2004;171(4 Suppl):96.

Moldwin RM, Fariello JY. Myofascial trigger points of the pelvic floor: associations with urological pain syndromes and treatment strategies including injection therapy. *Curr Urol Rep*. 2013;14(5):409–417.

Møller NE. Carbenicillin-induced hemorrhagic cystitis. *Lancet*. 1978;2(8096):946.

Moncada S, Higgs A. The l-arginine-nitric oxide pathway. *N Engl J Med*. 1993;329(27):2002–2012.

Monga M, Percival C, Zupkas P. Intravesical ethanol as quantitative measure of bladder hyperpermeability. *J Endourol*. 2001;15(6):641–644.

Moore KH, Nickson P, Richmond DH, et al. Detrusor mast cells in refractory idiopathic instability. *Br J Urol*. 1992;70(1):17–21.

Morales A, Emerson L, Nickel JC, et al. Intravesical hyaluronic acid in the treatment of refractory interstitial cystitis. *J Urol*. 1996;156(1):45–48.

Moran PA, Dwyer PL, Carey MP, et al. Oral methotrexate in the management of refractory interstitial cystitis. *Aust N Z J*

Obstet Gynaecol. 1999;39(4):468–471.

Morrissey D, El-Khawand D, Ginzburg N, et al. Botulinum toxin a injections into pelvic floor muscles under electromyographic guidance for women with refractory High-Tone pelvic floor dysfunction. *Female Pelvic Med Reconstr Surg*. 2015;21(5):277–282.

Moskowitz MO, Byrne DS, Callahan HJ, et al. Decreased expression of a glycoprotein component of bladder surface mucin (GP1) in interstitial cystitis. *J Urol*. 1994;151(2):343–345.

Muere A, Tripp DA, Nickel JC, et al. Depression and coping behaviors are key factors in understanding pain in interstitial cystitis/bladder pain syndrome. *Pain Manag Nurs*. 2018;19(5):497–505.

Murnaghan GF, Saalfeld J, Farnsworth RH. Interstitial cystitis—treatment with Clorpactin WCS-90. *Br J Urol*. 1970;42(6):744.

Naber SP. Molecular pathology—diagnosis of infectious disease. *N Engl J Med*. 1994;331:1212–1215.

Nails D. Socrates. Zalta EN. *The Stanford encyclopedia of philosophy*. 2018 [Available at] https://plato.stanford.edu/archives/spr2018/entries/socrates/.

National Institute on Drug Abuse. *Hallucinogens and dissociative drugs. NIH publication No. 15-4209*. U.S. Department of Health and Human Services, National Institutes of Health: Washington, D.C.; 2015.

Neal DE Jr, Dilworth JP, Kaack MB. Tamm-Horsfall autoantibodies in interstitial cystitis. *J Urol*. 1991;145(1):37–39.

Nesse RM. Proximate and evolutionary studies of anxiety, stress and depression: synergy at the interface. *Neurosci Biobehav Rev*. 1999;23:895–903.

Neuhaus J, Schulte-Baukloh H, Stolzenburg JU, et al. Individual receptor profiling as a novel tool to support diagnosis of bladder pain syndrome/interstitial cystitis (BPS/IC). *World J Urol*. 2012;30(5):693–700.

Nguan C, Franciosi LG, Butterfield NN, et al. A prospective, double-blind, randomized cross-over study evaluating changes in urinary pH for relieving the symptoms of interstitial cystitis. *BJU Int*. 2005;95(1):91–94.

Nguyen RH, Veasley C, Smolenski D. Latent class analysis of comorbidity patterns among women with generalized and localized vulvodynia: preliminary findings. *J Pain Res*. 2013;6:303–309.

Nickel JC. Epidemiology commentary. Hanno PM, Nordling J, Staskin DR, et al. *Bladder pain syndrome—an evolution*. 2nd ed. Springer International Publishing: Cham; 2018:23–25.

Nickel JC, Moldwin R. FDA BRUDAC 2018 criteria for interstitial cystitis/bladder pain syndrome clinical trials: future direction for research. *J Urol*. 2018;200(1):39–42.

Nickel JC, Emerson L, Cornish J. The bladder mucus (glycosaminoglycan) layer in interstitial cystitis. *J Urol*. 1993;149(4):716–718.

Nickel JC, Downey J, Morales A, et al. Relative efficacy of various exogenous glycosaminoglycans in providing a bladder surface permeability barrier. *J Urol*. 1998;160(2):612–614.

Nickel JC, Barkin J, Forrest J, et al. Randomized, double-blind, dose-ranging study of pentosan polysulfate sodium for interstitial cystitis. *Urology*. 2005;65(4):654–658.

Nickel JC, Tripp D, Teal V, et al. Sexual function is a determinant of poor quality of life for women with treatment refractory interstitial cystitis. *J Urol*. 2007;177(5):1832–1836.

Nickel JC, Egerdie B, Downey J, et al. A real-life multicentre clinical practice study to evaluate the efficacy and safety of intravesical chondroitin sulphate for the treatment of interstitial cystitis. *BJU Int*. 2009;103(1):56–60.

Nickel JC, Shoskes D, Irvine-Bird K. Clinical phenotyping of women with interstitial cystitis/painful bladder syndrome: a key to classification and potentially improved management. *J Urol*. 2009;182(1):155–160.

Nickel JC, Moldwin R, Lee S, et al. Intravesical alkalinized lidocaine (PSD597) offers sustained relief from symptoms of interstitial cystitis and painful bladder syndrome. *BJU Int*. 2009;103(7):910–918.

Nickel JC, Shoskes DA, Irvine-Bird K. Prevalence and impact of bacteriuria and/or urinary tract infection in interstitial cystitis/painful bladder syndrome. *Urology*. 2010;76(4):799–803.

Nickel JC, Tripp DA, Pontari M, et al. Interstitial cystitis/painful bladder syndrome and associated medical conditions with an emphasis on irritable bowel syndrome, fibromyalgia and chronic fatigue syndrome. *J Urol*. 2010;184(4):1358–1363.

Nickel JC, Tripp DA, Pontari M, et al. Childhood sexual trauma in women with interstitial cystitis/bladder pain syndrome: a case control study. *Can Urol Assoc J*. 2011;5(6):410–415.

Nickel JC, Hanno P, Kumar K, et al. Second multicenter, randomized, double-blind, parallel-group evaluation of effectiveness and safety of intravesical sodium chondroitin sulfate compared with inactive vehicle control in subjects with interstitial cystitis/bladder pain syndrome. *Urology*. 2012;79(6):1220–1224.

Nickel JC, Herschorn S, Whitmore KE, et al. Pentosan polysulfate sodium for treatment of interstitial cystitis/bladder pain syndrome: insights from a randomized, double-blind, placebo controlled study. *J Urol*. 2015;193(3):857–862.

Nielsen KK, Kromann-Andersen B, Steven K, et al. Failure of combined supratrigonal cystectomy and Mainz ileocecocystoplasty in intractable interstitial cystitis: is histology and mast cell count a reliable predictor for the outcome of surgery? *J Urol*. 1990;144(2 Pt 1):255–258.

Nigro DA, Wein AJ, Foy M, et al. Associations among cystoscopic and urodynamic findings for women enrolled in the Interstitial Cystitis Data Base (ICDB) study. *Urology*. 1997;49(5A Suppl):86–92.

Nigro DA, Wein AJ, Sant GR. Interstitial cystitis: clinical and endoscopic features. Sant GR. *Interstitial cystitis*. Lippincott-Raven: Philadelphia, PA; 1997:137–142.

Nomiya A, Naruse T, Niimi A, et al. On- and post-treatment symptom relief by repeated instillations of heparin and alkalized lidocaine in interstitial cystitis. *Int J Urol*. 2013;20(11):1118–1122.

Nordling J, van Ophoven A. Intravesical glycosaminoglycan replenishment with chondroitin sulphate in chronic forms of cystitis. A multi-national, multi-centre, prospective observational clinical trial. *Arzneimittelforschung*. 2008;58(7):328–335.

Nordling J, Blaivas JG. Should urinary diversion for bladder pain syndrome/interstitial cystitis include cystectomy? *J Urol*. 2014;191(2):293–295.

Nordling J, Staskin D, Yoshimura N. Etiology: etiological and pathogenic theories of interstitial cystitis/bladder pain syndrome. Springer International Publishing: Cham; 2017:37–39. *Bladder pain syndrome—an evolution*. vol 21.

Ochodnicky P, Cruz CD, Yoshimura N, et al. Nerve growth factor in bladder dysfunction: contributing factor, biomarker, and therapeutic target. *Neurourol Urodyn*. 2011;30(7):1227–1241.

Ochs RL. Autoantibodies and interstitial cystitis. *Clin Lab Med*. 1997;17(3):571–579.

Ochs RL, Stein TW Jr, Peebles CL, et al. Autoantibodies in interstitial cystitis. *J Urol*. 1994;151(3):587–592.

O'Connor VJ. Clorpactin WCS-90 in the treatment of interstitial cystitis. *Q Bull Northwest Univ Med Sch*. 1955;29(4):392–395.

Oerlemans DJ, van Kerrebroeck PE. Sacral nerve stimulation for neuromodulation of the lower urinary tract. *Neurourol Urodyn*. 2008;27(1):28–33.

Ogawa T, Homma T, Igawa Y, et al. CXCR3 binding chemokine and TNFSF14 over expression in bladder urothelium of patients with ulcerative interstitial cystitis. *J Urol*. 2010;183(3):1206–1212.

O’Hare PG 3rd, Hoffmann AR, Allen P, et al. Interstitial cystitis patients’ use and rating of complementary and alternative medicine therapies. *Int Urogynecol J*. 2013;24(6):977–982.

Oh-Oka H. Clinical efficacy of 1-year intensive systematic dietary manipulation as complementary and alternative medicine therapies on female patients with interstitial cystitis/bladder pain syndrome. *Urology*. 2017;106:50–54.

Okragly AJ, Niles AL, Saban R, et al. Elevated tryptase, nerve growth factor, neurotrophin-3 and glial cell line-derived neurotrophic factor levels in the urine of interstitial cystitis and bladder cancer patients. *J Urol*. 1999;161(2):438–441.

O'Leary MP, Sant GR. The interstitial cystitis symptom and problem indices: rationale, development, and application. Sant GR. *Interstitial cystitis*. Lippincott-Raven: Philadelphia, PA; 1997:271–276.

O'Leary MP, Sant GR, Fowler FJ Jr, et al. The interstitial cystitis symptom index and problem index. *Urology*. 1997;49(5A Suppl):58–63.

Olson LE, Dyer JE, Haq A, et al. A systematic review of the literature on cystodistension in bladder pain syndrome. *Int Urogynecol J*. 2018;29(2):251–257.

Oravisto KJ. Epidemiology of interstitial cystitis. *Ann Chir*

Gynaecol Fenn. 1975;64(2):75–77.

Oravisto KJ. Interstitial cystitis as an autoimmune disease. A review. *Eur Urol*. 1980;6(1):10–13.

Oravisto KJ, Alfthan OS. Treatment of interstitial cystitis with immunosuppression and chloroquine derivatives. *Eur Urol*. 1976;2(2):82–84.

O'Reilly BA, Dwyer PL, Hawthorne G, et al. Transdermal posterior tibial nerve laser therapy is not effective in women with interstitial cystitis. *J Urol*. 2004;172(5 Pt 1):1880–1883.

Oyama IA, Rejba A, Lukban JC, et al. Modified Thiele massage as therapeutic intervention for female patients with interstitial cystitis and high-tone pelvic floor dysfunction. *Urology*. 2004;64(5):862–865.

Palea S, Artibani W, Ostardo E, et al. Evidence for purinergic neurotransmission in human urinary bladder affected by interstitial cystitis. *J Urol*. 1993;150(6):2007–2012.

Pang X, Cotreau-Bibbo MM, Sant GR, et al. Bladder mast cell expression of high affinity oestrogen receptors in patients with interstitial cystitis. *Br J Urol*. 1995;75(2):154–161.

Pang X, Marchand J, Sant GR, et al. Increased number of substance P positive nerve fibres in interstitial cystitis. *Br J Urol*. 1995;75(6):744–750.

Pang X, Boucher W, Triadafilopoulos G, et al. Mast cell and substance P–positive nerve involvement in a patient with both irritable bowel syndrome and interstitial cystitis. *Urology*. 1996;47(3):436–438.

Pang X, Sant G, Theoharides TC. Altered expression of bladder mast cell growth factor receptor (c-kit) in interstitial cystitis. *Urology*. 1998;51(6):939–944.

Parekh MH, Chichester P, Lobel RW, et al. Effects of castration on female rabbit bladder physiology and morphology. *Urology*. 2004;64(5):1048–1051.

Parrish J. Tic douloureux of the urinary bladder. *Practical* *observations on strangulated hernia and some of the diseases of the urinary organs*. Key and Biddle: Philadelphia, PA; 1836:309–313.

Parsons CL. Successful management of radiation cystitis with sodium pentosanpolysulfate. *J Urol*. 1986;136:813–814.

Parsons CL. The role of the glycosaminoglycan layer in bladder defense mechanisms and interstitial cystitis. *Int Urogynecol J*. 1993;4:373–379.

Parsons CL. A model for the function of glycosaminoglycans in the urinary tract. *World J Urol*. 1994;12(1):38–42.

Parsons CL. Interstitial cystitis: new concepts in pathogenesis, diagnosis, and management. *AUA News*. 2000;20–31.

Parsons CL. Successful downregulation of bladder sensory nerves with combination of heparin and alkalinized lidocaine in patients with interstitial cystitis. *Urology*. 2005;65(1):45–48.

Parsons CL. Etiology of interstitial cystitis and the role of pentosanpolysulfate in ic therapy. Springer International Publishing: Cham; 2017:121–126. *Bladder pain syndrome—an evolution*. vol 107.

Parsons CL, Hurst RE. Decreased urinary uronic acid levels in individuals with interstitial cystitis. *J Urol*. 1990;143(4):690–693.

Parsons CL, Stein P. Role of toxic urine in interstitial cystitis. *J Urol*. 1990;143:373A.

Parsons CL, Albo M. Intravesical potassium sensitivity in patients with prostatitis. *J Urol*. 2002;168(3):1054–1057.

Parsons JK, Parsons CL. The historical origins of interstitial cystitis. *J Urol*. 2004;171(1):20–22.

Parsons CL, Tatsis V. Prevalence of interstitial cystitis in young women. *Urology*. 2004;64(5):866–870.

Parsons CL, Schmidt JD, Pollen JJ. Successful treatment of interstitial cystitis with sodium pentosanpolysulfate. *J Urol*.

1983;130(1):51–53.

Parsons CL, Mulholland SG. Successful therapy of interstitial cystitis with pentosanpolysulfate. *J Urol*. 1987;138(3):513–516.

Parsons CL, Boychuk D, Hurst R, et al. Bladder surface glycosaminoglycans: an epithelial permeability barrier. *J Urol*. 1990;143:139–142.

Parsons CL, Lilly JD, Stein P. Epithelial dysfunction in nonbacterial cystitis (interstitial cystitis). *J Urol*. 1991;145(4):732–735.

Parsons CL, Housley T, Schmidt JD, et al. Treatment of interstitial cystitis with intravesical heparin. *Br J Urol*. 1994;73(5):504–507.

Parsons CL, Stein PC, Bidair M, et al. Abnormal sensitivity to intravesical potassium in interstitial cystitis and radiation cystitis. *Neurourol Urodyn*. 1994;13(5):515–520.

Parsons CL, Greenberger M, Gabal L, et al. The role of urinary potassium in the pathogenesis and diagnosis of interstitial cystitis. *J Urol*. 1998;159(6):1862–1866.

Parsons CL, Bautista SL, Stein PC, et al. Cyto-injury factors in urine: a possible mechanism for the development of interstitial cystitis. *J Urol*. 2000;164(4):1381–1384.

Parsons CL, Bullen M, Kahn BS, et al. Gynecologic presentation of interstitial cystitis as detected by intravesical potassium sensitivity. *Obstet Gynecol*. 2001;98(1):127–132.

Parsons CL, Zupkas P, Parsons JK. Intravesical potassium sensitivity in patients with interstitial cystitis and urethral syndrome. *Urology*. 2001;57(3):428–432.

Parsons CL, Dell J, Stanford EJ, et al. Increased prevalence of interstitial cystitis: previously unrecognized urologic and gynecologic cases identified using a new symptom questionnaire and intravesical potassium sensitivity. *Urology*. 2002;60(4):573–578.

Parsons CL, Dell J, Stanford EJ, et al. The prevalence of interstitial cystitis in gynecologic patients with pelvic pain, as detected by intravesical potassium sensitivity. *Am J Obstet Gynecol*. 2002;187(5):1395–1400.

Parsons CL, Rosenberg MT, Sassani P, et al. Quantifying symptoms in men with interstitial cystitis/prostatitis, and its correlation with potassium-sensitivity testing. *BJU Int*. 2005;95(1):86–90.

Parsons CL, Stein P, Zupkas P, et al. Defective Tamm-Horsfall protein in patients with interstitial cystitis. *J Urol*. 2007;178(6):2665–2670.

Parsons CL, Proctor J, Teichman JS, et al. A multi-site study confirms abnormal glycosylation in the Tamm-Horsfall protein of patients with interstitial cystitis. *J Urol*. 2011;186(1):112–116.

Parsons CL, Zupkas P, Proctor J, et al. Alkalinized lidocaine and heparin provide immediate relief of pain and urgency in patients with interstitial cystitis. *J Sex Med*. 2012;9(1):207–212.

Patra PB, Tibbitts FD, Westfall DP. *Endocrine status and urinary mast cells: possible relationship to interstitial cystitis*. National Institutes of Health: Bethesda, MD; 1995:70.

Patnaik SS, Laganà AS, Vitale SG, et al. Etiology, pathophysiology and biomarkers of interstitial cystitis/painful bladder syndrome. *Arch Gynecol Obstet*. 2017;295(6):1341–1359.

Pearce WA, Chen R, Jain N. Pigmentary maculopathy associated with chronic exposure to pentosan polysulfate sodium. *Ophthalmology*. 2018;125(11):1793–1802.

Peeker R, Aldenborg F, Fall M. The treatment of interstitial cystitis with supratrigonal cystectomy and ileocystoplasty: difference in outcome between classic and nonulcer disease. *J Urol*. 1998;159(5):1479–1482.

Peeker R, Aldenborg F, Dahlstrom A, et al. Increased tyrosine hydroxylase immunoreactivity in bladder tissue from patients with classic and nonulcer interstitial cystitis. *J Urol*. 2000;163(4):1112–1115.

Peeker R, Enerback L, Fall M, et al. Recruitment, distribution and phenotypes of mast cells in interstitial cystitis. *J Urol*. 2000;163(3):1009–1015.

Peeker R, Fall M. Toward a precise definition of interstitial cystitis: further evidence of differences in classic and nonulcer disease. *J Urol*. 2002;167(6):2470–2472.

Peeker R, Atanasiu L, Logadottir Y. Intercurrent autoimmune conditions in classic and non-ulcer interstitial cystitis. *Scand J Urol Nephrol*. 2003;37:60–63.

Perez-Marrero R, Emerson LE, Feltis JT. A controlled study of dimethyl sulfoxide in interstitial cystitis. *J Urol*. 1988;140(1):36–39.

Perez-Marrero R, Emerson LE, Maharajh DO, et al. Prolongation of response to DMSO by heparin maintenance. *Urology*. 1993;41(Suppl):64–66.

Perzin AD, Hanno PM, Ruggieri MR. Effect of protamine and IC urine on dye penetration across urothelium. *J Urol*. 1991;145:259A.

Peters KM. Use of transcutaneous electrical nerve stimulation in the management of bladder pain syndrome: 2017 update. Springer International Publishing: Cham; 2017:131–133. *Bladder pain Syndrome—an evolution*. vol 100.

Peters KM, Konstandt D. Sacral neuromodulation decreases narcotic requirements in refractory interstitial cystitis. *BJU Int*. 2004;93(6):777–779.

Peters KM, Carey JM, Konstandt DB. Sacral neuromodulation for the treatment of refractory interstitial cystitis: outcomes based on technique. *Int Urogynecol J Pelvic Floor Dysfunct*. 2003;14(4):223–228.

Peters KM, Carrico DJ, Kalinowski SE, et al. Prevalence of pelvic floor dysfunction in patients with interstitial cystitis. *Urology*. 2007;70(1):16–18.

Peters KM, Killinger KA, Carrico DJ, et al. Sexual function and sexual distress in women with interstitial cystitis: a case-control study. *Urology*. 2007;70(3):543–547.

Peters KM, Feber KM, Bennett RC. A prospective, single-blind, randomized crossover trial of sacral vs pudendal nerve stimulation for interstitial cystitis. *BJU Int*. 2007;100(4):835–839.

Peters KM, Carrico DJ, Ibrahim IA, et al. Characterization of a clinical cohort of 87 women with interstitial cystitis/painful bladder syndrome. *Urology*. 2008;71(4):634–640.

Peters KM, Killinger KA, Ibrahim IA, et al. The relationship between subjective and objective assessments of sacral neuromodulation effectiveness in patients with urgency-frequency. *Neurourol Urodyn*. 2008;27(8):775–778.

Peters KM, Killinger KA, Ibrahim IA. Childhood symptoms and events in women with interstitial cystitis/painful bladder syndrome. *Urology*. 2009;73(2):258–262.

Peters KM, Killinger KA, Mounayer MH, et al. Are ulcerative and nonulcerative interstitial cystitis/painful bladder syndrome 2 distinct diseases? A study of coexisting conditions. *Urology*. 2011;78(2):301–308.

Peters KM, Killinger KA, Gilleran J, et al. Does patient age impact outcomes of neuromodulation? *Neurourol Urodyn*. 2013;32(1):30–36.

Peters KM, Jayyabalan N, Bui D, et al. Effect of sacral neuromodulation on outcome measures and urine chemokines in interstitial cystitis/painful bladder syndrome patients. *Low Urin Tract Symptoms*. 2015;7(2):77–83.

Pezzone MA, Liang R, Fraser MO. A model of neural cross-talk and irritation in the pelvis: implications for the overlap of chronic pelvic pain disorders. *Gastroenterology*. 2005;128(7):1953–1964.

Pinto R, Lopes T, Frias B, et al. Trigonal injection of botulinum toxin A in patients with refractory bladder pain syndrome/interstitial cystitis. *Eur Urol*. 2010;58(3):360–365.

Pinto R, Lopes T, Silva J, et al. Persistent therapeutic effect of repeated injections of onabotulinum toxin A in refractory bladder pain syndrome/interstitial cystitis. *J Urol*. 2013;189(2):548–553.

Pinto RA, Costa D, Morgado A, et al. Intratrigonal onabotulinumtoxin A improves bladder symptoms and quality of life in patients with bladder pain syndrome/interstitial cystitis: a pilot, single center, randomized, double-blind, placebo controlled trial. *J Urol*. 2018;199(4):998–1003.

Polackwich AS, Li J, Shoskes DA. Patients with pelvic floor muscle spasm have a superior response to pelvic floor physical therapy at specialized centers. *J Urol*. 2015;194(4):1002–1006.

Pontari MA, Hanno PM, Ruggieri MR. Comparison of bladder blood flow in patients with and without interstitial cystitis. *J Urol*. 1999;162(2):330–334.

Pool TL. Interstitial cystitis: clinical considerations and treatment. *Clin Obstet Gynecol*. 1967;10(1):185–191.

Pool TL, Rives HF. Interstitial cystitis: treatment with silver nitrate. *J Urol*. 1944;51:520–525.

Porru D, Campus G, Tudino D, et al. Results of treatment of refractory interstitial cystitis with intravesical hyaluronic acid. *Urol Int*. 1997;59(1):26–29.

Porru D, Politano R, Gerardini M, et al. Different clinical presentation of interstitial cystitis syndrome. *Int Urogynecol J Pelvic Floor Dysfunct*. 2004;15(3):198–202.

Porru D, Leva F, Parmigiani A, et al. Impact of intravesical hyaluronic acid and chondroitin sulfate on bladder pain syndrome/interstitial cystitis. *Int Urogynecol J*. 2012;23(9):1193–1199.

Potts JM, Ward AM, Rackley RR. Association of chronic urinary symptoms in women and Ureaplasma urealyticum. *Urology*. 2000;55(4):486–489.

Powell CR, Kreder KJ. Long-term outcomes of urgency-frequency syndrome due to painful bladder syndrome treated with sacral neuromodulation and analysis of failures. *J Urol*. 2010;183(1):173–176.

Pranikoff K, Constantino G. The use of amitriptyline in patients with urinary frequency and pain. *Urology*. 1998;51(5A Suppl):179–181.

Press SM, Moldwin R, Kushner L, et al. Decreased expression of GP-51 glycosaminoglycan in cats afflicted with feline interstitial cystitis. *J Urol*. 1995;153:288A.

Proaño A, Garde G, Garrido G, et al. ESSIC criteria for the diagnosis of bladder pain syndrome/interstitial cystitis (BPS/IC) and comparison with the NIDDK criteria. *Arch Esp Urol*. 2013;66(2):206–214.

Propert KJ, Schaeffer AJ, Brensinger CM, et al. A prospective study of interstitial cystitis: results of longitudinal followup of the Interstitial Cystitis Data Base cohort. The Interstitial Cystitis Data Base Study Group. *J Urol*. 2000;163(5):1434–1439.

Propert KJ, Mayer RD, Wang Y, et al. Responsiveness of symptom scales for interstitial cystitis. *Urology*. 2006;67(1):55–59.

Qin C, Malykhina AP, Akbarali HI, et al. Acute colitis enhances responsiveness of lumbosacral spinal neurons to colorectal distension in rats. *Dig Dis Sci*. 2008;53(1):141–148.

Ragab MM, Tawfik AM, El-enen MA, et al. Female urology evaluation of percutaneous tibial nerve stimulation for treatment of refractory painful bladder syndrome. *Urology*.

2015;86(4):707–711.

Rahnama'i MS, Marcelissen T, Apostolidis A, et al. The efficacy of botulinum toxin A and sacral neuromodulation in the management of interstitial cystitis (IC)/bladder pain syndrome (BPS), what do we know? ICI-RS 2017 think tank, Bristol. *Neurourol Urodyn*. 2018;37(S4):S99–S107.

Rais-Bahrami S, Friedlander JI, Herati AS, et al. Symptom profile variability of interstitial cystitis/painful bladder syndrome by age. *BJU Int*. 2012;109(9):1356–1359.

Rajkumar GN, Conn IG. Botulinum toxin: a new dimension in the treatment of lower urinary tract dysfunction. *Urology*. 2004;64(1):2–8.

Rashid HH, Reeder JE, O'Connell MJ, et al. Interstitial cystitis antiproliferative factor (APF) as a cell-cycle modulator. *BMC Urol*. 2004;4(1):3.

Ratliff TL, Klutke CG, McDougall EM. The etiology of interstitial cystitis. *Urol Clin North Am*. 1994;21(1):21–30.

Rawls WF, Cox L, Rovner ES. Dimethyl sulfoxide (DMSO) as intravesical therapy for interstitial cystitis/bladder pain syndrome: a review. *Neurourol Urodyn*. 2017;36(7):1677–1684.

Ray WA, Meredith S, Thapa PB, et al. Cyclic antidepressants and the risk of sudden cardiac death. *Clin Pharmacol Ther*. 2004;75(3):234–241.

Redmond EJ, Flood HD. The role of reconstructive surgery in patients with end-stage interstitial cystitis/bladder pain syndrome: is cystectomy necessary? *Int Urogynecol J*. 2017;28(10):1551–1556.

Reed BD, Harlow SD, Sen A, et al. Relationship between vulvodynia and chronic comorbid pain conditions. *Obstet Gynecol*. 2012;120(1):145–151.

Regauer S, Gamper M, Fehr MK, et al. Sensory hyperinnervation distinguishes bladder pain syndrome/interstitial cystitis from overactive bladder syndrome. *J Urol*. 2017;197(1):159–166.

Reinhart H, Obedeanu N, Hooton T, et al. Urinary excretion of Tamm-Horsfall protein in women with recurrent urinary tract infections. *J Urol*. 1990;144(5):1185–1187.

Renshaw DC. Desipramine for interstitial cystitis. *JAMA*. 1988;260(3):341.

Rice L, Kennedy D, Veach A. Pentosan induced cerebral sagittal sinus thrombosis: a variant of heparin induced thrombocytopenia. *J Urol*. 1998;160(6 Pt 1):2148.

Rickard A, Lagunoff D. *A novel model for the role of mast cells in interstitial cystitis*. National Institutes of Health: Bethesda, MD; 1995:69.

Riedl CR, Engelhardt PF, Daha KL, et al. Hyaluronan treatment of interstitial cystitis/painful bladder syndrome. *Int Urogynecol J Pelvic Floor Dysfunct*. 2008;19(5):717–721.

Rivas DA, Chancellor MB, Shupp-Byrne S, et al. Molecular marker for development of interstitial cystitis in rat model: isoactin gene expression. *J Urol*. 1997;157(5):1937–1940.

Roberts RO, Bergstralh EJ, Bass SE, et al. Incidence of physician-diagnosed interstitial cystitis in Olmsted County: a community-based study. *BJU Int*. 2003;91(3):181–185.

Rodriguez Villamil L, Batista Miranda JE, Smet CE, et al. Supratrigonal cystectomy and enterocystoplasty as treatment of advanced interstitial cystitis. *Urol Integr Invest*. 1999;4(4):350–353.

Rofeim O, Hom D, Freid RM, et al. Use of the neodymium:YAG laser for interstitial cystitis: a prospective study. *J Urol*. 2001;166(1):134–136.

Rogers RM. Pelvic denervation surgery: what the evidence and anatomy teach us. *Clin Obstet Gynecol*. 2003;46(4):767–772.

Roppolo JR, Tai C, Booth AM, et al. Bladder Adelta afferent nerve activity in normal cats and cats with feline interstitial cystitis. *J Urol*. 2005;173(3):1011–1015.

Rosales RL, Ariumura K, Ikenaga S. Extrafusal and intrafusal muscle effects in experimental botulinum toxin A injection. *Muscle Nerve*. 1996;19(4):488–496.

Rosamilia A, Cann L, Dwyer P, et al. Bladder microvasculature in women with interstitial cystitis. *J Urol*. 1999;161(6):1865–1870.

Rosamilia A, Clements JA, Dwyer PL, et al. Activation of the kallikrein kinin system in interstitial cystitis. *J Urol*. 1999;162(1):129–134.

Rosamilia A, Igawa Y, Higashi S. Pathology of interstitial cystitis. *Int J Urol*. 2003;10(Suppl):S11–S15.

Rose NR, Bona C. Defining criteria for autoimmune diseases. *Immunol Today*. 1993;14(9):426–430.

Rössberger J, Fall M, Jonsson O, et al. Long-term results of reconstructive surgery in patients with bladder pain syndrome/interstitial cystitis: subtyping is imperative. *Urology*. 2007;70(4):638–642.

Rothrock NE, Lutgendorf SK, Hoffman A, et al. Depressive symptoms and quality of life in patients with interstitial cystitis. *J Urol*. 2002;167(4):1763–1767.

Rothrock NE, Lutgendorf SK, Kreder KJ, et al. Stress and symptoms in patients with interstitial cystitis: a life stress model. *Urology*. 2001;57(3):422–427.

Rothrock NE, Lutgendorf SK, Kreder KJ. Coping strategies in patients with interstitial cystitis: relationships with quality of life and depression. *J Urol*. 2003;169(1):233–236.

Rowbotham M, Harden N, Stacey B, et al. Gabapentin for the treatment of postherpetic neuralgia: a randomized controlled trial. *JAMA*. 1998;280(21):1837–1842.

Roy H, Offiah I, Dua A. Neuromodulation for pelvic and urogenital pain. *Brain Sci*. 2018;8(10):pii: E180.

Rubin RS, Malphrus E. Interstitial cystitis and sexual dysfunction: diagnostic accuracy is essential. *Curr Sex Health Rep*. 2018;10(3):104–108.

Rubio-Diaz DE, Pozza ME, Dimitrakov J, et al. A candidate serum biomarker for bladder pain syndrome/interstitial cystitis. *Analyst*. 2009;134(6):1133–1137.

Rudick CN, Chen MC, Mongiu AK, et al. Organ cross talk modulates pelvic pain. *Am J Physiol Regul Integr Comp Physiol*. 2007;293(3):R1191–R1198.

Rudick CN, Bryce PJ, Guichelaar LA, et al. Mast cell-derived histamine mediates cystitis pain. *PLoS ONE*. 2008;3(5):e2096.

Rudick CN, Pavlov VI, Chen MC, et al. Gender specific pelvic pain severity in neurogenic cystitis. *J Urol*. 2012;187(2):715–724.

Ruggieri MR, Hanno PM, Levin RM. Nitrofurantoin not surface active agent in rabbit urinary bladder. *Urology*. 1987;29(5):534–537.

Ruggieri MR, Monson FC, Levin RM, et al. Interstitial cystitis: animal models. Hanno PM, Staskin DR, Krane RJ, et al. *Interstitial cystitis*. Springer-Verlag: London; 1990:49–62.

Ruggieri MR, Steinhardt GF, Hanno PM. Comparison of antiadherence activity of bladder extracts from interstitial cystitis patients with recurrent urinary tract infections. *Semin Urol*. 1991;9(2):136–142.

Ruggieri MR, Hanno PM, Whitmore KE, et al. Effect of repeated instillation of interstitial cystitis urine on the rabbit urinary bladder. *Urology*. 1993;42(6):646–652.

Ruoslahti E. Structure and biology of proteoglycans. *Annu Rev Cell Biol*. 1988;4:229–255.

Saban R, Keith IM, Bjorling DE, et al. Neuropeptide-mast cell interaction in interstitial cystitis. Sant GR. *Interstitial cystitis*. Lippincott-Raven: Philadelphia, PA; 1997:53–66.

Saban R, Saban MR, Maier J, et al. Urothelial expression of neuropilins and VEGF receptors in control and interstitial cystitis patients. *Am J Physiol Renal Physiol*. 2008;295(6):F1613–F1623.

Saban R, Saban MR, Nguyen NB, et al. Mast cell regulation of inflammation and gene expression during antigen-induced bladder inflammation in mice. *Physiol Genomics*. 2001;7(1):35–43.

Sahinkanat T, Guven A, Ekerbicer H, et al. Prevalence of positive potassium sensitivity test which is an indicator of bladder epithelial permeability dysfunction in a fixed group of Turkish women. *Urol Int*. 2008;80(1):52–56.

Sairanen J, Forsell T, Ruutu M. Long-term outcome of patients with interstitial cystitis treated with low dose cyclosporine A. *J Urol*. 2004;171(6 Pt 1):2138–2141.

Sairanen J, Tammela TL, Leppilahti M, et al. Cyclosporine A and pentosan polysulfate sodium for the treatment of interstitial cystitis: a randomized comparative study. *J Urol*. 2005;174(6):2235–2238.

Sairanen J, Hotakainen K, Tammela TL, et al. Urinary epidermal growth factor and interleukin-6 levels in patients with painful bladder syndrome/interstitial cystitis treated with cyclosporine or pentosan polysulfate sodium. *Urology*. 2008;71(4):630–633.

Sakakibara R, Uchiyama T, Yoshiyama M, et al. Urinary dysfunction in patients with systemic lupus erythematosus. *Neurourol Urodyn*. 2003;22(6):593–596.

Salavatore S, Khullar V, Cardozo L, et al. Evaluating ambulatory urodynamics: a prospective study in asymptomatic women. *Br J Obstet Gynaecol*. 2003;110(1):83–84.

Sanchez-Freire V, Blanchard MG, Burkhard FC, et al. Acid-sensing channels in human bladder: expression, function and alterations during bladder pain syndrome. *J Urol*.

2011;186(4):1509–1516.

Sant GR. Intravesical 50% dimethyl sulfoxide (Rimso-50) in treatment of interstitial cystitis. *Urology*. 1987;29(4 Suppl):17–21.

Sant GR. Interstitial cystitis. *Monogr Urol*. 1991;12:37–63.

Sant GR, Theoharides TC. The role of the mast cell in interstitial cystitis. *Urol Clin North Am*. 1994;21(1):41–53.

Sant GR, Kilaru P, Ucci AA. Mucosal mast cell contribution to bladder mastocytosis in interstitial cystitis. *J Urol*. 1988;139:276A.

Sant GR, Theoharides TC, Letourneau R, et al. Interstitial cystitis and bladder mastocytosis in a woman with chronic urticaria. *Scand J Urol Nephrol*. 1997;31(5):497–500.

Sant GR, Propert KJ, Hanno PM, et al. A pilot clinical trial of oral pentosan polysulfate and oral hydroxyzine in patients with interstitial cystitis. *J Urol*. 2003;170(3):810–815.

Santos JD, Lopes RI, Koyle MA. Bladder and bowel dysfunction in children: an update on the diagnosis and treatment of a common, but underdiagnosed pediatric problem. *Can Urol Assoc J*. 2017;11(1–2S):64–69.

Sasaki K, Smith CP, Chuang YC, et al. Oral gabapentin (Neurontin) treatment of refractory genitourinary tract pain. *Tech Urol*. 2001;7(1):47–49.

Scheepens WA, De Bie RA, Weil EH, et al. Unilateral versus bilateral sacral neuromodulation in patients with chronic voiding dysfunction. *J Urol*. 2002;168(5):2046–2050.

Schmidt RA. Neurostimulation of bladder and urethra. Webster G, Kirby R, King L, et al. *Reconstructive urology*. Blackwell Scientific Publications: Boston; 1993:591–601.

Schmidt RA. Urodynamic features of the pelvic pain patient and the impact of neurostimulation on these parameters. *World J Urol*. 2001;19:186–193.

Schmidt RA, Vapnek JM. Pelvic floor behavior and interstitial cystitis. *Semin Urol*. 1991;9(2):154–159.

Schrepf A, O'Donnell M, Luo Y, et al. Inflammation and inflammatory control in interstitial cystitis/bladder pain syndrome: associations with painful symptoms. *Pain*. 2014;155(9):1755–1761.

Schrepf A, Bradley CS, O'Donnell M, et al. Toll-like Receptor 4 and comorbid pain in interstitial cystitis/bladder pain syndrome: a multidisciplinary approach to the study of Chronic Pelvic Pain Research Network study. *Brain Behav Immun*. 2015;49:66–74.

Schulte G, Bryja V. The frizzled family of unconventional G-protein–coupled receptors. *Trends Pharmacol Sci*. 2007;28(10):518–525.

Seddon JM, Best L, Bruce AW. Intestinocystoplasty in treatment of interstitial cystitis. *Urology*. 1977;10(5):431–435.

Segura JW, Opitz JL, Greene LF. Prostatosis, prostatitis or pelvic floor tension myalgia? *J Urol*. 1979;122(2):168–169.

Serel TA, Soyupek S, Candir O. Association between mast cells and bladder carcinoma. *Urol Int*. 2004;72(4):299–302.

Seshadri P, Emerson L, Morales A. Cimetidine in the treatment of interstitial cystitis. *Urology*. 1994;44(4):614–616.

Seth A, Teichman JM. Differences in the clinical presentation of interstitial cystitis/painful bladder syndrome in patients with or without sexual abuse history. *J Urol*. 2008;180(5):2029–2033.

Shanberg AM, Baghdassarian R, Tansey LA. Treatment of interstitial cystitis with the neodymium-YAG laser. *J Urol*. 1985;134(5):885–888.

Shanberg AM, Smith JA, Stein BS, et al. Benign diseases of the bladder. *Lasers in urologic surgery*. Year Book: Chicago, IL; 1989:50–56.

Shanberg AM, Malloy TR, Sant GR. Use of lasers in interstitial cystitis. Sant GR. *Interstitial cystitis*. Lippincott-Raven: Philadelphia, PA; 1997:215–218.

Shea-O'Malley CC, Sant GR. Quality of life in interstitial cystitis. *Urol Integr Invest*. 1999;4(4):303–306.

Shankar GS. Serotonin and sexual dysfunction. *J Autacoids Horm*. 2015;5:1.

Shao Y, Shen ZJ, Rui WB, et al. Intravesical instillation of hyaluronic acid prolonged the effect of bladder hydrodistention in patients with severe interstitial cystitis. *Urology*. 2010;75(3):547–550.

Shear S, Mayer R. Development of glomerulations in younger women with interstitial cystitis. *Urology*. 2006;68(2):253–256.

Shie JH, Kuo HC. Higher levels of cell apoptosis and abnormal E-cadherin expression in the urothelium are associated with inflammation in patients with interstitial cystitis/painful bladder syndrome. *BJU Int*. 2011;108(2 Pt 2):E136–E141.

Shie JH, Liu HT, Wang YS, et al. Immunohistochemical evidence suggests repeated intravesical application of botulinum toxin A injections may improve treatment efficacy of interstitial cystitis/bladder pain syndrome. *BJU Int*. 2013;111(4):638–646.

Shim SR, Cho YJ, Shin I-S, et al. Efficacy and safety of botulinum toxin injection for interstitial cystitis/bladder pain syndrome: a systematic review and meta-analysis. *Int Urol Nephrol*. 2016;48(8):1215–1217.

Shintani Y, Takashima S, Asano Y, et al. Glycosaminoglycan modification of neuropilin-1 modulates VEGFR2 signaling. *EMBO J*. 2006;25(13):3045–3055.

Shirley SW, Stewart BH, Mirelman S. Dimethyl sulfoxide in treatment of inflammatory genitourinary disorders. *Urology*. 1978;11(3):215–220.

Shorter B, Lesser M, Moldwin RM, et al. Effect of comestibles on symptoms of interstitial cystitis. *J Urol*. 2007;178(1):145–152.

Shorter B, Ackerman M, Varvara M, et al. Statistical validation of the shorter-moldwin food sensitivity questionnaire for patients with interstitial cystitis/bladder pain syndrome. *J Urol*. 2014;191(6):1793–1801.

Shoskes DA, Berger R, Elmi A, et al. Muscle tenderness in men with chronic prostatitis/chronic pelvic pain syndrome: the chronic prostatitis cohort study. *J Urol*. 2008;179(2):556–560.

Shoskes DA, Nickel JC, Dolinga R, et al. Clinical phenotyping of patients with chronic prostatitis/chronic pelvic pain syndrome and correlation with symptom severity. *Urology*. 2009;73(3):538–542.

Siddiqui H, Lagesen K, Nederbragt AJ, et al. Alterations of microbiota in urine from women with interstitial cystitis. *BMC Microbiol*. 2012;12:205.

Siegel S, Paszkiewicz E, Kirkpatrick C, et al. Sacral nerve stimulation in patients with chronic intractable pelvic pain. *J Urol*. 2001;166(5):1742–1745.

Silk MR. Bladder antibodies in interstitial cystitis. *J Urol*. 1970;103(3):307–309.

Simmons JL. Interstitial cystitis: an explanation for the beneficial effect of an antihistamine. *J Urol*. 1961;85:149–155.

Simmons JL, Bunce PL. On the use of an antihistamine in the treatment of interstitial cystitis. *Am Surg*. 1958;24(9):664–667.

Simon LJ, Landis JR, Erickson DR, et al. The interstitial cystitis data base study: concepts and preliminary baseline descriptive statistics. *Urology*. 1997;49(5A Suppl):64–75.

Simons FE. Advances in H1-antihistamines. *N Engl J Med*. 2004;351(21):2203–2217.

Singh G, Thomas DG. Interstitial cystitis: involvement of the intestine. *Eur Urol*. 1996;29(3):322–324.

Singh R, Soriano ET, Gordon DA. Chronic pelvic pain: pudendal neuralgia and therapeutic neural blockade. 13th ed. Springer: New York, NY; 2017:269–277. *Pelvic floor dysfunction and pelvic surgery in the elderly*. vol 8.

Sinner B, Graf BM. Ketamine. Schüttler J, Schwilden H. *Modern anesthetics. Handbook of experimental pharmacology*. Springer-Verlag: Berlin, Germany; 2008:313–333.

Siroky MB. Is it interstitial cystitis? Diagnostic distinctions in reduced bladder capacity. *Contemp Urol*. 1994;6:13–22.

Skene AJC. *Diseases of the bladder and urethra in women*. William Wood: New York, NY; 1887.

Slobodov G, Feloney M, Gran C, et al. Abnormal expression of molecular markers for bladder impermeability and differentiation in the urothelium of patients with interstitial cystitis. *J Urol*. 2004;171(4):1554–1558.

Smith BH, Dehner LP. Chronic ulcerating interstitial cystitis (Hunner's ulcer). A study of 28 cases. *Arch Pathol*. 1972;93(1):76–81.

Smith GL, Christmas TJ. Interstitial ureteritis following cystectomy for interstitial cystitis. *Br J Urol*. 1996;77(4):607–608.

Smith SD, Wheeler MA, Foster HE, et al. Urinary nitric oxide synthase activity and cyclic GMP levels are decreased with interstitial cystitis and increased with urinary tract infections. *J Urol*. 1996;155(4):1432–1435.

Smith SD, Wheeler MA, Foster HE, et al. Improvement in interstitial cystitis symptom scores during treatment with oral l-arginine. *J Urol*. 1997;158(3 Pt 1):703–708.

Smith KM, Larive LL, Romanelli F. Club drugs: methylenedioxymethamphetamine, flunitrazepam, ketamine hydrochloride, and gamma-hydroxybutyrate. *Am J Health Syst Pharm*. 2002;59(11):1067–1076.

Sönmez MG, Kozanhan B. Complete response to acupuncture therapy in female patients with refractory interstitial cystitis/bladder pain syndrome. *Ginekol Pol*. 2017;88(2):61–67.

Song Y, Zhang W, Xu B, et al. Prevalence and correlates of painful bladder syndrome symptoms in Fuzhou Chinese women. *Neurourol Urodyn*. 2009;28(1):22–25.

Sorensen RB. Chondroitin sulphate in the treatment of interstitial cystitis and chronic inflammatory disease of the urinary bladder. *Eur Urol*. 2003;(Suppl 2):14–16.

Soucy F, Grégoire M. Efficacy of prednisone for severe refractory ulcerative interstitial cystitis. *J Urol*. 2005;173(3):841–843.

Spanos C, Pang X, Ligris K, et al. Stress-induced bladder mast cell activation: implications for interstitial cystitis. *J Urol*. 1997;157(2):669–672.

Srinivasan AK, Kaye JD, Moldwin R. Myofascial dysfunction associated with chronic pelvic floor pain: management strategies. *Curr Pain Headache Rep*. 2007;11(5):359–364.

Staehelin L, Chalpowski F, Bonneville M. Luminal plasma membrane of the urinary bladder: 1. Three-dimensional reconstruction of freeze-etch images. *J Cell Biol*. 1972;53(1):73–91.

Stav K, Beberashvili I, Lindner A, et al. Predictors of response to intravesical dimethyl-sulfoxide cocktail in patients with interstitial cystitis. *Urology*. 2012;80(1):61–65.

Steers WD, Tuttle JB, Sant GR. Neurogenic inflammation and nerve growth factor: possible roles in interstitial cystitis. Sant GR. *Interstitial cystitis*. Lippincott-Raven: Philadelphia, PA; 1997:67–76.

Stein PC, Santamaria PJ, Kurtz SB, et al. Evaluation of urothelial Tamm-Horsfall protein and serum antibody as a potential diagnostic marker for interstitial cystitis. *J Urol*. 1993;150(5 Pt 1):1405–1408.

Stein PC, Torri A, Parsons CL. Elevated urinary norepinephrine in interstitial cystitis. *Urology*. 1999;53(6):1140–1143.

Steinberg AC, Oyama IA, Whitmore KE. Bilateral S3 stimulator in patients with interstitial cystitis. *Urology*. 2007;69(3):441–443.

Steinert BW, Diokno AC, Robinson JE, et al. Complement C3, eosinophil cationic protein and symptom evaluation in interstitial cystitis. *J Urol*. 1994;151(2):350–354.

Steinhoff G, Ittah B, Rowan S. The efficacy of chondroitin sulfate 0.2% in treating interstitial cystitis. *Can J Urol*. 2002;9(1):1454–1458.

Stephens-Shields AJ, Clemens JQ, Jemielita T, et al. Symptom variability and early symptom regression in the MAPP study: a prospective study of urological chronic pelvic pain syndrome. *J Urol*. 2016;196(5):1450–1455.

Stewart BH, Shirley SW. Further experience with intravesical dimethyl sulfoxide in the treatment of interstitial cystitis. *J Urol*. 1976;116(1):36–38.

Stewart BH, Persky L, Kiser WS. The use of dimethyl sulfoxide (DMSO) in the treatment of interstitial cystitis. *J Urol*. 1967;98(6):671–672.

Stewart BH, Branson AC, Hewitt CB, et al. The treatment of patients with interstitial cystitis, with special reference to intravesical DMSO. *Trans Am Assoc Genitourin Surg*. 1971;63:69–74.

Stewart BH, Branson AC, Hewitt CB, et al. The treatment of patients with interstitial cystitis, with special reference to intravesical DMSO. *J Urol*. 1972;107(3):377–380.

Stone AR. Treatment of voiding complaints and incontinence in painful bladder syndrome. *Urol Clin North Am*.

1991;18(2):317–325.

Stone AR, Vogelsang P, Miller CH, et al. Tamm-Horsfall protein as a marker in interstitial cystitis. *J Urol*. 1992;148(5):1406–1408.

Stout L, Gerspach JM, Levy SM, et al. Dimethyl sulfoxide does not trigger urine histamine release in interstitial cystitis. *Urology*. 1995;46(5):653–656.

Sun Y, Chai TC. Up-regulation of P2X3 receptor during stretch of bladder urothelial cells from patients with interstitial cystitis. *J Urol*. 2004;171(1):448–452.

Sun Y, Keay S, De Deyne PG, et al. Augmented stretch activated adenosine triphosphate release from bladder uroepithelial cells in patients with interstitial cystitis. *J Urol*. 2001;166(5):1951–1956.

Sun Y, Fang Z, Ding Q, et al. Effect of amitriptyline in treatment interstitial cystitis or bladder pain syndrome according to two criteria: does ESSIC criteria change the response rate? *Neurourol Urodyn*. 2014;33(3):341–344.

Suskind AM, Berry SH, Ewing BA, et al. The prevalence and overlap of interstitial cystitis/bladder pain syndrome and chronic prostatitis/chronic pelvic pain syndrome in men: results of the RAND Interstitial Cystitis Epidemiology male study. *J Urol*. 2013;189(1):141–145.

Sutcliffe S, Colditz GA, Goodman MS, et al. Urological chronic pelvic pain syndrome symptom flares: characterisation of the full range of flares at two sites in the multidisciplinary approach to the study of Chronic Pelvic Pain (MAPP) Research Network. *BJU Int*. 2014;114(6):916–925.

Sutcliffe S, Jemielita T, Lai HH, et al. Infection/inflammation a case-crossover study of urological chronic pelvic pain syndrome flare triggers in the MAPP Research Network. *J Urol*. 2018;199(5):1245–1251.

Talati A, Ponniah K, Strug LJ, et al. Panic disorder, social anxiety disorder, and a possible medical syndrome previously linked to chromosome 13. *Biol Psychiatry*. 2008;63(6):594–601.

Tan EM. Antinuclear antibodies: diagnostic markers for autoimmune diseases and probes for cell biology. *Adv Immunol*. 1989;44:93.

Tanaka T, Kawashima H, Makino T, et al. Hyperbaric oxygen therapy for interstitial cystitis resistant to conventional treatments. *Int J Urol*. 2007;14(6):563–565.

Tanaka T, Nitta Y, Morimoto K, et al. Hyperbaric oxygen therapy for painful bladder syndrome/interstitial cystitis resistant to conventional treatments: long-term results of a case series in Japan. *BMC Urol*. 2011;11:11.

Taub HC, Stein M. Bladder distention therapy for symptomatic relief of frequency and urgency: a ten year review. *Urology*. 1994;43(1):36–39.

Teichman JM, Thompson IM, Taichman NS. Joseph Parrish, tic doloureux of the bladder and interstitial cystitis. *J Urol*. 2000;164(5):1473–1475.

Temml C, Wehrberger C, Riedl C, et al. Prevalence and correlates for interstitial cystitis symptoms in women participating in a health screening project. *Eur Urol*. 2007;51(3):803–808.

Thakkinstian A, Nickel JC. Efficacy of intravesical chondroitin sulphate in treatment of interstitial cystitis/bladder pain syndrome (IC/BPS): individual patient data (IPD) meta-analytical approach. *Can Urol Assoc J*. 2013;7(5–6):195–200.

Theoharides TC. Hydroxyzine in the treatment of interstitial cystitis. *Urol Clin North Am*. 1994;21(1):113–119.

Theoharides TC. Panic disorder, interstitial cystitis, and mast cells. *J Clin Psychopharmacol*. 2004;24(4):361–364.

Theoharides TC, Sant GR. Bladder mast cell activation in interstitial cystitis. *Semin Urol*. 1991;9(2):74–87.

Theoharides TC, Sant GR. Hydroxyzine therapy for interstitial cystitis. *Urology*. 1997;49(5A Suppl):108–110.

Theoharides TC, Cochrane DE. Critical role of mast cells in inflammatory diseases and the effect of acute stress. *J Neuroimmunol*. 2004;146(1–2):1–12.

Theoharides TC, Stewart JM. Anti-allergic compounds in chronic pelvic pain. 9th ed. Springer International Publishing: Cham; 2017:153–163. *Urological and gynaecological chronic pelvic pain*. vol 29.

Theoharides TC, Sant GR, El Mansoury M, et al. Activation of bladder mast cells in interstitial cystitis: a light and electron microscopic study. *J Urol*. 1995;153(3 Pt 1):629–636.

Theoharides TC, Sant GR, Sant GR. Hydroxyzine for symptomatic relief of interstitial cystitis symptoms. Sant GR. *Interstitial cystitis*. Lippincott-Raven: Philadelphia, PA; 1997:241–246.

Thilagarajah R, Witherow RO, Walker MM. Oral cimetidine gives effective symptom relief in painful bladder disease: a prospective, randomized, double-blind placebo-controlled trial. *BJU Int*. 2001;87(3):207–212.

Tietjen GE, Brandes JL, Peterlin BL, et al. Childhood maltreatment and migraine (part III). Association with comorbid pain conditions. *Headache*. 2010;50(1):42–51.

Tincello DG, Walker AC. Interstitial cystitis in the UK: results of a questionnaire survey of members of the Interstitial Cystitis Support Group. *Eur J Obstet Gynecol Reprod Biol*. 2005;118(1):91–95.

Tirlapur SA, Kuhrt K, Chaliha C, et al. The “evil twin syndrome” in chronic pelvic pain: a systematic review of prevalence studies of bladder pain syndrome and endometriosis. *Int J Surg*. 2013;11(3):233–237.

Tirlapur SA, Vlismas A, Ball E, et al. Nerve stimulation for chronic pelvic pain and bladder pain syndrome: a systematic review. *Acta Obstet Gynecol Scand*. 2013;92(8):881–887.

Tomaszewski JE, Landis JR, Brensinger C, et al. Baseline associations among pathologic features and patient symptoms in the national interstitial cystitis data base. *J Urol*. 1999;161:28.

Tomaszewski JE, Landis JR, Russack V, et al. Biopsy features are associated with primary symptoms in interstitial cystitis: results from the Interstitial Cystitis Data Base study. *Urology*. 2001;57(6 Suppl 1):67–81.

Tomoe H. In what type of interstitial cystitis/bladder pain syndrome is DMSO intravesical instillation therapy effective? *Transl Androl Urol*. 2015;4(6):600–604.

Toren PJ, Norman RW. Cyclophosphamide induced hemorrhagic cystitis successfully treated with pentosanpolysulfate. *J Urol*. 2005;173(1):103.

Tornero JI, Olarte H, Escudero F, et al. Long-term experience with sodium chondroitin sulfate in patients with painful bladder syndrome. *Actas Urol Esp*. 2013;37(8):523–526.

Traut JL, Macdonald ES, Spangler ML, et al. Montelukast for symptom control of interstitial cystitis. *Ann Pharmacother*. 2011;45(9):e49.

Trelstad RL. Glycosaminoglycans: mortar, matrix, mentor. *Lab Invest*. 1985;53(1):1–4.

Trinka PJ, Stanley BK, Noble MJ, et al. Mast-cell syndrome: a relative contraindication for continent urinary diversion. *J Urol*. 1993;149:506A.

Tripp DA, Nickel JC, Wong J, et al. Mapping of pain phenotypes in female patients with bladder pain syndrome/interstitial cystitis and controls. *Eur Urol*. 2012;62(6):1188–1194.

Tripp DA, Muere A, Nickel JC. Practical psychosocial management of urologic chronic pelvic pain syndromes. 4th ed. Springer International Publishing: Cham; 2017:25–42.

Urological and gynaecological chronic pelvic pain. vol 26.

Truong LD, Ostrowski ML, Wheeler TM. Tamm-Horsfall protein in bladder tissue. *Am J Surg Pathol*. 1994;18(6):615–622.

Truss MC, Stief CG, Uckert S, et al. Phosphodiesterase 1 inhibition in the treatment of lower urinary tract dysfunction: from bench to bedside. *World J Urol*. 2001;19(5):344–350.

Tsiriopoulos I, Lee G, O'Reilly A, et al. Primary splenic marginal zone lymphoma with bladder metastases mimicking interstitial cystitis. *Int Urol Nephrol*. 2006;38(3–4):475–476.

Tung A, Hepp Z, Bansal A, et al. Characterizing health care utilization, direct costs, and comorbidities associated with interstitial cystitis: a retrospective claims analysis. *J Manag Care Spec Pharm*. 2017;23(4):474–482.

Tunitsky E, Barber MD, Jeppson PC, et al. Bladder pain syndrome/interstitial cystitis in twin sisters. *J Urol*. 2012;187(1):148–152.

Twiss C, Kilpatrick L, Craske M, et al. Increased startle responses in interstitial cystitis: evidence for central hyperresponsiveness to visceral related threat. *J Urol*. 2009;181(5):2127–2133.

Tyagi P, Killinger K, Tyagi V, et al. Urinary chemokines as noninvasive predictors of ulcerative interstitial cystitis. *J Urol*. 2012;187(6):2243–2248.

Ueda T. Improvement of interstitial cystitis symptoms and problems that developed during treatment with oral IPD-1151T. *J Urol*. 2000;164(6):1917–1920.

Ueda T, Tamaki M, Ogawa O, et al. Improvement of interstitial cystitis symptoms and problems that developed during treatment with oral IPD-1151T. *J Urol*. 2000;164(6):1917–1920.

Ueda T, Tamaki M, Ogawa O, et al. Over expression of platelet-derived endothelial cell growth factor/thymidine phosphorylase in patients with interstitial cystitis and bladder carcinoma. *J Urol*. 2002;167(1):347–351.

Ueda T, Nakagawa M, Okamura M, et al. New cystoscopic diagnosis for interstitial cystitis/painful bladder syndrome using narrow-band imaging system. *Int J Urol*. 2008;15(12):1039–1043.

Uehling DT, Kelley E, Hopkins J, et al. Urinary glycosaminoglycan levels following induced cystitis in monkeys. *J Urol*. 1988;139(5):1103–1105.

Urban L, Nagy I, Bevan SJ. Chronic neuropathic pain: pathomechanism and pharmacology. *Drug Dev Res*. 2002;54:159–166.

Vaarala MH, Tammela TL, Perttila I, et al. Sacral neuromodulation in urological indications: the Finnish experience. *Scand J Urol Nephrol*. 2011;45(1):46–51.

Van Agt S, Gobet F, Sibert L, et al. Treatment of interstitial cystitis by intravesical instillation of hyaluronic acid: a prospective study on 31 patients]. *Prog Urol*. 2011;21(3):218–225.

van Balken MR, Vandoninck V, Gisolf KW, et al. Posterior tibial nerve stimulation as neuromodulative treatment of lower urinary tract dysfunction. *J Urol*. 2001;166(3):914–918.

van de Merwe JP. Sjögren's syndrome in patients with interstitial cystitis. Preliminary results in 100 patients. *Int J Urol*. 2003;10(Suppl):S69.

van de Merwe JP. *Interstitial cystitis and associated disorders*. https://www.researchgate.net/publication/242299005_Interstit disorders; 2007.

van de Merwe JP, Kamerling R, Arendsen E, et al. Sjögren's syndrome in patients with interstitial cystitis. *J Rheumatol*. 1993;20(6):962–966.

van de Merwe JP, Yamada T, Sakamoto Y. Systemic aspects of interstitial cystitis, immunology and linkage with autoimmune disorders. *Int J Urol*. 2003;10(Suppl):S35–S38.

van de Merwe JP, Nordling J, Bouchelouche P, et al. Diagnostic criteria, classification, and nomenclature for painful bladder syndrome/interstitial cystitis: an ESSIC proposal. *Eur Urol*. 2008;53(1):60–67.

van Kerrebroeck PE. Electrical stimulation in the management of interstitial cystitis. *Urol Integr Invest*. 1999;4(4):331–334.

van Ophoven A, Hertle L. Long-term results of amitriptyline treatment for interstitial cystitis. *J Urol*. 2005;174(5):1837–1840.

van Ophoven A, Oberpenning F, Hertle L. Long-term results of trigone-preserving orthotopic substitution enterocystoplasty for interstitial cystitis. *J Urol*. 2002;167(2 Pt 1):603–607.

van Ophoven A, Pokupic S, Heinecke A, et al. A prospective, randomized, placebo controlled, double-blind study of amitriptyline for the treatment of interstitial cystitis. *J Urol*. 2004;172(2):533–536.

van Ophoven A, Rossbach G, Oberpenning F, et al. Hyperbaric oxygen for the treatment of interstitial cystitis: long-term results of a prospective pilot study. *Eur Urol*. 2004;46(1):108–113.

van Ophoven A, Rossbach G, Pajonk F, et al. Safety and efficacy of hyperbaric oxygen therapy for the treatment of interstitial cystitis: a randomized, sham controlled, double-blind trial. *J Urol*. 2006;176(4):1442–1446.

Vasudevan V, Moldwin R. Addressing quality of life in the patient with interstitial cystitis/bladder pain syndrome. *Asian J Urol*. 2017;4(1):50–54.

Vemulakonda VM, Somogyi GT, Kiss S, et al. Inhibitory effect of intravesically applied botulinum toxin A in chronic bladder inflammation. *J Urol*. 2005;173(2):621–624.

Ventolini G. Vulvar pain: anatomic and recent pathophysiologic considerations. *Clin Anat*. 2013;26(1):130–133.

Vera PL, Preston DM, Moldwin RM, et al. Elevated urine levels of macrophage migration inhibitory factor in inflammatory bladder conditions: a potential biomarker for a subgroup of interstitial cystitis/bladder pain syndrome patients. *Urology*. 2018;116:55–62.

Vesela R, Aronsson P, Andersson M, et al. The potential of non-adrenergic, non-cholinergic targets in the treatment of interstitial cystitis/painful bladder syndrome. *J Physiol Pharmacol*. 2012;63(3):209–216.

Vliagoftis H, Dimitriadou V, Boucher W, et al. Estradiol augments while tamoxifen inhibits rat mast cell secretion. *Int Arch Allergy Immunol*. 1992;98(4):398–409.

Vrinten DH, Kalkman CJ, Adan RA, et al. Neuropathic pain: a possible role for the melanocortin system? *Eur J Pharmacol*. 2001;429(1–3):61–69.

Wabner CL, Pak CYC. Effect of orange juice consumption on urinary stone risk factors. *J Urol*. 1993;149(6):1405–1408.

Walker SJ, Zambon J, Andersson KE, et al. Bladder capacity is a biomarker for a bladder centric versus systemic manifestation in interstitial cystitis/bladder pain syndrome. *J Urol*. 2017;198(2):369–375.

Wallack H, Lome LG, Presman D. Management of interstitial cystitis with ileocecocystoplasty. *Urology*. 1975;5(1):51–55.

Walsh A. Interstitial cystitis. Campbell MF, Harrison JH. *Campbell's urology*. 4th ed. Saunders: Philadelphia, PA; 1978:693–707.

Walsh A. *Cystolysis (supratrigonal denervation) for intractable interstitial cystitis*. [Urologists' Correspondence Club] 1985:142.

Warren JW. Interstitial cystitis as an infectious disease. *Urol Clin North Am*. 1994;21(1):31–39.

Warren JW. Is interstitial cystitis an infectious disease? *Med*

Hypotheses. 1994;43(3):183–186.

Warren JW, Keay SK, Meyers D, et al. Concordance of interstitial cystitis in monozygotic and dizygotic twin pairs. *Urology*. 2001;57(6 Suppl 1):22–25.

Warren JW, Jackson TL, Langenberg P, et al. Prevalence of interstitial cystitis in first-degree relatives of patients with interstitial cystitis. *Urology*. 2004;63(1):17–21.

Warren JW, Meyer WA, Greenberg P, et al. Using the International Continence Society's definition of painful bladder syndrome. *Urology*. 2006;67(6):1138–1142.

Warren JW, Brown V, Jacobs S, et al. Urinary tract infection and inflammation at onset of interstitial cystitis/painful bladder syndrome. *Urology*. 2008;71(6):1085–1090.

Warren JW, Howard FM, Cross RK, et al. Antecedent nonbladder syndromes in case-control study of interstitial cystitis/painful bladder syndrome. *Urology*. 2009;73(1):52–57.

Warren JW, Clauw DJ, Langenberg P. Prognostic factors for recent-onset interstitial cystitis/painful bladder syndrome. *BJU Int*. 2013;111(3 Pt B):E92–E97.

Warren JW, Jian N, Gallicchio L, et al. Prodrome and non-prodrome phenotypes of bladder pain syndrome/interstitial cystitis. *Urology*. 2018;118:52–58.

Waxman JA, Sulak PJ, Kuehl TJ. Cystoscopic findings consistent with interstitial cystitis in normal women undergoing tubal ligation. *J Urol*. 1998;160(5):1663–1667.

Webster GD, Maggio MI. The management of chronic interstitial cystitis by substitution cystoplasty. *J Urol*. 1989;141(2):287–291.

Webster GD, MacDiarmid SA, Timmons SL, et al. Impact of urinary diversion procedures in the treatment of interstitial cystitis and chronic bladder pain. *Neurourol Urodyn*. 1992;11:417.

Wei DC, Politano VA, Selzer MG, et al. The association of elevated urinary total to sulfated glycosaminoglycan ratio and high molecular mass hyaluronic acid with interstitial cystitis. *J Urol*. 2000;163(5):1577–1583.

Wein A, Hanno PM, Gillenwater JY. Interstitial cystitis: an introduction to the problem. Hanno PM, Staskin DR, Krane RJ, et al. *Interstitial cystitis*. Springer-Verlag: London; 1990:3–15.

Wein AJ, Broderick GA. Interstitial cystitis. Current and future approaches to diagnosis and treatment. *Urol Clin North Am*. 1994;21(1):153–161.

Weisman MH, McDanald EC, Wilson CB. Studies of the pathogenesis of interstitial cystitis, obstructive uropathy, and intestinal malabsorption in a patient with systemic lupus erythematosus. *Am J Med*. 1981;70(4):875–881.

Weiss JM. Pelvic floor myofascial trigger points: manual therapy for interstitial cystitis and the urgency-frequency syndrome. *J Urol*. 2001;166(6):2226–2231.

Weiss JP, Neville EC. Hyperbaric oxygen: primary treatment of radiation-induced hemorrhagic cystitis. *J Urol*. 1989;142(1):43–45.

Weiss JP, Wein AJ, Hanno PM. Sigmoidocystoplasty to augment bladder capacity. *Surg Gynecol Obstet*. 1984;159(4):377–380.

Weissman MM, Gross R, Fyer A, et al. Interstitial cystitis and panic disorder: a potential genetic syndrome. *Arch Gen Psychiatry*. 2004;61(3):273–279.

Welk BK, Teichman JM. Dyspareunia response in patients with interstitial cystitis treated with intravesical lidocaine, bicarbonate, and heparin. *Urology*. 2008;71(1):67–70.

Wennevik GE, Meijlink JM, Hanno P, et al. The role of glomerulations in bladder pain syndrome: a review. *J Urol*. 2016;195(1):19–25.

White WM, Mobley JD Jr, Doggweiler R, et al. Incidence and predictors of complications with sacral neuromodulation. *Urology*. 2009;73(4):731–735.

Whitmore KE. Self-care regimens for patients with interstitial cystitis. *Urol Clin North Am*. 1994;21(1):121–130.

Wiesenfeld-Hallin Z, Xu XJ. Neuropeptides in neuropathic and inflammatory pain with special emphasis on cholecystokinin and galanin. *Eur J Pharmacol*. 2001;429(1–3):49–59.

Wilkins EG, Payne SR, Pead PJ, et al. Interstitial cystitis and the urethral syndrome: a possible answer. *Br J Urol*. 1989;64(1):39–44.

Wilson CB, Leopard J, Nakamura RM, et al. Selective type IV collagen defects in the urothelial basement membrane in interstitial cystitis. *J Urol*. 1995;154(3):1222–1226.

Wishard W Jr, Nourse MH, Mertz JH. Use of Clorpactin WCS 90 for relief of symptoms due to interstitial cystitis. *J Urol*. 1957;77(3):420–423.

Wolfe F, Walitt B, Perrot S, et al. Fibromyalgia diagnosis and biased assessment: sex, prevalence and bias. *PLoS ONE*. 2018;13(9):e0203755.

Worth PH. The treatment of interstitial cystitis by cystolysis with observations on cystoplasty. A review after 7 years. *Br J Urol*. 1980;52(3):232.

Worth PH, Turner-Warwick R. The treatment of interstitial cystitis by cystolysis with observations on cystoplasty. *Br J Urol*. 1973;45(1):65–71.

Worth P, Turner-Warwick R, Essenhigh DM. Interstitial cystitis. *Br Med J*. 1972;2(805):111–112.

Yamada T, Murayama T, Mita H, et al. Subtypes of bladder mast cells in interstitial cystitis. *Int J Urol*. 2000;7(8):292–297.

Yang CC, Burks DA, Propert KJ, et al. Early termination of a trial of mycophenolate mofetil for treatment of interstitial cystitis/painful bladder syndrome: lessons learned. *J Urol*.

2011;185(3):901–906.

Yang W, Kim Y, Kim TK, et al. Integration analysis of quantitative proteomics and transcriptomics data identifies potential targets of frizzled-8 protein-related antiproliferative factor in vivo. *BJU Int*. 2012;110(11 Pt C):E1138–E1146.

Yang W, Rudick CN, Hoxha E, et al. Ca(2+)/calmodulin-dependent protein kinase II is associated with pelvic pain of neurogenic cystitis. *Am J Physiol Renal Physiol*. 2012;303(3):F350–F356.

Yih JM, Killinger KA, Boura JA, et al. Changes in sexual functioning in women after neuromodulation for voiding dysfunction. *J Sex Med*. 2013;10(10):2477–2483.

Yilmaz U, Liu YW, Rothman I, et al. Intravesical potassium chloride sensitivity test in men with chronic pelvic pain syndrome. *J Urol*. 2004;172(2):548–550.

Yokoyama T, Chancellor MB, Oguma K, et al. Botulinum toxin type A for the treatment of lower urinary tract disorders. *Int J Urol*. 2012;19(3):202–215.

Yoshimura N, de Groat WC. Increased excitability of afferent neurons innervating rat urinary bladder after chronic bladder inflammation. *J Neurosci*. 1999;19(11):4644–4653.

Yukawa S, Tahara K, Hayashi H, et al. A case of lupus cystitis in a 74-year-old woman. *Nihon Rinsho Meneki Gakkai Kaishi*. 2008;31(3):183–189.

Yun SK, Laub DJ, Weese DL, et al. Stimulated release of urine histamine in interstitial cystitis. *J Urol*. 1992;148(4):1145–1148.

Zaslau S, Riggs DR, Jackson BJ, et al. In vitro effects of pentosan polysulfate against malignant breast cells. *Am J Surg*. 2004;188(5):589–592.

Zeng Y, Wu XX, Homma Y, et al. Uroplakin III-delta4 messenger RNA as a promising marker to identify nonulcerative interstitial cystitis. *J Urol*. 2007;178(4 Pt

1):1322–1327.

Zeng J, Lai H, Zheng D, et al. Effective treatment of ketamine-associated cystitis with botulinum toxin type a injection combined with bladder hydrodistention. *J Int Med Res*. 2017;45(2):792–797.

Zermann DH, Ishigooka M, Doggweiler R, et al. Postoperative chronic pain and bladder dysfunction: windup and neuronal plasticity—do we need a more neurourological approach in pelvic surgery? *J Urol*. 1998;160(1):102–105.

Zermann DH, Ishigooka M, Doggweiler R, et al. Neurourological insights into the etiology of genitourinary pain in men. *J Urol*. 1999;161(3):903–908.

Zhao J, Bai J, Zhou Y, et al. Posterior tibial nerve stimulation twice a week in patients with interstitial cystitis. *Urology*. 2008;71(6):1080–1084.

Zuraw BL, Sugimoto S, Parsons CL, et al. Activation of urinary kallikrein in patients with interstitial cystitis. *J Urol*. 1994;152(3):874–878.

58

Sexually Transmitted Diseases*

Kristy McKiernan Borawski MD

Epidemiology of Sexually Transmitted Diseases

A 1997 Institute of Medicine (IOM) report described sexually transmitted diseases (STDs) as, “hidden epidemics of tremendous health and economic consequence in the United States,” and stated that the “scope, impact, and consequences of STDs are under recognized by the public and healthcare professionals” (Institute of Medicine Committee on Prevention and Control of Sexually Transmitted Diseases et al., 1997). Unfortunately, this still holds true two decades later, and we are now seeing the resurgence of various STDs such as syphilis and gonorrhea that had previously seen a decline in reported cases. Data from the 2016 Centers for Disease Control and Prevention (CDC) report are summarized in Table 58.1 (CDC, 2016a). Nearly 20 million new STD cases occur every year, with one-half occurring among people 15 to 24 years of age (Satterwhite et al., 2013). The direct cost of treating STDs in the United States is nearly $16 billion annually (Owusu-Edusei et al., 2013).

TABLE 58.1

Sexually Transmitted Disease Cases 2016

	CASES REPORTED	RATE PER 100,000 PEOPLE	CHANGE FROM 2015
Chlamydia	1,598,354	497.3	4.7% increase
Gonorrhea	468,514	145.8	18.5% increase
Syphilis (primary and secondary)	27,814	8.7	17.6% increase

Centers for Disease Control and Prevention. Sexually transmitted disease surveillance; 2016a. Available at: https://www.cdc.gov/std/stats16/default.htm.

Clinical Prevention Guidance

Five major strategies should be used to guide prevention and control of STDs (Frieden et al., 2015). They are as follows:

- Accurate risk assessment, education, and counseling of persons

at risk in prevention strategies
- Pre-exposure vaccination of persons at risk for vaccine-preventable STDs
- Identification of symptomatic or asymptomatic persons infected with STDs
- Effective diagnosis, treatment, counseling, and follow-up of infected persons
- Evaluation, treatment, and counseling of sex partners of infected persons

The first step in prevention is identifying the at-risk population. Risk factors include higher numbers of lifetime sexual partners, unprotected sex without a condom, substance abuse, and risky sexual partners. Men who have sex with men (MSM) are at an increased risk for STDs. Although the incidence of human immunodeficiency virus (HIV) and bacterial STDs had been decreasing in this group in the mid-1990s, there has now been increasing rates of syphilis, gonorrhea, and chlamydial infections. In fact, approximately two-thirds of primary and secondary syphilis cases in the United States are in MSM (Chesson et al., 2010; Kerani et al., 2007; Patton et al., 2014).

Screening Recommendations

In 2014, a multi-organization report was released that recommended clinical and nonclinical providers assess an individual's behavior and biologic risk for acquiring and transmitting STDs and/or HIV and tailor risk-reduction counseling and screening based on those risk factors (CDC, 2014).

Screening recommendations are also tailored to an individual's risk. The 2015 CDC screening guidelines are listed in the following sections. (Please note that these recommendations summarize federal agency and medical professional organizations' clinical guidelines) (Workowski, 2015).

Young or at-Risk Women

Young or at-risk women should be screened for the following:

- Routine screening for *Chlamydia trachomatis* on an annual basis for all sexually active women younger than 25 years of age

(LeFevre, 2014)
- Routine screening for *Neisseria gonorrhoeae* on an annual basis for all sexually active women younger than 25 years of age (LeFevre, 2014)
- Annual screening for *C. trachomatis* and *N. gonorrhoeae* in women with risk factors

Pregnant Women

- All pregnant women in the United States should be screened for HIV infection at the first prenatal visit, even if they have been previously tested (Chou et al., 2012; Moyer, 2013).
- A serologic test for syphilis should be performed for all pregnant women at the first prenatal visit (US Preventive Services Task Force, 2009).
- All pregnant women younger than 25 years of age and older women at increased risk for infection should be screened for *C. trachomatis* and *N. gonorrhoeae* at the first prenatal visit (LeFevre, 2014).
- All pregnant women at risk for hepatitis C should be screened at the first prenatal visit.

Persons in Correctional Facilities

- Women younger than 35 years of age and men younger than 30 years of age in correctional facilities should be screened for *C. trachomatis* and *N. gonorrhoeae.*
- Universal screening should be conducted on the basis of local area and institutional prevalence of early infectious syphilis.

Men Who Have Sex With Men

Screening recommendations for MSM are as follows:

- HIV serology test if HIV status is unknown or negative and the

patient or his partner has had more than one sex partner since the most recent HIV test.
- Syphilis serology test to establish whether patients with reactive tests have untreated syphilis, have partially treated syphilis, are manifesting a slow serologic response to appropriate prior therapy, or are serofast.
- Test for urethral infection regardless of condom use during exposure for *C. trachomatis* and *N. gonorrhoeae* in men who have had insertive intercourse during the preceding year.
- Test for rectal infection regardless of condom use during exposure for *C. trachomatis* and *N. gonorrhoeae* in men who have had receptive intercourse during the preceding year.
- Test for pharyngeal infection regardless of condom use during exposure for *N. gonorrhoeae* in men who have had receptive oral intercourse during the preceding year.

Transgender Men and Women

- Assess STD and HIV-related risk based on current anatomy and sexual behaviors.

Reporting Sexually Transmitted Disease

There are six mandated reportable diseases in every state: syphilis (including congenital), gonorrhea, chlamydia, chancroid, HIV infection, and acquire immunodeficiency syndrome (AIDS). The requirements for reporting other STDs vary by state. State and local health department resources are useful to identify reportable STDs in your area.

Prevention Methods

There are several methods available for the prevention of STDs. These include pre-exposure vaccination, abstinence and reduction in the number of sex partners, condoms (both male and female), cervical diaphragms, and topical microbicides and spermicide.

When used correctly, male condoms are highly effective in preventing the transmission of HIV. In heterosexual serodiscordant relationships (i.e., one infected and one uninfected) in which condoms were consistently used, HIV-negative partners were 80% less likely to become infected with HIV compared with serodiscordant relationships in which condoms were not used. Condom use decreases the risk for other STDs and, by limiting lower genital tract inflammation, may reduce the risk for pelvic inflammatory disease. When the infected area or site of potential exposure is covered, condoms can also reduce the risk for HPV, genital herpes, syphilis, and chancroid transmission.

Because they are regulated as medical devices, condoms are subject to random sampling by the US Food and Drug Administration (FDA). Breakage rates are approximately 2 per 100 used in the United States with slightly higher rates of breakage with anal intercourse.

Alternatives to latex condoms include polyurethane or other synthetic condoms and natural membrane condoms. **Polyurethane male condoms provide comparable protection against STDs/HIV and pregnancy to that of latex condoms**. Polyurethane condoms are compatible with the use of both oil-based and water-based lubricants. The effectiveness of other synthetic condoms to prevent STDs had not been extensively studied. **Natural membrane condoms (“lambskin” condoms) are made from the lamb cecum and can have pores up to 1500 nm in diameter, and, although they prevent passage of sperm, the large pore size allows passage of HIV and hepatitis B virus** (Workowski, 2015).

Urethritis

STDs can cause urethritis, or urethral inflammation. Typical symptoms include urethral discharge, dysuria, urethral stinging/itching, and penile tip irritation, however, urethritis is often asymptomatic (Moi et al., 2015; Horner et al., 2016).

Etiology

There are an estimated 2.8 million cases of urethritis each year that can be associated with complications including acute epididymitis, orchitis, and prostatitis (Brill, 2010). Several organisms can cause infectious urethritis. *N. gonorrhoeae* is presumed the cause of urethritis in the presence of gram-negative intracellular diplococci. Nongonococcal urethritis (NGU) is caused by *C. trachomatis* in 15% to 40% of cases (Bradshaw et al., 2006; Frieden et al., 2015). *Mycoplasma genitalium* has emerged as the second most common cause of NGU accounting for 15% to 25% of all cases (Taylor-Robinson et al., 2004; Ross and Jensen, 2006; Manhart et al., 2007). Less common causes of NGU include *Trichomonas vaginalis*, herpes simplex virus (HSV), *Haemophilus vaginalis*, and adenovirus.

Diagnosis

Previously, urethritis was diagnosed by examination of the purulent discharge with Gram stain showing greater than or equal to 5 white blood cells (WBCs) per high-power field (hpf) (Workowski, Berman, 2010). The sensitivity of the urethral Gram stain is highly dependent on the experience of the provider and the method of collection (i.e., swab vs. loop vs. spatula [increasing yield in the same order]) (Frieden et al., 2015). Several studies demonstrated that utilizing a threshold of greater than or equal to 5 WBC/hpf could miss a significant proportion of individuals with *Chlamydia trachomonatis*, *N. gonorrhoeae*, and *M. genitalium* (Couldwell et al., 2010; Rietmeijer and Mettenbrenk, 2012, 2017; Bachmann et al., 2015). **In light of these studies, the current CDC guidelines recommend using a threshold of greater than or equal to 2 WBCs per oil immersion field for the diagnosis of urethritis** (Frieden et al., 2015). The diagnosis of urethritis can be documented on the basis of any of the following signs or tests (Frieden et al., 2015):

- Mucoid, mucopurulent, or purulent discharge on examination
- Gram stain of urethral secretions demonstrating greater than or equal to 2 WBCs per oil immersion field
- Positive leukocyte esterase from a first-void urine
- Greater than 10 WBCs/hpf from a first-void urine

If point-of-care diagnostic tests (Gram stain microscopy) are not available, all men should have a nucleic acid amplification test (NAAT). In males, urine is the preferred specimen for NAATs. NAATs are also recommended in the presence of greater than or equal to 2 WBCs per oil immersion field and no intracellular gram-negative or purple diplococci (Papp et al., 2014; Frieden et al., 2015).

Gonococcal Urethritis

In 2016, there were 468,514 cases of gonorrhea reported, a significant increase over previous years (CDC, 2016a). Screening for *N. gonorrhoeae* is covered earlier in this chapter. *N. gonorrhoeae* is a gram-negative dipplococcus that has an incubation period of 3 to 14 days. Men will usually have symptoms that prompt treatment such as urethritis, epididymitis, prostatitis, or proctitis and rarely disseminated gonococcal infection. Women are usually asymptomatic and may present with sequela of the disease, pelvic inflammatory disease (PID), tubal scarring, infertility, ectopic pregnancy, and chronic pelvic pain (Hook et al., 2008).

Diagnosis of Gonococcal Urethritis

A positive Gram stain of a male urethral specimen that demonstrates polymorphonuclear leukocytes with intracellular gram-negative diplococci can be considered diagnostic for *N. gonorrhoeae* in symptomatic men. Because of its low sensitivity, a negative Gram stain does not rule out infection with *N. gonorrhoeae*. Cultures and NAATs are available for the detection of genitourinary *N. gonorrhoeae* infections. Cultures for *N. gonorrhoeae require* urethral swabs, whereas NAATs can be performed on first-catch urine and urethral swabs (Papp et al., 2014). As an aside, NAATs are not FDA-cleared for diagnosing rectal, oropharyngeal, and conjunctival infections; culture is the preferred option in these instances. As of 2014, there were five commercially available NAAT assays available for detection of both *N. gonorrhoeae* and *C.*

trachomatis. **Because of their higher sensitivity, NAATs are now the preferred method for detecting *N. gonorrhoeae* and *C. trachomatis*.** In certain circumstances, however, culture for *N. gonorrhoeae* is recommended, such as in cases of sexual assault of prepubescent boys, to evaluate suspected gonorrhea treatment failures, and to monitor developing resistance to current treatment regimens. If multiple specimens are being collected from an anatomic site (e.g., urethral swab), *N. gonorrhoeae* cultures should be obtained first to maximize the sample and increase the likelihood of a successful culture (Elias and Vogel, 2011).

Treatment of Gonococcal Urethritis

Treatment of *N. gonorrhoeae* has become more complex given the evolution of antimicrobial resistance to the antibiotics historically used to treat gonorrhea and the decreased use of culture given the widespread availability and ease of NAATs (Kirkcaldy et al., 2016). In 1986, the CDC established the Gonococcal Isolate Surveillance Project (GISP) to monitor antimicrobial susceptibilities in the United States (Schwarcz et al., 1990). **Currently, the CDC recommends that gonococcal infections be treated with a single dose of both ceftriaxone 250 mg (intramuscularly) and azithromycin 1 g orally** (Workowski, 2015; Kirkcaldy et al., 2016)**. If ceftriaxone is not available, alternative regimens are cefixime 400 mg orally in a single dose plus Azithromycin 1 g orally in a single dose** (Workowski, 2015). The use of ceftriaxone is contraindicated in patients with allergies to cephalosporins and in those with an IgE-mediated penicillin allergy (Pichichero and Casey, 2007; Ahmed et al., 2012). **Patients in whom the use of cephalosporins is contraindicated should be treated with azithromycin 2 g orally in a single dose plus either gemifloxacin 320 mg orally or intramuscular gentamicin 240 mg** (Kirkcaldy et al., 2014, 2016; Workowski, 2015).

Increasing antibiotic resistance has been noted among *N. gonorrhoeae* isolates. In 2014, 25% of isolates were resistant to tetracycline, 19.2% were resistant to ciprofloxacin, and 16.2% were resistant to penicillin. There was also an increase in the percentage of isolates demonstrating reduced susceptibility to azithromycin (0.6% in 2013 to 2.5% in 2014). Reduced susceptibility to cefixime and ceftriaxone remained low in 2014 (0.8% and 0.1%, respectively) but followed similar increasing trends of resistance (Kirkcaldy et al., 2016).

Treatment failures, defined as lack of symptom resolution within 3 to 5 days and no sexual contact during this period and/or a patient with a positive test of cure when no sexual contact is reported, should be evaluated with a culture along with antimicrobial susceptibility testing (Kidd and Ye, 2012; Workowski, 2015).

All patients who are diagnosed with gonorrhea should be tested for other STDs, namely chlamydia, syphilis, and HIV. Patients who are diagnosed with gonorrhea should be instructed to abstain from sexual activity for 7 days after treatment and until all sex partners have been adequately treated. All sex partners with whom they have had sexual contact within the 60 days preceding the onset of symptoms should be referred for evaluation, testing, and presumptive treatment. Because of high rates of reinfection, a follow-up test is recommended in 3 to 4 months (Workowski, 2015).

Nongonococcal Urethritis

Five percent to 20% of urethritis cases are caused by gonorrhea. The remaining NGU cases are caused by a variety of organisms, the most common of which is *C. trachomatis*, which accounts for approximately 15% to 40% of NGU cases and is more common in younger men (Wetmore et al., 2011). Many men diagnosed with urethritis will have no definitive diagnosis (Bradshaw et al., 2006; Schwebke et al., 2011). The second most common identifiable cause of NGU, *M. genitalium*, is found in 15% to 25% of men with symptomatic NGU (Taylor-Robinson and Jensen, 2011; Manhart et al., 2013; Horner and Martin, 2017). *Ureaplasma urealyticum* has been weakly associated with NGU, specifically among young men with few sexual partners. It should, however, be considered in men with no other identifiable pathogens (Frølund et al., 2011; Bachmann et al., 2015). *Trichomonas vaginalis* rates vary greatly by age and geography and should be considered in areas of high prevalence (Bachmann et al., 2015; Workowski, 2015). Other causes of NGU include herpes simples virus (HSV)-1, HSV-2, and adenovirus (Bradshaw et al., 2002; Frølund et al., 2011).

Chlamydia

Chlamydia, caused by *C. trachomatis*, is the most frequently reported infectious disease in the United States, with the highest prevalence in persons younger than 24 years of age (CDC, 2016a). It has an incubation period of 3 to 14 days. Other sequela of *C. trachomatis* include epididymitis and Reiter syndrome. Diagnosis and treatment is also aimed to prevent transmission to their female partners as ascending chlamydial infections in women can lead to scarring of the fallopian tubes, pelvic inflammatory disease, pelvic pain, and infertility (Gottlieb et al., 2013; Lanjouw et al., 2016). As with gonorrhea, detecting *C. trachomatis* in men can be done both through urethral swab and NAATs. **NAATs using first-catch urine are the most sensitive test for detecting *C. trachomatis* infections in men and, as such, are the recommended test** (Papp et al., 2014; Workowski, 2015).

The recommended treatment for *C. trachomatis* is azithromycin 1 g orally in a single dose OR doxycycline 100 mg orally twice daily for 7 days (Workowski, 2015; Lanjouw et al., 2016). Alternative regimens include erythromycin base 500 mg orally four times daily for 7 days, erythromycin ethylsuccinate 800 mg orally four times a day for 7 days, levofloxacin 500 mg orally once daily for 7 days, or ofloxacin 300 mg orally twice a day for 7 days (Workowski, 2015). HIV status does not affect treatment recommendations.

Like in gonorrhea, persons testing positive for chlamydia should be advised to abstain from intercourse for 7 days after single-dose treatment or until completion of all 7 days of treatment with resolution of symptoms. **Concurrent testing for gonorrhea, HIV, and syphilis should be performed with any chlamydia diagnosis**. Although a test of cure is not advised for persons completing the advised treatment regimens (and, if retested within 3 weeks, the test may not be valid because of residual pathogen-derived nucleic acids), a 3-month retest is recommended (Fung et al., 2007; Hosenfeld et al., 2009; O'Connell and Ferone, 2016). All sex partners with whom the patient has had sexual contact within the 60 days preceding the onset of symptoms should be referred for evaluation, testing, and presumptive treatment.

Mycoplasma Genitalium

M. genitalium, first identified in the early 1980s, is responsible for 15% to 20% of NGU cases, 20% to 25% of nonchlamydial NGU cases, and approximately 30% of persistent or recurrent urethritis cases (Taylor-Robinson and Jensen, 2011; Workowski, 2015). Transmission is primarily by direct genital-genital mucosal contact. It has been detected in anorectal samples and as such, transmission from penile-anal sexual contact has been identified. Oral-genital transmission is less likely given decreased concentration of *M. genitalium* in the oro-pharynx (Jensen et al., 2016).

Cultures for *M. genitalium* can take up to 6 months, and, as such, few laboratories can recover clinical isolates (Workowski, 2015). As *M. genitalium* lacks a cell wall, it cannot be Gram stained. NAATs identifying *M. genitalium*–specific nucleic acid (DNA or RNA) are the only clinically useful methods for diagnosis. Unfortunately, although NAAT assays are commercially available, none have been approved by the FDA for diagnostic use (Horner and Martin, 2017; Sethi et al., 2017). **Because of the lack of approved diagnostic tests, *M. genitalium* should be suspected in cases of persistent or recurrent urethritis.***

Antimicrobial resistance has become quite prevalent for *M. genitalium*. Doxycycline, a first-line treatment option for NGU, has only a 31% median cure rate (Schwebke et al., 2011). Currently, the CDC recommends a single dose of 1 g of azithromycin (Workowski, 2015). Historically, this regimen had a median cure rate of 85%, however this has dropped to 40% in a recent study (Manhart et al., 2013). Because of the treatment failures associated with the single-dose azithromycin regimen, a longer course of azithromycin was considered (500 mg initial dose followed by 250 mg daily for 4 days). Although considered, the CDC still recommends a single 1-g azithromycin dose for first-line therapy. The European guidelines differ in treatment recommendations (Jensen et al., 2016).* Treatment failures should then receive moxifloxacin 400 mg daily for 7, 10, or 14 days. Moxifloxacin appears promising in early reports, with 100% cure rates. Treatment recommendations are not affected by HIV status.

Patients testing positive for *M. genitalium* should be advised to abstain from intercourse until they have completed treatments and symptoms have resolved. Sex partners should be managed according to guidelines for patients with NGU (Workowski, 2015; Horner and Martin, 2017). **Patients with *M. genitalium* infections should be screened for other STDs including *C. trachomatis, N. gonorrhoeae,* syphilis, HIV, and *T. vaginalis* when appropriate** (Jensen et al., 2016). All sex partners with whom the patient has had sexual contact within the 60 days preceding the onset of symptoms should be referred for evaluation, testing, and presumptive treatment.

Trichomaonas Vaginalis

T. vaginalis is a flagellated parasite that preferentially infects the urethra in men and women and the vaginal and vulvar area in women (Muzny and Schwebke, 2013; Meites et al., 2015). Occurrence rates of *T. vaginalis* vary by age and geography with ranges from 2% to 13% (Bachmann et al., 2011, 2015). NAATs, although not FDA-approved for use in males, are replacing wet mounts of cultures for diagnosing *T. vaginalis*. The low prevalence of *T. vaginalis* in NGU does not warrant using these tests in the initial workup, although they should be considered for male sexual partners to women with trichomoniasis and for other male populations in high prevalence areas of the country. The recommended treatment for *T. vaginalis* is metronidazole 2 g orally once or tinidazole 2 g orally once (Bachmann et al., 2015).

Persistent or Recurrent Nongonoccal Urethritis

Persistence or recurrence can be a result of resistance to the completed treatment course, noncompliance with the initial treatment regimen, or re-exposure to an untreated sex partner. Consideration should be given to resistant *M. genitalium* and/or infection with *T. vaginalis*. A urine specimen can be sent for testing. A treatment algorithm for NGU can be found in Fig. 58.1. In men with persistent symptoms, urologic evaluation does not usually identify a specific cause for the urethritis. One consideration is to make sure there is no pain elsewhere in the pelvis that could indicate chronic pelvic pain syndrome as opposed to localized urethritis (Nickel et al., 2003).

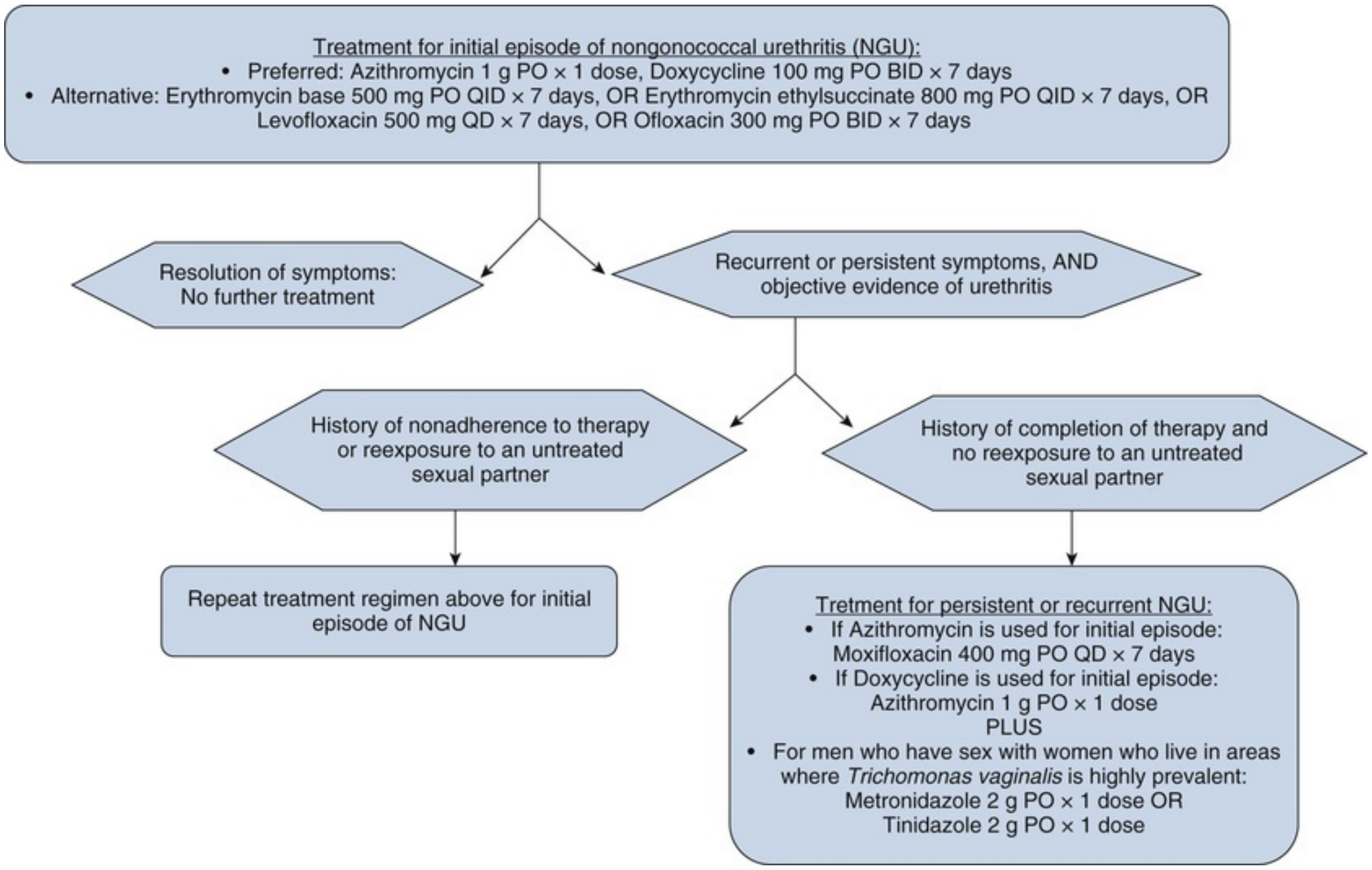
Treatment for initial episode of nongonococcal urethritis (NGU):
• Preferred: Azithromycin 1 g PO × 1 dose, Doxycycline 100 mg PO BID × 7 days
• Alternative: Erythromycin base 500 mg PO QID × 7 days, OR Erythromycin ethylsuccinate 800 mg PO QID × 7 days, OR Levofloxacin 500 mg QD × 7 days, OR Ofloxacin 300 mg PO BID × 7 days
Resolution of symptoms: No further treatment
Recurrent or persistent symptoms, AND objective evidence of urethritis
History of nonadherence to therapy or reexposure to an untreated sexual partner
History of completion of therapy and no reexposure to an untreated sexual partner
Repeat treatment regimen above for initial episode of NGU
Tretment for persistent or recurrent NGU:
• If Azithromycin is used for initial episode: Moxifloxacin 400 mg PO QD × 7 days
• If Doxycycline is used for initial episode: Azithromycin 1 g PO × 1 dose
PLUS
• For men who have sex with women who live in areas where *Trichomonas vaginalis* is highly prevalent: Metronidazole 2 g PO × 1 dose OR Tinidazole 2 g PO × 1 dose

FIG. 58.1 Treatment algorithm for nongonococcal urethritis (NGU). *BID,* Twice daily; *PO,* per os (orally); *QD,* once daily; *QID,* four times daily. (Data from Bachmann LH, Manhart LE, Martin DH, et al. Advances in the understanding and treatment of male urethritis. *Clin Infect Dis.* 2015;61(Suppl 8):S763–S769.).

Epididymitis

Acute epididymitis is characterized by pain, swelling, and inflammation of the epididymis that lasts less than 6 weeks (Tracy et al., 2008; Workowski, 2015). The testis may be involved (epididymo-orchitis). Given the often similar presentation, one should maintain a high index of suspicion for testicular torsion. Although concurrent urethritis is often present, it is often asymptomatic. In men younger than 35 years of age, epididymitis is often caused by *C. trachomatis* or *N. gonorrhoeae*. Enteric organisms (*Escherichia coli, Pseudomonas*) may be present among men who are the insertive partner during anal intercourse (Workowski, 2015). In men older than 35 years of age who do not report insertive anal intercourse, epididymitis is often caused by uropathogenic organisms (*E. coli)* resulting from bladder outlet obstruction, urinary tract surgery, or instrumentation (Street et al., 2017). Chronic epididymitis is characterized by a history of symptoms of discomfort in the scrotum, testicle, or epididymis for 6 weeks or longer. There are both infectious (most commonly from *Mycobacterium tuberculosis*) and noninfectious causes of chronic epididymitis.

Diagnosis of Epididymitis

Acute epididymitis routinely presents as unilateral testicular pain and tenderness with a reactive hydrocele and palpable swelling of the epididymis. **Ultrasonography should not be used to diagnose acute epididymitis as a negative ultrasound in the setting of the appropriate clinical context would not alter clinical management.** Ultrasonography can be helpful if torsion is suspected. The diagnosis of epididymitis should include one of the following (Workowski, 2015):

- Gram stain or methylene blue stain of urethral secretion demonstrating greater than or equal to 2 WBCs per oil immersion field
- Positive leukocyte esterase on first-void urine
- Greater than or equal to 10 WBCs per high-power field on spun first-void urine

All suspected cases of acute epididymitis should be tested for *C. trachomatis* and *N. gonorrhoeae* with NAATs. Urine bacterial cultures should be obtained in men with sexually transmitted enteric infections and in older men with epididymitis caused by genitourinary bacteriuria (Workowski, 2015).

Treatment of Epididymitis

Empiric therapy should be started before laboratory results are available. **For acute epididymitis likely caused by an STD, the CDC recommends ceftriaxone 250 mg* intramuscularly in a single dose PLUS doxycycline 100 mg orally twice daily for 10 days. For acute epididymitis most likely caused by STD and enteric organisms (MSM), the recommended treatment is ceftriaxone 250 mg intramuscularly in a single dose PLUS levofloxacin 500 mg orally once daily for 10 days OR ofloxacin 300 mg orally twice daily for 10 days. For acute epididymitis likely caused by enteric organisms and if gonorrhea has been ruled out, treatment can be either levofloxacin or oflaxacin using the same dose/duration.** Similar to other infections caused by *C. trachomatis* and *N. gonorrhoeae*, if positive for these pathogens, patients should be counseled to abstain from sexual intercourse until they and their partners have been treated and symptoms have resolved. Testing for other STDs and HIV should proceed as mentioned in previous sections (Workowski, 2015; Street et al., 2017)

Genital, Anal, and Perianal Ulcers

Most young sexually active patients with genital ulcers in the United States have either genital herpes (more common) or syphilis or less commonly chancroid and donovanosis (Table 58.2). Noninfectious causes include carcinoma, yeast, trauma, psoriasis, and fixed drug eruption. Because of the inaccuracies with history and physical examination alone, all patients with genital, anal, or perianal ulcers need serologic testing, darkfield examination of polymerase chain reaction (PCR) testing if available for syphilis, culture or PCR for genital herpes, and serologic testing for type-specific herpes simplex virus (HSV) antibody. In endemic areas, a test for *Haemophilus ducreyi* should also be performed. HIV testing should be done in patients without known HIV status. Despite evaluation, 25% of patients with genital ulcers will have no specific diagnosis, and ulcers that do not respond to initial therapy or appear unusual should be sent for biopsy (Workowski, 2015).

TABLE 58.2

Genital Ulcer Disease

DISEASE	LESIONS	LYMPHADENOPATHY	SYSTEMIC SYMPTOMS
Primary syphilis	Painless, indurated, with a clean base, usually singular	Nontender, rubbery, nonsuppurative bilateral lymphadenopathy	None
Genital herpes	Painful vesicles, shallow, usually multiple	Tender, bilateral inguinal adenopathy	Present during primary infection
Chancroid	Tender papule, then painful, undermined purulent ulcer, single or multiple	Tender, regional, painful, suppurative nodes	None
Lymphogranuloma	Small, painless vesicle or papule progresses to an ulcer	Painful, matted, large nodes with fistulous tracts	Present after genital lesion heals

Genital Herpes Simplex Virus Infections

Herpes simplex virus (HSV) type 1 and HSV-2 are double-stranded DNA viruses. Most cases of genital herpes are caused by HSV-2. In the United States, approximately 16% of adults are HSV-2 seropositive, but only 10% to 25% of persons with HSV-2 infections will have recognized genital herpes (Tronstein et al., 2011). **HSV-1 is now the leading cause of first-episode genital herpes in high-income countries, particularly in women and MSM younger than 25 years of age (**Johnston and Corey, 2016; Ryder et al., 2009). Although many persons may have mild or unrecognized infections, the virus is shed intermittently in the anogenital area. Shedding has been shown to occur on 10% of days, even among persons with asymptomatic HSV-2 infection (Tronstein et al., 2011). Transmission risk appears to be greatest during lesional recurrences or prodrome (Patel et al., 2017). All patients with genital herpes should be tested for HIV infection.

Pathophysiology of Genital Herpes

During primary infection, HSV-2 infects epithelial cells and then nerve endings followed by retrograde axonal transport to establish persistent infections in the sacral ganglia entering into a latent state. During reactivation, the virus travels down the axon to skin and mucosal surfaces, where viral shedding may be associated with genital ulcers, or more commonly, is asymptomatic (Johnston and Corey, 2016). **Periodic recurrence of genital, anal, or perianal ulcers are a hallmark of genital HSV infection, with a median of five recurrences in the first year after primary infection with genital HSV-2 and a median of one recurrence after infection with genital HSV-1** (Benedetti et al., 1999). After the first year of infection, the recurrence rate for HSV-2 decreases by a median of 2 recurrences per year, although recurrence rates may be highly variable (Johnston and Corey, 2016). Events that trigger HSV reactivation include local trauma such as surgery or ultraviolet light, immunosuppression, or fever (Gupta et al., 2007).

Presentation of Genital Herpes

Classic genital herpes can be recognized by the presence of a typical painful papular lesion progressing to vesicle (Fig. 58.2) and ulcer (Fig. 58.3) formation with local adenitis (Patel et al., 2017) that arises 4 to 7 days after exposure.

Many herpetic lesions do not have the classic appearance and can look like fissures and furuncles, and they can manifest as vulvar erythema in women (Koutsky et al., 1992). Primary genital HSV-1 cannot be distinguished from HSV-2 and requires serologic testing. Possible complications include aseptic meningitis and autonomic dysfunction that can lead to urinary retention (Corey et al., 1983). Recurrent cases are usually preceded by a prodromal lesion but then can have similar presentations as mentioned earlier.

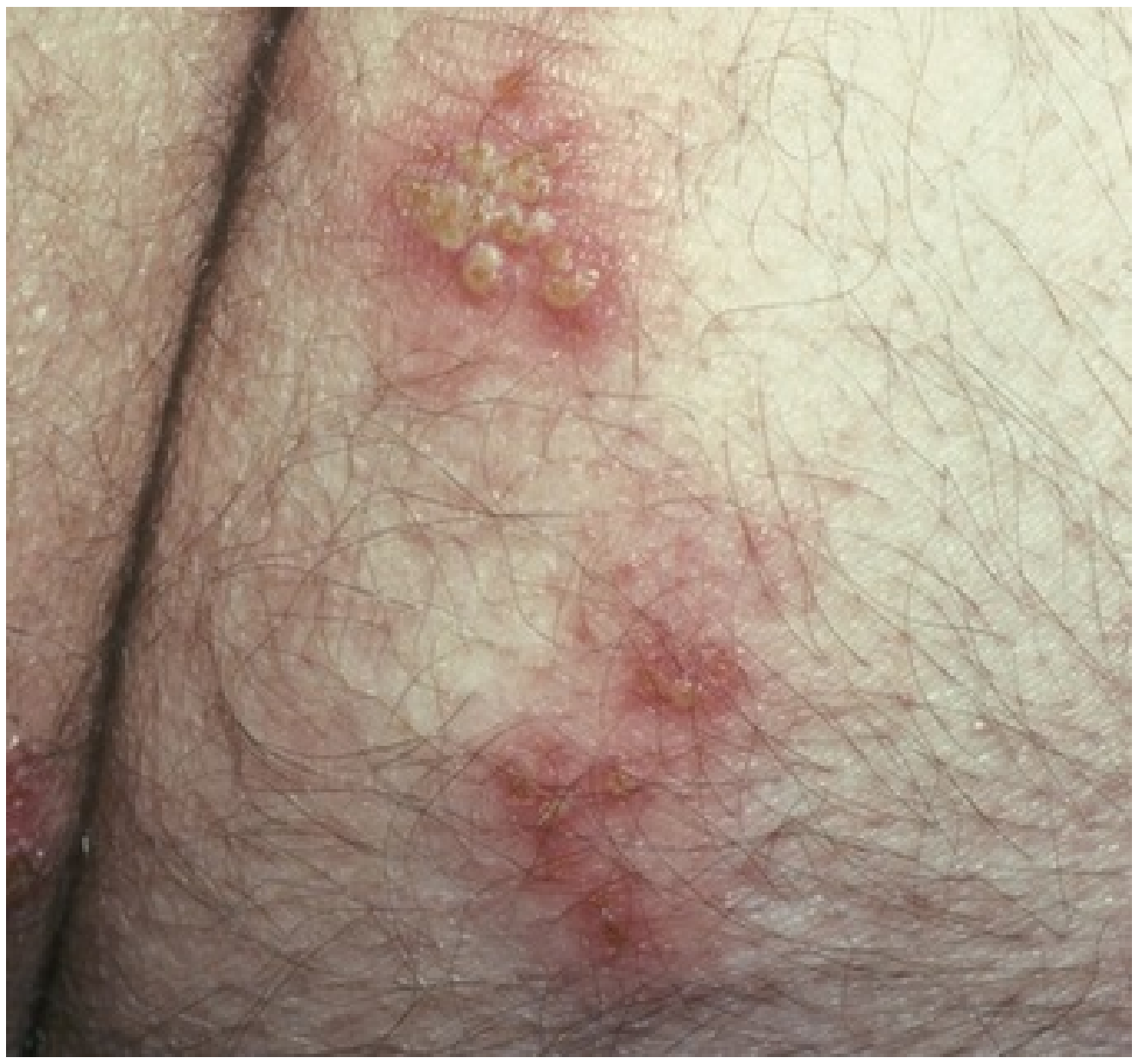

FIG. 58.2 Typical vesicular eruptions of herpes simplex virus.

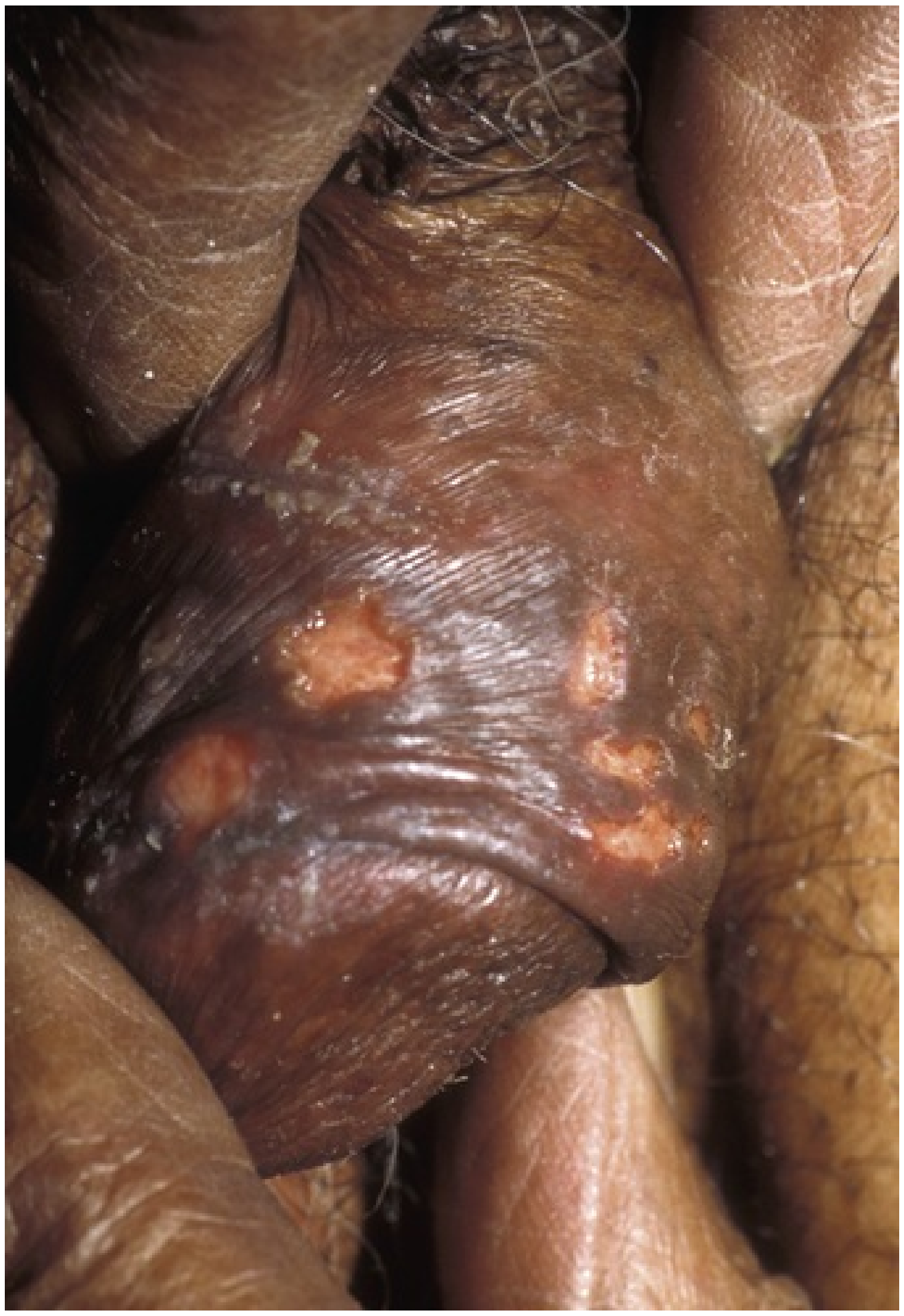

FIG. 58.3 Herpes simplex virus infection on the penis.

Diagnosis of Genital Herpes

Because the prognosis and the types of counseling needed depend on the type of genital herpes (HSV-1 or HSV-2), the clinical diagnosis of genital herpes should be confirmed by type-specific laboratory testing (Workowski, 2015). Cell culture and PCR are the preferred HSV testing and can be acquired from swabs from the base of genital ulcers. If needed, vesicles should be unroofed with a needle or scalpel blade (Gupta et al., 2007; Patel et al., 2017). Failure to detect HSC by culture or PCR, especially in the absence of active lesions, does not indicate an absence of HSV infection because viral shedding is intermittent (Workowski, 2015). Type-specific HSP serologic assays are useful in the following situations: (1) recurrent genital symptoms or atypical symptoms with negative HSV PCR or culture; (2) clinical diagnosis of herpes without laboratory confirmation; (3) a patient whose partner has genital herpes

(Workowski, 2015). Type-specific HSV serologic assays are based on the HS-specific glycoprotein GS2 (HSV-2) and glycoprotein GS1 (HSV-1) (Song et al., 2004). Repeat testing is indicated if recent acquisition of genital herpes is suspected (Workowski, 2015).

Treatment of Genital Herpes

Because of the potential for developing severe or prolonged symptoms, all patients with symptomatic first-episode genital herpes should receive antiviral therapy (Table 58.3) (Workowski, 2015).

TABLE 58.3

Recommended Treatment Regimens for First Clinical Episode of Genital Herpes[a]

Acyclovir 400 mg orally three times a day for 7–10 days
OR
Acyclovir 200 mg orally five times a day for 7–10 days
OR
Valacyclovir 1 g orally twice a day for 7–10 days
OR
Famciclovir 250 mg orally three times a day for 7–10 days

[a] Treatment can be extended if healing is incomplete after 10 days of therapy.

Data from Workowski KA, Bolan GA; Centers for Disease Control and Prevention. Sexually transmitted diseases treatment guidelines, 2015. *MMWR Recomm Rep.* 2015;64(RR-03):1–137.

Almost all persons with symptomatic first-episode genital HSV-2 infections will have recurrent episodes of genital lesions; recurrences are less frequent with HSV-1. Antiviral therapy for recurrent genital herpes can be administered either as suppressive therapy to reduce the frequency or recurrences or episodically to ameliorate the duration of lesions (Workowski, 2015). Suppressive therapy can also decrease the risk for genital HSV-2 transmission to susceptible partners (Romanowski et al., 2003; Corey et al., 2004). The 2015 CDC guideline recommendations for suppressive therapy for recurrent genital herpes can be found in Table 58.4, and recommendations for episodic therapy for recurrent genital herpes are in Table 58.5. Effective episodic treatment requires the initiation of therapy within 1 day of lesion onset or during the prodrome that precedes some outbreaks.

TABLE 58.4

Recommended Suppressive Treatment Regimens for Recurrent Genital Herpes

Acyclovir 400 mg orally twice a day

OR

Valacyclovir 500 mg orally once a day[a]

OR

Valacyclovir 1 g orally once a day

OR

Famciclovir 250 mg orally twice a day for 7–10 days

[a] Valacyclovir 500 mg once a day might be less effective than other valacyclovir or acyclovir regiments in patients who have frequent recurrences (≥10 per year).

Data from Workowski KA, Bolan GA; Centers for Disease Control and Prevention. Sexually transmitted diseases treatment guidelines, 2015. *MMWR Recomm Rep*. 2015;64(RR-03):1–137.

TABLE 58.5

Recommended Episodic Treatment Regimens for Recurrent Genital Herpes

Acyclovir 400 mg orally three times a day for 5 days

OR

Acyclovir 800 mg orally twice a day for 5 days

OR

Acyclovir 800 mg orally three times a day for 2 days

OR

Valacyclovir 500 mg orally twice a day for 3 days

OR

Valacyclovir 1 g orally once a day for 5 days

OR

Famciclovir 125 mg orally twice a day for 5 days

OR

Famciclovir 1 gram orally twice daily for 1 day

OR

Famciclovir 500 mg orally once followed by 250 mg twice daily for 2 days

Data from Workowski KA, Bolan GA; Centers for Disease Control and Prevention. Sexually transmitted diseases treatment guidelines, 2015. *MMWR Recomm Rep*. 2015;64(RR-03):1–137.

Counseling of infected persons and their sex partners is important in the management of genital herpes. A complete list of recommended topics can be found in the 2015 CDC guidelines (Workowski, 2015).

Syphilis

Syphilis is a systemic disease caused by *Treponema pallidum*, a coiled spiral spirochete bacterium, and is classified as acquired or congenital. The global burden of syphilis is high, with an estimated 10.6 million incident cases occurring annually (Stoltey and Cohen, 2015). **Syphilis rates are rising among MSM in the USA** (CDC, 2017). Acquired syphilis is usually caused by exposure during sexual contact (vaginal, anogenital, and orogenital) but rarely can be acquired through blood products, organ donation, and occupational exposures (Chambers et al., 1969; Perkins and Busch, 2010; Owusu-Ofori et al., 2011; Stoltey and Cohen, 2015). It is estimated that 50% to 60% of sexual contacts of individuals with early syphilis will acquire syphilis (Schober et al., 1983).

All patients who test positive for either primary or secondary syphilis should be tested for HIV infection. The incidence rate for syphilis in the HIV population has been reported as 77 times greater than that of the general population (Chesson et al., 2005). Syphilis is associated with HIV shedding in blood plasma (HIV concentrations can increase as much as 0.22 log values before syphilis treatment) and the genital tract (Kalichman et al., 2011, Workowski, 2015). Rarely, an unusual serologic response has been observed among patients with HIV infection who have syphilis. When clinical findings are suggestive or syphilis but serologic tests are nonreactive or unclear, alternative tests (biopsy, darkfield examination) can be considered (Workowski, 2015).

Primary Syphilis

The incubation period between contact and the development of a chancre is usually between 10 and 90 days. Primary syphilis is characterized by the development of an ulcer (chancre) usually with regional lymphadenopathy. **The chancre is usually painless, single, and indurated with a clean base discharging clear serum** (Figs. 58.4 and 58.5). Lesions are often atypical in appearance and may be multiple, deep, and indistinguishable from herpes (Rompalo et al., 2001a, 2001b; Hope-Rapp et al. 2010; Janier et al., 2014). Untreated lesions heal spontaneously in 3 to 8 weeks (Ho and Lukehart, 2011).

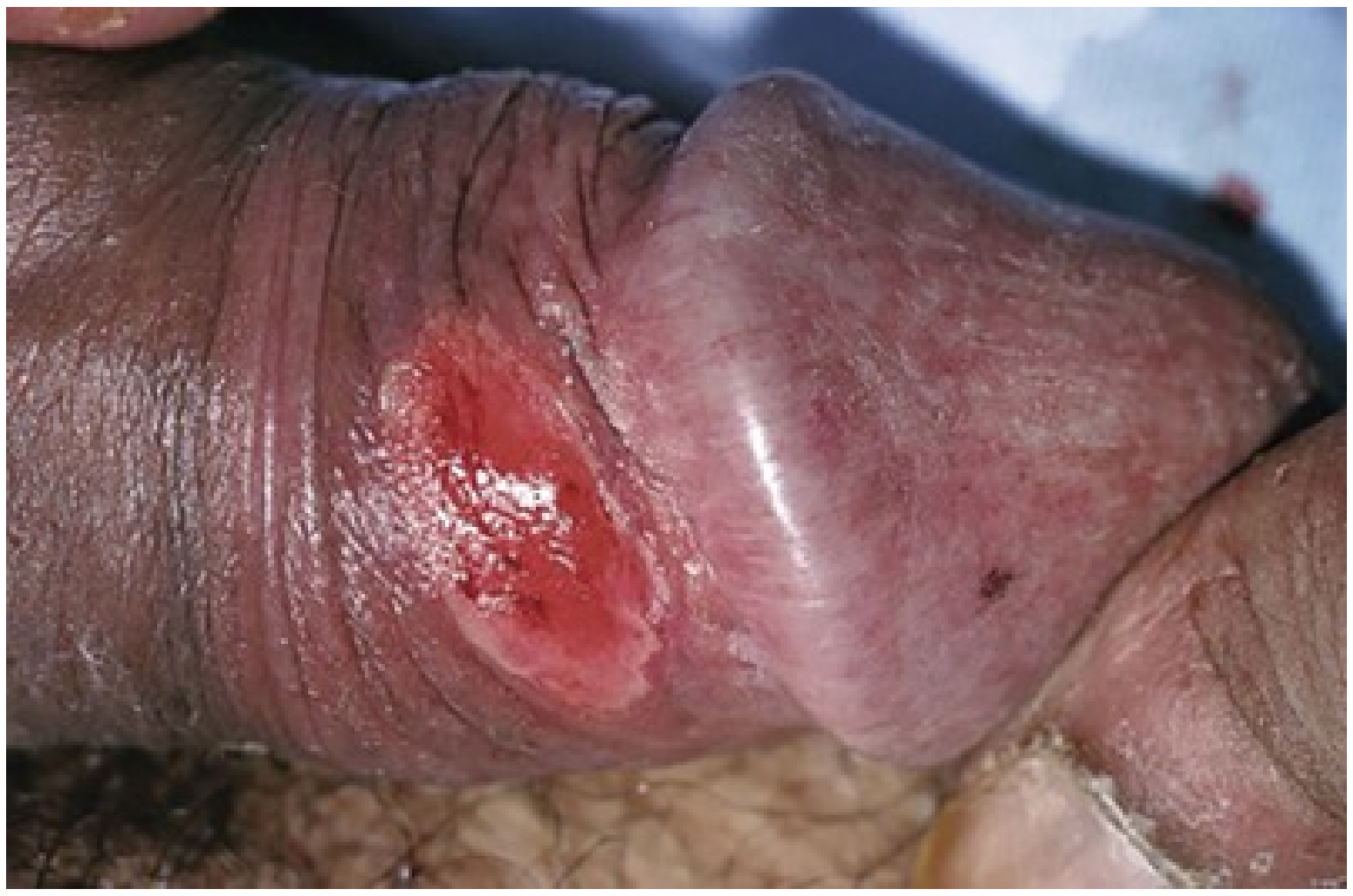

FIG. 58.4 Syphilis with penile chancre. (From James WD, Berger TG, Elston DM. Syphilis, yaws, bejel and pinta. In: *Andrews' diseases of the skin: clinical dermatology,* 12th ed. Philadelphia, PA: Elsevier; 2016:345).

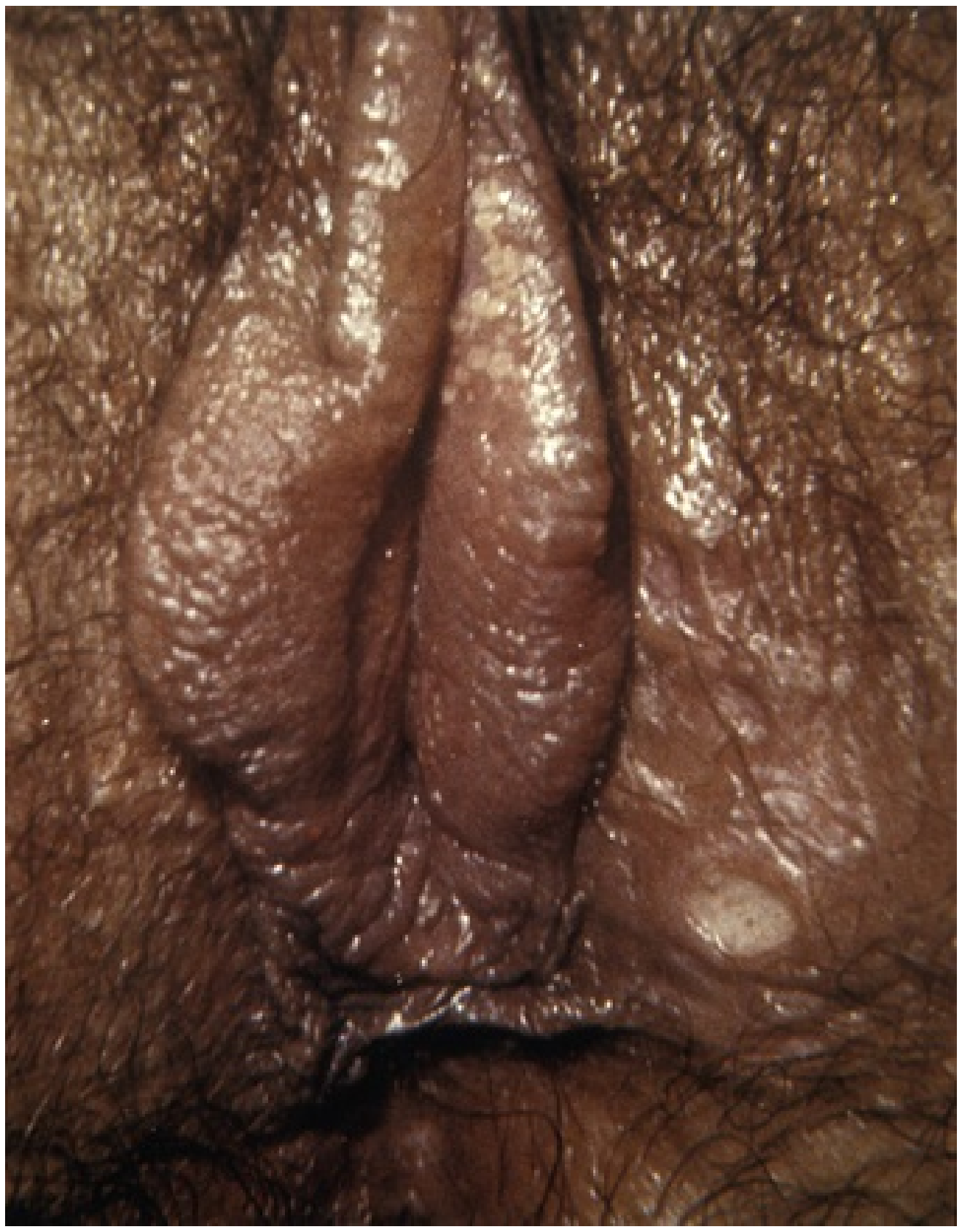

FIG. 58.5 Syphilis with vulvar chancre.

Secondary Syphilis

Secondary syphilis arises from the development of bacteremia that usually occurs 3 to 5 months after the initial infection. **It is characterized by a maculopapular rash (Fig. 58.6) involving the palms of the hands and soles of the feet (usually does not itch) and mucous membrane lesions involving the vagina or anus.** The rash can ulcerate and lead to condyloma lata (large, raised gray or white lesions). Additional symptoms include fever, lymphadenopathy, alopecia, and weight loss (CDC, 2017a). There is also a broad vasculitis that, in approximately 10% of patients, may lead to manifestations such as hepatitis, iritis, nephritis, and neurologic problems including headache and cranial nerve involvement (VIII, auditory) (Mindel et al., 1989). The neurologic sequelae should be individualized as early neurosyphilis (Janier et al., 2014).

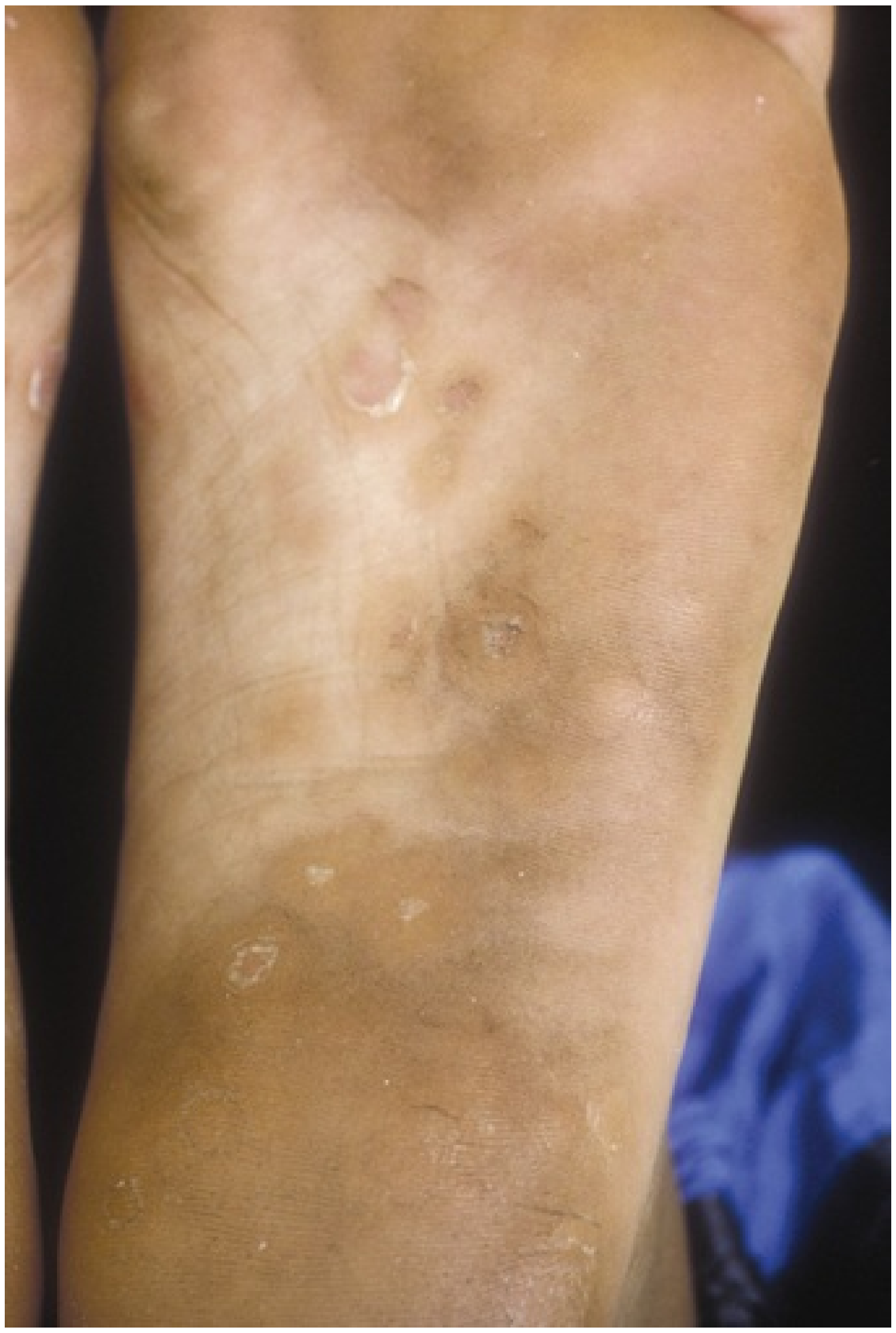

FIG. 58.6 Secondary syphilis affecting the soles of the feet.

Latent Syphilis

Latent syphilis is defined as seroreactivity with no clinical evidence of disease and is broken up into early versus late latent syphilis. Early latent syphilis includes patients with a positive serologic test for syphilis, preceded by a negative serology test within 1 year or recent contact with an infected person. All other cases of latent syphilis is defined as late latent syphilis or syphilis of unknown duration (Workowski, 2015).

Tertiary Syphilis

About 35% of individuals with late latent syphilis will develop the late manifestations of syphilis, which include neurosyphilis, cardiovascular

syphilis, and gummatous syphilis. These are rare outside of developing countries. Neurosyphilis can be seen in secondary syphilis, and meningovascular syphilis also occurs in tertiary syphilis. The incubation period is usually 5 to 12 years. After 10 to 20 years, the spinal column and brain can also be involved. The spinal cord syndrome is called *tabes dorsalis,* and the brain syndrome is called *general paralysis of the insane* (Danielsen et al., 2004; French, 2007). Cardiovascular syphilis occurs 15 to 30 years after infection and may occur in any large vessel (French, 2007).

Diagnosis of Syphilis

Darkfield Examination

Cultures for *T. pallidum* are not possible in vitro. A darkfield examination to detect *T. pallidum* directly from lesion exudate or tissue is the definitive method for diagnosing early syphilis. It is very cumbersome and is not widely utilized (Workowski, 2015).

Serology

A presumptive diagnosis of syphilis requires the use of two tests: a nontreponemal test and a treponemal test. Use of only one serology test is insufficient as it can result in false-negative results in patients tested during primary syphilis and false-positive results in patients without syphilis.

Nontreponemal Tests

Nontreponemal tests (NTTs) identify nontreponemal antibodies that bind lipids that have bound to the treponeme and become antigenic (Lafond and Lukehart, 2006). NTTs become positive 10 to 15 days after the beginning of the primary chancre. Nontreponemal tests include Venereal Disease Research Laboratory (VDRL) or rapid plasma reagin (RPR) (Janier et al., 2014). False-positive NTT results can be caused by other infections (HIV), autoimmune conditions, immunizations, pregnancy, drug use, and old age. **All persons with a reactive NTT should always receive a confirmatory treponemal test** (Workowski, 2015).

Nontreponemal test antibody titers might correlate with disease activity and can be used to follow treatment response. A fourfold change in titer, equivalent to a change of two dilutions (e.g., from 1:16 to 1:4 or from 1:8 to

1:32) is required to demonstrate a clinically significant difference between two NTTs. Sequential serologic tests in individual patients should be performed using the same NTT (Workowski, 2015). NTT titers usually decline after treatment and may become nonreactive with time. Some treponemal antibodies can persist for a long period (serofast) (Workowski, 2015).

Treponemal Tests

Treponemal antibodies are detected by immunofluorescence in the fluorescent treponemal antibody absorption test (FTA-ABS), the *T. pallidum* particle agglutination test (TP-PA), various enzyme immunoassays (EIAs), chemiluminescence immunoassays, immunoblots, or rapid treponemal assays (Workowski, 2015). False-positive results are uncommon but can occur in patients with collagen disease, lupus, and other infections (Hart, 1986). **Most patients who have a reactive treponemal test (TT) will have reactive tests for the remainder of their lives regardless of treatment or disease activity.** Fifteen percent to 25% of patients treated in the primary stage revert to nonreactive after 2 to 3 years (Romanowski et al., 1991; Workowski, 2015). Rapid syphilis tests including the enzyme-linked immunosorbent assay (ELISA) are available and approved by the FDA. These can give results in 5 to 10 minutes but cannot distinguish between active and treated syphilis. A reverse screening algorithm utilizes this rapid test as a screen and if positive, a reflexive NTT is performed. If the NTT is negative, a second TT should be performed (preferably one based on different antigens than the original). If the second TT is positive, persons with a history of previous treatment need no further management unless sexual history suggests re-exposure. In this instance, a repeat NTT is recommended in 2 to 4 weeks. Those without a history of treatment and a positive second TT should be offered treatment for latent syphilis. If the second TT is negative and risk factors are low, further evaluation is not indicated (Workowski, 2015).

Treatment for Syphilis

Intravenous penicillin G is the preferred drug for treating all stages of syphilis. The preparation used, dosage, and duration of treatment will depend on the stage and clinical manifestation of the disease. Treatment guidelines from the CDC for adults with syphilis are detailed in Table 58.6 (Workowski, 2015). **Combinations of different penicillin G preparations are not appropriate for**

the treatment of syphilis. Patients should be informed of the possibility for a Jarisch-Herxheimer reaction with the first 24 hours after initiation of treatment. This is an acute febrile reaction accompanied by headache, myalgia, and other symptoms that most commonly happens among persons who have early syphilis, presumably because of higher bacterial burdens. Patients should be counseled that this is not an allergic reaction to penicillin but a reaction to the treatment of treponemes. Treatment is conservative with nonsteroidal anti-inflammatory drugs (Workowski, 2015).

TABLE 58.6

Treatment of Syphilis

STAGE OF SYPHILIS	PENICILLIN TREATMENT	PENICILLIN-ALLERGIC PATIENTS
Primary, secondary, and early latent syphilis with no neurologic involvement	Benzathine penicillin G 2.4 million units IM, single dose	Doxycycline 100 mg PO bid for 14 days Tetracycline 500 mg PO qid for 14 days
Late latent or latent syphilis of unknown duration with no neurologic involvement	Benzathine penicillin G 2.4 million units IM once a week for 3 weeks	Doxycycline 100 mg PO bid for 28 days Tetracycline 500 mg PO qid for 28 days
Tertiary (late) syphilis with no neurologic involvement	Benzathine penicillin G 2.4 million units IM once per week for 3 weeks	Consult infectious disease specialist
Neurosyphilis Alternative regimen	Aqueous crystalline penicillin G 3–4 million units IV q4h or continuous IV infusion for total 18–24 million units per day, both for 10–14 days Procaine penicillin 2.4 million units IM daily plus probenecid 500 mg PO qid,	

	both for 10–14 days	

bid, Twice daily; *IM,* intramuscular; *IV,* intravenously; *PO,* per os (orally); *q4h,* every 4 hours; *qid,* four times daily.

From Workowski KA, Bolan GA; Centers for Disease Control and Prevention. Sexually transmitted diseases treatment guidelines, 2015. *MMWR Recomm Rep.* 2015;64(RR-03):1–137.

Clinical and serologic evaluation should be performed at 6 and 12 months. **Patients who have signs or symptoms that persist or recur and those with at least a fourfold increase in nontreponemal test titer persisting for longer than 2 weeks likely are either treatment failures or were reinfected.** These patients should be retreated and re-evaluated for HIV, and CSF examination can be considered. Retreatment consists of weekly injections of benzathine penicillin G 2.4 million units IM for 3 weeks unless neurosyphilis is diagnosed (Workowski, 2015).

Chancroid

Chancroid is caused by the gram-negative bacillis *Haemophilus ducreyi* (Albritton, 1989). *H. ducreyi* is usually spread through sexual intercourse, and it is believed that microabrasions are required to be present before infection can be established in the genital epithelium and underlying tissue (Morse, 1989; Lewis, 2003). Currently in the United States, chancroid is restricted to rare sporadic cases, although it remains endemic in North India and Malawi (Gonzalez-Beiras et al., 2016; Lautenschlager et al., 2017). Chancroid is more prevalent among individuals from lower socioeconomic groups, female commercial sex workers and their male partners, and uncircumcised men. Chancroid is a risk factor for HIV transmission (Lewis, 2003).

Chancroid initially starts as tender erythematous papules, most often on the prepuce and frenulum in men and on the vulva, cervix, and perianal area in women. The papules quickly progress into pustules that rupture after a few days and develop into superficial ulcers with ragged and undetermined edges (Fig. 58.7). The incubation period is usually 3 to 7 days. Inguinal lymphadenitis, usually unilateral and painful, develops in approximately 50% of patients, which may progress into fluctuant buboes that may spontaneously rupture (Lautenschlager et al., 2017).

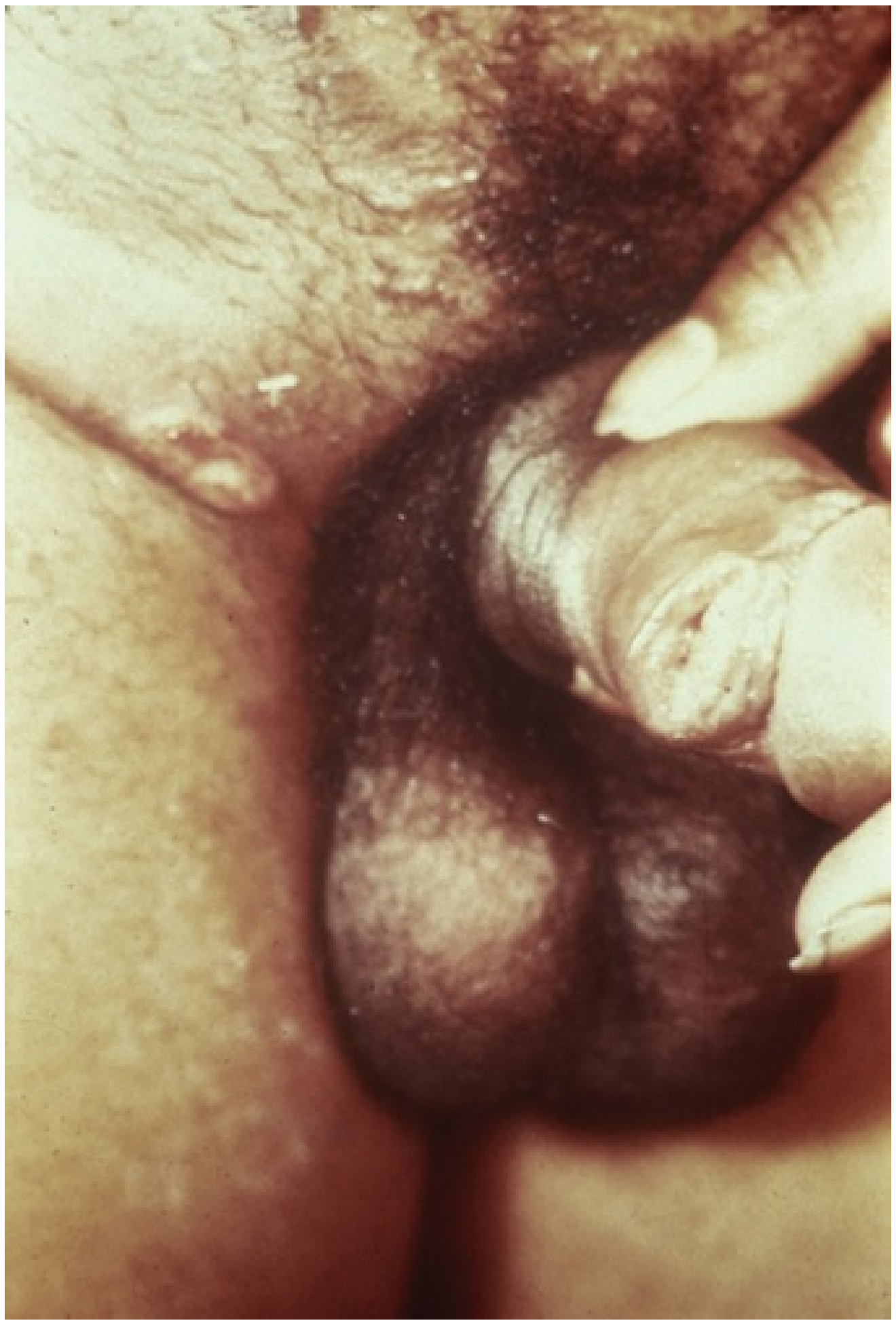

FIG. 58.7 Chancroid with regional lymphadenopathy.

A definitive diagnosis of chancroid requires identification of *H. ducreyi* on a special culture medium that is not widely available. Although no FDA-cleared PCA test for *H. ducreyi* is available in the United States, testing can be performed by laboratories that have developed their own PCR test and have conducted clinical laboratory improvement amendments (CLIA) verification studies (Workowski, 2015). **For both clinical and surveillance purposes, the diagnosis of chancroid can be made if the following criteria are met: (1) the patient has one or more painful genital ulcers; (2) the clinical presentation, appearance of genital ulcers and, if present, regional lymphadenopathy are typical for chancroid; (3) the patient has no evidence for *T. pallidum* infection by either darkfield examination of ulcer exudate or serologic testing for syphilis performed at least 7 days after onset of ulcers; and (4) an HSV PCR test or HSV culture performed on the ulcer exudate is negative** (Workowski, 2015)**.**

Treatment is with any *one* of the following options: azithromycin 1 g orally in a single dose, ceftriaxone 250 mg intramuscularly in a single dose, ciprofloxacin 500 mg orally twice a day for 3 days, or erythromycin base 500 mg orally three times a day for 7 days. Patients should be tested for HIV at the time of diagnosis and if negative, testing for syphilis and HIV should be repeated in 3 months. Patients with HIV or those who are uncircumcised do not respond as well to treatment and may require a prolonged course (Workowski, 2015). Patients with fluctuant buboes may require treatment in the form of either needle aspiration or incision and drainage (Lautenschlager et al., 2017).

Granuloma Inguinale (Donovanosis)

Granuloma inguinale is a genital ulcerative disease caused by the intracellular gram-negative bacterium *Klebsiella granulomatis* (formerly *Calymmatobacterium granulomatis)* (Carter et al., 1999). It occurs rarely in the United States, although cases are still reported from Papua New Guinea, South Africa, India, Brazil, and Australia (Velho et al., 2008; O'Farrell and Moi, 2016). The incubation period is approximately 50 days, after which papules develop into ulcers that gradually increase in size. These are usually painless, slowly progressive ulcerative lesions on the genitals or perineum without regional lymphadenopathy. Despite the name, only 10% of cases involve the inguinal region. The lesions are highly vascular (beefy red appearance) and tend to bleed easily (Fig. 58.8) (Workowski, 2015). The most common site of extragenital spread is the mouth, but it can also occur in the pelvis, intra-abdominal organs, and other bones (Velho et al., 2008). All patients who receive a diagnosis of granuloma inguinale should be tested for HIV (Workowski, 2015).

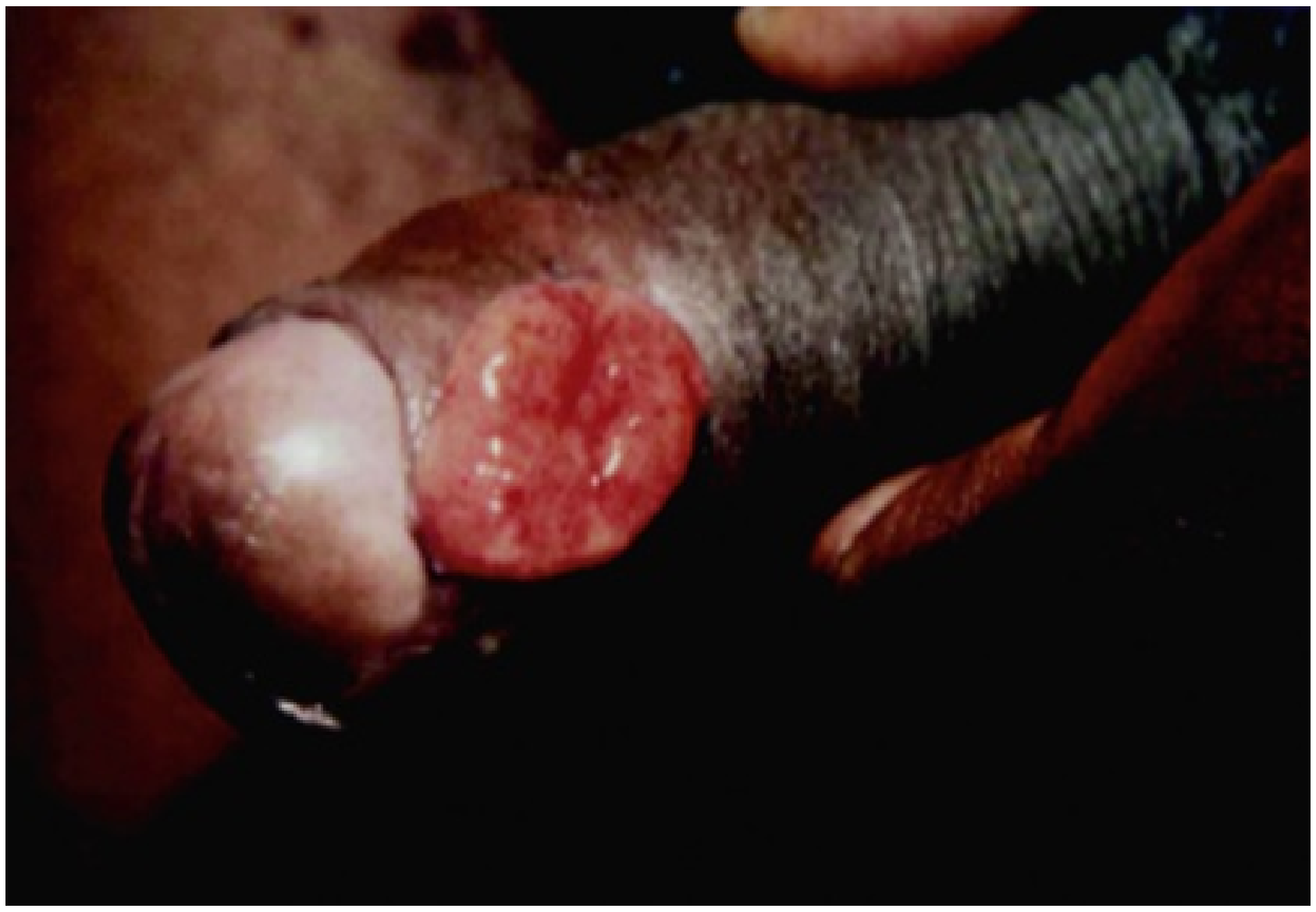

FIG. 58.8 Lymphogranuloma venereum (donovanosis) lesion on the penis. (From O'Farrell N. Donovanosis. *Sex Transm Infect.* 2002;78:452–457.).

There are no FDA-cleared molecular tests for the detection of *K. granulomatis*. Diagnosis requires visualization of dark-staining Donovan bodies on tissue crush preparation of biopsy (Workowski, 2015). The recommended treatment is azithromycin 1 g orally weekly or 500 mg daily for at least 3 weeks and until all lesions are completely healed. Alternative agents may be found in the CDC guidelines (Workowski, 2015). Squamous cell carcinoma of the penis may mimic granuloma inguinale and, as such, a biopsy should be done if antibiotics fail to resolve ulcers (O'Farrell and Moi, 2016).

Lymphogranuloma Venereum

C. trachomatis is an obligate intercellular pathogen. It's fifteen serovars can be classified into three groups based on type of infection; trachoma (serovars A, B, Ba, and C), anogenital infections (serovars D and K), and lymphogranuloma venereum (LGV; serovars L1, L2, and L3) (Schachter et al., 2008; Stamm, 2008). In Western countries, the incidence of LGV has been increasing since 2003, primarily among HIV men who have sex with men (Ronn et al., 2014). LGV symptoms are classically divided into three stages: local infection (primary stage), regional dissemination (second stage), and progressive tissue damage (tertiary stage). Although often asymptomatic, a self-limited genital ulcer or papule develops about 3 to 30 days after inoculation. Direct rectal inoculation can result in proctitis with rectal bleeding, rectal pain, tenesmus, constipation, or hemopurulent rectal discharge (Workowski, 2015; O'Byrne et al., 2016). About 2 to 6 weeks after the primary lesion appears, regional tissue invasion occurs with constitutional symptoms (i.e., fever, chills, malaise, myalgia). With penile, urethral, or vulvar inoculation, inguinal syndrome occurs characterized by unilateral, painful inguinal or femoral lymphadenopathy known as buboes (Fig. 58.9) (O'Byrne et al., 2016). Inguinal nodes are more common in men because the lymph drainage of the cervix and vagina are to the retroperitoneal rather than inguinal nodes (Mabey and Peeling, 2002). If left untreated, LGV can lead to irreversible tissue destruction and scarring resulting in regional lymphedema and genital elephantiasis. In cases of rectal involvement, perirectal abscesses, anal fissures, and strictures can form (Workowski, 2015; O'Byrne et al., 2016). LGV does not appear to occur more frequently or with more virulence in HIV-positive individuals (Jebbari et al., 2007).

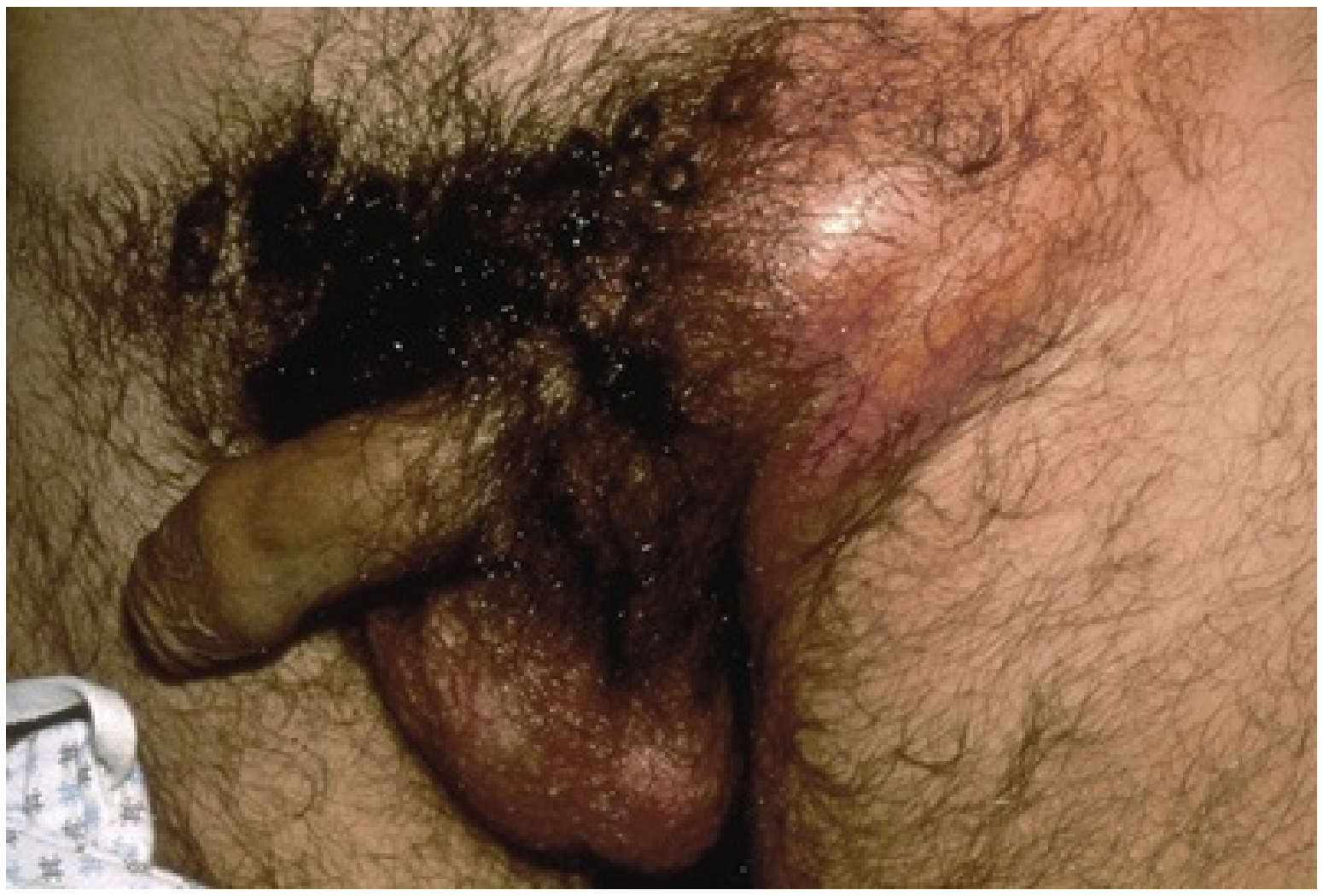

FIG. 58.9 Lymphogranuloma venereum with inguinal adenopathy.

Diagnosis is based on clinical suspicion, epidemiologic information, and the exclusion of other etiologies. Genital lesions, rectal specimens, and lymph node specimens can be tested for *C. trachomatis* by culture, direct immunofluorescence, or NAAT. Although NAATs for *C. trachomatis* detection from a rectal sample are not FDA-cleared for this purpose, many laboratories have performed CLIA validation studies needed and as such NAAT performed on rectal specimens is the preferred approach for testing. Chlamydia serology (complement fixation titers greater than or equal to 1:64 or microimmunofluorescence titers >1:256) might support the diagnosis of LGV in the appropriate clinical context (Workowski, 2015).

Recommended treatment is doxycycline 100 mg orally twice a day for 21 days. An alternative regimen is erythromycin base 500 mg orally four times a day for 21 days (Workowski, 2015). Recently, studies have evaluated the use of a 7-day course of doxycycline with excellent cure rates (Simons et al., 2018). As of now, however, the CDC guidelines still recommend a 21-day course of doxycycline. Patients who test positive for LGV should be screened for other STDs, especially HIV, gonorrhea, and syphilis.

Molluscum Contagiosum

Molluscum infection is a benign epidermal eruption of the skin caused by molluscum contagiosum, a large double-stranded DNA virus (Myskowski, 1997). Four serotypes of molluscum contagiosum have been identified, molluscum contagiosum virus (MCV)-1 followed by MCV-2. MCV-2 appears relatively common in the setting of immunocompromise and HIV (Fernando et al., 2015). **As an STD, molluscum infection usually affects young adults and appears to be increasing in frequency** (Villa et al., 2010). Sexually transmitted molluscum lesions usually affect the genitals, pubic region, lower abdomen, upper thigh, and/or buttocks.

Molluscum lesions present as smooth-surfaced, firm, dome-shaped papules with central umbilication. Lesions are usually 2 to 5 mm, and patients commonly have 1 to 30 lesions that are usually asymptomatic (Fig. 58.10). **Molluscum infection will usually spontaneously regress in 6 to 12 months in the immunocompetent individual with no sequelae** (Villa et al., 2010). Infections can be much more severe and extensive in immunocompromised patients, namely those with HIV. Molluscom infection in immunocompromised persons can be much more aggressive and widespread, presenting with 100 or more lesions and progressive as confluent, coalescing large lesions (Schwartz and Myskowski, 1992; Brown et al., 2000; Trope and Lenzi, 2005; Nakamura-Wakatsuki et al., 2011).

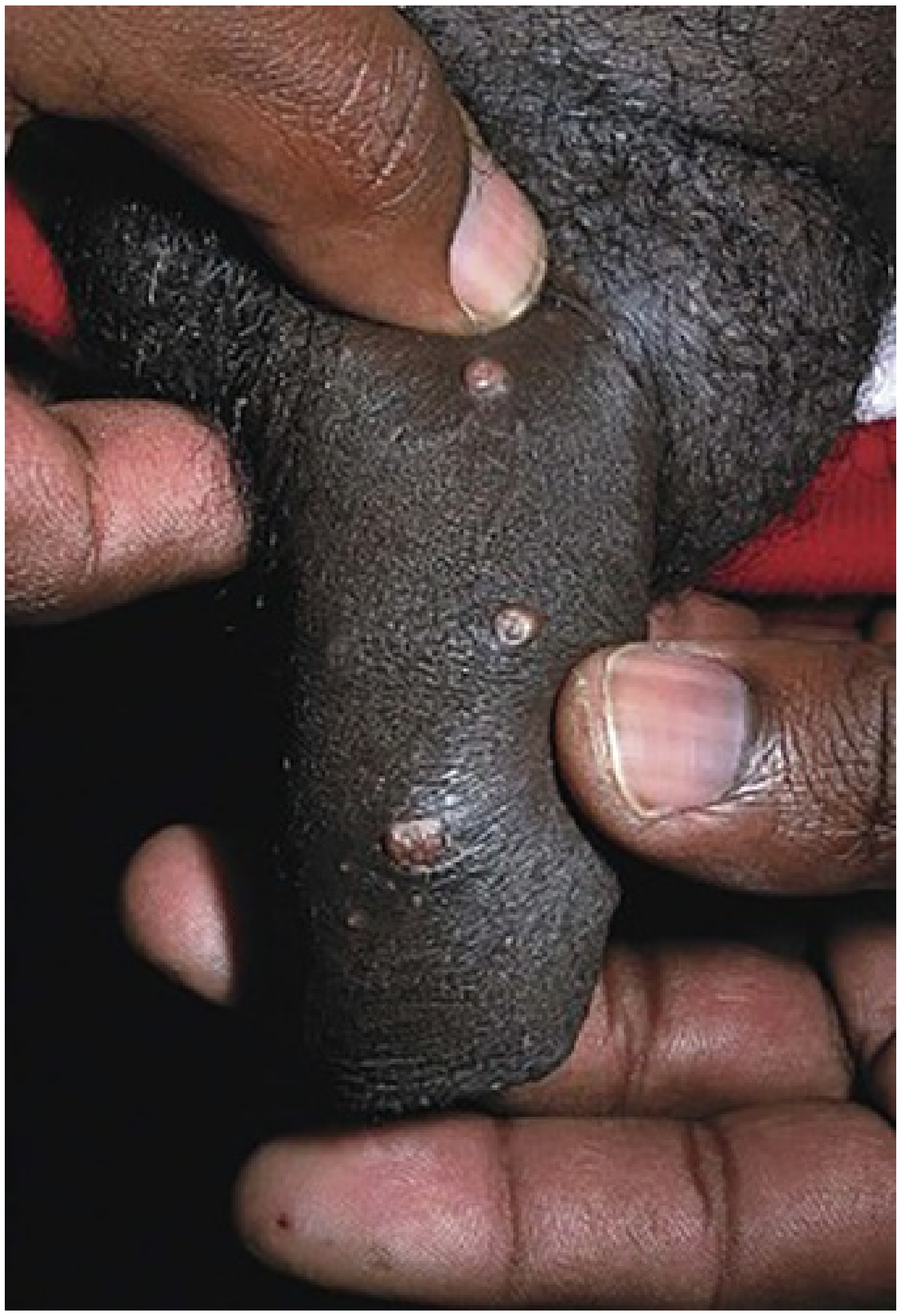

FIG. 58.10 Molluscum contagiosum on the penis. (From James WD, Berger TG, Elston DM. Viral diseases. In*: Andrews' diseases of the skin: clinical dermatology,* 12th ed. Philadelphia, PA: Elsevier; 2016:389).

Diagnosis is predominantly clinical on the basis of characteristic lesions. Biopsy is indicated in cases of atypical presentations in which malignancy must be excluded (Trope and Lenzi, 2005).

Expectant management (no treatment) is an option for immunocompetent patients. Patients should be warned of the risk for autoinoculation and advised against shaving or waxing the genitals to prevent further spread. Towels, bed linen, clothes, and so on should not be shared when active lesions are present (Fernando et al., 2015). For those seeking treatment, multiple options exist including cryotherapy, curettage, light emitting, and pulse dye lasers. Topical therapies include 0.5% podophyllotoxin (avoid in pregnancy), 5% imiquimod cream (avoid in pregnancy), and multiple other chemical preparations. For patients with HIV, the first treatment should be HAART as a low CD4 count is inversely proportional with the number of molluscum lesions, and lesions have been shown to regress after initiation of HAART in some cases (Myskowski 1997; Fernando et al., 2015).

Anogenital Warts

Human Papillomavirus

Human papillomaviruses (HPVs) are a small group of nonenveloped, double-stranded DNA viruses belonging to the *Papillomaviridae* family. To date, more than 170 types of HPV have been identified, one-half of which affect the genital tract (Boda et al., 2018). **High-risk mucosal HPV types, predominantly 16, 18, 31, 33, and 35, have been associated with most cervical, penile, vulvar, vaginal, anal, and oropharyngeal cancers and precancers.** HPV 16 and 18 are the most common high-risk types and are considered to be responsible for greater than 70% of all cervical cancer cases (Clifford et al., 2003; Boda et al., 2018). **HSV 6 and 11 are nononcogenic and are responsible for about 90% or anogenital warts** (Garland et al., 2009). HPV infections are often asymptomatic and unrecognized, and the majority of sexually active persons become infected with HPV at least once in their lifetime (Myers et al., 2000). Oncogenic high-risk HPV strains have the strongest contribution to the occurrences of precancerous and cancerous lesions (Stokley et al., 2014). In 2009, there were an estimated 34,788 new HPV-associated cancers and 355,000 new cases of anogenital warts (Chesson et al., 2012; Jemal et al., 2013; Patel et al., 2013).

Presentation and Diagnostic Considerations

Anogenital warts (condylomata acuminatum) are usually asymptomatic, but depending on the size and location, they can be painful or pruritic. The warts are usually flat, papular, or pedunculated growths (Fig. 58.11). They occur commonly at certain anatomic sites, including the vaginal introitus, under the foreskin of an uncircumcised penis, and on the shaft of a circumcised penis, although they may be seen at multiple sites in the anogenital epithelium or within the anogenital tract, such as the cervix, vagina, urethra (Fig. 58.12), perineum, perianal skin, anus, and scrotum (Workowski, 2015). Bowenoid papulosis is characterized by flat, often hyperpigmented papules a few millimeters to several centimeters in diameter. These occur singly or, more often, may be found in multiples on the penis, near the vulva, or perianally. Bowenoid papulosis is now called HSIL (high-grade squamous intraepithelial lesion) and is usually caused by HPV-16. Giant condyloma acuminatum is a rare, aggressive, wartlike growth that is a verrucous carcinoma. Unlike other HPV-induced genital carcinomas, this tumor is usually caused by HPV-6. It occurs most often on the glans or prepuce of an uncircumcised male; less often, it may occur on perianal skin or the vulva. Despite its bland histologic picture, it may invade deeply, and infrequently it may metastasize to regional lymph nodes (James and Elston, 2016).

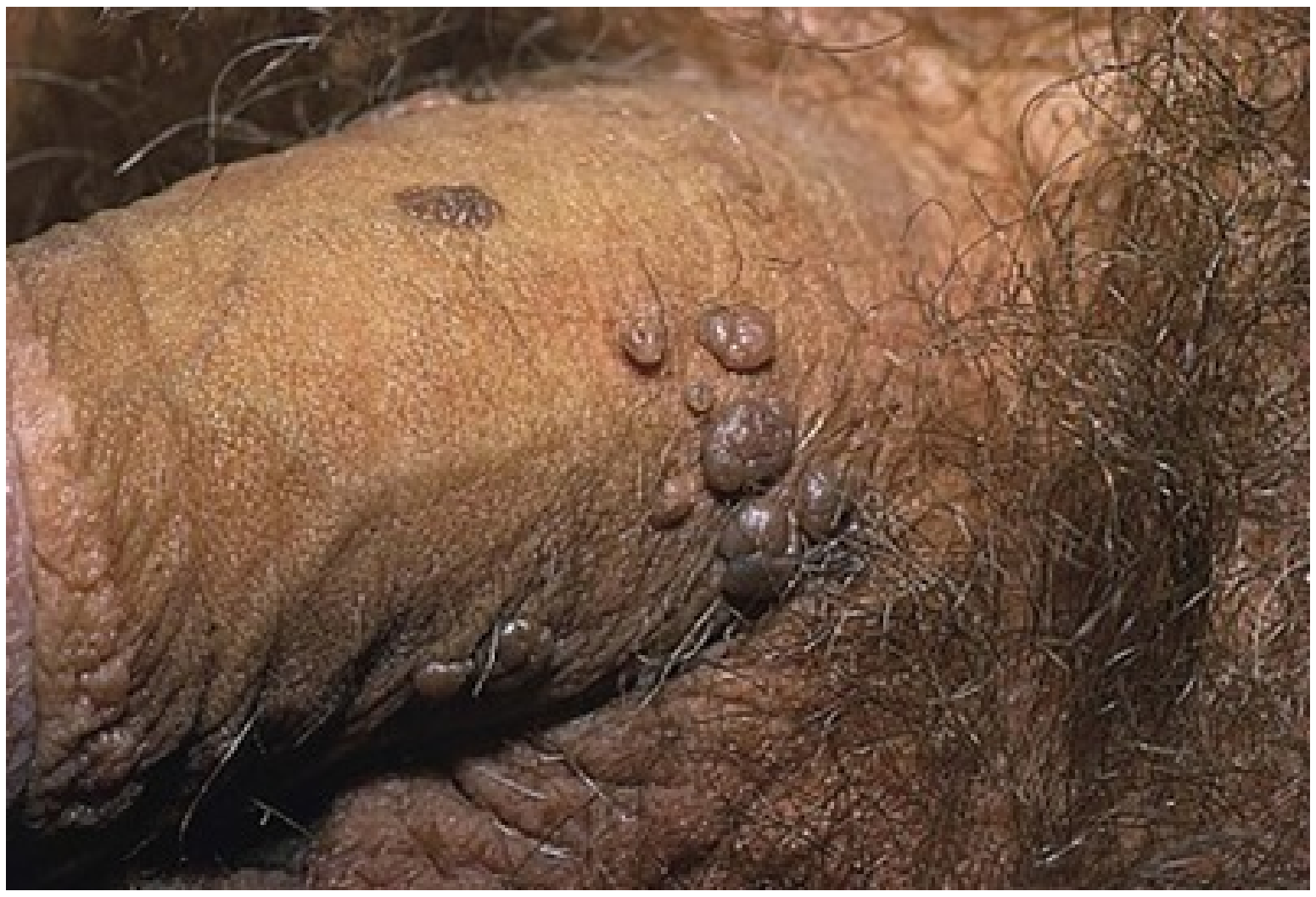

FIG. 58.11 Penile warts (Condylomata acuminata) caused by human papillomavirus. (From James WD, Berger TG, Elston DM. Viral diseases. In: *Andrews' diseases of the skin: clinical dermatology,* 12th ed. Philadelphia, PA: Elsevier; 2016:405).

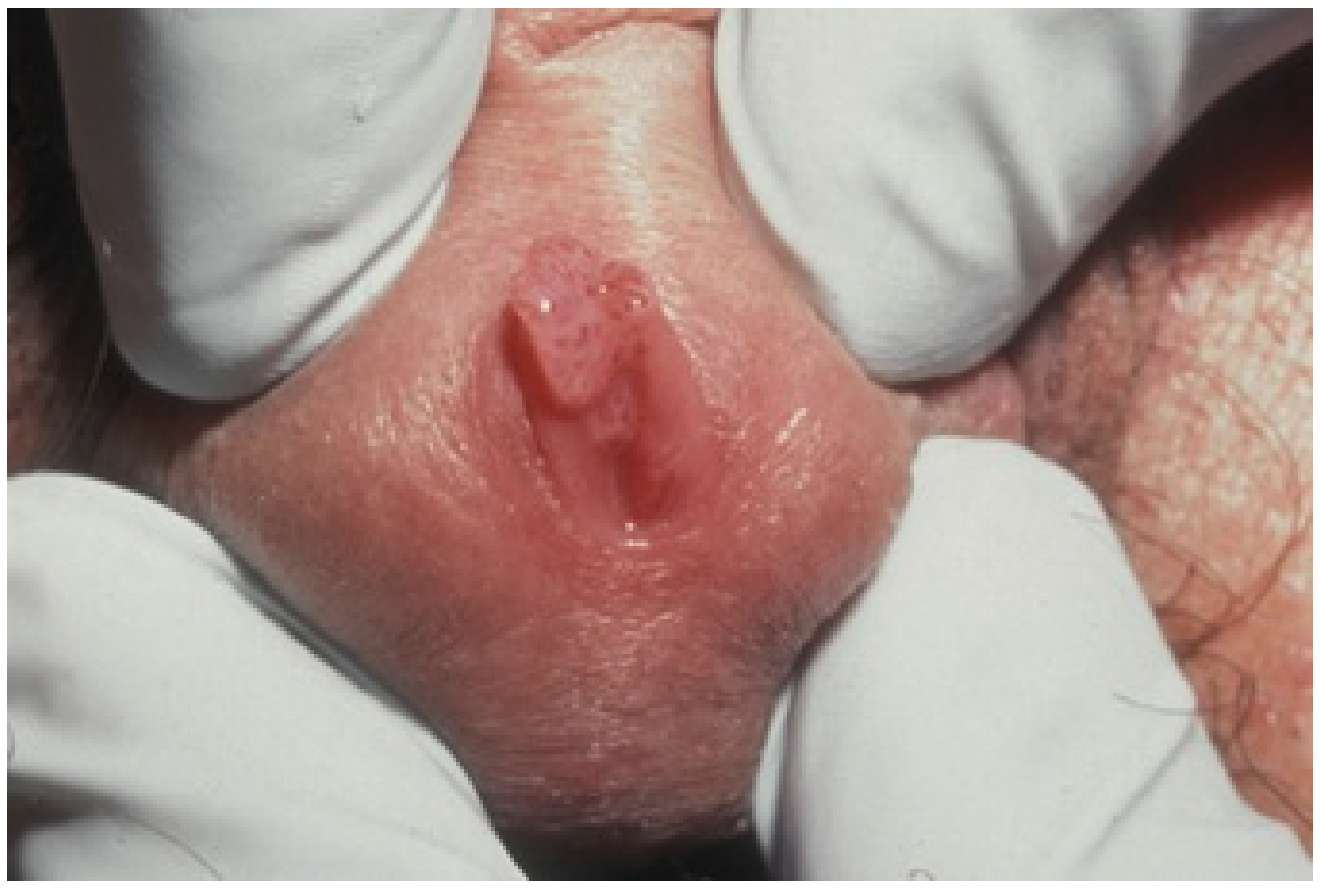

FIG. 58.12 Meatal wart caused by human papillomavirus.

The diagnosis of anogenital warts is usually made by clinical examination. Although HPV tests are available to detect oncogenic types of HPV, the tests should not be used for male partners of women with HPV or women younger than 25 years of age for diagnosis of genital warts or as a general STD test (Workowski, 2015). The use of 3% to 5% acetic acid to visualize potentially affected areas is not recommended. **Biopsy may be indicated in the following conditions: (1) the diagnosis is uncertain; (2) the lesions do not respond to standard therapy; (3) the disease worsens during therapy; (4) the patient is immunocompromised; (5) the warts are pigmented, indurated, or affixed to underlying tissue; or (6) there is persistent ulceration or bleeding** (Workowski, 2015).

Treatment of Anogenital Warts

The main goal of treatment is removal of the wart and improvement in associated symptoms. Some warts may spontaneously resolve within 1 year, and, as such, some patients may opt for observation. **Wart size, number, anatomic location, patient preference, cost, and potential adverse effects should guide treatment.** Treatment regimens are divided into patient-applied and provider-applied options (Workowski, 2015).

Patient-applied treatments for HPV are as follows:

- Imiquimod cream 3.75% applied once daily at bedtime for up to 16 weeks; should be washed off 6 to 10 hours after application
- Imiquimod cream 5% applied daily at bedtime three times a week for up to 16 weeks; should be washed off 6 to 10 hours after application
- Podofilox 0.5% solution or gel up to 0.5 mL/day, applied twice a day for 3 days, then no therapy for 4 days, up to four cycles. Total wart area should not exceed 10 cm^2.
- Sinecatechins 15% ointment three times per day for up to 16 weeks. This should not be washed off after application.

Provider-administered treatments for HPV are as follows:

- Cryotherapy such as liquid nitrogen, which induces cytolysis.

Application can be repeated every 1 to 2 weeks. Large warts may need local anesthesia because of possible pain with application.

- Surgical therapy including direct excision with scissors, tangential shave excision, curettage, or laser therapy using a CO_2 laser. Consider collaboration with a plastic surgeon for large lesions that require large areas of excision, especially on the penis or in the groin creases. Should be performed in an appropriately ventilated room using standard precautions and local exhaust ventilation (CDC, 1999; Siegel et al., 2007, updated 2017).
- Trichloroacetic acid (TCA) or bichloroacetic acid (BCA) 80% to 90%; these acids destroy warts by chemical coagulation of wart proteins. Apply to wart, and allow to dry before patient stands up; if intense pain ensues after administration, neutralize the acid with soap and water or sodium bicarbonate. Can be repeated weekly.

Imiquimod stimulates production of interferon and other cytokines, and, as a result, its use can result in local inflammatory reactions (redness, irritation, induration, ulceration, or vesicle formation) and hypopigmentation (Mashiah and Brenner, 2008; Workowski, 2015). There are limited data on the use of imiquimod in pregnancy, although animal data suggests that it may pose low risk (Ciavattini et al., 2012; Workowski, 2015). **Both the 3.75% and 5% imiquimod cream can weaken condoms and vaginal diaphragms.**

Podofilox (podophyllotoxin) is an antimitotic drug that causes wart necrosis. It is recommended that providers apply the initial treatment to demonstrate proper application technique. **Podofilox use is contraindicated in pregnancy** (Workowski, 2015).

Sinecatechins contains the green tea extract catechins, which exhibit specific antioxidant, antiviral, antitumor, and immunostimulatory properties (Tzellos et al., 2011). Genital, anal, and oral sexual contact should be avoided while using this ointment. Side effects include erythema pruritus, burning, pain, ulceration, edema, induration, and rash. This treatment is not recommended for immunocompromised or pregnant patients as its safety and efficacy has not been established. Sinecatechins may weaken condoms and vaginal diaphragms.

Most anogenital warts respond to treatment within 3 months. If significant improvement is not noted, another treatment modality should be used. As mentioned earlier, biopsy may be considered for lesions that do not respond to treatment.

Patients with anogenital warts should be screened for other STDs. Patients should be counseled that even with treatment of warts, HPV can still be transmitted to partners. **Because HPV can infect areas not covered by condoms, the routine use of condoms, although it can decrease the risk for transmission, does not eliminate its possibility** (Workowski, 2015).

Human Papillomavirus Vaccine

Abstaining from sexual activity is the most reliable method for preventing genital HPV infections. Other risk-reducing behaviors include correct condom use and limiting the number of sex partners (Boda et al., 2018). In 2006, a quadrivalent HPV vaccine (Gardasil) was introduced that prevents infection with HPV types 6, 11, 16, and 18. Initially, it was approved in 2006 for use in females 9 to 26 years of age. Later, in 2009, it was approved for use in males 9 to 26 years of age. There are currently two other HPV vaccines available in the United States: a bivalent vaccine (Cervarix) that covers HPV 16 and 18 and a 9-valent vaccine (Gardasil 9) that covers HPV 6, 11, 16, 18, 31, 33, 45, 52, and 58 (Nicol et al., 2015; Boda et al., 2018). All vaccines are given in a two- or three-dose series (depending on age of initiation) of intramuscular injections over a 6-month period. All vaccines offer coverage for HPV types 16 and 18, which account for 66% of all cervical cancers. The quadrivalent vaccines offers additional protection against HPV type 6 and 11, which accounts for 90% of anogenital warts. The 9-valent vaccine covers five additional HPV types (31, 33, 45, 52, and 58), which account for 15% of all cervical cancer cases (Workowski, 2015; Boda et al., 2018). **As of the end of 2016, only the 9-valent HPV vaccine will be available in the United States** (CDC, 2018c).

Currently, the 9-valent vaccine is recommended for males and females 11 to 12 years of age (can start at 9 years) and for females 13 to 26 years of age and males 13 to 21 years of age who were not adequately vaccinated previously. Vaccination is also recommended for gay, bisexual, and other MSM; transgendered persons; and persons 22 to 26 years of age with certain immunocompromising conditions who were not adequately vaccinated when they were younger (CDC, 2018c).

HPV vaccines were previously administered as a three-dose regimen. This has been updated and, currently, **if the first dose of any HPV vaccine is given before the 15th birthday, vaccination should be completed according to a two-dose schedule.** In this regimen, the second dose is recommended 6 to 12 months after the first dose, with a minimum of 5 months between the first and second dose (if a shorter interval, the third vaccine dose is given at a minimum of 12 weeks after the second dose and a maximum of 5 months after the second dose). If the first dose of any HPV vaccine is given after the 15th birthday, a three-dose series schedule should be used. In this series, the second dose is recommended 1 to 2 months after the first dose, and the third dose is recommended 6 months after the first dose (CDC, 2018c). All immunocompromised patients should receive the three-dose regimen.

Multiple studies have demonstrated the safety of HPV vaccines. One of the largest was released in 2013 that included over 300,000 young girls who had received nearly 700,000 doses of the HPV vaccine (quadrivalent). The study noted no increased number of cases of autoimmune disease, neurologic problems, or venous thromboembolic adverse effects in the girls who received the HPV vaccine compared with controls (Arnheim-Dahlstrom et al., 2013, Nicol et al., 2015). HPV vaccines have not been associated with earlier initiation of sexual activity, increased risky sexual behaviors, or perceptions about sexually transmitted infections (Workowski, 2015; Madhivanan et al., 2016). Rates of HPV vaccination are increasing; in 2016, more than 60% of adolescents 13 to 17 years of age have received at least one dose (Walker et al., 2017).

Zika Virus

Zika virus is a flavivirus related to dengue, yellow fever, and West Nile virus that was first isolated in 1947 in Uganda. Transmission by *Aedes aegypti* to laboratory animals was reported in 1956, and the first human infection was reported in 1964 (Petersen et al., 2016b; Wikan and Smith, 2017). The first large outbreak of Zika virus occurred in 2007 on the island of Yap in Micronesia followed by a second outbreak in French Polynesia during 2013 to 2014. It was during the French-Polynesian outbreak that the link between Zika virus and Guillain-Barré syndrome (GBS) was first reported (Stassen et al., 2018). In 2016, because of the rapid expansion of Zika virus and the suspected causal relationship between the virus and microcephaly in Brazil, the World Health Organization declared Zika virus a public health emergency of international concern (Hennessey et al., 2016; Stassen et al., 2018). By July 2017, more than 700,000 confirmed and suspected mosquito-borne cases of Zika virus had been reported to the Pan American Health Organization from 48 countries and territories in the Americas (Petersen et al., 2016b; Pan American Health Organization, 2017).

Transmission of Zika Virus

Like other flaviviruses, Zika virus is mainly transmitted by female mosquito vectors. Other modes of transmission include maternal-fetal transmission, blood donation, and sexual transmission (male to female, male to male, and female to male). The first suspected case of Zika sexual transmission occurred in 2008 (Foy et al., 2011; Magalhaes et al., 2018; Mead et al., 2018). Transmission has been reported for condomless vaginal and anal intercourse (Magalhaes et al., 2018).

Zika virus RNA has been detected in blood samples, male and female reproductive tract samples, urine, saliva, breast milk, and conjunctival and other body fluids. Infectious virus has been recovered from most of these body fluids but to a much lesser extent (Magalhaes et al., 2018; Uraki et al., 2017). The median time to Zika virus RNA clearance post–symptom onset from infected patients' urine and semen is 8.2 days (6.4 to 10.0) and 34.4 days (27.9 to 40.8), respectively (Paz-Bailey et al., 2017). Zika virus RNA has been detected as late as 188 days after symptom onset. The longest recorded time for Zika virus viability (infectious virus in cell culture) was 69 days after symptom onset (Moreira et al., 2017; Mead et al., 2018). Of note, Zika virus has been detected in the ejaculate of at least two vasectomized men (Magalhaes et al., 2018).

Symptoms

Symptoms of Zika virus can be highly variable. Most people (up to 80%) are asymptomatic. Symptoms, when present, tend to be mild and nonspecific and can include mild fever, conjunctivitis, maculopapular rash, myalgia, and headache (Rabaan et al., 2017; Mead et al., 2018). In Zika virus–infected men, prostatitis, hematospermia, and microhematospermia have been reported (Stassen et al., 2018). Although it is unknown what cells or tissues are affected with Zika virus, the presence of hematospermia in some patients suggests one or more tissues of accessary genital tract (seminal vesicles, prostate and bulbourethral gland) are likely infected (Magalhaes et al., 2018).

Zika virus infections have been associated with severe neurologic manifestations such as microcephaly and Guillain-Barré syndrome (Koppolu and Shantha Raju, 2018). In Brazil, an average of 163 cases of microcephaly were recorded annually between 2001 and 2014, however in the year leading up to January 30, 2016, 4783 microcephaly and/or CNS malformation cases had already been recorded (Rabaan et al., 2017). Zika virus infections have also been linked to other neurologic manifestations such as meningoencephalitis, fetal cerebral calcifications, central nervous system alterations, and myelitis. Although the ocular manifestations in adults are usually mild (conjunctivitis and uveitis), they can be much more severe in infants. Zika virus ocular manifestations in infants can include blindness, optic neuritis, chorioretinal atrophy, bilateral iris coloboma, and intraretinal hemorrhage (Koppolu and Shantha Raju, 2018).

Diagnosis

The CDC currently recommends Zika virus testing for anyone with possible Zika virus exposure (defined as living in, traveling to, or having unprotected intercourse with someone who lives in or traveled to an area with risk for Zika virus) who has recently experienced symptoms of Zika. Testing is recommended for symptomatic pregnant women with possible Zika exposure, asymptomatic pregnant women with ongoing possible Zika

exposure, and pregnant women with possible Zika exposure who have a fetus with prenatal ultrasound findings consistent with congenital Zika virus infection. Testing may be considered for asymptomatic pregnant women with recent possible but no ongoing Zika exposure. Zika virus testing is not recommended for nonpregnant asymptomatic individuals or for preconception counseling (CDC, 2018e).

Nonpregnant symptomatic individuals with possible Zika virus exposure should receive testing of serum and urine by Zika virus ribonucleic acid (RNA) NAAT and Zika virus and/or dengue virus IgM testing of serum. NAAT testing is dependent on the timing of specimen collection and should be performed only on specimens collected less than 14 days after symptom onset. Zika virus and dengue virus IgM serology testing should be performed on all NAAT-negative samples collected less than 14 days from symptom onset and on all samples collected 14 days or longer from symptom onset (CDC, 2018e).

Preconception Counseling and Prevention of Sexual Transmission of Zika Virus

Because of the range of time after symptom onset that Zika virus RNA has been detected in the semen of symptomatic men, the CDC recommends that men with possible Zika exposure, regardless of symptom status, wait at least 6 months from symptom onset (if symptomatic) or last possible exposure before attempting conception with their partner. Women with possible Zika virus exposure are recommended to wait to conceive until at least 8 weeks after symptom onset of last possible exposure. Couples who want to conceive in which one or both partners live in areas with active Zika virus transmission should be tested for Zika virus if they are symptomatic. Men with positive results should wait 6 months from onset of symptoms, and women should wait 8 weeks from symptom onset to attempt conception. If testing is negative, a discussion with a health care provider should be had regarding the timing of conception in the setting of ongoing risk for potential exposure. Couples with possible Zika exposure who are not pregnant and do not plan to become pregnant and who want to minimize their risk for sexual transmission of Zika virus should be advised to abstain from intercourse or use condoms for the same period mentioned earlier (men 6 months and women 8 weeks) (Petersen et al., 2016a).

Treatment for Zika Virus Infections

To date, there are no approved vaccine or antiviral therapies to treat Zika infection. Therefore, the best approach to control Zika virus infections relies on preventing transmission of the virus (both from the vector *A. aegypti* and sexual transmission). Avoiding travel to Zika-endemic areas (found at https://wwwnc.cdc.gov/travel/page/zika-information), utilizing insect repellent with DEET, treating clothes with permethrin, and eliminating standing water to prevent mosquito egg laying and larval development are recommended choices to prevent infection (Koppolu and Shantha Raju, 2018).

Human Immunodeficiency Virus (HIV) and Acquired Immunodeficiency Syndrome (AIDS)

Since AIDS was first described in 1981 and HIV identified in 1986, the HIV pandemic has affected millions of people worldwide (Heyns et al., 2013). As of 2016, there were 36.7 million people living with HIV worldwide (1.1 million in the United States as of 2015), with 1.8 million new cases of HIV diagnosed in 2016. Worldwide, 1 million people died from AIDS-related illnesses in 2016. In 2016, 39,782 people in the United States were diagnosed with HIV, a 5% decrease from 2011 to 2015, with MSM accounting for 67% (26,570) of the newly diagnosed cases. Heterosexual contact accounted for 24% (9578 cases), IV drug use accounted for 6% (2224 cases), and a combination of MSM and IV drug use accounted for 3% of newly diagnosed cases (1201 cases). African-Americans had the highest rate of newly diagnosed HIV (44%, or 17,528 cases) followed by Caucasians (26% or 10,345 cases) and Hispanic/Latinos (25%, or 9766 cases). Only 15%, or 1 in 7 people, know that they are infected with HIV (https://www.cdc.gov/hiv/basics/statistics.html).

HIV is a retrovirus that infects T cells and dendritic cells. HIV is spread through blood, semen, vaginal fluid, or breast milk. Immunosuppression occurs with the progressive loss of CD4 T-lymphocytes. There are two types of HIV: HIV-1 and HIV-2. Although HIV-1 accounts for the majority of infections in the United States, HIV-2 infections should be suspected in persons with an unusual clinical presentation or with risk factors including having lived in an endemic area or having sex with a partner from an endemic area (West Africa, Portugal), having a sex partner with known HIV-2, or having a blood transfusion or nonsterile injection in an endemic area (Workowski, 2015). There are three recognized stages of HIV infection. **Stage 1 (acute stage) occurs 2 to 4 weeks after infection and presents as flulike symptoms. Because of high viral load during this stage, patients are at an increased risk for transmitting the virus.** Unfortunately, routine tests for HIV antibodies are often negative during this phase. **Stage 2 (clinical latency, asymptomatic HIV infection or chronic HIV infection) is marked by slow viral replication that can last years to decades depending on treatment.** Patients are often asymptomatic during this phase. **Stage 3 (AIDS) is diagnosed when the CD4 count is less than 200 cells/mm^3 or if the patient acquires an AIDS-defining condition** (CDC, 2018a).

Diagnosis of Human Immunodeficiency Virus

The CDC currently recommends HIV screening for patients 13 to 64 years of age in a health care setting. Patients should be counseled and notified that testing will be performed and given the option to decline. **All persons who seek evaluation and treatment for STDs should be screened for HIV infection.**

HIV infection can be diagnosed by serologic tests that detect antibodies against HIV-1 and HIV-2 and by virologic tests that detect HIV antigens or RNA. Testing usually begins with a sensitive screening test, usually antigen/antibody combination or antibody immunoassay. Available serologic tests are highly sensitive and specific and can detect all known subtypes of HIV-1, and most can also detect HIV-2 and uncommon variants of HIV-1. These are rapid tests, but these rapid assays often become reactive later than conventional laboratory-based antibody or combination antigen/antibody serologic assays. This can result in a negative result in a recently infected person. The recommended algorithm for HIV infections consists of laboratory-based immunoassay which, if repeatedly reactive, is followed by a supplemental test (e.g., HIV-1/HIV-2 antibody differentiation assay, Western blot, or indirect immunofluorescence assay). A positive supplemental test confirms the diagnosis. Because laboratory antigen/antibody immunoassays detect HIV infection earlier than the supplemental tests, during very early infection, discordant HIV tests have been reported as negative (i.e., reactive immunoassay with negative supplemental test). To minimize this, a combination of HIV-1/HIV-2 antigen-antibody immunoassay, which, if reactive, is followed by an HIV-1/HIV-2 antibody differentiation assay. This allows for an additional advantage of detecting HIV-2 antibodies, which if present, carry different monitoring and treatment protocols. Discordant tests should be conformed with RNA testing to determine if the discordance is caused by acute HIV infection (Workowski, 2015).

Once diagnosed, persons with HIV infection should be encouraged to notify their partners and to refer them for counseling and testing. Partner notification services are usually available through the health department. Partners who have been reached and are not known to have HIV exposure should be offered postexposure prophylaxis (PEP) with combination retrovirals medications if they were exposed to genital secretions or blood of a partner with HIV infection.

Decreasing the Transmission Risk

Male Circumcision

Three randomized, controlled studies performed in sub-Saharan Africa demonstrated that circumcision decreased the risk for HIV infection by 50% to 60% (Auvert et al., 2005; Bailey et al., 2007; Gray et al., 2007). Similar reductions were also noted for STDs such as high-risk HPV and genital herpes. Several mechanisms have been shown to potentially account for the reduced risk for HIV acquisition with circumcision. Numerous HIV target cells are present under the dermis of the foreskin. The inner surface of the foreskin is poorly keratinized and potentially prone to lacerations, which can act as a site for HIV entry. Lastly, infection of the prepuce with anaerobic bacteria can lead to the infiltration Langerhans cells, which the HIV virus targets (Heyns et al., 2013). Circumcision has not been shown to reduce the risk for HIV transmission in a man who already has HIV (Wawer et al., 2009). Circumcision has not been shown to reduce the risk for HIV transmission in MSM, although limited data suggest it may be beneficial in MSM who were the insertive partner only in anal intercourse (Heyns et al., 2013; Workowski, 2015). The World Health Organization and the Joint United National Programme on HIV/AIDS (UNAIDS) have recommended that male circumcision efforts be scaled up as an effective intervention for the prevention of heterosexually acquired HIV infection.

Postexposure Prophylaxis

A case-controlled study demonstrating an 81% reduction in the odds of HIV transmission among health care workers (HCWs) with percutaneous exposure to HIV who received zidovudine prophylaxis was the first to describe the efficacy of PEP (Cardo et al., 1997). Because of ethical and operational challenges, no randomized controlled trials have been conducted to test the efficacy of non–occupational postexposure prophylaxis (nPEP) directly, and as such, this trial reports the strongest evidence of benefit of antiretroviral prophylaxis initiated after HIV exposure among humans (CDC, 2016b). **The current guidelines recommend that persons should be evaluated for nPEP when they present**

less than 72 hours after a potential nonoccupational HIV exposure that poses a substantial risk for HIV acquisition (source of body fluid is known to be HIV-positive, and the reported exposure presents a substantial risk for transmission). Evaluation includes determination of HIV status, and if this is either negative or results are unavailable, nPEP should be initiated without delay. nPEP is not recommended for exposures with no substantial risk for HIV transmission or if care is sought more than 72 hours after potential exposure. **All persons offered nPEP should be prescribed a 28-day course of a three-drug antiretroviral regimen**. The regimen consists of tenofivir disoproxil fumarate 300 mg with emtricitabine 200 mg daily PLUS raltegravir 400 mg twice daily OR dolutegravir 50 mg daily. HIV status should be monitored at 6 weeks, 3 months, and again at 6 months after exposure (CDC, 2016b).

Pre-Exposure Prophylaxis

Daily oral pre-exposure prophylaxis (PrEP) with the fixed-dose combination of tenofovir disoproxil fumarate (TDF) 300 mg and emtricitabine (FTC) 200 mg has been shown to be safe and effective in reducing the risk for sexual HIV acquisition in adults. PrEP is recommended in the following populations: as one prevention option for sexually active adult MSM who are at substantial risk for HIV acquisition; adult heterosexually active men and women who are at substantial risk for HIV acquisition; adult persons who inject drugs (PWID; also called injection drug users [IDU]) at substantial risk for HIV acquisition; and heterosexually active women and men whose partners are known to have HIV infection (i.e., HIV-discordant couples) as one of several options to protect the uninfected partner during conception and pregnancy so that an informed decision can be made in awareness of what is known and unknown about benefits and risks of PrEP for the mother and fetus (CDC, 2017c).

Urologic Manifestations of HIV/AIDS

HIV and Other STDs

Testing for HIV is recommended for anyone who is diagnosed with an STD or is at risk for an STD (Workowski, 2015). In many populations, the pattern of HIV infection mirrors that of other STDs (Quinn et al., 1988). Genital herpes, syphilis, and chancroid have all been associated with an increased risk for HIV transmission and acquisition. Several factors contribute to this finding including bleeding from irritated genital ulcers and the presence of HIV in ulcer exudate. In HIV-negative patients, genital ulcerations can increase the risk for acquisition of HIV by interrupting the mucosal integrity and recruiting HIV-positive immune cells to the site of the ulcer (Magro et al., 1996). HSV shedding is increased in persons with HIV, and HSV-2 is thought to affect 50% to 90% of HIV-positive patients (Strick et al., 2006). Coinfection with syphilis increases the viral load and decreases the CD4 count leading to rapid progression and immunosuppression (Heyns et al., 2013).

Nonulcerating Skin Infections

Cellulitis of the perineum is more common in men with HIV, and empiric coverage should cover the potential for methicillin-resistant *Staphylococcus auerus* (MRSA) (Shindel et al., 2011). Necrotizing fasciitis, although rare, occurs more commonly in HIV patients. Tuberculosis might involve the scrotal skin or penis resulting in sinuses, nodular lesions, or ulcerative lesions (Heyns et al., 2013).

Genital warts are present in 20% of HIV patients and are most commonly caused by HPV 6 and 11. These lesions can also be quite extensive in HIV/AIDS patients forming giant condyloma (Fig. 58.13). Molluscum contagiousum is found in 5% to 18% of HIV patients. Although it is usually self-limited in healthy individuals, the lesions may not regress in HIV-positive patients and can serve as a nidus for secondary bacterial infections (Shindel et al., 2011).

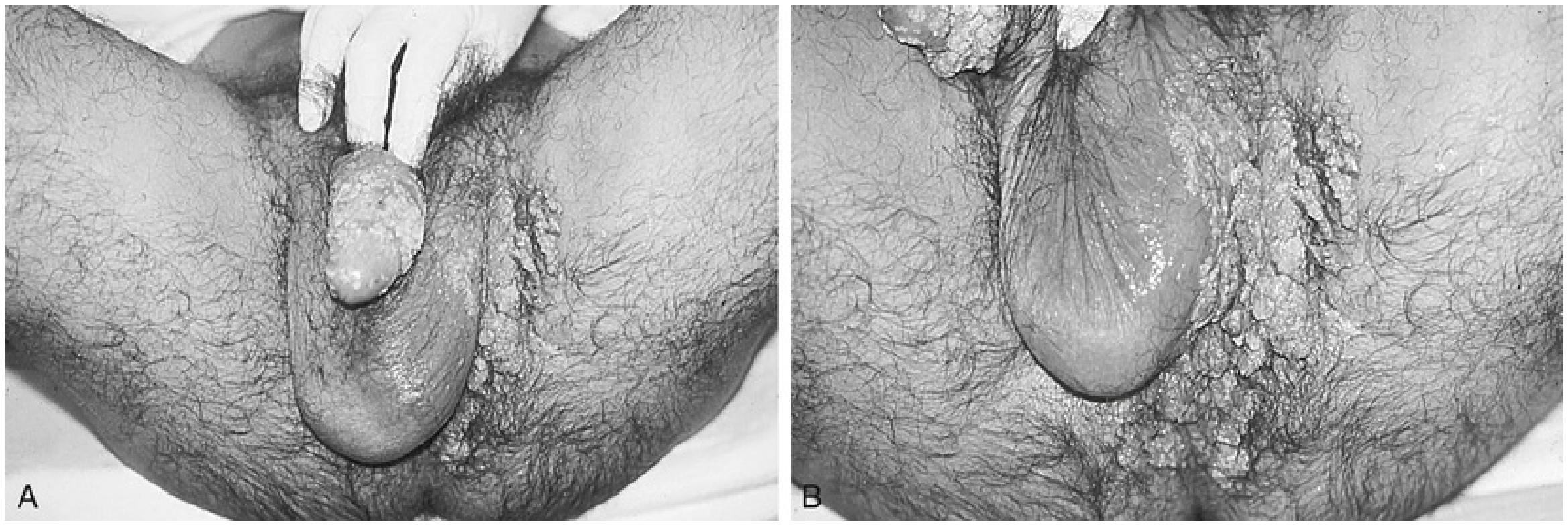

FIG. 58.13 (A and B) Acquired immunodeficiency syndrome patient with extensive genital condyloma.

Urinary Tract Infections

Patients who have HIV experience a greater risk for urinary tract infection (UTI) when their CD4 count is less than 500/mm^3 (Lee et al., 2001; Lebovitch and Mydlo, 2008). The risk for UTI is even higher among those with a CD4 count less than 200/mm^3 or those with a high viral load. Thirty percent of patients with a CD4 count less than 200/mm^3 have bacteriuria compared with 11% with CD4 counts between 200/mm^3 and 500/mm^3 and 0% for counts greater than 500/mm^3 (Hoepelman et al., 1992; Nicolle, 2014). Although immunosuppression is the principal driving factor behind the increased incidence of UTI, voiding dysfunction may also predispose to UTI development. Typical pathogens include the *E. coli, Enterobacter, Proteus, Klebsiella,* and other gram-negative bacteria (Hoepelman et al., 1992; Lebovitch and Mydlo, 2008). *Pseudomonas aeruginosa* can be found in up to 30% of HIV-infected patients with a UTI (Hyun and Lowe, 2003). ***Salmonella* UTI is of particular concern given its increased potential for fatal recurrence and as such, should be aggressively managed with lifelong prophylaxis** (Reddy et al., 2010; Shindel et al., 2011). Urine culture is recommended before initiation of empiric treatment because of the resistance patterns seen within this group (Vignesh et al., 2008).

HIV-infected patients who do not respond after a few days of empiric antibiotics and those with a CD4 count less than **500/mm^3 (especially <250/mm^3) should be screened for atypical and opportunistic infections.** Organisms of concern include fungi such as *Candida, Aspergillus, Blastomyces, Cryptococcus, Cryptosporidia,* and *Histoplasma;* parasites such as *Toxoplasma* and *Pneumocystis; M. tuberculosis,* and viruses such as cytomegalovirus (CMV) and adenovirus (Lee et al., 2001; Shindel et al., 2011; Heyns et al., 2013). The diagnosis of viral UTI can be confirmed with molecular techniques such as PCR, and treatment consists of cidofovir (Paduch, 2007; Heyns et al., 2013).

Renal Infections

Gram-negative bacteria are the most common cause of pyelonephritis in the HIV population. Opportunistic renal pathogens include *Pneumocystis carinii, Mycobacterium* spp., *Candida,* and *Histoplasmosis*. Renal mycobacterial infections have been detected at autopsy in 6% to 23% of AIDS patients, most of whom had not experienced any symptoms of infection before death (Shindel et al., 2011). The most common mycobacterial organism is *M. tuberculosis* followed by *Mycobacterium avium* and *Mycobacterium intracellulare*.

Mycobacterial infection of the urinary tract usually occurs in a descending fashion, and it can remain latent for many years after the initial infection until reactivation. Diagnosis of renal tuberculosis (TB) is made by a positive Ziehl-Nielsen stain of urine; urine culture for acid-fast bacilli, which requires three to six early morning cultures and may take up to 6 weeks to grow; or PCR, which, although it can produce quick results (48 hours), it is not widely available because of technical difficulties (Heyns et al., 2013). TB can also present as an iliopsoas abscess. Approximately 10% of iliopsoas abscesses are caused by *M. tuberculosis,* and approximately 25% of these are associated with HIV (Navarro Lopez et al., 2009). If treatment includes rifampin, HIV drug levels should be monitored as rifampin induces cytochrome p450, which can lower the concentration of protease inhibitors (PIs) and nonnucleoside reverse transcriptase inhibitors. **Because of the increased risk for relapse, HIV patients with treated renal TB should have an annual urine culture for acid-fast bacilli up to 10 years after treatment to screen for recurrence** (Shindel et al., 2011).

Prostatitis

Although relatively uncommon in the general population (1% to 2%), prostatitis is diagnosed in 3% of men with HIV and 14% of those with AIDS, although these numbers predate HAART treatment (Leport et al., 1989; Lebovitch and Mydlo, 2008). Common symptoms include chronic pelvic/perineal pain, dysuria, urgency frequency, and other lower urinary tract symptoms (LUTS). Prostatitis is usually caused by *E. coli*, but other organisms including *S. aureus*, *Klebsiella pneumonia*, *Pseudomonas aruginosa*, *Serratia marcescens*, *Salmonella typhi*, *M. tuberculosis*, *M. avium*, and *M. intracellulare* can also cause prostatitis in the HIV/AIDS population. Fungal infections can cause prostatitis, especially with CD4 counts less than 200/mm^3. These organisms include *Candida albicans, Aspergillus fumigatus*, *Cryptococcus neogormans*, and *Histoplasma capsulatum* (Weinberger et al., 1988; Benson and Smith, 1992; Santillo and Lowe, 2006). **The risk for developing a prostatic abscess or urosepsis is greater than in the general population because of the atypical pathogens that may be present.** Prolonged treatment with antimicrobial or antifungal therapy is needed (Leport et al., 1989; Hyun and Lowe, 2003). Despite prolonged therapy, up to 70% of HIV-infected patients have relapsing symptoms (Leport et al., 1989; Kwan and Lowe, 1992; Shindel et al., 2011; Heyns et al., 2013). Special consideration should be given to cryptococcal prostatitis, which may persist after treatment in up to 29% of cases and may serve as a reservoir for relapsing meningitis; as such, these patients may require long-term or even lifelong antifungals depending on their immune status (Lee et al., 2001; Shindel et al., 2011).

Testis, Epididymis, and Seminal Vesicles

Infection of the epididymis and/or testicle is a common finding in men with HIV and tends to be recurrent and chronic (Coburn, 1998). Changes have been found within the tubular structures of the epididymis in AIDS patients. These changes are likely caused by persistent inflammation and predispose patients to recurrent infections because of inadequate clearance of secretions (Dalton and Harcourt-Webster, 1991). Autopsy studies of AIDS patients who have succumbed to opportunistic infections have shown that 25% to 39% of men have the identical organism harvested from their testes, suggesting that the testes and epididymis may be a reservoir for delayed opportunistic infections. The most common organisms harvested from the testes in these cases were *Gonococcus, Salmonella,* CMV, *M. avium, M. intracellulare, Toxoplasma, Histoplasma,* and *Candida* (De Paepe and Waxman, 1989; Heyns et al., 2013). Treatment requires a period of initial antibiotics followed by maintenance suppression, particularly if *Salmonella* is present (Shindel et al., 2011).

Testicular atrophy is a frequent autopsy finding in HIV-infected patients. The etiology is likely multifactorial including fever, chronic illness, opportunistic infections, cachexia, activation of cytokines, and the cytotoxic effect of the HIV virus itself. Patients with an extremely low body mass index (BMI) (<20) were 3.5 times more likely to have testicular atrophy than those with a BMI greater than or equal to 20. An association between disseminated CMV infection and testicular atrophy has been noted. HIV-infected patients with CMV end-organ infection had a fivefold increased incidence of pronounced testicular atrophy (Mhawech et al., 2001).

Nephrolithiasis

Historically, PIs (indinavir specifically) have been implicated as a cause of nephrolithiasis in up to 22% of HIV-infected patients, and autopsy studies have demonstrated urinary stones in up to 40% of HIV-infected patients (Shindel et al., 2011; Raheem et al., 2012). Risk factors for nephrolithiasis in the HIV-infected population include hepatitis coinfection and exposure to PIs (Lin et al., 2015). Twenty percent of indinavir is not metabolized and is excreted by the kidneys within 24 hours. Indinavir is most soluble at a pH less than 5, and, as such, tends to precipitate in alkaline urine forming radiolucent stones (Raheem et al., 2012). Indinavir as a stone component is only seen in 29% of calculi, and the remaining stone components are calcium oxalate, ammonium acid urate, and uric acid (Lebovitch and Mydlo, 2008). Indinavir is used less often currently, although the newer PIs, such as lopinavir, atanaznavir, amprinavir, and belfinavir, have also been associated with the development of nephrolithiasis, although at much lower rates relative to indinavir (Shindel et al., 2011).

Other factors that may contribute to nephrolithiasis in HIV-infected patients include malnutrition, diarrhea, dehydration, urinary acidification, hypocitraturia, and hyperuricosuria secondary to cell lysis after chemotherapy for AIDS-associated lymphoma (Heyns et al., 2013).

Once diagnosed, patients should undergo a complete metabolic evaluation including stone analysis if possible, 24-hour urine collection, and serum studies (creatinine, uric acid, and calcium) (Lebovitch and Mydlo, 2008). In patients with protease stones and in whom conservative management is possible, first-line treatment involving discontinuation of the drug and hydration has been successful in up to 70% of cases (Kohan et al., 1999).

Renal Dysfunction

Despite HAART, kidney disease and renal failure are still common causes of death in HIV-positive patients (Croxford et al., 2017). Renal disease can be a consequence of both HIV infection and its treatments. Potential causes of renal dysfunction in persons with HIV or AIDS include the depletion of intravascular volume owing to diarrhea and vomiting, sepsis, metabolic dysfunction, nephrotoxic medications, intrinsic diseases such as HIV-associated nephropathy (HIVAN), and ureteric obstruction caused by urolithiasis, blood clots, retroperitoneal lymphoma, fungal collections, or fibrosis (Lebovitch and Mydlo, 2008, Heyns et al., 2013). Drugs that can cause acute kidney injury in HIV-infected patients include antibiotics, antifungal agents (amphotericin B and pentamidine), antiviral agents, and antiretroviral drugs (indinavir, atazanavir, abacavir, and tenofovir) (Kalyesubula and Perazella, 2011).

As life expectancy for HIV-infected patients has increased since the introduction of HAART, the risk for developing chronic kidney disease has also increased. Untreated HIV or AIDS increases the risk for acute kidney injury. With the initiation of HAART, renal failure persists but life expectancy increases

(Heyns et al., 2013). Additionally, with increased life expectancy comes an increased risk for age-related risk factors such as hypertension and diabetes. HIV-infected men on HAART have a fourfold higher incidence of diabetes than HIV-negative men (Kalyesubula and Perazella, 2011; Heyns et al., 2013).

HIVAN is characterized by an elevated serum creatinine and nephrotic-range proteinuria (>3.5g/day), although edema and hypertension are frequently absent. HIVAN typically occurs with CD4 counts less than 200 cells/mm^3 and a blood load of greater than 1000 copies/mL, and it affects 7% to 32% of HIV-positive patients. It has a 12:1 greater incidence in black patients compared with white patients and has become the third leading cause of end-stage renal disease among black patients 20 to 64 years of age. The diagnosis is made by biopsy that demonstrates a collapsing variant of focal segmental glomerulosclerosis, proliferation of renal tubular and visceral cells, tubular microcystic formation, edema, interstitial fibrosis, and infiltration of the interstitium with leukocytes. Patients progress rapidly to end-stage renal disease with dialysis requirement occurring within 10 months of diagnosis. **Treatment includes HAART if the patient is not already on HIV medications and angiotensin-converting enzyme inhibitors.** Despite treatment, 1-year mortality reaches 50% (Lebovitch and Mydlo, 2008; Shindel et al., 2011; Heyns et al., 2013; Ekrikpo et al., 2018).

Voiding Dysfunction

LUTS can be a common source of morbidity in the HIV-infected population and tends to worsen as the disease progresses. **In an Internet survey of MSM, HIV status was an independent risk factor for bothersome LUTS, and a history of AIDS was a risk factor for severe disease** (Breyer et al., 2011). With acute HIV infections, LUTS, including acute retention and sacral loss, may be the sentinel event that presages HIV conversion (Zeman and Donaghy, 1991; Lee et al., 2001; Shindel et al., 2011; Heyns et al., 2013). With disease progression, symptoms can worsen, possibly related to recurrent or chronic UTI, central nervous system disturbances (i.e., HIV encephalitis, cerebral toxoplasmosis, HIV demyelination disorders, CMV polyradiculopathy, central nervous system neoplasms, and HIV-related dementia), peripheral neurologic deficits, and side effects of HAART or other medications (Lebovitch and Mydlo, 2008; Shindel et al., 2011). Awareness of CMV infection is important in the HIV-positive population because there is a greater than 40% rate of virus reactivation with subsequent risk for bladder end-organ damage and life-threatening infection.

Combined bladder dysfunction, bowel dysfunction, and back or sciatic pain should prompt consideration for CMV polyradiculopathy. Diagnosis is made by lumbar puncture, and prompt treatment may improve symptoms (Collier et al., 1987; Shindel et al., 2011).

Erectile Dysfunction

In a study comparing the prevalence of erectile dysfunction (ED) in HIV-infected men compared with HIV-negative men, the prevalence of ED (mild, moderate, and severe) was shown to be higher in HIV-infected men in all decades of age, and on multivariate analysis HIV infection was the strongest predictor of ED (Zona et al., 2012). A larger meta-analysis confirmed the finding of increased prevalence of ED in HIV-infected men (Luo et al., 2017). ED is common in HIV-infected men younger than 50 years of age, reported as 50% of infected men younger than 30 years of age, 48% of those 31 to 40 years of age, and 53% of those 41 to 50 years of age (Zona et al., 2012). Sexual dysfunction may be caused by HIV-associated organic comorbidities affecting the neurologic, vascular, and hormonal systems; psychological stress; depression; hypogonadism; age; and BMI (Lebovitch and Mydlo, 2008; Heyns et al., 2013; Luo et al., 2017). Several studies have found that antiretroviral therapy, especially PIs, is associated with an increased prevalence of ED. Indinavir and ritonavir have been reported to worsen ED. HAART contributes to increased body weight circulating lipids, glycemia, and decrease in serum testosterone levels, which can lead to a metabolic pattern that promotes endothelial dysfunction (Luo et al., 2017). Sexual dysfunction is also a complex condition that not only includes ED, but disorders of ejaculation, sexual desire, orgasm, and satisfaction during intercourse. The prevalence of ejaculation disorders is higher in men with HIV infection (Jones et al., 1994). Libido has been shown to be lower in HIV-infected patients and even more so in those taking HAART (2% without HIV, 26% with HIV and no HAART, and 48% with HIV and HAART) (Lamba et al., 2004).

Treatment with PDE-5 may interact with PIs. PIs can block the CYP3A enzyme leading to a threefold to 10-fold increase in serum concentrations of sildenafil. Sildenafil should be started at a lower dose in the setting of PIs (Lebovitch and Mydlo, 2008; Heyns et al., 2013).

Malignancy

Malignancy is more common in the HIV-positive individual than in age-matched HIV-negative individuals. Possible mechanisms for this include decreased immune surveillance, a direct effect of viral proteins, or cytokine dysregulation. Other factors that can contribute to the increased risk include high-risk behaviors such as tobacco use, which is two to three times more prevalent in the HIV-infected patient (Albini et al., 2013). AIDS-defining cancers (ADCs) are Kaposi sarcoma (associated with the DNA viruses Kaposi sarcoma–associated herpesvirus (HHV 8), Epstein Barr virus (EBV), and HPV), non-Hodgkin lymphoma, cervical carcinoma, and anal carcinoma (Heyns et al., 2013). HAART has reduced the incidence and mortality for KS and NHL but not for cervical or anal cancer. Since the widespread use of HAART, there has been a threefold increase in non-ADCs including prostate cancer; carcinomas of the anus, lung, breast, skin, conjunctiva, head and neck, liver, and testis; Hodgkin lymphoma; plasma-cell neoplasia; multiple myeloma; leukemia; melanoma; and leiomyosarcoma. Currently these non-ADCs comprise 70% of all cancers diagnosed in HIV-infected people on HAART compared with 20% in the pre-HAART era (Crum-Cianflone et al., 2009; Heyns et al., 2013).

Kaposi Sarcoma

KS was first described in 1872 by a Hungarian dermatologist, Moritz Kaposi. It was the simultaneous occurrence of KS with *Pneumocystis* pneumonias in young MSM in 1981 that led to the first description of AIDS (Hoffmann et al., 2017). Measured at 5 years after AIDS onset, the cumulative incidence of KS in the United States has decreased from 14.3% in 1980 to 1989 to 6.7% in 1990 to 1995 and to 1.8% in 1996 to 2006 (Simard et al., 2011). KS is characterized by abnormal neoangiogenesis, inflammation, and the proliferation of tumor cells. KS is induced by infection with herpes virus 8 (HHV-8) also known as KS-associated herpesvirus (Hoffmann et al., 2017). HHV-8 is now considered a necessary condition for the development of KS, although not all persons with HHV-8 will develop KS. Transmission of HHV-8 occurs predominantly via saliva but also sexually, vertically, and via blood products (Haq et al., 2016).

KS can begin in any area of the skin but may also appear on oral, genital, or ocular mucous membranes. It typically manifests as a few asymptomatic purple macules or nodules usually along skin tension lines. The tumors can remain unchanged for a prolonged period or grow rapidly within a few weeks. Rapid growth can lead to localized pain and eventually develop central necrosis and ulceration. The prognosis depends on the extent of the tumor, immune status, and the presence of systemic illness.

Large randomized trials have shown the protective effect of HAART against the development of KS (Silverberg et al., 2007; Borges et al., 2016; Hoffmann et al., 2017). If KS is diagnosed in an HIV-infected patient naïve to HAART, HAART should be initiated. In patients on HAART without complete suppression of HIV plasma viremia, the regimen should be optimized. With decreasing plasma viremia and immune reconstitution, many KS lesions stabilize or even resolve without any KS-specific treatment. Treatment can be local or systemic. Local treatments include cryosurgery, intralesional injections, radiation, or imiquimod (Hoffmann et al., 2017). In patients with rapidly progressive disease, KS-related symptoms, or visceral disease or lymphedema, HAART should be combined with cytotoxic chemotherapy. Prognosis is favorable, even in advanced disease, with an 85% 5-year survival rate (Bower et al., 2014a). KS may dramatically flare after initiation of HAART in what is called *immune reconstitution inflammatory syndrome (IRIS),* which is seen in HIV-positive patients with initial low CD4 counts and high viral load. IRIS can be seen as early as 3 weeks with a mean onset of 5 weeks, and the syndrome can be fatal (Hoffmann et al., 2017).

Non–AIDS-Defining Urologic Malignancies

Testicular Tumors

HIV-infected men are at a slightly greater risk for testis cancer then HIV-negative men. In particular, seminoma and extragonadal germ cell cancer (GCC) occur more frequently in HIV-infected patients, and the risk for nonseminoma is not, or only marginally, increased (Hentrich and Pfister, 2017). The occurrence of GCC appears to be unrelated to CD4 count and duration of HIV/AIDS. Limited data are available on survival differences between HIV-positive and HIV-negative patients in the post-HAART era. Primary treatment should be the same as in HIV-negative patients. Three cycles of cisplatin, etoposide, and bleomycin (BEP) suppresses the CD4 count by 25% to 50%, and it is probable that one to two cycles of BEP will also be suppressive. Therefore, low-risk nonseminoma patients should be offered surveillance, and adjuvant therapy should only be considered for high-risk nonseminoma patients (Bower et al., 2014b).

Prostate Cancer

The risk for prostate cancer is not increased in the setting of HIV, with several studies showing a slightly lower risk for HIV-positive men compared with HIV-negative men, although its relevance in the HIV-positive population is increasing as life expectancy increases (Hentrich and Pfister, 2017). **The indications for prostate-specific antigen testing in the HIV-positive patient should be the same as in the general population.** Morbidity after prostate biopsy or prostate cancer treatment is not increased in HIV-positive patients compared with HIV-negative men. An increase in infectious complications with radical prostatectomy may be seen in patients with a lower CD4 count and higher viral loads, but no other adverse perioperative outcomes were noted (Lebovitch and Mydlo, 2008; Shindel et al., 2011; Heyns et al., 2013).

Renal Cell Carcinoma

The risk for renal cell carcinoma (RCC) appears modestly elevated in subjects infected with HIV. In the D:A:D study, 1.4% of all non-ADCs were reported to be RCC (Worm et al., 2013). There does not seem to be an association between CD4 count at AIDS onset and the risk for RCC (Hentrich and Pfister, 2017). Based on data from the two largest case series on HIV-related RCC, there does not seem to be a difference in clinical presentation, pathology, stage distribution, and outcomes between HIV-infected and uninfected patients (Gaughan et al., 2008; Ong et al., 2016).

Bladder Cancer

There does not appear to be an increased risk for bladder cancer in HIV-infected patients, and the risk may actually be lower compared with the general population. The age of onset, however, may be lower in the HIV-infected population (Chawki et al., 2015). The outcome of HIV-infected patients with bladder cancer seems to be similar to that for HIV-negative patients. Patients with HIV should be managed according to the standard guidelines for HIV-negative patients (Hentrich and Pfister, 2017). One possible difference in treatment of HIV-positive patients is to use caution in deciding to use intravesical bacillus Calmette-Guérin (BCG) therapy. Intravesical BCG is dependent on a functioning immune system to exert its local effects. There is a theoretical risk for disseminated infection, with one case report of documented bilateral interstitial pneumonitis in an HIV-positive patient after intravesical BCG therapy. Additionally, because of the decrease in CD4+ cells, BCG may not be able to sufficiently stimulate the host immune system to create the necessary antitumor activity in the HIV-infected patient. **Given the risk for disseminated infection and potential suboptimal response to this therapy in HIV-infected patients, BCG therapy should probably be used with caution in the HIV-infected patient** (Gaughan et al., 2009).

Penile Cancer

Penile cancers and precursor lesions, such as Bowen disease and penile carcinoma in situ (CIS), are more common in HIV-positive men. Squamous cell carcinoma and verrucous carcinoma are more common and typically follow a more aggressive course in HIV patients. Part of the increased susceptibility to these cancers may be related to the generally increased risk for STDs in HIV-positive individuals, including infection with HPV 16 and 18 (Shindel et al., 2011). The diagnosis and management of penile cancer is the same for HIV-infected men as for the general population (Shindel et al., 2011).

Viral Hepatitis

Hepatitis B

Hepatitis B virus (HBV) infection remains to be a major public health burden. Approximately 240 million people worldwide are chronically infected with HBV, which contributes to about 30% of cirrhosis cases and 45% of hepatocellular carcinoma (HCC) cases (Wu and Ning, 2017). Hepatitis B is caused by infection with the HBV, with an incubation period that can span 6 weeks to 6 months. Increased concentrations of the HBV are found in blood, with lower concentrations in other body fluids such as wound exudate, semen, vaginal fluid, and saliva. Hepatitis B infections are more stable in the environment than other blood-borne pathogens (HIV, hepatitis C virus), and, as such, they are more infectious. **The primary risk factors associated with infection among adolescents and adults are unprotected sex with an infected partner, multiple partners, MSM, history of other STDs, and IDU** (Frieden et al., 2015).

HBV infections can be self-limited or chronic. If present, symptoms of acute HBV infection can include constitutional symptoms such as fever, fatigue, and loss of appetite. Gastrointestinal symptoms such as abdominal pain, jaundice, nausea, and vomiting may be present. Discoloration of stool and urine may also be noted. **The risk for developing chronic HBV infections is inversely related to the age of acquisition, with 90% of infected infants developing chronic HBV infections verses 2% to 6% of infected adults** (Hyams, 1995). The risk for premature death from cirrhosis or HCC is 15% to 25% among those with chronic HBV (Frieden et al., 2015).

Diagnosis

The diagnosis of HBV infection requires serologic testing. Serologic testing allows for differentiation among those susceptible to HBV infections, those with either resolved HBV infection or vaccine-induced immunity, and those with either acute or chronic HBV infection. Table 58.7 details the interpretation of these serologic tests (CDC, 2018d).

TABLE 58.7

Interpretation of Serologic Tests for HBV Infection

SEROLOGIC TEST	**SUSCEPTIBLE**	**IMMUNE DUE TO NATURAL INFECTION**	**IMMUNE DUE TO HBV VACCINE**	**ACUTELY INFECTED**	**CHRONIC INFECTE**
HBsAg	Negative	Negative	Negative	Positive	Positive
Anti-HBc	Negative	Positive	Negative	Positive	Positive
Anti-HBs	Negative	Positive	Positive	Positive	Negative
IgM anti-HBc				Positive	Negative

HBsAg, Hepatitis B surface antigen; *anti-HBc,* antibody to hepatitis B core antigen; *anti-HBs,* antibody to hepatitis B surface antigen; *IgM anti-HBc,* IgM antibody to hepatitis B core antigen; *HBV,* hepatitis B virus.

From Centers for Disease Control and Prevention. Interpretation of hepatitis B serologic test results. 2018; Available at: https://www.cdc.gov/hepatitis/hbv/pdfs/SerologicChartv8.pdf.

Screening

The American Association for the Study of Liver Diseases (AASLD) 2017 practice guidelines recommends screening with HBsAg and anti-HBs. **Screening is recommended in all persons born in counties with an HBsAg seroprevalence of greater than or equal to 2%, US-born persons not vaccinated as infants whose parents were born in regions with high HBV endemicity (8%), pregnant women, persons needing immunosuppression, and at-risk groups.** All anti-HBs–negative screened persons should be vaccinated. Screening for anti-HBc to determine prior exposure is not routinely recommended (Terrault et al., 2018).

Treatment

The goal of anti-HBV therapy is to prevent the progression of disease to cirrhosis, end-stage liver disease, and HCC and to improve the survival of patients with chronic hepatitis B (Wu and Ning, 2017). Patients with HBV infections should be referred to providers who are familiar with recent updates in HBV infection. Although out of the scope of this chapter, the AASLD guidelines outline the management, including necessary surveillance and antiviral treatments, for HBV infection (Terrault et al., 2018).

Prevention

Prevention is a two-tier approach including decreasing the risk for transmission among HBV-infected individuals and vaccinating at-risk populations to prevent infection with HBV.

Counseling Patients Who Are HBsAg Positive

Counseling patients who are HBsAg positive is focused on preventing transmission of the HBV and maximizing overall health. These patients should be counseled on ways to reduce transmission, such as the following:

- Have household and sexual contacts vaccinated
- Use barrier protection during sexual intercourse if partner is not vaccinated or naturally immune
- Do not share toothbrush or razors
- Do not share injection equipment/glucose testing equipment
- Clean open cuts and scratches
- Clean blood spills with bleach solution
- Do not donate blood, organs, or sperm

Children with HBsAg should not be excluded from activities, day care, or school participation. **HCWs should not be excluded from training or practice because they have HBV infection**. **Those HCWs whose job requires performance of exposure-prone procedures should seek advice from their institution.** The AASLD states that HCWs should not perform exposure-prone procedures if their serum HBV DNA levels exceed 1000 IU/mL but may resume these procedures once levels are lower and maintained at less than 1000 IU/mL (Terrault et al., 2018).

The CDC recommends screening of all pregnant women for HBsAg and HBV DNA testing for women who are HBsAg positive. If HBV DNA is greater than 200,000 IU/mL, antiviral treatment is suggested to decrease the perinatal transmission risk (Schillie, 2018b).

Vaccination

The CDC recommends HBV vaccination for the following (Schillie, 2018b):

- Prophylaxis for infants born to HBsAG-positive women (also include hepatitis B immunoglobulin [HBIG])
- Universal vaccination of all infants beginning at birth as a

safeguard for infants born to HBV-infected mothers not identified prenatally

- Routine vaccination of all previously unvaccinated children younger than 19 years of age
- Vaccination of adults at risk for HBV infection, including those requesting protection from HBV without acknowledgment of a specific risk factor

Both single-antigen HepB vaccines and combination vaccines are available. The two single-antigen vaccines recommended for use in the United States, Engerix-B (GlaxoSmithKline Biologicals, Rixensart, Belgium) and Recombivax HB (Merck & Co., Inc., Whitehouse Station, New Jersey), are used for vaccination of persons starting at birth. Combination vaccines are Pediarix (GlaxoSmithKline Biologicals, Rixensart, Belgium), which contains recombinant HBsAg, diphtheria, and tetanus toxoids, acellular pertussis adsorbed, and inactivated poliovirus and is used for persons 6 weeks to 6 years of age, and Twinrix (GlaxoSmithKline Biologicals, Rixensart, Belgium), which contains recombinant HBsAg and inactivated hepatitis A virus and is used for persons 18 years of age and older (Schillie, 2018b). On November 9, 2017, Heplisav-B (HepB-CpG), a single-antigen HepB vaccine with a novel immunostimulatory sequence adjuvant, was approved by the FDA for prevention of HBV in persons 18 years of age and older. The vaccine is administered as 2 doses, 1 month apart (Schillie, 2018a). Vaccine schedules are determined on the basis of immunogenicity data, and the need for additional/concurrent immunizations. Updated vaccine schedules can be found in the CDC's Recommendations of the Advisory Committee on Immunization Practices (Schillie, 2018b).

Postvaccination Serologic Testing for Response

Postvaccination serologic testing for response is generally not indicated. Testing is recommended for those in whom knowledge of their immune status is needed (e.g., HCWs or public safety workers at high risk for continuous percutaneous or mucosal exposure to blood/bodily fluids). It is also recommended for persons with HIV infections and other immunocompromised persons to determine the need for revaccination. It is also recommended for sex partners and needle-sharing partners of HBsAg-positive persons to determine the need for revaccination and other methods to protect themselves from HBV infection (Frieden et al., 2015). Booster doses or revaccination is not recommended unless anti-HBs remains less than 10 mIU/mL, after initial vaccination of infants born to HBsAg-positive mothers, in HCWs, in hemodialysis patients, and in other immunocompromised individuals (Terrault et al., 2018).

Postexposure Prophylaxis

For those who are exposed to HBV through an identifiable exposure to blood or body fluids, all wounds and skin sites that have come into contact with potentially infected fluids should be washed with soap and water. Mucous membranes should be flushed with water. Applying caustic agents (e.g., bleach) or injection of antiseptics into the wound is not recommended (Schillie, 2018b).

Postexposure in a Previously Vaccinated Health Care Worker

Recommendations for postexposure in a previously vaccinated HCW are as follows:

- If anti-HBs is known to be greater than 10 mIU/mL, no testing of the source patient for HBV is indicated, and no postexposure prophylaxis is indicated.
- If anti-HBs is unknown, the HCW should be tested for anti-HBs levels, and the source patient should be tested for HBsAg.
- If anti-HBs is less than 10 mIU/mL and it is not known if the source patient is HBsAg-positive, the HCW should get one dose of HBIG and be revaccinated with two doses.
  - Check anti-HBs 1 to 2 months after the second vaccine dose.
- If anti-HBs is less than 10 mIU/mL and the source patient is HBsAg-negative, the HCW should receive one vaccine dose.
  - Check anti-HBs 1 to 2 months after vaccine dose.
- If anti-HBs is greater than 10 mIU/mL, no hepatitis B immunoglobulin (HBIG) or additional vaccine is indicated.

- For vaccinated HCWs with anti-HBs less than 10 mIU/mL after two vaccine series, the source patient should be tested as soon as possible.
- If source patient is positive, two doses of HBIG are indicated, one at the time of exposure and an additional dose 1 month later.
- No additional vaccine is indicated.

Postexposure in an Unvaccinated or Incompletely Vaccinated Health Care Worker

The source patient should be tested as soon as possible. If the source patient is HBsAg-positive or unknown, the dose regimen is as follows:

- HCW should receive one dose of HBIG and one vaccine dose.
  - Complete remainder of vaccine series
  - Anti-HBs 1 to 2 months after last vaccine dose (at least 6 months from HBIG dose)

If the source patient is HBsAg-negative, the dose regimen is as follows:

- HCW should complete vaccine schedule
  - Anti-HBs 1 to 2 months after last vaccine doses

Clinical Management of the Health Care Worker Exposed to HBV

In HCWs with anti-HBs less than 10 mIU/mL or unvaccinated/incompletely vaccinated HCWs with exposure to an HBsAg-positive or unknown status, testing for total anti-HBc should be done immediately followed by HBsAg and total anti-HBc 6 months later. **The exposed HCW should refrain from donating blood, plasma, organs, or semen. Sexual practices do not need to be modified, and exposed HCWs do not need to refrain from pregnancy. Breastfeeding does not have to discontinue based on exposure.** No modification of HCW patient-care responsibilities is necessary to prevent transmission to patients (Schillie, 2018b).

Hepatitis C

Approximately 2.7 to 3.9 million individuals are currently living with chronic hepatitis C virus (HCV) infection, with approximately 41,200 new cases of HCV in 2016 (CDC, 2018b). Approximately 50% of those infected are unaware they have HCV. HCV is transmitted primarily through percutaneous exposure that can result from intravenous drug use, needle-stick injuries, and inadequate infection control in health care settings. Injection drug use now accounts for 60% of acute HCV infections (American Association for the Study of Liver Diseases–Infectious Diseases Society of America [AASLD-IDSA], 2018; Tohme, 2010). Less commonly, HCV transmission occurs among HIV-positive individuals who have had sexual contact with an HCV-infected partner (especially among MSM), individuals who have received tattoos in an unregulated environment, and infants born to HCV-infected mothers (Tohme, 2010; CDC, 2018b).

Diagnosis

One-time testing is indicated for those born between 1945 and 1965 and for all persons with behaviors, exposures, or conditions/circumstances associated with increased risk for HCV infection. These other factors are listed as follows (AASLD-IDSA, 2018):

- Behaviors: any history of injection drug use or intranasal illicit drug use
- Risk exposures: long-term hemodialysis; percutaneous/parental exposure in an unregulated setting; HCW or public safety worker after needle-stick, sharps, or mucosal exposure to HCV-infected blood; children born to HCV-infected women; persons who received a transfusion of blood or blood component or underwent an organ transplant before July 1992; those who received clotting factor concentrates produced before 1987; and those who were incarcerated.
- Other conditions/circumstances: HIV infection, sexually active persons about to start pre-exposure prophylaxis for HIV, unexplained chronic liver disease, solid organ donors

Annual testing is recommended for persons who inject drugs and for HIV-infected MSM. Periodic testing should be offered to those with ongoing risk factors for HCV exposure (AASLD-IDSA, 2018).

HCV antibody testing is recommended for the initial diagnosis of HCV infection. A positive HCV antibody test indicates current infection (acute or chronic), resolved prior infection, or a false-positive result. Any positive HCV antibody test should be followed by a HCV nucleic acid test to detect HCV viremia. HCV RNA testing should be done in those with a negative HCV antibody test who are immunocompromised or who may have been exposed within 6 months of the test.

Occupational HCV Exposure in the Health Care Worker

The risk for HCV transmission after exposure to an HCV-positive needle stick or sharps exposure is 0.1% (Egro et al., 2017; CDC, 2018b). If known, the source should be tested for HCV RNA. If the source HCV RNA is negative, no further testing is indicated for the HCW. If the source HCV RNA is positive or unknown, the HCW should have an anti-HCV test within 48 hours. If positive, a reflexive HCV RNA should be sent and the HCW should be referred for treatment of a pre-existing HCV infection. If it is negative, follow-up testing should include an HCV RNA test 3 weeks or longer postexposure. If positive, refer for care. If negative, an optional anti-HCV test can be performed at 6 months postexposure.

As with HBV exposure, HCW who are exposed to an HCV-positive or unknown source should refrain from donating blood, plasma, organs, or semen. Sexual practices do not need to be modified, and exposed HCWs do not need to refrain from pregnancy. Breastfeeding does not have to discontinue based on exposure (CDC, 2001).

Treatment

The goal of treatment of HCV-infected persons is to reduce mortality and liver-related health conditions including end-stage liver disease and hepatocellular carcinoma (AASLD-IDSA, 2018). Since the approval of highly effective HCV protease inhibitor therapies in 2011, the treatment for HCV infections has evolved significantly. Current therapies can achieve a sustained virologic response (absence of detectable virus 12 weeks after treatment), indicative of a cure, in greater than 90% of HCV patients regardless of HCV genotype. Currently, the AASLD-IDSA recommend treatment for all individuals with chronic HCV infections except those with a short life expectancy who cannot be improved with HCV therapy, liver transplantation, or another directed therapy (AASLD-IDSA, 2018).

Treatment is driven by genotype and the presence and degree of cirrhosis. A complete list of treatment recommendations based on genotype and presence/absence and degree of cirrhosis is detailed in the joint AASLD-IDSA HCV guidelines (AASLD-IDSA, 2018).

Ectoparasitic Infections

Pediculosis Pubis (Phthirus Pubis): *Pubic or Crab Louse*

Pediculosis pubis is an infectious disease caused by the infestation with the parasite *Phthirus pubis*. The infection is transmitted by sexual contact, close body contact, or, less commonly, contact with objects. *Phthirus pubis* infects the terminal hairs of the pubic and perianal areas (Salavastru et al., 2017). The lifetime of the adult parasite is less than 1 month during which the female lays eggs that need 1 week to hatch (Galiczynski and Elston, 2008). The incubation period is usually less than 1 month but may be longer (Salavastru et al., 2017). Transmission is not prevented with the use of condoms. **The presence of pubic lice in children does not imply definite sexual contact as they can be acquired by contact with an infected person** (Chosidow, 2000). Patients with pediculosis pubis should be evaluated for other STDs including HIV (Workowski, 2015).

The main complaint is usually itching in the genital area. On examination, visible nits and/or lice are attached to hairs. Initial exposure can result in symptoms in 2 to 6 weeks, but subsequent exposures are associated with quicker onset of symptoms. Because empty egg shells can remain on the hair for many months, the diagnosis is only by identifying live lice or visible eggs (Chosidow, 2000). **Recommended treatments include permethrin 1% cream rinse (applied to affected areas and washed off after 10 minutes) or pyrethrins with piperonyl butoxide applied in the same manner** (Workowski, 2015). Reported resistance to perimethrin and pyrethrins has been increasing and becoming more widespread (Meinking et al., 2002; Yoon et al., 2003). Malathion 0.5% lotion (applied to affected areas and washed off after 8 to 12 hours) can be used when treatment failure is thought to be caused by resistance (Workowski, 2015).

Bedding and clothing should be machine washed (at 50°C), dry-cleaned, or sealed and stored in a plastic bag for 3 days (Workowski, 2015; Salavastru et al., 2017). Fumigation of living areas is not needed. Sex partners within the previous month should be treated. Follow-up evaluation should be done in 1 week, and if lice or eggs are found, retreatment may be necessary. If no clinical response was noted with the use of a recommended regimen, retreatment with an alternative regimen is recommended (Workowski, 2015).

Scabies

Scabies is an infectious disease caused by infestation with the parasite *Sarcoptes scabiei* var. *hominis*. The infection occurs by skin-to-skin contact including sexual intercourse, or less commonly, contact with infected fomites (e.g., clothing) (Salavastru et al., 2017). *S. scabiei* mites burrow into the epidermis in which the female parasite lays eggs that hatch and develop into adults in 2 weeks. Adult parasites die outside their human host within 24 to 36 hours (Arlian et al., 1984). The mites and mite products (feces, eggs, and dead parasites) generate an immediate or delayed (type IV) hypersensitivity reaction such that scabies symptoms usually start 3 to 6 weeks after primary infestation and then 1 to 3 days after reinfestation (Chosidow, 2006; Walton and Oprescu, 2013; Salavastru et al., 2017).

The most common presentations are skin rash and itching, especially at night**. Female scabies mites can burrow under the skin, producing tiny raised and serpiginous lines on the skin** (Salavastru et al., 2017). Scratching can lead to secondary infection with *S. aureus* or β-hemolytic streptococci, and these secondary infections have been associated with poststreptococcal glomerulonephritis (Svartman et al., 1972). A more concentrated area of mites can form a crust and is called *crusted* scabies (Norwegian scabies). This is an aggressive infestation that usually occurs in immunodeficient, debilitated, or malnourished individuals. Diagnosis is suspected based on the characteristics of itch, clinical findings, and suggestive history (e.g., exposure). **Definitive diagnosis is made by microscopic examination of skin scrapings, which identifies mites, eggs, or fecal pellets.** In sexually active patients, STD screening including HIV is recommended (Salavastru et al., 2017).

Recommended treatments include permethrin 5% cream or ivermectin 200 μg/kg orally, repeated in 2 weeks. Topical treatment should be applied at night to all skin regions, including the scalp, groin, navel, external genitalia, finger and toe web spaces, and the skin beneath the ends of nails, and is left in place for 8 to 12 hours. An alternative therapy is lindane 1%, however, because of its toxicity, it should only be used in patients >10 years of age who cannot tolerate the recommended therapies or if the therapies have failed (Mounsey et al., 2008, 2009, 2013; Workowski, 2015). Substantial treatment failures will likely happen with these treatment regimens in the management of crusted scabies. Combination treatment recommendations for crusted scabies consisting of a topical scabicide (25% topical benzyl benzoate or 5% permethrin cream) in a full body application repeated for 7 days and then twice weekly until cured) and oral ivermectin 200 µg/kg on days 1, 2, 8, 9, and 15 (additional treatment on days 22 and 29 for severe cases). Lindane should not be used for crusted scabies (Workowski, 2015). **Bedding and clothing should be machine washed (at 50°C), dry-cleaned, or sealed and stored in a plastic bag for 3 days.** Persons who have had sexual, close personal, or household contact with the patient within the preceding month should be examined, and those found to be infested should be treated.

Scabies epidemics frequently occur in nursing homes, hospitals, residential facilities, and other communities (Bouvresse and Chosidow, 2010). Ivermectin can be considered in this setting, although specialty consultation is recommended (Workowski, 2015).

Vaginitis

Vaginitis is characterized by vaginal symptoms including discharge, odor, itching, irritation, and burning. Most women have at least one episode of vaginitis in their lives. The most common forms of vaginitis are bacterial vaginosis (BV), vulvovaginal candidiasis, and trichomoniasis. BV accounts for 40% to 50% of cases in which a cause is identified, vulvovaginal candidiasis accounts for 20% to 25% of cases, and trichomoniasis accounts for 15% to 20% of cases. BV and trichomoniasis are sexually transmitted. **The diagnosis can be made by Amsel's criteria: pH, KOH test (potassium hydroxide preparation), and microscopic examination of fresh discharge** samples (Table 58.8) (Paladine and Desai, 2018).

TABLE 58.8

Differential Diagnosis of Vaginitis in Women

	VAGINAL DISCHARGE	pH	WHITE BLOOD CELLS	MICROSCOPY	SYMPTOMS
Normal	White, thick, smooth	≤4.5	Absent	Lactobacilli	None
Candidiasis	White, thick, curdlike	≤4.5	Absent	Mycelia	Vulvar pruritus, external or superficial dysuria
Trichomoniasis	Frothy or purulent	≥4.5	Present	Mobile trichomonads present Amine odor	Vulvar erythema and edema, punctate strawberry lesions on cervix
Bacterial vaginosis	Thin, white homogeneous	≥4.5	Absent	Paucity of lactobacilli (75% of patients) Amine odor Clue cells	Fishy odor and increased vaginal discharge

Bacterial Vaginosis

BV is a polymicrobial syndrome resulting from replacement of the normal hydrogen peroxide–producing *Lactobacillus* sp. in the vagina with high concentrations of anaerobic bacteria (i.e., *Prevotella* sp. and *Mobiluncus* sp.), *G. vaginalis*, Ureaplasma, Mycoplasma, and numerous fastidious or uncultivated anaerobes. Although BV is the most common diagnosis in women seeking care for vaginal symptoms, most women with BV are asymptomatic. BV is associated with having multiple male or female partners, douching, lack of condom use, and lack of vaginal lactobacilli. Women with BV are at an increased risk for STDs, complications after gynecologic surgery, pregnancy complications, and recurrence of BV. BV increases the risk for HIV transmission to the male partner. The gold standard for diagnosing BV is a Gram stain used to determine the relative concentration of lactobacilli, gram-negative and gram-variable rods and cocci, and curved gram-negative rods characteristic of BV. **Clinical diagnosis requires three of the following symptoms or signs: (1) homogeneous, thin, white discharge that smoothly coats the vaginal walls; (2) clue cells (vaginal epithelial cells studded with bacteria); (3) vaginal fluid pH greater than 4.5; or (4) fishy odor of vaginal discharge before or after addition of 10% KOH. Treatment is recommended for symptomatic women and consists of metronidazole 500 mg orally twice daily for 7 days or metronidazole gel 0.75% (one full applicator: 5 g) intravaginally once daily for 5 days.** An alternative option is clindamycin 2% cream (5 g) intravaginally at bedtime for 7 days. Importantly, clindamycin cream can weaken latex condoms and diaphragms for 5 days after use. **Routine treatment of sex partners is not recommended** (Workowski, 2015).

Trichomoniasis

Trichomoniasis, caused by the protozoan *T. vaginalis*, is the most prevalent nonviral sexually transmitted infection in the United States, affecting 3.7 million people. Although most patients are asymptomatic, symptoms can include diffuse, malodorous, yellow-green discharge with or without vulvar irritation. *T. vaginalis* infection is associated with twofold to threefold increased risk for HIV acquisition, preterm birth, and other pregnancy-related complications. **NAAT is highly sensitive in detecting *T. vaginalis* infections and can be used on vaginal, endocervical, or urine specimens from women.** Culture is available, but NAAT is more sensitive. Microscopic evaluation of wet preparations of genital secretions is common because of low cost. The sensitivity is quite low, however (51% to 65%). If used, slides should be evaluated immediately because sensitivity decreases by up to 20% within 1 hour after collection. **Recommended treatment is a single oral dose of 2 g of metronidazole or 2 g of tinidazole. Because of poor cure rates with a single dose of metronidazole in women with HIV, the CDC recommends metronidazole 500 mg orally twice daily for 7 days for trichomoniasis treatment in HIV-infected women**. Alcohol consumption should be avoided for 24 hours after completion of metronidazole or 72 hours after completion of tinidazole. Because of the high rate of reinfection for trichomoniasis, retesting for *T. vaginalis* is recommended for all sexually active women within 3 months after initial treatment. **All sex partners should be referred for presumptive therapy to avoid reinfection** (Workowski, 2015).

Candidiasis

Vulvovaginal candidiasis (VVC) is usually caused by *C. albicans* but occasionally by other species of *Candida* or yeasts. Seventy-five percent of women will have at least one episode of VVC. Vaginal candidiasis is classified as complicated or uncomplicated based on clinical criteria. Uncomplicated cases involve infections that are sporadic or infrequent, produce mild to moderate symptoms, and are likely to be caused by *C. albicans*, and they occur in immunocompetent women. Complicated cases involve recurrent candidiasis (four or more episodes of symptomatic vulvovaginal candidiasis in 1 year), severe infection, and non–*C. albicans* causes, and they occur in women with uncontrolled diabetes, debilitation, or immunocompromising conditions. Approximately 10% to 20% of cases of vulvovaginal candidiasis will be complicated. **Vaginal cultures should be obtained in patients with recurrent vulvovaginal candidiasis because conventional antimycotic treatments are not as effective against atypical species such as *Candida glabrata***. The diagnosis is made via wet prep with saline or KOH; a Gram stain of vaginal discharge that demonstrates yeast, hyphae, or pseudohyphae; or a culture that shows *Candida* or other yeast species. Wet mounts should first be done for all patients and culture used for those with symptoms with negative wet mounts. Treatment is not recommended for an asymptomatic patient with a positive culture as 10% to 20% of women are colonized with *Candida* sp. and other yeasts in the vagina.

Treatment for uncomplicated vulvovaginal candidiasis includes numerous over-the-counter intravaginal agents including clotrimazole creams, miconazole as a cream or intravaginal suppository, or tioconazole ointment. Prescription treatment formulations include butoconazole cream, terconazole cream or vaginal suppository, nystatin vaginal suppository, or one oral dose of fluconazole 150 mg. A woman who has persistent symptoms or a recurrence 2 months after having used an over-the-counter treatment should be evaluated. In cases of recurrence, a longer duration of therapy such as 7 to 14 days of topical therapy or a dose of fluconazole every third day for a total of three doses is recommended. Treatment for non–*C. albicans* vulvovaginal candidiasis is not standardized (Workowski, 2015).

Key Points

- Patients with urethritis need to be treated for both gonorrhea and chlamydia. Because of higher sensitivity, NAATs are now the preferred method for detecting *N. gonorrhoeae* and *C. trachomatis*. Urethral swab is no longer indicated.
- Most genital ulcers in the United States are either herpes (most common) or syphilis. Chancroid occurs in some parts of the United States, but granuloma inguinale usually does not. LGV is increasing in incidence in MSM.
- Men with possible Zika exposure, regardless of symptom status, should wait at least 6 months from symptom onset (if symptomatic) or from last possible exposure before attempting conception with their partner. Women with possible Zika virus exposure are recommended to wait to conceive until at least 8 weeks after symptom onset of last possible exposure.
- Vaccines to prevent HPV-associated diseases are available and recommended for men and women younger than 26 years of age, preferably to start before the onset of sexual activity.
- Testing for HIV is recommended for anyone with an STD or at risk for acquiring an STD.
- HIV is becoming a chronic disease, and many of the associated problems are from aging and chronic disease instead of immunosuppression.

References

Ahmed KA, Fox SJ, Frigas E, et al. Clinical outcome in the use of cephalosporins in pediatric patients with a history of penicillin allergy. *Int Arch Allergy Immunol*. 2012;158(4):405–410.

Albini L, Calabresi A, Gotti D, et al. Burden of non-AIDS-defining and non-virus-related cancers among HIV-infected patients in the combined antiretroviral therapy era. *AIDS Res Hum Retroviruses*. 2013;29(8):1097–1104.

Albritton WL. Biology of *Haemophilus ducreyi*. *Microbiol Rev*. 1989;53(4):377–389.

American Association for the Study of Liver Diseases–Infectious Diseases Society of America. *HCV guidance: recommendations for testing, managing, and treating hepatitis C*. [Available at] https://www.hcvguidelines.org; 2018.

Arlian LG, Runyan RA, Achar S, et al. Survival and infectivity of *Sarcoptes scabiei* var. canis and var. hominis. *J Am Acad Dermatol*. 1984;11(2 Pt 1):210–215.

Arnheim-Dahlstrom L, Pasternak B, Svanstrom H, et al. Autoimmune, neurological, and venous thromboembolic adverse events after immunisation of adolescent girls with quadrivalent human papillomavirus vaccine in Denmark and Sweden: cohort study. *BMJ*. 2013;347 [f5906].

Auvert B, Taljaard D, Lagarde E, et al. Randomized, controlled intervention trial of male circumcision for reduction of HIV infection risk: the ANRS 1265 Trial. *PLoS Med*. 2005;2(11):e298.

Bachmann LH, Hobbs MM, Sena AC, et al. Trichomonas vaginalis genital infections: progress and challenges. *Clin Infect Dis*. 2011;53(Suppl 3):S160–S172.

Bachmann LH, Manhart LE, Martin DH, et al. Advances in the understanding and treatment of male urethritis. *Clin Infect Dis*. 2015;61(Suppl 8):S763–S769.

Bailey RC, Moses S, Parker CB, et al. Male circumcision for HIV prevention in young men in Kisumu, Kenya: a randomised controlled trial. *Lancet*. 2007;369(9562):643–656.

Benedetti JK, Zeh J, Corey L. Clinical reactivation of genital herpes simplex virus infection decreases in frequency over time. *Ann Intern Med*. 1999;131(1):14–20.

Benson PJ, Smith CS. Cytomegalovirus prostatitis. *Urology*. 1992;40(2):165–167.

Boda D, Docea AO, Calina D, et al. Human papilloma virus: Apprehending the link with carcinogenesis and unveiling new research avenues (Review). *Int J Oncol*. 2018;52(3):637–655.

Borges AH, Neuhaus J, Babiker AG, et al. Immediate antiretroviral therapy reduces risk of infection-related cancer during early HIV infection. *Clin Infect Dis*. 2016;63(12):1668–1676.

Bouvresse S, Chosidow O. Scabies in healthcare settings. *Curr Opin Infect Dis*. 2010;23(2):111–118.

Bower M, Dalla Pria A, Coyle C, et al. Prospective stage-stratified approach to AIDS-related Kaposi's sarcoma. *J Clin Oncol*. 2014;32(5):409–414.

Bower M, Palfreeman A, Alfa-Wali M, et al. British HIV Association guidelines for HIV-associated malignancies 2014b. *HIV Med*. 2014;15(Suppl 2):1–92.

Bradshaw CS, Denham IM, Fairley CK. Characteristics of adenovirua associated urethritis. *Sex Transm Infect*. 2002;78(6):445–447.

Bradshaw CS, Tabrizi SN, Read TR, et al. Etiologies of nongonococcal urethritis: bacteria, viruses, and the association with orogenital exposure. *J Infect Dis*.

2006;193(3):336–345.

Breyer BN, Van den Eeden SK, Horberg MA, et al. HIV status is an independent risk factor for reporting lower urinary tract symptoms. *J Urol*. 2011;185(5):1710–1715.

Brill JR. Diagnosis and treatment of urethritis in men. *Am Fam Physician*. 2010;81(7):873–878.

Brown CW Jr, O'Donoghue M, Moore J, et al. Recalcitrant molluscum contagiosum in an HIV-afflicted male treated successfully with topical imiquimod. *Cutis*. 2000;65(6):363–366.

Cardo DM, Culver DH, Ciesielski CA, et al. A case-control study of HIV seroconversion in health care workers after percutaneous exposure. Centers for Disease Control and Prevention Needlestick Surveillance Group. *N Engl J Med*. 1997;337(21):1485–1490.

Carter JS, Bowden FJ, Bastian I, et al. Phylogenetic evidence for reclassification of Calymmatobacterium granulomatis as Klebsiella granulomatis comb. nov. *Int J Syst Bacteriol*. 1999;49(Pt 4):1695–1700.

Centers for Disease Control and Prevention. Control of smoke from laser/electric surgical procedures. National Institute for Occupational Safety and Health. *Appl Occup Environ Hyg*. 1999;14(2):71.

Centers for Disease Control and Prevention. Updated U.S. Public Health Service guidelines for the management of occupational exposures to HBV, HCV, and HIV and recommendations for postexposure prophylaxis. *MMWR Morb Mortal Wkly Rep*. 2001;50(RR–11):1–52.

Centers for Disease Control and Prevention. *CDC, Health Resources and Services Administration, National Institutes of Health American Academy of HIV Medicine, Association of Nurses on AIDS Care, International Association of Providers of AIDS Care, the National Minority AIDS Council and*

Urban Coalition for HIV/AIDS Prevention Services. Recommendations for HIV Prevention with Adults and Adolescents with HIV in the United States. [Available at] https://www.cdc.gov/hiv/guidelines/recommendations/person 2014.

Centers for Disease Control and Prevention. *Sexually transmitted disease surveillance*. [Available at] https://www.cdc.gov/std/stats16/default.htm; 2016.

Centers for Disease Control and Prevention. *Updated guidelines for antiretroviral postexposure prophylaxis after sexual, injection drug use, or other nonoccupational exposure to HIV—United States*. [Available at] https://www.cdc.gov/hiv/pdf/programresources/cdc-hiv-npep-guidelines.pdf; 2016.

Centers for Disease Control and Prevention. *Syphilis—CDC Fact Sheet (detailed)*. [Available at] https://www.cdc.gov/std/syphilis/stdfact-syphilis-detailed.htm; 2017.

Centers for Disease Control and Prevention. *Syphilis & MSM (men who have sex with men)—CDC Fact Sheet*. [Available at] https://www.cdc.gov/std/syphilis/stdfact-msm-syphilis.htm; 2017.

Centers for Disease Control and Prevention. *Pre-exposure Prophylaxis for the Prevnetion of HIV Infection in the United States—2017 Update: A Clinical Practice Guideline 2017*. [Available from] https://www.cdc.gov/hiv/pdf/guidelines/cdc-hiv-prep-guidelines-2017.pdf.

Centers for Disease Control and Prevention. *Preexposure prophylaxis for the prevention of HIV infection in the United States—2017 update: A Clinical Practice Guideline*. [Available at] https://www.cdc.gov/hiv/pdf/risk/prep/cdc-hiv-prep-guidelines-2017.pdf; 2017.

Centers for Disease Control and Prevention. *About HIV/AIDS*. [Available at] https://www.cdc.gov/hiv/basics/whatishiv.html; 2018.

Centers for Disease Control and Prevention. *Hepatitis C questions and answers for health professionals*. [Available at] https://www.cdc.gov/hepatitis/hcv/hcvfaq.htm; 2018.

Centers for Disease Control and Prevention. *HPV vaccine information for clinicians*. [Available at] https://www.cdc.gov/hpv/hcp/need-to-know.pdf; 2018.

Centers for Disease Control and Prevention. *Interpretation of hepatitis B serologic test results*. [Available at] https://www.cdc.gov/hepatitis/hbv/pdfs/SerologicChartv8.pdf 2018.

Centers for Disease Control and Prevention. *Testing guidance*. [Available at] https://www.cdc.gov/zika/hc-providers/testing-guidance.html; 2018.

Chambers RW, Foley HT, Schmidt PJ. Transmission of syphilis by fresh blood components. *Transfusion*. 1969;9(1):32–34.

Chawki S, Ploussard G, Montlahuc C, et al. Bladder cancer in HIV-infected adults: An emerging issue? Case-reports and systematic review. *PLoS ONE*. 2015;10(12) [e0144237].

Chesson HW, Heffelfinger JD, Voigt RF, et al. Estimates of primary and secondary syphilis rates in persons with HIV in the United States, 2002. *Sex Transm Dis*. 2005;32(5):265–269.

Chesson HW, Sternberg M, Leichliter JS, et al. Changes in the state-level distribution of primary and secondary syphilis in the USA, 1985–2007. *Sex Transm Infect*. 2010;86(Suppl 3):iii58–iii62.

Chesson HW, Ekwueme DU, Saraiya M, et al. Estimates of the annual direct medical costs of the prevention and treatment of disease associated with human papillomavirus in the United States. *Vaccine*. 2012;30(42):6016–6019.

Chosidow O. Scabies and pediculosis. *Lancet*. 2000;355(9206):819–826.

Chosidow O. Clinical practices. Scabies. *N Engl J Med*. 2006;354(16):1718–1727.

Chou R, Cantor AG, Zakher B, et al. Screening for HIV in pregnant women: systematic review to update the 2005 U.S. Preventive Services Task Force Recommendation. *Ann Intern Med*. 2012;157(10):719–728.

Ciavattini A, Tsiroglou D, Vichi M, et al. Topical Imiquimod 5% cream therapy for external anogenital warts in pregnant women: report of four cases and review of the literature. *J Matern Fetal Neonatal Med*. 2012;25(7):873–876.

Clifford GM, Smith JS, Plummer M, et al. Human papillomavirus types in invasive cervical cancer worldwide: a meta-analysis. *Br J Cancer*. 2003;88(1):63–73.

Coburn M. Urological manifestations of HIV infection. *AIDS Res Hum Retroviruses*. 1998;14(Suppl 1):S23–S25.

Collier AC, Meyers JD, Corey L, et al. Cytomegalovirus infection in homosexual men. Relationship to sexual practices, antibody to human immunodeficiency virus, and cell-mediated immunity. *Am J Med*. 1987;82(3 Spec No):593–601.

Corey L, Adams HG, Brown ZA, et al. Genital herpes simplex virus infections: clinical manifestations, course, and complications. *Ann Intern Med*. 1983;98(6):958–972.

Corey L, Wald A, Patel R, et al. Once-daily valacyclovir to reduce the risk of transmission of genital herpes. *N Engl J Med*. 2004;350(1):11–20.

Couldwell DL, Gidding HF, Freedman EV, et al. Ureaplasma urealyticum is significantly associated with non-gonococcal urethritis in heterosexual Sydney men. *Int J STD AIDS*. 2010;21(5):337–341.

Croxford S, Kitching A, Desai S, et al. Mortality and causes of death in people diagnosed with HIV in the era of highly active antiretroviral therapy compared with the general population: an analysis of a national observational cohort. *Lancet Public Health*. 2017;2(1):e35–e46.

Crum-Cianflone N, Hullsiek KH, Marconi V, et al. Trends in the incidence of cancers among HIV-infected persons and the impact of antiretroviral therapy: a 20-year cohort study. *AIDS*. 2009;23(1):41–50.

Dalton AD, Harcourt-Webster JN. The histopathology of the testis and epididymis in AIDS—a post-mortem study. *J Pathol*. 1991;163(1):47–52.

Danielsen AG, Weismann K, Jorgensen BB, et al. Incidence, clinical presentation and treatment of neurosyphilis in Denmark 1980–1997. *Acta Derm Venereol*. 2004;84(6):459–462.

De Paepe ME, Waxman M. Testicular atrophy in AIDS: a study of 57 autopsy cases. *Hum Pathol*. 1989;20(3):210–214.

Elias JFM, Vogel U. *Manual of clinical microbiology*. American Society of Microbiology: Washington, D.C.; 2011.

Egro FM, Nwaiwu CA, Smith S, et al. Seroconversion rates among health care workers exposed to hepatitis C virus-contaminated body fluids: the University of Pittsburgh 13-year experience. *Am J Infect Control*. 2017;45(9):1001–1005.

Ekrikpo UE, Kengne AP, Bello AK, et al. Chronic kidney disease in the global adult HIV-infected population: a systematic review and meta-analysis. *PLoS ONE*. 2018;13(4) [e0195443].

Fernando I, Pritchard J, Edwards SK, et al. UK national guideline for the management of Genital Molluscum in adults, 2014 Clinical Effectiveness Group, British Association for Sexual Health and HIV. *Int J STD AIDS*. 2015;26(10):687–695.

Foy BD, Kobylinski KC, Chilson Foy JL, et al. Probable non-vector-borne transmission of Zika virus, Colorado, USA. *Emerg Infect Dis*. 2011;17(5):880–882.

French P. Syphilis. *BMJ*. 2007;334(7585):143–147.

Frieden TR, Cono J, et al. Sexually transmitted diseases treatment guidelines, 2015. *MMWR Recomm Rep*. 2015;64(3).

Frølund M, Lidbrink P, Cullberg M, et al. The association of Ureaplasma urealyticum with male non-gonococcal urethritis. *Sex Transm Infect*. 2011;87(S1):A303–A304.

Fung M, Scott KC, Kent CK, et al. Chlamydial and gonococcal reinfection among men: a systematic review of data to evaluate the need for retesting. *Sex Transm Infect*. 2007;83(4):304–309.

Galiczynski EM Jr, Elston DM. What's eating you? Pubic lice *(Pthirus pubis)*. *Cutis*. 2008;81(2):109–114.

Garland SM, Steben M, Sings HL, et al. Natural history of genital warts: analysis of the placebo arm of 2 randomized phase III trials of a quadrivalent human papillomavirus (types 6, 11, 16, and 18) vaccine. *J Infect Dis*. 2009;199(6):805–814.

Gaughan EM, Dezube BJ, Aboulafia D, et al. Human immunodeficiency virus–associated renal cell carcinoma: a transatlantic case series. *Clin Genitourin Cancer*. 2008;6(2):86–90.

Gaughan EM, Dezube BJ, Bower M, et al. HIV-associated bladder cancer: a case series evaluating difficulties in diagnosis and management. *BMC Urol*. 2009;9:10.

Gonzalez-Beiras C, Marks M, Chen CY, et al. Epidemiology of *Haemophilus ducreyi* infections. *Emerg Infect Dis*. 2016;22(1):1–8.

Gottlieb SL, Xu F, Brunham RC. Screening and treating *Chlamydia trachomatis* genital infection to prevent pelvic inflammatory disease: interpretation of findings from randomized controlled trials. *Sex Transm Dis*. 2013;40(2):97–102.

Gray RH, Kigozi G, Serwadda D, et al. Male circumcision for HIV prevention in men in Rakai, Uganda: a randomised trial. *Lancet*. 2007;369(9562):657–666.

Gupta R, Warren T, Wald A. Genital herpes. *Lancet*. 2007;370(9605):2127–2137.

Haq IU, Dalla Pria A, Papanastasopoulos P, et al. The clinical application of plasma Kaposi sarcoma herpesvirus viral load as a tumour biomarker: results from 704 patients. *HIV Med*. 2016;17(1):56–61.

Hart G. Syphilis tests in diagnostic and therapeutic decision making. *Ann Intern Med*. 1986;104(3):368–376.

Hennessey M, Fischer M, Staples JE. Zika virus spreads to new areas—region of the Americas, May 2015–January 2016. *MMWR Morb Mortal Wkly Rep*. 2016;65(3):55–58.

Hentrich M, Pfister D. HIV-associated urogenital malignancies. *Oncol Res Treat*. 2017;40(3):106–112.

Heyns CF, Smit SG, van der Merwe A, et al. Urological aspects of HIV and AIDS. *Nat Rev Urol*. 2013;10(12):713–722.

Ho EL, Lukehart SA. Syphilis: using modern approaches to understand an old disease. *J Clin Invest*. 2011;121(12):4584–4592.

Hoepelman AI, van Buren M, van den Broek J, et al. Bacteriuria in men infected with HIV-1 is related to their immune status (CD4+ cell count). *AIDS*. 1992;6(2):179–184.

Hoffmann C, Sabranski M, Esser S. HIV-associated Kaposi's sarcoma. *Oncol Res Treat*. 2017;40(3):94–98.

Hook EW 3rd, Handsfield HH. Gonococcal infections in the adult. Holmes KK, Sparling PF, Stamm WE. *Sexually transmitted diseases*. 4th ed. McGraw-Hill: New York, NY; 2008:627–645.

Hope-Rapp E, Anyfantakis V, Fouere S, et al. Etiology of genital ulcer disease. A prospective study of 278 cases seen in an STD clinic in Paris. *Sex Transm Dis*. 2010;37(3):153–158.

Horner PJ, Blee K, Falk L, et al. 2016 European guidelines on the management of non-gonococcal urethritis. *Int J STD AIDS*. 2016;27(11):928–937.

Horner PJ, Martin DH. Mycoplasma genitalium Infection in Men. *J Infect Dis*. 2017;216(Suppl_2):S396–S405.

Hosenfeld CB, Workowski KA, Berman S, et al. Repeat infection with Chlamydia and gonorrhea among females: a systematic review of the literature. *Sex Transm Dis*. 2009;36(8):478–489.

Hyams KC. Risks of chronicity following acute hepatitis B virus infection: a review. *Clin Infect Dis*. 1995;20(4):992–1000.

Hyun G, Lowe FC. AIDS and the urologist. *Urol Clin North Am*. 2003;30(1):101–109.

Institute of Medicine (US). The hidden epidemic: confronting sexually transmitted diseases: summary. Eng TR, Butler WT. *Committee on Prevention and Control of Sexually Transmitted Diseases*. National Academies Press: Washington, DC; 1997.

James WD, Berger TG, Elston DM. Viral diseases. *Andrews' diseases of the skin: clinical dermatology*. 12th ed. Elsevier: Philadelphia, PA; 2016:359–417.

Janier M, Hegyi V, Dupin N, et al. 2014 European guideline on the management of syphilis. *J Eur Acad Dermatol Venereol*. 2014;28(12):1581–1593.

Jebbari H, Alexander S, Ward H, et al. Update on lymphogranuloma venereum in the United Kingdom. *Sex Transm Infect*. 2007;83(4):324–326.

Jemal A, Simard EP, Dorell C, et al. Annual report to the nation on the status of cancer, 1975–2009, featuring the burden and trends in human papillomavirus (HPV)–Associated cancers and HPV vaccination coverage levels. *J Natl Cancer Inst*. 2013;105(3):175–201.

Jensen JS, Cusini M, Gomberg M, et al. 2016 European guideline on *Mycoplasma genitalium* infections. *J Eur Acad Dermatol Venereol*. 2016;30(10):1650–1656.

Johnston C, Corey L. Current concepts for genital herpes simplex virus infection: diagnostics and pathogenesis of genital tract shedding. *Clin Microbiol Rev*. 2016;29(1):149–161.

Jones M, Klimes I, Catalan J. Psychosexual problems in people with HIV infection: controlled study of gay men and men with haemophilia. *AIDS Care*. 1994;6(5):587–593.

Kalichman SC, Pellowski J, Turner C. Prevalence of sexually transmitted co-infections in people living with HIV/AIDS: systematic review with implications for using HIV treatments for prevention. *Sex Transm Infect*. 2011;87(3):183–190.

Kalyesubula R, Perazella MA. Nephrotoxicity of HAART. *AIDS Res Treat*. 2011;2011 [562790].

Kerani RP, Handsfield HH, Stenger MS, et al. Rising rates of syphilis in the era of syphilis elimination. *Sex Transm Dis*. 2007;34(3):154–161.

Kidd S, Kirkcaldy R, Ye T, et al. *Cephalosporin-resistant* Neisseria gonorrhoeae *public health response plan*. [Available at] https://www.cdc.gov/std/treatment/ceph-r-responseplanjuly30-2012.pdf; 2012.

Kirkcaldy RD, Harvey A, Papp JR, et al. *Neisseria gonorrhoeae* antimicrobial susceptibility surveillance—The Gonococcal Isolate Surveillance Project, 27 Sites, United States, 2014. *MMWR Surveill Summ*. 2016;65(7):1–19.

Kirkcaldy RD, Weinstock HS, Moore PC, et al. The efficacy and safety of gentamicin plus azithromycin and gemifloxacin plus azithromycin as treatment of uncomplicated gonorrhea. *Clin Infect Dis*. 2014;59(8):1083–1091.

Kohan AD, Armenakas NA, Fracchia JA. Indinavir urolithiasis: an emerging cause of renal colic in patients with human immunodeficiency virus. *J Urol*. 1999;161(6):1765–1768.

Koppolu V, Shantha Raju T. Zika virus outbreak: a review of neurological complications, diagnosis, and treatment options. *J Neurovirol*. 2018;24(3):255–272.

Koutsky LA, Stevens CE, Holmes KK, et al. Underdiagnosis of genital herpes by current clinical and viral-isolation procedures. *N Engl J Med*. 1992;326(23):1533–1539.

Kwan DJ, Lowe FC. Acquired immunodeficiency syndrome. A venereal disease. *Urol Clin North Am*. 1992;19(1):13–24.

Lafond RE, Lukehart SA. Biological basis for syphilis. *Clin Microbiol Rev*. 2006;19(1):29–49.

Lamba H, Goldmeier D, Mackie NE, et al. Antiretroviral therapy is associated with sexual dysfunction and with increased serum oestradiol levels in men. *Int J STD AIDS*. 2004;15(4):234–237.

Lanjouw E, Ouburg S, de Vries HJ, et al. 2015 European guideline on the management of *Chlamydia trachomatis* infections. *Int J STD AIDS*. 2016;27(5):333–348.

Lautenschlager S, Kemp M, Christensen JJ, et al. 2017 European guideline for the management of chancroid. *Int J STD AIDS*. 2017;28(4):324–329.

Lebovitch S, Mydlo JH. HIV-AIDS: urologic considerations. *Urol Clin North Am*. 2008;35(1):59–68 [vi].

Lee LK, Dinneen MD, Ahmad S. The urologist and the patient infected with human immunodeficiency virus or with acquired immunodeficiency syndrome. *BJU Int*. 2001;88(6):500–510.

LeFevre M. USPSTF: screening for chlamydia and gonorrhea. *Ann Intern Med*. 2014;161:902–910.

Leport C, Rousseau F, Perronne C, et al. Bacterial prostatitis in patients infected with the human immunodeficiency virus. *J*

Urol. 1989;141(2):334–336.

Lewis DA. Chancroid: clinical manifestations, diagnosis, and management. *Sex Transm Infect*. 2003;79(1):68–71.

Lin KY, Liao SH, Liu WC, et al. Cholelithiasis and nephrolithiasis in HIV-positive patients in the era of combination antiretroviral therapy. *PLoS ONE*. 2015;10(9) [e0137660].

Luo L, Deng T, Zhao S, et al. Association between HIV infection and prevalence of erectile dysfunction: a systematic review and meta-analysis. *J Sex Med*. 2017;14(9):1125–1132.

Mabey D, Peeling RW. Lymphogranuloma venereum. *Sex Transm Infect*. 2002;78(2):90–92.

Madhivanan P, Pierre-Victor D, Mukherjee S, et al. Human papillomavirus vaccination and sexual disinhibition in females: a systematic review. *Am J Prev Med*. 2016;51(3):373–383.

Magalhaes T, Foy BD, Marques ETA, et al. Mosquito-borne and sexual transmission of Zika virus: Recent developments and future directions. *Virus Res*. 2018;254:1–9.

Magro CM, Crowson AN, Alfa M, et al. A morphological study of penile chancroid lesions in human immunodeficiency virus (HIV)-positive and -negative African men with a hypothesis concerning the role of chancroid in HIV transmission. *Hum Pathol*. 1996;27(10):1066–1070.

Manhart LE, Gillespie CW, Lowens MS, et al. Standard treatment regimens for nongonococcal urethritis have similar but declining cure rates: a randomized controlled trial. *Clin Infect Dis*. 2013;56(7):934–942.

Manhart LE, Holmes KK, Hughes JP, et al. Mycoplasma genitalium among young adults in the United States: an emerging sexually transmitted infection. *Am J Public Health*. 2007;97(6):1118–1125.

Mashiah J, Brenner S. Possible mechanisms in the induction of vitiligo-like hypopigmentation by topical imiquimod. *Clin Exp Dermatol*. 2008;33(1):74–76.

Mead PS, Hills SL, Brooks JT. Zika virus as a sexually transmitted pathogen. *Curr Opin Infect Dis*. 2018;31(1):39–44.

Meinking TL, Serrano L, Hard B, et al. Comparative in vitro pediculicidal efficacy of treatments in a resistant head lice population in the United States. *Arch Dermatol*. 2002;138(2):220–224.

Meites E, Gaydos CA, Hobbs MM, et al. A review of evidence-based care of symptomatic trichomoniasis and asymptomatic Trichomonas vaginalis infections. *Clin Infect Dis*. 2015;61(Suppl 8):S837–S848.

Mhawech P, Onorato M, Uchida T, et al. Testicular atrophy in 80 HIV-positive patients: a multivariate statistical analysis. *Int J STD AIDS*. 2001;12(4):221–224.

Mindel A, Tovey SJ, Timmins DJ, et al. Primary and secondary syphilis, 20 years' experience. 2. Clinical features. *Genitourin Med*. 1989;65(1):1–3.

Moi H, Blee K, Horner PJ. Management of non-gonococcal urethritis. *BMC Infect Dis*. 2015;15:294.

Moreira J, Peixoto TM, Siqueira AM, et al. Sexually acquired Zika virus: a systematic review. *Clin Microbiol Infect*. 2017;23(5):296–305.

Morse SA. Chancroid and *Haemophilus ducreyi*. *Clin Microbiol Rev*. 1989;2(2):137–157.

Mounsey KE, Holt DC, McCarthy J, et al. Scabies: molecular perspectives and therapeutic implications in the face of emerging drug resistance. *Future Microbiol*. 2008;3(1):57–66.

Mounsey KE, Holt DC, McCarthy JS, et al. Longitudinal evidence of increasing in vitro tolerance of scabies mites to ivermectin in scabies-endemic communities. *Arch Dermatol*.

2009;145(7):840–841.

Mounsey KE, McCarthy JS, Walton SF. Scratching the itch: new tools to advance understanding of scabies. *Trends Parasitol*. 2013;29(1):35–42.

Moyer V. US preventive service task force recommendation statement. *Ann Intern Med*. 2013;159:51–60.

Muzny CA, Schwebke JR. The clinical spectrum of Trichomonas vaginalis infection and challenges to management. *Sex Transm Infect*. 2013;89(6):423–425.

Myers ER, McCrory DC, Nanda K, et al. Mathematical model for the natural history of human papillomavirus infection and cervical carcinogenesis. *Am J Epidemiol*. 2000;151(12):1158–1171.

Myskowski PL. Molluscum contagiosum. New insights, new directions. *Arch Dermatol*. 1997;133(8):1039–1041.

Nakamura-Wakatsuki T, Kato Y, Miura T, et al. Eruptive molluscum contagiosums in a patient with rheumatoid arthritis and lung cancer. *Rheumatol Int*. 2011;31(8):1117–1118.

Navarro Lopez V, Ramos JM, Meseguer V, et al. Microbiology and outcome of iliopsoas abscess in 124 patients. *Medicine (Baltimore)*. 2009;88(2):120–130.

Nickel JC, Alexander RB, Schaeffer AJ, et al. Leukocytes and bacteria in men with chronic prostatitis/chronic pelvic pain syndrome compared to asymptomatic controls. *J Urol*. 2003;170(3):818–822.

Nicol AF, de Andrade CV, Russomano FB, et al. HPV vaccines: their pathology-based discovery, benefits, and adverse effects. *Ann Diagn Pathol*. 2015;19(6):418–422.

Nicolle LE. Urinary tract infections in special populations: diabetes, renal transplant, HIV infection, and spinal cord injury. *Infect Dis Clin North Am*. 2014;28(1):91–104.

O'Byrne P, MacPherson P, DeLaplante S, et al. Approach to lymphogranuloma venereum. *Can Fam Physician*. 2016;62(7):554–558.

O'Connell CM, Ferone ME. Chlamydia trachomatis Genital Infections. *Microb Cell*. 2016;3(9):390–403.

O'Farrell N, Moi H. 2016 European guideline on donovanosis. *Int J STD AIDS*. 2016;27(8):605–607.

Ong WL, King K, Koh TL, et al. HIV and renal cell carcinoma: Experience in an Australian statewide HIV center. *Asia Pac J Clin Oncol*. 2016;12(2):188–193.

Owusu-Edusei K Jr, Chesson HW, Gift TL, et al. The estimated direct medical cost of selected sexually transmitted infections in the United States, 2008. *Sex Transm Dis*. 2013;40(3):197–201.

Owusu-Ofori AK, Parry CM, Bates I. Transfusion-transmitted syphilis in teaching hospital, Ghana. *Emerg Infect Dis*. 2011;17(11):2080–2082.

Paduch DA. Viral lower urinary tract infections. *Curr Urol Rep*. 2007;8(4):324–335.

Paladine HL, Desai UA. Vaginitis: diagnosis and treatment. *Am Fam Physician*. 2018;97(5):321–329.

Pan American Health Organization. *Zika virus infection*. [Available at] http://www.paho.org/hq/index.php?option=com_topics&view=readall&cid=7880&Itemid=41484 2017.

Papp JR, Schachter J, Gaydos CA, et al. Recommendations for the laboratory-based detection of Chlamydia trachomatis and *Neisseria gonorrhoeae*—2014. *MMWR Recomm Rep*. 2014;63(RR–02):1–19.

Patel H, Wagner M, Singhal P, et al. Systematic review of the incidence and prevalence of genital warts. *BMC Infect Dis*. 2013;13:39.

Patel R, Kennedy OJ, Clarke E, et al. 2017 European guidelines for the management of genital herpes. *Int J STD AIDS*.

2017;28(14):1366–1379.

Patton ME, Su JR, Nelson R, et al. Primary and secondary syphilis—United States, 2005–2013. *MMWR Morb Mortal Wkly Rep*. 2014;63(18):402–406.

Paz-Bailey G, Rosenberg ES, Doyle K, et al. Persistence of Zika virus in body Fluids—Preliminary report. *N Engl J Med*. 2017;379(13):1234–1243.

Perkins HA, Busch MP. Transfusion-associated infections: 50 years of relentless challenges and remarkable progress. *Transfusion*. 2010;50(10):2080–2099.

Petersen EE, Meaney-Delman D, Neblett-Fanfair R, et al. Update: Interim guidance for preconception counseling and prevention of sexual transmission of Zika virus for persons with possible Zika virus exposure—United States, September 2016. *MMWR Morb Mortal Wkly Rep*. 2016;65(39):1077–1081.

Petersen LR, Jamieson DJ, Powers AM, et al. Zika virus. *N Engl J Med*. 2016;374(16):1552–1563.

Pichichero ME, Casey JR. Safe use of selected cephalosporins in penicillin-allergic patients: a meta-analysis. *Otolaryngol Head Neck Surg*. 2007;136(3):340–347.

Quinn TC, Glasser D, Cannon RO, et al. Human immunodeficiency virus infection among patients attending clinics for sexually transmitted diseases. *N Engl J Med*. 1988;318(4):197–203.

Rabaan AA, Bazzi AM, Al-Ahmed SH, et al. Overview of Zika infection, epidemiology, transmission and control measures. *J Infect Public Health*. 2017;10(2):141–149.

Raheem OA, Mirheydar HS, Palazzi K, et al. Prevalence of nephrolithiasis in human immunodeficiency virus infected patients on the highly active antiretroviral therapy. *J Endourol*. 2012;26(8):1095–1098.

Reddy EA, Shaw AV, Crump JA. Community-acquired bloodstream infections in Africa: a systematic review and meta-analysis. *Lancet Infect Dis*. 2010;10(6):417–432.

Rietmeijer CA, Mettenbrenk CJ. Recalibrating the Gram stain diagnosis of male urethritis in the era of nucleic acid amplification. *Sex Transm Dis*. 2012;39(1):18–20.

Rietmeijer CA, Mettenbrenk CJ. The diagnosis of nongonococcal urethritis in men: Can there be a universal standard? *Sex Transm Dis*. 2017;44(3):195–196.

Romanowski B, Marina RB, Roberts JN. Patients' preference of valacyclovir once-daily suppressive therapy versus twice-daily episodic therapy for recurrent genital herpes: a randomized study. *Sex Transm Dis*. 2003;30(3):226–231.

Romanowski B, Sutherland R, Fick GH, et al. Serologic response to treatment of infectious syphilis. *Ann Intern Med*. 1991;114(12):1005–1009.

Rompalo AM, Joesoef MR, O'Donnell JA, et al. Clinical manifestations of early syphilis by HIV status and gender: results of the syphilis and HIV study. *Sex Transm Dis*. 2001;28(3):158–165.

Rompalo AM, Lawlor J, Seaman P, et al. Modification of syphilitic genital ulcer manifestations by coexistent HIV infection. *Sex Transm Dis*. 2001;28(8):448–454.

Ronn M, Hughes G, Simms I, et al. Challenges presented by re-emerging sexually transmitted infections in HIV positive men who have sex with men: an observational study of lymphogranuloma venereum in the UK. *J AIDS Clin Res*. 2014;5(8) [1000329].

Ross JDC, Jensen JS. *Mycoplasma genitalium* as a sexually transmitted infection: implications for screening, testing and treatment. *Sex Transm Infect*. 2006;82(4):269–271.

Ryder N, Jin F, McNulty AM, et al. Increasing role of herpes simplex virus type 1 in first-episode anogenital herpes in heterosexual women and younger men who have sex with men, 1992–2006. *Sex Transm Infect*. 2009;85(6):416–419.

Salavastru CM, Chosidow O, Boffa MJ, et al. European guideline for the management of scabies. *J Eur Acad Dermatol Venereol*. 2017;31(8):1248–1253.

Salavastru CM, Chosidow O, Janier M, et al. European guideline for the management of pediculosis pubis. *J Eur Acad Dermatol Venereol*. 2017;31(9):1425–1428.

Santillo VM, Lowe FC. The management of chronic prostatitis in men with HIV. *Curr Urol Rep*. 2006;7(4):313–319.

Satterwhite CL, Torrone E, Meites E, et al. Sexually transmitted infections among US women and men: prevalence and incidence estimates, 2008. *Sex Transm Dis*. 2013;40(3):187–193.

Schachter J, Stephens RS. Biology of *Chlamydia trachomatis*. Holmes KK, Sparling PF, Stamm WE. *Sexually transmitted diseases*. 4th ed. McGraw-Hill: New York, NY; 2008:555–574.

Schillie S, Harris A, Link-Gelles R, et al. Recommendations of the Advisory Committee on Immunization Practices for Use of a Hepatitis B Vaccine with a Novel Adjuvant. *MMWR Morb Mortal Wkly Rep*. 2018;67(15):455–458.

Schillie S, Vellozzi C, Reingold A, et al. Prevention of hepatitis B virus infection in the United States: Recommendations of the Advisory Committee on Immunization Practices. *MMWR Recomm Rep*. 2018;67(RR–1):1–31.

Schober PC, Gabriel G, White P, et al. How infectious is syphilis? *Br J Vener Dis*. 1983;59(4):217–219.

Schwarcz SK, Zenilman JM, Schnell D, et al. National surveillance of antimicrobial resistance in *Neisseria gonorrhoeae.* The Gonococcal Isolate Surveillance Project. *JAMA*. 1990;264(11):1413–1417.

Schwartz JJ, Myskowski PL. Molluscum contagiosum in patients with human immunodeficiency virus infection. A review of twenty-seven patients. *J Am Acad Dermatol*. 1992;27(4):583–588.

Schwebke J, Rompalo A, Taylor S, et al. Re-evaluating the treatment of nongonococcal urethritis: emphasizing emerging pathogens—a randomized clinic trial. *Clin Infect Dis*. 2011;56:163–170.

Sethi S, Zaman K, Jain N. Mycoplasma genitalium infections: current treatment options and resistance issues. *Infect Drug Resist*. 2017;10:283–292.

Shindel AW, Akhavan A, Sharlip ID. Urologic aspects of HIV infection. *Med Clin North Am*. 2011;95(1):129–151.

Siegel JD, Rhinehart E, Jackson M. *2007 Guideline for isolation precautions: preventing transmission of infectious agents in healthcare settings*. [updated 2017; Available at] https://www.cdc.gov/infectioncontrol/pdf/guidelines/isolation guidelines-H.pdf; 2007.

Silverberg MJ, Neuhaus J, Bower M, et al. Risk of cancers during interrupted antiretroviral therapy in the SMART study. *AIDS*. 2007;21(14):1957–1963.

Simard EP, Pfeiffer RM, Engels EA. Cumulative incidence of cancer among individuals with acquired immunodeficiency syndrome in the United States. *Cancer*. 2011;117(5):1089–1096.

Simons R, Candfield S, French P, et al. Observed treatment responses to short-course doxycycline therapy for rectal lymphogranuloma venereum (LGV) in men who have sex with men. *Sex Transm Dis*. 2018;45(6):406–408.

Song B, Dwyer DE, Mindel A. HSV type specific serology in sexual health clinics: use, benefits, and who gets tested. *Sex Transm Infect*. 2004;80(2):113–117.

Stamm WE. Chlamydia trachomatis infections of the adult. Holmes KK, Sparling PF, Stamm WE. *Sexually transmitted diseases*. 4th ed. McGraw-Hill: New York, NY; 2008:575–

593.

Stassen L, Armitage CW, van der Heide DJ, et al. Zika virus in the male reproductive tract. *Viruses*. 2018;10(4).

Stokley S, Jeyarajah J, Yankey D, et al. Human papillomavirus vaccination coverage among adolescents, 2007–2013, and postlicensure vaccine safety monitoring, 2006–2014—United States. *MMWR Morb Mortal Wkly Rep*. 2014;63(29):620–624.

Stoltey JE, Cohen SE. Syphilis transmission: a review of the current evidence. *Sex Health*. 2015;12(2):103–109.

Street EJ, Justice ED, Kopa Z, et al. The 2016 European guideline on the management of epididymo-orchitis. *Int J STD AIDS*. 2017;28(8):744–749.

Strick LB, Wald A, Celum C. Management of herpes simplex virus type 2 infection in HIV type 1-infected persons. *Clin Infect Dis*. 2006;43(3):347–356.

Svartman M, Finklea JF, Earle DP, et al. Epidemic scabies and acute glomerulonephritis in Trinidad. *Lancet*. 1972;1(7744):249–251.

Taylor-Robinson D, Gilroy CB, Thomas BJ, et al. Mycoplasma genitalium in chronic non-gonococcal urethritis. *Int J STD AIDS*. 2004;15:21–25.

Taylor-Robinson D, Jensen JS. Mycoplasma genitalium: from Chrysalis to multicolored butterfly. *Clin Microbiol Rev*. 2011;24(3):498–514.

Terrault NA, Lok ASF, McMahon BJ, et al. Update on prevention, diagnosis, and treatment of chronic hepatitis B: AASLD 2018 hepatitis B guidance. *Hepatology*. 2018;67(4):1560–1599.

Tohme RA, Holmberg SD. Is sexual contact a major mode of hepatitis C transmission? *Hepatology*. 2010;52(4):497–505.

Tracy CR, Steers WD, Costabile R. Diagnosis and management of epididymitis. *Urol Clin North Am*. 2008;35(1):101–108

[vii].

Tronstein E, Johnston C, Huang ML, et al. Genital shedding of herpes simplex virus among symptomatic and asymptomatic persons with HSV-2 infection. *JAMA*. 2011;305(14):1441–1449.

Trope BM, Lenzi ME. AIDS and HIV infections: uncommon presentations. *Clin Dermatol*. 2005;23(6):572–580.

Tzellos TG, Sardeli C, Lallas A, et al. Efficacy, safety and tolerability of green tea catechins in the treatment of external anogenital warts: a systematic review and meta-analysis. *J Eur Acad Dermatol Venereol*. 2011;25(3):345–353.

Uraki R, Hwang J, Jurado KA, et al. Zika virus causes testicular atrophy. *Sci Adv*. 2017;3(2) [e1602899].

US Preventive Services Task Force. Screening for syphilis infection in pregnancy: reaffirmation recommendation statement. *Ann Intern Med*. 2009;150(10):705–709.

Velho PE, Souza EM, Belda Junior W. Donovanosis. *Braz J Infect Dis*. 2008;12(6):521–525.

Vignesh R, Shankar EM, Murugavel KG, et al. Urinary infections due to multi-drug-resistant *Escherichia coli* among persons with HIV disease at a tertiary AIDS care centre in South India. *Nephron Clin Pract*. 2008;110(1):c55–c57.

Villa L, Varela JA, Otero L, et al. Molluscum contagiosum: a 20-year study in a sexually transmitted infections unit. *Sex Transm Dis*. 2010;37(7):423–424.

Walker TY, Elam-Evans LD, Singleton JA, et al. National, regional, state, and selected local area vaccination coverage among adolescents aged 13–17 Years—United States, 2016. *MMWR Morb Mortal Wkly Rep*. 2017;66(33):874–882.

Walton SF, Oprescu FI. Immunology of scabies and translational outcomes: identifying the missing links. *Curr Opin Infect Dis*. 2013;26(2):116–122.

Wawer MJ, Makumbi F, Kigozi G, et al. Circumcision in HIV-infected men and its effect on HIV transmission to female partners in Rakai, Uganda: a randomised controlled trial. *Lancet*. 2009;374(9685):229–237.

Weinberger M, Cytron S, Servadio C, et al. Prostatic abscess in the antibiotic era. *Rev Infect Dis*. 1988;10(2):239–249.

Wetmore CM, Manhart LE, Lowens MS, et al. Demographic, behavioral, and clinical characteristics of men with nongonococcal urethritis differ by etiology: a case-comparison study. *Sex Transm Dis*. 2011;38:180–186.

Wikan N, Smith DR. First published report of Zika virus infection in people: Simpson, not MacNamara. *Lancet Infect Dis*. 2017;17(1):15–17.

Workowski KA, Berman S, Centers for Disease Control and Prevention. Sexually transmitted diseases treatment guidelines, 2010. *MMWR Recomm Rep*. 2010;59(RR–12):1–110.

Workowski KA, Bolan GA, Centers for Disease Control and Prevention. Sexually transmitted diseases treatment guidelines, 2015. *MMWR Recomm Rep*. 2015;64(RR–03):1–137.

Worm SW, Bower M, Reiss P, et al. Non-AIDS defining cancers in the D:A:D Study—time trends and predictors of survival: a cohort study. *BMC Infect Dis*. 2013;13:471.

Wu D, Ning Q. Toward a cure for hepatitis B virus infection: combination therapy involving viral suppression and immune modulation and long-term outcome. *J Infect Dis*. 2017;216(Suppl_8):S771–S777.

Yoon KS, Gao JR, Lee SH, et al. Permethrin-resistant human head lice, Pediculus capitis, and their treatment. *Arch Dermatol*. 2003;139(8):994–1000.

Zeman A, Donaghy M. Acute infection with human immunodeficiency virus presenting with neurogenic urinary retention. *Genitourin Med*. 1991;67(4):345–347.

Zona S, Guaraldi G, Luzi K, et al. Erectile dysfunction is more common in young to middle-aged HIV-infected men than in HIV-uninfected men. *J Sex Med*. 2012;9(7):1923–1930.

---

[*] The Centers for Disease Control and Prevention (CDC) provides national guidelines on the diagnosis and treatment of sexually transmitted diseases. The 2015 guidelines were used at the time this chapter was written (Workowski KA, Bolan GA; Centers for Disease Control and Prevention. Sexually transmitted diseases treatment guidelines, 2015. *MMWR Recomm Rep.* 2015;64[RR-03]:1–137). As these guidelines are periodically updated based on review of the most recent literature, readers are encouraged to check for updates from the CDC before treating patients with STDs.

[*] 2016 European guidelines on *M. genitalium* recommend the use of NAATs for the diagnosis of *M. genitalium*. The authors also strongly recommend that all positive NAATs be followed up with an assay capable of detecting macrolide resistance–mediating mutations.

[*] The 2016 European guidelines on *Mycoplasma genitalium* treatment differ from the CDC recommendations. For uncomplicated *M. genitalium* infections in the absence of macrolide resistance, the recommended treatment is azithromycin 500 mg on day 1 then 250 mg on days 2 to 5 OR josamycin 500 mg three times daily for 10 days. Uncomplicated *M. genitalium* macrolide-resistant infections should be treated with moxifloxacin 400 mg orally for 7 to 10 days. Second-line treatment for uncomplicated persistent *M. genitalium* infections is moxifloxacin 400 mg orally for 7 to 10 days. Please note that these guidelines also recommend a test of cure no earlier than 3 weeks after the start of treatment.

[*] 2016 European guidelines on the management of epididymo-orchitis recommends the same antibiotic choices with these notable dose differences: ceftriaxone 500 mg rather than 250 mg (CDC); ofloxacin 200 mg twice daily for 14 days rather than 300 mg twice daily for 10 days (CDC).

59

Cutaneous Diseases of the External Genitalia

Richard Edward Link MD, PhD, Nikki Tang MD

The diagnosis and treatment of cutaneous diseases of the external genitalia remain important elements of urologic practice. Often overlooked during formal urology residency training, this topic lies at the interface of multiple specialties, including urology, diagnosis of infectious diseases, rheumatology, allergy-immunology, and dermatology.

Introduction to Basic Dermatology

Dermatology is the clinical discipline focused on the normal biology and pathogenesis of diseases and disorders of the skin. The diagnosis of skin disease depends critically on the history and physical examination, with laboratory testing often relegated to a peripheral and confirmatory role. In many cases, visual inspection alone suffices to narrow the diagnosis significantly. On the other hand, the skin has a limited repertoire of morphologic expression. Therefore the urologist should not hesitate to perform a skin biopsy, when indicated, or to order a variety of laboratory investigations when needed to distinguish between two or more clinical mimics.

The skin is divided into three layers: the epidermis, dermis, and hypodermis (subcutaneous tissue; Fig. 59.1). The epidermis, composed of stratified squamous epithelia, can vary in thickness from 0.05 to 1.5 mm depending on location. Melanocytes (pigment-producing cells) populate the lower layers of the epidermis. The dermis, composed of collagen, elastin, and reticular fibers, can be divided into two layers: the thin superficial layer (papillary dermis) and the thicker deeper layer (reticular dermis). Located within the dermis are mesenchymal structures, such as blood vessels and nerves. The bottom layer of the skin, known as the hypodermis or subcutaneous tissue, is composed largely of fat.

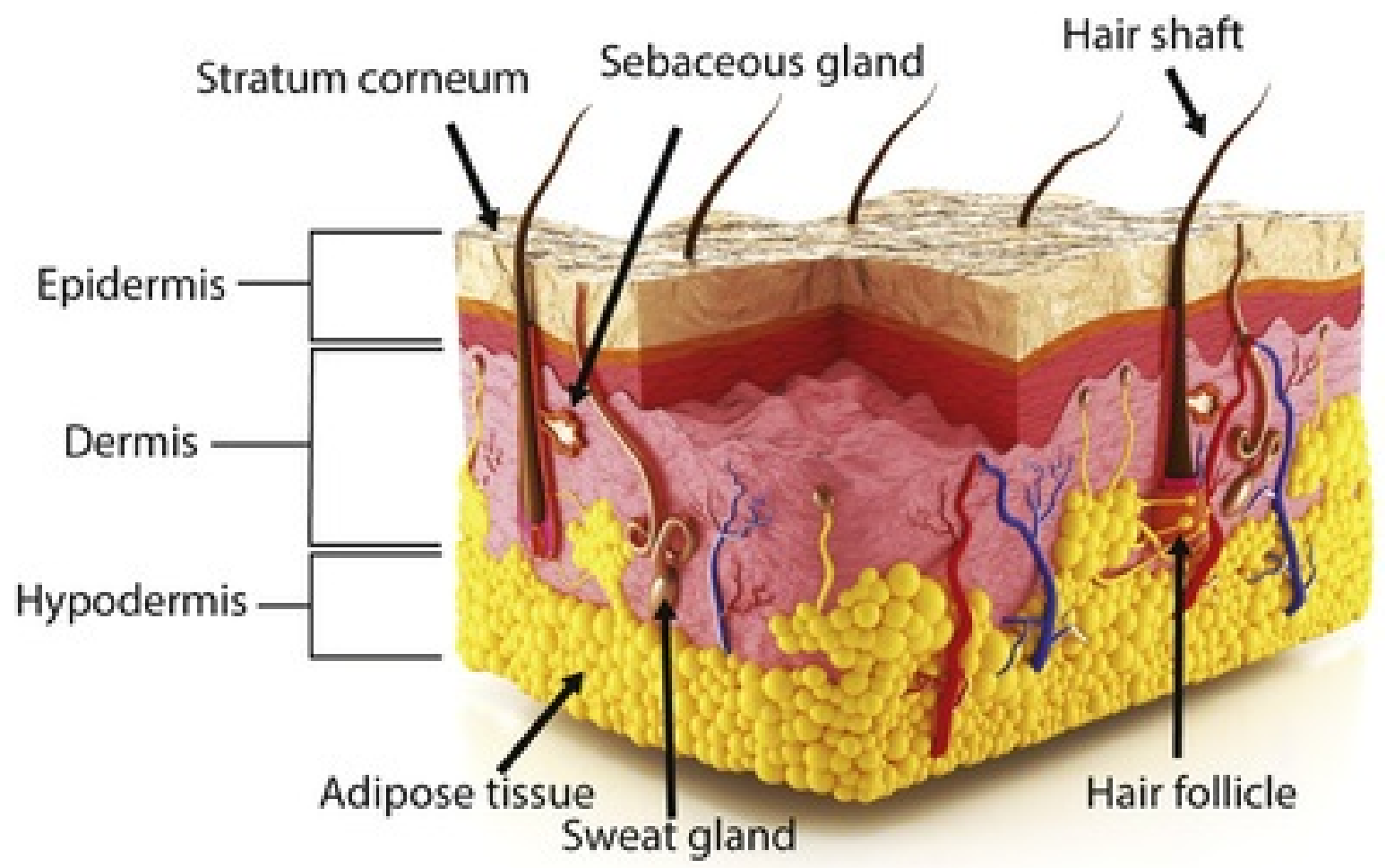

FIG. 59.1 Anatomy of hair-bearing human skin. (Used and modified under license, Anton Nalivayko/Shutterstock.com.)

Literally hundreds of cutaneous diseases exist that may involve the external genitalia. In addition, within each disease there may be significant variation in appearance and symptoms as the process for each condition evolves. For this reason, a methodical and systematic approach is essential to reach a rational diagnosis. The dermatologic history should focus on the duration, rate of onset, location, associated symptoms, family history, allergies, occupation, and previous treatment of the condition (Habif, 2004). Common symptoms include pruritus (itching), burning, stinging, and pain. The *lack* of symptoms, such as pain, can also be important in arriving at the correct diagnosis and should therefore be noted.

The physical examination should address the distribution of primary and secondary skin lesions. **It is important to perform a thorough skin survey and not to focus solely on the area of affected genital skin.** For example, the presence of red silvery-scaled plaques on the genital skin of a patient who has similar lesions on their extensor body surfaces may guide the physician toward adding psoriasis to the differential diagnosis.

Most skin conditions begin with a characteristic primary lesion that is an important key to diagnosis. A precise description of this lesion includes documenting its color (red, brown, black, yellow, white, blue, or green) and morphology (macule, papule, plaque, nodule, pustule, vesicle, bulla, or wheal; Table 59.1) (Habif, 2004). Because of the mucosal nature of genital skin, papular and macular lesions may present as erosions in this area (Margolis, 2002). Secondary skin lesions develop as the skin condition evolves or are caused by scratching, rubbing, or superinfection. A secondary lesion should also be classified morphologically as a scale, crust, erosion, ulcer, atrophy, thickening, or scar (Table 59.2).

TABLE 59.1

Primary Cutaneous Lesions

PRIMARY LESION	DESCRIPTION
Flat	
Macule	A circumscribed, **flat** discoloration that may be brown, blue, red, or hypopigmented
Elevated, Solid	
Papule	An **elevated**, **solid** lesion up to 0.5 cm in diameter of variable color. Papules may become confluent to become plaques

Nodule	A circumscribed, **elevated solid** lesion >0.5 cm in diameter
Plaque	A circumscribed, **elevated**, superficial, **solid** lesion >0.5 cm in diameter
Fluid-Filled	
Vesicle	A circumscribed **collection of free fluid** ≤0.5 cm in diameter
Bulla	A circumscribed **collection of free fluid** >0.5 cm in diameter
Pustule	A circumscribed collection of leukocytes and free fluid **(pus)**
Wheal (hive)	A firm **erythematous plaque** resulting from **infiltration** of the dermis with fluid (may be transient)

From Habif TP: *Clinical dermatology: a color guide to diagnosis and therapy,* Edinburgh, 2004, Mosby.

TABLE 59.2

Secondary Cutaneous Lesions

SECONDARY LESION	**DESCRIPTION**
Scale	Excess dead epidermal cells that are produced by abnormal keratinization and shedding
Crust	A collection of dried serum and cellular debris (a scab)
Erosion	A focal loss of epidermis. Erosions do not penetrate below the dermoepidermal junction and they heal without scarring
Ulcer	A focal loss of epidermis and dermis, which heals with scarring
Fissure	A linear loss of epidermis and dermis with sharply defined, vertical walls
Atrophy	A depression in the skin resulting from thinning of the epidermis or dermis
Scar	An abnormal formation of connective tissue implying dermal damage

From Habif TP: *Clinical dermatology: a color guide to diagnosis and therapy,* Edinburgh, 2004, Mosby.

After gross morphology is determined, laboratory testing may confirm the diagnosis. To identify cutaneous fungi such as dermatophytes and *Candida* species, potassium hydroxide (KOH) or periodic acid–Schiff staining may be applied to scraped or touched skin specimens. KOH dissolves keratin, leaving fungal hyphal walls prominently visible under the microscope. Likewise, mineral oil drops may help visualize mites or eggs, and Tzanck preparations may aid in identifying viral agents such as herpes simplex, varicella zoster, and molluscum contagiosum.

For difficult cases or those in which malignancy is suspected, skin biopsy may be indicated. A variety of techniques exist for this purpose, including curettage, punch, shave, and incisional and complete excisional biopsies. For small scrotal or phallic shaft lesions, these techniques can usually be performed in the office setting under local anesthesia. For larger lesions or those involving the urethral meatus, biopsy in the operating room is recommended. It is often possible to determine the correct diagnosis with a very small (2- to 3-mm) punch biopsy. The resultant defect can easily be closed with one or two 6-0 or 7-0 nylon sutures or even be left open to heal secondarily.

Additional diagnostic maneuvers that may prove invaluable in select situations include serologic testing (e.g., serologic tests for syphilis), culture (e.g., culture for *Pseudomonas aeruginosa*), Wood's ultraviolet lamp (e.g., skin fluorescence of skin affected by vitiligo or erythrasma), and immunohistochemistry stains of biopsy specimens (e.g., examination for specific types of cytokeratins associated with different variants of lichen sclerosus).

Dermatologic Therapy

Medical therapy for dermatologic conditions consists of a broad range of topical and systemic compounds.

For systemic therapy, useful drug classes include antibiotics, antifungals, antivirals, anti-inflammatories, and antipruritics. Less commonly used agents, including chemotherapeutic and biologic drugs (e.g., methotrexate, cyclophosphamide, adalimumab, etanercept, infliximab, and ustekinumab), immunosuppressants (e.g., azathioprine, cyclosporine, tacrolimus), and hydroxyurea, are discussed within the specific disease entities.

A lack of familiarity with cutaneous diseases affecting the genitalia may lower the threshold of urologists in prescribing systemic antibiotics for these conditions. Unfortunately, these agents carry significantly greater risks than topical preparations, including promotion of resistant organisms, interaction with other medications, and disruption of the normal bowel and vaginal flora. Alterations in bacterial flora or in their antimicrobial susceptibility patterns may persist for protracted periods, thus emphasizing the need for truly appropriate antibiotic use (Jernberg et al., 2010). Similar caveats apply to systemic antifungal agents such as fluconazole, ketoconazole, and terbinafine. Superficial dermatophytes, such as those causing tinea cruris, generally respond well to diligent application of topical antifungal preparations. **Systemic antifungals are indicated only for very extensive cutaneous dermatophytosis, endemic mycoses with skin involvement, deep infection involving the hair follicles (Majocchi granuloma), or fungal infections in severely immunocompromised individuals** (Lesher and McConnell, 2003). In some cases, even in immunocompetent individuals, systemic antifungals are necessary to treat infections resistant to local therapy (Lesher, 1999). On the other hand, warnings have emphasized the need to avoid the routine use of some systemic antifungal medications (such as ketoconazole) for superficial cutaneous infections because of the unpredictable risk of life-threatening hepatotoxicity and adrenal insufficiency (FDA, 2013). Systemic anti-inflammatory agents, in particular the glucocorticosteroids (GCS), deserve additional attention. Oral GCS are absorbed in the jejunum with peak plasma concentrations occurring in 30 to 90 minutes (Lester, 1989). Despite short plasma half-lives of 1 to 5 hours, the duration of effect of GCS lasts between 8 and 48 hours, depending on the agent (Nesbitt, 2003). These drugs have widespread anti-inflammatory effects.

They release neutrophils from bone marrow, but they inhibit their movement to sites of inflammation in tissue. They also impair T-cell activation and antigen presentation by dendritic cells (Nesbitt, 2003). **For short-term (≤3 weeks) treatment of dermatologic conditions such as allergic contact dermatitis** (Feldman, 1992), **a single morning dose of GCS is administered to minimize suppression of the hypothalamic-pituitary-adrenal axis** (Myles, 1971). Prednisone is generally the GCS of choice because of its low cost, intermediate duration of action, and variety of dosage forms, although methylprednisolone may be substituted to reduce the mineralocorticoid effects (Wolverton, 2001). **Longer-term treatment with systemic GCS may lead to a wide variety of adverse effects, including osteoporosis, cataract formation, hypertension, obesity, hyperglycemia, aseptic necrosis of the femoral head, immunosuppression, and psychiatric changes** (Nesbitt, 2003). For this reason, the use of topical steroids (see following) is preferable to reliance on systemic GCS whenever clinically feasible. Systemic antipruritic therapies include oral antihistamines such as hydroxyzine and diphenhydramine, and tricyclic agents such as doxepin and selective serotonin reuptake inhibitors (SSRIs).

Topical preparations are the mainstay of therapy for a wide range of cutaneous diseases affecting the genitalia. Urologists tend to be less familiar with the use of these medications than are dermatologists. **Topical medications can be broken down into five general classes: emollients, anti-inflammatories, antibiotics, antifungals, and chemotherapeutic agents.**

Topical preparations include active ingredients that also include a vehicle that determines the rate at which the active ingredients are absorbed by the skin. Emollients restore water and lipids to the epidermis and are useful for dry-skin diseases. Emollients should be applied to moist skin for maximal effect, such as after bathing. Ointments are generally preferred because they less often cause irritation or burning associated with creams (Edwards and Lynch, 2018). Preparations containing urea (e.g., Carmol, vanadine) or lactic acid (Lac-Hydrin, AmLactin) may be particularly potent hydrating agents (Habif, 2004). Ceramides (combinations of a fatty acid and a sphingoid base), the main natural intercellular lipids in the outermost layer of skin, are critical for maintaining normal cutaneous hydration and barrier function (Weber et al., 2012). For this reason, new formulations containing ceramides (CeraVe) may also be particularly useful for skin conditions characterized by xerosis (dryness). Topical corticosteroids are potent anti-inflammatory agents available in a myriad of preparations and strengths. A detailed review of the use and dosing of topical corticosteroids is beyond the scope of this chapter, and the reader is directed to several excellent dermatology textbooks for more detail (Bolognia et al., 2018; Edwards and Lynch, 2018; Habif, 2004). **Topical corticosteroids can include significant adverse effects from systemic absorption and from the results of local application. Local effects include epidermal atrophy and the development of striae on the upper portion of the inner thigh, dermal changes (telangiectasias, hypopigmentation), allergic reactions, and negative alterations in the usual course of skin infections and infestations** (Burry, 1973). Special care must be taken when applying corticosteroids to the skin of the male genitalia, which is at a higher risk for steroid atrophy because of its thin dermal depth. In most cases, atrophy is a reversible process that can be expected to resolve during the course of several months but can also be permanent (Sneddon, 1976). Atrophy is particularly troublesome if corticosteroids are applied under the foreskin, which can serve as an occlusive "dressing" and can enhance penetration of the drug (Fig. 59.2; Goldman and Kitzmiller, 1973).

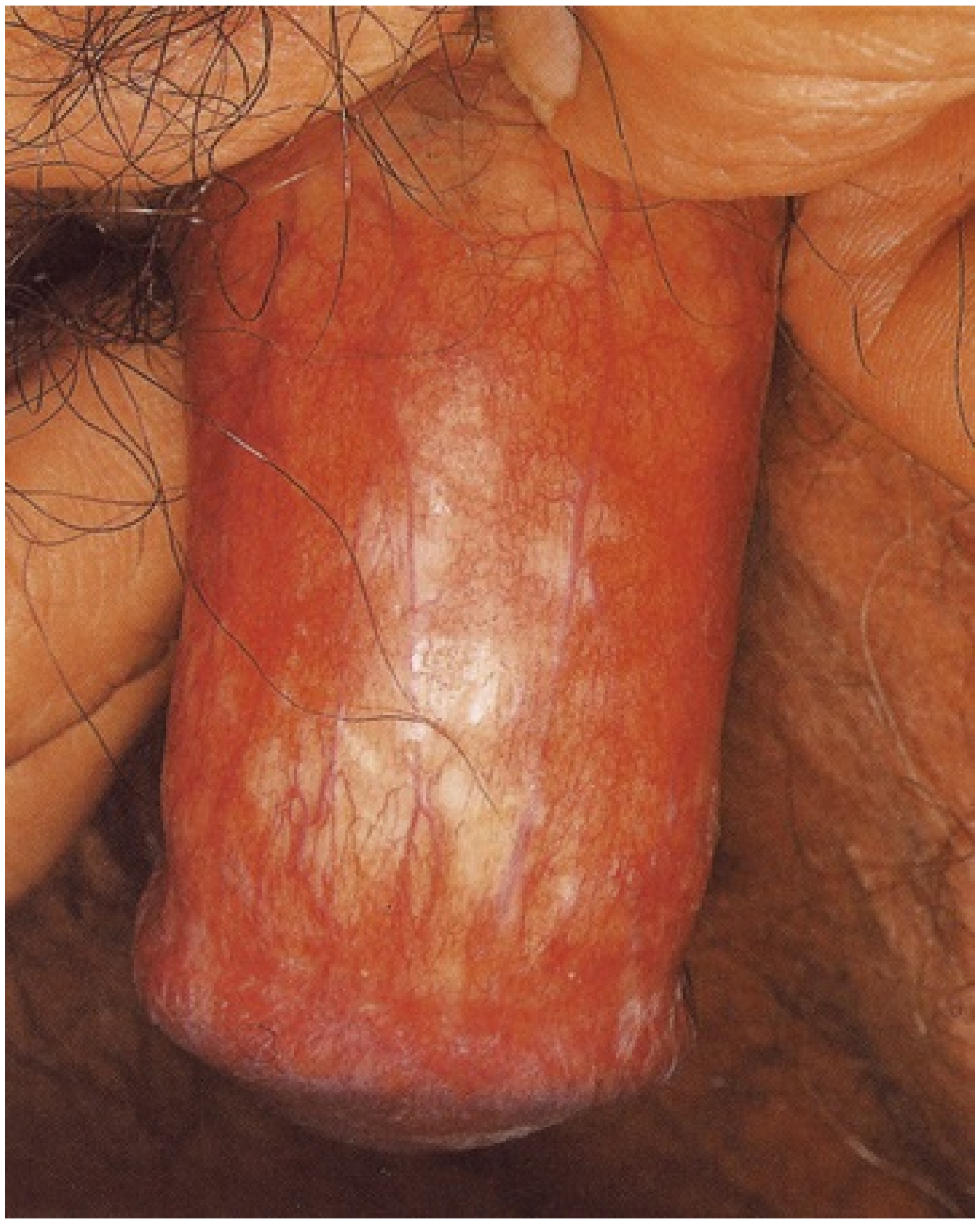

FIG. 59.2 Steroid atrophy of penile shaft skin after application of corticosteroid under the foreskin for 8 weeks. (From Habif TP: *Clinical*

dermatology, Edinburgh, 2004, Mosby; 2004, p 36.)

A variety of physical modalities have also been applied to treat dermatologic problems, including ultraviolet light therapy, photodynamic therapy, laser therapy, and cryosurgery. Ultraviolet light therapy, with broadband and narrow-band ultraviolet B (UVB), has been used to treat atopic dermatitis, psoriasis, seborrheic dermatitis, and vitiligo (Honigsmann and Schwarz, 2003). There are now several convenient single-wavelength UVB (308 nm) laser units with small spot sizes, which are particularly useful for treating vexing localized areas of genital psoriasis or vitiligo; such narrow-spectrum machines are believed not to carry the risk of inducing the nonmelanoma skin cancer that is associated with broadband full-body light boxes. Psoralens, when combined with long-wave ultraviolet A radiation (psoralen ultraviolet A [PUVA] therapy), generate a phototoxic effect that is beneficial for treating psoriasis (Honigsmann, 2001; Stern, 2007), vitiligo (Honigsmann and Schwarz, 2003), atopic dermatitis (Morison, 1992), and lichen planus (Honigsmann and Schwarz, 2003). In general, the narrow-band UVB boxes and lasers have supplanted PUVA therapy, as the latter carries a substantial risk of squamous cell carcinoma (SCC) when performed throughout a prolonged period (Stern and Study, 2012). One significant downside to these particular treatments is the inconvenience patients face in attending weekly or biweekly laser sessions. Photodynamic therapy involves the use of cytotoxic oxygen radicals generated from photoactivated molecules to achieve a therapeutic response (Braathen et al., 2007; Tope and Shaffer, 2003).

Photodynamic therapy is useful in treating a variety of inflammatory, malignant, and infectious skin conditions. Studies have shown its success as monotherapy and in combination with cryosurgery, CO_2 laser ablation, and curettage in the management of large or resistant condyloma acuminata or in genital warts occurring during pregnancy (Scheinfeld, 2013a). The downside to this promising modality is that there is not yet an established optimum regimen for off-label use, including for genital warts. Lasers so far play a smaller role in the management of genital lesions, although some lasers (CO_2, pulsed dye) have been used effectively to manage genital condyloma acuminata (Veitch et al., 2017). Overall, cryosurgery is more widely used than laser therapy to treat genital and suprapubic molluscum contagiosum.

Allergic Dermatitis

Allergic contact or "eczematous" dermatitis (ACD) consists of a group of allergy-mediated processes leading to pruritic skin lesions (Box 59.1).

Box 59.1

Differential Diagnosis of Allergic Dermatitis

- Eczema
- Allergic dermatitis
- Seborrheic dermatitis
- Intertrigo
- Contact dermatitis
- Irritant dermatitis
- Balanoposthitis
- Zoon balanitis
- Candidal-related illness
- Impetigo
- Herpes simplex
- Herpes zoster
- Drug reaction

From Margolis DJ: Cutaneous disease of the male external genitalia. In Walsh PC, ed: *Campbell's urology*, Philadelphia, 2002, Saunders.

Atopic Dermatitis (Eczema)

Atopic dermatitis (AD) is a chronic relapsing dermatitis with a predilection for skin flexures that is associated with intense pruritus and damage to the epidermis (Williams, 2005). **The characteristic lesions are erythematous papules and thin plaques with secondary excoriations** (Fig. 59.3; Kang et al., 2003). In general, the lesions do not have a precise border as is common for papulosquamous disorders (Margolis, 2002). Although any age can be affected, 90% of AD patients manifest their condition before the age of 5 years (Rajka, 1989). AD is associated with susceptibility to a wide variety of substances that act as irritants (e.g., fragrances, preservatives, and various proteins). Patients suffering from AD also have a propensity to develop asthma and allergic rhinitis.

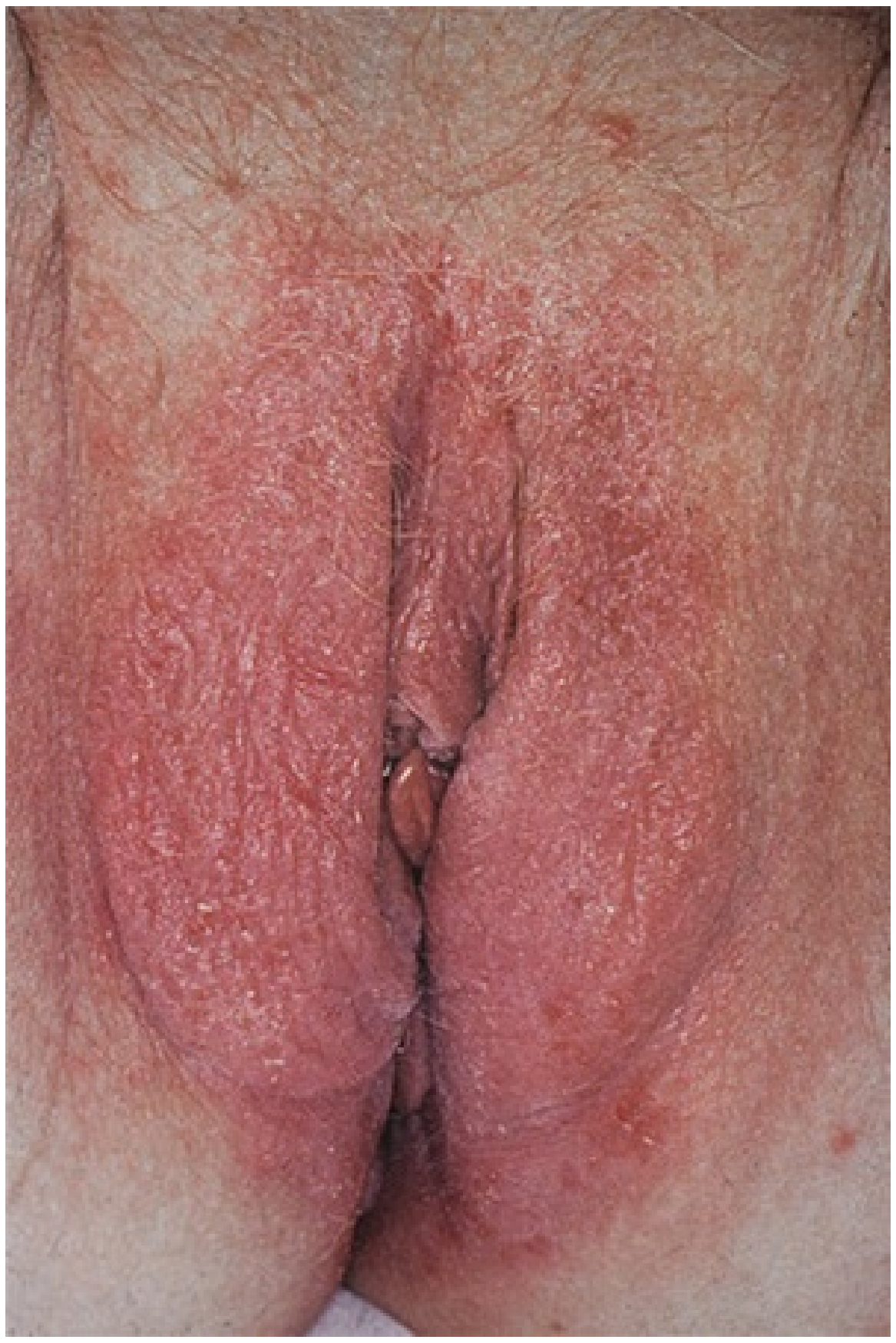

FIG. 59.3 Eczema involving the vulva. (From Simpson R, Nunns D: Skin diseases affecting the vulva. *Obstetrics, Gynaecology, and Reproductive Medicine* 27(3): 77–85, 2017. Fig. 2.)

The genetic susceptibility to AD has been extensively explored. In a study of 372 AD patients, 73% had a positive family history for atopy. Likewise, twin concordance studies have demonstrated an AD risk of 0.86 for monozygotic twins compared with only 0.21 for dizygotic twins. These findings have spurred an intense search for genes involved in atopy and AD (Wollenberg and Bieber, 2000). Although no single gene has been found to be a unique marker for the disease, at least 11 genetic foci seem to be closely associated with AD (Ellinghaus et al., 2013; Kang et al., 2003). The most important genetic defects confer an inability to synthesize functional filaggrin properly. This structural abnormality results in a “leaky” epithelial barrier and chronic immune activation, which contribute to the pathophysiology of this common skin disease (Heimall and Spergel, 2012).

Intense pruritus is the hallmark of AD, and controlling the patient's urge to scratch is critical for successful treatment (Przybilla et al., 1994). Itching is often worse during evening hours and can be exacerbated by sweating, occlusive undergarments, or wool clothing (Kang et al., 2003). Scratching of lesions may contribute to the clinical complications of AD, including superinfection with *Staphylococcus aureus* species (Ogawa et al., 1994). There is growing evidence that bacterial toxins may serve as superantigens that drive an inflammatory cascade that sustains AD (Skov and Baadsgaard, 2000; Skov et al., 2000).

Clinically, there is no pathognomonic laboratory test, biopsy result, or single clinical feature that allows the definitive diagnosis of AD. The association with a personal or family history of atopy is a critical clue to the diagnosis (Kang et al., 2003). For patients with genital findings, extragenital involvement is commonplace.

A variety of “trigger factors” have been implicated in the exacerbation of AD, including chemicals, detergents, and household dust mites. Removal of these factors from the environment may be beneficial on an individualized basis. Dust mite exposure, in particular, has received significant attention in the literature. Although several studies have demonstrated modest improvement in AD with mite reduction (Kubota et al., 1992; Tan et al., 1996), others report that reduction is associated with no significant clinical benefit (Colloff et al., 1989; Gutgesell et al., 2001).

Treatments for AD include gentle cleaning with nonalkali soaps or soap substitutes (e.g., Cetaphil, Aquanil) and the frequent use of emollients. Evaporation of liquid from the skin may trigger AD (Kang et al., 2003), so frequent bathing especially with hot water is not encouraged. Soaking may help during episodes of bacterial superinfection but should be discontinued after the infection has resolved (Margolis, 2002). Topical corticosteroids may be needed to control pruritus but should be used only for short courses with a rapid taper to avoid local complications of skin atrophy and dyschromia. Topical immunomodulatory agents such as the calcineurin inhibitors tacrolimus and pimecrolimus have shown efficacy in the treatment of AD (Leung et al., 2009; Luger and Paul, 2007; Meagher et al., 2002; Nghiem et al., 2002), and these agents may decrease the need for corticosteroids during long-term therapy (Zuberbier et al., 2007). Antihistamines such as diphenhydramine or a variety of nonsedating agents, such as cetirizine, loratadine, and analogues of these, may be helpful in breaking the "itch-scratch cycle" in AD, particularly when administered before bedtime (Kang et al., 2003). Oral antistaphylococcal drugs have not been shown to significantly improve AD in a randomized, double-blind trial (Ewing et al., 1998). Systemic treatment with azathioprine, corticosteroids, cyclosporine, methotrexate, or mycophenolate mofetil may rarely be indicated for severe, widely disseminated cases (Cooper, 1993; Denby and Beck, 2012; Salek et al., 1993). The newest systemic treatment for moderate to severe AD is dupilumab (Dupixent), the first monoclonal antibody injection approved by the U.S. Food and Drug Administration (FDA) to effectively treat AD by targeting the Th2 pathway (Simpson et al., 2016).

Contact Dermatitis

Contact dermatitis can be broken down into two distinct entities: irritant contact dermatitis (ICD) and ACD. Although the mechanisms differ significantly, the clinical presentation of ICD and ACD may be similar. Most notably, the affected area is usually sharply limited to an area of skin exposure to true allergen or irritating chemical. The primary mode of treatment is to identify and reduce exposure to the offending agent.

ICD results from a direct cytotoxic effect of an irritant chemical touching the skin and is responsible for approximately 80% of contact dermatitis cases (Marks et al., 2002). Examples of offending agents include soaps, solvents, metal salts, and acid- or alkali-containing compounds. Occupational ICD is a serious public health problem and contributes to costs on the scale of $1 billion annually in the United States (Cohen, 2000). The clinical manifestations of ICD depend on the identity of the irritating substance as well as the duration of contact, concentration, temperature, pH, and location of exposure. Acute ICD, such as may result from an occupational accident, generally peaks within minutes to hours after exposure and then begins to heal. Symptoms of burning, stinging, and soreness may be accompanied by erythema, edema, bullae, or frank necrosis in a sharply defined area corresponding to the exposed skin (Cohen and Bassiri-Tehrani, 2003). There are also a variety of subacute forms of ICD that result from repeated subthreshold skin insults. Pruritus is much more common in these more chronic conditions, and the skin lesions are not as well demarcated. The mainstay of treatment for ICD lies in avoiding skin contact with the causative irritants through the use of protective clothing, safe occupational practices, and the use of skin barrier preparations such as ointments, emollient creams, or protective foams. Some commercially available barrier products include Atopiclair, Biafine, EpiCeram, MimyX, Neosalus Foam, and PruMyx (Berndt et al., 2000; Draelos, 2012).

In contrast, ACD represents a local type IV hypersensitivity reaction to a skin allergen to which an individual has been previously exposed and sensitized. Although ACD is a common reason for outpatient dermatology visits, involvement of the genital skin is rare (2.4%) (Bhate et al., 2010). The typical appearance is a well-demarcated pruritic eruption, which may manifest blistering or weeping in the acute phase or the development of scaly plaques more chronically (Mowad and Marks, 2003). In 2003 and 2009 the North American Contact Dermatitis Group (NACDG) reported a long list of common allergens implicated in ACD based on patch testing results (Zug et al., 2009). Similar lists that were produced subsequently contain the same set of allergens, with only a few exceptions. Patch testing is a simple technique of exposing an area of skin to a variety of potential allergens at a known concentration in a grid template (Fig. 59.4). Generally performed by dermatologists, patch testing can help to confirm the diagnosis of ACD and the allergen involved. The most common sensitizing allergen identified by the NACDG was nickel sulfate (Zug et al., 2009), which is a common component of costume jewelry and belt buckles (Fig. 59.5). Although traditionally a cause of earlobe dermatitis from pierced earrings, nickel sensitivity may be a potential cause of genital ACD resulting from the increasing prevalence of genital piercing. Other important allergens include textile dyes, topical antibiotics (neomycin, bacitracin), perfumes and other fragrance materials, formaldehyde-releasing preservatives, the latex in condoms, and topical corticosteroids. When ACD is suspected, the urologist always should inquire about the use of over-the-counter products such as genital moisturizers, spermicides, antiyeast and anti-itch preparations, and lubricants used during sexual intercourse. Oral antihistamines may be helpful for the symptomatic control of ACD in combination with the removal of the inciting allergen. Severe ACD should *not* be treated with a short course of systemic steroids but rather with a 3-week tapering dose of prednisone.

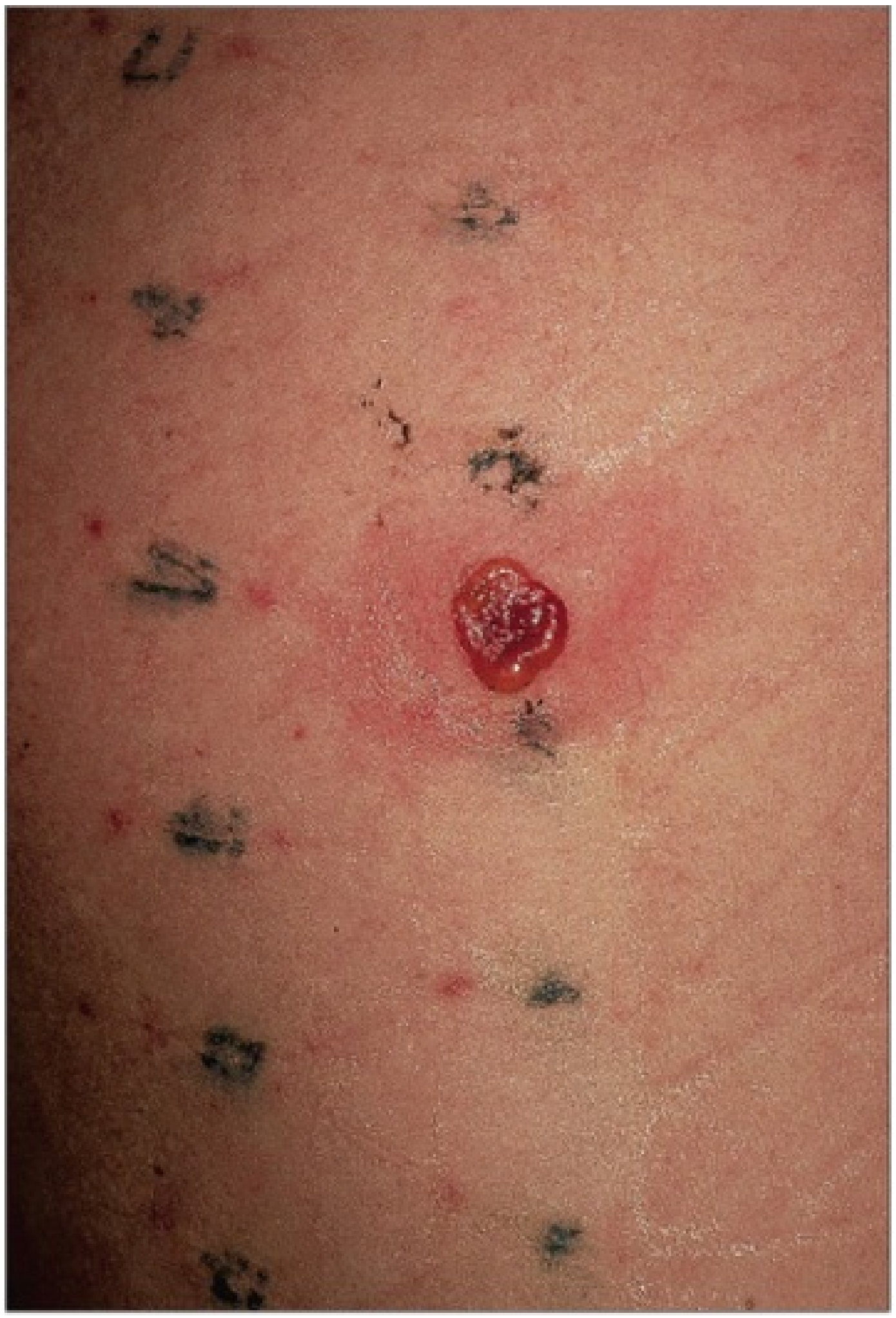

FIG. 59.4 An example of patch testing with a positive response to nickel. (From Bolognia JL, Jorizzo JL, Rapini RP: *Dermatology,* Edinburgh, 2003, Mosby, p 233.)

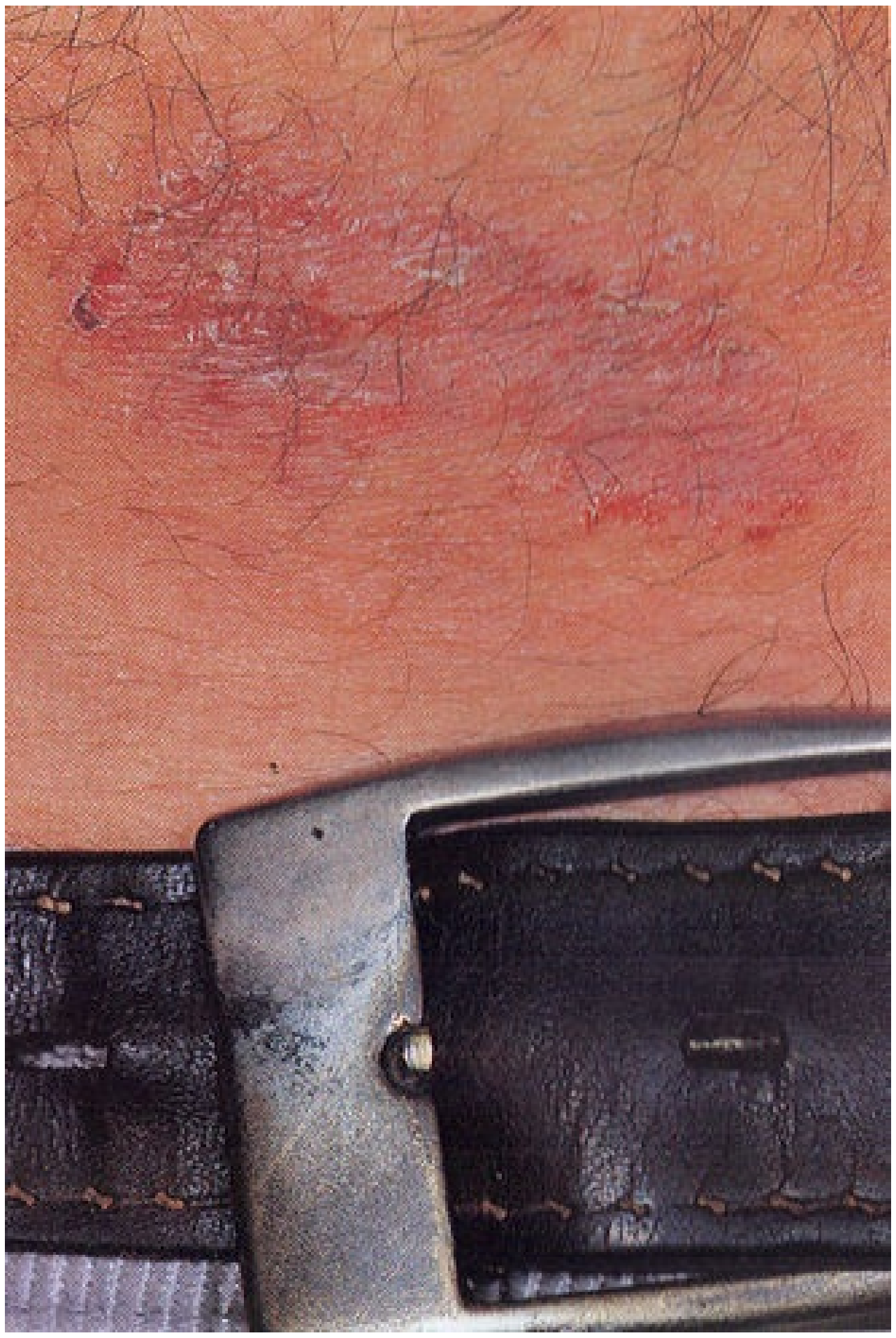

FIG. 59.5 Contact dermatitis caused by a nickel allergy from a belt buckle. (From Habif TP: *Clinical dermatology*, Edinburgh, 2004, Mosby, p 94.)

Erythema Multiforme and Stevens-Johnson Syndrome

Erythema multiforme (EM) is a generalized skin disease that may involve the genitalia. **EM can be subdivided into minor and major forms.**

EM minor was first described in 1860 by an Austrian dermatologist, Ferdinand von Hebra (von Hebra, 1860). **This condition is an acute, self-limited skin disease characterized by the abrupt onset of symmetrical fixed red papules that may evolve into target lesions** (Weston, 1996). EM is a clinical rather than a histologic diagnosis. Papules and target lesions are usually grouped and can be present anywhere on the body, including the genitalia (Fig. 59.6A). There is also a predilection for involvement of the oral mucous membranes, as well as the palms and soles.

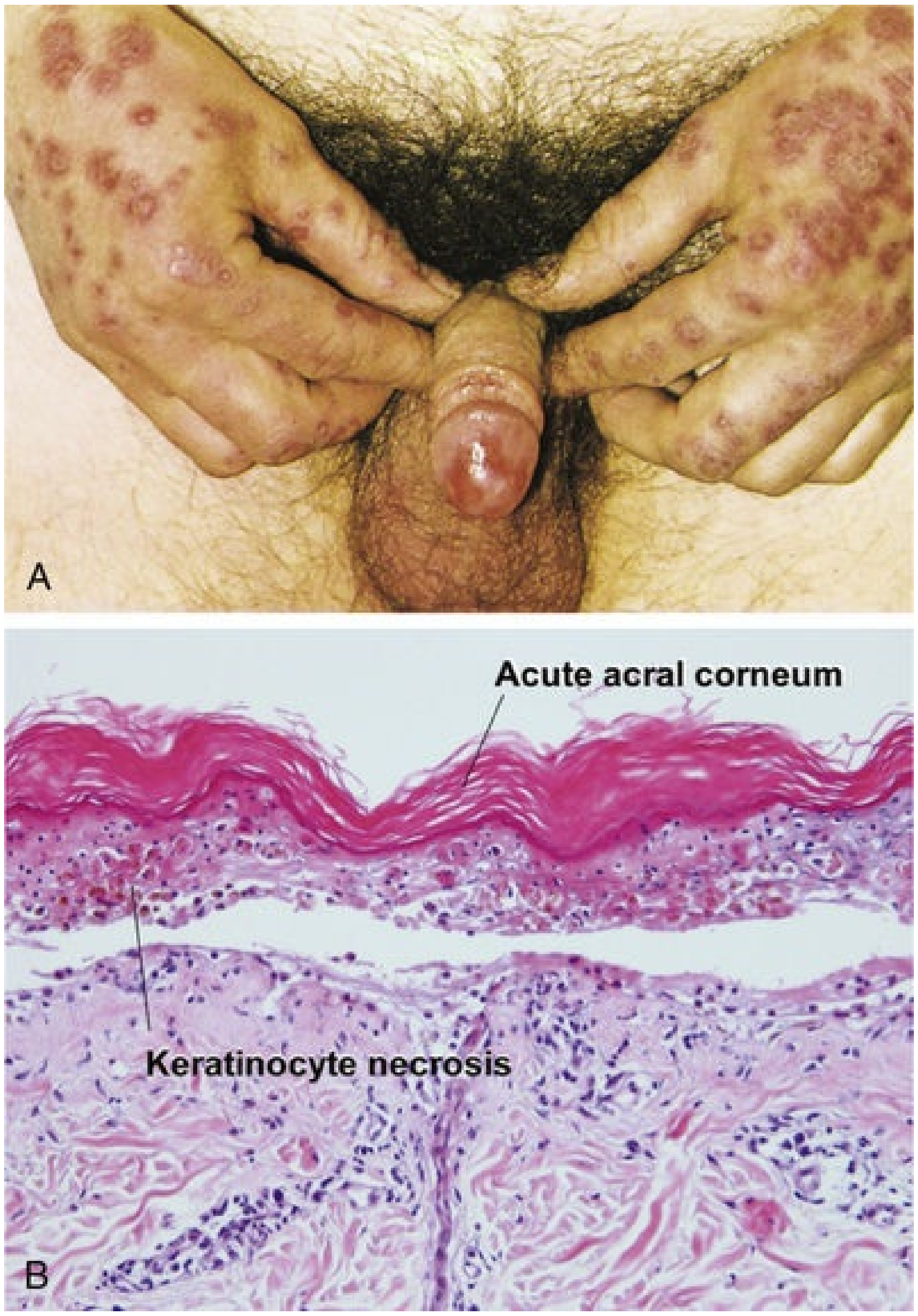

FIG. 59.6 Erythema multiforme (EM). (A) Targetoid lesions of the hands and penis. (B) Typical microscopic picture of EM with a normal stratum corneum, necrotic keratinocytes in the epidermis, and a lymphoid infiltrate. (A, From Korting GW: *Practical dermatology of the genital region*, Philadelphia, 1981, Saunders, p 16. B, From Elston DM, Ferringer T: *Dermatopathology,* Edinburgh, 2009, Saunders, p 147.)

The majority of cases of recurrent EM minor are precipitated by human herpesvirus 1 and 2 (Nikkels and Pierard, 2002; Schofield et al., 1993), **with herpetic lesions usually preceding the development of target lesions by 10 to 14 days** (Lemak et al., 1986). Although continuous suppressive acyclovir may prevent EM episodes in patients with herpes infection (Tatnall et al., 1995), administration of the drug after development of target lesions is of no benefit (Huff, 1988). The natural history of EM minor is spontaneous resolution after several weeks without sequelae (Schofield et al., 1993), although recurrences are common (Huff and Weston, 1989). Oral antihistamines may provide symptomatic relief. For immunosuppressed patients, the time course of EM minor outbreaks may be longer, and the frequency of recurrence may be greater (Schofield et al., 1993).

The major form of EM has been called Stevens-Johnson syndrome (SJS) in the past, although there remains some controversy as to whether EM major and SJS are distinct entities or are part of a spectrum of disease (Bachot and Roujeau, 2003; Williams and Conklin, 2005). SJS is a much more serious illness than EM minor, and it includes features similar to extensive skin burns (Parrillo, 2007). In its more severe forms, SJS may mimic life-threatening toxic epidermal necrolysis. Admission to the intensive care unit or burn unit may significantly reduce the morbidity and mortality of this condition (Wolf et al., 2005). **Most patients with SJS exhibit a prodromal upper respiratory illness (fever, cough, rhinitis, sore throat, and headache), which progresses after 1 to 14 days to the abrupt development of red macules with blister formation and areas of epidermal necrosis. Genital involvement includes erythema and erosions of the labia** (Fig. 59.7), **penis, and perianal region.**

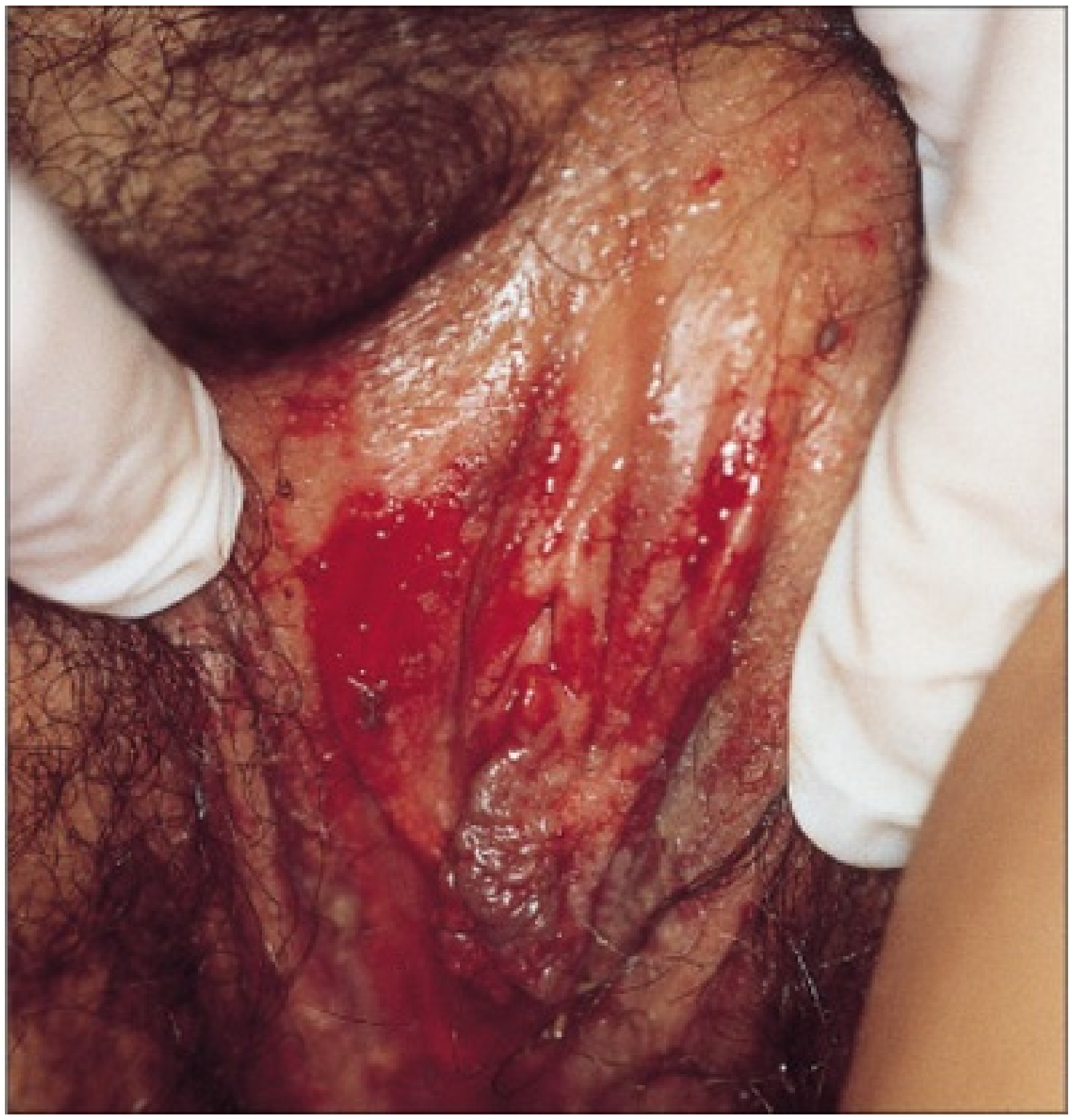

FIG. 59.7 Labial erosions in a case of Stevens-Johnson syndrome. (Courtesy of Yale Dermatology Residents' Slide Collection. From Bolognia JL, Jorizzo JL, Rapini RP. *Dermatology*. Edinburgh: Mosby; 2003.)

A vast array of inciting factors has been implicated in the development of SJS, with drug exposures being the most commonly identified. Among the most common offending agents are nonsteroidal anti-inflammatory agents, sulfonamides (particularly cotrimoxazole), tetracycline and doxycycline, penicillin and cephalosporins, and a wide range of anticonvulsants (Chan et al., 1990). In contrast to EM minor, there is rarely an association with an infectious agent (Weston, 2003). **SJS generally follows a protracted course of 4 to 6 weeks and may include a mortality rate approaching 30%. Severe scarring of denuded skin may result in a range of complications, including joint contractures, labial synechia, vaginal stenosis, urethral meatal stenosis, and anal strictures** (Brice et al., 1990; Weston, 2003). Treatment involves immediate removal of the offending drug and supportive care similar to the management of severe burns. There is currently no strong evidence for any specific medical therapy for SJS (Weston, 2003), and the role of systemic corticosteroids in treating SJS remains controversial (Rasmussen, 1976; Tripathi et al., 2000; Weston, 2003). Newer modalities that have had limited randomized controlled studies include cyclosporine (3 to 5 mg/kg/day), tumor necrosis factor (TNF)-α inhibitors, plasmapheresis, and, especially noted, intravenous immunoglobulin (Mockenhaupt, 2011; Paradisi et al., 2014; Worswick and Cotliar, 2011). Care of the SJS patient is best accomplished via a multispecialty team approach.

Papulosquamous Disorders

Papulosquamous disorders are a disparate group of diseases that share a common primary lesion: scaly papules and plaques (Box 59.2).

Box 59.2

Differential Diagnosis of Papulosquamous Lesions

Psoriasis
Seborrheic dermatitis
Dermatophyte infection
Erythrasma
Secondary syphilis
Pityriasis rosea
Discoid lupus
Mycosis fungoides
Lichen planus
Fixed drug eruption
Reactive arthritis
Pityriasis versicolor
Bowen disease
Extramammary Paget disease

From Margolis DJ: Cutaneous disease of the male external genitalia. In Walsh PC, ed: *Campbell's urology,* Philadelphia, 2002, Saunders.

Psoriasis

Psoriasis is a common disease affecting up to 2% of the population (Christophers, 2001; Nestle et al., 2009). For patients with a predisposition, which is likely polygenic in nature, triggering factors such as trauma, infection (streptococcal disease), psychological stress, or new medications can elicit a flare in the psoriatic phenotype. One-third of affected patients have a family history of psoriasis (Hensler and Christophers, 1985; Margolis, 2002; Melski and

Stern, 1981).

The characteristic lesion is a sharply demarcated erythematous plaque with silvery-white scales and results from rapid proliferation of the epidermis (van de Kerkhof, 2003). Its pattern can be limited to the elbows or knees or can be distributed on the entire surface of the skin. Although psoriasis can appear at any age, two peaks of onset have been identified: 20 to 30 and 50 to 60 years of age. Patients complain of a significant impairment in their quality of life as a result of pruritus and bleeding, as well as the cosmetic and psychosocial impact of these visible plaques.

Psoriatic involvement of the genitalia is relatively common, although it is usually within the context of a generalized cutaneous disorder. **Patients may present with concerns for malignancy or sexually transmitted disease (STD) when psoriatic lesions are present on the genitalia.** Genital psoriasis leads to impaired self-esteem and reduced sexual self-image, thereby interfering with normal intimate relationships, particularly in women (Magin et al., 2010; Meeuwis et al., 2011). The presence of characteristic lesions on the elbows, knees, buttocks, nails, scalp, and umbilicus may help direct the diagnosis (Fig. 59.8A) (Margolis, 2002). When lesions are present in the inguinal folds and intergluteal cleft, scaling may be absent (so-called inverse psoriasis) (Goldman, 2000). When evaluating nonscaling erythematous plaques in the inguinal folds, the diagnosis of fungal involvement (i.e., tinea or *Candida*) should be considered and ruled out by KOH preparation or fungal culture. In circumcised men, psoriatic plaques are often present on the glans and corona, whereas in uncircumcised men, lesions are commonly hidden under the preputial skin (Buechner, 2002). In some cases, however, psoriasis involves the entire penis and scrotum (Fig. 59.9).

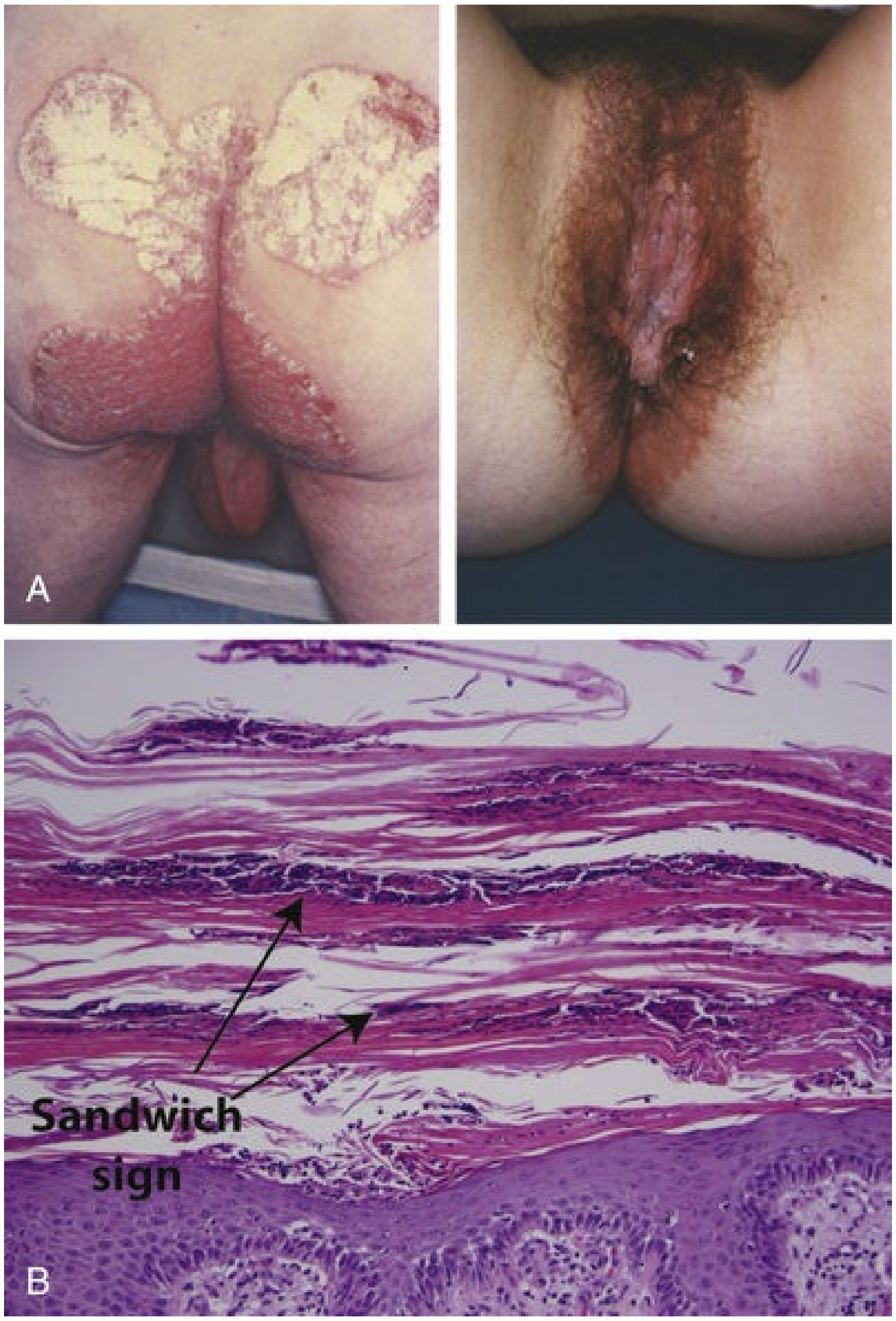

FIG. 59.8 Psoriasis. (A) Silver scales on an erythematous base. (B) Alternating neutrophils and parakeratosis in the stratum corneum of plaque psoriasis (sandwich sign). (A, From Callen JP, Greer DE, Hood AF, et al.: *Color atlas of dermatology,* Philadelphia, 1993, Saunders, p 320. B, From Elston DM, Ferringer T: *Dermatopathology,* Edinburgh, 2009, Saunders p 152.)

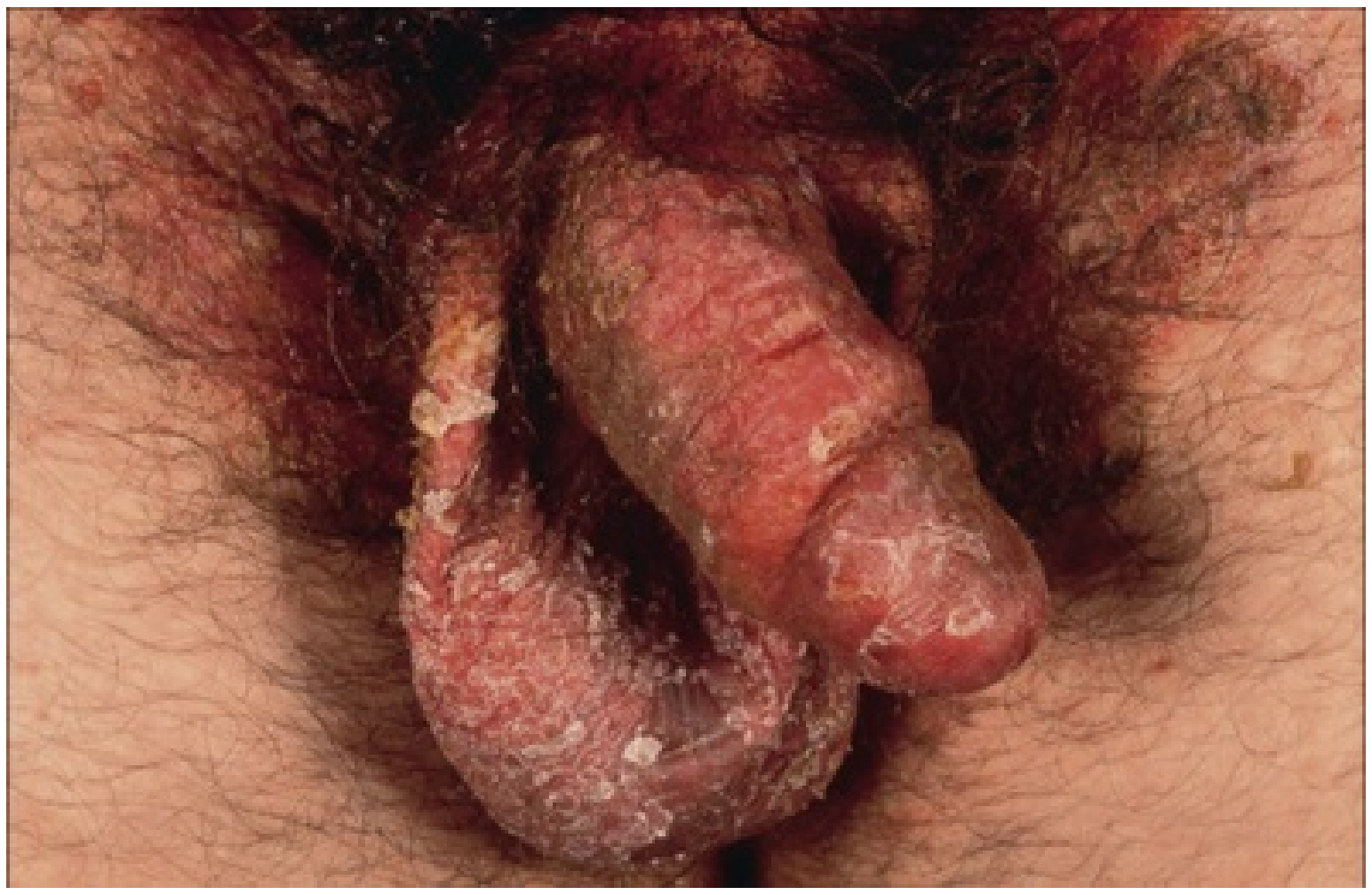

FIG. 59.9 Psoriasis involving the entire penis and scrotum. (Courtesy of Peter CM van de Kerkhof, MD. From Bolognia JL, Jorizzo JL, Rapini RP. *Dermatology*. Edinburgh: Mosby; 2003.)

Psoriasis is a chronic disease with a relapsing and remitting course. A variety of topical and systemic therapies have been developed and are applied to this difficult problem. Despite the variety of therapy, however, as many as 40% of psoriasis patients express frustration at the ineffectiveness of current treatments (Krueger et al., 2001). **For genital psoriasis, the mainstay of therapy is the use of low-potency topical corticosteroid creams for short courses** (Kalb et al., 2009). Examples include a preparation of 3% liquor carbonis detergens (a tar derivative) in 1% hydrocortisone cream or hydrocortisone butyrate 0.1% (Fisher and Margesson, 1998). These preparations should not be used for more than 2 weeks continuously on thin genital skin or in areas occluded by skin folds (Margolis, 2002). If the psoriatic plaque is very thick, a stronger topical corticosteroid such as triamcinolone 0.1% may be used initially. Other topical therapies for psoriasis include vitamin D_3 analogues (calcitriol, calcipotriene), topical calcineurin inhibitors (pimecrolimus cream and tacrolimus ointment), and low-potency retinoids, although these agents are sometimes too irritating or not sufficiently effective. Photochemotherapy combining an ingested PUVA has been used extensively to treat psoriasis (Stern, 2007). However, a dose-dependent increase in the risk of genital SCC has been associated with high-dose PUVA therapy for psoriasis elsewhere on the body (Stern, 1990; Stern et al., 2002). Genital shielding during PUVA therapy is strongly recommended; therefore this modality is contraindicated for treating psoriatic lesions localized to genital skin. For patients with extensive psoriasis, systemic therapy with methotrexate, cyclosporine, retinoids, phosphodiesterase 4 (PDE4) inhibitor (apremilast), or one of the approved TNF-α inhibitors (adalimumab, etanercept, infliximab), interleukin (IL)-17 inhibitor (ixekizumab) or IL-12/23 inhibitors (ustekinumab) may be appropriate. The 308-nm excimer laser (Gerber et al., 2003) is now approved for psoriasis treatment. Experimental therapies that have shown promise in treating psoriasis include vitamin D receptor ligands (Bos and Spuls, 2008) and antibodies or antisense oligonucleotides against T-lymphocyte surface molecules (Gottlieb et al., 2000), TNF (Bos and Spuls, 2008; Chaudhari et al., 2001), or intracellular adhesion molecules (Gottlieb et al., 2000).

Reactive Arthritis (Formerly Reiter Syndrome)

Reactive arthritis (formerly Reiter syndrome) is composed of urethritis, arthritis, ocular findings, oral ulcers, and skin lesions. Only about one-third of all patients with this disorder demonstrate all of the manifestations. The skin findings, particularly when present on the genitalia, may be mistaken for psoriatic lesions (Fig. 59.10). Reactive arthritis is more common in men than in women and is rarely diagnosed in children. **Reactive arthritis is generally preceded by an episode of either urethritis *(Chlamydia, Gonococcus)* or gastrointestinal infection (*Yersinia, Salmonella, Shigella, Campylobacter, Neisseria,* or *Ureaplasma* species) and is more common in human immunodeficiency virus (HIV)-positive patients** (Margolis, 2002; Rahman et al., 1992; Wu and Schwartz, 2008). **There is a strong genetic association with the human leukocyte antigen (HLA)-B27 haplotype.** Whether or not cross-reactivity between bacterial antigens and HLA-B27 leads to autoimmunity in reactive arthritis remains controversial (Ringrose, 1999; Yu and Kuipers, 2003).

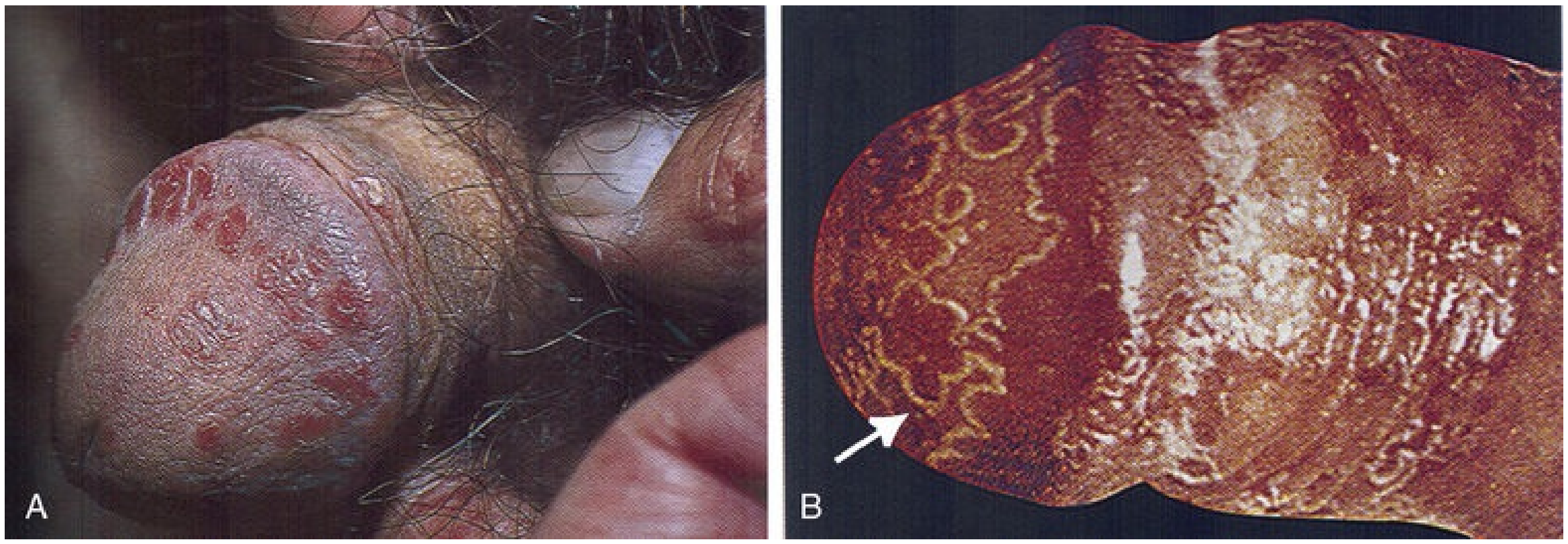

FIG. 59.10 Comparison of psoriasis (A) and reactive arthritis (B) (balanitis circinata) involving the glans penis. Note the highly characteristic

coalescence of lesions in this case of reactive arthritis forming a wavy pattern *(arrow).* (From Habif TP: *Clinical dermatology,* Edinburgh, 2004, Mosby, p 217.)

Conjunctivitis is the most common ocular manifestation, although iritis, uveitis, glaucoma, and keratitis may occur. Polyarthritis and sacroiliitis are the most common orthopedic complaints and may lead to chronic disability in a small minority of cases (van de Kerkhof, 2003). Scaly, erythematous psoriaform skin lesions appearing on the penis are referred to as *balanitis circinata* (Fig. 59.11), and similar lesions on the soles are referred to as *keratoderma blennorrhagicum*. **These lesions may be difficult to distinguish from psoriasis, and histologic analysis of biopsy specimens cannot consistently differentiate the two conditions** (Margolis, 2002). Other disease entities that should be excluded include pustular psoriasis, gonococcal infection, and Behçet syndrome. The course of reactive arthritis involving the genitalia is usually self-limited, lasting a few weeks to months. Lesions may respond to low-potency topical corticosteroids, and systemic therapy is rarely required. Lesions on soles, however, are more persistent; these respond well to the application of potent topical retinoids such as tazarotene or systemic retinoids such as acitretin (Lewis et al., 2000).

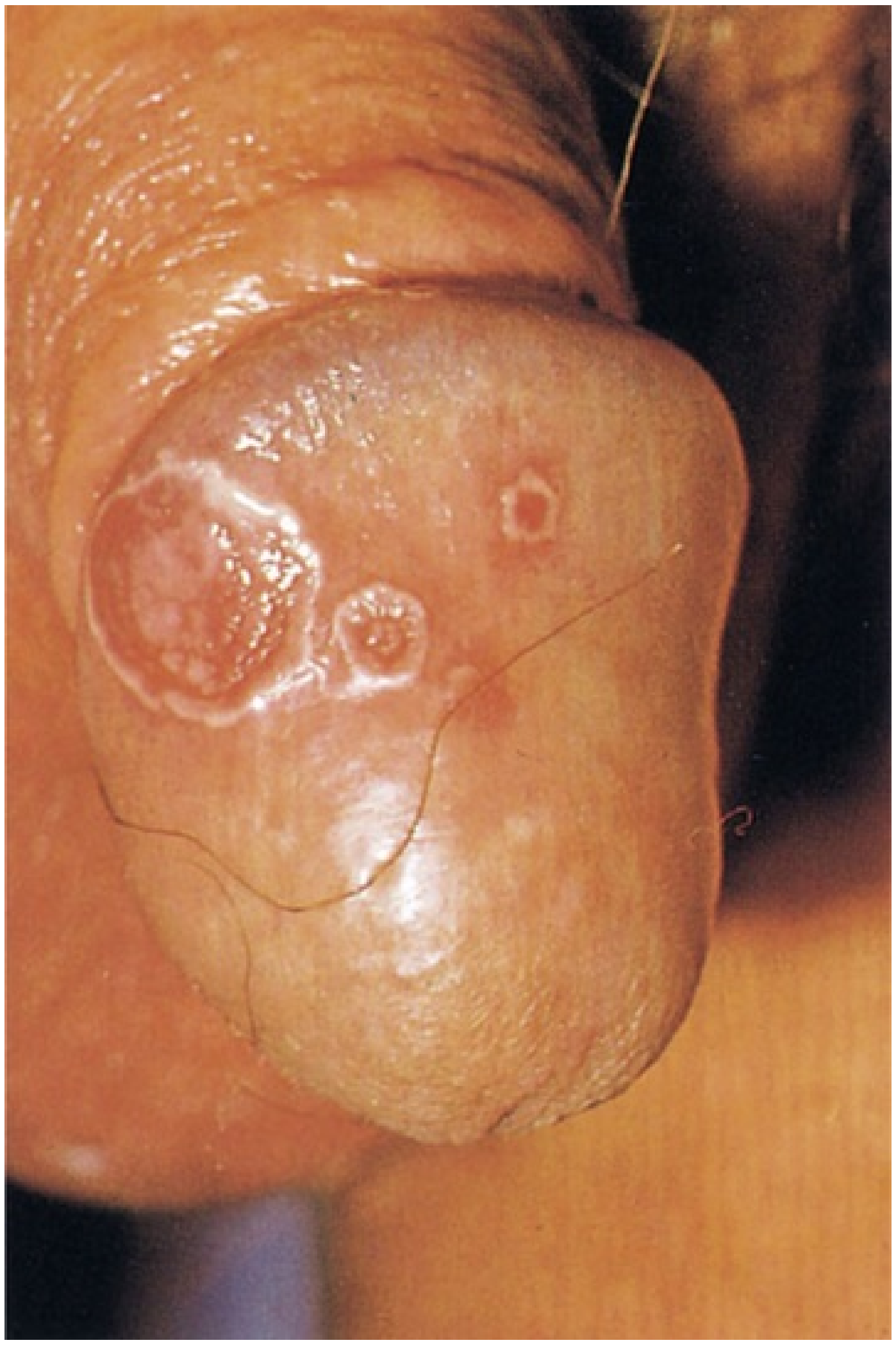

FIG. 59.11 Erosive psoriaform lesions of the glans penis (reactive arthritis; balanitis circinata) may also lack the wavy pattern, making them difficult to differentiate from genital psoriasis. (From Callen JP, Greer DE, Hood AF, et al.: *Color atlas of dermatology,* Philadelphia, 1993, Saunders, p 160.)

Lichen Planus

Lichen planus (LP), the prototype of the lichenoid dermatoses, is an idiopathic inflammatory disease of the skin and mucous membranes. The characteristic "lichenoid tissue reaction" is characterized by epidermal basal cell damage that is associated with a massive infiltration of mononuclear cells in the papillary dermis (Shiohara and Kano, 2003). Cutaneous LP may affect up to 1% of the adult population (Boyd and Neldner, 1991) and oral lesions may be present in as many as 4% (Scully et al., 1998). The pathogenesis of LP appears related to an autoimmune reaction against basal keratinocytes, which express altered self-antigens on their surfaces (Morhenn, 1986).

The primary lesion of LP is a small, polygonal-shaped, violaceous, flat-topped papule. These lesions may be widely separated or may coalesce into larger plaques that may ulcerate, particularly on mucosal surfaces. LP commonly involves the flexor surfaces of the extremities, the trunk, the lumbosacral area, the oral mucosa, and the glans penis (Margolis, 2002). **On the male genitalia, the clinical presentation of LP can vary and includes isolated or grouped papules, a white reticular pattern, or an annular (ringlike) arrangement with or without ulceration** (Fig. 59.12). In some cases, the lesions appear to form linear patterns related to skin trauma (the so-called Koebner phenomenon, which is also seen with psoriasis). On the female genitalia, painful erosion of erythematous plaques is common; in long-standing LP of the vulva, some areas of hyperhydrated hyperkeratosis (manifesting as white plaques) may surround shallow erosions. In women more than in men, concomitant oral LP may be found on the buccal mucosa or tongue (Santegoets et al., 2010). The differential diagnosis of LP includes invasive and in situ SCC, Zoon balanitis, psoriasis, secondary syphilis, herpes and extramammary Paget disease, and lupus erythematosus. Biopsy may be necessary to establish the diagnosis, particularly when the lesions are small, multiple, and ulcerated (Shiohara and Kano, 2003). Lichenoid reactions can also occur in response to ingested drugs and contact allergens, and a careful search for potential offending agents is appropriate.

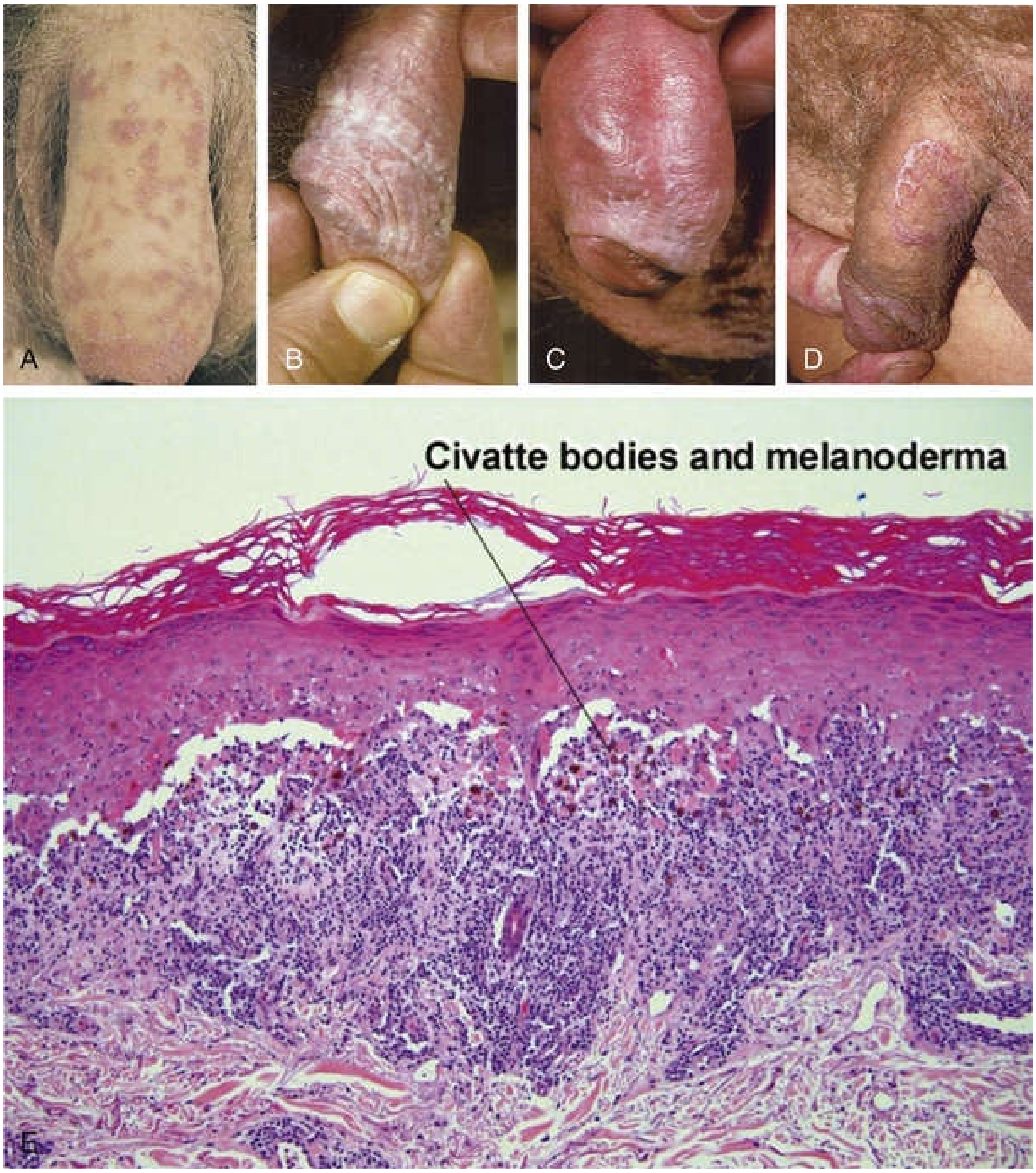

FIG. 59.12 Lichen planus (LP). Various presentations of LP on the male genitalia. (A and B) Individual and grouped purple papules on the penile shaft, some oriented in a linear pattern. (C) A white reticular pattern sometimes seen in LP. (D) An annular (ringlike) arrangement with a shiny surface. (E) Histologically, LP is characterized by destruction of the basal layer, a sawtooth rete ridge pattern, the presence of Civatte bodies and dermal melanocytes, and the absence of parakeratosis or eosinophils. (A, From Korting GW: *Practical dermatology of the genital region*, Philadelphia, 1981, Saunders, p 29. B, C, and D, From du Vivier A: *Atlas of clinical dermatology,* London, 2002, Churchill Livingstone, p 100. E, From Elston DM, Ferringer T: *Dermatopathology,* Edinburgh, 2009, Saunders p 137.)

The natural history of papular LP is benign, and the spontaneous resolution of cutaneous lesions has been observed in up to two-thirds of cases after 1 year (Shiohara and Kano, 2003)**. However, the oral and erosive forms may persist significantly longer, and isolated cases of SCC arising within chronic genital LP have been reported,** warranting regular skin checks throughout the course of the disease (Mignogna et al., 2000). Although bothersome pruritus (more often in men) or pain/burning (more often in women) is common with LP, asymptomatic lesions on the genitalia do not require treatment. Care should be taken with LP of the vagina because erosive disease can cause adhesions and permanent damage (Edwards and Lynch, 2018). The primary modality of treatment for symptomatic genital LP is the application of an ultrapotent topical corticosteroid (such as clobetasol 0.05% or halobetasol 0.05%). There is also a role for topical calcineurin inhibitors (pimecrolimus cream, tacrolimus ointment) in the management of genital LP (Luger and Paul, 2007). For severe cases, systemic corticosteroids (15 to 20 mg/day; 2- to 6-week course) (Boyd and Neldner, 1991) have been shown to shorten the time course to clearance of LP lesions from 29 weeks to 18 weeks (Cribier et al., 1998). Other systemic therapies for severe LP include cyclosporine, tacrolimus, griseofulvin, metronidazole, and acitretin (Boyd and Neldner, 1991; Buyuk and Kavala, 2000; Cribier et al., 1998; Ho et al., 1990; Madan and Griffiths, 2007), although randomized trials demonstrating efficacy are generally lacking. In fact, as pointed out in an exhaustive meta-analysis, there is no overwhelmingly reliable evidence for the efficacy of *any* single treatment for erosive mucosal LP, including application of an ultrapotent topical steroid, which is the widely accepted first-line therapy (Cheng et al., 2012).

Lichen Nitidus

Lichen nitidus (LN) is an unusual inflammatory eruption characterized by tiny, discrete, flesh-colored papules arranged in large clusters. Although there is some debate as to whether LN may represent a variant of LP (Aram, 1988), the two entities are histologically distinct. LN has a dense, well-circumscribed, lymphohistiocytic infiltrate that is closely apposed to the epidermis (Shiohara and Kano, 2003). Commonly involved sites include the flexor aspects of the upper extremities, the genitalia, the trunk, and the dorsal aspects of the hands. Nail involvement is common. Similar to LP, the natural history of LN is one of spontaneous resolution, with the majority of patients (69%) manifesting the disease for less than 1 year (Lapins et al., 1978). Patients should be reassured that these genital lesions are not infectious and should resolve with time. For symptomatic pruritus, genital lesions usually respond to mid- to low-potency topical corticosteroids and oral antihistamines (Shiohara and Kano, 2003).

Lichen Sclerosus

Lichen sclerosus et atrophicus (LS) is a chronic inflammatory disease of unknown cause with a predilection for the external genitalia. LS is 6 to 10 times more prevalent in women than in men, generally occurring either around the time of menopause or in the prepubertal years (Wojnarowska and Cooper, 2003). It tends to affect older men (>60 years of age) (Ledwig and Weigand, 1989) and can be associated with pain during voiding or erection (Margolis, 2002). There is a strong familial predisposition for this disorder, suggesting a genetic contribution (Sherman et al., 2010). For patients with genital LS, 15% to 20% experience extragenital disease (Powell and Wojnarowska, 1999). LS is ultimately a scarring disorder characterized by tissue pallor, loss of architecture resulting from fibrosis, and hyperkeratosis (Fig. 59.13). Some cases of LS may demonstrate prominent purpura and fissuring; the former may be so severe as to obscure the typical “white” color of the disease. The glans penis and foreskin are usually affected, and in contrast to women, perianal involvement in men is usually absent. Preputial scarring from LS can lead to phimosis, and circumcision is usually curative, although recurrence in the circumcision scar may occur. The late stage of this disease is called *balanitis xerotica obliterans*, which can involve the penile urethra and result in troublesome urethral strictures. In women, the disease can eventually lead to vulvar adhesions, labial fusion, clitoral phimosis, and vaginal obstruction. LS can also be the cause of considerable genital itching, burning, pain, and dyspareunia in women.

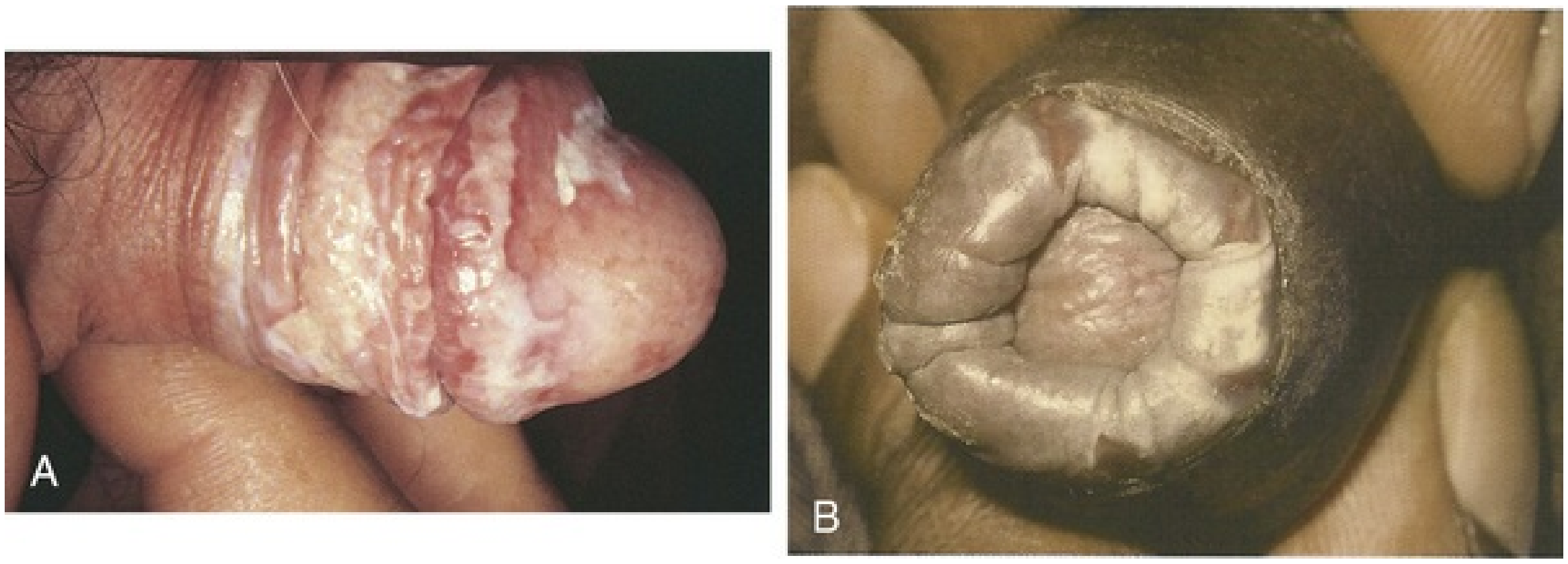

FIG. 59.13 (A and B) Lichen sclerosus et atrophicus (balanitis xerotica obliterans) of the penis. Note the erythematous and white plaques involving the penile shaft, preputial skin, and glans. (A, From Callen JP, Greer DE, Hood AF, et al.: *Color atlas of dermatology*, Philadelphia, 1993, Saunders p 327. B, Courtesy of Ron Rapini, MD. From Bolognia JL, Jorizzo JL, Rapini RP. *Dermatology*. Edinburgh: Mosby; 2003.)

Despite the similarities in name, LS shares little in common with LP and LN other than pruritus and a predilection for the genital region. **Another critical distinction is that LS has been associated with SCC of the penis and vulva, particularly those variants not associated with human papillomavirus (HPV), and LS may represent a premalignant condition** (Bleeker et al., 2009; van de Nieuwenhof et al., 2011; Velazquez and Cubilla, 2003). LS includes specific histologic features, including basal cell vacuolation, epidermal atrophy, marked dermal edema, collagen homogenization, focal perivascular infiltrate of the papillary dermis, and plugging of the ostia of follicular and eccrine structures (Margolis, 2002). Biopsy is worthwhile to confirm the diagnosis and to exclude malignant change (Powell and Wojnarowska, 1999). The differential diagnosis includes erosive LP, vulvar eczema, lichen simplex chronicus, child sexual abuse, morphea, and mucous membrane pemphigoid. It has been suggested that the expression of selected cellular markers (such as p53, survivin, telomerase, Ki-67, and cyclin D1) can help distinguish between indolent LS and LS with true malignant potential (Carlson et al., 2013). In the future, biopsy specimens may routinely be investigated for these (and other) protein markers to determine prognosis.

From a management standpoint, long-term follow-up of patients with LS is important because of the association with SCC. Fissures, ulcers, papules, or nodules that are nonhealing should be carefully monitored. The application of potent topical steroids (such as clobetasol propionate 0.05% or halobetasol

0.05%) for long courses (3 months) followed by tapering and limited (twice weekly) application to maintain remission is well established as a treatment for LS in women and may improve symptoms and reverse the disease process (Dalziel et al., 1991). This regimen is contrary to the usual policy of avoiding long courses of steroid application to genital skin. The efficacy of similar approaches has not been definitively confirmed in adult men, although benefits have been demonstrated in the pediatric age group (Kiss et al., 2001). Several studies show calcineurin inhibitors to have some positive effect on symptoms, but trials comparing calcineurin inhibitors to topical steroids demonstrate greater efficacy for topical steroids (Funaro et al., 2014). The application of topical and administration of systemic retinoids, as well as photodynamic therapy, may be therapeutic options in rare cases refractory to standard therapeutic interventions. Because of a high rate of recurrence (40% to 50%) after seemingly successful initial therapy, some experts suggest the routine use of proactive (prophylactic) maintenance therapy with either midpotency topical steroids (such as mometasone furoate 0.1%) or topical calcineurin inhibitors (Goldstein et al., 2011; Hengge et al., 2006; Virgili et al., 2013).

Fixed Drug Eruption

A fixed drug eruption is one of the most common types of cutaneous drug reactions and occurs in response to oral medications, usually 1 to 2 weeks after the first exposure. It typically involves the lips, face, hands, feet, and genitalia, particularly the glans penis (Fig. 59.14). After subsequent re-exposure to the drug, the reaction occurs in the exact same location, usually within 24 hours (hence the term “fixed”). The most common medications causing this reaction are sulfonamides, nonsteroidal anti-inflammatory agents, barbiturates, tetracyclines, carbamazepine, phenolphthalein, oral contraceptives, and salicylates (Kauppinen and Stubb, 1985; Stubb et al., 1989; Thankappan and Zachariah, 1991). There have been isolated reports of fixed drug eruption associated with urologic drugs, such as finasteride, tadalafil, and fluconazole (administered for vulvovaginal candidiasis).

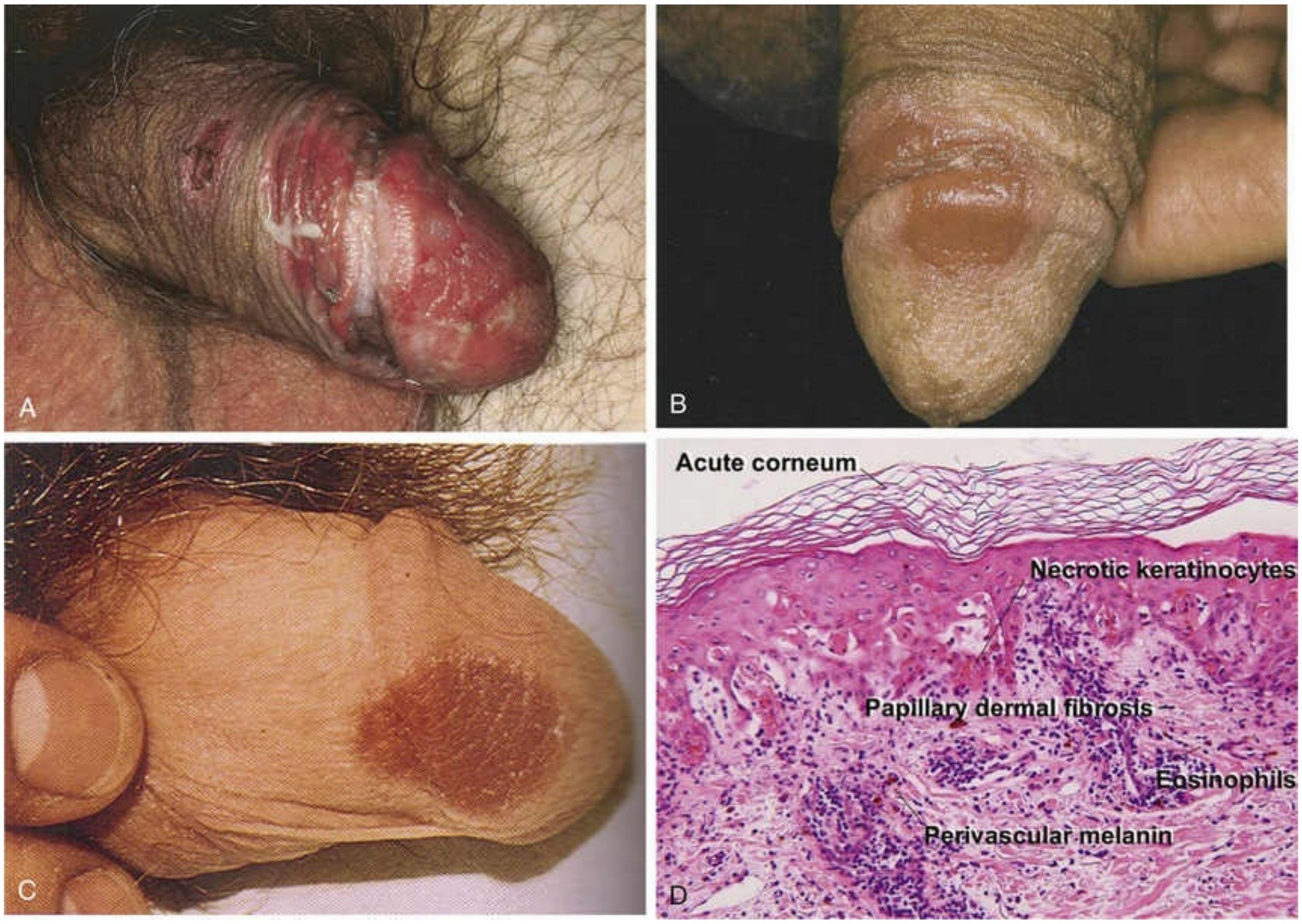

FIG. 59.14 Fixed drug eruptions. (A to C) Involvement of the penis. (D) Histologic features include a normal stratum corneum with chronic changes in the superficial dermis including an eosinophilic infiltrate. (A, From Callen JP, Greer DE, Hood AF, et al.: *Color atlas of dermatology,* Philadelphia, 1993, Saunders, p 160; B, Courtesy of Kalman Watsky, MD. From Bolognia JL, Jorizzo JL, Rapini RP. *Dermatology*. Edinburgh: Mosby; 2003. C, From Habif TP: *Clinical dermatology,* Edinburgh, 2004, Mosby, p 492, D, From Elston DM, Ferringer T: *Dermatopathology,* Edinburgh, 2009, Saunders, p 149.)

When present on the penile shaft or glans, these lesions usually appear as an asymptomatic, solitary, violaceous-colored, well-defined patch or plaque surrounded by an erythematous halo, and they may become bullous, pruritic, erosive, and painful (Margolis, 2002). On the genitalia, the differential diagnosis includes herpes simplex infection or an insect bite. Removing the offending agent usually results in resolution of the lesion, although a postinflammatory brown pigmentation may remain. There should be no long-lasting residual functional defect from this process.

Seborrheic Dermatitis

Seborrheic dermatitis (SD) is a common skin disease characterized by the presence of sharply demarcated pink-yellow to red-brown plaques covered with an adherent flaky scale. It shares a variety of features in common with eczematous dermatitis and could easily be grouped in that category. Common dandruff is a mild form of SD localized to the scalp. It has a predilection for areas rich in sebaceous glands and is generally present only during the first few months of life or postpuberty, when sebaceous glands are active. Commonly affected areas include the scalp, eyebrows, nasolabial folds, ears, and chest, although the anus, glans penis, and pubic areas may also be involved (Margolis, 2002). Circumcision may be somewhat protective against the development of SD. In one study of 357 patients, the risk of developing penile SD was 2.5 times greater in the uncircumcised state (Mallon et al., 2000).

Adult SD includes a chronic relapsing course (Webster, 1991). **This condition is particularly common in patients with Parkinson disease, and up to 83% of acquired immunodeficiency syndrome (AIDS) patients may manifest SD** (Froschl et al., 1990; Gupta and Bluhm, 2004). Particularly in immunosuppressed individuals, SD may involve a significant proportion of the body surface area. **Extensive and/or severe SD should raise concerns for possible underlying HIV infection** (Fritsch and Reider, 2003). SD may be pruritic, and differentiation from psoriasis may occasionally be problematic. Unlike psoriasis, however, SD rarely involves the nails and tends to have a thinner associated scale.

Controversy concerning the etiology of SD revolves around a possible autoimmune response to a component of normal skin flora, the yeast *Malassezia furfur (Pityrosporum ovale)*. Although *M. furfur* can be isolated from the lesions of SD, the number of organisms is only about twice that observed in normal control skin (Nenoff et al., 2001). Likewise, severely SD-affected HIV patients do not harbor more organisms than HIV patients who do not manifest SD (Pechere et al., 1999). Another factor potentially linked to SD is an elevated level of triglycerides and cholesterol at the skin surface (Fritsch and Reider, 2003).

Creams or foams containing topical antifungals (i.e., ketoconazole) are the mainstay of SD treatment on the body and include a 75% to 90% response rate (Elewski et al., 2007; Faergemann, 2000; Fritsch and Reider, 2003). For hair-bearing areas, “antidandruff” shampoos containing zinc, salicylic acid, selenium sulfide, tar, ciclopirox olamine, or 1% to 2% ketoconazole are effective (Margolis, 2002; Squire and Goode, 2002). Because of the chronic and relapsing nature of SD, treatment often must be repetitive and prolonged. Low-potency topical corticosteroids such as 2.5% hydrocortisone may play a role during the initial treatment of severe cases, but they should not be the primary mode of treatment for this condition because of the potential for local steroid side effects.

Vesicobullous Disorders

Vesicobullous disorders are uncommon conditions often characterized by autoimmune damage to the epidermis or basement membrane (Box 59.3). Although intact blisters may be found on the groin and suprapubic skin per se, the rupture of vesicles and bullae on the genitalia may only leave behind residual erosions (Margolis, 2002).

Box 59.3

Differential Diagnosis of Vesicobullous Disorders

Bullous pemphigoid
Pemphigus vulgaris
Pemphigus foliaceus
Zoon balanitis
Behçet syndrome
Contact dermatitis
Dermatitis herpetiformis
Porphyria cutanea tarda
Herpes zoster
Herpes simplex
Lymphangioma circumscriptum
Impetigo
Fixed drug eruption
Factitial
Innocent trauma
Benign familial pemphigoid (Hailey-Hailey disease)

From Margolis DJ: Cutaneous disease of the male external genitalia. In Walsh PC, ed: *Campbell's urology*, Philadelphia, 2002, Saunders.

Pemphigus Vulgaris

Pemphigus is a family of autoimmune blistering diseases characterized by intraepidermal blisters resulting from the loss of keratinocyte cell-cell adhesion (Martel and Joly, 2001). These blisters are located in the deep epidermis close to the basal cell layer. The proposed immunopathology includes the development of autoantibodies directed against keratinocyte cell surface markers and desmosomes, which show characteristic histologic changes on biopsies for routine H&E staining and direct immunofluorescence (Amagai et al., 1996; Joly et al., 2000; Zhou et al., 1997).

Almost all pemphigus patients exhibit painful oral mucosal erosions, and more than half experience cutaneous blisters that may involve the genitalia. Characteristic oral lesions are therefore an important clue to the diagnosis (Fig. 59.15). The cutaneous blisters are thin-walled and easily broken so that the presenting morphology is often a collection of nonspecific nonscarring erosions. The loss of epidermal cohesion seen in pemphigus leads to the characteristic Asboe-Hansen or indirect Nikolsky sign: spreading of fluid under the adjacent normal-appearing skin away from the direction of pressure on the blister (Amagai, 2003). **In severe cases without appropriate treatment, pemphigus may lead to fatal septicemia as a result of the loss of the epidermal barrier function of large areas of affected skin.** Treatment for pemphigus traditionally depends on systemic corticosteroids, although minimization of steroid dose is an important goal to limit side effects. The addition of immunosuppressive agents such as azathioprine, cyclophosphamide, and mycophenolate mofetil may be beneficial because of their corticosteroid-sparing effect (Amagai, 2003). In recent years, the use of rituximab as monotherapy (1000 mg administered intravenously on days 1 and 15; repeated in 1 month if necessary) has gained considerable support because of high efficacy rates (>70% with a single cycle) and low relapse rates (22% at 8 to 12 months) (Leshem et al., 2013). The infusion of intravenous immunoglobulin with or without rituximab may also prove effective and presents an inherent advantage of lowering infectious complication rates (Ruocco et al., 2013). The management of pemphigus is difficult and should always be performed in concert with a dermatologist or a rheumatologist who has experience with this disease.

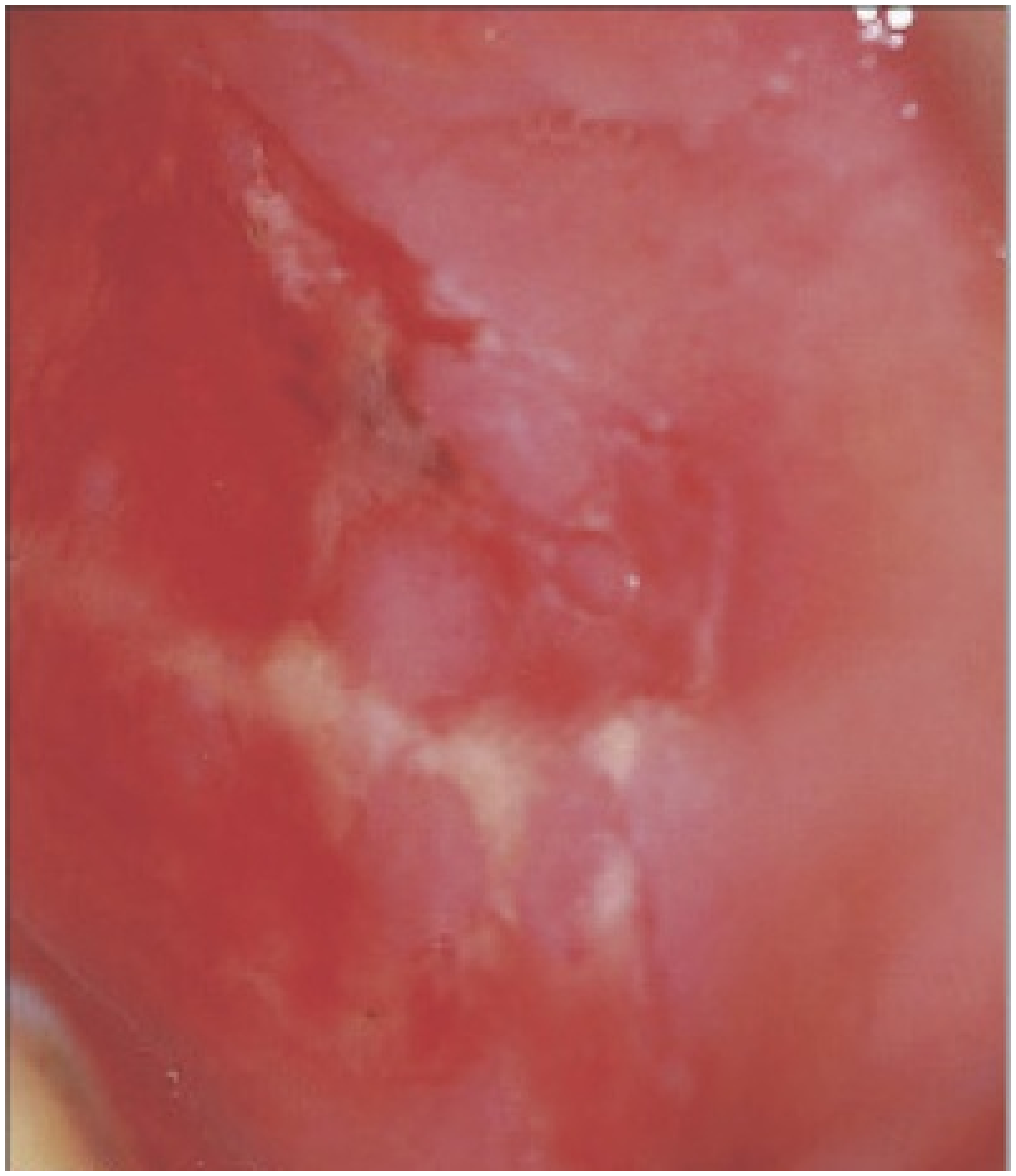

FIG. 59.15 Characteristic painful oral mucosal erosions in pemphigus vulgaris. (Courtesy of Masayuki Amagai. From Bolognia JL, Jorizzo JL, Rapini RP. *Dermatology*. Edinburgh: Mosby; 2003.)

Bullous Pemphigoid

Bullous pemphigoid (BP) is a subepidermal blistering disease that is more common in men and generally afflicts patients older than 60 years of age (Rzany and Weller, 2001). There is enrichment for specific HLA class II alleles in patients with BP as compared with normal controls (Delgado et al., 1996), supporting an autoimmune mechanism of pathogenesis. In BP autoantibodies against specific proteins involved in cell-cell adhesion (BP180, BP230) are present. These proteins are components of hemidesmosomes, which are structures that mediate epidermal-stromal adhesion. Binding of autoantibodies to these structures leads to complement activation and a cascade of events resulting in tissue damage, epidermal-dermal separation, and blister formation (Kitajima et al., 1994; Lin et al., 1997). Drugs such as furosemide, penicillins, ibuprofen, psoralens and angiotensin-converting enzyme inhibitors have been associated with BP (Stavropoulos et al., 2014).

The clinical presentation of BP can be highly variable. It generally begins with a nonbullous phase characterized by severe itching and nonspecific skin findings, including erythematous plaques that mimic urticaria. If the disease progresses into the bullous phase, vesicles and tense blisters filled with wheat-colored or hemorraghic fluid appear on normal skin. Skin involvement can be limited or extensive, tend to form on flexor surfaces, and favor the inner thighs and genitalia (Fig. 59.16A). Mucous membranes may also be involved, although this is less common than in pemphigus. **The diagnosis is made by a combination of clinical, histologic, and, often most importantly, immunohistochemical features such as the deposition of IgG antibodies along the basement membrane** (see Fig. 59.16B; De Jong et al., 1996). Treatment of BP in the United States is traditionally similar to that described for pemphigus, with systemic corticosteroids and various immunosuppressives playing primary roles (Kirtschig and Khumalo, 2004). However, based on the results of several randomized comparative studies, the Europeans favor the use of superpotent topical steroids for the management even of extensive pemphigoid (Joly et al., 2002; Joly et al., 2009). Certainly, treatment of limited-extent pemphigoid should rely heavily on topical, rather than systemic, corticosteroids. For treatment-resistant cases, oral methotrexate, intravenous immunoglobulin, plasmapheresis, or intravenous rituximab may be beneficial (Hatano et al., 2003; Lee et al., 2003; Ruetter and Luger, 2004; Shetty and Ahmed, 2013; Wetter et al., 2005).

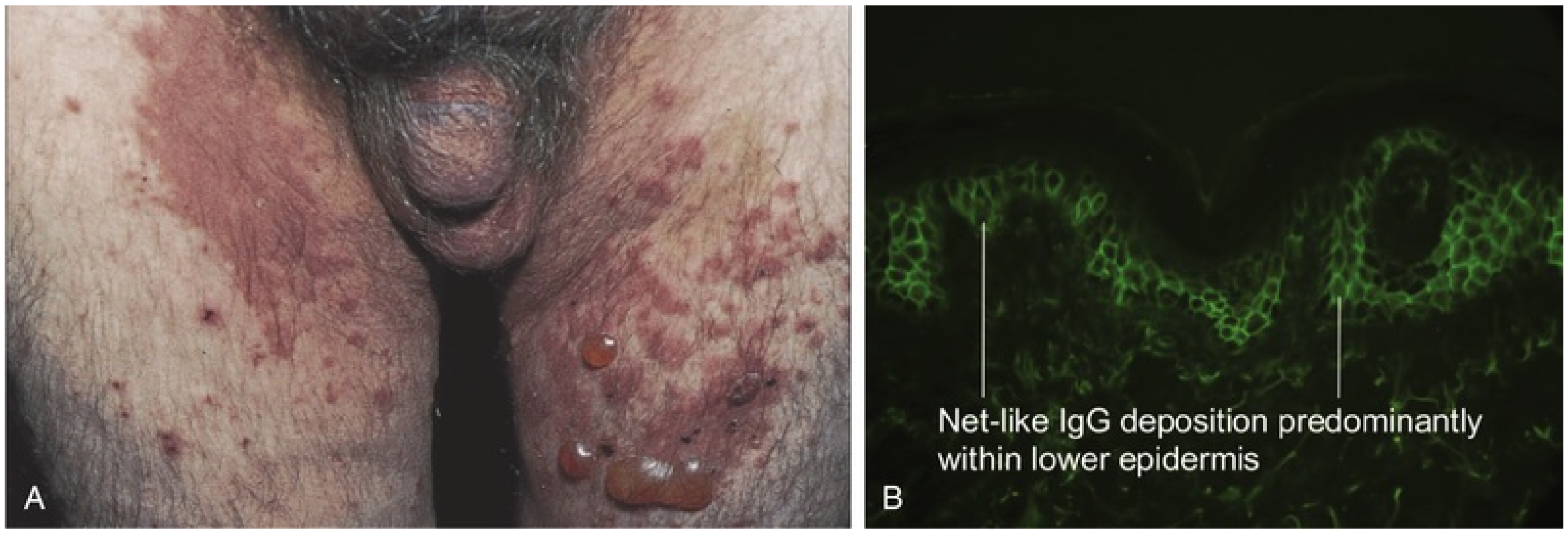
A
Net-like IgG deposition predominantly within lower epidermis
B

FIG. 59.16 Bullous pemphigoid (BP). (A) Involvement of the inner thighs. Note the confluent plaques and tense blisters in the inguinal area. (B) Direct immunofluorescence of BP showing deposition of autoantibodies (IgG) at the dermoepidermal junction. (A, Courtesy of Luca Borradori, MD, and Philippe Bernard, MD. From Bolognia JL, Jorizzo JL, Rapini RP.

Dermatology. Edinburgh: Mosby; 2003. B, From Elston DM, Ferringer T: *Dermatopathology,* Edinburgh, 2009, Saunders, p 169.)

Dermatitis Herpetiformis and Linear IgA Bullous Dermatosis

Both of these entities are blistering autoimmune skin diseases associated with the deposition of IgA antibodies at the basement membrane.

Dermatitis herpetiformis (DH) is a cutaneous manifestation of celiac disease and is generally associated with gluten sensitivity (Karpati, 2004). It is most common in people of northern European origin. There is a close association of dermatitis herpetiformis with certain HLA class II DQ2 alleles (DQA1*0501, DQB1*02) (Reunala, 1998). Epidermal transglutaminase is the autoantigen in DH. Pruritic plaques, papules, and vesicles in a symmetrical distribution characterize this disease. These vesicles may form “herpetiform” groups on an erythematous base. Patients may also complain of pain and burning over the lesions. Diagnosis can be confirmed by biopsy and direct immunofluorescence, which shows a granular pattern of IgA deposition at the basement membrane. Treatment includes the use of dapsone and a strict gluten-restricted diet (Andersson and Mobacken, 1992; Frodin et al., 1981).

Linear IgA bullous dermatosis (LABD), in contrast, is not associated with celiac disease. As the name implies, a linear pattern of antibody deposition at the basement membrane is found on immunohistochemistry in LABD (Fig. 59.17). Characteristic clinical features include vesicles and bullae arranged in a combination of circumferential and linear orientations. Treatment with either sulfapyridine or dapsone is usually effective in controlling LABD, and long-term spontaneous remission rates of 30% to 60% have been described (Wojnarowska et al., 1988). In contrast to pemphigus and BP, neither dermatitis herpetiformis nor LABD commonly affects genital or perigenital skin.

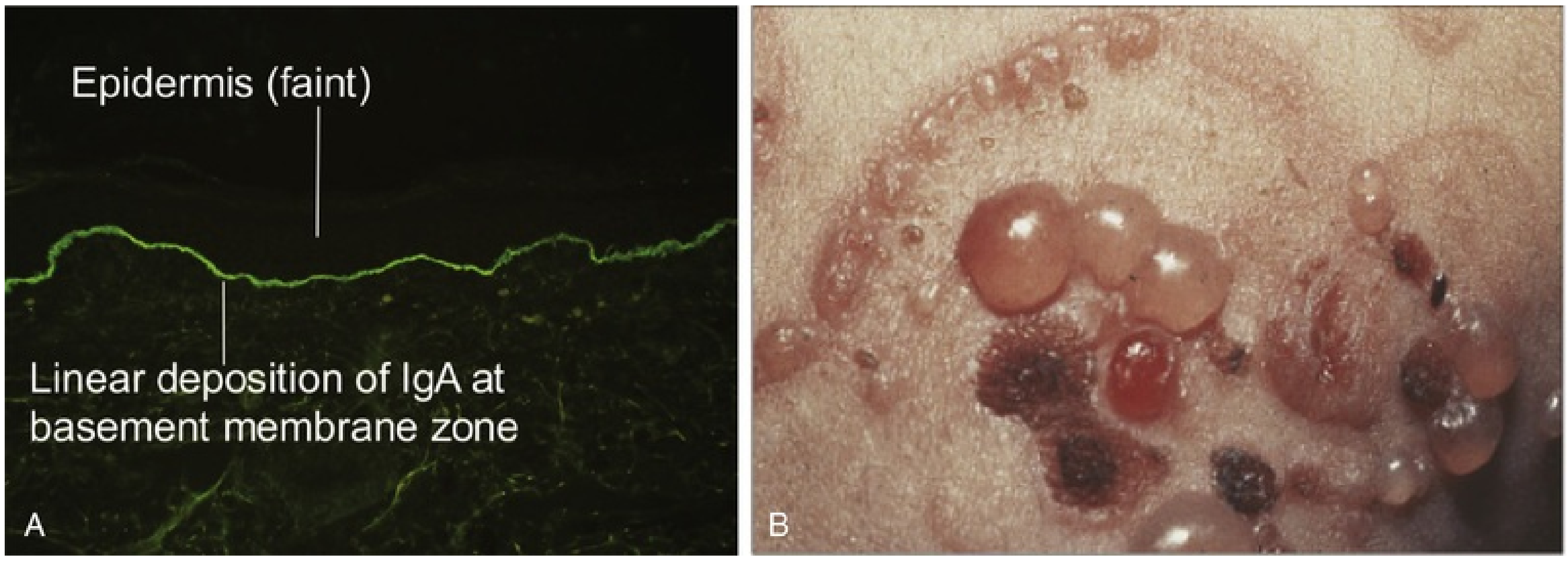

FIG. 59.17 Linear IgA bullous dermatosis. (A) Direct immunofluorescence showing linear deposition of IgA along the dermoepidermal junction. (B) Typical circumferential and linear patterns of vesicles. (A, From Elston DM, Ferringer T: *Dermatopathology,* Edinburgh, 2009, Saunders, p 170. B, Courtesy of Mark D Herron, MD, and John J Zone, MD. From Bolognia JL, Jorizzo JL, Rapini RP. *Dermatology*. Edinburgh: Mosby; 2003.)

Hailey-Hailey Disease

Hailey-Hailey disease, also known as benign familial pemphigus, is a rare autosomal dominant blistering dermatosis related to various mutations in the *ATP2C1* gene. The *ATP2C1* gene encodes the protein product hSPCA1, which is a Ca^{2+}/Mn^{2+} transporter. This protein is responsible for calcium homeostasis in the Golgi apparatus required for the post-translational processing of junctional proteins involved in proper epidermal cell-cell adhesion. Hailey-Hailey disease usually develops within the second or third decade of life (Burge, 1992)**. It has a characteristic predilection for the intertriginous areas including the neck, axillae, groin, and perianal region** (Fig. 59.18). In women, disease in the inframammary folds is common although vulvar disease is unusual (Wieselthier and Pincus, 1993). Symptoms include an unfortunate combination of pruritus, pain, and a foul odor. As heat and sweating exacerbate the condition, Hailey-Hailey disease tends to worsen dramatically during the summer months (Burge, 1992). Skin findings include confluent areas of fragile white skin with small linear fissures, exudate, vesicles, and pustules that form as a result of the aberrant keratinocyte cell adhesion. Mucous membrane involvement does not occur. Lesions may be confined to the axilla or groin, and superinfection with yeast, bacteria, or herpes simplex virus may compound the problem. Histologic examination may be helpful in differentiating Hailey-Hailey disease from impetigo, pemphigus, intertrigo, and Darier disease

(Margolis, 2002). **Treatment includes wearing lightweight, breathable clothing to avoid friction and sweating. Lesions may respond to topical or intralesional corticosteroids, with the caveats mentioned previously about the use of these agents on intertriginous skin. For disease that is resistant to medical therapy, wide excision and skin grafting have been effective, as have local ablative techniques such as dermabrasion, photodynamic therapy, electron beam radiotherapy, glycopyrrolate, afamelanotide, and CO_2 or erbium-YAG laser vaporization** (Alsahli et al., 2017; Christian and Moy, 1999; Farahnik et al., 2017; Hamm et al., 1994; Hohl et al., 2003). An innovative approach to this disorder is to inject infected areas with botulinum toxin type A; this therapy greatly reduces sweating and thereby reduces disease severity (Bessa et al., 2010).

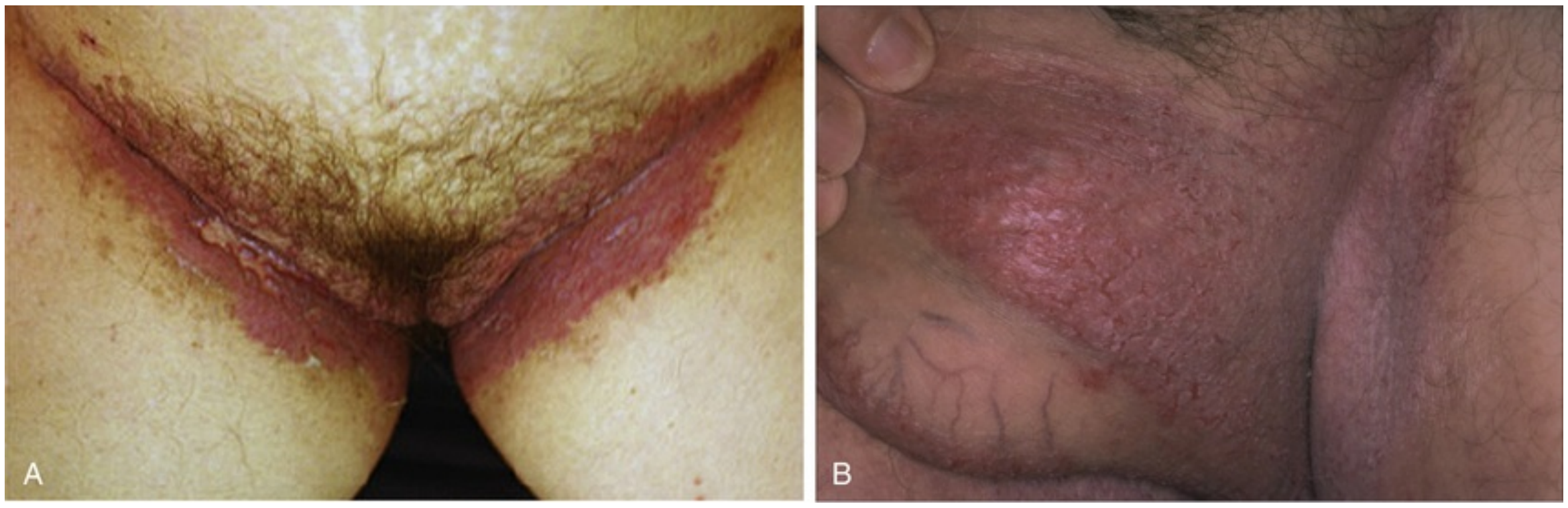

FIG. 59.18 Genital presentations of Hailey-Hailey disease. (A) The vulva and groin are covered in a vesicular eruption that has become confluent and macerated. (B) Erythematous plaque with maceration of the inguinal canal and scrotum. (**A,** From Zhao QF, Hasegawa T, Komiyama E, et al: Hailey-Hailey disease: a review of clinical features in 26 cases with special reference to the secondary infections and their control. *Dermatologica Sinica* 35(1): 7–11, 2016. Fig. 1A. B, Courtesy of Daniel Hohl, Theodora Maura, Jean Phillipe Görög. From Bolognia JL, Jorizzo JL, Rapini RP. *Dermatology*. Edinburgh: Mosby; 2003.)

Noninfectious Ulcers

Genital ulcers can be a result of infectious and noninfectious causes (Box 59.4).

Box 59.4

Differential Diagnosis of Ulcers

Syphilis
Chancroid
Herpes simplex
Crohn disease
Aphthous ulcer
Behçet disease
Granuloma inguinale
Genital bite wound
Lymphogranuloma venereum
Factitial dermatitis
Wegener granulomatosis
Leukocytoclastic vasculitis
Pyoderma gangrenosum

From Margolis DJ: Cutaneous disease of the male external genitalia. In Walsh PC, ed: *Campbell's urology*, Philadelphia, 2002, Saunders; 2002.

Aphthous Ulcers and Behçet Disease

Aphthous ulcers are small, painful erosions that commonly involve the oral cavity (so-called canker sores), but they can occasionally be present on the genitalia. **When oral and genital aphthous ulcers coexist, the clinician should seriously consider the diagnosis of Behçet disease (BD).** BD is a generalized relapsing and remitting ulcerative mucocutaneous disease that likely involves a genetic predisposition and an autoimmune mode of pathogenesis (Mendes et al., 2009; Sakane, 1997). Although many genetic loci have been implicated, perhaps the strongest association is with *HLA B51*. Oxidative stress related to the overproduction of superoxide radicals by neutrophils has also been implicated in the development of this condition (Freitas et al., 1998; Najim et al., 2007). However, a large number of other etiopathogenetic mechanisms have been proposed and supported by experimental findings (such as IL-10 gene mutations) (Remmers et al., 2010). The notable variability in efficacy for any of the therapeutic interventions enumerated later suggests that pathways of inflammation in BD are unlikely to be uniform. BD has a high prevalence in Turkey (80 per 100,000), Israel (15 per 100,000), and Japan (10 to 12 per 100,000), but it is rare in the United States (0.12 to 5.0 per 100,000) (Arbesfeld and Kurban, 1988; Calamia et al., 2009). Affected individuals may also suffer from epididymitis, thrombophlebitis, aneurysms (particularly of the pulmonary artery), and gastrointestinal, neurologic, and arthritic problems (Aykutlu et al., 2002; Cetinel et al., 1998; Koc et al., 1992; Krause et al., 1999; Margolis, 2002; Tuzun et al., 1997). BD occurs with roughly similar frequency among males and females, although men typically experience a more severe course.

Mucocutaneous lesions of the oral cavity and genitalia (Fig. 59.19) **and ocular involvement (uveitis) form a triad of clinical features in BD. The genital lesions are larger and generally more painful than the oral lesions.** Optic involvement occurs in 90% of cases and may lead to blindness (Moschella, 2003). It is now considered a multisystem disease, with new criteria classifying a patient as having BD if they score at least 4 points in the following: 2 points each (ocular lesions, oral aphthosis, and genital aphthosis) and 1 point each (skin lesions, central nervous system involvement, and vascular manifestations) (International Team for the Revision of the International Criteria for Behçet's Disease, 2014). Other causes for genital ulceration, however, including simple or complex aphthous ulcers, primary syphilis, herpes simplex, and chancroid, must be considered before a diagnosis of BD is made (Margolis, 2002). In the context of these accepted criteria, oral ulceration is the most sensitive lesion and genital ulceration is the most specific lesion. The latter therefore is the most clinically useful lesion in diagnosing BD according to this schema. Nonetheless the diagnosis of BD depends exclusively on the aggregate clinical findings, because there are no specific laboratory, radiologic, genetic, or histologic findings that conclusively confirm this diagnosis (Hatemi et al., 2013).

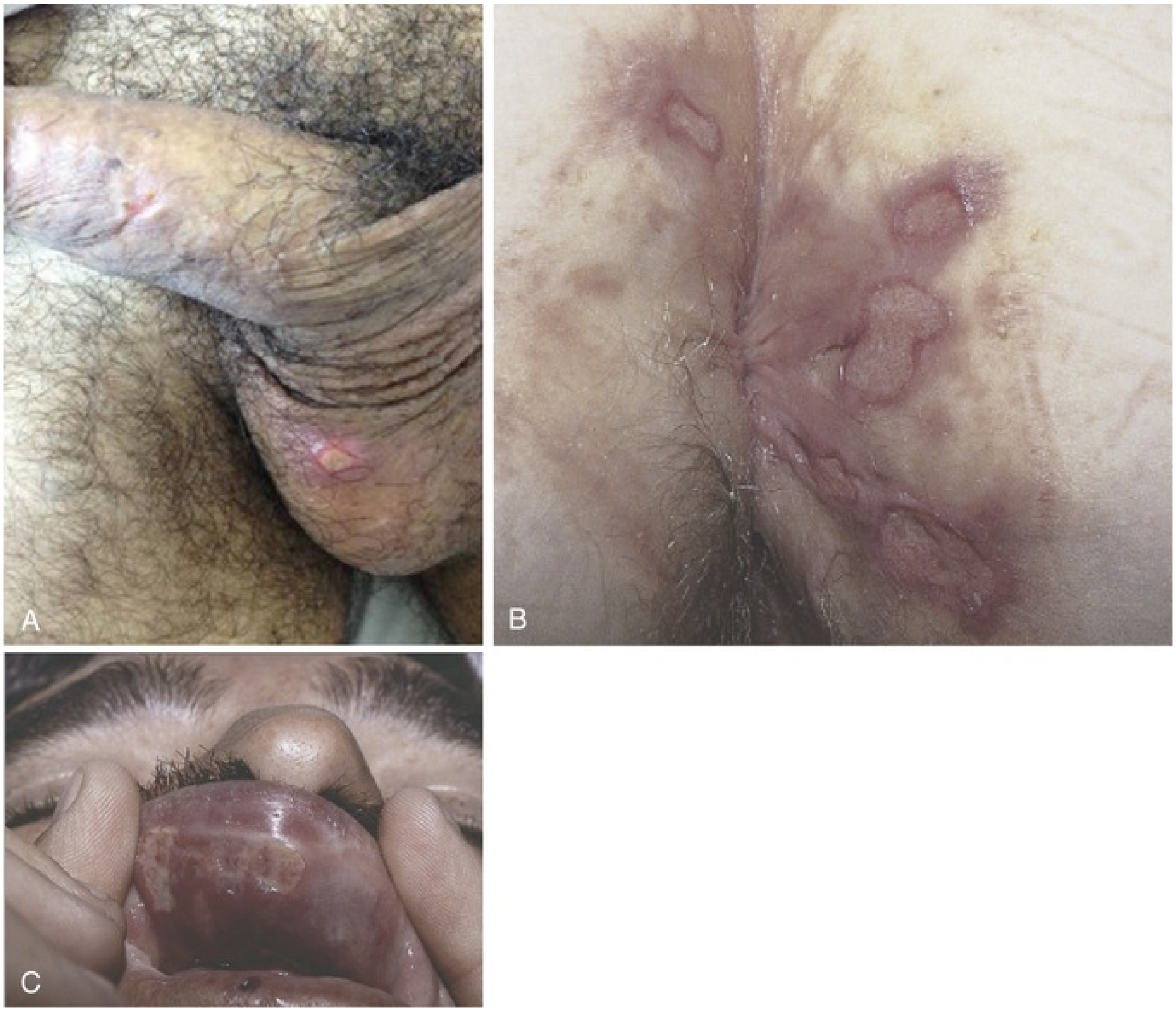

FIG. 59.19 Scrotal (A), perianal (B), and oral (C) ulcers seen in Behçet disease. (A, From Gül A. *Rheumatology*. Philadelphia, Elsevier, 2019. Fig. 167-1; B and C, Courtesy of Samuel L Moschella, MD. From Bolognia JL, Jorizzo JL, Rapini RP. *Dermatology*. Edinburgh: Mosby; 2003.)

The clinical course of BD is protean, and randomized controlled trials in support of specific therapy are currently limited (Kaklamani and Kaklamanis, 2001). A wide range of topical and systemic agents has been applied to treat BD with variable success, including corticosteroids, dapsone, colchicine, immunosuppressants, 5-aminosalicylic acid (5-ASA) derivatives, cyclosporine A, and TNF-α inhibitors (especially infliximab and adalimumab) (Kose et al., 2009; Moschella, 2003). It has become clear that earlier and more aggressive treatment of BD-associated significant organ involvement with immunosuppressives and biologics has improved the overall outcome. Rheumatologic consultation is advised when this diagnosis is suspected.

Pyoderma Gangrenosum

Pyoderma gangrenosum (PG) is a rare ulcerative neutrophilic skin disease associated with systemic illnesses including inflammatory bowel disease, arthritis, collagen vascular disease, chronic active hepatitis, HIV infection, and myeloproliferative disorders (Moschella, 2003). **It most commonly affects women between the second and fifth decade of life and likely has an autoimmune pathogenesis given its association with other autoimmune diseases.** Between 20% and 50% of cases, however, are idiopathic. The annual incidence of PG in the United States is about 1 case per 100,000 individuals.

The classic morphologic presentation of PG is painful cutaneous and mucous membrane ulceration, often with extensive loss of tissue and a purulent base (Fig. 59.20). The classic appearance is a rapidly developing ulcer on the lower legs with an overhanging, undermined violaceous border that developed at a site of trauma. Although unusual, PG can involve the penis, scrotum, vulva, and peristomal sites (Cairns et al., 1994). As was the case in BD, no specific diagnostic laboratory test or histopathologic feature is pathognomonic for PG, although a history of an underlying systemic disease may raise suspicion. Biopsy should be performed 5 to 10 mm from the edge of the ulcer, where a dense neutrophilic infiltrate will be present (Edwards and Lynch, 2018). Aside from ulcerative STDs, the differential diagnosis of penile PG includes calciphylaxis, BD, necrotizing fasciitis, cutaneous metastatic Crohn disease, deep fungal infection, pemphigus vegetans, Fournier gangrene, neoplastic conditions, erosive LP, trauma, and factitious damage (Badgwell and Rosen, 2006). Treatment includes a combination of local and systemic corticosteroid therapy with or without adjunctive immunosuppressants (i.e., cyclosporine, TNF-α inhibitors, and intravenous immunoglobulin) (Chow and Ho, 1996; Feldman et al., 2018; Song et al., 2018). Minocycline, sulfasalazine, and thalidomide have been used in combination with corticosteroids in a small number of cases. Genital PG may also be amenable to topical treatment with calcineurin inhibitors (Lally et al., 2005).

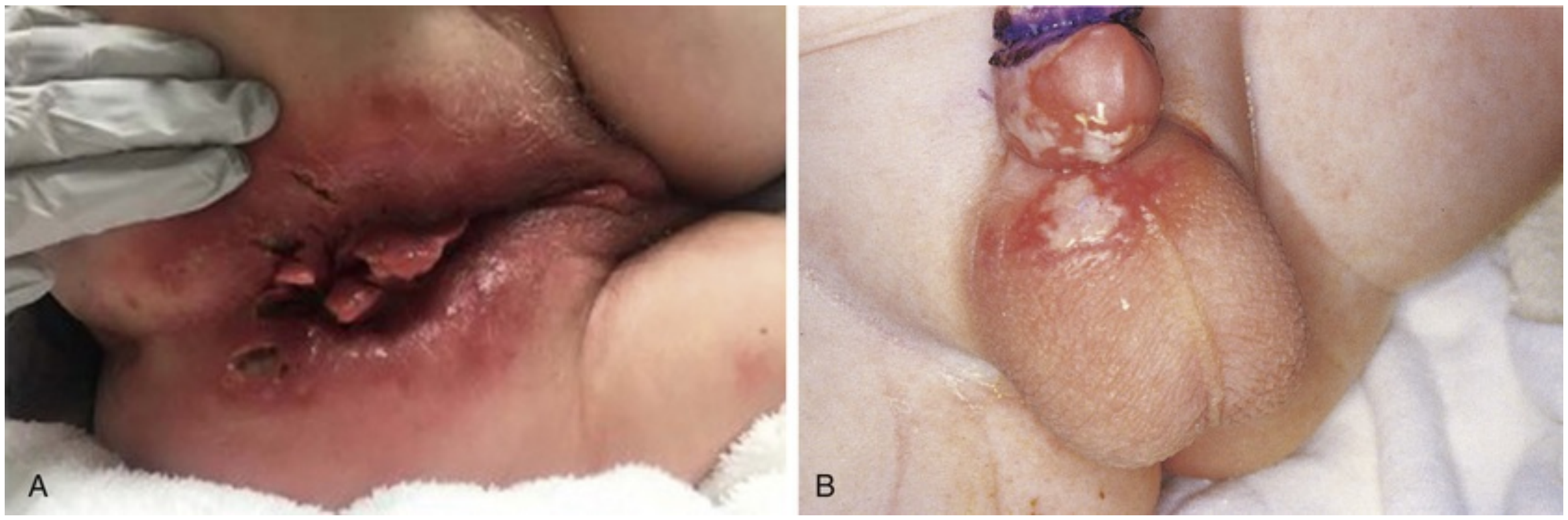

FIG. 59.20 Pyoderma gangrenosum involving the genitals of a woman with rheumatoid arthritis (A) and the penis and scrotum (B). (A, From Pinard J, Chiang DY, Mostaghimi A, et al: Wounds that would not heal: pyoderma gangrenosum. *Am J Med* 131(4): 377–379, 2018, Fig 1B; B, from Callen JP, Greer DE, Hood AF, et al. *Color atlas of dermatology*. Philadelphia: Saunders; 1993, p. 330.)

Traumatic Causes

Cutaneous lesions of the genitalia, including ulceration, can be caused by local trauma, which should be included in the differential diagnosis. **This can be either accidental ("innocent trauma") or self-inflicted ("factitial dermatitis/dermatitis artefacta," and "psychogenic neurotic excoriation").** Accidental injuries may be a result of trauma during sexual practices (including genital bite wounds), ornamentation (i.e., piercing), or unusual hygiene practices (i.e., cleaning) (Margolis, 2002). **Factitial dermatitis is a psychocutaneous disorder in which the individual self-inflicts cutaneous lesions usually for an unconscious motive or because of an underlying mental illness. Factitial lesions are occasionally produced deliberately with the hope of some secondary gain (such as product liability litigation).** An association between factitial dermatitis and borderline personality disorder appears to exist (Koblenzer, 2000). Other disorders to be considered include Munchausen syndrome by proxy, body dysmorphic disorder, and malingering, if secondary-gain issues exist. **Psychogenic excoriations are seen in patients with underlying psychological dysfunction, namely depression, bipolar disorder, delusional disorder, or obsessive-compulsive disorder** (Fig. 59.21; Ehsani et al., 2009; Mutasim and Adams, 2009). Although rare, factitial dermatitis or neurotic excoriations should always be considered in the differential diagnosis of unusual genital lesions, including oddly configured angulated erosions and ulcerations (Verma et al., 2012).

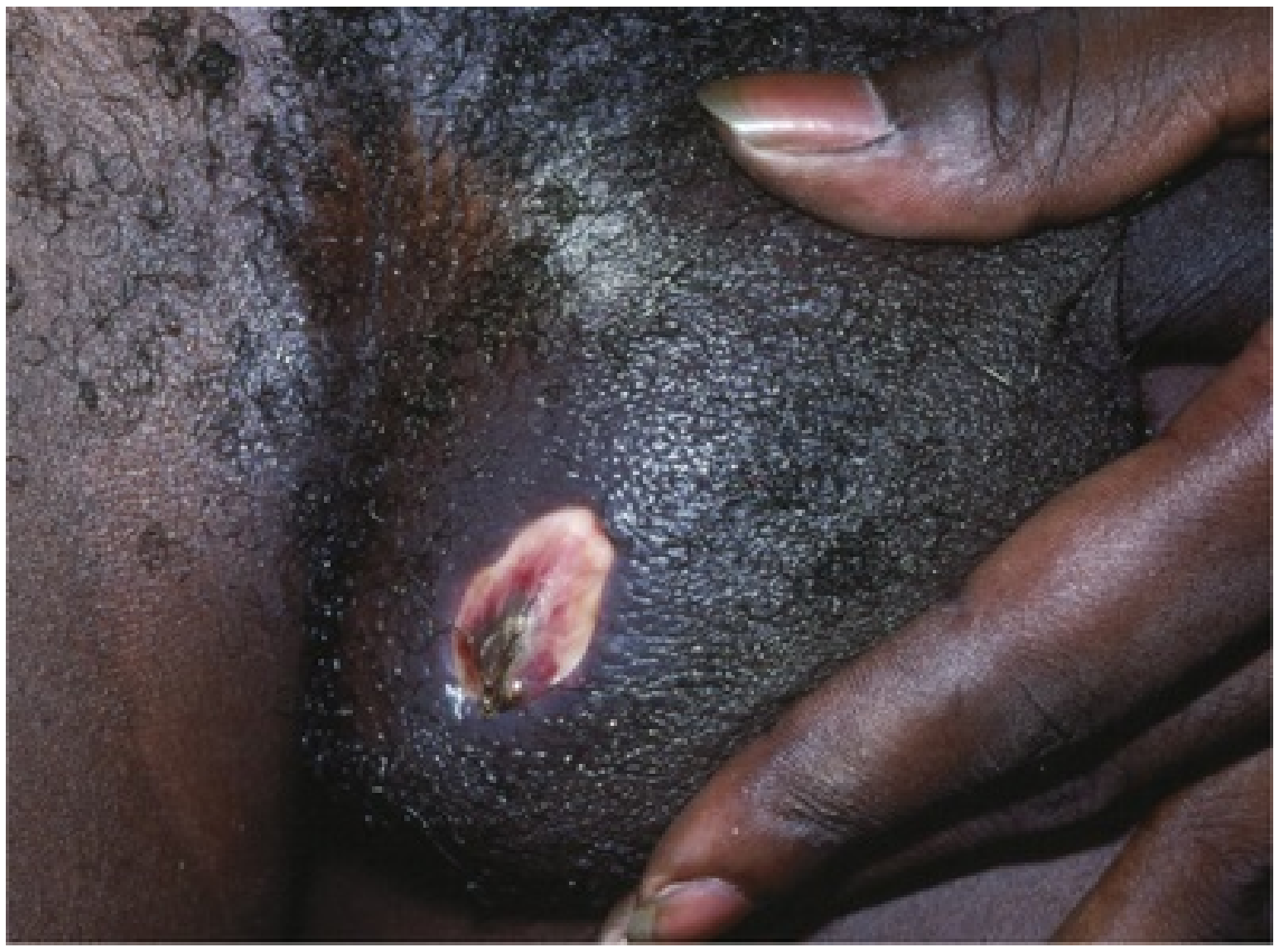

FIG. 59.21 Factitial ulcer of the scrotum caused by repeated picking at the scrotal skin.

Infections and Infestations

Sexually Transmitted Diseases

STDs with genital cutaneous manifestations include lymphogranuloma venereum, granuloma inguinale, herpes simplex, chancroid, molluscum contagiosum, HPV, and syphilis (Fig. 59.22). These conditions are discussed in detail in Chapter 15.

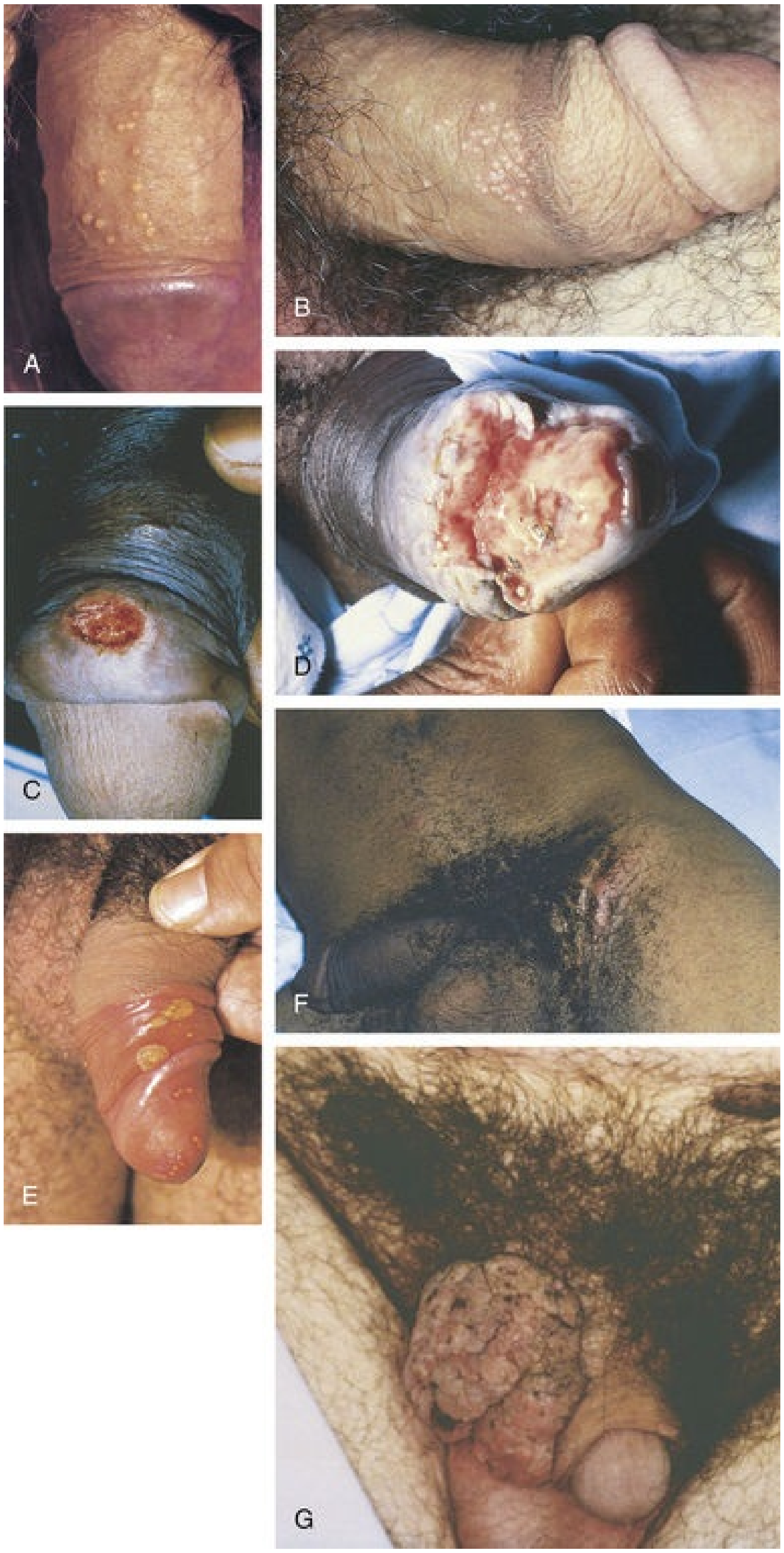

FIG. 59.22 Genital lesions associated with sexually transmitted diseases. (A) Herpes simplex virus. (B) Molluscum contagiosum. (C) Syphilitic chancre. (D) Granuloma inguinale. (E) Chancroid. (F) Lymphogranuloma venereum. (G) Condyloma accuminata. (From Callen JP, Greer DE, Hood AF, et al.: *Color atlas of dermatology,* Philadelphia, 1993, Saunders.)

Balanitis and Balanoposthitis

Balanitis is an inflammatory disorder of the glans penis. When the process involves the preputial skin in uncircumcised men, it is termed *balanoposthitis*. In children, bacterial infections are the predominant cause. In adult men, the cause may be intertrigo, ICD, local trauma, or candidal and bacterial infections (Fig. 59.23). Treatment includes removal of irritating agents, improved hygiene, topical antibiotics and antifungals, and occasionally short courses of low-potency topical corticosteroids (Margolis, 2002). When treatment fails, the differential should include neoplastic diseases, Zoon balanitis, psoriasis, and alternative infectious agents such as HPV (Wikstrom et al., 1994). Balanoposthitis tends to occur in patients with phimosis, and circumcision may be curative in select recurrent cases. Balanoposthitis may also result from bacterial superinfection in the setting of poor hygiene and neutropenia (Manian and Alford, 1987).

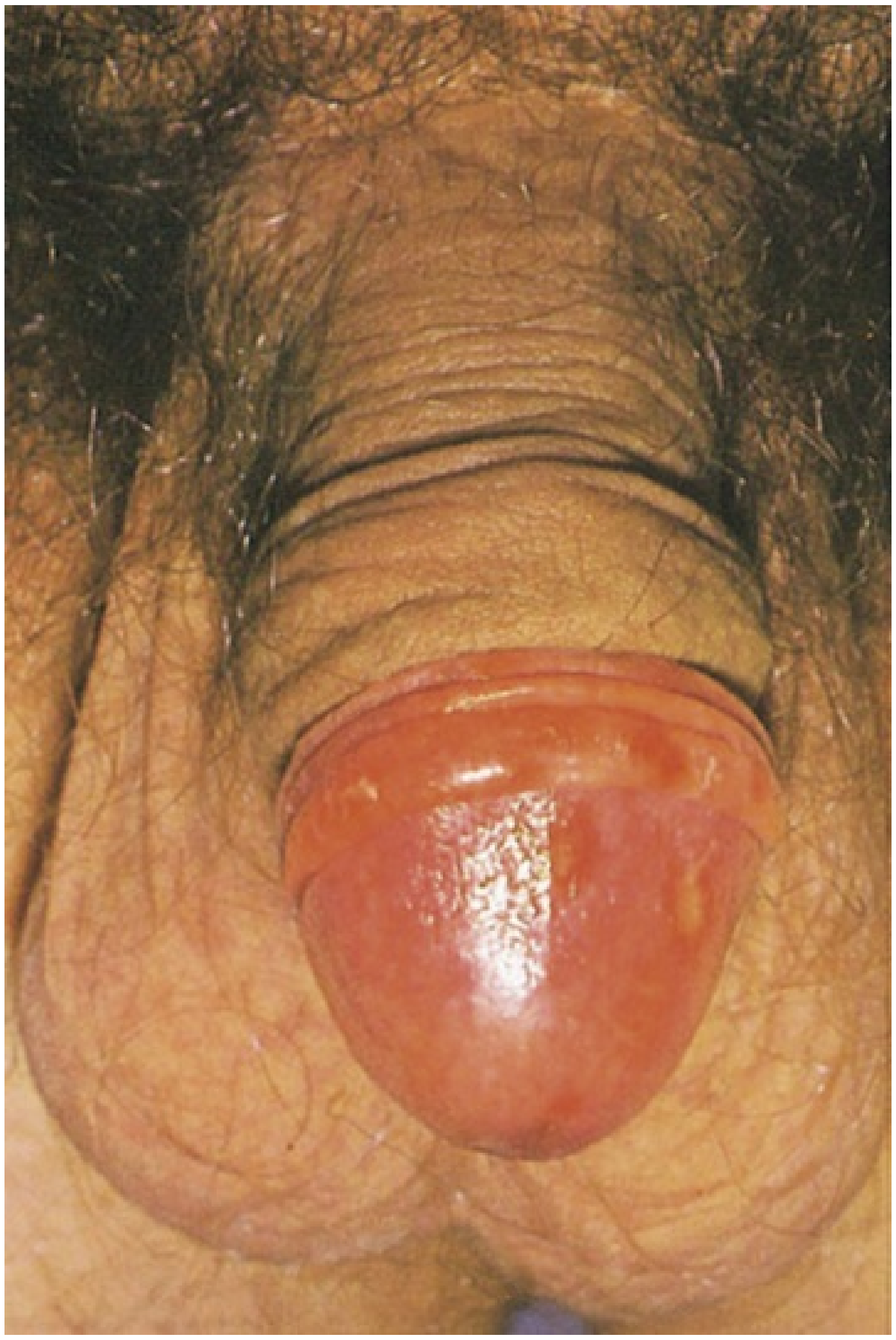

FIG. 59.23 Candidal balanoposthitis. (From Korting GW: *Practical dermatology of the genital region,* Philadelphia, 1981, Saunders, p 159.)

Cellulitis and Erysipelas

Cellulitis is an infection of the deep dermis and subcutaneous tissues most commonly caused by gram-positive organisms *(Streptococcus pyogenes* and *S. aureus)* (Lewis, 1998). In immunocompetent individuals, organisms usually gain entry to the site of infection through a break in the skin barrier. In immunocompromised patients, a blood-borne route of infection is more common. Systemic signs of illness include fever, chills, and general malaise. Local signs include erythema (rubor), warmth (calor), pain (dolor), and swelling (tumor) at the site with indistinct borders (Fig. 59.24). Treatment includes systemic antibiotics with activity against *S. pyogenes* and *S. aureus* species. The clinician may be forced to rely on known local antimicrobial sensitivity patterns because obtaining satisfactory material for culture may be difficult. In cases associated with diabetes, mixed flora may be present and antibiotic coverage should be broadened. Marking the zone of cellulitis at the onset of therapy is an important step to allow progression and resolution of cellulites to be monitored during therapy.

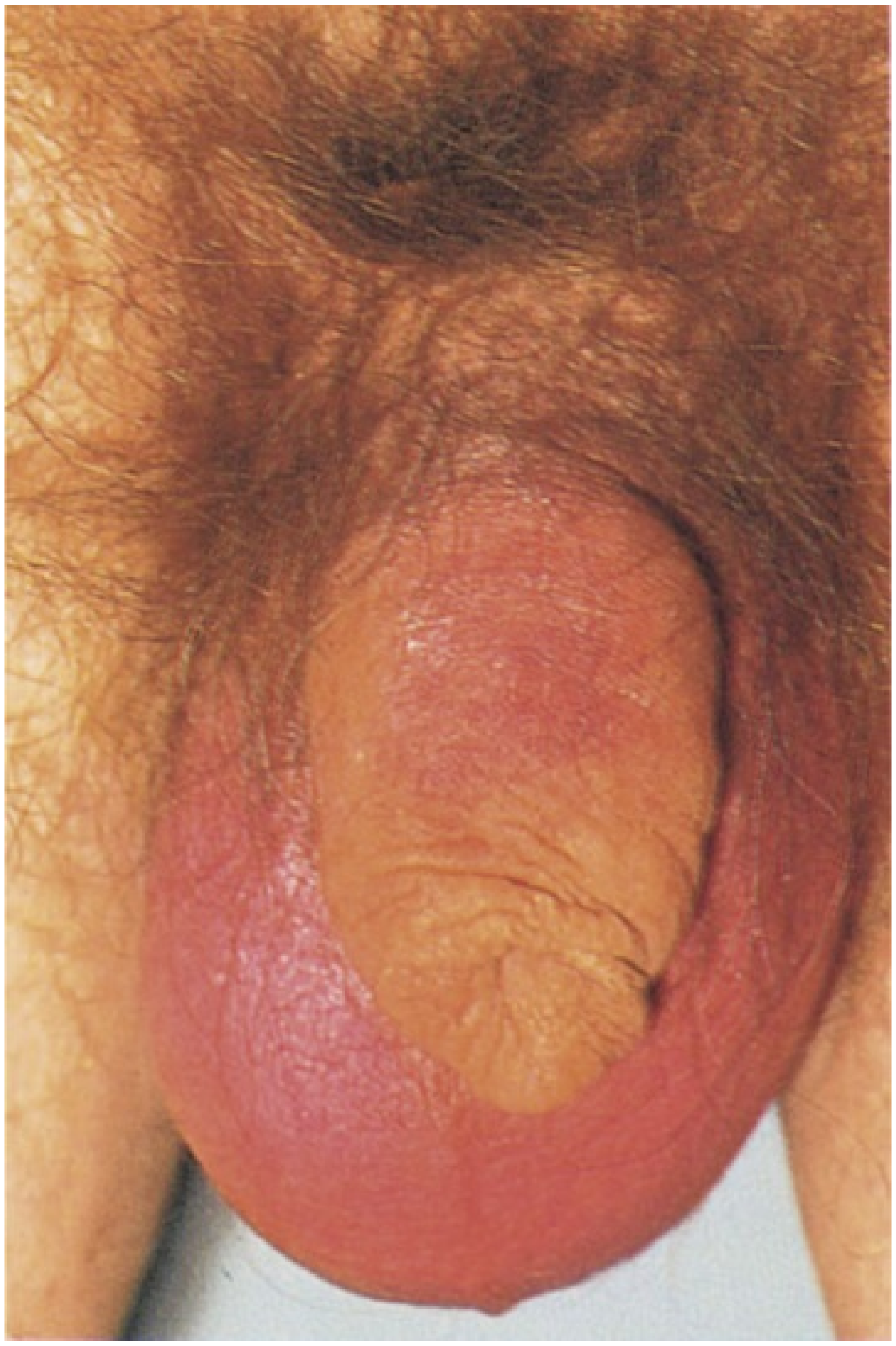

FIG. 59.24 Penoscrotal cellulitis. (From Korting GW: *Practical dermatology of the genital region,* Philadelphia, 1981, Saunders, p 37.)

Erysipelas is a superficial bacterial skin infection limited to the dermis with lymphatic involvement. This disease commonly occurs at the extremes of age and often involves the face. In contrast to the cutaneous lesion of cellulitis, erysipelas generally exhibits a raised and distinct border at the interface with normal skin. The causative organism is usually *S. pyogenes*.

Fournier Gangrene (Necrotizing Fasciitis of the Perineum)

Fournier gangrene (FG) is a potentially life-threatening progressive infection of the perineum and genitalia (Morpurgo and Galandiuk, 2002). In the genital region, most cases of FG are caused by mixed bacterial flora, which include gram-positive, gram-negative, and anaerobic bacteria. *Escherichia coli*, *Bacteroides* spp., *S. pyogenes*, and *S. aureus* are common etiologic pathogens. Risk factors for developing FG include underlying alcoholism, diabetes, cancer and malnutrition, advanced age, recent urogenital or colorectal instrumentation or trauma, and preexisting peripheral vascular disease. However, group A streptococcal necrotizing fasciitis can occur in healthy immunocompetent individuals.

The hallmark of FG is a rapid progression from the signs and symptoms of cellulitis (erythema, swelling, and pain) to blister formation, to clinically visible ischemia, and ultimately to foul-smelling necrotic lesions (Fig. 59.25). **Infection may spread along fascial planes; therefore the exterior skin findings may represent only a small proportion of the underlying infected and necrotic tissue. The diagnosis of FG is a surgical emergency because progression from genitalia to perineum to abdominal wall may occur extremely rapidly (often within hours). Spread of tissue infection is accompanied by an ever-increasing risk of bacterial septicemia, usually the eventual cause of death. The exclusion of FG therefore should be a priority during every consultation for soft-tissue infection of the genitalia.** Pain out of proportion to the visible extent of infection should raise suspicion for FG. The skin may also exhibit a grayish cast or fetid odor uncharacteristic of uncomplicated genital cellulitis. Imaging of the genitalia with plain radiographs, computed tomography, and/or bedside ultrasonography (Amendola et al., 1994; Avery and Scheinfeld, 2013) may demonstrate gas bubbles within the tissue, although the delay associated with imaging should not postpone surgical intervention in obvious cases.

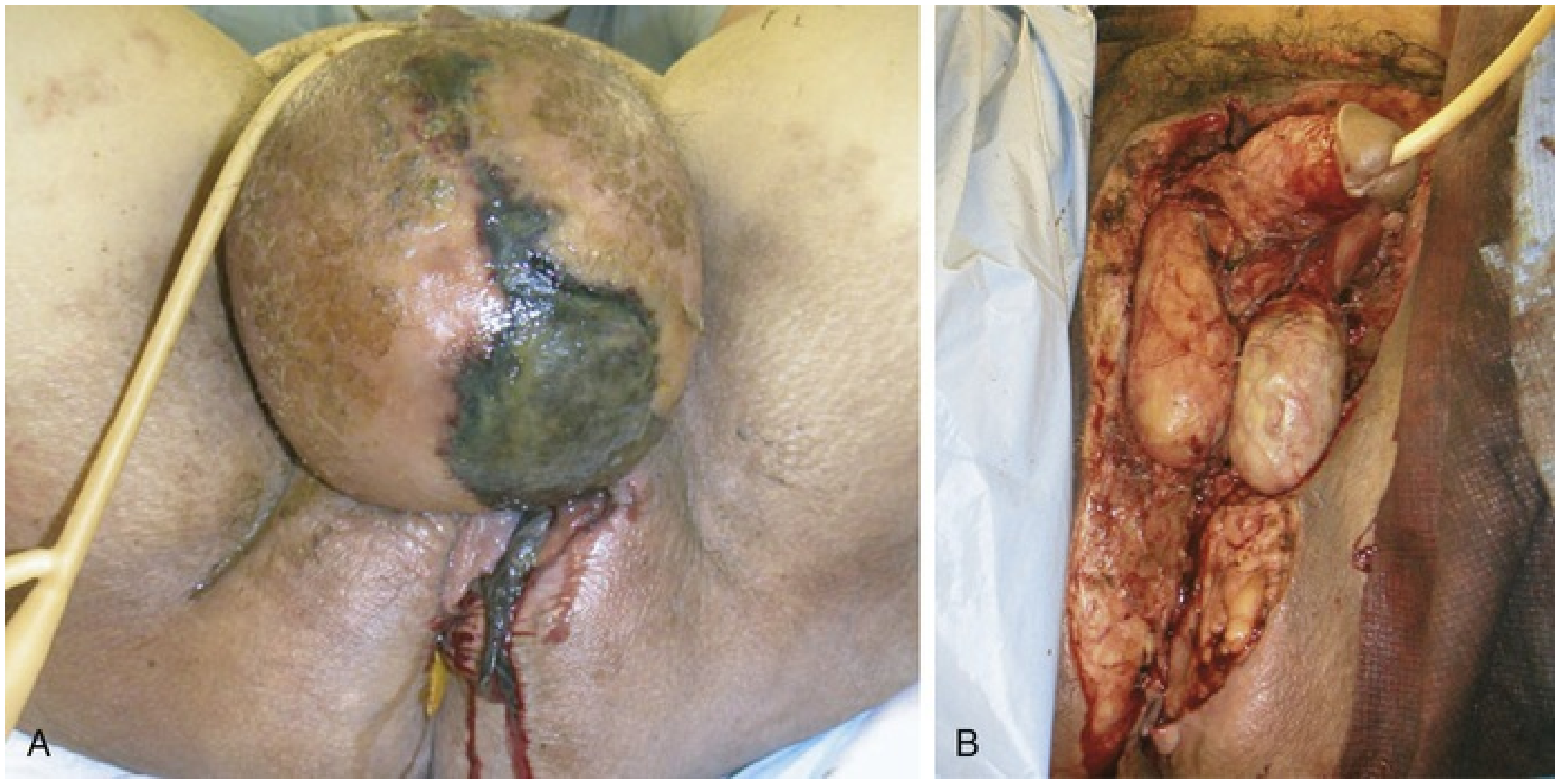

FIG. 59.25 Fournier gangrene of the scrotum. (A) Surface appearance of scrotum and perineum showing area of frank necrosis. (B) Extent of soft tissue debridement required to achieve margins of viable tissue. Note that the testes within their tunica vaginalis compartment are spared.

Treatment involves a combination of broad-spectrum antibiotics and extensive surgical debridement to margins of healthy bleeding tissue. These patients often require a second-look operation after 24 to 48 hours to exclude further disease progression (Gurdal et al., 2003). During surgical debridement for scrotal FG, the testicles and other structures within the tunica vaginalis can almost always be spared, although loss of tissue in the abdominal wall may be extensive because of bacterial spread along fascial planes. The indications for adjunctive hyperbaric oxygen therapy in FG remain controversial, although several groups have reported favorable results (Dahm et al., 2000; Eke, 2000; Jallali et al., 2005). There may also be potential benefit to the use of vacuum-assisted closure devices in FG (Czymek et al., 2009). However, despite aggressive modern management, the mortality of FG may be as high as 16% to 40% (Blume et al., 2003; Dahm et al., 2000; Eke, 2000; Sorensen et al., 2009; Yeniyol et al., 2004). A number of different numeric scoring scales have been applied to FG in an attempt to predict proactively the patients who are at the highest risk for mortality and who should receive the most aggressive intervention. These include the FG Severity Index and the Uludag FG Severity Index, as well as the more general Age-Adjusted Charlson Comorbidity Index (ACCI) and the recently introduced surgical Apgar score (sAPGAR). A study verified that *all* of these scoring systems are valid methods for assessing patients in the setting of

FG, and adoption of one may assist the clinician in making therapeutic decisions (Vyas et al., 2013).

Among patients who survive an episode of FG, there most likely will be ongoing disability and reduced functionality for months to years. Sexual dysfunction is common (~65%) (Czymek et al., 2013). Therefore FG survivors should expect to receive long-term care from a variety of specialists.

Folliculitis

Folliculitis is a common disorder characterized by perifollicular pustules on an erythematous base (Kelly, 2003). It occurs most frequently in heavily hair-bearing areas such as the scalp, beard, axilla, groin, and buttocks and can be exacerbated by local trauma from prolonged occlusion (e.g., truck drivers), shaving, rubbing, or clothing irritation (Margolis, 2002). Patients may complain of pruritus or pain over the area; conversely, symptoms may be entirely absent. Cultures are generally negative, and diagnosis is usually made clinically, although a variety of infectious organisms have been associated with folliculitis, including *S. aureus*, *Pseudomonas* spp., fungi, and herpes simplex virus. Folliculitis has also been associated with the use of contaminated hot tubs and swimming pools, with the offending organism usually *P. aeruginosa* (Fig. 59.26; Gregory and Schaffner, 1987; Rolston and Bodey, 1992). Treatment for folliculitis includes good hygiene, removal of offending irritants, and appropriate topical or systemic antiviral, antibiotic, or antifungal agents. However, recurrence is common. The results of a surveillance study indicate that 96% of *P. aeruginosa* isolates tested from swimming pools and hot tubs were multidrug resistant (Lutz and Lee, 2011). These results may have important implications for immune-suppressed individuals, where infection with multidrug-resistant *P. aeruginosa* has a greater potential impact. Failure to respond to conservative measures should lead to lesion culture with concomitant antimicrobial susceptibility testing.

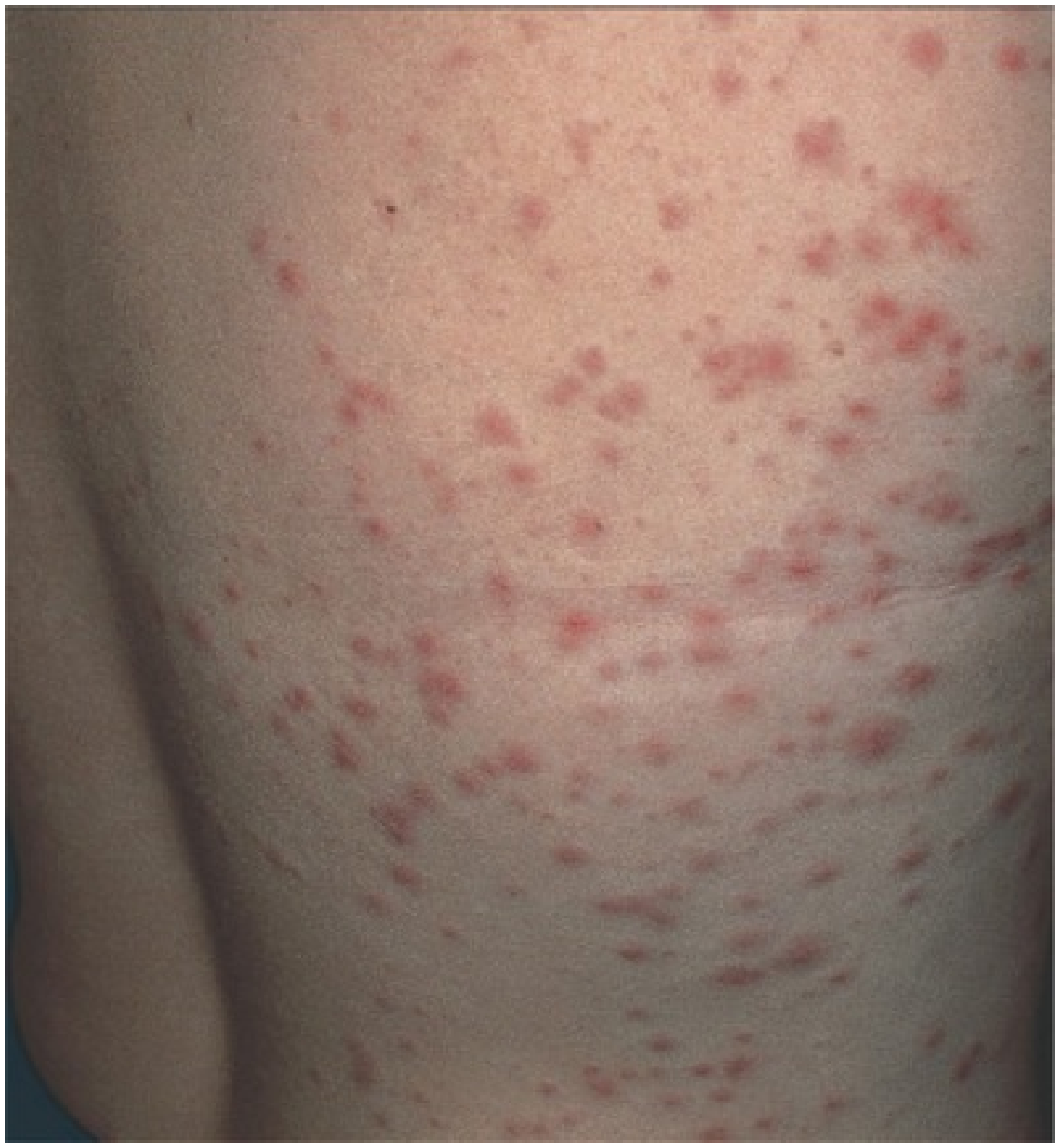

FIG. 59.26 Pseudomonal folliculitis caused by the use of a hot tub. (Courtesy of Yale Dermatology Residents' Slide Collection. From Bolognia JL, Jorizzo JL, Rapini RP. *Dermatology*. Edinburgh: Mosby; 2003.)

Furunculosis

Furuncles and abscesses are walled-off collections of pus. **Although abscesses can occur anywhere on the body, a furuncle is by definition associated with a hair follicle.** Although inflammation of the superficial portion of the hair follicle is present in folliculitis, furunculosis is characterized by involvement of the deeper follicle leading to a red and tender "boil" (Edwards and Lynch, 2018). Furuncles tend to occur in areas prone to minor trauma including the groin and buttocks (Fig. 59.27). *S. aureus* is the most common causative organism, although anaerobes may be present. Risk factors include diabetes mellitus, obesity, poor hygiene, and immunosuppression (Brook and Finegold, 1981). Warm compresses may be beneficial, and larger lesions may require incision and drainage, as for any abscess. Other lesions in the differential include an epidermal cyst or Bartholin's gland duct cyst. When there is associated cellulitis, a systemic antibiotic with activity against staphylococci should be administered.

In today's environment of methicillin-resistant staphylococci, coverage for such organisms is advisable if they are prevalent within the clinician's community. To reduce recurrence, mupirocin ointment to the nares may also be applied to eliminate carrier status.

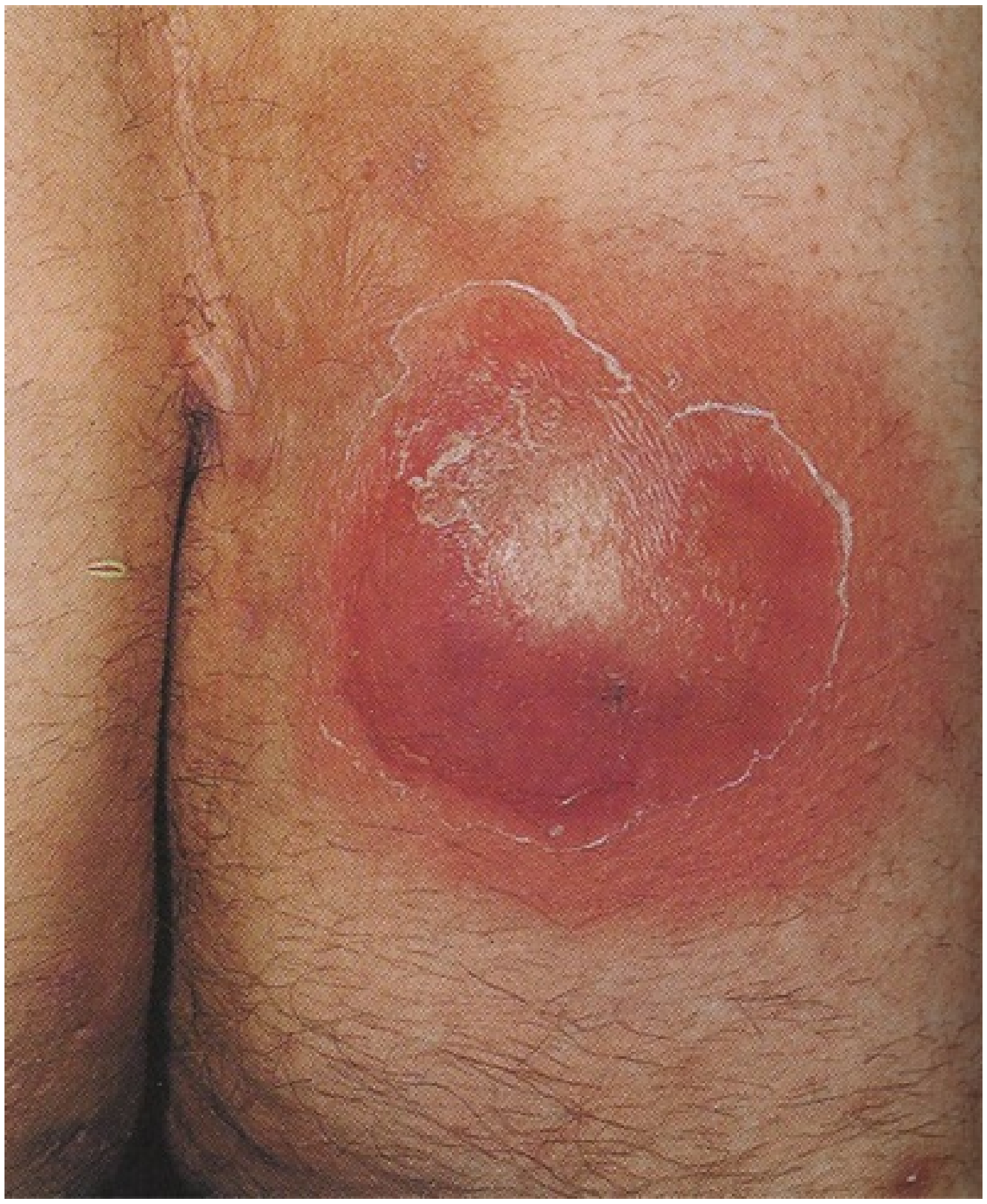

FIG. 59.27 A large furuncle located on the buttocks. (From Habif TP: *Clinical dermatology*, Edinburgh, 2004, Mosby, p 284.)

Hidradenitis Suppurativa (Acne Inversa)

Hidradenitis suppurativa (HS) is a chronic disease of apocrine gland-bearing skin with a predilection for the axillae and anogenital regions (Alikhan et al., 2009; Kelly, 2003)**. The condition generally begins after puberty and a familial form with an autosomal dominant pattern of inheritance has been described** (Von Der Werth et al., 2000). Originally believed to be a disease of apocrine glands, HS is now thought to be an epithelial disorder of hair follicles (Jansen et al., 2001). HS is more common in women and patients of African-American descent. Although superinfection of HS lesions may occur, bacterial infection does not appear to be the primary initiator. During the pathogenesis of HS, hair follicles become plugged and swollen. **Rupture of follicular contents (including bacteria and keratin) into the surrounding dermis initiates a marked inflammatory response with the formation of abscesses and sinus tracts** (Slade et al., 2003).

The clinical features of HS include painful inflammatory nodules and sterile abscesses developing in the axillae, groin, perianal, and inframammary areas (Fig. 59.28; Kelly, 2003). With time, draining sinus tracts and hypertrophic scars develop. Serious complications of HS can occur, including hypoproteinemia, secondary amyloidosis, the development of fistulae to the urethra (Gronau and Pannek, 2002), bladder, peritoneum, and rectum (Nadgir et al., 2001), and SCC in areas of heavy scarring (Altunay et al., 2002; Rosenzweig et al., 2005).

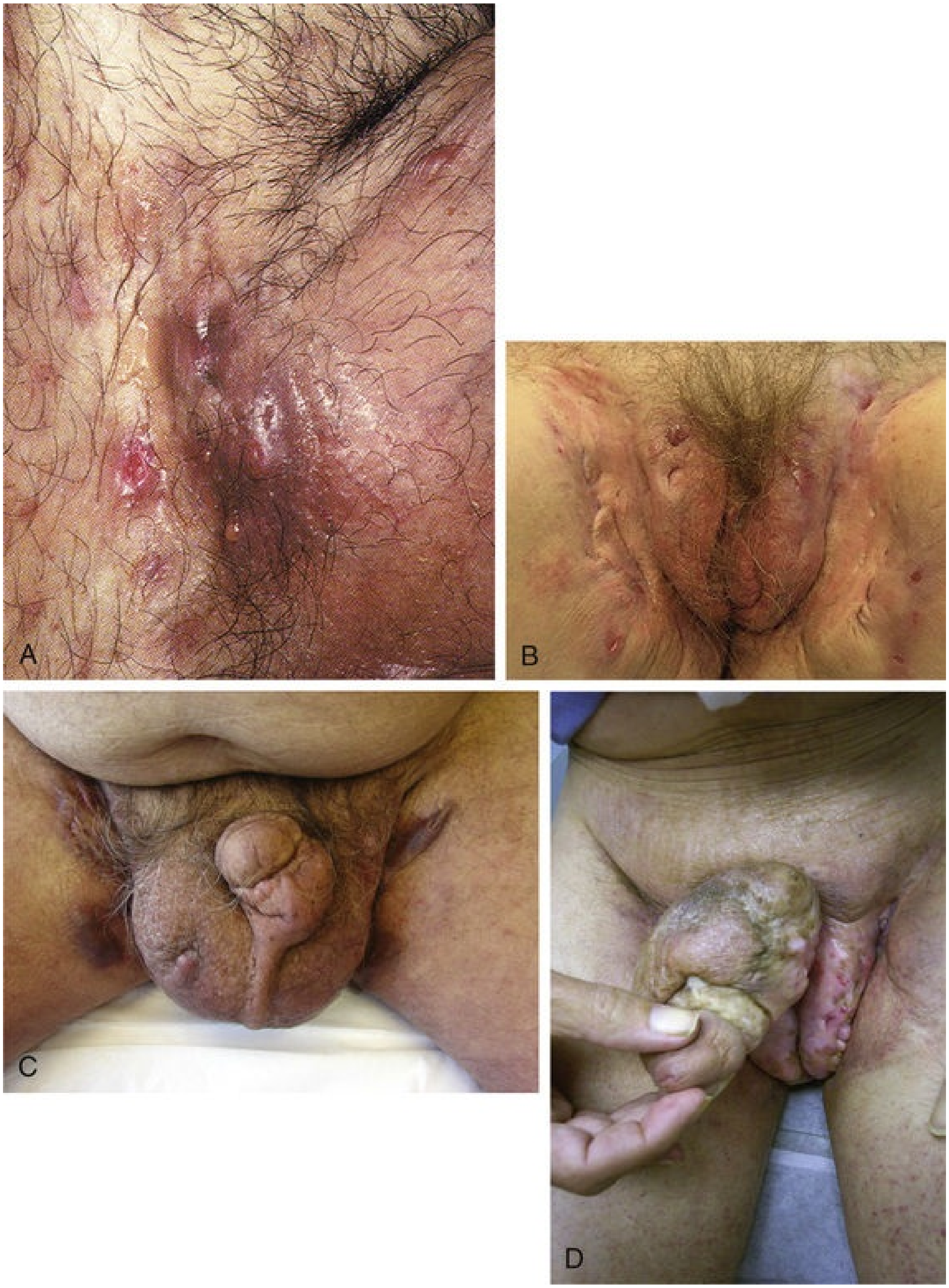

FIG. 59.28 Hidradenitis suppurativa. (A) Characteristic painful papules and draining sinus tracts. (B) Histology shows follicular plugging and connection to a dilated apocrine duct. (C and D) Examples of severe genital involvement of hidradenitis, which would make surgical management difficult. (A, From Danby FW, Margesson LJ: Hidradenitis suppurativa. *Dermatologic Clinics* 28(4): 779–793, 2010, Fig. 2. B,

Courtesy of Yale Dermatology Residents' Slide Collection. From Bolognia JL, Jorizzo JL, Rapini RP. *Dermatology.* Edinburgh: Mosby; 2003.)

Treatment of HS includes smoking cessation, improvement in hygiene, weight reduction, management of metabolic syndrome or underlying hormone-related disorders, and efforts to minimize friction and moisture in affected areas (i.e., loose undergarments, absorbent powder) (Kelly, 2003; Kohorst et al., 2015). No single therapeutic intervention is universally effective. Topical clindamycin or the combination of oral clindamycin or minocycline with oral rifampicin may be beneficial for some patients (Gener et al., 2009). In a double-blind randomized trial, systemic therapy with tetracycline was no more effective than topical clindamycin in HS (Jemec and Wendelboe, 1998). Other oral agents that sometimes prove beneficial include dapsone (50 to 200 mg/day), zinc (40 to 80 mg/day elemental zinc), retinoids (acitretin 25 to 50 mg/day or isotretinoin 1 mg/kg/day), cyclosporine (4 mg/kg/day), and hormone blockers (spironolactone and oral contraceptives in women and finasteride and dutasteride in men) (Scheinfeld, 2013b). Systemic corticosteroids may improve HS, but relapse is the rule after cessation of therapy (Slade et al., 2003). Lithium may exacerbate HS or limit its response to conventional medical therapy (Gupta et al., 1995). Although recurrent incision and drainage of HS lesions are discouraged, wide and deep excision with skin grafting has been effective (Bocchini et al., 2003; Rompel and Petres, 2000). A variety of new approaches, including the use of the CO_2 and Nd:YAG lasers to treat HS, are under investigation (Lapins et al., 1994; Madan et al., 2008; Tierney et al., 2009). Off-label administration of newer biologic agents such as TNF-α blockers (particularly subcutaneous adalimumab, 40 mg/week) has proven variably effective in the management of HS in select patients when surgery is simply not feasible (Shuja et al., 2010).

Corynebacterial Infection (Trichomycosis Axillaris and Erythrasma)

Trichomycosis axillaris is a superficial bacterial infection of axillary and pubic hair caused by corynebacteria. Yellow, red, or black nodules are visible on the hair shafts (Fig. 59.29) and there is frequently a characteristic odor (Blume et al., 2003). There is an association with hyperhidrosis (Margolis, 2002). The differential diagnosis includes infestation with pediculosis pubis or fungal infection (piedra) (Avram et al., 1987), although examination with magnification can generally distinguish trichomycosis axillaris from these conditions. Shaving can provide immediate improvement, and antibacterial soaps may prevent further infection (Blume et al., 2003). For pubic trichomycosis axillaris, clindamycin gel, bacitracin, and oral erythromycin have also proven effective (Bargman, 1984; Blume et al., 2003).

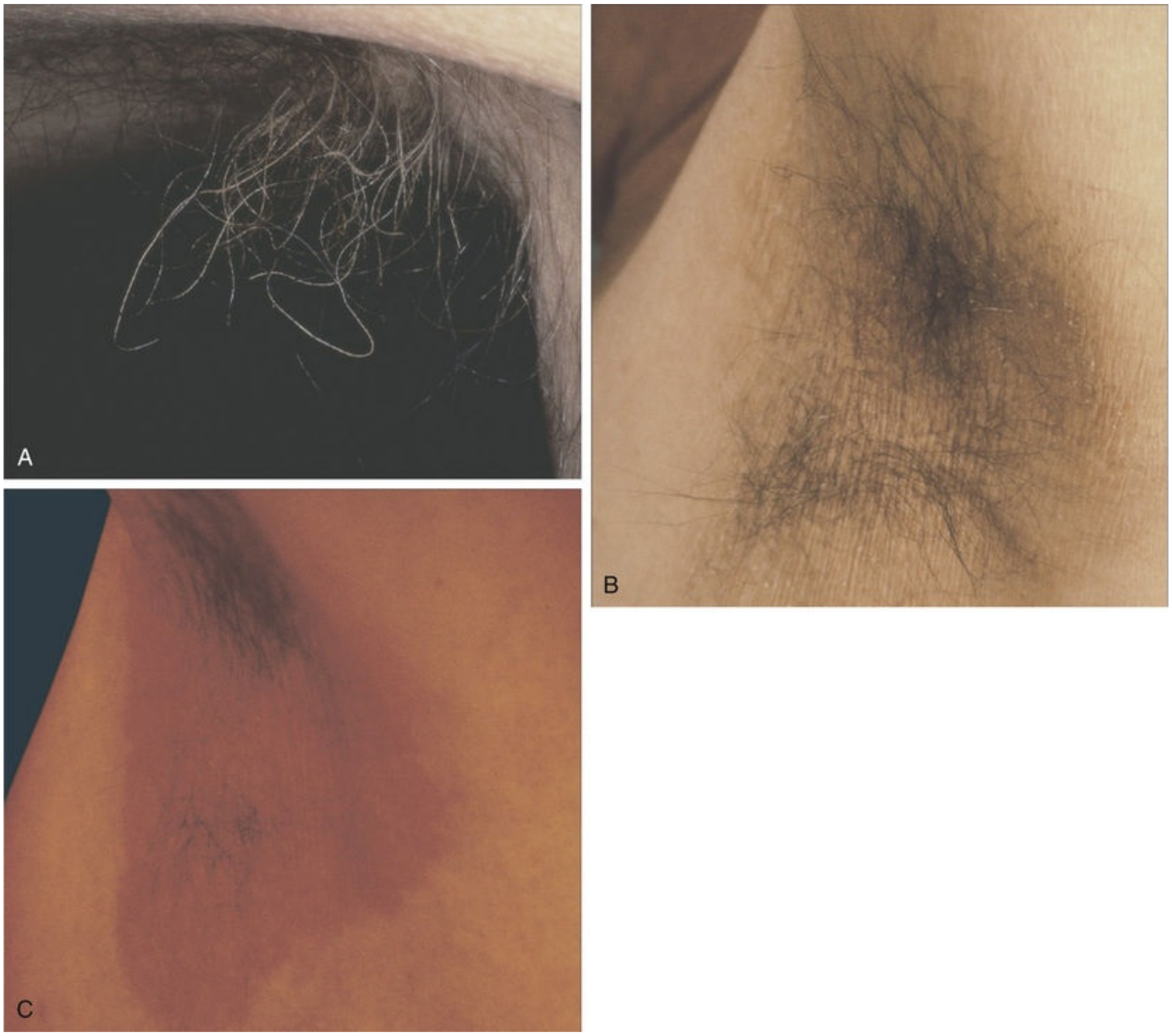

FIG. 59.29 Corynebacterial infections of the skin. (A) Trichomycosis axillaris. (B and C) Erythrasma under white light (B) and Wood lamp (C) showing coral-red fluorescence. (From Bolognia JL, Jorizzo JL, Rapini RP: *Dermatology,* Edinburgh, 2003, Mosby.)

Erythrasma is a *Corynebacterium minutissimum* infection of the skin that results in sharply bordered, light red to dark brown, scaling patches in moist areas, particularly the groin and axilla. These lesions may be pruritic or asymptomatic and may be confused with dermatophyte infection (tinea cruris)

(Sindhuphak et al., 1985). Under a Wood light, the lesions show a characteristic bright coral-red fluorescence (see Fig. 59.29) (Halprin, 1967). Effective treatments include antibacterial soaps, topical aluminum chloride, topical clindamycin 1% solution or gel, miconazole 1% cream, and oral erythromycin (500 to 1000 mg/day) (Cochran et al., 1981; Holdiness, 2002).

Ecthyma Gangrenosum

Ecthyma gangrenosum is a rare cutaneous manifestation of pseudomonal septicemia that presents most commonly on the anogenital area in debilitated, immunosuppressed, or neutropenic patients. The lesions of ecthyma gangrenosum are tender grouped erythematous macules that may progress to form bullae or rupture to produce a gangrenous ulcer covered by a thick, black eschar (Fig. 59.30; Blume et al., 2003). On histologic examination, necrotizing vasculitis and gram-negative organisms are present. The differential diagnosis includes PG, necrotizing vasculitis, cryoglobulinemia, and septic emboli containing other organisms, including *Candida*, *Aspergillus*, *Citrobacter*, *E. coli*, *Aeromonas hydrophila*, and *Fusarium* (Altwegg and Geiss, 1989; Gucluer et al., 1999; Martino et al., 1994; Reich et al., 2004). Consistent with the underlying sepsis, ecthyma gangrenosum carries a poor prognosis, and immediate treatment with intravenous antipseudomonal antibiotics is indicated. Wound debridement may also be necessary (Collini et al., 1986).

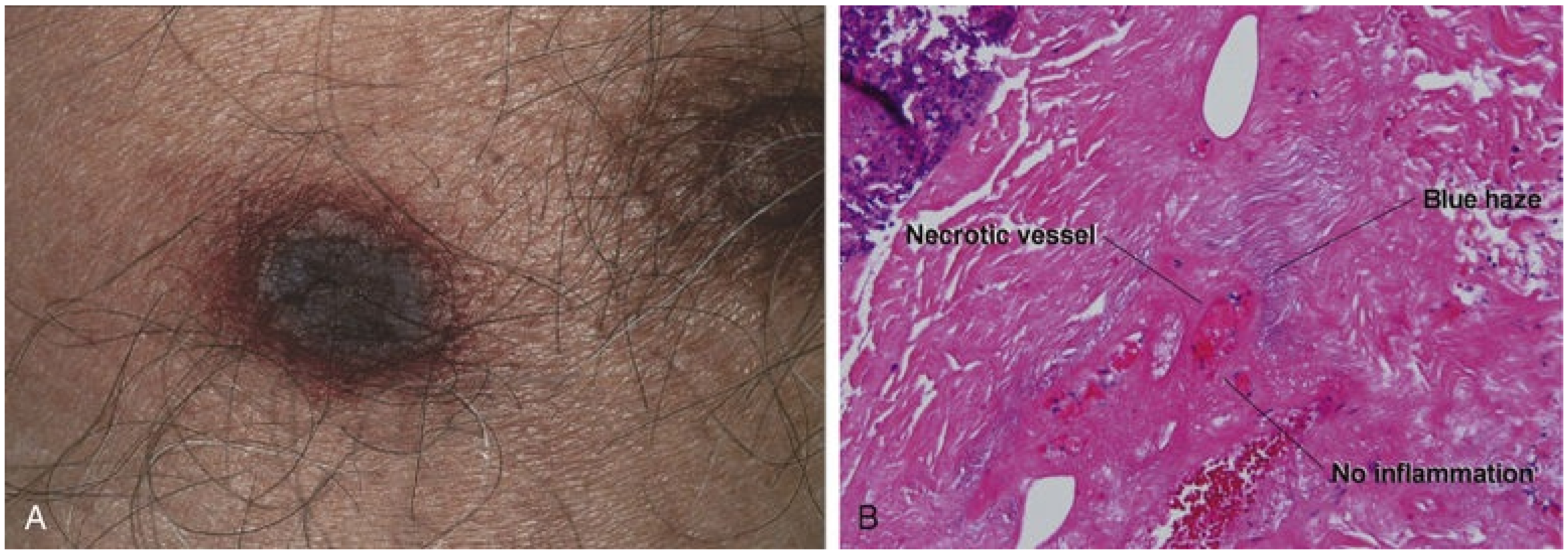

FIG. 59.30 Ecthyma gangrenosum. (A) Involvement on the chest wall. Note the necrotic center and erythematous border around the lesion. (B) Histologically, necrotic vessels surrounded by a “blue haze” of organisms characterize ecthyma gangrenosum. (A, Courtesy, Yale Residents’ Slide Collection. From Bolognia JL, Jorizzo JL, Rapini RP. *Dermatology.* Edinburgh: Mosby; 2003. B, From Elston DM, Ferringer T:

Dermatopathology, Edinburgh, 2009, Saunders, p 263.)

Genital Bite Wounds

After deliberate or accidental bite wounds to the genitalia, a normal component of the human oral flora, *Eikenella corrodens,* may be implanted into genital skin. This results in the rapid development of extremely painful, necrotic ulcerations at the bite site(s) (Fig. 59.31) (Rosen, 2005; Rosen and Conrad, 1999). The rapidity of ulceration, extraordinary degree of discomfort, and a history of traumatic orogenital contact help distinguish this type of infection from the more common STDs and other genital ulcers. The treatment is high-dose oral amoxicillin-clavulanate (1500 mg/day) until healing occurs.

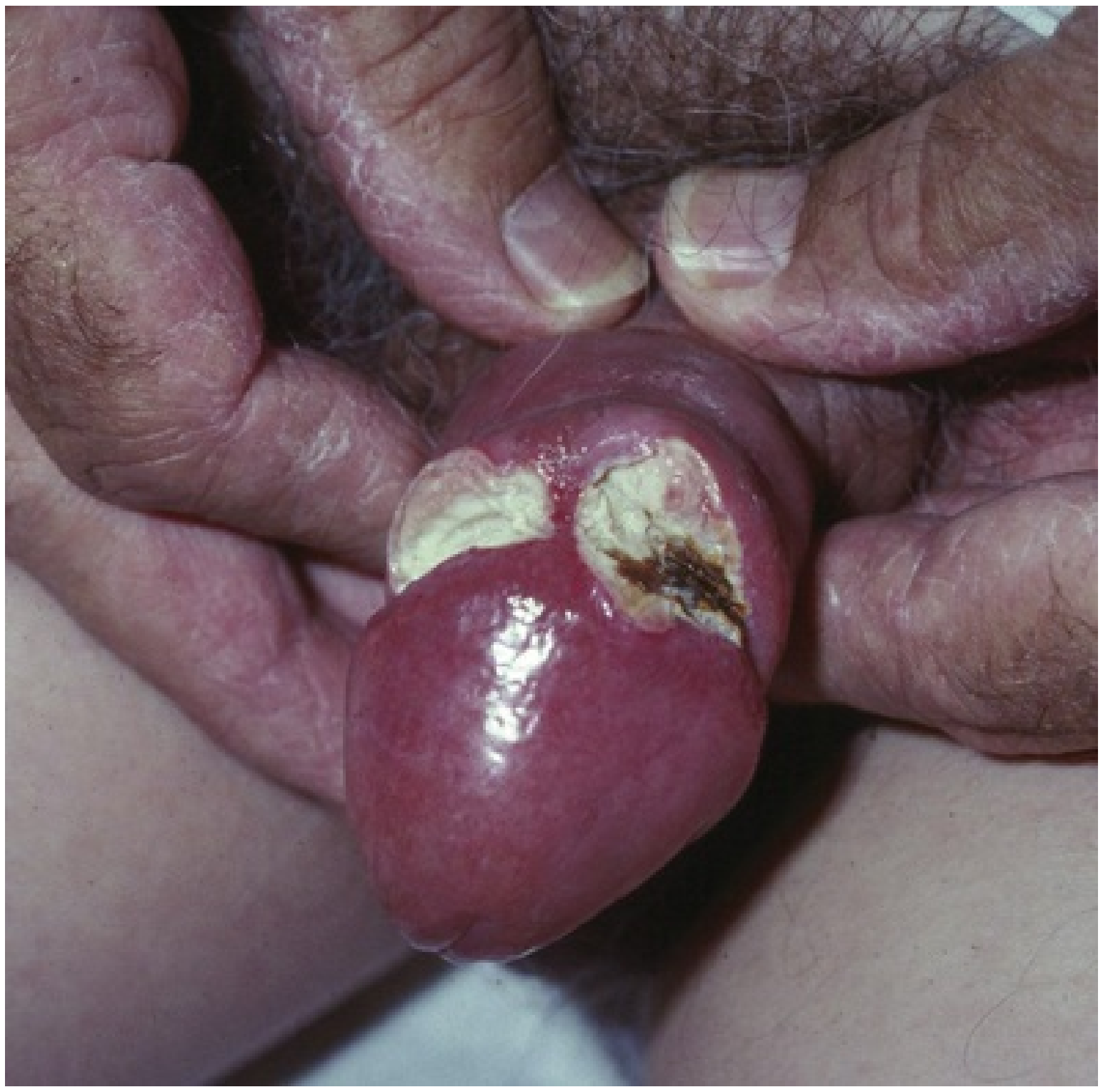

FIG. 59.31 Ulceration after a human bite wound to the penile shaft.

Candidal Intertrigo

Fungal infection of macerated skin folds can occur with candidal species and involve the finger webs and intertriginous areas. Affected pruritic skin is reddened and characteristic satellite lesions may be present (Fig. 59.32). The differential diagnosis includes dermatophyte infection (tinea cruris), pemphigoid, psoriasis, SD, and contact dermatitis (Margolis, 2002). Fungal forms (round yeast cells as well as elongate pseudohyphae) can be seen in scraped skin preparations after treatment with KOH, and culture is usually unnecessary. Daily topical treatment with any imidazole antifungal agent for at least 2 weeks is usually necessary for intertrigo, and oral antifungals (such as fluconazole 150 mg/day) are occasionally required (Cullin, 1977). Maneuvers to decrease moisture and skin maceration, such as the use of drying powders and loose clothing, may also help prevent relapse. Candida intertrigo may be a presenting sign of diabetes, and appropriate laboratory testing should be performed to rule this out as a predisposing condition.

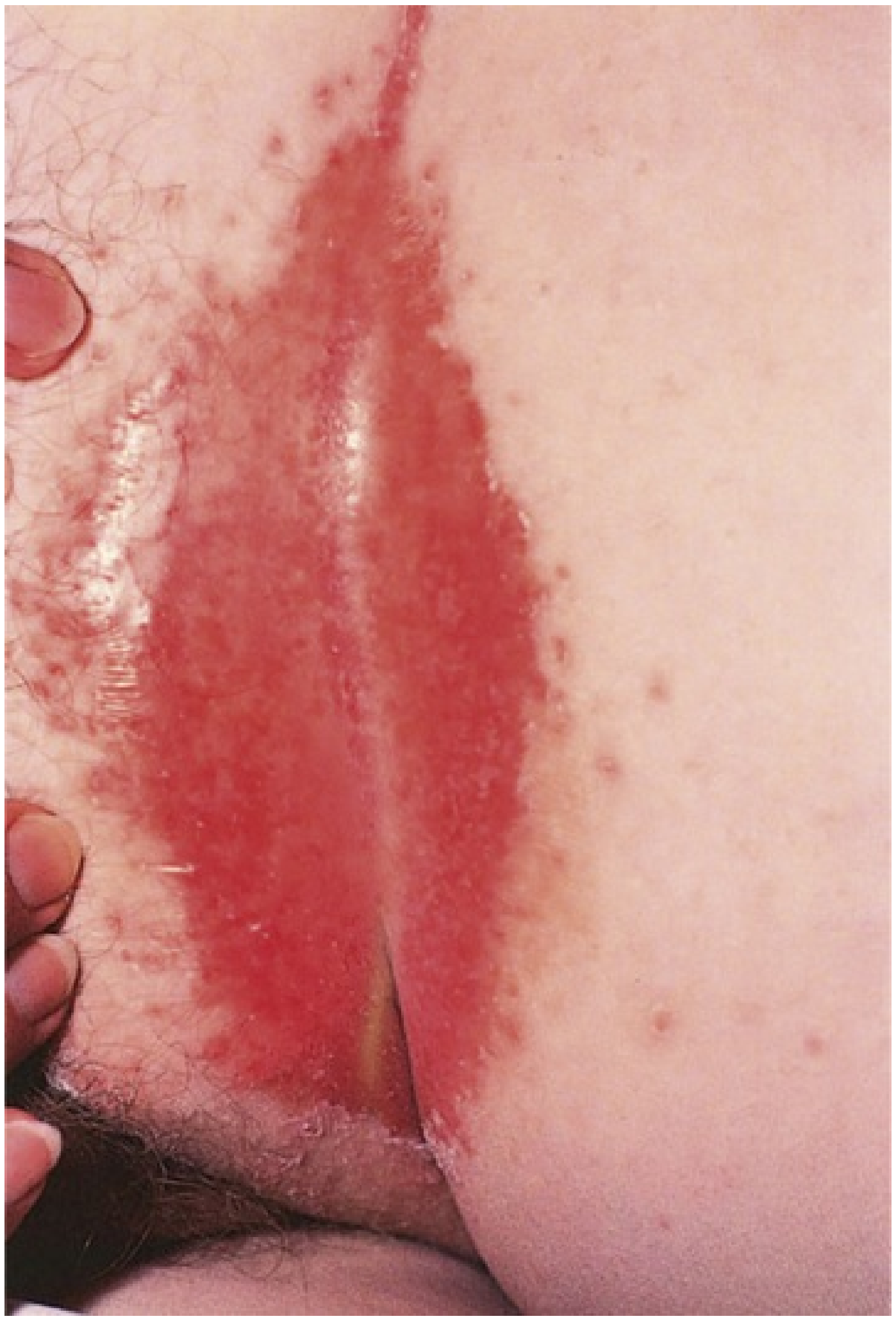

FIG. 59.32 Candidal intertrigo with erythema, areas of tissue maceration,

and satellite lesions. (From Callen JP, Greer DE, Hood AF, et al.: *Color atlas of dermatology,* Philadelphia, 1993, Saunders, p 318.)

Dermatophyte Infection

Dermatophytes are fungi of three genera *(Trichophyton, Microsporum, Epidermophyton)* that have the propensity to invade and grow within keratinized tissues such as the skin, hair, and nails. These fungi produce keratinases, which break down keratin and facilitate invasion (Viani et al., 2001). In addition, mannans in the cell wall of some dermatophytes produce immunoinhibitory effects (Dahl, 1994).

Tinea cruris is the term applied to dermatophyte infection of the groin and genital area and is commonly known as "jock itch." More common in males than females, this condition is favored by hot, humid environments and concomitant dermatophyte infection of the feet *(tinea pedis)*. Obesity may also be a significant risk factor (Scheinfeld, 2004). The inner thighs and inguinal region are the most commonly affected areas, and the scrotum and penis are usually spared in men. However, isolated penile dermatophytosis has been well described (Pielop and Rosen, 2001). **Conversely, significant scrotal involvement should raise suspicion for cutaneous candidiasis as an alternative diagnosis** (Sobera and Elewski, 2003). Characteristic lesions in tinea cruris are sharply demarcated erythematous plaques with a raised scaly border (Fig. 59.33), and they may be intensely pruritic. A variety of disorders can mimic dermatophytes infection, including SD, psoriasis, contact dermatitis, and erythrasma. The diagnosis of fungal infection can be confirmed with skin scrapings and a KOH preparation. Culture is rarely required, because organisms are easily visualized microscopically.

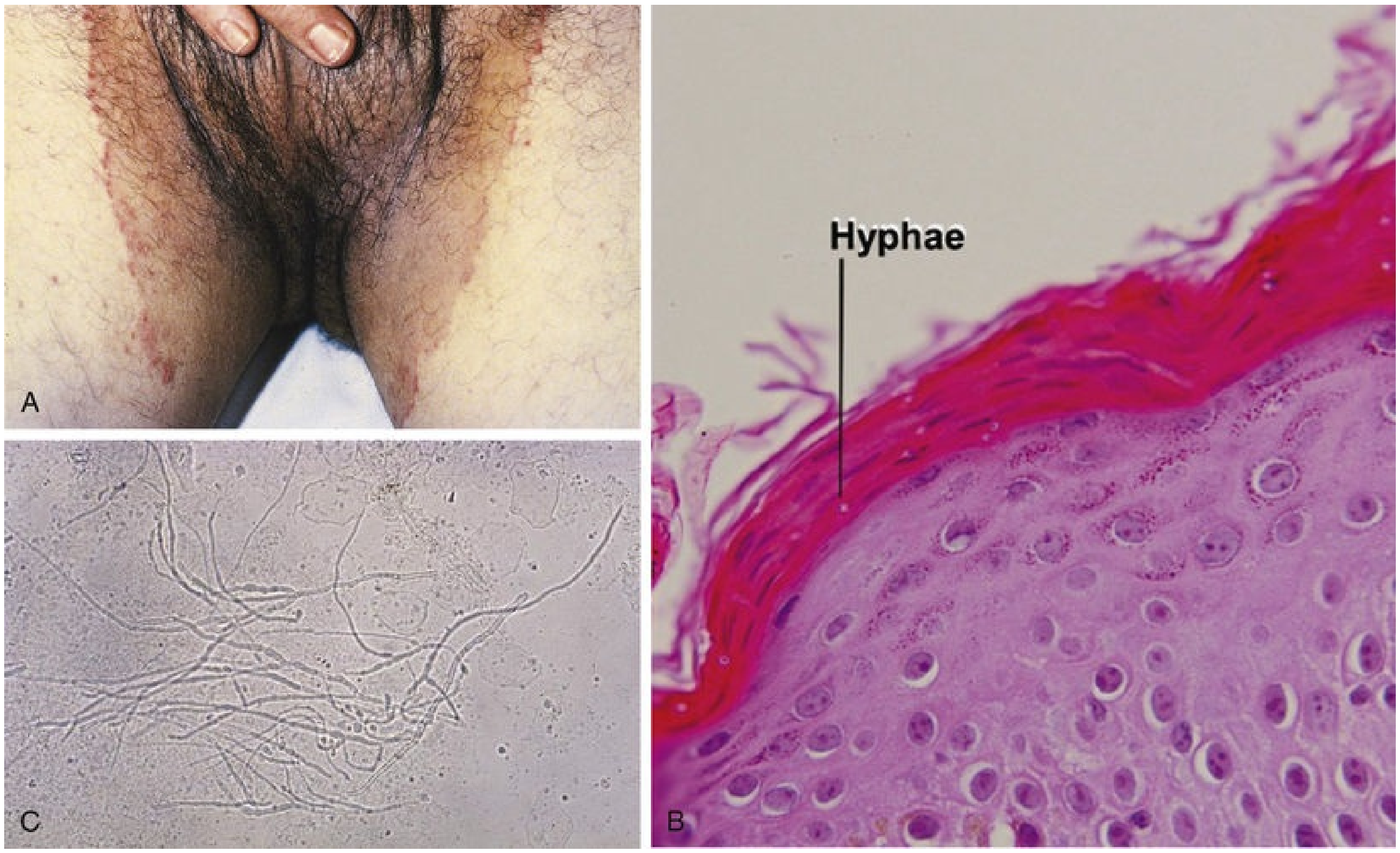

FIG. 59.33 Dermatophyte infection. (A) *Tinea cruris* showing areas of postinflammatory hyperpigmentation and active infection at the border of the lesions. (B) Histologically, fungal hyphae are localized within a compact stratum corneum layer. (C) Potassium hydroxide preparation from a scraping showing fungal forms. (A, From Callen JP, Greer DE, Hood AF, et al.: *Color atlas of dermatology,* Philadelphia, 1993, Saunders, p 318. B and C, From Elston DM, Ferringer T: Dermatopathology, Edinburgh, 2009, Saunders, p 275.)

Good hygienic practices can be beneficial in preventing recurrent disease, including wearing loose clothing, cleaning of contaminated garments, weight reduction, and the use of topical powders to keep the intertriginous areas dry (Sobera and Elewski, 2003). Topical antifungal preparations are the primary agents for treatment; the powdered forms have the added benefit of drying moist areas. Azoles have sufficient coverage against yeast as well as tinea-causing dermatophytes, whereas the allylamines terbinafine and naftifine are not as effective against yeast (Edwards and Lynch, 2018). Furthermore, although nystatin is effective to treat candidiasis, it is not effective against dermatophytes. **Care should be taken to treat only active disease and not the postinflammatory hyperpigmentation that can occur with recurrent chronic dermatophyte infection** (Margolis, 2002). Systemic antifungals are rarely necessary to treat groin infection with dermatophytes. However, should this prove necessary, as is sometimes the case when tinea infection has follicular involvement too deep for topical therapy to penetrate, the current drug of choice is terbinafine in a dosage of 250 mg/day for 1 week (Farag et al., 1994).

Infestation

Pediculosis pubis and scabies *(Sarcoptes scabiei)* are the most common infestations involving the genital region.

Infestation with the crab louse *(Phthirus pubis)* causes pediculosis pubis, a pruritic disorder of the genitalia, which may coexist with other STDs (Opaneye et al., 1993; Varela et al., 2003). In one study of adolescent males, patients with pediculosis pubis showed a risk of concomitant gonorrhea or chlamydial infection more than twofold higher than normal controls (Pierzchalski et al., 2002). Louse infestation is not limited to the genitals and may involve other hair-bearing areas such as the eyelashes, beard, and axillae (Meinking, 1999). The diagnosis is confirmed by identification of crab lice attached to hairs (Fig. 59.34), often with associated perifollicular erythema. **Transmission of pediculosis pubis is usually through sexual contact, although contaminated clothing, bedding, and towels have also been implicated in some cases** (Meinking, 1999). **The standard treatment is the application of 5% permethrin cream overnight to all affected hair-bearing areas with a repeat application 1 week later** (Meinking, 1999). Note that the second application of permethrin is important, because the rate of treatment success with a single application may be as low as 57% (Kalter et al., 1987). For rare cases refractory to topical therapy or those involving the eyelashes *(tinea palpebrarum)*, the addition of oral ivermectin may be curative (Burkhart and Burkhart, 2000). Interestingly, because of the adoption of the widespread removal of pubic hair among young adults of both genders (“Brazilian waxing”), the incidence of pubic louse infestation in industrialized countries has fallen dramatically in recent years.

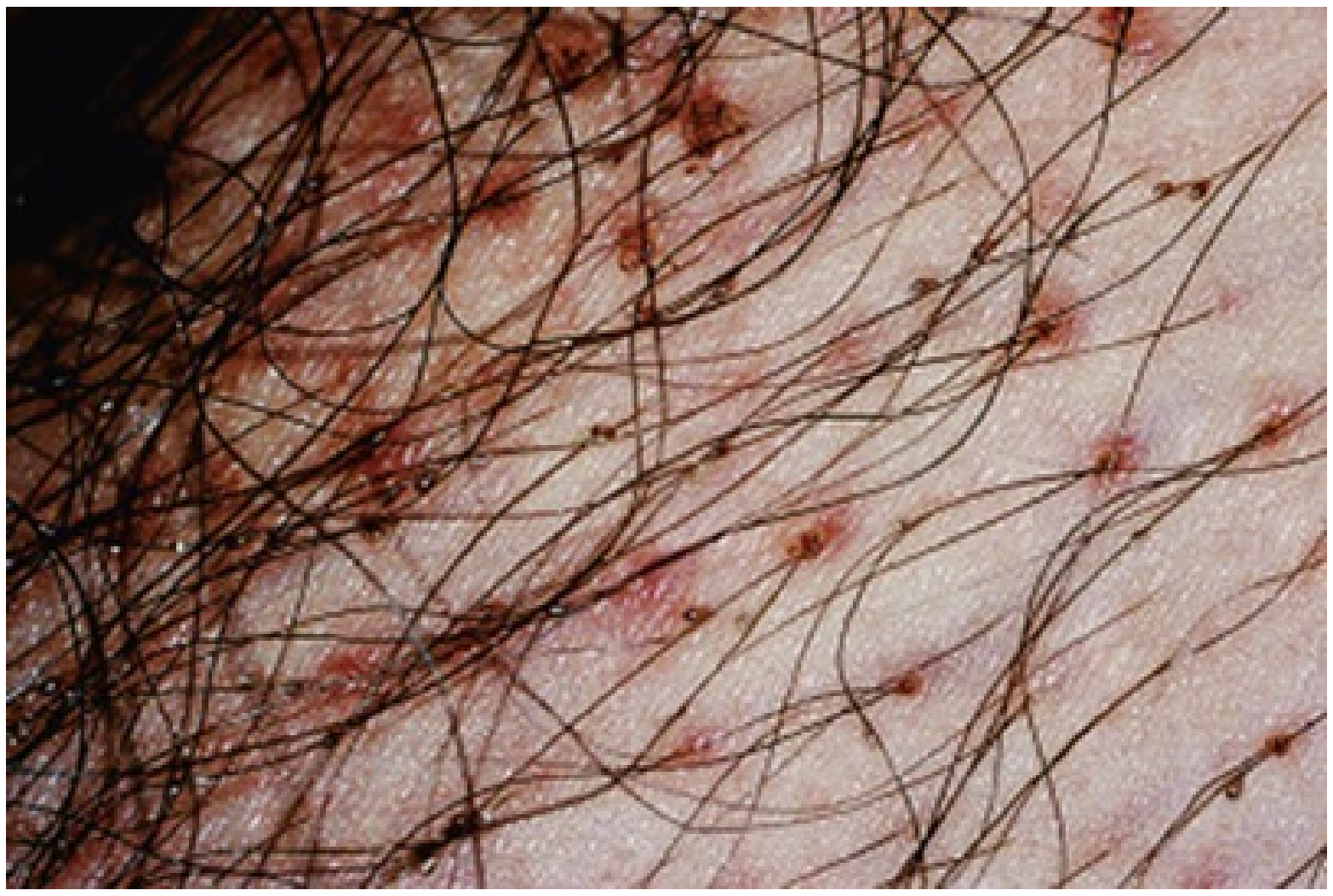

FIG. 59.34 Pediculosis pubis. Several crab lice are visible. (From Buttaravoli P, Leffler SM: *Minor Emergencies*. Philadelphia, Elsevier, 2012, Fig. 174-5.)

Another important infestation involving the genitalia is scabies, caused by the female itch mite *S. scabiei*. **Scabies is a worldwide problem, and factors such as overcrowding, delayed treatment of primary cases, and poor public awareness encourage spread** (Meinking et al., 2003). Transmission is common between close contacts and family members (Burkhart et al., 2000). The number of mites living on an immunocompetent host is usually small (<100) (Arlian et al., 1988), although far greater numbers may be recovered in cases of immunosuppression (so-called crusted or Norwegian scabies). The incubation period before symptoms develop after infestation can vary from days to months in duration but is most typically about 6 weeks.

Severe pruritus is the hallmark of scabies, often accentuated at night or after bathing (Meinking et al., 2003). In both genders, the genital areas are commonly affected. Small erythematous and pruritic papules are present, and excoriations with secondary bacterial infection may occur (Fig. 59.35). **Thin, gray or white burrows may be visible and are pathognomonic for scabies infestation. Crusted scabies affecting genital skin presents as it does in other anatomic sites: with thickly crusted plaque(s)** (Perna et al., 2004). In the absence of visible burrows, a broad differential must be considered, including AD, pyoderma, psoriasis, and other insect bites. As in the case of pediculosis pubis, the treatment of choice for scabies is 5% permethrin cream applied to the entire body overnight with a second application 1 week later. An alternative topical scabicide, lindane, is not favored because of central nervous system toxicity in children and a rising rate of resistance among mites (Boix et al., 1997; Elgart, 1996; Purvis and Tyring, 1991). Oral ivermectin (200 µg/kg/dose, 2 doses administered 2 weeks apart) is an alternate regimen that has been successfully used to treat scabies (Chouela et al., 2002; Heukelbach et al., 2004; Karthikeyan, 2005). A randomized comparative trial showed that permethrin was slightly more effective than ivermectin when the latter is only provided as a single dose (Goldust et al., 2012). **Note that pruritus may persist for several weeks despite successful treatment and that all intimate contacts should also be treated to prevent reinfestation.** Even with effective treatment, itchy nodules may remain on the glans penis; intralesional injections of minute amounts of dilute triamcinolone acetonide (2 to 3 mg/mL) may facilitate resolution of these postscabies nodules.

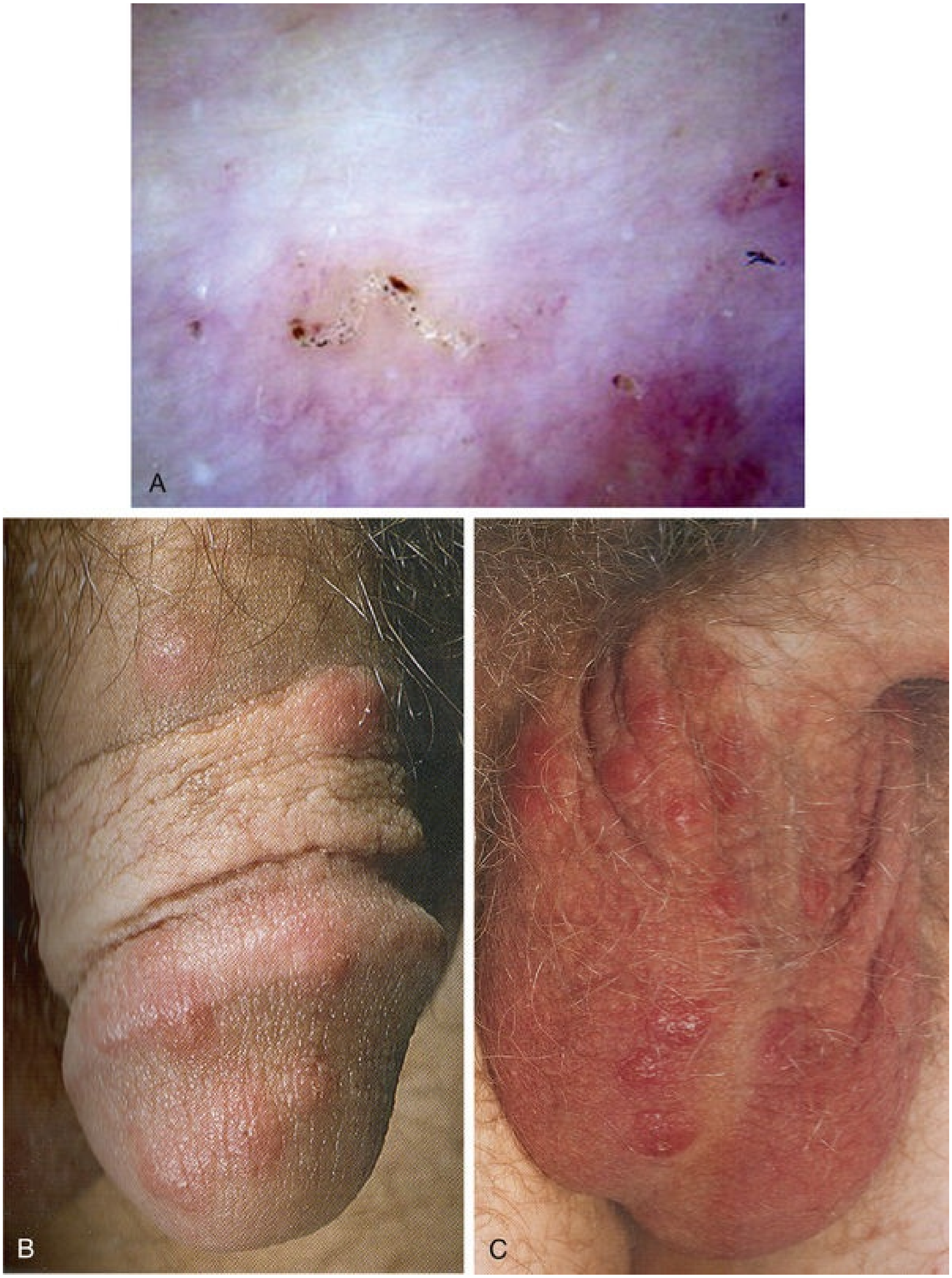

FIG. 59.35 Scabies. (A) A papular eruption with a visible characteristic burrow. (B and C) Classic established genital scabies with eroded papules on the glans penis and scrotum. (A, From Panuganti B, Tarbox M: Evaluation and management of pruritis and scabies in the elderly

population. *Clinics in Geriatric Medicine* 29(2): 479–499, 2013, Fig. 3. B and C, From Habif TP. *Clinical dermatology*. Edinburgh: Mosby; 2004, p. 501.)

Neoplastic Conditions

Squamous Cell Carcinoma in Situ

Squamous cell carcinoma in situ (SCCis) is a full thickness intraepidermal carcinoma (Miller and Moresi, 2003). Bowen originally described this condition in 1912, hence the term “Bowen disease” (Bowen, 1912). On extragenital sites, there is a strong association between SCCis and ultraviolet light exposure (Reizner et al., 1994). **Commonly presenting in the seventh decade of life with a slight female predominance** (Arlette, 2003; Hemminki and Dong, 2000), **SCCis usually has an indolent clinical course and rarely progresses to invasive disease. When it occurs on mucosal surfaces of the male genitalia, most notably the glans penis of uncircumcised men, this entity is referred to as erythroplasia of Queyrat** (Fig. 59.36). Yet another name for this entity is penile intraepithelial neoplasia. In the female, the comparable SCCis on the vulva would be called vulvar intraepithelial neoplasia. In these locations, coinfection with HPV types 8, 16 (70%), and other serotypes (30%) has been identified (Wieland et al., 2000). Other risk factors for SCCis include ionizing radiation, immunosuppression, thermal injury, arsenic exposure, chronic dermatoses (such as long-standing LP), and LS of the glans penis (Arlette, 2003; Centeno et al., 2002; Euvrard et al., 1995; Nasca et al., 1999; Powell et al., 2001).

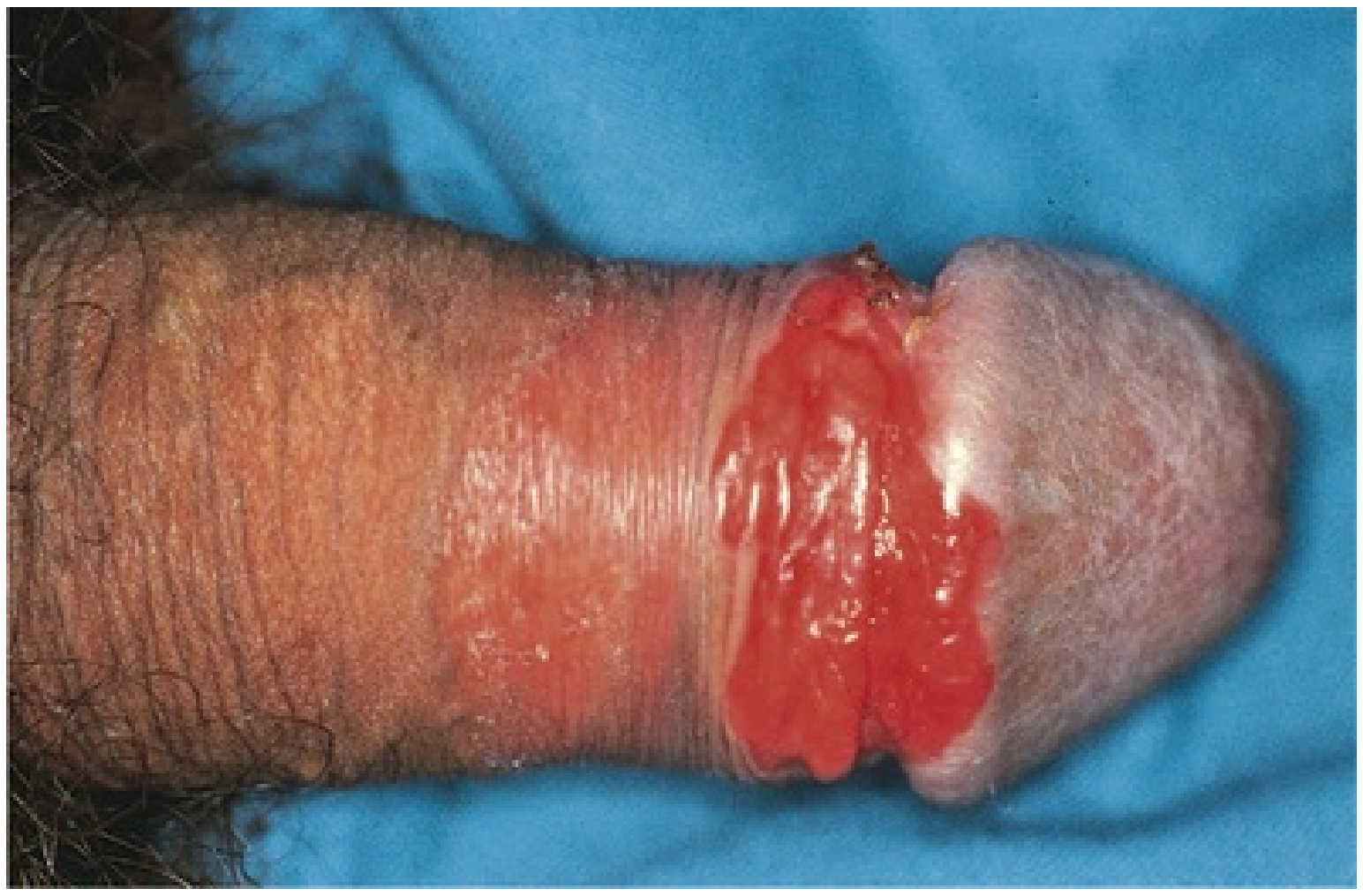

FIG. 59.36 Erythroplasia of Queyrat. Squamous cell carcinoma involving the glans penis. (From Callen JP, Greer DE, Hood AF, et al.: *Color atlas of*

dermatology, Philadelphia, 1993, Saunders, p 330.)

SCCis lesions are sharply demarcated, solitary, pink to red scaly plaques that may be confused with basal cell carcinoma, eczema, seborrhea, or psoriasis. SCCis on or near the vulva may be heavily pigmented and resemble melanoma and external genital warts. When localized to the penile shaft, SCCis may have a more thickened, verrucoid appearance. Although usually asymptomatic, these lesions may also be pruritic or painful. The diagnosis is confirmed by histologic evaluation, and several areas should be sampled to exclude the presence of dermal invasion (Margolis, 2002).

Primary treatment of SCCis involves either surgical excision or tissue ablation. For accessible areas, such as the scrotum, simple excision with a 5-mm margin is favored (Bissada, 1992; Margolis, 2002). For areas where tissue preservation is more critical, Mohs microsurgery, laser therapy, and cryoablation may play a role (Leibovitch et al., 2005; Sonnex et al., 1982b; van Bezooijen et al., 2001). Topical treatment with either 5-fluorouracil or imiquimod 5% can be effective for management of selected cases of SCCis involving the genitalia, although response is variable and the risk of recurrence is higher than with surgical treatment (Arlette, 2003; Deen and Burdon-Jones, 2017; Gerber, 1994; Micali et al., 2003; Orengo et al., 2002).

Bowenoid Papulosis

Bowenoid papulosis is an uncommon condition found on the penis and vulva of sexually active adults, with a peak incidence in the third decade of life (Schwartz and Janniger, 1991). **It histologically resembles Bowen disease except that the abnormal keratinocytes are spread discontinuously throughout the epidermis** (Margolis, 2002). Typical lesions are multiple small erythematous papules that may coalesce to form plaques with a verrucous surface similar to a genital wart (Fig. 59.37). There is a clear association with HPV type 16. **Female partners of men with bowenoid papulosis have an increased risk of cervical neoplasia and should receive close cervical follow-up** (Rosemberg et al., 1991). In men, however, bowenoid papulosis generally has a benign course and spontaneous regression may occur (Eisen et al., 1983; Feng et al., 2013; Giam and Ong, 1986). Therefore, in a young and reliable patient, observation alone may be justified. If treatment is desired, conservative local therapy with topical agents (0.5% 5-fluorouracil, 0.5% tazarotene cream, or imiquimod 5%) or ablative measures (electrodessication, liquid nitrogen cryotherapy, laser ablation) is usually appropriate (Margolis, 2002).

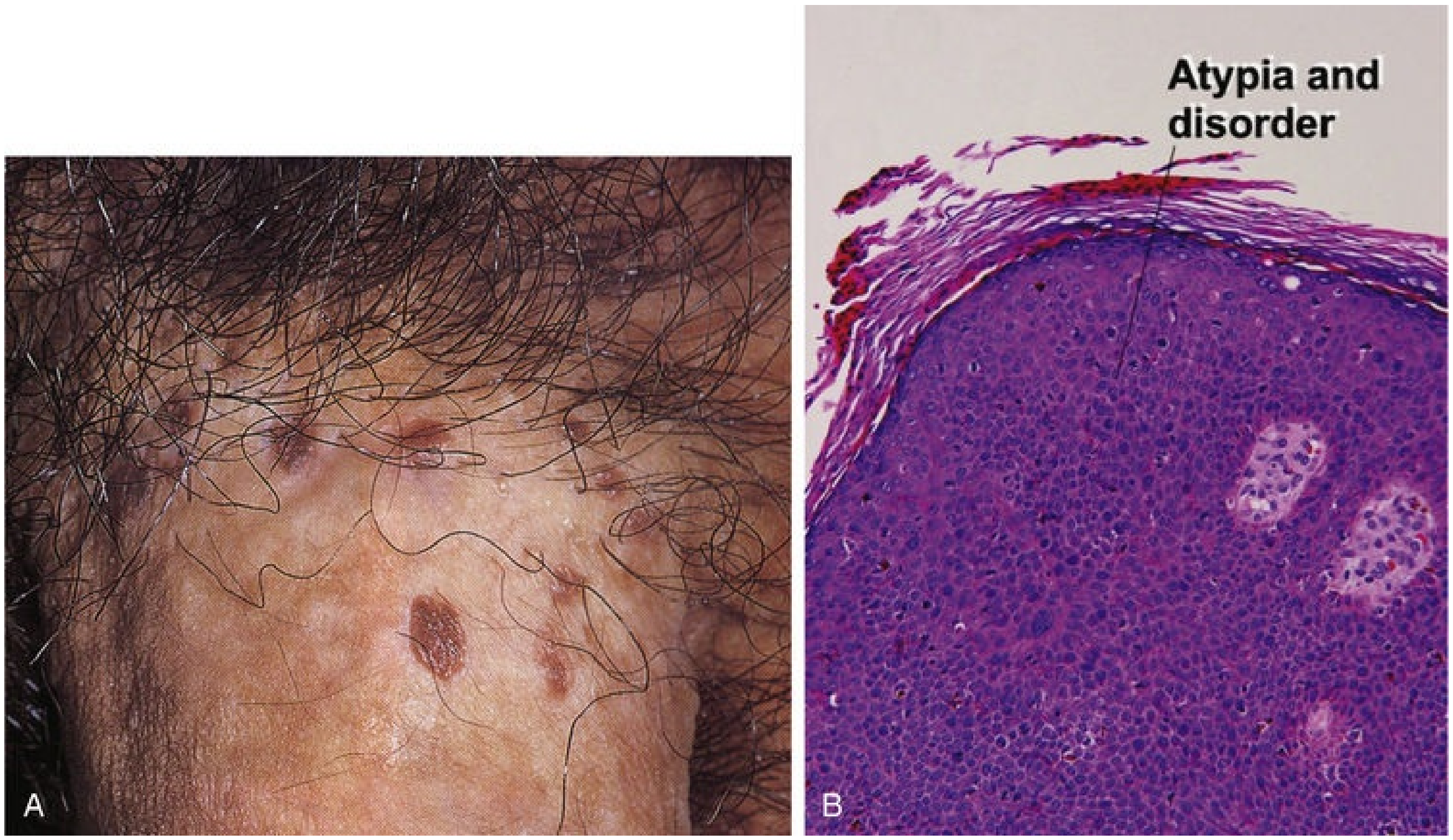

FIG. 59.37 Bowenoid papulosis. (A) Involvement of the penile shaft. Note multiple brown verrucous papules on the penile shaft. (B) Characteristic full thickness atypia, which may be mistaken for Bowen disease. (A, From Habif TP: *Clinical dermatology,* Edinburgh, 2004, Mosby, p 343. B, From Elston DM, Ferringer T: *Dermatopathology,* Edinburgh, 2009, Saunders, p 293.)

Squamous Cell Carcinoma

Invasive SCC involving the genitalia (Fig. 59.38) is covered in detail in Chapter 37.

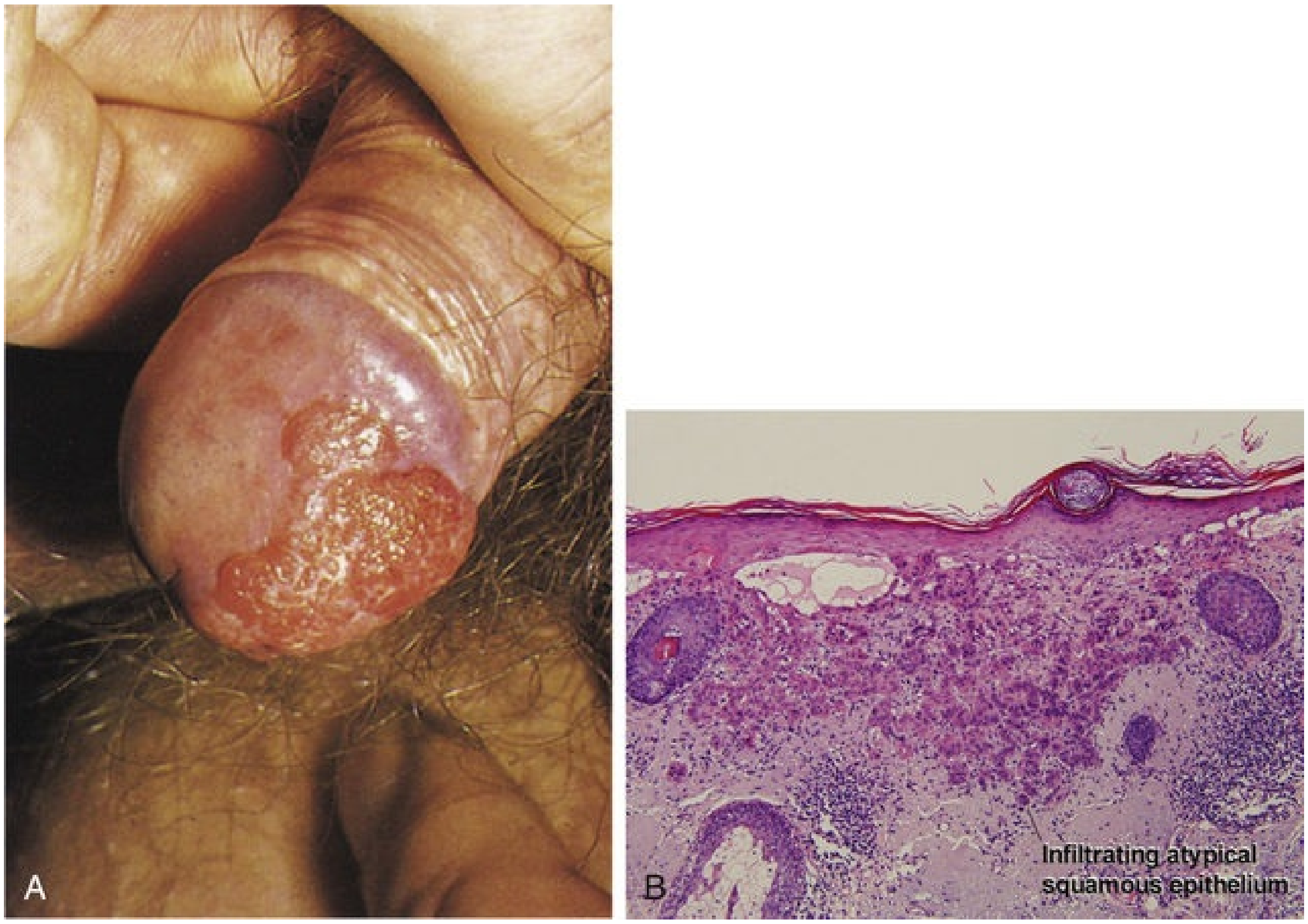

FIG. 59.38 Squamous cell carcinoma (SCC). (A) Exophytic erosive lesion on the glans with evident keratinization. (B) Atypical keratinocytes invading the dermis in SCC. (A, From Callen JP, Greer DE, Hood AF, et al.: *Color atlas of dermatology,* Philadelphia, 1993, Saunders, p 129. B, From Elston DM, Ferringer T: *Dermatopathology,* Edinburgh, 2009, Saunders, p 57.)

Verrucous Carcinoma (Buschke-Lowenstein Tumor)

Verrucous carcinoma is a locally aggressive, exophytic, low-grade variant of SCC that has little metastatic potential (Habif, 2004)**. The Buschke-Lowenstein tumor is a verrucous carcinoma of the anogenital mucosal surface and may represent up to 24% of all penile tumors** (Schwartz, 1995). It most commonly occurs in uncircumcised men on the glans or prepuce, although similar lesions can be found on the vulva, vagina cervix, or anus. Verrucous carcinoma has been associated with HPV types 6 and 11 infection but not with the more classically oncogenic types 16 and 18 (Ahmed et al., 2006; Chan et al., 1994; Margolis, 2002; Yasunaga et al., 1993).

Verrucous carcinoma lesions have a warty appearance and are often large and fungating when presenting on the genitalia (Fig. 59.39). Aside from genital sites, these lesions can also present within the oral and nasal cavities and plantar surfaces of the feet. They are slow growing and locally destructive, often extending deeply into underlying tissue. Preferred treatment is by local excision. Mohs micrographic surgery may be helpful in tracing out the tumor and minimizing tissue loss. **Primary radiotherapy is relatively contraindicated because of the potential for anaplastic transformation with a subsequent increase in metastatic potential** (Andersen and Sorensen, 1988; Fukunaga et al., 1994; Stehman et al., 1980; Vandeweyer et al., 2001).

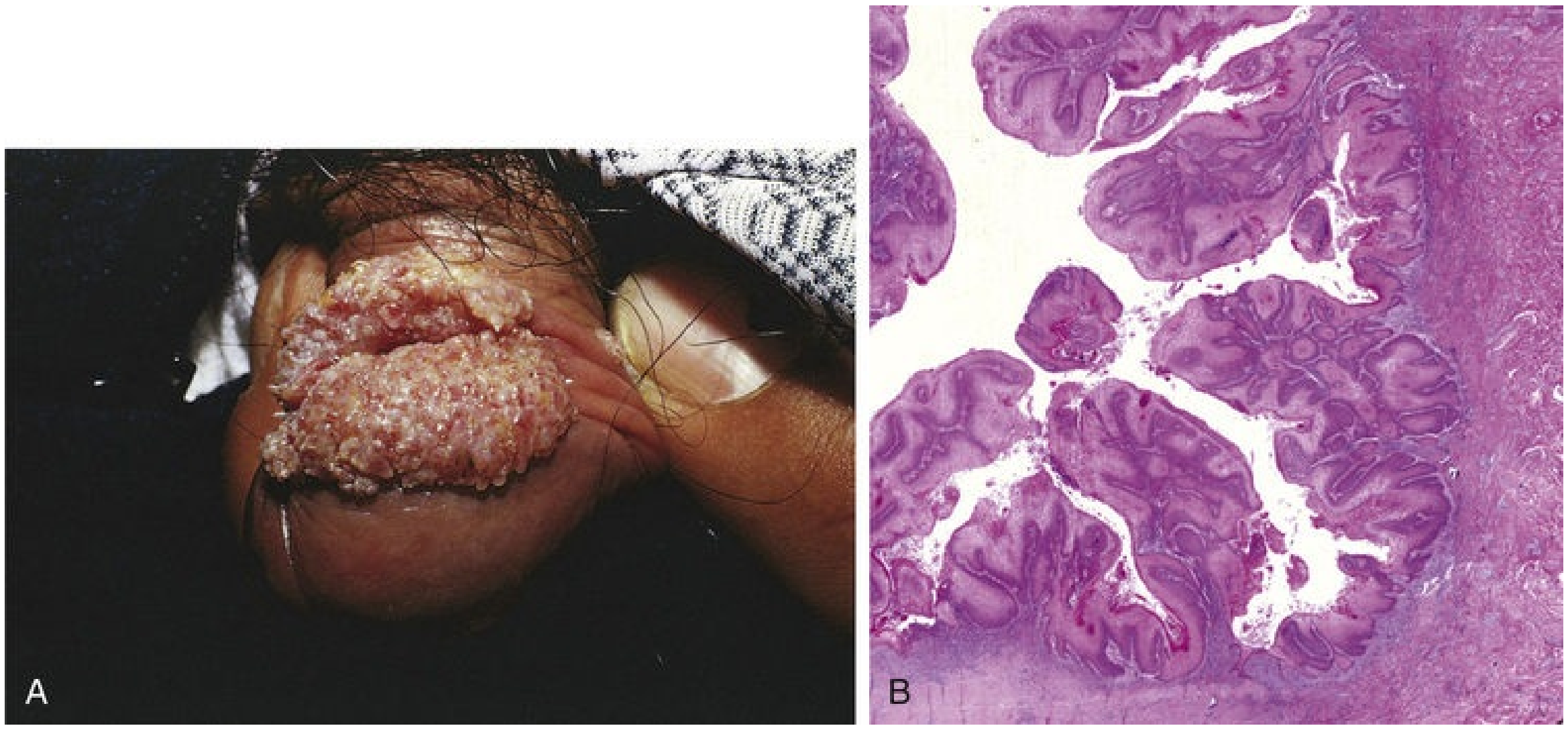

FIG. 59.39 Verrucous carcinoma of the penis (Buschke-Lowenstein tumor). (A) Note the exophytic and wartlike appearance. (B) Histologic features of verrucous carcinoma. (A, From Callen JP, Greer DE, Hood AF, et al.: *Color atlas of dermatology,* Philadelphia, 1993, Saunders, p 330, B, From Elston DM, Ferringer T: *Dermatopathology,* Edinburgh, 2009, Saunders, p 58.)

Basal Cell Carcinoma

Basal cell carcinoma (BCC) is the most common cutaneous neoplasm overall, arising most often on areas of chronically sun-exposed skin such as the head and neck. Genital BCC has also been described as a very rare entity, most commonly involving the scrotal skin in the male and the vulva in the female (Benedet et al., 1997; Esquivias Gomez et al., 1999; Kinoshita et al., 2005; Nahass et al., 1992). In the world medical literature, fewer than 100 total cases of BCC have been described involving all the potential genital sites (penis, scrotum, vulva). Several subtypes of BCC have been defined including nodular, superficial, micronodular morpheaform, and infiltrating. The nodular variant accounts for 60% of extragenital BCCs and almost all genital BCCs, and this variant presents as a pearly, skin-toned papule or plaque often with telangiectasias overlying the tumor (Fig. 59.40; Miller and Moresi, 2003). These lesions may ulcerate centrally and manifest a very low metastatic potential. Treatment is by local excision. Because preservation of genital skin is important, both for form and function, the use of Mohs micrographic surgery may be advisable for the rare genital BCC. In patients with metastatic, locally advanced, and/or unresectable BCC, vismodegib and sonidegib are Hedgehog signaling pathway inhibitors that were approved by the FDA in 2012 and 2015, respectively.

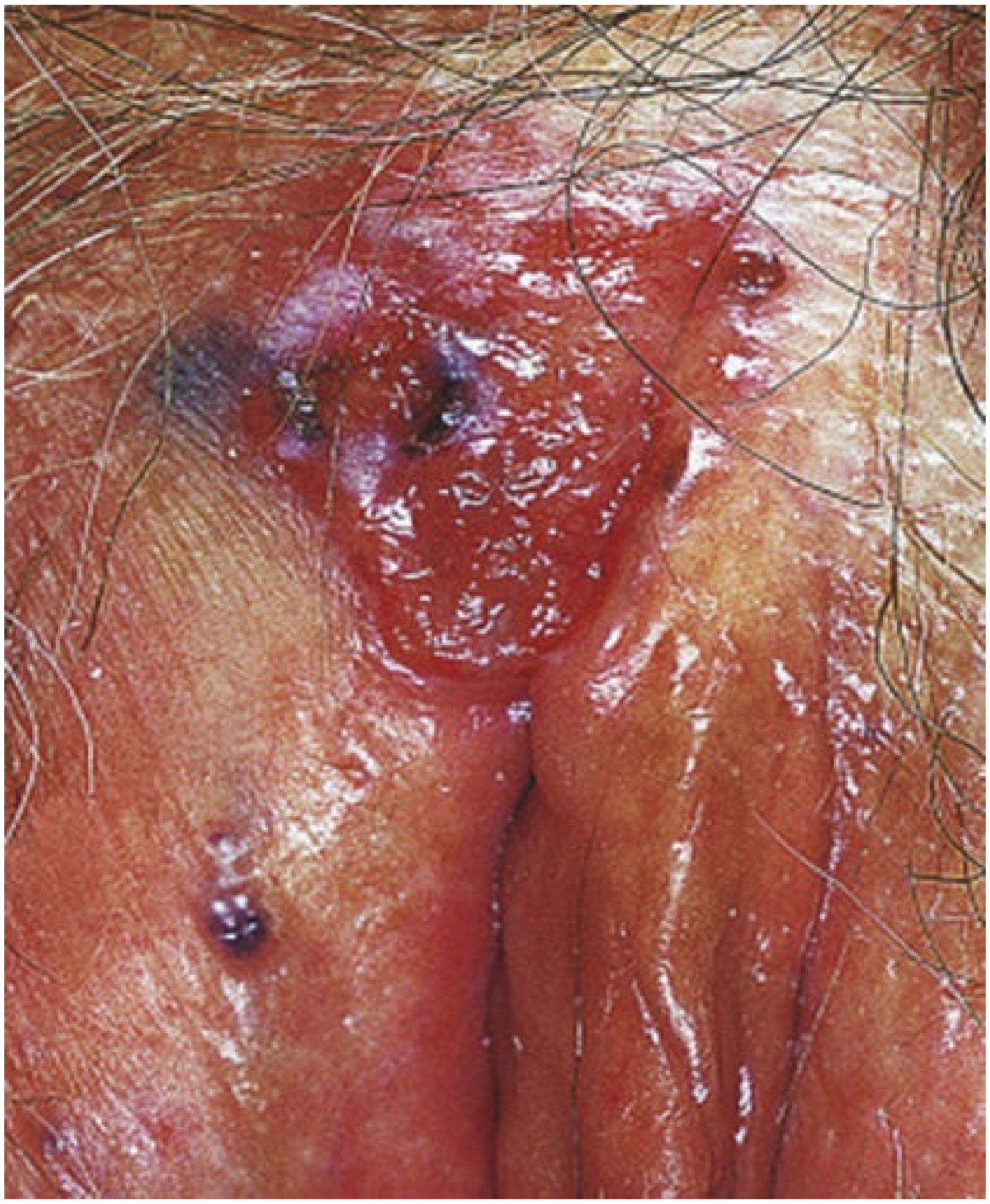

FIG. 59.40 Basal cell carcinoma involving the vulva. (From Chapman MS: *Skin disease: diagnosis and treatment*. Philadelphia, Elsevier, 2018. Fig.

17-11.)

Kaposi Sarcoma

Kaposi sarcoma (KS) is a disease of endothelial cell origin. Whether KS is a neoplastic or hyperplastic process remains controversial, and evidence exists for and against clonal expansion (Gill et al., 1998; Rabkin et al., 1997). Before the onset of the AIDS epidemic, KS was considered a chronic disease afflicting elderly men of Jewish, Mediterranean, or Eastern European descent (“classic KS”) (Safai, 1987). However, infection with HIV-1 has increased the incidence of KS by more than 7000-fold (Margolis, 2002; Miles, 1994). KS generally affects HIV-infected patients with advanced immune impairment (CD4+ T-cell counts of <500 cells/mm) (Tappero et al., 1993). Approximately 40% of homosexual men with AIDS have developed KS as compared with less than 5% in other risk groups (North et al., 2003; Rogers et al., 1987), although the prevalence in this population has decreased since the widespread use of highly active antiretroviral therapy. There is also a clear association between infection with human herpesvirus 8 and the development of KS (Boshoff and Weiss, 1997; Weiss et al., 1998). In this regard, the other group at risk for development of KS associated with human herpesvirus 8 infection includes recipients of solid organ transplants (Riva et al., 2012).

Classic KS in immunocompetent individuals presents as slowly growing, blue-red to overtly violaceous pigmented macules on the lower extremities. Although oral and gastrointestinal lesions may occur, the genitalia are seldom involved. This is in contrast to the case with AIDS (“epidemic KS”), in which a solitary genital lesion may be the first manifestation of KS (Lowe et al., 1989)**. The clinical features of KS in AIDS patients and solid organ transplant recipients are diverse, ranging from a single lesion to disseminated cutaneous and visceral disease** (Fig. 59.41). Lesions may coalesce to cover large areas of skin and may result in lymphatic or venous blockage leading to local edema (Margolis, 2002). When these lesions involve the glans penis, they can cause obstruction at the urethral meatus or fossa navicularis (Swierzewski et al., 1993). However, penile KS is still rare, even among those infected with HIV-1; only about 3% of AIDS patients will ever develop KS of the genitalia (Rosen et al., 1999).

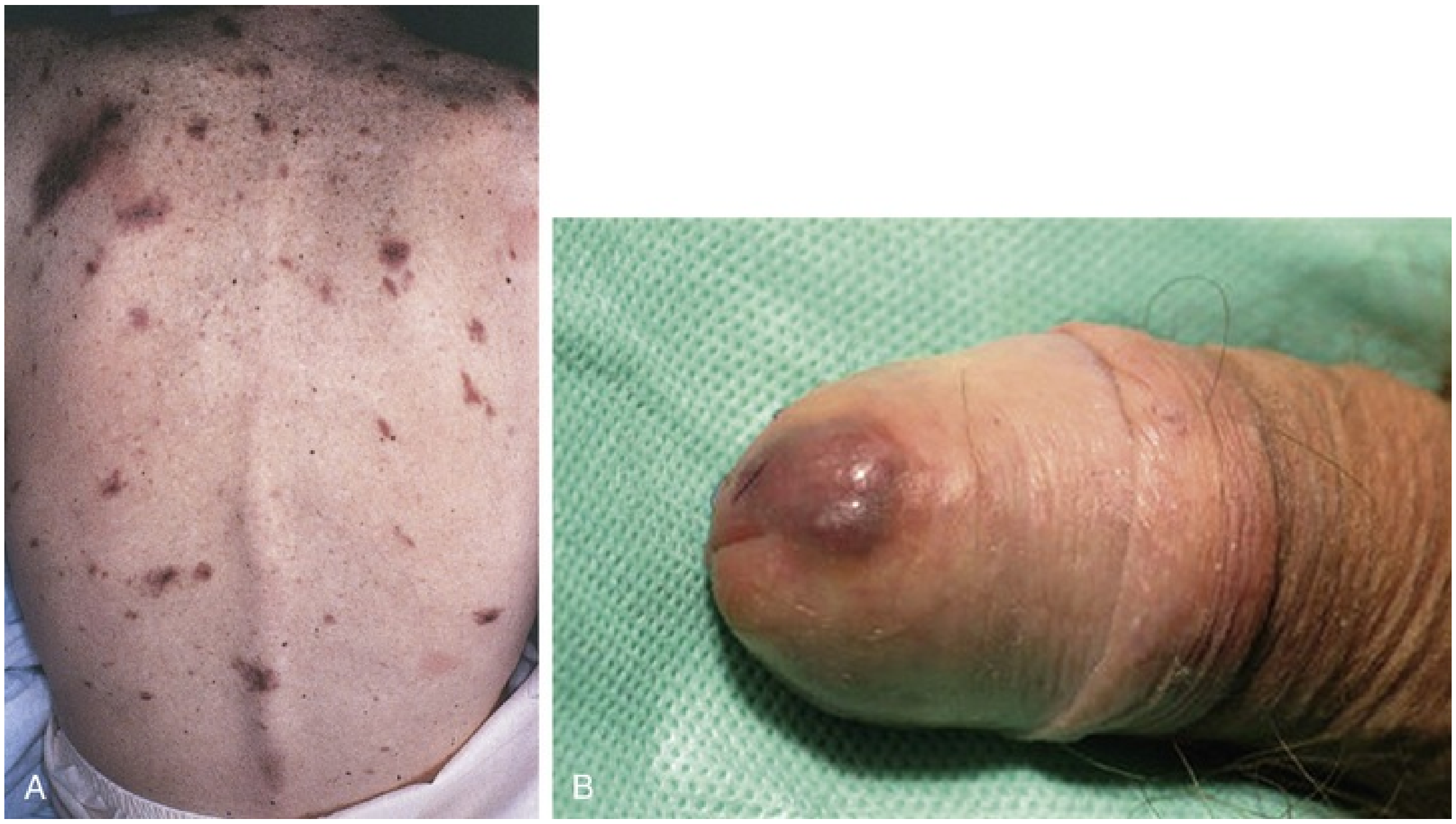

FIG. 59.41 Kaposi sarcoma. Classic macular lesions seen on the back (A) and glans penis **(B).** (A, From Callen JP, Greer DE, Hood AF, et al. *Color atlas of dermatology*. Philadelphia: Saunders; 1993, p. 220; B, From Imko-Walczuk B, Kielbowicz M, Malyszko J, et al: Kaposi sarcoma in the genital area in a kidney transplant patient: a case report and literature review. *Transplant Proc* 48(5):1843–1848, 2016, Fig. 1.)

Treatment must be tailored to the individual clinical case, and complete cure may be an unrealistic goal. No treatment is necessary for solitary lesions. However, if treatment is desired, local therapies such as surgical excision, laser ablation, cryotherapy, topical imiquimod 5%, or intralesional injection of chemotherapeutic agents (i.e., vinblastine) may be beneficial (Chun et al., 1999; Heyns and Fisher, 2005; Rosen, 2006; Schwartz, 2004). For extensive locoregional disease, radiotherapy (15 to 30 Gy) has an objective response rate of greater than 90% (Cattelan et al., 2002; Kirova et al., 1998). For widely disseminated KS, systemic chemotherapy with vincristine, doxorubicin, and bleomycin is the treatment of choice (Aversa et al., 1999). For KS associated with organ transplantation, reduction in the degree of postoperative immunosuppression or switching from a calcineurin inhibitor to an mTOR inhibitor may lead to KS resolution without any additional intervention (Riva et al., 2012).

Pseudoepitheliomatous, Keratotic, and

Micaceous Balanitis

Pseudoepitheliomatous, keratotic, and micaceous balanitis (PEKMB) is a rare entity characterized by the development of a thick, hyperkeratotic plaque on the glans penis of older men (Fig. 59.42). The term *micaceous* refers to the white, scaly appearance of the lesions (Child et al., 2000). PEKMB was originally thought to be a purely benign process, although several case reports have documented the presence of concurrent verrucous carcinomas associated with this lesion (Child et al., 2000). Controversy remains as to whether PEKMB is a premalignant condition (Beljaards et al., 1987; Jenkins and Jakubovic, 1988; Read and Abell, 1981). Histologic examination is essential to exclude the presence of SCC and verrucous carcinoma (Margolis, 2002). PEKMB is characterized on histology by a hyperplastic epidermis with ridges extending deeply into the dermis (Jenkins and Jakubovic, 1988). These lesions should be treated locally either by surgical excision or ablative techniques, and close follow-up is essential (Bargman, 1985; Read and Abell, 1981). There are also anecdotal reports of successful treatment using topical 5-fluorouracil cream (Bargman, 1985; Choo et al., 2017; Krunic et al., 1996).

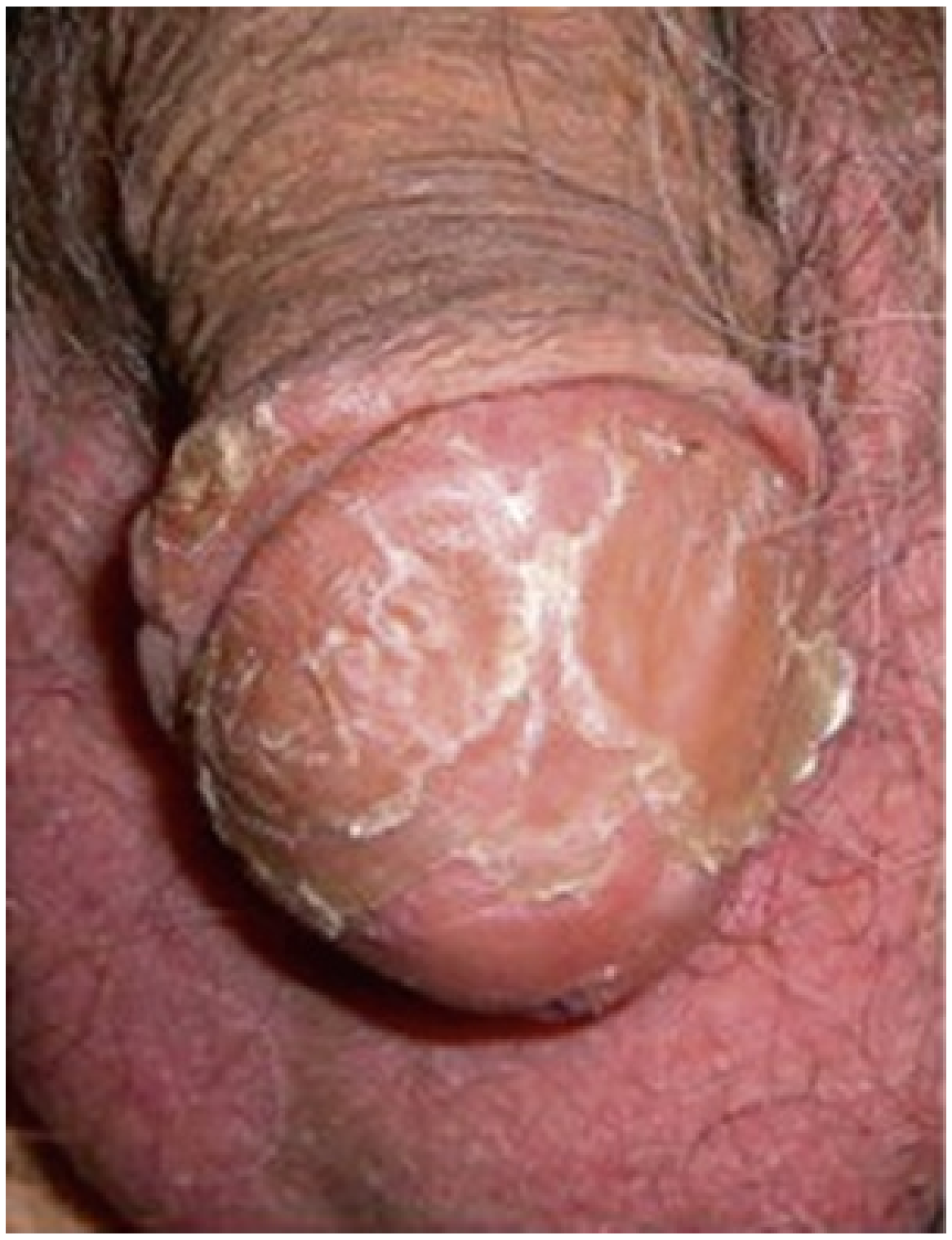

FIG. 59.42 Pseudoepitheliomatous, keratotic, and micaceous balanitis.

The glans becomes covered with mica (asbestos-like) scales and horny crusts. (From Ferràndiz-Pulido C, de Torres I, García-Patos V: Penile squamous cell carcinoma. *Dermatology* 103(6): 478–487, 2012, Fig. 1A.)

Melanoma

Malignant melanoma is a neoplasm arising from melanocytes. The incidence of melanoma has risen 3% to 7% during the past several decades (Nestle and Kerl, 2003). Risk factors for development of the disease include family history, certain genetic markers, fair skin, light eye color, and a history of excessive ultraviolet radiation exposure (especially multiple blistering sunburns as a child or adolescent). Primary melanoma of the male genitalia is an uncommon entity with only approximately 100 cases reported in the literature (Sanchez-Ortiz et al., 2005), and melanoma of the male urethra is even more rare (Oliva et al., 2000). The same cannot be said for females, as melanoma makes up about 7% to 10% of all vulvar malignancies and remains the second most common such lesion after SCC (Suwandinata et al., 2007). Although vulvar melanoma is more common among Caucasian women, the prognosis is worse among African-American women (Mert et al., 2013).

Genital melanoma usually presents as a pigmented macule or papule with an irregular border, although unpigmented lesions and ulceration may also be present (Margolis, 2002). **Early diagnosis is critical because local treatment of superficial lesions with wide local excision or partial penectomy can provide excellent disease control** (Sanchez-Ortiz et al., 2005; Stillwell et al., 1988)**. The same caveats are true in female patients.** In contrast, patients with biopsy-proven metastatic disease have traditionally had a universally poor prognosis despite aggressive surgical management and multiagent cytotoxic chemotherapy. In the last several years, however, several drugs have gained regulatory approval for the treatment of metastatic and unresectable melanoma as a result of an increase of knowledge in melanoma-specific molecular biology and immunology. The efficacy of small-molecule BRAF (e.g., vemurafenib, dabrafenib, trametinib) and MAP-ERK kinase (MEK) inhibitors, as well as the immune checkpoint inhibitors (e.g., ipilimumab and the anti-PD1/PDL1 antibodies lambrolizumab and nivolumab), have transformed the treatment of advanced melanoma.

Extramammary Paget Disease

Extramammary Paget disease (EPD) is an uncommon intraepithelial adenocarcinoma of sites bearing apocrine glands (Zollo and Zeitouni, 2000). The majority of patients with EPD are elderly Caucasian females, and involvement of the male penis and scrotum is exceedingly rare (Park et al., 2001; van Randenborgh et al., 2002). The vulva is the most commonly involved genital site in women followed by the perianal region in men (Wojnarowska and Cooper, 2003). **There is an important association between EPD and another underlying malignancy in at least 10% to 30% of cases** (Margolis, 2002; Ng et al., 2001; Payne and Wells, 1994). An investigation in a cancer specialty hospital suggested that this association may be even stronger in men than previously appreciated (Hegarty et al., 2011). In the male, associations between urethral, prostate, bladder, rectal, and apocrine malignancies with EPD have been described (Hayes et al., 1997; Hegarty et al., 2011; Salamanca et al., 2004). **It is critical, therefore, to perform a systematic evaluation for underlying carcinoma in all cases of EPD.**

The lesion in EPD is usually an erythematous plaque with a sharp border between normal and involved skin (Fig. 59.43). It may be asymptomatic, pruritic, or associated with burning pain. The diagnosis is confirmed histologically by the presence of vacuolated Paget cells in the epidermis that stain for glandular cytokeratins, epithelial membrane antigen, and carcinoembryonic antigen (Wojnarowska and Cooper, 2003). Treatment generally involves surgical excision or Mohs micrographic surgery, although radiotherapy, photodynamic therapy, and topical imiquimod 5% or 5-fluorouracil have also been used successfully (Bewley et al., 1994; Brown et al., 2000; Guerrieri and Back, 2002; Lee et al., 2009; Moreno-Arias et al., 2003; Qian et al., 2003; Sillman et al., 1985).

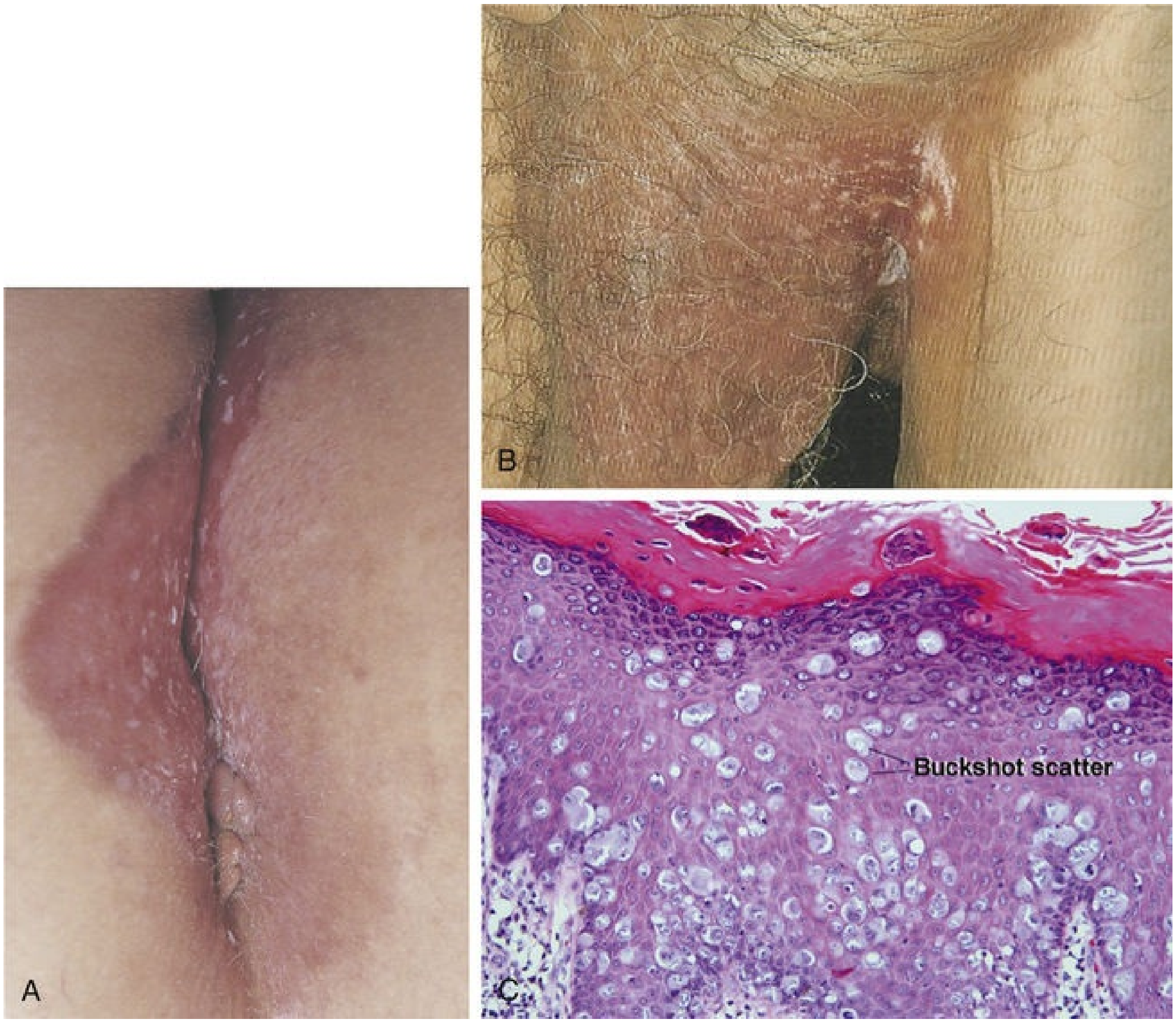

FIG. 59.43 Extramammary Paget disease involving the vulva (A) and base of scrotum (B). Note the well-demarcated border between the lesion and normal adjacent skin. (C) Tumor cells distributed throughout the epidermis (“buckshot scatter”). (A, Courtesy of Fenella Wojnarowska, MD, and Susan M. Cooper, MD. From Bolognia JL, Jorizzo JL, Rapini RP. *Dermatology.* Edinburgh: Mosby; 2003. B, From Bolognia JL, Jorizzo JL, Rapini RP: *Dermatology,* Edinburgh, 2003, Mosby, p 1108. C, From Elston DM, Ferringer T: *Dermatopathology,* Edinburgh, 2009, Saunders, p 66.)

Cutaneous T-Cell Lymphoma

Cutaneous T-cell lymphoma (CTCL) represents a group of related neoplasms derived from T cells that home to the skin. CTCL includes a variety of conditions including mycosis fungoides, Sézary syndrome, lymphoid papulosis, and pagetoid reticulosis (Willemze, 2003). There is an increased risk of CTCL associated with HIV infection (Biggar et al., 2001). Although these disorders may involve the genitalia of both genders, extragenital disease is usually also present. CTCL accounts for the majority of primary cutaneous lymphomas with B-cell–derived lymphomas accounting for only 20% to 25% (Willemze et al., 1997; Willemze et al., 2005). Definitive diagnosis depends on biopsy histopathology.

CTCL generally presents initially as pruritic patches that must be differentiated from a variety of benign dermatoses including psoriasis, eczema, superficial fungal infections, and drug reactions. **The initial lesions of CTCL have a strong predilection in both sexes to occur on suprapubic and/or buttock skin.** Patients may subsequently develop hematologic involvement (Sézary syndrome) and cutaneous plaques, erosions, ulcers, or frank skin tumors (Fig. 59.44) (Margolis, 2002). CTCL is a chronic condition that may progress throughout many years. Topical treatments include application of ultrapotent corticosteroids, nitrogen mustard, and carmustine with complete remission rates of approximately 60% (Vonderheid et al., 1989; Zackheim et al., 1998). Other treatments include radiotherapy (including total body electron beam treatment), phototherapy (PUVA or Narrowband Ultraviolet B), and systemic treatment with chemotherapy, interferons, or retinoids (Diederen et al., 2003; Hoppe et al., 1990; Olsen and Bunn, 1995; Querfeld et al., 2005).

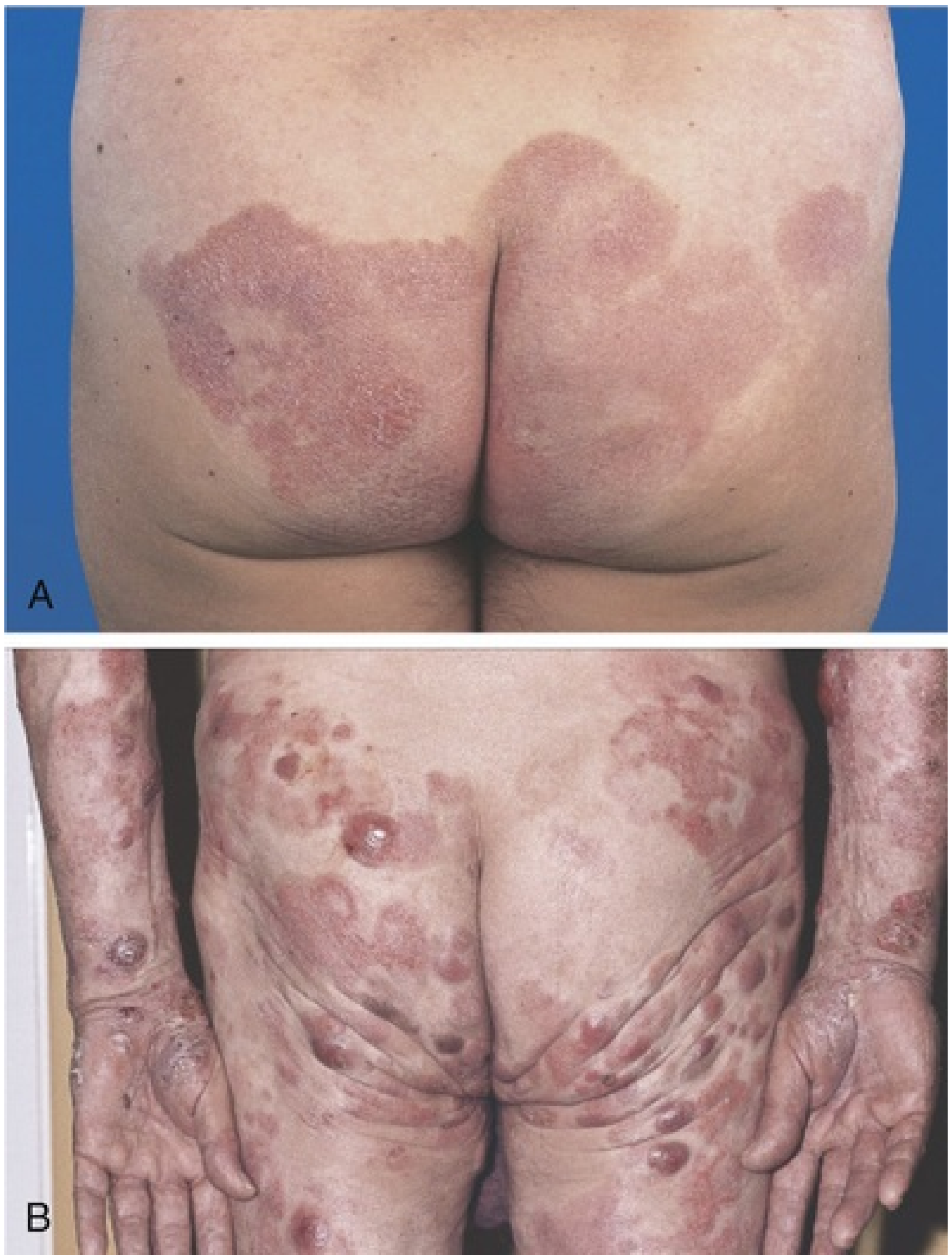

FIG. 59.44 Mycosis fungoides (a cutaneous T-cell lymphoma) involving the buttocks. (A) The limited plaque stage. (B) A more advanced case with plaques, patches, and tumors present. (From Bolognia JL, Jorizzo JL, Rapini RP: *Dermatology,* Edinburgh, 2003, Mosby.)

Benign Cutaneous Disorders Specific to the Male Genitalia

Angiokeratoma of Fordyce

Angiokeratomas of Fordyce are vascular ectasias of dermal blood vessels that may be visible on the penis and scrotum of adult men (Bechara et al., 2002). These lesions appear as 1- to 2-mm red or purple papules (Fig. 59.45A), and associated generalized scrotal redness may exist (Miller and James, 2002). This is usually a benign condition without systemic manifestations, although it may rarely be a source of troublesome scrotal bleeding (Hoekx and Wyndaele, 1998; Taniguchi et al., 1994). Similar lesions can be observed in Fabry disease (Fig. 59.45B), which is a rare glycogen storage deficiency. Although treatment is usually unnecessary for angiokeratoma of Fordyce, several authors have reported success using erbium:YAG, Nd:YAG, KTP, and Argon laser photocoagulation in select cases (Bechara et al., 2004; Occella et al., 1995; Ozdemir et al., 2009).

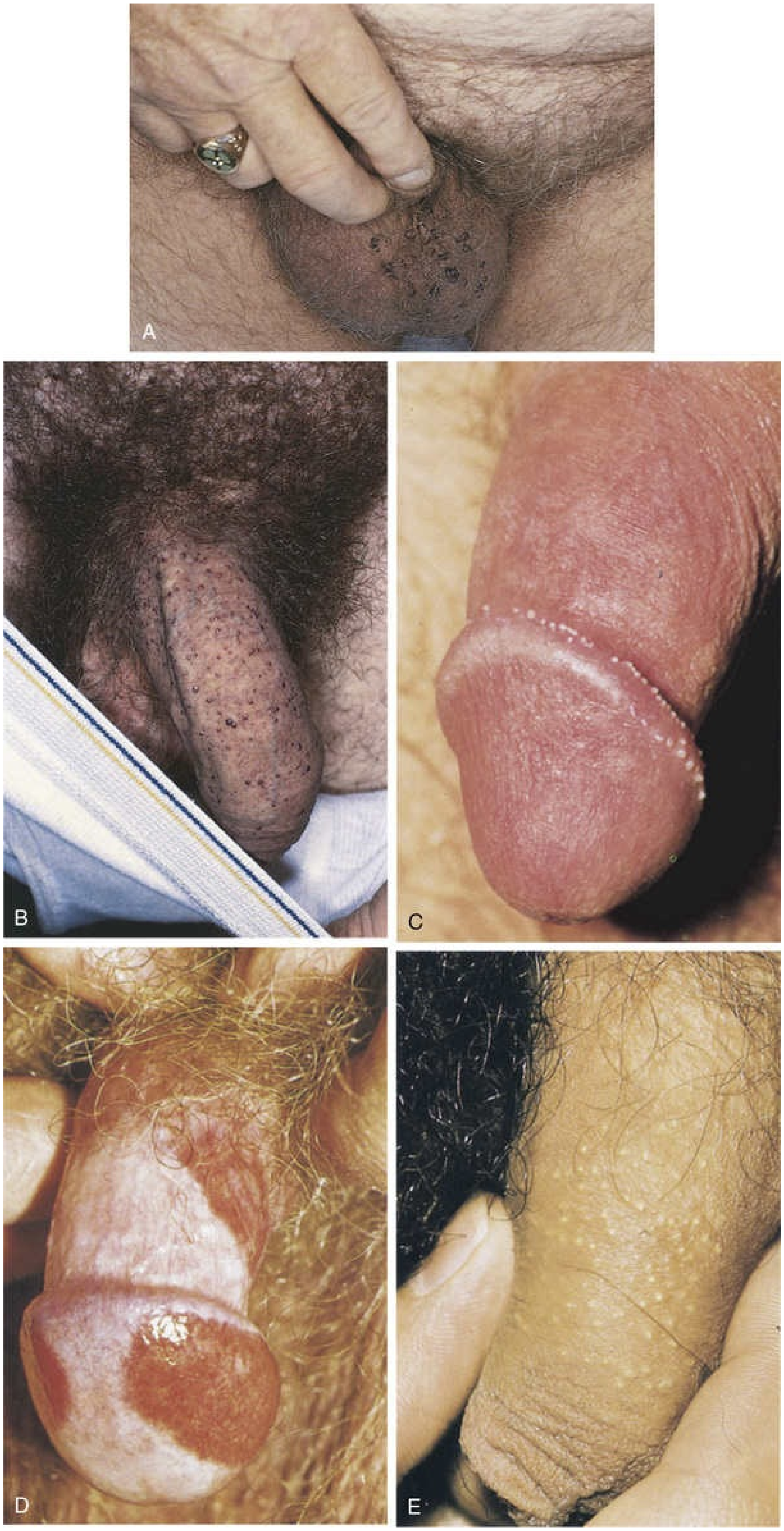
A
B
C
D
E

FIG. 59.45 Benign cutaneous disorders specific to the male genitalia. (A) Angiokeratoma of Fordyce showing purple scrotal vascular malformations. (B) Fabry disease: a glycogen storage deficiency with associated purple vascular malformations on the penile shaft. (C) Pearly penile papules located on the corona of the glans penis. (D) Zoon balanitis of the glans penis. (E) Ectopic sebaceous glands on the penile shaft. (A, B, and E, From Callen JP, Greer DE, Hood AF, et al.: *Color atlas of dermatology,* Philadelphia, 1993, Saunders. C and D, From Korting GW: *Practical dermatology of the genital region,* Philadelphia, 1981, Saunders.)

Pearly Penile Papules

Pearly penile papules are white, dome shaped or filiform, closely spaced small papules located on the glans penis (Fig. 59.45C). They are often arranged circumferentially at the corona. Pearly penile papules are common lesions found in up to 14% to 48% of young postpubertal adults, particularly if the penis is not circumcised (Khoo and Cheong, 1995; Rehbein, 1977; Sonnex and Dockerty, 1999). **Although pearly penile papules may occasionally be misdiagnosed as condyloma, the available evidence does not support a role for HPV in causing pearly penile papules, and no association with cervical intraepithelial neoplasia in female partners has been demonstrated** (Hogewoning et al., 2003). Patients should be reassured that this is a benign condition or normal variant that does not usually require treatment. If treatment is desired because of cosmetic concerns, local destruction with either the CO_2 laser or cryotherapy has been applied successfully (Lane et al., 2002; Ocampo-Candiani and Cueva-Rodriguez, 1996). **Histologically, these lesions are angiofibromas similar to the lesions seen on the face in tuberous sclerosis.**

Zoon Balanitis

Zoon balanitis, also called plasma cell balanitis and balanitis plasmacellularis, occurs in uncircumcised men from the third decade onward and has an unknown cause (Pastar et al., 2004). Smooth, moist, erythematous, well-circumscribed papules and plaques on the glans penis characterize the disease (see Fig. 59.14D). Shallow erosions are often present (Yoganathan et al., 1994), and the lesions can be large (up to 2 cm in diameter) (Margolis, 2002). Lesions may be asymptomatic or exhibit mild pruritus or tenderness. SCC and EPD must be excluded, typically by biopsy. Circumcision appears to be proof against development of the disease and can be performed to cure the majority of cases (Ferrandiz and Ribera, 1984; Sonnex et al., 1982a). For patients averse to circumcision, topical corticosteroids may provide symptomatic relief, and topical calcineurin inhibitors (tacrolimus or pimecrolimus), topical retinoids, and laser therapy may also play a role in alleviation (Albertini et al., 2002; Baldwin and Geronemus, 1989; Rallis et al., 2007; Retamar et al., 2003; Tang et al., 2001; Wojnarowska and Cooper, 2003).

Sclerosing Lymphangitis

Nonvenereal sclerosing lymphangitis is a rare penile lesion consisting of an indurated, slightly tender cord involving the coronal sulcus and adjacent penile skin (Gharpuray and Tolat, 1991; Rosen and Hwong, 2003). It is usually flesh colored but may occasionally be red. A mechanism related to thrombosis of lymphatic vessels has been proposed. There is an association with vigorous sexual activity, and resolution usually occurs within several weeks (Margolis, 2002; Sieunarine, 1987). Although somewhat controversial, a search for concomitant gonococcal and nongonococcal urethritis may be advisable in these cases.

Median Raphe Cysts

Median raphe cysts occur in young men on the ventral aspect of the penis, most commonly near the glans (Stone, 2003). Although these cysts are believed to develop from aberrant urethral epithelium, they do not communicate with the urethra (Asarch et al., 1979). Treatment is accomplished by surgical removal.

Ectopic Sebaceous Glands

Ectopic sebaceous glands on the penile shaft may be visible as pin-sized, flesh-colored papular lesions that may be mistaken for verruca (see Fig. 59.45E) (Margolis and Wein, 2002). There is no indication for treating these asymptomatic benign lesions and patient reassurance is sufficient.

Common Miscellaneous Cutaneous Disorders

Skin Tag

Skin tags (acrochordons, fibroepithelial polyps) are soft, skin-colored, pedunculated lesions that can be present anywhere on the body but have a clear predilection for the neck, axillae, and inguinal folds. Although usually asymptomatic, these lesions may become painful secondary to local trauma or as a result of torsion and infarction in rare cases. These are common lesions, and up to 50% of all individuals may have at least one skin tag (Banik and Lubach, 1987). **It is important to distinguish these lesions from the hamartomatous skin lesions (multiple fibrofolliculomas) associated with Birt-Hogg-Dube syndrome, which are histologically distinct from common skin tags** (De la Torre et al., 1999). When skin tags cause either discomfort or cosmetic distress, they can easily be removed by snip excision and light electrocautery or chemical cautery with aluminum chloride applied to the base to achieve hemostasis. When a large number of skin tags appear at a relatively young age (<40), there may be an association with benign and malignant lower gastrointestinal tract polyposis, and gastroenterologic referral for endoscopy should be considered (Piette et al., 1988).

Epidermoid Cysts

Epidermoid or epidermal-inclusion cysts are the most common cutaneous cysts, and these lesions can be found anywhere on the body, including the genitalia. They are particularly common on the scrotum (see Fig. 59.46E). **The term "sebaceous cyst" should be avoided because the contents of these cysts are not sebaceous in origin** (Stone, 2003). Although not painful at baseline, rupture of the cyst wall can lead to a severe inflammatory reaction that is extremely painful. Definitive treatment requires surgical excision of the entire cyst wall to prevent cyst recurrence. Inflamed or superinfected epidermoid cysts may require incision and drainage and antibiotic therapy if there is adjacent cellulitis. Dystrophic calcification of scrotal epidermoid cysts may be a cause of scrotal calcinosis (Dare and Axelsen, 1988; Michl et al., 1994).

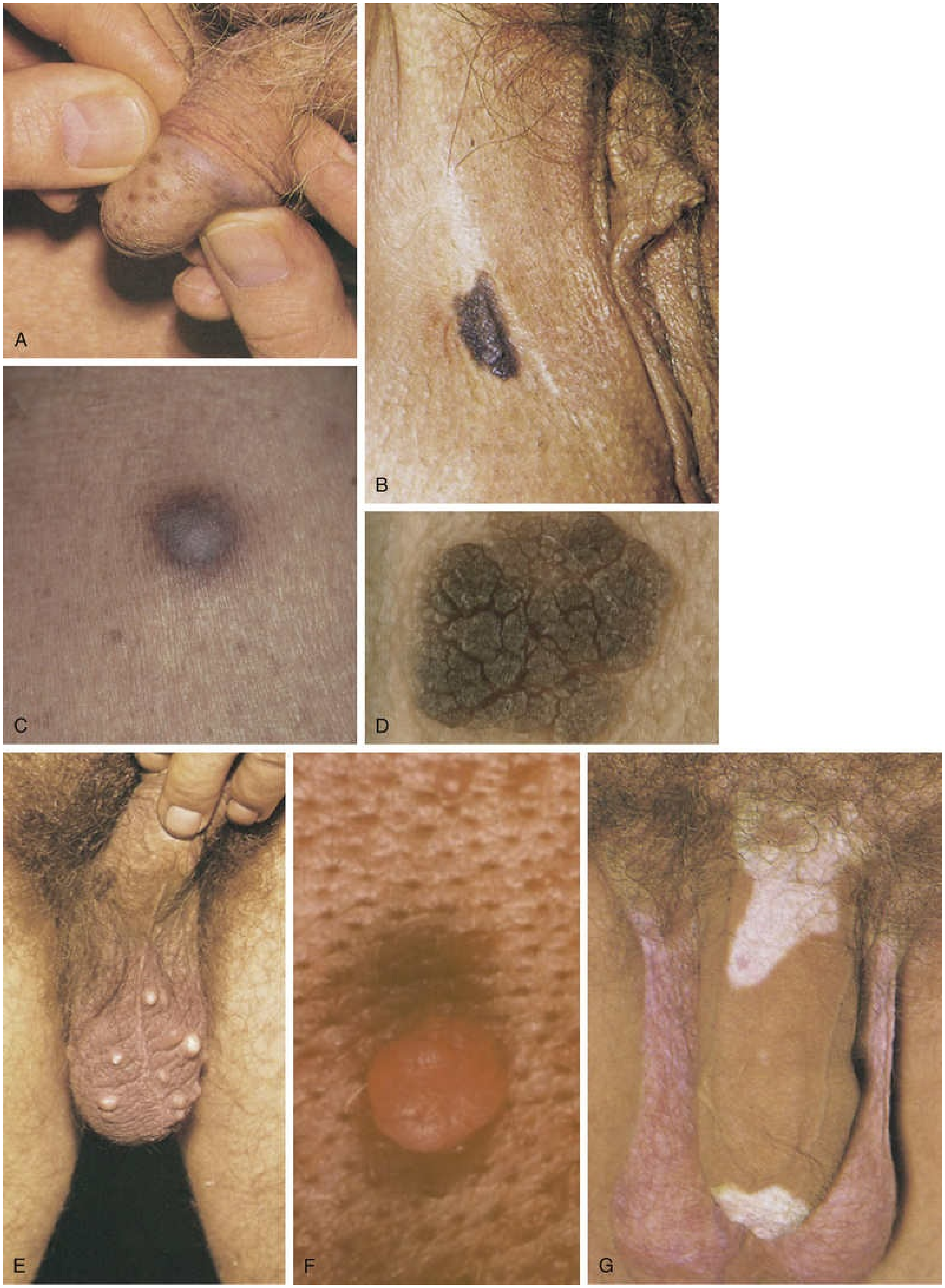

FIG. 59.46 Miscellaneous cutaneous disorders. (A) Lentigo simplex involving the glans penis (penile melanosis). (B) A compound melanocytic

nevus in the inguinal crease. (C) A dermatofibroma on the lower extremity. (D) A characteristic seborrheic keratosis showing the "stuck-on" waxy appearance. (E) Epidermoid cysts of the scrotum. (F) Pedunculated neurofibroma. (G) Vitiligo involving the penile shaft. (A, B, E, and G, From Korting GW: *Practical dermatology of the genital region*, Philadelphia, 1981, Saunders. C, From Bolognia JL, Jorizzo JL, Rapini RP: *Dermatology,* Edinburgh, 2003, Mosby. D, From Habif TP: *Clinical dermatology,* Edinburgh, 2004, Mosby.)

Seborrheic Keratosis

Seborrheic keratoses are very common beige to dark brown macules, plaques, and papules affecting individuals older than 30 years, and the incidence increases in frequency with advancing age. They are most common on the face, neck, and trunk although any body site except the palms, soles, and mucous membranes may be affected. The degree of pigmentation can vary significantly, and darker lesions may be confused with melanoma (Pierson et al., 2003). **These lesions have a waxy, "stuck-on" appearance** (see Fig. 59.46D) **and patients may note that they drop off spontaneously and then regrow** (Margolis, 2002). Treatment by shave excision or destruction with liquid nitrogen is usually performed for cosmetic reasons. **An abrupt increase in the size and number of multiple seborrheic keratoses has been termed the "Sign of Leser-Trelat" and has been implicated as a cutaneous marker of occult internal malignancy** (Chiba et al., 1996; Ginarte et al., 2001; Heaphy et al., 2000; Vielhauer et al., 2000).

Lentigo Simplex

Lentigo simplex is a condition characterized by the presence of brown-pigmented macules unrelated to sunlight exposure (Fig. 59.46A). These lesions can be found anywhere on the body, including the mucous membranes and nail beds. In the genital area (benign genital lentiginosis), these lesions present commonly on the labia, vaginal introitus, perineum, and glans penis (penile melanosis). The lesions of lentigo simplex are usually smaller than those seen in melanocytic nevi. Although usually benign, the lesions of lentigo simplex may deserve biopsy evaluation in cases demonstrating atypical shape or coloration. When present in a discontinuous manner at multiple sites, the diagnosis of genital melanoma becomes less likely compared with the probability of benign genital lentiginosis. **Finally, the combination of multiple pigmented lesions associated with intestinal polyposis should raise suspicion for Peutz-Jeghers syndrome.**

Mole (Nevus)

A mole or nevus of the skin is composed of slightly altered melanocytes called “nevus cells” arranged in a cluster. The location of the cluster determines the type of nevus. Junctional nevi are located between the epidermis and dermis and are usually flat, tan to black, small (<5 mm), and sharply bordered (Margolis, 2002). Intradermal nevi have clusters within the dermis and are usually small (<5 mm) and lighter in coloration, with sharp borders. Compound nevi have clusters in both locations and are usually darker and raised as a papule (Fig. 59.46B). As is the case for any pigmented lesion, marked irregularity in coloration or border and rapid morphologic change with time are indications for excisional biopsy to rule out dysplastic nevus or melanoma.

Dermatofibroma

Dermatofibromas are small hyperpigmented nodules that occur most commonly on the lower extremities and occasionally on the genitalia (see Fig. 59.46C). Pinching of these lesions causes a downward movement of the tumor (the so-called dimple sign) (Kamino and Pui, 2003). These are benign lesions with a characteristic histologic pattern of spindle-shaped fibroblasts and myofibroblasts arranged in fascicles. Treatment by surgical excision is usually unnecessary and may leave a scar that is cosmetically inferior to the original lesion (Kamino and Pui, 2003).

Neurofibroma

Neurofibromas are common tumors composed of neuromesenchymal tissue with residual nerve axons. They can be present anywhere on the body including the labia and scrotum (Kantarci et al., 2005; Mishra et al., 2002; Singh et al., 1992; Yoshimura et al., 1990). They are usually skin-colored, soft or rubbery nodules that may be pedunculated (Fig. 59.46F). **Digital pressure on the lesion causes invagination or so-called button-holing** (Habif, 2004). These can be solitary lesions or multiple, which should raise suspicion for neurofibromatosis or von

Recklinghausen disease.

Capillary Hemangioma

Capillary hemangiomas are proliferations of blood vessels that are either present at birth or develop rapidly during the neonatal period. These lesions can involve the anogenital region, can lead to bleeding, or can cause obstruction of the urethra, vagina, or anus (Roberts and Devine, 1983; Sharma et al., 1981). The majority will involute during childhood or early adolescence (Margolis, 2002). An innovation in the treatment of very large, persistent, and/or obstructive hemangiomas is the systemic administration of propranolol; because this treatment is not without some risk, it should be initiated and supervised by a clinician experienced with this modality (Izadpanah et al., 2013). Topical timolol therapy has also shown to be efficacious (Zheng and Li, 2018).

Vitiligo

Vitiligo is an acquired autoimmune disorder of the skin, leading to depigmentation, affecting 0.5% to 2% of the global population (Ortonne, 2003). It may occur at any age, and the precise pathogenesis of vitiligo remains a topic of intense research effort. Large patches of skin become completely amelanotic. Although the skin appears white, it is otherwise completely normal. The borders with unaffected skin are usually sharp and well defined (Fig. 59.46G). This condition is particularly noticeable in darker-skinned individuals and on body sites that are normally hyperpigmented. Vitiligo limited to the genitalia has been observed in less than 0.3% of the male population (Moss and Stevenson, 1981). Lesions have a tendency to enlarge circumferentially with time and may develop at sites of local trauma (Koebner phenomenon). Genital vitiligo must be differentiated from LS and postinflammatory hypopigmentation (Margolis, 2002). Wood's light can be used to accentuate vitiliginous areas. Treatments include temporary repigmentation with topical cosmetics, topical corticosteroids, topical calcipotriol (Vitamin D analogue), calcineurin inhibitor (pimecrolimus), ultraviolet light, PUVA therapy, and skin grafting. Use of the excimer laser to induce melanin production is particularly suited to the genitalia. **The diagnosis of vitiligo should prompt a screening for autoimmune thyroid disease.**

Key Points

- The diagnosis of cutaneous diseases of the external genitalia depends critically on a thorough history and physical examination. Extragenital findings may provide the key to diagnosis. The urologist should perform a thorough skin survey and should not focus solely on the area of affected genital skin.
- The side effects of topical corticosteroids are significant from systemic absorption and locally. Adverse effects may be worsened if these agents are applied under the foreskin, which may serve as an occlusive dressing. In general, when applied to genital skin, only low-potency topical corticosteroids should be used for short treatment courses.
- Cutaneous disorders of the external genitalia can be broken down into the general categories of allergic, papulosquamous, vesicobullous, ulcerative, infectious, neoplastic, and miscellaneous diseases.
- Histopathologic analysis of biopsy specimens plays an important role in differentiating cutaneous diseases with similar clinical features and in excluding malignancy.
- Local treatment modalities including the use of laser energy, photodynamic therapy, ultraviolet radiation, and cryotherapy are being applied successfully to a variety of genital cutaneous disorders and offer an alternative to surgical excision in some cases.

Suggested Readings

Bhate K, Landeck L, Gonzalez E, et al. Genital contact dermatitis: a retrospective analysis. *Dermatitis*. 2010;21(6):317–320.

Bhattacharya M, Kaur I, Kumar B. Lichen planus: a clinical and epidemiological study. *J Dermatol*. 2000;27:576–582.

Bolognia JL, Schaffer JV, Cerroni L. *Dermatology*. 4th ed. Elsevier: Edinburgh; 2018.

Criteria for diagnosis of Behçet's disease. International Study Group for Behçet's Disease. *Lancet*. 1990;335:1078–1080.

Czymek R, Kujath P, Bruch HP, et al. Treatment, outcome and quality of life after Fournier's gangrene: a multicentre study. *Colorectal Dis*. 2013;15:1529–1536.

Denby KS, Beck LA. Update on systemic therapies for atopic dermatitis. *Curr Opin Allergy Clin Immunol*. 2012;12:421–426.

Eke N. Fournier's gangrene: a review of 1726 cases. *Br J Surg*. 2000;87:718–728.

Ellinghaus D, Baurecht H, Esparza-Gordillo J, et al. High-density genotyping study identifies four new susceptibility loci for atopic dermatitis. *Nat Genet*. 2013;45:808–812.

Hatemi G, Yazici Y, Yazici H. Behçet's syndrome. *Rheum Dis Clin North Am*. 2013;39:245–261.

Krueger G, Koo J, Lebwohl M, et al. The impact of psoriasis on quality of life: results of a 1998 National Psoriasis Foundation patient-membership survey. *Arch Dermatol*. 2001;137:280–284.

Leibovitch I, Huilgol SC, Selva D, et al. Cutaneous squamous carcinoma in situ (Bowen's disease): treatment with Mohs micrographic surgery. *J Am Acad Dermatol*. 2005;52:997–1002.

Mallon E, Hawkins D, Dinneen M, et al. Circumcision and genital dermatoses. *Arch Dermatol*. 2000;136:350–354.

Morpurgo E, Galandiuk S. Fournier's gangrene. *Surg Clin North Am*. 2002;82:1213–1224.

Rompel R, Petres J. Long-term results of wide surgical excision in 106 patients with hidradenitis suppurativa. *Dermatol Surg*. 2000;26:638–643.

Ruocco E, Wolf R, Ruocco V, et al. Pemphigus: associations and management guidelines: facts and controversies. *Clin Dermatol*. 2013;31:382–390.

Sanchez-Ortiz R, Huang SF, Tamboli P, et al. Melanoma of the penis, scrotum and male urethra: a 40-year single institution experience. *J Urol*. 2005;173:1958–1965.

Scheinfeld N. Hidradenitis suppurativa: a practical review of possible medical treatments based on over 350 hidradenitis patients. *Dermatol Online J*. 2013;19:1.

Stern RS, PUVA Follow-Up Study. The risk of squamous cell and basal cell cancer associated with psoralen and ultraviolet A therapy: a 30-year prospective study. *J Am Acad Dermatol*. 2012;66:553–562.

Wolf R, Orion E, Marcos B, et al. Life-threatening acute adverse cutaneous drug reactions. *Clin Dermatol*. 2005;23:171–181.

Wollenberg A, Bieber T. Atopic dermatitis: from the genes to skin lesions. *Allergy*. 2000;55:205–213.

Worswick S, Cotliar J. Stevens-Johnson syndrome and toxic epidermal necrolysis: a review of treatment options. *Dermatol Ther*. 2011;24:207–218.

References

Ahmed AM, Madkan V, Tyring SK. Human papillomaviruses and genital disease. *Dermatol Clin*. 2006;24:157–165 [vi].

Albertini JG, Holck DE, Farley MF. Zoon's balanitis treated with Erbium:YAG laser ablation. *Lasers Surg Med*. 2002;30:123–126.

Alikhan A, Lynch PJ, Eisen DB. Hidradenitis suppurativa: a comprehensive review. *J Am Acad Dermatol*. 2009;60:539–561 [quiz 562–533].

Alsahli M, Debu A, Girard C, et al. Is photodynamic therapy a relevant therapeutic option in refractory benign familial pemphigus (Hailey-Hailey disease)? A series of eight patients. *J Dermatolog Treat*. 2017;28:678–682.

Altunay IK, Gokdemir G, Kurt A, et al. Hidradenitis suppurativa and squamous cell carcinoma. *Dermatol Surg*. 2002;28:88–90.

Altwegg M, Geiss HK. Aeromonas as a human pathogen. *Crit Rev Microbiol*. 1989;16:253–286.

Amagai M, Koch PJ, Nishikawa T, et al. Pemphigus vulgaris antigen (desmoglein 3) is localized in the lower epidermis, the site of blister formation in patients. *J Invest Dermatol*. 1996;106:351–355.

Amagai M. Pemphigus. Mosby: Edinburgh; 2003:449–462. Bolognia JL, Jorizzo JL, Rapini RP. *Dermatology*. vol 1.

Amendola MA, Casillas J, Joseph R, et al. Fournier's gangrene: CT findings. *Abdom Imaging*. 1994;19:471–474.

Andersen ES, Sorensen IM. Verrucous carcinoma of the female genital tract: report of a case and review of the literature. *Gynecol Oncol*. 1988;30:427–434.

Andersson H, Mobacken H. Dietary treatment of dermatitis herpetiformis. *Eur J Clin Nutr*. 1992;46:309–315.

Aram H. Association of lichen planus and lichen nitidus. Treatment with etretinate. *Int J Dermatol*. 1988;27:117.

Arbesfeld SJ, Kurban AK. Behcet's disease. New perspectives on an enigmatic syndrome. *J Am Acad Dermatol*. 1988;19:767–779.

Arlette JP. Treatment of Bowen's disease and erythroplasia of Queyrat. *Br J Dermatol*. 2003;149(Suppl 66):43–49.

Arlian LG, Estes SA, Vyszenski-Moher DL. Prevalence of Sarcoptes scabiei in the homes and nursing homes of scabietic patients. *J Am Acad Dermatol*. 1988;19:806–811.

Asarch RG, Golitz LE, Sausker WF, et al. Median raphe cysts of the penis. *Arch Dermatol*. 1979;115:1084–1086.

Aversa SM, Cattelan AM, Salvagno L, et al. Chemo-immunotherapy of advanced AIDS-related Kaposi's sarcoma. *Tumori*. 1999;85:54–59.

Avery LL, Scheinfeld MH. Imaging of penile and scrotal emergencies. *Radiographics*. 2013;33:721–740.

Avram A, Buot G, Binet O, et al. Clinical and mycological study of 11 cases of genitopubic trichosporosis nodosa (white piedra). *Ann Dermatol Venereol*. 1987;114:819–827.

Aykutlu E, Baykan B, Serdaroglu P, et al. Epileptic seizures in Behcet disease. *Epilepsia*. 2002;43:832–835.

Bachot N, Roujeau JC. Differential diagnosis of severe cutaneous drug eruptions. *Am J Clin Dermatol*. 2003;4:561–572.

Badgwell C, Rosen T. Penile pyoderma gangrenosum. *Dermatol Online J*. 2006;12:8.

Baldwin HE, Geronemus RG. The treatment of Zoon's balanitis with the carbon dioxide laser. *J Dermatol Surg Oncol*. 1989;15:491–494.

Banik R, Lubach D. Skin tags: localization and frequencies according to sex and age. *Dermatologica*. 1987;174:180–183.

Bargman H. Trichomycosis of the scrotal hair. *Arch Dermatol*.

1984;120:299.

Bargman H. Pseudoepitheliomatous, keratotic, and micaceous balanitis. *Cutis*. 1985;35:77–79.

Bechara FG, Huesmann M, Stucker M, et al. An exceptional localization of angiokeratoma of fordyce on the glans penis. *Dermatology*. 2002;205:187–188.

Bechara FG, Jansen T, Wilmert M, et al. Angiokeratoma Fordyce of the glans penis: combined treatment with erbium: YAG and 532 nm KTP (frequency doubled neodynium: YAG) laser. *J Dermatol*. 2004;31:943–945.

Beljaards RC, van Dijk E, Hausman R. Is pseudoepitheliomatous, micaceous and keratotic balanitis synonymous with verrucous carcinoma? *Br J Dermatol*. 1987;117:641–646.

Benedet JL, Miller DM, Ehlen TG, et al. Basal cell carcinoma of the vulva: clinical features and treatment results in 28 patients. *Obstet Gynecol*. 1997;90:765–768.

Berndt U, Wigger-Alberti W, Gabard B, et al. Efficacy of a barrier cream and its vehicle as protective measures against occupational irritant contact dermatitis. *Contact Dermatitis*. 2000;42:77–80.

Bessa GR, Grazziotin TC, Manzoni AP, et al. Hailey-Hailey disease treatment with Botulinum toxin type A. *An Bras Dermatol*. 2010;85:717–722.

Bewley AP, Bracka A, Staughton RC, et al. Extramammary Paget's disease of the scrotum: treatment with topical 5-fluorouracil and plastic surgery. *Br J Dermatol*. 1994;131:445–446.

Bhate K, Landeck L, Gonzalez E, et al. Genital contact dermatitis: a retrospective analysis. *Dermatitis*. 2010;21:317–320.

Biggar RJ, Engels EA, Frisch M, et al. Risk of T-cell lymphomas in persons with AIDS. *J Acquir Immune Defic*

Syndr. 2001;26:371–376.

Bissada NK. Conservative extirpative treatment of cancer of the penis. *Urol Clin North Am*. 1992;19:283–290.

Bleeker MC, Heideman DA, Snijders PJ, et al. Penile cancer: epidemiology, pathogenesis and prevention. *World J Urol*. 2009;27:141–150.

Blume JE, Levine EG, Heymann WR. Bacterial diseases. Mosby: Edinburgh; 2003:1117–1144. Bolognia JL, Jorizzo JL, Rapini RP. *Dermatology*. vol 1.

Bocchini SF, Habr-Gama A, Kiss DR, et al. Gluteal and perianal hidradenitis suppurativa: surgical treatment by wide excision. *Dis Colon Rectum*. 2003;46:944–949.

Boix V, Sanchez-Paya J, Portilla J, et al. Nosocomial outbreak of scabies clinically resistant to lindane. *Infect Control Hosp Epidemiol*. 1997;18:677.

Bolognia JL, Schaffer JV, Cerroni L. *Dermatology*. Elsevier: Edinburgh; 2018.

Bos JD, Spuls PI. Topical treatments in psoriasis: today and tomorrow. *Clin Dermatol*. 2008;26:432–437.

Boshoff C, Weiss RA. Aetiology of Kaposi's sarcoma: current understanding and implications for therapy. *Mol Med Today*. 1997;3:488–494.

Bowen JT. Precancerous dermatoses: a study of two cases of chronic atypical epithelial proliferation. *J Cutan Dis Syph*. 1912;30:241–255.

Boyd AS, Neldner KH. Lichen planus. *J Am Acad Dermatol*. 1991;25:593–619.

Braathen LR, Szeimies RM, Basset-Seguin N, et al. Guidelines on the use of photodynamic therapy for nonmelanoma skin cancer: an international consensus. International Society for Photodynamic Therapy in Dermatology, 2005. *J Am Acad Dermatol*. 2007;56:125–143.

Brice SL, Huff JC, Weston WL. Erythema multiforme. *Curr*

Probl Dermatol. 1990;II:3–26.

Brook I, Finegold SM. Aerobic and anaerobic bacteriology of cutaneous abscesses in children. *Pediatrics*. 1981;67:891–895.

Brown RS, McCormack M, Lankester KJ, et al. Spontaneous apparent clinical resolution with histologic persistence of a case of extramammary Paget's disease: response to topical 5-fluorouracil. *Cutis*. 2000;66:454–455.

Buechner SA. Common skin disorders of the penis. *BJU Int*. 2002;90:498–506.

Burge SM. Hailey-Hailey disease: the clinical features, response to treatment and prognosis. *Br J Dermatol*. 1992;126:275–282.

Burkhart CG, Burkhart CN, Burkhart KM. An epidemiologic and therapeutic reassessment of scabies. *Cutis*. 2000;65:233–240.

Burkhart CN, Burkhart CG. Oral ivermectin therapy for phthiriasis palpebrum. *Arch Ophthalmol*. 2000;118:134–135.

Burry J. Topical drug addiction: adverse effects of fluorinated corticosteroid creams and ointments. *Med J Aust*. 1973;1:393.

Buyuk AY, Kavala M. Oral metronidazole treatment of lichen planus. *J Am Acad Dermatol*. 2000;43:260–262.

Cairns BA, Herbst CA, Sartor BR, et al. Peristomal pyoderma gangrenosum and inflammatory bowel disease. *Arch Surg*. 1994;129:769–772.

Calamia KT, Wilson FC, Icen M, et al. Epidemiology and clinical characteristics of Behcet's disease in the US: a population-based study. *Arthritis Rheum*. 2009;61:600–604.

Carlson BC, Hofer MD, Ballek N, et al. Protein markers of malignant potential in penile and vulvar lichen sclerosus. *J Urol*. 2013;190:399–406.

Cattelan AM, Trevenzoli M, Aversa SM. Recent advances in the treatment of AIDS-related Kaposi's sarcoma. *Am J Clin*

Dermatol. 2002;3:451–462.

Centeno JA, Mullick FG, Martinez L, et al. Pathology related to chronic arsenic exposure. *Environ Health Perspect*. 2002;110(Suppl 5):883–886.

Cetinel B, Obek C, Solok V, et al. Urologic screening for men with Behcet's syndrome. *Urology*. 1998;52:863–865.

Chan HL, Stern RS, Arndt KA, et al. The incidence of erythema multiforme, Stevens-Johnson syndrome, and toxic epidermal necrolysis. A population-based study with particular reference to reactions caused by drugs among outpatients. *Arch Dermatol*. 1990;126:43–47.

Chan KW, Lam KY, Chan AC, et al. Prevalence of human papillomavirus types 16 and 18 in penile carcinoma: a study of 41 cases using PCR. *J Clin Pathol*. 1994;47:823–826.

Chaudhari U, Romano P, Mulcahy LD, et al. Efficacy and safety of infliximab monotherapy for plaque-type psoriasis: a randomised trial. *Lancet*. 2001;357:1842–1847.

Cheng S, Kirtschig G, Cooper S, et al. Interventions for erosive lichen planus affecting mucosal sites. *Cochrane Database Syst Rev*. 2012;(2) [CD008092].

Chiba T, Shitomi T, Nakano O, et al. The sign of Leser-Trelat associated with esophageal carcinoma. *Am J Gastroenterol*. 1996;91:802–804.

Child FJ, Kim BK, Ganesan R, et al. Verrucous carcinoma arising in pseudoepitheliomatous keratotic and micaceous balanitis, without evidence of human papillomavirus. *Br J Dermatol*. 2000;143:183–187.

Choo KJ, Ng SK, Sim CS, et al. Pseudoepitheliomatous keratotic and micaceous balanitis treated with topical 5-fluorouracil and liquid nitrogen. *Clin Exp Dermatol*. 2017.

Chouela E, Abeldano A, Pellerano G, et al. Diagnosis and treatment of scabies: a practical guide. *Am J Clin Dermatol*. 2002;3:9–18.

Chow RK, Ho VC. Treatment of pyoderma gangrenosum. *J Am Acad Dermatol*. 1996;34:1047–1060.

Christian MM, Moy RL. Treatment of Hailey-Hailey disease (or benign familial pemphigus) using short pulsed and short dwell time carbon dioxide lasers. *Dermatol Surg*. 1999;25:661–663.

Christophers E. Psoriasis–epidemiology and clinical spectrum. *Clin Exp Dermatol*. 2001;26:314–320.

Chun YS, Chang SN, Park WH. A case of classical Kaposi's sarcoma of the penis showing a good response to high-energy pulsed carbon dioxide laser therapy. *J Dermatol*. 1999;26:240–243.

Cochran RJ, Rosen T, Landers T. Topical treatment for erythrasma. *Int J Dermatol*. 1981;20:562–564.

Cohen DE. Occupational dermatoses. Harris RL. *Patty's industrial hygiene*. 5th ed. John Wiley: New York; 2000:165–210.

Cohen DE, Bassiri-Tehrani S. Irritant contact dermatitis. Mosby: Edinburgh; 2003:241–250. Bolognia JL, Jorizzo JL, Rapini RP. *Dermatology*. vol 1.

Collini FJ, Spees EK, Munster A, et al. Ecthyma gangrenosum in a kidney transplant recipient with Pseudomonas septicemia. *Am J Med*. 1986;80:729–734.

Colloff MJ, Lever RS, McSharry C. A controlled trial of house dust mite eradication using natamycin in homes of patients with atopic dermatitis: effect on clinical status and mite populations. *Br J Dermatol*. 1989;121:199–208.

Cooper KD. New therapeutic approaches in atopic dermatitis. *Clin Rev Allergy*. 1993;11:543–559.

Cribier B, Frances C, Chosidow O. Treatment of lichen planus. An evidence-based medicine analysis of efficacy. *Arch Dermatol*. 1998;134:1521–1530.

Cullin SI. Cutaneous candidiasis: treatment with miconazole nitrate. *Cutis*. 1977;19:126–129.

Czymek R, Kujath P, Bruch HP, et al. Treatment, outcome and quality of life after Fournier's gangrene: a multicentre study. *Colorectal Dis*. 2013;15:1529–1536.

Czymek R, Schmidt A, Eckmann C, et al. Fournier's gangrene: vacuumassisted closure versus conventional dressings. *Am J Surg*. 2009;197:168–176.

Dahl MV. Dermatophytosis and the immune response. *J Am Acad Dermatol*. 1994;31:S34–S41.

Dahm P, Roland FH, Vaslef SN, et al. Outcome analysis in patients with primary necrotizing fasciitis of the male genitalia. *Urology*. 2000;56:31–35 [discussion 35–36].

Dalziel KL, Millard PR, Wojnarowska F. The treatment of vulval lichen sclerosus with a very potent topical steroid (clobetasol propionate 0.05%) cream. *Br J Dermatol*. 1991;124:461–464.

Dare AJ, Axelsen RA. Scrotal calcinosis: origin from dystrophic calcification of eccrine duct milia. *J Cutan Pathol*. 1988;15:142–149.

De Jong MC, Bruins S, Heeres K, et al. Bullous pemphigoid and epidermolysis bullosa acquisita. Differentiation by fluorescence overlay antigen mapping. *Arch Dermatol*. 1996;132:151–157.

De la Torre C, Ocampo C, Doval IG, et al. Acrochordons are not a component of the Birt-Hogg-Dube syndrome: does this syndrome exist? Case reports and review of the literature. *Am J Dermatopathol*. 1999;21:369–374.

Deen K, Burdon-Jones D. Imiquimod in the treatment of penile intraepithelial neoplasia: An update. *Australas J Dermatol*. 2017;58:86–92.

Delgado JC, Turbay D, Yunis EJ, et al. A common major histocompatibility complex class II allele HLA-DQB1* 0301 is present in clinical variants of pemphigoid. *Proc Natl Acad*

Sci USA. 1996;93:8569–8571.

Denby KS, Beck LA. Update on systemic therapies for atopic dermatitis. *Curr Opin Allergy Clin Immunol*. 2012;12:421–426.

Diederen PV, van Weelden H, Sanders CJ, et al. Narrowband UVB and psoralen-UVA in the treatment of early-stage mycosis fungoides: a retrospective study. *J Am Acad Dermatol*. 2003;48:215–219.

Draelos ZD. New treatments for restoring impaired epidermal barrier permeability: skin barrier repair creams. *Clin Dermatol*. 2012;30:345–348.

Edwards L, Lynch PJ. *Genital dermatology atlas and manual*. Wolters Kluwer: Philadelphia; 2018.

Ehsani AH, Toosi S, Mirshams Shahshahani M, et al. Psycho-cutaneous disorders: an epidemiologic study. *J Eur Acad Dermatol Venereol*. 2009;23:945–947.

Eisen RF, Bhawan J, Cahn TH. Spontaneous regression of bowenoid papulosis of the penis. *Cutis*. 1983;32:269–272.

Eke N. Fournier's gangrene: a review of 1726 cases. *Br J Surg*. 2000;87:718–728.

Elewski BE, Abramovits W, Kempers S, et al. A novel foam formulation of ketoconazole 2% for the treatment of seborrheic dermatitis on multiple body regions. *J Drugs Dermatol*. 2007;6:1001–1008.

Elgart ML. A risk-benefit assessment of agents used in the treatment of scabies. *Drug Saf*. 1996;14:386–393.

Ellinghaus D, Baurecht H, Esparza-Gordillo J, et al. High-density genotyping study identifies four new susceptibility loci for atopic dermatitis. *Nat Genet*. 2013;45:808–812.

Esquivias Gomez JI, Gonzalez-Lopez A, Velasco E, et al. Basal cell carcinoma of the scrotum. *Australas J Dermatol*. 1999;40:141–143.

Euvrard S, Kanitakis J, Pouteil-Noble C, et al. Comparative epidemiologic study of premalignant and malignant epithelial cutaneous lesions developing after kidney and heart transplantation. *J Am Acad Dermatol*. 1995;33:222–229.

Ewing CI, Ashcroft C, Gibbs AC, et al. Flucloxacillin in the treatment of atopic dermatitis. *Br J Dermatol*. 1998;138:1022–1029.

Faergemann J. Management of seborrheic dermatitis and pityriasis versicolor. *Am J Clin Dermatol*. 2000;1:75–80.

Farag A, Taha M, Halim S. One-week therapy with oral terbinafine in cases of tinea cruris/corporis. *Br J Dermatol*. 1994;131:684–686.

Farahnik B, Blattner CM, Mortazie MB, et al. Interventional treatments for Hailey-Hailey disease. *J Am Acad Dermatol*. 2017;76:551–558 [e553].

FDA. Nizoral (ketoconazole): Drug Safety Communication - Potentially Fatal Liver Injury, Risk of Drug Interactions and Adrenal Gland Problems. *Clin Infect Dis*. 2013;57(8):i.

Feldman SR. The biology and clinical application of systemic corticosteroids. Callan JP. *Current problems in dermatology*. Mosby Year Book: St. Louis; 1992:211–235.

Feldman SR, Lacy FA, Huang WW. The safety of treatments used in pyoderma gangrenosum. *Expert Opin Drug Saf*. 2018;17:55–61.

Feng J, Wu F, Liu F, et al. Spontaneous regression of bowenoid papulosis. *Dermatol Online J*. 2013;19:18185.

Ferrandiz C, Ribera M. Zoon's balanitis treated by circumcision. *J Dermatol Surg Oncol*. 1984;10:622–625.

Fisher B, Margesson L. *Genital skin disorders*. Mosby: St. Louis; 1998.

Freitas JP, Filipe P, Yousefi A, et al. Oxidative stress in Adamantiades-Behcet's disease. *Dermatology*. 1998;197:343–348.

Fritsch PO, Reider N. Other eczematous eruptions. Mosby:

Edinburgh; 2003:215–226. Bolognia JL, Jorizzo JL, Rapini RP. *Dermatology*. vol 1.

Frodin T, Gotthard R, Hed J, et al. Gluten-free diet for dermatitis herpetiformis: the long-term effect on cutaneous, immunological and jejunal manifestations. *Acta Derm Venereol*. 1981;61:405–411.

Froschl M, Land HG, Landthaler M. Seborrheic dermatitis and atopic eczema in human immunodeficiency virus infection. *Semin Dermatol*. 1990;9:230–232.

Fukunaga M, Yokoi K, Miyazawa Y, et al. Penile verrucous carcinoma with anaplastic transformation following radiotherapy. A case report with human papillomavirus typing and flow cytometric DNA studies. *Am J Surg Pathol*. 1994;18:501–505.

Funaro D, Lovett A, Leroux N, et al. A double-blind, randomized prospective study evaluating topical clobetasol propionate 0.05% versus topical tacrolimus 0.1% in patients with vulvar lichen sclerosus. *J Am Acad Dermatol*. 2014;71:84–91.

Gener G, Canoui-Poitrine F, Revuz JE, et al. Combination therapy with clindamycin and rifampicin for hidradenitis suppurativa: a series of 116 consecutive patients. *Dermatology*. 2009;219:148–154.

Gerber GS. Carcinoma in situ of the penis. *J Urol*. 1994;151:829–833.

Gerber W, Arheilger B, Ha TA, et al. Ultraviolet B 308-nm excimer laser treatment of psoriasis: a new phototherapeutic approach. *Br J Dermatol*. 2003;149:1250–1258.

Gharpuray MB, Tolat SN. Nonvenereal sclerosing lymphangitis of the penis. *Cutis*. 1991;47:421–422.

Giam YC, Ong BH. Bowenoid papulosis: a recent entity in sexually transmitted diseases. *Ann Acad Med Singapore*. 1986;15:15–19.

Gill PS, Tsai YC, Rao AP, et al. Evidence for multiclonality in multicentric Kaposi's sarcoma. *Proc Natl Acad Sci USA*. 1998;95:8257–8261.

Ginarte M, Sanchez-Aguilar D, Toribio J. Sign of Leser-Trelat associated with adenocarcinoma of the rectum. *Eur J Dermatol*. 2001;11:251–253.

Goldman BD. Common dermatoses of the male genitalia. Recognition of differences in genital rashes and lesions is essential and attainable. *Postgrad Med*. 2000;108:89–91 [95–96].

Goldman L, Kitzmiller KW. Perianal atrophoderma from topical corticosteroids. *Arch Dermatol*. 1973;107:611.

Goldstein AT, Creasey A, Pfau R, et al. A double-blind, randomized controlled trial of clobetasol versus pimecrolimus in patients with vulvar lichen sclerosus. *J Am Acad Dermatol*. 2011;64:e99–e104.

Goldust M, Rezaee E. Hemayat S: Treatment of scabies: comparison of permethrin 5% versus ivermectin. *J Dermatol*. 2012;39:545–547.

Gottlieb AB, Lebwohl M, Shirin S, et al. Anti-CD4 monoclonal antibody treatment of moderate to severe psoriasis vulgaris: results of a pilot, multicenter, multiple-dose, placebo-controlled study. *J Am Acad Dermatol*. 2000;43:595–604.

Gregory DW, Schaffner W. Pseudomonas infections associated with hot tubs and other environments. *Infect Dis Clin North Am*. 1987;1:635–648.

Gronau E, Pannek J. Urethral fistula caused by acne inversa (hidradenitis suppurativa): a case report. *Int Urol Nephrol*. 2002;34:377–378.

Gucluer H, Ergun T, Demircay Z. Ecthyma gangrenosum. *Int J Dermatol*. 1999;38:299–302.

Guerrieri M, Back MF. Extramammary Paget's disease: role of radiation therapy. *Australas Radiol*. 2002;46:204–208.

Gupta AK, Knowles SR, Gupta MA, et al. Lithium therapy associated with hidradenitis suppurativa: case report and a review of the dermatologic side effects of lithium. *J Am Acad Dermatol*. 1995;32:382–386.

Gupta AK, Bluhm R. Seborrheic dermatitis. *J Eur Acad Dermatol Venereol*. 2004;18:13–26 [quiz 19–20].

Gurdal M, Yucebas E, Tekin A, et al. Predisposing factors and treatment outcome in Fournier's gangrene. Analysis of 28 cases. *Urol Int*. 2003;70:286–290.

Gutgesell C, Heise S, Seubert S, et al. Double-blind placebo-controlled house dust mite control measures in adult patients with atopic dermatitis. *Br J Dermatol*. 2001;145:70–74.

Habif TP. *Clinical dermatology: a color guide to diagnosis and therapy*. Mosby: Edinburgh; 2004.

Halprin KM. Diagnosis with Wood's light. Tinea capitis and erythrasma. *J Am Med Assoc*. 1967;199:841.

Hamm H, Metze D, Brocker EB. Hailey-Hailey disease. Eradication by dermabrasion. *Arch Dermatol*. 1994;130:1143–1149.

Hatano Y, Katagiri K, Arakawa S, et al. Successful treatment by double-filtration plasmapheresis of a patient with bullous pemphigoid: effects in vivo on transcripts of several genes for chemokines and cytokines in peripheral blood mononuclear cells. *Br J Dermatol*. 2003;148:573–579.

Hatemi G, Yazici Y, Yazici H. Behcet's syndrome. *Rheum Dis Clin North Am*. 2013;39:245–261.

Hayes MC, Meehan CJ, Ratan P, et al. Extramammary Paget's disease of the penis is associated with long-standing transitional cell carcinoma and radiotherapy. *Br J Urol*. 1997;80:673–674.

Heaphy MR Jr, Millns JL, Schroeter AL. The sign of Leser-Trelat in a case of adenocarcinoma of the lung. *J Am Acad Dermatol*. 2000;43:386–390.

Hegarty PK, Suh J, Fisher MB, et al. Penoscrotal extramammary Paget's disease: the University of Texas M. D. Anderson Cancer Center contemporary experience. *J Urol*. 2011;186:97–102.

Heimall J, Spergel JM. Filaggrin mutations and atopy: consequences for future therapeutics. *Expert Rev Clin Immunol*. 2012;8:189–197.

Hemminki K, Dong C. Subsequent cancers after in situ and invasive squamous cell carcinoma of the skin. *Arch Dermatol*. 2000;136:647–651.

Hengge UR, Krause W, Hofmann H, et al. Multicentre, phase II trial on the safety and efficacy of topical tacrolimus ointment for the treatment of lichen sclerosus. *Br J Dermatol*. 2006;155:1021–1028.

Hensler T, Christophers E. Psoriasis of early and late onset: Characterization of two types of psoriasis vulgaris. *J Am Acad Dermatol*. 1985;13:450.

Heukelbach J, Winter B, Wilcke T, et al. Selective mass treatment with ivermectin to control intestinal helminthiases and parasitic skin diseases in a severely affected population. *Bull World Health Organ*. 2004;82:563–571.

Heyns CF, Fisher M. The urological management of the patient with acquired immunodeficiency syndrome. *BJU Int*. 2005;95:709–716.

Ho VC, Gupta AK, Ellis CN, et al. Treatment of severe lichen planus with cyclosporine. *J Am Acad Dermatol*. 1990;22:64–68.

Hoekx L, Wyndaele JJ. Angiokeratoma: a cause of scrotal bleeding. *Acta Urol Belg*. 1998;66:27–28.

Hogewoning CJ, Bleeker MC, van den Brule AJ, et al. Pearly penile papules: still no reason for uneasiness. *J Am Acad Dermatol*. 2003;49:50–54.

Hohl D, Mauro T, Gorog JP. Darier's disease and Hailey-Hailey disease. Mosby: Edinburgh; 2003:823–833. Bolognia JL, Jorizzo JL, Rapini RP. *Dermatology*. vol 1.

Holdiness MR. Management of cutaneous erythrasma. *Drugs*. 2002;62:1131–1141.

Honigsmann H. Phototherapy for psoriasis. *Clin Exp Dermatol*. 2001;26:343–350.

Honigsmann H, Schwarz T. Ultraviolet light therapy. Mosby: Edinburgh; 2003:2109–2126. Bolognia JL, Jorizzo JL, Rapini RP. *Dermatology*. vol 2.

Hoppe RT, Wood GS, Abel EA. Mycosis fungoides and the Sezary syndrome: pathology, staging, and treatment. *Curr Probl Cancer*. 1990;14:293–371.

Huff JC. Therapy and prevention of erythema multiforme with acyclovir. *Semin Dermatol*. 1988;7:212–217.

Huff JC, Weston WL. Recurrent erythema multiforme. *Medicine (Baltimore)*. 1989;68:133–140.

International Team for the Revision of the International Criteria for Behcet's Disease. The International Criteria for Behcet's Disease (ICBD): a collaborative study of 27 countries on the sensitivity and specificity of the new criteria. *J Eur Acad Dermatol Venereol*. 2014;28:338–347.

Izadpanah A, Izadpanah A, Kanevsky J, et al. Propranolol versus corticosteroids in the treatment of infantile hemangioma: a systematic review and meta-analysis. *Plast Reconstr Surg*. 2013;131:601–613.

Jallali N, Withey S, Butler PE. Hyperbaric oxygen as adjuvant therapy in the management of necrotizing fasciitis. *Am J Surg*. 2005;189:462–466.

Jansen I, Altmeyer P, Piewig G. Acne inversa (alias hidradenitis suppurativa). *J Eur Acad Dermatol Venereol*. 2001;15:532–540.

Jemec GB, Wendelboe P. Topical clindamycin versus systemic tetracycline in the treatment of hidradenitis suppurativa. *J Am*

Acad Dermatol. 1998;39:971–974.

Jenkins D Jr, Jakubovic HR. Pseudoepitheliomatous, keratotic, micaceous balanitis. A clinical lesion with two histologic subsets: hyperplastic dystrophy and verrucous carcinoma. *J Am Acad Dermatol*. 1988;18:419–422.

Jernberg C, Lofmark S, Edlund C, et al. Long-term impacts of antibiotic exposure on the human intestinal microbiota. *Microbiology*. 2010;156:3216–3223.

Joly P, Richard C, Gilbert D, et al. Sensitivity and specificity of clinical, histologic, and immunologic features in the diagnosis of paraneoplastic pemphigus. *J Am Acad Dermatol*. 2000;43:619–626.

Joly P, Roujeau JC, Benichou J, et al. A comparison of oral and topical corticosteroids in patients with bullous pemphigoid. *N Engl J Med*. 2002;346:321–327.

Joly P, Roujeau JC, Benichou J, et al. A comparison of two regimens of topical corticosteroids in the treatment of patients with bullous pemphigoid: a multicenter randomized study. *J Invest Dermatol*. 2009;129:1681–1687.

Kaklamani VG, Kaklamanis PG. Treatment of Behcet's disease–an update. *Semin Arthritis Rheum*. 2001;30:299–312.

Kalb RE, Bagel J, Korman NJ, et al. Treatment of intertriginous psoriasis: from the Medical Board of the National Psoriasis Foundation. *J Am Acad Dermatol*. 2009;60:120–124.

Kalter DC, Sperber J, Rosen T, et al. Treatment of pediculosis pubis. Clinical comparison of efficacy and tolerance of 1% lindane shampoo vs 1% permethrin creme rinse. *Arch Dermatol*. 1987;123:1315–1319.

Kamino H, Pui J. Fibrous and fibrohistiocytic proliferations of skin and tendons. Mosby: Edinburgh; 2003:1863–1881. Bolognia JL, Jorizzo JL, Rapini RP. *Dermatology*. vol 2.

Kang K, Polster AM, Nedorost ST, et al. Atopic dermatitis. Mosby: Edinburgh; 2003:199–214. Bolognia JL, Jorizzo JL, Rapini RP. *Dermatology*. vol 1.

Kantarci M, Alper F, Aliagaoglu C, et al. Neurofibromatosis of the labium majus and clitoris: an unusual image reminiscent of ambiguous genitalia. *Acta Obstet Gynecol Scand*. 2005;84:96–98.

Karpati S. Dermatitis herpetiformis: close to unravelling a disease. *J Dermatol Sci*. 2004;34:83–90.

Karthikeyan K. Treatment of scabies: newer perspectives. *Postgrad Med J*. 2005;81:7–11.

Kauppinen K, Stubb S. Fixed eruptions: causative drugs and challenge tests. *Br J Dermatol*. 1985;112:575–578.

Kelly P. Folliculitis and the follicular occlusion tetrad. Mosby: Edinburgh; 2003:553–566. Bolognia JL, Jorizzo JL, Rapini RP. *Dermatology*. vol 1.

Khoo LS, Cheong WK. Common genital dermatoses in male patients attending a public sexually transmitted disease clinic in Singapore. *Ann Acad Med Singapore*. 1995;24:505–509.

Kinoshita R, Yamamoto O, Yasuda H, et al. Basal cell carcinoma of the scrotum with lymph node metastasis: report of a case and review of the literature. *Int J Dermatol*. 2005;44:54–56.

Kirova YM, Belembaogo E, Frikha H, et al. Radiotherapy in the management of epidemic Kaposi's sarcoma: a retrospective study of 643 cases. *Radiother Oncol*. 1998;46:19–22.

Kirtschig G, Khumalo NP. Management of bullous pemphigoid: recommendations for immunomodulatory treatments. *Am J Clin Dermatol*. 2004;5:319–326.

Kiss A, Csontai A, Pirot L, et al. The response of balanitis xerotica obliterans to local steroid application compared with placebo in children. *J Urol*. 2001;165:219–220.

Kitajima Y, Hirako Y, Owaribe K, et al. A possible cell-biologic mechanism involved in blister formation of bullous pemphigoid: anti-180-kD BPA antibody is an initiator.

Dermatology. 1994;189 Suppl 1:46–49.

Koblenzer CS. Dermatitis artefacta. Clinical features and approaches to treatment. *Am J Clin Dermatol*. 2000;1:47–55.

Koc Y, Gullu I, Akpek G, et al. Vascular involvement in Behcet's disease. *J Rheumatol*. 1992;19:402–410.

Kohorst JJ, Kimball AB, Davis MD. Systemic associations of hidradenitis suppurativa. *J Am Acad Dermatol*. 2015;73:S27–S35.

Kose O, Dinc A, Simsek I. Randomized trial of pimecrolimus cream plus colchicine tablets versus colchicine tablets in the treatment of genital ulcers in Behcet's disease. *Dermatology*. 2009;218:140–145.

Krause I, Leibovici L, Guedj D, et al. Disease patterns of patients with Behcet's disease demonstrated by factor analysis. *Clin Exp Rheumatol*. 1999;17:347–350.

Krueger G, Koo J, Lebwohl M, et al. The impact of psoriasis on quality of life: results of a 1998 National Psoriasis Foundation patient-membership survey. *Arch Dermatol*. 2001;137:280–284.

Krunic AL, Djerdj K, Starcevic-Bozovic A, et al. Pseudoepitheliomatous, keratotic and micaceous balanitis. Case report and review of the literature. *Urol Int*. 1996;56:125–128.

Kubota Y, Imayama S, Hori Y. Reduction of environmental mites improved atopic dermatitis patients with positive mite-patch tests. *J Dermatol*. 1992;19:177–180.

Lally A, Hollowood K, Bunker CB, et al. Penile pyoderma gangrenosum treated with topical tacrolimus. *Arch Dermatol*. 2005;141:1175–1176.

Lane JE, Peterson CM, Ratz JL. Treatment of pearly penile papules with CO_2 laser. *Dermatol Surg*. 2002;28:617–618.

Lapins J, Marcusson JA, Emtestam L. Surgical treatment of chronic hidradenitis suppurativa: CO2 laser stripping-secondary intention technique. *Br J Dermatol*. 1994;131:551–556.

Lapins NA, Willoughby C, Helwig EB. Lichen nitidus. A study of forty-three cases. *Cutis*. 1978;21:634–637.

Ledwig PA, Weigand DA. Late circumcision and lichen sclerosus et atrophicus of the penis. *J Am Acad Dermatol*. 1989;20:211–214.

Lee JB, Fumimori T, Kurose K, et al. A case of bullous pemphigoid successfully treated by plasmapheresis: assessment of the change in titers of circulating antibodies by immunoblotting and enzyme-linked immunosorbent assay. *J Dermatol*. 2003;30:326–331.

Lee KY, Roh MR, Chung WG, et al. Comparison of Mohs micrographic surgery and wide excision for extramammary Paget's Disease: Korean experience. *Dermatol Surg*. 2009;35:34–40.

Leibovitch I, Huilgol SC, Selva D, et al. Cutaneous squamous carcinoma in situ (Bowen's disease): treatment with Mohs micrographic surgery. *J Am Acad Dermatol*. 2005;52:997–1002.

Lemak MA, Duvic M, Bean SF. Oral acyclovir for the prevention of herpes-associated erythema multiforme. *J Am Acad Dermatol*. 1986;15:50–54.

Leshem YA, Hodak E, David M, et al. Successful treatment of pemphigus with biweekly 1-g infusions of rituximab: a retrospective study of 47 patients. *J Am Acad Dermatol*. 2013;68:404–411.

Lesher JL Jr. Oral therapy of common superficial fungal infections of the skin. *J Am Acad Dermatol*. 1999;40:S31–S34.

Lesher JL Jr, McConnell W. Antimicrobial drugs. Mosby: Edinburgh; 2003:2007–2031. Bolognia JL, Jorizzo JL, Rapini RP. *Dermatology*. vol 2.

Lester RS. Corticosteroids. *Clin Dermatol*. 1989;7:80–97.

Leung DY, Hanifin JM, Pariser DM, et al. Effects of pimecrolimus cream 1% in the treatment of patients with atopic dermatitis who demonstrate a clinical insensitivity to topical corticosteroids: a randomized, multicentre vehicle-controlled trial. *Br J Dermatol*. 2009;161:435–443.

Lewis A, Nigro M, Rosen T. Treatment of keratoderma blennorrhagicum with tazarotene gel 0.1. *J Am Acad Dermatol*. 2000;43:400–402.

Lewis RT. Soft tissue infections. *World J Surg*. 1998;22:146–151.

Lin MS, Mascaro JM Jr, Liu Z, et al. The desmosome and hemidesmosome in cutaneous autoimmunity. *Clin Exp Immunol*. 1997;107(Suppl 1):9–15.

Lowe FC, Lattimer DG, Metroka CE. Kaposi's sarcoma of the penis in patients with acquired immunodeficiency syndrome. *J Urol*. 1989;142:1475–1477.

Luger T, Paul C. Potential new indications of topical calcineurin inhibitors. *Dermatology*. 2007;215(Suppl 1):45–54.

Lutz JK, Lee J. Prevalence and antimicrobial-resistance of Pseudomonas aeruginosa in swimming pools and hot tubs. *Int J Environ Res Public Health*. 2011;8:554–564.

Madan V, Griffiths CE. Systemic ciclosporin and tacrolimus in dermatology. *Dermatol Ther*. 2007;20:239–250.

Madan V, Hindle E, Hussain W, et al. Outcomes of treatment of nine cases of recalcitrant severe hidradenitis suppurativa with carbon dioxide laser. *Br J Dermatol*. 2008;159:1309–1314.

Magin P, Heading G, Adams J, et al. Sex and the skin: a qualitative study of patients with acne, psoriasis and atopic eczema. *Psychol Health Med*. 2010;15:454–462.

Mallon E, Hawkins D, Dinneen M, et al. Circumcision and genital dermatoses. *Arch Dermatol*. 2000;136:350–354.

Manian FA, Alford RH. Nosocomial infectious balanoposthitis in neutropenic patients. *South Med J*. 1987;80:909–911.

Margolis DJ. Cutaneous diseases of the male external genitalia. Saunders: Philadelphia; 2002:715–727. Walsh PC. *Campbell's urology*. vol 1.

Margolis DJ, Wein AJ. Color atlas of genital dermatology. Saunders: Philadelphia; 2002:731–742. Walsh PC. *Campbell's urology*. vol 1.

Marks JGJ, Elsner P, DeLeo VA. Allergy and ICD. *Contact and occupational dermatology*. 3rd ed. Mosby: Philadelphia; 2002:3–15.

Martel P, Joly P. Pemphigus: autoimmune diseases of keratinocyte's adhesion molecules. *Clin Dermatol*. 2001;19:662–674.

Martino P, Gastaldi R, Raccah R, et al. Clinical patterns of Fusarium infections in immunocompromised patients. *J Infect*. 1994;28(Suppl 1):7–15.

Meagher LJ, Wines NY, Cooper AJ. Atopic dermatitis: review of immunopathogenesis and advances in immunosuppressive therapy. *Australas J Dermatol*. 2002;43:247–254.

Meeuwis KA, de Hullu JA, van de Nieuwenhof HP, et al. Quality of life and sexual health in patients with genital psoriasis. *Br J Dermatol*. 2011;164:1247–1255.

Meinking TL. Infestations. *Curr Probl Dermatol*. 1999;11:73–120.

Meinking TL, Burkhart CN, Burkhart CG. Infestations. Mosby: Edinburgh; 2003:1321–1332. Bolognia JL, Jorizzo JL, Rapini RP. *Dermatology*. vol 1.

Melski JW, Stern RS. The separation of susceptibility to psoriasis from age at onset. *J Invest Dermatol*. 1981;77:474–477.

Mendes D, Correia M, Barbedo M, et al. Behcet's disease–a contemporary review. *J Autoimmun*. 2009;32:178–188.

Mert I, Semaan A, Winer I, et al. Vulvar/vaginal melanoma: an updated surveillance epidemiology and end results database review, comparison with cutaneous melanoma and significance of racial disparities. *Int J Gynecol Cancer*. 2013;23:1118–1125.

Micali G, Nasca MR, Tedeschi A. Topical treatment of intraepithelial penile carcinoma with imiquimod. *Clin Exp Dermatol*. 2003;28(Suppl 1):4–6.

Michl UH, Gross AJ, Loy V, et al. Idiopathic calcinosis of the scrotum–a specific entity of the scrotal skin. Case report. *Scand J Urol Nephrol*. 1994;28:213–217.

Mignogna MD, Lo Muzio L, Lo Russo L, et al. Oral lichen planus: different clinical features in HCV-positive and HCV-negative patients. *Int J Dermatol*. 2000;39:134–139.

Miles SA. Pathogenesis of HIV-related Kaposi's sarcoma. *Curr Opin Oncol*. 1994;6:497–502.

Miller C, James WD. Angiokeratoma of Fordyce as a cause of red scrotum. *Cutis*. 2002;69:50–51.

Miller SJ, Moresi JM. Actinic keratosis, basal cell carcinoma and squamous cell carcinoma. Mosby: Edinburgh; 2003:1677–1696. Bolognia JL, Jorizzo JL, Rapini RP. *Dermatology*. vol 2.

Mishra VC, Kumar R, Cooksey G. Intrascrotal neurofibroma. *Scand J Urol Nephrol*. 2002;36:385–386.

Mockenhaupt M. The current understanding of Stevens-Johnson syndrome and toxic epidermal necrolysis. *Expert Rev Clin Immunol*. 2011;7:803–813 [quiz 814–815].

Moreno-Arias GA, Conill C, Sola-Casas MA, et al. Radiotherapy for in situ extramammary Paget disease of the vulva. *J Dermatolog Treat*. 2003;14:119–123.

Morhenn VB. The etiology of lichen planus. A hypothesis. *Am J Dermatopathol*. 1986;8:154–156.

Morison WL. Phototherapy and photochemotherapy. *Adv Dermatol*. 1992;7:255–270 [discussion 271].

Morpurgo E, Galandiuk S. Fournier's gangrene. *Surg Clin North Am*. 2002;82:1213–1224.

Moschella SL. Neutrophilic dermatoses. Mosby: Edinburgh; 2003:411–423. Bolognia JL, Jorizzo JL, Rapini RP. *Dermatology*. vol 1.

Moss TR, Stevenson CJ. Incidence of male genital vitiligo. Report of a screening programme. *Br J Vener Dis*. 1981;57:145–146.

Mowad CM, Marks JGJ. Allergic contact dermatitis. Mosby: Edinburgh; 2003:227–240. Bolognia JL, Jorizzo JL, Rapini RP. *Dermatology*. vol 1.

Mutasim DF, Adams BB. The psychiatric profile of patients with psychogenic excoriation. *J Am Acad Dermatol*. 2009;61:611–613.

Myles AB. Single daily dose corticosteroid treatment. *Ann Rheum Dis*. 1971;30:149–153.

Nadgir R, Rubesin SE, Levine MS. Perirectal sinus tracks and fistulas caused by hidradenitis suppurativa. *AJR Am J Roentgenol*. 2001;177:476–477.

Nahass GT, Blauvelt A, Leonardi CL, et al. Basal cell carcinoma of the scrotum. Report of three cases and review of the literature. *J Am Acad Dermatol*. 1992;26:574–578.

Najim RA, Sharquie KE, Abu-Raghif AR. Oxidative stress in patients with Behcet's disease: I correlation with severity and clinical parameters. *J Dermatol*. 2007;34:308–314.

Nasca MR, Innocenzi D, Micali G. Penile cancer among patients with genital lichen sclerosus. *J Am Acad Dermatol*. 1999;41:911–914.

Nenoff P, Reinl P, Haustein UF. The yeast fungus Malassezia: pathogen, pathogenesis and therapy. *Hautarzt*. 2001;52:73–86.

Nesbitt LTJ. Glucocorticosteroids. Mosby: Edinburgh; 2003:1979–1989. Bolognia JL, Jorizzo JL, Rapini RP.

Dermatology. vol 2.

Nestle FO, Kerl H. Melanoma. Mosby: Edinburgh; 2003:1789–1815. Bolognia JL, Jorizzo JL, Rapini RP. *Dermatology*. vol 2.

Nestle FO, Kaplan DH, Barker J. Psoriasis. *N Engl J Med*. 2009;361:496–509.

Ng LG, Yip SK, Tan PH. Extramammary Paget's disease of scrotum. *Urology*. 2001;58:105.

Nghiem P, Pearson G, Langley RG. Tacrolimus and pimecrolimus: from clever prokaryotes to inhibiting calcineurin and treating atopic dermatitis. *J Am Acad Dermatol*. 2002;46:228–241.

Nikkels AF, Pierard GE. Treatment of mucocutaneous presentations of herpes simplex virus infections. *Am J Clin Dermatol*. 2002;3:475–487.

North PE, Hull C, Kincannon J. Vascular neoplasms and neoplastic-like proliferations. Mosby: Edinburgh; 2003:1817–1841. Bolognia JL, Jorizzo JL, Rapini RP. *Dermatology*. vol 2.

Ocampo-Candiani J, Cueva-Rodriguez JA. Cryosurgical treatment of pearly penile papules. *J Am Acad Dermatol*. 1996;35:486–487.

Occella C, Bleidl D, Rampini P, et al. Argon laser treatment of cutaneous multiple angiokeratomas. *Dermatol Surg*. 1995;21:170–172.

Ogawa T, Katsuoka K, Kawano K, et al. Comparative study of staphylococcal flora on the skin surface of atopic dermatitis patients and healthy subjects. *J Dermatol*. 1994;21:453–460.

Oliva E, Quinn TR, Amin MB, et al. Primary malignant melanoma of the urethra: a clinicopathologic analysis of 15 cases. *Am J Surg Pathol*. 2000;24:785–796.

Olsen EA, Bunn PA. Interferon in the treatment of cutaneous T-cell lymphoma. *Hematol Oncol Clin North Am*. 1995;9:1089–

1107.

Opaneye AA, Jayaweera DT, Walzman M, et al. Pediculosis pubis: a surrogate marker for sexually transmitted diseases. *J R Soc Health*. 1993;113:6–7.

Orengo I, Rosen T, Guill CK. Treatment of squamous cell carcinoma in situ of the penis with 5% imiquimod cream: a case report. *J Am Acad Dermatol*. 2002;47:S225–S228.

Ortonne J-P. Vitiligo and other disorders of hypopigmentation. Mosby: Edinburgh; 2003:947–973. Bolognia JL, Jorizzo JL, Rapini RP. *Dermatology*. vol 1.

Ozdemir M, Baysal I, Engin B, et al. Treatment of angiokeratoma of Fordyce with long-pulse neodymium-doped yttrium aluminium garnet laser. *Dermatol Surg*. 2009;35:92–97.

Paradisi A, Abeni D, Bergamo F, et al. Etanercept therapy for toxic epidermal necrolysis. *J Am Acad Dermatol*. 2014;71:278–283.

Park S, Grossfeld GD, McAninch JW, et al. Extramammary Paget's disease of the penis and scrotum: excision, reconstruction and evaluation of occult malignancy. *J Urol*. 2001;166:2112–2116 [discussion 2117].

Parrillo SJ. Stevens-Johnson syndrome and toxic epidermal necrolysis. *Curr Allergy Asthma Rep*. 2007;7:243–247.

Pastar Z, Rados J, Lipozencic J, et al. Zoon plasma cell balanitis: an overview and role of histopathology. *Acta Dermatovenerol Croat*. 2004;12:268–273.

Payne WG, Wells KE. Extramammary Paget's disease of the scrotum. *Ann Plast Surg*. 1994;33:669–671.

Pechere M, Krischer J, Remondat C, et al. Malassezia spp carriage in patients with seborrheic dermatitis. *J Dermatol*. 1999;26:558–561.

Perna AG, Bell K, Rosen T. Localised genital Norwegian scabies in an AIDS patient. *Sex Transm Infect*. 2004;80:72–

73.

Pielop J, Rosen T. Penile dermatophytosis. *J Am Acad Dermatol*. 2001;44:864–867.

Pierson D, Bandel C, Ehrig T, et al. Benign epithelial tumors and proliferations. Mosby: Edinburgh; 2003:1697–1720. Bolognia JL, Jorizzo JL, Rapini RP. *Dermatology*. vol 2.

Pierzchalski JL, Bretl DA, Matson SC. Phthirus pubis as a predictor for chlamydia infections in adolescents. *Sex Transm Dis*. 2002;29:331–334.

Piette AM, Meduri B, Fritsch J, et al. Do skin tags constitute a marker for colonic polyps? A prospective study of 100 asymptomatic patients and metaanalysis of the literature. *Gastroenterology*. 1988;95:1127–1129.

Powell J, Robson A, Cranston D, et al. High incidence of lichen sclerosus in patients with squamous cell carcinoma of the penis. *Br J Dermatol*. 2001;145:85–89.

Powell JJ, Wojnarowska F. Lichen sclerosus. *Lancet*. 1999;353:1777–1783.

Przybilla B, Eberlein-Konig B, Rueff F. Practical management of atopic eczema. *Lancet*. 1994;343:1342–1346.

Purvis RS, Tyring SK. An outbreak of lindane-resistant scabies treated successfully with permethrin 5% cream. *J Am Acad Dermatol*. 1991;25:1015–1016.

Qian Z, Zeitoun NC, Shieh S, et al. Successful treatment of extramammary Paget's disease with imiquimod. *J Drugs Dermatol*. 2003;2:73–76.

Querfeld C, Rosen ST, Kuzel TM, et al. Long-term follow-up of patients with early-stage cutaneous T-cell lymphoma who achieved complete remission with psoralen plus UV-A monotherapy. *Arch Dermatol*. 2005;141:305–311.

Rabkin CS, Janz S, Lash A, et al. Monoclonal origin of multicentric Kaposi's sarcoma lesions. *N Engl J Med*. 1997;336:988–993.

Rahman MU, Cheema MA, Schumacher HR, et al. Molecular evidence for the presence of chlamydia in the synovium of patients with Reiter's syndrome. *Arthritis Rheum*. 1992;35:521–529.

Rajka G. *Essential aspects of atopic dermatitis*. Springer-Verlag: Berlin; 1989.

Rallis E, Korfitis C, Gregoriou S, et al. Assigning new roles to topical tacrolimus. *Expert Opin Investig Drugs*. 2007;16:1267–1276.

Rasmussen JE. Erythema multiforme in children. Response to treatment with systemic corticosteroids. *Br J Dermatol*. 1976;95:181–186.

Read SI, Abell E. Pseudoepitheliomatous, keratotic, and micaceous balanitis. *Arch Dermatol*. 1981;117:435–437.

Rehbein HM. Pearly penile papules: incidence. *Cutis*. 1977;19:54–57.

Reich HL, Williams Fadeyi D, Naik NS, et al. Nonpseudomonal ecthyma gangrenosum. *J Am Acad Dermatol*. 2004;50:S114–S117.

Reizner GT, Chuang TY, Elpern DJ, et al. Bowen's disease (squamous cell carcinoma in situ) in Kauai, Hawaii. A population-based incidence report. *J Am Acad Dermatol*. 1994;31:596–600.

Remmers EF, Cosan F, Kirino Y, et al. Genome-wide association study identifies variants in the MHC class I, IL10, and IL23R-IL12RB2 regions associated with Behcet's disease. *Nat Genet*. 2010;42:698–702.

Retamar RA, Kien MC, Chouela EN. Zoon's balanitis: presentation of 15 patients, five treated with a carbon dioxide laser. *Int J Dermatol*. 2003;42:305–307.

Reunala T. Dermatitis herpetiformis: coeliac disease of the skin. *Ann Med*. 1998;30:416–418.

Ringrose JH. HLA-B27 associated spondyloarthropathy, an autoimmune disease based on crossreactivity between bacteria and HLA-B27? *Ann Rheum Dis*. 1999;58:598–610.

Riva G, Luppi M, Barozzi P, et al. How I treat HHV8/KSHV-related diseases in posttransplant patients. *Blood*. 2012;120:4150–4159.

Roberts JW, Devine CJ Jr. Urethral hemangioma: treatment by total excision and grafting. *J Urol*. 1983;129:1053–1054.

Rogers MF, Thomas PA, Starcher ET, et al. Acquired immunodeficiency syndrome in children: report of the Centers for Disease Control National Surveillance, 1982 to 1985. *Pediatrics*. 1987;79:1008–1014.

Rolston KV, Bodey GP. Pseudomonas aeruginosa infection in cancer patients. *Cancer Invest*. 1992;10:43–59.

Rompel R, Petres J. Long-term results of wide surgical excision in 106 patients with hidradenitis suppurativa. *Dermatol Surg*. 2000;26:638–643.

Rosemberg SK, Herman G. Elfont E: Sexually transmitted papilloma viral infection in the male. VII. Is cancer of penis sexually transmitted? *Urology*. 1991;37:437–440.

Rosen T, Conrad N. Genital ulcer caused by human bite to the penis. *Sex Transm Dis*. 1999;26:527–530.

Rosen T, Hoffman J, Jones A. Penile Kaposi's sarcoma. *J Eur Acad Dermatol Venereol*. 1999;13:71–73.

Rosen T, Hwong H. Sclerosing lymphangitis of the penis. *J Am Acad Dermatol*. 2003;49:916–918.

Rosen T. Penile ulcer from traumatic orogenital contact. *Dermatol Online J*. 2005;11:18.

Rosen T. Limited extent AIDS-related cutaneous Kaposi's sarcoma responsive to imiquimod 5% cream. *Int J Dermatol*. 2006;45:854–856.

Rosenzweig LB, Brett AS, Lefaivre JF, et al. Hidradenitis suppurativa complicated by squamous cell carcinoma and paraneoplastic neuropathy. *Am J Med Sci*. 2005;329:150–152.

Ruetter A, Luger TA. Efficacy and safety of intravenous immunoglobulin for immune-mediated skin disease: current view. *Am J Clin Dermatol*. 2004;5:153–160.

Ruocco E, Wolf R, Ruocco V, et al. Pemphigus: associations and management guidelines: facts and controversies. *Clin Dermatol*. 2013;31:382–390.

Rzany B, Weller N. Epidemiology of autoimmune skin disorders. Hertl M. *Autoimmune diseases of the skin*. Springer Verlag: New York; 2001:21–38.

Safai B. Pathophysiology and epidemiology of epidemic Kaposi's sarcoma. *Semin Oncol*. 1987;14:7–12.

Sakane T. New perspective on Behcet's disease. *Int Rev Immunol*. 1997;14:89–96.

Salamanca J, Benito A, Garcia-Penalver C, et al. Paget's disease of the glans penis secondary to transitional cell carcinoma of the bladder: a report of two cases and review of the literature. *J Cutan Pathol*. 2004;31:341–345.

Salek MS, Finlay AY, Luscombe DK, et al. Cyclosporin greatly improves the quality of life of adults with severe atopic dermatitis. A randomized, double-blind, placebo-controlled trial. *Br J Dermatol*. 1993;129:422–430.

Sanchez-Ortiz R, Huang SF, Tamboli P, et al. Melanoma of the penis, scrotum and male urethra: a 40-year single institution experience. *J Urol*. 2005;173:1958–1965.

Santegoets LA, Helmerhorst TJ, van der Meijden WI. A retrospective study of 95 women with a clinical diagnosis of genital lichen planus. *J Low Genit Tract Dis*. 2010;14:323–328.

Scheinfeld N. Update on the treatment of genital warts. *Dermatol Online J*. 2013;19:18559.

Scheinfeld N. Hidradenitis suppurativa: a practical review of possible medical treatments based on over 350 hidradenitis patients. *Dermatol Online J*. 2013;19:1.

Scheinfeld NS. Obesity and dermatology. *Clin Dermatol*. 2004;22:303–309.

Schofield JK, Tatnall FM, Leigh IM. Recurrent erythema multiforme: clinical features and treatment in a large series of patients. *Br J Dermatol*. 1993;128:542–545.

Schwartz RA, Janniger CK. Bowenoid papulosis. *J Am Acad Dermatol*. 1991;24:261–264.

Schwartz RA. Verrucous carcinoma of the skin and mucosa. *J Am Acad Dermatol*. 1995;32:1–21 [quiz 22–24].

Schwartz RA. Kaposi's sarcoma: an update. *J Surg Oncol*. 2004;87:146–151.

Scully C, Beyli M, Ferreiro MC, et al. Update on oral lichen planus: etiopathogenesis and management. *Crit Rev Oral Biol Med*. 1998;9:86–122.

Sharma SK, Reddy MJ, Joshi VV, et al. Capillary haemangioma of male urethra. *Br J Urol*. 1981;53:277.

Sherman V, McPherson T, Baldo M, et al. The high rate of familial lichen sclerosus suggests a genetic contribution: an observational cohort study. *J Eur Acad Dermatol Venereol*. 2010;24:1031–1034.

Shetty S, Ahmed AR. Treatment of bullous pemphigoid with rituximab: critical analysis of the current literature. *J Drugs Dermatol*. 2013;12:672–677.

Shiohara T, Kano Y. Lichen planus and lichenoid dermatoses. 2003:175–198. Bolognia JL, Jorizzo JL, Rapini RP. *Dermatology*. vol 1 [Edinburgh].

Shuja F, Chan CS, Rosen T. Biologic drugs for the treatment of hidradenitis suppurativa: an evidence-based review. *Dermatol Clin*. 2010;28:511–521 [523–524; quiz 522–523].

Sieunarine K. Non-venereal sclerosing lymphangitis of the penis associated with masturbation. *Br J Urol*. 1987;59:194–195.

Sillman FH, Sedlis A, Boyce JG. A review of lower genital intraepithelial neoplasia and the use of topical 5-fluorouracil. *Obstet Gynecol Surv*. 1985;40:190–220.

Simpson EL, Bieber T, Guttman-Yassky E, et al. Two Phase 3 trials of dupilumab versus placebo in atopic dermatitis. *N Engl J Med*. 2016;375:2335–2348.

Sindhuphak W, MacDonald E, Smith EB. Erythrasma. Overlooked or misdiagnosed? *Int J Dermatol*. 1985;24:95–96.

Singh G, Wijesurendra CS, Sparks RA. Vulval neurofibromatosis masquerading as genital warts. *Int J STD AIDS*. 1992;3:369–370.

Skov L, Baadsgaard O. Bacterial superantigens and inflammatory skin diseases. *Clin Exp Dermatol*. 2000;25:57–61.

Skov L, Olsen JV, Giorno R, et al. Application of Staphylococcal enterotoxin B on normal and atopic skin induces up-regulation of T cells by a superantigen-mediated mechanism. *J Allergy Clin Immunol*. 2000;105:820–826.

Slade DE, Powell BW, Mortimer PS. Hidradenitis suppurativa: pathogenesis and management. *Br J Plast Surg*. 2003;56:451–461.

Sneddon IB. The treatment of steroid-induced rosacea and perioral dermatitis. *Dermatologica*. 1976;156(Suppl 1):231.

Sobera JO, Elewski BE. Fungal diseases. Mosby: Edinburgh; 2003:1171–1198. Bolognia JL, Jorizzo JL, Rapini RP. *Dermatology*. vol 1.

Song H, Lahood N, Mostaghimi A. Intravenous immunoglobulin as adjunct therapy for refractory pyoderma gangrenosum: systematic review of cases and case series. *Br J Dermatol*. 2018;178:363–368.

Sonnex C, Dockerty WG. Pearly penile papules: a common cause of concern. *Int J STD AIDS*. 1999;10:726–727.

Sonnex TS, Dawber RP, Ryan TJ, et al. Zoon's (plasma-cell) balanitis: treatment by circumcision. *Br J Dermatol*. 1982;106:585–588.

Sonnex TS, Ralfs IG, Plaza de Lanza M, et al. Treatment of erythroplasia of Queyrat with liquid nitrogen cryosurgery. *Br J Dermatol*. 1982;106:581–584.

Sorensen MD, Krieger JN, Rivara FP, et al. Fournier's gangrene: management and mortality predictors in a population based study. *J Urol*. 2009.

Squire RA, Goode K. A randomised, single-blind, single-centre clinical trial to evaluate comparative clinical efficacy of shampoos containing ciclopirox olamine (1.5%) and salicylic acid (3%), or ketoconazole (2%, Nizoral) for the treatment of dandruff/seborrhoeic dermatitis. *J Dermatolog Treat*. 2002;13:51–60.

Stavropoulos PG, Soura E, Antoniou C. Drug-induced pemphigoid: a review of the literature. *J Eur Acad Dermatol Venereol*. 2014;28:1133–1140.

Stehman FB, Castaldo TW, Charles EH, et al. Verrucous carcinoma of the vulva. *Int J Gynaecol Obstet*. 1980;17:523–525.

Stern RS. Genital tumors among men with psoriasis exposed to psoralens and ultraviolet A radiation (PUVA) and ultraviolet B radiation. The Photochemotherapy Follow-up Study. *N Engl J Med*. 1990;322:1093–1097.

Stern RS, Bagheri S, Nichols K. The persistent risk of genital tumors among men treated with psoralen plus ultraviolet A (PUVA) for psoriasis. *J Am Acad Dermatol*. 2002;47:33–39.

Stern RS. Psoralen and ultraviolet a light therapy for psoriasis. *N Engl J Med*. 2007;357:682–690.

Stern RS. Study PF-U: The risk of squamous cell and basal cell cancer associated with psoralen and ultraviolet A therapy: a 30-year prospective study. *J Am Acad Dermatol*. 2012;66:553–562.

Stillwell TJ, Zincke H, Gaffey TA, et al. Malignant melanoma of the penis. *J Urol*. 1988;140:72–75.

Stone MS. Cysts. Mosby: Edinburgh; 2003:1721–1732. Bolognia JL, Jorizzo JL, Rapini RP. *Dermatology*. vol 2.

Stubb S, Alanko K, Reitamo S. Fixed drug eruptions: 77 cases from 1981 to 1985. *Br J Dermatol*. 1989;120:583.

Suwandinata FS, Bohle RM, Omwandho CA, et al. Management of vulvar melanoma and review of the literature. *Eur J Gynaecol Oncol*. 2007;28:220–224.

Swierzewski SJ 3rd, Wan J, Boffini A, et al. The management of meatal obstruction due to Kaposi's sarcoma of the glans penis. *J Urol*. 1993;150:193–195.

Tan BB, Weald D, Strickland I, et al. Double-blind controlled trial of effect of housedust-mite allergen avoidance on atopic dermatitis. *Lancet*. 1996;347:15–18.

Tang A, David N, Horton LW. Plasma cell balanitis of Zoon: response to Trimovate cream. *Int J STD AIDS*. 2001;12:75–78.

Taniguchi S, Inoue A, Hamada T. Angiokeratoma of Fordyce: a cause of scrotal bleeding. *Br J Urol*. 1994;73:589–590.

Tappero JW, Conant MA, Wolfe SF, et al. Kaposi's sarcoma. Epidemiology, pathogenesis, histology, clinical spectrum, staging criteria and therapy. *J Am Acad Dermatol*. 1993;28:371–395.

Tatnall FM, Schofield JK, Leigh IM. A double-blind, placebo-controlled trial of continuous acyclovir therapy in recurrent erythema multiforme. *Br J Dermatol*. 1995;132:267–270.

Thankappan TP, Zachariah J. Drug-specific clinical pattern in fixed drug eruptions. *Int J Dermatol*. 1991;30:867–870.

Tierney E, Mahmoud BH, Hexsel C, et al. Randomized control trial for the treatment of hidradenitis suppurativa with a neodymium-doped yttrium aluminium garnet laser. *Dermatol Surg*. 2009;35:1188–1198.

Tope WD, Shaffer JJ. Photodynamic therapy. Mosby: Edinburgh; 2003:2127–2142. Bolognia JL, Jorizzo JL, Rapini RP. *Dermatology*. vol 2.

Tripathi A, Ditto AM, Grammer LC, et al. Corticosteroid therapy in an additional 13 cases of Stevens-Johnson syndrome: a total series of 67 cases. *Allergy Asthma Proc*. 2000;21:101–105.

Tuzun H, Besirli K, Sayin A, et al. Management of aneurysms in Behcet's syndrome: an analysis of 24 patients. *Surgery*. 1997;121:150–156.

van Bezooijen BP, Horenblas S, Meinhardt W, et al. Laser therapy for carcinoma in situ of the penis. *J Urol*. 2001;166:1670–1671.

van de Kerkhof PCM. Psoriasis. Mosby: Edinburgh; 2003:125–150. Bolognia JL, Jorizzo JL, Rapini RP. *Dermatology*. vol 1.

van de Nieuwenhof HP, Bulten J, Hollema H, et al. Differentiated vulvar intraepithelial neoplasia is often found in lesions, previously diagnosed as lichen sclerosus, which have progressed to vulvar squamous cell carcinoma. *Mod Pathol*. 2011;24:297–305.

van Randenborgh H, Paul R, Nahrig J, et al. Extramammary Paget's disease of penis and scrotum. *J Urol*. 2002;168:2540–2541.

Vandeweyer E, Sales F, Deraemaecker R. Cutaneous verrucous carcinoma. *Br J Plast Surg*. 2001;54:168–170.

Varela JA, Otero L, Espinosa E, et al. Phthirus pubis in a sexually transmitted diseases unit: a study of 14 years. *Sex Transm Dis*. 2003;30:292–296.

Veitch D, Kravvas G, Al-Niaimi F. Pulsed dye laser therapy in the treatment of warts: a review of the literature. *Dermatol Surg*. 2017;43:485–493.

Velazquez EF, Cubilla AL. Lichen sclerosus in 68 patients with squamous cell carcinoma of the penis: frequent atypias and correlation with special carcinoma variants suggests a precancerous role. *Am J Surg Pathol*. 2003;27:1448–1453.

Verma P, Pandhi D, Yadav P. Dermatitis artefacta manifesting as genital scars: a result of an unusual behaviour pattern. *Int J STD AIDS*. 2012;23:527–528.

Viani FC, Dos Santos JI, Paula CR, et al. Production of extracellular enzymes by Microsporum canis and their role in its virulence. *Med Mycol*. 2001;39:463–468.

Vielhauer V, Herzinger T, Korting HC. The sign of Leser-Trelat: a paraneoplastic cutaneous syndrome that facilitates early diagnosis of occult cancer. *Eur J Med Res*. 2000;5:512–516.

Virgili A, Minghetti S, Borghi A, et al. Proactive maintenance therapy with a topical corticosteroid for vulvar lichen sclerosus: preliminary results of a randomized study. *Br J Dermatol*. 2013;168:1316–1324.

Von Der Werth JM, Williams HC, Raeburn JA. The clinical genetics of hidradenitis suppurativa revisited. *Br J Dermatol*. 2000;142:947–953.

von Hebra F. *Handbuch der Speciellen Pathologie und Therapie*. Verlag von Ferdinand von Enke: Erlangen; 1860:190–200.

Vonderheid EC, Tan ET, Kantor AF, et al. Long-term efficacy, curative potential, and carcinogenicity of topical mechlorethamine chemotherapy in cutaneous T cell lymphoma. *J Am Acad Dermatol*. 1989;20:416–428.

Vyas HG, Kumar A, Bhandari V, et al. Prospective evaluation of risk factors for mortality in patients of Fournier's gangrene: a single center experience. Indian journal of urology. *Indian J Urol*. 2013;29:161–165.

Weber TM, Kausch M, Rippke F, et al. Treatment of xerosis with a topical formulation containing glyceryl glucoside, natural moisturizing factors, and ceramide. *J Clin Aesthet Dermatol*. 2012;5:29–39.

Webster G. Seborrheic dermatitis. *Int J Dermatol*. 1991;30:843–844.

Weiss RA, Whitby D, Talbot S, et al. Human herpesvirus type 8 and Kaposi's sarcoma. *J Natl Cancer Inst Monogr*. 1998;51–54.

Weston WL. What is erythema multiforme? *Pediatr Ann*. 1996;25:106–109.

Weston WL. Erythema multiforme and Stevens-Johnson syndrome. Mosby: Edinburgh; 2003:313–321. Bolognia JL, Jorizzo JL, Rapini RP. *Dermatology*. vol 1.

Wetter DA, Davis MD, Yiannias JA, et al. Effectiveness of intravenous immunoglobulin therapy for skin disease other than toxic epidermal necrolysis: a retrospective review of Mayo Clinic experience. *Mayo Clin Proc*. 2005;80:41–47.

Wieland U, Jurk S, Weissenborn S, et al. Erythroplasia of queyrat: coinfection with cutaneous carcinogenic human papillomavirus type 8 and genital papillomaviruses in a carcinoma in situ. *J Invest Dermatol*. 2000;115:396–401.

Wieselthier JS, Pincus SH. Hailey-Hailey disease of the vulva. *Arch Dermatol*. 1993;129:1344–1345.

Wikstrom A, von Krogh G, Hedblad MA, et al. Papillomavirus-associated balanoposthitis. *Genitourin Med*. 1994;70:175–181.

Willemze R, Kerl H, Sterry W, et al. EORTC classification for primary cutaneous lymphomas: a proposal from the Cutaneous Lymphoma Study Group of the European Organization for Research and Treatment of Cancer. *Blood*. 1997;90:354–371.

Willemze R. Cutaneous T-cell lymphoma. Mosby: Edinburgh; 2003:1921–1941. Bolognia JL, Jorizzo JL, Rapini RP. *Dermatology*. vol 2.

Willemze R, Jaffe ES, Burg G, et al. WHO-EORTC classification for cutaneous lymphomas. *Blood*.

2005;105:3768–3785.

Williams HC. Clinical practice. Atopic dermatitis. *N Engl J Med*. 2005;352:2314–2324.

Williams PM, Conklin RJ. Erythema multiforme: a review and contrast from Stevens-Johnson syndrome/toxic epidermal necrolysis. *Dent Clin North Am*. 2005;49:67–76 [viii].

Wolf R, Orion E, Marcos B, et al. Life-threatening acute adverse cutaneous drug reactions. *Clin Dermatol*. 2005;23:171–181.

Wojnarowska F, Marsden RA, Bhogal B, et al. Chronic bullous disease of childhood, childhood cicatricial pemphigoid, and linear IgA disease of adults. A comparative study demonstrating clinical and immunopathologic overlap. *J Am Acad Dermatol*. 1988;19:792–805.

Wojnarowska F, Cooper SM. Anogenital (non-venereal) disease. Mosby: Edinburgh; 2003:1099–1113. Bolognia JL, Jorizzo JL, Rapini RP. *Dermatology*. vol 1.

Wollenberg A, Bieber T. Atopic dermatitis: from the genes to skin lesions. *Allergy*. 2000;55:205–213.

Wolverton SE. Systemic corticosteroids. Wolverton SE. *Comprehensive dermatologic drug therapy*. Saunders: Philadelphia; 2001:109–146.

Worswick S, Cotliar J. Stevens-Johnson syndrome and toxic epidermal necrolysis: a review of treatment options. *Dermatol Ther*. 2011;24:207–218.

Wu IB, Schwartz RA. Reiter's syndrome: the classic triad and more. *J Am Acad Dermatol*. 2008;59:113–121.

Yasunaga Y, Takatera H, Kuroda H, et al. A case of verrucous carcinoma of the penis with detection of human papillomavirus using the in situ hybridization method. *Hinyokika Kiyo*. 1993;39:769–772.

Yeniyol CO, Suelozgen T, Arslan M, et al. Fournier's gangrene: experience with 25 patients and use of Fournier's gangrene severity index score. *Urology*. 2004;64:218–222.

Yoganathan S, Bohl TG, Mason G. Plasma cell balanitis and vulvitis (of Zoon). A study of 10 cases. *J Reprod Med*. 1994;39:939–944.

Yoshimura K, Maeda O, Saiki S, et al. Solitary neurofibroma of scrotum. *J Urol*. 1990;143:823.

Yu D, Kuipers JG. Role of bacteria and HLA-B27 in the pathogenesis of reactive arthritis. *Rheum Dis Clin North Am*. 2003;29:21–36 [v–vi].

Zackheim HS, Kashani-Sabet M, Amin S. Topical corticosteroids for mycosis fungoides. Experience in 79 patients. *Arch Dermatol*. 1998;134:949–954.

Zheng L, Li Y. Effect of topical timolol on response rate and adverse events in infantile hemangioma: a meta-analysis. *Arch Dermatol Res*. 2018.

Zhou S, Ferguson DJ, Allen J, et al. The location of binding sites of pemphigus vulgaris and pemphigus foliaceus autoantibodies: a post-embedding immunoelectron microscopic study. *Br J Dermatol*. 1997;136:878–883.

Zollo JD, Zeitouni NC. The Roswell Park Cancer Institute experience with extramammary Paget's disease. *Br J Dermatol*. 2000;142:59–65.

Zuberbier T, Heinzerling L, Bieber T, et al. Steroid-sparing effect of pimecrolimus cream 1% in children with severe atopic dermatitis. *Dermatology*. 2007;215:325–330.

Zug KA, Warshaw EM, Fowler JF Jr, et al. Patch-test results of the North American Contact Dermatitis Group 2005-2006. *Dermatitis*. 2009;20:149–160.

60

Tuberculosis and Parasitic Infections of the Genitourinary Tract

Alicia H. Chang MD, MS, Brian G. Blackburn MD, Michael Hsieh MD, PhD

Genitourinary Tuberculosis

Tuberculosis (TB) can affect any organ system of the body, including the genitourinary (GU) tract. **Untreated, GU TB can lead to irreparable tissue damage with serious consequences such as renal failure and infertility, making it critical for clinicians to consider TB in the differential diagnosis of GU disorders.** Described as the second “great imitator” (after syphilis; Sievers, 1961), TB can mimic many other diseases and complicate the correct diagnosis and treatment of infected patients. As TB becomes less common in industrialized nations, the diagnosis of GU TB increasingly relies on clinical recognition and a high index of suspicion.

History

Genomic analyses suggest that *Mycobacterium tuberculosis* coevolved with humans. Its early progenitor, *Mycobacterium prototuberculosis*, possibly infected early hominids more than 3 million years ago (Gutierrez et al., 2005). Bony lesions consistent with TB have been detected in a 500,000-year-old *Homo erectus* skeleton (Kappelman et al., 2008). The oldest microbiologic confirmation of *M. tuberculosis* infection in humans dates back to the Neolithic Period with use of DNA isolated from 9000-year-old skeletons of a woman and child found in a prehistoric site in the eastern Mediterranean (Hershkovitz et al., 2008). Microscopic and molecular findings of tubercle bacilli have been documented in Egyptian mummies from circa 3000 BCE (Nerlich et al., 1997; Zimmerman, 1979). Descriptions of TB can be found in written records of old civilizations from ancient East Asia, to New World cultures in the Americas, to Western hemisphere societies such as the Greeks and Romans, and continuing into modern history (Daniel, 2006). It was not until the 18th and 19th centuries, however, that TB reached epidemic proportions and ravaged Europe and North America. “Consumption,” as it was known, was responsible for as many as 25% of deaths during the Industrial Age (Chalke, 1959). The turning point in the history of TB came on March 24, 1882, when Robert Koch famously presented to the scientific community the first successful isolation and identification of the tubercle bacillus (Sakula, 1982). In honor of Dr. Koch, March 24 has become World Tuberculosis Day.

Microbiology

TB is caused by a group of closely related acid-fast bacteria referred to as the *Mycobacterium tuberculosis* complex (MTBC). The complex includes species known to cause disease in only humans: *M. tuberculosis* and *Mycobacterium africanum*; species that cause disease in humans and other mammals: *Mycobacterium bovis, Mycobacterium canettii, Mycobacterium microti, Mycobacterium caprae, Mycobacterium orygis,* and *Mycobacterium pinnipedii*; and species that thus far have only been identified in animals: *Mycobacterium mungi* and *Mycobacterium suricattae* (Alexander et al., 2010; Coscolla et al., 2013; Parsons et al., 2013). **By far, the most frequently isolated species in human TB worldwide is *M. tuberculosis,* followed *by M. bovis*.** Local geographic differences exist, however, such as in West Africa, where *M. africanum* causes up to 40% of human TB cases (Yeboah-Manu et al., 2017). The species *M. tuberculosis*, however, has become synonymous with TB and is often inaccurately used to represent the entire complex. The species in the complex that infect humans cause clinically indistinguishable disease, but drug susceptibility patterns may differ among them. *M. bovis*, for example, has innate resistance to pyrazinamide, which is one of the first-line agents against *M. tuberculosis*.

Epidemiology

The World Health Organization (WHO) 2013 estimates that one-quarter of the world's population is infected with MTBC in its latent form. In 2016 there were 10.4 million new cases of active TB disease and 1.7 million deaths from TB worldwide, a continued decline since the year 2000. TB mortality has fallen by 45% since 1990 (WHO, 2016). However, different obstacles in TB control remain. These include medical conditions that promote resurgence of TB such as the human immunodeficiency virus (HIV) epidemic in sub-Saharan Africa and the rapid increase in obesity and diabetes worldwide. The increase of multidrug and extensive drug resistance also compromises TB control.

In the United States, there were 9272 reported cases of active TB in 2016 (2.9 per 100,000 persons). TB incidence in the United States has been steadily declining since its resurgence in the 1980s and its peak in 1992. In the United States, TB disproportionately affects non–US-born persons. In 2016 the incidence among non–US-born individuals was 14 times higher than among US-born persons (Centers for Disease Control and Prevention [CDC], 2017).

The frequency of GU involvement among patients who develop TB varies significantly depending on the population studied. **More than 90% of GU TB cases occur in developing countries, where the frequency approaches 15% to 20% of patients with pulmonary TB. In contrast, the frequency of GU TB in developed countries is 2% to 10% of patients with pulmonary TB** (Figueiredo and Lucon, 2008). In the developing world, the GU tract is the second most common extrapulmonary site after lymph nodes (Wong et al., 2013). **In the United States, GU TB is the third most common form after pleural and lymphatic TB and is found in 27% of extrapulmonary** cases (Daher et al., 2013). Approximately two-thirds of those affected are men. GU TB is generally a disease of adults, although it has been reported in children as young as 2 years of age (Merchant et al., 2013).

Infection, Host Immune Response, and Transmission

The initial mode of entry of MTBC into the host is via inhalation of cough-generated infectious aerosols, although there are reported cases of direct inoculation of MTBC into soft tissues (Angus et al., 2001). Once the bacilli reach the alveoli, they are phagocytosed by alveolar macrophages. In some persons, MTBC organisms are killed by the macrophages at this point and effectively cleared from the body. These persons do not develop infection nor an adaptive immune response (Walzl et al., 2011). In others, MTBC bacilli escape killing, begin to replicate within macrophages, and establish infection. Up to 12 weeks may pass before a cellular immune response is detectable (Dannenberg, 1994), and before this development, the tubercle bacilli can spread through the lymphatics to the hilar lymph nodes and ultimately through the bloodstream to seed distant organs.

The host attempts to contain MTBC infection by forming granulomas. Infected macrophages secrete inflammatory cytokines, such as interleukin-6 (IL-6), IL-12, IL-1β, and tumor necrosis factor-α (TNF-α) and recruit a variety of immune cells to surround them. Foamy macrophages, epithelioid cells, and multinucleated giant cells (Langhans cells) cluster to the center of the granuloma and are surrounded by a cuff of lymphocytes (Silva et al., 2012). Antigen processing and presentation lead to T-cell activation and the mounting of an adaptive cellular response against MTBC (Schluger R et al., 1998). T cells secrete cytokines such as IL-2, TNF-α, and most important, interferon-γ (IFN-γ) to maintain the granuloma and to induce killing of the infected macrophages and the infectious bacilli. When killing is not achieved, the granuloma can still successfully sequester viable tubercle bacilli, which stop replicating and become dormant. In 90% to 95% of persons, TB is controlled at this point and enters what has historically been considered as latency (Boom et al., 2003). Latent TB is marked by cicatrization and granuloma calcification. In fewer than 5% of infected persons the initial infection fails to be controlled and progresses within the year to active TB disease (primary progression). After latency is established, MTBC can resurface years later to cause reactivation TB. The process of reactivation is not well understood. The development of some conditions such as old age, renal failure, diabetes mellitus, malnutrition, HIV infection, and other causes of immune suppression shifts the balance between host and pathogen in favor of the pathogen. A series of events then occur that lead to renewed bacillary replication and release, granuloma caseation (the characteristic lesion of TB), and reactivation. **The lifetime risk of reactivation TB is estimated at 5% to 15%, although the risk is higher in patients with the medical comorbidities mentioned previously.** Once TB reactivates, the patient can then generate infectious respiratory aerosols that are breathed in by close contacts. In general, those with exclusively extrapulmonary disease, such as GU TB, are not considered infectious, although transmission by direct skin inoculation or other aerosol producing procedures from infected fluids and tissues can occur. **The two forms of TB described—latent TB infection and active TB disease—represent a simplification of what is now understood to be a spectrum; a dynamic continuum between contained TB infection, subclinical TB disease, and progressively infectious TB disease.** An individual who has acquired TB can move forward and backward along this spectrum through his or her lifetime, depending on changes in host immunity such as imparted by medical comorbidities or changes in the bacilli such as imparted by treatment for latent TB infection (Pai et al., 2016).

Development of Genitourinary Disease

There are four means by which GU TB develops. The principal route is via hematogenous spread of MTBC. Clinical disease may occur soon after bacilli reach the GU system, or they may enter a period of latency before becoming clinically active (Figueiredo and Lucon, 2008; Patterson et al., 2012). Typically, GU TB becomes evident after a prolonged latency, ranging up to 46 years (Christensen, 1974; Narayana, 1982). Hematogenous seeding may localize to only the GU tract or widely disseminate to multiple organ systems. The typical sites for GU seeding are the kidneys and epididymis. Other organs of the GU tract become infected via contiguous spread from these initial landing sites.

Ascending or retrograde infection through the urinary system is the second route of infection, albeit significantly less common than hematogenous spread. This is the case in GU TB after bladder irrigation with bacille Calmette-Guérin (BCG) for the treatment of bladder cancer. BCG is a live, attenuated vaccine derived from *M. bovis*, a member of the *M. tuberculosis* complex. Although rare, GU TB complicates 0.9% of patients receiving BCG irrigation (Lamm et al., 1992). Cases described include pyelonephritis, renal abscesses, ureteric obstruction, cystitis, prostatitis, and epididymo-orchitis (Demers and Pelsser, 2012; Parker and Kommu, 2013; Squires et al., 1999).

Rarely, TB can also reach the GU system via contiguous spread from other organ systems or direct inoculation. TB is one of the few infectious diseases that does not respect anatomic boundaries. Extension of TB from the spine, psoas, and to the kidneys has been described (Kothari et al., 2001). Similarly, gastrointestinal (GI) TB can extend into the GU tract to form enterorenal and enterovesical fistulae (Merchant, et al., 2013; Ney and Friedenberg, 1981). Direct inoculation is exceedingly rare. Cases include autoinoculation of external genitalia from infected stool or urine, and person-to-person genital inoculation after contact with infected genital or oral lesions (Angus et al., 2001).

Clinical Manifestations and Pathologic Features

Symptoms and signs of GU TB are often nonspecific. Patients are often treated for other bacterial infections (sometimes repeatedly) or are evaluated for possible malignancy before GU TB is entertained. Symptoms correlate with the severity and location of disease. Renal TB, for example, can be progressive and destructive but symptomatically silent until it extends into the bladder. In developed countries, where patients with TB tend to seek medical attention earlier in the disease process, 8.4% of GU TB patients are asymptomatic (Figueiredo and Lucon, 2008). **The typical TB constitutional symptoms of fever, weight loss, night sweats, and malaise are present in fewer than 20% of patients** (Simon et al., 1977). Up to 50% of patients with GU TB have only dysuria on presentation, 50% have storage symptoms, and

33% have hematuria and flank pain (Figueiredo and Lucon, 2008). Renal colic occurs in fewer than 10% of patients, and corresponds to the passage of necrotic papillary tissue, clots, stones, and caseous phlegmon in patients with severe pyelonephritis (Eastwood et al., 2001; Simon et al., 1977). Typical laboratory findings include sterile pyuria and/or hematuria. **This combination is found in more than 90% of GU TB patients in developing countries.**

Kidney

Eighty percent of GU TB occurs in the kidney (Wong et al., 2013; Yadav et al., 2017). Renal infection is progressive and highly destructive over time. The pathological findings in the kidney vary greatly depending on disease severity.

The most insidious lesions are found in patients with pulmonary TB and renal failure, with or without pyuria, who have no changes visible on imaging of the GU tract. In these patients, kidney biopsies reveal TB-induced granulomatous interstitial nephritis (Ram et al., 2011). Renal histology shows granulomas, which are sometimes caseating. In some patients, treatment reverses the associated renal insufficiency (Eastwood et al., 2001). Other microscopic changes in the kidney include glomerulonephritis from immune complex deposition or amyloidosis secondary to TB (Sun et al., 2012). In these cases, the kidneys are collateral damage of pulmonary or systemic disease.

When renal infection is the outcome of widely disseminated TB in multiple organ systems, hematogenous spread of high number of bacilli leads to innumerable small (3-mm), pale clumps of granulomas that look like scattered millet seeds on gross pathological examination of the kidney. This form of disseminated TB is known as *miliary TB* and carries a high mortality. In the kidney, the “milia” can be found studding the renal cortex and medulla and do not usually affect renal function (Eastwood et al., 2001).

In more localized infection of the kidney, tubercle bacilli become lodged first in the periglomerular capillaries. Granulomas form in the renal parenchyma and coalesce. When they caseate, cavities with necrotic material form. These can result in frank abscesses, chronic pyelonephritis, and parenchymal and papillary necrosis. Sinus tracts may emerge along the flanks (Bhatt and Lodha, 2012; Patterson et al., 2012). Examination findings at this stage can include costovertebral angle tenderness (Gokce et al., 2002). As infection advances, the calyces become inflamed and eventually calcify, resulting in calyceal distortion, dilation, and stenosis (Merchant et al., 2013a).

With enough disease progression, the kidney becomes nonfunctional, a

process called *autonephrectomy* (Teo and Wee, 2011). This complication is present in up to 33% of patients with GU TB. There are two types of autonephrectomy. The first is the caseo-cavernous type, in which viable tissue is replaced with granulomas and cavities filled with inflammatory exudate. This type of autonephrectomy occurs with and without calcification. The second type is fibrotic, with severe scarring and calcification resulting in a shrunken kidney (Fischmann, 1951).

End-stage renal failure develops in approximately 7% of cases (Figueiredo and Lucon, 2008). Chronic inflammation may lead to squamous metaplasia in the renal pelvis that persists after treatment, posing a risk for squamous cell carcinoma (Byrd et al., 1976).

Ureter

TB in the ureters occurs via descent of infection from the kidneys. As bacilli pass in the urine through the ureter, granulomas can form along the walls. Infected calculi can also descend and lodge in the ureters. The ensuing inflammation leads to scarring and strictures, commonly in the distal end of the ureter at the vesicoureteral junction (Patterson et al., 2012). Strictures can also occur throughout the ureter in a “pan-ureteral” fashion, leading to a “beaded corkscrew” appearance (Wong et al., 2013). When ureters are distorted from scarring, obstruction and urinary reflux can develop (Eastwood et al., 2001). **Urinary obstruction resulting from strictures is an important cause of renal failure in GU TB** (Carl and Stark, 1997).

Bladder

Descending infection to the bladder usually begins near the ureteral orifices and spreads along the lymphatics to other areas. Similar to TB in the ureters, bacilli implant in the urothelium and cause a patchy cystitis. Ulcerations may develop in areas where large granulomas coalesce. The dome of the bladder is the most affected, whereas the trigone and neck usually remain normal. Mucosal inflammation, friability, and hematuria follow (Wong et al., 2013). After approximately a year of chronic inflammation and mucosal scarring, bladder contracture develops (Singh et al., 2013). Urinary frequency, urgency, pain, and dysuria become prominent when bladder capacity shrinks to less than 100 mL. The severely contracted “thimble” bladder typically has a capacity of less than 20 mL. Bladder contraction is a late complication of GU TB and is more common in the developing world (12% vs. 4% of GU cases in developed countries), where diagnosis occurs after disease is more advanced (Figueiredo and Lucon, 2008).

Epididymis, Vas Deferens, Testes, and Scrotum

The epididymis, the second most common GU site of hematogenous seeding after the kidney, is involved in 10% to 55% of GU TB patients. Infection is bilateral in 34%. The disease initially affects the more vascular globus minor. Granulomas in the epididymal epithelium elicit chronic inflammation leading to fibrous narrowing and obliteration of the lumen. With disease progression, large caseous granulomas result in a nodular epididymis. On examination, the epididymis may appear swollen or hardened (Fraietta et al., 2003). Granulomas may adhere to the overlying skin, ulcerate, and in up to 50% of patients, a tuberculous sinus tract develops on the posterior surface of the scrotum (Ferreira et al., 2011). After the infection spreads to the vas deferens, it becomes thickened and beaded on examination as a result of nodular scarring (Kulchavenya et al., 2012).

Isolated epididymis or testicular infections are rare but have been described (Kho and Chan 2012; Shenoy et al., 2012). More commonly, epididymal TB extends into the testes. Granulomas form within the seminiferous tubular epithelium as well as in the connective tissue of the testis. Eventually, normal tissue becomes replaced with granulomatous tissue and fibrosis. The hardened masses that develop mimic testicular tumors. Approximately 5% of patients develop hydrocele.

Prostate and Seminal Vesicles

The prostate is infected via either hematogenous spread or urinary contamination and is involved in 22% to 49% of GU TB patients (Yadav et al., 2017). With hematogenous spread, prostatic lesions can be found in the periphery with sparing of the urethra. Disease then remains asymptomatic and progresses to calcification and gland hardening. Infection via the urinary route often involves the urethra and manifests more like bacterial prostatitis. Prostatic nodules or fluctuation may be palpated on examination. **TB should be suspected in patients with chronic prostatitis that persists despite antibiotics. Quinolones used to treat routine bacterial prostatitis are also active against MTBC. However, the shorter courses used for bacterial prostatitis are not sufficient**

for TB prostatitis, and the symptoms will not resolve or will quickly recur. Prostatic abscesses are rare but do occur, particularly in acquired immunodeficiency syndrome (AIDS) patients (Figueiredo and Lucon, 2008).

TB of the seminal vesicles may cause infertility, which can be the first symptom of GU TB (Lubbe et al., 1996). The bacilli reach the seminal vesicles through the vas deferens in cases of TB of the testis or epididymis or through the urethra and ejaculatory ducts in cases of TB of the kidneys, bladder, or prostate. Granulomas develop in the walls of the seminal vesicles, and the lumen may be filled by caseation. Eventually calcification ensues. Patients may have low-volume ejaculate, oligospermia, azoospermia, or hemospermia. TB can rarely cause seminal vesicle abscesses (Eastham et al., 1999). Physical examination may reveal enlarged seminal vesicles in early disease or hardened nodules in advanced disease.

Urethra and Penis

The urethra appears somewhat resistant to TB infection and is involved in only 1.9% to 4.5% of GU TB cases. It is typically associated with prostate infection and can occur with urethroscrotal fistulae. Isolated urethral TB is very rare but has been reported (Bouchikhi et al., 2013). Similarly, primary TB in the penis is exceedingly rare. Penile lesions begin on the skin as an inflamed papule or a keratotic plaque (also known as lupus vulgaris). The lesions then ulcerate and spread to the cavernous tissue. Pea-sized nodules can be felt in the cavernous bodies and urethra corresponding to coalescing granulomas. These nodules can be painless and hard or appear as a fungating mass. Both presentations can mimic malignancy. When fibrosis develops, the penis can become distorted or the patient can experience erectile dysfunction (Angus et al., 2001; Gupta et al., 2008; Kar and Kar, 2012; Yadav et al., 2017).

Orificial TB, a rapidly necrotic form of penile TB, has also been reported (Ramesh and Vasanthi, 1989). It has been described in immunocompromised or severely debilitated patients. It arises from autoinoculation of the penile skin with infected stool or urine from the patient or rarely from hematogenous or lymphatic spread (Wilkinson et al., 2010). Painful ulcers coated with pseudomembrane appear and can erode into deeper structures (Chen et al., 2000). Orificial TB is a presentation of very advanced and severe TB elsewhere in the GU or GI tract and carries a poor prognosis.

An exceedingly rare form of penile TB is papulonecrotic tuberculid (PNT) (Dandale et al., 2013). This is a cutaneous manifestation of TB on the glans penis and can occur in other skin areas as well. PNT of the penis has been described in Japan, South Africa, and India. The tuberculids are red papules that erupt on the skin, ulcerate, and undergo varioliform scarring. Unlike primary TB of the penis, these ulcers can be painless and do not contain tubercle bacilli. The tuberculids are hypersensitivity reactions to MTBC antigens that were disseminated to the skin from other infectious foci, and as such they are culture negative and typically polymerase chain reaction (PCR) negative. Histology is often inconclusive; mature granulomas are not always seen. The recurrent lesions are easily confused with syphilis, Behçet disease, recurrent herpes simplex, balanitis, and squamous cell carcinoma. Recognizing this entity is the first step in diagnosis, and response to empirical TB treatment despite negative cultures confirms it.

Diagnosis

In developed countries, the primary goal of the diagnostic workup is isolation of MTBC in culture for drug susceptibility testing. In the right clinical context, tissue samples demonstrating caseating granulomas can support a diagnosis of TB when cultures or DNA tests are negative. Absent those, diagnosis of patients with GU TB relies on the constellation of consistent clinical findings in a patient with probable exposure and response to empirical medical treatment. Because up to 20% of GU TB occurs concurrently with pulmonary TB (Figueiredo and Lucon, 2008)**, it is useful to also assess for the presence of pulmonary disease.**

Culture

The current gold standard for the diagnosis of GU TB is urine acid-fast bacilli (AFB) culture. First-void urine is the best sample because urine is the most concentrated at that time. Three to five urine samples on consecutive days should be collected for maximum yield. These should be cultured immediately after collection because prolonged exposure to urine acidity can retard mycobacterial growth (American Thoracic Society, 2000). The sensitivity of urine AFB cultures is as high as 80% to 90% when done in this manner (Lewinsohn et al., 2017). Real-world practice, however, compounded by sporadic shedding of bacilli into urine, leads to sensitivity as low as 10% (Abbara and Davidson, 2011). Ziehl-Neelsen stains can be done on the urine as well, but the sensitivity is less than 50%. In addition, any tissue obtained from biopsy or surgery should also be cultured.

M. tuberculosis complex has traditionally been cultured on solid, egg-based, Lowenstein-Jensen (LJ) medium. This method is laborious and time consuming; usually 4 to 6 weeks are required before growth of MTBC can be detected. LJ remains the medium of choice in developing countries because it is the least expensive and requires no specialized equipment. In developed countries, urine is cultured on more expensive, agar-based, transparent, solid media such as Middlebrook 7H10. With this medium, colonies can be visualized approximately 1 week earlier than with LJ media. Liquid-based detection systems such as the BACTEC Mycobacteria Growth Indicator Tube (MGIT) are also used in the developed world. The MGIT is a fully automated system that uses fluorescence quenching to detect mycobacterial growth in as little as 10 days. Current guidelines recommend culturing on at least one solid medium concurrently with the liquid system to maximize yield (American Thoracic Society, 2000). Other available detection methods include semiautomated systems that use radiometric liquid culture. Antibiotic susceptibility can be tested using any of the culture methods described earlier. Typically, susceptibility to first-line TB drugs is tested "in house" using the MGIT instrument. Susceptibility testing for second-line TB drugs is generally performed only at reference laboratories.

Nucleic Acid Amplification Tests

Several nucleic acid amplification tests (NAATs) have been developed to speed the detection of MTBC, providing results within 1 to 2 days. NAATs can aid detection of MTBC in patients with low bacillary load, in whom culture may fail to isolate the organisms. However, nonrespiratory specimens such as urine contain natural inhibitors that interfere with the DNA or RNA amplification process, potentially lowering test sensitivity (Chawla et al., 2012; Mehta et al., 2012; Moussa et al., 2000). The sensitivity of PCR tests for GU TB depends on the type of specimen tested, the sequence amplification used, and the specific amplification protocol. Assays using the MTBC repetitive IS6110 insertion sequence and those using nested PCR techniques perform better than those amplifying 16S-rRNA (Moussa et al., 2000). Differences in test performance exist between NAAT assays that are commercially developed, automated, or in-house "home-brew" tests.

Since 2010, the newest commercial NAAT assay on the market, the GeneXpert MTB/RIF also provides molecular detection of rifampin drug resistance simultaneously with MTBC detection. The system is self-contained and automates sputum processing, DNA extraction, and amplification. Because more than 90% of rifampin-resistant strains are also isoniazid-resistant, rifampin resistance serves as a surrogate marker for multidrug-resistant TB (MDR-TB), defined as resistance to isoniazid and rifampin (Ioannidis et al., 2011).

Systematic review of the use of various NAATs in urinary tract TB patients indicate sensitivity ranging from 70% to 100%, although studies were small and heterogeneous and produced estimates with wide confidence intervals. The pooled sensitivity of GeneXpert MTB/RIF in urine samples ranged from 83% to 95% and specificity of 79% to 99% when compared with urine AFB culture (Altez-Fernandez et al., 2017). Sensitivity of NAAT on epididymal biopsy tissue was 87.5% in one study (Chawla et al., 2012).

In the United States, NAATs are recommended as an adjunct in the evaluation of GU TB but should not replace culture for diagnosis**.** They should also not be used to exclude extrapulmonary TB because there are insufficient high-quality studies to confirm sensitivity of the assays (Lewinsohn et al., 2017). In developing countries, the cost of NAATs and the need for expensive equipment have been obstacles, although the WHO recommends GeneXpert MTB/RIF as part of the initial workup of all patients with TB (2013). Unlike cultures, NAATs cannot be used to monitor response to treatment because nucleic acids are shed from dead organisms and tests can remain positive despite adequate treatment (American Thoracic Society, 2000).

Histopathology

Because urine AFB cultures in GU TB are sometimes negative, tissue biopsy can help establish a diagnosis of GU TB (Kulchavenya et al., 2013). Although mycobacteria are often not seen in the tissue, the finding of caseating granulomas and the appropriate clinical context can help establish a diagnosis of GU TB. Histopathology shows findings consistent with TB in 38.3% of GU TB cases in developed countries and 21.9% of cases globally. In patients with epididymal nodules, fine-needle aspiration cytology can provide a diagnosis in 67.5%. Adding a TB NAAT can further augment diagnostic sensitivity to tissue specimens (Yadav et al., 2017).

Screening Tests

The tuberculin skin test (TST) and interferon-gamma release assays (IGRAs) do not differentiate between latent infection and active TB disease.

They have limited utility in the diagnosis of active disease, although they are widely used and approved by the US Food and Drug Administration (FDA) for this purpose. A positive test cannot rule in TB disease, and a negative test cannot rule it out. The ideal use for these tests is in the screening of individuals for the presence of TB infection. **Of the two types of tests, IGRAs are currently recommended as the preferred method to screen persons 5 years or older born in TB-endemic countries, although TST is still an acceptable alternative** (Lewinsohn et al., 2017).

Tuberculin Skin Test, Purified Protein Derivative, Mantoux Test.

The TST evaluates the presence of an existing cellular immune response to MTBC antigens, which should be present in persons who have been infected. Tuberculin is a sterile suspension of protein extracted from cultures of *M. tuberculosis* and is injected intradermally into the volar aspect of the forearm. After 48 to 72 hours, delayed-type hypersensitivity will cause induration at the site of injection in those with prior immune priming. The CDC guidelines for interpretation of a positive test depend on the risk factors of the patient. Three distinct cut-points for positivity have been defined according to risk. For persons with recent contact with a patient with TB, with fibrotic changes on chest radiograph that are consistent with prior TB, or who are immunosuppressed, 5 mm or more of induration is positive. For immigrants from high prevalence countries, residents of or workers in high-risk institutions, injection drug users, and persons with medical comorbidities that increase risk of active TB, 10 mm or more of induration is positive. For the general public, 15 mm or more is positive (Table 60.1; Lewinsohn et al., 2017).

TABLE 60.1

Guidelines for Determining a Positive Tuberculin Skin Test Reaction

INDURATION ≥5 mm	**INDURATION ≥10 mm**	**INDURATION >15 mm**
• HIV-positive persons • Silicosis • Fibrotic changes on chest radiograph consistent with old TB	• Immigrants from high-prevalence countries (TB incidence >20/100,000) • Residents and employees[a] of high-risk congregate settings: prisons and jails, nursing homes and other health care facilities, residential facilities for AIDS patients, and homeless shelters	• Persons with no risk factors for TB

• Patients with organ transplants • Immunosuppressed therapy (receiving the equivalent of > 15 mg/d prednisone for ≥ 1 month, or TNF-α antagonists) • Recent contacts of person with TB disease • Children < 5 years of age	• Mycobacteriology laboratory personnel • Persons with clinical conditions that make them high risk: silicosis diabetes mellitus, chronic renal failure, some hematologic disorders (e.g., leukemias and lymphomas), other specific malignancies (e.g., carcinoma of the head or neck and lung), weight loss of >10% of ideal body weight, gastrectomy, jejunoileal bypass • Injection drug users	

[a] For persons who are otherwise at low risk and are tested at entry into employment, a reaction of >15 mm induration is considered positive.

AIDS, Acquired immunodeficiency syndrome; *HIV,* Human immunodeficiency virus; *TB,* tuerculosis; *TNF-α,* tumor necrosis factor-alpha.

From Lewinsohn DM, Leonard MK, LoBue PA, et al.: Official American Thoracic Society/Infectious Diseases Society of America/Centers for Disease Control and Prevention clinical practice guidelines: diagnosis of tuberculosis in adults and children. *Clin Infect Dis.* 64(2): 111-115, 2017.

Although initial training of personnel in test placement and interpretation is necessary, the TST has some advantages. It is cheap, does not require a laboratory, and is easy to perform. The main disadvantage is that the TST is not specific for MTBC. Vaccination with BCG and infection with nontuberculous mycobacteria may elicit a positive reaction. In addition, the TST requires a second visit from the patient for test reading, which can be difficult to ensure. False-negative results can occur in 10% to 25% of persons with active TB (Huebner et al., 1993). In one study, the TST result was positive in 85% to 95% of patients with GU TB (Figueiredo and Lucon, 2008).

Interferon-Gamma Release Assays.

IGRAs are blood tests that measure the level of IFN-α (a surrogate of cellular immune reactivity) produced in response to MTBC-specific antigens, akin to an in vitro MTBC-specific TST. Persons infected with MTBC have circulating T cells that quickly recognize MTBC antigens and secrete IFN-α upon re-exposure. The antigens used in IGRAs are absent from all BCG strains and most nontuberculous mycobacteria, and thus exposure to these organisms does not result in a positive IGRA. Results are available after 24 hours.

There are two IGRAs available in the United States, the Quanti-FERON (QFT) and the. The QFT assay has undergone several iterations and in 2017, the fourth-generation assay T-SPOT.TB test was introduced to the market, the QFT-Plus. In the QFT-Plus, whole blood is collected in four specialized test tubes: one containing the MTBC antigens ESAT-6, CFP-10; one containing proprietary MTBC antigens that activate CD8 T cells; and two controls (negative and positive). The blood is incubated directly in the collection tubes for 16 to 24 hours. Plasma is then separated and IFN-α is measured using enzyme-linked immunosorbent assay (ELISA). Test results are read as positive, negative, or indeterminate, based on the level of IFN-α produced in relation to the negative and positive controls.

In the T-SPOT.TB assay, peripheral blood mononuclear cells (PBMCs) are separated from whole blood and then incubated with ESAT-6 and CFP-10 in wells coated with antibodies that capture IFN-α. Enzyme-linked immunospot (ELISPOT) assay is used to detect an increase in the number of cells (appearing as spots in each test well) that secrete IFN-α in relation to a negative control. Spots are manually counted, and the test is read as positive, negative, or borderline. Despite the increased difficulty of performing T-SPOT.TB over QFT, it is the more sensitive test. Pooled studies estimate a sensitivity of 83% for third-generation QFT and 91% for T-SPOT.TB, versus 89% for TST in cases of for culture-confirmed TB (Mazurek et al., 2010). Pooled studies of the fourth-generation QFT are currently being undertaken.

Radiography

GU TB generates a wide spectrum of imaging findings. The test of choice depends on disease location and should be driven by symptoms and other clinical data. Imaging is often the first test that indicates TB is the cause of a GU disorder.

Plain Radiography.

The kidney-ureter-bladder (KUB) radiograph frequently demonstrates calcifications caused by TB, which are present in more than 50% of patients (Merchant et al., 2013a). Initial renal lesions may appear as faint punctate calcifications within the parenchyma. As TB progresses, the KUB film may show globular calcifications that correspond to a tubercular mass (Fig. 60.1). Papillary necrosis appears as triangular ringlike calcifications in the collecting system. With fibrotic autonephrectomy, the KUB film shows a small, shrunken, calcified “cement” or “putty” kidney, in which calcific rims outline the individual renal lobes; this lobar pattern is pathognomonic for end-stage renal TB.

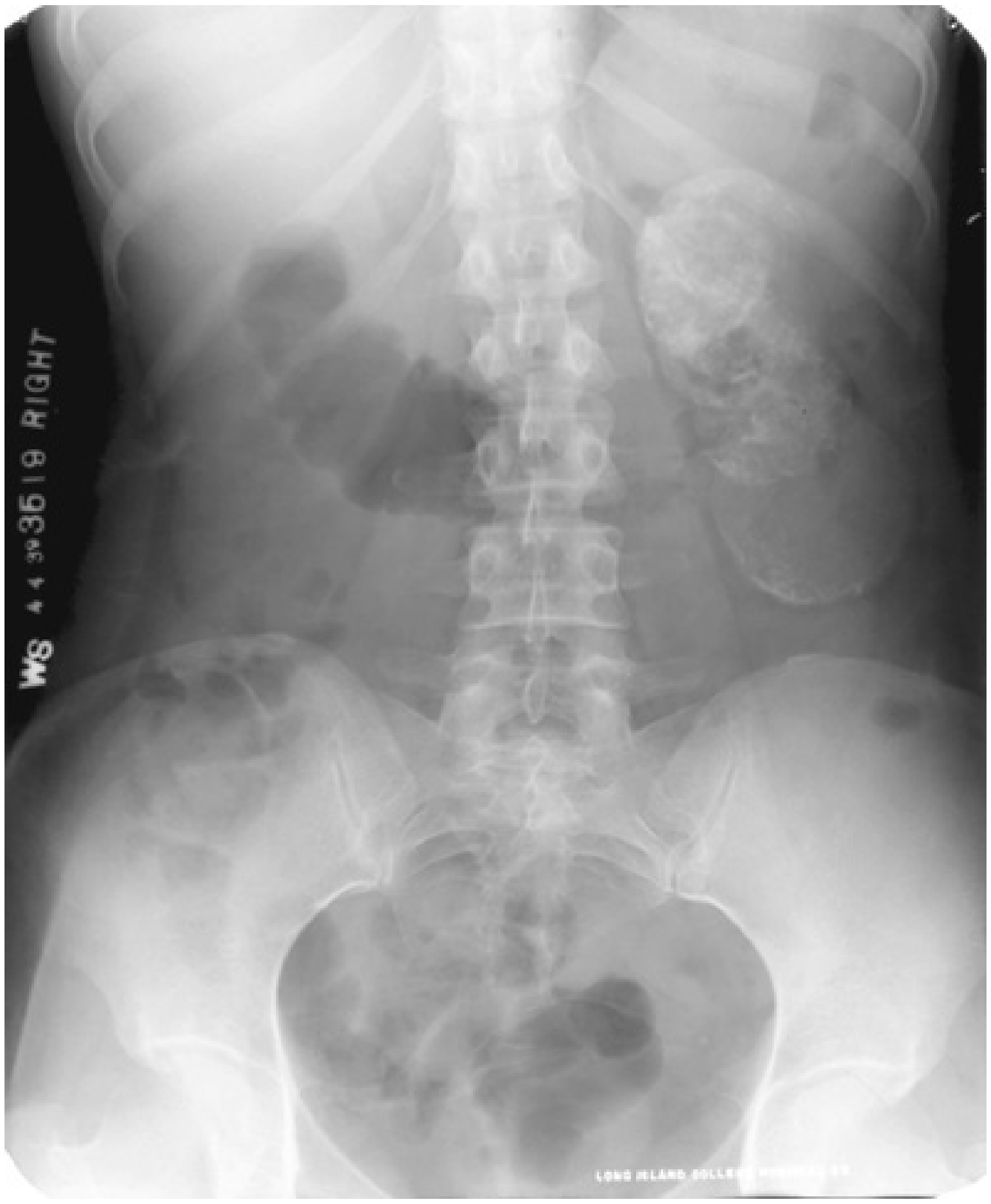

FIG. 60.1 Kidney-ureter-bladder radiographic view in a patient with left renal tuberculosis with associated calcifications.

A plain radiograph can also demonstrate renal and ureteral TB-infected calculi. Stones may take strange shapes as they form in a deformed and fibrosed renal pelvis. A stone in the shape of an upward arrowhead may indicate a renal pelvis that has been “hiked up” by contraction from scarring.

The KUB film can also show ureteral calcifications, which are characteristically intraluminal as opposed to the mural calcifications of schistosomiasis. Bladder wall calcifications are not very common except in late cases of bladder contraction. Calcifications of the prostate and seminal vesicles are seen in 10% of patients. Plain film findings suggestive of TB may be seen in surrounding tissues as well, appearing as erosions of the vertebral bodies or calcifications in cold abscesses of the psoas muscle (Merchant et al., 2013a; Teo and Wee, 2011).

All patients being evaluated for GU TB should also have a chest x-ray to exclude concomitant infectious pulmonary TB (American Thoracic Society, 2000).

Intravenous Urography.

Intravenous urography (IVU) is the gold standard for imaging early renal TB. Initial erosive changes of the urothelium appear as loss of sharpness and edge irregularities (Figueiredo and Lucon, 2008). Calyceal erosions have a “moth-eaten” appearance (Patterson et al., 2012). Filling defects may be seen, caused by tuberculomas rupturing into the calyx or by papillary necrosis. IVU can demonstrate medullary cavities that communicate with the collecting system. When a calyx or infundibulum is stenosed, contrast excretion by the renal parenchyma may fail, creating a “phantom calyx” in the location where the calyx should be visible (Eastwood et al., 2001). Ureteral TB can manifest as a rigid, calcified, straightened, pipestem ureter that is tubular and lacks normal peristaltic activity on IVU. The ureter may also take on the appearance of a beaded corkscrew as a result of nodular fibrosis along the entire ureter. The pipestem and corkscrew findings are highly suggestive of TB, particularly when seen concurrently with either kidney or bladder abnormalities. IVU can also detect nonfunctional kidneys because of autonephrectomy, as well as a fibrosed, contracted bladder (Fig. 60.2). On occasion, perinephric abscess may be suggested, particularly if there is restriction of renal movement with breathing or ureteral displacement on IVU.

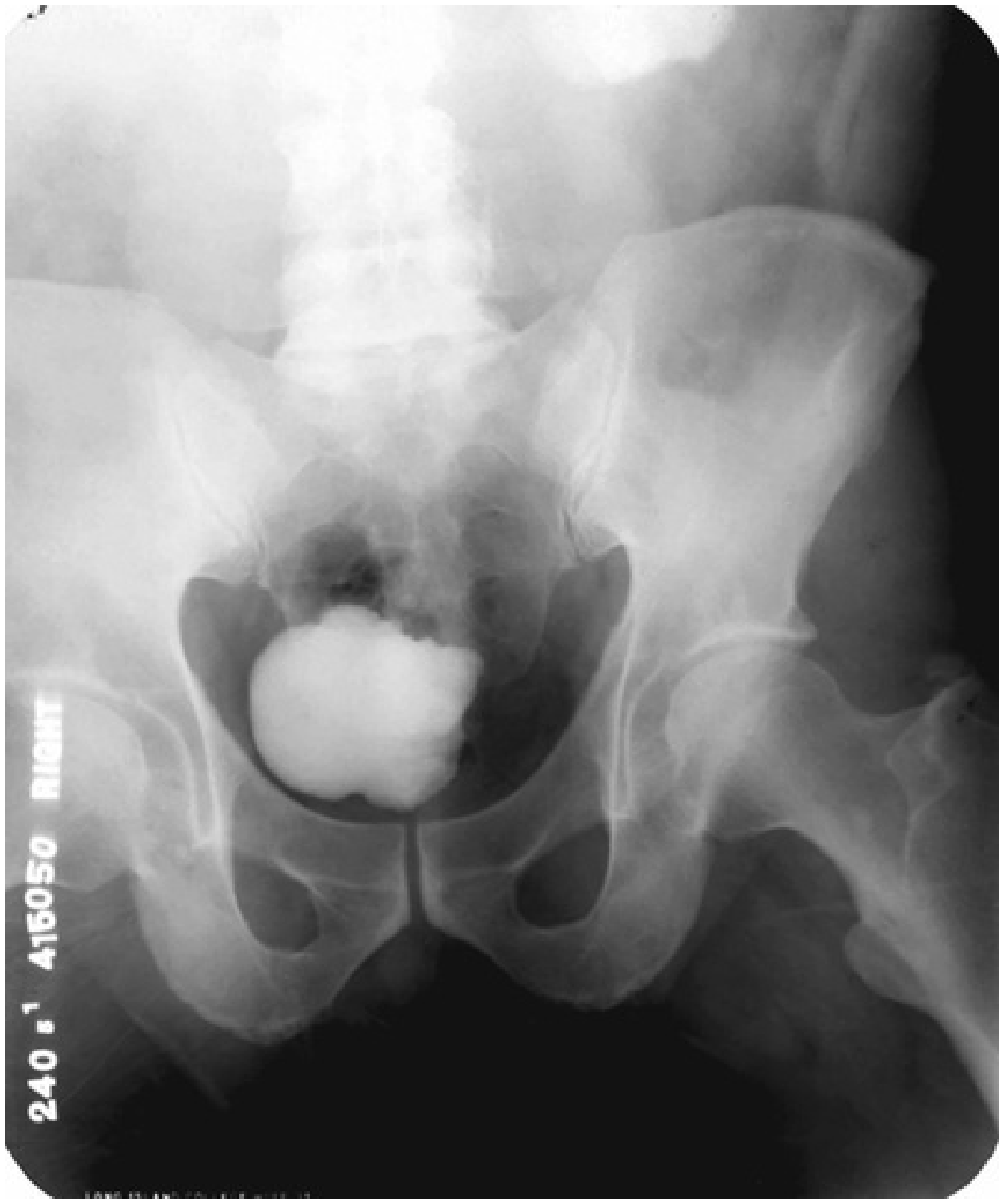

FIG. 60.2 The cystogram portion of an intravenous pyelogram in a patient with left renal tuberculosis. Note the contracted left side of the bladder that is secondary to fibrosis from the tuberculosis.

The most common findings on IVU, however, are obstructive changes resulting from scarring and distortion of the collecting system: calyceal obliteration, infundibular narrowing, hydrocalycosis, segmental or total hydronephrosis, and hydroureter (Figs. 60.3 and 60.4). Calyceal dilation and distortion present a typical cloverleaf pattern on film (Carl and Stark, 1997). Ureterovesical junction obstruction is caused by tuberculous cystitis or strictures of the distal third of the ureter (Fig. 60.5). The finding of a “hiked-up” renal pelvis, with sharp angulation of the ureteropelvic junction (UPJ), is known as “Kerr's kink” (Merchant et al., 2013a).

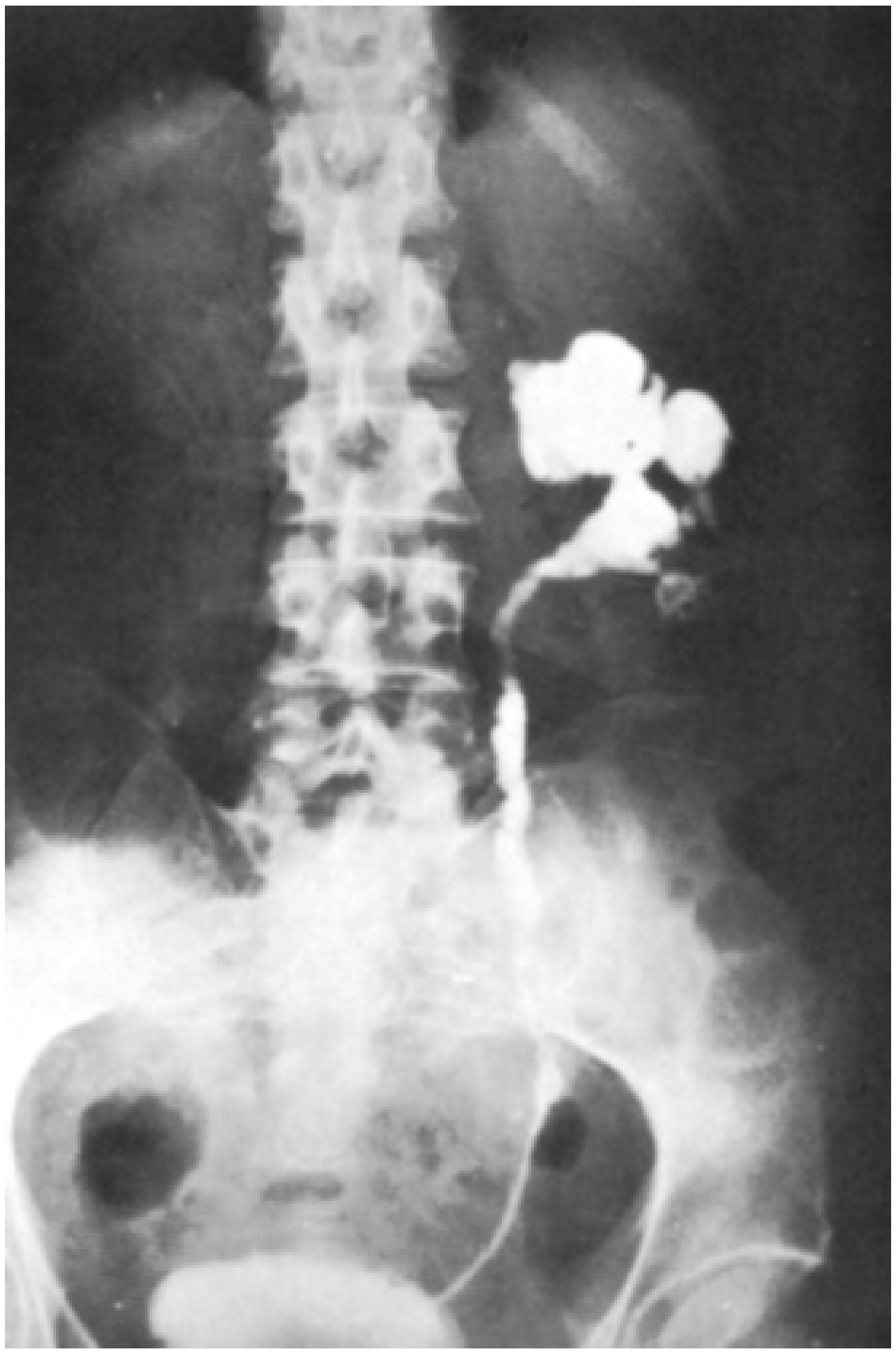

FIG. 60.3 Occluded calyx.

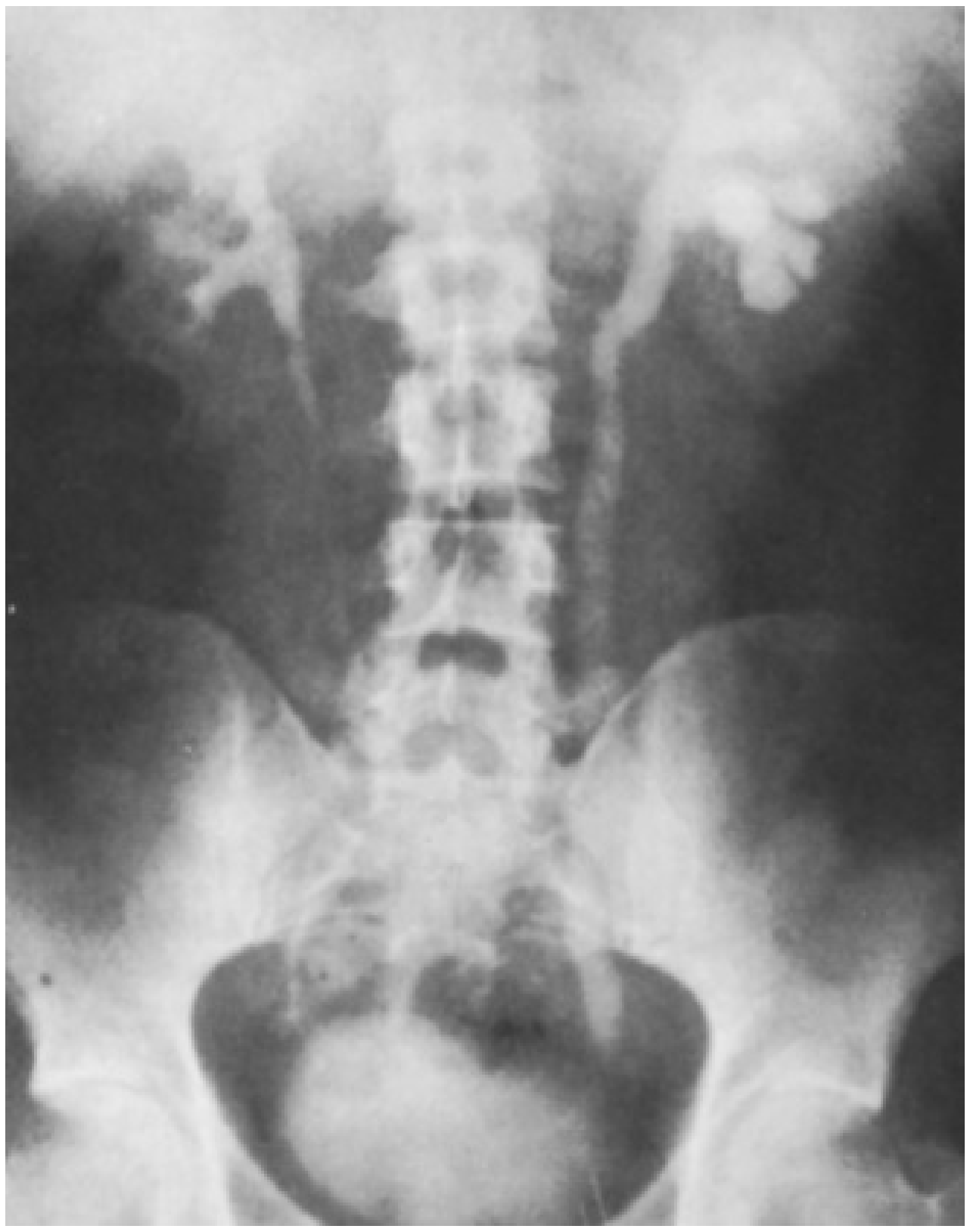

FIG. 60.4 Severe calyceal and parenchymal destruction.

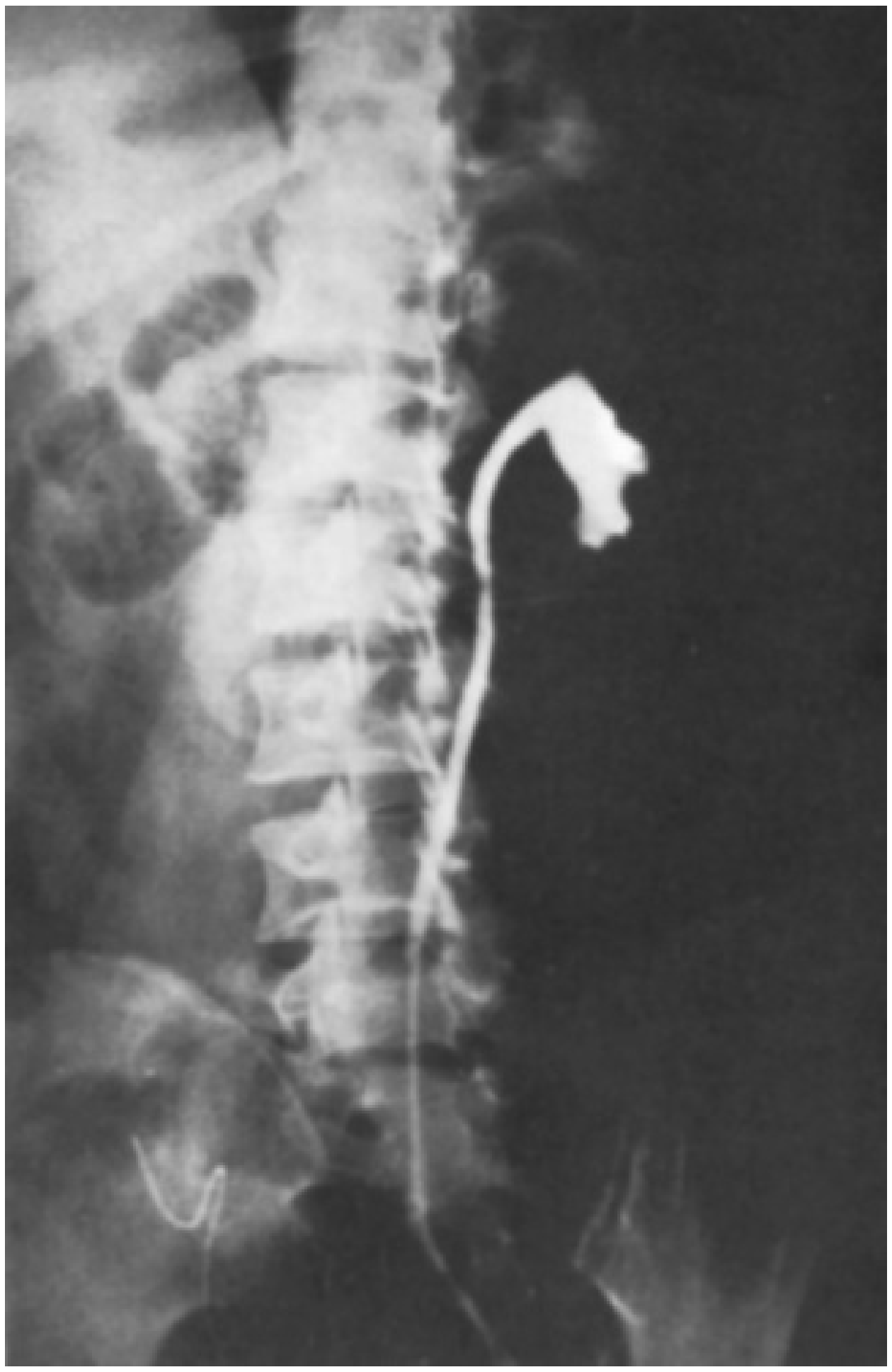

FIG. 60.5 Stricture at the distal left ureter.

Computed Tomography With Urography.

Computed tomography (CT) with urography is the most frequently used modality for imaging TB in developed countries, where it has largely replaced IVU (Merchant et al., 2013b). High-end multi-detector scanners can detect lesions as small as 3 to 4 mm. With the administration of intravenous contrast, CT can assess kidney function during different phases of excretion. Similar to KUB and IVU, CT reveals calcifications, scarring, and signs of obstruction (Fig. 60.6). CT is more sensitive than KUB in detecting calcifications and thickening of the collecting ducts. It is particularly useful in the evaluation of patients with complicated and extensive TB. Perinephric and psoas abscesses can be seen, as well as any pathology in lymph nodes, vertebrae, spleen, or liver. Pathology in the prostate and seminal vesicles can also be visualized, including enlargement, necrosis, cavitations and abscesses, as well as calcifications.

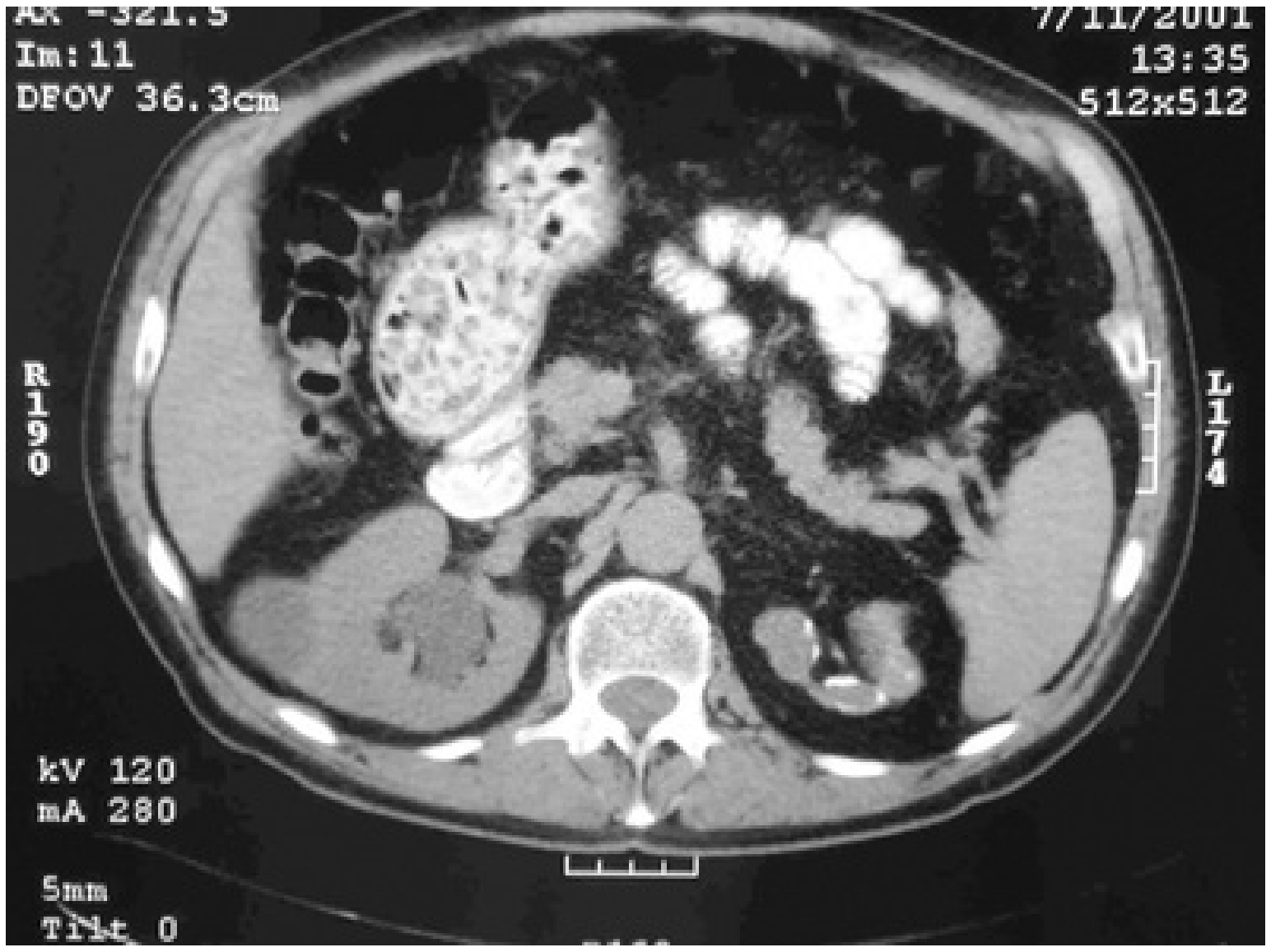

FIG. 60.6 CT after oral contrast medium in a patient with bilateral tuberculosis. The right kidney is hydronephrotic secondary to infundibular stenosis but has retained good function. The left kidney is an end-stage nonfunctioning atrophic kidney with calcification.

CT does have disadvantages. CT is less sensitive for detecting the minimal urothelial thickening, subtle papillary necrosis, and other changes of early renal TB, for which IVU is still the preferred study. In addition, CT imparts a higher radiation dose than IVU.

Retrograde Pyelography and Antegrade Pyelography.

Both retrograde and antegrade pyelography, with either percutaneously or endoscopically administered contrast, have been replaced by CT urography. However, when IVU or CT cannot be done because of renal insufficiency or contrast allergy, these modalities can be helpful in delineating the distortions in GU anatomy. In addition, these tests can be used in conjunction with IVU to determine whether cavitations are obstructive or nonobstructive, and whether they are in communication with the urinary collecting system or not (Merchant et al., 2013b).

Ultrasonography

Ultrasonography (US) has a limited role in the diagnosis of GU TB because findings are generally nonspecific, and visualization is not as clear as with CT. It is useful in pediatric or pregnant patients because of the lack of radiation exposure. US is also less expensive than CT. US is used to evaluate the testes, epididymis, and, with transrectal US, the prostate and seminal vesicles, which appear thickened. US can also locate abscesses or cavities in the kidney. Cystic lesions with septations suggest chronic infection (Wong et al., 2013). Focal calcifications appear as highly echogenic areas with distal shadowing. Restriction of renal movement during breathing suggests a perinephric or psoas abscess. Like CT, US can provide concurrent information about the abdomen, such as the presence of ascites, lymphadenopathy, or omental caking. A primary use of US in GU TB is to follow hydronephrosis in patients who are receiving medical treatment because fibrosis during healing can worsen urinary obstruction.

Magnetic Resonance Imaging

Magnetic resonance imaging (MRI) is not commonly used in the workup of GU TB because of the many other imaging modalities available (Merchant et al., 2013b). Like ultrasound, it can be useful in pediatric or pregnant patients to avoid exposure to radiation. MRI can detect a single granuloma. Small lesions are hypointense on T1 and T2 images. Larger lesions have central hyperintensity on T2 images because of the increased cellularity at the center of the granuloma. Larger TB lesions can mimic malignancy, and it is not always possible to differentiate the two.

A magnetic resonance urogram (MRU) can be more sensitive than IVU in showing urothelial thickening and caliectasis. The addition of diffusion-weighted imaging (DWI) can help distinguish hydronephrosis from pyonephrosis. Various techniques have been explored with MRI to study TB, including cineMRU and dynamic MRU, which can evaluate ureteral peristalsis. MRI with DWI can be used to monitor renal fibrosis. Apparent diffusion coefficients (ADCs) decrease with fibrosis and can be used to gauge the stage of TB, including the effect of treatment. Caution should be used when using gadolinium in renal failure patients because of the risk of developing nephrogenic systemic fibrosis.

Cystoscopy and Ureteroscopy

Endoscopy plays a limited role in the diagnosis of TB. Although it allows direct visualization of lesions, findings can be nonspecific. They include local hyperemia, mucosal erosion, ulceration, granulomatous masses, and irregularity of the ureteral orifices. Ulcerative lesions may mimic malignancy. A “golf-hole” ureteric orifice is suggestive of TB, and, when found, upper tract imaging or endoscopy should be obtained (Fig. 60.7). Biopsies should be performed when possible, especially if malignancy is a possibility. Although a positive urine culture for MTBC is sufficient for diagnosis, results may not be available quickly enough. Furthermore, in those with negative urine cultures, bladder biopsy can be 19% to 52% sensitive for TB (Figueiredo and Lucon, 2008).

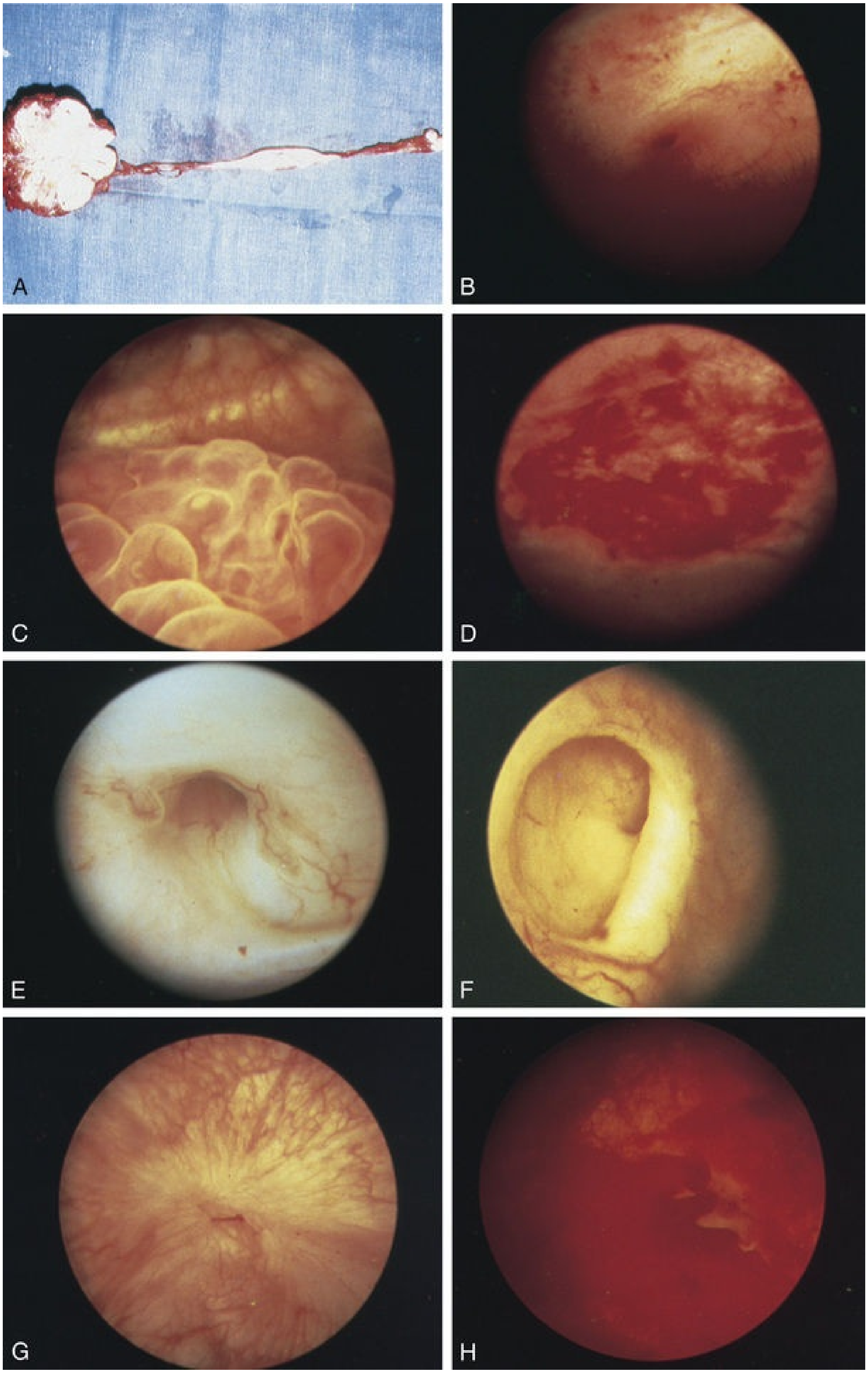
A
B
C
D
E
F
G
H

FIG. 60.7 (A) Extensive tuberculosis of the kidney and ureter with calcification and stricture formation. (B) Acutely inflamed ureteric orifice. (C) Tuberculous bullous granulations. (D) Acute tuberculous ulcer. (E) Tuberculous golf-hole ureter. (F) Tuberculous golf-hole ureter, severely withdrawn. (G) Healed tuberculous lesion. (H) Acute tuberculous cystitis with ulceration.

Treatment

Before the development of antimicrobials, treatment of TB relied primarily on rest and nourishment in sanatoria; and in those with severe GU disease, extirpative surgery was the best hope for cure. With the development of streptomycin in 1944, followed by isoniazid in 1952 and the rifamycins in 1957, medical treatment with antituberculous drugs replaced sanatoria and surgical procedures (Daniel, 2006). **Today, most TB patients can be treated medically and in the ambulatory setting, even those with MDR-TB. Surgery primarily establishes a diagnosis or is an adjunct to antibiotics in advanced cases** (Abbara and Davidson, 2011).

Medical Therapy

Successful medical treatment of TB requires multiple drugs for several reasons (CDC, 2003). First, the tubercle bacilli exist in different microenvironments within the host. These apply different pressures on the organism and cause it to exhibit different metabolic needs and replication speeds. The drugs vary in their activity against MTBC; some are bactericidal, whereas others are only bacteriostatic. Some drugs work best on rapidly replicating bacteria, whereas others are more effective against less metabolically active bacilli. The drugs also penetrate differently into various tissues and perform optimally at different pHs. In addition, multiple drug therapy prevents the emergence of drug-resistant strains.

Combination therapy with first-line antituberculous drugs achieves the best cure rates in the shortest timeframe (Table 60.2). Treatment should start with these—namely, isoniazid (INH), rifampin, pyrazinamide, and ethambutol. Before the start of treatment, baseline measurements should include platelet count and liver and kidney function tests. Patients should also be tested for HIV, and, when appropriate, for hepatitis B and C and diabetes. Medical therapy should be tailored according to drug susceptibility data when available. Directly observed treatment (DOT) should be employed to ensure medication adherence and minimize the likelihood of developing drug-resistant strains (Nahid et al., 2016).

TABLE 60.2

First-Line Antituberculous Drugs

DRUG/FORMULATION	ADULT DOSAGE (DAILY)[a]	ADULT DOSAGE (INTERMITTENT)[b]	MAIN ADVERSE EFFECTS
Isoniazid[c]	5 mg/kg (typically 300 mg)	3 times/week 15 mg/kg (typically 900 mg)	Hepatic toxicity, peripheral neuropathy
50-, 100-, 300-mg tablet			
50 mg/5 mL syrup			
100 mg/mL injection			
Rifampin[d]	10 mg/kg (typically 600 mg)	3 times/week 10 mg/kg (typically 600 mg)	Hepatic toxicity, flulike syndrome, pruritus, drug interactions
150-, 300-mg capsule 600-mg injection powder			
Rifabutin[e] 150-mg capsule	5 mg/kg (typically 300 mg)	Not recommended	Hepatic toxicity, flulike syndrome, uveitis, neutropenia, drug interactions
Rifapentine[f] 150-mg tablet		**Once weekly** 10–20 mg/kg/week PO (600 mg and higher) **in continuation phase only in very select patients**	Similar to rifampin
Pyrazinamide 500-mg tablet	40–55 kg: 1000 mg 56–75	3 times/week: 40–55 kg: 1500 mg 56–75 kg: 2500 mg 76–90 kg: 3000 mg	Arthralgias, hepatic toxicity, pruritus, rash, hyperuricemia, gastrointestinal upset

	kg: 1500 mg 76–90 kg[g]: 2000 mg		
Ethambutol 100-, 400-mg tablet	40–55 kg: 800 mg 56–75 kg: 1200 mg 76–90 kg[g]: 1600 mg	3 times/week: 40–55 kg: 1200 mg 56–75 kg: 2000 mg 76–90 kg: 2400 mg	Decreased red-green color discrimination, decreased visual acuity, optic neuritis

[a] Or 5 times/week daily observed therapy (DOT).

[b] Daily therapy is preferred. Intermittent therapy (administered by DOT) only during the continuation phase of therapy. The World Health Organization and CDC no longer recommend dosing intervals less frequent than 3 times/week.

[c] Pyridoxine 25–50 mg should be given to prevent neuropathy in malnourished or pregnant patients and those with HIV infection, renal failure, thyroid disease, alcoholism or diabetes.

[d] In general, cannot be taken by HIV-infected persons taking protease inhibitors or certain NNRTIs.

[e] When taken with efavirenz, the rifabutin dose is increased to 450 mg/day or 600 mg 3 times/week. When taken with fosamprenavir, nelfinavir or indinavir, the rifabutin dose is 150 mg/day or 300 mg 3 times/week. With lopinavir/ritonavir (Kaletra), ritonavir alone, atazanavir alone or ritonavir combined with other protease inhibitors, the rifabutin dose is 150 mg every other day or 3 times/week; some experts believe this dose to be subtherapeutic and recommend 150 mg daily or 300 mg 3 times/week with close monitoring for rifabutin toxicity, particularly uveitis.

[f] Rifapentine is contraindicated in HIV+ persons, in persons with cavitary pulmonary disease, or persons with extrapulmonary tuberculosis. Use of once weekly rifapentine is not advocated by WHO.

[g] In patients >90 kg, dosing is recommended based on lean body weight.

From The Medical Letter. Drugs for tuberculosis. *Treat Guidel Med Lett* 10(116): 29–36, 2012;

Modified from CDC: Treatment of tuberculosis, American Thoracic Society, CDC, and Infectious Diseases Society of America. *MMWR Recomm Rep.* 52(No. RR-11):1–77, 2003.

Second-line agents are reserved for patients who experience side effects from first-line agents, whose MTBC organisms exhibit drug resistance or in whom first-line agents fail. Second-line agents vary in tolerability and ease of administration (Table 60.3). Recent drugs added to the second-line agents are the fluoroquinolones and linezolid (Lee et al., 2012), both of which were developed to treat other bacterial infections, and bedaquiline, the first new drug in 40 years specifically developed for TB (CDC, 2013).

TABLE 60.3

Second-Line Antituberculous Drugs

DRUG/FORMULATION	ADULT DOSAGE (DAILY)[a]	MAIN ADVERSE EFFECTS
Streptomycin[b]	15 mg/kg IM, IV (max 1 g)	Vestibular and auditory toxicity, renal damage
Capreomycin[b]	15 mg/kg IM, IV (max 1 g)	Vestibular and auditory toxicity, renal damage, electrolyte imbalance
Amikacin/kanamycin[b]	15 mg/kg IM, IV daily	Ototoxicity, renal damage
Cycloserine[c]	10–15 mg/kg in two doses (250–500 mg bid) PO	Psychiatric symptoms, seizures
Ethionamide	15–20 mg/kg in 1 or 2 doses (250–500 mg qd or bid) PO	Gastrointestinal and hepatic toxicity, hypothyroidism, optic neuritis, neurotoxicity
Levofloxacin	500–1000 mg PO, IV	Gastrointestinal toxicity, central nervous system effects, rash, dysglycemia, QT prolongation, tendonitis/tendon rupture
Moxifloxacin	400 mg PO, IV	Gastrointestinal toxicity, central nervous system effects, rash, dysglycemia, QT prolongation, tendonitis/tendon rupture
Para-aminosalicylic acid	8–12 g split into 2–3 doses PO	Gastrointestinal disturbance, hepatitis, hypothyroidism

Linezolid	600 mg PO	Bone marrow suppression, peripheral and optic neuropathy, hepatic toxicity
Bedaquiline[d]	400 mg PO × 2 weeks, then 200 mg PO thrice-weekly	Headache, nausea, arthralgias, QT prolongation, hepatic toxicity

[a] Dosage may need to be adjusted for renal impairment.

[b] Generally given 5–7 times/week (15 mg/kg, or a maximum of 1 g per dose) for an initial 2 to 4 months, and then (if needed) 3 times/week (20 to 30 mg/kg, or a maximum of 1.5 g per dose). Dosing less frequently than 3 times/week is no longer recommended. For patients >59 years old, dosage is reduced to 10 mg/kg (max 750 mg per dose). Dosage should be decreased if renal function is diminished.

[c] Some authorities recommend pyridoxine 50 mg for every 250 mg of cycloserine to decrease the incidence of adverse neurologic effects.

[d] Bedaquiline is given at 400 mg orally with food, daily for 2 weeks, then 200 mg orally three times/week.

bid, Twice daily; *IM,* intramuscularly; *IV,* intravenously; *PO,* per os (orally); *qd,* every day.

Modified from Lewinsohn DM, Leonard MK, LoBue PA, et al.: Official American Thoracic Society/Infectious Diseases Society of America/Centers for Disease Control and Prevention Clinical Practice Guidelines: diagnosis of tuberculosis in adults and children. *Clin Infect Dis* 64(2):111–115, 2017; Lee M, Lee J, Carroll MW, et al.: Linezolid for treatment of chronic extensively drug-resistant tuberculosis. *N Engl J Med* 367(16):1508–1518, 2012; Centers for Disease Control and Infection (CDC): Provisional CDC guidelines for the use and safety monitoring of bedaquiline fumarate (Sirturo) for the treatment of multidrug-resistant tuberculosis. *MMWR Recomm Rep.* 62(RR-09):1–12, 2013.

GU TB can be successfully treated with the standard short-course regimen of 6 months of first-line antituberculous drugs (Nahid et al., 2016). Treatment begins with an intensive phase of 2 months of daily INH, rifampin, and pyrazinamide, followed by a continuation phase of 4 months of INH and rifampin given daily or alternatively, thrice weekly. Twice-weekly administration during the continuation phase is no longer recommended (WHO, 2010). Pyridoxine (vitamin B_6) administration minimizes the risk of INH-induced peripheral neuropathy. Ethambutol is added at the beginning of treatment pending drug susceptibilities and is discontinued if the strain is found to be susceptible to the other first-line drugs. First-line drugs reach high concentrations in the urine and work well in acidic environments. The intensive phase of treatment targets rapidly multiplying bacteria, whereas the continuation phase attempts to eradicate slow, sporadic multipliers and persistent bacteria.

Although 6 months is the duration of standard short-course therapy,

clinical scenarios regularly arise that require prolongation of treatment. The type of clinical disease present and the antituberculous drugs used affect duration of treatment (Nahid et al., 2016). For example, at least 9 months of treatment is recommended for extensive pockets of infection, concurrent smear-positive cavitary pulmonary disease, central nervous system involvement, or delay in positive cultures converting to negative. If the patient is unable to take pyrazinamide for at least 2 months, either because of side effects or drug resistance, therapy should also last 9 months or longer. Some clinicians recommend 12 months of therapy for GU TB because of high relapse rates of up to 22% when therapy is given for only 6 months (Gokalp et al., 1990). Because of the complexities that often arise with regimen choice, drug interactions, and side effects, any deviation from standard short-course therapy should be discussed with specialists experienced in treating TB.

During therapy, liver enzymes should be monitored monthly in those with preexisting liver disease because all first-line agents except ethambutol can cause hepatic toxicity that can be reversed with drug discontinuation. Patients should be advised to abstain from alcohol and other hepatotoxic drugs. Although treatment is, in general, well tolerated, severe hepatic injury has occurred. Visual acuity and red-green color perception also should be monitored while on ethambutol. Close follow-up of patients is necessary, not only to monitor for side effects, but also because renal lesions may worsen with drug treatment. **The healing process is sometimes accompanied with new fibrosis, which can worsen urinary obstruction and bladder contraction** (Psihramis and Donahoe, 1986)**. Steroids may help in the management of these patients (see following). Surgical intervention to relieve worsening or newly developed obstruction may be necessary.**

Corticosteroids.

The role of adjunctive corticosteroids for the treatment of TB disease still must be fully elucidated. The anti-inflammatory effects of corticosteroids are thought to prevent an unchecked host immune response from causing excessive tissue destruction and scarring. Steroids provide a mortality benefit in TB meningitis and are strongly recommended in that setting. Although not routinely recommended, steroids are sometimes used in patients with severe pulmonary TB, when antibiotic treatment leads to a paradoxic worsening of symptoms (Breen et al., 2004), and in some patients with TB pericarditis to prevent constrictive pericarditis (Nahid et al., 2016). Steroids have also been used in a few cases of GU TB to prevent ureteral strictures and bladder contraction, but these cases are anecdotal, and no clinical trials have been conducted. A recent review and meta-analysis of published clinical trials of corticosteroid use in pulmonary, meningeal, pleural, pericardial, and peritoneal TB showed that, regardless of which organ system was affected, steroids reduced mortality by 17% (Critchley et al., 2013).

Surgical Therapy

About 55% of patients with GU TB require surgical management during their course of disease (Wong et al., 2013). Intervention is more frequent as disease advances. **Surgical procedures are performed to relieve urinary obstruction and drain infected material, to remove nonworking infected kidneys in cases resisting cure, to improve medically resistant hypertension secondary to a functionally excluded kidney, or to reconstruct the urinary tract.** Abscesses that do not respond to therapy may require aspiration or percutaneous or open drainage. Currently, more than half of operations performed for TB are reconstructive (Gupta et al., 2008). The optimal timing of surgery is 4 to 6 weeks after the initiation medical therapy. This delay allows active inflammation to subside, the bacillary load to decrease, and lesions to stabilize.

Procedures to Relieve Obstruction.

Prompt relief of obstruction is emergently required in cases of uremia or sepsis. Bilateral obstruction or unilateral obstruction of a functionally solitary kidney is often the cause of renal failure. Early ureteral stenting or percutaneous nephrostomy (PCN) for tuberculous ureteral strictures limits the loss of renal function and increases the opportunity for later reconstructive surgery (Shin et al., 2002). Temporary and immediate drainage of obstruction is recommended, preferably by retrograde ureteric stenting. An indwelling double-J stent can be placed until the patient's condition has been optimized. Retrograde placement is successful in 41% of cases (Ramanathan et al., 1998). When this is not technically feasible, an antegrade, internalized or externalized ureteral stent is placed via percutaneous puncture of the obstructed kidney. If that also fails, a PCN is left in place until definitive management. Because strictures and fibrous scars may be present, more than one PCN may be necessary (Carl and Stark, 1997). PCN must be followed by correction of the cause of obstruction. A tuberculous cutaneous fistula can develop if the PCN is simply removed, although this is less likely to develop with effective concurrent medical therapy.

If the kidney is unsalvageable, a nephrectomy may become necessary. High-contrast injection pressures during stent and PCN placement should be avoided to prevent possible dissemination of infection (Salem, 2008).

Nephrectomy.

Organ preservation is the fundamental goal in surgical management of GU TB. However, total nephrectomy is considered in two settings. The first is the patient with a nonfunctional kidney and recalcitrant or recurrent TB despite optimal medical therapy. After nephrectomy of the infected kidney, relapse rates of less than 1% have been reported after short-course medical treatment (Figueiredo and Lucon, 2008). The second setting in which a nephrectomy is considered is the patient with a nonfunctional kidney and medically resistant hypertension. Nephrectomy improves hypertension in 65% of cases (Flechner and Gow, 1980). Overall, nephrectomy is performed in 27% of GU TB patients, and the frequency is similar between developed and developing countries (Figueiredo and Lucon, 2008).

Because of the extensive fibrosis often present, the traditional approach to the kidney is through an oblique retroperitoneal incision that can be extended dorsally or ventrally as needed. In rare patients the perinephric fat may appear to have granulomatous masses or caseous cavities. These should be removed with the specimen. Individual ligation of the renal artery and vein is preferred to limit risk of late arteriovenous fistula. The ureters are usually not taken out concurrently. Care must be taken to minimize disruption of the surrounding lymphatics and to avoid entering the pleural or peritoneal space during the procedure.

More recently, laparoscopic nephrectomy has gained popularity (Hemal, 2011; Lee et al., 2002) despite concerns that extensive fibrosis associated with TB would render a laparoscopic approach suboptimal. Several investigators have reported good outcomes and suggest that it should be the preferred approach because of decreased blood loss and more rapid patient recovery (Chibber et al., 2005; Gupta et al., 2008; Zhang et al., 2005). In experienced hands, laparoscopic nephrectomy for renal TB is a somewhat longer procedure than when it is done for other reasons, but in one study the procedure took only half an hour longer on average (Lee et al., 2002).

Ureteropelvic and Ureteral Surgery.

Strictures of the ureteropelvic junction (UPJ) and ureter may be temporarily stented to allow improvement of renal function before definitive management. Upper and midureteric strictures are rare and may be amenable to endourologic treatment. Lower ureteric strictures are more common and often require open surgical intervention. The length and degree of the stricture, whether it can be passed by a guidewire or not, vascular supply to the lesion, and renal function are important factors to be considered in the management of patients (Kim et al., 1993).

Endoscopic Management.

Tuberculous ureteric strictures are characterized by mucosal ischemia and dense fibrosis. Therefore success rates of endoscopic management of strictures resulting from other causes may not necessarily apply to TB strictures. In general, short strictures with residual lumens in patients with good renal function yield the best outcome. Strictures forming during medical treatment and managed by early stenting (double-J placement) can stabilize and require no further treatment (Shin et al., 2002). Balloon dilation by retrograde or antegrade access has been described for TB strictures of the ureter, UPJ, ureterovesical junction, and calyceal infundibula (Kim et al. 1993; Murphy et al., 1982). A stent is often placed after dilation. Because of high failure rates, repeat procedures are often needed.

Follow-up imaging (US or IVU) of all patients with ureteric strictures is needed, especially those managed endoscopically, because some strictures worsen during the healing process as a result of fibrosis and cicatrization. Corticosteroids may be added if deterioration is detected. Failure to improve or progression after 6 weeks of medical treatment is an indication for open surgical management.

Open Surgical Options.

Long, complex strictures require open surgical repair. Because of fibrosis, loss of elasticity, and reduced vascularity, mobilization of structures may be difficult. Repair of UPJ scarring is more challenging in TB cases than for congenital stenosis. Dismembered pyeloplasty is feasible for extrarenal pelves with short segment scarring. Nondismembered (flap) pyeloplasty is preferred for longer strictures but may not be feasible because of excessive scarring of the pelvis. When anatomic reconstruction is not possible, ureterocalicostomy (anastomosis of the ureter to the lower pole calyx) is an option. The renal capsule should be preserved to cover the lower pole of the kidney. If not enough capsule is available, omentum can be used to avoid stenosis at the calicoureteral anastomosis (Carl and Stark, 1997).

Upper and middle ureteric strictures can be managed by excision of the diseased segment, and, with adequate mobilization, a primary tension-free ureteroureterostomy can be performed. Alternatively, lysis of adhesions and intubation (Davis intubated ureterotomy) may be done. Lower ureter strictures requiring surgery are best managed by complete excision of the entire affected ureteric segment back to healthy ureteric mucosa that has good blood supply. The resultant gap is bridged with a tension-free, well-vascularized anastomosis to healthy bladder (ureteroneocystostomy). Various procedures exist to bring the bladder closer to the ureteric end. Simple mobilization of the lateral attachments of the bladder on the contralateral side, accompanied by dividing the superior vesical artery, may provide 2 to 3 cm of length to bridge a small gap. In patients with good bladder capacity, a psoas hitch may also be performed. Care must be taken to avoid the genitofemoral and femoral nerves when placing these sutures. A well-performed psoas hitch can bridge a gap of up to 5 cm. A Boari flap is another method of bridging a longer gap of 10 to 15 cm and may be performed in combination with a psoas hitch (Sankari, 2007). A poorly executed Boari flap can compromise bladder capacity. Contracted bladders from TB cystitis may not have sufficient surface area and elasticity to allow flap creation. Finally, ileal interposition (ileal ureteric replacement) can be done in cases of multiple or recurrent strictures in which the native ureter is no longer an adequate conduit (Goel and Dalela, 2008).

Bladder Surgery.

Augmentation cystoplasty and bladder substitution are options in the management of the tuberculous contracted bladder. First described in the 19th century for a tuberculous contracted bladder, augmentation is indicated when frequency, nocturia, urgency, pain, and hematuria, become intolerable—typically when bladder capacity is less than 100 mL (Gupta et al., 2008). For severely contracted bladders, ileocecum or sigmoid segments are most suitable. When only half the bladder is diseased, ileum is often used. Other segments used in augmentation include stomach and cecum. The general rules of incorporating the bowel into the urinary tract apply, such as thoroughly evaluating renal function, reconfiguring a low-pressure reservoir (de Figueiredo et al., 2006), providing patient education, and conducting long-term follow-up. Thimble bladders with capacity less than 20 mL are best managed by orthotopic bladder substitution

(Hemal and Aron, 1999). Complications of either bladder augmentation or substitution include mucus production, electrolyte derangements, and secondary bacterial infection.

Urethral Procedures.

Bladder neck contracture is best managed endoscopically by transurethral incision of the contracture. Urethral strictures are also managed endoscopically and often require repeated procedures. Tuberculous urethral fistulae are treated by initiation of medical therapy and suprapubic bladder drainage. Delayed reconstruction is preferred. Drainage of a seminal vesicle tuberculous cavity into the bladder by cold knife incision has been reported (Dewani et al., 2006).

Genital Surgery.

Extirpative surgery for genital TB is considered only for patients in whom medical therapy has failed. When the epididymis is infected with sparing of the testis, every effort should be made to perform an epididymectomy alone without orchiectomy. Preserving testicular blood supply is important during dissection of the epididymis. Initiating dissection at the globus minor after ligation of the vas facilitates excision. If the testes are infected, a scrotal orchiectomy can be done. Involvement of the vas deferens by TB is usually distal to the external ring and ligation of at the level of the ring is possible and sufficient.

Monitoring for Tuberculosis Relapse

Even with optimized treatment, as with any infection, TB can relapse in 2% to 6% of pulmonary TB patients, particularly within the first year after treatment (CDC, 2003). A second, longer, or different drug course is then required. GU TB patients may relapse at a higher rate than pulmonary TB patients, in 6.3% to 22% of cases, even after 12 months of medical therapy (Figueiredo and Lucon, 2008). The extensively diseased kidney can contain innumerable foci of tubercle bacilli. Difficulty in achieving complete sterilization of all foci with antituberculous drugs may be the reason for the higher relapse rate. Viable bacilli have been identified in the kidneys even after 9 months of treatment (Figueiredo and Lucon, 2008). In all cases of recurrent TB, extra effort should be exerted to isolate the organism for drug susceptibility testing. Pulmonary TB patients are usually followed for 2 years after completing treatment; for GU TB patients, some investigators have recommended 10 years of follow-up, as the average time of relapse was 5.3 years (Gokce et al., 2002).

Management of Genitourinary Tuberculosis in Special Situations

Each of the special situations below requires careful selection of the antituberculous regimen because of side effects, interactions, and drug toxicities. Expert advice should be sought from infectious diseases specialists or physicians experienced in the treatment of TB.

Multidrug-Resistant and Extensively Drug-Resistant Tuberculosis

Persons with MTBC strains that are resistant to both INH and rifampin (the two most important first-line agents) have MDR-TB by definition. Worldwide, approximately 3.3% of newly diagnosed patients and 20% of previously treated patients have MDR-TB (WHO, 2016). In the United States, 1.4% of TB cases were MDR-TB. The percentage of drug-resistant TB has remained stable in the United States for the last 20 years (CDC, 2017). Treatment is complicated by the need to use regimens typically longer than 18 months. The cure rate is 50% to 60% compared with 94% to 97% in patients with drug-susceptible TB (CDC, 2009). Among MDR-TB cases, 9.7% have additional drug resistance (WHO, 2016). Extensively drug-resistant TB (XDR-TB) is defined by resistance to INH, rifampin, any fluoroquinolone, and at least one of the injectable second-line aminoglycosides (amikacin, kanamycin, or capreomycin). XDR-TB is exceedingly difficult to cure, with complicated patient drug regimens involving 5 to 6 drugs for 2 years or more. As a result, the cure rate of patients with XDR-TB is only 30% to 50% (CDC, 2013)

Pregnancy and Lactation

Women of childbearing age should be advised to avoid pregnancy while being treated for active TB. If the diagnosis is discovered during pregnancy, prompt therapy should be initiated because the risk to the fetus from TB outweighs the risk of adverse drug effects. Treatment consists of INH, ethambutol, rifampin, and pyridoxine for 9 months. The use of pyrazinamide is controversial in the United States because drug effects on the fetus are not well established and because of the perceived increased risk for hepatotoxicity in the pregnant patient.

However, the WHO recommends using pyrazinamide in pregnant women as part of the standard first-line treatment. Postpartum women may breastfeed their infants once noninfectious because drug concentrations in breastmilk are too low to cause toxicity (Nahid et al., 2016).

Human Immunodeficiency Virus Infection

HIV infection increases the risk of active TB 30-fold. With HIV and TB coinfection, each disease accelerates the other. All TB patients should be tested for HIV. Among HIV-positive persons in the world, almost 25% of deaths are due to TB (WHO, 2016). This is reminiscent of TB mortality rates in 18th- and 19th-century Europe.

Extrapulmonary, and consequently, GU TB may be more common in HIV-positive patients. In a small study in India, GU TB was found postmortem in 49% of AIDS patients (Lanjewar et al., 1999). In HIV-positive patients, GU TB can be more disseminated, with more lymph node enlargement and bilateral renal disease. There is usually less caseation, necrosis, and fibrosis because a competent immune system is necessary for the vigorous inflammatory process that leads to fibrosis and scarring. As a result, among patients with GU TB, stenosis of the collecting system occurs less frequently (12.5% vs. 93.8% in HIV-negative persons), and there is a lower incidence of bladder contracture (12.5% vs. 65.3% in HIV-negative persons with GU TB) (Figueiredo et al., 2009). Despite the lower incidence of obstructive cicatricial lesions, GU TB in HIV-positive persons is associated with high mortality.

Treatment in HIV-positive patients with GU TB should not be delayed. Treatment guidelines are similar to those for persons without HIV infection. Short-course chemotherapy for 6 months is effective, and 9 months of treatment is no longer routinely recommended. Instead, duration of treatment is determined by the usual factors: disease location and severity, drugs tolerated, response, and also importantly, whether the patient is on effective antiretrovirals. If the HIV-infected patient is not on consistent and effective antiretrovirals, TB treatment for 9 months is recommended. Daily instead of intermittent treatment is recommended and preferred for HIV-positive patients (Nahid et al., 2016). Drug interactions with antiretrovirals can be complex and must be considered. The rifamycins (rifampin and, to a lesser degree, rifabutin) may decrease serum levels of antivirals to suboptimal levels. Dose increases may be needed as a result (Kaplan et al., 2009).

Renal Transplant Recipients

Renal allograft TB is rare. Infection usually presents in kidney transplant patients within 6 months of transplantation but can occur as late as 7 years after. The shorter interval may be a result of the immunosuppression required for the graft or of pre-existing TB in the donor kidney. Because patients are seen very early in the disease process, no changes are usually visible on imaging. Furthermore, the immunosuppression prevents much of the pathology that is part of the natural course of GU TB. Diagnosis is difficult because many of the symptoms and findings of GU TB are absent. Fever is the usual presenting symptom. Urinary symptoms are present in only 20% of cases (el-Agroudy et al., 2003). Chest x-ray findings are abnormal but not specific in 55% of patients. Regardless of chest x-ray findings, 56% have positive sputum cultures. In one study, urine AFB culture was positive in 100% of patients (Dowdy et al., 2001). Many patients are diagnosed after graft nephrectomy with histopathology (Lorimer et al., 1999).

Treatment is complicated by drug interactions between the rifamycins and the immunosuppressive drugs, necessitating frequent monitoring of serum drug levels and dosing adjustments. Rifamycin-free regimens are possible but lengthen the duration of treatment to at least 18 months. Complications in transplant patients include graft rejection, disseminated TB, and death in up to 36% of patients (Dowdy et al., 2001).

Key Points: Tuberculosis

- Untreated genitourinary TB can lead to irreparable tissue damage with serious consequences such as renal failure and infertility, making it critical for clinicians to consider TB in the differential diagnosis of GU disorders.
- Genitourinary tuberculosis is associated with nonspecific symptoms and can be indolent; typical constitutional symptoms of TB are infrequent. A high index of suspicion is necessary for correct diagnosis.
- The gold standard for diagnosis of genitourinary tuberculosis is a positive AFB culture from urine or tissue biopsy. However, often a diagnosis can be made using alternate methods such as with NAAT or the finding of granulomas on histopathology examination of tissue.
- The optimal timing of surgery is 4 to 6 weeks after the initiation medical

therapy. This delay allows active inflammation to subside, the bacillary load to decrease, and lesions to stabilize.

- Monitoring for relapse is important after treatment of genitourinary TB because it can occur in up to 22% of cases.

Parasitic Infections of the Urogenital Tract

A number of parasitic infections affect the urogenital tract. Although urologists practicing in nonendemic areas may encounter patients with urogenital parasitic infections only rarely, it is nevertheless critical for physicians to understand these diseases to facilitate appropriate diagnosis and therapy of affected individuals. Parasitic infections relevant to urology include urogenital schistosomiasis, filariasis, amebiasis, enterobiasis, and echinococcosis.

Schistosomiasis

More than 200 million people globally are infected by *Schistosoma* species. The three species of primary medical importance are *Schistosoma mansoni* (found primarily in Africa, the Arabian Peninsula, and South America), *Schistosoma japonicum* (China and Southeast Asia), and *Schistosoma haematobium* (Africa and the Arabian Peninsula). Whereas *S. mansoni* and *S. japonicum* affect primarily the liver and gastrointestinal tract, *S. haematobium* infection affects primarily the genitourinary tract and is the focus of this chapter. Urogenital schistosomiasis is a disease featuring a complex parasite life cycle, multifaceted human disease, and close ecological links to the environment. *S. haematobium* likely has coevolved with humans and non-human primates for millennia; as a result, even ancient civilizations realized the constellation of signs and symptoms associated with urogenital schistosomiasis.

History

The presence of schistosome antigens in Egyptian mummies (circa 3500 BCE), including more recent mummies with confirmed *S. haematobium* eggs in tissues (Deelder et al., 1990), confirms that urogenital schistosomiasis has been with *Homo sapiens* for millennia. Indeed, the Egyptians recognized this infection and named it “A-a-a disease”, which was depicted hieroglyphically by a penis dripping with bloody urine (Hanafy et al., 1974; Shokeir et al., 1999). Later, the German pathologist Theodore Bilharz, performing autopsies in Cairo in 1852, found worms in mesenteric veins and linked them to eggs found in human urine and stool.

Biology and Life Cycle

Human infection is initiated by the penetration of *S. haematobium* cercariae through (even intact) skin that is in contact with infested fresh water (Fig. 60.8). The average lifespan of cercariae is 1 day. Penetration success rates fall off quickly within hours of cercarial shedding from the intermediate snail host (King, 2006).

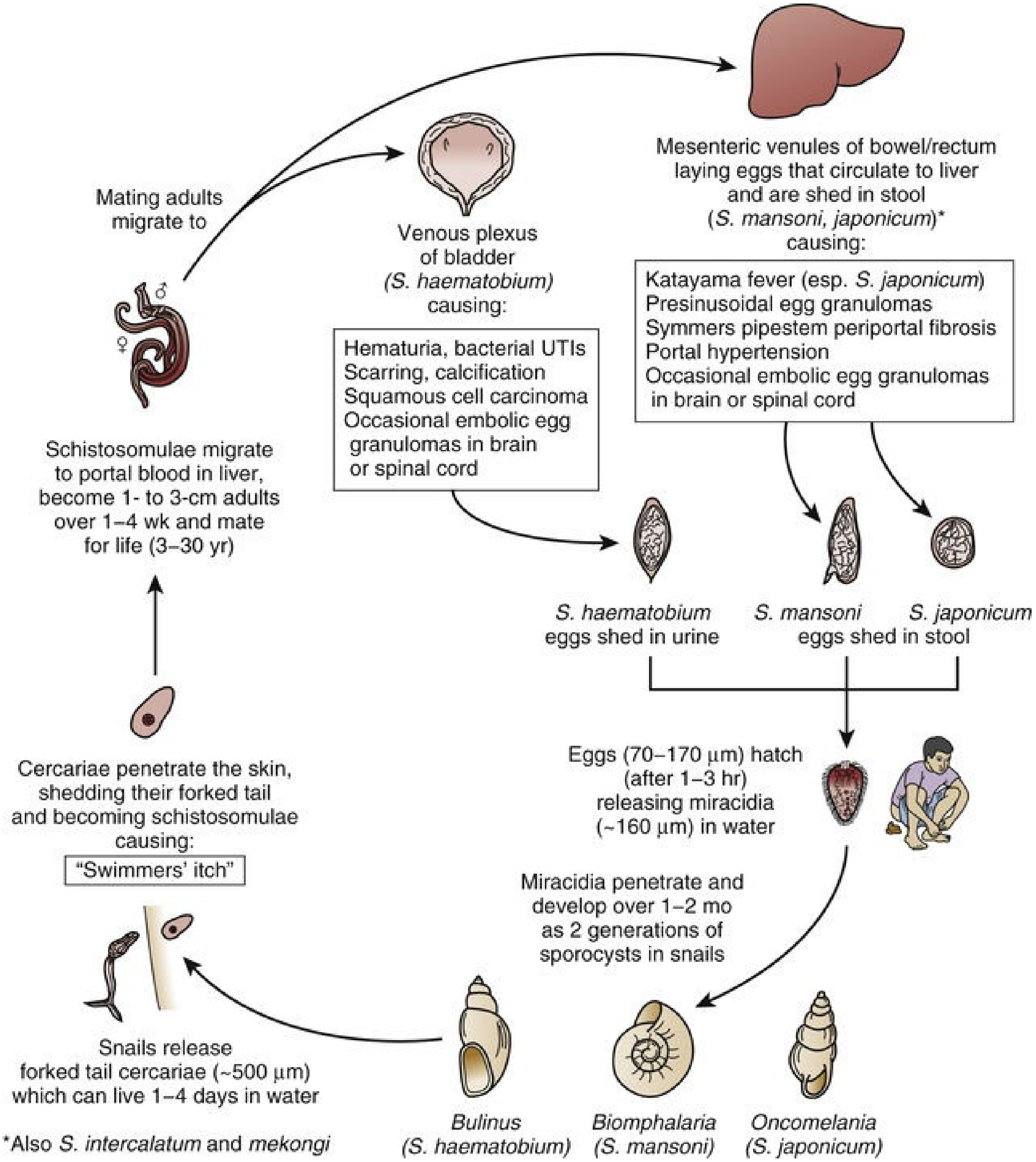
Mating adults migrate to
♂
♀
Venous plexus of bladder (*S. haematobium*) causing:
Hematuria, bacterial UTIs
Scarring, calcification
Squamous cell carcinoma
Occasional embolic egg granulomas in brain or spinal cord
Mesenteric venules of bowel/rectum laying eggs that circulate to liver and are shed in stool (*S. mansoni, japonicum*)* causing:
Katayama fever (esp. *S. japonicum*)
Presinusoidal egg granulomas
Symmers pipestem periportal fibrosis
Portal hypertension
Occasional embolic egg granulomas in brain or spinal cord
Schistosomulae migrate to portal blood in liver, become 1- to 3-cm adults over 1–4 wk and mate for life (3–30 yr)
S. haematobium eggs shed in urine
S. mansoni *S. japonicum* eggs shed in stool
Eggs (70–170 µm) hatch (after 1–3 hr) releasing miracidia (~160 µm) in water
Cercariae penetrate the skin, shedding their forked tail and becoming schistosomulae causing:
"Swimmers' itch"
Miracidia penetrate and develop over 1–2 mo as 2 generations of sporocysts in snails
Snails release forked tail cercariae (~500 µm) which can live 1–4 days in water
*Also *S. intercalatum* and *mekongi*
Bulinus (*S. haematobium*)
Biomphalaria (*S. mansoni*)
Oncomelania (*S. japonicum*)

FIG. 60.8 Life cycle of a schistosome. *UTIs,* Urinary tract infections.

(From King CH: Schistosomiasis. In Guerrant RL, Walker DH, Weller PF, editors: *Tropical infectious diseases, principles, pathogens, and practice*, ed 2, Philadelphia, 2006, Elsevier Churchill Livingstone, pp 1341–1348.)

After penetration, schistosomes transform from free-living cercariae into obligate parasites called *schistosomulae* by first shedding their tails over approximately 90 to 120 minutes and then undergoing a series of structural changes (Melo and Pereira, 1985). The transformed schistosomulae migrate to the lungs via the bloodstream or lymphatics and then the liver via the venous circulation (Wilson, 2009). Migration out of the skin and into the lungs takes several weeks (Rheinberg et al., 1998; Wilson, 2009).

The juvenile schistosomes then arrive at the liver sinusoids via the venous circulation, where they begin blood feeding. Soon thereafter, the now-mature worms preferentially migrate to the venous plexus of the bladder and other pelvic organs, where they live an average of 3 to 5 years. The developmental period from cercaria to adult worm ranges from 80 to 110 days. After worm pairing, males clasp the females in a ventral groove termed the “gynecophoric” canal, using their muscular bodies to help females pump host blood into their mouths and secreting chemical signals to stimulate oviposition (Gupta and Basch, 1987).

Eggs are laid by adult female worms in the pelvic venous circulation. Human schistosomes are very fecund, with egg-laying rates of hundreds to thousands of eggs per female per day. *S. haematobium* eggs are ovoid, measuring approximately 140 microns long and featuring a terminal spine (Loker, 1983; Ratard and Greer, 1991; Fig. 60.9). Eggs must penetrate the endothelium to reach the lumen of bladder to exit in the urinary stream, reach fresh water, and hatch to become miracidia. Some *S. haematobium* eggs are also excreted into the feces after expulsion from the intestinal wall. It is estimated that less than half of the eggs produced are successfully excreted in urine. The rest are retained in the body where the immune response causes significant pathology.

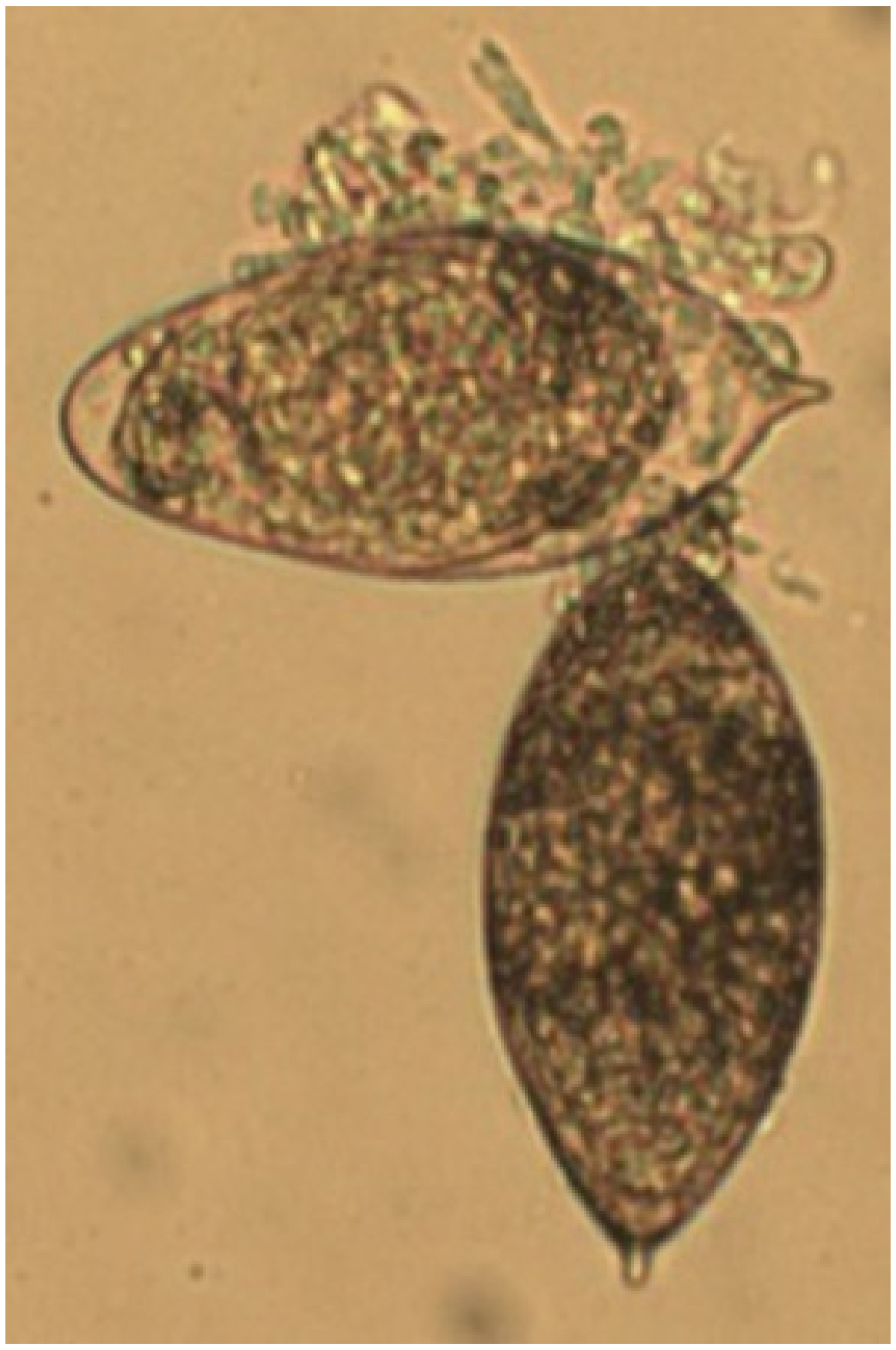

FIG. 60.9 Micrographs of *Schisosoma haematobium* eggs. Note the characteristic terminal spines of the eggs. (From Ray et al., 2012.)

Eggs can survive approximately 20 days as long as they remain wet. Upon contact with fresh water and light, the eggs hatch, releasing miracidia, which are the larval stage of the parasite. The ciliated miracidia of *S. haematobium* infect intermediate host snails of the *Bulinus* genus. *Bulinus* snails prefer slow-flowing fresh-water habitats and are able to withstand low oxygen conditions.

The typical life span of a miracidium is 6 hours. If during this brief period a *Bulinus* snail is encountered, the miracidia will penetrate the snail tissue and form a primary sporocyst. After several days, 20 to 40 daughter sporocysts are generated by the primary sporocyst. These eventually mature into 200 to 400 cercariae (per sporocyst) that are released back into water. The prepatent period (the time between initial penetration of the snail by a miracidium and release of the first cercariae) varies with water temperature, and at temperatures below 15°C or greater than 35°C, no cercariae are shed (Pflüger et al., 1984).

Epidemiology

The geographic distribution of urogenital schistosomiasis is dependent on the tropical conditions required by *S. haematobium* and its specific snail hosts. Consequently, *S. haematobium* is endemic throughout much of sub-Saharan Africa and in portions of North Africa and the Middle East. However, in 2013, 120 schistosomiasis cases were diagnosed on the French island of Corsica, representing the first time autochthonously transmitted schistosomiasis had been detected in Europe for more than a century (Holtfreter et al., 2014). The subsequent finding of additional cases there in 2015 suggests that this may now be an endemic focus of schistosomiasis (Berry et al., 2016). Interestingly, some of these infections may have been caused by *Schistosoma bovis* (typically a bovine-specific schistosome) or *S. haematobium*-*S. bovis* hybrids. Older calculations have estimated that most of the more than 200 million people worldwide with schistosomiasis have the urogenital form of infection (van der Werf et al., 2003). Newer estimates suggest that the number of people with schistosomiasis may be more than 440 million, including *S. haematobium*-induced infection (Colley et al., 2014). Up to 150,000 people die annually from *S. haematobium*-induced obstructive renal failure alone (van der Werf et al., 2003). It has been calculated that in a 2-week period in 2003, 70 million and 32 million individuals in sub-Saharan Africa experienced *S. haematobium*-induced hematuria and dysuria (respectively) and that major bladder wall pathology and major hydronephrosis were present in 18 and 10 million people, respectively (van der Werf et al., 2003).

For individuals, the risk of contracting urogenital schistosomiasis is driven primarily by the nature and length of contact with contaminated fresh water. Rural women and children can be exposed during domestic chores when they use *S. haematobium*-infested ponds, rivers, and lakes as their water supply (e.g., for laundry and dishwashing). Children may also be infected while playing and swimming in infested water. Men and women can be exposed during freshwater fishing, washing cars, and working in agricultural areas with high water-intensity crops such as rice and sugar cane (Hunter et al., 1993). In endemic areas, schistosomiasis prevalence is usually highly focal because of the localized nature of water-dependent transmission.

On a regional level, land-use patterns and ecological changes can lead to a higher burden of schistosomiasis in some areas, sometimes even resulting in outbreaks. For instance, it has been recognized for at least a century that building dams and irrigation schemes can increase schistosomiasis transmission by creating year-round, slow-flowing, fresh water habitats for the intermediate snail hosts and by promoting increased human population density associated with expanded agriculture. Accordingly, data from Africa consistently show that populations living near dams and irrigation schemes have a greater risk of contracting schistosomiasis compared with populations living distantly from these schemes (Steinmann et al., 2006).

In the 1930s, after the construction of the Aswan Low Dam in Egypt that led to a conversion from ancient, flood-based irrigation to perennial irrigation, the prevalence of schistosomiasis increased from less than 11% to more than 75% in some regions (Hunter et al., 1993). A similar series of events occurred after the construction of the Aswan High Dam in Egypt during the 1960s (Malek, 1975) and the Diama Dam in West Africa during the 1980s (Malek, 1975; Talla et al., 1990).

Communities in endemic areas with poor sanitary conditions and especially those without clean, running water generally have the highest prevalence rates of schistosomiasis (WHO, 2014a). Children are disproportionately affected, with the highest parasite burden occurring in those aged 5 to 15 (Anderson et al., 1992). It is unclear whether this age distribution results from higher exposure among children or a higher inherent susceptibility (Woolhouse et al., 1991).

Schistosomiasis is associated with poverty for a number of reasons. First, the aquatic snails that harbor the larval forms of schistosomes are distributed within tropical and subtropical developing countries, whereas they are not present in developed nations in temperate zones. Second, inadequate sanitation facilitates *Schistosoma* transmission because the schistosome life cycle requires an influx of eggs from human excreta into surface fresh waters. Moreover, prolonged contact with surface fresh water is promoted by lack of safe water supplies, leading to a higher risk of infection (Soares et al., 2011). Finally, schistosomiasis contributes to the perpetuation of poverty. Chronic infection adversely affects childhood growth, development, and learning, as well as worker productivity (Bonds et al., 2010).

Pathogenesis and Pathology

Cercarial skin penetration is facilitated by secreted molecules such as proteases, which initiate the cellular and humoral responses to schistosome infection (Curwen et al., 2006). However, likely as a result of the parasite strategy of modulating the host immune response from the moment of first contact, brief cercarial penetration does not typically induce an immune response beyond localized skin inflammation (Jenkins et al., 2005). Regardless, repeated exposure to schistosomulae can lead to hypersensitization and the development of a maculopapular rash.

During subsequent maturation into adult worms, schistosomulae begin to generate a double lipid bilayer outer surface (the tegument) that allows them to evade an immunopathologic response and remain in the host for years, facilitating chronic infection. As the survival of the worm within the host depends significantly on the tegument, numerous mechanisms are employed for immune evasion, including host antigenic mimicry, continual membrane turnover, immunomodulatory proteins and proteases, host-evading biophysical properties of the tegument, and modulation of expression of surface antigens (Abath and Werkhauser, 1996).

Because it is difficult to study the natural pathogenesis of egg-associated disease in humans, much of our knowledge stems from autopsy studies and animal models. In contrast to the relatively silent immune response to worms, the main immunopathologic responses raised against *S. haematobium* are triggered by oviposition in the walls of the bladder and other pelvic organs. With heavy worm burdens, egg deposition in the pelvic organs leads to granuloma development and eventual fibrosis, often obstructing the flow of blood or urine. Granulomas are characterized by a mixed leukocytic infiltration, including eosinophils, plasma cells, and lymphocytes. Because of continuous oviposition, all stages of granulomas are simultaneously present in individuals with chronic infection. Composite, coalescing granulomas are common, secondary to *S. haematobium* egg deposition in clusters. Grossly, granulomatous inflammation can form bulky, hyperemic, and polypoid masses projecting into the bladder lumen (Fig. 60.10). Other factors that have been shown to influence the host immune response and resulting disease severity include host genetics, in utero sensitization to parasitic antigens, and co-infection by other microbes/parasites (Pearce and MacDonald, 2002). *S. haematobium* eggs appear to rapidly induce bladder expression of type 2 inflammation–associated genes and suppress transcription of urothelial barrier function-related genes (Fu et al., 2012; Ray et al., 2012). These findings suggest that the parasite and human host may share the goal of expelling eggs from the bladder wall, across a temporarily lowered urothelial barrier, and out into the urinary stream.

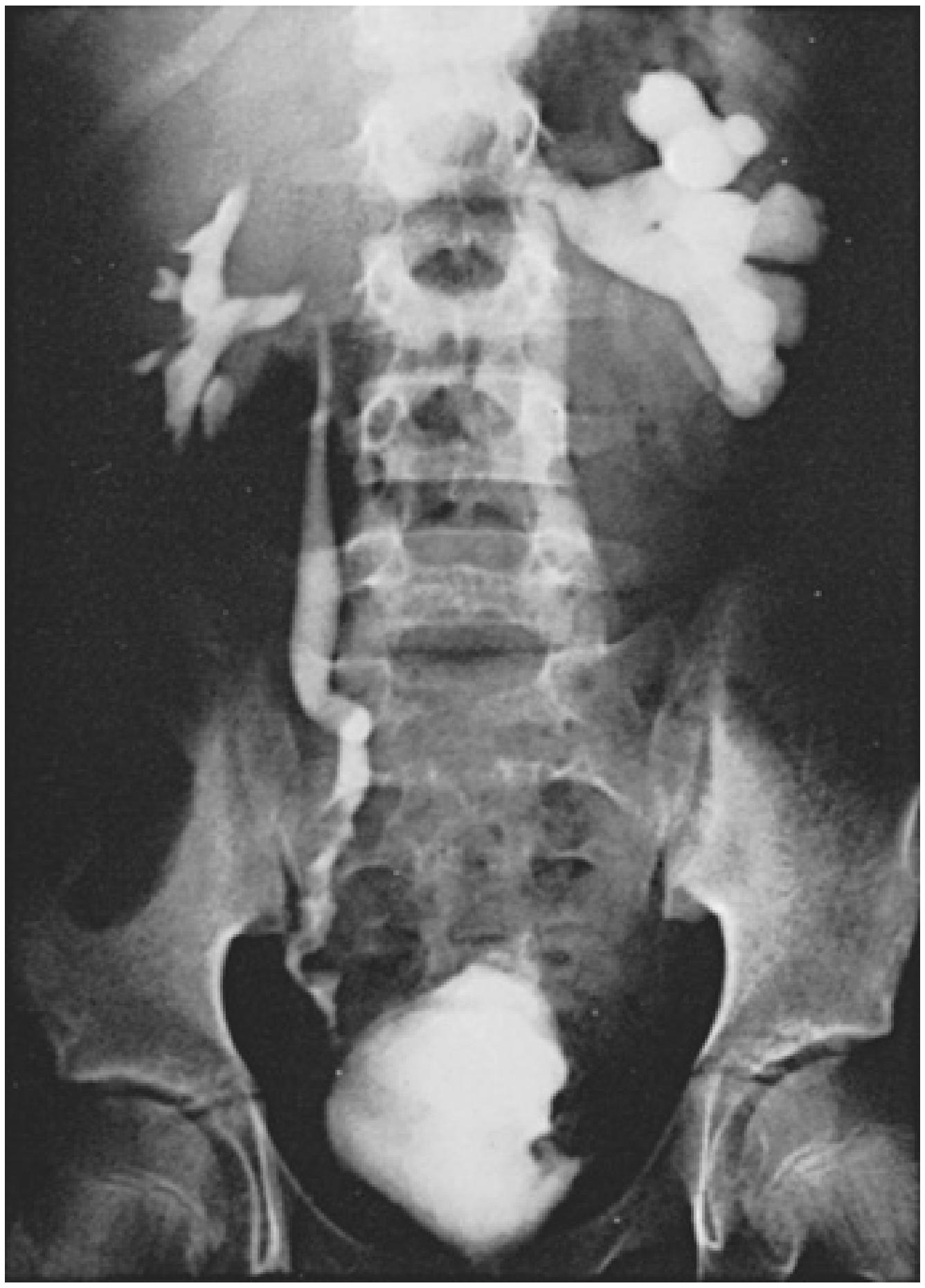

FIG. 60.10 Intravenous urogram in an Egyptian boy shows scalloping of the bladder and right lower ureter by schistosomal polypoid lesions.

Although *S. haematobium* has tropism for the pelvic organs, some oviposition occurs in the portal tract. As a result, portal hypertension can occur if a large burden of eggs are swept into the liver, clog pre-sinusoidal capillaries, induce granuloma formation, and consequently block the hepatic vasculature. Alternatively, embolized eggs can cause granulomatous and fibrotic portal areas and the dilation of collateral porto-systemic shunts, permitting the lodging of eggs in these vessels and the formation of pipe-stem fibrosis (Symmer's fibrosis) (Aubry et al., 1980). Hepatosplenomegaly is one clinical manifestation of Symmer's fibrosis, although susceptibility to its development depends largely on the variability of individual immune responses. Besides portal involvement, migration of worm pairs to the pulmonary vessels can result in oviposition in the lungs. Generally, pulmonary schistosomiasis develops only in very severe cases of infection and when pathogenesis in other organs (i.e., pelvic) has already occurred (Borgstein, 1964). When pulmonary oviposition occurs, eggs may obstruct the lung vasculature and lead to pulmonary fibrosis, pulmonary hypertension, and/or cor pulmonale (Bedford et al., 1946).

Naturally acquired immunity to urogenital schistosomiasis exists: some individuals maintain negative urine egg counts for at least 5 years despite never receiving anthelmintics in the face of continual exposure to *S. haematobium* (McManus and Loukas, 2008). The resistance of these individuals to reinfection has been attributed to the involvement of a T-helper type 1 (Th1) and a Th2-type cytokine response, whereas chronically infected individuals exclusively mount a Th2 response (McManus and Loukas, 2008). In some individuals, the activity of potentially protective IgE antibodies may be blocked by IgG4 antibodies generated against worm and egg antigens, possibly hampering the development of protective immunity to schistosomiasis (Hagan et al., 1991).

Because levels of IgE antibodies to worm antigens have been observed to increase with age (Roberts et al., 1993), many workers have suggested an immune-mediated development of resistance. This age-dependent trend, however, could be due to either behavioral or immunologic changes, because studies in endemic communities have ascertained a general decline in contact with infected water with increasing age (Dalton and Pole, 1978). Nevertheless, recent analyses suggest that even when exposure to infected water is controlled, age may play a role in the development of resistance.

Eggs that are not promptly expelled from pelvic organs calcify, including those in the bladder and ureters. The accumulation of eggs results in decreased compliance of the urinary tract and increases upper tract pressures. In turn, this promotes the development of urinary stasis, hydronephrosis, and hydroureter (Cheever et al., 1975). The extent of organ calcification can often be identified through radiologic imaging and is roughly correlated with the tissue burden of calcified eggs (Cheever et al., 1975). The anatomic level of obstruction involves the ureteral meatus (1%), interstitial ureter (10% to 30%), juxtavesical ureter (20% to 60%), lower third of the ureter (15% to 50%), or a contiguous combination of these areas (30% to 60%) (Al-Shukri and Alwan 1983; Gelfand, 1948; Smith et al., 1977). Three patterns of hydroureter are associated with urogenital schistosomiasis: segmental (i.e., cylindrical or fusiform), tonic, and atonic (Smith et al., 1977). About one-quarter of obstructive uropathy cases involve segmental ureteral dilation; 80% of those cases occur in the lower ureter. The dilations occur above areas of concentric ureteral muscular replacement by fibrosis and sandy patches. It is unusual for segmental lesions to cause significant hydronephrosis. Up to 30% of obstructive uropathy is caused by tonic hydroureter. This is characterized by dilated, tortuous, thick-walled, and trabeculated ureters with marked ureteral muscular hypertrophy and impaired peristalsis. Typically, the entire ureter proximal to an obstructive lesion is involved, generating a functional stenosis. This is often accompanied by significant hydronephrosis, which is reversible if the obstruction is relieved (Smith et al., 1977). Atonic hydroureters are found in the remaining patients with obstructive uropathy. These ureters are markedly dilated, very tortuous and thin-walled, lack peristalsis, and are associated with atrophic, fibrotic ureteral muscle.

Schistosomal hydroureter typically precedes hydronephrosis (Cheever et al., 1978; Lehman et al., 1973). Left untreated, schistosomal hydronephrosis progresses from worsening renal pelvic dilation to medullary atrophy to medullary effacement and cortical atrophy (Smith et al., 1974; Smith et al., 1977). This pathophysiological sequence accounts for the abrogation of tubular function (especially concentrating ability) before compromise of glomerular function (Lehman et al., 1971; Lehman et al., 1973).

Patients with chronic *S. haematobium* are at increased risk of bacterial urinary tract superinfections (Adeyeba and Ojeaga, 2002; Laughlin et al., 1978; Uneke, 2009), possibly because the bacteria can affix to the tegument of adult worms, or secondary to urinary stasis or immunomodulation. Patients infected with *S. haematobium* are also at higher risk for bladder cancer, especially squamous cell carcinoma. The relationship between *S. haematobium* and bladder cancer is perhaps the strongest of any helminthic infection-cancer association. This association is supported by epidemiologic studies (particularly in Egypt) and experimental models (Mostafa et al., 1999). Rates of bladder cancer are linked with duration and severity of infection and are associated with a mortality rate as high as 10.8 per 100,000 males in Egypt (Mustacchi, 2003).

Female genital schistosomiasis (FGS) remains poorly understood. Sequestration of eggs in the female reproductive tract results in the formation of fibrotic nodules, or “sandy patches,” in the uterus, cervix, and lower genital tract (Badawy, 1962) (Fig. 60.11). Little is known about the mechanism through which *S. haematobium* generates female genital disease aside from the increased vascularization of the female genital mucosa that occurs due to the presence of eggs (Jourdan et al., 2011).

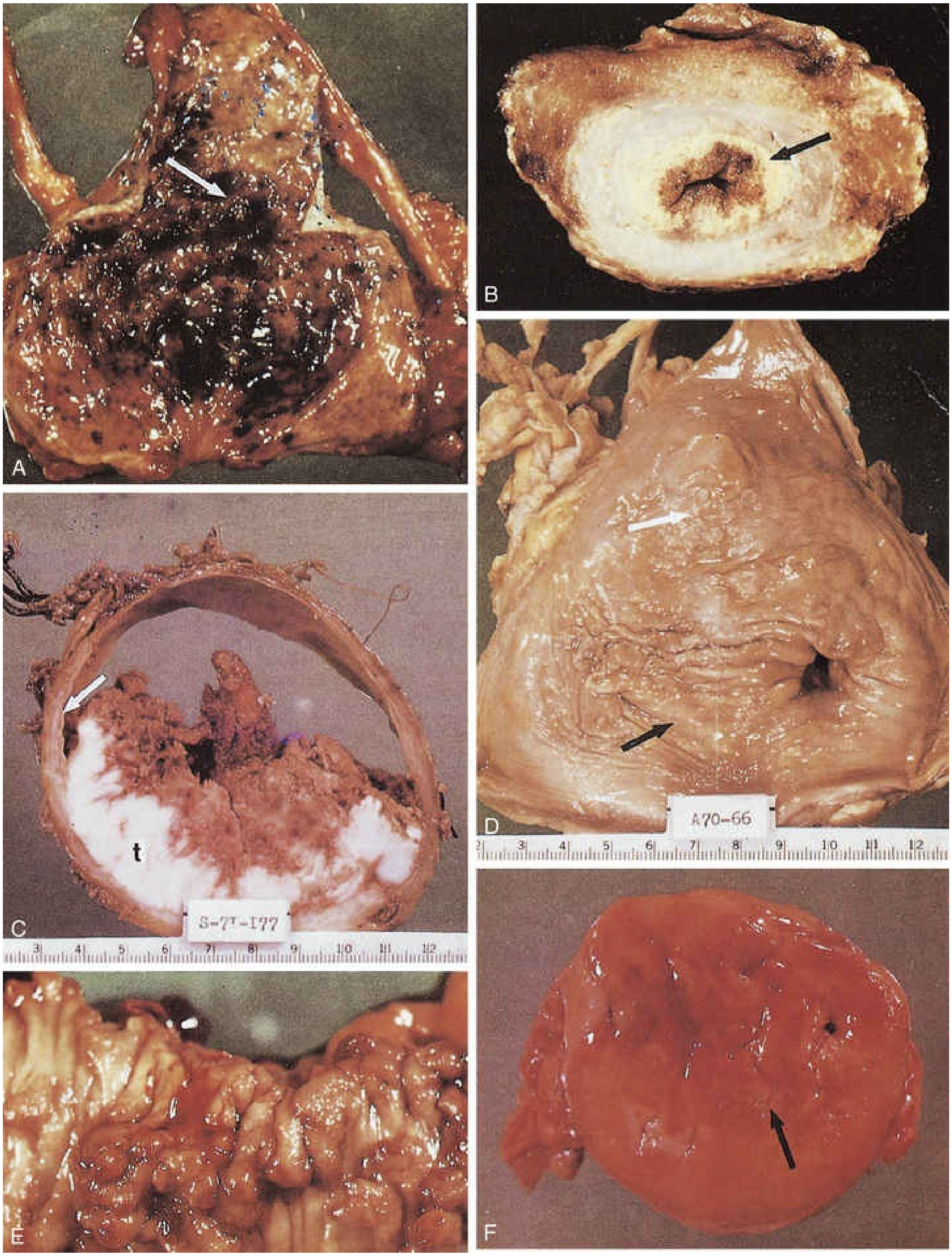

FIG. 60.11 Macroscopic appearance of human urinary schistosomiasis. (A) Urinary bladder opened with an anterior Y incision. The posterior and apical walls have many erythematous, granular, sessile, and pedunculated polyps *(arrow)* characteristic of the early active stage of urinary

schistosomiasis. (B) Coronal section through the apex of a formalin-fixed urinary bladder. The lamina propria has been expanded and is replaced by a yellow-tan, finely granular, sandy patch *(arrow),* which is characteristic of chronic inactive foci. Small, sandy patches are sprinkled through the fibrotic, atrophic detrusor muscle, even in perivesical fat. The more superficial erythematous portion of the lamina propria contains some viable eggs with granulomatous response (chronic active stage of urinary schistosomiasis). (C) Coronal section through the middle of a urinary bladder after formalin inflation and fixation. The lamina propria *(arrow)* has been replaced by a concentric sandy patch, most prominent at the margin of the exophytic, moderately differentiated squamous cell carcinoma. The bladder wall is attenuated except for the tumor (t). No evidence of recent oviposition was found in the lower urinary tract (chronic inactive stage of urinary schistosomiasis, usually found with the bilharzial bladder cancer syndrome). (D) Urinary bladder opened with anterior Y incision shows several features of severe chronic inactive urinary schistosomiasis. The entire lamina propria has been replaced by a sandy patch. Foci of epidermization are seen at or near the *white arrow.* The left ureteral orifice (right) is markedly dilated (the so-called golf-hole ureter of schistosomal uropathy). The right ureteral orifice *(point of black arrow)* is markedly stenotic. (E) Rectosigmoid colon with polyposis. Numerous sessile and pedunculated polyps are seen. Many are erythematous, indicative of active oviposition with granuloma formation. Some have necrotic hemorrhagic tips. (F) Mucosal surface of partial cystectomy specimen (4- to 5-cm ellipse) from a patient with the chronic inactive stage of the disease. There is a stellate chronic schistosomal ulcer. Despite the inactivity of the disease, these ulcers may bleed profusely. Pale mucoid flecks at the margin of the ulcer *(arrow)* are areas of adenoid (goblet cell) metaplasia.

Other bladder sequelae of long-term *S. haematobium* infection include the development of urothelial hyperplasia, squamous metaplasia, urothelial dysplasia, and eventually urothelial or squamous cell carcinoma. Bladder cancer is the final pathological sequela of schistosomiasis. Schistosomal bladder cancer features an early onset (40 to 50 years) and is often squamous cell carcinoma (60%–90%) or adenocarcinoma (5%–15%) (Al-Shukri et al., 1987; Bedwani et al., 1998; Cheever et al., 1978; Lucas, 1982; Thomas et al., 1990). More than 40% of schistosomiasis-associated bladder squamous cell carcinomas are well differentiated and verrucous and feature an overall good prognosis. Tumors are found on the posterior wall about half of the time and on the lateral wall approximately 30% of the time. Exophytic neoplasms account for roughly two-thirds of schistosomal bladder cancers, whereas the remainder are ulcerative endophytic tumors. Mass drug administration (MDA) campaigns in Egypt have been associated with an overall reduction of bladder neoplasms from 28% to 12% and a shift from squamous cell carcinomas to transitional cell carcinomas

(Gouda et al., 2007). Although transitional cell carcinomas of the bladder are less frequently associated with *S. haematobium* infection (Michaud, 2007), some epidemiologists believe that the relatively high rate of smoking in schistosomiasis-endemic regions may further increase the risk of bladder cancer, possibly synergistically with *S. haematobium* infection (Bedwani et al., 1998). However, some unselected autopsy series from the same regions have reported similar frequencies of bladder cancers in patients without schistosomiasis (Cheever et al., 1978; Smith et al., 1977).

Egg deposition into the bladder wall has been implicated as a major factor in carcinogenesis, and *S. haematobium* has recently been classified as a “Class I” agent (“carcinogenic to humans”) by the International Agency for Research on Cancer within the World Health Organization (Working Group, 2011). Vascular endothelial growth factor (VEGF) is increased in the bladder early after *S. haematobium* egg exposure (Fu et al., 2012; Ray et al., 2012; Salem et al., 2012). VEGF may promote tumor vasculogenesis and facilitate carcinogenesis and/or cancer progression. One potential pathway of schistosomal bladder oncogenesis may be initiated when papillomas merge with the basal transitional epithelium, forming benign fibro-epithelial papillary growths. After successive episodes of inflammation and fibrosis, some of the urothelial cells may sequester together (or expand clonally) and form potentially precancerous lesions, including squamous metaplasia (Mustacchi, 2003). Molecular profiling of the mouse bladder indicates that *S. haematobium* egg exposure induces transcriptional alterations in bladder carcinogenesis-related signaling pathways (Ray et al., 2012). Bacterial urinary tract co-infections may also contribute to *S. haematobium*-associated bladder carcinoma, given that *S. haematobium* increases the ability of bacteria to reduce nitrates to nitrosamines, which can alkylate proteins and nucleic acids (Grisham and Yamada, 1992). Resulting mutations in oncogenes (i.e., p53) may then contribute to neoplasia (Mustacchi, 2003).

Clinical Manifestations

Acute schistosomiasis encompasses the transient human responses to cercarial penetration and the longer-lasting responses to schistosome tissue migration and maturation. Chronic schistosomiasis results from the immune response to protracted oviposition, often lasting for years and leading to organ damage. As a result, clinically apparent chronic schistosomiasis is limited to long-term residents of endemic areas, who are continually re-infected, have long-term, high worm burdens, and are re-exposed to eggs. As with most human helminths, *Schistosoma* spp. cannot complete their life cycle nor replicate in the human host. Thus, in tourists or short-term visitors who are exposed once to the parasite, even in the absence of efficacious chemotherapy, adult worms die of senescence within 3 to 5 years, limiting subsequent pathology.

Acute Schistosomiasis.

The first clinical manifestation of schistosomiasis is often an itchy maculopapular rash (cercarial dermatitis), usually within 1 to 2 days of cercarial penetration. The rash usually resolves before travelers have returned from endemic areas, making the diagnosis more difficult (Stuiver, 1984).

Between 2 and 8 weeks later, acute schistosomiasis is seen in some patients during their primary infection (although it is silent in many). The well-known eponym for acute schistosomiasis, “Katayama fever,” is named after early descriptions of the syndrome in the Katayama Valley in Japan; it occurs most commonly with heavy primary *S. japonicum* infections, less commonly with *S. mansoni*, and rarely with *S. haematobium*. The initial signs and symptoms of Katayama fever include fever, dry cough, fatigue, headache, diarrhea, eosinophilia, neck pain, and urticaria (Jauréguiberry et al., 2010). Acute schistosomiasis is seen rarely among people living in endemic areas (Meltzer et al., 2006). Because the signs and symptoms of acute schistosomiasis are nonspecific, cases often remain undiagnosed or confused with other endemic diseases such as malaria or enteric fever (Jensen et al., 1995).

Because acute schistosomiasis may be clinically silent, all individuals with exposure to potentially infested water should be aware of the possibility of infection, with considerations for accurate diagnosis and treatment based on these factors (Jauréguiberry et al., 2010).

Chronic Schistosomiasis.

Adult *S. haematobium* worm pairs shed eggs into the bladder wall beginning about 8 to 12 weeks after infection. This is sometimes heralded by painless, recurrent hematuria, dysuria, or urinary frequency (Mahmoud, 2001). In some highly endemic cultures, hematuria in males is seen as a sign of puberty, and can be sufficiently severe as to result in anemia (Wilkins et al., 1985). Proteinuria is also often associated with urogenital schistosomiasis. Hematuria is a consistent and specific enough sign of infection that it is used as a primary diagnostic technique in endemic areas. However, given the many other possible causes of hematuria, urogenital schistosomiasis is often unsuspected and misdiagnosed in infected travelers returning to their nonendemic, home countries (Raglio et al., 1995).

Long-term urogenital schistosomiasis results in fibrosis that may obstruct urinary drainage and result in organ dysfunction. Egg deposition in the ureters and subsequent granuloma, polyp, and ulcer formation increases the risk of hydronephrosis and hydroureter because of impaired peristalsis of the walls of the renal pelvis and ureter, which in turn can result in obstruction and vesicoureteral reflux. Recovery of renal function may be achieved through anthelminthic therapy in shorter term infections, although surgical repair of the ureter or urinary diversion may be necessary during late stage or more severe disease (Mahmoud, 2001).

Female genital schistosomiasis (FGS) is another form of chronic schistosomiasis that occurs in 33% to 75% of females with *S. haematobium* infection as a result of eggs deposition into the Fallopian tubes, cervix, vagina, vulva, ovaries, and/or uterus (Kjetland et al., 2012). Friable mucosal lesions ("sandy patches") can result, which often bleed on contact during pelvic examinations or sexual intercourse (Hotez and Fenwick, 2009). Dyspareunia, pelvic and abdominal pain, vaginal bleeding and discharge, urinary frequency, and infertility are common, but resemble urinary tract infections and sexually transmitted diseases of other etiologies, so FGS is often misdiagnosed and left untreated (Hotez and Fenwick, 2009).

Men can carry high numbers of *S. haematobium* eggs in the ejaculatory ducts and seminal vesicles, and blood and/or schistosome eggs may be present in the ejaculate before they are detectable in the urine. Patients with involvement of these urogenital structures often present with a testicular mass or scrotal pain. Egg burdens of the epididymis, ovaries, and fallopian tubes are generally higher than those of the testes, uterus, and vagina (Cheever et al., 1977; Cheever et al., 1978; Helling-Giese et al., 1996).

As infection progresses, a late, chronic, active stage develops when tissue egg burdens peak. Chronic suprapubic and pelvic pain with associated urinary urgency, frequency, and incontinence are classic for the "schistosomal contracted bladder" (Duvie, 1986). Frequently the trigone appears normal or somewhat hyperemic and edematous, whereas the remainder of the detrusor muscle is thickened and indurated, as is the entire bladder wall. Functional bladder capacity can be as low as 50 mL in adults.

Over years, active infection becomes more quiescent, oviposition and egg excretion occur at a lower rate, and symptoms are dampened. More than 30% of light infections become asymptomatic in some endemic regions (Rutasitara and Chimbe, 1985). In spite of this, clinically silent obstructive uropathy may evolve throughout this period as fibrosis replaces polypoid lesions and the bladder and ureters undergo sometimes irreversible damage. As a result, severe hydroureteronephrosis can develop insidiously.

Infected individuals can enter a chronic inactive phase, in which viable eggs are no longer detected in urine or tissues. Signs and symptoms at this stage are caused by sequelae and complications of the immune reaction to the calcified, dead eggs rather than the schistosomal infection itself. Unfortunately, among patients with schistosomal obstructive uropathy, 40% to 60% see urologists at this end stage (Smith and Christie, 1986). In heavily endemic regions, poorly or nonfunctioning kidneys are common in patients who are asymptomatic. About half of patients develop bacterial urinary tract co-infections superimposed on their schistosomal obstructive uropathy. The bacteria associated with urogenital schistosomiasis are the same organisms that cause UTIs in patients without schistosomiasis. Some series have noted an association of chronic or recurring urinary tract infections caused by *Salmonella*, often associated with intermittent bacteremia in some patients with urogenital schistosomiasis (King, 2001). The latter association suggests that *Salmonella* bacteriuria in this setting may actually be “spillover” of bacteremia into the urinary stream. *Salmonella* organisms reside in the apical invaginations of the schistosome tegument, where they are sheltered from host defenses and antibiotics. Awareness of this association can lead to treatment of both infections with good response. Antibiotics alone do not fully resolve this process.

Another manifestation of urogenital schistosomiasis is the development of bladder urothelial ulcers (Smith et al., 1977). Acute schistosomal ulcers rarely are seen in the active stage, when necrotic polyps slough into the urine leaving behind a urothelial ulcer. The more common chronic bladder ulcer is a late sequela of heavy infection. This lesion is associated with a constant “burning” and intense suprapubic and pelvic pain. The majority of these patients exhibit gross hematuria and pyuria.

Eosinophilia is very common during acute schistosomiasis and is seen even during chronic infection. During chronic infection, the eosinophilia is usually low grade, and although neither sensitive nor specific for schistosomiasis, its presence can be a clue that a parasitic infection such as schistosomiasis may be present. Exceptions to this usual sequence of acute and chronic infection may occur and sometimes manifest in the form of ectopic pulmonary schistosomiasis, neuroschistosomiasis, and female genital schistosomiasis.

Diagnosis

Finding *S. haematobium* eggs in urine or stool remains the gold standard for diagnosis of active infection, although eggs do not appear until oviposition begins 8 to 12 weeks after initial infection. As maximal egg shedding in the urine peaks at noon, urine samples should be ideally collected between 9 AM and 3 PM for examination (Doehring et al., 1983; Doehring et al. 1985). Urine samples can be concentrated to increase sensitivity and detect low-intensity infections. If eggs are not found in the urine or stool but clinical suspicion remains high and serology is consistent with exposure, tissue biopsy can be considered. A rectal snip biopsy should be performed before a bladder biopsy, because eggs are common in the rectal mucosa and the risk of a bladder biopsy-related complication (i.e., infection, perforation) is avoided. A squash preparation of the biopsy specimen between glass slides is superior to histopathologic analysis, because it is more sensitive and allows determination of egg viability. In potential cases of female genital schistosomiasis, microscopic inspection of biopsies of lesions on the vulva, vagina, or cervix may result in egg identification and diagnosis (Helling-Giese et al., 1996). Visual- and dipstick-based detection of gross or microscopic hematuria and urine turbidity are also used to indirectly diagnose urogenital schistosomiasis, although these methods are less sensitive and specific and best combined with already-established diagnostic tools; they are most commonly used in the developing world as part of control and elimination campaigns (Adesola et al., 2012).

Serologic tests that combine a FAST-ELISA followed by Western blot analysis are available at the Centers for Disease Control and Prevention (CDC) (Al-Sherbiny et al., 1999; CDC, 2014; Wilson et al., 1995). Together, the assays are more than 90% sensitive and specific for *S. haematobium* infection. In cases in which the diagnosis is suspected but eggs are not present, serology can be useful but does not distinguish between acute and chronic infection because antibody titers remain positive even after curative chemotherapy. Other serologic assays are also available at commercial laboratories. Patients generally first become antibody positive about 4 to 6 weeks after infection (Schwartz et al., 2005).

Ultrasonography can also be useful and may demonstrate bladder or ureteral wall thickening, polypoid lesions, hydroureter, hydronephrosis, urinary tract calcifications, and even bladder carcinoma (Kardorff and Döhring, 2001). Plain abdominal radiographs may reveal urinary tract calcifications; a calcified bladder, which may resemble a fetal head in the pelvis, is characteristic of chronic urogenital schistosomiasis (Fig. 60.12). The prostate, seminal vesicles, posterior urethra, distal ureters, and, occasionally, colon may also demonstrate calcifications.

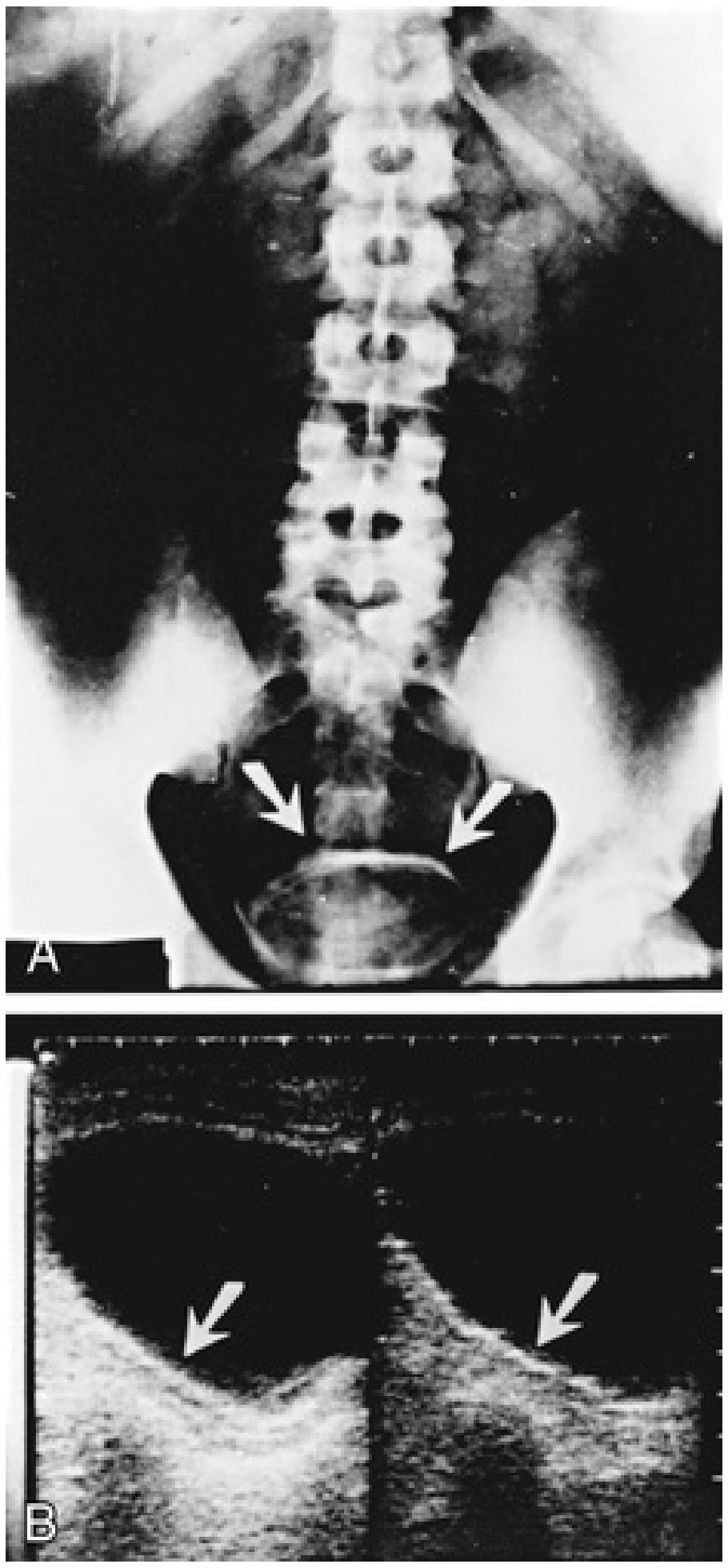

FIG. 60.12 Bladder calcification in a 30-year-old Egyptian farmer. (A) Plain x-ray film of the abdomen shows a rim of calcification surrounding the urinary bladder *(arrows).* (B) Abdominal ultrasound study shows a bright line surrounding the bladder with a definite dark rim behind it *(arrows).* (A and B, Courtesy G. Thomas Strickland, MD. From Abdel-Wahab MF, Ramzy I, Esmat G, et al.: Ultrasonography for detecting Schistosoma haematobium urinary tract complications: comparison with radiographic procedures. *J Urol.* 148:346, 1992.)

The earliest radiographic changes on intravenous urography appear to be striations in the ureters and renal pelvis (Hugosson, 1987). Ureteral calcification is typically intramural, and the ureters are dilated. This differs from the calcifications seen in tuberculosis, which form casts of nondilated ureters. Other findings on intravenous urography include hydronephrosis, hydroureter, nonfunctioning kidney, ureteral stenosis, and bladder and ureteral filling defects caused by polypoid lesions. Similar lesions can also be identified through ultrasonography. With intravenous urography, delayed films are often necessary in the presence of severe obstructive uropathy to discern distended ureters and kidneys. Postvoid views may reveal bladder neck obstruction with retention. Combining intravenous urography with fluoroscopy can differentiate between tonic and atonic ureters (Abdel-Halim et al., 1985) and identify nonstenotic, immobile ureters.

CT can detect obstructive uropathy and calcified lesions in the colon and urinary tract (Jorulf and Linstedt, 1985), a potential advantage over intravenous urography. MRI does not yet seem to provide enough diagnostic superiority to warrant widespread use (Kohno et al., 2008). Fluoroscopic voiding cystourethrography can detect vesicoureteral reflux, which occurs in 25% of infected ureters. Cystourethroscopy may reveal mucosal lesions in the bladder (Fig. 60.13). Retrograde fluoroscopic pyelography during cystourethroscopy may reveal important details regarding ureteral anatomy and drainage.

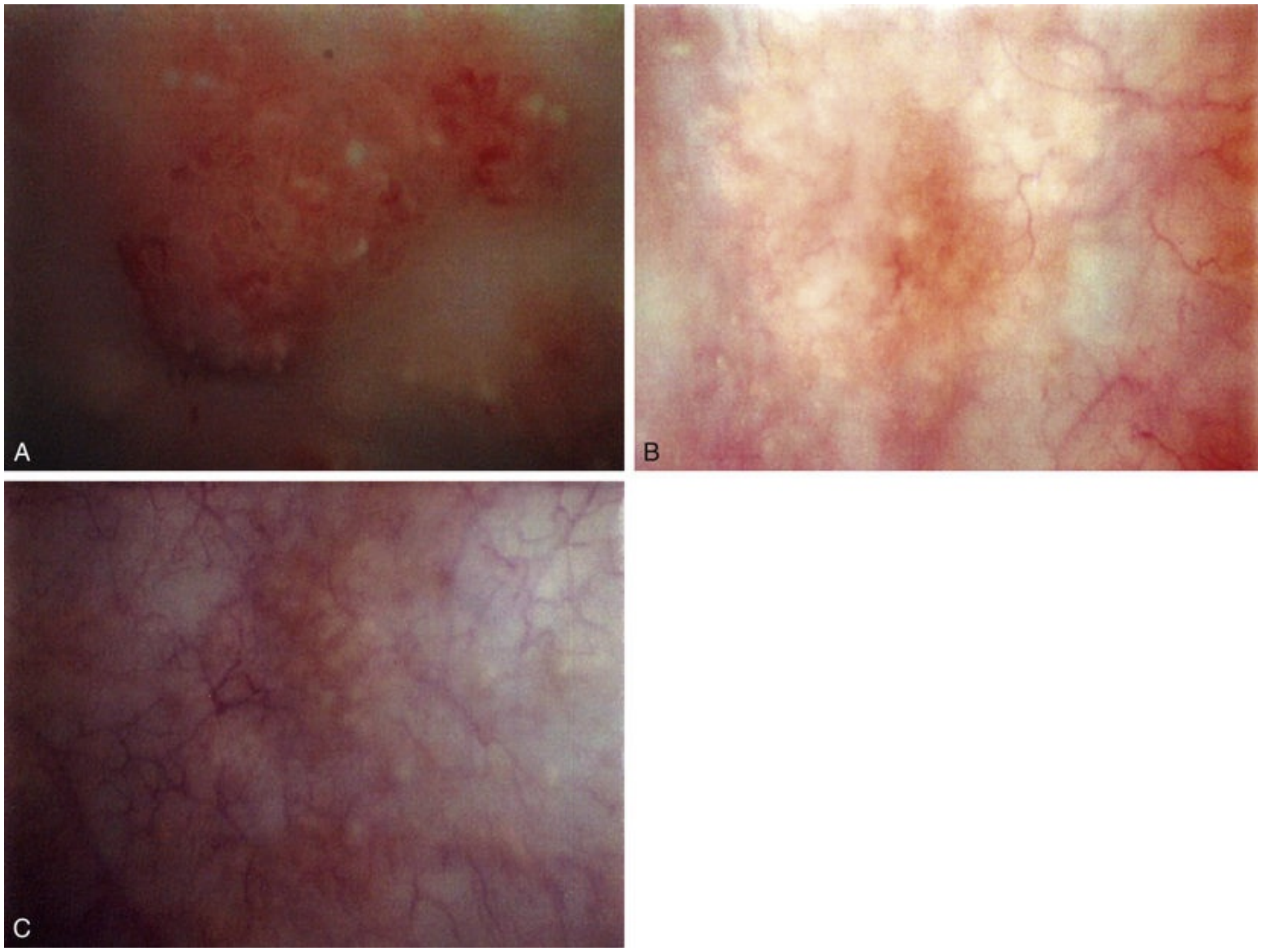

FIG. 60.13 (A to C) Cystourethroscopic views of bladder lesions. Both papillary mucosal and submucosal lesions are seen in the bladder of a child from Somalia who underwent cystourethroscopy to evaluate intermittent hematuria and dysuria. (Courtesy Craig Peters, MD.)

Antigen detection or PCR may be a more sensitive means of diagnosis. Serum or urine samples from infected individuals can be tested for the presence of circulating anodic and circulating cathodic schistosome antigens (CAA and CCA). CAA and CCA are specific for active infection because they are only released by viable adult worms and have the added benefit of producing quantitative measurements useful for determining infection severity (Agnew et al., 1995; Kremsner et al., 1994). Moreover, the development of an ELISA reagent strip test for urine samples has allowed for point-of-care detection of CCA that is more user friendly and field applicable (Midzi et al., 2009; van Dam et al., 2004). However, in some hands the CCA test completely failed to detect *S. haematobium* infection (versus >80% sensitivity and specificity for detection of *S. mansoni* infection) (Stothard et al., 2006) and is relatively expensive for widescale use in the developing world.

By far the most sensitive method for diagnosing urogenital schistosomiasis from urine or even stool samples is PCR (Obeng et al., 2008; ten Hove et al., 2008). PCR is also highly sensitive and specific for diagnosing female genital schistosomiasis from vaginal lavage samples, although detection may vary based on patient age and length of infection (Kjetland et al., 2009). Unfortunately, PCR is difficult to use in the developing world and in the field because it requires highly trained technicians and the use of organic solvents and commercial kits. Still, in the context of transmission control and disease surveillance, especially in settings of low-intensity transmission, PCR is a useful option.

Globally, many cases of urogenital schistosomiasis remain undetected and untreated because most are diagnosed only through direct egg detection rather than more sensitive methods. The need for more reliable and accessible diagnostic tools is thus particularly important for the development of more effective schistosomiasis control strategies in the developing world.

Treatment

Medical Management.

Praziquantel (PZQ) is currently the only WHO-recommended drug for schistosomiasis (WHO, 2014b) and has replaced metrifonate and oxamniquine as the main therapeutic agent. Although dependence on a single drug increases the potential for parasitic resistance, PZQ's efficacy, widespread availability, and low toxicity are favorable factors, and there has been little incentive for the development of alternative drugs. Two 20-mg/kg oral doses of PZQ are given on the same day, 6 to 8 hours apart (or alternatively, one 40-mg/kg dose) for *S. haematobium* infections. Corticosteroids are often added for the treatment of acute schistosomiasis (Katayama fever).

As measured by egg reduction and cure rate, PZQ's efficacy is 60% to 90% (Danso-Appiah et al., 2008; Doenhoff, et al., 2008). Even in those not cured, the worm burden is likely substantially reduced, which significantly decreases the chances of developing further infectious sequelae. After a patient is treated with PZQ, it is reasonable to monitor egg counts in urine and stool specimens and to perform serial ultrasonographic studies of the urogenital tract to assess response to drug therapy. Repeat PZQ courses can be given if there is a concern for persistent infection.

PZQ has a favorable pharmacokinetic and side effect profile. The most common side effects (abdominal pain, nausea, headache, and dizziness) are typically mild, generally occur within 3 to 4 hours postadministration, and resolve spontaneously. Most patients experience few or no side effects (N'Goran et al., 2003). However, PZQ pills are large and bitter tasting, making oral administration difficult to tolerate, especially for children (Meyer et al., 2009). A pediatric formulation of PZQ is in development. Perhaps because of its FDA classification as a Pregnancy Category B drug (deemed safe in lactating and pregnant women based only on animal studies), many chemotherapy programs exclude pregnant and lactating women. However, there are few reports of adverse effects resulting from PZQ among the millions of pregnant women treated with praziquantel (Olds, 2003).

PZQ is less efficacious against schistosomulae than adult worms, which may partly explain the lower cure rates in areas with high rates of schistosomiasis transmission and reinfection. In addition, it means that PZQ cannot be used to abort infection shortly after exposure. Multiple PZQ doses administered several weeks apart can ensure that juvenile schistosomes missed by the first administration are eradicated after maturation (Doenhoff et al., 2008).

Whether schistosomes are developing resistance to PZQ is debatable. Most large studies conducted on *S. haematobium*–infected individuals suggest little drug resistance in endemic areas (Guidi et al., 2010; King et al., 2000). However, there have been reports of PZQ failures in the treatment of travelers or military personnel returning from endemic areas (Doenhoff et al., 2008). Even if resistance to PZQ is not already evolving, it could occur in the future. Hopefully, use of alternative drugs and combining drug treatment programs with environmental control programs (snail control and sanitation improvement) may lower transmission and reduce the use of PZQ enough to prevent this.

Artemisinin and its analogues (artemether and artesunate, currently in use as antimalarials) are chemoprophylactic alternatives to PZQ because they specifically target the schistosomular stage of *S. haematobium*. Artemether or artesunate are 90% to 97% efficacious in preventing schistosomiasis but are poor treatments for established infections. Combined administration of PZQ and artemisinin derivatives results in lower infection rates than PZQ alone and thus offers a valuable tool for mass drug administration programs, especially in areas of high transmission and reinfection rates. However, a major concern regarding the use of artemesinins in this manner is the induction of malaria resistance to artemisinin derivatives. Because of this, widespread PZQ-artemisinin derivative combination therapy should not be used in schistosomiasis-malaria co-endemic areas (Liu et al., 2011).

Surgical Management.

The efficacy and ease of PZQ therapy for urogenital schistosomiasis, together with the possible reversibility of early stage disease (Richter et al., 1996; Richter, 2000) mean that, in most cases, trials of medical therapy should be undertaken before elective surgical approaches (Cioli,1995). Generally, surgery is reserved for complications that have not responded to adequate medical treatment within a reasonable follow-up period or for those settings where immediate surgical intervention is necessary. For example, severe bladder hemorrhage is one common cause for urgent surgical intervention.

Prostatitis and prostatic enlargement are uncommon in schistosomiasis. Accordingly, numerous autopsy studies have failed to demonstrate evidence of anatomic bladder outlet obstruction (Cheever et al., 1977; Cheever et al., 1978; Smith et al., 1974). However, clinical studies consistently report cystoscopic (FAM, 1964), urodynamic (Sabha and Nilsson, 1988), and elevated postvoid residual urine volumes, which are evidence of functional bladder outlet obstruction that occasionally requires surgical intervention in patients with severe inactive urinary schistosomiasis (Abdel-Halim et al., 1985). *S. haematobium* infection–associated scrotal induration, pain, and enlargement associated with epididymitis can lead to surgery for the suspicion of a testicular tumor.

Surgery is indicated for irreversibly contracted bladders; procedures include vesical denervation, urinary diversion, ileocystoplasty, or hydrodistention. Any treatment, however, must be performed in conjunction with medical chemotherapy. Chronic, deep bladder ulcers may necessitate a partial cystectomy, because fulguration rarely produces either symptomatic relief or ulcer healing. Urothelial hyperplasia is strongly associated with severe urogenital schistosomiasis, whereas urothelial dysplasia and metaplasia commonly accompany schistosomal bladder cancer (Khafagy et al., 1972). Treatment of bladder cancer secondary to schistosomiasis is typically surgical and discussed elsewhere (see Chapters 92 through 96).

The most frequent sequelae of urinary schistosomiasis result from ureteral involvement causing obstructive uropathy (Cheever et al., 1978; Lehman et al., 1973; Smith and Christie, 1986; Smith et al., 1974). Hydroureter and hydronephrosis are linked to the intensity of *S. haematobium* infection. **Because ureteral obstruction observed during schistosomiasis is most often caused by concentric or hemiconcentric polypoid lesions that “girdle” the ureteral muscle in the intramural and adjacent extravesical ureter, it often**

responds well to medical management alone. Complete resolution of deteriorated renal function because of active infection-associated obstructive uropathy responds within 1 to 2 months of PZQ chemotherapy (Lehman et al., 1973). Chemotherapy not only reverses schistosomal obstructive uropathy but also can prevent it, even in persons who are continually reinfected (Subramanian et al., 1999). However, in late, chronic, active and inactive urinary schistosomiasis, anatomic obstruction may be less amenable to chemotherapeutic cure.

Anatomic ureteral stenosis, with or without calculi, has been identified in up to 80% of patients with ureteral obstruction (Al-Shukri and Alwan, 1983; El-Nahas et al., 2003; Lehman et al., 1973; Smith et al., 1977). **When residual ureteral stenosis persists after chemotherapy, it is usually amenable to surgical intervention. Depending on the location and extent of the stricture, procedures involving dilation or excision have been employed.** Balloon dilation is efficacious with anatomic stenosis (Jacobsson et al., 1987), but mechanical dilation is frequently plagued by recurrent stenosis (Wishahi, 1987). When the ureteral meatus, intramural ureter, ureterovesical junction, or distal ureter is involved, options to reconstruct a functional valve include a variety of plastic operations. Most of these procedures are variants of the Politano-Leadbetter operation (Leadbetter and Leadbetter, 1961; Politano and Leadbetter, 1958). Although highly efficacious for some patients (Al-Shukri and Alwan, 1983; Smith et al., 1977), other authors have noted that restenosis can occur (Umerah, 1981).

In long or multifocal lesions of the ureter, excision of the affected portion may leave an inadequate residual ureter for reimplantation or simple ureteroureterostomy. In these cases, surgeons have successfully employed the Boari flap, ileal conduit, suprapubic intravesical ureterostomy (in which the obstructed ureteral segment is bypassed using a peritoneal dialysis catheter and drained into the bladder), and replacement of the ureter with ileal segments, taking care to maintain an isoperistaltic direction of the ileal segment (Abdel-Halim, 1980; Abdel-Halim, 1984; Abu-Aisha et al., 1985; Al-Shukri and Alwan, 1983). Isolated meatal stenosis of the ureter may be amenable to simple meatoplasty (Al-Shukri and Alwan, 1983). When a ureter is hopelessly obstructed and cannot be reconstructed, long-term nephrostomy drainage is another option.

Prognosis.

Most patients with urogenital schistosomiasis have mild infections and a good prognosis. The morbidity and mortality of urogenital schistosomiasis is determined by the overall intensity of infection and genetic polymorphisms for relevant immune response genes (He et al., 2008; Isnard et al., 2011; Isnard and Chevillard, 2008; Kouriba et al., 2005; Ouf et al., 2012). In regions of low *S. haematobium* prevalence, such as Nigeria, essentially no urogenital schistosomiasis-related mortality is observed and the frequency and severity of schistosomal obstructive uropathy is low. In contrast, when Egypt had a prevalence of 50%, schistosomiasis contributed to mortality in 10% of *S. haematobium*-infected individuals (Cheever et al., 1978; Smith et al., 1974). Among patients with severe disease, mortality approached 50% in 2 to 5 years (Lehman et al., 1970).

Patients who die of schistosomal obstructive uropathy (bilateral end-stage hydronephrosis, or unilateral hydronephrosis with contralateral non-schistosomal end-stage renal disease) are typically in their 20s and have heavy total egg burdens. Patients who develop the complications of pyelonephritis and urothelial cancer are commonly older than age 40, consistent with time- and intensity-related pathology (Christie et al., 1986; Smith and Christie, 1986).

The prognosis for patients with urinary tract lesions has dramatically improved with PZQ therapy. In children with obstructive polyps, the uropathy usually completely resolves within 2 to 6 weeks of treatment. For patients with chronic obstructive uropathy resulting from sandy patches and fibrosis, the prognosis is less clear. Some individuals tolerate advanced obstructive uropathy with little, if any, deterioration in renal function. **Schistosomal obstructive uropathy, urolithiasis, bladder outlet obstruction, and bacterial cystitis all predispose to pyelonephritis.** Bacterial superinfection can be life-threatening and should be treated aggressively and promptly. Finally, for **those who develop a bladder malignancy, their prognosis is dependent on the aggressiveness of their tumor.**

Prevention and Control

Travelers to endemic areas should be advised to avoid contact with potentially infested fresh water (streams, rivers, ponds, and lakes). Fast-flowing water can still harbor *S. haematobium*. Heating water to more than 125°F for 5 minutes kills the cercariae, as does chlorination and allowing the water to stand for more than 2 days in a setting free of snails. Since the advent of PZQ in the late 1970s and its subsequent mass distribution beginning in the 1980s and 1990s, schistosomiasis has become relatively simple and affordable to treat but remains difficult to control. For the past 3 to 4 decades, control efforts have focused heavily on reducing morbidity using periodic, typically annual targeted mass drug treatments with PZQ, a strategy advocated by the WHO. However, when access to safe water is not available, rural poor communities are subject to vicious cycles of infection, treatment, and reinfection, making more frequent PZQ administration necessary. Sanitation improvements, health education, and snail control are approaches used to break the cycle of transmission by slowing or halting the influx of eggs into the aquatic habitat, decreasing individual exposure, and reducing the availability of snail intermediate hosts, respectively. Although PZQ is inexpensive, the cost effectiveness of chemotherapy fluctuates widely among MDA settings because of variations in the number of doses of PZQ given per person, variability in transportation and delivery costs, and the potential to take advantage of pre-existing public health control programs or other infrastructure (Brooker et al., 2008). The per-person cost in control campaigns is typically under $0.50, although even this modest cost, at sufficient scale, may exceed the available resources of many endemic countries (Hotez et al., 2009). Fortunately, a number of pharmaceutical companies and foundations are donating PZQ for use in MDA campaigns.

Because asexual reproduction in the snail host allows the parasite to amplify rapidly, sanitation programs and drug treatment campaigns must reduce egg input into the environment by nearly 90% before a substantial decrease in transmission can be achieved (Woolhouse, 1992). Reductions in snail populations, in contrast, can theoretically effect proportional decreases in disease transmission risk; some experts feel snail control may be the best means of schistosomiasis control (Sokolow et al., 2016; Woolhouse, 1992). However, considering that adult worms can live for years in the human host, without concurrent mass treatment, snail population control alone would have to persist for many years to eliminate transmission. Thus integrated campaigns focusing on three aims (treating human cases, reducing contact of humans and their wastes with infested water, and controlling snails) offer the most promise (Sokolow et al., 2016; Sokolow et al., 2018).

Other control efforts include mollusciciding (Knopp et al., 2011; Knopp et al., 2012; Zhang and Jiang, 2011), biologic control using snail predators or competitors (Allen and Victory, 2003; Coelho et al., 2004; Mkoji et al., 1999;

Pointier and Jourdane, 2000; Roberts and Kuris, 1990; Sokolow et al., 2013), and vaccine development (although an efficacious vaccine currently remains out of reach) (Bethony et al., 2008; Gray et al., 2010). Water, sanitation, and hygiene ("WASH") programs are also, once again, taking center stage, and feature many additional benefits beyond potential schistosomiasis reduction (Giné Garriga and Pérez Foguet, 2013; Soares et al., 2011).

In contrast to the outcomes seen with attempts at elimination and control of other parasitic infections (e.g., malaria, lymphatic filariasis, onchocerciasis), the mass drug administration and other control programs aimed at schistosomiasis have not resulted in a reduction in the worldwide prevalence of this infection in recent years. At the same time, schistosomiasis has been eliminated in 10 countries to date (Iran, Japan, Lebanon, Malaysia, Martinique, Montserrat, Morocco, Thailand, Tunisia, and Turkey) (Amarir et al., 2011; Rollinson et al., 2012). At the 65th WHO World Health Assembly (May 2012), resolution WHA65.21 was passed, calling on the global community to "make available the necessary and sufficient means and resources…to intensify control programs in most disease-endemic countries and initiate elimination campaigns, where appropriate" (WHO, 2014). Representing a shift from morbidity control to a new focus on elimination, this marks an exciting and hopeful milestone in the global fight against schistosomiasis.

Key Points: Schistosomiasis

- *S. haematobium* worms can survive in human hosts for years to decades. A careful travel and social history is crucial to identify potential exposures, correlate them with urogenital symptoms, and determine the need to perform specific diagnostic assays.
- Praziquantel therapy of early stage urogenital schistosomiasis can reverse inflammatory lesions, including fibrosis of the urinary tract caused by the host response to eggs deposited in tissues.
- The gold standard for diagnosis of active urogenital schistosomiasis is the identification of eggs in urine, stool, or bladder or rectal biopsies. Serological and PCR-based assays are highly sensitive but may not distinguish between active versus resolved infection and are impractical in endemic regions.

Filariasis

The filariae are vector-borne tissue nematodes. Human pathogens in this group include the agents of **lymphatic filariasis** (LF), *Onchocerca volvulus,* and *Loa loa.*

LF is caused by the mosquito-borne helminths *Wuchereria bancrofti, Brugia malayi,* and *Brugia timori.* The symptoms of LF range from acute lymphatic inflammation to chronic lymphatic dilation with hydrocele, lymphedema, and elephantiasis of the limbs.

Organisms

W. bancrofti, B. malayi, and *B. timori* are threadlike nematodes. Infective (third-stage) larvae are transmitted to humans by mosquito bites. After entering humans, larvae migrate to central lymphatic vessels and eventually mature (over 6 to 9 months) into adult male or female worms. Adults (approximately 20 to 100 mm × 0.2 mm) are considerably larger than microfilariae (approximately 200 µm × 10 µm) (Fig. 60.14). Adult worms live primarily in the afferent lymphatics, especially in the lower extremities (inguinal, iliac, and periaortic lymphatics) and (for *W. bancrofti* only) male genitalia (epididymis, spermatic cord, testicles). The natural lifespan of adult worms is approximately 5 to 7 years.

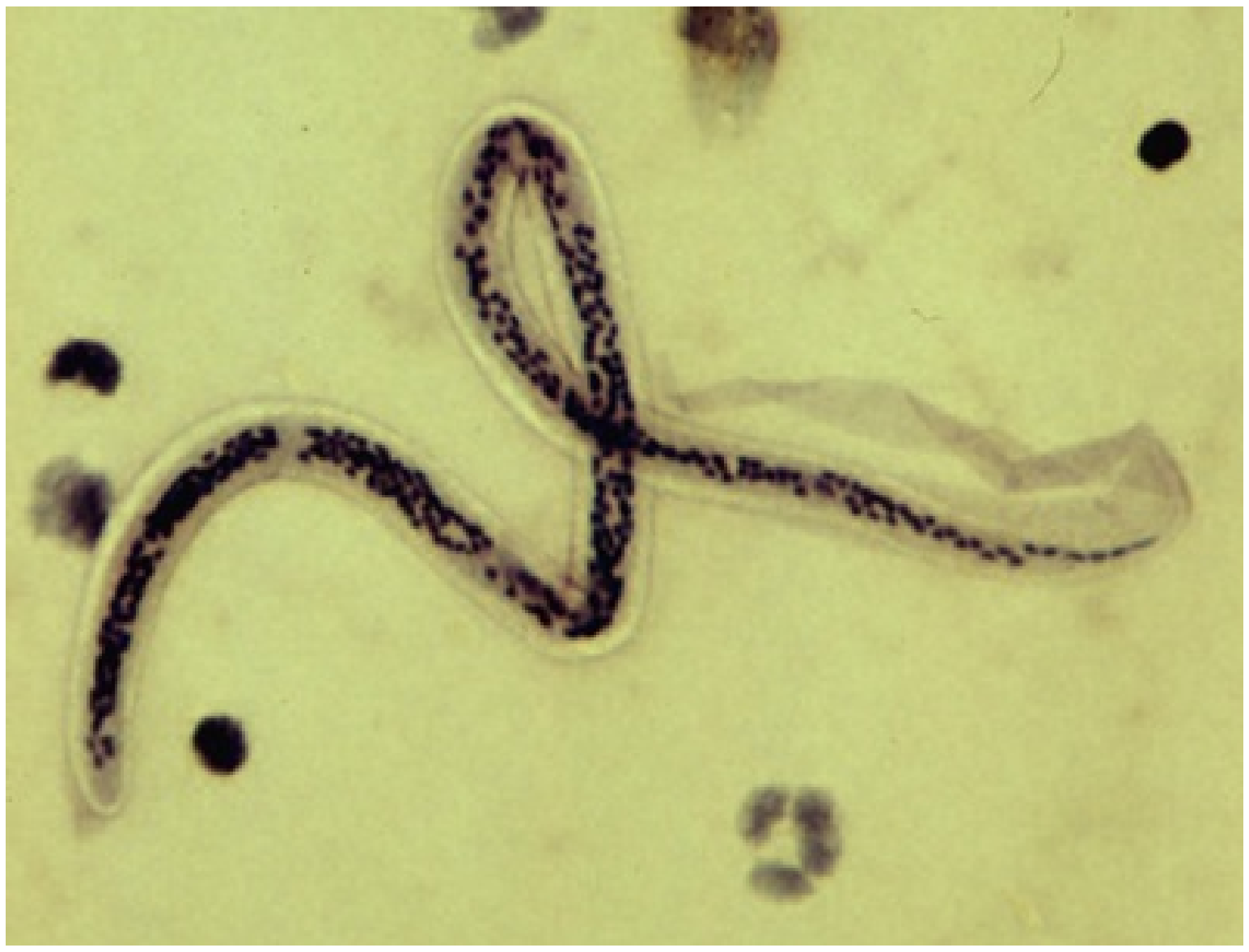

FIG. 60.14 Microfilaria of *Wuchereria bancrofti* in peripheral blood. (Courtesy Division of Parasitic Diseases and Malaria, Centers for Disease

Control and Prevention.)

After mating with males, female worms release large numbers of microfilariae. In most endemic areas, *W. bancrofti* and *Brugia* microfilaremia peak in the middle of the night as an adaptation to facilitate transmission, coinciding with peak local mosquito vector activity. In some parts of the Pacific, the periodicity of *W. bancrofti* is diurnal rather than nocturnal. After mosquito ingestion, microfilariae mature over 10 to 14 days into infective third-stage larvae.

W. bancrofti and *Brugia* species harbor an obligate rickettsia-like endosymbiont *(Wolbachia).* These endosymbionts are involved in embryogenesis, and antimicrobial therapy (e.g., doxycycline) kills them, resulting in decreased microfilariae release and suppressed larval molting (Hoerauf et al., 2001).

Epidemiology

Worldwide, millions of people are infected with LF, many of whom experience significant morbidity. Recent estimates place the global prevalence of LF at approximately 68 million, a substantial decline compared with the early 2000s (Ramaiah and Ottesen, 2014). More than 90% of infections are caused by *W. bancrofti,* mostly in sub-Saharan Africa, South and Southeast Asia, and the western Pacific. In the Americas, *W. bancrofti* is endemic only to Haiti, the Dominican Republic, Guyana, and Brazil. Infection with *B. malayi* is limited to Asia and several Pacific islands (e.g., Indonesia and the Philippines). *B. timori* infection occurs only in southeastern Indonesia. Within a given geographic area, the distribution of LF is often heterogeneous. Several genera of mosquitoes are capable of transmission, including *Anopheles* (rural Africa and the Pacific), *Culex* (urban areas, especially India), *Aedes aegypti* in some Pacific islands, and others.

Although varying among different locales and mosquito vectors, transmission of LF is relatively inefficient, and obstructive lymphatic disease is generally seen only in persons repeatedly infected over many years (i.e., usually long-term residents of endemic areas). In endemic communities, prevalence increases from childhood through the third or fourth decade of life, after which it remains fairly constant (because of the gradual accumulation of adult-stage worms in the population over time). Lymphedema and genital disease are rare before age 10 but increase in prevalence with age. Overall, about one-third of infected persons have clinically overt disease. The likelihood of developing clinical manifestations is particularly high in India, Papua New Guinea, and Africa, whereas it is lower in the Americas (Kazura et al., 1997).

Pathology and Clinical Manifestations

The initial immune response to infective larvae and early adult worms is mostly proinflammatory (involving Th1 and Th2 T-cell responses). The contribution of humoral immunity includes an increase in filaria-specific IgE titers. Eosinophil-mediated killing of microfilariae also likely plays a role. With the onset of microfilaremia, T-cell responses decrease, mediated by IL-10, IgG4-blocking antibodies, and antigen-specific suppressor T cells. Whether protective immunity develops has been difficult to determine, but groups of individuals have remained infection free despite long-term exposure in highly endemic settings (Steel et al., 1996).

Clinical manifestations in infected patients vary greatly, ranging from subclinical infection to severe disfigurement of the limbs and genitalia. Damage from established infection is cumulative because of progressive scarring and lymphatic obstruction over time. Medical therapy does not readily reverse such damage but can prevent further progression in patients with active LF infection. Although rarely fatal, LF can cause severe disability and among parasitic infections is responsible for the third-highest number of disability-adjusted life years (DALYs) lost globally.

The mechanisms leading to lymphedema have been poorly established. However, parasite-derived factors are at least partly responsible for initial lymphatic dilation, with subsequent contributions from secondary bacterial infections and inflammatory responses to dying or dead parasites. *Wolbachia* endosymbionts also appear to drive a proinflammatory response. Lesions vary from nodular inflammation to suppuration, histologically appearing as granulomas around worms, sometimes with tissue eosinophils (Fig. 60.15). A vicious cycle can result, with acute attacks worsening lymphedema, predisposing to more secondary infections, worsening lymphedema, and so on; episodic filarial inflammation eventually abates, leaving obliterated lymphatics surrounded by scar tissue. Elephantiasis or hydrocele is then the end stage in some patients.

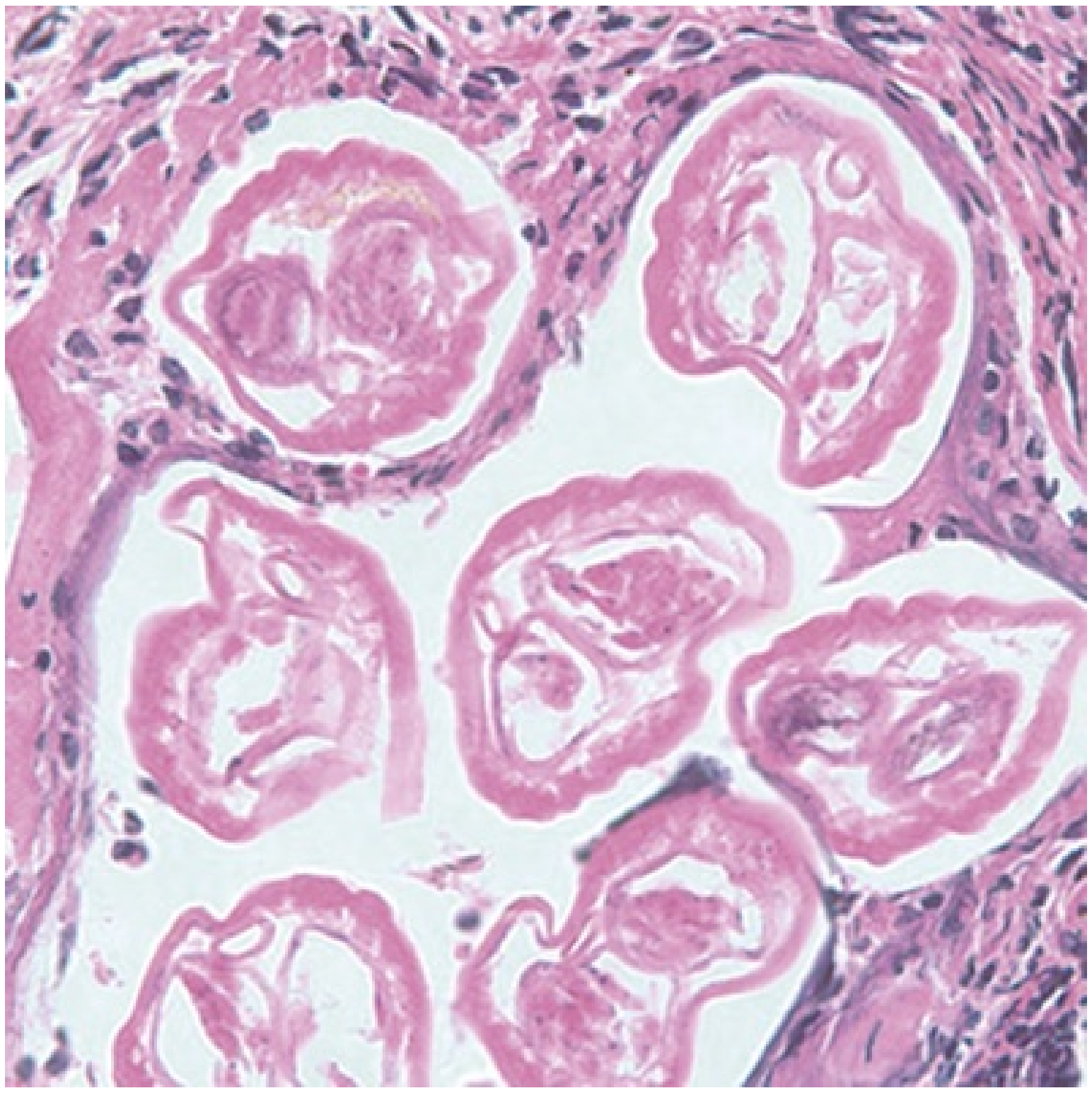

FIG. 60.15 Section of an adult *Brugia* organism in a lymph node. (Courtesy Division of Parasitic Diseases and Malaria, Centers for Disease Control and Prevention.)

Subclinical Infection.

Most LF-infected persons have few overt clinical manifestations, even with high-grade microfilaremia. However, though the infection is clinically asymptomatic, virtually all persons with patent *W. bancrofti* or *B. malayi* infection have at least some subclinical disease (e.g., dilated lymphatics, scrotal lymphangiectasia, microscopic hematuria, or proteinuria). Eosinophilia is also very common with most forms of LF.

Acute Adenolymphangitis.

Acute adenolymphangitis (ADL) is often the first clinical manifestation of LF, consisting of fever, lymphadenitis, lymphangitis, and edema that usually lasts days to a week. The lymphangitis is retrograde (extending peripherally), which distinguishes it from bacterial lymphangitis. Although all four extremities can be involved in bancroftian and brugian filariasis, the genital lymphatics are affected almost exclusively by *W. bancrofti* infection. This can result in funiculitis, epididymitis, scrotal pain, tenderness, and lymph scrotum (ruptured lymphatic vesicles on the scrotal skin that yield a whitish discharge and secondary bacterial infections).

Another acute manifestation, **dermatolymphangioadenitis** (DLA), is characterized by fever, chills, myalgias, and headache. Edematous inflammatory plaques occur, as well as hyperpigmentation, vesicles, and ulcers, often at the site of an inciting skin injury. Inflammation progresses proximally and is thought to be secondary to bacterial infections.

Lymphedema.

Lower or upper extremity edema is the most common chronic manifestation of LF, with lower extremity edema being the more prevalent. Bancroftian filariasis typically involves the entire limb, whereas brugian filariasis usually involves only the leg below the knee. Although both lower extremities are often affected, asymmetrical involvement is most common. The overlying skin may exude serous fluid. Breast involvement can also occur in females.

Genitourinary Manifestations.

Male genital involvement is very common with bancroftian filariasis but uncommon with *Brugia* infection. The prevalence of female genital involvement has not been well established, although anecdotal evidence suggests that it is uncommon (Nutman and Kazura, 2011). Genital disease is not usually experienced until at least the teenage years. Acute painful episodes of (usually unilateral) epididymitis or funiculitis accompanied by fever and malaise can last several days and are one of the most common consequences of bancroftian filariasis.

Funiculoepididymitis.

Funiculoepididymitis is characterized by palpable cordlike swellings and edema. Although the condition is usually self-limited, recurrences and the subsequent development of chronic lymphedema are common. Filarial funiculitis rarely results in sterility or orchitis, because the spermatic cord usually remains uninvolved. This manifestation is often mistaken for malignancy, and many patients undergo surgery as a result (including orchiectomy). Varicocele may complicate inflammation, increasing pain and swelling. Bacterial superinfection is a rare but severe complication, with exquisite pain and septic thrombophlebitis often present.

Hydroceles.

Chronic disease of the male genitals often results in hydroceles, which can be very large (Fig. 60.16). In endemic areas, differentiation of filarial from nonfilarial hydrocele is difficult, and parasites are rarely detected in the hydrocele fluid. Hydrocele accompanied by nodules in the cord or epididymis and a history of travel to or residence in an endemic area suggests LF. A thick, fibrous tunica, especially with cholesterol or calcium deposits, also suggests LF.

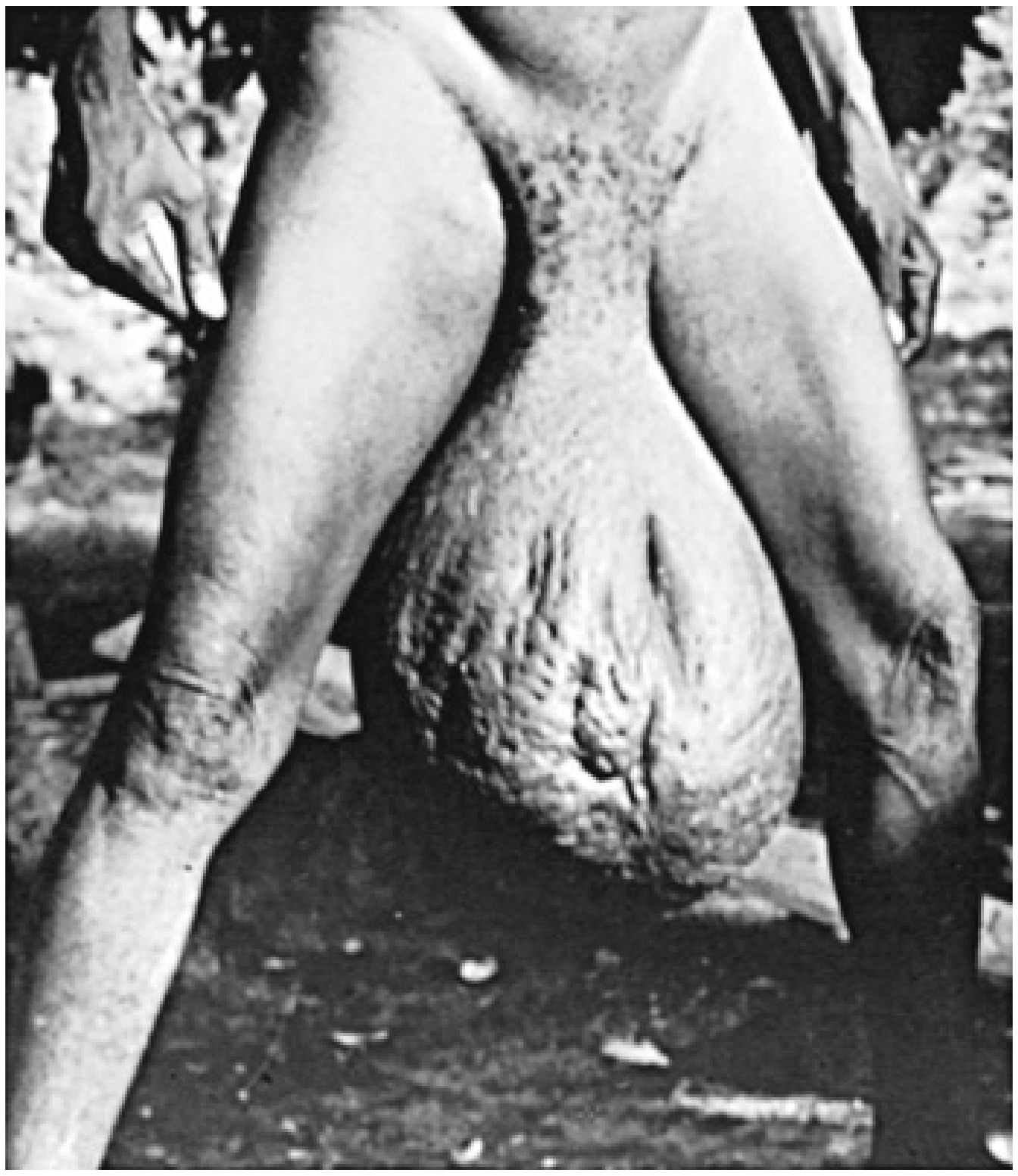

FIG. 60.16 Huge hydrocele and scrotal elephantiasis. (Courtesy Dr. B. H. Kean. From Zaiman H: A pictorial presentation of parasites, Valley City, ND.)

Hydroceles are usually painless unless complicated by acute epididymitis or funiculitis. The scrotal skin may also be thickened and brawny as a result of lymphedema, with oozing lymph. Patients with filarial hydrocele rarely experience bacterial superinfection, although those with elephantiasis and lymph scrotum are often superinfected.

Scrotal and Penile Elephantiasis.

Mild scrotal edema is not unusual during early infection or with established hydrocele. Conversely, penile edema is unusual, and massive enlargement of the scrotum or penis occurs late, largely in individuals with poor access to medical care. Genital elephantiasis rarely arises from causes other than LF.

Chyluria.

Chyluria occurs when GU tract lymphatics are damaged, resulting in lymph passage into the urine and massive fat and protein loss. Although rare, this can result in serious nutritional consequences. It usually occurs earlier in the natural history of filariasis than genital elephantiasis. Chyluria is usually intermittent and may spontaneously remit.

Tropical Pulmonary Eosinophilia.

Tropical pulmonary eosinophilia (TPE) is a syndrome characterized by paroxysmal cough and wheezing (usually nocturnal), fever, adenopathy, high-grade eosinophilia, and elevated IgE levels. It is caused by an allergic response to microfilarial antigens and is seen most commonly in South and Southeast Asia. Chest radiographs range from normal to diffuse reticulonodular infiltrates, and pulmonary function tests show restrictive (and sometimes obstructive) defects. If done, lung biopsy reveals an eosinophilic interstitial pneumonitis. Microfilaremia is usually absent.

Diagnosis

In residents of endemic areas, lymphedema or male genital disease is epidemiologically more likely a result of LF than a similar presentation in the developed world (assuming no other cause of secondary edema is present). Still, tuberculosis, *S. haematobium* infection (urogenital schistosomiasis), and gonorrhea may also produce funiculoepididymitis and are in the differential diagnosis. In addition, nonfilarial hydrocele is common in tropical and nontropical areas. However, hydrocele occurs at an earlier age and with greater frequency in filariasis-endemic areas.

For parasitologic confirmation, it is difficult to visualize adult worms directly because they are localized in the lymphatics; they are usually seen only via histologic examination of surgical or biopsy specimens (in which visualizing adult worms is diagnostically definitive but insensitive). However, ultrasound examination of lymphatics has at least 80% sensitivity in some settings, in part because live adult worms have a distinctive pattern of movement (the **“filaria dance sign”**) (Amaral et al., 1994). Online examples can be found at https://www.youtube.com/watch?v=ER1BFx4_qGc and http://www.filariajournal.com/content/2/1/3/figure/F1?highres=y. Plain radiographs may reveal calcifications, which are also suggestive of LF in the appropriate clinical setting.

Microfilariae can be found in blood and occasionally in other body fluids; they are best detected by a Giemsa-stained blood smear. The timing of blood collection should be based on the periodicity of the microfilariae in the geographic location involved (highest during the night in most cases). Microfilaremia is found in only a minority of infected persons, and definitive diagnosis in amicrofilaremic cases can be more difficult. Detection of circulating *W. bancrofti* antigens is one means to detect such infections, and this can be done with an ELISA and a point-of-care immunochromatographic card test (ICT). Recently, a new ICT (the Alere Filariasis Test Strip) has shown better sensitivity in field conditions than the BinaxNOW Filariasis ICT, which has been in use for the past 10 to 20 years (Weil et al., 2013). There are currently no tests for circulating antigens in brugian filariasis. PCR-based assays for *W. bancrofti* and *B. malayi* in blood are very sensitive but are not yet widely available.

Antibody-based assays for diagnosing LF have traditionally suffered from poor specificity. IgG4 antibodies are less cross-reactive to nonfilarial helminth antigens and thus are more specific. Specificity has also been improved with species-specific antigens for brugian and bancroftian infection. A dipstick antibody test has been developed for brugian filariasis (Weil et al., 2011).

Patients with so-called burned-out infections (e.g., those who have received antiparasitic therapy or who departed endemic areas years previously and in whom the worms have died) often have lasting damage (i.e., lymphedema, genital disease, and other clinical manifestations). In these patients, negative testing for microfilaremia and circulating antigens does not exclude the possibility that their lesions could be a result of LF. However, such patients are usually LF antibody positive.

Radionuclide lymphoscintigraphic imaging reliably demonstrates lymphatic abnormalities in patients with LF. Although helpful in documenting the degree of damage associated with infection, this is not useful for differentiating LF from other causes of lymphatic disease.

Treatment

Because most patients with microfilaremia have at least subclinical disease, treatment is recommended for symptomatic and asymptomatic individuals with microfilaremia. Diethylcarbamazine (DEC, 2 mg/kg orally three times a day) is the treatment of choice for active LF (microfilaremia, antigen positivity, or live adult worms on ultrasound). A 1-day course seems as effective as the traditional 12-day regimen for most patients (CDC, 2013a), although those with TPE should receive a 2- to 3-week course. DEC kills microfilariae but has only modest activity against adult worms and in the United States is available only through the CDC (phone: 404-639-3670; website: https://www.cdc.gov/parasites/health_professionals.htm). DEC should not be given to persons from areas co-endemic for onchocerciasis or *L. loa* (e.g., West and Central Africa) unless these infections have been excluded because of potentially serious side effects related to the killing of these parasites by DEC. Alternatives for LF include albendazole and ivermectin. Albendazole (400 mg orally twice daily for 21 days) has microfilaricidal and macrofilaricidal activity, but the activity of ivermectin (150 to 400 µg/kg orally once) is limited mostly to microfilariae.

Side effects of DEC include fever, chills, arthralgias/myalgias, headaches, nausea, and vomiting. In heavily infected patients, painful skin nodules, lymphadenitis, and epididymitis may occur as a reaction to dying parasites or *Wolbachia* endosymbionts, usually days to weeks after initiation of therapy. Ivermectin has a side effect profile similar to DEC when used for LF; it also must be used with caution if co-infection with *L. loa* is possible (see below). Albendazole (when used in single-dose regimens; see later) has relatively few side effects when used for LF.

Doxycycline (200 mg daily) augments the suppression of microfilaremia induced by antifilarial drugs and has some macrofilaricidal activity. Prolonged courses (4 to 8 weeks) render adult worms sterile (Kappagoda et al., 2011). Individuals treated with doxycycline can experience substantial improvements in lymphedema and hydrocele. These benefits are seen even in patients with lymphedema who do not have active infection, suggesting that the benefit of doxycycline extends beyond the macrofilaricidal and anti-*Wolbachia* activity of this drug (Mand et al., 2012). The prolonged course is problematic for administration in the developing world, and doxycycline cannot be given to pregnant women or young children. However, in the United States a 6-week treatment course of this drug is a reasonable consideration in properly selected patients.

In persons with chronic lymphedema, prevention of secondary bacterial infections, good hygiene, elastic stockings, elevation, and physiotherapy are important for morbidity control. Antiparasitic therapy in these patients should be reserved for those with active infection. Surgical correction is challenging and often unnecessary. Lymphatic-venous and nodal-venous anastomoses for elephantiasis have been somewhat successful in decreasing leg swelling as has reconstructive surgery for genital involvement. The long-term effects of these intensive surgical techniques have not been determined.

Genital elephantiasis is rarely amenable to surgery, and lymphadenectomy may further compromise lymph drainage and worsen symptoms. In some cases of funiculoepididymitis, surgery, such as decompression or excision of filarial nodules, may be indicated to preserve the testis and spermatic cord. When funiculoepididymitis is recurrent, painful, and deforming or complicated by blood vessel involvement, more radical surgery is warranted. Drainage of hydroceles provides immediate relief, although recurrence is common in the absence of medical and definitive surgical therapy. Hydrocelectomy is often indicated for large or symptomatic hydroceles. Excision of the intact hydrocele sac is the procedure of choice; alternatively, inversion with partial excision can be considered. When identified, leaking or dilated lymphatic vessels should be sutured or excised. Small hydroceles that do not enlarge usually do not require surgery. Reconstruction of the scrotum or vulva, with removal of redundant tissue, can also provide symptomatic relief to selected patients.

Prevention and Control

Individual protection against LF infection involves avoidance of infected mosquitoes through personal protective measures and long-lasting insecticide-treated bednets (LLINs); LLINs have been shown to be a valuable tool for the control and elimination of LF (Reimer et al., 2013). Elimination of microfilariae within communities can interrupt transmission because patent microfilaremia is necessary for mosquitoes to transmit the infection from person to person. However, because chemotherapy does not kill all of the adult worms, it is necessary to continue intermittent administration of antiparasitic drugs for many years, until the adult worms die of senescence. This strategy can be effective for *W. bancrofti* elimination (Molyneux, 2009) but is more challenging in *Brugia*-endemic areas because animals also serve as reservoirs of infection for the latter. MDA campaigns (involving distribution of single annual doses of albendazole plus either DEC or ivermectin, which have a sustained microfilaricidal effect to most of the population) are the mainstay of control programs in Africa (albendazole/ ivermectin) and elsewhere (albendazole/DEC). These campaigns have been successful in control and elimination of LF with many areas nearing elimination and are the primary reason for the decrease in global LF prevalence described previously. These programs have also prevented 19 million hydrocele cases globally since 2000, decreasing by half the number of hydroceles because of LF over that time period (Ramaiah and Ottesen, 2014). Encouragingly, recent small studies suggest that triple antiparasitic therapy (DEC + albendazole + ivermectin) reduces microfilaremia more profoundly and for a more prolonged time than dual antiparasitic therapy, with no additional serious adverse effects (Thomsen et al., 2016). If confirmed at a larger scale, this may herald a major advance for MDA programs in areas where all three drugs can be used together.

Onchocerciasis, also known as **river blindness**, is a filarial infection usually caused by *Onchocerciasis volvulus.* The infection is transmitted by *Simulium* black flies; 99% of onchocerciasis cases are found in Africa, with limited foci in Latin America (within Brazil and Venezuela) and the Arabian Peninsula (Yemen). About 17 million people are infected globally (WHO, 2017), which represents a 55% decrease in prevalence compared with 2000, largely because of successful MDA programs. As with LF, transmission is inefficient and highly focal. Adult worms live for up to 15 years in subcutaneous nodules (mean natural life span, 9 to 10 years) and release microfilariae that travel through the skin (and eye). *O. volvulus* adults also harbor *Wolbachia* endosymbionts. Infection classically causes dermatitis/pruritis, keratitis, and chorioretinitis, with blindness as an end result after many years, from corneal scarring. Diagnosis is confirmed by microscopically examining skin snips for microfilariae, finding adult worms in subcutaneous nodules, or seeing microfilariae in the anterior chamber of the eye via slit lamp. Antibody and antigen detection tests are less well developed than for LF.

In late stages, *Onchocerca* infection may produce “hanging groin” or scrotal elephantiasis as a result of recurrent lymphadenitis and loss of skin elasticity. Histology demonstrates atrophy and fibrosis of inguinal lymph nodes with subcutaneous edema and fibrosis. Onchocerciasis is also occasionally accompanied by massive inguinal lymphadenopathy. Recently, *Onchocerca lupi* (a parasite of canines) has been recognized as a rare cause of human disease, with infections in six US residents reported since 2013 (five of whom were children); all lived in the southwestern United States, and developed nodules that contained adult *O. lupi* worms (three in the spine, two in the skin/soft tissues, and one in the extraocular muscles) (Cantey et al., 2016).

Ivermectin is the treatment of choice (150 μg/kg orally once, repeated every 6 to 12 months until patients are asymptomatic) for onchocerciasis. Although the activity of ivermectin is primarily against microfilariae, emerging data suggest that it has at least some activity against adult worms and that macrofilariae life spans may be shortened 50% to 70% by multiple doses of ivermectin (Walker et al., 2017). As noted later, ivermectin must be used with caution if coinfection with *L. loa* is possible. Adverse effects include fever, rash, dizziness, pruritus, myalgias, arthralgias, and lymphadenopathy, mostly caused by dying filariae and *Wolbachia.* After ivermectin treatment, 6 weeks of doxycycline (200 mg/day orally) therapy kills or reduces the life span of most adult female *Onchocerca* worms and sterilizes most of the remainder, greatly reducing or clearing microfilaremia in most treated individuals (Debrah et al., 2014; Hoerauf, 2011; Walker et al., 2015). DEC should not be administered to persons infected with onchocerciasis because blindness and systemic toxicity can result from the resulting ocular and systemic inflammatory responses related to the dying parasites**.**

Loaiasis is caused by *L. loa,* a filarial infection that is limited to Central and West Africa and transmitted by *Chrysops* flies. Adult worms migrate in subcutaneous tissues, and microfilariae circulate diurnally in the blood. *L. loa* adults do not harbor *Wolbachia.* Most infected persons have asymptomatic eosinophilia; some have urticaria, migratory subcutaneous lesions, and visible worms migrating across the conjunctivae *(eye worms).* Hematuria and proteinuria occur in 30% of patients; lymphadenitis and hydrocele also rarely occur. DEC (2 to 3 mg/kg orally three times a day for 14 to 21 days) is effective against loaiasis, although multiple courses may be necessary (Klion and Nutman, 2011). Treatment can cause pruritus, arthralgias, migratory swellings, fever, eye worms, diarrhea, and renal failure. Patients with detectable microfilaremia (particularly more than 2500 to 8000 microfilariae per milliliter of blood) are at risk of treatment-associated encephalopathy (especially if they receive ivermectin), which may be ameliorated by pretreatment apheresis. Albendazole (200 mg orally twice daily for 3 weeks) is associated with a lower risk of encephalopathy than DEC and may be safer in patients with high-grade parasitemia (Kappagoda et al., 2011).

Other Nonfilarial Genitourinary Parasites

Echinococcosis

Echinococcus granulosus is a cestode (tapeworm) that causes cystic echinococcosis. Infection results from ingestion of food or water contaminated with *Echinococcus* eggs or contact with infected dogs. Prevalence is high in pastoral communities, particularly in South America, the Mediterranean littoral, Eastern Europe, the Middle East, East Africa, Central Asia, China, Russia, and Australia. After infection the parasites encyst, usually in the liver or (less commonly) in the lungs. Although rare, cysts can grow ectopically in almost any organ in the body, with the kidneys being the third most common organ affected after the liver and lungs (<2% to 3% of cases) (Moscatelli et al., 2013). Initially, cysts are asymptomatic, but over time they enlarge (1–2 cm/yr) and eventually cause pain or a palpable abdominal mass; hydatiduria and renal colic occur in a minority of patients. Renal function is usually unaffected. Imaging shows a thick-walled, fluid-filled spheric cyst, often with a calcified wall; the appearance helps define the stage of the disease and, in turn, management strategies. Serologic testing is adjunctive for diagnosis, with a sensitivity of only 60% to 90%. Although use of percutaneous puncture, aspiration, injection, and reaspiration (PAIR) is a good therapeutic option for liver cysts, this is not done for lung or renal cysts, for which the only options are surgical resection or antiparasitic chemotherapy. Albendazole (400 mg orally twice per day for 1 to 6 months) is the recommended medical therapy (Kappagoda et al., 2011). Surgical excision is indicated in some patients because of the size or location of the lesions. Cyst rupture can cause anaphylaxis. Some evidence suggests that PZQ plus albendazole preoperatively and postoperatively may minimize secondary seeding and metastatic infection (Bygott and Chiodini, 2009).

Enterobiasis

Enterobius vermicularis (pinworm) causes enterobiasis, which occurs worldwide (common in both temperate and tropical countries). The worms live in the proximal colon and migrate to the perianal region to lay eggs, which become infectious after 6 hours. Transmission is mainly person-to-person, often via fecal-oral contamination of hands or fomites. Although most infections are asymptomatic, perianal pruritus can be severe. Rarely, pinworms can also migrate ectopically, including through the vagina, uterus, and fallopian tubes and into the peritoneal cavity of females. Dead worms and eggs incite granulomas and adhesions. Vulvar and cervical granulomas, salpingitis, oophoritis, tubo-ovarian abscess, appendicitis, and peritonitis can result. Epididymal involvement and inguinal hernias have been rarely reported in men (Moore and McCarthy, 2011).

Treatment with single-dose albendazole (400 mg orally) or mebendazole (100 mg orally) is highly effective. Alternatives include ivermectin (200 µg/kg orally once). Household and other close contacts should be treated, and treatment should be repeated after 2 weeks because of frequent reinfection and autoinfection (Kappagoda et al., 2011).

Amebiasis

Entamoeba histolytica, a protozoan transmitted by the fecal-oral route, is most common in tropical regions. Most infected persons remain asymptomatic, but 10% develop symptoms in other organs, including (rarely) the kidneys. Cutaneous amebiasis can also occur, with painful ulcers often involving the perianal area and genitals (Peterson et al., 2011). Treatment is with tinidazole (2 g orally per day for 3 to 5 days) or metronidazole (750 mg orally three times a day for 10 days), followed by paromomycin (8 to 12 mg/kg orally three times a day for 7 days) or iodoquinol (650 mg orally three times a day for 20 days) (Kappagoda et al., 2011).

Trichomoniasis

Trichomonas vaginalis is a common sexually transmitted protozoan. See Chapter 58 for details.

Key Points: Lymphatic Filariasis

- Lymphatic filariasis is caused by three species of tissue nematodes that are transmitted to humans by mosquito vectors.
- LF is endemic to much of the tropics but is transmitted inefficiently, and clinically apparent LF is usually seen only in long-term residents of endemic countries.
- LF is diagnosed by blood smears, antibody/antigen assays, and radiologic and clinical means.
- Antiparasitic treatment for active LF is with diethylcarbamazine (DEC); ivermectin and albendazole also have activity, and all three drugs are used in mass chemotherapy control programs. Doxycycline also results in a clinical benefit in many patients.

Suggested Readings

A Rev. Hum. Carcinog. Biol. Agents (Working Group of the International Agency for Research on Cancer, W. H. O.) 100B, 377–390 (World Health Organization, 2011).

Doenhoff MJ, Cioli D, Utzinger J. Praziquantel: mechanisms of action, resistance and new derivatives for schistosomiasis. *Curr Opin Infect Dis*. 2008;21:659–667.

Drugs for Parasitic Infections. [The Medical Letter, Inc (website)] http://secure.medicalletter.org/TG-article-132b; 2013.

Elliott DE. Schistosomiasis: pathophysiology, diagnosis, and treatment. *Gastroenterol Clin North Am*. 1996;25:599–625.

Figueiredo AÉÉ, Lucon AÉÉ. Urogenital tuberculosis: update and review of 8961 cases from the world literature. *Rev Urol*. 2008;10(3):207–217.

Fu C-L, Odegaard JI, Herbert DR, et al. A novel mouse model of schistosoma haematobium egg-induced immunopathology. *PLoS Pathog*. 2012;8:e1002605.

Goel A, Dalela D. Options in the management of tuberculous ureteric stricture. *Indian J Urol*. 2008;24(3):376–381.

Gryseels B, Polman K, Clerinx J, et al. Human schistosomiasis. *Lancet*. 2006;368:1106–1118.

Gupta NP, Kumar A, Sharma S, et al. Reconstructive bladder surgery in genitourinary tuberculosis. *Indian J Urol*. 2008;24(3):382–387.

Hemal AK. Laparoscopic retroperitoneal extirpative and reconstructive renal surgery. *J Endourol*. 2011;25(2):209–216.

IARC Working Group on the Evaluation of Carcinogenic Risks to Humans. Biological agents. Volume 100 B. A review of human carcinogens. *IARC Monogr Eval Carcinog Risks to*

Humans. 2012;100:1–441.

Kappagoda S, Singh U, Blackburn BG. Antiparasitic therapy. *Mayo Clin Proc*. 2011;86:561–583.

King C. Schistosomiasis. Guerrant R, Walker D, Weller P. *Tropical infectious diseases: principles, pathogens, and practice*. Elsevier Churchill Livingstone: London; 2006:1341–1348.

Mahmoud AAF. *Schistosomiasis*. Imperial College Press: London; 2001:524.

Meltzer E, Artom G, Marva E, et al. Schistosomiasis among travelers: new aspects of an old disease. *Emerg Infect Dis*. 2006;12:1696–1700.

Merchant S, Bharati A, Merchant N. Tuberculosis of the genitourinary system—urinary tract tuberculosis: renal tuberculosis—Part I. *Indian J Radiol Imaging*. 2013;23(1):46–63.

Mustacchi P In Kufe D, Pollack R, and Wischselbaum R: Cancer Med. (BC Decker, 2003).

Nahid P, Dorman S, Alipanah N, et al. Executive summary: official American thoracic Society/Centers for disease control and Prevention/Infectious diseases society of America clinical practice guidelines: treatment of drug-susceptible tuberculosis. *Clin Infect Dis*. 2016;63(7):853–867.

Pai M, Behr MA, Dowdy D, et al. Tuberculosis. *Nat Rev Dis Primers*. 2016;2:1–23.

Ray D, Nelson T, Fu C-L, et al. Transcriptional profiling of the bladder in urogenital schistosomiasis reveals pathways of inflammatory fibrosis and urothelial compromise. *PLoS Negl Trop Dis*. 2012;6:e1912.

Sakula A. Robert Koch: centenary of the discovery of the tubercle bacillus, 1882. *Thorax*. 1982;37(4):246–251.

Shokeir AA, Hussein M. The urology of Pharaonic Egypt. *BJU Int*. 1999;84:755–761.

Stuiver PC. Acute schistosomiasis (Katayama fever). *Br Med J (Clin Res Ed)*. 1984;288:221–222.

van der Werf MJ, et al. Quantification of clinical morbidity associated with schistosome infection in sub-Saharan Africa. *Acta Trop*. 2003;86:125–139.

References

Abath FG, Werkhauser RC. The tegument of schistosoma mansoni: functional and immunological features. *Parasite Immunol*. 1996;18(1):15–20 http://www.ncbi.nlm.nih.gov/pubmed/9223152.

Abbara A, Davidson R. Etiology and management of genitourinary tuberculosis. *Nat Rev Urol*. 2011;8(12):678–688.

Abdel-Halim RE. Bilharzial uropathies and a scheme for primary medical care. *Br J Urol*. 1984;56(1):13–16 http://www.ncbi.nlm.nih.gov/pubmed/6697100.

Abdel-Halim RE, Al-Mashad S, Al-Dabbagh A. Fluoroscopic assessment of bilharzial ureteropathy. *Clin Radiol*. 1985;36(1):89–94 http://www.ncbi.nlm.nih.gov/pubmed/3933885.

Abdel-Halim RE. Ileal loop replacement and restoration of kidney function in extensive bilharziasis of the ureter. *Br J Urol*. 1980;52(4):280–284 http://www.ncbi.nlm.nih.gov/pubmed/7426992.

Abu-Aisha H, Reddy JJ, Hussain S, et al. Long-term ureterostomy with suprapubic intravesical drainage used to bypass severe schistosomal obstructive uropathy–preliminary report. *Urol Res*. 1985;13(5):263–266 http://www.ncbi.nlm.nih.gov/pubmed/3933154.

Adesola H, Uduak N, Olajumoke M, et al. Urine turbidity and microhaematuria as rapid assessment indicators for *Schistosoma Haematobium* infection among school children in endemic areas. *Am J Infect Dis*. 2012;8(1):60–64.

Adeyeba OAA, Ojeaga SGTGT. Urinary schistosomiasis and concomitant urinary tract pathogens among school children in metropolitan ibadan. *Afr J Biomed Res*. 2002;5(3):103–108.

Agnew A, Fulford AJCJ, De Jonge N, et al. The relationship between worm burden and levels of a circulating antigen (caa) of five species of schistosoma in mice. *Parasitology*. 1995;111(1):67–76.

Alexander KA, Laver PN, Michel AL, et al. Novel Mycobacterium tuberculosis complex pathogen, M. mungi. *Emerg Infect Dis*. 2010;16(8):1296–1299.

Allen EJ, Victory HD. Modelling and simulation of a schistosomiasis infection with biological control. *Acta Trop*. 2003;87:251–267.

Al-Sherbiny MM, Osman AM, Hancock K, et al. Application of immunodiagnostic assays: detection of antibodies and circulating antigens in human schistosomiasis and correlation with clinical findings. *Am J Trop Med Hyg*. 1999;60:960–966.

Al-Shukri S, Alwan MH. Bilharzial strictures of the lower third of the ureter: a critical review of 560 strictures. *Br J Urol*. 1983;55(5):477–482 http://www.ncbi.nlm.nih.gov/pubmed/6626892.

Al-Shukri S, Alwan MH, Nayef M, et al. Bilharziasis in malignant tumours of the urinary bladder. *Br J Urol*. 1987;59(1):59–62 http://www.ncbi.nlm.nih.gov/pubmed/3103810.

Altez-Fernandez C, Ortiz V, Mirzazadeh M, et al. Diagnostic accuracy of nucleic acid amplification tests (NAATs) in urine for genitourinary tuberculosis: a systematic review and meta-analysis. *BMC Infect Dis*. 2017;17(1):390.

Amaral F, Dreyer G, Figueredo-Silva J, et al. Live adult worms detected by ultrasonography in human bancroftian filariasis. *Am J Trop Med Hyg*. 1994;50:753–757.

Amarir F, El Mansouri B, Fellah H, et al. National serologic survey of haematobium schistosomiasis in Morocco: evidence for elimination. *Am J Trop Med Hyg*. 2011;84:15–

19; 10.4269/ajtmh.2011.10-0378.

American Thoracic Society. Diagnostic standards and classification of tuberculosis in adults and children. *Am J Respir Crit Care Med*. 2000;161(4 Pt 1):1376–1395.

Anderson RM, May RM, Anderson B. *Infectious diseases of humans: dynamics and control*. Oxford University Press: USA.; 1992 http://www.amazon.com/Infectious-Diseases-Humans-Dynamics-Publications/dp/019854040X.

Angus BJ, Yates M, Conlon C, et al. Cutaneous tuberculosis of the penis and sexual transmission of tuberculosis confirmed by molecular typing. *Clin Infect Dis*. 2001;33(11):E132–E134.

Aubry P, Capdevielle P, Durand G. [Hepatosplenic disorders in schistosomiasis (Author's transl)]. *Médecine Tropicale : Revue Du Corps de Santé Colonial*. 1980;40(1):53–57 http://www.ncbi.nlm.nih.gov/pubmed/7366366.

Badawy AH. Schistosomiasis of the cervix. *Br Med J*. 1962;1(5275):369–372.

Bedford DE, Aidaros SM, Girgis B. Bilharzial heart disease in Egypt: cor pulmonale due to bilharzial pulmonary endarteritis. *Br Heart J*. 1946;8(2):87–95 http://www.pubmedcentral.nih.gov/articlerender.fcgi?artid=480998&tool=pmcentrez&rendertype=abstract.

Bedwani R, Renganathan E, El Kwhsky F, et al. Schistosomiasis and the risk of bladder cancer in Alexandria, Egypt. *Br J Cancer*. 1998;77(7):1186–1189; 10.1038/bjc.1998.197.

Berry A, Fillaux J, Martin-Blondel G, et al. Evidence for a permanent presence of schistosomiasis in Corsica, France, 2015. *Euro Surveillance Eur Communicable Dis Bull*. 2016;21(1):30100.

Bethony JM, Diemert DJ, Oliveira SC, et al. Can schistosomiasis really be consigned to history without a vaccine? *Vaccine*. 2008; 10.1016/j.vaccine.2008.04.045.

Bhatt C, Lodha S. Paraspinal sinuses? Do remember renal tuberculosis. *BMJ Case Rep*. 2012.

Bonds MH, Keenan DC, Rohani P, et al. Poverty trap formed by the ecology of infectious diseases. *Proc Biol Sci*. 2010;277(1685):1185–1192.

Boom WH, Canaday D, Fulton S, et al. Human immunity to M. tuberculosis: T cell subsets and antigen processing. *Tuberculosis*. 2003;83(1–3):98–106.

Borgstein JA. Pulmonary complications of schistosoma haematobium. *East African Med J*. 1964;41(September):448–452.

Bouchikhi AA, Amiroune D, Tazi MF, et al. Isolated urethral tuberculosis in a middle-aged man: a case report. *J Med Case Rep*. 2013;7(1):97.

Breen RA, Smith CJ, Bettinson H, et al. Paradoxical reactions during tuberculosis treatment in patients with and without HIV co-infection. *Thorax*. 2004;59(8):704–707.

Brooker S, Kabatereine NB, Fleming F, et al. Cost and cost-effectiveness of nationwide school-based helminth control in Uganda: intra-country variation and effects of scaling-up. *Health Policy Plan*. 2008;23:24–35.

Bygott JM, Chiodini PL. Praziquantel: neglected drug? Ineffective treatment? Or therapeutic choice in cystic hydatid disease? *Acta Trop*. 2009;111:95–101.

Byrd RB, Viner NA, Omell GH, et al. Leukoplakia associated with renal tuberculosis in the chemotherapeutic era. *Br J Urol*. 1976;48(5):377–381.

Cantey PT, Weeks J, Edwards M, et al. The emergence of zoonotic *Onchocerca lupi* infection in the United States–a case-series. *Clin Infect Dis*. 2016;62:778–783.

Carl P, Stark L. Indications for surgical management of genitourinary tuberculosis. *World J Surg*. 1997;21(5):505–

510.

Centers for Disease Control and Infection (CDC). Treatment of tuberculosis, American thoracic society, CDC, and infectious diseases society of America. *MMWR Recomm Rep*. 2003;52(RR–11):1–77.

Centers for Disease Control and Infection (CDC). Plan to combat extensively drug-resistant tuberculosis: recommendations of the Federal Tuberculosis Task Force. *MMWR Recomm Rep*. 2009;58(RR–3):1–43.

Centers for Disease Control and Infection (CDC). Provisional CDC guidelines for the use and safety monitoring of bedaquiline fumarate (Sirturo) for the treatment of multidrug-resistant tuberculosis. *MMWR Recomm Rep*. 2013;62(RR–09):1–12.

Centers for Disease Control and Infection (CDC). *Extensively drug-resistant tuberculosis (XDR TB). Fact Sheet*. [2013, January 18; From] http://www.cdc.gov/tb/publications/factsheets/drtb/xdrtb.htm; 2014.

Centers for Disease Control and Infection (CDC). *Trends in tuberculosis*. [2016; November 15; (website)] http://www.cdc.gov/tb/publications/factsheets/statistics/TBTr 2017.

Centers for Disease Control and Prevention (CDC). *Parasites—lymphatic filariasis: guidance for evaluation and treatment*. [(website)] http://www.cdc.gov/parasites/lymphaticfilariasis/health_profe 2013.

Chalke HD. Some historical aspects of tuberculosis. *Public Health*. 1959;74:83–95.

Chawla A, Chawla K, Reddy S, et al. Can tissue PCR augment the diagnostic accuracy in genitourinary tract tuberculosis? *Urol Int*. 2012;88(1):34–38.

Cheever AW, Kamel IA, Elwi AM, et al. Schistosoma Mansoni and S. Haematobium infections in Egypt. II. Quantitative parasitological findings at necropsy. *Am J Trop Med Hyg*. 1977;26(4):702–716 http://www.ncbi.nlm.nih.gov/entrez/query.fcgi?cmd=Retrieve&db=PubMed&dopt=Citation&list_uids=88901

Cheever AW, Kamel IA, Elwi AM, et al. Schistosoma mansoni and S. Haematobium infections in Egypt. III. Extrahepatic pathology. *Am J Trop Med Hyg*. 1978;27(1 Pt 1):55–75 http://www.ncbi.nlm.nih.gov/entrez/query.fcgi?cmd=Retrieve&db=PubMed&dopt=Citation&list_uids=62628

Cheever AW, Young SW, Shehata A. Calcification of schistosoma haematobium eggs: relation of radiologically demonstrable calcification to eggs in tissues and passage of eggs in urine. *Trans R Soc Trop Med Hyg*. 1975;69(4):410–414 http://www.ncbi.nlm.nih.gov/pubmed/1240666.

Chen YJ, Shieh PP, Shen JL. Orificial tuberculosis and Kaposi's sarcoma in an HIV-negative individual. *Clin Exp Dermatol*. 2000;25(5):393–397.

Chibber PJ, Shah HN, Jain P. Laparoscopic nephroureterectomy for tuberculous nonfunctioning kidneys compared with laparoscopic nephroureterectomy for other diseases. *J Laparoendosc Adv Surg Tech A*. 2005;15(3):308–311.

Christensen WI. Genitourinary tuberculosis: review of 102 cases. *Medicine (Baltimore)*. 1974;53(5):377–390.

Christie JD, Crouse D, Smith JH, et al. Patterns of schistosoma haematobium egg distribution in the human lower urinary tract. II. Obstructive uropathy. *Am J Trop Med Hyg*. 1986;35(4):752–758 http://www.ncbi.nlm.nih.gov/pubmed/2425648.

Cioli D, Pica-Mattoccia L, Archer S. Antischistosomal drugs: past, present … and future? *Pharm Ther*. 1995;68:35–85; 10.1016/0163-7258(95)00026-7.

Coelho PMZ, Carvalho OS, Andrade ZA, et al. Biomphalaria tenagophila/schistosoma mansoni interaction: premises for a new approach to biological control of schistosomiasis. *Mem Inst Oswaldo Cruz*. 2004;99:109–111.

Colley DG, Bustinduy AL, Evan Secor W, et al. Human schistosomiasis. *The Lancet*. 2014;383:2253–2264.

Coscolla M, Lewin A, Metzger S, et al. Novel Mycobacterium tuberculosis complex isolate from a wild chimpanzee. *Emerg Infect Dis*. 2013;19(6):969–976.

Critchley JA, Young F, Orton L, et al. Corticosteroids for prevention of mortality in people with tuberculosis: a systematic review and meta-analysis. *Lancet Infect Dis*. 2013;13(3):223–237.

Curwen RS, Ashton PD, Sundaralingam S, et al. Identification of novel proteases and immunomodulators in the secretions of schistosome cercariae that facilitate host entry. *Mol Cellular Proteomics*. 2006;5(5):835–844.

Daher EDF, da Silva Junior GB, Barros EJGO. Renal tuberculosis in the modern era. *Am J Trop Med Hyg*. 2013;88(1):54–64.

Dalton PR, Pole D. Water-contact patterns in relation to schistosoma haematobium infection. *Bull World Health Org*. 1978;56:417–426.

Dandale AL, Dhurat RS, Ghate SS. Papulonecrotic tuberculid of glans penis: a common disease at an uncommon site. *Indian J Sex Transm Dis*. 2013;34(2):132–134.

Daniel TM. The history of tuberculosis. *Resp Med*. 2006;100(11):1862–1870.

Dannenberg AM Jr. Roles of cytotoxic delayed-type hypersensitivity and macrophage-activating cell-mediated immunity in the pathogenesis of tuberculosis. *Immunobiology*. 1994;191(4–5):461–473.

Danso-Appiah A, Utzinger J, Liu J, et al. Drugs for treating urinary schistosomiasis. *Cochr Datab Syst Rev*. 2008;(3) [CD000053].

de Figueiredo AA, Lucon AM, Srougi M. Bladder augmentation for the treatment of chronic tuberculous cystitis. Clinical and urodynamic evaluation of 25 patients after long term follow-up. *Neurourol Urodyn*. 2006;25(5):433–440.

Debrah AY, Specht S, Klarmann-Schulz U, et al. Doxycycline leads to sterility and enhanced killing of female onchocerca volvulus worms in an area with persistent microfilaridermia after repeated ivermectin treatment: a randomized, placebo-controlled, double-blind trial. *Clin Infect Dis*. 2015;61:517–526.

Deelder AM, Miller RL, de Jonge N, et al. Detection of schistosome antigen in mummies. *Lancet*. 1990;335(8691):724–725 http://www.ncbi.nlm.nih.gov/pubmed/1969079.

Demers V, Pelsser V. “BCGitis”: a rare case of tuberculous epididymo-orchitis following intravesical bacillus Calmette-Guerin therapy. *J Radiol Case Rep*. 2012;6(11):16–21.

Dewani CP, Dewani N, Bhatia D. Case report: tubercular cold abscess of seminal vesicle: minimally invasive endoscopic management. *J Endourol*. 2006;20(6):436–442.

Doehring E, Feldmeier H, Daffalla AA. Day-to-day variation and Circadian rhythm of egg excretion in urinary schistosomiasis in the Sudan. *Ann Trop Med Parasitol*. 1983;77:587–594.

Doehring E, Vester U, Ehrich JH, et al. Circadian variation of ova excretion, proteinuria, hematuria, and leukocyturia in urinary schistosomiasis. *Kidney Int*. 1985;27:667–671; 10.1038/ki.1985.62.

Doenhoff MJ, Cioli D, Utzinger J. Praziquantel: mechanisms of action, resistance and new derivatives for schistosomiasis. *Curr Opin Infectious Dis*. 2008;21:659–667.

Dowdy L, Ramgopal M, Hoffman T, et al. Genitourinary tuberculosis after renal transplantation: report of 3 cases and review. *Clin Infect Dis*. 2001;32(4):662–666.

Duvie SO. Cup-Patch ileocystoplasty in the treatment of bilharzial contracted bladder. *J R Coll Surg Edinburgh*. 1986;31(1):56–58.

Eastham JA, Spires KS, Abreo F, et al. Seminal vesicle abscess due to tuberculosis: role of tissue culture in making the diagnosis. *South Med J*. 1999;92(3):328–329.

Eastwood JB, Corbishley CM, Grange JM. Tuberculosis and the kidney. *J Am Soc Nephrol*. 2001;12(6):1307–1314.

el-Agroudy AE, Refaie AF, Moussa OM, et al. Tuberculosis in Egyptian kidney transplant recipients: study of clinical course and outcome. *J Nephrol*. 2003;16(3):404–411.

El-Nahas AR, Shoma AM, El-Baz M. Bilharzial pyelitis: a rare cause of secondary ureteropelvic junction obstruction. *J Urol*. 2003;170(5):1946–1947.

FAM, A. The problem of bilharzial ureter. *Br J Urol*. 1964;36(June):211–219 http://www.ncbi.nlm.nih.gov/pubmed/14191148.

Ferreira OC, Osorio F, Lisboa C, et al. Scrotal ulcers revealing pulmonary and genitourinary tuberculosis. *Dermatol Online J*. 2011;17(8):10.

Figueiredo AA, Lucon AM, Junior RF, et al. Urogenital tuberculosis in immunocompromised patients. *Int Urol Nephrol*. 2009;41(2):327–333.

Figueiredo AÉÉ, Lucon AÉÉ. Urogenital tuberculosis: update and review of 8961 cases from the world literature. *Rev Urol*. 2008;10(3):207–217.

Fischmann J. Two extreme forms of autonephrectomy in renal tuberculosis. *Br J Urol*. 1951;23(1):52–55.

Flechner SM, Gow JG. Role of nephrectomy in the treatment of non-functioning or very poorly functioning unilateral tuberculous kidney. *J Urol*. 1980;123(6):822–825.

Fraietta R, Mori MM, De Oliveira JM, et al. Tuberculosis of seminal vesicles as a cause of aspermia. *J Urol*. 2003;169(4):1472.

Fu C-L, Odegaard JI, Herbert DR, et al. A novel mouse model of schistosoma haematobium egg-induced immunopathology. *PLoS Pathog*. 2012;8(3):e1002605.

Gelfand M. Bilharzial affection of the ureter; a study of 110 consecutive necropsies showing vesical bilharziasis. *Br Med J*. 1948;1(4564):1228–1230 http://www.pubmedcentral.nih.gov/articlerender.fcgi?artid=2090099&tool=pmcentrez&rendertype=abstract.

Giné Garriga R, Pérez Foguet A. Unravelling the linkages between water, sanitation, hygiene and rural poverty: the WASH poverty index. *Water Res Manag*. 2013;27(5):1501–1515.

Goel A, Dalela D. Options in the management of tuberculous ureteric stricture. *Indian J Urol*. 2008;24(3):376–381.

Gokalp A, Gultekin EY, Ozdamar S. Genito-urinary tuberculosis: a review of 83 cases. *Br J Clin Pract*. 1990;44(12):599–600.

Gokce G, Kilicarslan H, Ayan S, et al. Genitourinary tuberculosis: a review of 174 cases. *Scand J Infect Dis*. 2002;34(5):338–340.

Gouda I, Mokhtar N, Bilal D, et al. Bilharziasis and bladder cancer: a time trend analysis of 9843 patients. *J Egypt Natl Cancer Inst*. 2007;19:158–162.

Gray DJ, McManus DP, Li Y, et al. Schistosomiasis elimination: lessons from the past guide the future. *Lancet Infect Dis*. 2010;10:733–736.

Grisham MB, Yamada T. Neutrophils, nitrogen oxides, and inflammatory bowel disease. *Ann New York Acad Sci*. 1992;664(January):103–

115 http://www.ncbi.nlm.nih.gov/pubmed/1456643.

Group, Working. Schistosoma haematobium. World Health Organization: Geneva; 2011:377–390. World Health Organization International Agency for Research on Cancer. *A review of human carcinogens: biological agents*. vol 100B.

Guidi A, Andolina C, Makame Ame S, et al. Praziquantel efficacy and Long-Term appraisal of schistosomiasis control in Pemba Island. *Trop Med Internat Health : TM & IH*. 2010;15:614–618.

Gupta BC, Basch PF. The role of schistosoma mansoni males in feeding and development of female worms. *J Parasitol*. 1987;73(3):481–486 http://www.ncbi.nlm.nih.gov/pubmed/3298599.

Gupta NP, Hemal AK, Mishra S, et al. Outcome of retroperitoneoscopic nephrectomy for benign nonfunctioning kidney: a single-center experience. *J Endourol*. 2008;22(4):693–698.

Gupta NP, Kumar A, Sharma S. Reconstructive bladder surgery in genitourinary tuberculosis. *Indian J Urol*. 2008;24(3):382–387.

Gutierrez MC, Brisse S, Brosch R, et al. Ancient origin and gene mosaicism of the progenitor of Mycobacterium tuberculosis. *PLoS Pathog*. 2005;1(1):e5.

Hagan P, Blumenthal UJ, Dunn D, et al. Human IgE, IgG4 and resistance to reinfection with schistosoma haematobium. *Nature*. 1991;349(6306):243–245.

Hanafy HM, Saad SM, Al-Ghorab MM, et al. Ancient Egyptian medicine: contribution to urology. *Urology*. 1974;4(1):114–120.

He H, Isnard A, Kouriba B, et al. A STAT6 gene polymorphism is associated with high infection levels in urinary schistosomiasis. *Genes Immun*. 2008;9(3):195–206.

Helling-Giese G, Sjaastad A, Poggensee G, et al. Diagnosis of female genital schistosomiasis by indirect disease markers: determination of eosinophil cationic protein, neopterin and IgA in vaginal fluid and swab eluates. *Acta Trop*. 1996;62(4):269–280.

Helling-Giese G, Kjetland EF, Gundersen SG, et al. Schistosomiasis in women: manifestations in the upper reproductive tract. *Acta Trop*. 1996;62:225–238.

Hemal AK, Aron M. Orthotopic neobladder in management of tubercular thimble bladders: initial experience and long-term results. *Urology*. 1999;53(2):298–301.

Hemal AK. Laparoscopic retroperitoneal extirpative and reconstructive renal surgery. *J Endourol*. 2011;25(2):209–216.

Hershkovitz I, Donoghue HD, Minnikin DE, et al. Detection and molecular characterization of 9,000-year-old Mycobacterium tuberculosis from a Neolithic settlement in the Eastern Mediterranean. *PLoS ONE*. 2008;3(10):e3426.

Hoerauf A, Mand S, Adjei O, et al. Depletion of *Wolbachia* endobacteria in *Onchocerca volvulus* by doxycycline and microfilaridermia after ivermectin treatment. *Lancet*. 2001;357:1415–1416.

Hoerauf A. Onchocerciasis. Guerrant RL, Walker DH, Weller PF. *Tropical infectious diseases: principles, pathogens, & practice*. ed 3. Elsevier Mosby Saunders: Philadelphia; 2011:741–749.

Holtfreter MC, Moné H, Müller-Stöver I, et al. Schistosoma haematobium infections acquired in Corsica, France, August 2013. *Eur Commun Dis Bull*. 2014;19(22) http://www.ncbi.nlm.nih.gov/pubmed/24925456.

Hotez PJ, Fenwick A. Schistosomiasis in Africa: an emerging tragedy in our new global health decade. *PLoS Neglected Tropical Diseases*. 2009;3(9):e485; 10.1371/journal.pntd.0000485.

Hotez PJ, Fenwick A, Kjetland EF. Africa's 32 cents solution for HIV/AIDS. *PLoS Negl Trop Dis*. 2009;3(5).

Huebner RE, Schein MF, Bass JB Jr. The tuberculin skin test. *Clin Infect Dis*. 1993;17(6):968–975.

Hugosson C. Striation of the renal pelvis and ureter in bilharziasis. *Clin Radiol*. 1987;38(4):407–409 http://www.ncbi.nlm.nih.gov/pubmed/3113809.

Hunter JM, Rey L, Chu KY, et al. *Parasitic diseases in water resources development : the need for intersectoral negotiation*. [Geneva] 1993.

Ioannidis P, Papaventsis D, Karabela S, et al. Cepheid GeneXpert MTB/RIF assay for Mycobacterium tuberculosis detection and rifampin resistance identification in patients with substantial clinical indications of tuberculosis and smear-negative microscopy results. *J Clin Microbiol*. 2011;49(8):3068–3070.

Isnard A, Kouriba B, Doumbo O, et al. Association of rs7719175, located in the IL13 gene promoter, with schistosoma haematobium infection levels and identification of a susceptibility haplotype. *Genes Immun*. 2011;12(1):31–39 http://www.ncbi.nlm.nih.gov/pubmed/20861864.

Isnard A, Chevillard C. Recent advances in the characterization of genetic factors involved in human susceptibility to infection by schistosomiasis. *Curr Genomics*. 2008;9(5):290–300; 10.2174/138920208785133262.

Jacobsson B, Lindstedt E, Narasimham DL, et al. Balloon dilatation of bilharzial ureteric strictures. *Br J Urol*. 1987;60(1):28–32 http://www.ncbi.nlm.nih.gov/pubmed/3113523.

Jauréguiberry S, Paris L, Caumes E. Acute schistosomiasis, a diagnostic and therapeutic challenge. *Clin Microbiol Infect*. 2010;16:225–231.

Jenkins SJ, Hewitson JP, Jenkins GR, et al. Modulation of the host's immune response by schistosome larvae. *Parasite Immunol*. 2005;27(10–11):385–393; 10.1111/j.1365-3024.2005.00789.x.

Jensen T, Rønne-Rasmussen JO, Bygbjerg IC. Acute schistosomiasis (katayama fever). *Ugeskr Laeger*. 1995;157:4825–4827.

Jorulf H, Lindstedt E. Urogenital schistosomiasis: CT evaluation. *Radiology*. 1985;157:745–749.

Jourdan PM, Roald B, Poggensee G, et al. Increased vascularity in cervicovaginal mucosa with schistosoma haematobium infection. *PLoS Negl Trop Dis*. 2011;5(6).

Kaplan JE, Benson C, Holmes KK, et al. Guidelines for prevention and treatment of opportunistic infections in HIV-infected adults and adolescents: recommendations from CDC, the national institutes of health, and the HIV medicine Association of the infectious diseases society of America. *MMWR Recomm Rep*. 2009;58(RR–4):1–207 [quiz CE201-204].

Kappagoda S, Singh U, Blackburn BG. Antiparasitic therapy. *Mayo Clin Proc*. 2011;86:561–583.

Kappelman J, Alcicek MC, Kazanci N, et al. First Homo erectus from Turkey and implications for migrations into temperate eurasia. *Am J Phys Anthropol*. 2008;135(1):110–116.

Kar JK, Kar M. Primary tuberculosis of the glans penis. *J Assoc Physicians India*. 2012;60:52–53.

Kardorff R, Döhring E. Ultrasound diagnosis of bilharziasis. *Ultraschall Med*. 2001;22:107–115.

Kazura JW, Bockarie M, Alexander N, et al. Transmission intensity and its relationship to infection and disease due to *Wuchereria bancrofti* in Papua New Guinea. *J Infect Dis*. 1997;176:242–246.

Khafagy MM, el-Bolkainy MN, Mansour MA. Carcinoma of the Bilharzial urinary bladder. a study of the associated mucosal lesions in 86 cases. *Cancer*. 1972;30(1):150–159 http://www.ncbi.nlm.nih.gov/pubmed/5040739.

Kho VK, Chan PH. Isolated tuberculous epididymitis presenting as a painless scrotal tumor. *J Chin Med Assoc*. 2012;75(6):292–295.

Kim SH, Yoon HK, Park JH, et al. Tuberculous stricture of the urinary tract: antegrade balloon dilation and ureteral stenting. *Abdom Imaging*. 1993;18(2):186–190.

King CH. Disease in schistosomiasis haematobia. Mahmoud AAF. *Schistosomiasis*. Imperial College Press: Lond; 2001:265.

King CH, Muchiri EM, Ouma JH. Evidence against rapid emergence of praziquantel resistance in schistosoma haematobium, Kenya. *Emerg Infect Dis*. 2000;6:585–594; 10.3201/eid0706.010633.

King CH. Schistosomiasis. Guerrant RL, Walker DH, Weller PF. *Tropical infectious diseases, principles, pathogens, and practice*. ed 2. Elsevier Churchill Livingstone: London; 2006:1341–1348.

Kjetland EF, Leutscher PDCC, Ndhlovu PD. A review of female genital schistosomiasis. *Trends Parasitol*. 2012;28(2); 10.1016/j.pt.2011.10.008.

Kjetland EF, Ten Hove RJ, Gomo E, et al. Schistosomiasis PCR in vaginal lavage as an indicator of genital Schistosoma haematobium infection in rural Zimbabwean women. *Am J Tropical Med Hyg*. 2009;81(6):1050–1055 http://www.ncbi.nlm.nih.gov/pubmed/19996436.

Klion AD, Nutman TB. Loiasis and *Mansonella* infections. Guerrant RL, Walker DH, Weller PF. *Tropical infectious diseases: principles, pathogens, & practice*. ed 3. Elsevier Mosby Saunders: Philadelphia; 2011:735–740.

Knopp S, Russell Stothard J, Rollinson D, et al. From morbidity control to transmission control: time to change tactics against helminths on Unguja Island, Zanzibar. *Acta Trop*. 2011;128(2):412–422.

Knopp S, Mohammed KA, Ali SM, et al. Study and implementation of urogenital schistosomiasis elimination in Zanzibar (Unguja and Pemba Islands) using an integrated multidisciplinary approach. *BMC Public Health*. 2012; 10.1186/1471-2458-12-930.

Kohno M, Kuwatsuru R, Suzuki K, et al. Imaging findings from a case of bilharziasis in a patient with gross hematuria of several years' duration. *Radiat Med*. 2008;26:553–556.

Kothari PR, Kumar T, Jiwane A, et al. Renal tuberculosis: an early presentation. *J Indian Assoc Pediatr Surg*. 2001;6(3):103–106.

Kouriba B, Chevillard C, Bream JH, et al. Analysis of the 5q31-q33 locus shows an association between IL13-1055C/T IL-13-591A/G polymorphisms and Schistosoma Haematobium infections. *J Immunol*. 2005;174(10):6274–6281 [doi:174/10/6274 [pii].

Kremsner PG, Enyong P, Krijger FW, et al. Circulating anodic and cathodic antigen in serum and urine from Schistosoma Haematobium-infected cameroonian children receiving praziquantel: a longitudinal study. *Clin Infect Dis*. 1994;18(3):408–413 http://www.ncbi.nlm.nih.gov/pubmed/8011824.

Kulchavenya E, Kim CS, Bulanova O, et al. Male genital tuberculosis: epidemiology and diagnostic. *World J Urol*. 2012;30(1):15–21.

Kulchavenya E, Zhukova I, Kholtobin D. Spectrum of urogenital tuberculosis. *J Infect Chemother*. 2013;19(5):880–883.

Lamm DL, van der Meijden PM, Morales A, et al. Incidence and treatment of complications of bacillus Calmette-Guerin intravesical therapy in superficial bladder cancer. *J Urol*.

1992;147(3):596–600.

Lanjewar DN, Ansari MA, Shetty CR, et al. Renal lesions associated with AIDS–an autopsy study. *Indian J Pathol Microbiol*. 1999;42(1):63–68.

Laughlin LW, Farid Z, Mansour N, et al. Bacteriuria in urinary Schistosomiasis in Egypt a prevalence survey. *Am J Trop Med Hyg*. 1978;27(5):916–918 http://www.ncbi.nlm.nih.gov/pubmed/362956.

Leadbetter GW, Leadbetter WF. Ureteral reimplantation and bladder neck reconstruction. four and one-half years' experience. *J Am Med Assoc*. 1961;175(February):349–353 http://www.ncbi.nlm.nih.gov/pubmed/13759904.

Lee KS, Kim HH, Byun SS, et al. Laparoscopic nephrectomy for tuberculous nonfunctioning kidney: comparison with laparoscopic simple nephrectomy for other diseases. *Urology*. 2002;60(3):411–414.

Lee M, Lee J, Carroll MW, et al. Linezolid for treatment of chronic extensively drug-resistant tuberculosis. *N Engl J Med*. 2012;367(16):1508–1518.

Lehman JS, Farid Z, Bassily S. Mortality in urinary schistosomiasis. *Lancet*. 1970;2(7677):822–823 http://www.ncbi.nlm.nih.gov/pubmed/4196042.

Lehman JS, Farid Z, Smith JH, et al. Urinary schistosomiasis in Egypt: clinical, radiological, bacteriological and parasitological correlations. *Trans R Soc Trop Med Hyg*. 1973;67(3):384–399 http://www.ncbi.nlm.nih.gov/pubmed/4591503.

Lehman JS, Farid Z, Bassily S, et al. Hydronephrosis, bacteriuria, and maximal urine concentration in urinary schistosomiasis. *Ann Intern Med*. 1971;75(1):49–55 http://www.ncbi.nlm.nih.gov/pubmed/5091567.

Lewinsohn DM, Leonard MK, LoBue PA, et al. Official American thoracic Society/Infectious diseases society of

America/Centers for disease control and prevention clinical practice guidelines: diagnosis of tuberculosis in adults and children. *Clin Infect Dis*. 2017;64(2):111–115.

Liu R, Dong H-F, Guo Y, et al. Efficacy of praziquantel and artemisinin derivatives for the treatment and prevention of human schistosomiasis: a systematic review and meta-analysis. *Parasit Vectors*. 2011; 10.1186/1756-3305-4-201.

Loker ES. A comparative study of the life-histories of mammalian schistosomes. *Parasitology*. 1983;87(Pt 2):343–369 http://www.ncbi.nlm.nih.gov/entrez/query.fcgi?cmd=Retrieve&db=PubMed&dopt=Citation&list_uids=63590

Lorimer I, Botha J, Pontin AR, et al. Tuberculosis isolated to the renal allograft. *Transpl Infect Dis*. 1999;1(1):83–86.

Lubbe J, Ruef C, Spirig W, et al. Infertility as the first symptom of male genitourinary tuberculosis. *Urol Int*. 1996;56(3):204–206.

Lucas SB. Squamous cell carcinoma of the bladder and schistosomiasis. *East Afr Med J*. 1982;59(5):345–351 http://www.ncbi.nlm.nih.gov/pubmed/7173071.

Mahmoud AAF. *Schistosomiasis*. Imperial College Press: London; 2001.

Malek EA. Effect of the Aswan High Dam on prevalence of schistosomiasis in Egypt. *Trop Geogr Med*. 1975;27(4):359–364 http://www.ncbi.nlm.nih.gov/pubmed/1216315.

Mand S, Debrah AY, Klarmann U, et al. Doxycycline improves filarial lymphedema independent of active filarial infection: a randomized controlled trial. *Clin Infect Dis*. 2012;55:621–630.

Mazurek GH, Jereb J, Vernon A, et al. Updated guidelines for using interferon gamma release assays to detect Mycobacterium tuberculosis infection—United States, 2010. *MMWR Recomm Rep*. 2010;59(RR–5):1–25.

McManus DP, Loukas A. Current status of vaccines for schistosomiasis. *Clin Microbiol Rev*. 2008;21(1):225–242 http://www.pubmedcentral.nih.gov/articlerender.fcgi?artid=2223839&tool=pmcentrez&rendertype=abstract.

Mehta PK, Raj A, Singh N, et al. Diagnosis of extrapulmonary tuberculosis by PCR. *FEMS Immunol Med Microbiol*. 2012;66(1):20–36.

Melo AL, Pereira LH. Kinetics of the Cercaria-Schistosomulum transformation in vivo. *Rev Soc Bras Med Trop*. 1985;18(1):17–21; 10.1590/S0037-86821985000100005.

Meltzer E, Artom G, Marva E, et al. Schistosomiasis among travelers: new aspects of an old disease. *Emerg Infect Dis*. 2006;12:1696–1700; 10.3201/eid1211.060340.

Merchant S, Bharati A, Merchant N. Tuberculosis of the genitourinary system-urinary tract tuberculosis: renal tuberculosis—part I. *Indian J Radiol Imaging*. 2013;23(1):46–63.

Merchant S, Bharati A, Merchant N. Tuberculosis of the genitourinary system-Urinary tract tuberculosis: renal tuberculosis—part II. *Indian J Radiol Imaging*. 2013;23(1):64–77.

Meyer T, Sekljic H, Fuchs S, et al. Taste, a new incentive to switch to (R)-Praziquantel in schistosomiasis treatment. *PLoS Neglected Tropical Diseases*. 2009;3(1):e357; 10.1371/journal.pntd.0000357.

Michaud DS. Chronic inflammation and bladder cancer. *Urol Oncol*. 2007;25:260–268 http://www.ncbi.nlm.nih.gov/entrez/query.fcgi?cmd=Retrieve&db=PubMed&dopt=Citation&list_uids=17483

Midzi N, Butterworth AE, Mduluza T, et al. Use of circulating cathodic antigen strips for the diagnosis of urinary schistosomiasis. *Trans R Soc Trop Med Hyg*. 2009;103(1):45–51; 10.1016/j.trstmh.2008.08.018.

Mkoji GM, Hofkin BV, Kuris AM, et al. Impact of the crayfish

Procambarus Clarkii on schistosoma haematobium transmission in Kenya. *Am J Trop Med Hyg*. 1999;61:751–759.

Molyneux DH. Filaria control and elimination: diagnostic, monitoring and surveillance needs. *Trans R Soc Trop Med Hyg*. 2009;103:338–341.

Moore TA, McCarthy JS. Enterobiasis. Guerrant RL, Walker DH, Weller PF. *Tropical infectious diseases: principles, pathogens, & practice*. ed 3. Elsevier Mosby Saunders: Philadelphia; 2011:788–790.

Moscatelli G, Moroni S, Freilij H, et al. A five-year-old child with renal hydatidosis. *Am J Trop Med Hyg*. 2013;89:554–556.

Mostafa MH, Sheweita SA, O'Connor PJ. Relationship between schistosomiasis and bladder cancer. *Clin Microbiol Rev*. 1999;12(1):97–111.

Moussa OM, Eraky I, El-Far MA, et al. Rapid diagnosis of genitourinary tuberculosis by polymerase chain reaction and non-radioactive DNA hybridization. *J Urol*. 2000;164(2):584–588.

Murphy DM, Fallon B, Lane V, et al. Tuberculous stricture of ureter. *Urology*. 1982;20(4):382–384.

Mustacchi P. Schistosomiasis and cancer of the bladder. Kufe D, Pollack R, Weischelbaum R. *Cancer medicine*. BC Decker: Hamilton; 2003.

N'Goran EK, Gnaka HN, Tanner M, et al. Efficacy and side-effects of two Praziquantel treatments against Schistosoma haematobium infection, among schoolchildren from Côte d'Ivoire. *Ann Trop Med Parasitol*. 2003;97:37–51; 10.1179/000349803125002553.

Nahid P, Dorman SE, Alipanah N, et al. Executive summary: official American thoracic Society/Centers for disease control and Prevention/Infectious diseases society of America clinical practice guidelines: treatment of drug-susceptible tuberculosis. *Clin Infect Dis*. 2016;63(7):853–867.

Narayana A. Overview of renal tuberculosis. *Urology*. 1982;19(3):231–237.

Nerlich AG, Haas CJ, Zink A, et al. Molecular evidence for tuberculosis in an ancient Egyptian mummy. *Lancet*. 1997;350(9088):1404.

Ney C, Friedenberg RM. *Radiographic atlas of the genitourinary system*. JB Lippincott Company: Philadelphia; 1981.

Nutman TB, Kazura JW. Lymphatic filariasis. Guerrant RL, Walker DH, Weller PF. *Tropical infectious diseases, - Principles, pathogens, & practice*. ed 3. Elsevier Mosby Saunders: Philadelphia; 2011:729–734.

Obeng BB, Aryeetey YA, de Dood CJ, et al. Application of a circulating-cathodic-antigen (CCA) strip test and real-time PCR, in comparison with microscopy, for the detection of schistosoma haematobium in urine samples from Ghana. *Ann Trop Med Parasitol*. 2008;102(7):625–633; 10.1179/136485908X337490.

Olds GR. Administration of Praziquantel to pregnant and lactating women. *Acta Trop*. 2003;86:185–195; 10.1016/S0001-706X(03)00033-0.

Ouf EA, Ojurongbe O, Akindele AA, et al. Ficolin-2 levels and FCN2 genetic polymorphisms as a susceptibility factor in schistosomiasis. *J Infect Dis*. 2012;206(4):562–570; 10.1093/infdis/jis396.

Pai M, Behr MA, Dowdy D, et al. Tuberculosis. *Nat Rev Dis Primers*. 2016;2:16076.

Parker SG, Kommu SS. Post-intravesical BCG epididymo-orchitis: case report and a review of the literature. *Int J Surg Case Rep*. 2013;4(9):768–770.

Parsons SD, Drewe JA, Gey van Pittius NC, et al. Novel cause of tuberculosis in meerkats, South Africa. *Emerg Infect Dis*. 2013;19(12):2004–2007.

Patterson IY, Robertus LM, Gwynne RA, et al. Genitourinary tuberculosis in Australia and New Zealand. *BJU Int*. 2012;109(Suppl 3):27–30.

Pearce EJ, MacDonald AS. The immunobiology of schistosomiasis. *Nat Rev Immunol*. 2002;2(7):499–511; 10.1038/nri843nri843 [pii].

Peterson KM, Singh U, Petri WA. Enteric amebiasis. Guerrant RL, Walker DH, Weller PF. *Tropical infectious diseases, principles, pathogens, & practice*. ed 3. Elsevier Mosby Saunders: Philadelphia; 2011:614–622.

Pflüger W, Roushdy MZ, El Emam M. The prepatent period and cercarial production of Schistosoma haematobium in bulinus truncatus (Egyptian Field Strains) at different constant temperatures. *Zeitschrift Für Parasitenkunde (Berlin, Germany)*. 1984;70(1):95–103 http://www.ncbi.nlm.nih.gov/pubmed/6695537.

Pointier JP, Jourdane J. Biological control of the snail hosts of schistosomiasis in areas of low transmission: the example of the Caribbean area. *Acta Trop*. 2000;77:53–60; 10.1016/S0001-706X(00)00123-6.

Politano VA, Leadbetter WF. An operative technique for the correction of vesicoureteral reflux. *J Urol*. 1958;79(6):932–941 http://www.ncbi.nlm.nih.gov/pubmed/13539988.

Psihramis KE, Donahoe PK. Primary genitourinary tuberculosis: rapid progression and tissue destruction during treatment. *J Urol*. 1986;135(5):1033–1036.

Raglio A, Parea M, Francesca V, et al. A family case report of Schistosoma haematobium infection in Italian travelers. *J Travel Med*. 1995;2:193–195 http://www.ncbi.nlm.nih.gov/pubmed/9815386.

Ram R, Swarnalatha G, Desai M, et al. Membranous nephropathy and granulomatous interstitial nephritis due to tuberculosis. *Clin Nephrol*. 2011;76(6):487–491.

Ramaiah KD, Ottesen EA. Progress and impact of 13 years of the global programme to eliminate lymphatic filariasis on reducing the burden of filarial disease. *PLoS Negl Trop Dis*.2014;8:e3319.

Ramanathan R, Kumar A, Kapoor R, et al. Relief of urinary tract obstruction in tuberculosis to improve renal function. Analysis of predictive factors. *Br J Urol*. 1998;81(2):199–205.

Ramesh V, Vasanthi R. Tuberculous cavernositis of the penis: case report. *Genitourin Med*. 1989;65(1):58–59.

Ratard RC, Greer GJ. A new focus of Schistosoma haematobium/S. Intercalatum hybrid in Cameroon. *Am J Trop Med Hyg*. 1991;45(3):332–338 http://www.ncbi.nlm.nih.gov/entrez/query.fcgi?cmd=Retrieve&db=PubMed&dopt=Citation&list_uids=19285

Ray D, Nelson TA, Fu C-L, et al. Transcriptional profiling of the bladder in urogenital schistosomiasis reveals pathways of inflammatory fibrosis and urothelial compromise. Edited by stephen john davies. *PLoS Negl Trop Dis*. 2012;6(11); 10.1371/journal.pntd.0001912.

Reimer LJ, Thomsen EK, Tisch DJ, et al. Insecticidal bed nets and filariasis transmission in Papua New Guinea. *N Engl J Med*. 2013;369:745–753.

Rheinberg CE, Moné H, Caffrey CR, et al. Schistosoma Haematobium, S. Intercalatum, S. Japonicum, S. Mansoni, and S. Rodhaini in mice: relationship between patterns of lung migration by schistosomula and perfusion recovery of adult worms. *Parasitol Res*. 1998;84(4):338–342 http://www.ncbi.nlm.nih.gov/entrez/query.fcgi?cmd=Retrieve&db=PubMed&dopt=Citation&list_uids=95691

Richter J, Poggensee G, Kjetland EF, et al. Reversibility of lower reproductive tract abnormalities in women with Schistosoma haematobium infection after treatment with Praziquantel–an interim report. *Acta Trop*. 1996;62.

Richter J. Evolution of Schistosomiasis-induced pathology after therapy and interruption of exposure to schistosomes: a review of ultrasonographic studies. *Acta Trop*. 2000;77(1):111–131 [doi:S0001-706X(00)00125-X [pii].

Roberts JK, Kuris AM. Predation and control of laboratory populations of the snail Biomphalaria glabrata by the freshwater prawn Macrobrachium rosenbergii. *Ann Trop Med Parasitol*. 1990;84:401–412.

Roberts M, Butterworth AE, Kimani G, et al. Immunity after treatment of human schistosomiasis: association between cellular responses and resistance to reinfection. *Infect Immun*. 1993;61:4984–4993.

Rollinson D, Knopp S, Levitz S, et al. Time to set the agenda for schistosomiasis elimination. *Acta Trop*. 2012; 10.1016/j.actatropica.2012.04.013.

Rutasitara WK, Chimbe A. Spontaneous cure in schistosomiasis. *East Afr Med J*. 1985;62(6):408–410 http://www.ncbi.nlm.nih.gov/pubmed/3930204.

Sabha M, Nilsson T. Urodynamic evaluation of calcified bilharzial bladders. *APMIS Suppl*. 1988;3(January):50–53 http://www.ncbi.nlm.nih.gov/pubmed/3140849.

Sakula A. Robert koch: centenary of the discovery of the tubercle bacillus, 1882. *Thorax*. 1982;37(4):246–251.

Salem B. Disseminated tuberculosis following the placement of ureteral stents: a case report. *Cases J*. 2008;1(1):383.

Salem HK, Ragab H, Abd El Maksoud N. 1068 vascular endothelial growth factor expression in schistosomiasis-associated bladder cancer, correlation with histopathological features and schistosomiasis. *J Urol*. 2012;187(4, Suppl):e433–e434.

Sankari BR. *Operative urology at the Cleveland Clinic*. Humana Press, Inc: Totowa, New Jersey; 2007.

Schluger NW, Rom WN. The host immune response to tuberculosis. *Am J Respir Crit Care Med*. 1998;157(3 Pt 1):679–691.

Schwartz E, Kozarsky P, Wilson M, et al. Schistosome infection among River Rafters on Omo River, Ethiopia. *J Travel Med*. 2005;12(1):3–8 http://www.ncbi.nlm.nih.gov/pubmed/15996460.

Shenoy VP, Viswanath S, D'Souza A, et al. Isolated tuberculous epididymo-orchitis: an unusual presentation of tuberculosis. *J Infect Dev Ctries*. 2012;6(1):92–94.

Shin KY, Park HJ, Lee JJ, et al. Role of early endourologic management of tuberculous ureteral strictures. *J Endourol*. 2002;16(10):755–758.

Shokeir AA, Hussein MI. The urology of pharaonic Egypt. *BJU Int*. 1999;84:755–761.

Sievers ML. The second “great imitator”, Äîtuberculosis. *J Am Med Assoc*. 1961;176(9):809–810.

Silva M, Breiman A, Allain S, et al. The tuberculous granuloma: an unsuccessful host defence mechanism providing a safety shelter for the bacteria? *Clin Dev Immunol*. 2012;2012:139127.

Simon HB, Weinstein AJ, Pasternak MS, et al. Genitourinary tuberculosis. clinical features in a general hospital population. *Am J Med*. 1977;63(3):410–420.

Singh O, Gupta SS, Arvind NK. A case of extensive genitourinary tuberculosis: combined augmentation ileo-cystoplasty, ureteric ileal replacement and buccal mucosal graft urethroplasty. *Updates Surg*. 2013;65(3):245–248.

Smith JH, Kelada AS, Khalil A, et al. Surgical pathology of schistosomal obstructive uropathy: a clinicopathologic correlation. *Am J Trop Med Hyg*. 1977;26(1):96–

103 http://www.ncbi.nlm.nih.gov/pubmed/842790.

Smith JH, Kelada AS, Khalil A. Schistosomal ulceration of the urinary bladder. *Am J Trop Med Hyg*. 1977;26(1):89–95 http://www.ncbi.nlm.nih.gov/pubmed/842789.

Smith JH, Christie JD. The pathobiology of Schistosoma haematobium infection in humans. *Hum Pathol*. 1986;17:333–345.

Smith JH, Kamel IA, Elwi A, et al. A quantitative post mortem analysis of urinary schistosomiasis in Egypt. I. Pathology and pathogenesis. *Am J Trop Med Hyg*. 1974;23(6):1054–1071 http://www.ncbi.nlm.nih.gov/pubmed/4429178.

Soares M, Ricardo J, Barnett AG, et al. Geographical analysis of the role of water supply and sanitation in the risk of helminth infections of children in West Africa. *Proc Natl Acad Sci USA*. 2011;108(50):20084–20089; 10.1073/pnas.1106784108.

Sokolow SH, Wood CL, Jones IJ, et al. Global assessment of schistosomiasis control over the past century shows targeting the snail intermediate host works best. *PLoS Neglected Trop Dis*. 2016;10(7) [e0004794].

Sokolow SH, Wood CL, Jones IJ, et al. To reduce the global burden of human schistosomiasis, use ‘Old Fashioned’ snail control. *Trends Parasitol*. 2018;34(1):23–40; 10.1016/j.pt.2017.10.002.

Sokolow SH, Lafferty KD, Kuris AM. Regulation of laboratory populations of snails (biomphalaria and bulinus spp.) by river prawns, Macrobrachium Spp. (Decapoda, Palaemonidae): implications for control of schistosomiasis. *Acta Trop*. 2013;December; 10.1016/j.actatropica.2013.12.013.

Squires FB, Coakley FV, Berg WJ, et al. Bilateral renal masses after local Bacillus Calmette-Guerin therapy for postcystectomy ureteral cancer. *Abdom Imaging*. 1999;24(2):200–201.

Steel C, Guinea A, Ottesen EA. Evidence for protective immunity to bancroftian filariasis in the Cook Islands. *J Infect Dis*. 1996;174:598–605.

Steinmann P, Keiser J, Bos R, et al. Schistosomiasis and water resources development: systematic review, meta-analysis, and estimates of people at risk. *Lancet Infect Dis*. 2006;6(7):411–425 [doi:S1473-3099(06)70521-7 [pii] 10.1016/S1473-3099(06)70521-7].

Stothard JR, Kabatereine NB, Tukahebwa EM, et al. Use of circulating cathodic antigen (CCA) dipsticks for detection of intestinal and urinary schistosomiasis. *Acta Trop*. 2006;97(2) [219–28. doi:S0001-706X(05)00344-X [pii]10.1016/j.actatropica.2005.11.004].

Stuiver PC. Acute schistosomiasis (Katayama Fever). *Br Med J (Clin Res Ed)*. 1984;288(6412):221–222 http://www.pubmedcentral.nih.gov/articlerender.fcgi?artid=1444502&tool=pmcentrez&rendertype=abstract.

Subramanian AK, Mungai P, Ouma JH, et al. Long-term suppression of adult bladder morbidity and severe hydronephrosis following selective population chemotherapy for Schistosoma haematobium. *Am J Tropl Med Hyg*. 1999;61(3):476–481 http://www.ncbi.nlm.nih.gov/pubmed/10497994.

Sun L, Yuan Q, Feng J, et al. Be alert to tuberculosis-mediated glomerulonephritis: a retrospective study. *Eur J Clin Microbiol Infect Dis*. 2012;31(5):775–779.

Talla I, Kongs A, Verlé P, et al. Outbreak of intestinal schistosomiasis in the senegal river basin. *Annales de La Société Belge de Médecine Tropicale*. 1990;70(3):173–180 http://www.ncbi.nlm.nih.gov/pubmed/2122819.

ten Hove RJ, Verweij JJ, Vereecken K, et al. Multiplex real-time PCR for the detection and quantification of Schistosoma mansoni and S. haematobium infection in stool samples collected in northern Senegal. *Trans R Soc Trop Med Hyg*. 2008;102(2):179–185; 10.1016/j.trstmh.2007.10.011.

Teo EY, Wee TC. Images in clinical medicine: renal tuberculosis. *N Engl J Med*. 2011;365(12):e26.

Thomas JE, Bassett MT, Sigola LB, et al. Relationship between bladder cancer incidence, Schistosoma haematobium infection, and geographical region in Zimbabwe. *Trans R Soc Trop Med Hyg*. 1990;84(4):551–553 http://www.ncbi.nlm.nih.gov/pubmed/2128668.

Thomsen EK, Sanuku N, Baea M, et al. Efficacy, safety, and pharmacokinetics of coadministered diethylcarbamazine, albendazole, and ivermectin for treatment of Bancroftian filariasis. *Clin Infect Dis*. 2016;62:334–341.

Umerah BC. Bilharzial hydronephrosis: a clinicoradiological study. *J Urol*. 1981;126(2):164–165 http://www.ncbi.nlm.nih.gov/pubmed/7265357.

Uneke CJ, Ugwuoke-Adibuah S, Nwakpu KO, et al. An assessment of Schistosoma haematobium infection and urinary tract bacterial infection amongst school children in rural Eastern Nigeria - ISPUB. *The Internal Journal of Laboratory Medicine*. 2009;4(1) http://archive.ispub.com/journal/the-internet-journal-of-laboratory-medicine/volume-4-number-1/an-assessment-of-schistosoma-haematobium-infection-and-urinary-tract-bacterial-infection-amongst-school-children-in-rural-eastern-nigeria-2.html#sthash.VyTbYQ5c.

van Dam GJ, Wichers JH, Falcao Ferreira TM, et al. Diagnosis of schistosomiasis by reagent strip test for detection of circulating cathodic antigen. *J Clin Microbiol*. 2004;42:5458–5461; 10.1128/JCM.42.12.5458-5461.2004.

van der Werf MJ, de Vlas SJ, Brooker S, et al. Quantification of clinical morbidity associated with schistosome infection in Sub-Saharan Africa. *Acta Trop*. 2003;86(2–3):125–139 [doi:S0001706X03000299 [pii].

Walker M, Pion SDS, Fang H, et al. Macrofilaricidal efficacy of repeated doses of ivermectin for the treatment of river blindness. *Clin Infect Dis*. 2017;65:2026–2034.

Walker M, Specht S, Churcher TS, et al. Therapeutic efficacy and macrofilaricidal activity of doxycycline for the treatment of river blindness. *Clin Infect Dis*. 2015;60:1199–1207.

Walzl G, Ronacher K, Hanekom W, et al. Immunological biomarkers of tuberculosis. *Nat Rev Immunol*. 2011;11(5):343–354.

Weil GJ, Curtis KC, Fakoli L, et al. Laboratory and field evaluation of a new rapid test for detecting *Wuchereria bancrofti* antigen in human blood. *Am J Trop Med Hyg*. 2013;89:11–15.

Weil GJ, Curtis KC, Fischer PU, et al. A multicenter evaluation of a new antibody test kit for lymphatic filariasis employing recombinant *Brugia malayi* antigen Bm-14. *Acta Trop*. 2011;120(Suppl 1):S19–S22.

WHO. *Investing to overcome the global impact of neglected tropical diseases*. [from] http://apps.who.int/medicinedocs/documents/s21840en/s2184 2015.

WHO. *Treatment of tuberculosis: guidelines*. World Health Organization: Geneva; 2010.

WHO. *Tuberculosis Fact Sheet No. 104*. [October 2017. Retrieved January 6, 2018, 2018; from] http://www.who.int/mediacentre/factsheets/fs104/en/index.ht 2016.

Wilkins HA, Goll PH, Moore PJ. Schistosoma haematobium infection and haemoglobin concentrations in a Gambian community. *Ann Trop Med Parasitol*. 1985;79:159–161.

Wilkinson E, Wilkinson A, Mhezi MP. A rare presentation of a common disease: orificial tuberculosis. *Trop Doct*.

2010;40(1):59–60.

Wilson M, Schantz P, Pieniazek N. Diagnosis of parasitic infections: immunologic and molecular methods. Murray PR. *The manual of clinical microbiology*. ed 6. American Society for Microbiology (ASM): Washington, DC; 1995.

Wilson RA. The saga of schistosome migration and attrition. *Parasitology*. 2009;136(12):1581–1592; 10.1017/S0031182009005708.

Wishahi MM. The role of dilatation in bilharzial ureters. *Br J Urol*. 1987;59(5):405–407 http://www.ncbi.nlm.nih.gov/pubmed/3109536.

Wong N, Hoag NA, Jones EC, et al. Genitourinary tuberculosis masquerading as a ureteral calculus. *Can Urol Assoc J*. 2013;7(5–6):E363–E366.

Woolhouse ME, Taylor P, Matanhire D, et al. Acquired immunity and epidemiology of schistosoma haematobium. *Nature*. 1991;351(6329):757–759; 10.1038/351757a0.

Woolhouse ME. On the application of mathematical models of schistosome transmission dynamics. II. Control. *Acta Trop*. 1992;50:189–204; 10.1016/0001-706X(92)90076-A.

World Health Organization (WHO). *WHO Guidelines Approved by the Guidelines Review Committee. Automated Real-Time nucleic acid amplification technology for rapid and simultaneous detection of tuberculosis and rifampicin resistance: Xpert MTB/RIF assay for the diagnosis of pulmonary and extrapulmonary TB in adults and children: policy update*. World Health Organization Copyright (c) World Health Organization 2013: Geneva; 2013.

World Health Organization (WHO). *Schistosomiasis*. [(website)] http://www.who.int/mediacentre/factsheets/fs115/en/; 2014.

World Health Organization (WHO). *Strategy*. [(website)] http://www.who.int/schistosomiasis/strategy/en/; 2014.

World Health Organization (WHO). *Zanzibar: gearing up to eliminate schistosomiasis*. [(website)] http://www.who.int/neglected_diseases/schistosomiasis_zanzi 2014.

World Health Organization. Progress report on the elimination of human onchocerciasis, 2016-2017. *Wkly Epidemiol Rec*.2017;92:681–694.

Yadav S, Singh P, Hemal A, et al. Genital tuberculosis: current status of diagnosis and management. *Transl Androl Urol*. 2017;6(2):222–233.

Yeboah-Manu D, de Jong BC, Gehre F. The biology and epidemiology of Mycobacterium africanum. *Adv Exp Med Biol*. 2017;1019:117–133.

Zhang X, Zheng T, Ma X, et al. Comparison of retroperitoneoscopic nephrectomy versus open approaches to nonfunctioning tuberculous kidneys: a report of 44 cases. *J Urol*. 2005;173(5):1586–1589.

Zhang Z, Jiang Q. Schistosomiasis elimination. *Lancet Infect Dis*. 2011;11(5):345; 10.1016/S1473-3099(11)70109-8 [author reply 346-7].

Zimmerman MR. Pulmonary and osseous tuberculosis in an Egyptian mummy. *Bull N Y Acad Med*. 1979;55(6):604–608.

PART V

Molecular and Cellular Biology

OUTLINE

61 Basic Principles of Immunology and Immunotherapy in Urologic Oncology

62 Molecular Genetics and Cancer Biology

61

Basic Principles of Immunology and Immunotherapy in Urologic Oncology

Charles G. Drake MD, PhD

Immunotherapy is an important treatment modality for multiple tumor types, including bladder cancer, kidney cancer, melanoma, and lung cancer (Drake et al., 2014; LaFleur et al., 2018). What is often underappreciated as the field advances is the prominent role that immunotherapy has long played in bladder cancer (Brandau and Suttmann, 2007). In fact, the use of bacille Calmette-Guérin (BCG) in bladder cancer provides an ideal framework through which to understand immunotherapy for genitourinary (GU) cancers, although there are still many unanswered questions regarding BCG's mechanism of action. In addition to BGC, which is a relatively nonspecific agent, immunotherapy for GU cancers has also involved the concept of inducing a specific anticancer immune response via a cancer vaccine. Vaccine approaches for prostate cancer and kidney cancer are discussed; more detailed clinical information is included in specific chapters dedicated to treatment. Perhaps most clinically relevant is the concept of immune checkpoint blockade (ICB); it is now clear that antigen-specific immune responses to cancer are restrained by a specific set of molecules expressed on CD4 and CD8 tumor-infiltrating lymphocytes (TILs) (LaFleur et al., 2018). These “checkpoint” molecules, typified by PD-1 and PD-L1, are critical in restraining an antitumor immune response so that treatment with monoclonal antibodies blocking immune checkpoint interactions can lead to objective clinical responses (i.e., tumor shrinkage) in approximately 20% of patients with kidney cancer or bladder cancer. The immunologic mechanisms underlying the efficacy of ICB are discussed, and key clinical data are highlighted. ICB is more effective when combined with other treatment modalities, and immune-based combination therapy will likely become standard of care in the future. Potential combination partners include conventional chemotherapy (in bladder cancer), vascular endothelial growth factor (VEGF) inhibition (in kidney cancer), and androgen-deprivation therapy (in prostate cancer). Finally, anti-CTLA-4, which likely targets suppressive CD4 populations, is an important component in combination approaches and is discussed as well.

Innate Immune System

For didactic purposes, the immune system is often divided into two subsystems, the **innate** and the **adaptive**. Evolutionarily, the innate immune system is the older of the two, and it is present in all vertebrate organisms. Functionally, the innate system recognizes its targets through repeated patterns associated with pathogens. These pathogen-associated molecular patterns (or PAMPs) are recognized by a series of receptors related to Toll molecules in drosophila and are known as Toll-like receptors, or TLRs (Medzhitov and Janeway, 2000). The binding of PAMPs to TLRs is a fundamental immunologic mechanism though which an organism recognizes "danger." Urologists who treat bladder cancer with intravesical BCG employ these innate immune immunologic mechanisms clinically; peptidoglycans in the BCG cell wall are canonical PAMPs, which bind to TLR2 on innate immune cells resident in the bladder wall, activating them and initiating a multi-step immune response (Brandau and Suttmann, 2007).

The initial immune cell that responds to an invading pathogen (or to instilled BCG) is most likely a tissue resident macrophage (Table 61.1). Their names are derived from the Greek *makros* (large) and *phagos* (to eat), thus macrophages are large cells that evolved to engulf and destroy pathogens. Recognition of PAMPs by tissue-resident macrophages leads to their activation, and subsequent secretion of chemical messengers are known as cytokines and chemokines (see following), which in turn recruit and activate additional immune cells important in controlling a local infection. Again, BCG therapy for bladder cancer provides an excellent example: recognition by macrophages and the adherence of bacteria to urothelial cells lining the bladder result in the secretion of a series of chemokines and cytokines (Fig. 61.1). Some of these secreted cytokines attract a second cell type of major importance in the innate immune system, the neutrophil (also known as a polymorphonuclear neutrophil, or PMN). PMNs are the most abundant immune cell in the peripheral circulation, comprising approximately 60% of the white cells in the blood. These cells have a half-life measured in hours in the peripheral blood but can survive for days in the tissue at a site of infection or inflammation. In that sense, PMNs are the major cellular constituent of pus and the hallmark of acute inflammation. One remarkable feature of neutrophil biology is the neutrophils' ability to emigrate from the circulation into tissues; this occurs when they squeeze between cells in the vascular endothelium as they follow a chemokine concentration gradient toward an area of infection within tissues. The hypersegmented configuration of their nucleus likely helps in this process by presenting a less formidable structural barrier to deformation. Like macrophages, neutrophils synthesize a variety of secretory granules, which are released upon PAMP recognition and facilitate destruction of an invading pathogen.

TABLE 61.1

Selected Cell Types Involved in the Immune Response to Genitourinary Cancers

---

CELL TYPE	IMMUNOLOGIC ROLE
Epithelial/urothelial cell	Secrete type I interferons as well as chemokines in response to stress, inflammation, viral infection, or danger signals mediated by pathogen-associated molecular patterns (PAMPs)
Macrophage	An innate immune cell that engulfs pathogens and dead/dying cells and secretes cytokines and chemokines to amplify or initiate an immune response
Neutrophil (PMN)	The most numerous of all innate immune cells in the peripheral blood, critically important in controlling bacterial infections. A collection of neutrophils (pus) is a characteristic of acute inflammation
Dendritic cell	The cell type that bridges the innate and adaptive immune systems by presenting antigens (peptides) from dead/dying cells or debris to T cells in the lymph node. Like macrophages, dendritic cells are activated by “danger” signals transmitted through PAMPs or by cytokines in the microenvironment
CD4 T cell	A “helper” T cell that can either help CD8 T cells to kill or B cells to secrete antibodies
CD8 T cell	A “killer” T cell that, once activated, serially lyses specific targets
Regulatory T cell (Treg)	A subset of CD4 T cells characterized by expression of the transcription factor FoxP3. Major role is to down-regulate an ongoing immune response. In cancer, this is generally a detrimental function.

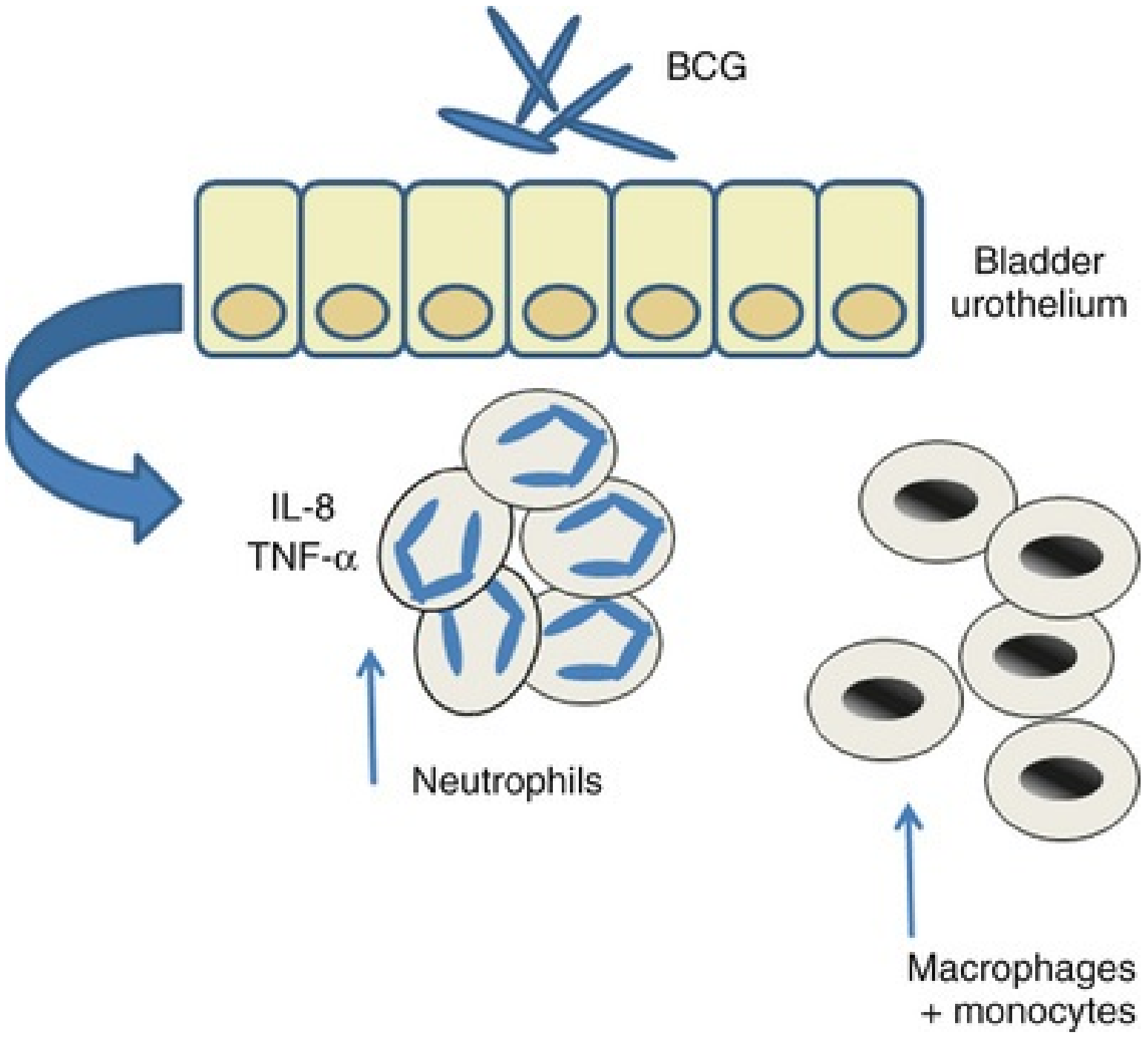

FIG. 61.1 Activation of the innate immune system by bacille Calmette-Guérin (BCG). *IL-8,* Interleukin-8; *TNF-α,* tumor necrosis factor-α. (Modified from Brandau S, Suttmann H: Thirty years of BCG immunotherapy for non-muscle invasive bladder cancer: a success story with room for improvement. *Biomed Pharmacother* 61:299–305, 2007.)

Cytokines and Chemokines

Cytokines and chemokines are small molecule chemical messengers through which epithelial cells communicate with key cells in the immune system and through which cells in the immune system communicate with each other. There are a large number of such molecules, and their nomenclature can be confusing. However, these molecules play a critical role in acute and chronic inflammation, the innate immune response, and the adaptive immune response to cancer, so understanding a few key members is important.

In that regard, the term *cytokine* is a rather general one, referring to any small immunologically relevant molecule secreted by a cell. Because many (but not all) of these molecules are involved in the migration of cells, the name derives from *cyto* (cell), and *kinesis* (movement). Typical cytokines include the type I interferons (IFN-α and IFN-β), which are produced by virally infected or otherwise stressed epithelial cells. Immunologically, type I interferons render epithelial cells more sensitive to immunologic attack by increasing their recognition by cells of the adaptive immune system and by directly facilitating epithelial cell death. As is discussed later, intravesical instillation of IFN-α has been evaluated in a number of clinical trials in bladder cancer, with encouraging but somewhat mixed results (Askeland et al., 2012).

The term *chemokine* refers to a subset of cytokines whose primary function is to induce the migration of immune cells along a chemical concentration gradient. The prototypical example is CXCL8, which can be secreted by most epithelial cell types, including bladder urothelium, in response to inflammatory signals. CXCL8 is a powerful chemoattractant for neutrophils and is likely important in the immune response to BCG in bladder cancer patients. The final subset of cytokines worthy of discussion are a series of molecules originally described as facilitating communication between leukocytes, the interleukins. Interleukins were numbered in the order of their discovery, leading to an unfortunately complex situation in which an interleukin's designation usually has very little to do with its functional role or cell of origin. Interleukin-1 (IL-1), for example, is really more of an innate cytokine than an interleukin; it is secreted from stressed epithelial cells, attracts a variety of immune cells, and in the systemic circulation is one of the primary mediators of an elevated temperature in response to infection. More generally, though, there are two discrete sets of cytokines associated with a broad polarization in the adaptive (T cell–mediated) immune response. These are termed the Th1 and Th2 families of cytokines (Table 61.2 and Fig. 61.2). These cytokines are secreted by CD4 (helper) T cells in response to various stimuli and are critically important in polarizing the immune system in one of several broad directions (Weaver et al., 2006).

TABLE 61.2

Selected Cytokines, Chemokines, and Interleukins Involved in the Immune Response to Genitourinary Cancers

CYTOKINE	CELL OF ORIGIN	ROLE
Type 1 Interferons		
Interferon-α	Urothelial cells, epithelial cells Macrophages	A type 1 interferon typically secreted by a virally infected cells, or cells sensing “danger” through Toll-like receptor (TLR) engagement. Up-regulates class I MHC and antigen processing, rendering cells more susceptible to immunologic attack
Interferon-β	Urothelial	Similar to IFN-α, another type 1 interferon

	cells, epithelial cells Macrophages	
Chemokines		
CXCL8	Urothelial cells Epithelial cells	A chemokine that is a powerful chemoattractant for neutrophils
IL-1	Epithelial cells Macrophages	Like IL-8, also attracts other immune cells such as monocytes from the circulation
SLC	Stromal cells in lymph nodes	Also known as CXCL21, SLC attracts activated dendritic cells and T cells into the lymph nodes. It is sensed by the receptor CCR-7
Interleukins and Th1/Th2 Polarization		
IL-12	Dendritic cells	A Th1-inducing cytokine, when naive CD4 T cells are activated in the presence of IL-12, they differentiate into Th1 cells
IL-4	Dendritic cells, natural killer T cells	A Th2 cytokine, when naive CD4 T cells are activated in the presence of IL-4, they differentiate into Th2 cells
IL-2, TNF-α and IFN- γ	Th1 cells (CD4 T cells)	Canonical cytokines secreted by Th1 cells, and which are associated with a favorable response to BCG in bladder cancer. These cytokines are also associated with inducing CD8 (killer) T-cell function
IL-4, IL-5, IL-10, IL-13	Th2 cells (CD4 T cells)	Canonical cytokines secreted by Th2 cells, and which are associated with an unfavorable response to BCG in bladder cancer. These cytokines are also associated with the induction of antibody production

BCG, Bacille-Calmette-Guérin; *IL,* interleukin; *MHC,* major histocompatibility complex.

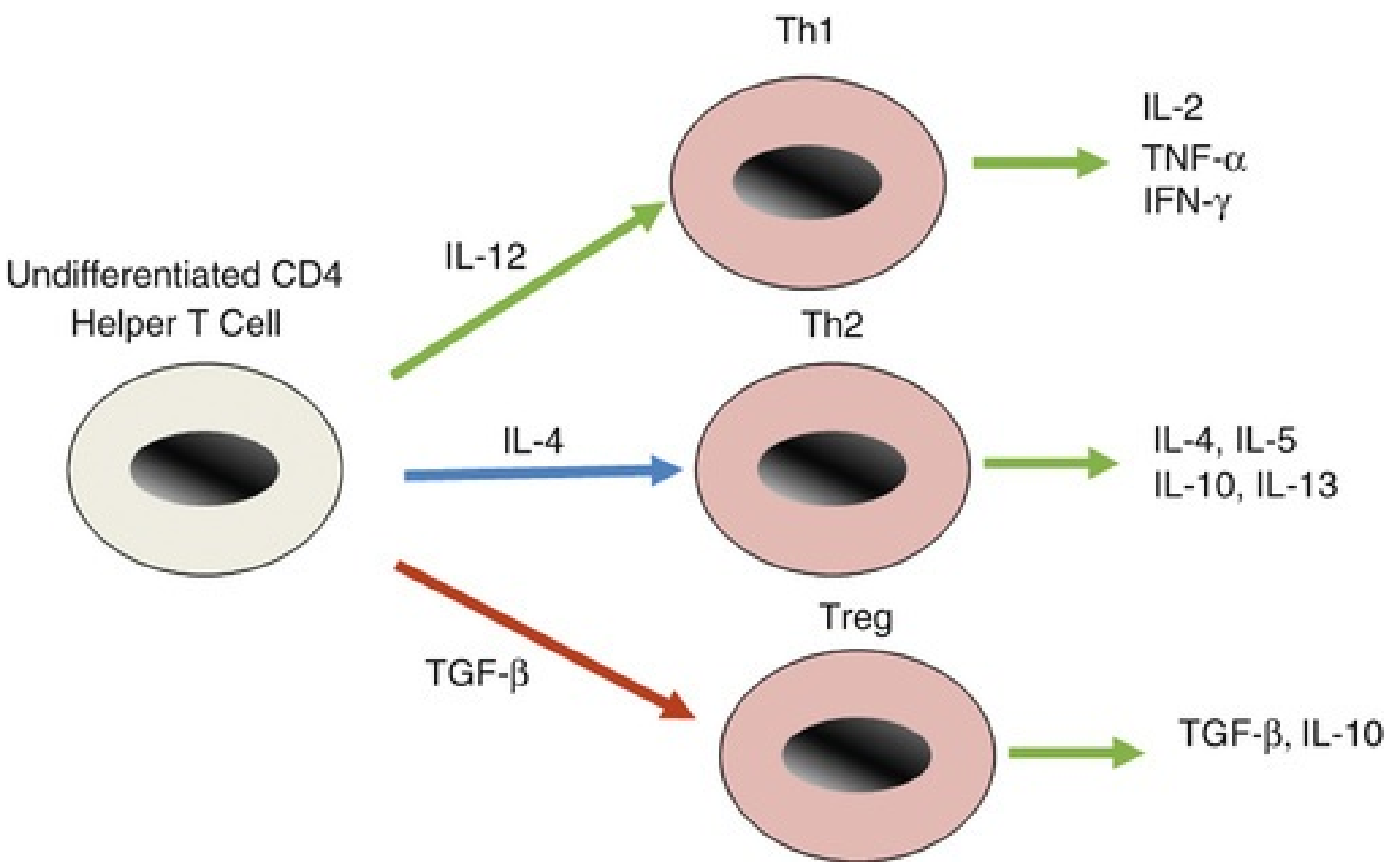

FIG. 61.2 CD4 T-cell polarization and the Th1 and Th2 families of cytokines. *IFN,* Interferon; *IL,* interleukin; *TGF,* transforming growth factor; *TNF,* tumor necrosis factor. (Modified from Weaver CT, Harrington LE, Mangan PR, et al.: Th17: an effector CD4 T cell lineage with T-cell ties. *Immunity* 24:677–688, 2006.)

In bladder cancer, these patterns of response are especially important because a Th1 response is associated with a successful response to BCG treatment, whereas a Th2 response is associated with BCG failure (de Reijke et al., 1996; Saint et al., 2001; Saint et al., 2002; Thalmann et al., 2000). Mechanistically, this skewing occurs as naive CD4 helper cells are activated (see Fig. 61.2). In an environment rich in IL-12, CD4 T cells differentiate into Th1 cells and in turn secrete interleukin 2 (IL-2), tumor necrosis factor-α (TNF-α) and interferon gamma (IFN-γ). These Th1 cytokines help to activate CD8 (killer) T cells and are important in a successful antitumor response. Conversely, when naive CD4 T cells recognize their targets in the context of interleukin 4 (IL-4), they differentiate into Th2 cells, which are associated with chronic inflammation and antibody production, and secrete IL-4, IL-5, IL-10, and IL-13. In bladder cancer these cytokines can be detected **systemically** after BCG treatment, so elevated serum IL-2 post-treatment is associated with a favorable outcome. These are important data, showing that the immune effects of BCG are not solely local and illustrating the point that activation of the immune system in one organ site can have detectable effects throughout the entire organism.

Adaptive Immune System

The adaptive immune system includes CD4 (helper) T cells, CD8 (killer) T cells, and B cells. These cells are recruited to an immune response in response to activation of the innate immune system and are vital to two key facets of the immune response: its specificity and its ability to “remember” prior antigen encounters and respond more robustly when that antigen is encountered again in the future. Before expounding on those properties, it is important to understand how information from the innate immune system is transferred to the adaptive immune system. This transfer depends on a unique cell type known as the dendritic cell, which serves as a bridge between an innate and an adaptive immune response. Dendritic cells (DCs) get their name from their long and fine cytoplasmic projections, which microscopically resemble nerve cells. Functionally, dendritic cells are scattered throughout the peripheral tissues, as exemplified by Langherhans cells in the skin. DCs spend the majority of their lifespan at rest, continually sampling their microenvironment, taking in fluid and protein antigens through the process of pinocytosis. In the absence of an activating or “danger” signal, DCs remain quiescent and sessile. A danger signal can come in the form of cytokines, such as TNF-α secreted from innate immune cells such as macrophages, or through direct contact with bacterial products through pattern receptors (TLRs) on DCs. When DCs are activated, a remarkable transition takes place. First, they cease taking in antigens because their new role is to present the antigens they have already taken up to T and B cells. Thus their dendrites are retracted and the cells develop a more compact morphology. Second, they upregulate cell surface molecules important for presenting the antigens they have engulfed to T cells. Key cell surface molecules include major histocompatibility molecules, which bind 9 to 12 amino acid peptide antigens in their grooves for interacting with specific receptors on T cells (TCRs), as well as a set of molecules designed to optimally stimulate T cells; these are called co-stimulatory molecules and include B7-1, B7-2, and others. Finally, DCs must solve a spatial problem: resting lymphocytes (T cells and B cells) reside in the secondary lymphoid structures (i.e., in the lymph nodes), while resting DCs are situated in the tissues. Thus DCs must migrate into the lymphatic system and enter into the lymph nodes (LNs) through afferent lymphatic vessels. This is accomplished via chemotaxis; activated DCs follow a gradient of secondary lymphoid chemokine (SLC) using a receptor known as CCR7 to traffic to the

LN. Once in the lymph nodes, DCs interact with (and activate) specific CD4, CD8, and B lymphocytes, completing the transfer of information from the innate immune system to the adaptive.

A naive CD4 T cell is activated when an antigen-presenting DC presents its cognate (specific) peptide antigen (usually 11 AA long) in the context of a Class II major histocompatibility complex (MHC). CD4 T cells are helper cells, they either help CD8 T cells to become fully activated and exert their lytic function or assist B cells in making antibodies. As described earlier, CD4 T-cell responses fall into several basic categories, including a Th1 response, which fully activates CD8 (killer cells) and a Th2 response, which helps B cells to mature into antibody-secreting plasma cells. An additional CD4 T cell subtype of interest is the regulatory T cell (Treg) (Chao and Savage, 2018; Sakaguchi et al., 2008). These cells suppress adaptive immune responses and appear to play a role in preventing a successful adaptive Th1/CD8–driven anticancer response. The origin of Treg is complex; a population of “natural” Treg arises de novo in the course of T-cell development in the thymus, while a second population is “induced” when naive CD4 T cells recognize their antigen in a microenvironment that is low in proinflammatory signals and rich in transforming growth factor beta (TGF-β) (see Fig. 61.2). The relative contribution of these two types of Treg to the progression of GU cancers in humans is unclear; however, recent laboratory data point to a critical role for natural, thymus-derived Treg (Savage et al., 2013).

Perhaps the most fascinating adaptive immune cell is the CD8 T cell. These cells recognize their specific cognate antigen as 9 amino acid peptides; these peptides are recognized when bound in the groove of Class I MHC molecules. Class I MHC molecules are present on almost all cell types and are upregulated in the context of inflammation and on virally infected cells. When a specific CD8 T cell recognizes its target, it secretes a series of molecules, which results in destruction of that cell type. This killing process is remarkably specific; in the autoimmune disease type 1 diabetes, CD8 T cells can lyse beta cells in the pancreas while leaving immediately adjacent alpha cells completely intact. The mechanism of killing itself is also exquisite; CD8 T cells employ multiple molecular mechanisms to induce their target cells to commit suicide (i.e., to undergo programmed cell death or apoptosis; Martinez-Lostao et al., 2015). Finally, CD8 T cells are serial killers, able to lyse multiple specific targets in a sequential manner. CD8 T cells can be specifically activated by cancer vaccines, as will be discussed later; blocking immune checkpoint molecules is an important clinical modality for augmenting the activity of CD8 T cells specific for cancer antigens.

Immune Editing Hypothesis

Before moving forward with a discussion of how the immune system may be manipulated to treat GU cancers, it is worthwhile considering the immune system's baseline role in either the promotion or the elimination of cancer. With the exception of certain virally mediated tumors that occur most commonly in immunocompromised individuals, human cancers develop in immunologically intact hosts. As tumorigenesis proceeds from low-grade/localized disease to distant metastases, an interaction between the host immune system and the evolving tumor occurs. This process has been well characterized in a number of animal models and can be divided into three distinct stages (Dunn et al., 2004). In the first stage of the process, early tumors are recognized by the immune system in a productive, proactive way, leading to **elimination** of small, clinically undetectable masses. Elimination is most likely mediated by a concerted effort between the innate (macrophages and dendritic cells) and the adaptive immune systems. As tumors progress, they acquire genetic, epigenetic, and stromal alterations that render an antitumor immune response less efficacious. Thus, in the next phase of tumor/immune system interactions, tumors are able to exist in a dynamic **equilibrium** with the host immune response, with progression slowed by an ongoing immune response, but in which tumors can no longer be successfully eliminated. Equilibrium may persist for a significant period of time, and some tumors may remain in the equilibrium stage for the life of the host. Eventually, though, many tumors proceed to **escape** the host immune response and become clinically apparent. The molecular mechanisms involved in the escape phase are multiple and include down-regulation of tumor antigens against which a host response is directed, down-regulation of MHC molecules, and the induction or expansion of regulatory T cells (Treg) that actively inhibit an immune response (Drake et al., 2006). Together, the three phases of tumor/host interactions (elimination, equilibrium, and escape) collectively form the “immune editing hypothesis,” which serves as a valuable framework through which to understand the immune response to cancer. Indeed, subversion of a productive host antitumor response is now designated as one of the hallmarks of cancer (Hanahan and Weinberg, 2011).

Key Points: Basic Immunology

- An immune response begins with an innate response, which is rapid but relatively nonspecific, then progresses to include the adaptive immune system, which is characterized by specificity and memory.
- For an antitumor immune response, a Th1 response dominated by IFN-γ, IL-2, and TNF-α is desired.
- CD4+ regulatory T cells (Treg) inhibit an adaptive immune response.
- The immune editing hypothesis explains how early tumors can be recognized and eliminated by the immune system, whereas clinically evident tumors must escape immune recognition to evolve.

Chronic Inflammation and the Endogenous Immune Response to Genitourinary Cancers

Although the immune editing hypothesis suggests that antitumor immune responses are generally beneficial, those data must be considered along with a great deal of apparently contradictory data suggesting that inflammation can promote tumor progression (Balkwill et al., 2005; de Visser et al., 2006). Human and animal studies showed that inflammation has a clear role in the development of bladder cancer (Michaud, 2007) and likely plays a role in the development of prostate cancer (PC) as well (De Marzo et al., 2007).

Chronic Inflammation and the Immune Response to Bladder Cancer

Among GU malignancies, bladder cancer provides the strongest evidence for a link between chronic inflammation and carcinogenesis. The evidence linking inflammatory schistosomiasis infections to bladder cancer is particularly robust, and *Schistosoma haematobium* has been classified as a known carcinogen by the International Agency for Research on Cancer. Epidemiologically, countries with high rates of endemic infection have high rates of bladder cancer, and elevated levels of infestation are associated with a squamous cell phenotype (Mostafa et al., 1999). Other sources of bladder inflammation that have been linked to carcinogenesis include chronic urinary tract infections (Kantor et al., 1984), chronic indwelling catheters (Groah et al., 2002), and cystitis induced by cyclophosphamide treatment (Talar-Williams et al., 1996). The cellular and molecular mechanisms by which chronic bladder infection leads to cancer have not been fully elucidated; they likely involve mechanisms similar to those described in other cancers (Mantovani et al., 2008), that is, dysfunctional (M2) macrophages that produce immune suppressive cytokines, a subset of myeloid cells that suppress an active immune response (myeloid-derived suppressor cells, MDSCs; Gabrilovich, 2017), and a polarization of the adaptive immune response toward a Th2 and Treg phenotype.

Once bladder tumors develop, the immune editing hypothesis (Fig. 61.3) would suggest that early tumors may be recognized by the immune system and eliminated. That hypothesis is supported by data showing that CD8 T-cell infiltration correlates with outcome in patients with muscle-invasive bladder cancer (Sharma et al., 2007). Obviously a successful CD8-mediated antitumor response does not occur in all cases, and recent data describe an important mechanism by which bladder tumors, kidney cancer, and other tumor types “escape” immune recognition (Drake et al., 2014; LaFleur et al., 2018). This occurs through the interaction between immune checkpoint molecules expressed on cancer-specific T cells and their ligands, expressed on either tumor cells or tumor-associated macrophages (Fig. 61.4). This interaction is profoundly inhibitory to T cell activity, attenuating proliferation as well as effector function. In this regard, several tissue-based studies showed that the epithelial cells in bladder cancer express the immune checkpoint ligand PD-L1. In one early study, PD-L1 expression was noted in approximately 15% to 35% of cases, and expression was associated with increased tumor grade (Nakanishi et al., 2007). Interestingly, in these patients, PD-L1 expression was more closely associated with prognosis than was World Health Organization grade, pointing to a functional role for the PD-1/PD-L1 interaction in bladder cancer progression. A second related study confirmed the relationship between PD-L1 expression and high-grade tumors and further demonstrated that PD-L1 expression was associated with tumor infiltration by immune cells (Inman et al., 2007). Interestingly, this group also showed that PD-L1 was highly expressed in BGG-induced granulomas in patients progressing on therapy, suggesting a possible escape mechanism. Mechanistically, these data support a model known as “adaptive immune resistance” (Fig. 61.5), which explains how PD-L1 expression is a critical mechanism by which tumors evade the immune response (Taube et al., 2012). In this model, mutations arising as a tumor progresses lead to an adaptive immune response defined by CD8 T cell recognition. These CD8 T cells migrate to the tumor, as a consequence of acquiring effector function secrete the cytokine IFN-γ. IFN-γ is a powerful inducer of PD-L1 expression in tumor cells and myeloid cells and epithelial cells, and it is these induced PD-L1 molecules on tumor cells that interact with PD-1 on the infiltrating CD8 T cells to effectively curtail their antitumor effector function (Taube et al., 2012). Those data would suggest that a monoclonal antibody that blocks either PD-1 or PD-L1 could potentially lead to objective tumor responses in patients with bladder cancer, a hypothesis strongly confirmed by phase II and III studies in bladder and kidney cancer (see following).

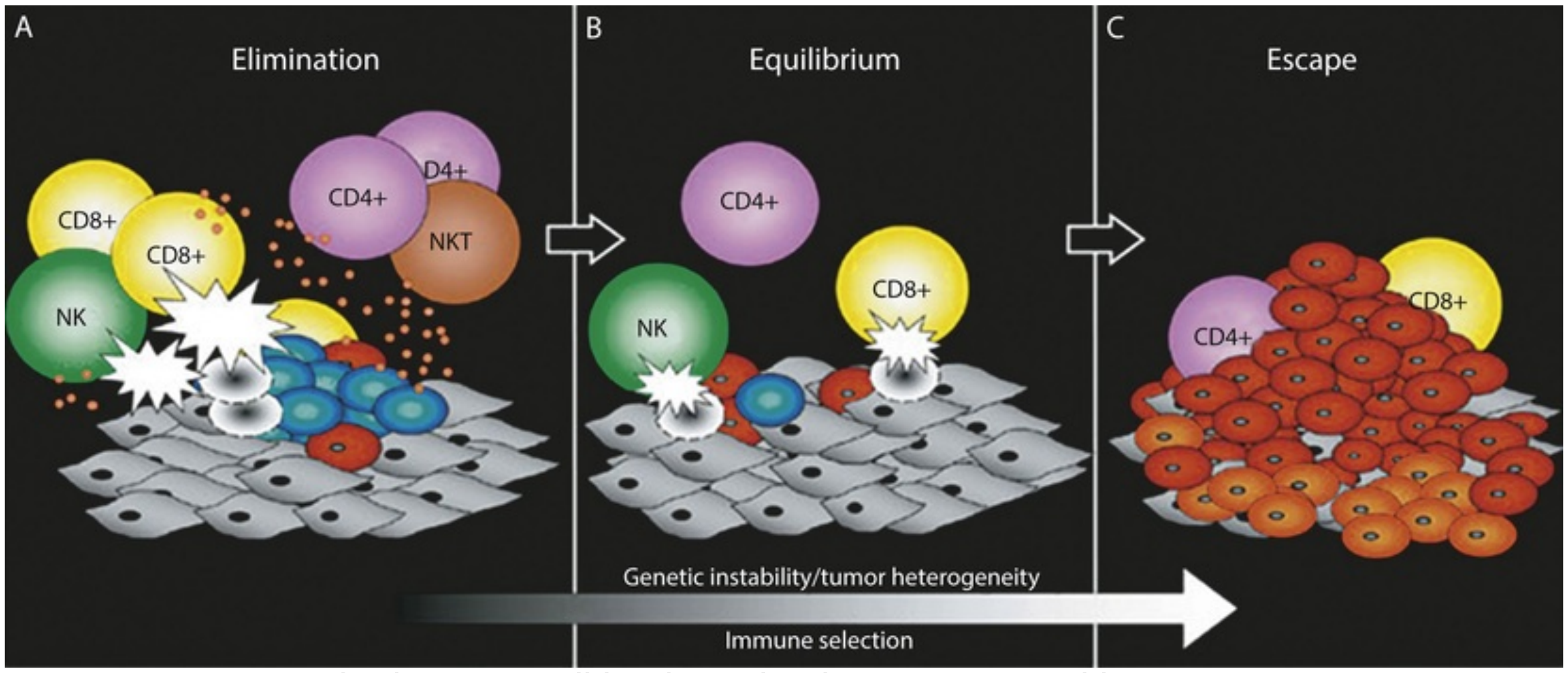

FIG. 61.3 The immune editing hypothesis. *NK,* Natural killer cell; *NKT,*

natural killer T cell. (From Dunn GP, Old LJ, Schreiber RD: The immunobiology of cancer immunosurveillance and immunoediting. *Immunity* 21:137–148, 2004.)

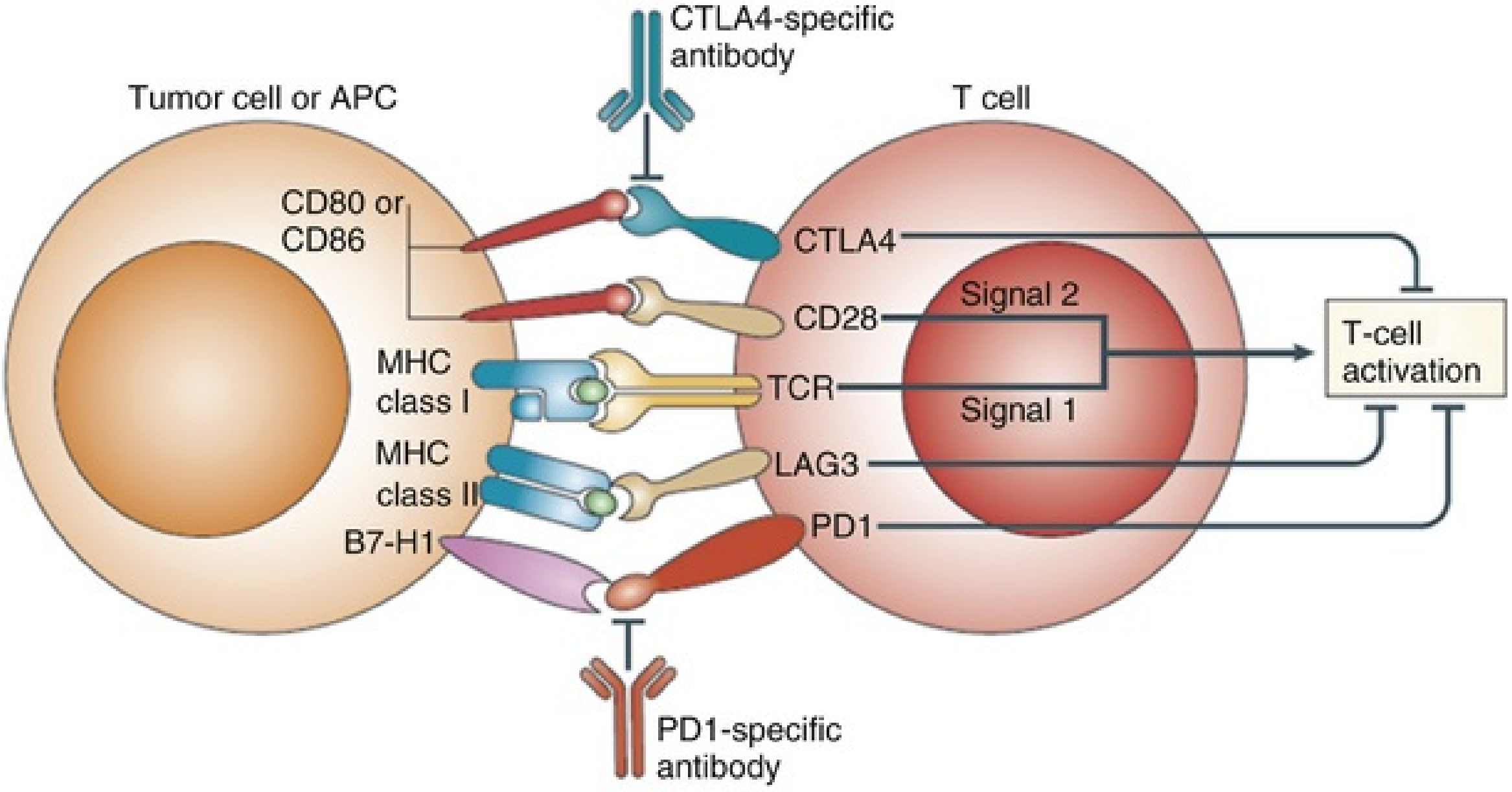
CTLA4-specific antibody
Tumor cell or APC
T cell
CD80 or CD86
CTLA4
CD28
Signal 2
T-cell activation
MHC class I
TCR
Signal 1
MHC class II
LAG3
B7-H1
PD1
PD1-specific antibody

FIG. 61.4 Immune checkpoint molecules. *APC,* Antigen-presenting cell; *MHC,* major histocompatibility complex. (From Drake CG: Prostate cancer as a model for tumour immunotherapy. *Nat Rev Immunol* 10:580–593, 2010.)

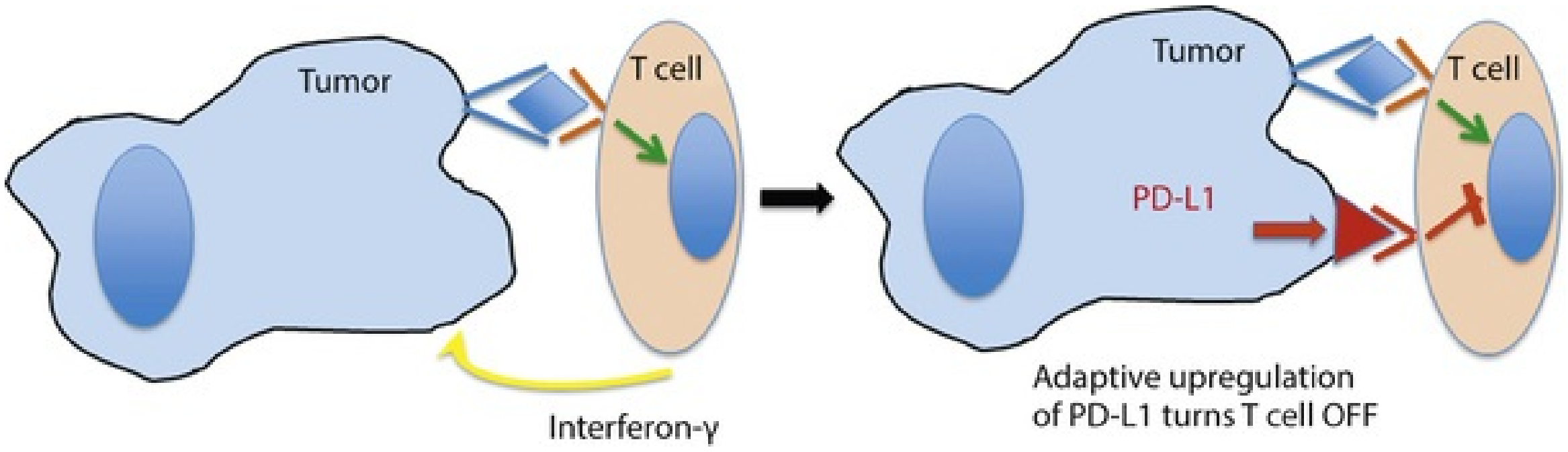
Tumor
T cell
Interferon-γ
Tumor
T cell
PD-L1
Adaptive upregulation of PD-L1 turns T cell OFF

FIG. 61.5 Adaptive immune resistance.

Immune Microenvironment in Kidney Cancer

Unlike bladder and prostate cancer, a link between chronic inflammation and kidney cancer is less clear and is only weakly suggested by the associations of kidney cancer with proinflammatory risk factors such as smoking or obesity (Chow et al., 2010). Several lines of evidence suggest that the tumor microenvironment (TME) of kidney cancer may be different from that of other tumor types. One important difference is the influence of tumor-infiltrating CD8 T cells; in most other cancers, increasing CD8 T cell density is associated with improved prognosis (Fridman et al., 2012). In kidney cancer, older (Nakano et al., 2001) and more contemporary (Giraldo et al., 2015) data show that an increased CD8 T cell density is associated with a **less favorable** outcome. This relationship holds for metastatic lesions and primary tumors (Remark et al., 2013). Unfortunately, the mechanisms underlying this paradoxic relationship are unknown. In terms of prognosis, one study identified a group of patients with elevated CD8 T cell infiltration, increased expression of immune checkpoint molecules such as PD-1 and lymphocyte activation gene–3 (LAG-3). That subgroup also had relatively few functional antigen presenting cells and showed a particularly poor outcome (Giraldo et al., 2015). To more fully understand the tumor microenvironment in kidney cancer, one group used an advanced flow cytometry method to deeply profile the immune landscape in a substantial number (>70) of biopsies from primary tumors (Chevrier et al., 2017). Those data revealed an impressive complexity; clustering analyses of the infiltrating immune cells showed a total of 17 macrophage subsets and 22 T cell subsets. PD-1 was broadly expressed on infiltrating lymphocytes, whereas other immune checkpoint molecules such as LAG-3 and TIM-3 were more narrowly expressed. In terms of potential future trials, these data identified a macrophage population highly that expressed the cell surface marker CD38, and which was associated with the presence of PD-1 expressing T cells. Clinically, these data suggest that CD38 blockade may be a reasonable target for combination therapies; this is important because several anti-CD38 antibodies are either FDA approved (Mateos et al., 2018) or are in clinical development.

Chronic Inflammation and the Immune Response to Prostate Cancer

The prostate microenvironment is infiltrated by several types of inflammatory cells, including innate cells such as macrophages and adaptive cells such as T and B cells even in the absence of symptoms or cancer. This baseline inflammation is likely tumor promoting, and accumulating data from several groups support a model in which chronic prostatic inflammation drives the development of cancer (De Marzo et al., 2007). Multiple lines of evidence link chronic inflammation to prostate cancer tumorigenesis. First, chronic inflammation in the prostate gland is frequently focused in the peripheral zone, the region in which more than 90% of tumors arise (McNeal et al., 1988). Second, epidemiologic studies show that western nations, in which chronic prostatic inflammation is endemic, have a significantly increased incidence in prostate cancer as compared with Asian populations, in which inflammation is less prevalent (Sfanos and De Marzo, 2012). Finally, and perhaps most convincing, are data surrounding a prostatic lesion known as prostatic inflammatory atrophy (PIA), a lesion characterized by flattened, but proliferating, epithelial cells and associated inflammatory cells (De Marzo et al., 1999). Morphologic studies showed that regions of PIA are located geographically proximal to high-grade prostatic intraepithelial neoplasia (PIN) lesions (Putzi and De Marzo, 2000), suggesting a possible causative link between PIA and the eventual development of cancer.

The adaptive T cell environment of prostate cancer is dominated by regulatory T cells (Treg), which have been described in the gland itself as well as in neoplastic lesions (Fox et al., 2007; Miller et al., 2006; Sfanos et al., 2008). A role for Treg likely extends to metastatic lesions; studies showed an increased prevalence of functional Treg in the bone marrow of patients with prostate cancer (Zhao et al., 2012). In keeping with the notion of immunosuppression in prostate cancer, data from humans (Kiniwa et al., 2007) and animals (Shafer-Weaver et al., 2009) suggest that, in prostate cancer, CD8 T cells can also have a suppressive, protumor phenotype. In perhaps the most convincing of these studies, one group showed that regulatory CD8 T cells in the peripheral blood were sufficiently suppressive as to mask an antigen-specific T cell response driven (Olson and McNeel, 2007). Finally, as in other GU cancers, there is some evidence that the PD-1/PD-L1 axis may restrain an adaptive T cell response to prostate cancer, because the CD8 T cells that infiltrate the prostate gland are clearly PD-1 positive (Sfanos et al., 2009) as well as clonally restricted. Taken together, these data suggest that prostate cancer develops in an environment characterized by chronic inflammation, as well as a nonproductive adaptive CD4 and CD8 T cell response (Bronte et al., 2005; Gannon et al., 2009).

Key Points: Chronic Inflammation and the Endogenous Immune Response to GU Cancers

- Bladder cancer is promoted by chronic inflammation initiated by infection or other stimuli.
- In kidney cancer, there is good evidence for an ongoing adaptive, CD8 T-cell–mediated response, but paradoxically, an increased CD8 density is associated with a worse prognosis.
- Prostate cancer may also be driven by chronic inflammation.
- Expression of immune checkpoint molecules on TILs attenuates the adaptive immune response to GU tumors.

Immunotherapy for Genitourinary Cancers

Bacille Calmette-Guérin in Bladder Cancer

The mechanism of action of BCG provides an excellent framework through which to understand the course of an induced immune response, an understanding that will be useful in appreciating the mechanisms of other immunotherapy modalities described in this chapter (Brandau and Suttmann, 2007; see Fig. 61.6). The process begins with the instillation of 1 to 5 × 10^8 viable mycobacteria into the bladder. Most of these will be washed out with the first postinstillation void, but a significant fraction will adhere to the urothelial cells lining the bladder via a fibronectin attachment protein (Kavoussi et al., 1990). Repeated patterns (PAMPs) on the bacterial cell wall stimulate urothelial cells to secrete cytokines, acting through the toll-like receptors TLR-2 and TLR-4. Direct activation of resident macrophages and dendritic cells by BCG components is also likely but has been less well described. The BCG-stimulated urothelial cells initiate a stepwise immune response by secreting the chemokine IL-8 (among many others); IL-8 is a powerful neutrophil attractant. TNF-α is also secreted, and this setting, this Th1 family cytokine recruits and activates macrophages. A few hours after BCG installation, a sizable wave of neutrophils migrates into bladder wall (de Boer et al., 1991). This influx of neutrophils is characteristic of acute inflammation, and the recruited neutrophils clear residual bacilli by secreting cytotoxic granules in addition to releasing a series of cytokines that help activate dendritic cells to potentiate the eventual involvement of the adaptive immune system. The next step in this inflammatory cascade occurs over several weeks as an adaptive immune response, primarily CD4 T cell driven, is recruited to the bladder (Kates et al., 2017). Although the precise mechanisms through which CD4 T cells are recruited have not been well documented, this most likely occurs in the same manner as it does in other immune responses: dendritic cells are activated by neutrophil and urothelial cell-derived cytokines (in addition to bacterial products) and traffic to the draining lymph nodes, where they present antigens to CD4 T cells to activate specific lymphocytes. The antigenic targets of CD4 T cells during BCG therapy for bladder cancer have not been well described, but likely include bacterial antigens as well as tissue-/tumor-specific antigens. Nevertheless, an adaptive immune response has been demonstrated to be required for successful BCG therapy of bladder cancer in laboratory studies (Ratliff et al., 1987), and the identification of CD4 T cell–rich granulomas in BCG-treated patients provides evidence that this is likely to be the case in humans as well (Prescott et al., 1992). As described earlier, the adaptive immune response is capable of generating long-lived memory T cells, which may persist for the life of a vaccinated patient. The generation of memory CD4 cells by BGC treatment of bladder cancer has not been well studied in patients, but their induction is strongly suggested by the significant fraction (approximately 50%) of patients whose non-muscle invasive disease remains in remission for years after BGG therapy. In summary, successful BCG immunotherapy for bladder cancer represents a typical immune response, initially characterized by activation and involvement of the innate immune system (neutrophils and macrophages), which then evolves toward an adaptive immune response driven by CD4 T cells polarized to secrete Th1 cytokines (IL-2, TNF-α, and IFN-γ), followed by consolidation in the form of long-lived T cell memory.

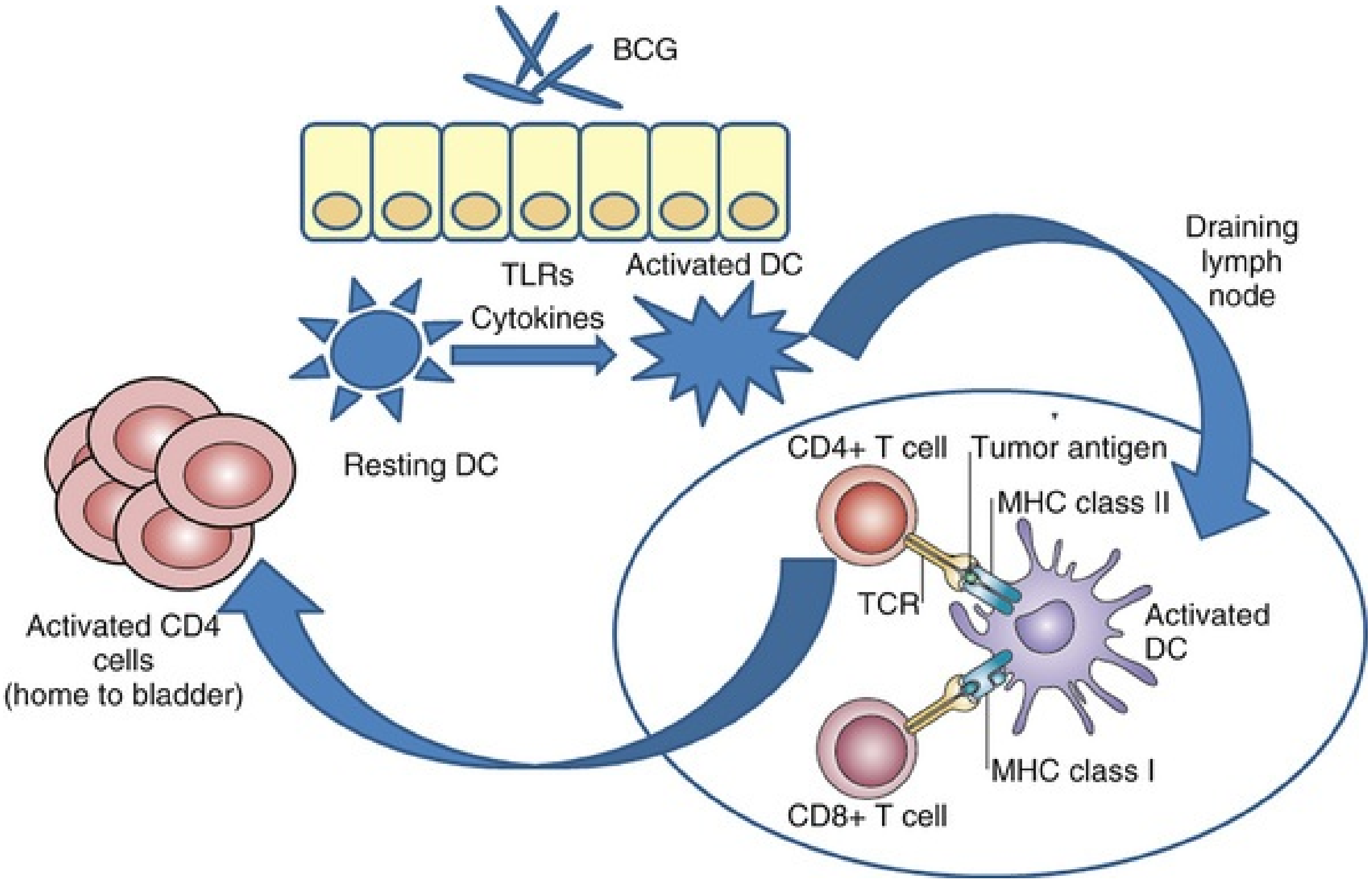
BCG
TLRs
Cytokines
Activated DC
Draining
lymph
node
Resting DC
CD4+ T cell
Tumor antigen
MHC class II
TCR
Activated
DC
MHC class I
CD8+ T cell
Activated CD4
cells
(home to bladder)

FIG. 61.6 Bacille Calmette-Guérin (BCG) and an adaptive immune response. *DC,* Dendritic cell; *MHC,* major histocompatibility complex; *TCR,* T-cell receptor; *TLRs,* Toll-like receptors. (Modified from Brandau S,

Suttmann H: Thirty years of BCG immunotherapy for non-muscle invasive bladder cancer: a success story with room for improvement. *Biomed Pharmacother* 61:299–305, 2007; Drake CG: Prostate cancer as a model for tumour immunotherapy. *Nat Rev Immunol* 10:580–593, 2010.)

Cancer Vaccines

Like BCG, a “cancer vaccine” aims to raise a T-cell response against cancer (Fig. 61.7). When a “vaccine” is injected into the skin, the components of the vaccine known as PAMPs (Medzhitov and Janeway, 2000) activate resting dendritic cells and program them to migrate to a local lymph node. Thus a vaccine necessarily includes some component(s) intended to activate dendritic cells, although the precise substances employed vary between different vaccines. Another common term for these activating components is “adjuvant,” because they “add” immunogenicity to the protein or peptide components of a vaccine. The other key component of a vaccine is a target protein or proteins that are expected to be relatively overexpressed in a tumor relative to normal tissue. The choice of vaccine antigen(s) is somewhat empiric and, like adjuvant choice, varies widely between approaches. Once a resting dendritic cell has been loaded with antigen, activated, and has migrated to a lymph node, it then displays fragments of antigen in the form of small peptides. Cellular recognition of these small peptide fragments (antigens) is complex; as introduced earlier, these peptides are not presented alone but instead are recognized when bound to a genetically diverse set of host molecules collectively encoded by a set of genes within the major histocompatibility complex (MHC). Specific receptors (TCRs) on CD4 and CD8 T cells recognize a structure composed of MHC molecules and a specific peptide. Simple recognition (a good fit) is insufficient for full T cell activation; T cells must also receive additional co-stimulatory signals provided by mature DCs to proliferate and acquire effector function. In the case of CD8 T cells, the principal desired effector function is the ability to lyse target cells expressing the same MHC/peptide complex that activated them (i.e., their target antigen). For CD4 T cells, a Th1 response is desired. Once fully activated, CD8 T cells leave the lymph node and traffic widely through the host in search of their targets.

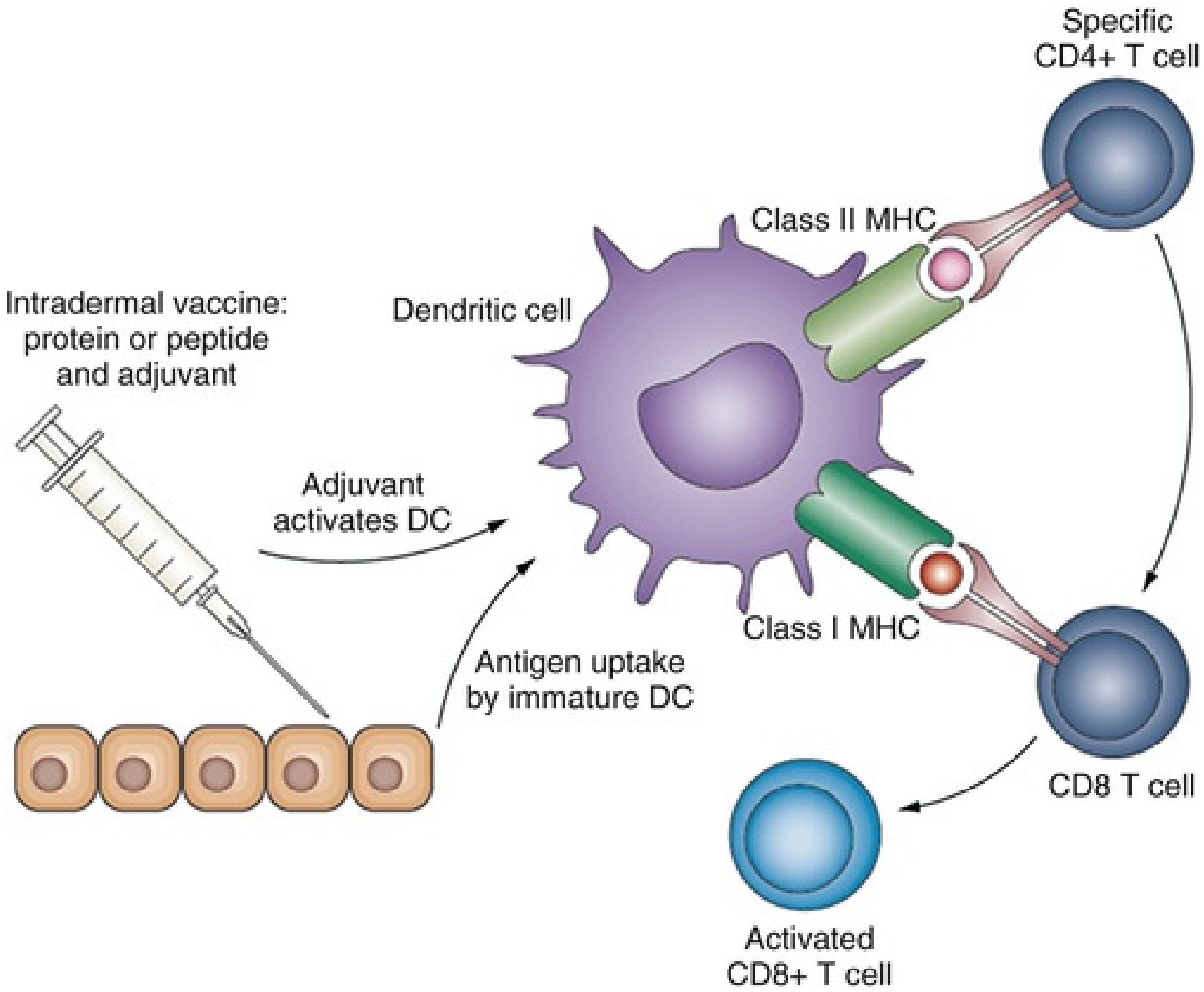
Specific
CD4+ T cell
Class II MHC
Intradermal vaccine:
protein or peptide
and adjuvant
Dendritic cell
Adjuvant
activates DC
Antigen uptake
by immature DC
Class I MHC
CD8 T cell
Activated
CD8+ T cell

FIG. 61.7 Cancer vaccines. *DC,* Dendritic cell; *MHC,* major histocompatibility complex. (From Drake CG, Lipson EJ, Brahmer JR: Breathing new life into immunotherapy: review of melanoma, lung and kidney cancer. *Nat Rev Clin Oncol* 11:24–37, 2014b.)

Vaccines for Kidney Cancer

Although an in-depth discussion of all the cancer vaccine approaches in GU cancers is beyond the scope of this chapter, several vaccines are highlighted. The examples chosen illustrate key immunologic principles, as well as the challenges inherent in developing vaccine-based immunotherapy. In that regard, one interesting vaccine approach for kidney cancer focused on targeting multiple carefully selected antigens with a fairly simple adjuvant. To select relevant antigens, resected kidney tumors from a series of patients expressing the common class I MHC allele HLA-A2 were isolated, and the cell surface peptides residing in class I MHC molecules eluted and analyzed using mass spectrometry (Walter et al., 2012). This approach identified a set of tumor-associated peptides, which were used to design a vaccine incorporating granulocyte-macrophage colony-stimulating factor (GM-CSF) as an adjuvant. GM-CSF is a strong inducer of DC migration, but perhaps less robust than the TLR agonists in terms of inducing DC activation. In the phase I study of this agent (IMA901), 28 patients with renal cell carcinoma (RCC) were enrolled; because the peptides in the vaccine are only presented by the MHC class I allele HLA-A2, patients were required to be A2 positive. These patients received up to eight multi-peptide vaccinations, each preceded by GM-CSF as an adjuvant. The vaccine was well tolerated, with no grade 3 or 4 adverse events reported. At a 3-month follow-up point, a single patient showed a partial response, 16 patients had disease progression, and 11 had stable disease. Immune responses to the targeted peptides were detected in several of the treated patients (Walter et al., 2012). To improve the relatively sparse clinical activity noted, investigators made use of data showing that low doses of the alkylating agent cyclophosphamide have vaccine-potentiating immune effects (North, 1982), these effects are at least partially mediated by the depletion of the regulatory T cells (Treg) that turn off an immune response (Machiels et al., 2001; Wada et al., 2009). In a randomized phase II trial, 68 HLA-A2 positive patients with RCC were randomly assigned to either vaccine, or to vaccine preceded by a single immunomodulatory dose of intravenous cyclophosphamide (300 mg/m^2). Objective tumor regressions were rare, with a single confirmed partial response among 64 patients. Subsequent immunologic analyses showed an increased T-cell response to the targeted peptides, and verified that low-dose cyclophosphamide depletes regulatory T cells in humans. Despite these phase II results, a randomized phase III trial comparing standard of care first-line sunitinib to the combination of sunitinib + vaccine was initiated (NCT01265901). With a median follow-up of approximately 3 years, overall survival was not improved by the addition of vaccine to TKI, with a nonsignificant trend toward improved survival **in the nonvaccinated group** (HR 1.34, $P = 0.087$). These data are consistent with the data described earlier, suggesting that CD8 T cell infiltration in RCC may be associated with a less favorable outcome (Giraldo et al., 2015).

A second illustrative vaccine approach in kidney cancer involved autologous vaccines, in which antigens are derived from a patient's individual tumor lysate or whole cells. Such vaccines were tested in RCC and lung cancer (Eager and Nemunaitis, 2005; Simons et al., 1997); autologous vaccine approaches are complicated by the complexity in generating a vaccine from variable amounts of patient material. To overcome these challenges, a novel approach was developed, whereby a vaccine is generated using RNA extracted from patient-derived tumor material, rather than tumor lysate or cells (Figlin et al., 2012). With this approach (AGS-003), substantial quantities of vaccine can be manufactured using a relatively small amount of resected tumor. Rather than relying on the patient's endogenous DCs (which are often defective or dysfunctional [Gabrilovich et al., 1997]), the AGS-003 vaccine uses autologous DCs generated ex vivo, through maturation of immature monocytes in the presence of the cytokines IL-4 and GM-CSF (Palucka et al., 2005). So, to manufacture AGS-003, patients undergo leukopheresis, and DCs are cultured. Simultaneously, tumor RNA is prepared from a resected mass and is used to transfect those autologous DCs to generate a mature, cell-based vaccine, which is then frozen and stored for repeated intranodal injections.

A phase III trial of AGS-003 randomly assigned approximately 600 patients with metastatic high-risk RCC to receive either ongoing treatment with the standard-of-care tyrosine kinase inhibitor sunitinib or one cycle of sunitinib followed by AGS-003 co-administered along with sunitinib (NCT01582672). The primary end point of the study was progression-free survival; unfortunately that study phase III also failed to meet its primary endpoint, although follow-up continues.

Vaccines for Prostate Cancer

As outlined earlier, one approach to overcoming DC dysfunction is to generate new DC outside of the patient's tolerogenic environment. In PC, this approach is exemplified by Sipuleucel-T, which was the first cancer vaccine approved by the FDA for the treatment of patients with a solid tumor (Kantoff et al., 2010a). Sipuleucel T is individually manufactured for each patient with PC in a process that includes multiple steps. Briefly, patients undergo leukopheresis and peripheral blood mononuclear cells (PBMCs) are extracted and then incubated with PAP2024, a fusion protein that links the target antigen prostatic acid phosphatase (PAP) to GM-CSF. After approximately 36 hours of incubation, cells are prepared for reinfusion. In this approach, GM-CSF serves as the adjuvant that helps to activate dendritic cells. Of interest, the final Sipuleucel-T product is heterogeneous and includes mature antigen-presenting cells (APCs) as well as other cell types, including T cells, B cells, and natural killer cells (Sonpavde et al., 2012). Once infused, the autologous ex vivo-activated APC prime PAP-specific CD4+ and CD8+ T cells (Antonarakis et al., 2018) in a manner similar to a classical vaccine-mediated prime-boost regimen, in which the first infusion primes the immune system and subsequent infusions boost the response.

A second prostate cancer vaccine that reached late stages of clinical development is ProstVac VF (Bavarian Nordic, USA; Madan et al., 2009). This vaccine approach is different from the peptide or cell-based vaccines discussed earlier and relies on the incorporation of a target antigen into a virus to specifically activate the immune system (Fig. 61.8). The antigen chosen here was prostate-specific antigen (PSA), and the viral backbone comes from poxviruses, which are related to the vaccine used in the campaign that led to the successful worldwide eradication of smallpox.

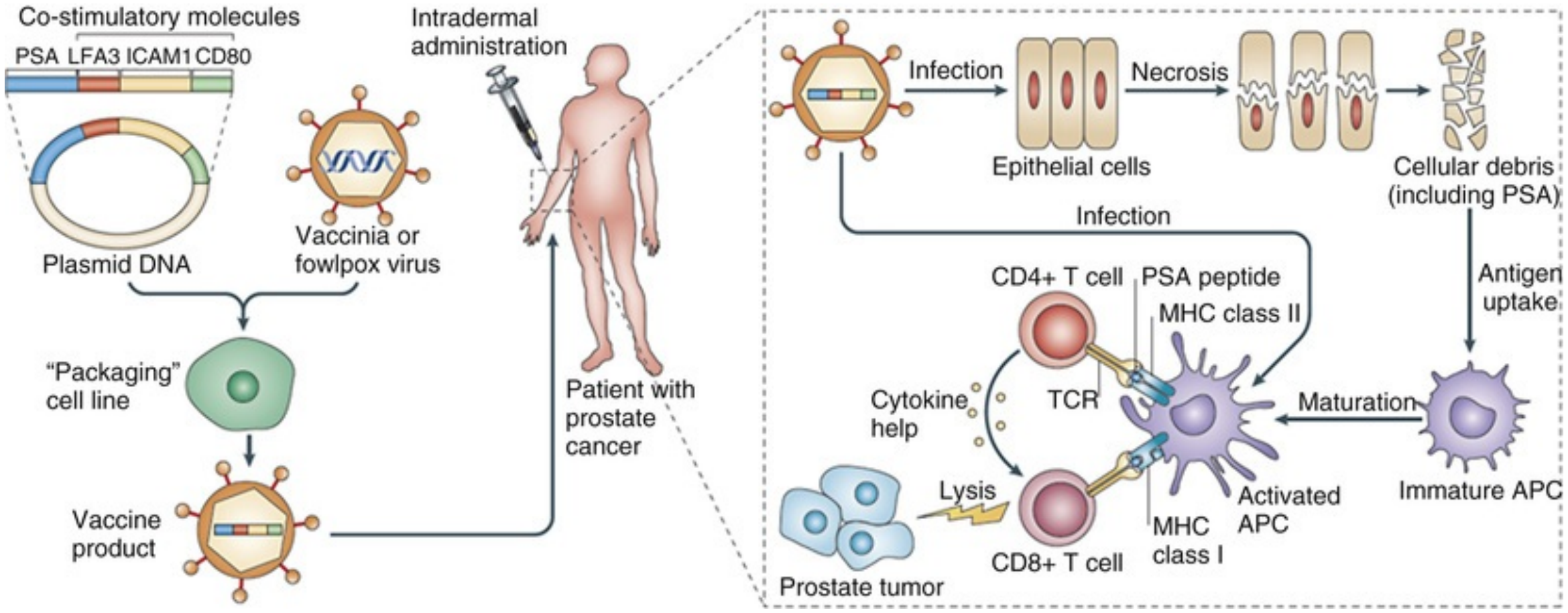
Co-stimulatory molecules
PSA
LFA3
ICAM1
CD80
Plasmid DNA
Vaccinia or fowlpox virus
"Packaging" cell line
Vaccine product
Intradermal administration
Patient with prostate cancer
Infection
Epithelial cells
Necrosis
Cellular debris (including PSA)
Infection
Antigen uptake
CD4+ T cell
PSA peptide
MHC class II
Cytokine help
TCR
Maturation
Immature APC
Activated APC
Lysis
MHC class I
CD8+ T cell
Prostate tumor

FIG. 61.8 Virus-based cancer vaccines (ProstVac VF). *APC,* Antigen-presenting cell; *MHC,* major histocompatibility complex; *PSA,* prostate-specific antigen; *TCR,* T-cell receptor. (From Drake CG: Prostate cancer as a model for tumour immunotherapy. *Nat Rev Immunol* 10:580–593, 2010.)

This technology has been honed over several decades, and the iteration in the phase III trial includes a number of important modifications designed to optimize immunogenicity. First, the vaccine involves a heterologous prime boost regimen, in which the initial vaccine is based on a modified vaccinia Ankara (MVA) backbone, followed by a series of booster vaccines with a fowlpox backbone. This is necessary because the humoral (antibody-mediated) immune response to the MVA backbone is robust, such that boosting with an identical vaccine is limited by the host's immune antibody response to the viral backbone itself. To further increase immunogenicity, the vaccine was engineered to incorporate a triad of co-stimulatory molecules designed to generate dendritic cells with an enhanced potential for T-cell activation (Hodge et al., 1999). Finally, similar to IMA901 in RCC, administration of GM-CSF at the vaccination site is used to help recruit local DCs and enhance antigen presentation. In patients, poxvirus vectors most likely infect epithelial cells, a proportion of which undergo cell death. Cellular debris, including encoded antigens, are then taken up by nearby immature DC, which, when appropriately activated, can present these antigens to CD4+ and CD8+ T cells in a proinflammatory context (Drake, 2010). Direct infection of DC, particularly the Langerhans cells in the skin, is another mechanism by which poxvirus vectors may prime an immune response. The end result of ProstVac treatment is postulated to be activation and proliferation of PSA-specific CD8 and CD4 T cells, which was demonstrated in early correlative studies. In contrast to Sipuleucel-T (GuhaThakurta et al., 2015), ProstVac-VF does not appear to prime an extensive antibody response; indeed antibodies specific for PSA are extremely rare with this agent. Based on a potential survival benefit shown in a randomized phase II trial (Kantoff et al., 2010b), an international randomized phase III of ProstVac VF was initiated (NCT01322490). This trial enrolled 1200 patients with metastatic castration-resistant prostate cancer and randomized them to placebo, ProstVac-VF plus subcutaneous GM-CSF, or to ProstVac-VF alone. The primary endpoint of the trial was overall survival. Unfortunately as was the case for the two RCC vaccine trials mentioned earlier, the phase III trial of ProstVac VF was closed by the data safety monitoring committee because it was deemed unlikely to meet its primary endpoint of an improved overall survival.

Key Points: Immunotherapy for Genitourinary Cancers

- BCG therapy for bladder cancer stimulates the innate and adaptive immune systems and is a prototype for successful cancer immunotherapy.
- Cancer vaccines have been evaluated in kidney and prostate cancer, and a single vaccine (Sipuleucel-T) is FDA approved for metastatic prostate cancer.
- Several other vaccine approaches failed in phase III trials in kidney and prostate cancer.

PD-1/PD-L1 Blockade in Genitourinary Cancers

As introduced earlier, most tumors involve multiple mechanisms to evade immune-mediated destruction (Drake et al., 2006). The most important of these mechanisms involves T-cell expression of one PD-1, which binds to its ligand PD-L1 to effectively limit T-cell proliferation and killing capacity (Drake et al., 2014; LaFleur et al., 2018; Fig. 61.9A).

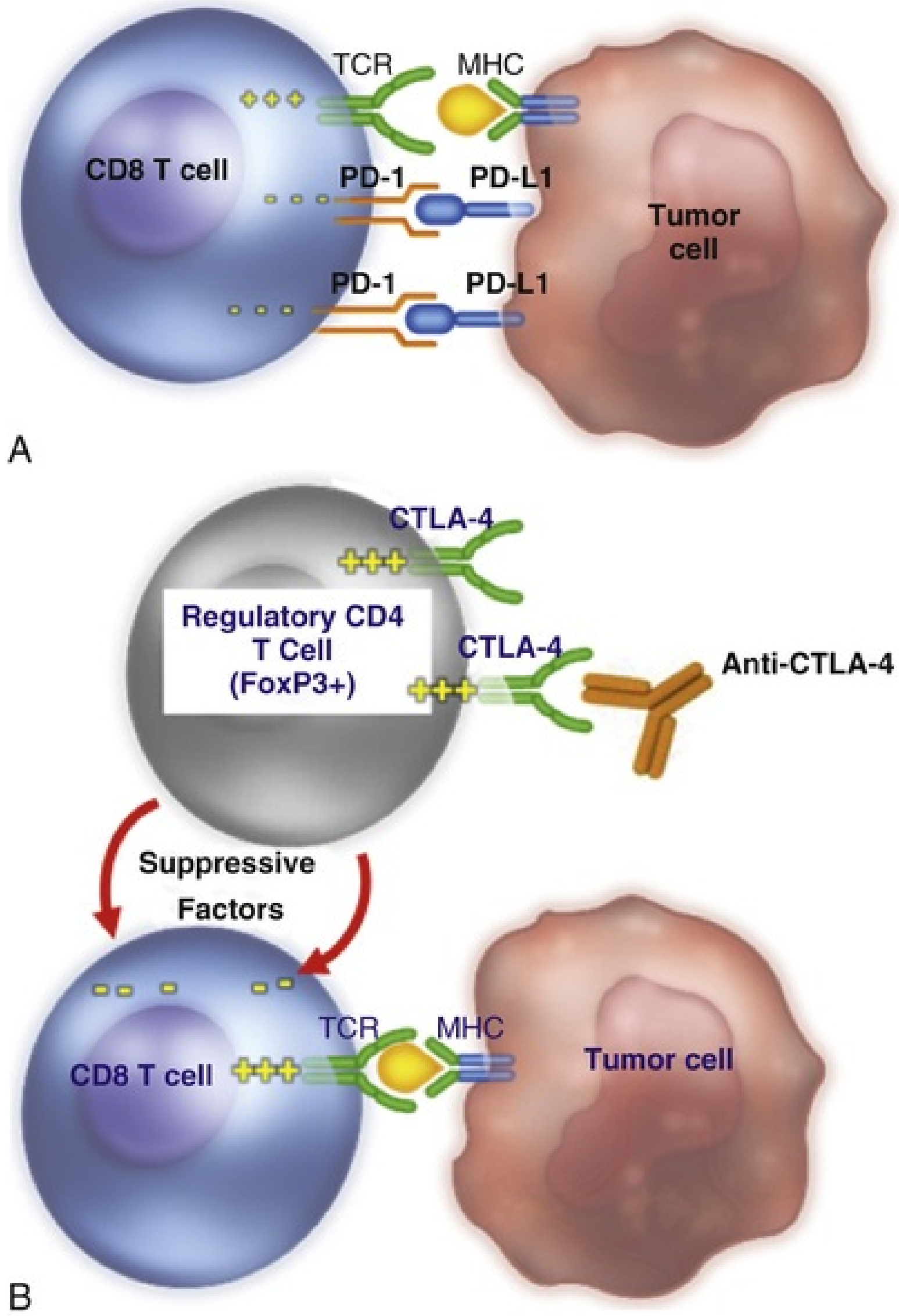
TCR
MHC
CD8 T cell
PD-1
PD-L1
Tumor cell
PD-1
PD-L1
A
CTLA-4
Regulatory CD4 T Cell (FoxP3+)
CTLA-4
Anti-CTLA-4
Suppressive Factors
TCR
MHC
CD8 T cell
Tumor cell
B

FIG. 61.9 Immune checkpoint blockade. (A) PD-1/PD-L1 blockade. (B) CTLA-4 blockade.

PD-1/PD-L1 Blockade in Second-Line Bladder Cancer

Because bladder cancer frequently expresses PD-L1, blocking PD-1 and/or PD-L1 in that disease would seem a logical approach; at this time five anti-PD-1/PD-L1 agents are FDA approved for *second-line* treatment of metastatic bladder cancer. All five have objective response rates (ORRs) between 15% and 23% in unselected patients in the second-line setting. The majority were approved based on single-arm studies comparing median overall survival (OS) and ORR with historical controls. These include the following:

1. **Atezolizumab**, a humanized anti-PD-L1 IgG1 antibody engineered to minimize binding to Fc receptors; this was the first immune checkpoint therapy granted approval by the FDA for urothelial bladder cancer (UBC). Approval was based on the IMvigor 210 study (Rosenberg et al., 2016), a single-arm phase II trial in which second-line bladder cancer patients were treated with 1200 mg of atezolizumab every 3 weeks. The ORR was 14.8% (CI 11.1–19.3) and based on a prespecified response rate of 10% in historical controls, approval was granted for patients who progress after platinum-based therapy or who have progressed within 1 year of neoadjuvant or adjuvant therapy with a platinum-containing regimen.
2. **Nivolumab**, a fully human IgG4 anti-PD1 antibody hinge-modified to improve half-life, received accelerated approval from the FDA for second-line therapy in bladder cancer patients previously treated with a platinum-containing regimen. This approval was based on data from a single-arm phase II study that enrolled 270 patients to receive nivolumab at 3 mg/kg every 2 weeks (Sharma et al., 2017) and had an overall response rate of 19.6%.
3. **Pembrolizumab**, a hinge-stabilized, humanized IgG4 anti-PD1 antibody that, like nivolumab, disrupts the engagement of PD-1 with its ligands PD-L1 and PD-L2. Of the FDA-approved antibodies blocking the PD-1/PD-L1 interaction, pembrolizumab is the only agent approved based on data from a randomized, phase III study (Bellmunt et al., 2017). Accelerated approval was granted by the FDA based on that open-label study, which randomly assigned 542 patients who had recurred or progressed after platinum-based therapy to investigator's choice chemotherapy (paclitaxel, docetaxel, or vinflunine) versus pembrolizumab at 200 mg every 3 weeks. The median overall survival in the pembrolizumab arm was improved as compared with the

chemotherapy arm (10.3 months vs. 7.4 months, *P* = 0.002), and the ORR for the pembrolizumab treated patients was significantly greater than that in the chemotherapy group (21.1% vs. 11.4%, *P* = 0.001).

4. **Durvalumab**, a fully human anti-PD-L1 antibody, was approved based on a single-arm phase I/II study evaluating 61 patients with platinum-treated advanced urothelial cancer (UC) (Massard et al., 2016). Patients were eligible if they had disease relapse within 1 year of neoadjuvant or first-line chemotherapy. In PD-L1 selected patients, the overall response rate was 31.0%. A follow-up analysis reporting on 191 unselected patients treated with durvalumab reported an ORR of 17.8% (Powles et al., 2017).
5. **Avelumab**, an IgG1 anti-PD-L1 antibody that blocks the interaction between PD-1 and PD-L1 but not PD-1 and PD-L2 evaluated in a phase Ib study of unselected patients with platinum refractory bladder cancer; the ORR was 18.2% with a reported median OS of 13.7 months (Apolo et al., 2017). A second pooled analysis of an additional cohort of 241 patients with platinum refractory UC demonstrated a confirmed ORR of 17.6%, with a median overall survival for the pooled cohort of approximately 7.0 months (CI 5.6–11.1) (Patel et al., 2018).

PD-1/PD-L1 Blockade in First-Line Bladder Cancer

With the idea that the immune system may be more intact in chemotherapy-naive patients, the anti-PD-L1 antibody atezolizumab was evaluated in the first-line setting in cisplatin-ineligible patients in one arm of the ImVigor 210 study. The majority of those patients suffered from renal impairment that prohibited cisplatin-based therapy (70%). The ORR for first-line cisplatin-ineligible patients was approximately 23%, with an overall survival of 15.9 months (95% CI 10.4 m. – not estimable). Based on those data, atezolizumab was approved for treating cisplatin-ineligible patients with metastatic urothelial carcinoma. Pembrolizumab was also approved for use as first-line therapy in cisplatin-ineligible patients in mUC based on data from an single-armed phase II study (Bajorin et al., 2015).

Selecting Bladder Cancer Patients for PD-1/PD-

L1–Based Immunotherapy

Although blocking the PD-1/PD-L1 interaction has clinical activity in patients with metastatic bladder cancer, it is clear that not all patients benefit. This is particularly important in the first-line setting, where cisplatin-ineligible patients can be treated either with a carboplatin-based regimen or with first-line anti-PD-1 (pembrolizumab) or first-line anti-PD-L1 (atezolizumab). Based on the notion that PD-L1 expression identifies tumors in which an adaptive immune response is engaged, it makes sense that PD-L1 expression, quantified by immunohistochemistry, could serve as a reasonable predictive biomarker to select patients for immunotherapy (Aggen and Drake, 2017). Indeed, the majority of the trials outlined earlier tested the predictive properties of PD-L1 expression, with the general finding that PD-L1 expression enriches for patients likely to respond to anti-PD-1/PD-L1 monotherapy. As a predictive biomarker, PD-L1 expression is far from perfect, with several factors limiting its capabilities. Perhaps the most obvious of those is sampling error; PD-L1 expression is expressed heterogeneously throughout a tumor nodule, so results may be critically dependent on the lesion interrogated by biopsy (McLaughlin et al., 2016). Complicating sampling error is the factor that at least five different immunohistochemical (IHC) assays have been developed, each with different staining protocols and antibodies. Although these may generally give concordant results (Hirsch et al., 2017), cutoffs for “positivity” vary between assays. Finally, in most of these studies objective responses, even complete responses, have been observed in patients whose tumors were completely negative for PD-L1 expression by IHC. Taken together, those data suggest that PD-L1 expression is at best a weak biomarker in bladder cancer.

PD-1/PD-L1 Blockade in Kidney Cancer

Because RCC is usually considered to be an immune-sensitive tumor type, the observation of single-agent objective responses in RCC patients treated with single-agent anti-PD-1 in phase I trials was not completely unexpected. Indeed, one patient with advanced RCC showed a stable partial response for more than 4 years in the first-in-man dose-escalation study (Brahmer et al., 2010). Perhaps more noteworthy, this sustained partial response eventually evolved into a documented complete response, and the patient has remained off treatment for more than 10 years at last follow-up (Lipson et al., 2013). This initial observation of clinical activity for PD-1 blockade in RCC was supported by data from a more dose-intense phase Ib trial; here, the objective response rate was 30% to 35%, with an additional 10% of patients showing stable disease (McDermott et al., 2015). Based on the activity seen in phase I trials, several phase I and II studies of PD-1 blockade using nivolumab in RCC were initiated. One interesting trial was a dose-ranging study (NCT01354431); this trial enrolled a total of 150 patients, randomized into treatment cohorts at doses of 0.3 mg/kg, 2 mg/kg, and 10 mg/kg, treated every 3 weeks (in contrast to the once-every-2-week dosing in the phase Ib study). The results of that trial showed surprisingly equivalent activity and toxicity for each of the three doses tested (i.e., in RCC there is not a clear dose-response relationship for anti-PD-l treatment using nivolumab). These findings led to a pivotal phase III trial (Checkmate 025) comparing 3 mg/kg of nivolumab to the mTOR inhibitor everolimus in patients with metastatic RCC (mRCC) after progression on TKI therapy; the primary endpoint of this trial was of OS (Motzer et al., 2015). With 821 patients randomized, median OS was 25.0 months with nivolumab versus 19.6 months with everolimus. The ORR was 24% with nivolumab versus 5% with everolimus. Similar to pembrolizumab in UC, there was no difference in progression-free survival (PFS). Unlike UBC, there is a single anti-PD-1/PD-L1 agent FDA approved for second-line RCC.

PD-1/PD-L1 Blockade in Prostate Cancer

PD-1 blockade was evaluated in a small number of patients with metastatic castrate-resistant prostate cancer, the majority of whom were heavily pretreated (Topalian et al., 2012). These data were generally disappointing; no objective responses were noted in approximately 20 men. Biologically, the lack of response to PD-1 blockade in prostate cancer may be explained by the notion that prostate cancer cells generally do not appear to express PD-L1 (Haffner et al., 2018), although the majority of CD8 T cells that infiltrate the gland do express PD-1 (Sfanos et al., 2009). Based on the observation that PD-L1 expression is increased after treatment with the second-generation androgen receptor inhibitor enzalutamide (Bishop et al., 2015), a single-armed study added PD-1 blockade to enzalutamide in patients progressing on enzalutamide. Early data from that trial were encouraging, with 3 out of the initial 10 treated patients showing PSA and/or objective responses (Graff et al., 2016). Those data are important because they suggest that, at least under certain circumstances, prostate cancer patients may respond to blockade of the PD-1/PD-L1 axis.

Taken together, the results mentioned earlier show that ICB will clearly play an important role in treating RCC and bladder cancer, but additional combinatorial efforts will almost certainly be required to achieve objective responses in men with prostate cancer.

Key Points: Immunotherapy for Genitourinary Cancers

- BCG therapy for bladder cancer stimulates the innate and adaptive immune systems and is a prototype for successful cancer immunotherapy.
- Cancer vaccines have been evaluated in kidney and prostate cancer.
- A single vaccine (Sipuleucel-T) is FDA approved for metastatic prostate cancer.
- Cancer vaccines are generally well tolerated but result in few objective clinical responses.
- Blocking the PD-1/PD-L1 interaction is effective in second-line bladder cancer and has activity in first-line patients who are cisplatin ineligible.
- PD-L1 expression may distinguish bladder cancer patients more likely to respond to anti-PD-1/anti-PD-L1 therapy.
- Anti-PD-1 is effective in second-line kidney cancer.
- Anti-PD-1/PD-L1 has not shown robust monotherapy activity in metastatic prostate cancer.

Combination Immunotherapy Regimens in Genitourinary Cancers

CTLA-4 Blockade in Prostate and Kidney Cancer

Cytotoxic T lymphocyte antigen–4 (CTLA-4) is an immune checkpoint molecule expressed on T cells within the tumor microenvironment. Its expression patterns are different than PD-1; CTLA-4 appears to be relatively overexpressed on the population of FoxP3+ CD4 T cells that down-regulate immune responses, regulatory T cells (Treg) (Peggs et al., 2009; Simpson et al., 2013) (see Fig. 61.9). Thus blockade of CTLA-4 likely attenuates the function of Treg, enabling the CD8 tumor infiltrating lymphocytes to exert antitumor activity (Fig. 61.9B).

ICB using anti-CTLA-4 (ipilimumab) monotherapy was evaluated in a number of early phase studies in men with prostate cancer. These data show that treatment is associated with a PSA response rate of approximately 15% to 20%, but with few objective (radiographic) responses (Slovin et al., 2013). In several of these studies, a low dose of radiation therapy was included in an effort to release antigen and potentiate an immune response. However, in those published data, there was no evidence for such an effect; for example, the PSA response rate in patients treated with a dose of 10 mg/kg of ipilimumab was 12% in the presence of radiation therapy (RT) versus 25% without.

Despite this relatively low PSA response rate, and little evidence that low-dose RT applied to a single lesion in men with metastatic disease improved the PSA response rate to ipilimumab, a phase III trial combining RT and ipilimumab, was launched in men with mCRPC who had progressed on or after treatment with docetaxel chemotherapy. This trial enrolled approximately 800 men and randomized them to a single low-dose treatment of RT alone versus RT followed by ipilimumab at a dose of 10 mg/kg every 3 weeks × 4 weeks, with every 3-month maintenance for men who were not progressing. The trial did not meet its primary endpoint (overall survival) with a median OS of 11.2 months in the ipilimumab arm versus 10.0 months for placebo (Kwon et al., 2014). The prespecified secondary endpoint was met, with a PFS of 4.0 months in the ipilimumab group versus 3.1 months in the placebo group (HR = .070, $P < 0.001$). These data provide evidence that ipilimumab may have clinical activity in prostate cancer but were insufficient for regulatory approval. Retrospective analyses of the phase III data showed that men with more favorable disease characteristics (no visceral metastases, normal alkaline phosphatase, normal hemoglobin) appeared to benefit from treatment. One fascinating finding of those post-hoc analyses was that men with visceral disease appeared to derive absolutely no benefit from ipilimumab treatment, whereas in men with bone-only disease there was a clear suggestion of clinical benefit. The precise mechanisms underlying this dichotomy are unclear but may reflect a different immune microenvironment in bone versus soft-tissue metastases in prostate cancer (Drake, 2014). Relevant to those findings, a second phase III trial in the pre-chemotherapy setting has completed enrollment; that trial specifically excluded men with soft-tissue disease; unfortunately that study also failed to meet its primary overall survival endpoint (Beer et al., 2017). Taken together, these phase III data showed that anti-CTLA-4 monotherapy is not an effective treatment for metastatic castration resistant prostate cancer.

If PD-1 is largely expressed on CD8 (killer) T cells that infiltrate tumors, and CTLA-4 is predominantly expressed on CD4 regulatory T cells (Treg), then combined blockade of both pathways could lead to therapeutic synergy. This was true in animal models; combined PD-1/CTLA-4 blockade was the first immune checkpoint combination to show synergistic effects in animals (Curran et al., 2010). Based on preclinical data, the combination of PD-1 and CTLA-4 inhibition has been tested in multiple tumor types, most notably in RCC. In a phase 1b study (CheckMate 016), patients with mRCC had a response rate of approximately 40% to combination therapy, an impressive result that should perhaps be tempered by the rate of grade III/IV immune-related adverse events, which was also in the 40% range (Hammers et al., 2014). Those data led to a phase III front-line trial (Checkmate 214), comparing the combination of anti-PD-1 and anti-CTLA-4 to standard of care sunitinib in front-line RCC patients. Phase III results were similar to the phase Ib data, with combined treatment reaching its combined endpoints of overall response rate (i.e., the ORR for ipilimumab plus nivolumab was 41.6% vs. 26.5% with sunitinib) (Motzer et al., 2018). Based on these data, combination immunotherapy is an FDA-approved first-line treatment option for patients with metastatic RCC.

Combining PD-1/PD-L1 Blockade With Androgen Deprivation Therapy in Prostate Cancer

In general, androgen-deprivation therapy (ADT) has proinflammatory effects. Some of these involve the thymus, which is an organ important for T cell ontogeny. In younger mammals, the thymus is sizable and functional, resulting in the ongoing output of naive T cells. As the organism ages, the thymus involutes so that the daily output of new naive T cells decreases progressively. In aged mice (and presumptively in humans as well), androgen ablation restores the size and cellularity of the thymus, resulting in an increased T-cell output (Sutherland et al., 2005). Consistent with those data, androgen ablation before prostate cancer surgery results in the infiltration of CD4+ T cells into the gland; these cells have an activated phenotype (Mercader et al., 2001). Also supporting a proimmunogenic role for androgen ablation are data demonstrating the induction of novel antibody specificities in treated patients (Nesslinger et al., 2007).

The FDA-approved prostate cancer vaccine was evaluated in combination with intermittent androgen ablation; the results of that study showed that administration of the vaccine before androgen ablation increased CD8 T cell responses to the target antigen, with a handful of patients maintaining low PSA levels even after recovery of testosterone (Antonarakis et al., 2017). Androgen ablation has been combined with immune checkpoint blockade, a phase III trial randomized patients progressing on the next-generation androgen synthesis inhibitor abiraterone acetate to either enzalutamide or the combination of enzalutamide plus anti-PD-L1 (atezolizumab). This trial (NCT03016312) has a primary endpoint of overall survival; the readout is expected in 2020.

Combining PD-1/PD-L1 Blockade With Chemotherapy in Bladder Cancer

Although chemotherapy is often thought of as antagonistic to the immune system, studies showed that some chemotherapy agents, particularly the alkylating agent cyclophosphamide, could in fact enhance a vaccine-directed immune response (Machiels et al., 2001; Wada et al., 2009). In-depth explorations of chemotherapy/immunotherapy combinations showed that additive effects were dependent on several factors. First among those is the chemotherapy agent under study; certain chemotherapy agents are more immunogenic than others in animal models (Galluzzi et al., 2015). This disparity even exists among agents in the same class, for example, among the platinum-based compounds, oxaliplatin appears to be more immunogenic than its sister agents carboplatin or cisplatin. Mechanistically, immunologically favorable chemotherapy agents appear to induce “immunogenic cell death” (Fig. 61.10), in which tumor cells are killed in a manner that facilitates antigen uptake by resting dendritic cells, followed by subsequent trafficking to the draining lymph node and presentation to tumor-antigen–specific T cells. In addition to the type of agent employed, the schedule seemed to be critically important, with small differences being crucial to a proimmune effect. The dose is also critical, with animal studies (Machiels et al., 2001; Wada et al., 2009) and human studies (Emens et al., 2009) showing that a lower dose of chemotherapy is generally required for optimal combinatorial activity. The majority of those data were generated using vaccine-based regimens; in humans, full-dose platinum-doublet–based chemotherapy clearly adds efficacy to anti-PD-1–based immunotherapy (Rizvi et al., 2016), and the combination of PD-1 blockade plus full-dose standard therapy is a standard-of-care treatment regimen for patients with non–small-cell lung cancer (Gandhi et al., 2018). Based to some degree on those data, there are currently a number of ongoing phase III trials in bladder cancer, adding

PD-1 or PD-L1 blockade to standard first-line gemcitabine/cisplatin regimen. Those are important trials; if successful they will transform first-line bladder cancer to a disease treated with a chemotherapy/immunotherapy combination. Such a result could provide patient benefit but would leave in question an optimal second-line treatment for progressing or nonresponsive patients.

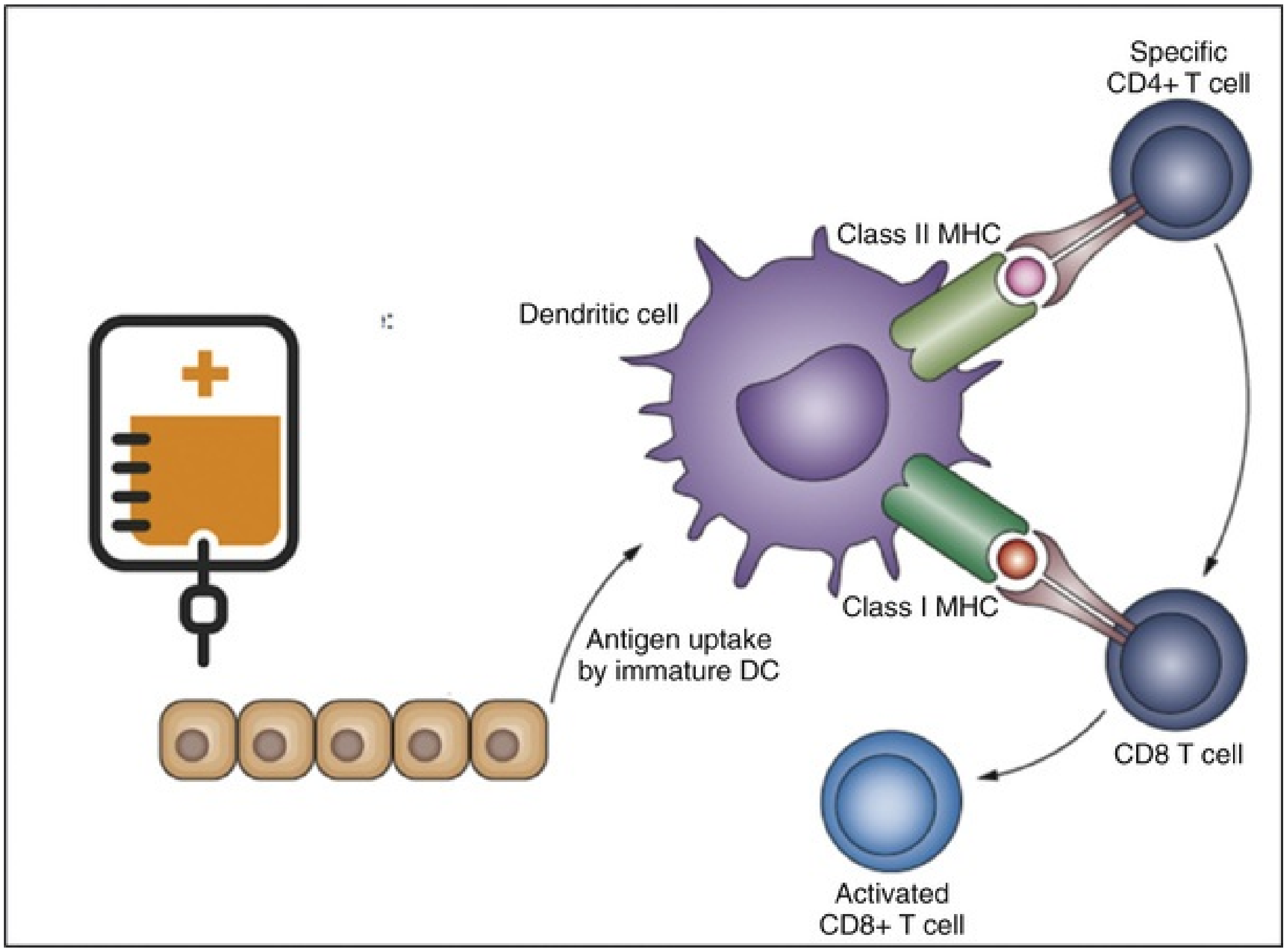
Specific
CD4+ T cell
Class II MHC
Dendritic cell
Class I MHC
Antigen uptake
by immature DC
CD8 T cell
Activated
CD8+ T cell

FIG. 61.10 Immunogenic cell death. *DC,* Dendritic cell; *MHC,* major histocompatibility complex.

Combining PD-1/PD-L1 Blockade With VEGF Inhibition in Kidney Cancer

Antiangiogenic therapy is the mainstay of therapy for metastatic RCC; by inhibiting the formation of new blood vessels, tumor progression can be diminished. In general, the blood vessels within tumors are abnormal, with increased tortuosity and permeability to soluble molecules (Jain, 2001). That permeability does not apply to T lymphocytes; the blood vessels in tumors generally inhibit T cell migration. Treatment with either small molecule agents that inhibit VEGF tyrosine kinase signaling or with antibodies that bind to VEGF promotes the normalization of tumor vasculature, promoting the emigration of T cells from the circulation into the tumor. This process was demonstrated in animal models and in cancer patients (Hegde et al., 2017). In one especially relevant example, a phase 1 trial combining anti-CTLA-4 (ipilimumab) with anti-VEGF (bevacizumab) in patients with metastatic melanoma (Hodi et al., 2014) showed a clear increase in the CD8 T cell infiltrate in the tumor bed. In RCC, combining bevacizumab with the anti-PD-L1 antibody atezolizumab also showed an increase in intratumoral CD8 T cell infiltration (Wallin et al., 2016), and clinical results from that trial drove a randomized phase III trial of the bevacizumab/atezolizumab combination regimen in the first-line setting in RCC patients. An additional notable aspect of VEGF biology is that the molecule itself is immunosuppressive (Kandalaft et al., 2011). Thus VEGF signaling promotes a tolerogenic phenotype in APCs, inducing them to mediate T cell suppression rather than activation. Inhibition of VEGF signaling reverses this process, restoring APC phenotype and function. It is also significant that VEGF TKIs are associated with objective responses in RCC, and in many models the level of cancer-driven immunosuppression correlates with tumor burden. Thus there are three major mechanisms by which VEGF inhibition may facilitate an antitumor immune response in RCC: (1) normalizing the tumor vasculature, enabling T cell infiltration; (2) reversing a suppressive effect on APCs; and (3) driving tumor regression, thus minimizing a tolerogenic tumor burden. A single-armed phase II study combining PD-1 blockade with VEGF-TKI treatment reported an overall response rate of 73%, supporting the notion that VEGF/immunotherapy combinations have clinical activity. Similar combinations are the subject of a number of first-line, randomized phase III trials in RCC.

Conclusions

Cancer immunotherapy is a rapidly advancing field, and progress in this area has been particularly strong in the case of GU cancers. A more robust understanding of basic immunology and immune resistance to tumors has driven recent progress, and there are a large number of ongoing trials. BCG immunotherapy for bladder cancer was one of the first immune-based treatments to enter into routine clinical practice in any cancer type. As discussed in other chapters, the future of immunotherapy will most likely involve combination approaches: the combination of PD-1 blockade with CTLA-4 blockade is now FDA approved in first-line RCC treatment. Other combinations of interest include ADT in prostate cancer, VEGF inhibition in RCC, and chemotherapy plus immunotherapy combinations in bladder cancer. Although these combinations hold considerable promise, it is unlikely that most patients will benefit; in the future it will be important to understand mechanisms of resistance to combined therapy in preclinical models as well as in patients.

Suggested Readings

Balkwill F, Charles KA, Mantovani A. Smoldering and polarized inflammation in the initiation and promotion of malignant disease. *Cancer Cell*. 2005;7:211–217.

Brandau S, Suttmann H. Thirty years of BCG immunotherapy for non-muscle invasive bladder cancer: a success story with room for improvement. *Biomed Pharmacother*. 2007;61:299–305.

De Marzo AM, Platz EA, Sutcliffe S, et al. Inflammation in prostate carcinogenesis. *Nat Rev Cancer*. 2007;7:256–269.

Drake CG, Jaffee E, Pardoll DM. Mechanisms of immune evasion by tumors. *Adv Immunol*. 2006;90:51–81.

Drake CG. Prostate cancer as a model for tumour immunotherapy. *Nat Rev Immunol*. 2010;10:580–593.

Dunn GP, Old LJ, Schreiber RD. The immunobiology of cancer immunosurveillance and immunoediting. *Immunity*. 2004;21:137–148.

Gabrilovich D. Mechanisms and functional significance of tumour-induced dendritic-cell defects. *Nat Rev Immunol*. 2004;4:941–952.

Gannon PO, Poisson AO, Delvoye N, et al. Characterization of the intra-prostatic immune cell infiltration in androgen-deprived prostate cancer patients. *J Immunol Methods*. 2009;348:9–17.

Hanahan D, Weinberg RA. Hallmarks of cancer: the next generation. *Cell*. 2011;144:646–674.

Hodi FS, O'Day SJ, McDermott DF, et al. Improved survival with ipilimumab in patients with metastatic melanoma. *N Engl J Med*. 2010;363:711–723.

Kantoff PW, Higano CS, Shore ND, et al. Sipuleucel-T immunotherapy for castration-resistant prostate cancer. *N*

Engl J Med. 2010;363:411–422.

Kantoff PW, Schuetz TJ, Blumenstein BA, et al. Overall survival analysis of a phase II randomized controlled trial of a Poxviral-based PSA-targeted immunotherapy in metastatic castration-resistant prostate cancer. *J Clin Oncol*. 2010;28:1099–1105.

Madan RA, Arlen PM, Mohebtash M, et al. Prostvac-VF: a vector-based vaccine targeting PSA in prostate cancer. *Expert Opin Investig Drugs*. 2009;18:1001–1011.

Medzhitov R, Janeway C Jr. Innate immune recognition: mechanisms and pathways. *Immunol Rev*. 2000;173:89–97.

Michaud DS. Chronic inflammation and bladder cancer. *Urol Oncol*. 2007;25:260–268.

Ostrand-Rosenberg S, Sinha P. Myeloid-derived suppressor cells: linking inflammation and cancer. *J Immunol*. 2009;182:4499–4506.

Palucka AK, Laupeze B, Aspord C, et al. Immunotherapy via dendritic cells. *Adv Exp Med Biol*. 2005;560:105–114.

Pardoll DM. The blockade of immune checkpoints in cancer immunotherapy. *Nat Rev Cancer*. 2012;12:252–264.

Ribas A. Tumor immunotherapy directed at PD-1. *N Engl J Med*. 2012;366:2517–2519.

Savage PA, Malchow S, Leventhal DS. Basic principles of tumor-associated regulatory T cell biology. *Trends Immunol*. 2013;34:33–40.

Slovin SF, Higano CS, Hamid O, et al. Ipilimumab alone or in combination with radiotherapy in metastatic castration-resistant prostate cancer: results from an open-label, multicenter phase I/II study. *Ann Oncol*. 2013.

Topalian SL, Hodi FS, Brahmer JR, et al. Safety, activity, and immune correlates of anti-PD-1 antibody in cancer. *N Engl J Med*. 2012;366:2443–2454.

References

Aggen DH, Drake CG. Biomarkers for immunotherapy in bladder cancer: a moving target. *J Immunother Cancer*. 2017;5:94.

Antonarakis ES, Kibel AS, Yu EY, et al. Sequencing of sipuleucel-T and androgen deprivation therapy in men with hormone-sensitive biochemically recurrent prostate cancer: a phase II randomized trial. *Clin Cancer Res*. 2017;23:2451–2459.

Antonarakis ES, Small EJ, Petrylak D, et al. Antigen-specific CD8 lytic phenotype induced by sipuleucel-T in hormone-sensitive or castration-resistant prostate cancer and association with overall survival. *Clin Cancer Res*. 2018;24(19):4662–4671.

Apolo AB, Infante JR, Balmanoukian A, et al. Avelumab, an anti-programmed death-ligand 1 antibody, in patients with refractory metastatic urothelial carcinoma: results from a multicenter, phase Ib study. *J Clin Oncol*. 2017;35:2117–2124.

Askeland EJ, Newton MR, O'Donnell MA, et al. Bladder cancer immunotherapy: BCG and beyond. *Adv Urol*. 2012;2012:181987.

Bajorin DF, Plimack ER, Siefker-Radtke AO, et al. KEYNOTE-052: Phase 2 study of pembrolizumab (MK-3475) as first-line therapy for patients (pts) with unresectable or metastatic urothelial cancer ineligible for cisplatin-based therapy. *J Clin Oncol*. 2015;33 [TPS4572-TPS4572].

Balkwill F, Charles KA, Mantovani A. Smoldering and polarized inflammation in the initiation and promotion of malignant disease. *Cancer Cell*. 2005;7:211–217.

Beer TM, Kwon ED, Drake CG, et al. Randomized, double-blind, phase III trial of ipilimumab versus placebo in asymptomatic or minimally symptomatic patients with metastatic chemotherapy-naive castration-resistant prostate cancer. *J Clin Oncol*. 2017;35:40–47.

Bellmunt J, de Wit R, Vaughn DJ, et al. Pembrolizumab as second-line therapy for advanced urothelial carcinoma. *N Engl J Med*. 2017;376:1015–1026.

Bishop JL, Sio A, Angeles A, et al. PD-L1 is highly expressed in Enzalutamide resistant prostate cancer. *Oncotarget*. 2015;6:234–242.

Brahmer JR, Drake CG, Wollner I, et al. Phase I study of single-agent anti-programmed death-1 (MDX-1106) in refractory solid tumors: safety, clinical activity, pharmacodynamics, and immunologic correlates. *J Clin Oncol*. 2010;28:3167–3175.

Brandau S, Suttmann H. Thirty years of BCG immunotherapy for non-muscle invasive bladder cancer: a success story with room for improvement. *Biomed Pharmacother*. 2007;61:299–305.

Bronte V, Kasic T, Gri G, et al. Boosting antitumor responses of T lymphocytes infiltrating human prostate cancers. *J Exp Med*. 2005;201:1257–1268.

Chao JL, Savage PA. Unlocking the complexities of tumor-associated regulatory T cells. *J Immunol*. 2018;200:415–421.

Chevrier S, Levine JH, Zanotelli VRT, et al. An immune atlas of clear cell renal cell carcinoma. *Cell*. 2017;169:736–749 [e718].

Chow WH, Dong LM, Devesa SS. Epidemiology and risk factors for kidney cancer. *Nat Rev Urol*. 2010;7:245–257.

Curran MA, Montalvo W, Yagita H, et al. PD-1 and CTLA-4 combination blockade expands infiltrating T cells and reduces regulatory T and myeloid cells within B16 melanoma tumors. *Proc Natl Acad Sci USA*. 2010;107:4275–4280.

de Boer EC, de Jong WH, van der Meijden AP, et al.

Leukocytes in the urine after intravesical BCG treatment for superficial bladder cancer. A flow cytofluorometric analysis. *Urol Res*. 1991;19:45–50.

De Marzo AM, Marchi VL, Epstein JI, et al. Proliferative inflammatory atrophy of the prostate: implications for prostatic carcinogenesis. *Am J Pathol*. 1999;155:1985–1992.

De Marzo AM, Platz EA, Sutcliffe S, et al. Inflammation in prostate carcinogenesis. *Nat Rev Cancer*. 2007;7:256–269.

de Reijke TM, de Boer EC, Kurth KH, et al. Urinary cytokines during intravesical bacillus Calmette-Guerin therapy for superficial bladder cancer: processing, stability and prognostic value. *J Urol*. 1996;155:477–482.

de Visser KE, Eichten A, Coussens LM. Paradoxical roles of the immune system during cancer development. *Nat Rev Cancer*. 2006;6:24–37.

Drake CG. Prostate cancer as a model for tumour immunotherapy. *Nat Rev Immunol*. 2010;10:580–593.

Drake CG. Visceral metastases and prostate cancer treatment: ‘die hard,’ ‘tough neighborhoods,’ or ‘evil humors’? *Oncology (Williston Park)*. 2014;28:974–980.

Drake CG, Jaffee E, Pardoll DM. Mechanisms of immune evasion by tumors. *Adv Immunol*. 2006;90:51–81.

Drake CG, Lipson EJ, Brahmer JR. Breathing new life into immunotherapy: review of melanoma, lung and kidney cancer. *Nat Rev Clin Oncol*. 2014;11:24–37.

Dunn GP, Old LJ, Schreiber RD. The immunobiology of cancer immunosurveillance and immunoediting. *Immunity*. 2004;21:137–148.

Eager R, Nemunaitis J. GM-CSF gene-transduced tumor vaccines. *Mol Ther*. 2005;12:18–27.

Emens LA, Asquith JM, Leatherman JM, et al. Timed sequential treatment with cyclophosphamide, doxorubicin, and an allogeneic granulocyte-macrophage colony-stimulating factor-secreting breast tumor vaccine: a chemotherapy dose-ranging factorial study of safety and immune activation. *J Clin Oncol*. 2009;27:5911–5918.

Figlin RA, Amin A, Dudek A, et al. Phase II study combining personalized dendritic cell (DC)-based therapy, AGS-003, with sunitinib in metastatic renal cell carcinoma (mRCC). *J Clin Oncol*. 2012;suppl 5.

Fox SB, Launchbury R, Bates GJ, et al. The number of regulatory T cells in prostate cancer is associated with the androgen receptor and hypoxia-inducible factor (HIF)-2alpha but not HIF-1alpha. *Prostate*. 2007;67:623–629.

Fridman WH, Pages F, Sautes-Fridman C, et al. The immune contexture in human tumours: impact on clinical outcome. *Nat Rev Cancer*. 2012;12:298–306.

Gabrilovich DI. Myeloid-derived suppressor cells. *Cancer Immunol Res*. 2017;5:3–8.

Gabrilovich DI, Corak J, Ciernik IF, et al. Decreased antigen presentation by dendritic cells in patients with breast cancer. *Clin Cancer Res*. 1997;3:483–490.

Galluzzi L, Buque A, Kepp O, et al. Immunological effects of conventional chemotherapy and targeted anticancer agents. *Cancer Cell*. 2015;28:690–714.

Gandhi L, Rodriguez-Abreu D, Gadgeel S, et al. Pembrolizumab plus chemotherapy in metastatic non-small-cell lung cancer. *N Engl J Med*. 2018;378:2078–2092.

Gannon PO, Poisson AO, Delvoye N, et al. Characterization of the intra-prostatic immune cell infiltration in androgen-deprived prostate cancer patients. *J Immunol Methods*. 2009;348:9–17.

Giraldo NA, Becht E, Pages F, et al. Orchestration and prognostic significance of immune checkpoints in the microenvironment of primary and metastatic renal cell cancer. *Clin Cancer Res*. 2015;21:3031–3040.

Graff JN, Alumkal JJ, Drake CG, et al. Early evidence of anti-PD-1 activity in enzalutamide-resistant prostate cancer. *Oncotarget*. 2016;7:52810–52817.

Groah SL, Weitzenkamp DA, Lammertse DP, et al. Excess risk of bladder cancer in spinal cord injury: evidence for an association between indwelling catheter use and bladder cancer. *Arch Phys Med Rehabil*. 2002;83:346–351.

GuhaThakurta D, Sheikh NA, Fan LQ, et al. Humoral immune response against nontargeted tumor antigens after treatment with Sipuleucel-T and its association with improved clinical outcome. *Clin Cancer Res*. 2015;21:3619–3630.

Haffner MC, Guner G, Taheri D, et al. Comprehensive evaluation of programmed death-Ligand 1 expression in primary and metastatic prostate cancer. *Am J Pathol*. 2018;188:1478–1485.

Hammers HJ, Plimack ER, Infante JR, et al. Phase I study of nivolumab in combination with ipilimumab in metastatic renal cell carcinoma (mRCC). *ASCO Meeting Abstracts*. 2014;32:4504.

Hanahan D, Weinberg RA. Hallmarks of cancer: the next generation. *Cell*. 2011;144:646–674.

Hegde PS, Wallin JJ, Mancao C. Predictive markers of anti-VEGF and emerging role of angiogenesis inhibitors as immunotherapeutics. *Semin Cancer Biol*. 2017;52(Pt 2):117–124.

Hirsch FR, McElhinny A, Stanforth D, et al. PD-L1 immunohistochemistry assays for lung cancer: results from phase 1 of the Blueprint PD-L1 IHC Assay Comparison Project. *J Thorac Oncol*. 2017;12:208–222.

Hodge JW, Sabzevari H, Yafal AG, et al. A triad of costimulatory molecules synergize to amplify T-cell activation. *Cancer Res*. 1999;59:5800–5807.

Hodi FS, Lawrence D, Lezcano C, et al. Bevacizumab plus ipilimumab in patients with metastatic melanoma. *Cancer Immunol Res*. 2014;2:632–642.

Inman BA, Sebo TJ, Frigola X, et al. PD-L1 (B7-H1) expression by urothelial carcinoma of the bladder and BCG-induced granulomata: associations with localized stage progression. *Cancer*. 2007;109:1499–1505.

Jain RK. Normalizing tumor vasculature with anti-angiogenic therapy: a new paradigm for combination therapy. *Nat Med*. 2001;7:987–989.

Kandalaft LE, Motz GT, Busch J, et al. Angiogenesis and the tumor vasculature as antitumor immune modulators: the role of vascular endothelial growth factor and endothelin. *Curr Top Microbiol Immunol*. 2011;344:129–148.

Kantoff PW, Higano CS, Shore ND, et al. Sipuleucel-T immunotherapy for castration-resistant prostate cancer. *N Engl J Med*. 2010;363:411–422.

Kantoff PW, Schuetz TJ, Blumenstein BA, et al. Overall survival analysis of a phase II randomized controlled trial of a Poxviral-based PSA-targeted immunotherapy in metastatic castration-resistant prostate cancer. *J Clin Oncol*. 2010;28:1099–1105.

Kantor AF, Hartge P, Hoover RN, et al. Urinary tract infection and risk of bladder cancer. *Am J Epidemiol*. 1984;119:510–515.

Kates M, Nirschl T, Sopko NA, et al. Intravesical BCG induces CD4(+) T-cell expansion in an immune competent model of bladder cancer. *Cancer Immunol Res*. 2017;5:594–603.

Kavoussi LR, Brown EJ, Ritchey JK, et al. Fibronectin-mediated Calmette-Guerin bacillus attachment to murine bladder mucosa. Requirement for the expression of an antitumor response. *J Clin Invest*. 1990;85:62–67.

Kiniwa Y, Miyahara Y, Wang HY, et al. CD8+ Foxp3+ regulatory T cells mediate immunosuppression in prostate cancer. *Clin Cancer Res*. 2007;13:6947–6958.

Kwon ED, Drake CG, Scher HI, et al. Ipilimumab versus placebo after radiotherapy in patients with metastatic castration-resistant prostate cancer that had progressed after docetaxel chemotherapy (CA184-043): a multicentre, randomised, double-blind, phase 3 trial. *Lancet Oncol*. 2014;15:700–712.

LaFleur MW, Muroyama Y, Drake CG, et al. Inhibitors of the PD-1 pathway in tumor therapy. *J Immunol*. 2018;200:375–383.

Lipson EJ, Sharfman WH, Drake CG, et al. Durable cancer regression off-treatment and effective reinduction therapy with an anti-PD-1 antibody. *Clin Cancer Res*. 2013;19:462–468.

Machiels JP, Reilly RT, Emens LA, et al. Cyclophosphamide, doxorubicin, and paclitaxel enhance the antitumor immune response of granulocyte/macrophage-colony stimulating factor-secreting whole-cell vaccines in HER-2/neu tolerized mice. *Cancer Res*. 2001;61:3689–3697.

Madan RA, Arlen PM, Mohebtash M, et al. Prostvac-VF: a vector-based vaccine targeting PSA in prostate cancer. *Expert Opin Investig Drugs*. 2009;18:1001–1011.

Mantovani A, Allavena P, Sica A, et al. Cancer-related inflammation. *Nature*. 2008;454:436–444.

Martinez-Lostao L, Anel A, Pardo J. How do cytotoxic lymphocytes kill cancer cells? *Clin Cancer Res*. 2015;21:5047–5056.

Massard C, Gordon MS, Sharma S, et al. Safety and efficacy of durvalumab (MEDI4736), an anti-PD-L1 immune checkpoint inhibitor, in patients with advanced urothelial bladder cancer. *J Clin Oncol*. 2016;34(26):3119–3125.

Mateos MV, Dimopoulos MA, Cavo M, et al. Daratumumab plus bortezomib, melphalan, and prednisone for untreated myeloma. *N Engl J Med*. 2018;378:518–528.

McDermott DF, Drake CG, Sznol M, et al. Survival, durable response, and long-term safety in patients with previously treated advanced renal cell carcinoma receiving nivolumab. *J Clin Oncol*. 2015;33(18):2013–2020.

McLaughlin J, Han G, Schalper KA, et al. Quantitative assessment of the heterogeneity of PD-L1 expression in non-small-cell lung cancer. *JAMA Oncol*. 2016;2:46–54.

McNeal JE, Redwine EA, Freiha FS, et al. Zonal distribution of prostatic adenocarcinoma. Correlation with histologic pattern and direction of spread. *Am J Surg Pathol*. 1988;12:897–906.

Medzhitov R, Janeway C Jr. Innate immune recognition: mechanisms and pathways. *Immunol Rev*. 2000;173:89–97.

Mercader M, Bodner BK, Moser MT, et al. T cell infiltration of the prostate induced by androgen withdrawal in patients with prostate cancer. *Proc Natl Acad Sci USA*. 2001;98:14565–14570.

Michaud DS. Chronic inflammation and bladder cancer. *Urol Oncol*. 2007;25:260–268.

Miller AM, Lundberg K, Ozenci V, et al. CD4+CD25high T cells are enriched in the tumor and peripheral blood of prostate cancer patients. *J Immunol*. 2006;177:7398–7405.

Mostafa MH, Sheweita SA, O'Connor PJ. Relationship between schistosomiasis and bladder cancer. *Clin Microbiol Rev*. 1999;12:97–111.

Motzer RJ, Escudier B, McDermott DF, et al. Nivolumab versus everolimus in advanced renal-cell carcinoma. *N Engl J Med*. 2015;373:1803–1813.

Motzer RJ, Tannir NM, McDermott DF, et al. Nivolumab plus ipilimumab versus sunitinib in advanced renal-cell carcinoma. *N Engl J Med*. 2018;378:1277–1290.

Nakanishi J, Wada Y, Matsumoto K, et al. Overexpression of B7-H1 (PD-L1) significantly associates with tumor grade and postoperative prognosis in human urothelial cancers. *Cancer Immunol Immunother*. 2007;56:1173–1182.

Nakano O, Sato M, Naito Y, et al. Proliferative activity of intratumoral CD8(+) T-lymphocytes as a prognostic factor in human renal cell carcinoma: clinicopathologic demonstration of antitumor immunity. *Cancer Res*. 2001;61:5132–5136.

Nesslinger NJ, Sahota RA, Stone B, et al. Standard treatments induce antigen-specific immune responses in prostate cancer. *Clin Cancer Res*. 2007;13:1493–1502.

North RJ. Cyclophosphamide-facilitated adoptive immunotherapy of an established tumor depends on elimination of tumor-induced suppressor T cells. *J Exp Med*. 1982;155:1063–1074.

Olson BM, McNeel DG. Antibody and T-cell responses specific for the androgen receptor in patients with prostate cancer. *Prostate*. 2007;67:1729–1739.

Palucka AK, Laupeze B, Aspord C, et al. Immunotherapy via dendritic cells. *Adv Exp Med Biol*. 2005;560:105–114.

Patel MR, Ellerton J, Infante JR, et al. Avelumab in metastatic urothelial carcinoma after platinum failure (JAVELIN Solid Tumor): pooled results from two expansion cohorts of an open-label, phase 1 trial. *Lancet Oncol*. 2018;19:51–64.

Peggs KS, Quezada SA, Chambers CA, et al. Blockade of CTLA-4 on both effector and regulatory T cell compartments contributes to the antitumor activity of anti-CTLA-4 antibodies. *J Exp Med*. 2009;206:1717–1725.

Powles T, O'Donnell PH, Massard C, et al. Efficacy and safety of durvalumab in locally advanced or metastatic urothelial carcinoma: updated results from a phase 1/2 open-label study. *JAMA Oncol*. 2017;3:e172411.

Prescott S, James K, Hargreave TB, et al. Intravesical Evans strain BCG therapy: quantitative immunohistochemical analysis of the immune response within the bladder wall. *J*

Urol. 1992;147:1636–1642.

Putzi MJ, De Marzo AM. Morphologic transitions between proliferative inflammatory atrophy and high-grade prostatic intraepithelial neoplasia. *Urology*. 2000;56:828–832.

Ratliff TL, Gillen D, Catalona WJ. Requirement of a thymus dependent immune response for BCG-mediated antitumor activity. *J Urol*. 1987;137:155–158.

Remark R, Alifano M, Cremer I, et al. Characteristics and clinical impacts of the immune environments in colorectal and renal cell carcinoma lung metastases: influence of tumor origin. *Clin Cancer Res*. 2013;19:4079–4091.

Rizvi NA, Hellmann MD, Brahmer JR, et al. Nivolumab in combination with platinum-based doublet chemotherapy for first-line treatment of advanced non-small-cell lung cancer. *J Clin Oncol*. 2016;34:2969–2979.

Rosenberg JE, Hoffman-Censits J, Powles T, et al. Atezolizumab in patients with locally advanced and metastatic urothelial carcinoma who have progressed following treatment with platinum-based chemotherapy: a single-arm, multicentre, phase 2 trial. *Lancet*. 2016.

Saint F, Patard JJ, Maille P, et al. Prognostic value of a T helper 1 urinary cytokine response after intravesical bacillus Calmette-Guerin treatment for superficial bladder cancer. *J Urol*. 2002;167:364–367.

Saint F, Patard JJ, Maille P, et al. T helper 1/2 lymphocyte urinary cytokine profiles in responding and nonresponding patients after 1 and 2 courses of bacillus Calmette-Guerin for superficial bladder cancer. *J Urol*. 2001;166:2142–2147.

Sakaguchi S, Yamaguchi T, Nomura T, et al. Regulatory T cells and immune tolerance. *Cell*. 2008;133:775–787.

Savage PA, Malchow S, Leventhal DS. Basic principles of tumor-associated regulatory T cell biology. *Trends Immunol*. 2013;34:33–40.

Sfanos KS, De Marzo AM. Prostate cancer and inflammation: the evidence. *Histopathology*. 2012;60:199–215.

Sfanos KS, Bruno TC, Maris CH, et al. Phenotypic analysis of prostate-infiltrating lymphocytes reveals TH17 and Treg skewing. *Clin Cancer Res*. 2008;14:3254–3261.

Sfanos KS, Bruno TC, Meeker AK, et al. Human prostate-infiltrating CD8+ T lymphocytes are oligoclonal and PD-1. *Prostate*. 2009;69:1694–1703.

Shafer-Weaver KA, Anderson MJ, Stagliano K, et al. Cutting edge: tumor-specific CD8+ T cells infiltrating prostatic tumors are induced to become suppressor cells. *J Immunol*. 2009;183:4848–4852.

Sharma P, Retz M, Siefker-Radtke A, et al. Nivolumab in metastatic urothelial carcinoma after platinum therapy (CheckMate 275): a multicentre, single-arm, phase 2 trial. *Lancet Oncol*. 2017;18:312–322.

Sharma P, Shen Y, Wen S, et al. CD8 tumor-infiltrating lymphocytes are predictive of survival in muscle-invasive urothelial carcinoma. *Proc Natl Acad Sci USA*. 2007;104:3967–3972.

Simons JW, Jaffee EM, Weber CE, et al. Bioactivity of autologous irradiated renal cell carcinoma vaccines generated by ex vivo granulocyte-macrophage colony-stimulating factor gene transfer. *Cancer Res*. 1997;57:1537–1546.

Simpson TR, Li F, Montalvo-Ortiz W, et al. Fc-dependent depletion of tumor-infiltrating regulatory T cells co-defines the efficacy of anti-CTLA-4 therapy against melanoma. *J Exp Med*. 2013;210:1695–1710.

Slovin SF, Higano CS, Hamid O, et al. Ipilimumab alone or in combination with radiotherapy in metastatic castration-resistant prostate cancer: results from an open-label, multicenter phase I/II study. *Ann Oncol*. 2013;24:1813–1821.

Sonpavde G, Di LG, Higano CS, et al. The role of sipuleucel-T in therapy for castration-resistant prostate cancer: a critical analysis of the literature. *Eur Urol*. 2012;61:639–647.

Sutherland JS, Goldberg GL, Hammett MV, et al. Activation of thymic regeneration in mice and humans following androgen blockade. *J Immunol*. 2005;175:2741–2753.

Talar-Williams C, Hijazi YM, Walther MM, et al. Cyclophosphamide-induced cystitis and bladder cancer in patients with Wegener granulomatosis. *Ann Intern Med*. 1996;124:477–484.

Taube JM, Anders RA, Young GD, et al. Colocalization of inflammatory response with b7-h1 expression in human melanocytic lesions supports an adaptive resistance mechanism of immune escape. *Sci Transl Med*. 2012;4:127ra137.

Thalmann GN, Sermier A, Rentsch C, et al. Urinary Interleukin-8 and 18 predict the response of superficial bladder cancer to intravesical therapy with bacillus Calmette-Guerin. *J Urol*. 2000;164:2129–2133.

Topalian SL, Hodi FS, Brahmer JR, et al. Safety, activity, and immune correlates of anti-PD-1 antibody in cancer. *N Engl J Med*. 2012;366:2443–2454.

Wada S, Yoshimura K, Hipkiss EL, et al. Cyclophosphamide augments antitumor immunity: studies in an autochthonous prostate cancer model. *Cancer Res*. 2009;69:4309–4318.

Wallin JJ, Bendell JC, Funke R, et al. Atezolizumab in combination with bevacizumab enhances antigen-specific T-cell migration in metastatic renal cell carcinoma. *Nat Commun*. 2016;7:12624.

Walter S, Weinschenk T, Stenzl A, et al. Multipeptide immune response to cancer vaccine IMA901 after single-dose cyclophosphamide associates with longer patient survival. *Nat Med*. 2012;18(8):1254–1261.

Weaver CT, Harrington LE, Mangan PR, et al. Th17: an effector

CD4 T cell lineage with regulatory T cell ties. *Immunity*. 2006;24:677–688.

Zhao E, Wang L, Dai J. Regulatory T cells in the bone marrow microenvironment in patients with prostate cancer. *Oncoimmunology*. 2012;1:152–161.

Molecular Genetics and Cancer Biology

Karen S. Sfanos PhD, Mark L. Gonzalgo MD, PhD

Despite decades of intensive biomedical research, cancer remains a significant cause of morbidity and mortality worldwide. In part, this is due to the complexity inherent in this disease, which is, in fact, not truly a single disease at all. It involves more than 100 separate subtypes, all grouped together under the single term, *cancer.*

In the United States cancer strikes more than half a million victims annually and is the second leading cause of death; it is poised to become the leading cause of death in the near future, should recent trends continue. **Genitourinary (GU) malignancies make up 25% (440,560) of all estimated cancer cases in 2018 in the United States (basal and squamous skin cancers excluded) and 16% (96,460) of all cancer deaths** (Siegel et al., 2018). However, significant advances in the diagnosis and treatment of certain GU cancers have been made. For example, the cure rate for testicular cancer now approaches 100% (Einhorn, 2002; Horwich et al., 2006). Unfortunately, this cancer is unusual in its responsiveness to therapy and is relatively uncommon. We have had less success with the more prevalent GU malignancies in men, such as prostate, bladder, and renal cancers; the first, fourth, and sixth most common cancers in men, respectively (Siegel et al., 2018). It is encouraging, however, that mortality figures for these malignancies have shown a slow but steady decline over the past decade, and there is every reason to believe that these trends will continue and even accelerate in the future.

Much of our current understanding of cancer is the direct result of the molecular biology revolution that developed rapidly after the elucidation of the molecular structure of DNA by Watson and Crick in 1953 (Watson and Crick, 1953). In subsequent years, the field of molecular genetics has complemented and greatly expanded upon knowledge gleaned by other disciplines, such as biochemistry and cell biology, providing important insights, at the molecular level, regarding the abnormalities present in cancer cells. Recent years have seen a tremendous expansion in the tools available for studying the genetic basis of human cancer. This includes whole genome and whole “exome” (the coding regions of the genome) sequencing efforts that have become relatively affordable and routine. Thus a great deal is now known concerning the numerous molecular signaling pathways that provide positive and negative regulatory signals that, in normal cells, stringently control cell proliferation so that any losses in cell number are precisely counterbalanced, thereby maintaining tissue and organ homeostasis, processes that go awry in cancer cells. Renegade populations of autonomously proliferating cells represent a serious threat to survival of the organism, particularly to large, long-lived species such as ourselves; therefore we have evolved multiple barriers to prevent such outbreaks from occurring. Notably, this means **that incipient cancer cells must overcome several hurdles on the way to becoming fully malignant, a multi-step process that takes many years or even decades to complete.** Consequently, it has been recognized that **cancer cells must acquire at least eight key attributes to make the transition from a normal cell to a malignant one. These attributes include (1) genetic instability and mutation, (2) autonomous growth, (3) insensitivity to internal and external antiproliferative signals, (4) resistance to apoptosis and other forms of induced cell suicide, (5) unlimited cell division potential, (6) the ability to induce new blood vessel formation (angiogenesis), (7) locally invasive behavior that uniquely distinguishes malignant from benign neoplasms, and (8) evasion of the immune system.** In addition, cancer cells must deal with various cellular stresses that are byproducts of their abnormal physiology as well as increase their energy metabolism required to fuel autonomous growth and unlimited replication. It is also currently recognized that tumor-associated inflammation may drive the development of early preneoplastic lesions into invasive cancers and/or promote tumor progression. **Finally, many cancers develop an additional, lethal attribute: the ability to leave the site of the primary tumor to colonize and thrive in distant organs or tissues as metastases** (Hanahan and Weinberg, 2000; Hanahan and Weinberg, 2011; Luo et al., 2009; Solimini et al., 2007).

This chapter outlines fundamental concepts of molecular genetics that are directly related to human cancer in general, with an emphasis on GU malignancies in particular. Spurred by recent technologic advances such as high-throughput DNA and RNA sequencing, our knowledge of the molecular genetics of cancer is rapidly expanding, providing new insights for use in novel diagnostic, prognostic, and therapeutic applications.

Tumor Suppressor Genes and Oncogenes

Basic Molecular Genetics

A glossary of molecular biology terms can be found in eBox 62.1.

eBox 62.1

Molecular Biology: Glossary of Terms

Allele: An alternative form of a gene.

Amplification: Additional copies of a chromosomal sequence; these sequences may include genes and may be extrachromosomal or intrachromosomal.

Aneuploid: Deviation in chromosomal number from the usual diploid state (e.g., tetraploidy).

Annealing: The pairing of two single strands of complementary DNA sequences to form a double helix.

Alternative splicing: A mechanism by which variations in the incorporation of a gene's coding regions during mRNA maturation leads to the production of multiple related forms of a gene.

Base pair: The physical relationship between adenine/thymidine and guanine/cytosine within the double helix of DNA. Abbreviated as bp, it provides the unit of measurement for DNA. Each base pair is stabilized by hydrogen bonds.

cDNA: A segment of DNA complementary to an RNA sequence.

Centromere: An essential structural element of chromosomes consisting of repetitive, noncoding DNA to which the spindle microtubules attach during mitosis.

Chromosome: A distinct segment of linear DNA containing a large number of genes. In humans there are 23 such segments, each containing hundreds to thousands of genes.

Codon: Three sequential nucleotides in protein coding genes that specify a particular amino acid in the protein or a STOP translation signal.

Deletion: The removal of a segment of DNA, with rejoining of the ends.

Diploid: A set of chromosomes containing two complete copies of the organism's genomic DNA.

Dominant: Allele determining the phenotypic manifestation of a gene.

Endonuclease: An enzyme that cuts DNA or RNA within the nucleotide chain.

Exon: A sequence of DNA that is represented with a complementary RNA sequence, also known as the coding sequence.

Expression vector: A vector designed to encode a particular DNA sequence or gene for transcription and translation into RNA or protein.

Epigenetic: Nongenetic information such as methylation or acetylation of histone proteins that modifies gene expression.

FISH: Fluorescence in situ hybridization. A technique in which a fluorescently-labeled nucleic acid probe is hybridized to its complementary target sequence in the genome allowing localization and enumeration of the target.

Frameshift mutation: A deletion or insertion of DNA that shifts the normal codons into a different order for translation into protein.

Gene: A segment of DNA that contributes to the formation of a protein, including the introns (noncoding regions) and the exons (coding regions) as well as the regulatory regions preceding and following the coding regions.

Genetic code: The correspondence between triplets of DNA or RNA (codons) and amino acids making up proteins.

Genotype: The genetic makeup of an organism as reflected in its DNA sequence.

Haplotype: A group of alleles in relative close proximity on a chromosome that are inherited together.

Hemizygote: Having only one copy of a gene owing, for example, to the loss of chromosomal material or an entire chromosome.

Heterozygote: Having two different copies (alleles) of a gene.

Homozygote: Having two identical copies (alleles) of a gene.

Hybridization: The physical pairing of complementary RNA and/or DNA sequences.

Intron: A segment of DNA that is transcribed but is removed by the splicing together of the exons on either side; part of the noncoding sequences of a gene.

Karyotype: A catalog of all the chromosomes within a particular cell. Typically accomplished by isolation and staining of metaphase chromosomes.

Linkage: The tendency for genes in proximity to one another on a chromosome to be inherited together.

Locus: The position of a particular gene on a particular chromosome.

Loss of heterozygosity (LOH): Deletion or mutation of a gene creating a hemizygous state or, if the remaining allele is duplicated, a homozygous state. In cancers arising in cancer predisposition syndromes caused by an inherited gene mutation, the remaining wild type allele is often lost via LOH.

Methylation: The addition of a methyl group to a molecule. Methylation of the nucleotide cytosine in the promoter regulatory region of a gene is often associated with decreased transcription of that gene.

Micro-RNA: (miRNA); small, single-strand RNA molecules 21–23 nucleotides in length that function to negatively regulate transcribed genes for which they have sequence complementarity.

Mutation: Any change in the sequence of genomic DNA.

Northern blotting: A technique of transferring RNA from an agarose gel to a nitrocellulose filter for hybridization with a complementary DNA.

Oncogenes: Genes that encode for proteins that have the ability to transform normal cells into cancerous cells.

Polymerase chain reaction (PCR): A technique using sequential temperature cycles favoring DNA denaturation, annealing of primer sequences, and primer extension with DNA polymerase to amplify a large number of copies of a particular sequence of DNA. This technique can be used to detect very small amounts of DNA by creating a huge number of identical copies.

Phenotype: The appearance or function of an organism, reflecting the contributions of the genotype and the environment.

Ploidy: The number or copies of entire chromosome complements (genomes) within a cell; diploid has two copies, triploid has three copies, tetraploid has four copies, etc.

Point mutation: A change in a DNA sequence involving a single base pair.

Polymorphism: A difference in normal DNA sequence between individuals. It can be a repetitive element or a single nucleotide polymorphism (SNP).

Promoter: The region of DNA in a gene where RNA polymerase binds and gene transcription begins. This region is often the sequence of DNA 100 to 500 base pairs immediately before the initiation site of the protein coding portion of the gene.

Recessive: An allele that is not represented phenotypically in the presence of a dominant allele.

Reporter gene: A gene encoding for a new or foreign protein that can easily be detected. For example, the luciferase gene, encoding the light-producing proteins of the firefly, is introduced into cells that do not express this gene.

Restriction enzyme: Recognizing specific short sequences of DNA (e.g., 4 or 6 base pairs), these enzymes cut the DNA at a particular location.

Silent mutation: An alteration in a DNA sequence that does not change the protein product of the gene.

Small interfering RNA *(siRNA):* Small, double-stranded RNA molecules 20–25 nucleotides in length that promote degradation of mRNA molecules to which they have complementarity, thus downregulating expression of the corresponding gene. Often employed by researchers as a means of reducing expression of specific genes.

Southern blotting: A technique of transferring denatured DNA from an agarose gel to a nitrocellulose filter for hybridization with complementary DNA.

Splicing: The removal of introns (spliced out) and the connection of exons (spliced together) in mRNA.

Telomere: An essential structural element of chromosomes consisting of repetitive, noncoding DNA and associated telomere-specific binding proteins which cap and stabilize the chromosomal termini.

Transcription: Synthesis of RNA on a DNA template.

Transfection: The introduction of DNA sequences into a cell.

Transgenic animals: Animals created by the introduction of new DNA into the germ line (into the egg).

Translation: Synthesis of protein from the messenger RNA (mRNA) template.

Vector: A plasmid, bacteriophage, or virus that carries new DNA into a cell. Vectors are often designed to produce large amounts of protein encoded by the gene within the host cell.

DNA

The molecular characteristics of deoxyribonucleic acid (DNA) were first described in 1953 (Watson and Crick, 1953). This molecule serves as the blueprint for determination of structure and function of all living organisms. **DNA comprises of three basic components: a pyrimidine or purine base, a sugar (2-deoxyribose), and a phosphate** (eFig. 62.1). The DNA structure exists as a double helix in which one strand of bases is ordered in one direction and the other strand is ordered in the opposite direction. The two strands are held together by hydrogen bonds and are organized via complementary base pairing. The four bases that primarily make up DNA are adenine, cytosine, guanine, and thymine. Uracil is substituted for thymine in ribonucleic acid (RNA). **Hydrogen bonding occurs specifically between the purine adenine (A) and the pyrimidine thymine (T) and between the purine guanine (G) and pyrimidine cytosine (C)** (eFig. 62.2). **In the RNA molecule, adenine base pairs with uracil (U).**

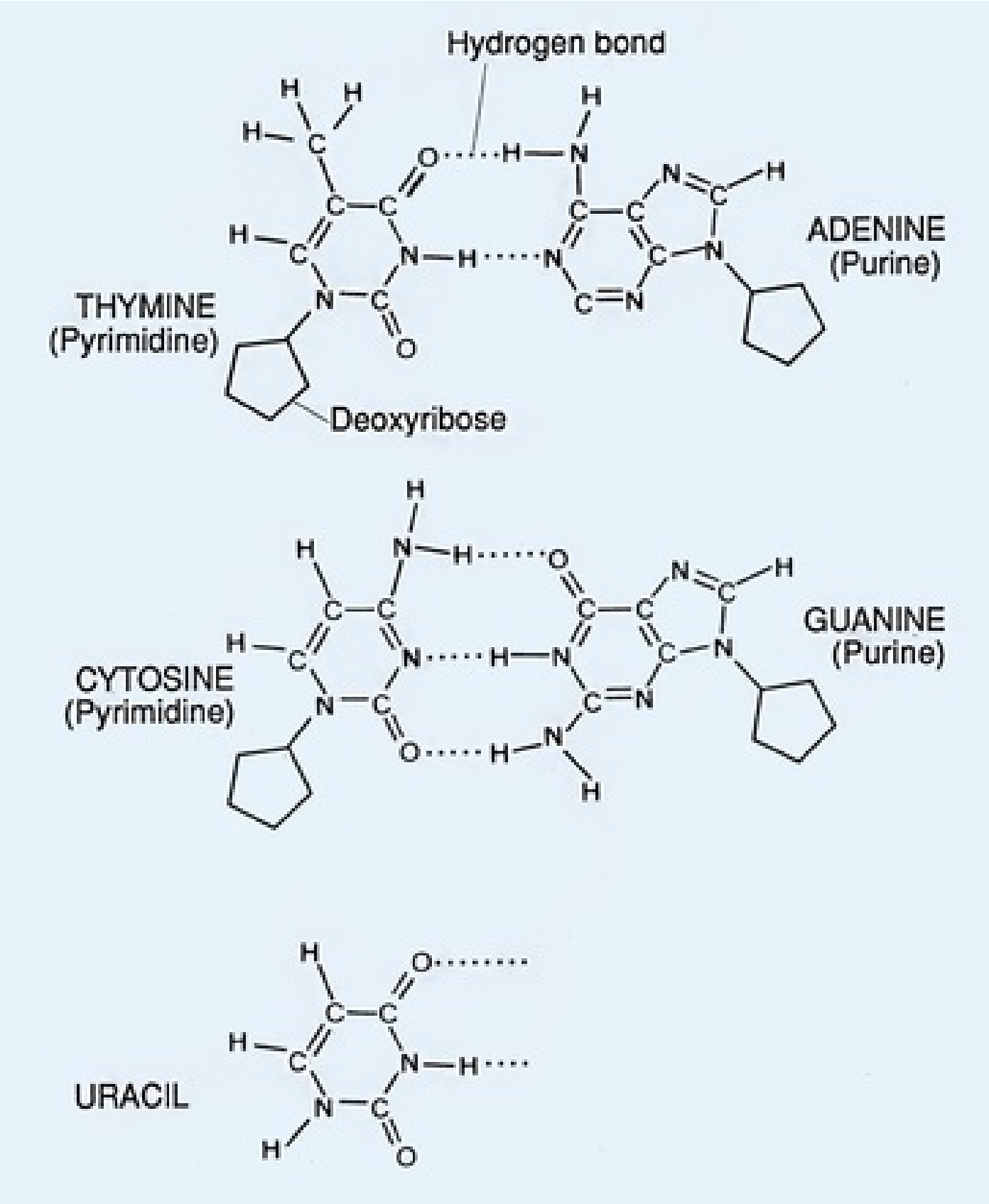
Hydrogen bond
THYMINE
(Pyrimidine)
Deoxyribose
ADENINE
(Purine)
CYTOSINE
(Pyrimidine)
GUANINE
(Purine)
URACIL

EFIG. 62.1 The nucleic acid alphabet consists of four bases: the purines adenine (A) and guanine (G) and the pyrimidines thymine (T) and cytosine (C). Uracil (U) is substituted for thymine in the case of RNA. The combination of a base and a sugar (deoxyribose) is referred to as a *nucleoside.*

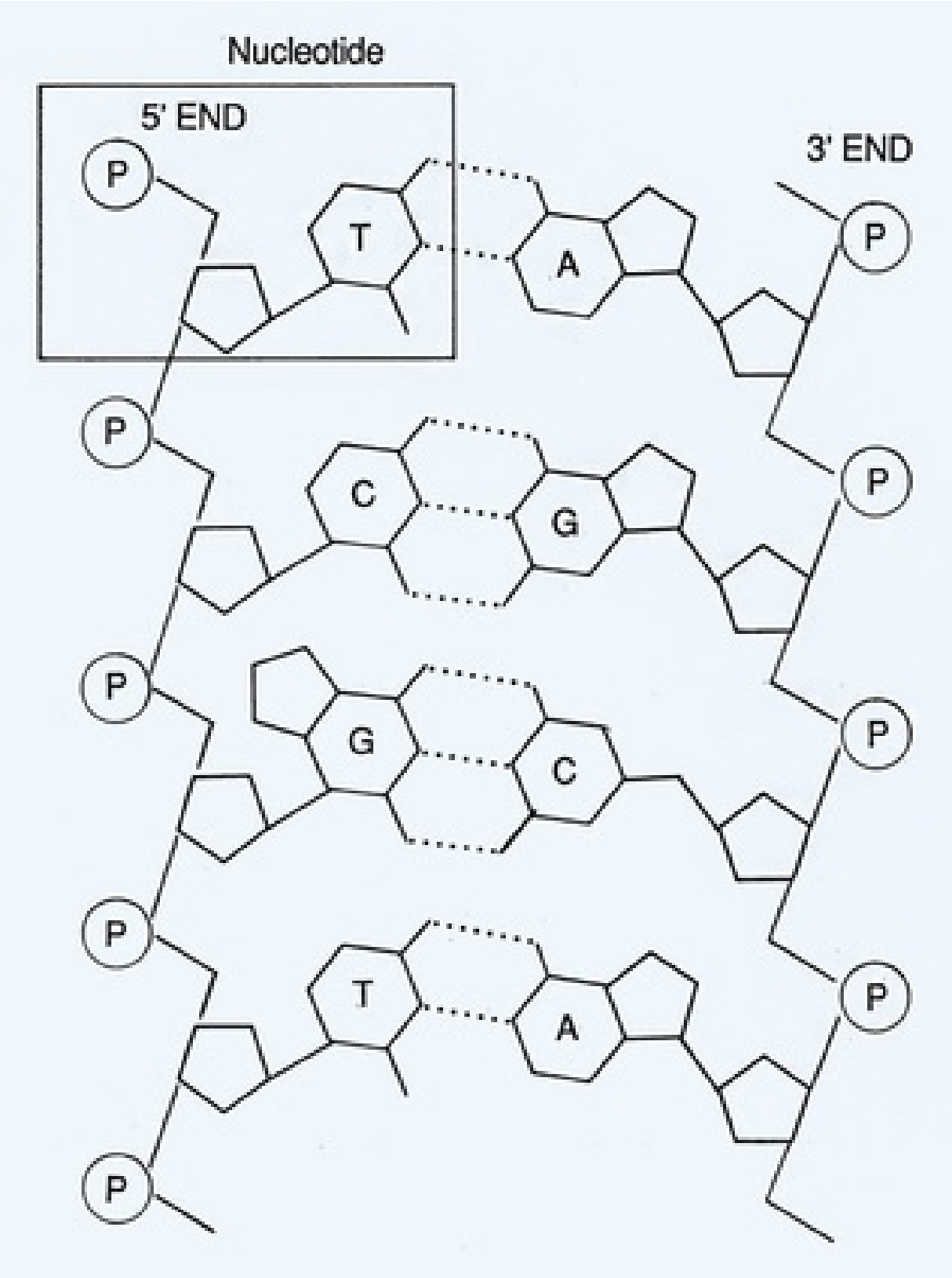

EFIG. 62.2 The combination of a sugar phosphate group and a base constitutes a *nucleotide*. The double helix is made from two polynucleotide chains, each of which consists of a series of 5′- to 3′-sugar phosphate links that form a backbone from which the bases protrude. The double helix maintains a constant width because purines always face pyrimidines in complementary A-T and G-C base pairs, respectively.

During the process of replication, each strand of the DNA double helix acts as a template for generation of the new strand of DNA. The precise ordering of DNA base pairs results in a code that will be processed to ultimately generate proteins responsible for a variety of cellular functions. Each single-stranded DNA molecule has two nonidentical ends referred to as the 5′ (5 prime) and 3′ (3 prime) termini. The 5′ and 3′ numbering refers to the carbon atoms in the deoxyribose sugar. The 5′ carbon of one deoxyribose is linked to the 3′ carbon of another deoxyribose by a phosphate group. Each strand ends with part of the sugar ring exposed based on these connections.

Transcription.

Transcription is the first step in converting information encoded in DNA into protein. During the process of transcription, linear DNA sequence is converted to linear RNA (messenger RNA; mRNA). mRNA is later translated into a linear set of amino acids that form a functional protein (eFig. 62.3). RNA polymerase II is the enzyme that synthesizes mRNA, which is complementary to the DNA template. This primary strand of RNA is called a pre-mRNA and contains protein coding sequences (exons) and intervening noncoding sequences (introns).

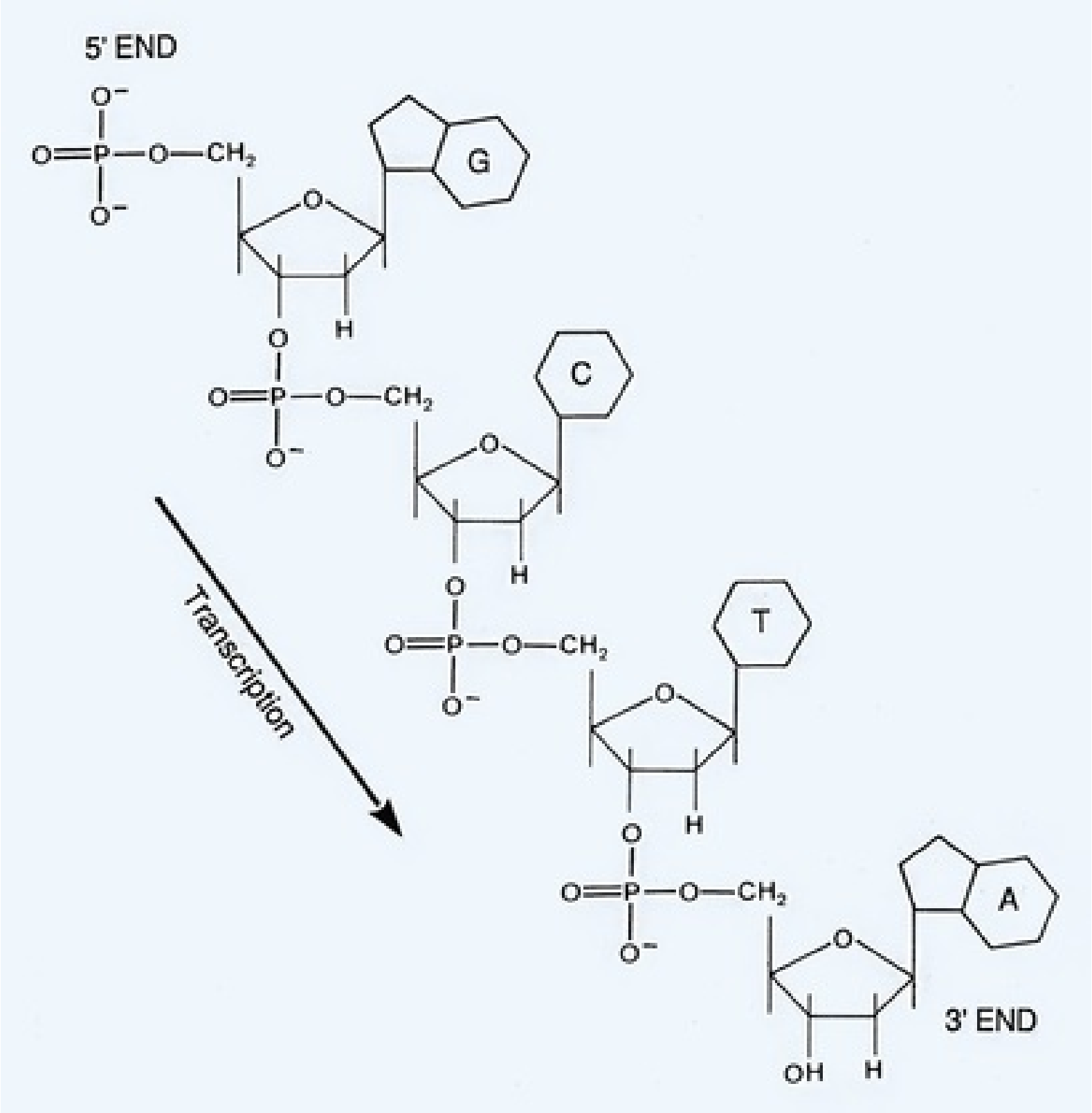

EFIG. 62.3 During transcription, a section of one DNA strand or the other is used as a template for the synthesis of messenger RNA (mRNA). This synthesis always occurs in a 5′ to 3′ direction.

The pre-mRNA molecule undergoes three major modifications: 5′ capping, 3′ polyadenylation, and RNA splicing. These processes occur in the nucleus before the RNA molecule is translated into protein. RNA splicing is a dynamic process that can result in the formation of different peptide sequences having different functional properties. For example, alternatively spliced versions of the androgen receptor (AR) lacking the androgen binding domain have been identified in prostate cancer cells. Such AR splice variants are active in the absence of bound ligand and therefore may contribute to the emergence of prostate cancer refractory to androgen ablative therapies (Dehm et al., 2008; Guo et al., 2009b; Hu et al., 2009). **Alternative RNA splicing is how a single gene can encode for multiple unique proteins by including or excluding certain exons in the mature mRNA transcript** (Sharp, 1987). The sequences contained within introns are not essential for protein synthesis; therefore introns are spliced out and exons are spliced together to generate the functional mRNA.

Protein Synthesis.

Translation of mRNA into protein occurs in the cytoplasm in which ribosomes are located. The mRNA message is translated in segments of three adjacent nucleotides called a codon. Each codon is translated into 1 of 20 amino acids (eFig. 62.4). A total of 64 different codons can be generated from the 4 bases found in RNA. Because of redundancy, more than one codon can encode for a single amino acid (eFig. 62.5). Genetic mutations or alterations can have a profound effect on protein translation of mRNA. For example, a single base insertion or deletion results in a frame-shift mutation and often results in a nonfunctioning protein product. In contrast, a single base substitution may or may not result in a change in the amino acid sequence, which may or may not alter protein function.

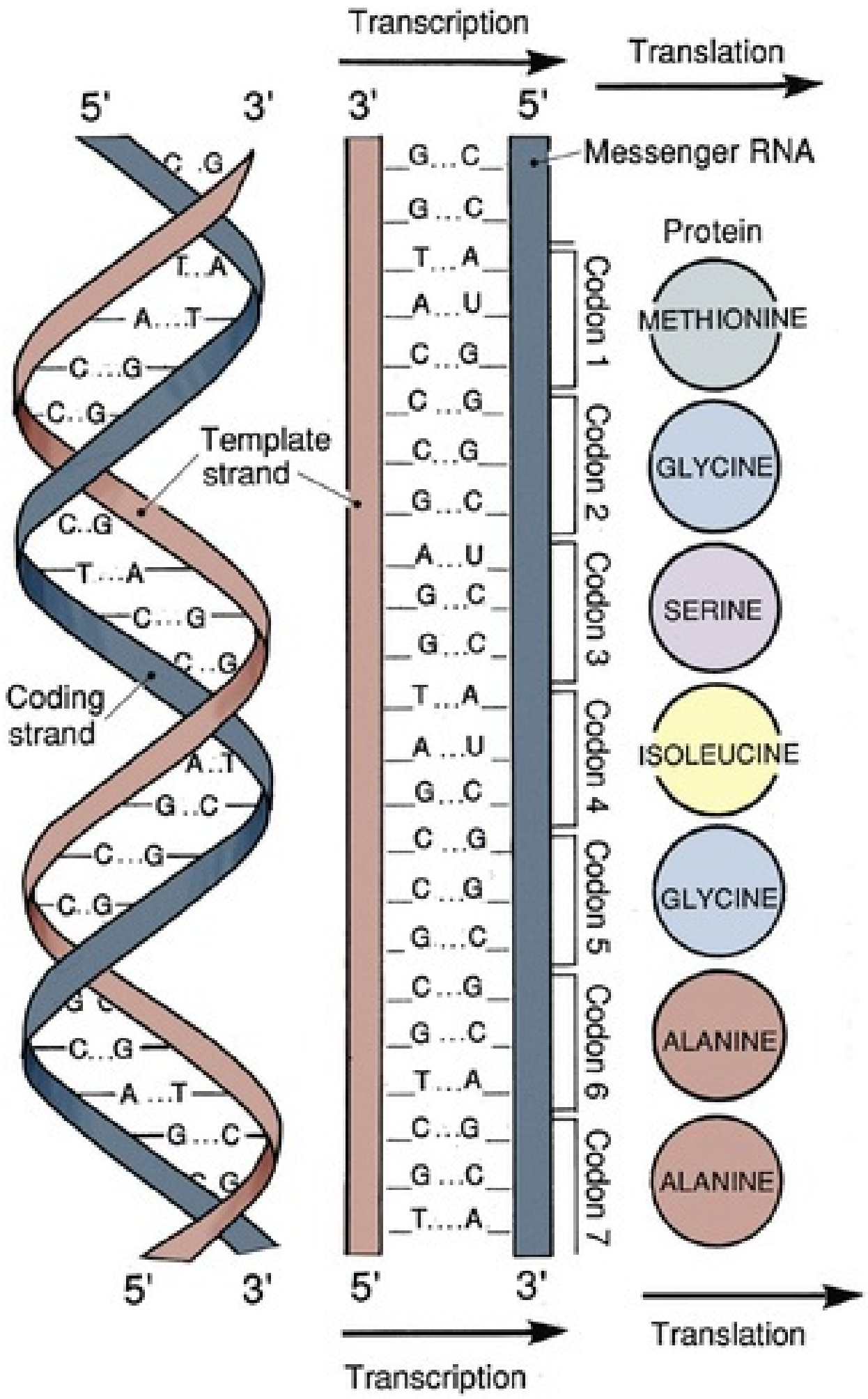
Transcription
Translation
5'
3'
3'
5'
Messenger RNA
Protein
Codon 1
Codon 2
Codon 3
Codon 4
Codon 5
Codon 6
Codon 7
METHIONINE
GLYCINE
SERINE
ISOLEUCINE
GLYCINE
ALANINE
ALANINE
Template strand
Coding strand
5'
3'
5'
3'
Translation
Transcription

EFIG. 62.4 During transcription, the coding strand conveys its message through the template strand to make messenger RNA that is eventually translated into polypeptides by ribosomes. The relationship between DNA sequence and corresponding protein is called the *genetic code*, which is read in nucleotide triplets or codons specifying amino acids or protein translational start and stop signals. The code is degenerate in that multiple codons may code for the same amino acid.

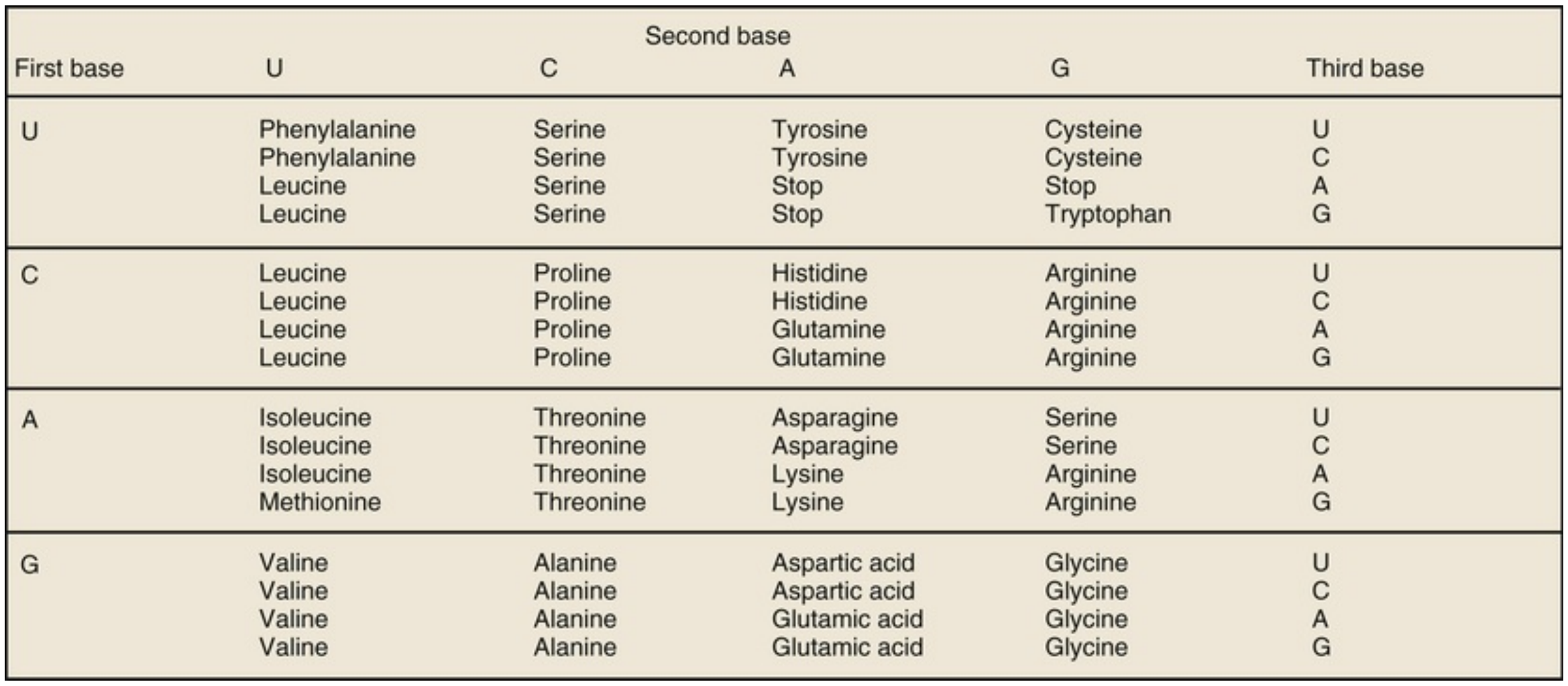

		Second base			
First base	U	C	A	G	Third base
U	Phenylalanine	Serine	Tyrosine	Cysteine	U
	Phenylalanine	Serine	Tyrosine	Cysteine	C
	Leucine	Serine	Stop	Stop	A
	Leucine	Serine	Stop	Tryptophan	G
C	Leucine	Proline	Histidine	Arginine	U
	Leucine	Proline	Histidine	Arginine	C
	Leucine	Proline	Glutamine	Arginine	A
	Leucine	Proline	Glutamine	Arginine	G
A	Isoleucine	Threonine	Asparagine	Serine	U
	Isoleucine	Threonine	Asparagine	Serine	C
	Isoleucine	Threonine	Lysine	Arginine	A
	Methionine	Threonine	Lysine	Arginine	G
G	Valine	Alanine	Aspartic acid	Glycine	U
	Valine	Alanine	Aspartic acid	Glycine	C
	Valine	Alanine	Glutamic acid	Glycine	A
	Valine	Alanine	Glutamic acid	Glycine	G

EFIG. 62.5 RNA codon table. The 20 amino acids found in proteins are listed. All 64 possible 3-letter combinations of the RNA coding units U, C, A, and G are used to encode an amino acid or one of the 3 stop codons. Note: The codon AUG codes for methionine and also serves as an initiation site (the first AUG in the mRNA coding region where translation in protein is initiated).

Two other forms of RNA are important for protein translation: transfer RNA (tRNA) and ribosomal RNA (rRNA). Transfer RNA is a small (75 to 85 bases long) adapter molecule that is covalently linked to a single amino acid at one end and an anticodon in the middle of the RNA chain. The anticodon comprises three nucleotides that are complementary to the mRNA codon representing a particular amino acid. Ribosomal RNA comprises approximately 80% of the RNA within a cell and makes up part of the ribosome, which is the macromolecular structure responsible for protein synthesis.

The three major stages of protein synthesis are initiation, elongation, and termination. Initiation is frequently the rate-limiting step in translation (Merrick, 1992). During the process of initiation, the 40S ribosome binds to mRNA and forms an initiation complex that binds a tRNA with an amino acid attached. All new proteins start with methionine because the initiation codon is AUG. During elongation, amino acids are sequentially added to the peptide chain and the ribosome moves along the mRNA chain similar to beads on a string. Elongation is the most rapid phase of protein synthesis. For any given mRNA transcript, multiple ribosomes can simultaneously move along the chain to generate new polypeptides (Rich et al., 1963). Termination is the last stage of protein synthesis and is signaled by one of three STOP codons (Tate and Brown, 1992).

Chromosomes and Gene Structure.

The long strands of DNA responsible for the genetic makeup of eukaryotic cells (the genome) are organized together with specialized proteins to form chromosomes. Eukaryotic cells contain large linear chromosomes, which are packaged by histone proteins into a condensed structure called *chromatin.* The local chromatin structure greatly affects gene expression and varies depending upon the specific cell type. During interphase, chromatin can be classified into two forms. Euchromatin consists of DNA that is actively being expressed as protein, whereas heterochromatin comprises inactive DNA that may serve a structural support role.

Tumor Suppressor Genes

Tumor suppressor genes negatively regulate cellular growth and play a critical role in the normal processes of the cell cycle. These genes are also important for DNA repair and cell signaling. The absence of tumor suppressor gene function may lead to dysregulation of normal growth control and malignancy. **Loss of function of both copies (alleles) of a tumor suppressor gene is typically required for carcinogenesis. This functional loss can occur via (1) homozygous gene deletion, (2) loss of one allele and mutational inactivation of the second allele, (3) mutational events involving both alleles, or (4) loss of one allele and epigenetic inactivation of the second allele, often involving DNA methylation, which suppresses expression of the gene.** Classic tumor suppressor genes discussed later in this chapter are the retinoblastoma gene *(RB1)* and the *TP53* gene (see Cell Cycle Deregulation).

The “two-hit” hypothesis was first proposed in cases of retinoblastoma, which required mutations in both alleles for disease manifestation (Knudson, 1971). This is due to the fact that if just one allele is inactivated, the remaining allele could produce sufficient amounts of the correct protein to maintain the normal state (Fig. 62.6). However, specific types of mutations in certain genes may not follow this two-hit rule and can function in a dominant negative capacity when mutated, inhibiting the function of the normal protein from the unaltered allele. An example is when two or more of the same protein molecules act together (such as dimerization), as is the case for TP53 (Baker et al., 1990). Alternatively, deletion or mutation of a single allele may result in insufficient protein production (haploinsufficiency), resulting in an increased carcinogen susceptibility as in the case of the *CDKN1B* (p27Kip1) gene (Fero et al., 1998).

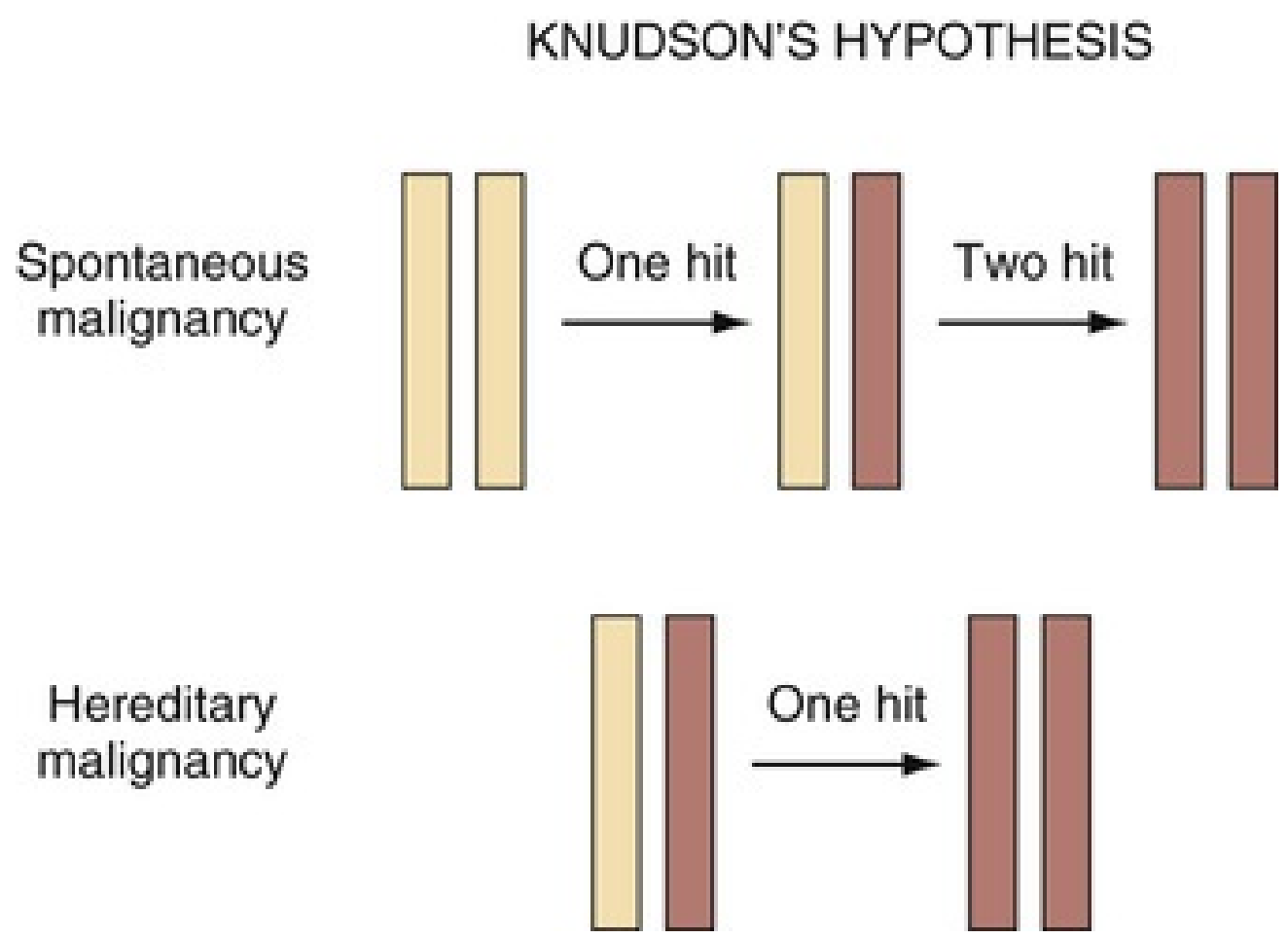

FIG. 62.6 Knudson's hypothesis was that inactivation of the same gene was responsible for sporadic and hereditary malignancies. Patients with sporadic tumors had two normal copies of the gene, and therefore the sporadic tumors required inactivation of both copies of the gene. Patients with hereditary tumor syndromes were born with only one functioning copy of the gene of interest, and therefore the hereditary tumors required inactivation of only one copy.

Oncogenes

Oncogenes are positively associated with cellular proliferation and are the mutated form of normal genes (proto-oncogenes). Two oncogenes that have been found to be overexpressed in a variety of cancers include *MYC* and *MET* (Bottaro et al., 1991; Wong et al., 1986). The proto-oncogene, *MYC*, encodes an early response gene product that is a transcription factor responsible for regulating cellular proliferation. Amplification of *MYC* is a frequent event in prostate cancer, and expression of MYC in human prostate epithelial cells has been associated with immortalization (Gil et al., 2005).

Hepatocyte growth factor acts through a receptor encoded by the proto-oncogene *MET* (Bottaro et al., 1991). Increased expression of *MET* has been reported in renal cell carcinoma and is also more frequent in higher grade cancers (Pisters et al., 1997). Missense mutations of the *MET* proto-oncogene may also result in constitutive activation of the MET protein in tumors associated with hereditary renal cell carcinoma (Schmidt et al., 1997).

Mechanisms by which a proto-oncogene can be converted to an activated oncogene are via (1) mutation of the proto-oncogene resulting in an active form of the gene product, (2) gene amplification, and (3) chromosomal rearrangement. A mutation occurring within the protein coding sequence of a gene can lead to a continuous proliferation signal from the mutant protein. For example, mutation of the proto-oncogene *ERBB*, which encodes for the epidermal growth factor receptor (EGFR), results in expression of a receptor that is constitutively active (Downward et al., 1984). Errors that occur during chromosomal replication may result in gene amplification and aneuploidy. Such an increase in gene copy number often results in an increased number of mRNA transcripts and overproduction of the corresponding protein. For instance, certain types of bladder cancer overexpress *MYC* by this mechanism (Christoph et al., 1999). Immunohistochemical staining of bladder cancer specimens has demonstrated overexpression of MYC protein in more than half of papillary and invasive tumors (Schmitz-Drager et al., 1997). Finally, chromosomal structural rearrangements such as translocation events can result in the formation of an oncogene; for example, genetic rearrangement leading to the fusion of a portion of the *TMPRSS2* gene and the *ERG* oncogene in a large proportion of prostate cancers (Tomlins et al., 2005).

Key Points: Tumor Suppressor Genes and Oncogenes

- Mutations in DNA can lead to changes in protein function or expression that increase the potential for cancer initiation, progression, or metastasis.
- Tumor suppressor genes normally negatively regulate and control cellular growth. Oncogenes normally promote cell growth.
- Loss of tumor suppressor gene function can occur primarily by (1) homozygous deletion, (2) loss of one allele and mutational inactivation of the second allele, (3) mutational events involving both alleles, and (4) loss of one allele and epigenetic inactivation of the second allele.
- Certain tumor suppressor genes do not follow the “two-hit” hypothesis and may be inactivated via dominant negative mutations or haploinsufficiency.
- Proto-oncogenes can be converted to oncogenes by (1) mutation of the proto-oncogene resulting in an activated form of the gene, (2) gene amplification, and (3) chromosomal rearrangement.

Cell Cycle Deregulation

Apart from development and growth, **cell division is tightly regulated so that the production of new cells precisely balances those lost during normal wear and tear, thus maintaining tissue and organ homeostasis.** Unlike single-celled eukaryotes, individual human cells are not allowed to make autonomous decisions regarding their proliferation. Rather, **a complex series of external growth inhibitory and growth stimulatory signals are integrated by the cell, resulting in either cell division or quiescence. In cancer, activated oncogenes and inactivated tumor suppressor genes alter the balance between these signals so that net proliferation is continuously favored.**

Quiescent cells are considered to be out of cycle in a reversible state known as “$G_{0,}$” which is the default state for most cells. When signaled to proliferate, cells activate their **cell cycle** machinery, initiating **an orderly, unidirectional, series of events resulting in (a) duplication of the cell's genome during the DNA synthetic phase (S phase), followed by (b) segregation of each genomic complement to each of two resulting daughter cells, a process referred to as mitosis (M phase)**. These two critical phases are **separated by two so-called “Gap” phases (G_1 and G_2).** Throughout the cell cycle, which takes approximately 24 hours to complete, each step is dependent upon completion of the prior step before progressing further (Hartwell et al., 1974). In addition, **checkpoint mechanisms closely monitor DNA integrity as well as certain critical cell cycle events. If problems are detected (e.g., DNA damage), the cell cycle will be paused to allow for repair** (Hartwell and Weinert, 1989). **If repair is not possible, normal cells often then commit cellular suicide through an active process termed *apoptosis.* Many oncogenes and tumor suppressors exert their effects by interfering with cell cycle checkpoints and apoptotic pathways, allowing cancer cells to divide continuously and accumulate. Loss of ability to respond appropriately to damaged DNA is particularly dangerous because it fosters genetic instability, a key attribute of cancer cells. Loss of DNA damage checkpoint controls results in an increased mutation rate, accelerating the mutation of cancer-associated genes, thus contributing to carcinogenesis and disease progression** (Bartek et al., 1999).

Cyclin-Dependent Kinases and Cyclins

The temporal sequencing of events occurring throughout the cell cycle is affected by a highly conserved set of serine and threonine-specific protein kinases termed cyclin-dependent kinases, or CDKs (Meyerson et al., 1992). CDKs phosphorylate specific protein substrates involved in executing the phase-specific activities of the cell cycle. As their name implies, **the enzymatic activities of the CDKs depend on a class of regulatory proteins called cyclins,** of which there are 12 known in mammals (Morgan, 1995). The abundance of specific cyclins within the cell is highly dynamic and tightly linked to specific phases of the cell cycle, during which they physically associate with and activate the CDK's enzymatic activity (De Bondt et al., 1993; Jeffrey et al., 1995; eFig. 62.7). **Thus, depending largely on the transitory presence of particular cyclins, which are rate limiting, specific cyclin/CDK complexes form and act during restricted periods within the cell cycle to initiate and regulate the events required during these precise phases, after which each cyclin is typically degraded via poly-ubiquitination of specific lysine residues, which serve as the signal for proteosomal degradation, thereby inactivating its CDK partner** (Sherr, 1993; van den Heuvel and Harlow, 1993). CDKs are also regulated by specific sites of phosphorylation on the CDKs (Lundgren et al., 1991). Finally, a group of proteins termed cyclin-dependent kinase inhibitors (CDKIs) can bind to and directly inhibit CDK activity or their activating phosphorylations (Peter and Herskowitz, 1994; Sherr and Roberts, 1995). Thus, although cyclins play major regulatory roles in orchestrating CDK activities, **CDKs are subject to additional levels of control,** and these processes are also commonly altered in cancer cells.

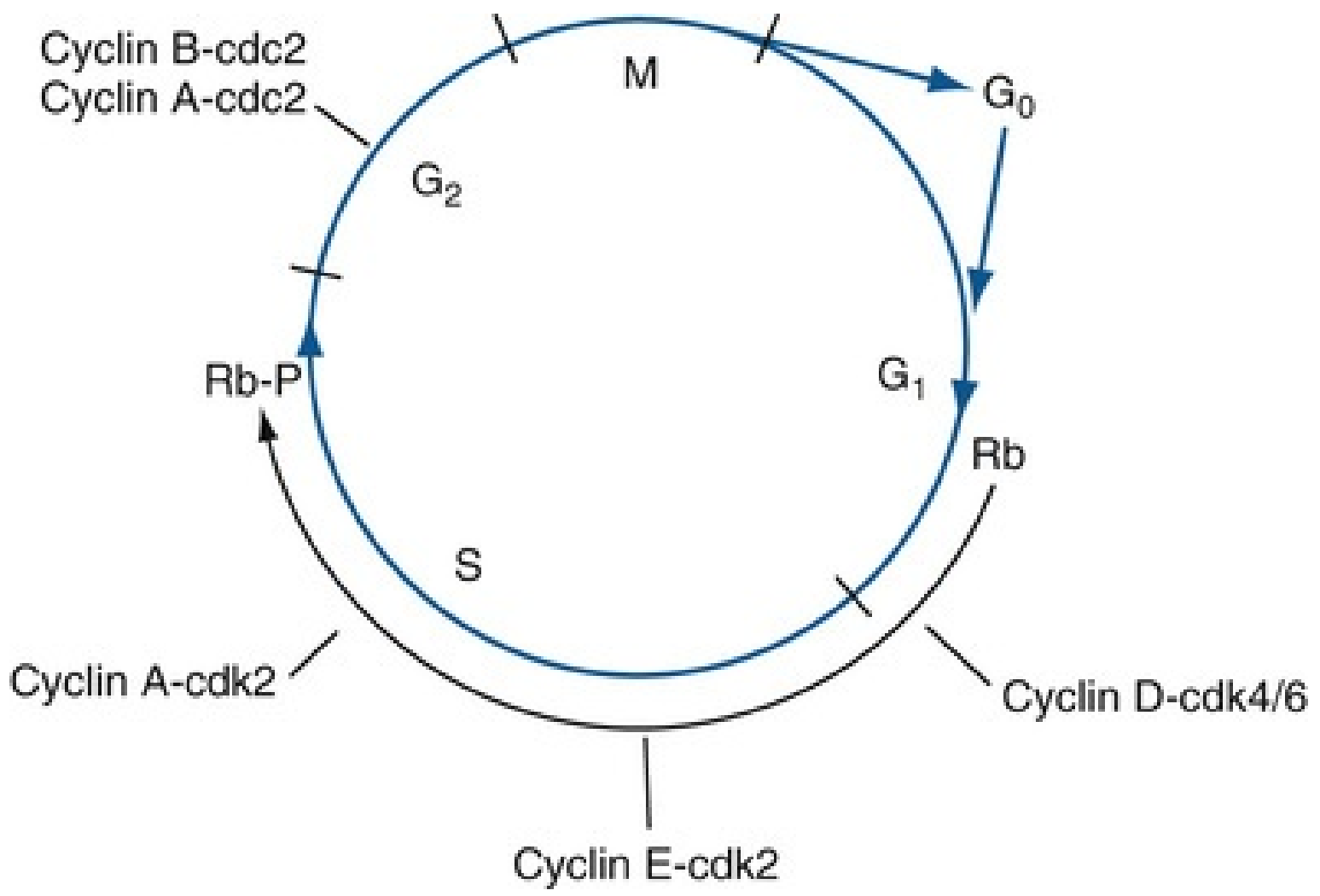

EFIG. 62.7 A schematic drawing of the cell cycle. Sequential activation of cyclin-CDK complexes is critical to the orderly progression of the cell's replication.

Cell Cycle Entry

Under normal conditions a cell is induced to proliferate when the balance between growth-stimulatory signals received from its environment (e.g., soluble growth factors in the extracellular space) outweighs growth inhibitory signals (e.g. TGF-β). If a cell in the G_0 state is stimulated to proliferate, it will proceed into **G_1, the first gap phase of the active cell cycle, during which sufficient macromolecules and organelles are synthesized to support cell replication.** Growth stimulatory signaling pathways (e.g., the Ras/Raf/MEK pathway) promote expression of the main G_1 cyclins; cyclin D and cyclin E, leading to their association with CDK4 and CDK6 kinases, thus activating these CDKs (Baldin et al., 1993; Sherr et al., 1994; Winston and Pledger, 1993). **Throughout early and mid-G_1, progress through the cell cycle remains sensitive to external signals, largely because persistent mitogenic stimulation is required for sustained expression of cyclin D** (Matsushime et al., 1991).

Retinoblastoma Protein and the Restriction Point

Because of cyclin D's dependence on the continued presence of mitogens and other favorable conditions (e.g., attachment to the substratum), the cell cycle remains responsive to external signals throughout early and mid-G_1 (Guadagno et al., 1993). However, **if the decision is made in late G_1 to continue on with cell division, then the subsequent phases of the cell cycle (S, G_2, and M) proceed in an autonomous fashion. This key point in time in late G_1, after which the cell cycle becomes insensitive to extracellular signals, is termed the restriction point (R-point)** and is highly regulated (Pardee, 1974).

The retinoblastoma susceptibility protein, RB1 (pRb), plays a central role in controlling the R-point. The inappropriate, continuous proliferation of cancer cells is largely because of a loss of R-point control, typically the result of functional inactivation of the Rb pathway (Pardee, 1989). RB1 is a substrate of G_1 cyclin/CDK complexes, and its activity is critically dependent on its phosphorylation state (Buchkovich et al., 1989; Mittnacht et al., 1994; Sherr, 1994). **In nondividing cells, RB1 is unphosphorylated, and in this state, RB1 physically associates with members of the E2F family of transcription factors, inhibiting their transcriptional activation of target genes required for cell cycle progression into S phase** (Lai et al., 1999b). In addition, RB1 recruits proteins such as histone deacetylases (HDACs) to E2F target genes promoting the formation of repressive heterochromatin at these sites. RB1 may play a role in maintaining this repressive chromatin state, further suppressing E2F target genes (Gonzalo and Blasco, 2005; Lai et al., 1999a). However, **during G_1, BB1 becomes progressively phosphorylated, on eight different sites, by cyclin D-CDK4/6 and cyclin E-CDK2 complexes, creating hyperphosphorylated RB1, causing its dissociation from E2F** (eFig. 62.8). The liberated E2F proteins, of which there are at least seven, heterodimerize with one of three DP subunits (DP1-3) and activate transcription of target genes, including essential S-phase genes (e.g., DNA polymerase and S-phase cyclins) (Dyson, 1998). Once the cell cycle is complete, RB1 returns to its unphosphorylated state, once more suppressing E2F until cell division is once again signaled (Ludlow et al., 1993).

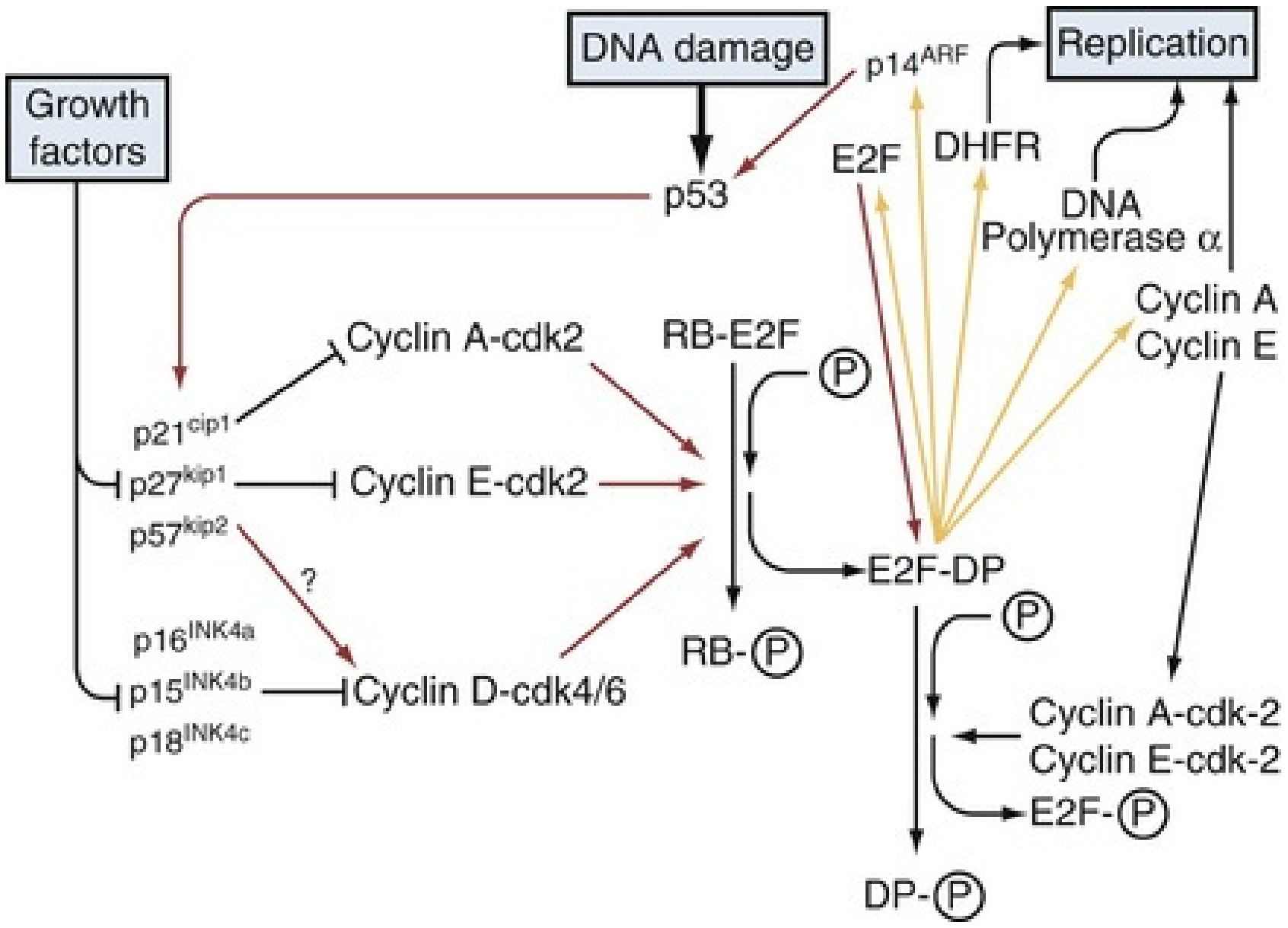
DNA damage
Replication
Growth factors
p14ARF
E2F
DHFR
p53
DNA Polymerase α
Cyclin A
Cyclin E
Cyclin A-cdk2
RB-E2F
P
p21cip1
p27kip1
Cyclin E-cdk2
p57kip2
E2F-DP
?
P
p16INK4a
RB-P
p15INK4b
Cyclin D-cdk4/6
p18INK4c
Cyclin A-cdk-2
Cyclin E-cdk-2
E2F-P
DP-P

EFIG. 62.8 Schematic representation of the stimulatory and inhibitory cascade at the G1S boundary. This finely tuned system takes advantage of multiple negative *(blunt arrows)* and positive *(arrows)* feedback loops.

There are many ways, direct and indirect, in which cancer cells inactivate RB1's function, including mutation or deletion of the *RB1* gene, silencing of the *RB1* gene via promoter DNA hypermethylation, overexpression of proteins such as cyclin D and E2F (in some cases because of increased copy number of the gene; gene amplification), as well as mutational inactivation, deletion, or promoter methylation of genes encoding specific CDK inhibitors. **It has been suggested that RB1 or components of the regulatory pathway it is associated with (e.g., cyclins D and E, CDK4, E2F, p16, and p27) are likely to be altered in almost all human cancers** (Hanahan and Weinberg, 2000; Sherr, 1996).

Cell Cycle Progression Through S Phase

During S phase a normal cell replicates its diploid genome once and only once. S-phase genes are activated as a result of cyclin A replacing cyclin E to form cyclin A-CDK2 complexes in early S phase, and later by cyclin A associating with CDK1 forming cyclin A-CDK1 complexes in late S phase (Girard et al., 1991; Pagano et al., 1992). Upon completion of S phase, cyclin A-CDK2 phosphorylates E2F-DP heterodimers, thus terminating E2F's activity (Dynlacht et al., 1994). At the end of S phase, cyclin B replaces cyclin A, forming cyclin B-CDK1 complexes, which move the cell into the second gap phase of the cell cycle, G_2, and on into mitosis (Pines and Hunter, 1989).

Mitosis

During mitosis, the two genomic complements present after S phase are precisely partitioned into what will become two separate daughter cells. The proper functioning of many of the proteins participating in mitosis depends upon phosphorylation of these substrates by cyclin B-CDK1. Early in mitosis, the chromosomes condense through the activity of condensin proteins. Each chromosome is tightly associated along its length with its corresponding S-phase copy, termed the sister chromatid, via cohesin proteins. During this time also, two structures called *centrosomes,* which act as microtubule organizers, migrate to opposite poles of the nucleus and assemble spindle microtubules that radiate through the nucleus and attach to the condensed chromosomes at constriction sites termed *centromeres,* via complex protein matrices termed kinetochores. The nuclear envelope and supporting intermediate filament proteins, the nuclear lamins, dissociate in response to phosphorylation by cyclin B-CDK1. Balanced tension along the spindle microtubules causes all of the chromosomes to align along the cell midline, creating a hallmark stage of mitosis termed *metaphase*. Once all metaphase chromosomes are properly aligned, microtubule-associated motors on the spindle microtubules to pull each diploid chromosome complement apart toward the centrosomes at opposite poles, a key mitotic event termed anaphase. Last, two new nuclei are assembled around the two separated chromosome complements, which decondense, and two separate daughter cells are formed in a cell-splitting process termed cytokinesis.

Mitotic abnormalities are commonly seen in human cancers and were noted by David Hanseman in the late 1800s, soon after the discovery of chromosomes, and in 1914 the eminent German biologist Theodor Boveri proposed that such abnormalities may underlie tumor formation (Harris, 2008).

G_1/S Checkpoint

The expression of cyclin D during G_1 is dependent upon the integration of proliferative and antiproliferative signals received from the extracellular environment (e.g., mitogens, nutrient and oxygen availability), thus the cell will not fully commit to division unless it receives a sustained signal to do so and conditions remain favorable (Matsushime et al., 1991).

A critical contributor to the G_1/S checkpoint is the TP53 tumor-suppressor protein. TP53 is a pleiotropic transcription factor that receives signals from multiple types of cell stress and damage and, in response, activates genes that function variously in cell cycle arrest, DNA damage repair, and apoptosis (programmed cell death), thus highlighting the link between cell cycle arrest and DNA repair (Elledge, 1996; eFig. 62.9). DNA damage has obvious relevance for the G_1/S checkpoint because a normal cell will not wish to proceed to S phase if the genomic template DNA is damaged; thus **intact checkpoint controls represent important antitumor mechanisms acting to limit the proliferation of cells bearing potentially oncogenic mutations.** During the cellular response to DNA damage, specific kinases are activated that phosphorylate the **TP53** protein, thereby protecting it from hdm2 ubiquitin ligase-mediated degradation (Momand et al., 1992). The accumulated **TP53** protein undergoes further modifications, which activate it and facilitate its translocation to the nucleus, where it induces various checkpoint and DNA repair proteins, including CDKN1A (p21) and 14-3-3-sigma, which cause cell cycle arrest by inactivating or sequestering G_1 CDK complexes (Giaccia and Kastan, 1998). **If the cell cannot arrest growth and/or repair the DNA damage, TP53 often induces apoptosis** (Levine, 1997).

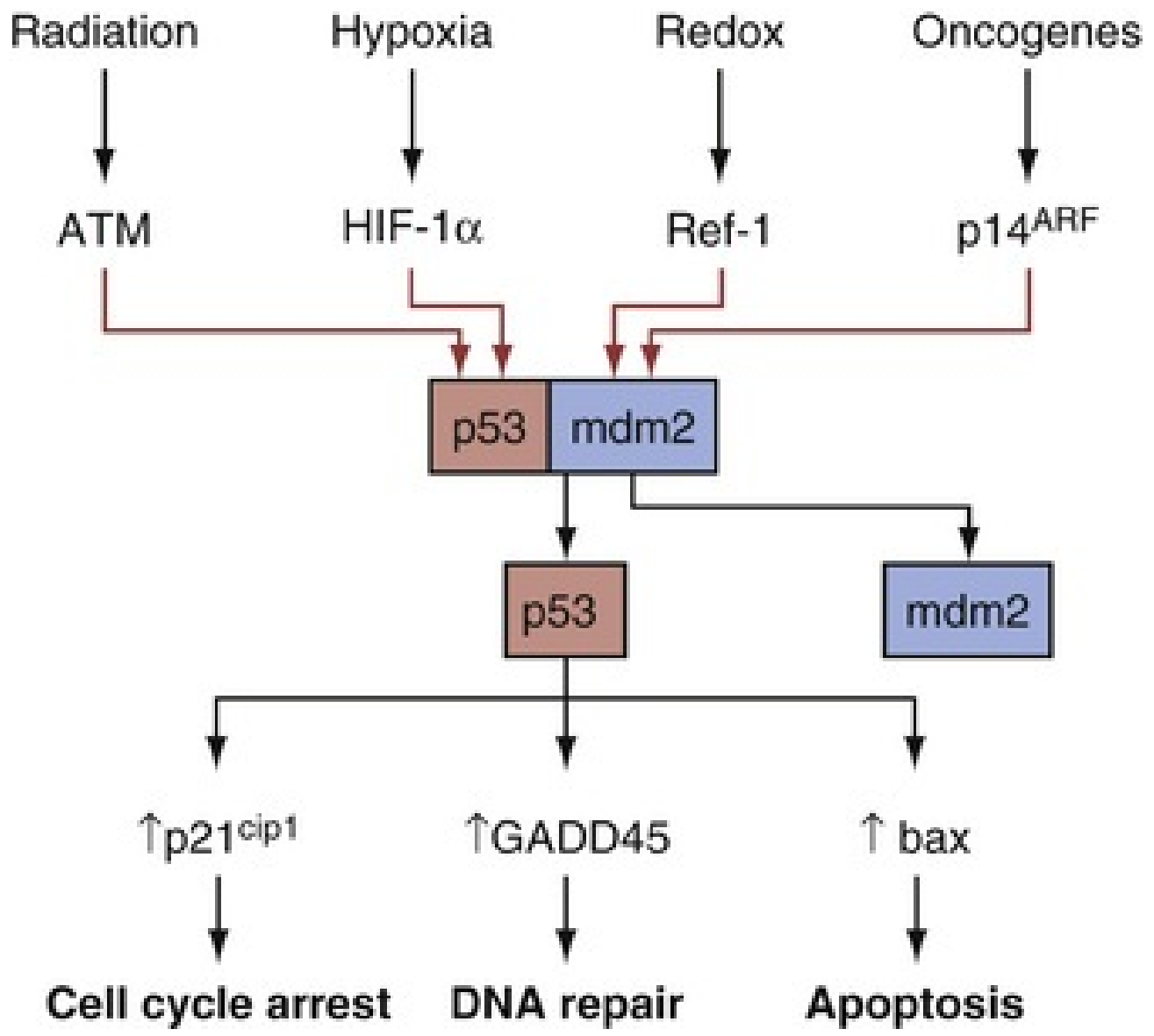

EFIG. 62.9 *TP53* plays a central role in the cell's response to extracellular stimuli. Radiation, hypoxia, redox reactions, and oncogenes can all increase *TP53* activity through different mechanisms. In response, the cell

initially stops dividing and then attempts to repair the DNA damage. If it fails to repair the DNA, it undergoes apoptosis (programmed cell death). These functions are mediated through transcriptional activation of a variety of genes, some examples of which are indicated in the figure.

S-Phase Arrest

Whereas S phase is not considered to have a checkpoint, such as those recognized during G_1/S and G_2/M, the cell does maintain the ability to arrest the cell cycle and repair DNA damage through two mechanisms, both mediated through the ATM kinase. First, in response to genotoxic insults, Cdc25A is targeted for destruction through an ATM-dependent cascade, resulting in a rapid decrease in Cdc25A levels. Because Cdc25 family members normally activate CDK2, the loss of Cdc25A maintains CDK2 in its inactive form; thus this cascade pauses the cell in S phase, ostensibly to allow time for DNA repair (Bartek et al., 2004).

The second mechanism mediated by ATM in response to DNA damage is phosphorylation of DNA repair enzymes (see DNA Repair). These two parallel pathways further highlight the interaction between DNA repair and checkpoint control. It is not surprising that such S-phase control has been documented in response to DNA-damaging agents because it is the last opportunity to repair DNA damage before replication (Falck et al., 2002; Pichierri and Rosselli, 2004).

G_2/M Checkpoint

The G_2/M checkpoint is a second major point of control during cell division. Unlike the G_1/S checkpoint, which responds to a variety of extracellular signals in addition to DNA damage, **the G_2/M checkpoint appears to be similar to S-phase arrest and responds only to DNA damage. It therefore serves as an important monitor of DNA replication errors** (Bartek et al., 1999; Weinert, 1997).

DNA damage secondary to radiation is believed to induce G_2/M arrest through ATM. ATM activates CHEK1 and CHEK2 kinases in response to DNA damage, and these in turn inactivate the Cdc25 family proteins through phosphorylation, which causes 14-3-3 sigma to bind and sequester it (Hermeking et al., 1997; Sanchez et al., 1997).

It has become apparent that, at least in part, G_2/M arrest may also be mediated by TP53 and the BRCA1 tumor suppressor (Bunz et al., 1998; Xu et al., 2001). Transcriptional upregulation of cell cycle inhibitors (e.g., p21, GADD45, and 14-3-3 sigma) by TP53 helps maintain the cell in G_2/M arrest (Nyberg et al., 2002). As a result, **it appears that TP53 mediates G_1/S and G_2/M arrest, consistent with its critical role in preserving genomic integrity.**

Mitotic Arrest: The Spindle Assembly Checkpoint

As detailed earlier, **one of the key events in mitosis is the proper attachment of each and every chromosome to the spindle microtubule apparatus**. It is critical that all chromosomes are attached before proceeding into anaphase, where the chromosome complements are pulled apart. Failure of one or more chromosomes to attach leads to chromosome nondisjunction, wherein one daughter cell receives an extra copy of the chromosome, becoming trisomic for that chromosome, while the other receives one copy too few, becoming monosomic. Both cases are abnormal and fall under the category of aneuploidy, a nearly universal characteristic of human solid tumors. Gene expression patterns often correlate with gene copy number; thus it has been proposed that aneuploidy may be a major contributor to cancer initiation and progression (Duesberg, 2005; Duesberg et al., 1999). **The mitotic checkpoint (spindle assembly checkpoint) apparatus monitors chromosome attachment and receives a “not ready” signal from any unattached chromosomes, preventing activation of the antigen-presenting cell (APC) complex, thus blocking the transition from metaphase to anaphase until all chromosomes are attached** (Chan et al., 1999; Holland and Cleveland, 2009). Although mutations have been identified in specific mitotic checkpoint genes, such as *hBUBR1*, in some cancers (Cahill et al., 1998), subsequent studies have shown these to be relatively rare (Wang et al., 2008b). Additional studies have found aberrant expression levels of mitotic checkpoint proteins, which may better explain the mitotic instability frequently observed in cancer cells (Yuan et al., 2006), including reports of reduced levels of the checkpoint proteins MAD1 and MAD2 in renal cell carcinoma (Pinto et al., 2007) and reduced MAD2 in testicular cancer (Fung et al., 2007).

Retinoblastoma Protein and Genitourinary Malignancies

The retinoblastoma susceptibility protein, RB1 (formerly pRb), plays a central role in controlling the R-point, a decision point in late G_1 beyond which an irreversible commitment to divide is made. The inappropriate, continuous proliferation of cancer cells is largely due to a loss of R-point control, typically the result of functional inactivation of the RB1 pathway (Pardee, 1989). *RB1* gene mutations have been identified in approximately one-third of bladder tumors (Horowitz et al., 1990), and reintroduction of the *RB1* gene into bladder carcinoma cell lines has been found to inhibit cell growth in vitro and tumor formation in vivo (Takahashi et al., 1991). Altered expression of RB1 protein has been also identified in approximately one-third of bladder carcinomas (Logothetis et al., 1992), and altered expression has been correlated with higher stage disease and decreased patient survival (Cordon-Cardo et al., 1992).

Prostate carcinoma has not been as strongly linked to *RB1*. Although *RB1* mutations are present in 10% to 30% of prostate cancer specimens (Bookstein et al., 1990; Kubota et al., 1995), decreased expression is not consistently identified with high-risk patients or recurrent disease (Kibel and Isaacs, 2000). In other studies, no correlation was found between expression and grade or stage (Ittmann and Wieczorek, 1996), but Theodorescu et al. (1997) reported that low RB1 protein expression correlated with decreased disease-specific survival in univariate and multivariate analysis.

Renal carcinoma has not been clearly linked to *RB1*. *RB1* is rarely inactivated in renal carcinoma cell lines or tumors (Ishikawa et al., 1991), and analysis of clinical specimens has not demonstrated a clear association between prognosis and *RB1* expression (Lipponen et al., 1995).

Cyclin-Dependent Kinase Inhibitors

The temporal sequencing of events occurring throughout the cell cycle is affected by a highly conserved set of protein kinases termed cyclin-dependent kinases, or CDKs (Meyerson et al., 1992). CDKs phosphorylate specific protein substrates involved in executing the phase-specific activities of the cell cycle. The enzymatic activities of the CDKs are dependent upon a class of regulatory proteins called cyclins, so named because their abundances are tightly linked to specific phases of the cell cycle, during which they physically associate with and activate the CDK enzymatic activity (De Bondt et al., 1993; Jeffrey et al., 1995) (see eFig. 62.7). Another group of proteins termed *cyclin-dependent kinase inhibitors (CDKIs)* bind to and directly inhibit CDK activity or their activating phosphorylations (Peter and Herskowitz, 1994; Sherr and Roberts, 1995). Thus, although cyclins play major regulatory roles in orchestrating CDK activities, CDKs are subject to additional levels of control, and these processes are commonly altered in cancer cells. CDKIs belong to either of two different classes, the Cip/Kip family, which includes the proteins CDKN1A (p21), CDKN1B (p27) and CDKN1C (p57); and the INK4 (*in*hibit CD*K4*) family, which includes INK4B (p15), INK4A (p16), INK4C (p18), and INK4D (p19). The Cip/Kip proteins are broadly acting, able to inhibit multiple cyclin-CDK complexes throughout the cell cycle (Clurman and Porter, 1998), whereas the INK4 group are more restricted in their activities, inhibiting CDK4 and CDK6-containing complexes; thus they are critical regulators of the R-point and the G_1/S transition because they can block RB1 phosphorylation (see eFig. 62.8). **Increased expression and accumulation of CDKIs is used by the cell as a means of halting the cell cycle in response to various stresses.** For example, p21 expression is increased in response to DNA damage (el-Deiry et al., 1993). CDKIs function in nonstress situations as well. For example, p27 levels are high in quiescent cells, and all of the Cip/Kip proteins appear to play some role in maintenance of the G_0 state in terminally differentiated cells (Halevy et al., 1995; Matsuoka et al., 1995; Parker et al., 1995).

Among the INK4 family, inactivating mutations and abnormal gene promoter methylation of p15 and p16 have been strongly implicated in cancer in general (Hirama and Koeffler, 1995; Kamb et al., 1994) and specifically in genitourinary malignancies (Cairns et al., 1995; Herman et al., 1995). The best studied of the INK4 proteins is p16. The p16 protein binds to cyclin-dependent kinases 4 and 6 and inhibits their interaction with cyclin D1 that normally mediates passage through G_1 phase of the cell cycle by phosphorylation of the RB1 protein (Serrano et al., 1993). The *INK4A* gene encoding p16 was initially found to be mutated and deleted in a wide variety of tumors including bladder and kidney (Kamb et al., 1994). Subsequent analysis has demonstrated that **inactivation often occurs by DNA hypermethylation at the *INK4A* promoter**—an alternative, epigenetic method of gene inactivation (Merlo et al., 1995).

The *INK4A* gene is frequently inactivated by deletion in bladder carcinomas (Cairns et al., 1995; Williamson et al., 1995). Importantly, despite its proximity, the *INK4B* gene was ruled out as the primary tumor suppressor at this site because it was not within the deletion interval. A study by Orlow et al. (1999) found that deletion and methylation of the *p16* gene occurred frequently in superficial bladder carcinoma, but only those deletions that affect both the *p16* and *p14* genes, which are located at the same locus, correlated with a decrease in disease-free survival. In contrast to bladder cancer, mutational inactivation of INK4 family members appears to be rare in prostate carcinoma. However, inactivation of *INK4A* by promoter hypermethylation has been implicated in prostate cancer. Herman et al. (1995, 1996) demonstrated *INK4A* hypermethylation in 60% of prostate cancer cell lines, whereas *INK4B* was rarely inactivated. However, these results are tempered by the fact that silencing of the *INK4A* gene by promoter hypermethylation often occurs during the establishment of cell lines in vitro.

Surprisingly, despite the critical role that Cip/Kip family members play in G1S cell cycle arrest, they are rarely mutated in a wide variety of malignancies, including genitourinary tumors, and there are only rare reports of promoter hypermethylation (Kawamata et al., 1995; Shiohara et al., 1994). However, expression of this family of CDK inhibitors plays an important role in cancer in general (Catzavelos et al., 1997; Loda et al., 1997; Yatabe et al., 1998) and in genitourinary carcinomas in particular. Stein et al. (1998) found increased expression of *CDKN1A* (p21) in 64% of bladder tumors and found that increased expression was associated with a decreased probability of tumor recurrence and improved patient survival. Decreased *CDKN1B* (p27) expression has also been linked to increasing tumor grade, pathologic stage, and poor survival in bladder carcinoma (Del Pizzo et al., 1999).

The expression of *CDKN1A* in prostate cancer has not demonstrated a clear correlation with advanced disease or poor outcome (Kibel and Isaacs, 2000). However, specific genetic polymorphisms in *CDKN1A* and *CDKN1B* have been associated with advanced disease (Kibel et al., 2003), and altered expression of *CDKN1B* has been implicated in aggressive disease in multiple studies. Cordon-Cardo et al. (1998) examined radical prostatectomy specimens and found that absent or low CDKN1B production by immunohistochemistry was an independent risk factor for decreased disease-free survival by multivariate analysis. Cote et al. (1998) found that decreased CDKN1B nuclear staining correlated with not only decreased disease-free survival but also overall survival in radical prostatectomy patients, whereas Freedland et al. (2003) found that CDKN1B-positive cells in the prostate needle biopsy specimen had a 2.5-fold increased risk of biochemical recurrence (PSA relapse).

The relevance of *CDKN1B* to prostate cancer is also supported by studies of mouse models. For example, mice deficient in *CDKN1B* develop prostate hyperplasia, confirming the potential importance of this gene in prostate tissue homeostasis (Cordon-Cardo et al., 1998). More excitingly, studies have shown that mice deficient in both CDKN1B and PTEN have a high incidence of prostate cancer (Di Cristofano et al., 2001).

TP53 Tumor Suppressor

The TP53 tumor suppressor protein is a key player in cell cycle checkpoints, responding to DNA damage by signaling cell cycle arrest and repair of the damage (see eFig. 62.9). If the DNA damage cannot be repaired, TP53 may trigger cell death (apoptosis). *TP53* is the most commonly mutated gene in cancer and plays a prominent role in GU malignancies. *TP53* was also recently found to be the most commonly mutated gene in the mutational landscape of metastatic cancer across a screen of 62 principal tumor types (Zehir et al., 2017). Alterations to *TP53* in regard to genitourinary cancers is discussed in detail in the following sections.

Key Points: Cell Cycle Deregulation

- The cell cycle consists of an ordered, unidirectional series of events, the main goal of which is to replicate the cell's genome and partition one copy into each of two resulting daughter cells.
- The cell cycle is divided up into four phases; G1, S, G2, and M. The transition from G1 into S is critically dependent on phosphorylation of the RB1 tumor suppressor protein. Mutations in *RB1* are common in urologic malignancies.
- Phase-specific phosphorylation of substrate proteins by cyclin-dependent kinases (CDKs) orchestrates progression through the cycle.
- The activities of CDKs depend upon their association with specific cyclin proteins. Cyclins accumulate and are rapidly degraded in a phase-specific manner, thus ensuring the proper sequencing and irreversibility of key events throughout the cell cycle.

- Primary points of cell cycle control are the G1S and G2M checkpoints. Checkpoints employ cyclin-dependent kinase inhibitor proteins (CDKIs) to pause the cell cycle in response to a variety of signals, including DNA damage, cell-cell contact, cytokine release, and hypoxia.
- The TP53 tumor suppressor protein is a key player in cell cycle checkpoints, responding to DNA damage by signaling cell cycle arrest and repair of the DNA damage. If the DNA damage cannot be repaired, TP53 may trigger cell death (apoptosis).
- *TP53* is the most commonly mutated gene in cancer and plays a prominent role in GU malignancies.
- Defects in cell cycle checkpoints lead to unregulated cell proliferation and genetic instability.

DNA Methylation

The covalent modification of the C-5 position of cytosine by a methyl group is mediated by DNA methyltransferase, resulting in the formation of 5-methylcytosine; an epigenetic modification of DNA that occurs in vertebrates and is essential for normal embryonic development (Bird, 1992; Jones, 1986). Methylation of cytosine occurs primarily at the CpG palindrome in DNA. The presence of 5-methylcytosine at CpG dinucleotides has resulted in a significant depletion of this sequence from the genome during the course of vertebrate evolution (Schorderet and Gartler, 1992). This reduction in frequency of CpG dinucleotides in the genome is the result of spontaneous deamination of 5-methylcytosine to thymine (Rideout et al., 1990; Sved and Bird, 1990). Notably, certain areas of the genome do not show a depletion of the CpG dinucleotides and contain the expected frequency of this sequence. These regions are referred to as CpG islands and make up approximately 1% of vertebrate genomes yet account for approximately 15% of the total number of CpG dinucleotides in DNA (Bird, 1986; Gardiner-Garden and Frommer, 1987). CpG islands are typically located upstream of many ubiquitous housekeeping and tissue-specific genes. CpG island methylation affects the levels of gene transcription (Cedar, 1988). Hypermethylation of CpG islands usually results in transcriptional downregulation, whereas hypomethylation of these regions may increase gene expression.

CpG islands located in the promoter regions of tumor suppressor genes are normally unmethylated. Abnormal methylation of these regions may result in a progressive reduction in gene expression, thus altering normal cellular growth control in favor of proliferation. Methylation of CpG islands may lead to decreased gene expression by mechanisms including changes in local chromatin structure, inhibition of transcription factor binding, or exclusion of transcriptional machinery from methylated promoter DNA (Bird and Wolffe, 1999). The epigenetic properties of methylation may therefore affect gene activity without altering the DNA sequence and represents an alternative means of gene inactivation apart from gene mutation or deletion.

Changes in global levels and regional patterns of DNA methylation are among the earliest and most frequent events known to occur in human cancer (Jones and Baylin, 2002). Alterations in DNA methylation have a direct impact on mutational and epigenetic components that may contribute neoplastic transformation. **Three major pathways by which DNA methylation may result in genetic dysregulation in human cancer include (1) inherent mutational effects of 5-methylcytosine, (2) epigenetic effects of promoter methylation on gene transcription, and (3) potential gene activation and induction of chromosomal instability by DNA hypomethylation** (Gonzalgo and Jones, 1997; Jones and Gonzalgo, 1997).

DNA Methylation and Prostate Cancer

Glutathione S-transferases belong to a superfamily of enzymes responsible for detoxification of a wide range of xenobiotics. These enzymes catalyze the nucleophilic attack of reduced glutathione on potentially damaging electrophilic compounds. **Aberrant methylation of the CpG island at the Glutathione S-transferase Pi-1 *(GSTP1)* locus is the most frequent somatic genome alteration reported in prostate cancer** (Jerónimo et al., 2001; Lee et al., 1994). Methylation of *GSTP1* has been detected in more than 90% of prostate carcinomas and approximately 70% of prostatic intraepithelial neoplasia (PIN) lesions but is not present in normal prostate tissue or benign prostatic hyperplasia (Lee et al., 1994). In normal prostate tissue, expression of *GSTP1* is limited to basal cells, but it can be upregulated in columnar epithelial cells exposed to oxidative stress. Increased levels of DNA methylation have also been associated with worse clinical outcomes in patients with prostate cancer (Maruyama et al., 2002).

The ras association domain family protein 1, isoform A *(RASSF1A)* gene is located on chromosome 3p21. *RASSF1A* is a tumor suppressor gene that is frequently altered in a variety of human cancers. Abnormal methylation of *RASSF1A* has been reported to occur in 60% to 70% of prostate carcinomas (Kuzmin et al., 2002). Loss of heterozygosity (LOH) of the 3p21 region is associated with methylation and silencing of the remaining *RASSF1A* allele during tumorigenesis. Methylation *RASSF1A* has been observed more frequently in higher-grade prostate cancers compared with less aggressive tumors (Liu et al., 2002).

Genome-wide methylation analyses have been conducted in prostate cancer, with the results indicating that there are widespread changes in methylation patterns (hypermethylation and hypomethylation) that occur in gene-associated and conserved intergenic regions. Interestingly, although interindividual heterogeneity in DNA methylation patterns was observed among prostate cancer patients, within individuals with metastatic prostate cancer, DNA methylation alterations were highly conserved across all of their metastases, suggesting that DNA methylation alterations undergo clonal selection (Aryee et al., 2013; Yegnasubramanian et al., 2011).

Role of DNA Methylation in Bladder Cancer

Mutations of the *TP53* gene are present in more than half of all human malignancies. Many of the mutational hotspots found in the *TP53* gene occur at CpG dinucleotides that are normally methylated, thus implicating 5-methylcytosine as an endogenous mutagen in the genome (Greenblatt et al., 1994; Rideout et al., 1990; Tornaletti and Pfeifer, 1995). Mutational inactivation of *TP53* is a frequent event in urothelial dysplasia, carcinoma in situ (CIS), and invasive bladder cancer (Spruck et al., 1994).

The contribution of DNA methylation to these mutational events varies depending upon the type of bladder cancer and the etiologic agent believed to be responsible for tumor formation (Jones et al., 1998). Urothelial carcinomas in western countries and Japan have relatively few mutations at CpG sites, suggesting that DNA methylation may not play a major role in inducing these changes. In contrast, a higher frequency of mutations at CpG dinucleotides consistent with 5-methylcytosine deamination is observed in patients with squamous cell carcinoma and urothelial carcinoma with a history of exposure to phenacetin or arsenic (Jones et al., 1998). These observations highlight the potential mutagenic effects of DNA methylation upon the genome and the contribution of methylation to *TP53* inactivation during bladder carcinogenesis.

INK4A (p16) Methylation in Bladder Cancer

Inactivation of the *INK4A* gene may occur by a variety of mechanisms including deletion, mutation, and promoter methylation (Gonzalez-Zulueta et al., 1995; Herman et al., 1995; Spruck et al., 1994). Mutation or deletion of one *INK4A* allele and concurrent methylation of the remaining allele results in complete loss of functional activity. Methylation of *INK4A* has been reported in 27% to 60% of primary urothelial carcinomas (Chan et al., 2002; Chang et al., 2003). Such epigenetic changes are among the earliest molecular events associated with transformation and may therefore precede morphologic alterations in cellular architecture.

The first detailed study investigating the effects of *INK4A* promoter methylation on transcriptional activity was performed in bladder cancer cells, where a reduction in *INK4A* expression was associated with higher levels of methylation in the upstream promoter region methylation of specific CpG sites in the *INK4A* promoter was shown to significantly downregulate transcriptional activity of the gene (Gonzalgo et al., 1998). Administration of the demethylating agent 5-aza-2′-deoxycytidine (5-Aza-CdR) was capable of reactivating *INK4A* expression in bladder cancer cells that were previously shown to contain methylated alleles of the gene. Methylation in exon 2 of the *INK4A* gene is also a frequent occurrence in a variety of cancers and is an excellent marker for transformation, although the presence of methylation in this region of the *INK4A* gene does not affect *INK4A* transcription in bladder cancer cells (Gonzalgo et al., 1998).

Hypermethylation of Other Genes in Bladder Cancer

The E-cadherin *(CDH1)* gene encodes a transmembrane glycoprotein that modulates calcium-dependent intercellular adhesion in epithelial tissues. Methylation of the CpG island located in the *CDH1* promoter is associated with decreased gene expression in high-grade urothelial carcinoma, including disease-associated with carcinoma in situ (Graff et al., 1995; Horikawa et al., 2003). *CDH1* methylation has also been reported in histologically normal urothelium; however, many of these cases were from patients older than 70 years of age and may be related to a potential link between methylation and aging (Ahuja and Issa, 2000; Bornman et al., 2001). Lower levels of CDH1 expression may increase β-catenin/TCF signaling activity and proliferation in urothelial carcinomas (Maruyama et al., 2002; Thievessen et al., 2003).

Methylation of *RASSF1A* has been reported in up to 97% of primary bladder tumors, suggesting that epigenetic inactivation of this gene may play an important role in bladder carcinogenesis (Lee et al., 2001). High tumor grade, nonpapillary growth pattern, and muscle invasive disease are associated with *RASSF1A* promoter methylation in bladder cancer (Maruyama et al., 2001).

Hypomethylation in Bladder Cancer

Global DNA hypomethylation is also a frequent event in tumorigenesis

(Jones and Baylin, 2002). **Hypomethylation may result in genomic instability via alterations in chromatin structure, increased genetic recombination between repetitive elements, or derepression of retrotransposons** (Baylin et al., 2001). Methylation of CpG sites is normally maintained by the enzymatic activities of DNA methyltransferase 1 *(DNMT1),* whereas de novo methylation of CpG sites is mediated by DNA methyltransferases 3A and 3B (*DNMT3A* and *DNMT3B*) (Jones and Baylin, 2002). **One important role for methylation is genomic imprinting, which results in monoallelic gene expression without altering the genetic sequence.** Loss of imprinting (LOI) is a reduction in the methylation of the normally methylated allele, which can lead to activation of the normally silent copy of a growth-promoting gene (Feinberg and Tycko, 2004). This phenomenon has been reported for the human insulin-like growth factor-2 gene *(IGF2)* in a variety of cancers (Sakatani et al., 2005; Woodson et al., 2004).

Methylation of long interspersed nuclear element (L1 LINE) sequences is reduced in bladder cancer cell lines and primary tumors compared with normal bladder mucosa (Jürgens et al., 1996). DNA methyltransferase expression, however, did not correlate with methylation status of cell lines, and methyltransferase activity was reduced in quiescent cells, suggesting that aberrant expression of DNMT1 does not account for the altered methylation patterns found in urothelial carcinoma (Jürgens et al., 1996). Decreased DNMT1 expression and induction of DNMT3A and DNMT3B in bladder cancer has also been reported (Kimura et al., 2003). These data suggest that downregulation of DNMT1 expression may be at least partly responsible for hypomethylation of repetitive elements in bladder cancer.

Key Points: DNA Methylation

- Methylation occurs specifically at CpG dinucleotides in the genome. The presence of 5-methylcytosine in DNA can result in spontaneous deamination to thymine and therefore the formation of C → T transition mutations.
- DNA methylation can affect gene function by subsequent mutational events or epigenetic mechanisms. Methylation of CpG islands associated with the promoter region of genes may result in suppression of gene expression.

- Loss of promoter methylation of normally methylated genes can lead to inappropriate gene expression (e.g., expression of oncogenes).

DNA Damage and Repair

Cancer is fundamentally a genetic disease. Alterations in numerous genes provide the malignant cell the means to activate cancer-associated pathways and inactivate tumor suppressive barriers, making possible the acquisition of the key set of attributes associated with the cancer phenotype. **The intrinsic accuracy of DNA polymerase coupled with associated error-correction mechanisms keeps the error rate during DNA replication to an astonishingly low estimated value of approximately 3 incorrect bases per cell division; this in a genome of more than 3 billion bases! These processes are not perfect, however, and cancer-causing changes do occur in oncogenes and tumor suppressor genes via epigenetic, mutational, and copy number alterations, in addition to epigenetic abnormalities.** Many of these genetic changes are thought to result from a variety of endogenous (e.g., mitochondrial respiratory byproducts) and exogenous (e.g., chemicals, radiation) DNA damaging agents that constantly assault the genome (Ames and Gold, 1991, 1998). To counter these threats, our cells employ a plethora of defensive mechanisms, including free-radical scavengers such as α-tocopherol, vitamin C, carotenoids, bilirubin, and urate, as well as protective enzymes such as superoxide dismutases, glutathione peroxidases, and glutathione transferases, which detoxify a wide range of carcinogens (Finkel and Holbrook, 2000; Mates and Sanchez-Jimenez, 1999). Loss of expression, because of promoter hypermethylation, of the glutathione S-transferase pi enzyme encoded by the *GSTP1* gene is observed in the vast majority of prostate cancer cases (Lee et al., 1994; Lin et al., 2001), and recent studies have found associations between genetic polymorphisms in GSTs and the risk of biochemical recurrence in prostate cancer patients (Nock et al., 2009). Epidemiologic and retrospective studies on prostate cancer risk have found a protective effect for selenium, which is used as a co-factor by glutathione peroxidases (Colli and Amling, 2009; Lowe and Frazee, 2006), raising hope that dietary intervention may be protective against prostate cancer. However, a recent large clinical trial showed no benefit for dietary supplementation with selenium (Hatfield and Gladyshev, 2009), and it now appears that selenium's observed protective effects may be limited to men with low baseline selenium levels. Results from other clinical chemoprevention trials in prostate cancer have, unfortunately, been similarly disappointing (Gaziano et al., 2009).

In addition to DNA damage prevention, the cell employs a host of DNA repair systems. The set of pathways dealing with DNA damage recognition and repair is **referred to as the DNA damage response, or DDR,** and encompasses a plethora of genes. The DDR includes the replication machinery (with its associated proofreading capability), as well as the many components of specific DNA repair systems such as base-excision repair, nucleotide-excision repair, double-strand break repair, and mismatch repair described in detail later (Loeb, 1998; Schmutte and Fishel, 1999).

As previously mentioned, **the cell cycle and the DDR are closely integrated. In response to DNA damage, the first step is to arrest the cell cycle so that the DNA can be repaired. It is therefore not surprising that there is substantial overlap between the initiators of DNA repair and cell cycle arrest** (Kastan and Bartek, 2004). For example, ATM and ATR kinases are activated in response to DNA damage, and both activate TP53, CHK1, and other proteins critical to cell cycle arrest (Bartek and Lukas, 2003).

Considering the number of genetic changes calculated to be required for cancer development, the large number of changes actually observed in cancer cells, and the extraordinarily low spontaneous mutation rates in normal human cells, Loeb was led to conclude that the spontaneous mutation rate is insufficient to explain the number of mutations observed in the majority of human cancers. Loeb hypothesized that, early in the process of tumorigenesis, preneoplastic cells may develop defects in one or more of the genes responsible for the fidelity of DNA replication (Cheng and Loeb, 1993; Loeb et al., 1974; Loeb, 1991). Such a defect would then lead to an increased mutation rate resulting in a so-called “mutator phenotype.” This hypothesis gains further support from the fact that most cells in proliferating tissues, such as epithelial tissues (the source of the vast majority of human cancers), are relatively short lived, being eliminated either by cell shedding or apoptosis. Thus the target population of cells at risk for becoming cancerous is far less than the total number of cells in the body, yet cancers are certainly not uncommon. In addition, cells with a “hypermutable” phenotype are often more difficult to treat because the selection pressure of therapy may rapidly select tumor cells with mutations conferring resistance (Tlsty et al., 1989).

The term *mutator phenotype* was originally used to refer to defects in the DNA replication and repair proteins, resulting in relatively small-scale errors in the DNA sequence, such as single base substitutions, deletions, and duplications. Despite (or perhaps because of?) the many potential targets

for mutator genes, few such genes have been found to be consistently mutated in significant proportions of common human cancers, a notable exception being the mismatch repair pathway. Mismatch repair defects are the underlying cause of hereditary nonpolyposis colorectal cancer (HNPCC) (Aaltonen et al., 1993) and have been reported in as many as 15% of sporadic colon cancers (Liu et al., 1995).

Although defects in DNA repair genes in sporadic malignancies, including genitourinary tumors, have been identified, Loeb's concept of the mutator phenotype, as originally stated, has yet to be fully evaluated. It currently appears that it may not be a major player in the development of the majority of common sporadic human cancers. **If, however, the mutator concept is broadened to include systems involved in *chromosomal* stability, then it may become widely applicable**. At any rate, **the current consensus is that genetic instability of *some* sort is required for cancer development.**

DNA Repair Mechanisms

It has been estimated that each cell's genome experiences approximately 10,000 lesions per day from reactions with oxidative species alone (Ames et al., 1993). Other processes such as spontaneous loss of individual DNA bases (depurination and depyrimidination) as well as spontaneous deamination of bases also occur at appreciable rates. Thus, in addition to damage prevention, the cell employs a host of DNA repair systems as well (eFig. 62.10). The relevance of DNA maintenance pathways to human cancer is borne out by the fact that many recessively inherited cancer predisposition syndromes (e.g., xeroderma pigmentosum, Bloom syndrome, Werner syndrome, ataxia telangiectasia, hereditary breast and colon cancer syndromes) are caused by defects in genes involved with DNA maintenance and repair, thus strongly implicating hypermutability in cancer causation (Modrich, 1994; Patel et al., 1998; Sancar et al., 1996). Three repair systems exist to deal with damage at the level of the DNA bases themselves. Such damage includes base modifications arising from reactive chemical species and from base mismatches resulting from rare misincorporation of incorrect bases or chemical conversions. The first of these, nucleotide excision repair (NER), is a major defense against DNA damage caused by ultraviolet radiation and chemical exposure. NER acts on a wide range of alterations that result in large local distortions in DNA by recognizing distortions in the DNA helix, excising the damaged DNA, and replacing it with the correct sequence (Wood, 1997).

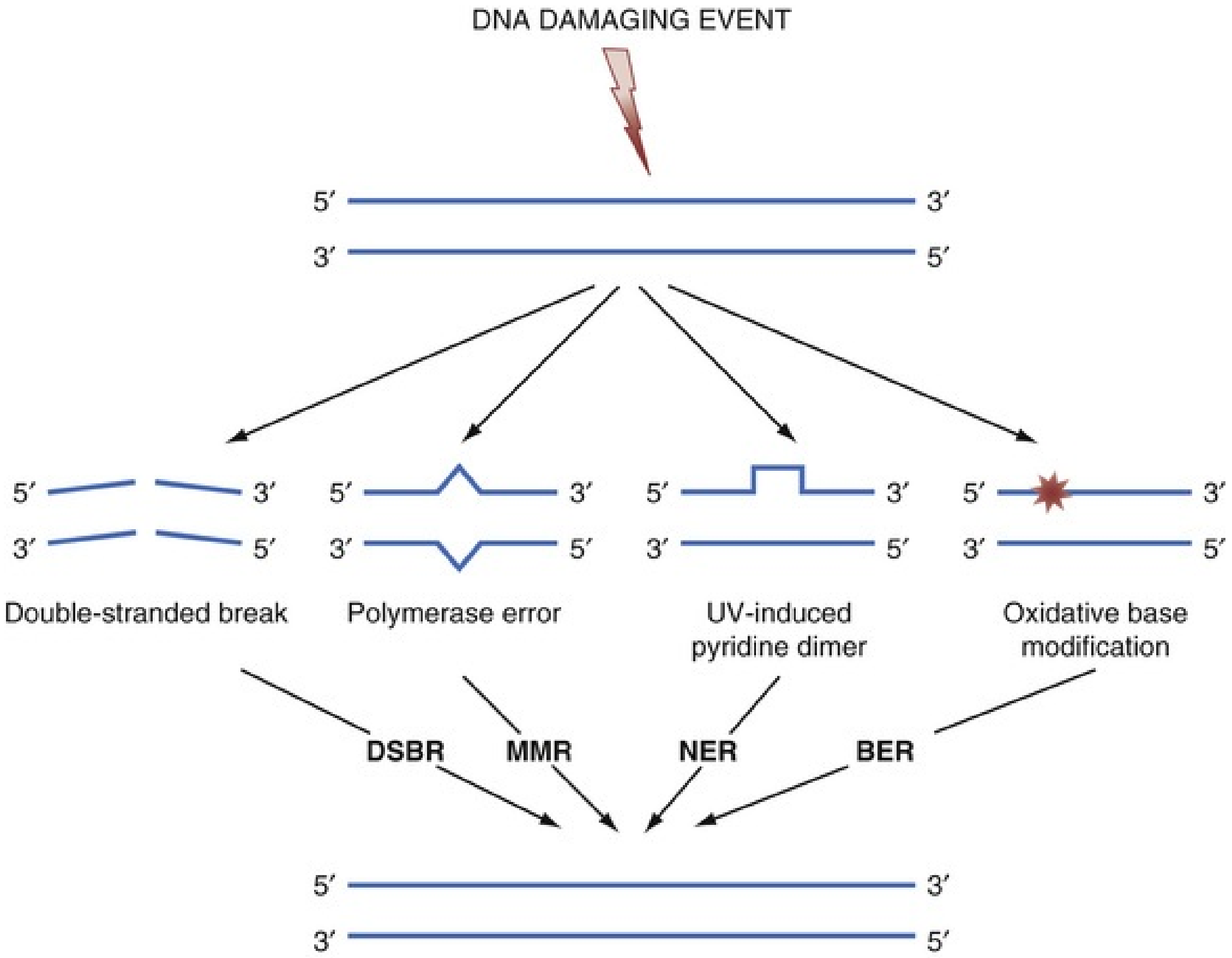
DNA DAMAGING EVENT
5′
3′
3′
5′
Double-stranded break
Polymerase error
UV-induced pyridine dimer
Oxidative base modification
DSBR
MMR
NER
BER

EFIG. 62.10 Schematic drawing of different DNA damaging events and repair mechanisms. *BER,* Base excision repair; *DSBR,* double-strand break repair; *MMR,* mismatch repair; *NER,* nucleotide excision repair.

In base excision repair (BER), damage caused by a variety of events, including spontaneous deamination of bases, radiation, oxidative stress, alkylating agents, or replication errors, is corrected. In particular, the pathway is critical for repair of oxidative lesions caused by reactive oxygen species (ROS). Unlike NER, lesions recognized by BER do not tend to create major distortions in the DNA molecule.

In human cancers, mutations in the MutYH glycosylase, a component of BER that removes damaged bases, are associated with colorectal carcinoma. This glycosidase functions with another glycosylase, OGG1, to correct A/G and A/C mismatches (Al-Tassan et al., 2002). Interestingly, polymorphic variants of OGG1 have been implicated in genitourinary malignancies, including renal cell carcinoma (Xu et al., 2002b). Mismatch repair (**MMR) removes nucleotides**

mispaired by DNA polymerases and insertion/deletion loops (ranging from 1 to 10 or more bases) that result from slippage during replication of repetitive sequences or during recombination. The MMR pathway functions primarily to reverse incorporation errors made by DNA polymerase. Defects in MMR compromise DNA replication fidelity by approximately 2 orders of magnitude, thus dramatically increasing mutation rates. Genetic inactivation of MMR genes, particularly *MLH1*, is a frequent event in sporadic colon carcinoma (Veigl et al., 1998) and has been implicated in prostate (Boyer et al., 1995) and bladder carcinoma (Christensen et al., 1998). The finding that MMR knockout mice are cancer prone provides additional evidence that defects in MMR can contribute substantially to tumorigenesis (Friedberg et al., 1998).

Double-Strand Break Repair

DNA double-strand breaks (DSBs) arise from a variety of causes, including ionizing radiation or x-rays, free radicals, reactive chemical species, as well as during replication of DNA containing single-strand breaks. After DSB detection, a complex cascade of reactions is triggered that halts the cell cycle and recruits specific repair factors (Kastan and Bartek, 2004). **DSBs have the potential to be the most disruptive form of DNA damage. If they are not repaired, the cell will often undergo apoptosis. This apoptotic response to DNA DSBs is the basis of radiation therapy and many chemotherapeutic agents that function primarily by inducing DSBs. Thus cancer cells that have abrogated this response may exhibit increased resistance to such therapies.** Incorrectly repaired DNA can lead to DNA mutations, deletions, and structural chromosomal rearrangements that are nearly ubiquitous in human solid tumors. There are two DSB repair pathways: homologous recombination (HR) and nonhomologous end joining (NHEJ) (Sancar et al., 2004).

The ATM kinase is a key player in DSB repair (Berkovich et al., 2007). By mechanisms that are still unclear, DSBs are quickly recognized, leading to rapid ATM activation via phosphorylation. In turn, activated ATM phosphorylates and activates TP53 and kinases CHECK1 and CHECK2, which, among other things, act to halt cell cycle progression to allow for DNA repair (eFig. 62.11). ATM also activates many proteins involved in DSB repair, such as the histone H2A variant H2AX (Lukas et al., 2003; Rogakou et al., 1998), *NBS1*, *BRCA1*, and *SMC1* (Kitagawa et al., 2004). Phosphorylated H2AX (also known as gamma H2AX) binds at the breakpoint and also occupies a sizeable stretch of DNA (up to 30 Mbp) on either side of the break, where it recruits other DDR factors, creating so-called repair foci (Bassal and El-Osta, 2005; Rogakou et al., 1999). Activated NBS1-MRE11-RAD50 (MRN) complex can then bind to Rad52 and the broken chromosomal ends (Lobachev et al., 2004). RAD51 along with the breast cancer susceptibility gene products, *BRCA1* and *BRCA2*, plus the BRCA1-associated-RING-domain 1 protein (BARD1) then participate in replicating the undamaged region from the sister chromosome template (Sancar et al., 2004; Welcsh et al., 2000). Homologous recombination involves the transfer of genetic information between sister chromatids. Essentially, **homologous repair allows the normal undamaged sister chromatid to act as a template to allow precise repair of a damaged segment of DNA** (Johnson et al., 1999). Use of the sister chromatid is only an option after S phase into G_2, before mitosis has occurred.

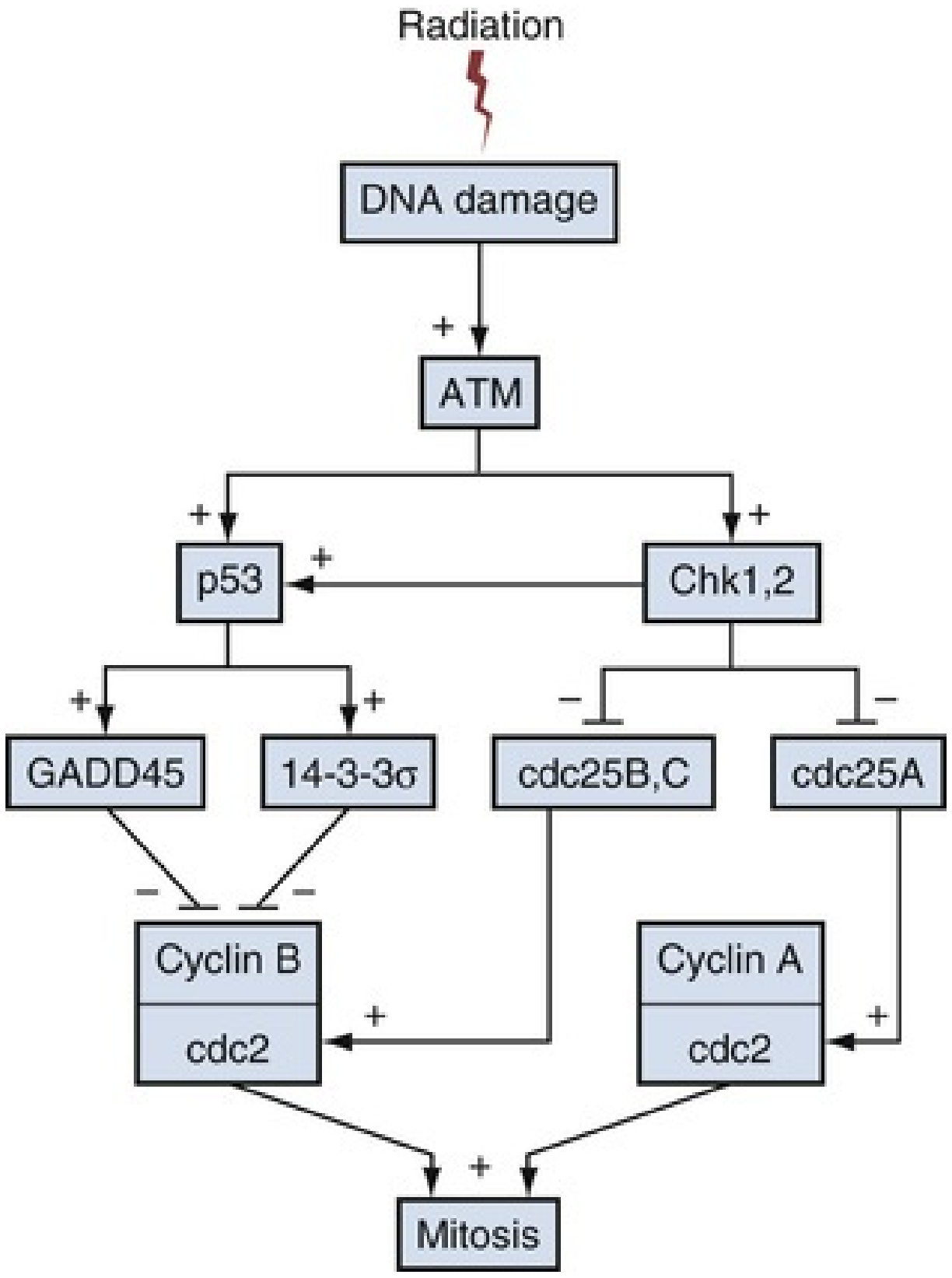

EFIG. 62.11 Schematic representation of the cascade at the G2M checkpoint in response to genotoxic events such as radiation. Increased ATM kinase activity eventually leads to inhibition of cyclin B through p53 and decreased stimulation of Cdc2 though Chk1 and Chk2. This leads to cell cycle arrest.

NHEJ is the more extreme of the two DSB repair pathways. In this instance, broken ends are brought together and ligated, often with a loss of some nucleotides at the resulting joint. In addition, the potential exists for incorrectly joining broken DNA ends that were not originally juxtaposed in the genome, thus creating chromosomal rearrangements such as chromosomal translocations. The Ku protein is a heterodimer consisting of XRCC6 (Ku70) and XRCC5 (Ku80) subunits that initiates NHEJ by binding to the broken ends of the DNA (Tuteja and Tuteja, 2000). Ku complexes with DNA-dependent protein kinase PRKDC (DNA-PK catalytic subunit) and in doing so activates PRKDC's kinase activity (Anderson, 1993). Active PRKDC phosphorylates a large number of proteins involved in the repair process, including Ku and also H2AX. Phosphorylated Ku uses its helicase activity to unwind the damaged DNA and allows the ligase 4/Xrcc4 heterodimer to repair the break (Tuteja and Tuteja, 2000).

Similar to other DNA repair mechanisms, defects in DSB repair have clearly been linked to cancer. *BRAC1* and *BRAC2* are associated with familial breast and ovarian cancer (Miki et al., 1994; Wooster et al., 1995). Such inherited cancer predisposition syndromes further highlight the existing link between genomic instability and cancer causation.

Key Points: DNA Damage and Repair

- DNA damage does not often lead to malignancy because the cell possesses multiple repair mechanisms.
- Defects in DNA repair facilitate the accumulation of the mutations critical for tumor formation and progression.
- NER is a major defense against DNA damage caused by ultraviolet radiation and chemical exposure.
- BER repairs damage caused by spontaneous deamination of bases, radiation, oxidative stress, alkylating agents, and replication errors.
- Mismatch repair removes nucleotides mispaired by DNA polymerase.
- DSB repair is a major defense against DNA damage caused by ionizing radiation, free radicals, and chemicals.
- Many syndromes involve inherited defects in DNA repair exhibit marked increases in cancer susceptibility; strongly linking genomic instability and

cancer.

Genomic Alterations

Research by many different groups on several different tumor types has strongly implicated genetic instability as an important determinant of tumorigenesis, although the ultimate source of genetic instability in cancer is still not entirely clear (Hartwell, 1992; Loeb, 1991). As mentioned previously, although certainly important in specific instances such as inherited cancer susceptibility syndromes, deficiencies in genes involved in the replication, maintenance, and repair of DNA have not yet been shown to play a major direct role in the genesis of most sporadic human cancers. **Recent studies on a number of human cancers found that the genomes of each cancer have numerous mutations (on average 33 to 66 somatic mutations in solid tumors) in gene coding sequences that are predicted to significantly alter the corresponding protein products** (Vogelstein et al., 2013)**. Comprehensive sequencing efforts coupled with statistical methods to predict the effects of individual mutations have revealed that approximately 140 genes, when mutated, can "drive" tumorigenesis (e.g., "driver" genes). Most tumors only contain two to eight such driver mutations, whereas the remaining mutations in any particular cancer case are considered "passengers" that do not confer a selective growth advantag**e (Sjoblom et al., 2006; Vogelstein et al., 2013; Wood et al., 2007).

Apart from the sequence alterations predicted to arise from the original mutator phenotype concept, *chromosomal* instability leads to gross changes in chromosome number and/or structure. The spectrum and severity of such chromosomal alterations may differ for different tumor types. For instance, **hematologic malignancies often are seen with simple diploid or near-diploid karyotypes with only one or very few detectable, often balanced, chromosomal rearrangements**. However, as a class these cancers only account for about 10% of all human cancers. **In stark contrast, the presence of large variations in chromosome numbers and complex structural rearrangements, as well as intratumoral variation in these aberrations, are hallmarks of most human solid tumors**, which represent the bulk of human malignancies. Important exceptions include certain tumors deficient in mismatch repair. **In prostate cancer, as well as most human tumor types and transplantable tumor models, the extent of chromosomal abnormalities correlates with disease severity and aggressiveness**, pointing to a role for these changes in cancer progression and spanning from premalignant lesions to localized primary tumors, and, finally, to metastatic disease to which patients typically succumb (Bostwick et al., 1996; Brothman et al., 1990; Isaacs et al., 1995; Lundgren et al., 1992; Sandberg, 1992). For example, in a study that used a computational method to infer aneuploidy based on gene expression data of genes that are located in adjacent chromosomal regions, greater levels of aneuploidy were found to confer worse survival rates (Carter et al., 2006). Likewise, a recent study in prostate cancer performed unsupervised hierarchical clustering of copy-number alterations (CNAs) in 218 tumor samples and found that tumors with the highest number of genome-wide CNAs had a significantly accelerated time to biochemical recurrence (Taylor et al., 2010).

The chromosomal changes seen in solid tumors can be broken down into two main classes: changes in the number of whole chromosomes and changes in chromosomal structure. Numerical chromosomal alterations can be further subdivided into changes in the numbers of specific individual chromosomes (aneusomies; e.g., monosomies and trisomies) and changes in the number of copies of the entire diploid set of chromosomes (ploidy changes; e.g., tetraploidy, octaploidy). Possible mechanisms responsible for such numerical changes include nondisjunction, endoreduplication (an abrupt doubling of the chromosome complement without cell division) cytokinesis defects, and cell fusion events. Likewise, structural changes can be subdivided into several distinct types of chromosomal aberrations as listed in Box 62.2. An additional mechanism for genomic rearrangement, termed chromothripsis (literally meaning “chromosome shattering”), has been described that was initially extrapolated from genomic sequencing studies on cancer cells (Stephens et al., 2011). Chromothripsis is evidenced by a large number (possibly hundreds) of chromosomal rearrangements in confined chromosomal regions that have occurred after apparent shattering and rejoining of a chromosomal region in a sometimes disordered fashion.

Box 62.2

Gross Chromosomal Abnormalities Frequently Observed in Cancer

Numerical Abnormalities

- Aneuploidies
    - Abnormal numbers of whole chromosome complement (e.g., triploidy, tetraploidy)
    - Losses or gains of single chromosomes (e.g., monosomy, trisomy)

Structural Abnormalities

- Rearrangements
    - Inversions
    - Translocations (either balanced or unbalanced)
    - Chromothripsis
- Chromosomal fusions
    - End-to-end fusion = dicentric chromosome
    - Intra-chromosomal fusion = ring chromosome
- Deletions (from small segments up to entire chromosome arms)
- Duplications, amplifications
- Double minutes (often containing amplified sequences)
- Isochromosomes (loss of one chromosomal arm, replaced by duplication of the remaining arm)
- Complex (a variety of combinations of the previously mentioned abnormalities)

As previously mentioned, cancer-associated chromosomal changes were recognized as early as the 1900s by Boveri, who proposed that such abnormalities may be involved in cancer causation. Much later, Klein put forth the idea that chromosomal rearrangements affect the expression of cancer-related genes located near the observed chromosomal breakpoints (Klein, 1981). This hypothesis has been validated over the ensuing years, in large part because of studies on what were observed to be consistent chromosomal changes found in hematologic malignancies and soft-tissue sarcomas, eventually leading to the isolation and cloning of the resident genes involved (Nowell, 1994). Over the years, painstaking dissection of chromosomal regions that are repeatedly found to undergo alteration in specific tumor types or subtypes has led to the discovery of hundreds of individual cancer-associated genes. Typically, genomic loci that are frequently lost tend to harbor tumor suppressor genes, whereas those loci exhibiting copy number gains (e.g., gene amplification) point toward oncogenes (Snijders et al., 2005). Examples of genes frequently amplified in cancers include members of the *MYC*, *RAS*, *EGFR*, and *FGF* gene families, as well as cell cycle regulatory genes such as *CCND1* (cyclin D gene), *CDK4*, and *HDM2*. **Gene amplifications in cancer are usually seen either as multiple small extrachromosomal copies called double minutes, or as amplified regions within chromosomes, so-called homogeneously staining regions (HSRs)** (Cowell, 1982).

Specific Chromosomal Rearrangements in Genitourinary Malignancies

Recurrent Gene Rearrangements in Prostate Cancer

Although they are much less frequently observed in common adult solid tumors, recurrent translocations do occur, often amid the backdrop of countless chromosomal abnormalities (Sandberg, 1985). **One of the most exciting recent findings in prostate cancer research has been the discovery of recurrent structural rearrangements in the majority of prostate cancer cases, primarily involving oncogenic ETS transcription factor family members.** The initial report by Tomlins et al. in 2005 described the use a novel bioinformatic approach that led to the identification of recurrent gene fusions between the upstream regulatory region of the androgen-regulated gene *TMPRSS2* and *ERG*, an ETS family member previously known to be involved in Ewing sarcoma and various leukemias (Tomlins et al., 2005). These two genes reside 3 Mb apart on chromosome 21 (*TMPRSS2*, 21q22.3; *ERG* 21q22.2), and detailed molecular analysis revealed that in the majority of rearranged cases (approximately 2/3), the gene fusion occurs via deletion of the intervening sequence, with the remaining fusions resulting from more complex, translocation-type of rearrangements (Perner et al., 2007; Tomlins et al., 2005). In either case, **the net result is to place a known oncogenic transcription factor under the control of an androgen-regulated promoter, resulting in androgen-driven expression of the fusion transcript** (Wang et al., 2008a). As expected, increased *ERG* transcription and ERG protein expression is positively correlated with presence of the gene fusion. In addition to a variety of splice variants, there are multiple forms of the genomic rearrangement, the most common one being a fusion between exon 1 of *TMPRSS2* to exon 4 of *ERG*. **These gene rearrangements can be readily detected, either by assaying for the presence of the fusion transcripts by reverse transcriptase polymerase**

chain reaction (RT-PCR) or by assaying for the rearrangement directly by multiprobe, multi-color fluorescence in situ hybridization (FISH), and such approaches are currently being evaluated for potential use in noninvasive diagnostic applications (e.g., in urine or blood). More recently, detection of ERG protein expression by immunostaining has been shown to be an excellent surrogate marker for chromosomal rearrangements involving the ERG gene, thus providing a simpler method for their detection (Chaux et al., 2011; Falzarano et al., 2011; Park et al., 2010).

Since the publication of the initial report by Tomlins et al. (2005), several large retrospective studies have been performed assessing these fusions in localized prostate cancers in PSA-screened cohorts. These studies confirmed the initial finding and found the prevalence of the *TMPRSS2-ERG* fusion in prostate cancer to be in the range of 40% to 60%, making this one of the most common somatic genetic alterations in prostate cancer (Gopalan et al., 2009b; Mehra et al., 2007; Mosquera et al., 2009; Nam et al., 2007; Perner et al., 2007; Tu et al., 2007; Wang et al., 2008a). One intriguing anatomic exception is cancer originating in the transition zone of the prostate, which appears to completely lack *TMPRSS2-ERG* gene rearrangements (Guo et al., 2009a).

As assessed by FISH in tissue sections, the *TMPRSS2-ERG* fusion has not been observed in benign prostate epithelial or stromal cells, although it has been reported to be present in high-grade prostatic intraepithelial neoplasia (HGPIN), the presumptive precursor lesion for prostate adenocarcinoma, at frequencies between 15% and 20%, which is about one-half the frequency observed in localized PSA-detected cancers (Cerveira et al., 2006; Han et al., 2009; Mosquera et al., 2008; Perner et al., 2007). This finding implies that, at least in a subset of cases, the rearrangement may be an early event in prostate tumorigenesis. **With the important exceptions of transition zone cancers and HGPIN, the prevalence and high degree of specificity of the *TMPRSS2-ERG* fusion for prostate cancer makes this a potentially useful biomarker for diagnosis and disease monitoring, one that could be used in conjunction with current markers such as serum PSA, which have limited specificity.** Indeed, the detection of *TMPRSS2-ERG* fusion-driven ERG overexpression in prostate biopsies from men found only to have HGPIN was shown to be predictive of cancer diagnosis on subsequent biopsy (Park et al., 2013), and multiple studies have demonstrated the utility of *TMPRSS2-ERG* detection in the blood or urine either alone or in combination with the non–protein-coding RNA prostate cancer antigen 3 (PCA3) in enhancing the sensitivity of prostate cancer diagnosis (Hessels et al., 2007; Leyten et al., 2012; Tomlins et al., 2011).

Apart from its promising potential as a diagnostic prostate cancer marker, it is as of yet unclear if additional clinical information may be provided by determining a patient's *TMPRSS2-ERG* gene fusion status. As such, **the prognostic significance of fusion status in prostate cancer remains uncertain.** Although several studies have reported associations between *TMPRSS2-ERG* rearrangement and various indicators of disease aggressiveness, including higher stage, presence of metastases, and disease-specific death (Attard et al., 2008a; Barwick et al., 2010; Cheville et al., 2008; Demichelis et al., 2007; Leyten et al., 2012; Mehra et al., 2007; Nam et al., 2007; Perner et al., 2007; Rajput et al., 2007), several other published studies failed to observe such associations (Albadine et al., 2009; Dai et al., 2008; Darnel et al., 2009; Fine et al., 2010; Gopalan et al., 2009b; Lapointe et al., 2007; Lotan et al., 2009; Rouzier et al., 2008; Tu et al., 2007; Yoshimoto et al., 2006). A large prospective study of 1180 men treated by radical prostatectomy found that the presence of the *TMPRSS2-ERG* rearrangement was not predictive of recurrence or mortality but was associated with tumor stage (Pettersson et al., 2012). Studies examining the prognostic capabilities of *TMPRSS2-ERG* positivity in predicting treatment outcomes to androgen deprivation (Leinonen et al., 2010), abiraterone (Danila et al., 2011), or radiotherapy (Dal Pra et al., 2013) show no association. In addition, one study reported a link between gene fusion and *favorable* prognosis (Saramaki et al., 2008), and Petrovics et al. reported that higher levels of *ERG* mRNA expression appeared to be positively associated with disease-free survival (Petrovics et al., 2005). Another study reported that *ERG* gene copy number gain without the presence of the gene fusion is prognostic for recurrence after radical prostatectomy (Toubaji et al., 2011). The precise reasons for these conflicting results are not apparent. A number of variables differ between many of these studies, including the nature of the study cohort, sample size, method of cancer detection, manner in which the tissues were obtained, intratumoral heterogeneity in the presence of the fusion (Minner et al., 2012), manner in which the gene fusions were detected (e.g., PCR or FISH), length of patient follow-up, and the clinical end points assessed. Further research in this area is clearly warranted to better resolve these issues.

After the report of *TMPRSS2-ERG* rearrangements, further study revealed additional gene fusions in prostate cancer. Thus the *TMPRSS2* gene can fuse to other ETS family member genes, including *ETV1*, *ETV4*, and *ETV5* (Helgeson et al., 2008; Tomlins et al., 2005; Tomlins et al., 2006). These additional translocations are much rarer than the *TMPRSS2-ERG* rearrangement, which is estimated to represent more than 90% of all fusions involving ETS genes in prostate cancer (Kumar-Sinha et al., 2008). In addition, fusions involving upstream fusion partners other than *TMPRSS2* have also been found, including the fusions *SLC45A3-ETV5*, *SLC45A3-ERG*, *HNRPA2B1-ETV5*, and *SLC45A3-ELK4*; however, these are also relatively rare (Attard et al., 2008a; Attard et al., 2008b; Hermans et al., 2008; Maher et al., 2009; Rickman et al., 2009; Tomlins et al., 2007). Whereas the fusion events in prostate cancer are typically driven by genomic rearrangements, the SLC45A3-ELK4 fusion was later found to be due to RNA cis-splicing events between these two genes (which are located adjacent to each other on chromosome 1 band q32) with no alterations to the DNA sequence (Zhang et al., 2012). Additional low frequency gene fusions have been identified in prostate cancer that involve non-ETS family members such as *CDKN1A*, *CD9*, *IKBKB*, the oncogene *PIGU*, the tumor suppressor *RSRC2*, and members of the RAF pathway *(BRAF, RAF1)* (Palanisamy et al., 2010; Pflueger et al., 2011; Ren et al., 2012). These studies have been facilitated by next-generation RNA sequencing (RNA-seq or whole “transcriptome” shotgun sequencing) technologies that unbiasedly sequence all RNA species in a sample with an analysis that is not limited to “annotated” sequences. The results of RNA-seq studies indicate that some of the fusion events that occur in prostate cancer may be “private events” (e.g., only occurring in one patient), implying that the frequency and range of fusion events in prostate cancer may be far greater than what is currently understood (Pflueger et al., 2011).

Recurrent Gene Rearrangements in Renal Cancer

A novel subtype of renal cell carcinoma, microphthalmia transcription factor (MiTF)/TFE family translocation carcinomas, has been described that features chromosomal translocations involving one of two members of the MiTF family (Argani and Ladanyi, 2005; Hemesath et al., 1994). The first involves the *TFE3* gene on chromosome Xp11.2, which translocates to one of several partner genes including *PRCC* (1q21), *ASPL* (17q25), *PSF* (1p34), *NonO* (Xq12; rearranged via inversion), and an unknown gene at 3q23 (Argani et al., 2001a; Argani et al., 2001b; Argani and Ladanyi, 2005; Argani et al., 2005; Martignoni et al., 2009; Sidhar et al., 1996; Weterman et al., 1996). These translocations place the *TFE3* gene under the control of strong promoters that then drive inappropriate expression of *TFE3* (or a *TFE3*-containing fusion protein). In these cancers, TFE3 protein is readily detectable in the nucleus by immunohistochemical (IHC) staining with anti-*TFE3* antibody, thus aiding in diagnosis. TFE3 renal cell carcinomas are found primarily in children and adolescents and account for the majority of pediatric renal cell carcinoma (RCC) cases (Argani and Ladanyi, 2005). It has recently been reported that activation of the *MET* proto-oncogene may play a role with *TFE3* in these tumors (Tsuda et al., 2007), which is of interest because these tumors display papillary histologic architecture, and mutations in the *MET* gene are the underlying cause of hereditary papillary renal cell carcinoma (Jeffers et al., 1997).

A second class of MiTF/TFE family translocation carcinomas contains a specific translocation between the *TFEB* gene on 6p21 and the *ALPHA* gene on 11q12 (Argani et al., 2005). Like the Xp11 translocation RCCs, this entity is also most commonly found in children and adolescents and shares many other features with the TFE3 translocation tumors. In addition to IHC staining for TFE3 and TFEB proteins, it was recently demonstrated that these tumors are also marked by staining for the protein cathepsin K, a shared transcriptional target gene of these transcription factors (Martignoni et al., 2009). The use of such markers or PCR to detect these specific gene fusions may have clinical importance because, as the cathepsin K example shows, these tumors likely are controlled by a different transcriptional program than conventional RCC, thus therapeutic targets used against these cancers may not be effective against translocation RCCs.

Recurrent Gene Rearrangements in Testicular Cancer

In testicular germ cell tumors (TGCTs), gain of the short arm of chromosome 12 is a nearly universal finding, with the notable exception of the rare spermatocytic seminoma subtype (Atkin and Baker, 1982; Rodriguez et al., 1993; Rosenberg et al., 1998; Verdorfer et al., 2004). In the majority of cases (approximately 80%) this occurs through a structural rearrangement producing an isochromosome 12p, that is, a version of chromosome 12 consisting of 2 p-arms and no q (long) arm. In the remainder of cases 12p material is gained through more complex chromosomal rearrangements (Looijenga et al., 2007; Ottesen et al., 2003; Rosenberg et al., 2000). More detailed analyses have revealed amplification of specific regions on 12p, including the area 12p11-12p13. One common region of amplification at 12p11.2-12p12.1 contains 22 potential genes, including *KRAS*, a promising candidate TGCT gene, which also undergoes activating mutations in TGCTs (Goddard et al., 2007; Moul et al., 1992; Olie et al., 1995; Rodriguez et al., 2003; Zafarana et al., 2003). An additional region of interest lies at 12p13.31, where the so-called “stem cell cluster region” resides. This region contains several stem cell–related genes, including *CD9*, *EDR1*, *GDF3*, *SCNN1A*, *NANOG*, and *STELLAR*, which exhibit coordinate overexpression (Clark et al., 2004; Korkola et al., 2006).

Other Genomic Alterations in Genitourinary Malignancies

Apart from chromosomal translocations, which are primarily specific changes in the spatial organization of the genome, an overall derangement of the chromosomal complement is nearly universal in human cancer, particularly in carcinomas; cancers that originate from epithelial cells and represent the majority of adult GU malignancies. Such abnormalities are wide ranging, affecting the genome at multiple scales, including losses and gains of entire chromosomes or chromosomal arms, as well as deletions and amplifications of chromosomal regions large and small. **These changes are generically referred to as CNAs. In addition to mutations, structural rearrangements, and epigenetic changes, CNAs are yet another reflection of the underlying genomic instability in cancer cells, resulting in the large number of genetic changes required for malignant transformation.** This instability generates a great degree of genetic heterogeneity. For instance, when metaphase chromosomes of tumor cells are examined during karyotypic analysis, a bewildering array of chromosomal aberrations is typically observed, such that no two karyotypes within a given cancer cell population are exactly the same. However, within this seemingly random assortment of alterations there are some changes that are seen in multiple different cells and multiple tumor samples, providing a strong indication that a gene or genes located in the region undergoing recurrent alteration is involved in the pathogenesis of the disease. Over the past several decades, using ever more sophisticated and higher-resolution molecular methods, many such changes have been catalogued and candidate cancer genes identified. Two general approaches are used here. In the first, inherited (germline) defects in genes that cause hereditary cancer predisposition syndromes are sought, often by performing genetic linkage analysis in affected and nonaffected family members in an attempt to find genetic loci that track in a Mendelian fashion with disease status. Several familial cancer predisposition syndromes are now understood in significant detail, some featuring GU malignancies, others not (Tables 62.1 and 62.2). In the second approach, a variety of techniques are employed to discover disease-associated genes in sporadic cancers that lack a strong familial component (caused by somatic rather than germline genetic alterations). **The detection of copy number alterations in a particular gene (or region containing the gene) coupled with mutations in the other allele is persuasive evidence for that gene functioning as a disease-relevant oncogene (with activating mutations) or tumor suppressor gene (featuring inactivating mutations or promoter methylation). In the case of cancer-related genes identified in hereditary predisposition syndromes, hopefully alterations of genes discovered in familial forms of the disease are also relevant to their more common sporadic counterparts. In a number of instances this has been found to be true:** for example, gene abnormalities linked to certain familial forms of kidney cancer are also involved in sporadic forms of the disease. In the following sections we describe some of the recurrent genetic changes identified in familial and sporadic forms of genitourinary malignancies.

TABLE 62.1

Tumor Syndromes Associated With Genitourinary Malignancies

SYNDROME	TUMOR	CHROMOSOME(S)	GENE(S)	(FUNCTION)
Wilms' tumor	Wilms' tumor	11p13	*WT1*	(Transcriptional repressor)
Beckwith-Wiedemann	Wilms' tumor	11p15	*CDKN1C*	(Cell cycle regulator)
Von Hippel-Lindau	Clear cell renal cell carcinoma	3p25	*VHL*	(Transcriptional elongation and ubiquitination)
	Pheochromocytoma			
Hereditary papillary renal cancer	Papillary renal cell carcinoma	7q31	*MET*	(Receptor tyrosi kinase)
Birt-Hogg-Dubé	Papillary renal cell carcinoma	17p11.2	*FLCN*	(Unknown function)
	Oncocytoma			
Multiple endocrine neoplasia type II	Pheochromocytoma	10q11	*RET*	(Receptor tyrosi kinase)

Hereditary nonpolyposis colorectal cancer	Upper tract transitional cell carcinoma	2p22, 3p21.3, 2p18, 2q31-q33, 7p22, 14q24.3	*MSH2*, *MLH1*,	(DNA mismatch repair)
			MSH6, *PMS1*, *PMS2*, *MLH3*	
Hereditary prostate cancer	Prostate cancer	1q24-25, 1p36, 1q42-43, 8p22-23, 17p11, 20q13, Xq27-28	*RNASEL*, *MSR1*, *ELAC2*	(Endoribonucleas macrophage specific receptor, cell cycle regulator)

TABLE 62.2

Selected Tumor Syndromes Not Strongly Associated With Genitourinary Malignancies

SYNDROME	PRIMARY TUMOR	CHROMOSOME(S)	GENE(S)	(FUNCTION)
Familial retinoblastoma	Retinoblastoma	13q14	*RB*	(Transcriptional regulation)
Li-Fraumeni	Sarcoma, breast carcinoma	17p13	*TP53*	(Transcription factor, serine kinase)
	22q12	*hCHK2*		
Familial adenomatous polyposis	Colorectal carcinoma	5q21	*APC*	(Regulates β-catenin activity)
Familial breast carcinoma	Breast carcinoma	17q21, 13q12	*BRCA1*, *BRCA2*	(DNA double-strand break repair)
Cowden's disease	Breast carcinoma	10q23	*PTEN*	(Phosphatase; PI3K antagonist)
Multiple endocrine neoplasia type I	Pancreatic islet cell carcinoma	11q13	*MEN1*	(Transcription factor)

Hereditary Prostate Cancer

Family history is one of the strongest prostate cancer risk factors (Steinberg et al., 1990), and criteria defining a hereditary form of the disease have been established (Carter et al., 1993). Twin studies have estimated a heritable risk for prostate cancer of approximately 50% (Lichtenstein et al., 2000; Page et al., 1997). Traditional linkage analysis is well suited to identify highly penetrant genetic alterations (Fig. 62.12). **The overall low yield and irreproducibility seen in hereditary prostate cancer (HPC) linkage studies have led to the conclusion that rather than being caused by a few high-impact genes, HPC is instead likely to depend upon alterations in many genes, each of which has only a modest effect** (Easton et al., 2003; Schaid, 2004).

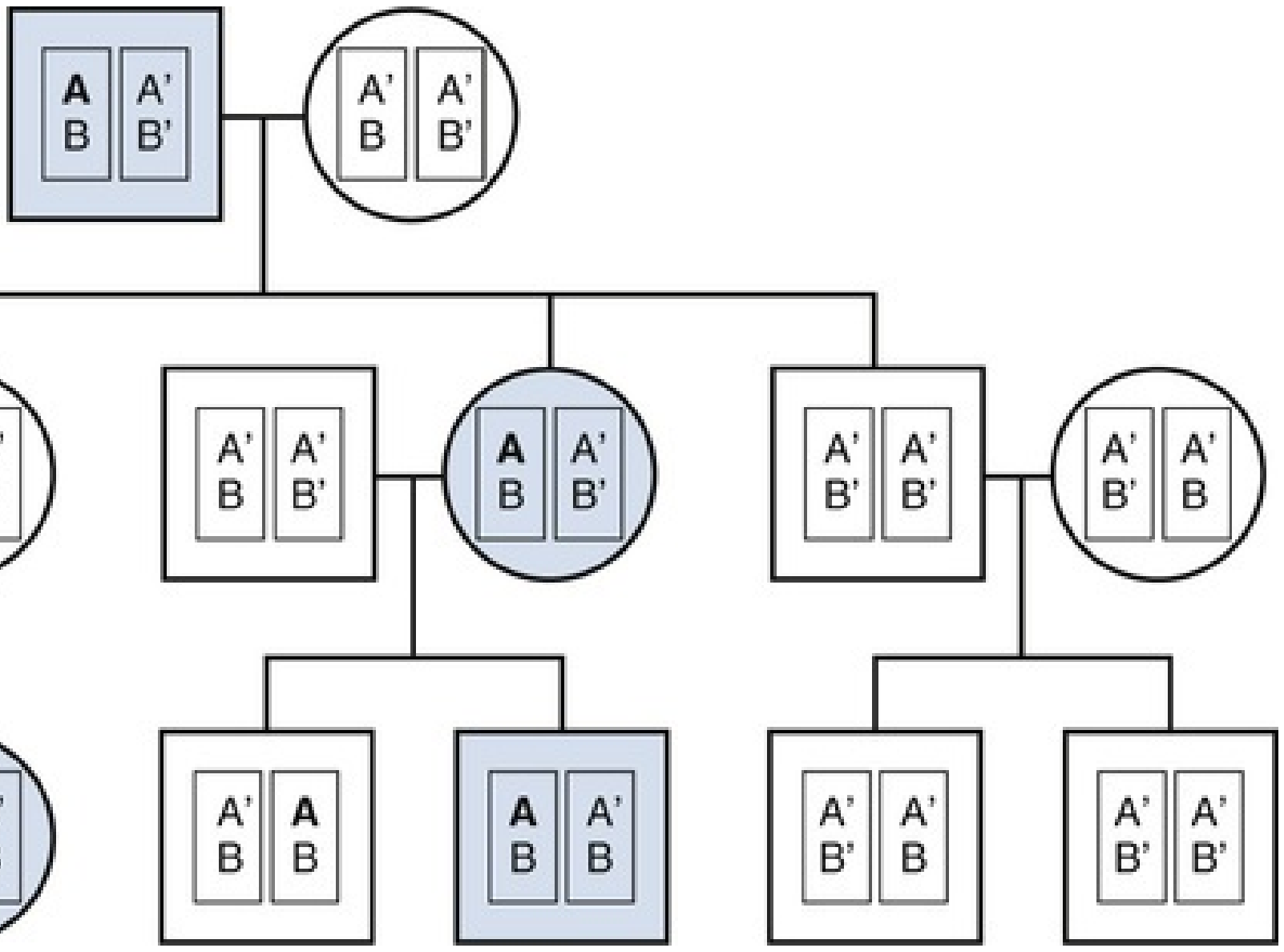

FIG. 62.12 The familial tumor syndrome is passed from generation to generation. Genotyping demonstrates that the polymorphic marker A *(marked in bold)* is passed also from generation to generation in concert with the phenotypic disease. Presumably a gene responsible for the syndrome is located near marker A. Linkage analysis is complicated by incomplete penetrance (not all members of the family with the allele get the disease), phenocopies (family members who have sporadic disease), inability to get DNA from all family members, and the large number of markers being simultaneously analyzed.

Initial genome-wide searches in HPC families uncovered evidence for susceptibility loci on chromosome 1q, 4q, 5p, 7p, 13q, and Xq (Smith et al., 1996). The first strong candidate locus, HPC1, was localized to the region

1q24.25 (Gronberg et al., 1997) and a gene, *RNASEL*, was later identified at this locus (Carpten et al., 2002; Rokman et al., 2002). Although this linkage was replicated in some studies, it was not confirmed in others (Bergthorsson et al., 2000; Cooney et al., 1997; Eeles et al., 1998; McIndoe et al., 1997). Similarly, a failure to consistently confirm linkage has plagued other candidate HPC loci/genes as well, highlighting the difficulty in conducting such studies. Because prostate cancer is a relatively common disease, HPC families are contaminated with sporadic cases ("phenocopies"). Furthermore, it has become apparent that familial prostate cancer may lack the type of high-risk susceptibility genes such as *BRCA1* or *BRCA2* that are clearly linked to hereditary forms of breast and ovarian cancers (Simard et al., 2003). Among other considerations, these facts underline the need for large, well-defined HPC cohorts, making genetic studies difficult to perform. One large HPC cohort of 175 pedigrees identified a region in chromosome 17q21-22 near *BRCA1* with linkage to prostate cancer susceptibility (Lange et al., 2003). This region has subsequently become one of the most intensively investigated regions of the genome for HPC susceptibility. Furthermore, germline mutations in *BRCA2* have subsequently been found to not only increase the risk of developing prostate cancer but also confer worse prognosis and have implications in the management of the disease, such as the use of platinum and taxane chemotherapy and PARP inhibitors (Castro and Eeles, 2012).

Targeted next-generation sequencing of exons in 202 genes on chromosome 17q21-22 from germline DNA of unrelated patients with prostate cancer from families that were selected for linkage to the 17q22-22 region identified a variant in the *HOXB13* gene (*HOXB13* G84E) that significantly increased the risk of HPC (Ewing et al., 2012). The carrier frequency of the G84E allele was found in 0.1% of men without prostate cancer and 1.4% of men with prostate cancer. Furthermore, the frequency of the allele was much higher in men with early-onset, familial prostate cancer (3.1%) versus men with late-onset, nonfamilial prostate cancer (0.6%) (Ewing et al., 2012). Although the carrier rate of the G84E allele is rare, the strong linkage to prostate cancer risk may warrant genetic testing for the variant, much like is currently performed for *BRCA1* or *BRCA2* in hereditary breast and ovarian cancers. Other candidate HPC susceptibility genes include *ELAC2* (HPC2), macrophage scavenger receptor-1 *(MSR-1)* and *PODXL* (Casey et al., 2006; Nupponen et al., 2004; Tavtigian et al., 2001; Xu et al., 2002a). It is intriguing that two of the HPC candidates, *RNASEL* and *MSR-1*, are associated with functions of the immune response, because inflammation is currently considered a likely contributor to the pathogenesis of prostate cancer (De Marzo et al., 2007; Sfanos and De Marzo, 2012).

Sporadic Prostate Cancer

In sporadic prostate cancer, initial studies found recurrent changes involving losses of genetic material at 6q, 7q, 8p, 10q, 13q, 16q, 17p, 17q, and 18q; however, in most cases the precise genes involved have yet to be identified (Karan et al., 2003). **Changes in chromosome 8, typically loss of the p-arm and gain of the q-arm, or portions of these arms, are the most frequently observed genetic alterations.** At least two or three separate regions are deleted on 8p, implying the existence of multiple tumor suppressor genes (TSG). Chromosome **8p22 is commonly deleted, with frequencies of 32% to 65% reported in primary tumors and 65% to 100% in metastases. *MSR-1* lies in this region** and sequence variants in *MSR-1* have been found to be associated with increased disease risk; however, mutations in *MSR-1* have not been reported in sporadic prostate cancers (Nupponen et al., 2004; Wiklund et al., 2009; Xu et al., 2002a). **Another promising candidate TSG on 8p is the prostate-restricted homeobox gene *NKX3.1* at 8p21** (He et al., 1997). Mice engineered with a loss of a single allele of *NKX3.1* develop prostate hyperplasia and PIN, an example of haploinsufficiency, wherein a phenotypic effect is observed because of the loss of a single allele (Abdulkadir et al., 2002; Bhatia-Gaur et al., 1999).

8q gain, often involving the entire chromosomal arm leading to isochromosome 8q formation, is the most common chromosomal abnormality found in advanced prostate cancer (e.g., hormone-refractory lymph node metastases) and is correlated with disease progression and resistance to hormone deprivation or blockade (Alers et al., 2000; Isaacs, 2002; van Dekken et al., 2003). **The proto-oncogene *MYC* at 8q24 is a likely candidate gene on 8q,** but the observed gains are large and more work is required to properly assess this possibility. Elevated expression of another gene in this region, *EIF3S3*, has been documented in cancer compared with benign prostatic hyperplasia (Savinainen et al., 2004). Mouse models lend support for a linkage to *MYC* because transgenic mice with forced prostate-specific expression of human *MYC* develop PIN and invasive adenocarcinomas (Ellwood-Yen et al., 2003). Furthermore, amplification at the *MYC* locus has been reported in some human prostate cancers and is associated with a poor prognosis (Jenkins et al., 1997; Sato et al., 1999).

Chromosome 7 abnormalities are also frequently observed in prostate cancer. Aneusomy of the entire chromosome (trisomy 7) has been reported in PIN and cancer and has been associated with advanced stage and a poor prognosis (Alcaraz et al., 1994; Arps et al., 1993; Macoska et al., 1993; Qian et al., 1995; Zitzelsberger et al., 1994). Apart from whole chromosome gains, losses involving 7q31.1 have been documented, suggesting a tumor suppressor resides here (Takahashi et al., 1995; Zenklusen et al., 1994). A potential candidate TSG in this region is caveolin *(CAV1)*, whose expression is reportedly decreased in cancer (Bender et al., 2000; Wiechen et al., 2001). On the other hand, positive IHC staining for caveolin has been associated with *poor* prognosis; thus its role in prostate cancer remains unclear (Tahir et al., 2001; Yang et al., 1999). Another attractive candidate gene in this region is *EZH2*, which codes for a histone methyl-transferase involved in gene silencing. In microarray analyses, *EZH2* has been found to be overexpressed in prostate cancer metastases and its expression in primary tumors is associated with disease (PSA) recurrence (Lapointe et al., 2004; Rhodes et al., 2003; Varambally et al., 2002).

Chromosome 10 also undergoes alteration in prostate cancer, with deletions observed at 10p11.2 and 10q23-q24 (Ittmann, 1996; Trybus et al., 1996). The tumor suppressor gene *PTEN*, a PI3 kinase antagonist, maps to this second region and has been linked to human prostate cancer in a number of studies (Ayala et al., 2004; Li et al., 1997a). *PTEN* undergoes homozygous (both copies) deletion, loss of heterozygosity (LOH), and promoter hypermethylation and is also mutated in prostate cancer. **Overall, *PTEN* is more frequently altered in advanced disease** (reported rates of 60% to 100%) compared with primary tumors (Cairns et al., 1997; Han et al., 2009; Pesche et al., 1998; Sarker et al., 2009; Whang et al., 1998). Interestingly, the frequency of *PTEN* LOH greatly exceeds *PTEN* mutation; therefore it is suggested that another gene or genes may be targeted for deletion in this region of chromosome 10. One possibility is the *MXI1* gene, whose protein product binds to and antagonizes *MYC*. In the mouse, *PTEN* deficiency exhibits synergy when combined with other mouse models of prostate cancer (Carver et al., 2009; Chen et al., 2006; Di Cristofano et al., 2001; Kim et al., 2002; King et al., 2009).

LOH on 13q has been reported in greater than 50% of prostate cancer cases examined. Three separate regions of loss have been identified, containing the potential cancer genes *BRCA2*, *RB1*, *EDNRB*, and *KLF5* (Chen et al., 2003; Cooney et al., 1996b; Hyytinen et al., 1999). High rates of *RB1* loss (up to 80%) have been reported in advanced cancers (Cher et al., 1996); however, the *RB1* mutation rate is relatively low, and RB1 expression is not well correlated with the gene dosage or disease status (Bookstein et al., 1990; Ittmann and Wieczorek, 1996; Kibel and Isaacs, 2000; Kubota et al., 1995). However, Theodorescu et al. reported that low RB1 protein expression was correlated with decreased disease-specific survival in univariate and multivariate analysis (Theodorescu et al., 1997).

Losses on 16q have been observed with reported frequencies ranging from 30% to 56% of prostate cancer cases, more commonly seen in advanced cancer and associated with a poor prognosis (Bergerheim et al., 1991; Carter et al., 1990; Elo et al., 1997; Li et al., 1999; Suzuki et al., 1996). A common region of loss at 16q22-q24 contains two likely candidate genes, the *CDH1* gene at 16q22.1 that codes for the calcium-dependent cell-cell adhesion protein E-cadherin (Morton et al., 1993; Murant et al., 2000; Rubin et al., 2001; Umbas et al., 1994) and the *ATBF1* gene at 16q22, coding for an AT-sequence binding transcription factor (Sun et al., 2005). Loss of *CDH1* has been associated with metastatic prostate cancer; however, IHC staining studies have produced mixed results and reports of mutation or LOH of E-cadherin are lacking; therefore *CDH1* may not be the primary target of the 16q deletion. The *ATBF1* gene, on the other hand, has been reported to be mutated in 40% of prostate cancers (Sun et al., 2005).

Reports of LOH on 6q range from 30% to 50%, with a minimal region of loss at 6q14-q22, although no strong candidate gene has been identified in this region (Cooney et al., 1996a; Hyytinen et al., 2002).

Allelic losses of a region on 17p that includes the *TP53* gene have been documented but are relatively infrequent in primary prostate cancer compared with more advanced disease (Brooks et al., 1996). This matches findings of mutational analyses in which TP53 mutations are rarely found in primary tumors but are reported in up to 40% of advanced disease (Bookstein et al., 1993; Navone et al., 1993; Visakorpi et al., 1992). A recurrent region of loss on 17q is located near the *BRCA1* gene at 17q21; however, the identified common area of loss does not include this critical tumor suppressor gene (Brothman et al., 1995; Williams et al., 1996).

Deletions on 18q are mainly observed in advanced prostate cancer, with a common region of deletion encompassing the known cancer-related genes *DCC*, *SMAD2*, and *SMAD4* (Ueda et al., 1997; Yin et al., 2001).

Loss of the cell cycle regulatory gene *CDKN2A* on 9p21, which encodes the cyclin-dependent kinase inhibitor p16, has been reported in 20% of prostate cancers and at twice this frequency in advanced disease (Cairns et al., 1995; Jarrard et al., 1997). As discussed previously, this locus also contains the p14 and p15 genes as well, making it difficult to pinpoint the exact target(s) of genetic loss in this region. Reduced expression and LOH of another *CDKI* gene, *CDKN1B* on 12p13.1-p12, which encodes the p27 protein, are also found in prostate cancer and are associated with more advanced disease (Guo et al., 1997; Kibel et al., 1998; Yang et al., 1998).

One additional locus that has particular relevance for prostate cancer is the androgen receptor *(AR)* gene located on Xq12. **The region Xq11-q13 containing *AR* is amplified in up to 30% of cases of advanced disease failing hormonal ablation therapy, in stark contrast with untreated (hormonally naive) cases that do not show *AR* amplification** (Chen et al., 2004; Linja and Visakorpi, 2004; Mellado et al., 2009; Visakorpi et al., 1995a). *AR* mutations, which often act to broaden the receptor's ligand specificity or otherwise provide a gain of function, occur in advanced as well as lower stage cancer, although they are rarely found in cases untreated by androgen deprivation therapy (Culig et al., 2001; Gottlieb et al., 2004; Hara et al., 2003; Newmark et al., 1992; Taplin et al., 1995; Tilley et al., 1996). Even in the absence of gene amplification, AR protein levels have been seen to be elevated in prostate cancer (Latil et al., 2001; Linja et al., 2001), further emphasizing the importance of AR hyperactivation in this disease. In addition to mutation, alternatively spliced versions of the *AR* lacking the androgen ligand-binding domain have been identified in prostate cancer cells (Dehm et al., 2008; Guo et al., 2009b; Hu et al., 2009). Such *AR* splice variants are active in the absence of bound ligand and therefore may contribute to the emergence of prostate cancer refractory to androgen ablative therapies.

Subsequent studies using the comparative genomic hybridization (CGH) technique, in which competitive reactions between differentially labeled tumor-derived versus normal-derived genomic DNA highlight regions lost or gained in the tumor sample, have largely confirmed and also extended the genomic alterations previously uncovered using LOH analysis. These CGH studies indicate that the number of different alterations is increased in advanced disease and that losses are more frequent than gains in early stages of the disease, with gains and genetic amplifications more commonly seen in advanced hormone-refractory disease (Cher et al., 1996; Nupponen and Visakorpi, 2000; Visakorpi et al., 1995b). Sun et al. reviewed all published prostate cancer CGH studies (Sun et al., 2007) and found that, overall, 13 regions were found to be altered in at least 10% of prostate cancer cases, with 8 regions showing deletion and 5 regions showing copy number gain. An additional 6 regions (3 with gains, 3 with losses) were found to be altered in more than 10% of advanced cancers. In agreement with earlier studies, 8p was the most frequent region of genomic loss (with a peak at 8p21.3), being observed in one-third of all cases and one-half of advanced disease. Likewise, 8q was gained most often (bimodal peaks at 8q22.2 and 8q24.13), being observed in one quarter and one half of all cases and in advanced disease, respectively (Sun et al., 2007). The other regions commonly lost, in decreasing order of frequency, included 13q21.q31, 6q14.1-q21, 16q13-q24.3, and 18q12.1-q23, while regions exhibiting gain included 7q11.21-q32.3, Xq11.1-q23, 17q24.1-q25.3, and 3q26.23-q33. Also in keeping with the general observation that more aggressive and advanced cancers typically harbor more genetic abnormalities than their lower grade and lower stage counterparts, advanced prostate cancers displayed 2- to 3-fold more copy number alterations.

The application of modern high-resolution methods for assessing CNA, such as representational oligonucleotide microarray analysis and single nucleotide polymorphism (SNP) mapping arrays, will vastly improve our ability to detect CNA, particularly smaller alterations below the resolution limit of CGH, as well as aid in the identification of the resident oncogenes and tumor suppressor genes (Liu et al., 2006; Lucito et al., 2003; Sebat et al., 2004; Slater et al., 2005; Zhao et al., 2005).

High-density SNP microarrays have been used in genome-wide association studies (GWASs); high-resolution association studies between common DNA sequence variants (SNPs) and prostate cancer risk. Unlike the more traditional linkage analyses of the past, the platform is amenable to very large cohorts and is better able to detect genetic variations with small to moderate effects on disease risk (Jorgenson and Witte, 2007; Manolio, 2010; Risch and Merikangas, 1996). Several GWASs have been published on prostate cancer, resulting in the identification of more than 70 germline variants (SNPs) that are associated with the risk of developing prostate cancer (Amundadottir et al., 2006; Breyer et al., 2009; Duggan et al., 2007; Eeles et al., 2008; Eeles et al., 2009; Eeles et al., 2013; Gudmundsson et al., 2007; Gudmundsson et al., 2008; Haiman et al., 2007; Nakagawa et al., 2012; Thomas et al., 2008; Witte, 2007; Yeager et al., 2009). With larger meta-analyses being conducted worldwide, the number of prostate cancer SNPs is expected to increase to more than 100 in the near future (Nakagawa, 2013).

Interestingly, most of the SNPs are not located in or even near genes previously shown to be involved in prostate cancer pathogenesis. Notably, three independent loci were identified on 8q24, all contained within 1 Mb of the DNA segment; however, no genes have yet been identified to account for these risk alleles (Cheng et al., 2008). Systematic review of replication studies in prostate cancer susceptibility loci identified from GWASs finds that the 8q24 region continues to be the most implicated in prostate cancer risk and among different racial cohorts (Ishak and Giri, 2011). Although the *MYC* gene is in this vicinity, it is still 200 Kb away from the nearest SNP, thus its relevance, if any, remains uncertain. Importantly, unlike the loci identified in earlier linkage studies in HPC families, the risk alleles identified in these GWASs have been independently confirmed. As predicted, the risk attributable to each locus is small to modest, yet, because of the large cohorts studied, each association is highly statistically significant and each has been shown to confer risk independent of the other loci, thus these risk alleles act in a fairly additive fashion (Kote-Jarai et al., 2008; Sun et al., 2008; Witte, 2009; Zheng et al., 2008).

The clinical utility of using SNP “panels” for prostate cancer risk assessment is currently being investigated (Chatterjee et al., 2013; Nam et al., 2009; Zheng et al., 2009). However, **although men in the top decile in terms of number of combined risk alleles have a two- to fourfold increased risk for prostate cancer compared with the bottom decile, the numbers of men harboring such large numbers of risk alleles is small, thus these SNPs are unlikely to have utility for population screening purposes**. An important facet to these studies is that so far most of these prostate cancer risk alleles do not appear to be associated specifically with risk for aggressive disease (Kader et al., 2009; Wiklund et al., 2009). This is unfortunate because the lack of strong prognostic markers is a key shortcoming in the field that must be resolved. **The majority of current GWASs used case-control designs; therefore it will likely require new case-case studies, comparing aggressive versus nonaggressive disease, to uncover new SNPs informative for disease aggressiveness. It is thought that the recently identified SNPs are therefore more likely related to prostate cancer initiation rather than progression.** One such study that compared SNP frequencies among prostate cancer patients who were defined as having aggressive versus nonaggressive disease identified a region of 17p12 (TT genotype of SNP rs4054823) that was consistently higher among patients with more aggressive disease (Xu et al., 2010). The SNP in 17p12 resides in a region that does not contain any known genes; therefore, at present, the molecular mechanism by which it is associated with aggressive disease remains unknown.

Another approach that has had some early success in other cancers is to use gene expression array data to develop “gene signatures” able to predict aggressive behavior (Cheville et al., 2008; Mucci et al., 2008; Setlur et al., 2008).

Recent rapid advances in next-generation sequencing technologies, allowing for whole-genome sequencing and whole-exome sequencing of multiple tumor samples at a time, have enabled comprehensive analyses of the complete landscape of genomic alterations (e.g., SNPs, CNAs, chromosomal rearrangements) present in human prostate cancer. One such study that conducted massively parallel sequencing of tumor and matched genomic DNA from seven patients with Gleason grade 7 or higher tumors identified a median of 3866 putative somatic base mutations (range 3192–5865) covering approximately 80% of the genome per tumor with a 10-fold higher mutation rate in CpG dinucleotides than all other genomic positions (Berger et al., 2011). Of the somatic mutations identified, a median of 20 mutations per tumor that cause a change in amino acid sequence were found to occur within protein-coding genes. Specific genes found to be mutated in multiple tumors included the scaffold protein *SPTA1*, a modulator of the transcriptional regulator DAXX called *SPOP*, chromatin modifiers *CHD1*, *CHD5*, and *HDAC9*, and members of the heat shock protein (HSP) stress response complex *HSPA2*, *HSPA5*, and *HSP90AB1*. In addition to somatic mutations, a median of 90 chromosomal rearrangements were identified per tumor genome (range 43–213), all of which produced balanced translocations without genomic loss and with the generation of “chimeric” chromosomes. Additional genes found to be specifically targeted by mutation and/or rearrangements were the tumor suppressor *PTEN* and the PTEN-interacting protein *MAGI2*. In a separate study of whole exome sequencing of 112 prostate tumor and normal pairs, mutations in *SPOP* were again detected, and this was found to be the most frequently mutated gene (Barbieri et al., 2012). Interestingly, Barbieri et al. found that *SPOP* mutations occurred in the tumors that lacked ETS family gene rearrangements, possibly defining a new molecular subtype of prostate cancer. Additional recurrent mutations were identified in the forkhead transcription factor gene *FOXA1* and *MED12*, a protein involved in transcription initiation. As exome sequencing becomes more and more routine, attention has turned to the possibility of performing rapid high-throughput sequencing of patient samples that can inform therapeutic decisions on men newly diagnosed with advanced prostate cancer (Roychowdhury et al., 2011).

In addition to novel gene fusions that have been identified via RNA-seq analyses, a number of novel noncoding RNA (ncRNA) species have been identified in prostate cancer samples. Much of the focus of ncRNAs in prostate cancer has been on microRNA (miRNA) species, which are small, approximately 22 nucleotide molecules that function in gene silencing and may be linked to prostate cancer aggressiveness, promote the development of castration resistance, or may serve as markers of prostate cancer stem cells (reviewed in Bolton et al., 2013). Recently, this also includes the discovery of multiple novel long noncoding RNA (lncRNA) transcripts that may play a functional role in prostate carcinogenesis (Lu et al., 2017). lncRNAs are distinguished from small ncRNA species (such as microRNAs, siRNAs, and small nucleolar RNAs) in that they are typically more than 200 nucleotides in length. Although they do not encode for functional peptides, lncRNAs do play a role in gene regulation and other cellular processes (Ulitsky and Bartel, 2013). One of the most clinically advanced biomarkers of prostate cancer, *PCA3* (also known as DD3), in fact happens to be an lncRNA (Bussemakers et al., 1999). RNA-seq performed on a cohort of 102 prostate tissues and cell lines identified 106 unannotated intergenic RNAs that were differentially expressed between prostate cancer and benign prostate samples (Prensner et al., 2011). One of the top upregulated transcripts, an lncRNA called *PCAT-1*, was markedly upregulated in metastases and was found to act as a target of the polycomb repressive complex 2 (PRC2). Interestingly, *PCAT-1* is located on chromosome 8q24, discussed previously in regard to susceptibility loci in prostate cancer, and is approximately 725 kb upstream of the *c-MYC* oncogene. Another lncRNA identified in this study, *SChLAP1*, was found in follow-up studies to antagonize chromatin remodeling complex activity and serve as a prognostic indicator of poor prostate cancer outcome (Mehra et al., 2016; Prensner et al., 2013).

Renal Cancer

Renal cell carcinomas (RCC) include a spectrum of subtypes and can be subdivided into at least five different categories: clear cell RCC (ccRCC), which account for the majority (70% to 80%) of adult cases; papillary RCC, which accounts for most of the remaining 10% to 20%; chromophobe RCC, collecting duct RCC, and the MiTF/TFE family translocation carcinomas described earlier. In addition, there are more than four inherited forms of RCC. **Importantly, the genes discovered to have germline mutations that cause these familial forms**

of the disease have also been found to play important roles in sporadic RCC as well (Coleman, 2008).

Patients with Von Hippel-Lindau (VHL) syndrome are predisposed to a number of tumor types, notably ccRCC (Coleman, 2008). The finding of consistent losses of 3p in this disease led to the identification of the von Hippel-Lindau *(VHL)* gene located at 3p25-p26, germline mutation of which causes VHL disease (Latif et al., 1993; Stolle et al., 1998; Tory et al., 1989; Zbar et al., 1987). **Once the *VHL* gene was identified, its status was assessed in sporadic (nonfamilial) RCC, where it was found to be mutated in more than half of sporadic ccRCC cases** (Gnarra et al., 1994; Shuin et al., 1994). More than 300 different *VHL* mutations have been catalogued and ccRCC cases not harboring *VHL* mutations often undergo LOH (deletion) or silencing of the gene by promoter hypermethylation; thus altogether, the vast majority of ccRCC have compromised *VHL*. **The VHL protein normally functions as part of a multiprotein complex with elonginB, elonginC, Cul-2 (cullin-2), and Rbx1 (ring box-1), which exhibits E3 ubiquitin ligase activity and targets subunits of the hypoxia-inducible factor-1 (HIF-1) transcription factor for ubiquitination and subsequent proteasomal destruction** (Iliopoulos et al., 1996; Kaelin, 2002; Kamura et al., 1999; Kibel et al., 1995; Pause et al., 1997). **HIF-1 functions as a master regulator of the cellular response to low oxygen levels.** Under normal conditions, specific proline amino acid residues in the two HIF-1 subunits, HIF-1α and HIF-1β, are hydroxylated by the oxygen-dependent proline hydroxylase enzymes *EGLN1-3*. This oxygen-dependent modification signals HIF-1's ubiquitination and thus HIF-1 is rapidly turned over (Bruick and McKnight, 2001; Ivan et al., 2001; Jaakkola et al., 2001; Maxwell et al., 1999). **Under conditions of oxygen deprivation (hypoxia) the prolyl hydroxylases fail to act; thus HIF-1 is spared and accumulates, allowing its translocation to the nucleus, where it activates a number of target genes,** including the glucose transporter *GLUT-1*, the proangiogenic growth factors *PDGF* and *VEGF*, the chemokine *CXCL-1* and its receptor *CXCL4*, TGFα and the HGF receptor, MET (Hu et al., 2003; Igarashi et al., 2002; Linehan et al., 2007; Staller et al., 2003; Wykoff et al., 2001). That the HIF-1 pathway is activated in ccRCC is supported by the highly vascular nature of these tumors and the fact that expression of HIF-1 target genes are found to be elevated. Thus, **in ccRCC, the loss of VHL function leads to a state of “pseudohypoxia,” in which the cells respond as if they are being starved for oxygen.**

Several of the genes activated by HIF-1 have been singled out for

therapeutic targeting, and positive results in clinical trials have led to FDA approval of some of these agents (Hansel and Rini, 2008; Linehan, 2002). For example, the monoclonal anti-vascular endothelial growth factor (VEGF) antibody bevacizumab and the small molecule kinase inhibitors sunitinib and sorafenib, which inhibit VEGF and PDGF, have shown improvements in progression-free survival in clinical trials for metastatic RCC, leading in the latter two cases to FDA approval (Hansel and Rini, 2008).

The VHL/sporadic ccRCC example epitomizes the potential for translational application of cancer molecular genetics, beginning with studies on a familial cancer that were then translated to the sporadic form of the disease, culminating in the rational design of therapeutic agents against revealed molecular targets having a positive impact in the clinic.

A second familial form of RCC is hereditary papillary renal carcinoma, the cause of which has been pinpointed to activation of the proto-oncogene tyrosine kinase c-Met, which is the cell surface receptor for the growth factor HGF (Jeffers et al., 1997). *MET* is located at 7q31-q34, which is notable because the vast majority of sporadic papillary RCC cases show trisomy of chromosome 7 (Kovacs, 1993). In addition, activating mutations, typically affecting the tyrosine kinase domain, leading to a constitutively active receptor, have also been found in sporadic cases (Schmidt et al., 1997).

A third type of hereditary RCC predisposition is Birt-Hogg-Dube (BHD) syndrome. Individuals with BHD most commonly develop chromophobe RCC, but other forms such as clear cell RCC, papillary RCC, and benign oncocytomas are also observed (Pavlovich et al., 2002; Pavlovich et al., 2005). The *BHD* gene underlying the disease is located at 17p11.12 and codes for the protein folliculin (Schmidt et al., 2001). A spectrum of disruptive mutations and gene deletions support a tumor suppressor gene function for folliculin (Khoo et al., 2002; Nickerson et al., 2002; Schmidt et al., 2005; Vocke et al., 2005); however, the precise function of this protein has not been elucidated, although evidence indicates it affects the ERK and Akt/mTOR signaling pathways (Baba et al., 2008).

A fourth familial RCC subtype, albeit rare, is hereditary leiomyomatosis RCC (HLRCC), featuring an aggressive form of papillary RCC (Kiuru and Launonen, 2004; Merino et al., 2007; Sudarshan et al., 2007). The cause of HLRCC has been traced to the fumarate hydratase gene at 1q42.3-q43, whose protein product converts fumarate to malate in the Krebs cycle. Once again, the HIF-1 pathway is implicated in RCC tumorigenesis, as the resulting accumulation of fumarate acts as a competitive inhibitor of the prolyl hydroxylases *EGLIN1-3*, preventing modification of HIF-1 subunits, prolonging their half-lives and leading to a pseudohypoxic state, as was the case for mutated *VHL*. In support of this pathogenetic scheme, increased expression of VEGF and a high microvessel density has been found in HLRCC tumors (Isaacs et al., 2005; Pollard et al., 2005).

In 2011 a germline missense substitution was discovered in microphthalmia-associated transcription factor (*MITF*, another member of the MiTF family discussed earlier in regard to MiTF/TFE family translocation carcinomas) that conferred a greater than fivefold increase in risk of developing RCC, melanoma, or both types of cancer (Bertolotto et al., 2011). The germline substitution in codon 318 (E318K) was found to impair SUMOylation of MITF, leading to transcriptional activation of genes that function in the hypoxia pathway *(HIF1A, CCR7, HMOX1)*, the importance of which in RCC has already been discussed.

Bladder Cancer

Although first-degree relatives of patients with bladder cancer are at increased risk of developing the disease, high-risk families are very rare and lack clear Mendelian inheritance patterns, precluding classical linkage analysis. Bladder cancer is therefore not considered a familial disease. Instead, it has been proposed that there likely exist many susceptibility genes with small to moderate effects on disease risk (Aben et al., 2006; Kiemeney, 2008). Recent attention has therefore turned to the use of GWAS, which are better suited to the discovery of low penetrance susceptibility loci. The first such studies that have been published and reported susceptibility loci include 8q24.21, near the *MYC* proto-oncogene, 3q28, associated with the *TP53* relative *TP63*, and at 5p15.33, which is near the *HTERT* gene coding for the cancer-associated telomere maintenance enzyme telomerase (Kiemeney et al., 2008; Kiemeney et al., 2009; Rafnar et al., 2009; Wang et al., 2009a). Notably, gain of 5p15.33 had previously been identified as being associated with bladder cancer progression (Yamamoto et al., 2007), and reduced or absent TP63 expression has been associated with disease progression and poor prognosis (Koga et al., 2003; Urist et al., 2002). An additional GWAS reported by Wu et al. found a missense variant in the prostate stem cell antigen *(PSCA)* gene to be associated with bladder cancer risk in Caucasians (Wu et al., 2009b) and was subsequently shown in a GWAS by Wang et al. to be associated with bladder cancer risk in a

Chinese population (Wang et al., 2010). Interestingly, the rs2294008 variant of PSCA has also been shown to be significantly associated with gastric cancer in Japan and China (Matsuo et al., 2009; Sakamoto et al., 2008; Wu et al., 2009a). This mutation is predicted to result in truncation of the first 9 amino acids of the PSCA protein. Earlier studies reported that PSCA mRNA and protein levels are increased in bladder cancer compared with normal urothelium, with mRNA expression serving as an independent predictor of recurrence in superficial bladder cancer (Amara et al., 2001; Elsamman et al., 2006; Wang et al., 2010). Recent years have seen an explosion in large-scale GWASs in Europe and the United States that have now accounted for at least 11 extensively replicated urinary bladder cancer susceptibility loci: 1p13.3 *(GSTM1)*, 2q37.1 (*UGT1A* cluster), 3q28 (*TP63*), 4p16.3 (*TMEM129* and *TACC3-FGFR3*), 5p15.33 *(HTERT-CLPTM1L)*, 8p22 *(NAT2)*, 8q24.21 *(MYC)*, 8q24.3 *(PSCA)*, 18q12.3 *(SLC14A1)*, 19q12 *(CCNE1)*, and 22q13.1 *(CBX6, APOBEC3A)* (García-Closas et al., 2011; García-Closas et al., 2005; Kiemeney et al., 2008; Kiemeney et al., 2010; Moore et al., 2011; Rafnar et al., 2009; Rothman et al., 2010; Tang et al., 2012; Thorunn Rafnar et al., 2011; Wu et al., 2009b) with additional loci recently reported on 3q26.2 and 11p15.5 and two suggested regions on 20p12.2 and 6q22.3 as well (Figueroa et al., 2014). Pathway analysis of 5 GWASs conducted on bladder cancer cases and controls of European background found that the genetic variants associated with bladder cancer to belong to three fundamental cellular processes: metabolic detoxification, mitosis, and clathrin-mediated vesicles (Menashe et al., 2012).

The majority (75% to 85%) of bladder cancer and cancer-associated lesions seen in the clinic are of superficial type (stages pTa, pTis, pT1). Recurrences after therapy are frequent, requiring diligent surveillance by urine cytology and cystoscopy resulting in frequent resections. In addition, the risk of progression is likewise high. Accurate assessment of risk for recurrence and progression to muscle-invasive disease are critical needs for which current predictive schemes based on histopathologic features are suboptimal. Hopefully the information at the molecular level will help improve current methods of risk stratification.

Much work has been done to identify genetic alterations in bladder cancer. In general, changes observed fall into two groups: those that are mostly unrelated to clinical subtype (e.g., changes in chromosome 9 and *RAS* mutations), and those that are related to specific grades and/or stages of the disease (e.g., *FGFR3* mutations in low-grade noninvasive papillary urothelial bladder cancer; *TP53* and *RB1* alterations in muscle-invasive disease) (Knowles, 2008). In 2014 work by The Cancer Genome Atlas (TCGA) Research Network identified several additional mutated genes that had not been previously reported as significantly mutated in bladder cancer (TCGA Research Network, 2014). These genes included genes involved in cell cycle regulation *(CDKN1A)*, nucleotide excision repair *(ERCC2)*, and retinoic acid-mediated gene activation *(RXRA)*.

More than half of urothelial cell carcinomas of all grades show chromosome 9 alterations; commonly these are losses of the entire chromosome or entire chromosomal arms, whereas LOH events of more restricted regions are also seen, leading to the current consensus that there are multiple tumor suppressor genes located on both chromosomal arms (Cairns et al., 1993; Linnenbach et al., 1993; Tsai et al., 1990). In otherwise near-diploid tumors, complete loss of one copy (monosomy 9) is the only karyotypic abnormality seen (Fadl-Elmula et al., 2000; Gibas et al., 1984). The region at 9p21 containing the genes for the CDKI proteins INK4B (p15) and INK4A (p16), which suppress the RB1 pathway, as well as harboring the TP53-stabilizing gene *p14ARF*, is a strong candidate bladder cancer TSG locus. This region commonly undergoes LOH or homozygous deletion in bladder cancers, including low-grade and low-stage tumors (Berggren et al., 2003; Devlin et al., 1994; Orlow et al., 1995; Williamson et al., 1995), and mutations have been associated with high-grade disease and tumor progression (Orlow et al., 1999).

At least three different regions of loss have been mapped on 9q. Candidate bladder cancer TSGs have been proposed, including the patched gene, *PTCH*, at 9q22, which shows mutations and LOH in up to 40% of cancers (Aboulkassim et al., 2003; McGarvey et al., 1998); the region termed DBC1 at 9q32-q33, which exhibits deletion and silencing in approximately 50% of cases (Habuchi et al., 1998; Nishiyama et al., 1999); and 9q34, which exhibits LOH and contains the gene *TSC1* (tuberous sclerosis gene 1), a strong candidate bladder TSG resulting from the finding of *TSC1* mutations in conjunction with LOH (Adachi et al., 2003; Hornigold et al., 1999; Knowles et al., 2003). The *TSC1* gene encodes the protein hamartin, which is a phosphorylation target of Akt and functions in negative regulation of mTOR (mammalian target of rapamycin), a downstream target of the PI3K pathway, which is also dysregulated in bladder cancer via inactivation of the PI3K antagonist *PTEN*, as well as mutational activation of the p110 catalytic subunit of PI3 kinase; *PIK3CA* (Aveyard et al., 1999; Cairns et al., 1998; Wang et al., 2000).

Noninvasive (superficial, pTa) papillary UCC represents a major bladder cancer subgroup at diagnosis. Apart from changes involving chromosome 9,

these tumors appear relatively stable with respect to chromosomal structural changes, with losses and gains reported for approximately a dozen different chromosomal locations, most in 20% or fewer of cases examined (Knowles, 2008; Koed et al., 2005). More subtle genetic alterations in oncogenes and tumor suppressor genes also occur with varying frequencies. As recently reviewed by Knowles (2008), activating mutations in the *RAS* family of proto-oncogenes (H-, K-, and N-RAS) have been reported in up to 15% of cases, mutations in *PIK3CA* in 16% of cases, and amplification/overexpression of *CCND1* and *HDM2* in 10% to 20% and approximately 30% of cases, respectively.

In addition to oncogene activation, inactivation of several tumor suppressor genes by either deletion or promoter hypermethylation has been reported in superficial papillary UCC. These genes include several genes on chromosome 9 such as *CDKN2A* (p16) affected in 30% to 60% of cases; *PTCH*, the *DBC1* locus and *TSC1*, all reportedly affected in 60% of cases (Knowles, 2008).

The most frequently altered TSG in superficial Ta disease is the fibroblast growth factor receptor 3 *(FGFR3)*, with mutation frequencies approaching 90% of cases reported (Billerey et al., 2001; Cappellen et al., 1999; Sibley et al., 2001; Tomlinson et al., 2007). The most common *FGFR3* mutation is a serine-to-cysteine mutation at amino acid 249, which has been shown to cause constitutive ligand-independent receptor activation because of induced receptor dimerization via intermolecular Cys-Cys disulfide bonding (Li et al., 2006). **The frequency of *FGFR3* mutations is much lower in higher stage, invasive bladder cancers, and mutations are lacking in the superficial Tis stage (CIS), which has a high propensity for recurrence and progression to invasive disease.** In addition, in Ta disease there is a strong inverse correlation between mutation and tumor grade (Billerey et al., 2001). The high preferential prevalence of *FGFR3* mutations in Ta disease suggests an association with low-risk bladder cancer (Tomlinson et al., 2007). *FGFR3* mutations are also associated with benign tumors of the skin (seborrheic keratoses) (Hafner et al., 2006; Logie et al., 2005). In a recent prospective study, Hernandez et al. (2006) concluded that *FGFR3* mutations are associated with a subgroup of tumors having good prognosis, and Burger et al. reported *FGFR3* status is useful in risk stratification for patients with high-grade non–muscle-invasive UCC. Finally, there are indications that *FGFR3* mutations and *RAS* family mutations are mutually exclusive (Hafner et al., 2006; Jebar et al., 2005; Logie et al., 2005). These findings may be rationalized by considering that FGFR3 is known to activate the RAS/RAF/MEK/ERK pathway (Choi et al., 2001). Likewise, reports of mutational exclusivity have been made regarding *FGFR3* and *TP53*, which are mutated in only about 5% of pTa cases and are associated with higher grade disease (Bakkar et al., 2003; Zieger et al., 2005). Interestingly, in pT1 disease, the frequency of *FGFR3* mutations is lower, *TP53* mutation frequency is higher, and unlike pTa disease, these mutations are not necessarily mutually exclusive (Bakkar et al., 2003; Tomlinson et al., 2007; van Rhijn et al., 2004).

Although the frequency of chromosome 9 alterations and *RAS* family mutations are comparable across all grades and stages of bladder cancer, **muscle-invasive urothelial carcinomas (stage pT2 and higher) exhibit more genetic alterations (qualitatively and quantitatively) than lower stage disease; in keeping with the general observation that more aggressive cancers tend to exhibit evidence of greater genetic instability than their less aggressive counterparts.** Invasive bladder tumors exhibit a wide range of copy number alterations across virtually every chromosome, although the gene targets of these changes are largely unknown at present (Koed et al., 2005). In a similar vein, Blaveri et al. used cluster analysis of array CGH (aCGH) data to successfully separate bladder tumors of differing stages and grades from one another. In addition, a quantitative measure of the fraction of genome altered (FGA) was shown to be inversely related to patient survival time in cases with muscle-invasive cancer (Blaveri et al., 2005). Ploidy, another reflection of genomic instability, has been found to be associated with progression from noninvasive to invasive bladder cancer (Holmang et al., 2001). Mutational inactivation of *TP53* is seen in greater than 40% of invasive pT2 tumors, in sharp contrast to the low mutational rate seen in pTa disease, where *TP53* mutation is associated with risk for progression (Fujimoto et al., 1992; George et al., 2007; Spruck et al., 1994; Uchida et al., 1995). Likewise, inactivation of *RB1*, either by LOH or through *INK4A* inactivation, is common in invasive bladder cancer but is infrequent in pTa tumors (Benedict et al., 1999; Cairns et al., 1991; Chatterjee et al., 2004; Shariat et al., 2004). Loss of the region of 10q harboring the *PTEN* tumor suppressor gene is also more frequent in muscle-invasive bladder cancer than in lower stage pTa tumors (Aveyard et al., 1999; Cappellen et al., 1997; Kagan et al., 1998).

Intrinsic Subtypes of High-Grade Bladder Cancer

At least two intrinsic subtypes of high-grade bladder cancer have been identified (Choi et al., 2014; Damrauer et al., 2014). Luminal and basal-like subtypes, which have characteristics of different stages of urothelial differentiation, have been correlated with patient outcomes. These subtypes are also similar to molecular changes that have been identified in breast cancer. Distinct genomic alterations such as *FGFR3* and *TSC1* mutations are commonly found in the luminal subtype, whereas alterations in the RB1 pathway are enriched in basal-like bladder cancer (Damrauer et al., 2014).

Low-grade papillary tumors are found to have frequent *FGFR3*, *RAS*, and receptor tyrosine kinase alterations, whereas high-grade tumors are characterized by loss of tumor suppressor genes, such as *PTEN*, *TP53*, and RB1 pathway alterations. A model of bladder cancer initiation and progression that incorporates data related to these distinct molecular subtypes suggests that low-grade tumors that progress are high-grade papillary tumors of the luminal molecular subtype, and high-grade tumors that originate de novo are more consistent with the basal-like expression subtype (Damrauer et al., 2014).

Using whole genome mRNA expression profiling, three molecular subtypes of muscle-invasive bladder cancer that resembled molecular subtypes of breast cancer have been identified (Choi et al., 2014). Basal-type bladder cancers are characterized by p63 activation, squamous differentiation, and more aggressive disease at presentation. Luminal-type bladder cancers had active PPARg and estrogen receptor transcription and are enriched with activating FGFR3 mutations. The p53-like bladder cancers are frequently resistant to neoadjuvant methotrexate, vinblastine, doxorubicin, and cisplatin chemotherapy, and all chemoresistant tumors were found to have a p53-like phenotype after therapy (Choi et al., 2014). These data suggest that the level of “p53-ness” plays an important role in bladder cancer chemoresistance.

Genetic Alterations in Bladder Pre-Neoplasia

Urothelial hyperplasias with flat or papillary histomorphology have been proposed to be precursors of low-grade bladder cancers, although this concept is somewhat controversial (Chow et al., 2000). In support, Hartman et al. reported that, when present, genetic alterations (assayed at 9q21, 9q22, and 17p13) in hyperplasias were also found in superficial papillary tumors from the same patient (Hartmann et al., 1999). Genetic studies on hyperplasias have reported moderate to high frequencies of chromosome 9 alterations, whereas other genetic changes that are associated with aggressive forms of bladder cancer are reportedly infrequent (Chow et al., 2000). Dysplastic urothelial lesions have been found to be have frequent changes of chromosome 9 and frequent aneuploidy, and approximately half are *TP53* mutated (Hartmann et al., 2002; Mallofre et al., 2003). The prevalence of changes seen in low-grade intraurothelial neoplasia was lower than that observed in high-grade (CIS) lesions (Hartmann et al., 2002). CIS lesions (pTis) are aggressive, high-grade precursor lesions, exhibiting high rates of recurrence and progression to invasive disease. In contrast with superficial papillary lesions, CIS exhibits frequent (50%–70% range) genetic alterations (LOH) of 4q, 8p, 11p, 13q, and 14q, in addition to several other chromosomal alterations observed at lower but still significant frequencies (Rosin et al., 1995). CIS lesions may be subdivided into primary lesions, which are isolated without associated cancer and cancer-associated secondary lesions. It has been reported that chromosome 9 changes are infrequent in primary lesions, whereas the majority of secondary lesions exhibit deletions on chromosome 9 (Billerey et al., 2001; Hartmann et al., 2002; Hopman et al., 2002; Spruck et al., 1994).

As expected, given their aggressive nature, *FGFR3* mutation rates are low in CIS, whereas the *TP53* pathway shows frequent alterations. *TP53* mutation occurs in more than half of CIS lesions and is correlated with strong nuclear TP53 staining by IHC (Hartmann et al., 2002; Hopman et al., 2002). Nuclear *TP53* expression in TCC has been associated with increased risk of recurrence and death, independent of tumor grade, stage, and lymph node status in TCC patients (Esrig et al., 1994; Lipponen, 1993; Sarkis et al., 1993).

Genetic Alterations in Normal and Benign Bladder Urothelium

Given bladder cancer's propensity to recur, plus the fact that it is often multifocal, it has been proposed that there may be genetic changes in broad areas of the urothelium. Such a hypothesis would be in keeping with the “field cancerization” concept (also known as “field effect”), first devised by Slaughter et al. in 1953 to help explain the multifocal nature and high local recurrence rates of cancers of the oral cavity, as well as the finding of histologically abnormal epithelium in areas adjacent to cancer. Slaughter et al. proposed that multiple cancer foci arose within a wider field of abnormal epithelium that had been preconditioned by some prior carcinogenic insult(s). Genetic changes have been detected in samples of histologically normal-appearing urothelium obtained from surgical samples from cancer patients. For example, Muto et al. (2000) found shared instances of LOH as well as promoter hypermethylation of the

INK4A gene between normal-appearing and tumor areas from the same case. Likewise, Stoehr et al. (2005) performed LOH analyses on a large number of cases in which normal-appearing epithelium was isolated by laser capture microdissection. They also reported cancer-associated genetic changes in the normal-appearing urothelium, which, in some cases, matched the changes found in concurrent cancers in the same case. However, caution is warranted when assessing such results, given the possibility of contamination of the normal areas sampled by small multifocal cancer lesions or by pagetoid spread of tumor cells (Junker et al., 2003). On the other hand, a study by Obermann et al. using interphase FISH in tissue sections detected losses involving chromosome 9 in normal-appearing cells, which, from a technical standpoint, should be effective at excluding possible confounding microscopic foci of cancer cells (Obermann et al., 2004).

Inverted papillomas of the urinary bladder are considered benign entities. In keeping with this, they exhibit infrequent LOH at cancer-associated chromosomal loci, as well as infrequent (less than 10%) mutations of *FGFR3* (Eiber et al., 2007; Sung et al., 2006). In contrast to inverted papillomas, papillary urothelial neoplasia of low malignant potential (PUN-LMP) exhibit high rates (85%) of *FGFR3* mutation (van Rhijn et al., 2002), a genetic alteration that, as described previously, is strongly associated with bladder tumors of low stage and low grade. However, a study by Cheng et al. found frequent LOH at several loci that typically undergo LOH in advanced bladder carcinoma (greater than or equal to pT2) (Cheng et al., 2004).

Molecular Genetic-Based Assays for Bladder Cancer Detection and Surveillance

The large amount of data concerning common genetic alterations in bladder cancer have been exploited to aid in detecting the presence of bladder cancer. One widely used test termed Urovysion (Abbott Molecular/Vysis) is a multiplex, multicolor FISH-based assay that features a cocktail of 4 hybridization probes that assess the status of 4 chromosomes (Bubendorf et al., 2001; Halling, 2003). Probes specific for the centromeres of chromosomes 3, 7, and 17 provide information on cancer-associated gains of these chromosomes, whereas the fourth probe is specific for 9p21, which harbors the p14 and p16 genes often deleted in bladder cancers. This test, approved by the US FDA in 2005, is used in conjunction with standard urine cytology in diagnosing suspected cases as well as monitoring for local recurrence in patients previously diagnosed and treated (Hajdinjak, 2008; Halling et al., 2000). In addition, the test may have utility in monitoring response in patients with superficial bladder cancer treated with intravesical bacille Calmette-Guérin (BCG) therapy (Kipp et al., 2005) and may be useful in distinguishing inverted papillomas from urothelial carcinoma with inverted growth pattern (Jones et al., 2007).

Currently there are 6 FDA-approved urine-based molecular tests for bladder cancer focused on either genetic or immunochemical targets, and many other potential markers are under development (Herman et al., 2008; Sullivan et al., 2009; van Rhijn et al., 2005; Zwarthoff, 2008). **However, although these tests improve upon standard urine cytology, they do not supplant it.**

Finally, a recent study by Wang et al. (2009b) reported the development of a quantitative-PCR (Q-PCR) gene signature for predicting progression in cases of non–muscle-invasive bladder cancer.

Testicular Cancer

Testicular germ cell tumors (TGCTs) are a fascinating set of malignancies possessing many unique features (Oosterhuis and Looijenga, 2005). These cancers appear to originate from totipotent stem cells, with evidence strongly supporting TGCT initiation in utero, whereby abnormal primordial germ cells (PGCs) or gonocytes are blocked in their differentiation, remaining dormant until puberty. This is supported by expression in TGCTs of markers closely associated with PGCs, including placental alkaline phosphatase (PLAP), the stem cell factor tyrosine kinase receptor KIT (c-kit), and the transcription factors POU5F1 (Oct3/4) and NANOG that are involved in maintenance of pluripotency or “stemness.” The presumptive common precursor to TGCTs is the intratubular germ cell neoplasia unclassified (ITGCNU), which closely resembles PGCs, sharing many of the same markers (PLAP, KIT, POU5F1) (Skakkebaek et al., 1987). ITGCNU, also traditionally referred to as CIS (carcinoma in situ), although this nomenclature is technically inaccurate, has a very high rate of progression to invasive disease, estimated to be almost 100% if allowed sufficient time (Linke et al., 2005).

TGCTs are classified into two main categories: seminomas and the nonseminomas. A third type, the so-called spermatocytic seminomas, are extremely rare and are not discussed here (Ulbright, 1993). **Like the TGCT precursor ITGCNU, seminomas closely resemble PGC/gonocytes,**

morphologically and in their expression of molecular markers (positive expression of PLAP, KIT, POU5F1, NANOG, STELLAR, SOX17) (de Jong et al., 2008; Sperger et al., 2003). **Nonseminomatous TGCTs resemble embryonic and extraembryonic tissues that have undergone varying extents of differentiation.** The nonseminomas include four subtypes. Embryonal carcinoma (EC) are similar in many respects to embryonic stem cells, or perhaps primitive ectoderm, and express POU5F1, NANOG, and STELLAR, as well as SOX2 (Gopalan et al., 2009a). Extraembryonic differentiation is apparent in the yolk sac tumors (YSTs) and choriocarcinoma (CC), whereas somatic tissue differentiation is found in the teratomas.

Besides their unique pathogenesis, TGCTs are also unique in their responsiveness to treatment modalities that induce DNA damage (e.g., ionizing radiation and cisplatin-based chemotherapy). Thus the majority of patients are currently curable, even those with advanced disseminated disease (Einhorn, 2002). This extreme sensitivity to DNA damage is thought to be related to the origins of TGCT; their normal stem cell counterparts are poised to undergo apoptosis in response to DNA damage, and the fact that **most TGCTs maintain wild type TP53 and apparently intact DDR** (Bartkova et al., 2007; Gorgoulis et al., 2005; Kersemaekers et al., 2002). Interestingly, responsiveness to therapy in TGCT is inverse that seen in most other cancers, that is, sensitivity decreases with increasing differentiation state, such that ITGCNU are eliminated with low-dose radiation, whereas teratomas exhibit resistance to radiation and chemotherapy.

Family history is a strong risk factor for the development of TGCT, stronger than that found in most other cancers (Czene et al., 2002; Forman et al., 1992; Mai et al., 2009; Westergaard et al., 1996). Despite this fact, initial reports of an association between specific losses on Yq and risk were not later confirmed (Krausz and Looijenga, 2008). Genetic polymorphisms in CAG tract length, which codes for polyglutamine repeats in the androgen receptor, were assessed but were not found to be associated with disease risk (Garolla et al., 2005; Giwercman et al., 2004; Rajpert-De Meyts et al., 2002). Furthermore, **linkage and more recent GWASs have not revealed evidence for major TGCT-related genetic loci, implying instead the existence of multiple loci having modest influence** (Crockford et al., 2006; Lutke Holzik et al., 2005; Rapley, 2007)**. However, in two recent GWASs, Kanetsky et al. and Rapley et al. reported that common genetic variants at 5q31.3 near sprouty 4 (*SPRY4*, an inhibitor of the MAPK signaling pathway) and in the *KITLG* gene region (c-**

KIT ligand, also known as stem cell factor or steel factor) on 12q22 are significantly associated with TGCT risk, including seminomas and nonseminomas (Kanetsky et al., 2009; Rapley et al., 2009). In addition, Rapley et al. (2009) identified a susceptibility locus on chromosome 6 in an intron of *BAK1*, a gene that promotes apoptosis.

Spontaneous (as opposed to inherited) genetic alterations have been catalogued in TGCTs. Apart from aneuploidy, there are relatively few genetic changes or gene mutations found in TGCTs, giving an overall picture of a relatively low level of genetic instability, which may be in large part the result of the aforementioned intact DDR and predominately wild type *TP53* status in these cancers (Bignell et al., 2006; Greenman et al., 2007). One recurrent nearly universal genetic alteration in TGCT (excluding the rare spermatocytic seminomas) is the previously described gain of 12p, which may involve the *KRAS* gene or genes such as *NANOG* and *STELLAR* located in the stem cell cluster region at 12p13.31. Additional evidence for *KRAS* involvement in TGCT includes reports of activating mutations in up to 40% of cases, as well as increases in expression in concert with increased gene copy number. Interestingly, *BRAF* mutations have also been identified in TGCT but are seen to be mutually exclusive to K-Ras overexpression (McIntyre et al., 2005b; Sommerer et al., 2005).

Other changes that have been reported in sporadic TGCT include gains of material on chromosomes 1, 5, 7, and X; and losses on chromosome 18 in ITGCNU and invasive cancer; and losses from chromosomes 4 and 13, plus gain of 2p, which were more restricted to invasive cancers (Summersgill et al., 2001).

In seminomas, recurrent gains of 4q12, 16p13, and Xq22 plus losses of 3q29, 11q12.1, and 14q13.2 have been reported (Goddard et al., 2007). The *KIT* gene, whose protein product is a receptor tyrosine kinase also known as CD117, is located at 4q12. *KIT* amplifications have been reported in 24% of seminomas and gene-specific amplifications in 17%, but these changes were lacking in nonseminomas and ITGCNU (McIntyre et al., 2005a). Also, mutations in c-kit represent the most common somatic mutations found in seminomas (25% of cases) but are rarely found in nonseminomas (Coffey et al., 2008; Forbes et al., 2006). Despite the apparent lack of c-kit gene amplifications in ITGCNU, activating mutations in *KIT* have been reported, and IHC staining is positive for this entity as well as seminomas, although it not seen in nonseminomas or spermatocytic seminomas (Goddard et al., 2007; Kemmer et al., 2004; Looijenga et al., 2003; Przygodzki et al., 2002; Tian et al., 1999).

Gains of 17q11.2-q21 have been reported in TGCT, and this region contains the *ERBB2* receptor tyrosine kinase gene as well as the *GRB7* adaptor protein gene. *ERBB2* ties into the RAS pathway, whereas GRB7 binds to and likely regulates KIT, ERBB2, and RAS and is reportedly overexpressed in TGCT and their ITGCNU precursor (Kraggerud et al., 2002; Skotheim et al., 2003).

The previously mentioned results create an emerging picture of derangement of growth stimulatory protein kinase signaling pathways in TGCT, including activations in the RAS and KIT pathways in most seminomas and nonseminomas (Kemmer et al., 2004; Sommerer et al., 2005). In keeping with the fact that **RAS and KIT activate the PI3K/AKT pathway,** activated Akt has also been observed (Kemmer et al., 2004). In addition, **the PI3K antagonist PTEN is reported to be frequently inactivated by either mutation or deletion in seminomas and nonseminomas,** further suggesting an important role for activated PI3K/AKT pathway in TGCT (Di Vizio et al., 2005; Teng et al., 1997).

Normal PGCs undergo programmed erasure of DNA CpG methylation marks and thus a loss of imprinting. Recent IHC studies using an anti-5-methyl cytosine antibody to assess global methylation status in situ have confirmed and extended prior reports focusing on specific loci. These new studies found very low to absent 5-methyl cytosine in the majority of ITGCNU and seminoma compared with robust detection of 5-methyl cytosine in nonseminomas (Netto et al., 2008; Peltomaki, 1991; Smiraglia et al., 2002; Zhang et al., 2005). These results are supportive of a model for TGCT pathogenesis, in which ITGCNU is derived from retained abnormal PGC, which have matured to the point of 5-methyl cytosine erasure but before the point in normal PGC development at which epigenetic marks are re-established via de novo DNA methylation. Such observed changes in global methylation do not necessarily rule out the existence of hypermethylation at specific gene promoters. For instance, epigenetic silencing of specific genes such as the tumor suppressor *RASSF1A* has been reported in seminoma (Honorio et al., 2003; Koul et al., 2002).

Key Points: Genomic Alterations

- Large variations in chromosome numbers and complex structural rearrangements, as well as intratumoral variation in these aberrations, are hallmarks of most human solid tumors.

- The extent of chromosomal abnormalities typically correlates with disease severity and aggressiveness.
- Recurrent structural rearrangements occur in prostate (ETS gene fusions), renal (MiTF/TFE family translocation carcinomas), and testicular cancers (isochromosome 12p).
- Copy number alterations in a particular gene, coupled with changes in the other allele, are evidence for gene functioning as a disease-relevant oncogene or tumor suppressor gene.
- Genes discovered to have germline mutations that cause familial forms of cancer may also be involved in the sporadic form of the disease (e.g., VHL in ccRCC).
- High-density SNP microarrays have been used in GWAS to identify DNA sequence variants associated with cancer risk.
- Low-grade bladder cancers that progress are typically high-grade papillary tumors of the luminal molecular subtype, and high-grade bladder cancers that originate de novo are more consistent with basal-like expression.

Telomeres and Telomerase

As we have seen, **cancer cells exhibit marked genetic, morphologic, and behavioral heterogeneity, a reflection of their underlying genetic complexity and instability.** In addition, **most cancers display a strong positive association with increasing age.** As discussed previously, it has been persuasively argued that an increase over the extremely low baseline mutation rate (a mutator phenotype) is needed for accrual of sufficient mutations to bring about malignant transformation (Loeb, 1991).

Cancer genomes exhibit clear evidence of genetic instability; however, defective DNA maintenance and repair genes do not appear to be major contributors to the development of most sporadic cancers, thus the source of the genetic instability involved in the majority of cancers has been unclear. This has been particularly true of chromosomal instability, a nearly ubiquitous feature of carcinomas. Although alterations in chromosome number may arise via defects in centrosomes or the mitotic spindle checkpoint, little information exists regarding the origins of structural chromosomal abnormalities (Pihan et al., 2003; Roh et al., 2003). **An attractive candidate for the source of chromosomal instability in cancer is telomere dysfunction. Telomeres may provide a common link between genetic instability, cellular proliferation, and aging** (DePinho, 2000; Shay, 1997).

Telomeres and Chromosomal Instability

Telomeres are structures composed of specialized repetitive DNA complexed with telomere-specific binding proteins, located at the ends of every human chromosome, where they stabilize and protect the ends (Blackburn, 1991). Telomeric DNA is noncoding and consists of tandem repeats of the six base pair sequence TTAGGG (Meyne et al., 1989; Moyzis et al., 1988). In normal human cells, telomere lengths typically range from 6 to 12 kilobases per chromosome. **Telomeres that are too short are dysfunctional ("uncapped"), causing chromosomal destabilization** (Karlseder, 2003; Saldanha et al., 2003).

Importantly, telomeres are dynamic; shortening by approximately 100 base pairs each time a cell divides because of inability of DNA polymerases to completely replicate terminal DNA sequences (Harley et al., 1990; Lindsey et al., 1991). **Thus telomere length is inversely correlated with the number of**

times a cell has divided (Hastie et al., 1990; Levy et al., 1992). Telomere shortening may also occur because of unrepaired single-strand breaks caused by oxidative damage to telomeric DNA (Kruk et al., 1995; von Zglinicki et al., 2000). Conversely, telomeres may be elongated through the action of the telomere synthetic enzyme telomerase or, uncommonly, via a telomerase-independent genetic recombination mechanism termed ALT (Greider and Blackburn, 1985; Heaphy et al., 2011; Reddel et al., 2001).

Chromosomes with short, dysfunctional telomeres are prone to fusion, leading to the formation of dicentric chromosomes that missegregate or break in mitosis during anaphase. The newly generated chromosomal breaks are fusogenic, thus perpetuating a cycle of chromosome fusion and breakage (Lo et al., 2002; McClintock, 1941). It is in this way that critically short telomeres initiate chromosomal instability (Artandi and DePinho, 2000; Feldser et al., 2003; Vukovic et al., 2007). **Numerous studies support the link between telomere dysfunction and chromosomal instability in human cancers**. For example, in head and neck tumors, chromosomes bearing severely short telomeres are associated with chromosomal fusions, rearrangements, anaphase bridges, and multipolar mitoses (Gisselsson et al., 2000).

Telomere Shortening Acts as a Tumor Suppressive Mechanism in Normal Cells

Normal cells closely monitor their telomere lengths. Moderate telomere shortening either signals entry into an irreversible cell cycle arrest termed *replicative senescence* or initiates programmed cell death, responses thought to have evolved as tumor suppressive barriers against abnormal clonal expansion and the development of excessive telomere shortening that would accompany further cell division, were it to be allowed to continue (Wright and Shay, 2001). Thus **progressive telomere shortening acts as a “mitotic clock,” counting down cell divisions and signaling cell cycle exit once one or more telomeres reaches a threshold length** (Harley et al., 1990).

Forced expression of the enzyme telomerase in presenescent cells counteracts telomere shortening, thus preventing replicative senescence and endowing the cells with unlimited cell division potential or “immortalization” (Bodnar et al., 1998; Vaziri and Benchimol, 1998). In normal somatic human cells, telomerase activity is stringently repressed, thus telomere length will decrease in proliferating cells and can be used as a signal to halt further expansion.

Although the precise mechanism(s) by which short telomeres trigger senescence and apoptosis are still under study, evidence implicates the tumor suppressors TP53 and RB1 as being involved in the response to shortened telomeres (Vaziri and Benchimol, 1999). Importantly, abrogation of this telomere length checkpoint allows continued cell division and, in the absence of telomerase, severe telomere shortening, beyond the minimum length required for proper telomere function, therefore causing telomere uncapping and chromosomal destabilization (Counter et al., 1992).

In summary, **telomere shortening presents two important barriers to incipient cancer cells. First, moderate shortening instigates the senescence cell cycle exit or apoptosis. Second, extreme telomere shortening causes chromosomal instability, which, although it increases, the mutation rate will also tend to result in genetic abnormalities lethal to the cell** (Fig. 62.13).

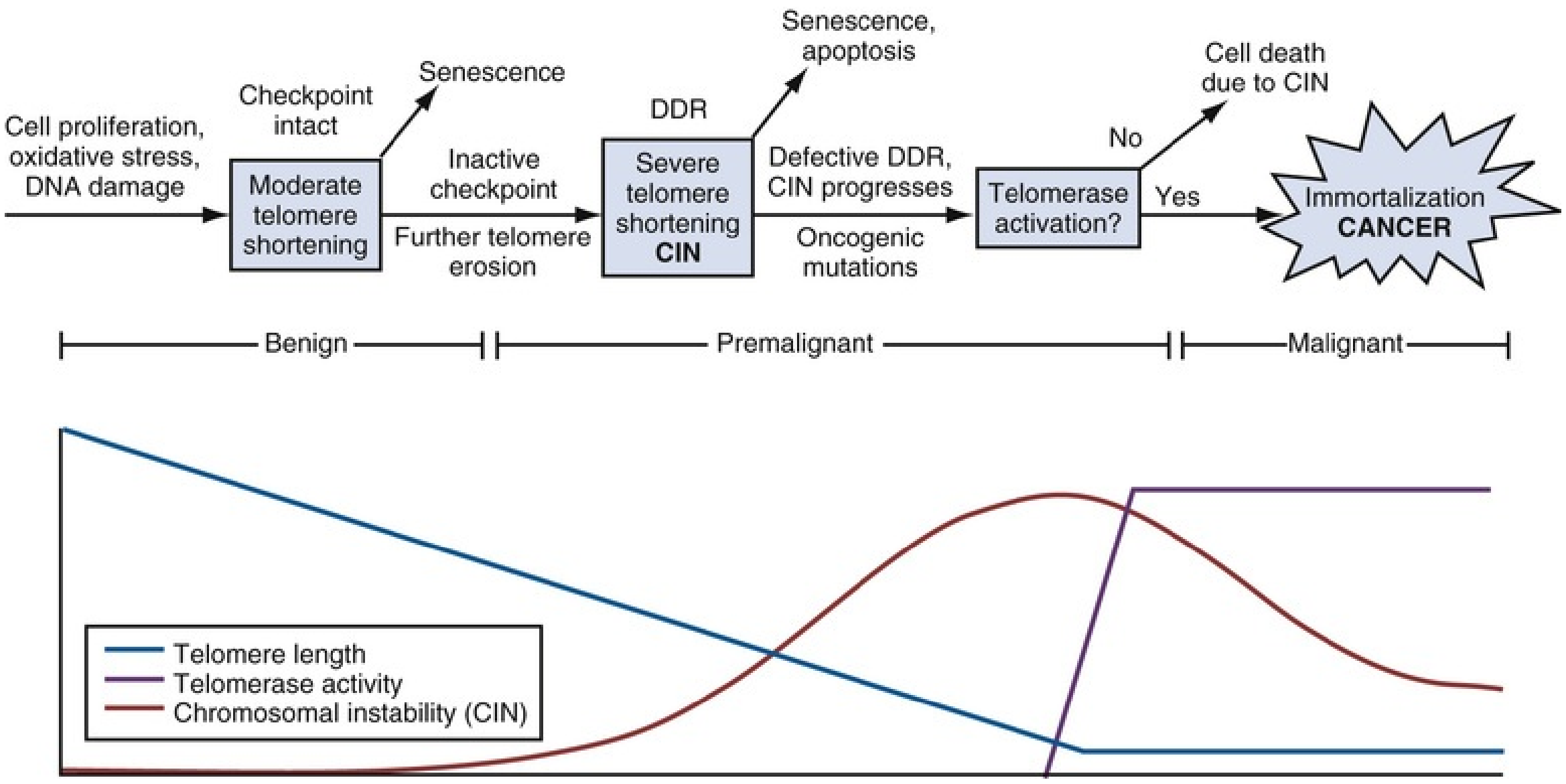
Cell proliferation, oxidative stress, DNA damage
Checkpoint intact
Moderate telomere shortening
Senescence
Inactive checkpoint
Further telomere erosion
DDR
Severe telomere shortening CIN
Senescence, apoptosis
Defective DDR, CIN progresses
Oncogenic mutations
Telomerase activation?
No
Cell death due to CIN
Yes
Immortalization CANCER
Benign
Premalignant
Malignant
Telomere length
Telomerase activity
Chromosomal instability (CIN)

FIG. 62.13 Contributions of telomere loss and telomerase activation to oncogenesis. Bypass of the normal telomere length-sensitive cell senescence checkpoint allows severe telomere loss which initiates chromosomal instability (CIN). Defective DNA damage response (DDR) allows CIN to continue, generating potentially oncogenic mutations but also producing intolerable levels of genomic damage. Transformed cells may proceed through this second barrier by activating telomerase, which stabilizes the telomeres and also provides an unlimited proliferative potential (“immortalization”).

Cancers and Premalignant Lesions Possess Abnormally Short Telomeres

The majority of human cancer tissues and cancer-derived cell lines examined have been found to contain abnormally short telomeres (Furugori et al., 2000; Hastie et al., 1990; Mehle et al., 1996; Remes et al., 2000; Takagi et al., 1999). For example, using a Southern blot technique for bulk telomere length assessment, Sommerfeld et al. and Konenman et al. observed substantial telomere shortening in primary prostate cancer tissues compared with matched adjacent normal-appearing and benign prostatic hyperplasia (BPH) areas in radical prostatectomy specimens (Koeneman et al., 1998; Sommerfeld et al., 1996). Likewise, results from direct telomere length assessment in archival tissue samples using telomere-specific FISH reveal significantly shorter telomeres in prostate cancer cells, when compared with their normal epithelial cell counterparts within the same tissue samples (Meeker et al., 2002a).

When examined using high-resolution telomere-specific FISH, it has been found that **premalignant lesions, including those of bladder and prostate cancer, tend to have abnormally short telomeres** (Hansel et al., 2006; Kawai et al., 2007; Meeker and Argani, 2004; Meeker et al., 2004; van Heek et al., 2002). This finding indicates that **telomere loss occurs early in the disease process**, at the IEN stage, **strongly implying a causal role for telomere shortening in carcinogenesis through the initiation of chromosomal instability** (O'Shaughnessy et al., 2002). In the prostate, the premalignant precursor is high-grade prostatic intraepithelial neoplasia (HGPIN) (Bostwick and Cheng, 2012). **A new regulatory motif in cell-cycle control causing specific inhibition of cyclin D/CDK4**, the majority of which (93%) were found to harbor abnormally short telomeres by FISH (Meeker et al., 2002b). Notably, in this study, telomere shortening in HGPIN foci was restricted to the *luminal* secretory epithelial cells only, whereas the underlying basal epithelial cells and surrounding stromal cells displayed normal telomere lengths. In a separate study, Vukovic et al. reported significant telomere shortening in 63% of HGPIN, with a higher rate of telomere shortening (80%) reported for foci situated near (within 2 mm) adenocarcinoma within the same tissue sample (Vukovic et al., 2003). Studying a cohort of men with a diagnosis exclusively of HGPIN in prostate needle biopsies, Joshua et al. (2007) reported an association between short telomeres in the PIN lesions or surrounding stromal cells and eventual diagnosis of prostate cancer, as well as time to diagnosis.

Because the majority of PIN lesions are not thought to progress to invasive cancers, intact telomere-based replicative senescence or apoptosis checkpoints may represent a critical bottleneck restraining the outgrowth of most PIN lesions. Even if incipient cancer cells manage to abrogate these checkpoints, as described later, they would still have to activate telomerase to avoid intolerable levels of genetic instability and provide an immortalized phenotype.

Telomerase Activity Restabilizing Chromosomes and Allowing Unlimited Cellular Replication

Although dysfunctional telomeres may help initiate cancer formation, if left unchecked, continued telomere shortening in premalignant lesions and cancers would cause increasing levels of genetic instability, ultimately becoming lethal to the tumor. Cancer cells overcome this problem by restabilizing their telomeres, primarily through activation of the enzyme telomerase, a specialized reverse transcriptase that adds back telomere DNA repeats to chromosome ends (Greider and Blackburn, 1987). Telomerase provides at least two critical functions to the tumor cell; namely, quelling chromosomal instability and supplying the capacity for unlimited replication ("immortalization") (Greider, 1998; Shay and Wright, 1996). Research has revealed that telomere length maintenance appears to be a necessary step for human cells to become malignant; confirming the long-held belief that cellular immortalization is a key attribute of cancer cells (Elenbaas et al., 2001; Hahn et al., 1999). Although telomerase activity appears to be the preferred way cancer cells stabilize their telomeres, 10% to 15% of human cancer cases lack detectable telomerase activity. At least a subset of these, particularly certain CNS tumors and some cancers of mesenchymal origin, maintain their telomeres via a telomerase-independent genetic recombination pathway known as *alternative lengthening of telomeres (ALTs)* (Heaphy et al., 2011; Reddel, 2003). With the exceptions of nonseminomatous testicular germ cell tumors (15%), chromophobe renal cell carcinoma (9%) and small cell carcinoma of the bladder (23%), ALT is rarely if ever observed in common GU malignancies (Heaphy et al., 2011). However, almost all tissue samples assayed for ALT thus far have been from primary tumors. Interestingly, despite a lack of ALT in more than 1000 primary prostate cancers examined, ALT was found in all distant metastases assayed in a single patient with lethal prostate cancer. In this case, detailed genomic analysis indicated that ALT was acquired during the transition from local to disseminated growth, raising the intriguing possibility that ALT may play a role in advanced disease (Haffner et al., 2013).

Several studies have reported on telomerase activity in clinical prostate samples with positivity ranging from 47% to 100%, whereas normal and BPH tissues taken from prostates without evidence of cancer are typically negative for telomerase activity (Caldarera et al., 2000; Engelhardt et al., 1997; Kallakury et al., 1997; Kamradt et al., 2003; Kim et al., 1994; Koeneman et al., 1998; Lin et al., 1997; Sommerfeld et al., 1996; Wullich et al., 1999; Zhang et al., 1998). Although two of these studies found a positive correlation between either the presence or level of telomerase activity and tumor grade, four other studies found no correlation with grade, stage, or preoperative PSA levels. However, the number of cases in many of these studies was small.

Telomerase Activity as a Potential Diagnostic Marker

The high prevalence and relatively strong activity found in prostate cancers compared with normal tissue plus the very high sensitivity of the standard telomerase activity assay have led to evaluation of the telomerase activity assay as a potential diagnostic marker for cancer. Unfortunately, the potential utility of aiding cancer diagnosis appears limited, primarily because of problems with false-negative and false-positive results seen with the technically demanding telomerase activity assay. False-negative results may occur as a result of inactivation of the labile enzyme during isolation, whereas false-positive results may stem from the presence of inflammatory cells in the sample (Meeker and Coffey, 1997). In addition, other molecular cancer biomarkers often outperform telomerase. For example, the detection of telomerase components by RT-PCR in urine provides some improvement in the sensitivity and specificity over urine cytology in bladder cancer detection, particularly in low-grade disease (Eissa et al., 2007). However, a review of the literature on urinary molecular markers for bladder cancer detection concluded that other markers (e.g., microsatellites, FISH, and Cytokeratin 20) outperform telomerase (van Rhijn et al., 2005).

In an intriguing study, Wu et al. (2003) found that shorter telomeres in peripheral blood leukocytes (PBLs), as measured with telomere-specific Q-PCR, were associated with increased risk for a number of cancers, including bladder and renal cancer. Similar associations between short telomeres and bladder cancer risk were observed when comparing telomere lengths measured in buccal cells and PBL (Broberg et al., 2005; McGrath et al., 2007). **In contrast, no association was observed between PBL telomere length and prostate cancer risk in a recent study** (Mirabello et al., 2009). The variations in the PBL telomere lengths measured in these studies are thought to be due to inherited interindividual differences in telomere lengths modified by changes occurring postnatally, perhaps because of diet and lifestyle factors.

Potential Prognostic Value of Telomere Length in Prostate Cancer

Telomere shortening is predictive of poor prognosis in several cancers, including those of the lung, endometrium, and breast and neuroblastoma (Bisoffi et al., 2006; Griffith et al., 1999; Hiyama et al., 1995a; Hiyama et al., 1995b; Smith and Yeh, 1992). A potential link between telomere length and prostate cancer prognosis was first reported by Donaldson et al. In this retrospective case-control study, biochemical recurrence and overall survival were significantly correlated with tumor telomere content, a surrogate for telomere length. Specifically, all 7 prostatectomy patients whose tumor telomeric DNA contents were less than that of control samples (placental DNA) showed evidence of biochemical recurrence (elevated PSA) within 10 years after surgery (Donaldson et al., 1999). Of the 9 patients in this study with short tumor telomeres, 7 died within 10 years, in contrast to 100% 10-year survival for patients with normal-to-long tumor telomeres. In addition, these patients also showed no evidence of biochemical recurrence. Potential drawbacks of this study include a small sample size (18 cases; only 7 of 9 men in the short telomere category underwent surgery), and the fact that it was not known whether the deaths observed were due specifically to prostate cancer.

In a more recent retrospective study using 77 prostatectomy samples and a more sensitive chemiluminescent slot blot assay, Fordyce et al. (2002) reported that less-than-normal telomere content in primary prostate cancers was associated with recurrence, independent of patient age, grade (Gleason sum), and regional lymph node status (Fordyce et al., 2005). The magnitude of the relative hazard for disease recurrence associated with low telomere content (RH = 5.02) was on par with that of Gleason grade and nodal status. Interestingly, a positive correlation was found between telomere content of the tumor and that of the surrounding normal-appearing prostate tissue within the same prostatectomy samples. An association was also found between telomere content of these normal-appearing prostate tissues and 72-month recurrence-free survival. The authors postulated that telomere loss in morphologically normal tissue represents areas at heightened risk of experiencing genetic instability. This is reminiscent of the so-called “field effect” phenomenon that has long been discussed in the cancer literature (Bostwick et al., 1998; Crissman et al., 1993; Foster et al., 2000; Yu et al., 2004). The authors further proposed that cancers arising in such areas may show greater genotypic and phenotypic heterogeneity and thus be more prone to behave aggressively because of a greater level of chromosomal instability caused by short telomeres (Fordyce et al., 2005; Heaphy et al., 2013). Finally, in a recent prospective population-based study of prostate cancer using telomere-specific FISH, it was found that short telomeres in tumor-associated stroma cells as well as greater cell-to-cell variability in telomere length among cancer cells were associated with higher risk of death resulting from prostate cancer. These associations were found to be largely independent of other traditional poor prognostic indicators and the risk associations were essentially additive, such that men with the shortest stromal telomeres and most variable cancer telomeres had a 14-fold increased risk of dying from their cancer compared with men with the longest stromal telomeres and the least variable cancer cell telomeres (Heaphy et al., 2013).

Telomerase-Based Opportunities for Therapy

Given that the majority of human tumors rely on telomerase for immortalization and genomic stabilization, this enzyme is an attractive target for anticancer therapy. There are two overall strategic paradigms for therapeutic targeting of telomerase in cancer. The first involves taking advantage of the tumor's dependence on telomerase enzymatic activity for survival. This strategy includes approaches aimed at directly inhibiting telomerase enzymatic activity or blocking its expression. The second approach attempts to exploit the fact that the telomerase gene *(HTERT)* promoter is selectively active in cancer cells, for example, by using the telomerase promoter to drive oncolytic virus or gene therapy vectors to limit their replication or expression to tumor cells or by directing immunotherapy against cells expressing hTERT protein.

Many of these approaches have undergone preclinical testing using prostate cancer cell lines and xenografts, and some are currently in early clinical trials. One point of concern with antitelomerase therapies has to do with the question of selectivity of action against tumor cells over normal telomerase-positive cells, such as the stem cells of the hematopoietic system and those within tissues with high turnover rates. This is of particular importance for those approaches in which telomerase-positive cells are actively targeted for destruction, including immunotherapy, gene therapy, and oncolytic viral therapies. Encouragingly, work to date describing the treatment of human tumor xenografts in mice have, in general, not produced major toxicity in normal tissues.

Key Points: Telomeres and Telomerase

- Telomeres contain stretches of terminal, noncoding, repetitive DNA that cap the ends of each chromosome, thereby stabilizing them.
- Telomere DNA repeats are progressively lost as cells divide and as a result of oxidative DNA damage at the telomeres
- Normal cells monitor their telomere lengths and permanently exit the cell cycle (cellular senescence) or commit suicide (apoptosis) in tumor suppressive responses to telomere shortening. This telomere length checkpoint involves TP53 and RB1.
- Loss of telomere length checkpoints leads to critical telomere shortening, which initiates chromosomal instability contributing to cancer initiation.
- Most cancers and premalignant lesions have abnormally short telomeres.
- Most cancers express the enzyme telomerase that restabilizes the telomeres and allows unlimited cell division potential (immortalization); thus telomerase represents an attractive therapeutic target.

Apoptosis

Apoptosis, also known as programmed cell death, is a tightly regulated process used by multicellular organisms to eliminate unwanted cells. For example, apoptosis is used in tissue remodeling during development and in the immune system to eliminate self-reactive T cells (Ashkenazi and Dixit, 1998; Kerr et al., 1972). **Apoptosis contrasts sharply with necrosis, a nonprogrammed form of cell death** in which cells that are acutely injured (e.g., by physical trauma) swell and burst, abruptly releasing their contents, and act as potent inducers of the inflammatory response. **Apoptosis is a more orderly, energy-requiring process in which the dying cell's contents are degraded and neatly packaged into so-called apoptotic bodies, which are then engulfed by neighboring cells or macrophages; a process that does not elicit a strong inflammatory response** (Fadok et al., 1992).

Apoptosis and Cancer

Unlike unicellular organisms, cancer poses a risk to multicellular life forms; thus a variety of potentially tumorigenic abnormalities can signal a cell to eliminate itself as a potential threat via apoptosis. For example, if a cell suffers DNA damage (potentially mutagenic) but fails to make repairs, it will be eliminated and replaced from the organism's pool of undamaged cells. Therefore it is not surprising that aberrations of apoptosis can be detrimental and that failure of dividing cells to initiate apoptosis contributes to cancer (Ashkenazi and Dixit, 1998).

Abnormalities in the apoptotic machinery have implications for malignancy beyond an individual cell's ability to respond appropriately to cell physiologic stresses such as DNA damage. First, **the apoptosis cascade is critical to the immune system's ability to eliminate cancer cells by inducing them to undergo apoptosis** (Nagata, 1997). This has clear implications for the organism's intrinsic immune surveillance for malignancy and the tumor's response to extrinsic immunotherapy. Second, because cytotoxic cancer therapies also depend in large part on inducing apoptosis, **defects in the apoptotic cascade can profoundly influence tumor responses to chemotherapy and radiotherapy** (Minn et al., 1995; Thornberry and Lazebnik, 1998; Walton et al., 1993).

Apoptosis, an Evolutionarily Conserved Process

Apoptosis is tightly regulated by an evolutionarily conserved system of positive and negative signals, the balance of which determines whether the cell will undergo apoptosis. These signals ultimately converge upon an important family of proteases called caspases (“cysteine proteases with aspartic acid specificity”), key components of the apoptotic machinery (Thornberry, 1998). Caspases, of which there are at least 13, are **broadly categorized as either initiator caspases (e.g., caspases-8, 9 and 10) or executioner caspases (e.g., caspases-3, 6, and 7). Caspases are synthesized as larger, inactive forms called procaspases, which require specific proteolytic cleavage to become active proteases themselves.** Often a procaspase is activated by another caspase, setting in motion a sequential, amplifying, proteolytic cascade. **Initiator caspases begin the cascade that ultimately leads to activation of executioner caspases downstream. Once activated, the executioner caspases attack several intracellular protein targets.** Executioner caspases cleave antiapoptotic proteins, such as Bcl-2 and Bcl-XL, which not only destroy their anti-apoptotic function but also actually release proapoptotic carboxyl-terminal fragments, further stimulating cell death (Wolf and Green, 1999). Executioner caspases then target proteins critical to cell survival. Cleavage of DNA repair and replication proteins, such as DNA-PKcs and replication factor C, leads to nuclear dysregulation. Nuclear structural proteins, such as lamins NuMa and SAF-A, are fragmented, contributing to dissolution of the nucleus and nuclear condensation, a hallmark of apoptosing cells. Proteolysis of cytoskeletal proteins such as keratin and actin lead to destruction of the internal structural integrity of the cell. Last, cleavage of proteins critical to cell-cell interaction, such as beta-catenin and focal adhesion kinase, precipitates the specific and irreversible phenotypic changes associated with apoptosis (Orth et al., 1996; Wen et al., 1997; Wolf and Green, 1999). **The end result is a stereotypical death in which the cytoplasm shrinks, the cell membrane blebs, and the nuclear chromatin condenses. The entire apoptotic process can be completed in just 60 minutes** (Thornberry and Lazebnik, 1998).

Intrinsic Apoptotic Pathway

Apoptosis can be initiated via two different routes: the intrinsic and the extrinsic apoptotic pathways (eFig. 62.14**). The intrinsic apoptotic pathway**

monitors conditions within the cell, responding to various forms of stress. Proapoptotic signals may arise because of unrepaired DNA damage or from a lack of pro-survival signals transduced from cell-surface receptors, such as when cell-cell or cell-ECM contact is disrupted or soluble factors such as hormones or growth factors are withdrawn.

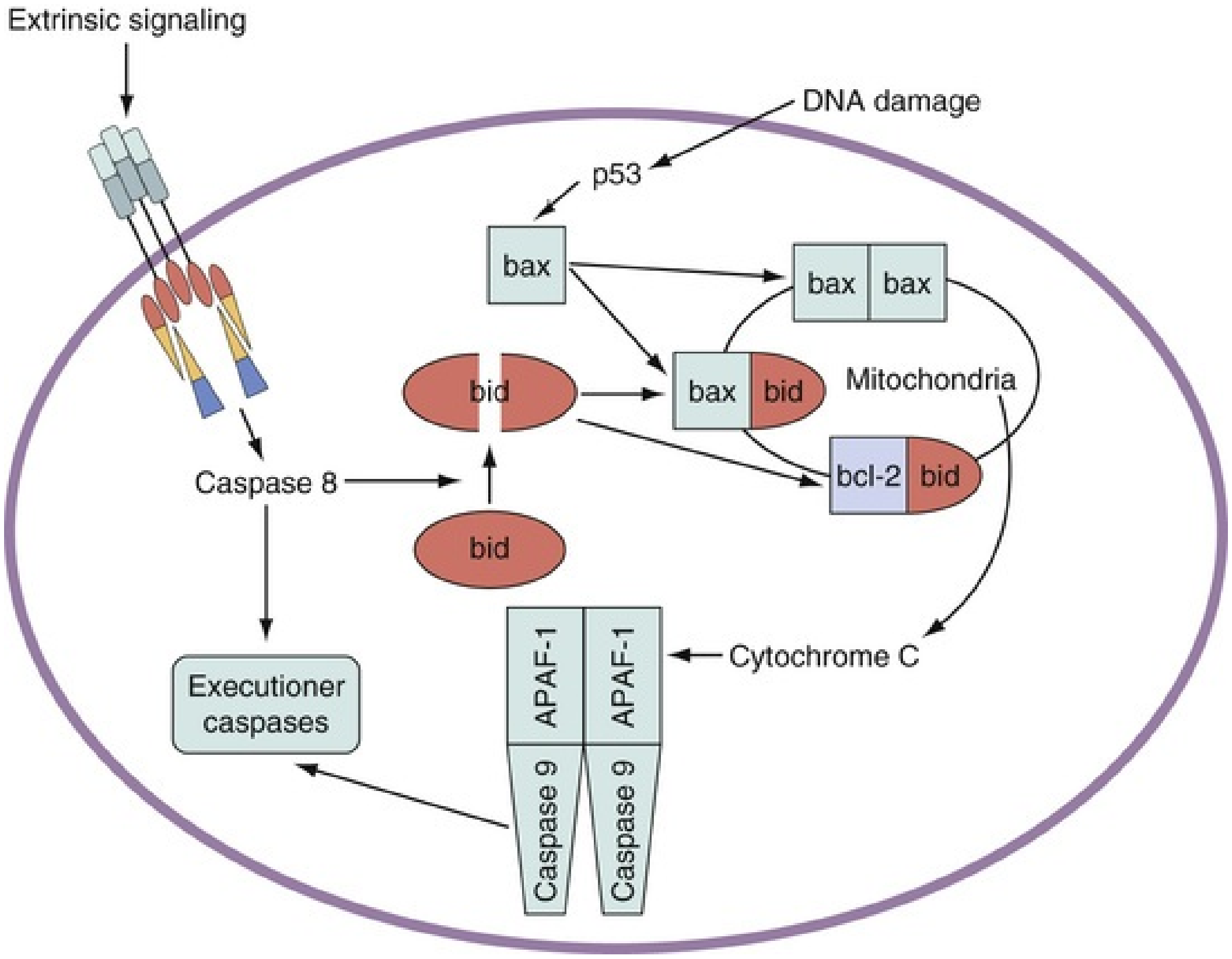
Extrinsic signaling
DNA damage
p53
bax
bax
bax
bid
bax
bid
Mitochondria
Caspase 8
bcl-2
bid
bid
APAF-1
APAF-1
Cytochrome C
Executioner caspases
Caspase 9
Caspase 9

EFIG. 62.14 Cascade of extrinsic and intrinsic mechanisms of apoptosis. The extrinsic system depends on ligand-induced activation of executioner caspases, whereas the intrinsic system depends on the dimerization of BCL2 family members to alter mitochondrial membrane permeability.

The mitochondrion is a main component of the intrinsic pathway, as are another conserved protein family, the Bcl-2 family. Bcl-2 family members include pro- and antiapoptotic proteins. The proapoptotic group consists of at least a dozen members, including Bax, Bak, Bok, Bik, Bad, Bid, and Bim. There are at least a half dozen antiapoptotic (pro-survival) Bcl-2 family members, including Bcl-2, Bcl-X_L, Bcl-W, and Mcl1 (Adams and Cory, 1998). All members contain one or more Bcl-2 homology domains (BH1 to BH4) that allow members of the family to heterodimerize with each other. Bcl-2 family members regulate each other's function through these BH domains (Cheng et al., 1996; Chittenden et al., 1995). Whereas each proapoptotic Bcl-2 member responds to different stimuli, **the principal mechanism by which each member induces cell death is by increasing mitochondrial membrane permeability** (Kroemer and Reed, 2000).When apoptosis is signaled via the intrinsic pathway, the balance between Bcl-2 family members shifts in favor of proapoptotic proteins that increase the permeability of the mitochondrial outer membrane, facilitating the release of cytochrome c from the intermembrane space into the cytoplasm (Jurgensmeier et al., 1998; Wolf and Eastman, 1999). **Once in the cytoplasm, cytochrome c molecules bind to Apaf-1 proteins, forming a complex known as the apoptosome. The apoptosome activates caspase-9, one of the initiator caspases, thus beginning the caspase cascade as described previously** (Li et al., 1997b).

Antiapoptotic Bcl-2 family members block apoptosis by inhibiting the proapoptotic family members and, in doing so, decreasing mitochondrial permeability (see eFig. 62.14; Li et al., 1997b; Srinivasula et al., 1998).

Bax is the most well-studied proapoptotic Bcl-2 family member. It is transcriptionally activated by TP53. Once activated, Bax dimerizes at the mitochondrial membrane. The dimer forms a channel that facilitates the release of cytochrome c from the mitochondria. Bcl-2 is the best studied antiapoptotic Bcl-2 family member. It functions by binding to Bax and, in doing so, blocks Bax-induced mitochondrial permeability (Adams and Cory, 1998; Miyashita et al., 1994)**.**

Other proapoptotic family members are activated by a variety of stimuli. Often they function not by inducing mitochondrial permeability directly but by activating or inhibiting other Bcl-2 family members. The first example is Bid. Bid is regulated by initiator caspases. Cytosolic Bid is activated by caspase-8 (see eFig. 62.14). This allows dimerization of Bid with either Bax or Bcl-2. This dimerization activates Bax activity and inhibits Bcl-2. The net result is to tip the balance in favor of apoptosis (Li et al., 1998). Because Bid is activated by caspases, it provides a link between the ligand-induced apoptotic machinery of the extrinsic pathway (described later) and Bcl-2 family members.

An additional level of regulation is provided by IAPs, a family of proteins that act to prevent apoptosis by inhibiting specific caspase proteases, either directly or by inhibiting the conversion from the procaspase to the active form (Deveraux et al., 1998).

Extrinsic Apoptotic Pathway

In addition to the intrinsic pathway, a second pathway termed the extrinsic pathway mediates apoptosis after receipt of extracellular signals from cell surface receptors called "death receptors," such as the tumor necrosis factor receptor, TNFR1, and the Fas receptor (eFig. 62.15). These receptors belong to the TNF superfamily and contain a ligand specific extracellular domain and an intracellular "death domain." The binding of extracellular signaling molecules to the receptor activates the receptor, which then signals through the death domain located on the cytoplasmic portion of the receptor. The death domain allows the receptor to bind to intracellular adaptor proteins that also contain a death domain (e.g. RIP, TRADD, FADD). In addition to their own death domain, the adaptor proteins have a death effector domain that allows the adaptor protein to bind to the caspase recruitment domain (CARD) of initiator caspases (Ashkenazi and Dixit, 1998). Once bound, the initiator caspases undergo self-cleavage and are then capable of activating effector caspases via the caspase cascade (Li et al., 1998; Muzio, 1998).

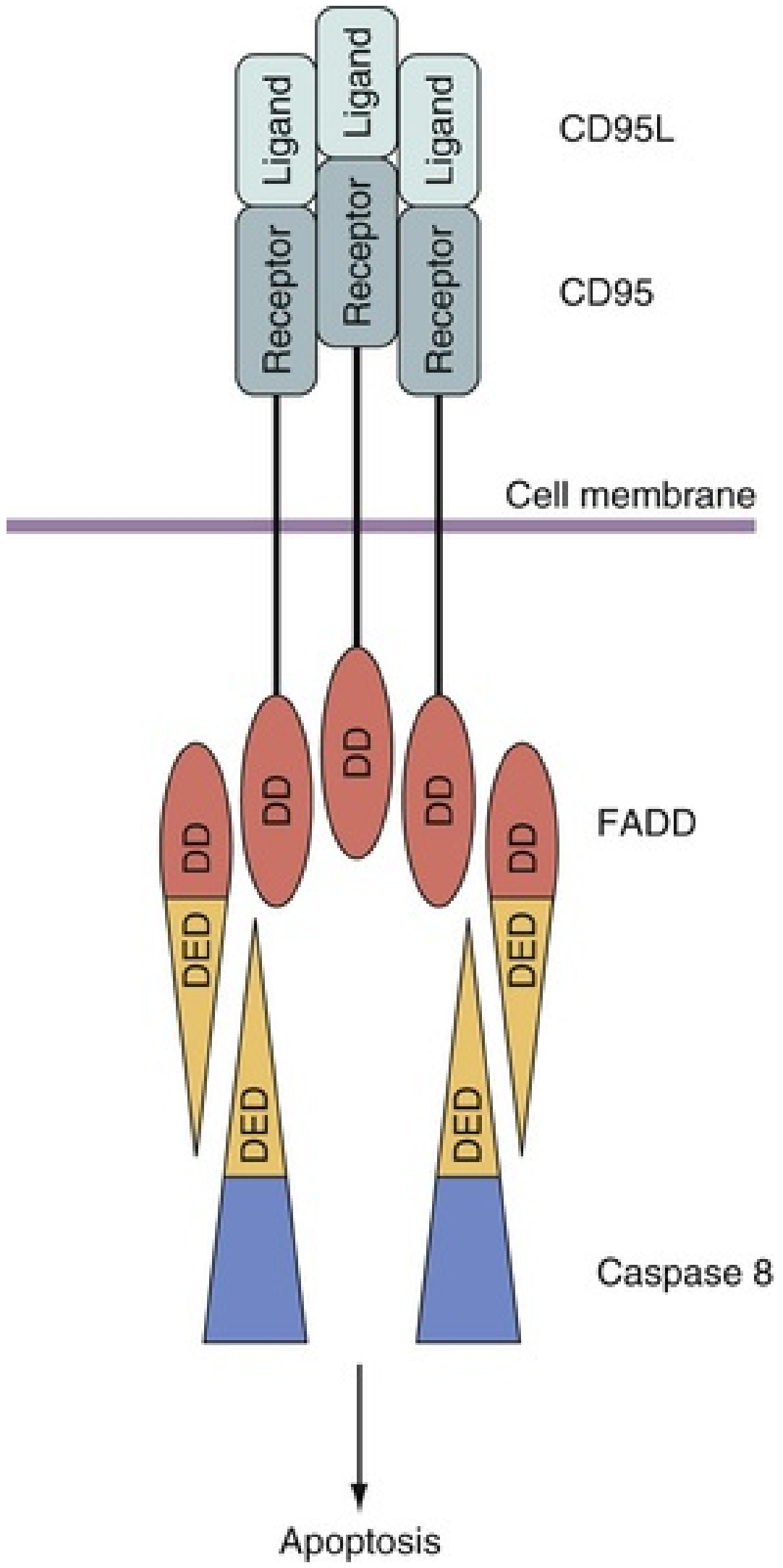
Ligand
Ligand
Ligand
CD95L
Receptor
Receptor
Receptor
CD95
Cell membrane
DD
DD
DD
DD
DD
FADD
DED
DED
DED
DED
Caspase 8
Apoptosis

EFIG. 62.15 Example of death receptor–mediated activation of initiator caspases. *DD,* Death domain; *DED,* death effector domain; *FADD,* Fas-associated protein with death domain.

The best-characterized death receptor is CD95, or FAS, which appears to play an important role in cancer immunosurveillance (Ashkenazi and Dixit, 1998). The ligand CD95L (also known as FAS ligand or FASL) forms a trimer that binds three CD95 receptors (Nagata, 1997). The clustering of CD95 allows the adaptor protein FADD to bind to CD95 via their death domains (see eFig. 62.15). In turn, procaspase-8, or FLICE, binds to FADD via the death effector domain. Procaspase-8 oligomerization promotes autoactivation to active caspase-8 (Muzio, 1998). Other initiator procaspases, such as procaspase-10, are activated through similar mechanisms (Vincenz and Dixit, 1997). Negative regulatory molecules, such as FLIP, bind to FADD and in doing so inhibit procaspase-8 binding and therefore apoptosis (Irmler et al., 1997).

The death receptor pathway does not appear to have a direct role in the cause of cancer. Patients with hereditary defects in this system and knockout mice are characterized by T-cell abnormalities and fatal autoimmune syndromes, not hereditary tumor syndromes (Nagata, 1997). **However, the identification of ligand-dependent apoptosis receptors may have a profound impact on therapy. Most cancer therapies (i.e., chemotherapy and external-beam radiation therapy) depend on TP53 to induce apoptosis in the cancer cell. Because TP53 is mutated in more than half of malignancies** (Hollstein et al., 1991), **TP53-independent pathways for apoptosis are of great clinical interest. Because the ligand-dependent apoptosis described earlier is independent of p53, this makes these receptors and ligands attractive novel treatment targets.** Unfortunately, compounds that bind to the receptors are extremely toxic (Nagata, 1997). Hopefully novel compounds will have improved toxicity profiles.

Role of TP53 in Apoptosis

In addition to the key roles played by TP53 in cell cycle arrest and DNA damage repair, TP53 can also induce apoptosis (May and May, 1999). TP53-induced apoptosis is mediated through the Bcl-2 family, via the intrinsic pathway, and dysregulation of this apoptotic pathway has direct relevance to the cause of cancer. TP53-induced apoptosis is mediated by transcriptional activation of genes that initiate the apoptotic cascade and inhibition of genes that block the cascade (Miyashita et al., 1994; Miyashita and Reed, 1995; Oda et al., 2000). TP53-induced apoptosis is dependent on the Apaf-1/caspase-9 activation pathway (Soengas et al., 1999). Whereas the Bcl-2 family member Bax has been implicated as the primary factor responsible for TP53 induction of this cascade (Miyashita and Reed, 1995), Bax is not essential for TP53-dependent apoptosis (Knudson et al., 1995). It is possible that inhibition of Bcl-2 (Miyashita et al., 1994) or upregulation of the proapoptotic Bcl-2 family member noxa may allow cells lacking Bax to still undergo TP53-dependent apoptosis (Oda et al., 2000).

Considering TP53's role in multiple tumor-suppressive pathways (DNA damage response, cellular senescence, and apoptosis), it is not surprising that it is so frequently mutated in cancer.

Apoptosis and Genitourinary Malignancies

Because a tumor cell's inability to undergo apoptosis is a hallmark of malignancy, multiple groups have attempted to characterize the apoptotic response of genitourinary malignancies. Because cells undergoing apoptosis exhibit a stereotypical death, global analysis of apoptosis is possible using assays designed to detect key hallmarks of the apoptotic process, such as the fragmentation of DNA characteristic of the process, as well as assays designed to detect abnormalities in specific apoptotic proteins.

Global Defects in Apoptosis

HGPIN and prostate carcinoma actually have significantly higher levels of apoptosis than normal prostatic epithelium. The level of apoptotic activity is relatively low compared with other malignancies and is opposed by increased replication. Importantly, many prostate cancer cells can be induced to undergo apoptosis in response to androgen withdrawal, which represents a front-line therapy for patients with advanced disease (Denmeade and Isaacs, 1996; Isaacs, 1994; Kyprianou et al., 1990; Tu et al., 1996). Unfortunately, clearly not all of a patient's cancer cells succumb, as recurrences inevitably arise. As the tumor progresses to androgen independence, it is unclear if the androgen-resistant cells have an increased or decreased rate of apoptosis, because studies have demonstrated both in hormone-refractory disease (Berges et al., 1995; Koivisto et al., 1997). The conflicting data may reflect the tumor's dynamics and the effect of therapy. There is a clear survival advantage for the advanced cancer cell that can protect itself from apoptosis. However, **a rapidly growing, infiltrative, advanced tumor, which is outgrowing its blood supply and mutating its DNA, may have a high apoptotic rate in spite of protective mechanisms the tumor's cells have acquired.**

Studies of apoptosis in bladder carcinoma have demonstrated an association with aggressive high-grade advanced disease but not with decreased disease-free survival (King et al., 1996; Lipponen and Aaltomaa, 1994). External-beam radiation therapy has been associated with a modest improvement in survival for tumors with high apoptotic rates. This may reflect the fact that external-beam radiation therapy requires an intact apoptotic mechanism to be effective (Rodel et al., 2000).

As previously mentioned, **most testicular germ cell tumors maintain intact DDR and wild type TP53, thus display high cure rates in response to therapies that induce DNA damage** (Bartkova et al., 2007; Einhorn, 2002;

Gorgoulis et al., 2005; Kersemaekers et al., 2002).

Individual members of the apoptotic machinery have been frequently studied. However, all studies are unable to assay all elements of the apoptotic machinery simultaneously and therefore to globally assess the tumor's ability to undergo programmed cell death.

***TP53* mutations and abnormalities in expression are among the most frequent in cancer and have been identified in prostate, bladder, and renal cancers (**Hollstein et al., 1991; Reiter et al., 1993; Sidransky et al., 1991). Abnormalities in *TP53* cause dysregulation of the cell cycle and DNA repair mechanisms in addition to apoptosis and are covered in more detail in the section Cell Cycle.

Bcl-2 family members have been studied in genitourinary malignancies. **Elevated levels of Bcl-2 have been identified in the majority of hormone-refractory prostate tumors, reflecting the tumor's relative resistance to apoptosis in the advanced state** (Colombel et al., 1993; McDonnell et al., 1992). Increased and decreased levels of Bcl-2 have been identified in localized prostate tumors, and few studies have found a correlation with grade, stage, and progression (Byrne et al., 1997; Lipponen and Vesalainen, 1997; Theodorescu et al., 1997). Other antiapoptotic members of the Bcl-2 gene family, Bcl-X_L and Mcl1, may also be linked to prostate carcinoma (Krajewska et al., 1996). Analysis of bladder carcinoma has demonstrated similar results. Bcl-2 levels are higher in more aggressive bladder carcinoma, but expression of Bcl-2 had no effect on treatment outcome (King et al., 1996; Rodel et al., 2000). As noted earlier, phosphorylation of Bad by Akt can also tilt the scales toward cell survival, especially in concert with elevated levels of Bcl-2. Akt activation is commonly seen in many urologic malignancies and can result from loss of the tumor suppressor *PTEN*, mutation and constitutive activation of PI3 kinase, and/or activation of tyrosine kinase receptors such as HER2/NEU, EGFR, and the insulin-like growth factor receptor (IGFR).

Other Bcl-2 family members have not been as well studied. Loss of Bax expression is apparently not a common mechanism for the development of prostate carcinoma (Johnson and Hamdy, 1998; Krajewska et al., 1996) but may play a role in progression of localized bladder carcinoma (Ye et al., 1998).

In summary, deficiencies in signal transduction pathways leading to apoptosis clearly play a role in the initiation and progression of malignancy. It is unclear if expression analysis of the apoptotic machinery will provide additional prognostic information from traditional histochemical analysis.

However, it is clear that effective chemotherapy and radiation therapy is in large part dependent on apoptosis. In addition, in the future the apoptotic machinery may be manipulated using novel ligands that bind to death receptors and promote TP53-independent cancer cell death.

Alternative Regulators of Apoptosis in Genitourinary Malignancies

In addition to the classic regulators of apoptosis, a number of other pathways for cell survival and death have been uncovered that play key roles in urologic cancer. Some of these pathways are being actively explored as targets for cancer therapy. The Vancouver group has mapped out a detailed gene profile of prostate tumors treated with neoadjuvant hormonal ablation therapy to identify key regulators of cell death and survival after castration. In addition to Bcl-2, which is upregulated in surviving cancer cells, they have also reported on clusterin and Hsp27. **Clusterin, or testosterone-repressed prostate message-2, is upregulated in patient samples after hormone ablation as well as in the Shionogi and CWR-22 xenograft models of hormone-sensitive tumors. Although its precise function is not known, a large body of evidence suggests that clusterin is induced by stress and functions to stabilize the cell during periods of stress** (Miyake et al., 2000). In this model, clusterin is believed to act like HSPs, whose role as a protein chaperone is also to stabilize client proteins. Clusterin is activated by heat shock protein 1 (HSP1). Functional evidence of clusterin's role comes from studies in which clusterin is either overexpressed or knocked down using antisense strategies. In the first scenario, clusterin expression promotes hormone-refractory cell growth and prevents androgen withdrawal–induced apoptosis. In the second scenario, treatment of hormone-refractory cells with antisense clusterin promotes apoptosis (Gleave and Miyake, 2005; July et al., 2002; Miyake et al., 2004). This same group of investigators has also reported that the heat shock protein HSP27 is also frequently overexpressed in hormone-refractory prostate cancers. Similar experiments using overexpression and antisense strategies have suggested that targeting HSP27 may influence the course of hormone-refractory cancers, in particular in combination with cytotoxic chemotherapies (Rocchi et al., 2004).

Another family of cellular signaling molecules that play a role in the regulation of cell survival and apoptosis is the sphingolipids. Sphingolipids are one of three major constituents of the cell membrane, along with phospholipids and cholesterol. Sphingolipid generation is regulated by a

large cast of enzymes, notably the sphingomyelinases, ceramide synthase, and the ceramidases. Ceramide is produced from sphingomyelin by sphingomyelinase and from sphinganine by ceramide synthase. Ceramidases, on the other hand, degrade ceramide and lead to formation of sphingosine and sphingosine-1-phosphate. Ceramide is a potent proapoptotic molecule that can promote apoptosis through the classical mitochondrial activation of caspases or through a nonclassical caspase-independent form of apoptosis (Kolesnick and Fuks, 2003). Sphingosine-1-phosphate, in contrast, is a powerful antiapoptotic molecule that may modulate the degree of apoptosis like a rheostat (Maceyka et al., 2002).

The importance of ceramide to genitourinary tumors is that it appears to be a key modulator of radiation-induced tissue damage and apoptosis. As with clusterin and other heat shock proteins, ceramide appears to be a critical mediator of stress response in cells, in this case promoting apoptosis as opposed to cell survival. Studies supporting ceramide's role in radiation-induced apoptosis are manifold, including studies demonstrating the direct cell death signal induced by exogenous treatment of cells with ceramide, studies of radiation response in mouse knockout models, and studies of radiation response in the presence and absence of inhibitors of sphingolipid metabolism. It is hoped that therapeutics that increase ceramide production and promote apoptosis can be developed. The role of sphingolipid-1-phosphate has also emerged from these studies, and recent work suggests that this molecule is a promising target for cancer therapy (Gulbins and Kolesnick, 2003; Kester and Kolesnick, 2003; Perry and Kolesnick, 2003).

Key Points: Apoptosis

- Apoptosis is a rapid, orderly programmed form of cell death that is used by multicellular organisms to eliminate unwanted cells.
- Apoptosis is believed to play an important role in tumor suppression because many of the signals that induce apoptosis arise from potentially tumorigenic cell stresses such as DNA damage.
- Cancer is characterized by interruptions in the normal process of apoptosis, resulting in inappropriate cell survival.
- Apoptosis is mediated by a conserved family of proteases known as

caspases. Initiator caspases start caspase proteolytic cascades terminating in the activation of executioner caspases which target several cellular proteins.

- Two main apoptotic pathways have been identified. In the intrinsic pathway, Bcl-2 family members modulate the release of cytochrome c from the mitochondria, which participates in the activation of initiator caspases. The extrinsic pathway activates caspases in response to signals from extracellular “death receptors.”
- In addition to its functions in cell cycle arrest and DNA repair, TP53 plays a key role in apoptosis.
- Bcl-2 is a classic inhibitor of the mitochondrial pathway of apoptosis and is overexpressed in some genitourinary malignancies.
- Therapeutic response is often dependent upon the integrity of apoptotic pathways in the cancer cells. Most TGCTs retain intact DDR, wild type TP53 and apoptotic responses, providing high cure rates with DNA damaging agents.
- Novel agonists and antagonists of apoptosis, such as ceramide and clusterin, may successfully be controlled to combat cancer.

Stem Cells and Cancer

Stem cells are found in multicellular organisms and are characterized by the ability of self-renewal through mitotic cell division and differentiation into a diverse range of specialized cell types. **Common properties of stem cells include the ability of self-renewal, generation of cellular progeny, localization within specialized niches, and the ability to give rise to all cell types within an organ.** For example, human prostate stem cells are believed to be localized within the basal epithelium and give rise to a hierarchy of progenitor cells that may differentiate into secretory or neuroendocrine cells (Burger et al., 2005; Xin et al., 2005).

Recent studies suggest that neoplastic cells mimic normal tissue development and may arise from and are dependent on a small population of stem cells. **The cancer stem cell hypothesis argues that cancers arise from transformation of stem or progenitor cells that are capable of multilineage differentiation.** Cancer stem cells may account for only a small percentage of any tumor, but this small population of cells is critical for tumor survival. The most readily accepted experimental demonstration of cancer stem cells relies on serial transplantation of tumor cell populations isolated based on one or numerous putative cancer stem cell markers into immune deficient mice or 3D culture systems and recapitulation of the heterogeneous primary tumor. Using this experimental strategy, initial evidence to support the cancer stem cell hypothesis was discovered in leukemia, breast, and neurologic cancers. For example, a CD44+/CD24low/- population of cells in primary breast tumors were specifically capable of new tumor formation when engrafted into nude mice (Al-Hajj et al., 2003; Dontu et al., 2003). Similar reports in glioblastoma suggest that a CD133 positive population as the putative stem cell (Dirks, 2005; Singh et al., 2003). One challenge to the field of cancer stem cell research is the lack of any one marker that is exclusively expressed by cancer stem cells. For any given tumor type, typically many different markers can be identified that confer a cancer stem cell phenotype, and absence of the marker does not always imply that a cell is not a cancer stem cell. For example, in glioblastoma, CD133+ and $CD133^{-}$ cell populations have been shown to possess cancer stem cell-like properties (Beier et al., 2007).

A tumor-initiating cell (T-IC) subpopulation has also been identified in human bladder cancer. This group of cells was found to express CD44$^+$/CK5$^+$/CK20$^-$ markers similar to normal bladder basal cells (Chan et al., 2009). The bladder T-IC subpopulation was also capable of forming xenograft tumors in vivo that recapitulated characteristics of the original tumor. Furthermore, CD47 was highly expressed in this group of cells and blockade of CD47 resulted in macrophage engulfment of bladder cancer stem cells in vitro. This finding suggests a potential role for therapeutic targeting of CD47 and the T-IC subpopulation in bladder cancer (Chan et al., 2009). A number of other putative cancer stem cell populations have been identified in bladder cancer, including CK17$^+$/67LR$^+$/CAECAM$^-$ cells, embryonic stem cell marker *POU5F1*$^+$ cells, and high aldehyde dehydrogenase activity (ALDH^{hi}) cells (reviewed in van der Horst et al., 2012).

Key Points: Stem Cells and Cancer

- Stem cells are defined by their ability to differentiate along multiple lineages and their immortality.
- Cancer is believed to be a stem cell disease in which a small population of cancer stem cells maintains the larger tumor.
- Cancer may ultimately be eradicated by targeting only the cancer stem cell.

Checkpoint Inhibition

Programmed cell death protein 1 (PD-1 or CD279) is a cell surface receptor involved with downregulation of the immune system and promotes self-tolerance by suppressing T-cell inflammatory activity (Pardoll, 2012). **The PD-1 pathway limits immune activity, resulting in decreased autoimmunity and cytokine secretion.** The 2 ligands for PD-1, PD-L1, and PD-L2 are cell surface glycoproteins within the B7 family of costimulatory and coinhibitory molecules. In the PD-1 pathway, antigen is typically presented to T cells by tumor cells or antigen-presenting cells (APCs) via expression of MHC molecules. PD-1 receptor is expressed on the T-cell surface in response to activation of the T-cell receptor complex. The T-cell mediated immune response is inhibited by the interaction of PD-L1 and PD-L2 ligands on APCs and tumor cells with PD-1 receptors.

PD-L1 is highly expressed in several cancer types, and the PD-1/PD-L1 pathway may be exploited by cancer cells to evade the immune system. Expression of PD-L1 by cancer cells is associated with an immunosuppressive phenotype that allows for tumor evasion. **Inhibition of the interaction between PD-1 and PD-L1 can enhance T-cell response and mediate antitumor activity. This is phenomenon is known as immune checkpoint blockade.** Blockade of the PD-1/PD-L1 interaction has been used for various malignancies, including metastatic urothelial carcinoma with significant response rates.

The utility of PD-1/PD-L1 blockade for treatment of bladder cancer has been investigated in several clinical trials. In an open-label, phase 3 trial of 542 patients with advanced urothelial cancer that recurred or progressed after platinum-based chemotherapy, treatment with pembrolizumab (antibody against PD-1) was associated with a median overall survival of 10.3 months compared with 7.4 months for patients treated with chemotherapy (Bellmunt et al., 2017). No significant difference was observed between groups with respect to progression-free survival or among patients who had a tumor PD-L1 combined positive score of ≥ 10%. Fewer treatment-related adverse events were observed among patients treated with pembrolizumab compared with patients treated with chemotherapy.

A multicenter, phase 2 study evaluated atezolizumab (anti PD-L1 antibody) as first-line therapy in a cohort of previously untreated patients with locally advanced or metastatic urothelial carcinoma who were cisplatin ineligible (Balar et al., 2017). Objective and complete response rates of 23% and 9% were observed among 119 patients treated with atezolizumab in the first-line setting, respectively. Median progression-free and overall survival was 2.7 and 15.9 months, respectively. **Atezolizumab shows potential as a first-line treatment option for patients who are not able to receive cisplatin-based chemotherapy.** Biomarker data was also validated in this study linking intrinsic TCGA subtypes and mutational load with immunotherapy response.

Expression of PD-L1 has also been evaluated as a prognostic marker for bladder cancer with mixed results. Increased expression of glycoprotein B7-H3 in bladder cancer may be an early event in upregulation of PD-1 (Boorjian et al., 2008). Expression of T-cell coregulators B7-H1, B7-H3, and PD-1 were evaluated in paraffin-embedded sections from 318 consecutive patients with urothelial carcinoma who underwent radical cystectomy. Expression of B7-H3 was significantly increased compared with adjacent, nontumor urothelium. Increased B7-H3 expression was independent of tumor stage and expression of B7-H1 by tumors and PD-1 by tumor infiltrating lymphocytes was significantly associated with increased pathologic stage.

The utility of checkpoint inhibitor therapy has also been investigated in RCC. Nivolumab is a fully human IgG4 programmed death 1 (PD-1) immune checkpoint inhibitor antibody that selectively blocks interaction between PD-1 and PD-L1 (and PD-L2). Previous studies have shown that PD-L1 expression is associated with a poor prognosis in RCC (Thompson et al., 2004). **A randomized, open-label, phase 3 study comparing nivolumab with everolimus in patients with RCC who received previous treatment demonstrated improved overall survival and fewer severe adverse events with nivolumab therapy** (Motzer et al., 2015). Whole exome sequencing of metastatic clear cell RCC has also been performed to identify genomic alterations that correlate with response to anti-PD-1 therapy. **In a cohort of 35 patients, loss-of-function mutations in PBRM1 were associated with clinical benefit** (Miao et al., 2018). This observation was confirmed in a validation cohort of 63 patients with clear cell RCC treated with PD-L1 blockade.

Key Points: Checkpoint Inhibition

- The PD-1 pathway limits immune activity resulting in decreased autoimmunity and cytokine.

- Inhibition of the interaction between PD-1 and PD-L1 can enhance T-cell response and mediate antitumor activity.
- PD-1/PD-L1 blockade for treatment of advanced or metastatic bladder cancer has demonstrated efficacy as first-line treatment for cisplatin-ineligible patients.
- Nivolumab has been shown to improve overall survival with fewer adverse events compared with everolimus in patients with RCC who received previous treatment.
- Loss-of-function mutations in PBRM1 were associated with clinical benefit among patients with metastatic clear cell RCC who received anti-PD-1 therapy.

Microbiome and Cancer: the Metagenome

Modern sequencing tools have allowed for a greater understanding of the molecular genetics of a previously less well recognized part of the human body that may nevertheless greatly influence cancer development, progression, and response to therapy: **the metagenome** (the genetic material comprising the human-associated microbiota). **Recent years have seen an explosion of studies aimed at characterizing the human microbiome (the environment, including the microbiota, any proteins or metabolites they make, their metagenome, as well as host proteins and metabolites in this environment) in health and disease**. One area of particular interest is the effect that the microbiome has on cancer. This effect may be through direct interactions at the site of cancer development in cancers with a known microbial cause (such as gastric and cervical cancer), as well as indirect interactions such as regulation of the immune system, effects on metabolism, and effects on cancer therapies. In many cases, direct and indirect interactions with the microbiome are in play.

Direct interactions of the microbiome with cancer include the induction of chronic inflammation by pathogenic microbes that drives cellular proliferation and DNA damage responses, direct genotoxicity (e.g., by bacteria-produced genotoxins [Balskus, 2015]), and the introduction of oncogenes (such as virally encoded oncogenes). **Of keen interest to the study of GU cancers is the recent discovery of a urinary microbiome**. Recent evidence has challenged the long-held clinical dogma that urine is “sterile” and found that urine contains microorganisms (e.g., bacterial, viral, fungal, protozoan) that are representative of a distinct flora in the urinary tract, including the urethra and the bladder (Whiteside et al., 2015). The urinary microbiome has been overlooked in the past partially because of reliance on standard urine culture and clinical microbiology practices that are not suitable for culturing most urinary microbiota. Slight changes to culture conditions, such as using anaerobic and aerobic culture and extending the length of culture time, increases the efficacy of detecting resident bacterial flora in the urine (Hilt et al., 2014). Although the urinary tract shares species with adjacent niches such as the skin and vaginal flora, the evidence suggests that the urinary microbiome is distinct to the other sites of the human body that harbor microbiota. There is not yet definitive evidence linking the urinary microbiome to the development and/or progression of genitourinary cancers; however, this is currently an area of active study in bladder cancer, prostate cancer, and other cancers (Alfano et al., 2016, Shrestha et al., 2018).

Indirect effects of the microbiome (e.g., the effects of the gastrointestinal [GI] microbiota on cancer at a distant anatomic site) on tumorigenesis are less understood and could include modulation of antitumor immune responses and effects on host metabolism (Schwabe and Jobin, 2013). Importantly, evidence is also emerging to indicate that the GI microbiota can exert a profound influence on the efficacy of certain cancer treatments, including chemotherapy and immunotherapy (Jobin, 2018). As with direct interactions, there are only a few published studies examining indirect interactions between the microbiome and genitourinary cancers; however, several compelling studies are emerging in the field of kidney cancer. One recent study demonstrated that the **GI microbiota composition, and specifically the presence of the mucin degrading bacterium *Akkermansia muciniphila*, predicts response to anti-PD-1 targeted immunotherapy in RCC** and other epithelial tumors (Routy et al., 2018). **Importantly, Routy et al. also demonstrated that T-cell activation stimulated by *Akkermansia* was related to patient response to anti-PD-1 treatment**. Studies in RCC have also shown a relationship between the GI microbiota and the symptoms of diarrhea after receiving vascular endothelial growth factor (VEGF)-tyrosine kinase inhibitors (Pal et al., 2015). Finally, **there is also recent evidence that antibiotic use (that would alter/abolish the GI flora) diminishes the effectiveness of immunotherapy in RCC** (Routy et al., 2018).

Key Points: Microbiome and Cancer

- The clinical dogma that urine is sterile has been challenged by studies describing distinct microbiota present in urine that are representative of species residing within the urinary tract. These microorganisms would have previously been under- or unrecognized using standard clinical microbiology culture techniques.
- Direct interactions between the urinary microbiome and genitourinary cancer development or progression is now an area of active study.

- Indirect interactions between the microbiome, such as the GI microbiota, and genitourinary cancers is also an area of active research. The GI microbiota may have a strong influence on treatment response and/or related toxicities to cancer therapies.

Suggested Readings

Ames BN, Gold LS. The causes and prevention of cancer: the role of environment. *Biotherapy*. 1998;11:205–220.

Blackburn EH. Telomeres. *Trends Biochem Sci*. 1991;16:378–381.

DePinho RA. The age of cancer. *Nature*. 2000;408:248–254.

Fearon ER. Human cancer syndromes: clues to the origin and nature of cancer. *Science*. 1997;278:1043–1050.

Feinberg AP. The epigenetics of cancer etiology. *Semin Cancer Biol*. 2004;14:427–432.

Greider CW. Telomerase activity, cell proliferation, and cancer. *Proc Natl Acad Sci USA*. 1998;95:90–92.

Guttmacher AE, Collins FS. Genomic medicine—a primer. *N Engl J Med*. 2002;347:1512–1520.

Hahn WC, Counter CM, Lundberg AS, et al. Creation of human tumour cells with defined genetic elements. *Nature*. 1999;400:464–468.

Hanahan D, Weinberg RA. The hallmarks of cancer. *Cell*. 2000;100:57–70.

Hanahan D, Weinberg RA. Hallmarks of cancer: the next generation. *Cell*. 2011;144:646–674.

Hartwell L, Weinert T, Kadyk L, et al. Cell cycle checkpoints, genomic integrity, and cancer. *Cold Spring Harb Symp Quant Biol*. 1994;59:259–263.

Jones PA, Baylin SB. The fundamental role of epigenetic events in cancer. *Nat Rev Genet*. 2004;3:415–428.

Jones PA, Baylin SB. The epigenomics of cancer. *Cell*. 2007;128:683–692.

Kaelin WG Jr. Molecular basis of the VHL hereditary cancer syndrome. *Nat Rev Cancer*. 2002;2:673–682.

Kastan MB, Bartek J. Cell-cycle checkpoints and cancer.

Nature. 2004;432:316–323.

Massague J. G1 cell-cycle control and cancer. *Nature*. 2004;432:298–306.

Rebbeck TR, Spitz M, Wu X. Assessing the function of genetic variants in candidate gene association studies. *Nat Rev Genet*. 2004;5:589–597.

Reya T, Morrison SJ, Clarke MF, et al. Stem cells, cancer, and cancer stem cells. *Nature*. 2001;414:105–111.

Sancar A, Lindsey-Boltz LA, Unsal-Kacmaz K, et al. Molecular mechanisms of mammalian DNA repair and the DNA damage checkpoints. *Annu Rev Biochem*. 2004;73:39–85.

Sjoblom T, Jones S, Wood LD, et al. The consensus coding sequences of human breast and colorectal cancers. *Science*. 2006;314:268–274.

Vogelstein B, Papadopoulos N, Velculescu VE, et al. Cancer genome landscapes. *Science*. 2013;339:1546–1558.

Watson J, Crick F. Molecular structure of nucleic acids: a structure for deoxyribose nucleic acid. *Nature*. 1953;171:737–738.

References

Aaltonen LA, Peltomaki P, Leach FS, et al. Clues to the pathogenesis of familial colorectal cancer. *Science*. 1993;260:812–816.

Abdulkadir SA, Magee JA, Peters TJ, et al. Conditional loss of Nkx3.1 in adult mice induces prostatic intraepithelial neoplasia. *Mol Cell Biol*. 2002;22:1495–1503.

Aben KK, Baglietto L, Baffoe-Bonnie A, et al. Segregation analysis of urothelial cell carcinoma. *Eur J Cancer*. 2006;42:1428–1433.

Aboulkassim TO, LaRue H, Lemieux P, et al. Alteration of the PATCHED locus in superficial bladder cancer. *Oncogene*. 2003;22:2967–2971.

Adachi H, Igawa M, Shiina H, et al. Human bladder tumors with 2-hit mutations of tumor suppressor gene TSC1 and decreased expression of. *J Urol*. 2003;170(601–604):p27.

Adams JM, Cory S. The Bcl-2 protein family: arbiters of cell survival. *Science*. 1998;281:1322–1326.

Ahuja N, Issa J. Aging, methylation and cancer. *Histol Histopathol*. 2000;15:835–842.

Albadine R, Latour M, Toubaji A, et al. TMPRSS2-ERG gene fusion status in minute (minimal) prostatic adenocarcinoma. *Mod Pathol*. 2009.

Alcaraz A, Takahashi S, Brown JA, et al. Aneuploidy and aneusomy of chromosome 7 detected by fluorescence in situ hybridization are markers of poor prognosis in prostate cancer. *Cancer Res*. 1994;54:3998–4002.

Alers JC, Rochat J, Krijtenburg PJ, et al. Identification of genetic markers for prostatic cancer progression. *Lab Invest*. 2000;80:931–942.

Alfano M, Canducci F, Nebuloni M, et al. The interplay of extracellular matrix and microbiome in urothelial bladder cancer. *Nat Rev Urol*. 2016;13:77–90.

Al-Hajj M, Wicha MS, Benito-Hernandez A, et al. Prospective identification of tumorigenic breast cancer cells. *Proc Natl Acad Sci*. 2003;100:3983–3988.

Al-Tassan N, Chmiel NH, Maynard J, et al. Inherited variants of MYH associated with somatic G:C–>T:A mutations in colorectal tumors. *Nat Genet*. 2002;30:227–232.

Amara N, Palapattu GS, Schrage M, et al. Prostate stem cell antigen is overexpressed in human transitional cell carcinoma. *Cancer Res*. 2001;61:4660–4665.

Ames BN, Gold LS. Endogenous mutagens and the causes of aging and cancer. *Mutat Res*. 1991;250:3–16.

Ames BN, Gold LS. The causes and prevention of cancer: the role of environment. *Biotherapy*. 1998;11:205–220.

Ames BN, Shigenaga MK, Hagen TM. Oxidants, antioxidants, and the degenerative diseases of aging. *Proc Natl Acad Sci USA*. 1993;90:7915–7922.

Amundadottir LT, Sulem P, Gudmundsson J, et al. A common variant associated with prostate cancer in European and African populations. *Nat Genet*. 2006;38:652–658.

Anderson CW. DNA damage and the DNA-activated protein kinase. *Trends Biochem Sci*. 1993;18:433–437.

Argani P, Antonescu CR, Illei PB, et al. Primary renal neoplasms with the ASPL-TFE3 gene fusion of alveolar soft part sarcoma: a distinctive tumor entity previously included among renal cell carcinomas of children and adolescents. *Am J Pathol*. 2001;159:179–192.

Argani P, Hawkins A, Griffin CA, et al. A distinctive pediatric renal neoplasm characterized by epithelioid morphology, basement membrane production, focal HMB45 immunoreactivity, and t(6;11)(p21.1;q12) chromosome translocation. *Am J Pathol*. 2001;158:2089–2096.

Argani P, Ladanyi M. Translocation carcinomas of the kidney. *Clin Lab Med*. 2005;25:363–378.

Argani P, Lae M, Hutchinson B, et al. Renal carcinomas with the t(6;11)(p21;q12): clinicopathologic features and demonstration of the specific alpha-TFEB gene fusion by immunohistochemistry, RT-PCR, and DNA PCR. *Am J Surg Pathol*. 2005;29:230–240.

Arps S, Rodewald A, Schmalenberger B, et al. Cytogenetic survey of 32 cancers of the prostate. *Cancer Genet Cytogenet*. 1993;66:93–99.

Artandi SE, DePinho RA. A critical role for telomeres in suppressing and facilitating carcinogenesis. *Curr Opin Genet Dev*. 2000;10:39–46.

Aryee MJ, Liu W, Engelmann JC, et al. DNA methylation alterations exhibit intraindividual stability and interindividual heterogeneity in prostate cancer metastases. *Sci Transl Med*. 2013;5 [169ra110].

Ashkenazi A, Dixit VM. Death receptors: signaling and modulation. *Science*. 1998;281:1305–1308.

Atkin NB, Baker MC. Specific chromosome change, i(12p), in testicular tumours? *Lancet*. 1982;2:1349.

Attard G, Clark J, Ambroisine L, et al. Duplication of the fusion of TMPRSS2 to ERG sequences identifies fatal human prostate cancer. *Oncogene*. 2008;27:253–263.

Attard G, Clark J, Ambroisine L, et al. Heterogeneity and clinical significance of ETV1 translocations in human prostate cancer. *Br J Cancer*. 2008;99:314–320.

Aveyard JS, Skilleter A, Habuchi T, et al. Somatic mutation of PTEN in bladder carcinoma. *Br J Cancer*. 1999;80:904–908.

Ayala G, Thompson T, Yang G, et al. High levels of phosphorylated form of Akt-1 in prostate cancer and non-neoplastic prostate tissues are strong predictors of biochemical recurrence. *Clin Cancer Res*. 2004;10:6572–

6578.

Baba M, Furihata M, Hong SB, et al. Kidney-targeted Birt-Hogg-Dube gene inactivation in a mouse model: Erk1/2 and Akt-mTOR activation, cell hyperproliferation, and polycystic kidneys. *J Natl Cancer Inst*. 2008;100:140–154.

Baker S, Markowitz S, Fearon E, et al. Suppression of human colorectal carcinoma cell growth by wild-type p53. *Science*. 1990;249:912–915.

Bakkar AA, Wallerand H, Radvanyi F, et al. FGFR3 and TP53 gene mutations define two distinct pathways in urothelial cell carcinoma of the bladder. *Cancer Res*. 2003;63:8108–8112.

Balar AV, Galsky MD, Rosenberg JE, et al. Atezolizumab as first-line therapy in cisplatin-ineligible patients with locally advanced and metastatic urothelial carcinoma: a single-arm, multicentre, phase 2 trial. *Lancet*. 2017;389:67–76.

Baldin V, Lukas J, Marcote MJ, et al. Cyclin D1 is a nuclear protein required for cell cycle progression in G1. *Genes Dev*. 1993;7:812–821.

Balskus EP. Colibactin: understanding an elusive gut bacterial genotoxin. *Nat Prod Rep*. 2015;32(11):1534–1540.

Barbieri CE, Baca SC, Lawrence MS, et al. Exome sequencing identifies recurrent SPOP, FOXA1 and MED12 mutations in prostate cancer. *Nat Genet*. 2012;44:685–689.

Bartek J, Lukas C, Lukas J. Checking on DNA damage in S phase. *Nat Rev Mol Cell Biol*. 2004;5:792–804.

Bartek J, Lukas J, Bartkova J. Perspective: defects in cell cycle control and cancer. *J Pathol*. 1999;187:95–99.

Bartek J, Lukas J. DNA repair: damage alert. *Nature*. 2003;421:486–488.

Bartkova J, Rajpert-De Meyts E, Skakkebaek NE, et al. DNA damage response in human testes and testicular germ cell tumours: biology and implications for therapy. *Int J Androl*. 2007;30:282–291 [discussion 291].

Barwick BG, Abramovitz M, Kodani M, et al. Prostate cancer genes associated with TMPRSS2-ERG gene fusion and prognostic of biochemical recurrence in multiple cohorts. *Br J Cancer*. 2010;102:570–576.

Bassal S, El-Osta A. DNA damage detection and repair, and the involvement of epigenetic states. *Hum Mutat*. 2005;25:101–109.

Baylin SB, Esteller M, Rountree MR, et al. Aberrant patterns of DNA methylation, chromatin formation and gene expression in cancer. *Hum Mol Genet*. 2001;10:687–692.

Beier D, Hau P, Proescholdt M, et al. CD133+ and CD133− glioblastoma-derived cancer stem cells show differential growth characteristics and molecular profiles. *Cancer Res*. 2007;67:4010–4015.

Bellmunt J, de Wit R, Vaughn DJ, et al. Pembrolizumab as second-line therapy for advanced urothelial carcinoma. *N Engl J Med*. 2017;376:1015–1026.

Bender FC, Reymond MA, Bron C, et al. Caveolin-1 levels are down-regulated in human colon tumors, and ectopic expression of caveolin-1 in colon carcinoma cell lines reduces cell tumorigenicity. *Cancer Res*. 2000;60:5870–5878.

Benedict WF, Lerner SP, Zhou J, et al. Level of retinoblastoma protein expression correlates with p16 (MTS-1/INK4A/CDKN2) status in bladder cancer. *Oncogene*. 1999;18:1197–1203.

Berger MF, Lawrence MS, Demichelis F, et al. The genomic complexity of primary human prostate cancer. *Nature*. 2011;470:214–220.

Bergerheim US, Kunimi K, Collins VP, et al. Deletion mapping of chromosomes 8, 10, and 16 in human prostatic carcinoma. *Genes Chromosomes Cancer*. 1991;3:215–220.

Berges RR, Vukanovic J, Epstein JI, et al. Implication of cell kinetic changes during the progression of human prostatic cancer. *Clin Cancer Res*. 1995;1:473–480.

Berggren P, Kumar R, Sakano S, et al. Detecting homozygous deletions in the CDKN2A(p16(INK4a))/ARF(p14(ARF)) gene in urinary bladder cancer using real-time quantitative PCR. *Clin Cancer Res*. 2003;9:235–242.

Bergthorsson JT, Johannesdottir G, Arason A, et al. Analysis of HPC1, HPCX, and PCaP in Icelandic hereditary prostate cancer. *Hum Genet*. 2000;107:372–375.

Berkovich E, Monnat RJ Jr, Kastan MB. Roles of ATM and NBS1 in chromatin structure modulation and DNA double-strand break repair. *Nat Cell Biol*. 2007;9:683–690.

Bertolotto C, Lesueur F, Giuliano S, et al. A SUMOylation-defective MITF germline mutation predisposes to melanoma and renal carcinoma. *Nature*. 2011;480:94–98.

Bhatia-Gaur R, Donjacour AA, Sciavolino PJ, et al. Roles for Nkx3.1 in prostate development and cancer. *Genes Dev*. 1999;13:966–977.

Bignell G, Smith R, Hunter C, et al. Sequence analysis of the protein kinase gene family in human testicular germ-cell tumors of adolescents and adults. *Genes Chromosomes Cancer*. 2006;45:42–46.

Billerey C, Chopin D, Aubriot-Lorton MH, et al. Frequent FGFR3 mutations in papillary non-invasive bladder (pTa) tumors. *Am J Pathol*. 2001;158:1955–1959.

Bird AP, Wolffe AP. Methylation-induced repression— belts, braces, and chromatin. *Cell*. 1999;99:451–454.

Bird AP. CpG-rich islands and the function of DNA methylation. *Nature*. 1986;321:209–213.

Bird AP. The essentials of DNA methylation. *Cell*. 1992;70:5–8.

Bisoffi M, Heaphy CM, Griffith JK. Telomeres: prognostic markers for solid tumors. *Int J Cancer*. 2006;119:2255–2260.

Blackburn EH. Telomeres. *Trends Biochem Sci*. 1991;16:378–381.

Blaveri E, Brewer JL, Roydasgupta R, et al. Bladder cancer stage and outcome by array-based comparative genomic hybridization. *Clin Cancer Res*. 2005;11:7012–7022.

Bodnar AG, Ouellette M, Frolkis M, et al. Extension of life-span by introduction of telomerase into normal human cells. *Science*. 1998;279:349–352.

Bolton EM, Tuzova AV, Walsh AL, et al. Non-coding RNAs in prostate cancer: the long and the short of it. *Clin Cancer Res*. 2013.

Bookstein R, MacGrogan D, Hilsenbeck SG, et al. p53 is mutated in a subset of advanced-stage prostate cancers. *Cancer Res*. 1993;53:3369–3373.

Bookstein R, Rio P, Madreperla SA, et al. Promoter deletion and loss of retinoblastoma gene expression in human prostate carcinoma. *Proc Natl Acad Sci USA*. 1990;87:7762–7766.

Boorjian SA, Sheinin Y, Crispen PL, et al. T-Cell coregulatory molecule expression in urothelial cell carcinoma: clinicopathologic correlations and association with survival. *Clin Cancer Res*. 2008;14:4800–4808.

Bornman DM, Mathew S, Alsruhe J, et al. Methylation of the E-cadherin gene in bladder neoplasia and in normal urothelial epithelium from elderly individuals. *Am J Pathol*. 2001;159:831–835.

Bostwick DG, Cheng L. Precursors of prostate cancer. *Histopathology*. 2012;60:4–27.

Bostwick DG, Pacelli A, Lopez-Beltran A. Molecular biology of prostatic intraepithelial neoplasia. *Prostate*. 1996;29:117–134.

Bostwick DG, Shan A, Qian J, et al. Independent origin of multiple foci of prostatic intraepithelial neoplasia: comparison with matched foci of prostate carcinoma. *Cancer*. 1998;83:1995–2002.

Bottaro D, Rubin J, Faletto D, et al. Identification of the hepatocyte growth factor receptor as the c-met proto-oncogene product. *Science*. 1991;251:802–804.

Boyer JC, Umar A, Risinger JI, et al. Microsatellite instability, mismatch repair deficiency, and genetic defects in human cancer cell lines. *Cancer Res*. 1995;55:6063–6070.

Breyer JP, McReynolds KM, Yaspan BL, et al. Genetic variants and prostate cancer risk: candidate replication and exploration of viral restriction genes. *Cancer Epidemiol Biomarkers Prev*. 2009;18:2137–2144.

Broberg K, Bjork J, Paulsson K, et al. Constitutional short telomeres are strong genetic susceptibility markers for bladder cancer. *Carcinogenesis*. 2005;26:1263–1271.

Brooks JD, Bova GS, Ewing CM, et al. An uncertain role for p53 gene alterations in human prostate cancers. *Cancer Res*. 1996;56:3814–3822.

Brothman AR, Peehl DM, Patel AM, et al. Frequency and pattern of karyotypic abnormalities in human prostate cancer. *Cancer Res*. 1990;50:3795–3803.

Brothman AR, Steele MR, Williams BJ, et al. Loss of chromosome 17 loci in prostate cancer detected by polymerase chain reaction quantitation of allelic markers. *Genes Chromosomes Cancer*. 1995;13:278–284.

Bruick RK, McKnight SL. A conserved family of prolyl-4-hydroxylases that modify HIF. *Science*. 2001;294:1337–1340.

Bubendorf L, Grilli B, Sauter G, et al. Multiprobe FISH for enhanced detection of bladder cancer in voided urine specimens and bladder washings. *Am J Clin Pathol*. 2001;116:79–86.

Buchkovich K, Duffy LA, Harlow E. The retinoblastoma protein is phosphorylated during specific phases of the cell cycle. *Cell*. 1989;58:1097–1105.

Bunz F, Dutriaux A, Lengauer C, et al. Requirement for p53 and p21 to sustain G2 arrest after DNA damage. *Science*.

1998;282:1497–1501.

Burger PE, Xiong X, Coetzee S, et al. Sca-1 expression identifies stem cells in the proximal region of prostatic ducts with high capacity to reconstitute prostatic tissue. *Proc Natl Acad Sci USA*. 2005;102:7180–7185.

Bussemakers MJG, van Bokhoven A, Verhaegh GW, et al. DD3: a new prostate-specific gene, highly overexpressed in prostate cancer. *Cancer Res*. 1999;59:5975–5979.

Byrne RL, Horne CH, Robinson MC, et al. The expression of waf-1, p53 and bcl-2 in prostatic adenocarcinoma. *Br J Urol*. 1997;79:190–195.

Cahill DP, Lengauer C, Yu J, et al. Mutations of mitotic checkpoint genes in human cancers. *Nature*. 1998;392:300–303.

Cairns P, Evron E, Okami K, et al. Point mutation and homozygous deletion of PTEN/MMAC1 in primary bladder cancers. *Oncogene*. 1998;16:3215–3218.

Cairns P, Okami K, Halachmi S, et al. Frequent inactivation of PTEN/MMAC1 in primary prostate cancer. *Cancer Res*. 1997;57:4997–5000.

Cairns P, Polascik TJ, Eby Y, et al. Frequency of homozygous deletion at p16/CDKN2 in primary human tumours. *Nat Genet*. 1995;11:210–212.

Cairns P, Proctor AJ, Knowles MA. Loss of heterozygosity at the RB locus is frequent and correlates with muscle invasion in bladder carcinoma. *Oncogene*. 1991;6:2305–2309.

Cairns P, Shaw ME, Knowles MA. Initiation of bladder cancer may involve deletion of a tumour-suppressor gene on chromosome 9. *Oncogene*. 1993;8:1083–1085.

Caldarera E, Crooks NH, Muir GH, et al. An appraisal of telomerase activity in benign prostatic hyperplasia. *Prostate*. 2000;45:267–270.

Cappellen D, De Oliveira C, Ricol D, et al. Frequent activating mutations of FGFR3 in human bladder and cervix carcinomas. *Nat Genet*. 1999;23:18–20.

Cappellen D, Gil Diez de Medina S, Chopin D, et al. Frequent loss of heterozygosity on chromosome 10q in muscle-invasive transitional cell carcinomas of the bladder. *Oncogene*. 1997;14:3059–3066.

Carpten J, Nupponen N, Isaacs S, et al. Germline mutations in the ribonuclease L gene in families showing linkage with HPC1. *Nat Genet*. 2002;30:181–184.

Carter BS, Bova GS, Beaty TH, et al. Hereditary prostate cancer: epidemiologic and clinical features. *J Urol*. 1993;150:797–802.

Carter BS, Ewing CM, Ward WS, et al. Allelic loss of chromosomes 16q and 10q in human prostate cancer. *Proc Natl Acad Sci USA*. 1990;87:8751–8755.

Carter SL, Eklund AC, Kohane IS, et al. A signature of chromosomal instability inferred from gene expression profiles predicts clinical outcome in multiple human cancers. *Nat Genet*. 2006;38:1043–1048.

Carver BS, Tran J, Gopalan A, et al. Aberrant ERG expression cooperates with loss of PTEN to promote cancer progression in the prostate. *Nat Genet*. 2009;41:619–624.

Casey G, Neville PJ, Liu X, et al. Podocalyxin variants and risk of prostate cancer and tumor aggressiveness. *Hum Mol Genet*. 2006;15:735–741.

Castro E, Eeles R. The role of *BRCA1* and *BRCA2* in prostate cancer. *Asian J Androl*. 2012;14(3):409–414.

Catzavelos C, Bhattacharya N, Ung YC, et al. Decreased levels of the cell-cycle inhibitor p27Kip1 protein: prognostic implications in primary breast cancer. *Nat Med*. 1997;3:227–230.

Cedar H. DNA methylation and gene activity. *Cell*. 1988;53:3–4.

Cerveira N, Ribeiro FR, Peixoto A, et al. TMPRSS2-ERG gene fusion causing ERG overexpression precedes chromosome copy number changes in prostate carcinomas and paired HGPIN lesions. *Neoplasia*. 2006;8:826–832.

Chan GK, Jablonski SA, Sudakin V, et al. Human BUBR1 is a mitotic checkpoint kinase that monitors CENP-E functions at kinetochores and binds the cyclosome/APC. *J Cell Biol*. 1999;146:941–954.

Chan KS, Espinosa I, Chao M, et al. Identification, molecular characterization, clinical prognosis, and therapeutic targeting of human bladder tumor-initiating cells. *Proc Natl Acad Sci*. 2009.

Chan MWY, Chan LW, Tang NLS, et al. Hypermethylation of multiple genes in tumor tissues and voided urine in urinary bladder cancer patients. *Clin Cancer Res*. 2002;8:464–470.

Chang L, Yeh W, Yang S, et al. Genetic alterations of p16INK4a and p14ARF genes in human bladder cancer. *J Urol*. 2003;170:595–600.

Chatterjee N, Wheeler B, Sampson J, et al. Projecting the performance of risk prediction based on polygenic analyses of genome-wide association studies. *Nat Genet*. 2013;45:400–405.

Chatterjee SJ, George B, Goebell PJ, et al. Hyperphosphorylation of pRb: a mechanism for RB tumour suppressor pathway inactivation in bladder cancer. *J Pathol*. 2004;203:762–770.

Chaux A, Albadine R, Toubaji A, et al. Immunohistochemistry for ERG expression as a surrogate for TMPRSS2-ERG fusion detection in prostatic adenocarcinomas. *Am J Surg Pathol*. 2011;35:1014–1020.

Chen C, Bhalala HV, Vessella RL, et al. KLF5 is frequently deleted and down-regulated but rarely mutated in prostate cancer. *Prostate*. 2003;55:81–88.

Chen CD, Welsbie DS, Tran C, et al. Molecular determinants of resistance to antiandrogen therapy. *Nat Med*. 2004;10:33–39.

Chen ML, Xu PZ, Peng XD, et al. The deficiency of Akt1 is sufficient to suppress tumor development in Pten+/- mice. *Genes Dev*. 2006;20:1569–1574.

Cheng EH, Levine B, Boise LH, et al. Bax-independent inhibition of apoptosis by Bcl-XL. *Nature*. 1996;379:554–556.

Cheng I, Plummer SJ, Jorgenson E, et al. 8q24 and prostate cancer: association with advanced disease and meta-analysis. *Eur J Hum Genet*. 2008;16:496–505.

Cheng KC, Loeb LA. Genomic instability and tumor progression: mechanistic considerations. *Adv Cancer Res*. 1993;60:121–156.

Cheng L, MacLennan GT, Zhang S, et al. Laser capture microdissection analysis reveals frequent allelic losses in papillary urothelial neoplasm of low malignant potential of the urinary bladder. *Cancer*. 2004;101:183–188.

Cher ML, Bova GS, Moore DH, et al. Genetic alterations in untreated metastases and androgen-independent prostate cancer detected by comparative genomic hybridization and allelotyping. *Cancer Res*. 1996;56:3091–3102.

Cheville JC, Karnes RJ, Therneau TM, et al. Gene panel model predictive of outcome in men at high-risk of systemic progression and death from prostate cancer after radical retropubic prostatectomy. *J Clin Oncol*. 2008;26:3930–3936.

Chittenden T, Flemington C, Houghton AB, et al. A conserved domain in Bak, distinct from BH1 and BH2, mediates cell death and protein binding functions. *EMBO J*. 1995;14:5589–5596.

Choi DY, Toledo-Aral JJ, Lin HY, et al. Fibroblast growth factor receptor 3 induces gene expression primarily through Ras-independent signal transduction pathways. *J Biol Chem*.

2001;276:5116–5122.

Choi W, Porten S, Kim S, et al. Identification of distinct basal and luminal subtypes of muscle-invasive bladder cancer with different sensitivities to frontline chemotherapy. *Cancer Cell*. 2014;25:152–165.

Chow NH, Cairns P, Eisenberger CF, et al. Papillary urothelial hyperplasia is a clonal precursor to papillary transitional cell bladder cancer. *Int J Cancer*. 2000;89:514–518.

Christensen M, Jensen MA, Wolf H, et al. Pronounced microsatellite instability in transitional cell carcinomas from young patients with bladder cancer. *Int J Cancer*. 1998;79:396–401.

Christoph F, Schmidt B, Schmitz-Dräger BJ, et al. Over-expression and amplification of the c-myc gene in human urothelial carcinoma. *Int J Cancer*. 1999;84:169–173.

Clark AT, Rodriguez RT, Bodnar MS, et al. Human STELLAR, NANOG, and GDF3 genes are expressed in pluripotent cells and map to chromosome 12p13, a hotspot for teratocarcinoma. *Stem Cells*. 2004;22:169–179.

Clurman BE, Porter P. New insights into the tumor suppression function of P27(kip1). *Proc Natl Acad Sci USA*. 1998;95:15158–15160.

Coffey J, Linger R, Pugh J, et al. Somatic KIT mutations occur predominantly in seminoma germ cell tumors and are not predictive of bilateral disease: report of 220 tumors and review of literature. *Genes Chromosomes Cancer*. 2008;47:34–42.

Coleman JA. Familial and hereditary renal cancer syndromes. *Urol Clin North Am*. 2008;35:563–572 [v].

Colli JL, Amling CL. Chemoprevention of prostate cancer: what can be recommended to patients? *Curr Urol Rep*. 2009;10:165–171.

Colombel M, Symmans F, Gil S, et al. Detection of the apoptosis-suppressing oncoprotein bc1-2 in hormone-refractory human prostate cancers. *Am J Pathol*. 1993;143:390–400.

Cooney KA, McCarthy JD, Lange E, et al. Prostate cancer susceptibility locus on chromosome 1q: a confirmatory study. *J Natl Cancer Inst*. 1997;89:955–959.

Cooney KA, Wetzel JC, Consolino CM, et al. Identification and characterization of proximal 6q deletions in prostate cancer. *Cancer Res*. 1996;56:4150–4153.

Cooney KA, Wetzel JC, Merajver SD, et al. Distinct regions of allelic loss on 13q in prostate cancer. *Cancer Res*. 1996;56:1142–1145.

Cordon-Cardo C, Koff A, Drobnjak M, et al. Distinct altered patterns of p27KIP1 gene expression in benign prostatic hyperplasia and prostatic carcinoma. *J Natl Cancer Inst*. 1998;90:1284–1291.

Cordon-Cardo C, Wartinger D, Petrylak D, et al. Altered expression of the retinoblastoma gene product: prognostic indicator in bladder cancer. *J Natl Cancer Inst*. 1992;84:1251–1256.

Cote RJ, Shi Y, Groshen S, et al. Association of p27Kip1 levels with recurrence and survival in patients with stage C prostate carcinoma. *J Natl Cancer Inst*. 1998;90:916–920.

Counter CM, Avilion AA, LeFeuvre CE, et al. Telomere shortening associated with chromosome instability is arrested in immortal cells which express telomerase activity. *EMBO J*. 1992;11:1921–1929.

Cowell JK. Double minutes and homogeneously staining regions: gene amplification in mammalian cells. *Annu Rev Genet*. 1982;16:21–59.

Crissman JD, Sakr WA, Hussein ME, et al. DNA quantitation of intraepithelial neoplasia and invasive carcinoma of the prostate. *Prostate*. 1993;22:155–162.

Crockford GP, Linger R, Hockley S, et al. Genome-wide linkage screen for testicular germ cell tumour susceptibility loci. *Hum Mol Genet*. 2006;15:443–451.

Culig Z, Klocker H, Bartsch G, et al. Androgen receptor mutations in carcinoma of the prostate: significance for endocrine therapy. *Am J Pharmacogenomics*. 2001;1:241–249.

Czene K, Lichtenstein P, Hemminki K. Environmental and heritable causes of cancer among 9.6 million individuals in the Swedish Family-Cancer Database. *Int J Cancer*. 2002;99:260–266.

Dai MJ, Chen LL, Zheng YB, et al. Frequency and transcript variant analysis of gene fusions between TMPRSS2 and ETS transcription factor genes in prostate cancer. *Zhonghua Yi Xue Za Zhi*. 2008;88:669–673.

Dal Pra A, Lalonde E, Sykes J, et al. TMPRSS2-ERG status is not prognostic following prostate cancer radiotherapy: implications for fusion status and DSB repair. *Clin Cancer Res*. 2013;19:5202–5209.

Damrauer JS, Hoadley KA, Chism DD, et al. Intrinsic subtypes of high-grade bladder cancer reflect the hallmarks of breast cancer biology. *Proc Natl Acad Sci USA*. 2014;111:3110–3115.

Danila D, Anand A, Sung C, et al. TMPRSS2-ERG status in circulating tumor cells as a predictive biomarker of sensitivity in castration-resistant prostate cancer patients treated with abiraterone acetate. *Eur Urol*. 2011;60:897–904.

Darnel AD, Lafargue CJ, Vollmer RT, et al. TMPRSS2-ERG fusion is frequently observed in Gleason pattern 3 prostate cancer in a Canadian cohort. *Cancer Biol Ther*. 2009;8:125–130.

De Bondt HL, Rosenblatt J, Jancarik J, et al. Crystal structure of cyclin-dependent kinase 2. *Nature*. 1993;363:595–602.

de Jong J, Stoop H, Gillis AJ, et al. Differential expression of SOX17 and SOX2 in germ cells and stem cells has biological and clinical implications. *J Pathol*. 2008;215:21–30.

De Marzo AM, Platz EA, Sutcliffe S, et al. Inflammation in prostate carcinogenesis. *Nat Rev Cancer*. 2007;7:256–269.

Dehm SM, Schmidt LJ, Heemers HV, et al. Splicing of a novel androgen receptor exon generates a constitutively active androgen receptor that mediates prostate cancer therapy resistance. *Cancer Res*. 2008;68:5469–5477.

Del Pizzo JJ, Borkowski A, Jacobs SC, et al. Loss of cell cycle regulators p27(Kip1) and cyclin E in transitional cell carcinoma of the bladder correlates with tumor grade and patient survival. *Am J Pathol*. 1999;155:1129–1136.

Demichelis F, Fall K, Perner S, et al. TMPRSS2:ERG gene fusion associated with lethal prostate cancer in a watchful waiting cohort. *Oncogene*. 2007;26:4596–4599.

Denmeade SR, Isaacs JT. Activation of programmed (apoptotic) cell death for the treatment of prostate cancer. *Adv Pharmacol*. 1996;35:281–306.

DePinho RA. The age of cancer. *Nature*. 2000;408:248–254.

Deveraux QL, Roy N, Stennicke HR, et al. IAPs block apoptotic events induced by caspase-8 and cytochrome c by direct inhibition of distinct caspases. *EMBO J*. 1998;17:2215–2223.

Devlin J, Keen AJ, Knowles MA. Homozygous deletion mapping at 9p21 in bladder carcinoma defines a critical region within 2 cM of IFNA. *Oncogene*. 1994;9:2757–2760.

Di Cristofano A, De Acetis M, Koff A, et al. Pten and p27KIP1 cooperate in prostate cancer tumor suppression in the mouse. *Nat Genet*. 2001;27:222–224.

Di Vizio D, Cito L, Boccia A, et al. Loss of the tumor suppressor gene PTEN marks the transition from intratubular germ cell neoplasias (ITGCN) to invasive germ cell tumors.

Oncogene. 2005;24:1882–1894.

Dirks PB. Brain tumor stem cells. *Biol Blood Marrow Transplant*. 2005;11:12–13.

Donaldson L, Fordyce C, Gilliland F, et al. Association between outcome and telomere DNA content in prostate cancer. *J Urol*. 1999;162:1788–1792.

Dontu G, Al-Hajj M, Abdallah WM, et al. Stem cells in normal breast development and breast cancer. *Cell Prolif*. 2003;36:59–72.

Downward J, Parker P, Waterfield MD. Autophosphorylation sites on the epidermal growth factor receptor. *Nature*. 1984;311:483–485.

Duesberg P, Rasnick D, Li R, et al. How aneuploidy may cause cancer and genetic instability. *Anticancer Res*. 1999;19:4887–4906.

Duesberg P. Does aneuploidy or mutation start cancer? *Science*. 2005;307:41.

Duggan D, Zheng SL, Knowlton M, et al. Two genome-wide association studies of aggressive prostate cancer implicate putative prostate tumor suppressor gene DAB2IP. *J Natl Cancer Inst*. 2007;99:1836–1844.

Dynlacht BD, Flores O, Lees JA, et al. Differential regulation of E2F transactivation by cyclin/CDK2 complexes. *Genes Dev*. 1994;8:1772–1786.

Dyson N. The regulation of E2F by pRB-family proteins. *Genes Dev*. 1998;12:2245–2262.

Easton DF, Schaid DJ, Whittemore AS, et al. Where are the prostate cancer genes?—A summary of eight genome wide searches. *Prostate*. 2003;57:261–269.

Eeles RA, Durocher F, Edwards S, et al. Linkage analysis of chromosome 1q markers in 136 prostate cancer families. The Cancer Research Campaign/British Prostate Group U.K. Familial Prostate Cancer Study Collaborators. *Am J Hum*

Genet. 1998;62:653–658.

Eeles RA, Kote-Jarai Z, Al Olama AA, et al. Identification of seven new prostate cancer susceptibility loci through a genome-wide association study. *Nat Genet*. 2009;41:1116–1121.

Eeles RA, Kote-Jarai Z, Giles GG, et al. Multiple newly identified loci associated with prostate cancer susceptibility. *Nat Genet*. 2008;40:316–321.

Eeles RA, Olama AAA, Benlloch S, et al. Identification of 23 new prostate cancer susceptibility loci using the iCOGS custom genotyping array. *Nat Genet*. 2013;45:385–391.

Eiber M, van Oers JM, Zwarthoff EC, et al. Low frequency of molecular changes and tumor recurrence in inverted papillomas of the urinary tract. *Am J Surg Pathol*. 2007;31:938–946.

Einhorn LH. Curing metastatic testicular cancer. *Proc Natl Acad Sci USA*. 2002;99:4592–4595.

Eissa S, Swellam M, Ali-Labib R, et al. Detection of telomerase in urine by 3 methods: evaluation of diagnostic accuracy for bladder cancer. *J Urol*. 2007;178:1068–1072.

el-Deiry WS, Tokino T, Velculescu VE, et al. WAF1, a potential mediator of p53 tumor suppression. *Cell*. 1993;75:817–825.

Elenbaas B, Spirio L, Koerner F, et al. Human breast cancer cells generated by oncogenic transformation of primary mammary epithelial cells. *Genes Dev*. 2001;15:50–65.

Elledge RM. Assessing p53 status in breast cancer prognosis: where should you put the thermometer if you think your p53 is sick? *J Natl Cancer Inst*. 1996;88:141–143.

Ellwood-Yen K, Graeber TG, Wongvipat J, et al. Myc-driven murine prostate cancer shares molecular features with human prostate tumors. *Cancer Cell*. 2003;4:223–238.

Elo JP, Harkonen P, Kyllonen AP, et al. Loss of heterozygosity at 16q24.1-q24.2 is significantly associated with metastatic and aggressive behavior of prostate cancer. *Cancer Res*. 1997;57:3356–3359.

Elsamman E, Fukumori T, Kasai T, et al. Prostate stem cell antigen predicts tumour recurrence in superficial transitional cell carcinoma of the urinary bladder. *BJU Int*. 2006;97:1202–1207.

Engelhardt M, Albanell J, Drullinsky P, et al. Relative contribution of normal and neoplastic cells determines telomerase activity and telomere length in primary cancers of the prostate, colon, and sarcoma. *Clin Cancer Res*. 1997;3:1849–1857.

Esrig D, Elmajian D, Groshen S, et al. Accumulation of nuclear p53 and tumor progression in bladder cancer. *N Engl J Med*. 1994;331:1259–1264.

Ewing CM, Ray AM, Lange EM, et al. Germline mutations in HOXB13 and prostate-cancer risk. *New Engl J Med*. 2012;366:141–149.

Fadl-Elmula I, Gorunova L, Mandahl N, et al. Karyotypic characterization of urinary bladder transitional cell carcinomas. *Genes Chromosomes Cancer*. 2000;29:256–265.

Fadok VA, Savill JS, Haslett C, et al. Different populations of macrophages use either the vitronectin receptor or the phosphatidylserine receptor to recognize and remove apoptotic cells. *J Immunol*. 1992;149:4029–4035.

Falck J, Petrini JH, Williams BR, et al. The DNA damage-dependent intra-S phase checkpoint is regulated by parallel pathways. *Nat Genet*. 2002;30:290–294.

Falzarano S, Zhou M, Carver P, et al. ERG gene rearrangement status in prostate cancer detected by immunohistochemistry. *Virchows Arch*. 2011;459:441–447.

Feinberg AP, Tycko B. The history of cancer epigenetics. *Nat Rev Cancer*. 2004;4:143–153.

Feldser DM, Hackett JA, Greider CW. Telomere dysfunction and the initiation of genome instability. *Nat Rev Cancer*. 2003;3:623–627.

Fero ML, Randel E, Gurley KE, et al. The murine gene p27Kip1 is haplo-insufficient for tumour suppression. *Nature*. 1998;396:177–180.

Figueroa JD, Ye Y, Siddiq A, et al. Genome-wide association study identifies multiple loci associated with bladder cancer risk. *Hum Mol Genet*. 2014;23(5):1387–1398.

Fine S, Gopalan A, Leversha M, et al. TMPRSS2-ERG gene fusion is associated with low Gleason scores and not with high-grade morphological features. *Mod Pathol*. 2010;23:1325–1333.

Finkel T, Holbrook NJ. Oxidants, oxidative stress and the biology of ageing. *Nature*. 2000;408:239–247.

Forbes S, Clements J, Dawson E, et al. Cosmic 2005. *Br J Cancer*. 2006;94:318–322.

Fordyce CA, Heaphy CM, Griffith JK. Chemiluminescent measurement of telomere DNA content in biopsies. *Biotechniques*. 2002;33:144–146 [148].

Fordyce CA, Heaphy CM, Joste NE, et al. Association between cancer-free survival and telomere DNA content in prostate tumors. *J Urol*. 2005;173:610–614.

Forman D, Oliver RT, Brett AR, et al. Familial testicular cancer: a report of the UK family register, estimation of risk and an HLA class 1 sib-pair analysis. *Br J Cancer*. 1992;65:255–262.

Foster CS, Bostwick DG, Bonkhoff H, et al. Cellular and molecular pathology of prostate cancer precursors. *Scand J Urol Nephrol Suppl*. 2000;19–43.

Freedland SJ, deGregorio F, Sacoolidge JC, et al. Preoperative p27 status is an independent predictor of prostate specific antigen failure following radical prostatectomy. *J Urol*. 2003;169:1325–1330.

Friedberg EC, Meira LB, Cheo DL. Database of mouse strains carrying targeted mutations in genes affecting cellular responses to DNA damage. Version 2. *Mutat Res*. 1998;407:217–226.

Fujimoto K, Yamada Y, Okajima E, et al. Frequent association of p53 gene mutation in invasive bladder cancer. *Cancer Res*. 1992;52:1393–1398.

Fung MK, Cheung HW, Wong HL, et al. MAD2 expression and its significance in mitotic checkpoint control in testicular germ cell tumour. *Biochem Biophys Acta*. 2007;1773:821–832.

Furugori E, Hirayama R, Nakamura KI, et al. Telomere shortening in gastric carcinoma with aging despite telomerase activation. *J Cancer Res Clin Oncol*. 2000;126:481–485.

García-Closas M, Malats N, Silverman D, et al. NAT2 slow acetylation, GSTM1 null genotype, and risk of bladder cancer: results from the Spanish Bladder Cancer Study and meta-analyses. *Lancet*. 2005;366:649–659.

García-Closas M, Ye Y, Rothman N, et al. A genome-wide association study of bladder cancer identifies a new susceptibility locus within SLC14A1, a urea transporter gene on chromosome 18q12.3. *Hum Mol Genet*. 2011;20:4282–4289.

Gardiner-Garden M, Frommer M. CpG Islands in vertebrate genomes. *J Mol Biol*. 1987;196:261–282.

Garolla A, Ferlin A, Vinanzi C, et al. Molecular analysis of the androgen receptor gene in testicular cancer. *Endocr Relat Cancer*. 2005;12:645–655.

Gaziano JM, Glynn RJ, Christen WG, et al. Vitamins E and C in the prevention of prostate and total cancer in men: the Physicians' Health Study II randomized controlled trial. *J Am Med Assoc*. 2009;301:52–62.

George B, Datar RH, Wu L, et al. p53 gene and protein status:

the role of p53 alterations in predicting outcome in patients with bladder cancer. *J Clin Oncol*. 2007;25:5352–5358.

Giaccia AJ, Kastan MB. The complexity of p53 modulation: emerging patterns from divergent signals. *Genes Dev*. 1998;12:2973–2983.

Gibas Z, Prout GR Jr, Connolly JG, et al. Nonrandom chromosomal changes in transitional cell carcinoma of the bladder. *Cancer Res*. 1984;44:1257–1264.

Gil J, Kerai P, Lleonart M, et al. Immortalization of primary human prostate epithelial cells by c-Myc. *Cancer Res*. 2005;65:2179–2185.

Girard F, Strausfeld U, Fernandez A, et al. Cyclin A is required for the onset of DNA replication in mammalian fibroblasts. *Cell*. 1991;67:1169–1179.

Gisselsson D, Pettersson L, Hoglund M, et al. Chromosomal breakage-fusion-bridge events cause genetic intratumor heterogeneity. *Proc Natl Acad Sci USA*. 2000;97:5357–5362.

Giwercman A, Lundin KB, Eberhard J, et al. Linkage between androgen receptor gene CAG trinucleotide repeat length and testicular germ cell cancer histological type and clinical stage. *Eur J Cancer*. 2004;40:2152–2158.

Gleave M, Miyake H. Use of antisense oligonucleotides targeting the cytoprotective gene, clusterin, to enhance androgen- and chemo-sensitivity in prostate cancer. *World J Urol*. 2005;23:38–46.

Gnarra JR, Tory K, Weng Y, et al. Mutations of the VHL tumour suppressor gene in renal carcinoma. *Nat Genet*. 1994;7:85–90.

Goddard NC, McIntyre A, Summersgill B, et al. KIT and RAS signalling pathways in testicular germ cell tumours: new data and a review of the literature. *Int J Androl*. 2007;30:337–348 [discussion 349].

Gonzalez-Zulueta M, Bender CM, Yang AS, et al. Methylation of the 5′ CpG island of the p16/CDKN2 tumor suppressor gene in normal and transformed human tissues correlates with gene silencing. *Cancer Res*. 1995;55:4531–4535.

Gonzalgo ML, Hayashida T, Bender CM, et al. The role of DNA methylation in expression of the p19/p16 locus in human bladder cancer cell lines. *Cancer Res*. 1998;58:1245–1252.

Gonzalgo ML, Jones PA. Mutagenic and epigenetic effects of DNA methylation. *Mutat Res Rev Mutat Res*. 1997;386:107–118.

Gonzalo S, Blasco MA. Role of Rb family in the epigenetic definition of chromatin. *Cell Cycle*. 2005;4:752–755.

Gopalan A, Dhall D, Olgac S, et al. Testicular mixed germ cell tumors: a morphological and immunohistochemical study using stem cell markers, OCT3/4, SOX2 and GDF3, with emphasis on morphologically difficult-to-classify areas. *Mod Pathol*. 2009;22:1066–1074.

Gopalan A, Leversha MA, Satagopan JM, et al. TMPRSS2-ERG gene fusion is not associated with outcome in patients treated by prostatectomy. *Cancer Res*. 2009;69:1400–1406.

Gorgoulis VG, Vassiliou LV, Karakaidos P, et al. Activation of the DNA damage checkpoint and genomic instability in human precancerous lesions. *Nature*. 2005;434:907–913.

Gottlieb B, Beitel LK, Wu JH, et al. The androgen receptor gene mutations database (ARDB): 2004 update. *Hum Mutat*. 2004;23:527–533.

Graff JR, Herman JG, Lapidus RG, et al. E-cadherin expression is silenced by DNA hypermethylation in human breast and prostate carcinomas. *Cancer Res*. 1995;55:5195–5199.

Greenblatt MS, Bennett WP, Hollstein M, et al. Mutations in the p53 tumor suppressor gene: clues to cancer etiology and molecular pathogenesis. *Cancer Res*. 1994;54:4855–4878.

Greenman C, Stephens P, Smith R, et al. Patterns of somatic mutation in human cancer genomes. *Nature*. 2007;446:153–158.

Greider CW, Blackburn EH. Identification of a specific telomere terminal transferase activity in Tetrahymena extracts. *Cell*. 1985;43:405–413.

Greider CW, Blackburn EH. The telomere terminal transferase of Tetrahymena is a ribonucleoprotein enzyme with two kinds of primer specificity. *Cell*. 1987;51:887–898.

Greider CW. Telomerase activity, cell proliferation, and cancer. *Proc Natl Acad Sci USA*. 1998;95:90–92.

Griffith JK, Bryant JE, Fordyce CA, et al. Reduced telomere DNA content is correlated with genomic instability and metastasis in invasive human breast carcinoma. *Breast Cancer Res Treat*. 1999;54:59–64.

Gronberg H, Xu J, Smith JR, et al. Early age at diagnosis in families providing evidence of linkage to the hereditary prostate cancer locus (HPC1) on chromosome 1. *Cancer Res*. 1997;57:4707–4709.

Guadagno TM, Ohtsubo M, Roberts JM, et al. A link between cyclin A expression and adhesion-dependent cell cycle progression. *Science*. 1993;262:1572–1575.

Gudmundsson J, Sulem P, Manolescu A, et al. Genome-wide association study identifies a second prostate cancer susceptibility variant at 8q24. *Nat Genet*. 2007;39:631–637.

Gudmundsson J, Sulem P, Rafnar T, et al. Common sequence variants on 2p15 and Xp11.22 confer susceptibility to prostate cancer. *Nat Genet*. 2008;40:281–283.

Gulbins E, Kolesnick R. Raft ceramide in molecular medicine. *Oncogene*. 2003;22:7070–7077.

Guo CC, Zuo G, Cao D, et al. Prostate cancer of transition zone origin lacks TMPRSS2-ERG gene fusion. *Mod Pathol*. 2009;22:866–871.

Guo Y, Sklar GN, Borkowski A, et al. Loss of the cyclin-dependent kinase inhibitor p27(Kip1) protein in human prostate cancer correlates with tumor grade. *Clin Cancer Res*. 1997;3:2269–2274.

Guo Z, Yang X, Sun F, et al. A novel androgen receptor splice variant is up-regulated during prostate cancer progression and promotes androgen depletion–resistant growth. *Cancer Res*. 2009;69:2305–2313.

Habuchi T, Luscombe M, Elder PA, et al. Structure and methylation-based silencing of a gene (DBCCR1) within a candidate bladder cancer tumor suppressor region at 9q32-q33. *Genomics*. 1998;48:277–288.

Haffner MC, Mosbruger T, Esopi DM, et al. Tracking the clonal origin of lethal prostate cancer. *J Clin Invest*. 2013;123:4918–4922.

Hafner C, Vogt T, Hartmann A. FGFR3 mutations in benign skin tumors. *Cell Cycle*. 2006;5:2723–2728.

Hahn WC, Counter CM, Lundberg AS, et al. Creation of human tumour cells with defined genetic elements. *Nature*. 1999;400:464–468.

Haiman CA, Patterson N, Freedman ML, et al. Multiple regions within 8q24 independently affect risk for prostate cancer. *Nat Genet*. 2007;39:638–644.

Hajdinjak T. UroVysion FISH test for detecting urothelial cancers: meta-analysis of diagnostic accuracy and comparison with urinary cytology testing. *Urol Oncol*. 2008;26:646–651.

Halevy O, Novitch BG, Spicer DB, et al. Correlation of terminal cell cycle arrest of skeletal muscle with induction of p21 by MyoD. *Science*. 1995;267:1018–1021.

Halling KC, King W, Sokolova IA, et al. A comparison of cytology and fluorescence in situ hybridization for the detection of urothelial carcinoma. *J Urol*. 2000;164:1768–1775.

Halling KC. Vysis UroVysion for the detection of urothelial carcinoma. *Expert Rev Mol Diagn*. 2003;3:507–519.

Han B, Mehra R, Lonigro RJ, et al. Fluorescence in situ hybridization study shows association of PTEN deletion with ERG rearrangement during prostate cancer progression. *Mod Pathol*. 2009;22:1083–1093.

Hanahan D, Weinberg RA. Hallmarks of cancer: the next generation. *Cell*. 2011;144:646–674.

Hanahan D, Weinberg RA. The hallmarks of cancer. *Cell*. 2000;100:57–70.

Hansel DE, Meeker AK, Hicks J, et al. Telomere length variation in biliary tract metaplasia, dysplasia, and carcinoma. *Mod Pathol*. 2006;19:772–779.

Hansel DE, Rini BI. Molecular genetics of hereditary renal cancer: new genes and diagnostic and therapeutic opportunities. *Expert Rev Anticancer Ther*. 2008;8:895–905.

Hara T, Miyazaki J, Araki H, et al. Novel mutations of androgen receptor: a possible mechanism of bicalutamide withdrawal syndrome. *Cancer Res*. 2003;63:149–153.

Harley CB, Futcher AB, Greider CW. Telomeres shorten during ageing of human fibroblasts. *Nature*. 1990;345:458–460.

Harris H. Standing on Boveri's shoulders. *J Cell Sci*. 2008;121:3.

Hartmann A, Moser K, Kriegmair M, et al. Frequent genetic alterations in simple urothelial hyperplasias of the bladder in patients with papillary urothelial carcinoma. *Am J Pathol*. 1999;154:721–727.

Hartmann A, Schlake G, Zaak D, et al. Occurrence of chromosome 9 and p53 alterations in multifocal dysplasia and carcinoma in situ of human urinary bladder. *Cancer Res*. 2002;62:809–818.

Hartwell LH, Culotti J, Pringle JR, et al. Genetic control of the cell division cycle in yeast. *Science*. 1974;183:46–51.

Hartwell LH, Weinert TA. Checkpoints: controls that ensure the order of cell cycle events. *Science*. 1989;246:629–634.

Hartwell LH. Defects in a cell cycle checkpoint may be responsible for the genomic instability of cancer cells. *Cell*. 1992;71:543–546.

Hastie ND, Dempster M, Dunlop MG, et al. Telomere reduction in human colorectal carcinoma and with ageing. *Nature*. 1990;346:866–868.

Hatfield DL, Gladyshev VN. The Outcome of Selenium and Vitamin E Cancer Prevention Trial (SELECT) reveals the need for better understanding of selenium biology. *Mol Interv*. 2009;9:18–21.

He WW, Sciavolino PJ, Wing J, et al. A novel human prostate-specific, androgen-regulated homeobox gene (NKX3.1) that maps to 8p21, a region frequently deleted in prostate cancer. *Genomics*. 1997;43:69–77.

Heaphy CM, Subhawong A, Hong S, et al. Prevalence of the alternative lengthening of telomeres telomere maintenance mechanism in human cancer subtypes. *Am J Pathol*. 2011;179:1608–1615.

Heaphy CM, Yoon GS, Peskoe SB, et al. Prostate cancer cell telomere length variability and stromal cell telomere length as prognostic markers for metastasis and death. *Cancer Discov*. 2013;3:1130–1141.

Helgeson BE, Tomlins SA, Shah N, et al. Characterization of TMPRSS2:ETV5 and SLC45A3:ETV5 gene fusions in prostate cancer. *Cancer Res*. 2008;68:73–80.

Hemesath TJ, Steingrimsson E, McGill G, et al. microphthalmia, a critical factor in melanocyte development, defines a discrete transcription factor family. *Genes Dev*. 1994;8:2770–2780.

Herman JG, Jen J, Merlo A, et al. Hypermethylation-associated inactivation indicates a tumor suppressor role for p15INK4B.

Cancer Res. 1996;56:722–727.

Herman JG, Merlo A, Mao L, et al. Inactivation of the CDKN2/p16/MTS1 gene is frequently associated with aberrant DNA methylation in all common human cancers. *Cancer Res*. 1995;55:4525–4530.

Herman MP, Svatek RS, Lotan Y, et al. Urine-based biomarkers for the early detection and surveillance of non-muscle invasive bladder cancer. *Minerva Urol Nefrol*. 2008;60:217–235.

Hermans KG, Bressers AA, van der Korput HA, et al. Two unique novel prostate-specific and androgen-regulated fusion partners of ETV4 in prostate cancer. *Cancer Res*. 2008;68:3094–3098.

Hermeking H, Lengauer C, Polyak K, et al. 14-3-3 sigma is a p53-regulated inhibitor of G2/M progression. *Mol Cell*. 1997;1:3–11.

Hernandez S, Lopez-Knowles E, Lloreta J, et al. Prospective study of FGFR3 mutations as a prognostic factor in nonmuscle invasive urothelial bladder carcinomas. *J Clin Oncol*. 2006;24:3664–3671.

Hessels D, Smit FP, Verhaegh GW, et al. Detection of TMPRSS2-ERG fusion transcripts and prostate cancer antigen 3 in urinary sediments may improve diagnosis of prostate cancer. *Clin Cancer Res*. 2007;13:5103–5108.

Hilt EE, McKinley K, Pearce MM, et al. Urine is not sterile: use of enhanced urine culture techniques to detect resident bacterial flora in the adult female bladder. *J Clin Microbiol*. 2014;52(3):871–876.

Hirama T, Koeffler HP. Role of the cyclin-dependent kinase inhibitors in the development of cancer. *Blood*. 1995;86:841–854.

Hiyama E, Hiyama K, Yokoyama T, et al. Correlating telomerase activity levels with human neuroblastoma outcomes. *Nat Med*. 1995;1:249–255.

Hiyama K, Hiyama E, Ishioka S, et al. Telomerase activity in small-cell and non-small-cell lung cancers. *J Natl Cancer Inst*. 1995;87:895–902.

Holland AJ, Cleveland DW. Boveri revisited: chromosomal instability, aneuploidy and tumorigenesis. *Nat Rev Mol Cell Biol*. 2009;10:478–487.

Hollstein M, Sidransky D, Vogelstein B, et al. p53 mutations in human cancers. *Science*. 1991;253:49–53.

Holmang S, Andius P, Hedelin H, et al. Stage progression in Ta papillary urothelial tumors: relationship to grade, immunohistochemical expression of tumor markers, mitotic frequency and DNA ploidy. *J Urol*. 2001;165:1124–1128 [discussion 1128–1130].

Honorio S, Agathanggelou A, Wernert N, et al. Frequent epigenetic inactivation of the RASSF1A tumour suppressor gene in testicular tumours and distinct methylation profiles of seminoma and nonseminoma testicular germ cell tumours. *Oncogene*. 2003;22:461–466.

Hopman AH, Kamps MA, Speel EJ, et al. Identification of chromosome 9 alterations and p53 accumulation in isolated carcinoma in situ of the urinary bladder versus carcinoma in situ associated with carcinoma. *Am J Pathol*. 2002;161:1119–1125.

Horikawa Y, Sugano K, Shigyo M, et al. Hypermethylation of an E-cadherin (CDH1) promoter region in high grade transitional cell carcinoma of the bladder comprising carcinoma in situ. *J Urol*. 2003;169:1541–1545.

Hornigold N, Devlin J, Davies AM, et al. Mutation of the 9q34 gene TSC1 in sporadic bladder cancer. *Oncogene*. 1999;18:2657–2661.

Horowitz JM, Park SH, Bogenmann E, et al. Frequent inactivation of the retinoblastoma anti-oncogene is restricted to a subset of human tumor cells. *Proc Natl Acad Sci USA*. 1990;87:2775–2779.

Horwich A, Shipley J, Huddart R. Testicular germ-cell cancer. *Lancet*. 2006;367:754–765.

Hu CJ, Wang LY, Chodosh LA, et al. Differential roles of hypoxia-inducible factor 1alpha (HIF-1alpha) and HIF-2alpha in hypoxic gene regulation. *Mol Cell Biol*. 2003;23:9361–9374.

Hu R, Dunn TA, Wei S, et al. Ligand-independent androgen receptor variants derived from splicing of cryptic exons signify hormone-refractory prostate cancer. *Cancer Res*. 2009;69:16–22.

Hyytinen ER, Frierson HF Jr, Boyd JC, et al. Three distinct regions of allelic loss at 13q14, 13q21-22, and 13q33 in prostate cancer. *Genes Chromosomes Cancer*. 1999;25:108–114.

Hyytinen ER, Saadut R, Chen C, et al. Defining the region(s) of deletion at 6q16-q22 in human prostate cancer. *Genes Chromosomes Cancer*. 2002;34:306–312.

Igarashi H, Esumi M, Ishida H, et al. Vascular endothelial growth factor overexpression is correlated with von Hippel-Lindau tumor suppressor gene inactivation in patients with sporadic renal cell carcinoma. *Cancer*. 2002;95:47–53.

Iliopoulos O, Levy AP, Jiang C, et al. Negative regulation of hypoxia-inducible genes by the von Hippel-Lindau protein. *Proc Natl Acad Sci USA*. 1996;93:10595–10599.

Irmler M, Thome M, Hahne M, et al. Inhibition of death receptor signals by cellular FLIP. *Nature*. 1997;388:190–195.

Isaacs JS, Jung YJ, Mole DR, et al. HIF overexpression correlates with biallelic loss of fumarate hydratase in renal cancer: novel role of fumarate in regulation of HIF stability. *Cancer Cell*. 2005;8:143–153.

Isaacs JT. Advances and controversies in the study of programmed cell death/apoptosis in the development of and therapy for cancer. *Curr Opin Oncol*. 1994;6:82–89.

Isaacs WB, Bova GS, Morton RA, et al. Molecular biology of prostate cancer progression. *Cancer Surv*. 1995;23:19–32.

Isaacs WB. Prostate cancer. Kinzler Va. *The genetic basis of human cancer*. McGraw-Hill; 2002:709–718.

Ishak MB, Giri VN. A systematic review of replication studies of prostate cancer susceptibility genetic variants in high-risk men originally identified from genome-wide association studies. *Cancer Epidemiol Biomarkers Prev*. 2011;20:1599–1610.

Ishikawa J, Xu HJ, Hu SX, et al. Inactivation of the retinoblastoma gene in human bladder and renal cell carcinomas. *Cancer Res*. 1991;51:5736–5743.

Ittmann M, Wieczorek R. Alterations of the retinoblastoma gene in clinically localized, stage B prostate adenocarcinomas. *Hum Pathol*. 1996;27:28–34.

Ittmann M. Allelic loss on chromosome 10 in prostate adenocarcinoma. *Cancer Res*. 1996;56:2143–2147.

Ivan M, Kondo K, Yang H, et al. HIFalpha targeted for VHL-mediated destruction by proline hydroxylation: implications for O2 sensing. *Science*. 2001;292:464–468.

Jaakkola P, Mole DR, Tian YM, et al. Targeting of HIF-alpha to the von Hippel-Lindau ubiquitylation complex by O2-regulated prolyl hydroxylation. *Science*. 2001;292:468–472.

Jarrard DF, Bova GS, Ewing CM, et al. Deletional, mutational, and methylation analyses of CDKN2 (p16/MTS1) in primary and metastatic prostate cancer. *Genes Chromosomes Cancer*. 1997;19:90–96.

Jebar AH, Hurst CD, Tomlinson DC, et al. FGFR3 and Ras gene mutations are mutually exclusive genetic events in urothelial cell carcinoma. *Oncogene*. 2005;24:5218–5225.

Jeffers M, Schmidt L, Nakaigawa N, et al. Activating mutations for the met tyrosine kinase receptor in human cancer. *Proc Natl Acad Sci USA*. 1997;94:11445–11450.

Jeffrey PD, Russo AA, Polyak K, et al. Mechanism of CDK activation revealed by the structure of a cyclinA-CDK2 complex. *Nature*. 1995;376:313–320.

Jenkins RB, Qian J, Lieber MM, et al. Detection of c-myc oncogene amplification and chromosomal anomalies in metastatic prostatic carcinoma by fluorescence in situ hybridization. *Cancer Res*. 1997;57:524–531.

Jerónimo C, Usadel H, Henrique R, et al. Quantitation of GSTP1 methylation in non-neoplastic prostatic tissue and organ-confined prostate adenocarcinoma. *J Natl Cancer Inst*. 2001;93:1747–1752.

Jobin C. Precision medicine using microbiota. *Science*. 2018;359:32–34.

Johnson MI, Hamdy FC. Apoptosis regulating genes in prostate cancer (review). *Oncol Rep*. 1998;5:553–557.

Johnson RD, Liu N, Jasin M. Mammalian XRCC2 promotes the repair of DNA double-strand breaks by homologous recombination. *Nature*. 1999;401:397–399.

Jones P, Baylin SB. The fundamental role of epigenetic events in cancer. *Nat Rev Genet*. 2002;3:415–428.

Jones P, Gonzalgo M, Tsutsumi M, et al. DNA methylation in bladder cancer. *Eur Urol*. 1998;33(Suppl 4):7–8.

Jones P, Gonzalgo ML. Altered DNA methylation and genome instability: a new pathway to cancer? *Proc Natl Acad Sci*. 1997;94:2103–2105.

Jones P. DNA methylation and cancer. *Cancer Res*. 1986;46:461–466.

Jones TD, Zhang S, Lopez-Beltran A, et al. Urothelial carcinoma with an inverted growth pattern can be distinguished from inverted papilloma by fluorescence in situ hybridization, immunohistochemistry, and morphologic analysis. *Am J Surg Pathol*. 2007;31:1861–1867.

Jorgenson E, Witte JS. Genome-wide association studies of cancer. *Future Oncol*. 2007;3:419–427.

Joshua AM, Vukovic B, Braude I, et al. Telomere attrition in isolated high-grade prostatic intraepithelial neoplasia and surrounding stroma is predictive of prostate cancer. *Neoplasia*. 2007;9:81–89.

July LV, Akbari M, Zellweger T, et al. Clusterin expression is significantly enhanced in prostate cancer cells following androgen withdrawal therapy. *Prostate*. 2002;50:179–188.

Junker K, Boerner D, Schulze W, et al. Analysis of genetic alterations in normal bladder urothelium. *Urology*. 2003;62:1134–1138.

Jürgens B, Schmitz-Dräger BJ, Schulz WA. Hypomethylation of L1 LINE sequences prevailing in human urothelial carcinoma. *Cancer Res*. 1996;56:5698–5703.

Jurgensmeier JM, Xie Z, Deveraux Q, et al. Bax directly induces release of cytochrome c from isolated mitochondria. *Proc Natl Acad Sci USA*. 1998;95:4997–5002.

Kader AK, Sun J, Isaacs SD, et al. Individual and cumulative effect of prostate cancer risk-associated variants on clinicopathologic variables in 5,895 prostate cancer patients. *Prostate*. 2009;69:1195–1205.

Kaelin WG Jr. Molecular basis of the VHL hereditary cancer syndrome. *Nat Rev Cancer*. 2002;2:673–682.

Kagan J, Liu J, Stein JD, et al. Cluster of allele losses within a 2.5 cM region of chromosome 10 in high-grade invasive bladder cancer. *Oncogene*. 1998;16:909–913.

Kallakury BV, Brien TP, Lowry CV, et al. Telomerase activity in human benign prostate tissue and prostatic adenocarcinomas. *Diagn Mol Pathol*. 1997;6:192–198.

Kamb A, Gruis NA, Weaver-Feldhaus J, et al. A cell cycle regulator potentially involved in genesis of many tumor types. *Science*. 1994;264:436–440.

Kamradt J, Drosse C, Kalkbrenner S, et al. Telomerase activity and telomerase subunit gene expression levels are not related in prostate cancer: a real-time quantification and in situ hybridization study. *Lab Invest*. 2003;83:623–633.

Kamura T, Koepp DM, Conrad MN, et al. Rbx1, a component of the VHL tumor suppressor complex and SCF ubiquitin ligase. *Science*. 1999;284:657–661.

Kanetsky PA, Mitra N, Vardhanabhuti S, et al. Common variation in KITLG and at 5q31.3 predisposes to testicular germ cell cancer. *Nat Genet*. 2009;41:811–815.

Karan D, Lin MF, Johansson SL, et al. Current status of the molecular genetics of human prostatic adenocarcinomas. *Int J Cancer*. 2003;103:285–293.

Karlseder J. Telomere repeat binding factors: keeping the ends in check. *Cancer Lett*. 2003;194:189–197.

Kastan MB, Bartek J. Cell-cycle checkpoints and cancer. *Nature*. 2004;432:316–323.

Kawai T, Hiroi S, Nakanishi K, et al. Telomere length and telomerase expression in atypical adenomatous hyperplasia and small bronchioloalveolar carcinoma of the lung. *Am J Clin Pathol*. 2007;127:254–262.

Kawamata N, Morosetti R, Miller CW, et al. Molecular analysis of the cyclin-dependent kinase inhibitor gene p27/Kip1 in human malignancies. *Cancer Res*. 1995;55:2266–2269.

Kemmer K, Corless CL, Fletcher JA, et al. KIT mutations are common in testicular seminomas. *Am J Pathol*. 2004;164:305–313.

Kerr JF, Wyllie AH, Currie AR. Apoptosis: a basic biological phenomenon with wide-ranging implications in tissue kinetics. *Br J Cancer*. 1972;26:239–257.

Kersemaekers AM, Mayer F, Molier M, et al. Role of P53 and MDM2 in treatment response of human germ cell tumors. *J*

Clin Oncol. 2002;20:1551–1561.

Kester M, Kolesnick R. Sphingolipids as therapeutics. *Pharmacol Res*. 2003;47:365–371.

Khoo SK, Giraud S, Kahnoski K, et al. Clinical and genetic studies of Birt-Hogg-Dube syndrome. *J Med Genet*. 2002;39:906–912.

Kibel A, Iliopoulos O, DeCaprio JA, et al. Binding of the von Hippel-Lindau tumor suppressor protein to Elongin B and C. *Science*. 1995;269:1444–1446.

Kibel AS, Isaacs WB. G(1)/S cell cycle proteins as markers of aggressive prostate carcinoma. *Urology*. 2000;55:316–322.

Kibel AS, Schutte M, Kern SE, et al. Identification of 12p as a region of frequent deletion in advanced prostate cancer. *Cancer Res*. 1998;58:5652–5655.

Kibel AS, Suarez BK, Belani J, et al. CDKN1A and CDKN1B polymorphisms and risk of advanced prostate carcinoma. *Cancer Res*. 2003;63:2033–2036.

Kiemeney LA, Grotenhuis AJ, Vermeulen SH, et al. Genome-wide association studies in bladder cancer: first results and potential relevance. *Curr Opin Urol*. 2009;19:540–546.

Kiemeney LA, Sulem P, Besenbacher S, et al. A sequence variant at 4p16.3 confers susceptibility to urinary bladder cancer. *Nat Genet*. 2010;42 [415-U467].

Kiemeney LA, Thorlacius S, Sulem P, et al. Sequence variant on 8q24 confers susceptibility to urinary bladder cancer. *Nat Genet*. 2008;40:1307–1312.

Kiemeney LA. Hereditary bladder cancer. *Scand J Urol Nephrol Suppl*. 2008;110–115.

Kim MJ, Cardiff RD, Desai N, et al. Cooperativity of Nkx3.1 and Pten loss of function in a mouse model of prostate carcinogenesis. *Proc Natl Acad Sci USA*. 2002;99:2884–2889.

Kim NW, Piatyszek MA, Prowse KR, et al. Specific association of human telomerase activity with immortal cells and cancer. *Science*. 1994;266:2011–2015.

Kimura F, Seifert H-H, Florl AR, et al. Decrease of DNA methyltransferase 1 expression relative to cell proliferation in transitional cell carcinoma. *Int J Cancer*. 2003;104:568–578.

King ED, Matteson J, Jacobs SC, et al. Incidence of apoptosis, cell proliferation and bcl-2 expression in transitional cell carcinoma of the bladder: association with tumor progression. *J Urol*. 1996;155:316–320.

King JC, Xu J, Wongvipat J, et al. Cooperativity of TMPRSS2-ERG with PI3-kinase pathway activation in prostate oncogenesis. *Nat Genet*. 2009;41:524–526.

Kipp BR, Karnes RJ, Brankley SM, et al. Monitoring intravesical therapy for superficial bladder cancer using fluorescence in situ hybridization. *J Urol*. 2005;173:401–404.

Kitagawa R, Bakkenist CJ, McKinnon PJ, et al. Phosphorylation of SMC1 is a critical downstream event in the ATM-NBS1-BRCA1 pathway. *Genes Dev*. 2004;18:1423–1438.

Kiuru M, Launonen V. Hereditary leiomyomatosis and renal cell cancer (HLRCC). *Curr Mol Med*. 2004;4:869–875.

Klein G. The role of gene dosage and genetic transpositions in carcinogenesis. *Nature*. 1981;294:313–318.

Knowles MA, Habuchi T, Kennedy W, et al. Mutation spectrum of the 9q34 tuberous sclerosis gene TSC1 in transitional cell carcinoma of the bladder. *Cancer Res*. 2003;63:7652–7656.

Knowles MA. Bladder cancer subtypes defined by genomic alterations. *Scand J Urol Nephrol Suppl*. 2008;116–130.

Knudson AG. Mutation and cancer: statistical study of retinoblastoma. *Proc Natl Acad Sci*. 1971;68:820–823.

Knudson CM, Tung KS, Tourtellotte WG, et al. Bax-deficient mice with lymphoid hyperplasia and male germ cell death. *Science*. 1995;270:96–99.

Koed K, Wiuf C, Christensen LL, et al. High-density single nucleotide polymorphism array defines novel stage and location-dependent allelic imbalances in human bladder tumors. *Cancer Res*. 2005;65:34–45.

Koeneman KS, Pan CX, Jin JK, et al. Telomerase activity, telomere length, and DNA ploidy in prostatic intraepithelial neoplasia (PIN). *J Urol*. 1998;160:1533–1539.

Koga F, Kawakami S, Fujii Y, et al. Impaired p63 expression associates with poor prognosis and uroplakin III expression in invasive urothelial carcinoma of the bladder. *Clin Cancer Res*. 2003;9:5501–5507.

Koivisto P, Visakorpi T, Rantala I, et al. Increased cell proliferation activity and decreased cell death are associated with the emergence of hormone-refractory recurrent prostate cancer. *J Pathol*. 1997;183:51–56.

Kolesnick R, Fuks Z. Radiation and ceramide-induced apoptosis. *Oncogene*. 2003;22:5897–5906.

Korkola JE, Houldsworth J, Chadalavada RS, et al. Down-regulation of stem cell genes, including those in a 200-kb gene cluster at 12p13.31, is associated with in vivo differentiation of human male germ cell tumors. *Cancer Res*. 2006;66:820–827.

Kote-Jarai Z, Easton DF, Stanford JL, et al. Multiple novel prostate cancer predisposition loci confirmed by an international study: the PRACTICAL Consortium. *Cancer Epidemiol Biomarkers Prev*. 2008;17:2052–2061.

Koul S, Houldsworth J, Mansukhani MM, et al. Characteristic promoter hypermethylation signatures in male germ cell tumors. *Mol Cancer*. 2002;1:8.

Kovacs G. Molecular cytogenetics of renal cell tumors. *Adv Cancer Res*. 1993;62:89–124.

Kraggerud SM, Skotheim RI, Szymanska J, et al. Genome profiles of familial/bilateral and sporadic testicular germ cell tumors. *Genes Chromosomes Cancer*. 2002;34:168–174.

Krajewska M, Krajewski S, Epstein JI, et al. Immunohistochemical analysis of bcl-2, bax, bcl-X, and mcl-1 expression in prostate cancers. *Am J Pathol*. 1996;148:1567–1576.

Krausz C, Looijenga LH. Genetic aspects of testicular germ cell tumors. *Cell Cycle*. 2008;7:3519–3524.

Kroemer G, Reed JC. Mitochondrial control of cell death. *Nat Med*. 2000;6:513–519.

Kruk PA, Rampino NJ, Bohr VA. DNA damage and repair in telomeres: relation to aging. *Proc Natl Acad Sci USA*. 1995;92:258–262.

Kubota Y, Fujinami K, Uemura H, et al. Retinoblastoma gene mutations in primary human prostate cancer. *Prostate*. 1995;27:314–320.

Kumar-Sinha C, Tomlins SA, Chinnaiyan AM. Recurrent gene fusions in prostate cancer. *Nat Rev Cancer*. 2008;8:497–511.

Kuzmin I, Gillespie JW, Protopopov A, et al. The RASSF1A tumor suppressor gene is inactivated in prostate tumors and suppresses growth of prostate carcinoma cells. *Cancer Res*. 2002;62:3498–3502.

Kyprianou N, English HF, Isaacs JT. Programmed cell death during regression of PC-82 human prostate cancer following androgen ablation. *Cancer Res*. 1990;50:3748–3753.

Lai A, Lee JM, Yang WM, et al. RBP1 recruits both histone deacetylase-dependent and -independent repression activities to retinoblastoma family proteins. *Mol Cell Biol*. 1999;19:6632–6641.

Lai A, Marcellus RC, Corbeil HB, et al. RBP1 induces growth arrest by repression of E2F-dependent transcription. *Oncogene*. 1999;18:2091–2100.

Lange EM, Gillanders EM, Davis CC, et al. Genome-wide scan for prostate cancer susceptibility genes using families from the University of Michigan prostate cancer genetics project finds evidence for linkage on chromosome 17 near BRCA1. *Prostate*. 2003;57:326–334.

Lapointe J, Kim YH, Miller MA, et al. A variant TMPRSS2 isoform and ERG fusion product in prostate cancer with implications for molecular diagnosis. *Mod Pathol*. 2007;20:467–473.

Lapointe J, Li C, Higgins JP, et al. Gene expression profiling identifies clinically relevant subtypes of prostate cancer. *Proc Natl Acad Sci USA*. 2004;101:811–816.

Latif F, Tory K, Gnarra J, et al. Identification of the von Hippel-Lindau disease tumor suppressor gene. *Science*. 1993;260:1317–1320.

Latil A, Bieche I, Vidaud D, et al. Evaluation of androgen, estrogen (ER alpha and ER beta), and progesterone receptor expression in human prostate cancer by real-time quantitative reverse transcription-polymerase chain reaction assays. *Cancer Res*. 2001;61:1919–1926.

Lee M-G, Kim H-Y, Byun D-S, et al. Frequent epigenetic inactivation of RASSF1A in human bladder carcinoma. *Cancer Res*. 2001;61:6688–6692.

Lee WH, Morton RA, Epstein JI, et al. Cytidine methylation of regulatory sequences near the pi-class glutathione S-transferase gene accompanies human prostatic carcinogenesis. *Proc Natl Acad Sci USA*. 1994;91:11733–11737.

Leinonen KA, Tolonen TT, Bracken H, et al. Association of SPINK1 expression and TMPRSS2:ERG fusion with prognosis in endocrine-treated prostate cancer. *Clin Cancer Res*. 2010;16:2845–2851.

Levine AJ. p53, the cellular gatekeeper for growth and division. *Cell*. 1997;88:323–331.

Levy MZ, Allsopp RC, Futcher AB, et al. Telomere end-replication problem and cell aging. *J Mol Biol*. 1992;225:951–960.

Leyten G, Hessels D, Jannink S, et al. Prospective multicentre evaluation of PCA3 and TMPRSS2-ERG gene fusions as diagnostic and prognostic urinary biomarkers for prostate cancer. *Eur Urol*. 2012.

Li C, Berx G, Larsson C, et al. Distinct deleted regions on chromosome segment 16q23-24 associated with metastases in prostate cancer. *Genes Chromosomes Cancer*. 1999;24:175–182.

Li E, You M, Hristova K. FGFR3 dimer stabilization due to a single amino acid pathogenic mutation. *J Mol Biol*. 2006;356:600–612.

Li H, Zhu H, Xu CJ, et al. Cleavage of BID by caspase 8 mediates the mitochondrial damage in the Fas pathway of apoptosis. *Cell*. 1998;94:491–501.

Li J, Yen C, Liaw D, et al. PTEN, a putative protein tyrosine phosphatase gene mutated in human brain, breast, and prostate cancer. *Science*. 1997;275:1943–1947.

Li P, Nijhawan D, Budihardjo I, et al. Cytochrome c and dATP-dependent formation of Apaf-1/caspase-9 complex initiates an apoptotic protease cascade. *Cell*. 1997;91:479–489.

Lichtenstein P, Holm NV, Verkasalo PK, et al. Environmental and heritable factors in the causation of cancer—analyses of cohorts of twins from Sweden, Denmark, and Finland. *N Engl J Med*. 2000;343:78–85.

Lin X, Tascilar M, Lee WH, et al. GSTP1 CpG island hypermethylation is responsible for the absence of GSTP1 expression in human prostate cancer cells. *Am J Pathol*. 2001;159:1815–1826.

Lin Y, Uemura H, Fujinami K, et al. Telomerase activity in primary prostate cancer. *J Urol*. 1997;157:1161–1165.

Lindsey J, McGill NI, Lindsey LA, et al. In vivo loss of telomeric repeats with age in humans. *Mutat Res*. 1991;256:45–48.

Linehan WM, Pinto PA, Srinivasan R, et al. Identification of the genes for kidney cancer: opportunity for disease-specific targeted therapeutics. *Clin Cancer Res*. 2007;13:671s–679s.

Linehan WM. Editorial: kidney cancer—a unique opportunity for the development of disease specific therapy. *J Urol*. 2002;168:2411–2412.

Linja MJ, Savinainen KJ, Saramaki OR, et al. Amplification and overexpression of androgen receptor gene in hormone-refractory prostate cancer. *Cancer Res*. 2001;61:3550–3555.

Linja MJ, Visakorpi T. Alterations of androgen receptor in prostate cancer. *J Steroid Biochem Mol Biol*. 2004;92:255–264.

Linke J, Loy V, Dieckmann KP. Prevalence of testicular intraepithelial neoplasia in healthy males. *J Urol*. 2005;173:1577–1579.

Linnenbach AJ, Pressler LB, Seng BA, et al. Characterization of chromosome 9 deletions in transitional cell carcinoma by microsatellite assay. *Hum Mol Genet*. 1993;2:1407–1411.

Lipponen P, Aaltomaa S. Apoptosis in bladder cancer as related to standard prognostic factors and prognosis. *J Pathol*. 1994;173:333–339.

Lipponen P, Eskelinen M, Syrjanen K. Expression of tumour-suppressor gene Rb, apoptosis-suppressing protein Bcl-2 and c-Myc have no independent prognostic value in renal adenocarcinoma. *Br J Cancer*. 1995;71:863–867.

Lipponen P, Vesalainen S. Expression of the apoptosis suppressing protein bcl-2 in prostatic adenocarcinoma is related to tumor malignancy. *Prostate*. 1997;32:9–15.

Lipponen P. Over-expression of p53 nuclear oncoprotein in transitional-cell bladder cancer and its prognostic value. *Int J Cancer*. 1993;53:365–370.

Liu B, Nicolaides NC, Markowitz S, et al. Mismatch repair gene defects in sporadic colorectal cancers with microsatellite instability. *Nat Genet*. 1995;9:48–55.

Liu L, Yoon J, Dammann R, et al. Frequent hypermethylation of the RASSF1A gene in prostate cancer. *Oncogene*. 2002;21:6835–6840.

Liu W, Chang B, Sauvageot J, et al. Comprehensive assessment of DNA copy number alterations in human prostate cancers using Affymetrix 100K SNP mapping array. *Genes Chromosomes Cancer*. 2006;45:1018–1032.

Lo AW, Sabatier L, Fouladi B, et al. DNA amplification by breakage/fusion/bridge cycles initiated by spontaneous telomere loss in a human cancer cell line. *Neoplasia*. 2002;4:531–538.

Lobachev K, Vitriol E, Stemple J, et al. Chromosome fragmentation after induction of a double-strand break is an active process prevented by the RMX repair complex. *Curr Biol*. 2004;14:2107–2112.

Loda M, Cukor B, Tam SW, et al. Increased proteasome-dependent degradation of the cyclin-dependent kinase inhibitor p27 in aggressive colorectal carcinomas. *Nat Med*. 1997;3:231–234.

Loeb LA, Springgate CF, Battula N. Errors in DNA replication as a basis of malignant changes. *Cancer Res*. 1974;34:2311–2321.

Loeb LA. Cancer cells exhibit a mutator phenotype. *Adv Cancer Res*. 1998;72:25–56.

Loeb LA. Mutator phenotype may be required for multistage carcinogenesis. *Cancer Res*. 1991;51:3075–3079.

Logie A, Dunois-Larde C, Rosty C, et al. Activating mutations of the tyrosine kinase receptor FGFR3 are associated with benign skin tumors in mice and humans. *Hum Mol Genet*. 2005;14:1153–1160.

Logothetis CJ, Xu HJ, Ro JY, et al. Altered expression of retinoblastoma protein and known prognostic variables in locally advanced bladder cancer. *J Natl Cancer Inst*. 1992;84:1256–1261.

Looijenga LH, de Leeuw H, van Oorschot M, et al. Stem cell factor receptor (c-KIT) codon 816 mutations predict development of bilateral testicular germ-cell tumors. *Cancer Res*. 2003;63:7674–7678.

Looijenga LH, Gillis AJ, Stoop HJ, et al. Chromosomes and expression in human testicular germ-cell tumors: insight into their cell of origin and pathogenesis. *Ann N Y Acad Sci*. 2007;1120:187–214.

Lotan TL, Toubaji A, Albadine R, et al. TMPRSS2-ERG gene fusions are infrequent in prostatic ductal adenocarcinomas. *Mod Pathol*. 2009;22:359–365.

Lowe JF, Frazee LA. Update on prostate cancer chemoprevention. *Pharmacotherapy*. 2006;26:353–359.

Lu Y, Hu Z, Mangala L, et al. MYC targeted long non-coding RNA DANCR promotes cancer in part by reducing. *Cancer Res*. 2017;p21 levels; 10.1158/0008-5472.CAN-17-0815.

Lucito R, Healy J, Alexander J, et al. Representational oligonucleotide microarray analysis: a high-resolution method to detect genome copy number variation. *Genome Res*. 2003;13:2291–2305.

Ludlow JW, Glendening CL, Livingston DM, et al. Specific enzymatic dephosphorylation of the retinoblastoma protein. *Mol Cell Biol*. 1993;13:367–372.

Lukas C, Falck J, Bartkova J, et al. Distinct spatiotemporal dynamics of mammalian checkpoint regulators induced by DNA damage. *Nat Cell Biol*. 2003;5:255–260.

Lundgren K, Walworth N, Booher R, et al. mik1 and wee1 cooperate in the inhibitory tyrosine phosphorylation of cdc2. *Cell*. 1991;64:1111–1122.

Lundgren R, Heim S, Mandahl N, et al. Chromosome abnormalities are associated with unfavorable outcome in prostatic cancer patients. *J Urol*. 1992;147:784–788.

Luo J, Solimini NL, Elledge SJ. Principles of cancer therapy: oncogene and non-oncogene addiction. *Cell*. 2009;136:823–837.

Lutke Holzik MF, Storm K, Sijmons RH, et al. Absence of constitutional Y chromosome AZF deletions in patients with testicular germ cell tumors. *Urology*. 2005;65:196–201.

Maceyka M, Payne SG, Milstien S, et al. Sphingosine kinase, sphingosine-1-phosphate, and apoptosis. *Biochim Biophys Acta*. 2002;1585:193–201.

Macoska JA, Micale MA, Sakr WA, et al. Extensive genetic alterations in prostate cancer revealed by dual PCR and FISH analysis. *Genes Chromosomes Cancer*. 1993;8:88–97.

Maher CA, Kumar-Sinha C, Cao X, et al. Transcriptome sequencing to detect gene fusions in cancer. *Nature*. 2009;458:97–101.

Mai PL, Friedlander M, Tucker K, et al. The International Testicular Cancer Linkage Consortium: a clinicopathologic descriptive analysis of 461 familial malignant testicular germ cell tumor kindred. *Urol Oncol*. 2009.

Mallofre C, Castillo M, Morente V, et al. Immunohistochemical expression of CK20, p53, and Ki-67 as objective markers of urothelial dysplasia. *Mod Pathol*. 2003;16:187–191.

Manolio TA. Genomewide association studies and assessment of the risk of disease. *New Engl J Med*. 2010;363:166–176.

Martignoni G, Pea M, Gobbo S, et al. Cathepsin-K immunoreactivity distinguishes MiTF/TFE family renal translocation carcinomas from other renal carcinomas. *Mod Pathol*. 2009;22:1016–1022.

Maruyama R, Toyooka S, Toyooka KO, et al. Aberrant promoter methylation profile of bladder cancer and its relationship to clinicopathological features. *Cancer Res*. 2001;61:8659–8663.

Maruyama R, Toyooka S, Toyooka KO, et al. Aberrant promoter methylation profile of prostate cancers and its relationship to clinicopathological features. *Clin Cancer Res*. 2002;8:514–519.

Mates JM, Sanchez-Jimenez F. Antioxidant enzymes and their implications in pathophysiologic processes. *Front Biosci*. 1999;4:D339–D345.

Matsuo K, Tajima K, Suzuki T, et al. Association of prostate stem cell antigen gene polymorphisms with the risk of stomach cancer in Japanese. *Int J Cancer*. 2009;125:1961–1964.

Matsuoka S, Edwards MC, Bai C, et al. p57KIP2, a structurally distinct member of the p21CIP1 CDK inhibitor family, is a candidate tumor suppressor gene. *Genes Dev*. 1995;9:650–662.

Matsushime H, Roussel MF, Ashmun RA, et al. Colony-stimulating factor 1 regulates novel cyclins during the G1 phase of the cell cycle. *Cell*. 1991;65:701–713.

Maxwell PH, Wiesener MS, Chang GW, et al. The tumour suppressor protein VHL targets hypoxia-inducible factors for oxygen-dependent proteolysis. *Nature*. 1999;399:271–275.

May P, May E. Twenty years of p53 research: structural and functional aspects of the p53 protein. *Oncogene*. 1999;18:7621–7636.

McClintock B. The stability of broken ends of chromosomes in Zea Mays. *Genetics*. 1941;26:234–282.

McDonnell TJ, Troncoso P, Brisbay SM, et al. Expression of the protooncogene bcl-2 in the prostate and its association with emergence of androgen-independent prostate cancer. *Cancer Res*. 1992;52:6940–6944.

McGarvey TW, Maruta Y, Tomaszewski JE, et al. PTCH gene mutations in invasive transitional cell carcinoma of the bladder. *Oncogene*. 1998;17:1167–1172.

McGrath M, Wong JY, Michaud D, et al. Telomere length, cigarette smoking, and bladder cancer risk in men and women. *Cancer Epidemiol Biomarkers Prev*. 2007;16:815–819.

McIndoe RA, Stanford JL, Gibbs M, et al. Linkage analysis of 49 high-risk families does not support a common familial prostate cancer-susceptibility gene at 1q24-25. *Am J Hum Genet*. 1997;61:347–353.

McIntyre A, Summersgill B, Grygalewicz B, et al. Amplification and overexpression of the KIT gene is associated with progression in the seminoma subtype of testicular germ cell tumors of adolescents and adults. *Cancer Res*. 2005;65:8085–8089.

McIntyre A, Summersgill B, Spendlove HE, et al. Activating mutations and/or expression levels of tyrosine kinase receptors GRB7, RAS, and BRAF in testicular germ cell tumors. *Neoplasia*. 2005;7:1047–1052.

Meeker AK, Argani P. Telomere shortening occurs early during breast tumorigenesis: a cause of chromosome destabilization underlying malignant transformation? *J Mammary Gland Biol Neoplasia*. 2004;9:285–296.

Meeker AK, Coffey DS. Telomerase: a promising marker of biological immortality of germ, stem, and cancer cells. A review. *Biochemistry Mosc*. 1997;62:1323–1331.

Meeker AK, Gage WR, Hicks JL, et al. Telomere length assessment in human archival tissues: combined telomere fluorescence in situ hybridization and immunostaining. *Am J Pathol*. 2002;160:1259–1268.

Meeker AK, Hicks JL, Iacobuzio-Donahue CA, et al. Telomere length abnormalities occur early in the initiation of epithelial carcinogenesis. *Clin Cancer Res*. 2004;10:3317–3326.

Meeker AK, Hicks JL, Platz EA, et al. Telomere shortening is an early somatic DNA alteration in human prostate tumorigenesis. *Cancer Res*. 2002;62:6405–6409.

Mehle C, Piatyszek MA, Ljungberg B, et al. Telomerase activity in human renal cell carcinoma. *Oncogene*. 1996;13:161–166.

Mehra R, Tomlins SA, Shen R, et al. Comprehensive assessment of TMPRSS2 and ETS family gene aberrations in clinically localized prostate cancer. *Mod Pathol*. 2007;20:538–544.

Mehra R, Udager A, Ahearn T, et al. Overexpression of the long non-coding RNA SChLAP1 independently predicts lethal prostate cancer. *Eur Urol*. 2016;70(4):549–552.

Mellado B, Codony J, Ribal MJ, et al. Molecular biology of androgen-independent prostate cancer: the role of the androgen receptor pathway. *Clin Transl Oncol*. 2009;11:5–10.

Menashe I, Figueroa JD, Garcia-Closas M, et al. Large-scale pathway-based analysis of bladder cancer genome-wide association data from five studies of European background. *PLoS ONE*. 2012;7:e29396.

Merino MJ, Torres-Cabala C, Pinto P, et al. The morphologic spectrum of kidney tumors in hereditary leiomyomatosis and renal cell carcinoma (HLRCC) syndrome. *Am J Surg Pathol*. 2007;31:1578–1585.

Merlo A, Herman JG, Mao L, et al. 5’ CpG island methylation is associated with transcriptional silencing of the tumour suppressor p16/CDKN2/MTS1 in human cancers. *Nat Med*. 1995;1:686–692.

Merrick WC. Mechanism and regulation of eukaryotic protein synthesis. *Microbiol Rev*. 1992;56:291–315.

Meyerson M, Enders GH, Wu CL, et al. A family of human cdc2-related protein kinases. *EMBO J*. 1992;11:2909–2917.

Meyne J, Ratliff RL, Moyzis RK. Conservation of the human telomere sequence (TTAGGG)n among vertebrates. *Proc Natl*

Acad Sci USA. 1989;86:7049–7053.

Miao D, Margolis CA, Gao W, et al. Genomic correlates of response to immune checkpoint therapies in clear cell renal cell carcinoma. *Science*. 2018; 10.1126/science.aan5951 [pii: eaan5951; [Epub ahead of print].

Miki Y, Swensen J, Shattuck-Eidens D, et al. A strong candidate for the breast and ovarian cancer susceptibility gene BRCA1. *Science*. 1994;266:66–71.

Minn AJ, Rudin CM, Boise LH, et al. Expression of bcl-xL can confer a multidrug resistance phenotype. *Blood*. 1995;86:1903–1910.

Minner S, Gartner M, Freudenthaler F, et al. Marked heterogeneity of ERG expression in large primary prostate cancers. *Mod Pathol*. 2012.

Mirabello L, Huang WY, Wong JY, et al. The association between leukocyte telomere length and cigarette smoking, dietary and physical variables, and risk of prostate cancer. *Aging Cell*. 2009;8:405–413.

Mittnacht S, Lees JA, Desai D, et al. Distinct sub-populations of the retinoblastoma protein show a distinct pattern of phosphorylation. *EMBO J*. 1994;13:118–127.

Miyake H, Hara I, Gleave ME, et al. Protection of androgen-dependent human prostate cancer cells from oxidative stress-induced DNA damage by overexpression of clusterin and its modulation by androgen. *Prostate*. 2004;61:318–323.

Miyake H, Nelson C, Rennie PS, et al. Acquisition of chemoresistant phenotype by overexpression of the antiapoptotic gene testosterone-repressed prostate message-2 in prostate cancer xenograft models. *Cancer Res*. 2000;60:2547–2554.

Miyashita T, Krajewski S, Krajewska M, et al. Tumor suppressor p53 is a regulator of bcl-2 and bax gene expression in vitro and in vivo. *Oncogene*. 1994;9:1799–

1805.

Miyashita T, Reed JC. Tumor suppressor p53 is a direct transcriptional activator of the human bax gene. *Cell*. 1995;80:293–299.

Modrich P. Mismatch repair, genetic stability, and cancer. *Science*. 1994;266:1959–1960.

Momand J, Zambetti GP, Olson DC, et al. The mdm-2 oncogene product forms a complex with the p53 protein and inhibits p53-mediated transactivation. *Cell*. 1992;69:1237–1245.

Moore LE, Baris DR, Figueroa JD, et al. GSTM1 null and NAT2 slow acetylation genotypes, smoking intensity and bladder cancer risk: results from the New England bladder cancer study and NAT2 meta-analysis. *Carcinogenesis*. 2011;32:182–189.

Morgan DO. Principles of CDK regulation. *Nature*. 1995;374:131–134.

Morton RA, Ewing CM, Nagafuchi A, et al. Reduction of E-cadherin levels and deletion of the alpha-catenin gene in human prostate cancer cells. *Cancer Res*. 1993;53:3585–3590.

Mosquera JM, Mehra R, Regan MM, et al. Prevalence of TMPRSS2-ERG fusion prostate cancer among men undergoing prostate biopsy in the United States. *Clin Cancer Res*. 2009;15:4706–4711.

Mosquera JM, Perner S, Genega EM, et al. Characterization of TMPRSS2-ERG fusion high-grade prostatic intraepithelial neoplasia and potential clinical implications. *Clin Cancer Res*. 2008;14:3380–3385.

Motzer RJ, Escudier B, McDermott DF, et al. Nivolumab versus everolimus in advanced renal-cell carcinoma. *N Engl J Med*. 2015;373:1803–1813.

Moul JW, Theune SM, Chang EH. Detection of RAS mutations in archival testicular germ cell tumors by polymerase chain reaction and oligonucleotide hybridization. *Genes Chromosomes Cancer*. 1992;5:109–118.

Moyzis RK, Buckingham JM, Cram LS, et al. A highly conserved repetitive DNA sequence, (TTAGGG)n, present at the telomeres of human chromosomes. *Proc Natl Acad Sci USA*. 1988;85:6622–6626.

Mucci LA, Pawitan Y, Demichelis F, et al. Testing a multigene signature of prostate cancer death in the Swedish Watchful Waiting Cohort. *Cancer Epidemiol Biomarkers Prev*. 2008;17:1682–1688.

Murant SJ, Rolley N, Phillips SM, et al. Allelic imbalance within the E-cadherin gene is an infrequent event in prostate carcinogenesis. *Genes Chromosomes Cancer*. 2000;27:104–109.

Muto S, Horie S, Takahashi S, et al. Genetic and epigenetic alterations in normal bladder epithelium in patients with metachronous bladder cancer. *Cancer Res*. 2000;60:4021–4025.

Muzio M. Signalling by proteolysis: death receptors induce apoptosis. *Int J Clin Lab Res*. 1998;28:141–147.

Nagata S. Apoptosis by death factor. *Cell*. 1997;88:355–365.

Nakagawa H, Akamatsu S, Takata R, et al. Prostate cancer genomics, biology, and risk assessment through genome-wide association studies. *Cancer Sci*. 2012;103:607–613.

Nakagawa H. Prostate cancer genomics by high-throughput technologies: genome-wide association study and sequencing analysis. *Endocr Relat Cancer*. 2013;20:R171–R181.

Nam RK, Sugar L, Wang Z, et al. Expression of TMPRSS2:ERG gene fusion in prostate cancer cells is an important prognostic factor for cancer progression. *Cancer Biol Ther*. 2007;6:40–45.

Nam RK, Zhang WW, Trachtenberg J, et al. Utility of incorporating genetic variants for the early detection of prostate cancer. *Clin Cancer Res*. 2009;15:1787–1793.

Navone NM, Troncoso P, Pisters LL, et al. p53 protein accumulation and gene mutation in the progression of human prostate carcinoma. *J Natl Cancer Inst*. 1993;85:1657–1669.

Netto GJ, Nakai Y, Nakayama M, et al. Global DNA hypomethylation in intratubular germ cell neoplasia and seminoma, but not in nonseminomatous male germ cell tumors. *Mod Pathol*. 2008;21:1337–1344.

Newmark JR, Hardy DO, Tonb DC, et al. Androgen receptor gene mutations in human prostate cancer. *Proc Natl Acad Sci USA*. 1992;89:6319–6323.

Nickerson ML, Warren MB, Toro JR, et al. Mutations in a novel gene lead to kidney tumors, lung wall defects, and benign tumors of the hair follicle in patients with the Birt-Hogg-Dube syndrome. *Cancer Cell*. 2002;2:157–164.

Nishiyama H, Hornigold N, Davies AM, et al. A sequence-ready 840-kb PAC contig spanning the candidate tumor suppressor locus DBC1 on human chromosome 9q32-q33. *Genomics*. 1999;59:335–338.

Nock NL, Bock C, Neslund-Dudas C, et al. Polymorphisms in glutathione S-transferase genes increase risk of prostate cancer biochemical recurrence differentially by ethnicity and disease severity. *Cancer Causes Control*. 2009.

Nowell PC. Cytogenetic approaches to human cancer genes. *FASEB J*. 1994;8:408–413.

Nupponen NN, Visakorpi T. Molecular cytogenetics of prostate cancer. *Microsc Res Tech*. 2000;51:456–463.

Nupponen NN, Wallen MJ, Ponciano D, et al. Mutational analysis of susceptibility genes RNASEL/HPC1, ELAC2/HPC2, and MSR1 in sporadic prostate cancer. *Genes Chromosomes Cancer*. 2004;39:119–125.

Nyberg KA, Michelson RJ, Putnam CW, et al. Toward maintaining the genome: DNA damage and replication checkpoints. *Annu Rev Genet*. 2002;36:617–656.

Obermann EC, Meyer S, Hellge D, et al. Fluorescence in situ hybridization detects frequent chromosome 9 deletions and aneuploidy in histologically normal urothelium of bladder cancer patients. *Oncol Rep*. 2004;11:745–751.

Oda E, Ohki R, Murasawa H, et al. Noxa, a BH3-only member of the Bcl-2 family and candidate mediator of p53-induced apoptosis. *Science*. 2000;288:1053–1058.

Olie RA, Looijenga LH, Boerrigter L, et al. N- and KRAS mutations in primary testicular germ cell tumors: incidence and possible biological implications. *Genes Chromosomes Cancer*. 1995;12:110–116.

Oosterhuis JW, Looijenga LH. Testicular germ-cell tumours in a broader perspective. *Nat Rev Cancer*. 2005;5:210–222.

Orlow I, Lacombe L, Hannon GJ, et al. Deletion of the p16 and p15 genes in human bladder tumors. *J Natl Cancer Inst*. 1995;87:1524–1529.

Orlow I, LaRue H, Osman I, et al. Deletions of the INK4A gene in superficial bladder tumors. Association with recurrence. *Am J Pathol*. 1999;155:105–113.

Orth K, O'Rourke K, Salvesen GS, et al. Molecular ordering of apoptotic mammalian CED-3/ICE-like proteases. *J Biol Chem*. 1996;271:20977–20980.

O'Shaughnessy JA, Kelloff GJ, Gordon GB, et al. Treatment and prevention of intraepithelial neoplasia: an important target for accelerated new agent development. *Clin Cancer Res*. 2002;8:314–346.

Ottesen AM, Skakkebaek NE, Lundsteen C, et al. High-resolution comparative genomic hybridization detects extra chromosome arm 12p material in most cases of carcinoma in situ adjacent to overt germ cell tumors, but not before the invasive tumor development. *Genes Chromosomes Cancer*. 2003;38:117–125.

Pagano M, Pepperkok R, Verde F, et al. Cyclin A is required at two points in the human cell cycle. *EMBO J*. 1992;11:961–971.

Page WF, Braun MM, Partin AW, et al. Heredity and prostate cancer: a study of World War II veteran twins. *Prostate*. 1997;33:240–245.

Pal SK, Li SM, Wu X, et al. Stool bacteriomic profiling in patients with metastatic renal cell carcinoma receiving vascular endothelial growth factor-tyrosine kinase inhibitors. *Clin Cancer Res*. 2015;21(23):5286–5293.

Palanisamy N, Ateeq B, Kalyana-Sundaram S, et al. Rearrangements of the RAF kinase pathway in prostate cancer, gastric cancer and melanoma. *Nat Med*. 2010;16:793–798.

Pardee AB. A restriction point for control of normal animal cell proliferation. *Proc Natl Acad Sci USA*. 1974;71:1286–1290.

Pardee AB. G1 events and regulation of cell proliferation. *Science*. 1989;246:603–608.

Pardoll DM. The blockade of immune checkpoints in cancer immunotherapy. *Nat Rev Cancer*. 2012;12:252–264.

Park K, Dalton JT, Narayanan R, et al. TMPRSS2:ERG gene fusion predicts subsequent detection of prostate cancer in patients with high-grade prostatic intraepithelial neoplasia. *J Clin Oncol*. 2013;32(3):206–211.

Park K, Tomlins S, Mudaliar K, et al. Antibody-based detection of ERG rearrangement-positive prostate cancer. *Neoplasia*. 2010;12:590–598.

Parker SB, Eichele G, Zhang P, et al. p53-independent expression of p21Cip1 in muscle and other terminally differentiating cells. *Science*. 1995;267:1024–1027.

Patel KJ, Yu VP, Lee H, et al. Involvement of Brca2 in DNA repair. *Mol Cell*. 1998;1:347–357.

Pause A, Lee S, Worrell RA, et al. The von Hippel-Lindau tumor-suppressor gene product forms a stable complex with human CUL-2, a member of the Cdc53 family of proteins. *Proc Natl Acad Sci USA*. 1997;94:2156–2161.

Pavlovich CP, Grubb RL 3rd, Hurley K, et al. Evaluation and management of renal tumors in the Birt-Hogg-Dube syndrome. *J Urol*. 2005;173:1482–1486.

Pavlovich CP, Walther MM, Eyler RA, et al. Renal tumors in the Birt-Hogg-Dube syndrome. *Am J Surg Pathol*. 2002;26:1542–1552.

Peltomaki P. DNA methylation changes in human testicular cancer. *Biochim Biophys Acta*. 1991;1096:187–196.

Perner S, Mosquera JM, Demichelis F, et al. TMPRSS2-ERG fusion prostate cancer: an early molecular event associated with invasion. *Am J Surg Pathol*. 2007;31:882–888.

Perry DK, Kolesnick RN. Ceramide and sphingosine 1-phosphate in anti-cancer therapies. *Cancer Treat Res*. 2003;115:345–354.

Pesche S, Latil A, Muzeau F, et al. PTEN/MMAC1/TEP1 involvement in primary prostate cancers. *Oncogene*. 1998;16:2879–2883.

Peter M, Herskowitz I. Joining the complex: cyclin-dependent kinase inhibitory proteins and the cell cycle. *Cell*. 1994;79:181–184.

Petrovics G, Liu A, Shaheduzzaman S, et al. Frequent overexpression of ETS-related gene-1 (ERG1) in prostate cancer transcriptome. *Oncogene*. 2005;24:3847–3852.

Pettersson A, Graff RE, Bauer SR, et al. The TMPRSS2:ERG rearrangement, ERG expression, and prostate cancer outcomes: a cohort study and meta-analysis. *Cancer Epidemiol Biomarkers Prev*. 2012;21:1497–1509.

Pflueger D, Terry S, Sboner A, et al. Discovery of non-ETS gene fusions in human prostate cancer using next-generation RNA sequencing. *Genome Res*. 2011;21:56–67.

Pichierri P, Rosselli F. The DNA crosslink-induced S-phase checkpoint depends on ATR-CHK1 and ATR-NBS1-FANCD2 pathways. *EMBO J*. 2004;23:1178–1187.

Pihan GA, Wallace J, Zhou Y, et al. Centrosome abnormalities and chromosome instability occur together in pre-invasive carcinomas. *Cancer Res*. 2003;63:1398–1404.

Pines J, Hunter T. Isolation of a human cyclin cDNA: evidence for cyclin mRNA and protein regulation in the cell cycle and for interaction with p34cdc2. *Cell*. 1989;58:833–846.

Pinto M, Soares MJ, Cerveira N, et al. Expression changes of the MAD mitotic checkpoint gene family in renal cell carcinomas characterized by numerical chromosome changes. *Virchows Arch*. 2007;450:379–385.

Pisters LL, El-Naggar AK, Luo W, et al. C-met proto-oncogene expression in benign and malignant human renal tissues. *J Urol*. 1997;158:724–728.

Pollard P, Wortham N, Barclay E, et al. Evidence of increased microvessel density and activation of the hypoxia pathway in tumours from the hereditary leiomyomatosis and renal cell cancer syndrome. *J Pathol*. 2005;205:41–49.

Prensner JR, Iyer MK, Balbin OA, et al. Transcriptome sequencing across a prostate cancer cohort identifies PCAT-1, an unannotated lincRNA implicated in disease progression. *Nat Biotechnol*. 2011;29:742–749.

Prensner JR, Iyer MK, Sahu A, et al. The long noncoding RNA SChLAP1 promotes aggressive prostate cancer and antagonizes the SWI/SNF complex. *Nat Genet*. 2013;45:1392–1398.

Przygodzki RM, Hubbs AE, Zhao FQ, et al. Primary mediastinal seminomas: evidence of single and multiple KIT mutations. *Lab Invest*. 2002;82:1369–1375.

Qian J, Bostwick DG, Takahashi S, et al. Chromosomal anomalies in prostatic intraepithelial neoplasia and carcinoma detected by fluorescence in situ hybridization. *Cancer Res*. 1995;55:5408–5414.

Rafnar T, Sulem P, Stacey SN, et al. Sequence variants at the TERT-CLPTM1L locus associate with many cancer types. *Nat Genet*. 2009;41:221–227.

Rafnar T, Vermeulen SH, Sulem P, et al. European genome-wide association study identifies SLC14A1 as a new urinary bladder cancer susceptibility gene. *Hum Mol Genet*. 2011;20:4268–4281.

Rajpert-De Meyts E, Leffers H, Daugaard G, et al. Analysis of the polymorphic CAG repeat length in the androgen receptor gene in patients with testicular germ cell cancer. *Int J Cancer*. 2002;102:201–204.

Rajput AB, Miller MA, De Luca A, et al. Frequency of the TMPRSS2:ERG gene fusion is increased in moderate to poorly differentiated prostate cancers. *J Clin Pathol*. 2007;60:1238–1243.

Rapley E. Susceptibility alleles for testicular germ cell tumour: a review. *Int J Androl*. 2007;30:242–250 [discussion 250].

Rapley EA, Turnbull C, Al Olama AA, et al. A genome-wide association study of testicular germ cell tumor. *Nat Genet*. 2009;41:807–810.

Reddel RR, Bryan TM, Colgin LM, et al. Alternative lengthening of telomeres in human cells. *Radiat Res*. 2001;155:194–200.

Reddel RR. Alternative lengthening of telomeres, telomerase, and cancer. *Cancer Lett*. 2003;194:155–162.

Reiter RE, Anglard P, Liu S, et al. Chromosome 17p deletions and p53 mutations in renal cell carcinoma. *Cancer Res*. 1993;53:3092–3097.

Remes K, Norrback KF, Rosenquist R, et al. Telomere length and telomerase activity in malignant lymphomas at diagnosis and relapse. *Br J Cancer*. 2000;82:601–607.

Ren S, Peng Z, Mao J-H, et al. RNA-seq analysis of prostate cancer in the Chinese population identifies recurrent gene fusions, cancer-associated long noncoding RNAs and aberrant alternative splicings. *Cell Res*. 2012;22:806–821.

Rhodes DR, Sanda MG, Otte AP, et al. Multiplex biomarker approach for determining risk of prostate-specific antigen-defined recurrence of prostate cancer. *J Natl Cancer Inst*. 2003;95:661–668.

Rich A, Penman S, Becker Y, et al. Polyribosomes: size in normal and polio-infected HeLa cells. *Science*. 1963;142:1658–1663.

Rickman DS, Pflueger D, Moss B, et al. SLC45A3-ELK4 is a novel and frequent erythroblast transformation-specific fusion transcript in prostate cancer. *Cancer Res*. 2009;69:2734–2738.

Rideout W, Coetzee G, Olumi A, et al. 5-Methylcytosine as an endogenous mutagen in the human LDL receptor and p53 genes. *Science*. 1990;249:1288–1290.

Risch N, Merikangas K. The future of genetic studies of complex human diseases. *Science*. 1996;273:1516–1517.

Rocchi P, So A, Kojima S, et al. Heat shock protein 27 increases after androgen ablation and plays a cytoprotective role in hormone-refractory prostate cancer. *Cancer Res*. 2004;64:6595–6602.

Rodel C, Grabenbauer GG, Rodel F, et al. Apoptosis, p53, bcl-2, and Ki-67 in invasive bladder carcinoma: possible predictors for response to radiochemotherapy and successful bladder preservation. *Int J Radiat Oncol Biol Phys*. 2000;46:1213–1221.

Rodriguez E, Houldsworth J, Reuter VE, et al. Molecular cytogenetic analysis of i(12p)-negative human male germ cell tumors. *Genes Chromosomes Cancer*. 1993;8:230–236.

Rodriguez S, Jafer O, Goker H, et al. Expression profile of genes from 12p in testicular germ cell tumors of adolescents and adults associated with i(12p) and amplification at 12p11.2-p12.1. *Oncogene*. 2003;22:1880–1891.

Rogakou EP, Boon C, Redon C, et al. Megabase chromatin domains involved in DNA double-strand breaks in vivo. *J Cell Biol*. 1999;146:905–916.

Rogakou EP, Pilch DR, Orr AH, et al. DNA double-stranded breaks induce histone H2AX phosphorylation on serine 139. *J Biol Chem*. 1998;273:5858–5868.

Roh M, Gary B, Song C, et al. Overexpression of the oncogenic kinase Pim-1 leads to genomic instability. *Cancer Res*. 2003;63:8079–8084.

Rokman A, Ikonen T, Seppala EH, et al. Germline alterations of the RNASEL gene, a candidate HPC1 gene at 1q25, in patients and families with prostate cancer. *Am J Hum Genet*. 2002;70:1299–1304.

Rosenberg C, Mostert MC, Schut TB, et al. Chromosomal constitution of human spermatocytic seminomas: comparative genomic hybridization supported by conventional and interphase cytogenetics. *Genes Chromosomes Cancer*. 1998;23:286–291.

Rosenberg C, Van Gurp RJ, Geelen E, et al. Overrepresentation of the short arm of chromosome 12 is related to invasive growth of human testicular seminomas and nonseminomas. *Oncogene*. 2000;19:5858–5862.

Rosin MP, Cairns P, Epstein JI, et al. Partial allelotype of carcinoma in situ of the human bladder. *Cancer Res*. 1995;55:5213–5216.

Rothman N, Garcia-Closas M, Chatterjee N, et al. A multi-stage genome-wide association study of bladder cancer identifies multiple susceptibility loci. *Nat Genet*. 2010;42:978–U998.

Routy B, Chatelier E, Derosa L, et al. Gut microbiome influences efficacy of PD-1–based immunotherapy against epithelial tumors. *Science*. 2018;359:91–97.

Rouzier C, Haudebourg J, Carpentier X, et al. Detection of the TMPRSS2-ETS fusion gene in prostate carcinomas: retrospective analysis of 55 formalin-fixed and paraffin-embedded samples with clinical data. *Cancer Genet Cytogenet*. 2008;183:21–27.

Roychowdhury S, Iyer MK, Robinson DR, et al. Personalized oncology through integrative high-throughput sequencing: a pilot study. *Sci Transl Med*. 2011;3 [111ra121].

Rubin MA, Mucci NR, Figurski J, et al. E-cadherin expression in prostate cancer: a broad survey using high-density tissue microarray technology. *Hum Pathol*. 2001;32:690–697.

Sakamoto H, Yoshimura K, Saeki N, et al. Genetic variation in PSCA is associated with susceptibility to diffuse-type gastric cancer. *Nat Genet*. 2008;40:730–740.

Sakatani T, Kaneda A, Iacobuzio-Donahue CA, et al. Loss of imprinting of Igf2 alters intestinal maturation and tumorigenesis in mice. *Science*. 2005;307:1976–1978.

Saldanha SN, Andrews LG, Tollefsbol TO. Assessment of telomere length and factors that contribute to its stability. *Eur J Biochem*. 2003;270:389–403.

Sancar A, Lindsey-Boltz LA, Unsal-Kacmaz K, et al. Molecular mechanisms of mammalian DNA repair and the DNA damage checkpoints. *Annu Rev Biochem*. 2004;73:39–85.

Sancar GB, Siede W, van Zeeland AA. Repair and processing of DNA damage: a summary of recent progress. *Mutat Res*. 1996;362:127–146.

Sanchez Y, Wong C, Thoma RS, et al. Conservation of the Chk1 checkpoint pathway in mammals: linkage of DNA damage to CDK regulation through Cdc25. *Science*. 1997;277:1497–1501.

Sandberg AA. Application of cytogenetics in neoplastic diseases. *Crit Rev Clin Lab Sci*. 1985;22:219–274.

Sandberg AA. Cytogenetic and molecular genetic aspects of human prostate cancer: primary and metastatic. *Adv Exp Med Biol*. 1992;324:45–75.

Saramaki OR, Harjula AE, Martikainen PM, et al. TMPRSS2:ERG fusion identifies a subgroup of prostate cancers with a favorable prognosis. *Clin Cancer Res*. 2008;14:3395–3400.

Sarker D, Reid AH, Yap TA, et al. Targeting the PI3K/AKT pathway for the treatment of prostate cancer. *Clin Cancer Res*. 2009;15:4799–4805.

Sarkis AS, Dalbagni G, Cordon-Cardo C, et al. Nuclear overexpression of p53 protein in transitional cell bladder carcinoma: a marker for disease progression. *J Natl Cancer Inst*. 1993;85:53–59.

Sato K, Qian J, Slezak JM, et al. Clinical significance of alterations of chromosome 8 in high-grade, advanced, nonmetastatic prostate carcinoma. *J Natl Cancer Inst*. 1999;91:1574–1580.

Savinainen KJ, Linja MJ, Saramaki OR, et al. Expression and copy number analysis of TRPS1, EIF3S3 and MYC genes in breast and prostate cancer. *Br J Cancer*. 2004;90:1041–1046.

Schaid DJ. The complex genetic epidemiology of prostate cancer. *Hum Mol Genet*. 2004;13(Spec1):R103–R121.

Schmidt L, Duh FM, Chen F, et al. Germline and somatic mutations in the tyrosine kinase domain of the MET proto-oncogene in papillary renal carcinomas. *Nat Genet*. 1997;16:68–73.

Schmidt L, Nickerson ML, Warren MB, et al. Germline BHD-mutation spectrum and phenotype analysis of a large cohort of families with Birt-Hogg-Dube syndrome. *Am J Hum Genet*. 2005;76:1023–1033.

Schmidt L, Warren MB, Nickerson ML, et al. Birt-Hogg-Dube syndrome, a genodermatosis associated with spontaneous pneumothorax and kidney neoplasia, maps to chromosome 17p11.2. *Am J Hum Genet*. 2001;69:876–882.

Schmitz-Drager B, Schulz W, Jurgens B, et al. c-myc in bladder cancer. Clinical findings and analysis of mechanism. *Urol Res*. 1997;25(Suppl 1):S45–S49.

Schmutte C, Fishel R. Genomic instability: first step to carcinogenesis. *Anticancer Res*. 1999;19:4665–4696.

Schorderet DF, Gartler SM. Analysis of CpG suppression in methylated and nonmethylated species. *Proc Natl Acad Sci*. 1992;89:957–961.

Schwabe RF, Jobin C. The microbiome and cancer. *Nat Rev Cancer*. 2013;13(11):800–812.

Sebat J, Lakshmi B, Troge J, et al. Large-scale copy number polymorphism in the human genome. *Science*. 2004;305:525–528.

Serrano M, Hannon GJ, Beach D. A new regulatory motif in cell-cycle control causing specific inhibition of cyclin D/CDK4. *Nature*. 1993;366:704–707.

Setlur SR, Mertz KD, Hoshida Y, et al. Estrogen-dependent signaling in a molecularly distinct subclass of aggressive prostate cancer. *J Natl Cancer Inst*. 2008;100:815–825.

Sfanos K, De Marzo A. Prostate cancer and inflammation: the evidence. *Histopathology*. 2012;60:199–215.

Shariat SF, Tokunaga H, Zhou J, et al. p53, p21, pRB, and p16 expression predict clinical outcome in cystectomy with bladder cancer. *J Clin Oncol*. 2004;22:1014–1024.

Sharp P. Splicing of messenger RNA precursors. *Science*. 1987;235:766–771.

Shay JW, Wright WE. The reactivation of telomerase activity in cancer progression. *Trends Genet*. 1996;12:129–131.

Shay JW. Molecular pathogenesis of aging and cancer: are telomeres and telomerase the connection? *J Clin Pathol*. 1997;50:799–800.

Sherr CJ, Kato J, Quelle DE, et al. D-type cyclins and their cyclin-dependent kinases: G1 phase integrators of the mitogenic response. *Cold Spring Harb Symp Quant Biol*. 1994;59:11–19.

Sherr CJ, Roberts JM. Inhibitors of mammalian G1 cyclin-dependent kinases. *Genes Dev*. 1995;9:1149–1163.

Sherr CJ. Cancer cell cycles. *Science*. 1996;274:1672–1677.

Sherr CJ. Mammalian G1 cyclins. *Cell*. 1993;73:1059–1065.

Sherr CJ. The ins and outs of RB: coupling gene expression to the cell cycle clock. *Trends Cell Biol*. 1994;4:15–18.

Shiohara M, el Deiry WS, Wada M, et al. Absence of WAF1 mutations in a variety of human malignancies. *Blood*. 1994;84:3781–3784.

Shrestha E, White J, Yu S, et al. Profiling the urinary microbiome in men with positive versus negative biopsies for prostate cancer. *J Urol*. 2018;199:161–171.

Shuin T, Kondo K, Torigoe S, et al. Frequent somatic mutations and loss of heterozygosity of the von Hippel-Lindau tumor suppressor gene in primary human renal cell carcinomas. *Cancer Res*. 1994;54:2852–2855.

Sibley K, Stern P, Knowles MA. Frequency of fibroblast growth factor receptor 3 mutations in sporadic tumours. *Oncogene*. 2001;20:4416–4418.

Sidhar SK, Clark J, Gill S, et al. The t(X;1)(p11.2;q21.2) translocation in papillary renal cell carcinoma fuses a novel gene PRCC to the TFE3 transcription factor gene. *Hum Mol Genet*. 1996;5:1333–1338.

Sidransky D, Von Eschenbach A, Tsai YC, et al. Identification of p53 gene mutations in bladder cancers and urine samples. *Science*. 1991;252:706–709.

Siegel R, Miller K, Jemal A. Cancer statistics, 2018. *CA Cancer J Clin*. 2018;68(1):7–30.

Simard J, Dumont M, Labuda D, et al. Prostate cancer susceptibility genes: lessons learned and challenges posed. *Endocr Relat Cancer*. 2003;10:225–259.

Singh SK, Clarke ID, Terasaki M, et al. Identification of a cancer stem cell in human brain tumors. *Cancer Res*. 2003;63:5821–5828.

Sjoblom T, Jones S, Wood LD, et al. The consensus coding sequences of human breast and colorectal cancers. *Science*. 2006;314:268–274.

Skakkebaek NE, Berthelsen JG, Giwercman A, et al. Carcinoma-in-situ of the testis: possible origin from gonocytes and precursor of all types of germ cell tumours except spermatocytoma. *Int J Androl*. 1987;10:19–28.

Skotheim RI, Abeler VM, Nesland JM, et al. Candidate genes for testicular cancer evaluated by in situ protein expression analyses on tissue microarrays. *Neoplasia*. 2003;5:397–404.

Slater HR, Bailey DK, Ren H, et al. High-resolution identification of chromosomal abnormalities using oligonucleotide arrays containing 116,204 SNPs. *Am J Hum Genet*. 2005;77:709–726.

Slaughter DP, Southwick HW, Smejkal W. Field cancerization in oral stratified squamous epithelium; clinical implications of multicentric origin. *Cancer*. 1953;6:963–968.

Smiraglia DJ, Szymanska J, Kraggerud SM, et al. Distinct epigenetic phenotypes in seminomatous and nonseminomatous testicular germ cell tumors. *Oncogene*. 2002;21:3909–3916.

Smith JK, Yeh G. Telomere reduction in endometrial adenocarcinoma. *Am J Obstet Gynecol*. 1992;167:1883–1887.

Smith JR, Freije D, Carpten JD, et al. Major susceptibility locus for prostate cancer on chromosome 1 suggested by a genome-wide search. *Science*. 1996;274:1371–1374.

Snijders AM, Schmidt BL, Fridlyand J, et al. Rare amplicons implicate frequent deregulation of cell fate specification pathways in oral squamous cell carcinoma. *Oncogene*. 2005;24:4232–4242.

Soengas MS, Alarcon RM, Yoshida H, et al. Apaf-1 and caspase-9 in p53-dependent apoptosis and tumor inhibition. *Science*. 1999;284:156–159.

Solimini NL, Luo J, Elledge SJ. Non-oncogene addiction and the stress phenotype of cancer cells. *Cell*. 2007;130:986–988.

Sommerer F, Hengge UR, Markwarth A, et al. Mutations of BRAF and RAS are rare events in germ cell tumours. *Int J Cancer*. 2005;113:329–335.

Sommerfeld HJ, Meeker AK, Piatyszek MA, et al. Telomerase activity: a prevalent marker of malignant human prostate tissue. *Cancer Res*. 1996;56:218–222.

Sperger JM, Chen X, Draper JS, et al. Gene expression patterns in human embryonic stem cells and human pluripotent germ cell tumors. *Proc Natl Acad Sci USA*. 2003;100:13350–13355.

Spruck CH 3rd, Ohneseit PF, Gonzalez-Zulueta M, et al. Two molecular pathways to transitional cell carcinoma of the bladder. *Cancer Res*. 1994;54:784–788.

Srinivasula SM, Ahmad M, Fernandes-Alnemri T, et al. Autoactivation of procaspase-9 by Apaf-1-mediated oligomerization. *Mol Cell*. 1998;1:949–957.

Staller P, Sulitkova J, Lisztwan J, et al. Chemokine receptor CXCR4 downregulated by von Hippel-Lindau tumour suppressor pVHL. *Nature*. 2003;425:307–311.

Stein JP, Ginsberg DA, Grossfeld GD, et al. Effect of p21WAF1/CIP1 expression on tumor progression in bladder cancer. *J Natl Cancer Inst*. 1998;90:1072–1079.

Steinberg GD, Carter BS, Beaty TH, et al. Family history and the risk of prostate cancer. *Prostate*. 1990;17:337–347.

Stephens PJ, Greenman CD, Fu B, et al. Massive genomic rearrangement acquired in a single catastrophic event during cancer development. *Cell*. 2011;144:27–40.

Stoehr R, Zietz S, Burger M, et al. Deletions of chromosomes 9 and 8p in histologically normal urothelium of patients with bladder cancer. *Eur Urol*. 2005;47:58–63.

Stolle C, Glenn G, Zbar B, et al. Improved detection of germline mutations in the von Hippel-Lindau disease tumor suppressor gene. *Hum Mutat*. 1998;12:417–423.

Sudarshan S, Pinto PA, Neckers L, et al. Mechanisms of disease: hereditary leiomyomatosis and renal cell cancer–a distinct form of hereditary kidney cancer. *Nat Clin Pract Urol*. 2007;4:104–110.

Sullivan PS, Nooraie F, Sanchez H, et al. Comparison of ImmunoCyt, UroVysion, and urine cytology in detection of recurrent urothelial carcinoma: a “split-sample” study. *Cancer Cytopathol*. 2009;117:167–173.

Summersgill B, Osin P, Lu YJ, et al. Chromosomal imbalances associated with carcinoma in situ and associated testicular germ cell tumours of adolescents and adults. *Br J Cancer*. 2001;85:213–220.

Sun J, Chang BL, Isaacs SD, et al. Cumulative effect of five genetic variants on prostate cancer risk in multiple study populations. *Prostate*. 2008;68:1257–1262.

Sun J, Liu W, Adams TS, et al. DNA copy number alterations in prostate cancers: a combined analysis of published CGH studies. *Prostate*. 2007;67:692–700.

Sun X, Frierson HF, Chen C, et al. Frequent somatic mutations of the transcription factor ATBF1 in human prostate cancer. *Nat Genet*. 2005;37:407–412.

Sung MT, Eble JN, Wang M, et al. Inverted papilloma of the urinary bladder: a molecular genetic appraisal. *Mod Pathol*. 2006;19:1289–1294.

Suzuki H, Komiya A, Emi M, et al. Three distinct commonly deleted regions of chromosome arm 16q in human primary and metastatic prostate cancers. *Genes Chromosomes Cancer*. 1996;17:225–233.

Sved J, Bird A. The expected equilibrium of the CpG dinucleotide in vertebrate genomes under a mutation model. *Proc Natl Acad Sci*. 1990;87:4692–4696.

Tahir SA, Yang G, Ebara S, et al. Secreted caveolin-1 stimulates cell survival/clonal growth and contributes to metastasis in androgen-insensitive prostate cancer. *Cancer Res*. 2001;61:3882–3885.

Takagi S, Kinouchi Y, Hiwatashi N, et al. Telomere shortening and the clinicopathologic characteristics of human colorectal carcinomas. *Cancer*. 1999;86:1431–1436.

Takahashi R, Hashimoto T, Xu HJ, et al. The retinoblastoma gene functions as a growth and tumor suppressor in human bladder carcinoma cells. *Proc Natl Acad Sci USA*. 1991;88:5257–5261.

Takahashi S, Shan AL, Ritland SR, et al. Frequent loss of heterozygosity at 7q31.1 in primary prostate cancer is associated with tumor aggressiveness and progression. *Cancer Res*. 1995;55:4114–4119.

Tang W, Fu Y-P, Figueroa JD, et al. Mapping of the UGT1A locus identifies an uncommon coding variant that affects mRNA expression and protects from bladder cancer. *Hum Mol Genet*. 2012;21:1918–1930.

Taplin ME, Bubley GJ, Shuster TD, et al. Mutation of the androgen-receptor gene in metastatic androgen-independent prostate cancer. *N Engl J Med*. 1995;332:1393–1398.

Tate WP, Brown CM. Translational termination: “stop” for protein synthesis or “pause” for regulation of gene expression. *Biochemistry*. 1992;31:2443–2450.

Tavtigian SV, Simard J, Teng DH, et al. A candidate prostate cancer susceptibility gene at chromosome 17p. *Nat Genet*. 2001;27:172–180.

Taylor BS, Schultz N, Hieronymus H, et al. Integrative genomic profiling of human prostate cancer. *Cancer Cell*. 2010;18:11–22.

TCGA Research Network. Comprehensive molecular characterization of urothelial bladder carcinoma. *Nature*. 2014;507(7492):315–322.

Teng DH, Hu R, Lin H, et al. MMAC1/PTEN mutations in primary tumor specimens and tumor cell lines. *Cancer Res*. 1997;57:5221–5225.

Theodorescu D, Broder SR, Boyd JC, et al. p53, bcl-2 and retinoblastoma proteins as long-term prognostic markers in localized carcinoma of the prostate. *J Urol*. 1997;158:131–137.

Thievessen I, Seifert HH, Swiatkowski S, et al. E-cadherin involved in inactivation of WNT//[beta]-catenin signalling in urothelial carcinoma and normal urothelial cells. *Br J Cancer*. 2003;88:1932–1938.

Thomas G, Jacobs KB, Yeager M, et al. Multiple loci identified in a genome-wide association study of prostate cancer. *Nat Genet*. 2008;40:310–315.

Thompson RH, Gillett MD, Cheville JC, et al. Costimulatory B7-H1 in renal cell carcinoma patients: indicator of tumor aggressiveness and potential therapeutic target. *Proc Natl Acad Sci USA*. 2004;101:17174–17179.

Thornberry NA, Lazebnik Y. Caspases: enemies within. *Science*. 1998;281:1312–1316.

Thornberry NA. Caspases: key mediators of apoptosis. *Chem Biol*. 1998;5:R97–R103.

Tian Q, Frierson HF Jr, Krystal GW, et al. Activating c-kit gene mutations in human germ cell tumors. *Am J Pathol*. 1999;154:1643–1647.

Tilley WD, Buchanan G, Hickey TE, et al. Mutations in the androgen receptor gene are associated with progression of human prostate cancer to androgen independence. *Clin Cancer Res*. 1996;2:277–285.

Tlsty TD, Margolin BH, Lum K. Differences in the rates of gene amplification in nontumorigenic and tumorigenic cell lines as measured by Luria-Delbruck fluctuation analysis. *Proc Natl Acad Sci USA*. 1989;86:9441–9445.

Tomlins SA, Aubin SMJ, Siddiqui J, et al. Urine TMPRSS2:ERG fusion transcript stratifies prostate cancer risk in men with elevated serum PSA. *Sci Transl Med*. 2011;3:94ra72.

Tomlins SA, Laxman B, Dhanasekaran SM, et al. Distinct classes of chromosomal rearrangements create oncogenic ETS gene fusions in prostate cancer. *Nature*. 2007;448:595–599.

Tomlins SA, Mehra R, Rhodes DR, et al. TMPRSS2:ETV4 gene fusions define a third molecular subtype of prostate cancer. *Cancer Res*. 2006;66:3396–3400.

Tomlins SA, Rhodes DR, Perner S, et al. Recurrent fusion of TMPRSS2 and ETS transcription factor genes in prostate cancer. *Science*. 2005;310:644–648.

Tomlinson DC, Baldo O, Harnden P, et al. FGFR3 protein expression and its relationship to mutation status and prognostic variables in bladder cancer. *J Pathol*. 2007;213:91–98.

Tornaletti S, Pfeifer G. Complete and tissue-independent methylation of CpG sites in the p53 gene: implications for mutations in human cancers. *Oncogene*. 1995;10:1493–1499.

Tory K, Brauch H, Linehan M, et al. Specific genetic change in tumors associated with von Hippel-Lindau disease. *J Natl Cancer Inst*. 1989;81:1097–1101.

Toubaji A, Albadine R, Meeker A, et al. Increased gene copy number of ERG on chromosome 21 but not TMPRSS2-ERG fusion predicts outcome in prostatic adenocarcinomas. *Mod*

Pathol. 2011;24:1511–1520.

Trybus TM, Burgess AC, Wojno KJ, et al. Distinct areas of allelic loss on chromosomal regions 10p and 10q in human prostate cancer. *Cancer Res*. 1996;56:2263–2267.

Tsai YC, Nichols PW, Hiti AL, et al. Allelic losses of chromosomes 9, 11, and 17 in human bladder cancer. *Cancer Res*. 1990;50:44–47.

Tsuda M, Davis IJ, Argani P, et al. TFE3 fusions activate MET signaling by transcriptional up-regulation, defining another class of tumors as candidates for therapeutic MET inhibition. *Cancer Res*. 2007;67:919–929.

Tu H, Jacobs SC, Borkowski A, et al. Incidence of apoptosis and cell proliferation in prostate cancer: relationship with TGF-beta1 and bcl-2 expression. *Int J Cancer*. 1996;69:357–363.

Tu JJ, Rohan S, Kao J, et al. Gene fusions between TMPRSS2 and ETS family genes in prostate cancer: frequency and transcript variant analysis by RT-PCR and FISH on paraffin-embedded tissues. *Mod Pathol*. 2007;20:921–928.

Tuteja R, Tuteja N. Ku autoantigen: a multifunctional DNA-binding protein. *Crit Rev Biochem Mol Biol*. 2000;35:1–33.

Uchida T, Wada C, Ishida H, et al. p53 mutations and prognosis in bladder tumors. *J Urol*. 1995;153:1097–1104.

Ueda T, Komiya A, Emi M, et al. Allelic losses on 18q21 are associated with progression and metastasis in human prostate cancer. *Genes Chromosomes Cancer*. 1997;20:140–147.

Ulbright TM. Germ cell neoplasms of the testis. *Am J Surg Pathol*. 1993;17:1075–1091.

Ulitsky I, Bartel DP. lincRNAs: genomics, evolution, and mechanisms. *Cell*. 2013;154:26–46.

Umbas R, Isaacs WB, Bringuier PP, et al. Decreased E-cadherin expression is associated with poor prognosis in patients with prostate cancer. *Cancer Res*. 1994;54:3929–3933.

Urist MJ, Di Como CJ, Lu ML, et al. Loss of p63 expression is associated with tumor progression in bladder cancer. *Am J Pathol*. 2002;161:1199–1206.

van Dekken H, Alers JC, Damen IA, et al. Genetic evaluation of localized prostate cancer in a cohort of forty patients: gain of distal 8q discriminates between progressors and nonprogressors. *Lab Invest*. 2003;83:789–796.

van den Heuvel S, Harlow E. Distinct roles for cyclin-dependent kinases in cell cycle control. *Science*. 1993;262:2050–2054.

van der Horst G, Bos L, van der Pluijm G. Epithelial plasticity, cancer stem cells, and the tumor-supportive stroma in bladder carcinoma. *Mol Cancer Res*. 2012;10:995–1009.

van Heek NT, Meeker AK, Kern SE, et al. Telomere shortening is nearly universal in pancreatic intraepithelial neoplasia. *Am J Pathol*. 2002;161:1541–1547.

van Rhijn BW, Montironi R, Zwarthoff EC, et al. Frequent FGFR3 mutations in urothelial papilloma. *J Pathol*. 2002;198:245–251.

van Rhijn BW, van der Kwast TH, Vis AN, et al. FGFR3 and P53 characterize alternative genetic pathways in the pathogenesis of urothelial cell carcinoma. *Cancer Res*. 2004;64:1911–1914.

van Rhijn BW, van der Poel HG, van der Kwast TH. Urine markers for bladder cancer surveillance: a systematic review. *Eur Urol*. 2005;47:736–748.

Varambally S, Dhanasekaran SM, Zhou M, et al. The polycomb group protein EZH2 is involved in progression of prostate cancer. *Nature*. 2002;419:624–629.

Vaziri H, Benchimol S. Alternative pathways for the extension of cellular life span: inactivation of p53/pRb and expression of telomerase. *Oncogene*. 1999;18:7676–7680.

Vaziri H, Benchimol S. Reconstitution of telomerase activity in normal human cells leads to elongation of telomeres and extended replicative life span. *Curr Biol*. 1998;8:279–282.

Veigl ML, Kasturi L, Olechnowicz J, et al. Biallelic inactivation of hMLH1 by epigenetic gene silencing, a novel mechanism causing human MSI cancers. *Proc Natl Acad Sci USA*. 1998;95:8698–8702.

Verdorfer I, Rogatsch H, Tzankov A, et al. Molecular cytogenetic analysis of human spermatocytic seminomas. *J Pathol*. 2004;204:277–281.

Vincenz C, Dixit VM. Fas-associated death domain protein interleukin-1beta-converting enzyme 2 (FLICE2), an ICE/Ced-3 homologue, is proximally involved in CD95- and p55-mediated death signaling. *J Biol Chem*. 1997;272:6578–6583.

Visakorpi T, Hyytinen E, Koivisto P, et al. In vivo amplification of the androgen receptor gene and progression of human prostate cancer. *Nat Genet*. 1995;9:401–406.

Visakorpi T, Kallioniemi AH, Syvanen AC, et al. Genetic changes in primary and recurrent prostate cancer by comparative genomic hybridization. *Cancer Res*. 1995;55:342–347.

Visakorpi T, Kallioniemi OP, Heikkinen A, et al. Small subgroup of aggressive, highly proliferative prostatic carcinomas defined by p53 accumulation. *J Natl Cancer Inst*. 1992;84:883–887.

Vocke CD, Yang Y, Pavlovich CP, et al. High frequency of somatic frameshift BHD gene mutations in Birt-Hogg-Dube-associated renal tumors. *J Natl Cancer Inst*. 2005;97:931–935.

Vogelstein B, Papadopoulos N, Velculescu VE, et al. Cancer genome landscapes. *Science*. 2013;339:1546–1558.

von Zglinicki T, Pilger R, Sitte N. Accumulation of single-strand breaks is the major cause of telomere shortening in human fibroblasts. *Free Radic Biol Med*. 2000;28:64–74.

Vukovic B, Beheshti B, Park P, et al. Correlating breakage-fusion-bridge events with the overall chromosomal instability and in vitro karyotype evolution in prostate cancer. *Cytogenet Genome Res*. 2007;116:1–11.

Vukovic B, Park PC, Al-Maghrabi J, et al. Evidence of multifocality of telomere erosion in high-grade prostatic intraepithelial neoplasia (HPIN) and concurrent carcinoma. *Oncogene*. 2003;22:1978–1987.

Walton MI, Whysong D, O'Connor PM, et al. Constitutive expression of human Bcl-2 modulates nitrogen mustard and camptothecin induced apoptosis. *Cancer Res*. 1993;53:1853–1861.

Wang DS, Rieger-Christ K, Latini JM, et al. Molecular analysis of PTEN and MXI1 in primary bladder carcinoma. *Int J Cancer*. 2000;88:620–625.

Wang J, Cai Y, Yu W, et al. Pleiotropic biological activities of alternatively spliced TMPRSS2/ERG fusion gene transcripts. *Cancer Res*. 2008;68:8516–8524.

Wang M, Wang M, Zhang W, et al. Common genetic variants on 8q24 contribute to susceptibility to bladder cancer in a Chinese population. *Carcinogenesis*. 2009;30:991–996.

Wang R, Morris DS, Tomlins SA, et al. Development of a multiplex quantitative PCR signature to predict progression in non-muscle-invasive bladder cancer. *Cancer Res*. 2009;69:3810–3818.

Wang S, Tang J, Wang M, et al. Genetic variation in PSCA and bladder cancer susceptibility in a Chinese population. *Carcinogenesis*. 2010;31:621–624.

Wang X, Cheung HW, Chun AC, et al. Mitotic checkpoint defects in human cancers and their implications to chemotherapy. *Front Biosci*. 2008;13:2103–2114.

Watson JD, Crick FH. Molecular structure of nucleic acids; a structure for deoxyribose nucleic acid. *Nature*. 1953;171:737–738.

Weinert T. A DNA damage checkpoint meets the cell cycle engine. *Science*. 1997;277:1450–1451.

Welcsh PL, Owens KN, King MC. Insights into the functions of BRCA1 and BRCA2. *Trends Genet*. 2000;16:69–74.

Wen LP, Fahrni JA, Troie S, et al. Cleavage of focal adhesion kinase by caspases during apoptosis. *J Biol Chem*. 1997;272:26056–26061.

Westergaard T, Olsen JH, Frisch M, et al. Cancer risk in fathers and brothers of testicular cancer patients in Denmark. A population-based study. *Int J Cancer*. 1996;66:627–631.

Weterman MA, Wilbrink M, Geurts van Kessel A. Fusion of the transcription factor TFE3 gene to a novel gene, PRCC, in t(X;1)(p11;q21)-positive papillary renal cell carcinomas. *Proc Natl Acad Sci USA*. 1996;93:15294–15298.

Whang YE, Wu X, Suzuki H, et al. Inactivation of the tumor suppressor PTEN/MMAC1 in advanced human prostate cancer through loss of expression. *Proc Natl Acad Sci USA*. 1998;95:5246–5250.

Whiteside SA, Razvi H, Dave S, et al. The microbiome of the urinary tract-a role beyond infection. *Nat Rev Urol*. 2015;12(2):81–90.

Wiechen K, Diatchenko L, Agoulnik A, et al. Caveolin-1 is down-regulated in human ovarian carcinoma and acts as a candidate tumor suppressor gene. *Am J Pathol*. 2001;159:1635–1643.

Wiklund FE, Adami HO, Zheng SL, et al. Established prostate cancer susceptibility variants are not associated with disease outcome. *Cancer Epidemiol Biomarkers Prev*. 2009;18:1659–1662.

Williams BJ, Jones E, Zhu XL, et al. Evidence for a tumor suppressor gene distal to BRCA1 in prostate cancer. *J Urol*.

1996;155:720–725.

Williamson MP, Elder PA, Shaw ME, et al. p16 (CDKN2) is a major deletion target at 9p21 in bladder cancer. *Hum Mol Genet*. 1995;4:1569–1577.

Winston JT, Pledger WJ. Growth factor regulation of cyclin D1 mRNA expression through protein synthesis-dependent and -independent mechanisms. *Mol Biol Cell*. 1993;4:1133–1144.

Witte JS. Multiple prostate cancer risk variants on 8q24. *Nat Genet*. 2007;39:579–580.

Witte JS. Prostate cancer genomics: towards a new understanding. *Nat Rev Genet*. 2009;10:77–82.

Wolf BB, Green DR. Suicidal tendencies: apoptotic cell death by caspase family proteinases. *J Biol Chem*. 1999;274:20049–20052.

Wolf CM, Eastman A. The temporal relationship between protein phosphatase, mitochondrial cytochrome c release, and caspase activation in apoptosis. *Exp Cell Res*. 1999;247:505–513.

Wong A, Ruppert J, Eggleston J, et al. Gene amplification of c-myc and N-myc in small cell carcinoma of the lung. *Science*. 1986;233:461–464.

Wood LD, Parsons DW, Jones S, et al. The genomic landscapes of human breast and colorectal cancers. *Science*. 2007;318:1108–1113.

Wood RD. Nucleotide excision repair in mammalian cells. *J Biol Chem*. 1997;272:23465–23468.

Woodson K, Flood A, Green L, et al. Loss of insulin-like growth factor-II imprinting and the presence of screen-detected colorectal adenomas in women. *J Natl Cancer Inst*. 2004;96:407–410.

Wooster R, Bignell G, Lancaster J, et al. Identification of the breast cancer susceptibility gene BRCA2. *Nature*. 1995;378:789–792.

Wright WE, Shay JW. Cellular senescence as a tumor-protection mechanism: the essential role of counting. *Curr Opin Genet Dev*. 2001;11:98–103.

Wu C, Wang GH, Yang M, et al. Two genetic variants in prostate stem cell antigen and gastric cancer susceptibility in a chinese population. *Mol Carcinog*. 2009;48:1131–1138.

Wu X, Amos CI, Zhu Y, et al. Telomere dysfunction: a potential cancer predisposition factor. *J Natl Cancer Inst*. 2003;95:1211–1218.

Wu X, Ye Y, Kiemeney LA, et al. Genetic variation in the prostate stem cell antigen gene PSCA confers susceptibility to urinary bladder cancer. *Nat Genet*. 2009;41:991–995.

Wullich B, Rohde V, Oehlenschlager B, et al. Focal intratumoral heterogeneity for telomerase activity in human prostate cancer. *J Urol*. 1999;161:1997–2001.

Wykoff CC, Pugh CW, Harris AL, et al. The HIF pathway: implications for patterns of gene expression in cancer. *Novartis Found Symp*. 2001;240:212–225 [discussion 225–231].

Xin L, Lawson DA, Witte ON. The Sca-1 cell surface marker enriches for a prostate-regenerating cell subpopulation that can initiate prostate tumorigenesis. *Proc Natl Acad Sci USA*. 2005;102:6942–6947.

Xu B, Kim S, Kastan MB. Involvement of Brca1 in S-phase and G(2)-phase checkpoints after ionizing irradiation. *Mol Cell Biol*. 2001;21:3445–3450.

Xu J, Zheng SL, Isaacs SD, et al. Inherited genetic variant predisposes to aggressive but not indolent prostate cancer. *Proc Natl Acad Sci*. 2010;107:2136–2140.

Xu J, Zheng SL, Komiya A, et al. Germline mutations and sequence variants of the macrophage scavenger receptor 1 gene are associated with prostate cancer risk. *Nat Genet*. 2002;32:321–325.

Xu J, Zheng SL, Turner A, et al. Associations between hOGG1 sequence variants and prostate cancer susceptibility. *Cancer Res*. 2002;62:2253–2257.

Yamamoto Y, Chochi Y, Matsuyama H, et al. Gain of 5p15.33 is associated with progression of bladder cancer. *Oncology*. 2007;72:132–138.

Yang G, Truong LD, Wheeler TM, et al. Caveolin-1 expression in clinically confined human prostate cancer: a novel prognostic marker. *Cancer Res*. 1999;59:5719–5723.

Yang RM, Naitoh J, Murphy M, et al. Low p27 expression predicts poor disease-free survival in patients with prostate cancer. *J Urol*. 1998;159:941–945.

Yatabe Y, Masuda A, Koshikawa T, et al. p27KIP1 in human lung cancers: differential changes in small cell and non-small cell carcinomas. *Cancer Res*. 1998;58:1042–1047.

Ye D, Li H, Qian S, et al. bcl-2/bax expression and p53 gene status in human bladder cancer: relationship to early recurrence with intravesical chemotherapy after resection. *J Urol*. 1998;160:2025–2028 [discussion 2029].

Yeager M, Chatterjee N, Ciampa J, et al. Identification of a new prostate cancer susceptibility locus on chromosome 8q24. *Nat Genet*. 2009;41:1055–1057.

Yegnasubramanian S, Wu Z, Haffner M, et al. Chromosome-wide mapping of DNA methylation patterns in normal and malignant prostate cells reveals pervasive methylation of gene-associated and conserved intergenic sequences. *BMC Genomics*. 2011;12:313.

Yin Z, Babaian RJ, Troncoso P, et al. Limiting the location of putative human prostate cancer tumor suppressor genes on chromosome 18q. *Oncogene*. 2001;20:2273–2280.

Yoshimoto M, Joshua AM, Chilton-Macneill S, et al. Three-color FISH analysis of TMPRSS2/ERG fusions in prostate cancer indicates that genomic microdeletion of chromosome

21 is associated with rearrangement. *Neoplasia*. 2006;8:465–469.

Yu YP, Landsittel D, Jing L, et al. Gene expression alterations in prostate cancer predicting tumor aggression and preceding development of malignancy. *J Clin Oncol*. 2004;22:2790–2799.

Yuan B, Xu Y, Woo JH, et al. Increased expression of mitotic checkpoint genes in breast cancer cells with chromosomal instability. *Clin Cancer Res*. 2006;12:405–410.

Zafarana G, Grygalewicz B, Gillis AJ, et al. 12p-amplicon structure analysis in testicular germ cell tumors of adolescents and adults by array CGH. *Oncogene*. 2003;22:7695–7701.

Zbar B, Brauch H, Talmadge C, et al. Loss of alleles of loci on the short arm of chromosome 3 in renal cell carcinoma. *Nature*. 1987;327:721–724.

Zehir A, Benayed R, Shah R, et al. Mutational landscape of metastatic cancer revealed from prospective clinical sequencing of 10,000 patients. *Nat Med*. 2017;23:703–713.

Zenklusen JC, Thompson JC, Troncoso P, et al. Loss of heterozygosity in human primary prostate carcinomas: a possible tumor suppressor gene at 7q31.1. *Cancer Res*. 1994;54:6370–6373.

Zhang C, Kawakami T, Okada Y, et al. Distinctive epigenetic phenotype of cancer testis antigen genes among seminomatous and nonseminomatous testicular germ-cell tumors. *Genes Chromosomes Cancer*. 2005;43:104–112.

Zhang W, Kapusta LR, Slingerland JM, et al. Telomerase activity in prostate cancer, prostatic intraepithelial neoplasia, and benign prostatic epithelium. *Cancer Res*. 1998;58:619–621.

Zhang Y, Gong M, Yuan H, et al. Chimeric transcript generated by cis-splicing of adjacent genes regulates prostate cancer cell proliferation. *Cancer Discov*. 2012;2:598–607.

Zhao X, Weir BA, LaFramboise T, et al. Homozygous deletions and chromosome amplifications in human lung carcinomas revealed by single nucleotide polymorphism array analysis. *Cancer Res*. 2005;65:5561–5570.

Zheng SL, Sun J, Wiklund F, et al. Cumulative association of five genetic variants with prostate cancer. *N Engl J Med*. 2008;358:910–919.

Zheng SL, Sun J, Wiklund F, et al. Genetic variants and family history predict prostate cancer similar to prostate-specific antigen. *Clin Cancer Res*. 2009;15:1105–1111.

Zieger K, Dyrskjot L, Wiuf C, et al. Role of activating fibroblast growth factor receptor 3 mutations in the development of bladder tumors. *Clin Cancer Res*. 2005;11:7709–7719.

Zitzelsberger H, Szucs S, Weier HU, et al. Numerical abnormalities of chromosome 7 in human prostate cancer detected by fluorescence in situ hybridization (FISH) on paraffin-embedded tissue sections with centromere-specific DNA probes. *J Pathol*. 1994;172:325–335.

Zwarthoff EC. Detection of tumours of the urinary tract in voided urine. *Scand J Urol Nephrol Suppl*. 2008;147–153.

PART VI

Reproductive and Sexual Function

OUTLINE

63 Surgical, Radiographic, and Endoscopic Anatomy of the Male Reproductive System

64 Male Reproductive Physiology

65 Integrated Men's Health Androgen Deficiency, Cardiovascular Risk, and Metabolic Syndrome

66 Male Infertility

67 Surgical Management of Male Infertility

68 Physiology of Penile Erection and Pathophysiology of Erectile Dysfunction

69 Evaluation and Management of Erectile Dysfunction

70 Priapism

71 Disorders of Male Orgasm and Ejaculation

72 Surgery for Erectile Dysfunction

73 Diagnosis and Management of Peyronie's Disease

74 Sexual Function and Dysfunction in the Female

63

Surgical, Radiographic, and Endoscopic Anatomy of the Male Reproductive System

Parviz K. Kavoussi MD, FACS

A fundamental comprehension of male genital anatomy is necessary for understanding normal reproduction as well as pathology and treatment options. This chapter provides a general anatomic framework of the surgical, radiographic, and endoscopic anatomy of the normal male reproductive system. Because this chapter is dedicated solely to the anatomy of the male reproductive system, please refer to Chapter 109 for further description of pelvic anatomy, including bones, soft tissue, circulation, and innervation of the pelvis not directly related to reproduction.

Testis

Gross Structure

The testicles are paired organs within the scrotum that have reproductive and endocrine functions. It is common for the right testis to hang lower than the left in approximately 85% of men. **The dimensions of the normal testis include a length of 4 to 5 cm, a width of 3 cm, and a depth of 2.5 cm; the testis normally has a volume of 15 to 25 mL.** The organ is ovoid and white (Prader, 1966; Tishler, 1971). There is a small, pedunculated or sessile body at the upper pole of the testis, which is known as the appendix testis. A tough capsule envelops the testis, composed from external to internal of the visceral tunica vaginalis, the tunica albuginea, and the tunica vasculosa, before reaching the parenchyma of the testis. The tunica albuginea is composed of smooth muscle cells that pass through collagenous tissue (Langford and Heller, 1973). It is believed that these smooth muscle cells provide the testicular capsule with some ability to contract and may affect arterial flow into the testis. They may also promote the flow of seminiferous tubule fluid on its way out of the testis (Davis and Horowitz, 1978; Rikmaru and Shirai, 1972; Schweitzer, 1929). The testis attaches to the epididymis on the posterolateral aspect of the testis (Figs. 63.1 and 63.2).

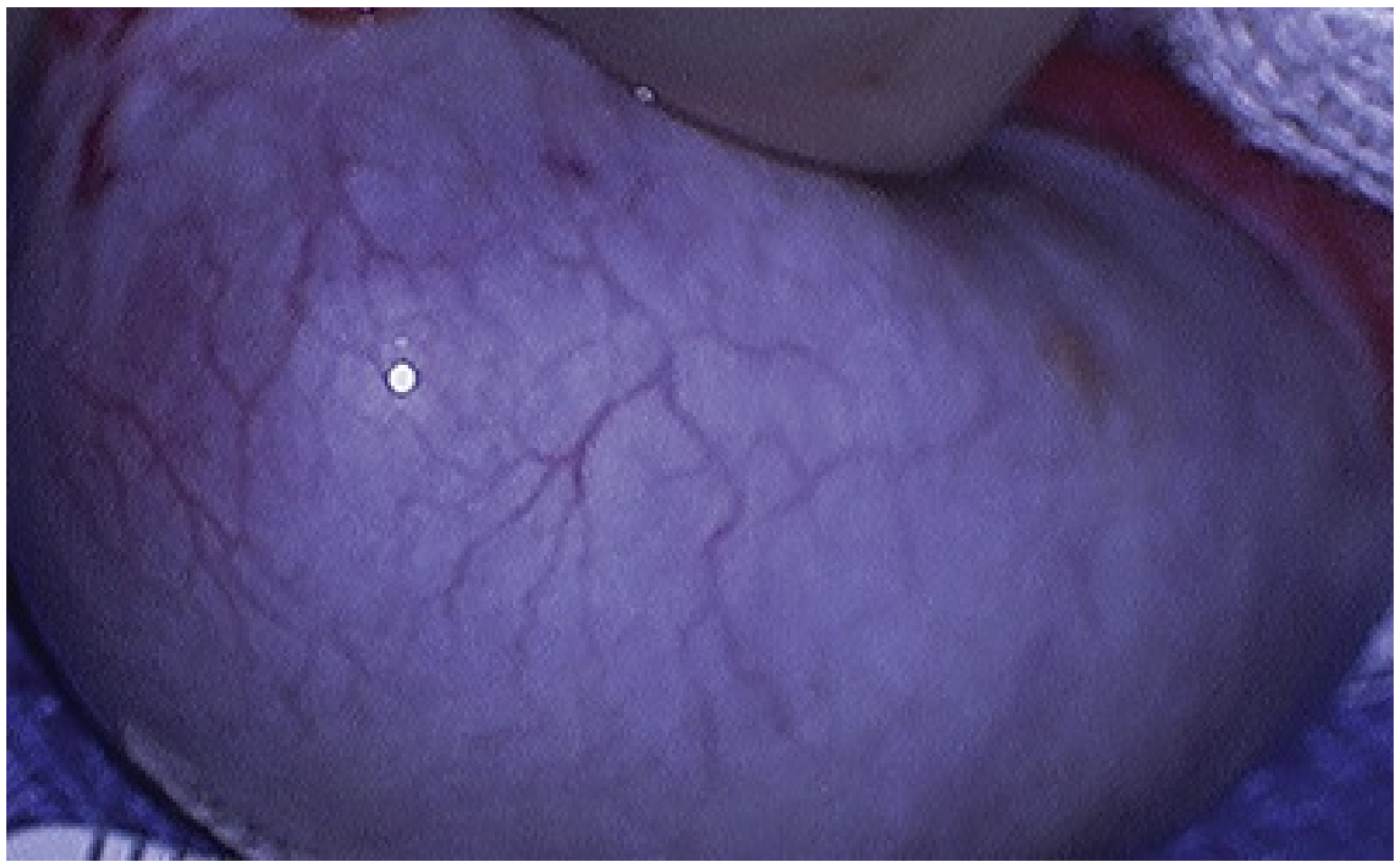

FIG. 63.1 The appearance of the testis with its shiny tunica albuginea layer.

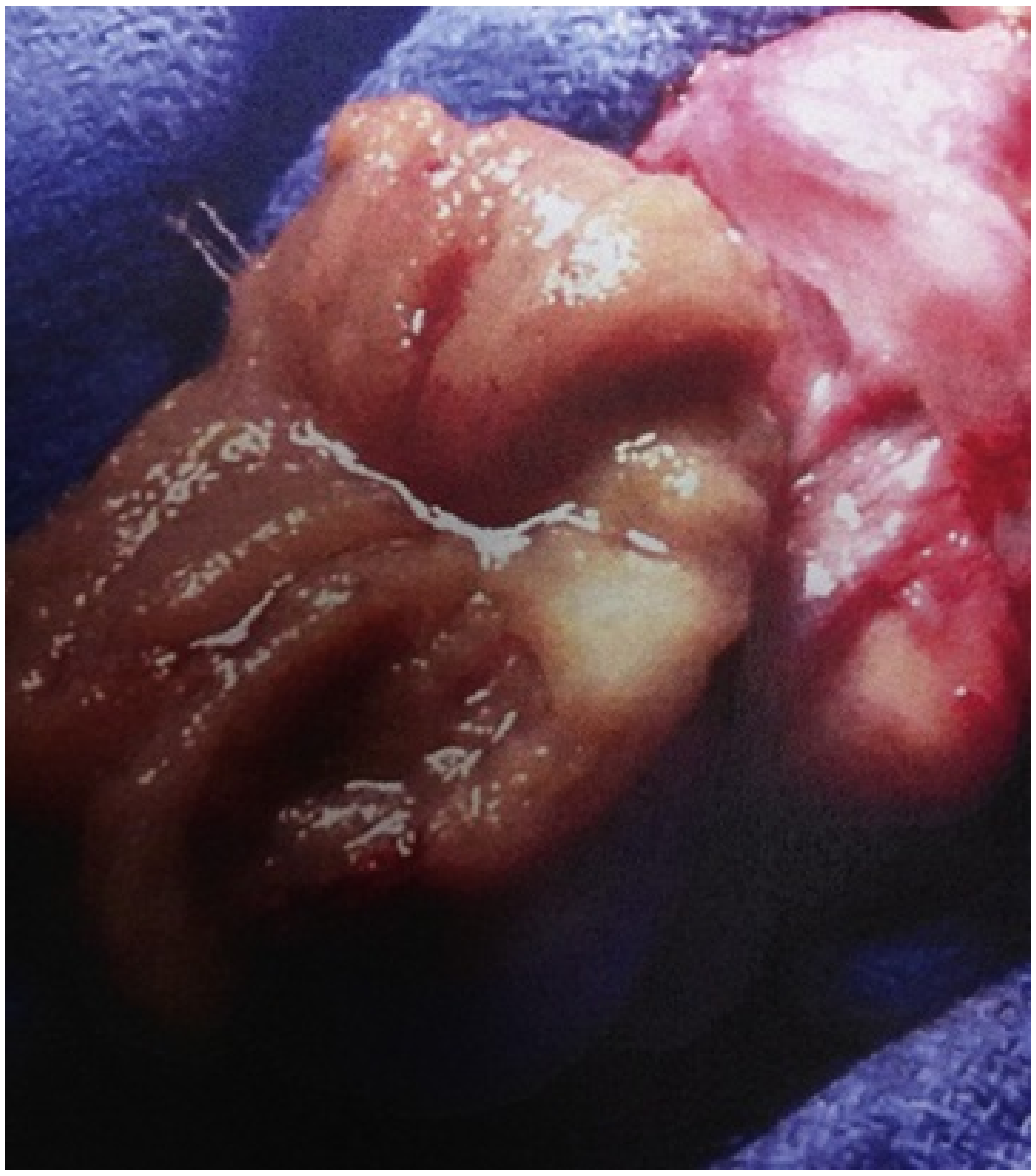

FIG. 63.2 The appearance of the testicular parenchyma when bivalved. The white nodule at the right inferior margin represents a sarcoid nodule.

Microanatomic Architecture

The tunica albuginea invaginates into the testis to form the mediastinum testis, where vessels and ducts traverse the testicular capsule. The mediastinum testis sends septa that attach to the inner surface of the tunica albuginea to form 200 to 300 cone-shaped lobules, each of which contains one or more convoluted seminiferous tubules. Each lobule contains a centrifugal artery. Seminiferous tubules are coiled and long, with both ends typically ending in the rete testis. The seminiferous tubules contain germ cells and supporting cells, including Sertoli cells, fibrocytes, and myoid cells of the basement membrane. Each seminiferous tubule is U-shaped, but if a seminiferous tubule were stretched out from its convoluted form, each would measure nearly 1 m in length. **Each seminiferous tubule in the normal testis contains developing germ cells. The testosterone-producing Leydig cells are interdispersed in the loose tissue around the seminiferous tubules.** The interstitial tissue includes Leydig cells, mast cells, macrophages, nerves, blood vessels, and lymphatic vessels. This interstitial tissue makes up a total of 20% to 30% of the testicular volume (Setchell and

Brooks, 1988). Sertoli cells line the seminiferous tubules and rest on the tubular basement membrane. The cellular characteristics of Sertoli cells include a low mitotic index, prominent nucleoli, and nuclei with irregular shapes. There are strong, tight junctions between the Sertoli cells, which compartmentalize the seminiferous tubular space into adluminal and basal spaces (Fig. 63.3). The seminiferous tubules straighten and become tubuli recti toward the apex of each lobule, where they enter the mediastinum testis and anastomose with a network of tubules lined by flattened epithelia. This tubular network is the rete testis and forms 12 to 20 efferent ductules that anastomose into the caput of the epididymis. At this point, the efferent ductules convolute, enlarge, and form conical lobules. Each lobule produces a duct that drains into a single epididymal duct. The epididymal duct would be approximately 6 m in length if it were stretched out. It winds within the epididymis to form the body and the tail of the epididymis, all of which are surrounded by a fibrous sheath. The thickening and straightening of the duct forms the vas deferens as it reaches the tail of the epididymis (Figs. 63.4 and 63.5).

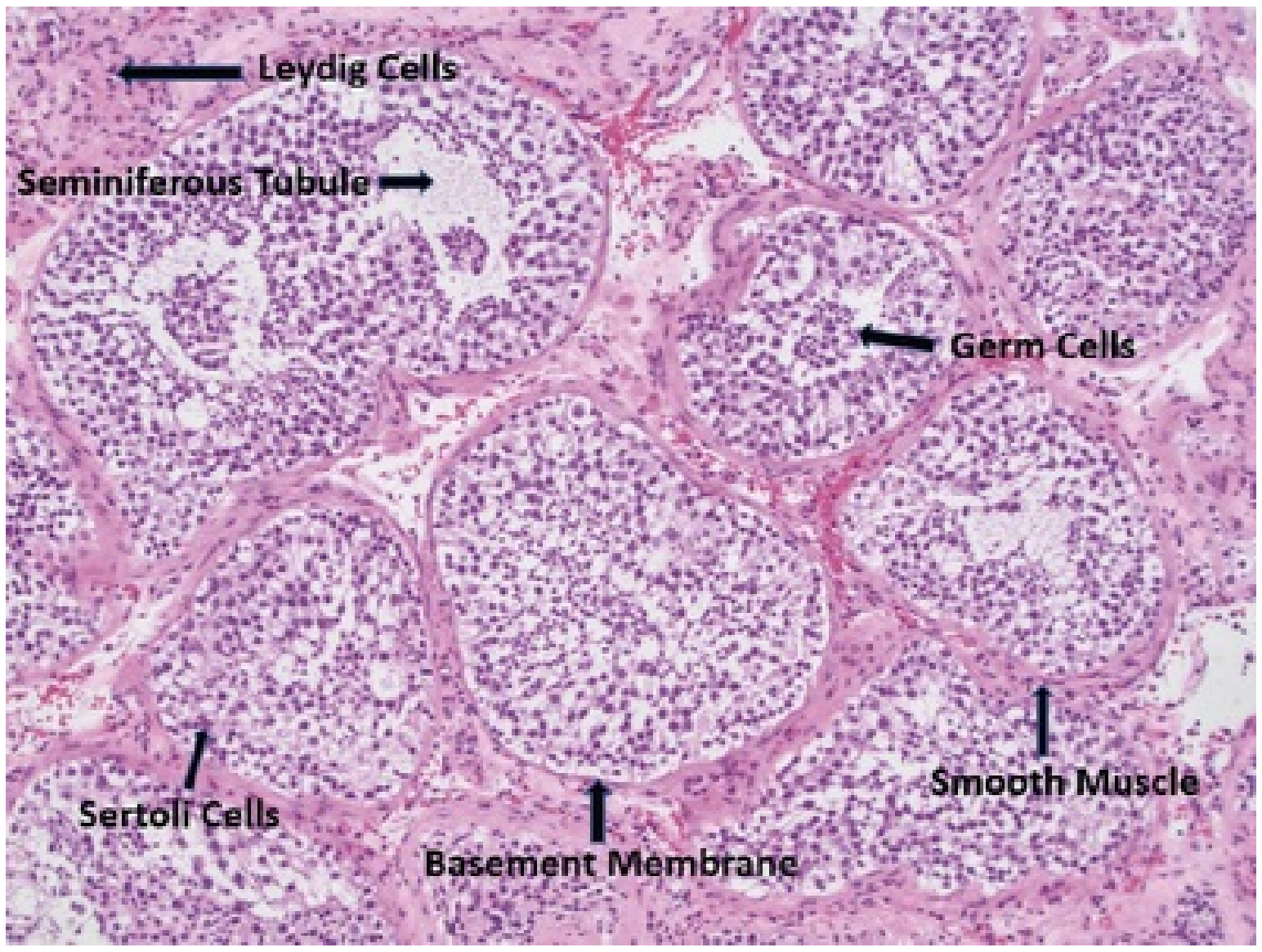

FIG. 63.3 Testicular microanatomic architecture with Leydig cells, seminiferous tubules, germ cells, Sertoli cells, basement membrane, and smooth muscle labeled at 10× magnification. (Courtesy Xiao Yun Wang, MD.)

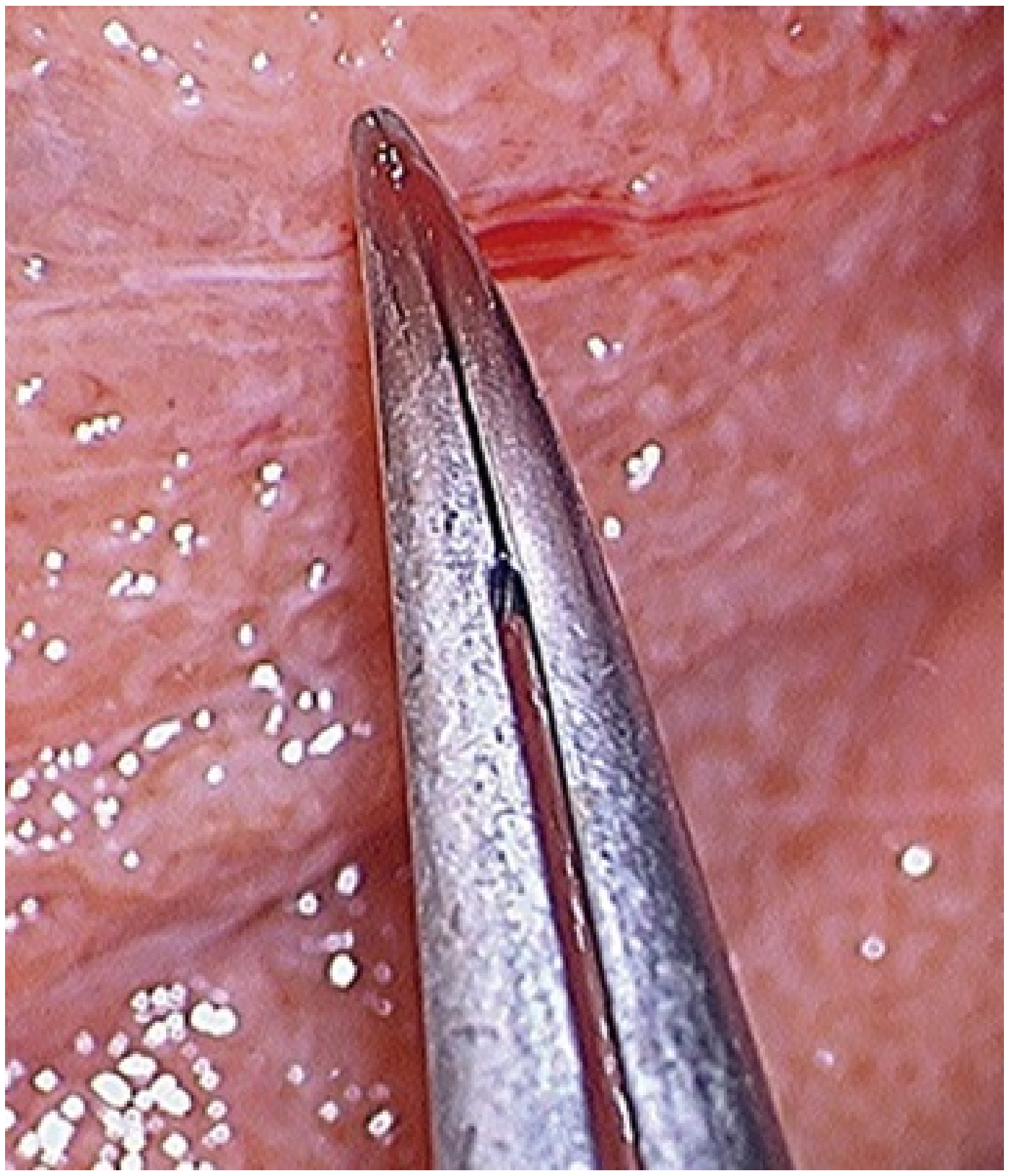

FIG. 63.4 Appearance of the seminiferous tubules under magnification.

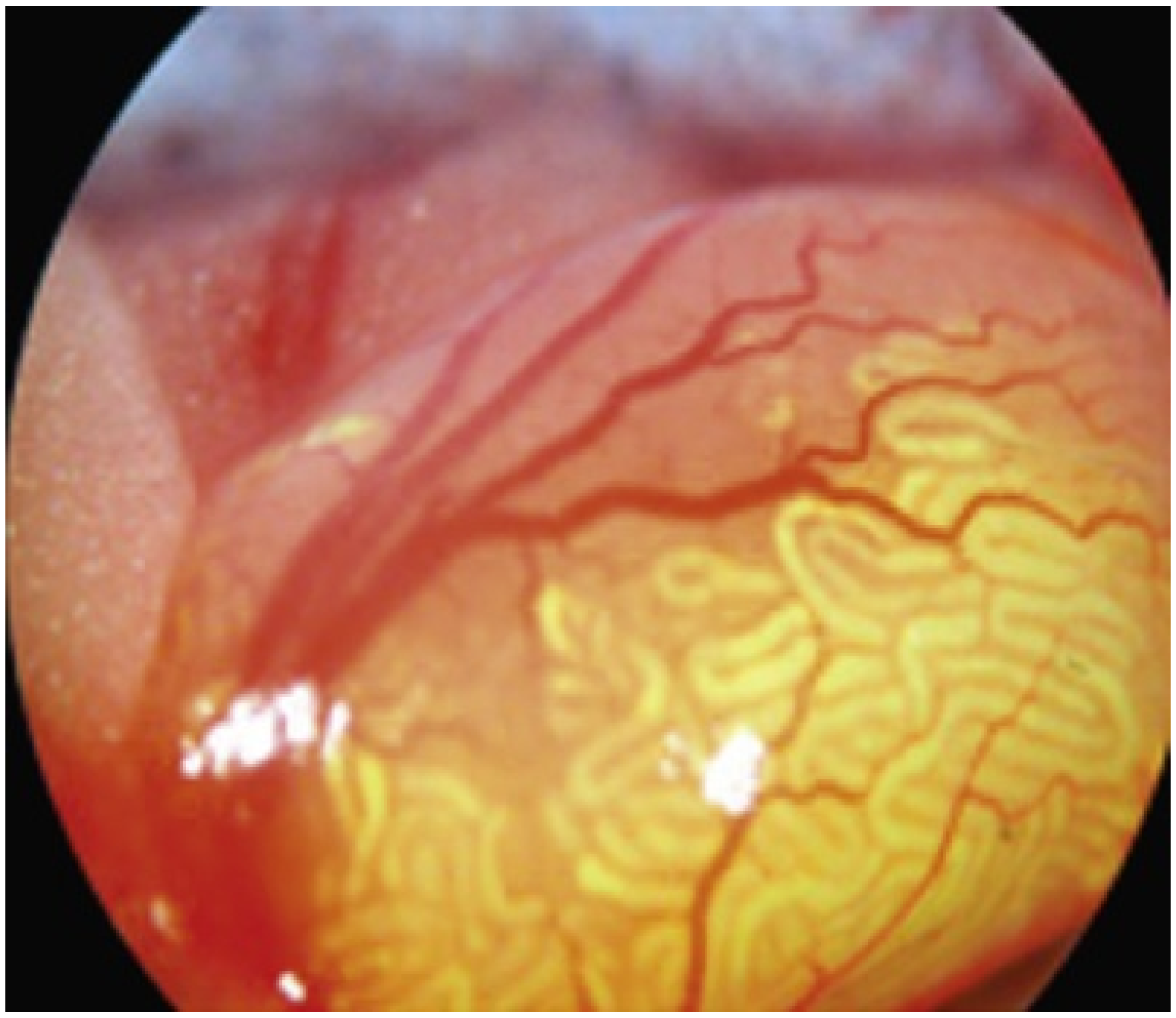

FIG. 63.5 Microbeads injected retrograde through the rete testis into the seminiferous tubules demonstrating the tubular structure. This is a mouse

testis that has very similar architecture to the human testis. (Courtesy Jeffrey Lysiak, PhD.)

Arterial Supply

There are three arterial supplies to the testis: the testicular (internal spermatic) artery, the artery of the vas deferens (deferential artery), and the cremasteric (external spermatic) artery (Harrison and Barclay, 1948). **The testicular artery is the main blood supply to the testis, and its diameter is greater than the deferential and cremasteric arteries combined** (Raman and Goldstein, 2004). The testicular artery arises from the abdominal aorta and descends in the intermediate stratum of the retroperitoneum to enter the internal inguinal ring. From its aortic origin, it crosses the psoas muscle and the ureter to reach the inguinal ring to enter the spermatic cord. As the testicular artery descends toward the testis, it branches into an internal artery and an inferior testicular artery and into a capital artery to the caput epididymis. There may be variation at the level of this branching, which has been found to occur within the inguinal canal in 31% to 88% of cases (Beck et al., 1992; Jarow et al., 1992). In 56% of cases, a single artery enters the testis. In 31% of cases, there are two branches, and in 13% there are three or more branches of this artery (Kormano and Suoranta, 1971). Arterial anastomosis occurs at the head of the epididymis, allowing for a rich blood supply between the testicular and capital arteries. At the tail of the epididymis, arterial anastomoses are formed between the testicular, epididymal, cremasteric, and vasal arteries. The testicular arteries pass into the mediastinum testis and supply the tunica vasculosa in the anterior portion of the upper pole of the testis and the anterior, medial, and lateral portions of the lower pole of the testis. Therefore care must be taken not to devascularize the testis by passing a traction suture through the lower pole, as well as by performing testis biopsies in the medial or lateral surfaces of the upper pole to minimize the risk of vascular injury. The middle of the testis has fewer vessels than the upper or lower poles. The deferential artery derives from the internal iliac artery or from the superior vesical artery. The cremasteric artery derives from the inferior epigastric artery and primarily supplies the tunica vaginalis, but it has branches going to the testis. Centrifugal arteries, which are the individual arteries supplying the seminiferous tubules, pass within the septa containing the seminiferous tubules and branch into arterioles that ultimately become intertubular and peritubular capillaries (Muller, 1957). Although in the case of testicular artery ligation, the deferential and cremasteric arteries can potentially provide adequate blood supply to the testis, atrophy and/or azoospermia has resulted from testicular artery ligation in adults and children. Men who have undergone vasectomy deserve special attention in preserving the testicular artery in future surgeries such as varicocelectomy because of the risk of having had the deferential artery compromised at the time of vasectomy (Lee et al., 2007; Figs. 63.6 and 63.7).

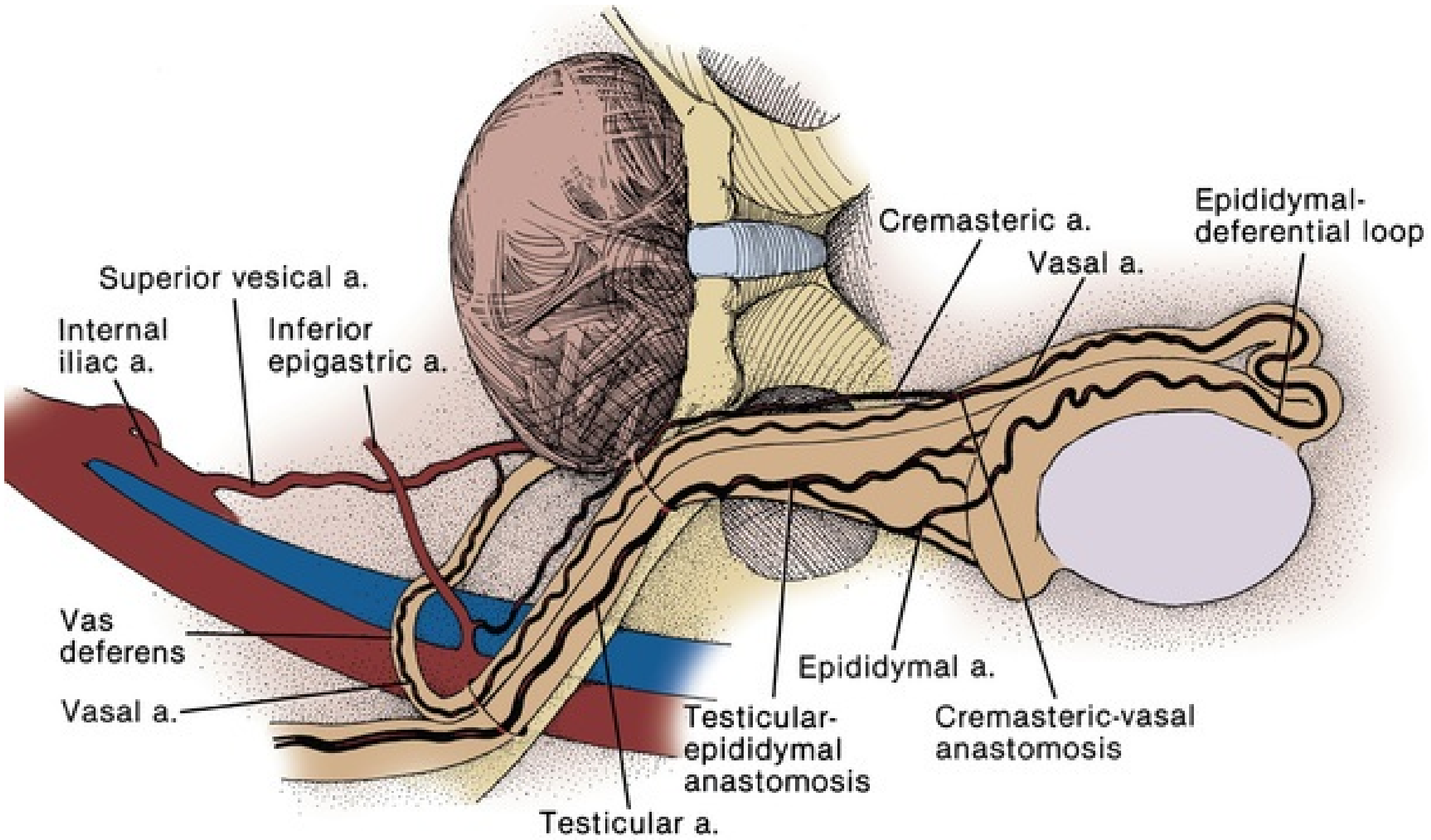
Superior vesical a.
Internal iliac a.
Inferior epigastric a.
Cremasteric a.
Vasal a.
Epididymal-deferential loop
Vas deferens
Vasal a.
Epididymal a.
Testicular-epididymal anastomosis
Cremasteric-vasal anastomosis
Testicular a.

FIG. 63.6 Collateral arterial circulation to the testis. (From Hinman F Jr: *Atlas of urosurgical anatomy*, Philadelphia, 1993, Saunders, p 497.)

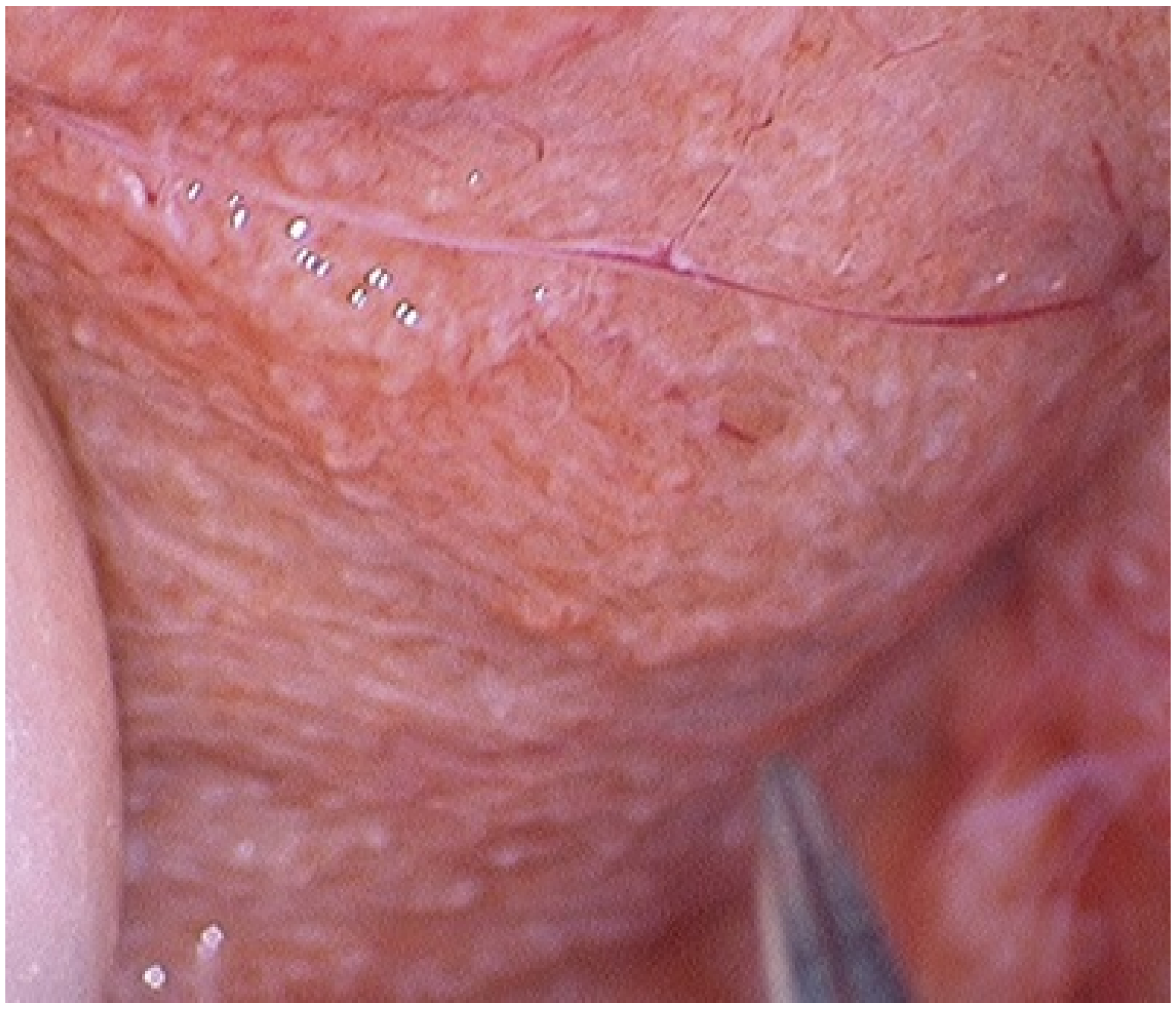

FIG. 63.7 Microsurgical view of arterial supply to the testicular parenchyma.

Venous Drainage

Unlike most other venous patterns in the human body, veins within the testis do not travel with their corresponding arteries. Small parenchymal veins drain into either a group of veins near the mediastinum testis or veins on the surface of the testis (Setchell and Brooks, 1988). These two groups of veins anastomose with each other and the deferential veins to form the pampiniform plexus. The pampiniform plexus is a network of testicular veins that anastomose as they ascend surrounding the testicular artery. This allows for a countercurrent heat exchange that cools the blood flow within the testicular artery. Ultimately, these veins join to form two or three veins at the level of the inguinal canal, and then they form one vein that ascends to drain into the inferior vena cava on the right and into the renal vein on the left side. There may be variations where the testicular veins can anastomose with the external pudendal, cremasteric, and vasal veins; this can allow varicocele ablations to result in recurrence (Figs. 63.8 and 63.9).

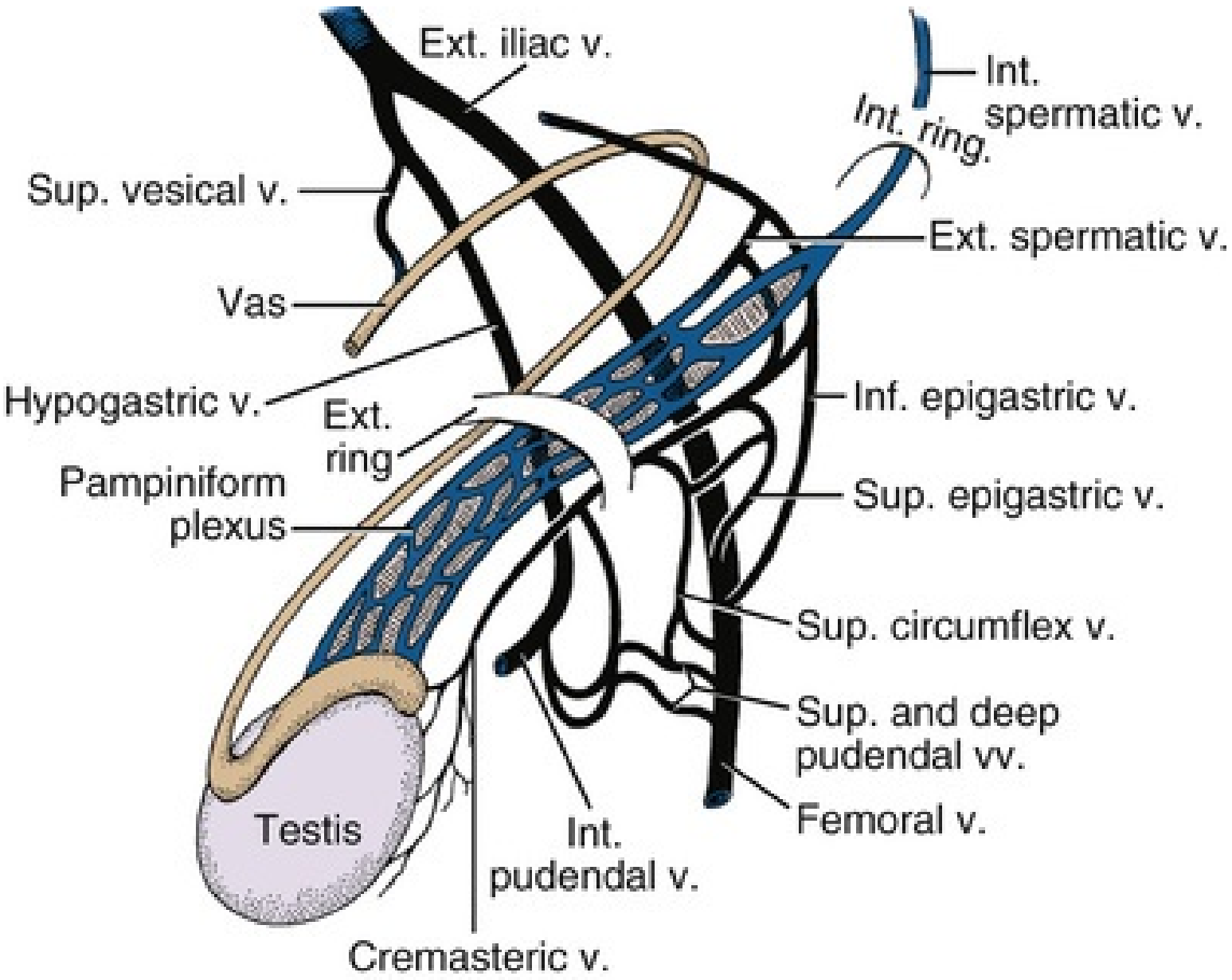
Ext. iliac v.
Int. spermatic v.
Int. ring.
Sup. vesical v.
Ext. spermatic v.
Vas
Hypogastric v.
Ext. ring
Inf. epigastric v.
Pampiniform plexus
Sup. epigastric v.
Sup. circumflex v.
Sup. and deep pudendal vv.
Testis
Femoral v.
Int. pudendal v.
Cremasteric v.

FIG. 63.8 Venous drainage of the testis and epididymis. Note connections between the pampiniform plexus and the saphenous, internal iliac, and external iliac veins.

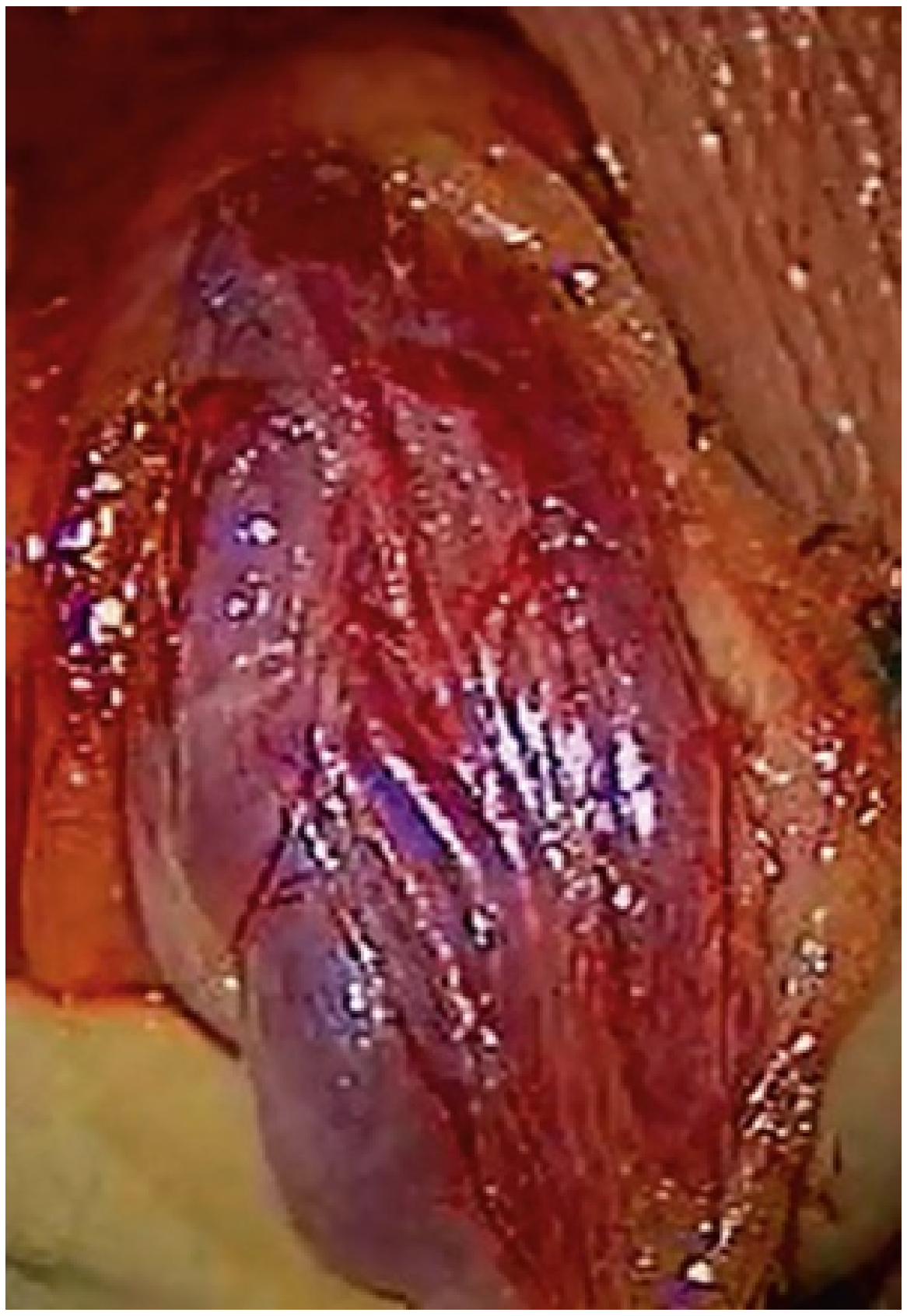

FIG. 63.9 Microsurgical view of the veins of the pampiniform plexus during varicocele ligation through a subinguinal approach.

Lymphatic Drainage

Lymphatic channels from the testis drain into the para-aortic and interaortocaval lymph nodes. These lymphatic channels ascend within the spermatic cord after leaving the testis (Hundeiker, 1969; Fig. 63.10).

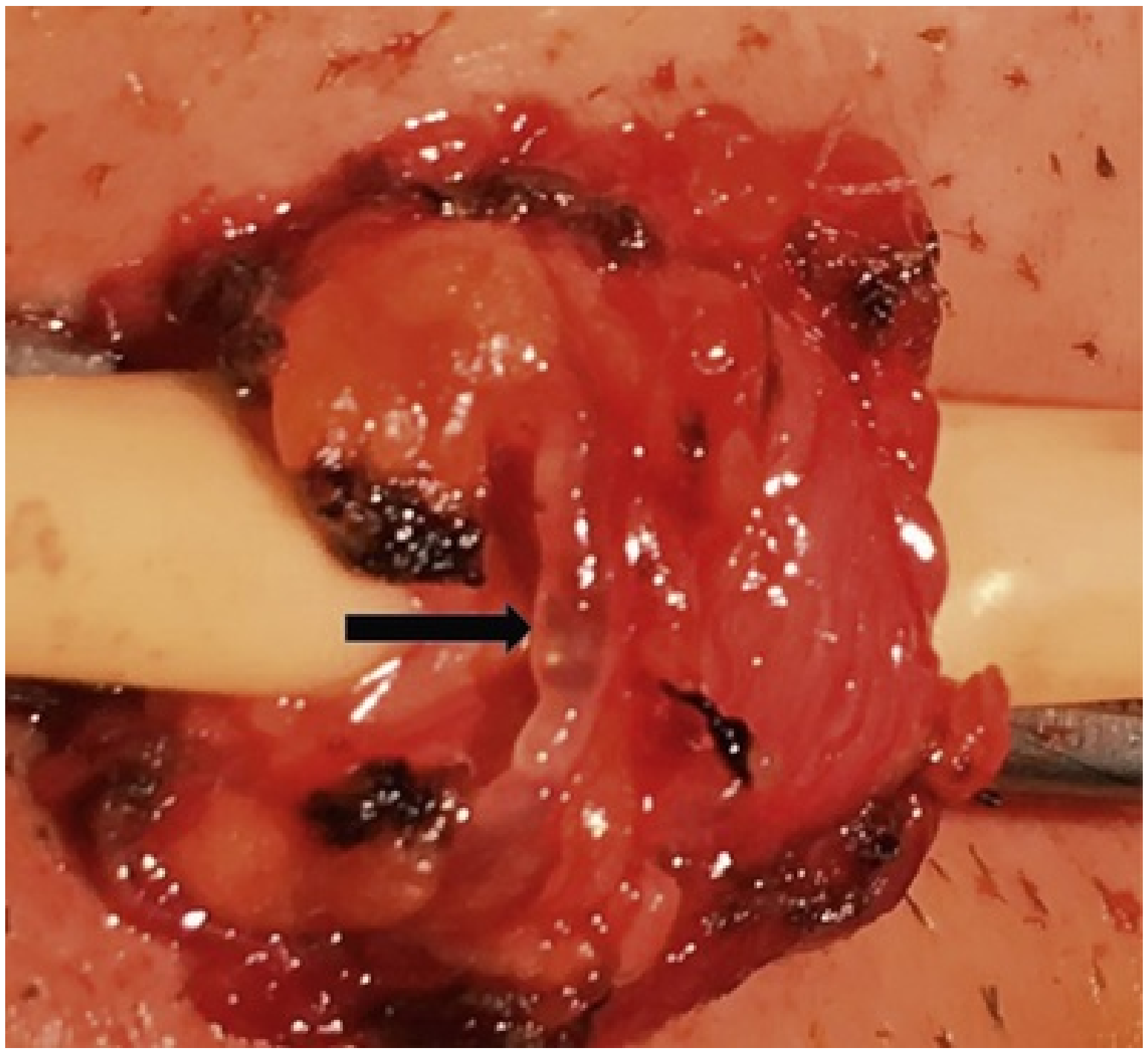

FIG. 63.10 Microsurgical view of a lymphatic channel *(arrow)* as it travels through the spermatic cord as identified during a subinguinal microsurgical varicocele repair.

Nerve Supply

Visceral innervation to the testis and epididymis arise in the renal and aortic plexuses and course alongside the gonadal vessels. This is autonomic innervation; the testis does not have any known somatic innervation (Mitchell, 1935). The pelvic plexus, in association with the vas deferens, offers additional gonadal afferent and efferent nerves (Rauchenwald et al., 1995). Three distinct anatomic distributions of nerves have been isolated within the spermatic cord and are thought to be the primary contributors in men with chronic orchialgia. These include a perivasal complex, posterior periarterial/lipomatous complex, and intracremasteric complex (Parekattil et al., 2013). Some afferent and efferent nerves cross over to the contralateral pelvic plexus (Taguchi et al., 1999). This may account for pathology in one testis affecting the function of the contralateral testis, which has been reported with varicoceles and testicular tumors. **The genital branch of the genitofemoral nerve primarily supplies sensation to the parietal and visceral tunica vaginalis and the overlying scrotum.** These nerves travel along the testicular artery to reach the testis. These nerves ramify within the tunica albuginea but do not enter the seminiferous tubules. Nerves are absent from the seminiferous epithelium.

Blood-Testis Barrier

The fluid passing from the seminiferous tubules and exiting from the testis has been found to have a substantially different fluid composition than that of blood plasma or lymphatics. This suggests that compounds do not freely diffuse to and from the tubules, indicating that a barrier exists, which is known as the blood-testis barrier (Setchell and Waites, 1975). There are extremely strong, tight junctions between Sertoli cells, which provide an intracellular barrier that allows for spermatogenesis in an immune privileged site. This is the barrier known as the blood-testis barrier (Ewing et al., 1980). This accounts for the anatomic component of the blood-testis barrier. The functional component is further discussed in Chapter 64.

Ultrasonography

Ultrasonography is the primary imaging modality used to interrogate the scrotum and its contents. Scrotal ultrasound uses high-frequency transducers (7.5 to 10 MHz), gray-scale real-time techniques, as well as color flow and power Doppler. The patient is placed in the supine position and a coupling gel is used with the transducer probe on the scrotal skin. The normal scrotal wall is 3 to 4 mm thick and is hypoechoic. An anechoic area between the echogenic scrotal wall and testicle is commonly visualized, which represents a small amount of physiologic fluid between the visceral and parietal layers of the tunica vaginalis. The mediastinum testis is visualized posteriorly as an echogenic band parallel to the epididymis. It may have variable lengths and thicknesses dependent on each patient's physiology (Dogra et al., 2003). **The echo pattern of the normal testis is fine, uniform, with a medium-level echo pattern.** Sonographically, the normal testis measures approximately 5 cm × 3 cm × 2 cm (Dogra et al., 2001). Color Doppler can identify testicular vessels in the majority of patients (Spirnak and Resnick, 2002). Waveforms from intratesticular arteries and testicular capsular arteries demonstrate consistently low-impedance patterns with high levels of diastolic flow. This represents the lower vascular resistance of the testis. Supratesticular arteries are also sonographically identifiable and show low-impedance waveforms from the testicular, deferential, and cremasteric arteries (Middleton et al., 1989; Figs. 63.11 and 63.12).

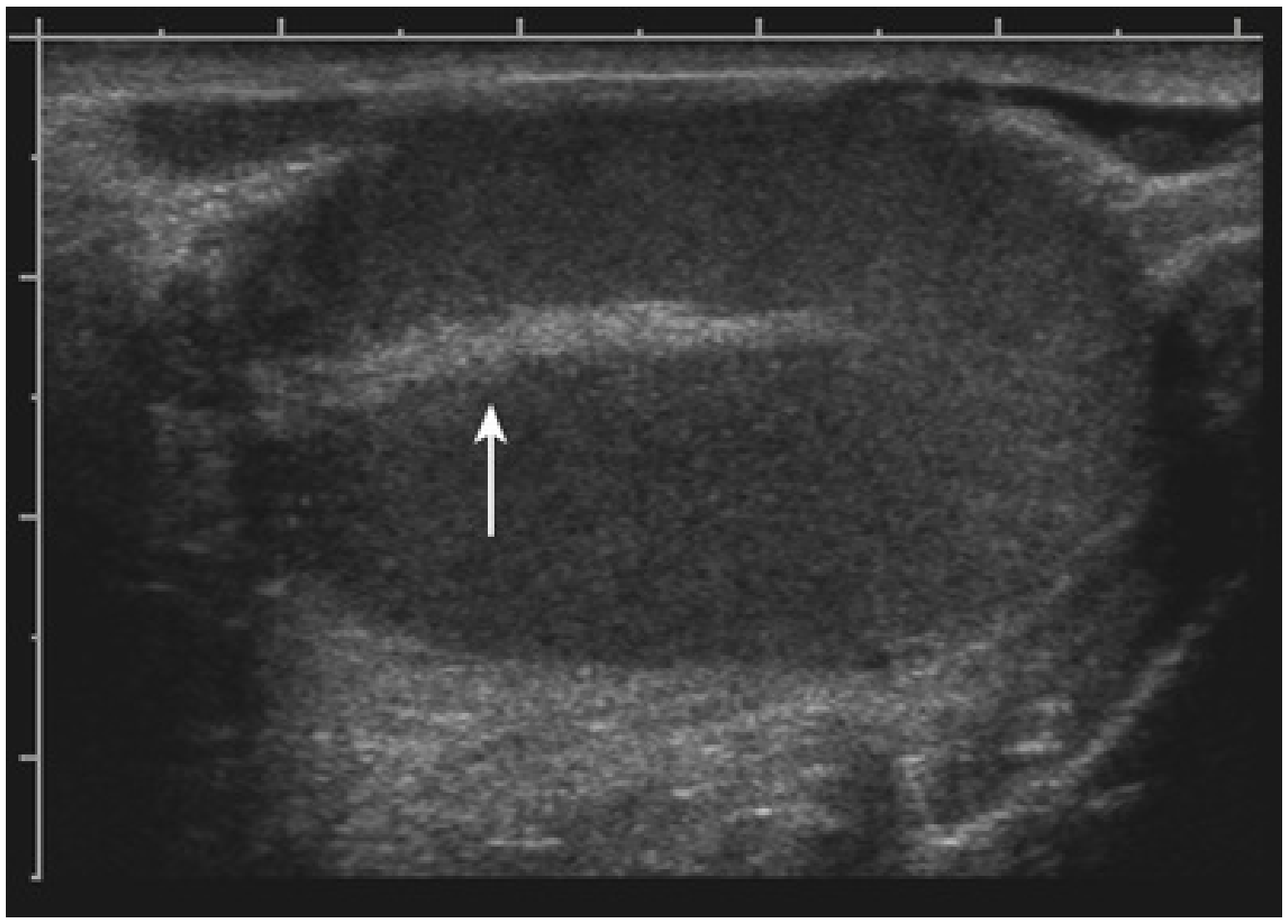

FIG. 63.11 Testis ultrasound image demonstrating rete testis *(arrow).*

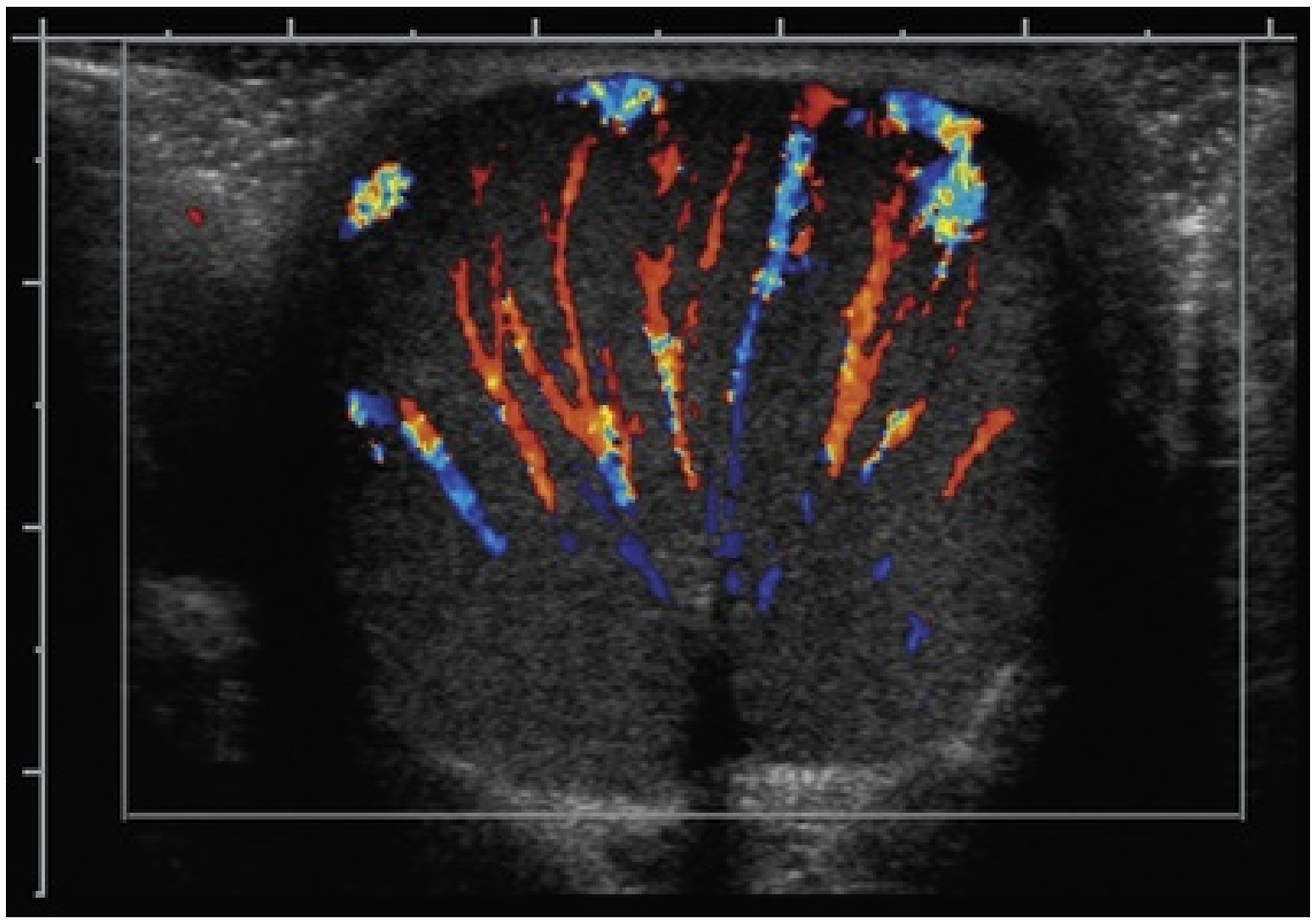

FIG. 63.12 Doppler ultrasound image of testis demonstrating spokelike radiation of testicular vessels originating from the mediastinum testis.

Magnetic Resonance Imaging

Ultrasonography is the primary imaging modality of the testis; however, magnetic resonance imaging (MRI) can be used to image the testis as a secondary imaging modality. The normal structures of the scrotum can be depicted clearly and the tunica albuginea can be easily differentiated from the testis parenchyma and the epididymis. MRI can distinguish intratesticular from extratesticular lesions and differentiate between solid and cystic lesions. Complicated and simple fluid collections can be differentiated (Rholl et al., 1987). Delineation of normal and pathologic structures greater than 1 mm is possible. An advantage of MRI is the ability to image both hemiscrota in one imaging plane as well as the inguinal region (Hajek, 1987). Magnetic resonance angiography (MRA) has also been performed for the evaluation of the nonpalpable testis and has identified inguinal testicular nubbin tissue (Eggener et al., 2005).

Key Points: Testis

- The seminiferous tubules contain developing germ cells.
- The Leydig cells produce testosterone.

- There are three arterial supplies to the testis, including the testicular artery, deferential artery, and cremasteric artery.
- Lymphatic channels from the testis drain into the para-aortic and interaortocaval lymph nodes.
- The nerves contributing to chronic orchialgia include a perivasal complex, posterior periarterial/lipomatous complex, and intracremasteric complex.
- Tight junctions between Sertoli cells make up the anatomic component of the blood-testis barrier.
- Ultrasonography is the primary imaging modality for intrascrotal content.

Epididymis

Gross Structure

The epididymis is a duct or tubule that is attached to the posterolateral aspect of the testis and is nearest to the testis at its upper pole. Its lower pole is connected to the testis with fibrous tissue. The epididymis is comma shaped. The epididymis is tightly coiled and encapsulated within the tunica vaginalis sheath and would measure 3 to 4 m in length if stretched out (Turner et al., 1978; Von Lanz and Neuhaeuser, 1964). Septa form by extensions of the tunica vaginalis sheath into interductal spaces that divide the duct into histologically characteristic areas (Kormano and Reijonen, 1976). The three areas are characterized as the caput (head), the corpus (body), and the cauda (tail) of the epididymis. Eight to 12 ductuli efferentes from the testis make up the caput epididymis. The caput epididymis is connected to the testis by multiple efferent ducts. The tightly coiled duct, which makes up the epididymis, is continuous with the vas deferens at the most distal portion of the cauda epididymis. Adjacent to the testis, this duct is irregularly shaped and comparatively large. The duct becomes more narrow and concentric near the junction with the ductus epididymis. The duct diameter remains unchanged throughout the corpus epididymis. The diameter of the duct enlarges and becomes irregular in shape in the cauda epididymis. The duct then progresses distally to form the vas deferens. A cystic body on the upper pole of the caput epididymis, which may be pedunculated or sessile, is known as the appendix of the epididymis (Figs. 63.13 through 63.15).

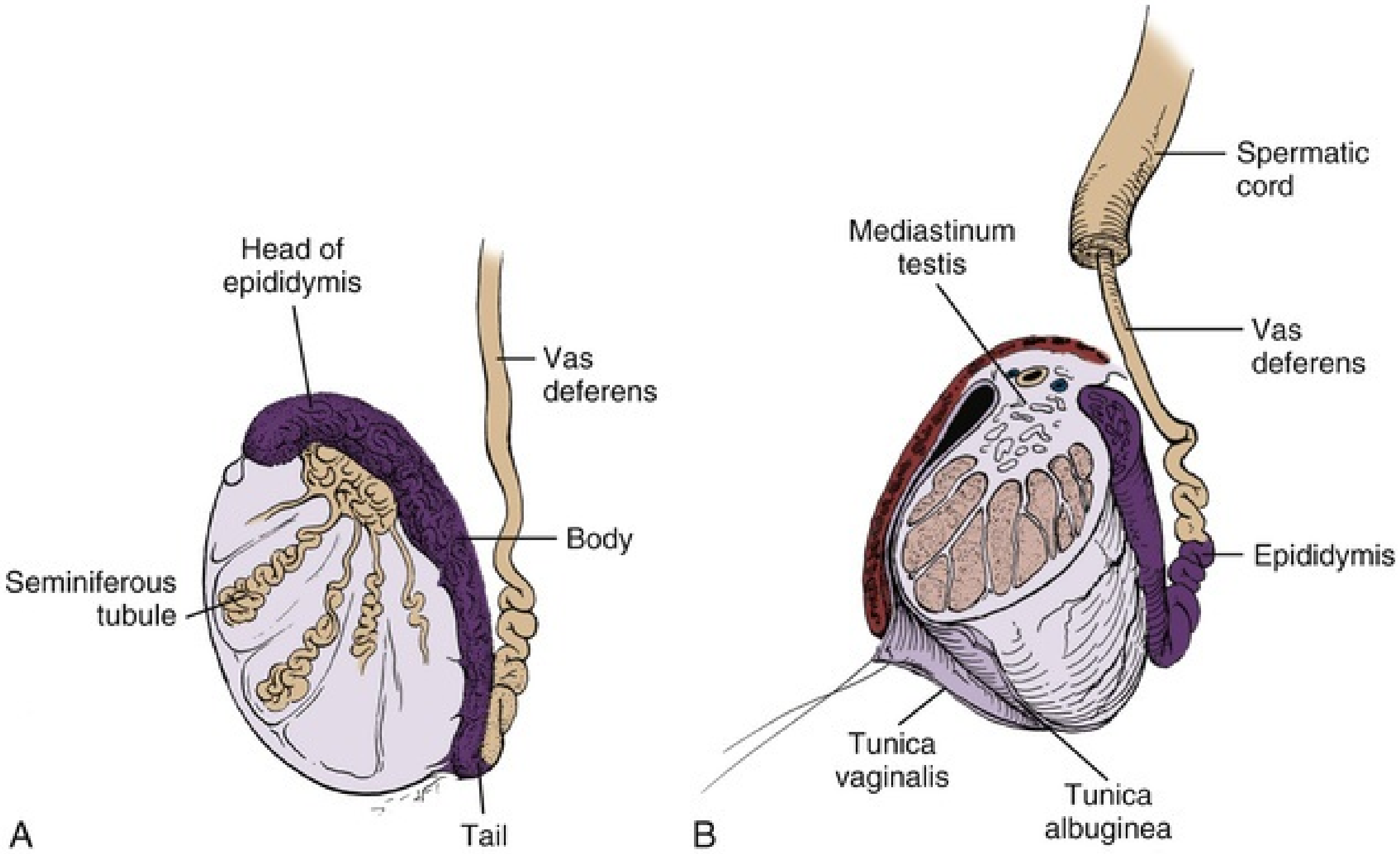
Head of epididymis
Vas deferens
Body
Seminiferous tubule
Tail
A
Spermatic cord
Mediastinum testis
Vas deferens
Epididymis
Tunica vaginalis
Tunica albuginea
B

FIG. 63.13 Testis and epididymis. (A) One to three seminiferous tubules fill each compartment and drain into the rete testis in the mediastinum. Twelve to 20 efferent ductules become convoluted in the head of the epididymis and drain into a single coiled duct of the epididymis. The vas is convoluted in its first portion. (B) Cross section of the testis, showing the mediastinum and septations continuous with the tunica albuginea. The parietal and visceral tunica vaginalis are confluent where the vessels and nerves enter the posterior aspect of the testis.

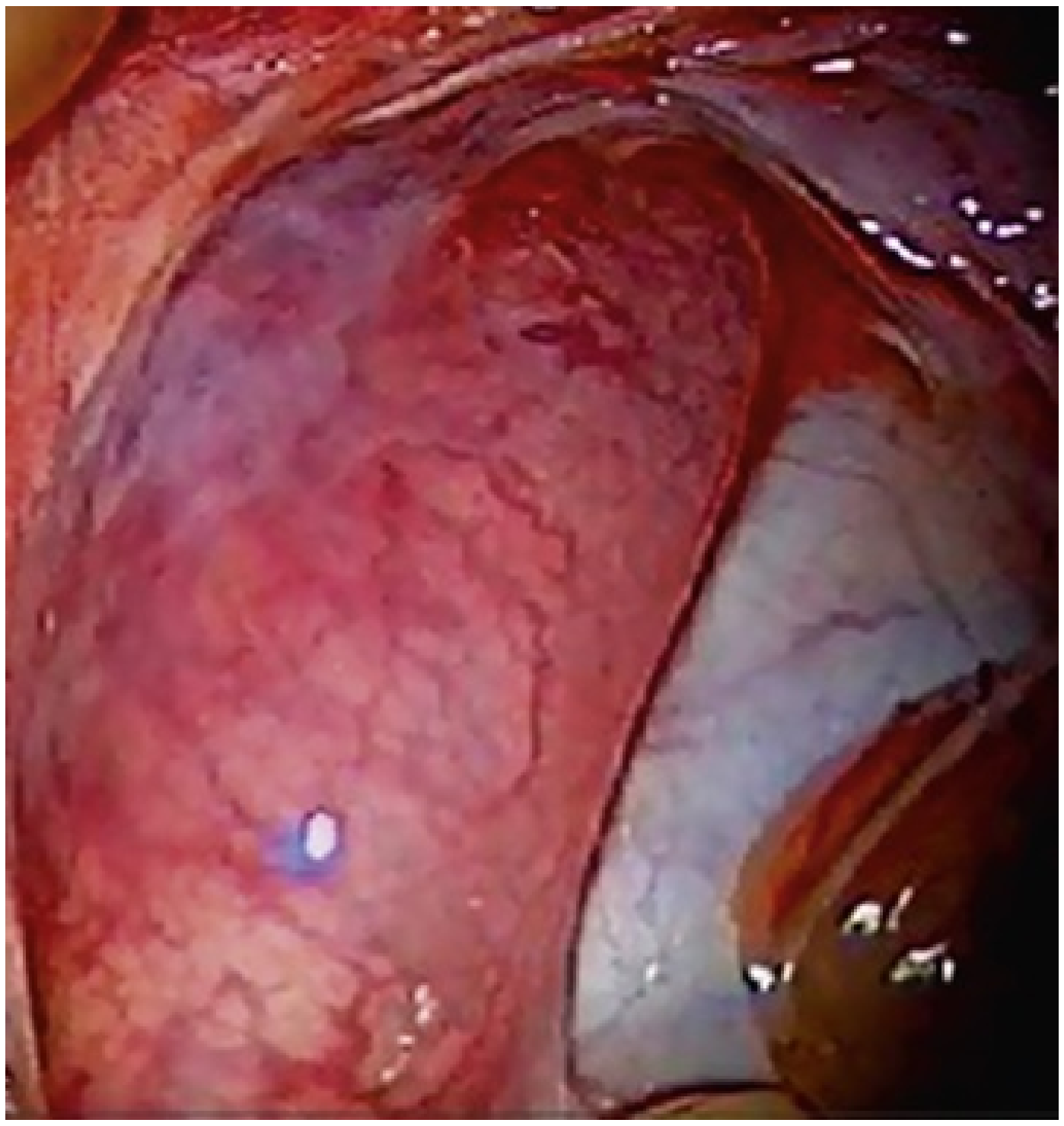

FIG. 63.14 Gross microsurgical appearance of the epididymal caput and corpus.

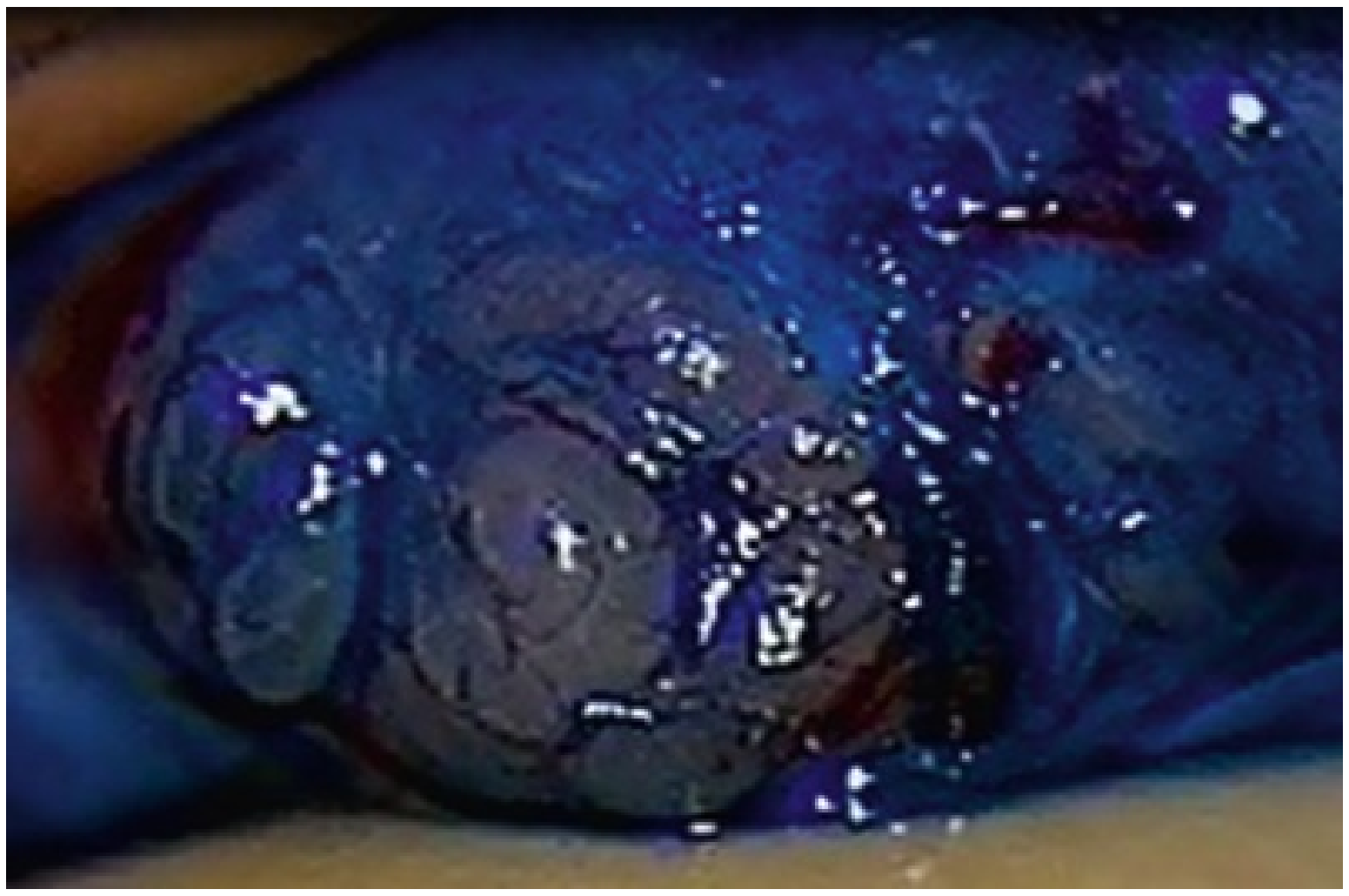

FIG. 63.15 Microsurgical appearance of the epididymal duct after being stained with methylene blue.

Microanatomic Architecture

There are two primary types of cells throughout the epididymis: principal cells and basal cells (Holstein, 1969; Vendrely, 1981). From caput to cauda, the height of the epithelium decreases, whereas the diameter of the ductus and lumen increases. There are stereocilia that shorten progressively from the proximal to the distal epididymis. In the proximal epididymis, these stereocilia measure 120 µm in height and decrease to 50 µm in the distal epididymis. The principal cells contain elongated nuclei that are commonly clefted, and they contain one or two nucleoli. As the principal cells have absorptive and secretive functions, the apex of each of these cells contains multiple coated pits, membranous vesicles, multivesicular bodies, micropinocytic vesicles, and an extensive Golgi apparatus (Vendrely and Dadoune, 1988). There is a much larger number of principal cells in the epididymal epithelium than the number of basal cells that exist there. The basal cells are interdispersed between the principal cells. The basal cells are tear-shaped. They are positioned on the basal lamina and are 25 µm in length as they reach up toward the lumen. As opposed to the morphology of the principal cells, which varies throughout the epididymis, the basal cells’ shape remains relatively consistent throughout the entirety of the epididymis. The basal cells are believed to be derived from macrophages and to be precursors of principal cells. There is a fair amount of variability in the nature of the epithelium of the epididymis, which is dependent on the region. There is a clear transition from a low to a high cuboidal epithelium where the rete testis and ductuli efferentes meet. The ductuli efferentes contain ciliated and nonciliated cells and the epithelium appears uneven (Holstein, 1969). The epithelium of the proximal ductuli efferentes primarily consists of nonciliated cells with extending apices thought to be for secretory function. The ciliated cells conduct sperm cells from the efferent duct to the epididymis, and they are widely dispersed throughout the epithelium (Vendrely, 1981). Junctional complexes join ciliated and nonciliated cells together at their apices, suggesting a blood-epididymis barrier (Hoffer and Hinton, 1984; Suzuki and Nagano, 1978; Turner, 1979). In the ductuli efferentes, the proximal corpus epididymis, and the distal caput epididymis there are contractile cells around the tubule in a loose, two- to four-cell–deep layer (Baumgarten et al., 1971). Nexus-like junctions connect these contractile cells, and each cell contains myofilaments. These cells are larger and appear like thin smooth muscle cells in the distal corpus epididymis, where they have fewer intracellular junctions. Thick smooth muscle cells are found in the cauda epididymis. The smooth muscle cells are organized in three layers. The cells have a longitudinal orientation in the two outer layers and a circular orientation in the central layer. The thickness of the distal contractile layer progressively increases as it forms the vas deferens.

Arterial Supply

A branch of the testicular artery supplies the caput and corpus epididymis. This arterial branch then further divides to supply the superior and inferior epididymal branches (Macmillan, 1954). **The deferential artery also provides vascular supply to the epididymis.** Branches from the deferential artery supply the cauda epididymis. As with the testis, the deferential and cremasteric arteries also supply the epididymis and can compensate for a ligated testicular artery. The connective tissue sheaths forming septa in the epididymis are the entry points for arterial supply within the epididymis. The coiled vessels ultimately straighten to form the microvascular bed within the epididymis (Kormano and Reijonen, 1976). The density of the microvasculature decreases progressively, with the caput containing the highest density of microvasculature and the more distal segments containing lower density (Clavert et al., 1981).

Venous Drainage

The corpus and cauda epididymis have their venous drainage through the vena marginalis of Haberer, draining into the pampiniform plexus via the vena marginalis testis, or through deferential or cremasteric veins (Macmillan, 1954).

Lymphatic Drainage

Similar to that of the testis, the caput and corpus epididymis have their lymphatic drainage through channels that travel with the internal spermatic vein, draining to the preaortic nodes. Lymphatic channels from the cauda epididymis join those leaving the vas deferens to drain ultimately into the external iliac nodes.

Nerve Supply

The superior portion of the hypogastric plexus and the pelvic plexus yield the intermediate and inferior spermatic nerves, respectively, which innervate the epididymis (Mitchell, 1935). Fibers from the sympathetic nervous system sparsely innervate the proximal portion of the epididymis as well as the ductuli efferentes (Baumgarten and Holstein, 1967; Baumgarten et al., 1971). These fibers form a peritubular plexus that is adjacent to the vasculature. The corpus epididymis includes sparse numbers of nerve fibers, and the density of nerve fibers increases progressively traveling toward the cauda epididymis. The density of fibers begins to increase at the midcorpus of the epididymis and the progressive increase in fibers is associated with the progressive proliferation of smooth muscle cells (Baumgarten et al., 1971).

Ultrasonography

The epididymis can be visualized ultrasonographically in its posterolateral position to the testis. **The epididymis appears either hyperechoic or isoechoic in comparison with the testis** (Spirnak and Resnick, 2002). Compared with the testis, the caput epididymis is typically isoechoic, the corpus epididymis is hypoechoic, and the vas deferens is anechoic (Puttemans et al., 2006). The epididymis is typically homogeneous, with well-defined echoes surrounding the epididymis that represent the fascial lining (Black and Patel, 1996). By sonographic measurement, the normal caput epididymis diameter measures between 10 mm and 12 mm, and the normal corpus epididymis measures between 2 mm and 5 mm (Pezzella et al., 2013). In 98% of men, the caput epididymis is above the upper pole of the testis, with the corpus epididymis typically lateral to the testis. The corpus epididymis is posterior to the body of the testis in 6% of men. The epididymis is inverted with the caput epididymis inferior to the lower pole of the testis in 2.4% of men (Puttemans et al., 2006). The appendix epididymis can be identified as an isoechoic structure attached to the caput epididymis (Black and Patel, 1996). Vascular flow is detectable with pulsed Doppler and color Doppler in all regions of the epididymis in nonpathologic states. The mean resistive index throughout the normal epididymis is approximately 0.55 (Keener et al., 1997; Fig. 63.16).

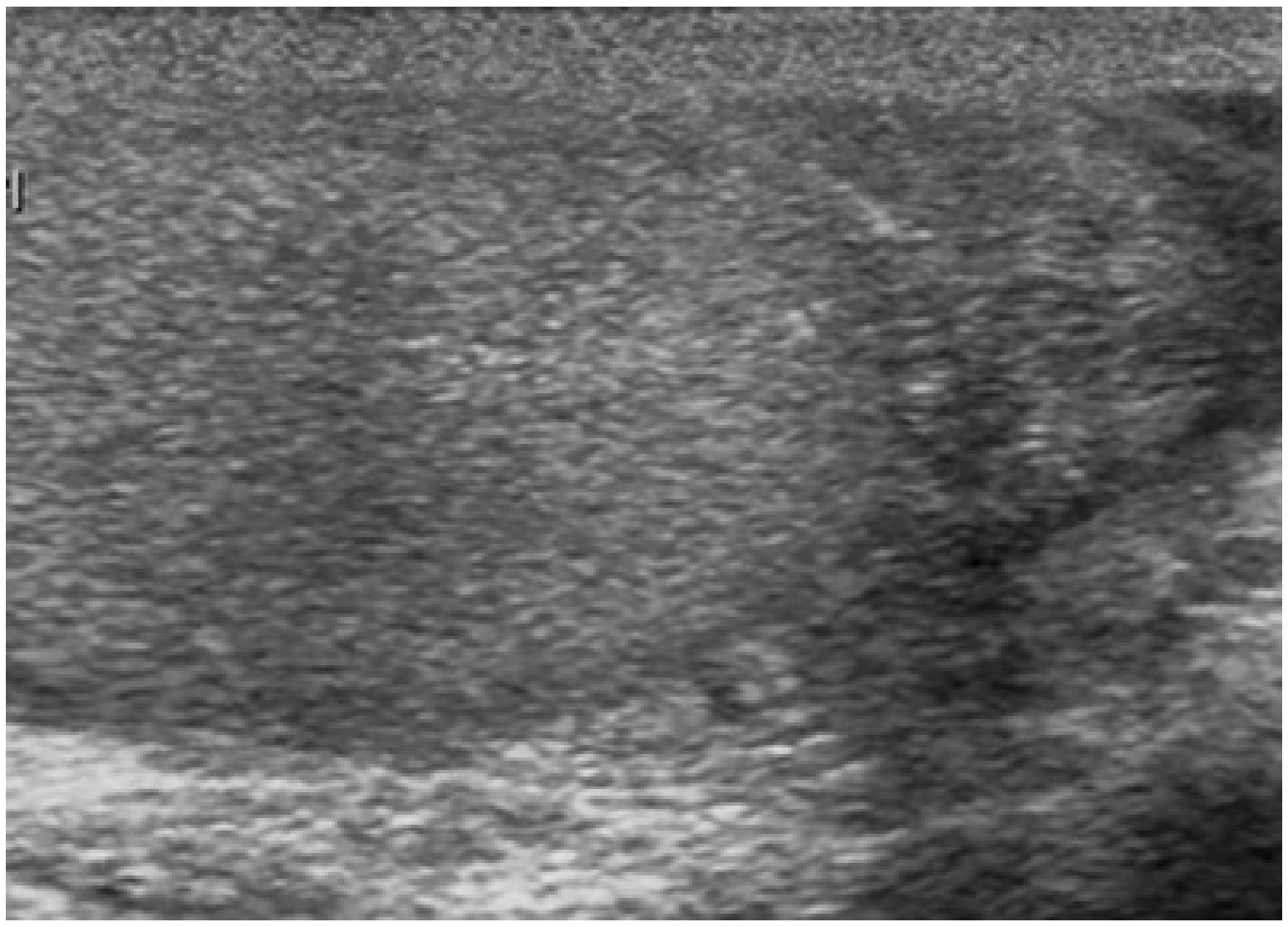

FIG. 63.16 Ultrasound imaging of the caput epididymis, which appears hyperechoic to the testis and is at the right of the testis on this image.

Magnetic Resonance Imaging

Ultrasonography is the primary modality of imaging of the epididymis, but MRI can be used as an adjunct to image the epididymis. Differences in signal intensity allow for clear delineation of the epididymis with high-resolution MRI (Baker et al., 1987).

Key Points: Epididymis

- The two primary cell types throughout the epididymis are principal cells and basal cells.
- The arterial supply to the caput and corpus epididymis is from a branch of the testicular artery and the cauda is supplied from deferential arterial branches.

Vas Deferens

Gross Structure

The vas deferens, also known as the ductus deferens, extends from the distal end of the cauda epididymis. It is tubular and its embryologic origin is the mesonephric (wolffian) duct. The vas deferens is tortuous for 2 to 3 cm as it leaves the epididymis (the convoluted vas deferens), after which it becomes the straight vas deferens. From the cauda epididymis to its termination at the ejaculatory duct, the vas deferens measures between 30 and 35 cm in length. **The vas deferens travels posteriorly along the spermatic cord, behind the vessels in the cord. The vas deferens passes through the inguinal canal and enters the pelvis lateral to the epigastric vessels** (Fig. 63.17)**.** On entering the pelvis, after passing through the internal inguinal ring, the vas deferens separates from the testicular vessels. The vas deferens ultimately reaches the posterior base of the prostate after traveling medial to the pelvic sidewall. The vas deferens is compartmentalized into five different regions. The first is the epididymal segment within the tunica vaginalis, which does not have a sheath. The second is the segment within the scrotum. The third segment is that within the inguinal canal. The fourth is the retroperitoneal segment, and the fifth is the ampulla of the vas deferens (Lich et al., 1978). **The lumen of the vas deferens ranges between 0.2 and 0.7 mm in diameter, depending on the segment.** The outer diameter of the vas deferens ranges between 1.5 and 2.7 mm (Middleton et al, 2009; Figs. 63.18 and 63.19).

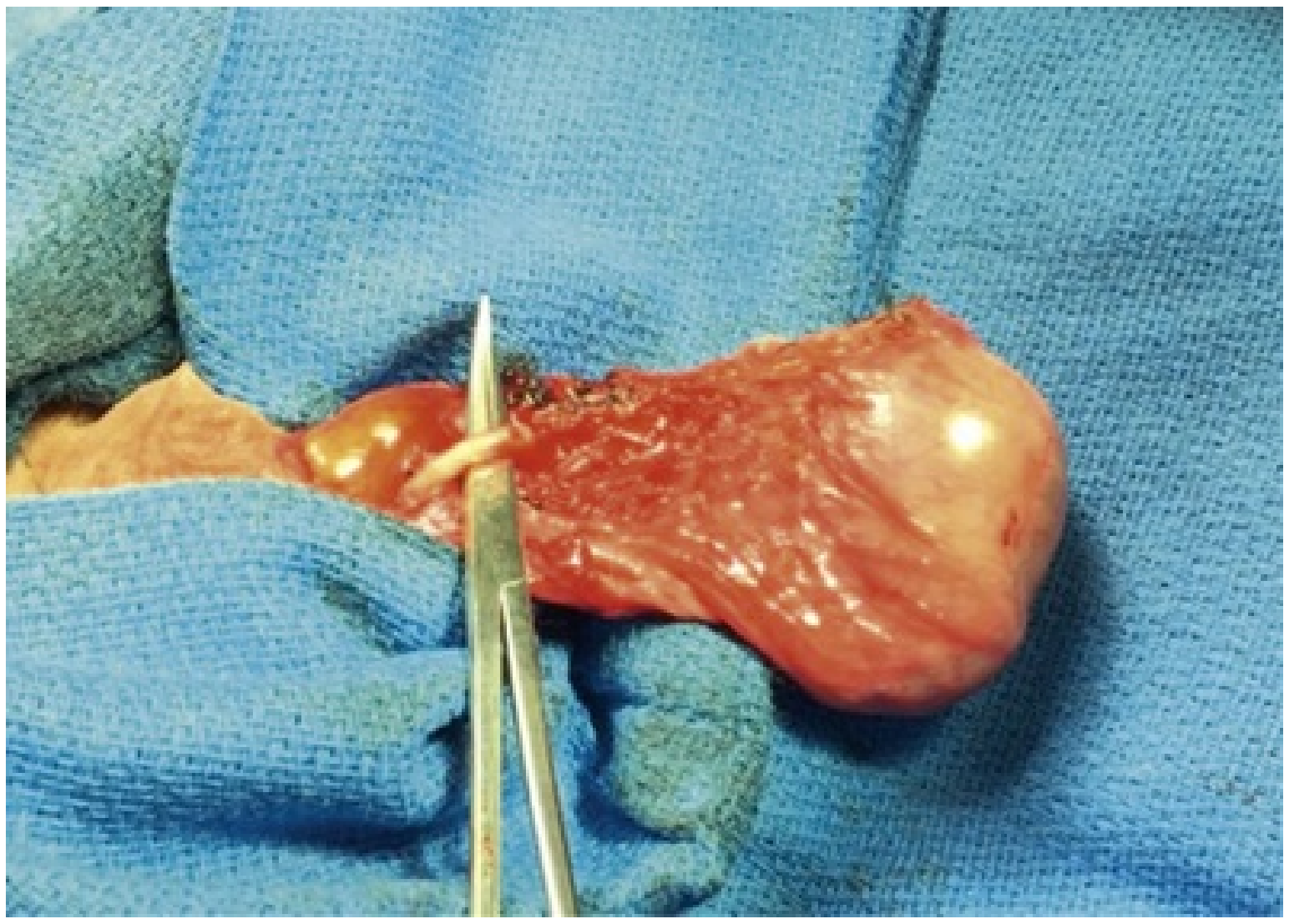

FIG. 63.17 Gross appearance of the vas deferens positioned in the posterior spermatic cord.

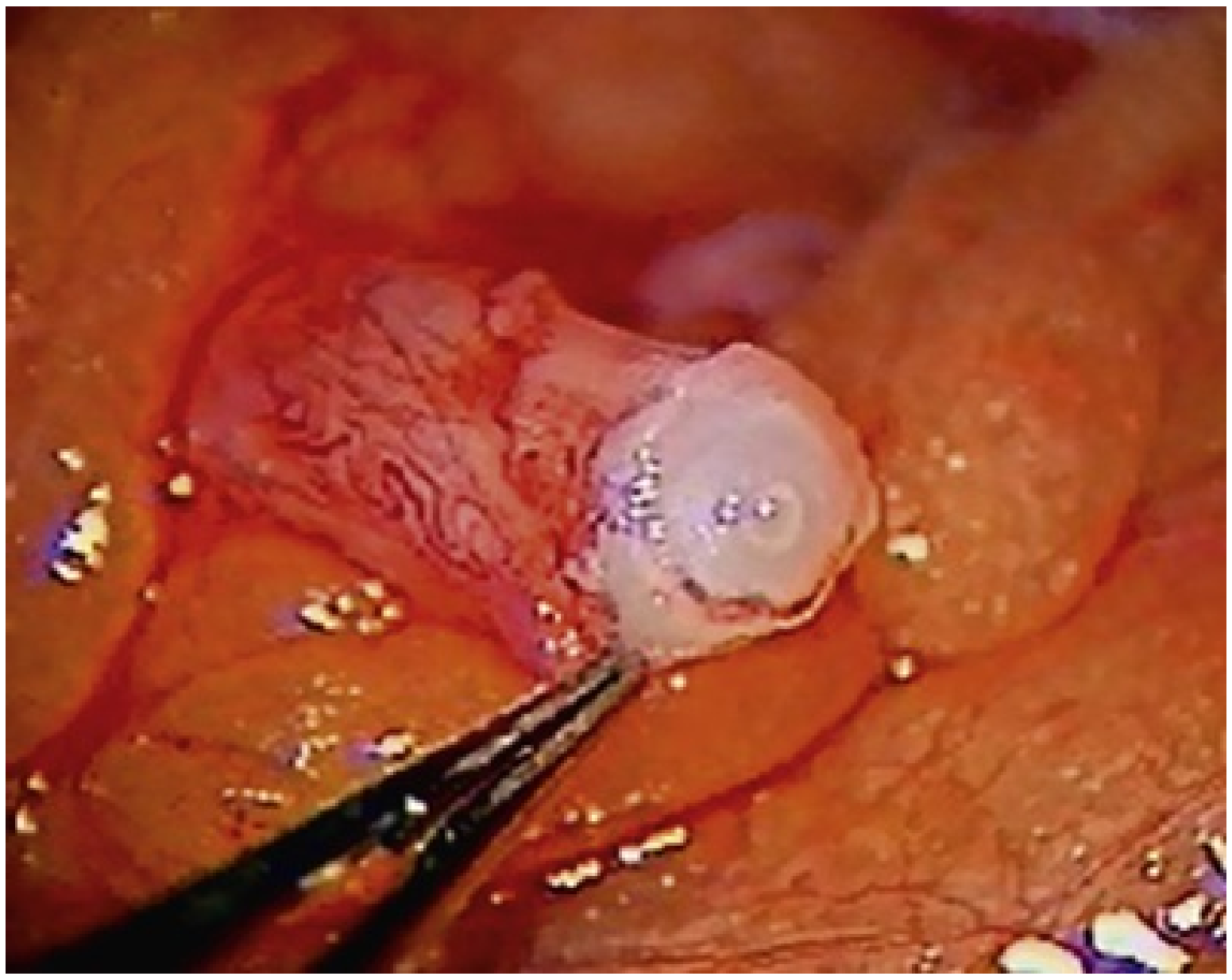

FIG. 63.18 Microsurgical appearance of the transected vas deferens at the time of vasovasostomy.

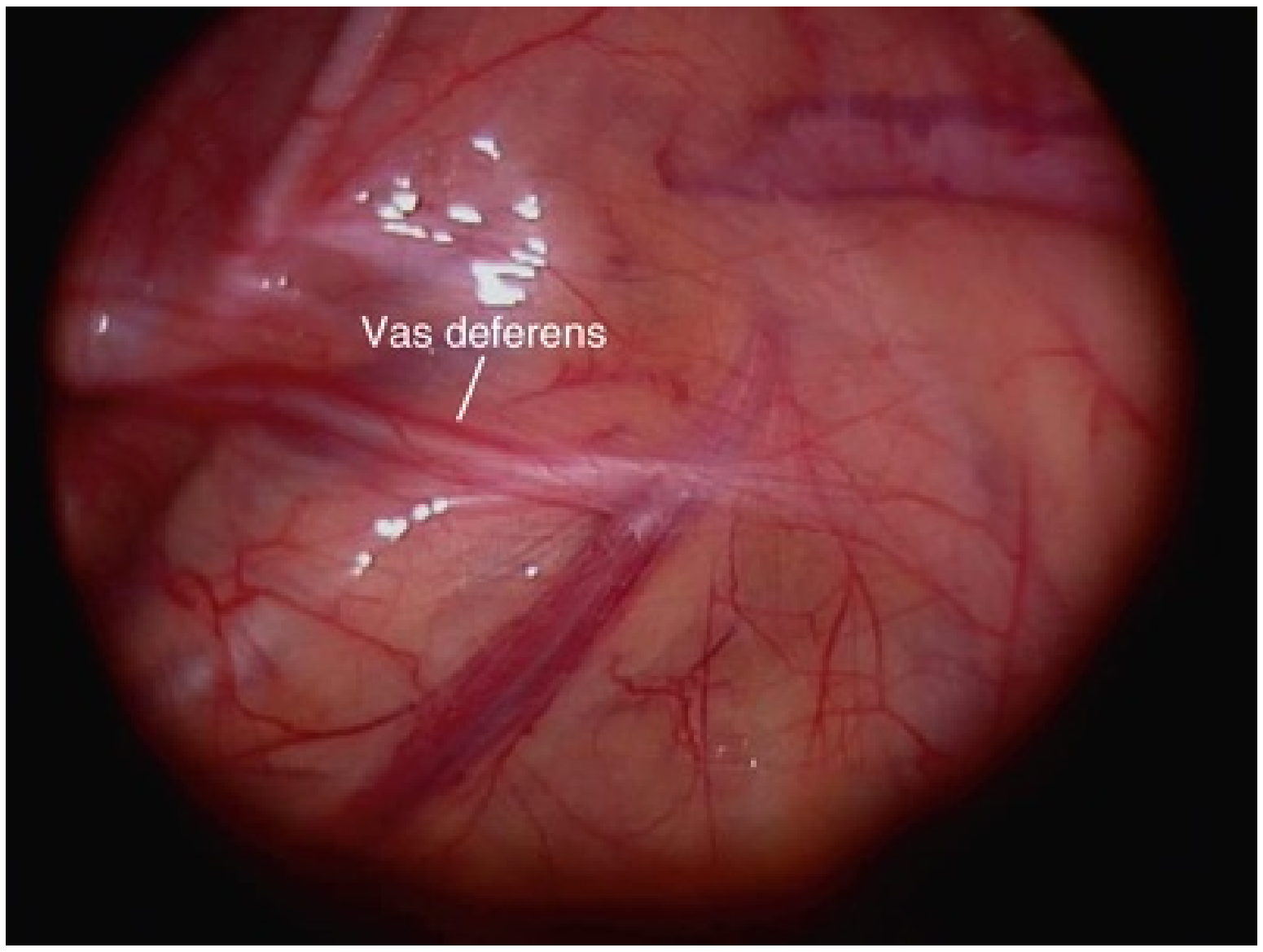

FIG. 63.19 Laparoscopic visualization of the vas deferens.

Microanatomic Architecture

There is an outer adventitial connective tissue layer surrounding the vas deferens that contains blood vessels and small nerves. Within this connective tissue layer, smooth muscle cells compose the thick wall of the vas deferens. These smooth muscle cells are organized as an inner and outer longitudinal layer, a middle circular layer, and a pseudostratified columnar epithelial layer with nonmotile stereocilia as the inner lining, known as its mucosa (Neaves, 1975; Paniagua et al., 1981). The epithelial cell height decreases progressively throughout the length of the vas deferens from the testis to the seminal vesicle. There are three types of tall, thin columnar cells, as well as basal cells, making up the pseudostratified epithelium of the vas deferens (Hoffer, 1976; Paniagua et al., 1981). Principal cells, pencil cells, and mitochondria-rich cells make up the columnar cells that extend from the epithelial base to the lumen. The columnar cells have irregularly shaped convoluted nuclei and have stereocilia. In the proximal vas deferens, principal cells are the predominant cell type. Traveling more distally throughout the vas deferens, more pencil cells and mitochondria-rich cells are present. The muscular layer of the vas deferens progressively decreases from proximal to distal.

Arterial Supply

The superior vesical artery gives off the deferential artery, which supplies the vas deferens (Sjostrand, 1965).

Venous Drainage

The venous drainage of the scrotal vas deferens is via the deferential vein, which drains into the pampiniform plexus. The pelvic vas deferens' venous drainage is to the pelvic venous plexus.

Lymphatic Drainage

Lymphatic drainage from the vas deferens travels to the external and internal iliac nodes.

Nerve Supply

The vas deferens receives sympathetic and parasympathetic innervation (Sjostrand, 1965). The sympathetic adrenergic nerves travel via the presacral nerve from the hypogastric nerve (Batra and Lardner, 1976; McConnell et al., 1982). All three layers of the vas deferens tunica muscularis contain adrenergic fibers, but the greatest density of these nerve fibers is found in the outer longitudinal layer (McConnell et al., 1982). Other types of neurotransmitters have been identified within neurons, such as somatostatin, galanin, enkephalin, neuropeptide Y, vasoactive intestinal peptide, and nitric oxide. The function of these neurotransmitters in the vas deferens is not well understood (Dixon et al., 1998).

Vasogram

The vasogram was previously considered to be the radiographic test of choice to evaluate the prostate, ejaculatory duct, and seminal vesicles in the infertile male. The vasogram has been replaced by transrectal ultrasonography for the most part, and the vasogram is used only in conjunction with reconstructive surgery (Honig, 1994).

Key Points: Vas Deferens

- The lumen of the vas deferens ranges between 0.2 and 0.7 mm in diameter, depending on the segment.
- The superior vesical artery gives off the deferential artery, which supplies the vas deferens.
- A vasogram should be performed only in conjunction with reconstructive surgery.

Seminal Vesicles and Ejaculatory Ducts

Gross Structure

The seminal vesicles are paired, viscous organs that are positioned posterior to the bladder and prostate. The seminal vesicle is a lateral outpouching of the vas deferens. It has the capacity for 3 to 4 mL of volume, and the nonobstructed seminal vesicle typically measures 5 to 7 cm in length and 1.5 cm in width. The seminal vesicle is a single tube that is highly coiled, and it forms several outpouchings and would measure 15 cm in length if stretched out. The joining of the seminal vesicle with the vas deferens creates the ejaculatory duct. The smooth muscle sheaths from the seminal vesicle and the vas deferens combine with the capsule of the prostate at the prostatic base. The seminal vesicles' excretory duct joins the duct of the ampullary vas deferens as it enters the prostate.

The ejaculatory ducts are positioned at the junction of the vas deferens and the seminal vesicle. The ejaculatory ducts are paired visceral organs. **They ultimately empty through the verumontanum into the prostatic urethra.** The ejaculatory duct is divided into three distinct anatomic regions. These include the extraprostatic region (proximal), intraprostatic region (mid), and the distal region, which joins the lateral aspect of the verumontanum to empty into the prostatic urethra (Nguyen et al., 1996). In contrast to the first two regions, the third distal region is not surrounded by an outer muscular layer and does not form an anatomic sphincter at the ejaculatory duct orifice at the verumontanum (Nguyen et al., 1996).

Microanatomic Architecture

The seminal vesicle has a columnar epithelium with goblet cells. The seminal vesicle tube is surrounded by a thin layer of smooth muscle cells, which is enveloped by a loose adventitia. The three layers composing the tubule of the seminal vesicle include an inner mucous membrane, a collagenous middle layer, and the outer circular and longitudinal muscle layers. The muscle layers account for 80% of the thickness of the wall of the seminal vesicle (Nguyen et al., 1996). The thin, folded mucosa of the seminal vesicle comprises nonciliated, pseudostratified cuboidal or columnar cells. The ejaculatory ducts have similar microanatomic architecture to the seminal vesicles, but they do not have the outer circular muscle layer that is found in the seminal vesicle (Nguyen et al., 1996). The inner epithelial layer of the ejaculatory duct is composed of simple and pseudostratified columnar cells in a folded pattern.

Arterial Supply

The arterial supply to the seminal vesicle originates from the superior vesical artery, which branches into the vesiculodeferential artery. The vesiculodeferential artery supplies the anterior surface of the seminal vesicle in proximity to its tip. The internal iliac artery and inferior vesical artery provide additional arterial supply to the seminal vesicle via the prostatovesicular branch (Clegg, 1955). Variations of arterial supply include the prostatovesicular branch originating from the pudendal artery or the superior vesical artery. Arterial supply to the ejaculatory duct arises from branches of the inferior vesical artery.

Venous Drainage

The venous drainage of the seminal vesicle follows the arterial supply draining through the vesiculodeferential veins and the inferior vesical plexus to the pelvic venous plexus.

Lymphatic Drainage

The lymphatic drainage from the seminal vesicle is to the internal iliac nodes (Mawhinney and Tarry, 1991).

Nerve Supply

Seminal vesicle parasympathetic innervation originates from the pelvic plexus with the sympathetic nervous system contributing fibers from the hypogastric nerves and the superior lumbar nerves (Kolbeck and Steers, 1993). The pelvic plexus innervates the ejaculatory ducts.

Transrectal Ultrasonography

The seminal vesicles can be imaged by transrectal ultrasonography, because they are positioned posteriorly at the base of the prostate. The seminal vesicles appear hypoechoic, compared with the prostate, and are crescent shaped, paired, and symmetrical. The normal seminal vesicle measures 2 cm in width and 4.5 to 5.5 cm in length. They can be visualized as oriented horizontally in the transverse plane. Hypoechoic fatty tissue can be seen separating the seminal vesicles from the base of the prostate. The ejaculatory ducts may occasionally be seen by transrectal ultrasonography, and they appear hypoechoic as they enter the prostate posteriorly.

Computed Tomography

Computed tomography (CT) can image the seminal vesicles. The mean measurements by CT of the seminal vesicles are 3 cm in length and 1.5 cm in width. No significant change is seen by CT in seminal vesicle length on the basis of age. However, the width of the seminal vesicle is smaller in men of increasing age. The pudendal venous plexus can be identified by CT as small punctuate densities along the lateral aspect of the seminal vesicle (Silverman et al., 1985).

Magnetic Resonance Imaging

MRI of the normal seminal vesicles demonstrates signal intensity similar to that of the bladder or muscle on T1 imaging. The seminal vesicles demonstrate a higher signal intensity than the surrounding fat on T2 imaging (King et al., 1989; Secaf et al., 1991; Fig. 63.20; also see Fig. 63.19).

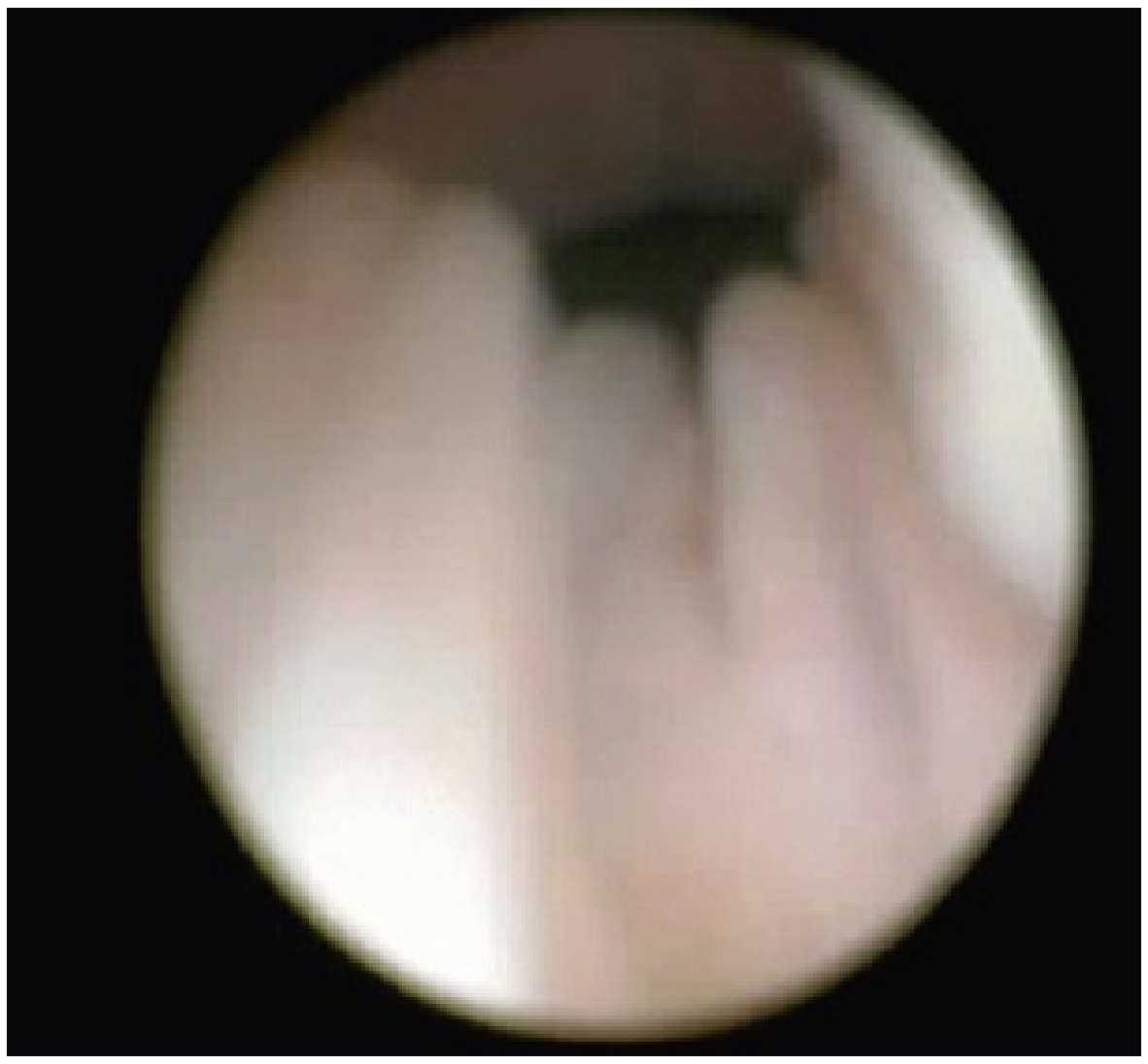

FIG. 63.20 Endoscopic view into the os of the ejaculatory duct

transurethrally.

Key Points: Seminal Vesicles and Ejaculatory Ducts

- The nonobstructed seminal vesicle typically measures 5 to 7 cm in length and 1.5 cm in width.
- The ejaculatory ducts empty through the verumontanum into the prostatic urethra.
- Transrectal ultrasound, CT, and MRI can image the seminal vesicles.

Prostate

Gross Structure

The normal prostate gland is ovoid and measures 3 cm in length, 4 cm in width, and 2 cm in depth; it has a weight of 18 to 20 g. It is homologous to the Skene glands in females. The prostate is composed of glandular elements and fibromuscular stroma. The prostate is positioned just inferior to the bladder. The prostatic urethra travels through the prostate gland. **The base of the prostate is at the bladder-prostate junction, and the narrowed apex is the most inferior portion of the prostate gland, reaching the urogenital diaphragm.** The prostate is palpable approximately 4 cm from the anus on digital rectal examination. **The apex of the prostate is continuous with the striated urethral sphincter.** The prostate comprises an anterior surface, a posterior surface, and lateral surfaces, and these are in relationship to the prostatic urethra traversing the prostate. A collagen, elastin, and smooth muscle capsule envelops the prostate. The capsule measures 0.5 mm in thickness posteriorly and laterally on average. There is no true prostatic capsule at the apex of the prostate, where normal prostate glands are seen blending into the striated muscle of the urethral sphincter. Similarly, there is no true capsule at the base separating the prostate from the bladder, where the detrusor muscle's outer longitudinal fibers fuse with the fibromuscular capsule of the prostate (Epstein, 1989). The prostate capsule blends with the continuation of the endopelvic fascia on the anterior and anterolateral aspects of the prostate. The prostate is fixed to the pubic bone anteriorly by the puboprostatic ligaments near the apex of the prostate. The superficial branch of the dorsal vein is positioned in the retropubic fat outside the prostatic fascia. It drains into the dorsal vein complex. The levator ani's pubococcygeal portion hugs the lateral aspects of the prostate and is related to its overlying endopelvic fascia. The prostate capsule and the pelvic fascia separate below the parietal and visceral endopelvic fascia juncture (arcus tendineus fascia pelvis). Fatty areolar tissue and the lateral branches of the dorsal vein complex take up the space of this separation between the prostate capsule and the pelvic fascia. **The cavernosal nerves travel within the parietal pelvic fascia, also known as the lateral prostatic fascia, posterolateral to the prostate.** As more anatomic attention has been taken with higher-magnification robotic techniques at the time of radical prostatectomy, the lateral prostatic fascia has been defined in greater detail in an effort to preserve the cavernosal nerves. Nerve bundles have been identified traveling along the prostate laterally and anterior to the previously defined neurovascular bundle (Eichelberg et al., 2007; Raychaudhuri and Cahill, 2008; Fig. 63.21).

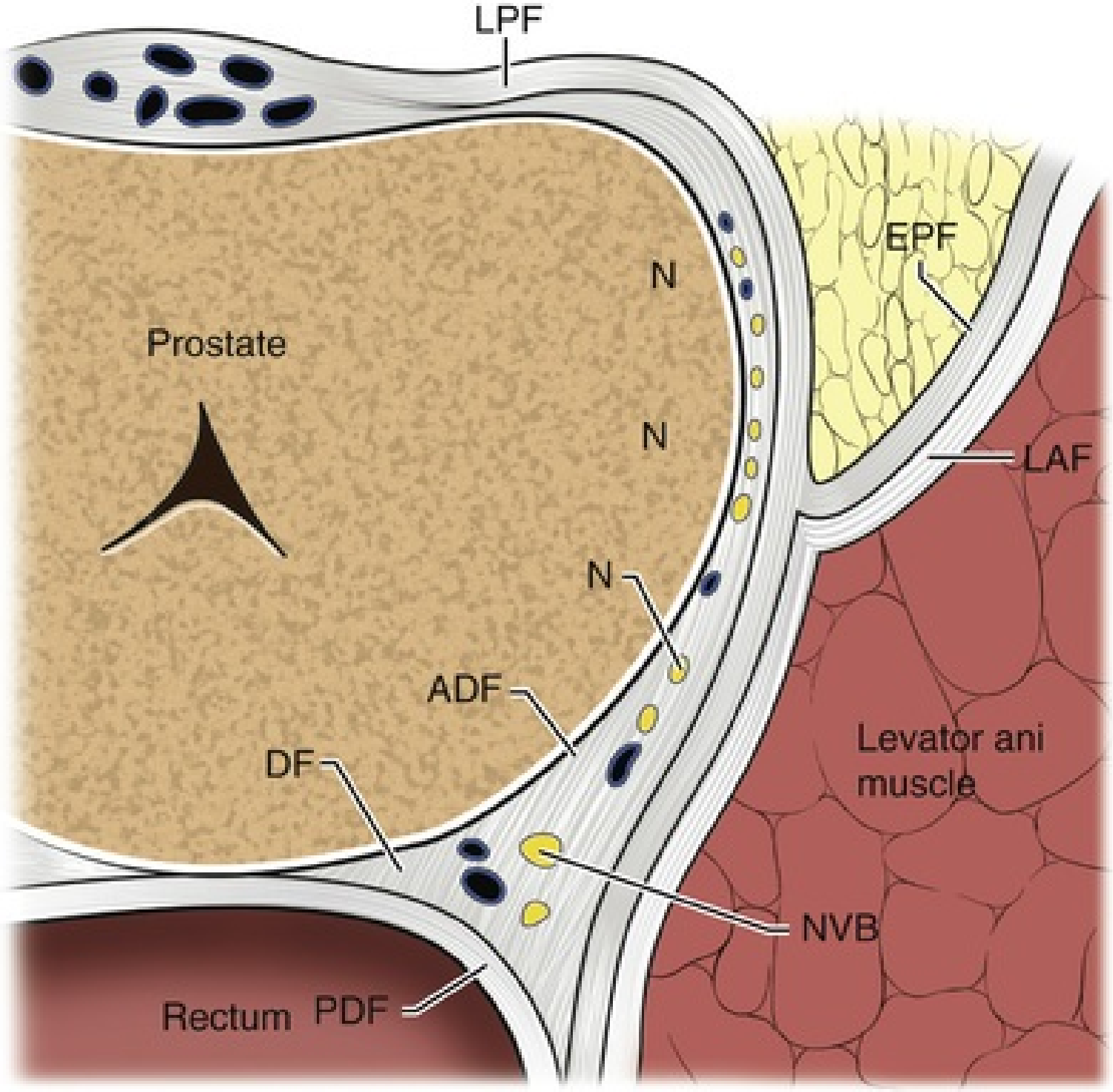

FIG. 63.21 Cross section of prostate with prostatic fascial layers outlined, including the lateral prostatic fascia (*LPF*), endopelvic fascia (*EPF*), levator ani fascia (*LAF*), Denonvilliers fascia (*DF*), anterior lamina of Denonvilliers fascia (*ADF*), posterior lamina of Denonvilliers fascia (*PDF*), neurovascular bundle (*NVB*), and lateral nerves (*N*). (From Walz J, Graefen M, Huland H: Basic principles of anatomy for optimal surgical treatment of prostate cancer. *World J Urol* 25:31–38, 2007.)

The prostate has been divided into distinct anatomic zones. These zones can be identified with transrectal ultrasonography. The transition zone is the smallest of the zones of the prostate. The ducts of the transition zone begin at the angle dividing the preprostatic and the prostatic urethra, and they travel beneath the preprostatic sphincter to course along its lateral and posterior sides. The transition zone makes up 5% to 10% of the glandular tissue of the normal prostate. The transition zone is separated from the rest of the glandular compartments of the prostate by a distinct fibromuscular band. Benign prostatic hyperplasia most commonly occurs in the transition zone. The central zone ducts are positioned circumferentially, surrounding the openings of the ejaculatory ducts. This zone expands toward the base of the bladder, surrounding the ejaculatory ducts, in the shape of a cone. The central zone makes up 25% of the glandular tissue of the prostate. The glands of the central zone are thought to be of wolffian duct origin; they differ immunohistochemically and structurally from the other glands of the prostate (McNeal, 1988). **The peripheral zone of the prostate is the largest zone. Seventy percent of the glandular tissue of the prostate is made up of the peripheral zone.** The peripheral zone makes up the posterior and lateral aspects of the prostate gland. The ducts of the peripheral zone drain into the prostatic sinus along the entire length of the postsphincteric prostatic urethra. Seventy percent of prostate cancers are found in the peripheral zone. The nonglandular anterior fibromuscular stroma is found extending from the bladder neck to the striated sphincter, and it may make up to one-third of the mass of the prostate. It is composed of collagen, smooth and striated muscle, and elastin. It is anatomically continuous with the anterior visceral fascia, the anterior preprostatic sphincter, and the prostatic capsule.

The prostate is also compartmentalized clinically, based on digital rectal examination and cystoscopic appearance. A central sulcus divides the two lateral lobes of the prostate and a middle lobe. The middle lobe may become hyperplastic and may extend into the bladder neck with age (Fig. 63.22).

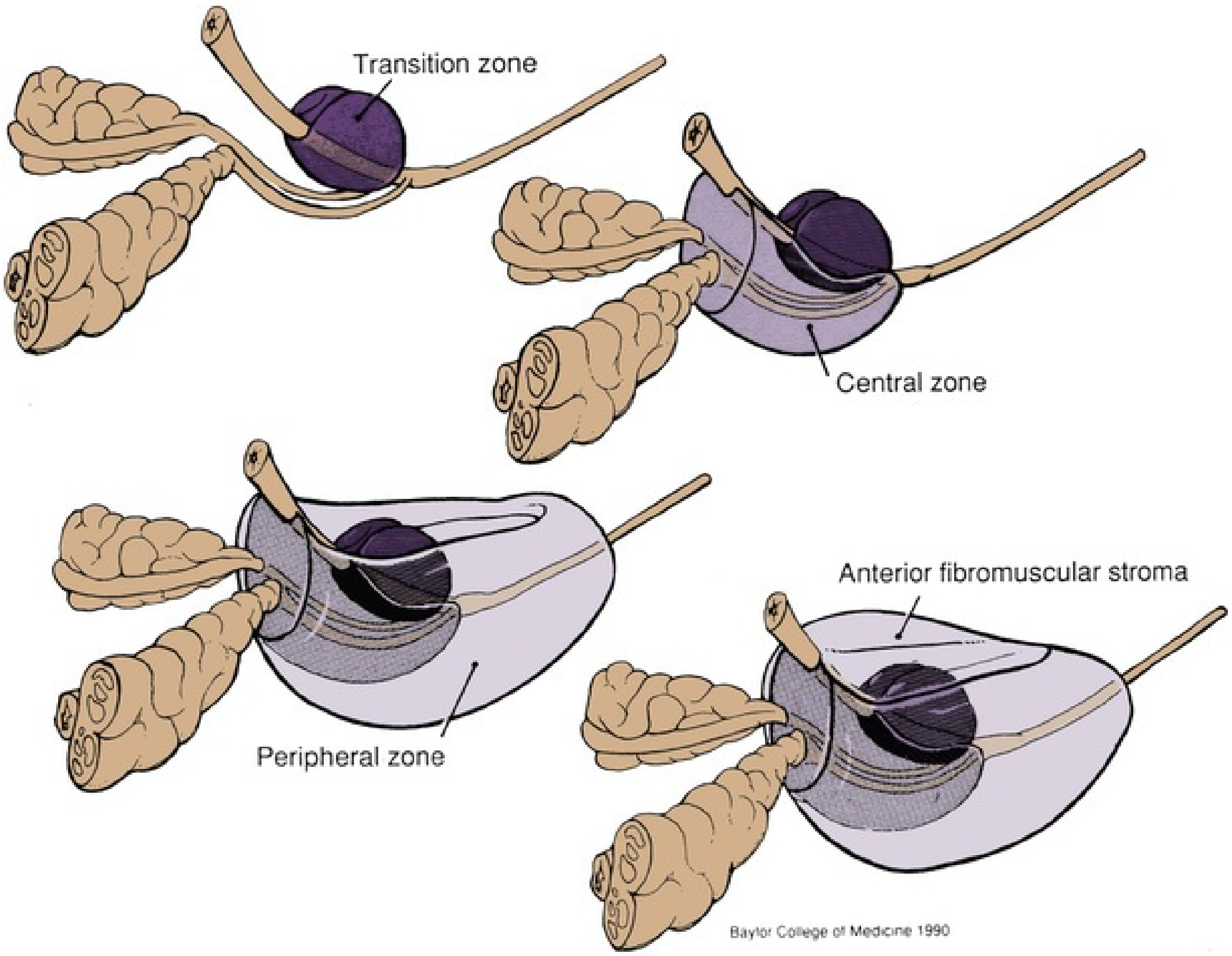
Transition zone
Central zone
Peripheral zone
Anterior fibromuscular stroma
Baylor College of Medicine 1990

FIG. 63.22 Zonal anatomy of the prostate as described by McNeal (1988). The transition zone surrounds the urethra proximal to the ejaculatory ducts. The central zone surrounds the ejaculatory ducts and projects under the bladder base. The peripheral zone constitutes the bulk of the apical, posterior, and lateral aspects of the prostate. The anterior fibromuscular stroma extends from the bladder neck to the striated urethral sphincter. (Copyright 1990, Baylor College of Medicine.)

Microanatomic Architecture

Seventy percent of the prostate's composition is glandular elements, whereas 30% is made up of fibromuscular stroma. The epithelial cells of the prostate glands are cuboidal or columnar. These secretory epithelial cells are terminally differentiated, have a low proliferative index, and measure 10 to 20 µm in height (De Marzo et al., 1998). These epithelial cells have abundant secretory granules and are organized in rows with their apices projecting into the lumen and their bases attached to a basement membrane (Knox et al., 1994). The nuclei of the cells are at their base, below the Golgi apparatus. The luminal apices have microvilli. The epithelial cells line the periphery of the acinus and secrete into the acinus, which drains into ducts to the urethra ultimately. The tubuloalveolar glands have simple branching patterns. Flattened, undifferentiated basal cells line each acinus beneath the epithelial cells. A thin layer of connective tissue and stromal smooth muscle surrounds each acinus. The secretory cells have scattered, terminally differentiated, nonproliferating neuroendocrine cells between them. Two types of neuroendocrine cells have been identified in the prostate. One is a closed cell with dendrite-like processes that extend toward epithelial cells and basal cells in its proximity. The other type of neuroendocrine cell type seen is an open one with microvilli extending into the lumen (Abrahamsson, 1999; di Sant'Agnese and De Mesy Jensen, 1984; Vashchenko and Abrahamsson, 2005). The stroma is composed of smooth muscle, which is rich in α-actin, myosin, and desmin, and it is also composed of collagen and is continuous with the prostatic capsule. At the junction of the prostate gland, the prostatic urethra, the transitional cells of the prostatic urethra's epithelium, may extend into prostatic ducts. The preprostatic (internal urethral) sphincter encloses the small periurethral prostatic glands without periglandular smooth muscle, and these glands are positioned between fibers of longitudinal smooth muscle. Posterior to the prostate, microscopic smooth muscle bands fuse with Denonvilliers fascia after extending from the posterior aspect of the prostatic capsule. There is a plane of loose, areolar tissue between Denonvilliers fascia and the rectum.

Arterial Supply

The inferior vesical artery is the typical arterial supply to the prostate. The inferior vesical artery branches into urethral arteries that enter the prostatovesical junction posterolaterally and course in a perpendicular route to the urethra. They travel toward the bladder neck with the largest branches posteriorly, approaching the bladder neck in the one o'clock to five o'clock positions and the seven o'clock to eleven o'clock positions. They then supply the urethra after making a caudal turn to run parallel to the urethra. These branches supply the urethra, the periurethral glands, and the transition zone of the prostate (Flocks, 1937). The inferior vesical artery also branches into the capsular artery. The capsular artery yields small branches that supply the anterior prostatic capsule. The capsular branches enter the prostate at 90-degree angles and provide arterial supply to the glandular tissues, coursing along the reticular bands of the stroma. The majority of the inferior vesical artery travels posterolateral to the prostate to form the neurovascular bundles coursing with the cavernous nerves, terminating at the pelvic diaphragm. Branches from the internal pudendal artery and the middle rectal (hemorrhoidal) artery also contribute a supply to the prostate (Fig. 63.23).

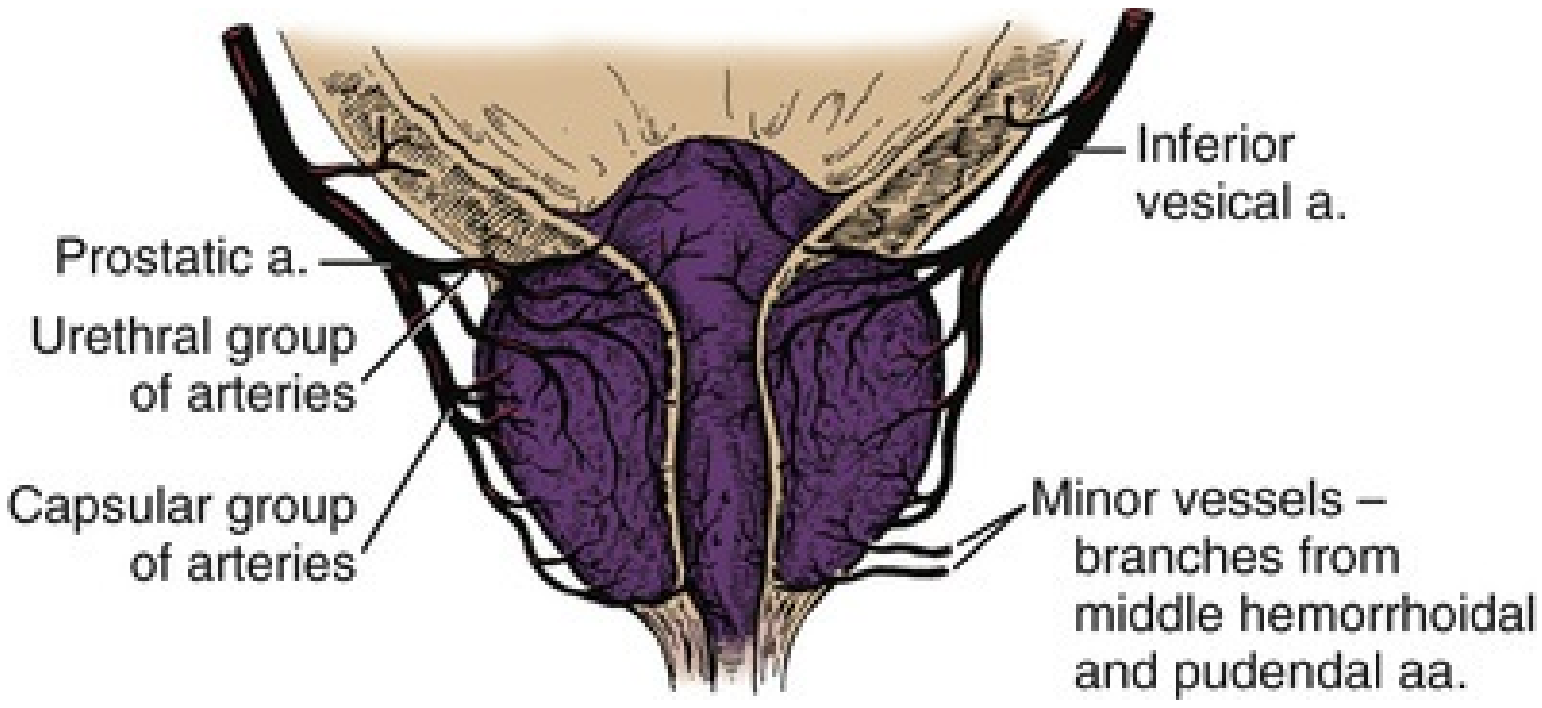
Inferior vesical a.
Prostatic a.
Urethral group of arteries
Capsular group of arteries
Minor vessels – branches from middle hemorrhoidal and pudendal aa.

FIG. 63.23 Arterial supply of the prostate. (Modified from Flocks RH: The arterial distribution within the prostate gland: its role in transurethral prostatic resection. *J Urol* 37:527, 1937.)

Venous Drainage

The prostate includes abundant venous drainage through the periprostatic plexus. **The periprostatic plexus anastomoses with the deep dorsal vein of the penis and the internal iliac (hypogastric) veins.**

Lymphatic Drainage

The obturator and internal iliac nodes are the primary sites of lymphatic drainage from the prostate. The presacral group or, infrequently, the external iliac nodes may receive a small portion of the initial lymphatic drainage.

Nerve Supply

The cavernous nerves provide sympathetic and parasympathetic innervation to the prostate from the pelvic plexus. Innervations to the glandular and stromal elements of the prostate are found traveling with branches of the capsular artery. Sympathetic fibers innervate the smooth muscle of the capsule and stroma for contraction. The parasympathetic nerves promote secretory function by terminating in the acini. Prostate smooth muscle relaxation may be affected by peptidergic and nitric oxide synthase–containing neurons that have been identified in the prostate (Burnett, 1995). The pelvic plexuses carry afferent neurons from the prostate to the pelvic and thoracolumbar spinal centers.

Transrectal Ultrasonography of the Prostate

Transrectal ultrasonography of the prostate provides multiple diagnostic utilities, including assessing prostate volume, locating focal abnormalities, assessing patients with infertility with suspicion of obstruction, and guiding prostate biopsies. The prostate is imaged with biplane, multiplane, and end-fire endorectal transducer probes with a frequency ranging from 6 to 8 MHz. The patient should be positioned either in the lateral decubitus or the dorsal lithotomy position, and a well-lubricated transrectal probe is gently passed into rectum above the anal verge. The prostate and seminal vesicles should be systematically examined in the longitudinal and transverse orientations. Pertinent images should be recorded and labeled (Terris et al., 1992). **The normal prostate has a stipple grey echogenicity and appears homogeneous.** The capsule appears echogenic, continuous, and well defined. **The zonal compartments can be identified.** A distinct layer of echogenic fibrous tissue separates the zones. The prostate presents a semilunar shape and appears symmetrical in the transverse orientation. The peripheral zone has a homogeneous, fine echo pattern. The periurethral tissue is centrally positioned and appears hypoechoic. The relation of the prostate to the surrounding structures, such as the seminal vesicles, bladder neck, and prostatic urethra, can be identified in the longitudinal orientation. The urethra will appear curved within the central portion of the prostate.

The prostate volume can be measured using transrectal ultrasonography with an accuracy of within 5% of its true weight (Hastak et al., 1982). Transverse and longitudinal orientations are used to measure the length, width, and height of the prostate. An ellipsoid formula is then used to estimate the volume of the prostate: Volume = $\frac{4}{3}\pi$ × length × width × height (Roehrborn et al., 1986; Fig. 63.24).

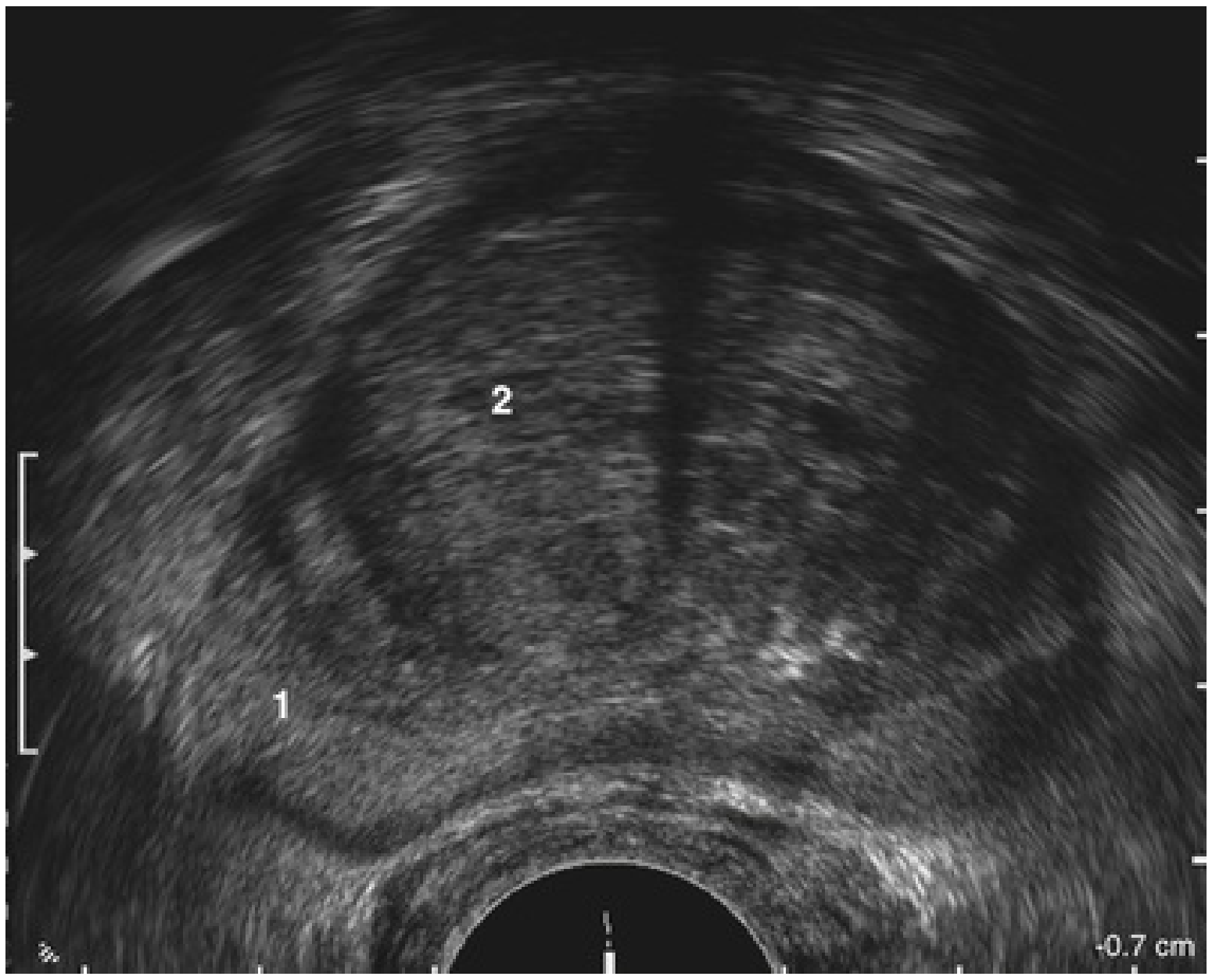

FIG. 63.24 Transrectal ultrasound of the prostate demonstrating the peripheral zone (*1*) and the transition zone (*2*).

Magnetic Resonance Imaging of the Prostate

MRI of the prostate has been used to provide high-quality, clear images. MRI's direct multiplanar imaging has allowed for detailed demonstration of prostate anatomy (Dooms and Hricak, 1986). Zonal anatomy can be more clearly demonstrated by MRI using 0.5-cm slices. The peripheral zone showed higher signal intensity than the other zones and can be well visualized in the coronal, sagittal, and transverse planes. The central zone was well visualized in the coronal and sagittal planes and was of low signal intensity. The transition zone showed similar MR parameters to the central zone (Hricak et al., 1987). **Zonal anatomy is best demonstrated by T2-weighted images** (Gevenois et al., 1990). Using a specific pulse sequence, the periprostatic venous plexus can be imaged (Poon et al., 1985). The endorectal surface coil has been used to enhance resolution (Schnall and Pollack, 1990). The use of MRI of the prostate has become more frequent for use with pathologic processes (Fig. 63.25).

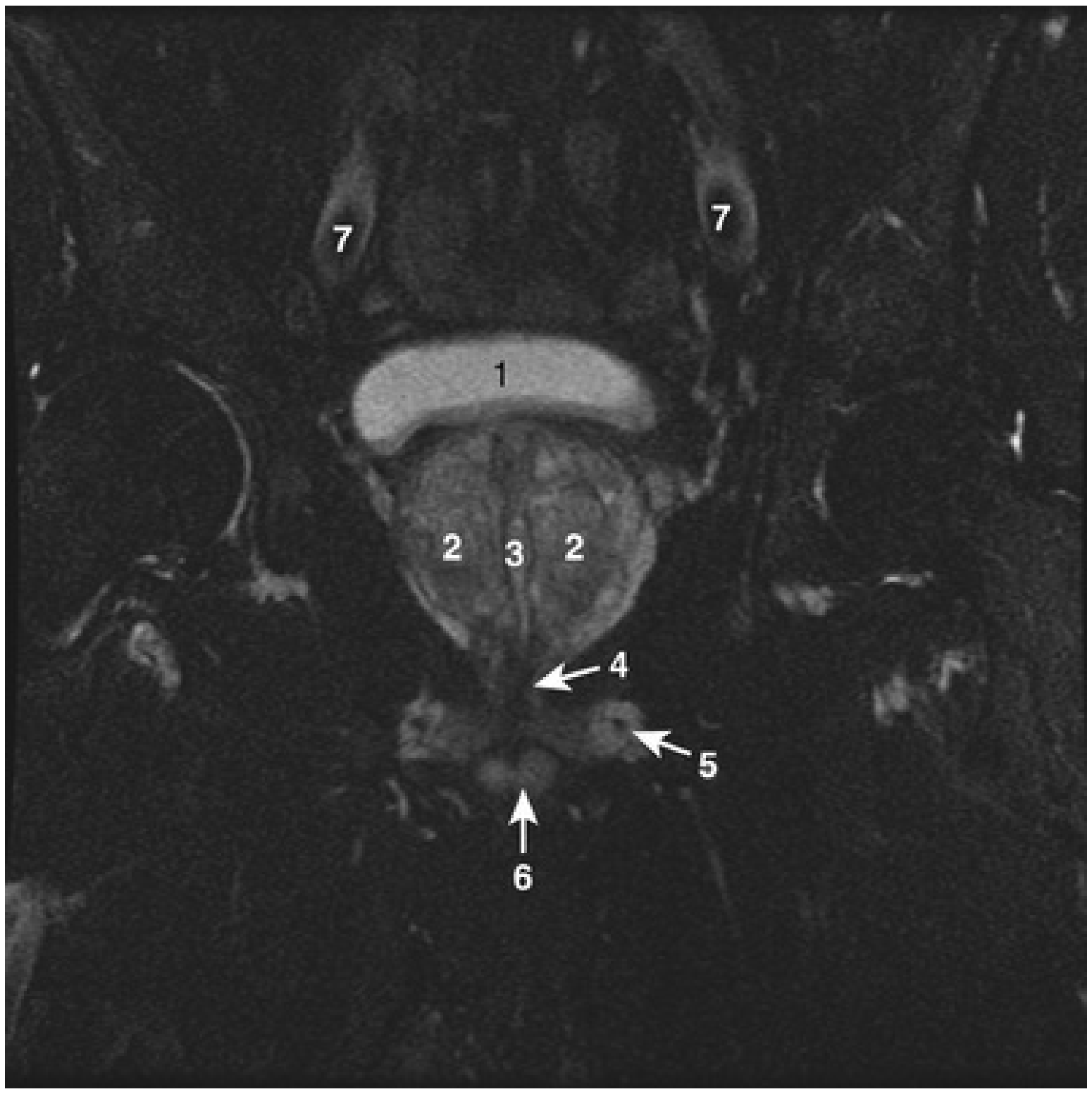

FIG. 63.25 Axial T2-weighted magnetic resonance image of the male pelvis through the prostate gland and adjacent structures. *1,* Urinary bladder; *2,* lateral lobes of prostate; *3,* verumontanum; *4,* striated urethral sphincter; *5,* inferior pubic ramus; *6,* corpus spongiosum in cross section; *7,* external iliac artery.

Key Points: Prostate

- The normal prostate gland measures 3 cm in length, 4 cm in width, and 2 cm in depth, and it has a weight of 18 to 20 g.
- There is no true prostatic capsule at the apex of the prostate.
- The cavernosal nerves travel within the lateral prostatic fascia, posterolateral to the prostate.
- Benign prostatic hyperplasia most commonly occurs in the transition zone of the prostate.
- A total of 70% of the glandular tissue of the prostate is composed of the peripheral zone, and 70% of prostate cancers are found in the peripheral zone.

- Seventy percent of the prostate's composition includes glandular elements, whereas 30% is made up of fibromuscular stroma.
- The inferior vesical artery is the typical arterial supply to the prostate.
- The periprostatic plexus anastomoses with the deep dorsal vein of the penis and the internal iliac (hypogastric) veins.
- The obturator and internal iliac nodes are the primary sites of lymphatic drainage from the prostate.
- Transrectal ultrasonography of the prostate is useful for assessing prostate volume, locating focal abnormalities, assessing patients with infertility with suspicion of obstruction, and guiding prostate biopsies.

Urethra

The urethra is contained within the vascular corpus spongiosum and the glans penis. **The normal urethral diameter is 8 to 9 mm.** Anatomists have organized the urethra into multiple different segmental divisions. It has been categorized in two broad segments: the anterior urethra and the posterior urethra. **The anterior urethra begins at the perineal membrane and continues distally to the urethral meatus. The posterior urethra begins distal to the bladder neck and the transition to the anterior urethra is made at the perineal membrane.** The segments have been further divided to characterize urethral anatomy more precisely. **The urethral epithelium is transitional until the urethral epithelium becomes squamous where it traverses the glans penis.** The submucosa contains smooth muscle, connective tissue, and elastic tissue. The glands of Littre are in the submucosa and their ducts empty into the urethral lumen. **The arterial supply to the urethra is from the internal pudendal artery whose bulbourethral branches supply the urethra, the corpus spongiosum, as well as the glans penis. The venous drainage from the urethra drains to the pudendal plexus, which drains into the internal pudendal vein. The lymphatics from the urethra drain to the internal iliac (hypogastric) and common iliac nodes** (Fig. 63.26).

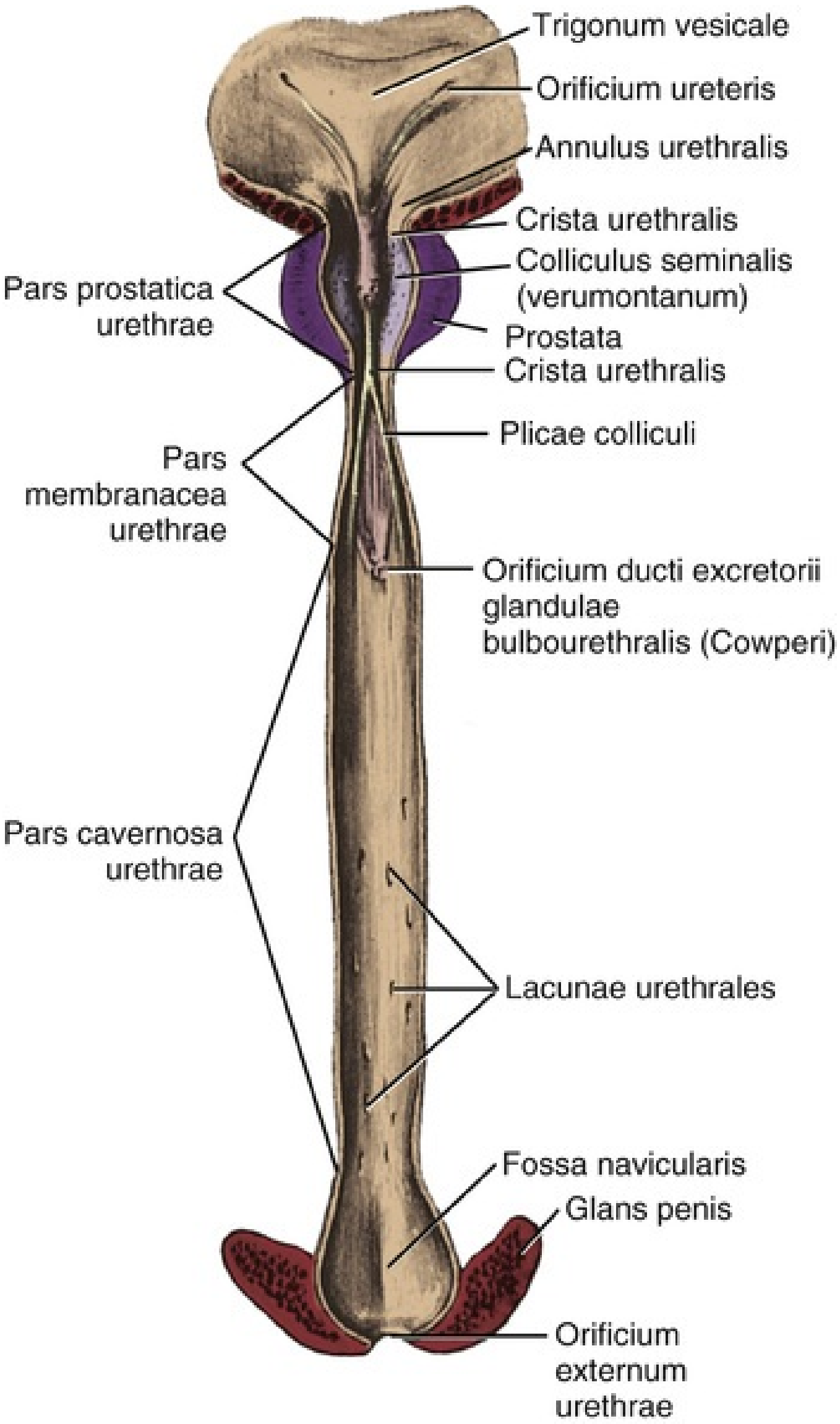
Trigonum vesicale
Orificium ureteris
Annulus urethralis
Crista urethralis
Colliculus seminalis (verumontanum)
Pars prostatica urethrae
Prostata
Crista urethralis
Plicae colliculi
Pars membranacea urethrae
Orificium ducti excretorii glandulae bulbourethralis (Cowperi)
Pars cavernosa urethrae
Lacunae urethrales
Fossa navicularis
Glans penis
Orificium externum urethrae

FIG. 63.26 Posterior wall of the male urethra. (From Anson BJ, McVay CB: *Surgical anatomy,* ed 6, Philadelphia, 1984, Saunders, p 833.)

Prostatic Urethra

The prostatic urethra travels the length of the prostate and is in greater proximity to the anterior surface of the prostate. A urethral crest extends inward from the posterior midline of the prostatic urethra and is present throughout the length of the prostatic urethra. This urethral crest is no longer present at the level of the striated sphincter. All glandular elements of the prostate drain into prostatic sinuses, which are positioned on either side of the urethral crest (McNeal, 1972). The urothelium of the prostatic urethra is made up of transitional epithelial cells. This transitional urothelium may extend into prostatic ducts. An angle at the midpoint of the prostatic urethra turns 35 degrees anteriorly and separates the prostatic urethra into anatomically and functionally distinct segments. These are termed the preprostatic (proximal) and prostatic (distal) segments of the prostatic urethra. This angle may range from zero to 90 degrees depending on variable anatomy (McNeal, 1972, 1988). All glandular elements of the prostate open into the prostatic urethra past the urethral angle. **The verumontanum is formed by the widening and protrusion of the urethral crest from the posterior wall. The prostatic utricles orifice appears like a slit at the apex of the verumontanum.** The utricle's orifice is cystoscopically visible and measures 6 mm. **The prostatic utricle is a müllerian remnant.** The two small openings of the ejaculatory ducts are located on either side of the utricular orifice. After forming at the juncture of the vas deferens and seminal vesicles, the ejaculatory ducts travel approximately 2 cm through the prostate surrounded by circular smooth muscle, until they finally open into the distal prostatic urethra. The preprostatic sphincter is made up of thickened circular smooth muscle, synonymous with the internal urethral sphincter in the proximal segment. The prostatic segment is innervated by motor somatic fibers with an absence of any autonomic innervation (Figs. 63.27 and 63.28).

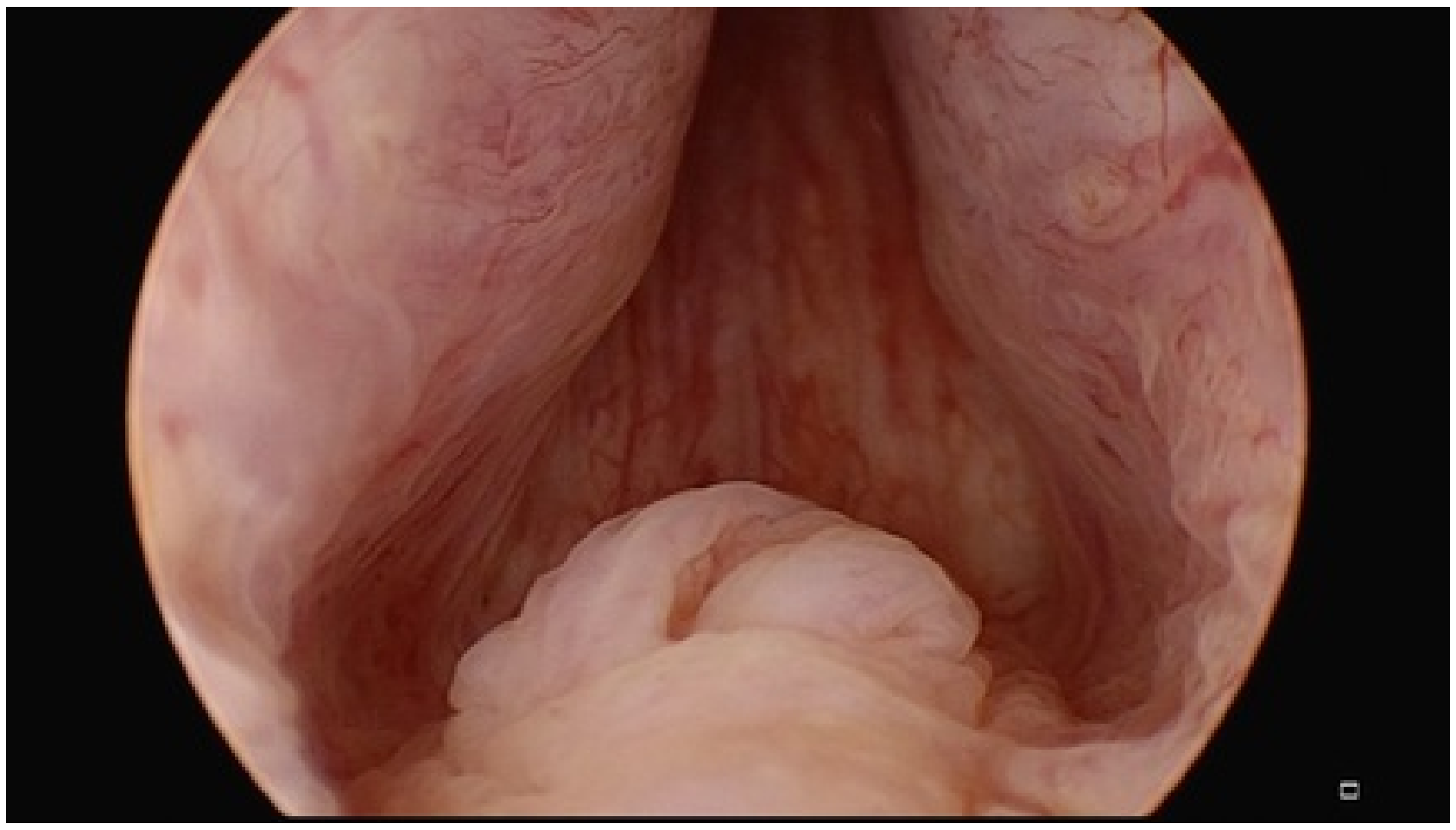

FIG. 63.27 Cystoscopic appearance of the verumontanum. (Courtesy David Leavitt, MD.)

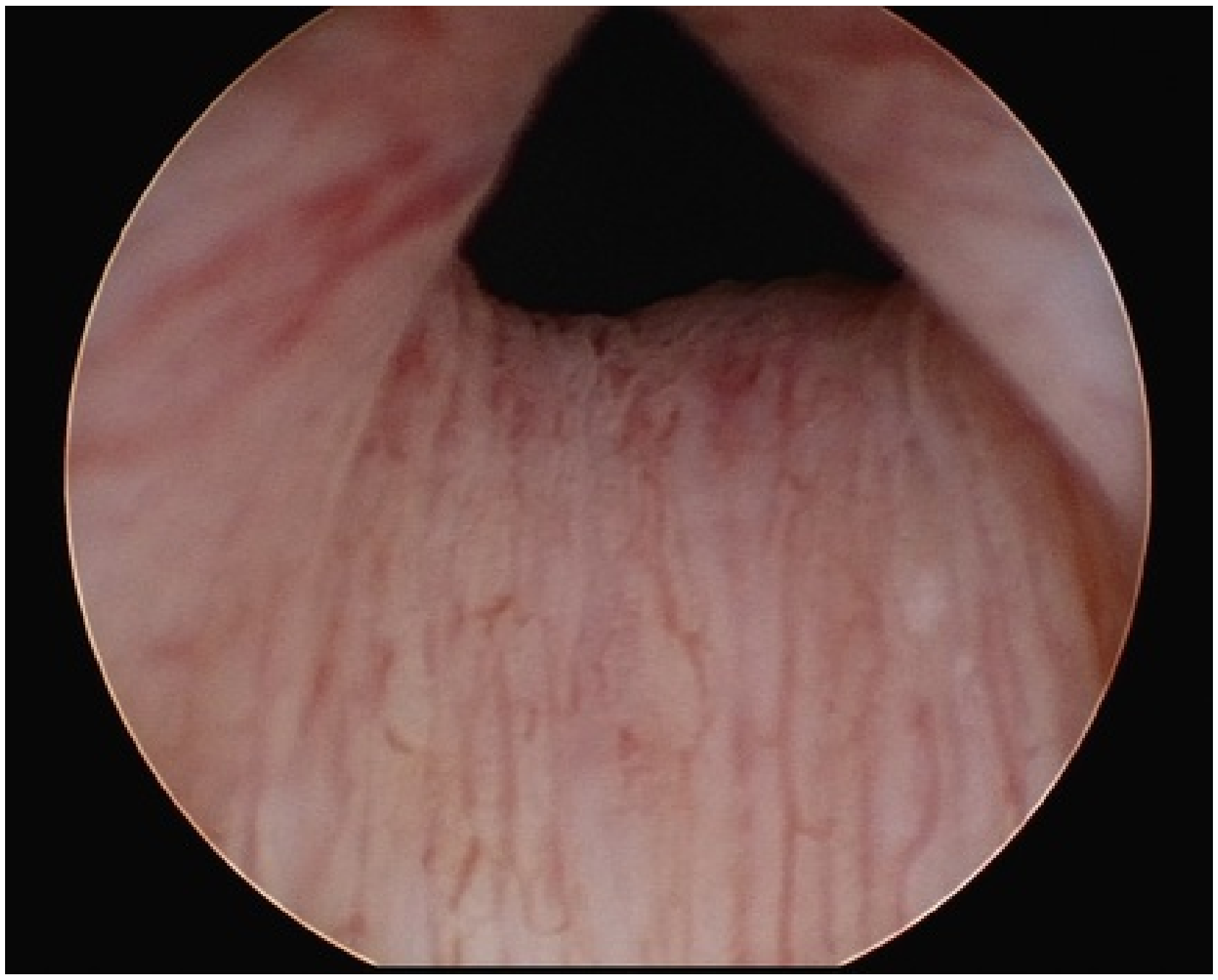

FIG. 63.28 Cystoscopic appearance of the bladder neck. (Courtesy David Leavitt, MD.)

Membranous Urethra

On average the membranous urethra measures 2 to 2.5 cm in length and spans between the prostatic apex and the perineal membrane (Myers, 1991). A thin, smooth muscle layer spans across the membranous urethra. An outer layer of circularly arranged striated muscle in the shape of a horseshoe near the prostatic apex is found on the anterior surface of the urethra. The striated muscle reaches from the base of the bladder and the anterior aspect of the prostate extending the complete length of the membranous urethra. This signet ring–shaped striated sphincter is broad based and narrows as it courses through the urogenital hiatus of the levator ani to reach the prostatic apex. The posterior portion of the striated sphincter inserts into the perineal body throughout its length (Strasser et al., 1998). The striated sphincter is anterior to the dorsal vein complex and lateral to the levator ani. The band of fibrous tissue that suspends the urethra from the pubis anteriorly and that forms the suspensory ligament of the penis posteriorly, is made up of connective tissue from deep within the anterior and lateral walls. The striated sphincter's lumen consists of a pseudostratified columnar epithelium. There is a vascular submucosa that is surrounded by the longitudinal and circular urethral smooth muscle, which is the instrinsic component of the external sphincter (Raz et al., 1972). The pudendal nerve supplies innervation to the striated sphincter (Tanagho et al., 1982). A branch of the sacral plexus that travels along the surface of the levator ani provides another source of somatic innervation to the sphincter (Hollabaugh et al., 1997). The cavernous nerves are believed to supply autonomic innervation to the intrinsic smooth muscle of the membranous urethra (Steiner et al., 1991). The urethral stroma contains longitudinally organized collagen fibers and elastin fibers (Hickey et al., 1982). Lymphatic drainage from the membranous urethra travels in front of the prostate to join lymphatic channels draining the anteroinferior bladder. These channels terminate in the anterior or medial retrofemoral nodes and the middle node of the medial group of the external iliac nodes. Innervation is solely by motor somatic fibers without autonomic innervation. The ventral root of S3, with some contribution from S2, provides the somatic supply. The supply branches to the pelvic (splanchnic) nerve and passes to the pelvic (inferior hypogastric) plexus. Sensory innervation from the striated sphincter travels through the pudendal nerves via S2, and to a lesser extent S3, to travel to the node of Onuf centrally (Fig. 63.29).

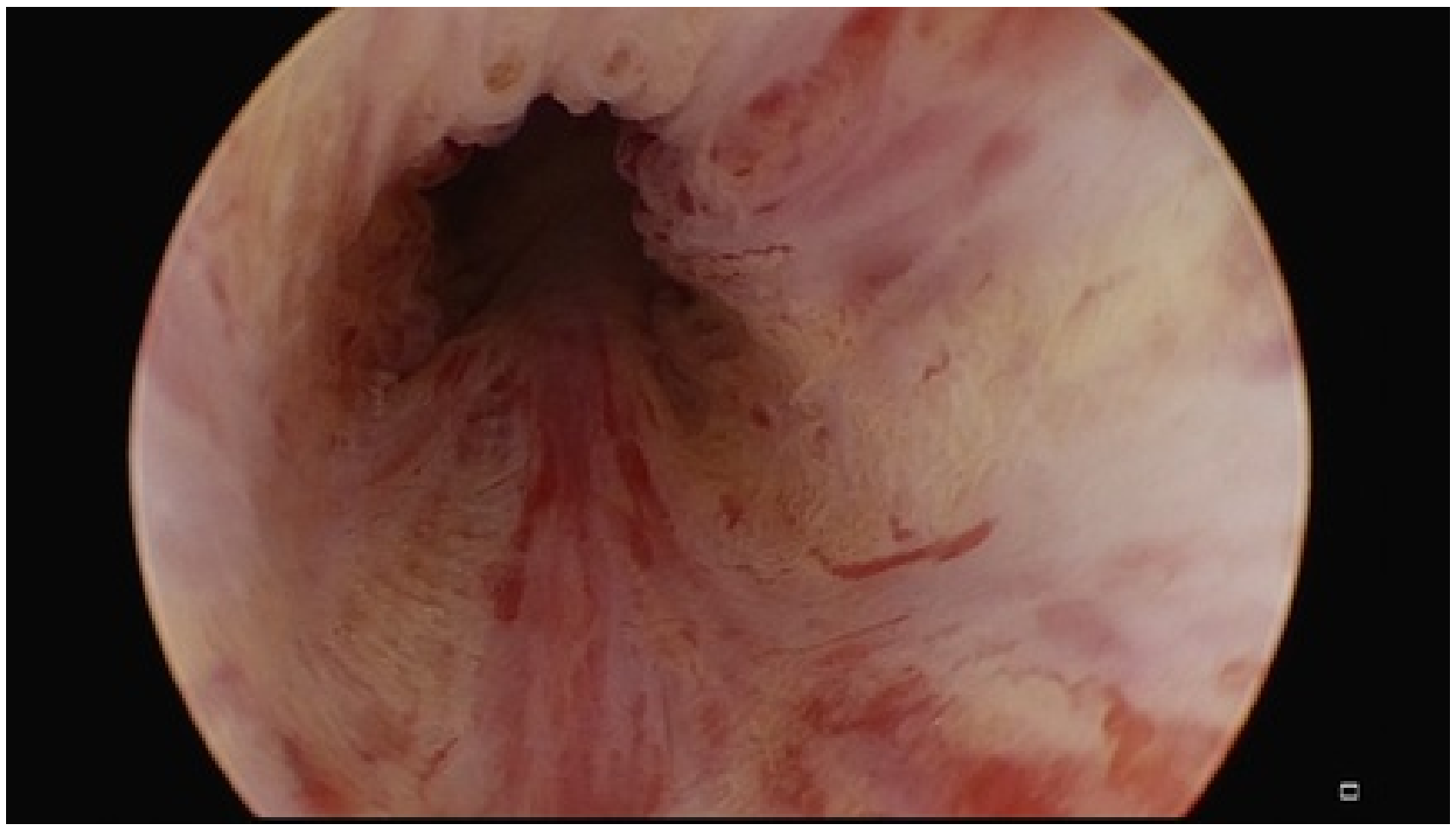

FIG. 63.29 Cystoscopic appearance of the striated sphincter. (Courtesy David Leavitt, MD.)

Penile Urethra

The penile urethra, also known as the pendulous urethra and the spongy urethra, as it is surrounded by the corpus spongiosum, makes up the urethra distal to the membranous urethra. The urethra is often subdivided even further at the junction of the membranous and penile urethra and is termed the bulbomembranous urethra. This region comprises a 2-cm length of urethra within the urogenital diaphragm as well as being within the striated urethral sphincter and the first few proximal centimeters of the bulbous urethra, just distal to the sphincter within the penile bulb. The bulbospongy urethra begins a few centimeters distal to the membranous urethra and extends distally to the level of the suspensory ligament. The lumen widens to form the urethral bulb. The bulbourethral glands, also known as Cowper glands, empty into this region at the three o'clock and nine o'clock positions. The bulbourethral glands are located more proximally on either side of the membranous urethra. The penile urethra measures approximately 15 cm in length in its entirety from the suspensory ligament to the meatus. It is positioned more dorsally than ventrally within the corpus spongiosum. The bulb and the fossa navicularis are the two segments of urethral lumen widening; otherwise the luminal diameter is relatively consistent throughout. The mucosa of the penile urethra includes a transitional epithelium until it reaches the fossa navicularis. The muscle layer is made up of an inner longitudinal, a middle circular, and an inconsistently characterized outer longitudinal stratum. The glands of Littre are composed of small, mucus-secreting cells that lubricate the urethra before ejaculation, and they empty into orifices on the posterior wall of the penile urethra. The glands of Littre are rich in goblet cells and enter the spongy tissue between the vascular spaces and the trabeculae. **The penile urethra receives arterial supply from a branch of the internal pudendal artery, which enters at the level of the penile bulb, and is known as the bulbourethral artery.** Venous drainage of the bulbar urethra is by bulbar veins that drain into the prostatic plexus, which is the internal pudendal vein. The penile urethral lymphatics drain through a lymphatic network that is associated with the mucous membrane. These lymphatic channels course longitudinally but anastomose transversely and obliquely. The lymphatic channels drain proximally into trunks at the bulbomembranous urethra. The bulbomembranous lymphatic drainage may be variable. Some lymphatic drainage travels along the urethral artery or artery of the bulb, whereas others drain to the medial retrofemoral node after traveling behind the symphysis pubis. The penile urethral sensory innervation runs through submucosal axons that pass centrally through the dorsal nerve of the penis (Fig. 63.30).

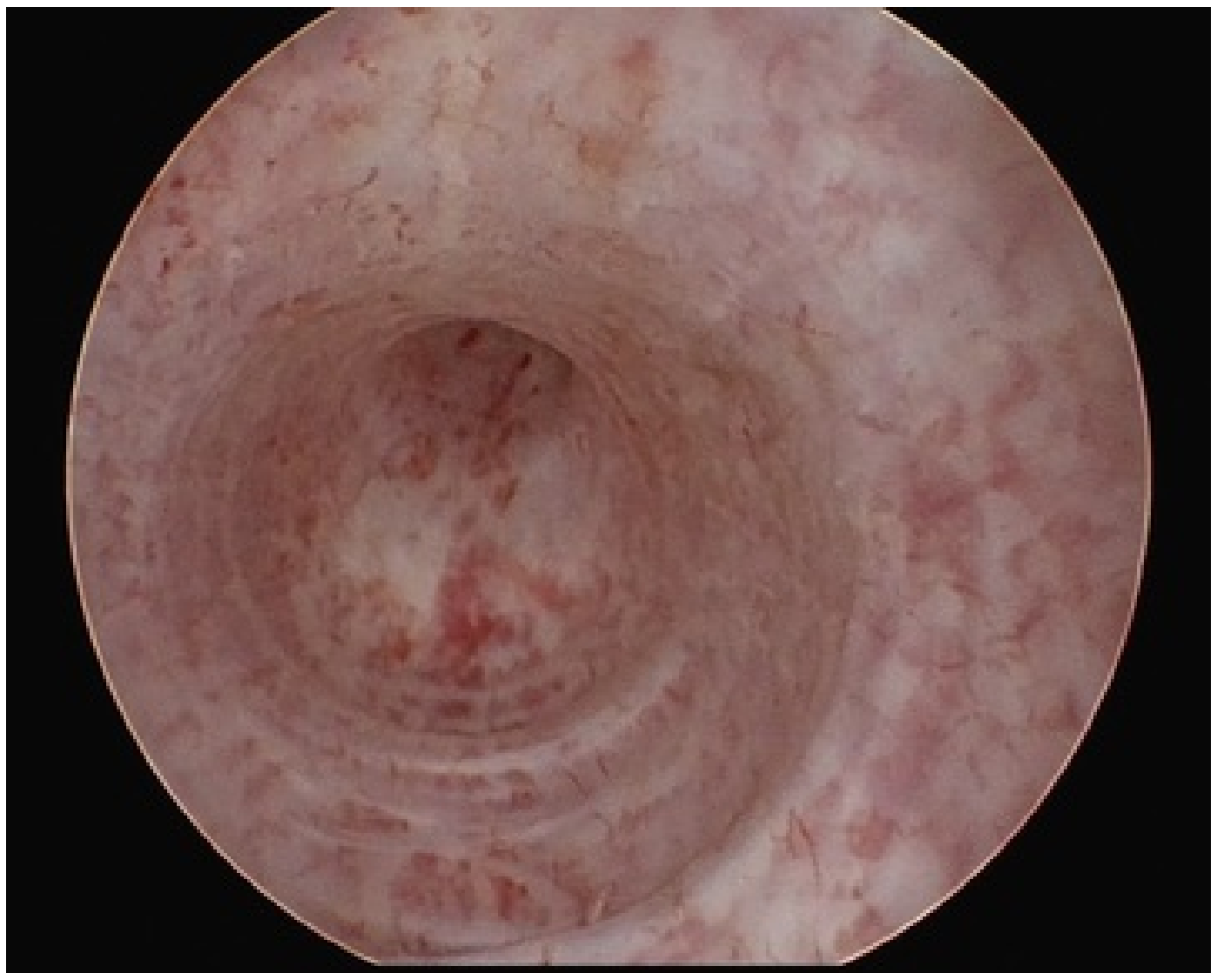

FIG. 63.30 Cystoscopic appearance of the bulbar urethra. (Courtesy David Leavitt, MD.)

Fossa Navicularis

The glanular portion of the urethra is known as the fossa navicularis, where its caliber dilates when compared with the urethra proximal to the fossa navicularis. It narrows again at the urethral meatus. **Unlike the transitional epithelium of the remainder of the urethra, the urethral mucosa that traverses the glans penis is a squamous epithelium.** These cells become keratinized near the meatus. The epithelium is separated from the smooth muscle of the spongy tissue by loose connective tissue, and a muscularis mucosa is absent. There are multiple pockets on the dorsal and lateral surfaces of the fossa navicularis. The lacuna magna (Morgagni) is a large pocket opening on the roof of the fossa navicularis (Figs. 63.31 through 63.33).

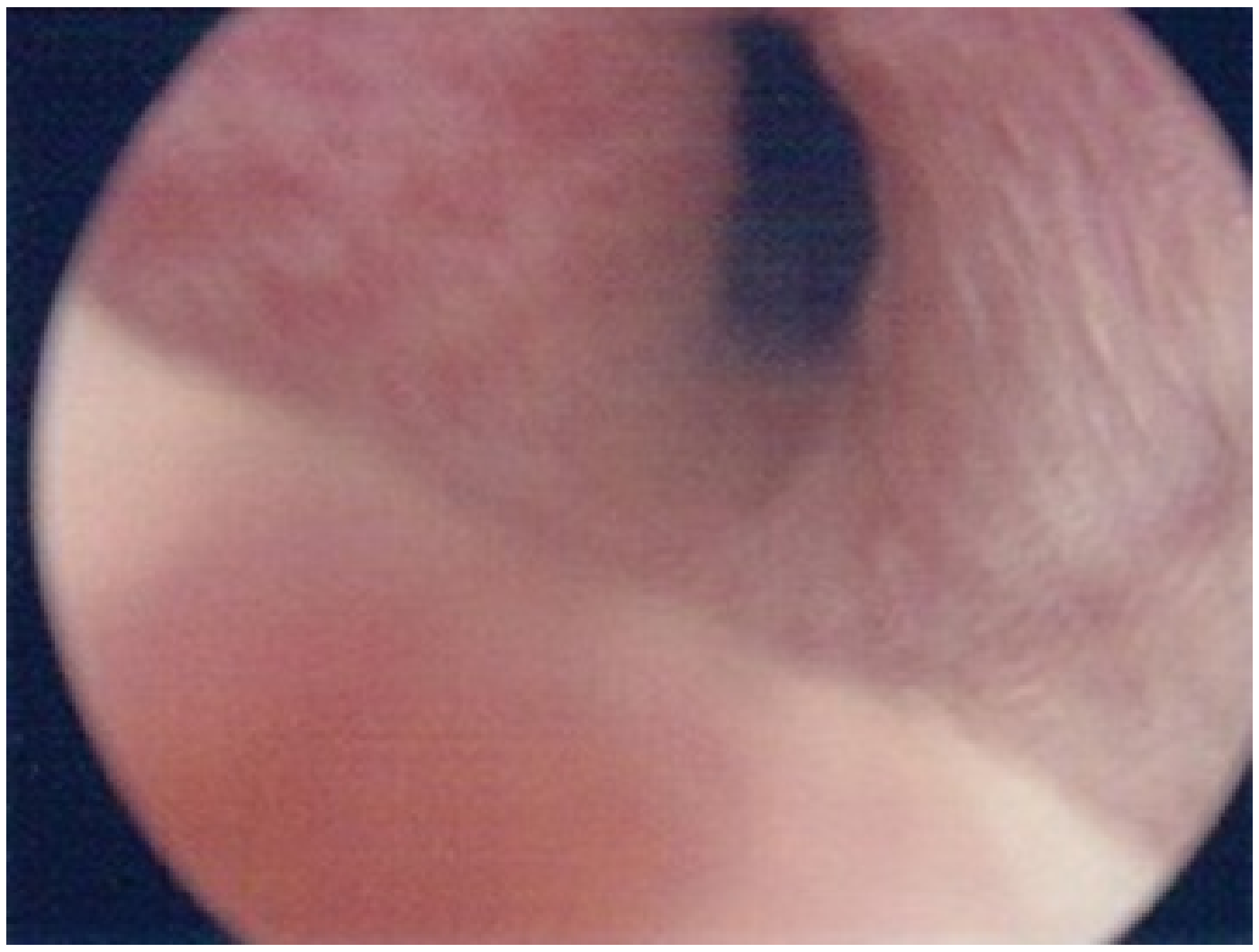

FIG. 63.31 Cystoscopic appearance of the fossa navicularis.

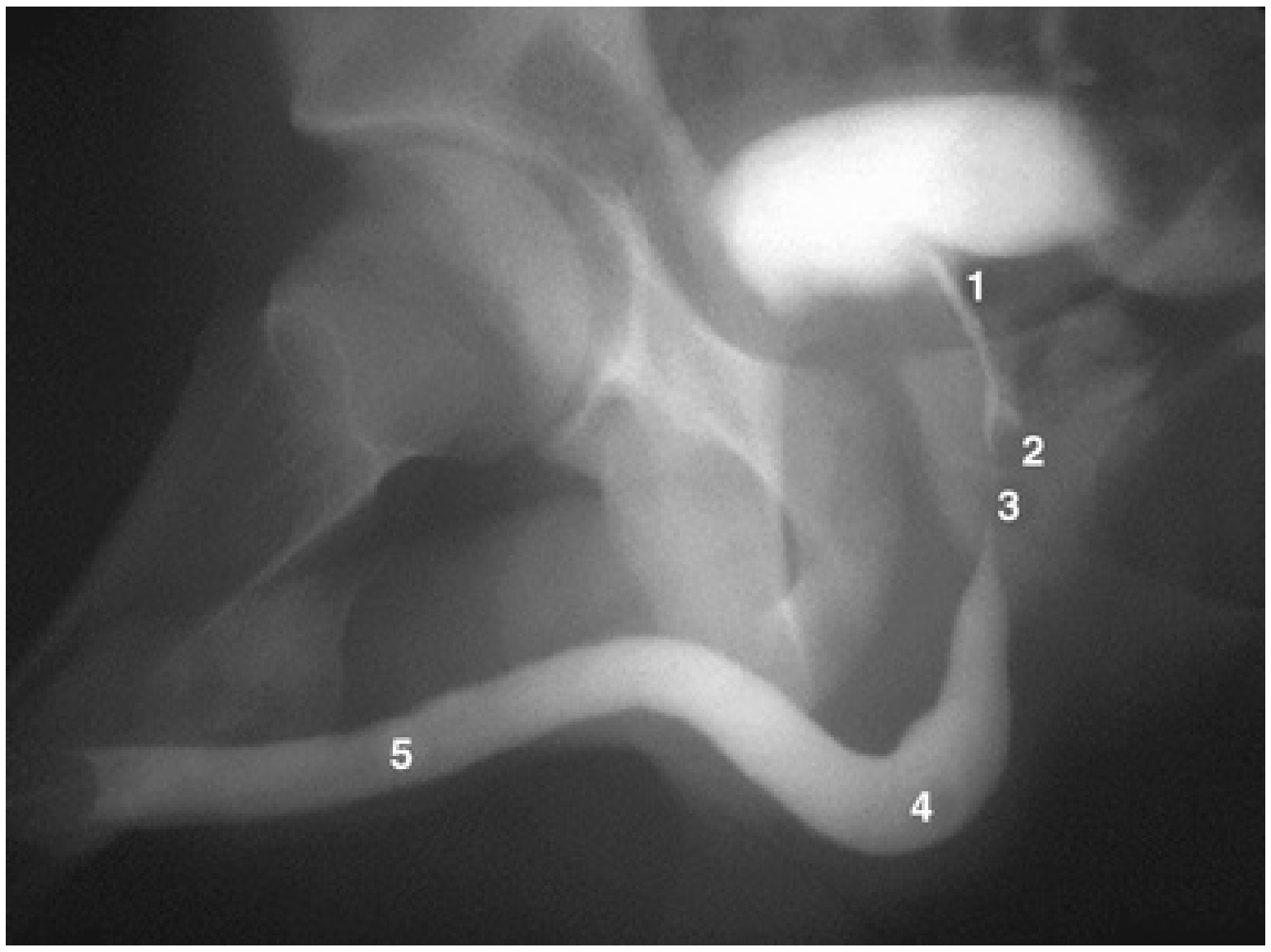

FIG. 63.32 Retrograde urethrogram of the male urethra demonstrating urethral anatomy. *1,* Prostatic urethra; *2,* verumontanum, into which enter the ejaculatory ducts; *3,* membranous urethra, note physiologic narrowing of urethral luminal diameter resulting from external striated sphincter; *4,* bulbar urethra; *5,* pendulous urethra.

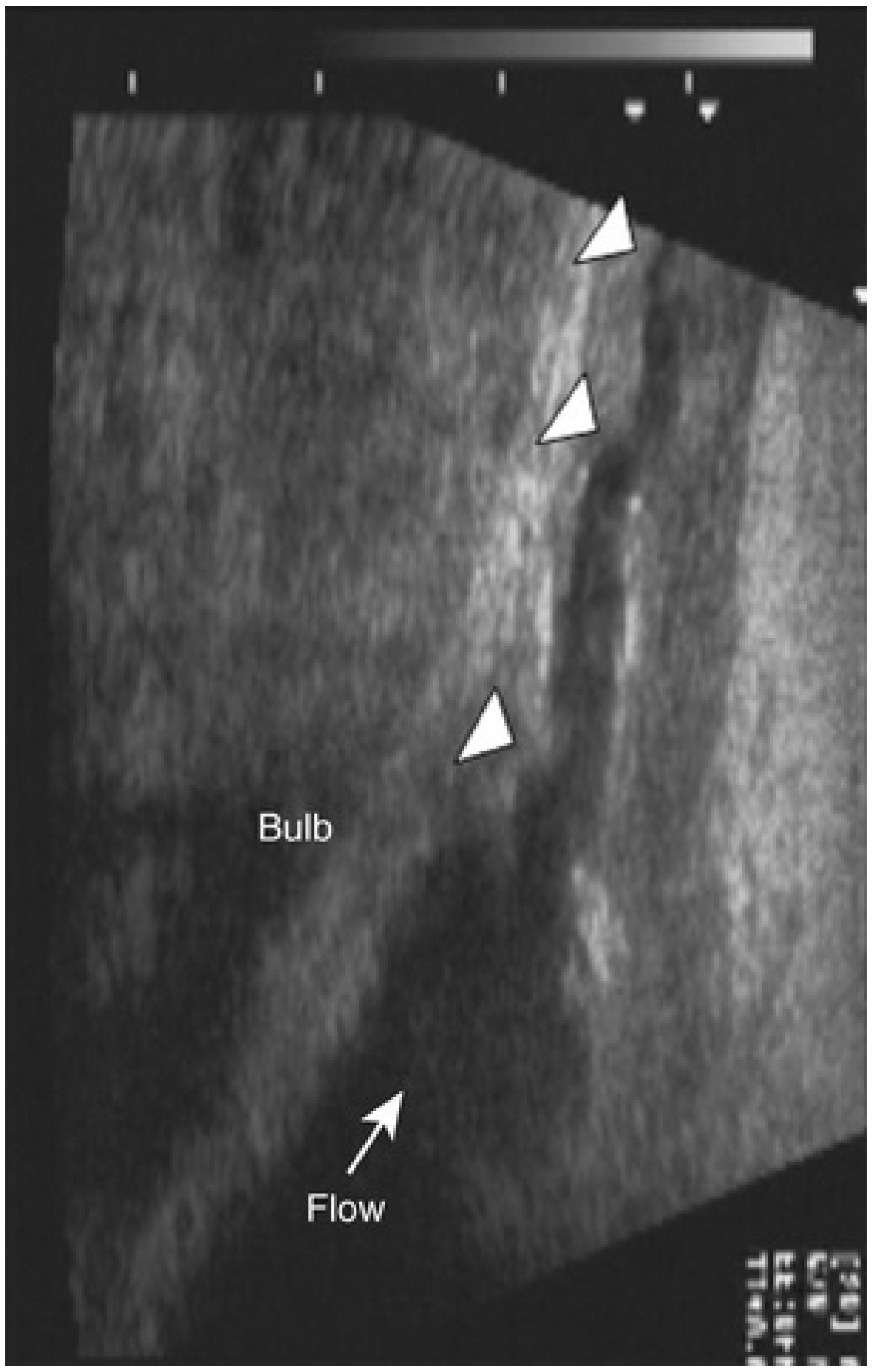

FIG. 63.33 Urethral ultrasonography has been used to assist in assessing the urethra in a noninvasive fashion. The *arrowheads* indicate the direction of urine flow during voiding in a normal urethra without stricture. (Courtesy Jonathan Rhee, MD.)

Key Points: Urethra

- The urethra is contained within the corpus spongiosum and the glans penis.
- The anterior urethra begins at the perineal membrane and continues distally to the urethral meatus.
- The posterior urethra begins distal to the bladder neck and the transition to anterior urethra is made at the perineal membrane.
- The urethral epithelium is transitional in type until the urethral epithelium becomes squamous where it traverses the glans penis at the fossa navicularis.

- The arterial supply to the urethra is from the internal pudendal artery whose bulbourethral branches supply the urethra, the corpus spongiosum, and glans penis.
- The verumontanum is formed by the widening and protrusion of the urethral crest from the posterior wall.
- The prostatic utricles (müllerian remnants) orifice appears like a slit at the apex of the verumontanum.

Penis

Structure

The gross structures of the penis can be divided into distinct anatomic compartments. **The paired corpora cavernosa, which are the erectile bodies, prolongate proximally as the crus and attach to the pubic arch. The urethra travels through the corpus spongiosum, with its proximal segment known as the bulb. The glans penis is an expansion of the corpus spongiosum.** The superior surface of the penis during erection is known as the dorsum and the inferior surface during erection, containing the urethra, is known as the ventrum. The major portion of the body of the penis is formed by the corpora cavernosa as they join beneath the pubis (penile hilum). **A septum separates the corpora cavernosa but is permeable distally to allow for free communication between their vascular spaces.** This incomplete septum allows the two corporal bodies to function physiologically and pharmacologically as a single unit. The tunica albuginea is the tough connective tissue layer that envelops the corpora cavernosa and is primarily collagenous with a mean thickness of 2 to 3 mm. The tunica albuginea is composed of elastic fibers, which form a tough irregular lattice that is predominantly collagenous with type I and type III fibers. The tunica albuginea becomes thicker ventrally to form a groove to accommodate the corpus spongiosum. The tunica albuginea is bilayered with an inner layer with circularly oriented bundles, which support and contain the cavernous tissue. Intercavenosal pillars radiate from the inner layer into the corpora, acting as struts supporting the erectile tissue. The outer layer is composed longitudinally, extending from the glans penis to the proximal crura, finally inserting on the inferior pubic ramus. With erection, the outer longitudinal layers and inner circular fibers of the tunica albuginea are tightly stretched, and in the flaccid state they form an undulating meshwork (Goldstein et al., 1982).

The cavernosal structure provides the penis with flexibility, strength, and rigidity. Smooth muscle bundles consisting mainly of collagen (types I, IV, and in lesser amounts type III), elastin, and fibroblasts traversing the corpora cavernosa form endothelial-lined cavernous sinuses. Smooth muscle makes up 45% of the corpora cavernosal volume. Smooth muscle cells in the corpora are thin, thick, and intermediate filamentous structures. Thin filaments, light chains, are composed mainly of actin, thick filaments of myosin, and the intermediate filaments of desmin or vimentin. Myoendothelial junctions, which are cellular extensions through the internal elastic lamina, have been identified as connecting the vascular smooth muscle cells to the endothelial cells. Gap junctions have been identified at the point of cell-to-cell contact in the myoendothelial junction (Kavoussi et al., 2015). Endothelial nitric oxide synthase (eNOS) is expressed in the endothelium of corporal tissue and is recognized to have a major function in the maintenance of erection (Musicki and Burnett, 2007; Fig. 63.34). The corpus spongiosum tapers and travels ventrally to the corpora cavernosa, distal to the bulb. The glans penis is the most distal expansion of the corpus spongiosum. The shaft of the penis and the base of the glans are separated by the corona. The corpora cavernosa are surrounded by Buck fascia dorsally. Buck fascia splits to surround the corpus spongiosum ventrally. The fundiform ligament of the penis is composed of collagenous and elastic fibers from the rectus sheath blending with and surrounding Buck fascia. The suspensory ligament of the penis is made up of deeper fibers from the pubis. Deep to the muscles of the corpora cavernosa, the tunica albuginea and the Buck fascia fuse (Uhlenhuth et al., 1949). Buck fascia joins the base of the glans at the corona distally. The penile shaft skin is very elastic and its only glandular elements are the smegma-producing glands, located at the base of the corona. The penile skin is very mobile as its dartos fascia backing is very loosely attached to Buck fascia. In uncircumcised men, the prepuce (foreskin) is the penile skin as it folds over the glans and attaches below the corona. The glans penis skin is immobile as it is attached to the tunica albuginea below it (Figs. 63.35 and 63.36).

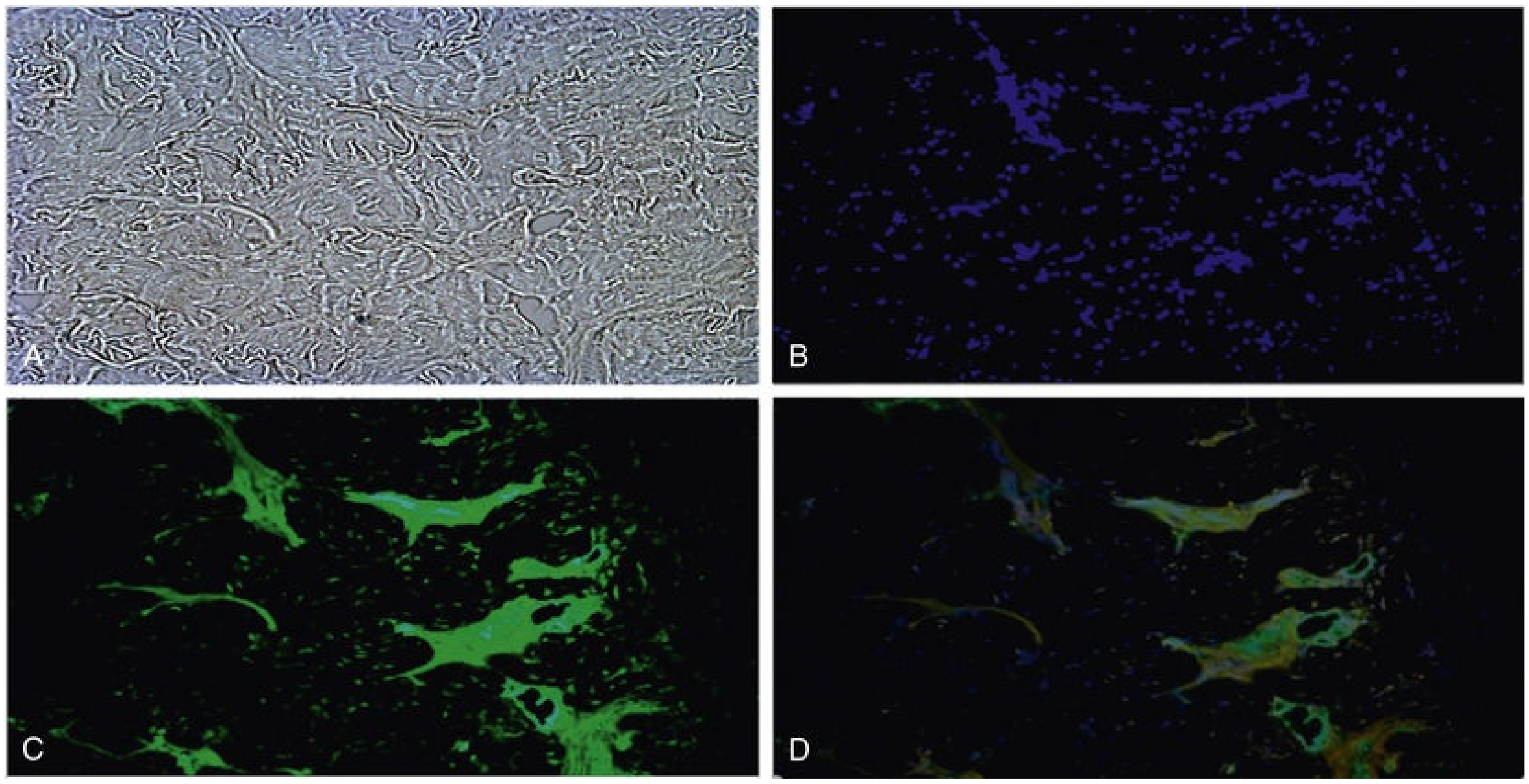

FIG. 63.34 Immunofluorescence of human corpus cavernosum. (A) Phase contrast. (B) DAPI identifying nuclei. (C) eNOS identifying endothelium. (D) DAPI and eNOS overlapped.

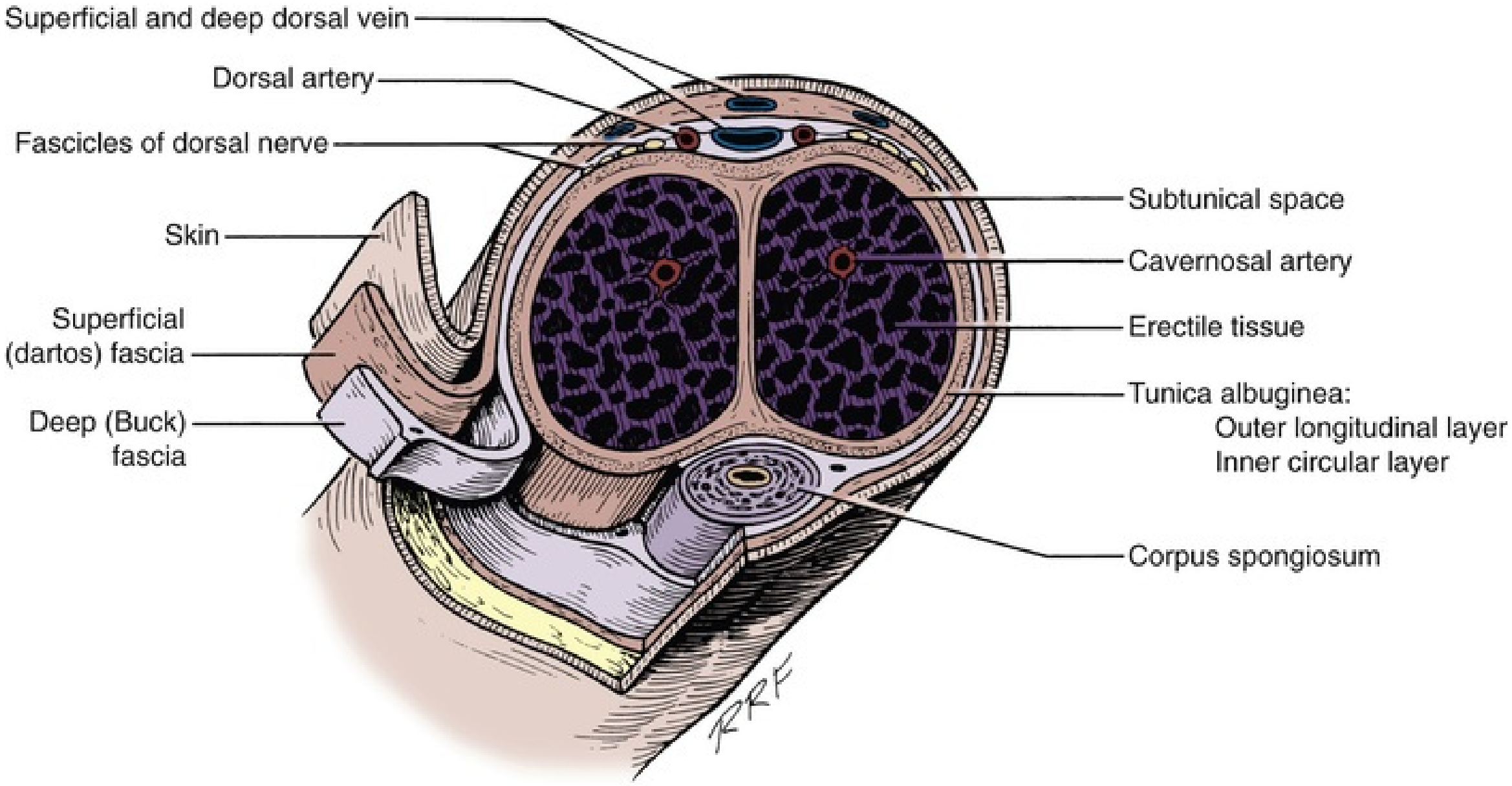
Superficial and deep dorsal vein
Dorsal artery
Fascicles of dorsal nerve
Skin
Superficial (dartos) fascia
Deep (Buck) fascia
Subtunical space
Cavernosal artery
Erectile tissue
Tunica albuginea:
Outer longitudinal layer
Inner circular layer
Corpus spongiosum
RRF

FIG. 63.35 Cross section of the penis, demonstrating the relationship between the corporal bodies, penile fascia, vessels, and nerves. (From Devine CJ Jr, Angermeier KW: Anatomy of the penis and male perineum, *AUA Update Series* 13:10–23, 1994.)

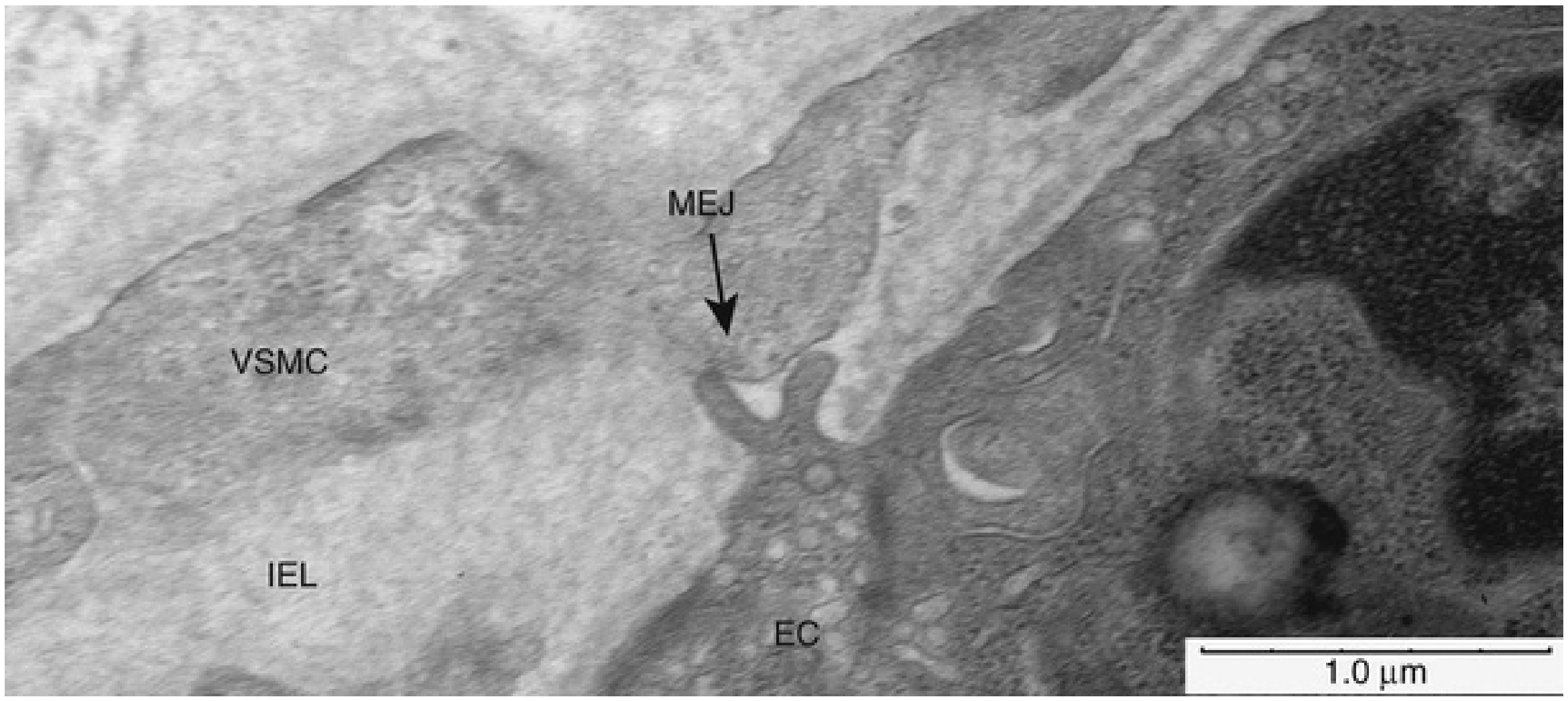

FIG. 63.36 Electron microscopy of a myoendothelial junction (*MEJ*) in human corpus cavernosal tissue. The MEJ is extending from the endothelial cell (*EC*) through the internal elastic lamina (*IEL*) to communicate with the vascular smooth muscle cell (*VSMC*).

Arterial Supply

There is a superficial arterial system supplying the penis, which originates from the external pudendal arteries, and a deep arterial system that arises from each side from the internal pudendal arteries. The pudendal artery branches into a deep artery, supplying the corpora cavernosa, a dorsal artery, and the bulbourethral artery. Above the perineal membrane, the common penile artery travels in the Alcock canal, and it supplies the corpora cavernosa via three branches. The bulbourethral artery penetrates the perineal membrane, where it enters the corpus spongiosum from above at its posterolateral border. This provides arterial supply to the corpus spongiosum, glans, and urethra. The cavernosal artery penetrates the corpus cavernosum in the penile hilum to nearly the center of the erectile tissue. It provides straight and helicine arteries that supply the cavernous sinuses. After it travels between the crus and the pubis, the dorsal artery of the penis supplies the dorsal surfaces of the corporeal bodies. The dorsal artery travels between the dorsal vein and the dorsal penile nerve, and they all attach to the underside of Buck fascia. The dorsal artery travels distally toward the glans and supplies cavernous branches and circumferential branches to the urethra and the corpus spongiosum (Devine and Angermeier, 1994). There can be a great deal of variability in penile arteries (Bare et al., 1994). A single cavernosal artery may supply both corpora cavernosa or it may be completely absent. In some cases, an accessory pudendal artery may supplement or completely take the place of branches of the common penile artery (Breza et al., 1989). The arterial supply to the penile skin is from the external pudendal branches of the femoral vessels. These vessels run longitudinally in the dartos fascia layer and provide a rich blood supply after entering the base of the penis (Fig. 63.37).

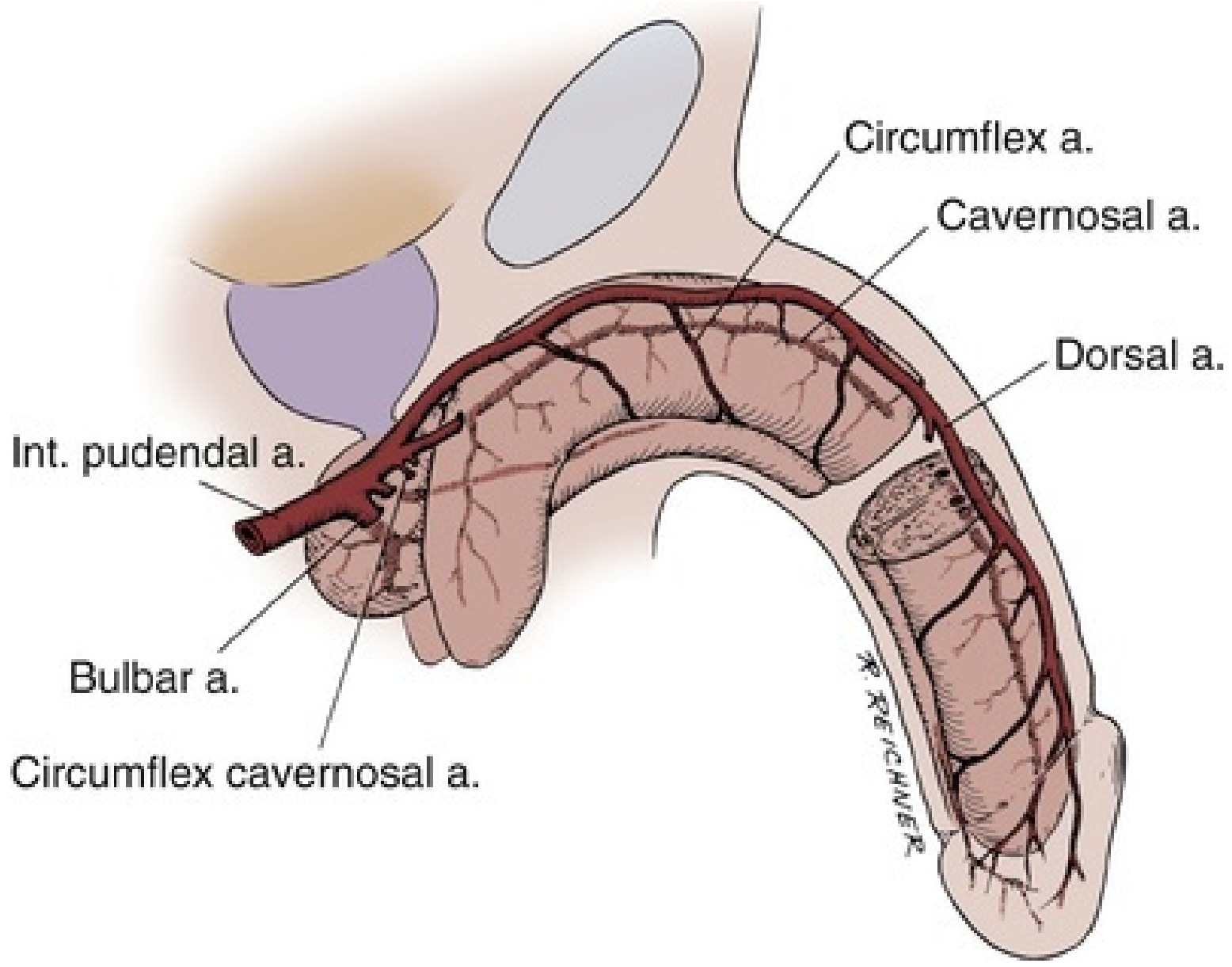

FIG. 63.37 Arterial supply of the penis.

Venous Drainage

The superficial dorsal vein lies external to Buck fascia, whereas the deep dorsal vein is beneath Buck fascia and runs between dorsal arteries. A number of venous channels anastomose at the base of the glans to form the dorsal vein of the penis. **The dorsal vein travels between the corporal bodies, in a groove, and drains into the preprostatic plexus**. In the distal two-thirds of the penile shaft, the circumflex veins from the corpus spongiosum course around the corpora cavernosa to enter the deep dorsal vein perpendicularly. There are typically 3 to 10 circumflex veins. The cavernous sinuses form intermediary venules that empty into the subtunical capillary plexus. Emissary veins from these plexuses travel obliquely between the layers of the tunica and drain into the circumflex veins dorsolaterally. Emissary veins form two to five cavernous veins in the proximal third of the penis, joining on the dorsomedial surface of the corpora cavernosa. These veins travel between the bulb and crura at the hilum of the penis. They receive branches from the bulb and the crura and empty into the internal pudendal veins.

Lymphatic Drainage

Lymphatics from the skin of the penis drain to the superficial inguinal and subinguinal lymph nodes. **Penile shaft lymphatics converge on the dorsum and ramify to both sides of the groin to drain into inguinal lymph nodes.** Lymphatics from the glans run deep to Buck fascia dorsally to drain to the superficial and deep inguinal nodes bilaterally. Some studies have suggested direct lymphatic channels from the glans to pelvic nodes as well as studies proposing lymphatic drainage through sentinel nodes positioned medial to the superficial epigastric veins. These models have been challenged (Catalona, 1988).

Nerve Supply

Sensory innervation of the penis is through the dorsal nerves. These nerves richly supply the glans. The dorsal nerves travel alongside the dorsal arteries. Small branches of the perineal nerve supply the ventrum of the penis as distally as the glans (Uchio et al., 1999). The somatic nerve supply originates from spinal nerves S2, S3, and S4 via the pudendal nerve. The pudendal nerve passes through the Alcock canal and continues as the dorsal nerve of the penis. The cavernous nerves supply sympathetic and parasympathetic innervation from the pelvic plexus to the corporeal bodies after penetrating them to ramify in the erectile tissue (Fig. 63.38).

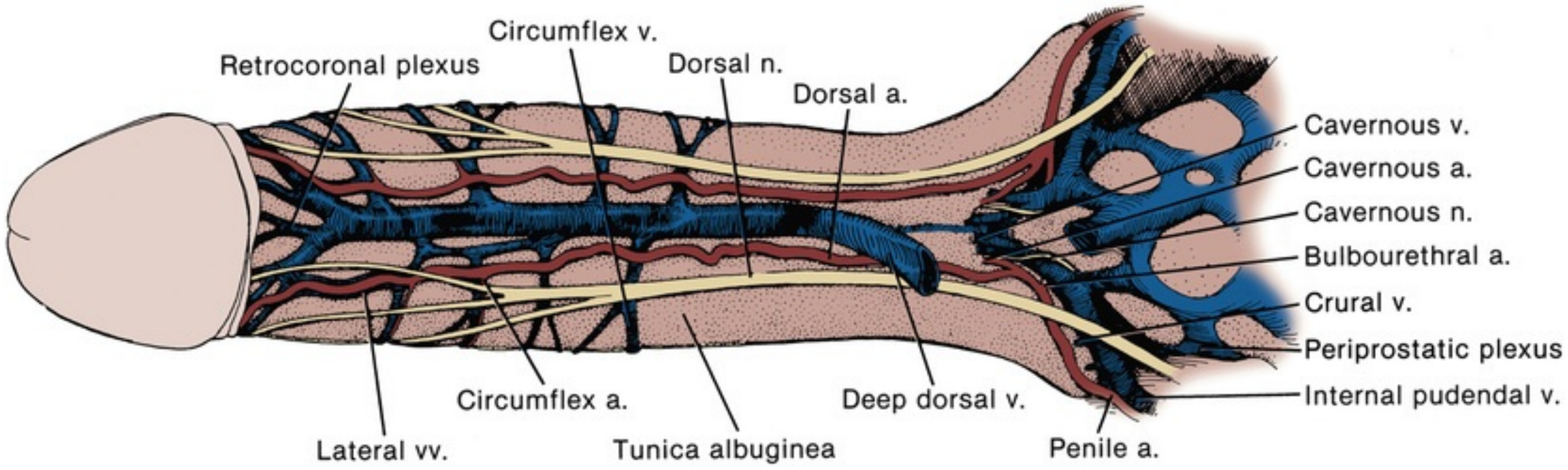
Circumflex v.
Retrocoronal plexus
Dorsal n.
Dorsal a.
Cavernous v.
Cavernous a.
Cavernous n.
Bulbourethral a.
Crural v.
Periprostatic plexus
Internal pudendal v.
Circumflex a.
Deep dorsal v.
Lateral vv.
Tunica albuginea
Penile a.

FIG. 63.38 Dorsal penile arteries, veins, and nerves. (From Hinman F Jr: *Atlas of urosurgical anatomy,* Philadelphia, 1993, Saunders, p 445.)

Cavernosogram

Cavernosograms historically were used primarily to assist in the diagnosis of venous leak erectile dysfunction. Radiopaque contrast is injected into the corporal body with plain film imaging. This is not a commonly used diagnostic test any longer, but it is occasionally used at the time of penile fracture repair (Fitzpatrick and Cooper, 1975; Mydlo et al., 1998; Fig. 63.39).

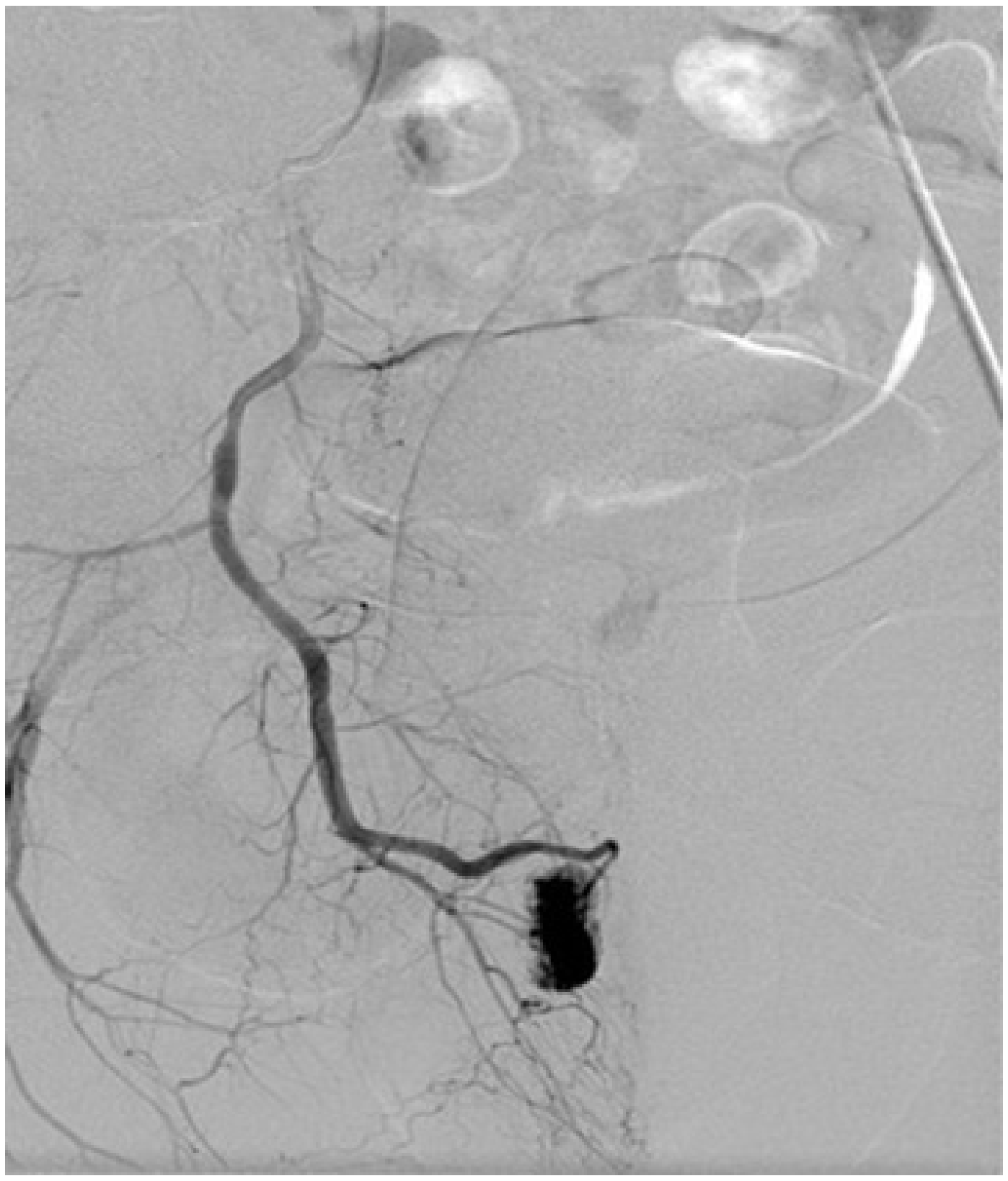

FIG. 63.39 Angiogram of arteriocorporeal fistula in patient with nonischemic priapism showing filling of the right corpus cavernosum.

Doppler Ultrasound of the Penis

Doppler penile ultrasound was first described in the 1970s and has been used over the years for assessment for erectile dysfunction, Peyronie disease, arteriocorporal fistulas (Fig. 63.40), and other penile pathologic processes (Malvar et al., 1973). High-resolution (7.5–12 MHz) real-time ultrasonography and color-pulsed Doppler can visualize the dorsal and cavernous arteries and can perform hemodynamic blood-flow analysis (Lue et al., 1989; Sikka et al., 2013). The entire length of the penis from the crura in the pelvis to the tip of the glans penis can be imaged. Color duplex demonstrates the direction of blood flow within the vessels, with blood flow toward the probe transducer appearing red and blood flow away from the probe transducer appearing blue (Broderick and Arger, 1993; Herbener et al., 1994). Penile arterial and venous flow velocities can be measured. The tunica alguinea can be assessed in cases of Peyronie disease (Chou et al., 1987).

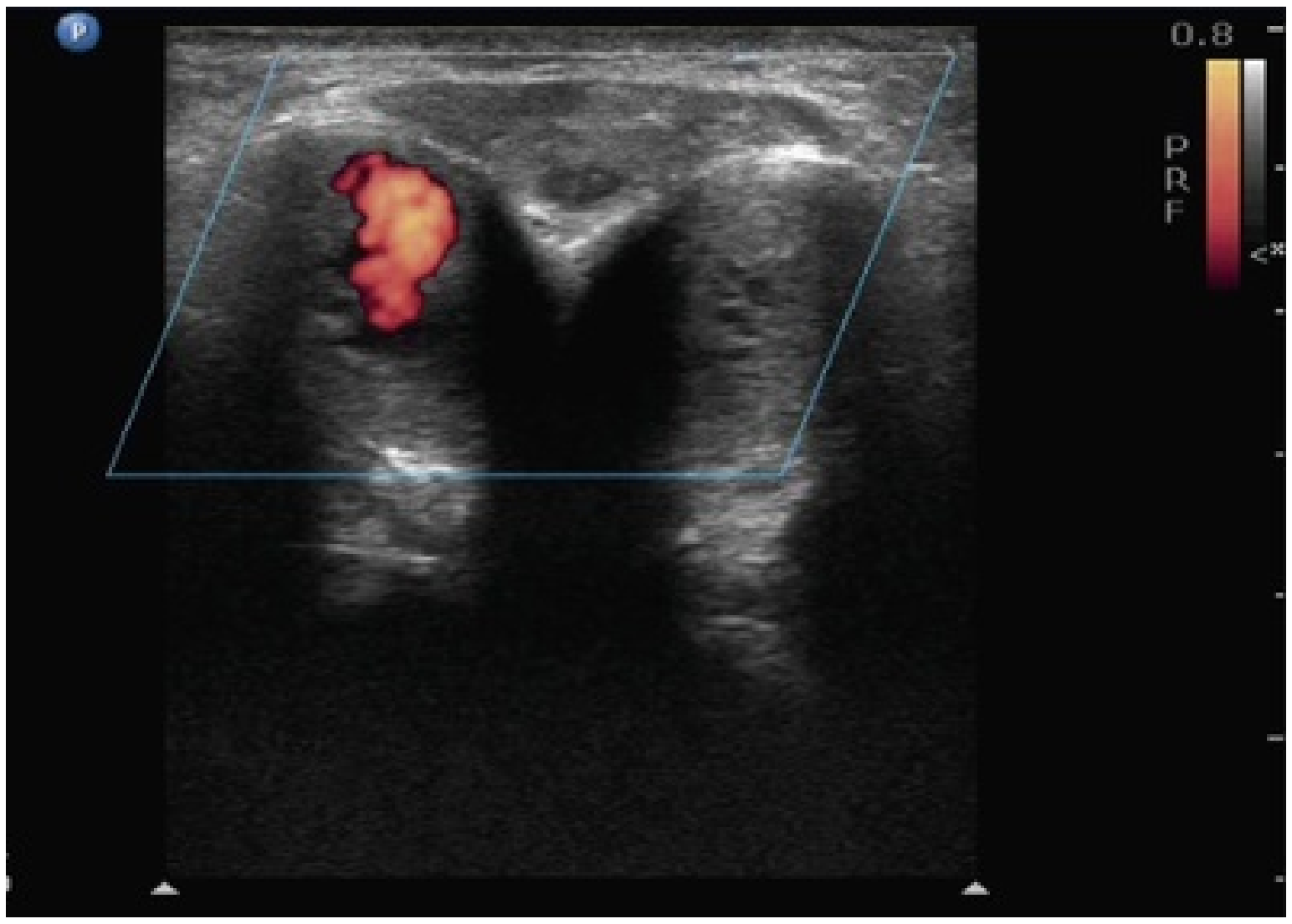

FIG. 63.40 Penile Doppler ultrasound of arteriocorporal fistula in patient with nonischemic priapism showing arterial flow into right corpus cavernosum *(red).*

Magnetic Resonance Imaging

Normal anatomy and pathologic anatomy of the penis can be evaluated with MRI. Anatomic detail and morphologic characteristics of the corpora cavernosa and corpus spongiosum can be demonstrated. Pathology such as congenital anomalies, penile prostheses, malignancies, hematoma, or fibrous tissue as a result of trauma, penile fractures, and fibrous plaques in men with Peyronie disease can be clearly visualized by MRI (Boudghene et al., 1992; Hricak et al., 1988). Complete morphologic analysis of the penis with fine anatomic detail can be obtained with combined evaluation of T1 and T2 images. Fine differentiation of penile tissues is possible with MRI, including penile skin, dartos fascia, hypodermal connective tissue, vascular characterization of corporus cavernosa and spongious tissue, the urethral lumen, deep penile arteries, superficial dorsal veins, and the tunica albuginea with high resolution (Satragno et al., 1989; Fig. 63.41).

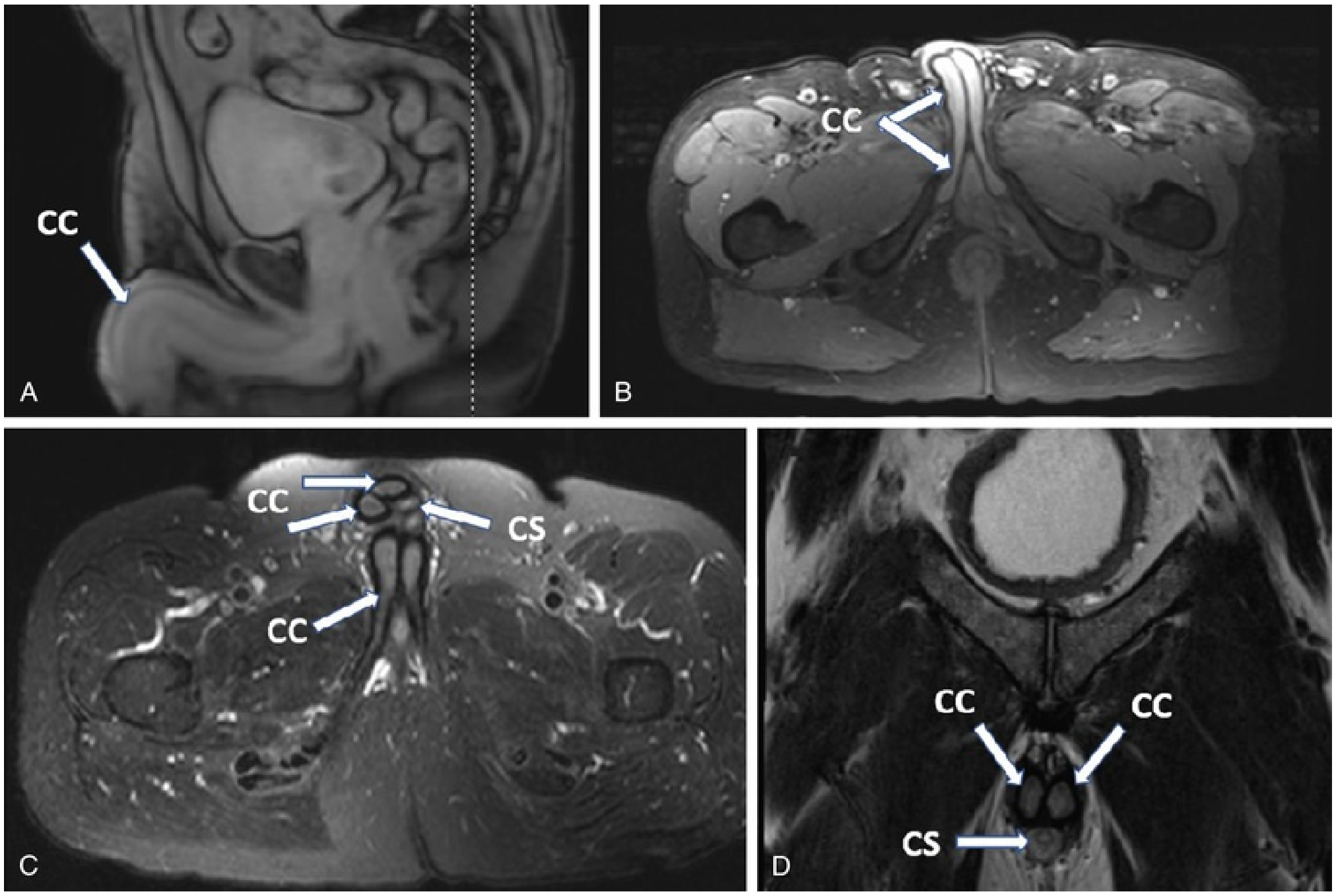

FIG. 63.41 MRI of the penis. *CC,* Corpus cavernosum; *CS,* corpus spongiosum. (A) T2 sagittal image of the penis. (B) T2 axial image of the corporal bodies with *arrows* showing them paired adjacent to each other and diverging at the crus. (C) T1 axial image of the penis in the deep pelvis as well as a cross-sectional view of the corporal bodies. (D) T2 coronal image demonstrating the corpora cavernosa and the corpus spongiosum in cross section.

Key Points: Penis

- The paired erectile bodies are known as the corpora cavernosa.

- The glans penis is an expansion of the corpus spongiosum.
- A permeable septum separates the corpora cavernosa for free communication between their vascular spaces.
- The superficial arterial system to the penis originates from the external pudendal arteries, and a deep arterial system arises from the internal pudendal arteries.
- The dorsal vein runs between the corporeal bodies and drains into the preprostatic plexus.
- Penile shaft lymphatics converge on the dorsum and ramify to both sides of the groin to drain into inguinal lymph nodes.
- Sensory innervation of the penis is through the dorsal nerves, and the somatic nerve supply originates from spinal nerves S2, S3, and S4 via the pudendal nerve.

Scrotum

Gross Structure

The scrotal skin is hair bearing, pigmented, with abundant sebaceous and sweat glands, and has an absence of fat. It is variable and may be folded with transverse rugae or it may appear loose and shiny. Its appearance depends on the tone of the underlying dartos smooth muscle. The median raphe runs longitudinally in the midline from the urethral meatus to the anus. Deep to the raphe, the scrotum is divided by a septum into two compartments, each containing a testis. The smooth muscle of the dartos fascia underlying the skin is continuous with Colles, Scarpa, and the dartos fascia of the penis. The spermatic fasciae are layers of the abdominal wall that extend to form parts of the scrotal wall. The external oblique extends to form the external spermatic fascia, which attaches to the borders of the external inguinal ring. The internal oblique extends to form the cremaster muscle and fascia, which attach to the inguinal ligament laterally, to the iliopsoas laterally, and to the pubic tubercle medially. The transversalis fascia continues to become the internal spermatic fascia in the scrotum. A peritoneal derivative known as the parietal and visceral tunica vaginalis surrounds the testis with a mesothelium-lined pouch. The tunica vaginalis is continuous with the testis posterolaterally at its mesentery, where it is attached to the scrotal wall. The gubernaculum fixes the testis at its inferior pole (Fig. 63.42).

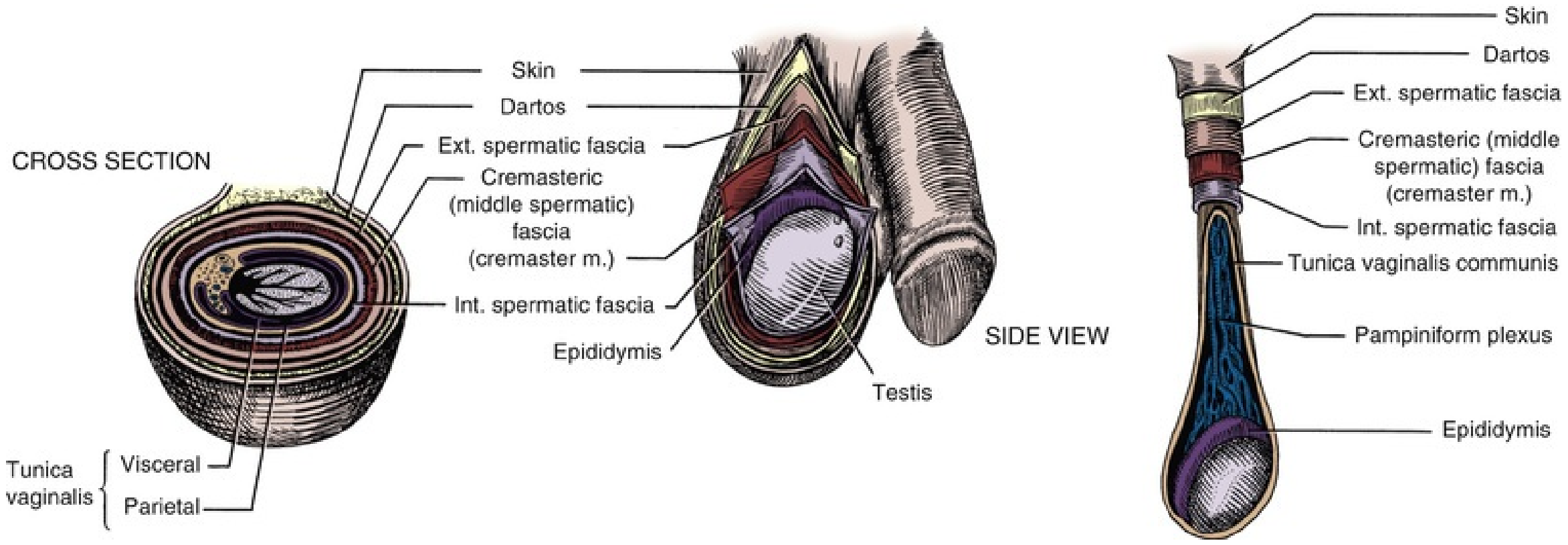
CROSS SECTION
Skin
Dartos
Ext. spermatic fascia
Cremasteric (middle spermatic) fascia (cremaster m.)
Int. spermatic fascia
Epididymis
Testis
SIDE VIEW
Tunica vaginalis
Visceral
Parietal
Skin
Dartos
Ext. spermatic fascia
Cremasteric (middle spermatic) fascia (cremaster m.)
Int. spermatic fascia
Tunica vaginalis communis
Pampiniform plexus
Epididymis

FIG. 63.42 Scrotum and its layers. (From Pansky B: *Review of gross anatomy,* ed 6, New York, 1987, McGraw-Hill.)

Arterial Supply

The external pudendal arteries supply the anterior wall of the scrotum. **The arteries run parallel to the rugae and do not cross the median raphe.** The posterior aspect of the scrotum has arterial supply from perineal branches. Arterial supply to the spermatic fascia is from the cremasteric, testicular, and deferential branches.

Venous Drainage

The external pudendal veins drain the anterior scrotal wall. The veins run parallel to the rugae and do not cross the median raphe.

Lymphatic Drainage

Scrotal lymphatics do not cross the median raphe and drain into the superficial inguinal nodes on the ipsilateral side.

Nerve Supply

Branches of the ilioinguinal and genitofemoral nerves innervate the anterior scrotal wall. The nerves run parallel to the rugae and do not cross the median raphe. The posterior aspect of the scrotum receives innervation from scrotal branches of perineal nerves as well as from branches of the posterior femoral cutaneous nerve (S3).

Key Points: Scrotum

- The smooth muscle of the dartos fascia underlying the scrotal skin is continuous with Colles, Scarpa, and the dartos fascia of the penis.
- The scrotal wall arteries run parallel to the rugae and do not cross over the median raphe.
- Branches of the ilioinguinal and genitofemoral nerves innervate the anterior scrotal wall.

Suggested Readings

Breza J, Aboseif SR, Orvis BR, et al. Detailed anatomy of penile neurovascular structures: surgical significance. *J Urol*. 1989;141(2):437–443.

Clegg EJ. The arterial supply of the human prostate and seminal vesicles. *J Anat*. 1955;89(2):209–216.

Devine CJ Jr, Angermeier KW. Anatomy of the penis and male perineum. *AUA Update Series*. 1994;13:10–23.

Dogra VS, Gottlieb RH, Oka M, et al. Sonography of the scrotum. *Radiology*. 2003;227(1):18–36.

Epstein J. *The prostate and seminal vesicles*. Raven: New York; 1989.

McNeal JE. The prostate and prostatic urethra: a morphologic synthesis. *J Urol*. 1972;107(6):1008–1016.

Setchell BP, Brooks DI. *Anatomy, vasculature, innervation and fluids of the male reproductive tract*. Raven Press: New York; 1988.

References

Abrahamsson PA. Neuroendocrine cells in tumour growth of the prostate. *Endocr Relat Cancer*. 1999;6(4):503–519.

Baker LL, Hajek PC, Burkhard TK, et al. MR imaging of the scrotum: normal anatomy. *Radiology*. 1987;163(1):89–92.

Bare RL, DeFranzo A, Jarow JP. Intraoperative arteriography facilitates penile revascularization. *J Urol*. 1994;151(4):1019–1021.

Batra SK, Lardner TJ. *Sperm transport in the vas deferens*. Mosby: St. Louis; 1976.

Baumgarten HG, Holstein AF. Catecholamine-containing nerve fibers in the testis of man. *Z Zellforsch Mirosk Anat*. 1967;79:389–395 [in German].

Baumgarten HG, Holstein AF, Rosengren E. Arrangement, ultrastructure, and adrenergic innervation of smooth musculature of the ductuli efferentes, ductus epididymis and ductus deferens of man. *Z Zellforsch Mirosk Anat*. 1971;120:37–79.

Beck EM, Schlegel PN, Goldstein M. Intraoperative varicocele anatomy: a macroscopic and microscopic study. *J Urol*. 1992;148(4):1190–1194.

Black JA, Patel A. Sonography of the normal extratesticular space. *Am J Roentgenol*. 1996;167(2):503–506.

Boudghene F, Chhem R, Wallays C, et al. MR imaging in acute fracture of the penis. *Urol Radiol*. 1992;14(3):202–204.

Breza J, Aboseif SR, Orvis BR, et al. Detailed anatomy of penile neurovascular structures: surgical significance. *J Urol*. 1989;141(2):437–443.

Broderick GA, Arger P. Duplex Doppler ultrasonography: noninvasive assessment of penile anatomy and function. *Semin Roentgenol*. 1993;28(1):43–56.

Burnett AL. Nitric oxide control of lower genitourinary tract functions: a review. *Urology*. 1995;45(6):1071–1083.

Catalona WJ. Modified inguinal lymphadenectomy for carcinoma of the penis with preservation of saphenous veins: technique and preliminary results. *J Urol*. 1988;140(2):306–310.

Chou YH, Tiu CM, Pan HB, et al. High-resolution real-time ultrasound in Peyronie's disease. *J Ultrasound Med*. 1987;6(2):67–70.

Clavert A, Cranz C, Brun B. *Epididymal vascularization and microvascularization*. Karger: Basel; 1981.

Clegg EJ. The arterial supply of the human prostate and seminal vesicles. *J Anat*. 1955;89(2):209–216.

Davis JR, Horowitz AM. Age-related differences in the response of the isolated testicular capsule of the rat to norepinephrine, acetylcholine and prostaglandins. *J Reprod Fertil*. 1978;54(2):269–274.

De Marzo AM, Meeker AK, Epstein JI, et al. Prostate stem cell compartments: expression of the cell cycle inhibitor p27Kip1 in normal, hyperplastic, and neoplastic cells. *Am J Pathol*. 1998;153(3):911–919.

Devine CJ Jr, Angermeier KW. Anatomy of the penis and male perineum. *AUA Update Series*. 1994;13:10–23.

di Sant'Agnese PA, De Mesy Jensen KL. Endocrine-paracrine cells of the prostate and prostatic urethra: an ultrastructural study. *Hum Pathol*. 1984;15(11):1034–1041.

Dixon JS, Jen PY, Gosling JA. Structure and autonomic innervation of the human vas deferens: a review. *Microsc Res Tech*. 1998;42(6):423–432.

Dogra VS, Gottlieb RH, Oka M, et al. Sonography of the scrotum. *Radiology*. 2003;227(1):18–36.

Dogra VS, Gottlieb RH, Rubens DJ, et al. Benign intratesticular cystic lesions: US features. *Radiographics*. 2001;21(Spec

No):S273–S281.
Dooms GC, Hricak H. Magnetic resonance imaging of the pelvis: prostate and urinary bladder. *Urol Radiol*. 1986;8(3):156–165.
Eggener SE, Lotan Y, Cheng EY. Magnetic resonance angiography for the nonpalpable testis: a cost and cancer risk analysis. *J Urol*. 2005;173(5):1745–1749.
Eichelberg C, Erbersdobler A, Michl U, et al. Nerve distribution along the prostatic capsule. *Eur Urol*. 2007;51(1):105–110 [discussion 110–111].
Epstein J. *The prostate and seminal vesicles*. Raven: New York; 1989.
Ewing LL, Davis JC, Zirkin BR. *Regulation of testicular function: a spatial and temporal view*. University Park Press: Baltimore; 1980.
Fitzpatrick TJ, Cooper JF. A cavernosogram study on the valvular competence of the human deep dorsal vein. *J Urol*. 1975;113(4):497–499.
Flocks R. The arterial distribution within the prostate gland; its role in transurethral resection. *J Urol*. 1937;37:524–548.
Gevenois PA, Salmon I, Stallenberg B, et al. Magnetic resonance imaging of the normal prostate at 1.5 T. *Br J Radiol*. 1990;63(746):101–107.
Goldstein AM, Meehan JP, Zakhary R, et al. New observations on microarchitecture of corpora cavernosa in man and possible relationship to mechanism of erection. *Urology*. 1982;20(3):259–266.
Hajek PC. Magnetic resonance tomography (MRT) of the scrotum—initial results and comparison with sonography. I: normal anatomy and extratesticular pathology. *Radiologe*. 1987;27(11):522–528.
Harrison RG, Barclay AE. The distribution of the testicular artery (internal spermatic artery) to the human testis. *Br J*

Urol. 1948;20(2):57–66.

Hastak SM, Gammelgaard J, Holm HH. Transrectal ultrasonic volume determination of the prostate—a preoperative and postoperative study. *J Urol*. 1982;127(6):1115–1118.

Herbener TE, Seftel AD, Nehra A, et al. Penile ultrasound. *Semin Urol*. 1994;12(4):320–332.

Hickey DS, Phillips JI, Hukins DW. Arrangements of collagen fibrils and muscle fibres in the female urethra and their implications for the control of micturition. *Br J Urol*. 1982;54(5):556–561.

Hoffer AP. The ultrastructure of the ductus deferens in man. *Biol Reprod*. 1976;14(4):425–443.

Hoffer AP, Hinton BT. Morphological evidence for a blood-epididymis barrier and the effects of gossypol on its integrity. *Biol Reprod*. 1984;30(4):991–1004.

Hollabaugh RS Jr, Dmochowski RR, Steiner MS. Neuroanatomy of the male rhabdosphincter. *Urology*. 1997;49(3):426–434.

Holstein AF. Morphologische studien am nebenhoden des menschen. *Zwanglose Abhaudl Gebeit Norm Pathol Anat*. 1969;20:1.

Honig SC. New diagnostic techniques in the evaluation of anatomic abnormalities of the infertile male. *Urol Clin North Am*. 1994;21(3):417–432.

Hricak H, Dooms GC, McNeal JE, et al. MR imaging of the prostate gland: normal anatomy. *Am J Roentgenol*. 1987;148(1):51–58.

Hricak H, Mariotti M, Gilbert TJ, et al. Normal penile anatomy and abnormal penile conditions: evaluation with MR imaging. *Radiology*. 1988;169(3):683–690.

Hundeiker M. Lymphatic vessels in the parenchyma of the human testis. Demonstrated by injections. *Arch Klin Exp Dermatol*. 1969;235(3):271–276 [in German].

Jarow JP, Ogle A, Kaspar J, et al. Testicular artery ramification within the inguinal canal. *J Urol*. 1992;147(5):1290–1292.

Kavoussi PK, Heberlein K, Straub AC, et al. Recombinant PAI-1 therapy restores myoendothelial junctions and erectile function in PAI-1 deficient mice. *Andrologia*. 2015;47(10):1147–1152.

Keener TS, Winter TC, Nghiem HV, et al. Normal adult epididymis: evaluation with color Doppler US. *Radiology*. 1997;202(3):712–714.

King BF, Hattery RR, Lieber MM, et al. Seminal vesicle imaging. *Radiographics*. 1989;9(4):653–676.

Knox JD, Cress AE, Clark V, et al. Differential expression of extracellular matrix molecules and the alpha 6-integrins in the normal and neoplastic prostate. *Am J Pathol*. 1994;145(1):167–174.

Kolbeck SD, Steers WD. Origin of neurons supplying the vas deferens of the rat. *J Urol*. 1993;149(4):918–921.

Kormano M, Reijonen K. Microvascular structure of the human epididymis. *Am J Anat*. 1976;145(1):23–27.

Kormano M, Suoranta H. An angiographic study of the arterial pattern of the human testis. *Anat Anz*. 1971;128(1):69–76.

Langford GA, Heller CG. Fine structure of muscle cells of the human testicular capsule: basis of testicular contractions. *Science*. 1973;179(4073):573–575.

Lee RK, Li PS, Goldstein M. Simultaneous vasectomy and varicocelectomy: indications and technique. *Urology*. 2007;70(2):362–365.

Lich R Jr, Howerton LW, Amin M. *Anatomy and surgical approach to the urogenital tract in the male*. Saunders: Philadelphia; 1978.

Lue TF, Mueller SC, Jow YR, et al. Functional evaluation of penile arteries with duplex ultrasound in vasodilator-induced erection. *Urol Clin North Am*. 1989;16(4):799–807.

Macmillan EW. The blood supply of the epididymis in man. *Br J Urol*. 1954;26(1):60–71.

Malvar T, Baron T, Clark SS. Assessment of potency with the Doppler flowmeter. *Urology*. 1973;2(4):396–400.

Mawhinney MG, Tarry WF. *Male accessory sex organs and androgen action*. Churchill Livingstone: New York; 1991.

McConnell J, Benson GS, Wood JG. Autonomic innervation of the urogenital system: adrenergic and cholinergic elements. *Brain Res Bull*. 1982;9(1–6):679–694.

McNeal JE. The prostate and prostatic urethra: a morphologic synthesis. *J Urol*. 1972;107(6):1008–1016.

McNeal JE. Normal histology of the prostate. *Am J Surg Pathol*. 1988;12(8):619–633.

Middleton WD, Dahiya N, Naughton CK, et al. High-resolution sonography of the normal extrapelvic vas deferens. *J Ultrasound Med*. 2009;28(7):839–846.

Middleton WD, Thorne DA, Melson GL. Color Doppler ultrasound of the normal testis. *Am J Roentgenol*. 1989;152(2):293–297.

Mitchell GA. The innervation of the kidney, ureter, testicle and epididymis. *J Anat*. 1935;70(Pt 1):10–32 [15].

Muller I. Architectonic of the canals and capillaries of rat testes. *Z Zellforsch Mikrosk Anat*. 1957;45:522–537 [in German].

Musicki B, Burnett AL. Endothelial dysfunction in diabetic erectile dysfunction. *Int J Impot Res*. 2007;19(2):129–138.

Mydlo JH, Hayyeri M, Macchia RJ. Urethrography and cavernosography imaging in a small series of penile fractures: a comparison with surgical findings. *Urology*. 1998;51(4):616–619.

Myers RP. Male urethral sphincteric anatomy and radical prostatectomy. *Urol Clin North Am*. 1991;18(2):211–227.

Neaves W. *Biological aspects of vasectomy*. Williams & Wilkins: Baltimore; 1975.

Nguyen HT, Etzell J, Turek PJ. Normal human ejaculatory duct anatomy: a study of cadaveric and surgical specimens. *J Urol*. 1996;155(5):1639–1642.

Paniagua R, Regadera J, Nistal M, et al. Histological, histochemical and ultrastructural variations along the length of the human vas deferens before and after puberty. *Acta Anat*. 1981;111:190.

Parekattil SJ, Gudeloglu A, Brahmbhatt JV, et al. Trifecta nerve complex: potential anatomical basis for microsurgical denervation of the spermatic cord for chronic orchialgia. *J Urol*. 2013;190(1):265–270.

Pezzella A, Barbonetti A, Micillo A, et al. Ultrasonographic determination of caput epididymis diameter is strongly predictive of obstruction in the genital tract in azoospermic men with normal serum FSH. *Andrology*. 2013;1(1):133–138.

Poon PY, McCallum RW, Henkelman MM, et al. Magnetic resonance imaging of the prostate. *Radiology*. 1985;154(1):143–149.

Prader A. Testicular size: assessment and clinical importance. *Triangle*. 1966;7(6):240–243.

Puttemans T, Delvigne A, Murillo D. Normal and variant appearances of the adult epididymis and vas deferens on high-resolution sonography. *J Clin Ultrasound*. 2006;34(8):385–392.

Raman JD, Goldstein M. Intraoperative characterization of arterial vasculature in spermatic cord. *Urology*. 2004;64(3):561–564.

Rauchenwald M, Steers WD, Desjardins C. Efferent innervation of the rat testis. *Biol Reprod*. 1995;52(5):1136–1143.

Raychaudhuri B, Cahill D. Pelvic fasciae in urology. *Ann R Coll Surg Engl*. 2008;90(8):633–637.

Raz S, Caine M, Zeigler M. The vascular component in the production of intraurethral pressure. *J Urol*. 1972;108(1):93–

96.

Rholl KS, Lee JK, Ling D, et al. MR imaging of the scrotum with high resolution surface coil. *Radiology*. 1987;163(1):99–103.

Rikmaru A, Shirai M. Response of the human testicular capsule to electrical stimulation and autonomic drugs. *Tokohu J Exp Med*. 1972;108:303–304.

Roehrborn CG, Chinn HK, Fulgham PF, et al. The role of transabdominal ultrasound in the preoperative evaluation of patients with benign prostatic hypertrophy. *J Urol*. 1986;135(6):1190–1193.

Satragno L, Martinoli C, Cittadini G. Magnetic resonance imaging of the penis: normal anatomy. *Magn Reson Imaging*. 1989;7(1):95–100.

Schnall MD, Pollack HM. Magnetic resonance imaging of the prostate gland. *Urol Radiol*. 1990;12(2):109–114.

Schweitzer. Uber die Bedeutung der Vascularisation, der Binnendruckes und der Zwischenzellen fur die Biologies des Hodens. *Anat Entwickl*. 1929;89:775–796.

Secaf E, Nuruddin RN, Hricak H, et al. MR imaging of the seminal vesicles. *Am J Roentgenol*. 1991;156(5):989–994.

Setchell BP, Brooks DI. *Anatomy, vasculature, innervation and fluids of the male reproductive tract*. Raven Press: New York; 1988.

Setchell BP, Waites GMH. *The blood-testis barrier*. Williams & Wilkins: Baltimore; 1975.

Sikka SC, Hellstron WJ, Brock G, et al. Standardization of vascular assessment of erectile dysfunction: standard operating procedures for duplex ultrasound. *J Sex Med*. 2013;10(1):120–129.

Silverman PM, Dunnick NR, Ford KK. Computed tomography of the normal seminal vesicles. *Comput Radiol*. 1985;9(6):379–385.

Sjostrand NO. The adrenergic innervation of the vas deferens and the accessory male genital glands. *Acta Physiol Scand*. 1965;65:7–82.

Spirnak JP, Resnick MI. *Ultrasound*. Lippincott, Williams & Wilkins: Philadelphia; 2002.

Steiner MS, Morton RA, Walsh PC. Impact of anatomical radical prostatectomy on urinary continence. *J Urol*. 1991;145(3):512–514 [discussion 514–515].

Strasser H, Frauscher F, Helweg G, et al. Transurethral ultrasound: evaluation of anatomy and function of the rhabdosphincter of the male urethra. *J Urol*. 1998;159(1):100–104 [discussion 104–105].

Suzuki F, Nagano T. Development of tight junctions in the caput epididymal epithelium of the mouse. *Dev Biol*. 1978;63(2):321–334.

Taguchi K, Tsukamoto T, Murakami G. Anatomical studies of the autonomic nervous system in the human pelvis by the whole-mount staining method: left-right communicating nerves between bilateral pelvic plexuses. *J Urol*. 1999;161(1):320–325.

Tanagho EA, Schmidt RA, de Araujo CG. Urinary striated sphincter: what is its nerve supply? *Urology*. 1982;20(4):415–417.

Terris MK, McNeal JE, Stamey TA. Detection of clinically significant prostate cancer by transrectal ultrasound-guided systematic biopsies. *J Urol*. 1992;148(3):829–832.

Tishler PV. Diameter of testicles. *N Engl J Med*. 1971;285(26):1489.

Turner TT. On the epididymis and its function. *Invest Urol*. 1979;16(5):311–321.

Turner TT, D'Addario D, Howards SS. Further observations on the initiation of sperm motility. *Biol Reprod*. 1978;19:1095–1101.

Uchio EM, Yang CC, Kromm BG, et al. Cortical evoked responses from the perineal nerve. *J Urol*. 1999;162(6):1983–1986.

Uhlenhuth E, Smith RD, Day EC, et al. A re-investigation of Colles' and Buck's fasciae in the male. *J Urol*. 1949;62(4):542–563.

Vashchenko N, Abrahamsson PA. Neuroendocrine differentiation in prostate cancer: implications for new treatment modalities. *Eur Urol*. 2005;47(2):147–155.

Vendrely E. *Histology of the epididymis in the human adult*. Karger: Basel; 1981.

Vendrely E, Dadoune JP. Quantitative ultrastructural analysis of the principal cells in the human epididymis. *Reprod Nutr Dev*. 1988;28(5):1225–1235.

Von Lanz T, Neuhaeuser G. Morphometric analysis of the human epididymis. *Z Anat Entwicklungsgesch*. 1964;124:126–152 [in German].

Male Reproductive Physiology

Paul J. Turek MD, FACS, FRSM

The male reproductive axis of hormones and organs is a well-orchestrated and precisely managed biologic system that has evolved over millions of years. It is responsible for reproductive tract formation and development, fertility potential at puberty, and the maintenance of adult maleness. This chapter explores our current understanding of this complex system by defining its anatomy and physiology, including the hypothalamic-pituitary-gonadal (HPG) hormonal axis, spermatogenesis, and androgen production within the testicle and maturation and transport of sperm in the ductal system. In addition, new concepts in genetic and epigenetic infertility, stem cell science, and ejaculatory physiology are explained. Through such rigorous intellectual dissection, the true beauty and sophistication of the reproductive process is appreciated.

Hypothalamic-Pituitary-Gonadal Axis

The HPG axis plays a critical role during development and adulthood in four physiologic processes: (1) **phenotypic gender** development during embryogenesis, (2) **sexual maturation** at puberty, (3) testis endocrine function—**testosterone production,** and (4) testis exocrine function—**sperm production.**

Basic Endocrine Concepts

Two types of hormones mediate communication in the reproductive axis: peptide and steroid. **Peptide hormones are small, secretory proteins that act through cell surface receptors.** Hormone signals are transduced by one of several second-messenger pathways (Fig. 64.1). Most peptide hormones induce phosphorylation of proteins that alter cell function. Examples of peptide hormones are luteinizing hormone (LH) and follicle-stimulating hormone (FSH). In contrast, **steroid hormones are derived from cholesterol. They are not stored in secretory granules; consequently, steroid secretion directly reflects rates of hormone production.** In plasma, these hormones are usually bound to carrier proteins, and because they are lipophilic, steroid hormones are cell membrane permeable. After binding to intracellular receptors, steroids are translocated to nuclear DNA recognition sites and regulate target gene transcription. Examples of reproductive axis steroid hormones are testosterone and estradiol.

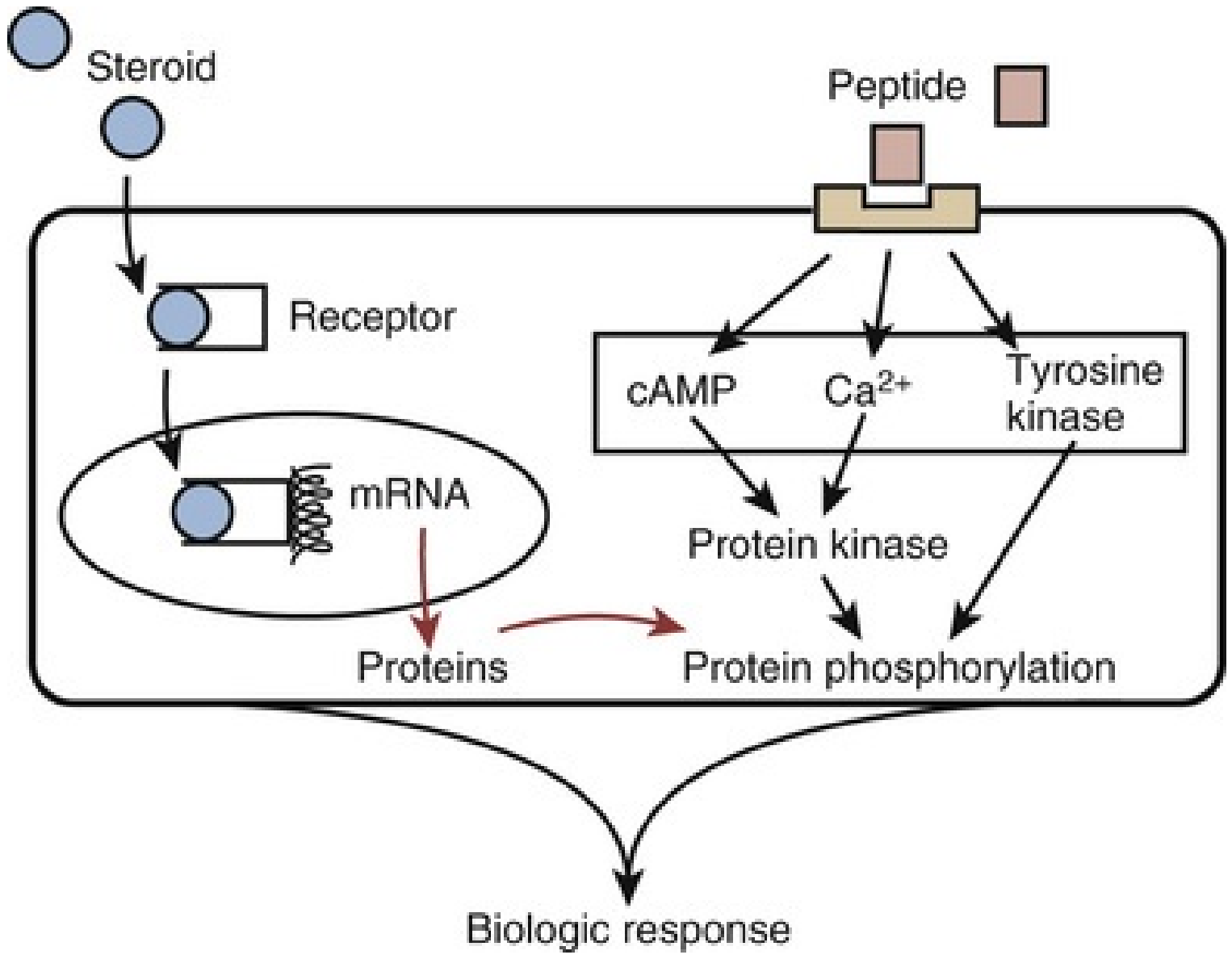
Steroid
Peptide
Receptor
cAMP
Ca^{2+}
Tyrosine kinase
mRNA
Protein kinase
Proteins
Protein phosphorylation
Biologic response

FIG. 64.1 Two kinds of hormone classes mediate intercellular communication in the reproductive hormone axis: peptide and steroid. (Modified from Turek PJ: Male infertility. In Tanagho EA, McAninch JC, editors: *Smith's urology,* ed 16, Stamford, CT, 2008, Appleton & Lange.)

Hormonal signaling within the HPG axis is hierarchically governed by a free-running pulse generator within the hypothalamus. The amplitude and frequency with which hormone secretions occur within the reproductive axis determine downstream organ responsiveness. Feedback control is the principal mechanism through which hormonal regulation occurs (Fig. 64.2). With feedback control, a hormone can regulate the synthesis and action of itself or of another hormone. **In the HPG axis, negative feedback activity is primarily responsible for minimizing perturbations and maintaining homeostasis.**

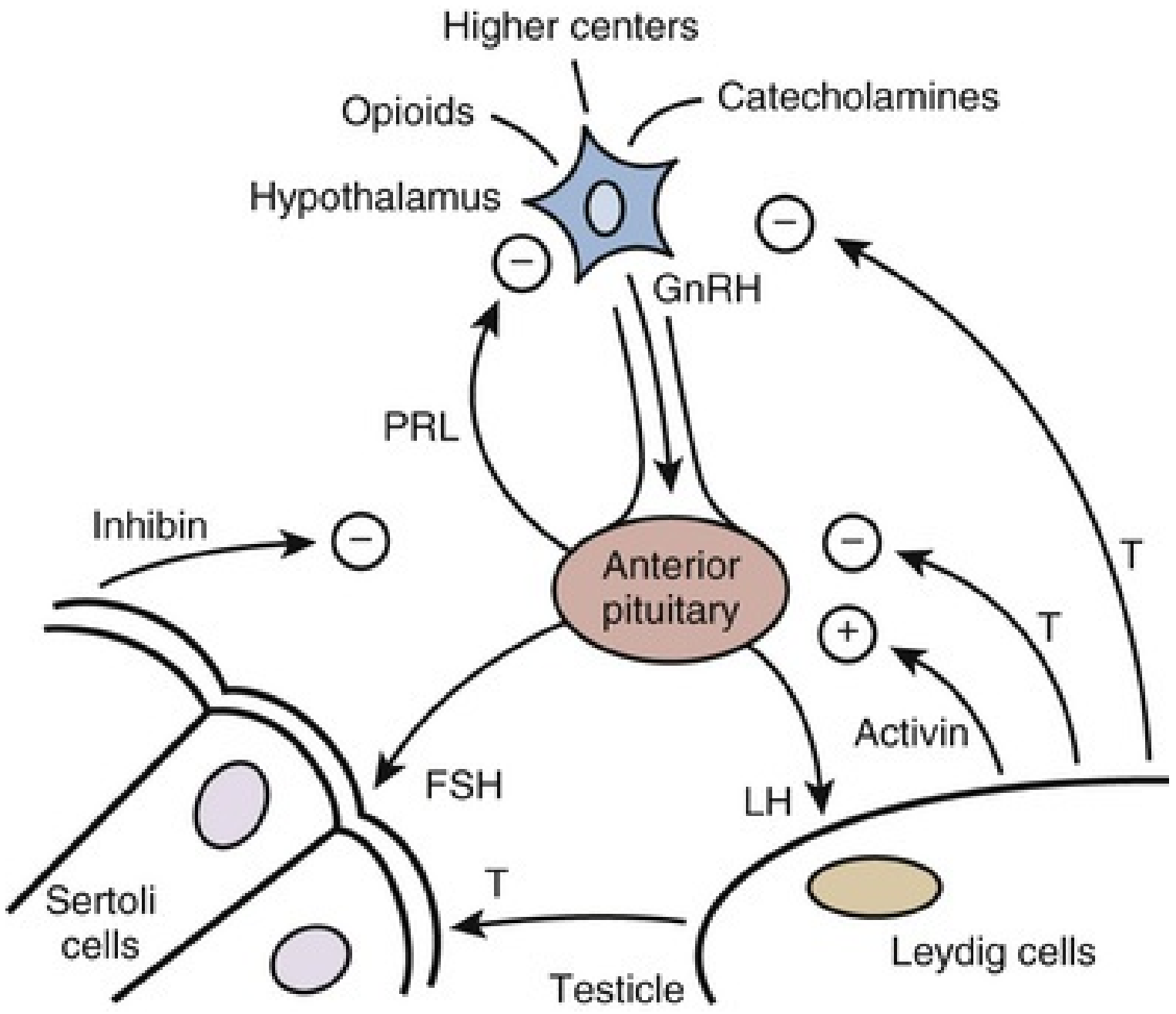

FIG. 64.2 Diagram of the hypothalamic-pituitary-testis hormonal axis. +, Positive feedback; −, negative feedback; *FSH,* follicle-stimulating hormone; *GnRH,* gonadotropin-releasing hormone; *LH,* luteinizing hormone; *PRL,* prolactin; *T,* testosterone. (Modified from Turek PJ: Male infertility. In Tanagho EA, McAninch JC, editors: *Smith's urology*, ed 16, Stamford, CT, 2008, Appleton & Lange.)

Components of the Reproductive Axis

Hypothalamus

As the integrative center of the HPG axis, the hypothalamus receives neuronal input from the amygdala, thalamus, pons, retina, olfactory cortex, and many other areas (see Fig. 64.2). The pulse generator for the cyclic secretion of pituitary hormones, **the hypothalamus is anatomically linked to the pituitary gland by a portal vascular system and neuronal pathways.** By avoiding the systemic circulation, the portal vascular system allows direct delivery of hypothalamic hormones to the anterior pituitary.

The most important hypothalamic hormone for reproduction is gonadotropin-releasing hormone (GnRH), a 10–amino acid peptide generated in the neuronal cell bodies in the preoptic and arcuate nuclei. **Currently, the only known function of GnRH is to stimulate the secretion of LH and FSH from the anterior pituitary.** GnRH has a plasma half-life of approximately 5 to 7 minutes and is almost entirely removed on the first pass through the pituitary either by receptor internalization or enzymatic degradation. GnRH secretion results from integrated input of stress, exercise, and diet from higher brain centers, gonadotropins secreted from the pituitary, and circulating gonadal hormones. Substances known to regulate GnRH secretion are listed in Table 64.1. In **Kallman syndrome,** characterized by congenital hypogonadotropic hypogonadism, the GnRH precursor neurons fail to migrate normally, with a subsequent absence of hypothalamic GnRH secretion (Bick et al., 1992; Dode et al., 2003). Affected individuals have delayed puberty or infertility because of lack of testosterone production.

TABLE 64.1

Substances That Modulate Gonadotropin-Releasing Hormone (GnRH) Secretion

GnRH MODULATOR	TYPE OF FEEDBACK	EXAMPLES
Opioids	Negative	β-Endorphin
Catecholamines	Variable	Dopamine
Peptide hormones	Negative	FSH, LH
Sex steroids	Negative	Testosterone
Prostaglandins	Positive	PGE_2
Insulin	Positive	Insulin
Kisspeptins	Positive	Kisspeptin (puberty)
Leptins	Positive	Leptin

FSH, Follicle-stimulating hormone; *LH,* luteinizing hormone; *PGE_2,* prostaglandin E_2.

GnRH output exhibits several types of rhythmicity: seasonal, on a time scale of months and peaking in the spring; circadian, resulting in higher testosterone levels during the early morning hours; and pulsatile, with GnRH peaks occurring every 90 to 120 minutes on average. The importance of pulsatile GnRH secretions in normal HPG axis function is aptly demonstrated by the ability of exogenous GnRH agonists (e.g., leuprolide acetate) to stop testicular testosterone production by changing pituitary exposure to GnRH from a cyclic to a constant pattern.

Anterior Pituitary

Located within the bony sella turcica of the skull, the pituitary has two lobes: posterior and anterior. The posterior lobe, or neurohypophysis, secretes two hormones, oxytocin and vasopressin, and is driven by neural stimuli. In contrast,

the anterior pituitary, or adenohypophysis, is regulated by blood-borne factors and is the site of action of GnRH (see Fig. 64.2). GnRH stimulates the production and release of FSH and LH by a calcium flux–dependent mechanism. The sensitivity of pituitary gonadotrophs for GnRH varies with an individual's age and hormonal status. **LH and FSH are the primary pituitary hormones that regulate testis function.** They are glycoproteins composed of two polypeptide chain subunits, termed α and β, each coded by a separate gene. The α subunit of each hormone is identical and is similar to that of all other pituitary hormones; biologic and immunologic activities are conferred by the unique β subunit. Both subunits are required for endocrine activity. Sugars linked to these peptide subunits, consisting of oligosaccharides with sialic acid residues, differ in content between FSH and LH and likely account for differences in their plasma clearance rates. Secretory pulses of LH vary in frequency from 8 to 16 pulses in 24 hours and vary in amplitude by onefold to threefold. These pulse patterns closely reflect GnRH release. **Androgens and estrogens regulate LH secretion through negative feedback.** On average, FSH pulses occur every 1.5 hours and vary in amplitude by 25%. The FSH response to GnRH is more difficult to assess than that of LH for two reasons: (1) FSH has a smaller amplitude response and a longer serum half-life and (2) **the gonadal proteins inhibin and activin may affect FSH secretion and are thought to account for the relative secretory independence of FSH from GnRH secretion.**

FSH and LH are only known to act in the gonads. They activate adenylate cyclase, which leads to increases in intracellular cyclic adenosine monophosphate (cAMP). In the testis, LH stimulates steroidogenesis within Leydig cells by inducing the mitochondrial conversion of cholesterol to pregnenolone and testosterone. **FSH binds to Sertoli cells and spermatogonial membranes within the testis and is the major stimulator of seminiferous tubule growth during development. FSH is essential for the initiation of spermatogenesis at puberty.** In the adult, the major physiologic role of FSH is to stimulate **quantitatively normal** levels of spermatogenesis (Tapanainen et al., 1997).

A third anterior pituitary hormone, prolactin, can also affect the HPG axis and fertility. Prolactin is a large, globular protein of 199 amino acids (23 kD) that is responsible for milk synthesis during pregnancy and lactation in women. No human mutations have been found in either the human prolactin gene or its receptor (Goffin et al., 2002). **The role of prolactin in men is less clear, but it may increase the concentration of LH receptors on Leydig cells and sustain**

normal, high intratesticular testosterone levels. It may also potentiate the effects of androgens on the growth and secretions of the male accessory sex glands (Steger et al., 1998; Wennbo et al., 1997). Normal prolactin levels may be important to maintain libido. Although low prolactin levels are not necessarily pathologic, hyperprolactinemia abolishes gonadotropin pulsatility by interfering with episodic GnRH release. In addition, the anterior pituitary contains cells that secrete other glycoprotein hormones: adrenocorticotropic hormone (ACTH), growth hormone (GH), and thyroid-stimulating hormone (TSH). These glycoprotein hormones can also have significant effects on male reproduction.

Testis

Normal male virility and fertility require the collaboration of the exocrine and endocrine testis (see Fig. 64.2). The interstitial compartment, composed mainly of Leydig cells, is responsible for steroidogenesis. The seminiferous tubules produce spermatozoa.

Normal testosterone production in men is approximately 5 g/day, and secretion occurs in a damped, irregular, pulsatile manner (nyctohemeral). Testosterone is metabolized into two major active metabolites in target tissue: (1) the major androgen **dihydrotestosterone (DHT)** from the action of **5α-reductase,** and (2) the estrogen **estradiol** through the action of **aromatases.** DHT is a much more potent androgen than is testosterone. In most peripheral target tissues, testosterone reduction to DHT is required for androgen action, but in the testis and skeletal muscle, conversion to DHT is not essential for hormonal activity.

The primary site of FSH action is on Sertoli cells within seminiferous tubules. In response to FSH, Sertoli cells produce androgen-binding protein (ABP), transferrin, lactate, ceruloplasmin, clusterin, plasminogen activator, prostaglandins, and growth factors. Through these FSH-mediated factors, seminiferous tubule growth is stimulated during development, and sperm production is initiated during puberty. Mice FSH knockout studies suggest that FSH is not essential for spermatogenesis; indeed, affected mice can be fertile (Levallet et al., 1999).

The testis also produces the protein hormones inhibin and activin (Itman et al., 2006). Inhibin is a 32-kD protein made by Sertoli cells that inhibits FSH release from the pituitary. Within the testis, **inhibin production is stimulated by FSH and acts by negative feedback at the pituitary or hypothalamus.**

Activin, a testis protein with close structural homology to transforming growth factor-β (TGF-β), exerts a stimulatory effect on FSH secretion. Activin receptors are found in a host of extragonadal tissues, suggesting that this hormone may have growth factor or regulatory roles in the body.

Negative feedback suppression of GnRH release by testosterone occurs through androgen receptors (ARs) in hypothalamic neurons and in the pituitary. **In studies of genetic mutations, it is clear that testosterone and estrogen participate in negative feedback** (Shupnik and Schreihofer, 1997). Steroid negative feedback results mainly from AR binding to testosterone, with a smaller contribution from estradiol binding. **Testosterone feedback occurs mainly at the hypothalamus, whereas estrogen feedback is mainly in the pituitary** (Santen, 1975). It also appears that although testosterone is the primary regulator of LH secretion, estradiol (along with inhibin from Sertoli cells) is the predominant regulator of FSH secretion (Hayes et al., 2001).

Development of the Hypothalamic-Pituitary-Gonadal Axis

Sex determination is genetic in humans. **A critical gene for sex determination is *SRY* (sex-determining region Y gene) on the short arm of the Y chromosome.** The *SRY* gene product is a protein with a high mobility group (HMG) box sequence, a highly conserved DNA-binding motif that kinks DNA. This DNA bending effect alters gene expression, leading to testis formation and subsequently to the male phenotype. However, the *SRY* gene does not act in isolation to determine human sex. ***DAX1,*** a nuclear hormone receptor gene, can alter *SRY* activity during development by suppressing genes downstream to *SRY* that would normally induce testis differentiation. A second gene, ***WNT4,*** largely confined to the adult ovary, may also serve as an “antitestis” gene. The discovery of these genes has significantly altered theories of sex determination. In the past, the female genotype was considered the “default,” *SRY*-negative, developmental pathway. **It is now clear that genes such as *WNT4* and *DAX1* can proactively induce female gonadal development, even in the presence of *SRY*** (DiNapoli and Capel, 2008).

Once gonadal sex is determined, Leydig cells make **testosterone,** which induces development of the **internal genitalia** (Fig. 64.3). Leydig cells also synthesize **insulin-like growth factor-3** to promote **transabdominal testis migration** into the scrotum. **DHT** masculinizes the genital anlage to form the

external genitalia (see Fig. 64.3). In addition, Sertoli cells within the developing testis synthesize **müllerian-inhibiting substance (MIS, or antimüllerian hormone [AMH]),** which **prevents the müllerian duct from developing into uterus and fallopian tubes and keeps the early germ cells quiescent** in the testis (Fig. 64.4). In general, deficiencies in these developmental pathways result in either birth defects or intersex disorders.

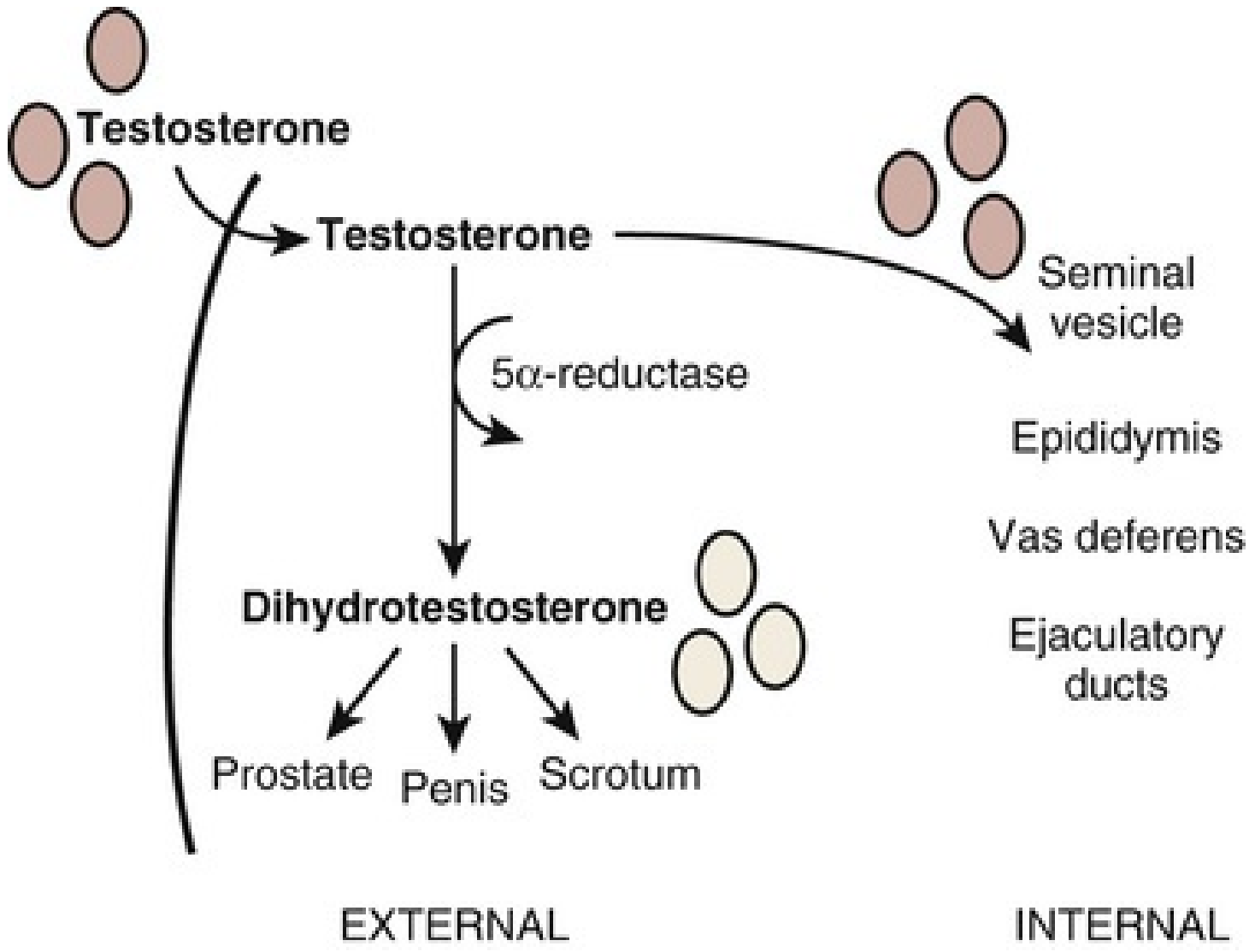
Testosterone
Testosterone
5α-reductase
Dihydrotestosterone
Prostate
Penis
Scrotum
Seminal vesicle
Epididymis
Vas deferens
Ejaculatory ducts
EXTERNAL
INTERNAL

FIG. 64.3 Diagram of internal and external genitalia development. Testosterone is the main androgenic steroid responsible for the developing male internal genitalia, whereas dihydrotestosterone is the main androgen responsible for development of male external genitalia.

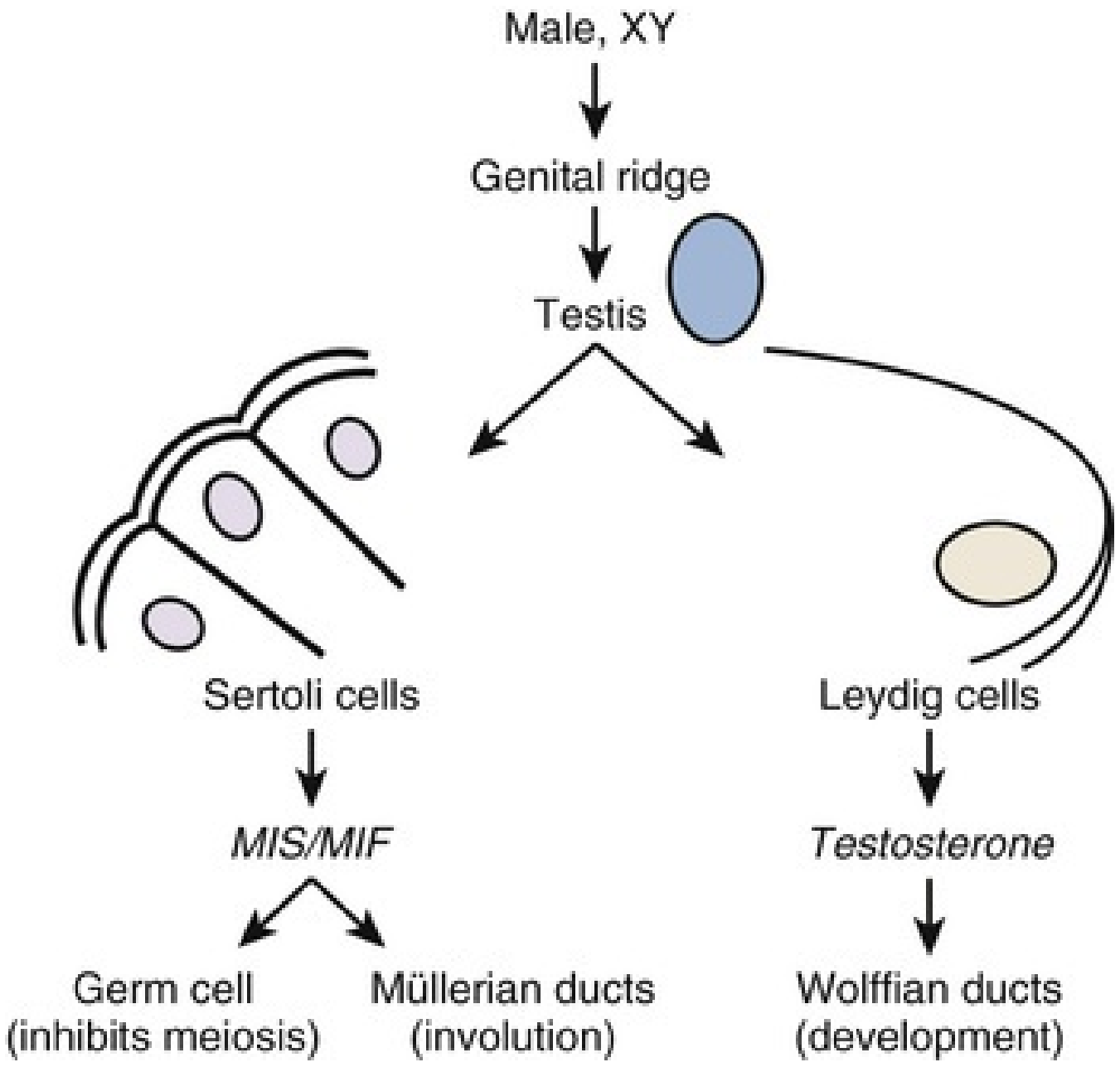

FIG. 64.4 Early differentiation pathway of the male. *MIS/MIF,* Müllerian inhibiting substance/factor. (Modified from Turek PJ. Male infertility. In Tanagho EA, McAninch JC, editors: *Smith's urology,* ed 16, Stamford, CT, 2008, Appleton & Lange.)

The hormonal feedback relationships within the HPG axis become established during gestation. **The expression of kisspeptin protein is in part responsible for activating GnRH neurons and triggering GnRH release.** In addition, SF-1, an orphan nuclear receptor, is secreted by developing Sertoli cells and contributes to HPG axis development (Val et al., 2003). After the withdrawal of placental steroids at birth, there is a period of high gonadotropin secretion in the neonate. Subsequently, as axis sensitivity to gonadotropins increases, FSH and LH secretions fall to the low levels characteristic of childhood. Puberty begins with GnRH pulsing, leading gonadotropins to increase to adult levels and subsequently to increase sex hormones. **The hypothalamic capacity to generate GnRH pulses arises at puberty, usually starting around the 12th year in males. Puberty begins at critical growth, weight, and nutritional rates for boys and girls and is likely initiated by kisspeptin, melatonin, and leptin** (Clement et al., 1998). The adipocyte hormone leptin is the body's regulatory signal governing the size of the fat stores, and there is increasing evidence that leptin modulates hypothalamic and pituitary activity (Caprio et al., 1999; Kiess et al., 1999; Quinton et al., 1999).

Aging and the Hypothalamic-Pituitary-Gonadal

Axis

A progressive decline in testosterone and sperm production occurs with age, such that men in the seventh decade have mean plasma testosterone levels 35% lower than young men (Vermeulen et al., 1995). The consequence of this is a phenomenon that has been variously termed **male menopause, male climacteric, andropause, or, more appropriately, partial androgen deficiency in the aging male (PADAM).** The changes to the seminiferous epithelium with age include decreases in seminiferous tubule volume and length. **An age-related decrease in sperm production in older testes appears to stem from decreased germ cell proliferation rather than increased cellular degeneration.** Correspondingly, **FSH levels also increase with age,** with mean values threefold higher in older than younger men. The cause of the age-related decline in HPG axis function is multifactorial. Testosterone production is reduced because of fewer Leydig cells and more testosterone-binding proteins. Diurnal variation of testosterone secretion is also lost in elderly men. With age, there is also evidence for a blunted HPG feedback response to low testosterone (despite generally high levels of gonadotropins) and to GnRH stimulation. Finally, normal pulsatile GnRH release is replaced by irregular pulses that are less effective in stimulating gonadotropin release (Mulligan et al., 1997). A combination of these effects is likely responsible for diminished HPG axis function with age.

Key Points: Hypothalamic-Pituitary-Gonadal Axis

- Normal testosterone and sperm production depends on the pulsatile secretion of hypothalamic GnRH and LH and FSH from the anterior pituitary gland.
- Regulation of HPG axis hormones occurs primarily through negative feedback.
- The determination of maleness is derived from the *SRY* gene on the Y chromosome. However, developmental genes such as *WNT4* and *DAX1* are considered antitestis genes and can proactively induce female gonadal development.
- Changes to the HPG axis with paternal age include lower testosterone levels, blunted axis feedback, and irregular hormone pulsatility.

Testis

Gross Architecture

The testis is a white, ovoid organ that is normally 15 to 25 mL in volume (Prader, 1966) and has a length of 4.5 to 5.1 cm (Tishler, 1971; Winter and Faiman, 1972). The tunica albuginea has smooth muscle cells that course through collagenous tissue (Langford and Heller, 1973). Smooth muscle cells may impart contractile capability to the capsule (Rikmaru and Shirai, 1972), may affect blood flow into the testis (Schweitzer, 1929), and promote the flow of seminiferous tubule fluid from the testis (Davis and Horowitz, 1978).

The testis parenchyma is divided into compartments by septa. Each septum divides seminiferous tubules into lobes that each contain a centrifugal artery. **Individual seminiferous tubules harbor developing germ cells. Interstitial tissue is composed of Leydig cells, mast cells, macrophages, nerves, and blood and lymph vessels. In humans, interstitial tissue makes up 20% to 30% of total testicular volume** (Setchell and Brooks, 1988). The relationship between seminiferous tubules and interstitial tissue anatomy is demonstrated in Fig. 64.5. Seminiferous tubules are long, highly coiled, and looped. Both ends terminate in the rete testis. **The combined length of the 600 to 1200 tubules in the human testis is estimated to be 250 m** (Lennox and Ahmad, 1970; Fig. 64.6). The “hub” of the testis, also termed the **rete testis,** coalesces to form 6 to 12 **ductuli efferentes** that carry testicular fluid and spermatozoa into the **caput epididymis** (see Fig. 64.6).

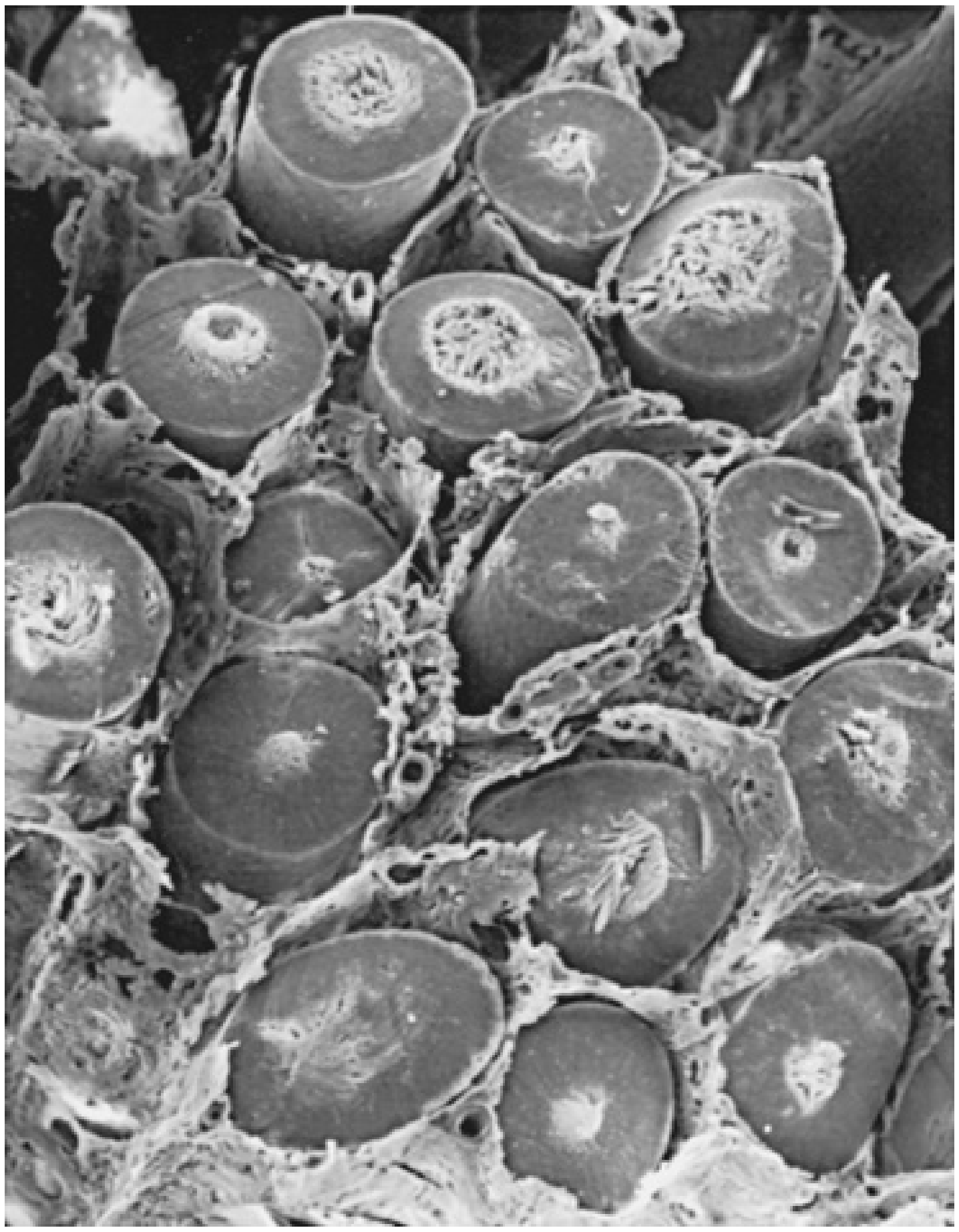

FIG. 64.5 Scanning electron micrograph of the cut surface of the human testis. Note the relationship of interstitial tissue to seminiferous tubules. (From Christensen AK. Leydig cells. In Greep RO, Astwood EB, editors: *Handbook of physiology*, Washington, DC, 1975, American Physiology Society, pp 57–94.)

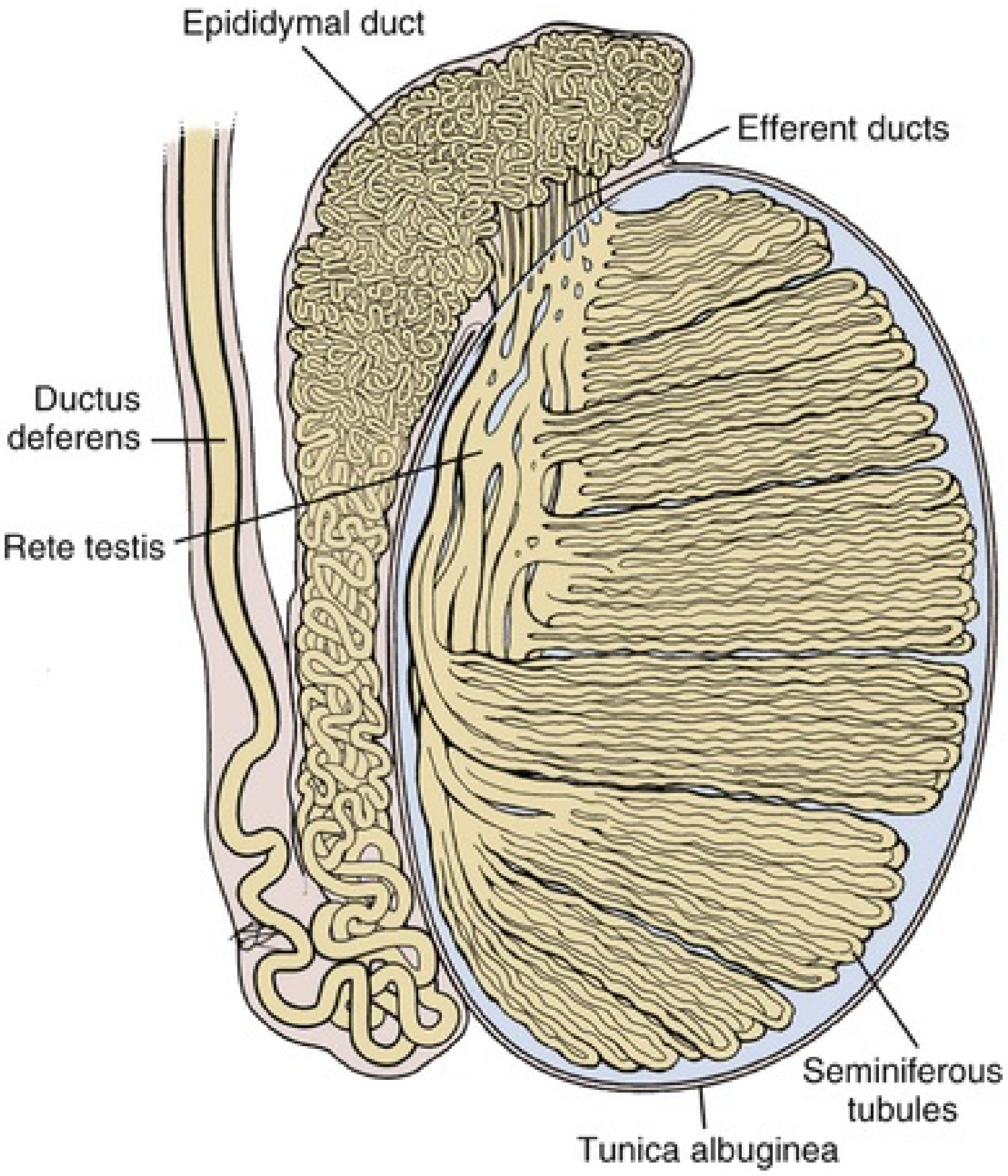

FIG. 64.6 Drawing of the human testis showing the seminiferous tubules (250 m in length), epididymis (3 to 4 m in length), and vas deferens. (Based on Hirsh AV: The anatomical preparations of the human testis and epididymis in the Glasgow Hunterian Collection. *Hum Reprod Update* 1:515–521, 1995.)

The arterial supply to the testis and epididymis is derived from three sources: the internal spermatic artery, the deferential (vasal) artery, and the external spermatic (or cremasteric) artery (Harrison and Barclay, 1948). The internal spermatic artery arises from the abdominal aorta and is intimately associated with the pampiniform plexus of veins. The vascular arrangement within the pampiniform plexus, with counterflowing artery and veins, facilitates the exchange of heat and small molecules. For example, testosterone passively diffuses from veins to the artery in a concentration-limited manner (Bayard et al., 1975). **The countercurrent heat exchange supplies arterial blood to the testis that is 2°C to 4°C lower than the rectal temperature in normal men** (Agger, 1971). A loss of the temperature differential is associated with testicular dysfunction in men with varicocele (Goldstein and Eid, 1989) and cryptorchidism (Marshall and Edler, 1982). As the spermatic cord is commonly dissected during varicocele repair, it is surgically relevant to know that a single artery is observed in 50% of spermatic cords, with two arteries in 30% and three arteries in 20% of cases (Beck et al., 1992).

Inferior to the scrotal pampiniform plexus and near the mediastinal testis, the spermatic artery is highly coiled and branches before entering the testis. Extensive interconnections, especially between the internal spermatic and deferential arteries, allow maintenance of testis viability even after division of the internal spermatic artery (Fig. 64.7). From angiographic studies, a single artery enters the testis in 56% of cases; two branches in 31% of cases, and three or more branches in 13% of testes (Kormano and Suoranta, 1971). In men with a single testicular artery, its interruption can result in testicular atrophy (Silber, 1979). The testicular arteries penetrate the tunica albuginea and travel inferiorly along the posterior surface of the testis within the parenchyma. Branching arteries pass anteriorly over the testicular parenchyma. Major testicular artery branches also travel over the inferior pole of the testis, pass anteriorly, and branch out over the surface of the testis. The location of these vessels is clinically important, because they may be injured during orchiopexy, testis biopsy, or sperm retrieval procedures (Jarow, 1991; Schlegel and Su, 1997). **The midsection of the testis has relatively fewer vessels compared with superior or inferior areas.** Individual arteries to the seminiferous tubules, termed **centrifugal arteries,** travel within the septa. Centrifugal artery branches give rise to arterioles that supply individual intertubular and peritubular capillaries (Muller, 1957). The intertubular capillaries are located within the columns of interstitial tissue, whereas the ladder-like capillaries running near the seminiferous tubule are called **peritubular capillaries.** Through this vascular complex, the human testis is provided with 9 mL of blood per 100 g of tissue per minute (Pettersson et al., 1973).

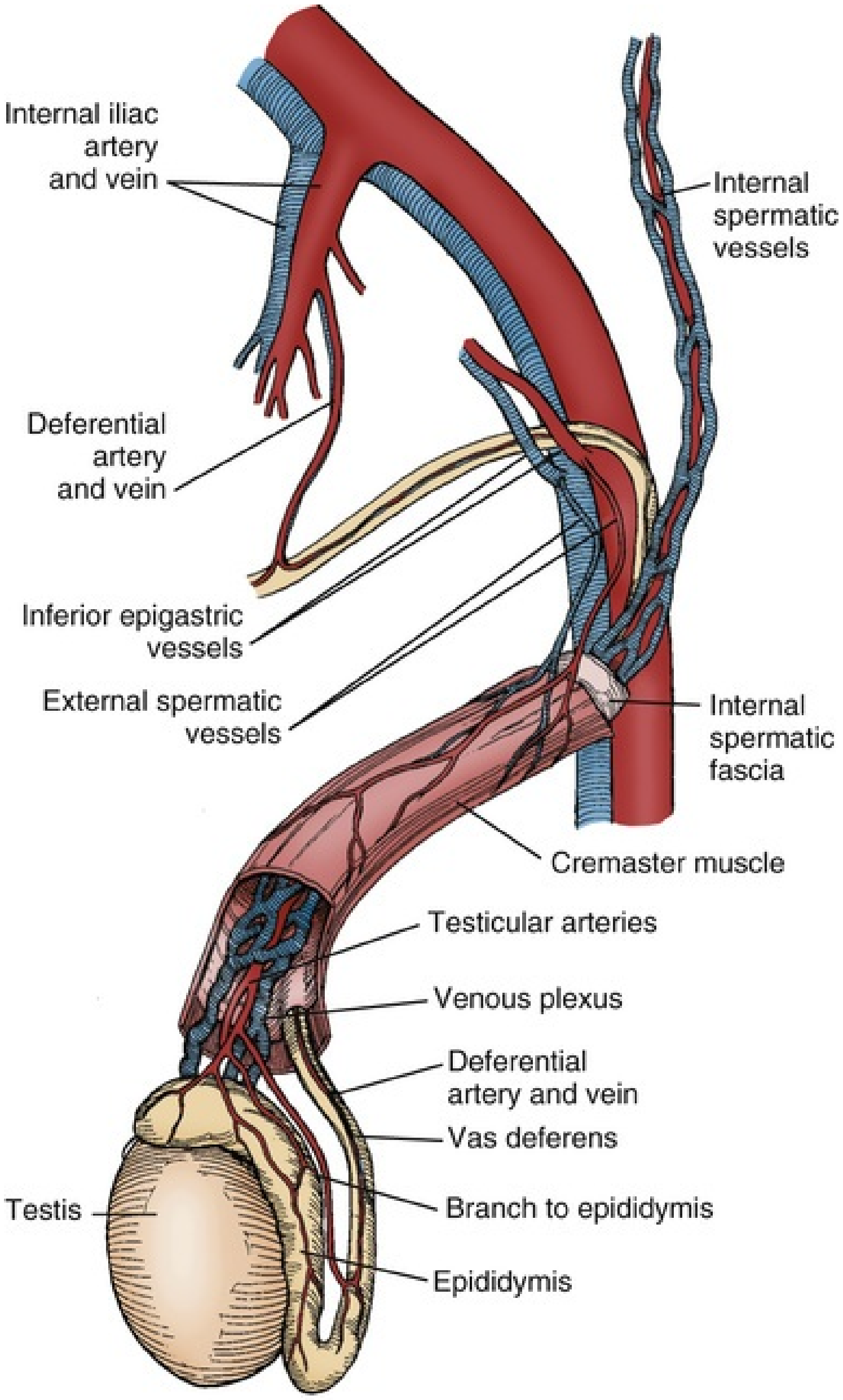
Internal iliac artery and vein
Internal spermatic vessels
Deferential artery and vein
Inferior epigastric vessels
External spermatic vessels
Internal spermatic fascia
Cremaster muscle
Testicular arteries
Venous plexus
Deferential artery and vein
Vas deferens
Testis
Branch to epididymis
Epididymis

FIG. 64.7 Schematic illustration of interconnections between internal spermatic, external spermatic (cremasteric), and deferential vessels in the peritesticular region and spermatic cord.

Veins within the testis are unusual in that they do not run with the corresponding intratesticular arteries. Small parenchymal veins empty either into the veins on the testis surface or into a group of veins near the mediastinum testis that travels along the rete testis (Setchell and Brooks, 1988). These two sets of veins join together with deferential veins to form the pampiniform plexus as they ascend into the scrotum. Pampiniform plexus veins are thin walled, which likely contributes to the effective diffusion of testosterone and heat with the closely associated spermatic artery.

The testis has no known somatic innervation. It receives autonomic innervation primarily from the intermesenteric nerves and renal plexus (Mitchell, 1935). These nerves run along the testicular artery into the testis. It appears that testicular adrenergic innervation is restricted primarily to small blood vessels that supply Leydig cell clusters that may regulate Leydig cell steroidogenesis (Baumgarten et al., 1968; Turnbull and Rivier, 1997). It is thought that vascular tone in the testis is regulated at several levels (Linzell and Setchell, 1969), including autoregulation of capsular arteries (Davis et al., 1990), and regional variation is based on local metabolic need and governed by peptides such as atrial natriuretic peptide (Collin et al., 1997) and assisted transport of molecules such as LH across the vascular endothelium (Milgrom et al., 1997). Indeed, these observations suggest a highly specialized function for the microvasculature of the testis (see review by Desjardins [1989]).

Prominent lymphatics can be observed within the spermatic cord (Hundeiker, 1971). Obstruction of these ducts results in dilation of the testis interstitium but not the seminiferous tubules, suggesting that the interstitial space is drained by lymphatics.. **Lymphatic obstruction can also result in hydrocele formation, a known complication of varicocelectomy and herniorrhaphy procedures.** The sperm-containing intratubular fluid that bathes Sertoli cells flows from the seminiferous tubules into the rete testis and subsequently into the caput epididymis. This fluid, isosmotic with plasma, is thought to be mainly of seminiferous tubule origin (Setchell and Brooks, 1988). **Reabsorption of this fluid within the rete testis and efferent ductules is regulated by estrogens** (Lee et al., 2000). Tubular fluid composition is markedly different from blood plasma or lymphatics, suggesting that substances are not freely diffusible into and out of the tubules (Setchell and Waites, 1975). This has led to the concept of a “blood-testis barrier” to be discussed later.

Testis Cytoarchitecture

Interstitium

Leydig Cells.

The testis interstitium contains blood vessels, lymphatics, fibroblasts, macrophages, mast cells, and Leydig cells (Fig. 64.8). **Leydig cells are responsible for the bulk of testicular steroid production. Leydig cells**

differentiate from mesenchymal precursor cells by the seventh week of gestation. The activation of Leydig cell steroidogenesis correlates with the onset of androgen-dependent differentiation of the male reproductive system. Leydig cells differentiate from stem cell precursors under the influence of LH and placental-derived human chorionic gonadotropin (hCG) and from the effect of local paracrine factors such as insulin-like growth factor-1 (IGF-1) (Huhtaniemi and Pelliniemi, 1992; Le Roy et al., 1999; Teerds and Dorrington, 1993). **By 3 months after birth, a second wave of Leydig cell differentiation occurs in response to pituitary LH production, briefly elevating testosterone levels.** Androgen produced during the early male neonate's life is thought to hormonally imprint the hypothalamus, liver, and prostate such that they respond appropriately to androgen stimulation later in life. **After reactivation of the HPG axis at puberty, stereologic analysis has revealed that a single testis from a young adult contains approximately 700 million Leydig cells** (Kaler and Neaves, 1978).

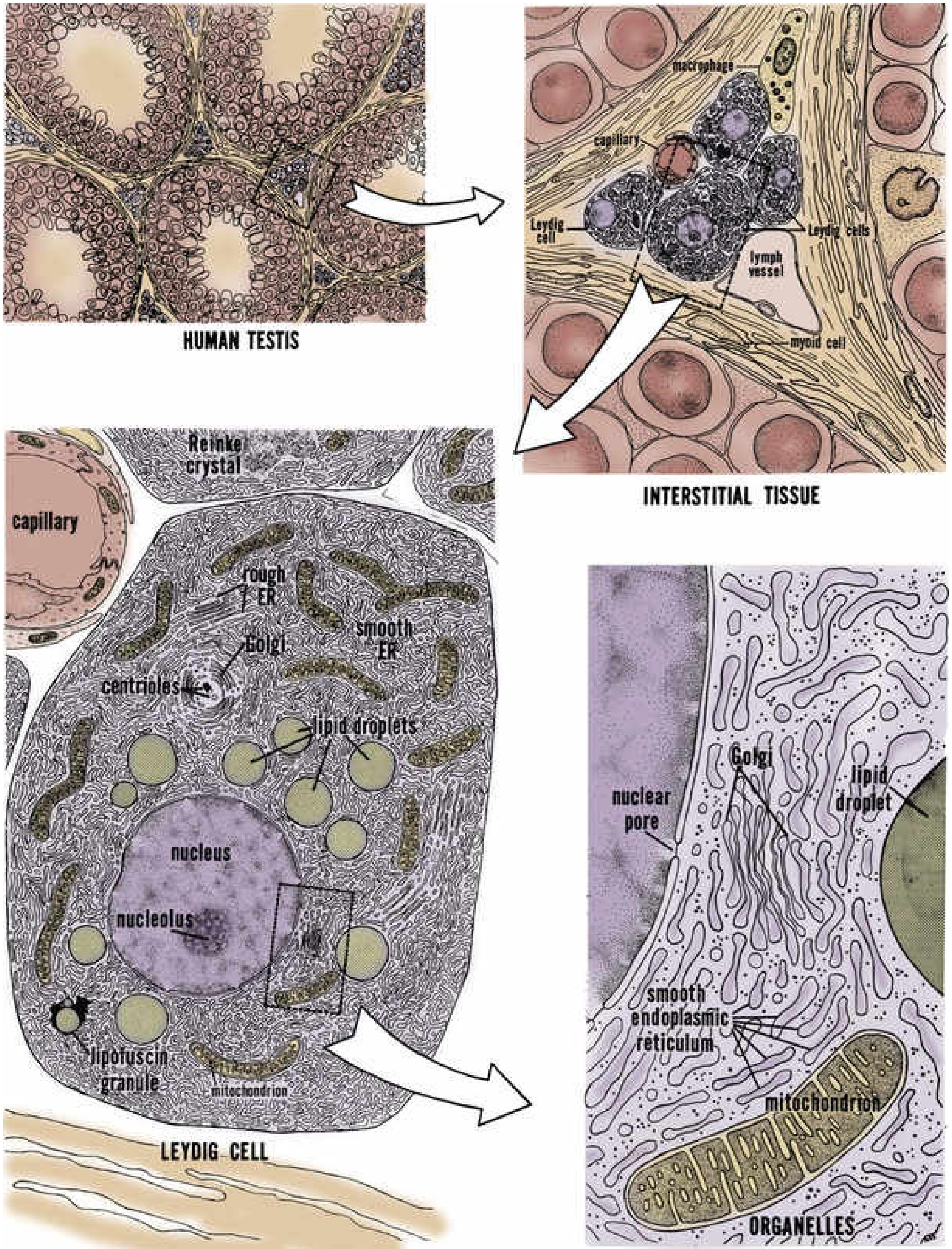

HUMAN TESTIS

INTERSTITIAL TISSUE

LEYDIG CELL

ORGANELLES

macrophage
capillary
Leydig cell
Leydig cells
lymph vessel
myoid cell
Reinke crystal
capillary
rough ER
smooth ER
Golgi
centrioles
lipid droplets
nucleus
nucleolus
lipofuscin granule
mitochondrion
Golgi
lipid droplet
nuclear pore
smooth endoplasmic reticulum
mitochondrion

FIG. 64.8 Fine structure of human Leydig cells. Leydig cells occur in clusters in the interstitium between seminiferous tubules *(upper left).* Interstitial tissue *(upper right)* contains macrophages and fibroblasts and capillaries and lymph vessels. The most abundant organelle within the Leydig cell cytoplasm is the smooth endoplasmic reticulum *([ER], lower*

left). Organelles seen in greater detail *(lower right).* (From Christensen AK: Leydig cells. In Greep RO, Astwood WB, editors: *Handbook of physiology*, Baltimore, 1975, Williams & Wilkins. Copyright 1975, American Physiological Society, Bethesda, MD.)

Testosterone.

Testosterone, synthesized from cholesterol, is the principal steroid produced by the testis (Lipsett, 1974). Numerous C18, C19, and C21 steroids are also produced (Ewing and Brown, 1977; Lipsett, 1974). Cholesterol is transported into Leydig cell mitochondria, where the cholesterol side-chain cleavage enzyme converts it to pregnenolone. Maintenance of cholesterol stores is part of normal Leydig cell function; LH stimulation evokes cholesterol mobilization through cholesterol esterase activity. Pregnenolone is transported out of the mitochondrial membrane into the smooth endoplasmic reticulum, where it is converted into testosterone. Testosterone diffuses across the cell membrane and is trapped within the extracellular fluid and blood plasma by steroid-binding proteins.

Cholesterol transport to the inner membrane of the mitochondrion is regulated by two transport proteins: steroidogenic acute regulatory (StAR) protein and peripheral benzodiazepine receptor (PBR). LH binding elicits StAR synthesis in the Leydig cell, which then threads through the outer mitochondrial membrane to facilitate cholesterol transport (Stocco, 2000). PBR forms a channel for cholesterol in the mitochondrial membrane (Culty et al., 1999), but it is not clear whether PBR functionally interacts with StAR (West et al., 2001).

The four major enzymes participating in testosterone biosynthesis from pregnenolone are cholesterol side-chain cleavage enzyme, 3β-hydroxysteroid dehydrogenase, cytochrome P450 17α-hydroxylase/C17-20-lyase, and 17β-hydroxysteroid dehydrogenase. The enzymology, chromosomal locations, and molecular genetics of these enzymes are well described (Payne and Hales, 2004). Mutations in the genes encoding these enzymes have been described, and the resulting disorders of androgen biosynthesis are a relatively rare cause of sexual ambiguity in chromosomally normal males (Miller, 2002).

Control of Testosterone Synthesis.

The control of Leydig cell steroidogenesis is complex and involves pituitary and nonpituitary factors (Payne and Youngblood, 1995). **The most important**

regulator of testosterone production is LH. After binding LH, through the second messenger cAMP, Leydig cells initiate transport of cholesterol into mitochondria. Pituitary peptides other than LH (e.g., FSH and prolactin) modify the response to LH (Ewing, 1983). Other, nonpituitary factors capable of modifying steroid production by Leydig cells include **GnRH** (Sharpe, 1984); **inhibin** and **activin** (Bardin et al., 1989); **epidermal growth factor (EGF), IGF-1, and TGF-β** (Ascoli and Segaloff, 1989; Saez et al., 1991); prostaglandins (Eik-Nes, 1975); and adrenergic stimulation (Eik-Nes, 1975). Moreover, direct inhibition of Leydig cell steroidogenesis may also occur through **estrogens and androgens** (Darney et al., 1996; Ewing, 1983).

Testosterone Cycles.

Testosterone blood levels change dramatically during human fetal, neonatal, and adult life. Fig. 64.9 shows that a testosterone peak occurs in the human fetus at 12 to 18 weeks of gestation. Another testosterone peak occurs at approximately 2 months of age. A third testosterone peak occurs during the second decade of life. After this, there is a plateau, and then a slow decline with age. Superimposed on this, there are annual and daily rhythms of testosterone production (see Fig. 64.9, *insets A and B*) and irregular daily fluctuations in testosterone (see Fig. 64.9, *inset C*). These temporal changes in testosterone production reflect a complex and continuous interaction between the pituitary gland and testis. **The testosterone peaks correspond temporally to four developmental events: (1) the development of the fetal reproductive tract, (2) the neonatal "imprinting" of androgen-dependent target tissues, (3) masculinization at puberty, and (4) the maintenance of growth and function of androgen-dependent organs in the adult.** This topic has been reviewed thoroughly by Swerdloff and Heber (1981).

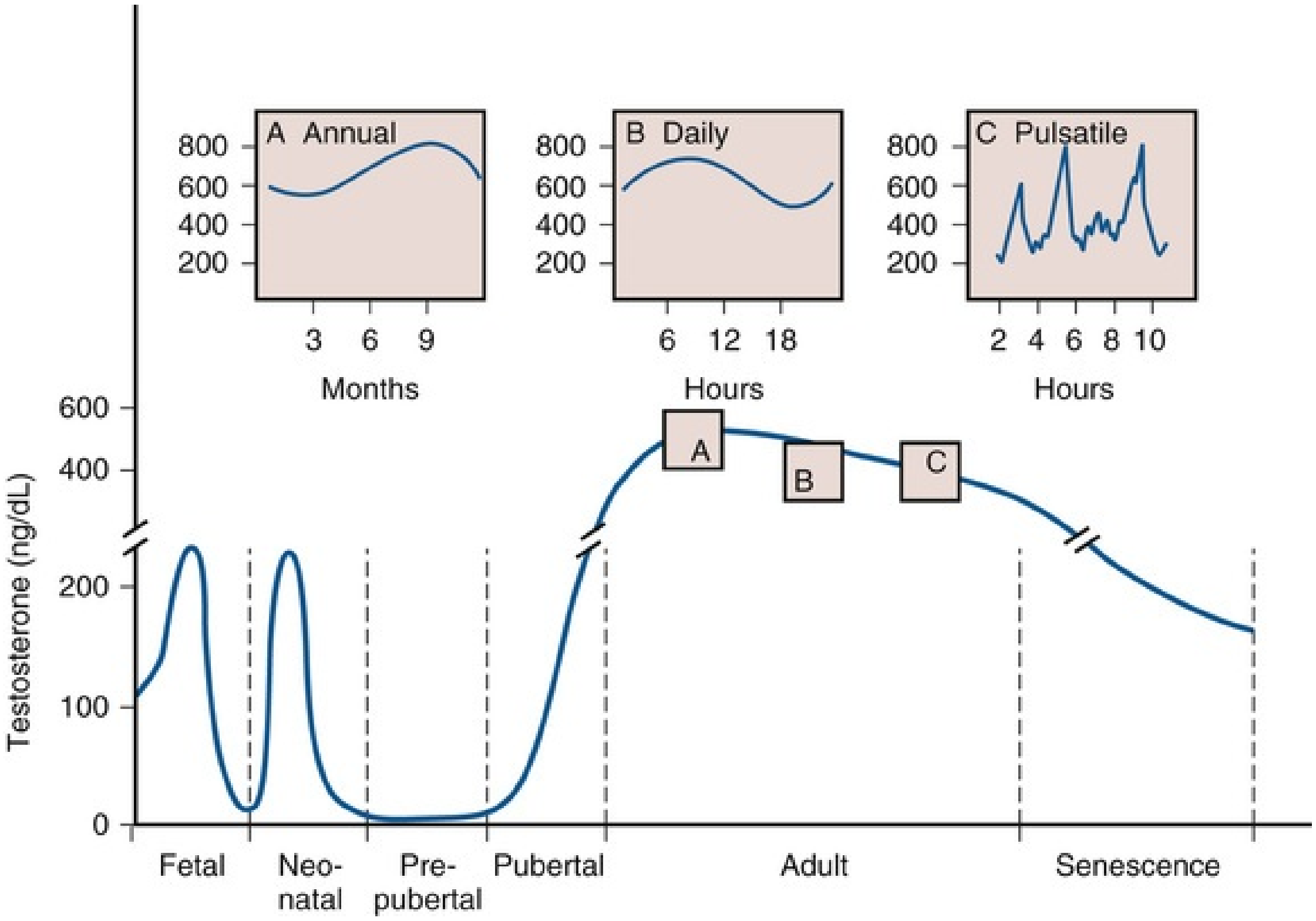

FIG. 64.9 Peripheral blood testosterone levels in the human male during the life cycle. The fetal testosterone peak occurs at 12 to 18 weeks' gestation *(lower left corner; gestational age not shown).* The neonatal peak occurs at approximately 2 months of age. Testosterone declines to low levels during the prepubertal period. The pubertal increase in testosterone occurs at 12 to 17 years of age. Testosterone concentration in the adult reaches its maximum during the second or third decade of life and then declines slowly. Testosterone declines dramatically during senescence. *Inset A* shows the annual rhythm in testosterone concentration in the human male. The peak and nadir occur in the fall and spring, respectively. *Inset B* shows the daily rhythm in testosterone concentration. The peak and nadir occur in the morning and evening, respectively. *Inset C* shows the frequent and irregular fluctuations in testosterone concentration. (From Ewing LL, Davis JC, Zirkin BR: Regulation of testicular function: a spatial and temporal view. In Greep RO, editor: *International review of physiology,* Baltimore, 1980, University Park Press, p 41.)

Seminiferous Tubules

The seminiferous tubules consist of germ cells and supporting cells and are a unique environment for gamete production. Support cells include Sertoli cells and fibrocyte and myoid cells of the basement membrane. The germ cells include a slowly dividing stem cell population, more rapidly proliferating spermatogonia and spermatocytes, and metamorphosing spermatids.

Sertoli Cells.

The seminiferous tubules are lined with Sertoli cells that rest on the tubular basement membrane and extend cytoplasmic ramifications into its lumen (Fig. 64.10). The ultrastructural features of Sertoli cells are well described (Bardin et al., 1994). They have irregularly shaped nuclei, prominent nucleoli, and a low mitotic index and exhibit unique **tight junctional complexes** between adjacent Sertoli cells. **These tight junctions are the strongest intercellular barriers in the body. They divide the seminiferous tubule space into basal (basement membrane) and adluminal (lumen) compartments** (see Fig. 64.10). This anatomic arrangement forms the basis for the **blood-testis barrier** and allows spermatogenesis to occur in an immunologically privileged site. **Sertoli cells serve as nurse cells for spermatogenesis, nourishing developing germ cells within and between Sertoli cell cytoplasmic projections.** The undifferentiated **spermatogonia are near the basement membrane of the tubule, whereas** the more advanced **spermatocytes and spermatids are near the luminal surface.** Thus the Sertoli cell is a polarized epithelium in which the base approximates the plasma environment, and its apex harbors an environment unique to the seminiferous tubule (Ewing et al., 1980).

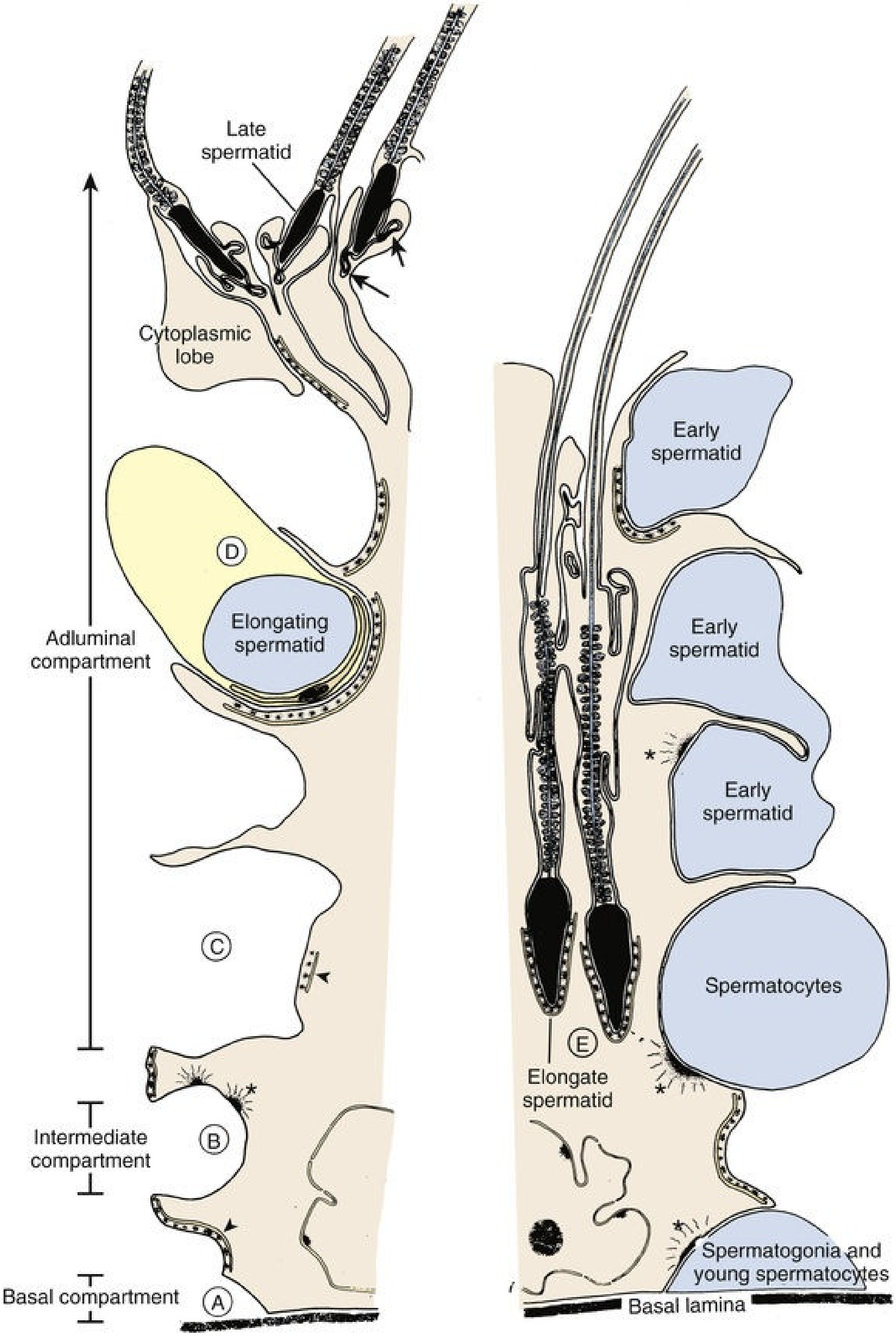
Late spermatid
Cytoplasmic lobe
Adluminal compartment
D
Elongating spermatid
C
B
Intermediate compartment
Basal compartment
A
Early spermatid
Early spermatid
Early spermatid
Spermatocytes
E
Elongate spermatid
Spermatogonia and young spermatocytes
Basal lamina

FIG. 64.10 Representation of the tree-shaped Sertoli cell with a thickened

central portion, or “trunk,” and more delicate processes, or “limbs.” Note the basal, intermediate, and adluminal compartments of the seminiferous epithelium. *(A)* Spermatogonia and early spermatocytes share positions on the basal lamina and are enveloped by adjacent Sertoli cells that join to form tight junctional complexes (site of blood-testis barrier). *(B)* Sertoli cells form junctional complexes above and below leptotene-zygotene spermatocytes as they translocate from the basal to adluminal compartments. *(C)* The spermatocytes enter the adluminal compartment when Sertoli tight junctions dissociate. *(D)* The elongating spermatid is situated within a narrow recess of the Sertoli cell trunk. *(E)* As the spermatid elongates further, the cell becomes lodged within the body of the Sertoli cell. The advanced spermatid moves toward the lumen of the epithelium in preparation for spermiation. Only the sperm head remains in intimate contact with the Sertoli cell. Specialized cell-to-cell contacts: *asterisks,* desmosome-gap junction complex; *arrowheads,* ectoplasmic specializations; *isolated arrows,* tubulobulbar complexes. (From Russell L: Sertoli-germ cell interactions: a review. *Gamete Res.* 3:179, 1980.)

Sertoli cells nurture germ cell development by (1) providing a specialized adluminal microenvironment, (2) supporting germ cells through gap junctions between Sertoli and germ cells, and (3) allowing migration of developing germ cells within the tubule (see Fig. 64.10). The tight junctions between Sertoli cells are constantly remodeled to allow “opening” and “closing” necessary for germ cell interaction and migration (Mruk and Cheng, 2004). Ligand-receptor complexes, such as c-kit and kit ligand, are likely involved in mediating communication between germ and Sertoli cells. Sertoli cells also participate in germ cell phagocytosis and produce and secrete fluid and important effector molecules. Androgen-binding protein (ABP) is one of earliest described Sertoli cell secretory products (Hansson and Djoseland, 1972). ABP is an intracellular carrier of androgen within the Sertoli cell. **By binding testosterone, ABP maintains high levels of androgen (50-fold higher than serum) within the seminiferous tubules.** Testosterone also plays an important role in the regulation of Sertoli cell function, including ABP production (Griswold et al., 1988). **Inhibin is Sertoli cell derived** and plays an important regulatory role in the negative feedback loop of FSH secretion. Inhibin B is an important endocrine marker of Sertoli cell function in the male infertility evaluation (Pierik et al., 1998).

As keepers of the testis immunologic sanctuary, Sertoli cells maintain a germ cell microenvironment entirely distinct from that of plasma. As such, Sertoli cells secrete numerous other products, including extracellular matrix components (lamin, collagen type IV, and collagen type I) and proteins such as ceruloplasmin, transferrin, glycoprotein 2, plasminogen activator, somatomedin-like substances, T proteins, H-Y antigen, clusterin, cyclic proteins, growth factors, and somatomedin (Mruk and Cheng, 2004). Dihydrotestosterone, testosterone, androstenediols, 17β-estradiol, and other C21 steroids are also produced by Sertoli cells (Ewing et al., 1980; Mather et al., 1983), although the roles they play in Sertoli cell function are largely unknown.

Germ Cells.

Within the human seminiferous tubule, germ cells give rise to approximately 123 × 10^6 (range, 21 to 374 × 10^6) spermatozoa daily (Amann and Howards, 1980). This equates to the production of about 1000 sperm per heartbeat. Within the seminiferous tubule, germ cells are arranged in a highly ordered sequence from the basement membrane to the lumen. **Morphologic analysis of the various germ cells reveals at least 13 recognizable germ cell types in the human testis** (Clermont, 1963; Heller and Clermont, 1964; Fig. 64.11). Each cell type is thought to represent a different step in the spermatogenic process. Proceeding from the least to the most differentiated, based on morphologic appearance, they have been named **dark type A spermatogonia (Ad); pale type A (Ap) spermatogonia; type B spermatogonia (B); preleptotene (R), leptotene (L), zygotene (Z), and pachytene (P) primary spermatocytes; secondary spermatocytes (II); and Sa, Sb, Sc, Sd_1, and Sd_2 spermatids.** Sertoli cell tight junctions maintain spermatogonia and early spermatocytes within the basal compartment and all subsequent germ cells in the adluminal compartment.

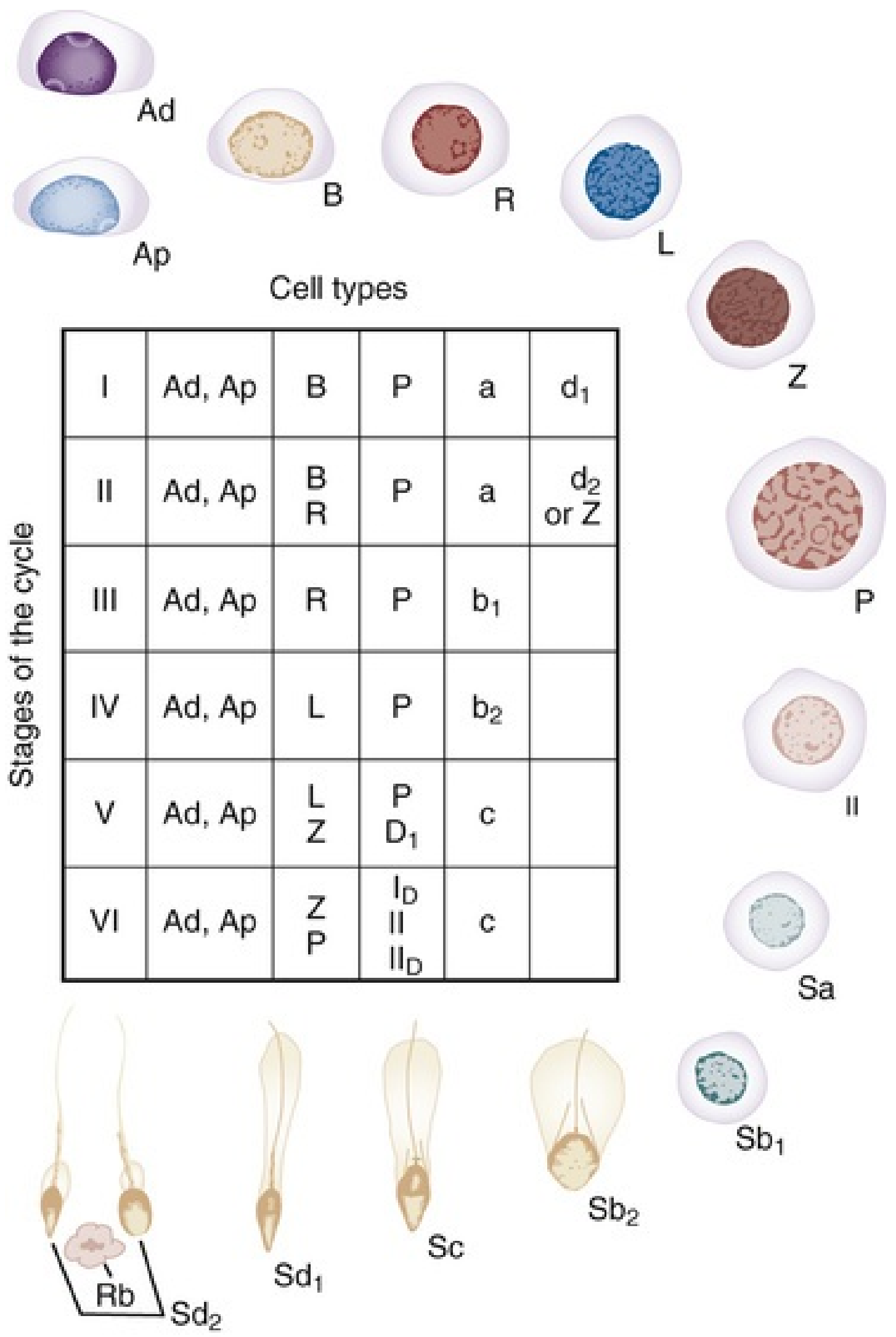

I	Ad, Ap	B	P	a	d_1
II	Ad, Ap	B R	P	a	d_2 or Z
III	Ad, Ap	R	P	b_1	
IV	Ad, Ap	L	P	b_2	
V	Ad, Ap	L Z	P D_1	c	
VI	Ad, Ap	Z P	I_D II II_D	c	

FIG. 64.11 The steps of spermatogenesis in man. *Ad,* Dark type A spermatogonium; *Ap,* pale type A spermatogonium; *B,* type B spermatogonium; *II,* secondary spermatocyte; *L,* leptotene spermatocyte; *P,* pachytene spermatocyte; *R,* resting or preleptotene primary spermatocyte; *Rb,* residual body; *Sa(a),* Sb_1 (b_1), Sb_2 (b_2), *Sc (c),* Sd_1 (d_1), Sd_2 (d_2), spermatids; *Z,* zygotene spermatocyte. The table shows cells that make up the six stages of the "cycle" of the seminiferous epithelium (I to VI): D_1, diakinesis; ID and IID, first and second maturation divisions of spermatocytes. (Modified from Clermont Y: Renewal of spermatogonia in man. *Am J Anat.* 118:509, 1966.)

Peritubular Structure

The human seminiferous tubule is surrounded by several layers of peritubular tissue (Hermo et al., 1977; Fig. 64.12). The outer adventitial layer consists of fibrocytes. In the middle layer are myoid cells interspersed with connective tissue lamellae. The inner layer consists of a collagen matrix. The peritubular myoid cells are thought to have contractile function (Toyama, 1977). Myoid cells also actively secrete extracellular matrix components fibronectin and collagen type I and produce the inner collagenous layer (Tung et al., 1984). Notably, myoid cells are known to associate with Sertoli cells in a precise mesenchymal-epithelial interaction. Skinner et al. (1988) isolated a myoid-derived paracrine factor produced, P-Mod-S (peritubular modifies Sertoli), that profoundly affects Sertoli cell synthetic functions in vitro.

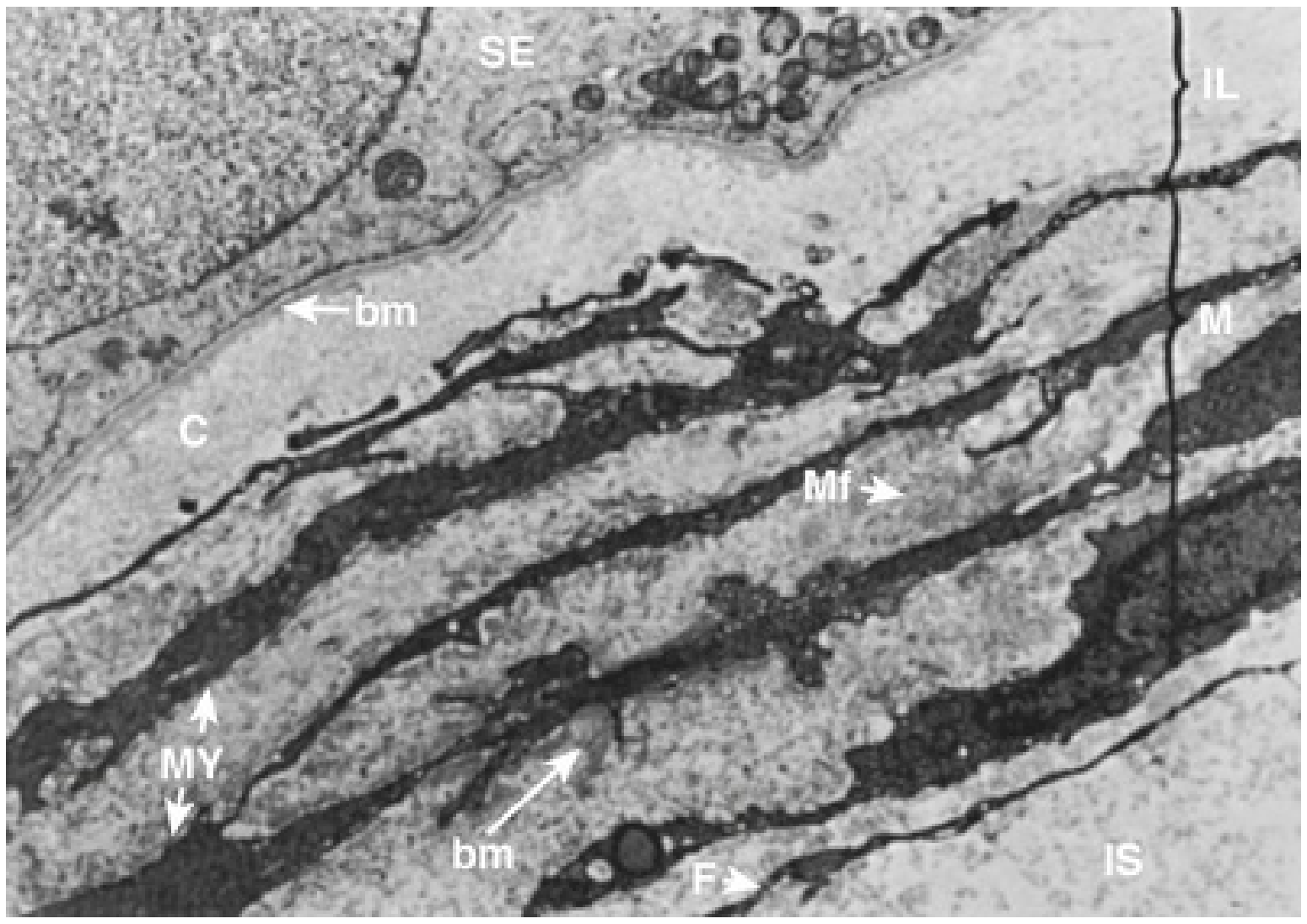

FIG. 64.12 Low-power electron micrograph of human peritubular testis tissue. Peritubular tissue lies between the basement membrane *(bm)* of the seminiferous epithelium *(SE)* and the interstitial tissue *(IS)*. Peritubular tissue has three zones: the inner lamella *(IL)*; the myoid layer *(M)*, containing myoid cells *(MY)* with abundant microfibrils *(Mf)*; and an adventitial layer containing fibroblasts *(F)*. (From Hermo L, Lalli M, Clermont Y: Arrangement of connective tissue elements in the walls of seminiferous tubules of man and monkey. *Am J Anat.* 148:433–446, 1977.)

Blood-Testis Barrier

Dyes and other substances, when injected into the bloodstream of animals, rapidly appear throughout all body tissues but fail to penetrate regions of the brain and testis. This led to the concept of the existence of a blood-testis barrier. **More appropriately termed the “blood–seminiferous tubule barrier,” it has two components: an anatomic or mechanical element and functional**

elements. The mechanical barrier is created, in part, by muscle-like myoid cells that surround seminiferous tubules (Dym and Fawcett, 1970; Fawcett et al., 1970). Regulation of molecular traffic also occurs at the level of capillary endothelial cells. However, the most important component of this barrier is the synaptic tight junctions between Sertoli cells that preclude the passage of large molecules and lymphocytes. These anatomic elements are necessary but not sufficient for maintaining the immunologic “sanctuary” status within the tubule, because they are not observed in other protected areas of the reproductive tract (Brown et al., 1972; Tung et al., 1971).

Thus, although the mechanical barrier contributes to the isolation of the testis, other “functional” components must also exist to suppress the normal immune response. Several mechanisms likely work in concert to protect sperm from destruction. First, the types and number of lymphocytes are restricted in anatomically vulnerable regions in the germinal epithelium (Anderson and Hill, 1988; el-Demiry et al., 1985; Mahi-Brown et al., 1988). There is also evidence to suggest that immunologic tolerance plays a role in the functional blood-testis barrier. The leading theory proposes that within the anatomically weaker areas (rete testis, efferent tubule, epididymis) of the barrier, there is a small, continuous leak of sperm antigens (Tung, 1980). This leak generates T-suppressor cells and immune tolerance, similar to desensitization protocols for common environmental allergens. However, with larger antigenic challenges, a true immune response results (Turek, 1997). Contributing to this tolerance, it is now clear that Sertoli cells express various mediators that act locally to generate an immunosuppressive environment within the testis (Filippini et al., 2001). These include the “master immune regulator” molecule galectin 1 (Chui et al., 2011) as well as the cytokines interferon-γ, soluble Fc receptor, and TGF-β (Ben-Rafael and Orvieto, 1992; Perussia et al., 1987; Turek, 1997), and androgens (Diemer et al., 2003).

Why does the blood-testis barrier exist? Because it develops at spermarche (Kormano, 1967), it is likely important for meiosis, because it may immunologically isolate developing male gametes that are not recognized as self by the adult male immune system. In this sense, **the value of a blood-testis barrier is fully realized after puberty, because foreign “antigens” on postmeiotic germ cells exist only after spermarche. A testicular insult such as biopsy, torsion, or trauma will not induce antisperm antibodies if it occurs before puberty.** After puberty, however, immunologic infertility is a known risk (Turek, 1997). Clinically, the blood-testis barrier may also limit chemotherapy access to cancer cells sequestered behind it and result in isolated cancer recurrence within the testis.

Spermatogenesis

Spermatogenesis is a remarkably complex and specialized process of DNA reduction and germ cell metamorphosis. Older studies have estimated that the entire process in humans requires approximately 64 days (Clermont, 1972). However, an in vivo kinetic study in healthy men revealed that **the total time to produce an ejaculated sperm ranges from 42 to 76 days,** suggesting that the duration of spermatogenesis can vary widely among individuals (Misell et al., 2006; Fig. 64.13). **Spermatogenesis involves (1) a proliferative phase** as spermatogonia divide to replace their number (self-renewal) or differentiate into daughter cells that become mature gametes; (2) **a meiotic phase** when germ cells undergo a reduction division, resulting in haploid (half the normal DNA complement) spermatids; and (3) **a spermiogenesis phase** in which spermatids undergo a profound metamorphosis to become mature spermatozoa. (For excellent reviews, see Steinberger [1976] and de Kretser and Kerr [1988].)

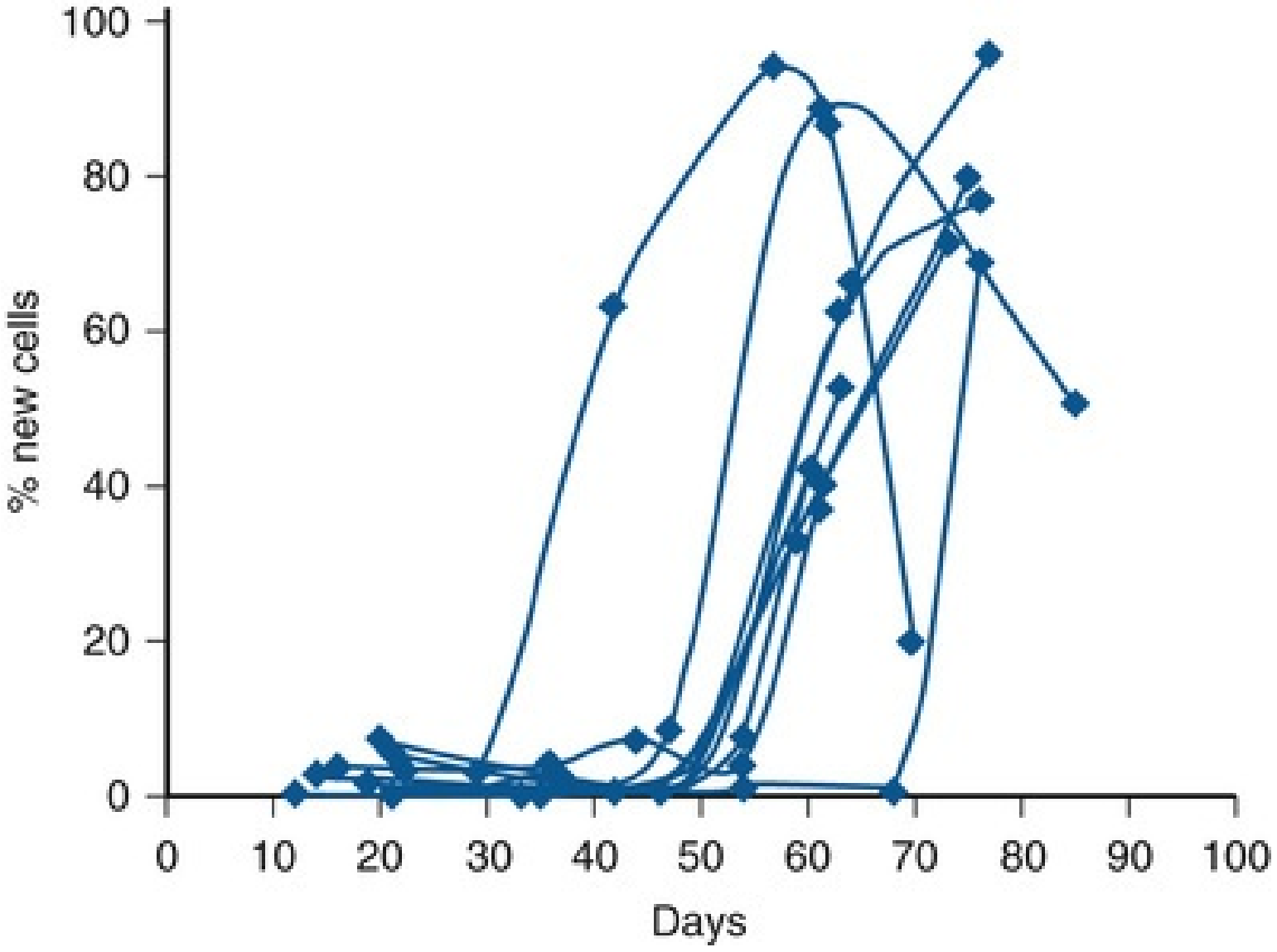

FIG. 64.13 Time to make and ejaculate human sperm. Combined spermatocyte labeling curves for 11 individuals with normal semen quality who ingested 50 mL of ^2H_2O twice daily for 3 weeks. New ejaculated sperm was found as early as 42 days after ingestion of label, and there was considerable interindividual variation in the time to make and ejaculate sperm. (From Misell LM, Holochwost D, Boban D, et al.: A stable

isotope/mass spectrometric method for measuring the kinetics of human spermatogenesis in vivo. *J Urol.* 175:242–246, 2006.)

A **cycle of spermatogenesis** involves the division of primitive spermatogonial stem cells into subsequent germ cells. Several cycles of spermatogenesis coexist within the germinal epithelium, and they are described morphologically as **stages.** If spermatogenesis is viewed from a single fixed point within a seminiferous tubule, six recognizable cellular associations or stages are predictably observed in humans (Heller and Clermont, 1964) (see Fig. 64.11). In addition, there is also a specific organization of spermatogenic cycles within the tubular space, termed **spermatogenic waves.** The best evidence suggests that human spermatogenesis exists in a spiral or helical cellular arrangement that ensures sperm production is a continuous and not a pulsatile process (Schulze, 1989; Fig. 64.14).

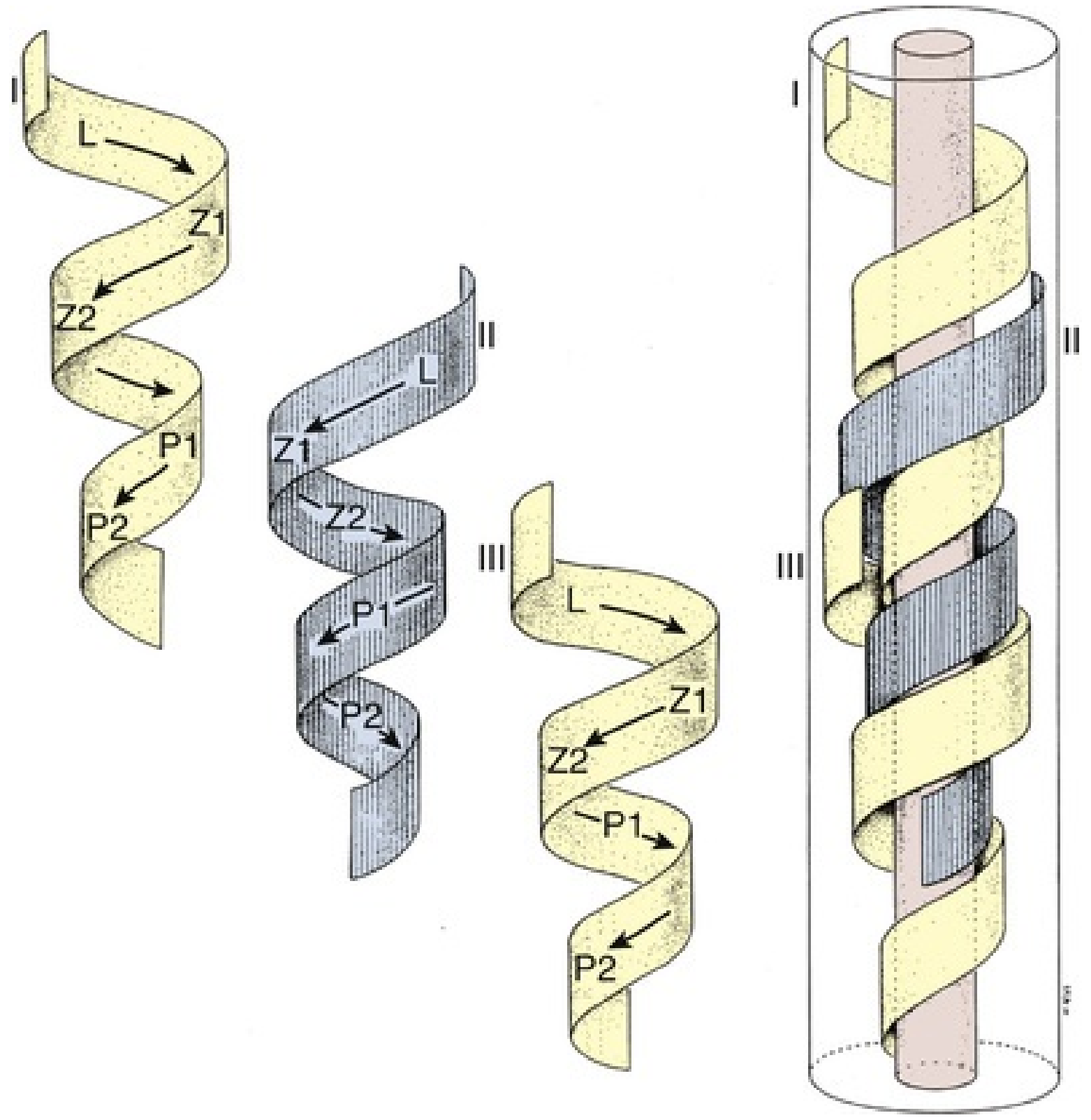

FIG. 64.14 Helical configuration of seminiferous tubule epithelial cycles in man, forming overlapping waves of spermatogenesis that keep sperm production constant. (From Schulze W, Rehder U: Organization and morphogenesis of the human seminiferous epithelium. *Cell Tissue Res.*237:395–407, 1984.)

Testis Stem Cell Migration, Renewal, and Proliferation

Testis Stem Cell Migration.

During early prenatal development, **primordial germ cells** migrate to the gonadal ridge and associate with Sertoli cells to form primitive testicular cords (Witschi, 1948). These primitive germline stem cells are termed **gonocytes** after the gonad differentiates into a testis by forming seminiferous cords. They are called **spermatogonia** after migration to the periphery of the tubule (Gondos and Hobel, 1971). **These early migrating germ cells have properties similar to embryonic stem cells and are likely the source of adult germ cell tumors** (Ezeh et al., 2005). The failure of germ cells to migrate into the primitive testicle is also thought to be a cause of **extragonadal germ cells tumors** and adult infertility resulting from **azoospermia** with Sertoli cell–only testicular histology (Nikolic et al., 2016).

Testis Stem Cell Renewal.

Spermatogonia within the testis stem cell niche are replenished in a process termed **stem cell renewal.** The growth factor receptor kit ligand/c-kit receptor system and the niche factor glial cell line–derived neurotrophic factor (GDNF) appear involved in this process (Oatley and Brinster, 2008). **Recent studies have also shown that human spermatogonial stem cells can be reprogrammed in vitro to become embryonic-like stem cells** (Conrad et al., 2008; Kossack et al., 2009; Fig. 64.15). Obtained from adult testis biopsies, the embryonic-like cells express distinct markers of pluripotency *(OCT-4, SOX-2, STELLAR, GDF-3),* can form all three germ layers, maintain a normal karyotype, form teratomas, and express appropriate levels of epigenetic markers and telomerase (Kossack et al., 2009). This finding suggests that in the future the testis may be a source of patient-specific stem cells for cell-based therapy.

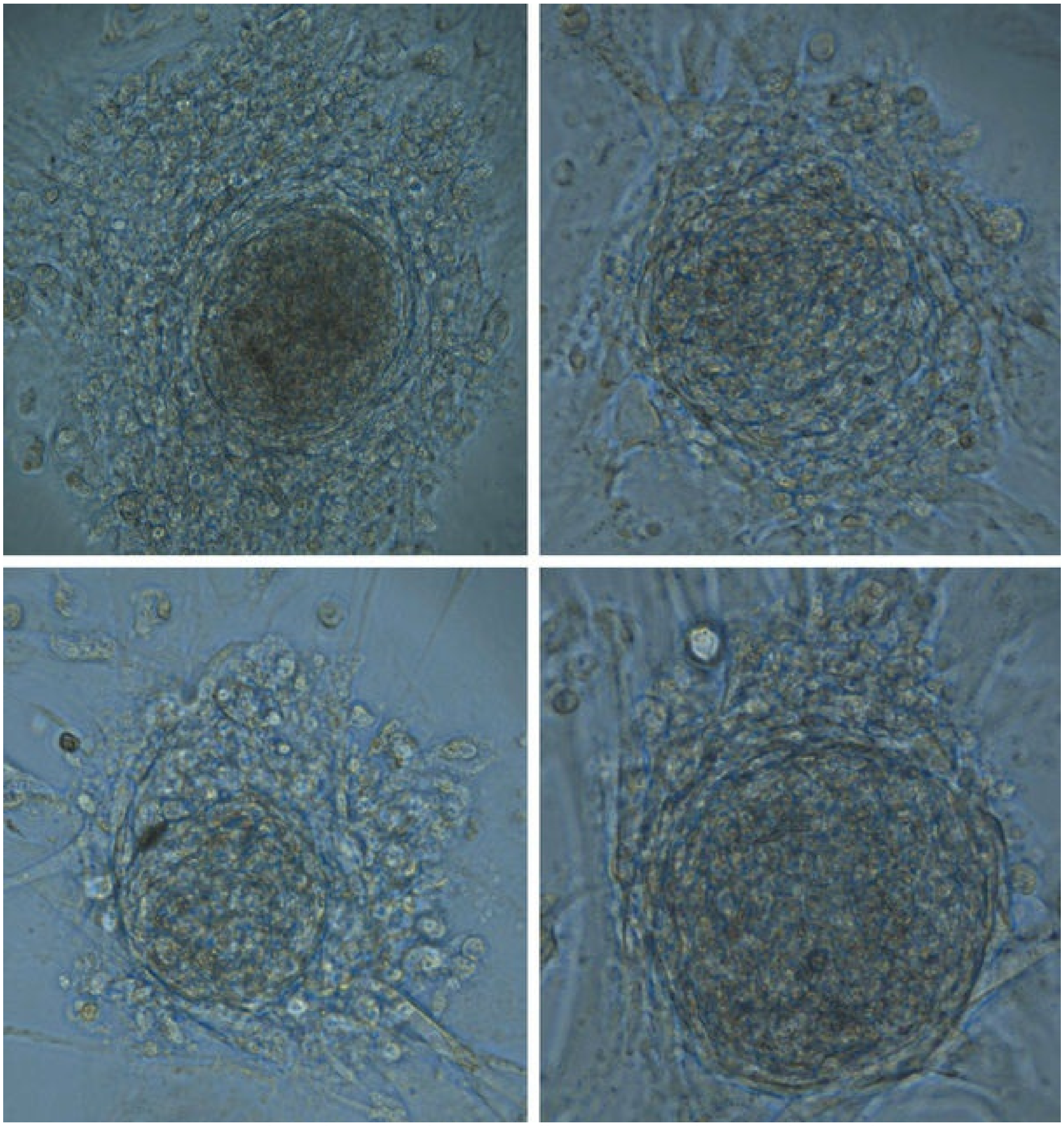

FIG. 64.15 Microphotograph of four different colonies of adult testis spermatogonial-derived stem cells. Cell clusters are the result of reprogramming of adult spermatogonia in culture conditions used for human embryonic stem cells (HESCs). They exhibit the typical cobblestone appearance of HESCs and are functionally multipotent.

Testis Stem Cell Proliferation.

In the human, pale type A (Ap) spermatogonia in the basal stem cell niche of the seminiferous tubule divide at 16-day intervals (Clermont, 1972) to form B spermatogonia. B spermatogonia are committed to become spermatocytes, but the cytoplasm between spermatogonial daughter cells remains conjoined after mitosis, forming cytoplasmic bridges between adjacent cells. These **cytoplasmic bridges are observed between germ cells of all classes throughout spermatogenesis** (Ewing et al., 1980). These bridges could be important for synchronized cellular proliferation and differentiation and for regulation of gene expression.

Meiosis

Somatic cells replicate by mitosis, in which genetically identical daughter cells are formed. **Germ cells replicate by meiosis, in which the genetic material is halved to allow reproduction.** Meiosis generates genetic diversity, providing a richer source of material on which natural selection can act. Cell replication by mitosis is a precise, well-orchestrated sequence of events involving duplication of the genetic material (chromosomes), breakdown of the nuclear envelope, and equal division of the chromosomes and cytoplasm into daughter cells. **The essential difference between mitotic and meiotic replication is that a single DNA duplication step is followed by only one cell division in mitosis but two cell divisions in meiosis (four daughter cells).** Consequently, daughter cells contain only half of the chromosome content of parent cells. Thus a diploid (2*n*) parent cell becomes a haploid *(n)* gamete. Other major differences between mitosis and meiosis are outlined in Table 64.2. Research has shown that small RNA molecules (small RNAs), including small interfering RNAs (siRNAs), microRNAs (miRNAs), and piwi-interacting RNAs (piRNAs), are important regulators of gene germ cell expression at the post-transcriptional or translation level (He et al., 2009; Tolia and Joshua-Tor, 2007).

TABLE 64.2

Essential Differences: Mitosis and Meiosis

MITOSIS	MEIOSIS
Occurs in somatic cells	Occurs in sexual cells
One cell division, two daughter cells	Two cell divisions, four daughter cells
Chromosome number maintained	Chromosome number halved
No pairing, chromosome homologs	Synapse of homologs, prophase I
No crossovers	More than one crossover per homolog pair
Centromeres divide, anaphase	Centromeres divide, anaphase II
Identical daughter genotype	Genetic variation in daughter cells

Spermatogenesis begins with type B spermatogonia dividing mitotically to form primary spermatocytes within the adluminal compartment. **Primary spermatocytes are the first germ cells to undergo meiosis** (Kerr and de Kretser, 1981). In this process, a meiotic division is followed by a typical mitotic reduction division, resulting in daughter cells with a haploid chromosome complement. In addition, as a consequence of chromosomal recombination, each daughter cell contains different genetic information. The resultant cell is the Sa spermatid (see Fig. 64.11).

Chromosomal recombination, the defining feature of mammalian meiosis, ensures that haploid gametes differ genetically from their adult precursors and is the real engine of genetic diversity and evolution. During meiotic prophase, formation of a synaptonemal complex with pairing of homologous (maternal and paternal) chromosomes occurs, along with physical interaction and exchange of DNA through reciprocal sites of crossing over **(chiasmata)** between homologs. Recent research has shown that defects in the fidelity of recombination within human male germ cells can cause azoospermia and male infertility (Walsh et al., 2009). **In one study, 10% of nonobstructive azoospermic men had significant defects in recombination compared with men with normal spermatogenesis** (Gonsalves et al., 2004). In addition, among men with maturation arrest pattern on testis biopsy, faulty recombination was observed in about half of cases, providing evidence that faulty recombination is linked to poor sperm production (Gonsalves et al., 2004). Variations in recombination also have implications for sperm aneuploidy, because alterations in crossover position are risk factors for chromosomal nondisjunction. **Indeed, evidence suggests that the correlation of faulty recombination and sperm aneuploidy in azoospermic men is strong enough to explain the higher rate of chromosomal abnormalities in offspring conceived with in vitro fertilization (IVF) and intracytoplasmic sperm injection (ICSI)** (Sun et al., 2008).

Spermiogenesis

During spermiogenesis, round Sa spermatids mature into spermatozoa (see Fig. 64.11). During this maturation sequence, cell division does not occur, but there are extensive changes to the spermatid nucleus and cytoplasm. **These include the loss of cytoplasm, migration of cytoplasmic organelles, formation of the acrosome from the Golgi apparatus, formation of the flagellum from the centriole, nuclear compaction to about 10% of former size, and**

reorganization of mitochondria around the sperm midpiece (Kerr and de Kretser, 1981). The nucleus of the round spermatid changes from spheric to asymmetrical as chromatin condenses. Many cellular elements contribute to the reshaping process, including chromosome structure, associated chromosomal proteins, the perinuclear cytoskeletal theca layer, the manchette of nuclear microtubules, subacrosomal actin, and Sertoli cell interactions. With completion of spermatid elongation, the Sertoli cell cytoplasm retracts around the developing sperm, stripping it of all unnecessary cytoplasm and extruding it into the tubule lumen. The mature sperm has remarkably little cytoplasm and is produced in massive quantities—up to 300 per gram of testis per second.

Sertoli Cell–Germ Cell Interaction

A complex network of cell-cell interactions exists within the testis between Leydig cells and Sertoli cells, between Leydig cells and peritubular cells, between Sertoli and peritubular cells, and between Sertoli cells and germ cells. Several Sertoli cell–germ cell associations in mammalian testes are illustrated in Fig. 64.10 (Romrell and Ross, 1979; Russell and Clermont, 1976; Skinner, 1995). In addition, there are factors that can reversibly disrupt the blood-testis barrier, including TGF-β3 and tumor necrosis factor-α (TNF-α). These substances act by reducing the levels of occludin and zonula occludens-1 (ZO-1) in the barrier through a p38 mitogen-activated protein (MAP) kinase signaling pathway (Xia et al., 2009). This represents only a piece of the remarkably complex and highly interactive process that characterizes spermatogenesis.

Genetics

Genetic causes of abnormal spermatogenesis have been identified as point mutations in single genes inherited in Mendelian fashion (e.g., cystic fibrosis), and as chromosomal disorders in which segments of (or entire) chromosomes have structural or numerical abnormalities. The reader is referred to Turek and Reijo Pera (2002) for a comprehensive review of such disorders. The postulation that deletions in the long arm of the Y chromosome cause azoospermia was made over three decades ago (Tiepolo et al., 1976). Based on cytogenetic analysis, this theoretic region was termed the *azoospermia factor (AZF).* **Currently, the positional patterns of deletions (termed *microdeletions*) in the AZF region are used to subdivide this region into AZFa, AZFb, and AZFc subregions** (Vogt et al., 1996)**. Regional deletions of the Y chromosome,**

termed *Yq microdeletions*, occur in 6% to 8% of severely oligospermic men and in 15% of azoospermic men (Reijo et al., 1996). Taken together, such deletions are the most commonly defined molecular cause of male infertility (Kostiner et al., 1998).

There is emerging literature addressing the prognostic value of AZF deletions. In contrast to partial and complete AZFc-deletion patients, in whom sperm is often found on semen analysis or testis biopsy, finding ejaculated or testis sperm in men with complete AZFa or AZFb deletions is highly unlikely (Hopps et al., 2003; Park et al., 2013). Complete AZFa deletions are associated with germ cell aplasia or Sertoli cell–only histology. In general, complete AZFb deletions are associated with maturation arrest at the primary spermatocyte (early) or spermatid (late) stages, but ejaculated sperm has also been reported in isolated cases (Park et al., 2013). AZFc deletions are associated with hypospermatogenesis or a Sertoli cell–only pattern with foci of spermatogenesis. Sperm have been detected in ejaculates of men with presumed and confirmed *partial* AZFa and AZFb deletions (Foresta et al., 2001). Similarly, ejaculated sperm in men with AZFa + b, and AZFb + c deletions (presumably partial deletions) has also been reported (Park et al., 2013), but the finding of AZFa − c deletions has been associated with azoospermia and no sperm on testis biopsy.

More recently, it has become clear that the **X chromosome** is also important for spermatogenesis. In 2001 Wang et al. reported on a systematic search for genes expressed exclusively in mouse spermatogonia and found that 10 were localized to the X chromosome (Wang et al., 2001). Further studies of X-linked genes in male infertility patients have identified the *SOX3* gene (sex determining region Y box 3) and the *FATE* gene as two potential candidate fertility genes (Olesen et al., 2003; Raverot et al., 2004), confirming the concept that X chromosome genes may contribute significantly to currently unexplained cases of male infertility (Mueller et al., 2013).

Genetics and Paternal Age

Age-Related Sperm Chromosomal Anomalies.

The chromosomal status of sperm was first investigated because of concern that advanced paternal age was associated with increased cases of trisomy, especially trisomy 21 or Down syndrome, in offspring. With fluorescence in situ hybridization (FISH) technology, subtle paternal-age effects on sperm aneuploidy are now evident. **The paternal age effect appears to increase the**

fraction of sperm with sex chromosomal aneuploidies (Wyrobek et al., 1996). However, there is **little evidence to support a paternal age–related increase in aneuploid births, except for possibly trisomy 21 and disomy 1 (very rare).** Examining sperm chromosome structural abnormalities, Martin and Rademaker (1987) described a significant linear relationship between paternal age and the frequency of structural anomalies in sperm ($r = 0.63$). One explanation for this association may be that **continued cell division during spermatogenesis places germ cells at risk for chromosomal injury, especially with advanced paternal age.** Except for reciprocal translocations, however, there is little evidence to indicate that this association leads to an increased frequency of offspring with de novo structural chromosomal anomalies.

Age-Related Sperm Genetic Mutations.

Single gene defects in sperm result from errors in DNA replication. Although it has been difficult to assess the presence or absence of such defects in sperm, the effect of advanced paternal age on conditions in offspring associated with single-gene mutations is clear. These disorders are listed in Box 64.1 and consist of autosomal dominant diseases that have known associations with advanced paternal age. They are termed *sentinel phenotypes* because they are disorders of significant frequency and low fitness and stem from highly penetrant mutations. **One mechanism for the development of new single-gene mutations with age implicates the characteristic and continuous process of spermatogonial cell division.** By puberty, 30 cell divisions of spermatogonia have occurred; however, after puberty, 23 divisions occur per year in these cells. **The simple fact that the spermatogonia of older men have undergone numerous cell divisions may increase the chance of errors in DNA transcription, the source of single-gene defects.** Formal risk estimates exist for the contribution of advanced paternal age to autosomal dominant mutations. In men younger than 29 years, the risk of a mutation occurring in offspring is 0.22 per 1000 births. This risk doubles (0.45 per 1000) at paternal ages 40 to 44, and then climbs to 3.7 per 1000 births at ages older than 45 (Friedman, 1981).

Box 64.1

Genetic Disorders in Offspring Associated With Advanced Paternal Age

Achondroplasias
  Aniridia
  Apert syndrome
  Bilateral retinoblastoma
  Crouzon syndrome
  Fibrodysplasia ossificans
  Hemophilia A
  Lesch-Nyhan syndrome
  Marfan syndrome
  Neurofibromatosis
  Oculodentodigital syndrome
  Polycystic kidney disease
  Polyposis coli
  Progeria
  Treacher Collins syndrome
  Tuberous sclerosis
  Waardenburg syndrome
  Schizophrenia
  Bipolar disorder
  Autism
  Attention deficit disorders
  Alzheimer disease (postulated)

Age-Related Sperm Epigenetic Changes.

There is also emerging evidence that DNA methylation marks in sperm that control gene expression, termed epigenetics, are altered with paternal age (Jenkins et al., 2014). Sperm appear to accumulate hundreds of DNA methylation defects with age that localize to specific genomic sites, many of which control genes associated with neurodevelopment (e.g., schizophrenia, bipolar disease, autism, mood disorders). In a study of sperm donated twice by men, once when young and again when older, the rate of epigenetic change in sperm doubled that estimated for other body tissues (Jenkins et al., 2014). Even more intriguing, the epigenetics changes that occurred in sperm as men age tended to cluster in genes associated with schizophrenia and bipolar disorder, diseases known to occur more in offspring as paternal age increases. Thus at least a subset of paternal age-related disorders in offspring may be a consequence of epigenetic alterations transmitted in sperm (Yatsenko and Turek,

2018).

Key Points: Testis

- The testis contains 250 m of seminiferous tubules and 700 million Leydig cells in the young adult.
- Spermatogenesis occurs in stages, cycles, and waves to ensure constant sperm production.
- Genes on the X, as well as the Y, chromosome govern spermatogenesis and contribute to male infertility.
- With paternal age, there are increases in sperm structural chromosomal abnormalities, autosomal-dominant mutations, and epigenetic alterations leading to disease in offspring.

Epididymis

Gross Architecture

The epididymis is a comma-shaped organ located along the posterolateral surface of the testis. **Passage through the epididymis induces many changes to newly formed sperm, including gains in functional motility, and alterations in surface charge, membrane proteins, immunoreactivity, phospholipids, fatty acid content, and adenylate cyclase activity. These changes improve cell membrane structural integrity, improve motility and sperm chemotaxis, and increase fertilization ability.** Spermatozoa within the testis have very poor or no motility. They become progressively motile and functional only after traversing the epididymis.

The epididymis is a tubule or duct 3 to 4 m in length and tightly coiled and encapsulated within the sheath of connective tissue of the tunica vaginalis (Lanz and Neuhauser, 1964; Turner et al., 1978). Extensions from the sheath enter interductal spaces and form septa that divide the duct into histologically characteristic regions (Kormano and Reijonen, 1976). Anatomically, these are classically divided into caput or head, corpus or body, and cauda or tail (Fig. 64.16). The caput epididymis consists of 8 to 12 ductuli efferentes from the testis. The lumen of the ductuli efferentes is large and somewhat irregular in shape near the testis, becoming narrow and oval near the junction with the ductus epididymis. Distal to this junction, the duct diameter increases slightly and thereafter remains constant in the corpus epididymis. In the bulky cauda epididymis, the tubule diameter enlarges substantially and acquires an irregular shape. Progressing distally, the tubule gradually assumes the characteristic appearance of the vas deferens.

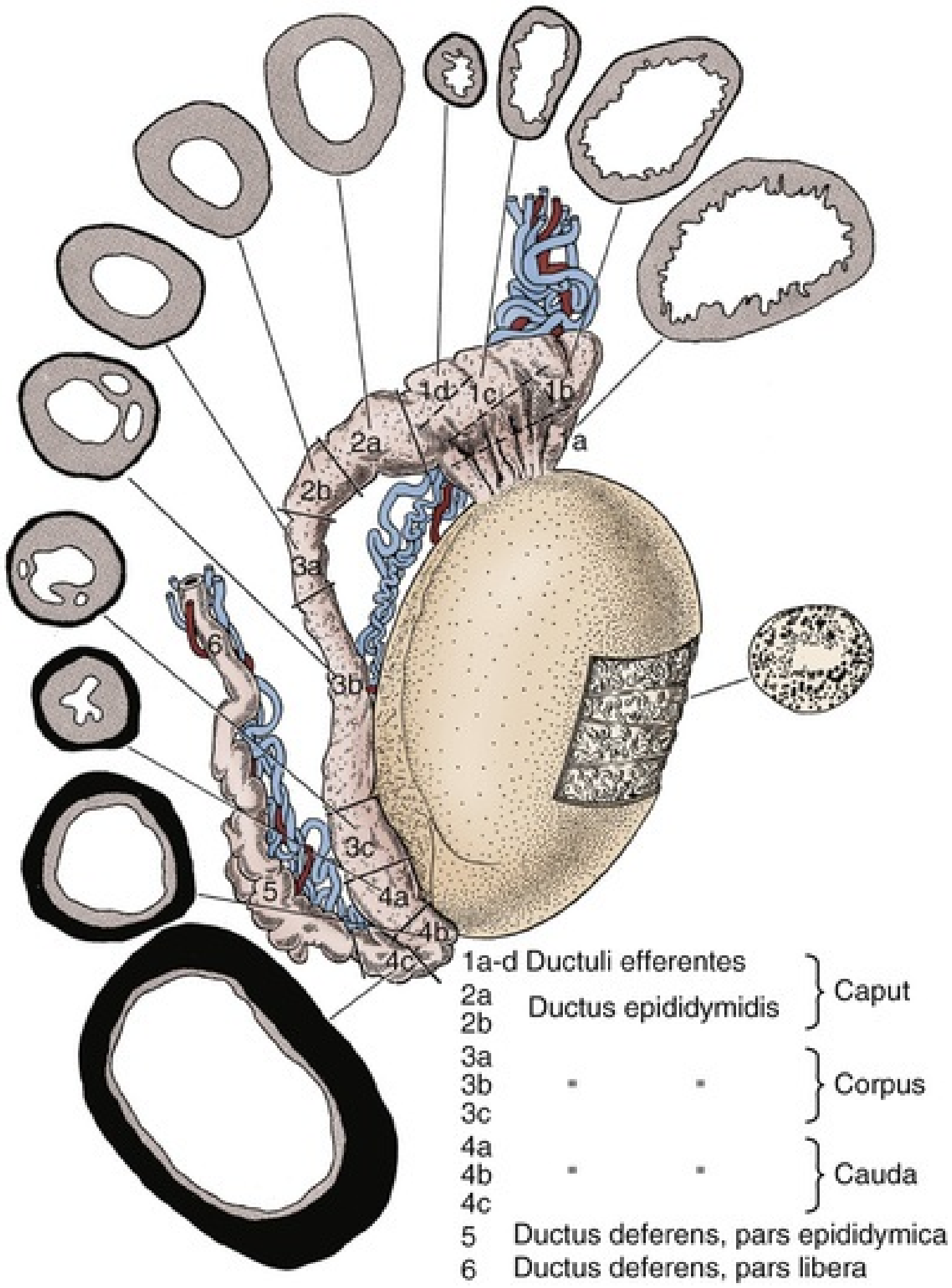
1d
1c
1b
1a
2a
2b
3a
3b
6
3c
5
4a
4b
4c
1a-d Ductuli efferentes
2a
2b
Ductus epididymidis
Caput
3a
3b
3c
Corpus
4a
4b
4c
Cauda
5 Ductus deferens, pars epididymica
6 Ductus deferens, pars libera

FIG. 64.16 Drawing of the human epididymis showing regionalization of the ductal epithelium and muscle layer. Epididymal segment locations are shown in cross section and are identified by number. (From Baumgarten HG, Holstein AF, Rosengren E: Arrangement, ultrastructure, and adrenergic innervation of smooth musculature of the ductal efferentes, ductus epididymidis, and ductus deferens in man. *Z Zellforsch Mikrosk Anat.* 120:37, 1971.)

Vascular and Lymph Supply

In humans, the caput and the corpus epididymis receive arterial blood from a branch of the testicular artery (see Fig. 64.7). It subsequently divides into superior and inferior epididymal branches (MacMillan, 1954). The epididymis also receives blood from branches of the deferential arteries (artery of the vas deferens), and collateral vessels connect the deferential artery to the testicular blood supply. The cauda epididymis is supplied by branches of the deferential artery. **The deferential and cremasteric arteries serve as collateral sources to the epididymis, when the main testicular artery is obstructed or ligated.** The arterial branches within the epididymis enter along septa formed from the connective tissue sheath. These vessels coil extensively before transforming into the straight vessels of the microvascular bed (Kormano and Reijonen, 1976). Microvascularization density varies significantly along the length of the epididymis, with the proximal caput containing the densest subepithelial capillary network and the more distal segments harboring less dense vascularization. From animal studies, the epididymal capillary network is under hormonal control. For example, in rabbits, bilateral hormonal castration results in progressive deterioration and eventual disappearance of the epididymal capillary network (Clavert et al., 1981). It is not clear whether vascularization in the human epididymis is similarly controlled.

According to MacMillan (1954), venous drainage from the corpus and cauda epididymis joins to form the vena marginalis epididymis of Haberer. These veins drain into the pampiniform plexus through the vena marginalis testis or through the cremasteric or deferential veins. Lymphatic drainage of the epididymis occurs through two routes (Wenzel and Kellermann, 1966). Lymph from the caput and corpus epididymis are removed through the same route as that described for the testis. These vessels course beside the internal spermatic vein and ultimately terminate in the preaortic nodes. Lymph vessels from the cauda epididymis join those draining the vas deferens and terminate in the external iliac nodes.

Innervation

The innervation of the human epididymis is derived primarily from the intermediate and inferior spermatic nerves that arise from the superior portion of the hypogastric plexus and pelvic plexus, respectively (Mitchell, 1935). The ductuli efferentes and the proximal segments of the epididymis are sparsely innervated by sympathetic fibers (Baumgarten et al., 1968; Baumgarten and Holstein, 1967). In these regions, the fibers are principally associated with blood vessels. Many more fibers are observed in the midcorpus epididymis, and their density increases progressively with progression along the epididymis, coincident with the appearance and proliferation of smooth muscle cells in these areas (Baumgarten et al., 1971). The distribution of contractile cells and sympathetic nerves within the epididymis may explain the rhythmic peristaltic movements of the ductuli efferentes and initial epididymal segments, as well as the intermittent contractile activity of the cauda epididymis and the vas deferens during emission (Risely, 1963). These physiologic contractions are critical to the movement of sperm through the epididymis.

Cytoarchitecture

Epididymal Epithelium

The histology of the human epididymis has been reviewed by Holstein (1969) and Vendrely (1981). It consists of two main cell types: **principal cells and basal cells** (seen at low ultrastructural magnification in Fig. 64.17). Principal cells vary in height along the length of the epididymis because of the length of stereocilia (microvilli, not cilia). In general, tall stereocilia (120 µm) are found in the proximal epididymis, and smaller or shorter stereocilia (50 µm) are observed in more distal regions. The nuclei in principal cells are elongated and often possess large clefts and one or two nucleoli. Consistent with the idea that principal cells carry out absorptive and secretive processes, their cellular apices have numerous coated pits, micropinocytotic vesicles, multivesicular bodies, irregularly shaped membranous vesicles, and an extensive Golgi apparatus. Because these cytologic features vary along the length of the epididymis, it suggests that there is varying absorptive and secretory capacity along the length of the duct (Vendrely and Dadoune, 1988).

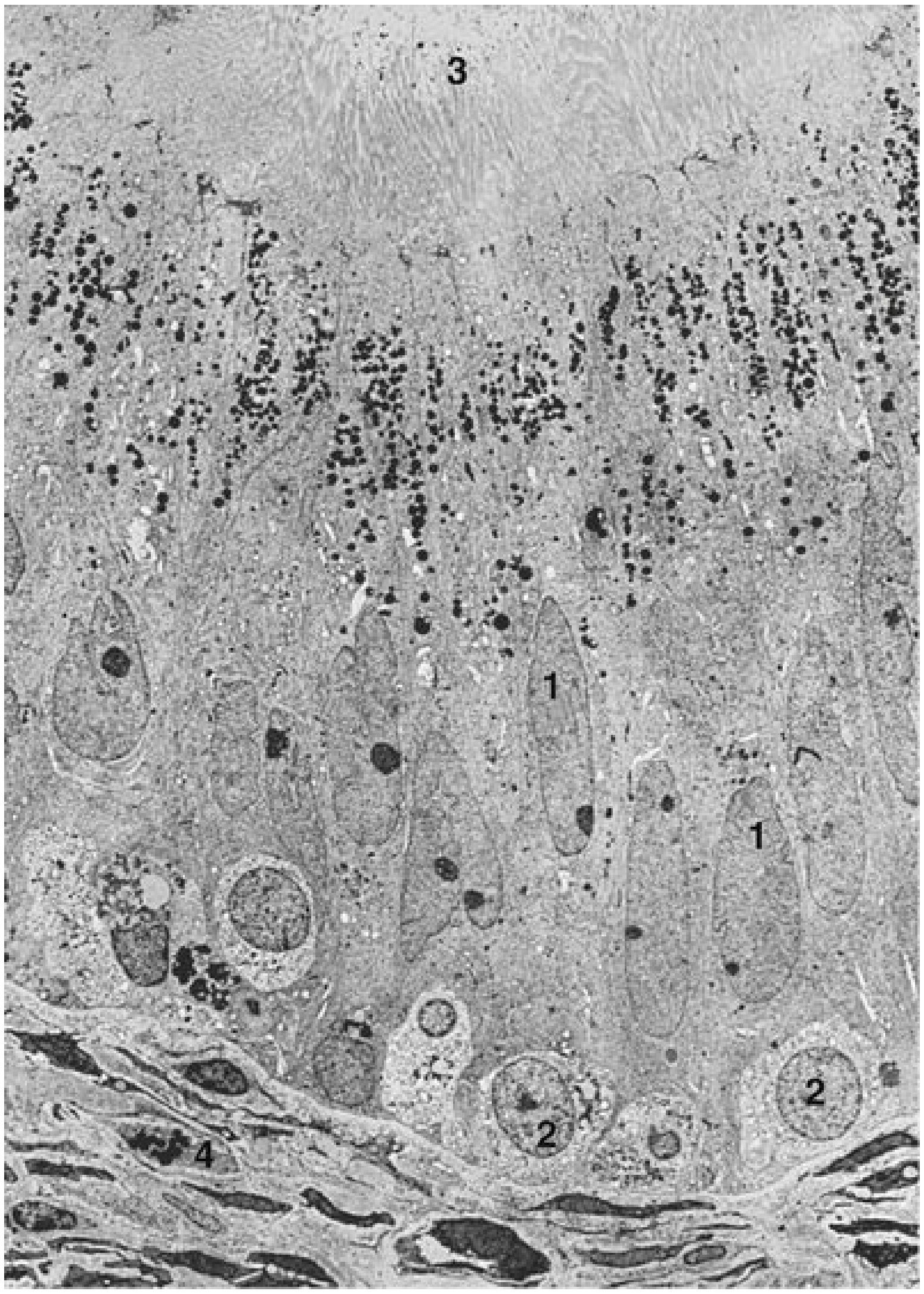

FIG. 64.17 Electron micrograph of a human epididymis in cross section. Major components of the luminal epithelium are principal cells *(1),* basal cells *(2),* stereocilia *(3),* and myofilaments *(4)*. Magnification approximately ×1800. (From Holstein AF: In Hafez ESE, editor: *Human semen and fertility regulation in men,* St. Louis, 1976, Mosby.)

There are far fewer basal cells than principal cells lining the epididymal epithelium. Tear-shaped basal cells rest on the basal lamina and extend toward the lumen, their apices forming threads between adjacent principal cells. They are thought to be derived from macrophages and may in fact be the precursors of principal cells. Unlike the principal cells, the morphology of basal cells remains relatively constant throughout the epididymal duct.

The epithelium of the epididymis exhibits regional differences along its length. Within the epididymis proper, the epithelium is pseudostratified and consists of principal and basal cells as described earlier. Proximally, at the junction of the rete testis and ductuli efferentes, there is a distinct transition from a low to a high cuboidal epithelium. The epithelium in the ductuli efferentes consists of ciliated and nonciliated cells (Holstein, 1969). The ciliated cells conduct sperm from the efferent ducts into the epididymis. The nonciliated cells with protruding apices are likely secretory in nature and predominate in the proximal ductuli efferentes (Vendrely, 1981). Other nonciliated cells have microvilli suggestive of resorptive activity and predominate in the distal ductuli efferentes. Nonciliated and ciliated cells are joined apically through junctional complexes. This suggests the existence of a blood-epididymis barrier analogous to the blood-testis barrier (Hoffer and Hinton, 1984; Suzuki and Nagano, 1978). **Although not as dense as the blood-testis barrier, the blood-epididymis barrier extends from the caput to the cauda epididymis and may play an important role in influencing the composition of fluid within the epididymal lumen of its differing segments** (Turner, 1979).

Epididymal Contractile Tissue.

Peripheral to the basal lamina of the ductuli efferentes are various contractile cells (Baumgarten et al., 1971) (see Fig. 64.17). In the ductuli efferentes (distal regions of the caput and the proximal corpus epididymis), the contractile cells form a loose layer, two to four cells deep, around the tubule. These cells contain myofilaments and are connected by numerous nexus-like junctions. In the corpus epididymis, there are larger contractile cells with fewer nexus-like intracellular junctions that resemble smooth muscle cells. In the cauda epididymis, the thin contractile cells are replaced by thick smooth muscle cells that form three layers —the outer two layers oriented longitudinally and the central layer circularly. This distal contractile layer increases in thickness as it forms the vas deferens. The contractile tissue throughout the epididymis is likely involved in sperm transport.

Epididymal Function

Described variations in the anatomy and histology of the epididymal tubule from the caput to cauda regions suggest that the epididymis actually consists of several different functional tissues (Vendrely, 1981). It is clear that sperm transport and storage, fertilizing ability, and motility maturation are several consequences of epididymal passage. This is addressed more fully in reviews by Robaire and Hermo (1988) and Moore and Smith (1988).

Sperm Transport

Sperm transport through the human epididymis has been calculated to take from 2 to 12 days (Johnson and Varner, 1988). Sperm transit time through the caput-corpus epididymis is roughly similar to the transit time through the cauda epididymis and is more likely related to daily testicular sperm production rather than a man's age or the frequency of ejaculation (Amann, 1981; Johnson and Varner, 1988). In one study, sperm epididymal transit time averaged 2 days in men with a high daily rate of sperm production, compared with 6 days in men with low daily sperm production (Johnson and Varner, 1988). Although the frequency of sexual activity does not affect sperm transit time through the caput and corpus epididymis, “recent emissions” can reduce transit time through the cauda epididymis by 68% (Amann, 1981).

Because normal human testicular sperm are immotile as they enter the epididymis and remain relatively immotile within the caput, **mechanisms other than sperm motility must exist to transport sperm through the epididymis.** Animal studies have been very revealing in this regard (Bedford, 1975; Courot, 1981; Hamilton, 1977; Jaakkola, 1983; Jaakkola and Talo, 1982). Initially, sperm are carried into the ductuli efferentes by rete testis fluid, and **fluid flow is facilitated by fluid resorption by ductal epithelial cells mediated by the estrogen receptor**. Motile cilia and myoid cell contractions within the ductuli efferentes also assist with sperm movement. **Within the epididymis proper, the principal mechanism responsible for sperm transport is likely the spontaneous, rhythmic contraction of the contractile cells surrounding the epididymal duct.**

Sperm Storage

After migrating through the caput and corpus epididymis, sperm are retained in the cauda epididymis for varying lengths of time, depending on the frequency of sexual activity. In men 21 to 55 years of age, **an average of 155 to 209 million sperm are present in each epididymis** (Amann, 1981; Johnson and Varner, 1988), **and approximately half are stored in the caudal region.**

Spermatozoa stored in the cauda epididymis, unlike testicular sperm, are capable of progressive motility and are able to fertilize eggs. The exact amount of time that sperm can remain fertile within the epididymis is unclear, but animal studies have shown that sperm can remain viable for several weeks after vas deferens ligation (Hammond and Asdell, 1926; Young, 1929).

However, it is also clear that sperm fertility measured in vivo diminishes when sperm are maintained in the epididymis for prolonged periods of time (Cooper and Orgebin-Crist, 1977; Cuasnicu and Bedford, 1989). In humans, sperm aging as a result of extended epididymal transit time and prolonged storage may contribute to reduced fertility (Johnson and Varner, 1988).

The exact fate of unejaculated epididymal sperm is unknown. In animals, sperm are lost through spontaneous seminal discharge, through oral self-cleaning (Martan, 1969), in urine (Lino et al., 1967), or by epididymal reabsorption (Amann and Almquist, 1961). Phagocytosis of spermatozoa by macrophages (spermiophages) within the epididymal lumen has been observed in humans after ligation of the vas deferens (Alexander, 1972). However, whether this mechanism can remove large numbers of spermatozoa from the epididymis of unvasectomized men is unclear.

Sperm Maturation

Sperm Motility.

Sperm gain the capacity for motility with migration through the epididymis. This is observed as a change in the pattern of motility and as an increase in the proportion of sperm exhibiting “mature” motility patterns. Bedford et al. (1973) first observed that most sperm from the ductuli efferentes, when placed in culture medium, are immotile or show only weak, twitching movement or “immature” tail movements characterized by “thrashing” beats in wide arcs that result in little forward progression. Within the initial epididymal segment, this immature motility pattern persisted. However, in the corpus region, there was an increase in the fraction of sperm with a “mature” motility pattern characterized by high-frequency, low-amplitude beats that result in progressive motility (Fig. 64.18). Within the cauda epididymis, the majority of sperm had a mature motility pattern.

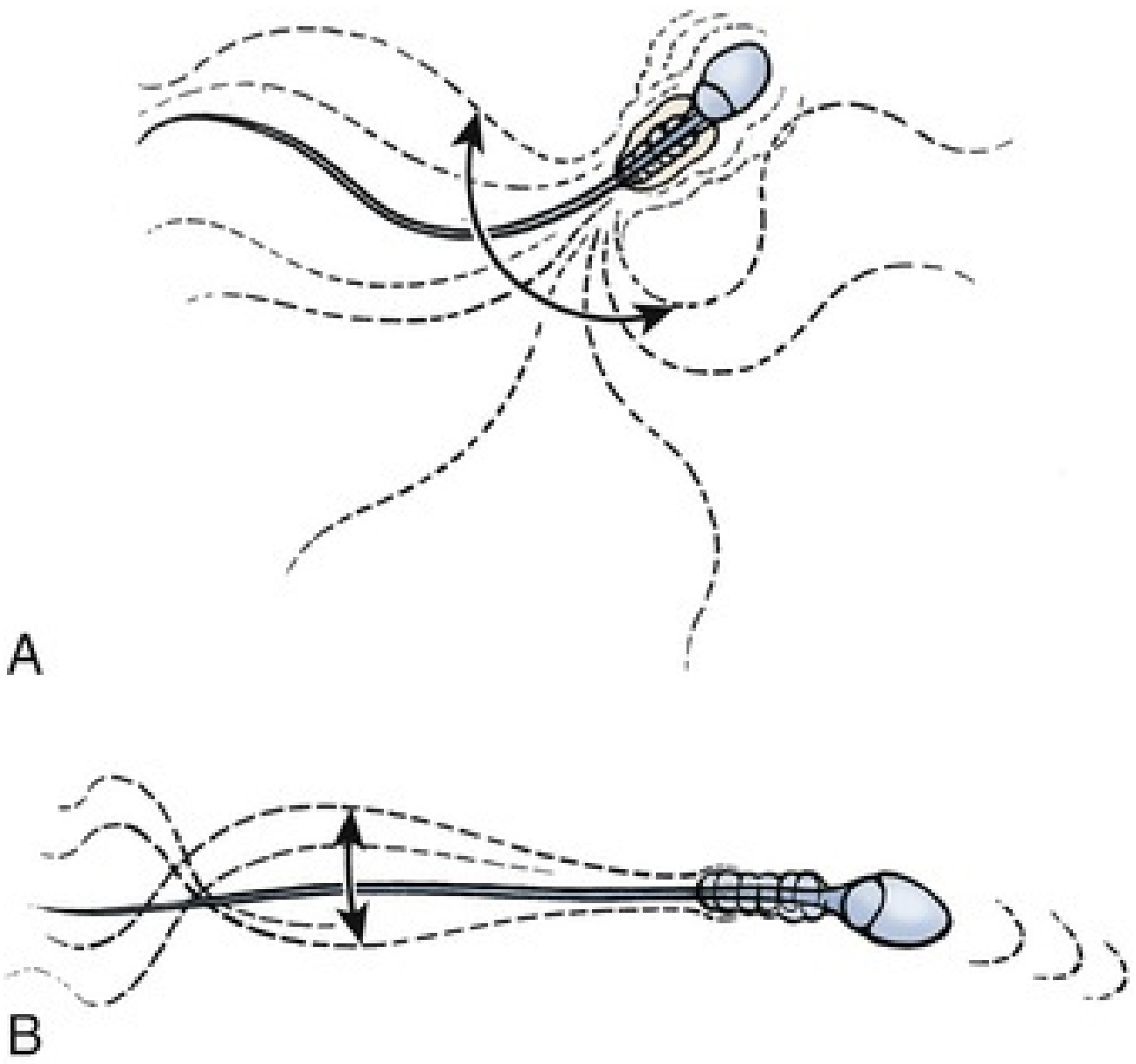

FIG. 64.18 Patterns of tail movement of human epididymal sperm. (A) The pattern shown by sperm taken from the proximal epididymis is characterized by high-amplitude, low-frequency beats producing little forward movement. (B) In contrast, tail movement in a large proportion of sperm from the cauda epididymis is characterized by low-amplitude, rapid beats with forward progression. (From Bedford JM, Calvin HI, Cooper GW: The maturation of spermatozoa in the human epididymis. *J Reprod Fertil.* 18:199–213, 1973.)

The relative importance of epididymal contact time versus region-specific maturation to gains in sperm motility patterns is unknown. Animal studies indicate that motility maturation may, in part, be an intrinsic process that occurs independent of epididymal interactions (Horan and Bedford, 1972; Orgebin-Crist, 1969). Human studies in obstructed patients with congenital absence of the vas deferens or epididymal obstruction also frequently report poor motility in spermatozoa aspirated from the distal epididymis and better sperm motility in the proximal epididymis (Matthews et al., 1995; Silber, 1989). When combined, **these observations suggest that spermatozoa are able to develop motility based on contact time with the proximal epididymal epithelium.** However, this maturation process may not be identical to that which occurs through sperm interaction with the epididymis during migration through all ductal regions.

Sperm Fertility.

Testicular sperm are incapable of fertilizing eggs unless injected into them with micromanipulation (Bedford, 1974; Orgebin-Crist, 1969; Yanagimachi, 2005). In most animals, the ability of sperm to fertilize eggs is acquired gradually as the sperm pass through the epididymis (Fig. 64.19). Indeed, it has been shown in rabbits that sperm from the caput, corpus, and cauda epididymis can fertilize 1%, 63%, and 92% of rabbit eggs, respectively (Orgebin-Crist, 1969). Human in vitro experiments using zona pellucida–free hamster eggs have corroborated these findings (Moore et al., 1988). In a study that assessed the fertilizing capacity of human epididymal sperm, Hinrichsen and Blaquier (1980) demonstrated that, although sperm from the proximal epididymis are able to bind to zona-free eggs, only sperm from the cauda epididymis can actually penetrate eggs. **Thus sperm fertility maturation is, for the most part, achieved at the level of the late corpus or early cauda epididymis.**

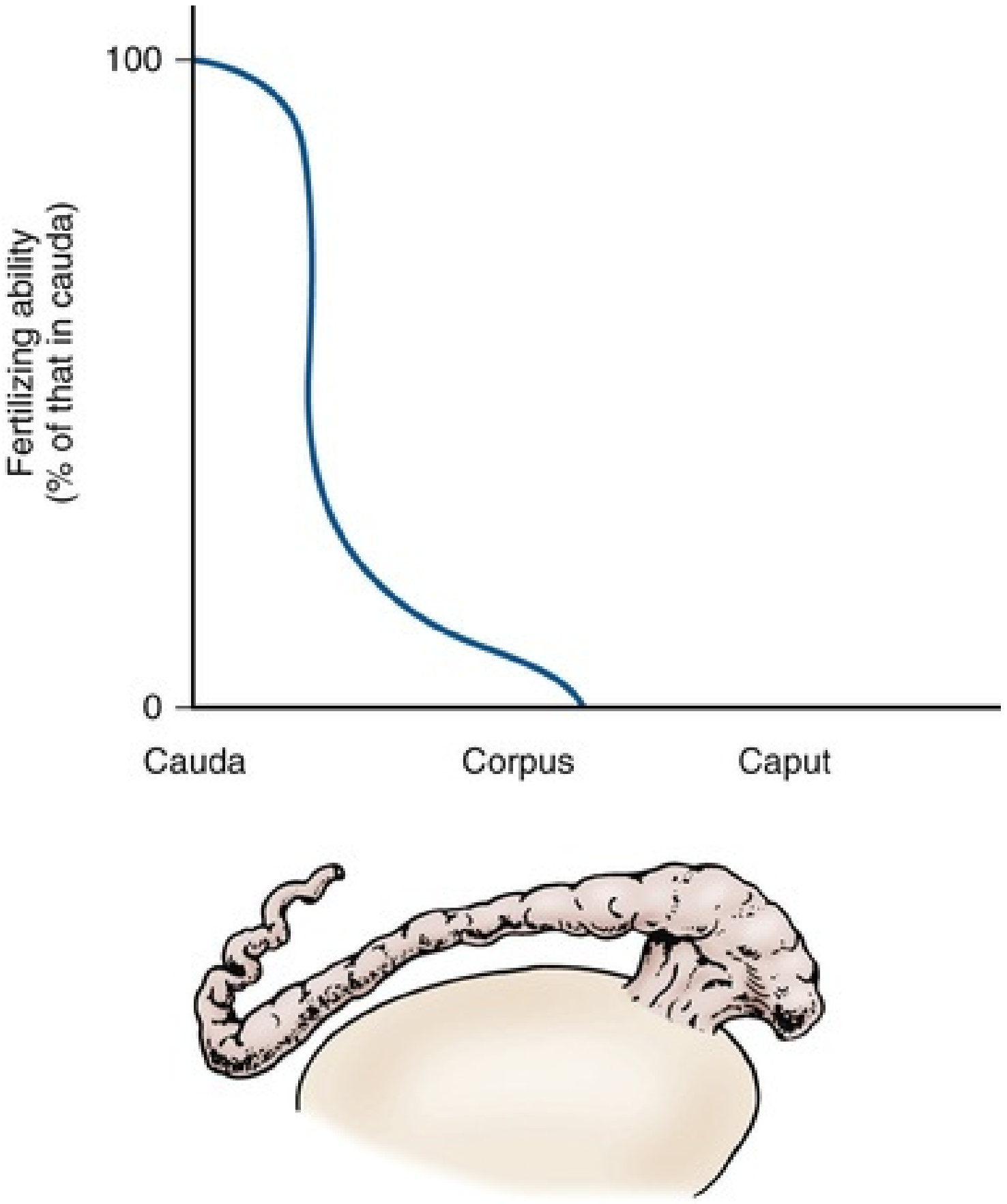

FIG. 64.19 Sperm fertility maturation in the human epididymis. Sperm fertilizing ability was assessed using zona pellucida–free hamster eggs and by changes in motility. (From Bedford JM: The bearing of epididymal function in strategies for in vitro fertilization and gamete intrafallopian transfer. *Ann N Y Acad Sci.* 541:284–291, 1988.)

Recent clinical observations, however, challenge the idea that fertility maturation requires sperm migration through the entire epididymis. Indeed, patients with epididymal obstruction or congenital absence of the vas deferens can achieve natural pregnancies after vasoepididymostomy at the level of the ductuli efferentes (Schoysman and Bedford, 1986; Silber, 1989). This suggests that obstruction induces proximal skewing of the maturation sequence along the epididymal duct or that there may be a reduced flow of sperm through the epididymis after such bypass procedures, allowing more contact and sperm maturation time (Orgebin-Crist, 1969; Turner and Roddy, 1990). Despite this observation, **it is generally believed that the likelihood of fertility is greater as the surgical anastomosis is performed more distally in the epididymis** (Thomas, 1987). Additional findings from the reversal of older vasectomies (>15 years of obstruction) suggest that, although postoperative ejaculated sperm concentrations are maintained after reversals with prolonged obstructive intervals, sperm motility is significantly decreased. This indicates that acquired epididymal dysfunction resulting from prolonged blockage may play an important role in the fertility potential of men after vasectomy reversal (Mui et al., 2014).

Sperm Biochemical Changes.

Sperm undergo many biochemical changes with passage through the epididymis (Brooks, 1983). **Epididymal sperm transit induces a net negative surface membrane charge** (Bedford et al., 1973), **and sperm membrane sulfhydryl groups oxidize to disulfide bonds, improving sperm structural rigidity necessary for progressive motility and egg penetration** (Bedford et al., 1973; Reyes et al., 1976). Other post-testicular modifications of sperm membranes include changes in sperm lectin-binding properties (Courtens and Fournier-Delpech, 1979; Olson and Danzo, 1981), phospholipid and lipid content (Nikolopoulou et al., 1985), glycoprotein composition (Brown et al., 1983), immunoreactivity (Tezón et al., 1985), and iodination characteristics (Olson and Danzo, 1981). **Overall, these membrane modifications during epididymal passage may enhance sperm adherence to the egg zona pellucida** (Blobel et al., 1990; Orgebin-Crist and Fournier-Delpech, 1982). Sperm also undergo numerous metabolic changes during epididymal transit (Dacheux and Paquignon, 1980). These include an increased capacity for glycolysis (Hoskins et al., 1975), changes in intracellular pH and calcium content, modification of adenylate cyclase activity (Casillas et al., 1980), and alterations in cellular phospholipid and phospholipid-like fatty acid content (Voglmayr, 1975).

Regulation of Epididymal Function

Sperm changes within the epididymis are likely influenced by fluids and secretions within the epididymal lumen (Blaquier et al., 1989; Robaire and Hermo, 1988). The biochemical composition of epididymal fluid differs from that of serum and also shows regional differences in osmolarity, electrolyte content, and protein composition (Robaire and Hermo, 1988). These differences are likely the consequence of variations in vascularization, blood-epididymis barrier activity, and selective absorption and secretion of substances such as glycerylphosphorylcholine (GPC), carnitine, and sialic acids along the epididymal duct. Proteins within epididymal fluid that are known to have physiologic effects on sperm in vitro include forward motility protein (Brandt et al., 1978), sperm survival factor (Morton et al., 1978), progressive motility sustaining factor (Sheth et al., 1981), sperm motility-inhibiting factor (Turner and Giles, 1982), acidic epididymal glycoprotein (Pholpramool et al., 1983), and the EP2-EP3 proteins that induce sperm binding to zona pellucida (Cuasnicu et al., 1984; Blaquier et al., 1988). Thus variations in epididymal tubule fluid characteristics play an important role in sperm maturation during epididymal transit. It is not surprising, then, that the epididymis is a potentially important source of sperm dysfunction and male infertility.

Epididymal function is hormonally regulated. Testosterone and DHT are found in very high concentrations within the epididymis (Leinonen et al., 1980). This suggests the importance of androgens for epididymal function (Brooks and Tiver, 1983). In animals, castration results not only in the loss of androgen-dependent epididymal proteins but also in losses in epididymal weight, changes in luminal histology, and alterations in the synthesis and secretion of epididymal fluid GPC, carnitine, and sialic acid. Ultimately, the castrated epididymis loses the ability to sustain sperm motility, fertility maturation, and sperm storage capacities, processes that are reversed with androgen replacement.

Compared with other accessory sex glands, the epididymis requires relatively higher levels of androgen to maintain its structure and function (Prasad and Rajalakshmi, 1976). **Androgen effects on the epididymis are mediated mainly through DHT, the primary androgen in epididymal tissue** (Pujol et al., 1976), and/or 5α-androstane-3α, 17β-diol (3α-diol) (Orgebin-Crist et al., 1975). Indeed, this is corroborated by the fact that the enzymes Δ4-5α-reductase (catalyzes DHT formation from testosterone) and 3α-hydroxysteroid dehydrogenase (converts DHT to 3α-diol), which produce testosterone metabolites, are also found in the human epididymis (Kinoshita et al., 1980; Larminat et al., 1980). It may also help to explain the recent observation that the clinical use of 5α-reductase inhibitors is associated with impaired semen quality (Amory et al., 2007).

Epididymal function is also influenced by temperature (Foldesy and Bedford, 1982; Wong et al., 1982). Chronic exposure of the epididymis to elevated temperatures, for example, by placing them within the abdomen, results in the loss of sperm storage and electrolyte transport functions. The effect of temperature on epididymal function may help explain how varicocele and cryptorchidism affect male infertility. Abnormalities in epididymal myoid cell contractility may also influence epididymal function. In the rat, partial surgical denervation of the epididymis results in an abnormal accumulation of sperm within the cauda epididymis and a decrease in the swimming speed of sperm (Billups et al., 1990). These findings have implications for infertility from neuropathic causes such as spinal cord injury and diabetes mellitus.

Key Points: Epididymis

- The epididymis consists of principal cells with absorptive and secretory function, basal cells derived from macrophages, and contractile cells that facilitate sperm transport.
- During epididymal passage, sperm mature by gaining progressive motility and the ability to bind to and penetrate the egg zona pellucida.
- Epididymal function is temperature and androgen (mainly DHT) dependent, important considerations for cryptorchidism, varicocele, and 5α-reductase use.

Ductus (Vas) Deferens

Gross Architecture

The vas deferens is a tubular organ derived from the mesonephric (wolffian) duct. In humans, the vas deferens is 30 to 35 cm long, beginning at the cauda epididymis and terminating in the ejaculatory duct, medial to the seminal vesicle and posterior to the prostate. It is classically divided into five regions: (1) the sheathless epididymal segment contained within the tunica vaginalis, (2) the scrotal segment, (3) the inguinal segment, (4) the retroperitoneal or pelvic portion, and (5) the ampulla (Lich et al., 1978). In cross section, the vas deferens consists of an outer adventitial connective tissue sheet containing blood vessels and small nerves, a muscular coat that consists of a middle circular layer surrounded by inner and outer longitudinal muscle layers, and an inner mucosal layer with an epithelial lining (Neaves, 1975). The outer diameter of the vas deferens varies from 1.5 to 3 mm, and the lumen of the unobstructed vas deferens varies from 200 to 700 µm in diameter (Middleton et al., 2009).

The vas deferens receives its blood supply from the deferential artery, a branch of the superior vesical artery. Venous drainage corresponds to arterial supply. The vas deferens receives innervation from the sympathetic and the parasympathetic nervous systems (Sjostrand, 1965). The cholinergic supply does not appear important for motor activity of the vas deferens (Baumgarten et al., 1975). There is a rich supply of sympathetic adrenergic nerves derived from hypogastric nerve coursing via the presacral nerve (Batra and Lardner, 1976; McConnell et al., 1982). Adrenergic nerve fibers have been observed in all three layers of the vas muscularis, with the greatest concentration in the outer longitudinal layer (McConnell et al., 1982). The vas deferens also receives a short adrenergic nerve (Sjostrand, 1965) and has an abundance of purinergic receptors in its smooth muscle membranes, suggesting sympathetic and purinergic cotransmission in sperm transport and ejaculation (Gur et al., 2007). Neurons containing other neurotransmitters, including neuropeptide Y, enkephalin, galanin, somatostatin, vasoactive intestinal polypeptide, and nitric oxide, have also been identified; however, their role in vas deferens function is unknown (Dixon et al., 1998). Notably, human vas deferens specimens obtained at vasovasostomy after vasectomy show a marked reduction in the density of muscular noradrenergic and subepithelial secretomotor nerves in testicular compared with abdominal segments. These changes may influence subsequent sperm transport in the vas deferens and therefore procedural success after vasectomy reversal (Dixon et al., 1998).

Cytoarchitecture

The human vas deferens is lined by pseudostratified epithelium (Paniagua et al., 1981). The height of the epithelium decreases along the length of the vas deferens from the testis to the seminal vesicle. In addition, the longitudinal epithelial folds are simpler near the testis and become more complex distally. The pseudostratified epithelium vasal lining is composed of basal cells and three types of tall, thin columnar cells (Hoffer, 1976; Paniagua et al., 1981). The columnar cells, extending from the epithelial base to the lumen, include principal cells, pencil cells, and mitochondria-rich cells. All columnar cells exhibit stereocilia and irregular convoluted nuclei. Principal cells are the most frequent columnar cell type in the proximal vas deferens, whereas pencil cells and mitochondria-rich cells increase in density distally. The thickness of the total muscle layer gradually decreases along the length of the vas deferens. This complex cytoarchitecture strongly suggests that the vas deferens is more than simply a passive conduit for sperm transport.

Vas Deferens Function

Sperm Transport

Sperm transport through the vas deferens is influenced by several physiologic processes. First, **the human vas deferens exhibits spontaneous motility** (Ventura et al., 1973)**. It also has the capacity to respond when stretched** (Bruschini et al., 1977)**. Finally, fluid within the vas deferens can be propelled into the urethra by strong peristaltic contractions elicited either by electrical stimulation of the hypogastric nerve** (Bruschini et al., 1977) **or by adrenergic neurotransmitters** (Bruschini et al., 1977; Lipshultz et al., 1981). This suggests that immediately before emission, with sympathetic stimulation, sperm is rapidly transported from the distal epididymis through the vas deferens to the ejaculatory duct. **This rapid transport is consistent with the vas deferens having the highest muscle-to-lumen ratio (approximately 10 : 1) of any hollow viscus in the body.**

Sperm reserves in the vas deferens have been estimated at approximately

130 million, suggesting that a significant proportion of human ejaculated sperm is stored in the vas deferens (Amann and Howards, 1980). In addition, vasal sperm quality, as assessed from fertile men at the time of vasectomy, is very similar to that of the ejaculate, with 71% motility and 91% viability (Bachtell et al., 1999). In the rabbit, it has been shown that during sexual rest, epididymal sperm are transported through the vas deferens and leak into the urethra in small amounts (Prins and Zaneveld, 1979, 1980a, 1980b). This suggests that the vas deferens is involved in ridding the epididymis of excess, stored sperm. On sexual stimulation, rabbit sperm are transported through the vas deferens similar to humans. **After sexual stimulation, however, the vas deferens contents are propelled proximally toward the epididymis because the distal vas deferens contracts with greater amplitude, frequency, and duration than the proximal segment** (Prins and Zaneveld, 1980a). Notably, with prolonged sexual rest, excess epididymal sperm are once again transported distally, supporting the idea that the vas deferens is important for sperm transport and for maintenance of epididymal sperm reserves.

Absorption and Secretion

Based on its cytoarchitecture, the human vas deferens likely has absorptive and secretory functions (Hoffer, 1976; Paniagua et al., 1981). The principal cells are typical of cells that synthesize and secrete glycoproteins (Bennett et al., 1974; Gupta et al., 1974). The stereocilia, apical blebbing, and primary and secondary lysosomes within principal cells are also characteristic of cells involved in absorptive function (Friend and Farquhar, 1967; Murakami et al., 1988). Last, spermiophagy by epithelial cells in the ampullary vas deferens has been observed with scanning electron microscopy in men and monkeys (Murakami et al., 1988). **Normal vas deferens function is likely to be androgen dependent because the vas deferens actively converts testosterone to DHT** (Dupuy et al., 1979). Castration causes atrophy of—and testosterone treatment, restoration of—monkey vas cytoarchitecture (Dinakar et al., 1977), and spontaneous and α- and β-adrenergic–stimulated contractions of the rat vas deferens are altered by castration (Borda et al., 1981). Thus, although once thought to be a simple muscular conduit for sperm, the vas deferens is now viewed as a complex reproductive organ.

Seminal Vesicle and Ejaculatory Ducts

Gross Architecture and Cytoarchitecture

Seminal Vesicle

In the adult, the seminal vesicles are paired, elongated, hollow viscous organs located posterior to the prostate and bladder. Each seminal vesicle is 5 to 7 cm long and up to 1.5 cm wide. Each seminal vesicle actually consists of a tubule that is 15 cm long and highly coiled and convoluted. **The tubule is composed of three layers: the inner lining is a moist and folded mucous membrane; the middle layer is largely collagenous; and the outer layer consists of circular and longitudinal muscle layers that constitute 80% of the wall thickness** (Nguyen et al., 1996). The mucosa of the seminal vesicle, mainly nonciliated, pseudostratified columnar or cuboidal cells, is notable for many thin, complicated folds that produce numerous crypts. The excretory duct of the seminal vesicle opens into the ampullary vas deferens as it enters the prostate gland.

The blood supply to the seminal vesicle arises from the internal iliac artery and inferior vesicular artery through the prostatovesicular branch (Clegg, 1955). The prostatovesicular artery can also arise from the superior vesicular artery or from the pudendal artery. Most commonly, the prostatovesicular artery has anterior and posterior branches that supply the respective surfaces of the seminal vesicle. The lymphatic drainage of the seminal vesicle is through the internal iliac lymph nodes. The seminal vesicles are innervated through sympathetic nerves from the superior lumbar and hypogastric nerves. Parasympathetic innervation occurs through the pelvic plexus.

Ejaculatory Ducts

The ejaculatory ducts are paired, collagenous, tubular structures that commence at the junction of the vas deferens and seminal vesicle, course through the prostate, and empty into the prostatic urethra at the verumontanum. Histologically, the ejaculatory ducts are a continuation of the seminal vesicle, except that the outer circular muscle layer does not extend into the ducts (Nguyen et al., 1996). There are three distinct anatomic regions to the ejaculatory duct: the proximal, extraprostatic portion; the middle intraprostatic segment; and a short distal segment incorporating the lateral aspect of the verumontanum in the urethra (Nguyen et al., 1996; Fig. 64.20). Although the ejaculatory duct contains an outer muscular layer in its extraprostatic and intraprostatic segments, as the duct courses distally the outer muscular layer dissipates, and **there is no valvelike, muscular "sphincter" at the ejaculatory duct orifice,** as was once thought (Nguyen et al., 1996; Fig. 64.21). Instead, urinary reflux is prevented and ejaculatory continence is maintained by the acute angle of duct insertion into the urethra. The inner epithelial layer of the ejaculatory ducts is also complex and folded and consists of simple and pseudostratified columnar cells. The ejaculatory ducts receive their blood supply from branches of the inferior vesical artery and are innervated through the pelvic plexus.

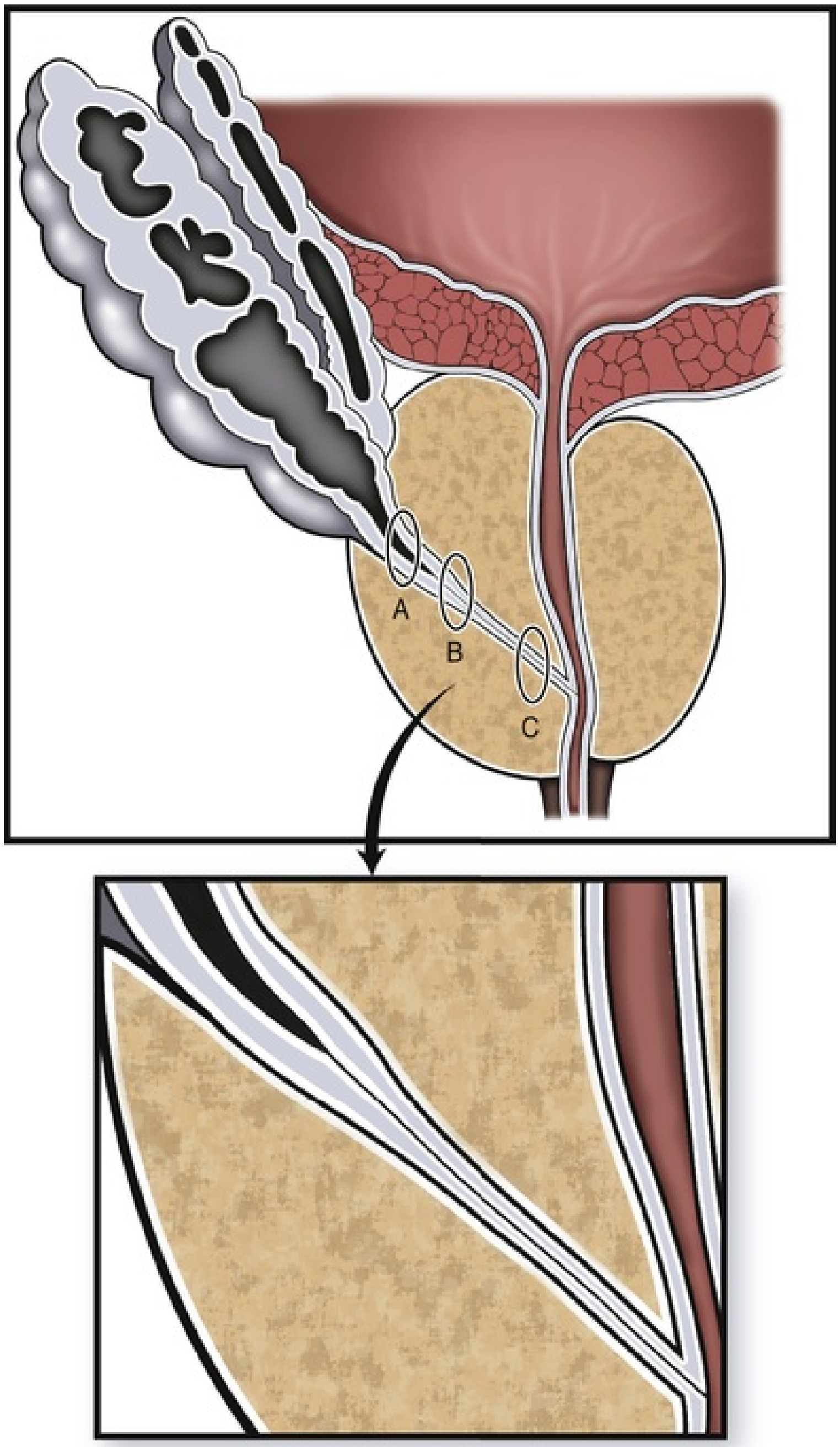

FIG. 64.20 Schematic anatomy of the human ejaculatory duct complex. *(A)* Proximal; *(B)* intraprostatic or middle; and *(C)* distal ejaculatory duct regions. The *inset* shows how the muscle layer thins out in the middle segment. (From Nguyen HT, Etzell J, Turek PJ, et al.: Normal human ejaculatory duct anatomy: a study of cadaveric and surgical specimens. *J Urol.* 155:1639–1642, 1996.)

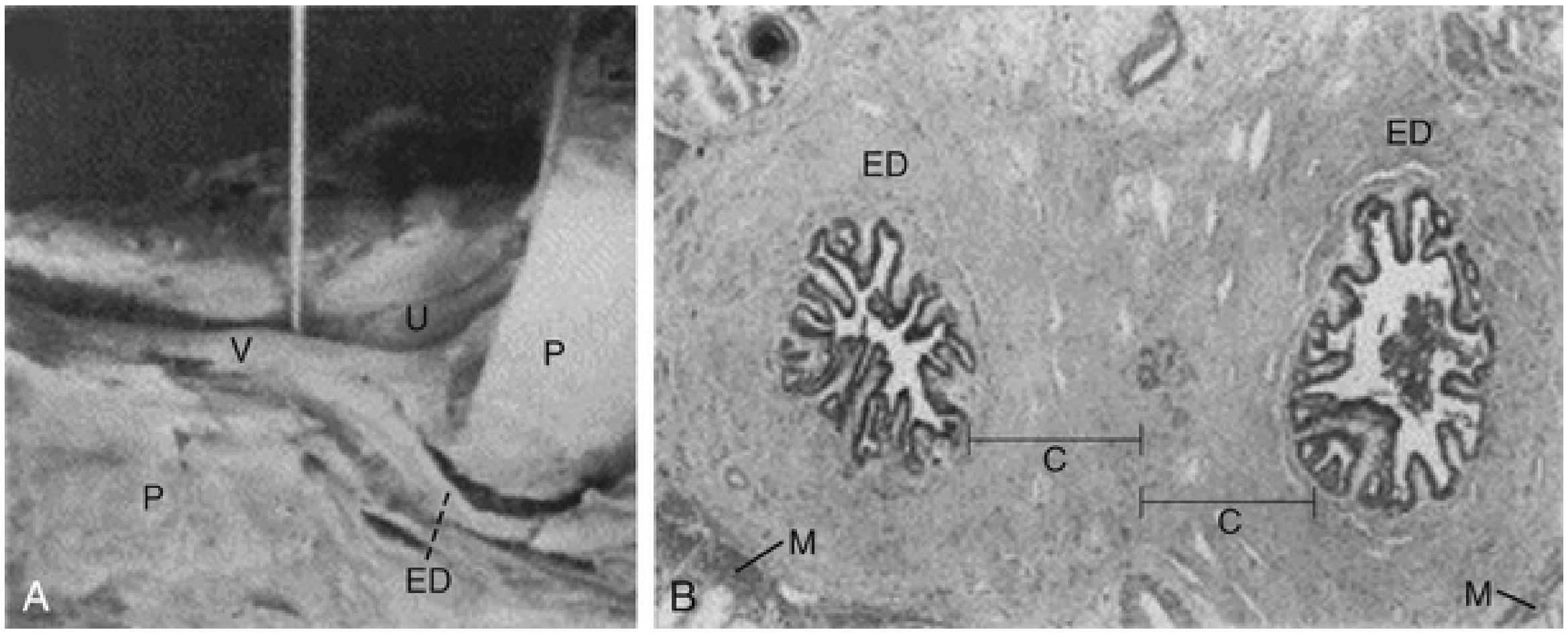

FIG. 64.21 Human ejaculatory duct gross and microscopic anatomy from cadaver specimens. (A) Sagittal section through the midline with pin in ejaculatory duct orifice and ejaculatory duct *(ED)* and veru *(V)*, urethra *(U)*, and prostate *(P)* visible. (B) Microphotograph of the paired ejaculatory ducts in the middle intraprostatic segment showing the thick collagenous layer *(C)* surrounding the mucosa with a thin, outer muscular layer *(M)*. (From Nguyen HT, Etzell J, Turek PJ, et al.: Normal human ejaculatory duct anatomy: a study of cadaveric and surgical specimens. *J Urol.* 155:1639–1642, 1996.)

Seminal Vesicle and Ejaculatory Duct–Unit Function

Animal studies suggest that **the seminal vesicle and ejaculatory duct relationship is functionally similar to that of the bladder and urethra** (Turek et al., 1998)**. The seminal vesicle is a contractile, compliant, smooth muscular organ with dynamic properties analogous to those of the bladder, and the ejaculatory duct serves as a urethra-like conduit.** This theory allows the classification of ejaculatory duct obstruction into **two types of disorders, analogous to bladder outlet obstruction: (1) obstruction resulting from physical blockage of the ducts, similar to bladder outlet obstruction and (2) “functional” obstruction of the seminal vesicle, similar to voiding dysfunction caused by bladder myopathy.** In addition, this has implications for the diagnosis of ejaculatory duct disorders because “static” anatomic imaging, such as transrectal ultrasonography, may not be sufficient to differentiate between these disorders, and medications and conditions (such as diabetes) may predispose the system to seminal vesicle dysfunction (Smith et al., 2008).

Seminal Vesicle Function

The seminal vesicles secrete a significant proportion (80%) of the seminal fluid, and these secretions are found in later fractions of the ejaculate, after the sperm-rich epididymal and prostatic secretions. After ejaculation, sperm pass into and through the female cervical mucus and subsequently the uterus to enter the oviduct, where fertilization occurs. During residence in the female reproductive tract, sperm must undergo capacitation before oocyte fertilization. During capacitation, the acrosome reaction and development of hyperactivated motility occurs (Yanagimachi, 1994). It is not clear if prostatic or seminal vesicle secretions contribute to capacitation.

In fact, the exact physiologic role of seminal vesicle fluid is not clear, although in rodents it functions as a plug or barrier that reduces the chances for sperm from a subsequent male to fertilize the oocyte. Before ejaculation, semen is a liquid, and after all components mix with the seminal vesicle secretions, it coagulates. The major component of the coagulum is **semenogelin I, a 52-kD protein expressed exclusively in the seminal vesicles** (Robert et al., 1999)**. Through coagulating semen, seminal vesicle secretions may promote sperm motility, increase stability of sperm chromatin, and suppress immune activity in the female reproductive tract.** The best-elucidated function of **human semen** is its ability to **provide antioxidative protection to sperm.** Semen is rich in antioxidant enzymes, including glutathione peroxidase, superoxide dismutase, and catalase (Yeung et al., 1998). In addition, the antioxidant molecules taurine, hypotaurine, and tyrosine are present in high concentrations (van Overveld et al., 2000). Lipofuscin granules from dead epithelial cells give seminal vesicle secretions a yellow-white color. In addition, seminal vesicle secretions are alkaline and contain fructose, mucus, vitamin C, flavins, phosphoryl choline, and prostaglandins. High fructose levels provide nutrient energy for sperm. The mixing of seminal vesicle with prostatic secretions results in human semen having a mildly alkaline pH. **Acidic ejaculate (pH <7.2) is associated with blockage or absence of seminal vesicles** (Turek, 2005).

Key Points: Vas Deferens, Seminal Vesicle, and Ejaculatory Ducts

- The vas deferens is of wolffian (mesonephric) duct origin and transports sperm from the cauda epididymis to the ejaculatory duct during seminal emission.
- The seminal vesicle and ejaculatory duct unit is analogous to the bladder and urethra and is subject to physical blockage and functional disorders that result in infertility.

Spermatozoa

Anatomy and Physiology

The human spermatozoon is approximately 60 μm in length and is divided into three morphologic sections: head, neck, and tail (Fig. 64.22). The oval **sperm head,** about 4.5 μm long and 3 μm wide, contains a nucleus with highly compacted **chromatin** and an **acrosome,** a membrane-bound organelle that harbors enzymes required for penetration of the outer vestments of the egg before fertilization (Yanagimachi, 1978). The **sperm neck** maintains the connection between the sperm head and tail. It consists of the **connecting piece** and **proximal centriole.** The **axonemal complex** extends from the proximal centriole through the sperm tail. The **tail** harbors the **midpiece, principal piece, and endpiece** (Zamboni, 1992). The midpiece is 7 to 8 μm long and is the most proximal segment of the tail, terminating in the annulus. It contains **the axoneme**, with its characteristic microtubule arrangement and surrounding **outer dense fibers** (Fig. 64.23). It also contains the **mitochondrial sheath,** which is helically arranged around the outer dense fibers. The outer dense fibers, rich in disulfide bonds, are not contractile proteins but are thought to provide the sperm tail with the elastic rigidity necessary for progressive motility (Oko and Clermont, 1990). Similar in structure to the midpiece, the principal piece has several columns of outer dense fibers that are replaced by the fibrous sheath. The fibrous sheath consists of **longitudinal columns** and **transverse ribs.** The sperm terminates in the endpiece, the most distal segment of the sperm tail, and contains axonemal structures and the fibrous sheath. Except for the endpiece region, the sperm is enveloped by a highly specialized plasma membrane that regulates the transmembrane movement of ions and other molecules (Friend, 1989).

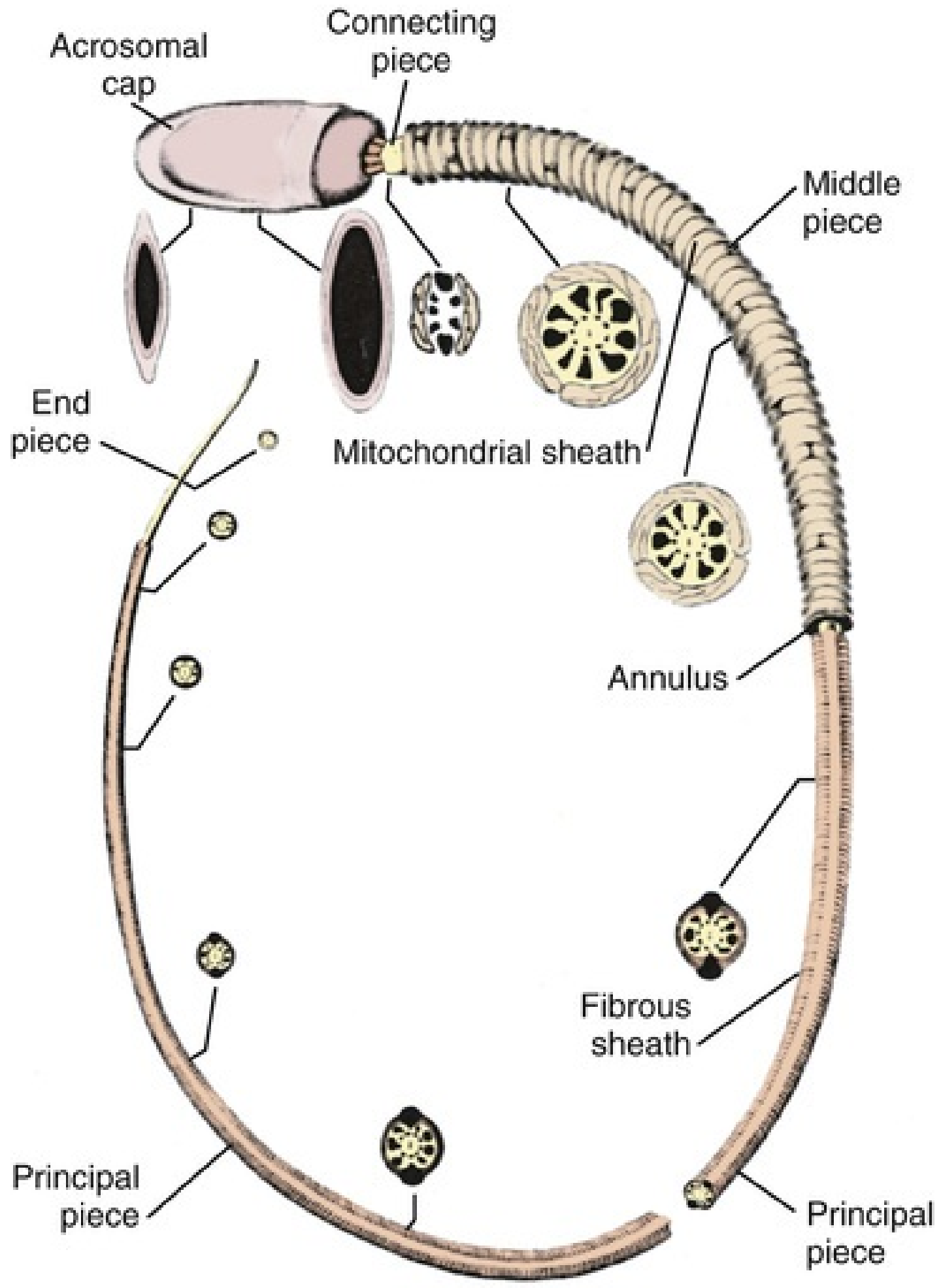
Acrosomal cap
Connecting piece
Middle piece
End piece
Mitochondrial sheath
Annulus
Fibrous sheath
Principal piece
Principal piece

FIG. 64.22 Diagram of a typical mammalian spermatozoon. The plasma membrane is omitted to illustrate the major cellular components. Cross-sectional insets show the orientation of the internal cell structures. (From Fawcett DW: The mammalian spermatozoon. *Dev Biol.* 44:394–436, 1975.)

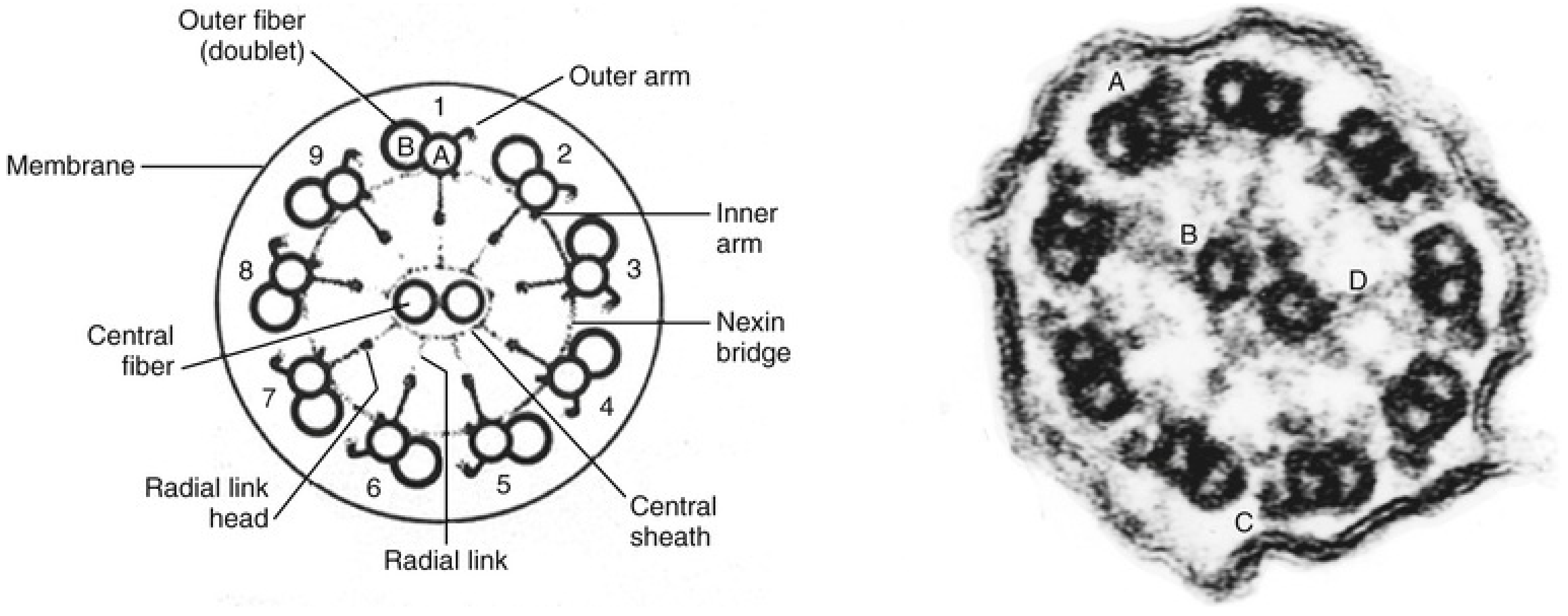
Outer fiber (doublet)
Outer arm
Membrane
1
B
A
2
9
Inner arm
8
3
Central fiber
Nexin bridge
7
4
Radial link head
6
5
Central sheath
Radial link
A
B
D
C

FIG. 64.23 The “9 + 2” sperm axonemal structure. *Left,* Schematic cross section of axoneme, demonstrating microtubule arrangement. *Right,* Electron micrograph of axoneme. *(A)* Outer doublet; *(B)* inner central doublet; *(C)* outer dynein arm; *(D)* radial link.

The spermatozoon is a remarkably complex metabolic and genetic machine. The 75 sperm mitochondria that surround the axoneme contain enzymes required for oxidative metabolism and produce adenosine triphosphate (ATP), the primary energy molecule for the cell. Mitochondria are organelles that produce cellular energy and can also cause apoptotic cell death through the release of cytochrome *c*. Mitochondria are composed of outer and inner membranes. The inner membrane forms deep folds into the matrix, called the cristae, which make the surface area of the inner membrane larger than that of the outer membrane. Five distinct respiratory chain complexes span the width of the inner membrane and are necessary for oxidative phosphorylation: nicotinamide adenosine diphosphate (NADPH) dehydrogenase, succinate dehydrogenase, cytochrome *bc1*, cytochrome *c* oxidase, and ATP synthase complexes. Contained within the matrix are citric acid cycle, fatty acid, and amino acid oxidative enzymes; newly made ATP; mitochondrial DNA (mtDNA); and ribosomes.

Human mitochondria contain DNA (mtDNA) that is distinct from sperm nuclear DNA. mtDNA consists of a circular, histone-free chromosome of 16,569 base pairs of DNA arranged in a single heavy and single light strand and **encodes respiratory-chain–complex subunit proteins, mitochondrial rRNAs, and tRNAs used for protein synthesis.** These genes have no introns. mtDNA is also far more susceptible to mutations than is nuclear DNA (estimated 40 to 100 times higher). Reasons for this may include the fact that mitochondria are near respiratory-chain complexes and may be easily attacked by reactive oxygen species. **In addition, mtDNA is not coated with protective histones, and mitochondria have very limited DNA repair mechanisms** (Hirata et al., 2002)**. The fact that mitochondria rapidly accumulate mutations suggests the necessity of degrading all paternal mtDNA in the fertilized egg.** This degradation is likely mediated by the small proteolytic polypeptide ubiquitin, which regulates proteolysis in many tissues (Sutovsky et al., 1999).

From animal studies, it is clear that the plasma membrane covering the sperm-head region harbors specialized proteins that participate in sperm-egg interaction (Saling, 1989). Indeed, carbohydrate-binding proteins on the sperm membrane interact with the species-specific ZP3 protein in the egg zona pellucida, resulting first in sperm binding to the zona and subsequently to induction of the acrosome reaction (Shabanowitz, 1990). Another sperm membrane protein, PH30, is present on testicular sperm, is modified during sperm migration through the epididymis, and functions as a fusion protein between the sperm and egg membranes at fertilization (Blobel et al., 1990; Primakoff et al., 1987).

Physiologically, the axoneme is the true motor assembly and requires 200 to 300 proteins for proper function. Among these, the “9 + 2” pattern of outer and inner doublets of microtubules is the best-understood component (see Fig. 64.23). The dynein proteins extend from one microtubule doublet to the adjacent doublet and form the inner and outer arms of the axoneme. **The sperm axoneme contains the enzymes and structural proteins necessary for the chemical transduction of ATP into mechanical movement and motility.** Dynein is a large (2000 kD), Mg^{2+}-stimulated ATPase responsible for ATP-generated microtubule sliding that causes axonemal bending and, ultimately, sperm flagellar movement. The dynein structure has two or three globular, outer (heavy) chain heads (500 kD) joined to a common stem. The heads control movement along the microtubules. The inner (light) chain arms (14 to 120 kD) are the primary effectors of movement and are associated with the radial spokes of the dynein assembly. Sperm with outer arm mutants have reduced motility, and those with inner arm mutants have no motility. Radial links or spokes connect a microtubule of each doublet to the central inner doublet and consist of a complex of proteins. The central inner doublet is surrounded by a ringlike helical sheath to which the radial links from the outer doublets are attached. Tektins are proteins associated with the outer microtubular doublets, and nexin links are proteins that connect the outer doublets to one another and maintain the cylindric axonemal shape.

The phenotype of defective sperm structure has been recognized as ciliary dyskinesia. Although infertility is the rule with ciliary dyskinesias, ejaculated sperm can be motile and sperm concentrations can be normal. With ICSI, clinical pregnancies and live births have been reported after use of affected sperm (Cayan et al., 2001). Because the inheritance is usually recessive, normal offspring are likely. In general, patients suspected of harboring sperm structural defects exhibit severely compromised sperm motility (<10%). Sperm electron microscopy can reveal ultrastructural or functional sperm abnormalities. Sperm structural abnormalities are currently categorized by Chemes (2000) as follows:

1. **Nonspecific flagellar anomalies.** This is the most frequent flagellar

anomaly underlying severely low motility and shows a structural phenotype of random, heterogeneous, microtubular alterations. These anomalies can arise from correctable disorders such as varicocele, reactive oxygen species, and gonadotoxin exposure. There is no evidence of familial occurrence.

2. **Dysplasia of the fibrous sheath.** This condition is a systematic sperm abnormality, usually associated with near-complete or total immotility. It has a more homogenous and distinctive phenotype characterized by sperm fibrous sheath, axonemal, and periaxonemal distortions. A subset of these patients exhibit the classic **ciliary dyskinesia** (formerly **immotile cilia syndrome) in which sperm immotility is associated with respiratory disease and dextrocardia.** There is a strong familial incidence, suggesting that such conditions are genetic.

Key Points: Sperm

- Sperm are ciliated cells that possess a “9 + 2” axonemal structure that allows motility.
- It is estimated that 200 to 300 genes regulate sperm motility.
- Sperm motility defects, termed *ciliary dyskinesias*, are common and can be either correctable (nonspecific flagellar anomalies) or genetic (dysplasia of the fibrous sheath).
- Human sperm mtDNA is a circular, histone- and intron-free DNA ring that encodes for respiratory-chain–complex proteins and is very susceptible to mutations.

Summary

Spermatogenesis is a remarkably intricate and complex process that is driven by precisely regulated secretions of GnRH, LH, and FSH from the HPG axis. Perturbations in this hormonal milieu are common causes of male infertility. Sperm production in the testis functions optimally at 2°C to 4°C below body temperature and generates mature human sperm in 64 days. Well-integrated cycles and waves of spermatogenesis ensure that human sperm production is constant at about 1200 sperm per second. Spermatogenesis is an androgen-dependent process that occurs with very high intratesticular testosterone levels. The product of spermatogenesis, the spermatozoa, leave the testis as immotile cells with limited capacity to fertilize oocytes. After epididymal transit, sperm are typically motile and capable of fertilization. During ejaculation, sperm are rapidly transported through the ejaculatory ducts into the urethra from the distal epididymis. The ejaculate supports sperm metabolism and motility, serves as an antioxidant, and acts as a barrier to exclude subsequent gamete deposits from gaining access to the egg.

Suggested Readings

Akre O, Richiardi L. Does a testicular dysgenesis syndrome exist? *Hum Reprod*. 2009;24:2053–2060.

Carrell DT. Epigenetics of the male gamete. *Fert Steril*. 2012;97:267–292.

Cornwall GA. New insights into epididymal biology and function. *Hum Reprod Update*. 2009;15:213–227.

De Jonge CJ, Barratt CL. *The sperm cell: production, maturation, fertilization, regeneration*. Cambridge University Press: New York; 2006.

DiNapoli L, Capel B. SRY and the standoff in sex determination. *Mol Endocrinol*. 2008;22:1–9.

Itman C, Mendis S, Barakat B, et al. All in the family: TGF-beta family action in testis development. *Reproduction*. 2006;132:233–246.

Masters V, Turek PJ. Ejaculatory physiology and dysfunction. *Urol Clin North Am*. 2001;28:363.

Payne AH, Hales DB. Overview of steroidogenic enzymes in the pathway from cholesterol to active steroid hormones. *Endocr Rev*. 2004;25:947–970.

Robaire B, Hinton BT. *The epididymis: from molecules to clinical practice: a comprehensive survey of the efferent ducts, the epididymis and vas deferens*. Kluwer Academic and Plenum: New York; 2002.

Skinner MK, Griswold MD. *Sertoli cell biology*. Elsevier: San Diego; 2005.

Smith JF, Turek PJ. Ejaculatory duct obstruction. *Urol Clin North Am*. 2008;35:221–227.

Turek PJ. Male infertility. Tanagho EA, McAninch JC. *Smith's urology*. ed 17. Lange Clinical Medicine: Stamford (CT); 2007.

Turek PJ, Reijo Pera RA. Current and future genetic screening for male infertility. *Urol Clin North Am*. 2002;29:767–792.

Walker WH. Molecular mechanisms of testosterone action in spermatogenesis. *Steroids*. 2009;74:602.

References

Agger P. Scrotal and testicular temperature: its relation to sperm count before and after operation for varicocele. *Fertil Steril*. 1971;22:286–297.

Alexander NJ. Prenatal development of the ductus epididymidis in the rhesus monkey: the effects of fetal castration. *Am J Anat*. 1972;135:119–134.

Amann RP. A critical review of methods for evaluation of spermatogenesis from seminal characteristics. *J Androl*. 1981;2:37–58.

Amann RP, Almquist JO. Reproductive capacity of dairy bulls: VI. Effect of unilateral vasectomy and ejaculation frequency on sperm reserves: aspects of epididymal physiology. *J Reprod Fertil*. 1961;3:260–268.

Amann RP, Howards SS. Daily spermatozoal production and epididymal spermatozoal reserves of the human male. *J Urol*. 1980;124:211–215.

Amory JK, Wang C, Swerdloff RS, et al. The effect of 5-alpha-reductase inhibition with dutasteride and finasteride on semen parameters and serum hormones in healthy men. *J Clin Endocrinol Metab*. 2007;92:1659–1665.

Anderson DJ, Hill JA. Cell-mediated immunity in infertility. *Am J Reprod Immunol Microbiol*. 1988;17:22.

Ascoli M, Segaloff DL. Regulation of the differentiated functions of Leydig tumor cells by epidermal growth factor. *Ann N Y Acad Sci*. 1989;564:99–115.

Bachtell N, Conaghan J, Turek PJ. The relative viability of human spermatozoa from the testis, epididymis and vas deferens before and after cryopreservation. *Hum Reprod*. 1999;14:101–104.

Bardin CW, Cheng CY, Musto N, et al. *The Sertoli cell*. Raven

Press: New York; 1994.

Bardin CW, Morris PL, Shaha C, et al. Inhibin structure and function in the testis. *Ann N Y Acad Sci*. 1989;564:10–23.

Batra SK, Lardner TJ. *Sperm transport in the vas deferens*. Mosby: St Louis; 1976.

Baumgarten HG, Falck B, Holstein AF, et al. Adrenergic innervation of the human testis, epididymis, ductus deferens and prostate: a fluorescence microscopic and fluorimetric study. *Z Zellforsch Mikrosk Anat*. 1968;90:81–95.

Baumgarten HG, Holstein AF. Catecholaminehaltige nervenfasern im hoden des menschen. *Z Zellforsch Mirosk Anat*. 1967;79:389–395.

Baumgarten HG, Holstein AF, Rosengren E. Arrangement, ultrastructure, and adrenergic innervation of smooth musculature of the ductuli efferentes, ductus epididymidis and ductus deferens of man. *Z Zellforsch Mikrosk Anat*. 1971;120:37–79.

Baumgarten HG, Owan C, Sjoberg NO. *Neural mechanisms in male fertility*. Harper & Row: New York; 1975.

Bayard F, Boulard PY, Huc A, et al. Arteriovenous transfer of testosterone in the spermatic cord of man. *J Clin Endocrinol Metab*. 1975;40:345–346.

Beck EM, Schlegel PN, Goldstein M. Intraoperative varicocele anatomy: a macroscopic and microscopic study. *J Urol*. 1992;148:1190–1194.

Bedford JM. Report of a workshop: maturation of the fertilizing ability of mammalian spermatozoa in the male and female reproductive tract. *Biol Reprod*. 1974;11:346–362.

Bedford JM. Maturation, transport and fate of spermatozoa in the epididymis. Greep RO, Astman EB. *Handbook of physiology*. Williams & Wilkins: Baltimore; 1975:303–317.

Bedford JM, Calvin HI, Cooper GW. The maturation of spermatozoa in the human epididymis. *J Reprod Fertil*.

1973;18:199–213.

Bennett G, Leblond CP, Haddal A. Migration of glycoprotein from the Golgi apparatus to the surface of various cell types as shown by autoradiography after labelled fucose injection into rats. *J Cell Biol*. 1974;60:258–284.

Ben-Rafael Z, Orvieto R. Cytokines—involvement in reproduction. *Fertil Steril*. 1992;58:1093.

Bick DP, Franco B, Sherins RJ, et al. Brief report: intragenic deletion of the *Kalig-1* gene in Kallmann's syndrome. *N Engl J Med*. 1992;326:1752.

Billups KL, Tillman S, Chang TSK. Ablation of the inferior mesenteric plexus in the rat: alteration of sperm storage in the epididymis and vas deferens. *J Urol*. 1990;143:625–629.

Blaquier J, Cameo MS, Dawidowski A, et al. On the role of epididymal factors in sperm maturation in man. *Serono Symp Publ*. 1989;53:37–44.

Blaquier JA, Cameo MS, Cuasnicu PS, et al. The role of epididymal factors in human sperm fertilizing ability. *Ann N Y Acad Sci*. 1988;541:292–296.

Blobel CP, Myles DG, Primakoff P, et al. Proteolytic processing of a protein involved in sperm-egg fusion correlates with acquisition of fertilization competence. *J Cell Biol*. 1990;111:69–78.

Borda E, Agostini M, Gimeno MF, et al. Alpha and beta sympathetic responses to isoproterenol by the isolated rat vas deferens. *Pharmacol Res Comm*. 1981;13:487–499.

Brandt H, Acott TS, Johnson DJ, et al. Evidence for an epididymal origin of bovine sperm forward motility protein. *Biol Reprod*. 1978;19:830–835.

Brooks DE. Epididymal functions and their hormonal regulation. *Aust J Biol Sci*. 1983;36:205–221.

Brooks DE, Tiver K. Analysis of surface proteins of rat spermatozoa during epididymal transit and identification of antigens common to spermatozoa, rete testis fluid and cauda epididymal plasma. *J Reprod Fertil*. 1983;71:249–257.

Brown CR, von Glos KI, Jones R. Changes in plasma membrane glycoproteins of rat spermatozoa during maturation in the epididymis. *J Cell Biol*. 1983;96:256–264.

Brown PC, Dorling J, Glynn LE. Ultrastructural changes in experimental allergic orchitis in guinea-pigs. *J Pathol*. 1972;106:229.

Bruschini H, Schmidt RA, Tanagho EA. Studies on the neurophysiology of the vas deferens. *Invest Urol*. 1977;15:112–116.

Caprio M, Isidori AM, Carta AR, et al. Expression of functional leptin receptors in rodent Leydig cells. *Endocrinology*. 1999;140:4939–4947.

Casillas ER, Elder CM, Hoskins DD. Adenylate cyclase activity of bovine spermatozoa during maturation in the epididymis and the activation of sperm particulate adenylate cyclase by GTP and polyamines. *J Reprod Fertil*. 1980;59:297–302.

Cayan S, Schriock E, Conaghan J, et al. Birth after intracytoplasmic sperm injection using testicular sperm from men with Kartagener/immotile cilia syndrome. *Fertil Steril*. 2001;76:1.

Chemes HE. Phenotypes of sperm pathology: genetic and acquired forms in infertile men. *J Androl*. 2000;21:799.

Chui K, Trivedi A, Cheng CY, et al. Characterization and functionality of proliferative human Sertoli cells. *Cell Transplant*. 2011;20:619–635.

Clavert A, Cranz C, Brun B. Epididymal vascularization and microvascularization. Bollack C, Clavert A. *Progress in reproductive biology*. Karger: Basel; 1981:48–57.

Clegg EJ. The arterial supply of the human prostate and seminal vesicle. *J Anat*. 1955;89:205–216.

Clement K, Vaisse C, Lahlou S, et al. A mutation in the human leptin receptor gene causes obesity and pituitary dysfunction. *Nature*. 1998;392:398–401.

Clermont Y. The cycle of the seminiferous epithelium in man. *Am J Anat*. 1963;112:35–51.

Clermont Y. Kinetics of spermatogenesis in mammals: seminiferous epithelium cycle and spermatogonial renewal. *Physiol Rev*. 1972;52:198–236.

Collin O, Lissbrant E, Bergh A. Atrial natriuretic peptide, brain natriuretic peptide and c-type natriuretic peptide: effects on testicular microcirculation and immunohistochemical localization. *Int J Androl*. 1997;20:55–60.

Conrad S, Renninger M, Hennenlotter J, et al. Generation of pluripotent stem cells from adult human testis. *Nature*. 2008;456:344–349.

Cooper TG, Orgebin-Crist MC. Effect of aging on the fertilizing capacity of testicular spermatozoa from the rabbit. *Biol Reprod*. 1977;16:258–266.

Courot M. Transport and maturation of spermatozoa in the epididymis of mammals. Bollack C, Clavert A. *Progress in reproductive biology*. Karger: Basel; 1981:67.

Courtens JL, Fournier-Delpech S. Modifications in the plasma membranes of epididymal ram spermatozoa during maturation and incubation in utero. *J Ultrastruct Res*. 1979;68:136–148.

Cuasnicu PS, Bedford JM. The effect of moderate epididymal aging on the kinetics of the acrosome reaction and fertilizing ability of hamster spermatozoa. *Biol Reprod*. 1989;40:1067–1073.

Cuasnicu PS, Gonzales-Echeverria F, Piazza A, et al. Epididymal proteins mimic the androgenic effect of zona pellucida recognition by immature hamster spermatozoa. *J Reprod Fertil*. 1984;71:427–431.

Culty M, Li H, Boujrad N, et al. In vitro studies on the role of the peripheral-type benzodiazepine receptor in steroidogenesis. *J Steroid Biochem Mol Biol*. 1999;69:123–130.

Dacheux JL, Paquignon M. Relations between the fertilizing ability, motility and metabolism of epididymal spermatozoa. *Reprod Nutr Dev*. 1980;20:1085–1089.

Darney KJ Jr, Zirkin BR, Ewing LL. Testosterone autoregulation of its biosynthesis in the rat testis: inhibition of 17 alpha-hydroxylase activity. *J Androl*. 1996;17:137–142.

Davis AG, Horowitz AM. Age-related differences in the response of the isolated testicular capsule of the rat to norepinephrine, acetylcholine and prostaglandins. *J Reprod Fertil*. 1978;54:269–274.

Davis CM, Papadopoulos V, Sommers CL, et al. Differential expression of extracellular matrix components in rat Sertoli cells. *Biol Reprod*. 1990;43:860–869.

de Kretser DM, Kerr JB. *The cytology of the testis*. Raven Press: New York; 1988.

Desjardins C. The microcirculation of the testis. *Ann N Y Acad Sci*. 1989;564:243–249.

Diemer T, Hales DB, Weidner W. Immune-endocrine interactions and Leydig cell function: the role of cytokines. *Andrologia*. 2003;35:55.

Dinakar RA, Dinaker N, Prasad MR. Response of the epididymis, ductus deferens and accessory glands of the castrated prepubertal rhesus monkey to exogenous administration of testosterone of 5α-dihydrotestosterone. *Indian J Exp Biol*. 1977;15:829–834.

DiNapoli L, Capel B. SRY and the standoff in sex determination. *Mol Endocrinol*. 2008;22:1–9.

Dixon JS, Jen PY, Gosling JA. Structure and autonomic innervation of the human vas deferens: a review. *Microsc Res Tech*. 1998;42:423–432.

Dode C, Levilliers J, Dupont JM, et al. Loss-of-function mutations in FGFR1 cause autosomal dominant Kallmann syndrome. *Nat Genet*. 2003;33:463–465.

Dupuy GM, Boulanger KD, Roberts KD, et al. Metabolism of sex steroids in the human and canine vas deferens. *Endocrinology*. 1979;104:1553–1558.

Dym M, Fawcett DW. The blood-testis barrier in the rat and the physiological compartmentation of the seminiferous epithelium. *Biol Reprod*. 1970;3:308.

Eik-Nes KB. Biosynthesis and secretion of testicular steroids. Greep RO, Astwood EB. *Handbook of physiology*. Williams & Wilkins: Baltimore; 1975:95.

el-Demiry MI, Hargreave TB, Busuttil A, et al. Lymphocyte sub-populations in the male genital tract. *Br J Urol*. 1985;57:769.

Ewing LL. Leydig cell. Lipshultz LI, Howards S. *Infertility in the male*. Churchill Livingstone: New York; 1983:43.

Ewing LL, Brown B. Testicular steroidogenesis. Johnson AD, Gomes WR. *The testis*. Academic Press: New York; 1977:239.

Ewing LL, Davis JC, Zirkin BR. Regulation of testicular function: a spatial and temporal view. Greep RO. *International review of physiology*. University Park Press: Baltimore; 1980:41.

Ezeh UI, Turek PJ, Reijo RA, et al. Human embryonic stem cell genes *OCT4*, *NANOG, STELLAR,* and *GDF3* are expressed in both seminoma and breast carcinoma. *Cancer*. 2005;104:2255–2265.

Fawcett DW, Leak LV, Heidger PM Jr. Electron microscopic observations on the structural components of the blood-testis barrier. *J Reprod Fertil Suppl*. 1970;10:105.

Filippini A, Riccioli A, Padula F, et al. Control and impairment of immune privilege in the testis and in semen. *Hum Reprod*

Update. 2001;7:444–449.

Foldesy RG, Bedford JM. Biology of the scrotum: I. Temperature and androgen as determinants of the sperm storage capacity of the rat cauda epididymis. *Biol Reprod*. 1982;26:673–682.

Foresta C, Moro E, Ferlin A. Prognostic value of Y deletion analysis. The role of current methods. *Hum Reprod*. 2001;16:1543–1547.

Friedman JM. Genetic disease in the offspring of older fathers. *Obstet Gynecol*. 1981;57:745.

Friend DS. Sperm maturation: membrane domain boundaries. *Ann N Y Acad Sci*. 1989;567:208–221.

Friend DS, Farquhar MG. Functions of coated vesicles during protein absorption in the rat vas deferens. *J Cell Biol*. 1967;35:357.

Goffin V, Binart N, Touraine P, et al. Prolactin: the new biology of an old hormone. *Annu Rev Physiol*. 2002;64:47–67.

Goldstein M, Eid JF. Elevation of intratesticular and scrotal skin surface temperature in men with varicocele. *J Urol*. 1989;142:743–745.

Gondos B, Hobel CJ. Ultrastructure of germ cell development in the human fetal testis. *Z Zellforsch Mikrosk Anat*. 1971;119:1–20.

Gonsalves J, Sun F, Schlegel PN, et al. Defective recombination in infertile men. *Hum Mol Genet*. 2004;13:2875–2883.

Griswold MD, Morales C, Sylvester SR. Molecular biology of the Sertoli cell. *Oxf Rev Reprod Biol*. 1988;10:53–123.

Gupta G, Rajalakshmi N, Prasad MR, et al. Alteration of epididymal function and its relation to maturation of spermatozoa. *Andrologia*. 1974;6:35–44.

Gur S, Kadowitz PJ, Hellstrom WJ. Purinergic (P2) receptor control of lower genitourinary tract function and new avenues for drug action: an overview. *Curr Pharm Des*.

2007;13:3236–3244.

Hamilton DW. The epididymis. Greep RO, Koblinsky MA. *Frontiers in reproduction and fertility control: II*. MIT Press: Cambridge, MA; 1977:411.

Hammond J, Asdell SA. The vitality of the spermatozoa in the male and female reproductive tract. *J Exp Biol*. 1926;4:155.

Hansson V, Djoseland O. Preliminary characterization of the 5α-dihydrotestosterone binding protein in the epididymal cytosol fraction: in vivo studies. *Acta Endocrinol*. 1972;71:614–624.

Harrison RG, Barclay AE. The distribution of the testicular artery (internal spermatic artery) to the human testis. *Br J Urol*. 1948;20:5.

Hayes FJ, Pitteloud N, DeCruz S, et al. Importance of inhibin B in the regulation of FSH secretion in the human male. *J Clin Endocrinol Metab*. 2001;86:5541–5546.

He Z, Kokkinaki M, Pant D, et al. Small RNA molecules in the regulation of spermatogenesis. *Reproduction*. 2009;137:901–911.

Heller CG, Clermont Y. Kinetics of the germinal epithelium in man. *Rec Prog Horm Res*. 1964;20:545–575.

Hermo L, Lalli M, Clermont Y. Arrangement of connective tissue elements in the walls of seminiferous tubules of man and monkey. *Am J Anat*. 1977;148:433–446.

Hinrichsen MJ, Blaquier JA. Evidence supporting the existence of sperm maturation in the human epididymis. *J Reprod Fertil*. 1980;60:291–294.

Hirata S, Hoshi K, Shoda T, et al. Spermatozoon and mitochondrial DNA. *Reprod Med Biol*. 2002;1:41.

Hoffer AP. The ultrastructure of the ductus deferens in man. *Biol Reprod*. 1976;14:425–443.

Hoffer AP, Hinton BT. Morphological evidence for a blood-epididymis barrier and the effects of gossypol on its integrity.

Biol Reprod. 1984;30:991–1004.

Holstein AF. Morphologische studien am nebenhoden des menschen. *Zwanglose Abhaudl Gebeit Norm Pathol Anat*. 1969;20:1.

Hopps CV, Mielnik A, Goldstein M, et al. Detection of sperm in men with Y chromosome microdeletions of the AZFa, AZFb and AZFc regions. *Hum Reprod*. 2003;18:1660–1665.

Horan AH, Bedford JM. Development of the fertilizing ability of spermatozoa in the epididymis of the Syrian hamster. *J Reprod Fertil*. 1972;30:417–423.

Hoskins DD, Munsterman D, Hall ML. The control of bovine sperm glycolysis during epididymal transit. *Biol Reprod*. 1975;12:566–572.

Huhtaniemi I, Pelliniemi LJ. Fetal Leydig cells: cellular origin, morphology, life span, and special functional features. *Proc Soc Exp Biol Med*. 1992;201:125–140.

Hundeiker M. Lymphgefasse in parenchym des menschlichen hoden. *Arch Klin Exp Dermatol*. 1971;235:271.

Itman C, Mendis S, Barakat B, et al. All in the family: TGF-beta family action in testis development. *Reproduction*. 2006;132:233–246.

Jaakkola UM. Regional variations in transport of the luminal contents of the rat epididymis in vivo. *J Reprod Fertil*. 1983;68:465–470.

Jaakkola UM, Talo A. Relation of electrical activity to luminal transport in the cauda epididymis of the rat in vitro. *J Reprod Fertil*. 1982;64:121–126.

Jarow JP. Clinical significance of intratesticular arterial anatomy. *J Urol*. 1991;145:777–779.

Johnson L, Varner DD. Effect of daily spermatozoan production but not age on transit time of spermatozoa through the human epididymis. *Biol Reprod*. 1988;39:812–817.

Kaler LW, Neaves WB. Attrition of human Leydig cell population with advancing age. *Anat Rec*. 1978;192:513–521.

Kerr JB, de Kretser DM. The cytology of the human testis. Burger H, de Kretser D. *The testis*. Raven Press: New York; 1981:141–169.

Kiess W, Reich A, Meyer K, et al. A role for leptin in sexual maturation and puberty? *Horm Res*. 1999;51:55–63.

Kinoshita Y, Hosaka M, Nishimura R, et al. Partial characterization of 5a-reductase in the human epididymis. *Endocrinol Jpn*. 1980;27:277–284.

Kormano M. Dye permeability and alkaline phosphatase activity of testicular capillaries in the postnatal rat. *Histochemie*. 1967;9:327–338.

Kormano M, Reijonen K. Microvascular structure of the human epididymis. *Am J Anat*. 1976;145:23–27.

Kormano M, Suoranta H. An angiographic study of the arterial pattern of the human testis. *Anat Anz*. 1971;128:69–76.

Kossack N, Meneses J, Shefi S, et al. Isolation and characterization of pluripotent human spermatogonial stem cell-derived cells. *Stem Cells*. 2009;27:138–149.

Kostiner DR, Turek PJ, Reijo RA. Male infertility: analysis of the markers and genes on the human Y chromosome. *Hum Reprod*. 1998;13:3032–3038.

Langford GA, Heller CG. Fine structure of muscle cells of the human testicular capsule: basis of testicular contractions. *Science*. 1973;179:573.

Lanz TV, Neuhauser G. Morphometrische Analyse des menschlichen Nebenhodens. *Z Anat Entwicklungsgesch*. 1964;124:126.

Larminat MA, Hinrichsen MJ, Scroticati C, et al. Uptake and metabolism of androgen by the human epididymis in vitro. *J Reprod Fertil*. 1980;59:397–402.

Le Roy C, Lejeune H, Chuzel F, et al. Autocrine regulation of Leydig cell differentiated functions by insulin-like growth factor I and transforming growth factor beta. *J Steroid Biochem Mol Biol*. 1999;69:379–384.

Lee KH, Hess RA, Bahr JM, et al. Estrogen receptor alpha has a functional role in the mouse rete testis and efferent ductules. *Biol Reprod*. 2000;63:1873–1880.

Leinonen P, Hammond GL, Vihko R. Testosterone and some of its precursors and metabolites in the human epididymis. *J Clin Endocrinol Metab*. 1980;51:423–428.

Lennox B, Ahmad KN. The total length of tubules in the human testis. *J Anat*. 1970;107:191.

Levallet J, Pakarinen P, Huhtaniemi IT. Follicle-stimulating hormone ligand and receptor mutations, and gonadal dysfunction. *Arch Med Res*. 1999;30:486–494.

Lich R Jr, Howerton LW, Amin M. Anatomy and surgical approach to the urogenital tract in the male. WB Saunders: Philadelphia; 1978:3–33. Harrison JH, Gittes RF, Perlmutter AD, et al. *Campbell's urology*. vol 1.

Lino BF, Braden AW, Turnbull KE. Fate of unejaculated spermatozoa. *Nature*. 1967;213:594–595.

Linzell JL, Setchell BP. Metabolism, sperm and fluid production of the isolated perfused testis of the sheep and goat. *J Physiol*. 1969;201:129–143.

Lipsett MB. Steroid secretion by the testis in man. James VH, Serio M, Martini L, et al. *The endocrine function of the human testis*. Academic Press: New York; 1974.

Lipshultz LI, McConnell J, Benson GS. Current concepts of the mechanism of ejaculation. *J Reprod Med*. 1981;26:499–507.

MacMillan EW. The blood supply of the epididymis in man. *Br J Urol*. 1954;26:60–71.

Mahi-Brown CA, Yule TD, Tung KS. Evidence for active immunological regulation in prevention of testicular autoimmune disease independent of the blood-testis barrier. *Am J Reprod Immunol Microbiol*. 1988;16:165.

Marshall FF, Edler JS. *Cryptorchidism and related anomalies*. Praeger: New York; 1982.

Martan J. Epididymal histochemistry and physiology. *Biol Reprod*. 1969;1:34–54.

Martin RH, Rademaker AW. The effect of age on the frequency of sperm chromosomal abnormalities in normal men. *Am J Hum Genet*. 1987;41:484.

Mather JP, Gunsalus GL, Musto NA, et al. The hormonal and cellular control of Sertoli cell secretion. *J Steroid Biochem*. 1983;19:41–51.

Matthews GJ, Schlegel PN, Goldstein M. Patency following microsurgical vasoepididymostomy and vasovasostomy: temporal considerations. *J Urol*. 1995;154:2070–2073.

McConnell J, Benson GS, Wood JG. Autonomic innervation of the urogenital system: adrenergic and cholinergic elements. *Brain Res Bull*. 1982;9:679–694.

Middleton WD, Dahiya N, Naughton CK, et al. High-resolution sonography of the normal extrapelvic vas deferens. *J Ultrasound Med*. 2009;28:839–846.

Milgrom E, de Roux N, Ghinea N, et al. Gonadotrophin and thyrotrophin receptors. *Horm Res*. 1997;48:33–37.

Miller WL. Disorders of androgen biosynthesis. *Semin Reprod Med*. 2002;20:205–216.

Misell LM, Holochwost D, Boban D, et al. A stable isotope/mass spectrometric method for measuring the kinetics of human spermatogenesis in vivo. *J Urol*. 2006;175:242–246.

Mitchell GA. The innervation of the kidney, ureter, testicle and epididymis. *J Anat*. 1935;70:10.

Moore HD, Smith CA. The role of the epididymis during maturation of mammalian spermatozoa in vivo and in vitro. *Reprod Nutr Dev*. 1988;28:1217–1224.

Morton BE, Sagadraca R, Fraser CF. Sperm motility within the mammalian epididymis: species variation and correlation with free calcium levels in epididymal plasma. *Fertil Steril*. 1978;29:695–698.

Mruk DD, Cheng CY. Sertoli-Sertoli and Sertoli–germ cell interactions and their significance in germ cell movement in the seminiferous epithelium during spermatogenesis. *Endocr Rev*. 2004;25:747–806.

Mueller JL, Skaletsky H, Brown LG, et al. Independent specialization of the human and mouse X chromosomes for the male germline. *Nat Genet*. 2013;45:1083–1087.

Mui P, Perkins A, Burrows PJ, et al. The need for epididymovasostomy at vasectomy reversal plateaus in older vasectomies: a study of 1229 cases. *Andrology*. 2014;2:25–29.

Muller I. Kanalchen und Capillararchitektonik des ratten Hodens. *Z Zellforsch*. 1957;45:522–537.

Mulligan T, Iranmanesh A, Johnson ML, et al. Aging alters feed-forward and feedback linkages between LH and testosterone in healthy men. *Am J Physiol*. 1997;273(4 Pt 2):1407–1413.

Murakami M, Yokoyama R, Nishida T, et al. Scanning and transmission electron microscope observations of the terminal segment of the cat seminiferous tubule: epithelial phagocytosis of spermatozoa and latex beads. *Arch Histol Cytol*. 1988;51:185–192.

Neaves WB. Biological aspects of vasectomy. Greep RO, Astwood EB. *Handbook of physiology*. Williams & Wilkins: Baltimore; 1975:383–404.

Nguyen HT, Etzell J, Turek PJ. Normal human ejaculatory duct anatomy: a study of cadaveric and surgical specimens. *J Urol*. 1996;155:1639–1642.

Nikolic A, Volarevic V, Armstrong L, et al. Primordial germ cells: current knowledge and perspectives. *Stem Cells Int*.

2016;2016:1741072.

Nikolopoulou M, Soucek DA, Vary JC. Changes in the lipid content of boar sperm plasma membranes during epididymal maturation. *Biochim Biophys Acta*. 1985;815:486–498.

Oatley JM, Brinster RL. Regulation of spermatogonial stem cell self-renewal in mammals. *Annu Rev Cell Dev Biol*. 2008;24:263–286.

Oko R, Clermont Y. Mammalian spermatozoa: structure and assembly of the tail. Gagnon C. *Controls of sperm motility: biological and clinical aspects*. CRC Press: Boca Raton (FL; 1990:3–27.

Olesen C, Silber J, Eiberg H, et al. Mutational analysis of the human *FATE* gene in 144 infertile men. *Hum Genet*. 2003;113:195–201.

Olson GE, Danzo BJ. Surface changes in rat spermatozoa during epididymal transit. *Biol Reprod*. 1981;24:431–443.

Orgebin-Crist MC. Studies on the function of the epididymis. *Biol Reprod*. 1969;1:155–175.

Orgebin-Crist MC, Danzo BJ, Davies J. Endocrine control of the development and maintenance of sperm fertilizing ability in the epididymis. Greep RO, Astwood EB. *Handbook of physiology*. Williams & Wilkins: Baltimore; 1975:319–338.

Orgebin-Crist MC, Fournier-Delpech S. Sperm-egg interaction: evidence for maturational changes during epididymal transit. *J Androl*. 1982;3:429–433.

Paniagua R, Regader J, Nistal M, et al. Histological, histochemical and ultrastructural variations along the length of the human vas deferens before and after puberty. *Acta Anat*. 1981;111:190.

Park SH, Lee HS, Choe JH, et al. Success rate of microsurgical multiple testicular sperm extraction and sperm presence in the ejaculate in Korean men with Y chromosome microdeletions. *Korean J Urol*. 2013;54:536–540.

Payne AH, Hales DB. Overview of steroidogenic enzymes in the pathway from cholesterol to active steroid hormones. *Endocrinol Rev*. 2004;25:947–970.

Payne AH, Youngblood GL. Regulation of expression of steroidogenic enzymes in Leydig cells. *Biol Reprod*. 1995;52:217–225.

Perussia B, Kobayashi M, Rossi ME, et al. Immune interferon enhances functional properties of human granulocytes: role of Fc receptors and effect of lymphotoxin, tumor necrosis factor, and granulocyte-macrophage colony-stimulating factor. *J Immunol*. 1987;138:765.

Pettersson S, Soderholm B, Persson JE, et al. Testicular blood flow in man measured with venous occlusion plethysmography and xenon-133. *Scand J Urol Nephrol*. 1973;7:115–119.

Pholpramool C, Lea OA, Burrow PV, et al. The effects of acidic epididymal glycoprotein (AEG) and some other proteins on the motility of rat epididymal spermatozoa. *Int J Androl*. 1983;6:240–248.

Pierik FH, Vreeburg JTM, Stijnen T, et al. Serum Inhibin B as a marker of spermatogenesis. *J Clin Endo Metab*. 1998;83:3110–3114.

Prader A. Testicular size: assessment and clinical importance. *Triangle*. 1966;7:240–243.

Prasad MR, Rajalakshmi M. Target sites for suppressing fertility in the male. *Adv Sex Horm Res*. 1976;2:263–287.

Primakoff P, Hyatt H, Tredick-Kline J. Identification and purification of a sperm surface protein with a potential role in sperm-egg membrane fusion. *J Cell Biol*. 1987;104:141–149.

Prins GS, Zaneveld LJ. Distribution of spermatozoa in the rabbit vas deferens. *Biol Reprod*. 1979;21:181–185.

Prins GS, Zaneveld LJ. Contractions of the rabbit vas deferens following sexual activity: a mechanism for proximal transport of spermatozoa. *Biol Reprod*. 1980;23:904.

Prins GS, Zaneveld LJ. Radiographic study of fluid transport in the rabbit vas deferens during sexual rest and after sexual activity. *J Reprod Fertil*. 1980;58:311–319.

Pujol A, Bayard F, Louvet JP, et al. Testosterone and dihydrotestosterone concentrations in plasma, epididymal tissues and seminal fluid of adult rats. *Endocrinology*. 1976;98:111–113.

Quinton ND, Smith RF, Clayton PE, et al. Leptin binding activity changes with age: the link between leptin and puberty. *J Clin Endocrinol Metab*. 1999;84:2336–2341.

Raverot G, Lejeune H, Kotlar T, et al. X-linked sex-determining region Y box 3 *(SOX3)* gene mutations are uncommon in men with idiopathic oligoazoospermic infertility. *J Clin Endocrinol Metab*. 2004;89:4146–4148.

Reijo R, Alagappan RK, Patrizio P, et al. Severe oligozoospermia resulting from deletions of azoospermia factor gene on Y chromosome. *Lancet*. 1996;347:1290–1293.

Reyes FI, Winter JS, Faiman C. Gonadotropin-gonadal interrelationships in the fetus. *Prog Clin Biol Res*. 1976;10:83–106.

Rikmaru A, Shirai M. Response of the human testicular capsule to electrical stimulation and to autonomic drugs. *Tohoku J Exp Med*. 1972;108:303–304.

Risely PL. *Physiology of the male accessory organs*. Pergamon Press: New York; 1963.

Robaire B, Hermo L. Efferent ducts, epididymis, and vas deferens: structure, function, and their regulation. Knobil E, Neil J. *The physiology of reproduction*. Raven Press: New York; 1988:999–1080.

Robert M, Gagnon C, Semenogelin I. A coagulum forming, multifunctional seminal vesicle protein. *Cell Mol Life Sci*. 1999;55:944–960.

Romrell LJ, Ross MH. Characterization of Sertoli cell-germ junctional specializations in disassociated testicular cells. *Anat Rec*. 1979;193:23–41.

Russell L, Clermont Y. Anchoring device between Sertoli cells and late spermatids in rat seminiferous tubules. *Anat Rec*. 1976;185:259–278.

Saez JM, Avallet O, Lejeune H, et al. Cell-cell communication in the testis. *Horm Res*. 1991;36:104–115.

Saling PM. Mammalian sperm interaction with extracellular matrices of the egg. *Oxf Rev Reprod Biol*. 1989;11:339–388.

Santen RJ. Is aromatization of testosterone to estradiol required for inhibition of luteinizing hormone secretion in men? *J Clin Invest*. 1975;56:1555–1563.

Schlegel PN, Su LM. Physiological consequences of testicular sperm extraction. *Hum Reprod*. 1997;12:1688–1692.

Schoysman RJ, Bedford JM. The role of the human epididymis in sperm maturation and sperm storage as reflected in the consequences of epididymovasostomy. *Fertil Steril*. 1986;46:293–299.

Schulze W. Structural principles underlying the spermatogenic process in man and a non-human primate *(Macaca cynomolgus)*. *Reproductive biology and medicine*. Diesbach Verlag: Berlin; 1989:58–65.

Schweitzer R. Uber die Bedeutung der Vascularisation, der Binnendruckes und der Zwischenzellen fur die Biologie des Hodens. *Anat Entwickl*. 1929;89:775–796.

Setchell BP, Brooks DE. Anatomy, vasculature, innervation and fluids of the male reproductive tract. Knobil E, Neill JD. *The physiology of reproduction*. Raven Press: New York; 1988:753–836.

Setchell BP, Waites GM. The blood-testis barrier. Greep RO, Astwood EB. *Handbook of physiology*. Williams & Wilkins: Baltimore; 1975:143–172.

Shabanowitz RB. Mouse antibodies to human zona pellucida: evidence that human ZP3 is strongly immunogenic and contains two distinct isomer chains. *Biol Reprod*. 1990;43:260–270.

Sharpe RM. Intratesticular factors controlling testicular function. *Biol Reprod*. 1984;30:29–49.

Sheth AR, Gunjikar AN, Shah GV. The presence of progressive motility sustaining factor (PMSF) in human epididymis. *Andrologia*. 1981;13:142–146.

Shupnik MA, Schreihofer DA. Molecular aspects of steroid hormone action in the male reproductive axis. *J Androl*. 1997;18:341–344.

Silber SJ. Microsurgical aspects of varicocele. *Fertil Steril*. 1979;31:230–232.

Silber SJ. Apparent fertility of human spermatozoa from the caput epididymidis. *J Androl*. 1989;10:263–269.

Sjostrand NO. The adrenergic innervation of the vas deferens and the accessory male genital glands. *Acta Physiol Scand*. 1965;65:7–82.

Skinner MK. Interactions between germ cells and Sertoli cells in the testis. *Biol Reprod*. 1995;52:211–216.

Skinner MK, Fetterhoff PM, Anthony CT. Purification of a paracrine factor, P-Mod-S, produced by testicular peritubular cells that modulates Sertoli cell function. *J Biol Chem*. 1988;263:2884–2890.

Smith JF, Walsh TM, Turek PJ. Ejaculatory duct obstruction. *Urol Clin North Am*. 2008;35:221–227.

Steger RW, Chandrashekar V, Zhao W, et al. Neuroendocrine and reproductive functions in male mice with targeted disruption of the prolactin gene. *Endocrinology*. 1998;139:3691–3695.

Steinberger E. Molecular mechanisms concerned with hormonal effects on the seminiferous tubule and endocrine relationships at puberty in the male. Spilman CH, Lobl TJ, Kirton KT, et al. *Regulatory mechanisms of male reproductive physiology*. Excerpta Medica: Amsterdam; 1976:29–34.

Stocco DM. Intramitochondrial cholesterol transfer. *Biochim Biophys Acta*. 2000;1486:184–197.

Sun F, Mikhaail-Philips M, Oliver-Bonet M, et al. Reduced meiotic recombination on the XY bivalent is correlated with an increased incidence of sex chromosome aneuploidy in men with nonobstructive azoospermia. *Mol Hum Reprod*. 2008;14:399–404.

Sutovsky P, Moreno R, Ramalho-Santos J, et al. Ubiquitin tag for sperm mitochondria. *Nature*. 1999;402:371–372.

Suzuki F, Nagano T. Development of tight junctions in caput epididymal epithelium of mouse. *Dev Biol*. 1978;63:321.

Swerdloff RS, Heber D. Endocrine control of testicular function from birth to puberty. Burger H, de Kretser D. *The testis*. Raven Press: New York; 1981:107–126.

Tapanainen JS, Aittomaki K, Min J, et al. Men homozygous for an inactivating mutation of the follicle-stimulating hormone (FSH) receptor gene present variable suppression of spermatogenesis and fertility. *Nat Genet*. 1997;15:205–206.

Teerds KJ, Dorrington JH. Localization of transforming growth factor beta 1 and beta 2 during testicular development in the rat. *Biol Reprod*. 1993;48:40–45.

Tezón JG, Ramella E, Cameo MS, et al. Immunochemical localization of secretory antigens in the human epididymis and their association with spermatozoa. *Biol Reprod*. 1985;32:591–597.

Thomas AJ Jr. Vasoepididymostomy. *Urol Clin N Am*. 1987;14:527–538.

Tiepolo L, Zuffardi O. Localization of factors controlling spermatogenesis in the nonfluorescent portion of the human Y chromosome long arm. *Hum Genet*. 1976;34:119–124.

Tishler PV. Diameter of testicles. *N Engl J Med*. 1971;285:1489.

Tolia NH, Joshua-Tor L. Slicer and the argonautes. *Nat Chem Biol*. 2007;3:36–44.

Toyama Y. Actin-like filaments in the myoid cell of the testis. *Cell Tissue Res*. 1977;177:221–226.

Tung KS. Autoimmunity of the testis. Dhindsa DS, Schumacher GF. *Immunological aspects of infertility and fertility regulation*. Elsevier-North Holland: New York; 1980:33.

Tung KS, Skinner MK, Fritz IB. Fibronectin synthesis is a marker for peritubular cell contaminants in Sertoli cell–enriched cultures. *Biol Reprod*. 1984;30:199–211.

Tung KS, Unanue ER, Dixon FJ. Pathogenesis of experimental allergic orchitis. II. The role of antibody. *J Immunol*. 1971;106:1463.

Turek PJ. Immunopathology and infertility. Lipshultz LI, Howards SS. *Infertility in the male*. ed 3. Mosby–Year Book: Philadelphia; 1997.

Turek PJ. Practical approach to the diagnosis and management of male infertility. *Nat Clin Pract Urol*. 2005;2:1–13.

Turek PJ, Aslam KH, Younes AK, et al. Observations on seminal vesicle dynamics in an in vivo rat model. *J Urol*. 1998;159:1731–1734.

Turek PJ, Reijo Pera RA. Current and future genetic screening for male infertility. *Urol Clin North Am*. 2002;29:767–792.

Turnbull AV, Rivier C. Inhibition of gonadotropin-induced testosterone secretion by the intracerebroventricular injection of interleukin-1 beta in the male rat. *Endocrinology*. 1997;138:1008–1013.

Turner TT. On the epididymis and its function. *Invest Urol*. 1979;16:311–321.

Turner TT, D'Addario D, Howards SS. Further observations on the initiation of sperm motility. *Biol Reprod*. 1978;19:1095–1101.

Turner TT, Giles RD. Sperm motility-inhibiting factor in rat epididymis. *Am J Physiol*. 1982;242:R199–R203.

Turner TT, Roddy MS. Intraluminal androgen binding protein alters 3H-androgen uptake by rat epididymal tubules in vitro. *Biol Reprod*. 1990;43:414–419.

Val P, Lefrançois-Martinez AM, Veyssière G, et al. SF-1: a key player in the development and differentiation of steroidogenic tissues. *Nucl Recept*. 2003;1:8.

van Overveld FW, Haenen GR, Rhemrev J, et al. Tyrosine as important contributor to the antioxidant capacity of seminal plasma. *Chem Biol Interact*. 2000;127:151–161.

Vendrely E. Histology of the epididymis in the human adult. Bollack C, Clavert A. *Progress in reproductive biology,* vol. 8. *Epididymis and fertility: biology and pathology*. Karger: Basel; 1981:21–33.

Vendrely E, Dadoune JP. Quantitative ultrastructural analysis of the principal cells in the human epididymis. *Reprod Nutr Dev*. 1988;28:1225–1235.

Ventura WP, Freund M, Davis J, et al. Influence of norepinephrine on the motility of the human vas deferens: a new hypothesis of sperm transport by the vas deferens. *Fertil Steril*. 1973;24:68–77.

Vermeulen A, Kaufman JM. Ageing of the hypothalamo-pituitary-testicular axis in men. *Horm Res*. 1995;43:25–28.

Voglmayr JK. Metabolic changes in spermatozoa during epididymal transit. Greep RO, Astwood EB. *Handbook of physiology, section 7, Endocrinology*. Williams & Wilkins: Baltimore; 1975:437–451.

Vogt PH, Edelmann A, Kirsch S, et al. Human Y chromosome azoospermia factors (AZF) mapped to different subregions in Yq11. *Hum Mol Genet*. 1996;5:933–943.

Walsh TJ, Reijo Pera RA, Turek PJ. Genetic male infertility. *Semin Reprod Med*. 2009;2:124–136.

Wang PJ, McCarrey JR, Yang F, et al. An abundance of X-linked genes expressed in spermatogonia. *Nat Genet*. 2001;27:422–426.

Wennbo H, Kinblom J, Isaksson OG, et al. Transgenic mice overexpressing the prolactin gene develop dramatic enlargement in the prostate gland. *Endocrinology*. 1997;138:4410–4415.

Wenzel J, Kellermann P. Vergleichende untersuchungen uber das Lymphgefasssytem des Nebenhodens und Hodesn von Mensch, hund unk Kaninchwen. *Z Mikrosk Anat Forsch*. 1966;75:368–387.

West LA, Horvat RD, Roess DA, et al. Steroidogenic acute regulatory protein and peripheral-type benzodiazepine receptor associate at the mitochondrial membrane. *Endocrinology*. 2001;142:502–505.

Winter JS, Faiman C. Pituitary-gonadal relations in male children and adolescents. *Pediatr Res*. 1972;6:126–131.

Witschi E. Migration of the germ cells of human embryos from the yolk sac to the primitive gonadal fold. *Carnegie Institute Wash Contrib Embryol*. 1948;209:67–80.

Wong PY, Au CL, Bedford JM. Biology of the scrotum: II. Suppression by abdominal temperature of transepithelial ion and water transport in the cauda epididymidis. *Biol Reprod*. 1982;26:683–689.

Wyrobek AJ, Aardema M, Eichenlaub-Ritter U, et al. Mechanisms and targets involved in maternal and paternal age effects on numerical aneuploidy. *Environ Mol Mutag*. 1996;28:254–264.

Xia W, Wong EW, Mruk DD, et al. TGF-beta3 and TNFalpha perturb blood-testis barrier (BTB) dynamics by accelerating the clathrin-mediated endocytosis of integral membrane proteins: a new concept of BTB regulation during spermatogenesis. *Dev Biol*. 2009;327:48–61.

Yanagimachi R. Sperm-egg association in mammals. Moscona AA, Monroy A. *Current topics in developmental biology*. Academic Press: New York; 1978:83–105.

Yanagimachi R. Fertilization. Knobil E, Neill JD, Greenwald GS, et al. *The physiology of reproduction*. Raven: New York; 1994:189–317.

Yanagimachi R. Fertilization and developmental initiation of oocytes by injection of spermatozoa and pre-spermatozoal cells. *Ital J Anat Embryol*. 2005;110:145–150.

Yatsenko AN, Turek PJ. Reproductive genetics and the aging male. *J Assist Reprod Gen*. 2018;35(6):933–941.

Yeung CH, Sonnenberg-Riethmacher E, Cooper TG. Receptor tyrosine kinase c-ros knockout mice as a model for the study of epididymal regulation of sperm function. *J Reprod Fertil*. 1998;53(Suppl):137–147.

Young WC. A study of the function of the epididymis: II. The importance of an ageing process in sperm for the length of the period during which fertilizing capacity is retained by sperm isolated in the epididymis of the guinea pig. *J Morphol*. 1929;48:475–491.

Zamboni L. Sperm structure and its relevance to infertility. An electron microscopic study. *Arch Pathol Lab Med*. 1992;116:325.

65

Integrated Men's Health

Androgen Deficiency, Cardiovascular Risk, and Metabolic Syndrome

Neil Fleshner MD, MPH, FRCSC, Miran Kenk PhD, Steven Kaplan MD

Rationale for Integrative Men's Health

Introduction to the Problem

In almost every corner of our planet, health outcomes among boys and men are significantly inferior to those among girls and women. Despite these differences, attention from health policy leadership and local, national, and supranational entities toward addressing this issue has remained scant. Efforts to reduce gender inequality in health are desperately needed and require a substantial adjustment in multiple facets of life, including workplace safety, global peace, sociology, psychology, and lifestyle.

Gender Longevity Gap

Human longevity continues to increase on a global scale (Fries, 1980; Oeppen and Vaupel, 2002). Emphasis on perinatal care, labor and delivery, childhood vaccinations, smoking cessation, and healthier lifestyles in terms of diet and exercise have made a true impact on extending human life span around the world (Mathers and Loncar, 2006; Oeppen and Vaupel, 2002). Interestingly, one peculiar statistic seems to stand out from the general progress: the gap in longevity between male and female humans. **On average, men throughout the world live shorter lives than women.** Average life expectancy in the United States is currently 79.3 years (World Health Organization [WHO], 2016b). However, when one breaks this statistic out by gender, women live on average 81.6 years, whereas men live only 76.9; a difference of 4.7 years. Table 65.1 presents global data on life expectancy, demonstrating the differences in longevity between men and women. The gap exists across the globe and across all strata of industrial development; eastern Europe demonstrates the largest gap, approximately 7 years. Even in sub-Saharan Africa, the region with the shortest life expectancy in the world, men are living on average 5.3 years less than women (Jamison et al., 2013). In fact, there is not one part of the world where men on average outlive women.

TABLE 65.1

Gender Longevity Gap

COUNTRY	POPULATION (000s)	MALE	FEMALE	OVERALL	GENDER GAP (YEARS)
Afghanistan	32,527	59.3	61.9	60.5	2.6
Albania	2897	75.1	80.7	77.8	5.6
Algeria	39,667	73.8	77.5	75.6	3.7
Angola	25,022	50.9	54.0	52.4	3.1
Antigua and Barbuda	92	74.1	78.6	76.4	4.5
Argentina	43,417	72.7	79.9	76.3	7.2
Armenia	3018	71.6	77.7	74.8	6.1
Australia	23,969	80.9	84.8	82.8	3.9
Austria	8545	79.0	83.9	81.5	4.9
Azerbaijan	9754	69.6	75.8	72.7	6.2
Bahamas	388	72.9	79.1	76.1	6.2
Bahrain	1377	76.2	77.9	76.9	1.7
Bangladesh	160,996	70.6	73.1	71.8	2.5
Barbados	284	73.1	77.9	75.5	4.8
Belarus	9496	66.5	78.0	72.3	11.5
Belgium	11,299	78.6	83.5	81.1	4.9
Belize	359	67.5	73.1	70.1	5.6
Benin	10,880	58.8	61.1	60.0	2.3
Bhutan	775	69.5	70.1	69.8	0.6
Bolivia (Plurinational State of)	10,725	68.2	73.3	70.7	5.1
Bosnia and Herzegovina	3810	75.0	79.7	77.4	4.7
Botswana	2262	63.3	68.1	65.7	4.8
Brazil	207,848	71.4	78.7	75.0	7.3
Brunei Darussalam	423	76.3	79.2	77.7	2.9
Bulgaria	7150	71.1	78.0	74.5	6.9
Burkina Faso	18,106	59.1	60.5	59.9	1.4
Burundi	11,179	57.7	61.6	59.6	3.9
Cabo Verde	521	71.3	75.0	73.3	3.7
Cambodia	15,578	66.6	70.7	68.7	4.1
Cameroon	23,344	55.9	58.6	57.3	2.7
Canada	35,940	80.2	84.1	82.2	3.9
Central African Republic	4900	50.9	54.1	52.5	3.2
Chad	14,037	51.7	54.5	53.1	2.8
Chile	17,948	77.4	83.4	80.5	6
China	1,383,925	74.6	77.6	76.1	3
Colombia	48,229	71.2	78.4	74.8	7.2

Comoros	788	61.9	65.2	63.5	3.3
Congo	4620	63.2	66.3	64.7	3.1
Costa Rica	4808	77.1	82.2	79.6	5.1
Côte d'Ivoire	22,702	52.3	54.4	53.3	2.1
Croatia	4240	74.7	81.2	78.0	6.5
Cuba	11,390	76.9	81.4	79.1	4.5
Cyprus	1165	78.3	82.7	80.5	4.4
Czechia	10,543	75.9	81.7	78.8	5.8
Democratic People's Republic of Korea	25,155	67.0	74.0	70.6	7
Democratic Republic of the Congo	77,267	58.3	61.5	59.8	3.2
Denmark	5669	78.6	82.5	80.6	3.9
Djibouti	888	61.8	65.3	63.5	3.5
Dominican Republic	10,528	70.9	77.1	73.9	6.2
Ecuador	16,144	73.5	79.0	76.2	5.5
Egypt	91,508	68.8	73.2	70.9	4.4
El Salvador	6127	68.8	77.9	73.5	9.1
Equatorial Guinea	845	56.6	60.0	58.2	3.4
Eritrea	5228	62.4	67.0	64.7	4.6
Estonia	1313	72.7	82.0	77.6	9.3
Ethiopia	99,391	62.8	66.8	64.8	4
Fiji	892	67.0	73.1	69.9	6.1
Finland	5503	78.3	83.8	81.1	5.5
France	64,395	79.4	85.4	82.4	6
Gabon	1725	64.7	67.2	66.0	2.5
Gambia	1991	59.8	62.5	61.1	2.7
Georgia	4000	70.3	78.3	74.4	8
Germany	80,689	78.7	83.4	81.0	4.7
Ghana	27,410	61.0	63.9	62.4	2.9
Greece	10,955	78.3	83.6	81.0	5.3
Grenada	107	71.2	76.1	73.6	4.9
Guatemala	16,343	68.5	75.2	71.9	6.7
Guinea	12,609	58.2	59.8	59.0	1.6
Guinea-Bissau	1844	57.2	60.5	58.9	3.3
Guyana	767	63.9	68.5	66.2	4.6
Haiti	10,711	61.5	65.5	63.5	4
Honduras	8075	72.3	77.0	74.6	4.7
Hungary	9855	72.3	79.1	75.9	6.8
Iceland	329	81.2	84.1	82.7	2.9

India	1,311,051	66.9	69.9	68.3	3
Indonesia	257,564	67.1	71.2	69.1	4.1
Iran (Islamic Republic of)	79,109	74.5	76.6	75.5	2.1
Iraq	36,423	66.2	71.8	68.9	5.6
Ireland	4688	79.4	83.4	81.4	4
Israel	8064	80.6	84.3	82.5	3.7
Italy	59,798	80.5	84.8	82.7	4.3
Jamaica	2793	73.9	78.6	76.2	4.7
Japan	126,573	80.5	86.8	83.7	6.3
Jordan	7595	72.5	75.9	74.1	3.4
Kazakhstan	17,625	65.7	74.7	70.2	9
Kenya	46,050	61.1	65.8	63.4	4.7
Kiribati	112	63.7	68.8	66.3	5.1
Kuwait	3892	73.7	76.0	74.7	2.3
Kyrgyzstan	5940	67.2	75.1	71.1	7.9
Lao People's Democratic Republic	6802	64.1	67.2	65.7	3.1
Latvia	1971	69.6	79.2	74.6	9.6
Lebanon	5851	73.5	76.5	74.9	3
Lesotho	2135	51.7	55.4	53.7	3.7
Liberia	4503	59.8	62.9	61.4	3.1
Libya	6278	70.1	75.6	72.7	5.5
Lithuania	2878	68.1	79.1	73.6	11
Luxembourg	567	79.8	84.0	82.0	4.2
Madagascar	24,235	63.9	67.0	65.5	3.1
Malawi	17,215	56.7	59.9	58.3	3.2
Malaysia	30,331	72.7	77.3	75.0	4.6
Maldives	364	76.9	80.2	78.5	3.3
Mali	17,600	58.2	58.3	58.2	0.1
Malta	419	79.7	83.7	81.7	4
Mauritania	4068	61.6	64.6	63.1	3
Mauritius	1273	71.4	77.8	74.6	6.4
Mexico	127,017	73.9	79.5	76.7	5.6
Micronesia (Federated States of)	104	68.1	70.6	69.4	2.5
Mongolia	2959	64.7	73.2	68.8	8.5
Montenegro	626	74.1	78.1	76.1	4
Morocco	34,378	73.3	75.4	74.3	2.1
Mozambique	27,978	55.7	59.4	57.6	3.7
Myanmar	53,897	64.6	68.5	66.6	3.9

Myanmar	53,897	64.6	68.5	66.6	3.9
Namibia	2459	63.1	68.3	65.8	5.2
Nepal	28,514	67.7	70.8	69.2	3.1
Netherlands	16,925	80.0	83.6	81.9	3.6
New Zealand	4529	80.0	83.3	81.6	3.3
Nicaragua	6082	71.5	77.9	74.8	6.4
Niger	19,899	60.9	62.8	61.8	1.9
Nigeria	182,202	53.4	55.6	54.5	2.2
Norway	5211	79.8	83.7	81.8	3.9
Oman	4491	75.0	79.2	76.6	4.2
Pakistan	188,925	65.5	67.5	66.4	2
Panama	3929	74.7	81.1	77.8	6.4
Papua New Guinea	7619	60.6	65.4	62.9	4.8
Paraguay	6639	72.2	76.0	74.0	3.8
Peru	31,377	73.1	78.0	75.5	4.9
Philippines	100,699	65.3	72.0	68.5	6.7
Poland	38,612	73.6	81.3	77.5	7.7
Portugal	10,350	78.2	83.9	81.1	5.7
Qatar	2235	77.4	80.0	78.2	2.6
Republic of Korea	50,293	78.8	85.5	82.3	6.7
Republic of Moldova	4069	67.9	76.2	72.1	8.3
Romania	19,511	71.4	78.8	75.0	7.4
Russian Federation	143,457	64.7	76.3	70.5	11.6
Rwanda	11,610	61.9	67.4	64.8	5.5
Saint Lucia	185	72.6	77.9	75.2	5.3
Saint Vincent and the Grenadines	109	71.3	75.2	73.2	3.9
Samoa	193	70.9	77.5	74.0	6.6
Sao Tome and Principe	190	65.6	69.4	67.5	3.8
Saudi Arabia	31,540	73.2	76.0	74.5	2.8
Senegal	15,129	64.6	68.6	66.7	4
Serbia	8851	72.9	78.4	75.6	5.5
Seychelles	96	69.1	78.0	73.2	8.9
Sierra Leone	6453	49.3	50.8	50.1	1.5
Singapore	5604	80.0	86.1	83.1	6.1
Slovakia	5426	72.9	80.2	76.7	7.3
Slovenia	2068	77.9	83.7	80.8	5.8
Solomon Islands	584	67.9	70.8	69.2	2.9
Somalia	10,787	53.5	56.6	55.0	3.1
South Africa	54,490	59.3	66.2	62.9	6.9
South Sudan	12,340	56.1	58.6	57.3	2.5

Spain	46,122	80.1	85.5	82.8	5.4
Sri Lanka	20,715	71.6	78.3	74.9	6.7
Sudan	40,235	62.4	65.9	64.1	3.5
Suriname	543	68.6	74.7	71.6	6.1
Swaziland	1287	56.6	61.1	58.9	4.5
Sweden	9779	80.7	84.0	82.4	3.3
Switzerland	8299	81.3	85.3	83.4	4
Syrian Arab Republic	18,502	59.9	69.9	64.5	10
Tajikistan	8482	66.6	73.6	69.7	7
Thailand	67,959	71.9	78.0	74.9	6.1
The former Yugoslav Republic of Macedonia	2078	73.5	77.8	75.7	4.3
Timor-Leste	1185	66.6	70.1	68.3	3.5
Togo	7305	58.6	61.1	59.9	2.5
Tonga	106	70.6	76.4	73.5	5.8
Trinidad and Tobago	1360	67.9	74.8	71.2	6.9
Tunisia	11,254	73.0	77.8	75.3	4.8
Turkey	78,666	72.6	78.9	75.8	6.3
Turkmenistan	5374	62.2	70.5	66.3	8.3
Uganda	39,032	60.3	64.3	62.3	4
Ukraine	44,824	66.3	76.1	71.3	9.8
United Arab Emirates	9157	76.4	78.6	77.1	2.2
United Kingdom	64,716	79.4	83.0	81.2	3.6
United Republic of Tanzania	53,470	59.9	63.8	61.8	3.9
United States of America	321,774	76.9	81.6	79.3	4.7
Uruguay	3432	73.3	80.4	77.0	7.1
Uzbekistan	29,893	66.1	72.7	69.4	6.6
Vanuatu	265	70.1	74.0	72.0	3.9
Venezuela (Bolivarian Republic of)	31,108	70.0	78.5	74.1	8.5
Viet Nam	93,448	71.3	80.7	76.0	9.4
Yemen	26,832	64.3	67.2	65.7	2.9
Zambia	16,212	59.0	64.7	61.8	5.7
Zimbabwe	15,603	59.0	62.3	60.7	3.3
WHO Region					
African Region	989,173	58.2	61.7	60.0	3.5
Region of the Americas	986,705	74.0	79.9	77.0	5.9
South-East Asia Region	1,928,174	67.3	70.7	68.9	3.4

European Region	910,053	73.2	80.2	76.8	7
Eastern Mediterranean Region	643,784	67.4	70.4	68.8	3
Western Pacific Region	1,855,126	74.5	78.7	76.6	4.2
Global	7,313,015	69.1	73.7	71.4	4.6

From World Health Organization, 2015.

In addition to the discrepancy present in current statistics, trends recorded over the past 50 years do not demonstrate a narrowing of the longevity gap. The Global Burden of Disease Study (Wang et al., 2016) demonstrated not only that, between 1970 and 2010, women had a higher life expectancy than men, but also that the gains in longevity over this period were more pronounced among women than men. Average gain in life duration for men was 11.1 years, compared with 12.1 for women. Thus, **although the average longevity of men and women is improving, it tends to be improving more among women than among men** (Klenk et al., 2016; Fig. 65.1).

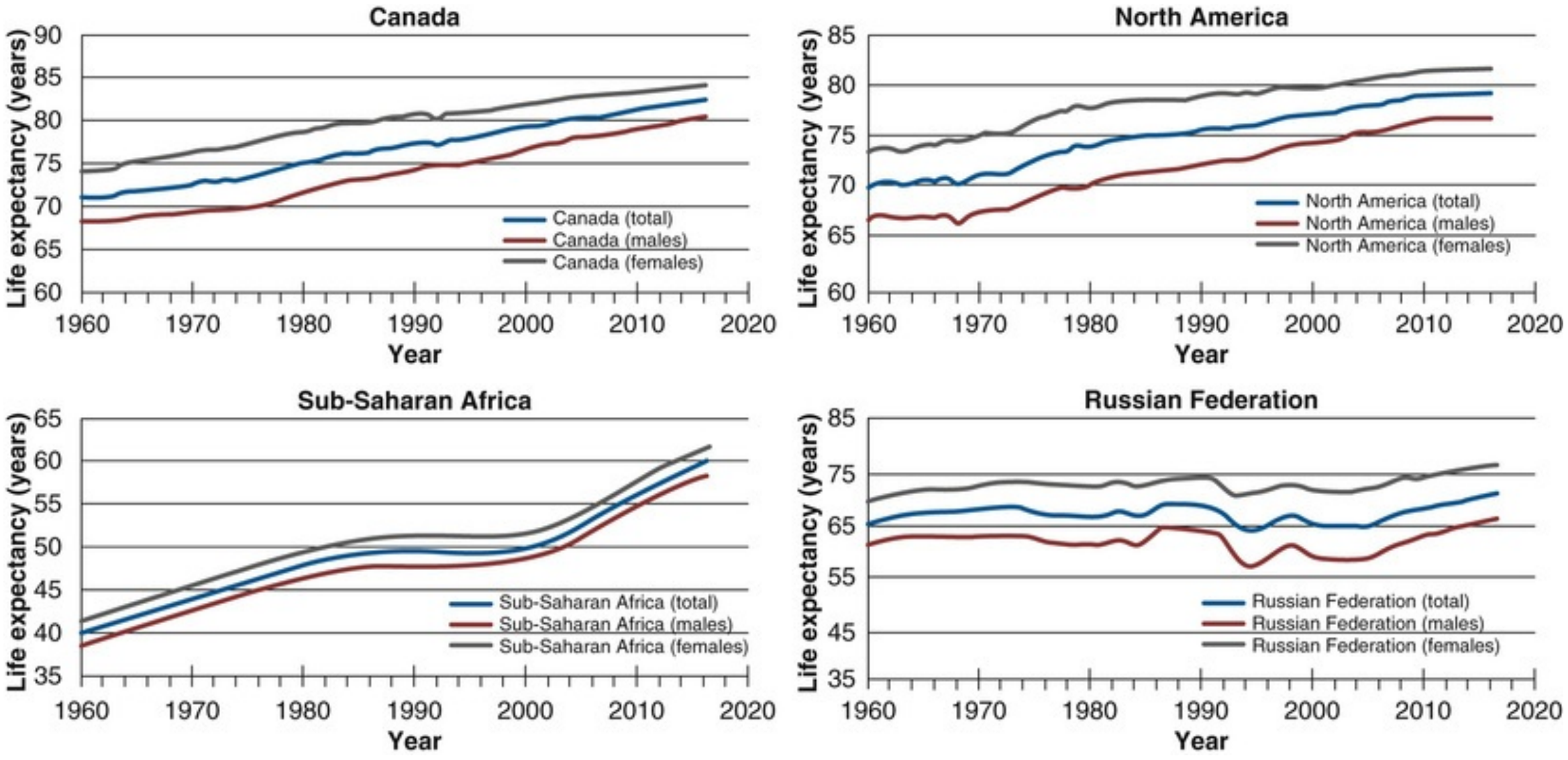

FIG. 65.1 Life expectancy at birth over recent decades, demonstrating improvements in longevity for males and females. (Data from The World Bank.)

Health and Wellness Gap by Gender

Men live not only shorter lives than women but also sicker lives. Men fall ill younger and are more prone to major chronic diseases such as cancer, hypertension, and cardiovascular disease. Table 65.2 lists the major causes of death among Americans, along with the ratios of their prevalence in males and females. The 10 conditions listed are responsible for 75% of all deaths in the United States. As is evident from this table (Murphy et al., 2017), **6 of the 10 most common causes of death are more prevalent among males.** The discordance between genders is glaringly obvious in cancer, heart disease, accidents, diabetes, and suicide. Similar trends are reported around the world and are even more disparate, not surprisingly, in nations with a larger gender longevity gap (WHO, 2016a). In addition to the total life duration, differences in healthy-life expectancy (HLE) are commonly observed between genders. HLE is a metric that corrects the mean life expectancy by weighted disability factors to derive the number of years on average that a particular country's citizens are free from chronic illness (GBD 2015 DALYs and HALE Collaborators, 2016). Between 2008 and 2010 HLE for males at birth in the United Kingdom was 63.5 years, equivalent to more than 81% of total life expectancy spent in very good or good general health. For women in the United Kingdom, HLE at birth was more than 2 years higher in the same period, at 65.7 years (Tokudome et al., 2016; UK Office for National Statistics, 2012; Van Oyen et al., 2013).

TABLE 65.2

Major Causes of Death, United States 2016

CAUSE OF DEATH	ANNUAL NO. OF DEATHS	MALE-TO-FEMALE INCIDENCE RATIO
Heart disease	633,842	1.12
Cancer	595,930	1.11
Chronic obstructive lung disease	155,041	0.88
Accidents	146,571	1.73
Stroke	140,323	0.71
Dementia	110,561	0.44
Diabetes	79,535	1.18
Influenza/pneumonia	57,062	0.89
Nephrological conditions	49,959	1.03
Suicide	44,193	3.33

From Centre for Disease Control and Prevention/National Center for Health Statistics (CDC/NCHS): *National vital statistics system, mortality 2017*, Atlanta 2017, US Department of

Health and Human Services.

Explanation of the Poorer Health of Men

In most societies men possess more power, opportunity, and wealth than women; yet these privileges do not seem to translate into an advantage or parity between the genders in regard to health and comorbidity. **A series of factors have been identified that place men at higher risk of death and disease. These include increased exposure to physical and environmental harm in the workplace, propensity for risk-taking behaviors, and masculinity-defined norms of health behavior that may negatively affect acute and chronic illness-related outcomes**.

Propensity for Risk-Taking Behavior

Men are more likely to engage in risk-taking behaviors than women. This has been demonstrated across cultures and is a recognized world-wide phenomenon (Byrnes et al., 1999). Hazardous pursuits such as alcohol use, smoking, and risky sexual practices are more prevalent among men (Creighton and Oliffe, 2010; Dolan, 2011; Stergiou-Kita et al., 2015). Men tend to consume more alcohol than women and are more likely to binge drink. In a study by Wilsnack et al. (2009), global samples of individuals of various ages were questioned about their drinking habits. As expected, ratios of drinking rates between males and females were greater than 1.0 in 98 of 104 evaluated countries. Furthermore, lifetime abstainers from alcohol were far more likely to be female. High-volume alcohol consumption was also more prevalent among men. Other studies have demonstrated similar findings (Balabanova and McKee, 1999; Hao et al., 2004; Lim et al., 2007; Parry et al., 2005; Popova et al., 2007; Slone et al., 2006; Van Gundy et al., 2005; Wilsnack et al., 2000). It was estimated that in 2010, 3.14 million men, as opposed to 1.72 million women, died from causes linked to excessive alcohol use (Lim et al., 2012).

In most of the world being male is one of the greatest predictors of tobacco use. Global consumption of tobacco is fourfold higher among men than among women (48% vs. 12%) (WHO, 2015). Although the differences are smaller in the United States (with approximately 1 in 4 Americans using tobacco), tobacco use is, according to the 2016 National Survey on Drug Use and Health (NSDUH) more prevalent among men (Substance Abuse and Mental Health Services Administration, 2017). In a recent study, 16.7% of men and 13.6% of adult women in the United States used cigarettes on a regular basis (Jamal et al., 2018; Ng et al., 2014; Preston and Wang, 2006; Syamlal et al., 2017).

There are three major reasons underlying this difference in tobacco use: cultural, behavioral, and physiologic. Of particular interest are recent neuropsychologic studies suggesting that exposure to tobacco products stimulates different parts of the brain in men compared with women (Birge et al., 2017). This neurophysiologic difference between genders may explain why women are less likely to quit smoking than men. The ill effects of tobacco exposure are well known, accounting for almost 25% of all cardiovascular disease. Importantly, a recent study has demonstrated that almost 50% of deaths associated with 12 different cancer types were related to smoking, including liver, colon and rectum, lung, oral cavity and throat, esophagus, larynx, stomach, pancreas, bladder, kidney, and cervical cancer, as well as acute myeloid leukemia (Abdel-Rahman et al., 2017; Botteri et al., 2008; Gandini et al., 2008; Haverkos et al., 2003; International Collaboration of Epidemiological Studies of Cervical Cancer et al., 2006; Iodice et al., 2008; Lee et al., 2016; Ugai et al., 2018).

Unhealthy sexual practices are also more prevalent among men than among women. Sexual promiscuity and high-risk sexual practices affect health in many separate domains. Sexually transmitted diseases such as human immunodeficiency virus (HIV), syphilis, and hepatitis are associated with ill health and early death (McElligott, 2014). Multiple studies from almost every country in the world have demonstrated that men are more apt to engage in higher-risk sexual practices and less likely to use protection such as condoms or antiretroviral therapies as compared with women (Dir et al., 2014; Lan et al., 2017; Vagenas et al., 2013; Ward-Peterson et al., 2018).

On a neurohormonal level, studies have observed more intense changes in dopaminergic activity (Spear, 2000) and higher levels of sensation seeking and risk taking (Bongers et al., 2003; Eysenck et al., 1984) in young males, whereas higher levels of negative urgency were found in females (d'Acremont and Van der Linden, 2005). In the domain of sexual activity, males start having sex at a younger age compared with females, report greater number of sexual partners over their lifetimes, and tend to engage in multiple risky sexual behaviors (Grunbaum et al., 2002; Kotchick et al., 2001; Newman and Zimmerman, 2000; Romer and Hennessy, 2007).

Aside from the mentioned three hazardous practices, men across different cultures tend to engage in higher risk activities, such as drag racing, parachuting, and extreme sports more frequently than women.

Masculinity Defined Norms of Behavior and Attitudes Toward Health

No dissertation on men's health can omit the concept of "masculinity," its attributes and its influence on the perception of health and disease. Men throughout the globe are more likely than women to adopt beliefs and behaviors that increase the risks to their health and safety and are less likely to engage in behaviors that are linked with preservation or improvement of health and longevity. Gender is constructed from cultural and subjective meanings that constantly shift and vary, depending on the time and geographic location (Kimmel, 1996). Stereotypes used by society in the construction of gender are composed of characteristics generally believed to be typical either of women or of men. There is widespread agreement in western society about what are considered to be typically feminine and typically masculine characteristics (Golombok and Fivush, 1994; Street et al., 1995; Williams and Best, 1982). People of both genders are encouraged to adhere to stereotypic beliefs and behaviors and commonly do conform to and adopt the dominant norms of femininity and masculinity present in their culture (Bohan, 1993; Deaux, 1984; Eagly, 1983).

Research indicates that men and boys experience relatively more social pressure than females to endorse gender stereotypes such as the health-related beliefs that men are independent, self-reliant, strong, robust, and tough (Golombok and Fivush, 1994; Martin, 1995; Williams and Best, 1982). It is therefore not surprising that male behaviors tend to be more stereotypic than those of women and girls (Katz and Ksansnak, 1994; Levant et al., 1998; Rice and Coates, 1995; Street et al., 1995).

In most parts of the world, the resources used by males to construct their masculinity are largely not conducive to preservation of health (Courtenay, 2000). Men construct their gender in part by dismissing their health care needs. They boast about not visiting physicians, refuse to take time off work when ill, and idolize high tolerance to alcohol (e.g., by boasting that drinking alcohol does not impair their driving skills). As a result, global masculinity has evolved, in part, into a construct that predisposes men to early death and disability. There are many examples of how this plays out in the practical world. Men, for instance, do not visit primary care doctors as often as women do. Although women may have a reproductive bias in favor of more visits, even when maternity-related visits are accounted for, women in the United States visit their practitioners one-third more times than men (Centers for Disease Control and Prevention [CDC], 2015). Similar studies in Europe, Australia, United Kingdom, Lithuania, and Canada have corroborated this observation (Galdas et al., 2005; UCL Institute of Health Equity, 2013), which is particularly pronounced at ages between 20 and 44 (Hippisley-Cox and Vinogradova, 2009).

Men are less likely to be compliant with prescribed medications (Berg et al., 2004; Hadji et al., 2016; Monane et al., 1996), although a few exceptions have been noted (Li and Froelicher, 2007; Manteuffel et al., 2014). Men are also less likely to adhere to physician care plans than women and are less likely to undergo recommended screening services (Henry J. Kaiser Family Foundation [KFF], 2015).

Physical and Chemical Exposure in the Workplace

One of the most obvious domains of risk to men's health is the workplace. Throughout the globe, men are more likely to die from work-related injuries than women. In the United States, Australia, and Canada, 92%, 96%, and 97% of all risk fatalities were among men, respectively (Bilsker et al., 2010). Significant work-associated health care and workers’ compensation costs are prevalent throughout the developed world (Safe Work Australia, 2016; US Bureau of Labor Statistics, 2016). For example, in the United States it is estimated that more than $1 billion per week (US Department of Labor, 2018) was spent for expenses related to workplace injury and illness in 2012. The costs of workplace injuries and illnesses include direct and indirect costs. Direct costs include workers’ compensation stipends, medical charges, and legal outlays. Indirect costs include training for replacement workers, accident inquiry, lost productivity, equipment and property damage repairs, and charges linked to diminished worker morale and absenteeism.

A host of reasons explain why the male gender is at higher risk of work-related illness and injury. First is the largely gender-segregated and specific aspects of either occupations themselves or the subdivision of labor within certain job categories. Male employees are statistically represented in greater numbers in certain industries, including mining, military, farming, protective services (fire/police), and fishing (Arcury et al., 2014; Curtis Breslin et al., 2007; Desmond, 2006; Ibanez and Narocki, 2011; Lawson, 2010; Messing et al., 2003; Phakathi, 2013; Power and Baqee, 2010; Power, 2008). Furthermore, even within many of the more gender-balanced industries, heavy, “physical” work tasks are disproportionately performed by male workers (Arcury et al., 2014; Desmond, 2006). Men are thus overexposed to high-risk workplaces and associated hazards and injuries.

Targets and Effective Interventions

Improving men's health on the epidemiologic scale requires innovative solutions creatively implemented to reverse the aforementioned causes of the gender gap in life expectancy and health outcomes. The health of people in local communities is linked to global systems. The world economy and labor markets, for example, can have a powerful effect on men's health outcomes. As industrial production expands, workers face a range of occupational health and safety hazards, particularly in relatively economically disadvantaged countries. The social structural relationships that organize men's work life and their health are not simply imposed on men by global forces; these relationships are local, global, and reciprocal. Any positive change in these relationships requires us not only to improve overall health and longevity but also to ideally position men's health on par with that of their female counterparts. To do this, the major change must come in the form of a social movement, one that undoes the risk factors for early demise and reduces the risk or prevalence of high-risk activities in which men tend to engage. Such a change would, specifically, work toward improving the work environment and creating a gender balance, minimizing high-risk behaviors, and, last, altering the construct of masculinity to one that encourages healthy lifestyles, facilitates open communication among peers, and engages men to interact more frequently with the health care systems (particularly between the ages of 18 and 40). Urologists can have a major impact in this regard: many men re-enter the health care systems by way of a urologist's office complaining of lower urinary tract symptoms resulting from benign prostatic hyperplasia (BPH) or erectile dysfunction (ED) or seeking a vasectomy. Indeed, the urologist should develop training to recognize and even intervene among his or her male patients who demonstrate adverse risk factors for chronic disease or death, such as smoking, excess alcohol usage, and metabolic syndrome. It is clear that simple public health messaging about healthy choices and lifestyle have limited results. Despite intensive education campaign, much of the developed world has a problem with increasing body weight (Swinburn et al., 2011), especially in North America, where obesity prevalence is approaching 40% in the United States (Hales et al., 2017), 32.4% in Mexico, and 26.7% in Canada (Organization of Economic Co-operation and Development [OECD], 2017).

In recent decades, research has been devoted to improving health outcomes of vulnerable men, with findings suggesting novel directions to move forward. Innovative programs designed to reach out to men through their preferred sport activities have been shown to be promising (Bottorff et al., 2015). The interest of men in soccer in Europe (Gray et al., 2013; Hunt et al., 2014) and hockey in Canada (Blunt et al., 2017; Petrella et al., 2017) demonstrate particular effectiveness and potential for affecting health perspectives on health. Public health campaigns featuring prominent athletes and celebrities targeting the 18- to 40-year-old demographic have begun to emerge (Canadian Men's Health Foundation, 2018; Movember Foundation, 2011), although it is too early to conclusively measure their outcomes. Societal change does not happen overnight, and thoughtful change in men's lifestyle choices requires a sustained and innovative effort, which is unlikely to pay off for decades. On a more microepidemiologic level, clinicians must strive to counsel their patients on healthier lifestyle choices.

Global Men's Health Movement

The awareness of men's health as a unique need in the medical, psychological, and sociologic fields has taken root. A host of national and international organizations have sprung forward to aid in this regard. The WHO has recognized that decreasing the gender health gap is required for achieving the stated goal of global health equity (Baker et al., 2014). Fundraising organizations such as Movember have also fueled these efforts via grassroots funding campaigns seeking to augment governmental supports (Movember Foundation, 2018; Ontario gov).

Clearly, one of the major challenges in these efforts is reaching men living in societies with the greatest discrepancies, such as the countries in sub-Saharan Africa and Eastern Europe. In addition to the efforts by the supranational organizations, most major national urologic associations have their own efforts. A number of countries have published, or are developing, national men's health programs such as those put forward by Ireland, Australia, and Brazil. These programs are seeking to address the specific health care needs of men by improving their engagement with the medical practice, standardizing the approaches to addressing men's health, and researching best practices that would lead to improving health outcomes in men.

Key Points: Rationale for Integrative Men's Health

- Men throughout the world live shorter lives then women throughout the world.
- The gender gap persists despite improvements in overall life expectancy at birth.
- Men live not only shorter lives than women but also sicker lives.
- Gender differences in illness-related outcomes reflect social, environmental, and physiologic factors.
- Innovative and coordinated programs targeting men are required to promote social and behavioral changes that would improve men's health.

Metabolic Syndrome and Men's Health

Introduction, History, and Definitions

Metabolic syndrome is defined as a series of interconnected biochemical, physiologic, metabolic, and clinical factors that increase the individual's risk of type 2 diabetes mellitus (T2DM), heart disease, and early mortality. The syndrome was first conceived in 1920 when a Swedish investigator (Kylin, 1923) noted an association between hypertension, gout, and elevated blood glucose levels. In 1947 the concept was further refined when Vague (1947) noted that visceral organ fatty deposits were linked with cardiovascular disease and type 2 diabetes mellitus. In 1988 Reaven (Reaven, 1988; Reaven, 1993) described an aggregate of risk factors for cardiovascular disease and diabetes that he named Syndrome X. Syndrome X was renamed the deadly quartet in 1989, incorporating glucose intolerance, hypertriglyceridemia, hypertension, and upper body obesity (Kaplan, 1989). Finally, the term metabolic syndrome was coined in 1998 by the World Health Organization (Alberti and Zimmet, 1998; WHO, 1999). Since then, other subspecialty societies concerned with this condition have released their own definitions and criteria (Fig. 65.2). Table 65.3 lists the criteria set out by major organizations for the diagnosis of metabolic syndrome.

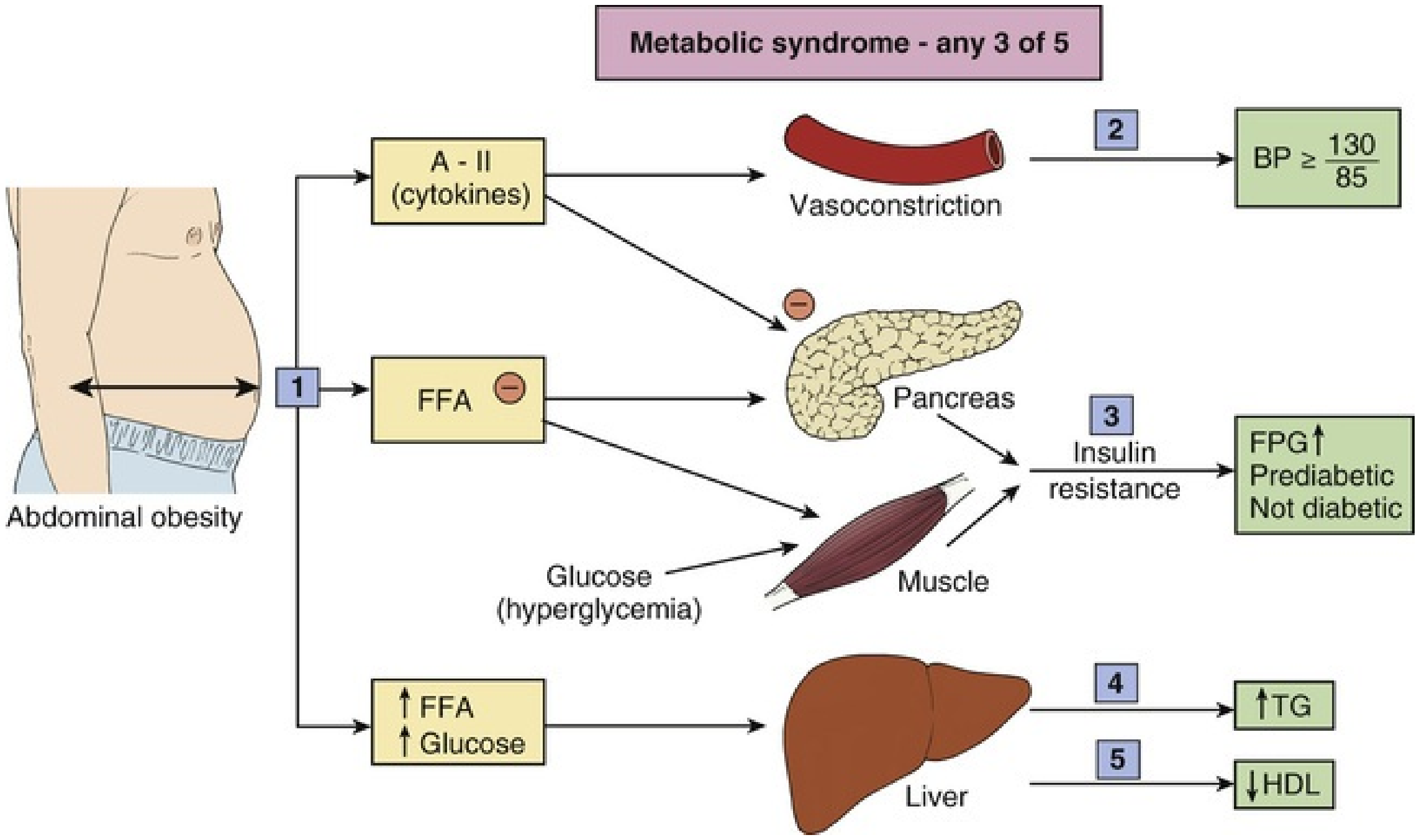
Metabolic syndrome - any 3 of 5
A - II
(cytokines)
Vasoconstriction
2
BP ≥ 130/85
Abdominal obesity
1
FFA
Pancreas
3
Insulin
resistance
FPG↑
Prediabetic
Not diabetic
Glucose
(hyperglycemia)
Muscle
↑FFA
↑Glucose
Liver
4
↑TG
5
↓HDL

FIG. 65.2 Diagnosis of metabolic syndrome requires a tape measure, an accurate eye, and fasting lipogram, plasma glucose measurements, and blood pressure measurements. (Adapted from Lionel H. *Circulation* 115-e32-e35, 2007.)

TABLE 65.3

Metabolic Syndrome Definitions and Criteria

CLINICAL PARAMETER	WHO (1999)	EGIR (Balkau and Charles, 1999)	ATP III (NCEP, 2001)	AACE (Einhorn et al., 2003)	IDF (et al.
Obesity/body fat distribution	Waist/hip ratio >0.90 in men, >0.85 in women; or BMI >30 kg/m^2	Waist circumference ≥94 cm in men, ≥80 cm in women	Waist circumference >102 cm in men, >88 cm in women	BMI ≥25 kg/m^2	Wais circu ≥94 men, in wo
Insulin resistance/ hyperglycemia	IGT, IFG, T2DM, or other evidence of insulin resistance	Hyperinsulinemia (plasma insulin >75th percentile)	Fasting glucose ≥110 mg/dL	Fasting glucose ≥110 mg/dL	Fasti gluco mg/d T2D
Triglyceridemia	≥150 mg/dL	≥177 mg/dL	≥150 mg/dL	>150 mg/dL	>150 or on treat

Cholesterol	HDL-C <35 mg/dL in men or <39 mg/dL in women	HDL-C <39 mg/dL	HDL-C <40 mg/dL in men; <50 mg/dL in women	HDL-C <40 mg/dL in men; <50 mg/dL in women	HDL mg/d men; mg/d wom treat
Blood Pressure	≥140/90 mm Hg	≥140/90 mm Hg or on treatment	>130/85 mm Hg	≥130/85 mm Hg	>130 Hg o treat
Other	Microalbuminuria[a]			Other features of insulin resistance[b]	

[a] Microalbuminuria defined as urinary albumin excretion ≥70 µg/min or albumin/creatine ratio ≥30 mg/g.

[b] Family history of T2DM, hypertension, or CVD; polycystic ovary syndrome; sedentary lifestyle; advancing age; ethnic groups having high risk for T2DM or CVD.

AACE, American Association of Clinical Endocrinologists; *ATP III,* National Cholesterol Education Program Adult Treatment Panel III Report; *BMI,* body mass index; *EGIR,* European Group for the Study of Insulin Resistance; *HDL-C,* high-density lipoprotein cholesterol; *IDF,* International Diabetes Federation; *IFG,* impaired fasting glucose; *IGT,* impaired glucose tolerance; *T2DM,* type II diabetes mellitus; *WHO,* World Health Organization.

Although the listed definitions possess a number of common criteria, the WHO, American Association of Clinical Endocrinologists (AACE), and the European Group for the Study of Insulin Resistance criteria emphasize insulin resistance, which requires a cumbersome oral glucose tolerance test to be ascertained. The Adult Treatment Panel III criteria were developed to use readily available anthropometric measures and clinical laboratory tests, thereby facilitating epidemiologic research. Defining obesity cutoffs for specific ethnic groups also remains problematic, which is why the International Diabetes Federation (IDF) have further adjusted their specific criteria to provide cutoff points that are specific for different racial/ethnic populations (Ritchie and Connell, 2007).

Prevalence and Predictors of Metabolic Syndrome

Metabolic syndrome is a prevalent condition across the world. Depending on the ethnic, gender, racial, and geographic makeup of the studied group, prevalence of metabolic syndrome ranges between 10% and 84% of the population. Choice of definition used can lead to significant differences in the estimates of prevalence. In a paper by Morote et al., the range of patients with a diagnosis of prostate cancer before commencing androgen deprivation therapy afflicted by metabolic syndrome ranged between 9.4% by the WHO definition and 50% by International Diabetes Federation definition within the same cohort (Morote et al., 2015). The IDF estimates that about one-fourth of adults in the world meet the criteria for metabolic syndrome.

Risk factors for metabolic syndrome include sedentary lifestyle, excess caloric intake, and higher socioeconomic status. It is interesting to ponder that, for the first time in human history, we are witnessing the emergence of medical syndromes that arise from overconsumption and sedentary lifestyle; this would have been unimaginable 100 years ago. In the National Health and Nutrition Examination Survey (NHANES) advancing age and advancing weight were associated with metabolic syndrome. As an example, 5% of subjects with normal weight had metabolic syndrome compared with 60% of obese individuals. Similarly, 10% of individuals aged 20 to 29 had metabolic syndrome compared with 45% of those 60 to 69 years old (Ford et al., 2002).

Physiology of Metabolic Syndrome

Although the physiologic alterations associated with metabolic syndrome have not been fully elucidated, recent research has greatly expanded our understanding of the condition. In general**, it is believed that genetic risk factors interact with lifestyle exposure (physical inactivity, smoking, caloric excess, psychological stress) to create a positive energy imbalance.** This in turn leads to adiposity with concomitant alteration in fatty acid metabolism and increased release of adipokines (Fig. 65.3). Ultimately, this leads to endothelial dysfunction, atherogenic dyslipidemia, insulin resistance, hypertension, hypercoagulability, and low-grade inflammation.

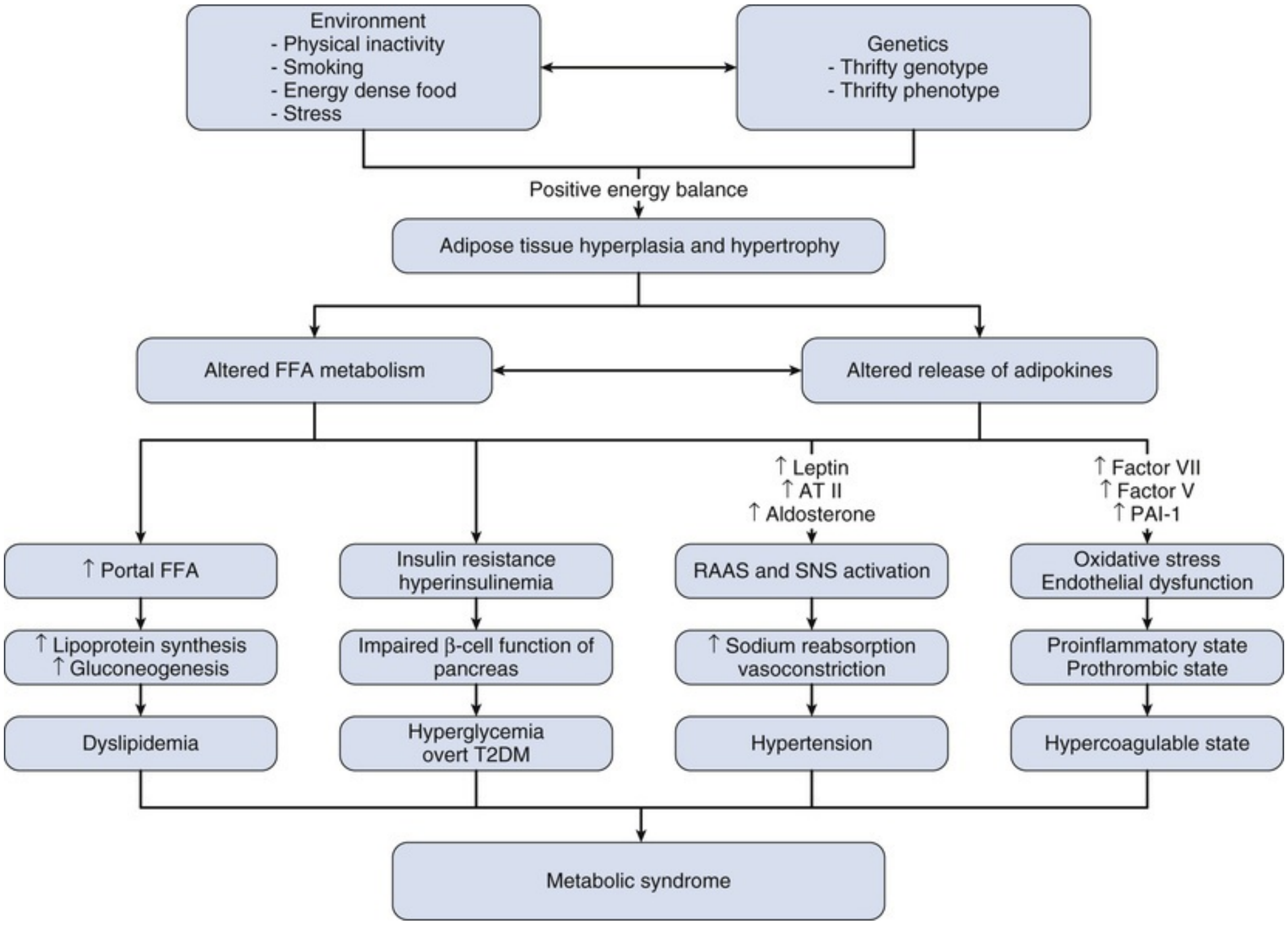
Environment
- Physical inactivity
- Smoking
- Energy dense food
- Stress
Genetics
- Thrifty genotype
- Thrifty phenotype
Positive energy balance
Adipose tissue hyperplasia and hypertrophy
Altered FFA metabolism
Altered release of adipokines
↑ Leptin
↑ AT II
↑ Aldosterone
↑ Factor VII
↑ Factor V
↑ PAI-1
↑ Portal FFA
Insulin resistance hyperinsulinemia
RAAS and SNS activation
Oxidative stress Endothelial dysfunction
↑ Lipoprotein synthesis
↑ Gluconeogenesis
Impaired β-cell function of pancreas
↑ Sodium reabsorption vasoconstriction
Proinflammatory state Prothrombic state
Dyslipidemia
Hyperglycemia overt T2DM
Hypertension
Hypercoagulable state
Metabolic syndrome

FIG. 65.3 Schematic presentation of metabolic syndrome. *AT II,* Angiotensin II; *FFA,* free fatty acids; *PAI-1,* plasminogen activator inhibitor 1; *RAAS,* renin-angiotensin-aldosterone system; *SNS,* sympathetic nervous system; *T2DM,* type 2 diabetes mellitus.

Abdominal Obesity

Obesity is largely driven by excess consumption of calorie-dense foods and diminished physical activity. Adipose tissue is composed of adipocytes, stromal preadipocytes, immune cells, and endothelium. It responds rapidly and dynamically to excess caloric intake with adipocyte hypertrophy and hyperplasia (Halberg et al., 2008). With obesity and progressive adipocyte enlargement, adipocyte hypoxia ensues (Cinti et al., 2005), leading to necrosis and macrophage infiltration into adipose tissue. This progressive process is accompanied by the release of biologically active metabolites known as adipokines, which include glycerol, free fatty acids (FFAs), proinflammatory mediators (such as tumor necrosis factor-α and interleukin-6 [IL-6]), plasminogen activator inhibitor-1 (PAI-1), and C-reactive protein [CRP]) (Lau et al., 2005). This localized inflammatory process in the adipose tissue propagates an overall systemic inflammation, which is associated with the development of comorbidities (Trayhurn and Wood, 2004). Adipokines integrate the endocrine, autocrine, and paracrine signals to mediate multiple processes, including insulin sensitivity (Saleem et al., 2009), oxidative stress (Tsimikas et al., 2009), energy metabolism, blood coagulation, and inflammatory responses (Jacobs et al., 2009). Combined, these physiologic changes accelerate atherosclerosis, plaque rupture, and atherothrombosis. Thus the adipose tissue no longer only acts to store excess energy as lipids but rather evolves into an endocrine organ, releasing numerous cytokines and eliciting systemic physiologic alterations.

Insulin Resistance

Insulin-resistant individuals exhibit impaired glucose metabolism and tolerance, which manifests as an abnormal response to a glucose challenge, elevated blood fasting glucose levels, and/or overt hyperglycemia, or a reduction in the effect of insulin after its intravenous administration. Insulin resistance is defined as a pathophysiologic condition in which normal insulin concentration fails to induce normal responses in target tissues, such as adipose, muscle, and liver. Under this abnormal condition, pancreatic beta cells are stimulated to secrete more insulin (thereby inducing hyperinsulinemia) to overcome the hyperglycemia. Although hyperinsulinemia may compensate for insulin resistance in regard to some of its biologic effects, including maintenance of normoglycemia, it can result in exaggerated insulin effects in normally sensitive tissues. This accentuation of a subset of insulin actions, coupled with a resistance to its other actions, results in the clinical manifestations of metabolic syndrome (Gill et al., 2005). An inability of the pancreatic beta cells over time to produce sufficient amounts of insulin to correct the worsening insulin resistance in target tissues leads to hyperglycemia and overt type 2 diabetes mellitus (Petersen and Shulman, 2006).

Dyslipidemia

Dyslipidemia in metabolic syndrome is characterized by a host of lipid anomalies reflecting disturbances in the structure, metabolism, and activity of atherogenic lipoproteins and antiatherogenic high-density lipoprotein cholesterol. Insulin resistance leads to atherogenic dyslipidemia through multiple processes. First, because insulin normally inhibits lipolysis in adipocytes, impaired insulin signaling increases lipid breakdown and increases circulating FFA levels. In the hepatic tissue, FFAs serve as substrates for triglyceride formation. Second, insulin resistance directly increases very low-density lipoprotein (VLDL) production. Third, insulin regulates the activity of enzyme lipoprotein lipase, the rate-limiting enzyme and a major mediator of VLDL clearance. Hypertriglyceridemia in insulin resistance is therefore the result of an increase in VLDL production and a decrease in VLDL clearance. VLDL is metabolized to remnant lipoproteins and small, dense low-density lipoproteins (LDL), both of which can promote the formation of atherosclerotic deposits. On balance, it is believed that the dyslipidemia associated with insulin resistance is a direct consequence of increased VLDL secretion from the liver (Ginsberg et al., 2005). These anomalies are closely associated with increased oxidative stress and endothelial dysfunction, thereby reinforcing the proinflammatory phenotype of atherosclerotic disease.

Hypertension

Essential hypertension is frequently associated with several metabolic abnormalities, of which obesity, glucose impairment, and dyslipidemia are the most prevalent (Ferrannini and Natali, 1991). Studies suggest that hyperglycemia and hyperinsulinemia activate the renin-angiotensin system (RAS). There is also evidence that insulin resistance and hyperinsulinemia lead to sympathetic nervous system hyperactivation, which increases renal sodium reabsorption, persistently increases cardiac output, and causes arterial vasoconstriction, resulting in hypertension (Morse et al., 2005). Evidence also suggests that adipocytes produce aldosterone in response to the stimulation of angiotensin ATII receptors (Briones et al., 2012).

Genetics

Increasing evidence suggests that genetics plays a major role in the cause of metabolic syndrome (Ordovas, 2007). Some individuals who are not obese by traditional measures develop insulin resistance and exhibit metabolic risk factors. This occurrence is particularly frequently encountered in individuals who have a family history of T2DM, with either both parents or one parent and a first- or second-degree relative suffering from the disease (Perseghin et al., 1997). A similar paradigm also is found more frequently in people of South Asian heritage (Abate et al., 2004; Martin et al., 2003). It is probable that the expression of each metabolic risk factor falls partially under its own genetic control, which then influences the individual's response to environmental exposures. This is exemplified by data suggesting that polymorphisms in genes affecting lipoprotein metabolism are associated with the worsening of dyslipidemia among obese people (Laakso, 2004; Poulsen et al., 2005).

Neel et al. (1962) proposed the *thrifty genotype hypothesis*, postulating that **persons living in a calorically depleted environment would maximize their probability of survival if they could maximize storage of surplus energy**. Genetic selection would thus favor the energy-conserving genotypes in such environments. However, these same selected genetic variations may become unfavorable when the nutrition improved and high-calorie food becomes abundant. This may explain why certain immigrant populations are at highest risk for metabolic syndrome in the United States and other countries (Banerjee and Shah, 2018; Berkowitz et al., 2016; Ogden et al., 2014). This hypothesis assumes that the common genetic variants of thrifty genes predispose to metabolic syndrome. Hales and Barker in 1992 hypothesized that babies who experienced a fetal caloric deprivation in utero adapted to a poor nutritional environment by reducing energy expenditure and becoming “thrifty.” Support for this postulated construct is found in the association between diminished birth weight and risk of adult-onset insulin resistance and T2DM (Hales et al., 1997).

Endothelial Dysfunction

Metabolic syndrome is characterized by impaired endothelium-dependent vasodilation, reduced arterial compliance, and accelerated atherosclerosis (Kraemer-Aguiar et al., 2008). Mediators of these anomalies include elevated levels of oxidative stress reactants, hyperglycemia, advanced glycation products, FFAs, inflammatory cytokines, and adipokines.

Hypercoagulable State

Metabolic syndrome induces a proinflammatory state characterized by elevated circulating cytokines and acute-phase reactants (e.g., CRP). In addition, anomalies in the procoagulant factors fibrinogen, factors VII and VIII, and the antifibrinolytic factor plasminogen activator inhibitor-1 (PAI-1) have been demonstrated. Grundy (2004) has shown that fibrinogen is an acute-phase reactant protein. Therefore prothrombotic and proinflammatory states appear to be linked metabolically.

Dietary Factors

Numerous studies (Aljada et al., 2004) have shown that diets high in fat and processed foods are associated with the generation of reactive oxygen species and an activation of the proinflammatory transcription factor nuclear factor-κB (NF-κB) (Aljada et al., 2004). In contrast, a diet rich in fruits and fiber tends not to induce these changes.

Glucocorticoid and Stress-Response Mediators

Chronic hypersecretion of stress mediators, such as the stress hormone cortisol, may lead to the accumulation of visceral fat in the body. Low levels of growth hormone and low testosterone may also potentiate the interaction between stress and metabolism (Charmandari et al., 2005). Stress steroids also increase the activity of enzymes involved in fatty acid synthesis, promote the secretion of lipoproteins (Wang et al., 1995), induce hepatic gluconeogenesis (Argaud et al., 1996), induce the differentiation of preadipocytes to adipocytes (which may promote increased body fat mass) (Hauner et al., 1989), and increase lipolysis, which leads to peripheral insulin resistance (Guillaume-Gentil et al., 1993). Investigators have demonstrated associations between blood cortisol levels and a number of features of metabolic syndrome, including visceral obesity and sarcopenia, which are known to lead to dyslipidemia, hypertension, and T2DM (Chrousos, 2009).

Obstructive Sleep Apnea

Increasing evidence points to linkages between obstructive sleep apnea (OSA) and metabolic syndrome. OSA is estimated to affect 4% of male and 2% of female adults in the United States (Young et al., 1993). The results of the Sleep Heart Health Study demonstrate that increased degree of sleep-disordered breathing is associated with metabolic syndrome components, including high body mass index (BMI), waist-to-hip ratio, hypertension, diabetes, and blood lipid levels. The presence of alterations in sympathetic activity and hypothalamic-pituitary-adrenal axis in OSA could suggest a possible mechanistic linkage between the two disorders (Calvin et al., 2009).

Metabolic Syndrome and Urologic Disorders

Although metabolic syndrome was classically associated with elevated risk of cardiovascular disease, diabetes, and stroke, it in fact has a broader range of manifestations. Certainly, cancers common in developed nations, such as colorectal and breast cancers, may be linked to metabolic syndrome (Bhandari et al., 2014; Esposito et al., 2012; Esposito et al., 2013a; Esposito et al., 2013b; Jinjuvadia et al., 2013). **Urologic conditions are recognized to be highly prevalent among aging men, especially those with metabolic syndrome.** Awareness of metabolic syndrome and its constituent conditions is important for urologists in terms of counseling and diagnostic suspicion.

Renal Conditions

Metabolic syndrome and frank T2DM have a significant impact on renal physiology, as described earlier in this chapter. The three major renal conditions associated with metabolic syndrome are renal insufficiency, urolithiasis, and renal cell carcinoma (RCC).

Renal Insufficiency.

Renal disorders are a major cause of death and disability in the developed world (see the earlier section on men's health). It is estimated that 1 in 10 residents of the United States suffers from chronic kidney disease (De Nicola and Zoccali, 2016). Rates of renal replacement therapy, transplantation and dialysis, are growing (Tonelli et al., 2011; Tonelli et al., 2018) as populations age and risk factors for renal disease become more prevalent. Furthermore, even patients with chronic kidney failure who do not require renal replacement therapy appear to have accelerated rates of death, largely from cardiovascular disease (Go et al., 2004). Hypertension and diabetes (Kastarinen et al., 2010), obesity (Bruck et al., 2018), and perhaps nontraditional risk factors such as anemia, hyperphosphatemia, high plasma C reactive protein and fibrinogen, high sympathetic activity, and accumulation of endogenous inhibitors of nitric oxide synthase (Salem, 2002) appear to be the main drivers of chronic kidney disease at the population level. These processes are consequences of metabolic syndrome.

Stones.

Urolithiasis is more frequently found among patients exhibiting features of metabolic syndrome. In the study by Chou et al. (2011), calcium oxalate and uric acid stones were more prevalent among patients with obesity. Okomoto et al. used a murine model fed a diet including 1% ethylene glycol to study metabolic syndrome and potential for urolithiasis. The study showed an increased formation of calcium oxalate crystals as well as higher calcium deposits within the renal tissue (Okamoto et al., 2010). Several mechanisms have been suggested to explain these associations, including lipase activity, mitochondrial dysfunction, and lipid peroxidation, factors known to cause cellular damage and result in debris, which in turn leads to nucleation phenomenon (Jonassen et al., 2005) and hypercalciuria (Baggio and Budakovic, 2005).

Hypercalciuria is associated with components of metabolic syndrome (Conen et al., 2004; Nakagawa et al., 2006; Schachter, 2005), such as obesity, dyslipidemia, hyperglycemia, and hypertension. The burden of elevated uric acid levels is further worsened by the fact that patients with metabolic syndrome tend to excrete slightly acidic urine. A defect in the production of ammonia in the proximal tubule at the mitochondrial level has been identified as the primary source of aciduria, as reinforced by studies demonstrating that obesity and urinary pH are inversely associated (Powell et al., 2000). Drugs used to manage hypertension among patients with metabolic syndrome may also influence renal stone formation (Alexander et al., 2017).

Tumors.

Demonstrating an association between metabolic syndrome and RCC is a challenging epidemiologic exercise. Diagnostic bias exists: patients with hypertension and glucose intolerance are more frequently exposed to renal imaging than the general population, resulting in discovery of small renal masses. Emerging evidence, however, does suggest an association with components of the metabolic syndrome. Obesity, for example, is a well-established risk factor for RCC among women, although emerging data suggest that frank T2DM is also associated with higher rate of the disease. A systematic review conducted by Larsson and Wolk (2011) demonstrated that a history of T2DM is associated with a 26% increase in risk of RCC in men (relative risk [RR] 1.26, 95% confidence interval [CI] 1.06–1.49). These results were subsequently confirmed by Bao et al. (2013) and Tseng et al. (2015). In addition, T2DM may lead to a worse prognosis in RCC and worse overall survival in these patients (hazard ratio [HR] 1.56, $P < 0.001$) (Chen et al., 2015).

Bladder Cancers

Only a small number of studies have examined the association between metabolic syndrome and bladder cancer. In a prospective cohort study of 580,000 subjects, Haggstrom et al. (2011) showed that metabolic syndrome was associated with a significantly increased risk of bladder cancer in men (RR 1.10, 95% CI 1.01–1.18) but not in women. Russo et al., using a different study design to evaluate medication-exposed cohorts, showed a similar association limited to men (2008). In the meta-analysis by Esposito et al., metabolic syndrome was significantly associated with bladder cancer (RR 1.10, 95% CI 1.02–1.18) (2012). Certainly the well-accepted association with tobacco exposure and of both bladder cancer and metabolic syndrome remains a confounder difficult to disentangle from an etiologic perspective. Several epidemiologic studies have demonstrated a positive association between obesity and an increased risk of bladder cancer (Holick et al., 2007; Koebnick et al., 2008), whereas others did not observe this relationship (Haggstrom et al., 2011; Larsson et al., 2008). Qin et al. (2013) published a meta-analysis of 11 cohort studies, showing an overall significant correlation between obesity and an increased risk of bladder cancer (RR 1.10, 95% CI 1.06–1.16).

Obesity has been examined as a risk factor in terms of prognosis of superficial bladder cancer. Kluth et al. (2013), in a retrospective cohort study, showed that obese patients experienced worse outcomes than those who were nonobese, with an increased risk of disease recurrence (HR 2.66, 95% CI 2.12–3.32), disease progression (HR 1.49, 95% CI 1.00–2.21), cancer-specific mortality (HR 3.15, 95% CI 1.74–5.67), and any cause of mortality (HR 1.42, 95% CI 1.06–1.92). Similarly, Wyszynski et al. (2014), in a US population-based study of 726 patients with superficial bladder cancer, reported that high BMI at diagnosis was modestly associated with an increased risk of recurrence (HR 1.33, 95% CI 0.94–1.89). Taken together, these observations suggest further clinical studies are required to elucidate this possible relationship.

Overactive Bladder

There is increasing evidence for a link between overactive bladder (OAB) and metabolic syndrome. Because it is often difficult to uncouple the effects of OAB and BPH on lower urinary tract symptoms (LUTS), the best evidence for a link between OAB and metabolic syndrome is obtained by studying female populations (Bunn et al., 2015). From a pathophysiologic point of view, there are a host of reasons why women with metabolic syndrome may be at greater risk of developing OAB. These include sympathetic hyperactivity, proinflammatory status, endothelial dysfunction leading to ischemic damage during bladder distention, and diminished bladder perfusion. As discussed previously, insulin resistance resulting from obesity is a significant component of metabolic syndrome, and it is argued that the proinflammatory state, increased FFAs, hypercoagulability, and cellular oxidative stress combined lead to premature vascular disease (Gallagher et al., 2011). A positive correlation between serum insulin levels and OAB has been reported in women. In addition, circulating HDL cholesterol levels were shown to be lower in patients with OAB (Uzun et al., 2012) compared with healthy controls. Bunn et al. recently conducted a literature review of published studies on this topic (2015), noting that many of the studies were limited by methodologic challenges, as well as by being focused on the individual components (e.g., obesity or hyperlipidemia) as opposed to metabolic syndrome as an aggregate construct. Pertinent findings include the fact that all studies examining the postulated linkage between metabolic syndrome and OAB were positive (i.e., suggesting a correlation between the two entities), but the evidence was deemed to be of modest quality. Similarly, the majority of studies that examined connections between obesity and OAB were positive. Overall, these data support an association between OAB and obesity at the very least, and likely metabolic syndrome as well. Further work in this area is encouraged.

Lower Urinary Tract Symptoms

Epidemiologic data suggest that LUTS may be associated with metabolic syndrome. Inflammation has been proposed as a common mechanistic link between these clinical entities. Several studies have demonstrated that components of metabolic syndrome such as hyperinsulinemia, T2DM, dyslipidemia, and hypertension directly correlate with a proinflammatory and fibrotic state (Devaraj et al., 2009; Fagerberg et al., 2008; Fibbi et al., 2010; Greenfield and Campbell, 2006; Powell, 2007). One cause may be the presence of inflamed adipose tissue (Devaraj et al., 2009; Kalyani and Dobs, 2007). IL-8 is a proinflammatory chemokine that contributes to inflammation by acting with IL-1β and IL-6. IL-8 seems to be the most reliable and predictive surrogate marker of prostatitis (Fibbi et al., 2010; Kalyani and Dobs, 2007; Penna et al., 2007), and elevated IL-8 levels have been reported in the expressed prostatic secretions of subjects with BPH (Hochreiter et al., 2000; Liu et al., 2009). IL-8 has been shown to be actively involved in BPH-associated chronic inflammation and mediates epithelial and stromal cell proliferation (Lotti et al., 2014; Lotti et al., 2015; Penna et al., 2009).

Further evidence suggests that IL-8 may stimulate prostatic growth (Lotti and Maggi, 2013; Penna et al., 2007). The majority of observational clinical studies suggest that inflammation is linked to the development of BPH and LUTS. These observations around prostatic inflammation may explain why men with metabolic syndrome are more likely to have larger prostates than men without and why LUTS symptomatology is more adverse even with comparable prostate volumes among men with metabolic syndrome than those without (Bhindi et al., 2014). Not surprisingly, the degree of inflammation has been directly correlated with prostatic volume and IPSS scores (He et al., 2016).

Prostate Cancer

The inflammatory and cytokine-induced mitogenic environment associated with metabolic syndrome is also highly carcinogenic. Pivotal work by Bhindi et al. demonstrated that **men with metabolic syndrome are more likely to have cancer and to exhibit high-risk features among a cohort of men presenting for prostate biopsy** (Bhindi et al., 2014, 2015, 2016). Importantly, combinations of individual components of metabolic syndrome increased the risk of aggressive disease in a “dose-response” relationship. Obese men who undergo active surveillance were also found to be at higher risk for disease progression (Bhindi et al., 2016). A recent meta-analysis (Gacci et al., 2017) of more than 24 studies examined the published literature regarding this potential association. The authors concluded that the risk of prostate cancer per se was only minimally increased (odds ratio [OR] 1.17, 95% CI 1.00–1.36) but that the risk of advanced/high-grade features such as high Gleason score, adverse pathologic stage, and biochemical recurrence was increased, with the rates of biochemical failure almost doubled. An important consideration in these studies is that many men, particularly in the developed world, receive therapy that abrogates metabolic syndrome pathways such as statins or antidiabetic agents, which have been linked with protection from these adverse features (Hamilton, 2017; Hamilton and Freedland, 2008a; Hamilton and Freedland, 2008b; Hamilton et al., 2008; Margel, 2014; Margel et al., 2013a, 2013b). It thus remains possible that the strength of these associations is actually larger than those reported in the epidemiologic literature.

Low Testosterone and Erectile Dysfunction

A number of epidemiologic studies support the associations between obesity (Bajos et al., 2010; Larsen et al., 2007), the metabolic syndrome, (Bal et al., 2007; Kupelian et al., 2006), T2DM (Malavige and Levy, 2009), and low serum testosterone (Wu et al., 2010) with sexual dysfunction, including ED (Diaz-Arjonilla et al., 2009). These studies highlight the complex and often multidirectional relationships between obesity, metabolic status, low testosterone levels, and ED in men. Cohort and case-control studies support a bidirectional association between low serum testosterone concentration and metabolic syndrome. Low serum total testosterone is associated with the development of central obesity and intra-abdominal adiposity (Allan and McLachlan, 2010; Brand et al., 2011; MacDonald et al., 2010). In addition, lower androgen axis measures such as total and free testosterone and sex hormone binding globulin (SHBG) levels are associated with an increased risk of metabolic syndrome (Allan and McLachlan, 2010; Brand et al., 2011; MacDonald et al., 2010). Castration therapy among older men with prostate cancer induces metabolic syndrome (Faris and Smith, 2010; Morote et al., 2015) and elevated risk of cardiovascular disease and type 2 diabetes (Alibhai et al., 2009; Keating et al., 2006). From the opposite point of view, high BMI, central adiposity, and the metabolic syndrome are also associated with low androgen axis parameters (Allan and McLachlan, 2010; Brand et al., 2011; Laaksonen et al., 2005; MacDonald et al., 2010). **It therefore appears that the association between these two clinical entities is bidirectional. ED is also associated with metabolic syndrome, given its interaction with hypertension, diabetes (extreme of glucose intolerance), obesity, vasculopathy, and generalized inflammation** (Wang et al., 2011).

Targeting Metabolic Syndrome as a Novel Strategy in Disease Etiology

Despite the growing recognition of the myriad of associations between metabolic syndrome and numerous chronic urologic disorders, the extent to which reversing the constituent features (e.g., obesity, insulin resistance) either via lifestyle adjustment or pharmacologic means can alter the natural history of the disease remains debatable.

Diet and Exercise

Extensive physiologic studies have been conducted in lean and obese men evaluating the effects of exercise on the androgen axis parameters. Blood concentrations of testosterone and cortisol were found to increase after exercise: testosterone levels increase immediately after exercise, whereas the cortisol response tends to be slightly delayed into recovery, depending on the exercise protocol. For these endocrine changes to occur, an exercise protocol must be of sufficient length and intensity. Obese men require more vigorous exercise (Moradi, 2015).

Statins

Statins inhibit the HMG-CoA reductase enzyme of the mevalonate pathway. This group of drugs is approved for the management of hypercholesterolemia and prevention of secondary cardiac events among at-risk men. A high proportion of patients prescribed statins exhibit at least a subset of the components of metabolic syndrome, if not the disorder. **Although significant epidemiologic literature suggests that statins may provide protection from the progression of prostate cancer** (Hamilton and Freedland, 2008b)**, the only evidence has come from association studies.** Randomized intervention trials, such as the Canadian LIGAND trial examining atorvastatin in patients with biochemical failure, are currently underway (Clinicaltrials.gov, 2018).

Metformin

Metformin is a biguanide drug that has recently received attention in the epidemiologic literature (Sayyid and Fleshner, 2016), as well as the lay press. Metformin has been used to treat T2DM for decades and is an inexpensive (because of being available in generic formulations) drug with a well-established safety profile. Metformin exhibits many newly discovered properties but essentially elicits its metabolism-modifying effects by generating energetic stress in the liver through inhibition of oxidative phosphorylation (Fleshner and Bhindi, 2014). These properties are of particular interest in the context of early stage prostate cancer, which predominantly uses the oxidative phosphorylation pathway for energy generation. **Numerous epidemiologic studies suggest that men with diabetes treated with metformin have lower risk of incidence and death from a number of cancers, including prostate** (Margel et al., 2013b) **and potentially bladder carcinoma** (Richard et al., 2018). Most studies using metformin are association studies. In one small interventional trial, metformin was administered to nondiabetic men before radical prostatectomy and elicited a reduction in cancer cell proliferation and perturbation of the PTEN/PI3K-AKT pathway (a major cancer progression pathway) (Joshua et al., 2014). Although positive randomized trials are lacking to date, a number of studies are currently underway, including the Canadian MAST trial (Clinicaltrials.gov), which aims to accrue 408 active surveillance patients and randomize them between metformin and placebo. This study was modeled after the REDEEM study (Fleshner et al., 2012).

Testosterone Therapy

As previously stated, although metabolic syndrome is associated with low testosterone levels, treatment with exogenous testosterone may partially reverse individual aspects of metabolic syndrome, such as facilitating weight loss, reducing lipolysis, and potentially providing additional benefits that are covered elsewhere in this book (Anaissie et al., 2017; Shigehara et al., 2018).

Metabolic Syndrome in Integrative Men's Health

Integrative men's health engenders the need for urologists and their associates to be facile and comfortable when discussing nutrition and exercise. Given the association of obesity with various urologic conditions such as BPH, sexual dysfunction, hypogonadism, and urologic cancer, a more holistic approach is a valuable addition in providing quality care. **Obesity, defined as a BMI of at least 30 kg/m^2 in adults by the National Institutes of Health, has been associated with a myriad of conditions, including various aspects of metabolic dysfunction such as dyslipidemia, T2DM, hypertension, cardiovascular disease, and stroke** (Chu et al., 2015). Downstream consequences of obesity include increased risk of falls and fractures and increased rates of orthopedic surgery on weight-bearing joints (Derman et al., 2014). Between 1980 and 2008 mean global BMI increased by 0.4 to 0.5 kg/m^2 per decade in men and women. In 2008 an estimated 1.46 billion adults worldwide had a BMI of 25 kg/m^2 or greater, and of these, 205 million men and 297 million women were obese (Finucane et al., 2011).

As with many cancers, numerous risk factors are related to prostate cancer, including age, race, and hormonal and genetic factors. **However, there are several modifiable risk factors, such as diet and physical fitness, which may affect incidence and outcomes in men with prostate cancer on numerous levels. Dietary or lifestyle modifications may improve outcomes in many of these urologic diseases.** Research has demonstrated that frequent physical exercise reduces the risk of chronic diseases, including T2DM, CVD, and cancers, by a number of mechanisms. First, exercise is well known to increase insulin-mediated glucose uptake. Exercise also decreases inflammation by reducing levels of insulin-like growth factor-1 (IGF-1). A recent study of 26 men with prostate cancer treated with androgen deprivation therapy (ADT) found that IGF-1 levels were reduced ($P = 0.019$) at month 3 but not month 6 in those who competed in a 24-week home-based aerobic or resistance-based exercise training program versus controls. Modifications in outcomes, including weight and BMI, were also directly correlated with changes in biomarkers, demonstrating physiologic benefit of exercise (Santa Mina et al., 2013).

Exercise is also a universally known practice that helps people reduce excess weight or prevent weight gain; therefore obesity and exercise are interconnected. **There is a growing body of data linking obesity, inactivity, and prostate cancer with regard to risk and outcomes such as biochemical recurrence (BR).** A large meta-analysis has demonstrated that physical exercise imparts a small benefit with regard to reducing prostate cancer risk. The authors scrutinized 43 articles that met the inclusion criteria and included 19 cohort and 24 case-controlled studies in their analysis (Liu et al., 2011). They confirmed that there was a statistically significant 10% reduction in risk of prostate cancer between men with the highest versus lowest levels of activity (RR 0.90, 95% CI 0.84–0.95, $P = 0.001$) (Liu et al., 2011). Studies examining the impact of high BMI (25–29 overweight, >30 obese) on prostate cancer risk have also been performed, with a recent meta-analysis incorporating 12 and 13 studies of localized and advanced prostate cancer, respectively. The analysis found an inverse linear relationship between BMI and localized prostate cancer ($P_{trend} < 0.001$, RR 0.94, 95% CI 0.91–0.97 for every 5 kg/m^2 increase) and a direct relationship between BMI and advanced prostate cancer ($P_{trend} = 0.001$, RR 1.09, 95% CI 1.02–1.16 for every 5 kg/m^2 increase) (D'Amico et al., 2002). This study strongly suggests a twofold effect of adiposity on the development of prostate cancer; however, the cause of this correlation is still unclear. Interestingly, a number of studies have demonstrated the association between low circulating concentrations of free testosterone and aggressive prostate cancer (Dai et al., 2012; Severi et al., 2006), although other studies have showed no relationship between testosterone levels and aggressive prostate cancer (Sher et al., 2009).

The consequences of obesity on surgical outcomes in prostate cancer have also been established. Robotic-assisted radical prostatectomy, although safe in the hands of experienced surgeons, is known to be more technically demanding in obese patients. **Moreover, numerous studies linking the effects of obesity on disease outcomes and biochemical recurrence have been suggested.** A recent study demonstrated that metabolic syndrome and specifically obesity and hypertension were risk factors for biochemical recurrence in 1428 men after radical prostatectomy (adjusted hazard ratio [aHR] = 1.37, 95% CI 0.92–2.09) (Asmar et al., 2013). A retrospective analysis of 1038 patients treated with radical prostatectomy demonstrated that elevated BMI (mean BMI 28.5 kg/m^2) was associated with increased risk of biochemical recurrence (HR 1.06, P = 0.007), noting that adjusting for PSA nadir attenuated, but did not eliminate, the association (HR 1.04, P = 0.043) (Ho et al., 2012b). Another recent study comprising 1734 men who underwent radical prostatectomy or radiation therapy demonstrated that men with elevated blood glucose (serum glucose closest to the date of diagnosis, ≥100 mg/dL) had a 50% increased risk of recurrence (HR 1.5, 95% CI 1.1–2.0) compared with those with normal glucose levels (<100 mg/dL) in men who underwent either radical prostatectomy (HR 1.9, 95% CI 1.0-3.6) or radiation therapy, respectively (HR 1.4, 95% CI 1.0–2.0) (Wright et al., 2013).

A few prospective studies have evaluated exercise interventions in men with prostate cancer, with one study demonstrating that physical activity had a significant and positive association with improved sexual functioning in men who had received external beam radiation therapy (P < 0.001) (Dahn et al., 2005) However a more recent study demonstrated that an aerobic training program was safe and feasible but did not improve ED in men after radical prostatectomy (Jones et al., 2014).

In addition, studies have shown that supervised exercise training for prostate cancer survivors benefits cardiorespiratory fitness and physical function and strength in comparison with patients who received educational material alone (Galvao et al., 2014). **A recent meta-analysis of studies examining exercise interventions in men with advanced prostate cancer have indicated that various types of programs, including aerobic and resistance type training, improve many quality-of-life factors** (Gardner et al., 2014).

Finally, one compelling prospective study supporting the impact of exercise in prostate cancer was a recent analysis of the effect of exercise on gene expression. This study examined the association between self-reported physical activity and gene expression patterns in the prostate tissue of 71 men with low-risk PCa undergoing surveillance. Results revealed that 25 gene sets were upregulated in men who engaged in more than 3 hours per week of vigorous physical activity compared with those who did not. **Upregulated gene sets included many that regulate cell and DNA repair pathways.** Twelve gene sets associated with obesity and steroid hormone metabolism were also upregulated in men who were overweight or obese versus men with a normal BMI (Magbanua et al., 2014).

There are other global risk factors associated with metabolic dysfunction and urologic conditions. However, there have been few studies examining the effects of cardiovascular risk factor modification on urologic conditions such as ED (Kalka et al., 2013). **A number of studies suggest that dietary change, weight loss, and exercise may result in improvement of ED in some patients** (DeLay et al., 2016; Gupta et al., 2011). Few studies have evaluated whether cardiovascular risk factor modification can have ameliorative effects on ED. Shared risk factors include modification of tobacco use, hyperlipidemia, and dietary change/weight loss/exercise in targeted patients, each of which can result in improvement in ED (DeLay et al., 2016; Kalka et al., 2013; Kostis and Dobrzynski, 2014). Esposito et al. conducted a randomized single-blind study of 110 obese men aged between 35 and 55 years without diabetes, hypertension, or hyperlipidemia, who had an International Index of Erectile Function (IIEF) score of 21 or less, examining the effects of weight loss and increased physical activity on erectile and endothelial function. At 2 years, BMI decreased more in the intervention group compared with control patients, as did serum concentrations of interleukin-6 and C-reactive protein (Esposito et al., 2004). **These data suggest that aggressive risk modification for ED and CVD may alter the arc of progression.**

Ultimately, how can we translate the conclusions of these studies to meaningful recommendations for the urologist? What does this mean to our patients? **The challenge is less in instructing a patient to eat better and exercise, but more in promoting long-term, standardized, working strategies for every type of patient.** Among the key steps needed for implementing treatment plans that will meaningfully affect these modifiable risk factors for patients is more high-quality research. The implementation of safe and effective programs that prioritize the importance of exercise in the general health care setting and our own urology departments is a priority. **Our shared aim should be directed at creating optimal and individualized interventional approaches that address the dietary and physical activity needs for all urologic conditions and improve men's health overall.**

Conclusion

Metabolic syndrome is a complex pathophysiologic disorder with far-reaching implications for integrative men's health, public health, and healthy aging. Much has been learned about the cause of this condition in recent years. In the next decade, interventional trials should confirm whether targeting metabolic syndrome or its components can provide tangible benefits to patients with cancer and other chronic conditions apart from those already known to the medical community (e.g., heart disease).

Key Points: Metabolic Syndrome and Men's Health

- Metabolic syndrome, defined as a combination of dyslipidemia, glucose insensitivity, and obesity, is increasingly prevalent around the world.
- In addition to its association with increased CVD risks, metabolic syndrome is linked with pelvic health issues, including LUTS, ED, and hypogonadism, as well as genitourinary tumors (kidney, bladder, prostate).
- Dietary or lifestyle modifications may improve outcomes in many of these urologic diseases, with clinical trials currently testing metabolic modulators statins and metformin.
- Exercise-based interventions in men with advanced prostate cancer improve quality of life.
- Dietary change, weight loss, and exercise may improve erectile function.
- Men's health should include individualized and precision-based intervention programs to alter the arc of pelvic conditions.

Testosterone Therapy and Cardiovascular Risk: Advances and Controversies

Introduction and Historical Context

Perhaps no topic in the field of men's health is currently more controversial than the indications, efficacy, and potential adverse effects associated with testosterone replacement therapy. Testosterone was initially isolated in 1935 by Brown-Sequard, with synthetic forms commercially available since the 1950s (Brinkmann, 2011). Testosterone formulations were approved and made available for treatment of frankly hypogonadal males, including men with testicular trauma and those with rare bilateral tumors. The benefits and safety profile of exogenous testosterone administration have not been established for the treatment of low testosterone levels that occur as part of aging, even if a man's symptoms appear to reflect a deficiency in this hormone. Indeed, large-scale, placebo-controlled, decades-long trials (ideal in the setting of a possible long-term commitment to prolonged testosterone supplementation) have not been completed at this time.

Despite the lack of conclusive clinical trial data, use of testosterone supplements has increased significantly over the past decade. Handelsman (2013) demonstrated that global trends of testosterone prescribing increased in 37 of 41 studied countries between 2001 and 2011. In the United Kingdom, prescriptions almost doubled over the period in question (Gan et al., 2013). Perhaps in no jurisdiction did prescriptions for testosterone replacement therapy increase more than in the United States (Gabrielsen et al., 2016; Rao et al., 2017). The value of annual testosterone prescriptions filled in the United States have increased from $18 million in 1988 to $70 million in 2000, and to more than $2 billion in 2013, with most of these sales oriented toward middle-aged and older men without frank hypogonadism (Bhasin, 2016).

Testosterone replacement therapy has been studied for potential benefits in a host of medical conditions, including depression, dementia, cardiac failure, osteopenia, chronic obstructive pulmonary disease, rheumatoid arthritis, ED, and anemia (Amanatkar et al., 2014; Katznelson et al., 1996; Snyder et al., 2016). Testosterone is also taken by some to abate the general effects of aging and to improve athletic performance (Page et al., 2005). There are many forms of testosterone supplementation currently available, including oral, intramuscular, transdermal, sublingual, subdermal, or transnasal routes (Bassil et al., 2009).

In light of the increased use of testosterone replacement therapy and lack of long-term well-conducted randomized clinical trials, it remains important to understand the risks and benefits associated with testosterone supplementation. Lack of clear understanding of the physiologic effects of low testosterone levels may be particularly relevant for estimating the patient's risk of developing cardiovascular disease, which is a major cause of death in aging men. Potential clinically relevant interactions between cardiovascular risks and circulating testosterone levels were brought to the forefront by the FDA with a warning issued regarding this connection in January of 2014 (Nguyen et al., 2015).

Clinical Trials: Evidence of Effectiveness

Recent larger-scale (albeit short-term) placebo-controlled randomized trials have been conducted to evaluate the benefits of testosterone replacement therapy in aging men with symptomatic hypogonadism. Snyder et al. (2016) randomized 790 patients to receive either testosterone or placebo gel for 1 year in the context of an overall program assessing testosterone supplementation (Testosterone Trials). Despite the fact that the study was a combination of seven coordinated clinical trials, three specific domains of aging were recently reported: sexual function, vitality, and physical functioning. In terms of ***sexual function substudy,*** testosterone replacement therapy was associated with significantly improved sexual performance, as well as increased sexual desire and erectile function. In terms of ***physical functioning substudy***, no significant differences were observed between the groups in the proportion of men whose 6-minute walking distance significantly improved (primary trial outcome). In addition, no change was detected in 6-minute walking distance or the percentage of men whose physical functioning subscore of the 36-Item Short Form Health Survey (SF36) increased by at least 8 points. However, significant differences were reported between treatment groups in the change from baseline in physical functioning scores (mean difference, 2.75 points; $P = 0.03$). When the populations of all three trials were pooled, improvements in physical functioning were noted in testosterone-treated participants. In addition, men who received testosterone were more likely than those who received placebo to perceive an improvement in their walking ability since the beginning of the trial ($P = 0.002$).

Taken together, these data suggest a modest impact on physical functioning associated with testosterone replacement therapy. In terms of the ***vitality t substudy***, testosterone replacement elicited no significant benefit with respect to vitality, as assessed by the Functional Assessment of Chronic Illness Therapy (FACIT)–Fatigue scale. Once again, when study populations of all three trials were combined, testosterone was associated with small but significant benefits with respect to mood and depression symptoms. Men in the testosterone-treated group were more likely to report improved energy levels. A smaller Asian study confirmed these findings (Tong et al., 2012).

Meta-analyses have been performed to summarize the accumulated trial information and assess the risks and benefits associated with testosterone replacement therapy (Amanatkar et al., 2014; Bolona et al., 2007; Calof et al., 2005; Corona et al., 2014; Elliott et al., 2017; Fernandez-Balsells et al., 2010; Guo et al., 2016; Haddad et al., 2007; Xu et al., 2013; Zarrouf et al., 2009). These pooled analyses, although not perfect, provide a method of overcoming power deficiencies of many smaller or shorter-term randomized clinical trials (Higgins et al., 2008). Although there are a number of differences in terms of these analyses, credible evidence suggests that, among healthy aging males with symptomatic hypogonadism, testosterone replacement therapy does improve a number of factors, including overall quality of life, depression symptoms, libido, and erectile function. Taken together, these data do provide credible evidence of benefit of testosterone replacement among appropriately selected men with age-related symptomatic hypogonadism.

Cardiovascular Risk

Credibly assessing cardiac risk associated with testosterone replacement is methodologically challenging. Men who exhibit signs of hypogonadism disproportionately exhibit comorbidities such as obesity, hypertension, and glucose intolerance, risk factors that by themselves place them at elevated risk of cardiovascular events. It is therefore difficult to disentangle the adverse events associated with drug exposure from the risk associated with the disease unless randomized data are available. Randomized trials in this space, however, are limited by short- or intermediate-term drug exposure (i.e., there are no studies with 10- to 20-year exposure data) and are often insufficiently powered to analyze rare events such as cardiovascular conditions. Publication biases are also potentially relevant (Xu et al., 2013). Among the published randomized clinical trials that have assessed the risk of mortality resulting from cardiovascular factors, 19 trials reported on these risks (Ho et al., 2012a; Hoyos et al., 2012; Jones et al., 2011; Kalinchenko et al., 2010; Kaufman and Vermeulen, 2005; Srinivas-Shankar et al., 2010; Xu et al., 2013), with a total of 4 deaths reported among 1851 placebo-treated men and 9 among 2088 men receiving testosterone replacement therapy (OR 2.15, $P > 0.05$).

Nonfatal cardiac events, however, were shown in some studies to be more prevalent among testosterone users in randomized trials. In 2010 Basaria et al. conducted a relatively small randomized study (n = 209) that demonstrated an almost fivefold higher incidence of cardiovascular events among testosterone-treated men (23 in testosterone replacement therapy group vs. 5 in placebo). Xu et al. subsequently assessed adverse event rates in a meta-analysis and estimated a 54% increase in the risk of cardiovascular events associated with testosterone therapy (Xu et al., 2013). Interestingly, trials sponsored by pharmaceutical companies demonstrated no increased risk, whereas those that were not funded by the industry demonstrated a twofold increase in risk (OR 2.06, $P < 0.05$), suggestive of a publication bias.

As alluded to earlier, retrospective cohort analyses and health record linkage studies are sometimes the only way to assess risk with longer-term exposures when such data are not available from randomized clinical trials. Although these analyses suffer from biases mentioned earlier, studies by Finkle et al. (2014) and Vigen et al. (2013) demonstrated increased risk with testosterone therapy. In the study by Vigen et al., men in the Veterans' Affairs system who underwent coronary angiography were included in the study analysis. Men who had hypogonadism and were on testosterone replacement therapy exhibited a 1.29-fold increase in cardiac events, corresponding to a 5.8% increase in absolute risk. Finkle et al. evaluated a cohort of almost 56,000 men, assessing the risk of myocardial infarction following testosterone-replacement therapy institution (Finkle et al., 2014). An excess risk was noted among older men and younger men with pre-existing cardiovascular disease. The results of these trials led the FDA, as well as other jurisdictional agencies (Health Canada, WHO, etc.) to issue a warning regarding the potential association between cardiac events and testosterone supplementation (Nguyen et al., 2015).

Investigators eagerly await the results of the cardiovascular trial substudy of the Testosterone Trials (Alamir). In this substudy, atherosclerotic plaque progression will be measured using computed tomography (CT) angiography, with results hopefully available by the end of 2018. These trials will, however, not represent the final word on this controversy because, even if plaque progression is not worsened by testosterone replacement therapy, other cardiovascular events such as plaque rupture or arrhythmia could, in theory, be affected. Indeed, electrocardiographs conducted in testosterone-treated patients demonstrated a prolongation in the QT interval in one pooled analysis of data from two separate randomized control trials (Gagliano-Juca et al., 2017).

What Is a Clinician to Do?

The scope of current knowledge regarding testosterone replacement therapy, like most other medical conundrums, requires the practicing clinician to understand the controversies and be able to communicate them to his or her patients. Professional guidelines can also help. The Endocrine Society in 2018 updated their guidelines regarding testosterone replacement therapy (Bhasin et al., 2018). The main points outlined in their document include (1) limiting the diagnosis of testosterone deficiency to symptomatic males with unequivocally low testosterone levels; (2) recommending against testosterone replacement therapy in men planning fertility in the near term, in men with breast or prostate cancer, or in those with significant prostate cancer risk, elevated hematocrit, untreated severe obstructive sleep apnea, severe lower urinary tract symptoms, uncontrolled heart failure, myocardial infarction or stroke within the last 6 months, or thrombophilia; and (3) discussing the potential risks of therapy associated with testosterone replacement therapy, clarifying that there are currently insufficient data to establish a causal association between cardiovascular disease and testosterone supplementation.

Key Points: Testosterone Replacement Therapy

- The use of testosterone replacement therapy in countering low testosterone levels that occur as part of the aging process is controversial because of inadequately elucidated effectiveness and safety profile.
- Recent large-scale randomized trials demonstrated some improvements in sexual and physical function and vitality.
- Limited clinical trial evidence and retrospective cohort analyses suggest that testosterone replacement therapy increases the risk of cardiovascular events.

- Practicing urologists should keep current with the recently updated guidelines and current research on testosterone replacement therapy to be able to discuss the risks and benefits for individual patients.

Association Between Cardiovascular Disease and Erectile Dysfunction

Predisposing Factors

There are a host of predisposing risk factors and underlying pathophysiologic processes for CVD and ED. These include, but are not limited to dyslipidemia, smoking, hypertension, and T2DM. The underlying mechanisms of CVD and ED include inflammation, atherosclerosis, and endothelial dysfunction (Vlachopoulos et al., 2013). There is emerging consensus that ED and CVD are independent risk factors for each other. The Princeton Consensus Conference (Nehra et al., 2012) identified ED as a substantial independent risk factor for CVD, and the QRISK group published one of the first risk scores to incorporate ED as an independent risk factor into their updated 10-year CVD risk model, calculating a 25% increased risk for average middle-aged men with ED (Hippisley-Cox et al., 2017).

Erectile Dysfunction and Subclinical Cardiovascular Disease

The temporal relationship between ED and subclinical CVD progression is less clear. Is ED a precursor to CVD, or does underlying CVD first manifest as ED? Available data come from either cross-sectional studies correlating symptoms of ED and overt CVD or highly limited prospective cohort studies correlating ED incidence and severity with incident CV events (Banks et al., 2013; Chew et al., 2010; Fung et al., 2004; Montorsi et al., 2006). The data suggest that there is a 2- to 3-year time interval between the onset of ED and CVD symptoms (Montorsi et al., 2006), whereas more recent studies have examined the interrelationships between subclinical CVD (i.e., early atherosclerosis), ED, and overt CVD (myocardial infarction [MI] or major adverse cardiac events [MACEs]; Chew et al., 2010; Inman et al., 2009). A landmark study, the Multi-Ethnic Study of Atherosclerosis (MESA; Feldman et al., 2016) demonstrated that subclinical CVD is a predictor of ED and potentially of ensuing MACEs. **Among the key findings in the study was that the coronary artery calcium (CAC) score can serve as a “disease score” and**

surrogate marker of accelerated atherosclerosis process in arteries, including penile arteries and vascular ED (Jackson et al., 2010).

About 50% of men with sudden CVD events may have had no previous symptoms of CAD, and between 70% and 89% of sudden cardiac events occur in men (Fox et al., 2004; Ni et al., 2009; Podrid and Myerburg, 2005). **More importantly, ED may be the single warning of the elevated risk of sudden CVD events** (Gandaglia et al., 2014). Finally, severity and duration of ED has been correlated with the magnitude of coronary disease, with the presence of ED being independently associated with CVD events (Gandaglia et al., 2014; Shin et al., 2011).

It appears that development of ED may occur during the progression of baseline subclinical vascular disease to more clinically manifest CVD. In the MESA study, there was a strong association between baseline subclinical disease, as assessed by CAC and carotid plaque burden, and subsequent ED. This further suggests the value of atherosclerosis testing (i.e., CAC scoring and measurement of carotid plaque burden) in predicting ED and overt CVD (Feldman et al., 2016). More important, given the strengths of ED as a predictor of future vascular events, it may be prudent to implement increased evaluation of subclinical CVD in at-risk patients before and after the onset of ED (Detrano et al., 2008; Gibson et al., 2014).

Key Points: Cardiovascular Disease and Erectile Dysfunction

- There are a number of overlapping risk factors for CVD and ED.
- The temporal relationship between ED and subclinical CVD remains to be determined.
- CAC score can serve as a “disease score” and a surrogate for accelerated atherosclerosis process in arteries, including penile arteries, with implications for vascular ED.

Mental Health and Opioid Abuse in Men

Mental Illness in Men

Mental illnesses, including anxiety, depression, and suicide, are becoming increasingly prevalent in men, while concomitantly being underdiagnosed. Any mental illness (AMI), defined as a mental, behavioral, or emotional disorder, occurs in 14.5% of men and in 14.5% of men age 50 or older in the United States (National Institute of Mental Health, 2018; Substance Abuse and Mental Health Services Administration [SAMHSA], 2017). Among men with AMI, 33.9% received treatment, including 46.8% of men aged 50 or over. The prevalence in US adults of serious mental illness (SMI), defined as AMI that substantially interferes with or limits one or more major life activities, is 4.2% (5.3% in women and 3.0% in men). In 2016, among the 10.4 million adults with SMI, 6.7 million received treatment (68.8% in women and 57.4% in men) (Substance Abuse and Mental Health Services Administration [SAMHSA], 2017).

More specifically, more than 6 million men suffer from depression, including symptoms such as fatigue, irritability, and loss of interest in work or hobbies. It has been estimated that 3,020,000 men in the United States suffer from panic disorder and a myriad of phobias. An equal number of men and women (total: 2.3 million) develop bipolar disorder, and 90% of people who are diagnosed with schizophrenia by age 30 are men (NIMH, 2018; Substance Abuse and Mental Health Services Administration [SAMHSA], 2017; http://www.cdc.gov/msmhealth/mental-health.htm). These high rates of AMI and SMI have led to a significant increase in incidences of suicide and substance abuse. More than 44,000 people in the United States in 2015 committed suicide, defined as ending one's own life, according to the CDC, making it the 10th leading cause of death overall. Although many suicide prevention programs focus on helping teenagers, the highest number of suicides in the United States in 2015 occurred among people ages 45 to 54. Men are especially at risk, with a suicide rate approximately four times higher than that of women. There are a host of underlying risk and predisposing factors, including a significant decline in traditional male industries such as manufacturing, forestry, and fisheries, with subsequent unemployment. About 76% of suicides in the United Kingdom are in men, and suicide is the most common cause of death for men under the age of 35

(UK Office of National Statistics, 2012). A review by the Samaritans in 2012 noted that men who are predisposed to suicide include those who are middle aged and of lower socioeconomic class (Wyllie et al., 2012). Six key themes identified in this group were personality traits, sense of masculinity, relationship breakdowns, challenges of midlife, emotional illiteracy, and socioeconomic factors.

Consequences of Opioid Abuse

In recent years the emotional and economic consequences of opioid misuse on public health has increased dramatically and is now understood as a major source of morbidity and mortality in the United States. Despite a decrease in the number of total opioids prescribed in the United States from a peak in 2012, some 33,000 people died of opioid overdoses in 2015 (including 15,000 from prescription sources), and currently more than 115 Americans die daily after overdosing on opioids (Centers for Disease Control and Prevention/National Center for Health Statistics [CDC/NCHS], 2017).

From a men's health perspective, understanding the magnitude of this crisis and in particular how urologists will interact with patients will be a very important part of our training in the future. Efforts to decrease the supply of opioids will require increasing commitment from all prescribers, including surgeons. As drug monitoring programs seek to offer greater scrutiny, urologists are tasked with improving their understanding of how opioids are dispensed to patients and how best to reduce overprescription. Moreover, there are direct endocrine consequences of opioid use, including hypogonadism, that adversely affect men's health (Leapman and Kaplan, 2017).

The opioid epidemic is notable for the expansiveness of the problem in the United States, spanning divisions of gender, race, age, and income level. Although greater increases in prescription pain reliever opioid deaths were seen between 1999 and 2010 among women (400%) compared with men (273%), men are still significantly more likely to misuse, overdose, and die from opioids.

Opioid Prescriptions

There appears to be a high degree of variability in the dispensing of pain medications after surgery and there are some who routinely dispense above recommended safety thresholds. Not only do these overprescribed doses represent potential dangers for the patients receiving the prescriptions, but they also are a source of risk for those in the individual's family and community. The potential supply of opioids is vast given that most patients report using far less than is prescribed by their surgeons (Hill et al., 2017; Kumar et al., 2017). This is magnified by the fact that most patients who are prescribed opioids after surgery report they store unused opioids in unsecured locations (Bartels et al., 2016).

The risks of new-onset opioid use or overdose after general and urologic surgery is also increasing and should be a concern to trainees and prescribers in those specialties (Brummett et al., 2017; Shah et al., 2017). There are particular verticals that are predisposed to increased pain and the potential for opioid overprescribing, including cancer surgery and stone disease. **In a publication examining nearly 70,000 patients undergoing cancer surgery with curative intent, the risk of new persistent opioid use was 10.4% and more common in patients receiving adjuvant chemotherapy** (Lee et al., 2017).

Gonadal Dysfunction

Male gonadal function is affected by opioid use and abuse. By disrupting the pulsatile release of gonadotropin-releasing hormone (GnRH), opioids suppress the hypothalamic-pituitary-gonadal axis and result in hypogonadism (Ceccarelli et al., 2006). Sustained gonadal suppression is commonly noted in chronic opioid users and may impair male sexual health, with manifestations including low libido, fatigue, depression, anxiety, osteoporosis, and loss of muscle mass (Aloisi et al., 2009; Reddy et al., 2010).

For some individuals, the identification of opioid-related endocrine dysfunction can serve as an opportunity to seek formal treatment. **In light of the growing prevalence of opioid use, clinicians who treat hypogonadism should continue to take note of the potential contributions of chronic opioid use as a causative agent for symptomatic hypogonadism.** Nevertheless, with a growing population of opioid users—including those receiving chronic opioid substitution therapies such as methadone—there is a potential role to consider exogenous androgen supplementation. For example, in a randomized, double-blind, placebo-controlled trial of testosterone replacement in men with opioid-induced androgen deficiency, patients receiving testosterone supplementation experienced greater improvements in pain sensitivity, sexual desire, body composition, and overall quality of life (Basaria et al., 2015). These findings suggest that in selected patients who do have nonmodifiable opioid use, consideration of supplementation may be warranted.

Role of Urology

As part of an expanding integrative men's health program, there will be a need for urologists to foster greater awareness of the potential harms associated with even short courses of opioids (Leapman and Kaplan, 2017). Those prescribing are encouraged to adopt responsible prescribing practices, such as **initially prescribing the *lowest effective dose*** and offering repeat assessments as needed, rather than upfront high-dose therapy. In addition to direct consequences of overdose and dependence, opioids can adversely affect men's health by resulting in hypogonadism, and a urology consult should be regarded as a potential opportunity to primarily address chronic use.

Key Points: Mental Health

- Mental health issues, including anxiety, depression, and suicide, are increasingly prevalent in men and are concomitantly being underdiagnosed.
- More than 6 million men in the United States suffer from depression, including symptoms such as fatigue, irritability, and loss of interest in work or hobbies.
- Men are at higher risk for suicide, with a rate approximately four times higher than that of women.
- Opioid abuse is now a leading health care crisis, with significant morbidity and mortality.
- The opioid epidemic is notable for the expansiveness of the problem in the United States, spanning divisions of gender, race, age, and income level.
- Clinicians who treat hypogonadism should be cognizant of the relationship between chronic opioid and symptomatic hypogonadism.

Building an Integrative Men's Health Center

Components

Inherent to the delivery of more efficient men's health care is an understanding of why men seem to lag women in entering the health care space. Concurrently, identifying how men do or do not seek health care, and, more importantly, how men interpret and deal with acute and chronic health conditions will help elucidate a more comprehensive and successful approach. Urologic and cardiac conditions make up a significant portion of men's health issues, but a broader approach based on age and geographic location will provide a more sustainable program for diagnoses and therapy. Moreover, attention toward exercise, nutrition, and complementary and alternative solutions will provide a more robust approach. Finally, health care providers need to be adequately trained to care for men who have sex with men, transgender patients, and complex geriatric men.

Curriculum

Miner et al. (2018) developed a comprehensive and sensible approach to integrative men's health. The four general categories are the following:

1. Conditions that are unique to men (e.g., prostate cancer, prostate disease, and ED)
2. Diseases or illnesses more prevalent in men compared with women (e.g., CVD, stroke, and renal disease)
3. Health issues for which risk factors and adverse outcomes are different in men (e.g., obesity)
4. Health issues for which different interventions to achieve improvements in health and well-being at the individual or population level are required for men (e.g., access to care)

A men's health curriculum must be rooted in the deep understanding of the impact of masculinity factors on health care engagement and outcomes. Various psychosocial stressors, including employment, culture, and geographic location, can directly and indirectly contribute to high rates of unhealthy behaviors, chronic disease diagnoses, and premature mortality among men. These underlying factors should be considered in a multi-specialty and tiered approach to improving receipt of appropriate health care services (Miner et al., 2018).

Future Business Plan

Before a business plan is developed for an integrative men's health center (IMHC), it has to be decided what and whom it will encompass, organization, revenue versus expenses, sustainability, and opportunities for growth. From a ground-level perspective and in building a pathway to sustainable success, there must be a buy-in from leadership (in either an academic or private practice setting) as well as a host of medical specialties, including partnerships with various subspecialists in cardiology, endocrinology, psychiatry, orthopedics, and dermatology. All these partners should be vested in the need for integration of thought, goals, and vision.

In the past, many IMHCs have focused on aging, sexual health, and the administration of testosterone (Miner et al., 2018). There is a rapidly evolving health care landscape, wherein there is an increased stress on the medical system and health care providers. This includes the need for adaptation of a patient-centered medical home model, electronic medical records, and increasing scrutiny of testing and outcomes dovetailing with patient satisfaction metrics, which add to the burden of clinical management of male patients.

The future of men's health will be predicated on improving more efficient entry pathways to enhance the patient journey and experience. This includes a more holistic and integrated approach including proper education and testing and careful shared decision making between the patient and provider.

References

Abate N, Chandalia M, Snell PG, et al. Adipose tissue metabolites and insulin resistance in nondiabetic Asian Indian men. *J Clin Endocrinol Metab*. 2004;89:2750–2755.

Abdel-Rahman O, Helbling D, Schob O, et al. Cigarette smoking as a risk factor for the development of and mortality from hepatocellular carcinoma: an updated systematic review of 81 epidemiological studies. *J Evid Based Med*. 2017;10:245–254.

Alberti KG, Zimmet PZ. Definition, diagnosis and classification of diabetes mellitus and its complications. Part 1: diagnosis and classification of diabetes mellitus provisional report of a WHO consultation. *Diabet Med*. 1998;15:539–553.

Alexander RT, McArthur E, Jandoc R, et al. Antihypertensive medications and the risk of kidney stones in older adults: a retrospective cohort study. *Hypertens Res*. 2017;40:837–842.

Alibhai SM, Duong-Hua M, Sutradhar R, et al. Impact of androgen deprivation therapy on cardiovascular disease and diabetes. *J Clin Oncol*. 2009;27:3452–3458.

Aljada A, Mohanty P, Ghanim H, et al. Increase in intranuclear nuclear factor kappaB and decrease in inhibitor kappaB in mononuclear cells after a mixed meal: evidence for a proinflammatory effect. *Am J Clin Nutr*. 2004;79:682–690.

Allan CA, McLachlan RI. Androgens and obesity. *Curr Opin Endocrinol Diabetes Obes*. 2010;17:224–232.

Aloisi AM, Aurilio C, Bachiocco V, et al. Endocrine consequences of opioid therapy. *Psychoneuroendocrinology*. 2009;34(Suppl 1):S162–S168.

Amanatkar HR, Chibnall JT, Seo BW, et al. Impact of exogenous testosterone on mood: a systematic review and meta-analysis of randomized placebo-controlled trials. *Ann*

Clin Psychiatry. 2014;26:19–32.

Anaissie J, Roberts NH, Wang P, et al. Testosterone replacement therapy and components of the metabolic syndrome. *Sex Med Rev*. 2017;5:200–210.

Arcury TA, Summers P, Carrillo L, et al. Occupational safety beliefs among Latino residential roofing workers. *Am J Ind Med*. 2014;57:718–725.

Argaud D, Zhang Q, Pan W, et al. Regulation of rat liver glucose-6-phosphatase gene expression in different nutritional and hormonal states: gene structure and 5’-flanking sequence. *Diabetes*. 1996;45:1563–1571.

Asmar R, Beebe-Dimmer JL, Korgavkar K, et al. Hypertension, obesity and prostate cancer biochemical recurrence after radical prostatectomy. *Prostate Cancer Prostatic Dis*. 2013;16:62–66.

Baggio B, Budakovic A. Fatty acids and idiopathic calcium nephrolithiasis. *Urol Int*. 2005;75:97–101.

Bajos N, Wellings K, Laborde C, et al. Sexuality and obesity, a gender perspective: results from French national random probability survey of sexual behaviours. *BMJ*. 2010;340:c2573.

Baker P, Dworkin SL, Tong SF, et al. The men's health gap: men must be included in the global health equity agenda. *Bull World Health Organ*. 2014;92:618–620.

Bal K, Oder M, Sahin AS, et al. Prevalence of metabolic syndrome and its association with erectile dysfunction among urologic patients: metabolic backgrounds of erectile dysfunction. *Urology*. 2007;69:356–360.

Balabanova D, McKee M. Patterns of alcohol consumption in Bulgaria. *Alcohol Alcohol*. 1999;34:622–628.

Banerjee AT, Shah BR. Differences in prevalence of diabetes among immigrants to Canada from South Asian countries. *Diabet Med*. 2018.

Banks E, Joshy G, Abhayaratna WP, et al. Erectile dysfunction severity as a risk marker for cardiovascular disease hospitalisation and all-cause mortality: a prospective cohort study. *PLoS Med*. 2013;10:e1001372.

Bao C, Yang X, Xu W, et al. Diabetes mellitus and incidence and mortality of kidney cancer: a meta-analysis. *J Diabetes Complications*. 2013;27:357–364.

Bartels K, Mayes LM, Dingmann C, et al. Opioid use and storage patterns by patients after hospital discharge following surgery. *PLoS ONE*. 2016;11.

Basaria S, Coviello AD, Travison TG, et al. Adverse events associated with testosterone administration. *N Engl J Med*. 2010;363:109–122.

Basaria S, Travison TG, Alford D, et al. Effects of testosterone replacement in men with opioid-induced androgen deficiency: a randomized controlled trial. *Pain*. 2015;156:280–288.

Bassil N, Alkaade S, Morley JE. The benefits and risks of testosterone replacement therapy: a review. *Ther Clin Risk Manag*. 2009;5:427–448.

Berg KM, Demas PA, Howard AA, et al. Gender differences in factors associated with adherence to antiretroviral therapy. *J Gen Intern Med*. 2004;19:1111–1117.

Berkowitz SA, Fabreau GE, Raghavan S, et al. Risk of developing diabetes among refugees and immigrants: a longitudinal analysis. *J Community Health*. 2016;41:1274–1281.

Bhandari R, Kelley GA, Hartley TA, et al. Metabolic syndrome is associated with increased breast cancer risk: a systematic review with meta-analysis. *Int J Breast Cancer*. 2014;2014:189384.

Bhasin S. A perspective on the evolving landscape in male reproductive medicine. *J Clin Endocrinol Metab*.

2016;101:827–836.

Bhasin S, Brito JP, Cunningham GR, et al. Testosterone therapy in men with hypogonadism: an endocrine society clinical practice guideline. *J Clin Endocrinol Metab*. 2018.

Bhindi B, Margel D, Trottier G, et al. Obesity is associated with larger prostate volume but not with worse urinary symptoms: analysis of a large multiethnic cohort. *Urology*. 2014;83:81–87.

Bhindi B, Locke J, Alibhai SMH, et al. Dissecting the association between metabolic syndrome and prostate cancer risk: analysis of a large clinical cohort. *Eur Urol*. 2015;67:64–70.

Bhindi B, Xie WY, Kulkarni GS, et al. Influence of metabolic syndrome on prostate cancer stage, grade, and overall recurrence risk in men undergoing radical prostatectomy. *Urology*. 2016;93:77–85.

Bilsker D, Goldenberg L, Davison J. *A roadmap to men's health: current status, research, policy & practice*. [website] http://summit.sfu.ca/item/11205; 2010.

Birge M, Duffy S, Miler JA, et al. What proportion of people who try one cigarette become daily smokers? A meta analysis of representative surveys. *Nicotine Tob Res*. 2017.

Blunt W, Gill DP, Sibbald SL, et al. Optimization of the Hockey Fans in Training (Hockey FIT) weight loss and healthy lifestyle program for male hockey fans. *BMC Public Health*. 2017;17:916.

Bohan JS. Regarding gender—essentialism, constructionism, and feminist psychology. *Psychol Women Quart*. 1993;17:5–21.

Bolona ER, Uraga MV, Haddad RM, et al. Testosterone use in men with sexual dysfunction: a systematic review and meta-analysis of randomized placebo-controlled trials. *Mayo Clin Proc*. 2007;82:20–28.

Bongers IL, Koot HM, van der Ende J, et al. The normative development of child and adolescent problem behavior. *J Abnorm Psychol*. 2003;112:179–192.

Botteri E, Iodice S, Bagnardi V, et al. Smoking and colorectal cancer: a meta-analysis. *J Am Med Assoc*. 2008;300:2765–2778.

Bottorff JL, Seaton CL, Johnson ST, et al. An updated review of interventions that include promotion of physical activity for adult men. *Sports Med*. 2015;45:775–800.

Brand JS, van der Tweel I, Grobbee DE, et al. Testosterone, sex hormone-binding globulin and the metabolic syndrome: a systematic review and meta-analysis of observational studies. *Int J Epidemiol*. 2011;40:189–207.

Brinkmann AO. Molecular mechanisms of androgen action—a historical perspective. *Methods Mol Biol*. 2011;776:3–24.

Briones AM, Nguyen Dinh Cat A, Callera GE, et al. Adipocytes produce aldosterone through calcineurin-dependent signaling pathways: implications in diabetes mellitus-associated obesity and vascular dysfunction. *Hypertension*. 2012;59:1069–1078.

Bruck K, Jager KJ, Zoccali C, et al. Different rates of progression and mortality in patients with chronic kidney disease at outpatient nephrology clinics across Europe. *Kidney Int*. 2018.

Brummett CM, Waljee JF, Goesling J, et al. New persistent opioid use after minor and major surgical procedures in US adults. *JAMA Surg*. 2017;152:e170504.

Bunn F, Kirby M, Pinkney E, et al. Is there a link between overactive bladder and the metabolic syndrome in women? A systematic review of observational studies. *Int J Clin Pract*. 2015;69:199–217.

Byrnes JP, Miller DC, Schafer WD. Gender differences in risk taking: a meta-analysis. *Psychol Bull*. 1999;125:367–383.

Calof OM, Singh AB, Lee ML, et al. Adverse events associated with testosterone replacement in middle-aged and older men: a meta-analysis of randomized, placebo-controlled trials. *J Gerontol A Biol Sci Med Sci*. 2005;60:1451–1457.

Calvin AD, Albuquerque FN, Lopez-Jimenez F, et al. Obstructive sleep apnea, inflammation, and the metabolic syndrome. *Metab Syndr Relat Disord*. 2009;7:271–278.

Canadian Men's Health Foundation. *Canadian Men's Health Foundation*. [website] https://menshealthfoundation.ca/; 2018.

Ceccarelli I, De Padova AM, Fiorenzani P, et al. Single opioid administration modifies gonadal steroids in both the CNS and plasma of male rats. *Neuroscience*. 2006;140:929–937.

Centers for Disease Control and Prevention/National Center for Health Statistics (CDC/NCHS). *National vital statistics system, mortality, 2017*. US Department of Health and Human Services: Atlanta; 2017.

Centre for Disease Control and Prevention (CDC), and National Centre for Health Statistics: Statistics, 2015. Ambulatory care use and physician office visits. Vol. 2018. Centre for Disease Control (CDC).

Charmandari E, Tsigos C, Chrousos G. Endocrinology of the stress response. *Annu Rev Physiol*. 2005;67:259–284.

Chen L, Li H, Gu L, et al. The impact of diabetes mellitus on renal cell carcinoma prognosis: a meta-analysis of cohort studies. *Medicine (Baltimore)*. 2015;94:e1055.

Chew KK, Finn J, Stuckey B, et al. Erectile dysfunction as a predictor for subsequent atherosclerotic cardiovascular events: findings from a linked-data study. *J Sex Med*. 2010;7:192–202.

Chou YH, Su CM, Li CC, et al. Difference in urinary stone components between obese and non-obese patients. *Urol Res*. 2011;39:283–287.

Chrousos GP. Stress and disorders of the stress system. *Nat Rev*

Endocrinol. 2009;5:374–381.

Chu KF, Rotker K, Ellisworth P. The impact of obesity on benign and malignant urologic conditions. *Postgrad Med*. 2015;125:53–69.

Cinti S, Mitchell G, Barbatelli G, et al. Adipocyte death defines macrophage localization and function in adipose tissue of obese mice and humans. *J Lipid Res*. 2005;46:2347–2355.

Clinicaltrials.gov. *LIpitor and biGuanide to Androgen Delay trial (LIGAND)*. [USA; website] http://clinicaltrials.gov/ct2/show/NCT02497638; 2018.

Clinicaltrials.gov. *The Metformin Active Surveillance Trial (MAST) Study*. [USA; website] http://clinicaltrials.gov/ct2/show/NCT01864096; 2018.

Conen D, Wietlisbach V, Bovet P, et al. Prevalence of hyperuricemia and relation of serum uric acid with cardiovascular risk factors in a developing country. *BMC Public Health*. 2004;4:9.

Corona G, Maseroli E, Rastrelli G, et al. Cardiovascular risk associated with testosterone-boosting medications: a systematic review and meta-analysis. *Expert Opin Drug Saf*. 2014;13:1327–1351.

Courtenay WH. Constructions of masculinity and their influence on men's well-being: a theory of gender and health. *Soc Sci Med*. 2000;50:1385–1401.

Creighton G, Oliffe JL. Theorising masculinities and men's health: a brief history with a view to practice. *Health Sociol Rev*. 2010;19:409–418.

Curtis Breslin F, Polzer J, MacEachen E, et al. Workplace injury or “part of the job”?: towards a gendered understanding of injuries and complaints among young workers. *Soc Sci Med*. 2007;64:782–793.

d'Acremont M, Van der Linden M. Adolescent impulsivity: findings from a community sample. *J Youth Adolesc*.

2005;34:427–435.

D'Amico AV, Chen MH, Malkowicz SB, et al. Lower prostate specific antigen outcome than expected following radical prostatectomy in patients with high grade prostate and a prostatic specific antigen level of 4 ng/ml or less. *J Urol*. 2002;167:2025–2030 [discussion 2030–2031].

Dahn JR, Penedo FJ, Molton I, et al. Physical activity and sexual functioning after radiotherapy for prostate cancer: beneficial effects for patients undergoing external beam radiotherapy. *Urology*. 2005;65:953–958.

Dai B, Qu Y, Kong Y, et al. Low pretreatment serum total testosterone is associated with a high incidence of Gleason score 8-10 disease in prostatectomy specimens: data from ethnic Chinese patients with localized prostate cancer. *BJU Int*. 2012;110:E667–E672.

GBD 2015 DALYs and HALE Collaborators. Global, regional, and national disability-adjusted life-years (DALYs) for 315 diseases and injuries and healthy life expectancy (HALE), 1990-2015: a systematic analysis for the Global Burden of Disease Study 2015. *Lancet*. 2016;388:1603–1658.

De Nicola L, Zoccali C. Chronic kidney disease prevalence in the general population: heterogeneity and concerns. *Nephrol Dial Transplant*. 2016;31:331–335.

Deaux K. From individual-differences to social categories: analysis of a decades research on gender. *Am Psychol*. 1984;39:105–116.

DeLay KJ, Haney N, Hellstrom WJ. Modifying risk factors in the management of erectile dysfunction: a review. *World J Mens Health*. 2016;34:89–100.

Derman PB, Fabricant PD, David G. The role of overweight and obesity in relation to the more rapid growth of total knee arthroplasty volume compared with total hip arthroplasty volume. *J Bone Joint Surg Am*. 2014;96:922–928.

Desmond M. Becoming a firefighter. *Ethnography*. 2006;7:387–421.

Detrano R, Guerci AD, Carr JJ, et al. Coronary calcium as a predictor of coronary events in four racial or ethnic groups. *N Engl J Med*. 2008;358:1336–1345.

Devaraj S, Singh U, Jialal I. Human C-reactive protein and the metabolic syndrome. *Curr Opin Lipidol*. 2009;20:182–189.

Diaz-Arjonilla M, Schwarcz M, Swerdloff RS, et al. Obesity, low testosterone levels and erectile dysfunction. *Int J Impot Res*. 2009;21:89–98.

Dir AL, Coskunpinar A, Cyders MA. A meta-analytic review of the relationship between adolescent risky sexual behavior and impulsivity across gender, age, and race. *Clin Psychol Rev*. 2014;34:551–562.

Dolan A. ‘You can't ask for a Dubonnet and lemonade!’: working class masculinity and men's health practices. *Sociol Health Illn*. 2011;33:586–601.

Eagly AH. Gender and social-influence—a social psychological analysis. *Am Psychol*. 1983;38:971–981.

Elliott J, Kelly SE, Millar AC, et al. Testosterone therapy in hypogonadal men: a systematic review and network meta-analysis. *BMJ Open*. 2017;7:e015284.

Esposito K, Giugliano F, Di Palo C, et al. Effect of lifestyle changes on erectile dysfunction in obese men: a randomized controlled trial. *J Am Med Assoc*. 2004;291:2978–2984.

Esposito K, Chiodini P, Capuano A, et al. Metabolic syndrome and postmenopausal breast cancer: systematic review and meta-analysis. *Menopause*. 2013;20:1301–1309.

Esposito K, Chiodini P, Capuano A, et al. Colorectal cancer association with metabolic syndrome and its components: a systematic review with meta-analysis. *Endocrine*. 2013;44:634–647.

Esposito K, Chiodini P, Colao A, et al. Metabolic syndrome and risk of cancer: a systematic review and meta-analysis. *Diabetes Care*. 2012;35:2402–2411.

Eysenck SBG, Easting G, Pearson PR. Age norms for impulsiveness, venturesomeness and empathy in children. *Pers Indiv Differ*. 1984;5:315–321.

Fagerberg B, Behre CJ, Wikstrand J, et al. C-reactive protein and tumor necrosis factor-alpha in relation to insulin-mediated glucose uptake, smoking and atherosclerosis. *Scand J Clin Lab Invest*. 2008;68:534–541.

Faris JE, Smith MR. Metabolic sequelae associated with androgen deprivation therapy for prostate cancer. *Curr Opin Endocrinol Diabetes Obes*. 2010;17:240–246.

Feldman DI, Cainzos-Achirica M, Billups KL, et al. Subclinical vascular disease and subsequent erectile dysfunction: the Multiethnic Study of Atherosclerosis (MESA). *Clin Cardiol*. 2016;39:291–298.

Fernandez-Balsells MM, Murad MH, Lane M, et al. Clinical review 1: adverse effects of testosterone therapy in adult men: a systematic review and meta-analysis. *J Clin Endocrinol Metab*. 2010;95:2560–2575.

Ferrannini E, Natali A. Essential hypertension, metabolic disorders, and insulin resistance. *Am Heart J*. 1991;121:1274–1282.

Fibbi B, Penna G, Morelli A, et al. Chronic inflammation in the pathogenesis of benign prostatic hyperplasia. *Int J Androl*. 2010;33:475–488.

Finkle WD, Greenland S, Ridgeway GK, et al. Increased risk of non-fatal myocardial infarction following testosterone therapy prescription in men. *PLoS ONE*. 2014;9:e85805.

Finucane MM, Stevens GA, Cowan MJ, et al. National, regional, and global trends in body-mass index since 1980: systematic analysis of health examination surveys and epidemiological studies with 960 country-years and 9.1

million participants. *Lancet*. 2011;377:557–567.

Fleshner NE, Bhindi B. Metabolic syndrome and diabetes for the urologist. *Can Urol Assoc J*. 2014;8:S159–S161.

Fleshner NE, Lucia MS, Egerdie B, et al. Dutasteride in localised prostate cancer management: the REDEEM randomised, double-blind, placebo-controlled trial. *Lancet*. 2012;379:1103–1111.

Ford ES, Giles WH, Dietz WH. Prevalence of the metabolic syndrome among US adults: findings from the third National Health and Nutrition Examination Survey. *J Am Med Assoc*. 2002;287:356–359.

Fox CS, Evans JC, Larson MG, et al. Temporal trends in coronary heart disease mortality and sudden cardiac death from 1950 to 1999: the Framingham Heart Study. *Circulation*. 2004;110:522–527.

Fries JF. Aging, natural death, and the compression of morbidity. *N Engl J Med*. 1980;303:130–135.

Fung MM, Bettencourt R, Barrett-Connor E. Heart disease risk factors predict erectile dysfunction 25 years later: the Rancho Bernardo Study. *J Am Coll Cardiol*. 2004;43:1405–1411.

Gabrielsen JS, Najari BB, Alukal JP, et al. Trends in testosterone prescription and public health concerns. *Urol Clin North Am*. 2016;43:261–271.

Gacci M, Russo GI, De Nunzio C, et al. Meta-analysis of metabolic syndrome and prostate cancer. *Prostate Cancer Prostatic Dis*. 2017;20:146–155.

Gagliano-Juca T, Icli TB, Pencina KM, et al. Effects of testosterone replacement on electrocardiographic parameters in men: findings from two randomized trials. *J Clin Endocrinol Metab*. 2017;102:1478–1485.

Galdas PM, Cheater F, Marshall P. Men and health help-seeking behaviour: literature review. *J Adv Nurs*. 2005;49:616–623.

Gallagher EJ, Leroith D, Karnieli E. The metabolic syndrome—

from insulin resistance to obesity and diabetes. *Med Clin North Am*. 2011;95:855–873.

Galvao DA, Spry N, Denham J, et al. A multicentre year-long randomised controlled trial of exercise training targeting physical functioning in men with prostate cancer previously treated with androgen suppression and radiation from TROG 03.04 RADAR. *Eur Urol*. 2014;65:856–864.

Gan EH, Pattman S, H S Pearce S, et al. A UK epidemic of testosterone prescribing, 2001-2010. *Clin Endocrinol (Oxf)*. 2013;79:564–570.

Gandaglia G, Briganti A, Jackson G, et al. A systematic review of the association between erectile dysfunction and cardiovascular disease. *Eur Urol*. 2014;65:968–978.

Gandini S, Botteri E, Iodice S, et al. Tobacco smoking and cancer: a meta-analysis. *Int J Cancer*. 2008;122:155–164.

Gardner JR, Livingston PM, Fraser SF. Effects of exercise on treatment-related adverse effects for patients with prostate cancer receiving androgen-deprivation therapy: a systematic review. *J Clin Oncol*. 2014;32:335–346.

Gibson AO, Blaha MJ, Arnan MK, et al. Coronary artery calcium and incident cerebrovascular events in an asymptomatic cohort. The MESA Study. *JACC Cardiovasc Imaging*. 2014;7:1108–1115.

Gill H, Mugo M, Whaley-Connell A, et al. The key role of insulin resistance in the cardiometabolic syndrome. *Am J Med Sci*. 2005;330:290–294.

Ginsberg HN, Zhang YL, Hernandez-Ono A. Regulation of plasma triglycerides in insulin resistance and diabetes. *Arch Med Res*. 2005;36:232–240.

Go AS, Chertow GM, Fan D, et al. Chronic kidney disease and the risks of death, cardiovascular events, and hospitalization. *N Engl J Med*. 2004;351:1296–1305.

Golombok S, Fivush R. *Gender development*. Cambridge

University Press: Cambridge; 1994:275.

Gray CM, Hunt K, Mutrie N, et al. Football Fans in Training: the development and optimization of an intervention delivered through professional sports clubs to help men lose weight, become more active and adopt healthier eating habits. *BMC Public Health*. 2013;13:232.

Greenfield JR, Campbell LV. Relationship between inflammation, insulin resistance and type 2 diabetes: ‘cause or effect’? *Curr Diabetes Rev*. 2006;2:195–211.

Grunbaum JA, Kann L, Kinchen SA, et al. Youth risk behavior surveillance - United States, 2001. *J Sch Health*. 2002;72:313–328.

Grundy SM. Obesity, metabolic syndrome, and cardiovascular disease. *J Clin Endocrinol Metab*. 2004;89:2595–2600.

Guillaume-Gentil C, Assimacopoulos-Jeannet F, Jeanrenaud B. Involvement of non-esterified fatty acid oxidation in glucocorticoid-induced peripheral insulin resistance in vivo in rats. *Diabetologia*. 1993;36:899–906.

Guo C, Gu W, Liu M, et al. Efficacy and safety of testosterone replacement therapy in men with hypogonadism: a meta-analysis study of placebo-controlled trials. *Exp Ther Med*. 2016;11:853–863.

Gupta BP, Murad MH, Clifton MM, et al. The effect of lifestyle modification and cardiovascular risk factor reduction on erectile dysfunction: a systematic review and meta-analysis. *Arch Intern Med*. 2011;171:1797–1803.

Haddad RM, Kennedy CC, Caples SM, et al. Testosterone and cardiovascular risk in men: a systematic review and meta-analysis of randomized placebo-controlled trials. *Mayo Clin Proc*. 2007;82:29–39.

Hadji P, Jacob L, Kostev K. Gender- and age-related treatment compliance in patients with osteoporosis in Germany. *Patient Prefer Adherence*. 2016;10:2379–2385.

Haggstrom C, Stocks T, Rapp K, et al. Metabolic syndrome and risk of bladder cancer: prospective cohort study in the metabolic syndrome and cancer project (Me-Can). *Int J Cancer*. 2011;128:1890–1898.

Halberg N, Wernstedt-Asterholm I, Scherer PE. The adipocyte as an endocrine cell. *Endocrinol Metab Clin North Am*. 2008;37:753–768 [x–xi].

Hales CM, Carroll MD, Fryar CD, et al. Prevalence of obesity among adults and youth: United States, 2015-2016. *NCHS Data Brief*. 2017;1–8.

Hales CN, Barker DJ. Type 2 (non-insulin-dependent) diabetes mellitus: the thrifty phenotype hypothesis. *Diabetologia*. 1992;35:595–601.

Hales CN, Desai M, Ozanne SE. The thrifty phenotype hypothesis: how does it look after 5 years? *Diabet Med*. 1997;14:189–195.

Hamilton RJ. Making sense of the statin-prostate cancer relationship: is it time for a randomized controlled trial? *Eur Urol Focus*. 2017;3:221–222.

Hamilton RJ, Freedland SJ. Rationale for statins in the chemoprevention of prostate cancer. *Curr Urol Rep*. 2008;9:189–196.

Hamilton RJ, Freedland SJ. Review of recent evidence in support of a role for statins in the prevention of prostate cancer. *Curr Opin Urol*. 2008;18:333–339.

Hamilton RJ, Goldberg KC, Platz EA, et al. The influence of statin medications on prostate-specific antigen levels. *J Natl Cancer Inst*. 2008;100:1511–1518.

Handelsman DJ. Global trends in testosterone prescribing, 2000-2011: expanding the spectrum of prescription drug misuse. *Med J Aust*. 2013;199:548–551.

Hao W, Su Z, Liu B, et al. Drinking and drinking patterns and health status in the general population of five areas of China.

Alcohol Alcohol. 2004;39:43–52.

Hauner H, Entenmann G, Wabitsch M, et al. Promoting effect of glucocorticoids on the differentiation of human adipocyte precursor cells cultured in a chemically defined medium. *J Clin Invest*. 1989;84:1663–1670.

Haverkos HW, Soon G, Steckley SL, et al. Cigarette smoking and cervical cancer: part I: a meta-analysis. *Biomed Pharmacother*. 2003;57:67–77.

He Q, Wang Z, Liu G, et al. Metabolic syndrome, inflammation and lower urinary tract symptoms: possible translational links. *Prostate Cancer Prostatic Dis*. 2016;19:7–13.

Henry J. Kaiser Family Foundation (KFF). *Gender differences in health care, status, and use: spotlight on men's health*. [Vol. 2018] 2015.

Higgins JPT, Green S, Cochrane Collaboration. *Cochrane handbook for systematic reviews of interventions*. Wiley-Blackwell: Chichester, England; Hoboken, NJ; 2008:xxi [649 p].

Hill MV, McMahon ML, Stucke RS, et al. Wide variation and excessive dosage of opioid prescriptions for common general surgical procedures. *Ann Surg*. 2017;265:709–714.

Hippisley-Cox J, Vinogradova Y. *Trends in consultation rates in general practice 1995/1996 to 2008/2009: analysis of the QResearch database*. [NHS Information Centre] 2009.

Hippisley-Cox J, Coupland C, Brindle P. Development and validation of QRISK3 risk prediction algorithms to estimate future risk of cardiovascular disease: prospective cohort study. *BMJ*. 2017;357:j2099.

Ho CC, Tong SF, Low WY, et al. A randomized, double-blind, placebo-controlled trial on the effect of long-acting testosterone treatment as assessed by the Aging Male Symptoms scale. *BJU Int*. 2012;110:260–265.

Ho T, Gerber L, Aronson WJ, et al. Obesity, prostate-specific antigen nadir, and biochemical recurrence after radical prostatectomy: biology or technique? Results from the SEARCH database. *Eur Urol*. 2012;62:910–916.

Hochreiter WW, Nadler RB, Koch AE, et al. Evaluation of the cytokines interleukin 8 and epithelial neutrophil activating peptide 78 as indicators of inflammation in prostatic secretions. *Urology*. 2000;56:1025–1029.

Holick CN, Giovannucci EL, Stampfer MJ, et al. Prospective study of body mass index, height, physical activity and incidence of bladder cancer in US men and women. *Int J Cancer*. 2007;120:140–146.

Hoyos CM, Yee BJ, Phillips CL, et al. Body compositional and cardiometabolic effects of testosterone therapy in obese men with severe obstructive sleep apnoea: a randomised placebo-controlled trial. *Eur J Endocrinol*. 2012;167:531–541.

Hunt K, Wyke S, Gray CM, et al. A gender-sensitised weight loss and healthy living programme for overweight and obese men delivered by Scottish Premier League football clubs (FFIT): a pragmatic randomised controlled trial. *Lancet*. 2014;383:1211–1221.

Ibanez M, Narocki C. Occupational risk and masculinity: the case of the construction industry in Spain. *J Workplace Rights*. 2011;16:195–217.

Inman BA, Sauver JL, Jacobson DJ, et al. A population-based, longitudinal study of erectile dysfunction and future coronary artery disease. *Mayo Clin Proc*. 2009;84:108–113.

International Collaboration of Epidemiological Studies of Cervical Cancer, Appleby P, Beral V, et al. Carcinoma of the cervix and tobacco smoking: collaborative reanalysis of individual data on 13,541 women with carcinoma of the cervix and 23,017 women without carcinoma of the cervix from 23 epidemiological studies. *Int J Cancer*. 2006;118:1481–1495.

Iodice S, Gandini S, Maisonneuve P, et al. Tobacco and the risk of pancreatic cancer: a review and meta-analysis. *Langenbecks Arch Surg*. 2008;393:535–545.

Jackson G, Boon N, Eardley I, et al. Erectile dysfunction and coronary artery disease prediction: evidence-based guidance and consensus. *Int J Clin Pract*. 2010;64:848–857.

Jacobs M, van Greevenbroek MM, van der Kallen CJ, et al. Low-grade inflammation can partly explain the association between the metabolic syndrome and either coronary artery disease or severity of peripheral arterial disease: the CODAM study. *Eur J Clin Invest*. 2009;39:437–444.

Jamal A, Phillips E, Gentzke AS, et al. Current cigarette smoking among adults - United States, 2016. *MMWR Morb Mortal Wkly Rep*. 2018;67:53–59.

Jamison DT, Summers LH, Alleyne G, et al. Global health 2035: a world converging within a generation. *Lancet*. 2013;382:1898–1955.

Jinjuvadia R, Lohia P, Jinjuvadia C, et al. The association between metabolic syndrome and colorectal neoplasm: systemic review and meta-analysis. *J Clin Gastroenterol*. 2013;47:33–44.

Jonassen JA, Kohjimoto Y, Scheid CR, et al. Oxalate toxicity in renal cells. *Urol Res*. 2005;33:329–339.

Jones LW, Hornsby WE, Freedland SJ, et al. Effects of nonlinear aerobic training on erectile dysfunction and cardiovascular function following radical prostatectomy for clinically localized prostate cancer. *Eur Urol*. 2014;65:852–855.

Jones TH, Arver S, Behre HM, et al. Testosterone replacement in hypogonadal men with type 2 diabetes and/or metabolic syndrome (the TIMES2 study). *Diabetes Care*. 2011;34:828–837.

Joshua AM V, Zannella E, Downes MR, et al. A pilot ‘window of opportunity’ neoadjuvant study of metformin in localised prostate cancer. *Prostate Cancer Prostatic Dis*. 2014;17:252–258.

Kalinchenko SY, Tishova YA, Mskhalaya GJ, et al. Effects of testosterone supplementation on markers of the metabolic syndrome and inflammation in hypogonadal men with the metabolic syndrome: the double-blinded placebo-controlled Moscow study. *Clin Endocrinol (Oxf)*. 2010;73:602–612.

Kalka D, Domagala Z, Dworak J, et al. Association between physical exercise and quality of erection in men with ischaemic heart disease and erectile dysfunction subjected to physical training. *Kardiol Pol*. 2013;71:573–580.

Kalyani RR, Dobs AS. Androgen deficiency, diabetes, and the metabolic syndrome in men. *Curr Opin Endocrinol Diabetes Obes*. 2007;14:226–234.

Kaplan NM. The deadly quartet. Upper-body obesity, glucose intolerance, hypertriglyceridemia, and hypertension. *Arch Intern Med*. 1989;149:1514–1520.

Kastarinen M, Juutilainen A, Kastarinen H, et al. Risk factors for end-stage renal disease in a community-based population: 26-year follow-up of 25,821 men and women in eastern Finland. *J Intern Med*. 2010;267:612–620.

Katz PA, Ksansnak KR. Developmental aspects of gender-role flexibility and traditionality in middle childhood and adolescence. *Dev Psychol*. 1994;30:272–282.

Katznelson L, Finkelstein JS, Schoenfeld DA, et al. Increase in bone density and lean body mass during testosterone administration in men with acquired hypogonadism. *J Clin Endocrinol Metab*. 1996;81:4358–4365.

Kaufman JM, Vermeulen A. The decline of androgen levels in elderly men and its clinical and therapeutic implications. *Endocr Rev*. 2005;26:833–876.

Keating NL, O'Malley AJ, Smith MR. Diabetes and cardiovascular disease during androgen deprivation therapy for prostate cancer. *J Clin Oncol*. 2006;24:4448–4456.

Kimmel MS. *Manhood in America: a cultural history*. Free Press: New York; 1996 [xiii, 544 p., 516 p. of plates pp].

Klenk J, Keil U, Jaensch A, et al. Changes in life expectancy 1950-2010: contributions from age- and disease-specific mortality in selected countries. *Popul Health Metr*. 2016;14:20.

Kluth LA, Xylinas E, Crivelli JJ, et al. Obesity is associated with worse outcomes in patients with T1 high grade urothelial carcinoma of the bladder. *J Urol*. 2013;190:480–486.

Koebnick C, Michaud D, Moore SC, et al. Body mass index, physical activity, and bladder cancer in a large prospective study. *Cancer Epidemiol Biomarkers Prev*. 2008;17:1214–1221.

Kostis JB, Dobrzynski JM. The effect of statins on erectile dysfunction: a meta-analysis of randomized trials. *J Sex Med*. 2014;11:1626–1635.

Kotchick BA, Shaffer A, Forehand R. Adolescent sexual risk behavior: a multi-system perspective. *Clin Psychol Rev*. 2001;21:493–519.

Kraemer-Aguiar LG, Laflor CM, Bouskela E. Skin microcirculatory dysfunction is already present in normoglycemic subjects with metabolic syndrome. *Metabolism*. 2008;57:1740–1746.

Kumar K, Gulotta LV, Dines JS, et al. Unused opioid pills after outpatient shoulder surgeries given current perioperative prescribing habits. *Am J Sports Med*. 2017;45:636–641.

Kupelian V, Shabsigh R, Araujo AB, et al. Erectile dysfunction as a predictor of the metabolic syndrome in aging men: results from the Massachusetts Male Aging Study. *J Urol*. 2006;176:222–226.

Kylin E. Studien Hypertonie-Hyperglykamie-Hyperurikamiesyndrome. *Zentralblatt fur innere Medizin*. 1923.

Laakso M. Gene variants, insulin resistance, and dyslipidaemia. *Curr Opin Lipidol*. 2004;15:115–120.

Laaksonen DE, Niskanen L, Punnonen K, et al. The metabolic syndrome and smoking in relation to hypogonadism in middle-aged men: a prospective cohort study. *J Clin Endocrinol Metab*. 2005;90:712–719.

Lan CW, Scott-Sheldon LA, Carey KB, et al. Prevalence of Alcohol Use, Sexual Risk Behavior, and HIV Among Russians in high-risk settings: a systematic review and meta-analysis. *Int J Behav Med*. 2017;24:180–190.

Larsen SH, Wagner G, Heitmann BL. Sexual function and obesity. *Int J Obes (Lond)*. 2007;31:1189–1198.

Larsson SC, Wolk A. Diabetes mellitus and incidence of kidney cancer: a meta-analysis of cohort studies. *Diabetologia*. 2011;54:1013–1018.

Larsson SC, Andersson SO, Johansson JE, et al. Diabetes mellitus, body size and bladder cancer risk in a prospective study of Swedish men. *Eur J Cancer*. 2008;44:2655–2660.

Lau DC, Dhillon B, Yan H, et al. Adipokines: molecular links between obesity and atheroslcerosis. *Am J Physiol Heart Circ Physiol*. 2005;288:H2031–H2041.

Lawson J. Explaining workplace injuries among BC loggers: cultures of risk and of desperation. *BC Stud: B C Quart*. 2010;164:51–74.

Leapman MS, Kaplan SA. Separating opioid fact and fiction in urology. *J Urol*. 2017;198:990–992.

Lee JS, Hu HM, Edelman AL, et al. New persistent opioid use among patients with cancer after curative-intent surgery. *J Clin Oncol*. 2017;35:4042–4049 [2017].

Lee PN, Thornton AJ, Hamling JS. Epidemiological evidence on environmental tobacco smoke and cancers other than lung or breast. *Regul Toxicol Pharmacol*. 2016;80:134–163.

Levant RF, Majors RG, Kelley ML. Masculinity ideology among young African American and European American women and men in different regions of the United States. *Cult Divers Ment Health*. 1998;4:227–236.

Li WW, Froelicher ES. Gender differences in Chinese immigrants: predictors for antihypertensive medication adherence. *J Transcult Nurs*. 2007;18:331–338.

Lim SS, Vos T, Flaxman AD, et al. A comparative risk assessment of burden of disease and injury attributable to 67 risk factors and risk factor clusters in 21 regions, 1990-2010: a systematic analysis for the Global Burden of Disease Study 2010. *Lancet*. 2012;380:2224–2260.

Lim WY, Fong CW, Chan JM, et al. Trends in alcohol consumption in Singapore 1992 2004. *Alcohol Alcohol*. 2007;42:354–361.

Liu L, Kron KJ, Pethe VV, et al. Association of tissue promoter methylation levels of APC, TGFbeta2, HOXD3 and RASSF1A with prostate cancer progression. *Int J Cancer*. 2011;129:2454–2462.

Liu L, Li Q, Han P, et al. Evaluation of interleukin-8 in expressed prostatic secretion as a reliable biomarker of inflammation in benign prostatic hyperplasia. *Urology*. 2009;74:340–344.

Lotti F, Maggi M. Interleukin 8 and the male genital tract. *J Reprod Immunol*. 2013;100:54–65.

Lotti F, Corona G, Vignozzi L, et al. Metabolic syndrome and prostate abnormalities in male subjects of infertile couples. *Asian J Androl*. 2014;16:295–304.

Lotti F, Corona G, Vitale P, et al. Current smoking is associated with lower seminal vesicles and ejaculate volume, despite higher testosterone levels, in male subjects of infertile couples. *Hum Reprod*. 2015;30:590–602.

MacDonald AA, Herbison GP, Showell M, et al. The impact of body mass index on semen parameters and reproductive hormones in human males: a systematic review with meta-analysis. *Hum Reprod Update*. 2010;16:293–311.

Magbanua MJ, Richman EL, Sosa EV, et al. Physical activity and prostate gene expression in men with low-risk prostate cancer. *Cancer Causes Control*. 2014;25:515–523.

Malavige LS, Levy JC. Erectile dysfunction in diabetes mellitus. *J Sex Med*. 2009;6:1232–1247.

Manteuffel M, Williams S, Chen W, et al. Influence of patient sex and gender on medication use, adherence, and prescribing alignment with guidelines. *J Womens Health (Larchmt)*. 2014;23:112–119.

Margel D. Metformin to prevent prostate cancer: a call to unite. *Eur Urol*. 2014;66:1021–1022.

Margel D, Urbach D, Lipscombe LL, et al. Association between metformin use and risk of prostate cancer and its grade. *J Natl Cancer Inst*. 2013;105:1123–1131.

Margel D, Urbach DR, Lipscombe LL, et al. Metformin use and all-cause and prostate cancer-specific mortality among men with diabetes. *J Clin Oncol*. 2013;31:3069–3075.

Martin CL. Stereotypes about children with traditional and nontraditional gender roles. *Sex Roles*. 1995;33:727–751.

Martin LJ, North KE, Dyer T, et al. Phenotypic, genetic, and genome-wide structure in the metabolic syndrome. *BMC Genet*. 2003;4(Suppl 1):S95.

Mathers CD, Loncar D. Projections of global mortality and burden of disease from 2002 to 2030. *PLoS Med*. 2006;3:e442.

McElligott KA. Mortality from sexually transmitted diseases in reproductive-aged women: United States, 1999-2010. *Am J Public Health*. 2014;104:e101–e105.

Messing K, Punnett L, Bond M, et al. Be the fairest of them all: challenges and recommendations for the treatment of gender in occupational health research. *Am J Ind Med*. 2003;43:618–629.

Miner MM, Heidelbaugh J, Paulos M, et al. The intersection of medicine and urology: an emerging paradigm of sexual function, cardiometabolic risk, bone health, and men's health centers. *Med Clin North Am*. 2018;102:399–415.

Monane M, Boh RL, Gurwitz JH, et al. Compliance with antihypertensive therapy among elderly Medicaid enrollees: the roles of age, gender, and race. *Am J Public Health*. 1996;86:1805–1808.

Montorsi P, Ravagnani PM, Galli S, et al. Association between erectile dysfunction and coronary artery disease. Role of coronary clinical presentation and extent of coronary vessels involvement: the COBRA trial. *Eur Heart J*. 2006;27:2632–2639.

Moradi F. Changes of serum adiponectin and testosterone concentrations following twelve weeks resistance training in obese young men. *Asian J Sports Med*. 2015;6:e23808.

Morote J, Gomez-Caamano A, Alvarez-Ossorio JL, A.I. Group, et al. The metabolic syndrome and its components in patients with prostate cancer on androgen deprivation therapy. *J Urol*. 2015;193:1963–1969.

Morse SA, Zhang R, Thakur V, et al. Hypertension and the metabolic syndrome. *Am J Med Sci*. 2005;330:303–310.

Wang H, Naghavi M, Allen C, et al. Global, regional, and national life expectancy, all-cause mortality, and cause-specific mortality for 249 causes of death, 1980–2015: a systematic analysis for the Global Burden of Disease Study 2015. *Lancet*. 2016;388:1459–1544.

Movember Foundation. *Movember's got a winning team with Mo athletes*. [2011 (website)] https://us.movember.com/news/2660/movember-s-got-a-winning-team-with-mo-athletes; 2011.

Movember Foundation. [website] https://us.movember.com; 2018.

Murphy SL, Xu J, Kochanek KD, et al. Deaths: final data for 2015. *Natl Vital Stat Rep*. 2017;66:1–75.

Nakagawa T, Hu H, Zharikov S, et al. A causal role for uric acid in fructose-induced metabolic syndrome. *Am J Physiol Renal Physiol*. 2006;290:F625–F631.

National Institute of Mental Health (NIMH). *Mental Illness Statistics*. [Vol. 2018. The National Institute of Mental Health Information Resource Center] 2018.

Neel JV. Diabetes mellitus: a “thrifty” genotype rendered detrimental by “progress”? *Am J Hum Genet*. 1962;14:353–362.

Nehra A, Jackson G, Miner M, et al. The Princeton III Consensus recommendations for the management of erectile dysfunction and cardiovascular disease. *Mayo Clin Proc*. 2012;87:766–778.

Newman PA, Zimmerman MA. Gender differences in HIV-related sexual risk behavior among urban African American youth: a multivariate approach. *AIDS Educ Prev*. 2000;12:308–325.

Ng M, Freeman MK, Fleming TD, et al. Smoking prevalence and cigarette consumption in 187 countries, 1980-2012. *J Am Med Assoc*. 2014;311:183–192.

Nguyen CP, Hirsch MS, Moeny D, et al. Testosterone and “age-related hypogonadism”—FDA concerns. *N Engl J Med*. 2015;373:689–691.

Ni H, Coady S, Rosamond W, et al. Trends from 1987 to 2004 in sudden death due to coronary heart disease: the Atherosclerosis Risk in Communities (ARIC) study. *Am Heart J*. 2009;157:46–52.

Oeppen J, Vaupel JW. Demography. Broken limits to life expectancy. *Science*. 2002;296:1029–1031.

Ogden CL, Carroll MD, Kit BK, et al. Prevalence of childhood and adult obesity in the United States, 2011-2012. *J Am Med Assoc*. 2014;311:806–814.

Okamoto M, Kohjimoto Y, Iba A, et al. Calcium oxalate crystal deposition in metabolic syndrome model rat kidneys. *Int J Urol*. 2010;17:996–1003.

Ordovas JM. Genetic links between diabetes mellitus and coronary atherosclerosis. *Curr Atheroscler Rep*. 2007;9:204–210.

Organization of Economic Co-operation and Development (OECD). *OECD obesity update 2017*. 2017.

Page ST, Amory JK, Bowman FD, et al. Exogenous testosterone (T) alone or with finasteride increases physical performance, grip strength, and lean body mass in older men with low serum T. *J Clin Endocrinol Metab*. 2005;90:1502–1510.

Parry CD, Pluddemann A, Steyn K, et al. Alcohol use in South Africa: findings from the first Demographic and Health Survey (1998). *J Stud Alcohol*. 2005;66:91–97.

Penna G, Fibbi B, Amuchastegui S, et al. Human benign prostatic hyperplasia stromal cells as inducers and targets of chronic immuno-mediated inflammation. *J Immunol*. 2009;182:4056–4064.

Penna G, Mondaini N, Amuchastegui S, et al. Seminal plasma cytokines and chemokines in prostate inflammation: interleukin 8 as a predictive biomarker in chronic prostatitis/chronic pelvic pain syndrome and benign prostatic hyperplasia. *Eur Urol*. 2007;51:524–533 [discussion 533].

Perseghin G, Ghosh S, Gerow K, et al. Metabolic defects in lean nondiabetic offspring of NIDDM parents: a cross-sectional study. *Diabetes*. 1997;46:1001–1009.

Petersen KF, Shulman GI. Etiology of insulin resistance. *Am J*

Med. 2006;119:S10–S16.

Petrella RJ, Gill DP, Zou G, et al. Hockey fans in training: a pilot pragmatic randomized controlled trial. *Med Sci Sports Exerc*. 2017;49:2506–2516.

Phakathi S. “Getting on” and “getting by” underground: gold miners’ informal working practice of making a plan (PLANISA). *J Org Ethnogr*. 2013;2:126–149.

Podrid PJ, Myerburg RJ. Epidemiology and stratification of risk for sudden cardiac death. *Clin Cardiol*. 2005;28:I3–I11.

Popova S, Rehm J, Patra J, et al. Comparing alcohol consumption in central and eastern Europe to other European countries. *Alcohol Alcohol*. 2007;42:465–473.

Poulsen P, Levin K, Petersen I, et al. Heritability of insulin secretion, peripheral and hepatic insulin action, and intracellular glucose partitioning in young and old Danish twins. *Diabetes*. 2005;54:275–283.

Powell CR, Stoller ML, Schwartz BF, et al. Impact of body weight on urinary electrolytes in urinary stone formers. *Urology*. 2000;55:825–830.

Powell K. Obesity: the two faces of fat. *Nature*. 2007;447:525–527.

Power N, Baqee S. Constructing a “culture of safety”: an examination of the assumptions embedded in occupational safety and health curricula delivered to high school students and fish harvesters in Newfoundland and Labrador, Canada. *Policy Pract Health Saf*. 2010;8:5–23.

Power NG. Occupational risks, safety and masculinity: Newfoundland fish harvesters’ experiences and understandings of fishery risks. *Health Risk Soc*. 2008;10:565–583.

Preston SH, Wang H. Sex mortality differences in the United States: the role of cohort smoking patterns. *Demography*. 2006;43:631–646.

Qin Q, Xu X, Wang X, et al. Obesity and risk of bladder cancer: a meta-analysis of cohort studies. *Asian Pac J Cancer Prev*. 2013;14:3117–3121.

Rao PK, Boulet SL, Mehta A, et al. Trends in testosterone replacement therapy use from 2003 to 2013 among reproductive-age men in the United States. *J Urol*. 2017;197:1121–1126.

Reaven GM. Banting lecture 1988. Role of insulin resistance in human disease. *Diabetes*. 1988;37(12):1595–1607.

Reaven GM. Role of insulin resistance in human disease (syndrome X): an expanded definition. *Annu Rev Med*. 1993;44:121–131.

Reddy RG, Aung T, Karavitaki N, et al. Opioid induced hypogonadism. *Br Med J (Clin Res Ed)*. 2010;341:c4462.

Rice TW, Coates DL. Gender-role attitudes in the southern United-States. *Gender Soc*. 1995;9:744–756.

Richard PO, Ahmad AE, Bashir S, et al. Impact of oral hypoglycemic agents on mortality among diabetic patients with non-muscle-invasive bladder cancer: a population-based analysis. *Can Urol Assoc J*. 2018.

Ritchie SA, Connell JM. The link between abdominal obesity, metabolic syndrome and cardiovascular disease. *Nutr Metab Cardiovasc Dis*. 2007;17:319–326.

Romer D, Hennessy M. A biosocial-affect model of adolescent sensation seeking: the role of affect evaluation and peer-group influence in adolescent drug use. *Prev Sci*. 2007;8:89–101.

Russo A, Autelitano M, Bisanti L. Metabolic syndrome and cancer risk. *Eur J Cancer*. 2008;44:293–297.

Safe Work Australia. *Work-related traumatic injury fatalities Australia 2016*. 2016.

Saleem U, Khaleghi M, Morgenthaler NG, et al. Plasma carboxy-terminal provasopressin (copeptin): a novel marker of insulin resistance and metabolic syndrome. *J Clin Endocrinol Metab*. 2009;94:2558–2564.

Salem MM. Pathophysiology of hypertension in renal failure. *Semin Nephrol*. 2002;22:17–26.

Santa Mina D, Connor MK, Alibhai SM, et al. Exercise effects on adipokines and the IGF axis in men with prostate cancer treated with androgen deprivation: a randomized study. *Can Urol Assoc J*. 2013;7:E692–E698.

Sayyid RK, Fleshner NE. Potential role for metformin in urologic oncology. *Investig Clin Urol*. 2016;57:157–164.

Schachter M. Uric acid and hypertension. *Curr Pharm Des*. 2005;11:4139–4143.

Severi G, Morris HA, MacInnis RJ, et al. Circulating steroid hormones and the risk of prostate cancer. *Cancer Epidemiol Biomarkers Prev*. 2006;15:86–91.

Shah AS, Blackwell RH, Kuo PC, et al. Rates and risk factors for opioid dependence and overdose after urological surgery. *J Urol*. 2017;198:1130–1136.

Sher DJ, Mantzoros C, Jacobus S, et al. Absence of relationship between steroid hormone levels and prostate cancer tumor grade. *Urology*. 2009;73:356–361 [discussion 361–362].

Shigehara K, Konaka H, Nohara T, et al. Effects of testosterone replacement therapy on metabolic syndrome among Japanese hypogonadal men: a subanalysis of a prospective randomised controlled trial (EARTH study). *Andrologia*. 2018;50.

Shin D, Pregenzer G Jr, Gardin JM. Erectile dysfunction: a disease marker for cardiovascular disease. *Cardiol Rev*. 2011;19:5–11.

Slone LB, Norris FH, Gutierrez Rodriguez F, et al. Alcohol use and misuse in urban Mexican men and women: an epidemiologic perspective. *Drug Alcohol Depend*. 2006;85:163–170.

Snyder PJ, Bhasin S, Cunningham GR, et al. Effects of testosterone treatment in older men. *N Engl J Med*. 2016;374:611–624.

Spear LP. The adolescent brain and age-related behavioral manifestations. *Neurosci Biobehav Rev*. 2000;24:417–463.

Srinivas-Shankar U, Roberts SA, Connolly MJ, et al. Effects of testosterone on muscle strength, physical function, body composition, and quality of life in intermediate-frail and frail elderly men: a randomized, double-blind, placebo-controlled study. *J Clin Endocrinol Metab*. 2010;95:639–650.

Stergiou-Kita M, Mansfield E, Bezo R, et al. Danger zone: men, masculinity and occupational health and safety in high risk occupations. *Saf Sci*. 2015;80:213–220.

Street S, Kimmel EB, Kromrey JD. Revisiting university-student gender-role perceptions. *Sex Roles*. 1995;33:183–201.

Substance Abuse and Mental Health Services Administration (SAMHSA). *Key substance use and mental health indicators in the United States: Results from the 2016 National Survey on Drug Use and Health*. [In NSDUH Series H-52. Center for Behavioral Health Statistics and Quality, Substance Abuse and Mental Health Services Administration, Rockville, MD] 2017.

Substance Abuse and Mental Health Services Administration. *Key substance use and mental health indicators in the United States: Results from the 2016 National Survey on Drug Use and Health (HHS Publication No. SMA 17-5044, NSDUH Series H-52)*. [Center for Behavioral Health Statistics and Quality, Substance Abuse and Mental Health Services Administration, Rockville, MD] 2017.

Swinburn BA, Sacks G, Hall KD, et al. The global obesity pandemic: shaped by global drivers and local environments. *Lancet*. 2011;378:804–814.

Syamlal G, King BA, Mazurek JM. Tobacco use among working adults—United States, 2014-2016. *MMWR Morb*

Mortal Wkly Rep. 2017;66:1130–1135.

Tokudome S, Hashimoto S, Igata A. Life expectancy and healthy life expectancy of Japan: the fastest graying society in the world. *BMC Res Notes*. 2016;9:482.

Tonelli M, Wiebe N, Knoll G, et al. Systematic review: kidney transplantation compared with dialysis in clinically relevant outcomes. *Am J Transplant*. 2011;11:2093–2109.

Tonelli M, Wiebe N, James MT, et al. A population-based cohort study defines prognoses in severe chronic kidney disease. *Kidney Int*. 2018;93(5):1217–1226.

Tong SF, Ng CJ, Lee BC, et al. Effect of long-acting testosterone undecanoate treatment on quality of life in men with testosterone deficiency syndrome: a double blind randomized controlled trial. *Asian J Androl*. 2012;14:604–611.

Trayhurn P, Wood IS. Adipokines: inflammation and the pleiotropic role of white adipose tissue. *Br J Nutr*. 2004;92:347–355.

Tseng CH. Type 2 diabetes mellitus and kidney cancer risk: a retrospective cohort analysis of the national health insurance. *PLoS ONE*. 2015;10:e0142480.

Tsimikas S, Willeit J, Knoflach M, et al. Lipoprotein-associated phospholipase A2 activity, ferritin levels, metabolic syndrome, and 10-year cardiovascular and non-cardiovascular mortality: results from the Bruneck study. *Eur Heart J*. 2009;30:107–115.

UCL Institute of Health Equity. World Health Organization (WHO), Regional Office for Europe: Copenhagen; 2013. *Review of social determinants and the health divide in the WHO European Region: final report*. vol 2018.

Ugai T, Matsuo K, Oze I, Research Group for the, and J. Evaluation of Cancer Prevention Strategies in, et al. Smoking and subsequent risk of acute myeloid leukaemia: a pooled analysis of 9 cohort studies in Japan. *Hematol Oncol*. 2018;36:262–268.

UK Office for National Statistics. *Health expectancies at birth and at age 65 in the United Kingdom: 2008-10*. [Office for National Statistics] 2012.

UK Office for National Statistics. *Leading Causes of Death, 2009*. [UK Office for National Statistics] 2019.

US Department of Labor. *Occupational Safety & Health Administration web site*. [Vol. 2018. United States Department of Labor] 2018.

US Bureau of Labor Statistics. *2016 Census of Fatal Occupational Injuries (CFOI) US Bureau of Labor Statistics*. 2016.

Uzun H, Yilmaz A, Kemik A, et al. Association of insulin resistance with overactive bladder in female patients. *Int Neurourol J*. 2012;16:181–186.

Vagenas P, Lama JR, Ludford KT, et al. A systematic review of alcohol use and sexual risk-taking in Latin America. *Rev Panam Salud Publica*. 2013;34:267–274.

Vague J. Sexual differentiation. A factor affecting the forms of obesity. *Presse Medicale*. 1947;30:S39–S40.

Van Gundy K, Schieman S, Kelley MS, et al. Gender role orientations and alcohol use among Moscow and Toronto adults. *Soc Sci Med*. 2005;61:2317–2330.

Van Oyen H, Nusselder W, Jagger C, et al. Gender differences in healthy life years within the EU: an exploration of the “health-survival” paradox. *Int J Public Health*. 2013;58:143–155.

Vigen R, O'Donnell CI, Baron AE, et al. Association of testosterone therapy with mortality, myocardial infarction, and stroke in men with low testosterone levels. *J Am Med Assoc*. 2013;310:1829–1836.

Vlachopoulos CV, Terentes-Printzios DG, Ioakeimidis NK, et al. Prediction of cardiovascular events and all-cause mortality with erectile dysfunction: a systematic review and meta-analysis of cohort studies. *Circ Cardiovasc Qual Outcomes*. 2013;6:99–109.

Wang C, Jackson G, Jones TH, et al. Low testosterone associated with obesity and the metabolic syndrome contributes to sexual dysfunction and cardiovascular disease risk in men with type 2 diabetes. *Diabetes Care*. 2011;34:1669–1675.

Wang CN, McLeod RS, Yao Z, et al. Effects of dexamethasone on the synthesis, degradation, and secretion of apolipoprotein B in cultured rat hepatocytes. *Arterioscler Thromb Vasc Biol*. 1995;15:1481–1491.

Ward-Peterson M, Fennie K, Mauck D, et al. Using multilevel models to evaluate the influence of contextual factors on HIV/AIDS, sexually transmitted infections, and risky sexual behavior in sub-Saharan Africa: a systematic review. *Ann Epidemiol*. 2018;28:119–134.

Williams JE, Best DL. *Measuring sex stereotypes: a thirty-nation study*. Sage Publications: Beverly Hills; 1982:368.

Wilsnack RW, Vogeltanz ND, Wilsnack SC, et al. Gender differences in alcohol consumption and adverse drinking consequences: cross-cultural patterns. *Addiction*. 2000;95:251–265.

Wilsnack RW, Wilsnack SC, Kristjanson AF, et al. Gender and alcohol consumption: patterns from the multinational GENACIS project. *Addiction*. 2009;104:1487–1500.

World Health Organization (WHO). *Definition, diagnosis, and classification of diabetes mellitus and its complications*. [Report of a WHO Consultation Part 1: Diagnosis and classification of diabetes mellitus, Geneva; website] http://apps.who.int/iris/bitstream/handle/10665/66040/WHO_ sequence=1; 1999.

World Health Organization (WHO). *Prevalence of tobacco smoking*. [Global Health Observatory (GHO) data; website] https://www.who.int/gho/tobacco/use/en/; 2018.

World Health Organization (WHO). *Global health estimates 2015: deaths by cause, age, sex, by country and by region, 2000-2015*. [Geneva (website)] http://www.who.int/healthinfo/global_burden_disease/en/; 2016.

World Health Organization (WHO). *World Health Statistics 2016: monitoring health for the SDGs (Sustainable Development Goals)*. [website] https://www.who.int/gho/publications/world_health_statistics 2016.

Wright JL, Plymate SR, Porter MP, et al. Hyperglycemia and prostate cancer recurrence in men treated for localized prostate cancer. *Prostate Cancer Prostatic Dis*. 2013;16:204–208.

Wu FC, Tajar A, Beynon JM, et al. Identification of late-onset hypogonadism in middle-aged and elderly men. *N Engl J Med*. 2010;363:123–135.

Wyllie C, Platt S, Brownlie J, et al. *Men, suicide and society: why disadvantaged men in mid-life die by suicide*. [Samaritans] 2012.

Wyszynski A, Tanyos SA, Rees JR, et al. Body mass and smoking are modifiable risk factors for recurrent bladder cancer. *Cancer*. 2014;120:408–414.

Xu L, Freeman G, Cowling BJ, et al. Testosterone therapy and cardiovascular events among men: a systematic review and meta-analysis of placebo-controlled randomized trials. *BMC Med*. 2013;11:108.

Young T, Palta M, Dempsey J, et al. The occurrence of sleep-disordered breathing among middle-aged adults. *N Engl J Med*. 1993;328:1230–1235.

Zarrouf FA, Artz S, Griffith J, et al. Testosterone and depression: systematic review and meta-analysis. *J Psychiatr Pract*. 2009;15:289–305.

Male Infertility

Craig Stuart Niederberger MD, FACS, Samuel John Ohlander MD, Rodrigo Lessi Pagani MD

Epidemiology

The disease of infertility affects approximately 15% of couples, rendering nearly one of six childless (World Health Organization [WHO], 1991). Multiple sources of bias historically have distorted assessment of the contribution of each gender to infertility, but we can reasonably expect men and women to contribute an equal number of faulty gametes (Tielemans et al., 2002). Therefore accurate evaluation and treatment of males is of great importance in addressing this significant health care issue.

Unfortunately, much of infertility care for men is delivered outside of well-established reimbursement systems, compromising accurate calculation of epidemiologic metrics (Meacham et al., 2007). Fortunately, the American Society for Reproductive Medicine's professional group, the Society for Assisted Reproductive Technologies (SART), compels in vitro fertilization (IVF) clinics to report outcomes in a systematic fashion, allowing limited evaluation of the impact of male infertility. However, this assessment is through the lens of women seeking the most evolved technology for female reproductive care and necessarily skews the appraisal of the incidence and prevalence of the male contribution to the disease. Recent data compiled from the National Survey of Family Growth (NSFG) found that 18% to 27% of men within infertile couples were never evaluated, further supporting the likely underreporting of male factor infertility (Eisenberg et al., 2013). Based upon the NSFG data, approximately 7.5% of sexually active men seek care at some point in their lifetime for difficulty conceiving, of which 18% of men reported a clinician-diagnosed male reproductive problem (Anderson et al., 2009).

The Urologic Diseases in America (UDA) Project included collection of male reproductive epidemiologic data from a variety of sources, which, albeit sparse, allowed for some limited analysis of the parameters of the disease of male infertility (Meacham et al., 2007). Considering ambulatory surgery for conditions associated with male infertility, it is unsurprising that men aged 25 to 34 years had higher usage with an average rate of 126 per 100,000 compared with men aged 35 to 44 with 83 per 100,000 and those aged 45 and older at 20 per 100,000 (Meacham et al., 2007). Thus younger men represent more than half of male infertility cases, and nearly 1 in 11 cases occurs in men in the 5th decade and older (Meacham et al., 2007). Considering geographic distribution in the United States, men living in the west had lower use of ambulatory surgery compared with those in the northeast and midwest (29 per 100,000, 104 per 100,000, and 72 per 100,000, respectively) (Meacham et al., 2007).

From an economic perspective, the UDA Project estimated total expenditures for treating primary male infertility at $17 million dollars in 2000, clearly an underestimate because of the delivered care absent from traditional databases (Meacham et al., 2007). Because a significant amount of male reproductive medical care delivery involves assisted technologies for the female partner, accounting for this care, the assessed total cost is a sizable $18 billion (Meacham et al., 2007). A cost questionnaire completed by men pursuing fertility care demonstrated that patients spent 16% to 20% of their annual income on infertility-related expenses (Elliott et al., 2016).

Complicating epidemiologic assessment is the fact that the primary assay for male infertility, the semen analysis, is a poor predictor with a low receiver operating characteristic (ROC) curve area for all available parameters (Guzick et al., 2001). Consequently, men with some presence of sperm on semen analysis may be inaccurately judged to be fertile and omitted from accurate accrual in a tabulation of insufficient reproductive potential.

History

The production and delivery of the male gamete requires orchestration among endocrine, immune, and neural systems, passage through intricately constructed anatomy, complex orchestrated sequences of gene expression and chromosomal structural events, and the proper embryologic and postnatal development of all systems. It is consequently unsurprising that myriad disparate conditions contribute to male reproductive dysfunction. Table 66.1 enumerates percentages of final diagnoses made in one infertility clinic (Sigman et al., 2009). As will become clear in this chapter, the percentages in Table 66.1 for each condition are highly variable depending on how the individual conditions are assessed in published studies, and the data contained within the table are an indictment of how poorly male reproductive information is systematically collected. However, the table does demonstrate the wide variety of diagnoses associated with male infertility. To address all potential possibilities, the practitioner must approach inquiring about past history in a methodical fashion. For the sake of efficiency, the patient may complete a form at home or in the waiting area before the physician encounter.

TABLE 66.1

Distribution of Final Diagnoses From a Male Infertility Clinic

CATEGORY	NUMBER	%
Immunologic	121	2.6%
Idiopathic	1535	32.6%
Varicocele	1253	26.6%
Obstruction	720	15.3%
Normal female factor	503	10.7%
Cryptorchidism	129	2.7%
Ejaculatory failure	95	2.0%
Endocrinologic	70	1.5%
Drug or radiation	64	1.4%
Genetic	56	1.2%
Testicular failure	52	1.1%
Sexual dysfunction	32	0.7%
Pyospermia	25	0.5%
Cancer	20	0.4%

Systemic disease	15	0.3%
Infection	10	0.2%
Torsion	5	0.1%
Ultrastructural	5	0.1%
Total	4710	100.0%

From Sigman M, Lipshultz LI, Howards SS: Office evaluation of the subfertile male. In Lipshultz LI, Howards SS, Niederberger CS, editors: *Infertility in the male*, ed 4, New York, 2009, Cambridge University Press, p 153–176.

Reproductive health is an unusual aspect of medicine: two patients are required for a positive outcome. Several consequences arise from this unique circumstance, the first being that a probabilistic approach to diagnosing infertility is necessary. In the best circumstances, with intercourse timed to menstruation and a rigorous calculation of optimal timing, including assessment of quality of cervical mucus and measurement of basal body temperature, cumulative pregnancy rates for all tracked subjects in one well-conducted study were 38% at one cycle, 68% at three cycles, 81% at six cycles, and 92% at 12 cycles (Gnoth et al., 2003). For those who ultimately became pregnant, the cumulative pregnancy rates were 42% at one cycle, 75% at three cycles, 88% at six cycles, and 98% at 12 cycles (Gnoth et al., 2003). Therefore a couple seeking treatment for infertility a month or two after discontinuing contraceptive measures should be counseled to continue to try for a few more months unless other significant conditions exist. **A minority of couples who have not conceived after 6 cycles may still do so. It is reasonable to initiate an evaluation after 6 months with the understanding that some couples will still conceive shortly afterward.** It is useful to communicate to patients the probabilistic nature of reproduction by describing each month of trying as rolling a die or flipping a coin.

An important question to ask is how often the couple is having intercourse. In general, semen parameters peak after 1 or 2 days of abstinence and then decline (Levitas et al., 2005). Often in an attempt to accumulate sperm, men wait long periods before attempting to impregnate their partners. Data suggest that not only is this practice unhelpful, it actually results in poorer sperm quality (Levitas et al., 2005). **For an optimal characterization of semen, a man should be instructed to wait 1 or 2 days after an ejaculation to submit a specimen for semen analysis** (Levitas et al., 2005)**. However, for increasing the probability of conception and pregnancy, intercourse every day around the time of ovulation is likely the best strategy** (Scarpa et al., 2007).

Another consequence of the fact that two patients are required for a positive outcome in this unique area of medicine is that consideration of the female partner's age is a critical component in judging reproductive potential and planning therapeutic strategies. Whereas the effects of male age on reproductive potential remain to be fully elucidated, advancing male age appears to affect bulk seminal parameters and sperm DNA packaging to only a limited degree, allowing a male to father children well into his later years (Cocuzza et al., 2008a; Colin et al., 2010; Hellstrom et al., 2006; Henkel et al., 2005; Moskovtsev et al., 2006; Schmid et al., 2007; Silva et al., 2012; Sloter et al., 2007; Yang et al., 2007). For the woman, age is a critical predictor of reproductive potential, especially when artificial reproductive technologies are used (Balasch and Gratacós, 2012; te Velde and Pearson, 2002). **On average, female fecundity declines precipitously after age 35** (Balasch and Gratacós, 2012). In some geographic regions, female fertility appears to decline more rapidly than others (Zargar et al., 1997). Therefore determining the female partner's age and assessing it in the context of her locale are essential aspects of the reproductive history.

An important general question to ask is whether the man and his partner have previously conceived children, or if each has with other partners, and the age or ages of the offspring. Proven fertility at some point in time demonstrates a functioning reproductive system after puberty, which eliminates a number of concerns regarding congenital issues.

The typical enumeration of systemic diseases and past surgeries in taking the reproductive history reveals a number of conditions associated with reproductive dysfunction. Diabetes mellitus and multiple sclerosis interfere with normal coordinated ejaculatory function, as does spinal cord injury (Kafetsoulis et al., 2006; Tepavcevic et al., 2008; Vinik et al., 2003). **Even before spermatotoxic chemotherapy, cancer appears to negatively affect spermatogenesis, especially if the cancer is of testicular origin** (de Bruin et al., 2009). Azoospermia may reveal cancer, and the physician considering a man with no sperm on semen analysis should regard testis cancer as a possible cause (Mancini et al., 2007). Surgeries such as transurethral resection of the prostate and minimally invasive therapies for prostatic enlargement are associated with ejaculatory dysfunction (Elshal et al., 2012; Jaidane et al., 2010). As discussed elsewhere in this text, retrograde ejaculation of varying degrees may occur after retroperitoneal lymph node dissection for testis cancer, depending on the type of dissection and the clinical context within which the dissection occurs.

Herniorrhaphy may result in obstruction of the vas deferens (Hallén et al., 2011, 2012; Shin et al., 2005; Tekatli et al., 2012). Mesh in particular appears to incite a dense foreign body inflammatory response that may entrap the vas deferens even if the placement of mesh is not immediately adjacent to the vas (Hallén et al., 2011, 2012; Maciel et al., 2007; Tekatli et al., 2012). If vasal occlusion is the sole cause of infertility, then both vasa must be occluded, an expectedly infrequent event. However, occlusion of one vasa from herniorrhaphy with contralateral spermatogenic dysfunction of another source may cause infertility in the male.

Aside from the typical questions regarding medical and surgical history, answers to a number of questions specifically related to male reproduction may elucidate causes of infertility. If the practitioner is not using a history form, a helpful mnemonic is *TICS*, as if one is ticking off items on a list. *T* stands for toxins, *I* for infectious/inflammatory disease, *C* for childhood history, and *S* for sexual history.

Spermatotoxicity

In the *TICS* mnemonic, *T* is for toxins. A variety of substances interfere with spermatogenesis, mature sperm function, and sperm delivery. Many common medications, prescribed and over the counter, can be associated with male reproductive dysfunction.

Endocrine Modulators

Medications may affect the ratio of estrogen to androgen through a variety of mechanisms, including a molecular similarity to estrogen, increased estrogen synthesis, increased aromatase activity, dissociation of steroids from sex hormone–binding globulin (SHBG), decreased testosterone synthesis, competitive and noncompetitive binding to steroid receptors, decreased synthesis of adrenal steroids, and induction of hyperprolactinemia (Bowman et al., 2012). **Some of the more commonly encountered agents warranting inquiry include the antiandrogens bicalutamide, flutamide, and nilutamide; the antihypertensive spironolactone; the antiretroviral protease inhibitors such as indinavir; the nucleoside reverse transcriptase inhibitors such as stavudine; corticosteroids, especially in adolescence; and exogenous estrogen** (Bowman et al., 2012).

Although a source of debate, the 5α-reductase inhibitors finasteride and dutasteride appear to have only limited spermatogenic suppressive effects if at all (Amory et al., 2007; Overstreet et al., 1999). Occasional anecdotal case reports and a prospective database review suggest that sperm parameters dramatically improve in an individual man after discontinuation of a 5α-reductase inhibitor, including the low dose for androgenic alopecia, but the substantial interassay variability of semen parameters calls into question whether these effects could simply be the result of chance (Chiba et al., 2011; Samplaski et al., 2013).

Primarily through conversion to estradiol by aromatase and consequent inhibition of luteinizing hormone (LH) secretion by the pituitary, exogenous testosterone acts to decrease intratesticular testosterone synthesis and reduce spermatogenesis (Grimes et al., 2012). Agents with androgenic properties similarly diminish sperm production (de Souza and Hallak, 2011). In fact, investigators have studied testosterone and androgenic steroids as potential targets for male contraception since the 1970s (Grimes et al., 2012; Gu et al., 2009; Ilani et al., 2012; WHO Task Force, 1990). In general, these studies have a duration of 2 years or less of application of testosterone or androgenic steroid and demonstrate reversibility with return to sperm in the ejaculate after approximately 4 months or more of discontinuation of the contraceptive agent (Grimes et al., 2012; Gu et al., 2009; Ilani et al., 2012; WHO Task Force, 1990). However, whether and when spermatogenesis returns after longer periods of use are unknown.

Recreational Drugs

Although data are conflicting, most studies suggest that cannabis decreases plasma testosterone in a dose-dependent and duration-dependent manner (Gorzalka et al., 2010). Recent data identified a nonlinear decrease in semen concentration and total sperm count with frequency of cannabis use and suggested a threshold effect at use of more than once per week (Gundersen et al., 2015). More robust data associate chronic alcohol intake with decreases in androgens and sperm parameters (Pasqualotto et al., 2004; Villalta et al., 1997). Heavy chronic alcohol intake also appears to increase aromatization of testosterone to estradiol (Purohit, 2000). Investigators have observed that more moderate use of alcohol may decrease intracytoplasmic sperm injection (ICSI) outcomes (Braga et al., 2012).

Early studies suggested worsening of bulk seminal parameters with cigarette smoking (Stillman et al., 1986). **Although the results of subsequent studies**

associating smoking and bulk parameters were conflicting, more recent cross-sectional analysis has supported deterioration of seminal parameters in a dose-dependent manner, arguing more strongly that cigarette smoking impairs male reproductive potential (Ramlau-Hansen et al., 2007). Investigators observed that cigarette smoking increased seminal oxidative stress parameters and decreased metrics of sperm DNA quality (Pasqualotto et al., 2008b; Sharma et al., 2016; Taha et al., 2012). An abnormal ratio of protamines 1 and 2 was observed in smokers with evidence of atypical protamine 2 expression, pointing to DNA packaging as directly compromised by tobacco use (Hammadeh et al., 2010). The negative effects of cigarette smoking on sperm bulk parameters and DNA quality appear to be especially acute in the presence of a clinical varicocele, suggesting the possibility of additive toxicity (Fariello et al., 2012b). Researchers studied effects of an aryl hydrocarbon receptor ligand present in cigarette smoke and found that it induced apoptosis in the fetal testis in a manner that was preventable with an aryl hydrocarbon receptor antagonist, providing evidence that maternal smoking may affect the reproductive potential of male offspring (Coutts et al., 2007). Consistent with these laboratory findings, epidemiologic data associated maternal cigarette smoking to smaller testes, lower sperm counts, and alterations in sex hormones in the adult male offspring (Jensen et al., 2005; Ravnborg et al., 2011). Epidemiologic evidence supports that the secondary sex ratio, the ratio of boys to girls born, is altered in mothers who smoke (Beratis et al., 2008). One explanation is that cigarette smoking alters circulating testosterone concentrations in pregnant women (James, 2002).

Electronic cigarettes that aerosolize with typically a nicotine-containing solvent are becoming increasingly popular, although there remains of paucity of data related to potential health consequences. There are reports of lower levels for carcinogens and toxicants compared with smokers, although no long-term data exist (Goniewicz et al., 2017; Hecht et al., 2015; McRobbie et al., 2015). At this time, no data exist related to impact on androgens or semen parameters.

Antihypertensives

The relationship between antihypertensive medication and erectile dysfunction is well known and discussed elsewhere in this text. The direct effects of antihypertensives on male reproductive function is less clear. Investigators have proposed that calcium channel blockers impair fertilization by inhibiting expression of mannose-ligand binding receptors and preventing sperm from attaching to the zona pellucida (Benoff et al., 1994). Although laboratory evidence supports this hypothesis, limited clinical data from IVF cycles question whether calcium channel blockers affect fertilization (Katsoff and Check, 1997). **Angiotensin-converting enzyme inhibitors appear to improve sperm motility through a presumptive effect on seminal plasma kinins** (Somlev and Subev, 1998). In a limited controlled clinical trial with crossover design, 2.5 mg of lisinopril daily increased sperm count, motility, and morphology (Mbah et al., 2012). If these results are replicated in larger future studies, they suggest an effect beyond that of altering seminal plasma characteristics alone.

Antipsychotics

The most common mechanism of action for antipsychotic drugs is antagonism of dopamine, which causes loss of libido as a side effect in the majority of patients (Stimmel and Gutierrez, 2006). Another proposed reason for diminished libido with use of antipsychotics is elevation of prolactin levels, which appears to be most acute for risperidone and to a lesser extent olanzapine (Melkersson, 2005). As discussed elsewhere in this text, selective serotonin reuptake inhibitors (SSRIs) are commonly associated with anorgasmia and delayed or absent ejaculation (Clayton and Montejo, 2006; Stimmel and Gutierrez, 2006).

Opioids

Opioid analgesics suppress LH release primarily through hypothalamic-mediated mechanisms and consequently reduce testosterone synthesis (Subirán et al., 2011). Experimental evidence in animals demonstrates endogenous opioid peptides, their precursors, and their receptors in various testis cell types (Subirán et al., 2011). Endogenous opioid peptides are primarily synthesized by Leydig and Sertoli cells and inhibit Sertoli cell function via autocrine and paracrine mechanisms (Subirán et al., 2011). Therefore opioids not only can induce the hypogonadotropic hypogonadism commonly observed in chronic use but may also diminish spermatogenesis directly in the testis (Brennan, 2013; Subirán et al., 2011). Evidence suggests that discontinuation of opioid analgesics may be associated with rapid return of androgen, perhaps as early as within 1 month (Brennan, 2013). **With the widespread prescribing of opioid analgesics and the epidemic of opioid abuse, their use as a cause of hypogonadotropic hypogonadism should be suspected in all such hypoandrogenic men.**

Antibiotics

Data derived from animal studies indict drugs in each of the major classes of antibiotics as toxic to spermatogenesis or sperm function (Schlegel et al., 1991). However, evidence broadly suggesting male reproductive toxicity for antibiotics in humans is, in general, lacking. Animal studies and limited human data demonstrate testis dysfunction and reduced spermatogenesis with tetracycline, potentially through an oxidative stress mechanism (Farombi et al., 2008; Kushniruk, 1973; Pasqualotto et al., 2004; Schlegel et al., 1991). Because tetracycline binds mature sperm, direct toxicity on sperm function is also possible (Pasqualotto et al., 2004). Spermatotoxic effects of tetracycline may be paternally transmitted to male offspring (Zeh et al., 2012). Investigators observed in animals that high doses of nitrofurantoin reduced epididymal sperm density and sperm motility (Chapin et al., 1997). In humans, male reproductive toxicity of nitrofurantoin is unclear in the typical dose range for a discrete duration. Surgeons irrigating vasa with nitrofurantoin solution reported spermatotoxicity in the immediate postoperative period, but this experimental model does not accurately mimic the typical pharmacodynamic distribution of the drug (Albert et al., 1975).

Cytotoxic Chemotherapeutics

Because chemotherapeutic agents are most effectively applied to suppress a briskly proliferating population of cells, and the pathway of male gamete development primarily involves a rapidly dividing stem cell cohort, it is unsurprising that medical therapies directed toward cancers impair spermatogenesis. Alkylating agents such as the nitrogen mustard cyclophosphamide have been long identified to impair sperm production (Vaisheva et al., 2007). These spermatogenic suppressive effects were noted to be dose and time dependent, with lower doses and shorter durations of therapy leading to reversible dysfunction but ultimate return to male fertility potential, and higher doses and longer durations of therapies resulting in permanently impaired fertility (Vaisheva et al., 2007). Other chemotherapeutic agents commonly used in conjunction with cyclophosphamide to treat non-Hodgkin lymphoma, including doxorubicin, vincristine, and prednisone, have been reported to impair spermatogenesis as individual agents (Vaisheva et al., 2007). Likewise, investigators reported that cisplatin, etoposide, and bleomycin were associated with diminished sperm parameters in a dose- and time-dependent manner (Gandini et al., 2006).

One concern of patients and physicians is how much chemotherapy damages the DNA of sperm (Delbes et al., 2007; O'Flaherty et al., 2008, 2010; Robbins, 1996; Smit et al., 2010; Spermon et al., 2006; Stahl et al., 2006; Tempest et al., 2008). Evidence suggests that sperm DNA damage can be detected at least up to 2 years after chemotherapy, arguing that cryopreservation of sperm before treatment with cytotoxic chemotherapeutic agents is preferable to awaiting the return of sperm after chemotherapy (Tempest et al., 2008). The question is whether sperm is “safe” to use after a discrete amount of time after the induction of chemotherapeutic agents that may mutate cellular DNA in a way that may be translated through the germ line into offspring. An informed answer to that question based on well-conducted clinical trials is not yet available.

This lack of knowledge frustrates male reproductive specialists who counsel patients on whether their own biologic material or donor sperm would be the best choice after cytotoxic chemotherapy. **Questions about sperm DNA integrity and mutagenicity after chemotherapy serve as a second reason to encourage men undergoing such oncologic therapy to cryopreserve sperm before induction, because cryopreservation presents a well-established means for fertility preservation in the setting of cancer** (Anger et al., 2003; Crha et al., 2009; Meseguer et al., 2006). Proper cryopreservation of sperm results in long-term potential for reproductive success, and patients may be assured that should they store sperm in this way, it will be available when they need it (Rofeim and Gilbert, 2005). Although many patients may recover sperm in the ejaculate after cytotoxic chemotherapy, and it is very possible that, after a period as yet to be determined, ejaculated sperm after chemotherapy will be safe for conception, many men do not develop sufficient ejaculated sperm for fertility. These men do use cryopreserved sperm if available to successfully father offspring (Meseguer et al., 2006).

Systemic application of antitumor medication is not necessarily the only form of chemotherapy that may alter fertility potential. Investigators noted in a small series of young men that local instillation of bacille Calmette-Guérin into the bladder for superficial transitional cell carcinoma resulted in a significant decrease in sperm concentration and motility (Raviv et al., 2005).

A special case arises in peripubertal boys undergoing cytotoxic chemotherapy for cancer. Oncologists are often in a rush to apply lifesaving therapy, and parents may be uncomfortable discussing topics such as masturbation for semen collection with their children. However, if oncologic therapy is successful, it is precisely these patients with a potentially long life expectancy who would benefit from sperm cryopreservation as an option for future fertility. Peripubertal boys are capable of producing semen samples suitable for cryopreservation, and it is entirely feasible to obtain an ejaculate suitable for storage (Menon et al., 2009; van Casteren et al., 2008). The urologist must simply be comfortable enough to discuss the advantages of fertility preservation and the methods to achieve it.

Anti-Inflammatory Agents

The agent sulfasalazine prescribed for inflammatory bowel conditions is associated with oligoasthenospermia (Stein and Hanauer, 2000). If sulfasalazine is substituted with enteric-coated mesalazine, adverse effects on sperm are usually reversible (Riley et al., 1987). **If oligoasthenospermia is found in a patient prescribed sulfasalazine who has male infertility, substitution with mesalazine should consequently be recommended.**

Because colchicine arrests cell division and inhibits cell motility dependent on microtubular function, it was suspected as a spermatotoxic agent (Haimov-Kochman and Ben-Chetrit, 1998). However, its actual role in male reproductive dysfunction is unclear.

Phosphodiesterase V Inhibitors

In animal studies, the phosphodiesterase type 5 inhibitor sildenafil was observed to induce a premature acrosome reaction and to impair fertilization and early embryo development (Glenn et al., 2007, 2009). Sildenafil was also associated with an increase in sperm motility, whereas tadalafil was noted to decrease sperm motility (Glenn et al., 2007; Mostafa, 2007; Pomara et al., 2007). Investigators observed vardenafil to increase motility and possibly sperm concentration (Rago et al., 2012). It is unclear whether these effects have significance in actual clinical use.

Environmental Toxicants

Researchers have investigated a large number of potential male reproductive environmental toxicants. A very concerning analysis projected that sperm counts declined between 1938 and 1991, and, more recently, a comprehensive review and meta-analysis identified a 50% to 60% decline in semen parameters of Western men unselected for fertility over the last 40 years (Carlsen et al., 1992;

Levine et al., 2017). Whereas commentators noted a number of sources of error and bias both analyses, the initial report spawned several investigations into an environmental basis for the putative cause of this phenomenon that likely hold true for the contemporary report as well (Carlsen et al., 1992; Fisch, 2008; Jørgensen et al., 2001; Levine et al., 2017). One hypothesis explaining this observation was that an increase in pollutants with estrogenic activity was at fault (Carlsen et al., 1992). If that were the case, it would be expected that naturally occurring estrogenic substances should interfere with spermatogenesis. However, the limited data support that phytoestrogens, or plant compounds with estrogenic properties, do not display significant negative effects on male reproductive potential (Fraser et al., 2006; Hamilton-Reeves et al., 2010; Messina, 2010). Hinting at a more nuanced relationship, data correlated urine levels of the potent industrial endocrine disruptor bisphenol A and decreased sperm concentration and total sperm count, implying that environmental estrogens may play a role in hampering male reproductive potential (Li et al., 2011). Congruent with these observations, maternal beef consumption was correlated with decreased sperm concentration in the mothers' adult sons, with estrogenic xenobiotics as a possible causative mechanism (Swan et al., 2007).

Evidence supports insecticide and pesticide exposure as male reproductive toxicants. Investigators observed an association of increased DNA damage with urinary metabolites of the insecticides carbaryl and chlorpyrifos (Meeker et al., 2004). In a model system, researchers exposed human fetal testes to the insecticide and endocrine disruptor dieldrin and noted a variety of Leydig cell dysfunctional effects, including reduced testosterone secretion and LH receptor and steroid regulatory protein concentrations (Fowler et al., 2007). **Suggesting that a man consume locally grown produce to avoid ill effects of pesticides may not be in his best interest. In one study, men consuming locally produced vegetables had lower serum free testosterone, LH, and sperm concentration and normal sperm morphology** (Dhooge et al., 2007).

Regarding metal and metalloid exposure, various reports suggest an array of potential male reproductive toxicities. **The heavy metal lead was associated with increased morphologic abnormalities and decreased metrics of DNA quality in sperm** (Hsu et al., 2009). These negative effects of lead on sperm DNA appear to be potentiated by cigarette smoking (Hsu et al., 2009). In one study, molybdenum was associated with a 37% reduction in circulating testosterone levels (Meeker et al., 2010). Environmental and workplace exposure to the metalloid boron was associated with decreased ratio of sperm bearing a Y chromosome to those with an X chromosome (Robbins et al., 2008).

Air pollution may also serve as a male reproductive toxin. Researchers observed an association of particulate air pollution with reduced sperm motility (Hammoud et al., 2010a). Exposure to episodes of high air pollution was also associated with increased sperm DNA fragmentation (Rubes et al., 2005). An animal model demonstrated a decrease in the secondary sex ratio with increased air pollution (Lichtenfels et al., 2007). The authors argued that as litter sizes were similar in exposed and nonexposed animals, the most likely explanation was alteration in the ratio of Y- and X-bearing sperm (Lichtenfels et al., 2007).

Thermal Toxicity

For reasons not entirely clear but engendering much speculation, mammals evolved so that the scrotal container of the testis was housed outside the body cavity, keeping its contents at a temperature considerably cooler than that of the internal organs (Setchell, 1998; Thonneau et al., 1998). **Scrotal temperature in humans is maintained to be 2°C to 4°C below core body temperature by mechanisms including a countercurrent heat exchange between a central set of linear arteries directing blood toward the testis and a plexus of veins surrounding the arteries draining blood back toward the vena cava** (Setchell, 1998; Thonneau et al., 1998). Many investigators have exhaustively studied the effects of heat on spermatogenesis in animals, observing depopulation of germ cells, perturbations in the various spermatogenic cell types, and apoptosis within specific cell types (Absalan et al., 2010; Setchell, 1998). Cryptorchidism provides a model by which the effects of heat can be studied on sperm production: increasing testis temperature to that of the abdominal cavity significantly impairs spermatogenesis (Setchell, 1998).

The degree to which scrotal temperature can be raised without affecting male fertility remains an open question. Clothing, physical activity, and body posture (e.g., whether the legs are crossed or not in a sitting position) change scrotal temperature to an incremental degree, but whether that translates to alterations in spermatogenesis is purely speculative (Jung et al., 2005; Mieusset et al., 2007). Researchers observed an increase in scrotal temperature on the order of a half a degree Celsius with prolonged sitting on heated car seats and speculated that such an effect may be additive to the intrascrotal temperature rise that occurs when sitting (Jung et al., 2008). One study observed that when a man was naked, mean scrotal temperature was significantly lower on the left than on the right, but when he was clothed, the temperature was significantly higher on the left than on the right (Bengoudifa and Mieusset, 2007). Clothing may thus confer a greater differential increase in left scrotal temperature than right scrotal temperature (Bengoudifa and Mieusset, 2007).

A number of studies associate occupational exposure resulting in a significant increase in intrascrotal temperature with detrimental effects on sperm (De Fleurian et al., 2009; Thonneau et al., 1998). However, other researchers have observed no significant negative effects on sperm in fertile men exposed to high heat at work and postulated that in the normal state, compensatory mechanisms protect the testis when a prolonged rise in ambient temperature occurs (Momen et al., 2010).

Laptop computers radiate heat, and researchers have studied the effects of these devices on scrotal temperature. In one study, under controlled conditions, having a laptop computer resting on the lap for 1 hour raised the scrotal temperature an average 2.6°C on the left and 2.8°C on the right side (Sheynkin et al., 2005). However, simply sitting without a laptop raised the scrotal temperature an average of 2.1°C (Sheynkin et al., 2005). Whether the extra approximately half-degree Celsius imparts significant damage to spermatogenesis remains an open question. However, investigators have observed that a man sitting with his legs apart and for shorter periods of time experiences less of an increase in scrotal temperature (Sheynkin et al., 2011).

Radiation

Testes directly exposed to ionizing radiation suffer germ cell loss and Leydig cell dysfunction (Bahadur and Ralph, 1999; Castillo et al., 1990; Clermont, 1972; Gandini et al., 2006; Green et al., 2010). In one survey of boys with acute lymphoblastic leukemia who underwent testicular irradiation at 12, 15, and 24 Gray (Gy), all became azoospermic, but those receiving less than 24 Gy had normal testosterone production (Castillo et al., 1990). The investigators observed elevated gonadotropins and noted that this finding indicated the possibility of subclinical Leydig cell damage (Castillo et al., 1990). **In a survey of childhood cancer survivors, chances of having future offspring were lessened by radiation doses to the testes of 7.5 Gy and above** (Green et al., 2010). The testis need not be directly irradiated for spermatogenic impairment to occur; if the radiation field is proximal to the testis and the dose is sufficient, sperm production may be diminished even if the testis is shielded (Gandini et al., 2006).

With widespread use of radiofrequency devices for telecommunications and wireless networks, investigators have questioned the effects of this band of the electromagnetic spectrum on sperm (Agarwal et al., 2008b; Agarwal et al., 2009; Avendano et al., 2012; Baste et al., 2008; Erogul et al., 2006; Falzone et al, 2008). Researchers observed negative effects on sperm motility parameters, viability, and reactive oxygen species (ROS) generation after electromagnetic radiation generated by 850- and 900-MHz cell phone transmission systems in vitro (Agarwal et al., 2009; Erogul et al., 2006; Falzone et al., 2008). A similar analysis was performed in vitro by exposing aliquots of semen to 4 hours under a wireless Internet-connected laptop computer, emitting 7 to 15 times more radiofrequency electromagnetic waves compared with unexposed controls (Avendano et al., 2012). The authors identified a significant decrease in motility and an increase in DNA fragmentation of the exposed aliquot (Avendano et al., 2012). However, in vitro exposure of sperm to electromagnetic radiation does not account for the distance and material, including biologic tissues, that separate a cell phone transceiver or laptop computer and sperm during common use. To address a more typical usage scenario, investigators have used epidemiologic data to gauge potential in vivo effects. In one questionnaire-based study of Norwegian sailors exposed to high-power electromagnetic fields in a military environment, researchers noted a significant linear relationship between increasing exposure and reported infertility (Baste et al., 2008). The offspring's sex ratio at birth also revealed a linear relationship, with a decreasing ratio of boys to girls with higher degrees of exposure to electromagnetic radiation (Baste et al., 2008). Researchers in another epidemiologic study divided men into four groups based on cell phone talking time: no use; less than 2 hours per day; 2 to 4 hours per day; and more than 4 hours per day (Agarwal et al., 2008b). The investigators observed that semen analyses in the four groups of increasing cell phone use revealed a linear decrease in sperm count, motility, viability, and normal morphology (Agarwal et al., 2008b).

Infections and Inflammation

In the *TICS* mnemonic, *I* stands for infectious and inflammatory disease leading to male reproductive dysfunction. Infections of the testis, epididymis, prostate, and urethra may lead to male infertility through anatomic and functional means (Kasturi et al., 2009). Common organisms affecting the prostate include *Escherichia coli*, *Pseudomonas aeruginosa*, and *Klebsiella*, *Proteus*, and *Enterococcus* species (Kasturi et al., 2009). Typical epididymal organisms include *Neisseria gonorrhoeae, Chlamydia trachomatis,* and *E. coli* (Kasturi et al., 2009). Infectious urethral organisms in the context of impaired male reproduction include *N. gonorrhoeae, C. trachomatis, Mycoplasma* species, and *Trichomonas vaginalis* (Kasturi et al., 2009). Although relatively infrequently encountered, infections of the testis may include the Rubulavirus mumps, coxsackievirus B, *N. gonorrhoeae, C. trachomatis, E. coli, P. aeruginosa,* and *Klebsiella, Staphylococcus,* and *Streptococcus* species (Kasturi et al., 2009). Mumps orchitis is typically so painful and bizarre to the person so affected that, even at a very young age, a boy whose case of mumps travels into his testis is unlikely to forget the event. Infrequently encountered in modern industrialized nations, *Mycobacterium tuberculosis* may affect any reproductive organ and cause scarring of the vas deferens and epididymis (Niederberger, 2011).

Infectious consequences may be anatomic, such as urethral infection leading to stricture, or functional, impairing sperm (Kasturi et al., 2009). Functional alterations may derive from direct effects of the infectious organism on sperm or through induction of immunologic responses in any male reproductive organ, leading to sperm dysfunction (La Vignera et al., 2011). As an example of direct effects, investigators observed that incubating sperm with increasing concentrations of *C. trachomatis* serovar E elementary bodies was associated with degradation of sperm DNA in a time-dependent manner (Satta et al., 2005). **Although in vitro laboratory experiments have also demonstrated a negative effect of *E. coli* on sperm, the majority of bacteria including *E. coli* have limited or no effects on sperm motility in vivo** (Diemer et al., 2003; Lackner et al., 2006). Whereas bacteria may coexist with sperm without significant pathologic consequence, sexually transmitted organisms may play a more virulent role (Bezold et al., 2007). The differential effects on sperm of common bacteria and sexually transmitted infectious agents remain far from clear.

Viruses proffer a potentially unique negative direct effect on sperm by integration into a man's genome and vertical transmission through his germ line (La Vignera et al., 2011). **Although viral nucleic material appears to be present in the seminal plasma, neither hepatitis C nor human immunodeficiency virus appear to be correlated with a direct negative effect on sperm function** (Garrido et al., 2005). Human papillomavirus was associated with impairment of bulk seminal parameters, and in vitro treatment of sperm in the laboratory with heparinase III appeared to diminish viral load without significantly altering functional semen parameters (Garolla et al., 2012).

Researchers have studied a wide variety of indirect negative effects of infection on sperm, including through leukocytosis, ROSs, interleukins 1, 6, and 8, interferon-γ, macrophage migration inhibitory factor, tumor necrosis factor-α, epididymal macrophages, and dendritic cells (La Vignera et al., 2011). It is logical that any part of the immune system may lose self-recognition of sperm or, in the presence of an active infection, overwhelm sperm defenses.

Evidence suggests that noninfectious or postinfectious inflammatory processes of the prostate may lead to sperm alterations and male infertility, but the degree to which inflammation alters male reproductive potential beyond what infection imparts remains unknown (Ausmees et al., 2013; Schoor, 2002; Wagenlehner et al., 2008). One putative mechanism by which nonbacterial prostatitis may lead to male infertility is through seminal leukocytosis or pyospermia and the release of ROSs resulting in sperm damage (Schoor, 2002). Other possible means of sperm dysfunction via prostatic inflammation include generation of antisperm antibodies and biochemical alterations in prostatic ions such as zinc, magnesium, calcium, or selenium (Schoor, 2002). Prostatitis may damage sperm by inducing ROSs without leukocytosis as an intermediary (Pasqualotto et al., 2000; Schoor, 2002).

Childhood Diseases

The *C* in *TICS* stands for childhood diseases. Maladies of early development include anatomic maldevelopment leading to obstruction or misdirection of the male gamete as it traverses the journey from the testis to the female reproductive tract and disorders that lead to disturbed sperm production or to conditions that damage mature sperm.

Pediatric Surgery

Hydroceles and hernias repaired during childhood are associated with a low but discrete incidence of complications causing vasal obstruction (Lao et al., 2012). In one large series, the rate of testis atrophy after pediatric inguinal hernia was 0.3% (Ein et al., 2006). As hernias repaired during adolescence often include surgical mesh, vasal occlusion as a result of inflammation associated with this material should be considered in an infertile man with such a procedure in his surgical history (Hallén et al., 2011, 2012; Lao et al., 2012; Shin et al., 2005; Tekatli et al., 2012). Other surgical procedures during childhood may also affect future reproductive status. In earlier series, investigators associated scarring from posterior urethral valve ablation with male reproductive dysfunction, but in more recent series, fertility complications with urethral valve surgery are rarely observed (Caione and Nappo, 2011). Older procedures for restoring bladder neck anatomy in children were associated with retrograde ejaculation, but these surgeries are rarely performed today (Sigman et al., 2009).

Testis Torsion

For males 25 years old and younger, testis torsion is more than three times more common than testis cancer, with an estimated incidence of 4.5 cases per 100,000 per year (Mansbach et al., 2005; Mellick, 2012). Contralateral testicular biopsy findings are abnormal in 57% to 88% of males when torsion occurs, which suggests either that unnoticed torsion is damaging the testis before torsion becomes clinically evident or that some underlying pathology is present that manifests as abnormal scrotal anatomy and as spermatogenic dysfunction (Visser and Heyns, 2003). **Approximately half of men with torsion develop adverse spermatogenic effects** (Visser and Heyns, 2003). Overall after torsion, 36% to 39% of men will have sperm concentrations below 20 million/mL (Visser and Heyns, 2003). Because torsion is a traumatic event that disrupts intratesticular architecture, including the tight junctions between the Sertoli cells that make up the blood-testis barrier, it is unsurprising that up to 11% of men develop antisperm antibodies after torsion (Visser and Heyns, 2003).

Cryptorchidism

As described elsewhere in this text, during the fifth week of gestation, cells destined to become gonads arise in the posterior abdominal wall of the developing embryo (Lewis and Kaplan, 2009). A complex set of highly orchestrated sequenced events occurs, including differentiation of the various testis cell types, organization into what will ultimately become histologic compartments within the testicle, and development of the outer container of the testis and its connection to the distal organs where sperm ultimately will be routed (Lewis and Kaplan, 2009). The most overt anatomic change is migration of germ cells from the posterior abdominal wall toward the nascent inguinal canals and eventually into the scrotum, resulting in an extra-abdominal localization of the male gonads (Lewis and Kaplan, 2009). This process does not conclude until the third trimester (Lewis and Kaplan, 2009). Researchers have identified multiple regulatory triggers in animal models that direct descent of the testis, including the insulin-like 3 *(INSL3)* gene, the relaxin/insulin-like family peptide receptor 2 *(LGRF8)* gene, antimüllerian hormone (AMH), and members of the *HOX* gene family such as *HOX10* (Hughes and Acerini, 2008; Lewis and Kaplan, 2009). Dysfunction of certain of these genes may result primarily in arresting the mechanical journey of the germ cells, whereas aberrant expression of others may be involved in the processes of spermatogenesis and descent, causing infertility in ways beyond the thermal toxicity to which undescended testes are subject in later reproductive life. **Androgens are required to induce regression of the cranial suspensory ligament during the fourth month of gestation to allow descent of the testis** (Hughes and Acerini, 2008; Lewis and Kaplan, 2009). Failure of any of these processes impedes descent of the testis into the scrotum, resulting in cryptorchidism, which is widely known to be associated with impaired reproductive potential in later life (Sigman et al., 2009).

Undescended testes occur in up to 4% of newborn boys at term (Barthold and González, 2003). The prevalence of cryptorchid testes decreases to less than 1.5% by 1 year of age (Barthold and González, 2003; Chung and Brock, 2011). Cryptorchidism concordance analysis in twins and siblings indicates a pattern of maternal inheritance but also suggests that the intrauterine environment plays an important role (Jensen et al., 2010). In most series, the incidence of unilateral cryptorchidism is usually around twice that of bilateral undescended testes (Barthold and González, 2003). The distinction is important, because prognosis is related to whether cryptorchidism is unilateral or bilateral. The reproductive prognosis in later life is similar in men with no history of cryptorchidism and in those with a unilateral undescended testis who underwent orchidopexy as a child, regardless of age at surgery or the size of the undescended testis (Lee et al., 2001; Miller et al., 2001). **In one large epidemiologic study of men who had orchidopexy during childhood, successful rates for those attempting paternity with a history of surgically treated unilateral cryptorchidism were 96% compared with a control population, but only 70% for those who had bilateral cryptorchidism** (Lee, 2005). In that study, men with bilateral cryptorchidism had levels of the Sertoli cell product and marker of spermatogenesis inhibin B that were nearly one-third of the levels in controls compared with men with unilateral undescended testes repaired in childhood who had inhibin B levels approximately two-thirds that of controls (Lee, 2005). Differences in testosterone concentrations were less than those of inhibin B, arguing that fertility impairment caused by cryptorchidism is less based in Leydig cell steroidogenesis than in dysfunction of the seminiferous epithelium

(Lee, 2005). Congruent with the identified differences in inhibin B between men with neither, one, or both testes undescended, researchers observed that sperm density on semen analysis is lower in men who had surgical repair of bilateral cryptorchidism than in those with a unilateral undescended testis, which in turn is lower than in men with normally descended testes (Lee, 1993; Lee and Coughlin, 2001; Moretti et al., 2007). With transmission electron microscopy, investigators also found a greater number of ultrastructural defects in men who had cryptorchidism surgically treated as a child compared with controls, and sperm from men with bilateral undescended testes had more defects than from those with unilateral disease (Moretti et al., 2007).

Conclusive data associating the timing of orchidopexy with reproductive outcomes in later life remain elusive. It is widely recognized that surgical correction of undescended testes after puberty likely has minimal effect on bulk semen analysis parameters (Grasso et al., 1991). However, the age before puberty at which orchidopexy results in optimal effect in reproductive potential has not been definitively established. Regression analysis demonstrated that serum testosterone concentrations in men were negatively correlated to increasing age at orchidopexy, indicating that Leydig cell function is better spared by earlier age of surgical correction for cryptorchidism (Lee, 2005). Conventional wisdom contended that full germ cell development is arrested and remains quiescent before puberty, implying that orchidopexy performed at any earlier age would have similar outcomes. However, maturational alterations may occur in the hypothalamic, pituitary, and testicular endocrine axis much earlier than adolescence (Hadziselimovic, 2002). Likewise, a transition from the spermatogonial cell types of the fetal germ cell reservoir to that of the adult occurs at a very early age (Hadziselimovic, 2002).

Studies of men undergoing testis sperm extraction with the intent for use in ICSI and who had cryptorchidism and orchidopexy at an earlier time offer some information about the optimal timing of surgical correction of undescended testes, although results are conflicting. In an early study of 30 azoospermic men who had bilateral cryptorchidism, no correlation was found between the age at bilateral orchidopexy and the rate of successful surgical sperm retrieval, which was 73% overall (Negri et al., 2003). In a later study of 42 azoospermic men in whom all but two had bilateral cryptorchidism, no significant differences in surgical sperm retrieval rate were observed comparing men who had orchidopexy up to 10 years of age (61.9%) and men whose testes were brought into the scrotum after 10 years of age (57.1%) (Wiser et al., 2009). However, in an early study of 38 azoospermic men with 30 having had bilateral cryptorchidism, the successful surgical retrieval of sperm in 94% for men who had orchidopexy before 11 years old, 43% from 11 to 20 years old, and 44% after age 20 years was statistically different at the selected threshold of 10 years ($P < 0.01$) (Raman and Schlegel, 2003). Congruent with these results, in 79 azoospermic men, 62% having had bilateral orchidopexy and 20.3% having had unilateral orchidopexy (with 17.7% unknown), ROC curve analysis revealed age at orchidopexy to have the second greatest area under the curve (AUC) after testosterone in discriminating successful surgical sperm retrieval (Vernaeve et al., 2004). **It consequently appears prudent to recommend orchidopexy before 10 years of age from a reproductive perspective, recognizing that cryptorchid boys who pass that threshold still may have sperm surgically retrieved for use in ICSI later in life.**

Testes that change in position after descent and those that are nearly but not fully descended present special challenges in assessing potential alterations in reproductive potential. Numerous reports clearly document testes as being descended that are later observed to have ascended to varying degrees (Barthold and González, 2003; Gracia et al., 1997). Whereas most appear to ascend to a location distal to the inguinal canal, clinicians have reported ascent as high as to an intra-abdominal position (Barthold and González, 2003; Gracia et al., 1997). Unfortunately, the fertility potential for these patients has not yet been systematically studied, and their reproductive prognosis must be considered unknown at present. For men with retractile testes, limited data suggest that although sperm are often observed in the ejaculate in a man, sperm density is lower than would be expected in a man with normal fertility, approaching that of men with a history of cryptorchidism (Caroppo et al., 2005).

Testicular Dysgenesis Hypothesis

Investigators have noted an increase in the incidence of testis cancer and genitourinary abnormalities such as hypospadias and cryptorchidism and a concomitant decrease in seminal bulk parameters in general over time (Carlsen et al., 1992). The actual existence of each effect can be individually debated, and internal covariates are difficult to statistically assess (Akre and Richiardi, 2009; Thorup et al., 2010). However, the fact that sufficient evidence exists to posit the correlation of possible adverse male reproductive epidemiologic trends begs the question of what would be potentially responsible for a common “testicular dysgenesis syndrome” that would lead to multiple manifestations in reproductive dysfunction, cancer, and anatomic birth defects (Skakkebaek et al., 2001). Researchers have reported a paternal concordance, with fathers of boys with hypospadias having an increased probability of decreased sperm density and of also having hypospadias (Asklund et al., 2007). This observation indicates a potential genetic component to a possible testicular dysgenesis syndrome. Investigators have also correlated environmental estrogenic compounds such as dichlorodiphenyltrichloroethylene, polychlorinated biphenyls, and dibutylphthalate exposure to cryptorchidism, suggesting that environmental toxicants may lead to testicular maldescent and potentially other reproductive system impairments (Brucker-Davis et al., 2008). These observations and conjectures must be tempered by the difficulties inherent in assessing male reproductive epidemiologic data (Akre and Richiardi, 2009; Thorup et al., 2010). However, it would seem prudent to continue to investigate whether such a testicular dysgenesis syndrome exists, and if so, what its root causes may be to ameliorate it.

Genetics

Current knowledge of the genetic basis of male infertility is discussed systematically later in this chapter. A good reproductive history should include whether any blood relatives experienced difficulty conceiving offspring. The evaluating physician should also inquire as to the presence in the patient's family of genetic syndromes known to be related to reproductive dysfunction such as cystic fibrosis and other entities detailed in the latter part of this chapter (Anguiano et al., 1992).

Sexual History

The *S* in *TICS* is for the sexual history. Although it may seem intuitive that a couple would engage in a sufficient frequency of intercourse when attempting to conceive, lifestyle or proclivities may intervene and interfere. As discussed previously in this chapter, optimum timing for intercourse appears to be daily around the time of ovulation (Scarpa et al., 2007). Some women accurately predict the periovulatory period by symptoms, the so-called mittelschmerz (O'Herlihy et al., 1980). However, many women mistake bodily sensations as ovulation, and symptoms alone cannot reliably be used to assess optimal timing for intercourse. **Because ovulation is detectable by basal body temperature or home hormonal kits *after* it has occurred, a couple should be encouraged if**

possible to record the day of ovulation for two or three menstrual cycles and begin daily intercourse several days before the earliest recorded day. Such a method is impractical for women with advanced age, because it delays potential reproductive therapies. In the setting of advanced maternal age, more aggressive strategies in collaboration with the female fertility specialist should be considered.

Lubricants commonly used during sexual activity such as K-Y Jelly, Keri Lotion, Astroglide, and others are associated with impaired sperm motility (Sigman et al., 2009). Saliva should also be considered toxic to sperm (Sigman et al., 2009). Researchers incubated a variety of lubricants with sperm and observed that the isotonic preparation Pre-Seed did not result in a significant decrease in sperm motility or chromatin integrity as assessed by an acridine orange–based sperm chromatin structure assay (Agarwal et al., 2008a). In that study, FemGlide, Replens, and Astroglide lubricants resulted in a significant decrease in motility, and FemGlide and K-Y Jelly resulted in a significant decline in sperm chromatin quality (Agarwal et al., 2008a). Laboratory investigators have also provided evidence that use of Pre-Seed during semen collection for analysis does not affect assessment of bulk seminal parameters, sperm membrane functional integrity, levels of ROSs, total antioxidant capacity (TAC), and DNA integrity (Agarwal et al., 2013).

The urologist should inquire about erectile function, because obviously if intercourse is impeded or impossible, sperm will not be deposited successfully in the vaginal vault near the cervical os. The physiology, evaluation, and treatment of erectile dysfunction are discussed extensively elsewhere in this text.

The psychological weight of having a diagnosis of infertility and the stress of therapy are significant (Schanz et al., 2005; Volgsten et al., 2008). One metric of whether infertility is exerting an adverse psychological effect on the male is frequency of intercourse, which may be altered in up to half of men being treated for infertility and is associated with libido and sexual satisfaction (Ramezanzadeh et al., 2006). A revealing question for a man undergoing male reproductive evaluation is whether the frequency of coitus has changed during the process.

Men and women adapt to the stress of infertility in different ways with different coping mechanisms (Peterson et al., 2006). Men tend to distance themselves and problem solve, whereas women are more likely to seek social support (Peterson et al., 2006). Men and women may consequently interpret their partner's natural adaptive strategy as problematic, when in fact it is simply a different means of coping. **A common misconception is that men conflate fertility with masculinity, which in fact happens only infrequently** (Fisher et al., 2010).

Stress may impair semen quality, creating a vicious circle for men experiencing infertility and its related psychological distress (Gollenberg et al., 2010). Fortunately, evidence suggests that once men have entered into reproductive medical therapy including IVF with their partners, the diagnosis of male infertility does not disturb psychological well-being and well-adjusted relationships (Holter et al., 2007). The clinician treating male reproductive dysfunction should consider referral to a qualified psychologist to ease the transition from the fearsome diagnosis of infertility to the many effective therapies that are available. If the discussion is couched in terms of problem solving, many men are very willing to engage in psychological counseling.

Key Points: Male Reproductive History

- The most important determinant of a couple's reproductive potential is maternal age.
- Many conditions may affect male reproductive function. The examining physician may organize the male reproductive history into toxicants, infectious processes, childhood conditions, and sexual history.

Physical Examination

General Physical Examination

Because male infertility may be related to many systemic and genetic conditions, the general physical examination often yields clues as to the source of reproductive dysfunction. Male and female faces are morphologically distinct, and female facial characteristics alert the examining physician to potential sex chromosomal and androgenization disorders (Velemínská et al., 2012). Alterations in secondary sexual characteristics such as facial, truncal, axillary, and pubic hair suggest inadequate androgenization (Sigman et al., 2009). If androgenization is significantly impaired through puberty, a high-pitched voice may result (Sokol, 2009). An overabundance of endogenous or therapeutically induced estradiol may lead to gynecomastia (Sigman et al., 2009). If testosterone production during puberty is so low that closure of the epiphyses of the long bones of the extremities fails to occur, typical body morphology will include an arm span 5 cm longer than the patient's height and a lower body segment as defined by pubic-to-heel distance more than 5 cm longer than the upper body segment as measured from the crown to the pubis (Sokol, 2009).

With the lack of virilization at the anticipated time of puberty, Klinefelter syndrome is classically detailed in textbooks as resulting in gynecomastia, an eunuchoid appearance, and tall height for age (Oates and Lamb, 2009). However, it should be noted that many men with a 47,XXY karyotype do not display the typical body morphology and habitus so described.

Obesity should be noted because substantial evidence associates it with male reproductive dysfunction. **It is well established that obese men have elevated estradiol as a result of peripheral conversion from testosterone by an overabundance of adipose cells that contain the enzyme aromatase** (Aggerholm et al., 2008; Chavarro et al., 2010; Hammoud et al., 2006; Hammoud et al., 2010b; Hofny et al., 2010). A TTTA aromatase polymorphism appears to be particularly related to increasing estradiol with increasing body mass, and those with the polymorphism are most likely to experience decreasing estradiol when they lose weight (Hammoud et al., 2010b). **Serum testosterone is also well known to be lower in obese men** (Hammoud et al., 2006). Four main causes are hypothesized: negative feedback of estradiol on the hypothalamic-pituitary axis resulting in decreased LH release; increased leptin;

insulin resistance; and sleep apnea (Hammoud et al., 2006; Hofny et al., 2010). Although some studies correlate increasing obesity with decreased LH, others do not, and the mechanism of reduced testosterone in obese men may be unrelated to gonadotropins (Aggerholm et al., 2008; Hammoud et al., 2006; Hofny et al., 2010; Paasch et al., 2010; Pauli et al., 2008; Teerds et al., 2011).

SHBG is typically reduced in obese men, in general ascribed to increased circulating insulin in obesity (Hammoud et al., 2006; 2008; Pauli et al., 2008; Teerds et al., 2011). The consequence of lowered SHBG is that bioavailable testosterone may be greater than what total testosterone predicts, and an obese man may be more androgenized than expected on superficial laboratory assessment.

Researchers observed an inverse correlation between serum inhibin B concentrations and body mass index (BMI) in men but not prepubertal boys (Winters et al., 2006). The association between decreasing inhibin B and increasing obesity in men potentially indicates decreased Sertoli cell number, and the fact that the relationship is not seen before puberty suggests that obesity exerts its negative effect on Sertoli cells during puberty (Winters et al., 2006).

Although these kinds of studies have associated obesity with altered male hormones that consequently result in infertility through an endocrine effect, researchers have also implicated increased BMI with decreased paternity in investigations that suggest that the adverse effects of obesity on male reproduction may be independent of the endocrine system (Pauli et al., 2008; Stewart et al., 2009). Some evidence suggests that only extreme obesity negatively affects male fertility through an endocrine pathway (Chavarro et al., 2010). Other published studies have observed a relationship only between sperm motility and BMI but not an association with sperm concentration, suggesting that obesity may interfere primarily with epididymal function that imparts motility to sperm (Martini et al., 2010). Some studies indicate that obesity may degrade sperm DNA integrity and mitochondrial activity, whether through the final common pathway of the endocrine system or another hormonal-independent mechanism (Fariello et al., 2012a). Although this evidence suggests that the endocrine system is a probable target for impairment of reproductive effects in the male, it is likely that the full elucidation of the means by which excess adiposity exerts its effects on male reproduction is beyond such a singular process.

Male Reproductive Physical Examination

Fortunately for the examining physician, much of the male reproductive system is located outside of the body cavity, where it can be easily palpated. Because much of the male reproductive physical examination is most effectively performed with the patient standing, it is important to put the patient at ease and before a low examining table or chair, because some men develop syncope during palpation of the scrotum. Asking a man about his work often distracts him from the male genital examination (Niederberger, 2011).

If the partner of the patient is present during the history, she may relate valuable information. However, the patient may also feel reluctant to divulge specific facts of reproductive significance before his partner, and the physical examination presents an opportunity to tactfully ask her to leave the room to allow the man time to discuss issues with his physician privately (Niederberger, 2011).

Examining the Scrotum

Visual observation of the scrotum may be revealing. One or both sides may be hypoplastic, indicating an absence of the scrotal contents since birth (Niederberger, 2011). One side may be substantially larger than the other, suggesting a reactive hydrocele or tumor. A varicocele may be so large as to be visible. Finally, proximity to the thighs in a large or obese male may indicate an insufficient difference between intrascrotal and body temperature.

Examining the Testis and Epididymis

The examiner first palpates the testis and epididymis through the scrotum, noting any abnormalities. The epididymis is typically difficult to appreciate; if it is easily palpated, it is likely engorged, which suggests obstruction. Segmentation of the epididymis is also worthwhile to note: if the portion near the upper pole is easy to discern but the lower pole is not, wolffian ductal development may have been incomplete (Lewis and Kaplan, 2009).

Testis size correlates with sperm production and is consequently an important assessment in the physical examination of the infertile male (Bujan et al., 1989; Takihara et al., 1987). The size of the testis may be assessed by calipers often referred to as the *Seager orchidometer* (Fig. 66.1; Niederberger, 2011). **The long axis of the testis is gently grasped between the jaws of the calipers, and a measurement of 4.6 cm or less is associated with spermatogenic impairment**

(Schoor et al., 2001). A second method to ascertain testis size is to compare the examiner's palpation findings with a string of ellipsoids of increasing size with marked volumes as shown in Fig. 66.2 (Niederberger, 2011). **A volume of 20 mL or less is considered low** (Sigman et al., 2009). Finally, testis volume may be more directly measured by ultrasonography of the scrotum (Abdulwahed et al., 2013; Sakamoto et al., 2007a, 2007b). However, it is unclear the degree to which the incremental increase in accuracy that testis ultrasound adds to that obtained by the caliper or Prader orchidometer translates to clinically useful information (Sakamoto et al., 2007a).


SEAGER
ORCHIDOMETER
34.13
10
20
30
1
100
110
120
130
140
150
mm
4
5
6
inch
ON
OFF
ZERO

FIG. 66.1 Caliper (Seager) orchidometer.



FIG. 66.2 Prader orchidometer. (Courtesy Erler Zimmer GmbH and Co. KG, Germany.)

Examining the Spermatic Cord

Palpation of the spermatic cord yields two features of reproductive significance: whether the vas deferens is palpable, and whether a varicocele is present. The vas is a firm, cordlike structure differentiated from vasculature within the spermatic cord by the compressibility of the vessels. Because the veins within the cord may be mistaken for the vas on manual examination of the upper scrotum, absence of the vas can be a difficult physical sign to identify. **For the clinician with experience in vasectomy, one useful method of identifying whether the structure is absent is to search for the vas as if performing the first step of a vasectomy, bringing it to the surface of the skin.** If what is presumed to be the vas disappears from the examiner's fingers three times, the clinician can be confident that the vas is absent. This pearl is referred to as *Meacham's maxim* after Randall Meacham, who described the technique

(Niederberger, 2011).

Unilateral absence of the vas deferens suggests the possibility of a complete lack of wolffian ductal development on that side, including renal agenesis. In such patients, a renal ultrasound may be considered to investigate whether the patient has a solitary kidney (Niederberger, 2011). **If both vasa are absent, the man has a high likelihood of a cystic fibrosis gene mutation** (Anguiano et al., 1992). In such patients, laboratory genetic assessment of the cystic fibrosis transmembrane conductance regulator gene sequence is indicated (Bombieri et al., 2011; Lyon and Miller, 2003). As investigators observed renal agenesis in 11% of men with congenital bilateral absence of the vas deferens (CBAVD), renal ultrasound may also be considered to investigate whether a solitary kidney is present (Schlegel et al., 1996).

In addition to assessing the presence, absence, and continuity of the vas deferens, the clinician examining the upper scrotum views its surface to determine if a plexus of varicose veins arising from the spermatic cord is visible and then gently palpates to identify whether a varicocele may be felt. Although sporadic reports before 1955 described cases in which surgery on varicocele yielded evidence of improved reproductive potential, W. Selby Tulloch was the first to systematically report a series of cases of infertile men undergoing high ligation of a varicocele and subsequent improvement in sperm counts (Tulloch, 1955). Lawrence Dubin and Richard Amelar studied varicocele and its treatment in larger series and broadly educated urologic surgeons on its pathology and the merits of therapy (Dubin and Amelar, 1975; Nagler and Grotas, 2009).

The varicocele is the most commonly encountered nonductal surgically addressable pathologic entity potentially affecting male reproductive potential (Nagler and Grotas, 2009). **In general, incidence estimates in the general population range from one-fifth to one-sixth, whereas most studies suggest the incidence of varicocele in infertile males to be between one-third and one-half** (Fretz and Sandlow, 2002; Nagler and Grotas, 2009; Pryor and Howards, 1987). That not all men with varicocele are infertile remains one of the most perplexing problems in male reproductive medicine; the choice of therapy for a particular man with a varicocele is challenging.

Clinical studies of varicocele have used multiple grading systems to describe the severity of the entity, further complicating the task of the evaluating physician (Nagler and Grotas, 2009; Williams, 2011). Most systems use three or four grades; the first usually is a varicocele that cannot be palpated but can be detected only by radiographic evaluation, typically ultrasound (Dubin and

Amelar, 1970; Nagler and Grotas, 2009; Williams, 2011). Some systems differentiate varicoceles that can be palpated only during the Valsalva maneuver (Dubin and Amelar, 1970; Nagler and Grotas, 2009). Because the majority of studies concur that treatment of subclinical varicoceles does not significantly improve male reproductive potential, a sensible grading system would include these entities, which are best left untreated, to differentiate them from those that ought to be addressed with therapy (Niederberger, 2011). Likewise, the difference between varicoceles that can be seen and those that can only be felt is clinically obvious, and a reasonable grading system would differentiate the two (Niederberger, 2011). **Therefore the modern evidence-based clinical grading varicocele system includes subclinical, which is not palpable or visible and can only be detected by radiographic evaluation such as Doppler ultrasound; grade I, which is palpable only with the patient standing and performing a Valsalva maneuver; grade II, which is palpable but not visible; and grade III, a varicocele that is so large as to be visible by the examining physician through the rugae of the scrotum** (Dubin and Amelar, 1970; Nagler and Grotas, 2009; Practice Committee of the American Society for Reproductive Medicine, 2014).

Examining the Phallus

In the typical setting of intercourse, semen must be deposited proximal to the cervical os for optimal chance of reproduction. Consequently, any abnormality of the phallus that may prevent placement of the semen at that locale should be noted by the examining physician. These abnormalities include phimosis, meatal displacement in hypospadias or epispadias, and significant penile curvature (Niederberger, 2011).

Examining the Prostate and Seminal Vesicles

In general, examination of the prostate and seminal vesicles does not add a significant amount of information to the evaluation of the infertile male. If the patient is sufficiently apprehensive about digital rectal examination, it may be prudently omitted. Should rectal examination be performed, the clinician notes the size of the prostate, because it may be aplastic or hypoplastic in cases of congenital malformation or significant hypoandrogenism (Niederberger, 2011). **The seminal vesicles cannot typically be palpated; if they are palpable, it is an abnormal finding suggesting engorgement and possible ejaculatory**

ductal obstruction (Niederberger, 2011).

Key Points: Male Reproductive Physical Examination

- Obesity impairs male reproductive potential by endocrine-dependent and endocrine-independent mechanisms.
- Testis size directly reflects spermatogenic mass.
- Unilateral absence of the vas deferens suggests a wolffian ductal anomaly; bilateral absence is associated with mutations in the gene responsible for cystic fibrosis. In both, renal agenesis may result.

Laboratory Evaluation of Male Infertility

Like other aspects of urology, much can be learned about the condition of male infertility from blood tests, in this case, primarily of the endocrine system. Also similar to other urologic fields, genomic assessment of male reproductive function is a burgeoning area of research and increasing clinical usefulness. However, the laboratory inquiry into male infertility also includes a way of directly appraising the severity of the condition by observing the male gametes in the semen analysis. These three general laboratory assessments make up the laboratory evaluation of male infertility: the endocrine evaluation, analysis of semen, and genomic assessment.

Endocrine Evaluation

Because spermatogenesis is highly dependent on intratesticular testosterone synthesis, it is unsurprising that hypoandrogenism is associated with male infertility. Testosterone levels in men vary widely, and most investigators use either 280 ng/dL or 300 ng/dL as a threshold for adequate androgenization in a man (Petak et al., 2002; Sokol, 2009). Approximately 45% of men with azoospermia caused by spermatogenic dysfunction are observed to have testosterone levels less than 300 ng/dL. Serum testosterone below that threshold is found in 43% of men with oligospermia and 35% of men in an infertility clinic with sperm density greater than the threshold of 20 million/mL specified in the fourth edition of the WHO laboratory manual for the examination and processing of human semen (Sussman et al., 2008). Because 90% of men with sperm density of 22 million/mL or less will not have conceived with their partners within 1 year, many with sperm density less than that value are expected to have pathologic reproductive dysfunction; consequently in approximately one-third, it is likely related to endocrinopathy (WHO, 2010). **Androgenization should therefore be assessed by laboratory evaluation in all men presenting for infertility, including those in whom sperm density is greater than 20 million/mL.** An upper limit of sperm density has not been established above which endocrine dysfunction is unlikely to be discovered. Clinicians may reasonably use the 50th percentile value in the 5th edition of the WHO manual of 73 million/mL with time to pregnancy within 1 year as a guide, suggesting that a full endocrine evaluation is not necessary (WHO, 2010).

Testosterone circulates in three main forms: tightly bound to SHBG; loosely bound to protein, primarily albumin; and unbound or free (Matsumoto and Bremner, 2011). The forms inducing cellular activity are free and loosely bound together, comprising what is referred to as *bioavailable testosterone* (Matsumoto and Bremner, 2011). In the healthy man, 30% to 44% of circulating testosterone is bound to SHBG, 54% to 68% is loosely bound to albumin, and 0.5% to 3.0% is unbound (Matsumoto and Bremner, 2011). **Using a threshold of 300 ng/dL for testosterone and the lower limit of 54.5% for percent bioavailable testosterone, a reasonable lower limit for the concentration of bioavailable testosterone would consequently be 164 ng/dL.**

SHBG is altered in a variety of medical conditions and states such as obesity and aging (Box 66.1; Bhasin et al., 2010). The clinician cannot rely on total testosterone to gauge bioavailable testosterone. Because obtaining an accurate laboratory assessment of free testosterone can be difficult, a practical method of determining bioavailable testosterone is to calculate it from total testosterone, SHBG, and albumin (Vermeulen et al., 1999). Internet-based and smartphone calculators are available; as of this writing, the International Society for the Study of the Aging Male hosts a calculator at www.issam.ch/freetesto.htm, and a calculator for iOS devices may be found at http://itunes.apple.com/us/app/bioavailable-testosterone/id308770722.

Box 66.1

Conditions Associated With Altered Sex Hormone–Binding Globulin (SHBG) Concentrations

Conditions Associated With Decreased SHBG

- Obesity
- Nephrotic syndrome
- Hypothyroidism
- Glucocorticoids, progestins, and androgenic steroid therapy
- Acromegaly
- Diabetes mellitus

Conditions Associated With Increased SHBG

Aging
Hepatic cirrhosis and hepatitis
Hyperthyroidism
Anticonvulsant therapy
Estrogen therapy
Human immunodeficiency virus disease

Modified from Bhasin S, Cunningham GR, Hayes FJ, et al.: Testosterone therapy in men with androgen deficiency syndromes: an Endocrine Society clinical practice guideline. *J Clin Endocrinol Metab* 95:2536–2559, 2010.

In young, healthy men, total serum testosterone exhibits a circadian rhythm, with a peak in the early morning and trough levels in the late afternoon (Plymate et al., 1989). SHBG displays an opposing circadian rhythm in men of all ages, with a peak in the late afternoon and a trough in the early morning (Plymate et al., 1989). **Consequently, bioavailable testosterone demonstrates a marked circadian rhythm in young, healthy men, with a peak in the early morning and trough in the late afternoon** (Plymate et al., 1989). In older men, total testosterone and its circadian rhythm are attenuated, and the circadian rhythm and concentration of bioavailable testosterone are substantially diminished (Plymate et al., 1989). To standardize sampling of total and bioavailable testosterone in all men, assays are typically performed in the morning, although the necessity of such timing is more important in younger men.

In the case of hypoandrogenism, a pituitary or testicular source is identified by assessing LH (Niederberger, 2011). If testicular Leydig cell dysfunction is the cause, LH is elevated to varying degrees (Niederberger, 2011). In the case of pituitary dysfunction, LH is decreased (Niederberger, 2011). The clinician may assess LH after total or bioavailable testosterone returns with a low value, or, for efficiency, both assays may be performed simultaneously. Because testosterone and LH are released in a pulsatile fashion, borderline results may be investigated further by obtaining three morning samples at 20-minute intervals (Sokol, 2009). Historically, clinicians pooled these samples for a single measure, but three separate assay results may be determined and arithmetically averaged.

The Sertoli cell products inhibin B and activin regulate pituitary follicle-stimulating hormone (FSH) by respectively inhibiting and stimulating its release (Caroppo, 2011). Because the Sertoli cells are regulated by robust paracrine interaction with germ cells, with depopulation of the latter, inhibin levels decrease and FSH consequently increases (Niederberger, 2011). Clinicians have consequently used FSH as an indirect assessment of germ cell mass; higher concentrations of FSH indicate increasing germ cell dysfunction and depopulation (Niederberger, 2011). **Combined with testis size as measured by a caliper orchidometer, FSH is an accurate predictor of whether azoospermia is a result of obstruction or spermatogenic dysfunction: 96% of men with obstructive azoospermia had FSH assay values of 7.6 IU/L or less and testis long axis greater than 4.6 cm, whereas 89% of men with azoospermia caused by spermatogenic dysfunction had FSH values greater than 7.6 IU/L and testis long axis 4.6 cm or less** (Schoor et al., 2001). In the case of male reproductive dysfunction in which sperm is present in the ejaculate, the odds ratio of abnormal sperm concentration increased markedly at an FSH value of 4.5 IU/L, suggesting another threshold that the clinician may use to assess male reproductive dysfunction (Gordetsky et al., 2011).

Assays of inhibin B are clinically available, and investigators have investigated whether measuring inhibin B directly is a more accurate assessment of spermatogenic function than the indirect assay of FSH (Grunewald et al., 2013; Jørgensen et al., 2010; Kumanov et al, 2006; Muttukrishna et al., 2007; Myers et al., 2009; van Beek et al., 2007). In general, these studies include analyses of correlation between inhibin B or FSH and sperm parameters or testis parameters measured by physical examination. Many studies observe greater accuracy with measuring inhibin B than with FSH in these correlations, and some data suggest that lower ranges of inhibin B allow improved correlation (Grunewald et al., 2013; Kumanov et al., 2006; Myers et al., 2009; van Beek et al., 2007). **However, the incremental improvement in accuracy is typically small, and inhibin and FSH provide clinically useful markers of spermatogenic function** (Myers et al., 2009). The clinician may consequently use either marker based on cost and availability.

Like inhibin B, AMH is a member of the transforming growth factor-β (TGF-β) family synthesized by Sertoli cells, and investigators have studied its use as an assay in assessing spermatogenic function (Fénichel et al., 1999; Fujisawa et al., 2002; Muttukrishna et al., 2007). Although results from pilot studies are encouraging, reported data sets remain small, and use of AMH is considered primarily experimental.

Aromatase enzymes convert cholesterol-based molecules such as testosterone to estrogens and are found in many organ systems including testis, adipose tissue, liver, and brain (Kim et al., 2013). Estradiol is consequently measurable in men, and investigators have proposed that elevated estradiol adversely affects male reproductive potential (Gregoriou et al., 2012; Raman and Schlegel, 2002; Schlegel, 2012). **A ratio of total testosterone to estradiol below 10 : 1 is suggested to indicate reproductive dysfunction** (Gregoriou et al., 2012; Raman and Schlegel, 2002; Schlegel, 2012). Unfortunately, the full scope of the role of estradiol is unknown, but low levels may adversely affect male reproductive potential as well (Schulster et al., 2016). Although there is a primarily inhibitory effect in somatic cells, and, subsequently, spermatogenesis, there is a stimulatory effect in germ cells. It has been shown that estradiol has a dose-dependent, nonadditive effect in germ cell proliferation. Lack of functional aromatase also leads to dysfunctional spermatogenesis (Carreau et al., 2002; Robertson et al., 1999).

The pituitary hormone prolactin is known to inhibit gonadotropins and suppress testosterone production in men; prolactin levels may be elevated in pituitary hyperplasia, adenoma, or tumors (Sokol, 2009). Clinically significant disease of the pituitary is typically associated with symptoms such as visual field changes, headache, or erectile dysfunction (Niederberger, 2011). Prolactin assay should be considered when these symptoms accompany male infertility, especially if total or bioavailable testosterone is low. However, the incidence of clinically significant prolactinoma is very low in infertile males, with only four detected in 1035 men in one large screening study, and prolactin need not be routinely included in the initial endocrine evaluation of an infertile man (Sigman and Jarow, 1997). Prolactin is commonly a labile assay; if its levels are elevated, repetition of the test is warranted (Niederberger, 2011). Assessment of other pituitary hormones such as thyroid-stimulating hormone, adrenocorticotropic hormone, or growth hormone is indicated if a space-occupying pituitary lesion is suspected or found on imaging examination (Sokol, 2009). Likewise, should signs of other endocrine disease such as exophthalmos, striations, moon facies, or facial bony changes be observed, thyroid hormone, cortisol, or growth hormone assays may be entertained. However, they need not be included in the initial screening evaluation of an infertile man. **A reasonable initial laboratory screen to assess an endocrine basis for male reproductive dysfunction should be performed in the morning and includes total testosterone, SHBG, and albumin to calculate bioavailable testosterone; LH and FSH to gauge pituitary function; and estradiol to evaluate aromatization.**

Men with a history of congenital adrenal hyperplasia (CAH) may develop testicular adrenal rest tumors and infertility later in life (Aycan et al., 2013; Pierre et al., 2012). In these patients, serum 17-hydroxyprogesterone, Δ4-androstenedione, renin, and testosterone can be used to assess response to therapy (Pierre et al., 2012).

Evaluation of Semen

Reproduction is a probabilistic system: the more viable sperm that begin their journey in the female reproductive tract, the greater the chance that one will penetrate and fertilize the ovum. In this sense, there is only one definitive result of a semen analysis, and that is the condition in which no sperm are present; only in that case can a man be absolutely considered sterile.

In 1951 the physiologist John MacLeod published the first stringent statistical assessment comparing what could be observed under the light microscope in semen from men who had successfully impregnated their partners versus semen of men who had not done so (MacLeod, 1951). MacLeod applied a descriptive statistical approach, computing cumulative probability histograms for each observable parameter and determining quartiles for each of the two groups of men (MacLeod, 1951). Basic parameters studied included the concentration of sperm, their movement, and their shape (MacLeod, 1951). What is immediately evident from MacLeod's seminal publication is that the histograms for sperm parameters from fertile and infertile men are largely overlapping, meaning that a substantial range of values for any parameter does not discriminate between male fertility and infertility (MacLeod, 1951). MacLeod sensibly approached this problem by considering lower sperm parameter values to be more appropriate thresholds for suggesting male infertility; however, values above these lower thresholds do not confirm fertility (MacLeod, 1951). This was difficult to grasp in clinical implementation. The field of reproductive medicine is rife with the incorrect assumption that should a parameter be above a threshold—for example, sperm concentration greater than 20 million/mL—then the man is considered fertile. The only conclusion that may be drawn from such a comparison is that if the parameter is lower than the threshold, the man is likely to be infertile; the converse is not necessarily true.

One general approach to the problem of an assay for which the values representing disease and health are overly coincident is to establish two thresholds, beyond which health or disease is probable, and within which no predictive statement can be made. In one study to develop two such sets of thresholds for semen analysis, investigators applied the computational method classification and regression tree (CART) analysis to semen analyses from fertile men and those whose wives were undergoing intrauterine insemination (IUI) and for whom female infertility had been largely excluded (Guzick et al., 2001). **As an example, for sperm concentration, 13.5 million/mL was found to be the lower parameter, and 48.0 million/mL was identified as the upper parameter** (Guzick et al., 2001). Using these parameters, the clinician would counsel a man whose sperm concentration was less than 13.5 million/mL that he was likely infertile, and one with a concentration greater than 48.0 million/mL that he was likely fertile. Should the man's concentration be greater than 13.5 million/mL and less than 48.0 million/mL, no assessment of fertility potential could be accurately made.

Bulk Semen Parameters and the World Health Organization Criteria

Building on the original work by MacLeod and deriving consensus from a group of experts, WHO established criteria for semen analysis parameters in its laboratory manual for the examination and processing of human semen (Cooper et al., 2010; Niederberger, 2011; Murray et al., 2012; WHO, 2010). For the first four editions of the manual, criteria were set by both expert panel and survey data and included such thresholds as sperm density of 20 million/mL, which would be judged as a reasonable number below which a man should be considered likely infertile (Cooper et al., 2010; Murray et al, 2012; Niederberger, 2011; WHO, 2010). The problems with such a set of criteria are evident: the sperm density of fertile men may be found below the thresholds and that of infertile men above.

The 5th edition of the WHO laboratory manual departed from the previous four by emphasizing the statistical description of the population of men on which it was based (Cooper et al., 2010; WHO, 2010). Values for percentiles of semen parameters from men whose partners became pregnant within 1 year of discontinuation of contraceptives are tabulated, allowing the clinician to compare an infertile patient's results with a fertile cohort (Table 66.2; Cooper et al, 2010; WHO, 2010). Two limitations of such an approach are clear: first, the data are derived from a fertile population and not an infertile one, and second, the clinician cannot rely on descriptive statistics to predict outcomes. Nonetheless, the manual's tables offer the physician useful comparative information that would be otherwise unavailable in evaluating and treating infertile men.

TABLE 66.2

Bulk Semen Analysis Parameter Percentiles

PERCENTILE	2.5	95% CI	5	95% CI	10	25	50	75	90	95	97.5
Semen volume (mL)	1.2	(1.0–1.3)	1.5	(1.4–1.7)	2	2.7	3.7	4.8	6	6.8	7
Sperm concentration (million/mL)	9	(8–11)	15	(12–16)	22	41	73	116	169	213	259
Total number (million/ejaculate)	23	(18–29)	39	(33–46)	69	142	255	422	647	802	928
Total motility (%)	34	(33–37)	40	(38–42)	45	53	61	69	75	78	81
Progressive motility (%)	28	(25–29)	32	(31–34)	39	47	55	62	69	72	75
Normal forms (%)	3	(2.0–3.0)	4	(3.0–4.0)	5.5	9	15	24.5	36	44	48
Vitality (%)	53	(48–56)	58	(55–63)	64	72	79	84	88	91	92

CI, Confidence interval.

Modified from Cooper TG, Noonan E, von Eckardstein S, et al.: World Health Organization reference values for human semen characteristics. *Hum Reprod Update* 16(3):231–245, 2010.

Somewhat confusingly, the 5th edition of the manual published alongside the full percentile table a separate list of the 5th percentiles and their 95% confidence intervals (CIs) (Cooper et al., 2010; WHO, 2010). For example, the 5th percentile value for sperm density is 15 million/mL with a 95% CI range of 12 to 16 million/mL (Cooper et al., 2010; WHO, 2010). Although the authors of the companion publication to the manual very clearly describe the problems inherent in using thresholds derived from descriptive statistics of a fertile male population, the enumeration of the 5th percentile values has appeared to spur their use as new thresholds. The best use of the tables in the 5th edition of the manual would be for the urologist to present to a man alongside the patient's own parameters as a reference for an ultimately fertile population, but clinical reality dictates that physicians and patients are interested in defining what represents infertility to consider when medical or surgical therapy is appropriately invoked. Communicating the 5th percentile value as one that likely represents infertility and the 50th percentile as typical for a man conceiving with his wife within 1 year is reasonable practice for clinical urology. As an example, sperm density lower than 15 million/mL would suggest infertility, and 73 million/mL would be considered typical (Cooper et al., 2010; WHO, 2010).

To complicate matters, semen analysis parameters are highly variable, and investigators typically recommend a minimum of two analyses separated by 2 to 3 weeks for assessment (Centola, 2011). Although data exist to the contrary, most investigators observe a decline in bulk seminal parameters with increasing days of abstinence, and variability in abstinence may be responsible for variability in semen analysis results (Elzanaty, 2008; Levitas et al., 2005; Keel, 2006; Keihani et al., 2017). Consequently, the physician evaluating a man for his reproductive potential should ensure that the duration of abstinence before an ejaculated specimen is as constant as possible. **Historically, men were instructed to wait 2 to 5 days after an ejaculation to submit a sample for semen analysis** (Centola, 2011; WHO, 2010). **More recent studies suggest that a single day of abstinence is optimal for assessing bulk seminal parameters** (Elzanaty, 2008; Levitas et al., 2005).

A nontoxic wide-mouthed glass or plastic cup is used to collect the semen sample (WHO, 2010). In the case of religious or cultural stipulations that do not allow collection by masturbation, a special nontoxic condom may be used (WHO, 2010).

The physical and chemical characteristics of a semen sample are first assessed before microscopic examination. Ejaculated semen first forms a coagulum, and the sample is allowed to liquefy for 30 minutes before evaluation (Centola, 2011). Viscosity is assessed by aspiration into a pipette and measuring the length of the drop that forms, which should be no longer than 2 cm (Centola, 2011; WHO, 2010). The sample is then inspected visually for coloration. A normal ejaculate is white or light gray; a yellow or green hue may indicate infection, jaundice, or vitamins or medication; brown is often observed in spinal cord–injured men; and red suggests blood (Centola, 2011; WHO, 2010).

Historically, semen pH was reported, but its measurement is no longer recommended because environmental conditions may alter it, and the original intent of using pH to gauge whether obstruction exists is hampered by the vast difference in size between a hydrogen ion and sperm head (Centola, 2011). For bulk seminal parameters describing microscopic features, a specialized slide with a compartment with defined volume such as a hemocytometer or Makler counting chamber is typically used (Centola, 2011).

Semen Volume.

Often unreported by laboratories infrequently performing semen analysis, semen volume is clinically important (Niederberger, 2011). Conditions causing seminal hypovolemia include anatomic factors, such as ejaculatory ductal obstruction or hypoplasia of the prostate and seminal vesicles as may occur in severe androgen deficiency or CBAVD; functional issues, such as in retrograde ejaculation; neurologic conditions, such as in spinal cord injury, diabetes mellitus, or multiple sclerosis; and pharmacologic factors, which may occur in men prescribed α-adrenergic blocking agents such as tamsulosin (Niederberger, 2011; Sigman et al., 2009). The 5th percentile for volume according to the 5th edition of the WHO laboratory manual is 1.5 mL with a 95% CI of 1.4 to 1.7 mL, and the 2.5th percentile is 1.2 mL with a 95% CI of 1.0 to 1.3 mL (WHO, 2010). **For practical purposes, the most frequently used threshold value for volume is 1.0 mL to initiate evaluation for seminal hypovolemia** (Niederberger, 2011).

Aspermia, dry ejaculate, and *anejaculation* refer to the condition in which no fluid is discharged from the urethra during male orgasm (Sigman et al., 2009). It is caused by the same conditions associated with seminal hypovolemia (Niederberger, 2011; Sigman et al., 2009). **If aspermia or seminal hypovolemia is observed, a postejaculatory urinalysis is performed to identify retrograde ejaculation, and some form of investigation such as transrectal ultrasonography (TRUS) is conducted to evaluate whether ejaculatory ductal obstruction may be present** (Niederberger, 2011; Sigman et al., 2009). For postejaculatory urinalysis, the patient is instructed to void before ejaculation for a semen analysis and then to urinate after collection of the semen sample into separate containers (Sigman et al., 2009). The urine is reconstituted by centrifugation, and the number of sperm in the pellet is counted (Sigman et al., 2009). A small number of sperm in the urine is of little consequence if the number of sperm in the antegrade sample is large. In general, if the number of sperm in the urine nears or exceeds that in the antegrade specimen, retrograde ejaculation is considered clinically significant (Sigman et al., 2009).

Seminal hypervolemia with an ejaculate volume exceeding 5 mL is a rare condition (Sigman et al., 2009). It is proposed to interfere with male reproduction by diluting sperm (Sigman et al., 2009). If a too-large seminal volume is of concern, the sperm may be reconstituted by processing into a smaller volume and IUI performed (Centola, 2011; Sigman et al., 2009).

Sperm Density.

Sperm density or concentration is typically recorded in millions per milliliter. The term *oligospermia* or *oligozoospermia* refers to low sperm density, and *cryptozoospermia* denotes sperm so few as to be difficult to reliably measure (Niederberger, 2011). The 5th percentile for sperm density according to the 5th edition of the WHO laboratory manual is 15 million/mL with a 95% CI of 12 to 16 million/mL, and the 50th percentile is 73 million/mL (Cooper et al., 2010; WHO, 2010). Previous editions of the WHO laboratory manual included a threshold for sperm density of 20 million/mL, and it was common in the past for practitioners to define oligospermia as lower than that value. With the descriptive tabulation of sperm parameters in the 5th edition of the WHO manual, oligospermia is more appropriately defined in a clinical context: a man with a single semen sample demonstrating 10 million/mL who has had no difficulty impregnating his wife may not be oligospermic, whereas one with small testes, an elevated FSH, and densities on several semen analyses ranging from 20 to 25 million/mL may be reasonably considered oligospermic. **As mentioned previously, a large CART analysis revealed 13.5 million/mL to be a lower parameter for sperm density and 48.0 million/mL to be an upper parameter** (Guzick et al., 2001). In CART analysis, the ROC AUC for sperm density was 0.60, indicating relatively poor discriminating ability between fertile and subfertile subgroups (Guzick et al., 2001).

Total sperm count or number is calculated by multiplying semen volume and sperm density and is typically recorded in millions (Niederberger, 2011). The 5th percentile for total sperm number according to the 5th edition of the WHO laboratory manual is 39 million with a 95% CI of 33 to 46 million, and the 50th percentile is 255 million (Cooper et al., 2010; WHO, 2010).

Sperm Motility.

Sperm motility is assessed optimally within 30 minutes of liquefaction and refers to a percentage of sperm observed with defined motion (WHO, 2010). Low motility is termed *asthenospermia* or *asthenozoospermia* (Niederberger, 2011). The 5th edition of the WHO manual classifies motility into three categories—progressive, nonprogressive, and immotility—replacing the four categories of older grading systems (a through d, where a and b indicated “rapid” and “slow” progressive motility; WHO, 2010). *Progressive motility* is defined as sperm “moving actively, either linearly or in a large circle, regardless of speed,” and nonprogressive motility is defined as “all other patterns of motility with an absence of progression” (WHO, 2010). The 5th percentile for progressive motility according to the 5th edition of the WHO laboratory manual is 32% with a 95% CI of 31% to 34%, and the 50th percentile is 55% (Cooper et al., 2010; WHO, 2010). **CART analysis revealed 32% to be a lower parameter for sperm motility and 63% to be an upper parameter** (Guzick et al., 2001). In CART analysis, the ROC AUC for sperm motility was 0.59, revealing low discriminating ability for this parameter (Guzick et al., 2001).

Sperm Morphology.

Human sperm is highly pleomorphic with more bizarrely shaped sperm in any man's ejaculate than those with configuration anticipated to successfully penetrate and fertilize an ovum (Niederberger, 2011). An overabundance of abnormal forms is termed *teratospermia* or *teratozoospermia* (Niederberger, 2011). Earlier editions of the WHO manual described fairly generous criteria as characterizing an acceptably shaped sperm, and even then, the majority of sperm were classified as misshapen in a normal semen analysis (Niederberger, 2011). **In an attempt to improve the predictive capability of sperm morphology, Kruger proposed a grading system in which several aspects of sperm were assessed, and if any one was out of range, the sperm was counted as abnormal** (Kruger et al., 1987; van der Merwe et al., 2005). This system is variably referred to as “strict” morphology, “Kruger” morphology, and “Tygerberg” morphology, and as a result of the more stringent criteria defining a normal sperm, thresholds in the range of 5% typically characterize a normal ejaculate (van der Merwe et al., 2005). The 5th edition of the WHO manual adopted strict morphology as its assessment of sperm shape (WHO, 2010). The 5th percentile for normal morphologic forms according to the 5th edition is 4% with a 95% CI of 3.0% to 4.0%, and the 50th percentile is 15% (Cooper et al., 2010; WHO, 2010). CART analysis revealed 9% to be a lower parameter for strict morphology and 12% to be an upper parameter (Guzick et al., 2001). In CART analysis, the ROC AUC for sperm motility was 0.66, with the bulk parameters of density and motility revealing low discriminating capacity (Guzick et al., 2001).

The clinical predictive value of strict morphology is questionable. Although limited data suggest that the parameter may be associated with embryo formation, the majority of studies support that strict morphology is unassociated with sperm nuclear integrity and that it does not predict natural conception, IUI, or IVF outcomes (Avendaño et al., 2009; Dayal et al., 2010; Dubey et al., 2008; French et al., 2010; Keegan et al., 2007; Lockwood et al., 2015; Morbeck et al., 2011; Sripada et al., 2010). To complicate matters, evidence suggests that as laboratory technicians have learned to inspect each sperm more closely for eccentricities of shape, an increasing number of men are described as having lower percentages of sperm with normal morphology (Morbeck et al., 2011). The practical implication of this trend is that currently many men who seek evaluation are identified as having isolated teratozoospermia and are likely to have adequate reproductive potential.

Conditions exist in which specific biologic defects are associated with the majority of sperm. For example, should the acrosome fail to form, the preponderance of sperm will have small, round heads, a disorder referred to as *globozoospermia* (WHO, 2010). During spermiation, if the basal plate does not attach to the nucleus opposite the acrosome, the heads are absorbed (WHO, 2010). This defect results in only tails observed and is termed *pinhead sperm* (WHO, 2010). Undoubtedly, these relatively uncommon specific morphologic conditions affect male reproductive potential.

In an attempt to correlate sperm nuclear ultrastructure with reproductive outcomes, investigators examined sperm with an inverted light microscope outfitted with high-power Nomarski differential interference contrast optics, allowing for magnification of the field over 6000× (Bartoov et al., 2001). This technique was termed *motile sperm organelle morphology examination (MSOME)* (Bartoov et al., 2001). The theoretic advantage of MSOME is that it is a nondestructive method of assessing sperm nuclear morphology, and a sperm chosen by this method of high magnification visual inspection could be subsequently used in IVF techniques (Bartoov et al., 2001). Early use of MSOME appeared to lead to improved pregnancy rates in IVF by screening those sperm with an overabundance of vacuoles in the sperm nucleus (Bartoov et al., 2001, 2003; Berkovitz et al., 2006). However, later studies questioned whether sperm so chosen actually led to improved IVF outcomes (Gatimel et al., 2016; Perdrix and Rives, 2013). In fact, one study argued that sperm nuclear vacuoles are a physiologic part of a normal sperm maturational process (Tanaka et al., 2012). At this point, MSOME is best considered primarily an investigational rather than a clinical tool.

Sperm Vitality.

Vitality refers to the portion of sperm that are metabolically active living cells (Niederberger, 2011; WHO, 2010). *Necrospermia* or *necrozoospermia* is the condition describing a large number of nonliving sperm (Niederberger, 2011).

The assessment of whether sperm are living is essential if near or total asthenospermia is observed to discriminate whether the lack of motility is a result of cell death or of dysfunction of molecular processes involved in sperm motion (Niederberger, 2011; WHO, 2010). If the test is purely diagnostic and the sperm are not to be used in IVF, it is performed by staining with eosin Y and with or without nigrosin (Niederberger, 2011; WHO, 2010). A metabolically active sperm excludes the eosin Y dye, whereas a dead one cannot and absorbs the pigment (Niederberger, 2011; WHO, 2010). Nigrosin darkens the background and increases the contrast between it and the live sperm heads, allowing them to be identified more easily (WHO, 2010). The 5th percentile for sperm vitality according to the 5th edition of the WHO laboratory manual is 58% with a 95% CI of 55% to 63%, and the 50th percentile is 79% (Cooper et al., 2010; WHO, 2010).

A method of assessing sperm vitality in a nondestructive manner amenable to subsequent use in IVF is the hypo-osmotic swelling (HOS) test (Jeyendran et al., 1984). When incubated in hypo-osmotic medium, the tails of live sperm with unimpaired membranes swell within 5 minutes, allowing for identification of viable gametes (WHO, 2010).

Computer-Assisted Semen Analysis.

Assessment of bulk seminal parameters is complex and laborious (Rothmann and Reese, 2009; WHO, 2010). The quality control mechanisms required for an accurate and reliable semen analysis performed by a capable laboratory technician are exacting and involved (Rothmann and Reese, 2009; WHO, 2010). Unfortunately, not all laboratories that offer semen analyses adhere to rigid quality assurance methods (Rothmann and Reese, 2009). It is consequently incumbent on the urologist to ensure that the semen analysis laboratory providing results uses sufficient quality standards to allow meaningful interpretation.

With the complexity associated with providing an accurate and reliable semen analysis, several manufacturers provide systems that automate the process of assessing sperm parameters such as motility, density, and morphology (Rothmann and Reese, 2009; WHO, 2010). Along with image motion analysis, these computer-assisted semen analysis (CASA) systems also provide a variety of additional parametric assessments for moving sperm, including curvilinear velocity, rectilinear velocity, average path velocity, amplitude of lateral head displacement, linearity, wobble, straightness, beat-cross frequency, and mean angular displacement (WHO, 2010). Unfortunately, although CASA systems can rival or even exceed the precision and reproducibility of bulk semen analyses performed manually by a technician, they are still plagued by the same methodologic challenges such as optics and sample preparation, and their performance notably degrades at low sperm concentrations (Rothmann and Reese, 2009; WHO, 2010). Consequently, most high-quality laboratories combine some or much manual assistance if CASA is used (Rothmann and Reese, 2009). The highly specialized parametric assessments of motion such as curvilinear velocity are at this time primarily research rather than clinical tools (Rothmann and Reese, 2009).

Secondary Semen Assays

The haploid male gamete expresses different surface antigens than the remainder of diploid cells in the male body and consequently must be protected from the immune system by tight junctions between Sertoli cells (Walsh and Turek, 2009). If this “blood-testis barrier” is disrupted, sperm exposed to the immune system may incite an immune response of varying severity involving secretory and humoral immunoglobulins and affecting multiple regions of the surface of the sperm cell (Walsh and Turek, 2009). **Conditions observed to be associated with antisperm antibody formation include vasectomy, testis trauma, orchitis, cryptorchidism, testis cancer, and varicocele** (Walsh and Turek, 2009).

Leukocytes may be harmful to sperm, with evidence suggesting that production of ROSs may be the destructive mechanism (Agarwal et al., 2006; Aktan et al., 2013; Desai et al., 2009; Domes et al., 2012; Lackner et al., 2006; Pasqualotto et al., 2000). Moderate levels of leukocytes in semen may be physiologic and may even be beneficial for sperm function (Barraud-Lange et al., 2011).

Use of an assay for antisperm antibodies should be entertained if agglutination of sperm is observed or if sperm motility is decreased, especially if conditions associated with antisperm antibodies exist (Brannigan, 2011; Niederberger, 2011; Walsh and Turek, 2009; WHO, 2010). Two types of assays for antisperm antibodies are available: those that test for immunoglobulins on the surface of sperm are referred to as *direct* tests, and those that measure antibodies in fluid such as seminal plasma or serum are *indirect* assays (Brannigan, 2011; WHO, 2010). **Direct assays are preferred for clinical relevance, because antibodies in plasma or serum may not correlate to sperm surface binding** (Brannigan, 2011; Niederberger, 2011; Walsh and Turek, 2009). Because of its large size, immunoglobulin M (IgM) is present in very low quantities if at all in semen, and consequently IgG and IgA are the primary assay targets (Brannigan, 2011; Niederberger, 2011; Walsh and Turek, 2009).

Two direct assays are available: the mixed antiglobulin reaction (MAR) test and the immunobead assay (Brannigan, 2011; WHO, 2010). The MAR test uses latex beads coated with an anti-IgG or anti-IgA “bridging” antibody incubated with sperm, whereas the direct immunobead test involves polyacrylamide beads coated with rabbit immunoglobulins against human IgG or IgA (Brannigan, 2011; WHO, 2010). **In both cases, after incubation the technician identifies the presence of antisperm antibodies by association of moving particles proximal to motile sperm, and thus some amount of sperm motion is essential for these assays; complete asthenospermia renders direct antisperm antibody assays unable to be performed** (Brannigan, 2011; Niederberger, 2011; WHO, 2010). The direct immunobead test is more laborious than the MAR assay but yields more precise information (WHO, 2010).

The WHO laboratory manual loosely specifies 50% as a threshold for the MAR and immunobead tests and notes that reference values are not established, leaving the interpretation of these assays to the physician considering the degree and localization of antisperm antibody binding and the clinical context (WHO, 2010). Sperm head binding is considered to be of greater clinical significance than tail binding (Niederberger, 2011).

Pyospermia Assays.

Under phase contrast microscopy without staining, leukocytes and immature germ cells are indistinguishable (Brannigan, 2011). Consequently, when faced with a report indicating an abundance of cells resembling leukocytes observed only with phase contrast microscopy, the evaluating physician cannot accurately diagnose pyospermia (Brannigan, 2011). Fortunately, laboratory testing to evaluate the presence of leukocytes is not difficult. The Papanicolaou stain may be used to differentiate leukocytes from immature germ cells based on nuclear morphology (WHO, 2010). **The current consensus threshold for leukocytes according to the WHO laboratory manual is 1 million/mL** (WHO, 2010). Semen cultures are generally unhelpful because positive results in asymptomatic men have not been shown to have clinical significance (Moretti et al., 2009; Shalika et al., 1996). If a patient is symptomatic, the prostatitis algorithm found elsewhere in this book may be followed. If pyospermia is excluded, the patient can be reassured that the presence of immature germ cells is common and not of pathologic significance (Brannigan, 2011).

Tertiary and Investigational Sperm Assays

The limitations of bulk seminal parameters spawned myriad additional means to assess sperm structure and function in hopes of better diagnosing male reproductive dysfunction, applying therapies, and predicting outcomes in techniques such as IVF. Most are promising, but few are even close to proven. Many provide insight into the biologic processes involved in reproduction, but similarly designed studies report conflicting results when these assays are applied to clinical problems. Emphasizing a lack of consensus on how they are to be used clinically, the 5th edition of the WHO manual details these assays in its “research procedures” chapter (WHO, 2010). The prudent practitioner will continue to follow the literature as it evolves and use these assays clinically should a clear consensus emerge regarding usefulness.

Sperm DNA Integrity Assays.

Sperm DNA molecular and spatial organization is highly specific to cells of the male gamete. Sperm DNA is six times more compact than in somatic cells, and it is arranged with protamines to form tightly linear side-by-side sheets (Ward and Coffey, 1991). Investigators have hypothesized that fragmentation or disturbances in DNA arrangement lead to aberrations in sperm function, fertilization, implantation, and pregnancy (Agarwal et al., 2003; Lewis et al., 2013). Conflicting data and opinions abound in testing this hypothesis, indicating that our understanding of the role of sperm DNA quaternary structure is limited, the assays available are imperfect, or both. Poor sensitivity and specificity of the current testing modalities have prevented widespread acceptance of the utility of DNA integrity testing. The lack of standardized testing protocols and diagnostic thresholds has led to a significant ongoing debate on the applicability and prognostic value of such testing. The current published literature does not provide clear evidence to support routine use.

In general, there are two types of test methods that assess DNA structural integrity (Sakkas and Alvarez, 2010). In one, DNA fragmentation is measured directly (Sakkas and Alvarez, 2010). In general, this type of assessment is preferred by andrology laboratories at present because it appears to more effectively correlate with clinical outcomes (Sakkas and Alvarez, 2010). In the other, DNA is denatured before analysis (Sakkas and Alvarez, 2010). In a comprehensive meta-analysis, higher rates of miscarriage were associated with an overall approximately double risk ratio with increasing sperm DNA fragmentation, but different assays yielded markedly different risk ratios (Robinson et al., 2012).

TUNEL Assay.

The terminal deoxynucleotidyl transferase dUTP nick end labeling (TUNEL) assay represents a general method in widespread use in molecular biology to assess DNA fragmentation by labeling the terminal end of nucleic acid strands with a fluorescent marker, and it was adopted in the andrology laboratory with various modifications to detect sperm head DNA fragmentation (Gavrieli et al., 1992; Mitchell et al., 2011). Fig. 66.3 details one method. In panels A and B, a fluorescent stain that binds to DNA regions, rich in adenine and thymine, 4′,6-diamidino-2-phenylindole (DAPI), identifies sperm heads containing packed DNA. Panel A is a brightfield image that allows sperm tails to be seen, confirming that the area under scrutiny is a sperm. Panel B is a fluorescent image, allowing comparison with TUNEL-positive sperm, which are identified in panel C. In general, results are reported as a DNA fragmentation index (DFI), which is calculated as the ratio of TUNEL-positive sperm to all sperm and expressed as a percentage. **TUNEL is considered a direct measure of sperm DNA fragmentation, and in a meta-analysis of miscarriage rates, TUNEL had the highest associated risk ratio at nearly 4** (Robinson et al., 2012; Sakkas and Alvarez, 2010).

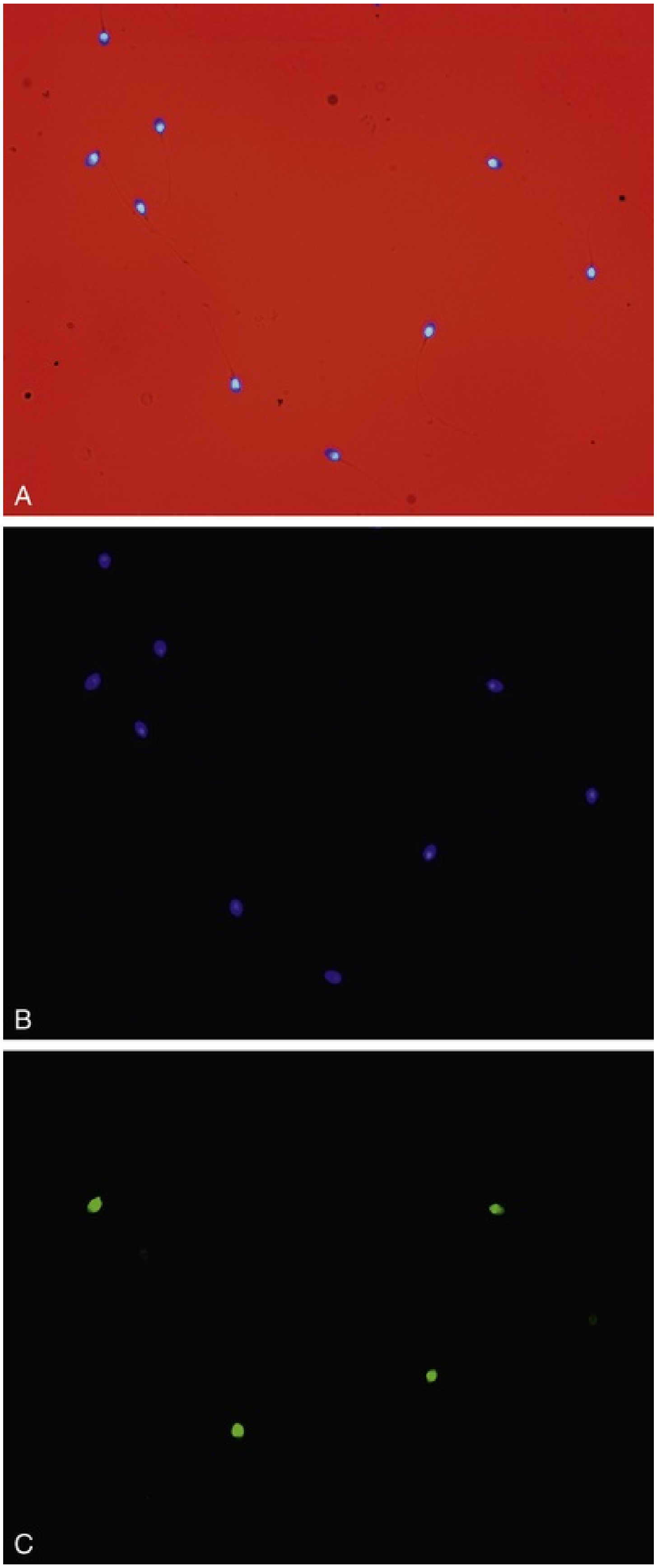
A
B
C

FIG. 66.3 TUNEL assay. (A) Brightfield. (B) Sperm heads by fluorescence are demonstrated. (C) TUNEL-positive sperm.

Comet Assay.

Like the TUNEL assay, the comet assay, also referred to as the *single-cell gel electrophoresis assay,* is widely used in molecular biology laboratories to assess DNA fragmentation and has been adopted in the andrology laboratory for sperm (Sakkas and Alvarez, 2010; Tice et al., 2000). It is a simple assay that involves migration of single sperm head DNA in an electrophoretic agarose gel, and the tail, resembling a comet, indicates the degree of fragmentation (Tice et al., 2000). At neutral pH, this assay is considered a direct measure of sperm DNA fragmentation (Sakkas and Alvarez, 2010). Data are conflicting regarding its use as a tool for predicting clinical outcomes (Ribas-Maynou et al., 2012; Robinson et al., 2012; Simon et al., 2010, 2011). Investigators have used the comet assay in a variety of research settings to understand the effects of various entities on sperm DNA, including varicocele, toxins, male age, and testis cancer (Bertolla et al., 2006; Blumer et al., 2008; Cho et al., 2016; Delbes et al., 2007; Fariello et al., 2012b; Lacerda et al., 2011; Meeker et al., 2004, 2008; O'Flaherty et al., 2008; Schmid et al., 2007; Wu et al., 2009).

Denatured Sperm DNA Assays.

A number of assays denature sperm DNA before structural analysis (Sakkas and Alvarez, 2010). The comet assay performed in acidic or alkaline conditions denatures DNA, and like the comet assay, the sperm chromatin dispersion (SCD) assay allows visual identification of individual sperm head DNA structure by dispersion on agarose followed by nucleic acid staining (Fernández et al., 2003; Sakkas and Alvarez, 2010). The most established assay for sperm head DNA structure is the Sperm Chromatin Structure Assay (SCSA) (SCSA Diagnostics, Brookings, SD) (Boe-Hansen et al., 2006; Chohan et al., 2006; Evenson and Jost, 2000; Evenson and Melamed, 1983; Larson et al., 2000). The SCSA does not identify individual sperm but rather a population of cells by flow cytometry after denaturation in acidic conditions followed by staining with acridine orange (Evenson and Jost, 2000; Larson et al., 2000). Graphic analysis of flow cytometric data yields several outcome parameters for SCSA; the DFI and high DNA stainability (HDS) are the two reported in common clinical use (Evenson and Jost, 2000; Larson et al., 2000). Although a number of studies have associated human reproductive outcomes with SCSA reported values, many failed to find statistically valid correlations (Boe-Hansen et al., 2006; Bungum et al., 2007, 2008; Evenson and Jost, 2000; Larson et al., 2000; Lin et al., 2008; Payne et al., 2005). In a meta-analysis of miscarriage rates, SCSA had a risk ratio of 1.47 with a 95% CI of 1.04 to 2.09, indicating a weak likely association.

Reactive Oxygen Species.

Naturally occurring chemical reactions generate highly reactive molecules with unpaired electrons termed *free radicals.* Free radicals produced from oxidative reactions are referred to as *reactive oxygen species.* ROS are involved in multiple physiologic processes important to sperm function, but investigators theorize that if present in excess, seminal ROS may cause reproductive dysfunction (Agarwal et al., 2006, 2008c; Desai et al., 2009). TAC may be quantified in seminal fluid, and one popular method of quantifying how ROSs may affect sperm function is calculation of a ROS-TAC score (Rice-Evans and Miller, 1994; Sharma et al., 1999). Researchers have assessed ROS activity in aging, prostatitis, varicocele, lubricants, radiation, smoking, toxins, and obesity (Agarwal et al., 2009, 2013; Cocuzza et al., 2008a, 2008b; Farombi et al., 2008; Hsu et al., 2009; Palmer et al., 2012; Pasqualotto et al., 2000, 2008a; Smith et al., 2005; Taha et al., 2012).

Acrosome Reaction.

Functional sperm have an appendage at the head originating from the Golgi apparatus termed the *acrosome,* which contains primarily hydrolytic enzymes necessary for entering the ovum (Cross and Meizel, 1989). After binding to the zona pellucida of the ovum, the acrosome releases its contents, and the sperm penetrates the zona pellucida. Because of its importance in normal fertilization, investigators have devised ways of assessing acrosomal function; the first is fluorescent labeling of acrosomal contents (Cross and Meizel, 1989). Subsequent use of flow cytometry allowed real-time analysis of acrosomal function (Zoppino et al., 2012). Tests of acrosomal function are not in common clinical use and primarily serve as research tools.

Sperm Mucus Interaction.

Interaction with cervical mucus is a prerequisite for successful transit of sperm through the female reproductive tract. The postcoital test, also known as the

Sims-Huhner test, assesses sperm interaction with mucus in two parts: first, it appraises mucus characteristics favorable to sperm penetration; and second, it gauges the number and motility of observed sperm (Griffith and Grimes, 1990). Although the postcoital test has been used by clinicians for a very long time, it is notorious for a lack of standardization and reproducibility (Griffith and Grimes, 1990). Furthermore, researchers have demonstrated that medical history and semen analysis could accurately replace the postcoital test result in approximately half of couples (van der Steeg et al., 2004).

In an attempt to standardize and improve reproducibility of assessment of sperm interaction with cervical mucus, investigators devised model systems in which sperm and mucus could be observed ex vivo (Niederberger et al., 1993). The Penetrak assay standardized the female component by replacing human with bovine cervical mucus and measuring the penetration of sperm in the latter, and the Tru-Trax assay provides two wells, allowing sperm penetration to be compared in either human and bovine cervical mucus or with either donor or patient sperm (Niederberger et al., 1993). Although bulk seminal parameters measure typical populations of sperm, evidence suggests that these standardized sperm-mucus interaction assays assessed motility of the unusual sperm that would ultimately fertilize the ovum (Niederberger et al., 1993). These assays are not presently in common clinical use.

Sperm Ovum Interaction.

Final structural barriers to the sperm on its journey through the female reproductive organs include the zona pellucida, the species-specific barrier to sperm, and the oolemma, and investigators have designed assays for both (Zini and Sigman, 2009). In the sperm penetration assay (SPA), hamster zona pellucida are removed, and human sperm are incubated with the denuded hamster ova, simulating IVF (Margalioth et al., 1986; Yanagimachi et al., 1976). Results of the SPA are reported as either percentage of ova penetrated or average number of sperm penetrating ova (Zini and Sigman, 2009). Before ICSI, clinicians used SPA results to counsel patients about the likelihood of IVF success; after the introduction of ICSI, clinicians used SPA results to decide whether ICSI was preferable to incubational IVF (Zini and Sigman, 2009). With widespread use of ICSI as a primary modality for IVF, the SPA is currently rarely used. Researchers also developed a modified SPA to predict ICSI outcomes in which sperm are microinjected directly into hamster ova and nuclear decondensation is assessed (Gvakharia et al., 2000). Because the majority of couples undergoing ICSI would do so independently of prognostication based on this assay, the SPA modified for ICSI is not in common clinical use.

Andrology laboratory investigators designed assays to investigate the initial union of sperm and ovum—the binding to the zona pellucida (Burkman et al., 1988; Coddington et al., 1991; Liu and Baker, 1988, 1992; Yanagimachi et al., 1979). These tests compare subject with control sperm binding to the zona pellucida (Burkman et al., 1988; Coddington et al., 1991; Liu and Baker, 1988, 1992). Either the zona can be halved, with each half subjected to subject or control sperm, or sperm may be labeled and differentiated visually with fluorescent microscopy (Burkman et al., 1988; Liu and Baker, 1988, 1992). The test using halves of ova is referred to as the *hemizona assay* (HZA) (Burkman et al., 1988; Coddington et al., 1991). Whereas ova may be stored in salt for use when needed, the fact that the zona pellucida is the species-specific barrier to sperm requires that human ova be used to assess zona binding (Burkman et al., 1988; Coddington et al., 1991; Liu and Baker, 1988, 1992; Yanagimachi et al., 1979). Because of the paucity of human sources and readily available ova, the HZA is rarely used.

Sperm Ultrastructural Assessment.

MSOME involving sperm head morphologic inspection with high-power Nomarski differential interference contrast optics that magnify the field more than 6000× is discussed in the section on sperm morphology in this chapter. Although electron microscopy is widely used in scientific research on the male gamete, it also has a place in the clinical assessment of the infertile male (Chemes and Rawe, 2003). **Sperm motility is dependent on the ultrastructural arrangement of microtubules in the tail with a peripheral array of nine pairs and a central two microtubules connected by dynein arms** (Chemes and Rawe, 2003). **This “9 + 2” architecture is shared with cilia, and genetic disorders affecting it can manifest as respiratory pathology associated with male reproductive dysfunction, referred to as the *immotile cilia syndrome, primary ciliary dyskinesia* (PCD), or *Kartagener syndrome*** (Chemes and Rawe, 2003; Eliasson et al., 1977; Guichard et al., 2001). Kartagener syndrome results in sperm that are nearly totally or completely immotile but metabolically active (Peeraer et al., 2004). Semen samples with less than 10% motility and vitality demonstrated by testing may be investigated with electron microscopy to assess tail ultrastructural defects (Zini and Sigman, 2009). Electron microscopy is not available in all andrology laboratories.

Sperm Fluorescence in situ Hybridization.

With the introduction of assisted reproductive technologies (ARTs), many males affected by errors occurring during stem cell division are now able to yield offspring with increased risk of aneuploidies, in particular of the sex chromosomes (Hansen et al., 2005; Rimm et al., 2004). Fluorescence in situ hybridization (FISH) employs fluorescent-labeled primers that bind specifically to each chromosome in the sperm, allowing measurement of sperm aneuploidies that are of major clinical importance (Templado et al., 2013). One advantage of FISH is that it offers the ability to investigate the cytogenetics of somatic and germ cells, which may differ beyond the expected halving of chromosomes (Martin, 2008). Unfortunately, sperm that undergo a FISH analysis cannot be used for in vitro fertilization afterward.

Sarrate et al. (2010) have verified that the relationship between sperm count and the overall increased rates of chromosome abnormalities in sperm accurately demonstrates an inverse correlation between these two parameters. In reality, exceptionally high levels of sperm aneuploidy were identified in testicular sperm extraction samples of men with azoospermia resulting from spermatogenic dysfunction (Huang et al., 1999). Currently, it has been used as a diagnostic tool for couples with recurrent pregnancy loss or recurrent implantation failure (Kohn et al., 2016; Ramasamy et al., 2015; Zidi-Jrah et al., 2016).

Genomic Assessment

Ironically, genes passed from parent to male offspring may be responsible for a condition that, if left untreated, would prevent those genes from being passed to future generations; evidence suggests that genetics plays a significant role in male reproductive dysfunction (Oates and Lamb, 2009). Known genetic conditions associated with the male sex are detailed in later sections of this chapter. In this section, clinically available assays are described.

Karyotype

Staining chromosomes with dyes binding to various moieties of the chemical structure of DNA resulting in banding patterns represents the classic means of cytogenetic analysis of chromosomes (Swansbury, 2003). FISH uses fluorescent probes hybridizing to determine sequences on chromosomes, allowing for identification of specific regions or entire chromosomes depending on the specificity of the probe (Swansbury, 2003). Other techniques, such as the spectral karyotype (SKY), use combinatorial methods to visualize all chromosomes in multiple colors (Swansbury, 2003). **The American Urological Association Best Practice Statement on the Optimal Evaluation of the Infertile Male recommends that genetic testing including karyotype be performed in all males with azoospermia caused by spermatogenic dysfunction and in those with severe oligospermia defined as less than 5 million sperm/mL** (Jarow et al., 2010). However, because numerical and structural chromosomal anomalies vary by geographic region, and obtaining a karyotype may represent a significant expense to the patient, the treating physician may judge whether this assay is indicated in his or her patient population.

Y Chromosome Microdeletion Testing

The Y chromosome is one of the smallest in humans at approximately 60 megabase (Mb) pairs (Navarro-Costa, 2012; Tilford et al., 2001). It is the determinant of the male gender and is the only chromosome passed directly from father to son (Navarro-Costa, 2012). It consists of a male-specific region with no homologous chromosomal mate and two pseudoautosomal regions (PAR1 and PAR2) (Graves et al., 1998; Krausz and Casamonti, 2017; Navarro-Costa, 2012; Tilford et al., 2001). In an elegant series of cytogenetic analyses for the time, **Tiepolo and Zuffardi determined in 1976 that a region in the long arm of the Y chromosome was critical to the formation of sperm in man, which became known as the *azoospermia factor*** (Chandley et al., 1989; Tiepolo and Zuffardi, 1976).

The portion of the Y chromosome that does not recombine represents approximately 95% of its sequence (Tilford et al., 2001). About one-third of this nonrecombinant region consists of palindromic inner sequences present at least twice in forward and reverse reading frames referred to as *amplicons* (Tilford et al., 2001). This sequence structure is believed to substitute in part in place of sexual recombination in repair of the Y chromosome but may also engender a particular fragility in increasing the likelihood of the loss of segments, or microdeletions (Oates and Lamb, 2009). Based on the work of Tiepolo and Zuffardi, investigators observed microdeletions of three regions on the Y chromosome to be commonly associated with azoospermia or oligospermia, which were termed *AZFa*, *AZFb*, and *AZFc* (Oates and Lamb, 2009). Once thought to be separate and distinct regions, AZFb and AZFc overlap, whereas AZFa is distant and isolated (Jobling and Tyler-Smith, 2003). The *DAZ* genes, believed to be integrally associated with spermatogenesis, are housed within the AZFc region (Saxena et al., 2000). Investigators have also referred to the proximal portion of AZFc as *AZFd*, but the usefulness of isolating this subregion remains unclear (Müslümanoğlu et al., 2005).

Some microdeletions of AZFc appear to be associated with spermatogenic impairment but not failure (Mulhall et al., 1997; Oates et al., 2002). Likewise, the clinical relevance of analysis of AZFc subregions such as gr/gr is unclear, because sperm may be present in the ejaculate and in the testis (Giachini et al., 2008; Lardone et al., 2007; Stouffs et al., 2008; Visser et al., 2009; Wu et al., 2007). However, evidence strongly suggests that deletion of genes *USP9Y* and *DDX3Y* in the AZFa region and deletion of genes *EIF1AY*, *RPS4Y2*, and *KDM5D* in the AZFb region cause significant pathology of the testis resulting in diminishing low likelihood of sperm retrieval by surgery (Hopps et al., 2003). **It is reasonable practice to recommend Y chromosomal microdeletion assessment to azoospermic men before surgical sperm extraction to counsel them on the likelihood of retrieval** (Jarow et al., 2010). However, it is also reasonable to omit testing based on the relative rarity of AZFa and AZFb microdeletions in clinical practice.

Genomic Sequence Assessment

A variety of technologies such as DNA microarrays allow multiple single nucleotide polymorphisms (SNPs) and mutations associated with known diseases to be screened for and reported (Hunter et al., 2008; Lazarin et al., 2013; Schena et al., 1995). These reports can be used to identify whether parents are carriers for a large number of genetic diseases and the probability of affected offspring. Recessive disorder carrier screening is increasingly used in couples undergoing assisted reproduction, particularly those who suffer from early pregnancy loss and recurrent miscarriages. Whole-genome sequencing as a clinical tool is also under current development (Moorthie et al., 2013). It is used in research and select diagnostic applications but is not widely used in clinical diagnosis. Although these technologies may ultimately be used to diagnose underlying causes of male reproductive dysfunction, use as general screening tools in evaluating male infertility is not yet warranted.

Cystic Fibrosis Transmembrane Conductance Regulator Mutation Assessment

The relationship between alterations in the CFTR and maldevelopment of the vas is discussed in the section on developmental disorders in this chapter. This section describes what testing is available.

The protein encoded by CFTR forms a channel for chloride ions and possibly bicarbonate and may regulate transport of other ions (Hampton and Stanton, 2010). More than 1600 CFTR mutations have been identified, and they may be mild or severe, defined by whether the full cystic fibrosis disease phenotype results from the mutation (Bombieri et al., 2011; Hampton and Stanton, 2010; Oates and Lamb, 2009; Ratbi et al., 2007; Yu et al., 2012). **The most common severe mutation is ΔF508, which results from deletion of three base pairs that consequently remove the amino acid phenylalanine typically at position 508 of the encoded protein** (Hampton and Stanton, 2010). A high incidence of patients harbor more than one mutation; approximately 46% have two (Yu et al., 2012). **A severe mutation such as ΔF508 on each allele will result in a child with cystic fibrosis, making screening imperative for the prospective father and mother for those suspected of harboring genetic alterations in CFTR.**

Currently available CFTR screening panels typically include 25 to 40 of the most common mutations. Because a subset of known mutations is screened for, a negative result still carries a defined risk. Testing is commercially available for all known mutations but is, not surprisingly, more expensive. CFTR mutation prevalence varies by ethnicity and geography (Bombieri et al., 2011; Boyd et al., 2004; Foresta et al., 2005; Hamosh et al., 1998; Havasi et al., 2010; Li et al., 2010; Ratbi et al., 2007; Schulz et al., 2006). Consequently, the clinician should take into account location and ethnicity in interpreting results. Typically, CFTR screening panel reports are stratified by ethnicity.

Key Points: Laboratory Evaluation of Male Infertility

- Endocrine assessment of male reproductive status includes total testosterone, the portion of testosterone not bound to SHBG, estradiol, and the pituitary gonadotropins LH and FSH.
- The semen analysis represents a probabilistic assessment of male reproductive potential. Aside from azoospermia, no specific threshold

applied to any parameter absolutely discerns infertility from fertility.

- The differential diagnosis for men with semen volumes less than 1.0 mL includes ejaculatory ductal obstruction, retrograde ejaculation, and vasal and accessory sex gland maldevelopment such as that occurring with CBAVD.
- Sperm vitality staining differentiates complete asthenospermia from necrospermia. Common laboratory staining methods differentiate pyospermia from immature germ cells.
- A preponderance of sperm with round heads, a condition referred to as *globozoospermia*, indicates deficient acrosome formation. The treatment is IVF with ICSI.
- Disruption in the blood-testis barrier formed by tight junctions between Sertoli cells results in antisperm antibodies, which have varying clinical significance depending on the degree of binding to sperm heads.
- Genetic screening of the CFTR in men with CBAVD and their partners identifies the presence of severe mutations such as ΔF508 that may result in clinically overt cystic fibrosis in offspring.

Imaging in the Evaluation of Male Infertility

Radiographic or ultrasonographic imaging is infrequently needed in the diagnosis of male reproductive dysfunction and should be ordered cautiously. Likely benign conditions such as testicular microlithiasis may be detected, resulting in patient distress and often unnecessary additional testing (Dagash and MacKinnon, 2007). The following descriptions of imaging in the evaluation of male reproductive dysfunction should not be interpreted as indicated in typical screening.

Scrotal Ultrasonography

Evaluation of the infertile male includes a detailed manual examination of the scrotum and its contents. As with the scrotal physical examination for any urologic evaluation, abnormalities may be detected that warrant scrotal ultrasonography for further investigation. Scrotal ultrasonography is performed by using a high-frequency linear array transducer. Transverse and longitudinal ultrasonography of the testes and color flow Doppler ultrasonography of testicular and spermatic cord vascularity are performed (Mittal et al., 2017). Testicular volume is calculated as (length × width × anteroposterior diameter) × $\pi/6$ and the normal value range is 15 to 20 mL (Ammar et al., 2012). In Fig. 66.4, color duplex Doppler ultrasonography demonstrates a varicocele. Panel A reveals the varicocele to be adjacent to the testis, and the colored areas in panel B demonstrate the direction of flow. The diameter of the largest vein can be measured and reported.

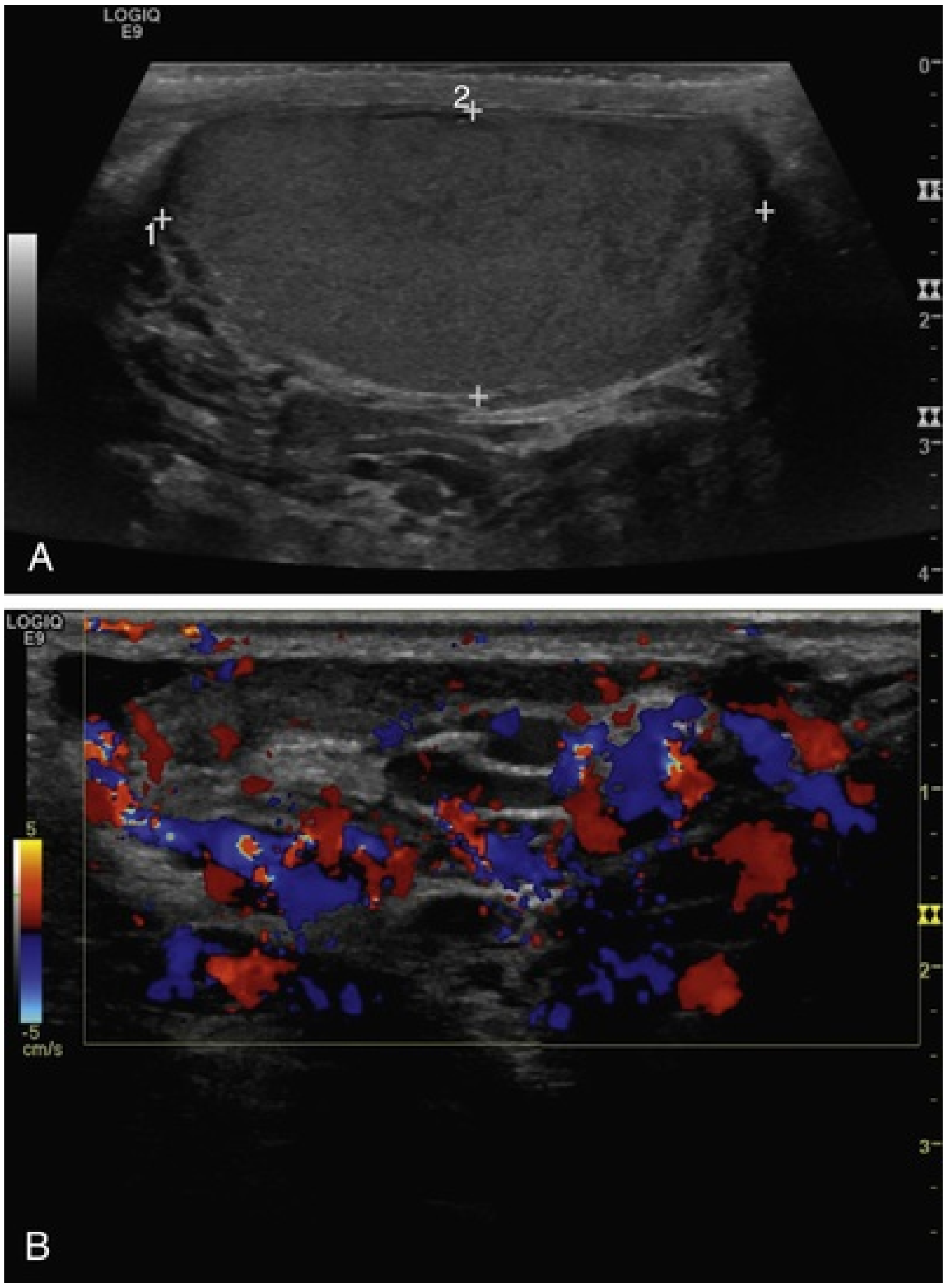

FIG. 66.4 Color duplex Doppler ultrasonography of scrotum demonstrating varicocele. (A) Dilated veins adjacent to the testis. (B) Directional flow in the vessels.

Ultrasonography of the spermatic cord may be indicated if the evaluating physician is uncertain whether a varicocele is present on palpation (Nagler and Grotas, 2009). However, the varicoceles so identified are often so small as to be of questionable clinical significance. Varicoceles become palpable at approximately 2.7 to 3.6 mm in diameter, and surgical treatment of varicoceles smaller than 3.0 mm that are not palpable on physical examination but observed on ultrasound does not result in improved seminal outcomes (Eskew et al., 1993; Hoekstra and Witt, 1995; Jarow et al., 1996; Schiff et al., 2006). **Consequently, the most rational approach based on whether identification of a varicocele is likely to affect treatment outcomes is not to rely on ultrasound as a necessary diagnostic tool.**

Direction of flow may be assessed by color Doppler ultrasound, and investigators have reported that reversal of flow is a positive prognostic sign that surgical treatment of varicocele may result in improved seminal parameters (Hussein, 2006; Schiff et al., 2006). At this time, insufficient numbers of men with nonpalpable varicoceles that are identified with reversal of flow are reported in studies investigating surgical treatment to conclude that color Doppler ultrasound is indicated as a screening modality for infertile men.

In conjunction with TRUS, investigators have observed sensitivity of 75% and specificity of 72% for diagnosing azoospermia caused by spermatogenic dysfunction and sensitivity of 29.8% and specificity of 87% for diagnosing azoospermia caused by obstruction (Abdulwahed et al., 2013). However, given the high accuracy in differentiating azoospermia caused by spermatogenic dysfunction versus obstruction yielded by measuring testis longitudinal axis and assaying serum FSH, it seems more prudent and cost effective not to use ultrasonography in an attempt to diagnose the cause of azoospermia in men with adequate seminal volumes.

Vasography

Contrast vasography in the direction of the abdomen allows determination of patency of the vas deferens from the scrotum to the ejaculatory ducts (Ammar et al., 2012). It is currently rarely performed because image modalities such as TRUS and magnetic resonance imaging (MRI) have superseded it; it is invasive and may result in scar tissue formation in the vasal lumen and obstruction; and injection of saline into the vasal lumen during intended vasal reconstructive procedures with the manual feedback of whether fluid flows easily or backflow occurs offers similar information. **Fluid, contrast or otherwise, should never be injected into the vasal lumen in the direction of the epididymis because it will rupture the delicate epididymal tubules.** Should backflow be identified during intraoperative saline vasography, a monofilament suture such as 4-0 polypropylene may be inserted into the vasal lumen, advanced until resistance is encountered, and then withdrawn and the distance measured to determine the location of the obstruction.

Venography

Venography is rarely performed for the diagnosis of varicocele. For the same reasons that scrotal ultrasound is infrequently necessary (i.e., clinically significant varicoceles are palpable and require no further imaging, and the treatment of varicoceles that are identifiable only by imaging and are not palpable does not improve seminal outcomes), venography is usually not useful in assessing the import of a varicocele. If a clinically significant varicocele is to be treated by embolization, then venography is used to plan the radiographic interventional approach. Venography is very useful in providing confirmation of reflux in the veins as wells as to define varicocele anatomy in challenging recurrences (Jurewicz and Gilbert, 2016).

Transrectal Imaging

The diagnosis of ejaculatory ductal obstruction is considered when azoospermia in conjunction with low seminal volume is encountered (Niederberger, 2011). The earliest and still currently the most prevalent method of investigating whether ejaculatory ductal obstruction in present is TRUS (Jarow, 1996; Niederberger, 2011). **TRUS imaging evidence of ejaculatory duct obstruction includes an anteroposterior seminal vesicle diameter of greater than 1.5 cm with or without a midline prostatic cyst** (Ammar et al., 2012; Jarow, 1996; Niederberger, 2011). Fig. 66.5 demonstrates an intraprostatic cyst, with panel A exhibiting the transverse view and panel B the longitudinal view. Unfortunately, although TRUS is convenient and common, its specificity is low compared with other modalities for identifying whether or not obstruction is present (Purohit et al., 2004). EDO is not always associated with seminal vesicle dilation, and, conversely, normal fertile men can at times have dilated seminal vesicles depending on the duration of sexual abstinence (Mogdil et al., 2016). These other assessments include radiographic imaging after injection of contrast directly into the seminal vesicles, or vesiculography; aspiration of the seminal vesicles to determine whether sperm is present; and injection of diluted indigo carmine or methylene blue dye into the seminal vesicles and observation by cystoscopy of whether the colored dye flows from the ductal orifices at the verumontanum, a technique referred to as *chromotubation* (Purohit et al., 2004). In a small series, vesiculography and chromotubation were more accurate than TRUS by a margin of 25% (Purohit et al., 2004). However, these techniques are more invasive and expensive, and an incremental improvement in diagnostic accuracy compared with TRUS if conclusively demonstrated in larger studies may not justify the additional risk and cost.

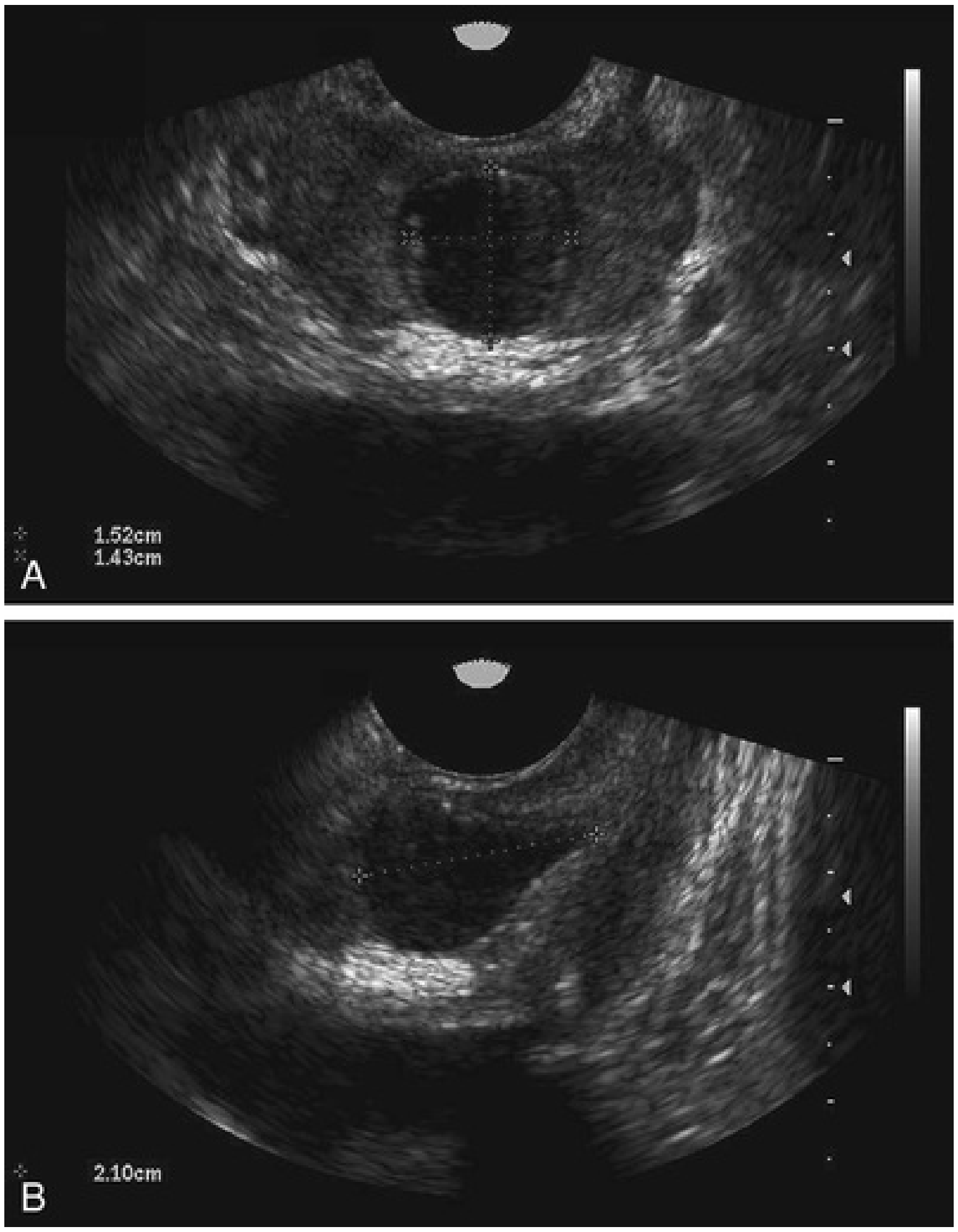

FIG. 66.5 Transrectal ultrasonography revealing an intraprostatic cyst. (A) Transverse. (B) Longitudinal. (Courtesy Marcelo Vieira.)

MRI with an endorectal coil can be used to evaluate anatomic features consistent with ejaculatory ductal obstruction (Engin et al., 2000). It has the same challenges as ultrasound, which is that ejaculatory ductal obstruction may not correlate with the observed anatomy. In one study comparing TRUS and MRI, MRI identified 23% of anatomic aberrations that were not discernible on TRUS (Engin et al., 2000). However, the clinical significance of these additional identified lesions is not established, and TRUS found anomalies not observed by MRI (Engin et al., 2000). Engin et al. concluded that TRUS is a good screening modality and that MRI should be reserved for situations in which TRUS results are ambiguous (Engin et al., 2000). Although the use of an endorectal coil may facilitate a higher signal-to-noise ratio, it often results in obscuration of the pathologic condition because of local field distortion and cause patient discomfort, and for these reasons higher-field-strength (3.0 tesla) MRI systems may preclude endorectal coil (De Visschere et al., 2015).

As with any hydraulic system, anatomic features may not correlate to resistance, which is ultimately a functional assessment of flow and pressure. Investigators have described use of manometry to establish baseline functional characteristics of the ejaculatory ducts (Eisenberg et al., 2008). In one method, dye was injected into the seminal vesicles until it could be visualized with a cystoscope flowing from the ductal orifices at the verumontanum, and the pressure at that point was measured (Eisenberg et al., 2008). In another method, a constant infusion flow was applied to the seminal vesicles, and the pressure was measured (Eisenberg et al., 2008). Investigators have also injected technetium-99m–containing solution into the seminal vesicles and assessed emptying over time by scintigraphy (Orhan et al., 2008). These promising procedures should not yet be considered standard evaluation until further studies have established validity.

Abdominal Imaging

Abdominal imaging in the evaluation of the infertile male is used primarily to study whether renal sequelae of congenital vasal maldevelopment is present. As previously described, unilateral absence of the vas deferens may be associated with loss of wolffian ductal development on that side and renal agenesis, and a solitary kidney was observed in one of nine men with CBAVD (Niederberger, 2011; Schlegel et al., 1996). Renal ultrasound is typically sufficient to identify whether both kidneys are present.

Cranial Imaging

Cranial MRI allows assessment of whether hyperprolactinemia is associated with an anatomic pituitary lesion and is more useful when prolactin levels are twice the upper limit of normal (Niederberger, 2011; Rhoden et al., 2003). MRI may distinguish between microadenomas and macroadenomas and may assist in judging whether medical or surgical therapy is indicated (Johnsen et al., 1991). Fig. 66.6 demonstrates a cranial MRI revealing a large pituitary macroadenoma.

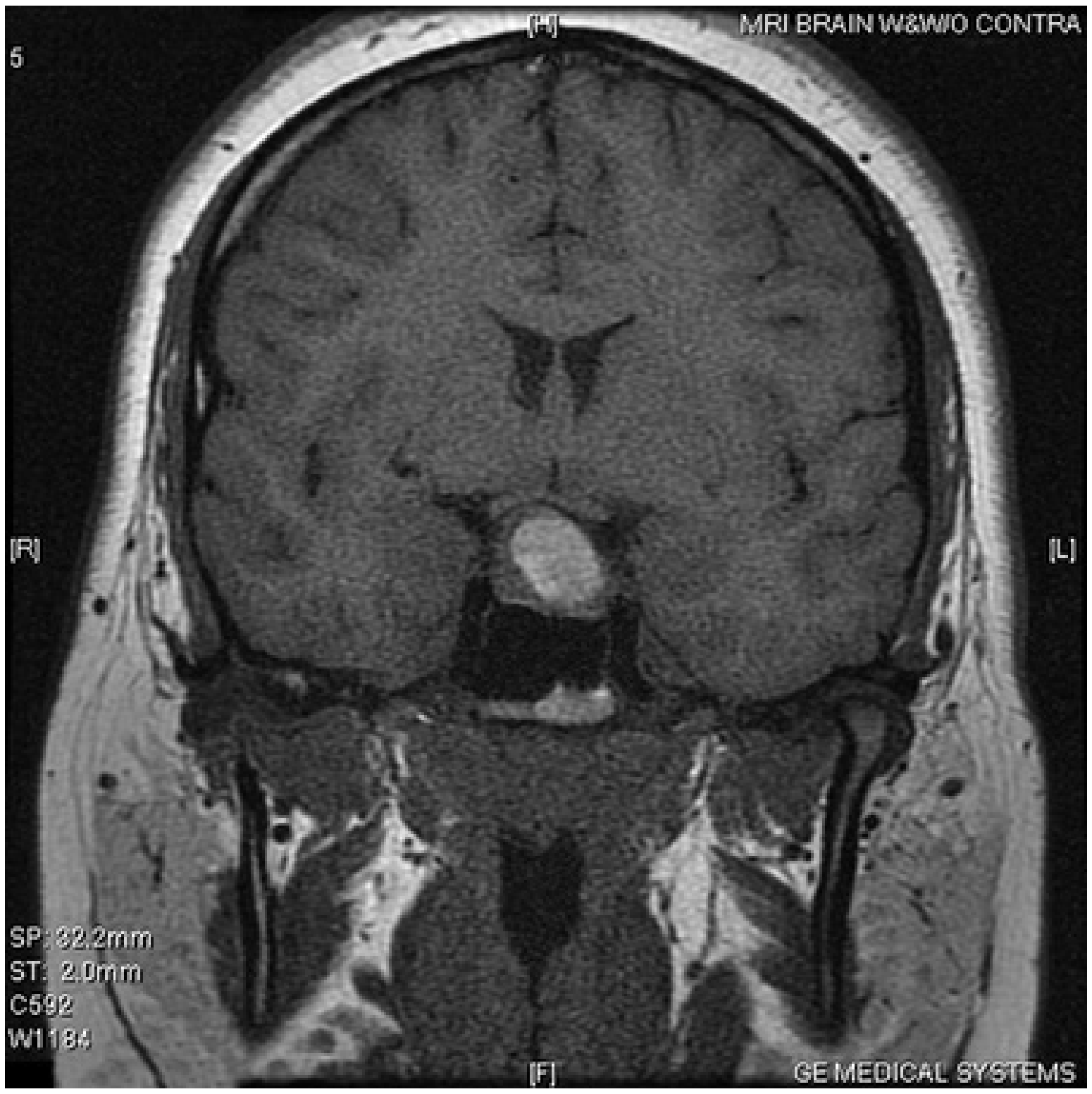
[H]
MRI BRAIN W&WO CONTRA
5
[R]
[L]
SP:32.2mm
ST: 2.0mm
C592
W1184
[F]
GE MEDICAL SYSTEMS

FIG. 66.6 Large pituitary macroadenoma revealed by cranial magnetic resonance imaging.

Key Point: Imaging

- Imaging can reveal sequelae of genetic conditions, such as congenital absence of the vas deferens and renal aplasia, and it can differentiate reasons for seminal hypovolemia, such as ejaculatory ductal obstruction, but it is infrequently necessary to establish diagnoses such as varicocele or spermatogenic dysfunction.

Testis Histopathology

Historically, men found to have azoospermia were subject to testis biopsy to diagnose whether the condition was caused by obstruction or spermatogenic dysfunction. However, as previously described, the majority of azoospermic men can be successfully diagnosed with a single laboratory assay and one measurement on physical examination (Schoor et al., 2001). The combination of the FSH assay result and testis size as measured by caliper orchidometer accurately predicts whether azoospermia is the result of obstruction or spermatogenic dysfunction: 96% of men with obstructive azoospermia had FSH assay values of 7.6 IU/L or less and testis long axis greater than 4.6 cm, and 89% of men with azoospermia caused by spermatogenic dysfunction had FSH values greater than 7.6 IU/L and testis long axis 4.6 cm or less (Schoor et al., 2001). Coupled with the observation that a biopsy in one location of the testis does not predict histopathology and full spermatogenesis in other areas, the fact that the prognostic information afforded by biopsy could be supplanted with FSH and testis longitudinal axis called into question the value of testis biopsy in the evaluation of male reproductive dysfunction in general (Ramasamy and Schlegel, 2007; Schoor et al., 2001; Turek et al., 1997). **Consequently, testis biopsy is not indicated in the initial diagnostic evaluation of the infertile man.**

Men with infertility and azoospermia in particular appear to be at increased risk for certain diseases such as cancer (Eisenberg et al., 2013; Walsh et al., 2010). This observation is not unexpected, because azoospermia is likely to result from dysregulation of molecular systems that may be associated with oncogenesis. Therefore testis biopsy simultaneously with other procedures such as testis sperm extraction may yield pathologic information that can explain procedural outcomes as well as provide information about other related future diseases.

Testis biopsy should be considered as an incomplete sampling of testicular histology and germ cell development. In one series, one-third of men who underwent testis biopsy that demonstrated no sperm were found to have sperm at a site distant from the biopsy location (Turek et al., 1997). In another series assessing outcomes of microsurgical testis sperm extraction in which the testis was globally and systematically visually explored for tubules likely to contain sperm, approximately two of five men with one or two prior biopsies demonstrating no germ cells were found to have mature sperm (Ramasamy and Schlegel, 2007). Even with three or four prior biopsies with only Sertoli cells seen, mature sperm was extracted in one of nine men (Ramasamy and Schlegel, 2007). **These observations confirm that spermatogenesis may be highly focal in men with azoospermia, and a biopsy may not describe the entirety of the histology of a testis.**

Should biopsy be performed in conjunction with testis sperm extraction to sample testis histology, spermatogenesis is typically characterized histologically by light microscopy as to whether germ cells are present at all, and if so, the volume of active spermatogenesis and the degree of development of the farthest advanced cell. In the most extreme case, germ cells are lacking entirely and only Sertoli cells are visible in the germinal epithelium. This condition is often referred to as *Sertoli cell–only syndrome* and is demonstrated by low-power light microscopy in eFig. 66.7. For comparison, eFig. 66.8 exhibits normal spermatogenesis on light microscopy. The low-power view in panel A reveals a robust and full seminiferous epithelium with a variety of germ cells in various stages of spermatogenesis. In the high-power view demonstrated in panel B, the *arrow* indicates the typical triangular shape of a mature sperm head. As sperm develop in a three-dimensional epithelial surface, it is unusual to find an entire mature sperm with its full tail in one single microscopic plane. **Consequently, visualization of a mature sperm head is typically sufficient to confirm completion of the stages of spermatogenesis.**

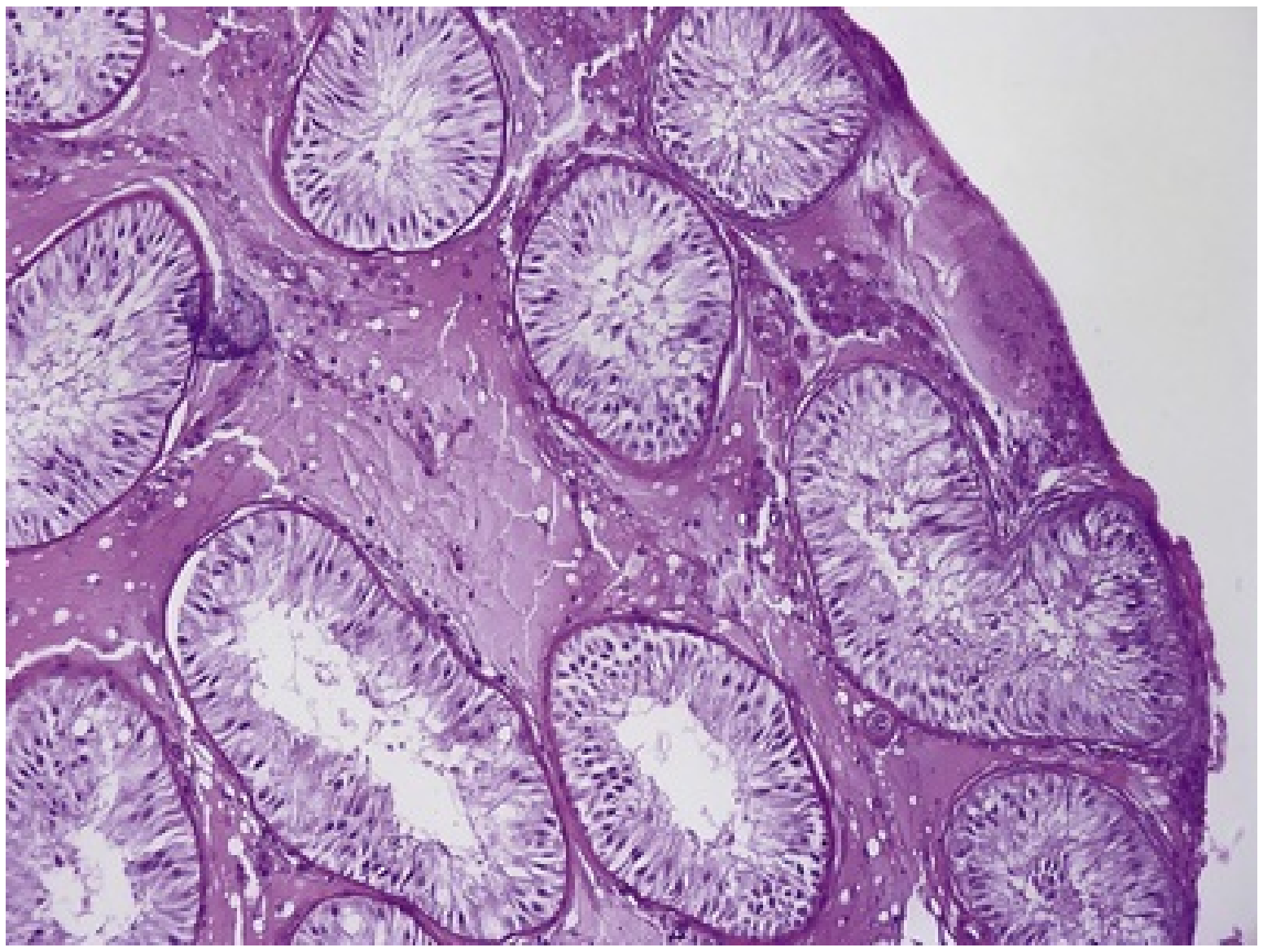

EFIG. 66.7 Low-power light microscopy demonstrating Sertoli cell–only

syndrome.

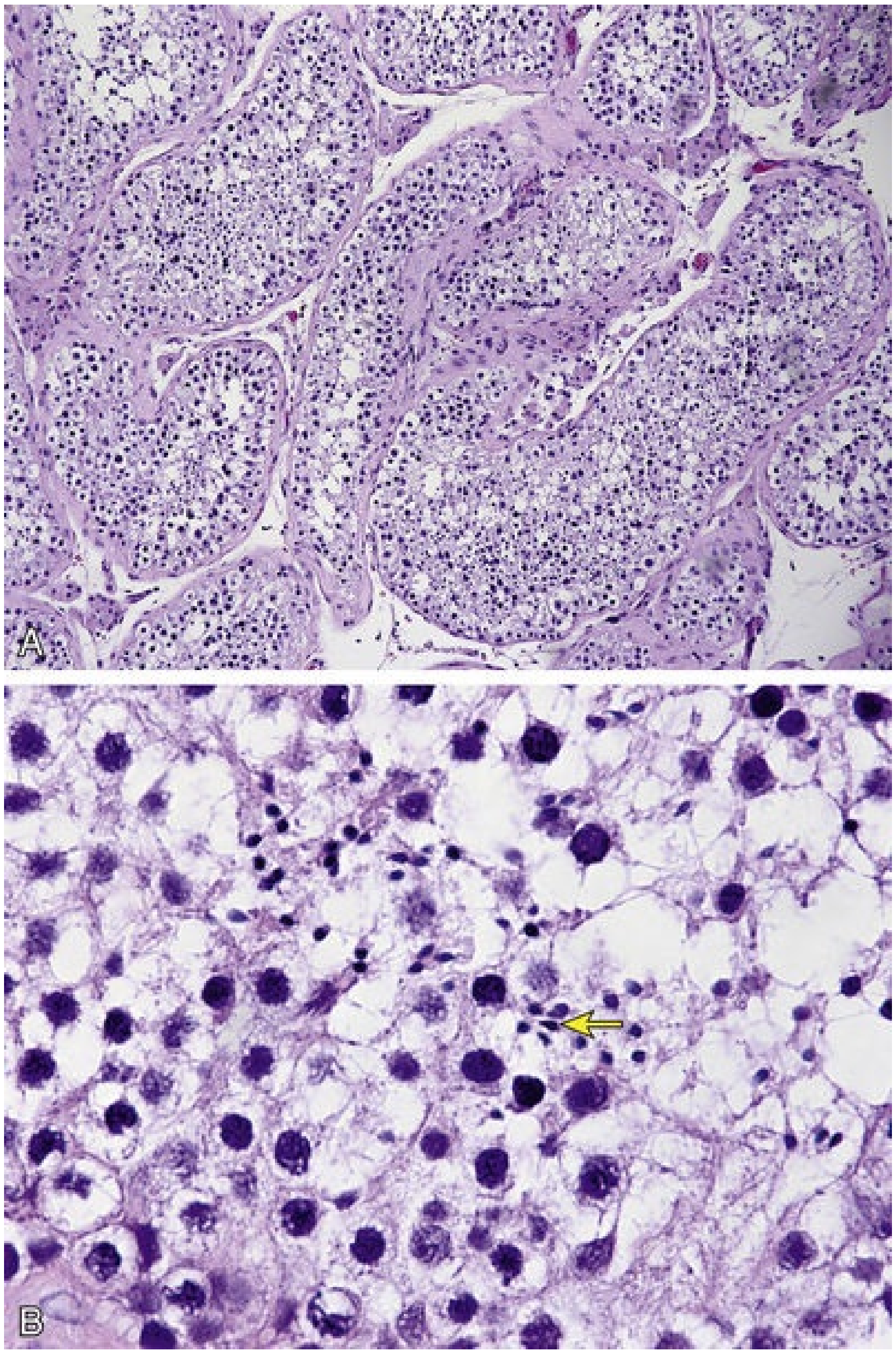

EFIG. 66.8 Light microscopy demonstrating normal spermatogenesis. (A) Low power. (B) High power. The *arrow* in B indicates a mature sperm head.

eFig. 66.9 reveals general depopulation of the seminiferous epithelium. A variety of germ cells in differing stages of spermatogenesis are observed, but the seminiferous epithelium appears diminished in luminal caliber. This condition is referred to as *hypospermatogenesis.* In eFig. 66.10, varying stages of spermatogenesis are observed but without completely formed sperm. This condition is referred to as *maturation arrest.* Spermatogenesis may be arrested before meiotic division, which is termed *early maturation arrest*, or during or after meiotic division, which is referred to as *late maturation arrest* (Alukal et al., 2009). In eFig. 66.10, small nuclei consistent with postmeiotic germ cells are observed but not maturing or mature sperm; this is therefore considered late maturation arrest.

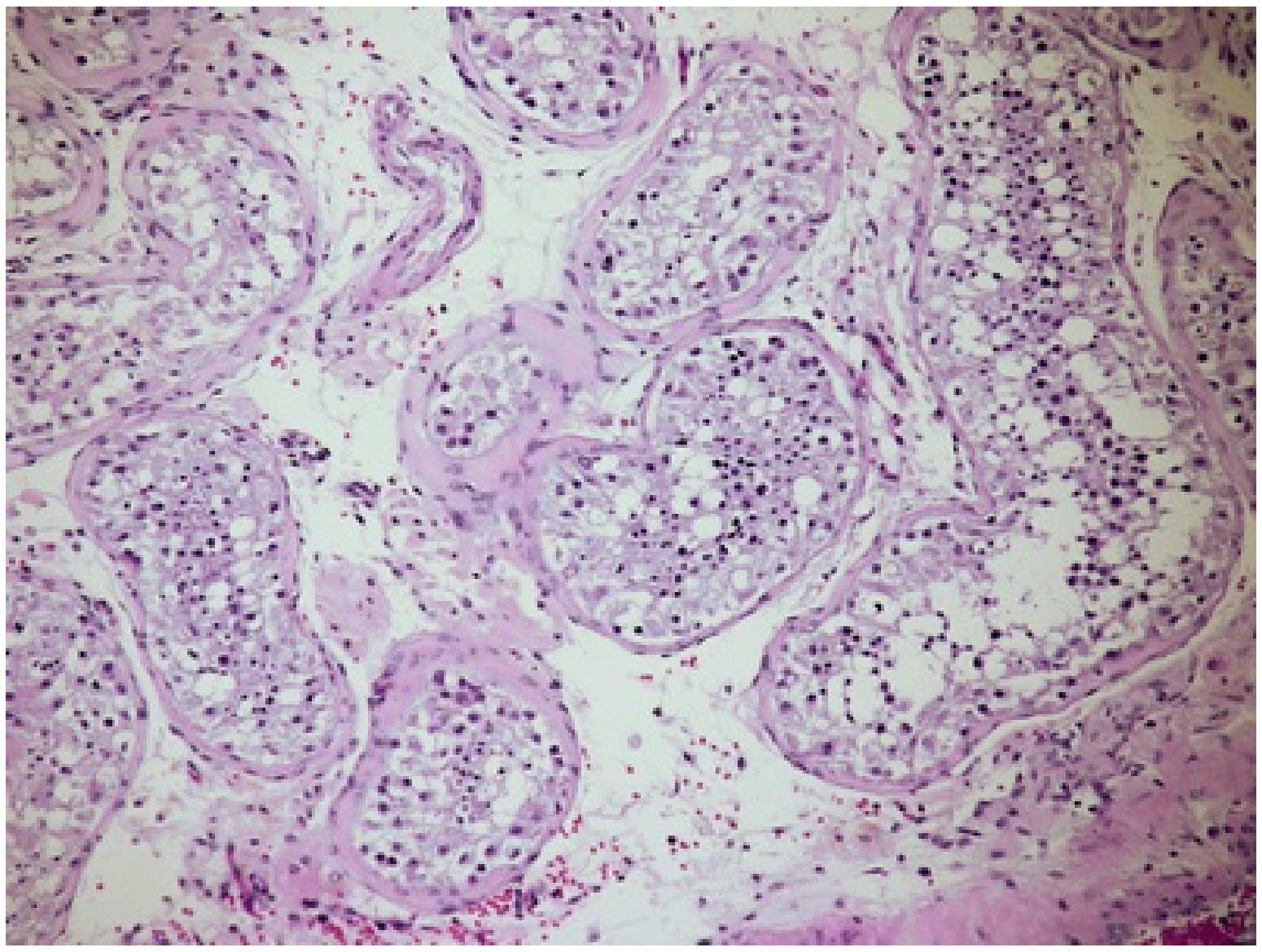

EFIG. 66.9 Low-power light microscopy demonstrating hypospermatogenesis.

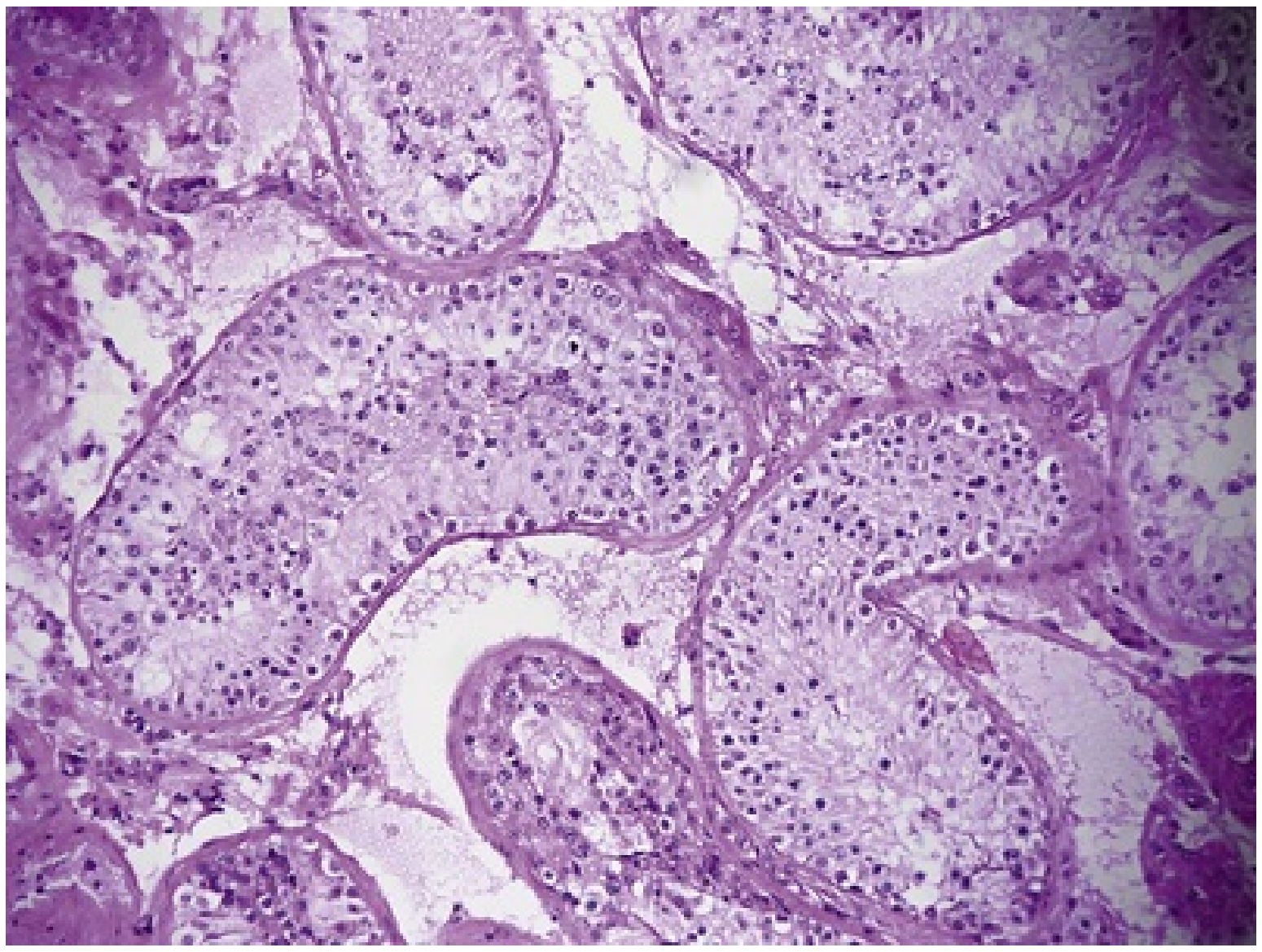

EFIG. 66.10 Low-power light microscopy demonstrating maturation

arrest.

Key Point: Testis Histopathology

- In general, testis biopsy is unnecessary to identify whether azoospermia is the result of spermatogenic dysfunction or obstruction; 96% of men with obstructive azoospermia have FSH assay values of 7.6 IU/L or less and testis long axis greater than 4.6 cm, and 89% of men with azoospermia caused by spermatogenic dysfunction have FSH values greater than 7.6 IU/L and testis long axis of 4.6 cm or less.

Assisted Reproduction

Reproductive medicine is unique in that it includes not one but two patients for a healthy outcome to occur. For natural conception, pregnancy, and delivery, a functional female reproductive system must be present, and coitus must be occurring at regular intervals. Several methods may be used by specialists in female fertility to control variables related to conception and the female reproductive tract. The urologist treating the infertile male works closely in integrated fashion with the gynecologist or reproductive endocrinologist caring for his partner. Even when the female reproductive system is fully functional and normal on evaluation, these methods may be used to overcome male factors impeding fertilization.

As previously described, chronologic age is a significant determinant of female reproductive potential, especially in the consideration of the use of more invasive reproductive techniques (Balasch and Gratacós, 2012; te Velde and Pearson, 2002). Female fecundity begins to decline after age 35, and this decline accelerates after age 37 (Balasch and Gratacós, 2012; Van Voorhis, 2011). The urologist must take into account maternal age and other female factors when planning therapy for the man. Because spermatogenesis is a lengthy process, treatment directed toward improving it and waiting to determine the effect may be appropriate with a female partner at age 30 years, but more aggressive therapy for the couple including more invasive techniques for the woman may be better suited if she is 38 years of age or older.

In the assessment of success rates for any therapy directed toward reproduction, outcomes must be carefully identified. If the embryo is cultured outside of the woman's body, a fertilization rate may be calculated. Pregnancy rate is different and greater than delivery rate, with the latter of greater interest to the couple.

Intrauterine Insemination

In general, external augmentation of reproduction takes two forms. In one form, semen is delivered by instrumentation into the female reproductive tract. The most common type of this form is IUI, during which a small catheter is placed through the cervical os to deliver sperm directly into the uterus, thus bypassing the cervical barrier (Van Voorhis, 2011). Often, sperm are processed in the laboratory to enrich the motile fraction before IUI. IUI decreases in effectiveness when the number of motile sperm in the ejaculate is low, in general considered to be in the range of less than 10 million, or if the motile sperm in the processed sample total fewer than 1 million (Van Voorhis, 2011).

eTable 66.3 lists outcome data for various interventions for the female partner based on 2008 national data from SART (Van Voorhis, 2011). IUI alone results in an average per-cycle delivery rate of 5%; adding the oral medicine clomiphene citrate increases it to 8%, and adding the injectable medication human menopausal gonadotropin (hMG) increases the delivery rate to 15% to 18% (Van Voorhis, 2011).

eTABLE 66.3

Per-Cycle Success Rates of Various Forms of Intervention for the Female Partner and the Associated Multiple Birth Rate Based on 2008 National Data From the Society for Assisted Reproductive Technologies (SART)

TECHNIQUE	DELIVERY RATE PER CYCLE	MULTIPLE BIRTH RATE PER PREGNANCY
Timed intercourse	2%–3%	1%
IUI alone	5%	1%
Clomid alone	5%	10%
Clomid and IUI	8%	10%
hMG alone	12%–15%	15%
hMG and IUI	15%–18%	15%
In vitro fertilization	30%–32%	31%

hMG, Human menopausal gonadotropin; *IUI,* intrauterine insemination.

From Van Voorhis BJ: What to know about the infertile female. In Niederberger CS, editor: *An introduction to male reproductive medicine*, New York, 2011, Cambridge University Press, p 134–151.

The essential value of IUI is that it controls variables related to the initial voyage of sperm in the reproductive tract. If the penile urethra, vaginal vault, and cervix is misaligned or hostile, IUI begins the journey of sperm at a point within the uterus. Sperm must then transit through the fallopian tubes to ultimately join the ovum, but a considerable barrier to reproduction is bypassed.

In vitro Fertilization

A variety of methods currently exist to manipulate gametes and embryos outside of a woman's body and to return the results into the female reproductive tract. These techniques are collectively known as *assisted reproductive technologies* (ART). With the culmination of a great body of scientific work leading to the first live birth reported in 1978 after incubation of sperm and ovum outside of a mother who had both fallopian tubes removed and replacement of the embryo into her uterus, an entirely new way of treating female and male infertility was born (Steptoe and Edwards, 1978). Later, investigators developed methods of inserting a single sperm into an ovum, dramatically lowering the number of male gametes needed for IVF (Palermo et al., 1992).

ICSI revolutionized IVF, allowing consideration of sperm that had not transited the epididymis for use in ART. Shortly after its introduction, investigators began to compare ICSI outcomes for sperm derived from the testis and epididymis, finding that fertilization and pregnancy rates were similar (Ubaldi et al., 1996; Watkins et al., 1997). Subsequent studies confirmed these initial observations and demonstrated that ICSI was equally effective with sperm from either testicular or epididymal origin (Kalsi et al., 2010; Nicopoullos et al., 2004;). **ICSI also made possible usage of cryopreserved testicular sperm for ART, which has the advantage of permitting the man and woman to undergo testicular sperm extraction and ova retrieval on separate days and the benefit to the female reproductive specialist and couple of knowing whether biologic sperm could be procured before hormonal stimulation of the woman** (Friedler et al., 1997; Gil-Salom et al., 1996; Prins et al., 1999). Investigators have observed similar outcomes when using ICSI with cryopreserved testicular sperm and sperm extracted from the testis on the day of ova retrieval (Kalsi et al., 2010; Nicopoullos et al., 2004).

Diagnoses and Therapies

The understanding of the pathophysiology of male reproductive dysfunction has expanded in past years but remains incomplete. The difficulties inherent in the probabilistic nature of reproduction and its assessment pose challenges to the physician evaluating and consequently treating male infertility. However, sufficient information is known for the treating physician to make reasoned assumptions about whether a pathologic explanation involving the man exists, its likely basis, and plausible therapy. This section reviews discrete diagnoses and possible medical therapies.

Genetic Syndromes

With the completion of sequencing of the human genome in 2004, knowledge of how the genes involved in human reproduction conspire to create fully formed and viable sperm will follow (International Human Genome Sequencing Consortium, 2004). As discussed in the section of this chapter describing genomic sequence assessment, broad panels are available that identify carrier risk of known genetic diseases, and whole-genomic sequencing is being used in research. However, current use of broad panels and use of whole-genome sequencing, should it become immediately available, as general screening tools for male reproductive dysfunction are hampered by the lack of an understanding of how the majority of the genetic mechanisms involved in spermatogenesis function in concert to produce viable sperm. A certain number of genetic associations are known to be involved in male infertility, and these are detailed in subsequent sections. In this section, general genetic causes of male fertility involving chromosomal number, structure, and epigenetic mechanisms are discussed.

Chromosomal Numerical Disorders

The presence of a supernumerary X chromosome yielding 47,XXY, or Klinefelter syndrome, is the most commonly identified genetic cause of male infertility (Groth et al., 2013; Oates and Lamb, 2009; Sigman, 2012). A 47,XXY genotype is observed in 1 in 500 to 1000 live births, and in more than 95% of affected adults results in azoospermia, small testes, and elevated gonadotropin levels (Groth et al., 2013; Maiburg et al., 2012). Approximately 75% of children have learning disabilities, and 63% to 85% of men have low testosterone levels (Groth et al., 2013). **Body morphology features such as increased height are observed in only 30% of Klinefelter males, and consequently the condition cannot be excluded by physical examination and physical inspection alone** (Groth et al., 2013). Increased incidence of other disorders related to the testis such as mediastinal germ cell tumors is documented in men with Klinefelter syndrome, suggesting broader testicular effects (Sokol, 2012).

A nonmosaic 47,XXY karyotype is observed in 80% to 90% of men with Klinefelter syndrome (Maiburg et al., 2012). The remainder are mosaic 46,XY/47,XXY or have additional or structurally abnormal X chromosomes (Maiburg et al., 2012). In the man, approximately 8% have sperm in the ejaculate, and the remainder are azoospermic (Oates, 2012). Within the testis, approximately half of men with Klinefelter syndrome have sufficient mature sperm amenable to surgical sperm retrieval for use with IVF and ICSI (Oates, 2012). **Early age at diagnosis appears to offer a more favorable prognosis** (Mehta and Paduch, 2012).

Until recently, fertility management of men with Klinefelter syndrome was limited to diagnosing the condition with karyotype analysis, assessing whether sperm was present in the ejaculate, and attempting to extract sperm from the testis if it was not. Many of these men are identified shortly after puberty with low testosterone levels and prescribed exogenous testosterone alone, suppressing native spermatogenesis if present. Citing the progressive decline in spermatogenesis over time, investigators have argued for aggressive management including surgical extraction of sperm at early to mid puberty before initiation of therapy with exogenous testosterone and aromatase inhibitor (Mehta and Paduch, 2012; Mehta et al., 2013). This approach is primarily investigational at this time.

Structural Chromosomal Anomalies

As discussed in the section detailing Y chromosome microdeletion testing, investigators observed three regions on the Y chromosome, designated AZFa, AZFb, and AZFc, to be associated with azoospermia or oligospermia (Oates and Lamb, 2009). **Microdeletions of AZFc currently have unclear clinical significance, whereas AZFa and AZFb microdeletions are nearly always associated with absence of retrievable sperm from the testis** (Giachini et al., 2008; Hopps et al., 2003; Lardone et al., 2007; Mulhall et al., 1997; Oates et al., 2002; Stouffs et al., 2008; Visser et al., 2009; Wu et al., 2007). **AZFa microdeletions have particular clinical significance because spatially the AZFa region appears to be localized distinctly from AZFb and AZFc, with the latter two overlapping** (Oates and Lamb, 2009). In deletion carriers presenting with oligozoospermia, there is a potential risk of a progressive decrease of sperm concentration over time, and sperm cryopreservation can be considered (Krausz and Casamonti, 2017).

Other structural anomalies of the Y chromosome may be identified by karyotypic analysis (Oates and Lamb, 2009). Two terminal breaks in both chromosome arms and subsequent fusion may lead to a ring Y chromosome, or r(Y), with variable phenotype depending on the amount of chromosomal material lost (Arnedo et al., 2005). Karyotypic anomalies in somatic chromosomes may also be associated with infertility (Mau-Holzmann, 2005).

Epigenetic Anomalies

Not only must the DNA sequence be intact for successful function of the male gamete, but also the DNA must be tightly coiled and packaged (O'Flynn O'Brien et al., 2010). As discussed in the section describing denatured sperm DNA assays, investigators have constructed various methods of interrogating sperm DNA structure with unclear prognostic outcomes at present. Other components of sperm DNA packaging may yield future diagnostic tools; for example, animal studies revealed that premature translation of protamine 1 resulted in postmeiotic maturational arrest in mouse spermatogenesis, and protamine 2 deficiency led to sperm DNA damage and embryo demise (Cho et al., 2003; Lee et al., 1995). In humans, evidence links protamine 2 precursors and the protamine 1–protamine 2 ratio to sperm DNA quality and IVF outcomes (Aoki et al., 2006; de Mateo et al., 2009; Torregrosa et al., 2006). Histones also offer a future target for clinical assessment. They are highly, specifically localized along human sperm DNA, and researchers have observed histone variants to relate to fertility in bulls (de Oliveira et al., 2013; Hammoud et al., 2009). Sonnack et al. (2002) observed that infertile men have significantly decreased levels of histone H4 acetylation associated with impaired spermatogenesis.

DNA methylation allows coordination of gene expression in somatic cell development (Boissonnas et al., 2013). Once thought to be of little consequence in sperm, this epigenetic modification is now considered to play key roles in spermatogenesis and embryogenesis (Boissonnas et al., 2013; Carrell, 2012; Molaro et al., 2011). The pattern of gene promoter methylation is substantially different in somatic and sperm cell DNA and may have future clinical applicability in the assessment of male reproductive potential (Molaro et al., 2011). In addition, multiple RNA species (mRNA, microRNA, Piwi-interacting RNA, etc.) can directly and indirectly affect the sperm's expression profile (Craig et al., 2017).

Testicular Causes

The testis essentially consists of two compartments, the seminiferous tubules that house the developing male gametes and the interstitial spaces between the tubules, inhabited by Leydig cells. Both are required for sperm production, which then must conclude with transit of the male gamete outward. Testicular causes of male reproductive dysfunction may consequently be considered to derive from pathology in the production of sperm in the seminiferous epithelium or in the synthesis of testosterone by Leydig cells, or obstruction in the microductal system transporting sperm toward the ejaculatory ducts.

Spermatogenic Dysfunction

As discussed in the section describing testis histopathology, dysfunction in the seminiferous epithelium may be globally described as hypospermatogenesis, which indicates a decrease in sperm production; maturation arrest, which represents halting of the sequence of steps of the male gamete at some point through premeiotic, meiotic, and postmeiotic development; and Sertoli cell–only syndrome, which denotes a complete depopulation of spermatogonial cells. The molecular mechanisms leading to completion of spermatogenesis are still under investigation, and in the future it is likely that genomic, proteomic, and metabolomic markers will become available for clinical use to diagnose specific causes of spermatogenic dysfunction (Kovac et al., 2013). At present, the primary means of assessing deficiencies in spermatogenesis is histopathologic inspection. As previously described, if azoospermia is present, in 89% of cases spermatogenic dysfunction is identified as the cause with an FSH value greater than 7.6 IU/L and the testis long axis 4.6 cm or less (Schoor et al., 2001).

Another form of spermatogenic pathology arises in the testis and impedes sperm in the ejaculate. In the seminiferous epithelium, Sertoli cell tight junctions protect haploid germ cells from circulating immunologic cells, forming a blood-testis barrier (Brannigan, 2011). **Pathologic conditions that disrupt this blood-testis barrier may expose the immunologically protected spermatids and spermatozoa to antibody formation, which may cause sperm agglutination, impeded sperm motility, and reduced fertilizing potential** (Brannigan, 2011). These conditions include obstruction in the male reproductive tract such as that occurring after vasectomy; inflammation associated with orchitis, prostatitis, or sexually transmitted disease; exposure to heat with varicocele, cryptorchidism, or external sources such as hot tubs; trauma and testis torsion; and genetic associations including thymic maldevelopment and the HLA-B28 haplotype (Walsh and Turek, 2009). Assays for antisperm antibodies are detailed in the section describing the laboratory evaluation of semen.

For treatment of antisperm antibodies, simple measures include use of condoms and washing sperm. Neither has good evidence to substantiate its use (Walsh and Turek, 2009). Washing may remove unbound antibodies, but those that matter remain bound to sperm (Walsh and Turek, 2009). More direct treatments include immunosuppression with corticosteroids and ART. Two controlled trials of corticosteroids offer conflicting results, with one demonstrating improved fertility and the other not (Haas and Manganiello, 1987; Hendry et al., 1990). Whether because of a lack of compelling evidence or because of more direct results, IVF and ICSI have become common treatment for antisperm antibodies.

Steroidogenic Dysfunction

The terms *hypergonadotropic hypogonadism*, *primary hypogonadism*, and *primary hypoandrogenism* refer to impaired testosterone synthesis caused by Leydig cell dysfunction (Sokol, 2009). **This entity is typically identified by elevated LH levels and decreased circulating testosterone** (Sokol, 2009). However, Leydig cell dysfunction may exist concurrently with pituitary insufficiency, and these men will have decreased testosterone concentrations and variable LH levels that do not reflect the typical increase associated with primary Leydig cell insufficiency (Sokol, 2009). Increasing age is a condition associated with decreasing androgen and blunted pituitary response (Feldman et al., 2002; Sokol, 2009).

An absolute requirement for spermatogenesis is intratesticular steroidogenesis, which appears to be especially important for the postmeiotic maturation of sperm (Caroppo, 2011). Men with Klinefelter syndrome often have lower levels of circulating testosterone, but impaired Leydig cell function may not be the only mechanism responsible for a phenotype that resembles those of hypoandrogenic males (Oates, 2012; Sokol, 2009). Investigators have reported evidence of Leydig cell dysfunction in humans associated with mutations in the LH receptor gene and in FSH receptor–deficient mice, and as the genes responsible for steroidogenesis become clinically available for assessment in humans, it is anticipated that more cases of Leydig cell dysfunction with genetic causes will be identified (Baker et al., 2003; Latronico et al., 1996). Other potential clinical causes of Leydig cell dysfunction include orchitis, cytotoxic chemotherapy, and exposure to environmental toxicants (Skakkebaek et al., 2001; Sokol, 2009).

There is currently no accepted therapy for hypoandrogenism caused by Leydig cell insufficiency (Sokol, 2009). Exogenous testosterone is not indicated, because insufficient testicular testosterone concentrations are achieved for spermatogenesis, and pituitary LH release is suppressed (Niederberger, 2011). **Should azoospermia be associated with low testosterone concentrations and significantly elevated LH levels, if the patient desires paternity, the**

treatment is surgical sperm extraction.

Microductal Obstruction

Either by congenital or acquired means, the epididymis or scrotal vas deferens may be obstructed. If obstruction is bilateral, azoospermia typically results. As discussed in the section describing the endocrine evaluation, the physician may use the FSH level combined with the testis longitudinal axis as measured by calipers to predict whether azoospermia is associated with obstruction; 96% of men with obstructive azoospermia had FSH concentration of 7.6 IU/L or less and testis long axis greater than 4.6 cm (Schoor et al., 2001). Fig. 66.11 illustrates an algorithm for the evaluation of azoospermia. Microductal obstruction may also be unilateral: in that case, bulk seminal parameters may be reduced or not depending on the function of the contralateral testis. If unilateral obstruction is present with adequate spermatogenesis in the ipsilateral testis and the existence of spermatogenic pathology in the contralateral testis, impaired bulk seminal parameters may result and microductal reconstruction may be indicated.

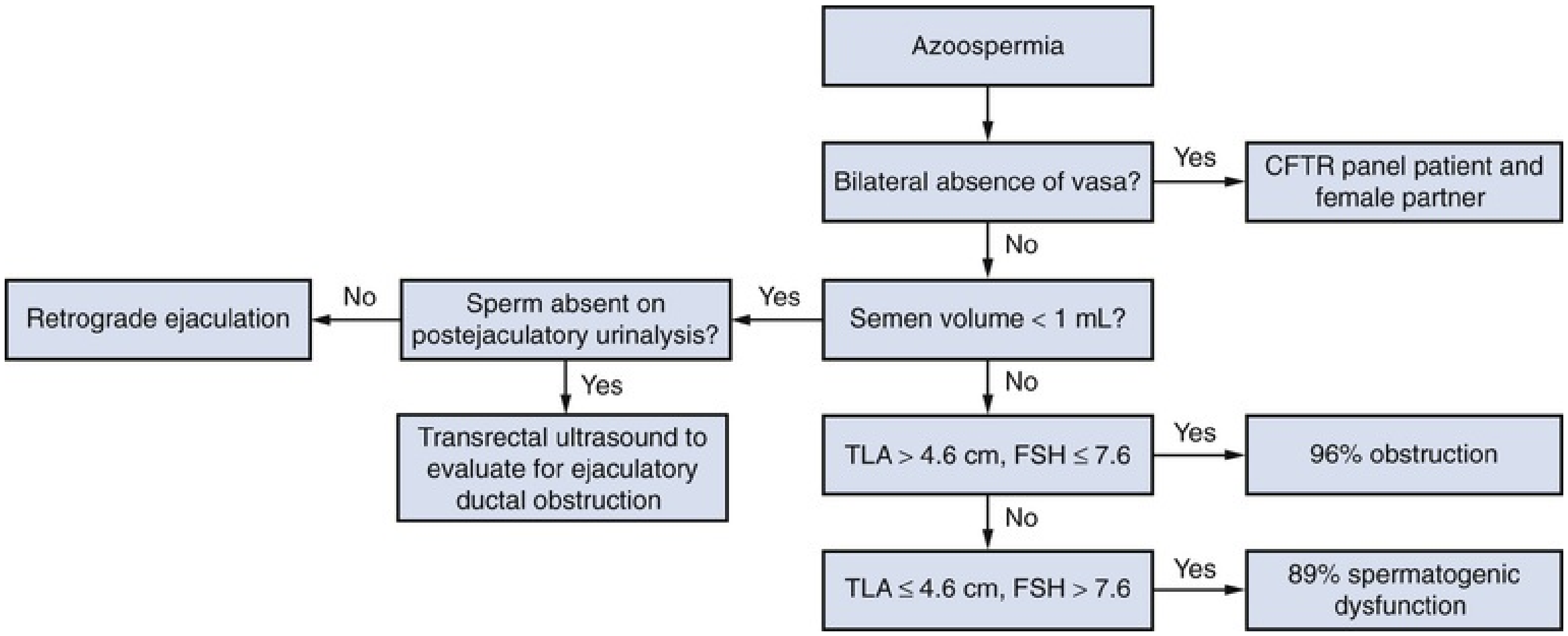
Azoospermia
Bilateral absence of vasa?
Yes
CFTR panel patient and female partner
No
Semen volume < 1 mL?
Yes
Sperm absent on postejaculatory urinalysis?
No
Retrograde ejaculation
Yes
Transrectal ultrasound to evaluate for ejaculatory ductal obstruction
No
TLA > 4.6 cm, FSH ≤ 7.6
Yes
96% obstruction
No
TLA ≤ 4.6 cm, FSH > 7.6
Yes
89% spermatogenic dysfunction

FIG. 66.11 Algorithm for evaluation of azoospermia. *CFTR,* Cystic fibrosis transmembrane conductance regulator; *FSH,* follicle-stimulating hormone; *TLA,* testis longitudinal axis measured by caliper orchidometer.

As discussed in the section describing evaluation of the surgical history of an infertile male, herniorrhaphy especially with mesh may result in obstruction of the vas deferens in the inguinal canal (Hallén et al., 2011, 2012; Maciel et al., 2007; Shin et al., 2005; Tekatli et al., 2012). If both vasa are occluded, azoospermia likely results.

Pituitary Dysfunction

The pituitary hormones LH and FSH regulate spermatogenesis: LH directs Leydig cell steroidogenesis; and FSH controls spermatogenesis via the Sertoli cells (Caroppo, 2011). If by intrinsic dysfunction or external pathology LH, FSH, or both are suppressed, spermatogenesis suffers.

Hypogonadotropic Hypogonadism

Hypogonadotropic hypogonadism refers to the condition of decreased pituitary hormonal secretion. **Kallmann described anosmia associated with decreased pituitary function, and the syndrome bears his name** (Kallmann and Schoenfeld, 1944). The incidence of the syndrome is approximately 1 in 10,000 males, and the mode of inheritance is most frequently autosomal recessive, but autosomal-dominant and X-linked recessive patterns are also observed (Bhagavath et al., 2006; Sokol, 2009). Investigators have identified associations with Kallmann syndrome and the *KAL1* gene encoding anosmin-1 responsible for neurotropic growth factors during embryogenesis, the *GNRHR* gene encoding gonadotropin-releasing hormone (GnRH) receptor, the pituitary-specific transcription factor PIT1, the PIT1-related transcription factor PROP1, the G protein–coupled Kisspeptin receptor GPR54, the homeobox genes *HESX1*, *LEX3*, and *LEX4*, and others (Bhagavath et al., 2006; Dattani et al., 1998; de Roux et al., 2003; Kim et al., 2003; Newbern et al., 2013; Sobrier et al., 2004; Wu et al., 1998). Researchers noted approximately 10% of men with Kallmann syndrome to harbor mutations in either the *GNRHR* or *KAL1* gene (Bhagavath et al., 2006).

Treatment includes replacement of LH with human chorionic gonadotropin (hCG) and replacement of FSH with recombinant FSH (rFSH) or hMG, which exhibits LH- and FSH-like activity (Sokol, 2009). Treatment with hCG alone may initiate spermatogenesis; if hMG or rFSH is prescribed, after spermatogenesis returns, these agents may be withdrawn after several months of therapy (Sokol, 2009). Men who are identified as having Kallmann syndrome later in life when reproductive interests occur have often been prescribed exogenous androgen since adolescence. These men may require gonadotropin therapy for 1 to 2 years before sperm becomes evident in the ejaculate. Typical doses for intramuscular or subcutaneous hCG are 1500 to 5000 IU two to three times weekly to a maximum of 10,000 IU/wk and are titrated to serum testosterone results (Hussein et al., 2013; Sokol, 2009). The dose of hMG is 75 IU two to three times weekly, typically administered subcutaneously (Sokol, 2009).

Rarely, men may have isolated decreased secretion of either LH or FSH (Giltay et al., 2004; Sokol, 2009). Isolated LH deficiency was termed the "fertile eunuch syndrome" and characterizes men who have features of hypoandrogenism because of low levels of LH but who produce sperm as a result of adequate FSH (Sokol, 2009). Conversely, men with isolated FSH deficiency have suppressed spermatogenesis but adequate androgenization (Giltay et al., 2004). Treatment of these uncommon conditions includes replacement with the appropriate gonadotropin (Giltay et al., 2004; Sokol, 2009). Men may also infrequently have isolated hypothalamic GnRH deficiency (Nachtigall et al., 1997). Treatment includes GnRH administration by a subcutaneous portable mini-infusion pump every 2 hours, and, as with treatment for Kallmann syndrome, long-term courses of at least 6 months' duration may be required (Nachtigall et al., 1997).

Kallmann and the associated syndromes of hypogonadotropic hypogonadism are the most severe forms of conditions resulting in diminished pituitary hormonal secretion. **Incomplete forms with hypoandrogenism associated with serum LH concentrations above those observed with Kallmann syndrome but lower than expected for the diminished testosterone are common** (Bhagavath et al., 2006). For these men, pituitary stimulation with antiestrogenic agents such as clomiphene or tamoxifen or with aromatase inhibitors such as anastrozole or letrozole may restore testosterone levels and possibly improve spermatogenesis (Hussein et al., 2005, 2013; Ioannidou-Kadis et al., 2006; Katz et al., 2012; Moskovic et al., 2012; Raman and Schlegel, 2002; Roth et al., 2013; Siddiq and Sigman, 2002; Sussman et al., 2008; Whitten et al., 2006). Clomiphene citrate is a selective estrogen receptor modulator that is currently FDA approved for women. It has been used as an off-label treatment for male hypogonadism and infertility for more than 40 years, and it is proven to significantly increase testosterone levels without changes in PSA or hematocrit levels (Chandrapal et al., 2016). The initial dose of clomiphene citrate is typically 25 mg every day or 50 mg every other day and is increased by titrating to serum testosterone to a maximum of 100 mg daily (Hussein et al., 2005, 2013; Sussman et al., 2008). In some studies, the titration target is restoration of normal androgen levels; in others, it is elevated at 600 to 800 ng/dL (Hussein et al., 2005, 2013; Sussman et al., 2008). The typical dosage of anastrozole is 1 mg daily, although there is not a current standardization of dosing given the increasing knowledge of the role of estradiol in male sexual and reproductive health (Raman and Schlegel, 2002).

Prader-Willi syndrome is characterized by failure to thrive in infancy associated with a poor suck reflex followed by loss of satiety in early childhood, which may lead to marked obesity if poorly controlled (Cassidy and Driscoll, 2009). Its incidence is approximately 1 in 15,000 to 30,000 (Cassidy and Driscoll, 2009). Features associated with the syndrome include hypogonadism, small testes, dysmorphic facies, growth hormone deficiency with short stature and small hands and feet, pain insensitivity, and cognitive disorders such as obsessive-compulsive traits (Bervini and Herzog, 2013). Researchers have suspected that the association of growth hormone deficiency and hypogonadism with the syndrome derive from hypothalamic dysfunction, but the precise pathophysiology is still uncertain (Bervini and Herzog, 2013). Prader-Willi syndrome is typically caused by the loss of expression of genes located on human chromosome 15q11-q13 by means of failed imprinting, which is the epigenetic phenomenon that allows genes on only one chromosome to be active (Bervini and Herzog, 2013). **In the healthy state, the genes located on the maternal chromosome 15q11-q13 are silenced, and those on the paternal chromosome are active; in Prader-Willi syndrome, the maternal genes are silenced and the paternal ones inactive** (Bervini and Herzog, 2013).

Pituitary Tumors and Diseases

Space-occupying lesions in the sella turcica such as secretory and nonsecretory tumors and craniopharyngiomas may compress the anterior pituitary and result in varying degrees of LH and FSH suppression (Sokol, 2009). The most common kind of pituitary tumor resulting in male reproductive dysfunction secretes prolactin and is commonly associated with other symptoms such as erectile dysfunction (Sokol, 2009). These tumors are rare; as described in the section discussing the endocrine evaluation, in one series of 1035 men undergoing an infertility evaluation, only 4, or 0.4%, had hyperprolactinemia (Sigman and Jarow, 1997). This finding questions the value of including prolactin as a routine assay in screening infertile men, especially those who are otherwise asymptomatic (Niederberger, 2011; Sigman and Jarow, 1997; Sokol, 2009). **In general, mild elevations of prolactin in the range of 20 to 50 μg/L do not warrant further evaluation; if prolactin is significantly elevated, cranial MRI is indicated** (Niederberger, 2011). The dopamine agonists bromocriptine and cabergoline may be prescribed for prolactin-secreting adenomas for which surgery is not indicated, with cabergoline exhibiting fewer side effects (Klibanski, 2010).

Other Pituitary Lesions

Diseases infiltrating the pituitary may also suppress its secretion of hormones, including granulomata of infection, sarcoidosis, and histiocytosis (Sokol, 2009). Deposition of iron by hemochromatosis or repeated blood transfusions may also invoke hypogonadotropic hypogonadism (Sokol, 2009). Systemic diseases such as morbid obesity, chronic malnutrition, and type 2 diabetes may also be associated with hypogonadotropic hypogonadism (Dhindsa et al., 2004; Sokol, 2009). Treatment of these disorders is aimed at ameliorating the underlying condition.

Extrapituitary Endocrine Modulators

As described in the section discussing the role of investigating endocrine modulators when taking the history of an infertile man, exogenous androgenic agents, especially testosterone, suppress pituitary gonadotropins (Grimes et al., 2012). Also discussed in that section are cannabis, antipsychotics, opioids, and environmental toxicants, which inhibit pituitary function via estrogenic and dopaminergic pathways (Carlsen et al., 1992; Gorzalka et al., 2010; Stimmel and Gutierrez, 2006; Subirán et al., 2011). Treatment is directed toward removing the offending agent when possible. CAH, especially in milder forms that manifest clinically in adolescence or adult life, may be associated with hypogonadotropic hypogonadism (Reisch et al., 2011). A high incidence of testicular adrenal rest tumors adds to the reproductive dysfunction present in these men (Claahsen-van der Grinten et al., 2008; Reisch et al., 2011). Fertility may be restored with corticosteroid therapy (Claahsen-van der Grinten et al., 2007). However, side effects such as weight gain and skin changes from the lengthy application of therapy required to address the long duration of spermatogenesis may prove problematic (Claahsen-van der Grinten et al., 2007).

Extratesticular Endocrine Dysfunction

Because estradiol inhibits gonadotropin release, conditions that increase its concentration may lead to hypogonadotropic hypogonadism. These include the pharmacologic agents described in the section discussing medications that alter the ratio of estrogen to androgen through a variety of means (Bowman et al., 2012). When possible, use of another agent may improve fertility. As described in the section discussing the general physical examination of the infertile male, elevated estradiol is associated with obesity by the mass of adipose cells containing aromatase (Aggerholm et al., 2008; Chavarro et al., 2010; Hammoud et al., 2006, 2010b; Hofny et al., 2010). Multiple factors are suspected to associate obesity with male infertility, and hypogonadotropic hypogonadism may or may not be involved, including "neohormones" leptin and kisspeptin and other comorbidities such as diabetes and sleep apnea (Aggerholm et al., 2008; Craig et al., 2017; George et al., 2010; Hammoud et al., 2006; Hofny et al., 2010; Munzberg et al., 2005; Paasch et al., 2010; Pauli et al., 2008; Teerds et al., 2011). In 2006 a study conducting a group of 20,620 families in Iowa and North Carolina demonstrated a dose-response relationship between BMI and male infertility (Sallmen et al., 2006). These findings were confirmed in other studies around the globe (Nguyen et al., 2007; Ramlau-Hansen et al., 2007). Besides increased aromatization of testosterone to estradiol peripherally, obesity is also responsible for reducing pulse amplitude of the LH secretion from the pituitary as well as decreased response to LH by the testis (Vermeulen et al., 1993). The question remains regarding whether diet, exercise, and weight reduction improve male reproductive potential. Limited animal studies in an obese rodent model suggest that diet and exercise improve sperm parameters, but human studies are sparse and inconclusive (Braga et al., 2012; Luconi et al., 2013; Nguyen et al., 2007; Palmer et al., 2012). In the absence of conclusive data demonstrating a causative effect between weight loss and improved male fertility, it still seems prudent to recommend it in obese men because the ancillary health benefits are certain. Nonetheless, male obesity appears to affect clinical pregnancy, miscarriage, and live birth rates in couples submitted to assisted reproductive technology (Campbell et al., 2015; Provost et al., 2016; Thomsen et al., 2014).

Researchers have investigated the use of aromatase inhibitors such as anastrozole, letrozole, and testolactone for elevated estradiol, demonstrating that for the typical male patient, testosterone levels increase and estradiol levels decline (Gregoriou et al., 2012; Raman and Schlegel, 2002; Schlegel, 2012; Shoshany et al., 2017). Limited data support that sperm parameters may concurrently improve (Gregoriou et al., 2012; Raman and Schlegel, 2002; Schlegel, 2012; Shoshany et al., 2017). As described in the section discussing the endocrine evaluation of male infertility, researchers have proposed that a testosterone-to-estradiol ratio in nanograms per deciliter (ng/dL) to picograms per milliliter (pg/mL) of less than 10 : 1 indicates aromatase overactivity that would benefit from inhibitory therapy (Gregoriou et al., 2012; Raman and Schlegel, 2002; Schlegel, 2012). Prescribers should be cautious in the long-term use of aromatase inhibitors, because bone density in the male may be estradiol dependent, and long-term studies of this class of drug in men are lacking (Khosla et al., 2001; Kim et al., 2013).

Mutations in the androgen receptor *(AR)* gene located on the long arm of the X chromosome at banding region Xq11-12 lead to a spectrum of disorders from complete testicular feminization to male infertility (Davis-Dao et al., 2007; Dowsing et al., 1999; Sokol, 2009). Male reproductive dysfunction appears to be related to a longer cytosine-adenine-guanine (CAG) repeat length in exon one of the *AR* gene (Davis-Dao et al., 2007; Dowsing et al., 1999; Sokol, 2009; Xiao et al., 2016). **Male infertility associated with AR insensitivity is characterized by increased testosterone, estradiol, and LH to variable degrees with typical FSH levels; significantly elevated testosterone in the presence of impaired male fertility should consequently raise the suspicion of AR resistance** (Sokol, 2009). High-dose testosterone therapy may result in improved spermatogenesis, but data on this form of treatment are limited (Tordjman et al., 2014). Pregnancy may be achieved by ICSI with ejaculated sperm or that derived by surgical extraction from the testis (Massin et al., 2012; Tordjman et al., 2014).

Because dihydrotestosterone regulates the anatomic development of external male genitalia, mutations in the gene encoding isozyme 2 of 5α-reductase located on the short arm of chromosome 2 at banding region 2p23 result in a spectrum ranging from a female to a male phenotype (Johnson et al., 1986; Sokol, 2009; Thigpen et al., 1993). Phenotypic females with 5α-reductase 2 mutations may harbor testes with intact spermatogenesis (Johnson et al., 1986; Thigpen et al., 1993). No medical treatment is currently available for this disorder. Pregnancies have been successfully attained with ICSI from sperm from men with 5α-reductase-2 deficiency (Kang et al., 2011; Matsubara et al., 2010).

Developmental Disorders

Anatomic development that results in aberrant genital formation may manifest in later life as male infertility. Main areas of maldevelopment include the testes, the external genitalia, and the reproductive microductal system.

Intersex or Disorders of Sexual Development

Disorders of sex development (DSD) are congenital diseases in which the chromosomal, gonadal, or anatomic sex is abnormal and embraces a wide-ranging spectrum of phenotypes classified in five different groups (Hughes et al., 2006). The first class involves disorders of gonadal differentiation; the second comprehends ovotesticular DSD (formerly known as true hermaphroditism); the third includes 46,XX DSD (formerly known as female pseudohermaphroditism); the fourth encloses 46,XY DSD (formerly known as male pseudohermaphroditism); and the fifth group consists of unclassified forms (Hughes et al., 2006). DSDs are increasingly being understood as the consequence of specific aberrant genes, and the current nomenclature used to describe intersex now includes the karyotype, a clinically descriptive term, and the molecular basis of the disorder if it is known (Ono and Harley, 2013). An example of an intersex description using this nomenclature may be “46,XY DSD complete gonadal dysgenesis with SF1 mutation” (Ono and Harley, 2013). Genes identified to be involved in DSD are too numerous to be listed here, and the reader is referred to Ono and Harley for a current review (Ono and Harley, 2013). In general, the genes involved in DSDs that manifest as male infertility do so by developmental anatomic abnormalities, abnormal or absent spermatogenesis, general endocrinopathy, or encoding for defective endocrine receptors and target complexes (Oates and Lamb, 2009; Ono and Harley, 2013).

Hypospadias and Epispadias

Aberrant anatomic location of the urethra in hypospadias or epispadias may result in deposition of semen too distal in the vaginal vault (Niederberger, 2011). These men may have adequate bulk seminal parameters, and if screening semen analysis is performed before physical examination of the man, the diagnosis may be missed. Hypospadias appears to have genetic and environmental causes, with genetic polymorphisms playing a predominant role rather than isolated gene defects (Macedo et al., 2012). The pathophysiology of epispadias is different from that of hypospadias, and it is typically considered on the spectrum of bladder-exstrophy-epispadias complex (BEEC) disorders (Rasouly and Lu, 2013).

Cryptorchidism

The basis of cryptorchidism and the relationship of the disorder to male reproductive function is detailed in the section of this chapter describing childhood diseases in the reproductive history of the infertile male. The most significant feature related to the prognosis of cryptorchidism is whether the condition is unilateral or bilateral (Lee, 2005; Lee et al., 2001; Miller et al., 2001).

Microductal Aplasia

The vas deferens may fail to develop on one side or both. The distinction is significant, because the pathophysiologic basis of each is different.

Congenital Unilateral Absence of the Vas Deferens.

As described in the section detailing the physical examination of the infertile male, unilateral absence of the vas deferens implies that wolffian, or mesonephric, ductal development on the ipsilateral side was aberrant. As these ducts become in embryogenesis the epididymis, vas deferens, and ejaculatory duct, the proximal and distal portions may be malformed or absent as well (Lewis and Kaplan, 2009). The most important consideration if unilateral absence of the vas is observed is that because renal development is coupled with wolffian ductal development, a solitary absent vas deferens may signal renal agenesis (Niederberger, 2011).

Congenital Bilateral Absence of the Vas Deferens.

Oates et al. reported in the early 1990s that males with CBAVD had a high frequency of genetic sequence abnormalities associated with cystic fibrosis (Anguiano et al., 1992). **Coupled with the observation that in nearly all men with cystic fibrosis the vasa are absent bilaterally, these findings suggested that CBAVD is frequently a phenotype for a spectrum of disorders involving mutations in the gene responsible for cystic fibrosis** (Anguiano et al., 1992). As described in the section discussing genomic sequence assessment in the laboratory evaluation of the infertile male, that gene encodes a predominantly chloride ion channel termed the *cystic fibrosis transmembrane conductance regulator,* and currently more than 1600 mutations in the gene have been identified, which vary in the severity of the phenotype from CBAVD to cystic fibrosis (Bombieri et al., 2011; Hampton and Stanton, 2010; Oates and Lamb, 2009; Ratbi et al., 2007; Yu et al., 2012).

It is currently believed that two genetic causes of CBAVD exist: one that results from mutations in CFTR and another that results from alterations in as-yet-unidentified other genes involved in mesonephric ductal development (Oates and Lamb, 2009). CFTR mutations represent a spectrum of disease severity; if both alleles harbor severe mutations, cystic fibrosis results, and if one or both alleles contain the milder forms, CBAVD may occur (Bombieri et al., 2011; Hampton and Stanton, 2010; Oates and Lamb, 2009; Ratbi et al., 2007; Yu et al., 2012). As described in the section detailing genomic sequence assessment, the most common mutation is ΔF508, which is severe (Hampton and Stanton, 2010). **The carrier frequency for cystic fibrosis gene mutations is high—approximately 1 in 20 in persons of northern European descent—and it is consequently important to investigate the CFTR status of the female partner of a man identified to have CBAVD in addition to his genetic evaluation** (Oates and Lamb, 2009). Symptoms such as chronic sinus or respiratory infections may be overlooked if mild, and the urologist diagnosing CBAVD may be the first to uncover an indolent form of cystic fibrosis (Oates and Lamb, 2009).

Spermatogenesis in men with CBAVD is typically normal, and ICSI with surgically extracted sperm is typically effective (Kamal et al., 2010). Nevertheless, one study has shown that sperm obtained from men with CFTR mutations and CBAVD were associated with an increased risk of miscarriage and stillbirth after ICSI (Lu et al., 2014). Genetic counseling taking into account the CFTR genetic assessment of the affected man and his female partner allows for the couple to understand the likelihood of cystic fibrosis in offspring and the implications of carrier status, and it may be performed by the urologist or a clinical geneticist.

Varicocele

The diagnosis of varicocele was discussed in the section detailing the physical examination of the infertile man: why imaging such as ultrasound is most rationally not recommended for the screening evaluation of a varicocele is discussed in the section describing imaging.

That most men with varicocele have sperm present on semen analysis has proved to be one of the most confounding aspects of its diagnosis and treatment. As discussed in the section describing the semen analysis, the results of this assay are assessed in a probabilistic context with substantial variability, making analytical statements concerning its effect on male reproductive potential difficult. Taking into account confounding factors involving the female partner that are often opaque and difficult to control in analyses, determining the effect of a varicocele on pregnancy, miscarriage, and birth becomes intractable. However, substantial evidence links varicocele to spermatogenic dysfunction and impaired male reproductive potential.

Because the left internal spermatic vein drains into the left renal vein approximately 8 to 10 cm superior to the entry of the right internal spermatic vein draining into the vena cava, the hydrostatic column of blood on the left predisposes that side to incompetence in its venous valves more so than on the right (Gat et al., 2005; Masson and Brannigan, 2014; Shafik and Bedeir, 1980). **As a result, varicose veins in the pampiniform plexus are more common on the left than on the right** (Gat et al., 2005; Masson and Brannigan, 2014). The incidence of bilateral varicoceles depends on the techniques involved in detection, with more than 80% observed to be bilateral on contact thermography, Doppler sonography, and venography in one series (Gat et al., 2004). Whether these bilateral varicoceles so identified are clinically significant remains an open question. **One clinical consequence of the infrequency of solitary right varicoceles is that should one be identified, renal pathology such as tumor should be considered, especially if the right-sided varicocele is of abrupt onset** (Masson and Brannigan, 2014).

Varicoceles likely arise as most varicose veins do by intravenous valvular incompetence (Gat et al., 2005; Wishahi, 1991). Genetics may predispose to a valvular defect, because investigators have noted an increased incidence of varicoceles in first-degree relatives of men with a known varicocele (Raman et al., 2005).

Substantial evidence correlates the presence of palpable varicoceles to male reproductive dysfunction. Bulk seminal parameters are poorer in men with varicocele than in the fertile population (Al-Ali et al., 2010; WHO, 1992). Testis size, which reflects the mass of spermatogenesis, is smaller in men with varicocele, and investigators have documented progressive atrophy associated with the condition (Lipshultz and Corriere, 1977; Patel and Sigman, 2010; Sakamoto et al., 2008).

Most studies investigating how varicocele exerts deleterious effects on male reproductive function consider the primary event to be an increase in intratesticular temperature secondary to interruption in the countercurrent heat exchange provided in the pampiniform plexus with opposing flow vectors in a central arterial system and surrounding veins (Goldstein and Eid, 1989; Masson and Brannigan, 2014; Zorgniotti and MacLeod, 1973).

Varicoceles are also associated with the presence of higher oxidative stress in the semen of patients seeking care for infertility, which in turn can increase DNA fragmentation (Clavijo et al., 2017). Another possible mechanism by which varicocele can affect spermatogenesis is through testicular hypoperfusion and stasis of blood, leading to hypoxia and toxin accumulation (Chakraborty et al., 1985; Gat et al., 2005; Lee et al., 2006). A study conducted by Mostafa et al. (2016) found that men with varicoceles have elevated levels of apoptosis-associated microRNA in seminal fluid. The proposed mechanisms by which male fertility is impaired by this effect mainly include DNA fragmentation and apoptosis, oxidative stress, predisposition to aneuploidy, and intracellular metabolic and ionic changes (Abd-Elmoaty et al., 2010; Agarwal et al., 2008c; Baccetti et al., 2006; Benoff et al., 2004; Bertolla et al., 2006; Blumer et al., 2008; El-Domyati et al., 2010; Enciso et al., 2006; Ghabili et al., 2009; Lima et al., 2006; Pasqualotto et al., 2008a; Shiraishi and Naito, 2007; Smith et al., 2005; Wu et al., 2009; Zucchi et al., 2006).

Varicocele repair can improve semen parameters, pregnancy rates, live birth rates, and sperm DNA fragmentation for most infertile men with clinical varicocele (Baazeem et al., 2011; Kohn et al., 2017; Smit et al., 2013; Wang et al., 2012; Zini et al., 2011). In couples seeking fertility using assisted reproduction techniques, varicocele repair may offer improvement in semen parameters and allow couples to use less invasive forms of treatment (Samplaski et al., 2017).

Ejaculatory Dysfunction

Disorders of ejaculation may be anatomic, functional, or neuropathic in origin, resulting in absence of emission, resistance, or misdirection. The three main categories of ejaculatory dysfunction encountered in a clinical setting include ejaculatory ductal obstruction, retrograde ejaculation, and anejaculation.

Ejaculatory Ductal Obstruction

The ejaculatory ducts are primarily intraprostatic structures that originate at the terminus of the seminal vesicles and serve as their extensions but without their musculature, functioning within the prostate as simple conduits (Nguyen et al., 1996). The ampulla of the vas enters the prostate medially and at an acute angle with the terminating limb of the seminal vesicle (Nguyen et al., 1996). The intraprostatic conduit ends angled at the verumontanum, which contains two layers of longitudinal muscular bundles extending into the urethra (Nguyen et al., 1996).

Obstruction of the ejaculatory ducts is infrequent and is the cause of azoospermia in less than 5% of men without sperm in the ejaculate (Wosnitzer and Goldstein, 2014). Patients with ejaculatory duct obstruction without underlying cause present with 50% prevalence of cystic fibrosis gene *(CFTR)* mutations and should be considered for genetic evaluation (Jarvi et al., 1995). It may occur at any point along the transit of the ducts within the prostate and result from infection, inflammation, prior surgery, or compression by congenital cysts (Wosnitzer and Goldstein, 2014). As detailed in the section discussing the semen analysis, an evaluation for ejaculatory ductal obstruction is indicated when the seminal volume is less than 1.0 mL. Men with partial ejaculatory duct obstruction can have severe oligospermia or azoospermia, decreased motility, and decreased ejaculatory volume (Mogdil et al., 2016). As noted in the section describing imaging to evaluate for ejaculatory ductal obstruction, techniques to investigate it include TRUS, MRI, chromotubation, and hydraulic pressure measurements. TRUS-guided seminal vesicle aspiration can be useful in diagnosing partial ejaculatory duct obstruction. The finding of three or more sperm per high-powered microscopic field (400×) in the aspirate is considered positive and suggestive of obstruction (Jarow, 1996). If clinically significant ejaculatory ductal obstruction is suspected and if the position of the obstruction is amenable to surgery, transurethral resection of the ejaculatory ducts (TURED) is warranted. The level of the resection is guided by synchronous TRUS to avoid inadvertent injury to the rectum (Mogdil et al., 2016). Different studies have shown elimination of painful ejaculation and hematospermia in all patients (Popken et al., 1998; Weintraub et al., 1993), increased ejaculatory volumes (Yurdakul et al., 2008), and improvements in semen quality (Smith et al., 2008).

Retrograde Ejaculation

Ejaculation is a multiphasic event that includes coordinated neural activity and muscular contraction and relaxation (Jefferys et al., 2012; Phillips et al., 2014). Afferent genital stimulation and cognitive ideation initiate the process, which induces emission through sympathetic stimulation of the bladder neck, vasal ampullae, seminal vesicles, and prostate (Jefferys et al., 2012; Phillips et al., 2014). **Essential to antegrade ejaculation, the bladder neck must first close while temporal neural sequencing first causes closure of the external**

sphincter to create a high pressure compartment that is emptied with its subsequent opening (Shafik, 1995).

Failure of sufficient resistance at the bladder neck during generation of the high-pressure system within the prostatic urethra may redirect emission into the bladder, causing retrograde ejaculation. Pathologic causes include congenital abnormalities of or surgery to the bladder neck, spinal cord or neural injury during trauma or retroperitoneal lymph node dissection, diabetes mellitus, or idiopathic causes (Jefferys et al., 2012). **Like ejaculatory ductal obstruction, retrograde ejaculation is infrequent and is established as the diagnosis in less than 2% of infertile men** (Jefferys et al., 2012).

As detailed in the section discussing the semen analysis, an evaluation for ejaculatory ductal obstruction is indicated when the seminal volume is less than 1.0 mL and includes a postejaculatory urinalysis, which is considered significant if the number of sperm in the urine nears or exceeds that in the antegrade specimen (Sigman et al., 2009). **Primary treatment modalities include retrieval of retrograde ejaculated sperm and increasing resistance at the bladder neck with sympathomimetic agents.** In both cases, the sperm so obtained is processed for use in IUI or IVF. If retrieval is to be attempted, the urine is typically first alkalinized with oral bicarbonate or diluted by oral fluid intake, and then the voided urine or a catheterized specimen is obtained after masturbation and orgasm (Jefferys et al., 2012). Investigators have also described ejaculation on a full bladder with successful results (Crich and Jequier, 1978; Templeton and Mortimer, 1982). **Clinicians may also use sympathomimetic agents such as synephrine, pseudoephedrine, ephedrine, or phenylpropanolamine, with approximately one in four patients achieving antegrade ejaculation** (Jefferys et al., 2012). Researchers have described other therapy such as anticholinergic agents, acupuncture, and surgery, but these should be considered investigational (Jefferys et al., 2012).

Anejaculation

Anejaculation refers to lack of seminal emission and projectile ejaculation, and it must be distinguished from anorgasmia, in which the absence of an ejaculation has a cerebral cause (Brackett et al., 2009). Conditions that result in anejaculation are primarily neurologic and include retroperitoneal lymph node dissection, pelvic surgery, multiple sclerosis, transverse myelitis, congenital neural tube defects, diabetes mellitus, and spinal cord injury (Brackett et al., 2009; Phillips et al., 2014).

For patients with sufficient peripheral neural function, neurostimulation with penile vibratory devices or application of current with a rectal electrode, or electroejaculation, may result in sufficient sperm for IUI or IVF (Brackett et al., 2009; Phillips et al., 2014). **For men with spinal cord injuries at a level of T6 or above, stimulation may cause autonomic dysreflexia, an uninhibited sympathetic reflex accompanied by headache, diaphoresis, hypertension, bradycardia, and diaphoresis, which may be life threatening.** Autonomic dysreflexia can be addressed before stimulation by treatment with nifedipine and during the procedure with monitoring of cardiac activity and blood pressure (Brackett et al., 2009; Phillips et al., 2014).

The sperm achieved by stimulation in patients with spinal cord injury is typically characterized by adequate count but impaired motility (Brackett et al., 2009). Evidence supports impairment of sexual accessory gland function, a noxious seminal plasma milieu, and immunopathic mechanisms as causative (Brackett et al., 2009).

Stimulation with penile vibratory devices serves as first-line therapy, with electroejaculation used if the former is unsuccessful (Brackett et al., 2009). If electroejaculation does not yield sperm or if other factors prevent its use, surgical extraction is indicated (Brackett et al., 2009).

Structural Sperm Abnormalities

As discussed in the section describing evaluation of sperm morphology, the majority of sperm in fertile men are eccentrically shaped, and associating the typical variation of sperm shape to clinical relevance in a quantifiable manner has proved challenging. Investigators have characterized certain infrequent discrete structural abnormalities with overt clinical manifestations.

Evidence suggests genetic bases and consequences for two rare types of specific sperm head abnormalities, globozoospermia and macrocephaly. In globozoospermia, the majority of the sperm lack acrosomal caps, rendering the heads spheric rather than ovoid. Sperm macrocephaly is characterized by large-headed and multiflagellated spermatozoa (Nistal et al., 1977). Investigators have associated globozoospermia in humans with mutations in the genes *SPATA16* at chromosome band 3q26.32, *PICK1* at 22q12.3-q13.2, and *DPY19L2* at 12q14.2 (Perrin et al., 2013). Both *SPATA16* and *PICK1* localize to proacrosomal granules that are involved in formation of the acrosome during spermatogenesis (Perrin et al., 2013). Sperm macrocephaly can be caused by the occurrence in homozygosity of a 1-bp deletion in the *AURKC* gene, which is essential for correct meiotic chromosomal segregation and cytokinesis (Dietrich et al., 2007). **It is debatable whether higher rates of aneuploidy are present in patients with globozoospermia or teratozoospermia in general; however, for men in whom nearly all sperm have enlarged heads, multiple tails, and abnormal acrosomes, a very high rate of aneuploidy is found** (Machev et al., 2005; Sun et al., 2006). The treatment for globozoospermia is IVF with ICSI as no acrosome reaction can occur to fertilize the egg; owing to the high rate of aneuploidy in sperm associated with macrocephaly and multiple tails, ICSI is not recommended (Machev et al., 2005; Perrin et al., 2013; Sun et al., 2006). Recently, assisted oocyte activation has been proposed as treatment for globozoospermic patients (Kunetz et al., 2013).

As discussed in the section describing the ultrastructural assessment of sperm, *primary ciliary dyskinesia* refers to a rare condition in which the microtubular architecture of cilia is disrupted (Boon et al., 2013). Because structures such as the sperm tail share similar microtubular construction with cilia, conditions that affect this architecture frequently result in a variety of other clinical manifestations such as immotile sperm, congenital heart disease, chronic respiratory and otolaryngologic infections, and laterality defects (Ferkol and Leigh, 2012). PCD occurs in 1 in 15,000 to 30,000 live births and is typically inherited in an autosomal recessive manner, with occasional X-linked inheritance reported (Boon et al., 2013; Ferkol and Leigh, 2012). Investigators have associated numerous genetic mutations with PCD, with mutations in dynein axonemal heavy chain 5 *(DNAH5)* and intermediate chain 1 *(DNAI1)* accounting for 38% of patients with the condition (Boon et al., 2013; Davis and Katsanis, 2012; Ferkol and Leigh, 2012; Hildebrandt et al., 2011; Zariwala et al., 2011). The sperm of infertile male patients with PCD are usually immotile to varying degrees or are even completely static and manifest defective morphology (Sha et al., 2014). ICSI may achieve pregnancy in cases of PCD (Peeraer et al., 2004). The sperm for ICSI could be obtained from ejaculate, epididymis or testis, but it has been demonstrated that fertilization is improved with immotile testicular spermatozoa (Nijs et al., 1996).

Empirical Treatment

In general, empirical treatment falls within two categories: endocrine or nutraceutical based. The highly variable character of the semen analysis and its probabilistic nature make empirical treatments of male infertility difficult to assess without carefully conducted controlled clinical trials. Unfortunately, few exist. Investigators have reported results of many uncontrolled trials of selective endocrine receptor modulators such as clomiphene or gonadotropins in men, but the few available clinical trials usually do not demonstrate pregnancy rates to be greater than that expected by nature acting alone (Attia et al., 2007; Siddiq and Sigman, 2002; Vandekerckhove et al., 2000). **Consequently, should endocrine treatment be applied, identified endocrine dysfunction should be first demonstrated.**

Aside from endocrine therapy, nutraceuticals serve as the subject of many published reports, with antioxidant activity a common theme for proposed benefit. A Cochrane collaboration review concluded that results from small randomized controlled trials supported that for subfertile couples undergoing ART, antioxidant supplementation in subfertile men may increase live birth rates, especially for vitamin E, zinc, and a multivitamin (Vandekerckhove et al., 2000). Investigators have studied the effects of Coenzyme Q10, or ubiquinone, a component of the mitochondrial electron transport chain, on semen analysis parameters in several small controlled trials, with improvement in sperm density and motility observed compared with placebo (Balercia et al., 2009; Lafuente et al., 2013; Safarinejad, 2009; Safarinejad et al., 2012). Larger, blinded and randomized controlled trials will be required before definitive recommendations may be made regarding nutraceutical efficacy for improving male reproductive potential. The reproductive medical literature is rife with numerous noncontrolled trials of various nutraceuticals and sperm parameters, but, in general, because of the highly variable nature of seminal metrics, the effect of regression to the mean prevents assessment of results.

Key Points: Diagnoses and Therapies

- Klinefelter syndrome, characterized by 47,XXY, is the most commonly identified genetic cause of male infertility. Bodily morphologic features cannot reliably exclude the presence of the condition.
- The clinical evaluation of a man identified with CBAVD includes CFTR assessment of him and his female partner to determine risk of cystic fibrosis in offspring.

- Severe hypogonadotropic hypogonadism may be associated with anosmia and is treated with gonadotropin replacement. Less severe forms are more common, and patients may respond to antiestrogenic agents or aromatase inhibitors.

Fertility Preservation in Cancer

Oncofertility is a interdisciplinary approach designed to maximize the reproductive future of people who have had cancer by presenting several fertility preservation techniques (Tournaye et al., 2014). Chemotherapy and radiation therapy can cause DNA abnormalities of germ cells and theoretically increase the risk of disturbed growth, childhood diseases, congenital abnormalities, and cancer in the children of individuals who have had cancer (Stahl et al., 2011; Tournaye et al., 2014). High-risk treatments encompass whole-body irradiation, pelvic or testicular radiotherapy, chemotherapy conditioning for bone marrow transplantation and treatment with alkylating drugs (Wallace et al., 2005). Irradiation doses of 0.1 to 1.2 Gy can instigate deficiency of spermatogenesis, whereas doses of more than 4 Gy may cause long-lasting damage (Wallace et al., 2005). Low-dose chemotherapy can lessen the progenitor-type A_{pale} spermatogonia and the differentiation B spermatogonia, directing to temporary oligozoospermia or azoospermia. When the testis is severely impaired, the spermatogonial stem cells (SSCs) go into apoptosis and/or the Sertoli cells are not capable to sustain them, ultimately leading to a depletion of the SSCs pool causing permanent infertility (Jahnukainen and Stukenborg, 2012).

Mutations suffered by the SSCs can potentially be repaired by intrinsic DNA mechanisms or deleted by the cell's apoptotic apparatus. Nevertheless, as these SSCs embody the progenitor from which all imminent germ lines are originated, any continued mutations that escape repair or elimination will be passed on, resulting in the possible production of mutation-carrying sperm for the duration of man's lifetime (Meistrich, 2009). Tempest et al. (2008) observed significantly increased frequencies of XY disomy and nullisomy 13 and 21 in sperm after either bleomycin, etoposide, and cisplatin (BEP), or doxorubicin, bleomycin, vinblastine, and dacarbazine (ABVD) chemotherapeutic regimens. The risk for future generations may become even more pronounced with the use of ICSI, which circumvent several natural barriers, including capacitation, acrosomal reaction, and zona pellucida penetration, that may have avoided functionally incompetent spermatozoa from achieving fertilization (Choy and Brannigan, 2013). There is a lack of definitive clinical guidelines, but some investigators have suggested that 18 to 24 months interval after ending chemotherapy may be required to allow for an eventual decline of aneuploidy rates to baseline frequencies (Choy and Brannigan, 2013). In fact, the only guidelines currently available, issued by the European Society for Medical Oncology, encourage the postponement of gestation for at least 12 months after cancer therapy, as a Grade C recommendation based on level IV evidence (Pentheroudakis et al., 2010).

Sperm Cryopreservation

Ideally, several semen samples should be collected 48 hours apart, but because time is always a concern, patients should provide samples without delay, which can mean obtaining more than one sample in a day (Gilbert et al., 2011). Unfortunately, poor adherence to recommendations by health care professionals and the paucity of robust comprehensive systems require urgent attention (Sheth et al., 2012). In addition, not all men who are offered sperm storage actually bank sperm. Some patients have difficulty producing semen because of stress, severe illness, and sexual inexperience. For these individuals, electro-ejaculation or testicular sperm extraction may be appropriate (Hovav et al., 2001; Schrader et al., 2003).

van Casteren et al. (2010) noted reduced semen quality in 64% of men referred for sperm banking; in 12% of these men, azoospermia or only nonmotile spermatozoa were present and cryopreservation could not be done. The total number of motile sperm in semen is significantly lower in men with testicular cancer, myeloid leukemia, and lymphoid leukemia, than in semen from controls. In addition, these patients had a significantly lower percentage survival of motility after cryopreservation (Hotaling et al., 2013). Investigators also noted that seminomas changed sperm production more than did nonseminoma tumors and seemed to preferentially impair spermatogenesis in the tumor-bearing testes. Semen quality was decreased in patients with advanced testicular tumors and in men with a history of cryptorchidism. The main conclusions were that sperm banking should be done before orchiectomy and that testicular sperm extraction should be offered during scrotal surgery in cases of azoospermia (Rives et al., 2012).

Testicular Tissue Cryopreservation

Testicular tissue freezing preserves the cell-cell contacts but requires more permeable cryoprotectants. The best preservation of morphology and hormonal activity was achieved when dimethylsulphoxide was used to freeze adult testicular tissue (Keros et al., 2005). The feasibility of the selected protocol was later confirmed using prepubertal testicular tissue (Keros et al., 2007). The technique of a single large volume biopsy instead of multiple biopsy sampling method is preferred to avoid the risk of postoperative fibrosis and to preserve maximal endocrine testicular function. One group from Belgium proposed to remove at least half of one testis, for two reasons: (1) testes of children are small and contain only very few SSCs and (2) to obtain enough SSCs to recolonize an adult testis, small biopsies may be inadequate and to have enough testicular tissue for several fertility restoration methods (Goossens et al., 2013).

An alternative to conventional freezing is vitrification. Vitrification involve the use of increasing concentrations of cryoprotectants and ultrarapid cooling to avoid ice crystal formation. Recently, the efficiency of vitrification was explored using immature human testicular tissue. The tubular integrity and the proliferation potential of spermatogonia could be maintained (Curaba et al., 2011).

Prepubescent Considerations

Luckily, childhood prognoses have improved substantially over the past years. In the period 1999 to 2006, an 81.4% survival was seen in an all-site study for children and adolescent cancers in the United States (Murk and Seli, 2011). Treatment regimens for cancer patients involve chemotherapy and radiotherapy, which target rapidly dividing cells. Although there is no active production of spermatozoa in the prepubertal testis, it is not a quiescent period of testicular development. The SSCs are constantly dividing to populate the growing seminiferous tubules and are thus targets for gonadotoxic treatments (Jahnukainen et al., 2011).

Prepubertal boys who need gonadotoxic treatment may render sterile for the rest of their life. As these boys do not yet produce sperm cells, they cannot benefit from sperm banking. For these patients, spermatogonial stem cell banking has been proposed as a fertility preservation strategy, although implementation exists only under experimental protocols (Goossens et al., 2013).

Future Perspectives

Two transplantation strategies are currently being studied: the injection of SSCs and the grafting of testicular tissue: the latter has the advantage that SSCs can remain within their natural niche, thereby preservation interactions between the germ cells and their supporting cells (Goossens et al., 2013). In animals, grafting was performed to ectopic sites, such as in the peritoneal space, the ear or under the skin on the back (Schlatt et al., 2002). The higher temperature at these ectopic sites compared with the scrotum was suggested to be the cause of either sclerosis of the graft or meiotic arrest. Consequently, tissue was grafted to the scrotum (Leutjens et al., 2008). Recently it has been shown that even after long-term cryopreservation of SSCs, these cells are capable to regenerate complete spermatogenesis and produce fertile offspring after transplantation (Wu et al., 2012).

As well as testicular stem cell transplantation, in vitro culture of testicular stem cells is being studied in the mouse for its potential to generate postmeiotic male gametes. In vitro spermatogenesis would circumvent the risk of cotransplanting cancer cells and allow the production of male gametes in boys or men who had bilateral orchiectomy (Stukenborg et al., 2009). Although still experimental, these approaches offer hope to many men in whom germ cell loss is associated with sterility. The first attempt to inject cells in human cadaver testes was made in 1999 (Schlatt et al., 1999).

Suggested Readings

Anguiano A, Oates RD, Amos JA, et al. Congenital bilateral absence of the vas deferens. A primarily genital form of cystic fibrosis. *J Am Med Assoc*. 1992;267:1794–1797.

Dubin L, Amelar RD. Varicocelectomy as therapy in male infertility: a study of 504 cases. *Fertil Steril*. 1975;26:217–220.

Dubin L, Amelar RD. Varicocele size and results of varicocelectomy in selected subfertile men with varicocele. *Fertil Steril*. 1970;21:606–609.

Jarow JP, Sigman M, Kolettis PN, et al. *The evaluation of the azoospermic male: AUA best practice statement*. American Urological Association Education and Research.: Linthicum, MD; 2011.

Lipshultz LI, Howards SS, Niederberger CS. *Infertility in the male*. 4th ed. Cambridge University Press: New York; 2009.

MacLeod J. Semen quality in 1000 men of known fertility and in 800 cases of infertile marriage. *Fertil Steril*. 1951;2:115–139.

Meacham RB, Joyce GF, Wise M, et al. Male infertility. *J Urol*. 2007;177:2058–2066.

Niederberger CS. *An introduction to male reproductive medicine*. Cambridge University Press: New York; 2011.

Niederberger CS. Current management of male infertility. *Urol Clin North Am*. 2014;41(1).

Sigman M. A meta-analysis of meta-analyses. *Fertil Steril*. 2011;96:11–14.

Sigman M, Kolettis PN, McClure RD, et al. *The optimal evaluation of the infertile male: AUA best practice statement*. American Urological Association Education and Research: Linthicum (MD); 2011.

Tilford CA, Kuroda-Kawaguchi T, Skaletsky H, et al. A physical map of the human Y chromosome. *Nature*. 2001;409:943–945.

Vermeulen A, Verdonck L, Kaufman JM. A critical evaluation of simple methods for the estimation of free testosterone in serum. *J Clin Endocrinol Metab*. 1999;84:3666–3672.

World Health Organization (WHO). *World Health Organization laboratory manual for the examination and processing of human semen*. World Health Organization: Geneva; 2010.

References

Abd-Elmoaty MA, Saleh R, Sharma RK, et al. Increased levels of oxidants and reduced antioxidants in semen of infertile men with varicocele. *Fertil Steril*. 2010;94:1531–1534.

Abdulwahed SR, Mohamed E-EM, Taha EA, et al. Sensitivity and specificity of ultrasonography in predicting etiology of azoospermia. *Urology*. 2013;81:967–971.

Absalan F, Movahedin M, Mowla SJ. Germ cell apoptosis induced by experimental cryptorchidism is mediated by molecular pathways in mouse testis. *Andrologia*. 2010;42:5–12.

Agarwal A, Deepinder F, Cocuzza M, et al. Effect of vaginal lubricants on sperm motility and chromatin integrity: a prospective comparative study. *Fertil Steril*. 2008;89:375–379.

Agarwal A, Deepinder F, Sharma RK, et al. Effect of cell phone usage on semen analysis in men attending infertility clinic: an observational study. *Fertil Steril*. 2008;89:124–128.

Agarwal A, Desai NR, Makker K, et al. Effects of radiofrequency electromagnetic waves (RF-EMW) from cellular phones on human ejaculated semen: an in vitro pilot study. *Fertil Steril*. 2009;92:1318–1325.

Agarwal A, Makker K, Sharma RK. Clinical relevance of oxidative stress in male factor infertility: an update. *Am J Reprod Immunol*. 2008;59:2–11.

Agarwal A, Malvezzi H, Sharma RK. Effect of an isotonic lubricant on sperm collection and sperm quality. *Fertil Steril*. 2013;99:1581–1586.

Agarwal A, Sharma RK, Nallella KP, et al. Reactive oxygen species as an independent marker of male factor infertility. *Fertil Steril*. 2006;86:878–885.

Agarwal A, Said TM. Role of sperm chromatin abnormalities and DNA damage in male infertility. *Hum Reprod Update*. 2003;9:331–345.

Aggerholm AS, Thulstrup AM, Toft G, et al. Is overweight a risk factor for reduced semen quality and altered serum sex hormone profile? *Fertil Steril*. 2008;90:619–626.

Akre O, Richiardi L. Does a testicular dysgenesis syndrome exist? *Hum Reprod*. 2009;24:2053–2060.

Aktan G, Doğru-Abbasoğlu S, Küçükgergin C, et al. Mystery of idiopathic male infertility: is oxidative stress an actual risk? *Fertil Steril*. 2013;99:1211–1215.

Al-Ali BM, Marszalek M, Shamloul R, et al. Clinical parameters and semen analysis in 716 Austrian patients with varicocele. *Urology*. 2010;75:1069–1073.

Albert PS, Mininberg DT, Davis JE. The nitrofurans as sperm immobilising agents: their tissue toxicity and their clinical application. *Br J Urol*. 1975;47:459–462.

Alukal JP, Khera M, Wheeler TM. Testicular biopsy in male infertility evaluation. Lipshultz LI, Howards SS, Niederberger CS. *Infertility in the male*. 4th ed. Cambridge University Press: New York; 2009:215–225.

Ammar T, Sidhu PS, Wilkins CJ. Male infertility: the role of imaging in diagnosis and management. *Br J Radiol*. 2012;85(Spec. 1):S59–S68.

Amory JK, Wang C, Swerdloff RS, et al. The effect of 5alpha-reductase inhibition with dutasteride and finasteride on semen parameters and serum hormones in healthy men. *J Clin Endocrinol Metab*. 2007;92:1659–1665.

Anderson JE, Farr SL, Jamieson DJ, et al. Infertility services reported by men in the United States: national survey data. *Fertil Steril*. 2009;91:2466–2470.

Anger JT, Gilbert BR, Goldstein M. Cryopreservation of sperm: indications, methods and results. *J Urol*. 2003;170:1079–

1084.

Anguiano A, Oates RD, Amos JA, et al. Congenital bilateral absence of the vas deferens. A primarily genital form of cystic fibrosis. *J Am Med Assoc*. 1992;267:1794–1797.

Aoki VW, Liu L, Jones KP, et al. Sperm protamine 1/protamine 2 ratios are related to in vitro fertilization pregnancy rates and predictive of fertilization ability. *Fertil Steril*. 2006;86:1408–1415.

Arnedo N, Nogués C, Bosch M, et al. Mitotic and meiotic behaviour of a naturally transmitted ring Y chromosome: reproductive risk evaluation. *Hum Reprod*. 2005;20:462–468.

Asklund C, Jørgensen N, Skakkebaek NE, et al. Increased frequency of reproductive health problems among fathers of boys with hypospadias. *Hum Reprod*. 2007;22:2639–2646.

Attia AM, Al-Inany HG, Farquhar C, et al. Gonadotrophins for idiopathic male factor subfertility. *Cochrane Database Syst Rev*. 2007;(4) [CD005071].

Ausmees K, Korrovits P, Timberg G, et al. Semen quality and associated reproductive indicators in middle-aged males: the role of non-malignant prostate conditions and genital tract inflammation. *World J Urol*. 2013;31(6):1411–1425.

Avendano C, Mata A, Sanchez Sarmiento CA, et al. Use of laptop computers connected to internet through Wi-Fi decreases human sperm motility and increases sperm DNA fragmentation. *Fertil Steril*. 2012;97:39–45.

Avendaño C, Franchi A, Taylor S, et al. Fragmentation of DNA in morphologically normal human spermatozoa. *Fertil Steril*. 2009;91:1077–1084.

Aycan Z, Bas VN, Cetinkaya S, et al. Prevalence and long-term follow-up outcomes of testicular adrenal rest tumours in children and adolescent males with congenital adrenal hyperplasia. *Clin Endocrinol (Oxf)*. 2013;78:667–672.

Baazeem A, Belzile E, Ciampi A, et al. Varicocele and male factor infertility treatment: a new meta-analysis and review of the role of varicocele repair. *Eur Urol*. 2011;60:796–808.

Baccetti BM, Bruni E, Capitani S, et al. Studies on varicocele III: ultrastructural sperm evaluation and 18, X and Y aneuploidies. *J Androl*. 2006;27:94–101.

Bahadur G, Ralph D. Gonadal tissue cryopreservation in boys with paediatric cancers. *Hum Reprod*. 1999;14:11–17.

Baker PJ, Pakarinen P, Huhtaniemi IT, et al. Failure of normal Leydig cell development in follicle-stimulating hormone (FSH) receptor-deficient mice, but not FSHbeta-deficient mice: role for constitutive FSH receptor activity. *Endocrinology*. 2003;144:138–145.

Balasch J, Gratacós E. Delayed childbearing: effects on fertility and the outcome of pregnancy. *Curr Opin Obstet Gynecol*. 2012;24:187–193.

Balercia G, Buldreghini E, Vignini A, et al. Coenzyme Q10 treatment in infertile men with idiopathic asthenozoospermia: a placebo-controlled, double-blind randomized trial. *Fertil Steril*. 2009;91:1785–1792.

Barraud-Lange V, Pont JC, Ziyyat A, et al. Seminal leukocytes are Good Samaritans for spermatozoa. *Fertil Steril*. 2011;96:1315–1319.

Barthold JS, González R. The epidemiology of congenital cryptorchidism, testicular ascent and orchiopexy. *J Urol*. 2003;170:2396–2401.

Bartoov B, Berkovitz A, Eltes F. Selection of spermatozoa with normal nuclei to improve the pregnancy rate with intracytoplasmic sperm injection. *N Engl J Med*. 2001;345:1067–1068.

Bartoov B, Berkovitz A, Eltes F, et al. Pregnancy rates are higher with intracytoplasmic morphologically selected sperm injection than with conventional intracytoplasmic injection. *Fertil Steril*. 2003;80:1413–1419.

Baste V, Riise T, Moen BE. Radiofrequency electromagnetic fields; male infertility and sex ratio of offspring. *Eur J Epidemiol*. 2008;23:369–377.

Bengoudifa B, Mieusset R. Thermal asymmetry of the human scrotum. *Hum Reprod*. 2007;22:2178–2182.

Benoff S, Cooper GW, Hurley I, et al. The effect of calcium ion channel blockers on sperm fertilization potential. *Fertil Steril*. 1994;62:606–617.

Benoff SH, Millan C, Hurley IR, et al. Bilateral increased apoptosis and bilateral accumulation of cadmium in infertile men with left varicocele. *Hum Reprod*. 2004;19:616–627.

Beratis NG, Asimacopoulou A, Varvarigou A. Association of secondary sex ratio with smoking and parity. *Fertil Steril*. 2008;89:662–667.

Berkovitz A, Eltes F, Ellenbogen A, et al. Does the presence of nuclear vacuoles in human sperm selected for ICSI affect pregnancy outcome? *Hum Reprod*. 2006;21:1787–1790.

Bertolla RP, Cedenho AP, Hassun Filho PA, et al. Sperm nuclear DNA fragmentation in adolescents with varicocele. *Fertil Steril*. 2006;85:625–628.

Bervini S, Herzog H. Mouse models of Prader-Willi Syndrome: a systematic review. *Front Neuroendocrinol*. 2013;34:107–119.

Bezold G, Politch JA, Kiviat NB, et al. Prevalence of sexually transmissible pathogens in semen from asymptomatic male infertility patients with and without leukocytospermia. *Fertil Steril*. 2007;87:1087–1097.

Bhagavath B, Podolsky RH, Ozata M, et al. Clinical and molecular characterization of a large sample of patients with hypogonadotropic hypogonadism. *Fertil Steril*. 2006;85:706–713.

Bhasin S, Cunningham GR, Hayes FJ, et al. Testosterone therapy in men with androgen deficiency syndromes: an

Endocrine Society clinical practice guideline. *J Clin Endocrinol Metab*. 2010;95:2536–2559.

Blumer CG, Fariello RM, Restelli AE, et al. Sperm nuclear DNA fragmentation and mitochondrial activity in men with varicocele. *Fertil Steril*. 2008;90:1716–1722.

Boe-Hansen GB, Fedder J, Ersbøll AK, et al. The sperm chromatin structure assay as a diagnostic tool in the human fertility clinic. *Hum Reprod*. 2006;21:1576–1582.

Boissonnas CC, Jouannet P, Jammes H. Epigenetic disorders and male subfertility. *Fertil Steril*. 2013;99:624–631.

Bombieri C, Claustres M, De Boeck K, et al. Recommendations for the classification of diseases as CFTR-related disorders. *J Cyst Fibros*. 2011;10(Suppl 2):S86–S102.

Boon M, Jorissen M, Proesmans M, et al. Primary ciliary dyskinesia, an orphan disease. *Eur J Pediatr*. 2013;172:151–162.

Bowman JD, Kim H, Bustamante JJ. Drug-induced gynecomastia. *Pharmacotherapy*. 2012;32:1123–1140.

Boyd JM, Mehta A, Murphy DJ. Fertility and pregnancy outcomes in men and women with cystic fibrosis in the United Kingdom. *Hum Reprod*. 2004;19:2238–2243.

Brackett NL, Ohl DA, Sonksen J, et al. Abnormalities of ejaculation. Lipshultz LI, Howards SS, Niederberger CS. *Infertility in the male*. 4th ed. Cambridge University Press: New York; 2009:454–473.

Braga DP, Halpern G, Figueira Rde C, et al. Food intake and social habits in male patients and its relationship to intracytoplasmic sperm injection outcomes. *Fertil Steril*. 2012;97:53–59.

Brannigan RE. Male reproductive immunology. Niederberger CS. *An introduction to male reproductive medicine*. Cambridge University Press: New York; 2011:84–102.

Brennan MJ. The effect of opioid therapy on endocrine function. *Am J Med*. 2013;126:S12–S18.

Brucker-Davis F, Wagner-Mahler K, Delattre I, et al. Cryptorchidism at birth in Nice area (France) is associated with higher prenatal exposure to PCBs and DDE, as assessed by colostrum concentrations. *Hum Reprod*. 2008;23:1708–1718.

Bujan L, Mieusset R, Mansat A, et al. Testicular size in infertile men: relationship to semen characteristics and hormonal blood levels. *Br J Urol*. 1989;64:632–637.

Bungum M, Humaidan P, Axmon A, et al. Sperm DNA integrity assessment in prediction of assisted reproduction technology outcome. *Hum Reprod*. 2007;22:174–179.

Bungum M, Spanò M, Humaidan P, et al. Sperm chromatin structure assay parameters measured after density gradient centrifugation are not predictive for the outcome of ART. *Hum Reprod*. 2008;23:4–10.

Burkman LJ, Coddington CC, Franken DR, et al. The hemizona assay (HZA): development of a diagnostic test for the binding of human spermatozoa to the human hemizona pellucida to predict fertilization potential. *Fertil Steril*. 1988;49:688–697.

Caione P, Nappo SG. Posterior urethral valves: long-term outcome. *Pediatr Surg Int*. 2011;27:1027–1035.

Campbell JM, Lane M, Owens JA, et al. Paternal obesity negatively affects male fertility and assisted reproduction outcomes: a systematic review and meta-analysis. *Reprod Biomed Online*. 2015;31:593–604.

Carlsen E, Giwercman A, Keiding N, et al. Evidence for decreasing quality of semen during past 50 years. *BMJ*. 1992;305:609–613.

Caroppo E. Male reproductive medicine: anatomy and physiology. Niederberger CS. *An introduction to male reproductive medicine*. Cambridge University Press: New York; 2011:1–28.

Caroppo E, Niederberger CS, Elhanbly S, et al. Effect of cryptorchidism and retractile testes on male factor infertility: a multicenter, retrospective, chart review. *Fertil Steril*. 2005;83:1581–1584.

Carreau S, Bourguiba S, Lambard S, et al. Reproductive system: aromatase and estrogens. *Mol Cell Endocrinol*. 2002;193:137–143.

Carrell DT. Epigenetics of the male gamete. *Fertil Steril*. 2012;97:267–274.

Cassidy SB, Driscoll DJ. Prader-Willi syndrome. *Eur J Hum Genet*. 2009;17:3–13.

Castillo LA, Craft AW, Kernahan J, et al. Gonadal function after 12-Gy testicular irradiation in childhood acute lymphoblastic leukaemia. *Med Pediatr Oncol*. 1990;18:185–189.

Centola GM. Semen: analysis and processing. Niederberger CS. *An introduction to male reproductive medicine*. Cambridge University Press: New York; 2011:121–133.

Chakraborty J, Hikim APS, Jhunjhunwala JS. Stagnation of blood in the microcirculatory vessels in the testes of men with varicocele. *J Androl*. 1985;6:117–126.

Chandley AC, Gosden JR, Hargreave TB, et al. Deleted Yq in the sterile son of a man with a satellited Y chromosome (Yqs). *J Med Genet*. 1989;26:145–153.

Chandrapal JC, Nielson S, Patel D, et al. Characterising the safety of clomiphene citrate in male patients through prostate-specific antigen, haematocrit, and testosterone levels. *BJU Int*. 2016;118:994–1000.

Chapin R, Gulati D, Hope E, et al. Reproductive toxicology. Nitrofurantoin. *Environ Health Perspect*. 1997;105(Suppl 1):329–330.

Chavarro JE, Toth TL, Wright DL, et al. Body mass index in relation to semen quality, sperm DNA integrity, and serum reproductive hormone levels among men attending an infertility clinic. *Fertil Steril*. 2010;93:2222–2231.

Chemes EH, Rawe YV. Sperm pathology: a step beyond descriptive morphology. Origin, characterization and fertility potential of abnormal sperm phenotypes in infertile men. *Hum Reprod Update*. 2003;9:405–428.

Chiba K, Yamaguchi K, Li F, et al. Finasteride-associated male infertility. *Fertil Steril*. 2011;95:1786 [e9–11].

Cho C, Jung-Ha H, Willis WD, et al. Protamine 2 deficiency leads to sperm DNA damage and embryo death in mice. *Biol Reprod*. 2003;69:211–217.

Cho CL, Esteves SC, Agarwal A. Novel insights into the pathophysiology of varicocele and its association with reactive oxygen species and sperm DNA fragmentation. *Asian J Androl*. 2016;18:186–193.

Chohan KR, Griffin JT, Lafromboise M, et al. Comparison of chromatin assays for DNA fragmentation evaluation in human sperm. *J Androl*. 2006;27:53–59.

Choy JT, Brannigan RD. The determination of reproductive safety in men during and after cancer treatment. *Fertil Steril*. 2013;100:1187–1191.

Chung E, Brock GB. Cryptorchidism and its impact on male fertility: a state of art review of current literature. *Can Urol Assoc J*. 2011;5:210–214.

Claahsen-van der Grinten HL, Otten BJ, Hermus ARMM, et al. Testicular adrenal rest tumors in patients with congenital adrenal hyperplasia can cause severe testicular damage. *Fertil Steril*. 2008;89:597–601.

Claahsen-van der Grinten HL, Otten BJ, Sweep FCGJ, et al. Repeated successful induction of fertility after replacing hydrocortisone with dexamethasone in a patient with congenital adrenal hyperplasia and testicular adrenal rest tumors. *Fertil Steril*. 2007;88:705 [e5–8].

Clavijo RI, Carrasquillo R, Ramasamy R. Varicoceles:

prevalence and pathogenesis in adult men. *Fertil Steril*. 2017;108:364–369.

Clayton AH, Montejo AL. Major depressive disorder, antidepressants, and sexual dysfunction. *J Clin Psychiatry*. 2006;67(Suppl 6):33–37.

Clermont Y. Kinetics of spermatogenesis in mammals: seminiferous epithelium cycle and spermatogonial renewal. *Physiol Rev*. 1972;52:198–236.

Cocuzza M, Athayde KS, Agarwal A, et al. Age-related increase of reactive oxygen species in neat semen in healthy fertile men. *Urology*. 2008;71:490–494.

Cocuzza M, Athayde KS, Agarwal A, et al. Impact of clinical varicocele and testis size on seminal reactive oxygen species levels in a fertile population: a prospective controlled study. *Fertil Steril*. 2008;90:1103–1108.

Coddington CC, Franken DR, Burkman LJ, et al. Functional aspects of human sperm binding to the zona pellucida using the hemizona assay. *J Androl*. 1991;12:1–8.

Colin A, Barroso G, Gómez-López N, et al. The effect of age on the expression of apoptosis biomarkers in human spermatozoa. *Fertil Steril*. 2010;94:2609–2614.

Cooper TG, Noonan E, von Eckardstein S, et al. World Health Organization reference values for human semen characteristics. *Hum Reprod Update*. 2010;16:231–245.

Coutts SM, Fulton N, Anderson RA. Environmental toxicant-induced germ cell apoptosis in the human fetal testis. *Hum Reprod*. 2007;22:2912–2918.

Craig JR, Jenkins TG, Carrell D, et al. Obesity, male infertility, and the sperm epigenome. *Fertil Steril*. 2017;107:848–859.

Crha I, Ventruba P, Zakova J, et al. Survival and infertility treatment in male cancer patients after sperm banking. *Fertil Steril*. 2009;91:2344–2348.

Crich JP, Jequier AM. Infertility in men with retrograde ejaculation: the action of urine on sperm motility, and a simple method for achieving antegrade ejaculation. *Fertil Steril*. 1978;30:572–576.

Cross NL, Meizel S. Methods for evaluating the acrosomal status of mammalian sperm. *Biol Reprod*. 1989;41:635–641.

Curaba M, Poels J, van Langendonckt A, et al. Can prepubertal human testicular tissue be cryopreserved by vitrification? *Fertil Steril*. 2011;95:2123 [e9–e12].

Dagash H, MacKinnon EA. Testicular microlithiasis: what does it mean clinically? *BJU Int*. 2007;99:157–160.

Dattani MT, Martinez-Barbera JP, Thomas PQ, et al. Mutations in the homeobox gene HESX1/Hesx1 associated with septo-optic dysplasia in human and mouse. *Nat Genet*. 1998;19:125–133.

Davis EE, Katsanis N. The ciliopathies: a transitional model into systems biology of human genetic disease. *Curr Opin Genet Dev*. 2012;22:290–303.

Davis-Dao CA, Tuazon ED, Sokol RZ, et al. Male infertility and variation in CAG repeat length in the androgen receptor gene: a meta-analysis. *J Clin Endocrinol Metab*. 2007;92:4319–4326.

Dayal MB, Gindoff PR, Zarek S, et al. Profound teratospermia does not influence sex chromosomal aneuploidy rate in in vitro fertilization–preimplantation genetic diagnosis cycles. *Fertil Steril*. 2010;93:666–668.

de Bruin D, de Jong IJ, Arts EG, et al. Semen quality in men with disseminated testicular cancer: relation with human chorionic gonadotropin beta-subunit and pituitary gonadal hormones. *Fertil Steril*. 2009;91:2481–2486.

De Fleurian G, Perrin J, Ecochard R, et al. Occupational exposures obtained by questionnaire in clinical practice and their association with semen quality. *J Androl*. 2009;30:566–579.

de Mateo S, Gázquez C, Guimerà M, et al. Protamine 2 precursors (Pre-P2), protamine 1 to protamine 2 ratio (P1/P2), and assisted reproduction outcome. *Fertil Steril*. 2009;91:715–722.

de Oliveira RV, Dogan S, Belser LE, et al. Molecular morphology and function of bull spermatozoa linked to histones and associated with fertility. *Reproduction*. 2013;146:263–272.

de Roux N, Genin E, Carel JC, et al. Hypogonadotropic hypogonadism due to loss of function of the KiSS1-derived peptide receptor GPR54. *Proc Natl Acad Sci USA*. 2003;100:10972–10976.

de Souza GL, Hallak J. Anabolic steroids and male infertility: a comprehensive review. *BJU Int*. 2011;108:1860–1865.

De Visschere P, Nezzo M, Pattyn E, et al. Prostate magnetic resonance spectroscopic imaging at 1.5 tesla with endorectal coil versus 3.0 tesla without endorectal coil: comparison of spectral quality. *Clin Imaging*. 2015;39:636–641.

Delbes G, Hales BF, Robaire B. Effects of the chemotherapy cocktail used to treat testicular cancer on sperm chromatin integrity. *J Androl*. 2007;28:241–249 [discussion 250–1].

Desai NR, Sharma RK, Makker K, et al. Physiologic and pathologic levels of reactive oxygen species in neat semen of infertile men. *Fertil Steril*. 2009;92:1626–1631.

Dhindsa S, Prabhakar S, Sethi M, et al. Frequent occurrence of hypogonadotropic hypogonadism in type 2 diabetes. *J Clin Endocrinol Metab*. 2004;89:5462–5468.

Dhooge W, Van Larebeke N, Comhaire F, et al. Reproductive parameters of community-dwelling men from 2 regions in Flanders are associated with the consumption of self-grown vegetables. *J Androl*. 2007;28:836–846.

Diemer T, Huwe P, Ludwig M, et al. Urogenital infection and sperm motility. *Andrologia*. 2003;35:283–287.

Dietrich K, Soto Rifo R, Faure AK, et al. Homozygous mutation of AURKC yields large-headed polyploid spermatozoa and causes male infertility. *Nat Genet*. 2007;39:661–665.

Domes T, Lo KC, Grober ED, et al. The incidence and effect of bacteriospermia and elevated seminal leukocytes on semen parameters. *Fertil Steril*. 2012;97:1050–1055.

Dowsing AT, Yong EL, Clark M, et al. Linkage between male infertility and trinucleotide repeat expansion in the androgen-receptor gene. *Lancet*. 1999;354:640–643.

Dubey A, Dayal MB, Frankfurter D, et al. The influence of sperm morphology on preimplantation genetic diagnosis cycles outcome. *Fertil Steril*. 2008;89:1665–1669.

Dubina L, Amelar RD. Varicocele size and results of varicocelectomy in selected subfertile men with varicocele. *Fertil Steril*. 1970;21:606–609.

Dubin L, Amelar RD. Varicocelectomy as therapy in male infertility: a study of 504 cases. *Fertil Steril*. 1975;26:217–220.

Ein SH, Njere I, Ein A. Six thousand three hundred sixty-one pediatric inguinal hernias: a 35-year review. *J Pediatr Surg*. 2006;41:980–986.

Eisenberg ML, Betts P, Herder D, et al. Increased risk of cancer among azoospermic men. *Fertil Steril*. 2013;100:681–685 [e1].

Eisenberg ML, Lathi RB, Baker VL, et al. Ferquency of the male infertility evaluation: data from the National Survey of Family Growth. *J Urol*. 2013;189:1030–1034.

Eisenberg ML, Walsh TJ, Garcia MM, et al. Ejaculatory duct manometry in normal men and in patients with ejaculatory duct obstruction. *J Urol*. 2008;180:255–260 [discussion 260].

El-Domyati MM, Al-Din A-BM, Barakat MT, et al. The expression and distribution of deoxyribonucleic acid repair and apoptosis markers in testicular germ cells of infertile varicocele patients resembles that of old fertile men. *Fertil Steril*. 2010;93:795–801.

Eliasson R, Mossberg B, Camner P, et al. The immotile-cilia syndrome. A congenital ciliary abnormality as an etiologic factor in chronic airway infections and male sterility. *N Engl J Med*. 1977;297:1–6.

Elliott PA, Hoffman J, Abad-Santos M, et al. Out of pocket costs of male infertility care and associated financial strain. *Urol Pract*. 2016;3:256–261.

Elshal AM, Elmansy HM, Elkoushy MA, et al. Male sexual function outcome after three laser prostate surgical techniques: a single center perspective. *Urology*. 2012;80:1098–1104.

Elzanaty S. Time-to-ejaculation and the quality of semen produced by masturbation at a clinic. *Urology*. 2008;71:883–888.

Enciso M, Muriel L, Fernández JL, et al. Infertile men with varicocele show a high relative proportion of sperm cells with intense nuclear damage level, evidenced by the sperm chromatin dispersion test. *J Androl*. 2006;27:106–111.

Engin G, Kadioglu A, Orhan I, et al. Transrectal US and endorectal MR imaging in partial and complete obstruction of the seminal duct system. A comparative study. *Acta Radiol*. 2000;41:288–295.

Erogul O, Oztas E, Yildirim I, et al. Effects of electromagnetic radiation from a cellular phone on human sperm motility: an in vitro study. *Arch Med Res*. 2006;37:840–843.

Eskew LA, Watson NE, Wolfman N, et al. Ultrasonographic diagnosis of varicoceles. *Fertil Steril*. 1993;60:693–697.

Evenson D, Jost L. Sperm chromatin structure assay is useful for fertility assessment. *Methods Cell Sci*. 2000;22:169–189.

Evenson DP, Melamed MR. Rapid analysis of normal and abnormal cell types in human semen and testis biopsies by flow cytometry. *J Histochem Cytochem*. 1983;31:248–253.

Falzone N, Huyser C, Fourie F, et al. In vitro effect of pulsed 900 MHz GSM radiation on mitochondrial membrane potential and motility of human spermatozoa. *Bioelectromagnetics*. 2008;29:268–276.

Fariello RM, Pariz JR, Spaine DM, et al. Association between obesity and alteration of sperm DNA integrity and mitochondrial activity. *BJU Int*. 2012;110:863–867.

Fariello RM, Pariz JR, Spaine DM, et al. Effect of smoking on the functional aspects of sperm and seminal plasma protein profiles in patients with varicocele. *Hum Reprod*. 2012;27:3140–3149.

Farombi EO, Ugwuezunmba MC, Ezenwadu TT, et al. Tetracycline-induced reproductive toxicity in male rats: effects of vitamin C and *N*-acetylcysteine. *Exp Toxicol Pathol*. 2008;60:77–85.

Feldman HA, Longcope C, Derby CA, et al. Age trends in the level of serum testosterone and other hormones in middle-aged men: longitudinal results from the Massachusetts male aging study. *J Clin Endocrinol Metab*. 2002;87:589–598.

Fénichel P, Rey R, Poggioli S, et al. Anti-müllerian hormone as a seminal marker for spermatogenesis in non-obstructive azoospermia. *Hum Reprod*. 1999;14:2020–2024.

Ferkol TW, Leigh MW. Ciliopathies: the central role of cilia in a spectrum of pediatric disorders. *J Pediatr*. 2012;160:366–371.

Fernández JL, Muriel L, Rivero MT, et al. The sperm chromatin dispersion test: a simple method for the determination of sperm DNA fragmentation. *J Androl*. 2003;24:59–66.

Fisch H. Declining worldwide sperm counts: disproving a myth. *Urol Clin North Am*. 2008;35:137–146 [vii].

Fisher JR, Baker GH, Hammarberg K. Long-term health, well-being, life satisfaction, and attitudes toward parenthood in men diagnosed as infertile: challenges to gender stereotypes and implications for practice. *Fertil Steril*. 2010;94:574–580.

Foresta C, Garolla A, Bartoloni L, et al. Genetic abnormalities among severely oligospermic men who are candidates for intracytoplasmic sperm injection. *J Clin Endocrinol Metab*. 2005;90:152–156.

Fowler PA, Abramovich DR, Haites NE, et al. Human fetal testis Leydig cell disruption by exposure to the pesticide dieldrin at low concentrations. *Hum Reprod*. 2007;22:2919–2927.

Fraser LR, Beyret E, Milligan SR, et al. Effects of estrogenic xenobiotics on human and mouse spermatozoa. *Hum Reprod*. 2006;21:1184–1193.

French DB, Sabanegh ES, Goldfarb J, et al. Does severe teratozoospermia affect blastocyst formation, live birth rate, and other clinical outcome parameters in ICSI cycles? *Fertil Steril*. 2010;93:1097–1103.

Fretz PC, Sandlow JI. Varicocele: current concepts in pathophysiology, diagnosis, and treatment. *Urol Clin North Am*. 2002;29:921–937.

Friedler S, Raziel A, Soffer Y, et al. Intracytoplasmic injection of fresh and cryopreserved testicular spermatozoa in patients with nonobstructive azoospermia—a comparative study. *Fertil Steril*. 1997;68:892–897.

Fujisawa M, Yamasaki T, Okada H, et al. The significance of anti-müllerian hormone concentration in seminal plasma for spermatogenesis. *Hum Reprod*. 2002;17:968–970.

Gandini L, Sgrò P, Lombardo F, et al. Effect of chemo- or radiotherapy on sperm parameters of testicular cancer patients. *Hum Reprod*. 2006;21:2882–2889.

Garolla A, Lenzi A, Palù G, et al. Human papillomavirus sperm infection and assisted reproduction: a dangerous hazard with a possible safe solution. *Hum Reprod*. 2012;27:967–973.

Garrido N, Meseguer M, Remohí J, et al. Semen characteristics in human immunodeficiency virus (HIV)– and hepatitis C (HCV)–seropositive males: predictors of the success of viral removal after sperm washing. *Hum Reprod*. 2005;20:1028–1034.

Gat Y, Bachar GN, Zukerman Z, et al. Varicocele: a bilateral disease. *Fertil Steril*. 2004;81:424–429.

Gat Y, Zukerman Z, Chakraborty J, et al. Varicocele, hypoxia and male infertility. Fluid mechanics analysis of the impaired testicular venous drainage system. *Hum Reprod*. 2005;20:2614–2619.

Gatimel N, Parinaud J, Leandri RD. Intracytoplasmic morphologically selected sperm injection (IMSI) does not improve outcome in patients with two successive IVF-ICSI failures. *J Assist Reprod Genet*. 2016;33:349–355.

Gavrieli Y, Sherman Y, Ben-Sasson SA. Identification of programmed cell death in situ via specific labeling of nuclear DNA fragmentation. *J Cell Biol*. 1992;119:493–501.

George JT, Millar RP, Anderson RA. Hypothesis: kisspeptin mediates male hypogonadism in obesity and type 2 diabetes. *Neuroendocrinology*. 2010;91:302–307.

Ghabili K, Shoja MM, Agutter PS, et al. Hypothesis: intracellular acidification contributes to infertility in varicocele. *Fertil Steril*. 2009;92:399–401.

Giachini C, Laface I, Guarducci E, et al. Partial AZFc deletions and duplications: clinical correlates in the Italian population. *Hum Genet*. 2008;124:399–410.

Gil-Salom M, Romero J, Minguez Y, et al. Pregnancies after intracytoplasmic sperm injection with cryopreserved testicular spermatozoa. *Hum Reprod*. 1996;11:1309–1313.

Gilbert E, Adams A, Mehanna H, et al. Who should be offered sperm banking for fertility preservation? A survey of UK oncologists and haematologists. *Ann Oncol*. 2011;22:1209–1214.

Giltay JC, Deege M, Blankenstein RA, et al. Apparent primary follicle-stimulating hormone deficiency is a rare cause of treatable male infertility. *Fertil Steril*. 2004;81:693–696.

Glenn DR, McClure N, Cosby SL, et al. Sildenafil citrate (Viagra) impairs fertilization and early embryo development in mice. *Fertil Steril*. 2009;91:893–899.

Glenn DR, McVicar CM, McClure N, et al. Sildenafil citrate improves sperm motility but causes a premature acrosome reaction in vitro. *Fertil Steril*. 2007;87:1064–1070.

Gnoth C, Godehardt D, Godehardt E, et al. Time to pregnancy: results of the German prospective study and impact on the management of infertility. *Hum Reprod*. 2003;18:1959–1966.

Goldstein M, Eid JF. Elevation of intratesticular and scrotal skin surface temperature in men with varicocele. *J Urol*. 1989;142:743–745.

Gollenberg AL, Liu F, Brazil C, et al. Semen quality in fertile men in relation to psychosocial stress. *Fertil Steril*. 2010;93:1104–1111.

Goniewicz ML, Gawron M, Smith DM, et al. Exposure to nicotine and selected toxicants in cigarette smokers who switched to electronic cigarettes: a longitudinal within-subjects observation study. *Nicotine Tob Res*. 2017;19:160–167.

Goossens E, Van Saen D, Tournaye H. Spermatogonial stem cell preservation and transplantation: from research to clinic. *Hum Reprod*. 2013;28:897–907.

Gordetsky J, van Wijngaarden E, O'Brien J. Redefining abnormal follicle-stimulating hormone in the male infertility population. *BJU Int*. 2011;110:568–572.

Gorzalka BB, Hill MN, Chang SCH. Male-female differences in the effects of cannabinoids on sexual behavior and gonadal hormone function. *Horm Behav*. 2010;58:91–99.

Gracia J, Navarro E, Guirado F, et al. Spontaneous ascent of the testis. *Br J Urol*. 1997;79:113–115.

Grasso M, Buonaguidi A, Lania C, et al. Postpubertal cryptorchidism: review and evaluation of the fertility. *Eur Urol*. 1991;20:126–128.

Graves JA, Wakefield MJ, Toder R. The origin and evolution of the pseudoautosomal regions of human sex chromosomes. *Hum Mol Genet*. 1998;7:1991–1996.

Green DM, Kawashima T, Stovall M, et al. Fertility of male survivors of childhood cancer: a report from the Childhood Cancer Survivor Study. *J Clin Oncol*. 2010;28:332–339.

Gregoriou O, Bakas P, Grigoriadis C, et al. Changes in hormonal profile and seminal parameters with use of aromatase inhibitors in management of infertile men with low testosterone to estradiol ratios. *Fertil Steril*. 2012;98:48–51.

Griffith CS, Grimes DA. The validity of the postcoital test. *Am J Obstet Gynecol*. 1990;162:615–620.

Grimes DA, Lopez LM, Gallo MF, et al. Steroid hormones for contraception in men. *Cochrane Database Syst Rev*. 2012;(3) [CD004316].

Groth KA, Skakkebæk A, Høst C, et al. Clinical review: klinefelter syndrome—a clinical update. *J Clin Endocrinol Metab*. 2013;98:20–30.

Grunewald S, Glander HJ, Paasch U, et al. Age-dependent inhibin B concentration in relation to FSH and semen sample qualities: a study in 2448 men. *Reproduction*. 2013;145:237–244.

Gu Y, Liang X, Wu W, et al. Multicenter contraceptive efficacy trial of injectable testosterone undecanoate in Chinese men. *J Clin Endocrinol Metab*. 2009;94:1910–1915.

Guichard C, Harricane MC, Lafitte JJ, et al. Axonemal dynein intermediate-chain gene (DNAI1) mutations result in situs inversus and primary ciliary dyskinesia (Kartagener syndrome). *Am J Hum Genet*. 2001;68:1030–1035.

Gundersen TD, Jørgensen N, Andersson AM, et al. Association between use of marijuana and male reproductive hormones and semen quality: a study among 1,215 healthy young men. *Am J Epidemiol*. 2015;1826:473–481.

Guzick DS, Overstreet JW, Factor-Litvak P, et al. Sperm morphology, motility, and concentration in fertile and infertile men. *N Engl J Med*. 2001;345:1388–1393.

Gvakharia MO, Lipshultz LI, Lamb DJ. Human sperm microinjection into hamster oocytes: a new tool for training and evaluation of the technical proficiency of intracytoplasmic sperm injection. *Fertil Steril*. 2000;73:395–401.

Haas GG, Manganiello P. A double-blind, placebo-controlled study of the use of methylprednisolone in infertile men with sperm-associated immunoglobulins. *Fertil Steril*. 1987;47:295–301.

Hadziselimovic F. Cryptorchidism, its impact on male fertility. *Eur Urol*. 2002;41:121–123.

Haimov-Kochman R, Ben-Chetrit E. The effect of colchicine treatment on sperm production and function: a review. *Hum Reprod*. 1998;13:360–362.

Hallén M, Sandblom G, Nordin P, et al. Male infertility after mesh hernia repair: a prospective study. *Surgery*. 2011;149:179–184.

Hallén M, Westerdahl J, Nordin P, et al. Mesh hernia repair and male infertility: a retrospective register study. *Surgery*. 2012;151:94–98.

Hamilton-Reeves JM, Vazquez G, Duval SJ, et al. Clinical studies show no effects of soy protein or isoflavones on reproductive hormones in men: results of a meta-analysis. *Fertil Steril*. 2010;94:997–1007.

Hammadeh ME, Hamad MF, Montenarh M, et al. Protamine contents and P1/P2 ratio in human spermatozoa from smokers and non-smokers. *Hum Reprod*. 2010;25:2708–2720.

Hammoud A, Carrell DT, Gibson M, et al. Decreased sperm motility is associated with air pollution in Salt Lake City. *Fertil Steril*. 2010;93:1875–1879.

Hammoud A, Carrell DT, Meikle AW, et al. An aromatase polymorphism modulates the relationship between weight and estradiol levels in obese men. *Fertil Steril*. 2010;94:1734–1738.

Hammoud AO, Gibson M, Peterson CM, et al. Obesity and male reproductive potential. *J Androl*. 2006;27:619–626.

Hammoud AO, Gibson M, Peterson CM, et al. Impact of male obesity on infertility: a critical review of the current literature. *Fertil Steril*. 2008;90:897–904.

Hammoud SS, Nix DA, Zhang H, et al. Distinctive chromatin in human sperm packages genes for embryo development. *Nature*. 2009;460:473–478.

Hamosh A, FitzSimmons SC, Macek M, et al. Comparison of the clinical manifestations of cystic fibrosis in black and white patients. *J Pediatr*. 1998;132:255–259.

Hampton TH, Stanton BA. A novel approach to analyze gene expression data demonstrates that the DeltaF508 mutation in CFTR downregulates the antigen presentation pathway. *Am J Physiol Lung Cell Mol Physiol*. 2010;298:L473–L482.

Hansen M, Bower C, Milne E, et al. Assisted reproductive technologies and the risk of birth defects – a systematic review. *Hum Reprod*. 2005;20:328–338.

Havasi V, Rowe SM, Kolettis PN, et al. Association of cystic fibrosis genetic modifiers with congenital bilateral absence of the vas deferens. *Fertil Steril*. 2010;94:2122–2127.

Hecht SS, Carmella SG, Kotandeniya D, et al. Evaluation of toxicant and carcinogen metabolites in the urine of e-cigarette users versus cigarette smokers. *Nicotine Tob Res*. 2015;17:704–709.

Hellstrom WJ, Overstreet JW, Sikka SC, et al. Semen and sperm reference ranges for men 45 years of age and older. *J Androl*. 2006;27:421–428.

Hendry WF, Hughes L, Scammell G, et al. Comparison of prednisolone and placebo in subfertile men with antibodies to spermatozoa. *Lancet*. 1990;335:85–88.

Henkel R, Maass G, Schuppe HC, et al. Molecular aspects of declining sperm motility in older men. *Fertil Steril*. 2005;84:1430–1437.

Hildebrandt F, Benzing T, Katsanis N. Ciliopathies. *N Engl J Med*. 2011;364:1533–1543.

Hoekstra T, Witt MA. The correlation of internal spermatic vein palpability with ultrasonographic diameter and reversal of venous flow. *J Urol*. 1995;153:82–84.

Hofny ER, Ali ME, Abdel-Hafez HZ, et al. Semen parameters and hormonal profile in obese fertile and infertile males. *Fertil Steril*. 2010;94:581–584.

Holter H, Anderheim L, Bergh C, et al. The psychological influence of gender infertility diagnoses among men about to start IVF or ICSI treatment using their own sperm. *Hum Reprod*. 2007;22:2559–2565.

Hopps CV, Mielnik A, Goldstein M, et al. Detection of sperm in men with Y chromosome microdeletions of the AZFa, AZFb and AZFc regions. *Hum Reprod*. 2003;18:1660–1665.

Hotaling JM, Lopushnyan NA, Davenport M, et al. Raw and test-thaw semen parameters after cryopreservation among men with newly diagnosed cancer. *Fertil Steril*. 2013;99:464–469.

Hovav Y, Dan-Goor M, Yaffe H, et al. Electroejaculation before chemotherapy in adolescents and young men with cancer. *Fertil Steril*. 2001;75:811–813.

Hsu PC, Chang HY, Guo YL, et al. Effect of smoking on blood lead levels in workers and role of reactive oxygen species in lead-induced sperm chromatin DNA damage. *Fertil Steril*. 2009;91:1096–1103.

Huang WJ, Lamb DJ, Kim ED, et al. Germ-cell nondisjunction in testes biopsies of men with idiopathic infertility. *Am J Hum Genet*. 1999;64:1638–1645.

Hughes IA, Houk C, Ahmed SF, et al. Consensus statement on management of intersex disorders. *Arch Dis Child*. 2006;91:554–563.

Hughes IA, Acerini CL. Factors controlling testis descent. *Eur J Endocrinol*. 2008;159(Suppl 1):S75–S82.

Hunter DJ, Khoury MJ, Drazen JM. Letting the genome out of the bottle—will we get our wish? *N Engl J Med*. 2008;358:105–107.

Hussein A, Ozgok Y, Ross LS, et al. Clomiphene administration for cases of nonobstructive azoospermia: a multicenter study. *J Androl*. 2005;26:787–791 [discussion 792–3].

Hussein A, Ozgok Y, Ross LS, et al. Optimization of spermatogenesis-regulating hormones in patients with non-obstructive azoospermia and its impact on sperm retrieval: a multicentre study. *BJU Int*. 2013;111:E110–E114.

Hussein AF. The role of color Doppler ultrasound in prediction of the outcome of microsurgical subinguinal varicocelectomy. *J Urol*. 2006;176:2141–2145.

Ilani N, Roth MY, Amory JK, et al. A new combination of testosterone and nestorone transdermal gels for male hormonal contraception. *J Clin Endocrinol Metab*. 2012;97:3476–3486.

International Human Genome Sequencing Consortium. Finishing the euchromatic sequence of the human genome. *Nature*. 2004;431:931–945.

Ioannidou-Kadis S, Wright PJ, Neely RD, et al. Complete reversal of adult-onset isolated hypogonadotropic hypogonadism with clomiphene citrate. *Fertil Steril*. 2006;86:1513 [e5–9].

Jaidane M, Arfa NB, Hmida W, et al. Effect of transurethral resection of the prostate on erectile function: a prospective comparative study. *Int J Impot Res*. 2010;22:146–151.

James WH. Smoking, sperm quality and testosterone level. *Hum Reprod*. 2002;17:3275–3276.

Jahnukainen K, Ehmcke J, Hou M, et al. Testicular function and fertility preservation in male cancer patients. *Best Pract Res Clin Endocrinol Metab*. 2011;25:287–302.

Jahnukainen K, Stukenborg JB. Clinical review: present and future prospects of male fertility preservation for children and adolescents. *J Clin Endocrinol Metab*. 2012;97:4341–4351.

Jarow J, Sigman M, Kolettis PN, et al. *The optimal evaluation of the infertile male: AUA best practice statement*. [website] http://www.auanet.org/common/pdf/education/clinical-guidance/Male-Infertility-d.pdf; 2010.

Jarow JP. Transrectal ultrasonography in the diagnosis and management of ejaculatory duct obstruction. *J Androl*. 1996;17:467–472.

Jarow JP, Ogle SR, Eskew LA. Seminal improvement following repair of ultrasound detected subclinical varicoceles. *J Urol*. 1996;155:1287–1290.

Jarow JP. Seminal vesicle aspiration of fertile men. *J Urol*. 1996;156:1005–1007.

Jarvi K, Zielenski J, Wilschanski M, et al. Cystic fibrosis transmembrane conductance regulator and obstructive azoospermia. *Lancet*. 1995;345:1578.

Jefferys A, Siassakos D, Wardle P. The management of retrograde ejaculation: a systematic review and update. *Fertil Steril*. 2012;97:306–312.

Jensen MS, Mabeck LM, Toft G, et al. Lower sperm counts following prenatal tobacco exposure. *Hum Reprod*. 2005;20:2559–2566.

Jensen MS, Toft G, Thulstrup AM, et al. Cryptorchidism concordance in monozygotic and dizygotic twin brothers, full brothers, and half-brothers. *Fertil Steril*. 2010;93:124–129.

Jeyendran RS, Van der Ven HH, Perez-Pelaez M, et al. Development of an assay to assess the functional integrity of the human sperm membrane and its relationship to other semen characteristics. *J Reprod Fertil*. 1984;70:219–228.

Jobling MA, Tyler-Smith C. The human Y chromosome: an evolutionary marker comes of age. *Nat Rev Genet*. 2003;4:598–612.

Johnsen DE, Woodruff WW, Allen IS, et al. MR imaging of the sellar and juxtasellar regions. *Radiographics*. 1991;11:727–758.

Johnson L, George FW, Neaves WB, et al. Characterization of the testicular abnormality in 5 alpha-reductase deficiency. *J Clin Endocrinol Metab*. 1986;63:1091–1099.

Jørgensen N, Andersen AG, Eustache F, et al. Regional differences in semen quality in Europe. *Hum Reprod*. 2001;16:1012–1019.

Jørgensen N, Liu F, Andersson AM, et al. Serum inhibin-b in fertile men is strongly correlated with low but not high sperm counts: a coordinated study of 1,797 European and U.S. men. *Fertil Steril*. 2010;94:2128–2134.

Jung A, Leonhardt F, Schill WB, et al. Influence of the type of undertrousers and physical activity on scrotal temperature. *Hum Reprod*. 2005;20:1022–1027.

Jung A, Strauss P, Lindner HJ, et al. Influence of heating car seats on scrotal temperature. *Fertil Steril*. 2008;90:335–339.

Jurewicz M, Gilbert BR. Imaging and angiography in male factor infertility. *Fertil Steril*. 2016;105:1432–1442.

Kafetsoulis A, Brackett NL, Ibrahim E, et al. Current trends in the treatment of infertility in men with spinal cord injury. *Fertil Steril*. 2006;86:781–789.

Kallmann FJ, Schoenfeld WA. The genetic aspects of primary eunuchoidism. *Am J Ment Defic*. 1944;48:203–236.

Kalsi J, Thum MY, Muneer A, et al. Analysis of the outcome of intracytoplasmic sperm injection using fresh or frozen sperm. *BJU Int*. 2010;107:1124–1128.

Kamal A, Fahmy I, Mansour R, et al. Does the outcome of ICSI in cases of obstructive azoospermia depend on the origin of the retrieved spermatozoa or the cause of obstruction? A comparative analysis. *Fertil Steril*. 2010;94:2135–2140.

Kang HJ, Imperato-McGinley J, Zhu YS, et al. The first successful paternity through in vitro fertilization-intracytoplasmic sperm injection with a man homozygous for the 5α-reductase-2 gene mutation. *Fertil Steril*. 2011;95:2125 [e5–8].

Kasturi SS, Osterberg EC, Tanner J, et al. The effect of genital tract infection and inflammation on male infertility. Lipshultz LI, Howards SS, Niederberger CS. *Infertility in the male*. 4th ed. Cambridge University Press: New York; 2009:295–329.

Katsoff D, Check JH. A challenge to the concept that the use of calcium channel blockers causes reversible male infertility. *Hum Reprod*. 1997;12:1480–1482.

Katz DJ, Nabulsi O, Tal R, et al. Outcomes of clomiphene citrate treatment in young hypogonadal men. *BJU Int*. 2012;110:573–578.

Keegan BR, Barton S, Sanchez X, et al. Isolated teratozoospermia does not affect in vitro fertilization outcome and is not an indication for intracytoplasmic sperm injection. *Fertil Steril*. 2007;88:1583–1588.

Keel BA. Within- and between-subject variation in semen parameters in infertile men and normal semen donors. *Fertil Steril*. 2006;85:128–134.

Keihani S, Craig JR, Zhang C, et al. Impacts of abstinence time on semen parameters in a large population-based cohort of subfertile men. *Urology*. 2017;108:90–95.

Keros V, Rosenlund B, Hultenby K, et al. Optimizing cryopreservation of human testicular tissue: comparison of protocols with glycerol, propanediol and dimethylsulphoxide as cryoprotectans. *Hum Reprod*. 2005;20:1676–1687.

Keros V, Hultenby K, Borgström B, et al. Methods of cryopreservation of testicular tissue with viable spermatogonia in pre-pubertal boys undergoing gonadotoxic cancer treatment. *Hum Reprod*. 2007;22:1384–1395.

Khosla S, Melton LJ, Atkinson EJ, et al. Relationship of serum sex steroid levels to longitudinal changes in bone density in young versus elderly men. *J Clin Endocrinol Metab*. 2001;86:3555–3561.

Kim ED, Crosnoe L, Bar-Chama N, et al. The treatment of hypogonadism in men of reproductive age. *Fertil Steril*. 2013;99:718–724.

Kim SS, Kim Y, Shin YL, et al. Clinical characteristics and molecular analysis of PIT1, PROP1, LHX3, and HESX1 in combined pituitary hormone deficiency patients with abnormal pituitary MR imaging. *Horm Res*. 2003;60:277–283.

Klibanski A. Clinical practice. Prolactinomas. *N Engl J Med*. 2010;362:1219–1226.

Kohn TP, Kohn JR, Darilek S, et al. Genetic counseling for men with recurrent pregnancy loss or recurrent implantation failure due to abnormal sperm chromosomal aneuploidy. *J Assist Reprod Genet*. 2016;33:571–576.

Kohn TP, Kohn JR, Pastuszak AW. Varicocelectomy before assisted reproductive technology: are outcomes improved? *Fertil Steril*. 2017;108:385–391.

Kovac JR, Pastuszak AW, Lamb DJ. The use of genomics, proteomics, and metabolomics in identifying biomarkers of male infertility. *Fertil Steril*. 2013;99:998–1007.

Krausz C, Casamonti E. Spermatogenic failure and the Y chromosome. *Hum Genet*. 2017;136:637–655.

Kruger TF, Acosta AA, Simmons KF, et al. New method of evaluating sperm morphology with predictive value for human in vitro fertilization. *Urology*. 1987;30:248–251.

Kunetz P, Vanden Meerschaut F, Elinati E, et al. Assisted oocyte activation overcomes fertilization failure in globozoospermic patients regardless of the DPY19L2 status. *Hum Reprod*. 2013;28:1054–1061.

Kumanov P, Nandipati K, Tomova A, et al. Inhibin B is a better marker of spermatogenesis than other hormones in the evaluation of male factor infertility. *Fertil Steril*. 2006;86:332–338.

Kushniruk II. Effect of streptomycin and tetracycline on spermatogenesis. *Vrach Delo*. 1973;12:65–68.

La Vignera S, Vicari E, Condorelli RA, et al. Male accessory gland infection and sperm parameters (review). *Int J Androl*. 2011;34:e330–e347.

Lacerda JI, Del Giudice PT, da Silva BF, et al. Adolescent varicocele: improved sperm function after varicocelectomy. *Fertil Steril*. 2011;95:994–999.

Lackner JE, Herwig R, Schmidbauer J, et al. Correlation of leukocytospermia with clinical infection and the positive effect of antiinflammatory treatment on semen quality. *Fertil Steril*. 2006;86:601–605.

Lafuente R, González-Comadrán M, Solà I, et al. Coenzyme Q10 and male infertility: a meta-analysis. *J Assist Reprod Genet*. 2013;30:1147–1156.

Lao OB, Fitzgibbons RJ, Cusick RA. Pediatric inguinal hernias, hydroceles, and undescended testicles. *Surg Clin North Am*. 2012;92:487–504 [vii].

Lardone MC, Parodi DA, Ebensperger M, et al. AZFc partial deletions in Chilean men with severe spermatogenic failure. *Fertil Steril*. 2007;88:1318–1326.

Larson KL, DeJonge CJ, Barnes AM, et al. Sperm chromatin structure assay parameters as predictors of failed pregnancy following assisted reproductive techniques. *Hum Reprod*. 2000;15:1717–1722.

Latronico AC, Anasti J, Arnhold IJ, et al. Brief report: testicular and ovarian resistance to luteinizing hormone caused by inactivating mutations of the luteinizing hormone-receptor gene. *N Engl J Med*. 1996;334:507–512.

Lazarin GA, Haque IS, Nazareth S, et al. An empirical estimate of carrier frequencies for 400+ causal mendelian variants: results from an ethnically diverse clinical sample of 23,453 individuals. *Genet Med*. 2013;15:178–186.

Lee JD, Jeng SY, Lee TH. Increased expression of hypoxia-inducible factor 1α in the internal spermatic vein of patients with varicocele. *J Urol*. 2006;175:1045–1048.

Lee K, Haugen HS, Clegg CH, et al. Premature translation of protamine 1 mRNA causes precocious nuclear condensation and arrests spermatid differentiation in mice. *Proc Natl Acad Sci USA*. 1995;92:12451–12455.

Lee PA. Fertility in cryptorchidism. Does treatment make a difference. *Endocrinol Metab Clin North Am*. 1993;22:479–490.

Lee PA. Fertility after cryptorchidism: epidemiology and other outcome studies. *Urology*. 2005;66:427–431.

Lee PA, Coughlin MT. Fertility after bilateral cryptorchidism. Evaluation by paternity, hormone, and semen data. *Horm Res*. 2001;55:28–32.

Lee PA, Coughlin MT, Bellinger MF. No relationship of testicular size at orchiopexy with fertility in men who previously had unilateral cryptorchidism. *J Urol*.

2001;166:236–239.

Leutjens CM, Stukenborg JB, Nieschlag E, et al. Complete spermatogenesis in orthotopic but not in ectopic transplants of autologously grafted marmoset testicular tissue. *Endocrinology*. 2008;149:1736–1747.

Levine H, Jorgensen N, Martino-Andrade A, et al. Temporal trends in sperm count: a systematic review and meta-regression analysis. *Hum Reprod Update*. 2017;23:646–659.

Levitas E, Lunenfeld E, Weiss N, et al. Relationship between the duration of sexual abstinence and semen quality: analysis of 9,489 semen samples. *Fertil Steril*. 2005;83:1680–1686.

Lewis SE, Aitken RJ, Conner SJ, et al. The impact of sperm DNA damage in assisted conception and beyond: recent advances in diagnosis and treatment. *Reprod Biomed Online*. 2013;27:325–337.

Lewis JM, Kaplan WE. Anatomy and embryology of the male reproductive tract and gonadal development. Lipshultz LI, Howards SS, Niederberger CS. *Infertility in the male*. 4th ed. Cambridge University Press: New York; 2009:1–13.

Li CY, Jiang LY, Chen WY, et al. CFTR is essential for sperm fertilizing capacity and is correlated with sperm quality in humans. *Hum Reprod*. 2010;25:317–327.

Li DK, Zhou Z, Miao M, et al. Urine bisphenol-A (BPA) level in relation to semen quality. *Fertil Steril*. 2011;95:625–630 [e1–4].

Lichtenfels AJ, Gomes JB, Pieri PC, et al. Increased levels of air pollution and a decrease in the human and mouse male-to-female ratio in São Paulo, Brazil. *Fertil Steril*. 2007;87:230–232.

Lima SB, Cenedeze MA, Bertolla RP, et al. Expression of the *HSPA2* gene in ejaculated spermatozoa from adolescents with and without varicocele. *Fertil Steril*. 2006;86:1659–1663.

Lin MH, Kuo-Kuang Lee R, Li SH, et al. Sperm chromatin structure assay parameters are not related to fertilization rates, embryo quality, and pregnancy rates in in vitro fertilization and intracytoplasmic sperm injection, but might be related to spontaneous abortion rates. *Fertil Steril*. 2008;90:352–359.

Lipshultz LI, Corriere JN. Progressive testicular atrophy in the varicocele patient. *J Urol*. 1977;117:175–176.

Liu DY, Baker HW. The proportion of human sperm with poor morphology but normal intact acrosomes detected with *Pisum sativum* agglutinin correlates with fertilization in vitro. *Fertil Steril*. 1988;50:288–293.

Lockwood GM, Deveneau NE, Shridharani AN, et al. Isolated abnormal strict morphology is not a contraindication for intrauterine insemination. *Andrology*. 2015;3:1088–1093.

Liu DY, Baker HW. Tests of human sperm function and fertilization in vitro. *Fertil Steril*. 1992;58:465–483.

Lu S, Cui Y, Li X, et al. Association of cystic fibrosis transmembrane-conductance regulator gene mutation with negative outcome of intracytoplasmic sperm injection pregnancy in cases of congenital bilateral absence of vas deferens. *Fertil Steril*. 2014;101:1255–1260.

Luconi M, Samavat J, Seghieri G, et al. Determinants of testosterone recovery after bariatric surgery: is it only a matter of reduction of body mass index? *Fertil Steril*. 2013;99:1872–1879 [e1].

Lyon E, Miller C. Current challenges in cystic fibrosis screening. *Arch Pathol Lab Med*. 2003;127:1133–1139.

Macedo A, Rondon A, Ortiz V. Hypospadias. *Curr Opin Urol*. 2012;22:447–452.

Machev N, Gosset P, Viville S. Chromosome abnormalities in sperm from infertile men with normal somatic karyotypes: teratozoospermia. *Cytogenet Genome Res*. 2005;111:352–357.

Maciel LC, Glina S, Palma PCR, et al. Histopathological alterations of the vas deferens in rats exposed to polypropylene mesh. *BJU Int*. 2007;100:187–190.

MacLeod J. Semen quality in 1000 men of known fertility and in 800 cases of infertile marriage. *Fertil Steril*. 1951;2:115–139.

Maiburg M, Repping S, Giltay J. The genetic origin of Klinefelter syndrome and its effect on spermatogenesis. *Fertil Steril*. 2012;98:253–260.

Mancini M, Carmignani L, Gazzano G, et al. High prevalence of testicular cancer in azoospermic men without spermatogenesis. *Hum Reprod*. 2007;22:1042–1046.

Mansbach JM, Forbes P, Peters C. Testicular torsion and risk factors for orchiectomy. *Arch Pediatr Adolesc Med*. 2005;159:1167–1171.

Margalioth EJ, Navot D, Laufer N, et al. Correlation between the zona-free hamster egg sperm penetration assay and human in vitro fertilization. *Fertil Steril*. 1986;45:665–670.

Martin RH. Cytogenetic determinants of male fertility. *Hum Reprod Update*. 2008;14:379–390.

Martini AC, Tissera A, Estofán D, et al. Overweight and seminal quality: a study of 794 patients. *Fertil Steril*. 2010;94:1739–1743.

Massin N, Bry H, Vija L, et al. Healthy birth after testicular extraction of sperm and ICSI from an azoospermic man with mild androgen insensitivity syndrome caused by an androgen receptor partial loss-of-function mutation. *Clin Endocrinol (Oxf)*. 2012;77:593–598.

Masson P, Brannigan RE. The varicocele. *Urol Clin North Am*. 2014;41:129–144.

Matsubara K, Iwamoto H, Yoshida A, et al. Semen analysis and successful paternity by intracytoplasmic sperm injection in a man with steroid 5α-reductase-2 deficiency. *Fertil Steril*. 2010;94:2770 [e7–10].

Matsumoto AM, Bremner WJ. Testicular disorders. Melmed S, Polonsky KS, Larsen PR, et al. *Williams textbook of endocrinology*. 12th ed. Saunders; 2011:688–777.

Mau-Holzmann UA. Somatic chromosomal abnormalities in infertile men and women. *Cytogenet Genome Res*. 2005;111:317–336.

Mbah AU, Ndukwu GO, Ghasi SI, et al. Low-dose lisinopril in normotensive men with idiopathic oligospermia and infertility: a 5-year randomized, controlled, crossover pilot study. *Clin Pharmacol Ther*. 2012;91:582–589.

McRobbie H, Phillips A, Goniewicz ML, et al. Effects of switching to electronic cigarettes with and without concurrent smoking on exposure to nicotine, carbon monoxide, and acrolein. *Cancer Prev Res (Phila)*. 2015;8:873–878.

Meacham RB, Joyce GF, Wise M, et al. Male infertility. *J Urol*. 2007;177:2058–2066.

Meeker JD, Barr DB, Hauser R. Human semen quality and sperm DNA damage in relation to urinary metabolites of pyrethroid insecticides. *Hum Reprod*. 2008;23:1932–1940.

Meeker JD, Rossano MG, Protas B, et al. Environmental exposure to metals and male reproductive hormones: circulating testosterone is inversely associated with blood molybdenum. *Fertil Steril*. 2010;93:130–140.

Meeker JD, Singh NP, Ryan L, et al. Urinary levels of insecticide metabolites and DNA damage in human sperm. *Hum Reprod*. 2004;19:2573–2580.

Mehta A, Paduch DA. Klinefelter syndrome: an argument for early aggressive hormonal and fertility management. *Fertil Steril*. 2012;98:274–283.

Mehta A, Bolyakov A, Roosma J, et al. Successful testicular sperm retrieval in adolescents with Klinefelter syndrome treated with at least one year of topical testosterone and aromatase inhibitor. *Fertil Steril*. 2013;100:970–974.

Meistrich ML. Male gonadal toxicity. *Pediatr Blood Cancer*. 2009;53:261–266.

Melkersson K. Differences in prolactin elevation and related symptoms of atypical antipsychotics in schizophrenic patients. *J Clin Psychiatry*. 2005;66:761–767.

Mellick LB. Torsion of the testicle: it is time to stop tossing the dice. *Pediatr Emerg Care*. 2012;28:80–86.

Menon S, Rives N, Mousset-Simeon N, et al. Fertility preservation in adolescent males: experience over 22 years at Rouen University Hospital. *Hum Reprod*. 2009;24:37–44.

Meseguer M, Molina N, García-Velasco JA, et al. Sperm cryopreservation in oncological patients: a 14-year follow-up study. *Fertil Steril*. 2006;85:640–645.

Messina M. Soybean isoflavone exposure does not have feminizing effects on men: a critical examination of the clinical evidence. *Fertil Steril*. 2010;93:2095–2104.

Mieusset R, Bengoudifa B, Bujan L. Effect of posture and clothing on scrotal temperature in fertile men. *J Androl*. 2007;28:170–175.

Miller KD, Coughlin MT, Lee PA. Fertility after unilateral cryptorchidism. Paternity, time to conception, pretreatment testicular location and size, hormone and sperm parameters. *Horm Res*. 2001;55:249–253.

Mitchell LA, De Iuliis GN, Aitken RJ. The TUNEL assay consistently underestimates DNA damage in human spermatozoa and is influenced by DNA compaction and cell vitality: development of an improved methodology. *Int J Androl*. 2011;34:2–13.

Mittal PK, Little B, Harri PA, et al. Role of imaging in the evaluation of male infertility. *Radiographics*. 2017;37:837–854.

Mogdil V, Rai S, Ralph DJ, et al. An update on the diagnosis and management of ejaculatory duct obstruction. *Nat Rev*

Urol. 2016;13:13–20.

Molaro A, Hodges E, Fang F, et al. Sperm methylation profiles reveal features of epigenetic inheritance and evolution in primates. *Cell*. 2011;146:1029–1041.

Momen MN, Ananian FB, Fahmy IM, et al. Effect of high environmental temperature on semen parameters among fertile men. *Fertil Steril*. 2010;93:1884–1886.

Moorthie S, Hall A, Wright CF. Informatics and clinical genome sequencing: opening the black box. *Genet Med*. 2013;15:165–171.

Morbeck DE, Leonard PH, Weaver AL, et al. Sperm morphology: classification drift over time and clinical implications. *Fertil Steril*. 2011;96:1350–1354.

Moretti E, Capitani S, Figura N, et al. The presence of bacteria species in semen and sperm quality. *J Assist Reprod Genet*. 2009;26:47–56.

Moretti E, Di Cairano G, Capitani S, et al. Cryptorchidism and semen quality: a TEM and molecular study. *J Androl*. 2007;28:194–199.

Moskovic DJ, Katz DJ, Akhavan A, et al. Clomiphene citrate is safe and effective for long-term management of hypogonadism. *BJU Int*. 2012;110:1524–1528.

Moskovtsev SI, Willis J, Mullen JBM. Age-related decline in sperm deoxyribonucleic acid integrity in patients evaluated for male infertility. *Fertil Steril*. 2006;85:496–499.

Mostafa T. In vitro sildenafil citrate use as a sperm motility stimulant. *Fertil Steril*. 2007;88:994–996.

Mostafa T, Rashed LA, Nabil NI, et al. Seminal miRNA relationship with apoptotic markers and oxidative stress in infertile men with varicocele. *Biomed Res Int*. 2016;2016:4302754.

Mulhall JP, Reijo R, Alagappan R, et al. Azoospermic men with deletion of the *DAZ* gene cluster are capable of completing spermatogenesis: fertilization, normal embryonic development and pregnancy occur when retrieved testicular spermatozoa are used for intracytoplasmic sperm injection. *Hum Reprod*. 1997;12:503–508.

Munzberg H, Myers MG Jr. Molecular and anatomical determinants of central leptin resistance. *Nat Neurosci*. 2005;8:566–570.

Murk W, Seli E. Fertility preservation as a public health issue: an epidemiological perspective. *Curr Opin Obstet Gynecol*. 2011;23:143–150.

Murray KS, James A, McGeady JB, et al. The effect of the new 2010 World Health Organization criteria for semen analyses on male infertility. *Fertil Steril*. 2012;98:1428–1431.

Müslümanoğlu MH, Turgut M, Çilingir O, et al. Role of the AZFd locus in spermatogenesis. *Fertil Steril*. 2005;84:519–522.

Muttukrishna S, Yussoff H, Naidu M, et al. Serum anti-müllerian hormone and inhibin B in disorders of spermatogenesis. *Fertil Steril*. 2007;88:516–518.

Myers GM, Lambert-Messerlian GM, Sigman M. Inhibin B reference data for fertile and infertile men in Northeast America. *Fertil Steril*. 2009;92:1920–1923.

Nachtigall LB, Boepple PA, Pralong FP, et al. Adult-onset idiopathic hypogonadotropic hypogonadism—a treatable form of male infertility. *N Engl J Med*. 1997;336:410–415.

Nagler HM, Grotas AB. Varicocele. Lipshultz LI, Howards SS, Niederberger CS. *Infertility in the male*. 4th ed. Cambridge University Press: New York; 2009:331–361.

Navarro-Costa P. Sex, rebellion and decadence: the scandalous evolutionary history of the human Y chromosome. *Biochim Biophys Acta*. 2012;1822:1851–1863.

Negri L, Albani E, DiRocco M, et al. Testicular sperm extraction in azoospermic men submitted to bilateral orchidopexy. *Hum Reprod*. 2003;18:2534–2539.

Newbern K, Natrajan N, Kim HG, et al. Identification of HESX1 mutations in Kallmann syndrome. *Fertil Steril*. 2013;99:1831–1837.

Nguyen HT, Etzell J, Turek PJ. Normal human ejaculatory duct anatomy: a study of cadaveric and surgical specimens. *J Urol*. 1996;155:1639–1642.

Nguyen RH, Wilcox AJ, Skjaerven R, et al. Men's body mass index and infertility. *Hum Reprod*. 2007;22:2488–2493.

Nicopoullos JD, Gilling-Smith C, Almeida PA, et al. Use of surgical sperm retrieval in azoospermic men: a meta-analysis. *Fertil Steril*. 2004;82:691–701.

Niederberger CS. Clinical evaluation of the male. Niederberger CS. *An introduction to male reproductive medicine*. Cambridge University Press: New York; 2011:29–57.

Niederberger CS, Lamb DJ, Glinz M, et al. Tests of sperm function for evaluation of the male: penetrak and Tru-Trax. *Fertil Steril*. 1993;60:319–323.

Nijs M, Vanderzwalmen P, Vandamme B, et al. Fertilizing ability of immotile spermatozoa after intracytoplasmic sperm injection. *Hum Reprod*. 1996;11:2180–2185.

Nistal M, Paniagua R, Herruzo A. Multi-tailed spermatozoa in a case with asthenospermia and teratospermia. *Virchows Arch B Cell Pathol*. 1977;26:111–118.

Oates RD. The natural history of endocrine function and spermatogenesis in Klinefelter syndrome: what the data show. *Fertil Steril*. 2012;98:266–273.

Oates RD, Lamb DJ. Genetic aspects of infertility. Lipshultz LI, Howards SS, Niederberger CS. *Infertility in the male*. 4th ed. Cambridge University Press: New York; 2009:251–276.

Oates RD, Silber SJ, Brown LG, et al. Clinical characterization of 42 oligospermic or azoospermic men with microdeletion of the AZFc region of the Y chromosome, and of 18 children conceived via ICSI. *Hum Reprod*. 2002;17:2813–2824.

O'Flaherty C, Hales BF, Chan P, et al. Impact of chemotherapeutics and advanced testicular cancer or Hodgkin lymphoma on sperm deoxyribonucleic acid integrity. *Fertil Steril*. 2010;94:1374–1379.

O'Flaherty C, Vaisheva F, Hales BF, et al. Characterization of sperm chromatin quality in testicular cancer and Hodgkin's lymphoma patients prior to chemotherapy. *Hum Reprod*. 2008;23:1044–1052.

O'Flynn O'Brien KL, Varghese AC, Agarwal A. The genetic causes of male factor infertility: a review. *Fertil Steril*. 2010;93:1–12.

O'Herlihy C, Robinson HP, de Crespigny LJ. Mittelschmerz is a preovulatory symptom. *BMJ*. 1980;280:986.

Ono M, Harley VR. Disorders of sex development: new genes, new concepts. *Nat Rev Endocrinol*. 2013;9:79–91.

Orhan I, Duksal I, Onur R, et al. Technetium Tc 99m sulphur colloid seminal vesicle scintigraphy: a novel approach for the diagnosis of the ejaculatory duct obstruction. *Urology*. 2008;71:672–676.

Overstreet JW, Fuh VL, Gould J, et al. Chronic treatment with finasteride daily does not affect spermatogenesis or semen production in young men. *J Urol*. 1999;162:1295–1300.

Paasch U, Grunewald S, Kratzsch J, et al. Obesity and age affect male fertility potential. *Fertil Steril*. 2010;94:2898–2901.

Palermo G, Joris H, Devroey P, et al. Pregnancies after intracytoplasmic injection of single spermatozoon into an oocyte. *Lancet*. 1992;340:17–18.

Palmer NO, Bakos HW, Owens JA, et al. Diet and exercise in an obese mouse fed a high-fat diet improve metabolic health and reverse perturbed sperm function. *Am J Physiol Endocrinol Metab*. 2012;302:E768–E780.

Pasqualotto FF, Lucon AM, Sobreiro BP, et al. Effects of medical therapy, alcohol, smoking, and endocrine disruptors on male infertility. *Rev Hosp Clin Fac Med Sao Paulo*. 2004;59:375–382.

Pasqualotto FF, Sharma RK, Potts JM, et al. Seminal oxidative stress in patients with chronic prostatitis. *Urology*. 2000;55:881–885.

Pasqualotto FF, Sundaram A, Sharma RK, et al. Semen quality and oxidative stress scores in fertile and infertile patients with varicocele. *Fertil Steril*. 2008;89:602–607.

Pasqualotto FF, Umezu FM, Salvador M, et al. Effect of cigarette smoking on antioxidant levels and presence of leukocytospermia in infertile men: a prospective study. *Fertil Steril*. 2008;90:278–283.

Patel SR, Sigman M. Prevalence of testicular size discrepancy in infertile men with and without varicoceles. *Urology*. 2010;75:566–568.

Pauli EM, Legro RS, Demers LM, et al. Diminished paternity and gonadal function with increasing obesity in men. *Fertil Steril*. 2008;90:346–351.

Payne JF, Raburn DJ, Couchman GM, et al. Redefining the relationship between sperm deoxyribonucleic acid fragmentation as measured by the sperm chromatin structure assay and outcomes of assisted reproductive techniques. *Fertil Steril*. 2005;84:356–364.

Peeraer K, Nijs M, Raick D, et al. Pregnancy after ICSI with ejaculated immotile spermatozoa from a patient with immotile cilia syndrome: a case report and review of the literature. *Reprod Biomed Online*. 2004;9:659–663.

Pentheroudakis G, Orecchia R, Hoekstra HJ, et al. Cancer, fertility and pregnancy: ESMO Clinical Practive Guidelines for diagnosis, treatment and follow-up. *Ann Oncol*. 2010;21(Suppl 5):v266–v273.

Perdrix A, Rives N. Motile sperm organelle morphology examination (MSOME) and sperm head vacuoles: state of the art in 2013. *Hum Reprod Update*. 2013;19(5):527–541.

Perrin A, Coat C, Nguyen MH, et al. Molecular cytogenetic and genetic aspects of globozoospermia: a review. *Andrologia*. 2013;45(1):1–9.

Petak SM, Nankin HR, Spark RF, et al. American Association of Clinical Endocrinologists. American Association of Clinical Endocrinologists Medical Guidelines for clinical practice for the evaluation and treatment of hypogonadism in adult male patients—2002 update. *Endocr Pract*. 2002;8:440–456.

Peterson BD, Newton CR, Rosen KH, et al. Gender differences in how men and women who are referred for IVF cope with infertility stress. *Hum Reprod*. 2006;21:2443–2449.

Phillips E, Carpenter C, Oates RD. Ejaculatory dysfunction. *Urol Clin North Am*. 2014;41:115–128.

Pierre P, Despert F, Tranquart F, et al. Adrenal rest tissue in gonads of patients with classical congenital adrenal hyperplasia: multicenter study of 45 French male patients. *Ann Endocrinol (Paris)*. 2012;73:515–522.

Plymate SR, Tenover JS, Bremner WJ. Circadian variation in testosterone, sex hormone-binding globulin, and calculated non-sex hormone-binding globulin bound testosterone in healthy young and elderly men. *J Androl*. 1989;10:366–371.

Pomara G, Morelli G, Canale D, et al. Alterations in sperm motility after acute oral administration of sildenafil or tadalafil in young, infertile men. *Fertil Steril*. 2007;88:860–865.

Popken G, Wetterauer U, Schultze-Seemann W, et al. Transurethral resection of cystic and non-cystic ejaculatory duct obstructions. *Int J Androl*. 1998;21:196–200.

Practice Committee of the American Society for Reproductive

Medicine. Report on varicocele and infertility. *Fertil Steril*. 2014;102:1556–1560.

Prins GS, Dolgina R, Studney P, et al. Quality of cryopreserved testicular sperm in patients with obstructive and nonobstructive azoospermia. *J Urol*. 1999;161:1504–1508.

Provost MP, Acharya KS, Yeh JS, et al. Pregnancy outcomes decline with increasing body mass index: analysis of 239,127 fresh autologous in vitro fertilization cycles from the 2008-2010 Society for Assisted Reproductive Technology registry. *Fertil Steril*. 2016;105:663–669.

Pryor JL, Howards SS. Varicocele. *Urol Clin North Am*. 1987;14:499–513.

Purohit RS, Wu DS, Shinohara K, et al. A prospective comparison of 3 diagnostic methods to evaluate ejaculatory duct obstruction. *J Urol*. 2004;171:232–235 [discussion 235–236].

Purohit V. Can alcohol promote aromatization of androgens to estrogens? A review. *Alcohol*. 2000;22:123–127.

Rago R, Salacone P, Caponecchia L, et al. Effect of vardenafil on semen parameters in infertile men: a pilot study evaluating short-term treatment. *J Endocrinol Invest*. 2012;35:897–900.

Raman JD, Schlegel PN. Aromatase inhibitors for male infertility. *J Urol*. 2002;167:624–629.

Raman JD, Schlegel PN. Testicular sperm extraction with intracytoplasmic sperm injection is successful for the treatment of nonobstructive azoospermia associated with cryptorchidism. *J Urol*. 2003;170:1287–1290.

Raman JD, Walmsley K, Goldstein M. Inheritance of varicoceles. *Urology*. 2005;65:1186–1189.

Ramasamy R, Schlegel PN. Microdissection testicular sperm extraction: effect of prior biopsy on success of sperm retrieval. *J Urol*. 2007;177:1447–1449.

Ramasamy R, Scovell JM, Kovac JR, et al. Fluorescence in-situ hybridization detects increased sperm aneuploidy in men with recurrent pregnancy loss. *Fertil Steril*. 2015;103:906–909.

Ramezanzadeh F, Aghssa MM, Jafarabadi M, et al. Alterations of sexual desire and satisfaction in male partners of infertile couples. *Fertil Steril*. 2006;85:139–143.

Ramlau-Hansen CH, Thulstrup AM, Aggerholm AS, et al. Is smoking a risk factor for decreased semen quality? A cross-sectional analysis. *Hum Reprod*. 2007;22:188–196.

Ramlau-Hansen CH, Thulstrup AM, Nohr EA, et al. Subfecundity in overweight and obese couples. *Hum Reprod*. 2007;22:1634–1637.

Rasouly HM, Lu W. Lower urinary tract development and disease. *Wiley Interdiscip Rev Syst Biol Med*. 2013;5:307–342.

Ratbi I, Legendre M, Niel F, et al. Detection of cystic fibrosis transmembrane conductance regulator (CFTR) gene rearrangements enriches the mutation spectrum in congenital bilateral absence of the vas deferens and impacts on genetic counselling. *Hum Reprod*. 2007;22:1285–1291.

Raviv G, Pinthus JH, Shefi S, et al. Effects of intravesical chemotherapy and immunotherapy on semen analysis. *Urology*. 2005;65:765–767.

Ravnborg TL, Jensen TK, Andersson A-M, et al. Prenatal and adult exposures to smoking are associated with adverse effects on reproductive hormones, semen quality, final height and body mass index. *Hum Reprod*. 2011;26:1000–1011.

Reisch N, Arlt W, Krone N. Health problems in congenital adrenal hyperplasia due to 21-hydroxylase deficiency. *Horm Res*. 2011;76:73–85.

Rhoden EL, Estrada C, Levine L, et al. The value of pituitary magnetic resonance imaging in men with hypogonadism. *J Urol*. 2003;170:795–798.

Ribas-Maynou J, Garcia-Peiro A, Abad C, et al. Alkaline and neutral Comet assay profiles of sperm DNA damage in clinical groups. *Hum Reprod*. 2012;27:652–658.

Rice-Evans C, Miller NJ. Total antioxidant status in plasma and body fluids. *Methods Enzymol*. 1994;234:279–293.

Riley SA, Lecarpentier J, Mani V, et al. Sulphasalazine induced seminal abnormalities in ulcerative colitis: results of mesalazine substitution. *Gut*. 1987;28:1008–1012.

Rimm AA, Katayama AC, Diaz M, et al. A meta-analysis of controlled studies comparing major malformation rates in IVF and ICSI infants with naturally conceived children. *J Assist Reprod Genet*. 2004;21:437–443.

Rives N, Perdrix A, Hennebicq S, et al. The semen quality of 1158 men with testicular cancer at the time of cryopreservation: results of the French National CECOS Network. *J Androl*. 2012;33:1394–1401.

Robbins WA. Cytogenetic damage measured in human sperm following cancer chemotherapy. *Mutat Res*. 1996;355:235–252.

Robbins WA, Wei F, Elashoff DA, et al. Y:X sperm ratio in boron-exposed men. *J Androl*. 2008;29:115–121.

Robertson KM, O'Donnell L, Jones ME, et al. Impairment of spermatogenesis in mice lacking a functional aromatase (cyp 19) gene. *Proc Natl Acad Sci USA*. 1999;96:7986–7991.

Robinson L, Gallos ID, Conner SJ, et al. The effect of sperm DNA fragmentation on miscarriage rates: a systematic review and meta-analysis. *Hum Reprod*. 2012;27:2908–2917.

Rofeim O, Gilbert BR. Long-term effects of cryopreservation on human spermatozoa. *Fertil Steril*. 2005;84:536–537.

Roth LW, Ryan AR, Meacham RB. Clomiphene citrate in the management of male infertility. *Semin Reprod Med*. 2013;31:245–250.

Rothmann SA, Reese AA. Semen analysis. Lipshultz LI, Howards SS, Niederberger CS. *Infertility in the male*. 4th ed.

Cambridge University Press: New York; 2009:550–573.

Rubes J, Selevan SG, Evenson DP, et al. Episodic air pollution is associated with increased DNA fragmentation in human sperm without other changes in semen quality. *Hum Reprod*. 2005;20:2776–2783.

Safarinejad MR. Efficacy of coenzyme Q10 on semen parameters, sperm function and reproductive hormones in infertile men. *J Urol*. 2009;182:237–248.

Safarinejad MR, Safarinejad S, Shafiei N, et al. Effects of the reduced form of coenzyme Q10 (ubiquinol) on semen parameters in men with idiopathic infertility: a double-blind, placebo controlled, randomized study. *J Urol*. 2012;188:526–531.

Sakamoto H, Ogawa Y, Yoshida H. Relationship between testicular volume and varicocele in patients with infertility. *Urology*. 2008;71:104–109.

Sakamoto H, Saito K, Ogawa Y, et al. Testicular volume measurements using Prader orchidometer versus ultrasonography in patients with infertility. *Urology*. 2007;69:158–162.

Sakamoto H, Saito K, Oohta M, et al. Testicular volume measurement: comparison of ultrasonography, orchidometry, and water displacement. *Urology*. 2007;69:152–157.

Sakkas D, Alvarez JG. Sperm DNA fragmentation: mechanisms of origin, impact on reproductive outcome, and analysis. *Fertil Steril*. 2010;93:1027–1036.

Sallmen M, Sandler DP, Hoppin JA, et al. Reduced fertility among overweight and obese men. *Epidemiology*. 2006;17:520–523.

Samplaski MK, Lo KC, Grober ED, et al. Varicocelectomy to “upgrade” semen quality to allow couples to use less invasive forms of assisted reproductive technology. *Fertil Steril*. 2017;108:609–612.

Samplaski MK, Lo K, Grober E, et al. Finasteride use in the male infertility population: effects on semen and hormonal parameters. *Fertil Steril*. 2013;100:1542–1546.

Sarrate Z, Vidal F, Blanco J. Role of sperm fluorescent in situ hybridization studies in infertile patients: indications, study approach, and clinical relevance. *Fertil Steril*. 2010;93:1892–1902.

Satta A, Stivala A, Garozzo A, et al. Experimental *Chlamydia trachomatis* infection causes apoptosis in human sperm. *Hum Reprod*. 2005;21:134–137.

Saxena R, de Vries JW, Repping S, et al. Four DAZ genes in two clusters found in the AZFc region of the human Y chromosome. *Genomics*. 2000;67:256–267.

Scarpa B, Dunson DB, Giacchi E. Bayesian selection of optimal rules for timing intercourse to conceive by using calendar and mucus. *Fertil Steril*. 2007;88:915–924.

Schanz S, Baeckert-Sifeddine IT, Braeunlich C, et al. A new quality-of-life measure for men experiencing involuntary childlessness. *Hum Reprod*. 2005;20:2858–2865.

Schena M, Shalon D, Davis RW, et al. Quantitative monitoring of gene expression patterns with a complementary DNA microarray. *Science*. 1995;270:467–470.

Schiff JD, Li PS, Goldstein M. Correlation of ultrasound-measured venous size and reversal of flow with Valsalva with improvement in semen-analysis parameters after varicocelectomy. *Fertil Steril*. 2006;86:250–252.

Schlatt S, Rosiepen G, Weinbauer G, et al. Germ cell transfer into rat, bovine, monkey and human testes. *Hum Reprod*. 1999;14:144–150.

Schlatt S, Kim SS, Gosden R. Spermatogenesis and steroidogenesis in mouse, hamster and monkey testicular tissue after cryopreservation and heterotopic grafting to castrated hosts. *Reproduction*. 2002;124:339–346.

Schlegel PN. Aromatase inhibitors for male infertility. *Fertil Steril*. 2012;98:1359–1362.

Schlegel PN, Chang TS, Marshall FF. Antibiotics: potential hazards to male fertility. *Fertil Steril*. 1991;55:235–242.

Schlegel PN, Shin D, Goldstein M. Urogenital anomalies in men with congenital absence of the vas deferens. *J Urol*. 1996;155:1644–1648.

Schmid TE, Eskenazi B, Baumgartner A, et al. The effects of male age on sperm DNA damage in healthy non-smokers. *Hum Reprod*. 2007;22:180–187.

Schoor RA. Prostatitis and male infertility: evidence and links. *Curr Urol Rep*. 2002;3:324–329.

Schoor RA, Elhanbly S, Niederberger CS, et al. The role of testicular biopsy in the modern management of male infertility. *J Urol*. 2001;167:197–200.

Schrader M, Müller M, Sofikitis N, et al. “Onco-tese”: testicular sperm extraction in azoospermic cancer patients before chemotherapy – new guidelines? *Urology*. 2003;61:421–425.

Schulster M, Bernie AM, Ramasamy R. The role of estradiol in male reproductive function. *Asian J Androl*. 2016;18:435–440.

Schulz S, Jakubiczka S, Kropf S, et al. Increased frequency of cystic fibrosis transmembrane conductance regulator gene mutations in infertile males. *Fertil Steril*. 2006;85:135–138.

Setchell BP. The Parkes Lecture. Heat and the testis. *J Reprod Fertil*. 1998;114:179–194.

Sha YW, Ding L, Li P. Management of primary ciliary dyskinesia/Kartagener's syndrome in infertile male patients and current progress in defining the underlying genetic mechanism. *Asian J Androl*. 2014;16:101–106.

Shafik A. Response of the urethral and intracorporeal pressures to cavernosus muscle stimulation: role of the muscles in erection and ejaculation. *Urology*. 1995;46:85–88.

Shafik A, Bedeir GA. Venous tension patterns in cord veins. I. In normal and varicocele individuals. *J Urol*. 1980;123:383–385.

Shalika S, Dugan K, Smith RD, et al. The effect of positive semen bacterial and Ureaplasma cultures on in-vitro fertilization success. *Hum Reprod*. 1996;11:2789–2792.

Sharma RK, Pasqualotto FF, Nelson DR, et al. The reactive oxygen species–total antioxidant capacity score is a new measure of oxidative stress to predict male infertility. *Hum Reprod*. 1999;14:2801–2807.

Sharma R, Harlev A, Agarwal A, et al. Cigarette smoking and semen quality: a new meta-analysis examining the effect of the 2010 World Health Organization laboratory methods for the examination of human semen. *Eur Urol*. 2016;70:635–645.

Sheth KR, Sharma V, Helfand BT, et al. Improved fertility preservation care for male patients with cancer after establishment of formalized oncofertility program. *J Urol*. 2012;187:979–986.

Sheynkin Y, Jung M, Yoo P, et al. Increase in scrotal temperature in laptop computer users. *Hum Reprod*. 2005;20:452–455.

Sheynkin Y, Welliver R, Winer A, et al. Protection from scrotal hyperthermia in laptop computer users. *Fertil Steril*. 2011;95:647–651.

Shin D, Lipshultz LI, Goldstein M, et al. Herniorrhaphy with polypropylene mesh causing inguinal vasal obstruction: a preventable cause of obstructive azoospermia. *Ann Surg*. 2005;241:553–558.

Shiraishi K, Naito K. Effects of 4-hydroxy-2-nonenal, a marker of oxidative stress, on spermatogenesis and expression of p53 protein in male infertility. *J Urol*. 2007;178:1012–1017 [discussion 1017].

Shoshany O, Abhyankar N, Mufarreh N, et al. Outcomes of anastrozole in oligozoospermic hypoandrogenic subfertile men. *Fertil Steril*. 2017;107:589–594.

Siddiq FM, Sigman M. A new look at the medical management of infertility. *Urol Clin North Am*. 2002;29:949–963.

Sigman M. Klinefelter syndrome: how, what, and why? *Fertil Steril*. 2012;98:251–252.

Sigman M, Jarow JP. Endocrine evaluation of infertile men. *Urology*. 1997;50:659–664.

Sigman M, Lipshultz LI, Howards SS. Office evaluation of the subfertile male. Lipshultz LI, Howards SS, Niederberger CS. *Infertility in the male*. 4th ed. Cambridge University Press: New York; 2009:153–176.

Silva LF, Oliveira JB, Petersen CG, et al. The effects of male age on sperm analysis by motile sperm organelle morphology examination (MSOME). *Reprod Biol Endocrinol*. 2012;10:19.

Simon L, Brunborg G, Stevenson M, et al. Clinical significance of sperm DNA damage in assisted reproduction outcome. *Hum Reprod*. 2010;25:1594–1608.

Simon L, Lutton D, McManus J, et al. Sperm DNA damage measured by the alkaline comet assay as an independent predictor of male infertility and in vitro fertilization success. *Fertil Steril*. 2011;95:652–657.

Skakkebaek NE, Rajpert-De Meyts E, Main KM. Testicular dysgenesis syndrome: an increasingly common developmental disorder with environmental aspects. *Hum Reprod*. 2001;16:972–978.

Sloter ED, Marchetti F, Eskenazi B, et al. Frequency of human sperm carrying structural aberrations of chromosome 1 increases with advancing age. *Fertil Steril*. 2007;87:1077–1086.

Smit M, van Casteren NJ, Wildhagen MF, et al. Sperm DNA integrity in cancer patients before and after cytotoxic treatment. *Hum Reprod*. 2010;25:1877–1883.

Smit M, Romjin JC, Wildhagen MF, et al. Decreased sperm DNA fragmentation after surgical varicocelectomy is associated with increased pregnancy rate. *J Urol*. 2013;189:S146–S150.

Smith JF, Walsh TJ, Turek PJ. Ejaculatory duct obstruction. *Urol Clin North Am*. 2008;35:221–227.

Smith R, Kaune H, Parodi DA, et al. Increased sperm DNA damage in patients with varicocele: relationship with seminal oxidative stress. *Hum Reprod*. 2005;21:986–993.

Sobrier ML, Attié-Bitach T, Netchine I, et al. Pathophysiology of syndromic combined pituitary hormone deficiency due to a LHX3 defect in light of LHX3 and LHX4 expression during early human development. *Gene Expr Patterns*. 2004;5:279–284.

Sokol RZ. Endocrine evaluation. Lipshultz LI, Howards SS, Niederberger CS. *Infertility in the male*. 4th ed. Cambridge University Press: New York; 2009:199–214.

Sokol RZ. It's not all about the testes: medical issues in Klinefelter patients. *Fertil Steril*. 2012;98:261–265.

Somlev B, Subev M. Effect of kininase II inhibitors on bradykinin-stimulated bovine sperm motility. *Theriogenology*. 1998;50:651–657.

Sonnack V, Failing K, Bergmann M, et al. Expression of hyperacetylated histone H4 during normal and impaired human spermatogenesis. *Andrologia*. 2002;34:383–390.

Spermon JR, Ramos L, Wetzels AM, et al. Sperm integrity pre- and post-chemotherapy in men with testicular germ cell cancer. *Hum Reprod*. 2006;21:1781–1786.

Sripada S, Townend J, Campbell D, et al. Relationship between semen parameters and spontaneous pregnancy. *Fertil Steril*. 2010;94:624–630.

Stahl O, Eberhard J, Jepson K, et al. Sperm DNA integrity in testicular cancer patients. *Hum Reprod*. 2006;21:3199–3205.

Stahl O, Boyd HA, Giwercman A, et al. Risk of birth abnormalities in the offspring of men with a history of cancer: a cohort study using Danish and Swedish national registries. *J Natl Cancer Inst*. 2011;103:398–406.

Stein RB, Hanauer SB. Comparative tolerability of treatments for inflammatory bowel disease. *Drug Saf*. 2000;23:429–448.

Steptoe PC, Edwards RG. Birth after the reimplantation of a human embryo. *Lancet*. 1978;2:366.

Stewart TM, Liu DY, Garrett C, et al. Associations between andrological measures, hormones and semen quality in fertile Australian men: inverse relationship between obesity and sperm output. *Hum Reprod*. 2009;24:1561–1568.

Stillman RJ, Rosenberg MJ, Sachs BP. Smoking and reproduction. *Fertil Steril*. 1986;46:545–566.

Stimmel GL, Gutierrez MA. Sexual dysfunction and psychotropic medications. *CNS Spectr*. 2006;11:24–30.

Stouffs K, Tournaye H, Van der Elst J, et al. Do we need to search for gr/gr deletions in infertile men in a clinical setting? *Hum Reprod*. 2008;23:1193–1199.

Stukenborg JB, Schlatt S, Simoni M, et al. New horizons for in vitro spermatogenesis? An update on novel three-dimensional culture systems as tools for meiotic and post-meiotic differentiation of testicular germ cells. *Mol Hum Reprod*. 2009;15:521–529.

Subirán N, Casis L, Irazusta J. Regulation of male fertility by the opioid system. *Mol Med*. 2011;17:846–853.

Sun F, Ko E, Martin RH. Is there a relationship between sperm chromosome abnormalities and sperm morphology? *Reprod Biol Endocrinol*. 2006;4:1.

Sussman EM, Chudnovsky A, Niederberger CS. Hormonal evaluation of the infertile male: has it evolved? *Urol Clin*

North Am. 2008;35:147–155 [vii].

Swan SH, Liu F, Overstreet JW, et al. Semen quality of fertile U.S. males in relation to their mothers' beef consumption during pregnancy. *Hum Reprod*. 2007;22:1497–1502.

Swansbury J. *Cancer cytogenetics*. Humana Press: Totowa, NJ; 2003.

Taha EA, Ez-Aldin AM, Sayed SK, et al. Effect of smoking on sperm vitality, DNA integrity, seminal oxidative stress, zinc in fertile men. *Urology*. 2012;80:822–825.

Takihara H, Cosentino MJ, Sakatoku J, et al. Significance of testicular size measurement in andrology: II. Correlation of testicular size with testicular function. *J Urol*. 1987;137:416–419.

Tanaka A, Nagayoshi M, Tanaka I, et al. Human sperm head vacuoles are physiological structures formed during the sperm development and maturation process. *Fertil Steril*. 2012;98:315–320.

te Velde ER, Pearson PL. The variability of female reproductive ageing. *Hum Reprod Update*. 2002;8:141–154.

Teerds KJ, de Rooij DG, Keijer J. Functional relationship between obesity and male reproduction: from humans to animal models. *Hum Reprod Update*. 2011;17:667–683.

Tekatli H, Schouten N, van Dalen T, et al. Mechanism, assessment, and incidence of male infertility after inguinal hernia surgery: a review of the preclinical and clinical literature. *Am J Surg*. 2012;204:503–509.

Tempest HG, Ko E, Chan P, et al. Sperm aneuploidy frequencies analysed before and after chemotherapy in testicular cancer and Hodgkin's lymphoma patients. *Hum Reprod*. 2008;23:251–258.

Templado C, Uroz L, Estop A. New insights on the origin and relevance of aneuploidy in human spermatozoa. *Mol Hum Reprod*. 2013;19:634–643.

Templeton A, Mortimer D. Successful circumvention of retrograde ejaculation in an infertile diabetic man. Case report. *Br J Obstet Gynaecol*. 1982;89:1064–1065.

Tepavcevic DK, Kostic J, Basuroski ID, et al. The impact of sexual dysfunction on the quality of life measured by MSQoL-54 in patients with multiple sclerosis. *Mult Scler*. 2008;14:1131–1136.

Thigpen AE, Silver RI, Guileyardo JM, et al. Tissue distribution and ontogeny of steroid 5 alpha-reductase isozyme expression. *J Clin Invest*. 1993;92:903–910.

Thomsen L, Humaidan P, Bungum L, et al. The impact of male overweight on semen quality and outcome of assisted reproduction. *Asian J Androl*. 2014;16:749–754.

Thonneau P, Bujan L, Multigner L, et al. Occupational heat exposure and male fertility: a review. *Hum Reprod*. 1998;13:2122–2125.

Thorup J, McLachlan RI, Cortes D, et al. What is new in cryptorchidism and hypospadias—a critical review on the testicular dysgenesis hypothesis. *J Pediatr Surg*. 2010;45:2074–2086.

Tice RR, Agurell E, Anderson D, et al. Single cell gel/comet assay: guidelines for in vitro and in vivo genetic toxicology testing. *Environ Mol Mutagen*. 2000;35:206–221.

Tielemans E, Burdorf A, te Velde E, et al. Sources of bias in studies among infertility clients. *Am J Epidemiol*. 2002;156:86–92.

Tiepolo L, Zuffardi O. Localization of factors controlling spermatogenesis in the nonfluorescent portion of the human Y chromosome long arm. *Hum Genet*. 1976;34:119–124.

Tilford CA, Kuroda-Kawaguchi T, Skaletsky H, et al. A physical map of the human Y chromosome. *Nature*. 2001;409:943–945.

Tordjman KM, Yaron M, Berkovitz A, et al. Fertility after high-dose testosterone and intracytoplasmic sperm injection in a patient with androgen insensitivity syndrome with a previously unreported androgen receptor mutation. *Andrologia*. 2014;46(6):703–706.

Torregrosa N, Domínguez-Fandos D, Camejo MI, et al. Protamine 2 precursors, protamine 1/protamine 2 ratio, DNA integrity and other sperm parameters in infertile patients. *Hum Reprod*. 2006;21:2084–2089.

Tournaye H, Dohle GR, Barratt CL. Fertility preservation in men with cancer. *Lancet*. 2014;384:1295–1301.

Tulloch WS. Varicocele in subfertility; results of treatment. *BMJ*. 1955;2:356–358.

Turek PJ, Cha I, Ljung BM. Systematic fine-needle aspiration of the testis: correlation to biopsy and results of organ ‘mapping’ for mature sperm in azoospermic men. *Urology*. 1997;49:743–748.

Ubaldi F, Camus M, Tournaye H, et al. Results of microsurgical epididymal sperm aspiration (MESA) and testicular sperm extraction (TESE) in azoospermic men using intracytoplasmic sperm injection (ICSI). *Andrologia*. 1996;28(Suppl 1):71–75.

Vaisheva F, Delbes G, Hales BF, et al. Effects of the chemotherapeutic agents for non-Hodgkin lymphoma, cyclophosphamide, doxorubicin, vincristine, and prednisone (CHOP), on the male rat reproductive system and progeny outcome. *J Androl*. 2007;28:578–587.

van Beek RD, Smit M, van den Heuvel-Eibrink MM, et al. Inhibin B is superior to FSH as a serum marker for spermatogenesis in men treated for Hodgkin's lymphoma with chemotherapy during childhood. *Hum Reprod*. 2007;22:3215–3222.

van Casteren NJ, Dohle GR, Romijn JC, et al. Semen cryopreservation in pubertal boys before gonadotoxic treatment and the role of endocrinologic evaluation in predicting sperm yield. *Fertil Steril*. 2008;90:1119–1125.

van Casteren NJ, Boellaard WP, Romjim JC, et al. Gonadal dysfunction in male cancer patients before cytotoxic treatment. *Int J Androl*. 2010;33:73–79.

van der Merwe FH, Kruger TF, Oehninger SC, et al. The use of semen parameters to identify the subfertile male in the general population. *Gynecol Obstet Invest*. 2005;59:86–91.

van der Steeg JW, Steures P, Eijkemans MJC, et al. Should the post-coital test (PCT) be part of the routine fertility work-up? *Hum Reprod*. 2004;19:1373–1379.

Van Voorhis BJ. What to know about the infertile female. Niederberger CS. *An introduction to male reproductive medicine*. Cambridge University Press: New York; 2011:34–151.

Vandekerckhove P, Lilford R, Vail A, et al. Clomiphene or tamoxifen for idiopathic oligo/asthenospermia. *Cochrane Database Syst Rev*. 2000;(2) [CD000151].

Velemínská J, Bigoni L, Krajíček V, et al. Surface facial modelling and allometry in relation to sexual dimorphism. *Homo*. 2012;63:81–93.

Vermeulen A, Kaufman JM, Deslypere JP, et al. Attenuated luteinizing hormone (LH) pulse amplitude but normal LH pulse frequency, and its relation to plasma androgens in hypogonadism of obese men. *J Clin Endocrinol Metab*. 1993;76:1140–1146.

Vermeulen A, Verdonck L, Kaufman JM. A critical evaluation of simple methods for the estimation of free testosterone in serum. *J Clin Endocrinol Metab*. 1999;84:3666–3672.

Vernaeve V, Krikilion A, Verheyen G, et al. Outcome of testicular sperm recovery and ICSI in patients with non-obstructive azoospermia with a history of orchidopexy. *Hum Reprod*. 2004;19:2307–2312.

Villalta J, Ballescà JL, Nicolás JM, et al. Testicular function in asymptomatic chronic alcoholics: relation to ethanol intake. *Alcohol Clin Exp Res*. 1997;21:128–133.

Vinik AI, Maser RE, Mitchell BD, et al. Diabetic autonomic neuropathy. *Diabetes Care*. 2003;26:1553–1579.

Visser AJ, Heyns CF. Testicular function after torsion of the spermatic cord. *BJU Int*. 2003;92:200–203.

Visser L, Westerveld GH, Korver CM, et al. Y chromosome gr/gr deletions are a risk factor for low semen quality. *Hum Reprod*. 2009;24:2667–2673.

Volgsten H, Skoog Svanberg A, Ekselius L, et al. Prevalence of psychiatric disorders in infertile women and men undergoing in vitro fertilization treatment. *Hum Reprod*. 2008;23:2056–2063.

Wagenlehner FM, Diemer T, Naber KG, et al. Chronic bacterial prostatitis (NIH type II): diagnosis, therapy and influence on the fertility status. *Andrologia*. 2008;40:100–104.

Wallace W, Anderson R, Irvine D. Fertility preservation for young patients with cancer: who is at risk and what can be offered? *Lancet Oncol*. 2005;6:209–218.

Walsh TJ, Schembri M, Turek PJ, et al. Increased risk of high-grade prostate cancer among infertile men. *Cancer*. 2010;116:2140–2147.

Walsh TJ, Turek PJ. Immunologic infertility. Lipshultz LI, Howards SS, Niederberger CS. *Infertility in the male*. 4th ed. Cambridge University Press: New York; 2009:277–294.

Wang YJ, Zhang RQ, Lin YJ, et al. Relationship between varicocele and sperm DNA damage and the effect of varicocele repair: a meta-analysis. *Reprod Biomed Online*. 2012;25:307–314.

Ward WS, Coffey DS. DNA packaging and organization in mammalian spermatozoa: comparison with somatic cells. *Biol Reprod*. 1991;44:569–574.

Watkins W, Nieto F, Bourne H, et al. Testicular and epididymal sperm in a microinjection program: methods of retrieval and results. *Fertil Steril*. 1997;67:527–535.

Weintraub MP, De Mouy E, Hellstrom WJ. Newer modalities in the diagnosis and treatment of ejaculatory duct obstruction. *J Urol*. 1993;150:1150–1154.

Whitten SJ, Nangia AK, Kolettis PN. Select patients with hypogonadotropic hypogonadism may respond to treatment with clomiphene citrate. *Fertil Steril*. 2006;86:1664–1668.

Williams DB. An introduction to male reproductive surgery. Niederberger CS. *An introduction to male reproductive medicine*. Cambridge University Press: New York; 2011:58–76.

Winters SJ, Wang C, Abdelrahaman E, et al. Inhibin-B levels in healthy young adult men and prepubertal boys: is obesity the cause for the contemporary decline in sperm count because of fewer Sertoli cells? *J Androl*. 2006;27:560–564.

Wiser A, Raviv G, Weissenberg R, et al. Does age at orchidopexy impact on the results of testicular sperm extraction? *Reprod Biomed Online*. 2009;19:778–783.

Wishahi MM. Detailed anatomy of the internal spermatic vein and the ovarian vein. Human cadaver study and operative spermatic venography: clinical aspects. *J Urol*. 1991;145:780–784.

World Health Organization (WHO). *Infertility: a tabulation of available data on prevalence of primary and secondary infertility*. WHO: Geneva; 1991.

World Health Organization (WHO). The influence of varicocele on parameters of fertility in a large group of men presenting to infertility clinics. *Fertil Steril*. 1992;57:1289–1293.

World Health Organization (WHO). *World Health Organization laboratory manual for the examination and processing of human semen*. World Health Organization: Geneva; 2010.

World Health Organization (WHO). Task Force on Methods for the Regulation of Male Fertility. Contraceptive efficacy of testosterone-induced azoospermia in normal men. *Lancet*. 1990;336:955–959.

Wosnitzer MS, Goldstein M. Obstructive azoospermia. *Urol Clin North Am*. 2014;41:83–95.

Wu B, Lu NX, Xia YK, et al. A frequent Y chromosome b2/b3 subdeletion shows strong association with male infertility in Han-Chinese population. *Hum Reprod*. 2007;22:1107–1113.

Wu GJ, Chang FW, Lee SS, et al. Apoptosis-related phenotype of ejaculated spermatozoa in patients with varicocele. *Fertil Steril*. 2009;91:831–837.

Wu W, Cogan JD, Pfäffle RW, et al. Mutations in PROP1 cause familial combined pituitary hormone deficiency. *Nat Genet*. 1998;18:147–149.

Wu X, Goodyear S, Abramowitz Bartolomei M, et al. Fertile offspring derived from mouse spermatogonial stem cells cryopreserved for more than 14 years. *Hum Reprod*. 2012;27:1249–1259.

Xiao F, Lan A, Lin Z, et al. Impact of CAG repeat length in the androgen receptor gene on male infertility – a meta-analysis. *Reprod Biomed Online*. 2016;33:39–49.

Yanagimachi R, Lopata A, Odom CB, et al. Retention of biologic characteristics of zona pellucida in highly concentrated salt solution: the use of salt-stored eggs for assessing the fertilizing capacity of spermatozoa. *Fertil Steril*. 1979;31:562–574.

Yanagimachi R, Yanagimachi H, Rogers BJ. The use of zona-free animal ova as a test-system for the assessment of the fertilizing capacity of human spermatozoa. *Biol Reprod*. 1976;15:471–476.

Yang Q, Wen SW, Leader A, et al. Paternal age and birth defects: how strong is the association? *Hum Reprod*.

2007;22:696–701.

Yurdakul T, Gokce G, Kilic O, et al. Transurethral resection of ejaculatory ducts in the treatment of complete ejaculatory duct obstruction. *Int Urol Nephrol*. 2008;40:369–372.

Yu J, Chen Z, Ni Y, et al. CFTR mutations in men with congenital bilateral absence of the vas deferens (CBAVD): a systemic review and meta-analysis. *Hum Reprod*. 2012;27:25–35.

Zargar AH, Wani AI, Masoodi SR, et al. Epidemiologic and etiologic aspects of primary infertility in the Kashmir region of India. *Fertil Steril*. 1997;68:637–643.

Zariwala MA, Omran H, Ferkol TW. The emerging genetics of primary ciliary dyskinesia. *Proc Am Thorac Soc*. 2011;8:430–433.

Zeh JA, Bonilla MM, Adrian AJ, et al. From father to son: transgenerational effect of tetracycline on sperm viability. *Sci Rep*. 2012;2:375.

Zidi-Jrah I, Hajlaoui A, Mougou-Zerelli S, et al. Relationship between sperm aneuploidy, sperm DNA integrity, chromatin packaging, traditional semen parameters, and recurrent pregnancy loss. *Fertil Steril*. 2016;105:58–64.

Zini A, Sigman M. Evaluation of sperm function. Lipshultz LI, Howards SS, Niederberger CS. *Infertility in the male*. 4th ed. Cambridge University Press: New York; 2009:177–198.

Zini A, Azhar R, Baazeem A, et al. Effect of microsurgical varicocelectomy on human sperm chromatin and DNA integrity: a prospective trial. *Int J Androl*. 2011;34:14–19.

Zoppino FC, Halón ND, Bustos MA, et al. Recording and sorting live human sperm undergoing acrosome reaction. *Fertil Steril*. 2012;97:1309–1315.

Zorgniotti AW, MacLeod J. Studies in temperature, human semen quality, and varicocele. *Fertil Steril*. 1973;24:854–863.

Zucchi A, Mearini E, Porena M, et al. Cytosolic calcium levels in spermatozoa are modulated differently in healthy subjects and patients with varicocele. *Fertil Steril*. 2006;85:144–148.

67

Surgical Management of Male Infertility

Marc Goldstein MD, DSc (hon), FACS

Since the 11th edition of this text was published, the indications for and techniques of surgery for male infertility have been further refined, resulting in substantially increased success in the management of male factor infertility. These advances include (1) increasing use of genetic and molecular biologic markers (see Chapters 64 and 66) to better select patients for surgical treatment; (2) improved techniques for microsurgical reconstruction of obstruction; (3) the use of varicocelectomy for enhancement of spermatogenesis in azoospermic or severely oligospermic men (Kim et al., 1999; Matthews et al., 1998) and for prevention of future infertility and androgen deficiency in young men as well as for treatment of androgen deficiency in men of all ages (Tanrikut et al., 2011); (4) refined microsurgical techniques for sperm retrieval combined with in vitro fertilization (IVF) with intracytoplasmic sperm injection (ICSI) for men with nonobstructive azoospermia. Even men with nonobstructive azoospermia resulting from Klinefelter syndrome and microY deletions, once regarded as hopeless cases, can now father biologic offspring with in vitro fertilization and intracytoplasmic sperm injection (Palermo et al., 1998; Ramasamy et al., 2009; Tournaye et al., 1996).

Experimental use of flow cytometry of semen and testicular tissue has identified viable sperm, whereas conventional microscopy has not (Bolyakov et al., 2016). IVF with ICSI has expanded our ability to treat even the most severe forms of male-factor infertility such as unreconstructable reproductive tract obstruction and nonobstructive azoospermia. However, it is a costly procedure and an intense process for the female partner, with associated risks of complications, including ovarian hyperstimulation, multiple gestations, as well as complications of the procedures for oocyte retrieval. Furthermore, as ICSI bypasses all natural biologic barriers, it raises realistic concerns of passing genetic abnormalities to the offspring (Foresta et al., 2005; Kim et al., 1998) and is associated with an increased incidence of birth defects in resultant children (Davies et al., 2012). On the other hand, recent analyses clearly indicate that **specific treatments for male-factor infertility, such as microsurgical reconstruction for obstructive azoospermia and varicocelectomy for impaired testis function, in properly selected patients, remain the safest and most cost-effective ways of managing infertile men** (Kolettis and Thomas, 1997; Lee et al., 2008; Marmar et al., 2007; Pavlovich and Schlegel, 1997; Smit et al., 2010)**. Specific treatment aimed at correcting or enhancing male infertility can upgrade a couple from donor sperm to IVF/ICSI with testicular microdissection to IVF/ICSI with ejaculated sperm or intrauterine insemination or even to naturally conceived pregnancies** (Samplaski et al., 2013).

For men with unreconstructable obstruction as well as men with nonobstructive azoospermia, surgical retrieval of sperm to achieve fertilization, pregnancy, and live birth with IVF/ICSI is a feasible management option. The development and recent refinement of the various techniques of surgical sperm retrieval, from testes, epididymides, or seminal vesicles, with percutaneous or open surgical approaches, have expanded the armamentarium of urologists treating infertile men. In particular, the employment of the operating microscope to evaluate and identify individual seminiferous tubules more likely to contain sperm has significantly improved the success of testicular sperm extraction (Dabaja and Schlegel, 2013; Schlegel, 1999) while minimizing morbidity significantly (Ramasamy et al., 2005; Tsujimura et al., 2002).

The use of microsurgical techniques has also been extended to varicocelectomy. Varicoceles have long been known to be associated with male infertility and have now clearly been shown to result in progressive, duration-dependent testicular injury (Lipshultz and Corriere, 1977; Nagler et al., 1985; Russell, 1957; Sigman and Jarow, 1997). **Furthermore, microsurgical varicocelectomy, previously reserved only for men with oligospermia, has now been applied to men with nonobstructive azoospermia, resulting in induction of spermatogenesis and successful return of sperm to the ejaculate in many cases** (Ishikawa et al., 2008; Kim et al., 1999; Matthews et al., 1998; Pasqualotto et al., 2003, 2006; Youssef et al., 2009). Although varicocelectomy has historically been reserved for the treatment of infertile men as well as varicocele-induced pain, there is an emerging concept of **early repair of varicoceles to prevent future infertility and Leydig cell dysfunction.** Substantial evidence has accumulated suggesting that varicocele adversely affects Leydig cell function, resulting in lower serum testosterone levels when compared with age-matched controls without varicocele (Tanrikut et al., 2011). Varicocelectomy can halt and even partially reverse this decline (Castro-Magana et al., 1989; Cayan et al., 1999; Su et al., 1995; Tanrikut et al., 2011). **In selected men, varicocelectomy may be an effective treatment for symptomatic, age-related androgen deficiency.**

Thus, with safer and more effective microsurgical techniques, early varicocelectomy has expanded the urologist's role from that of salvaging remaining testicular function to that of preventing future infertility and androgen deficiency.

When surgery for male infertility is undertaken, only rarely is the life (or death) of the patient at stake. What is at stake when the surgery described in this chapter is undertaken is new life, with the potential for altering not only the quality of a couple's life but also the future of our species. The responsibilities assumed by the surgeon in these circumstances demand the utmost in judgment and skill. **Many of the procedures described in this chapter are among the most technically demanding in all of urology.** Acquisition of the skills required to perform them demands intensive laboratory training in microsurgery and a thorough knowledge of the anatomy and physiology of the male reproductive system. **Attempting such surgery only occasionally and without proper training is a terrible disservice to the patient, the couple, and future humanity.**

Surgical Anatomy

The scrotal contents are unique in their accessibility for physical examination, imagining modalities, and surgical intervention. The success of surgery for male infertility and scrotal disorders is predicated upon selection of the correct operation and the most appropriate surgical approach. The details of the history and careful physical examination followed by confirmatory, judiciously selected laboratory and imaging procedures, are presented in Chapter 66. When surgical intervention for diagnostic or therapeutic purposes is indicated, a thorough understanding of the anatomy (see Chapter 63) and physiology (see Chapter 64) of the male reproductive system is requisite for planning and carrying out a surgical procedure with the highest probability of success and lowest morbidity.

The key points of surgical anatomy follow.

Testicular Blood Supply

The main blood supply to the testis is from the testicular (internal spermatic) artery arising directly from the aorta (Table 67.1). A second blood supply comes from the artery of the vas deferens (deferential artery), which derives from the hypogastric (internal iliac) artery or the superior vesicle artery (also a branch of the hypogastric). The third blood supply, primarily to the tunica vaginalis but with branches going to the testes, comes from the cremasteric (external spermatic) artery, which derives from the inferior epigastric artery. **The testicular artery is the main blood supply to the testes.** Its diameter exceeds the diameter of the deferential (vasal) artery plus the cremasteric artery combined (Raman and Goldstein, 2004). Although vasal and cremasteric arteries can provide adequate blood supply to the testes in the event that the testicular artery is ligated, especially in children, **atrophy and/or azoospermia has resulted from testicular artery ligation in the adult and in children** (Maluf, 1957; Silber, 1979).

TABLE 67.1

Blood Supply to Testis, Epididymis, and Vas Deferens

TESTIS
1. Testicular (internal spermatic) artery from aorta (main blood supply)

2. Deferential artery from internal iliac (hypogastric) artery/superior vesicle artery 3. Cremasteric (external spermatic) artery from inferior epigastric artery
EPIDIDYMIS
1. Superior epididymal artery derived from testicular artery 2. Inferior epididymal artery derived from vassal (deferential) artery
VAS DEFERENS
1. Seminal vesicle end: deferential artery 2. Testicular end: deferential artery and inferior epididymal artery

Special attention should be paid to men who have undergone vasectomy, where the vasal artery has likely been compromised. In these men, maintaining the integrity of the testicular artery in any future operations, such as varicocelectomy, is critical (Lee et al., 2007).

Epididymal Blood Supply

The epididymis has a rich blood supply (see Table 67.1). The superior and the medial epididymal arteries derive from the testicular artery. The blood supply to the cauda (inferior pole) of the epididymis derives from the vasal (deferential) artery. The two main blood supplies to the epididymis, running superiorly and inferiorly, form an extensive interconnection such that if the vasal artery is ligated from previous vasectomy, the blood supply to the epididymis from the testicular artery is more than adequate. In addition, in preparation for vasoepididymostomy or vasovasostomy, the epididymis can be intentionally dissected off of the testis and mobilized to the caput (see Fig. 67.13) with the inferior and medial epididymal arteries intentionally ligated without adverse consequence. **As long as the superior epididymal artery remains intact, the blood supply to the epididymis will be adequate.**

Blood Supply of the Vas Deferens

The vas deferens obtains its blood supply from two sources (see Table 67.1). The seminal vesical (abdominal) end of the vas derives its blood supply from the deferential (vasal) artery. The testicular end of the vas receives additional blood supply from the inferior epididymal arterial interconnections, which extend onto the vas deferens. The two blood supplies to the vas deferens freely anastomose with each other. **After vasectomy, if the vasal vessels are ligated, the testicular end of the vas receives all of its blood supply from branches of the testicular artery and epididymal artery, although the seminal vesical**

(abdominal) end of the vas receives all of its blood supply from the deferential artery. The vas deferens receives no blood supply from the surrounding cremaster muscle or from any blood vessels from the spermatic cord. Therefore, if the vas deferens is sectioned or obstructed in two different locations, the intervening segment will fibrose because of lack of blood supply. Therefore two simultaneous vasovasostomies cannot be safely performed on the same vas if the vasal vessels have been interrupted in both locations.

Anatomy of the Excurrent Ducts

Sperm and testicular fluid exit the testes through 7 to 11 tiny efferent ducts. These ducts become convoluted when they exit the testes and form the caput of the epididymis (see Chapter 63). At that level, they freely anastomose with each other. They all coalesce at the distal caput to form a single epididymal tubule from the caput-corpus junction all the way to the vas deferens. Therefore, **if the epididymis is accidentally injured or ligated distal to the caput, the entire system on that side will be completely obstructed**. This is an important consideration when performing epididymal surgery or surgery near the epididymis. **Hydrocelectomy** is a common surgical procedure that can result in **iatrogenic injury to the epididymis.** In long-standing large hydroceles, the epididymis is often splayed out and difficult to identify. Use of an operating microscope and transillumination of the hydrocele sac help avoid injury to the epididymis, vas, and testicular blood supply (Dabaja et al., 2013). **Generous margins from the epididymis should be allowed when performing hydrocelectomy** (see Chapter 63). Orchiopexy for torsion can also result in inadvertent injury to the epididymis. **A single stitch through an epididymal tubule in the corpus or cauda will result in complete obstruction** of that side. Because there are multiple lobules at the levels of the caput, **puncture of a single tubule for sperm aspiration can be safely performed at the most proximal region of the caput** without significantly compromising the flow of sperm into the corpus. Multiple punctures of many tubules at the caput or any puncture distal to the caput, however, can cause obstruction (Zhang et al., 2013).

Ejaculatory Ducts

The left and right ejaculatory ducts enter the prostatic urethra at the level of the utricle. Obstruction of ejaculatory ducts can lead to azoospermia. Multiple transrectal prostatic biopsies to diagnose or follow men with prostate cancer can cause stricture or obstruction of the ejaculatory ducts. Those men potentially interested in future fertility, regardless of age, should be encouraged to bank sperm before biopsy. Transurethral resection of the ejaculatory ducts (TURED) can relieve the obstruction. TURED should not be considered a benign procedure because it is occasionally associated with significant morbidity (see later). Normally, the ejaculatory ducts contain a valvelike mechanism that prevents reflux of urine into the ejaculatory duct. **After TURED, a significant percentage of men develop reflux of urine up the excurrent ductal system** (Vazquez-Levin et al., 1994), **causing chemical and/or bacterial epididymitis.**

Key Points: Surgical Anatomy

- The testicular artery is the main blood supply to the testis.
- If the epididymis is accidentally injured or ligated distal to the caput, the entire system on that side will be obstructed.

Testis Biopsy

Indications

The indications for testis biopsy are detailed in Chapter 66. Briefly, **testis biopsy is indicated in azoospermic men with testis of normal size and consistency, palpable vasa deferentia, normal serum follicle-stimulating hormone (FSH) levels, and a negative serum antisperm antibody assay.** Under these circumstances, **biopsy will distinguish obstructive from nonobstructive azoospermia.** In men with **congenital absence of vasa and normal serum FSH levels,** biopsy always reveals spermatogenesis (Goldstein and Schlossberg, 1988), and **biopsy is not necessary** before definitive sperm aspiration and IVF with ICSI. Men with a highly positive serum antisperm antibody test, especially with a history consistent with iatrogenic injury to the vasa (inguinal hernia repair) or epididymides (hydrocelectomy), do not require biopsy before reconstruction because obstruction is almost certain. **Diagnostic biopsy should usually be performed bilaterally irrespective of the size discrepancy of the two testes.** Good spermatogenesis is sometimes found in small, firm testes, whereas biopsies of large, healthy testes may reveal maturation arrest.

The ability to achieve pregnancy with only a single testicular sperm has turned biopsy into a potentially therapeutic, as well as diagnostic, procedure. Even men with markedly elevated serum FSH levels and small, soft testes in whom testicular failure is certain often harbor rare mature sperm in their testes. These sperm can be extracted using techniques described later in this chapter and employed for IVF with intracytoplasmic injection of testicular sperm.

The recently discovered heterogeneity of the testes of men with nonobstructive azoospermia coupled with the ability of testicular sperm to acquire motility (Jow et al., 1993) has resulted in changes in the techniques of testis biopsy. **Examination of fresh, unfixed tissue for the presence of sperm with tails** and possible motility, **and examination of multiple samples if sperm are not found initially, is now recommended. Furthermore, optimal care requires the availability, at the time of biopsy, of an andrology laboratory capable of processing and cryopreserving any sperm found at the time of biopsy.**

Open Testis Biopsy: Microsurgical Technique

Open biopsy remains the gold standard because it provides an optimal amount of tissue for accurate diagnosis and retrieval of sperm for IVF (Dardashti et al., 2000; Rosenlund et al., 1998; Schlegel, 1999). Open testis biopsy may be performed using either general, spinal, or local anesthetic. Although local anesthesia of just the skin and tunicas without a cord block is uncomfortable, local anesthesia with spermatic cord block can be effective and comfortable. However, there are limitations of the cord block. In animal studies, the incidence of accidental damage to the testicular artery during blind cord block is 5% (Goldstein and Einer-Jensen, 1983). In addition, if there has been previous scrotal surgery with scar or adhesions and more extensive dissection and manipulation may be required, I prefer to use general or spinal anesthetic.

The surgeon's goals when performing a testis biopsy are to provide an optimal tissue sample, avoid trauma to the specimen, and avoid injury to the epididymis or testicular blood supply. Open biopsy under magnification (preferably with an operating microscope) satisfies these requirements.

An assistant stretches the scrotal skin tightly over the anterior surface of the testis and confirms that the epididymis is posterior. Bilateral 1-cm transverse scrotal incisions within the scrotal skinfolds provide good exposure with a minimum of scrotal bleeding. Alternatively, a single vertical incision in the median raphe may be employed. The incision is carried through the skin and dartos muscle, and the tunica vaginalis is opened. **If the anatomy is distorted from previous surgery, the epididymis cannot be clearly palpated posteriorly, or if the tunica albuginea cannot be clearly identified, the incision should be enlarged and the testis delivered.** The edges of the tunica vaginalis are held open with hemostats and any bleeding vessels are cauterized. **Use of loupes or, better yet, the operating microscope allows ready identification of a spot on the tunica albuginea relatively free of visible surface vessels.** The wound should be dry before incising the tunica albuginea to prevent saturation of the biopsy with blood. A 3- to 4-mm incision is made in the tunica albuginea with a 15-degree microknife (Fig. 67.1A). Small crossing vessels are cauterized with bipolar cautery and divided before excising a pea-sized sample of seminiferous tubules with razor-sharp iris scissors (Fig. 67.1B). **When handling testis biopsy material for permanent fixation, avoid tissue handling in any way (including with forceps) because this may traumatize and distort the testicular architecture.** The specimen is then deposited directly into either Bouin's, Zenker's, or collidine-buffered glutaraldehyde solution. **Formalin fixation** results in distortion of testicular histology and **should not be used for testis biopsy. A “touch prep” is made by blotting the cut surface of the testis several times with a glass slide** (Fig. 67.1C) **and adding a drop of saline, lactated Ringer's, or human tubal fluid with IVF medium and a coverslip. Examination under high power using a light microscope with or without phase contrast will reveal the presence of sperm with tails and allow assessment of motility** (Fig. 67.1D). If no sperm are found in the touch prep, a second specimen may be cut for a wet “squash prep.” In this case, the specimen is placed on a slide, a drop of saline is added, and the specimen is crushed under a coverslip (Jow et al., 1993). If no sperm are found, the tunica is closed with 2 to 3 interrupted sutures of 5-0 vicryl (Fig. 67.1E), and another area is biopsied through the same skin incision. As described later in this chapter, **use of an operating microscope providing 10× to 25× magnification may allow selective sampling of larger seminiferous tubules more likely to contain sperm** (Schlegel, 1999)**. If sperm are identified,** the slide as well as additional **tissue removed are sent for cryopreservation** in the andrology laboratory. **The location of the biopsy site where sperm were found is noted, and the tunica albuginea is closed with 2 to 3 interrupted sutures of 6-0 nylon. This facilitates identification of sites of spermatogenesis for future testicular sperm extraction for IVF/ICSI.**

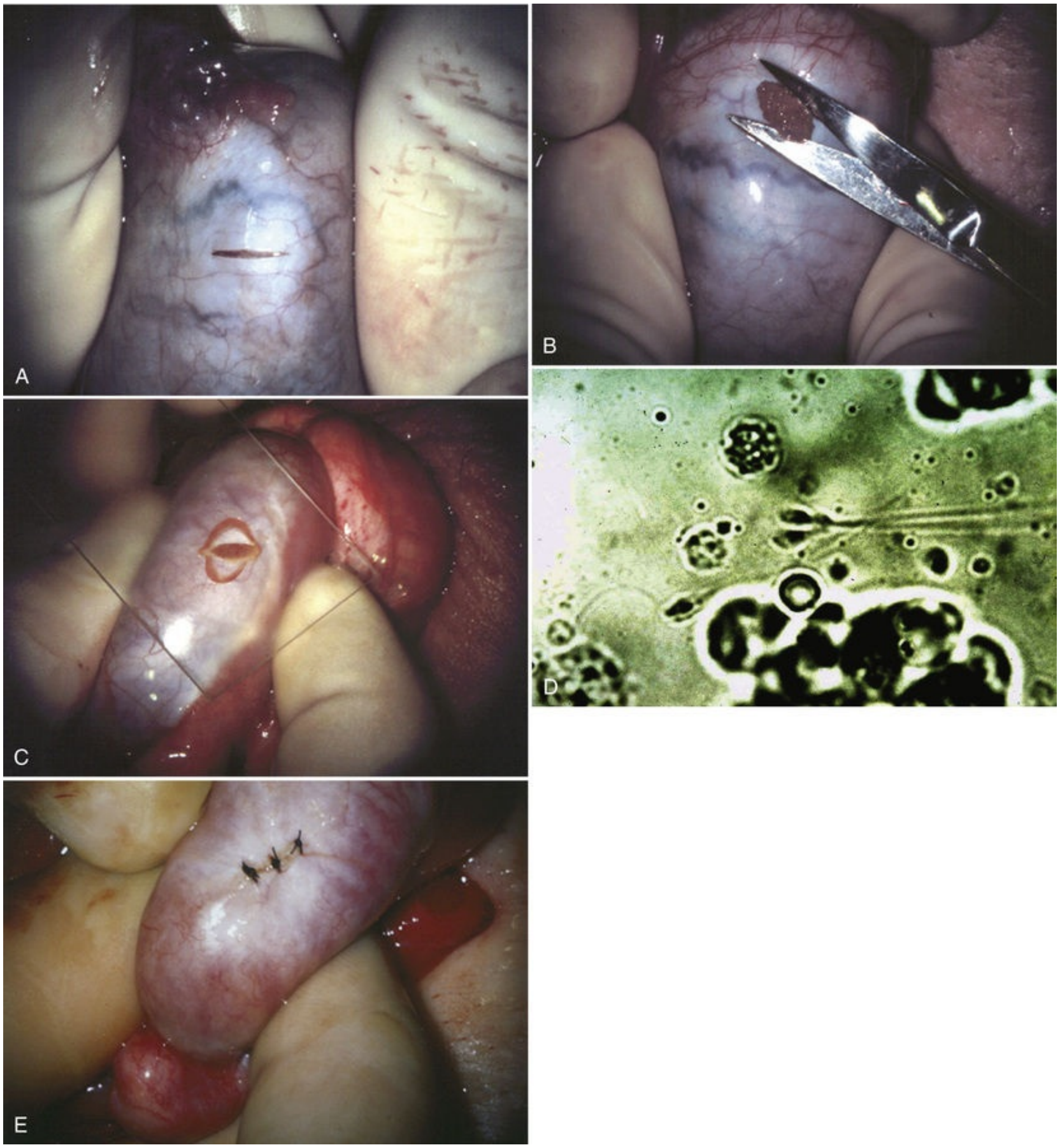

FIG. 67.1 (A) A 3- to 4-mm incision is made in the tunica albuginea with a 15-degree microknife. (B) Small crossing vessels are cauterized with bipolar cautery and divided before excising a pea-sized sample of seminiferous tubules with razor sharp iris scissors. (C) A "touch-prep" is made by blotting the cut surface of the testis several times with a glass slide. (D) Examination under high power using a light microscope with or without phase contrast will reveal the presence of sperm with tails and allow assessment of motility. (E) If no sperm are found, the tunica is closed with 2 to 3 interrupted sutures of 5-0 Vicryl.

The tunica vaginalis is closed with 5-0 monofilament nonabsorbable suture for hemostasis. Use of a nonabsorbable suture facilitates identification of the biopsy site if sperm were found at that site, and subsequent testicular sperm extraction is required at the time of IVF with ICSI. The testis is returned to the tunica vaginalis, which is closed with a continuous 5-0 Vicryl suture. The skin is closed with a subcuticular 5-0 Monocryl. The wounds are covered with bacitracin ointment and a fluff-type dressing secured with a snug scrotal support. Antibiotics are unnecessary.

Percutaneous Testis Biopsy

Percutaneous testis biopsy using the same 14-gauge biopsy gun employed for prostatic biopsy **is a blind procedure and could result in unintentional injury to either the epididymis or testicular artery. This technique should not be used when previous surgery has resulted in scarring and obliteration of normal anatomy.** Fine-needle aspiration usually yields specimens that contain few tubules with poorly preserved architecture. When performed under local anesthesia, a cord block is necessary to minimize pain. The technique of percutaneous biopsy is described in the section Scrotal Operations. As a therapeutic tool for sperm retrieval, **percutaneous biopsy or aspiration is most useful for fresh sperm retrieval for IVF/ICSI in men with obstructive azoospermia and normal spermatogenesis.**

Percutaneous Testicular Aspiration

Testicular aspiration performed with a 23-gauge needle or angiocath sheath (Marmar et al., 1993) is probably less invasive and less painful than percutaneous biopsy but usually yields few tubules with poorly preserved architecture. Although flow cytometric evaluation of this material can distinguish haploid from diploid cells and therefore confirm the presence or absence of late stages of spermatogenesis (Chan et al., 1984), direct wet examination of the aspirate for sperm and assessment of motility provide the most practical clinical information. Three or four aspirations can be performed until sperm are identified. In cases of obstructive azoospermia, these sperm can be used for IVF with ICSI (Craft et al., 1995) when sperm cannot be retrieved from the epididymis (see later). Fine-needle aspiration has a significantly lower yield of sperm than open micro-TESE in men with nonobstructive azoospermia.

Complications of Testis Biopsy

Carefully performed, testis biopsy is associated with few complications (Dardashti et al., 2000; Schlegel and Su, 1997). **The most serious complication associated with testis biopsy is inadvertent biopsy of the epididymis.** If histologic evaluation of the biopsy material reveals epididymis with sperm within the epididymal tubule, obstruction of the epididymis at the site of the biopsy is certain. If, however, there are no sperm within the epididymal tubules, the patient is either obstructed above the level of the epididymal biopsy or has primary seminiferous tubular failure and no harm has been done.

The most common complication of testis biopsy is hematoma. Hematomas can be large and may require drainage. Use of magnification to avoid vessels and a bipolar cautery for hemostasis helps prevent this complication. Proper closure of the well-vascularized tunica vaginalis with a continuous 5-0 suture minimizes bleeding and adhesions.

With the rich blood supply of the scrotum and its contents, wound infection is rare in the absence of hematoma, and antibiotics are unnecessary.

Key Points: Testis Biopsy

- Biopsy is a potentially therapeutic, as well as diagnostic, procedure.

Vasography

Indications

The absolute indications for vasography are the following (must include all three):

1. **Azoospermia**
2. **Complete spermatogenesis with many mature spermatids on testis biopsy**
3. **At least one palpable vas**

Relative indications for vasography are the following:

1. Severe oligospermia with normal testis biopsy
2. High level of sperm-bound antibodies, which indicates unilateral, bilateral, or partial obstruction (Lee et al., 2009)
3. Low semen volume and very poor sperm motility (partial ejaculatory duct obstruction)

Vasography should answer the following questions:

1. **Are there sperm in the vasal fluid?**
2. **Is the vas obstructed?**

If the testis biopsy reveals many sperm, the following are indications:

1. **Absence of sperm in vasal fluid indicates** obstruction on the testicular side of the vasotomy site, most likely an **epididymal obstruction.** Vasography is done in this case with saline or indigo carmine to confirm patency of the seminal vesicle (distal) end of the vas before vasoepididymostomy.
2. **Copious vasal fluid containing many sperm indicates vasal or ejaculatory duct obstruction,** and formal contrast vasography is performed as described later to document the exact location of the obstruction.

3. **Copious thick, white fluid without sperm in a dilated vas indicates secondary epididymal obstruction** in addition to a potential vasal or ejaculatory duct obstruction.

Vasography with radiographic contrast media and intraoperative radiographs are rarely indicated. There is no need to perform vasography at the time of testis biopsy for azoospermia unless immediate reconstruction is planned and the touch/wet-prep biopsy reveals mature sperm with tails. If not meticulously performed, vasography can cause stricture or even obstruction at the vasography site, which can complicate subsequent reconstruction (Howards et al., 1975; Poore et al., 1997). In addition, vasography is of no value in making the diagnosis of epididymal obstruction, and the majority of non–vasectomy-related obstructions are epididymal.

If testis biopsy reveals normal spermatogenesis and the vasa are palpable, vasography, if necessary, should be performed only at the time of definitive repair of obstruction. General anesthesia provides the most flexibility for scrotal exploration, vasography, and repair of obstruction. Although local anesthesia can provide adequate analgesia, patients are often unable to lie still through several hours of microsurgery. Long-acting hypobaric spinal or continuous epidural anesthesia can be satisfactory alternatives.

Technique of Vasography and Interpretation of Findings

Inguinal hernia repair, particularly when performed in childhood, is known to be associated with vasal injury leading to obstruction. If there is no previous inguinal incision and the site of obstruction is unknown, the testis is delivered through a high vertical scrotal incision (see Fig. 67.11). The vas deferens is identified and isolated at the junction of the straight and convoluted portions of the vas deferens. Using an operating microscope and 10× power magnification, the vasal sheath is longitudinally incised and the vasal vessels carefully preserved (Fig. 67.2A).

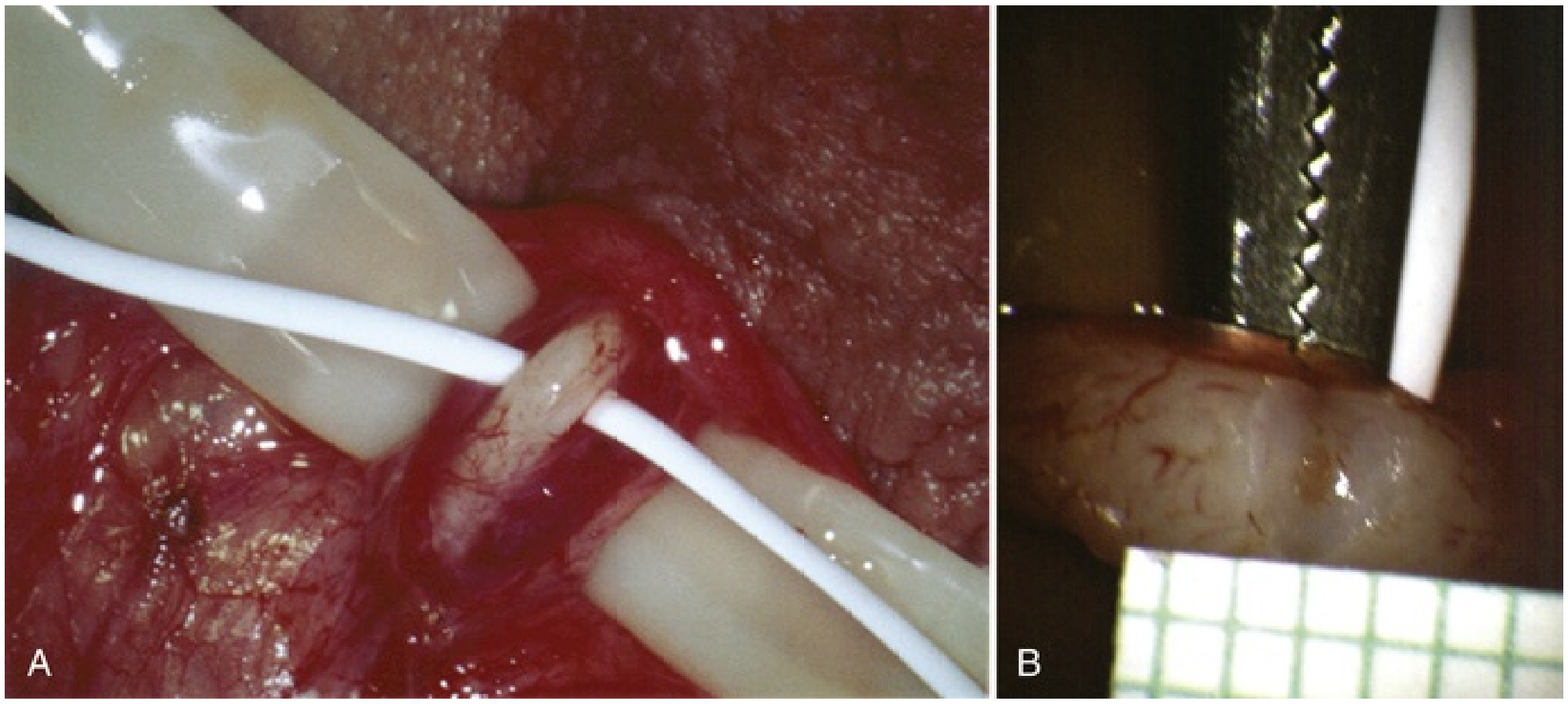

FIG. 67.2 (A) The vasal sheath is longitudinally incised and the vasal vessels carefully preserved. (B) A 15-degree microknife is used to hemitransect the vas until the lumen is revealed.

A clean segment of bare vas is delivered and surrounded with a vessel loop. A straight clamp is placed beneath the vas to act as a platform. Under 25× power magnification, a 15-degree microknife is used to hemitransect the vas until the lumen is revealed (Fig. 67.2B). **Any fluid exuding from the lumen is placed on a slide, mixed with a drop of saline, and sealed with a coverslip for microscopic examination. If the vasal fluid is devoid of sperm with repeated sampling** after milking the epididymis and convoluted vas, **epididymal obstruction is present.** The end of the vas toward the seminal vesicles is then cannulated with a 24-gauge angiocatheter sheath and is injected with 1 mL of Ringer's lactate solution with a 1-mL tuberculin syringe to confirm its patency (Fig. 67.3). If the Ringer's passes easily, formal vasography is not necessary. If further proof of patency of the vas deferens is desired, 1 mL of 50% dilute indigo carmine may be injected and the bladder catheterized. The presence of blue/green dye in the urine confirms patency of the vas. Indigo carmine diluted 50/50 with Ringer's solution is preferred instead of methylene blue because, even at low concentrations, methylene blue kills sperm and renders them useless for cryopreservation or for immediate IVF/ICSI (Chang et al., 1998; Sheynkin et al., 1999a; Wood et al., 2003). **If motile sperm are found in the vas, the testicular end should be gently barbotaged with 0.2 mL of human tubal fluid media, and the fluid processed by the andrology laboratory for sperm cryopreservation for potential future use for ICF/ICSI. This should be done before injection with indigo carmine or x-ray contrast material** (Sheynkin et al., 1999a).

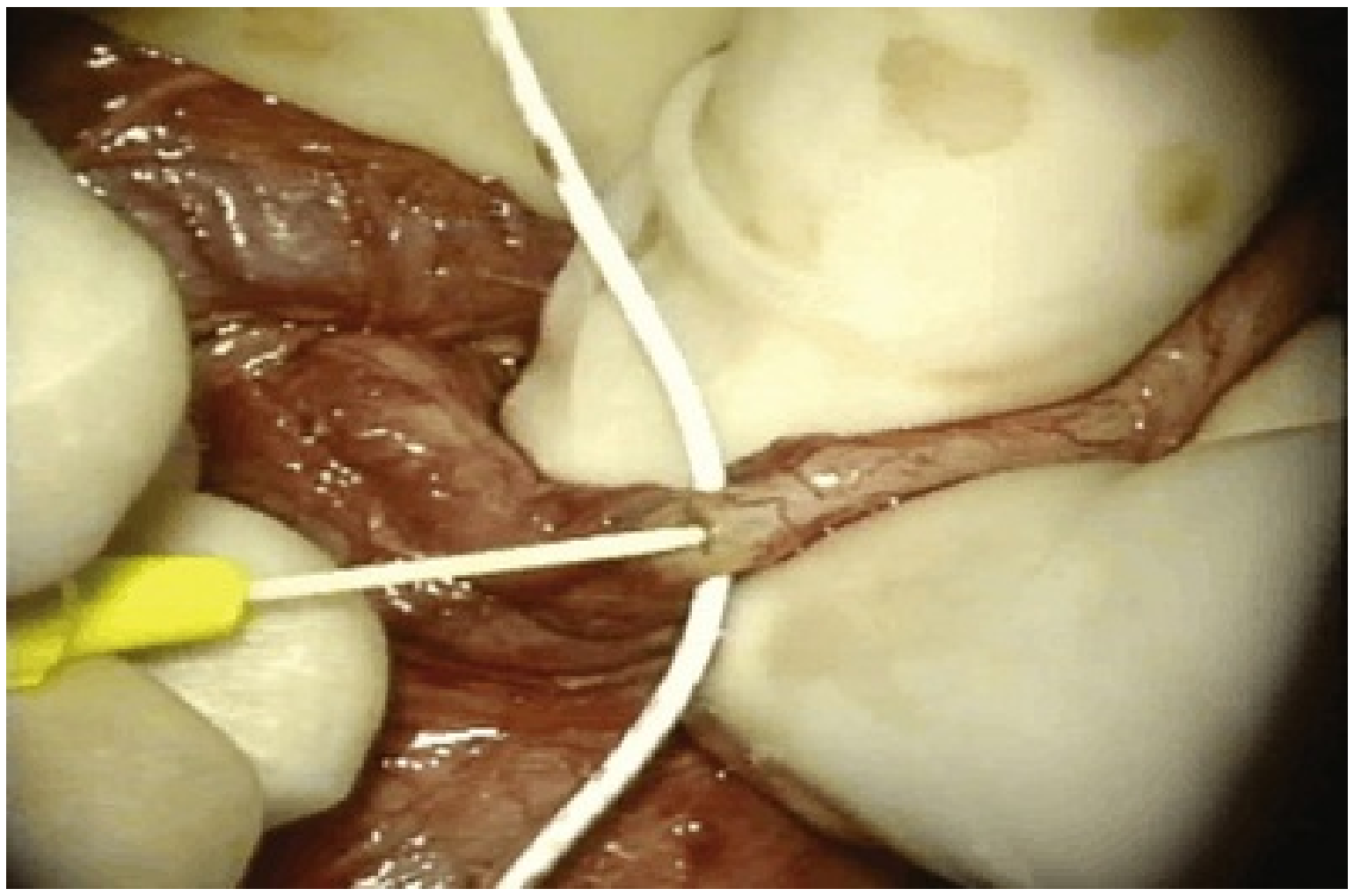

FIG. 67.3 The end of the vas towards the seminal vesicles is cannulated with a 24-gauge angiocatheter sheath and is injected with 1 mL of Ringer's lactate solution with a 1 mL tuberculin syringe to confirm its patency.

If a large amount of fluid (typically brownish “crank-case oil”–appearing fluid) is found in the vasal lumen and microscopic examination reveals the presence of sperm, the obstruction is toward the seminal vesicle end of the vas. In these cases, the vas is usually markedly dilated. A 2-0 Proline suture can be passed toward the seminal vesicle end of the vas and a clamp placed on the Proline when the suture passes no further. This is particularly useful for delineating the site of inguinal obstruction from prior groin surgery. If the obstruction is proximal to the inguinal scar, formal vasography is performed by passing a No. 3 ureteral catheter toward the seminal vesicle end of the vas. A 16-Fr Foley catheter is placed in the bladder, and the balloon is filled with 5 mL of air. Placing the balloon on gentle traction before vasography prevents reflux of contrast into the bladder, which can obscure detail (Fig. 67.4). The air-filled balloon also identifies the location of the bladder neck relative to any obstruction. After the vasa have been cannulated, vasograms are performed with the injection of 0.5 mL of water-soluble contrast media (Fig. 67.5). **If vasography reveals obstruction at the site of the ejaculatory ducts** (Fig. 67.6)**, indigo carmine or, after sperm has been aspirated and cryopreserved, methylene blue is injected in both vasa to facilitate a transurethral resection (TUR) of the ejaculatory ducts** (see the section on electroejaculation indications). If both vasa are visualized after injection of contrast into only one vas (Fig. 67.7), it means both vasa empty into a single cavity, usually a midline ejaculatory duct cyst.

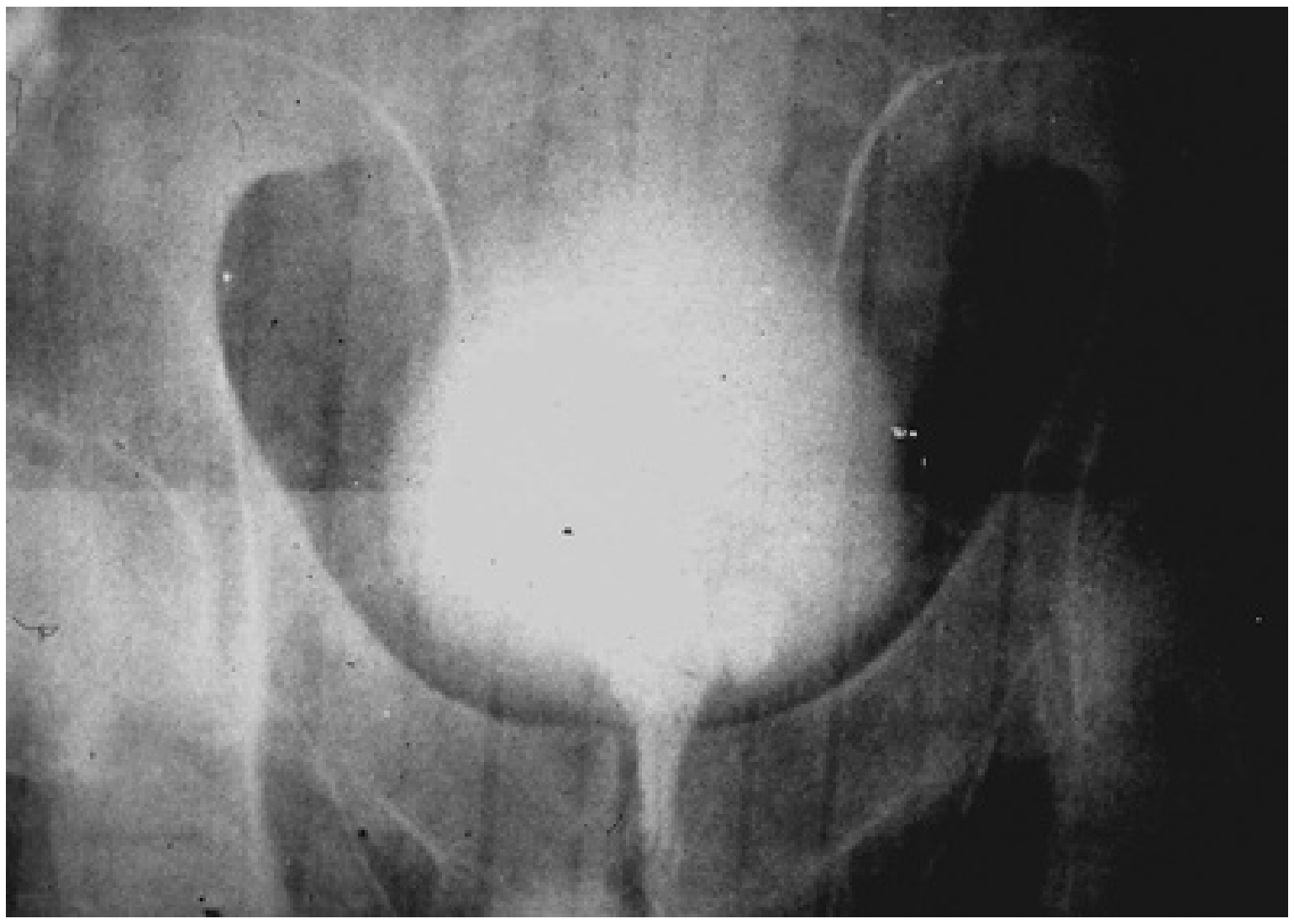

FIG. 67.4 Placing a balloon on gentle traction prior to vasography prevents reflux on contrast into the bladder.

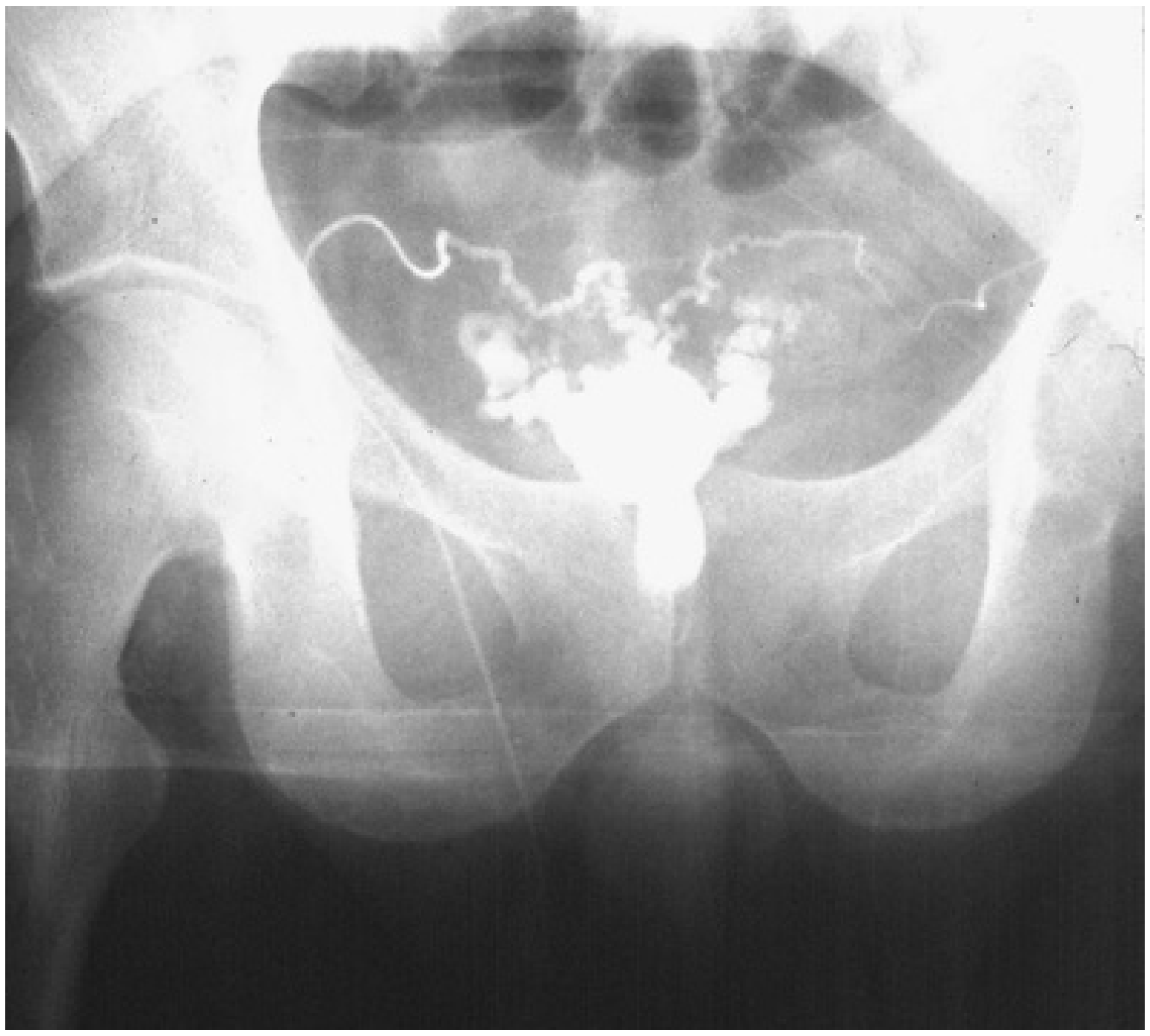

FIG. 67.5 After the vasa have been cannulated, vasograms are performed with the injection of 0.5 mL of water-soluble contrast media.

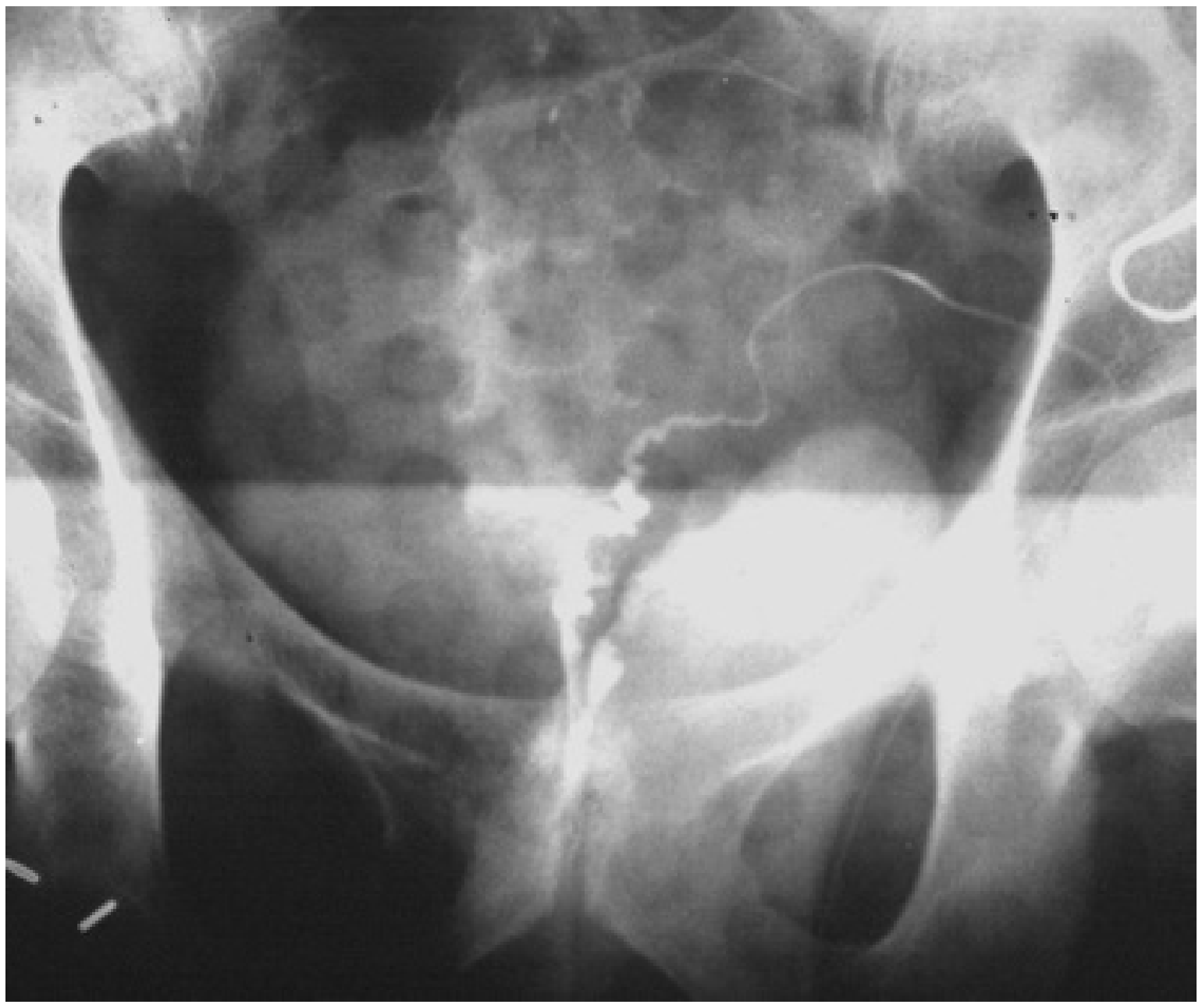

FIG. 67.6 Vasography reveals obstruction at the site of the ejaculatory ducts.

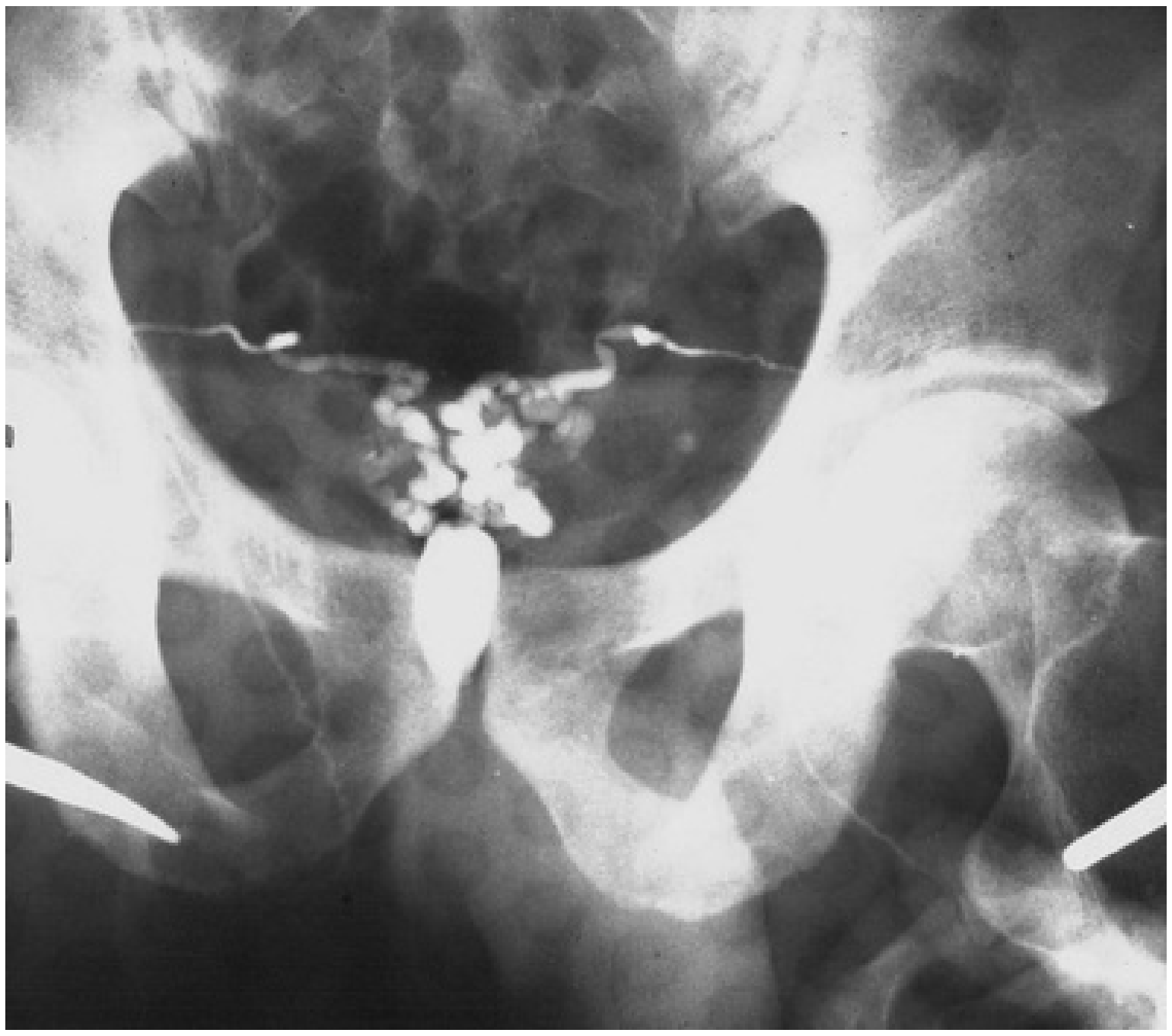

FIG. 67.7 Both vasa are visualized after injection of contrast into only one vas.

Vasography may reveal the vas deferens ending blindly, far from the ejaculatory ducts (Fig. 67.8). This finding indicates congenital partial absence of the vas deferens, and these patients should be tested for cystic fibrosis mutations (see Chapter 24). If this is found bilaterally (Fig. 67.9), reconstruction is impossible, but vasal or epididymal sperm can be aspirated into standard laboratory pipettes (see Varicocelectomy) and cryopreserved for future IVF with ICSI. If vasography reveals obstruction in the inguinal region (Fig. 67.10), either inguinal vasovasostomy or crossed transseptal vasovasostomy, using the contralateral unobstructed vas (see Fig. 67.24), may be performed. **The hemitransected vasography sites are carefully closed microsurgically** using two or three interrupted 10-0 monofilament nylon sutures for the mucosa and 9-0 for the muscularis and adventitia.

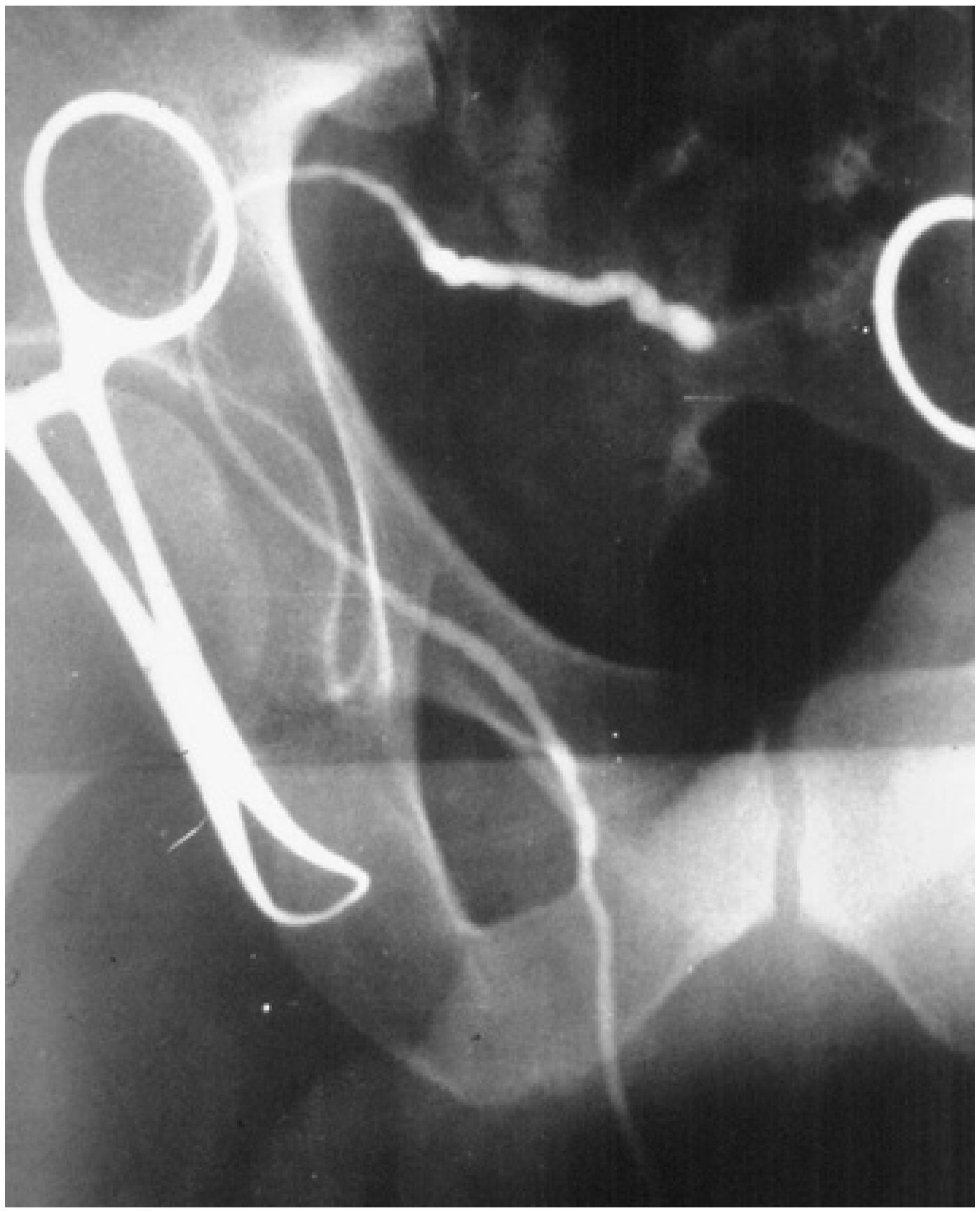

FIG. 67.8 The vas deferens ending blindly, far from the ejaculatory ducts.

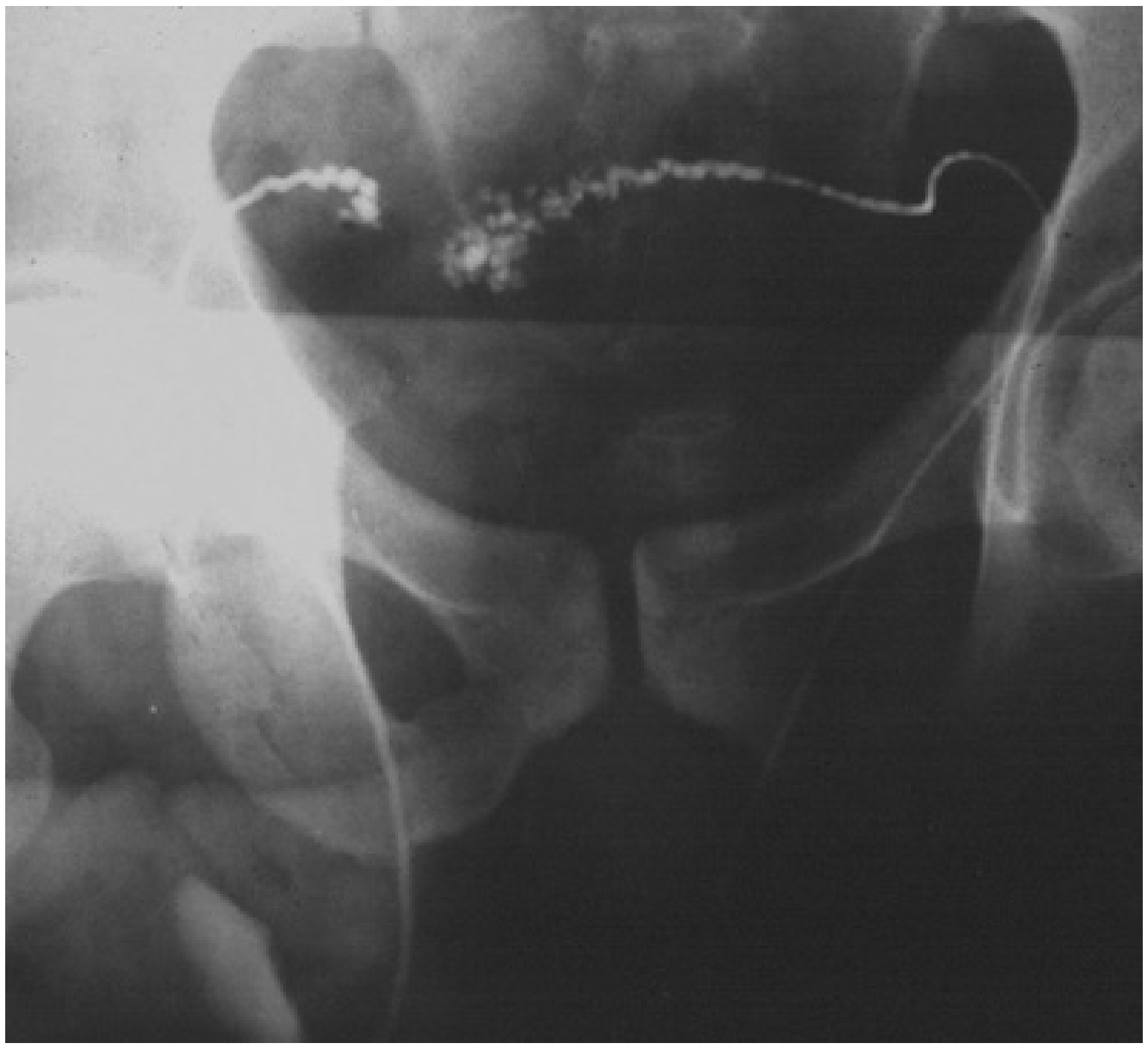

FIG. 67.9 Bilateral congenital partial absence of the vas deferens.

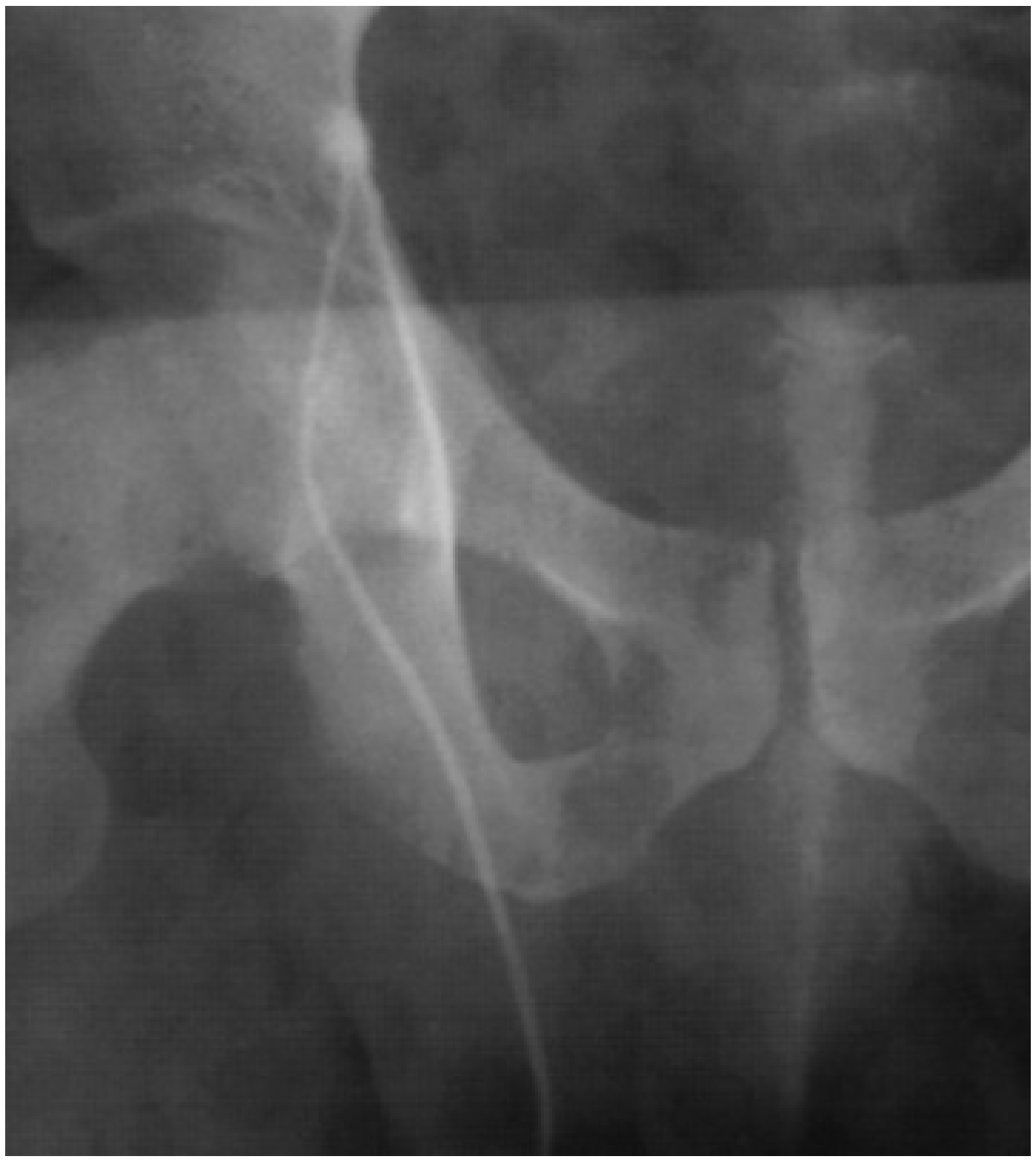

FIG. 67.10 Vasography reveals obstruction in the inguinal region.

If the vasal fluid reveals no sperm and vasography confirms patency of the seminal vesicle end of the vas, the vas is completely transected, and the seminal vesicle end is prepared for vasoepididymostomy (see Fig. 67.27). If the vasal fluid reveals many sperm and vasography is normal, either retrograde ejaculation, lack of emission, or aperistalsis of the vas (Tiffany and Goldstein, 1985; Tillem and Mellinger, 1999) is the cause of the azoospermia.

Complications of Vasography

Stricture

Multiple attempts at percutaneous vasography using sharp needles can result in stricture or obstruction at the vasography site. Imprecise closure of a vasotomy can also result in stricture and obstruction (Howards et al., 1975; Poore et al., 1997). Non–water-soluble contrast agents may also result in stricture and should not be employed for vasography.

Injury to the Vasal Blood Supply

If the vasal blood supply is injured at the site of vasography, vasovasostomy proximal to the vasography site may result in ischemia, necrosis, and obstruction of the intervening segment of vas.

Hematoma

A bipolar cautery should be used for meticulous hemostasis to prevent hematoma in the perivasal sheath.

Sperm Granuloma

Leaky closure of a vasography site may lead to the development of a sperm granuloma, which can result in stricture or obstruction of the vas. The microsurgical technique for closure of vasography sites is identical to that employed for vasovasostomy described later in this chapter.

Transrectal Vasography and Seminal Vesiculography

If transrectal ultrasound reveals markedly dilated seminal vesicles and/or a midline müllerian duct cyst in a man with obstructive azoospermia,

transrectal aspiration followed by instillation of indigo carmine mixed with radiographic contrast is a useful diagnostic maneuver (Eisenberg et al., 2008; Jarow, 1994; Katz and Nagler, 1994; Riedenklau et al., 1995).

The same bowel prep and antibiotic coverage used for transrectal prostate biopsy is employed. The fine-needle aspirate is examined for sperm. If sperm are present. it means at least one vas and epididymis are patent. Then 0.5 mL of indigo carmine is diluted with 1.5 mL of 50% water-soluble contrast and instilled. If a flat plate reveals a potentially resectable lesion, a TUR of the ejaculatory ducts is performed (see Electroejaculation). Visualization of blue dye effluxing from the ejaculatory ducts or an unroofed cyst aids in determining the adequacy of the resection (Cornel et al., 1999).

This technique obviates the need for formal open scrotal vasography in men with transrectally accessible lesions. If sperm are found in the aspirate, a TUR may immediately be undertaken without violating the scrotum. Sperm-laden aspirates may be frozen for future IVF with ICSI if surgery fails.

If no sperm are found in the aspirated fluid, it suggests that secondary epididymal obstruction exists. Simultaneous TUR of the ejaculatory ducts and vasoepididymostomy is rarely successful. In the face of both ejaculatory duct obstruction and bilateral epididymal obstruction, the best option would be epididymal sperm aspiration for cryopreservation for future IVF/ICSI.

Summary

1. **Vasography is performed only if testicular biopsy confirms spermatogenesis consistent with obstructive azoospermia.**
2. **Vasography is performed only at the time of planned reconstruction.**
3. **Vasal fluid is always sampled first to allow cryopreservation of motile sperm if found.**
4. **Indigo carmine is used instead of methylene blue to confirm patency.**
5. **Formal vasography with x-ray contrast is needed only to locate obstructions proximal to the internal inguinal ring.**
6. **If transrectal ultrasound reveals dilated seminal vesicles and/or a midline (müllerian duct) cyst, transrectal fine-needle aspiration followed by instillation of contrast and indigo carmine should be performed. If motile sperm are found, they should be**

cryopreserved.

Key Points: Vasography

- Perform vasography only at the time of planned reconstruction.

Vasovasostomy

The number of American men who undergo vasectomy has remained stable at about 500,000 per year, as has the divorce rate of 50%. Surveys suggest that 2% to 6% of vasectomized men will ultimately seek reversal, and up to 20% express interest in future fertility. Furthermore, obstructive azoospermia can be the result of iatrogenic injuries to the vas deferens, usually from hernia repair, in 6% of azoospermic men (Sheynkin et al., 1998a; Shin et al., 2005).

Preoperative Evaluation

Before attempted surgical reconstruction of the reproductive tract, adequate spermatogenesis should be documented. A prior history of natural fertility prevasectomy is usually adequate.

Physical Examination

1. Testis: Small or soft testes suggest impaired spermatogenesis and predict a poor outcome.
2. Epididymis: An indurated irregular epididymis often predicts secondary epididymal obstruction, necessitating vasoepididymostomy.
3. Sperm granuloma: **A sperm granuloma at the testicular end of the vas suggests that sperm have been leaking at the vasectomy site. This vents the high pressures away from the epididymis and is associated with a better prognosis for restored fertility** regardless of the time interval since vasectomy (Wosnitzer and Goldstein, 2013).
4. Vasal gap: When a very destructive vasectomy has been performed, most of the scrotal straight vas may be absent or fibrotic, and the patient should be advised that inguinal extension of the scrotal incision will be necessary to mobilize adequate length of vas to enable a tension-free anastomosis.
5. Scars from previous surgery: Operative scars in the inguinal or scrotal region should alert the surgeon to the possibility of iatrogenic inguinal (hernia repair) vasal or epididymal obstruction (hydrocelectomy, orchiopexy) (Hopps and Goldstein, 2006; Sheynkin et al., 1998a).

Laboratory Tests

1. Semen analysis with centrifugation and examination of the pellet for sperm should be performed preoperatively. Complete sperm with tails are found in 10% of preoperative pellets a mean of 10 years after vasectomy (Lemack and Goldstein, 1996). Under these circumstances sperm are certain to be found in the vas on at least one side, indicating a favorable prognosis for restored fertility. Men with a low semen volume should have a transrectal ultrasound to ascertain the possibility of an additional ejaculatory duct obstruction.
2. Serum and antisperm antibody studies: The presence of serum antisperm antibodies corroborates the diagnosis of obstruction and the presence of active spermatogenesis (Lee et al., 2009).
3. Serum FSH: Men with small, soft testes should have serum FSH measured. An elevated FSH level predicts impaired spermatogenesis and a poorer prognosis.
4. Prostate specific antigen (PSA): Vasectomy reversal candidates over age 40 should have serum PSA measured.

Anesthesia

General anesthesia is ideal. Slight movements are greatly magnified by the operating microscope and disturb performance of the anastomosis. In cooperative patients regional or even local anesthesia with sedation can be employed if the vasal ends are easily palpable, a sperm granuloma is present, and/or the time interval since vasectomy is short, decreasing the likelihood of secondary epididymal obstruction. When large vasal gaps are present, extensions of the incisions high into the inguinal canal may be necessary. Furthermore, if vasoepididymostomy is necessary, the operating time could exceed 4 or 5 hours. Hypobaric spinal anesthesia with long-acting agents such as Marcaine can provide 4 to 5 hours of anesthesia time and has the advantage of eliminating lower body motion. Epidural anesthesia with an indwelling catheter can be equally effective. Local anesthesia with liposomal bupivacaine and sedation is also workable, especially in men with small vasal gaps and under 10-year interval since vasectomy.

Surgical Approaches: Scrotal

Bilateral high vertical scrotal incisions provide the most direct access to the obstructed site in cases of vasectomy reversal. Length is usually a problem on the abdominal end but not on the testicular end. The location of the external inguinal ring must be marked (Fig. 67.11). **If the vasal gap is large, or the vasectomy site is high, this incision can easily be extended toward the external ring.** If the vasectomy site is low, it is easy to pull up the testicular end. This incision should be made at least 1 cm lateral to the base of the penis. **The testis should be delivered with the tunica vaginalis left intact.** This provides excellent exposure of the entire scrotal vas deferens and, if necessary, the epididymis.

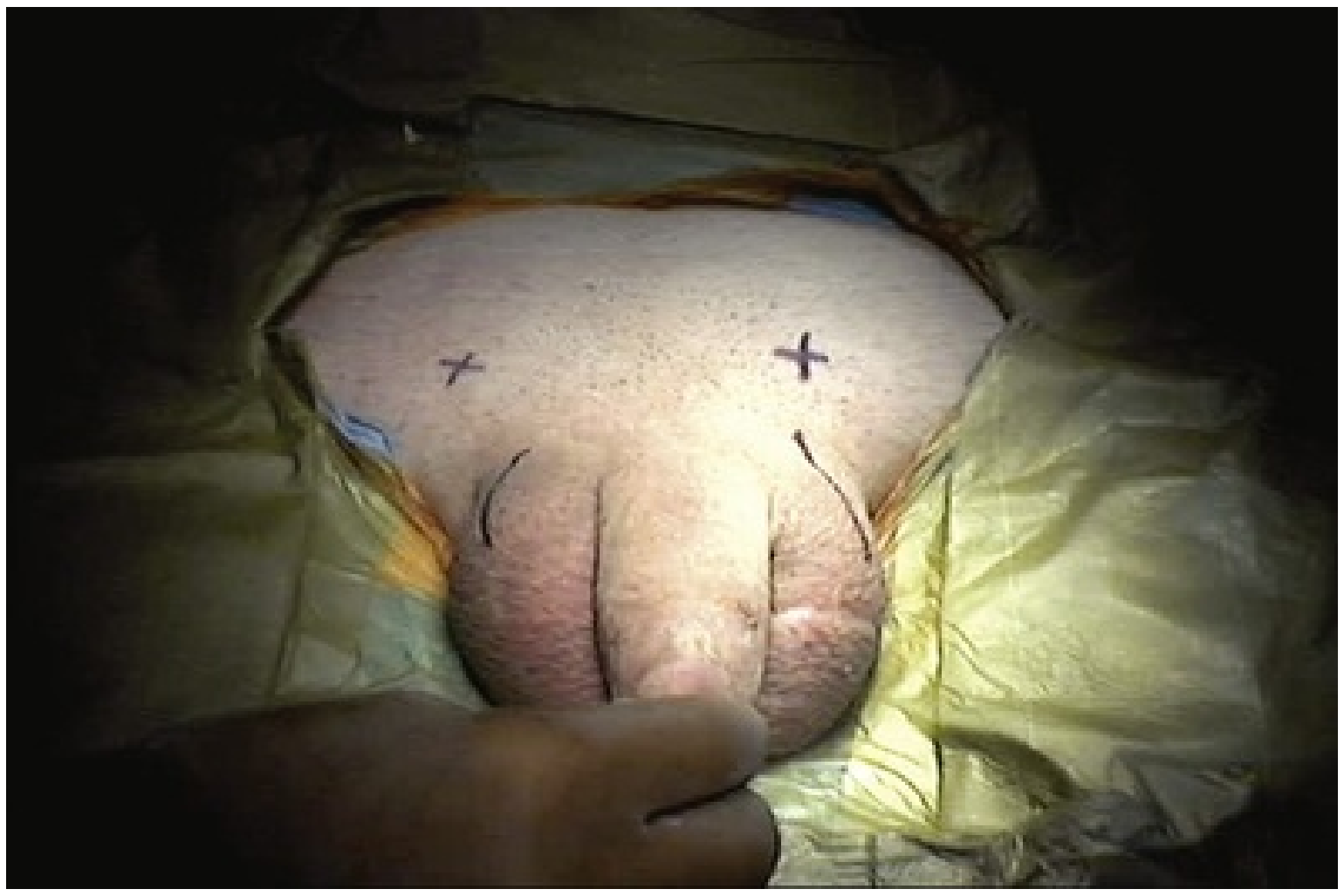

FIG. 67.11 The location of the external inguinal ring is marked.

Surgical Approaches: Inguinal

An inguinal incision is the preferred approach in men when obstruction of the inguinal vas deferens from prior herniorrhaphy or orchiopexy is strongly suspected. Incision through the previous scar usually leads directly to the site of obstruction. If the obstruction turns out to be scrotal or epididymal, it is a simple matter to deliver the testis through the inguinal incision or through a separate scrotal incision to perform the anastomosis.

Preparation of the Vasa

The vas is grasped above and below the site of obstruction with two Babcock clamps. Penrose drains replace the Babcock clamps and facilitate the dissection. The vasal vessels and periadventitial sheath are included. **Transillumination of the periadventitial sheath**, by properly adjusting the operating light, **allows clear visualization of the blood vessels, which facilitates dissection of the periadventitial sheath and prevents damage to the vasal vessels**. The vas is mobilized enough to allow a tension-free anastomosis. To preserve good blood supply **the vas should not be stripped of its sheath.** The obstructed segment and, if present, sperm granuloma at the vasectomy site should be dissected out and excised. By staying right on the vas and/or sperm granuloma during this dissection, the risk of injuring the testicular artery is reduced. **Injury to adjacent cord structures, especially the testicular artery, is likely to result in testicular atrophy because the vasal artery has usually been interrupted at the vasectomy site.**

When large vasal gaps are present, a gauze-wrapped index finger is used to bluntly separate the cord structures from the vas. Blunt finger dissection through the external ring will free the vas to the internal inguinal ring if additional abdominal side length is necessary. These maneuvers leave all the vasal vessels intact. **When the vasal gap is extremely large, additional length can be achieved by dissecting the entire convoluted vas free of its attachments to the epididymal tunica** (Fig. 67.12), allowing the testis to drop upside down. These maneuvers can provide an additional 4 to 6 cm of length. To maintain the integrity of the vasal vessels, this dissection is best performed using magnifying loupes or the operating microscope under low power. If the amount of vas removed is so large that even these measures fail to allow a tension-free anastomosis, the incision can be extended to the internal inguinal ring, the floor of the inguinal canal cut, and the vas rerouted under the floor, as in a difficult orchiopexy. An additional 4 to 6 cm of length can be obtained by dissecting the epididymis off of the testis from the vasoepididymal junction to the caput epididymis (Fig. 67.13A and B). The superior epididymal vessels are left intact and provide adequate blood supply to the testicular end of the vas. With this combination of maneuvers, up to 10-cm gaps can be bridged.

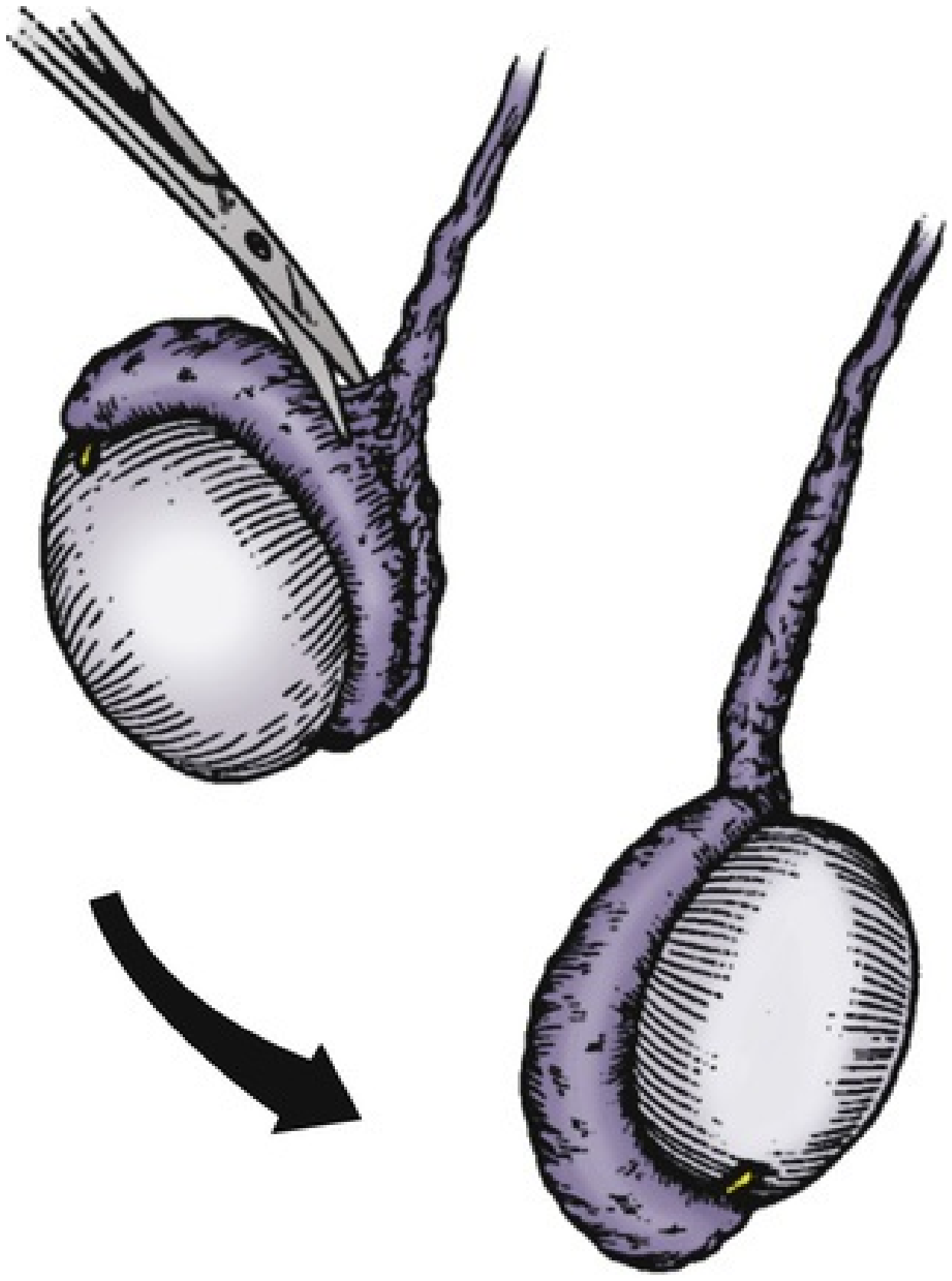

FIG. 67.12 When the vasal gap is extremely large, additional length can be achieved by dissecting the entire convoluted vas free of its attachments to the epididymal tunica.

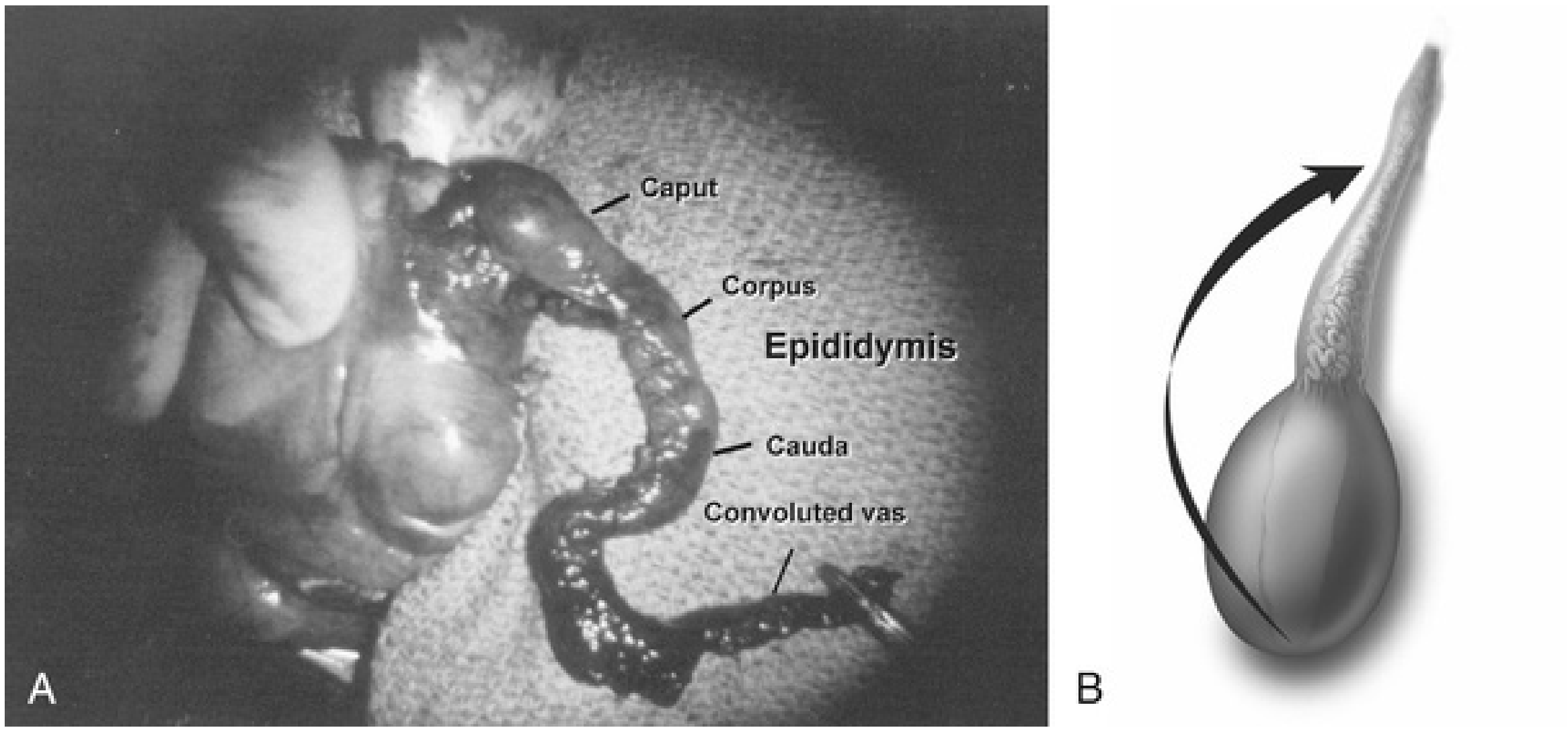
Caput
Corpus
Epididymis
Cauda
Convoluted vas
A
B

FIG. 67.13 (A and B) An additional 4 to 6 cm of length can be obtained by dissecting the epididymis off of the testis from the vasoepididymal junction to the caput epididymis.

After the vasa have been freed, the testicular end of the vas is cut transversely. An ultrasharp knife drawn through a slotted 2-, 2.5-, or 3-mm diameter nerve-holding clamp (Accurate Surgical and Scientific Instrument Corp., Westbury, NY) yields a perfect 90-degree cut (Fig. 67.14). The cut surface of the testicular end of the vas deferens is inspected using 15× to 25× power magnification. **A healthy white mucosal ring should be seen, which springs back immediately after gentle dilation. The muscularis should appear smooth and soft. A gritty-looking muscularis layer indicates the presence of scar/fibrotic tissues.** The cut surface should look like a bullseye with the three vasal layers distinctly visible. Healthy bleeding should be noted from the cut edge of the mucosa and the surface of the muscularis. If the blood supply is poor or the muscularis is gritty, the vas is recut until healthy tissue is found. The vasal artery and vein are then clamped and ligated with 6-0 nylon. Small bleeders are controlled with a microbipolar forceps set at low power. Once a patent lumen has been established on the testicular end, the vas is milked and a clean glass slide is touched to its surface. The vasal fluid is immediately mixed with a drop or two of saline or Ringer's lactate and preserved under a coverslip for microscopic examination. The abdominal end of the vas deferens is prepared in a similar manner and the lumen gently dilated with a microvessel dilator and cannulated with a 24-gauge angiocatheter sheath. Injection of saline or Ringer's lactate confirms its patency. After Ringer's injection and a test dilation the vas is recut to obtain a fresh surface. **A minimum of instrumentation of the mucosa should be performed.**

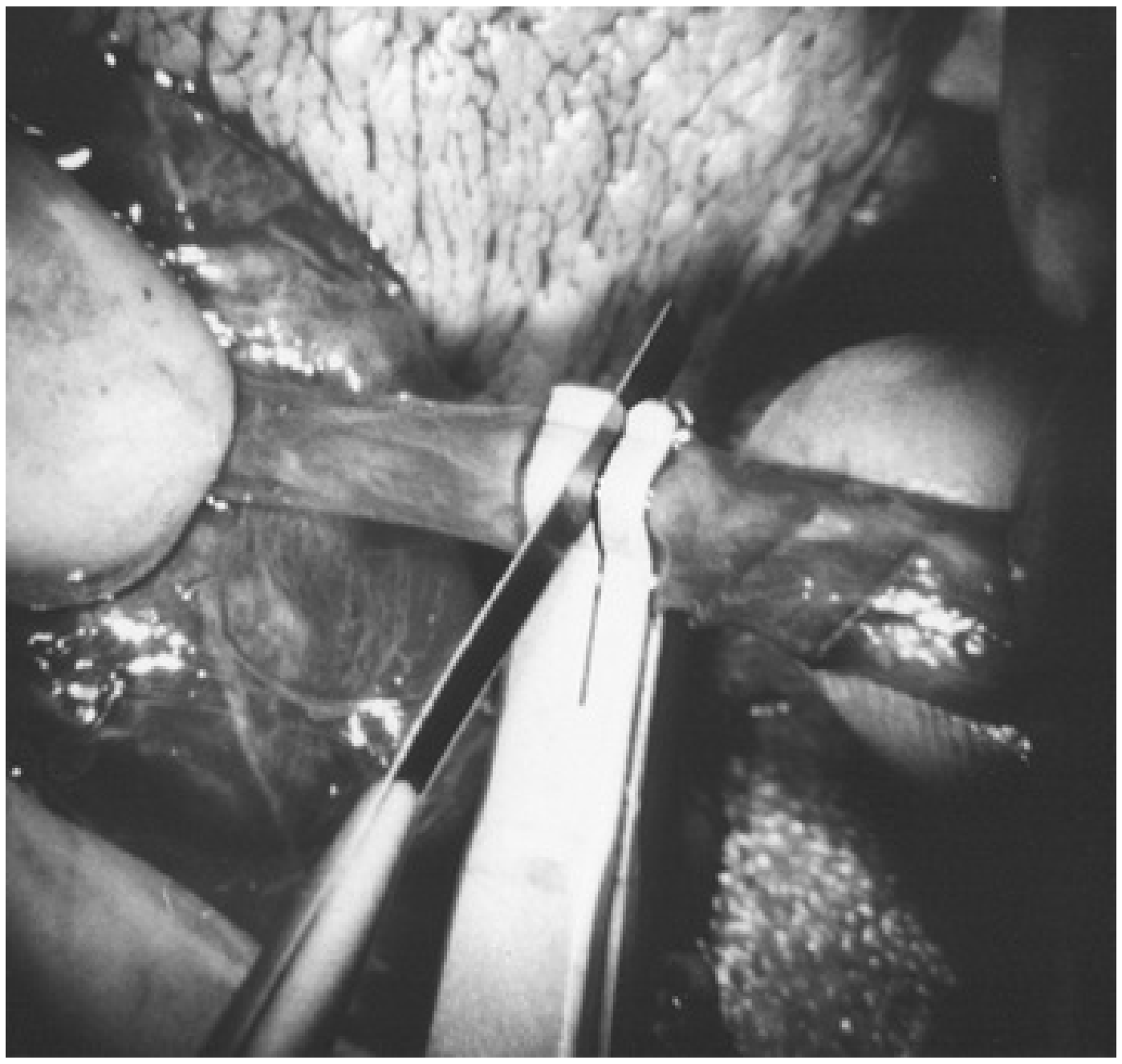

FIG. 67.14 An ultrasharp knife drawn through a slotted nerve holding clamp yields a perfect 90-degree cut.

After preparation, the ends of the vasa are stabilized with a Microspike approximating clamp (Goldstein, 1985) to remove all tension before the anastomosis is performed. Isolating the field through a slit in a rubber dam prevents microsutures from sticking to the surrounding tissue. A sterile tongue blade covered with a large Penrose drain is placed beneath the ends of the vasa to provide a platform on which to perform the anastomosis.

When to Perform Vasoepididymostomy

The gross appearance of fluid expressed from the testicular end of the vas is usually predictive of findings on microscopic examination (Table 67.2). If microscopic examination of the vasal fluid reveals the presence of sperm with tails, vasovasostomy is performed. If no fluid is found, a 24-gauge angiocatheter sheath is inserted into the lumen of the testicular end of the vas and barbotaged with 0.1 mL of saline while the convoluted vas is vigorously milked. The barbotage fluid is expressed onto a slide and examined. **Men with large sperm granulomas often have virtually no dilation of the testicular end of the vas and little or no fluid initially. However, with barbotage and vigorous milking, invariably sperm can be found in this scant fluid.** If there is no sperm granuloma, and the vas is absolutely dry and spermless after multiple samples are examined, vasoepididymostomy is indicated. If the fluid expressed from the vas is found to be thick, white, water insoluble and toothpaste-like in quality, microscopic examination rarely reveals sperm. Under these circumstances, the tunica vaginalis is opened and the epididymis inspected. If clear evidence of obstruction is found (i.e., an epididymal sperm granuloma with dilated tubules above and collapsed tubules below), vasoepididymostomy is performed. **When in doubt, or if the surgeon is not very experienced with vasoepididymostomy, vasovasostomy should be performed.** However, only 15% of men with bilateral absence of sperm in the vasal fluid after barbotage and an intensive search will have sperm return to the ejaculate after vasovasostomy (Sheynkin et al., 2000).

TABLE 67.2

Relationship Between Gross Appearance of Vasal Fluid and Microscopic Findings

---

APPEARANCE OF VASAL FLUID	INTRAOPERATIVE EVALUATION OF ASPIRATE	RECOMMENDED SURGICAL PROCEDURE	
Copious, crystal clear, watery	No sperm	Vasovasostomy	
Copious, cloudy thin, water soluble	Sperm with tails, including short tails, motile or nonmotile	Vasovasostomy	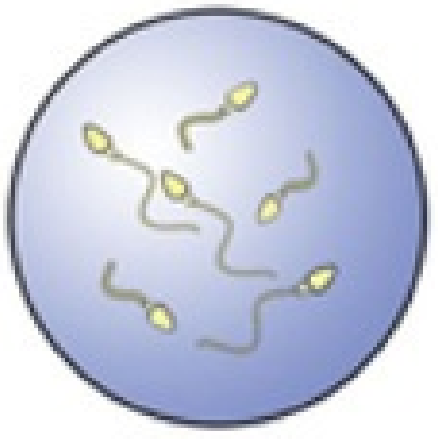
Copious, creamy yellow, water insoluble	Many sperm heads, often with acrosome visible, scattered throughout the slide	Vasovasostomy	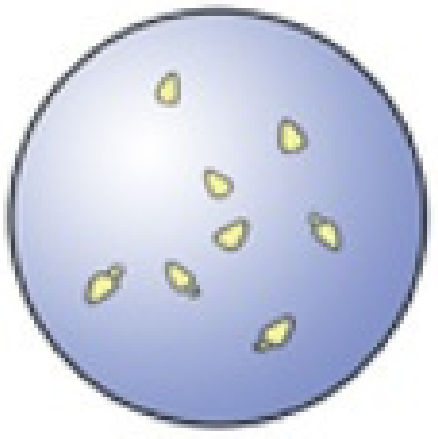
Copious, thick white toothpaste-	No sperm or sperm heads	Vasoepididymostomy	

like, water insoluble			
Scant white thin fluid	No sperm or sperm heads	Vasoepididymostomy	
Scant fluid, no granuloma at vasectomy site	No sperm or sperm heads	Vasoepididymostomy	
Scant fluid, granuloma present at vasectomy site	Barbotage fluid reveals sperm, usually with tails, often motile	Vasovasostomy	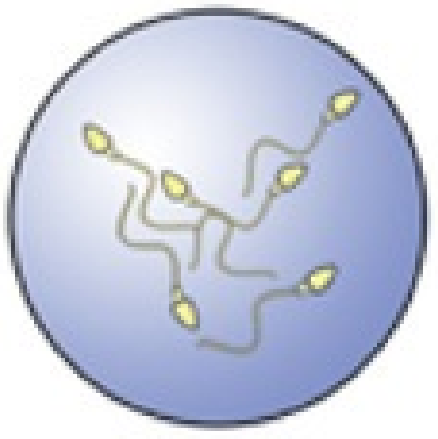
Any fluid	Fluid with occasional grapelike clusters of sperm heads	Vasoepididymostomy	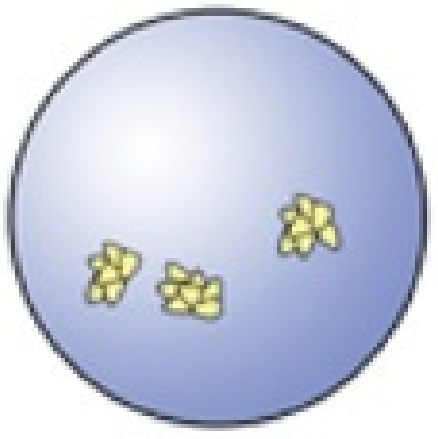

When copious, crystal clear, waterlike fluid squirts out from the vas and no sperm are found in this fluid, a vasovasostomy is performed because the likelihood is that sperm will return to the ejaculate after vasovasotomy is performed.

Multiple Vasal Obstructions

If saline injection reveals that the abdominal end of the vas deferens is not patent, a 2-0 nylon or polypropylene suture is gently threaded into the vas lumen to determine the site of obstruction. If the obstruction is within 5 cm of the original vasectomy site, the abdominal end of the vas deferens may be dissected to this site and excised. The incision should then be extended inguinally to free the vas up extensively toward the internal inguinal ring. The testicular end then should also be freed up to the vasoepididymal junction. If the site of the second obstruction is so far from the vasectomy site that two vasovasostomies are necessary, a single crossed vasovasostomy should be performed to yield one good system. If this is not possible, vasal or epididymal sperm is aspirated into micropipettes and cryopreserved for future IVF with ICSI. **Simultaneous vasovasostomies at two separate sites will usually lead to devascularization of the intervening segment with fibrosis and necrosis.**

Varicocelectomy and Vasovasostomy

When men presenting for vasovasostomy or vasoepididymostomy are found to have significant varicoceles on physical examination, it is tempting to repair the varicoceles at the same time. **When varicocelectomy is properly performed, all spermatic veins are ligated and the only remaining avenues for testicular venous return are the vasal veins. In men who have had vasectomy and are presenting for reversal, the vasal veins are likely to be compromised from either the original vasectomy or the reversal. Furthermore, the integrity of the vasal artery in those men is also likely to be compromised. Varicocelectomy in such men requires preservation of the testicular artery as the primary remaining testicular blood supply as well as preservation of some avenue for venous return.**

Microscopic varicocelectomy can ensure preservation of the testicular artery in most cases. Deliberate preservation of small cremasteric or perivasal veins provides venous return. In one series of 570 men presenting for vasectomy reversal, 19 had large varicoceles (20 left, 7 bilateral). Microsurgical varicocelectomy was performed at the same time as vasovasostomy. The cremasteric veins and the fine network of veins adherent to the testicular artery were left intact for venous return and to minimize the chances of injury to the testicular artery. Postoperatively 5/26 varicoceles recurred (22%) (Goldstein, 1995). This compares to a recurrence rate of less than 1% in 3500 varicocelectomies performed by the author in nonvasectomized men in whom the vasal vessels were intact and the cremasteric veins and periarterial venous network were ligated. However, Mullhall et al. (1997) performed a series of simultaneous microsurgical vasovasostomies and varicocelectomies without intentionally preserving the cremasteric and periarterial network. They reported a low recurrence rate and no cases of atrophy. Interestingly, the increase in recurrences when the cremasteric veins and periarterial venous network were left intact suggests that these veins contribute to a significant proportion of varicocele recurrences.

If varicocelectomy is performed at the same time as vasovasostomy or vasoepididymostomy, it is important that a microscope be used and the testicular artery preserved. Another approach, especially when the female partner is young, is to do the vasovasostomy or vasoepididymostomy first. The semen quality is then assessed postoperatively. **If necessary, varicocelectomy can be safely performed 6 months or more later when venous and arterial channels have formed across the anastomotic line.** This two-stage delayed approach has been completed a dozen times with no atrophy or recurrence.

Anastomotic Techniques: Keys to Success

All successful vasovasostomy techniques depend on adherence to surgical principles that are universally applicable to anastomoses of all tubular structures. These include the following:

1. **Accurate mucosa-to-mucosa approximation**
   In human vasovasostomy, the lumen on the testicular side is usually dilated, often to diameters 2 to 5 times that of the abdominal side. Techniques that work well with lumina of equal diameters may be less successful when applied to lumina of markedly discrepant diameters.
2. **Leakproof anastomosis**
   Sperm are highly antigenic and provoke an inflammatory reaction when they escape from the normally intact lining of the excurrent ducts of the male reproductive tract. Extravasated sperm adversely influence the success of vasovasostomy (Hagan and Coffey, 1977). **Unlike blood vessel anastomoses, in which platelets and clotting factors seal the gaps between sutures, vasal and epididymal fluid contain no platelets or clotting factors, so the water tightness of the anastomosis is entirely dependent on the mucosal sutures.**
3. **Tension-free anastomosis**
   When an anastomosis is performed under tension, sperm may appear in the ejaculate for several months after surgery. Ultimately, sperm counts and motility will decrease, and

azoospermia may ensue. At re-exploration only a thin fibrotic band is found at the anastomotic site. This can be prevented by adequately freeing up the vasa and placement of re-enforcing sutures in the sheath of the vas.

4. **Good blood supply**

   If the cut vas exhibits poor blood supply, it should be recut until healthy bleeding is encountered. If extensive resection is necessary, additional length should be obtained using the techniques previously described.

5. **Healthy mucosa and muscularis**

   If the mucosa or cut surface of the vas exhibits poor distensibility after dilation, peels away from the underlying muscularis, or shreds easily, then the vas should be cut back until healthy mucosa is found. Surgeons should be aware that if a needle electrocautery was used in vasectomy, the area of damage to the mucosa and muscularis by the electric current may extend far beyond the tip of the needle cautery. If the muscularis is found to be fibrotic or gritty, the vas must be recut until healthy tissue is found.

6. **Good atraumatic anastomotic technique**

   If multiple surgical errors occur during the procedure, such as inadvertent cutting of the mucosa with the needles when placing sutures, tearing through of sutures, or backwalling of the mucosa, the anastomosis should be resected and redone immediately.

Setup

An operating microscope providing variable magnification from 6× to 32× power is employed. A diploscope providing identical fields for surgeon and assistant is preferred. Foot pedal controls for a motorized zoom and focus leave the surgeon's hands free.

The surgeon and assistant should be comfortably seated on microsurgical chairs that stabilize the chest and arms. This dramatically improves stability and accuracy. An inexpensive alternative is a simple rolling stool with a round bean bag (meditation pillow) taped on top for padding. Two arm boards placed on either side of the surgeon and built up to the appropriate height with folded blankets taped to the board provide excellent arm support. **Right-handed surgeons should sit on the patient's right side** so that their forehand stitch is always on the smaller, more difficult abdominal side lumen.

Microsurgical Multilayer Microdot Method

This method of vasovasostomy can handle lumina of markedly discrepant diameters in the straight or convoluted vas. **The microdot technique ensures precise suture placement by exact mapping of each planned suture. The microdot method separates the planning from the placement** (Dabaja et al., 2013; Goldstein et al., 1998). This allows focus on only one task at a time and results in substantially improved accuracy.

A microtip marking pen (Devon Skin Marker Extra Fine #151) is used to map out planned needle exit points. **Exactly six mucosal sutures are used for every anastomosis** because it is easy to map out and always results in a leakproof closure even when the lumen diameters are markedly discrepant.

Immediately after the cut surface of the testicular end of vas is dried with a Weck-cel sponge, a dot is made at 3 o'clock halfway between the mucosal ring and the outer edge of the muscle layer. A line is extended out from this dot to serve as a reference point. The second dot is made at 9 o'clock, and a line is extended from this dot as well. Additional dots are placed at 11, 1, 5, and 7 o'clock for a total of six. The abdominal end of the vas is marked in the same way to exactly match the testicular end (Fig. 67.15). Monofilament 10-0 nylon sutures are used, double-armed with 70-micron diameter taper-point needles bent into a fish-hook configuration (available from Sharpoint and Ethicon). **Double-armed sutures allow inside-out placement** (Fig. 67.16)**, eliminating the need for manipulation of the mucosa and the possibility of back-walling.** If the mucosal rings are not sharply defined, the cut surfaces of the vasal ends are stained with indigo carmine to highlight the mucosa (Sheynkin et al., 1999a). The anastomosis is begun with the placement of three 10-0 mucosal sutures anteriorly (Fig. 67.17). **On the small abdominal side lumen, the lumen is gently and momentarily dilated with a microvessel dilator just before placement of the sutures.** For accurate mucosal approximation only a small amount of mucosa is included but one-third to one-half the muscle wall thickness. **Exactly the same amount of tissue is included in the bites on each side. The needle should exit through the center of each dot.** After placement, the three mucosal sutures are tied. Two 9-0 monofilament nylon deep muscularis sutures are placed exactly in between the previously placed mucosal sutures, just above but not through the mucosa (Fig. 67.18) and then tied. These sutures seal the gaps between the mucosal sutures without trauma to the mucosa from the larger 100-micron diameter cutting needle required to penetrate the tough vas muscularis and adventitia. The vas is rotated 180 degrees (Fig. 67.19), and three additional 10-0 sutures are placed through each microdot and then tied to complete the mucosal portion of the anastomosis (Fig. 67.20). Just before tying the last mucosal suture, the lumen is irrigated with heparinized Ringer's solution to prevent the formation of clot in the lumen. After completion of the mucosal layer (Fig. 67.21), four more 9-0 deep muscularis sutures are placed exactly in between each mucosal suture, just above but not penetrating the mucosa. Four to six 9-0 nylon interrupted sutures are placed between each muscular suture. This is a purely adventitial later that covers the underlying mucosal suture. The anastomosis is finished by approximating the vasal sheath with six to eight interrupted sutures of 8-0 nylon, completely covering the anastomosis and relieving it of all tension (Fig. 67.22).

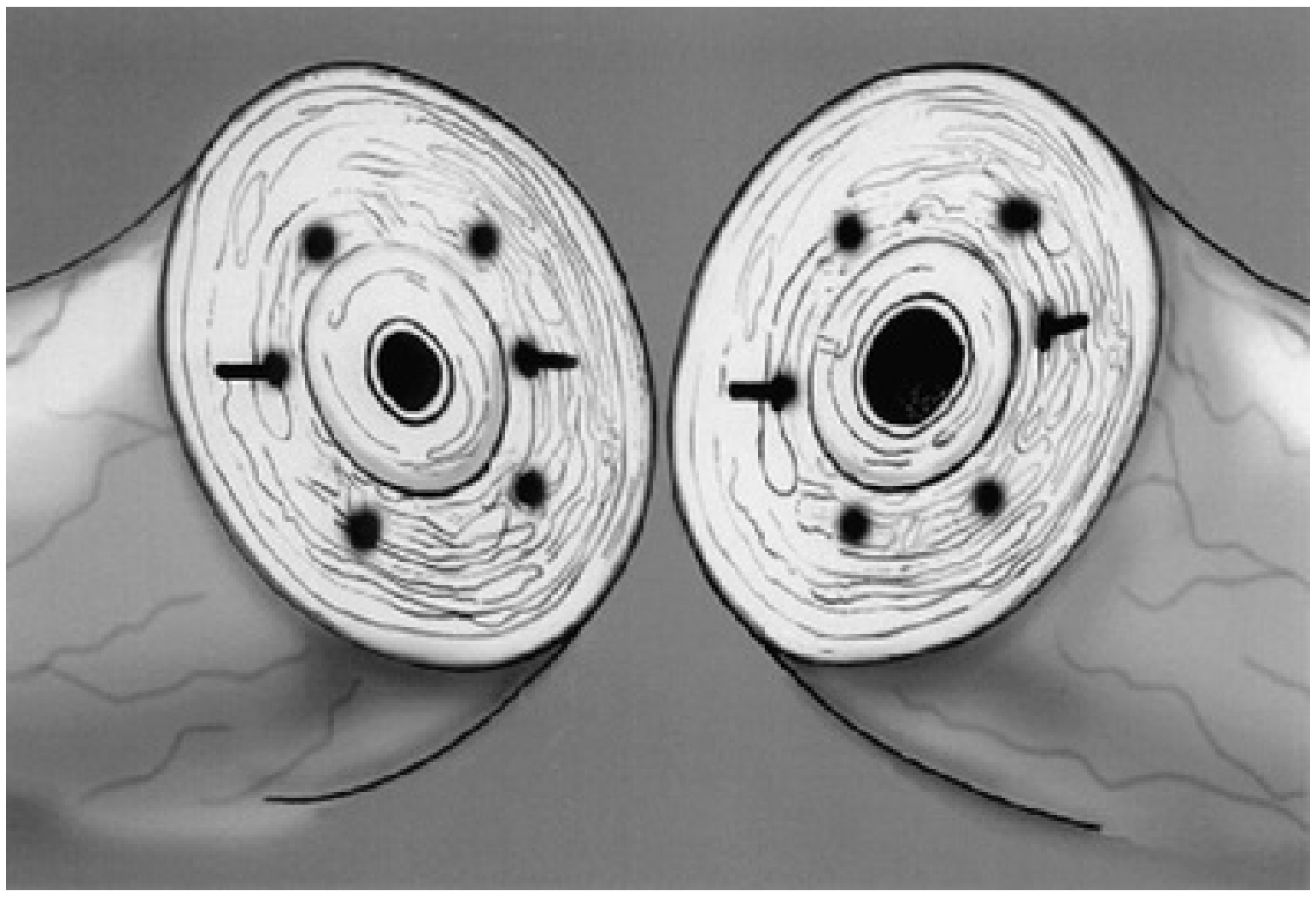

FIG. 67.15 The abdominal end of the vas is marked in the same way to exactly match the testicular end.

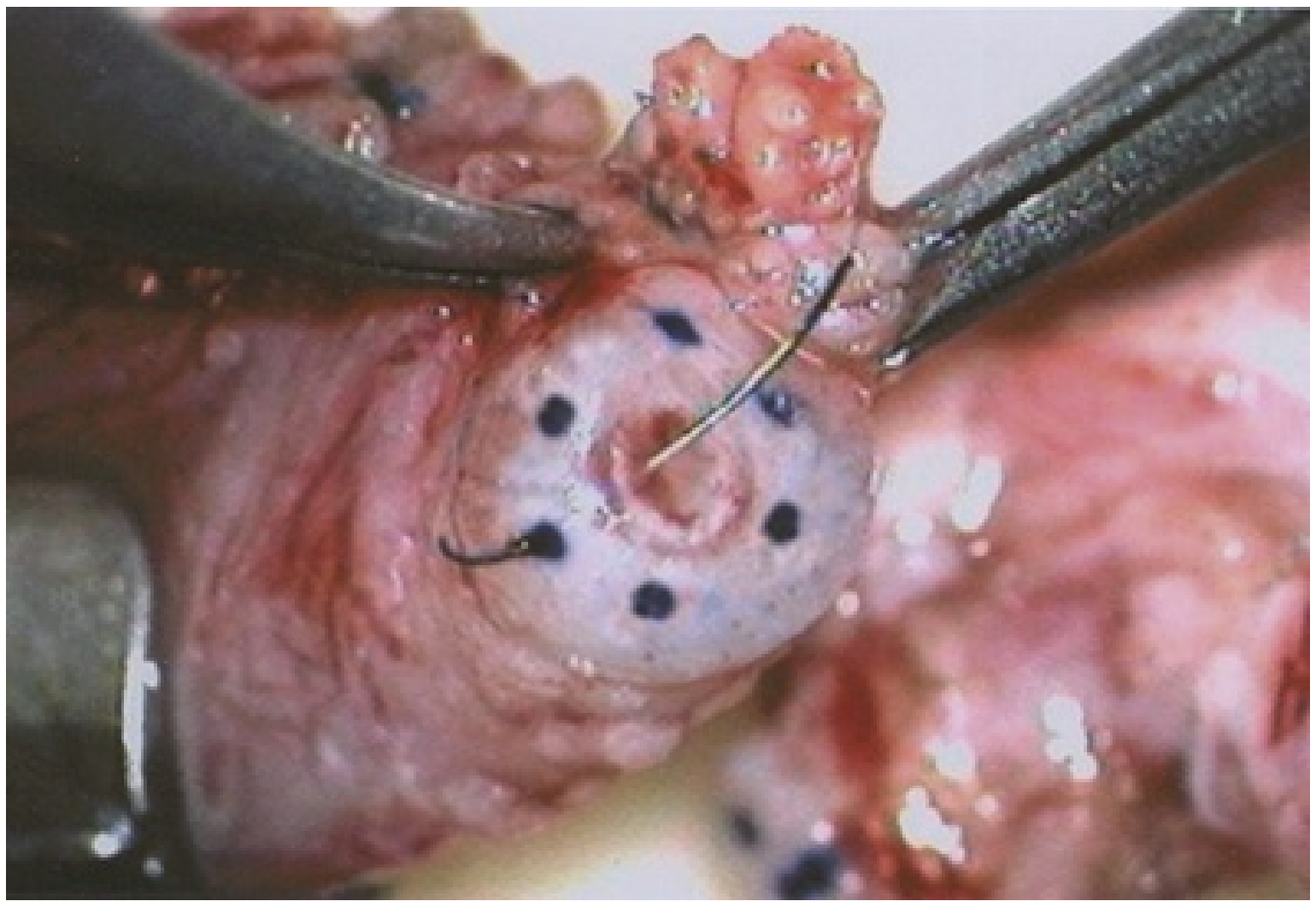

FIG. 67.16 Double-armed sutures allow inside-out placement.

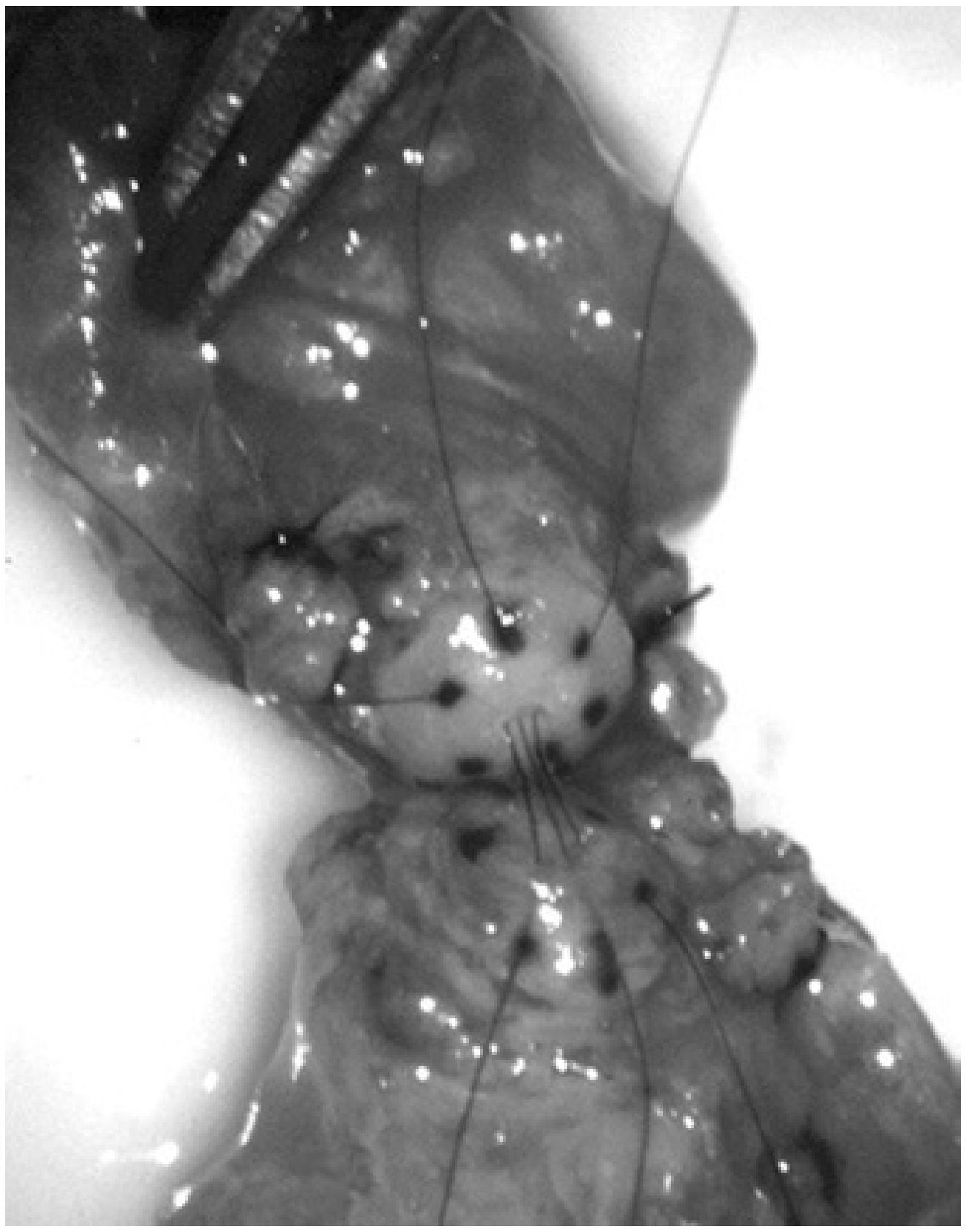

FIG. 67.17 The anastomosis is begun with the placement of three 10-0 mucosal sutures anteriorly.

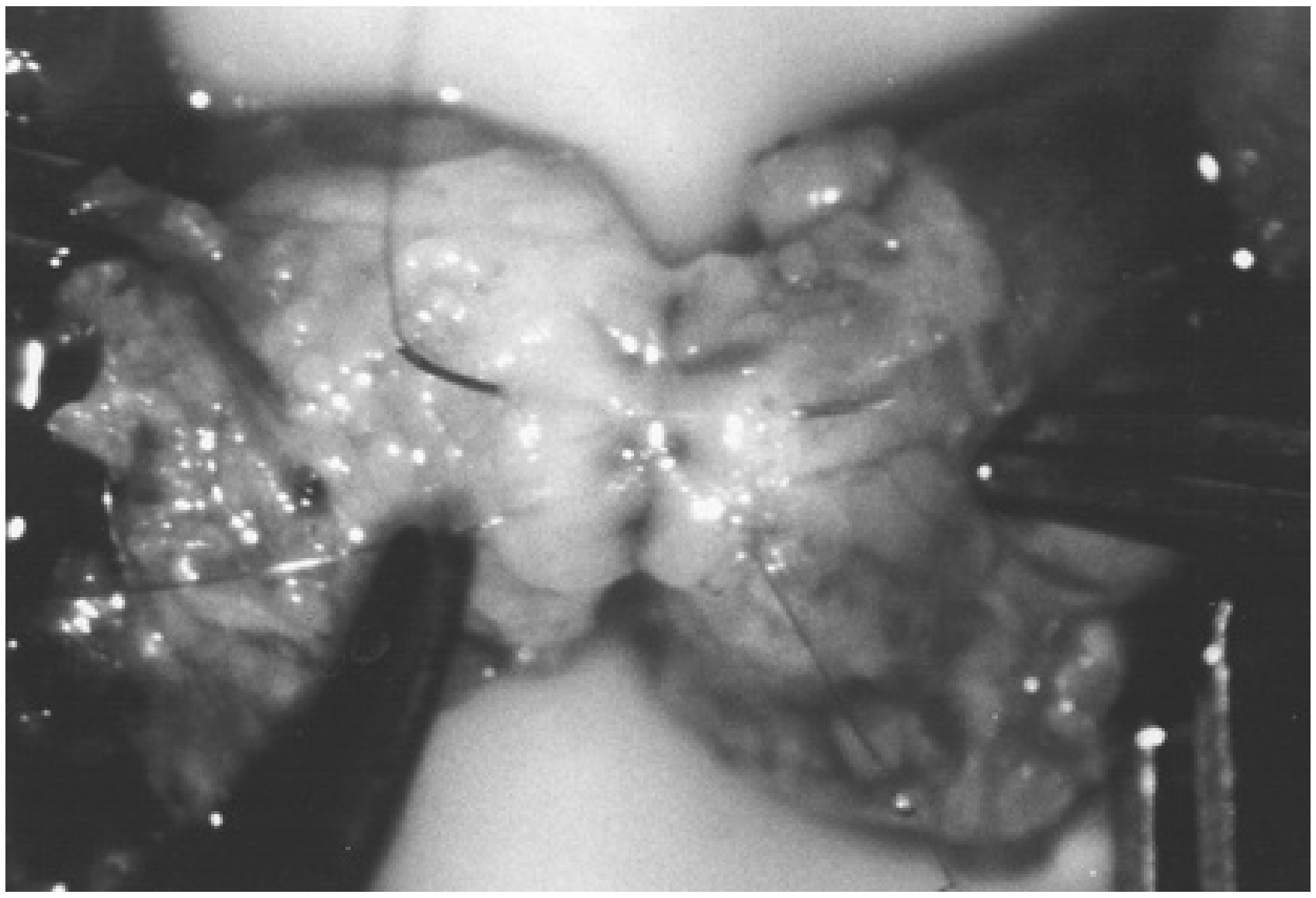

FIG. 67.18 Two 9-0 monofilament nylon deep muscularis sutures are placed exactly in between the previously placed mucosal sutures, just above, but not through the mucosa.

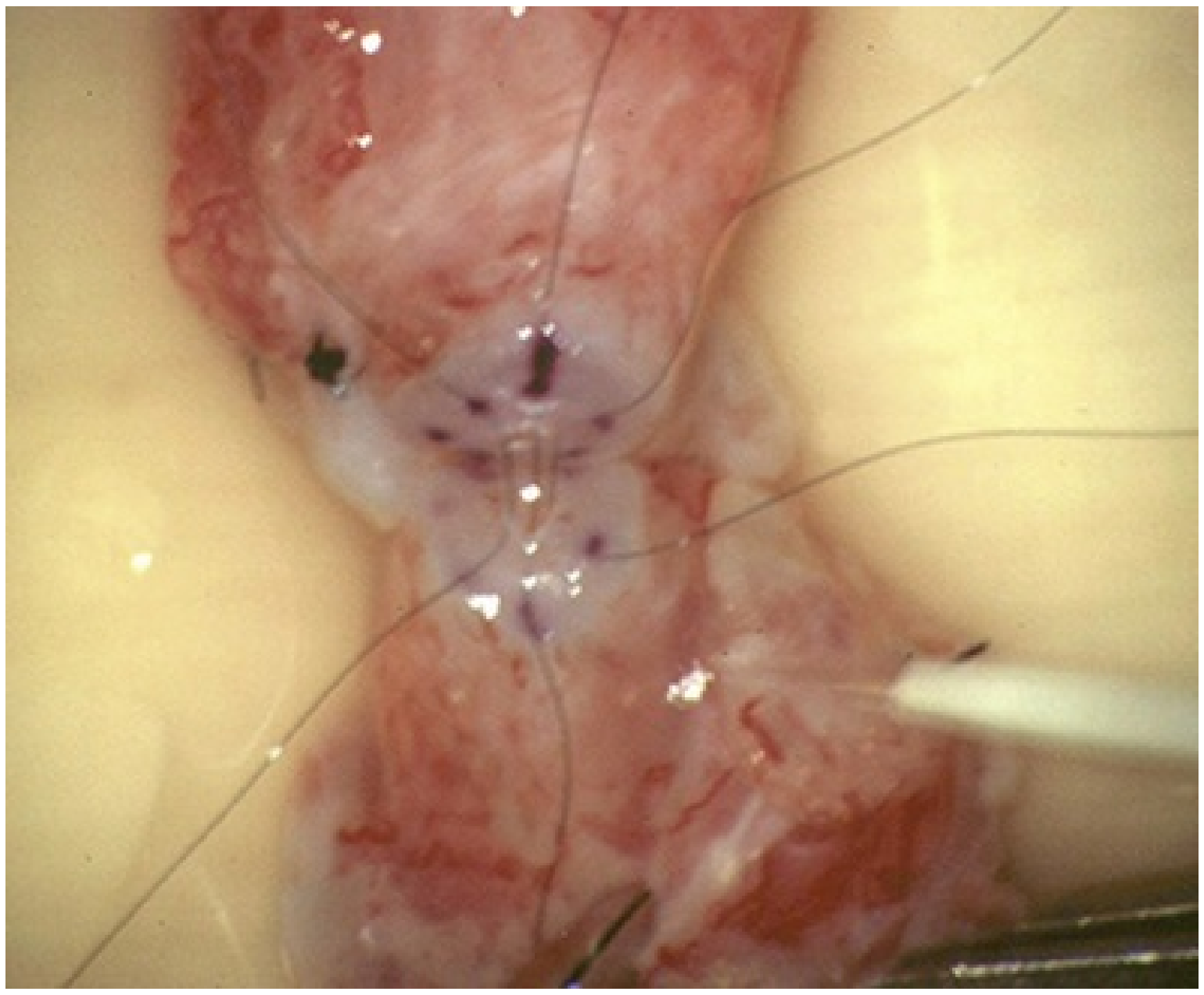

FIG. 67.19 The vas is rotated 180 degrees.

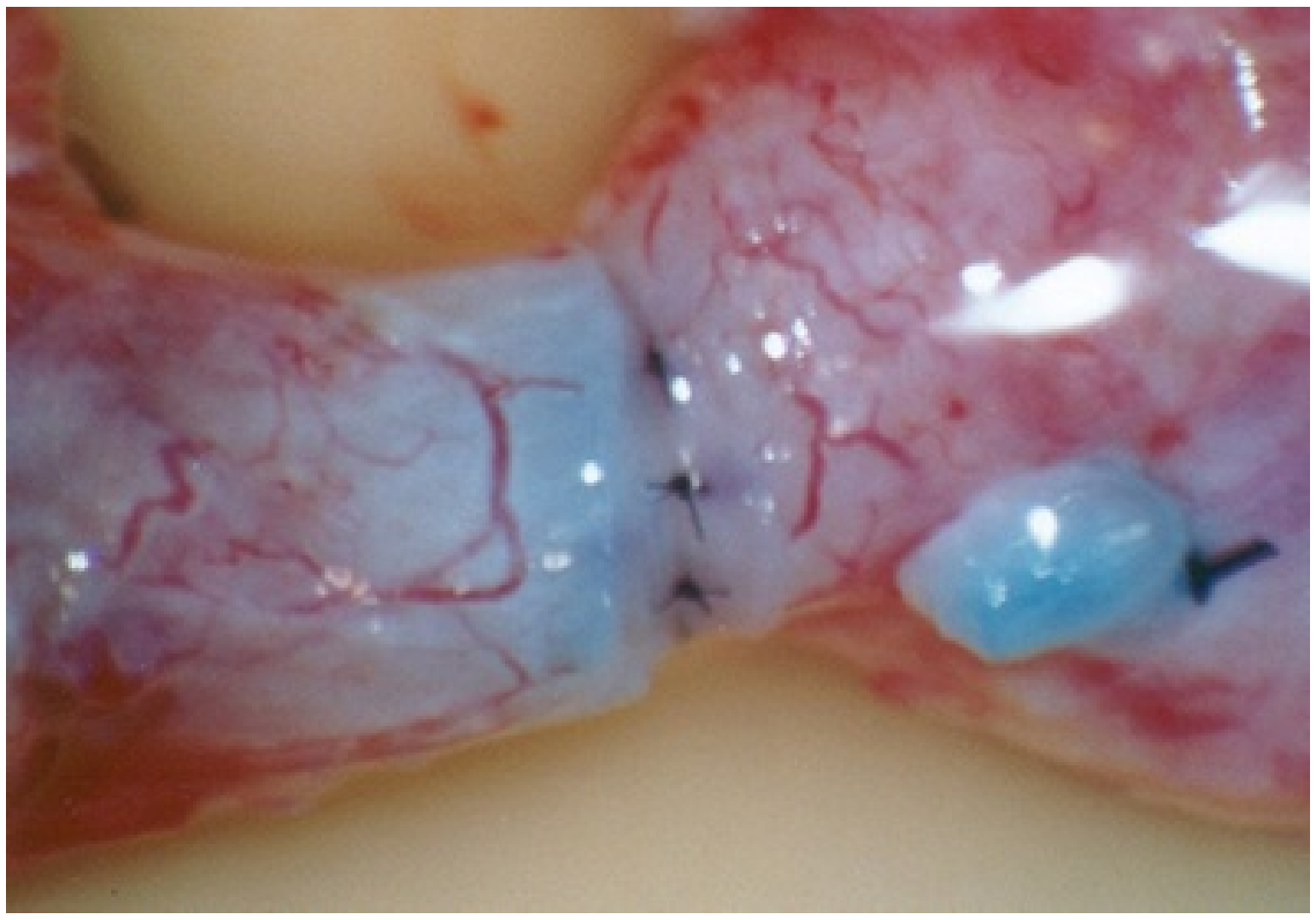

FIG. 67.20 Three additional 10-0 sutures are placed through each microdot and then tied to complete the mucosal portion of the anastomosis.

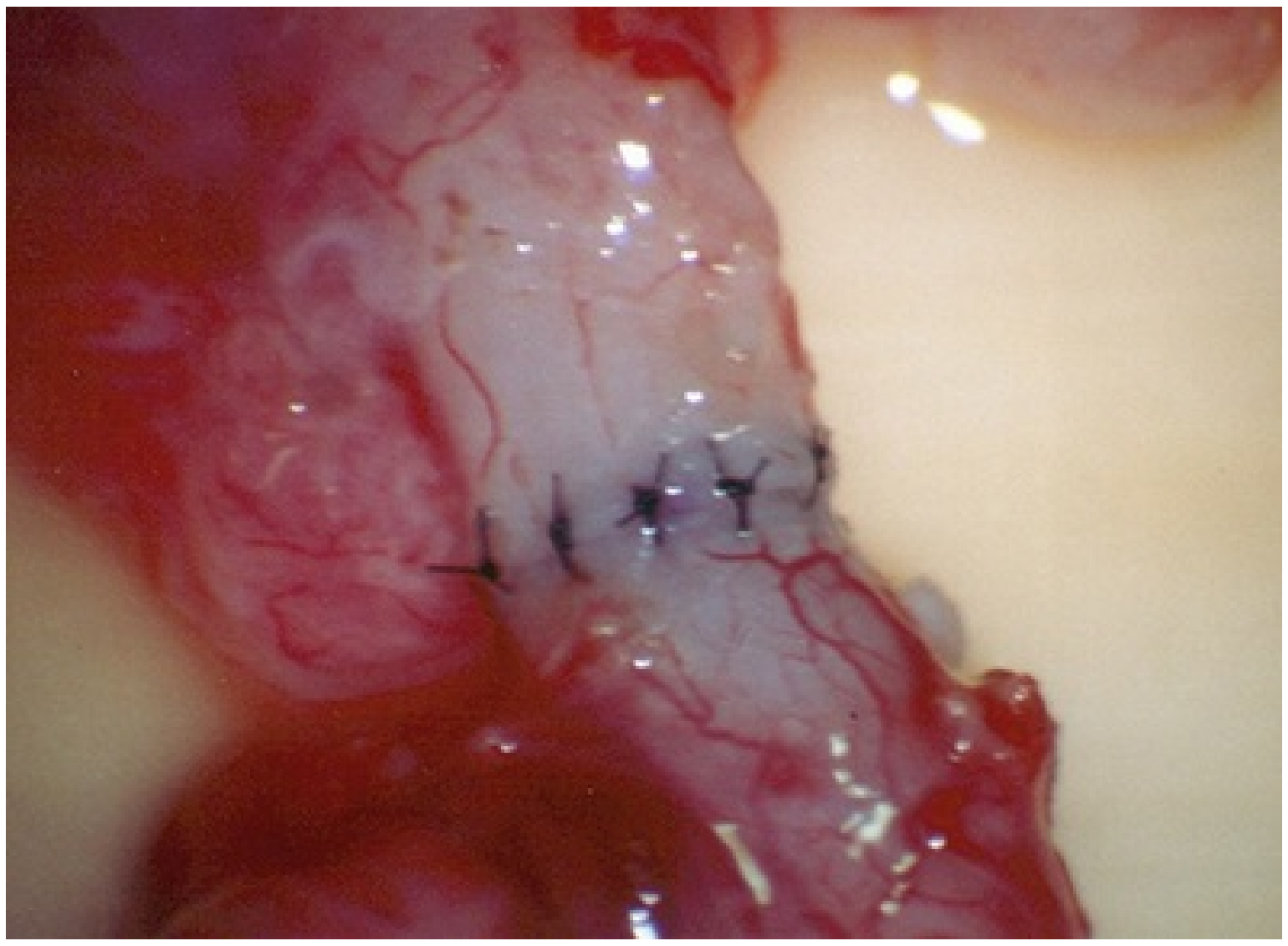

FIG. 67.21 Completion of the mucosal layer.

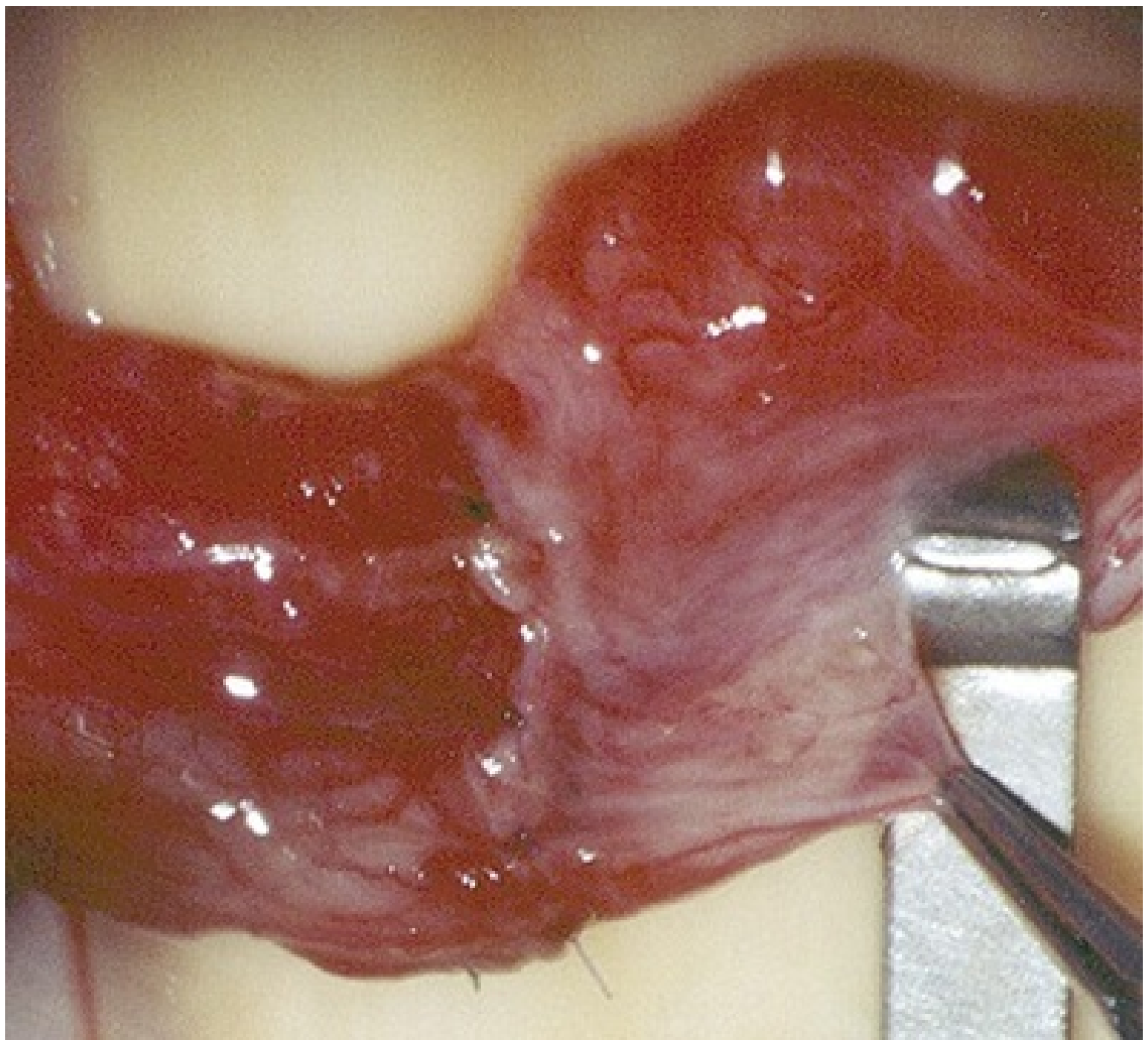

FIG. 67.22 The anastomosis is finished by approximating the vasal sheath with six to eight interrupted sutures of 8-0 nylon completely covering the anastomosis and relieving it of all tension.

Anastomosis in the Convoluted Vas

Vasovasostomy performed in the convoluted portion of the vas deferens is technically more demanding than anastomoses in the straight portion. **Fear of cutting back into the convoluted vas to obtain healthy tissue may lead surgeons to complete an anastomosis in the straight portion when the testicular end of the vas has poor blood supply, unhealthy or friable mucosa, or gritty fibrotic muscularis.** Adherence to the following principles will enable anastomosis in the convoluted vas to succeed as often as those in the straight portion.

1. **A perfect transverse cut yielding a round ring of mucosa and a lumen directed straight down is essential.** A very oblique lumen with a thin flap of muscle and mucosa on one side is not acceptable (Fig. 67.23). The vas should be recut at 0.5-mm intervals until a perfect cut with good blood supply and healthy tissue is obtained. A slotted nerve clamp 2.5 or 3 mm in diameter and ultrasharp knife facilitates this part of the procedure (see Fig. 67.14). Often the vas must be recut 2 or 3

times until a satisfactory cut is obtained.

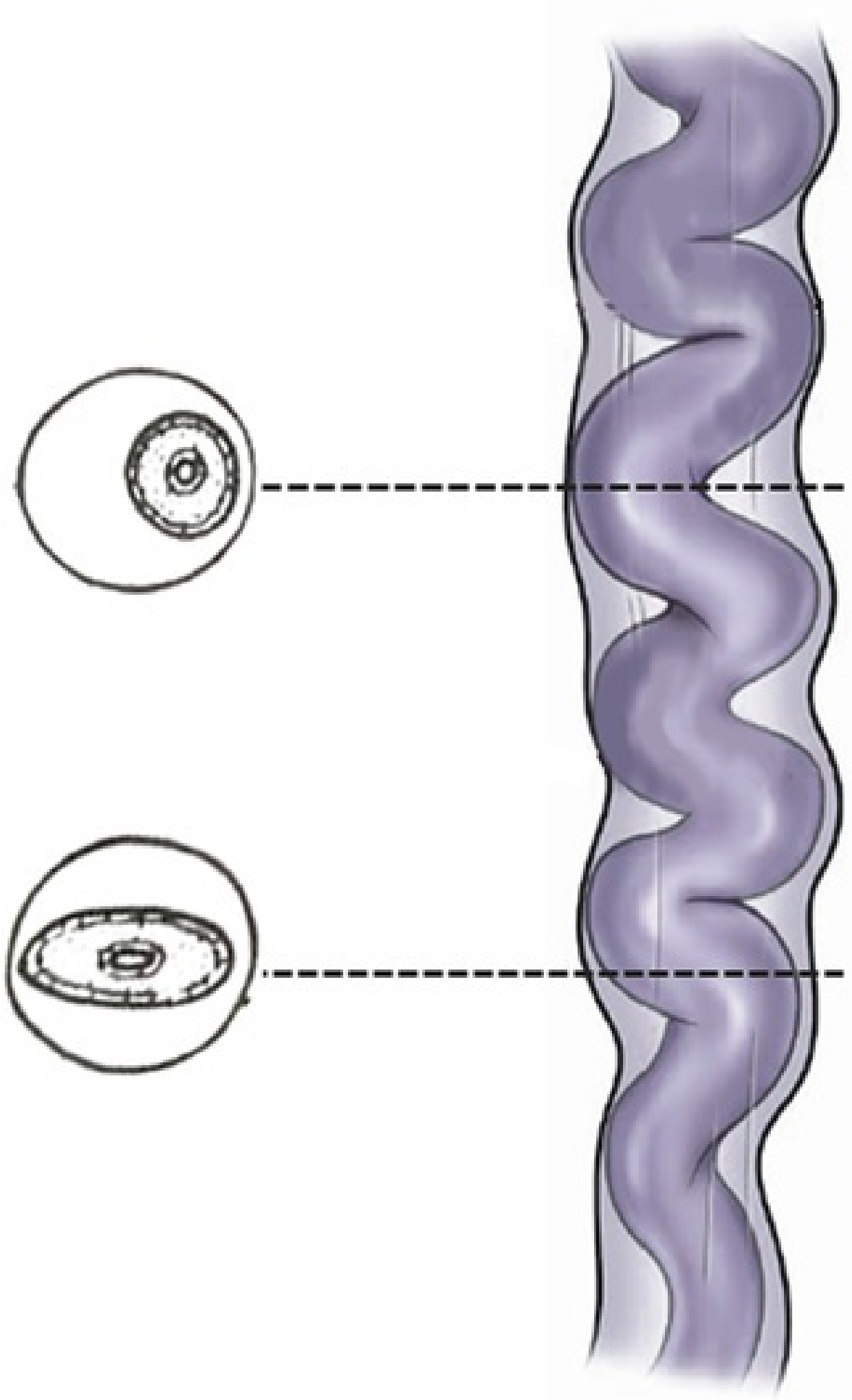

FIG. 67.23 An oblique lumen with a thin flap of muscle and mucosa on one side is not acceptable.

2. **The convoluted vas should not be unraveled.** This disturbs the blood supply at the anastomotic line.
3. The sheath of the convoluted vas may be carefully dissected free of its attachments to the epididymal tunica (see Fig. 67.12). This minimizes disturbance of its blood supply and provides the necessary length to perform a tension-free anastomosis.
4. Care must be taken to avoid taking large bites of the muscularis and adventitial layers on the convoluted side to prevent inadvertent perforation of adjacent convolutions.

5. Reinforce the anastomosis by approximating the vasal sheath of the straight portion to the sheath of the convoluted portion with six interrupted sutures of 7-0 nylon. This removes all tension from the anastomosis.

Crossed Vasovasostomy

This useful procedure often provides an easy solution for otherwise difficult problems (Hamidinia, 1988; Lizza et al., 1985; Sheynkin et al., 1998a). Crossover is indicated in the following circumstances:

1. Unilateral inguinal obstruction of the vas deferens associated with an atrophic testis on the contralateral side. A crossover vasovasostomy should be performed to connect a healthy testicle to the contralateral unobstructed vas.
2. Obstruction or aplasia of the inguinal vas or ejaculatory duct on one side and epididymal obstruction on the contralateral side

It **is preferable to perform one anastomosis with a high probability of success (vasovasostomy) than two operations with a much lower chance of success** (e.g., unilateral vasoepididymostomy and contralateral TURED).

Technique

The vas attached to the atrophic testis is transected at the junction of its straight and convoluted portion and its patency confirmed with a Ringer's or indigo carmine vasogram (Fig. 67.24). The contralateral vas is dissected with the normal testis toward the inguinal obstruction. It is clamped and transected as high up as possible with a right angle clamp. The testicular end of the vas is crossed through a capacious opening made in the scrotal septum; the surgeon proceeds with vasovasostomy as described earlier. This procedure is much easier than inguinal vasovasostomy, which requires finding both ends of the vas within the dense scar of a previous inguinal operation.

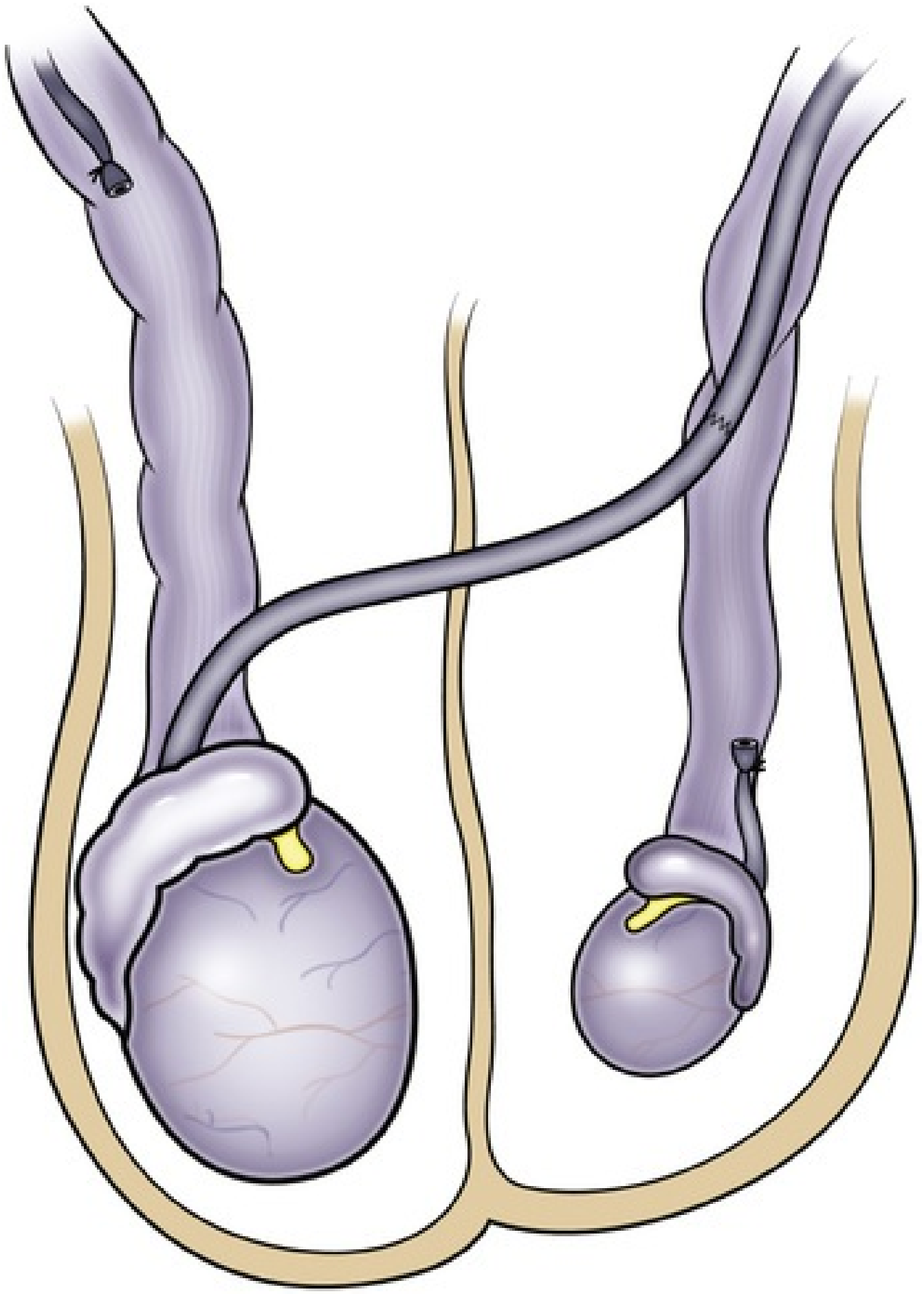

FIG. 67.24 Technique for vasovasostomy or vasoepididymostomy with contralateral testis.

Transposition of the Testis

Occasionally when vasal length is critically short, a tension-free crossed anastomosis can best be accomplished by testicular transposition (Fig. 67.25). The spermatic cord is always longer than the vas. The testes will comfortably cross through a generous opening in the septum and sit nicely in the contralateral scrotal compartment.

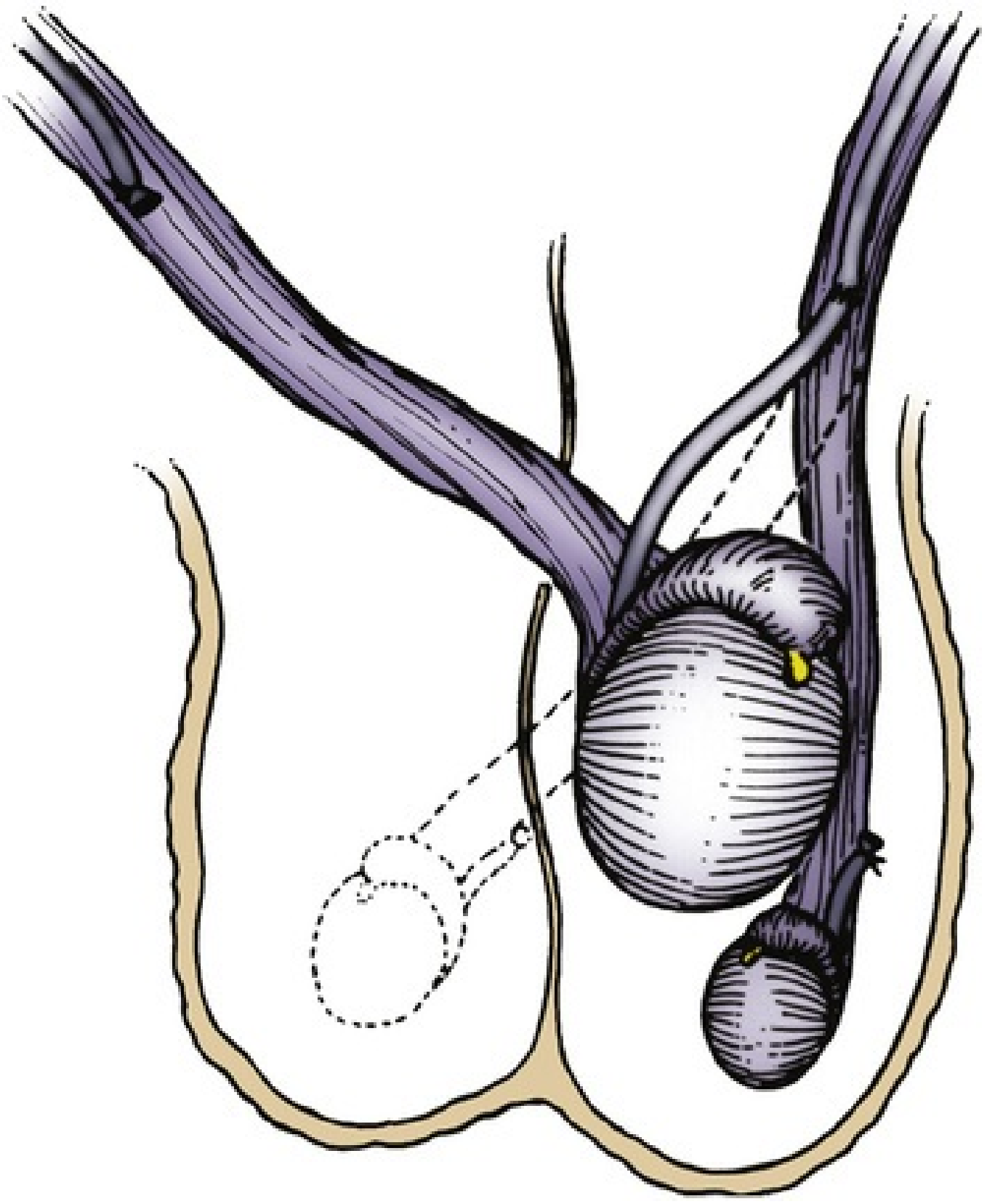

FIG. 67.25 When vasal length is critically short, a tension-free crossed anastomosis can best be accomplished by testicular transposition.

Wound Closure

If the vasal dissection was extensive, Penrose drains are brought out the dependent portion of the right and left hemiscrota and fixed in place with sutures and safety pins preferably before the anastomosis is begun. Placement of drains at the end of the procedure may potentially disturb the anastomosis. The dartos layer is approximated with interrupted 4-0 absorbable sutures and the skin with subcuticular sutures of 5-0 Monocryl. The wound heals with a fine scar. The use of through-and-through skin closures, which give an unacceptable “railroad-track”-looking scar, should be avoided. **Almost all of our procedures are performed on an ambulatory basis.** If drains were placed, the patients are given detailed instructions (with explicit drawings) on how to remove the drains the next morning.

Postoperative Management

Sterile fluffs gauze dressings are held in place with a snug-fitting scrotal supporter. Only perioperative antibiotics are used. Patients are discharged with a prescription for acetaminophen with codeine. They shower 48 hours after surgery. **They wear a scrotal supporter at all times (except in the shower), even when sleeping, for 6 weeks postoperatively. Thereafter, a scrotal supporter is worn during athletic activity, until pregnancy is achieved.** Desk work is resumed in 3 days. No heavy work or sports are allowed for 3 weeks. **No intercourse or ejaculation is allowed for 3 weeks postoperatively.** Semen analyses are obtained at 1, 3, and 6 months postoperatively and every 6 months thereafter. If azoospermia persists at 6 months, a redo vasovasostomy or vasoepididymostomy is necessary.

Postoperative Complications

The most common complication is hematoma. In 2500 operations, 7 small hematomas occurred. None required surgical drainage. Most were walnut sized and perivasal. They take 6 to 12 weeks to resolve. Wound infection did not occur. Late complications include sperm granuloma at the anastomotic site (approximately 5%). This usually is a harbinger of eventual obstruction. Late stricture and obstruction are disappointingly common (see following). **Progressive loss of motility followed by decreasing counts indicates stricture.** Our recent change from Proline to **nylon sutures** (Sheynkin, 1999b)**, use of the microdot system to prevent leaks, extensive dissection of the vas until healthy mucosa and muscularis is identified, constant attention to the preservation of good blood supply, and generous use of scrotal support until pregnancy is established have reduced the incidence of late obstruction from 12%** (Matthews et al., 1995) **to 5%** (Kolettis and Thomas, 1997) **at 18 months after surgery. Because of the risk of late stricture and obstruction, we strongly encourage cryopreservation of semen specimens as soon as motile sperm appear in the ejaculate.**

Long-Term Follow-Up Evaluation After Vasovasostomy

When sperm are found in the vasal fluid on at least one side at the time of surgery, the anastomotic technique described results in appearance of sperm in the ejaculate in 99.5% of men (Dabaja et al., 2013; Goldstein et al., 1998). Pregnancy has occurred in 52% of couples followed for at least 2 years and 63% when female factors are excluded with outcomes dependent on the time since vasectomy and female partner age (Boorjian et al., 2004; Gerrard et al., 2007; Kolettis et al., 2003, 2005; Wosnitzer and Goldstein, 2013).

Key Points: Vasovasostomy

- The presence of serum antisperm antibodies corroborates the diagnosis and presence of active spermatogenesis.
- The vas deferens should not be stripped of its sheath.
- When the vasal gap is extremely large, additional length can be achieved by dissecting the convoluted vas free of its attachments to the epididymal tunica. The convoluted vas should not be unraveled.
- Successful vasovasostomy relies on an accurate mucosa-to-mucosa approximation, a tension-free and leakproof anastomosis, good blood supply, healthy mucosa and muscularis, and good atraumatic anastomotic technique.

Surgery of the Epididymis

Detailed knowledge of epididymal anatomy and physiology (presented in Chapters 63 and 64) is essential before undertaking surgery of this delicate but important structure. Sperm motility and fertilizing capacity progressively increase during passage through the 200-micron diameter, 12- to 15-foot long, tightly coiled single tubule. When the epididymis is obstructed and functionally shortened after vasoepididymostomy, even very short lengths of epididymis are able to adapt and allow some sperm to acquire motility and fertilizing capacity (Jow et al., 1993; Silber, 1989). Adaptation may gradually continue up to 2 years after surgical reconstruction, with progressive improvement in the fertility and motility of sperm. Nevertheless, preservation of the greatest possible length of functional epididymis is most likely to result in the best sperm quality after vasoepididymostomy (Schlegel and Goldstein, 1993; Schoysman and Bedford, 1986). Furthermore, because the wall of the epididymis is thinnest in the caput region and gradually thickens and because of the increasing numbers of smooth muscle cells in its more distal (inferior) end, anastomoses are technically easier to perform and more likely to succeed in its distal regions. **Because the corpus and cauda epididymis is a single tubule with a very small diameter, injury or occlusion of a tubule anywhere along its length will lead to total obstruction of outflow at that level.** For these reasons, **magnification, with loupes for macrodissection and with the operating microscope for anastomosis, is essential for performing all epididymal surgery.**

Fortunately, the epididymis is blessed with a rich blood supply derived from the testicular vessels superiorly and the deferential vessels inferiorly (see Testicular Blood Supply and Chapter 21). Because of the extensive interconnections between these branches, either the testicular or deferential branches (but not both) to the epididymis may be divided without compromising epididymal viability.

Conversely, because the epididymal branches of the testicular artery are medial to and separate from the main testicular artery and veins, surgical procedures may be performed on the epididymis without compromise to testicular blood supply.

Vasoepididymostomy

Before the development of microsurgical techniques, accurate approximation of the vasal lumen to that of a specific epididymal tubule was not possible. Vasoepididymostomy was performed by aligning the vas deferens adjacent to a slash made in multiple epididymal tubules and hoping a fistula would form. Results with this primitive technique were poor. Microsurgical approaches allow accurate approximation of the vasal mucosa to that of a single epididymal tubule (Silber, 1978) resulting in marked improvement in the patency and pregnancy rates (Chan et al., 2005; Schlegel, 1993). **However, microsurgical vasoepididymostomy is the most technically demanding procedure in all of microsurgery.** In almost no other operation are results so dependent upon technical perfection. **Microsurgical vasoepididymostomy should be attempted only by experienced microsurgeons who perform the procedure frequently.**

Indications

The indications for vasoepididymostomy at the time of vasectomy reversal were reviewed earlier. For obstructive azoospermia not resulting from vasectomy, **vasoepididymostomy is indicated when complete spermatogenesis in at least one testis is confirmed by either prior biopsy or highly positive serum antisperm antibodies** (Lee et al., 2009), **and scrotal exploration reveals the absence of sperm in the vasal lumen with no vasal or ejaculatory duct obstruction.** The preoperative evaluation is identical to that described for vasovasostomy.

Microsurgical End-to-Side Vasoepididymostomy

End-to-side techniques of vasoepididymostomy have the advantage of being minimally traumatic to the epididymis and relatively bloodless (Table 67.3; Chan et al., 2005; Fogdestam et al., 1986; Krylov and Borovikov, 1984; Schiff et al., 2005; Thomas, 1987; Wagenknecht et al., 1980). The end-to-side technique does not disturb the epididymal blood supply. When the level of epididymal obstruction is clearly demarcated by the presence of markedly dilated tubules proximally and collapsed tubules distally, the site at which the anastomosis should be performed is readily apparent. The end-to-side approach has the advantage of allowing accurate approximation of the muscularis and adventitia of the vas deferens to a precisely tailored opening in the tunica of the epididymis. This is the preferred technique when vasoepididymostomy is performed simultaneously with inguinal vasovasostomy because it is possible to preserve the vasal blood supply deriving from epididymal branches of the testicular artery (Fig. 67.26). This provides blood supply to the segment of vas intervening between the two anastomoses. Maintenance of the deferential artery's contribution to the testicular blood supply is also important in situations in which the integrity of the testicular artery is in doubt because of prior surgery such as orchiopexy, nonmicroscopic varicocelectomy, or hernia repair.

TABLE 67.3

Comparison of Three Common Techniques for Vasoepididymostomy

TECHNIQUES	ADVANTAGES	DISADVANTAGES
Intussusception (LIVE)	Two sutures placed longitudinally in the dilated epididymal tubule provide four points of fixation Virtually bloodless anastomosis	Cannot assess tubular fluid for sperm before anastomosis setup
End-Side	Virtually bloodless anastomosis Epididymal fluid can be examined before anastomosis	Difficult suture placement to a collapsed tubule
End-End	Epididymal fluid can be examined before anastomosis Easy and rapid identification of the level of obstruction in the epididymis Allows upward mobilization of epididymis to bridge a large vasal gap	Difficult hemostasis on transected epididymis Difficult to identify the proper tubule for anastomosis Difficult outer layer closure Vasal blood supply from inferior epididymal artery is sacrificed

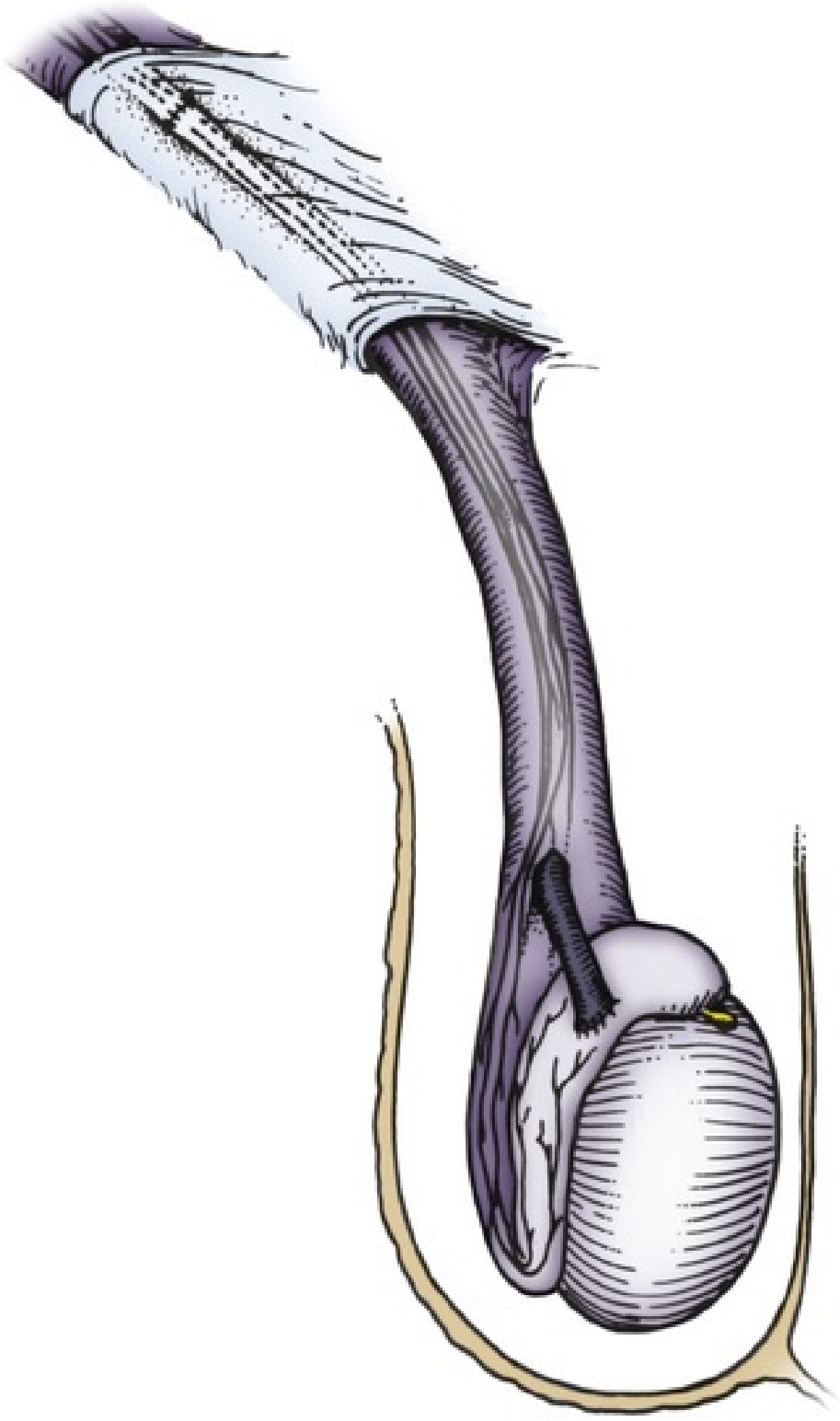

FIG. 67.26 Vasoepididymostomy is performed simultaneously with inguinal vasovasostomy because it is possible to preserve the vasal blood supply deriving from the epididymal branches of the testicular artery.

The testis is delivered through a 3- to 4-cm high vertical scrotal incision. The vas deferens is identified, isolated with a Babcock clamp, and then surrounded with a Penrose drain at the junction of the straight and convoluted portions of the vas deferens. Using 8× to 15× power magnification provided by the operating microscope, the vasal sheath is longitudinally incised with a microknife, and a bare segment of vas stripped of its carefully preserved vessels is delivered. The vas is hemitransected with the ultrasharp knife until the lumen is entered (Fig. 67.27). **The vasal fluid is sampled. If microscopic examination of this fluid reveals the absence of sperm, the diagnosis of epididymal obstruction is confirmed.** Patency of the vas and ejaculatory ducts is confirmed by cannulating the abdominal end of the vas with a 24-gauge angiocatheter sheath and gently injecting lactated Ringer's solution with a 1-mL tuberculin syringe (see Fig. 67.3). Further confirmation of patency may be obtained by injecting indigo carmine, catheterizing the bladder, and observing blue-tinged urine. The vas is then completely transected using a 2.5-mm slotted nerve clamp (see Fig. 67.27), and the vas is prepared as for vasovasostomy as described earlier.

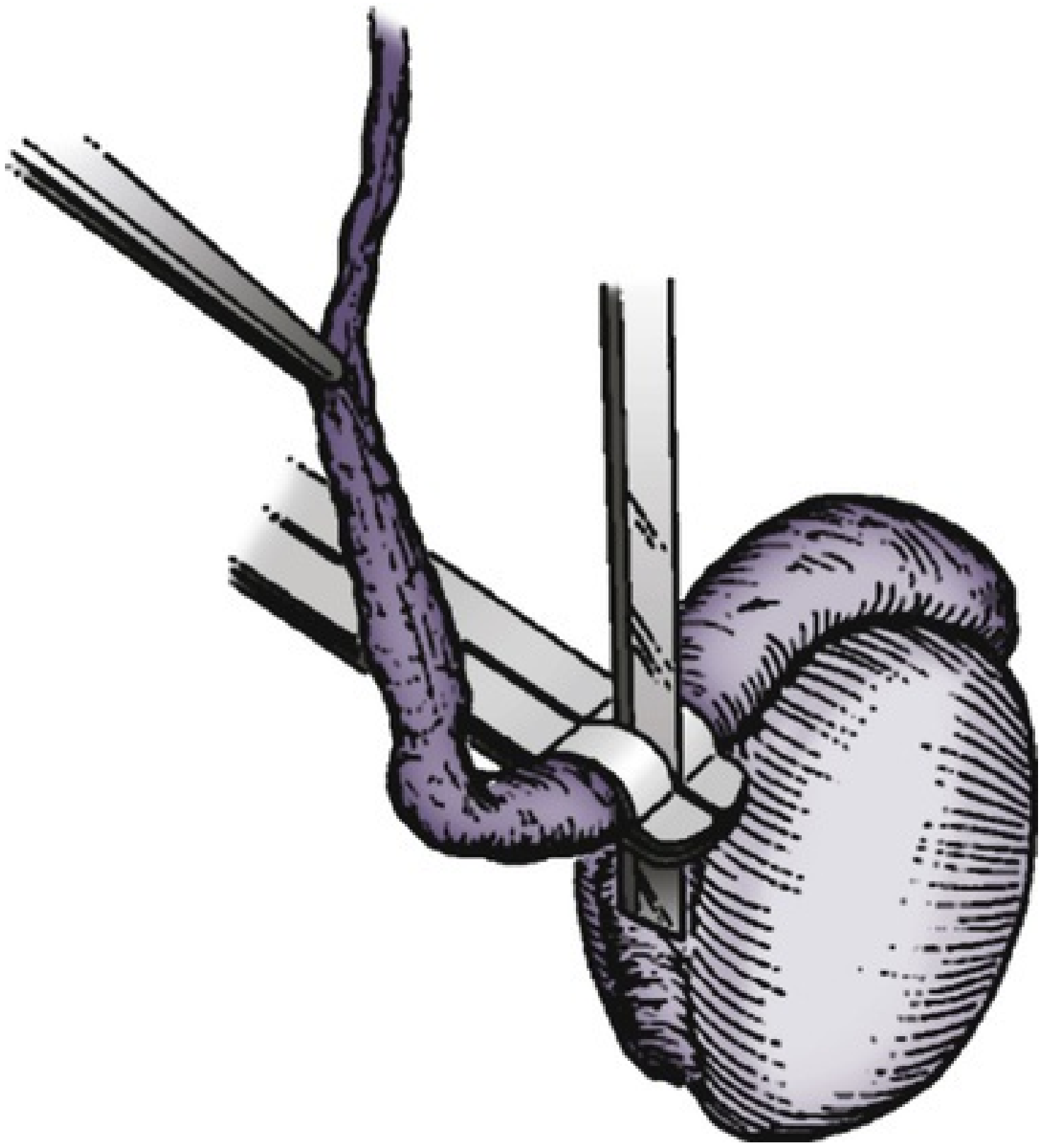

FIG. 67.27 The vas is completely transected using a 2.5-mm slotted nerve clamp.

After opening the tunica vaginalis, the epididymis is inspected under the operating microscope. An anastomotic site is selected above the area of suspected obstruction, proximal to any visible sperm granulomas, where dilated epididymal tubules are clearly seen beneath the epididymal tunica (Fig. 67.28). A relatively avascular area is grasped with sharp jewelers forceps and the epididymal tunica tented upward. **A 3- to 4-mm buttonhole is made in the tunica with microscissors to create a round opening that matches the outer diameter of the previously prepared vas deferens.** The epididymal tubules are then gently dissected with a combination of sharp and blunt dissections until dilated loops of tubule are clearly exposed (Fig. 67.29). **If the level of**

obstruction is not clearly delineated, after the buttonhole opening is made in the tunic, a 70-μm diameter tapered needle from the 10-0 nylon microsuture is used to puncture the epididymal tubule beginning as distal as possible and fluid sampled from the puncture site. When sperm are found, the puncture sites are sealed with microbipolar forceps, a new buttonhole made in the epididymal tunic just proximally, and the tubule prepared as described previously.

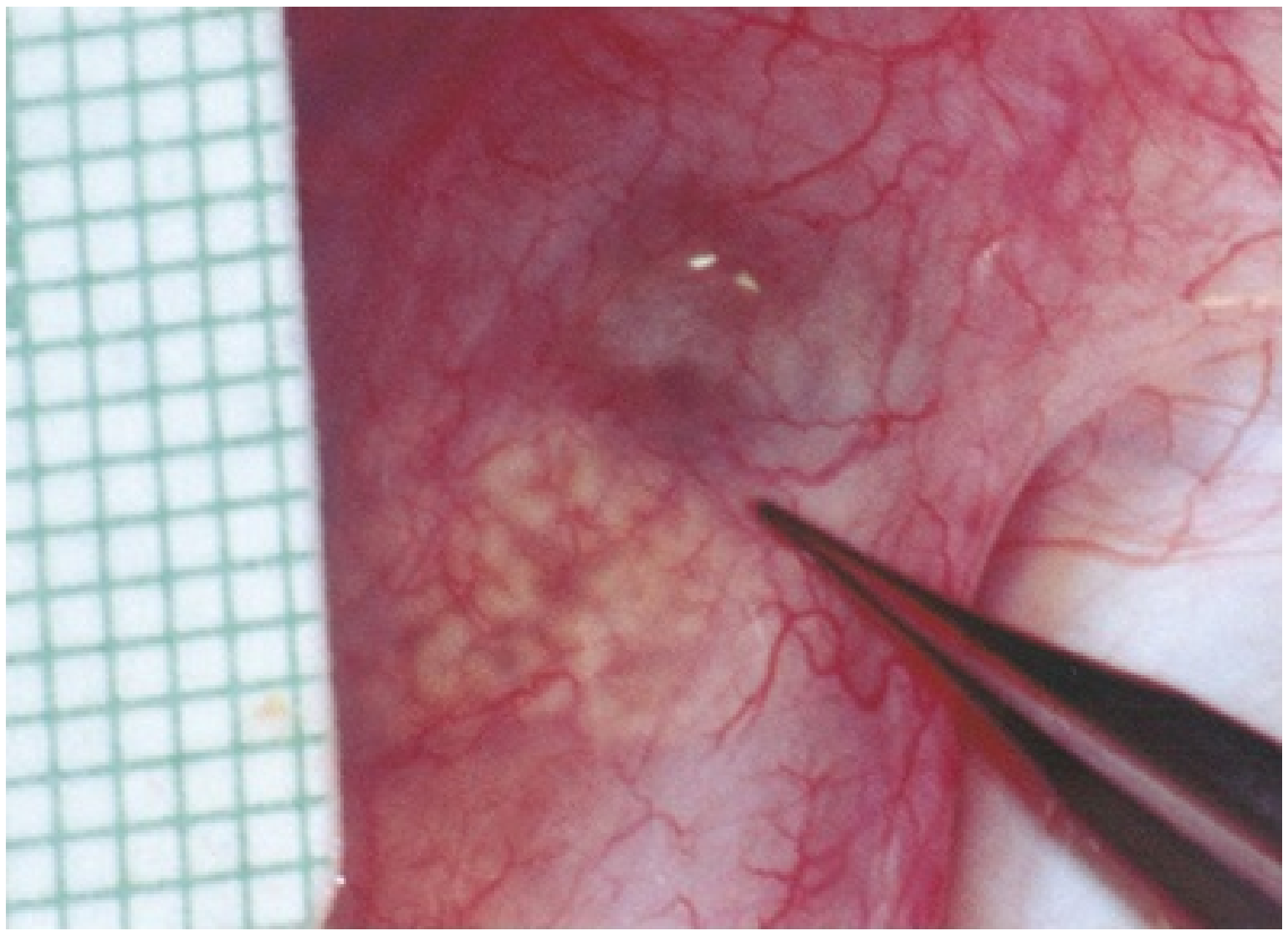

FIG. 67.28 Diluted epididymal tubules are clearly seen beneath the epididymal tunica.

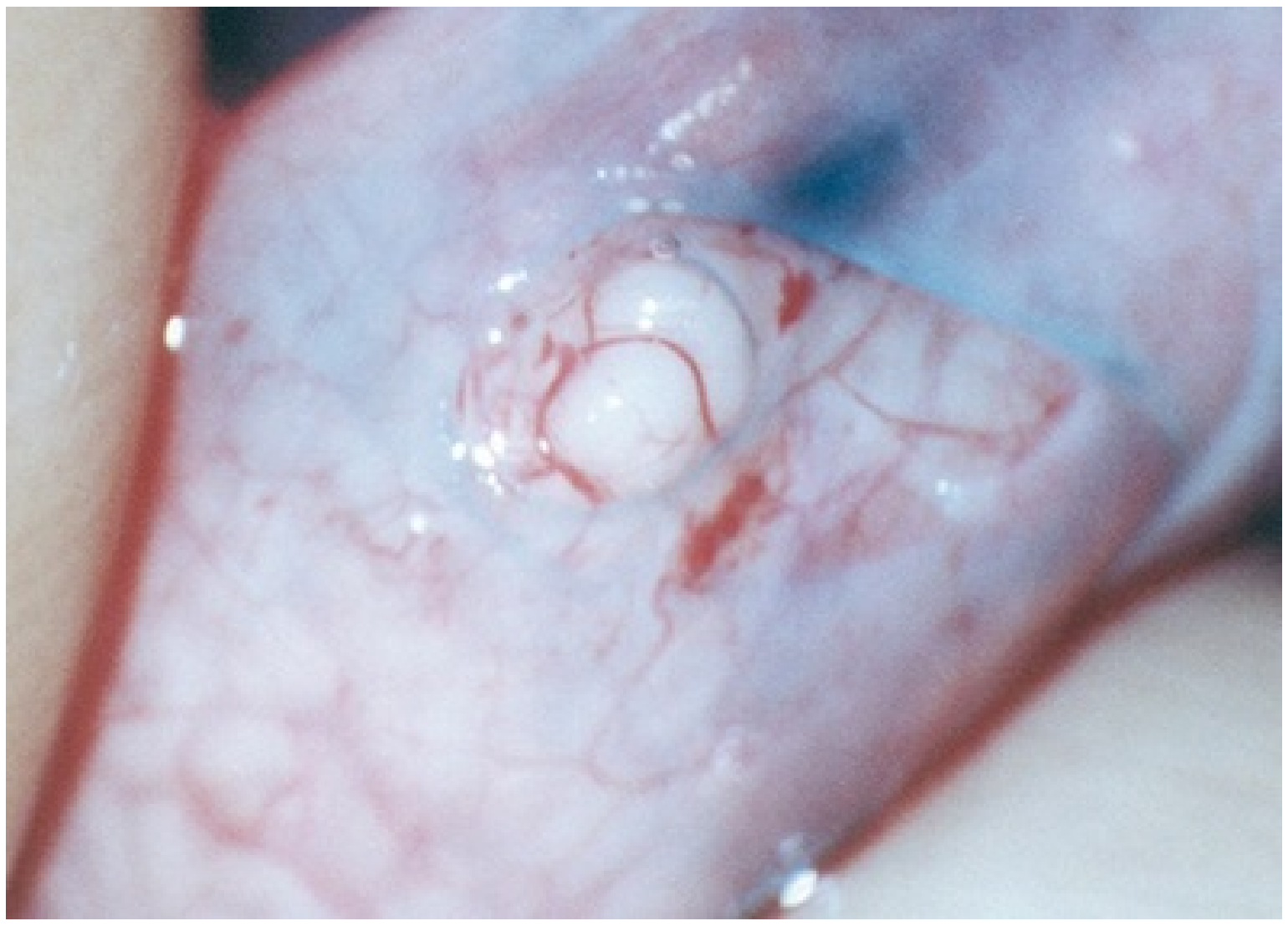

FIG. 67.29 Epididymal tubules are then gently dissected with a combination of sharp and blunt dissection until dilated loops of tubule are clearly exposed.

The vas deferens is drawn thru an opening in the tunica vaginalis and secured in proximity to the anastomotic site with two to four interrupted sutures of 6-0 polypropylene placed through the vasal adventitia and the tunica vaginalis. **The vasal lumen should reach the opening in the epididymal tunica easily, with length to spare.** The posterior edge of the epididymal tunica is then approximated to the posterior edge of the vas muscularis and adventitia with two to three interrupted sutures of double-armed 9-0 nylon (Fig. 67.30). This is done in such a way as to bring the vasal lumen in close approximation to the epididymal tubule selected for anastomosis.

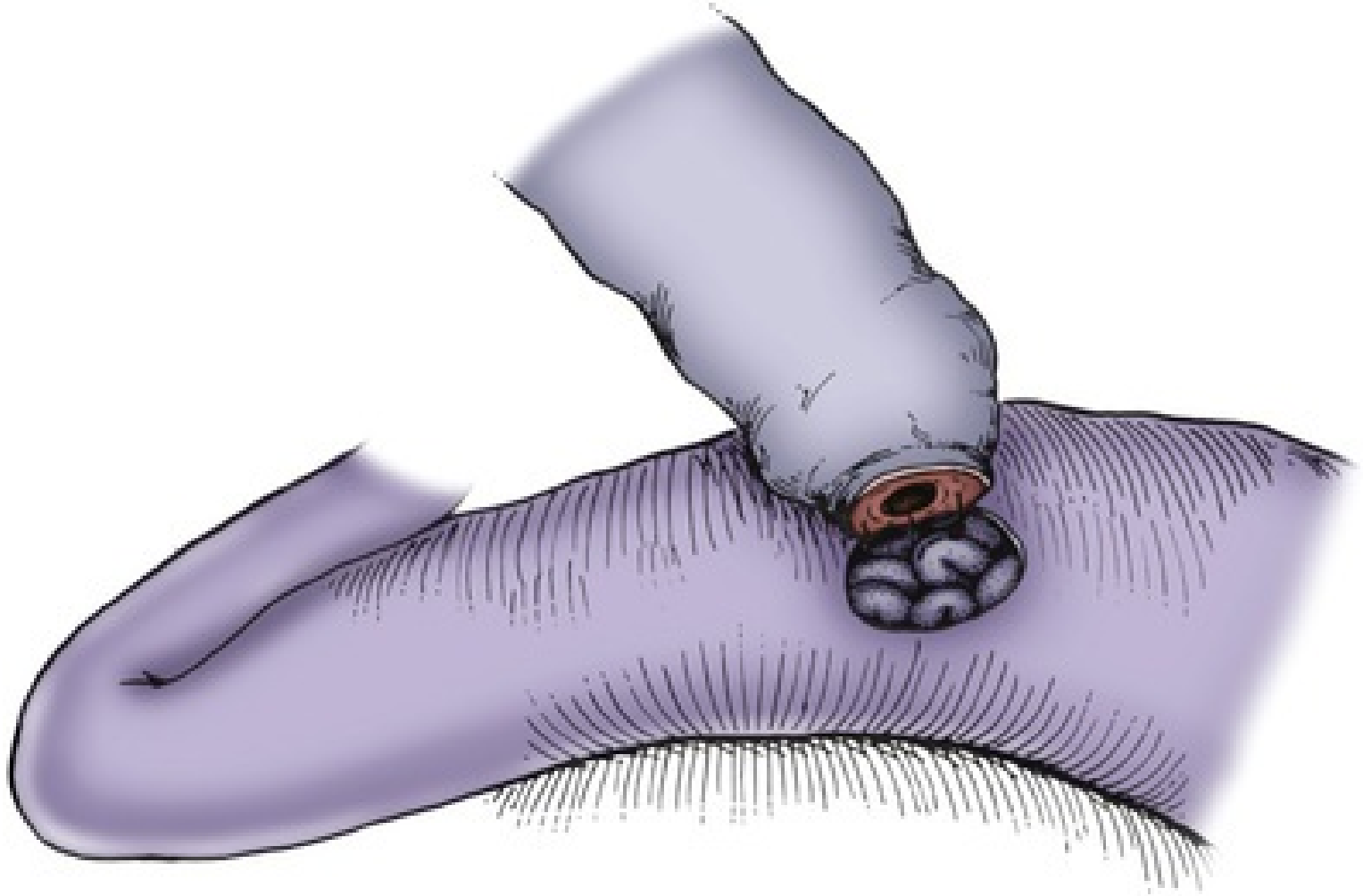

FIG. 67.30 The posterior edge of the epididymal tunica is reapproximated to the posterior edge of the vas muscularis and adventitia with two to three interrupted sutures.

Intussusception Vasoepididymostomy

Intussusception techniques have supplanted the older end-to-side techniques because they allow needle placement in a dilated tubule. Intussusception also plasters the wall of the epididymis against the inner vasal mucosa, and the normal flow of epididymal fluid from the epididymal tubule to the vas encourages this apposition and makes it more leakproof than older techniques in which the opening in the epididymal tubule was made before needle placement.

The original intussusception technique described by Berger (1998) employed three double-armed 10-0 sutures placed in the epididymal tubule in a triangular fashion and the use of a 9-0 needle to tear an opening in the middle of the triangle. **We now employ a two-stitch longitudinal intussusception (LIVE) technique for all vasoepididymostomies. It is much easier to perform and is even more successful.** With this method, four microdots are marked on the cut surface of the vas deferens and two parallel sutures are placed in the distended epididymal tubule longitudinally but not pulled through (Fig. 67.31). Marmar (2000) suggests mounting two needles in the needle holder and placing them simultaneously transversely in the tubule. However, if the needles are not pulled through to avoid leakage of fluid and tubular collapse, they can be placed one at a time with greater control and accuracy (Chan et al., 2005; Schiff et al., 2005). Longitudinal placement also allows a larger opening to be made in the epididymal tubule without risk of completely transecting it. Using a 15-degree microknife, an opening is made exactly between and parallel to the two previously placed sutures. We have also developed a single-arm technique of vasoepididymostomy that is almost as effective as the double-arm technique (Fig. 67.32; Monoski, 2007). This technique may prove valuable when double-arm sutures are not available.

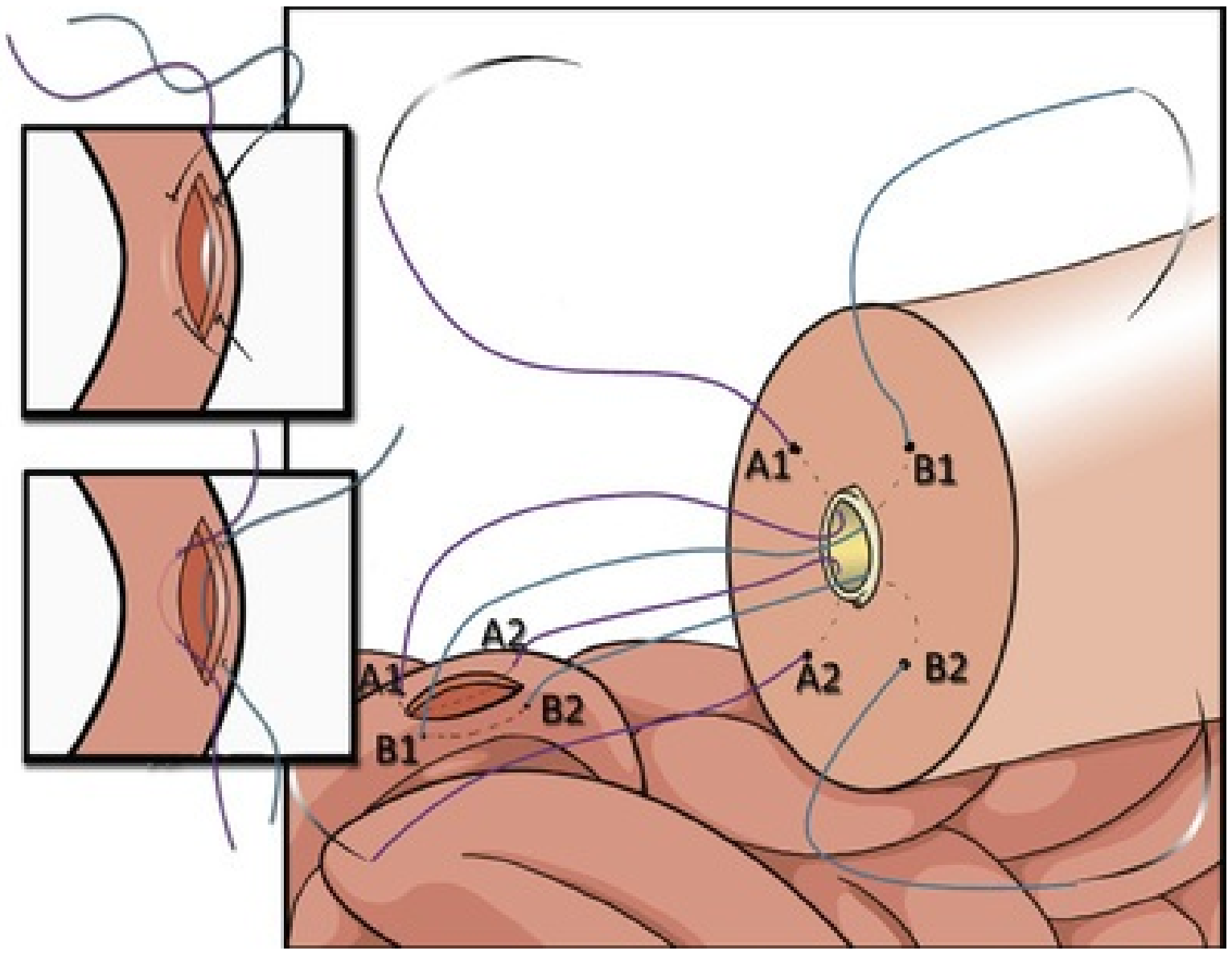

FIG. 67.31 Four microdots are marked on the cut surface of the vas deferens and two parallel sutures are placed in the distended epididymal tubule longitudinally but not pulled through.

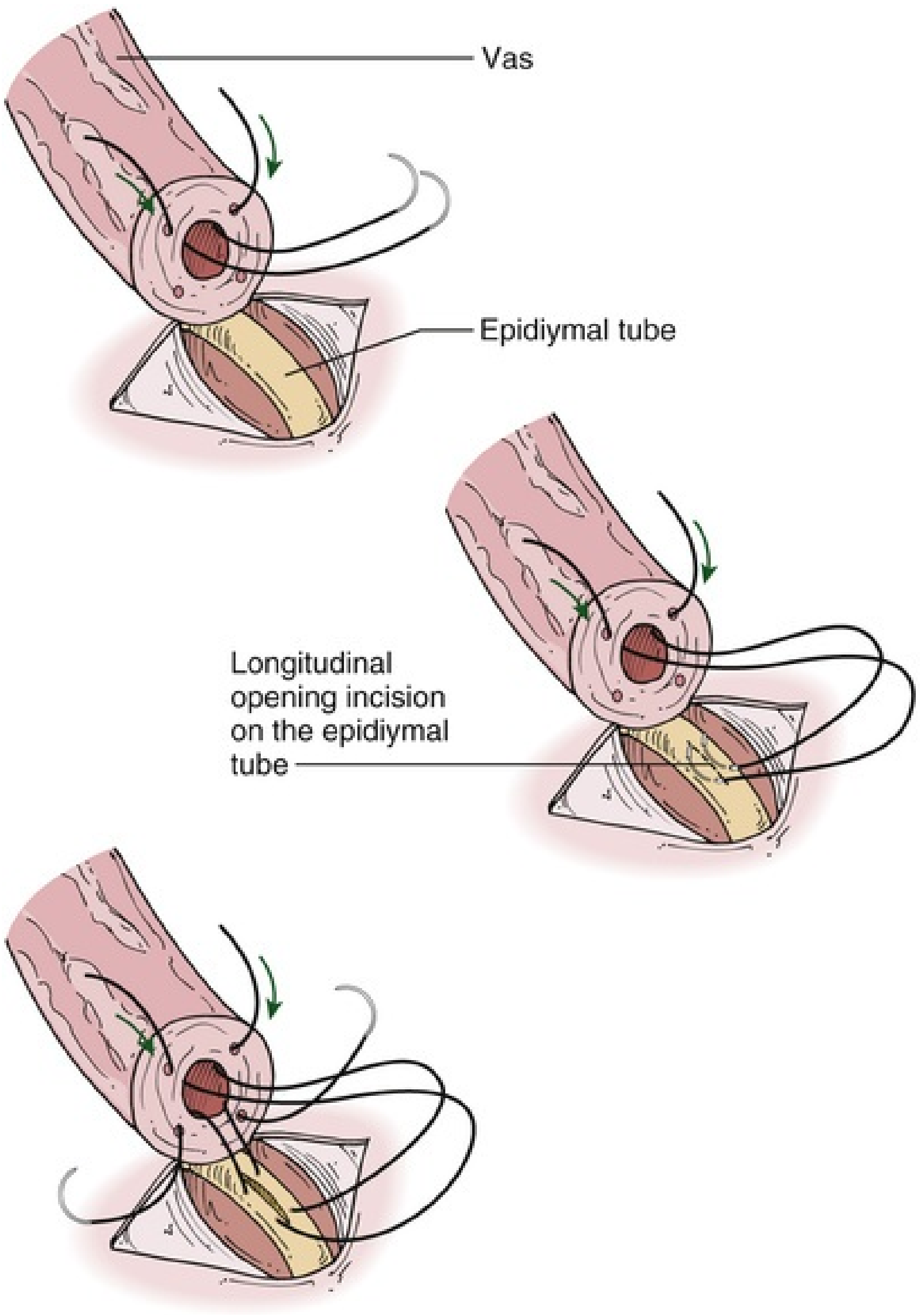
Vas
Epidiymal tube
Longitudinal opening incision on the epidiymal tube

FIG. 67.32 A single-arm technique of vasoepididymostomy is almost as effective as the double-arm technique.

Technique When Vasal Length Is Severely Compromised

When there is inadequate length of the vas deferens to reach the dilated epididymal tubule without tension, the epididymis can be dissected down to the vasoepididymal junction and then dissected off the testes as in the older end-to-end operation.

After the vas has been prepared, the tunica vaginalis is opened and the testis delivered. Inspection of the epididymis under the operating microscope may reveal a clearly delineated site of obstruction. Often a discrete yellow sperm granuloma is noted, above which the epididymis is indurated and the tubules dilated and below which the epididymis is soft and the tubules collapsed. **If the level of obstruction is not clearly delineated, a 70-micron tapered needle from the 10-0 nylon microsuture is used to puncture the epididymal tubule beginning as distal as possible, and fluid is sampled from the puncture site until sperm are found. At that level the puncture is sealed with microbipolar forceps, and the epididymis is ligated just proximal to the puncture site with a 6-0 nylon suture. The epididymis is then dissected off the testis and flipped up to obtain additional length.** To do this, the epididymis is encircled with a small Penrose drain at the level of obstruction and, using 2.5× power loupe magnification, dissected off of the testis for 3 to 5 cm, yielding sufficient length to perform the anastomosis. Usually a nice plane can be found between the epididymis and testis, and injury to the epididymal blood supply can be avoided by staying right on the tunica albuginea of the testis. The inferior and, if necessary, middle epididymal branches of the testicular artery are ligated and divided to free up an adequate length of epididymis. The superior-epididymal branches entering the epididymis at the caput are always preserved and can provide adequate blood supply to the entire epididymis. The tunica vaginalis in then closed over the testis with 5-0 Vicryl. This prevents drying of the testis and thrombosis of the surface testicular vessels during the anastomosis. The dissected epididymis remains outside the tunica vaginalis.

If the epididymis is indurated and dilated throughout its length, the epididymis is dissected to the vasoepididymal (VE) junction. This dissection is often facilitated by first dissecting the convoluted vas to the VE junction from below, and then, after encircling the epididymis with a Penrose drain, dissecting the epididymis to the VE junction from above. In this way the entire VE junction can be freed up. This will allow preservation of maximal epididymal length in cases of distal obstruction near the VE junction. After the epididymis is dissected off of the testis and flipped-up, a two-stitch end-to-side intussusception anastomosis is performed as described earlier.

Varicocelectomy and Vasoepididymostomy

Although varicocelectomy can be simultaneously performed at the time of vasovasostomy (Mulhall et al., 1997), especially if intact deferential veins can be identified going across the anastomosis, I do not recommend doing simultaneous varicocelectomy and vasoepididymostomy. After varicocelectomy, the venous pressure in the epididymal vein is very high and, because vasoepididymostomy is a significantly more delicate and difficult procedure with a lower success rate than vasovasostomy, the increased bleeding at the site of the vasoepididymostomy may negatively affect the success rate. I recommend performing the vasoepididymostomy first, waiting 6 months, and, if sperm quality remains poor, and/or serum testosterone levels are low, then repairing the varicocele microsurgically.

Long-Term Follow-Up Evaluation and Results

Microsurgical vasoepididymostomy in the hands of experienced and skilled microsurgeons results in the appearance of sperm in the ejaculate in 50% to 85% of men. Patency rates with the intussusception technique can exceed 80% (Berger, 1953; Brandell, 1999; Marmar, 2000). With the classic end-to-side or older end-to-end method, the patency rate is about 70%, and 43% of men with sperm will impregnate their wives after a minimum follow-up of 2 years (Pasqualotto et al., 1999; Schlegel and Goldstein, 1993). With the intussception techniques, patency rates are 70% to 90% (Chan et al., 2005; Kolettis and Thomas, 1997; Schiff et al., 2005). Regardless of technique, pregnancy rates are higher the more distal the anastomosis is performed (Silber, 1989). **With the older end-to-end or end-to-side methods, at 14 months after surgery 25% of initially patent anastomoses have shut down** (Matthews et al., 1995)**. With intussusception technique, the late shutdown rates appear to be less than 10%,** but long-term follow-up with these techniques have not been reported. **Nevertheless, we recommend banking sperm intraoperatively** (Matthews and Goldstein, 1996) **and as soon as they appear in the ejaculate postoperatively after vasoepididymostomy, regardless of technique employed.** In men with very low counts or poor sperm quality postoperatively and men who remain azoospermic, the sperm intraoperatively can be used for IVF with intracytoplasmic sperm injection. Persistently azoospermic men without cryopreserved sperm can opt for either a redo vasoepididymostomy and/or microscopic epididymal sperm aspiration combined with IVF and intracytoplasmic sperm injection (see Varicocelectomy).

Key Points: Vasoepididymostomy

- Vasoepididymostomy is the most technically demanding procedure in all of microsurgery and should only be attempted by experienced microsurgeons who perform the procedure frequently.

Transurethral Resection of the Ejaculatory Ducts

Ejaculatory duct obstruction is usually a congenital anomaly that represents the opposite end of the spectrum of excurrent ductal system anomalies, which begin with congenital complete absence of the vas deferens and most of the epididymis. When the aplastic segment occurs at the terminal end of the vas, where the ejaculatory duct enters the urethra, it is potentially correctable by transurethral resection (TUR; Kadioglu et al., 2001; Ozgok et al., 2001; Paick et al., 2000; Schroeder-Printzen, 2000; Yurdakul et al., 2008). Occasionally ejaculatory duct obstruction results from chronic prostatitis or extrinsic compression of the ejaculatory ducts by prostate or seminal vesical duct cysts (Cornel et al., 1999; Kadioglu et al., 2001; Paick et al., 2000). Higher ejaculatory duct pressures have been directly measured in men with ejaculatory duct obstruction (Eisenberg et al., 2008).

Diagnosis

The workup leading to the diagnosis of probable ejaculatory duct obstruction is covered in Chapter 66. Briefly, **ejaculatory duct obstruction is suspected in azoospermic or severely oligo- and/or asthenospermic men with at least one palpable vas deferens, a low semen volume, acid semen pH, and negative, equivocal, or low semen fructose levels.** If these men have normal serum levels of FSH and testis biopsy reveals normal spermatogenesis, the diagnosis of ejaculatory duct obstruction is entertained.

Digital rectal examination may reveal a midline cystic structure. **Transrectal sonography is key for the diagnosis and treatment of ejaculatory duct obstruction.** A midline cystic lesion or dilated ejaculatory ducts and seminal vesicles can be visualized sonographically. As described earlier in this chapter, **transrectal ultrasound-guided aspiration of the cystic or dilated ejaculatory ducts or seminal vesicles is performed** (Jarow, 1994)**. The aspirate is examined microscopically and, if motile sperm are found, they are cryopreserved and 2 to 3 mL indigo carmine diluted with water-soluble radiographic contrast is instilled. If a radiograph confirms a potentially resectable lesion, TUR of the ejaculatory ducts is performed without the**

need for prior vasography because the presence of sperm in the seminal vesicles indicates that at least one epididymis is patent and that the cyst or dilated ejaculatory duct communicates with a nonobstructed vas. The instillation of indigo carmine assists in localizing the opening of the ejaculatory duct and confirms when resection has successfully opened the obstructed system. **Transrectal sonography with aspiration should be performed immediately before anticipated surgery and employs the same bowel prep and antibiotic prophylaxis used for transrectal prostate biopsy.**

If no sperm are found in the aspirate, vasography is necessary, as described in Technique of Vasography and Interpretation of Findings. **If no sperm are found in either vas when the vasotomy is made and vasography reveals ejaculatory duct obstruction, it is best to abandon attempts at reconstruction and simply perform microsurgical epididymal sperm aspiration and cryopreservation for future IVF/ICSI. Simultaneous vasoepididymostomy and TUR of the ejaculatory ducts has never worked in my experience.** If ejaculatory duct obstruction is confirmed by vasography employing a 50% water-soluble contrast medium and sperm are present in the vasa, the 3-Fr whistle tip ureteral vasography stents are left in place so that a dilute indigo carmine solution can be injected by the assistant to aid resection.

Technique

Cold knife incision alone almost always leads to reobstruction. The resectoscope, with the 24-Fr cutting loop, is engaged with a finger placed in the rectum, providing anterior displacement of the posterior lobe of the prostate. The ejaculatory ducts course between the bladder neck and the verumontanum and exit at the level of and along the lateral aspect of the verumontanum (Fig. 67.33). **Resection of the veru often reveals the dilated ejaculatory duct orifice or cyst cavity. Resection should be carried out in this region with great care to preserve the bladder neck proximally, the striated sphincter distally, and the rectal mucosa posteriorly.** Efflux of indigo carmine from dilated orifices confirms adequate resection. **Excessive coagulation must be avoided.** If formal vasography was performed, the hemivasotomies are carefully closed, employing microsurgical technique. A Foley catheter is left overnight, and the patient receives an additional 7 days of oral antibiotics.

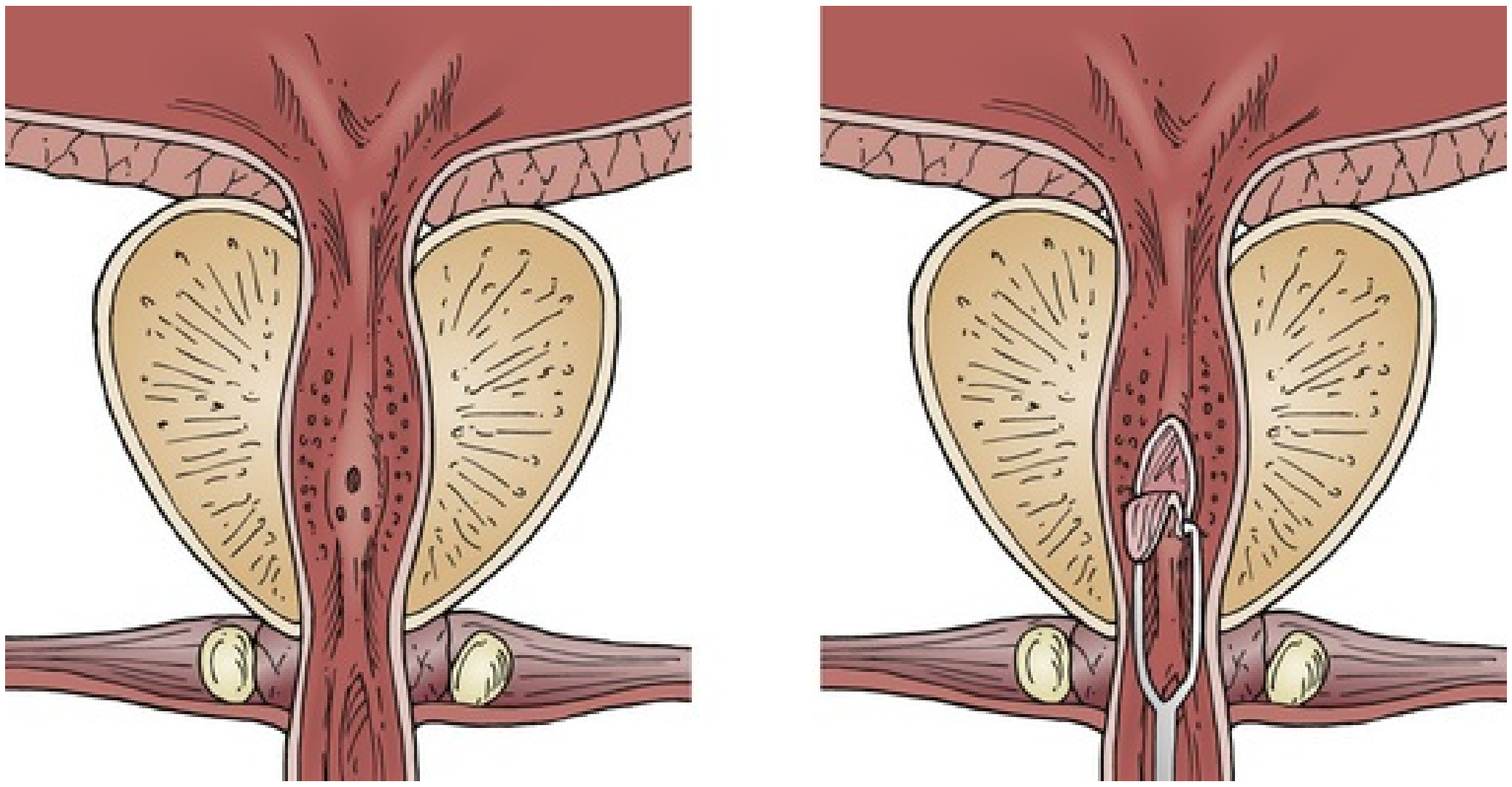

FIG. 67.33 The ejaculatory ducts course between the bladder neck and the verumontanum and exit at the level of and along the lateral aspect of the verumontanum.

Complications

Reflux

Reflux of urine into the ejaculatory ducts, vas, and seminal vesicles occurs after a majority of resections. This can be documented by voiding cystourethography or measuring semen creatinine levels (Malkevich and Nagler, 1994). Contamination of semen by urine impairs sperm quality.

Epididymitis

Reflux can lead to acute and chronic epididymitis. Recurrent epididymitis often results in epididymal obstruction. The incidence of epididymitis after TUR is probably underestimated. Symptomatic chemical epididymitis may occur from refluxing urine. **Chronic low-dose antibacterial suppression, such as that employed for vesicoureteral reflux, may be necessary until pregnancy is achieved.** If epididymitis is chronic and recurrent, vasectomy or even epididymectomy may be necessary.

Retrograde Ejaculation

Even when care has been taken to spare the bladder neck, retrograde ejaculation is common after TUR. Pseudoephedrine 60 mg orally, 90 minutes before ejaculation or Ornade spansules (chlorpheniramine and phenylpropanolamine) twice a day for a week may prevent this. If this is not successful, sperm can be retrieved from alkalinized urine and used for either intrauterine insemination or IVF with ICSI.

Results

TUR of the ejaculatory ducts results in increased semen volume about two-thirds of the time and appearance of sperm in the ejaculate in about half of previously azoospermic men. Pregnancy rates are based on case reports and small series (Fuse et al., 2003; Goldwasser et al., 1985; Ozgok et al., 2001; Paick et al., 2000; Yurdakul et al., 2008). If viable sperm appear in the ejaculate but the quality is poor, IVF with ICSI is recommended, which currently yields delivery rates of up to 38.5% per attempt. Because of the potential for serious complications, **TUR should be performed only in azoospermic men or in severely oligoasthenospermic men and only after the couple has stated they are unwilling to do IVF and have been fully apprised of the risks of TUR**.

Electroejaculation

Indications

Men with neurologic impairments in sympathetic outflow, such as seen in traumatic spinal cord injury, demyelinating neuropathies (multiple sclerosis), diabetes, or after retroperitoneal lymph node dissection, frequently have abnormalities in or absence of seminal emission. **Ejaculation can be induced in most of these men, especially those with high spinal cord injury, with vibratory stimulation** (Bennett et al., 1987; Brackett et al., 1997; Brindley, 1981; Ohl et al., 1997; Schellan, 1968)**. For men who do not respond to vibratory stimulation, electroejaculation has proven to be a safe and effective means of obtaining motile sperm suitable for assisted reproduction techniques (IUI, IVF/ICSI).**

Anesthesia

The procedure is performed under general anesthesia except for in men with a complete spinal cord injury, who do not require anesthesia. **In men with a high thoracic spinal cord lesion (above T6) or in those men with prior history of autonomic dysreflexia, pretreatment with 20 mg of sublingual nifedipine 15 minutes before the procedure is employed.** These men should have intravenous access and their blood pressure and pulse monitored every 2 minutes before, during, and for 20 minutes after electroejaculation. In the event of a sympathetic outflow (autonomic dysreflexia) termination of the procedure should be sufficient to break the response; however, intravenous access allows for delivery of sympatheticolytic agents if they become necessary.

Technique

Before the patient is placed in the lateral decubitus position, the bladder is catheterized and emptied. A 12-Fr or 14-Fr silastic catheter lubricated with a small amount of mineral oil is used because commonly employed lubricants are spermicidal; 10 cc of buffer (HEPES-BSA) is instilled into the bladder. Before the electroejaculation sequence, a digital rectal exam and anoscopy are performed. A rectal probe with 3 large horizontal stripes is well lubricated, inserted with the electrodes facing anteriorly, and applied against the posterior aspect of the prostate and seminal vesicles. The probe is connected to a variable output power source, which simultaneously records probe temperature through a thermistor in the rectal probe. Electrostimulation is started at 3 to 5 volts and increased in 1 volt increments with each stimulation (Ohl et al., 2001). An assistant records probe temperatures and number of stimulations to full erection and ejaculation and collects the ejaculate in a sterile wide-mouth plastic container. The number of stimulations and maximum voltage required are variable and the ejaculate may be retrograde. If probe temperature rises rapidly or above 40°C, stimulation is suspended until the temperature falls below 38°C or probes are changed. At the completion of stimulation, anoscopy is again performed to check for rectal injury. The bladder is recatheterized to obtain any retrograde-ejaculated sperm. The specimens are then delivered to the laboratory for processing. **A second EEJ sequence can be immediately performed under the same anesthetic to obtain additional sperm.**

With use of this technique, sperm can be recovered in greater than 90% of men. Overall pregnancy rates of up to 40% can be achieved after multiple cycles with intrauterine insemination. Use of IVF with ICSI will yield 50% live delivery rates for a single (albeit costly) procedure if motile sperm are obtained.

Key Points: Electroejaculation

- Indicated in men who do not respond to vibratory stimulation.

Sperm Retrieval Techniques

Men with congenital absence or bilateral partial aplasia of vas deferens or those with failed or surgically unreconstructable obstructions are treated by using sperm retrieval techniques in conjunction with in vitro fertilization (Table 67.4; Anger et al., 2004; Craft et al., 1995; Janzen et al., 2000; Levine et al., 2003; Qiu et al., 2003; Schlegel et al., 1994; Sheynkin et al., 1998b; Silber et al., 1990; Temple-Smith et al., 1985). These techniques are also useful for intraoperative retrieval of sperm during reconstructive procedures such as vasoepididymostomy, which have significant failure rates. The intraoperatively retrieved sperm may be used immediately if the wife has been prepared for IVF or may be cryopreserved for a future IVF with ICSI cycle in the event the reconstructive surgery is unsuccessful. Sperm obtained from chronically obstructed systems usually have poor motility and decreased fertilizing capacity. **The use of ICSI combined with IVF is essential regardless of the count and motility of the aspirated sperm.**

TABLE 67.4

Surgical Techniques for Sperm Retrieval

	ADVANTAGES	DISADVANTAGES
MESA (microsurgical epididymal sperm aspiration)	Microsurgical procedure allows lower complication rate Epididymal sperm has better motility than testicular sperm Large number of sperm can be harvested for cryopreservation of multiple vials in a single procedure	Requires anesthesia and microsurgical skills Not indicated for nonobstructive azoospermia
PESA (percutaneous epididymal sperm aspiration)	No microsurgical skill required Local anesthesia Epididymal sperm has better motility than testicular sperm	Complications include hematoma, pain, and vascular injury to testes and obstruction of the epididymis Variable success in obtaining sperm Small quantity of sperm obtained than with MESA Not indicated in nonobstructive

		azoospermia
TESA (testicular sperm aspiration)	No microsurgical skill required Local anesthesia Can be used for obstructive azoospermia	Immature or immotile testicular sperm Small quantity of sperm obtained Poor results in nonobstructive azoospermia Complications include hematoma, pain, and vascular injury to testes and epididymis
TESE (testicular sperm extraction)	Low complication rate if performed microsurgically Preferred technique for nonobstructive azoospermia	Requires anesthesia DNA microsurgical skills

Microsurgical Epididymal Sperm Aspiration Techniques

Open Tubule Technique

The technique described here can be employed for either intraoperative sperm retrieval at the time of vasoepididymostomy or as an isolated procedure in men with congenital absence of the vas or unreconstructable obstructions (Matthews and Goldstein, 1996; Nudell et al., 1998). A median raphe approach through two small transverse scrotal incisions within the scrotal skinfolds are made. After delivery of the testis, the tunica vaginalis is opened and the epididymis inspected under 16× to 25× magnification using the operating microscope. The epididymal tunica is incised over a dilated tubule as described previously for vasoepididymostomy. Meticulous hemostasis is obtained using the bipolar cautery. A dilated tubule is isolated and incised with a 15-degree microknife. The fluid is touched to a slide, a drop of human tubal fluid media is added, a cover slip is placed, and the fluid is examined. If no sperm are obtained, the epididymal tubule and tunica are closed with 10-0 and 9-0 monofilament nylon sutures, respectively, and an incision is made more proximally in the epididymis or even at the level of the efferent ductules until motile sperm are obtained.

As soon as motile sperm are found, a dry micropipette (5 µL; Drummond Scientific Co., Broomall, PA) is placed adjacent to the effluxing epididymal tubule (Fig. 67.34). A standard hematocrit pipette is less satisfactory but can be used if micropipettes are not available. **Sperm are drawn into the micropipette**

by simple capillary action. Negative pressure, as is generated by action of an in-line syringe, should not be applied during sperm recovery because this may disrupt the delicate epididymal mucosa. Two micropipettes may be employed simultaneously to increase speed of sperm recovery.

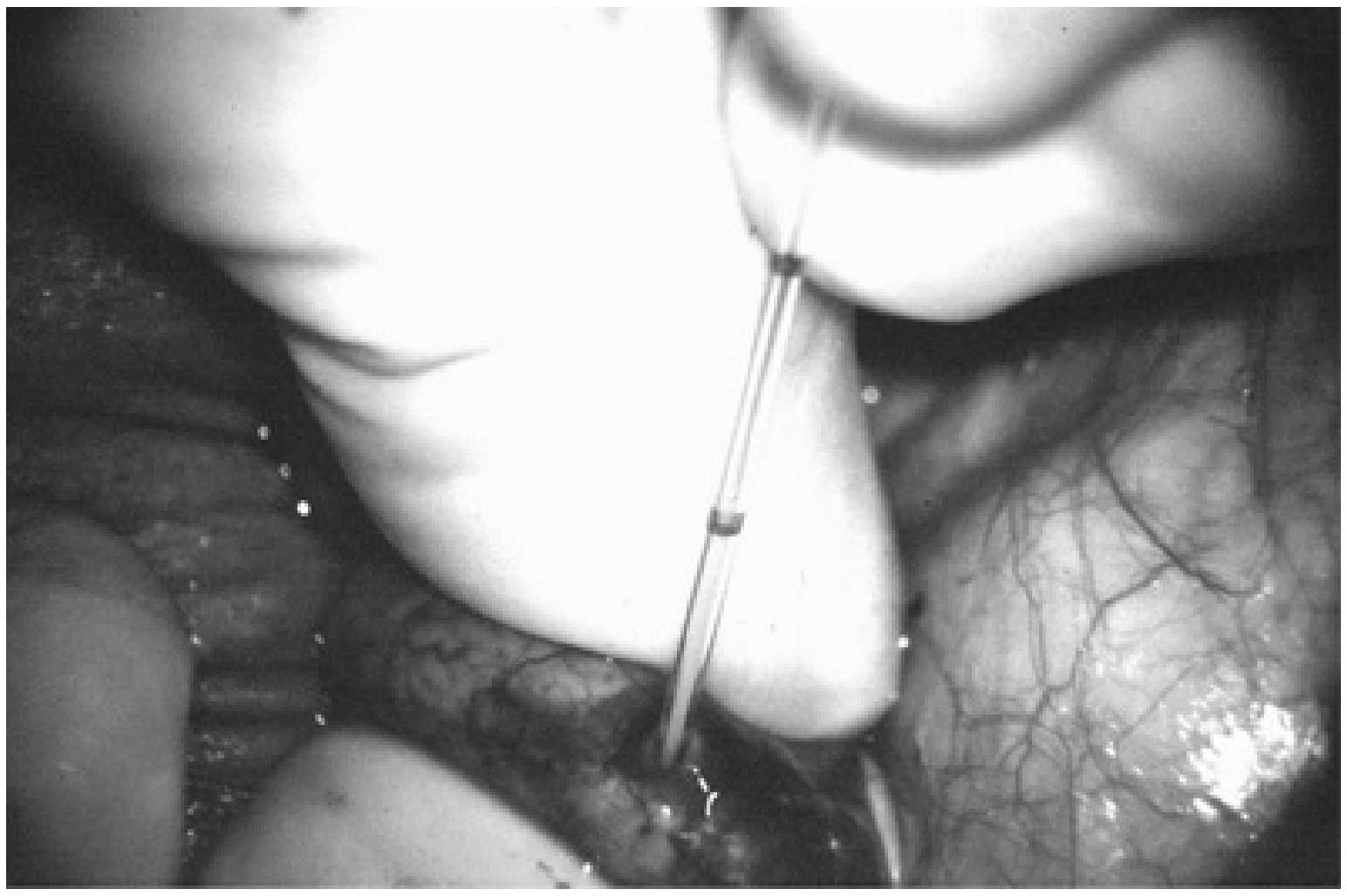

FIG. 67.34 A dry micropipette is placed adjacent to the effluxing epididymal tubule.

The highest rate of flow is observed immediately after incision of the tubule. Progressively better quality sperm are often found after the initial washout. **Gentle compression of the testis and epididymis enhances flow from the incised tubule.** With patience, 10 to 20 µL of epididymal fluid can be recovered.

The micropipette is connected to a short (3–5 cm) segment of medical grade silicone tubing (American Scientific Products, McGaw Park, IL). Alternatively, the tubing attached to a 25-gauge butterfly needle may be employed. A 20-gauge needle fitted to a Luer-tip syringe is then placed in line. The fluid is flushed with IVF media (0.5–1.0 mL) into a sterile container. Once a micropipette has been used, it is discarded. Residual fluid in the pipette will disrupt capillary action. A typical procedure requires 4 to 12 micropipettes. The sperm bank should be instructed to cryopreserve the aspirate in multiple vials (aliquots) so that several IVF cycles may be attempted if required (Anger et al., 2004; Janzen et al., 2000).

Experience with the technique has revealed that, **paradoxically in obstructed systems, sperm motility is better more proximally in the epididymis with the most motile sperm often found in the efferent ductules** (Fig. 67.35). Interestingly, fertilization rates are highest in men who have the longest length of epididymal tubule available, assuming motile sperm are found at some point in the epididymis. This is likely because the more epididymis present, the more factors are present in the epididymal fluid to promote fertilizing capacity. Even when packed with debris distally, the epididymal tubule may be capable of secreting substances that can diffuse proximally and benefit sperm motility and fertilizing capacity.

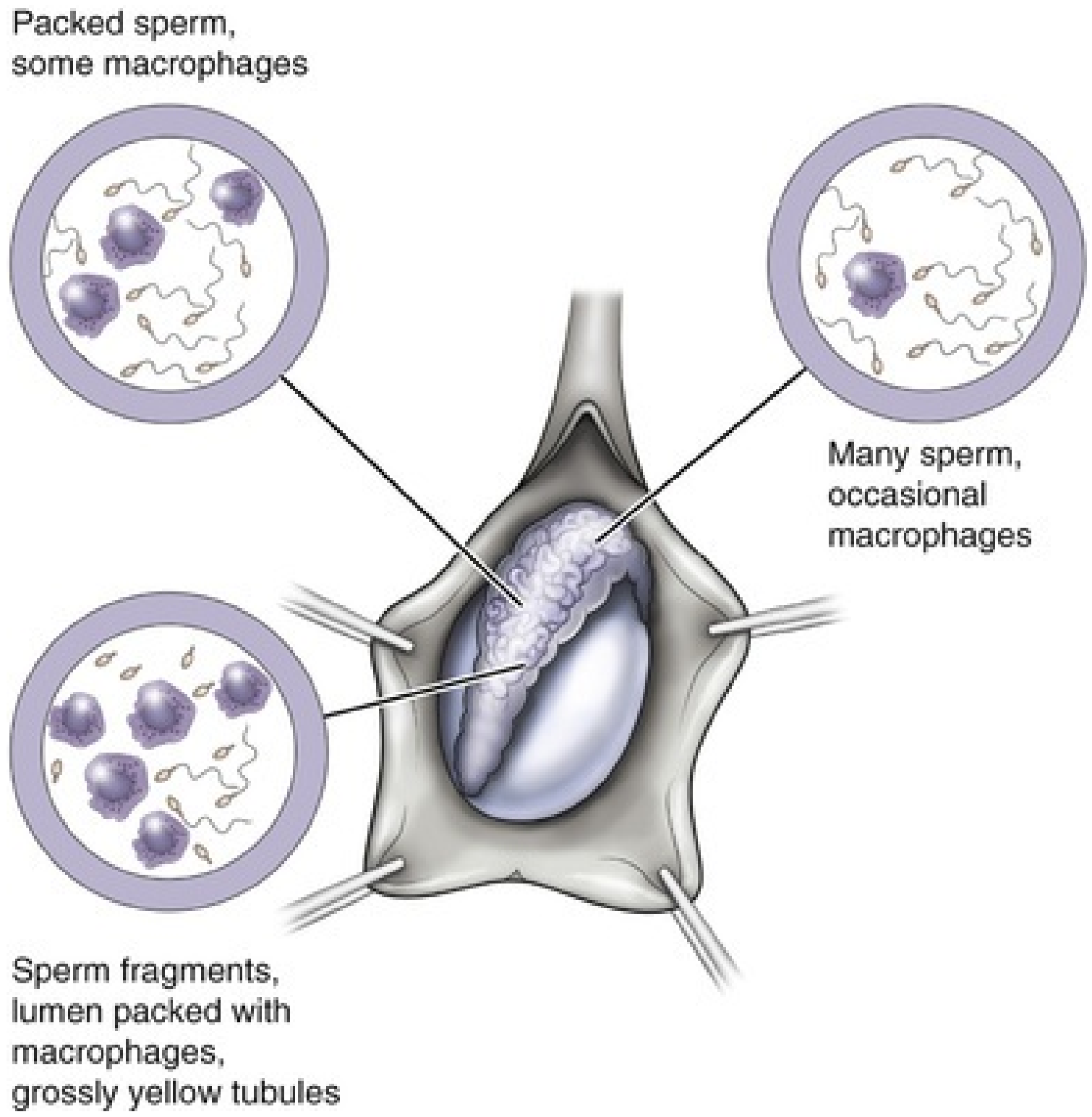
Packed sperm,
some macrophages
Many sperm,
occasional
macrophages
Sperm fragments,
lumen packed with
macrophages,
grossly yellow tubules

FIG. 67.35 Sperm motility is better more proximally in the epididymis with the most motile sperm often found in the efferent ductules.

With use of ICSI, ongoing pregnancy or delivery rates exceeding 60% have been achieved with this technique using either fresh or cryopreserved epididymal sperm (Nudell et al., 1998; Schlegel et al., 1995)**. Epididymal sperm aspiration can be done electively, with the cryopreserved sperm used for multiple future IVF cycles** (Anger et al., 2004; Janzen et al., 2000).

Percutaneous Epididymal Sperm Aspiration

Percutaneous puncture of the epididymis with a fine needle (Fig. 67.36), or percutaneous epididymal sperm aspiration (PESA), has been successfully employed to obtain sperm and achieve pregnancies (Craft and Tsirigotis, 1995; Levine et al., 2003; Lin et al., 2004; Qiu et al., 2003; Shrivastav et al., 1994).

The technique is less reliable than the open retrieval, and the small quantities of sperm obtained are sometimes inadequate for cryopreservation. Reported pregnancy rates are half those achieved with open techniques (Sheynkin et al., 1998b). It can also potentially obstruct the epididymis in men in whom future vasoepididymostomy is considered. In view of the enormous costs and effort involved in IVF, epididymal sperm retrieval under direct vision is the preferred technique (Zhang et al., 2013).

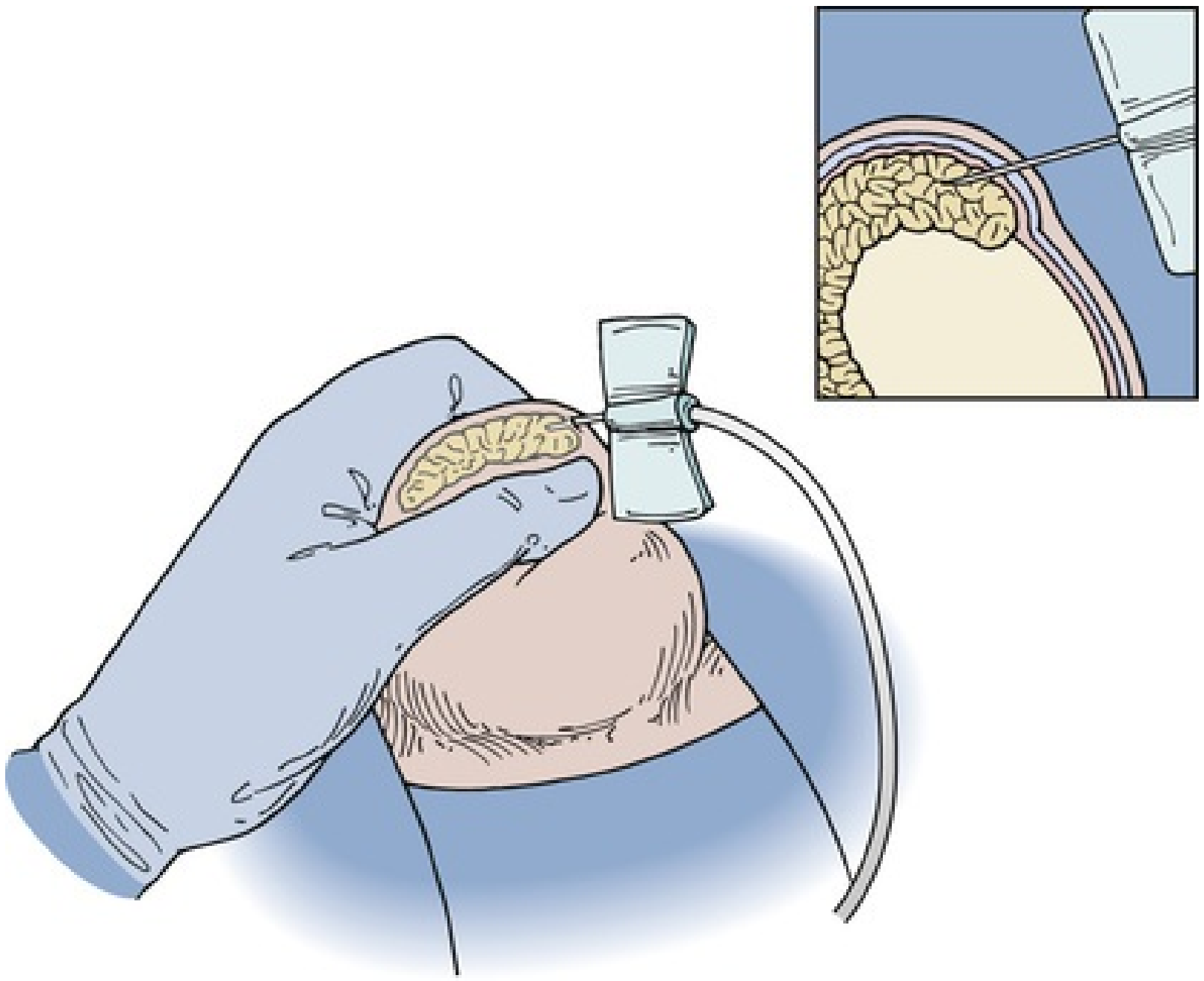

FIG. 67.36 Percutaneous puncture of the epididymis with a fine needle.

Key Points: Epididymal Sperm Aspiration

- Puncture of a single tubule for sperm aspiration can be safely performed at the most proximal region of the caput epididymis.
- In obstructed systems, sperm motility is better more proximally in the epididymis with the most sperm found in the efferent ductules.

Testicular Sperm Extraction

The indications for testicular sperm extraction (TESE) are the following:

1. **Failure to find sperm in the epididymis** in the presence of the spermatogenesis or complete absence of the epididymis
2. **Nonobstructive azoospermia** (Ostad et al., 1998; Schlegel et al., 1997; Su et al., 1999; Tsujimura et al., 2002)

Testicular sperm has been retrieved employing one of three techniques:

1. **Open microsurgical testicular sperm extraction:** preferably employing an operating microscope (micro-TESE) allows retrieval of the largest number of sperm with removal of the smallest amount of testicular tissue; this **is the best technique in men with nonobstructive azoospermia.**
2. Percutaneous core biopsy: uses the same 14-gauge biopsy gun used for prostate biopsy (Fig. 67.37).

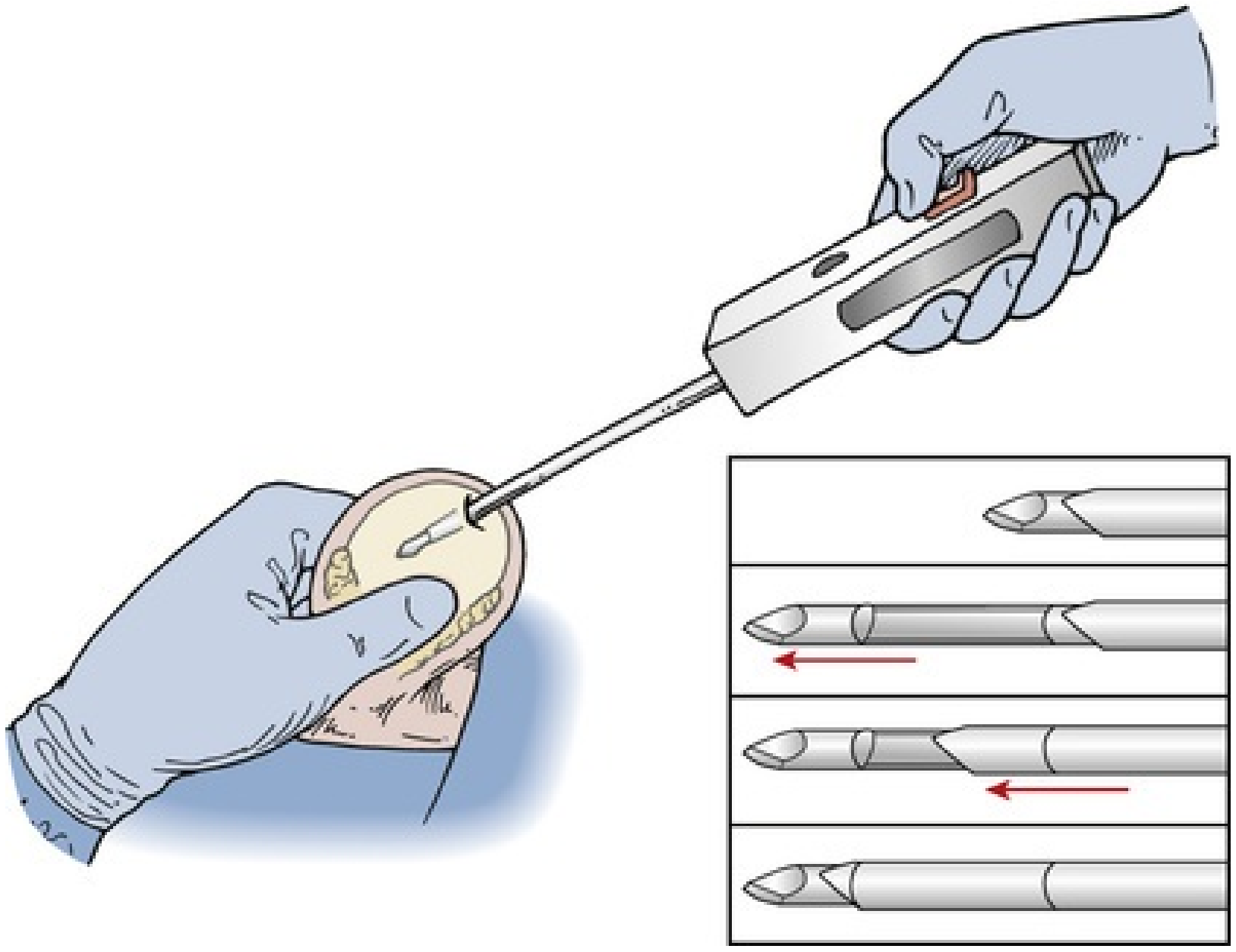

FIG. 67.37 Percutaneous core biopsy using a 14-gauge biopsy gun.

3. Percutaneous aspiration (testicular sperm aspiration, TESA) with a high-suction glass syringe and a 23-gauge needle. This is the least invasive but often requires 10 to 20 passes to obtain an adequate yield (Fig. 67.38) (Carpi et al., 2005; Friedler et al., 1997; Harrington et al., 1996; Mercan et al., 2000; Rajfer and Binder, 1989; Sheynkin et al., 1998b).

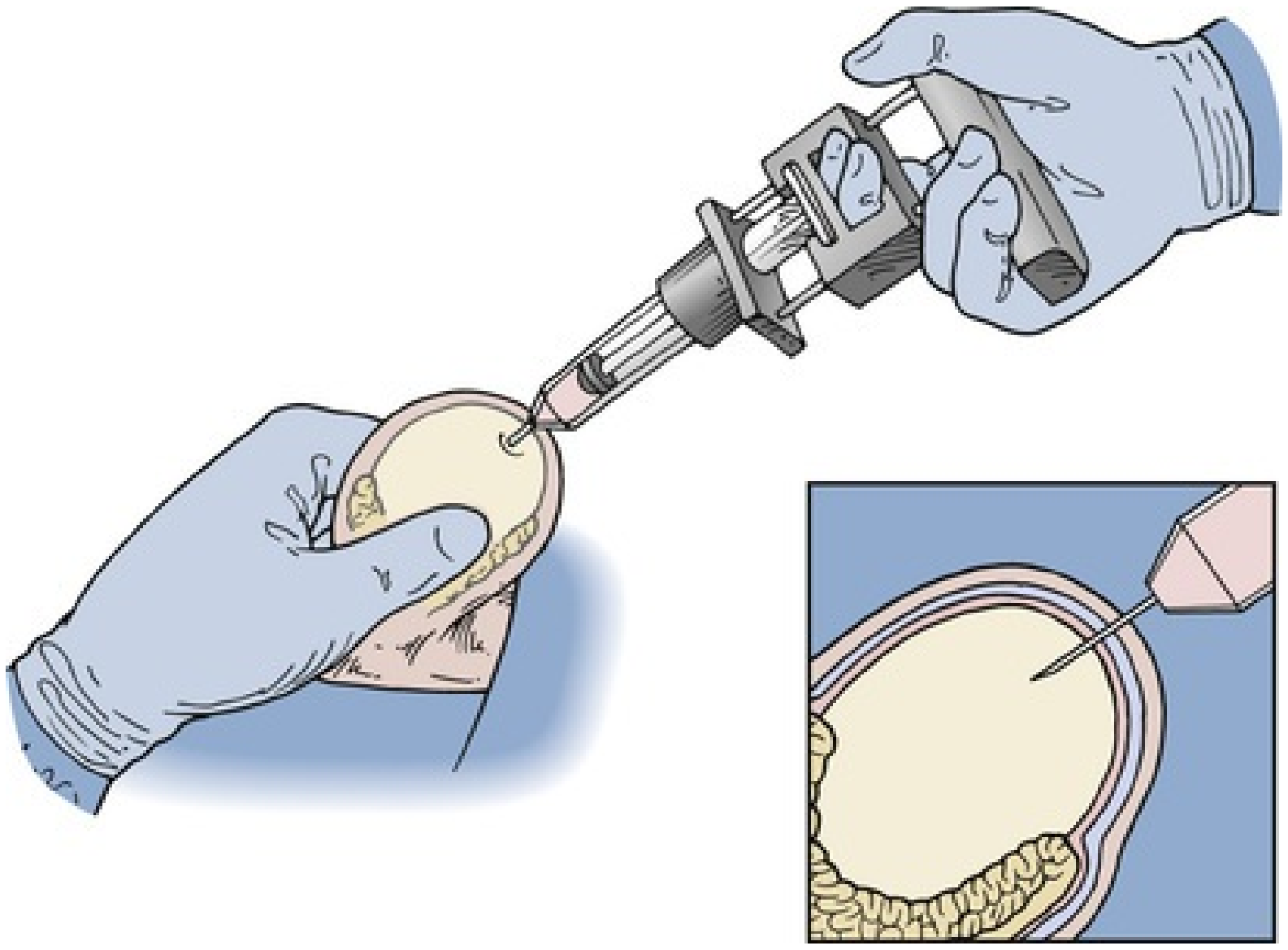

FIG. 67.38 Percutaneous aspiration with a high suction glass syringe and a 23-gauge needle.

The percutaneous methods are most appropriate in men with normal spermatogenesis and obstructive azoospermia in whom adequate numbers of sperm can be retrieved in a small amount of tissue (Craft et al., 1995). The pros and cons of these three methods are discussed in Testis Biopsy.

Microsurgical Testicular Sperm Extraction

The use of an operating microscope for standard open diagnostic testes biopsy allows identification of an area in the tunica albuginea free of blood vessels (Fig. 67.39), minimizing the risk of injury to testicular blood supply and allowing a relatively blood-free biopsy specimen (Dardashti et al., 2000). Employing the microscope for testis biopsy, Schlegel (1999) discovered that in men with nonobstructive azoospermia, some of the tubules were larger than others. **The larger tubules are more likely to yield sperm.** Previous studies revealed that testicular biopsy in men with nonobstructive azoospermia displays considerable heterogeneity. Examination of permanently fixed biopsy specimens that display heterogeneity reveals that **tubules with spermatogenesis are of considerably larger diameter than tubules that are Sertoli cell–only**. **This difference can be readily observed under the operating microscope** (Fig. 67.40).

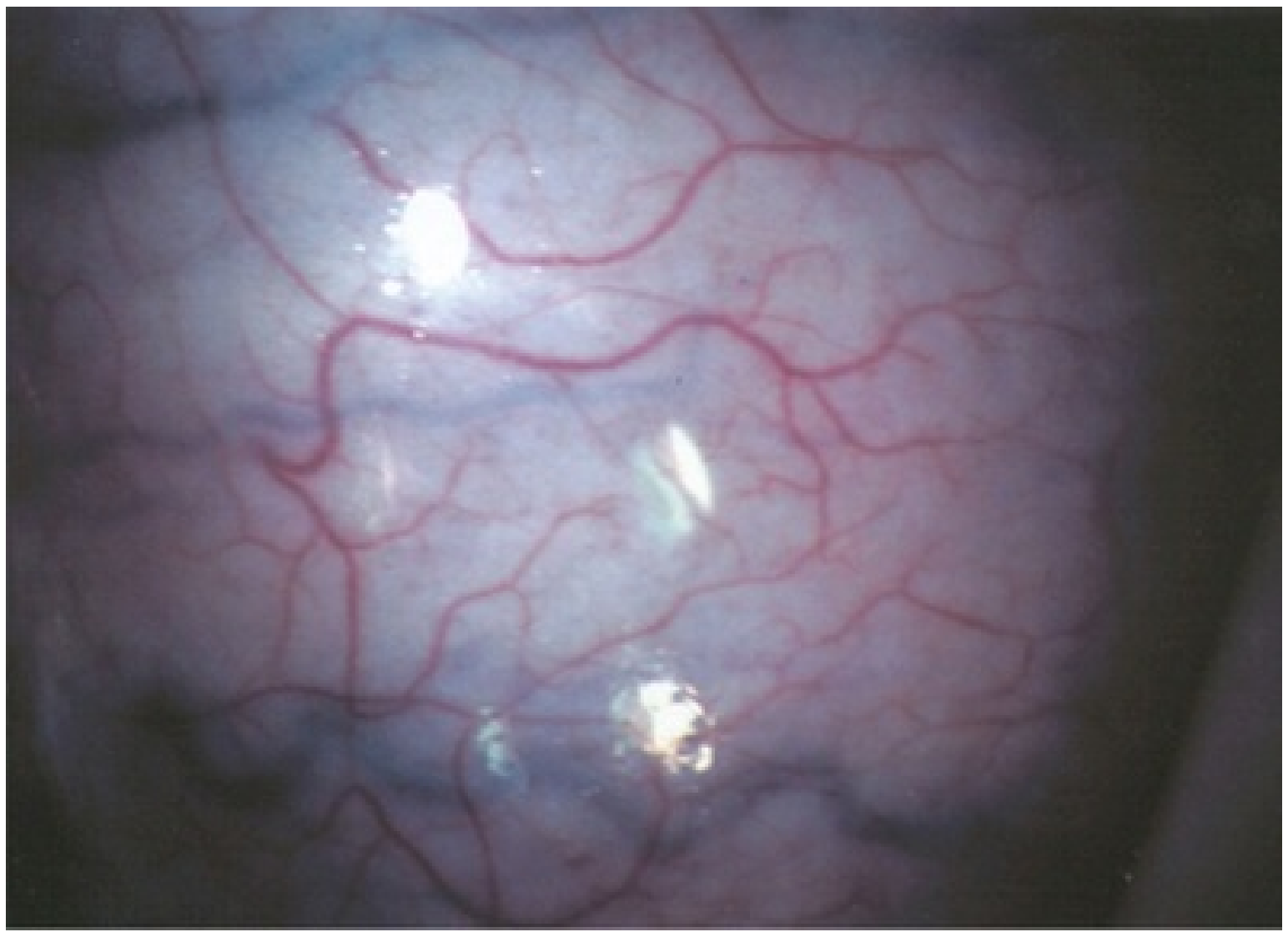

FIG. 67.39 Open diagnostic testis biopsy allows identification of an area in the tunica albuginea free of blood vessels.

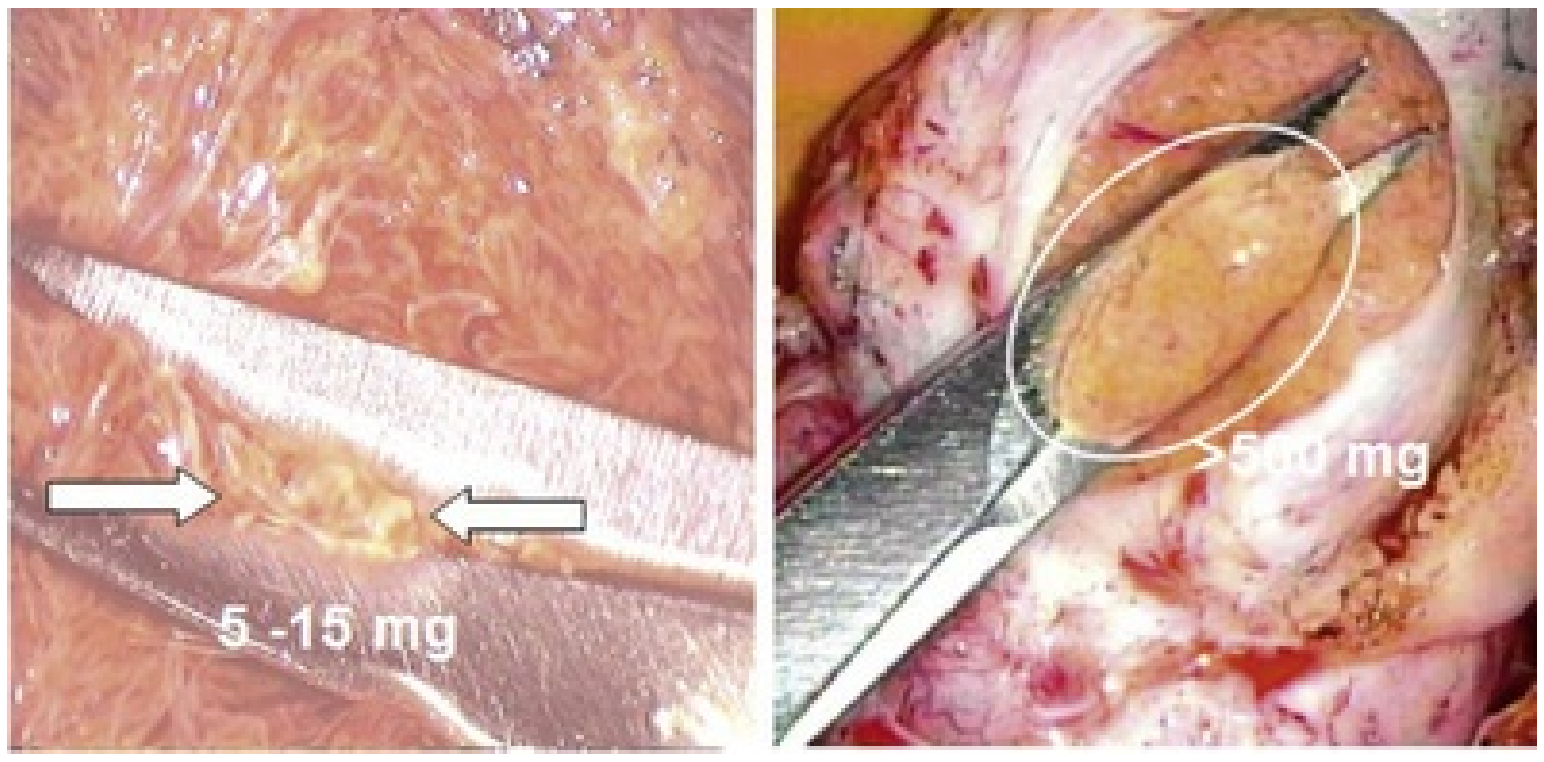

FIG. 67.40 Tubules with spermatogenesis have a considerable larger diameter than tubules that are Sertoli cell-only.

Technique.

With the patient under general or regional anesthetic, the testes are exposed through either a single midline median raphe incision or two transverse incisions within the skin lines and between the scrotal blood vessels. The testes is delivered into the wound. The tunica vaginalis is opened and the operating microscope is brought into the field. Using 10× magnification, an avascular plane is identified on the anterior surface of the tunica albuginea. Using a 15-degree microknife, a generous transverse incision is made between the blood vessels through the tunica albuginea. Small blood vessels that are seen coursing across the incision are coagulated with the microbipolar cautery before incising them. This yields a blood-free field. The seminiferous tubules are observed. **Sertoli cell–only tubules tend to be thin, white, and stringy. Tubules with active spermatogenesis are larger, plumper, and somewhat yellow.** Using a micro-needle holder or micro-bipolar forceps, the seminiferous tubules are dissected in an attempt to identify larger tubules. If such a tubule is found, a sharp curved iris scissors is used to selectively excise these tubules. The sample is placed in human tubal fluid media, microdissected with iris scissors, and passed multiple times through a 24-gauge angiocath sheath. This breaks up the tubules and improves the chances of finding sperm (Schlegel, 1999). The processed specimen is then immediately examined by an andrology laboratory technician present in the operating room. After sperm have been found, hemostasis is obtained with the microbipolar cautery. The incision in the tunica albuginea is closed with a 6-0 nylon or Proline suture. The testis is returned to the tunica vaginalis, which is closed with a continuous suture of 5-0 Vicryl. If necessary the opposite testis is explored.

Results.

Using the microdissection technique, sperm have been identified in 50% of men explored (Dabaja and Schlegel, 2013; Schlegel, 1999). In those men in whom sperm are found, a pregnancy rate of 45%, with a live delivery rate of almost 40%, has been achieved at Cornell using IVF/ICSI. The spontaneous abortion rate is 19%. The high rate of spontaneous abortion is probably because of the increased incidence of chromosomal abnormalities and DNA damage in the sperm of men with nonobstructive azoospermia (Rucker et al., 1998). Even in severe cases of congenital or acquired testicular failure, as in Sertoli cell–only syndrome (Su et al., 1999), post-chemotherapy azoospermia (Chan et al., 2001), and nonmosaic (47XXY) Klinefelter syndrome (Palermo et al., 1998; Ramasamy et al., 2009), sperm have been found and pregnancy and live births achieved (Table 67.5). An experimental technique using flow cytometry has been able to find sperm, often motile or twitching, in 80% of testicular specimens in which light microscopy by an experienced technician found none (Bolyakov et al., 2016). The technique employs SYTO 17 red fluorescent nucleic acid stain (Invitrogen), which attaches only to sperm. The safety of the dye on human sperm has yet to be proven, but studies on living cells have not demonstrated increased cellular stress (Wlodkowic et al., 2008; Zhao et al., 2009).

TABLE 67.5

TESE Outcomes by Diagnosis

CONDITION	RETRIEVAL
Klinefelter syndrome	68%
AZFc deletions	70%
Sertoli cell–only	30%
Postchemotherapy	53%
Cryptorchidism (postorchiopexy)	74%
Maturation arrest	40%
AZFa, AZFb deletions	0

TESE, Testicular sperm extraction.

Data from Chan et al., 2001; Hopps et al., 2003; Hung et al., 2007; Raman and Schlegel, 2003; Ramasamy et al., 2009; Ramasamy and Schlegel, 2007.

Key Points: Testicular Sperm Extraction

- Open microsurgical testicular sperm extraction is the best technique in men with nonobstructive azoospermia.

Postmortem Sperm Retrieval

Postmortem sperm retrieval and cryopreservation (but no pregnancies) were initially reported by Rothman in 1980 and employed removal and mincing of the epididymis. The retrieved sperm can be frozen and subsequently used to achieve pregnancy. Pregnancy has now been achieved with sperm retrieved postmortem using IVF with ICSI (Benshushan and Schenker, 1998; Dostal et al., 2005; Tash et al., 2003).

Retrieval of sperm from the vas can be performed using the technique described for vasectomy (see Vasovasostomy). Once the vas has been delivered, a hemivasotomy is made with a 15-degree microknife (as described in Technique of Vasography and Interpretation of Findings). The testicular end of the vas is cannulated with a 22-gauge angiocatheter and the vas irrigated with a 0.2-mL volume of human tubal fluid medium, while the convoluted vas and epididymis are massaged.

The ethical appropriateness of such retrieval is the most important issue surrounding its use, and current guidelines require the patient to have given permission for sperm retrieval and use before death (Trinkoff and Barone, 2013).

Varicocelectomy

Varicocelectomy is by far the most commonly performed operation for the treatment of male infertility. **Varicocele is found in approximately 15% of the general population: 35% of men with primary infertility and in 75% to 81% of men with secondary infertility.** Animal and human studies have demonstrated that **varicocele is associated with a progressive and duration-dependent decline in testicular function** (Chehval and Purcell, 1992; Gorelick and Goldstein, 1993; Hadziselimovic et al., 1989; Harrison et al., 1986; Kass and Belman, 1987; Lipshultz and Corriere, 1977; Nagler et al., 1985; Russell, 1957; Witt and Lipshultz, 1993).

Repair of varicocele will halt any further damage to testicular function (Gorelick and Goldstein, 1993; Kass and Belman, 1987) and, in a large percentage of men, result in improved spermatogenesis (Dubin and Amelar, 1977; Marmar et al., 2007; Schlegel and Goldstein, 1992), improved live birth rates, and better IVF/ICSI outcomes (Kirby et al., 2016). It also enhances Leydig cell function (Su et al., 1995; Tanrikut et al., 2011). The potentially important role of urologists in preventing future infertility and/or androgen deficiency underscores the importance of utilizing a varicocelectomy technique that minimizes the risk of complications and recurrence. Table 67.6 summarizes the pros and cons of various methods of varicocele repair.

TABLE 67.6

Techniques of Varicocelectomy

TECHNIQUE	ARTERY PRESERVED	HYDROCELE (%)	FAILURE (%)	POTENTIAL FOR SERIOUS MORBIDITY
Retroperitoneal	No	7	15–25	No
Conventional inguinal	No	3–30	5–15	No
Laparoscopic	Yes	12	3–15	Yes
Radiographic	Yes	0	15–25	Yes
Microscopic inguinal or subinguinal	Yes	0	0.5–1.0	No

Scrotal Operations

A variety of surgical approaches have been advocated for varicocelectomy. The earliest recorded attempts at repair of varicocele date to antiquity and involved external clamping of the scrotal skin, including the enlarged veins. In the early 1900s an open scrotal approach was employed, involving the mass ligation and excision of the varicosed plexus of veins. At the level of the scrotum, however, the pampiniform plexus of veins are intimately entwined with the coiled testicular artery. Therefore **scrotal operations are to be avoided because damage to the arterial supply of the testis frequently results in testicular atrophy and further impairment of spermatogenesis and fertility.**

Retroperitoneal Operations

Retroperitoneal repair of varicocele involves incision at the level of the internal inguinal ring (Fig. 67.41), splitting of the external and internal oblique muscles and exposure of the internal spermatic artery and vein retroperitoneally near the ureter. This approach has the advantage of isolating the internal spermatic veins proximally, near the point of drainage into the left renal vein. At this level, only one or two large veins are present and, in addition, the testicular artery has not yet branched and is often distinctly separate from the internal spermatic veins. Retroperitoneal approaches involve ligation of the fewest number of veins. This approach is still a commonly employed method for the repair of varicocele, especially in children.

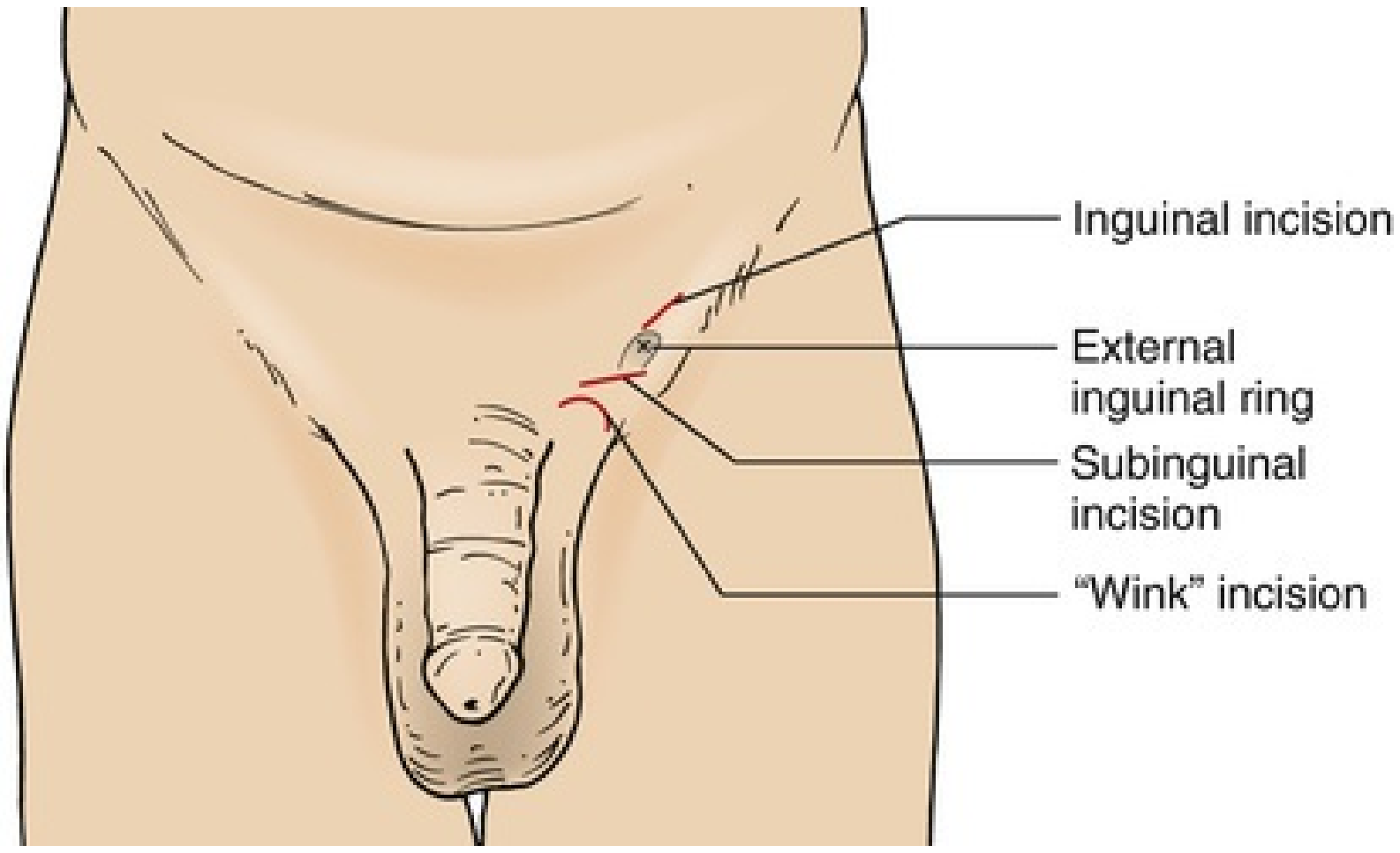

FIG. 67.41 Retroperitoneal repair of varicocele involves incision at the level of the internal inguinal ring.

A disadvantage of a retroperitoneal approach is the high incidence of varicocele recurrence, especially in children and adolescents, when the testicular artery is intentionally preserved. Recurrence rates after retroperitoneal varicocelectomy are in the range of 15% (Homonnai et al., 1980; Rothman et al., 1981; Watanabe et al., 2005). Failure is usually due to preservation of the periartertial plexus of fine veins (venae comitantes) along with the artery. These veins have been shown to communicate with larger internal spermatic veins. If left intact, they may dilate and cause recurrence. Less commonly, failure is due to the presence of parallel inguinal or retroperitoneal collaterals, which may exit the testis and bypass the ligated retroperitoneal veins rejoining the internal spermatic vein proximal to the site of ligation (Murray et al., 1986; Sayfan et al., 1981). Dilated cremasteric veins (Sayfan et al., 1980) and scrotal collaterals (Kaufman et al., 1983) are also causes of varicocele recurrence and cannot be identified with a retroperitoneal approach. Positive identification and preservation of the 1.0- to 1.5-mm testicular artery via the retroperitoneal approach is difficult, especially in children in whom the artery is small. The operation involves working in a deep hole, and, because at this level the internal spermatic vessels cannot be delivered into the wound, they must be dissected and ligated in situ in the retroperitoneum. **In addition, the difficulty in positively identifying and preserving lymphatics using this approach results in postoperative hydrocele formation after 7% to 33% of retroperitoneal operations** (Szabo and Kessler, 1984). The incidence of recurrence appears to be higher in children, with rates reported between 15% and 45% in adolescents (Gorenstein et al., 1986; Levitt et al., 1987; Reitelman et al., 1987). Kass and Marcol (1992) report that **recurrence can be markedly reduced in children and adolescents by intentional ligation of the testicular artery.** This ensures ligation of the periarterial network of fine veins. Although reversal of testicular growth failure has been documented with intentional testicular artery ligation at the time of retroperitoneal repair in children, **the effect of artery ligation on subsequent spermatogenesis is uncertain.** In adults bilateral artery ligation has been documented to occasionally cause azoospermia and testicular atrophy (Silber, 1979). At least **it is inarguable that testicular artery ligation will not enhance testicular function.**

Laparoscopic Varicocelectomy

Laparoscopic repair is in essence a retroperitoneal approach, and many of the advantages and disadvantages are similar to those of the open retroperitoneal approach (Donovan and Winfield, 1992; Enquist et al., 1994; Hagood et al., 1992; Hirsch et al., 1998; Riccabona et al., 2003; Watanabe, 2005).

With use of the laparoscope, the internal spermatic vessels and vas deferens can be clearly visualized through the laparoscope as they course through the internal inguinal ring. **The magnification provided by the laparoscope allows visualization of the testicular artery** (Kobori et al., 2013)**. With experience, the lymphatics may be visualized and preserved as well** (Glassberg et al., 2008). With laparoscopic varicocelectomy the internal spermatic veins are ligated at the same level as the retroperitoneal (Palomo) approach. Laparoscopic varicocelectomy should allow preservation of the testicular artery in a majority of cases, as well as preservation of lymphatics. The incidence of varicocele recurrence would be expected to be similar to that associated with the open retroperitoneal operations. These recurrences would be due to collaterals joining the internal spermatic vein near its entrance to the renal vein or entering the renal vein separately.

Currently reported series of laparoscopic varicocelectomy report a recurrence rate of 2.9% to 4.5% in most recent series (Barroso et al., 2009; May et al., 2006; Glassberg et al., 2008) but up to 17% in some (Al-Said et al., 2008). An artery ligation but lymphatic-sparing laparoscopic technique has markedly reduced the incidence of postoperative hydrocele formation in children (Glassberg et al., 2008). The potential complications of laparoscopic varicocelectomy (injury to bowel, vessels, or viscera; air embolism; peritonitis) are significantly more serious than those associated with the open techniques. Furthermore, laparoscopic varicocelectomy requires a general anesthetic. The microsurgical techniques described next can be performed using local or regional anesthesia and employ an incision of 2 to 3 cm for unilateral repair. This is often no greater than the sum of incisions employed for a laparoscopic approach. Postoperative pain and recovery from the laparoscopic technique are the same as those associated with subinguinal varicocelectomy (Hirsch et al., 1998). In the hands of an experienced laparoscopist, the approach is a reasonable alternative for the repair of bilateral varicoceles (Diamond et al., 2009; Donovan and Winfield, 1992; Mendez-Gallart et al., 2009; Tong et al., 2009).

Microsurgical Inguinal and Subinguinal Operations: the Preferred Approaches

Subinguinal microsurgical varicocelectomy is currently the most popular approach. It has the advantage of allowing the spermatic cord structures to be pulled up and out of the wound so that the testicular artery, lymphatics, and small periarterial veins may be more easily identified. In addition, **an inguinal or subinguinal approach allows access to external spermatic and even gubernacular veins** (Kaufman et al., 1983), which may bypass the spermatic cord and result in recurrence if not ligated. Last, an inguinal or subinguinal approach allows access to the testis for biopsy or examination of the epididymis for obstruction or repair of hydrocele (Dabaja et al., 2013).

Traditional approaches to inguinal varicocelectomy involve a 5-cm incision made over the inguinal canal, opening of the external oblique aponeurosis, and encirclement and delivery of the spermatic cord. The cord is then dissected and all the internal spermatic veins are ligated (Dubin and Amelar, 1977). The vas deferens and its vessels are preserved. An attempt is made to identify and preserve the testicular artery and, if possible, the lymphatics. In addition, the cord is elevated, and any external spermatic veins that are running parallel to the spermatic cord or perforating the floor of the inguinal canal are identified and ligated. Compared with retroperitoneal operations, conventional nonmagnified inguinal approaches lower the incidence of varicocele recurrence but do not alter the incidence of either hydrocele formation or testicular artery injury. **Conventional inguinal operations are associated with an incidence of postoperative hydrocele formation varying from 3% to 15% with an average incidence of 7%** (Szabo and Kessler, 1984). Analysis of the hydrocele fluid has clearly indicated that hydrocele formation after varicocelectomy is due to ligation of the lymphatics (Szabo and Kessler, 1984). The incidence of testicular artery injury during nonmagnified inguinal varicocelectomy is unknown. However, case reports suggest that this complication may be more common than realized. It can result in testicular atrophy and, if the operation is performed bilaterally, azoospermia may ensue in a previously oligospermic man. Furthermore, Starzl and his transplant group reported a 14% incidence of testicular atrophy and 70% incidence of hydrocele formation when the spermatic cord was divided and only the vas and vasal vessels preserved (Penn et al., 1972).

The introduction of **microsurgical technique** to varicocelectomy **has**

resulted in a substantial reduction in the incidence of hydrocele formation (Cayan et al., 2000; Goldstein et al., 1992; Marmar and Kim, 1994; Matthews et al., 1998). This is **because the lymphatics can be more easily identified and preserved.** Furthermore, the use of **magnification enhances the ability to identify and preserve the 0.5- to 1.5-mm testicular artery, thus avoiding the complications of atrophy or azoospermia.**

Advocates of nonmicrosurgical techniques contend that the deferential (vassal) artery and, if preserved, the cremasteric artery provide adequate blood supply to the testes to prevent atrophy. However, anatomic studies have known that the diameter of the testicular artery is greater than the diameter of the deferential artery and cremasteric artery combined (Raman and Goldstein, 2004). **The testicular artery is the main blood supply to the testis.** Experience with the one-stage Fowler and Steven's orchiopexy, in which the testicular artery is intentionally ligated, reveals that a substantial percentage of such procedures result in an atrophic testis. Also, animal models indicate that artery preservation varicocelectomy results in improved testicular ultrastructure, whereas artery ligation resulted in further deterioration of ultrastructure (Zheng et al., 2008). At the very least, it is inarguable that **ligation of the testicular artery is unlikely to enhance testicular function.**

Anesthesia

If the testis is delivered, as described below, regional or light general anesthesia is preferred. If only the cord is delivered, local anesthesia with a 50-50 combination of 0.25% bupivacaine (preferably liposomal) and 1% lidocaine is satisfactory with adjunctive intravenous sedation. After infiltration of the skin and subcutaneous tissues the cord is infiltrated before delivery. Blind cord block carries with it a small risk of inadvertent testicular artery injury (Goldstein and Einer-Jensen, 1983). A 30-gauge needle should therefore be employed for cord block to minimize the risk of injury and hematoma.

Inguinal and Subinguinal Approaches

The introduction of the subinguinal approach, just below the external inguinal ring (Marmar et al., 1985) obviates the necessity for opening any fascial layer and is associated with less pain and a rapid recovery. At the subinguinal level, however, significantly more veins are encountered, the artery is more often surrounded by a network of tiny veins that must be ligated, and the testicular artery has often divided into two or three branches, making arterial identification and preservation more difficult (Hopps et al., 2003).

Subinguinally, the arterial pulsations are often dampened by compression on the edge of the external ring, making its identification somewhat more difficult than when the external oblique is opened. Table 67.7 summarizes the criteria for performing the operation inguinally (external oblique opened) versus subinguinally (fascia intact). **In general, it is best to use a subinguinal approach in men with a history of any prior inguinal surgery.** Under these circumstances the cord is usually stuck to the undersurface of the external oblique, and opening the fascia risks injury to the cord. A subinguinal approach is easier in obese men in whom opening and closing the fascia is difficult through a small incision. A subinguinal approach is easier in men with high, lax, capacious external rings and in men with long cords and low-lying testes. In these men the level of the external ring is fairly proximal to the testis, and opening the fascia will not result in a significant diminution in the number of veins to be ligated or in the branching of the testicular artery.

TABLE 67.7

Indications for Inguinal (External Oblique Opened) Versus Subinguinal (Fascia Intact) Varicocelectomy

INGUINAL	SUBINGUINAL
Prepubertal children	Prior inguinal surgery
Solitary testis	Obesity
Tight, low external ring	Lax, capacious external ring
	High external ring
Short cord, high-lying testis	Long cord with low-lying testis
Less experienced with microsurgical repair	Very experienced with microsurgical repair

I recommend always opening the external oblique in prepubertal children without prior inguinal surgery. In children the testicular artery is very small and systemic blood pressure is low, making identification of the artery very difficult in a subinguinal approach. The fascia could also be opened in men with a solitary testis in whom preservation of the artery is critical. Exposure of the cord more proximally (at the inguinal level) allows identification of the artery before it has branched, where clear pulsations are more readily observed.

Consider opening the fascia in men with prior failed subinguinal varicocelectomy to dissect proximal to the prior scarred ligation area. The microdissection will be quicker and easier. **A subinguinal operation is significantly more difficult than a high inguinal operation and should only be used by surgeons who perform the operation frequently.** Less experienced microsurgeons should start out doing inguinal operations because they are easier. **An inguinal operation is employed when simultaneous ipsilateral hernia repair is performed** (Schulster et al., 2017).

Before the incision is made, the location of the external inguinal ring is determined by invagination of the scrotal skin and is marked. The size of the incision is determined by the size of the testis when delivery of the testis (see following) is planned. Atrophic testes can be delivered through a 2- to 2.5-cm incision. Larger testes require a 3-cm incision. The incision is made within Langer lines to minimize scarring.

If the decision is made to perform an inguinal operation and thus to open the fascia, the incision is begun at the external ring and extended laterally 2 to 3.5 cm along Langer lines (Fig. 67.42). If the operation is to be performed subinguinally, the incision is placed in the skin lines right over the external ring (Fig. 67.43).

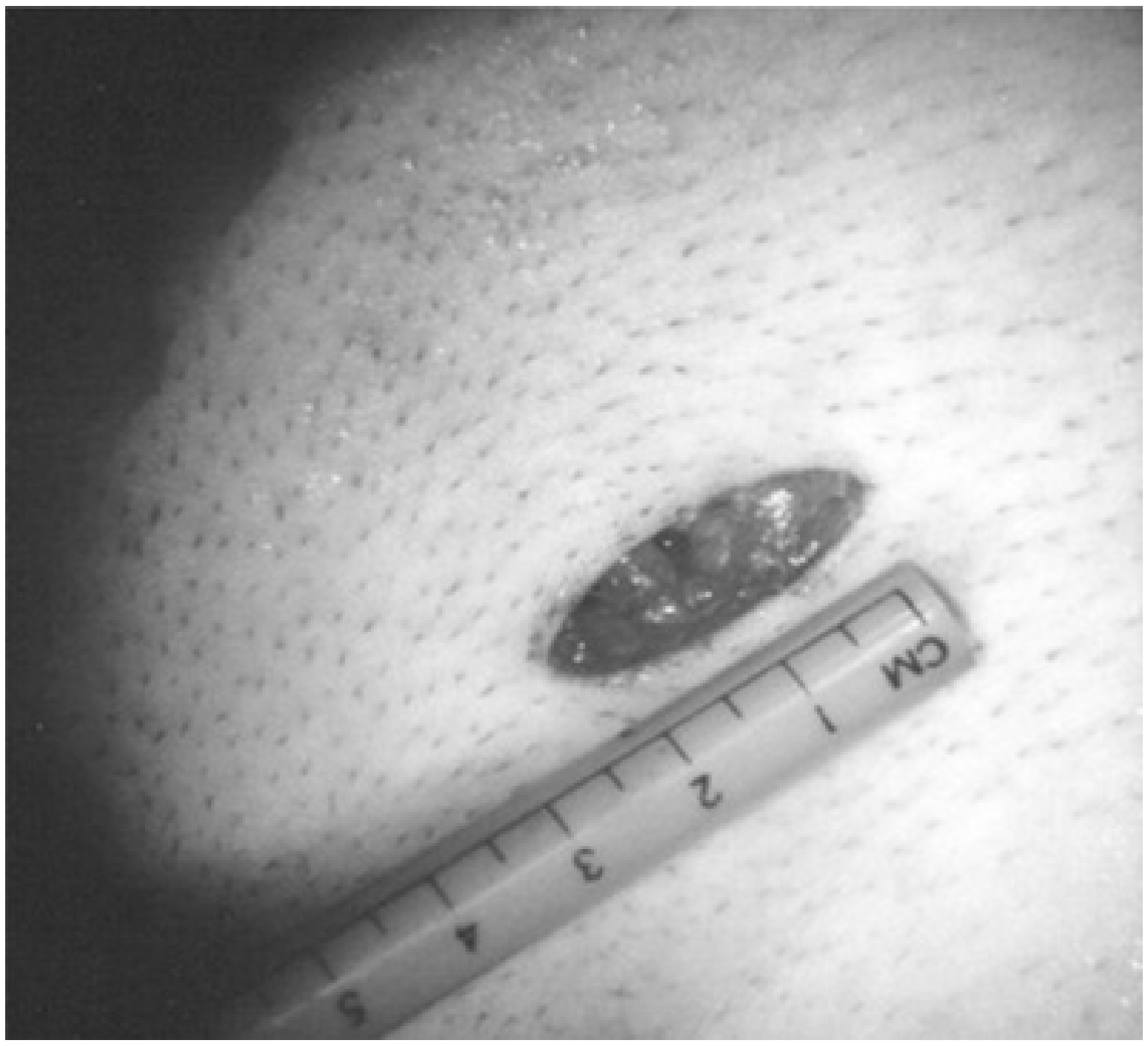

FIG. 67.42 An incision is begun at the external ring and extended laterally 2 to 3.5 cm along Langer lines.

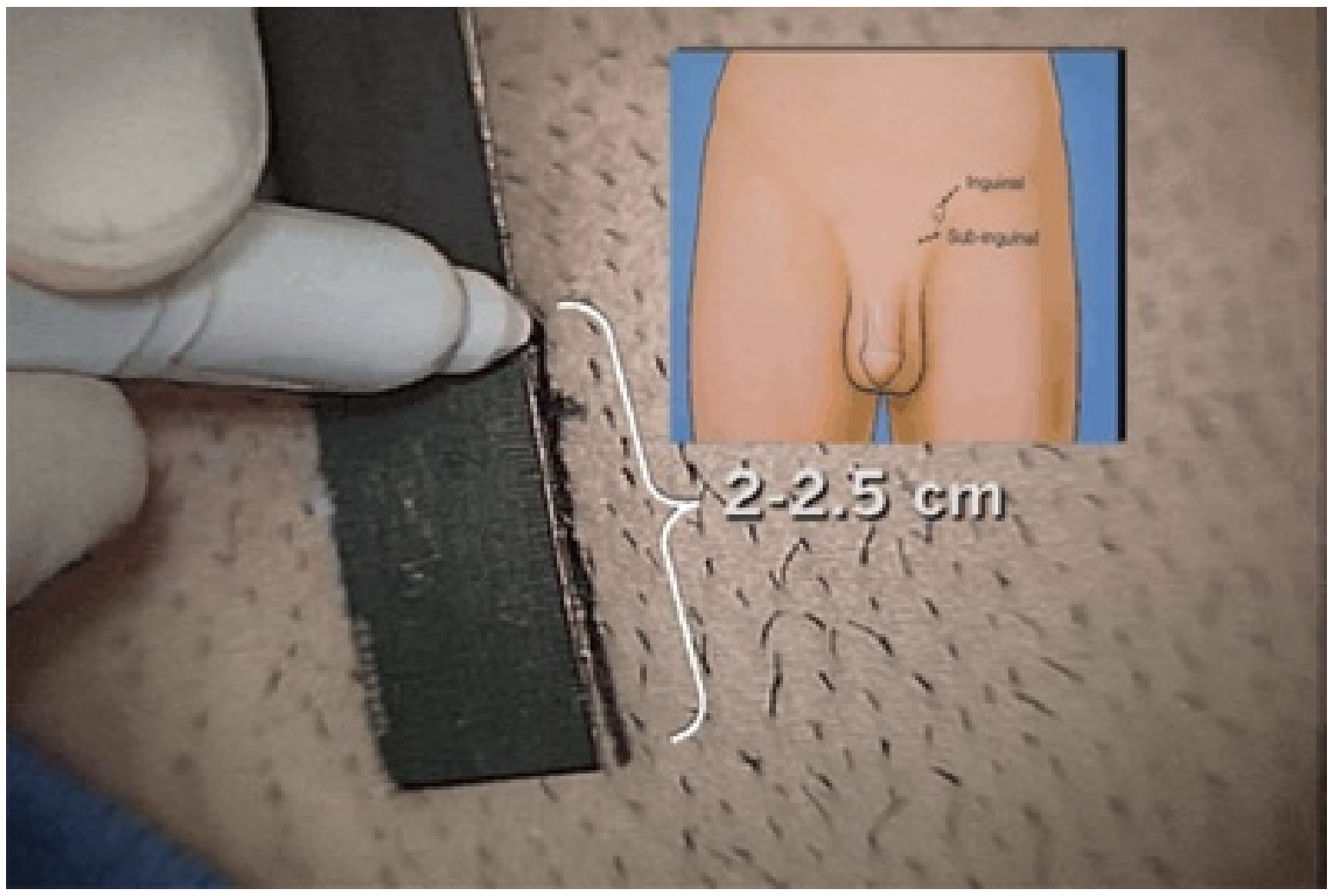

FIG. 67.43 When not performed subinguinally, the incision is placed in the skin lines right over the external ring.

Camper fascia and Scarpa fascia are divided with the electrocautery between the blades of a Crile clamp. The superficial epigastric artery and vein at the superior aspect of the incision and/or the superficial external pudendal artery and vein at the inferior aspect of the incision, if encountered, are retracted or, if in the middle of the incision, may be clamped, divided, and ligated. If an inguinal approach is selected, the external oblique aponeurosis is cleaned and opened the length of the incision to the external inguinal ring in the direction of its fibers. A 3-0 absorbable suture placed at the apex of the opening in the external oblique facilitates later closure.

The spermatic cord is grasped with a Babcock clamp and delivered through the wound. The ilioinguinal and genital branches of the genitofemoral nerve are excluded from the cord, which is then surrounded with a large Penrose drain. If a subinguinal incision was made, Camper and Scarpa fasciae are incised as described earlier. An index finger is introduced into the wound and along the cord into the scrotum. The index finger is then hooked under the external inguinal ring, retracting it cephalad. A small Richardson retractor is slid along the back of the index finger and retracted caudad over the cord toward the scrotum (Fig. 67.44). The spermatic cord will be revealed between the index finger and retractor. The assistant grasps the cord with a Babcock clamp and delivers it through the wound. The cord is surrounded with a large Penrose drain.

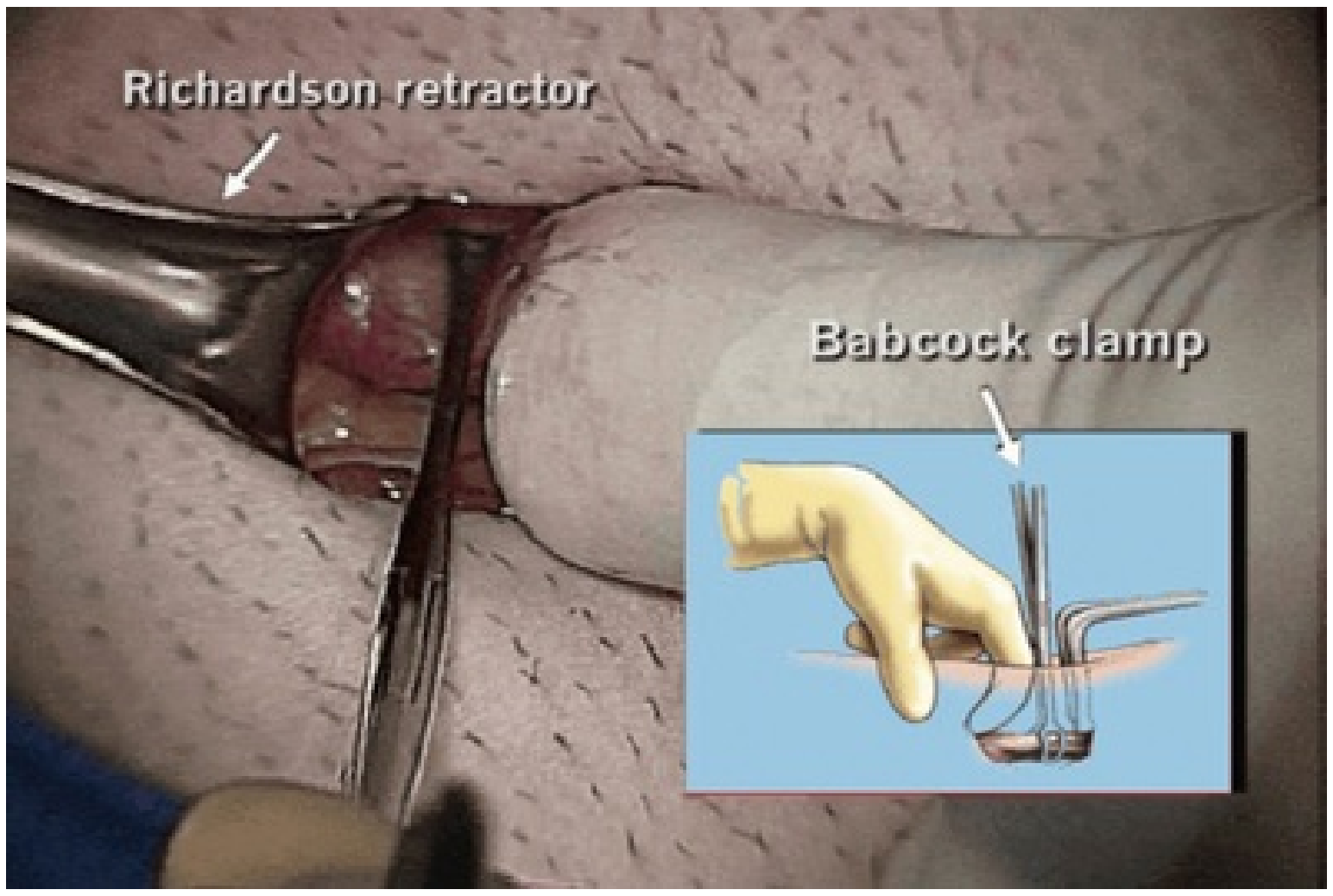

FIG. 67.44 A Richardson retractor is slid along the back of the index finger and retracted caudad over the cord toward the scrotum.

Dissection of the Cord

The operating microscope is then brought into the field. Under 6× to 10× power magnification the external spermatic fascia is opened with a Bovie electrocautery in the direction of the cremasteric fibers to avoid injury to the cremasteric arteries. A 5-0 Vicryl suture is placed at the apex of the opening to facilitate later closure. The relatively avascular internal spermatic fascia is opened with scissors as high as possible and held open with the straight mosquito forceps, which are sequentially applied as high as possible while pulling down on the testis (Fig. 67.45A and B). The magnification is increased to 10× to 25× power and, after irrigation with 1% papaverine solution, the cord is inspected for the presence of pulsations revealing the location of the testicular artery.

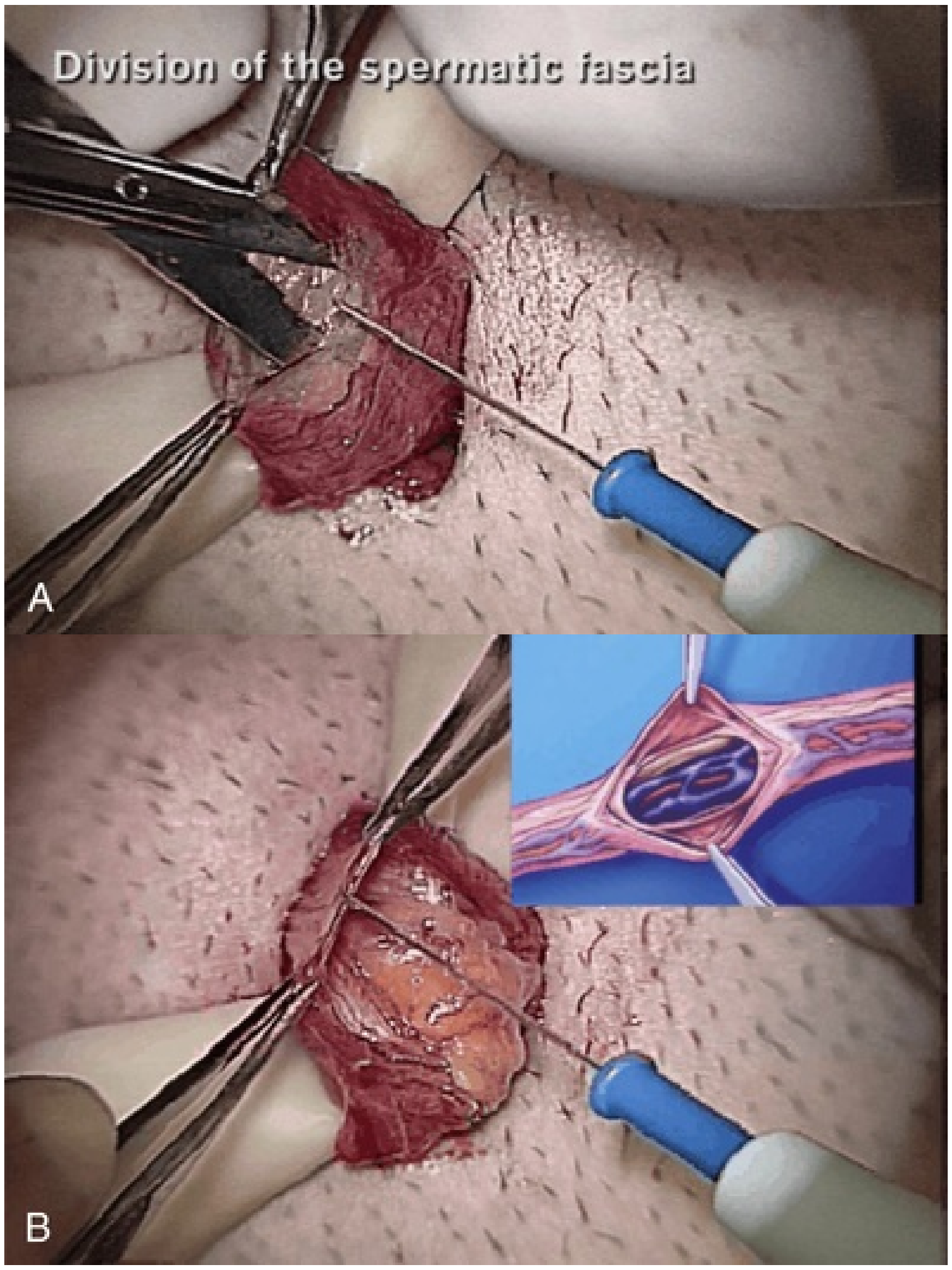

FIG. 67.45 (A and B) The internal spermatic fascia opened with scissors as high as possible (A) and held open with the straight mosquito forceps (B).

A micro-Doppler is extremely useful in identifying arteries (Fig. 67.46)**. Once the testicular artery is identified, it is dissected free of all surrounding tissue, tiny veins, and lymphatics using a fine-tip nonlocking micro needle holder and microforceps.** The artery is encircled with a vessel loop for positive identification and gentle retraction (Fig. 67.47). The suspected artery is tested by elevating the artery with the tips of the micro needle holder until it is completely occluded and then slowly lowering it until a pulsating blush of blood appears just over the needle holder. The artery is often surrounded by X- or H-like networks of small veins (Fig. 67.48). If the artery is not immediately identified, the cord is carefully dissected beginning with the largest veins. The veins are stripped clean of adherent lymphatics (Fig. 67.49) and the underside of the largest veins inspected for an adherent artery.

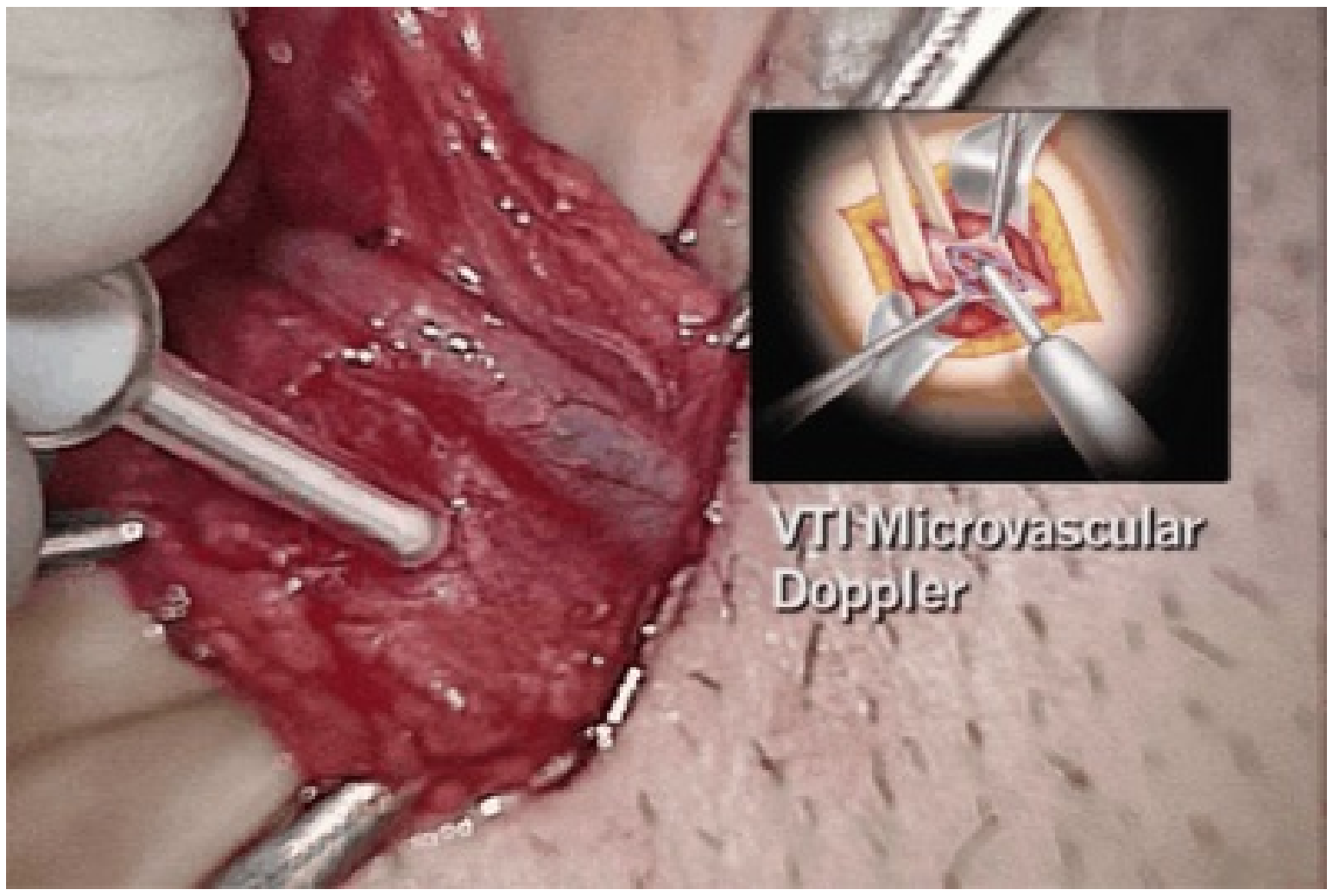
VTI Microvascular
Doppler

FIG. 67.46 Use of a micro-Doppler to identify arteries.

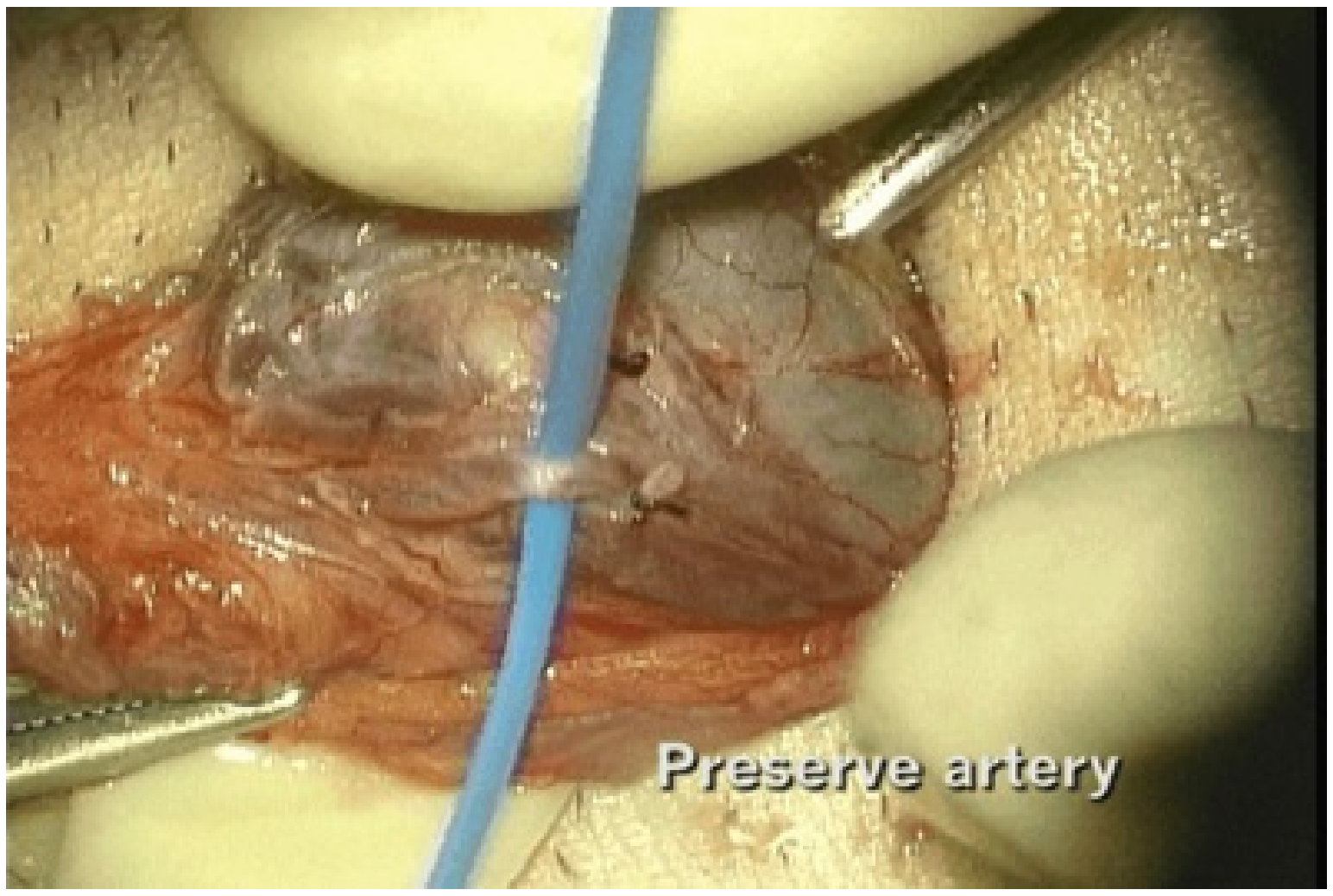
Preserve artery

FIG. 67.47 The testicular artery encircled with a vessel loop.

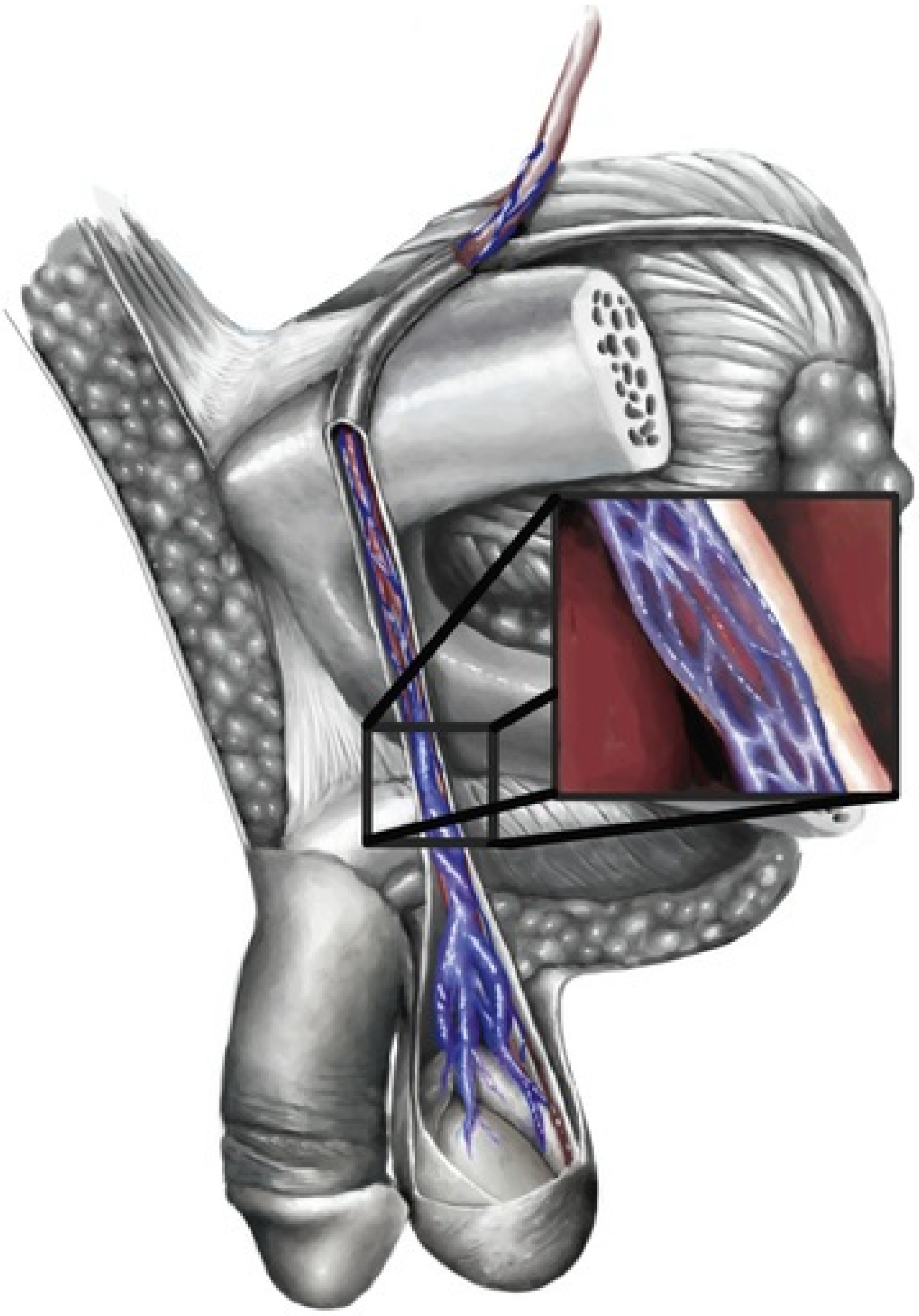

FIG. 67.48 The testicular artery shown surrounded by X- or H-like networks of small veins.

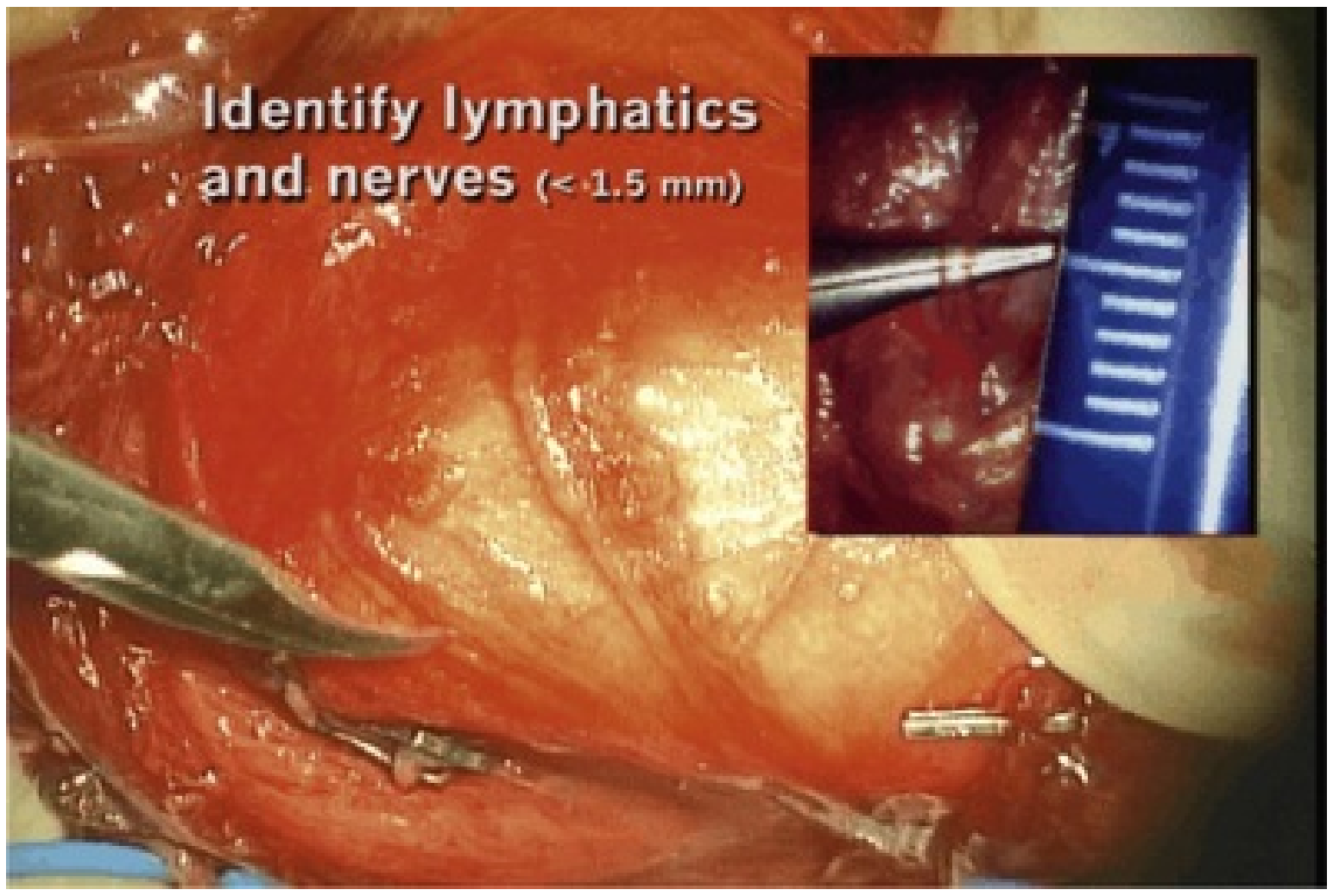
Identify lymphatics and nerves (< 1.5 mm)

FIG. 67.49 Lymphatics.

In approximately 50% of cases the testicular artery is adherent to the undersurface of a large vein (Beck et al., 1992). All veins within the cord, with the exception of the vasal veins, are doubly ligated with either hemoclips (Fig. 67.50A) or by passing two 4-0 silk ligatures, one black and one white, beneath the vein (Fig. 67.50B). These are then tied and the vein divided. Medium hemoclips are used for veins 5 mm or larger, small auto-hemoclips for veins 1 to 5 mm, and 4-0 silk for veins smaller than 2 mm. The bipolar cautery can be used for veins smaller than 0.5 mm. The vasal veins are preserved, providing venous return. If the vas deferens is accompanied by a dilated vein greater than 2.5 mm in diameter, they are dissected free of the vasal artery and ligated. The vas deferens is always accompanied by two sets of vessels. **As long as at least one set of deferential veins remains intact, venous return will be adequate.**

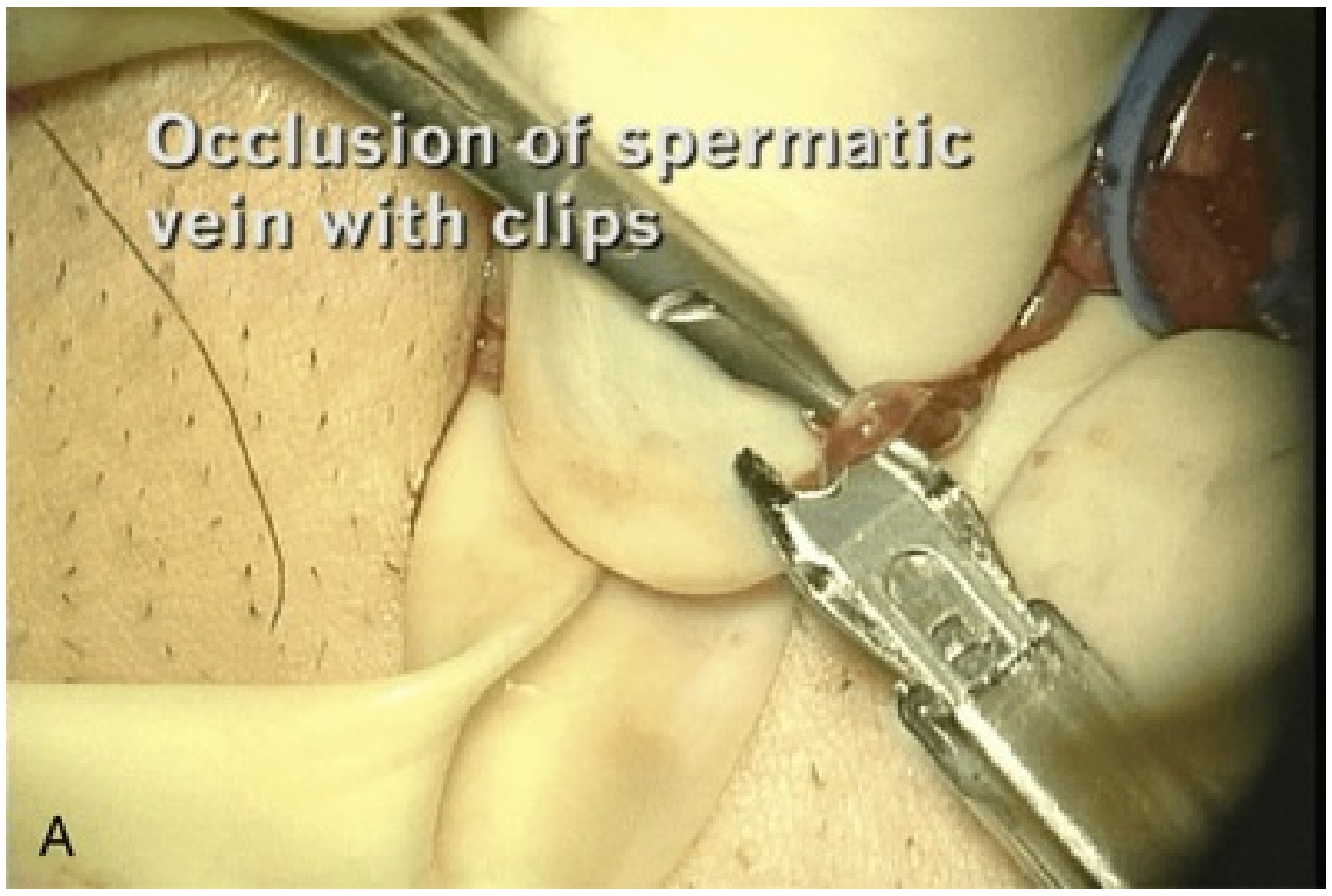

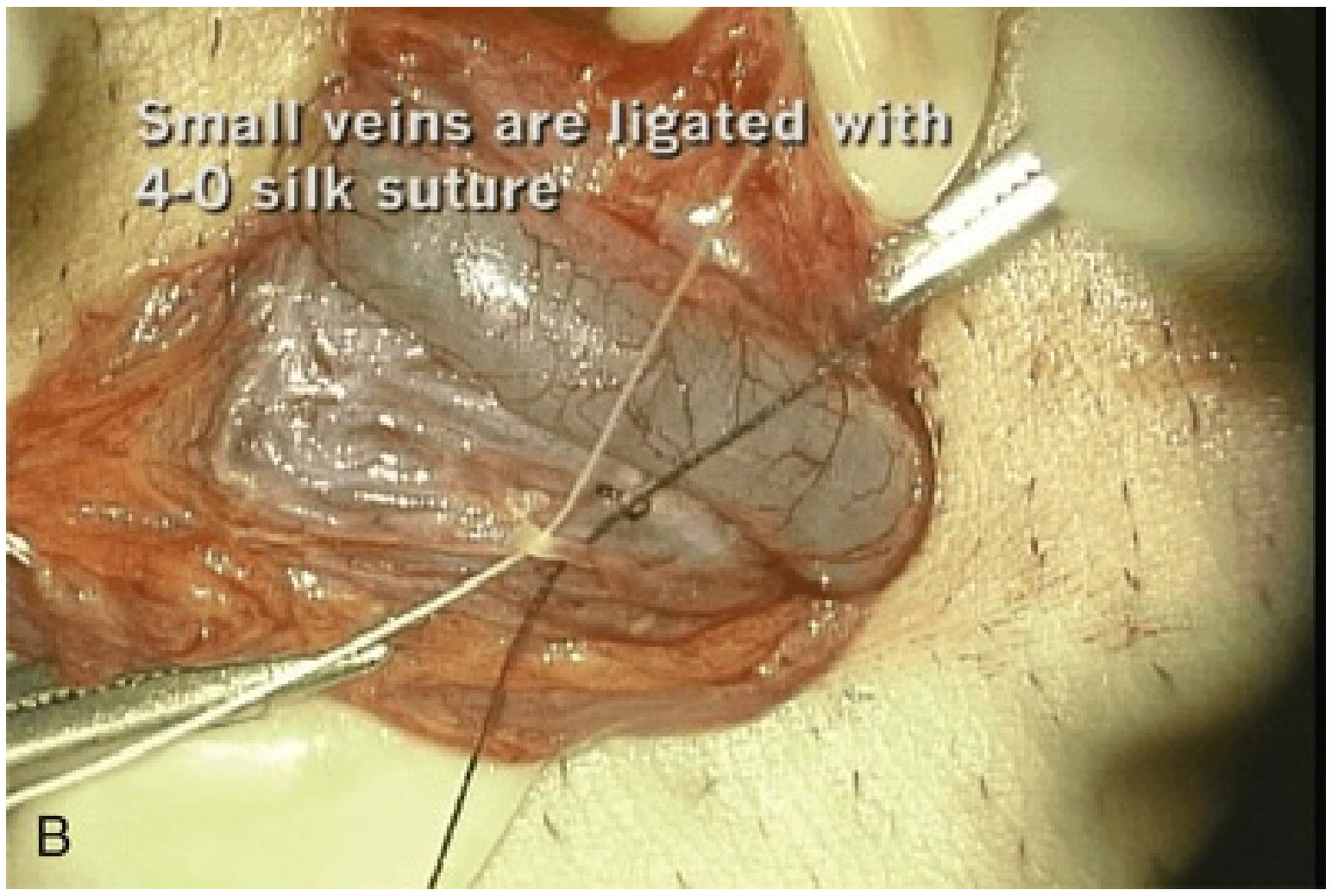

FIG. 67.50 Veins within the cord ligated with hemoclips (A) or by passing two 4-0 silk ligatures, one black and one white, beneath the vein (B).

At the completion of the dissection, the cord is run over the index finger and inspected to verify that all veins have been identified and ligated. Small veins adherent to the testicular artery are dissected free and ligated or, if smaller than 1 mm, cauterized using a bipolar unit with a jeweler's forceps tip and divided. Cremasteric arteries are found (usually between and adherent of two cremasteric veins) and preserved in at least 90% of cases. Recent studies employing power Doppler in men with nonobstructive azoospermia undergoing testicular sperm extraction have found that tubules containing sperm are most likely to be found in areas of the testis with the greatest blood supply. Therefore logic would dictate that preservation of maximum testicular blood supply, including testicular and cremasteric arteries, would be beneficial to testicular function. **At the completion of the dissection, only the testicular arteries, cremasteric arteries, lymphatics, and vas deferens with its vessels remain** (Fig. 67.51). Dissection is not deemed complete until a run through the cord reveals no additional internal or external spermatic veins. Each time a vein is found and ligated, any remaining veins dilate up.

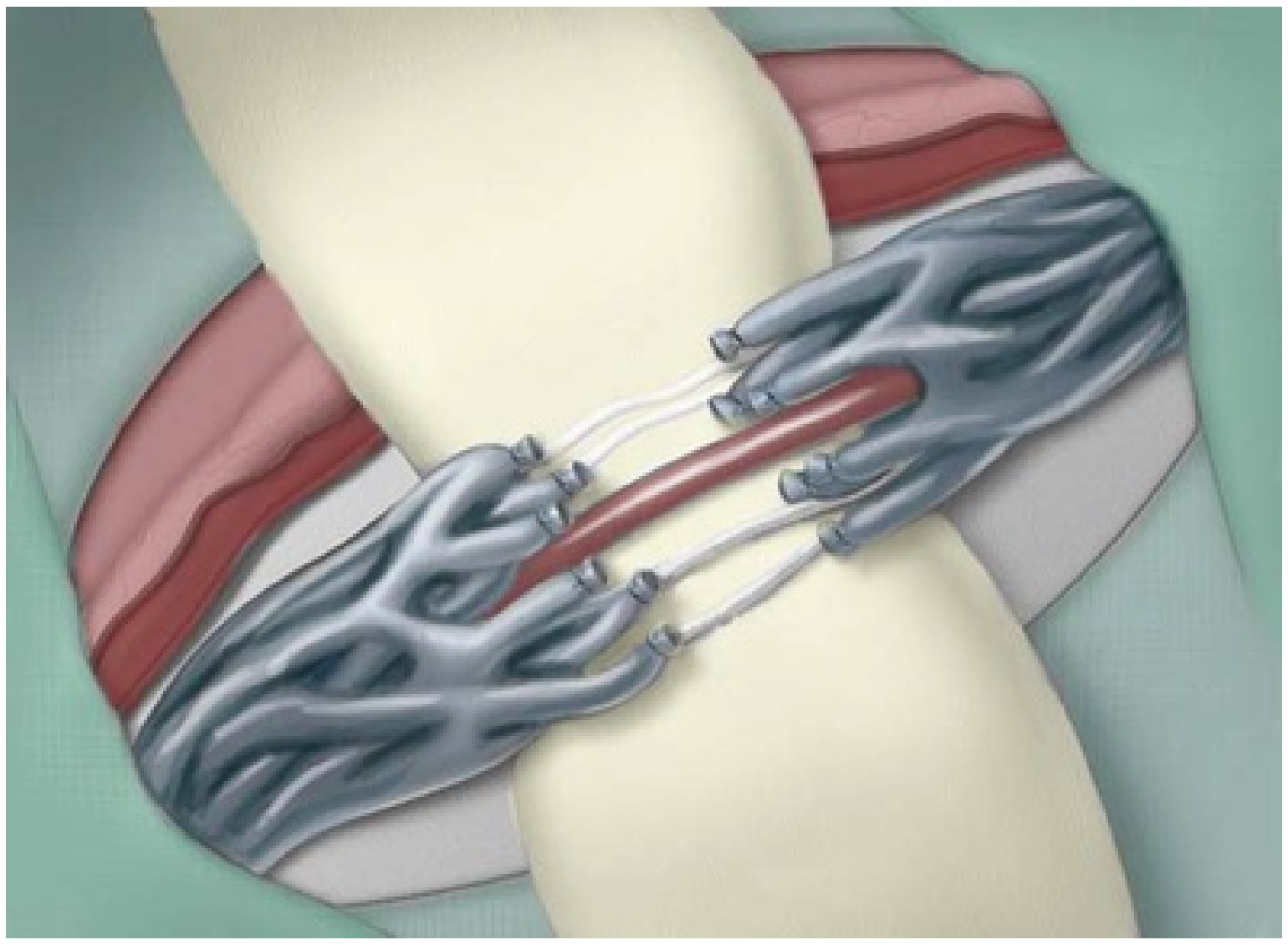

FIG. 67.51 Completed dissection showing the testicular artery, cremasteric arteries, lymphatics, and vas deferens with its vessels remaining.

Delivery of the Testis

Delivery of the testis through a small inguinal or subinguinal incision guarantees direct visual access to all possible avenues of testicular venous drainage. Delivery of only the cord allows access to most external spermatic collaterals but may miss those close to the testis and will not allow access to scrotal or gubernacular collaterals, which have been demonstrated radiographically to be the cause of 10% of recurrent varicoceles (Kaufman et al., 1983).

Orhan et al. retrospectively evaluated these new operative approaches: 82 microsurgical inguinal varicocelectomies and 65 subinguinal cases (Wosnitzer and Roth, 1983). The authors reported no significant difference between the two groups in operative time, semen improvement, or pregnancy rate, although the number of veins and arteries was higher in the subinguinal group. The author delivers the testis to address scrotal collaterals. His rationale for ligating scrotal collaterals is based on the publication of an article by Walsh et al., who found that 10% of failed varicocelectomies were due to scrotal collaterals (Kaufman et al., 1983). Interestingly, Patrick Walsh, the world-renowned urologist at Johns Hopkins who is best known for developing nerve-sparing radical prostatectomy, started out as a male fertility specialist. After completing his urology residency at the University of California, Los Angeles, he did a fellowship in male reproductive endocrinology with Jean Wilson, MD, at the University of Texas, Southwestern. Walsh's original interest in the prostate was on androgen action on the prostate and benign prostatic hypertrophy. He was the first author of the first description of embolization for varicocelectomy published in the *Journal of the American Medical Association* in 1981 (Walsh and White, 1981). The venography images of scrotal collaterals in men with prior failed varicocelectomy in the 1983 article in *Radiology* are very clear (Kaufman et al., 1983), and the authors of the study show that they contribute to the significantly higher failure rate of embolization techniques compared with current microsurgical techniques. Walsh also coauthored a book titled *Male Infertility* with Amelar and Dubin (1977). **It is undeniable that delivery of the testis provides direct visual access to every possible route of venous return,** and in more than 4000 cases done by the author, the failure rate was less than 1% with minimal morbidity (Goldstein et al., 1992; Goldstein, 2016). Finally, open microsurgical varicocelectomy has demonstrated lower recurrence rates and fewer complications compared with a laparoscopic or a high retroperitoneal approach (Goldstein, 2016).

With gentle upward traction on the cord and upward pressure on the testis through the invaginated scrotum, the testis is easily delivered through the wound. All external spermatic veins are identified and doubly ligated with hemoclips and divided (Fig. 67.52). The gubernacula are inspected for the presence for veins exiting from the tunica vaginalis. These are either cauterized or doubly clipped and divided. **When this step is completed, all testicular venous return must be within the Penrose surrounding cord,** which is again run over the index finger, and any remaining internal or external spermatic veins are clipped or ligated. **If the varicocelectomy has been performed successfully, squeezing on the dilated scrotal pampinoform plexus of veins just above the testis will result in transmission of a distinct impulse felt in the biggest veins just on the testicular side of the ligation.** This is similar to transmission of a fluid wave in diagnosing ascites. Absence of a distinct impulse suggests that a significant internal, external, or gubernacular vein has been missed, allowing venous blood to go straight across the area of ligation and warrants rerunning the cord and redelivery of the testis. The reason this “impulse test” works is that it takes time for the testicular venous return to find its way through the deferential veins, so immediately after ligation the venous pressure is high.

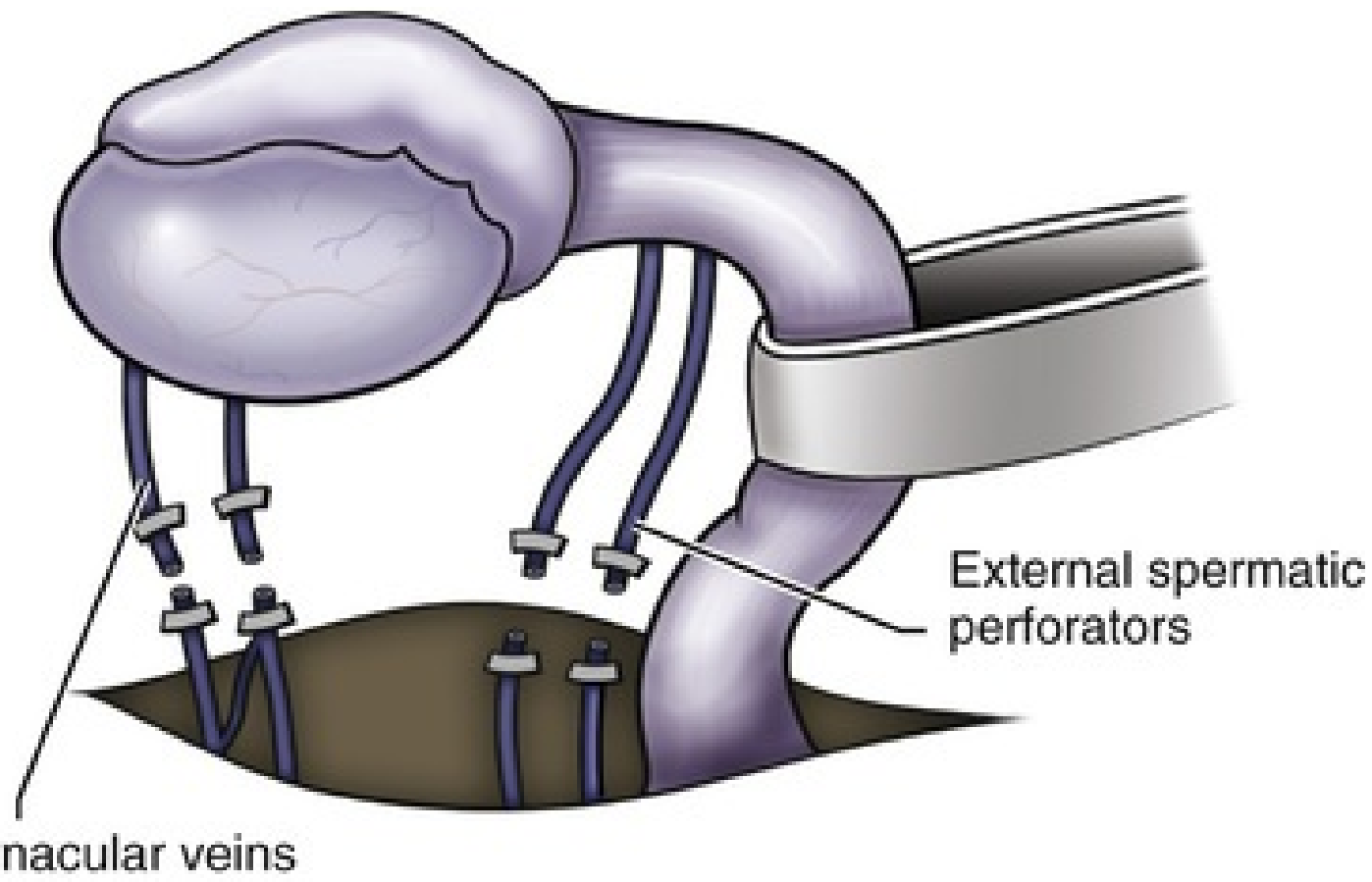

FIG. 67.52 External spermatic and gubernacular veins are doubly ligated with hemoclips and divided.

The external spermatic fascia is reapproximated with 2 or 3 interrupted sutures of 5-0 Vicryl, facilitated by pulling up on the suture previously placed at the apex of the opening in the external spermatic fascia. This covers up the exposed testicular arteries.

Hydroceles are found in 15% of testes associated with varicoceles. **As little as 3 cc of hydrocele fluid can significantly alter testicular temperature regulation** (Wysock and Goldstein, 2009). If a hydrocele is noted when the testis is delivered, it is repaired. Small ones may be treated with excision of a segment of the hydrocele sac and cauterization of the edges. Larger hydroceles are treated with either a bottleneck or excision technique. **The temporary high venous pressure immediately after varicocelectomy can make good hemostasis difficult to achieve after excisional hydrocelectomy. Therefore there should be no hesitation to employ a scrotal Penrose drain placed in the dependent portion of the scrotum for 24 hours after combined varicocelectomy and excisional hydrocelectomy.** The testis is then returned to the scrotum and the Penrose drain is left beneath the cord structures.

The external oblique aponeurosis, if opened, is reapproximated with continuous suturing using the previously placed 3-0 suture. Scarpa fascia and Camper fascia are reapproximated with a single or continuous 3-0 plain catgut suture, and the skin is approximated with a 5-0 monofilament absorbable subcuticular suture reinforced by 2 to 3 Steri-Strips (Fig. 67.53). A scrotal supporter is applied and stuffed with fluff type dressings. The patient is discharged on the day of surgery with a prescription for acetaminophen with codeine. The patient is instructed to apply ice to his or her wounds intermittently for 20 minutes for 20 days postoperatively to prevent further swelling and ease discomfort on the effected site. The patient should shower in 48 hours, and light desk work may be resumed in 2 or 3 days. Ejaculation and intercourse may be resumed 1 week postoperatively, light exercise in 2 weeks, and all activities 3 weeks postoperatively.

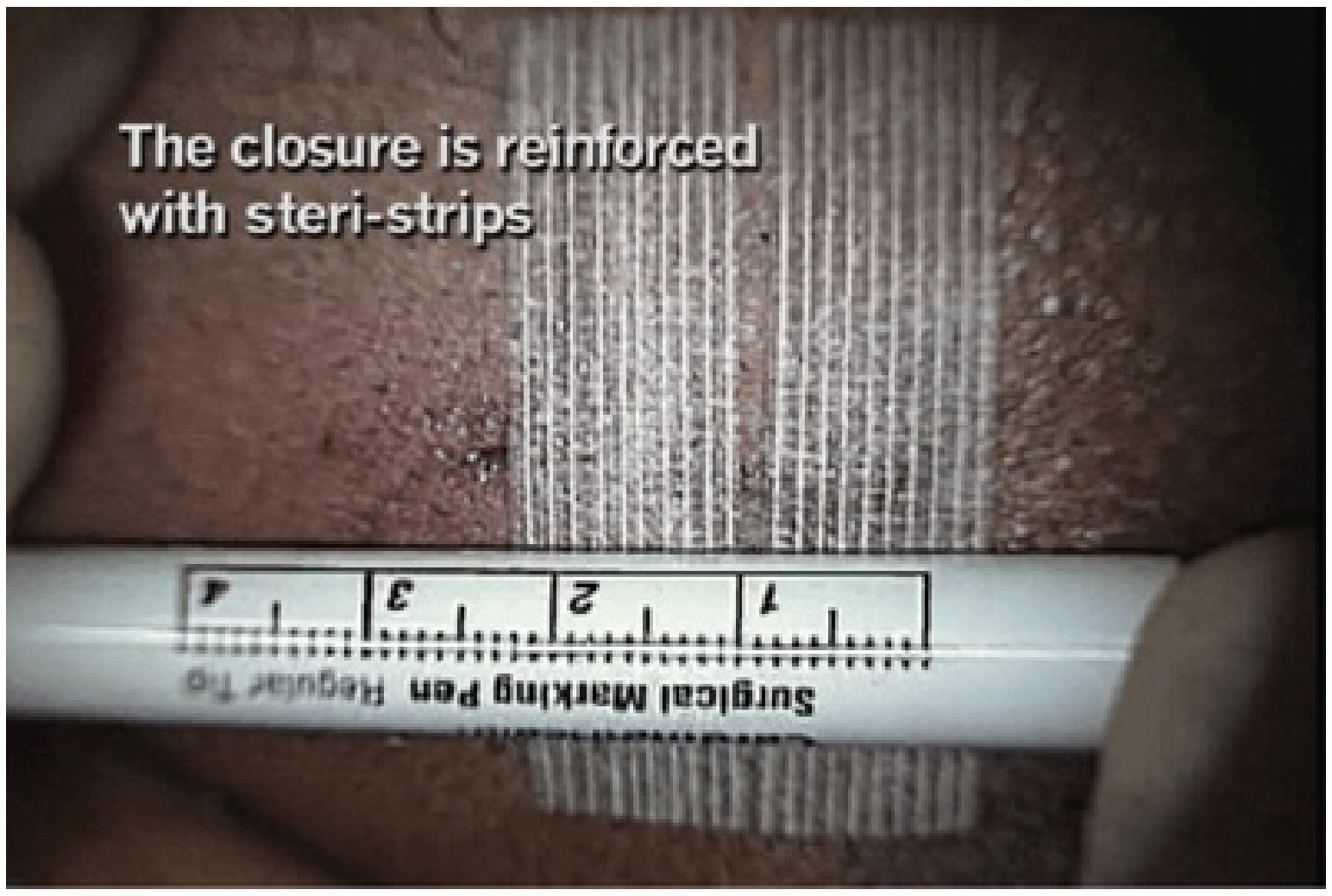
The closure is reinforced with steri-strips
Surgical Marking Pen Regular Tip
1
2
3
4

FIG. 67.53 Subcuticular suture reinforced by two to three Steri-Strips.

Radiographic Occlusion Techniques

Radiographic coil occlusion of the internal spermatic veins has been successfully employed for varicoceles (Lima et al., 1978; Walsh and White, 1981; Weissbach et al., 1981). These techniques are performed under a local anesthetic through a small cut-down incision over the femoral vein. The recurrence rate after balloon occlusion was originally 11% and more recently is reportedly as low as 4% (Kaufman et al., 1983; Matthews et al., 1992; Mitchell et al., 1985; Murray et al., 1986). Failure to successfully cannulate small collaterals and external spermatic veins and scrotal collaterals results in recurrence. **Venographic placement of a balloon or coil in the internal spermatic vein is successfully accomplished in 75% to 90% of attempts** (Morag et al., 1984; Sivanathan and Abernethy, 2003; White et al., 1981; Winkelbauer et al., 1994)**. Therefore a significant number of men undergoing attempted radiographic occlusion will ultimately require a surgical approach.** In addition, the radiographic techniques take between 1 and 3 hours to perform compared with 25 to 45 minutes required for surgical repair. Although rare, serious complications of radiographic balloon or coil occlusion have included migration of the balloon or coil into the renal vein, resulting in loss of a kidney, pulmonary embolization of the coil or balloon (Matthews et al., 1992), femoral vein perforation or thrombosis, and anaphylactic reaction to radiographic contrast medium. Antegrade scrotal sclerotherapy via cannulation of a scrotal vein has been employed in Europe (Ficarra et al., 2002; Minucci et al., 2004; Tauber and Johnsen, 1994). The recurrence rate is similar to balloon or coil techniques. Long-term follow-up is not available, and the consequence of escape of the sclerosing agent into the renal vein and vena cava is unknown. In addition, the larger the varicocele, the higher the failure and recurrence rate with this technique. **We have seen many men referred with late (2–5 years) recurrence after radiographic occlusion. They typically present as slow-filling veins that become prominent at the end of the day. Initial cursory physical examination can miss these recurrences. We believe these recurrences are likely due to recanalization through the coils because, unlike in surgical repair, the veins are not ligated and divided.** Although often initially successful, I believe that radiographic occlusion is less durable than microsurgical ligation.

Complications of Varicocelectomy

Hydrocele

Hydrocele formation is the most common complication reported after nonmicroscopic varicocelectomy. The incidence of this complication varies from 3% to 33%, with an average incidence of about 7%. Analysis of the protein concentration of hydrocele fluid indicates that **hydrocele formation after varicocelectomy is due to lymphatic obstruction** (Szabo and Kessler, 1984). At least half of postvaricocelectomy hydroceles grow to a size large enough to warrant surgical excision because of the discomfort and growth of the hydrocele to a large size. The effect of hydrocele formation on sperm function and fertility is uncertain. It is known that men with varicocele have significantly elevated intratesticular temperatures (Goldstein and Eid, 1989; Zorgniotti et al., 1979). This appears to be an important pathophysiologic phenomenon mediating the adverse effects of varicocele on fertility (Saypol et al., 1981). The development of a large hydrocele creates an abnormal insulating layer that surrounds the testis. This may impair the efficiency of the counter-current heat exchange mechanism and therefore obviate some of the benefits of varicocelectomy (Wysock and Goldstein, 2009).

Use of magnification to identify and preserve lymphatics almost eliminates the risk of hydrocele formation after varicocelectomy (Glassberg et al., 2008; Goldstein et al., 1992; Marmar and Kim, 1994). The management of postvaricocelectomy hydrocele is identical to that of other hydroceles (see Chapter 41).

Key Points: Hydrocele

- A single stitch through an epididymal tubule in the corpus or cauda will result in complete obstruction.

Testicular Artery Injury

The diameter of the testicular artery in humans is 1.0 to 1.5 mm. The testicular artery supplies two-thirds of the testicular blood supply and the vasal and cremasteric arteries the remaining one-third (Raman and Goldstein, 2004). Microdissections of the human spermatic cord have revealed that the testicular artery is closely adherent to a large internal spermatic vein in 40% of men. In another 20% of men the testicular artery is surrounded by a network of tiny veins (Beck et al., 1992). During the course of cord dissection for varicocelectomy, the artery may go into spasm and even in its unconstricted state is often difficult to positively identify and preserve. **Injury or ligation of the testicular artery carries with it the risk of testicular atrophy and/or impaired spermatogenesis.** Starzl's transplant group (Penn et al., 1972) reported a 14% incidence of frank testicular atrophy when the testicular artery was purposely ligated. The actual incidence of testicular artery ligation during varicocelectomy is unknown, but some studies suggest it is common (Wosnitzer and Roth, 1983). Animal studies indicate that the risk of testicular atrophy after testicular artery ligation varies from 20% to 100% (Goldstein and Einer-Jensen, 1983; MacMahon et al., 1976). In humans, atrophy after artery ligation is probably less likely because of the contribution of the cremasteric as well as vasal arterial supply (Raman and Goldstein, 2004). **In children the potential for neovascularization and compensatory hypertrophy of the vasal and cremasteric vessels is probably greater than in adults, making atrophy after testicular artery ligation less likely.** Use of magnifying loupes, or preferably an operating microscope and/or a fine-tip Doppler probe, facilitates identification and preservation of the testicular artery and therefore minimizes the risk of testicular injury. Radiographic balloon or coil occlusion techniques also eliminate this risk.

Varicocele Recurrence

The incidence of varicocele recurrence after surgical repair varies from 0.6% to 45% (Al-Kandari et al., 2007; Barbalias et al., 1998; Cayan et al., 2000; Lemack et al., 1998). Recurrence is more common after repair of pediatric varicoceles. Radiographic studies of recurrent varicoceles visualize periarterial, parallel inguinal, or midretroperitoneal collaterals or, more rarely, trans-scrotal collaterals (Kaufman et al., 1983). **Retroperitoneal operations miss parallel inguinal and scrotal collaterals.** Nonmagnified inguinal operations have a lower incidence of varicocele recurrence but fail to address the issue of scrotal collaterals or small veins surrounding the testicular artery. The microsurgical approach with delivery of the testis lowers the incidence of varicocele recurrence to less than 1% compared with 9% using conventional inguinal techniques (Goldstein et al., 1992; Marmar and Kim, 1994).

Results

Varicocelectomy results in significant improvement in semen analysis in 60% to 80% of men. Reported pregnancy rates after varicocelectomy vary from 20% to 60% (Marmar et al., 2007). A randomized controlled trial of surgery versus no surgery in infertile men with varicoceles revealed a pregnancy rate of 44% at 1 year in the surgery group versus 10% in the control group (Madgar et al., 1995). In our series of 1500 microsurgical operations, 43% of couples were pregnant at 1 year (Goldstein and Tanrikut, 2006) and 69% at 2 years when couples with female factors were excluded. **Microsurgical varicocelectomy results in return of sperm to the ejaculate in up to 50% of azoospermic men with palpable varicoceles** (Ishikawa et al., 2008; Kim et al., 1999; Lee et al., 2007; Matthews et al., 1998; Pasqualotto et al., 2006).

The results of varicocelectomy are also related to the size of the varicocele. **Repair of large varicoceles results in a significantly greater improvement in semen quality than repair of small varicoceles** (Jarow et al., 1996; Steckel et al., 1993). In addition, large varicoceles are associated with greater preoperative impairment in semen quality than small varicoceles, and consequently overall pregnancy rates are similar regardless of varicocele size. Some evidence suggests that the younger the patient is at the time of varicocele repair, the greater the improvement after repair and the more likely the testis is to recover from varicocele-induced injury (Kass et al., 1987). Varicocele recurrence, testicular artery ligation, and postvaricocelectomy hydrocele formation are often associated with poor postoperative results. **In infertile men with low serum testosterone levels, microsurgical varicocelectomy alone results in substantial improvement in serum testosterone levels** (Cayan et al., 1999; Rosoff et al., 2009; Su et al., 1995; Tanrikut et al., 2011; Younes, 2003).

Summary

Varicocele is an extremely common entity, present in 15% of the male population. Varicoceles are found in approximately 35% of men with primary infertility but 75% to 81% of men with secondary infertility. Mounting evidence clearly demonstrates that varicocele causes progressive duration-dependent injury to the testis. Larger varicoceles appear to cause more damage than small varicoceles and, conversely, repair of large varicoceles results in greater improvement of semen quality. **Varicocelectomy can halt the progressive duration-dependent decline in semen quality found in men with varicoceles.** The earlier the age at which varicocele is repaired, the more likely is recovery of spermatogenic function. **Variococelectomy can also improve Leydig cell function resulting in increased testosterone levels** (Cayan et al., 1999; Su et al., 1995; Tanrikut et al., 2011; Younes, 2003)**. Repair improves live birth rates as well as IVF/ICSI outcomes and increases the chances of finding sperm in men with NOA.**

The most common complications after varicocelectomy are hydrocele formation, testicular artery injury, and varicocele persistence or recurrence. **The incidence of** these **complications can be reduced by employing microsurgical techniques, inguinal or subinguinal operations, and exposure of the external spermatic and scrotal veins.** Employment of these advanced techniques of varicocelectomy provide a safe, effective approach to elimination of varicocele, preservation of testicular function, and, in a substantial number of men, an increase in semen quality and likelihood of pregnancy, as well as increase in serum testosterone in men with androgen deficiency.

Key Points: Varicocelectomy

- Early repair of varicoceles prevents both future infertility and Leydig cell dysfunction.
- In select men, varicocelectomy may be an effective treatment for symptomatic, age-related androgen deficiency.
- Micro-Doppler is extremely useful in identifying arteries.
- As long as at least one set of deferential veins remains intact, venous return will be adequate.
- At the completion of the dissection, only the testicular arteries, cremasteric arteries, lymphatics, and vas deferens with its vessels remain.
- Ligation of the testicular artery is unlikely to enhance testicular function.
- Microsurgical varicocelectomy results in return of sperm to the ejaculate in approximately 40% of men with nonobstructive azoospermia.

Orchiopexy in Adults

It is well known that cryptorchidism is associated with a high incidence of infertility even when unilateral. Long, hot baths and saunas in humans, on a regular basis, have been shown to impair spermatogenesis. Elevated testicular temperature is also thought to be the primary pathophysiologic feature of varicocele (Goldstein and Eid, 1989; Saypol et al., 1981; Wright et al., 1997; Zorgniotti, 1980). Spermatogenesis is exquisitely temperature sensitive. Animal and human studies have shown that artificial elevation of testicular temperature results in impaired spermatogenesis (Perez-Crespo et al., 2008; Shin et al., 1997; Shiraishi et al., 2009). It will also preserve testicular hormonal function. The technique of orchiopexy in adults is identical to that employed for children. Even with a normal contralateral testis, orchiopexy is worthwhile to bring down a unilateral undescended testis to, if possible, a scrotal location where it can be examined. Leydig cell function in undescended testis can be retained. Orchiopexy in adults with bilateral undescended testes can induce spermatogenesis and allow pregnancy (Shin et al., 1997). Even **a solitary cryptorchid testis, when properly placed in scrotum, can provide enough testosterone to obviate the need for hormone replacement. When orchiopexy is performed in adults, regular self-examination and yearly sonography is mandatory.**

Retractile or Ectopic Testes in Adults

Retractile testes in boys are usually not surgically repaired if the testes can be manually manipulated to stay down in the scrotum either in the office or under anesthesia. The fate of persistently retractile testis in adults is unknown. A subset of infertile men have retractile testis (Caucci et al., 1997). The semen analyses of these men often demonstrate a typical stressed pattern similar to those of men with varicoceles. These men, however, do not have palpable varicoceles. They all have at least one and frequently both testes that retract out of the scrotum and into the abdomen and remain there for an hour or more a day. In some men these testes remain in the abdomen virtually all the time, except when in a warm shower or under anesthesia. It is likely that these testes will suffer from impaired temperature regulation and impaired spermatogenesis. Scrotal orchiopexy can improve the semen quality and fertility of some of these men. Some men have ectopic testis in which, instead of the testes being side to side, one testis is behind (Fig. 67.54) the other, almost in the perineum. This is also likely to elevate testis temperature.

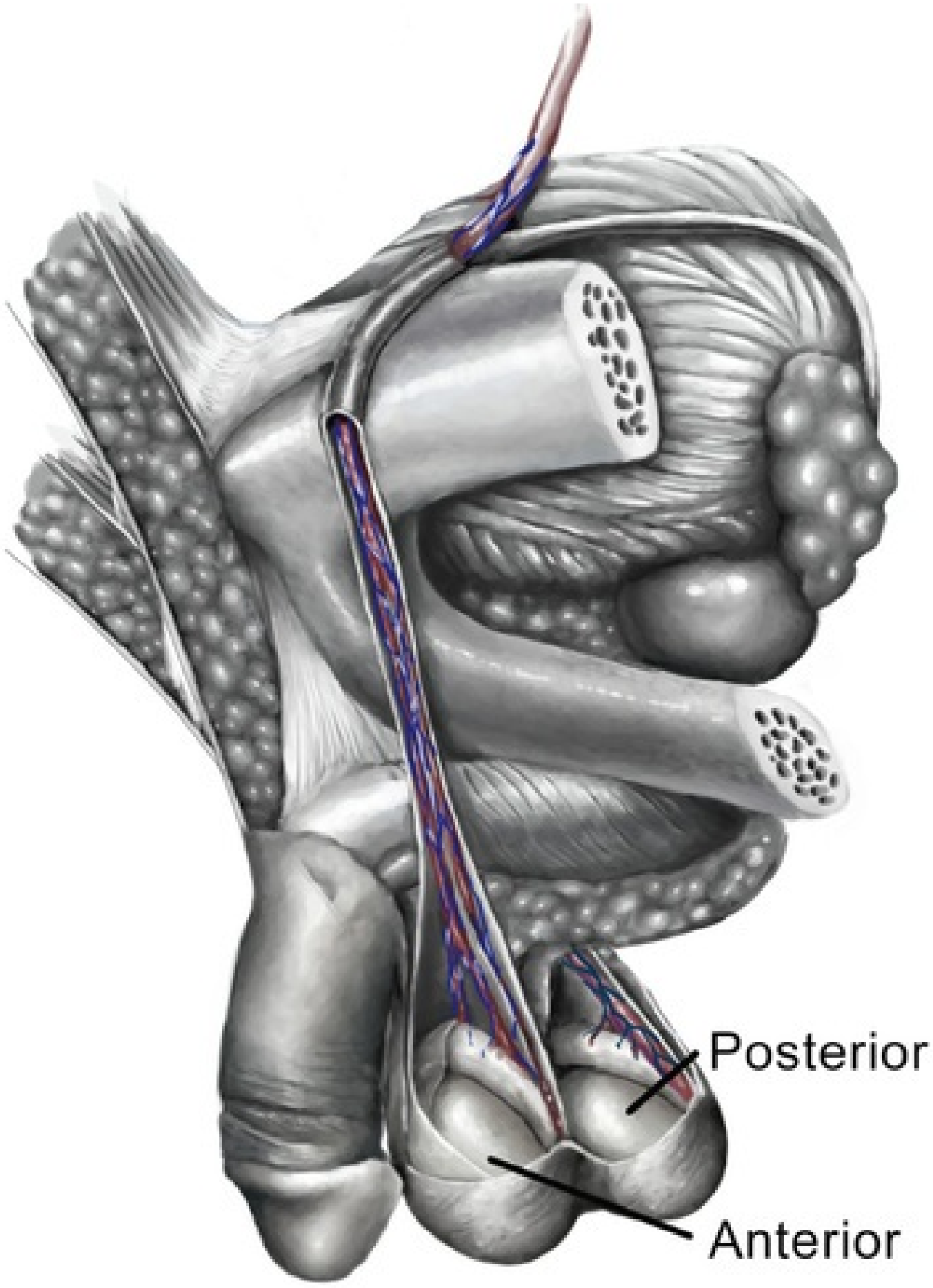

FIG. 67.54 Ectopic testis, where one testis is behind the other, almost in the perineum.

When scrotal orchiopexy is performed for retractile or ectopic testis in adults, a dartos pouch operation should be performed. Simple suture orchiopexy of the tunica albuginea of the testis to the dartos, such as is performed sometimes to prevent torsion, will not prevent retraction of these testes into the groin. Creation of a dartos pouch keeps the testis well down into the scrotum and permanently prevent retraction. **This is also the most reliable and safest technique for the prevention of testicular torsion** (Redman and Barthold, 1995).

A 3- to 4-cm transverse incision is made in the low scrotal skinfolds overlying the testis. **The incision is kept very superficial, just through the dermis and not into the dartos. A large pouch must be created to accommodate the adult testis.** The place of dissection is above the dartos and just below the skin, which is kept thin.

After a capacious pouch is created, the dartos and underlying tunica vaginalis are vertically incised and the testis delivered. The cremasteric fibers overlying the spermatic cord are divided and ligated to minimize the tendency of the testis to retract. The opening in the dartos is closed around the cord (but not too tightly) to prevent the testis from falling out of the pouch. The cut edge of the everted tunica is approximated to the opening in the dartos with interrupted synthetic monofilament absorbable sutures. This allows placement of the testis in the pouch without the need for fixation sutures in the tunica albuginea (Redman and Barthold, 1995). The skin is closed over the testis with interrupted sutures of 4-0 chromic catgut. This technique obviates the risk of inadvertent injury to and bleeding from the testicular artery, which courses just under the tunica albuginea (Jarow, 1990).

Videos 67.1▶Videos 67.2▶Videos 67.3▶Videos 67.4▶Videos 67.5▶Videos 67.6▶Videos 67.7▶Videos 67.8▶ show procedures related to this topic.

Key Points: Orchiopexy

- When orchiopexy is performed for retractile or ectopic testis in adults, a dartos pouch should be performed.

Acknowledgments

I thank Vanessa L. Dudley and Philip Shihua Li, MD, for their immeasurable assistance in the preparation of this manuscript.

References

Al-Kandari AM, Shabaan H, Ibrahim HM, et al. Comparison of outcomes of different varicocelectomy techniques: open inguinal, laparoscopic, and subinguinal microscopic varicocelectomy: a randomized clinical trial. *Urology*. 2007;69(3):417–420.

Al-Said S, Al-Naimi A, Al-Ansari A, et al. Varicocelectomy for male infertility: a comparative study of open, laparoscopic and microsurgical approaches. *J Urol*. 2008;180(1):266–270.

Amelar R, Dubin L, Walsh P. *Male infertility*. W.B. Saunders: Philadelphia; 1977.

Anger JT, Wang GJ, Boorjian SA, et al. Sperm cryopreservation and in vitro fertilization/intracytoplasmic sperm injection in men with congenital bilateral absence of the vas deferens: a success story. *Fertil Steril*. 2004;82(5):1452–1454.

Barbalias GA, Liatsikos EN, Nikiforidis G, et al. Treatment of varicocele for male infertility: a comparative study evaluating currently used approaches. *Eur Urol*. 1998;34(5):393–398.

Barroso U Jr, Andrade DM, Novaes H, et al. Surgical treatment of varicocele in children with open and laparoscopic Palomo technique: a systematic review of the literature. *J Urol*. 2009;181(6):2724–2728.

Beck EM, Schlegel PN, Goldstein M. Intraoperative varicocele anatomy: a macroscopic and microscopic study. *J Urol*. 1992;148(4):1190–1194.

Bennett CJ, Ayers JW, Randolph JF Jr, et al. Electroejaculation of paraplegic males followed by pregnancies. *Fertil Steril*. 1987;48(6):1070–1072.

Benshushan A, Schenker JG. The right to an heir in the era of assisted reproduction. *Hum Reprod*. 1998;13(5):1407–1410.

Berger RE. Triangulation end-to-side vasoepididymostomy. *J*

Urol. 1998;159(6):1951–1953.

Bolyakov A, Mittal S, Mielnik A, et al. *P-350: identification of live sperm by flow cytometry using visible spectrum membrane permeable syto red nucleic acid stains*. American Society of Reproductive Medicine: Salt Lake City, UT; 2016.

Boorjian S, Lipkin M, Goldstein M. The impact of obstructive interval and sperm granuloma on outcome of vasectomy reversal. *J Urol*. 2004;171(1):304–306.

Brackett NL, Padron OF, Lynne CM. Semen quality of spinal cord injured men is better when obtained by vibratory stimulation versus electroejaculation. *J Urol*. 1997;157(1):151–157.

Brandell RA. Reconstruction of the male reproductive tract using the microsurgical triangulation technique for vasoepididymostomy. *J Urol*. 1999;161(Suppl):350.

Brindley GS. Reflex ejaculation under vibratory stimulation in paraplegic men. *Paraplegia*. 1981;19(5):299–302.

Carpi A, Menchini Fabris FG, Palego P, et al. Fine-needle and large-needle percutaneous aspiration biopsy of testicles in men with nonobstructive azoospermia: safety and diagnostic performance. *Fertil Steril*. 2005;83(4):1029–1033.

Castro-Magana M, Angulo MA, Canas JA, et al. Improvement of Leydig cell function in male adolescents after varicocelectomy. *J Pediatr*. 1989;115(5 Pt 1):809–812.

Caucci M, Barbatelli G, Cinti S. The retractile testis can be a cause of adult infertility. *Fertil Steril*. 1997;68(6):1051–1058.

Cayan S, Kadioglu A, Orhan I, et al. The effect of microsurgical varicocelectomy on serum follicle stimulating hormone, testosterone and free testosterone levels in infertile men with varicocele. *BJU Int*. 1999;84(9):1046–1049.

Cayan S, Kadioglu TC, Tefekli A, et al. Comparison of results and complications of high ligation surgery and microsurgical high inguinal varicocelectomy in the treatment of varicocele.

Urology. 2000;55(5):750–754.

Chan PT, Brandell RA, Goldstein M. Prospective analysis of outcomes after microsurgical intussusception vasoepididymostomy. *BJU Int*. 2005;96(4):598–601.

Chan PT, Palermo GD, Veeck LL, et al. Testicular sperm extraction combined with intracytoplasmic sperm injection in the treatment of men with persistent azoospermia postchemotherapy. *Cancer*. 2001;92(6):1632–1637.

Chan SL, Lipshultz LI, Schwartzendruber D. Deoxyribonucleic acid (DNA) flow cytometry: a new modality for quantitative analysis of testicular biopsies. *Fertil Steril*. 1984;41(3):485–487.

Chang HC, Chen SC, Hsieh JT, et al. The effect of biological dyes and contrast media on the vas deferens in Long Evans rats. *Int J Androl*. 1998;21(5):308–312.

Chehval MJ, Purcell MH. Deterioration of semen parameters over time in men with untreated varicocele: evidence of progressive testicular damage. *Fertil Steril*. 1992;57(1):174–177.

Cornel EB, Dohle GR, Meuleman EJ. Transurethral deroofing of midline prostatic cyst for subfertile men. *Hum Reprod*. 1999;14(9):2297–2300.

Craft I, Tsirigotis M, Bennett V, et al. Percutaneous epididymal sperm aspiration and intracytoplasmic sperm injection in the management of infertility due to obstructive azoospermia. *Fertil Steril*. 1995;63(5):1038–1042.

Dabaja AA, Mehta A, Wosnitzer MS, et al. *Microdot vasovasostomy improves patency and reduces time for return of sperm to the ejaculate*. [Abstract presented at American Society for Reproductive Medicine, Boston] 2013.

Dabaja AA, Mehta A, Wosnitzer MS, et al. *Microsurgical assisted hydrocelectomy*. [Abstract presented at American Society for Reproductive Medicine, Boston] 2013.

Dabaja AA, Schlegel PN. Microdissection testicular sperm extraction: an update. *Asian J Androl*. 2013;15(1):35–39.

Dardashti K, Williams RH, Goldstein M. Microsurgical testis biopsy: a novel technique for retrieval of testicular tissue. *J Urol*. 2000;163(4):1206–1207.

Davies MJ, Moore VM, Willson KJ, et al. Reproductive technologies and the risk of birth defects. *N Eng J Med*. 2012;399(19):1803–1813.

Diamond DA, Xuewu J, Cilento BG Jr, et al. Varicocele surgery: a decade's experience at a children's hospital. *BJU Int*. 2009;104(2):246–249.

Donovan JF, Winfield HN. Laparoscopic varix ligation. *J Urol*. 1992;147(1):77–81.

Dostal J, Utrata R, Loyka S, et al. Post-mortem sperm retrieval in new European Union countries: case report. *Hum Reprod*. 2005;20(8):2359–2361.

Dubin L, Amelar RD. Varicocelectomy: 986 cases in a twelve-year study. *Urology*. 1977;10(5):446–449.

Eisenberg ML, Walsh TJ, Garcia MM, et al. Ejaculatory duct manometry in normal men and in patients with ejaculatory duct obstruction. *J Urol*. 2008;180(1):255–260 [discussion 260].

Enquist E, Stein BS, Sigman M. Laparoscopic versus subinguinal varicocelectomy: a comparative study. *Fertil Steril*. 1994;61(6):1092–1096.

Ficarra V, Porcaro AB, Righetti R, et al. Antegrade scrotal sclerotherapy in the treatment of varicocele: a prospective study. *BJU Int*. 2002;89(3):264–268.

Fogdestam I, Fall M, Nilsson S. Microsurgical epididymovasostomy in the treatment of occlusive azoospermia. *Fertil Steril*. 1986;46(5):925–929.

Foresta C, Garolla A, Bartoloni L, et al. Genetic abnormalities among severely oligospermic men who are candidates for intracytoplasmic sperm injection. *J Clin Endocrinol Metab*. 2005;90(1):152–156.

Friedler S, Raziel A, Strassburger D, et al. Testicular sperm retrieval by percutaneous fine needle sperm aspiration compared with testicular sperm extraction by open biopsy in men with non-obstructive azoospermia. *Hum Reprod (Oxford, England)*. 1997;12(7):1488–1493.

Fuse H, Mizuno I, Iwasaki M, et al. Transurethral treatment of ejaculatory duct obstruction in infertile men. *Arch Androl*. 2003;49(6):429–431.

Gerrard ER Jr, Sandlow JI, Oster RA, et al. Effect of female partner age on pregnancy rates after vasectomy reversal. *Fertil Steril*. 2007;87(6):1340–1344.

Glassberg KI, Poon SA, Gjertson CK, et al. Laparoscopic lymphatic sparing varicocelectomy in adolescents. *J Urol*. 2008;180(1):326–330 [discussion 330–321].

Goldstein M, Eid JF. Elevation of intratesticular and scrotal skin surface temperature in men with varicocele. *J Urol*. 1989;142:743–745.

Goldstein MYG, Einer-Jensen N. Testicular artery damage due to infiltration with a fine gauge needle: experimental evidence suggesting that blind cord block should be abandoned. *Surg Forum*. 1983;24:653–656.

Goldstein M, Gilbert BR, Dicker AP, et al. Microsurgical inguinal varicocelectomy with delivery of the testis: an artery and lymphatic sparing technique. *J Urol*. 1992;148(6):1808–1811.

Goldstein M, Li PS, Matthews GJ. Microsurgical vasovasostomy: the microdot technique of precision suture placement. *J Urol*. 1998;159(1):188–190.

Goldstein M, Schlossberg S. Men with congenital absence of the vas deferens often have seminal vesicles. *J Urol*. 1988;140(1):85–86.

Goldstein M, Tanrikut C. Microsurgical management of male infertility. *Nat Clin Pract Urol*. 2006;3(7):381–391.

Goldstein M. Microspike approximator for vasovasostomy. *J Urol*. 1985;134(1):74.

Goldstein M. *Simultaneous microsurgical vasovasostomy and varicocelectomy: caveat emptor*. [Paper presented at American Society of Reproductive Medicine] 1995.

Goldstein M. Surgical management of male infertility. Wein AJ, Kavoussi LR, Partin AW, et al. *Campbell-Walsh urology*. ed 11. Elsevier: Philadelphia, PA; 2016:580–611.

Goldwasser BZ, Weinerth JL, Carson CC 3rd. Ejaculatory duct obstruction: the case for aggressive diagnosis and treatment. *J Urol*. 1985;134(5):964–966.

Gorelick JI, Goldstein M. Loss of fertility in men with varicocele. *Fertil Steril*. 1993;59(3):613–616.

Gorenstein A, Katz S, Schiller M. Varicocele in children: “to treat or not to treat”–venographic and manometric studies. *J Pediatr Surg*. 1986;21(12):1046–1050.

Hadziselimovic F, Herzog B, Liebundgut B, et al. Testicular and vascular changes in children and adults with varicocele. *J Urol*. 1989;142(2 Pt 2):583–585 [discussion 603–585].

Hagan KF, Coffey DS. The adverse effects of sperm during vasovasostomy. *J Urol*. 1977;118(2):269–273.

Hagood PG, Mehan DJ, Worischeck JH, et al. Laparoscopic varicocelectomy: preliminary report of a new technique. *J Urol*. 1992;147(1):73–76.

Hamidinia A. Transvasovasostomy—an alternative operation for obstructive azoospermia. *J Urol*. 1988;140(6):1545–1548.

Harrington TG, Schauer D, Gilbert BR. Percutaneous testis biopsy: an alternative to open testicular biopsy in the evaluation of the subfertile man. *J Urol*. 1996;156(5):1647–1651.

Harrison RM, Lewis RW, Roberts JA. Pathophysiology of varicocele in nonhuman primates: long-term seminal and testicular changes. *Fertil Steril*. 1986;46(3):500–510.

Hirsch IH, Abdel-Meguid TA, Gomella LG. Postsurgical outcomes assessment following varicocele ligation: laparoscopic versus subinguinal approach. *Urology*. 1998;51(5):810–815.

Homonnai ZT, Fainman N, Engelhard Y, et al. Varicocelectomy and male fertility: comparison of semen quality and recurrence of varicocele following varicocelectomy by two techniques. *Int J Androl*. 1980;3(4):447–458.

Hopps CV, Goldstein M. Microsurgical reconstruction of iatrogenic injuries to the epididymis from hydrocelectomy. *J Urol*. 2006;176:2077–2080.

Hopps CV, Lemer ML, Schlegel PN, et al. Intraoperative varicocele anatomy: a microscopic study of the inguinal versus subinguinal approach. *J Urol*. 2003;170(6 Pt 1):2366–2370.

Hopps CV, Mielnik A, Goldstein M, et al. Detection of sperm in men with Y chromosome microdeletions of the AZFa, AZFb and AZFc regions. *Hum Reprod*. 2003;18(8):1660–1665.

Howards SS, Jessee S, Johnson A. Micropuncture and microanalytic studies of the effect of vasectomy on the rat testis and epididymis. *Fertil Steril*. 1975;26(1):13–27.

Hung AJ, King P, Schlegel PN. Uniform testicular maturation arrest: a unique subset of men with nonobstructive azoospermia. *J Urol*. 2007;178(2):608–612 [discussion 612].

Ishikawa T, Kondo Y, Yamaguchi K, et al. Effect of varicocelectomy on patients with unobstructive azoospermia and severe oligospermia. *BJU Int*. 2008;101(2):216–218.

Janzen N, Goldstein M, Schlegel PN, et al. Use of electively cryopreserved microsurgically aspirated epididymal sperm with IVF and intracytoplasmic sperm injection for obstructive azoospermia. *Fertil Steril*. 2000;74(4):696–701.

Jarow JP, Ogle SR, Eskew LA. Seminal improvement following repair of ultrasound detected subclinical varicoceles. *J Urol*. 1996;155(4):1287–1290.

Jarow JP. Intratesticular arterial anatomy. *J Androl*. 1990;11(3):255–259.

Jarow JP. Seminal vesicle aspiration in the management of patients with ejaculatory duct obstruction. *J Urol*. 1994;152(3):899–901.

Jow WW, Steckel J, Schlegel PN, et al. Motile sperm in human testis biopsy specimens. *J Androl*. 1993;14(3):194–198.

Kadioglu A, Cayan S, Tefekli A, et al. Does response to treatment of ejaculatory duct obstruction in infertile men vary with pathology? *Fertil Steril*. 2001;76(1):138–142.

Kass EJ, Belman AB. Reversal of testicular growth failure by varicocele ligation. *J Urol*. 1987;137(3):475–476.

Kass EJ, Chandra RS, Belman AB. Testicular histology in the adolescent with a varicocele. *Pediatrics*. 1987;79(6):996–998.

Kass EJ, Marcol B. Results of varicocele surgery in adolescents: a comparison of techniques. *J Urol*. 1992;148(2 Pt 2):694–696.

Katz DMM, Nagler HM. *Ultrasound guided transrectal seminal vesiculaography; a new approach to the diagnosis of male reproductive tract abnormalities*. [Paper presented at American Urological Association Annual Meeting, San Francisco] 1994.

Kaufman SL, Kadir S, Barth KH, et al. Mechanisms of recurrent varicocele after balloon occlusion or surgical ligation of the internal spermatic vein. *Radiology*. 1983;147(2):435–440.

Kim ED, Bischoff FZ, Lipshultz LI, et al. Genetic concerns for the subfertile male in the era of ICSI. *Prenat Diagn*. 1998;18(13):1349–1365.

Kim ED, Leibman BB, Grinblat DM, et al. Varicocele repair improves semen parameters in azoospermic men with spermatogenic failure. *J Urol*. 1999;162(3 Pt 1):737–740.

Kirby E, Weiner L, Rajanahally S, et al. Undergoing varicocele repair prior to assisted reproduction improves pregnancy rate and live birth rate in azoospermic and oligospermic men with varicocele: a systematic review and meta-analysis. *Fertil Steril*. 2016;106:1338–1343.

Kobori Y, Okada H, Ota S, et al. *Laparoendoscopic single-site artery and lymphatic sparing varicocelectomy (less-V) versus subinguinal microscopic varicocelectomy for infertile men*. American Society for Reproductive Medicine: Boston, MA; 2013.

Kolettis PN, Fretz P, Burns JR, et al. Secondary azoospermia after vasovasostomy. *Urology*. 2005;65(5):968–971.

Kolettis PN, Sabanegh ES, Nalesnik JG, et al. Pregnancy outcomes after vasectomy reversal for female partners 35 years old or older. *J Urol*. 2003;169(6):2250–2252.

Kolettis PN, Thomas AJ Jr. Vasoepididymostomy for vasectomy reversal: a critical assessment in the era of intracytoplasmic sperm injection. *J Urol*. 1997;158(2):467–470.

Krylov VS, Borovikov AM. Microsurgical method of reuniting ductus epididymis. *Fertil Steril*. 1984;41(3):418–423.

Lee JS, Park HJ, Seo JT. What is the indication of varicocelectomy in men with nonobstructive azoospermia? *Urology*. 2007;69(2):352–355.

Lee R, Goldstein M, Ullery BW, et al. Value of serum antisperm antibodies in diagnosing obstructive azoospermia. *J Urol*. 2009;181(1):264–269.

Lee R, Li PS, Goldstein M, et al. A decision analysis of treatments for obstructive azoospermia. *Hum Reprod*. 2008;23(9):2043–2049.

Lee RK, Li PS, Goldstein M. Simultaneous vasectomy and varicocelectomy: indications and technique. *Urology*.

2007;70(2):362–365.

Lemack GE, Goldstein M. Presence of sperm in the pre-vasectomy reversal semen analysis: incidence and implications. *J Urol*. 1996;155(1):167–169.

Lemack GE, Uzzo RG, Schlegel PN, et al. Microsurgical repair of the adolescent varicocele. *J Urol*. 1998;160(1):179–181.

Levine LA, Dimitriou RJ, Fakouri B. Testicular and epididymal percutaneous sperm aspiration in men with either obstructive or nonobstructive azoospermia. *Urology*. 2003;62(2):328–332.

Levitt S, Gill B, Katlowitz N, et al. Routine intraoperative post-ligation venography in the treatment of the pediatric varicocele. *J Urol*. 1987;137(4):716–718.

Lima SS, Castro MP, Costa OF. A new method for the treatment of varicocele. *Andrologia*. 1978;10(2):103–106.

Lin YH, Huang LW, Seow KM, et al. Intentional cryopreservation of epididymal spermatozoa from percutaneous aspiration for dissociated intracytoplasmic sperm injection cycles. *Acta Obstet Gynecol Scand*. 2004;83(8):745–750.

Lipshultz LI, Corriere JN Jr. Progressive testicular atrophy in the varicocele patient. *J Urol*. 1977;117(2):175–176.

Lizza EF, Marmar JL, Schmidt SS, et al. Transseptal crossed vasovasostomy. *J Urol*. 1985;134(6):1131–1132.

MacMahon RA, O'Brien MC, Cussen LJ. The use of microsurgery in the treatment of the undescended testis. *J Pediatr Surg*. 1976;11(4):521–526.

Madgar I, Weissenberg R, Lunenfeld B, et al. Controlled trial of high spermatic vein ligation for varicocele in infertile men. *Fertil Steril*. 1995;63(1):120–124.

Malkevich DA, Mieza M, Nagler HM. Patency of ejaculatory ducts after transurethral resection of ejaculatory ducts verified by reflux seen on voiding cystourethrogram. *J Urol*.

1994;151:301A.

Maluf N. Effect of division of testicular artery on viability of testis in man. *J Urol*. 1957;78:437.

Marmar J. Modified vasoepididymostomy with simultaneous double needle placement, tubulotomy and tubular invagination. *J Urol*. 2000;163(2):483–486.

Marmar JL, Agarwal A, Prabakaran S, et al. Reassessing the value of varicocelectomy as a treatment for male subfertility with a new meta-analysis. *Fertil Steril*. 2007;88(3):639–648.

Marmar JL, DeBenedictis TJ, Praiss D. The management of varicoceles by microdissection of the spermatic cord at the external inguinal ring. *Fertil Steril*. 1985;43(4):583–588.

Marmar JL, Corson SL, Batzer FR, et al. Microsurgical aspiration of sperm from the epididymis: a mobile program. *J Urol*. 1993;149(5 Pt 2):1368–1373.

Marmar JL, Kim Y. Subinguinal microsurgical varicocelectomy: a technical critique and statistical analysis of semen and pregnancy data. *J Urol*. 1994;152(4):1127–1132.

Matthews GJ, Goldstein M. A simplified method of epididymal sperm aspiration. *Urology*. 1996;47(1):123–125.

Matthews GJ, Matthews ED, Goldstein M. Induction of spermatogenesis and achievement of pregnancy after microsurgical varicocelectomy in men with azoospermia and severe oligoasthenospermia. *Fertil Steril*. 1998;70(1):71–75.

Matthews GJ, Schlegel PN, Goldstein M. Patency following microsurgical vasoepididymostomy and vasovasostomy: temporal considerations. *J Urol*. 1995;154(6):2070–2073.

Matthews RD, Roberts J, Walker WA, et al. Migration of intravascular balloon after percutaneous embolotherapy of varicocele. *Urology*. 1992;39(4):373–375.

May M, Johannsen M, Beutner S, et al. Laparoscopic surgery versus antegrade scrotal sclerotherapy: retrospective comparison of two different approaches for varicocele treatment. *Eur Urol*. 2006;49(2):384–387.

Mendez-Gallart R, Bautista-Casasnovas A, Estevez-Martinez E, et al. Laparoscopic Palomo varicocele surgery: lessons learned after 10 years' follow up of 156 consecutive pediatric patients. *J Pediatr Urol*. 2009;5(2):126–131.

Mercan R, Urman B, Alatas C, et al. Outcome of testicular sperm retrieval procedures in non-obstructive azoospermia: percutaneous aspiration versus open biopsy. *Hum Reprod*. 2000;15(7):1548–1551.

Minucci S, Mazzoni G, Gallina A, et al. Evolution in varicocele sclerosing treatment: the ante/retrograde (A/R) approach. *Arch Ital Urol Androl*. 2004;76(1):29–33.

Mitchell SE, Shuman LS, Kaufman SL, et al. Biliary catheter drainage complicated by hemobilia: treatment by balloon embolotherapy. *Radiology*. 1985;157(3):645–652.

Monoski MA, Schiff J, Li PS, et al. Innovative single-armed suture technique for microsurgical vasoepididymostomy. *Urology*. 2007;69(4):800–804.

Morag B, Rubinstein ZJ, Goldwasser B, et al. Percutaneous venography and occlusion in the management of spermatic varicoceles. *Am J Roentgenol*. 1984;143(3):635–640.

Mulhall J, Stokes S, Andrawis R, et al. Simultaneous microsurgical vasal reconstruction and varicocele ligation: safety profile and outcomes. *Urology*. 1997;50(3):438–442.

Murray RR Jr, Mitchell SE, Kadir S, et al. Comparison of recurrent varicocele anatomy following surgery and percutaneous balloon occlusion. *J Urol*. 1986;135(2):286–289.

Nagler HM, Li XZ, Lizza EF, et al. Varicocele: temporal considerations. *J Urol*. 1985;134(2):411–413.

Nudell DM, Conaghan J, Pedersen RA, et al. The mini-micro-epididymal sperm aspiration for sperm retrieval: a study of urological outcomes. *Hum Reprod*. 1998;13(5):1260–1265.

Ohl DA, Sonksen J, Menge AC, et al. Electroejaculation versus vibratory stimulation in spinal cord injured men: sperm quality and patient preference. *J Urol*. 1997;157(6):2147–2149.

Ohl DA, Wolf LJ, Menge AC, et al. Electroejaculation and assisted reproductive technologies in the treatment of anejaculatory infertility. *Fertil Steril*. 2001;76(6):1249–1255.

Ostad M, Liotta D, Ye Z, et al. Testicular sperm extraction for nonobstructive azoospermia: results of a multibiopsy approach with optimized tissue dispersion. *Urology*. 1998;52(4):692–696.

Ozgok Y, Tan MO, Kilciler M, et al. Diagnosis and treatment of ejaculatory duct obstruction in male infertility. *Eur Urol*. 2001;39(1):24–29.

Paick J, Kim SH, Kim SW. Ejaculatory duct obstruction in infertile men. *BJU Int*. 2000;85(6):720–724.

Palermo GD, Schlegel PN, Sills ES, et al. Births after intracytoplasmic injection of sperm obtained by testicular extraction from men with nonmosaic Klinefelter's syndrome. *N Engl J Med*. 1998;338(9):588–590.

Pasqualotto FF, Agarwal A, Srivastava M, et al. Fertility outcome after repeat vasoepididymostomy. *J Urol*. 1999;162(5):1626–1628.

Pasqualotto FF, Lucon AM, Hallak J, et al. Induction of spermatogenesis in azoospermic men after varicocele repair. *Hum Reprod*. 2003;18(1):108–112.

Pasqualotto FF, Sobreiro BP, Hallak J, et al. Induction of spermatogenesis in azoospermic men after varicocelectomy repair: an update. *Fertil Steril*. 2006;85(3):635–639.

Pavlovich CP, Schlegel PN. Fertility options after vasectomy: a cost-effectiveness analysis. *Fertil Steril*. 1997;67(1):133–141.

Penn I, Mackie G, Halgrimson CG, et al. Testicular complications following renal transplantation. *Ann Surg*.

1972;176(6):697–699.

Perez-Crespo M, Pintado B, Gutierrez-Adan A. Scrotal heat stress effects on sperm viability, sperm DNA integrity, and the offspring sex ratio in mice. *Mol Reprod Dev*. 2008;75(1):40–47.

Poore RE, Schneider A, DeFranzo AJ, et al. Comparison of puncture versus vasotomy techniques for vasography in an animal model. *J Urol*. 1997;158(2):464–466.

Qiu Y, Yang DT, Wang SM, et al. Successful pregnancy and birth after intrauterine insemination using caput epididymal sperm by percutaneous aspiration. *Asian J Androl*. 2003;5(1):73–75.

Rajfer J, Binder S. Use of biopty gun for transcutaneous testicular biopsies. *J Urol*. 1989;142(4):1021–1022.

Raman JD, Goldstein M. Intraoperative characterization of arterial vasculature in spermatic cord. *Urology*. 2004;64(3):561–564.

Raman JD, Schlegel PN. Testicular sperm extraction with intracytoplasmic sperm injection is successful for the treatment of nonobstructive azoospermia associated with cryptorchidism. *J Urol*. 2003;170(4 Pt 1):1287–1290.

Ramasamy R, Ricci JA, Palermo GD, et al. Successful fertility treatment for Klinefelter's syndrome. *J Urol*. 2009;182(3):1108–1113.

Ramasamy R, Schlegel PN. Microdissection testicular sperm extraction: effect of prior biopsy on success of sperm retrieval. *J Urol*. 2007;177(4):1447–1449.

Ramasamy R, Yagan N, Schlegel PN. Structural and functional changes to the testis after conventional versus microdissection testicular sperm extraction. *Urology*. 2005;65(6):1190–1194.

Redman JF, Barthold JS. A technique for atraumatic scrotal pouch orchiopexy in the management of testicular torsion. *J*

Urol. 1995;154(4):1511–1512.

Reitelman C, Burbige KA, Sawczuk IS, et al. Diagnosis and surgical correction of the pediatric varicocele. *J Urol*. 1987;138(4 Pt 2):1038–1040.

Riccabona M, Oswald J, Koen M, et al. Optimizing the operative treatment of boys with varicocele: sequential comparison of 4 techniques. *J Urol*. 2003;169(2):666–668.

Riedenklau E, Buch JP, Jarow JP. Diagnosis of vasal obstruction with seminal vesiculography: an alternative to vasography in select patients. *Fertil Steril*. 1995;64(6):1224–1227.

Rosenlund B, Kvist U, Ploen L, et al. A comparison between open and percutaneous needle biopsies in men with azoospermia. *Hum Reprod*. 1998;13(5):1266–1271.

Rosoff JSTC, Goldstein M, Chu DI, et al. *Prognostic nomogram for the estimation of serum testosterone level following varicocele ligation*. [Presented at American Urological Asssociation Annual Meeting, Chicago] 2009.

Rothman CM, Newmark H 3rd, Karson RA. The recurrent varicocele—a poorly recognized problem. *Fertil Steril*. 1981;35(5):552–556.

Rucker GB, Mielnik A, King P, et al. Preoperative screening for genetic abnormalities in men with nonobstructive azoospermia before testicular sperm extraction. *J Urol*. 1998;160(6 Pt 1):2068–2071.

Russell JK. Varicocele, age, and fertility. *Lancet*. 1957;273(6988):222.

Samplaski MK, Zini A, Lo KC, et al. *Varicocelectomy to “upgrade” semen quality to allow couples to use less invasive forms of assisted reproductive technologies*. [Presented at American Society for Reproductive Medicine meeting, Boston] 2013.

Sayfan J, Adam YG, Soffer Y. A natural “venous bypass” causing postoperative recurrence of a varicocele. *J Androl*.

1981;2:108–110.

Sayfan J, Adam YG, Soffer Y. A new entity in varicocele subfertility: the “cremasteric reflux. *Fertil Steril*. 1980;33(1):88–90.

Saypol DC, Howards SS, Turner TT, et al. Influence of surgically induced varicocele on testicular blood flow, temperature, and histology in adult rats and dogs. *J Clin Invest*. 1981;68(1):39–45.

Schellan T. Induction of ejaculation by electrovibration. *Fertil Steril*. 1968;19:566.

Schiff J, Chan P, Li PS, et al. Outcome and late failures compared in 4 techniques of microsurgical vasoepididymostomy in 153 consecutive men. *J Urol*. 2005;174(2):651–655 [quiz 801].

Schlegel PN, Berkeley AS, Goldstein M, et al. Epididymal micropuncture with in vitro fertilization and oocyte micromanipulation for the treatment of unreconstructable obstructive azoospermia. *Fertil Steril*. 1994;61(5):895–901.

Schlegel PN, Goldstein M. Anatomical approach to varicocelectomy. *Semin Urol*. 1992;10(4):242–247.

Schlegel PN, Goldstein M. Microsurgical vasoepididymostomy: refinements and results. *J Urol*. 1993;150(4):1165–1168.

Schlegel PN, Palermo GD, Alikani M, et al. Micropuncture retrieval of epididymal sperm with in vitro fertilization: importance of in vitro micromanipulation techniques. *Urology*. 1995;46(2):238–241.

Schlegel PN, Palermo GD, Goldstein M, et al. Testicular sperm extraction with intracytoplasmic sperm injection for nonobstructive azoospermia. *Urology*. 1997;49(3):435–440.

Schlegel PN, Su LM. Physiological consequences of testicular sperm extraction. *Hum Reprod*. 1997;12(8):1688–1692.

Schlegel PN. Testicular sperm extraction: microdissection improves sperm yield with minimal tissue excision. *Hum*

Reprod. 1999;14(1):131–135.

Schoysman RJ, Bedford JM. The role of the human epididymis in sperm maturation and sperm storage as reflected in the consequences of epididymovasostomy. *Fertil Steril*. 1986;46(2):293–299.

Schroeder-Printzen I, Ludwig M, Kohn F, et al. Surgical therapy in infertile men with ejaculatory duct obstruction: technique and outcome of a standardized surgical approach. *Hum Reprod*. 2000;15(6):1364–1368.

Schulster M, Cohn M, Najari B, et al. Microsurgically assisted inguinal hernia repair and simultaneous male fertility procedures: rationale, technique and outcomes. *J Urol*. 2017.

Sheynkin YR, Chen ME, Goldstein M. Intravasal azoospermia: a surgical dilemma. *BJU Int*. 2000;85(9):1089–1092.

Sheynkin YR, Hendin BN, Schlegel PN, et al. Microsurgical repair of iatrogenic injury to the vas deferens. *J Urol*. 1998;159:137–141.

Sheynkin YR, Li PS, Magid ML, et al. Comparison of absorbable and nonabsorbable sutures for microsurgical vasovasostomy in rats. *Urology*. 1999;53(6):1235–1238.

Sheynkin YR, Starr C, Li PS, et al. Effect of methylene blue, indigo carmine, and Renografin on human sperm motility. *Urology*. 1999;53(1):214–217.

Sheynkin YR, Ye Z, Menendez S, et al. Controlled comparison of percutaneous and microsurgical sperm retrieval in men with obstructive azoospermia. *Hum Reprod*. 1998;13(11):3086–3089.

Shin D, Lemack GE, Goldstein M. Induction of spermatogenesis and pregnancy after adult orchiopexy. *J Urol*. 1997;158(6):2242.

Shin D, Lipshultz LI, Goldstein M, et al. Herniorrhaphy with polypropylene mesh causing inguinal vasal obstruction: a preventable cause of obstructive azoospermia. *Ann Surg*.

2005;241(4):553–558.

Shiraishi K, Takihara H, Matsuyama H. Elevated scrotal temperature, but not varicocele grade, reflects testicular oxidative stress-mediated apoptosis. *World J Urol*. 2009.

Shrivastav P, Nadkarni P, Wensvoort S, et al. Percutaneous epididymal sperm aspiration for obstructive azoospermia. *Hum Reprod*. 1994;9(11):2058–2061.

Sigman M, Jarow JP. Ipsilateral testicular hypotrophy is associated with decreased sperm counts in infertile men with varicoceles. *J Urol*. 1997;158(2):605–607.

Silber S. Microsurgical aspects of varicocele. *Fertil Steril*. 1979;31(2):230–232.

Silber SJ, Ord T, Balmaceda J, et al. Congenital absence of the vas deferens. The fertilizing capacity of human epididymal sperm. *N Engl J Med*. 1990;323(26):1788–1792.

Silber SJ. Results of microsurgical vasoepididymostomy: role of epididymis in sperm maturation. *Hum Reprod*. 1989;4(3):298–303.

Silber SJ. Role of epididymis in sperm maturation. *Urology*. 1989;33(1):47–51.

Silber SJ. Vasectomy and its microsurgical reversal. *Urol Clin North Am*. 1978;5(3):573–584.

Sivanathan C, Abernethy LJ. Retrograde embolisation of varicocele in the paediatric age group: a review of 10 years' practice. *Ann R Coll Surg Engl*. 2003;85(1):50–51.

Smit M, Romihn JC, Wildhagen MF, et al. Decreased sperm DNA fragmentation after surgical varicocelectomy is associated with increased pregnancy rate. *J Urol*. 2010;183:270–274.

Steckel J, Dicker AP, Goldstein M. Relationship between varicocele size and response to varicocelectomy. *J Urol*. 1993;149(4):769–771.

Su LM, Goldstein M, Schlegel PN. The effect of varicocelectomy on serum testosterone levels in infertile men with varicoceles. *J Urol*. 1995;154(5):1752–1755.

Su LM, Palermo GD, Goldstein M, et al. Testicular sperm extraction with intracytoplasmic sperm injection for nonobstructive azoospermia: testicular histology can predict success of sperm retrieval. *J Urol*. 1999;161(1):112–116.

Szabo R, Kessler R. Hydrocele following internal spermatic vein ligation: a retrospective study and review of the literature. *J Urol*. 1984;132(5):924–925.

Tanrikut C, Goldstein M, Rosoff JS, et al. Varicocele as a risk factor for androgen deficiency and effect of repair. *BJU Int*. 2011;108:1480–1484.

Tash JA, Applegarth LD, Kerr SM, et al. Postmortem sperm retrieval: the effect of instituting guidelines. *J Urol*. 2003;170(5):1922–1925.

Tauber R, Johnsen N. Antegrade scrotal sclerotherapy for the treatment of varicocele: technique and late results. *J Urol*. 1994;151(2):386–390.

Temple-Smith PD, Southwick GJ, Yates CA, et al. Human pregnancy by in vitro fertilization (IVF) using sperm aspirated from the epididymis. *J in Vitro Fert Embryo Transf*. 1985;2(3):119–122.

Thomas AJ Jr. Vasoepididymostomy. *Urol Clin North Am*. 1987;14(3):527–538.

Tiffany P, Goldstein M. Aperistalsis of the vas deferens corrected with administration of ephedrine. *J Urol*. 1985;133(6):1060–1061.

Tillem SM, Mellinger BC. Azoospermia due to aperistalsis of the vas deferens: successful treatment with pseudoephedrine. *Urology*. 1999;53(2):417–419.

Tong Q, Zheng L, Tang S, et al. Lymphatic sparing laparoscopic Palomo varicocelectomy for varicoceles in children: intermediate results. *J Pediatr Surg*. 2009;44(8):1509–1513.

Tournaye H, Staessen C, Liebaers I, et al. Testicular sperm recovery in nine 47,XXY Klinefelter patients. *Hum Reprod*. 1996;11(8):1644–1649.

Trinkoff A, Barone M. Posthumous reproduction:do parents of a deceased son have the right to use his sperm? American Society of Reproductive Medicine. *Boston*. 2013.

Tsujimura A, Matsumiya K, Miyagawa Y, et al. Conventional multiple or microdissection testicular sperm extraction: a comparative study. *Hum Reprod*. 2002;17(11):2924–2929.

Vazquez-Levin MH, Dressler KP, Nagler HM. Urine contamination of seminal fluid after transurethral resection of the ejaculatory ducts. *J Urol*. 1994;152(6 Pt 1):2049–2052.

Wagenknecht LV, Klosterhalfen H, Schirren C. Microsurgery in andrologic urology. I. Refertilization. *J Microsurg*. 1980;1(5):370–376.

Walsh P, White R. Balloon occlusion of the internal spermatic vein for the treatment of varicoceles. *J Am Med Assoc*. 1981;246:1701.

Watanabe M, Nagai A, Kusumi N, et al. Minimal invasiveness and effectivity of subinguinal microscopic varicocelectomy: a comparative study with retroperitoneal high and laparoscopic approaches. *Int J Urol*. 2005;12(10):892–898.

Weissbach L, Thelen M, Adolphs HD. Treatment of idiopathic varicoceles by transfemoral testicular vein occlusion. *J Urol*. 1981;126(3):354–356.

White RI Jr, Kaufman SL, Barth KH, et al. Occlusion of varicoceles wih detachable balloons. *Radiology*. 1981;139(2):327–334.

Winkelbauer FW, Ammann ME, Karnel F, et al. Doppler sonography of varicocele: long-term follow-up after venography and transcatheter sclerotherapy. *J Ultrasound Med*. 1994;13(12):953–958.

Witt MA, Lipshultz LI. Varicocele: a progressive or static lesion? *Urology*. 1993;42(5):541–543.

Wlodkowic D, Skommer J, Darzynkiewicz Z. SYTO probes in the cytometry of tumor cell death. *Cytometry A*. 2008;73(6):496–507.

Wood BL, Doncel GF, Reddy PR, et al. Effect of diltiazem and methylene blue on human sperm motility, viability and cervical mucus penetration: potential use as vas irrigants at the time of vasectomy. *Contraception*. 2003;67(3):241–245.

Wosnitzer M, Roth JA. Optical magnification and Doppler ultrasound probe for varicocelectomy. *Urology*. 1983;22(1):24–26.

Wosnitzer MS, Goldstein M. *Relationship of sperm granuloma to obstructive interval and vasectomy reversal patency outcomes*. [Presented at American Society for Reproductive Medicine, Boston] 2013.

Wright EJ, Young GP, Goldstein M. Reduction in testicular temperature after varicocelectomy in infertile men. *Urology*. 1997;50(2):257–259.

Wysock JSSM, Goldstein M. *Hydroceles associated with varicoceles: incidence and mathematical model of their insulating effects*. [Presented at: American Urological Association Annual meeting, Chicago] 2009.

Younes AK. Improvement of sexual activity, pregnancy rate, and low plasma testosterone after bilateral varicocelectomy in impotence and male infertility patients. *Arch Androl*. 2003;49(3):219–228.

Youssef T, Abd-Elaal E, Gaballah G, et al. Varicocelectomy in men with nonobstructive azoospermia: is it beneficial? *Int J Surg*. 2009;7(4):356–360.

Yurdakul T, Gokce G, Kilic O, et al. Transurethral resection of ejaculatory ducts in the treatment of complete ejaculatory duct obstruction. *Int Urol Nephrol*. 2008;40(2):369–372.

Zhang Y, Chohan KR, Landas SK, et al. *Repetitive* *percutaneous epididymal sperm aspiration (PESA's) in a rat model resulted in immediate asthenospermia and significant inflammatory changes*. [Presented at American Society for Reproductive Medicine meeting, Boston, October 17] 2013.

Zhao H, Traganos F, Dobrucki J, et al. Induction of DNA damage response by supravital probes of nucleic acids. *Cytometry A*. 2009;75(6):510–519.

Zheng YQ, Zhang XB, Zhou JQ, et al. The effects of artery-ligating and artery-preserving varicocelectomy on the ipsilateral testes in rats. *Urology*. 2008;72(5):1179–1184.

Zorgniotti AW, Toth A, Macleod J. Infrared thermometry for testicular temperature determinations. *Fertil Steril*. 1979;32(3):347–348.

Zorgniotti AW. Testis temperature, infertility, and the varicocele paradox. *Urology*. 1980;16(1):7–10.

Physiology of Penile Erection and Pathophysiology of Erectile Dysfunction

---

Alan W. Shindel MD, MAS, Tom F. Lue MD, ScD (Hon), FACS

“The penis does not obey the order of its master, who tries to erect or shrink it at will. Instead, the penis erects freely while its master is asleep. The penis must be said to have its own mind, by any stretch of the imagination.”

Leonardo da Vinci

Physiology of Penile Erection

Historical Contexts on Our Understanding of Erectile Physiology

The oldest known recorded description of erectile dysfunction (ED) dates from circa 2000 BCE and was set down on Egyptian papyrus. Two types were described: natural (“the man is incapable of accomplishing the sex act”) and supernatural (evil charms and spells). Later, Hippocrates reported many cases of ED among the rich inhabitants of Scythia and ascribed it to excessive horseback riding (Brenot, 1994). Aristotle stated that three branches of nerves carry spirit and energy to the penis and that erection is produced by the influx of air (Brenot, 1994). Aristotle's theory was well accepted until Leonardo da Vinci proposed that erection was derived from penile blood flow, based on observations of a large amount of blood in the erect penis of hanged men. These writings were not widely known until the beginning of the 20th century (Brenot, 1994). Although Da Vinci's observation was not widely publicized, in 1585 Ambroise Paré gave a reasonably accurate account of penile anatomy and the concept of blood-derived penile erection. He described the penis as concentric coats of nerves, veins, arteries, two ligaments (corpora cavernosa), a urinary tract, and four muscles. Paré accurately wrote, “When the man becomes inflamed with lust and desire, blood rushes into the male member and causes it to become erect.” Dionis elaborated on Paré's theory by stressing the importance of retaining blood in the penis for maintenance of erection (Brenot, 1994). The mechanism of blood retention was thought by Dionis to be related to muscular contraction compressing proximal penile veins. In 1787 Hunter hypothesized that venous spasm prevented the exit of blood from the penis during erection.

Modern investigations of penile hemodynamics began in the 1970s with xenon washout and caversonography studies in human men exposed to audiovisual sexual stimuli. Limitations of these technologies led to conflicting results: Shirai concluded that penile venous flow is increased during erection, but markedly increased arterial flow compensates for this (Shirai et al., 1978). Wagner (1981) advanced the alternative hypothesis that venous drainage is decreased during erection.

Introduction of Doppler ultrasound and improved understanding of molecular biology revolutionized our understanding of erection physiology near the turn of the 20th century (Lue et al., 1985). In the 1980s it was confirmed that increased blood inflow (via arterial vasodilation) and decreased venous outflow (via venous coaptation) were key drivers of penile erection (Lue, 1986; Lue et al., 1983, 1984). In the 1990s nitric oxide (NO) and the enzymes that produce it (endothelial and neuronal nitric oxide synthase, eNOS and nNOS, respectively) were identified as key regulators of penile erection (Rajfer et al., 1992). The antierectile activity of phosphodiesterase type 5 (PDE5) was identified around the same time (Boolell et al., 1996). This understanding led to the development of effective oral pharmacotherapy for ED, which has revolutionized the medical management of sexual dysfunction (Goldstein et al., 1998). Many other molecular determinants of penile erection have been identified, including intracellular gap junctions, potassium, and calcium channels, and alternate molecular pathways such as RHO/Rho-kinase (Matsui et al., 2015). Our understanding of penile tissues has also improved, bettering our understanding of the role of elasticity and fibrosis in penile erection and detumescence (Gonzalez-Cadavid, 2009). Our current understanding of the physiology of erection and pathophysiology of ED is detailed in this chapter.

Functional Anatomy of the Penis

The penis is composed primarily of three cylindric structures. Dorsally, there are paired corpora cavernosa that extend from the pubic rami to the tip of the penis. The ventrally located corpus spongiosum encircles the urethra and is covered by a loose subcutaneous layer and skin. All three corporal bodies contain spongy vascular tissue that has the capacity to expand to contain large volumes of blood (Yiee and Baskin, 2010).

There is wide variability in penile length and girth (Table 68.1; Awwad et al., 2005). The flaccid length and girth of the penis is controlled by content of blood within the corporal bodies, which is in turn controlled by the degree of contraction within the smooth muscles of the spongy erectile tissue. There is marked variability in penile length, and neither age nor the size of the flaccid penis are necessarily accurate predictors of erect penile length (Wessells et al., 1996). There is also a fair degree of variability with respect to congenital penile curvature. Up to 15% of men have a downward penile curvature during erection, and approximately one-quarter have an erect penile angle less than horizontal (Sparling, 1997). Some experts have posited that certain variations in penile anatomy may lead to functional ED (e.g., penile buckling during intercourse) even in the presence of normal arterial and venous function. During attempted penetration, buckling forces from axial load on the penis are dependent not only on intracavernous pressures but also on penile geometry and corporal expandability. Some patients with normal penile hemodynamics may experience sexual difficulty even in the context of full tumescence; in such cases structural causes (i.e., penile curvature from chordee or Peyronie disease) should be considered (Udelson et al., 1998).

TABLE 68.1

Penile Length in Adults

FIRST AUTHOR	YEAR OF REPORT	NO. SUBJECTS	AGE IN YEARS (RANGE)	FLACCID LENGTH (cm)	STRETCHED OR ERECT LENGTH (cm)	COUNT
Kinsey	1948	2770	20–59	9.7	15.5 (E)	United States
Bondil	1992	905	17–91	10.7	16.74 (S)	France
Wessells	1996	80	21–82	8.85 +/- 2.38	12.45 +/- 2.71 (S), 12.89 +/- 2.91 (E)	United States
Ponchietti	2001	3300	17–19	9	12.5 (S)	Italy
Ajmani	1985	320	17–23	8.16 +/- 0.94	NA	Nigeria
Schneider	2001	111	18–19	8.6 +/- 1.50	14.48 +/- 1.99 (E)	Germany
		32	40–68	9.22 +/-1.67	14.18 +/- 1.83 (E)	Germany
Awwad	2005	271 (N)	17–83	9.3 +/- 1.9	13.5 +/- 2.3 (S)	Jordan
		109 (ED)	22–68	7.7 +/- 1.3	11.6 +/- 1.4 (S)	Jordan

E, Erect length; *ED,* erectile dysfunction; *N,* normal; *NA,* not available; *S,* stretched length.

Modified from Awwad Z, Abu-Hijleh M, Basri S, et al.: Penile measurements in normal adult Jordanians and in patients with erectile dysfunction. *Int J Impot Res* 17:191–195, 2005.

Corpora Cavernosa, Corpus Spongiosum, and Glans Penis

The corpora cavernosa are paired, dorsally located cylinders of expansile vascular tissue ensheathed by the tunica albuginea. Their proximal ends, the crura, originate at the undersurface of the puboischial rami as two separate structures but merge under the pubic arch and remain attached up to the glans penis. **Connections are present between the corpora cavernosa in men; in some species (e.g., dogs) a septum completely separates the corporal bodies** (Lue et al., 1983, 1984; Yiee and Baskin, 2010).

Each corpus cavernosum is a conglomeration of vascular sinusoids, larger in the center and smaller in the periphery (Goldstein and Padma-Nathan, 1990). These interconnected sinsusoids are separated by smooth muscle trabeculae surrounded by elastic fibers, collagen, and loose areolar tissue. The structure of the corpus spongiosum and glans is similar to that of the corpora cavernosa except that the sinusoids are larger.

The terminal cavernous nerves and helicine arteries of the phallus are intimately associated with the smooth muscle of the corpora. In the flaccid state, blood slowly diffuses from the central to the peripheral sinusoids, and the blood gas levels are similar to those found in venous blood. During erection, rapid entry of arterial blood to central and peripheral sinusoids enhances oxygen tension and raises pH (Sattar et al., 1995).

Tunica Albuginea

The tunica albuginea are paired, bilayered, fibrous sheaths that cover the corpora cavernosa and afford great flexibility, rigidity, and tissue strength to the penis (Fig. 68.1; Goldstein and Padma-Nathan, 1990). The principle constituent of the tunica is fibrillar collagen (mostly type I but also type III); however, elastic fibers are also present in an irregular, latticed network interwoven with the collagen fibers (Fig. 68.2). Elastin permits the penis to expand during penile erection.

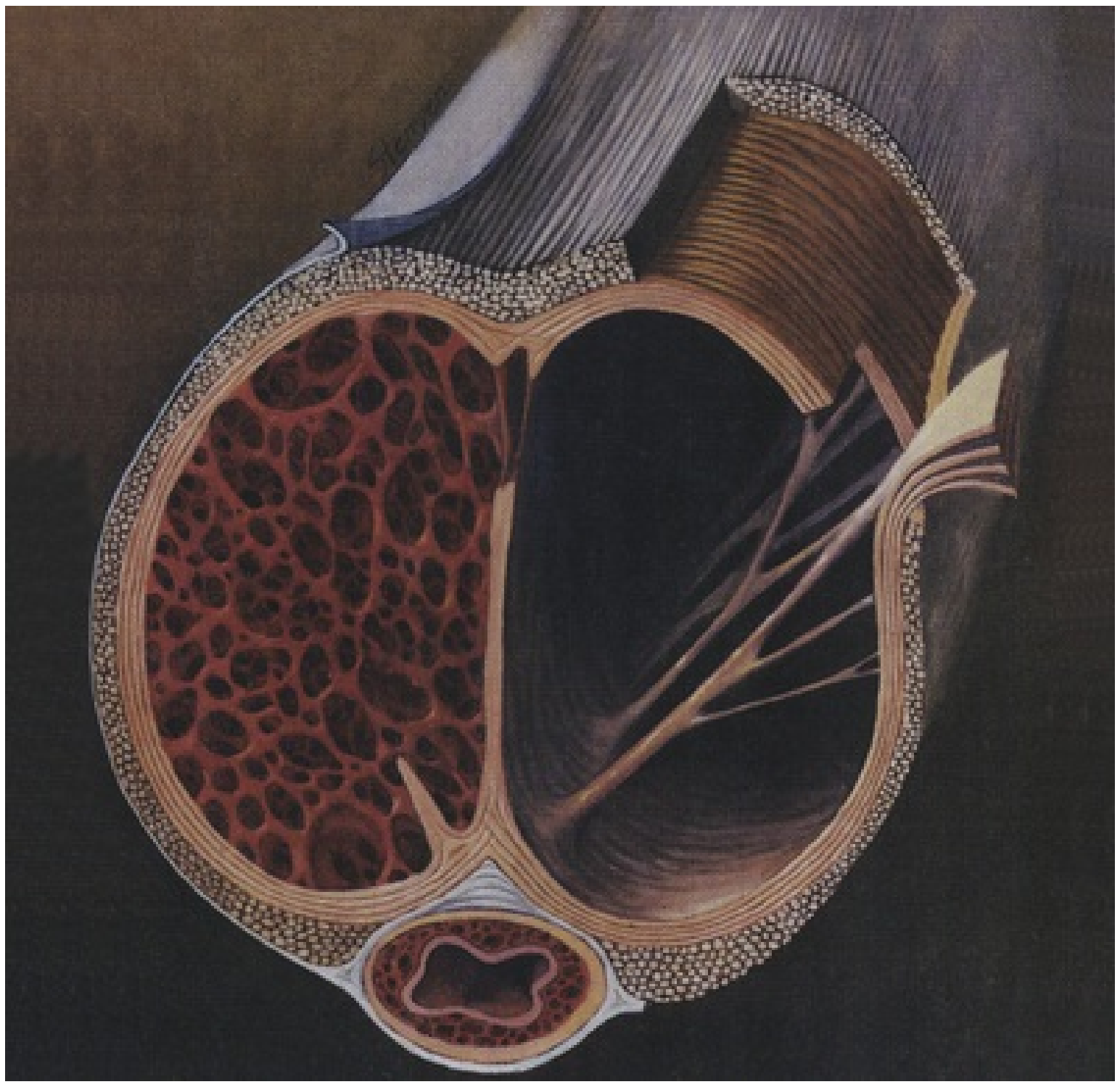

FIG. 68.1 Artist's cross-sectional drawing of the penis, depicting the inner circular and outer longitudinal layers of the tunica albuginea and the intracavernous pillars. The longitudinal layer is absent in the ventral groove housing the corpus spongiosum. (From Lue TF, Akkus E, Kour NW: Physiology of erectile function and dysfunction. *Campbell's Urol Update* 12:1–10, 1994.)

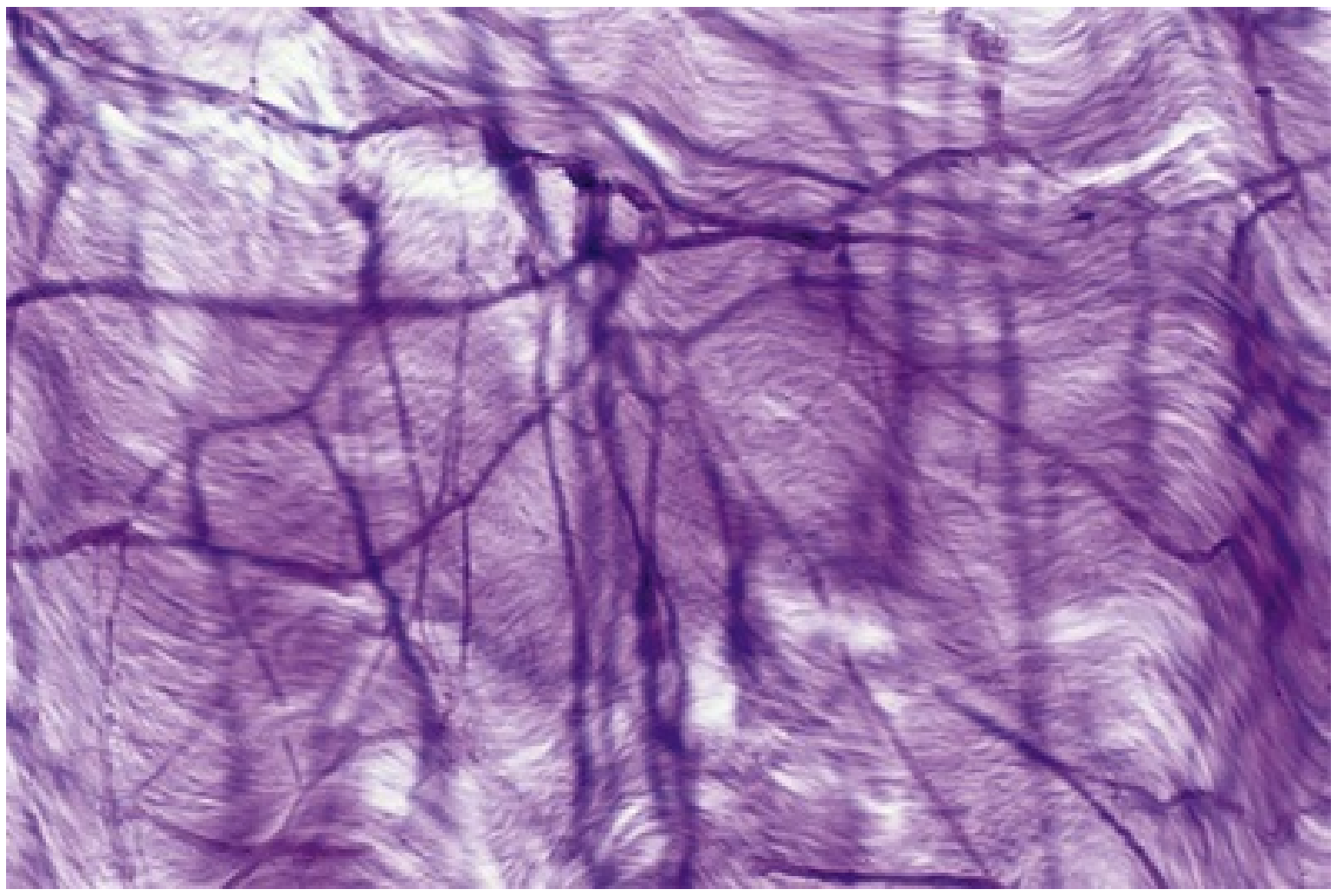

FIG. 68.2 Micrograph of the human tunica albuginea, showing the interwoven elastic fibers and the finer collagen fibers (Hart stain ×100).

The outer-layer tunica collagen bundles are oriented longitudinally, extending from the glans penis to the proximal crura. Inner-layer collagen bundles support and contain the cavernous tissue and are oriented circularly. Radiating from this inner layer are intracavernous pillars that act as struts to augment the septum between the corpora and to provide essential support to the erectile tissue. These structures insert into the inferior pubic rami but are absent between the 5 o'clock and the 7 o'clock positions. Between the inner and outer tunica layer are oblique-oriented fibers that connect the two main layers.

The detailed histologic composition of the tunica varies with anatomic location and function. The ventral portion of the corporal tunica tends to be thinner (mean thickness 0.8 mm) relative to the dorsal tunica (mean thickness 2.2 mm) because of variations in the outer corporal layer thickness. The absence of intracavernous pillars and thinner tunica layer create an area of relative weakness on the ventrum of the penis that has clinical relevance in cases of penile fracture and implant surgery (Hsu et al., 1994).

The bilayered structure of the tunica is critical to normal erectile function. Emissary veins that drain the corporal bodies run between the inner and outer layers of the tunica for a short distance, often piercing the outer bundles obliquely. These veins are compressed by the expanding corporal sinuses during the early phases of penile erection; this has the effect of obstructing venous outflow and promoting tumescence (Yiee and Baskin, 2010). The cavernous artery and branches of the dorsal artery that supply blood supply to the corpus cavernosum are protected from this compression because they run within the corporal bodies and are surrounded by a periarterial soft-tissue sheath.

The corpus spongiosum is also ensheathed by a tunica layer; however, the spongiosal tunica lacks an outer layer or intracorporeal struts, ensuring a low-pressure system during erection. Furthermore, the tunica of the corpus spongisoum does not extend into the glans penis.

External support of the corpora consists of two ligamentous structures: the fundiform and suspensory ligaments. The fundiform ligament arises from Colles fascia and is lateral, superficial, and not adherent to the tunica albuginea of the corpora cavernosa. The suspensory ligament arises from Buck fascia and consists of two lateral bundles and one median bundle that circumscribe the dorsal vein of the penis. Its main function is to attach the tunica albuginea of the corpora cavernosa to the pubis, and it provides support for the mobile portion of the penis (Hoznek et al., 1998). In patients with congenital deficiency or in whom this ligament has been severed in “penile elongation” surgery, the erect penis may be unstable during attempted penetration.

Arteries

The primary source of penile blood in most men is the paired internal pudendal arteries, which are branches of the internal iliac arteries (Fig. 68.3A). The internal pudendal artery becomes the common penile artery after giving off a branch to the perineum. The three branches of the penile artery are the cavernous, dorsal, and bulbourethral. Distally, they join to form a vascular ring near the glans. The cavernous artery effects tumescence of the corpus cavernosum and enters at the hilum of the penis, where the two crura converge. It gives off many helicine arteries along its course, which supply the trabecular erectile tissue and the sinusoids (Fig. 68.3B). These helicine arteries are contracted and tortuous in the flaccid state and become dilated and straight during erection. The dorsal artery of the penis is responsible for engorgement of the glans during erection; in many men it also supplies branches that penetrate the tunica and merge with the cavernous arteries to supply the distal penis (Diallo et al., 2013). The bulbourethral artery supplies the proximally located penile bulb and corpus spongiosum. The bulbourethral and urethral arteries are situated outside the tunica albuginea of the corpus spongiosum on the lateral and dorsal sides.

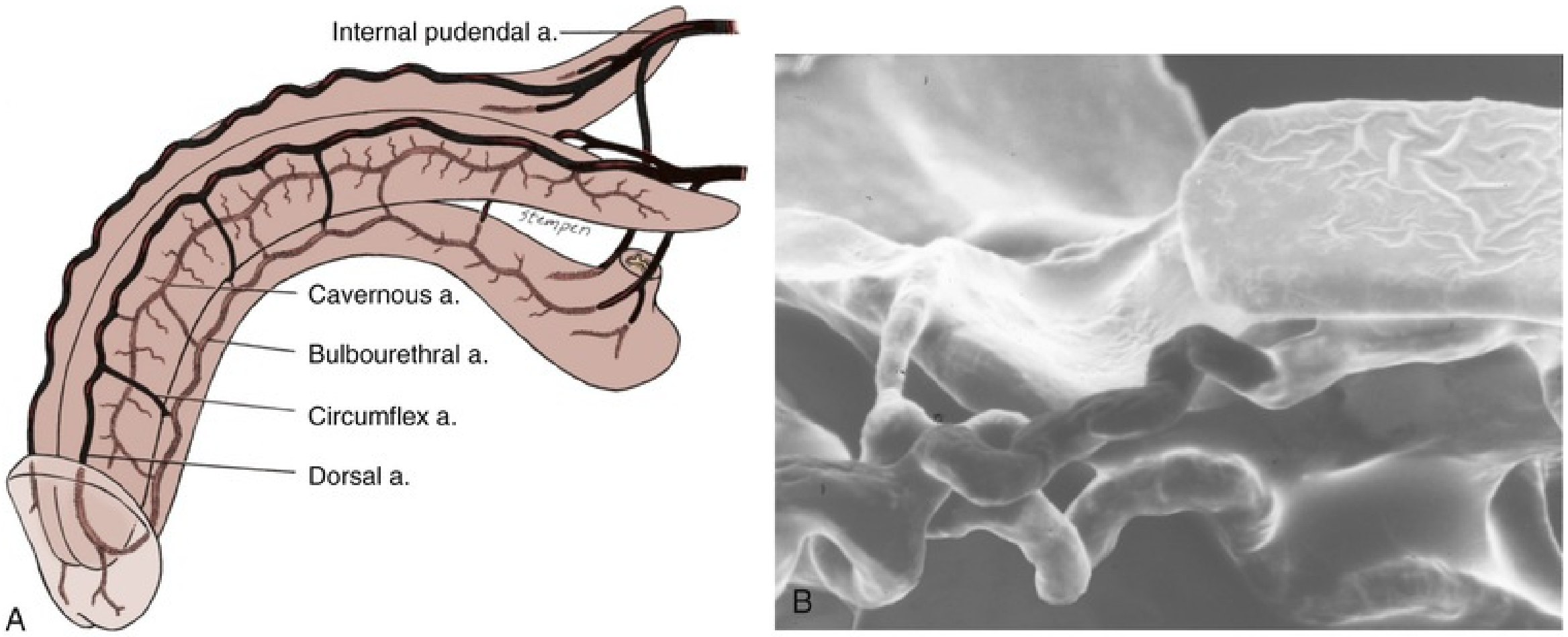

FIG. 68.3 (A) Penile arterial supply. (B) Scanning electron micrograph of a human penile cast showing helicine arteries opening directly into the sinusoids without intervening capillaries. *a,* Artery.

In approximately one-third of cases, accessory arteries from the external iliac, obturator, and vesical and femoral arteries also supply the penis; in some men these accessory arteries may be the dominant or only arterial supply to the corpus cavernosum (Breza et al., 1989; Nehra et al., 2008). Penile circulation in approximately 70% of men is thought to be derived from both the internal pudendal and accessory arteries, with circulation entirely from either internal pudendal or accessory arteries in about 15% each (Droupy et al., 1997). Preservation of accessory pudendal arteries is associated with more rapid recovery of sexual function in men after radical prostatectomy (Mulhall et al., 2008).

Veins

The venous drainage from the three corpora originates in tiny venules leading from the peripheral sinusoids immediately beneath the tunica albuginea. These venules travel in the trabeculae between the tunica and the peripheral sinusoids to form the subtunical venous plexus before exiting the inner tunica layer as the emissary veins (Fig. 68.4A). There is wide variability in penile venous circulation (Fig. 68.4B and C; Hsu et al., 2012).

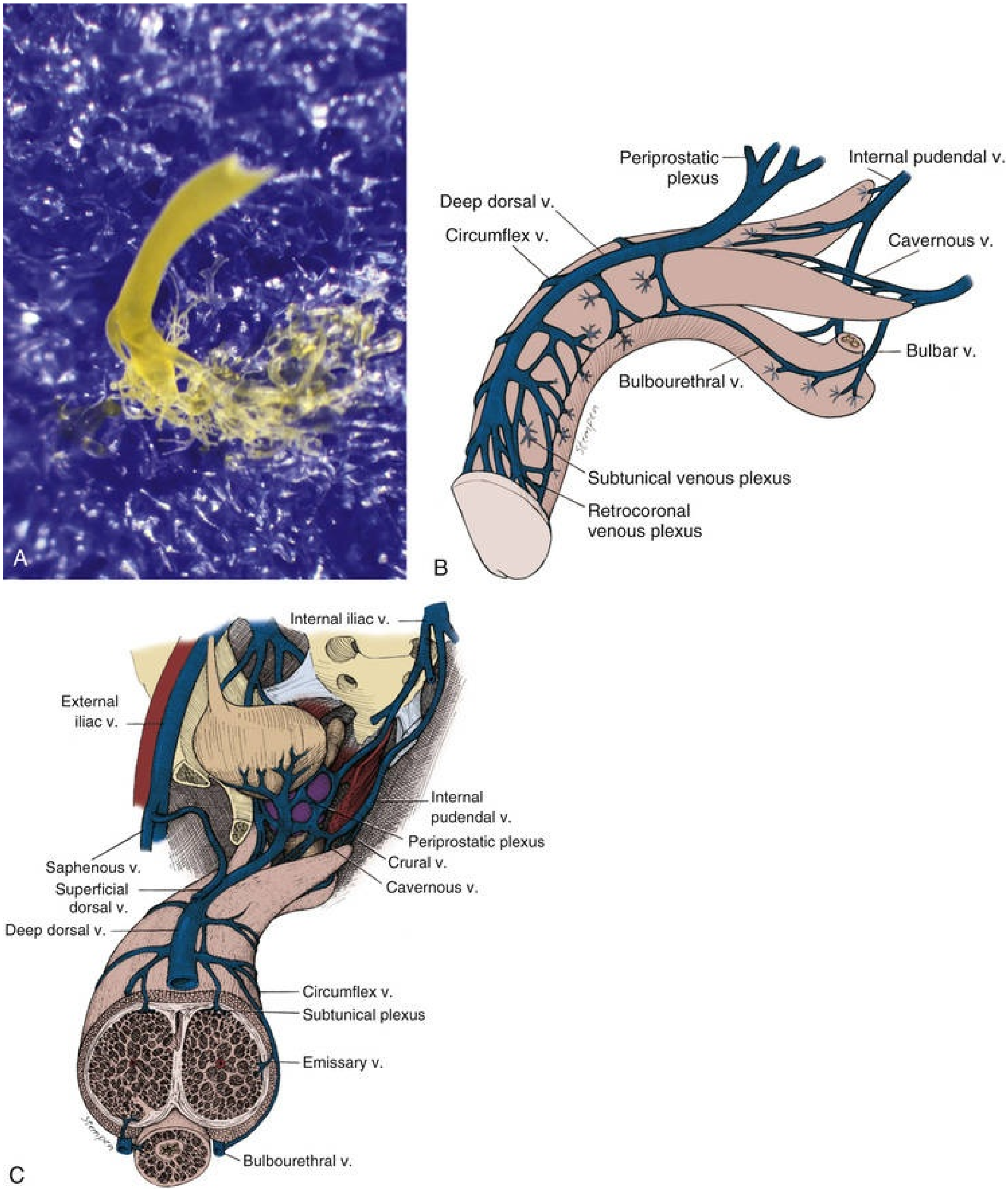
A
Periprostatic plexus
Internal pudendal v.
Deep dorsal v.
Circumflex v.
Cavernous v.
Bulbar v.
Bulbourethral v.
Subtunical venous plexus
Retrocoronal venous plexus
B
Internal iliac v.
External iliac v.
Internal pudendal v.
Periprostatic plexus
Crural v.
Cavernous v.
Saphenous v.
Superficial dorsal v.
Deep dorsal v.
Circumflex v.
Subtunical plexus
Emissary v.
Bulbourethral v.
C

FIG. 68.4 (A) Photograph of an emissary vein with subtunical venous plexus of a human penile cast. The cast was made by injecting blue material into the corpus cavernosum and yellow material into the deep dorsal vein. The skin and tunica albuginea were then digested away with potassium hydroxide solution. (B and C) Penile venous drainage. *v,* Vein.

The emissary veins from the corpus cavernosum and spongiosum drain dorsally to the deep dorsal vein, which originates near the coronal sulcus and serves as the primary venous drainage of the glans and distal two-thirds of the corpora (corresponding to the pendulous portion of the penis). The deep dorsal vein runs cephalad and posterior to the symphysis pubis to join the periprostatic venous plexus; occasionally there are two deep dorsal veins. Additional sources of venous drainage include circumflex veins laterally, periurethral veins ventrally, and small venous channels accompanying the paired dorsal artery. Periarterial veins also travel longitudinally to join the dorsal vein or Santorini plexus proximally (Hsu et al., 2003). These become enlarged after the deep dorsal vein is ligated and may be the cause of recurrent leakage in venogenic ED (Chen et al., 2005). Emissary veins from the proximal (infrapubic) penis join to form cavernous and crural veins. These join the periurethral veins from the urethral bulb to form the internal pudendal veins.

The venous drainage of penile skin and subcutaneous tissues is derived from subcutaneous veins that unite near the base of the penis to form a single (or paired) superficial dorsal vein that drains into the saphenous veins. Occasionally, the superficial dorsal vein may also drain a portion of the corpora cavernosa.

Hemodynamics and Mechanism of Erection and Detumescence

Erection involves sinusoidal relaxation, arterial dilation, and venous compression (Lue, 1986). The importance of smooth muscle relaxation has been demonstrated in animal and human studies (Ignarro et al., 1990; Saenz de Tejada et al., 1989, 1991). To summarize the hemodynamic events of erection and detumescence, seven phases have been observed in animal experiments that reflect the changes in and the relationship between penile arterial flow and intracavernous pressure (Fig. 68.5).

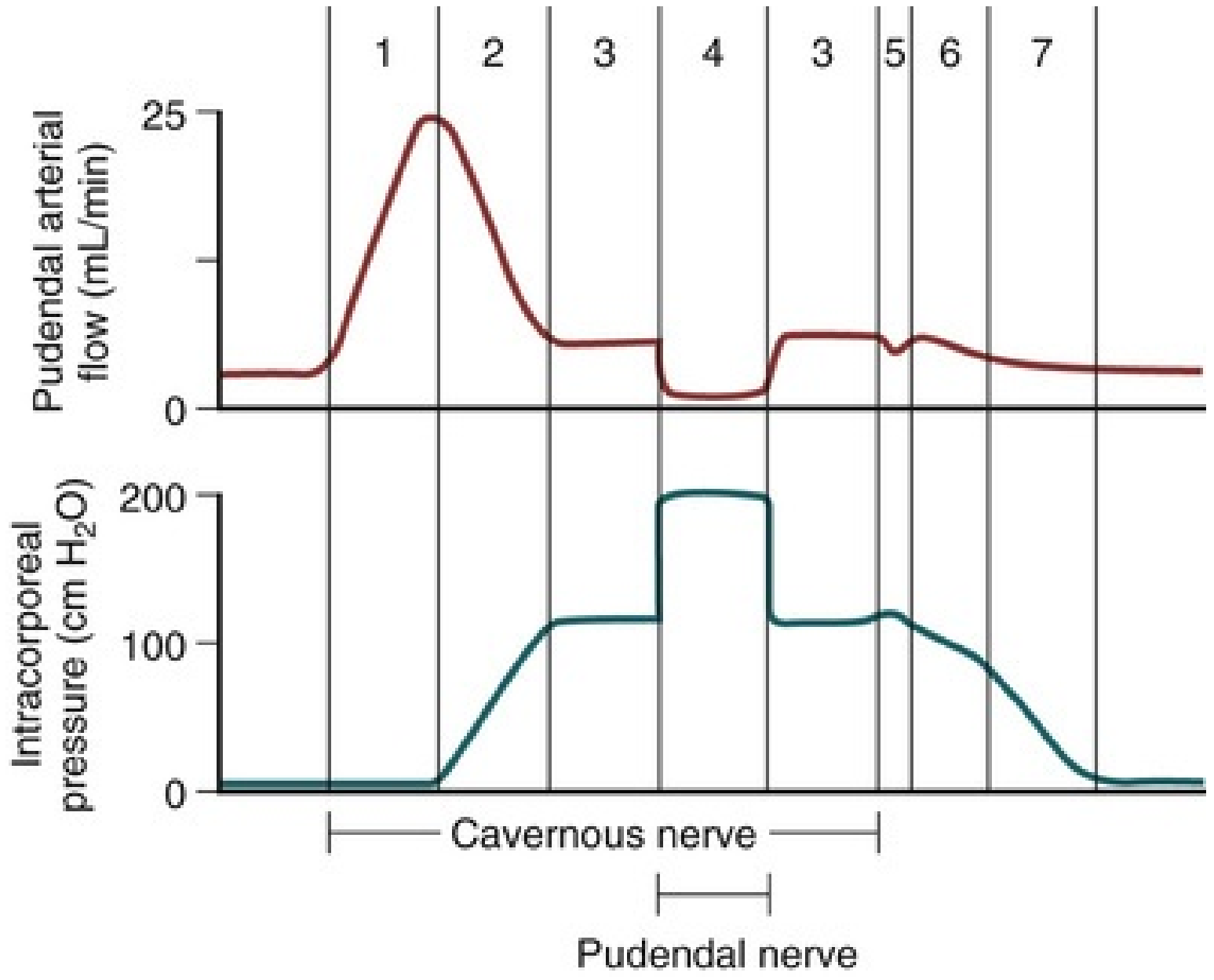

FIG. 68.5 Blood flow and intracavernous pressure changes during the seven phases of penile erection and detumescence: *0,* flaccid; *1,* latent; *2,* tumescence; *3,* full erection; *4,* rigid erection; *5,* initial detumescence; *6,* slow detumescence; *7,* fast detumescence.

Corpora Cavernosa

The penile erectile tissue, specifically the cavernous smooth musculature and the smooth muscles of the arteriolar and arterial walls, plays a key role in the erectile process. In the **flaccid state**, these smooth muscles are tonically contracted, allowing only a small amount of arterial flow into the corpora (Sattar et al., 1995).

Sexual stimulation triggers release of neurotransmitters from the cavernous nerve terminals. This release of neurotransmitters results in relaxation of these smooth muscles, leading to dilation of arterioles and arteries and increased corporal blood flow. The increased corporal blood supply pools in the vascular sinusoids, which expand and compress the subtunical venous plexuses between the tunica albuginea and the peripheral sinusoids, reducing venous outflow during the **latent phase**. As the tunica albuginea expand and are stretched to capacity, the penis enlarges and compresses the emissary veins between the inner circular and outer longitudinal layers; this is the **tumescent phase**. With maximal occlusion of the emissary veins, intracavernous pressure increases to approximately 100 mm Hg, raising the penis from the dependent position to the **full-erection phase.** Intracavernous pressure may be further elevated (up to several hundred millimeters of mercury) with reflex contractions of the ischiocavernosus muscles during maximal sexual arousal (i.e., the **rigid-erection phase). During rigid erection intracavernosal pressures exceeding systolic blood pressure may lead to reversal of flow in cavernous arteries** (Fig. 68.6; Lue, 1986).

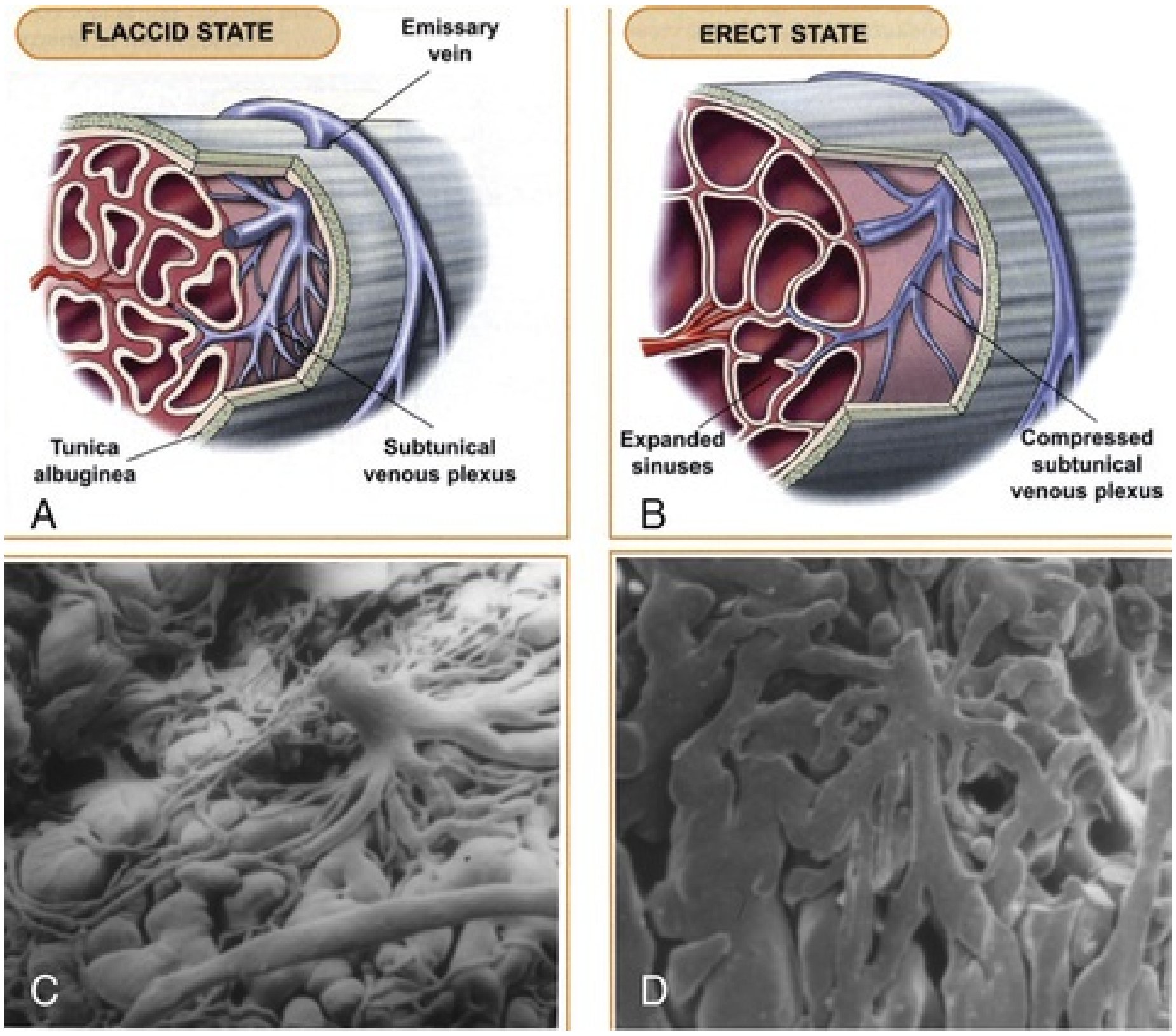
FLACCID STATE
Emissary vein
Tunica albuginea
Subtunical venous plexus
A
ERECT STATE
Expanded sinuses
Compressed subtunical venous plexus
B
C
D

FIG. 68.6 The mechanism of penile erection. (A) In the flaccid state, the arteries, arterioles, and sinusoids are contracted. The intersinusoidal and subtunical venous plexuses are wide open, with free flow to the emissary veins. (B) In the erect state, the muscles of the sinusoidal wall and the arterioles relax, allowing maximal flow to the compliant sinusoidal spaces. Most of the venules are compressed between the expanding sinusoids. The larger venules are sandwiched and flattened between the distended sinusoids and the tunica albuginea. This effectively reduces the venous capacity to a minimum. (C and D) Scanning electron micrographs of casts of a canine subtunical venous plexus in the flaccid (C) and erect (D) states. (A and B, From Lue TF, Giuliano F, Khoury S, et al.: *Clinical manual of sexual medicine: sexual dysfunction in men*, Paris, 2004, Health Publications.)

The angle of the erect penis is determined by its size and attachment to the puboischial rami (the crura) and the anterior surface of the pubic bone (the suspensory and fundiform ligaments). In men with a large penis or a loose suspensory ligament, the penis often points downward even with full rigidity.

After sexual climax or cessation of arousal, the penis detumesces in three overlapping phases. The first **(initial detumescence)** entails a transient intracorporeal pressure increase as arteries vasocontrict and compress vascular sinusoids that are engorged with corporal blood by occlusion of the emissary veins. The second phase consists of a slow pressure decrease as the emissary veins gradually open and permit venous outflow (**slow detumescence)**. The final phase involves rapid pressure decrease as venous outflow capacity returns to baseline (**rapid detumescence)** (Bosch et al., 1991).

Corpus Spongiosum and Glans Penis

The hemodynamics of the corpus spongiosum and glans penis differ from those of the corpora cavernosa. **During erection, arterial flow increases, but pressure in the corpus spongiosum and glans is only one-third to one-half of pressure within the corpora cavernosa.** The thin tunica covering of the corpus spongiosum and complete absence of a tunica layer over the glans ensure minimal venous occlusion during tumescence. During the full-erection phase, partial compression of the deep dorsal and circumflex veins between Buck fascia and the engorged corpora cavernosa contributes to glanular tumescence, although the spongiosum and glans essentially function as a large arteriovenous shunt during this phase. In the rigid-erection phase, the ischiocavernosus and bulbocavernosus muscles forcefully compress the spongiosum and penile veins, increasing engorgement and pressure inside the spongiosum and glans (Table 68.2; Lue, 1986).

TABLE 68.2

Comparison of Corpus Spongiosum and Glans Penis

	CORPUS SPONGIOSUM	**GLANS PENIS**
Tunica albuginea	Thin (circular layer only)	Absent
Main blood supply	Bulbar and spongiosal arteries	Dorsal artery
Venous occlusion during erection	No	No
Compression by skeletal muscle	Yes (ischiocavernosus, bulbocavernosus)	No

Key Points

- Penile erection is dependent on increased arterial blood flow and coaptation of venous structures.
- The structure of the corporal bodies of the penis is essential to the erectile process.
- There is substantial variability in penile vascular anatomy between patients; this may have functional relevance in case of pelvic surgery.

Neuroanatomy and Neurophysiology of Penile Erection

Spinal Centers and Peripheral Pathways

The innervation of the penis is autonomic (sympathetic and parasympathetic) and somatic (sensory and motor) (Fig. 68.7). From neurons in the spinal cord and peripheral ganglia, the sympathetic and parasympathetic fibers merge to form the cavernous nerves, which enter the corpora cavernosa and corpus spongiosum. Somatic nerves to the penis are primarily responsible for sensation but also play an important motor function by modulating contraction of the bulbocavernosus and ischiocavernosus muscles during rigid erection and ejaculation (Giuliano, 2011).

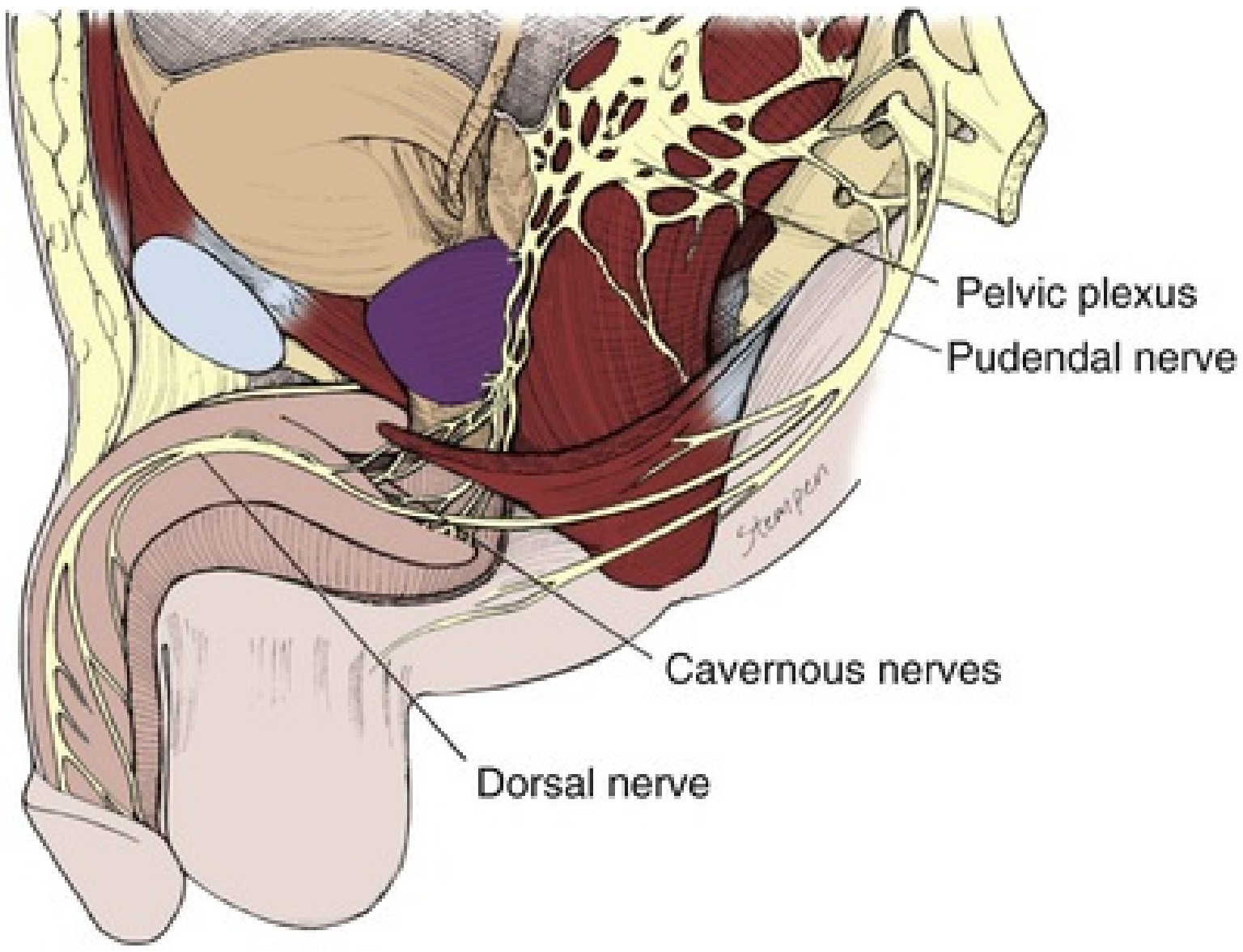

FIG. 68.7 Penile neuroanatomy.

Autonomic Pathways.

The sympathetic innervation of the penis originates from the 11th thoracic to the 2nd lumbar spinal segments and passes through the white rami to the sympathetic chain ganglia. Some fibers travel through the lumbar splanchnic nerves to the inferior mesenteric and superior hypogastric plexuses, from which fibers travel in the hypogastric nerves to the pelvic plexus. In humans, the T10 to T12 segments are most often the origin of the sympathetic fibers to the penis. Sympathetic chain ganglia cells projecting to the penis are located in the sacral and caudal ganglia (Giuliano, 2011).

The parasympathetic innervation of the penis arises from neurons in the intermediolateral cell columns of the second, third, and fourth sacral spinal cord segments. The preganglionic fibers pass in the pelvic nerves to the pelvic plexus, where they are joined by the sympathetic nerves from the superior hypogastric plexus. **The cavernous nerves are branches of the pelvic plexus that innervate the penis.** Human cadaveric dissection has revealed medial and lateral branches of the cavernous nerves (the former accompanying the urethra and the latter piercing the urogenital diaphragm 4 to 7 mm lateral to the sphincter) and multiple communications between the cavernous and dorsal nerves (Fig. 68.8; Paick et al., 1993). In addition to the cavernous nerve proper, pelvic ganglion cells exist in and along the nerve components and pelvic viscera. These ganglia are localized to the bladder/prostate junction, the dorsal aspect of the seminal vesicles, and along the prostate. There are widespread individual variations in distribution of these extramural ganglion cells in the male pelvis (Takenaka et al., 2005).

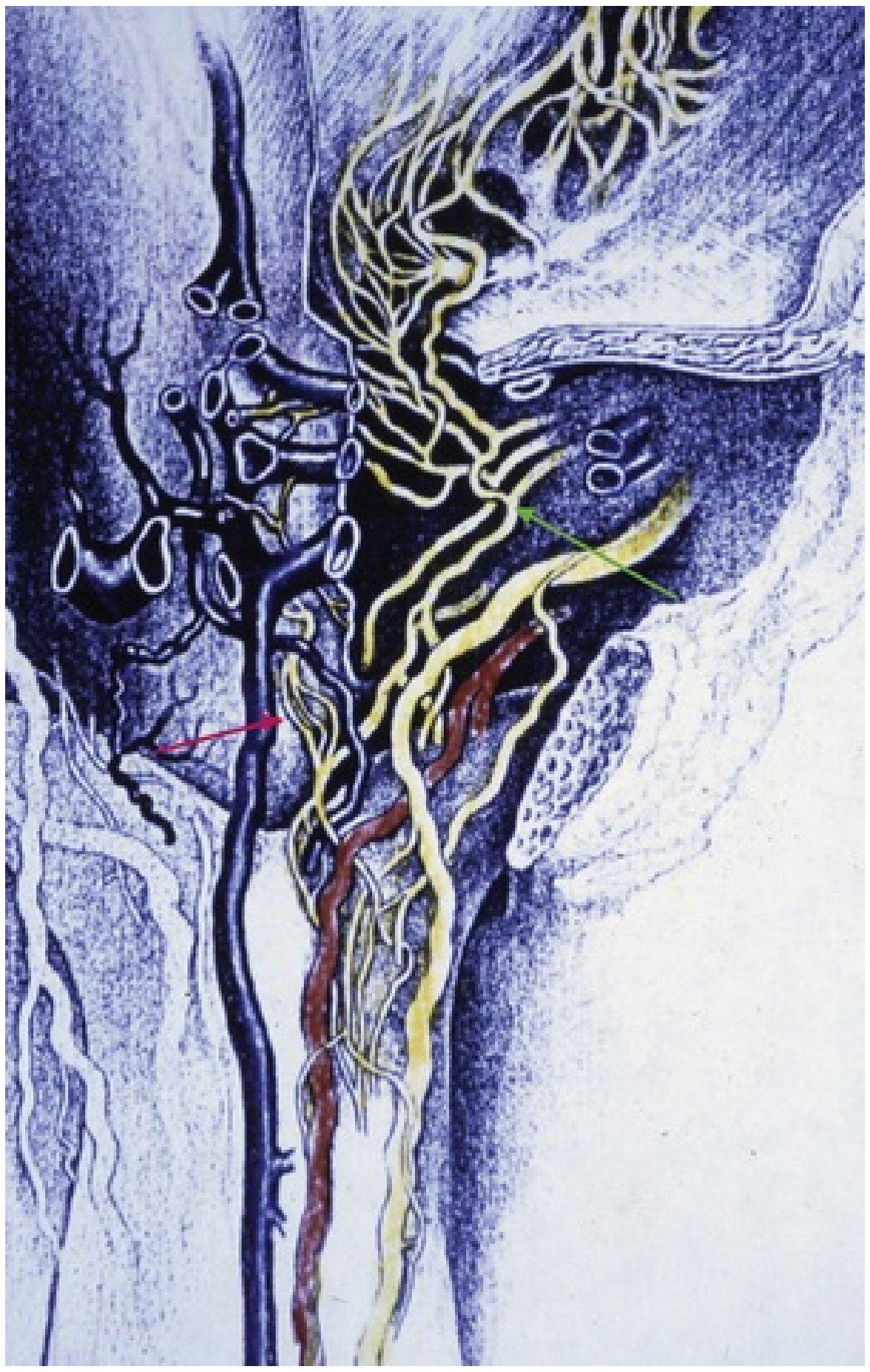

FIG. 68.8 Drawing from a human cadaveric dissection shows the medial *(red arrow)* and lateral *(green arrow)* bundles of the cavernous nerve distal to the prostate. (From Paick JS, Donatucci EF, Lue TF: Anatomy of cavernous nerves distal to prostate: microdissection study in adult male cadavers. *Urology* 42:145–149, 1993, with permission from Excerpta Medica, Inc.)

Stimulation of the pelvic plexus and the cavernous nerves induces erection, whereas stimulation of the sympathetic trunk causes detumescence. In animal models, removal of the spinal cord below L4 or L5 eliminates reflex erectile response to genital contact. Placement of these animals with a female animal in estrous, electrical stimulation of the medial preoptic area (MPOA), and central administration of the dopamine agonist apomorphine produce erections (Giuliano et al., 1996; Paick and Lee, 1994; Sato and Christ, 2000). Similarly, many men with sacral spinal cord injury retain psychogenic erectile ability even though reflexogenic erection in response to penile stimulation is abolished. These cerebrally elicited erections are found more frequently in patients with lower motor neuron lesions below T12, implying that central inhibition of tonic sympathetic tone is largely responsible for centrally mediated penile erection (Courtois et al., 1999). Further evidence for this relationship is that psychogenic erections do not typically occur in patients with spinal lesions above T9 (Chapelle et al., 1980). Although psychogenic erections may occur in men with spinal cord lesions, the degree of tumescence is often marginal and insufficient for intercourse (Chapelle et al., 1980).

Somatic Pathways.

The somatosensory innervation of the penis originates at sensory receptors in the penile skin, glans, and urethra and within the corpus cavernosum. There are numerous afferent terminations in the human glans penis; free nerve endings (sensitive to touch and temperature) are the most common nerve structure and connect to thinly myelinated A_δ and C fibers (Halata and Munger, 1986). Pressure sensitive corpuscular receptors are also present, albeit at a much lower density (Halata and Munger, 1986). Nerve fibers from the various skin receptors converge to form bundles of the dorsal nerve of the penis, which joins other nerves to become the pudendal nerve. The latter enters the spinal cord via the S2-S4 roots to terminate on spinal neurons and interneurons in the central gray region of the lumbosacral segment. Activation of these sensory neurons sends messages of pain, temperature, and touch by means of spinothalamic and spinoreticular pathways to the thalamus and sensory cortex for sensory perception (McKenna, 1998).

The dorsal nerve of the penis is composed of two to six branches. In the majority of men, branches of the dorsal nerve perforate the tunica albuginea and connect to the corpus cavernosum (Kozacioglu et al., 2014). Although largely made up of somatic sensory nerves, the dorsal nerve of the penis in humans and animals also includes nNOS-containing fibers (Burnett et al., 1993; Carrier et al., 1995). These NOS-positive nerve bundles in the dorsal nerve are reduced after damage of the cavernous nerve near the rat prostate (Podlasek et al., 2001). Stimulation of the sympathetic chain at the L4-L5 level elicits an evoked discharge of the dorsal nerve (Giuliano et al., 1993). These findings illustrate that the dorsal nerve has somatic and autonomic components that regulate erectile and ejaculatory functions.

Onuf's nucleus is the center of somatomotor penile innervation and is localized to the second to fourth sacral spinal segments. Somatomotor fibers from this nucleus travel in the sacral nerves to the pudendal nerve to innervate the ischiocavernosus and bulbocavernosus muscles. **Contraction of the ischiocavernosus muscles produces the rigid-erection phase.** Rhythmic contraction and compression of the bulbocavernosus muscle on the proximal corpus is also responsible for the ejection phase of ejaculation (Clement and Giuliano, 2016). Antegrade flow of semen is also dependent on relaxation of the external urinary sphincter and compression of the corpus spongiosum. In animal studies, direct innervation of the sacral spinal motoneurons by brainstem sympathetic centers (A5-catecholaminergic cell group and locus ceruleus) has been identified (Marson and McKenna, 1996). This adrenergic innervation of pudendal motoneurons may be involved in rhythmic contractions of perineal muscles during ejaculation (Chehensse et al., 2017; Facchinetti et al., 2014). Oxytocinergic and serotoninergic innervation of lumbosacral nuclei controlling penile erection and perineal muscles in male rats has also been demonstrated (Tang et al., 1998).

Several spinal reflexes can be elicited by stimulation of the glans penis (Table 68.3). The best known is the bulbocavernosus reflex, which is the basis of genital neurologic examination and electrophysiologic latency testing. The significance of bulbocavernosus reflex testing in assessment of sexual dysfunction assessment is unclear (Giuliano and Rowland, 2013).

TABLE 68.3

Spinal Reflexes Involved in Stimulation of Penile Dorsal Nerve

STIMULATION	SPINAL CENTER	EFFERENT	EFFECT
Noxious, abrupt stimulation	Sacral motor neurons	Pudendal nerve (motor)	Bulbocavernous reflex
Low-intensity continuous (e.g., vibratory, manual)	Sacral parasympathetic neurons and interneurons	1. Pelvic nerves 2. Cavernous nerve	1. Detrusor inhibition and closure of bladder neck 2. Penile erection
High-intensity continuous	Sacral motor and parasympathetic Thoracolumbar sympathetic neurons	Pudendal, pelvic, and cavernous nerves	Ejaculation

Supraspinal Pathways and Centers

Positron emission tomography (PET) and functional magnetic resonance imaging (fMRI) have facilitated a greater understanding of brain activation during sexual arousal in animals and humans (Table 68.4; Hubscher et al., 2010; Tsujimura et al., 2006). Psychogenic ED, premature ejaculation, and orgasmic dysfunction may be associated with alterations in higher brain function. Advanced brain imaging is able to precisely identify brain areas with increased and decreased activity during sexual stimuli (typically induced by exposure to erotic media) and erection relative to activation during nonsexual activities (e.g., exposure to neutral media) (Table 68.5; Chen et al., 2017; Kuhn and Gallinat, 2011; Parada et al., 2016; Tsujimura et al., 2006). These studies are generally well designed but are limited by the complexity and individuality of human emotional and sexual responses.

TABLE 68.4

Brain Centers Involved in Sexual Function

LEVEL	REGION	FUNCTION
Forebrain	Medial amygdala	Control sexual motivation
	Stria terminalis	
	Pyriform cortex	Inhibits sexual drive (hypersexuality when destroyed)
	Hippocampus	Involved in penile erection
	Right insula and inferior frontal cortex	Increased activity during visually evoked sexual stimulation (sexual arousal)
	Left anterior cingulate cortex	
Hypothalamus	Medial preoptic area	Ability to recognize a sexual partner, integration of hormonal and sensory cues
	Lateral preoptic area	Control nocturnal penile tumescence in rats
	Paraventricular nucleus	Facilitates penile erection (via oxytocin neurons to lumbosacral spinal autonomic and somatic efferents)
Brainstem	Nucleus paragigantocellularis	Inhibits penile erection (via serotonin neurons to lumbosacral spinal neurons and interneurons)
	A5-catecholaminergic cell group	Major noradrenergic center

	Locus ceruleus	
Midbrain	Periaqueductal gray	Relay center for sexually relevant stimuli

TABLE 68.5

Common Brain Activation Regions With Visual Sexual Stimuli[a]

BRAIN ACTIVATION REGIONS	FUNCTIONAL ASSOCIATION
Bilateral inferior temporal cortex (right > left)	Visual association area
Right insula	Processes somatosensory information with motivational states
Right inferior frontal cortex	Processes sensory information
Left anterior cingulate cortex	Controls autonomic and neuroendocrine function
Right occipital gyrus	Visual processing
Right hypothalamus	Male copulatory behavior
Left caudate (the striatum)	Processes attention and guides responsiveness to new environmental stimuli

[a] These regions demonstrate activation with visual sexual stimuli in multiple studies.

Integration and processing of afferent inputs (e.g., visual, olfactory, imaginative, genital stimulation) in the supraspinal centers is essential in the initiation and maintenance of penile erection. Spinal transection at the T8 level by revealed neuronal projections from the external genitalia project to the medullary reticular formation via bilateral projections in the dorsal, dorsolateral, and ventrolateral white matter of the spinal cord (Hubscher et al., 2010). In animal studies, the central supraspinal systems controlling sexual arousal are localized predominantly in the limbic system (e.g., olfactory nuclei, MPOA, nucleus accumbens, amygdala, and hippocampus) and hypothalamus (paraventricular and ventromedial nuclei). In particular, the medial amygdala, MPOA, paraventricular nucleus (PVN), periaqueductal gray, and ventral tegmentum are recognized as key structures in the central control of the male sexual response (Andersson, 2011; Melis and Argiolas, 2011). The lateral hypothalamus and anterior part of the middle cingulate cortex show increased blood flow during sexual arousal, whereas the anteroventral hypothalamus and subgenual anterior cingulate cortex show increased flow during penile detumescence after arousal. (Georgiadis et al., 2010). These brain regions are thought to play complementary regulatory roles in the autonomic modulation of sexual response.

In a meta-analysis of fMRI studies of brain activity in response to erotic stimuli, a neural network was identified that appears to constitute a core circuit of male sexual arousal in humans. This neural circuit involves the following components: cognitive (parietal cortex, anterior cingulate gyrus, thalamus, insula), emotional (amygdala, insula), motivational (precentral gyrus, parietal cortex), and physiologic (hypothalamus/thalamus, insula) (Kuhn and Gallinat, 2011). Visual association cortices are also intimately involved in response to erotic stimuli; in sum, the activated regions appear to play roles in cognitive evaluation of external stimuli, modulation of sensory processing, and regulation of urge behavior (Poeppl et al., 2014). Deactivation of the temporal and parietal lobes occurs in men during sexual arousal and/or erection. These areas govern aspects of introspection and self-reflective behaviors, including planning for the future. Inhibition of these regions may play a role in disinhibition before engaging in sexual activity (Poeppl et al., 2014).

Differential brain activation is associated with some discrete sexual issues in men. Men with hypoactive sexual desire retain activity in the left gyrus rectus (within the medial orbitofrontal cortex) during exposure to sexually arousing media; men with normal desire experienced deactivation of this brain region (Stoleru et al., 2003). This region is believed to mediate inhibition of motivated behavior, implying that men with hypoactive sexual desire disorder experience continued inhibition of behavior even with exposure to erotic stimuli. Men with psychogenic ED evidence extended activation of the cingulated gyrus, frontal mesial, and frontal basal cortex during exposure to sexually arousing media. With administration of the dopamine agonist apomorphine activity in these areas became similar to what was observed in healthy controls without ED (Montorsi et al., 2003). Separate studies have suggested that men with psychogenic ED evidence decreased connectivity in the “default mode network” (related to states of wakeful rest and attention to self and other's emotional state and thoughts) and the “salience network” (responsible for processing which environmental cues merit attention). The implication is that psychogenic ED may be related to aberrant appraisal of erotic stimuli and lack of awareness of the self's body state (Cera et al., 2014). Disruption of brain areas responsible for integrating external stimuli and visceral arousal is observed in some patients with ED related to cerebrovascular injury (Winder et al., 2017).

The structures discussed earlier are responsible for the three types of erection: psychogenic, reflexogenic, and nocturnal. Psychogenic erection is a result of audiovisual stimuli or fantasy. Impulses from the brain modulate the spinal erection centers (T11-L2 and S2-S4) to activate the erectile process, primarily by suppression of baseline sympathetic tone that limits penile circulation. Reflexogenic erection is produced by tactile stimulation of the genital organs. The impulses reach the spinal erection centers; some then follow the ascending tract, resulting in sensory perception, whereas others activate the autonomic nuclei to send messages via the cavernous nerves to the penis to induce erection. This type of erection is preserved in patients with upper spinal cord injury (Courtois et al., 2013; Giuliano and Rampin, 2004).

Nocturnal erection occurs mostly during rapid eye movement (REM) sleep (Karacan et al., 1989). PET scanning of humans in REM sleep shows increased activity in the pontine area, the amygdalae, and the anterior cingulate gyrus but decreased activity in the prefrontal and parietal cortex. The mechanism that triggers REM sleep is located in the pontine reticular formation; the cholinergic neurons in the lateral pontine tegmentum are activated, whereas the adrenergic neurons in the locus ceruleus and the serotoninergic neurons in the midbrain raphe are silent**.** In a brain stimulation study in rats, the sites for eliciting erection during REM sleep were located in the dorsal and intermediate parts of the lateral septum, whereas the ventral part of the lateral septum was the most effective site for eliciting erections during wakefulness (Gulia et al., 2008).

PET has been used to measure increases in regional cerebral blood flow during ejaculation versus sexual stimulation without orgasm in heterosexual volunteers. Primary brain activation was found in the mesodiencephalic transition zone (including the ventral tegmental area), an area frequently activated with “reward” behaviors and with injection of opioids such as heroin. Other activated mesodiencephalic structures included the midbrain lateral central tegmental field; the zona incerta; the subparafascicular nucleus; and the ventroposterior, midline, and intralaminar thalamic nuclei. Increased activation was also observed in the lateral putamen and adjoining parts of the claustrum. Neocortical activity was found in Brodmann areas 7/40, 18, 21, 23, and 47, exclusively on the right side. Conversely, in the amygdala and adjacent entorhinal cortex, a decrease in activation was noted. Remarkably strong increases in blood flow were observed in the cerebellum (Holstege et al., 2003). These findings corroborate the notion that the cerebellum plays an important role in emotional processing.

Although activation of these various brain areas is of great interest, further studies are necessary to better understand the neurobiology of orgasm, ejaculation, and sexual satisfaction in men and to use the results for treatment (Table 68.6; Tsujimura et al., 2006).

TABLE 68.6

Brain Centers of Orgasm

	BRAIN AREAS	RELEVANCE
Increased activity: primary area	Mesodiencephalic transition zone (including the ventral tegmental area)	"Reward" center also activated by opioid
Increased activity: secondary areas	Midbrain lateral central tegmental field, the zona incerta, subparafascicular nucleus, ventroposterior, midline, and intralaminar thalamic nuclei Lateral putamen and adjoining parts of the claustrum Brodmann areas 7/40, 18, 21, 23, and 47, exclusively on the right side	
Increased activity: other area	Cerebellum	Emotional processing
Decreased activity	Amygdala and adjacent entorhinal cortex	

Neurotransmitters

Peripheral Neurotransmitters and Endothelium-Derived Factors Facilitating Penile Erection.

NO released from nonadrenergic/noncholinergic (NANC, also known as nitrergic) neurons and from the endothelium is thought to be the principal neurotransmitter mediating penile erection. NO activates guanylate cyclase, which increases the production of cyclic guanosine monophosphate (cGMP), which in turn relaxes the cavernous smooth muscle by a number of downstream mechanisms (Andersson, 2011). **NO derived from nNOS in NANC nerves is responsible for initiation of corporal smooth muscle relaxation; NO from eNOS is thought to drive maintenance of smooth muscle relaxation and penile erection** (Hurt et al., 2002).

Aside from its role in releasing NO, a number of endothelium-derived substances have also been linked to corporal smooth muscle relaxation.

Examples include carbon monoxide (CO), (Decaluwe et al., 2012) hydrogen sulfide (H_2S), (d'Emmanuele di Villa Bianca et al., 2011), endothelium-derived hyperpolarizing factor (EDHF), prostacyclin (PGI_2), and endothelin (which may induce relaxation via activation of endothelin-B receptors) (Saenz de Tejada et al., 1991).

Acetylcholine is released with electrical field stimulation of human erectile tissue, and cholinergic receptors have been localized to the cavernous tissue and endothelium (Blanco et al., 1988; Traish et al., 1990). Although acetylcholine is not the predominant neurotransmitter mediating penile erection, it may contribute indirectly to penile erection by presynaptic inhibition of adrenergic neurons and stimulation of NO release from endothelial cells (Saenz de Tejada et al., 1989). The effect may be minor as inhibition of cholinergic action by intravenous or intracavernous injection of atropine does not abolish erection induced in animals by electrical neurostimulation (Stief et al., 1989).

Peripheral Neurotransmitters and Endothelium-Derived Factors Opposing Penile Erection.

Maintenance of intracorporal smooth muscle in a semi-contracted (flaccid) state likely results from three factors: intrinsic myogenic activity (Andersson and Wagner, 1995); **adrenergic neurotransmission; and endothelium-derived contracting factors such as angiotensin II, $PGF_{2\alpha}$, and endothelin-1.** Detumescence after erection results from resumption of these factors as well as cessation of NO release, the breakdown of cyclic guanosine monophosphate (cGMP) by phosphodiesterases (PDEs), and/or sympathetic discharge during ejaculation.

Norepinephrine is generally accepted as the principal neurotransmitter mediating penile flaccidity (Andersson, 2011). Both α_1-adrenergic and α_2-adrenergic fibers and receptors have been demonstrated in the corpora cavernosa and surrounding the cavernous arteries (Prieto, 2008). Research findings support a functional predominance of postjunctional α_1-adrenergic receptors for contraction and of prejunctional α_2-adrenergic receptors for downregulating release of norepinephrine and the vasodilator nitric oxide (NO) (Prieto, 2008). Stimulation of adrenergic receptors by norepinephrine produces contraction in penile vessels and the corpora cavernosa; this process is mediated by Ca^{2+} entry into smooth muscle cells via membrane calcium channels. Cellular calcium sensitization mechanisms also contribute and are mediated by protein kinase C

(PKC), tyrosine kinases, and Rho-kinase (Andersson, 2011).

Endothelin-1 is a potent vasoconstrictor and mediator of penile detumescence (Holmquist et al., 1990; Saenz de Tejada et al., 1991). Two receptors for endothelin, endothelin-A and endothelin-B_1, mediate the biologic effects of endothelin in vascular endothelial tissue: endothelin-A receptors mediate contraction, whereas endothelin-B_1 receptors induce relaxation. By action on endothelin-A receptors, endothelin induces slow-developing, long-lasting contractions in the corpora cavernosa and cavernosal arteries. Endothelin also potentiates the constrictor effects of catecholamines on trabecular smooth muscle (Christ et al., 1995). Blockade of the endothelin-A receptor ameliorates impaired penile hemodynamics in animal models of obesity (Sanchez et al., 2014).

Several constrictor prostanoids, including prostaglandin I_2 (PGI_2), prostaglandin $F_{2\alpha}$ ($PGF_{2\alpha}$), and thromboxane A_2 (TXA_2), are synthesized by the human cavernous tissue. Prostanoids induce spontaneous contraction in isolated trabecular muscle (Christ et al., 1990) and inhibit the relaxant effects of NO (Azadzoi et al., 1992; Minhas et al., 2001). The contractile effects of prostanoids in corporal tissue appear to be mediated by thromboxane A_2 (TP) receptors (Angulo et al., 2002).

The renin-angiotensin system (RAS) is a well-known mediator of systemic vascular tone, and RAS sensitive receptors have been identified in penile smooth muscle. The RAS consists of two components: a vasoconstrictor/proliferative arm, in which the main mediator is angiotensin II acting on angiotensin (AT1) receptors, and a vasodilator/antiproliferative arm, in which the major effector is angiotensin-(1-7) acting via the G protein–coupled receptor (GPCR) Mas (Fraga-Silva et al., 2013). The opposing functions of the RAS system suggest that this axis may induce pro- and antierectile effects. Administration of angiotensin II with activation of AT1 receptors is associated with increased activity of RhoA/rho-kinase, increased intracellular calcium, and oxidative stress (Fraga-Silva et al., 2013). Administration of angiotensin II in mouse cavernosal cells has also been linked to increased expression of the toll-like receptor 4 (TLR4), a component of the immune system. Inhibition of TLR4 attenuated the enhancement in adrenergic-induced contraction and preserved NOS activity cavernous relaxation (Nunes et al., 2017). The implication is that immune modulation and inflammation (known to be associated with vascular disease) may play a role in alteration of penile hemodynamics (Stallmann-Jorgensen et al., 2015).

Transforming growth factor-beta (TGF-β) is associated with corporal smooth muscle apoptosis, oxidative stress, and reduced smooth muscle-to-collagen ratio (Li et al., 2013). TGF-β appears to be responsible for some of the impaired hemodynamic parameters observed in rat models of diabetes (Li et al., 2013). These effects may be mediated by the Smad2 protein complex, the downstream effectors of TGF-β. Treatment with TGF-β has also been associated with upregulation of the Rho A/Rho-Kinase pathway (Li et al., 2013), increased expression of plasminogen activator inhibitor-1 (PAI-1), and increased activity of the profibrotic Wnt10 pathway (Shin et al., 2014).

Tyrosine kinases induce contraction in rat small penile arteries (Villalba et al., 2010). In a cavernous nerve injury model of ED in rats, treatment with a tyrosine kinase inhibitor led to preservation of NANC nerve fibers and downregulation of sympathetic tyrosine hydroxylase–containing nerve fibers. Also noted in this study was improved smooth muscle-to-collagen ratio and intracorporal pressure response to cavernous nerve stimulation (Lin et al., 2015). These effects may be related to activation of large conductance potassium channels, an effect observed in human cavernous nerve strips exposed to a tyrosine kinase inhibitor in vitro (Gur et al., 2013).

Interactions Among Nerves and Neurotransmitters.

There is marked cross-reactivity between pro- and antitumescence pathways and modulation by health conditions in corporal tissue (Angulo et al., 2001; Brave et al., 1993). Numerous factors have been reported to increase NOS activity and NO release, including molecular oxygen, androgen, long-term administration of L-arginine, and repeated intracavernous injection of PGE_1 (Escrig et al., 1999; Kim et al., 1993; Marin et al., 1999). Decreased NOS activity has been associated with castration, denervation, hypercholesterolemia, and diabetes mellitus (Alves-Lopes et al., 2017; Lin et al., 2015; Yang et al., 2013). In some cases this may be related to action of adrenergic neurons known to inhibit NO release by binding prejunctional α_2 receptors. NOS isoforms may also regulate the activity of other isoforms. For example, nNOS activity has been shown to decrease expression of inducible nitric oxide synthase (iNOS) after administration of TGF-β1 into the penis (Bivalacqua et al., 2000). NOS isoforms may also be upregulated to compensate for defects in N-production; in nNOS knockout mice, eNOS levels are higher than in control animals, suggesting a possible compensatory mechanism (Burnett et al., 1996).

cAMP-dependent and cGMP-dependent protein kinases can be activated by either cAMP or cGMP, although cross-activation requires an approximately 10-fold higher concentration of the alternate cyclic nucleotide (Walsh, 1994). Although protein kinase A (PKA) and protein kinase G (PKG) may phosphorylate numerous common substrates, several lines of evidence indicate that the activation of PKG by cGMP and cAMP is the predominant mechanism by which cyclic nucleotides decrease intracellular Ca^{2+} to cause vascular smooth muscle relaxation and corporal vasorelaxation (Jiang et al., 1992; Lincoln et al., 1990).

Molecules That Modulate Penile Erection via the Central Nervous System.

Major neuropeptides involved in regulation of erectile response include dopamine, oxytocin, NO, norepinephrine, serotonin (5-hydroxytryptamine [5-HT]), and prolactin. **In general, central dopaminergic and adrenergic receptors promote sexual function, and 5-HT receptors inhibit it** (Foreman and Wernicke, 1990). Androgens also play an important role in modulating central nervous system (CNS) control of sexual response.

Dopamine.

There are many dopaminergic systems in the brain with ultrashort, intermediate, and long axons. The cell bodies are located primarily in the ventral tegmentum, substantia nigra, and hypothalamus. Five different dopamine receptors have been cloned (D_1 to D_5), and several of these exist in multiple forms (Ganong, 1999b). Neuroscientists have discovered that specific dopamine receptors (D_2, D_3, and D_4), nNOS, and oxytocin are co-expressed in the cell bodies of oxytocinergic neurons in the PVN and MPOA (Baskerville et al., 2009; Xiao et al., 2005).

In men, the D_1 and D_2 receptor agonist apomorphine induces erection that is unaccompanied by sexual arousal (Danjou et al., 1988). In male rats, injection of dopaminergic agonists to the PVN stimulates D_2, but not D_3 or D_4, receptors, and increases Ca^{2+} influx in cell bodies of oxytocinergic neurons. The net effect is increased production of NO, which activates oxytocinergic neurotransmission in extrahypothalamic brain areas and spinal cord, leading to penile erection and yawning. Dopamine may also regulate prolactin secretion by actions on the pituitary gland (Ganong, 1999a). The stimulation of D_4 receptors increases Ca^{2+} influx and NO production leading to penile erection but not yawning. Nevertheless, D_4 receptors are thought to play only a modest role in the proerectile effects of central dopamine (Melis and Argiolas, 2011).

Oxytocin.

Oxytocin is a neural hormone secreted by the neurons into the circulation. Oxytocin is localized primarily to the posterior pituitary gland but may also function as a neurotransmitter in neurons projecting from the PVN to the brainstem and spinal cord (Courtois et al., 2013). Serum oxytocin levels are increased during sexual activity in humans and animals. Oxytocin is a potent inducer of penile erection when injected into the central nervous system (CNS). In rats, the most sensitive brain area for the proerectile effect of oxytocin is the PVN of the hypothalamus. Oxytocin release after stimulation of dopamine receptors in the PVN influences the appetitive and reinforcing effects of sexual activity (Succu et al., 2007). PVN neurons contain NOS; interestingly, NOS inhibitors prevent apomorphine-induced and oxytocin-induced erections, implying that NO is a common downstream pathway for dopamine- and oxytocin-mediated erections (Melis and Argiolas, 2011; Vincent and Kimura, 1992).

Nitric Oxide.

The NO/cGMP pathway is a critical mediator of erections in the periphery but also plays important roles in the CNS. NO and its downstream effector soluble guanylyl cyclase is localized throughout the human brain, including at the level of the PVN (Melis et al., 1998). Activity of the NO/cGMP pathways in the brain declines with aging (Ibarra et al., 2001) and experimentally induced diabetes (Zheng et al., 2007). Testosterone supplementation has been shown to enhance apomorphine-induced erections and NOS activity in the MPOA; these effects may be mediated by enhanced expression of dopamine-responsive NOS in the MPOA and by NO-induced enhancement of dopamine release in response to external stimuli (Hull et al., 1999).

Serotonin.

Neurons containing 5-HT have their cell bodies in the midline raphe nuclei of the brainstem and project to a portion of the hypothalamus, limbic system, neocortex, and spinal cord (Ganong, 1999a). There are numerous 5-HT receptors in the brain, which are classified by type and subtype (Ganong, 1999b). **The general effect of 5-HT in the CNS is inhibitory toward sexual desire and erectile function** (Foreman et al., 1989). However, there is evidence to support a role for 5-HT in facilitating and opposing sexual response, depending on the receptor subtype, the receptor location, and the species investigated (de Groat and Booth, 1993). For instance, activation of the 5-HT_{1A} and 5-HT_2 receptors appears to inhibit erectile activity but facilitate ejaculation. Conversely, activation of 5-HT_{2C} receptors facilitates erection in rats (Kimura et al., 2006; Steers and de Groat, 1989). 5-HT_{2C} receptors are localized to the lumbosacral spine and are thought to be potential downstream effectors of the dopamine-oxytocin and melanocortin pathways (Kimura et al., 2008).

Norepinephrine.

The cell bodies of norepinephrine-containing neurons are located in the locus ceruleus and the A5-catecholaminergic cell group in the pons and medulla. The axons of these noradrenergic neurons ascend to innervate the paraventricular, supraoptic, and periventricular nuclei of the hypothalamus, thalamus, and neocortex (Courtois et al., 1999). These fibers also descend into the spinal cord and the cerebellum. In contrast to peripheral effects of norepinephrine, **central norepinephrine transmission seems to have a stimulatory effect on sexual function.** In humans and rats, inhibition of norepinephrine release by clonidine, an α_2-adrenergic agonist, is associated with a decrease in sexual behavior. Conversely, yohimbine, an α_2-receptor antagonist, has been shown to increase sexual activity (Clark et al., 1985).

Melanocortins.

Melanocortin-4 receptor (MC4R) is expressed in the human and rat CNS, pelvic ganglia, and nerve fibers of the glans penis. This receptor is involved in the control of food intake and energy expenditure and appears to modulate erectile function and sexual behavior. Evidence supporting this notion is based on mouse studies indicating enhanced copulatory behavior and augmentation of erectile response from electrostimulation in mice given an MC4R agonist (Van der Ploeg et al., 2002).

Prolactin.

Hyperprolactinemia is known to suppress sexual function in men and experimental animals (Paick et al., 2006; Rehman et al., 2000). **The purported mechanism of action is through inhibition of dopaminergic activity in the MPOA and decreased serum testosterone. Prolactin may also have a direct**

contractile effect on cavernous smooth muscle (Table 68.7; Ra et al., 1996).

TABLE 68.7

Central Neurotransmitters and Their Function

NEUROTRANSMITTER	RECEPTOR AND FUNCTION
Dopamine	D1 and D4 receptor—enhances erection
	D2 receptor—enhances seminal emission
Serotonin (5-HT)	5-HT—inhibits sex drive and spinal sexual reflex
	5-HT1A—inhibits erection, facilitates ejaculation
	5-HT2C—enhances erection
Norepinephrine	Enhances sexual function
γ-Aminobutyric acid	Inhibits erectile signals
Opioids	Inhibit penile erection
Cannabinoids	Inhibit sexual function
Oxytocin	Enhances appetitive and reinforcing effects of sexual activity
Nitric oxide	Mediates erection at paraventricular nucleus
Melanocortins	MCR4—enhances erection
Prolactin	Suppresses sexual function

γ-Aminobutyric Acid.

γ-Aminobutyric acid (GABA) activity in the PVN inhibits proerectile signaling. Systemic administration or intrathecal injection at the lumbosacral level of the $GABA_B$ receptor agonist baclofen decreases erection in rats (Bitran and Hull, 1987). At least some of GABA's antierectile effects seem to be mediated by activation of $GABA_A$ receptors, which reduce erectile response to dopamine agonists and oxytocin (Melis and Argiolas, 2002).

Opioids.

Endogenous opioids affect sexual function, although the magnitude varies depending on dose and site of administration. Injection of small amounts of morphine into the MPOA induces sexual behavior in rats. However, larger doses of narcotics inhibit penile erection and yawning induced by stimulation of oxytocinergic or dopaminergic pathways (Argiolas, 1992; Melis et al., 1999). Injection of morphine into the PVN of the hypothalamus prevents noncontact penile erections and impairs copulation in rats. It is speculated that intracellular

NO may be involved in this process (Melis et al., 1999).

Cannabinoids.

Cannabinoid CB_1 receptor activation inhibits sexual function by modulating paraventricular oxytocinergic neurons, which mediate erection. Antagonism of CB_1 receptors in the PVN of male rats induces penile erection via the downstream effectors glutamic acid and NO (Melis et al., 2004, 2006).

Key Points: Physiology of Penile Erection

- Neuronal integrity at the brain, spinal cord, and peripheral level is essential to modulation of penile erections.
- A wide range of neurotransmitters are involved in modulating sexual arousal and penile erection; key examples include dopamine, serotonin, oxytocin, nitric oxide, and norepinephrine.
- Integration of erotic stimuli in the central nervous system is complex; MRI and PET scanning have provided new insight on central mechanisms of sexual arousal in men.

Smooth Muscle Physiology

Cytosolic Calcium and the Calcium Sensitization Pathway

The smooth muscle of the corpora cavernosa are contracted in their normal state. Myosin isoforms in smooth muscle of the corpus cavernosum contain phasic and tonic characteristics (DiSanto et al., 1998). Contractions of the corpus cavernosum smooth muscle may be spontaneous or induced (Yarnitsky et al., 1995). Spontaneous phasic contractions of corpus cavernosum smooth muscle appear to be dependent on an endogenous pacemaker driven by a cytosolic Ca^{2+} oscillator that releases Ca^{2+} from the sarcoplasmic reticulum periodically (Berridge, 2008; Cellek et al., 2002). This cytosolic oscillator can be modulated by neurotransmitters and hormones and may play a role in maintaining corporal smooth muscle function.

Smooth muscle contraction is controlled by two major factors: cytosolic calcium concentration and Rho-kinase signaling (Berridge, 2008). Smooth muscle contraction can occur with or without change in membrane potential

(Berridge, 2008; Somlyo and Somlyo, 2000).

Cytosolic Free Calcium.

Smooth muscle contraction is regulated by intracellular free calcium (Ca^{2+}) acting through calmodulin. Calcium-bound calmodulin undergoes a conformational change, increasing its affinity for myosin light chain (MLC) kinase. MLC kinase is activated by binding of the calcium-calmodulin complex, leading to phosphorylation of the serine-19 residue of regulatory MLC_{20}. In the presence of adenosine triphosphate (ATP), this phosphorylation enables actin to activate the myosin ATPase and initiates cross-bridge cycling. Hydrolysis of ATP by ATPase supplies the energy for the contractile process (Fig. 68.9; Walsh, 1991).

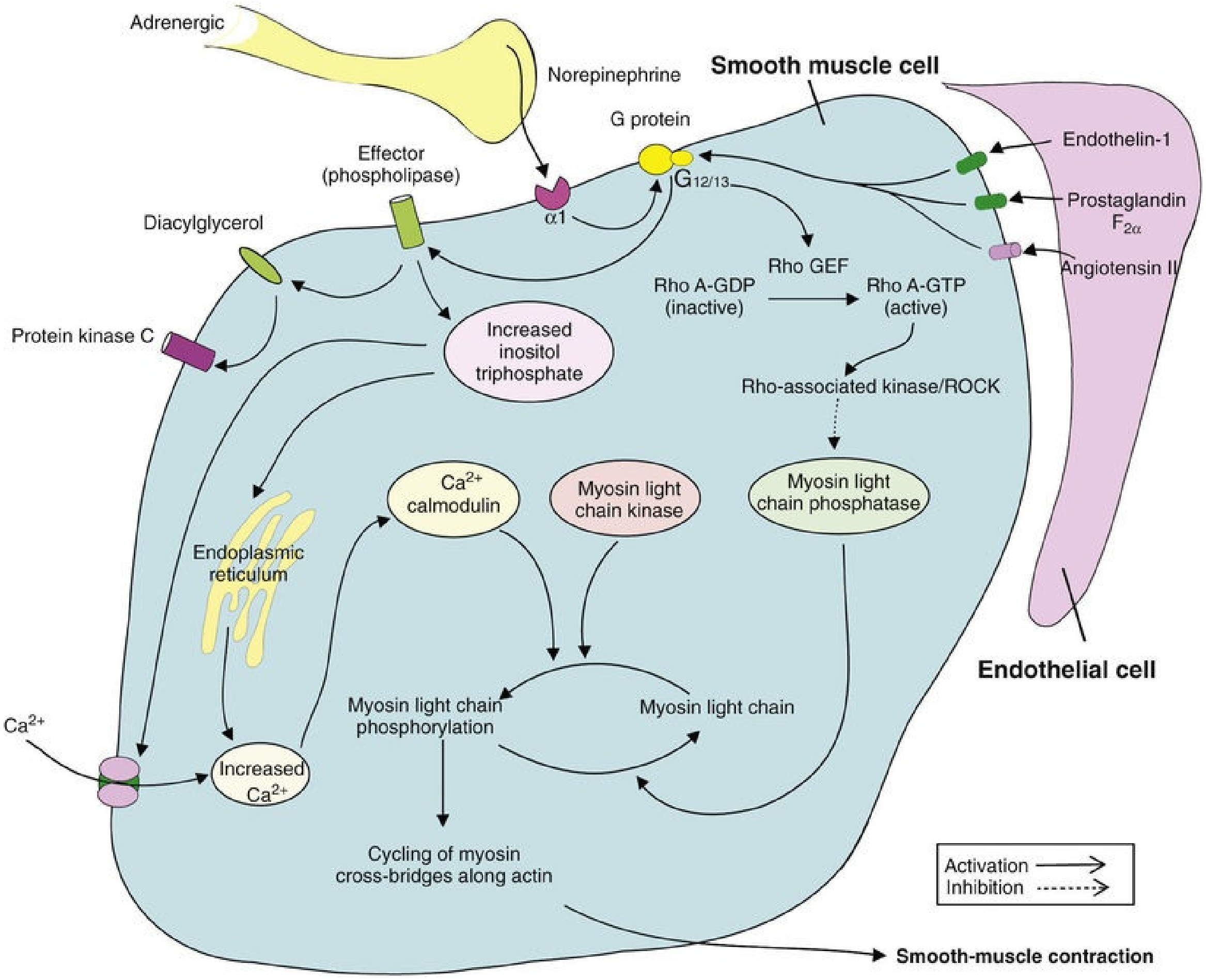
Adrenergic
Norepinephrine
Smooth muscle cell
G protein
Effector (phospholipase)
Endothelin-1
G12/13
α1
Prostaglandin F2α
Diacylglycerol
Rho GEF
Angiotensin II
Rho A-GDP (inactive)
Rho A-GTP (active)
Protein kinase C
Increased inositol triphosphate
Rho-associated kinase/ROCK
Ca2+ calmodulin
Myosin light chain kinase
Myosin light chain phosphatase
Endoplasmic reticulum
Endothelial cell
Myosin light chain phosphorylation
Myosin light chain
Ca2+
Increased Ca2+
Cycling of myosin cross-bridges along actin
Activation
Inhibition
Smooth-muscle contraction

FIG. 68.9 Molecular mechanism of penile smooth muscle contraction. Norepinephrine from sympathetic nerve endings and endothelins, angiotensin II, and prostaglandin $F_{2\alpha}$ from the endothelium activate

receptors on smooth muscle cells to initiate the cascade of reactions that eventually result in elevation of intracellular calcium concentrations, activation of Rho-kinase, and smooth muscle contraction. Protein kinase C is a regulatory component of the Ca^{2+}-independent, sustained phase of agonist-induced contractile responses. *GDP,* Guanosine diphosphate; *GEF,* guanine nucleotide exchange factor; *GTP,* guanosine triphosphate.

Smooth muscle relaxation requires cessation of MLC kinase activity, which is induced by a decrease of free Ca^{2+} in the sarcoplasm. With decreased intracellular Ca^{2+}, calmodulin dissociates from MLC kinase, inactivating it (Fig. 68.10; Walsh, 1991). MLC_{20} is dephosphorylated (inactivated) by myosin light chain phosphatase (MLCP). MLCP is a holoenzyme consisting of a type 1 phosphatase (PP1c), a myosin-targeting subunit (MYPT1), and a 20-kD subunit of unknown function (Hersch et al., 2004; Ito et al., 2004).

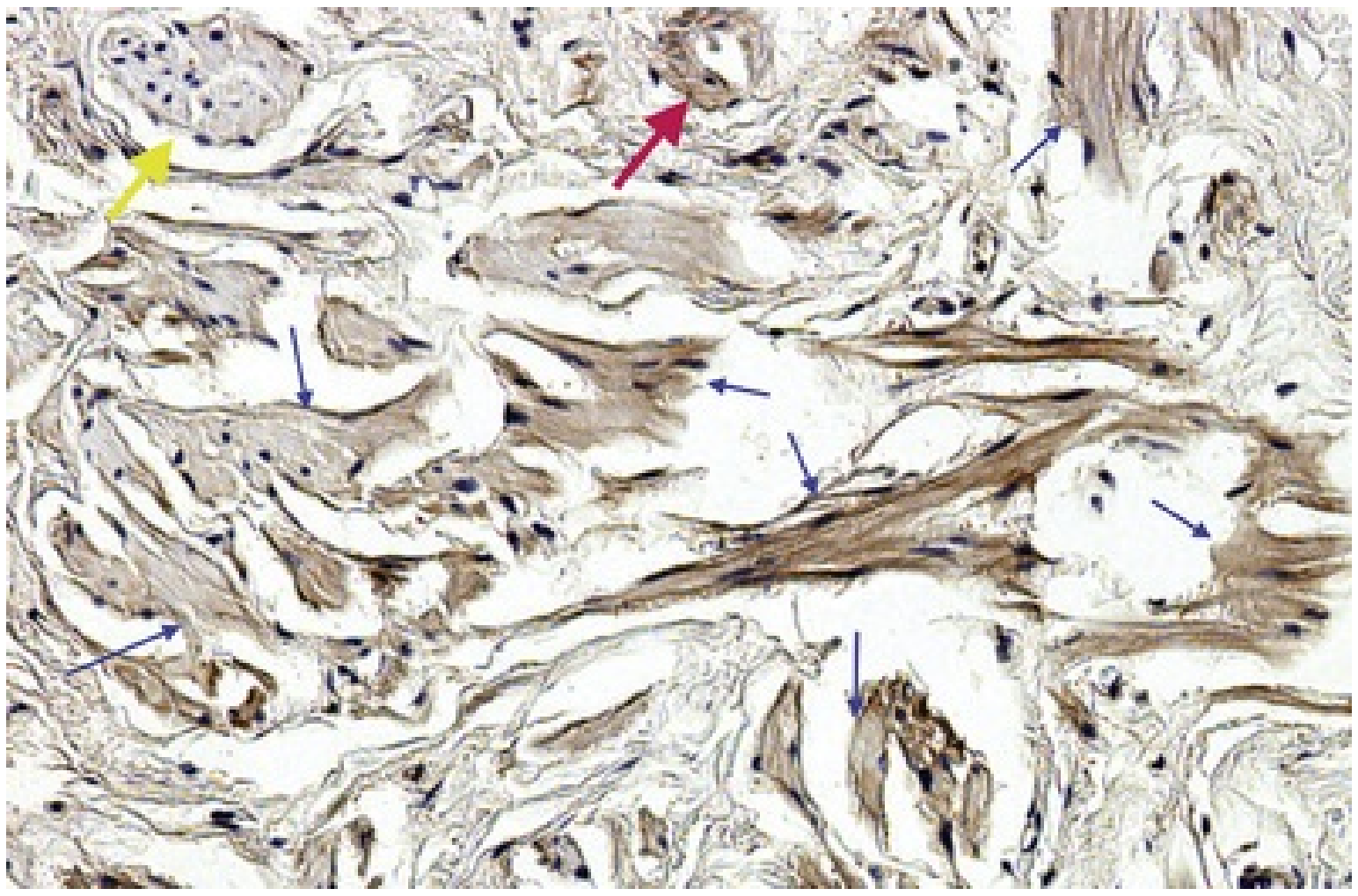

FIG. 68.10 Immunohistochemistry of human penile tissue, showing positive phosphodiesterase type 5 staining of cavernous smooth muscle fibers *(small blue arrows)*, nerve *(yellow arrow)*, and blood vessel wall *(red arrow)* (×100).

Rho Kinase Signaling Pathway.

MLCP inhibition leads to enhanced smooth muscle contraction by preventing inactivation of MLC_{20}. The activity of MLCP can be modulated by Rho/Rho-kinase, an important constituent of the *calcium sensitization pathway* that is expressed in penile smooth muscle (Fig. 68.11; Sopko et al., 2014). Agonist activation causes dissociation of RhoA from Rho-guanine dissociation inhibitor;

this process leads to activation of Rho-kinase. Rho-kinase phosphorylates the regulatory subunit of MLCP, inhibiting phosphatase activity and enhancing smooth muscle contraction (Hirano, 2007). Tonic contraction of the corporal smooth muscle is thought to be governed primarily by the calcium-sensitizing pathway (Cellek et al., 2002). Tonic contraction of the corporal smooth muscle is also reliant on dephosphorylated myosin remaining bound to actin in the high-affinity state. Calponin may also play a role by simultaneously binding actin and myosin to stabilize cross-bridge interactions and slow the rate of detachment (Szymanski, 2004). These efficiencies have been termed the ***latch*** state and are critical for sustaining the basal tone of smooth muscle. Evidence from a rat model of cavernous nerve injury also suggests that Rho-kinase activation may contribute to activation of enzymes that drive the transformation of fibroblasts to myofibroblasts, which may contribute to fibrotic changes in tissues (Song et al., 2015).

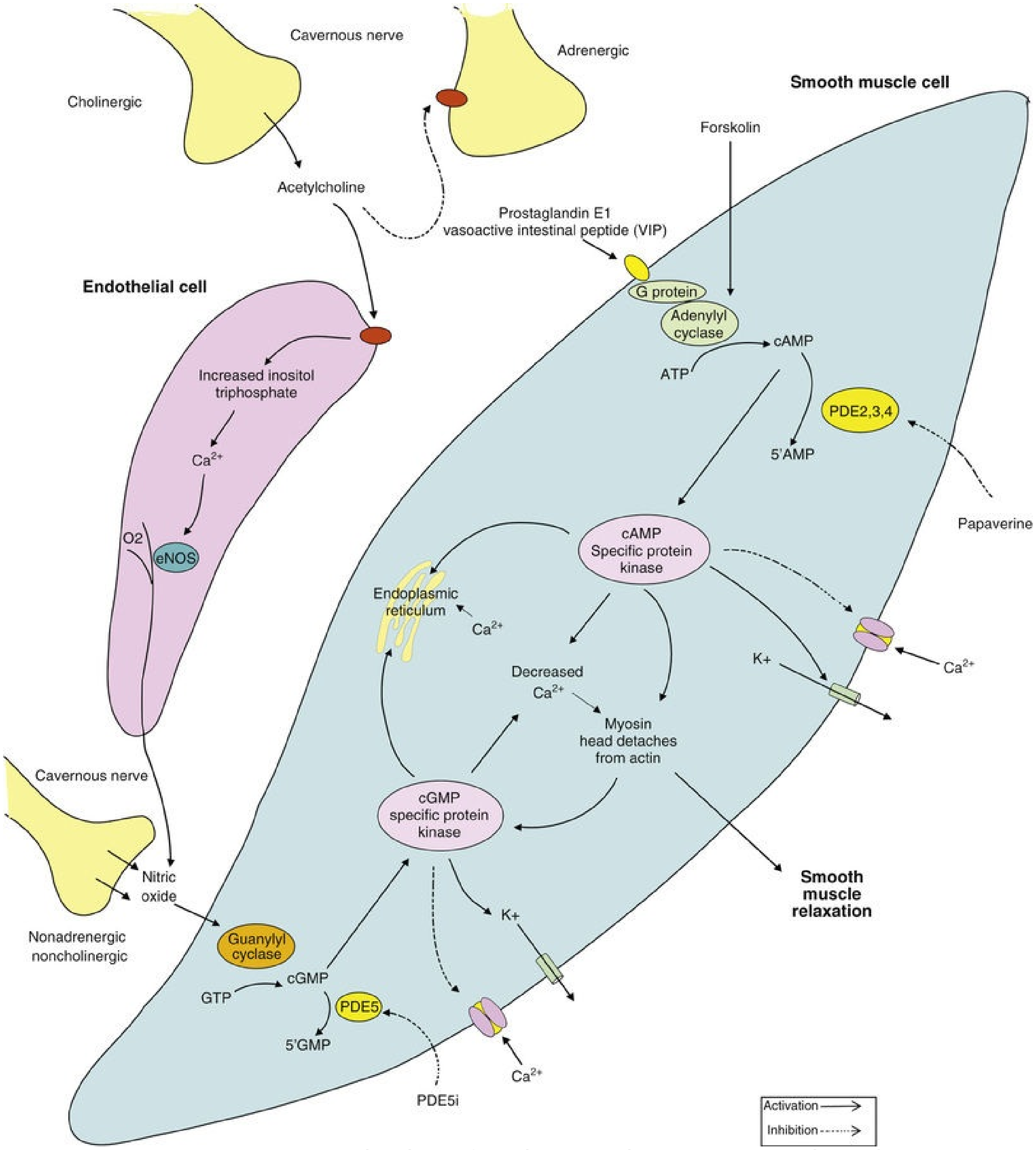
Cavernous nerve
Cholinergic
Adrenergic
Smooth muscle cell
Forskolin
Acetylcholine
Prostaglandin E1
vasoactive intestinal peptide (VIP)
Endothelial cell
G protein
Adenylyl cyclase
cAMP
ATP
Increased inositol triphosphate
PDE2,3,4
5'AMP
Ca2+
Papaverine
O2
eNOS
cAMP Specific protein kinase
Endoplasmic reticulum
Ca2+
Decreased Ca2+
K+
Ca2+
Myosin head detaches from actin
Cavernous nerve
cGMP specific protein kinase
Smooth muscle relaxation
Nitric oxide
K+
Nonadrenergic noncholinergic
Guanylyl cyclase
cGMP
GTP
PDE5
5'GMP
Ca2+
PDE5i
Activation
Inhibition

FIG. 68.11 Molecular mechanism of penile smooth muscle relaxation. The intracellular second messengers mediating smooth muscle relaxation, cyclic adenosine monophosphate (cAMP) and cyclic guanosine monophosphate (cGMP), activate their specific protein kinases, which phosphorylate certain proteins to cause opening of potassium channels, closing of calcium channels, and sequestration of intracellular calcium by the endoplasmic reticulum. The resultant decrease in intracellular calcium leads to smooth muscle relaxation. Sildenafil inhibits the action of phosphodiesterase (PDE) type 5 and increases the intracellular concentration of cGMP. Papaverine is a nonspecific phosphodiesterase inhibitor. *ATP,* Adenosine triphosphate; *eNOS,* endothelial nitric oxide synthase; *GTP,* guanosine triphosphate.

Molecular Pathways That Directly Modulate Intracellular Free Calcium

Vasoconstrictor agonists such as norepinephrine (α_1-adrenergic receptors), endothelin-1 (endothelin-A receptors), angiotensin II (AT1 receptors), prostaglandin $F_{2\alpha}$ (FP receptors), and TXA_2 (TP receptors) bind their respective receptors to activate Gq, which stimulates phospholipase C beta. This membrane-bound enzyme hydrolyzes phosphatidylinositol 4,5-bisphosphate to liberate IP_3 and 1,2-diacylglycerol. IP_3 binds to specific receptors (IP_3 receptor) on the smooth endoplasmic reticulum to stimulate the release of Ca^{2+} from intracellular stores. Binding of IP_3 to these receptors not only activates Ca^{2+} release but also increases the sensitivity of the IP_3 receptor to Ca^{2+} and assists **calcium-induced calcium release**. Increased intracellular Ca^{2+} may also be accomplished by entry of extracellular Ca^{2+} through **receptor-operated channels** without a change in membrane potential (Large, 2002). Norepinephrine, endothelin, vasopressin, and angiotensin II activate Ca^{2+}-permeable, nonselective cation channels, which increase intracellular calcium levels.

Molecular Pathways That Indirectly Modulate Intracellular Free Calcium

Cyclic adenosine monophosphate (cAMP) and cGMP are second messenger molecules involved in smooth muscle relaxation. cAMP-dependent and cGMP-dependent protein kinases phosphorylate proteins and ion channels, the net result of which include (1) opening of potassium channels and membrane hyperpolarization; (2) sequestration of intracellular calcium by the endoplasmic reticulum; and (3) inhibition of voltage-dependent calcium channels, blocking calcium influx. **The net result is a decrease in cytosolic-free calcium and subsequent smooth muscle relaxation** (Lin et al., 2005).

Modulation of Antitumescence Pathways By Protumescence Pathways

The NO–cGMP–PKG-I pathway suppresses antitumescence pathways by modulating several components of the noradrenergic contractile system; the net impact of these processes is impairment of inositol 1,4,5-triphosphate (IP3) production by phospholipase C (Hirata et al., 1990), IP3 receptor activity (Schlossmann et al., 2000), the RhoA/Rho-kinase pathway (Sauzeau et al., 2000), and the vasoconstrictive activity of endothelin (Mills et al., 2001). Acetylcholine and prostaglandin E1 (PGE_1) can also inhibit norepinephrine release, the former by binding to presynaptic receptors on adrenergic neurons (Molderings et al., 1992; Saenz de Tejada et al., 1989).

Cyclic Guanosine Monophosphate–Signaling Pathway

Nitric Oxide.

NO is the best characterized activator of the cGMP pathway. Because of its small size, NO can diffuse inside its target cell, where it interacts with molecules that contain iron in either a heme or an iron-sulfur complex. The most physiologically relevant receptor for NO is soluble guanylate cyclase (sGC), which contains a heme moiety that appears essential for NO-induced vasorelaxation in corporal tissues (Decaluwe et al., 2017). The NO-sGC-cGMP pathway is responsible for the vasorelaxation effect of many endothelium-dependent vasodilators, including histamine, estrogens, insulin, corticotropin-releasing hormone, nitrovasodilators, and acetylcholine (Burnett and Musicki, 2005). **Because of these numerous effects NO is believed to be the molecule principally responsible for initiating physiologic penile erection.**

Synthesis of NO is catalyzed by NOS, which converts L-arginine and oxygen to L-citrulline and NO. NOS exists as three isoforms in mammals: nNOS and eNOS are preferentially expressed in neurons/nerves and endothelial cells, respectively. iNOS is expressed in almost all cell types. All three NOS isoforms have been identified in the corpus cavernosum, with nNOS and eNOS being considered responsible for initiating and sustaining erection, respectively (Hurt et al., 2002; Musicki et al., 2009). A variant of nNOS (penile nNOS) has been identified as two distinct isoforms in the penis of rats and mice (Magee et al., 1996).

nNOS and eNOS have critical roles in penile erection. The activity and bioavailability of eNOS are regulated by multiple mechanisms, including eNOS phosphorylation, eNOS interaction with regulatory proteins and contractile pathways, and actions of reactive oxygen species**.** Downregulation of NOS is associated with ED and is identified in the corpus cavernosum of animal models of aging, hypogonadism, and diabetes (Carrier et al., 1997; Penson et al., 1996;

Rehman et al., 1997). In human studies single nucleotide polymorphisms of the nNOS (Lacchini et al., 2014) and eNOS genes (Liu et al., 2015) and specific microRNA expression patterns (GamalEl Din et al., 2017) have been associated with greater risk of impaired erectile function and/or differential response to erectogenic medications. An association between microRNA expression and impairment of erectile function in hyperlipidemic (Barbery et al., 2015) and aged rats (Pan et al., 2015, 2016) has also been reported. Interestingly, mice with congenital knockout of nNOS or eNOS often have normal erectile function (Burnett et al., 1996). Compensatory mechanisms, alternative splicing of the disrupted gene (Ferrini et al., 2003), and/or other unknown mechanisms may be involved in the preservation of erectile function in NOS-knockout mice. The NO/cGMP pathway is also known to modulate other relevant pathways in penile erection, including the RhoA/Rho-kinase pathway (Bivalacqua et al., 2007; Chitaley et al., 2001; Priviero et al., 2010).

Carbon Monoxide.

CO is a gaseous second messenger that occurs in biologic systems during the oxidative catabolism of heme by the heme oxygenase (HO) enzyme (Wu and Wang, 2005). HO exists in constitutive (HO-2, HO-3) and inducible (HO-1) isoforms and is found in endothelial corporal tissue (Hedlund et al., 2000). CO regulates vascular processes, such as vessel tone, smooth muscle proliferation, and platelet aggregation, and may function as a neurotransmitter (Yetik-Anacak et al., 2015). It is thought to play a potentially important role in penile erection (Abdel Aziz et al., 2009). The neurotransmitter effect of CO may work in part by activation of guanylate cyclase by direct binding to the heme moiety of the enzyme, stimulating the production of cGMP. However, there is also evidence that CO-induced relaxation of corporal tissues may act by non-guanylate cyclase dependent mechanisms (Decaluwe et al., 2012).

Hydrogen Sulfide.

H_2S is a gaseous second messenger produced in vascular tissues by breakdown of L-cysteine by the enzyme cystathionine γ-lyase (Zhao and Wang, 2002). Exogenous H_2S or L-cysteine causes relaxation of strips of corpus cavernosum, an effect that is modulated at least in part by membrane potassium channels and appears to work by NOS-dependent and independent pathways (Abd Elmoneim et al., 2017; Meng et al., 2013; Yetik-Anacak et al., 2015). There are species-level differences in precise pathways involved with H_2S-mediated effects (Abd Elmoneim et al., 2017; Meng et al., 2013; Yetik-Anacak et al., 2015). Intracavernosal administration of either H_2S, sodium hydrosulfide (NaHS), or L-cysteine elicits penile erection in rats (d'Emmanuele di Villa Bianca et al., 2011). These observations indicate that a functional L-cysteine/H_2S pathway may be involved in mediating penile erection in men and some mammals, although there appear to be specifies-level differences in effect.

Natriuretic Peptides.

The natriuretic peptide family is involved in the regulation of cardiovascular homeostasis and consists of atrial (ANP), brain (BNP), and C-type (CNP) natriuretic peptides (Matsuo, 2001). ANP and BNP are ligands for the natriuretic peptide receptor NPR-A, whereas CNP is a ligand for the natriuretic peptide receptor NPR-B. Both receptors are members of the guanylyl cyclase family and are called GC-A and GC-B.

CNP increases cGMP and cAMP production in isolated human corporal cells (Rahardjo et al., 2016). CNP appears to be the most potent natriuretic peptide. Whether CNP and NPR-B play a role in physiologic erection has not been determined (Kim et al., 1998; Kuthe et al., 2003; Matsuo, 2001; Sousa et al., 2010).

Guanylyl Cyclase Pathway.

In mammals, seven membrane-bound (particulate) guanylyl cyclase isoforms (GC-A to GC-G) and one soluble isoform (sGC) have been identified (Andreopoulos and Papapetropoulos, 2000). Although the membrane-bound guanylyl cyclase system is not known to play a role in physiologic erection, expression of GC-B in human and rat corpus cavernosum and induction of cavernous smooth muscle relaxation by CNP (ligand for GC-B) have been demonstrated (Guidone et al., 2002; Kuthe et al., 2003).

The soluble isoform sGC plays a pivotal role in erectile function because it provides the link between NO and cGMP, the principle extracellular and intracellular signaling molecules, respectively, in physiologic erection (Andersson, 2011). A heterodimeric protein, sGC, consists of α and β subunits, each of which exists in two isoforms (α_1, α_2, and β_1, β_2) that are encoded by two separate genes (Andreopoulos and Papapetropoulos, 2000).

Protein Kinase G.

PKG, also called cGMP-dependent kinase, is the principal receptor and mediator for cGMP signaling. In mammals, PKG exists in two major forms, PKG-I and PKG-II, which are encoded by two separate genes. In smooth muscle, only PKG-I is expressed and exists as two splice variants (PKG-Iα and PKG-Iβ). **cGMP and/or PKG-I induce smooth muscle relaxation via activation of the plasma membrane Ca^{2+}-ATPase pump, inhibition of IP_3 generation, inhibition of Rho-kinase, stimulation of MLCP, and phosphorylation of heat shock proteins** (Francis et al., 2010). Cavernous smooth muscle strips from PKG-I knockout mice cannot be relaxed by agents that raise cGMP levels, and these mice have a low ability to reproduce, presumably because of ED (Hedlund et al., 2000).

Adenylyl Cyclase Pathway.

Signaling molecules in the cAMP pathway bind to and activate specific cytoplasmic membrane receptors that, through their coupled G proteins, activate adenylyl cyclases (Dessauer et al., 2017). Although individual membrane-bound adenylyl cyclases are regulated differently, they all are stimulated by the GTP-bound form of the G_a subunit, and all (except AC9) are stimulated by forskolin in the normal state (Sullivan et al., 1998).

Protein Kinase A.

Protein kinase A (PKA), also called cAMP-dependent kinase, is the principal receptor for cAMP, and it mediates most of the cellular effects of cAMP by phosphorylating a wide variety of downstream targets in the cytoplasmic and nuclear compartments (Johnson et al., 2001). In the penis and pelvic ganglion one of these targets is nNOS, which is phosphorylated at serine 1412 by activated PKA (Hurt et al., 2012). PKA is composed of two regulatory (R) and two catalytic (C) subunits that form a tetrameric holoenzyme R_2C_2. Binding of cAMP to the R subunits causes the holoenzyme to dissociate into an $R_2(cAMP)_4$ dimer and two free catalytically active C subunits. The presence of multiple C subunit genes further adds to the diversity and complexity of the various holoenzyme complexes, which differ in biochemical and functional properties as well as patterns of expression and localization. These differences among the isozymes contribute to the broad specificity of PKA in a wide variety of physiologic processes in response to cAMP signaling.

More than 100 different cellular proteins have been identified as physiologic substrates of PKA, with more than 90% (135 of 145) being phosphorylated at serine and the remainder at threonine (Shabb, 2001). The predominant target sequence (>50%) is Arg-Arg-X-Ser, in which Ser is the phosphate acceptor. Three PKA substrate proteins have been identified in penile tissue: phosphodiesterases, cAMP-responsive element-binding protein, and ATP-sensitive potassium (K_{ATP}) channel.

Phosphodiesterase.

In each episode of cyclic nucleotide signaling, the increase of intracellular cAMP or cGMP concentration is typically twofold to threefold baseline. Decline occurs rapidly and often during the continued presence of the signaling hormone (Francis et al., 2001). Degradation of cyclic nucleotide signals occurs principally by action of phosphodiesterases (PDE), which catalyze the hydrolysis of cAMP and cGMP to AMP and GMP, respectively. Feedback mechanisms that increase PDE activity and/or expression by the increased cyclic nucleotide level assist cyclic nucleotide degradation (Corbin et al., 2000; Lin et al., 2001a, 2001b).

The superfamily of mammalian PDEs consists of 11 families (PDE1 to PDE11) that are encoded from 21 distinct genes (Lin et al., 2003; Montorsi et al., 2004). Each PDE gene usually encodes more than one isoform; the specific isoform may be determined via alternative splicing or from alternative gene promoters. PDE1, PDE3, PDE4, PDE7, and PDE8 are multigene families, whereas PDE2, PDE5, PDE9, PDE10, and PDE11 are single-gene families. PDE1, PDE2, PDE3, PDE10, and PDE11 hydrolyze cAMP and cGMP; PDE4, PDE7, and PDE8 hydrolyze only cAMP; and PDE5, PDE6, and PDE9 hydrolyze only cGMP.

With the exception of PDE6, which is specifically expressed in photoreceptor cells, all PDEs have been identified in the corpus cavernosum (Kuthe et al., 2001). **PDE5 is the principal PDE for the termination of cavernous cGMP signaling** (Jeremy et al., 1997; Kuthe et al., 2001). Increased expression of PDE5 is noted in serum-starved cultured corporal cells (Carosa et al., 2014) and in mice fed a high-fat diet (Ellati et al., 2013); enhancement of PDE5 activity diminishes erectile response. Inhibition of the cGMP-catalytic activity by PDE5 inhibitors is highly effective in treating ED (Goldstein et al., 1998). Inhibition of PDE5 may also increase cellular levels of cAMP (Stief et al., 2000). This activity is thought to be due to competitive inhibition of PDE3 by cGMP binding, which reduces the ability of PDE3 to break down cAMP (Francis et al., 2001). **Direct**

inhibition of PDE3 also promotes penile erection (Kuthe et al., 2002).

Caveolae.

Caveolae are invaginated microdomains of plasma membrane that are rich in eNOS and caveolins as well as cholesterol, sphingolipids, and glycosylphosphatidylinositol-linked proteins. Caveolae contain numerous other signaling proteins, such as receptors with seven-transmembrane domains, G proteins, adenylyl cyclase, phospholipase C, protein kinase C, calcium pumps, and calcium channels. Decreased caveolin-1 expression has been reported in the cavernous smooth muscle of aged rats (Bakircioglu et al., 2001). In rodent studies, penile erection appears to require association of sGC in corpus cavernosum with endothelial caveolin-1 (Linder et al., 2006; Shakirova et al., 2009). Decreased caveolin-1 expression has been noted in the corpora of rats after bilateral cavernous nerve injury and in experimentally induced diabetes in mice (Parikh et al., 2017), suggesting that loss of caveolin may contribute to common causes for ED. However, in a rat model of diabetes induced by fructose and streptozotocin, decreased erectile responses were associated with an increase in caveolin-1 expression and decreased eNOS activity (Elcioglu et al., 2010). Caveolae and caveolin are clearly involved in the regulation of erectile function, although the relationship appears complex and may vary based on species and ED cause.

Ion Channels.

Hyperpolarization of smooth muscle cells is associated with smooth muscle relaxation, a process mediated in part by membrane ion channels. In general, there are four major types of ion channels: (1) external ligand-gated, which open to a specific extracellular molecule (e.g., acetylcholine); (2) internal ligand-gated, which open or close in response to an intracellular molecule (e.g., ATP); (3) voltage-gated, which open in response to a change in membrane potential (e.g., sodium, potassium, and calcium channels); and (4) mechanically gated, which open in response to mechanical pressure (Christ et al., 1993).

Calcium channels play a key role in regulation of corporal smooth muscle. Smooth muscle has neither a T-tubule system nor a well-developed sarcoplasmic reticulum. Extracellular calcium is the primary source of calcium in smooth muscle cells and must cross the plasma membrane via ion channels during an action potential. Three transmembrane proteins are known to specifically regulated calcium inflow and outflow: calcium channels are the major inflow regulators, whereas the calcium-sodium exchanger and calcium-ATPase regulate calcium exit from muscle cells (Christ et al., 1993; Large, 2002).

Calcium permeable channels are known to play an important role in corporal smooth muscle physiology. Although ion channel activity is critical to calcium metabolism in smooth muscle cells, mobilization of intracellular calcium stores also plays a role in induced smooth muscle contraction (Christ et al., 1993).

There are at least four types of potassium channel subtypes in the cavernous smooth muscle: (1) Ca^{2+}-activated K^+ channels (e.g., K_{Ca}); (2) ATP-sensitive K^+ channels (K_{ATP}); (3) delayed rectifier; and (4) fast transient A current (Christ, 2000; Christ et al., 1993). Activation (opening) of K+ channels leads to movement of positively charged K^+ out of the cell, causing hyperpolarization and relaxation of smooth muscle (Andersson, 2011). Hyperpolarization may facilitate smooth muscle relaxation even in the setting of blockade of NO and prostaglandin synthesis (Angulo et al., 2003).

Activation of K_{Ca} channels enhances relaxant response to PDE5I in human diabetic corporal tissue through endothelial mechanisms (Gonzalez-Corrochano et al., 2013). K^+ channels appear to be activated by endogenous PKA, PKG, or cGMP. Pharmacologic activation of K_{ATP} channels and large-conductance K_{Ca} channels (i.e., Maxi-K) has been shown to relax corporal smooth muscle in humans (Spektor et al., 2002; Vick et al., 2002). Acetylcholine induces endothelium dependent and independent relaxation of penile arteries, an action that is blocked by inhibition of large conductance K channels. Direct activation of small, medium, and large conductance K channels also produces penile arterial vasodilation (Comerma-Steffensen et al., 2017; Kiraly et al., 2013; Sung et al., 2017); these effects appear to be mediated in part by NO activity but may also have an endothelium independent mechanism of action (Sung et al., 2015).

Calcium-activated chloride channels on the smooth muscle cells of corpus cavernosum are thought to be involved in the maintenance of spontaneous tone and the contractile response to adrenaline and other agonists (Hannigan et al., 2017). The activity of these channels is enhanced in cavernosal tissue from a rabbit model of diabetes-related ED (Lau and Adaikan, 2014).

Additional Cyclic Adenosine Monophosphate–Signaling Pathways

Adenosine.

Adenosine is released from various cells as a result of increased metabolic rates and its actions on the vasculature are most prominent when oxygen demand is high (Tabrizchi and Bedi, 2001). The vascular response to adenosine can be either relaxation or constriction, depending on which type of adenosine receptor is activated. Activation of A1 adenosine receptors (coupled to G_i and G_o proteins) and A3 adenosine receptors (coupled to G_i and G_q proteins) results in inhibition of adenylyl cyclase and activation of phospholipase C, both of which lead to vasoconstriction. A2 adenosine receptors are coupled to G_s proteins, and their activation stimulates adenylyl cyclase and subsequent vasorelaxation. The differential distribution of these adenosine receptor subtypes largely determines whether a particular vessel relaxes or contracts as a result of adenosine stimulation (Tabrizchi and Bedi, 2001). Whether adenosine plays a role in physiologic erection is unclear. However, excessive adenosine accumulation in the penis, coupled with increased $A2_B$ receptor signaling, contributes to spontaneously prolonged penile erection in adenosine deaminase–deficient mice and sickle cell disease transgenic mice, a well-accepted animal model for priapism (Bivalacqua et al., 2009; Dai et al., 2009) Adenosine receptor deficient mice have reduced erectile response to cavernous nerve stimulation, possibly related to an attenuated reduction in phosphorylated (i.e., activated) myosin light chain during electrostimulation. These animals also manifested higher serum levels of norepinephrine (Ning et al., 2012).

Calcitonin Gene–Related Peptide Family.

Calcitonin gene-related peptide (CGRP), amylin, and adrenomedullin are members of the CGRP family. These short-chain peptides are potent vasodilators released from perivascular nerve fibers. They act through the calcitonin receptor–like receptor, which belongs to the G protein-coupled receptor (GPCR) superfamily (Conner et al., 2002).

In rats, CGRP levels in the penis, bladder, kidney, testis, and adrenal gland increase gradually up to maturity and then rapidly decline (Wimalawansa, 1992). Administration of CGRP has been associated with enhanced erectile responses in rats with increased age (Bivalacqua et al., 2001) or diabetes (El-Kamshoushi et al., 2013); the mechanism of erection is thought to involve an increase in corporal cAMP.

Prostaglandins.

Prostaglandins are a family of eicosanoids capable of initiating numerous biologic functions. The prime mode of prostaglandin action is through specific prostaglandin receptors that all belong to the GPCR family. There are at least nine known prostaglandin receptor subtypes in mice and humans and several additional splice variants with divergent carboxyl termini (Narumiya and Fitzgerald, 2001). There is variability with respect to ligand specificity and activity between different prostaglandin receptors. “Relaxant” receptors IP, DP1, EP2, and EP4 are coupled to an α_s-containing G protein and are capable of stimulating adenylyl cyclase to increase intracellular cAMP. “Contractile” receptors EP1, FP, and TP are coupled to an α_q-containing G protein, which activates phospholipase C instead of adenylyl cyclase. These contractile receptors do not signal through the cAMP pathway, and their signaling outcome is an increase of intracellular calcium. The EP3 receptor is also a contractile receptor, but it is coupled to an α_i-containing G protein that inhibits adenylyl cyclase to result in a decrease of cAMP formation.

Animal and human corpora cavernosa produce several prostaglandins, including $PGF_{2\alpha}$, PGE_2, PGD_2, PGI_2, and TXA_2 (Moreland et al., 2001). In studies in isolated human penile tissue, different PGs elicit different effects in human corpus cavernosum, corpus spongiosum, and cavernous artery (Hedlund and Andersson, 1985). $PGF_{2\alpha}$, PGI_2, and TXA_2 contract corporal tissue. Conversely, PGE_1 and PGE_2 (but not PGI_2) relax corporal tissue pre-contracted with noradrenaline or $PGF_{2\alpha}$. Although PGI_2 is the predominant vasorelaxant in blood vessels, its action in the erectile tissue is either contractile or neutral. Differences in the action of PGI_2 between blood vessels and the corporal tissue and the variable response to specific prostaglandins in corporal tissue are most likely due to differences in the distribution of prostaglandin receptors (Angulo et al., 2002).

Although the production of prostaglandins and the expression of prostaglandin receptors in the erectile tissue have been clearly demonstrated, their roles in physiologic erection are still undefined. However, **the erectogenic effect of PGE_1 as a pharmaceutical agent for ED has been extensively documented** (Stackl et al., 1988).

Vasoactive Intestinal Peptide.

The penis is richly supplied with nerves containing vasoactive intestinal peptide (VIP) and VIP-related peptides such as pituitary adenylate cyclase–activating polypeptide. Most of these nerves also contain immunoreactivity to NOS (Andersson, 2001). Two subtypes of VIP receptors, VPAC1 and VPAC2, belonging to the GPCR family have been cloned from human and rat tissues. VPAC2, but not VPAC1, messenger RNA has been identified in cultured rat cavernous smooth muscle cells (Guidone et al., 2002). In dogs, intracavernous VIP injection induces penile erection (Juenemann et al., 1987). However, in human men the erectile response to VIP as a monotherapy is not robust (Kiely et al., 1989), and VIP release is not essential for neurogenic relaxation of human cavernous smooth muscle (Pickard et al., 1993). The physiologic role of VIP in human penile erection appears minimal (Rahardjo et al., 2016).

Molecular Oxygen as a Modulator of Penile Erection.

The P_{O_2} level of cavernous blood in the flaccid state is similar to that of venous blood (≈35 mm Hg). During erection, influx of arterial blood increases P_{O_2} to approximately 90 mm Hg (Sattar et al., 1995). Molecular oxygen is a substrate, together with L-arginine, for the synthesis of NO by NOS. In the flaccid state, the low oxygen concentration inhibits NO synthesis; during erection, the higher level of substrate induces NO synthesis. It is estimated that the minimum concentration of oxygen in the cavernous bodies necessary to reach full NOS activity is 50 to 60 mm Hg (Kim et al., 1993).

Similarly, prostaglandin H synthase is also an oxygenase (cyclooxygenase) and uses oxygen as substrate for the synthesis of prostanoids (Lands, 1979; Minhas et al., 2001); low oxygen tension tends to suppress and high oxygen tension tends to facilitate prostaglandin production. Endothelin synthesis is promoted in the setting of low oxygen tension and inhibited when oxygen tension is high (e.g., during erection) (Mills et al., 2001).

Intercellular Communication.

Synchronized relaxation and contraction of the corporal smooth muscle requires intercellular communication (Christ et al., 1991). **Gap junctions in the membranes of adjacent smooth muscle cells permit intercellular exchange of ions such as calcium and second-messenger molecules** (Christ et al., 1993). The major component of gap junctions is connexin-43, a membrane-sparing protein of less than 0.25 µm present between smooth muscle cells of human corpus cavernosum (Campos de Carvalho et al., 1993). Cell-to-cell communication through these gap junctions is the most likely explanation for the synchronized responses of corporal smooth muscle to relaxant and contractile stimuli.

Intracavernous Tissue Architecture and Erectile Response

The trabeculae of the corpora cavernosa provide the structural support and regulatory mechanism for the endothelial-lined sinusoidal spaces as well as the conduit for blood vessels and nerves. Relaxation of the trabeculae allows the expansion and filling of the sinusoids by the incoming blood, whereas recoil of the trabeculae expels blood to the emissary veins and returns the penis to a flaccid state. Decreased smooth muscle and elastin content has been associated with impairment of erectile response (Costa et al., 2006).

The complex architecture of the penis is maintained by the dynamic expression and interaction of numerous trophic factors. Sonic hedgehog (SHH) plays a key role in regulating vertebrate organogenesis, cell division, and development of some cancers. **SHH has been identified in the penis; inhibition of SHH in adult rats leads to rapid atrophy and disorganization of the corpus cavernosum** (Podlasek et al., 2003, 2005). In addition, SHH stimulates the expression of vascular endothelial growth factor (VEGF), NOS, and brain-derived neurotrophic factor (BDNF) in the penis (Bond, et al., 2013; Podlasek et al., 2005). Administration of SHH has been linked to improved erectile responses and tissue histology parameters in a number of animal studies (Table 68.8; Choe et al., 2016, 2017).

TABLE 68.8

Key Molecules Involved in Physiologic Regulation of Cavernous Smooth Muscle

NAME	FUNCTION
CONTRACTION	
High cytosolic calcium	Binds calmodulin to activate MLC kinase
MLC kinase	Converts MLC to active form, MLCP
Phosphorylated MLC (MLCP)	Cycling of myosin cross-bridges along actin results in muscle contraction (vasoconstriction)
MLCP	Dephosphorylates MLCP to inactive form, MLC, reversing vasoconstriction
Rho-kinase (calcium sensitization pathway)	Inhibits MLC phosphatase to maintain muscle contraction and vasoconstriction
RELAXATION	

Nitric oxide	Binds soluble guanylyl cyclase to produce cGMP
cGMP	Activates protein kinase G
Protein kinase G	Opens potassium channels and closes calcium channels
Low cytosolic calcium	Calcium dissociates from calmodulin, muscle relaxation (vasodilation)

cGMP, Cyclic guanosine monophosphate; *MLC,* myosin light chain; *MLCP,* myosin light chain phosphatase.

Key Points: Smooth Muscle Physiology

- Relaxation of the cavernous smooth muscle is key to penile erection.
- NO released by nNOS contained in the terminals of the cavernous nerve initiates the erection process; NO released from eNOS in the endothelium helps maintain erection.
- NO stimulates the production of cGMP by action on guanylate cyclase.
- cGMP activates PKG, which opens potassium channels and closes calcium channels.
- Low cytosolic calcium favors smooth muscle relaxation.
- Smooth muscle contraction is restored when cGMP is degraded by PDE and intracellular calcium levels return to baseline levels.

Pathophysiology of Erectile Dysfunction

Just a Water Spout

My nookie days are over, My pilot light is out.

What used to be my sex appeal, Is now my water spout.

Time was when, on its own accord, From my trousers it would spring.

But now I've got a full time job, To find the gosh darn thing.

It used to be embarrassing, The way it would behave.

For every single morning, It would stand and watch me shave.

Now as old age approaches, It sure gives me the blues.

To see it hang its little head, And watch me tie my shoes!!

(Randolph, 1992)

ED is defined as "inability to attain and/or maintain an erection sufficient for satisfactory sexual intercourse" (Montorsi et al., 2010). The term "ED" replaces the antiquated and pejorative term "impotence."

Incidence and Epidemiology

The prevalence of ED increases with advancing age; this relationship was first reported by Kinsey et al. (1948), who reported that ED was present in 2% of men at age 40 but 25% of men by age 65. Contemporary studies using more rigorous definitions have confirmed this relationship between age and ED (Laumann et al., 2005, 2009; Lewis et al., 2004). However, medical and social conditions often comorbid with aging are significant confounding factors in this epidemiologic trend (Johannes et al., 2000; Laumann et al., 1999).

The National Health and Social Life Survey **(NHSLS)** was a national probability survey of men (N = 1410) and women between the ages of 18 and 59 years living in households in the United States in 1992 and was principally a broad-ranging inquiry into sexual practices and beliefs within that age group (Laumann et al., 1999). The survey collected only limited information on sexual function via single-item questions. **The prevalence of ED (based on a single-item question about attaining/maintain erection) was 7%, 9%, 11%, and 18% for men aged 18 to 29, 30 to 39, 40 to 49, and 50 to 59, respectively.**

The Massachusetts Male Aging Study (MMAS) was the first cross-sectional, community-based, random-sample, prospective epidemiologic survey on ED and its physiologic and psychosocial correlates in men in the United States. A population of 1709 noninstitutionalized men between the ages of 40 and 70 years living in the greater Boston area were surveyed between 1987 and 1989 and resurveyed between 1995 and 1997. Extensive physiologic measures, demographic information, and self-reported ED status (nine items related to erections on a questionnaire) were components of this report (Feldman et al., 1994). **From the incidence rates reported in the MMAS study, per 1000 man-years there were 12.4, 29.8, and 46.4 new cases of ED in men aged 40 to 49, 50 to 59, and 60 to 69, respectively** (Johannes et al., 2000). Similar prevalence rates for ED have been reported from other nations/regions (Moreira Jr., et al., 2003; Schouten et al., 2005). Although the prevalence of ED is higher with advanced age, the degree of subjective bother from ED also tends to decline with age (Gades et al., 2009). Conditions commonly comorbid with age are also strong predictors of incident ED; age-adjusted risk (per 1000 man-years) of ED was higher for men with diabetes mellitus (50.7 cases), treated heart disease (58.3 cases), and treated hypertension (HTN) (42.5 cases).

A large-scale international study of sexual dysfunction in men aged 40 to 80 years of age reported some regional variations in ED prevalence (range 6% to 33%, age standardized). (Laumann et al., 2005; Moreira et al., 2008; Nicolosi, et al., 2005, 2006a, 2006b). Whether these differences represent actual differences in ED prevalence or cultural variability in what constitutes clinically relevant impairment in erectile response is unclear. However, the common risk factors for

ED appear to be consistent across geographic regions.

Risk Factors

Conditions commonly associated with ED include poor health status/chronic disease states, vascular and metabolic diseases, conditions of the nervous system, hormonal issues, medication use, psychiatric/psychological disorders, substance abuse, and certain sociodemographic factors (Fig. 68.12)**.** The latter category may relate to comorbid medical conditions (more common in men of lower socioeconomic status), differential expectations of sexual response, or as yet undetermined factors (Kupelian et al., 2008). A unifying theme of most established biologic risk factors for ED is perturbation of vascular and endothelial dysfunction, either directly (as in the case of vascular and metabolic disease) or indirectly (e.g., by effects on neural innervation or hormonal milieu) (Lewis et al., 2004).

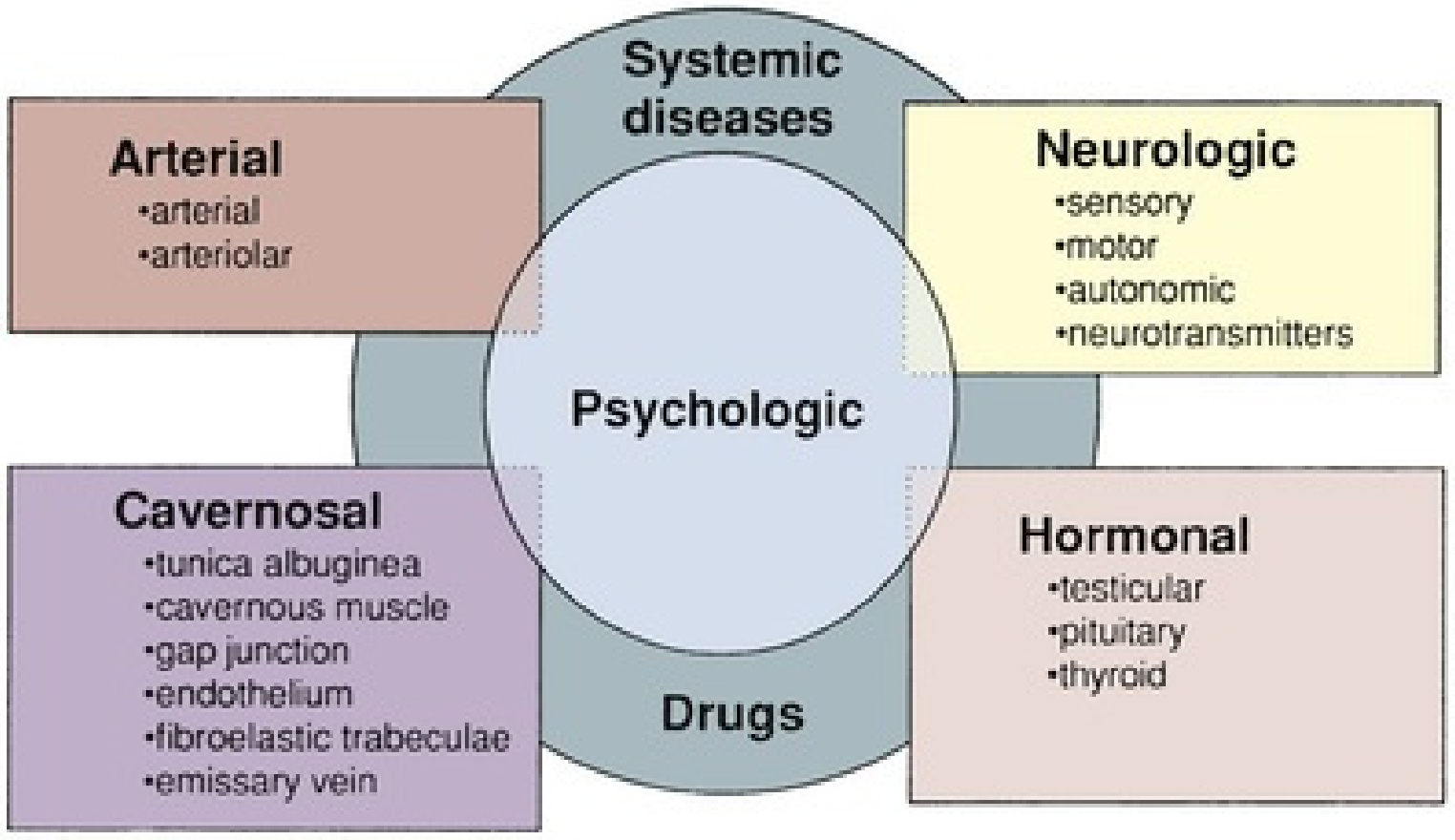
Systemic diseases
Arterial
•arterial
•arteriolar
Neurologic
•sensory
•motor
•autonomic
•neurotransmitters
Psychologic
Cavernosal
•tunica albuginea
•cavernous muscle
•gap junction
•endothelium
•fibroelastic trabeculae
•emissary vein
Hormonal
•testicular
•pituitary
•thyroid
Drugs

FIG. 68.12 Functional classification of erectile dysfunction. It is unlikely for erectile dysfunction in an individual patient to derive solely from one source. Most cases have a psychogenic component of varying degree, and systemic diseases and pharmacologic effects can be concomitant and causative. (Modified from Carrier S, Brock G, Kour NW, et al.: Pathophysiology of erectile dysfunction. *Urology* 42:468–481, 1993, with permission of Excerpta Medica, Inc.)

Many classification schemes have been proposed for ED cause (Fig. 68.13). Some are based on the cause (diabetic, iatrogenic, traumatic); others are based on the neurovascular mechanism (e.g., failure to initiate [neurogenic], failure to fill [arterial], and failure to store [venous]). One commonly used classification scheme is shown in Box 68.1 (Lizza and Rosen, 1999).

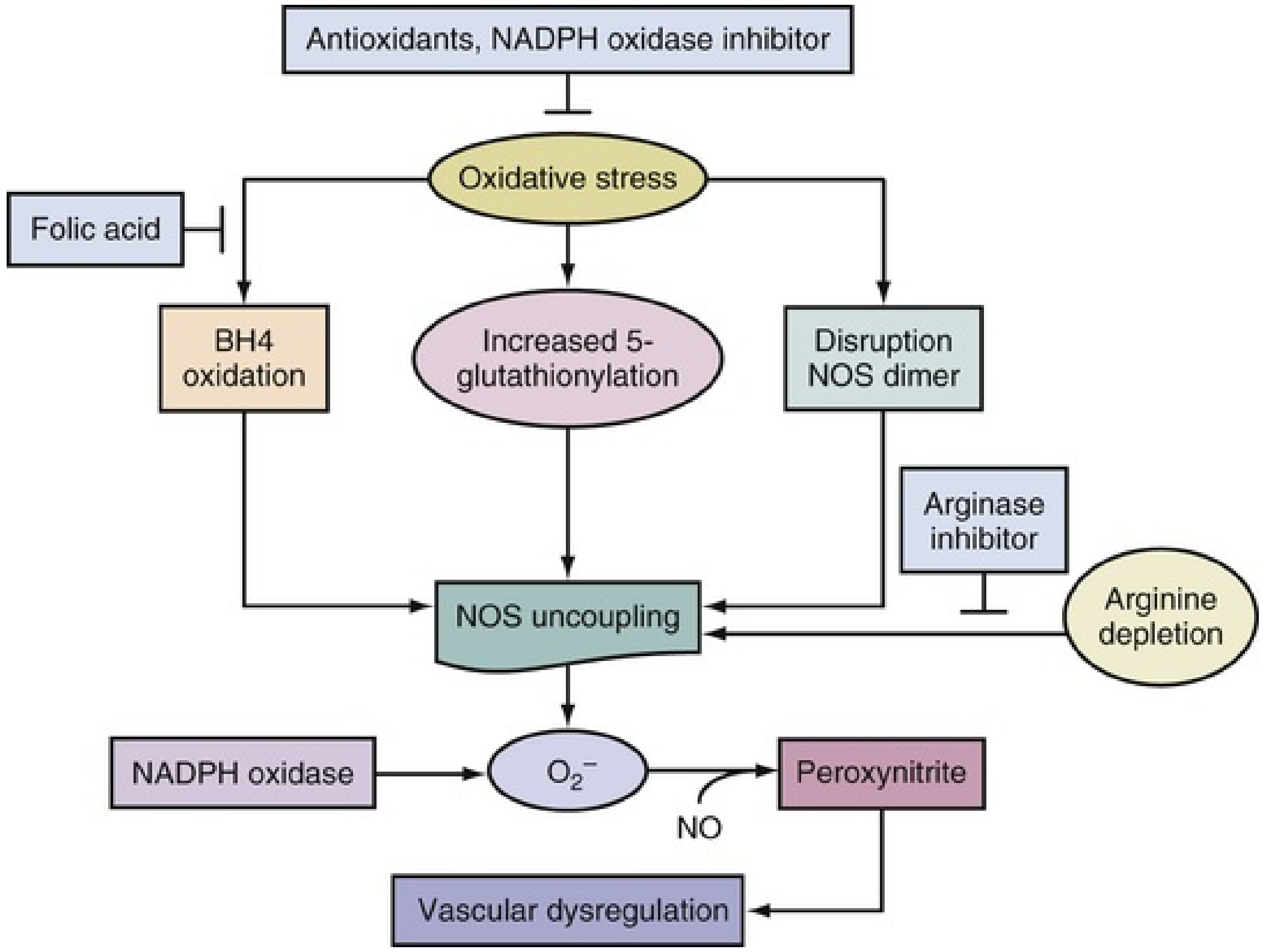
Antioxidants, NADPH oxidase inhibitor
Oxidative stress
Folic acid
BH4 oxidation
Increased 5-glutathionylation
Disruption NOS dimer
Arginase inhibitor
Arginine depletion
NOS uncoupling
NADPH oxidase
O_2^-
NO
Peroxynitrite
Vascular dysregulation

FIG. 68.13 Factors contributing to nitric oxide synthase (NOS) uncoupling and the potential inhibitors. *BH4,* Tetrahydrobiopterin; *NADPH,* reduced nicotinamide adenine dinucleotide phosphate.

Box 68.1

Classification of Male Erectile Dysfunction

Organic

- I. Vasculogenic
  - A. Arteriogenic
  - B. Cavernosal
  - C. Mixed
- II. Neurogenic
- III. Anatomic
- IV. Endocrinologic
- V. Medication induced

Psychogenic

- I. Generalized
  - A. Generalized unresponsiveness
    - 1. Primary lack of sexual arousability
    - 2. Aging-related decline in sexual arousability
  - B. Generalized inhibition
    - 1. Chronic disorder of sexual intimacy
- II. Situational
  - A. Partner related
    - 1. Lack of arousability in specific relationship
    - 2. Lack of arousability because of sexual object preference
    - 3. High central inhibition because of partner conflict or threat
  - B. Performance related
    - 1. Associated with other sexual dysfunction (e.g., rapid ejaculation)
    - 2. Situational performance anxiety (e.g., fear of failure)
  - C. Psychological distress or adjustment related
    - 1. Associated with negative mood state (e.g., depression) or major life stress (e.g., death of partner)

Psychogenic

Previously, psychogenic issues were believed to be the primary cause in up to 90% of men with ED (Masters and Johnson, 1965). Mental health issues (e.g., depression, psychosis) are risk factors for ED (Tan et al., 2012; Zemishlany and Weizman, 2008). The prevalence of ED in men with a range of mental health disorders may be as high as 83% (Mosaku and Ukpong, 2009). Although psychogenic factors are likely to play a role in virtually all cases of ED, most experts now agree that **ED is most often a predominantly functional or physical disorder.**

Sexual behavior and penile erection are controlled by the hypothalamus, limbic system, and cerebral cortex. Stimulatory or inhibitory messages can be relayed to the spinal erection centers to assist or inhibit erection. **Two possible mechanisms have been proposed to explain the inhibition of erection in psychogenic ED: (1) direct inhibition of the spinal erection center by the brain as an exaggeration of the normal suprasacral inhibition (Steers, 2000) and (2) excessive sympathetic nervous system activation and/or elevated**

peripheral catecholamine levels, which may increase penile smooth muscle tone to prevent relaxation (Kim and Oh, 1992). Animal studies confirm that the stimulation of sympathetic nerves or systemic infusion of epinephrine causes detumescence of the erect penis (Diederichs, et al., 1991a, 1991b). This finding supports the observation that human men with psychogenic ED have higher levels of serum norepinephrine than healthy controls or patients with vasculogenic ED (Kim and Oh, 1992).

Neurogenic

Because erection is a neurovascular event, **any disease, dysfunction, or injury (including surgical) affecting the brain, spinal cord, or peripheral erectogenic nerves (i.e., pudendal and cavernous) can induce ED.** Neurogenic ED may also be comorbid with other diseases that cause ED. The presence of a neurologic disorder or neuropathy does not exclude other causes, and confirming that ED is neurogenic can be challenging.

In the brain the MPOA, PVN, thalamus, and hippocampus are important integration centers for sexual drive and erection (Jeon et al., 2009; McKenna, 1998); lesions of these brain areas are more likely to be associated with ED. Pathologic processes such as **Parkinson disease, stroke, encephalitis, temporal lobe epilepsy tumors, dementias (including Alzheimer disease), multiple system atrophy, and traumatic brain injury (TBI) are often associated with ED.** Insufficiency of dopaminergic and/or oxytocinergic pathways is thought to account for many cases of central neurogenic ED (Chaudhuri and Schapira, 2009). Disruptions of sexual desire are common after CVA and other brain injuries and may contribute to neurogenic ED (Jung et al., 2008).

Spinal lesions, most commonly spinal cord injury but including spina bifida, disk herniation, syringomelia, tumor, and multiple sclerosis, are common causes of ED. The nature, location, and extent of the spinal lesion dictate the effect on erectile function. **Reflexogenic erection (in response to tactile stimulation of the penis) is preserved in approximately 95% of patients with complete upper cord lesions** (Biering-Sorensen and Sonksen, 2001; Chapelle et al., 1980). Sacral parasympathetic neurons are important in the preservation of these reflexogenic erections, which are typically of short duration and require continuous stimulation for maintenance. **Reflexogenic erections are preserved in approximately 25% of patients with complete lower cord lesions** (Biering-Sorensen and Sonksen, 2001; Chapelle et al., 1980). These patients may experience psychogenic erections (Chapelle et al., 1980); preservation of psychogenic erections in these patients is thought to be mediated by cortically induced inhibition of tonic sympathetic tone from the thoracic spinal cord (Giuliano, 2011). In addition to their impact upon ED, spinal cord lesions may impair the ejaculation reflex; this is particularly apparent in men who have disruption of the emission phase of ejaculation after injury to the sympathetic chain ganglia during retroperitoneal surgery (Dimitropoulos et al., 2016).

Because of the close relationship between the cavernous nerves and the pelvic organs, the incidence of iatrogenic impotence from pelvic surgical procedures (e.g., radical prostatectomy, abdominoperineal resection) is high, ranging up to 100% in some series (Borchers et al., 2006; Walsh and Donker, 1982; Weinstein and Roberts, 1977). **Thorough understanding of the neuroanatomy of the pelvic and cavernous nerves** led to modifications in surgery for cancer of the rectum, bladder, and prostate, which were associated with a lower incidence of iatrogenic ED (Walsh and Donker, 1982). Although nerve-sparing approaches have markedly improved erectile outcomes after pelvis surgery, the majority of men experience at least a temporary decline in erectile function after surgery, and few recover completely to baseline levels. Men with ED at baseline and older than 60 are at greater risk (Nelson et al., 2013).

Animals models indicate that cavernous nerve injury is associated with: (1) upregulation of neurotoxic type M1 macrophages, inflammatory cytokines, RhoA/Rho-kinase signaling, and tyrosine hydroxylase containing neurons; (2) increase in oxidative stress, collagen to smooth muscle ratio, and apoptosis; and (3) downregulation of Sonic hedgehog protein and diminished response to cavernous nerve-induced penile erection (Angeloni et al., 2013; Hannan et al., 2016; Lin et al., 2015; Matsui et al., 2017).

Pelvic fracture can lead to ED secondary to either (or both) cavernous nerve or vascular injury. In men with posterior urethral injury, early realignment has been associated with better potency preservation rate relative to delayed anastomosis (ED rate 34% vs. 42%) (Mouraviev et al., 2005). **Diabetes** may also cause ED via neurogenic or vascular damage, either of which can impair NO release (Saenz de Tejada, et al., 1989). **Finally, age-related declines in penile tactile** sensitivity may contribute to ED by reducing sacral reflexogenic responses (Rowland et al., 1993). Sensory input from the genitalia is essential to achieve and maintain reflexogenic erection and may be particularly important with declines in psychogenic erectile stimuli associated with age or other conditions.

Endocrinologic

Low serum testosterone (T) is a frequent finding in patients with ED. Androgens influence the growth and development of the male reproductive tract and secondary sex characteristics by binding to the androgen receptor (AR) in target tissues; their effects on libido and sexual behavior are well established (Cattabiani et al., 2012; Corona et al., 2016). **In men with low serum T, supplementation (1) enhances sexual interest, (2) increases erectile response, and (3) is linked to improvements in several nonsexual quality-of-life parameters** (Corona et al., 2014; Rosen et al., 2017). The threshold level of T for normal nocturnal erections has been reported at about 200 ng/dL (Granata et al., 1997), although many men experience symptoms (including loss of nocturnal erections) at levels of less than 320 ng/dL (Wu et al., 2010). In a study of patients presenting with ED, reported androgen deficiency symptoms in 47% of men with T levels of less than 200 ng/dL, 33% of men with levels less than 300 ng/dL, 23% of men with levels less than 346 ng/dL, and 7% of men with levels less than 400 ng/dL (Kohler et al., 2008).

Recent investigation has suggested that the number of cytosine-adenine-guanine (CAG) repeats in exon 1 of the AR gene is inversely associated with transcriptional activity of this gene; hypothetically, longer CAG repeats may reduce testosterone/AR activity by limiting the number of available receptors. A weak but significant relationship between CAG repeat length and erectile dysfunction symptoms has been reported but the relationship was significant only for those patients with at least low normal serum T levels (e.g., >330 ng/dL) (Liu et al., 2015; Tirabassi et al., 2016). This effect remains controversial as some studies have not detected a significant relationship between CAG repeats and ED (Andersen et al., 2011).

Low libido is the most common sexual symptom of low T. Older men are at greater risk of symptoms in the context of low T, although whether this relationship is cause or effect is unclear. Importantly, **many men with low T levels are asymptomatic.** Therefore the Endocrine Society recommends that T supplementation be considered only in the context of at least two clearly low morning serum T levels and symptoms clearly referable to low T (Bhasin et al., 2010).

Age, diabetes, high total cholesterol, anemia, increased waist circumference, and obesity (BMI > 30 kg/m^2) are correlated with significantly decreased testosterone levels in men with ED (Hall et al., 2008; Hofstra et al., 2008). In a comprehensive literature review, low serum T predicted elevated fasting insulin, glucose, and hemoglobin A_{1c} values in men who develop diabetes, suggesting that hypogonadism may be a sentinel event in the pathogenesis of diabetes (Traish et al., 2009). **The authors further suggested that androgen deficiency is associated with insulin resistance, type 2 diabetes, metabolic syndrome (MetS), and increased deposition of visceral fat.** Visceral fat may serve as an endocrine organ, producing inflammatory cytokines and promoting endothelial dysfunction and vascular disease (Armani et al., 2017).

Testosterone exerts some effects by regulation of the NO/cGMP pathway and may play a role in RhoA/Rho Kinase signaling, adrenergic tone, and cavernous smooth muscle (Corona et al., 2016). Castration is associated with decreased arterial flow, venous leakage, and reduced erection response to stimulation of the cavernous nerves (Penson et al., 1996; Wang et al., 2015). Castration also increases α-adrenergic responsiveness of smooth muscle (Traish et al., 1999) and decreases smooth muscle and nNOS content in penile tissue (Alves-Lopes et al., 2017). Androgens promote endothelial cell survival, reduce endothelial expression of proinflammatory markers, and inhibit proliferation and intimal migration of vascular smooth muscle cells in in vivo studies. Castration has also been associated with decreased autophagy in cavernous cells in rats; it is speculated that autophagy may help to prevent apoptosis (Wang et al., 2015). At low levels of androgen, increased apoptosis is noted in endothelial cells and smooth muscle cells (Alves-Lopes et al., 2017). Low androgen levels also impairs proliferation, migration, and homing of endothelial progenitor cells as well as myogenic differentiation of mesenchymal progenitor cells (Mirone et al., 2009; Traish and Galoosian, 2013). Clinically, many men receiving long-term androgen ablation therapy for prostate cancer report poor libido and ED (Benedict et al., 2014). Some studies have indicated that testosterone supplementation improves erectile function in men with hypogonadism (Haider et al., 2017; Snyder et al., 2016) but may take sustained treatment for maximal efficacy (Hackett et al., 2016). Other studies have suggested that the benefit of testosterone supplementation relates primarily to sexual desire rather than erectile function (Cunningham et al., 2016).

Any dysfunction of the hypothalamic-pituitary axis can result in low serum T. Hypogonadotropic hypogonadism can be congenital or caused by a tumor or injury of the hypothalamus or pituitary gland. Hypergonadotropic hypogonadism may result from a tumor, injury, testicular surgery, or severe orchitis. In most cases, low serum T is not associated with marked abnormality of gonadotropins (i.e., luteinizing hormone and follicle stimulating hormone) (Kaprara and

Huhtaniemi, 2017).

Hyperprolactinemia may occur in the setting of pituitary adenoma or with certain drugs such as antipsychotics (Milano et al., 2017). **High levels of serum prolactin are associated with loss of libido, ED, galactorrhea, gynecomastia, and infertility. Hyperprolactinemia is associated with low serum T, which is thought to be related to inhibition of gonadotropin-releasing hormone secretion at the level of the hypothalamus** (Freeman et al., 2000; Maggi et al., 2013). Although hyperprolactinemia has been clearly linked to sexual issues in men, epidemiologic data have also suggested that low serum prolactin is associated with metabolic syndrome and arteriogenic ED as well as with premature ejaculation and anxiety symptoms (Corona et al., 2009).

ED may also be associated with hyperthyroidism and hypothyroidism. Hyperthyroidism is commonly associated with diminished libido (which may be caused by the increased circulating estrogen levels) and less often with ED. In hypothyroidism, low testosterone secretion and elevated prolactin levels may contribute to ED (Freeman et al., 2000; Maggi et al., 2013).

Arteriogenic

Atherosclerotic or traumatic arterial occlusive disease of the hypogastric-cavernous-helicine arterial tree can decrease the perfusion pressure and arterial flow to the sinusoidal spaces. This has the effect of increasing the time to maximal erection and decreasing rigidity of the erect penis. **In most patients with arteriogenic ED, impaired penile perfusion is a component of a generalized atherosclerotic process. Common health factors associated with penile arterial insufficiency include hypertension, hyperlipidemia, tobacco use, diabetes mellitus, blunt perineal or pelvic trauma, metabolic syndrome, sedentary lifestyle, obesity, and pelvic irradiation** (Bacon et al., 2006; Feldman et al., 1994; Giugliano et al., 2010; Kupelian et al., 2010; Martin-Morales et al., 2001). Abnormalities on penile Doppler examination are associated with vascular disease and greater risk of major cardiac events (Corona et al., 2010). Focal stenosis of the common penile or cavernous artery is most often detected in young patients who have sustained blunt pelvic or perineal trauma (Munarriz et al., 1995). There is a significant relationship between cycling-induced perineal compression leading to vascular, endothelial, and neurogenic dysfunction in men and the development of ED (Sommer et al., 2010). Nevertheless, ED does not commonly occur in men who engage in recreational bicycle riding (Kim et al., 2011). The cardiovascular benefits of routine exercise may mitigate any local effect on the perineal circulation.

Arterogenic disease is common in men with ED; arterogenic causes are also potentially amenable to intervention that may yield benefit in terms of erectile function. Men who engage in routine physical activity and maintain healthy body weight are at reduced risk of developing ED (Esposito et al., 2010; Kupelian et al., 2010). Statin-based therapy for hypercholesterolemia has been associated with enhanced erections and improved responsiveness to erectogenic therapy (Cui et al., 2014). Tobacco cessation, weight loss, and exercise have also been associated with improvements in erectile function among men with vascular disease (Meldrum et al., 2012; Verze et al., 2015).

Cardiovascular Diseases.

ED is highly prevalent in men with coronary, cerebral, and peripheral vascular disease (Bener et al., 2008; Chai et al., 2009; Lahoz et al., 2016; Montorsi et al., 2006). The epidemiologic and mechanistic links between ED and cardiovascular disease include (1) endothelial dysfunction (e.g., eNOS and oxidative stress); (2) smooth muscle defects (e.g., hyperplasia and altered contractility); (3) autonomic dysregulation (e.g., neuropathy and diminished nNOS content); (4) hormonal disruption (e.g., hypogonadism); and (5) metabolic defects (e.g., hyperlipidemia, advanced glycation end products) (Musicki et al., 2015).

Because penile arteries are smaller than coronary arteries, the effect of endothelial dysfunction may be noted in the penis before clinical cardiac disease manifests. In one study of men with CAD, ED preceded CAD in 93% of cases at a mean time interval of 2 years (Montorsi et al., 2006). Microvascular and arterial disease may contribute to the ED phenotype. Reactive hyperemia (a measure of microvascular integrity) had a stronger association with ED than flow-mediated dilation (a measure of larger conduit artery function); the implication is that microvascular disease may play a primary role in the development of ED (Gerber et al., 2015). **ED has thus been promoted by many experts as an early indicator of systemic endothelial dysfunction and an indication for cardiac risk stratification** (Gandaglia et al., 2016; Shah et al., 2016; Vlachopoulos et al., 2013).

Hyperlipidemia.

ED is common in hyperlipidemia (Roumeguere et al., 2003). Hypercholesterolemia at baseline was a predictor of incident ED over a 25-year study in the Rancho Bernardo Study (Fung et al., 2004). However, a survey of men in the Boston area did not show an association between untreated hyperlipidemia and ED (Hall et al., 2009).

The effect of hypercholesterolemia on erectile function has been studied in various experimental models. Histologic examination of the corpus cavernosum ultrastructure in hyperlipidemia reveals an early atherosclerotic process in the sinusoids (Kim et al., 1994). High levels of oxidized low-density lipoproteins inhibit endothelium-dependent NO-mediated relaxation and enhance corporal smooth muscle contractility (Ahn et al., 1999; Fraga-Silva et al., 2014). Impairment of the NO/cGMP pathway in hyperlipidemia is thought to be due to oxidative stress (Kim et al., 1997), endogenous NOS inhibitors such as NG-monomethyl-L-arginine monoacetate and asymmetrical dimethylarginine (ADMA) (Maas et al., 2005), depletion of the arginine required for production of NO by increased activity of arginase (Fraga-Silva et al., 2014), and production of procontractile factors such as thromboxane and prostaglandin (Azadzoi et al., 1998, 1999) Downregulation of the angiogenic factor VEGF has been detected in rats fed a high-cholesterol diet (Ryu et al., 2006); this has been linked to impairment of endothelium-dependent relaxation (Xie et al., 2005).

Although the eNOS/cGMP pathway is clearly impaired in hyperlipidemic model systems, neuronal vasodilation is not affected (Azadzoi et al., 1998). However, loss of the endothelial layer coupled with a high fat diet has been linked to impaired arterial reactivity and fibrotic changes of the corpora in a rabbit model (Azadzoi et al., 1997; Nehra et al., 1998). This severe phenotype led to impairment of neuronal and endothelial NOS activity (Azadzoi et al., 1999).

Obesity.

High body weight, BMI, and total body fat percentage are independently associated with greater prevalence of moderate to severe and complete ED (Esposito et al., 2005; Garimella et al., 2013; Gunduz et al., 2004). Animals models of obesity/metabolic syndrome have demonstrated upregulation of endothelin receptor expression, increased oxidative stress, and decreased reactivity to NO and acetylcholine in cavernous tissues (Sanchez et al., 2014). Visceral fat is an endocrine organ and is thought to produce a number of inflammatory mediators that may promote oxidative stress and insulin resistance in penile and other vascular tissue (Chitaley et al., 2009). Perivascular adipose tissue (PVAT) is another recognized contributor to vascular function. Adipocytes and stromal cells contained within PVAT are sources of molecules with varied paracrine effects on the underlying smooth muscle and endothelial cells, including adipokines, cytokines, reactive oxygen species, and gaseous compounds. In obesity and diabetes, the expanded PVAT and its downstream effects contribute to vascular insulin resistance and atherogenesis. A common denominator of PVAT dysfunction in all these conditions is immune cell infiltration, which triggers the subsequent inflammation, oxidative stress, and hypoxic processes to promote vascular dysfunction (Szasz et al., 2013).

Hypertension.

Hypertension (HTN) is an independent risk factor for ED (Feldman et al., 1994; Johannes et al., 2000). In two analyses including more than 270,000 men with ED from a US claims database, the prevalence of hypertension in men with versus without ED was 41.2% versus 19.2%, respectively (Seftel et al., 2004; Sun and Swindle, 2005). Hypertensive damage to end organs (e.g., ischemic heart disease and renal failure) is associated with higher prevalence of ED (Feldman et al., 1994; Johannes et al., 2000; Kaufman et al., 1994). Other determinants of ED in hypertensive men include older age, longer duration of disease, greater severity of hypertension, and the use of antihypertensive medications, some of which may themselves contribute to ED (Doumas et al., 2006).

The cause of HTN-related ED is thought to be related to biochemical and structural changes as opposed to direct effect on vascular walls (Shimizu et al., 2014). Arterial hypertension is characterized by altered vascular tone and increased vascular contractility resulting in high blood pressure. It is accompanied by proliferation, migration of vascular smooth muscle cells, and varying levels of inflammation of the arterial wall. The Rho-kinase pathway plays a crucial role in the regulation of arterial blood pressure (Nunes et al., 2010). Toll-like receptor activation on cells of the vasculature in response to the release of damage-associated molecular patterns and the consequences of this activation on inflammation, vasoreactivity, and vascular remodeling has been proposed as a novel link between inflammation and hypertension (McCarthy et al., 2014). In addition, endoplasmic reticulum stress leading to endothelium-dependent contractile responses in aorta has been proposed as a cause of hypertension in a spontaneously hypertensive rat (SHR) model (Spitler et al., 2013). The RAS pathway, activated in many cases of hypertension, may contribute to reduced nicotinamide adenine dinucleotide phosphate oxidase and subsequent increase in oxidative stress (Jin et al., 2008; Shimizu et al., 2014). Recent evidence from an animal study has also implicated the Rho-kinase pathway in the pathogenesis of hypertension-related ED, with inhibition of Rho-kinase ameliorating the effects of hypertensive state on penile hemodynamics (Zhu et al., 2014).

Mechanism of Vascular Erectile Dysfunction

Arteriogenic ED.

In arteriogenic ED, oxygen tension in the corpus cavernosum blood is less than that in psychogenic ED (Tarhan et al., 1997). Formation of PGE_1 and PGE_2 is oxygen dependent, and in rabbit and human corpus cavernosum, increased oxygen tension was associated with elevation of PGE_2 and suppression of TGF-β1-induced collagen synthesis (Moreland et al., 1995; Nehra et al., 1999). Chronic hypoxia leads to decreased smooth muscle content, increased production of TGF-β, and increased production of type I and III collagen in corporal tissue. These effects may be mediated in part by expression of hypoxia inducible factor-1α (HIF-1α) (Lv et al., 2014).

An increased wall/lumen ratio in arteries contributes to increased peripheral vascular resistance in hypertension. Increased resistance has also been detected in the penile vasculature of SHR—an alteration ascribed to structural changes of the arterial and erectile tissue (Arribas et al., 2008; Gradin et al., 2006). Mitochondrial damage (in smooth muscle and endothelial cells), nerve degeneration, oxidative stress, increased contractility in response to adrenergic stimulation, and disruption of NOS expression have also been described in animal models of hypertension (Jiang et al., 2005; Shimizu et al., 2014). These structural changes are mediated in part by action of the RAS pathway, as evidenced by partial prevention from administration of a type 1 angiotensin II receptor blockers (Mazza et al., 2006). Interestingly, comparison arms in these studies using the vasodilator hydralazine or a calcium channel blocker did not show mitigation of penile end organ damage despite lowering systemic blood pressure (Mazza et al., 2006; Shimizu et al., 2014). A similar study comparing the NOS potentiating beta-blocker nebivolol to the calcium channel blocker amlodipine demonstrated that both treatments reduced blood pressure, but only nebivolol mitigated corporal tissue changes (Toblli et al., 2006).

Enhanced Smooth Muscle Contraction and Vasoconstriction.

In animal models, increased RhoA/Rho-kinase activity leading to increased contractility of the corporeal smooth muscle has been linked to ED in diabetes (Bivalacqua et al., 2004), hypercholesterolemia (Morikage et al., 2006), hypertension (Fibbi et al., 2008), hypogonadism (Vignozzi et al., 2007), cavernous nerve injury (Martinez-Salamanca et al., 2015), and aging (Jin et al., 2006). Inhibition of Rho-kinase has been associated with decreased pelvic atherosclerosis, improved penile hemodynamics, reduced apoptosis, and preservation of NOS activity in rat models of ED (Hannan et al., 2013; Park et al., 2006). Rho-kinase inhibition has also been linked to relaxation of human corporal cells in vivo (Uvin et al., 2017).

Endothelin-1 levels are elevated in plasma of men with atherosclerosis, hypertension, and hypercholesterolemia. Men with organic ED have higher venous and cavernous blood levels of endothelin-1 as well (El Melegy et al., 2005; Nohria et al., 2003). However, a pilot study using an endothelin-A receptor antagonist as a treatment for men with ED did not produce positive results (Kim et al., 2002).

Angiotensin II may restrict corporal vasodilation by action on the AT1 receptor (Kilarkaje et al., 2013). AT1 receptor antagonists and angiotensin-converting enzyme (ACE) inhibitors have shown promise in the treatment of men with ED and hypertension and men with ED and atherosclerosis, respectively (Baumhakel et al., 2008; Speel et al., 2005).

Defects of maxi-K^+ channel in cells in men with ED are thought to alter hyperpolarization and calcium homeostasis in corporal smooth muscle (Fan et al., 1995). Alterations of intracellular communication between smooth muscle cells via gap junctions (intercellular communication channels) has also been noted in ED (Traish et al., 2013). Specific defects that have been reported include increased collagen content in arteriogenic and obesity-related ED (Tomada et al., 2013) and decreased content of the essential gap junction protein connexin 43 in diabetes and aged animal models of ED (Suadicani et al., 2009; Traish et al., 2013).

High adrenergic tone (related to medical or psychological issues) may lead to insufficient trabecular smooth muscle relaxation (Prieto, 2008). This has the effect of not only reducing arterial inflow but also impairing coaptation of the emissary veins by expanding corporal sinusoids.

Impaired Endothelium-Dependent Smooth Muscle Relaxation.

Endothelial dysfunction has been proposed as a common link between cardiovascular disease and ED (Brunner et al., 2005; Musicki et al., 2015). Impairment of endothelium-dependent flow-mediated dilation of the brachial artery has been reported in men with ED; the degree of impairment correlated with the severity of ED (Kovacs et al., 2008). Men with ED related to heart disease, obesity, and low serum testosterone also have fewer circulating endothelial progenitor cells; these regenerative cells are produced in bone marrow and migrate to peripheral vessels to repair endothelial defects (Baumhakel et al., 2006; Esposito et al., 2009; Foresta et al., 2005; Maiorino et al., 2015). Impairment of endothelium-dependent relaxation in hypertensive animal models has been ascribed to angiotensin II (Rajagopalan et al., 1996), thromboxane, superoxide (Cosentino et al., 1998), and direct effects of increased vascular pressure (Paniagua et al., 2000; Table 68.9).

TABLE 68.9

Vascular and Structural Changes Leading to Erectile Dysfunction

PENILE STRUCTURE	CHANGES IN ERECTILE DYSFUNCTION
Cavernous artery	Increased vascular resistance, narrow lumen
Smooth muscle	Increased tone (hypertonicity)
	Decreased smooth muscle content
	Alteration of potassium channels and gap junctions
Cavernous tissue	Fibrosis (collagen deposition, loss of elastin)
	Impaired veno-occlusive mechanism
Endothelium	Impaired endothelium-dependent relaxation
Tunica albuginea	Alteration of elastic and collagen fibers
Neurotransmitters	Decreased nNOS, eNOS

eNOS, Endothelial nitric oxide synthase; *nNOS,* neuronal nitric oxide synthase.

Corporal Structural Defects

Failure to restrict venous outflow from the penis during erection is one of the most common causes of vasculogenic ED (Rajfer et al., 1988). **Veno-occlusive dysfunction may result from various pathophysiologic processes, including degenerative tunica changes, fibroelastic structural alterations, insufficient trabecular smooth muscle relaxation, and venous shunts.**

Degenerative changes (e.g., tissue senescence, diabetes) or traumatic injury to the tunica albuginea (e.g., penile fracture) can impair the compression of the subtunical and emissary veins (Gonzalez-Cadavid, 2009).

In Peyronie disease, inelasticity of the tunica albuginea may prevent coaptation of emissary veins (Chiang et al., 1992; Metz et al., 1983). Surgery for correction of Peyronie disease may also contribute to inadequate corporal veno-occlusion by disruption of the subtunical areolar layer or the tunica (Flores et al., 2011). Acquired venous shunts—the result of operative correction of priapism—may cause persistent glans/cavernosum or cavernosum/spongiosum shunting and venous leakage during erection; however, in these cases ED may also relate to corporal fibrosis from priapism (Pal et al., 2016).

Structural or functional alterations in the fibroelastic components of the trabeculae, cavernous smooth muscle, and endothelium may result in venous leakage. Increased deposition of collagen and decreased elastic fiber content within the corpora has been linked to ED as well as associated disease conditions including diabetes, hypercholesterolemia, vascular disease, and penile injury (Sattar et al., 1994).

Loss of corporal smooth muscle content and functionality is also strongly associated with ED (Mersdorf et al., 1991; Pickard et al., 1993; Saenz de Tejada, et al., 1989). Reductions in smooth muscle content is commonly observed in animal models of vasculogenic and neurogenic ED (Azadzoi et al., 1997; Junemann et al., 1991; Nehra et al., 1998). Interestingly, in a human study penile smooth muscle content was reduced in arteriogenic and venogenic ED but was lowest in men with arterogenic ED (Pickard et al., 1994; Sattar et al., 1996).

Sonic Hedgehog Protein.

SHH is one of three proteins in the mammalian hedgehog family, the others being desert hedgehog and Indian hedgehog (Hammerschmidt et al., 1997). SHH plays a key role in regulating neuronal differentiation and axon guidance and appears to play an important role in penile development (Charron et al., 2003; Podlasek et al., 2005). Decreased levels of SHH have been demonstrated after cavernous nerve injury and diabetes; these findings are associated with neve degeneration, corporal apoptosis, and decreased smooth muscle content (Angeloni et al., 2013; Podlasek et al., 2005). Administration of SHH in cavernous nerve injured rats ameliorates many of these findings and improves erectile function (Choe et al., 2017). The mechanism of action may involve brain-derived neurotrophic factor activation (Bond et al., 2013).

Endothelium.

The endothelium is an important source of NO and many other signaling

molecules, including EDHF, PGI_2, and hydrogen peroxide. The endothelium also modulates flow-mediated vasodilation and influences mitogenic activity, platelet aggregation, and neutrophil adhesion; these effects are mediated via transferred chemical mediators (e.g., NO and PGI_2) and/or low-resistance electrical coupling through myoendothelial gap junctions.

Disruption of endothelial function is an early indicator of vascular disease (Triggle et al., 2012). Diabetes and hypercholesterolemia alter the function of endothelium-mediated relaxation of the cavernous muscle and impair erection (Azadzoi and Saenz de Tejada, 1991). Specific mechanisms by which endothelial dysfunction may contribute to ED include decreased endothelial cell density and downregulation of endothelium-specific cell-to-cell junction proteins (e.g., claudin-5, vascular endothelial–cadherin, platelet endothelial cell adhesion molecule 1) (Ryu et al., 2013).

Drug-Induced

Medical therapy is commonly associated with self-reported ED (Razdan et al., 2017). Numerous conditions common in the ED population are themselves risk factors for ED, such as depression, diabetes, and cardiovascular disease (Derby et al., 2001). Medical management of these and other conditions may exacerbate or cause ED. In some cases, sexual symptoms related to medication primarily effect sexual desire, ejaculation, or orgasm; these issues may be reported by patients as “ED” or may lead to secondary issues in erectile response. Self-reported and questionnaire data concerning ED as a side effect of medication should be interpreted with caution.

Antihypertensive Agents.

Almost all antihypertensive drugs have ED listed as a potential side effect. However, certain antihypertensives carry greater risk of ED than others, and there is evidence that some antihypertensives can be beneficial for erectile function (La Torre et al., 2015). Given the relationship between hypertension and ED, it can be challenging to elucidate the precise cause of ED in men under treatment with antihypertensives; some evidence suggests that the underlying disease process is the principle driver of ED in this population (Kupelian et al., 2013).

Diuretics.

Thiazide diuretics are carbonic anhydrase inhibitors that alkalinize cells and cause vasodilation. The predominant activity of thiazide diuretics is to inhibit a directly coupled Na-Cl cotransporter along the distal convoluted tubule of the kidney (Ellison and Loffing, 2009).

Data from a large trial in the United Kingdom showed that twice as many men taking thiazides for mild hypertension reported ED compared with men taking propranolol or placebo (Adverse reactions, 1981). Similar findings were documented from the Treatment of Mild Hypertension Study (TOMHS), in which the prevalence of ED at 2 years in men taking low-dose thiazide was twice that of men taking placebo or alternative agents. After 4 years of treatment, the prevalence of ED in the placebo group approached that of the thiazide group, a finding not fully explained by dropouts (Grimm et al., 1997). A study comparing sexual side effects of thiazide, placebo, or atenolol in hypertensive patients also found a higher rate of ED in the thiazide group, although weight loss was a more powerful mediator of ED resolution (Wassertheil-Smoller et al., 1991). **The mechanism of diuretic-induced ED remains to be elucidated.**

β-Adrenergic Blockers.

Receptor studies show that only 10% of adrenoceptors in the penile tissue are of the β type, and their stimulation is thought to mediate smooth muscle relaxation (Andersson and Wagner, 1995). **This response is attenuated in vitro by nonselective drugs such as propranolol, possibly via a prejunctional β_2-receptor effect but not by cardiac-selective agents such as practolol** (Srilatha et al., 1999). β antagonists also exert an inhibitory effect within the CNS, perhaps leading to decreased sex hormone levels (Suzuki et al., 1988).

The differential effects of β-adrenoceptor antagonists on erectile function may be explained in part by whether they are general or selective antagonists, and whether they possess vasodilatory properties. **Nonselective β-antagonists such as propranolol are associated with higher prevalence of ED** compared with placebo or ACE inhibitors (Croog et al., 1986). Carvedilol, a general β-adrenoceptor antagonist that also causes vasodilation by blocking α_1-adrenoceptors, has been associated with worsening sexual function (Fogari et al., 2001). Selective β-antagonists have a much lower rate of ED that does not significantly differ from what is observed with placebo or ACE inhibitors (Grimm et al., 1997). Some novel β_1-adrenoceptor antagonists have vasodilatory effects mediated by release of NO (Reidenbach et al., 2007). In crossover studies using the vasodilating β-antagonist nebivolol versus the selective β_1-antagonists metoprolol and atenolol, nebivolol did not decrease sexual intercourse activity in hypertensive men and in some cases had positive effects on erectile function (Boydak et al., 2005; Brixius et al., 2007).

α-Adrenoceptor Blockers.

In animal studies, α antagonists (particularly antagonists acting on the α_1 receptor) increase and/or prolong the relaxant response of cavernous smooth muscle (Andersson and Wagner, 1995). In addition, prejunctional α_2-receptor activation modulates the release of noradrenaline, suggesting a putative relaxant role for α_2-antagonists. α-Antagonists used to treat hypertension and/or BPH (e.g., doxazosin) or reduce urinary tract symptoms have not associated with increased prevalence of ED (Flack, 2002; Grimm et al., 1997). Conversely, **α_2-receptor agonists (e.g., clonidine) are associated with decreased erectile function thought to relate to** peripheral and central mechanisms (Srilatha et al., 1999). **Methyldopa,** a centrally acting drug, **has also been associated with ED** in controlled trials comparing it with placebo and other antihypertensive agents and is thought to act by antagonizing hypothalamic α_2-adrenoceptors (Croog et al., 1988).

Angiotensin-Converting Enzyme Inhibitors.

ACE inhibitors lack any easily appreciated peripheral or central effect that would interfere with sexual function. Given the relevance of the RAS pathway to ED pathogenesis it is reasonable to hypothesize that these agents may be beneficial in terms of erectile response, an observation that has been confirmed in a number of studies (Toblli et al., 2007). In a rat model of diabetes intracerebroventricular administration of an ACE inhibitor was associated with enhancement of centrally induced erections from sodium nitroprusside or stimulation of the NMDA receptor (Zheng et al., 2013). In the majority of human studies ACE inhibitor use is associated with a neutral to beneficial effect on erectile function (Shindel et al., 2008).

Angiotensin II Type 1 Receptor Antagonists.

In studies of hypertensive or aging normotensive animals, AT1 receptor antagonists (e.g., losartan, valsartan, candesartan) reverse structural changes in the penile vasculature and appear to conserve erectile function (Hale et al., 2001, 2002; Hannan et al., 2006; Park et al., 2005; Shindel et al., 2008). In a rat model of diabetes, intracerebroventricular administration of an AT1 receptor antagonist was associated with enhancement of centrally induced erections from sodium nitroprusside or stimulation of the NMDA receptor (Zheng et al., 2013). In human clinical cross-sectional studies, AT1 receptor antagonists, in contrast to other antihypertensive drugs, seem to improve erectile function (Doumas et al., 2006). In a crossover study comparing valsartan with the β-adrenoceptor antagonist carvedilol, valsartan had a beneficial effect on preexisting sexual dysfunction and had no adverse sexual effects during 12 months of treatment (Fogari et al., 2001). Treatment with losartan for 3 months has been associated with improved sexual function (Llisterri et al., 2001).

Calcium Channel Blockers.

Clinical studies of calcium channel blockers have demonstrated **no adverse effect on erection** (Cushman et al., 1998; Grimm et al., 1997). However, this class has been linked to ejaculatory complaints, which may be due to decreased force of bulbocavernous muscles (Suzuki et al., 1988).

Aldosterone Receptor Antagonists.

Mineralocorticoid receptors have been identified in human corporal tissue (Kishimoto et al., 2013). Spironolactone and eplerenone are mineralocorticoid-blocking agents. Spironolactone is a nonselective mineralocorticoid receptor antagonist with moderate affinity for progesterone and androgen receptors (Corvol et al., 1975). The latter property increases the likelihood of endocrine side effects, including loss of libido, gynecomastia, and ED. Aldosterone has also been linked to adrenergic sensitization in human corporal cells, an effect that tends to promote contraction (Muguruma et al., 2008). However, mineralocorticoids themselves exert inflammatory effects on corporal tissue (including synthesis of tumor necrosis factor-α, nuclear factor-kappa B, and interleukin-6), which may impair erectile responses; treatment of these tissues with spironolactone reduced this effect and thus may theoretically improve peripheral erectile function (Wu et al., 2018). Eplerenone is a next-generation aldosterone receptor antagonist selective for aldosterone receptors alone. It has less affinity for progesterone and androgen receptors (Sica, 2005).

Summary on Antihypertensives.

Treatment of mild to moderate hypertension requires agents with an acceptable side-effect profile to minimize noncompliance. Thiazide diuretics and nonselective β-antagonists are associated with higher rates of ED, although this may be reduced by combination therapy and weight loss. α_1-Blockers, ACE inhibitors, and angiotensin II receptor blockers tend to have fewer negative effects on sexual functioning during treatment and may be preferred when starting antihypertensive therapy in men with preexisting ED (Table 68.10).

TABLE 68.10

Effect of Antihypertensive Agents on Sexual Function

AGENT	EFFECT	MECHANISM
Diuretics	ED (twice as common as placebo)	Unknown
Beta-blocker (nonselective)	ED	Prejunctional α_2-receptor inhibition
α_1-Blocker	Decreases ED rate but may cause alteration of ejaculation	Failure of sympathetic-induced (1) closure of internal sphincter and proximal urethra and (2) failure of seminal emission during ejaculation
α_2-Blocker	ED	Inhibition of central α_2-receptor
Angiotensin-converting enzyme inhibitor	Possible reduction in ED	
Angiotensin II receptor blocker	Possibly reduction in ED	

ED, Erectile dysfunction.

Psychotropic Medication.

Receptor complexity and the convoluted interrelationship of pathways within the CNS make it extremely likely that neurons and ganglia involved in sexual functioning will be affected by psychotropic drugs, leading to functional changes that may be positive and/or negative. For example, nonmedicated patients with schizophrenia are at increased risk of low sexual desire; treatment has been associated with increases in sexual desire but decreased erectile and ejaculatory function (Aizenberg et al., 1995).

Antipsychotics.

In a nonrandomized comparative study of antipsychotic medications, the prevalence of sexual dysfunction ranged from 40% to 70% (Wirshing et al., 2002). Newer agents such as clozapine and risperidone are associated with less frequent deficits in sexual desire and erectile function. This class of drugs has many effects on CNS receptors and may act peripherally. The therapeutic effect of antipsychotics is thought to relate to dopaminergic receptor blockade within the limbic and prefrontal areas of the brain. Adverse events with respect to sexual function are thought to be due to β-adrenergic blockade and anticholinergic properties and to antidopaminergic actions within the basal ganglia (Sullivan and Lukoff, 1990).

The occurrence of extrapyramidal effects (i.e., repetitive involuntary muscle movements) differentiates older "typical" antipsychotics (frequent extrapyramidal effects) from newer "atypical" antipsychotics (less common extrapyramidal effects). This variation probably relates to differential affinities for particular classes of receptor or avidity for particular areas of the cerebral cortex (Strange, 2001; Westerink, 2002). An additional effect of dopamine blockade is hyperprolactinemia, which may reduce serum testosterone levels and cerebral dopamine release in permissive cerebral centers. Hyperprolactinemia is more common with older "typical" antipsychotic agents (Smith and Talbert, 1986).

The clinical effect of antipsychotics on sexual function varies according to their affinity for particular receptors. Animal experiments, chiefly in rats, show that D1 receptor activation in the MPOA of the hypothalamus facilitates erection through intermediary oxytocinergic and spinal cholinergic pathways. Activation of D2 receptors in this area may have the opposite effect (Zarrindast et al., 1992). Older agents such as haloperidol and flupenthixol reduce apomorphine-induced erections in experimental animals by means of D1 receptor antagonism (Andersson and Wagner, 1995). However, systemic administration of antipsychotic agents in rabbits produced erection by a local nondopaminergic action, possibly involving antagonism of α_1-adrenoceptors (Naganuma et al., 1993).

Antidepressants.

Sexual side effects of antidepressants in men are varied but are important factors governing compliance because these drugs are commonly prescribed to younger and middle-aged adults.

Tricyclics act by inhibiting the reuptake of catecholamines in the CNS. **Their sexual side-effect profile is thought to relate to peripheral anticholinergic and β-adrenergic effects.** It is also possible that they antagonize 5-HT receptors. Controlled clinical studies suggest that **orgasmic disorders in both sexes are frequent,** explaining the use of these drugs as inhibitors of ejaculation (Harrison et al., 1986; Monteiro et al., 1987). ***Monoamine oxidase inhibitors*** (MAOIs) are associated with **higher rates of orgasmic dysfunction** in controlled trials but the nature of the central or peripheral mechanisms involved is uncertain (Harrison et al., 1986).

Tricyclics and MAOI are used relatively infrequently in the modern era. ***Selective serotonin reuptake inhibitors*** (SSRIs) are the class of drug most commonly used to treat depression currently. These drugs inhibit the reuptake of 5-HT into CNS neurons and can produce stimulatory effects on various 5-HT receptors.

It is estimated that **up to 50% of patients taking SSRIs experience a change in sexual function** (Keltner et al., 2002; Rosen et al., 1999). Possible mechanisms include stimulation of 5-HT$_2$ and 5-HT$_3$ receptors, which may inhibit erectogenic pathways within the spinal cord (Tang et al., 1998); decreased dopamine release in the MPOA (Maeda et al., 1994); and alteration of NO metabolism (Angulo et al., 2001). A controlled clinical study suggested that the improvement in sexual function resulting from alleviation of clinical depression with use of SSRIs outweighed any negative effect (Michelson et al., 2001) However, other placebo-controlled randomized studies revealed increased sexual dysfunction, mainly anorgasmia, in the group treated with SSRIs (Croft et al., 1999; Labbate et al., 1998). Further studies have suggested that **these adverse effects can be modified by co-treatment with other drugs such as PDE5 inhibitors** (Fava et al., 2006) or an adjunctive antidepressant agent with dopaminergic activity (e.g., buproprion) (Rudkin et al., 2004) or 5-HT$_{1A}$ activity (e.g., buspirone) (Gitlin et al., 2002).

SSRIs differ in their ability to cause ED. A high incidence of ED has been observed in patients treated with paroxetine (Kennedy et al., 2000), whereas a lesser impact has been reported with citalopram (Mendels et al., 1999). This difference suggests that mechanisms other than inhibition of serotonin reuptake may be involved, which is supported by a report that short-term or long-term administration of paroxetine, but not citalopram, caused ED in rats by inhibiting NO production (Angulo et al., 2001). The inhibitory effects induced by short-term administration of paroxetine on erectile function in the rat can be prevented by inhibition of PDE5 (Angulo et al., 2003).

Other Antidepressants.

Animal experiments suggest that stimulation of 5-HT$_{1c}$ receptors within the CNS induces erection (Stancampiano et al., 1994). Newer antidepressants such as mirtazapine and nefazodone tend to have beneficial effects on sexual function, possibly by activating the 5-HT$_{1C}$ receptor, which augments sexual response (Stancampiano et al., 1994), although they may also antagonize the 5-HT$_{2C}$ receptor (Millan et al., 2000). The isolated reports of priapism seen with a prototype agent, trazodone, may be related to the 5-HT$_{1C}$ erectogenic effect seen with its primary metabolite, *m*-chlorophenylpiperazine, in experimental animals. (Andersson and Wagner, 1995). In a clinical study, trazodone was shown to increase nocturnal erectile activity, despite reducing REM sleep (Ware et al., 1994).

Anxiolytics.

Anxiolytics have been implicated in sexual problems (Derby et al., 2001). Benzodiazepines are thought to potentiate the action of GABA in the reticular and limbic system; they may also affect the serotonin and dopaminergic pathways. Experimental studies suggest that GABAergic drugs inhibit erection induced by apomorphine, a dopamine agonist (Zarrindast and Farahvash, 1994). A controlled clinical study demonstrated that a combination of lithium and benzodiazepine was associated with a significantly higher rate of sexual dysfunction than treatment with lithium alone (Ghadirian et al., 1992). More recent anxiolytic agents, such as bupropion, acting mainly by inhibiting dopamine reuptake, and buspirone, acting on 5-HT$_{1A}$ receptors, are less commonly associated with sexual side effects in placebo-controlled trials (Coleman et al., 2001; Gitlin et al., 2002).

Anticonvulsants.

Epileptic discharges may affect the function of the hypothalamic-pituitary axis and the level of hormones important for sexual function (Morris and Vanderkolk, 2005). Sexual function, bioavailable testosterone levels, and gonadal efficiency in men with epilepsy who take lamotrigine are comparable with control and untreated values and significantly greater than in men treated with carbamazepine or phenytoin (Herzog et al., 2004). Orgasmic dysfunction is common in patients who receive carbamazepine therapy, and loss of sexual desire is common in men treated with valproate (Kuba et al., 2006). There are reports of improved sexual function and hypersexuality in patients treated with lamotrigine (Gil-Nagel et al., 2006; Grabowska-Grzyb et al., 2006).

Antiandrogens.

Androgens are believed to modify sexual behavior by modulating androgen receptors within the CNS. **Antiandrogens cause partial or near-complete blockade of androgen's action by inhibiting production of or antagonizing the androgen receptor.** The effects of androgen deficiency on sexual activity are variable, ranging from complete loss to normal function. Experimental studies in humans suggest that nocturnal erections during REM sleep are androgen dependent, whereas erections in response to visual sexual stimulation are independent (Andersson and Wagner, 1995). An additional peripheral effect has been suggested from animal experiments in which castration decreased NOS activity within the rat corpus cavernosum, leading to reduced erectile activity. Testosterone restored NOS activity, but treatment with finasteride prevented this recovery, suggesting that dihydrotestosterone (DHT) may be the important androgen in penile tissue (Lugg et al., 1995).

The 5α-reductase inhibitors (i.e., finasteride and dutasteride) are antiandrogens with the least effect on circulating testosterone. In randomized placebo-controlled studies of patients given finasteride (5 mg daily) for prostatic symptoms, approximately **5% complained of decreased desire and ED compared with 1% in the placebo group** (Gormley et al., 1992). At the lower dose used to treat male-pattern alopecia (1 mg daily), no sexual dysfunction was seen (Tosti et al., 2001). However, persistent sexual dysfunction for months to years after discontinuation of finasteride for alopecia has been reported. Purported effects include low libido, ED, decreased arousal, and difficulty with orgasm (Irwig and Kolukula, 2011). A rodent study of chronic treatment with a 5α-reductase inhibitor demonstrated decreased erectile response to cavernous nerve electrostimulation, a finding associated with reduced smooth muscle to collagen ratio, depression of eNOS, increased apoptosis, and decreased autophagy (Zhang et al., 2013).

Antagonism at the androgen receptor prevents signal transduction of testosterone and DHT. Nonsteroidal drugs such as flutamide and bicalutamide have relatively pure effects on the androgen receptor. These drugs are used in the palliative treatment of locally advanced and metastatic prostate cancer (Helsen et al., 2014). When used alone, nonsteroidal antiandrogens are associated with an increase in serum testosterone levels. Luteinizing hormone–releasing hormone (LHRH) agonists and antagonists are also frequently used in advanced prostate cancer used to suppress serum testosterone (Clinton et al., 2017; Dellis and Papatsoris, 2017). When a nonsteroidal antiandrogen is used in conjunction with an LHRH agonist or antagonist, the combination reduces testosterone to the castrate range. The main side effect is a reduction of sexual desire, which occurs in up to 70% of patients (Iversen et al., 2001).

In a clinical trial with larger sample size and longer duration, treatment with bicalutamide alone resulted in a smaller decrease in sexual desire than did castration (Iversen et al., 2000). However, in another large controlled trial, treatment with either flutamide or cyproterone resulted in a gradual loss of sexual desire over 2 to 6 years in approximately 80% of patients (Schroder et al., 2000). In a placebo-controlled study, half of patients receiving bicalutamide therapy experienced loss of erectile function, even at a low dose of 50 mg (Eri and Tveter, 1994).

The near-complete androgen deprivation achieved by medical castration with LHRH antagonist (immediate testosterone suppression) or agonists (with an initial surge of testosterone) results in a profound loss of sexual desire, which is usually accompanied by ED (Basaria et al., 2002). In a small study, nocturnal penile tumescence (NPT) monitoring before and after initiation of therapy indicated reductions in nocturnal penile tumescence with medical castration (Marumo et al., 1999).

Miscellaneous Drugs.

Many other drugs are purported to induce ED in men. These reports are usually based on anecdotal case reports or post-marketing drug alerts rather than controlled trials.

Digoxin.

In an experimental in vitro study with isolated human corpus cavernosum tissue, digoxin attenuated the relaxant response to acetylcholine and intrinsic nerve stimulation; this was linked to findings of reduced penile rigidity not seen in men given a placebo after visual sexual stimulation (Gupta et al., 1998). A randomized clinical study confirmed a negative effect on general sexual functioning linked to a decrease in plasma testosterone (Neri et al., 1987). However, other investigators did not find change in sex and adrenal hormone levels in men taking digoxin (Kley et al., 1984).

Statins.

Statins are used to reduce lipid levels and are commonly used in men likely to have established risk factors for sexual dysfunction, particularly ED. Several studies have suggested that statins are associated with worsening of ED (Bruckert et al., 1996; Solomon et al., 2006). Although this may relate to drug therapy, it is also plausible that worsening ED in this context may relate to progression of vascular disease in men with hyperlipidemic issues severe enough to warrant medical therapy. Other studies have suggested beneficial erectile effects in men taking statins for ED, including (1) improvement in nocturnal penile activity and mean scores on the Sexual Health Inventory in Men questionnaire from 14.2 to 20.7 in hyperlipidemic patients treated for 4 months (Saltzman et al., 2004); (2) positive effects on ED in men with established penile disease and suboptimal response to PDE inhibitors who were given a statin and an ACE inhibitor (Bank et al., 2006); (3) improvement in the response to sildenafil in men with ED not initially responsive to sildenafil (Herrmann et al., 2006); (4) improvement in erectile function recovery in men who had undergone bilateral nerve-sparing radical prostatectomy and received sildenafil (Hong et al., 2007); and (5) positive effect on International Index of Erectile Function (IIEF) questionnaire scores in patients with hyperlipidemia followed for 12 months (Dogru et al., 2008). A recent meta-analysis of studies concluded that statins are associated with improvements in mean IIEF (Cui et al., 2014).

Histamine H_2 Receptor Antagonists.

Cimetidine and ranitidine are widely prescribed for prophylaxis and treatment of peptic ulcer disease. A single in vitro animal study suggested that H_2 receptor stimulation causes cavernous relaxation, possibly via endothelial release of NO (Andersson and Wagner, 1995). Inhibition of this H_2 by these drugs may theoretically contribute to ED.

Opiates.

Long-term intrathecal administration of opiates results in hypogonadotropic hypogonadism and associated sexual dysfunction that can be restored with appropriate supplementation (Abs et al., 2000). However, administration of opioid antagonists to older men with ED was not found to improve erectile function measured objectively by nocturnal penile tumescence monitoring (Billington et al., 1990). Opioids have a generalized depressant effect on sexual function when directly administered to the MPOA in rat brain, but treatment with the opioid receptor antagonist naloxone had no sexual effect on healthy male volunteers (Andersson and Wagner, 1995).

Antiretroviral Agents.

Hypogonadism and ED appear to be more common among men infected with human immunodeficiency virus (HIV) compared with age-matched men in the general US population (Crum et al., 2005). Sexual dysfunction seems to be a common event after the introduction of antiretroviral therapy (Collazos, 2007). These disturbances seemed to be more common in patients treated with protease inhibitors. Because these patients may have diseases involving several organ systems and may be taking multiple drugs, the precise mechanism of antiretroviral therapy related ED is difficult to determine.

Tobacco.

Tobacco use has been clearly linked to ED (Biebel et al., 2016). The Boston Area Community Health (BACH) survey reported a significant dose-response association between smoking and ED with a statistically significant effect observed at 20 or more pack-years of exposure**.** Passive smoking (i.e., frequent exposure to another individual who is a smoker) was associated with a small, statistically insignificant increase in risk of ED comparable with approximately 10 to 19 pack-years of active smoking (Kupelian et al., 2007).

Nicotine binds to nicotinic receptors and induced contraction of corporal cells in rabbits; inhibition of cyclo-oxygenase, Rho Kinase, and thromboxane A2 synthesis reduces this contractile effect of nicotine (Nguyen et al., 2015). Rats exposed to tobacco smoke have impaired penile hemodynamics in response to cavernous nerve electrostimulation; this is associated with decreased NOS expression and increased oxidative stress and apoptosis in corporal tissues (Huang et al., 2015). Chronic exposure to tobacco extracts has also been linked to impaired NO production from blunted NOS activity, downregulation of nNOS protein, accumulation of endogenous NOS inhibitors, enhanced arginase activity, and upregulation of arginase I protein in cavernous tissue (Imamura et al., 2007).

Alcohol.

Alcohol in small amounts has been associated with improved erection and

sexual drive because of its vasodilatory effect and suppression of anxiety. In larger quantities, alcohol can cause central sedation, decreased libido, and transient ED. In the Western Australia Men's Health Study the age-adjusted odds of ED were lower among current, weekend, and binge drinkers compared with nondrinkers; the odds of ED were higher in ex-drinkers (Chew et al., 2009).

Chronic alcoholism may result in liver dysfunction, decreased testosterone and increased estrogen levels, and alcoholic polyneuropathy, which may also affect penile nerves (Miller and Gold, 1988). In an in vitro study of rabbits given 5% alcohol for 6 weeks, augmented smooth muscle contraction and relaxation to electrical field stimulation and vasoconstrictors such as phenylephrine and potassium chloride was noted. However, there was no increase in relaxation in response to sodium nitroprusside (Saito et al., 1994). Some of the effects of alcohol may be mediated by increased oxidative stress, reactivity to the constrictor effects of endothlin-1, and activation of the RhoA/Rho-kinase pathway (Muniz et al., 2015). Duration of exposure may also play a role; impaired endothelium-dependent relaxation of cavernous smooth muscle and damage of endothelium was reported in mice exposed to subacute ethanol dosing for 14 days; a 7-day exposure group did not manifest significant changes (Table 68.11; Aydinoglu et al., 2008).

TABLE 68.11

Drug-Induced Erectile Dysfunction and Suggested Alternatives

CLASS	KNOWN TO CAUSE ERECTILE DYSFUNCTION	SUGGESTED ALTERNATIVES
Antihypertensives	Thiazide diuretics General beta-blockers	**Angiotensin-converting enzyme inhibitors** **Angiotensin II receptor antagonists** **Selective beta-blockers** Alpha-blockers Calcium channel blockers
Psychotropics	Antipsychotics Antidepressants Anxiolytics	Newer anxiolytics (bupropion, buspirone)
Antiandrogen	Androgen receptor antagonists Luteinizing hormone–releasing hormone agonists 5α-Reductase inhibitors	n/a

Recreational drugs	Tobacco Alcohol (large volume)	Tobacco cessation Alcohol in moderate

Aging, Systemic Disease, and Other Causes

Numerous studies have indicated a progressive decline in sexual function in healthy aging men. **Greater latency to erection, less turgidity, decreased force and volume of ejaculation, a longer refractory period, reduced penile sensitivity, and reduced nocturnal erections are commonly reported with increasing age** (Masters and Johnson, 1977; Rowland et al., 1989; Schiavi and Schreiner-Engel, 1988)**. The cause of age-related declines in erectile function in healthy men is incompletely understood but may relate to** heightened cavernous muscle tone (Christ et al., 1990) and age-related decline in serum androgens (Kaiser et al., 1988). Age is also associated with impaired endothelial function through reduced eNOS expression and action, accelerated NO degradation, increased PDE activity, inhibition of NOS activity by endogenous NOS inhibitors, increased arginase activity, increased production of reactive oxygen species, inflammatory reactions, decreased endothelial progenitor cell number and function, and impaired telomerase activity or telomere shortening (Ferrini et al., 2001a, 2001b; Segal et al., 2012; Toda, 2012). Enhanced activity of the RhoA/Rho-kinase (Jin et al., 2006) and RAS pathways (Park et al., 2005) and decreased activity of the relaxant angiotensin-(1-7) pathway (Yousif et al., 2007) have also been associated with aging, At the structural level, age-associated changes in animal models of ED include decreased smooth muscle content and increased caliber of vascular spaces in the corpus cavernosum (Costa and Vendeira, 2008). Additional age-associated changes include decreased gap junction protein connexin 43 content (Suadicani et al., 2009) and increased apoptosis (Ferrini et al., 2001a, 2001b).

Diabetes Mellitus.

Diabetes mellitus is a common chronic disease, affecting 0.5% to 2% of the worldwide population. **ED is up to three times more common in men with diabetes (28% vs. 9.6%)** and tends to present at an earlier age (Feldman et al., 1994). The prevalence of ED increases with diabetes of increasing duration (McCulloch et al., 1980; McCulloch et al., 1984). ED among men with diabetes is more frequent in men with coexisting neuropathy and other signs of end-organ damage from diabetes (Fukui et al., 2012). **The presence of ED in a man with**

diabetes is associated with a greater than 14-fold higher risk of coronary artery disease, and cardiac mortality in men with diabetes (Gazzaruso et al., 2004). Diabetes mellitus may contribute to ED by disruption of penile arterial circulation (Wang et al., 1993), reduced androgen secretion, peripheral neuropathy, impaired endothelium-dependent relaxation of the corporeal smooth muscle (Saenz de Tejada et al., 1989), loss of smooth muscle structure and activity (Mersdorf et al., 1991), endothelial apoptosis (Condorelli et al., 2013), and oxidative stress (Belba et al., 2016).

Numerous type 1 and type 2 diabetic animal models have been used to study the basic mechanisms of diabetes-induced ED. In these animals, diabetes is associated with endothelial cell dysfunction, incompetent cavernous endothelial cell-cell junctions resulting in an increased prevalence of vascular disease (Ryu et al., 2013). Other effects include decreased nNOS, reduced activity of eNOS, oxidative stress, increased advanced glycation end products, decreased elastin, reduced VEGF, hypercontractility of cavernous erectile tissue, and decreased smooth muscle/collagen ratio leading to impairment of the veno-occlusive mechanism (Yang et al., 2013). Upregulation of the Wnt 10b pathway in corporal cells and fibroblasts of diabetic rats has been associated with fibrotic changes in the penis (Shin et al., 2014). Angiotensin II signaling has also been implicated in diabetes-induced structural changes and oxidative DNA damage in the corpus cavernosum of rats. The mechanisms of angiotensin II–mediated erectile impairment may relate to activation of TGF-β and the RhoA/Rho kinase pathway (Li et al., 2017). Modulation of angiotensin II by captopril, losartan, or angiotensin-(1-7) ameliorated the negative effects of diabetes mellitus (Kilarkaje et al., 2013; Yousif et al., 2014). Activated Rho-kinase mediates diabetes-induced elevation of vascular arginase activation and impairs corpora cavernosa relaxation (Toque et al., 2013). Insulin-like growth factor binding protein 3 (IGFBP3) is increased in animals models of ED; inhibition of IGFBP3 has been associated with improvement in corporal erectile response (Yang et al., 2013). Neuropathy, possibly related to the effect of advanced glycation end products on neuronal microcirculation, may also contribute to diabetes-induced ED (Cellek et al., 2013). Evolving evidence suggests a role for impairment of H_2S metabolism as a potential contributor to the diabetic ED phenotype (Zhang et al., 2016). Summaries of mechanistic studies in humans and animal models, derived from the committee report of the Second International Consultation of Sexual Medicine, are shown in Tables 68.12 and 68.13 (Saenz de Tejada et al., 2005).

TABLE 68.12

Summary Findings of Studies in Patients With Diabetes

FOCUS	FINDING
Anatomic	• Atheromatous lesions in large vessels and stenosis in pudendal and iliac arteries
Functional	• Decreased frequency and rigidity of nocturnal erections
	• Lower penile rigidity after intracavernous injection of vasodilators
	• High prevalence of penile arterial insufficiency on Doppler ultrasound
CAVERNOUS TISSUE STUDIES	
Ultrastructural	• Decreased smooth muscle content, increased collagen, thickening of basal lamina, and loss of endothelial cells (more severe in men with diabetes)
Functional	• Reduced eNOS and nNOS-mediated penile smooth muscle relaxation with preservation of NO-donor mediated relaxation • Increased advanced glycation end products in cavernous tissue • Contractile response to α-adrenergic agonist is higher in patients with type 1 but not type 2 diabetes • In human penile arteries, EDHF-mediated endothelium-dependent relaxation is significantly reduced in penile resistance arteries from patients with diabetes • Increased expression of collagen • Increased apoptosis in smooth muscle cells • Expression of tumor necrosis factor-α is also increased • Decreased insulin mediated transport of L-arginine and the essential cofactor NADPH, reducing NOS activity by absence of substrate • Increased expression of inducible arginase (arginase II) while depletes bioavailable L-arginine for NO production

EDHF, Endothelium-derived hyperpolarizing factor; *eNOS,* endothelial nitrous oxide synthase; *NADPH,* reduced nicotinamide adenine dinucleotide phosphate; *nNOS,* neuronal nitrous oxide synthase; *NO,* nitric oxide; *NOS,* nitric oxide synthase.

TABLE 68.13

Summary Findings of Studies in Diabetic Animal Models

MODEL	FINDING
Streptozocin-induced diabetic rats or mice	• NO-dependent selective nitrergic nerve degeneration in diabetes • Decreased endothelial and neurogenic NO-mediated cavernous muscle relaxation • Increased prostacyclin synthesis

	• Increased cavernous muscle tone owing to upregulation of ET-A receptors • Increased contractile prostaglandins and free oxygen radicals in hyperglycemic state, resulting in reduced response to acetylcholine • Increased glycated hemoglobin, which impairs endothelium-dependent relaxation in aorta and corpus cavernosum from diabetic rats • Impaired responses attributable to EDHF in the vasculature of diabetic animals • Reduced concentration and vascular content of L-arginine
Diabetic rabbit	• Production of cAMP in response to PGE_1 or forskolin is reduced after 6 months • Increased glucose-induced production of PKC mediated by oxidative stress • Oxidative stress interferes with endothelium-dependent relaxation of corpus cavernosum from rabbits

cAMP, Cyclic adenosine monophosphate; *EDHF,* endothelium-derived hyperpolarizing factor; *ET-A,* endothelin-A; *NO,* nitric oxide; *PGE_1,* prostaglandin E_1; *PKC,* protein kinase C.

Metabolic Syndrome.

The metabolic syndrome (MetS) refers to the constellation of glucose intolerance, insulin resistance, dyslipidemia, and hypertension which are often comorbid and related to visceral adiposity (Kaur, 2014). **MetS is an independent risk factor for ED, and the prevalence of ED increases as the number of metabolic syndrome components increases** (Esposito et al., 2005). MetS is associated with aging and decreased serum testosterone levels (Rodriguez et al., 2007). MetS has also been associated with elevated levels of estrogen, and some of the negative effects of MetS in an animal model (i.e., decreased smooth muscle content and impaired relaxation response to acetylcholine) were mitigated by administration of an estrogen receptor antagonist (Vignozzi et al., 2014). Additional molecular defects that may contribute to ED in MetS include impaired endothelial function and increased systemic inflammation (Esposito et al., 2005; La Vignera et al., 2012). Uncoupling of nNOS and dysfunctional nitrergic vasorelaxation of penile arteries has been reported in an animal model of MetS (see Fig. 68.13) (Sanchez et al., 2012). The various molecular and histologic defects associated with the component elements of MetS also contribute to ED.

Chronic Renal Failure.

Decreased sexual desire, ED, and ejaculatory impairment is common in men with chronic renal failure (Lai et al., 2007; Lew-Starowicz and Gellert, 2009). Up to 80% of men with end-stage renal disease manifest evidence of arterial and veno-occlusive ED (Kaufman et al., 1994). Many of the effects of uremia can potentially contribute to the development of ED, including disturbance of the hypothalamic–pituitary–testicular axis, hyperprolactinemia, and accelerated atheromatous disease (Ayub and Fletcher, 2000). Evidence from animal models of chronic uremia suggest that ED in renal failure may also be due to **decreased production and/or reduced bioavailability of endogenous NO, calcification of pudendal arteries, and decreased endothelial reactivity** (Bagcivan et al., 2003; Kielstein and Zoccali, 2005; Maio et al., 2014). Abnormalities of vascular and bulbocavernous reflexes in men with uremia suggest that autonomic neuropathy may also contribute to ED (Campese et al., 1982; Vita et al., 1999). In the setting of uremia nerves are thought to exist in a chronically depolarized state, likely related to serum potassium level. This effect may be mitigated by dialysis and may contribute to ED in this population (Krishnan and Kiernan, 2007). The presence of depressive symptoms is also an independent factor predicting sexual dysfunction in male hemodialysis patients (Peng et al., 2007).

Significant improvement of sexual function may occur after kidney transplantation (Tavallaii et al., 2009). Nevertheless, in a report of 182 men who had undergone kidney transplantation, 49% of men continued to have ED and 18% were sexually inactive (Espinoza et al., 2006).

Hyperuricemia.

Elevated serum uric acid has been linked to worse erectile function in men (Aribas et al., 2014), although in one study the effect lost significance after controlling for glomerular filtration rate (Solak et al., 2014). In animal models of hyperuricemia impairment of erectile responses are noted; these findings are associated with decreased expression of NOS isoforms and oxidative stress in the penis (Long et al., 2016).

Other Chronic Medical Conditions.

HIV appears to be a direct cause of ED; men with HIV also experience substantial stress (fear of virus transmission, changes in body image, HIV-related comorbidities, infection stigma, obligatory condom use), which may contribute to psychogenic ED (Santi et al., 2014). Other chronic diseases such as hepatitis

(Chung et al., 2012), dermatitis (Chung et al., 2012), scleroderma (Rosato et al., 2013), chronic obstructive pulmonary disease (Lauretti et al., 2016), and likely many others are known to be associated with ED.

Primary Erectile Dysfunction

Primary ED refers to a **lifelong inability to initiate and/or maintain erections beginning with the first sexual encounter or masturbation.** Primary psychological ED is often related to anxiety about sexual performance stemming from adverse childhood events, traumatic early sexual experience, or misinformation. Although some cases of primary ED are primarily due to psychological factors and all cases feature psychological components, maldevelopment of the penis or its blood/nerve innervation may also lead to primary ED. Endocrine abnormalities, particularly low testosterone levels, are also implicated in some cases of primary ED, although decreased sex drive is likely to be the main symptom in this situation. Evidence to support these concepts is confined to observational studies with varying numbers of cases (Stief et al., 1989).

Micropenis.

Micropenis is defined as symmetrical hypoplasia of the phallus and is often related to urethral developmental abnormalities such as hypospadias and epispadias or endocrine deficiency (Reilly and Woodhouse, 1989). The erectile tissue in such cases often functions normally; sexual dysfunction usually relates to lack of penile length or the degree of chordee, rather than to ED (Woodhouse, 1998).

Vascular Abnormalities.

Primary ED in the presence of an externally normal phallus is unusual. Authors have described structural abnormalities of the cavernous tissue, such as absence (Teloken et al., 1993) or replacement by fibrous tissue (Aboseif et al., 1992). Other authors have found vascular abnormalities, including hypoplasia of the cavernous arteries (Montague et al., 1995) or veno-occlusive dysfunction because of aberrant cavernous venous drainage (Lue, 1999). The underlying cause of these congenital abnormalities is unknown. Treatment in most cases is vascular surgery or implantation of a penile prosthesis; data on outcomes are scant.

Key Points: Other Causes of Erectile Dysfunction

- Aging is an important contributing factor to ED. The aging process can affect central regulation of erections, hormone levels, neuronal integrity, vascular flow, and penile structures.
- Diabetes mellitus and metabolic syndrome affect many organ systems and are associated with particularly severe ED phenotypes.
- ED is associated with a number of chronic health conditions and may be a sentinel event for serious disease.
- Drugs most commonly associated with ED include antiandrogens, antidepressants, and antihypertensives.
- Primary ED may be due to psychogenic causes, inexperience, congenital penile anomalies, or defects of penile vascular structures.

Perspectives

The past two decades have seen a continuing explosion of new information on the physiology of penile erection and the pathophysiology of ED. These new discoveries not only enhance our understanding of the disease process but also provide a solid basis for improving diagnosis and treatment. We can expect that the application of new research tools and information in molecular biology, signal transduction, growth factors, microarrays, and stem cells will improve our understanding of erectile function and ability to help men (and their partners) who are suffering from this condition.

Suggested Readings

Andersson KE. Mechanisms of penile erection and basis for pharmacological treatment of erectile dysfunction. *Pharmacol Rev*. 2011;63:811–859.

Gandaglia G, Briganti A, Jackson G, et al. A systematic review of the association between erectile dysfunction and cardiovascular disease. *Eur Urol*. 2014;65:968–978.

Gratzke C, Angulo J, Chitaley K, et al. Anatomy, physiology, and pathophysiology of erectile dysfunction. *J Sex Med*. 2010;7(1 Pt 2):445–475.

Montorsi F, Adaikan G, Becher E, et al. Summary of the recommendations on sexual dysfunctions in men. *J Sex Med*. 2010;7:3572–3588.

Musicki B, Bella AJ, Bivalacqua TJ, et al. Basic science evidence for the link between erectile dysfunction and cardiometabolic dysfunction. *J Sex Med*. 2015;12:2233–2255.

Nehra A, Jackson G, Miner M, et al. The Princeton III Consensus recommendations for the management of erectile dysfunction and cardiovascular disease. *Mayo Clin Proc*. 2012;87:766–778.

References

Abd Elmoneim H, Sharabi F, Mohy El Din M, et al. Potassium channels modulate the action but not the synthesis of hydrogen sulfide in rat corpus cavernosum. *Life Sci*. 2017;189:39–43.

Abdel Aziz MT, Mostafa T, Atta H, et al. Putative role of carbon monoxide signaling pathway in penile erectile function. *J Sex Med*. 2009;6(1):49–60; 10.1111/j.1743-6109.2008.01050.x.

Aboseif SR, Baskin LS, Yen TS, et al. Congenital defect in sinusoidal smooth muscles: a cause of organic impotence. *J Urol*. 1992;148(1):58–60.

Abs R, Verhelst J, Maeyaert J, et al. Endocrine consequences of long-term intrathecal administration of opioids. *J Clin Endocrinol Metab*. 2000;85(6):2215–2222.

Adverse reactions to bendrofluazide and propranolol for the treatment of mild hypertension. Report of Medical Research Council Working Party on Mild to Moderate Hypertension. *Lancet*. 1981;2(8246):539–543.

Ahn TY, Gomez-Coronado D, Martinez V, et al. Enhanced contractility of rabbit corpus cavernosum smooth muscle by oxidized low density lipoproteins. *Int J Impot Res*. 1999;11(1):9–14.

Aizenberg D, Zemishlany Z, Dorfman-Etrog P, et al. Sexual dysfunction in male schizophrenic patients. *J Clin Psychiatry*. 1995;56(4):137–141.

Alves-Lopes RU, Neves KB, Silva MA, et al. Functional and structural changes in internal pudendal arteries underlie erectile dysfunction induced by androgen deprivation. *Asian J Androl*. 2017;19(5):526–532; 10.4103/1008-682X.173935.

Andersen ML, Guindalini C, Santos-Silva R, et al. Androgen receptor CAG repeat polymorphism is not associated with erectile dysfunction complaints, gonadal steroids, and sleep parameters: data from a population-based survey. *J Androl*. 2011;32(5):524–529; 10.2164/jandrol.110.012013.

Andersson KE. Pharmacology of penile erection. *Pharmacol Rev*. 2001;53(3):417–450.

Andersson KE. Mechanisms of penile erection and basis for pharmacological treatment of erectile dysfunction. *Pharmacol Rev*. 2011;63(4):811–859.

Andersson KE, Wagner G. Physiology of penile erection. *Physiol Rev*. 1995;75(1):191–236.

Andreopoulos S, Papapetropoulos A. Molecular aspects of soluble guanylyl cyclase regulation. *Gen Pharmacol*. 2000;34(3):147–157.

Angeloni NL, Bond CW, McVary KT, et al. Sonic hedgehog protein is decreased and penile morphology is altered in prostatectomy and diabetic patients. *PLoS ONE*. 2013;8(8):e70985.

Angulo J, Bischoff E, Gabancho S, et al. Vardenafil reverses erectile dysfunction induced by paroxetine in rats. *Int J Impot Res*. 2003;15(2):90–93.

Angulo J, Cuevas P, Fernandez A, et al. Combination of phentolamine and L-arginine or sildenafil synergistically improves neurogenic relaxation of rabbit corpus cavernosum smooth muscle. *Urology*. 2001;57(3):585–589.

Angulo J, Cuevas P, Fernandez A, et al. Calcium dobesilate potentiates endothelium-derived hyperpolarizing factor-mediated relaxation of human penile resistance arteries. *Br J Pharmacol*. 2003;139(4):854–862.

Angulo J, Cuevas P, La Fuente JM, et al. Regulation of human penile smooth muscle tone by prostanoid receptors. *Br J Pharmacol*. 2002;136(1):23–30.

Angulo J, Peiro C, Sanchez-Ferrer CF, et al. Differential effects of serotonin reuptake inhibitors on erectile responses, NO-production, and neuronal NO synthase expression in rat corpus cavernosum tissue. *Br J Pharmacol*. 2001;134(6):1190–1194.

Argiolas A. Oxytocin stimulation of penile erection. Pharmacology, site, and mechanism of action. *Ann N Y Acad Sci*. 1992;652:194–203.

Aribas A, Kayrak M, Ulucan S, et al. The relationship between uric acid and erectile dysfunction in hypertensive subjects. *Blood Press*. 2014;23(6):370–376.

Armani A, Berry A, Cirulli F, et al. Molecular mechanisms underlying metabolic syndrome: the expanding role of the adipocyte. *FASEB J*. 2017;31(10):4240–4255; 10.1096/fj.201601125RRR.

Arribas SM, Briones AM, Bellingham C, et al. Heightened aberrant deposition of hard-wearing elastin in conduit arteries of prehypertensive SHR is associated with increased stiffness and inward remodeling. *Am J Physiol Heart Circ Physiol*. 2008;295(6):H2299–H2307; 10.1152/ajpheart.00155.2008.

Awwad Z, Abu-Hijleh M, Basri S, et al. Penile measurements in normal adult Jordanians and in patients with erectile dysfunction. *Int J Impot Res*. 2005;17(2):191–195; 10.1038/sj.ijir.3901272.

Aydinoglu F, Yilmaz SN, Coskun B, et al. Effects of ethanol treatment on the neurogenic and endothelium-dependent relaxation of corpus cavernosum smooth muscle in the mouse. *Pharmacol Rep*. 2008;60(5):725–734.

Ayub W, Fletcher S. End-stage renal disease and erectile dysfunction. Is there any hope? *Nephrol Dial Transplant*. 2000;15(10):1525–1528.

Azadzoi KM, Goldstein I, Siroky MB, et al. Mechanisms of ischemia-induced cavernosal smooth muscle relaxation impairment in a rabbit model of vasculogenic erectile dysfunction. *J Urol*. 1998;160(6 Pt 1):2216–2222.

Azadzoi KM, Kim N, Brown ML, et al. Endothelium-derived nitric oxide and cyclooxygenase products modulate corpus cavernosum smooth muscle tone. *J Urol*. 1992;147(1):220–225.

Azadzoi KM, Krane RJ, Saenz de Tejada I, et al. Relative roles of cyclooxygenase and nitric oxide synthase pathways in ischemia-induced increased contraction of cavernosal smooth muscle. *J Urol*. 1999;161(4):1324–1328.

Azadzoi KM, Park K, Andry C, et al. Relationship between cavernosal ischemia and corporal veno-occlusive dysfunction in an animal model. *J Urol*. 1997;157(3):1011–1017.

Azadzoi KM, Saenz de Tejada I. Hypercholesterolemia impairs endothelium-dependent relaxation of rabbit corpus cavernosum smooth muscle. *J Urol*. 1991;146(1):238–240.

Bacon CG, Mittleman MA, Kawachi I, et al. A prospective study of risk factors for erectile dysfunction. *J Urol*. 2006;176(1):217–221.

Bagcivan I, Kilicarslan H, Sarac B, et al. The evaluation of the effects of renal failure on erectile dysfunction in a rabbit model of chronic renal failure. *BJU Int*. 2003;91(7):697–701.

Bakircioglu ME, Sievert KD, Nunes L, et al. Decreased trabecular smooth muscle and caveolin-1 expression in the penile tissue of aged rats. *J Urol*. 2001;166(2):734–738.

Bank AJ, Kelly AS, Kaiser DR, et al. The effects of quinapril and atorvastatin on the responsiveness to sildenafil in men with erectile dysfunction. *Vasc Med*. 2006;11(4):251–257.

Barbery CE, Celigoj FA, Turner SD, et al. Alterations in microRNA expression in a murine model of diet-induced vasculogenic erectile dysfunction. *J Sex Med*. 2015;12(3):621–630; 10.1111/jsm.12793.

Basaria S, Lieb J 2nd, Tang AM, et al. Long-term effects of androgen deprivation therapy in prostate cancer patients. *Clin*

Endocrinol (Oxf). 2002;56(6):779–786.

Baskerville TA, Allard J, Wayman C, et al. Dopamine-oxytocin interactions in penile erection. *Eur J Neurosci*. 2009;30(11):2151–2164.

Baumhakel M, Schlimmer N, Bohm M, et al. Effect of irbesartan on erectile function in patients with hypertension and metabolic syndrome. *Int J Impot Res*. 2008;20(5):493–500.

Baumhakel M, Werner N, Bohm M, et al. Circulating endothelial progenitor cells correlate with erectile function in patients with coronary heart disease. *Eur Heart J*. 2006;27(18):2184–2188.

Belba A, Cortelazzo A, Andrea G, et al. Erectile dysfunction and diabetes: association with the impairment of lipid metabolism and oxidative stress. *Clin Biochem*. 2016;49(1–2):70–78.

Benedict C, Traeger L, Dahn JR, et al. Sexual bother in men with advanced prostate cancer undergoing androgen deprivation therapy. *J Sex Med*. 2014;11(10):2571–2580.

Bener A, Al-Hamaq AO, Kamran S, et al. Prevalence of erectile dysfunction in male stroke patients, and associated co-morbidities and risk factors. *Int Urol Nephrol*. 2008;40(3):701–708.

Berridge MJ. Smooth muscle cell calcium activation mechanisms. *J Physiol*. 2008;586(21):5047–5061.

Bhasin S, Cunningham GR, Hayes FJ, et al. Testosterone therapy in men with androgen deficiency syndromes: an Endocrine Society clinical practice guideline. *J Clin Endocrinol Metab*. 2010;95(6):2536–2559.

Biebel MG, Burnett AL, Sadeghi-Nejad H. Male sexual function and smoking. *Sex Med Rev*. 2016;4(4):366–375.

Biering-Sorensen F, Sonksen J. Sexual function in spinal cord lesioned men. *Spinal Cord*. 2001;39(9):455–470.

Billington CJ, Shafer RB, Morley JE. Effects of opioid blockade with nalmefene in older impotent men. *Life Sci*. 1990;47(9):799–805.

Bitran D, Hull EM. Pharmacological analysis of male rat sexual behavior. *Neurosci Biobehav Rev*. 1987;11(4):365–389.

Bivalacqua TJ, Champion HC, Abdel-Mageed AB, et al. Gene transfer of prepro-calcitonin gene-related peptide restores erectile function in the aged rat. *Biol Reprod*. 2001;65(5):1371–1377.

Bivalacqua TJ, Champion HC, Usta MF, et al. RhoA/Rho-kinase suppresses endothelial nitric oxide synthase in the penis: a mechanism for diabetes-associated erectile dysfunction. *Proc Natl Acad Sci USA*. 2004;101(24):9121–9126.

Bivalacqua TJ, Diner EK, Novak TE, et al. A rat model of Peyronie's disease associated with a decrease in erectile activity and an increase in inducible nitric oxide synthase protein expression. *J Urol*. 2000;163(6):1992–1998.

Bivalacqua TJ, Liu T, Musicki B, et al. Endothelial nitric oxide synthase keeps erection regulatory function balance in the penis. *Eur Urol*. 2007;51(6):1732–1740.

Bivalacqua TJ, Musicki B, Hsu LL, et al. Establishment of a transgenic sickle-cell mouse model to study the pathophysiology of priapism. *J Sex Med*. 2009;6(9):2494–2504.

Blanco R, Saenz de Tejada I, Goldstein I, et al. Cholinergic neurotransmission in human corpus cavernosum. II. Acetylcholine synthesis. *Am J Physiol*. 1988;254(3 Pt 2):H468–H472.

Bond CW, Angeloni N, Harrington D, et al. Sonic Hedgehog regulates brain-derived neurotrophic factor in normal and regenerating cavernous nerves. *J Sex Med*. 2013;10(3):730–737.

Boolell M, Allen MJ, Ballard SA, et al. Sildenafil: an orally active type 5 cyclic GMP-specific phosphodiesterase inhibitor for the treatment of penile erectile dysfunction. *Int J Impot Res*. 1996;8(2):47–52.

Borchers H, Brehmer B, Kirschner-Hermanns R, et al. Erectile function after non-nerve-sparing radical prostatectomy: fact or fiction? *Urol Int*. 2006;76(3):213–216.

Bosch RJ, Benard F, Aboseif SR, et al. Penile detumescence: characterization of three phases. *J Urol*. 1991;146(3):867–871.

Boydak B, Nalbantgil S, Fici F, et al. A Randomised Comparison of the Effects of Nebivolol and Atenolol with and without Chlorthalidone on the Sexual Function of Hypertensive Men. *Clin Drug Investig*. 2005;25(6):409–416.

Brave SR, Bhat S, Hobbs AJ, et al. The influence of L-NG-nitro-arginine on sympathetic nerve induced contraction and noradrenaline release in the rat isolated anococcygeus muscle. *J Auton Pharmacol*. 1993;13(3):219–225.

Brenot PH. *L'impuissance masculine*. [France] 1994.

Breza J, Aboseif SR, Orvis BR, et al. Detailed anatomy of penile neurovascular structures: surgical significance. *J Urol*. 1989;141(2):437–443.

Brixius K, Middeke M, Lichtenthal A, et al. Nitric oxide, erectile dysfunction and beta-blocker treatment (MR NOED study): benefit of nebivolol versus metoprolol in hypertensive men. *Clin Exp Pharmacol Physiol*. 2007;34(4):327–331.

Bruckert E, Giral P, Heshmati HM, et al. Men treated with hypolipidaemic drugs complain more frequently of erectile dysfunction. *J Clin Pharm Ther*. 1996;21(2):89–94.

Brunner H, Cockcroft JR, Deanfield J, Endothelial Factors of the European Society of, H, et al. Endothelial function and dysfunction. Part II: association with cardiovascular risk factors and diseases. A statement by the Working Group on

Endothelins and Endothelial Factors of the European Society of Hypertension. *J Hypertens*. 2005;23(2):233–246.

Burnett AL, Musicki B. The nitric oxide signaling pathway in the penis. *Curr Pharm Des*. 2005;11(31):3987–3994.

Burnett AL, Nelson RJ, Calvin DC, et al. Nitric oxide-dependent penile erection in mice lacking neuronal nitric oxide synthase. *Mol Med*. 1996;2(3):288–296.

Burnett AL, Tillman SL, Chang TS, et al. Immunohistochemical localization of nitric oxide synthase in the autonomic innervation of the human penis. *J Urol*. 1993;150(1):73–76.

Campese VM, Procci WR, Levitan D, et al. Autonomic nervous system dysfunction and impotence in uremia. *Am J Nephrol*. 1982;2(3):140–143.

Campos de Carvalho AC, Roy C, Moreno AP, et al. Gap junctions formed of connexin43 are found between smooth muscle cells of human corpus cavernosum. *J Urol*. 1993;149(6):1568–1575.

Carosa E, Castri A, Forcella C, et al. Platelet-derived growth factor regulation of type-5 phosphodiesterase in human and rat penile smooth muscle cells. *J Sex Med*. 2014;11(7):1675–1684.

Carrier S, Hricak H, Lee SS, et al. Radiation-induced decrease in nitric oxide synthase–containing nerves in the rat penis. *Radiology*. 1995;195(1):95–99.

Carrier S, Nagaraju P, Morgan DM, et al. Age decreases nitric oxide synthase-containing nerve fibers in the rat penis. *J Urol*. 1997;157(3):1088–1092.

Cattabiani C, Basaria S, Ceda GP, et al. Relationship between testosterone deficiency and cardiovascular risk and mortality in adult men. *J Endocrinol Invest*. 2012;35(1):104–120.

Cellek S, Cameron NE, Cotter MA, et al. Pathophysiology of diabetic erectile dysfunction: potential contribution of vasa nervorum and advanced glycation endproducts. *Int J Impot*

Res. 2013;25(1):1–6.

Cellek S, Rees RW, Kalsi J. A Rho-kinase inhibitor, soluble guanylate cyclase activator and nitric oxide-releasing PDE5 inhibitor: novel approaches to erectile dysfunction. *Expert Opin Investig Drugs*. 2002;11(11):1563–1573.

Cera N, Di Pierro ED, Ferretti A, et al. Brain networks during free viewing of complex erotic movie: new insights on psychogenic erectile dysfunction. *PLoS ONE*. 2014;9(8):e105336.

Chai SJ, Barrett-Connor E, Gamst A. Small-vessel lower extremity arterial disease and erectile dysfunction: the Rancho Bernardo study. *Atherosclerosis*. 2009;203(2):620–625.

Chapelle PA, Durand J, Lacert P. Penile erection following complete spinal cord injury in man. *Br J Urol*. 1980;52(3):216–219.

Charron F, Stein E, Jeong J, et al. The morphogen sonic hedgehog is an axonal chemoattractant that collaborates with netrin-1 in midline axon guidance. *Cell*. 2003;113(1):11–23.

Chaudhuri KR, Schapira AH. Non-motor symptoms of Parkinson's disease: dopaminergic pathophysiology and treatment. *Lancet Neurol*. 2009;8(5):464–474.

Chehensse C, Facchinetti P, Bahrami S, et al. Human spinal ejaculation generator. *Ann Neurol*. 2017;81(1):35–45.

Chen G, Yang B, Chen J, et al. Changes in male rat sexual behavior and brain activity revealed by functional magnetic resonance imaging in response to chronic mild stress. *J Sex Med*. 2017.

Chen SC, Hsieh CH, Hsu GL, et al. The progression of the penile vein: could it be recurrent? *J Androl*. 2005;26(1):53–60.

Chew KK, Bremner A, Stuckey B, et al. Alcohol consumption and male erectile dysfunction: an unfounded reputation for risk? *J Sex Med*. 2009;6(5):1386–1394.

Chiang PH, Chiang CP, Shen MR, et al. Study of the changes in collagen of the tunica albuginea in venogenic impotence and Peyronie's disease. *Eur Urol*. 1992;21(1):48–51.

Chitaley K, Kupelian V, Subak L, et al. Diabetes, obesity and erectile dysfunction: field overview and research priorities. *J Urol*. 2009;182(6 Suppl):S45–S50.

Chitaley K, Webb RC, Mills TM. RhoA/Rho-kinase: a novel player in the regulation of penile erection. *Int J Impot Res*. 2001;13(2):67–72.

Choe S, Bond CW, Harrington DA, et al. Peptide amphiphile nanofiber hydrogel delivery of sonic hedgehog protein to the cavernous nerve to promote regeneration and prevent erectile dysfunction. *Nanomedicine (Lond)*. 2017;13(1):95–101.

Choe S, Veliceasa D, Bond CW, et al. Sonic hedgehog delivery from self-assembled nanofiber hydrogels reduces the fibrotic response in models of erectile dysfunction. *Acta Biomater*. 2016;32:89–99.

Christ GJ. K+ channels and gap junctions in the modulation of corporal smooth muscle tone. *Drug News Perspect*. 2000;13(1):28–36.

Christ GJ, Brink PR, Melman A, et al. The role of gap junctions and ion channels in the modulation of electrical and chemical signals in human corpus cavernosum smooth muscle. *Int J Impot Res*. 1993;5(2):77–96.

Christ GJ, Lerner SE, Kim DC, et al. Endothelin-1 as a putative modulator of erectile dysfunction: I. Characteristics of contraction of isolated corporal tissue strips. *J Urol*. 1995;153(6):1998–2003.

Christ GJ, Maayani S, Valcic M, et al. Pharmacological studies of human erectile tissue: characteristics of spontaneous contractions and alterations in alpha-adrenoceptor responsiveness with age and disease in isolated tissues. *Br J*

Pharmacol. 1990;101(2):375–381.

Christ GJ, Moreno AP, Parker ME, et al. Intercellular communication through gap junctions: a potential role in pharmacomechanical coupling and syncytial tissue contraction in vascular smooth muscle isolated from the human corpus cavernosum. *Life Sci*. 1991;49(24):PL195–PL200.

Chung SD, Keller JJ, Liang YC, et al. Association between viral hepatitis and erectile dysfunction: a population-based case-control analysis. *J Sex Med*. 2012;9(5):1295–1302.

Chung SD, Keller JJ, Lin HC. Association of erectile dysfunction with atopic dermatitis: a population-based case-control study. *J Sex Med*. 2012;9(3):679–685.

Clark JT, Smith ER, Davidson JM. Evidence for the modulation of sexual behavior by alpha-adrenoceptors in male rats. *Neuroendocrinology*. 1985;41(1):36–43.

Clement P, Giuliano F. Physiology and pharmacology of ejaculation. *Basic Clin Pharmacol Toxicol*. 2016;119(Suppl 3):18–25.

Clinton TN, Woldu SL, Raj GV. Degarelix versus luteinizing hormone-releasing hormone agonists for the treatment of prostate cancer. *Expert Opin Pharmacother*. 2017;18(8):825–832.

Coleman CC, King BR, Bolden-Watson C, et al. A placebo-controlled comparison of the effects on sexual functioning of bupropion sustained release and fluoxetine. *Clin Ther*. 2001;23(7):1040–1058.

Collazos J. Sexual dysfunction in the highly active antiretroviral therapy era. *AIDS Rev*. 2007;9(4):237–245.

Comerma-Steffensen SG, Carvacho I, Hedegaard ER, et al. Small and intermediate calcium-activated potassium channel openers improve rat endothelial and erectile function. *Front Pharmacol*. 2017;8:660.

Condorelli RA, Calogero AE, Favilla V, et al. Arterial erectile dysfunction: different severities of endothelial apoptosis between diabetic patients “responders” and “non responders” to sildenafil. *Eur J Intern Med*. 2013;24(3):234–240.

Conner AC, Hay DL, Howitt SG, et al. Interaction of calcitonin-gene-related peptide with its receptors. *Biochem Soc Trans*. 2002;30(4):451–455.

Corbin JD, Turko IV, Beasley A, et al. Phosphorylation of phosphodiesterase-5 by cyclic nucleotide-dependent protein kinase alters its catalytic and allosteric cGMP-binding activities. *Eur J Biochem*. 2000;267(9):2760–2767.

Corona G, Isidori AM, Aversa A, et al. Endocrinologic control of men's sexual desire and arousal/erection. *J Sex Med*. 2016;13(3):317–337.

Corona G, Isidori AM, Buvat J, et al. Testosterone supplementation and sexual function: a meta-analysis study. *J Sex Med*. 2014;11(6):1577–1592.

Corona G, Mannucci E, Jannini EA, et al. Hypoprolactinemia: a new clinical syndrome in patients with sexual dysfunction. *J Sex Med*. 2009;6(5):1457–1466.

Corona G, Monami M, Boddi V, et al. Male sexuality and cardiovascular risk. A cohort study in patients with erectile dysfunction. *J Sex Med*. 2010;7(5):1918–1927.

Corvol P, Michaud A, Menard J, et al. Antiandrogenic effect of spirolactones: mechanism of action. *Endocrinology*. 1975;97(1):52–58.

Cosentino F, Patton S, d'Uscio LV, et al. Tetrahydrobiopterin alters superoxide and nitric oxide release in prehypertensive rats. *J Clin Invest*. 1998;101(7):1530–1537.

Costa C, Vendeira P. Does erectile tissue angioarchitecture modify with aging? An immunohistological and morphometric approach. *J Sex Med*. 2008;5(4):833–840.

Costa WS, Carrerete FB, Horta WG, et al. Comparative analysis of the penis corpora cavernosa in controls and patients with erectile dysfunction. *BJU Int*. 2006;97(3):567–569.

Courtois F, Carrier S, Charvier K, et al. The control of male sexual responses. *Curr Pharm Des*. 2013;19(24):4341–4356.

Courtois FJ, Goulet MC, Charvier KF, et al. Posttraumatic erectile potential of spinal cord injured men: how physiologic recordings supplement subjective reports. *Arch Phys Med Rehabil*. 1999;80(10):1268–1272.

Croft H, Settle E Jr, Houser T, et al. A placebo-controlled comparison of the antidepressant efficacy and effects on sexual functioning of sustained-release bupropion and sertraline. *Clin Ther*. 1999;21(4):643–658; 10.1016/S0149-2918(00)88317-4.

Croog SH, Levine S, Sudilovsky A, et al. Sexual symptoms in hypertensive patients. A clinical trial of antihypertensive medications. *Arch Intern Med*. 1988;148(4):788–794.

Croog SH, Levine S, Testa MA, et al. The effects of antihypertensive therapy on the quality of life. *N Engl J Med*. 1986;314(26):1657–1664.

Crum NF, Furtek KJ, Olson PE, et al. A review of hypogonadism and erectile dysfunction among HIV-infected men during the pre- and post-HAART eras: diagnosis, pathogenesis, and management. *AIDS Patient Care STDS*. 2005;19(10):655–671.

Cui Y, Zong H, Yan H, et al. The effect of statins on erectile dysfunction: a systematic review and meta-analysis. *J Sex Med*. 2014;11(6):1367–1375.

Cunningham GR, Stephens-Shields AJ, Rosen RC, et al. Testosterone treatment and sexual function in older men with low testosterone levels. *J Clin Endocrinol Metab*. 2016;101(8):3096–3104; 10.1210/jc.2016-1645.

Cushman WC, Cohen JD, Jones RP, et al. Comparison of the fixed combination of enalapril/diltiazem ER and their monotherapies in stage 1 to 3 essential hypertension. *Am J Hypertens*. 1998;11(1 Pt 1):23–30.

d'Emmanuele di Villa Bianca R, Sorrentino R, Mirone V, et al. Hydrogen sulfide and erectile function: a novel therapeutic target. *Nat Rev Urol*. 2011;8(5):286–289.

Dai Y, Zhang Y, Phatarpekar P, et al. Adenosine signaling, priapism and novel therapies. *J Sex Med*. 2009;6(Suppl 3):292–301.

Danjou P, Alexandre L, Warot D, et al. Assessment of erectogenic properties of apomorphine and yohimbine in man. *Br J Clin Pharmacol*. 1988;26(6):733–739.

de Groat WC, Booth AM. *Neural control of penile erection*. Harwood: London; 1993.

Decaluwe K, Pauwels B, Boydens C, et al. Erectile dysfunction in heme-deficient nitric oxide-unresponsive soluble guanylate cyclase knock-in mice. *J Sex Med*. 2017;14(2):196–204.

Decaluwe K, Pauwels B, Boydens C, et al. Divergent molecular mechanisms underlay CO- and CORM-2-induced relaxation of corpora cavernosa. *J Sex Med*. 2012;9(9):2284–2292.

Dellis A, Papatsoris A. Therapeutic outcomes of the LHRH antagonists. *Expert Rev Pharmacoecon Outcomes Res*. 2017;17(5):481–488.

Derby CA, Barbour MM, Hume AL, et al. Drug therapy and prevalence of erectile dysfunction in the Massachusetts Male Aging Study cohort. *Pharmacotherapy*. 2001;21(6):676–683.

Dessauer CW, Watts VJ, Ostrom RS, et al. International Union of Basic and Clinical Pharmacology. CI. Structures and small molecule modulators of mammalian adenylyl cyclases. *Pharmacol Rev*. 2017;69(2):93–139.

Diallo D, Zaitouna M, Alsaid B, et al. What is the origin of the arterial vascularization of the corpora cavernosa? A computer-assisted anatomic dissection study. *J Anat*. 2013;223(5):489–494.

Diederichs W, Stief CG, Benard F, et al. The sympathetic role as an antagonist of erection. *Urol Res*. 1991;19(2):123–126.

Diederichs W, Stief CG, Lue TF, et al. Sympathetic inhibition of papaverine induced erection. *J Urol*. 1991;146(1):195–198.

Dimitropoulos K, Karatzas A, Papandreou C, et al. Sexual dysfunction in testicular cancer patients subjected to post-chemotherapy retroperitoneal lymph node dissection: a focus beyond ejaculation disorders. *Andrologia*. 2016;48(4):425–430.

DiSanto ME, Wang Z, Menon C, et al. Expression of myosin isoforms in smooth muscle cells in the corpus cavernosum penis. *Am J Physiol*. 1998;275(4 Pt 1):C976–C987.

Dogru MT, Basar MM, Simsek A, et al. Effects of statin treatment on serum sex steroids levels and autonomic and erectile function. *Urology*. 2008;71(4):703–707; 10.1016/j.urology.2007.11.059.

Doumas M, Tsakiris A, Douma S, et al. Factors affecting the increased prevalence of erectile dysfunction in Greek hypertensive compared with normotensive subjects. *J Androl*. 2006;27(3):469–477.

Droupy S, Benoit G, Giuliano F, et al. Penile arteries in humans. Origin–distribution–variations. *Surg Radiol Anat*. 1997;19(3):161–167.

El-Kamshoushi AA, Abdallah WI, Helal SF, et al. A study of the early changes of the level of calcitonin gene-related Peptide and histopathology of penises of rats with experimentally induced type I diabetes mellitus by streptozocin. *Sex Med*. 2013;1(1):21–29.

El Melegy NT, Ali ME, Awad EM. Plasma levels of endothelin-1, angiotensin II, nitric oxide and prostaglandin E in the venous and cavernosal blood of patients with erectile dysfunction. *BJU Int*. 2005;96(7):1079–1086.

Elcioglu KH, Kabasakal L, Cetinel S, et al. Changes in caveolin-1 expression and vasoreactivity in the aorta and corpus cavernosum of fructose and streptozotocin-induced diabetic rats. *Eur J Pharmacol*. 2010;642(1–3):113–120.

Ellati RT, Dokun AO, Kavoussi PK, et al. Increased phosphodiesterase type 5 levels in a mouse model of type 2 diabetes mellitus. *J Sex Med*. 2013;10(2):362–369.

Ellison DH, Loffing J. Thiazide effects and adverse effects: insights from molecular genetics. *Hypertension*. 2009;54(2):196–202.

Eri LM, Tveter KJ. Safety, side effects and patient acceptance of the antiandrogen Casodex in the treatment of benign prostatic hyperplasia. *Eur Urol*. 1994;26(3):219–226.

Escrig A, Marin R, Mas M. Repeated PGE1 treatment enhances nitric oxide and erection responses to nerve stimulation in the rat penis by upregulating constitutive NOS isoforms. *J Urol*. 1999;162(6):2205–2210.

Espinoza R, Gracida C, Cancino J, et al. Prevalence of erectile dysfunction in kidney transplant recipients. *Transplant Proc*. 2006;38(3):916–917.

Esposito K, Ciotola M, Maiorino MI, et al. Circulating CD34+ KDR+ endothelial progenitor cells correlate with erectile function and endothelial function in overweight men. *J Sex Med*. 2009;6(1):107–114.

Esposito K, Giugliano F, Maiorino MI, et al. Dietary factors, Mediterranean diet and erectile dysfunction. *J Sex Med*. 2010;7(7):2338–2345.

Esposito K, Giugliano F, Martedi E, et al. High proportions of erectile dysfunction in men with the metabolic syndrome. *Diabetes Care*. 2005;28(5):1201–1203.

Facchinetti P, Giuliano F, Laurin M, et al. Direct brain projections onto the spinal generator of ejaculation in the rat. *Neuroscience*. 2014;272:207–216.

Fan SF, Brink PR, Melman A, et al. An analysis of the Maxi-K+

(KCa) channel in cultured human corporal smooth muscle cells. *J Urol*. 1995;153(3 Pt 1):818–825.

Fava M, Nurnberg HG, Seidman SN, et al. Efficacy and safety of sildenafil in men with serotonergic antidepressant-associated erectile dysfunction: results from a randomized, double-blind, placebo-controlled trial. *J Clin Psychiatry*. 2006;67(2):240–246.

Feldman HA, Goldstein I, Hatzichristou DG, et al. Impotence and its medical and psychosocial correlates: results of the Massachusetts Male Aging Study. *J Urol*. 1994;151(1):54–61.

Ferrini M, Magee TR, Vernet D, et al. Aging-related expression of inducible nitric oxide synthase and markers of tissue damage in the rat penis. *Biol Reprod*. 2001;64(3):974–982.

Ferrini M, Wang C, Swerdloff RS, et al. Aging-related increased expression of inducible nitric oxide synthase and cytotoxicity markers in rat hypothalamic regions associated with male reproductive function. *Neuroendocrinology*. 2001;74(1):1–11.

Ferrini MG, Magee TR, Vernet D, et al. Penile neuronal nitric oxide synthase and its regulatory proteins are present in hypothalamic and spinal cord regions involved in the control of penile erection. *J Comp Neurol*. 2003;458(1):46–61.

Fibbi B, Morelli A, Marini M, et al. Atorvastatin but not elocalcitol increases sildenafil responsiveness in spontaneously hypertensive rats by regulating the RhoA/ROCK pathway. *J Androl*. 2008;29(1):70–84.

Flack JM. The effect of doxazosin on sexual function in patients with benign prostatic hyperplasia, hypertension, or both. *Int J Clin Pract*. 2002;56(7):527–530.

Flores S, Choi J, Alex B, et al. Erectile dysfunction after plaque incision and grafting: short-term assessment of incidence and predictors. *J Sex Med*. 2011;8(7):2031–2037.

Fogari R, Zoppi A, Poletti L, et al. Sexual activity in hypertensive men treated with valsartan or carvedilol: a crossover study. *Am J Hypertens*. 2001;14(1):27–31.

Foreman MM, Hall JL, Love RL. The role of the 5-HT2 receptor in the regulation of sexual performance of male rats. *Life Sci*. 1989;45(14):1263–1270.

Foreman MM, Wernicke JF. Approaches for the development of oral drug therapies for erectile dysfunction. *Semin Urol*. 1990;8(2):107–112.

Foresta C, Caretta N, Lana A, et al. Circulating endothelial progenitor cells in subjects with erectile dysfunction. *Int J Impot Res*. 2005;17(3):288–290.

Fraga-Silva RA, Costa-Fraga FP, Faye Y, et al. An increased arginase activity is associated with corpus cavernosum impairment induced by hypercholesterolemia. *J Sex Med*. 2014;11(5):1173–1181.

Fraga-Silva RA, Montecucco F, Mach F, et al. Pathophysiological role of the renin-angiotensin system on erectile dysfunction. *Eur J Clin Invest*. 2013;43(9):978–985.

Francis SH, Busch JL, Corbin JD, et al. cGMP-dependent protein kinases and cGMP phosphodiesterases in nitric oxide and cGMP action. *Pharmacol Rev*. 2010;62(3):525–563.

Francis SH, Turko IV, Corbin JD. Cyclic nucleotide phosphodiesterases: relating structure and function. *Prog Nucleic Acid Res Mol Biol*. 2001;65:1–52.

Freeman ME, Kanyicska B, Lerant A, et al. Prolactin: structure, function, and regulation of secretion. *Physiol Rev*. 2000;80(4):1523–1631.

Fukui M, Tanaka M, Toda H, et al. Andropausal symptoms in men with Type 2 diabetes. *Diabet Med*. 2012;29(8):1036–1042.

Fung MM, Bettencourt R, Barrett-Connor E. Heart disease risk factors predict erectile dysfunction 25 years later: the Rancho Bernardo Study. *J Am Coll Cardiol*. 2004;43(8):1405–1411.

Gades NM, Jacobson DJ, McGree ME, et al. Longitudinal evaluation of sexual function in a male cohort: the Olmsted county study of urinary symptoms and health status among men. *J Sex Med*. 2009;6(9):2455–2466.

GamalEl Din SF, Rashed LA, Alghobary HA, et al. Are the cavernous tissue and serum levels of micro RNAs 200a and 206 elevated in patients with refractory veno-occlusive erectile dysfunction? A comparative study. *Urology*. 2017;108:108–113.

Gandaglia G, Briganti A, Montorsi P, et al. Diagnostic and therapeutic implications of erectile dysfunction in patients with cardiovascular disease. *Eur Urol*. 2016;70(2):219–222.

Ganong WF. *Neural basis of instinctual behavior and emotions*. 19th ed. Appleton and Lange: Stamford, CT; 1999.

Ganong WF. *Synaptic and junctional transmission*. 19th ed. Appleton and Lange: Samford, CT; 1999.

Garimella PS, Paudel ML, Ensrud KE, et al. Association between body size and composition and erectile dysfunction in older men: osteoporotic fractures in men study. *J Am Geriatr Soc*. 2013;61(1):46–54.

Gazzaruso C, Giordanetti S, De Amici E, et al. Relationship between erectile dysfunction and silent myocardial ischemia in apparently uncomplicated type 2 diabetic patients. *Circulation*. 2004;110(1):22–26.

Georgiadis JR, Farrell MJ, Boessen R, et al. Dynamic subcortical blood flow during male sexual activity with ecological validity: a perfusion fMRI study. *Neuroimage*. 2010;50(1):208–216.

Gerber RE, Vita JA, Ganz P, et al. Association of peripheral microvascular dysfunction and erectile dysfunction. *J Urol*. 2015;193(2):612–617.

Ghadirian AM, Annable L, Belanger MC. Lithium, benzodiazepines, and sexual function in bipolar patients. *Am*

J Psychiatry. 1992;149(6):801–805.

Gil-Nagel A, Lopez-Munoz F, Serratosa JM, et al. Effect of lamotrigine on sexual function in patients with epilepsy. *Seizure*. 2006;15(3):142–149.

Gitlin MJ, Suri R, Altshuler L, et al. Bupropion-sustained release as a treatment for SSRI-induced sexual side effects. *J Sex Marital Ther*. 2002;28(2):131–138.

Giugliano F, Maiorino M, Bellastella G, et al. Determinants of erectile dysfunction in type 2 diabetes. *Int J Impot Res*. 2010;22(3):204–209.

Giuliano F. Neurophysiology of erection and ejaculation. *J Sex Med*. 2011;8(Suppl 4):310–315.

Giuliano F, Rampin O. Neural control of erection. *Physiol Behav*. 2004;83(2):189–201.

Giuliano F, Rampin O, Brown K, et al. Stimulation of the medial preoptic area of the hypothalamus in the rat elicits increases in intracavernous pressure. *Neurosci Lett*. 1996;209(1):1–4.

Giuliano F, Rampin O, Jardin A, et al. Electrophysiological study of relations between the dorsal nerve of the penis and the lumbar sympathetic chain in the rat. *J Urol*. 1993;150(6):1960–1964.

Giuliano F, Rowland DL. Standard operating procedures for neurophysiologic assessment of male sexual dysfunction. *J Sex Med*. 2013;10(5):1205–1211.

Goldstein AM, Padma-Nathan H. The microarchitecture of the intracavernosal smooth muscle and the cavernosal fibrous skeleton. *J Urol*. 1990;144(5):1144–1146.

Goldstein I, Lue TF, Padma-Nathan H, et al. Oral sildenafil in the treatment of erectile dysfunction. Sildenafil Study Group. *N Engl J Med*. 1998;338(20):1397–1404.

Gonzalez-Cadavid NF. Mechanisms of penile fibrosis. *J Sex Med*. 2009;6(Suppl 3):353–362; 10.1111/j.1743-

6109.2008.01195.x.

Gonzalez-Corrochano R, La Fuente J, Cuevas P, et al. Ca2+ -activated K+ channel (KCa) stimulation improves relaxant capacity of PDE5 inhibitors in human penile arteries and recovers the reduced efficacy of PDE5 inhibition in diabetic erectile dysfunction. *Br J Pharmacol*. 2013;169(2):449–461.

Gormley GJ, Stoner E, Bruskewitz RC, et al. The effect of finasteride in men with benign prostatic hyperplasia. The Finasteride Study Group. *N Engl J Med*. 1992;327(17):1185–1191.

Grabowska-Grzyb A, Naganska E, Wolanczyk T. Hypersexuality in two patients with epilepsy treated with lamotrigine. *Epilepsy Behav*. 2006;8(3):663–665.

Gradin KA, Buus CL, Li JY, et al. Neuropeptide Y2 receptors are involved in enhanced neurogenic vasoconstriction in spontaneously hypertensive rats. *Br J Pharmacol*. 2006;148(5):703–713.

Granata AR, Rochira V, Lerchl A, et al. Relationship between sleep-related erections and testosterone levels in men. *J Androl*. 1997;18(5):522–527.

Grimm RH Jr, Grandits GA, Prineas RJ, et al. Long-term effects on sexual function of five antihypertensive drugs and nutritional hygienic treatment in hypertensive men and women. Treatment of Mild Hypertension Study (TOMHS). *Hypertension*. 1997;29(1 Pt 1):8–14.

Guidone G, Muller D, Vogt K, et al. Characterization of VIP and PACAP receptors in cultured rat penis corpus cavernosum smooth muscle cells and their interaction with guanylate cyclase-B receptors. *Regul Pept*. 2002;108(2–3):63–72.

Gulia KK, Jodo E, Kawauchi A, et al. The septal area, site for the central regulation of penile erection during waking and rapid eye movement sleep in rats: a stimulation study.

Neuroscience. 2008;156(4):1064–1073.

Gunduz MI, Gumus BH, Sekuri C. Relationship between metabolic syndrome and erectile dysfunction. *Asian J Androl*. 2004;6(4):355–358.

Gupta S, Salimpour P, Saenz de Tejada I, et al. A possible mechanism for alteration of human erectile function by digoxin: inhibition of corpus cavernosum sodium/potassium adenosine triphosphatase activity. *J Urol*. 1998;159(5):1529–1536.

Gur S, Sikka SC, Abdel-Mageed AB, et al. Imatinib mesylate (Gleevec) induces human corpus cavernosum relaxation by inhibiting receptor tyrosine kinases (RTKs): identification of new RTK targets. *Urology*. 2013;82(3):745 e711–e746.

Hackett G, Cole N, Saghir A, et al. Testosterone undecanoate improves sexual function in men with type 2 diabetes and severe hypogonadism: results from a 30-week randomized placebo-controlled study. *BJU Int*. 2016;118(5):804–813.

Haider KS, Haider A, Doros G, et al. Long-term testosterone therapy improves urinary and sexual function, and quality of life in men with hypogonadism: results from a Propensity Matched Subgroup of a Controlled Registry Study. *J Urol*. 2017.

Halata Z, Munger BL. The neuroanatomical basis for the protopathic sensibility of the human glans penis. *Brain Res*. 1986;371(2):205–230.

Hale TM, Okabe H, Bushfield TL, et al. Recovery of erectile function after brief aggressive antihypertensive therapy. *J Urol*. 2002;168(1):348–354.

Hale TM, Okabe H, Heaton JP, et al. Antihypertensive drugs induce structural remodeling of the penile vasculature. *J Urol*. 2001;166(2):739–745.

Hall SA, Esche GR, Araujo AB, et al. Correlates of low testosterone and symptomatic androgen deficiency in a population-based sample. *J Clin Endocrinol Metab*. 2008;93(10):3870–3877.

Hall SA, Kupelian V, Rosen RC, et al. Is hyperlipidemia or its treatment associated with erectile dysfunction?: results from the Boston Area Community Health (BACH) Survey. *J Sex Med*. 2009;6(5):1402–1413.

Hammerschmidt M, Brook A, McMahon AP. The world according to hedgehog. *Trends Genet*. 1997;13(1):14–21.

Hannan JL, Albersen M, Kutlu O, et al. Inhibition of Rho-kinase improves erectile function, increases nitric oxide signaling and decreases penile apoptosis in a rat model of cavernous nerve injury. *J Urol*. 2013;189(3):1155–1161.

Hannan JL, Matsui H, Sopko NA, et al. Caspase-3 dependent nitrergic neuronal apoptosis following cavernous nerve injury is mediated via RhoA and ROCK activation in major pelvic ganglion. *Sci Rep*. 2016;6:29416.

Hannan JL, Smallegange C, Hale TM, et al. Impact of antihypertensive treatments on erectile responses in aging spontaneously hypertensive rats. *J Hypertens*. 2006;24(1):159–168.

Hannigan KI, Griffin CS, Large RJ, et al. The role of Ca(2+)-activated Cl(-) current in tone generation in the rabbit corpus cavernosum. *Am J Physiol Cell Physiol*. 2017;313(5):C475–C486.

Harrison WM, Rabkin JG, Ehrhardt AA, et al. Effects of antidepressant medication on sexual function: a controlled study. *J Clin Psychopharmacol*. 1986;6(3):144–149.

Hedlund H, Andersson KE. Comparison of the responses to drugs acting on adrenoreceptors and muscarinic receptors in human isolated corpus cavernosum and cavernous artery. *J Auton Pharmacol*. 1985;5(1):81–88.

Hedlund P, Aszodi A, Pfeifer A, et al. Erectile dysfunction in cyclic GMP-dependent kinase I-deficient mice. *Proc Natl*

Acad Sci USA. 2000;97(5):2349–2354.

Hedlund P, Ny L, Alm P, et al. Cholinergic nerves in human corpus cavernosum and spongiosum contain nitric oxide synthase and heme oxygenase. *J Urol*. 2000;164(3 Pt 1):868–875.

Helsen C, Van den Broeck T, Voet A, et al. Androgen receptor antagonists for prostate cancer therapy. *Endocr Relat Cancer*. 2014;21(4):T105–T118.

Herrmann HC, Levine LA, Macaluso J Jr, et al. Can atorvastatin improve the response to sildenafil in men with erectile dysfunction not initially responsive to sildenafil? Hypothesis and pilot trial results. *J Sex Med*. 2006;3(2):303–308.

Hersch E, Huang J, Grider JR, et al. Gq/G13 signaling by ET-1 in smooth muscle: MYPT1 phosphorylation via ETA and CPI-17 dephosphorylation via ETB. *Am J Physiol Cell Physiol*. 2004;287(5):C1209–C1218.

Herzog AG, Drislane FW, Schomer DL, et al. Differential effects of antiepileptic drugs on sexual function and reproductive hormones in men with epilepsy: interim analysis of a comparison between lamotrigine and enzyme-inducing antiepileptic drugs. *Epilepsia*. 2004;45(7):764–768.

Hirano K. Current topics in the regulatory mechanism underlying the Ca2+ sensitization of the contractile apparatus in vascular smooth muscle. *J Pharmacol Sci*. 2007;104(2):109–115.

Hirata M, Kohse KP, Chang CH, et al. Mechanism of cyclic GMP inhibition of inositol phosphate formation in rat aorta segments and cultured bovine aortic smooth muscle cells. *J Biol Chem*. 1990;265(3):1268–1273.

Hofstra J, Loves S, van Wageningen B, et al. High prevalence of hypogonadotropic hypogonadism in men referred for obesity treatment. *Neth J Med*. 2008;66(3):103–109.

Holmquist F, Andersson KE, Hedlund H. Actions of endothelin on isolated corpus cavernosum from rabbit and man. *Acta Physiol Scand*. 1990;139(1):113–122.

Holstege G, Georgiadis JR, Paans AM, et al. Brain activation during human male ejaculation. *J Neurosci*. 2003;23(27):9185–9193.

Hong SK, Han BK, Jeong SJ, et al. Effect of statin therapy on early return of potency after nerve sparing radical retropubic prostatectomy. *J Urol*. 2007;178(2):613–616.

Hoznek A, Rahmouni A, Abbou C, et al. The suspensory ligament of the penis: an anatomic and radiologic description. *Surg Radiol Anat*. 1998;20(6):413–417.

Hsu GL, Brock G, Martinez-Pineiro L, et al. Anatomy and strength of the tunica albuginea: its relevance to penile prosthesis extrusion. *J Urol*. 1994;151(5):1205–1208.

Hsu GL, Hsieh CH, Wen HS, et al. Penile venous anatomy: an additional description and its clinical implication. *J Androl*. 2003;24(6):921–927.

Hsu GL, Hung YP, Tsai MH, et al. Penile veins are the principal component in erectile rigidity: a study of penile venous stripping on defrosted human cadavers. *J Androl*. 2012;33(6):1176–1185.

Huang YC, Chin CC, Chen CS, et al. Chronic cigarette smoking impairs erectile function through increased oxidative stress and apoptosis, decreased nnos, endothelial and smooth muscle contents in a rat model. *PLoS ONE*. 2015;10(10):e0140728.

Hubscher CH, Reed WR, Kaddumi EG, et al. Select spinal lesions reveal multiple ascending pathways in the rat conveying input from the male genitalia. *J Physiol*. 2010;588(Pt 7):1073–1083.

Hull EM, Lorrain DS, Du J, et al. Hormone-neurotransmitter interactions in the control of sexual behavior. *Behav Brain Res*. 1999;105(1):105–116.

Hunter J. *Treité des maladies vénériennes*. Mequignon: Paris; 1787.

Hurt KJ, Musicki B, Palese MA, et al. Akt-dependent phosphorylation of endothelial nitric-oxide synthase mediates penile erection. *Proc Natl Acad Sci USA*. 2002;99(6):4061–4066.

Hurt KJ, Sezen SF, Lagoda GF, et al. Cyclic AMP-dependent phosphorylation of neuronal nitric oxide synthase mediates penile erection. *Proc Natl Acad Sci USA*. 2012;109(41):16624–16629.

Ibarra C, Nedvetsky PI, Gerlach M, et al. Regional and age-dependent expression of the nitric oxide receptor, soluble guanylyl cyclase, in the human brain. *Brain Res*. 2001;907(1–2):54–60.

Ignarro LJ, Bush PA, Buga GM, et al. Nitric oxide and cyclic GMP formation upon electrical field stimulation cause relaxation of corpus cavernosum smooth muscle. *Biochem Biophys Res Commun*. 1990;170(2):843–850.

Imamura M, Waseda Y, Marinova GV, et al. Alterations of NOS, arginase, and DDAH protein expression in rabbit cavernous tissue after administration of cigarette smoke extract. *Am J Physiol Regul Integr Comp Physiol*. 2007;293(5):R2081–R2089.

Irwig MS, Kolukula S. Persistent sexual side effects of finasteride for male pattern hair loss. *J Sex Med*. 2011;8(6):1747–1753.

Ito M, Nakano T, Erdodi F, et al. Myosin phosphatase: structure, regulation and function. *Mol Cell Biochem*. 2004;259(1–2):197–209.

Iversen P, Melezinek I, Schmidt A. Nonsteroidal antiandrogens: a therapeutic option for patients with advanced prostate cancer who wish to retain sexual interest and function. *BJU Int*. 2001;87(1):47–56.

Iversen P, Tyrrell CJ, Kaisary AV, et al. Bicalutamide monotherapy compared with castration in patients with nonmetastatic locally advanced prostate cancer: 6.3 years of followup. *J Urol*. 2000;164(5):1579–1582.

Jeon SW, Yoo KH, Kim TH, et al. Correlation of the erectile dysfunction with lesions of cerebrovascular accidents. *J Sex Med*. 2009;6(1):251–256; 10.1111/j.1743-6109.2008.00923.x.

Jeremy JY, Ballard SA, Naylor AM, et al. Effects of sildenafil, a type-5 cGMP phosphodiesterase inhibitor, and papaverine on cyclic GMP and cyclic AMP levels in the rabbit corpus cavernosum in vitro. *Br J Urol*. 1997;79(6):958–963.

Jiang H, Colbran JL, Francis SH, et al. Direct evidence for cross-activation of cGMP-dependent protein kinase by cAMP in pig coronary arteries. *J Biol Chem*. 1992;267(2):1015–1019.

Jiang R, Chen JH, Jin J, et al. Ultrastructural comparison of penile cavernous tissue between hypertensive and normotensive rats. *Int J Impot Res*. 2005;17(5):417–423.

Jin L, Lagoda G, Leite R, et al. NADPH oxidase activation: a mechanism of hypertension-associated erectile dysfunction. *J Sex Med*. 2008;5(3):544–551.

Jin L, Liu T, Lagoda GA, et al. Elevated RhoA/Rho-kinase activity in the aged rat penis: mechanism for age-associated erectile dysfunction. *FASEB J*. 2006;20(3):536–538.

Johannes CB, Araujo AB, Feldman HA, et al. Incidence of erectile dysfunction in men 40 to 69 years old: longitudinal results from the Massachusetts male aging study. *J Urol*. 2000;163(2):460–463.

Johnson DA, Akamine P, Radzio-Andzelm E, et al. Dynamics of cAMP-dependent protein kinase. *Chem Rev*. 2001;101(8):2243–2270.

Juenemann KP, Lue TF, Luo JA, et al. The role of vasoactive intestinal polypeptide as a neurotransmitter in canine penile erection: a combined in vivo and immunohistochemical study. *J Urol*. 1987;138(4):871–877.

Junemann KP, Aufenanger J, Konrad T, et al. The effect of impaired lipid metabolism on the smooth muscle cells of rabbits. *Urol Res*. 1991;19(5):271–275.

Jung JH, Kam SC, Choi SM, et al. Sexual dysfunction in male stroke patients: correlation between brain lesions and sexual function. *Urology*. 2008;71(1):99–103.

Kaiser FE, Viosca SP, Morley JE, et al. Impotence and aging: clinical and hormonal factors. *J Am Geriatr Soc*. 1988;36(6):511–519.

Kaprara A, Huhtaniemi IT. The hypothalamus-pituitary-gonad axis: tales of mice and men. *Metabolism*. 2017.

Karacan I, Salis PJ, Hirshkowitz M, et al. Erectile dysfunction in hypertensive men: sleep-related erections, penile blood flow and musculovascular events. *J Urol*. 1989;142(1):56–61.

Kaufman JM, Hatzichristou DG, Mulhall JP, et al. Impotence and chronic renal failure: a study of the hemodynamic pathophysiology. *J Urol*. 1994;151(3):612–618.

Kaur J. A comprehensive review on metabolic syndrome. *Cardiol Res Pract*. 2014;2014:943162.

Keltner NL, McAfee KM, Taylor CL. Mechanisms and treatments of SSRI-induced sexual dysfunction. *Perspect Psychiatr Care*. 2002;38(3):111–116.

Kennedy SH, Eisfeld BS, Dickens SE, et al. Antidepressant-induced sexual dysfunction during treatment with moclobemide, paroxetine, sertraline, and venlafaxine. *J Clin Psychiatry*. 2000;61(4):276–281.

Kielstein JT, Zoccali C. Asymmetric dimethylarginine: a cardiovascular risk factor and a uremic toxin coming of age? *Am J Kidney Dis*. 2005;46(2):186–202.

Kiely EA, Bloom SR, Williams G. Penile response to intracavernosal vasoactive intestinal polypeptide alone and in combination with other vasoactive agents. *Br J Urol*. 1989;64(2):191–194.

Kilarkaje N, Yousif MH, El-Hashim AZ, et al. Role of angiotensin II and angiotensin-(1-7) in diabetes-induced oxidative DNA damage in the corpus cavernosum. *Fertil Steril*. 2013;100(1):226–233.

Kim DG, Kim DW, Park JK. Does bicycle riding impact the development of lower urinary tract symptoms and sexual dysfunction in men? *Korean J Urol*. 2011;52(5):350–354.

Kim JH, Klyachkin ML, Svendsen E, et al. Experimental hypercholesterolemia in rabbits induces cavernosal atherosclerosis with endothelial and smooth muscle cell dysfunction. *J Urol*. 1994;151(1):198–205.

Kim N, Vardi Y, Padma-Nathan H, et al. Oxygen tension regulates the nitric oxide pathway. Physiological role in penile erection. *J Clin Invest*. 1993;91(2):437–442.

Kim NN, Dhir V, Azadzoi KM, et al. Pilot study of the endothelin-A receptor selective antagonist BMS-193884 for the treatment of erectile dysfunction. *J Androl*. 2002;23(1):76–83.

Kim SC, Kim IK, Seo KK, et al. Involvement of superoxide radical in the impaired endothelium-dependent relaxation of cavernous smooth muscle in hypercholesterolemic rabbits. *Urol Res*. 1997;25(5):341–346.

Kim SC, Oh MM. Norepinephrine involvement in response to intracorporeal injection of papaverine in psychogenic impotence. *J Urol*. 1992;147(6):1530–1532.

Kim SZ, Kim SH, Park JK, et al. Presence and biological activity of C-type natriuretic peptide-dependent guanylate cyclase-coupled receptor in the penile corpus cavernosum. *J Urol*. 1998;159(5):1741–1746; 10.1097/00005392-199805000-00104.

Kimura Y, Naitou Y, Wanibuchi F, et al. Characterization of intracavernous pressure increase induced by Ym348, a novel 5-HT2C receptor agonist, in anesthetized rats. *J Urol*. 2006;175(5):1953–1957.

Kimura Y, Naitou Y, Wanibuchi F, et al. 5-HT(2C) receptor activation is a common mechanism on proerectile effects of apomorphine, oxytocin and melanotan-II in rats. *Eur J Pharmacol*. 2008;589(1–3):157–162.

Kinsey AC, Pomeroy WJ, Martin CE. *Sexual behavior in the human male*. Saunders: Philadelphia; 1948.

Kiraly I, Pataricza J, Bajory Z, et al. Involvement of large-conductance Ca(2+) -activated K(+) channels in both nitric oxide and endothelium-derived hyperpolarization-type relaxation in human penile small arteries. *Basic Clin Pharmacol Toxicol*. 2013;113(1):19–24.

Kishimoto T, Fukawa T, Yamaguchi K, et al. Mineralocorticoid receptor expression in human penile corpus cavernosum. *J Med Invest*. 2013;60(1–2):21–26.

Kley HK, Abendroth H, Hehrmann R, et al. No effect of digitalis on sex and adrenal hormones in healthy subjects and in patients with congestive heart failure]. *Klin Wochenschr*. 1984;62(2):65–73.

Kohler TS, Kim J, Feia K, et al. Prevalence of androgen deficiency in men with erectile dysfunction. *Urology*. 2008;71(4):693–697.

Kovacs I, Csaszar A, Toth J, et al. Correlation between flow-mediated dilation and erectile dysfunction. *J Cardiovasc Pharmacol*. 2008;51(2):148–153.

Kozacioglu Z, Kiray A, Ergur I, et al. Anatomy of the dorsal nerve of the penis, clinical implications. *Urology*. 2014;83(1):121–124; 10.1016/j.urology.2013.07.075.

Krishnan AV, Kiernan MC. Uremic neuropathy: clinical features and new pathophysiological insights. *Muscle Nerve*. 2007;35(3):273–290.

Kuba R, Pohanka M, Zakopcan J, et al. Sexual dysfunctions and blood hormonal profile in men with focal epilepsy. *Epilepsia*. 2006;47(12):2135–2140.

Kuhn S, Gallinat J. A quantitative meta-analysis on cue-induced male sexual arousal. *J Sex Med*. 2011;8(8):2269–2275.

Kupelian V, Araujo AB, Chiu GR, et al. Relative contributions of modifiable risk factors to erectile dysfunction: results from the Boston Area Community Health (BACH) Survey. *Prev Med*. 2010;50(1–2):19–25.

Kupelian V, Hall SA, McKinlay JB. Common prescription medication use and erectile dysfunction: results from the Boston Area Community Health (BACH) survey. *BJU Int*. 2013;112(8):1178–1187.

Kupelian V, Link CL, McKinlay JB. Association between smoking, passive smoking, and erectile dysfunction: results from the Boston Area Community Health (BACH) Survey. *Eur Urol*. 2007;52(2):416–422.

Kupelian V, Link CL, Rosen RC, et al. Socioeconomic status, not race/ethnicity, contributes to variation in the prevalence of erectile dysfunction: results from the Boston Area Community Health (BACH) Survey. *J Sex Med*. 2008;5(6):1325–1333.

Kuthe A, Montorsi F, Andersson KE, et al. Phosphodiesterase inhibitors for the treatment of erectile dysfunction. *Curr Opin Investig Drugs*. 2002;3(10):1489–1495.

Kuthe A, Reinecke M, Uckert S, et al. Expression of guanylyl cyclase B in the human corpus cavernosum penis and the possible involvement of its ligand C-type natriuretic polypeptide in the induction of penile erection. *J Urol*. 2003;169(5):1918–1922.

Kuthe A, Wiedenroth A, Magert HJ, et al. Expression of different phosphodiesterase genes in human cavernous smooth muscle. *J Urol*. 2001;165(1):280–283.

La Torre A, Giupponi G, Duffy D, et al. Sexual dysfunction related to drugs: a critical review. Part IV: cardiovascular drugs. *Pharmacopsychiatry*. 2015;48(1):1–6.

La Vignera S, Condorelli RA, Tumino S, et al. Original evaluation of endothelial dysfunction in men with erectile dysfunction and metabolic syndrome. *Int J Impot Res*. 2012;24(4):150–154.

Labbate LA, Grimes JB, Arana GW. Serotonin reuptake antidepressant effects on sexual function in patients with anxiety disorders. *Biol Psychiatry*. 1998;43(12):904–907.

Lacchini R, Muniz JJ, Nobre YT, et al. nNOS polymorphisms are associated with responsiveness to sildenafil in clinical and postoperative erectile dysfunction. *Pharmacogenomics*. 2014;15(6):775–784.

Lahoz C, Mostaza JM, Salinero-Fort MA, et al. Peripheral atherosclerosis in patients with erectile dysfunction: a population-based study. *J Sex Med*. 2016;13(1):63–69.

Lai CF, Wang YT, Hung KY, et al. Sexual dysfunction in peritoneal dialysis patients. *Am J Nephrol*. 2007;27(6):615–621.

Lands WE. The biosynthesis and metabolism of prostaglandins. *Annu Rev Physiol*. 1979;41:633–652.

Large WA. Receptor-operated Ca2(+)-permeable nonselective cation channels in vascular smooth muscle: a physiologic perspective. *J Cardiovasc Electrophysiol*. 2002;13(5):493–501.

Lau LC, Adaikan PG. Possibility of inhibition of calcium-activated chloride channel rescuing erectile failures in diabetes. *Int J Impot Res*. 2014;26(4):151–155.

Laumann EO, Glasser DB, Neves RC, et al. A population-based survey of sexual activity, sexual problems and associated help-seeking behavior patterns in mature adults in the United States of America. *Int J Impot Res*. 2009;21(3):171–178.

Laumann EO, Nicolosi A, Glasser DB, et al. Sexual problems among women and men aged 40-80 y: prevalence and correlates identified in the Global Study of Sexual Attitudes and Behaviors. *Int J Impot Res*. 2005;17(1):39–57.

Laumann EO, Paik A, Rosen RC. Sexual dysfunction in the United States: prevalence and predictors. *J Am Med Assoc*. 1999;281(6):537–544.

Lauretti S, Cardaci V, Barrese F, et al. Chronic obstructive pulmonary disease (COPD) and erectile dysfunction (ED): results of the BRED observational study. *Arch Ital Urol Androl*. 2016;88(3):165–170.

Lew-Starowicz M, Gellert R. The sexuality and quality of life of hemodialyzed patients–ASED multicenter study. *J Sex Med*. 2009;6(4):1062–1071.

Lewis RW, Fugl-Meyer KS, Bosch R, et al. Epidemiology/risk factors of sexual dysfunction. *J Sex Med*. 2004;1(1):35–39.

Li WJ, Wang H, Zhou J, et al. P144, A TGF-beta1 antagonist peptide, synergizes with sildenafil and enhances erectile response via amelioration of cavernosal fibrosis in diabetic rats. *J Sex Med*. 2013;10(12):2942–2951.

Li WJ, Xu M, Gu M, et al. Losartan preserves erectile function by suppression of apoptosis and fibrosis of corpus cavernosum and corporal veno-occlusive dysfunction in diabetic rats. *Cell Physiol Biochem*. 2017;42(1):333–345.

Lin CS, Chow S, Lau A, et al. Identification and regulation of human PDE5A gene promoter. *Biochem Biophys Res Commun*. 2001;280(3):684–692.

Lin CS, Chow S, Lau A, et al. Regulation of human PDE5A2 intronic promoter by cAMP and cGMP: identification of a critical Sp1-binding site. *Biochem Biophys Res Commun*. 2001;280(3):693–699.

Lin CS, Lin G, Lue TF. Cyclic nucleotide signaling in cavernous smooth muscle. *J Sex Med*. 2005;2(4):478–491.

Lin CS, Xin ZC, Lin G, et al. Phosphodiesterases as therapeutic targets. *Urology*. 2003;61(4):685–691.

Lin G, Li H, Zhang X, et al. Novel therapeutic approach for neurogenic erectile dysfunction: effect of neurotrophic tyrosine kinase receptor type 1 monoclonal antibody. *Eur Urol*. 2015;67(4):716–726.

Lincoln TM, Cornwell TL, Taylor AE. cGMP-dependent protein kinase mediates the reduction of Ca2+ by cAMP in vascular smooth muscle cells. *Am J Physiol*. 1990;258(3 Pt 1):C399–C407.

Linder AE, Leite R, Lauria K, et al. Penile erection requires association of soluble guanylyl cyclase with endothelial caveolin-1 in rat corpus cavernosum. *Am J Physiol Regul Integr Comp Physiol*. 2006;290(5):R1302–R1308.

Liu C, Lu K, Tao T, et al. Endothelial nitric oxide synthase polymorphisms and erectile dysfunction: a meta-analysis. *J Sex Med*. 2015;12(6):1319–1328.

Liu CC, Lee YC, Tsai VF, et al. The interaction of serum testosterone levels and androgen receptor CAG repeat polymorphism on the risk of erectile dysfunction in aging Taiwanese men. *Andrology*. 2015;3(5):902–908.

Liu T, Peng YF, Jia C, et al. Effect of HGF on the apoptosis of rat corpus cavernosum smooth muscle cells induced by TGFbeta1. *Andrologia*. 2015;47(9):1020–1027.

Lizza EF, Rosen RC. Definition and classification of erectile dysfunction: report of the Nomenclature Committee of the International Society of Impotence Research. *Int J Impot Res*. 1999;11(3):141–143.

Llisterri JL, Lozano Vidal JV, Aznar Vicente J, et al. Sexual dysfunction in hypertensive patients treated with losartan. *Am J Med Sci*. 2001;321(5):336–341.

Long H, Jiang J, Xia J, et al. Hyperuricemia is an independent risk factor for erectile dysfunction. *J Sex Med*.

2016;13(7):1056–1062.

Lue TF. The mechanism of penile erection in the monkey. *Semin Urol*. 1986;4(4):217–224.

Lue TF. Surgery for crural venous leakage. *Urology*. 1999;54(4):739–741.

Lue TF, Hricak H, Marich KW, et al. Vasculogenic impotence evaluated by high-resolution ultrasonography and pulsed Doppler spectrum analysis. *Radiology*. 1985;155(3):777–781.

Lue TF, Takamura T, Schmidt RA, et al. Hemodynamics of erection in the monkey. *J Urol*. 1983;130(6):1237–1241.

Lue TF, Takamura T, Umraiya M, et al. Hemodynamics of canine corpora cavernosa during erection. *Urology*. 1984;24(4):347–352.

Lugg JA, Rajfer J, Gonzalez-Cadavid NF. Dihydrotestosterone is the active androgen in the maintenance of nitric oxide-mediated penile erection in the rat. *Endocrinology*. 1995;136(4):1495–1501.

Lv B, Zhao J, Yang F, et al. Phenotypic transition of corpus cavernosum smooth muscle cells subjected to hypoxia. *Cell Tissue Res*. 2014;357(3):823–833.

Maas R, Wenske S, Zabel M, et al. Elevation of asymmetrical dimethylarginine (ADMA) and coronary artery disease in men with erectile dysfunction. *Eur Urol*. 2005;48(6):1004–1011 [discussion 1011–1012].

Maeda N, Matsuoka N, Yamaguchi I. Role of the dopaminergic, serotonergic and cholinergic link in the expression of penile erection in rats. *Jpn J Pharmacol*. 1994;66(1):59–66.

Magee T, Fuentes AM, Garban H, et al. Cloning of a novel neuronal nitric oxide synthase expressed in penis and lower urinary tract. *Biochem Biophys Res Commun*. 1996;226(1):145–151.

Maggi M, Buvat J, Corona G, et al. Hormonal causes of male sexual dysfunctions and their management (hyperprolactinemia, thyroid disorders, GH disorders, and DHEA). *J Sex Med*. 2013;10(3):661–677.

Maio MT, McCabe KM, Pruss CM, et al. Calcification of the internal pudendal artery and development of erectile dysfunction in adenine-induced chronic kidney disease: a sentinel of systemic vascular changes. *J Sex Med*. 2014;11(10):2449–2465.

Maiorino MI, Bellastella G, Petrizzo M, et al. Circulating endothelial progenitor cells in type 1 diabetic patients with erectile dysfunction. *Endocrine*. 2015;49(2):415–421.

Marin R, Escrig A, Abreu P, et al. Androgen-dependent nitric oxide release in rat penis correlates with levels of constitutive nitric oxide synthase isoenzymes. *Biol Reprod*. 1999;61(4):1012–1016.

Marson L, McKenna KE. CNS cell groups involved in the control of the ischiocavernosus and bulbospongiosus muscles: a transneuronal tracing study using pseudorabies virus. *J Comp Neurol*. 1996;374(2):161–179.

Martin-Morales A, Sanchez-Cruz JJ, Saenz de Tejada I, et al. Prevalence and independent risk factors for erectile dysfunction in Spain: results of the Epidemiologia de la Disfuncion Erectil Masculina Study. *J Urol*. 2001;166(2):569–574 [discussion 574–575].

Martinez-Salamanca JI, La Fuente JM, Fernandez A, et al. Nitrergic function is lost but endothelial function is preserved in the corpus cavernosum and penile resistance arteries of men after radical prostatectomy. *J Sex Med*. 2015;12(3):590–599.

Marumo K, Baba S, Murai M. Erectile function and nocturnal penile tumescence in patients with prostate cancer undergoing luteinizing hormone-releasing hormone agonist therapy. *Int J Urol*. 1999;6(1):19–23.

Masters WH, Johnson VE. *Human sexual response*. Little, Brown, & Company: Boston; 1965.

Masters WH, Johnson VE. Sex after sixty-five. *Reflections*. 1977;12:31–43.

Matsui H, Sopko NA, Hannan JL, et al. Pathophysiology of erectile dysfunction. *Curr Drug Targets*. 2015;16(5):411–419.

Matsui H, Sopko NA, Hannan JL, et al. M1 macrophages are predominantly recruited to the major pelvic ganglion of the rat following cavernous nerve injury. *J Sex Med*. 2017;14(2):187–195.

Matsuo H. Discovery of a natriuretic peptide family and their clinical application. *Can J Physiol Pharmacol*. 2001;79(8):736–740.

Mazza ON, Angerosa M, Becher E, et al. Differences between Candesartan and Hydralazine in the protection of penile structures in spontaneously hypertensive rats. *J Sex Med*. 2006;3(4):604–611.

McCarthy CG, Goulopoulou S, Wenceslau CF, et al. Toll-like receptors and damage-associated molecular patterns: novel links between inflammation and hypertension. *Am J Physiol Heart Circ Physiol*. 2014;306(2):H184–H196.

McCulloch DK, Campbell IW, Wu FC, et al. Impotence in diabetic and non-diabetic hospital outpatients. *Br Med J*. 1980;281(6249):1216.

McCulloch DK, Young RJ, Prescott RJ, et al. The natural history of impotence in diabetic men. *Diabetologia*. 1984;26(6):437–440.

McKenna KE. Central control of penile erection. *Int J Impot Res*. 1998;10(Suppl 1):S25–S34.

Meldrum DR, Gambone JC, Morris MA, et al. Lifestyle and metabolic approaches to maximizing erectile and vascular health. *Int J Impot Res*. 2012;24(2):61–68.

Melis MR, Argiolas A. Reduction of drug-induced yawning and penile erection and of noncontact erections in male rats by the activation of GABAA receptors in the paraventricular nucleus: involvement of nitric oxide. *Eur J Neurosci*. 2002;15(5):852–860.

Melis MR, Argiolas A. Central control of penile erection: a re-visitation of the role of oxytocin and its interaction with dopamine and glutamic acid in male rats. *Neurosci Biobehav Rev*. 2011;35(3):939–955.

Melis MR, Succu S, Mascia MS, et al. Antagonism of cannabinoid CB1 receptors in the paraventricular nucleus of male rats induces penile erection. *Neurosci Lett*. 2004;359(1–2):17–20.

Melis MR, Succu S, Mascia MS, et al. The cannabinoid receptor antagonist SR-141716A induces penile erection in male rats: involvement of paraventricular glutamic acid and nitric oxide. *Neuropharmacology*. 2006;50(2):219–228.

Melis MR, Succu S, Mauri A, et al. Nitric oxide production is increased in the paraventricular nucleus of the hypothalamus of male rats during non-contact penile erections and copulation. *Eur J Neurosci*. 1998;10(6):1968–1974.

Melis MR, Succu S, Spano MS, et al. Morphine injected into the paraventricular nucleus of the hypothalamus prevents noncontact penile erections and impairs copulation: involvement of nitric oxide. *Eur J Neurosci*. 1999;11(6):1857–1864.

Mendels J, Kiev A, Fabre LF. Double-blind comparison of citalopram and placebo in depressed outpatients with melancholia. *Depress Anxiety*. 1999;9(2):54–60.

Meng J, Ganesan Adaikan P, Srilatha B. Hydrogen sulfide promotes nitric oxide production in corpus cavernosum by enhancing expression of endothelial nitric oxide synthase. *Int J Impot Res*. 2013;25(3):86–90.

Mersdorf A, Goldsmith PC, Diederichs W, et al. Ultrastructural changes in impotent penile tissue: a comparison of 65 patients. *J Urol*. 1991;145(4):749–758.

Metz P, Ebbehoj J, Uhrenholdt A, et al. Peyronie's disease and erectile failure. *J Urol*. 1983;130(6):1103–1104.

Michelson D, Schmidt M, Lee J, et al. Changes in sexual function during acute and six-month fluoxetine therapy: a prospective assessment. *J Sex Marital Ther*. 2001;27(3):289–302.

Milano W, Colletti C, Capasso A. Hyperprolactinemia induced by antipsychotics: from diagnosis to treatment approach. *Endocr Metab Immune Disord Drug Targets*. 2017;17(1):38–55.

Millan MJ, Gobert A, Rivet JM, et al. Mirtazapine enhances frontocortical dopaminergic and corticolimbic adrenergic, but not serotonergic, transmission by blockade of alpha2-adrenergic and serotonin2C receptors: a comparison with citalopram. *Eur J Neurosci*. 2000;12(3):1079–1095.

Miller NS, Gold MS. The human sexual response and alcohol and drugs. *J Subst Abuse Treat*. 1988;5(3):171–177.

Mills TM, Pollock DM, Lewis RW, et al. Endothelin-1-induced vasoconstriction is inhibited during erection in rats. *Am J Physiol Regul Integr Comp Physiol*. 2001;281(2):R476–R483.

Minhas S, Cartledge J, Eardley I. The pathophysiological role of prostaglandins in penile erection. *Expert Opin Pharmacother*. 2001;2(5):799–811.

Minhas S, Cartledge JJ, Eardley I, et al. The interaction of nitric oxide and prostaglandins in the control of corporal smooth muscle tone: evidence for production of a cyclooxygenase-derived endothelium-contracting factor. *BJU Int*. 2001;87(9):882–888.

Mirone V, Imbimbo C, Fusco F, et al. Androgens and morphologic remodeling at penile and cardiovascular levels: a common piece in complicated puzzles? *Eur Urol*.

2009;56(2):309–316.
Molderings G, Malinowska B, Schlicker E. Inhibition of noradrenaline release in the rat vena cava via prostanoid receptors of the EP3-subtype. *Br J Pharmacol*. 1992;107(2):352–355.
Montague DK, Lakin MM, Angermeier KW, et al. Primary erectile dysfunction in a man with congenital isolation of the corpora cavernosa. *Urology*. 1995;46(1):114–116.
Monteiro WO, Noshirvani HF, Marks IM, et al. Anorgasmia from clomipramine in obsessive-compulsive disorder. A controlled trial. *Br J Psychiatry*. 1987;151:107–112.
Montorsi F, Adaikan G, Becher E, et al. Summary of the recommendations on sexual dysfunctions in men. *J Sex Med*. 2010;7(11):3572–3588.
Montorsi F, Briganti A, Salonia A, et al. The use of phosphodiesterase type 5 inhibitors for erectile dysfunction. *Curr Opin Urol*. 2004;14(6):357–359.
Montorsi F, Perani D, Anchisi D, et al. Brain activation patterns during video sexual stimulation following the administration of apomorphine: results of a placebo-controlled study. *Eur Urol*. 2003;43(4):405–411.
Montorsi P, Ravagnani PM, Galli S, et al. Association between erectile dysfunction and coronary artery disease. Role of coronary clinical presentation and extent of coronary vessels involvement: the COBRA trial. *Eur Heart J*. 2006;27(22):2632–2639.
Moreira ED, Glasser DB, Nicolosi A, et al. Sexual problems and help-seeking behaviour in adults in the United Kingdom and continental Europe. *BJU Int*. 2008;101(8):1005–1011.
Moreira ED Jr, Lbo CF, Diament A, et al. Incidence of erectile dysfunction in men 40 to 69 years old: results from a population-based cohort study in Brazil. *Urology*. 2003;61(2):431–436.

Moreland RB, Albadawi H, Bratton C, et al. O2-dependent prostanoid synthesis activates functional PGE receptors on corpus cavernosum smooth muscle. *Am J Physiol Heart Circ Physiol*. 2001;281(2):H552–H558.

Moreland RB, Traish A, McMillin MA, et al. PGE1 suppresses the induction of collagen synthesis by transforming growth factor-beta 1 in human corpus cavernosum smooth muscle. *J Urol*. 1995;153(3 Pt 1):826–834.

Morikage N, Kishi H, Sato M, et al. Cholesterol primes vascular smooth muscle to induce Ca2 sensitization mediated by a sphingosylphosphorylcholine-Rho-kinase pathway: possible role for membrane raft. *Circ Res*. 2006;99(3):299–306.

Morris GL 3rd, Vanderkolk C. Human sexuality, sex hormones, and epilepsy. *Epilepsy Behav*. 2005;7(Suppl 2):S22–S28.

Mosaku KS, Ukpong DI. Erectile dysfunction in a sample of patients attending a psychiatric outpatient department. *Int J Impot Res*. 2009;21(4):235–239; 10.1038/ijir.2009.16.

Mouraviev VB, Coburn M, Santucci RA. The treatment of posterior urethral disruption associated with pelvic fractures: comparative experience of early realignment versus delayed urethroplasty. *J Urol*. 2005;173(3):873–876.

Muguruma H, Kawanishi Y, Sugiyama H, et al. Effect of aldosterone on isolated human penile corpus cavernosum tissue. *BJU Int*. 2008;102(4):500–503.

Mulhall JP, Secin FP, Guillonneau B. Artery sparing radical prostatectomy–myth or reality? *J Urol*. 2008;179(3):827–831.

Munarriz RM, Yan QR, ZNehra A, et al. Blunt trauma: the pathophysiology of hemodynamic injury leading to erectile dysfunction. *J Urol*. 1995;153(6):1831–1840.

Muniz JJ, Leite LN, De Martinis BS, et al. Chronic ethanol consumption induces erectile dysfunction: role of oxidative stress. *Life Sci*. 2015;141:44–53.

Musicki B, Bella AJ, Bivalacqua TJ, et al. Basic science evidence for the link between erectile dysfunction and cardiometabolic dysfunction. *J Sex Med*. 2015;12(12):2233–2255.

Musicki B, Ross AE, Champion HC, et al. Posttranslational modification of constitutive nitric oxide synthase in the penis. *J Androl*. 2009;30(4):352–362.

Naganuma H, Egashira T, Fujii I. Neuroleptics induce penile erection in the rabbit. *Clin Exp Pharmacol Physiol*. 1993;20(3):177–183.

Narumiya S, Fitzgerald GA. Genetic and pharmacological analysis of prostanoid receptor function. *J Clin Invest*. 2001;108(1):25–30.

Nehra A, Azadzoi KM, Moreland RB, et al. Cavernosal expandability is an erectile tissue mechanical property which predicts trabecular histology in an animal model of vasculogenic erectile dysfunction. *J Urol*. 1998;159(6):2229–2236.

Nehra A, Gettman MT, Nugent M, et al. Transforming growth factor-beta1 (TGF-beta1) is sufficient to induce fibrosis of rabbit corpus cavernosum in vivo. *J Urol*. 1999;162(3 Pt 1):910–915.

Nehra A, Kumar R, Ramakumar S, et al. Pharmacoangiographic evidence of the presence and anatomical dominance of accessory pudendal artery(s). *J Urol*. 2008;179(6):2317–2320.

Nelson CJ, Scardino PT, Eastham JA, et al. Back to baseline: erectile function recovery after radical prostatectomy from the patients’ perspective. *J Sex Med*. 2013;10(6):1636–1643.

Neri A, Zukerman Z, Aygen M, et al. The effect of long-term administration of digoxin on plasma androgens and sexual dysfunction. *J Sex Marital Ther*. 1987;13(1):58–63.

Nguyen HB, Lee SY, Park SH, et al. Nicotine in high concentration causes contraction of isolated strips of rabbit corpus cavernosum. *Korean J Physiol Pharmacol*. 2015;19(3):257–262.

Nicolosi A, Buvat J, Glasser DB, et al. Sexual behaviour, sexual dysfunctions and related help seeking patterns in middle-aged and elderly Europeans: the global study of sexual attitudes and behaviors. *World J Urol*. 2006;24(4):423–428.

Nicolosi A, Glasser DB, Kim SC, et al. Sexual behaviour and dysfunction and help-seeking patterns in adults aged 40-80 years in the urban population of Asian countries. *BJU Int*. 2005;95(4):609–614.

Nicolosi A, Laumann EO, Glasser DB, et al. Sexual activity, sexual disorders and associated help-seeking behavior among mature adults in five Anglophone countries from the Global Survey of Sexual Attitudes and Behaviors (GSSAB). *J Sex Marital Ther*. 2006;32(4):331–342.

Ning C, Qi L, Wen J, et al. Excessive penile norepinephrine level underlies impaired erectile function in adenosine A1 receptor deficient mice. *J Sex Med*. 2012;9(10):2552–2561.

Nohria A, Garrett L, Johnson W, et al. Endothelin-1 and vascular tone in subjects with atherogenic risk factors. *Hypertension*. 2003;42(1):43–48.

Nunes KP, Bomfim GF, Toque HA, et al. Toll-like receptor 4 (TLR4) impairs nitric oxide contributing to Angiotensin II-induced cavernosal dysfunction. *Life Sci*. 2017;191:219–226.

Nunes KP, Rigsby CS, Webb RC. RhoA/Rho-kinase and vascular diseases: what is the link? *Cell Mol Life Sci*. 2010;67(22):3823–3836.

Paick JS, Donatucci CF, Lue TF. Anatomy of cavernous nerves distal to prostate: microdissection study in adult male cadavers. *Urology*. 1993;42(2):145–149.

Paick JS, Lee SW. The neural mechanism of apomorphine-induced erection: an experimental study by comparison with electrostimulation-induced erection in the rat model. *J Urol*.

1994;152(6 Pt 1):2125–2128.

Paick JS, Yang JH, Kim SW, et al. The role of prolactin levels in the sexual activity of married men with erectile dysfunction. *BJU Int*. 2006;98(6):1269–1273.

Pal DK, Biswal DK, Ghosh B. Outcome and erectile function following treatment of priapism: an institutional experience. *Urol Ann*. 2016;8(1):46–50.

Pan F, Qiu XF, Yu W, et al. MicroRNA-200a is up-regulated in aged rats with erectile dysfunction and could attenuate endothelial function via SIRT1 inhibition. *Asian J Androl*. 2016;18(1):74–79.

Pan L, Ma J, Pan F, et al. Long non-coding RNA expression profiling in aging rats with erectile dysfunction. *Cell Physiol Biochem*. 2015;37(4):1513–1526; 10.1159/000438519.

Paniagua OA, Bryant MB, Panza JA. Transient hypertension directly impairs endothelium-dependent vasodilation of the human microvasculature. *Hypertension*. 2000;36(6):941–944.

Parada M, Gerard M, Larcher K, et al. Neural representation of subjective sexual arousal in men and women. *J Sex Med*. 2016;13(10):1508–1522.

Parikh J, Zemljic-Harpf A, Fu J, et al. Altered penile caveolin expression in diabetes: potential role in erectile dysfunction. *J Sex Med*. 2017;14(10):1177–1186.

Park K, Kim SW, Rhu KS, et al. Chronic administration of an oral Rho kinase inhibitor prevents the development of vasculogenic erectile dysfunction in a rat model. *J Sex Med*. 2006;3(6):996–1003.

Park K, Shin JW, Oh JK, et al. Restoration of erectile capacity in normotensive aged rats by modulation of angiotensin receptor type 1. *J Androl*. 2005;26(1):123–128.

Peng YS, Chiang CK, Hung KY, et al. The association of higher depressive symptoms and sexual dysfunction in male haemodialysis patients. *Nephrol Dial Transplant*.

2007;22(3):857–861.

Penson DF, Ng C, Cai L, et al. Androgen and pituitary control of penile nitric oxide synthase and erectile function in the rat. *Biol Reprod*. 1996;55(3):567–574.

Pickard RS, King P, Zar MA, et al. Corpus cavernosal relaxation in impotent men. *Br J Urol*. 1994;74(4):485–491.

Pickard RS, Powell PH, Zar MA. Evidence against vasoactive intestinal polypeptide as the relaxant neurotransmitter in human cavernosal smooth muscle. *Br J Pharmacol*. 1993;108(2):497–500.

Podlasek CA, Gonzalez CM, Zelner DJ, et al. Analysis of NOS isoform changes in a post radical prostatectomy model of erectile dysfunction. *Int J Impot Res*. 2001;13(Suppl 5):S1–S15.

Podlasek CA, Meroz CL, Korolis H, et al. Sonic hedgehog, the penis and erectile dysfunction: a review of sonic hedgehog signaling in the penis. *Curr Pharm Des*. 2005;11(31):4011–4027.

Podlasek CA, Zelner DJ, Jiang HB, et al. Sonic hedgehog cascade is required for penile postnatal morphogenesis, differentiation, and adult homeostasis. *Biol Reprod*. 2003;68(2):423–438.

Poeppl TB, Langguth B, Laird AR, et al. The functional neuroanatomy of male psychosexual and physiosexual arousal: a quantitative meta-analysis. *Hum Brain Mapp*. 2014;35(4):1404–1421.

Prieto D. Physiological regulation of penile arteries and veins. *Int J Impot Res*. 2008;20(1):17–29.

Priviero FB, Jin LM, Ying Z, et al. Up-regulation of the RhoA/Rho-kinase signaling pathway in corpus cavernosum from endothelial nitric-oxide synthase (NOS), but not neuronal NOS, null mice. *J Pharmacol Exp Ther*. 2010;333(1):184–192.

Ra S, Aoki H, Fujioka T, et al. In vitro contraction of the canine corpus cavernosum penis by direct perfusion with prolactin or growth hormone. *J Urol*. 1996;156(2 Pt 1):522–525.

Rahardjo HE, Reichelt K, Sonnenberg JE, et al. Effects of endopeptidase inhibition on the relaxation response of isolated human penile erectile tissue to vasoactive peptides. *Andrologia*. 2016;48(10):1214–1219; 10.1111/and.12562.

Rajagopalan S, Kurz S, Munzel T, et al. Angiotensin II-mediated hypertension in the rat increases vascular superoxide production via membrane NADH/NADPH oxidase activation. Contribution to alterations of vasomotor tone. *J Clin Invest*. 1996;97(8):1916–1923.

Rajfer J, Aronson WJ, Bush PA, et al. Nitric oxide as a mediator of relaxation of the corpus cavernosum in response to nonadrenergic, noncholinergic neurotransmission. *N Engl J Med*. 1992;326(2):90–94.

Rajfer J, Rosciszewski A, Mehringer M. Prevalence of corporeal venous leakage in impotent men. *J Urol*. 1988;140(1):69–71.

Randolph V. Blow the candle out: “unprintable” Ozark folksongs and folklore. University of Arkansas Press: Fayetteville, AR; 1992. *Folk rhymes and other lore*. Volume II.

Razdan S, Greer AB, Patel A, et al. Effect of prescription medications on erectile dysfunction. *Postgrad Med J*. 2017.

Rehman J, Chenven E, Brink P, et al. Diminished neurogenic but not pharmacologic erections in the 2- to 3-month experimentally diabetic F-344 rat. *Am J Physiol*. 1997;272(4 Pt 2):H1960–H1971.

Rehman J, Christ G, Alyskewycz M, et al. Experimental hyperprolactinemia in a rat model: alteration in centrally mediated neuroerectile mechanisms. *Int J Impot Res*. 2000;12(1):23–32.

Reidenbach C, Schwinger RH, Steinritz D, et al. Nebivolol induces eNOS activation and NO-liberation in murine corpus cavernosum. *Life Sci*. 2007;80(26):2421–2427.

Reilly JM, Woodhouse CR. Small penis and the male sexual role. *J Urol*. 1989;142(2 Pt 2):569–571 [discussion 572].

Rodriguez A, Muller DC, Metter EJ, et al. Aging, androgens, and the metabolic syndrome in a longitudinal study of aging. *J Clin Endocrinol Metab*. 2007;92(9):3568–3572.

Rosato E, Gigante A, Barbano B, et al. Doppler indices of intrarenal arterial stiffness are useful in monitoring scleroderma renal crisis. *Scand J Rheumatol*. 2013;42(1):80–81.

Rosen RC, Lane RM, Menza M. Effects of SSRIs on sexual function: a critical review. *J Clin Psychopharmacol*. 1999;19(1):67–85.

Rosen RC, Wu F, Behre HM, et al. Quality of life and sexual function benefits of long-term testosterone treatment: longitudinal results from the Registry of Hypogonadism in Men (RHYME). *J Sex Med*. 2017;14(9):1104–1115.

Roumeguere T, Wespes E, Carpentier Y, et al. Erectile dysfunction is associated with a high prevalence of hyperlipidemia and coronary heart disease risk. *Eur Urol*. 2003;44(3):355–359.

Rowland DL, Greenleaf W, Mas M, et al. Penile and finger sensory thresholds in young, aging, and diabetic males. *Arch Sex Behav*. 1989;18(1):1–12.

Rowland DL, Greenleaf WJ, Dorfman LJ, et al. Aging and sexual function in men. *Arch Sex Behav*. 1993;22(6):545–557.

Rudkin L, Taylor MJ, Hawton K. Strategies for managing sexual dysfunction induced by antidepressant medication. *Cochrane Database Syst Rev*. 2004;(4) [CD003382].

Ryu JK, Jin HR, Yin GN, et al. Erectile dysfunction precedes other systemic vascular diseases due to incompetent cavernous endothelial cell-cell junctions. *J Urol*. 2013;190(2):779–789.

Ryu JK, Shin HY, Song SU, et al. Downregulation of angiogenic factors and their downstream target molecules affects the deterioration of erectile function in a rat model of hypercholesterolemia. *Urology*. 2006;67(6):1329–1334.

Saenz de Tejada I, Angulo J, Cellek S, et al. Pathophysiology of erectile dysfunction. *J Sex Med*. 2005;2(1):26–39; 10.1111/j.1743-6109.2005.20103.x.

Saenz de Tejada I, Carson MP, de las Morenas A, et al. Endothelin: localization, synthesis, activity, and receptor types in human penile corpus cavernosum. *Am J Physiol*. 1991;261(4 Pt 2):H1078–H1085.

Saenz de Tejada I, Goldstein I, Azadzoi K, et al. Impaired neurogenic and endothelium-mediated relaxation of penile smooth muscle from diabetic men with impotence. *N Engl J Med*. 1989;320(16):1025–1030.

Saenz de Tejada I, Kim N, Lagan I, et al. Regulation of adrenergic activity in penile corpus cavernosum. *J Urol*. 1989;142(4):1117–1121.

Saenz de Tejada I, Moroukian P, Tessier J, et al. Trabecular smooth muscle modulates the capacitor function of the penis. Studies on a rabbit model. *Am J Physiol*. 1991;260(5 Pt 2):H1590–H1595.

Saito M, Broderick GA, Wein AJ, et al. Effect of chronic ethanol consumption on the pharmacological response of the rabbit corpus cavernosum. *Pharmacology*. 1994;49(6):386–391.

Saltzman EA, Guay AT, Jacobson J. Improvement in erectile function in men with organic erectile dysfunction by correction of elevated cholesterol levels: a clinical observation. *J Urol*. 2004;172(1):255–258.

Sanchez A, Contreras C, Martinez MP, et al. Role of neural NO synthase (nNOS) uncoupling in the dysfunctional nitrergic vasorelaxation of penile arteries from insulin-resistant obese Zucker rats. *PLoS ONE*. 2012;7(4):e36027.

Sanchez A, Martinez P, Munoz M, et al. Endothelin-1 contributes to endothelial dysfunction and enhanced vasoconstriction through augmented superoxide production in penile arteries from insulin-resistant obese rats: role of ET(A) and ET(B) receptors. *Br J Pharmacol*. 2014;171(24):5682–5695.

Santi D, Brigante G, Zona S, et al. Male sexual dysfunction and HIV–a clinical perspective. *Nat Rev Urol*. 2014;11(2):99–109.

Sato Y, Christ GJ. Differential ICP responses elicited by electrical stimulation of medial preoptic area. *Am J Physiol Heart Circ Physiol*. 2000;278(3):H964–H970.

Sattar AA, Merckx LA, Wespes E. Penile electromyography and its smooth muscle content: interpretation of 25 impotent patients. *J Urol*. 1996;155(3):909–912.

Sattar AA, Salpigides G, Vanderhaeghen JJ, et al. Cavernous oxygen tension and smooth muscle fibers: relation and function. *J Urol*. 1995;154(5):1736–1739.

Sattar AA, Wespes E, Schulman CC. Computerized measurement of penile elastic fibres in potent and impotent men. *Eur Urol*. 1994;25(2):142–144.

Sauzeau V, Le Jeune H, Cario-Toumaniantz C, et al. Cyclic GMP-dependent protein kinase signaling pathway inhibits RhoA-induced Ca2+ sensitization of contraction in vascular smooth muscle. *J Biol Chem*. 2000;275(28):21722–21729.

Schiavi RC, Schreiner-Engel P. Nocturnal penile tumescence in healthy aging men. *J Gerontol*. 1988;43(5):M146–M150.

Schlossmann J, Ammendola A, Ashman K, et al. Regulation of intracellular calcium by a signalling complex of IRAG, IP3 receptor and cGMP kinase Ibeta. *Nature*. 2000;404(6774):197–201.

Schouten BW, Bosch JL, Bernsen RM, et al. Incidence rates of erectile dysfunction in the Dutch general population. Effects of definition, clinical relevance and duration of follow-up in the Krimpen Study. *Int J Impot Res*. 2005;17(1):58–62.

Schroder FH, Collette L, de Reijke TM, et al. Prostate cancer treated by anti-androgens: is sexual function preserved? EORTC Genitourinary Group. European Organization for Research and Treatment of Cancer. *Br J Cancer*. 2000;82(2):283–290.

Seftel AD, Sun P, Swindle R. The prevalence of hypertension, hyperlipidemia, diabetes mellitus and depression in men with erectile dysfunction. *J Urol*. 2004;171(6 Pt 1):2341–2345.

Segal R, Hannan JL, Liu X, et al. Chronic oral administration of the arginase inhibitor 2(S)-amino-6-boronohexanoic acid (ABH) improves erectile function in aged rats. *J Androl*. 2012;33(6):1169–1175.

Shabb JB. Physiological substrates of cAMP-dependent protein kinase. *Chem Rev*. 2001;101(8):2381–2411.

Shah NP, Cainzos-Achirica M, Feldman DI, et al. Disease prevention in men with vascular erectile dysfunction: the view of the preventive cardiologist Cardiovascular. *Am J Med*. 2016;129(3):251–259; 10.1016/j.amjmed.2015.08.038.

Shakirova Y, Hedlund P, Sward K. Impaired nerve-mediated relaxation of penile tissue from caveolin-1 deficient mice. *Eur J Pharmacol*. 2009;602(2–3):399–405; 10.1016/j.ejphar.2008.11.033.

Shimizu S, Tsounapi P, Honda M, et al. Effect of an angiotensin II receptor blocker and a calcium channel blocker on hypertension associated penile dysfunction in a rat model. *Biomed Res*. 2014;35(3):215–221.

Shin SH, Kim WJ, Choi MJ, et al. Aberrant expression of Wnt family contributes to the pathogenesis of diabetes-induced erectile dysfunction. *Andrology*. 2014;2(1):107–116.

Shindel AW, Kishore S, Lue TF. Drugs designed to improve endothelial function: effects on erectile dysfunction. *Curr Pharm Des*. 2008;14(35):3758–3767.

Shirai M, Ishii N, Mitsukawa S, et al. Hemodynamic mechanism of erection in the human penis. *Arch Androl*. 1978;1(4):345–349.

Sica DA. Pharmacokinetics and pharmacodynamics of mineralocorticoid blocking agents and their effects on potassium homeostasis. *Heart Fail Rev*. 2005;10(1):23–29.

Smith PJ, Talbert RL. Sexual dysfunction with antihypertensive and antipsychotic agents. *Clin Pharm*. 1986;5(5):373–384.

Snyder PJ, Bhasin S, Cunningham GR, et al. Testosterone trials, I: effects of testosterone treatment in older men. *N Engl J Med*. 2016;374(7):611–624.

Solak Y, Akilli H, Kayrak M, et al. Uric acid level and erectile dysfunction in patients with coronary artery disease. *J Sex Med*. 2014;11(1):165–172.

Solomon H, Samarasinghe YP, Feher MD, et al. Erectile dysfunction and statin treatment in high cardiovascular risk patients. *Int J Clin Pract*. 2006;60(2):141–145.

Somlyo AP, Somlyo AV. Signal transduction by G-proteins, rho-kinase and protein phosphatase to smooth muscle and non-muscle myosin II. *J Physiol*. 2000;522(*Pt 2*):177–185.

Sommer F, Goldstein I, Korda JB. Bicycle riding and erectile dysfunction: a review. *J Sex Med*. 2010;7(7):2346–2358; 10.1111/j.1743-6109.2009.01664.x.

Song SH, Park K, Kim SW, et al. Involvement of Rho-kinase/LIM kinase/cofilin signaling pathway in corporal fibrosis after cavernous nerve injury in male rats. *J Sex Med*. 2015;12(7):1522–1532.

Sopko NA, Hannan JL, Bivalacqua TJ. Understanding and targeting the Rho kinase pathway in erectile dysfunction. *Nat Rev Urol*. 2014;11(11):622–628.

Sousa CM, Havt A, Santos CF, et al. The relaxation induced by uroguanylin and the expression of natriuretic peptide receptors in human corpora cavernosa. *J Sex Med*. 2010;7(11):3610–3619.

Sparling J. Penile erections: shape, angle, and length. *J Sex Marital Ther*. 1997;23(3):195–207.

Speel TG, Kiemeney LA, Thien T, et al. Long-term effect of inhibition of the angiotensin-converting enzyme (ACE) on cavernosal perfusion in men with atherosclerotic erectile dysfunction: a pilot study. *J Sex Med*. 2005;2(2):207–212.

Spektor M, Rodriguez R, Rosenbaum RS, et al. Potassium channels and human corporeal smooth muscle cell tone: further evidence of the physiological relevance of the Maxi-K channel subtype to the regulation of human corporeal smooth muscle tone in vitro. *J Urol*. 2002;167(6):2628–2635.

Spitler KM, Matsumoto T, Webb RC. Suppression of endoplasmic reticulum stress improves endothelium-dependent contractile responses in aorta of the spontaneously hypertensive rat. *Am J Physiol Heart Circ Physiol*. 2013;305(3):H344–H353.

Srilatha B, Adaikan PG, Arulkumaran S, et al. Sexual dysfunction related to antihypertensive agents: results from the animal model. *Int J Impot Res*. 1999;11(2):107–113.

Stackl W, Hasun R, Marberger M. Intracavernous injection of prostaglandin E1 in impotent men. *J Urol*. 1988;140(1):66–68.

Stallmann-Jorgensen I, Ogbi S, Szasz T, et al. A toll-like receptor 1/2 agonist augments contractility in rat corpus cavernosum. *J Sex Med*. 2015;12(8):1722–1731.

Stancampiano R, Melis MR, Argiolas A. Penile erection and yawning induced by 5-HT1C receptor agonists in male rats:

relationship with dopaminergic and oxytocinergic transmission. *Eur J Pharmacol*. 1994;261(1–2):149–155.

Steers WD. Neural pathways and central sites involved in penile erection: neuroanatomy and clinical implications. *Neurosci Biobehav Rev*. 2000;24(5):507–516.

Steers WD, de Groat WC. Effects of m-chlorophenylpiperazine on penile and bladder function in rats. *Am J Physiol*. 1989;257(6 Pt 2):R1441–R1449.

Stief C, Benard F, Bosch R, et al. Acetylcholine as a possible neurotransmitter in penile erection. *J Urol*. 1989;141(6):1444–1448.

Stief CG, Bahren W, Scherb W, et al. Primary erectile dysfunction. *J Urol*. 1989;141(2):315–319.

Stief CG, Uckert S, Becker AJ, et al. Effects of sildenafil on cAMP and cGMP levels in isolated human cavernous and cardiac tissue. *Urology*. 2000;55(1):146–150.

Stoleru S, Redoute J, Costes N, et al. Brain processing of visual sexual stimuli in men with hypoactive sexual desire disorder. *Psychiatry Res*. 2003;124(2):67–86.

Strange PG. Antipsychotic drugs: importance of dopamine receptors for mechanisms of therapeutic actions and side effects. *Pharmacol Rev*. 2001;53(1):119–133.

Suadicani SO, Urban-Maldonado M, Tar MT, et al. Effects of ageing and streptozotocin-induced diabetes on connexin43 and P2 purinoceptor expression in the rat corpora cavernosa and urinary bladder. *BJU Int*. 2009;103(12):1686–1693.

Succu S, Sanna F, Melis T, et al. Stimulation of dopamine receptors in the paraventricular nucleus of the hypothalamus of male rats induces penile erection and increases extra-cellular dopamine in the nucleus accumbens: involvement of central oxytocin. *Neuropharmacology*. 2007;52(3):1034–1043.

Sullivan G, Lukoff D. Sexual side effects of antipsychotic medication: evaluation and interventions. *Hosp Community Psychiatry*. 1990;41(11):1238–1241.

Sullivan M, Thompson CS, Mikhailidis DP, et al. Differential alterations of prostacyclin, cyclic AMP and cyclic GMP formation in the corpus cavernosum of the diabetic rabbit. *Br J Urol*. 1998;82(4):578–584.

Sun P, Swindle R. Are men with erectile dysfunction more likely to have hypertension than men without erectile dysfunction? A naturalistic national cohort study. *J Urol*. 2005;174(1):244–248.

Sung HH, Choo SH, Han DH, et al. Effect of the novel BKCa channel opener LDD175 on the modulation of corporal smooth muscle tone. *J Sex Med*. 2015;12(1):29–38.

Sung HH, Kang SJ, Chae MR, et al. Effect of BKCa channel oener LDD175 on erectile function in an in vivo diabetic rat model. *J Sex Med*. 2017;14(1):59–68.

Suzuki H, Tominaga T, Kumagai H, et al. Effects of first-line antihypertensive agents on sexual function and sex hormones. *J Hypertens Suppl*. 1988;6(4):S649–S651.

Szasz T, Bomfim GF, Webb RC. The influence of perivascular adipose tissue on vascular homeostasis. *Vasc Health Risk Manag*. 2013;9:105–116.

Szymanski PT. Calponin (CaP) as a latch-bridge protein–a new concept in regulation of contractility in smooth muscles. *J Muscle Res Cell Motil*. 2004;25(1):7–19.

Tabrizchi R, Bedi S. Pharmacology of adenosine receptors in the vasculature. *Pharmacol Ther*. 2001;91(2):133–147.

Takenaka A, Kawada M, Murakami G, et al. Interindividual variation in distribution of extramural ganglion cells in the male pelvis: a semi-quantitative and immunohistochemical study concerning nerve-sparing pelvic surgery. *Eur Urol*. 2005;48(1):46–52 [discussion 52].

Tan HM, Tong SF, Ho CC. Men's health: sexual dysfunction, physical, and psychological health–is there a link? *J Sex Med*. 2012;9(3):663–671.

Tang Y, Rampin O, Calas A, et al. Oxytocinergic and serotonergic innervation of identified lumbosacral nuclei controlling penile erection in the male rat. *Neuroscience*. 1998;82(1):241–254.

Tarhan F, Kuyumcuoglu U, Kolsuz A, et al. Cavernous oxygen tension in the patients with erectile dysfunction. *Int J Impot Res*. 1997;9(3):149–153.

Tavallaii SA, Mirzamani M, Heshmatzade Behzadi A, et al. Sexual function: a comparison between male renal transplant recipients and hemodialysis patients. *J Sex Med*. 2009;6(1):142–148.

Teloken C, Busato WF Jr, Neto JF, et al. Congenital abnormality of corpora cavernosa and erectile dysfunction: a case report. *J Urol*. 1993;149(5):1135–1136.

Tirabassi G, Corona G, Falzetti S, et al. Influence of androgen receptor gene CAG and GGC polymorphisms on male sexual function: a cross-sectional study. *Int J Endocrinol*. 2016;2016:5083569; 10.1155/2016/5083569.

Toblli JE, Cao G, Casas G, et al. In vivo and in vitro effects of nebivolol on penile structures in hypertensive rats. *Am J Hypertens*. 2006;19(12):1226–1232.

Toblli JE, Cao G, Lombrana A, et al. Functional and morphological improvement in erectile tissue of hypertensive rats by long-term combined therapy with phosphodiesterase type 5 inhibitor and losartan. *J Sex Med*. 2007;4(5):1291–1303.

Toda N. Age-related changes in endothelial function and blood flow regulation. *Pharmacol Ther*. 2012;133(2):159–176.

Tomada N, Tomada I, Botelho F, et al. Endothelial function in patients with metabolic syndrome and erectile dysfunction: a question of angiopoietin imbalance? *Andrology*.

2013;1(4):541–548.

Toque HA, Nunes KP, Yao L, et al. Akita spontaneously type 1 diabetic mice exhibit elevated vascular arginase and impaired vascular endothelial and nitrergic function. *PLoS ONE*. 2013;8(8):e72277.

Tosti A, Piraccini BM, Soli M. Evaluation of sexual function in subjects taking finasteride for the treatment of androgenetic alopecia. *J Eur Acad Dermatol Venereol*. 2001;15(5):418–421.

Traish AM, Carson MP, Kim N, et al. Characterization of muscarinic acetylcholine receptors in human penile corpus cavernosum: studies on whole tissue and cultured endothelium. *J Urol*. 1990;144(4):1036–1040.

Traish AM, Galoosian A. Androgens modulate endothelial function and endothelial progenitor cells in erectile physiology. *Korean J Urol*. 2013;54(11):721–731; 10.4111/kju.2013.54.11.721.

Traish AM, Park K, Dhir V, et al. Effects of castration and androgen replacement on erectile function in a rabbit model. *Endocrinology*. 1999;140(4):1861–1868.

Traish AM, Saad F, Guay A. The dark side of testosterone deficiency: II. Type 2 diabetes and insulin resistance. *J Androl*. 2009;30(1):23–32.

Traish AM, Stottrup C, van Renterghem K, et al. Density and distribution of connexin 43 in corpus cavernosum tissue from diabetic and hypogonadal patients with erectile dysfunction. *Horm Mol Biol Clin Investig*. 2013;13(1):7–12.

Triggle CR, Samuel SM, Ravishankar S, et al. The endothelium: influencing vascular smooth muscle in many ways. *Can J Physiol Pharmacol*. 2012;90(6):713–738.

Tsujimura A, Miyagawa Y, Fujita K, et al. Brain processing of audiovisual sexual stimuli inducing penile erection: a positron emission tomography study. *J Urol*.

2006;176(2):679–683.

Udelson D, Nehra A, Hatzichristou DG, et al. Engineering analysis of penile hemodynamic and structural-dynamic relationships: part III–Clinical considerations of penile hemodynamic and rigidity erectile responses. *Int J Impot Res*. 1998;10(2):89–99.

Uvin P, Albersen M, Bollen I, et al. Additive effects of the Rho kinase inhibitor Y-27632 and vardenafil on relaxation of the corpus cavernosum tissue of patients with erectile dysfunction and clinical phosphodiesterase type 5 inhibitor failure. *BJU Int*. 2017;119(2):325–332.

Van der Ploeg LH, Martin WJ, Howard AD, et al. A role for the melanocortin 4 receptor in sexual function. *Proc Natl Acad Sci USA*. 2002;99(17):11381–11386.

Verze P, Margreiter M, Esposito K, et al. The link between cigarette smoking and erectile dysfunction: a systematic review. *Eur Urol Focus*. 2015;1(1):39–46.

Vick RN, Benevides M, Patel M, et al. The efficacy, safety and tolerability of intracavernous PNU-83757 for the treatment of erectile dysfunction. *J Urol*. 2002;167(6):2618–2623.

Vignozzi L, Filippi S, Comeglio P, et al. Estrogen mediates metabolic syndrome-induced erectile dysfunction: a study in the rabbit. *J Sex Med*. 2014;11(12):2890–2902.

Vignozzi L, Morelli A, Filippi S, et al. Testosterone regulates RhoA/Rho-kinase signaling in two distinct animal models of chemical diabetes. *J Sex Med*. 2007;4(3):620–632.

Villalba N, Kun A, Stankevicius E, et al. Role for tyrosine kinases in contraction of rat penile small arteries. *J Sex Med*. 2010;7(6):2086–2095.

Vincent SR, Kimura H. Histochemical mapping of nitric oxide synthase in the rat brain. *Neuroscience*. 1992;46(4):755–784.

Vita G, Bellinghieri G, Trusso A, et al. Uremic autonomic neuropathy studied by spectral analysis of heart rate. *Kidney*

Int. 1999;56(1):232–237.

Vlachopoulos CV, Terentes-Printzios DG, Ioakeimidis NK, et al. Prediction of cardiovascular events and all-cause mortality with erectile dysfunction: a systematic review and meta-analysis of cohort studies. *Circ Cardiovasc Qual Outcomes*. 2013;6(1):99–109.

Wagner G. Erection, physiology and endocrinology. Wagner G, Green R. *Impotence: physiological, and surgical diagnosis and treatment*. Plenum: New York; 1981:25–36.

Walsh MP. The Ayerst Award Lecture 1990. Calcium-dependent mechanisms of regulation of smooth muscle contraction. *Biochem Cell Biol*. 1991;69(12):771–800.

Walsh MP. Regulation of vascular smooth muscle tone. *Can J Physiol Pharmacol*. 1994;72(8):919–936.

Walsh PC, Donker PJ. Impotence following radical prostatectomy: insight into etiology and prevention. *J Urol*. 1982;128(3):492–497.

Wang CJ, Shen SY, Wu CC, et al. Penile blood flow study in diabetic impotence. *Urol Int*. 1993;50(4):209–212.

Wang XJ, Xu TY, Xia LL, et al. Castration impairs erectile organ structure and function by inhibiting autophagy and promoting apoptosis of corpus cavernosum smooth muscle cells in rats. *Int Urol Nephrol*. 2015;47(7):1105–1115.

Ware JC, Rose FV, McBrayer RH. The acute effects of nefazodone, trazodone and buspirone on sleep and sleep-related penile tumescence in normal subjects. *Sleep*. 1994;17(6):544–550.

Wassertheil-Smoller S, Blaufox MD, Oberman A, et al. Effect of antihypertensives on sexual function and quality of life: the TAIM Study. *Ann Intern Med*. 1991;114(8):613–620.

Weinstein M, Roberts M. Sexual potency following surgery for rectal carcinoma. A followup of 44 patients. *Ann Surg*. 1977;185(3):295–300.

Wessells H, Lue TF, McAninch JW. Penile length in the flaccid and erect states: guidelines for penile augmentation. *J Urol*. 1996;156(3):995–997.

Westerink BH. Can antipsychotic drugs be classified by their effects on a particular group of dopamine neurons in the brain? *Eur J Pharmacol*. 2002;455(1):1–18.

Wimalawansa SJ. Age-related changes in tissue contents of immunoreactive calcitonin gene-related peptide. *Aging (Milano)*. 1992;4(3):211–217.

Winder K, Seifert F, Kohrmann M, et al. Lesion mapping of stroke-related erectile dysfunction. *Brain*. 2017;140(6):1706–1717.

Wirshing DA, Pierre JM, Marder SR, et al. Sexual side effects of novel antipsychotic medications. *Schizophr Res*. 2002;56(1–2):25–30.

Woodhouse CR. Sexual function in boys born with exstrophy, myelomeningocele, and micropenis. *Urology*. 1998;52(1):3–11.

Wu F, Xiong ZQ, Mao SH, et al. Aldosterone induces inflammatory cytokines in penile corpus cavernosum by activating the NF-kappaB pathway. *Asian J Androl*. 2018;20(1):24–29.

Wu FC, Tajar A, Beynon JM, et al. Identification of late-onset hypogonadism in middle-aged and elderly men. *N Engl J Med*. 2010;363(2):123–135.

Wu L, Wang R. Carbon monoxide: endogenous production, physiological functions, and pharmacological applications. *Pharmacol Rev*. 2005;57(4):585–630.

Xiao M, Ding J, Wu L, et al. The distribution of neural nitric oxide synthase-positive cerebrospinal fluid-contacting neurons in the third ventricular wall of male rats and coexistence with vasopressin or oxytocin. *Brain Res*. 2005;1038(2):150–162.

Xie D, Thompson MA, Pippen AM, et al. Decreases in corporeal vascular endothelial growth factor expression precede vasoreactivity changes in cholesterol fed rabbits. *J Urol*. 2005;173(4):1418–1422.

Yang J, Wang T, Yang J, et al. S-allyl cysteine restores erectile function through inhibition of reactive oxygen species generation in diabetic rats. *Andrology*. 2013;1(3):487–494.

Yang Z, Zhou Z, Wang X, et al. Short hairpin ribonucleic acid constructs targeting insulin-like growth factor binding protein-3 ameliorates diabetes mellitus-related erectile dysfunction in rats. *Urology*. 2013;81(2):464.e411–464.e466.

Yarnitsky D, Sprecher E, Barilan Y, et al. Corpus cavernosum electromyogram: spontaneous and evoked electrical activities. *J Urol*. 1995;153(3 Pt 1):653–654.

Yetik-Anacak G, Sorrentino R, Linder AE, et al. Gas what: NO is not the only answer to sexual function. *Br J Pharmacol*. 2015;172(6):1434–1454.

Yiee JH, Baskin LS. Penile embryology and anatomy. *ScientificWorldJournal*. 2010;10:1174–1179; 10.1100/tsw.2010.112.

Yousif MH, Kehinde EO, Benter IF. Different responses to angiotensin-(1-7) in young, aged and diabetic rabbit corpus cavernosum. *Pharmacol Res*. 2007;56(3):209–216.

Yousif MH, Makki B, El-Hashim AZ, et al. Chronic treatment with Ang-(1-7) reverses abnormal reactivity in the corpus cavernosum and normalizes diabetes-induced changes in the protein levels of ACE, ACE2, ROCK1, ROCK2 and omega-hydroxylase in a rat model of type 1 diabetes. *J Diabetes Res*. 2014;2014:142154.

Zarrindast MR, Farahvash H. Effects of GABA-ergic drugs on penile erection induced by apomorphine in rats. *Psychopharmacology (Berl)*. 1994;115(1–2):249–253.

Zarrindast MR, Shokravi S, Samini M. Opposite influences of dopaminergic receptor subtypes on penile erection. *Gen Pharmacol*. 1992;23(4):671–675.

Zemishlany Z, Weizman A. The impact of mental illness on sexual dysfunction. *Adv Psychosom Med*. 2008;29:89–106.

Zhang MG, Wang XJ, Shen ZJ, et al. Long-term oral administration of 5alpha-reductase inhibitor attenuates erectile function by inhibiting autophagy and promoting apoptosis of smooth muscle cells in corpus cavernosum of aged rats. *Urology*. 2013;82(3):743.e9–743.e15.

Zhang Y, Yang J, Wang T, et al. Decreased endogenous hydrogen sulfide generation in penile tissues of diabetic rats with erectile dysfunction. *J Sex Med*. 2016;13(3):350–360.

Zhao W, Wang R. H(2)S-induced vasorelaxation and underlying cellular and molecular mechanisms. *Am J Physiol Heart Circ Physiol*. 2002;283(2):H474–H480.

Zheng H, Bidasee KR, Mayhan WG, et al. Lack of central nitric oxide triggers erectile dysfunction in diabetes. *Am J Physiol Regul Integr Comp Physiol*. 2007;292(3):R1158–R1164.

Zheng H, Liu X, Patel KP. Centrally mediated erectile dysfunction in rats with type 1 diabetes: role of angiotensin II and superoxide. *J Sex Med*. 2013;10(9):2165–2176.

Zhu X, Lin H, Jiang R, et al. Improving erectile function of spontaneously hypertensive rats by silencing ROCK2. *Urology*. 2014;84(4):983 e911–983 e988.

69

Evaluation and Management of Erectile Dysfunction

Arthur L. Burnett II, MD, MBA, Ranjith Ramasamy MD

Historical Perspective

Sexual medicine has evolved into a mature clinical discipline in the past few decades as a result of steady, considerable progress made in the basic science, epidemiology, clinical investigation, and health services research within this dynamic field. Erectile dysfunction (ED) management, a subcategory of the field addressing specifically difficulty with penile erection/arousal function, has advanced from its well-intended beginnings of psychoanalysis and sex therapy, accompanied by the use of aphrodisiacs, herbal supplements, and hormonal treatments, typifying the knowledge and approach to clinical practice in the 1970s, to an increasingly structured, balanced, and evidence-based process of clinical evaluation and intervention of the contemporary era (Table 69.1).

TABLE 69.1

Evolution in the Management of Erectile Dysfunction

	DIAGNOSTICS	TREATMENTS	GUIDES
Pre-1970	Psychosexual history	Psychosexual therapy Herbal supplements	Studies of Masters and Johnson
1970s	Medical and psychosexual history Nocturnal penile tumescence testing	Penile prosthesis surgery Penile revascularization	International Conferences on Corpus Cavernosum Revascularization
1980s	Physical examination Endocrine evaluation Penile duplex ultrasonography, DICC	Oral medications Intracavernous pharmacotherapy Vacuum device therapy	Goal-directed management
1990s	Combined intracavernous injection and stimulation	Intraurethral pharmacotherapy Oral phosphodiesterase type 5 therapy	NIH Consensus Statement Process of Care Model

2000–Present	Biomarkers of vascular health neuroimaging	? Gene therapy ? Stem cell therapy ? Tissue engineering ? Shock wave therapy	ICUD algorithms (patient-centered approach) AUA Practice Guidelines (evidence-based approach) EAU guidelines

AUA, American Urological Association; *DICC,* dynamic infusion cavernosometry and cavernosography; *EAU,* European Association of Urology; *ICUD,* International Consultation on Urological Diseases; *NIH,* National Institutes of Health.

Well-grounded ED management principles, premised on the highest clinical standards of ethics, quality, safety, and cost effectiveness, are now well accepted by the scientific and clinical community in sexual medicine. These “guidelines” have derived from rigorous and timely review, organization, and reassessments of the constantly evolving body of knowledge in this field performed by assorted consensus bodies representing the spectrum of international and interdisciplinary authorities in sexual medicine. Most notably, the International Consultations on Sexual Medicine (ICSM), cosponsored variously by the World Health Organization, International Consultation on Urological Diseases, American Urological Association (AUA), Société Internationale D'Urologie, and the International Society for Sexual Medicine, have served this role and have published topical proceedings (Hatzimouratidis et al., 2016; Jardin et al., 2000; Lue et al., 2004).

Public Health Significance

ED is defined as the inability to attain and/or maintain penile erection sufficient for satisfactory sexual performance (National Institutes of Health [NIH] Consensus Statement, 1992). The definition has been revised over time with recent opinion accepting sufficiency for sexual satisfaction as a valid purpose of this function in the complex human context (McCabe et al., 2016). ED is a medical condition of major health significance, with implications that extend beyond treating the occasional patient who possesses a problem of seemingly non–life-threatening magnitude. **The value of properly assessing and managing ED relates not only to affected individuals and their partners but also to society as a whole, and its scope encompasses physical and mental wellness aspects related to addressing (or failing to address) the sexual dysfunction, concurrent disease management issues, as well as its socioeconomic burden.**

Epidemiology

Epidemiologic investigation, which specifies that study results are readily generalized to the overall male population, has provided powerful information regarding the nature, cause, and prognostic ramifications of ED. **As the most thoroughly studied sexual dysfunction in the context of epidemiologic research, ED is estimated to carry an overall adult male (older than 20 years of age) prevalence rate of 10% to 20% worldwide, with the majority of studies reporting a rate closer to 20%** (Derogatis and Burnett, 2008; Lewis et al., 2010). An age correlation exists for the prevalence of ED, with a worldwide prevalence of 1% to 10% for men younger than the age of 40 years, up to 15% for men age 40 to 49 years, up to 30% for men age 50 to 59 years, up to 40% for men 60 to 69 years, and 50% to 100% for men between 70 and 90 years (Lewis et al., 2010). A cross-sectional study among men seeking first-time medical help for new-onset ED found that one in four men was younger than age 40, and almost 50% of the young men complained of severe ED (Capogrosso et al., 2013). It was estimated that there were more than 152 million men worldwide who experienced ED in 1995, with a projection of the prevalence reaching approximately 322 million men having ED by 2025 (Aytac et al., 1999). This trend is maintained irrespective of racial/ethnic background or geographic region.

Current data have also confirmed that the prevalence of ED mounts with the presence of comorbid medical conditions, which include type 2 diabetes mellitus, obesity, cardiovascular disease, hypertension, dyslipidemia, depression, and prostate disease/benign prostatic hyperplasia (Braun et al., 2000; Laumann et al., 2007; Martin-Morales et al., 2001; Nicolosi et al., 2004; Rosen et al., 2004; Saigal et al., 2006; Seftel et al., 2013). This correlation has supported the premise that ED and comorbid medical conditions share pathophysiologic mechanisms, such as endothelial dysfunction, arterial occlusion, and systemic inflammation (Billups, 2005; Ganz, 2005; Guay, 2007; Kloner, 2005; Montorsi et al., 2004; Solomon et al., 2003).

Novel disease-risk relationships for ED have been described, likely also exhibiting such concomitant pathophysiologic mechanistic associations as endothelial dysfunction and systemic inflammation. These disease relationships include epilepsy (Keller et al., 2012a-e, Pavone et al., 2017), sensorineural hearing loss (Keller et al., 2012a-e), open-angle glaucoma (Chung et al., 2012a-d), urinary calculi (Chung et al., 2011), psoriasis (Cabete et al., 2014; Chung et al., 2012a-d), atopic dermatitis (Chung et al., 2012a-d), chronic periodontitis (Keller et al., 2012a-e), viral hepatitis (Chung et al., 2012a-d), varicocele (Keller et al., 2012a-e), gastric ulcers (Keller et al., 2012a-e), ankylosing spondylitis (Chung et al., 2013a), gout (Gelber, 2015; Schlesinger et al., 2015), inflammatory bowel disease/ulcerative colitis (Kao et al., 2016), interstitial cystitis (Chung et al., 2013b), Parkinson disease (Yang et al., 2017), obstructive sleep apnea (Bozorgmehri et al, 2017; Chung et al., 2016), and premature ejaculation (Brody and Weiss, 2015; Corona et al., 2015).

Although they are few in number, prospectively conducted longitudinal studies have documented the true incidence and disease-risk relationships for ED. In one study, a crude ED incidence rate was 25.9 cases/1000 man-years among men aged 40 to 69 years (Johannes et al., 2000). According to another study, incident ED statistics were 57% at 5 years and 65% at 7 years in men 55 years or older (Thompson et al., 2005). **Such studies have uniquely affirmed predictors for the development of ED, which include age, lower education, diabetes, cardiovascular disease, hypertension, cigarette smoking, cigar smoking, passive exposure to cigarette smoke, and overweight condition** (Buvat et al., 2010; Feldman et al., 2000; Inman et al., 2009; Jackson et al., 2010; Johannes et al., 2000; Salonia et al., 2012b).

However, the strength of the risk association is also gauged from the opposite analytic direction, and incident ED may indeed inform the risk of subsequent disease morbidity and mortality. This relationship has been best demonstrated so far with respect to cardiovascular disease. The placebo arm of the Prostate Cancer Prevention Trial found that ED is a sentinel for future risk of cardiovascular events, comparable with that of current cigarette smoking or a family history of myocardial infarction (Thompson et al., 2005). This study established that men with ED were 45% more likely than men without ED to experience a cardiac event after 5 years of follow-up (Thompson et al., 2005). In another population-based study of community-dwelling men followed longitudinally, ED was associated with an approximately 80% higher risk of subsequent coronary artery disease at 10 years (Inman et al., 2009). In a long-term follow-up (15 years) of the Massachusetts Male Aging Study (Feldman et al., 1994), ED was found to be positively associated with subsequent all-cause and cardiovascular disease mortality and constituted a risk in this regard similar to that of conventional risk factors, such as increased body mass index, diabetes, and hypertension (Araujo et al., 2009). It is an increasingly recognized and striking observation, made in epidemiologic studies demonstrating the risk association of ED with cardiovascular events, that the development of ED at a younger age heightens this particular risk (Chew et al., 2010; Miner et al., 2012; Vlachopoulos et al., 2014).

Recent meta-analyses of longitudinal studies have supported the findings of earlier reports and have provided relative risk estimates. A meta-analysis of seven prospective cohort studies provided adjusted relative risks for ED subjects compared with healthy subjects, calculating 1.47-fold increased cardiovascular disease events overall and 1.23-fold increased all-cause mortality (Guo et al., 2010). Another meta-analysis of 12 cohort studies calculated overall combined relative risk for men with ED compared with the reference group to be 1.48 with cardiovascular disease, 1.46 for coronary heart disease, 1.35 for stroke, and 1.19 for all-cause mortality (Dong et al., 2011). A further meta-analysis comprising 14 studies documented relative risk of 1.44 for cardiovascular mortality, 1.19 for myocardial infarction, 1.62 for cerebrovascular events, and 1.25 for all-cause mortality for men with ED versus those without ED (Vlachopoulos et al., 2014). A recent study found a significant association between ED severity and overall men's health (measured by the Charlson Comorbidity Index), irrespective of cardiovascular risk factors (Capogrosso et al., 2017).

Besides a predictive relationship of cardiovascular disease based on incident ED, a similar relationship has been suggested with respect to carcinogenesis risk.

The Longitudinal Health Insurance Database study in Taiwan showed that cancer risk was 1.42-fold higher in ED patients than in patients without ED during a 5-year follow-up, after adjusting for socioeconomic and comorbid health variables (Chung et al., 2011).

These compelling data regarding occurrence rates and risk factors for ED foster an understanding of the importance of this medical condition. **The subject of ED offers a veritable clinical barometer of overall male health status, and efforts geared toward advancing its management are immediately consequential for disease prevention, health promotion, and survival improvement.**

Health Policy

Sexual dysfunctions and ED specifically have taken on increasing importance with respect to their socioeconomic impact. **In addition to its medical comorbidity associations, ED is recognized to affect adversely quality of life, decrease occupational productivity, and increase the use of health care resources** (Krane et al., 1989; Litwin et al., 1998). Because of the heightened ease of use and availability of effective first-line treatments combined with a growing societal awareness of ED and an acceptance of its treatment, it is understandable that a trend toward increased use of health care services surrounding ED has been observed (Polinski and Kesselheim, 2011; Wessells et al., 2007).

ED can be included among a host of urologic diseases having a substantial burden on the public financially. Total expenditures for outpatient clinical management of ED (exclusive of pharmaceutical costs) in the United States in the year 2000 approximated $330 million, ranking it the ninth most costly among the most frequent urologic diagnoses (Litwin et al., 2005). By contrast, this cost was approximately $185 million in 1994 (Wessells et al., 2007). Individual-level expenditures on an annual basis associated with an ED diagnosis (inclusive of pharmaceutical costs) among affected 18- to 64-year-old males in the United States in 2002 were calculated to be $1107 (Wessells et al., 2007). The Congressional Budget Office estimate of government expense for ED drugs in 2005 was $2 billion for the subsequent 10 years (Polinski and Kesselheim, 2011). These data have enormous implications for governmental as well as nongovernmental agencies in the United States and worldwide, whose work must consider the practical distribution and fiscal allocation of health care services for ED. Some experts have accordingly urged an account of the medical necessity and cost of ED therapy when formulating grounds for insurance coverage (Polinski and Kesselheim, 2011). However, evidence points to rational coverage for ED therapy, and in fact a significantly lower use of this therapy has been shown as compared with ED prevalence (Hornbrook and Holup, 2011). Arguments support the fact that ED is not a frivolous indication for clinical intervention, having quality-of-life and well-being implications as well as importance with respect to health and life preservation.

Key Points: Epidemiology and Health Policy

- Approximately 20% of adult men worldwide experience ED.
- Risk factors for ED include increasing age and presence of comorbid medical conditions, such as DM, obesity, CVD, hypertension, depression, and prostate disease.
- Outcomes research has shown that ED merits clinical intervention, having quality-of-life implications and importance regarding health and life preservation.
- ED ranks among the top 10 most costly urologic diagnoses in the United States and must be included in considerations for fiscal allocation of health care services.

Management Principles

The approach to the evaluation and treatment of ED is most assuredly different from that of many other urologic diseases in several basic respects. The diagnosis of ED customarily involves an acknowledgment of the subjective complaint of erectile inability by the patient (or patient and partner), and extensive diagnostic procedures are generally not required to proffer the diagnosis. In addition, current first-line intervention in the form of effective oral pharmacotherapy is easily prescribed and administered and is frequently successful for the majority of patients. **However, notwithstanding the semblance that the management of ED is fairly uncomplicated, it is a structured process that critically incorporates several clinical practice concepts for bringing the best therapeutic outcomes to patients.**

Early Detection

Epidemiologic and clinical investigation has suggested that many patients with ED retain adverse clinical conditions and also lifestyle factors (e.g., diabetes, cardiovascular disease, prostate disease, overweight condition, current cigarette smoking, and physical inactivity) that potentially compromise erectile function (Laumann et al., 2007; Lewis et al., 2010; Saigal et al., 2006; Selvin et al., 2007). The extent of these risk factors results in an increased global cardiometabolic risk profile in patients with ED (Miner et al., 2012; Nehra et al., 2012). Calculated odds ratios underscore the extent to which various ED risk factors correlate with ED (Table 69.2). **These data support the contention that patients with identifiable ED risk factors likely experience the sexual dysfunction currently or will eventually develop it at some time. Clinical screening of such patients based on these indications is advantageous in allowing opportunities to diagnose and treat ED.**

TABLE 69.2

Major Erectile Dysfunction Risk Factors

CONDITION	MULTIVARIATE ADJUSTED ODDS RATIO
Diabetes mellitus	2.9

Hypertension	1.6
Cardiovascular disease	1.1
Hypercholesterolemia	1.0
Benign prostate enlargement	1.6
Obstructive urinary symptoms	2.2
Increased body mass index (>30 kg/m^2)	1.5
Physical inactivity	1.5
Current cigarette smoking	1.6
Antidepressant use	9.1
Antihypertensive use	4.0

Data from Francis ME, Kusek JW, Nyberg LM, Eggers PW: The contribution of common medical conditions and drug exposures to erectile dysfunction in adult males. *J Urol* 178:591–596, 2007; and Selvin E, Burnett AL, Platz EA: Prevalence and risk factors for erectile dysfunction in the US. *Am J Med* 120:151–157, 2007.

Growing evidence has also suggested that a patient's genotype influences the risk of developing ED, consistent with proposals that molecular and genetic mechanisms account for the ED phenotype (Andersen et al., 2011; Lippi et al., 2012). This concept fits with the perspective that genetically determined biomarkers will eventually be defined to assess ED risk profile as well as level of responsiveness to a specific ED therapy in the advancing era of precision medicine. Genetic polymorphisms have already been identified among patients with pulmonary hypertension that can predict which patients will benefit most from phosphodiesterase type 5 (PDE5) inhibitors (Hatzimouratidis and Hatzichristou, 2008; Sekine et al., 2014). Precision medicine has the potential not only to optimize treatment but also to guide screening and management of comorbidities. Identifying genes that may link ED and cardiovascular risk would assist in identifying patients in need of further screening and management (Mata et al., 2017).

Medication use has also been associated with ED in up to 25% of presentations (Francis et al., 2007; Keene and Davies, 1999). The most commonly implicated classes of drug include antihypertensive drugs, such as thiazide diuretics and β-adrenoceptor antagonists, and psychotherapeutic drugs, particularly selective serotonin reuptake inhibitor (SSRI) antidepressants. Table 69.3 lists several drug classes commonly associated with ED. It is important to recognize that medications may affect other components of the male sexual response cycle, including sexual desire, arousal, and orgasm, which secondarily hamper erectile function. Of additional importance, the assignment of causation of ED for any particular medication is conditional, requiring that an increased prevalence exists in the target population compared with the placebo group after stratification for known risk factors or compared with another drug with an equivalent therapeutic effect, and, further, a credible physiologic mechanism should be established experimentally (Sáenz de Tejada et al., 2005).

TABLE 69.3

Drugs Associated With Erectile Dysfunction

CLASS	SPECIFIC AGENTS
Antihypertensives	Thiazide diuretics, nonselective beta-blockers
Antidepressants	Tricyclics; selective serotonin reuptake inhibitors
Antipsychotics	Phenothiazines
Antiandrogens	Nonsteroidal (flutamide); steroidal; luteinizing hormone–releasing hormone analogues
Antiulcer drugs	Histamine H_2 receptor antagonists (cimetidine)
Cytotoxic agents	Cyclophosphamide, methotrexate
Opiates	Morphine

Shared Decision Making and Treatment Planning

The therapeutic plan may vary for every patient and couple, and it ultimately depends on a host of factors, including patient considerations and clinical indications and contraindications. **An informed decision-making process should dictate the best therapeutic option. It follows a balanced and thorough discussion led by the clinician of *all treatment options*, medical and nonmedical, and their expected advantages and disadvantages. Perceived risks and benefits, which may be influenced by the individual clinical situation, should be weighed.** The patient may appropriately select a preferred treatment option without necessarily adhering to a strictly prescribed succession of attempted therapies. Patients are supported during the decision-making process to express preferences and values that align with their informed choice (Elwyn et al., 2012). Indeed, the patient may elect to defer treatment altogether. Whatever the patient (or couple) chooses, this option can then be pursued within the boundaries of safety, under the supportive partnership of his clinician. This approach borrows to some extent from the goal-directed ED management approach, which is clearly described by Lue (1990) and fits with the patient-centered framework of managing ED (Hatzichristou et al., 2010). A meta-analysis of randomized clinical trials comparing shared decision making to routine care found that patients participating in shared decision making are more knowledgeable and have higher congruence between the chosen therapy and their values (Stacey et al., 2014). The American Urological Association (AUA) ED guideline panel has endorsed shared decision making as the state of the art in ED management (Burnett et al., 2018; Fig. 69.1).

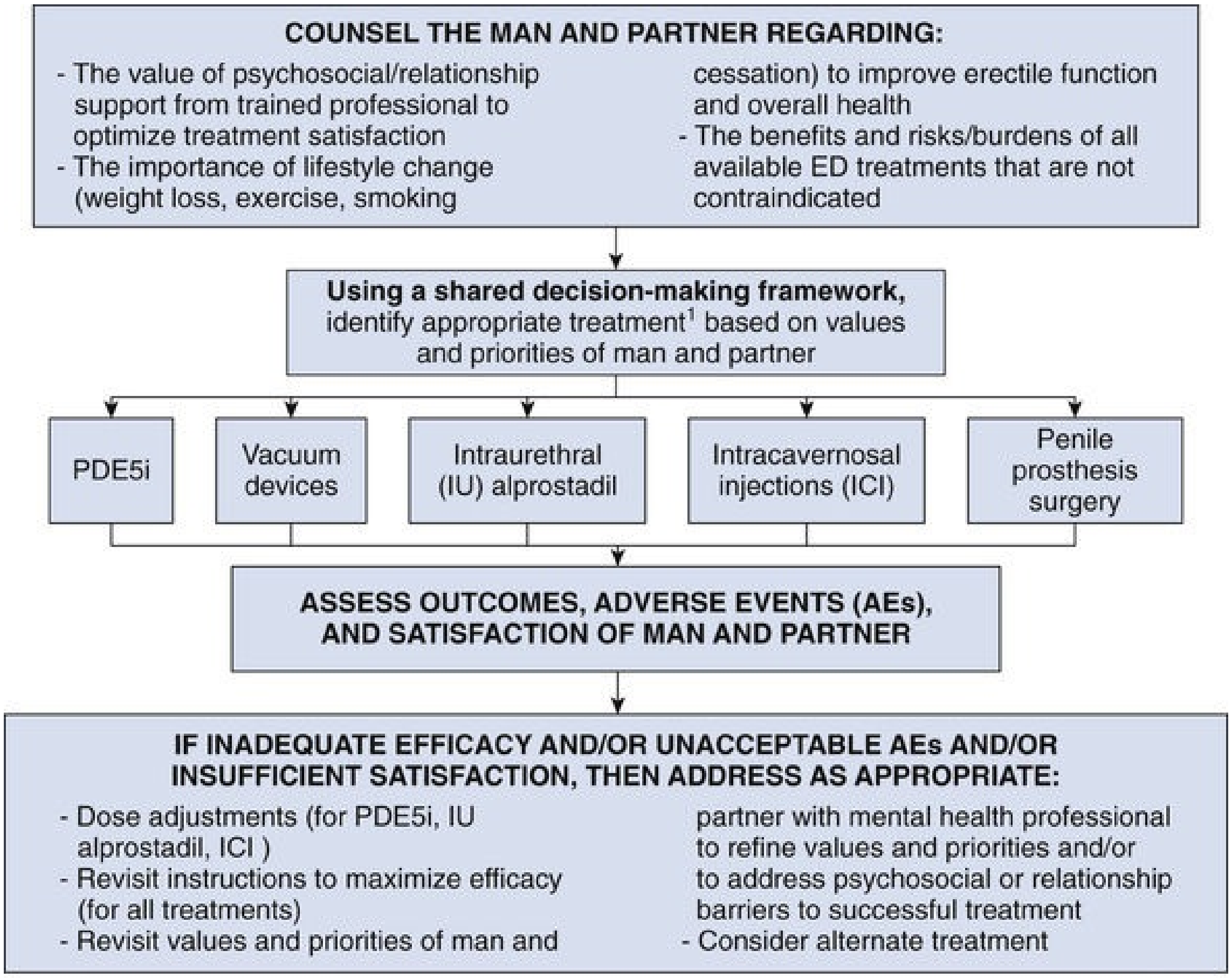
COUNSEL THE MAN AND PARTNER REGARDING:
- The value of psychosocial/relationship support from trained professional to optimize treatment satisfaction
- The importance of lifestyle change (weight loss, exercise, smoking cessation) to improve erectile function and overall health
- The benefits and risks/burdens of all available ED treatments that are not contraindicated
Using a shared decision-making framework, identify appropriate treatment¹ based on values and priorities of man and partner
PDE5i
Vacuum devices
Intraurethral (IU) alprostadil
Intracavernosal injections (ICI)
Penile prosthesis surgery
ASSESS OUTCOMES, ADVERSE EVENTS (AEs), AND SATISFACTION OF MAN AND PARTNER
IF INADEQUATE EFFICACY AND/OR UNACCEPTABLE AEs AND/OR INSUFFICIENT SATISFACTION, THEN ADDRESS AS APPROPRIATE:
- Dose adjustments (for PDE5i, IU alprostadil, ICI)
- Revisit instructions to maximize efficacy (for all treatments)
- Revisit values and priorities of man and partner with mental health professional to refine values and priorities and/or to address psychosocial or relationship barriers to successful treatment
- Consider alternate treatment

1 for men with testosterone deficiency, defined as the presence of symptoms and signs and a total testosterone <300 ng/dL, counseling should emphasize that restoration of testosterone levels to therapeutic levels is likely to increase efficacy of ED treatment other than prosthesis surgery.

FIG. 69.1 Algorithm for shared decision making and treatment planning. *ED,* Erectile dysfunction; *PDE5i,* phosphodiesterase type 5.

Step-Care Approach

Practitioners of ED management have always sought a rational approach for implementing diagnostic and therapeutic options. The Process of Care

Model for Erectile Dysfunction was proposed as a stepwise methodology, combining processes, actions, and outcomes in the management of the ED patient (Process of Care Consensus Panel, 1999). It specified an algorithm for therapeutic decision making that takes into account patient needs and preferences (goal-directed management), although it was also based on specific criteria such as ease of administration, reversibility, relative invasiveness, and cost of therapies. This algorithm presented a strategy of staged therapy (i.e., first-, second-, and third-line interventions), which ranged from lifestyle modification to surgery. **In concept, the scheme has been borrowed and endorsed by other consensus panels that acknowledged the purpose of patient education and counseling along with medical therapies as initial forms of ED management in common practice** (Hatzichristou et al., 2010; Montague et al., 2005). Although the step-care approach has commonly been used, the contemporary of management of ED emphasize the shared decision-making model (Burnett et al., 2018).

Role of Partner Interview

The partner interview is a critical component in initiating management of ED. Partner interviews have been shown to affect diagnosis and treatment in as many as 58% of cases (Chun and Carson, 2001; Tiefer and Schuetz-Mueller, 1995). **The partner may be the source of important information that guides optimal intervention and response to therapy. The partner may share a new and different perspective on sexual issues affecting the couple, provide insight into the quality of the couple's relationship, and relate his/her role in the sexual dysfunction** (Fisher et al., 2009; Speckens et al., 1995). **The partner's involvement and attitude may also affect the patient's initiation of and adherence to therapy** (Fisher et al., 2005; Jackson and Lue, 1998).

An important additional consideration is that partners' well-being may be affected by the patients' ED conditions. Studies have shown that women partners of men with ED are more likely to have sexual dysfunction or to cease sexual activity entirely (Fisher et al., 2005; Ichikawa et al., 2004; Montorsi and Althof, 2004; Sand and Fisher, 2007). This observation further prompts the facilitatory role of the partner in ED management, which maximizes the success of therapy and inherently the satisfaction of the couple.

In practice, and as necessary, additional office visits, during which the partner accompanies the patient and the patient communicates educational information to the partner, are recommended techniques for involving partners in ED management (Dean et al., 2008).

Cardiac Risk Assessment

The frequent coexistence of ED and cardiovascular disease, as established by clinical epidemiologic study and by basic science research, has steered ED management to include procedures that account for the ED patient's cardiovascular health risks. The Princeton Consensus Conferences, a multidisciplinary forum convened successively on three occasions since the early 2000s, have emphasized the link between sexual activity and cardiac risk and have pronounced that all men with ED, even in the absence of manifesting cardiac symptoms, should be regarded as having potential risks for cardiovascular disease (DeBusk et al., 2000; Jackson et al., 2006a,b; Kostis et al., 2005; Nehra et al., 2012). The presence of ED improves the sensitivity of screening asymptomatic cardiovascular disease in men with diabetes (Gazzaruso, 2011; Turek, 2013) and increases the risk of cardiovascular disease, coronary artery disease, and stroke (Dong, 2011; Gandaglia, 2014; Vlachopoulos, 2014).

According to the Princeton Consensus expert panel guidelines, patients with ED are recommended to undergo a full medical assessment with stratification of cardiovascular risk as high, medium, or low (Fig. 69.2). **Patients classified as having a high risk would be those with unstable or refractory angina, a recent history of myocardial infarction, certain arrhythmias, or uncontrolled hypertension. For these patients, sexual activity with any particular ED therapy should be deferred until the cardiac condition is stabilized. Such patients should ideally undergo cardiologic referral for cardiovascular stress testing and subsequent risk-reduction therapy. Importantly, even patients at low risk for cardiovascular events should receive the minimum recommendations of cardiovascular disease management.** Basic intervention includes counseling for lifestyle modifications such as increased physical activity and improved weight control combined with regular health monitoring by the patient's general practitioner (Kostis et al., 2005). A more comprehensive approach specifies cardiovascular risk reduction and affirmation of exercise tolerance for sexual activity after noninvasive cardiovascular risk assessment that may involve a specialist or collaborative medical team having such expertise (Nehra et al., 2012).

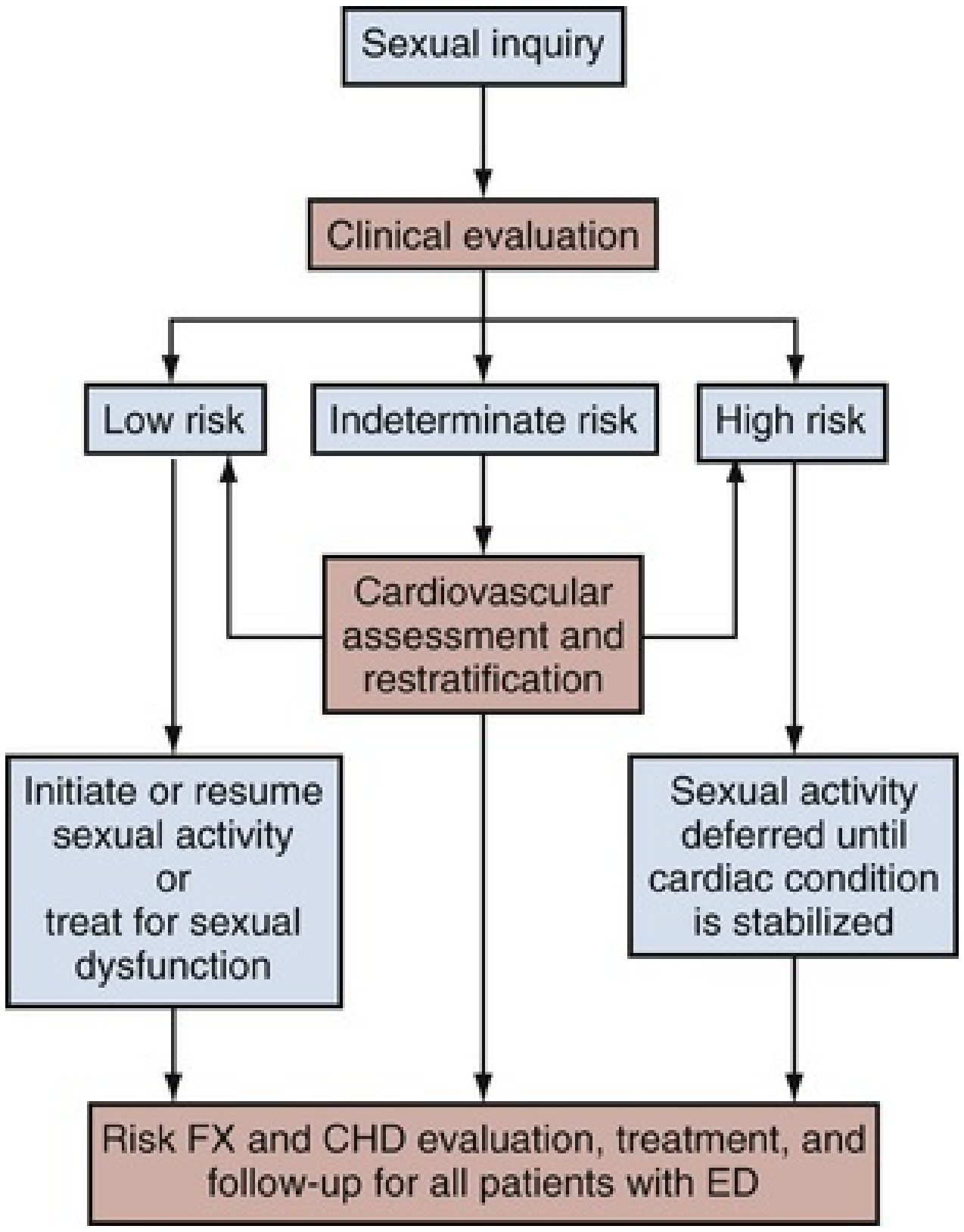
Sexual inquiry
Clinical evaluation
Low risk
Indeterminate risk
High risk
Cardiovascular assessment and restratification
Initiate or resume sexual activity or treat for sexual dysfunction
Sexual activity deferred until cardiac condition is stabilized
Risk FX and CHD evaluation, treatment, and follow-up for all patients with ED

FIG. 69.2 Algorithm for evaluation of the patient with cardiovascular disease recommended by the Second Princeton Panel. *CHD,* Coronary heart disease; *ED,* erectile dysfunction; *FX,* factors.

Specialist Referral

The advent of effective oral pharmacotherapy for ED has enabled many primary practitioners to feel comfortable with managing the majority of clinical presentations of ED. At the same time, it is understood that situations arise in which the patient or primary practitioner may request the assistance of a consultant/specialist (e.g., cardiologist, endocrinologist, psychologist, or urologist) for further diagnostic evaluation and treatment beyond the boundaries of initial management (Process of Care Consensus Panel, 1999). **Such referrals may be required for individuals with complicated or atypical presentations of ED, representing diagnostic challenges that exceed common clinical practices of nonspecialists. Specialized evaluation and management potentially offer improved therapeutic outcomes for these presentations.**

Generally recommended indications for specialized evaluations and associated consultants are failure of initial treatment, referred to a

urologist; younger patients with a history of pelvic or perineal trauma, referred to a urologist; patients with significant penile deformity (e.g., Peyronie disease, congenital chordee), referred to a urologist; complicated endocrinopathies (e.g., secondary hypogonadism, pituitary adenoma), referred to an endocrinologist; complicated psychiatric or psychosexual disorders (e.g., refractory depression, hypoactive sexual desire), referred to a psychiatrist; presentations requiring vascular or neurosurgical intervention (e.g., aortic aneurysm, lumbosacral disk disease), referred to a vascular surgeon or neurosurgeon, respectively; and medicolegal reasons (e.g., workers' compensation claims), referred to a urologist.

A caveat is that effort should be made at the time of referral to ensure that patients are fully informed about the rationale, costs, potential risks, and potential outcomes of the referral and possible additional procedures. This recommendation is made in accordance with the principles of patient-centered medicine, by which patients (and partners where possible) should be included in the decision-making process.

Follow-Up Care

Follow-up care is an essential part of ED management and should not be overlooked. The objectives of this action are manifold. **A primary basis is to ensure continual success with the therapeutic outcome. It has been shown that treatment discontinuation occurs at high rates among patients who are not reassessed regularly** (Albaugh et al., 2002). Additional purposes are to reassess medical and psychosocial conditions adversely affecting ED and success of therapy, evaluate the need for dosage titration or treatment substitution, and monitor adverse drug interactions or drug-interaction effects. As always, follow-up attention offers educational opportunities for patient and partner with regard to addressing sexual health concerns as well as lending guidance for related health care matters.

Diagnostic Evaluation

The cornerstone in the evaluation of ED involves a detailed case history, preferably taken from patient and partner, physical examination, and proper laboratory tests (Fig. 69.3). **The diagnosis can be submitted based on an individual's report of consistent inability to attain and maintain an erection of the penis sufficient to permit satisfactory sexual intercourse** (Lewis et al., 2004; NIH Consensus Statement, 1992). The original National Institutes of Health definition did not specify a parameter for the duration of symptoms to accept the diagnosis. Subsequent organizational statements did apply a 3-month interval as a minimal requirement diagnostically, except for in cases of trauma or surgically induced ED (Lewis et al., 2004).

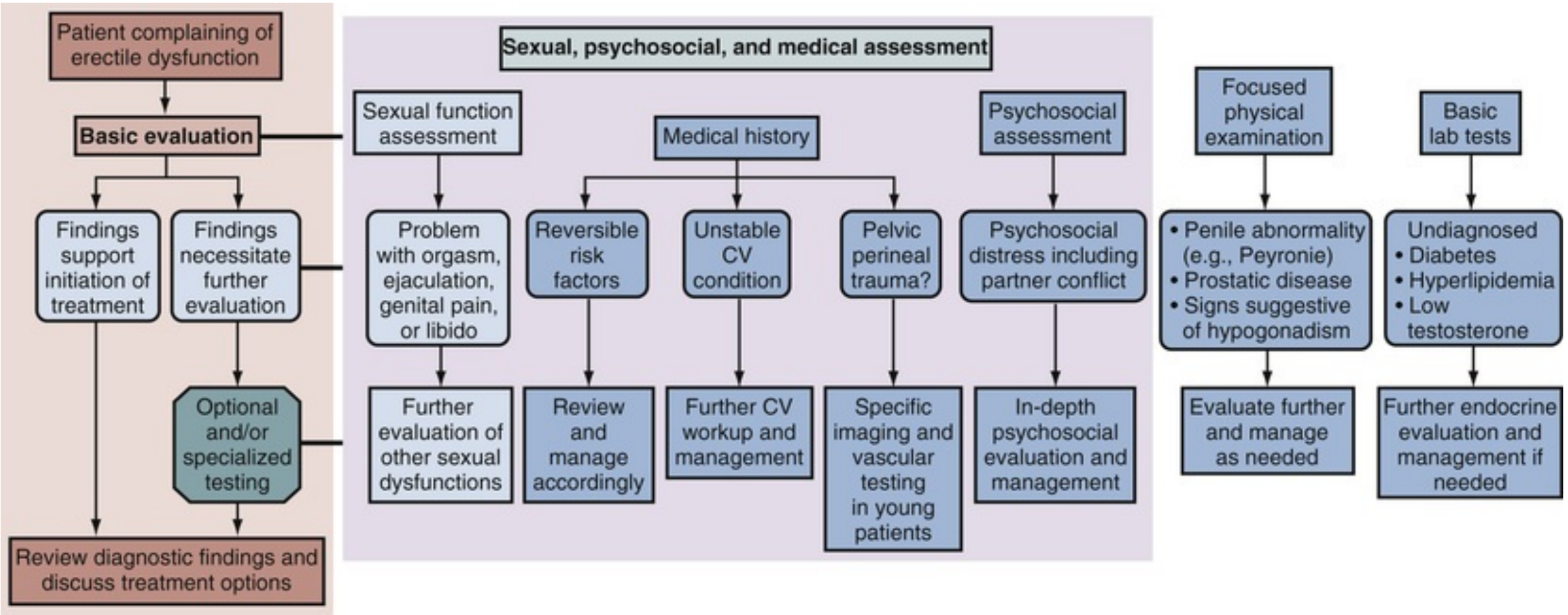

Patient complaining of erectile dysfunction
Basic evaluation
Findings support initiation of treatment
Findings necessitate further evaluation
Optional and/or specialized testing
Review diagnostic findings and discuss treatment options
Sexual, psychosocial, and medical assessment
Sexual function assessment
Medical history
Psychosocial assessment
Problem with orgasm, ejaculation, genital pain, or libido
Reversible risk factors
Unstable CV condition
Pelvic perineal trauma?
Psychosocial distress including partner conflict
Further evaluation of other sexual dysfunctions
Review and manage accordingly
Further CV workup and management
Specific imaging and vascular testing in young patients
In-depth psychosocial evaluation and management
Focused physical examination
Basic lab tests
• Penile abnormality (e.g., Peyronie)
• Prostatic disease
• Signs suggestive of hypogonadism
Undiagnosed
• Diabetes
• Hyperlipidemia
• Low testosterone
Evaluate further and manage as needed
Further endocrine evaluation and management if needed

FIG. 69.3 Diagnostic algorithm for erectile dysfunction (ED) recommended by the International Consultations on Sexual Medicine. *CV,* Cardiovascular.

Sexual, Medical, and Psychosocial History

The comprehensive assessment of any sexual problem begins with the performance of a detailed case history, including sexual, medical, and psychosocial components. The clinician may use brief checklists or questionnaires for the purpose of recognizing the problem and initiating its evaluation, although he or she should routinely perform a detailed interview to understand the nature of the sexual complaint. The sexual history component in particular should be elicited with utmost sensitivity, given the intrapersonal and interpersonal aspects of sexual dysfunction (Althof et al., 2013; Rosen et al., 2004d). Additional emphasis has been directed toward providing cultural competence when interacting with patients (Hatzichristou et al., 2010). **All discussion of sexual matters is done privately and confidentially, and the clinician is required to express trust and concern as well as a nonjudgmental manner that epitomizes the doctor-patient relationship.** The clinician should not assume that every patient is involved in a monogamous, heterosexual relationship. However, the situation may be presented in which the partner can be interviewed, and this opportunity may be used, with the approval of the patient, to corroborate aspects of the clinical history and to confirm mutual therapeutic goals.

Sexual History

The sexual history is the central component of the clinical history and can confirm the patient's sexual dysfunction complaint of ED. **Objectives of the interview are also to delineate the problem according to such features as its onset, duration, conditions, severity, and cause. The conditions of the problem are often determined by reviewing circumstances that facilitate or hinder erectile function.** Circumstances for achievable erections include stimuli used during sexual encounters, erections on awakening, and the role of self-stimulation. Circumstances associated with erectile difficulty include performance anxiety, inability to perform with a designated partner, and motivational factors affecting lovemaking. Other pertinent issues include availability, interest and health of the partner, changes in medical status or other events relating to the onset of ED, and previous attempts to manage the problem by the patient or another caregiver.

The severity of ED can be defined as mild, moderate, or severe/complete, according to increasing degrees of loss of penile rigidity and the associated interference with sexual activity. For instance, mild ED may refer to a minimally decreased ability to attain and/or maintain an erection with intermittent satisfactory sexual performance, moderate ED may refer to a minimally decreased ability to attain and/or maintain an erection with infrequent satisfactory sexual performance, and severe ED may refer to a substantially decreased ability to attain and/or maintain an erection with rare or absent satisfactory performance.

The potential cause of ED is commonly probed and may be categorized as

psychogenic, organic, or mixed according to whether there is a presumed psychological or interpersonal determinant (psychogenic), a specific endocrinologic, neurologic, or cardiovascular cause (organic), or the coexistence of psychological or relationship factors and organic causes (mixed) (Table 69.4) (Hatzichristou et al., 2010; Ralph and McNicholas, 2000). Often ED cannot be fully dichotomized into psychogenic and organic categories. However, its characterization by a predominant etiologic basis may nonetheless facilitate therapeutic objectives. The interview should also assess whether ED is the primary source of the presenting complaint or secondary to some other aspect of the sexual response cycle (e.g., desire, ejaculation, orgasm) that may also relate to the clinical presentation (Rosen, 2004a). The association of decreased arousal, if present, may be explored as well and evaluated to determine whether it preceded or was incidental to the development of ED.

TABLE 69.4

Classification of Erectile Dysfunction

PSYCHOGENIC	ORGANIC
Sudden onset	Gradual onset
Complete immediate loss	Incremental progression
Situational dysfunction	Global dysfunction
Waking erections present	Waking erections poor/absent

Modified from Ralph D, McNicholas T: UK management guidelines for erectile dysfunction. *Br Med J* 321:499–503, 2000.

Medical History

The medical history primarily identifies and evaluates predictors and risk factors associated with ED. **The main objective is to explore the role of possibly related or underlying medical conditions and to ascertain the existence of comorbidities. Recognition of the association between medical conditions and ED may not only lend insight into the possible basis for the ED, which may guide the choice of therapy but also specify reversible or treatable factors associated with ED that may be corrected with an expectation of improving the level of erectile function.**

Medical conditions associated with ED include disease states (e.g., type 2 diabetes mellitus, cardiovascular disease, hypertension, dyslipidemia, neurologic disease, hypogonadism, thyroid disorders), consequences of trauma involving aspects of the body, pelvis, or genitalia (e.g., spinal cord injury, pelvic surgery or radiation, sexual injury), and side effects of medications or recreational substances that disturb biochemical processes of penile erection. Age is recorded in accordance with the well-known association between aging and ED. It is important that comorbidities (e.g., depression, anxiety, anger) are registered because of their bidirectional relationship with ED.

Psychosocial History

The intake of psychosocial history is a necessary part of the clinical history**. The very best sexual performance implies wellness of mind and body acting together, and unstable psychosocial circumstances of intrapersonal and interpersonal contexts may adversely affect sexual function.** Accordingly, the presence and interaction of mental health problems, emotional stressors, and interpersonal relationship difficulties, past and present, should be ascertained. Additional questions may be asked relating to occupational status, financial security, family life, and social support, which may also influence sexual function.

Physical Examination

The physical examination is a highly recommended component of the comprehensive assessment of sexual dysfunctions and complements the clinical case history (Ghanem et al., 2013). It may show possible causes for ED.

This evaluation consists of basic anthropometrics (i.e., height, weight, waist circumference), assessment of body habitus (appearance of secondary sexual characteristics), and examination of relevant body parts pertaining to cardiovascular, neurologic, and genital systems, with a particular focus on the external genitalia. The observation of a classically distinctive body habitus consistent with Kallman or Klinefelter syndrome or obvious physical signs of hypogonadism, such as gynecomastia and general poor masculine development, may suggest an endocrinologic basis for ED.

Findings of obesity, elevated blood pressure, or abnormal femoral or pedal pulses, all signs representative of cardiovascular disease, convey a potential vascular causation. Findings of abnormal genital and perineal sensation or bulbocavernosus reflex (squeezing of the glans penis resulting in contraction of the bulbocavernosus muscle detected by a finger in the anus) may indicate the presence of a peripheral neuropathy in association with a neurologic disorder or diabetes.

Detection of a penile deformity, such as micropenis, congenital chordee, or Peyronie disease–related fibrous plaques in the corpora cavernosa, supports the possibility that a physical impediment accounts for ED. Genital examination findings of abnormal position, size, and consistency of testes may also suggest hypogonadism and indicate that ED exists on endocrinologic grounds.

Questionnaires and Sexual Function Symptom Scores

Self-administered ED questionnaires are extremely useful adjuncts to the case history, and they concur with the patient's self-report in establishing the diagnosis. Questionnaires supplied early in the field were very detailed, such as the Derogatis Sexual Function Inventory (245 items) (Derogatis and Melisaratos, 1979) and the Golombok Rust Inventory of Sexual Satisfaction (GRISS) (28 items) (Rust and Golombok, 1986), and they commonly aimed to differentiate psychogenic and organic ED or to evaluate sexual functioning in the context of the couple. Instruments developed more recently were implemented primarily in clinical trials associated with new drug development, and they particularly captured efficacy end points including sexual interest, performance, and satisfaction. However, as part of pattern shifts of practice that have occurred in ED management in recent years, there has been a growing emphasis on and application of patient self-reported instruments for clinical practice. **These self-report measures have been meant to be brief and practical and to document the presence and severity of ED and the responsiveness of ED to treatment.**

The most widely referenced instruments include the International Index of Erectile Function (IIEF) by Rosen et al. (1997), the Brief Male Sexual Function Inventory (BMSFI) by O'Leary et al. (1995), the Center for Marital and Sexual Health Sexual Functioning Questionnaire by Glick et al. (1997), the Changes in Sexual Functioning Questionnaire by Clayton et al. (1997), and the Erectile Dysfunction Inventory of Treatment Satisfaction (EDITS) by Althof et al. (1999). The IIEF, which contains 15 items that address and quantify five domains (erectile function, orgasmic function, sexual desire, intercourse satisfaction, and overall satisfaction) is the most widely used questionnaire (Fig. 69.4). An abridged five-item version of this instrument, the IIEF-5, has been useful to clinicians in routine clinical practice specifically for the evaluation of ED (Rosen et al., 1999a). The instrument classifies ED severity into five categories: severe (5 to 7), moderate (8 to 11), mild to moderate (12 to 16), mild (17 to 21), and no ED (22 to 25). The Sexual Health Inventory for Men (SHIM) is an abridged version of the IIEF, which also assess the five different sexual function domains. The Male Sexual Health Questionnaire offers another instrument that assesses core components of male sexual function (i.e., desire, erection, ejaculation, satisfaction) and is useful in clinical and research settings (Rosen et al., 2004b). The Sexual Experience Questionnaire is a brief but comprehensive tool for evaluating health-related quality-of-life concepts, and it comprises erection, individual satisfaction, and couple satisfaction domains (Mulhall et al., 2008). A new Visual-Scale Questionnaire has been developed as a quick screening tool for ED (Glavas et al., 2015).

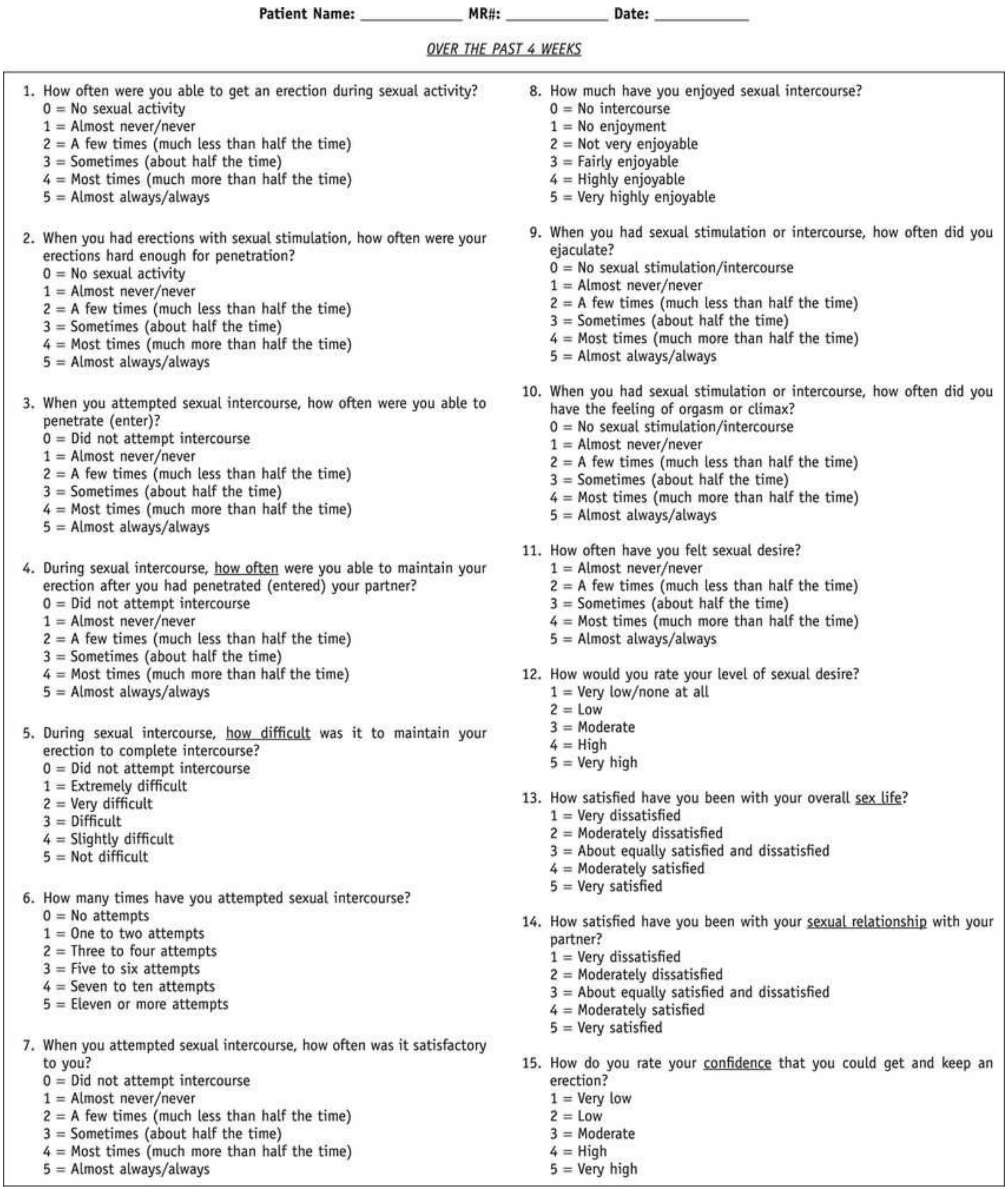

Patient Name: ____________ **MR#:** ____________ **Date:** ____________

OVER THE PAST 4 WEEKS

1. How often were you able to get an erection during sexual activity?
   0 = No sexual activity
   1 = Almost never/never
   2 = A few times (much less than half the time)
   3 = Sometimes (about half the time)
   4 = Most times (much more than half the time)
   5 = Almost always/always

2. When you had erections with sexual stimulation, how often were your erections hard enough for penetration?
   0 = No sexual activity
   1 = Almost never/never
   2 = A few times (much less than half the time)
   3 = Sometimes (about half the time)
   4 = Most times (much more than half the time)
   5 = Almost always/always

3. When you attempted sexual intercourse, how often were you able to penetrate (enter)?
   0 = Did not attempt intercourse
   1 = Almost never/never
   2 = A few times (much less than half the time)
   3 = Sometimes (about half the time)
   4 = Most times (much more than half the time)
   5 = Almost always/always

4. During sexual intercourse, how often were you able to maintain your erection after you had penetrated (entered) your partner?
   0 = Did not attempt intercourse
   1 = Almost never/never
   2 = A few times (much less than half the time)
   3 = Sometimes (about half the time)
   4 = Most times (much more than half the time)
   5 = Almost always/always

5. During sexual intercourse, how difficult was it to maintain your erection to complete intercourse?
   0 = Did not attempt intercourse
   1 = Extremely difficult
   2 = Very difficult
   3 = Difficult
   4 = Slightly difficult
   5 = Not difficult

6. How many times have you attempted sexual intercourse?
   0 = No attempts
   1 = One to two attempts
   2 = Three to four attempts
   3 = Five to six attempts
   4 = Seven to ten attempts
   5 = Eleven or more attempts

7. When you attempted sexual intercourse, how often was it satisfactory to you?
   0 = Did not attempt intercourse
   1 = Almost never/never
   2 = A few times (much less than half the time)
   3 = Sometimes (about half the time)
   4 = Most times (much more than half the time)
   5 = Almost always/always

8. How much have you enjoyed sexual intercourse?
   0 = No intercourse
   1 = No enjoyment
   2 = Not very enjoyable
   3 = Fairly enjoyable
   4 = Highly enjoyable
   5 = Very highly enjoyable

9. When you had sexual stimulation or intercourse, how often did you ejaculate?
   0 = No sexual stimulation/intercourse
   1 = Almost never/never
   2 = A few times (much less than half the time)
   3 = Sometimes (about half the time)
   4 = Most times (much more than half the time)
   5 = Almost always/always

10. When you had sexual stimulation or intercourse, how often did you have the feeling of orgasm or climax?
    0 = No sexual stimulation/intercourse
    1 = Almost never/never
    2 = A few times (much less than half the time)
    3 = Sometimes (about half the time)
    4 = Most times (much more than half the time)
    5 = Almost always/always

11. How often have you felt sexual desire?
    1 = Almost never/never
    2 = A few times (much less than half the time)
    3 = Sometimes (about half the time)
    4 = Most times (much more than half the time)
    5 = Almost always/always

12. How would you rate your level of sexual desire?
    1 = Very low/none at all
    2 = Low
    3 = Moderate
    4 = High
    5 = Very high

13. How satisfied have you been with your overall sex life?
    1 = Very dissatisfied
    2 = Moderately dissatisfied
    3 = About equally satisfied and dissatisfied
    4 = Moderately satisfied
    5 = Very satisfied

14. How satisfied have you been with your sexual relationship with your partner?
    1 = Very dissatisfied
    2 = Moderately dissatisfied
    3 = About equally satisfied and dissatisfied
    4 = Moderately satisfied
    5 = Very satisfied

15. How do you rate your confidence that you could get and keep an erection?
    1 = Very low
    2 = Low
    3 = Moderate
    4 = High
    5 = Very high

FIG. 69.4 International Index of Erectile Function Questionnaire.

A known limitation of self-administered questionnaires is that they do not distinguish a causative basis for ED; that is, they do not differentiate among the various causes of ED (Blander et al., 1999; Kassouf and Carrier, 2003). **Further, they may not sufficiently indicate the severity of ED that is evidenced on objective grounds** (Tokatli et al., 2006). Although the exact nature of the ED diagnosis arguably is not absolutely necessary to initiate ED treatment today with current management options, it is understood that further clinical evaluation with diagnostic tests may be required to discern the basis and extent of the ED by system (e.g., vascular, neurologic, endocrinologic) and take action that may be most effective and possibly corrective.

Cardiovascular Risk Assessment Tools

A trend in ED assessment is the application of cardiovascular disease-risk prediction models, which are used as scoring instruments to aid in the assessment of any man evaluated for ED (Nehra et al., 2013). **Such models as the Framingham Risk Score or an alternate global risk score, which incorporate such cardiovascular predictive variables as family history of coronary heart disease, body mass index, and metabolic laboratory biomarkers, offer a powerful initial step to characterize and possibly mitigate cardiovascular risk in this clinical setting.**

Laboratory Tests

Appropriate laboratory testing can be considered part of a systematic clinical evaluation for individuals presenting with ED (Ghanem et al., 2013). **Such evaluation may confirm or define etiologic medical conditions associated with the sexual dysfunction. At times, it may identify treatable conditions or previously undetected disease states that may contribute to ED.** A standardized panel of tests can be offered for the man who routinely seeks medical attention for sexual dysfunction including ED. Further laboratory testing can be tailored to the clinical situation. Similarly, specialized endocrinologic assessment can be performed when indicated for select clinical presentations.

Recommended laboratory tests for men with sexual problems typically include serum chemistries, fasting glucose or HbA1c, complete blood count, lipid profile, and serum total testosterone. Total testosterone, measured from a morning-time blood draw, screens androgenic status, and, if abnormally low, serum-free (or bioavailable) testosterone and luteinizing hormone (LH) should be measured. Prolactin measurement may also be done for hormonal assessment. Thyroid function tests may be performed at the clinician's discretion. Serum prostate-specific antigen (PSA) testing is performed as needed if there is a suspicion of prostate pathology that may be promoted by exogenously administered testosterone. Dipstick analysis of urine may show glucosuria, which suggests the diagnosis of diabetes.

Specialized Evaluation and Testing

The implicit goal of specialized evaluations in medicine in general is to improve diagnostic accuracy and direct successful therapy based on the specific diagnosis. A similar principle applies to sexual medicine. However, at the present time, despite the availability of various technologies that may specify and define the causation for ED (i.e., vasculogenic, neurogenic, endocrinologic, psychogenic), the treatment plan for this sexual dysfunction can often be formulated without performing extensive diagnostic testing. **Nonetheless, such testing is frequently applied for diagnostic precision, typically by specialists, particularly in settings of complex clinical presentations.** Table 69.5 summarizes the most frequently used evidence-based test procedures for diagnostic evaluations of ED (Rosen et al., 2004d).

TABLE 69.5

Evidence-Based Tests for Organic Erectile Dysfunction and Recommendations

TEST	RECOMMENDATION
VASCULAR	
Dynamic infusion cavernosometry and cavernosography (DICC)	B
Intracavernous injection pharmacotesting (ICI)	B
ICI and color duplex ultrasound	B
Arteriography	C
Computed tomography angiography	D
Magnetic resonance imaging (MRI)	D
Infrared spectrophotometry	D
Radioisotope penography	D
AUDIOVISUAL SEXUAL STIMULATION (AVSS)	
Independent or jointly with vascular testing	C
With or without pharmacologic stimulation (oral, ICI)	C
NEUROPHYSIOLOGIC	
Nocturnal penile tumescence and rigidity (NPTR)	B
Erectiometer/rigidometer	D
Biothesiometry (vibratory thresholds)	C
Dorsal nerve conduction velocity	C

Bulbocavernosus reflex latency	B
Plethysmography/electrobioimpedance	D
Corpus cavernosum electromyography (CC-EMG)	C
MRI or positron emission tomography scanning of brain (during AVSS)	D

Grades of recommendation:

- A: At least one meta-analysis, systematic review, or randomized controlled trial with a low level of bias and directly applicable to the target population.
- B: A body of evidence including high-quality systematic reviews of case-control or cohort studies directly applicable to the target population and demonstrating overall consistency of results.
- C: A body of evidence including well-conducted case-control or cohort studies with a low risk of confounding, bias, or chance and a moderate probability that the relationship is causal, directly applicable to the target population, with overall consistency of results.
- D: Nonanalytic studies (e.g., case reports, case series, expert opinion).

Data from Harbour R, Miller J: A new system for grading recommendations in evidence-based guidelines. *Br Med J* 323:334–336, 2001; Rosen RC, Hatzichristou D, Broderick G, et al.: Clinical evaluation and symptom scales: sexual dysfunction assessment in men. In Lue TF, Basson R, Rosen F, et al., editors: *Sexual medicine: sexual dysfunctions in men and women,* Paris, 2004, Health Publications, pp 173–220.

Vascular Evaluation

The vascular evaluation for ED conceptually connotes surveying the vascular requirements of the sexual organ for the erectile response: arterial blood inflow, blood engorgement, and blood retention within the corporeal structures. **From a diagnostic standpoint, the studies aim to assist in deriving the classic diagnoses of arterial impairment and veno-occlusive dysfunction.** As for all diagnostic testing, hemodynamic tests of the penis require patient counseling regarding the purpose, alternatives, risks, and benefits of any procedure before its implementation.

Combined Intracavernosal Injection and Stimulation

The combined intracavernosal injection and stimulation (CIS) test is a first-line evaluation of penile blood flow because of its very basic manner of administration and assessment. **The test involves the intracavernosal injection of a vasodilatory drug or drugs as a direct pharmacologic stimulus, combined with genital or audiovisual sexual stimulation, and the erectile response is observed and rated by an independent assessor** (Donatucci and Lue, 1992; Katlowitz et al., 1993)**. The test is designed to bypass neurologic and hormonal influences involved in the erectile response and allows the clinician to evaluate the vascular status of the penis directly and objectively.**

The clinician may decide the protocol for using vasodilator drugs. Alternative regimens include alprostadil alone (Caverject or Edex, 10 to 20 µg), a combination of papaverine and phentolamine (Bimix, 0.3 mL), or a mixture of all three of these agents (Trimix, 0.3 mL). The procedure requires a syringe with a ¼-inch needle (27- to 29-gauge), which is inserted at the lateral base of the penis directly into the corpus cavernosum for medication delivery. After needle withdrawal, manual compression is applied to the injection site for 5 minutes to prevent local hematoma formation. The assessment is done periodically subsequently with rating of rigidity and duration of response. Repeated dosing may be performed if the initial erectile response is poor. Return to penile flaccidity is required before allowing the patient to leave the office, and if detumescence does not occur spontaneously in approximately an hour after dosing, intracavernosal injection of a diluted phenylephrine solution (500 µg/mL) can be administered every 3 to 5 minutes until flaccidity returns.

A normal CIS test, based on the assessment of a sustainably rigid erection, is understood to signify normal erectile hemodynamics. Alternative diagnoses of psychogenic, neurogenic, or endocrinologic ED may then be considered. However, it is known that false-positive results may occur in as many as 20% of patients with borderline arterial inflow (as defined by the measurement of 25 to 35 cm/s peak cavernous artery systolic flow on duplex ultrasonography) (Pescatori et al., 1994). False-negative results are also possible and occur most commonly because of patient anxiety, needle phobia, or inadequate dosage.

Duplex Ultrasonography (Gray Scale or Color-Coded)

Duplex ultrasound of the penis after pharmacostimulation or CIS represents second-line evaluation of penile blood flow. However, it is the most reliable and least-invasive diagnostic modality for assessing ED. The test adds an imaging dimension and a quantification component to the evaluation of blood flow in the penis distinct from first-line evaluation, which relies solely on the assessor's judgment.

The technique consists of high-resolution (7.5 to 12 MHz) real-time ultrasonography and color-pulsed Doppler, which helps visualize the dorsal and cavernous arteries selectively and perform hemodynamic blood-flow analysis (Lue et al., 1989; Sikka et al., 2013). Scanning is applied to the surface of the penis and may include the entire penis from the crura in the perineum to the tip. Color-coded duplex ultrasonography indicates the direction of blood flow within vessels, with red designating direction toward the probe and blue designating direction away from the probe (Broderick and Arger, 1993; Herbener et al., 1994). Flow velocities are measured at baseline before injection and commonly every 5 minutes afterward up to 20 minutes. Cavernous arterial diameters may also be measured. Vascular anatomic communications between the paired cavernous arteries or between the dorsal and cavernous arteries should be noted (Fig. 69.5). Erection quality should also be simultaneously assessed and rated. An observed poor erection, possibly associated with patient anxiety, should prompt vasodilator redosing as recommended for the CIS test.

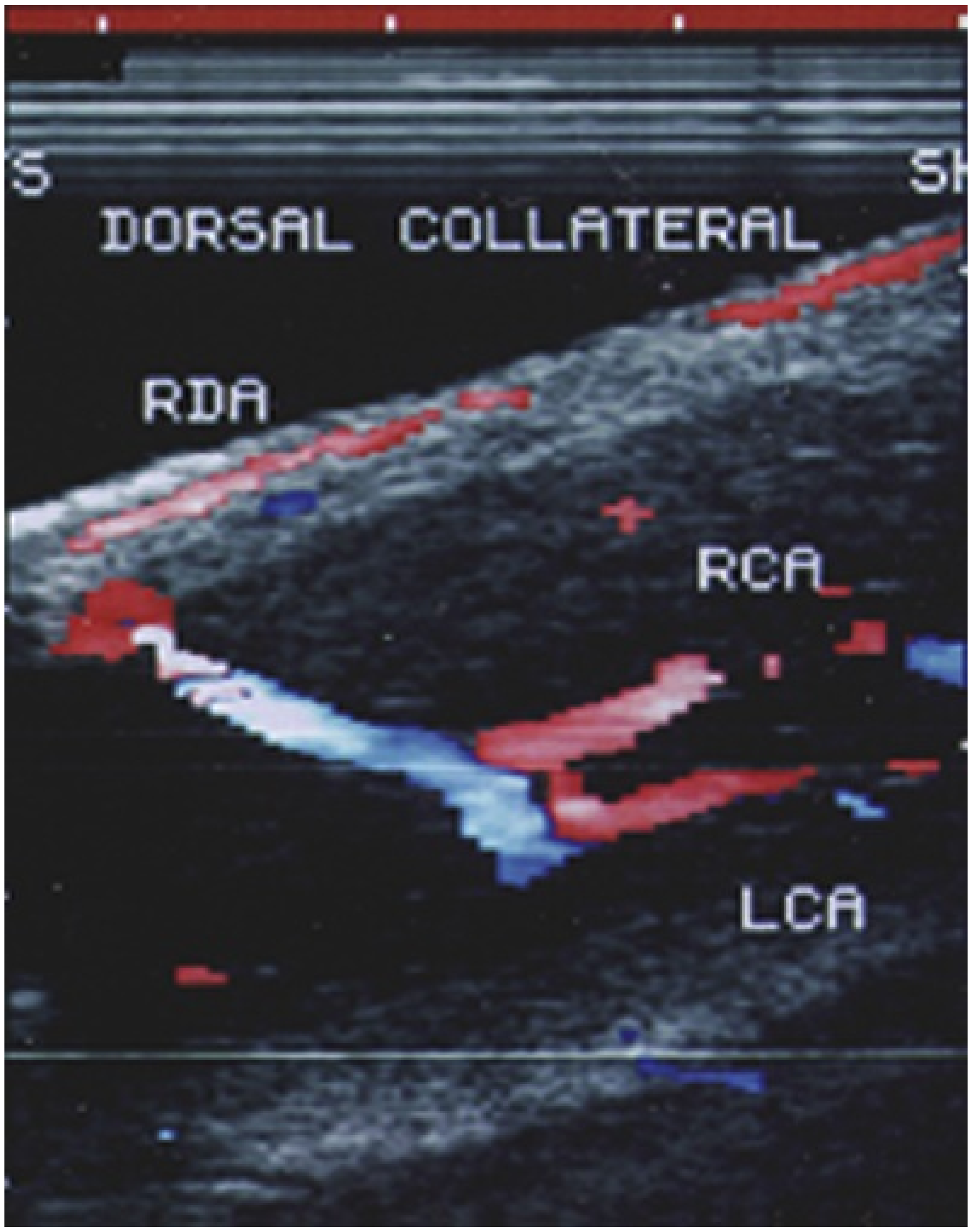

FIG. 69.5 Collateral circulation connecting the right dorsal artery *(RDA)* to the right cavernous artery *(RCA)*, and the left cavernous artery *(LCA)* is shown by color duplex ultrasonography in a longitudinal view.

A standard pattern of Doppler waveforms occurs with hemodynamic changes in corporeal pressure during progression to normal full erection (Fig. 69.6; Schwartz et al., 1991). In the filling phase when sinusoidal resistance is low (within 5 minutes after vasodilator injection), the waveform increases in size consistent with high forward flow during systole and diastole. As intracavernous pressure increases, diastolic velocities decrease. With full erection, the systolic waveforms sharply peak and may be slightly less than during full tumescence. At maximal rigidity, when intracavernous pressure exceeds systemic diastolic blood pressure, diastolic flow may be zero. The sonographic color pattern of the cavernous artery may demonstrate an impressive shift from red to blue in association with the reversal of diastolic flow.

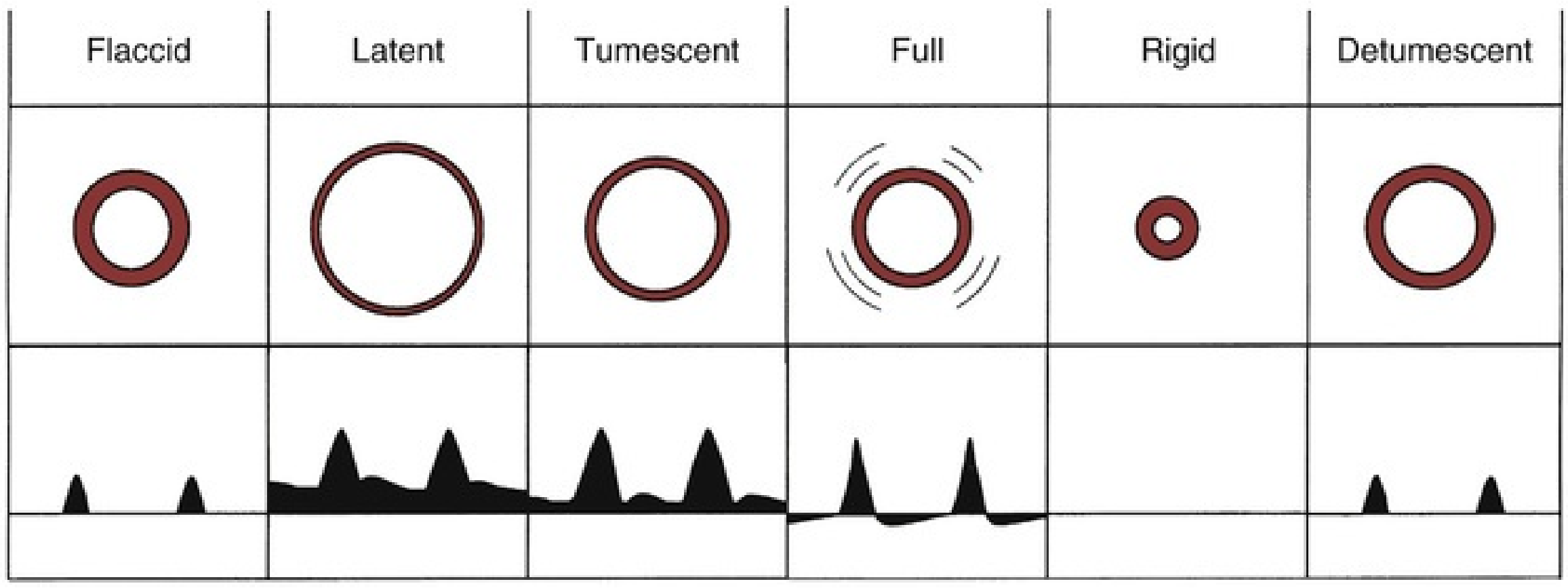

FIG. 69.6 Artist's conception of the changes in diameter and flow waveform in the cavernous arteries induced by intracavernous injection of prostaglandin E_1 in a potent young man as demonstrated by duplex ultrasound. Forceful concentric pulsations are particularly noticeable during full erection.

Normative values have been described for peak systolic velocity (PSV) and diameter of the cavernous arteries during increases in arterial inflow to the penis. Early studies documented that the PSV of the cavernous arteries consistently exceeded 25 cm/s within 5 minutes of vasodilator injection in patients with nonarteriogenic causes of ED (i.e., psychogenic, neurogenic) (Lue et al., 1985; Mueller and Lue, 1988). Investigators subsequently confirmed mean PSV of cavernous arteries after pharmacostimulation to range from 35 cm/s to 47 cm/s in normal subjects (Benson and Vickers, 1989; Shabsigh et al., 1990). A cut point at 25 cm/s included a sensitivity of 100% and a specificity of 95% in patients with abnormal pudendal arteriography (Quam et al., 1989). Diameter changes of the cavernous artery after vasodilator injection were found to increase less than 75% and rarely to exceed 0.7 mm in patients with severe vascular ED (Lue and Tanagho, 1987; Mueller and Lue, 1988). Importantly, unlike PSV changes, a percentage of cavernous arterial vasodilation was not found to correlate well with findings on pudendal arteriography (Jarow et al., 1993).

Vascular arterial anatomic variants may confound the interpretation of duplex ultrasonography (Breza et al., 1989; Jarow et al., 1993). Early cavernous arterial branching or the presence of multiple such branches may affect blood-flow velocity determinations of the main cavernous artery. The presence of distal arterial perforators extending from the dorsal or spongiosal arteries also may alter the measurement of cavernous arterial blood-flow velocity. Accordingly cavernosal artery velocity measurements may vary based on anatomic location (e.g. crus, proximal, and mid-cavernosal) (Pagano and Stahl, 2015). The clinician must recognize these variants as well as anatomic imaging location to avoid making the incorrect diagnosis of arteriogenic ED. On the other hand, asymmetrical blood flow of the cavernous arteries may have diagnostic significance. The findings of dissimilar cavernous artery velocity measurements, which are greater than 10 cm/s between sides, or reversal of flow across a collateral may suggest a significant atherosclerotic lesion (Benson et al., 1993).

Duplex ultrasound measurements are informative for diagnosing vasculogenic ED (Rosen et al., 2004d). **Cavernous arterial insufficiency is suggested when PSV is less than 25 cm/s; a PSV consistently greater than 35 cm/s defines normal cavernous arterial inflow.** Cavernous artery acceleration time (i.e., PSV divided by systolic rise time) greater than 122 ms may also indicate this diagnosis. Cavernous veno-occlusive dysfunction, which refers to failure of erection maintenance despite adequate cavernous arterial inflow, is suggested by assorted sonographic parameters. Generally meaningful at 15 to 20 minutes after stimulatory onset, these parameters include persistent high systolic flow velocities (i.e., PSV >25 cm/s) and high end-diastolic flow velocities (EDV >5 cm/s), accompanied by rapid detumescence, after stimulatory onset. In addition, vascular resistive index (RI), based on the formula written as

$$\mathrm{RI} = (\mathrm{PSV} - \mathrm{EDV})/\mathrm{PSV}$$

has had tremendous diagnostic usefulness in this regard. The parameter is based on the concept that, as penile intracavernous pressure during erection achievement equals or exceeds diastolic pressure, diastolic flow in the corporeal bodies will approach 0 and the value for RI will approach 1. An RI greater than 0.9 has been associated with normal penile vascular function, and one less than 0.75 is consistent with veno-occlusive dysfunction (Naroda et al., 1996).

Several technical modifications of sonographic evaluation of the penis have been described. A portable Midus-pulsed Doppler unit connected to a laptop computer for in-office testing reliably records the Doppler waveform of the cavernous arteries despite the lack of a real-time ultrasound image (Metro and Broderick, 1999). Power Doppler offers an even more specialized technique to visualize distal ramifications of the main cavernous artery down to the level of arterioles (Golubinski and Sikorski, 2002; Sarteschi et al., 1998). A somewhat more invasive approach that evaluates the integrity of cavernosal arterial flow involves the measurement of the cavernous artery systolic occlusion pressure

(CASOP) by a Doppler transducer during saline intracavernosal infusion (Rhee et al., 1995). As a variation on the stimulatory component of penile sonographic testing, a combination of an oral phosphodiesterase type 5 (PDE5) inhibitor in association with visual erotic stimulation has proven an effective, noninvasive method (Baçar et al., 2001; Speel et al., 2001). Sonographically measured postocclusive vasodilation of the cavernous arteries, which is believed to relate to the level of intact endothelial function in the penis, has been found diagnostic for organic ED (Virag et al., 2004). Cavernous artery intima-media thickness as demonstrated by high-resolution echo color Doppler ultrasound has been suggested as being more accurate than PSV in predicting vasculogenic ED (Caretta et al., 2009).

Dynamic Infusion Cavernosometry and Cavernosography

Cavernosometry and cavernosography, precisely referring to functional hemodynamic and radiographic assessments of the corpora cavernosa, represents third-line evaluation of the vascular integrity of the penis. **The testing is indicated for select patients who are suspected of having a site-specific vasculogenic leak resulting from perineal or pelvic trauma or who have had lifelong ED (primary ED). When used, it generally precedes consideration for corrective penile vascular surgery.**

The technique involves two needles inserted into the penis for simultaneous saline infusion and intracavernous pressure monitoring after intracavernosal pharmacologic injection (Glina and Ghanem, 2013). The testing requires complete trabecular smooth muscle relaxation to avoid erroneous results, and repeated and maximal pharmacologic dosing protocols are recommended (Hatzichristou et al., 1995). Measurements of maintenance flow rate, pressure drop, and CASOP are performed to verify complete smooth muscle relaxation (Fig. 69.7).

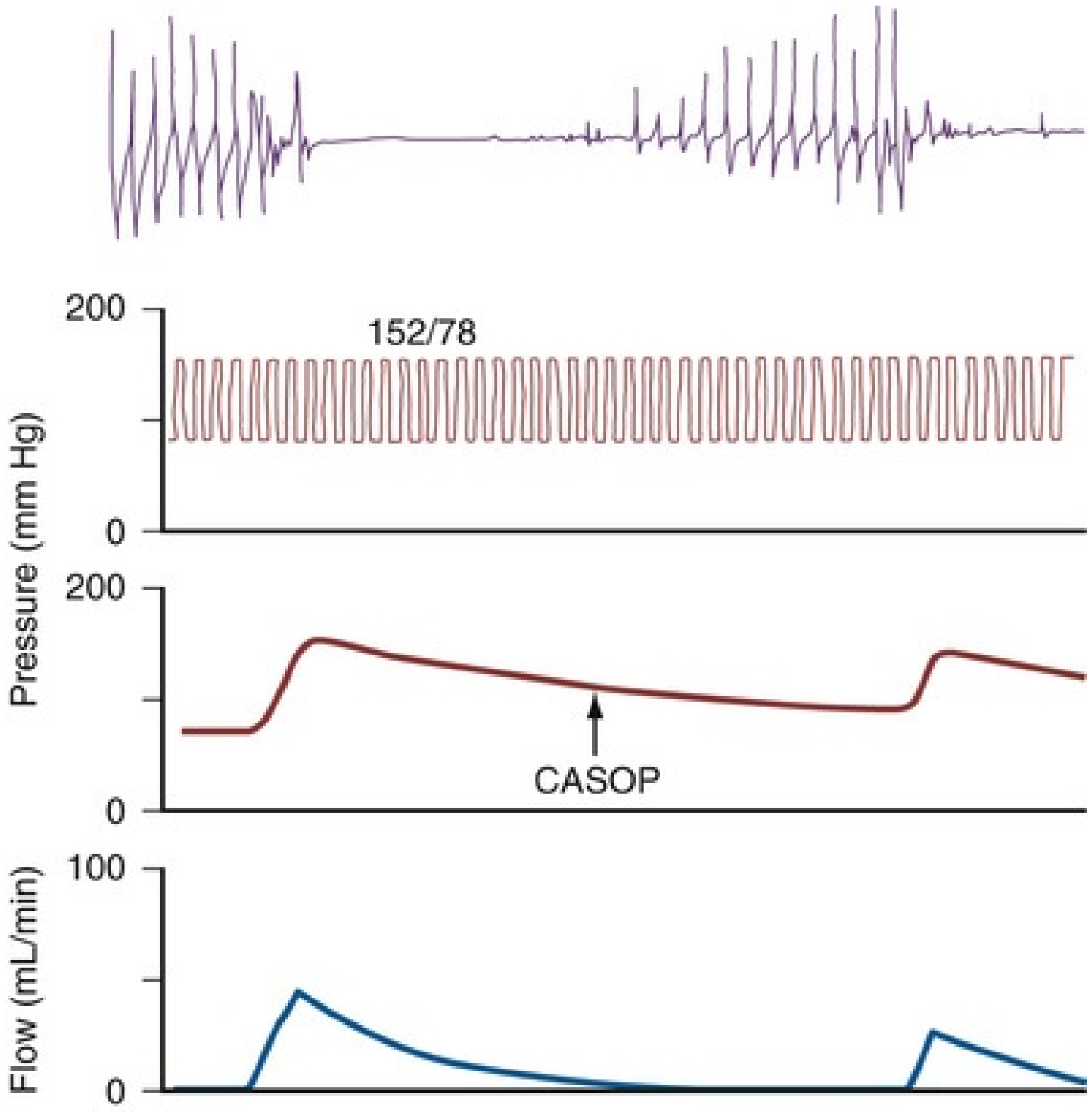

FIG. 69.7 This tracing depicts four simultaneous variables obtained during the third phase of dynamic infusion cavernosometry and cavernosography. *Top to bottom:* Cavernosal artery flow recorded by using a continuous-wave Doppler ultrasound probe; systemic brachial systolic and diastolic arterial blood pressure (150/87 mm Hg); intracavernosal pressure, which varied from 70 to 160 mm Hg in this tracing; and intracavernosal heparinized saline inflow. The intracavernosal pressure at which the cavernosal artery pulsations returned, which is the effective cavernous artery systolic occlusion pressure *(CASOP)*, was 108 mm Hg. The gradient between the brachial and the cavernosal artery systolic occlusion pressures was 150 to 108, or 42 mm Hg, which is abnormal.

Dynamic infusion cavernosometry and cavernosography evaluate the penile venous outflow system. **The existence of veno-occlusive dysfunction is indicated by the failure to increase intracavernous pressure to the level of the mean systolic blood pressure with saline infusion or the demonstration of a rapid drop of intracavernous pressure after cessation of saline infusion** (Motiwala, 1993; Puyau and Lewis, 1983; Rudnick et al., 1991; Shabsigh et al., 1991). The flow rate required to maintain erection at an intracavernous pressure of more than 100 mm Hg is normally less than 3 to 5 mL/min, and the pressure decrease in 30 seconds from 150 mm Hg is normally less than 45 mm Hg. Cavernosography follows cavernosometric evaluation and is intended to show the site of venous leakage (Fig. 69.8). With normal veno-occlusive function, there should be opacification of the corpora cavernosa with minimal or no visualization of venous structures or corpus spongiosum. With impaired veno-occlusive function, leakage may be identified into such sites as the glans, corpus spongiosum, superficial dorsal veins, and cavernous and crural veins. More than one site is visualized in the majority of patients (Lue et al., 1986; Rajfer et al., 1988; Shabsigh et al., 1991).

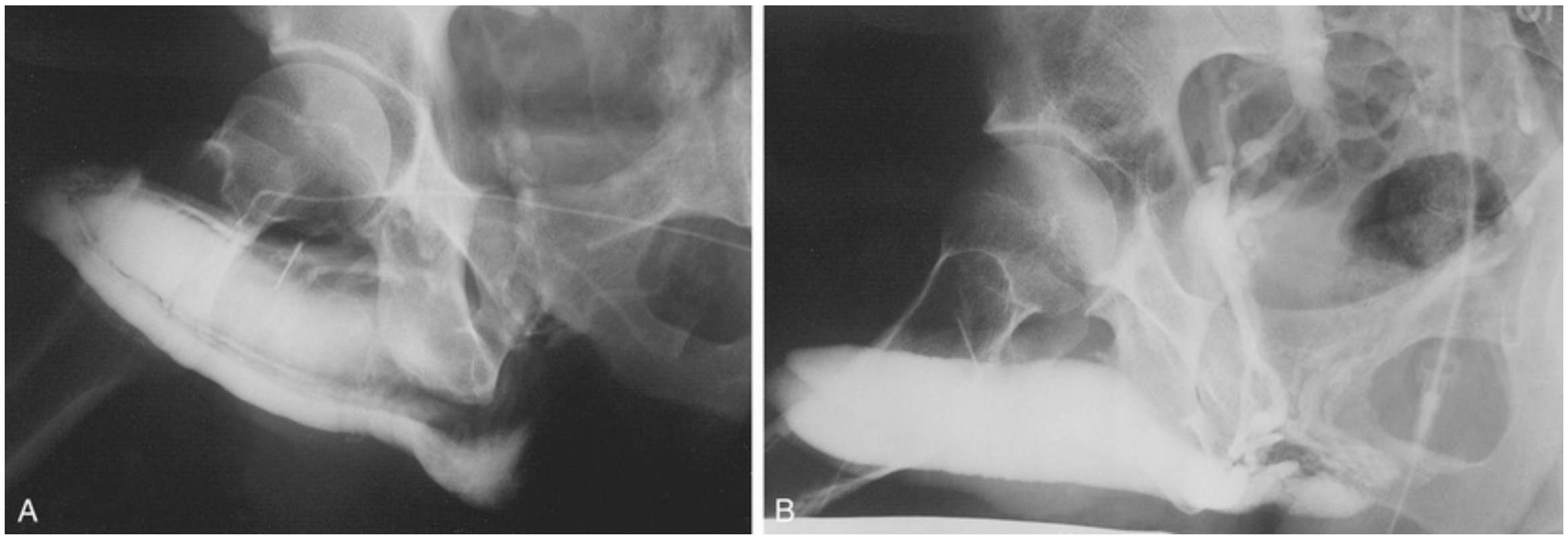

FIG. 69.8 Pharmacologic cavernosography. (A) In a patient 1 year after a penile fracture, a communication between the corpus cavernosum and the spongiosum is seen. (B) In a 27-year-old man with primary impotence, venous leakage from the crura is seen.

Penile Angiography

Penile angiography is an anatomic study of the arterial vasculature of the penis and represents third-line evaluation of the penile vascular system. **It is commonly reserved for the young patient with ED secondary to a traumatic arterial disruption or the patient with a history of penile compression injury who is being considered for penile revascularization surgery** (Sikka et al., 2013).

The procedure involves selective cannulation of the internal pudendal artery and injection of radiographic contrast. The intracavernosal injection of a vasodilating agent is optimally used to induce maximal vasodilation of the penile arterial supply. The anatomy and radiographic appearance of the iliac, internal pudendal, and penile arteries are then evaluated and documented (Fig. 69.9). The inferior epigastric arteries are frequently studied as well to determine their suitability for use in surgical revascularization. Significant variation of the intrapenile arterial anatomy exists, challenging the angiographer to differentiate congenital variations from acquired abnormalities and to establish their clinicopathologic relevance (Bähren et al, 1988; Benson et al., 1993).

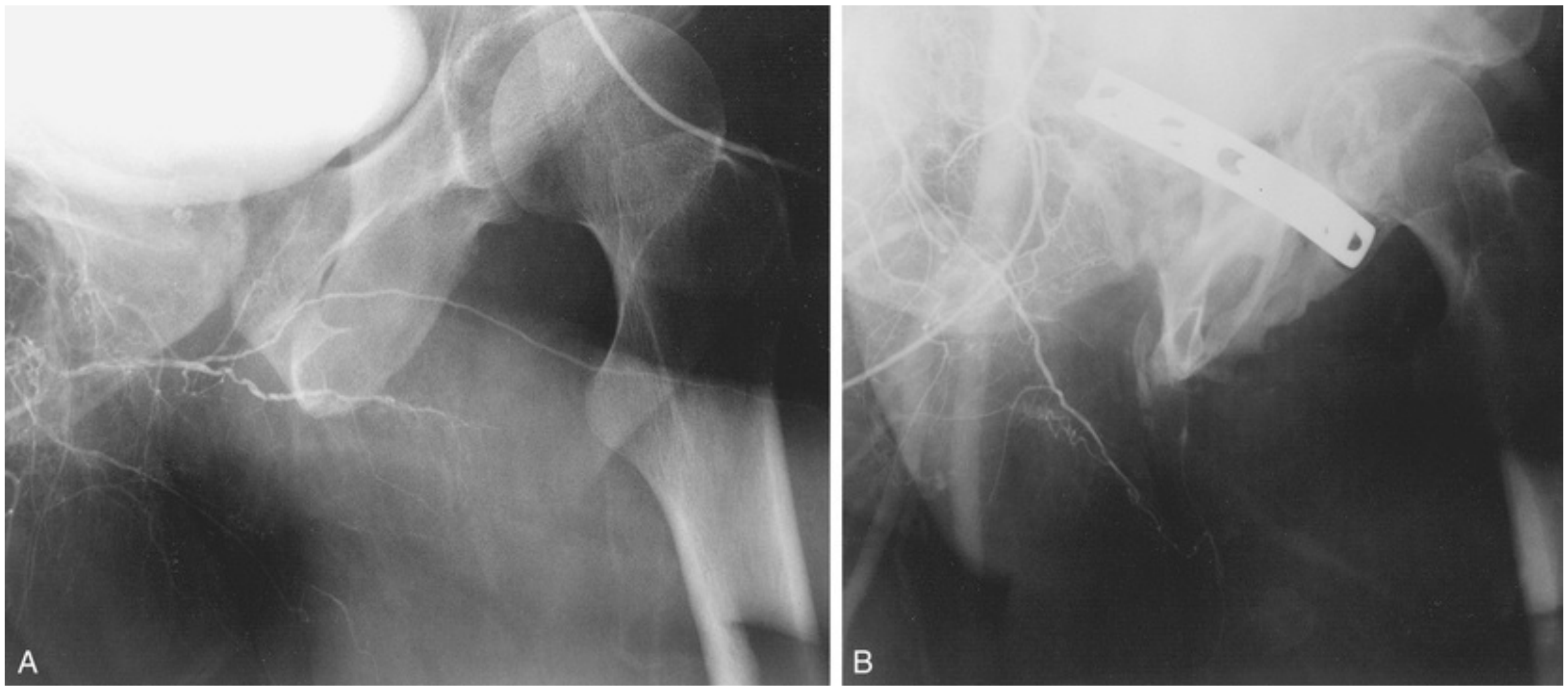

FIG. 69.9 In this patient with a pelvic injury, pharmacologic penile arteriography (after intracavernous injection of 60 mg of papaverine) shows patent common penile, dorsal, and cavernous arteries (A) and nonvisualization of the common penile artery and its branches (B).

Historical and Investigational Studies of Penile Blood Flow

Penile Brachial Pressure Index

The penile brachial pressure index (PBI) test refers to the penile systolic blood pressure divided by the brachial systolic blood pressure. The technique involves applying a small pediatric blood pressure cuff to the base of the flaccid penis and measuring the systolic blood pressure with a continuous-wave Doppler probe. A PBI of 0.7 or less has been used to indicate arteriogenic ED (Metz and Bengtsson, 1981). **The technique has not been found valid because it does not assess the hemodynamic properties of a functionally relevant, induced erection, and thus it is not recommended for use** (Aitchison et al., 1990; Mueller et al., 1990).

Penile Plethysmography (Penile Pulse Volume Recording)

This test evaluates arterial pressure waveforms in the penis with an aggregate of the contributions of all penile vessels (Kedia, 1983). It requires the application of a 2.5- or 3-cm cuff connected to an air plethysmograph applied to the base of the penis, inflating the cuff to a pressure greater than brachial systolic pressure and then decreasing the pressure by 10-mm Hg increments while recording pressure waveform tracings. Abnormal pressure waveforms by diagnostic criteria have been used to indicate vasculogenic ED (Doyle and Yu, 1986). **Because this study is performed in the flaccid penis, as is the PBI, its clinical relevance has been questioned.** Despite this concern, a technical modification that measures postischemic flow-mediated dilation was introduced as being informative regarding penile vascular endothelial function (Dayan et al, 2005; Vardi et al., 2009).

Radioisotopic Penography

This test quantifies changes in penile blood volume after intracavernosal injection of a vasoactive agent using ^{99m}Tc-labeled red blood cells (Shirai et al., 1976). Extremely low flow is understood to mean arteriogenic ED (Smith et al., 1998). An evaluation comparing color duplex ultrasonography and radionuclide penography showed poor correlation (Glass et al., 1996).

Penile Magnetic Resonance Imaging

This test has significant potential applications for the assessment of anatomic details of the penis and penile microcirculation. Angiographic techniques may be combined with this test to evaluate the anatomic condition of the internal iliac and penile vasculature. Magnetic resonance angiography has been shown to correlate well with color duplex ultrasound testing (John et al., 1999; Stehling et al., 1997).

Penile Near Infrared Spectrophotometry

This test provides continuous, quantitative measurements of penile blood flow using a specialized near infrared spectrophotometry instrument (Burnett et al., 2000). It may be applied with an erectile stimulus and documents the hemodynamic phenomena of erection. Penile spectrophotometry has been further investigated in combination with intraurethral pharmacotherapy documenting blood-flow increase to the penis with this erectogenic modality (Padmanabhan and McCullough, 2007). Further investigation of this technique is needed to establish its clinical usefulness.

Cavernous Smooth Muscle Content

This test evaluates the smooth muscle composition of the corporeal tissue by light microscopic and computed morphometric assessment of biopsies of the penis and may serve adjunctively in the diagnosis of vasculogenic ED (Wespes et al., 1992). A reduced proportion of corporeal smooth muscle (and correspondingly increased collagen) has been observed in older men with veno-occlusive dysfunction (19% to 36% smooth muscle) and arteriogenic ED (10% to 25%), compared with that of young, healthy men with normal erections and penile curvature (40% to 52%) (Wespes et al., 1991). In part because of its invasiveness, the test is controversial and thus it remains investigational.

Psychophysiologic Evaluation

The psychophysiologic evaluation of ED seeks to assess the erectile response by applying techniques that directly measure penile tumescence and rigidity. From the historical perspective of ED diagnostics, testing was applied primarily to differentiate psychogenic from organic ED. In general, the documentation of a full erection indicates functional integrity of the neurovascular axis regulating penile erection and thereby raises suspicion of a psychogenic cause.

There are several approaches to perform this evaluation. Importantly, the psychophysiologic evaluation does not currently represent first-line evaluation for ED, largely because of technical and cost limitations associated with current techniques. When considered to undergo any of these tests as part of a diagnostic plan, patients are counseled regarding the expected use, risks, and benefits of the tests.

Penile Tumescence and Rigidity Monitoring

Nocturnal penile tumescence (NPT) monitoring, which describes the study of erections that occur with nighttime sleep, was classically described as a technique offering the assessment of physiologic erectile ability (Wasserman et al., 1980). **As a standard, sleep laboratory nocturnal penile tumescence and rigidity (NPTR) testing applies nocturnal monitoring devices that measure the number of episodes, tumescence (circumference change by strain gauges), maximal penile rigidity, and duration of nocturnal erections** (Kessler, 1988). The conventional approach is to perform monitoring in conjunction with electroencephalography, electro-oculography, and electromyography (EMG), with nasal airflow and oxygen saturation to document rapid eye movement (REM) sleep and the presence or absence of hypoxia (sleep apnea). Documentation of REM sleep is undertaken because of the observation that true erectile phenomena occurring during sleep are associated with the REM sleep phase (Fisher et al., 1965). Sleep movement patterns are also monitored because periodic limb movement disorders are associated with abnormal NPT. Axial rigidity is measured along with photography of the erect penis when awakening the patient at maximal tumescence; a buckling device is applied to the tip of the penis to measure resistance (500 g minimum for vaginal penetration, 1.5 kg suggestive of complete rigidity) (Karacan et al., 1977). NPT traditionally has been performed during two to three nights to overcome the so-called first-night effect when REM sleep is inconsistent. Formal testing, which involves a specially equipped sleep laboratory staffed with trained observers, is costly. The monitoring of diurnal penile tumescence, in reference to monitoring performed during daytime napping, has served alternatively as an in-office evaluation (Morales et al., 1994).

RigiScan (Timm Medical Technologies, Minneapolis, MN) is an automated, portable device used for NPTR, which combines the monitoring of radial rigidity, tumescence, number, and duration of erectile events (Bradley et al., 1985). The device employs two loops, one placed at the base of the penis and the other placed at the coronal sulcus (respectively, base and tip recording sites), and these loops record penile tumescence (circumference) and radial rigidity with timed, standardized constrictions of the loops. A baseline initialization is performed with the patient in the office, and then it is calibrated for home use. At home, registrations of penile rigidity are done every 3 minutes and increased to every 30 seconds when the base loop detects a circumference increase of greater than 10 mm (Fig. 69.10). **Recommended criteria for normal NPTR include four to five normal erectile episodes per night** (Hatzichristou et al., 1998). A computerized program has yielded standardized data measurements according to cumulative distribution of time-intensity measures, defined as tumescence activity units (TAU) and radial rigidity activity units (RAU) (Burris et al., 1989; Levine and Carroll, 1994). A recent study found that RigiScan can accurately predict veno-occlusive dysfunction (Elhanbly and Elkholy, 2012). Potential limitations of RigiScan include the fact that radial rigidity does not accurately predict axial rigidity (Allen et al., 1993; Licht et al., 1995), and considerable variability apparently exists even in normal subjects (Levine and Carroll, 1994).

Further, the manner of testing does not allow verification of the presence of REM sleep.

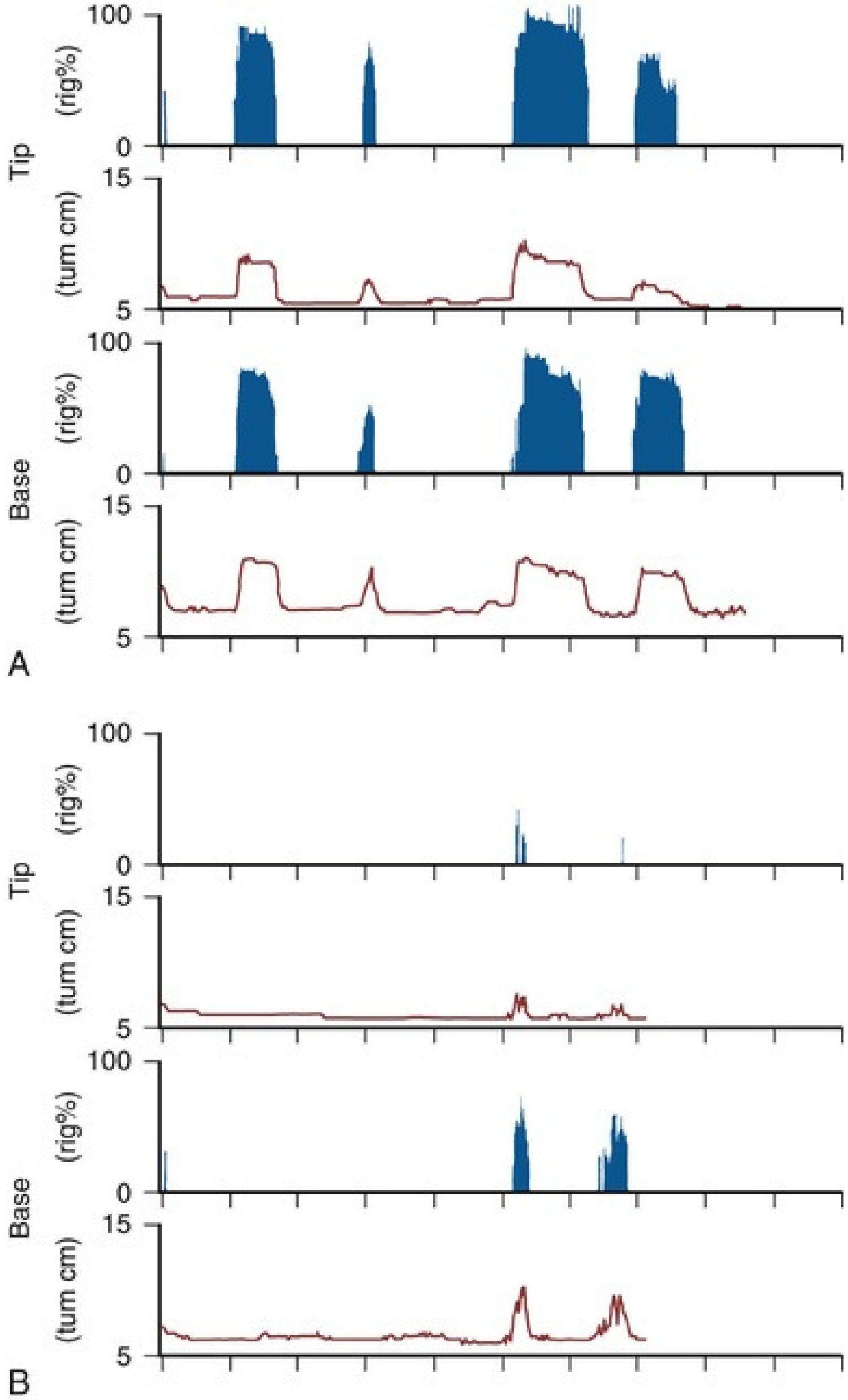

FIG. 69.10 The RigiScan device has been designed to measure penile rigidity during home nocturnal monitoring. (A) A study in a patient with at least two episodes of well-sustained, completely rigid nocturnal erections. (B) A study with two episodes of poorly sustained, poorly rigid nocturnal erections. Such home studies fail to document sleep quality.

NPT electrobioimpedance (NEVA, American Medical Systems, Minnetonka, MN) is a device introduced more recently that assesses volumetric changes in the penis during nocturnal erections (Knoll and Abrams, 1999). The device consists of three small electrode pads applied to the hip and the penile base and glans and a small recording device attached to the patient's thigh. In operation, an undetectable alternating current is transmitted from the glans electrode to the hip ground, and the penile base electrode measures impedance and changes in penile length. Impedance measures decrease in concert with increases in cross-sectional area of the penis during nocturnal tumescence. Further investigation is needed to establish the relationship of volumetric changes and the rigidity of the penis. Similar to RigiScan, the technique also does not include REM sleep monitoring and correlations.

In summary, NPTR monitoring is an attractive approach for objectively evaluating the somatic basis of erectile ability, theoretically devoid of psychological interference. However, it has several apparent shortcomings that limit its routine use for diagnostic purposes (Jannini et al., 2009). Central issues are that the testing does not indicate the cause and severity of ED and that the results may be poorly reproducible. Another fundamental issue is whether the testing appropriately evaluates wakeful, sexually relevant erections. Indeed, erections observed during NPTR monitoring do not unequivocally equate with erections sufficient for sexual performance, and false-positive results are possible for various clinical situations (e.g., multiple sclerosis). False-negative results may occur in aging patients and in patients with depression or anxiety, which may conditionally affect the physiology of sleep-related erectile phenomena. Nonetheless, NPTR monitoring may be considered in special circumstances such as when the cause of ED is obscure and noninvasive testing is desirable.

Audiovisual and Vibratory Stimulation

Alternative erectogenic methods can be used in conjunction with diagnostic testing of erectile function. **Erotic stimulation by explicit videotape material with monitoring has been used as a reliable as well as a time- and cost-effective alternative to NPTR for differentiating between organic and psychogenic ED presentations** (Bancroft et al., 1991; Sakheim et al., 2007). **It is also considered more physiologic, consistent with erectile behavior when awake.** The testing has potential limitations, with possible false-negative responses occurring in the presence of endocrine abnormalities (Carani et al., 1992; Greenstein et al., 1995) and false-positive responses occurring in psychological situations such as erotic excitement inhibition (Chung and Choi, 1990). As one may infer, these methods can be applied in conjunction with other stimulatory conditions (e.g., pharmacologic erection testing) as well as erectile function assessment approaches (e.g., RigiScan monitoring) (Katlowitz et al., 1993; Martins and Reis, 1997).

Neuroimaging

Diagnostic techniques to evaluate central mechanisms of male sexual arousal have contributed to the psychophysiologic investigation of ED. Positron emission tomography (Miyagawa et al., 2007) and functional magnetic resonance imaging (fMRI; Ferretti et al., 2005; Montorsi et al., 2003; Mouras et al., 2003; Park et al., 2001) have been used in association with video sexual stimulation or an erectogenic pharmacologic stimulus (e.g., oral apomorphine). Studies have documented key brain regions associated with sexual arousal that induce penile erection (i.e., anterior cingulate, insula, amygdala, hypothalamus, and secondary somatosensory cortices). Interestingly, functional abnormalities in the brain have been shown in patients with psychogenic ED, suggesting that this diagnosis may be attributable to an actual biologic basis. More investigation in this area is necessary before determining its clinical role.

Psychological Evaluation

The psychological evaluation of ED addresses psychogenic contributions to clinical presentations, essentially psychological and interpersonal factors interfering with erectile function. These aspects should not be underestimated, and it is well documented in population studies that ED is associated with anxiety, depression, low degrees of self-esteem, negative outlook on life, self-reported emotional stress, and a history of sexual coercion (Feldman et al., 1994; Laumann et al., 2007). The urologist's role in initiating a psychological evaluation is not necessarily complicated, and a basic attempt to use queries about a patient's psychological health is helpful in assessing sexual health (Rowland et al., 2005). A two-question scale may be used in every day clinical practice: “During the past month, have you often been bothered by feeling down, depressed, or hopeless? During the past month, have you often been bothered by little interest or pleasure in doing things?” (Whooley et al., 1997).

The diagnostic interview is central to the psychological evaluation, and this process should be handled in a straightforward manner. Readily discernible causes of sexual dysfunction may be elicited, such as fear of failure, performance anxiety (for widowers, this may include complex interactions of dating, new partners, and unresolved mourning/guilt), insufficient sexual stimulation, loss of attraction for the partner, adjustment to a chronic illness or surgery, and relationship conflicts. In addition, causes that are less immediately discernible may be identified to include unresolved parental attachments, sexual identity issues, history of sexual trauma, occurrence of extramarital affairs, and cultural-religious taboos (Laumann et al., 2007; Leach and Bethune, 1996).

The interviewer should be mindful of the possibility of a primary psychogenic ED presentation (Turnbull and Weinberg, 1983). In the absence of organic risk factors, a primary psychogenic ED causation may be suspected. Further support for the diagnosis may follow the confirmation of noncoital erections (i.e., masturbatory, nocturnal, or when awakening). Clinical subtypes of psychogenic ED may be further identified: (1) generalized versus situational and (2) lifelong (primary) versus acquired (secondary, including substance abuse or major psychiatric illness).

The interviewer should also inquire about relationship factors (Rosen, 2001). Relationship conflicts may be the source of psychogenic ED or otherwise may exacerbate organic ED. A couple's issues include intimacy and trust, status and dominance, loss of sexual attraction, ability to achieve sexual satisfaction without erection, and communication problems. Not only is important information derived from interviewing the patient alone, but also interviews with the couple together and of partners separately may provide insight.

Complex intrapsychic causes of sexual dysfunction are often relevant for the ED presentation and may become evident during the diagnostic interview. The clinical history may show a significant traumatic life experience, cultural or religious strife, compulsive sexual behavior, or neurotic process. It may suggest the presence of serious psychiatric comorbidities, such as substance abuse, depressive symptoms, anxiety disorder, or personality disorder. The urologist may not have the professional background, comfort, or time to address these issues definitively, and a referral to a psychological expert for further attention would be appropriate.

Neurologic Evaluation

The neurologic evaluation of ED is concerned with neurogenic associations with ED presentations. The importance of testing for deficits in the neurologic system relates to the principal regulatory role of this system for governing erectile function. Target sites for evaluation include peripheral, spinal, and supraspinal centers as well as somatic and autonomic pathways involved in this biologic response. In line with this purpose, several diagnostic tests have been introduced. However, thus far they have had limited impact on routine clinical management decisions, and much of the available testing in this realm is reserved for research protocols and medicolegal investigations (Giuliano and Rowland, 2013). In addition, fundamental problems surround the lack of sensitivity, reproducibility, reliability, and validity for many of these tests. This concern is particularly so for autonomic function tests, distinct from somatic function testing, which has been shown to be reproducible and valid. Otherwise, tests that could be most useful for evaluating penile erection, for example, neurotransmitter release, are altogether undeveloped.

Somatic Nervous System

Biothesiometry.

This test represents a technique to assess afferent sensory function of the penis (Padma-Nathan, 1988). Testing involves a handheld electromagnetic device placed on the pulp of the index fingers, both sides of the penile shaft, and the glans penis. Measurements of sensory perception threshold are obtained in response to various amplitudes of vibratory stimulation. Investigators have questioned the usefulness of penile glans biothesiometry, which does not accurately portray neurophysiologic function of the dorsal penile nerve because of limitations in recording responses to vibratory stimuli of glanular skin (Bemelmans et al., 1995).

Sacral Evoked Response: Bulbocavernosus Reflex Latency.

This test is used to assess the somatosensory reflexogenic mechanism of penile erection. Testing consists of a direct-current stimulator, which delivers square-wave impulses via two stimulating ring electrodes placed around the penis, one secured near the corona and the other secured 3 cm more proximally, and a recorder that gauges responses via concentric needle electrodes placed in the right and left bulbocavernous muscles. Latency period is measured as the interval from the beginning of each stimulus to the beginning of each response. An abnormal latency time, defined as a value more than three standard deviations above the mean (30 to 40 ms), indicates a high probability of neuropathology (Padma-Nathan, 1988). However, the use of this test has been questioned, and it has been shown that a full battery of electrophysiologic tests evaluating limb nerve function is more sensitive in diagnosing neuropathy than such tests specific to pudendal nerve function alone (Ho et al., 1996; Vodusek et al., 1993).

Dorsal Nerve Conduction Velocity.

This test, in concept, extends from pudendal nerve function reflex testing and involves electrophysiologic stimulation with two stimulating electrodes placed at the glans and at the base of the penis for obtaining two bulbocavernosus reflex latency measurements. Conduction velocity of the dorsal nerve is represented by dividing the distance between the two stimulating electrodes by the difference in latency times recorded from both sites. An average conduction velocity of 23.5 m/s with a range of 21.4 to 29.1 m/s is found in normal subjects (Gerstenberg and Bradley, 1983). Abnormal nerve conduction velocities were found to be diagnostic for neurogenic ED in patients with diabetes (Kaneko and Bradley, 1987).

Genitocerebral Evoked Potential.

This test is designed to assess afferent sensory mechanisms and stimulus processing at spinal and supraspinal nervous system levels. The testing requires complex electronic equipment for recording the evoked potential waveforms overlying the sacral spinal cord and cerebral cortex in response to dorsal penile nerve electrical stimulation (Spudis et al., 1989). Central conduction time is recorded as the difference between the latency times after stimulation of the first replicated spinal response and the first replicated cerebral response (Padma-Nathan, 1988). The test has been questioned as having poor discriminatory value of response latencies (Pickard et al., 1994). However, it may still serve as an objective tool to define characteristics of afferent penile sensory dysfunction in patients with subtle abnormalities on neurologic examination.

Autonomic Nervous System

Heart Rate Variability and Sympathetic Skin Response.

The test of heart rate control (mainly parasympathetic) consists of measuring heart rate variations during quiet breathing, deep breathing, and in response to raising the feet. Normative parameters have been documented. The test of sympathetic skin response involves producing an electrical shock stimulus at a certain location (e.g., median or tibial nerve) and recording the evoked potential elsewhere (e.g., contralateral hand or foot or penis). Recording from the penis is considered to be a potentially useful method of testing penile autonomic innervation (Daffertshofer et al., 1994).

Penile Thermal Sensory Testing.

This test assesses the conductance of small sensory nerve fibers that are affected by autonomic disturbances consistent with neuropathy. The testing measures thermal threshold. In studies of the penis, it seems to correlate well with the clinical determination of neurogenic ED (Bleustein et al., 2003; Lefaucheur et al., 2001).

Electrochemical Skin Conductance Testing.

Electrochemical skin conductance measured using Sudoscan can be used to assess neurogenic ED. A feasibility study has shown promising results in using Sudoscan in patients with diabetes by measuring electrochemical skin conductance (Lefaucheur, 2017). Diabetic neuropathies can affect penile innervation without causing distal neuropathy, such that penile neuropathy cannot be reliably determined by assessing whether a distal neuropathy has affected the feet. Sudoscan results were more sensitive than sympathetic skin responses in assessing sympathetic innervation impairment. Further studies and clinical trials are needed to determine its diagnostic accuracy.

Corpus Cavernosum Electromyography and Single Potential Analysis of Cavernous Electrical Activity.

This test offers a direct recording of cavernous electrical activity, which varies between penile flaccidity and tumescence (Leddy et al., 2012; Wagner et al., 1989). In the normally flaccid penis, electrical activity is described as exhibiting a rhythmic slow wave with intermittent bursts of activity. As penile tumescence occurs (such as in response to visual sexual stimulation or after intracavernosal injection of a smooth muscle relaxant), this activity ceases. During detumescence, the baseline electrical activity returns. Patients with suspected autonomic neuropathy were demonstrated to display a discordant pattern, having continued electrical activity during erectogenic stimuli (Wagner et al., 1989). Recording techniques have been standardized, and normative values have been defined to include maximum peak-to-peak amplitudes between 120 and 500 mV and mean potential durations of 12 seconds (Stief et al., 1994). However, the clinical utility of this test remains in question (Jiang et al., 2003; Kellner et al., 2000).

Hormonal Evaluation

The hormonal evaluation for ED explores an endocrinologic basis for this sexual dysfunction and recognizes accumulating evidence that endocrinopathies potentially affect the physiology of penile erection (Mirone et al., 2009; Traish and Guay, 2006). **Several endocrine conditions are particularly relevant in this regard: testosterone deficiency, formerly termed hypogonadism (decrease or absence of hormonal secretion from the gonads), hyperthyroidism (excessive thyroid hormone release), and diabetes (altered modulation of androgen function** (Maggi et al., 2013; Wang et al., 2011). The diagnostic evaluation may be undertaken in view of their possible influences on erectile function. The clinical history may raise suspicion regarding the diagnosis, although the clinical presentation of an endocrinopathy may be variable. Several questionnaires have been proposed for use in screening, particularly with respect to testosterone deficiency (Daig et al., 2003; Heinemann, 2005; Morley et al., 2000). A new psychometrically validated hypogonadism screener has been developed to identify men with symptoms of testosterone deficiency (Rosen et al., 2011). However, their general lack of specificity for most presentations and the lack of sensitivity for some others has limited their widespread applications (Morales et al., 2007). The central feature of this evaluation involves biochemical testing for serum hormonal levels (Bhasin et al., 2010).

Serum Testosterone Measurements

Much focus in assessing the impact of endocrinopathies on male sexual function has centered on the role of androgens. Androgen deficiency or low testosterone levels are observed in as few as 2% and as many as 33% of men presenting clinically with ED (Citron et al., 1996; Korenman et al., 1990; Soran and Wu, 2005). Differences in patient populations under study likely account for the variation in statistics. In acknowledging that aging may represent a primary cause of declining androgens, thought leaders have variously applied such terms as androgen deficiency of the aging male (ADAM), partial androgen deficiency of the aging male (PADAM), hypoandrogenism, symptomatic late-onset hypogonadism (SLOH), and andropause to designate this association. Adult-onset hypogonadism (AOH) was recently proposed to describe syndromes of testosterone deficiency in men with relationship to adverse adult-onset health conditions rather than aging per se (Khera et al., 2016).

It is important to understand the biology of testosterone production and function to proceed with its laboratory evaluation. **Testosterone circulates in three fractions: free (0.5% to 3%), tightly bound to sex hormone–binding globulin (SHBG) (~30%), and loosely bound to albumin and other serum proteins (~67%)** (Basaria and Dobs, 2001; Freeman et al., 2001). **Free testosterone and albumin-bound portions make up the bioavailable testosterone fraction. The relative concentrations of the carrier proteins (SHBG and albumin) modulate androgen function.** Numerous conditions can alter the SHBG fraction and accordingly affect bioavailable testosterone to some extent even if the total testosterone measurement is unchanged (Bhasin et al., 2010). Decreased SHBG is associated with moderate obesity, nephrotic syndrome, hypothyroidism, and the use of glucocorticoids, progestins, and androgenic steroids, and it produces an elevation in bioavailable testosterone. Increased SHBG is associated with aging, hepatic cirrhosis, hyperthyroidism, human immunodeficiency virus infection, and the use of anticonvulsants and estrogens, and it produces a lowering in bioavailable testosterone. Despite the observation that lower levels of SHBG are associated with insulin resistance (Stellato et al., 2000), variable SHBG levels have been documented in men with diabetes, possibly because of confounding obesity and aging factors, and the diagnosis of hypogonadism in this population should rely on the measurement of a low bioavailable testosterone level (see later) (Kapoor et al., 2007).

Theoretically, the unbound or free fraction measurement of testosterone offers the most relevant determination of testosterone bioavailability. However, commercial assays for free testosterone are known to be inconsistent and have been considered as invalid by some investigators (Field and Wheeler, 2013; Ly et al., 2010; Vermeulen et al., 1999). **The best indicator of androgen status is the calculated bioavailable testosterone (free testosterone and albumin-bound testosterone).** A formula for this calculation is found on the website of the International Society for the Study of the Aging Male (http://www.issam.ch/freetesto.htm), and this formula requires entries for the values of total testosterone and SHBG. In men with serious liver disease or hypoalbuminemia, entry of the serum albumin value may be useful for obtaining the best calculation.

For screening purposes, measurement of total serum testosterone level is generally sufficient. It is recommended that the blood draw be performed between 7:00 AM and 11:00 AM when there is a peak serum testosterone level, accounting for the fact that diurnal variation occurs in younger and middle-aged men (Wang et al., 2009). **The typical reference range for the total testosterone measurement is 280 to 1000 ng/dL. Because of individual variability, the normal range for testosterone beyond which replacement therapy should be initiated remains unresolved.** However, there is a low threshold of testosterone needed to maintain sexual function; the correlation between sexual function and testosterone is weak for levels above 8 nmol/L or 300 ng/dL (Bhasin et al., 2010; Isidori et al., 2014; O'Connor et al., 2011). If the testosterone level is below or at the low limit of normal, blood draw should be repeated for confirmation. On the other hand, a mildly abnormal testosterone level may be found to be normal in 30% of patients on repeat testing (Bhasin et al., 2010). The clinical scenario, such as the presence of conditions that alter testosterone carrier proteins, may prompt further testing and assessment decisions.

Serum Gonadotropin Measurements

With a second total testosterone determination, assessment of LH and prolactin should also be included. Measurement of serum gonadotropins helps to localize the source of the hypogonadism. Testosterone release involves the integrative activity of the hypothalamic-pituitary-gonadal axis and its regulatory feedback mechanisms, and disruption at any level of this axis may account for hypogonadism (Bhasin et al., 2010). A result of low testosterone is decreased negative feedback to the hypothalamus and pituitary, causing increased secretion of LH and follicle-stimulating hormone (FSH). Elevated serum LH and FSH releases are appropriate pituitary responses to low serum testosterone levels, which is consistent with testicular failure (primary hypogonadism). In contrast, normal or low serum LH and FSH releases in the setting of low serum testosterone levels indicate an inappropriate response and suggest a central disorder (secondary hypogonadism).

Serum Prolactin Measurement

Hyperprolactinemia causes hypogonadism by suppression of gonadotropin-releasing hormone from the hypothalamus, which impairs the pulsatile LH secretion required for serum testosterone production by the gonads (Morales et al., 2004). An additional possible mechanism for sexual dysfunction, specifically loss of sexual libido, in patients with hyperprolactinemia independent of the circulating level of testosterone relates to an interference of the peripheral conversion of testosterone to dihydrotestosterone (DHT) (Lobo and Kletzky, 1983). **Suspicion of hyperprolactinemia is raised in the patient with low serum testosterone and low or inappropriately normal LH.** However, controversy surrounds the consideration of routine determinations of prolactin in men with ED, with some indicating the low yield in doing so (Govier et al., 1996; Johnson and Jarow, 1992) and others finding that low serum testosterone or low sexual desire does not always coincide with the diagnosis (Buvat and Lemaire, 1997; Johri et al., 2001). Causes of the condition include various medications such as antipsychotic agents, tricyclic depressants and opiates, prolactin-secreting tumors, hypothyroidism, hypothalamic lesions, renal insufficiency, cirrhosis, and chest wall lesions (Molitch, 2005; Zeitlin and Rajfer, 2000).

Magnetic Resonance Imaging Scans

Cases of central (hypogonadotropic) hypogonadism as well as unexplained hyperprolactinemia prompt central imaging of the pituitary. This evaluation commonly involves magnetic resonance imaging, which can identify structural abnormalities (Citron et al., 1996; Petak et al., 2002; Rhoden et al., 2003). **Generally accepted guidelines provide indications for pituitary imaging: cases of severe central hypogonadism (testosterone <150 ng/dL) and suspicion of pituitary disease (i.e., panhypopituitarism, persistent hyperprolactinemia, or symptoms of tumor mass effect).**

Serum Thyroid Function Tests

Hyperthyroidism is associated with ED, possibly by increasing aromatization of testosterone into estrogen (which raises levels of SHBG) (Morales et al., 2004) **or by increasing adrenergic tone (which causes smooth muscle contractile effects or exerts psychobehavioral effects)** (Carani et al., 2005). Symptoms of hyperthyroidism, such as hyperactivity, irritability, heat intolerance, palpitations, fatigue, and weight loss, are often reported, and physical signs such as tachycardia, tremor, goiter, and eyelid retraction are often identified. The diagnosis is made biochemically by measurement of high levels of thyroid hormone (total or free thyroxine [T_4] or triiodothyronine [T_3]) with a low-serum thyroid-stimulating hormone level.

Key Points: Diagnostic Evaluation

- The basic evaluation of ED consists of a detailed case history, physical examination, and proper laboratory tests.
- The sexual history should define the characteristics of the ED presentation according to features such as onset, duration, conditions, severity, and cause.
- Cardiac risk assessment and risk reduction interventions are appropriate when necessary for all patients undergoing ED evaluations.
- Hormonal evaluation of ED explores an endocrinologic cause, with special consideration given to testosterone deficiency, hyperthyroidism, and diabetes.
- Questionnaires and other patient self-report measures offer practical help in documenting the presence, severity, and responsiveness to treatment of ED.
- Specialized evaluation and testing may be required for individuals with complicated or atypical presentations of ED.

Treatment Considerations

The treatment of ED axiomatically follows an appropriate diagnostic workup. Although current interventions are etiologically specific and nonspecific, an intervention that is specific for the cause of ED ideally offers the opportunity to treat ED with a corrective purpose in mind. **Current recommendations adhere to a shared decision-making approach to therapy and specify that all therapeutic options are presented to the patient with advantages and disadvantages of each. The perceived risks and benefits based on the patient's clinical situation should be presented and weighed to make an informed decision** (see Fig. 69.1) (Makarov et al., 2016).

Lifestyle Modification

The risk of developing ED is significantly associated with the presence of comorbid health conditions such as diabetes, cardiovascular disease, and metabolic syndromes that are either preventable or to a minimal extent treatable in endeavoring to optimize health status (Kostis et al., 2005). Optimization of these diseases offers opportunities to prevent the development of ED or to ameliorate its extent (Glina et al., 2013).

Epidemiologic studies have shown examinations of potentially modifiable risk factors and in some instances have provided support that risk modification may indeed improve erectile function. For instance, several reports have suggested that the discontinuation of cigarette smoking results in a recovery of functional erection status (Bacon et al., 2006; Feldman et al., 2000; Mannino et al., 1994). A beneficial role of increasing exercise for those with a sedentary lifestyle in men with ED was also evident (Derby et al., 2000; Feldman et al., 1994). In a prospective study, obese men with moderate ED and no overt symptoms of cardiovascular disease showed significant improvements in IIEF scores after exercise and weight control when compared with a control group that followed an educational program alone (Esposito et al., 2004). Significant changes in body mass index, C-reactive protein, and physical activity scores were observed in the intervention group compared with the control group. Mediterranean-style diets and a reduction in caloric intake have been found to improve erectile function in men with metabolic syndrome (Esposito et al., 2006). A change to a no-nose saddle from a conventional saddle was shown to recover erectile function, presumably by alleviating perineal trauma, in a short-term interventional study of men with ED associated with occupational bicycle riding (Schrader et al., 2008).

Reports indicating that ED is potentially ameliorated by lifestyle modifications of risk factors that predispose this sexual dysfunction are most illuminative. The role of lifestyle modifications to prevent or to treat ED has gained support by way of systematic reviews and meta-analysis (Gupta et al., 2011; Kupelian et al., 2010; Porst et al., 2013). The mechanisms of this effect may include reduced cardiovascular risk factors, increased serum testosterone levels, and overall improved mood and self-esteem (Glina et al., 2013; Gupta et al., 2011; Meldrum et al., 2012). **Ongoing clinical and basic science investigation may further affirm the benefits of lifestyle modification and clarify its mechanistic basis.**

Medication Change

It is possible that a certain medication is an offending factor resulting in the clinical presentation of ED. After this inference is made, an appropriate next step would be to change to a different dose or type of medication entirely, considering that this action may reverse ED in some patients (Ralph and McNicholas, 2000). For instance, switching antihypertensive therapies from thiazide diuretics and beta-blockers to calcium channel blockers and renin-angiotensin system inhibitors (i.e., angiotensin-converting enzyme inhibitors and angiotensin receptor blockers) may recover erectile function in men developing ED in this clinical setting. Similarly, in patients suffering adverse sexual dysfunction effects from the use of SSRIs (e.g., ED, retarded ejaculation), treatment strategies such as drug substitution (e.g., bupropion, nefazodone, buspirone, mirtazapine), drug holidays, SSRI dosage reduction, watchful waiting, and administration of PDE5 inhibitors have enabled sexual function recovery (Nurnberg et al., 2001; Rosen et al., 1999b).

Psychosexual Therapy

Because of the frequent interplay of psychological and interpersonal factors in clinical presentations of ED, it is hardly surprising to consider that psychosexual therapy should be included in the therapeutic armamentarium for this sexual dysfunction. A strong limitation in this area is that evidence-based investigation and well-controlled, large-scale outcome research that documents the efficacy of interventions are generally lacking. In practice, psychosexual therapy does represent an ill-defined combination of interventions and interpretations based on behavioral, relational, psychoanalytic, and cognitive psychology concepts. **A variety of interventions are used: systematic anxiety reduction/desensitization, sensate focus, interpersonal therapy, cognitive-behavior therapy, sex education, couples' communication and sexual skills training, and masturbation exercises** (Althof et al., 2005). **Integrated treatments, which combine psychosexual interventions with medical therapies such as oral therapy, intracavernosal injection, or vacuum device therapy, have also proved successful in managing ED presentations, particularly those associated with motivational obstacles** (Althof et al., 2005; Hawton, 1998). The urologist understandably may not feel comfortable or may not possess the necessary training to address complicated psychosocial concerns. However, for mild to moderate psychosocial matters, the urologist may be prepared to proceed with a "biopsychosocial" model that minimally involves awareness of psychosocial issues and preparedness to counsel a patient or couple about normal sexual function and acceptable sexual behaviors (Althof and Needle, 2011). Collaborative efforts with a mental health clinician who has expertise in psychosexual therapy may be necessary to implement intensive therapy techniques.

Hormonal Therapy

A prescription of hormonal therapy is considered for the patient in whom a hormonal disturbance is identified. The urologist's role is appropriate for the treatment of testosterone deficiency and hyperprolactinemia, whereas endocrinologists would be considered as the foremost consultants for other endocrinopathies.

Testosterone Therapy

Androgen replacement directly addresses the clinical complaint associated with testosterone deficiency. As a general principle of sex steroid replacement therapy, serum hormone levels to be achieved daily throughout 24 hours should ideally achieve normal reference values and resemble the normal diurnal pattern. **Evaluating serum testosterone levels before and during treatment is**

imperative, although the efficacy of testosterone therapy is best judged by clinical response rather than a precise testosterone determination. Current recommendations suggest that a short (e.g., 3-month) therapeutic trial is justified, and, in the absence of a response, testosterone administration should be discontinued (Bhasin et al., 2010; Wang et al., 2009). Potential adverse effects of androgen therapy (i.e., erythrocytosis, sleep apnea, urinary symptoms, prostate cancer progression risk, gynecomastia, acne) should be recognized (Morales et al., 2004; Wald et al., 2006). The role of testosterone in men's cardiovascular health has been debated; however, a recent meta-analysis of all placebo-controlled randomized controlled trials on how testosterone affects cardiovascular health did not support a causal relationship between testosterone and cardiovascular events (Corona et al., 2014). **Monitoring of patients on therapy consists of a baseline assessment that includes digital rectal examination and serum PSA testing along with laboratory evaluation (i.e., hemoglobin/hematocrit levels, liver function tests, cholesterol level, and lipid profile) followed by the assessment of treatment efficacy after 3 to 6 months and annually thereafter to ascertain symptom response and any adverse events** (Bhasin et al., 2010; Morales et al., 2004). Short-acting preparations may be preferred in favor of long-acting depot preparations in the initial treatment of patients so that therapy can be discontinued on the occasion of an adverse event (Wang et al., 2009).

For the treatment of testosterone deficiency, several testosterone preparations are offered and can be delivered by various routes: intramuscular, subcutaneous, transdermal (patch and gel), buccal, and oral (Bhasin et al., 2010; Corona et al., 2011; Edelstein et al., 2006; Morgentaler et al., 2008; Wang et al., 2009). A brief description of available therapies follows (see also Table 69.6).

TABLE 69.6

Testosterone Preparations

FORMULATION	CHEMICAL STRUCTURE	T½	STANDARD DOSAGE	ADVANTAGES	DISADVA
ORAL AGENTS (Not FDA approved)					
Testosterone undecanoate	17-α-hydroxyl-ester	4 h	120–240 mg 2-3 times daily	Oral convenience Modifiable dosage	Serum testoste levels a clinical respons

					Must b with m
Methyltestosterone	17-α-alkylated	3.5 h	20–50 mg 2–3 times daily	Oral convenience Modifiable dosage	Potenti hepatot Treatm conside obsolet
Mesterolone	1-alkylated	8 h	100–150 mg 2–3 times daily	Oral convenience Modifiable dosage	Nonaromat estrogen
INTRAMUSCULAR AGENTS					
Testosterone enanthate	17-α-hydroxyl-ester	4–5 days	250 mg every 2–3 wk	Low cost Modifiable dosage	Wide fluctua circula levels Multip injectio Relativ risk of polycy
Testosterone cypionate	17-α-hydroxyl-ester	8 days	200 mg every 2–3 wk	Low cost Modifiable dosage	Wide fluctua circula levels Multip injectio
Testosterone propionate	17-α-hydroxyl-ester	20 h	100 mg every 2 days	Low cost	Wide fluctua circula levels Multip injectio Relativ risk of polycy
Testosterone undecanoate	17-α-hydroxyl-ester	34 days	1000 mg every 10–14 wk	Testosterone levels maintained within normal range Long lasting	Pain at inje

				Less frequent administration	
SUBCUTANEOUS AGENTS					
Surgical implants	Native testosterone	—	4 6 200-mg implants lasting ≤6 mo	Treatment 3–4×/yr	Placem invasiv Risk of extrusi site inf
CONTROLLED-RELEASE T-BUCCAL FORMULATION AGENTS					
Testosterone buccal	Native testosterone	12 h	30 mg 2 times daily	Testosterone levels within physiologic range	Possibl irritatic Twice- irritatic Unplea
TRANSDERMAL AGENTS					
Testosterone patches	Native testosterone	10 h	5–10 mg/day	Mimics circadian rhythm Simple administration	Skin ir Daily admini
Testosterone gel 1%–2%	Native testosterone	6 h	5–10 g/day	Testosterone levels maintained within normal range Flexible dose modification Skin irritation less common than with patches	Possibl during contact Daily admini
Testosterone nasal gel	Native testosterone	1 h	33 mg/day	Quick onset of action, short half-life, no risk of transference	Two-three day admini
Testosterone solution 2%	Native testosterone	NA	60–120 mg/day	Testosterone levels maintained within normal range	Possibl during contact Daily admini

NA, Not available; *T,* testosterone; *T½*, drug half-life.

Modified from Corona G, Rastrelli G, Forti G, et al.: Update in testosterone therapy for men. *J Sex Med* 8:639–654, 2011.

Intramuscular.

Testosterone enanthate or cypionate, an injectable depot preparation of testosterone, is delivered by deep intramuscular injection (200 to 250 mg every 2 to 3 weeks). The schedule of therapy results in supraphysiologic levels of testosterone for 72 hours with a steady exponential decline to subphysiologic levels by 10 to 12 days. Alternative dosing of 100 mg every 7 to 10 days can be considered in situations in which patients experience symptomatic mood changes or sexual fluctuations associated with documented early low testosterone level troughs. Another parenteral preparation, testosterone propionate, is also delivered intramuscularly at a dosage of 200 mg every 2 to 3 days because of its shorter half-life, and it may also display serum testosterone fluctuations. Testosterone undecanoate (TU), as a depot formulation consisting of 750- or 1000-mg dosages administered at 10-week dosing intervals, has been used in Europe since 2003, although it is not yet available in the United States.

Subcutaneous.

Pellets offer a subcutaneous, long-acting depot formulation of testosterone. Testopel is a pellet containing 75 mg of testosterone. Dosing usually is 2 to 6 pellets (150 to 450 mg testosterone) implanted subcutaneously every 3 to 6 months.

Transdermal.

Transdermal delivery options comprise patches and gels, with a delivery approach that intentionally simulates normal circadian levels of testosterone. When patients apply medication in the morning, higher initial absorption mimics normal diurnal variation.

Testoderm was approved initially as a scrotal patch administered daily without adhesive (4 to 6 mg), but its use faltered because of difficulties with its application, the requirement for scrotal shaving, and the finding that it significantly produced high levels of DHT by conversion by 5α-reductase activity that is plentifully present in the scrotal skin. Testoderm TTS represented an alternative formulation avoiding the inconveniences of the scrotal application. Its application is to the arm, back, or buttock as a 5-mg patch. Androderm, an alternative product, delivers 2.5 or 5 mg of testosterone daily. Both patches have been associated with itching, chronic skin irritation, and allergic contact dermatitis. The skin irritation is alleviated by the local application of cortisone cream. Patients are advised to alternate application sites and avoid sun-exposed areas.

AndroGel (testosterone 1% gel) is a topical gel pack that contains 50, 75, or 100 mg of testosterone, with only 10% of the drug being absorbed during a 24-hour period. Testim, also providing 1% testosterone, is an alternative product packaged as a 5-g tube containing 50 mg of testosterone. Both are similarly applied once daily in the morning to clean, dry skin on the shoulders, upper arms, or abdomen, and it is allowed to dry before dressing. Axiron (testosterone 2% solution) is another transdermal product approved by the US Food and Drug Administration (FDA), consisting of 30 mg of testosterone applied to each axilla once daily using a metered applicator. Special considerations for axillary administration include the concealable location and high permeability of the axilla, which has a relatively high level of 5α-reductase activity. Testosterone nasal gel (Natesto) is applied to the nostrils. The recommended dosage of Natesto is 11 mg of testosterone (2 pump actuations; 1 actuation per nostril) administered intranasally two to three times daily for a total daily dose of 22 to 33 mg. The advantages are its quick onset of action, short half-life, and lack of risk of transference. Some of the disadvantages are the possibly irritating nasal route of administration and necessity for administration up to 3 times a day.

Buccal.

Striant is a tabletlike, mucoadhesive treatment system (30 mg of testosterone) that continuously delivers medication. It is applied twice daily to the gum tissue above the incisors, allowing testosterone to be absorbed through the buccal mucosa.

Oral.

Oral testosterone preparations are limited. Concern is associated with the liver toxicity of testosterone (i.e., hepatitis, cholestatic jaundice, hepatomas, hemorrhagic liver cysts, and hepatocellular carcinoma) related to the large doses necessary to achieve normal serum levels (Bagatell and Bremner, 1996). Large doses (>200 mg/day) are required orally because much of the administration is rendered metabolically inactive during the "first-pass" circulation through the liver. Chemical modifications of oral testosterone have been explored to overcome adverse reactions. Both 17α-methyltestosterone and fluoxymesterone have been formulated, but because of their patient variability of effect with potential liver toxicity risk, they should not be prescribed (Wang et al., 2009). TU, as an oral formulation in oleic acid, is safe by partly escaping hepatic inactivation (Köhn and Schill, 2003). However, it has shown a large individual variability for the time of maximal responses as well as when maximal serum testosterone is attained. Oral TU remains unapproved in the United States. A formulation of TU manufactured by Lipocine, Tlando was reportedly well tolerated in early phase 3 clinical trials and has undergone two additional phase 3 clinical trials with pending results. Lipocine has developed an additional drug with increased solubility and absorption, currently in phase 2 clinical trials.

Alternative Hormone Treatments

Alternative hormonal replacement therapies have been suggested, with certain desirable features and some caveats. DHT as a direct mode of therapy is attractive because of its action as a pure androgen that is not aromatizable to estradiol, and accordingly it has been demonstrated that the hormone does not exert adverse estrogenic effects on prostate growth or lipid profile measurements (Kunelius et al., 2002; Sakhri and Gooren, 2007). A therapeutic DHT gel is available at a dose of 125 to 250 mg/day, yielding plasma DHT levels comparable with physiologic testosterone levels (Kunelius et al., 2002). Dehydroepiandrosterone (DHEA), a hormone supplement with androgen-like and estrogen-like effects, has been used, although limited evidence exists showing it improves sexual function (Baulieu et al., 2000; Morales et al., 2004). The treatment cannot be considered harmless, and the potential exists for DHEA and other nontestosterone androgen precursor preparations (e.g., DHEA-S, androstenediol, androstenedione) to stimulate hormone-sensitive diseases such as breast or prostate cancer. Human chorionic gonadotropin (hCG) has been found to increase total and free testosterone and estradiol 50% above baseline; it would conceivably be of benefit to hypogonadal men in a way similar to the effects of androgen administration. Clinical investigation of hCG has shown some anthropometric effects (i.e., decrease in fat mass, increase in lean body mass) and improvements in serum testosterone concentrations in androgen-deficient men without documented benefits for sexual function (Liu et al., 2002; Tsujimura et al., 2005). Antiestrogens and aromatase inhibitors have been shown to increase endogenous testosterone levels, and selective androgen receptor modulators are under development. Because of insufficient evidence about the therapeutic benefits and adverse effects of alternative replacement therapies in older men with testosterone deficiency, they are not currently recommended for use (Wang et al., 2009).

Hyperprolactinemia Treatments

The treatment of hyperprolactinemia is undertaken with the acknowledgment that testosterone replacement therapy is neither corrective nor sufficient to improve sexual function. The therapeutic objective, rather, is to identify and address the underlying cause, which may then ameliorate ED. Offending drugs, such as estrogens, morphine, sedatives, and neuroleptics, should be discontinued (Molitch, 2008). A prolactin-secreting adenoma should be treated medically and, if necessary, surgically. Bromocriptine, a dopamine agonist that lowers prolactin level and restores testosterone to normal, reduces the size of the tumor. Neurosurgical ablation becomes necessary if the therapeutic response to medication does not occur or visual effects are noted in association with optic nerve compression (Gillam et al., 2006). Erection recovery is most evident after treatment of men with significant serum elevations of prolactin (higher than 40 ng/mL) (Netto Júnior and Claro, 1993).

Pharmacologic Therapies

The premise of pharmacologic therapies is that they simulate the biochemical and molecular mechanisms of action naturally governing the erectile response. **Conceptually, erectogenic therapies strategically either promote proerectile mechanisms or oppose antierectile mechanisms, at peripheral and central levels of the neurovascular axis responsible for penile erection** (Rowland and Burnett, 2000). At a peripheral level, these mechanisms influence corporeal smooth muscle tone. Promotion of proerectile mechanisms is achieved by either inducing corporeal smooth muscle activation through cell-receptor agonists or effectors of tissue relaxant pathways (e.g., stimulating second messenger cyclic nucleotide [cyclic guanosine monophosphate, or cGMP, or cyclic adenosine monophosphate, or cAMP] synthesis) or inhibiting the deactivation of smooth muscle relaxation pathways (e.g., inhibiting phosphodiesterases), whereas opposition of antierectile mechanisms are achieved by decreasing smooth muscle contraction through receptor antagonists of tissue contractile pathways (e.g., α_1-adrenergic inhibitors). At a central nervous system level (i.e., brain or spinal cord), neuronal pathways are affected, and potential opportunities exist to promote proerectile pathways (e.g., agonists of dopaminergic D_2 receptors in the medial hypothalamus) or to oppose antierectile pathways (e.g., antagonists of 5-$HT_{1A/2}$ [serotonergic] receptors in the spinal cord).

Diverse therapies have been touted throughout time, although their efficacy and safety characteristics have not always been clearly defined. Current standards of regulatory agency approval have helped to clarify the qualifications of commercially developed and marketed therapies (Hirsch et al., 2004).

Oral Therapy

Orally administered medication for ED meets many of the attributes of "ideal therapy," which include convenience, simplicity, and noninvasiveness (Morales et al., 1995). Oral therapies are increasingly in demand to meet the therapeutic objective of clinical efficacy as well.

Phosphodiesterase Type 5 Inhibitors.

This class of medication was famously inaugurated as an effective ED treatment in the United States after the FDA approval of sildenafil citrate (Viagra, Pfizer, New York, NY) in 1998, vardenafil hydrochloride (Levitra, Bayer Schering Pharma AG, Berlin, Germany), and tadalafil (Cialis, Lilly, Indianapolis, IN) in 2003, and avanafil (Stendra, Vivus, Mountain View, CA) in 2012 (Bruzziches et al., 2013; Porst et al., 2013). **PDE5 inhibitors similarly work to block the catalytic action of the enzyme that degrades cGMP, the downstream effector of the erection mediator nitric oxide, which then facilitates the signal transductional mechanisms of corpus cavernosal smooth muscle relaxation required for penile erection. The medications augment but do not induce the erectile response, and the induction of penile erection requires the release of nitric oxide from penile nerve endings and vascular endothelium under the influence of sexual stimulation** (Burnett, 2005). The high concentration of PDE5 inhibitors in the smooth muscle of the penile corpora cavernosa accounts for the selectivity of their effect.

Despite their similar modes of actions, PDE5 inhibitors differ somewhat in their biochemical properties, pharmacokinetic profiles, and clinical performances (Table 69.7). The chemical structure of PDE5 inhibitors are similar, containing a guaninelike base, a riboselike or desoxyribose-like system, and a phosphate diester-like bond, which confers their ability to bind effectively to the catalytic site of the PDE5 enzyme. The chemical structures of sildenafil and vardenafil are similar, unlike that for tadalafil, and this difference explains some phenomenologic distinctions observed between these agents (Corbin and Francis, 1999). The chemical structure of avanafil differs from the standard model of the other three agents, which may account for some of its selective actions (Kedia et al., 2013). **Distinct from the actions of tadalafil and avanafil, sildenafil and vardenafil cross-react to a greater extent with PDE6, which is expressed in the retina; this difference may explain the complaint of visual disturbances observed with sildenafil and vardenafil use.** Tadalafil minimally cross-reacts with PDE11, unlike the other three PDE5 inhibitors, although the significance of this effect is unclear. The remaining side effects commonly observed with PDE5 inhibitor treatment are associated with inhibition of PDE5 localized in other target tissues, such as vascular and gastrointestinal smooth muscle. Tadalafil possesses a longer half-life of elimination than the other three PDE5 inhibitors. This feature suggests a longer therapeutic window uniquely afforded for tadalafil, which may translate into increased convenience for couples using this agent.

TABLE 69.7

Comparison of Four Phosphodiesterase Type 5 Inhibitors Currently Available in the United States

	SILDENAFIL	VARDENAFIL	TADALAFIL	AVANAFIL
Cmax (ng/mL)	450	20.9	378	2153
Tmax (h)	0.8	0.7–0.9	2	0.3–0.5
Onset of action (min)	15–60	15–60	15–120	15–60
Half-life (h)	3–5	4–5	17.5	3–5
Bioavailability	40%	15%	Not tested	30%
Fatty food	Reduced absorption	Reduced absorption	No effect	Reduced absorption
Recommended dosage	25, 50, 100 mg	5, 10, 20 mg	5, 10, 20 mg	50, 100, 200 mg
Side effects:				
Headache, dyspepsia, facial flushing	Yes	Yes	Yes	Yes
Backache, myalgia	Rare	Rare	Yes	Rare
Blurred/blue vision	Yes	Rare	Rare	No
Precaution with antiarrhythmics	No	Yes	No	No
Contraindication with nitrates	Yes	Yes	Yes	Yes

Cmax, Maximal plasma concentration; *half-life,* time required for elimination of one half of the medication from plasma; *Tmax,* time required to attain Cmax.

All four PDE5 inhibitors have demonstrated equivalent efficacy and tolerability in clinical trials for the treatment of ED of varying severity and cause (Carson and Lue, 2005; Bruzziches et al., 2013; Giuliano et al., 2010; Hellstrom, 2007; Porst et al., 2013; Yuan et al., 2013). Trial designs for these agents have differed, limiting useful comparisons among them, and superiority cannot be claimed for any particular agent in the absence of directly comparative studies (Carson and Lue, 2005; Khera and Goldstein, 2011). **In general, the agents effectively result in successful sexual intercourse rates of approximately 70%** (Carson and Lue, 2005; Khera and Goldstein, 2011). A somewhat reduced intercourse success rate of 40% to 50% has been reported in patients with diabetes and ED (Fonseca et al., 2004; Safarinejad, 2004) and in patients with ED associated with radical prostatectomy in general (Hatzimouratidis et al., 2009). However, the intercourse success rate for patients after bilateral nerve-sparing radical prostatectomy specifically is somewhat better than for the entire group, and reports have commonly documented rates that approach 60% to 70% for functional erections with therapy.

According to standard dosing recommendations, patients are instructed to take the medications on demand between 30 and 60 minutes before intended sexual activity. This lead-time interval is specified to take advantage of the duration by which the medications achieve peak serum concentrations (i.e., approximately 30 minutes for avanafil, 1 hour for sildenafil and vardenafil, and 2 hours for tadalafil). Although the onset of activity has been documented to occur possibly within 20 minutes for each agent, this characteristic is less important to patients than erection hardness and maintenance of erections with therapy (Claes et al., 2008). A daily dosing regimen has been approved for tadalafil as an alternative treatment schedule to afford patients greater convenience in having sexual intercourse while using this agent (Porst et al., 2006; Shabsigh et al., 2010). **Optimization of effect for all PDE5 inhibitors is also achieved by applying sexual stimulation properly as a prerequisite for nitric oxide release, by reducing food intake, which may delay drug absorption, by escalating drug dosing as needed, and by repeating attempts with the medications several times (up to 9 or 10 attempts affords maximal probability of success)** (Barada, 2003; McCullough et al., 2002; Shindel, 2009). **Correcting or improving adverse health conditions (e.g., glycemic control, hyperlipidemic control, androgen replacement), which affect drug efficacy, has also been**

demonstrated as potentially beneficial (Guay, 2003; Sadovsky et al., 2009). As evidence of therapeutic efficacy, patient and partner satisfaction with therapy (as shown for sildenafil) has been well demonstrated (Montorsi and Althof, 2004). Suboptimal acceptance or lack of long-term adherence to therapy (up to 47% of patients) has been reported, which may indicate the influence of psychosocial factors or challenges of a treatment that requires repeated dosing (Al-Shaiji and Brock, 2009; Seftel, 2002). There is controversial evidence that combining testosterone and PDE5 inhibitors may improve response to PDE5 inhibitor therapy (Greco et al., 2006; Spitzer et al., 2012, 2013). A combination of daily doses of 5 mg tadalafil (long-acting) with 50 mg sildenafil (short-acting) may be used in patients with severe ED without increasing side effects (Cui et al., 2015).

Patients using PDE5 inhibitors should be thoroughly counseled regarding precautions (Box 69.1). Cardiovascular safety using this class of compounds has been well demonstrated, although it should be emphasized that given the cardiovascular risks of sexual activity and potential for adverse drug interactions with this therapy, cardiovascular risk assessment and stabilization should be considered for all men before the institution of PDE5 inhibitor therapy. **Controlled and postmarketing studies involving these agents have shown that they do not cause an increase in myocardial infarction or death rates when compared with expected rates in study control populations** (Hellstrom, 2007; Jackson et al., 2006a,b; Nehra, 2009). In addition, patients with known coronary artery disease or heart failure receiving PDE5 inhibitors did not exhibit worsening ischemia, coronary vasoconstriction, or worsening hemodynamics on exercise testing or cardiac catheterization. Caution is advised for the use of PDE5 inhibitors in patients with certain conditions: aortic stenosis, left ventricular outflow obstruction, hypotension, and hypovolemia. The agents have a minimal effect on QTc interval (Morganroth et al., 2004). Vardenafil among PDE5 inhibitors is not recommended in patients who take type 1A antiarrhythmics (e.g., quinidine or procainamide) or type 3 antiarrhythmics (e.g., sotalol or amiodarone) or in patients with congenital prolonged QT syndrome.

Box 69.1

Warnings and Drug Interactions

The package inserts of all four phosphodiesterase type 5 (PDE5) inhibitors warn against their use in patients with severe cardiovascular diseases and left ventricular outflow obstruction (e.g., aortic stenosis, idiopathic subaortic stenosis), those with severely impaired autonomic control of blood pressure, and patients not studied in clinical trials (US prescribing information of Viagra, Cialis, and Levitra and Stendra, September 2013). These include patients with the following:

- Myocardial infarction, stroke, or life-threatening arrhythmia within the previous 6 months
- New York Heart Association class II or greater heart failure or coronary artery disease causing unstable angina
- Resting hypotension (<90/50 mm Hg) or hypertension (>170/100 mm Hg)
- Known hereditary degenerative retinal disorders, including retinitis pigmentosa
- Severe hepatic impairment (Child-Pugh C) or end-stage renal disease requiring dialysis

Certain drugs such as ketoconazole and itraconazole and protease inhibitors such as ritonavir can impair the metabolic breakdown of PDE5 inhibitors by blocking the CYP3A4 pathway. Such agents may increase blood levels of inhibitors, requiring a PDE5 dose reduction. On the other hand, agents such as rifampin may induce CYP3A4, enhancing the breakdown of inhibitors and requiring higher PDE5 doses. Kidney or hepatic dysfunction may require dose adjustments or warnings.

Nitrate use in any form (e.g., sublingual nitroglycerin, isosorbide dinitrate, other nitrate preparations used to treat angina, amyl nitrite, and amyl nitrate “poppers”) represents an absolute contraindication. Past use of nitrates, that is, more than 2 weeks before the use of PDE5 inhibitors, is not considered a contraindication. **If angina occurs during sexual activity when using a PDE5 inhibitor, patients should cease this activity and seek emergency care immediately.** They should inform medical personnel that a PDE5 inhibitor was taken and should avoid nitroglycerin use for a period of 24 hours for sildenafil and vardenafil and 48 hours for tadalafil (Cheitlin et al., 1999). If acute myocardial infarction occurs with the use of PDE5 inhibitors, usual therapies, with the exception of organic nitrates, may be administered. If hypotension results from PDE5 inhibitor use, patients should be placed in the Trendelenburg position and given intravenous fluids along with administration of α-adrenergic agonists (e.g., phenylephrine) as needed. Refractory hypotension warrants intra-aortic balloon counterpulsation, as specified by the American College of Cardiology/American Heart Association guidelines. No pharmacologic antidote to the PDE5 inhibitor/nitrate interaction exists. Caution is advised when PDE5 inhibitors are coadministered with α-adrenergic blockers, because both agents are vasodilators with blood pressure–lowering effects.

Side effects observed with PDE5 inhibitor therapy include headache (7% to 16%), dyspepsia (4% to 10%), flushing (4% to 10%), myalgia/back pain (0 to 3%), nasal congestion (3% to 4%), and visual disturbances (e.g., photophobia, blue vision) (0 to 3%). Randomized controlled trials have documented that flushing and visual side effects are more common in patients receiving sildenafil or vardenafil, whereas back pain/myalgia is more common in patients receiving tadalafil. These events have been found to be mild and to abate with time, and the side effects prompt discontinuation only in few patients (Hellstrom, 2007; Porst et al., 2013).

The concern has been posed with PDE5 inhibitor therapy regarding the development of nonarteritic anterior optic neuropathy (NAION), which can cause blindness, although several systematic reviews of the safety of this class of compounds have not shown an increased risk of NAION or other adverse ocular events associated with their use (Laties, 2009; Porst et al., 2013). Affected patients in postmarketing reports possibly carried risk factors for blindness to include hypertension, diabetes, and hyperlipidemia. At this time, despite the absence of a proven link between PDE5 inhibitor use and serious ocular disorders, physicians should continue to advise patients to stop use of PDE5 inhibitors and to seek immediate medical attention as a safety measure in the event of a sudden loss of vision (Laties, 2009; Porst et al., 2013).

Several investigations have addressed the possible relationship between PDE5 inhibitor use and increased risk for skin cancers, particularly malignant melanoma (Lian Y et al., 2016; Loeb et al., 2015). However, study design flaws and confounders of increased medical surveillance among PDE5 inhibitor users limit any conclusive risk relationship. Similar considerations of a risk relationship for prostate cancer recurrence have also been refuted (Gallina et al., 2015; Loeb et al., 2016).

The interest in extending the use of PDE5 inhibitors beyond an on-demand erectogenic role and rather applying them to recovery or maintenance of the natural vitality of the penis in the face of an ED-associated disease state or condition has been investigated. This proposal

has been considered particularly in the clinical context of radical prostatectomy and has been introduced as a therapeutic strategy as "penile rehabilitation," in which the medications are taken in some regularly scheduled fashion to promote the recovery of spontaneous erectile function. Presently, this role remains unclear, because of limited well-designed and conducted (i.e., randomized controlled) clinical trials of PDE5 inhibitor use in this clinical setting (Mulhall et al., 2013). In one supportive trial involving sildenafil treatment of 36 weeks starting 4 weeks after the surgery, 27% of patients using the agent recovered erections defined as "good enough for sexual activity" compared with 4% of patients on placebo at about 1 year after surgery (Padma-Nathan et al., 2008). However, in another trial involving vardenafil treatment of 9 months either on-demand or daily starting 14 days after surgery, erection recovery was no different in patients using vardenafil by either form of administration or placebo at about 1 year after surgery (Montorsi et al., 2008). Another trial randomizing patients to the use of sildenafil nightly or on-demand for 12 months with a 1-month washout showed that erection recovery was not different between patient groups (Pavlovich et al., 2013). By contrast, another study showed that sildenafil administered daily for 6 months improved sexual function among men undergoing radiotherapy; results at 12 months showed that 73% of patients on sildenafil versus 50% of patients on placebo had mild or no ED (Zelefsky et al., 2014). Randomized controlled trials in other ED contexts have failed to show sustained natural erectile function improvement after discontinuing continuous regimens of PDE5 inhibitor therapy (Burnett et al., 2009; Zumbe et al., 2008).

The notion of combining PDE5 inhibitors with other ED therapies such as vasoactive penile pharmacotherapies has been proposed (Lau et al., 2006; McMahon et al., 2006). This strategy is to be considered "off-label," and clinical precautions are advised.

α-Adrenoceptor Antagonists.

Phentolamine mesylate is a nonspecific α-adrenergic receptor antagonist with equal affinity for blocking α_1- and α_2 -adrenoreceptors. Its mode of action presumably is to produce corporeal smooth muscle relaxation by blocking the (antierectile) postsynaptic α_1-adrenergic receptor (Juenemann et al., 1986). Clinical trials suggested an efficacy rate in men with minimal ED of approximately 40% (Goldstein, 2000). The drug was considered relatively safe; less than 10% of patients using the 40-mg dosage experienced headaches, facial flushing, or nasal congestion. However, further investigation is required before determining whether it will produce erectile responses of sufficient quality for reliable sexual intercourse, particularly in men with more severe ED.

Yohimbine hydrochloride (Yocon), an indolalkylamine alkaloid derived from the bark of the yohimbe tree, reportedly exerts central effects on the mediation of penile erection operating as an α_2-adrenoreceptor antagonist (Clark, 1991; Giuliano and Rampin, 2000). Originally proposed to be an erectogenic and aphrodisiac agent, the drug has been investigated as an authentic ED treatment. It is conventionally prescribed orally at a dosage of 5.4 mg three times daily with observation for improvement throughout at least a month. A meta-analysis of all randomized, placebo-controlled trials involving yohimbine suggested a superior effect for the medication compared to placebo (Ernst and Pittler, 1998). **However, the drug does not appear to enable successful sexual intercourse any better than placebo in men with confirmed organic ED** (Montague et al., 1996; Teloken et al., 1998). Adverse effects appear to be relatively infrequent but include hypertension, anxiety, tachycardia, and headache. Although yohimbine may be well tolerated, its modest results suggest that it may be best limited to men with psychogenic ED (Porst et al., 2013).

Dopaminergic Agonists.

Apomorphine (Uprima, TAP Pharmaceutical Products, Lake Forest, IL) is a dopaminergic agent activating D_1 and D_2 receptors at a central level within the paraventricular nucleus of the brain, indicating its particular relevance in the treatment of men with psychogenic ED (Lal et al., 1987). The medication is administered in sublingual form with a dosage range of 2, 4, and 6 mg, and it has no erectile efficacy if it is swallowed (Heaton, 2000). It has a rapid onset of action, with a mean time to erection of 12 minutes. Apomorphine achieves a maximal plasma concentration in 50 minutes, although its window of opportunity extends for approximately 2 hours from administration. In clinical trials involving men with ED of varying severities and causes, the drug achieved a successful sexual intercourse rate of 50.6% at the 4-mg dosage compared with the 33.8% placebo rate (Heaton, 2000). Side effects include nausea (16.9%), dizziness (8.3%), yawning (7.9%), somnolence (5.8%), sweating (5%), and emesis (3.7%). Syncope occurred in 0.6% of patients using the medication at the highest recommended dosage, and this was accompanied by a prodrome consisting of nausea, vomiting, sweating, dizziness, and lightheadedness but no cardiac sequelae. Side effects were minimized when patients were titrated from higher to lower dosages. The drug achieved regulatory approval for commercialization by European authorities in early 2001, but it has not been so approved in the United States.

Melanocortin-Receptor Agonists.

Melanocortin analogues (e.g., melanotan II, PT-141) have been studied showing efficacy in inducing erectile responses in early clinical trials (Diamond et al., 2004; Wessells et al., 2000). These drugs operate centrally at melanocortin-4 receptors, which have been implicated in controlling food intake and energy expenditure as well as modulating erectile function and sexual behavior. Flushing and nausea have been reported as side effects. The drugs have not achieved regulatory approval for the treatment of ED.

Serotonin-Receptor Effectors.

Trazodone (Desyrel) is an antidepressant that has been associated with priapism, prompting its “off-label” investigation as a possible treatment for ED (Lal et al., 1990). It is purported to work through mechanisms at the spinal-cord level with multiple serotonergic effects (Allard and Giuliano, 2001). The active metabolite of trazodone acts as an agonist of the proerectile 5-HT$_{2C}$ receptor through reuptake inhibition, with some affinity for the 5-HT$_{2A}$ receptor, although it may also operate as an antagonist of antierectile 5-HT$_{1A}$ receptors (Andersson and Wagner, 1995). Rigorous evaluations have not shown clinical efficacy that exceeds placebo responses in eliciting penile erection (Costabile and Spevak, 1999). Given its potential side effects (i.e., drowsiness, nausea, emesis, blood pressure changes, urinary retention, and priapism) and general lack of effect, this medication would appear to have a limited role for ED treatment.

Other Oral Therapies.

Additional possibilities for the oral treatment of ED, including l-arginine (the amino acid precursor of nitric oxide), L-dopa (dopamine precursor), limaprost (prostaglandin E$_1$), and naltrexone (opioid antagonist), have been proposed (Burnett, 1999). Each of these agents has a plausible mechanism of action to induce erections. However, they remain insufficiently studied, and their clinical roles remain unclear (Porst et al., 2013).

Intracavernosal Injection

The discovery in 1982 that vasoactive agents, delivered by injection into the penis, induced erections is credited with launching the movement toward medical therapies for the treatment of ED (Virag, 1982; Zorgniotti, 1985). **Since that time, there has been an explosion of basic scientific and clinical research leading to the development and use of various locally administered vasoactive medications having mechanisms of action that result in corporeal smooth muscle relaxation.** Although a host of medications have been explored for this purpose, three medications are used regularly in clinical practice: alprostadil, papaverine, and phentolamine (Table 69.8). **These have been administered clinically as a single agent (i.e., monotherapy) or in various combinations (e.g., bimix, trimix). Combination therapy offers a synergistic mechanism of the vasoactive agents to elicit maximal erectile responses, particularly among patients who have failed monotherapy** (Bennett et al., 1991; Floth and Schramek, 1991; Khera and Goldstein, 2011; Porst et al., 2013; Zorgniotti and Lefleur, 1985). This alternative may also be used to circumvent side effects of a certain agent (e.g., penile pain associated with alprostadil).

TABLE 69.8

Intracavernosal Pharmacotherapies

TRADE NAME	DRUG	DOSAGES	EFFICACY (INTERCOURSE)
Caverject	Alprostadil (Prostin VR)	5–40 µg/mL	≈70%
Viradal/Edex	Alprostadil (Prostin VR)	5–40 µg/mL	≈70%
Bimix	Alprostadil + phentolamine	20 µg/mL + 0.5 mg/mL	≈90%
Bimix Androskat (EU)	Papaverine + phentolamine	30 mg/mL + 0.5 mg/mL	≈90%
Trimix	Alprostadil + papaverine + phentolamine	10 µg/mL + 30 mg/mL + 1.0 mg/mL	≈90%
Invicorp	VIP + phentolamine	NA	≈80%

EU, European Union; *NA,* not available; *VIP,* vasoactive intestinal polypeptide.

A general rule of thumb is to start with a small dose of medication, especially in patients with nonvasculogenic forms of ED. In-office self-injection training and education are recommended before home injection, and this opportunity may also be used to titrate medication toward a dosage that safely yields an erection of sufficient rigidity for sexual intercourse yet lasts no more than an hour (Bénard and Lue, 1990; Fallon, 1995). Comparing empirical and risk-based approaches to intracavernosal injection therapy found no statistically significant differences in patient satisfaction, outcomes, or complications between the two groups (Bernie et al., 2017). **The therapy is contraindicated for men with psychological instability, a history or risk for priapism, histories of severe coagulopathy or unstable cardiovascular disease, reduced manual dexterity (although the partner can be trained in the injection technique), and use of monoamine oxidase inhibitors (because of the risk of precipitating a life-threatening hypertensive crisis in the event that an intracavernosal α-adrenergic agonist is used to reverse a priapic episode)** (Sharlip, 1998).

Alprostadil.

Alprostadil (Prostin VR) is a synthetic form of a naturally occurring fatty acid, prostaglandin E_1, which binds with specific receptors on smooth muscle cells and activates intracellular adenylate cyclase to produce cAMP, which in turn induces tissue relaxation through a second messenger system (Palmer et al., 1994). It currently is the only FDA-approved injectable medication for ED, and it is marketed for this purpose under the trade names Caverject (Pfizer, New York, NY) and Viradel/Edex (Schwarz Pharma, Milwaukee, WI) (Buvat et al., 1998; Linet and Ogrinc, 1996; Porst, 1996). After intracavernosal injection, the medication is locally metabolized by 96% within 60 minutes and does not appreciably enter the peripheral circulation (van Ahlen et al., 1994). **At dosages of 10 to 20 µg, alprostadil produces full erections in 70% to 80% of patients with ED** (Khera and Goldstein, 2011; Linet and Neff, 1994; Porst et al., 2013). The most common side effects of treatment are pain at the injection site or during erection (in 11% of patients), hematoma/ecchymosis (1.5%), prolonged erection/priapism (1% to 5%), and penile fibrotic lesions (2%) (Linet and Ogrinc, 1996). **Perceived advantages of alprostadil for intracavernosal pharmacotherapy relative to other agents are lower incidences of prolonged erection, systemic side effects, and penile fibrosis. Disadvantages include a higher incidence of painful erection and higher cost, and, after reconstitution into liquid from powder, alprostadil has a shortened half-life if not refrigerated.**

Papaverine.

Papaverine, an alkaloid isolated from the opium poppy, is a nonspecific PDE inhibitor that prevents the degradation of cAMP and cGMP so that these cyclic nucleotides accumulate in smooth muscle cells, thereby increasingly promoting tissue relaxation (Kukovetz et al., 1975). The compound also blocks voltage-dependent calcium channels along the membrane wall, thus impeding calcium influx to the cell, a process known to trigger smooth muscle contraction (Brading et al., 1983; Sunagane et al., 1985). Papaverine is metabolized in the liver, and the plasma half-life is 1 to 2 hours. Its general efficacy in promoting penile erection after intracavernosal administration is approximately 60% (Porst et al., 2013). The drug is inexpensive and stable at room temperature. However, disadvantages include commonly observed liver enzyme elevations, priapism risk (up to 35%), and penile fibrosis risk (1% to 33%), which have led to its abandonment as monotherapy (Fallon, 1995; Lakin et al., 1990; Moemen et al., 2004; Porst, 1996).

Phentolamine.

In addition to its purported oral role for ED therapy, phentolamine mesylate is more familiarly applied as an intracavernosal agent. Although its erectogenic effect is mediated by blocking the (antierectile) postsynaptic α_1-adrenergic receptor (Sironi et al., 2000), because of its potential inhibition of the prejunctional α_2-adrenergic receptor, which interferes with norepinephrine reuptake, the drug's tissue relaxant effect for penile erection is believed to be antagonized (Juenemann et al., 1986). This dual effect of the drug probably accounts for its limited success when administered intracavernosally as a sole agent (Blum et al., 1985). It has a short plasma half-life (30 minutes). Common side effects associated with the drug include systemic hypotension, reflex tachycardia, nasal congestion, and gastrointestinal upset.

Vasoactive Intestinal Polypeptide.

Vasoactive intestinal polypeptide (VIP), a hormone having 28 amino acids originally isolated from the small intestine, was proposed early on to be the elusive nonadrenergic noncholinergic (NANC) mediator of penile erection because of its potent vasodilatory effects in various tissues (Adaikan et al., 1986). Its mechanism of action in smooth muscle is achieved through specific protein receptor binding and activation of adenylate cyclase, thereby promoting synthesis of cAMP and subsequent tissue relaxation (Anderson and Wagner, 1995). The drug has had disappointing effects when administered alone, although when separately combined with other drugs such as papaverine and phentolamine, erection responses were elicited (Dinsmore and Wyllie, 2008; Kiely et al., 1989). VIP, in combination with phentolamine (Invicorp), is currently being sought for regulatory approval in the United States.

Intraurethral Suppositories

The administration of vasoactive drugs via the urethral channel of the penis was introduced with the hope of affording a less invasive procedure than intracavernosal needle injections to induce penile erection. **This technique relies on the absorption of the medication through the mucosal lining into the surrounding corpus spongiosum, with passage via small vascular channels into the main erectile bodies, the corpora cavernosa.** The transfer of drug from the urethra to the cavernous tissue varies across men according to anatomic variability. After an initial trial, which demonstrated that prostaglandin E_2 was effective in inducing full tumescence in 30% of patients and partial tumescence in 40% of patients (Wolfson et al., 1993), a synthetic formulation of prostaglandin E_1 was developed and the FDA approved it in November 1996 as MUSE (Medicated Urethral System for Erection; MEDA Pharmaceuticals, Somerset, NJ) (Hellstrom et al., 1996; Padma-Nathan et al., 1997). MUSE uses a suppository inserted into the urethral opening that dispenses a semisolid pellet (1 × 3 mm) of alprostadil (125-, 250-, 500-, and 1000-µg doses) into the distal urethra (3 cm from the external urethral meatus). Several technical procedures optimize the success of the treatment including properly depositing and manually distributing the medication into the penis and the patient's remaining in the upright position for several minutes after its application. In-office training and monitoring of initial response may afford advantages for optimizing technique and making dosage adjustments before performing the treatment at home.

A calculated final responder rate to MUSE is approximately 50%, and among responders approximately 70% of administrations result in sexual intercourse (Guay et al., 2000; Hellstrom et al, 1996; Khera and Goldstein 2011; Padma-Nathan et al, 1997; Porst et al., 2013). The combined use of an adjustable penile constriction band (ACTIS) was designed and was approved by the FDA to enhance the local retention and effect of the medication (Lewis, 2000). A transurethral bimix consisting of alprostadil and α_1-adrenergic antagonist prazosin (ALIBRA) was introduced and in a multicenter trial of nearly 400 patients was shown to increase the at-home responder rate for successful sexual intercourse from 47% with alprostadil alone to 70% with ALIBRA (Qureshi, 2001).

Intraurethral therapy is perceived to have a niche role, associated with its inferior efficacy with regard to PDE5 inhibitors and intracavernosal self-injection therapy (Khera and Goldstein, 2011; Porst et al., 2013). The main indications for this therapy are patients who are nonresponsive to PDE5 inhibitors resulting from damage of the autonomic penile nerve supply (e.g., radical prostatectomy, cystectomy, and trauma) or those who wish to use the therapy in combination with PDE5 inhibitors. Another rare indication for intraurethral therapy is patients complaining about a soft (cold) glans syndrome, which may occur after penile prosthesis implantation or as a clinical entity (Porst et al., 2013).

The most common side effects of MUSE include local urogenital pain (approximately one-third of patients) and minor urethral bleeding (5%) (Guay et al., 2000; Padma-Nathan et al., 1997). Other complications such as hypotension (3%), dizziness (4%), and priapism (0.1%) have been observed as well. MUSE is contraindicated in patients with known hypersensitivity to alprostadil, abnormal penile anatomy, and conditions that increase the risk of priapism. MUSE seems safe for female partners, producing only a 5.8% incidence of vaginal burning or itching, although it should not be used without a condom for intercourse with a pregnant woman.

Transdermal/Topical Pharmacotherapy

The notion to apply vasoactive drugs directly to the surface of the penis is consistent with the general appeal of many transdermal therapies (e.g., gels and creams) in medicine based on their delivery route: convenience, simplicity, and putatively limited systemic adverse effects. Several topical therapies have been explored for ED treatments, although certain obstacles have limited their widespread use. Nitroglycerin, a nitric oxide donor formulated as a 2% paste, was found to produce tumescence but rarely penile rigidity sufficient for sexual intercourse (Owen et al., 1989). This relative inefficacy combined with its headache side effects for patient and partner after absorption and action of the drug as a potent systemic vasodilator have precluded its use in clinical practice. Papaverine, formulated as a gel, was investigated but then abandoned as a topical ED treatment when it was found that its large molecular size (molecular weight 376 Da) interfered with its transdermal absorption (Kim et al., 1995).

Alprostadil has been a more promising prospect, subjected to commercial development for penile glans administration in combination with transdermal delivery enhancers: alprostadil 0.3% in combination with a proprietary permeation enhancer, referred to as Vitaros (Apricus Biosciences, San Diego, CA), and alprostadil combined with NexACT, referred to as Alprox-TD (NexMed, Inc., Robbinsville, NJ). Applied intrameatally, such agents in clinical trials have shown efficacy with rates of vaginal penetration and intercourse success that were small but significantly greater than placebo rates and caused minor side effects of site-specific burning or warmth that were comparable to placebo rates (Goldstein et al., 2001; McMahon, 2002; McVary et al., 1999; Padma-Nathan and Yeager, 2006; Porst et al., 2013; Rooney et al., 2009). Prostaglandin E_1 ethyl ester, which is a prodrug of prostaglandin E_1, is believed to possess an improved transdermal permeation and less skin irritation than enhancing agents because of its esterification (Schanz et al., 2009). Applied to the shaft of the penis in early clinical trials, this drug achieved significantly higher rigidity scores than placebo. In general, transdermal therapy with alprostadil is likely to meet similar clinical roles as that assigned to transurethral pharmacotherapy. Further clinical trials will be useful to define and establish their place in the treatment of ED.

Medical Device

In patients who do not respond to or who decline oral or local vasoactive pharmacotherapeutic options, vacuum erection device therapy may be alternatively explored. **The principle of vacuum erection device therapy is to mechanically create negative pressure surrounding the penis to engorge it with blood and then restrain blood egress from the organ to maintain the erection-like effect** (Broderick et al., 1992; Nadig et al., 1986). Although the treatment does not produce a truly physiologic erection and the engorged blood predominantly consists of venous blood (Bosshardt et al., 1995), the effect resembles a normal erection and is sufficient for coitus. A particular feature is that the glans penis, and not solely the corpora cavernosa, is engorged with blood by the treatment, such that the treatment is further advantageous for patients experiencing glanular insufficiency (soft glans syndrome).

The standard vacuum erection device consists of a usually clear plastic suction cylinder and vacuum-generating source (manual or battery-operated pump) in one piece. It is placed directly over the flaccid penis and operated, and after the penis is erected an elastic constriction ring or band

is positioned at the base of the penis; then the vacuum is released and the device is removed (McMahon, 1997; Montague et al., 1996)**. The cylinder has a pressure-release valve designed to prevent penile injury from excessive negative pressure. Sexual intercourse may then ensue, although it is recommended that the ring should not be left in place for longer than 30 minutes. Prescription devices are advised, and metal or other inelastic rings are contraindicated.**

Efficacy rates as high as 90% have been reported for achieving satisfactory erections for ED associated with various severities and causes, but satisfaction rates with the device are lower, ranging commonly from 30% to 70% (Hellstrom et al., 2010; Porst et al., 2013). Attrition is reported to occur and may relate to lack of efficacy with more severe forms of ED, although long-term continuation rates have ranged up to 60% (Porst et al., 2013). Success is limited in patients with severe vascular abnormalities such as proximal venous leakage or arterial insufficiency or fibrosis secondary to priapism or prosthesis infection (Marmar et al., 1988). Patient preferences also dictate long-term success. The device is more acceptable to older men in a steady relationship compared with young, single men. Among basic expectations of the treatment, patients should be informed of possible local discomfort or pain associated with the constriction band, a pivoting effect of the penis because turgidity exists only distal to the band's location, a cyanotic discoloration and coolness of the penis resulting from extracorporeal congestion, and trapping of the ejaculation caused by urethral constriction (Cookson and Nadig, 1993; Sidi et al., 1990; Witherington, 1989). Common complications are minor and include penile pain and numbness, difficult ejaculation, ecchymosis, and petechiae, and major complications (e.g., penile skin necrosis, urethral varicosities, Fournier gangrene) are infrequent. Patients receiving anticoagulant therapy (e.g., aspirin, warfarin) and patients with bleeding disorders should use the device with caution (Limoge et al., 1996). Special uses for this therapy have been sought. It has been successfully combined with oral, intracavernosal, and intraurethral pharmacotherapies to produce erectile responses (Canguven et al., 2009; Chen et al., 1995, 2004; John et al., 1996; Marmar et al., 1988). The device has enhanced erectile effects in the presence of a malfunctioning penile prosthesis (Korenman and Viosca, 1992; Sidi et al., 1990). Further, it may offer a means to preserve the elasticity of penile tissues after priapism or penile prosthesis explantation (Moul and McLeod, 1989; Soderdahl et al., 1997) or after surgical correction of Peyronie disease (Yurkanin et al., 2001), and it has been suggested to facilitate erection recovery after treatments for prostate cancer (Köhler et al., 2007; Raina et al., 2006).

Surgery

Surgical interventions have always served an important role in the armamentarium of ED treatments. **They are often applied in the face of penile injury resulting from genital or pelvic trauma, penile structural deformity occurring in association with Peyronie disease, or possibly cavernosal fibrosis secondary to prolonged ischemic priapism or infection. They are also considered when medical therapy for ED is contraindicated, unsuccessful, or undesirable.**

Penile Prosthesis Surgery

Penile prosthesis or implant surgery is a mechanism for creating penile rigidity that differs from a physiologic or pharmacologically induced erection. Malleable (semirigid) and inflatable (hydraulic) devices are both currently available for this purpose. Details of this treatment option are presented in Chapter 72.

Penile Revascularization Surgery

Based on the requirements of inflow of blood and its retention in the penis for penile erection to occur, vascular surgeries have aggressively been pursued to facilitate or restore these biologic processes.

Arterial Revascularization.

In concept, arterial revascularization surgery was designed to create arterial inflow to the corpora cavernosa, in turn addressing the presentation of arteriogenic ED. Several procedures have been described to meet this objective, similarly creating an anastomosis of the inferior epigastric artery either to the corpus cavernosum directly or to vascular conduits of the penis such as the dorsal artery (i.e., revascularization), the deep dorsal vein (i.e., arterialization), or the deep dorsal vein with venous ligation (i.e., arterialization with venous reconstruction) (Hellstrom et al., 2010). Success of these surgeries has been variable and depends on careful patient selection. Penile arteriography is required to establish a penile arterial anatomic defect, and other organic causes of ED (e.g., venous incompetence) that would limit surgical success should be excluded. **According to the current literature, the following inclusion criteria**

should be met when selecting patients for arterial surgery: age less than 55 years, nonsmoker, nondiabetic, absence of venous leakage, and radiographic confirmation of stenosis of the internal pudendal artery (Hellstrom et al., 2010; Sohn et al., 2013). **The highest success rates are reported in young men (less than 30 years of age) with isolated arterial stenosis after perineal or pelvic trauma** (Babaei et al., 2009). Complications of arterial revascularization surgery include glans hyperemia (13%), shunt thrombosis (8%), and inguinal hernias (6.5%) (Kawanishi et al., 2004; Manning et al., 1998).

Venous Reconstruction.

Venous reconstruction was proposed to prevent the pathologic blood egress from the penis, understandably to correct veno-occlusive ED. Most surgical procedures have centered on ligating or embolizing penile veins (e.g., superficial dorsal vein, deep dorsal vein, crural vein) or surgically compressing the penile crura (e.g., crural plication/ligation, pericavernoplasty) (Hellstrom et al., 2010). **Success with these surgeries has not been affirmed, primarily because of inaccurate or deficient methods for diagnosing and correcting the relevant anatomic defect. The optimal surgical approach remains to be defined, and thus venous reconstructive surgery is presently considered investigational** (Hellstrom et al., 2010; Montague et al., 2005; Sohn et al., 2013). Reported complications of this surgery include glanular hypoanesthesia, skin necrosis, wound infections, penile curvature/shortening, and glans hyperemia.

Combination Therapies

Many patients with ED do not respond acceptably to monotherapy, with nonresponder rates documented in as many as 40% of patients (Porst et al., 2013). Some patients may achieve optimal therapeutic responses by combining treatment options. In addition, it is possible that a dose-limiting adverse effect is associated with ED monotherapy such that combined treatments may then seem advantageous. Multiple combinations may certainly be proposed for ED treatment. The extant literature describes several successful combinations: tadalafil 5 mg daily with 50 mg sildenafil on demand (Cui et al., 2015), oral PDE5 inhibitors with psychosocial counseling (Althof et al., 2005), oral PDE5 inhibitors with testosterone replacement therapy (Greco et al., 2006; Shabsigh et al., 2004; Spitzer et al., 2012, 2013), oral PDE5 inhibitors with transurethral alprostadil (Mydlo et al., 2000; Nehra et al., 2002), oral PDE5 inhibitors and intracavernosal pharmacotherapy (McMahon et al., 1999), oral PDE5 inhibitors and vacuum erection device (Canguven et al., 2009; Chen et al., 2004), intracavernosal pharmacotherapy and vacuum erection device (Chen et al., 1995), transurethral pharmacotherapy and vacuum erection device (John et al., 1996), and transurethral pharmacotherapy and penile prosthesis surgery (Benevides and Carson, 2000). **Caution is advised when initiating combination therapy to observe for potential complications that may be compounded by combined treatments, and in-office evaluations before continuing treatments at home may be considered to offer an additional measure of safety**.

Alternative Therapies

Alternative therapies have long been considered for the treatment of ED, from herbs, ointments, nutraceuticals, and dietary supplements in commercial supply today. The movement toward alternative medicines in this field actually gained momentum during the past decade with the emergence of effective oral therapy in the form of PDE5 inhibitors, which created avenues for producing PDE5 inhibitor-like counterfeit and imitation substances and promoting regulatory agency unapproved products in general. Indeed, the true efficacies of proposed alternative therapies (e.g., ginkgo biloba, L-arginine, Korean red ginseng) remain uncertain in the absence of evidenced benefit in rigorously performed, randomized controlled clinical trials (Khera and Goldstein, 2011; Moyad et al., 2004). The success of these products is ascribed in some measure to the known placebo effect of agents to treat ED, which has been observed to amount to as much as 25% to 50% in properly conducted clinical trials.

Recently, low-intensity extracorporeal shock wave therapy (Li-ESWT), stem cell therapies, and platelet-rich plasma have been proposed as an effective, noninvasive treatment option for ED among men who respond poorly to PDE5 inhibitors. Investigations into the mechanism of action using diabetic animal models treated with Li-ESWT found that erectile function improved by promoting regeneration of nerves, endothelium, and smooth muscle of the penis (Qiu et al., 2013). Studies among men with ED who do not respond to PDE5 inhibitors and after prostatectomy found improved hydrodynamics, endothelial function, and IIEF scores (Frey et al., 2016; Gruenwald et al., 2012, 2013). A meta-analysis of seven randomized clinical trials involving 602 patients with mild to moderate ED showed significant improvement in pooled IIEF-EF scores among men undergoing Li-ESWT compared with placebo (6.40 vs 1.65 points, *P* = 0.047) (Clavijo et al., 2017). The Sexual Medicine Society of North America (SMSNA) released a position statement on restorative and regenerative therapies for erectile dysfunction. Given the current lack of regulatory agency approval for any restorative (regenerative) therapies for the treatment of ED and until such time as approval is granted, SMSNA believes that the use of shock waves, stem cells, or platelet-rich plasma is experimental and requires research protocols in compliance with Institutional Review Board approval. **Before the use of alternative therapies can be advocated, further research that demonstrates their mechanisms of action and meaningful efficacy/safety must be performed.**

Key Points: Treatment Considerations

- Although definitive evidence is necessary, risk modification for preserving erectile health includes recommendation to maintain a healthy and fit lifestyle.
- Psychosexual therapy offers a role in the integrative management of ED.
- Various modalities of drug administration including oral, intracavernosal, intraurethral, and transdermal routes are successfully applied or are under study.
- Vacuum erection device therapy offers an alternative to oral or local vasoactive pharmacotherapeutic options for ED.
- Surgical intervention (penile prosthesis surgery) are an important treatment when nonsurgical therapy is contraindicated, unsuccessful, or undesirable.
- Arterial revascularization surgery is offered only to select patients with ED who meet stringent clinical and radiographic criteria for surgical success.

Future Directions

Consistent with the ongoing progress in the field of sexual medicine more broadly, advancements in ED management will likely continue. Much has been learned in the physiology and molecular science of penile erection in recent decades, indicative of the amazing scientific discovery occurring in this arena. Science and technology represent the cornerstones for new developments in diagnosis and treatment. In the therapeutic arena, we can expect to see the next generation of pharmacotherapeutics as well as gene, stem cell, and regenerative therapies. Surgical procedures will continue to evolve, including penile reconstructive to prosthetic to tissue replacement surgeries (e.g., penile transplantation). The treatment paradigm will expectedly evolve from treatment based on symptomatic presentation and severity extent of ED to cause-specific ED treatments associated with disease states and genetic factors related to precision medicine. Ongoing progress will likely define the ultimate level of ED management: interventions that restore and maximize natural erectile function.

Acknowledgment

The authors would like to thank Aubrey B. Greer for assisting with updating and editing this chapter.

References

Adaikan PG, Kottegoda SR, Ratnam SS. Is vasoactive intestinal polypeptide the principal transmitter involved in human penile erection? *J Urol*. 1986;135:638–640.

Aitchison M, Aitchison J, Carter R. Is the penile brachial index a reproducible and useful measurement? *Br J Urol*. 1990;66:202–204.

Albaugh J, Amargo I, Capelson R, et al. Health care clinicians in sexual health medicine: focus on erectile dysfunction. *Urol Nurs*. 2002;22:217–231.

Allard J, Giuliano F. Central nervous system agents in the treatment of erectile dysfunction: how do they work? *Curr Urol Rep*. 2001;2:488–494.

Allen RP, Smolev JK, Engel RM, et al. Comparison of RigiScan and formal nocturnal penile tumescence testing in the evaluation of erectile rigidity. *J Urol*. 1993;149:1265–1268.

Al-Shaiji TF, Brock GB. Phosphodiesterase type 5 inhibitors for the management of erectile dysfunction: preference and adherence to treatment. *Curr Pharm Des*. 2009;15:3486–3495.

Althof SE, Corty EW, Levine SB, et al. EDITS: development of questionnaires for evaluating satisfaction with treatments for erectile dysfunction. *Urology*. 1999;53:793–799.

Althof SE, Leiblum SR, Chevret-Measson M, et al. Psychological and interpersonal dimensions of sexual function and dysfunction. *J Sex Med*. 2005;2:793–800.

Althof SE, Needle RB. Psychological factors associated with male sexual dysfunction: screening and treatment for the urologist. *Urol Clin North Am*. 2011;38:141–146.

Althof SE, Rosen RC, Perelman MA, et al. Standard operating procedures for taking a sexual history. *J Sex Med*.

2013;10:26–35.

Andersen ML, Guindalini C, Tufik S. Genetics of erectile dysfunction: a review of the interface between sex and molecular biomarkers. *J Sex Med*. 2011;8:3030–3039.

Andersson KE, Wagner G. Physiology of penile erection. *Physiol Rev*. 1995;75:191–236.

Araujo AB, Travison TG, Ganz P, et al. Erectile dysfunction and mortality. *J Sex Med*. 2009;6:2445–2454.

Aytac IA, McKinlay JB, Krane RJ. The likely worldwide increase in erectile dysfunction between 1995 and 2025 and some possible policy consequences. *BJU Int*. 1999;84:50–56.

Babaei AR, Safarinejad MR, Kolahi AA. Penile revascularization for erectile dysfunction: a systematic review and meta-analysis of effectiveness and complications. *Urol J*. 2009;6:1–7.

Baçar MM, Batislam E, Altinok D, et al. Sildenafil citrate for penile hemodynamic determination: an alternative to intracavernosal agents in Doppler ultrasound evaluation of erectile dysfunction. *Urology*. 2001;57:623–626.

Bacon CG, Mittleman MA, Kawachi I, et al. A prospective study of risk factors for erectile dysfunction. *J Urol*. 2006;176:217–221.

Bagatell CJ, Bremner WJ. Androgens in men—uses and abuses. *N Engl J Med*. 1996;334:707–714.

Bähren W, Gall H, Scherb W, et al. Arterial anatomy and arteriographic diagnosis of arteriogenic impotence. *Cardiovasc Intervent Radiol*. 1988;11:195–210.

Bancroft J, Smith G, Munoz M, et al. Erectile response to visual erotic stimuli before and after intracavernosal papaverine, and its relationship to nocturnal penile tumescence and psychometric assessment. *Br J Urol*. 1991;68:629–638.

Barada JH. Optimizing outcomes of oral therapy for patients with erectile dysfunction. *Rev Urol*. 2003;5:S28–S34.

Basaria S, Dobs AS. Hypogonadism and androgen replacement therapy in elderly men. *Am J Med*. 2001;110:563–572.

Baulieu EE, Thomas G, Legrain S, et al. Dehydroepiandrosterone (DHEA), DHEA sulfate, and aging: contribution of the DHEAge Study to a sociobiomedical issue. *Proc Natl Acad Sci USA*. 2000;97:4279–4284.

Bemelmans BL, Hendrikx LB, Koldewijn EL, et al. Comparison of biothesiometry and neuro-urophysiological investigations for the clinical evaluation of patients with erectile dysfunction. *J Urol*. 1995;153:1483–1486.

Bénard F, Lue TF. Self-administration in the pharmacological treatment of impotence. *Drugs*. 1990;39:394–398.

Benevides MD, Carson CC. Intraurethral application of alprostadil in patients with failed inflatable penile prosthesis. *J Urol*. 2000;163:785–787.

Bennett AH, Carpenter AJ, Barada JH. An improved vasoactive drug combination for a pharmacological erection program. *J Urol*. 1991;146:1564–1565.

Benson CB, Aruny JE, Vickers MA. Correlation of duplex sonography with arteriography in patients with erectile dysfunction. *AJR Am J Roentgenol*. 1993;160:71–73.

Benson CB, Vickers MA. Sexual impotence caused by vascular disease: diagnosis with duplex sonography. *AJR Am J Roentgenol*. 1989;153:1149–1153.

Bernie HL, Segal R, Le B, et al. An empirical vs risk-based approach algorithm to intracavernosal injection therapy: a prospective study. *Sex Med*. 2017;5(1):e31–e36.

Bhasin S, Cunningham GR, Hayes FJ, et al. Testosterone therapy in men with androgen deficiency syndromes: an Endocrine Society clinical practice guideline. *J Clin Endocrinol Metab*. 2010;95:2536–2559.

Billups KL. Erectile dysfunction as a marker for vascular disease. *Curr Urol Rep*. 2005;6:439–444.

Blander DS, Sánchez-Ortiz RF, Broderick GA. Sex inventories: can questionnaires replace erectile dysfunction testing? *Urology*. 1999;54:719–723.

Bleustein CB, Eckholdt H, Arezzo JC, et al. Quantitative somatosensory testing of the penis: optimizing the clinical neurological examination. *J Urol*. 2003;169:2266–2269.

Blum MD, Bahnson RR, Porter TN, et al. Effect of local alpha-adrenergic blockade on human penile erection. *J Urol*. 1985;134:479–481.

Bosshardt RJ, Farwerk R, Sikora R, et al. Objective measurement of the effectiveness, therapeutic success and dynamic mechanisms of the vacuum device. *Br J Urol*. 1995;75:786–791.

Bozorgmehri S, Fink HA, Parimi N, et al. Association of sleep disordered breathing with erectile dysfunction in community dwelling older men. *J Urol*. 2017;197(3 Pt 1):776–782.

Brading AF, Burdyga TV, Scripnyuk ZD. The effects of papaverine on the electrical and mechanical activity of the guinea-pig ureter. *J Physiol*. 1983;334:79–89.

Bradley WE, Timm GW, Gallagher JM, et al. New method for continuous measurement of nocturnal penile tumescence and rigidity. *Urology*. 1985;26:4–9.

Braun M, Wassmer G, Klotz T, et al. Epidemiology of erectile dysfunction: results of the ‘Cologne Male Survey. *Int J Impot Res*. 2000;12:305–311.

Breza J, Aboseif SR, Orvis BR, et al. Detailed anatomy of penile neurovascular structures: surgical significance. *J Urol*. 1989;141:437–443.

Broderick GA, Arger P. Duplex Doppler ultrasonography: noninvasive assessment of penile anatomy and function. *Semin Roentgenol*. 1993;28:43–56.

Broderick GA, McGahan JP, Stone AR, et al. The hemodynamics of vacuum constriction erections: assessment by color Doppler ultrasound. *J Urol*. 1992;147:57–61.

Brody S, Weiss P. Erectile dysfunction and premature ejaculation: interrelationships and psychosexual factors. *J Sex Med*. 2015;12(2):398–404.

Bruzziches R, Francomano D, Gareri P, et al. An update on pharmacological treatment of erectile dysfunction with phosphodiesterase type 5 inhibitors. *Expert Opin Pharmacother*. 2013;14:1333–1344.

Burnett AL. Oral pharmacotherapy for erectile dysfunction: current perspectives. *Urology*. 1999;54:392–400.

Burnett AL. Phosphodiesterase 5 mechanisms and therapeutic applications. *Am J Cardiol*. 2005;96:29M–31M.

Burnett AL, Allen RP, Davis DM, et al. Near infrared spectrophotometry for the diagnosis of vasculogenic erectile dysfunction. *Int J Impot Res*. 2000;12:247–254.

Burnett AL, Nehra A, Breau RH, et al. Erectile dysfunction: AUA guideline. *J Urol*. 2018.

Burnett AL, Strong T, Trock BJ, et al. Serum biomarker measurements of endothelial function and oxidative stress after daily dosing of sildenafil in type 2 diabetic men with erectile dysfunction. *J Urol*. 2009;181:245–251.

Burris AS, Banks SM, Sherins RJ. Quantitative assessment of nocturnal penile tumescence and rigidity in normal men using a home monitor. *J Androl*. 1989;10:492–497.

Buvat J, Costa P, Morlier D, et al. Double-blind multicenter study comparing alprostadil alpha-cyclodextrin with moxisylyte chlorhydrate in patients with chronic erectile dysfunction. *Urology*. 1998;159:116–119.

Buvat J, Lemaire A. Endocrine screening in 1,022 men with erectile dysfunction: clinical significance and cost-effective strategy. *J Urol*. 1997;158:1764–1767.

Buvat J, Maggi M, Gooren L, et al. Endocrine aspects of male sexual dysfunctions. *J Sex Med*. 2010;7(4 Pt 2):1627–1656.

Cabete J, Torres T, Vilarinho T, et al. Erectile dysfunction in psoriasis patients. *Eur J Dermatol*. 2014;24(4):482–486.

Canguven O, Bailen J, Fredriksson W, et al. Combination of vacuum erection device and PDE5 inhibitors as salvage therapy in PDE5 inhibitor nonresponders with erectile dysfunction. *J Sex Med*. 2009;6:2561–2567.

Capogrosso P, Colicchia M, Ventimiglia E, et al. One patient out of four with newly diagnosed erectile dysfunction is a young man–worrisome picture from the everyday clinical practice. *J Sex Med*. 2013;10(7):1833–1841.

Capogrosso P, Ventimiglia E, Boeri L, et al. Sexual functioning mirrors overall men's health status, even irrespective of cardiovascular risk factors. *Andrology*. 2017;5:63–69.

Carani C, Bancroft J, Granata A, et al. Testosterone and erectile function, nocturnal penile tumescence and rigidity, and erectile response to visual erotic stimuli in hypogonadal and eugonadal men. *Psychoneuroendocrinology*. 1992;17:647–654.

Carani C, Isidori AM, Granata A, et al. Multicenter study on the prevalence of sexual symptoms in male hypo- and hyperthyroid patients. *J Clin Endocrinol Metab*. 2005;90:6472–6479.

Caretta N, Palego P, Schipilliti M, et al. Cavernous artery intima-media thickness: a new parameter in the diagnosis of vascular erectile dysfunction. *J Sex Med*. 2009;6:1117–1126.

Carson CC, Lue TF. Phosphodiesterase type 5 inhibitors for erectile dysfunction. *BJU Int*. 2005;96:257–280.

Cheitlin MD, Hutter AM, Brindis RG, et al. ACC/AHA expert consensus document. Use of sildenafil (Viagra) in patients with cardiovascular disease. *J Am Coll Cardiol*. 1999;33:273–282.

Chen J, Godschalk MF, Katz PG, et al. Combining intracavernous injection and external vacuum as treatment for erectile dysfunction. *J Urol*. 1995;153:1476–1477.

Chen J, Sofer M, Kaver I, et al. Concomitant use of sildenafil and a vacuum entrapment device for the treatment of erectile dysfunction. *J Urol*. 2004;171:292–295.

Cheng JD, Hitt J, Koczwara B, et al. Impact of quality of life on patient expectations regarding phase I clinical trials. *J Clin Oncol*. 2000;18:421–428.

Chew KK, Finn J, Stuckey B, et al. Erectile dysfunction as a predictor for subsequent atherosclerotic cardiovascular events: findings from a linked-data study. *J Sex Med*. 2010;7:192–202.

Chun J, Carson CC. Physician-patient dialogue and clinical evaluation of erectile dysfunction. *Urol Clin North Am*. 2001;28:249–258.

Chung SD, Chen YK, Liu SP, et al. Association between ED in ankylosing spondylitis: a population-based study. *Int J Impot Res*. 2013;25(6):229–233.

Chung SD, Hu CC, Ho JD, et al. Open-angle glaucoma and the risk of erectile dysfunction: a population-based case-control study. *Ophthalmology*. 2012;119:289–293.

Chung SD, Hung SH, Lin HC, et al. Obstructive sleep apnea and urological comorbidities in males: a population-based study. *Sleep Breath*. 2016;20(4):1203–1208.

Chung SD, Keller JJ, Chu TW, et al. Psoriasis and the risk of erectile dysfunction: a population-based case-control study. *J Sex Med*. 2012;9:130–135.

Chung SD, Keller JJ, Liang YC, et al. Association between viral hepatitis and erectile dysfunction: a population-based case-control analysis. *J Sex Med*. 2012;9:1295–1302.

Chung SD, Keller JJ, Lin HC. Association between urinary calculi and erectile dysfunction: a case-control study. *J Sex Med*. 2011;8:2876–2882.

Chung SD, Keller JJ, Lin HC. Association of erectile dysfunction with atopic dermatitis: a population-based case-control study. *J Sex Med*. 2012;9:679–685.

Chung SD, Keller J, Lin HC. A nationwide population-based study on bladder pain syndrome/interstitial cystitis and ED. *Int J Impot Res*. 2013;25(6):224–228.

Chung WS, Choi HK. Erotic erection versus nocturnal erection. *J Urol*. 1990;143:294–297.

Citron JT, Ettinger B, Rubinoff H, et al. Prevalence of hypothalamic-pituitary imaging abnormalities in impotent men with secondary hypogonadism. *J Urol*. 1996;155:529–533.

Claes H, Opsomer RJ, Andrianne R, et al. Characteristics and expectations of patients with erectile dysfunction: results of the SCORED study. *Int J Impot Res*. 2008;20:418–424.

Clark JT. Suppression of copulatory behavior in male rats following central administration of clonidine. *Neuropharmacology*. 1991;30:373–382.

Clavijo RI, Kohn TP, Kohn JR, et al. Effects of low-intensity extracorporeal shockwave therapy on erectile dysfunction: a systematic review and meta-analysis. *J Sex Med*. 2017;14(1):27–35.

Clayton AH, McGarvey EL, Clavet GJ. The Changes in Sexual Functioning Questionnaire (CSFQ): development, reliability, and validity. *Psychopharmacol Bull*. 1997;33:731–745.

Cookson MS, Nadig PW. Long-term results with vacuum constriction device. *J Urol*. 1993;149:290–294.

Corbin JD, Francis SH. Cyclic GMP phosphodiesterase-5: target of sildenafil. *J Biol Chem*. 1999;274:13729–13732.

Corona G, Rastrelli G, Forti G, et al. Update in testosterone therapy for men. *J Sex Med*. 2011;8:639–654.

Corona G, Maseroli E, Rastrelli G, et al. Cardiovascular risk associated with testosterone-boosting medications: a systematic review and meta-analysis. *Expert Opin Drug Saf*.

2014;13(10):1327–1351.

Corona G, Rastrelli G, Limoncin E, et al. Interplay between premature ejaculation and erectile dysfunction: a systematic review and meta-analysis. *J Sex Med*. 2015;12(12):2291–2300.

Costabile RA, Spevak M. Oral trazodone is not effective therapy for erectile dysfunction: a double-blind, placebo controlled trial. *J Urol*. 1999;161:1819–1822.

Cui H, Liu B, Song Z, et al. Efficacy and safety of long-term tadalafil 5 mg once daily combined with sildenafil 50 mg as needed at the early stage of treatment for patients with erectile dysfunction. *Andrologia*. 2015;47(1):20–24.

Daffertshofer M, Linden D, Syren M, et al. Assessment of local sympathetic function in patients with erectile dysfunction. *Int J Impot Res*. 1994;6:213–225.

Daig I, Heinemann LA, Kim S, et al. The Aging Males' Symptoms (AMS) scale: review of its methodological characteristics. *Health Qual Life Outcomes*. 2003;15:77.

Dayan L, Greunwald I, Vardi Y, et al. A new clinical method for the assessment of penile endothelial function using the flow mediated dilation with plethysmography technique. *J Urol*. 2005;173:1268–1272.

Dean J, Rubio-Aurioles E, McCabe M, et al. Integrating partners into erectile dysfunction treatment: improving the sexual experience for the couple. *Int J Clin Pract*. 2008;62:127–133.

DeBusk R, Drory Y, Goldstein I, et al. Management of sexual dysfunction in patients with cardiovascular disease: recommendations of the Princeton Consensus Panel. *Am J Cardiol*. 2000;86:62F–68F.

Derby CA, Mohr BA, Goldstein I, et al. Modifiable risk factors and erectile dysfunction: can lifestyle changes modify risk? *Urology*. 2000;56:302–306.

Derogatis LR, Burnett AL. The epidemiology of sexual dysfunctions. *J Sex Med*. 2008;5:289–300.

Derogatis LR, Melisaratos N. The DSFI: a multidimensional measure of sexual functioning. *J Sex Marital Ther*. 1979;5:244–281.

Diamond LE, Earle DC, Rosen RC, et al. Double-blind, placebo-controlled evaluation of the safety, pharmacokinetic properties and pharmacodynamic effects of intranasal PT-141, a melanocortin receptor agonist, in healthy males and patients with mild-to-moderate erectile dysfunction. *Int J Impot Res*. 2004;16:51–59.

Dinsmore WW, Wyllie MG. Vasoactive intestinal polypeptide/phentolamine for intracavernosal injection in erectile dysfunction. *BJU Int*. 2008;102:933–937.

Donatucci CF, Lue TF. The combined intracavernous injection and stimulation test: diagnostic accuracy. *J Urol*. 1992;148:61–62.

Dong JY, Zhang YH, Qin LQ. Erectile dysfunction and risk of cardiovascular disease: meta-analysis of prospective cohort studies. *J Am Coll Cardiol*. 2011;58:1378–1385.

Doyle DL, Yu J. Comparison of Doppler and strain-gauge plethysmography to detect vasculogenic impotence. *Can J Surg*. 1986;29:338–339.

Edelstein D, Dobs A, Basaria S. Emerging drugs for hypogonadism. *Expert Opin Emerg Drugs*. 2006;11:685–707.

Elhanbly S, Elkholy A. Nocturnal penile erections: the role of RigiScan in the diagnosis of vascular erectile dysfunction. *J Sex Med*. 2012;9(12):3219–3226.

Elwyn G, Frosch D, Thomson R, et al. Shared decision making: a model for clinical practice. *J Gen Intern Med*. 2012;27(10):1361–1367.

Ernst E, Pittler MH. Yohimbine for erectile dysfunction: a systematic review and meta-analysis of randomized clinical

trials. *J Urol*. 1998;159:433–436.
Esposito K, Ciotola M, Giugliano F, et al. Mediterranean diet improves erectile function in subjects with the metabolic syndrome. *Int J Impot Res*. 2006;18:405–410.
Esposito K, Giugliano F, Di Palo C, et al. Effect of lifestyle changes on erectile dysfunction in obese men: a randomized controlled trial. *J Am Med Assoc*. 2004;291:2978–2984.
Fallon B. Intracavernous injection therapy for male erectile dysfunction. *Urol Clin North Am*. 1995;22:833–845.
Feldman HA, Goldstein I, Hatzichristou DG, et al. Impotence and its medical and psychosocial correlates: results of the Massachusetts Male Aging Study. *J Urol*. 1994;151:54–61.
Feldman HA, Johannes CB, Derby CA, et al. Erectile dysfunction and coronary risk factors: prospective results from the Massachusetts male aging study. *Prev Med*. 2000;30:328–338.
Ferretti A, Caulo M, Del Gratta C, et al. Dynamics of male sexual arousal: distinct components of brain activation revealed by fMRI. *Neuroimage*. 2005;26:1086–1096.
Field HP, Wheeler MJ. The measurement of androgens. *Methods Mol Biol*. 2013;1065:211–226.
Fisher C, Gorss J, Zuch J. Cycle of penile erection synchronous with dreaming (REM) sleep. Preliminary report. *Arch Gen Psychiatry*. 1965;12:29–45.
Fisher WA, Eardley I, McCabe M, et al. Erectile dysfunction (ED) is a shared sexual concern of couples, I: couple conceptions of ED. *J Sex Med*. 2009;6:2746–2760.
Fisher WA, Rosen RC, Eardley I, et al. Sexual experience of female partners of men with erectile dysfunction: the female experience of men's attitudes to life events and sexuality (FEMALES) study. *J Sex Med*. 2005;2:675–684.
Floth A, Schramek P. Intracavernous injection of prostaglandin E1 in combination with papaverine: enhanced effectiveness in

comparison with papaverine plus phentolamine and prostaglandin E1 alone. *J Urol*. 1991;145:56–59.

Fonseca V, Seftel A, Denne J, et al. Impact of diabetes mellitus on the severity of erectile dysfunction and response to treatment: analysis of data from tadalafil clinical trials. *Diabetologia*. 2004;47:1914–1923.

Francis ME, Kusek JW, Nyberg LM, et al. The contribution of common medical conditions and drug exposures to erectile dysfunction in adult males. *J Urol*. 2007;178:591–596.

Freeman ER, Bloom DA, McGuire EJ. A brief history of testosterone. *J Urol*. 2001;165:371–373.

Frey A, Sonksen J, Fode M. Low-intensity extracorporeal shockwave therapy in the treatment of postprostatectomy erectile dysfunction: a pilot study. *Scand J Urol*. 2016;50(2):123–127.

Gallina A, Bianchi M, Gandaglia G, et al. A detailed analysis of the association between postoperative phosphodiesterase type 5 inhibitor use and the risk of biochemical recurrence after radical prostatectomy. *Eur Urol*. 2015;68(5):750–753.

Gandaglia G, Briganti A, Jackson G, et al. A systematic review of the association between erectile dysfunction and cardiovascular disease. *Eur Urol*. 2014;65(5):968–978.

Ganz P. Erectile dysfunction: pathophysiologic mechanisms pointing to underlying cardiovascular disease. *Am J Cardiol*. 2005;96:8M–12M.

Gazzaruso C, Coppola A, Montalcini T, et al. Erectile dysfunction can improve the effectiveness of the current guidelines for the screening for asymptomatic coronary artery disease in diabetes. *Endocrine*. 2011;40(2):273–279.

Gelber AC. Gout and association with erectile dysfunction. *J Rhematol*. 2015;42(10):1731–1733.

Gerstenberg TC, Bradley WE. Nerve conduction velocity measurement of dorsal nerve of penis in normal and impotent males. *Urology*. 1983;21:90–92.

Ghanem HM, Salonia A, Martin-Morales A. SOP: physical examination and laboratory testing for men with erectile dysfunction. *J Sex Med*. 2013;10:108–110.

Gillam MP, Molitch ME, Lombardi G, et al. Advances in the treatment of prolactinomas. *Endocr Rev*. 2006;27:485–534.

Giuliano F, Jackson G, Montorsi F, et al. Safety of sildenafil citrate: review of 67 double-blind placebo-controlled trials and the postmarketing safety database. *Int J Clin Pract*. 2010;64:240–255.

Giuliano F, Rampin O. Central noradrenergic control of penile erection. *Int J Impot Res*. 2000;12:S13–S19.

Giuliano F, Rowland DL. Standard operating procedures for neurophysiologic assessment of male sexual dysfunction. *J Sex Med*. 2013;10:1205–1211.

Glass JM, Vale JA, Belcaro G, et al. A comparison of isotope penile blood flow and colour Doppler ultrasonography in the assessment of erectile dysfunction. *Br J Urol*. 1996;77:566–570.

Glavas S, Valencic L, Trbojevic N, et al. Erectile function in cardiovascular patients: its significance and a quick assessment using a visual-scale questionnaire. *Acta Cardiol*. 2015;70:712–719.

Glick HA, McCarron TJ, Althof SE, et al. Construction of scales for the Center for Marital and Sexual Health (CMASH) Sexual Functioning Questionnaire. *J Sex Marital Ther*. 1997;23:103–117.

Glina S, Ghanem H. SOP: corpus cavernosum assessment (cavernosography/cavernosometry). *J Sex Med*. 2013;10:111–114.

Glina S, Sharlip ID, Hellstrom WJG. Modifying risk factors to prevent and treat erectile dysfunction. *J Sex Med*. 2013;10:115–119.

Goldstein I. Oral phentolamine: an alpha-1, alpha-2 adrenergic antagonist for the treatment of erectile dysfunction. *Int J Impot Res*. 2000;12:S75–S80.

Goldstein I, Payton TR, Schechter PJ. A double-blind, placebo-controlled, efficacy and safety study of topical gel formulation of 1% alprostadil (Topiglan) for the in-office treatment of erectile dysfunction. *Urology*. 2001;57:301–305.

Golubinski AJ, Sikorski A. Usefulness of power Doppler ultrasonography in evaluating erectile dysfunction. *BJU Int*. 2002;89:779–782.

Govier FE, McClure RD, Kramer-Levien D. Endocrine screening for sexual dysfunction using free testosterone determinations. *J Urol*. 1996;156:405–408.

Greco EA, Spera G, Aversa A. Combining testosterone and PDE5 inhibitors in erectile dysfunction: basic rationale and clinical evidences. *Eur Urol*. 2006;50(5):940–947.

Greenstein A, Plymate SR, Katz PG. Visually stimulated erection in castrated men. *J Urol*. 1995;153:650–652.

Gruenwald I, Appel B, Kitrey ND, et al. Shockwave treatment of erectile dysfunction. *Ther Adv Urol*. 2013;5(2):95–99.

Gruenwald I, Appel B, Vardi Y. Low-intensity extracorporeal shock wave therapy—a novel effective treatment for erectile dysfunction in severe ED patients who respond poorly to PDE5 inhibitor therapy. *J Sex Med*. 2012;9(1):259–264.

Guay AT. Optimizing response to phosphodiesterase therapy: impact of risk-factor management. *J Androl*. 2003;24:S59–S62.

Guay AT. ED2: erectile dysfunction = endothelial dysfunction. *Endocrinol Metab Clin North Am*. 2007;36:453–463.

Guay AT, Perez JB, Velásquez E, et al. Clinical experience with intraurethral alprostadil (MUSE) in the treatment of men with erectile dysfunction. A retrospective study: medicated urethral system for erection. *Eur Urol*. 2000;38:671–676.

Guo W, Liao C, Zou Y, et al. Erectile dysfunction and risk of clinical cardiovascular events: a meta-analysis of seven cohort studies. *J Sex Med*. 2010;7:2805–2816.

Gupta BP, Murad MH, Clifton MM, et al. The effect of lifestyle modification and cardiovascular risk factor reduction on erectile dysfunction: a systematic review and meta-analysis. *Arch Intern Med*. 2011;171:1797–1803.

Hatzichristou DG, Hatzimouratidis K, Ioannides E, et al. Nocturnal penile tumescence and rigidity monitoring in young potent volunteers: reproducibility, evaluation criteria and the effect of sexual intercourse. *J Urol*. 1998;159(6):1921–1926.

Hatzichristou DG, Rosen RC, Derogatis LR, et al. Recommendations for the clinical evaluation of men and women with sexual dysfunction. *J Sex Med*. 2010;7:337–348.

Hatzichristou DG, Sáenz de Tejada I, Kupferman S, et al. In vivo assessment of trabecular smooth muscle tone, its application in pharmaco-cavernosometry and analysis of intracavernous pressure determinants. *J Urol*. 1995;153:1126–1135.

Hatzimouratidis K, Hatzichristou DG. Looking to the future for erectile dysfunction therapies. *Drugs*. 2008;68:231–250.

Hatzimouratidis K, Burnett AL, Hatzichristou D, et al. Phosphodiesterase type 5 inhibitors in postprostatectomy erectile dysfunction: a critical analysis of the basic science rationale and clinical application. *Eur Urol*. 2009;55:334–347.

Hatzimouratidis K, Salonia A, Adaikan G, et al. Pharmacotherapy for erectile dysfunction: recommendations from the fourth international consultation for sexual medicine (ICSM 2015). *J Sex Med*. 2016;13(4):465–488.

Hawton K. Integration of treatments for male erectile dysfunction. *Lancet*. 1998;351:7–8.

Heaton JP. Apomorphine: an update of clinical trial results. *Int J Impot Res*. 2000;12:S67–S73.

Heinemann LA. Aging Males’ Symptoms scale: a standardized instrument for the practice. *J Endocrinol Invest*. 2005;28:34–38.

Hellstrom WJ. Current safety and tolerability issues in men with erectile dysfunction receiving PDE5 inhibitors. *Int J Clin Pract*. 2007;61:1547–1554.

Hellstrom WJ, Bennett AH, Gesundheit N, et al. A double-blind, placebo-controlled evaluation of the erectile response to transurethral alprostadil. *Urology*. 1996;48:851–856.

Hellstrom WJ, Montague DK, Moncada I, et al. Implants, mechanical devices, and vascular surgery for erectile dysfunction. *J Sex Med*. 2010;7:501–523.

Herbener TE, Seftel AD, Nehra A, et al. Penile ultrasound. *Semin Urol*. 1994;12:320–332.

Hirsch M, Donatucci C, Glina S. Standards for clinical trials in male sexual dysfunction: erectile dysfunction and rapid ejaculation. *J Sex Med*. 2004;1:87–91.

Ho KH, Ong BK, Chong PN, et al. The bulbocavernosus reflex in the assessment of neurogenic impotence in diabetic and non-diabetic men. *Ann Acad Med Singapore*. 1996;25:558–561.

Hornbrook MC, Holup J. Insurance coverage for erectile dysfunction drugs. *Clin Pharmacol Ther*. 2011;89:19–21.

Ichikawa T, Takao A, Manabe D, et al. The female partner's satisfaction with sildenafil citrate treatment of erectile dysfunction. *Int J Urol*. 2004;11:755–762.

Inman BA, Sauver JL, Jacobson DJ, et al. A population-based, longitudinal study of erectile dysfunction and future coronary artery disease. *Mayo Clin Proc*. 2009;84:108–113.

Isidori AM, Buvat J, Corona G, et al. A critical analysis of the role of testosterone in erectile function: from pathophysiology to treatment-a systematic review. *Eur Urol*. 2014;65(1):99–112.

Jackson G, Montorsi P, Adams MA, et al. Cardiovascular aspects of sexual medicine. *J Sex Med*. 2010;7(4 Pt 2):1608–1626.

Jackson G, Montorsi P, Cheitlin MD. Cardiovascular safety of sildenafil citrate (Viagra): an updated perspective. *Urology*. 2006;68:47–60.

Jackson G, Rosen RC, Kloner RA, et al. The second Princeton consensus on sexual dysfunction and cardiac risk: new guidelines for sexual medicine. *J Sex Med*. 2006;3:28–36.

Jackson SE, Lue TF. Erectile dysfunction: therapy health outcomes. *Urology*. 1998;51:874–882.

Jannini EA, Granata AM, Hatzimouratidis K, et al. Use and abuse of Rigiscan in the diagnosis of erectile dysfunction. *J Sex Med*. 2009;7:1820–1829.

Jardin A, Wagner G, Khoury S, et al. *Erectile dysfunction*. Health Publication Ltd: United Kingdom; 2000.

Jarow JP, Pugh VW, Routh WD, et al. Comparison of penile duplex ultrasonography to pudendal arteriography. Variant penile arterial anatomy affects interpretation of duplex ultrasonography. *Invest Radiol*. 1993;28:806–810.

Jiang XG, Speel TG, Wagner G, et al. The value of corpus cavernosum electromyography in erectile dysfunction: current status and future prospect. *Eur Urol*. 2003;43:211–218.

Johannes CB, Araujo AB, Feldman HA, et al. Incidence of erectile dysfunction in men 40 to 69 years old: longitudinal results from the Massachusetts male aging study. *J Urol*. 2000;163:460–463.

John H, Kacl GM, Lehmann K. Clinical value of pelvic and penile magnetic resonance angiography in preoperative evaluation of penile revascularization. *Int J Impot Res*.

1999;11:83–86.

John H, Lehmann K, Hauri D. Intraurethral prostaglandin improves quality of vacuum erection therapy. *Eur Urol*. 1996;29:224–226.

Johnson AR, Jarow J. Is routine endocrine testing of impotent men necessary? *J Urol*. 1992;147:1542–1543.

Johri AM, Heaton JP, Morales A. Severe erectile dysfunction is a marker for hyperprolactinemia. *Int J Impot Res*. 2001;13:176–182.

Juenemann KP, Lue TF, Fournier GR, et al. Hemodynamics of papaverine- and phentolamine-induced penile erection. *J Urol*. 1986;136:158–161.

Kaneko S, Bradley WE. Penile electrodiagnosis. Value of bulbocavernosus reflex latency versus nerve conduction velocity of the dorsal nerve of the penis in diagnosis of diabetic impotence. *J Urol*. 1987;137:933–935.

Kao CC, Lin CL, Huang WY, et al. Association between inflammatory bowel disease and erectile dysfunction: a nationwide population-based study. *Inflamm Bowel Dis*. 2016;22(5):1065–1070.

Kapoor D, Aldred H, Clark S, et al. Clinical and biochemical assessment of hypogonadism in men with type 2 diabetes: correlations with bioavailable testosterone and visceral adiposity. *Diabetes Care*. 2007;30:911–917.

Karacan I, Scott FB, Salis PJ, et al. Nocturnal erections, differential diagnosis of impotence, and diabetes. *Biol Psychiatry*. 1977;12:373–380.

Kassouf W, Carrier S. A comparison of the International Index of Erectile Function and erectile dysfunction studies. *BJU Int*. 2003;91:667–669.

Katlowitz NM, Albano GJ, Morales P, et al. Potentiation of drug-induced erection with audiovisual sexual stimulation. *Urology*. 1993;41:431–434.

Kawanishi Y, Kimura K, Nakanishi R, et al. Penile revascularization surgery for arteriogenic erectile dysfunction: the long-term efficacy rate calculated by survival analysis. *BJU Int*. 2004;94:361–368.

Kedia GT, Ückert S, Assadi-Pour F, et al. Avanafil for the treatment of erectile dysfunction: initial data and clinical key properties. *Ther Adv Urol*. 2013;5:35–41.

Kedia KR. Penile plethysmography useful in diagnosis of vasculogenic impotence. *Urology*. 1983;22:235–239.

Keene LC, Davies PH. Drug-related erectile dysfunction. *Adverse Drug React Toxicol Rev*. 1999;18:5–24.

Keller JJ, Chen YK, Lin HC. A case-control analysis on the association between erectile dysfunction and sudden sensorineural hearing loss in Taiwan. *J Sex Med*. 2012;9:1411–1417.

Keller JJ, Chen YK, Lin HC. Association between epilepsy and erectile dysfunction: evidence from a population based study. *J Sex Med*. 2012;9:2248–2255.

Keller JJ, Chen YK, Lin HC. Varicocele is associated with erectile dysfunction: a population-based case-control study. *J Sex Med*. 2012;9:1745–1752.

Keller JJ, Chung SD, Lin HC. A nationwide population-based study on the association between chronic periodontitis and erectile dysfunction. *J Clin Peridontol*. 2012;39:507–512.

Keller JJ, Lin HY, Chung SD, et al. A population-based study on the association between gastric ulcers and erectile dysfunction in Taiwan. *J Sex Med*. 2012;9:686–693.

Kellner B, Stief CG, Hinrichs H, et al. Computerized classification of corpus cavernosum electromyogram signals by the use of discriminate analysis and artificial neural networks to support diagnosis of erectile dysfunction. *Urol Res*. 2000;28:6–13.

Kessler WO. Nocturnal penile tumescence. *Urol Clin North Am*.

1988;15:81–86.

Khera M, Broderick GA, Carson CC 3rd, et al. Adult-onset hypogonadism. *Mayo Clin Proc*. 2016;91(7):908–926.

Khera M, Goldstein I. Erectile dysfunction. *Clin Evid (Online)*. 2011;1803.

Kiely EA, Bloom SR, Williams G. Penile response to intracavernosal vasoactive intestinal polypeptide alone and in combination with other vasoactive agents. *Br J Urol*. 1989;64:191–194.

Kim ED, el Rashidy R, McVary KT. Papaverine topical gel for treatment of erectile dysfunction. *J Urol*. 1995;153:361–365.

Kloner RA. Erectile dysfunction and cardiovascular risk factors. *Urol Clin North Am*. 2005;32:397–402.

Knoll LD, Abrams JH. Application of nocturnal electrobioimpedance volumetric assessment: a feasibility study in men without erectile dysfunction. *J Urol*. 1999;161:1137–1140.

Köhler TS, Pedro R, Hendlin K, et al. A pilot study on the early use of the vacuum erection device after radical retropubic prostatectomy. *BJU Int*. 2007;100:858–862.

Köhn FM, Schill WB. A new oral testosterone undecanoate formulation. *World J Urol*. 2003;21:311–315.

Korenman SG, Morley JE, Mooradian AD, et al. Secondary hypogonadism in older men: its relation to impotence. *J Clin Endocrinol Metab*. 1990;71:963–969.

Korenman SG, Viosca SP. Use of a vacuum tumescence device in the management of impotence in men with a history of penile implant or severe pelvic disease. *J Am Geriatr Soc*. 1992;40:61–64.

Kostis JB, Jackson G, Rosen R, et al. Sexual dysfunction and cardiac risk (the Second Princeton Consensus Conference). *Am J Cardiol*. 2005;96:85M–93M.

Krane RJ, Goldstein I, Sáenz de Tejada I. Impotence. *N Engl J*

Med. 1989;321:1648–1659.

Kukovetz WR, Pöch G, Wurm A. Quantitative relations between cyclic AMP and contraction as affected by stimulators of adenylate cyclase and inhibitors of phosphodiesterase. *Adv Cyclic Nucleotide Res*. 1975;5:395–414.

Kunelius P, Lukkarinen O, Hannuksela ML, et al. The effects of transdermal dihydrotestosterone in the aging male: a prospective, randomized, double blind study. *J Clin Endocrinol Metab*. 2002;87:1467–1472.

Kupelian V, Araujo AB, Chiu GR, et al. Relative contributions of modifiable risk factors to erectile dysfunction: results from the Boston Area Community Health (BACH) survey. *Prev Med*. 2010;50:19–25.

Lakin MM, Montague DK, VanderBrug Medendorp S, et al. Intracavernous injection therapy: analysis of results and complications. *J Urol*. 1990;143:1138–1141.

Lal S, Laryea E, Thavundayil JX, et al. Apomorphine-induced penile tumescence in impotent patients—preliminary findings. *Prog Neuropsychopharmacol Biol Psychiatry*. 1987;11:235–242.

Lal S, Rios O, Thavundayil JX. Treatment of impotence with trazodone: a case report. *J Urol*. 1990;143:819–820.

Laties AM. Vision disorders and phosphodiesterase type 5 inhibitors: a review of the evidence to date. *Drug Saf*. 2009;32:1–18.

Lau DH, Kommu S, Mumtaz FH, et al. The management of phosphodiesterase-5 (PDE5) inhibitor failure. *Curr Vasc Pharmacol*. 2006;4:89–93.

Laumann EO, West S, Glasser D, et al. Prevalence and correlates of erectile dysfunction by race and ethnicity among men aged 40 or older in the United States: from the male attitudes regarding sexual health survey. *J Sex Med*.

2007;4:57–65.

Leach MM, Bethune C. Assisting sexually abused adults. Practical guide to interviewing patients. *Can Fam Physician*. 1996;42:82–86.

Leddy LS, Jiang X, Gottsch HP, et al. Corpus cavernosum electromyography revisited: defining the origin of the signal. *J Urol*. 2012;187:589–593.

Lefaucheur JP. Measurement of electrochemical conductance of penile skin using Sudoscan(R): a new tool to assess neurogenic impotence. *Neurophysiol Clin*. 2017;47:253–260.

Lefaucheur JP, Yiou R, Colombel M, et al. Relationship between penile thermal sensory threshold measurement and electrophysiologic tests to assess neurogenic impotence. *Urology*. 2001;57:306–309.

Levine LA, Carroll RA. Nocturnal penile tumescence and rigidity in men without complaints of erectile dysfunction using a new quantitative analysis software. *J Urol*. 1994;152:1103–1107.

Lewis RW. Intraurethral and topical agents. *Drugs Today (Barc)*. 2000;36:113–119.

Lewis RW, Fugl-Meyer KS, Bosch R, et al. Epidemiology/risk factors of sexual dysfunction. *J Sex Med*. 2004;1:35–39.

Lewis RW, Fugl-Meyer KS, Corona G, et al. Definitions/epidemiology/risk factors for sexual dysfunction. *J Sex Med*. 2010;7:1598–1607.

Lian Y, Yin H, Pollak MN, et al. Phosphodiesterase type 5 inhibitors and the risk of melanoma skin cancer. *Eur Urol*. 2016;70(5):808–815.

Licht MR, Lewis RW, Wollan PC, et al. Comparison of RigiScan and sleep laboratory nocturnal penile tumescence in the diagnosis of organic impotence. *J Urol*. 1995;154:1740–1743.

Limoge JP, Olins E, Henderson D, et al. Minimally invasive therapies in the treatment of erectile dysfunction in anticoagulated cases: a study of satisfaction and safety. *J Urol*. 1996;155:1276–1279.

Linet OI, Neff LL. Intracavernous prostaglandin E1 in erectile dysfunction. *Clin Investig*. 1994;72:139–149.

Linet OI, Ogrinc FG. Efficacy and safety of intracavernosal alprostadil in men with erectile dysfunction. The Alprostadil Study Group. *N Engl J Med*. 1996;334:873–877.

Lippi G, Plebani M, Montagnana M, et al. Biochemical and genetic markers of erectile dysfunction. *Adv Clin Chem*. 2012;57:139–162.

Litwin MS, Nied RJ, Dhanani N. Health-related quality of life in men with erectile dysfunction. *J Gen Intern Med*. 1998;13:159–166.

Litwin MS, Saigal CS, Yano EM, et al. Urologic diseases in America project: analytical methods and principal findings. *J Urol*. 2005;173:933–937.

Liu PY, Wishart SM, Handelsman DJ. A double-blind, placebo-controlled, randomized clinical trial of recombinant human chorionic gonadotropin on muscle strength and physical function and activity in older men with partial age-related androgen deficiency. *J Clin Endocrinol Metab*. 2002;87:3125–3135.

Lobo RA, Kletzky OA. Normalization of androgen and sex hormone-binding globulin levels after treatment of hyperprolactinemia. *J Clin Endocrinol Metab*. 1983;56:562–566.

Loeb S, Folkvaljon Y, Lambe M, et al. Use of phosphodiesterase type 5 inhibitors for erectile dysfunction and risk of malignant melanoma. *J Am Med Assoc*. 2015;313(24):2449–2455.

Loeb S, Folkvaljon Y, Robinson D, et al. Phosphodiesterase type 5 inhibitor use and disease recurrence after prostate cancer treatment. *Eur Urol*. 2016;70(5):824–828.

Lue TF. Impotence: a patient's goal-directed approach to treatment. *World J Urol*. 1990;8:67–74.

Lue TF, Giuliano F, Montorsi F, et al. Summary of the recommendations on sexual dysfunctions in men. *J Sex Med*. 2004;1:6–23.

Lue TF, Hricak H, Marich KW, et al. Evaluation of arteriogenic impotence with intracorporeal injection of papaverine and the duplex ultrasound scanner. *Semin Urol*. 1985;3:43–48.

Lue TF, Hricak H, Schmidt RA, et al. Functional evaluation of penile veins by cavernosography in papaverine-induced erection. *J Urol*. 1986;135:479–482.

Lue TF, Mueller SC, Jow YR, et al. Functional evaluation of penile arteries with duplex ultrasound in vasodilator-induced erection. *Urol Clin North Am*. 1989;16:799–807.

Lue TF, Tanagho EA. Physiology of erection and pharmacological management of impotence. *J Urol*. 1987;137:829–836.

Ly LP, Sartorius G, Hull L, et al. Accuracy of calculated free testosterone formulae in men. *Clin Endocrinol (Oxf)*. 2010;73:382–388.

Maggi M, Buvat J, Corona G, et al. Hormonal causes of male sexual dysfunctions and their management (hyperprolactinemia, thyroid disorders, GH disorders, and DHEA). *J Sex Med*. 2013;10:661–677.

Makarov DV, Chrouser K, Gore JL, et al. AUA White Paper on implementation of shared decision making into urological practice. *Urol Pract*. 2016;3(5):355–363.

Manning M, Jünemann KP, Scheepe JR, et al. Long-term followup and selection criteria for penile revascularization in erectile failure. *J Urol*. 1998;160:1680–1684.

Mannino DM, Klevens RM, Flanders WD. Cigarette smoking: an independent risk factor for impotence? *Am J Epidemiol*.

1994;140:1003–1008.

Marmar JL, DeBenedictis TJ, Praiss DE. The use of a vacuum constrictor device to augment a partial erection following an intracavernous injection. *J Urol*. 1988;140:975–979.

Martin-Morales A, Sanchez-Cruz JJ, Sáenz de Tejada I, et al. Prevalence and independent risk factors for erectile dysfunction in Spain: results of the Epidemiologia de la Disfuncion Erectil Masculina Study. *J Urol*. 2001;166:569–574.

Martins FE, Reis JP. Visual erotic stimulation test for initial screening of psychogenic erectile dysfunction: a reliable noninvasive alternative? *J Urol*. 1997;157:134–139.

Mata DA, Katchi FM, Ramasamy R. Precision medicine and men's health. *Am J Mens Health*. 2017;11(4):1124–1129.

McCabe MP, Sharlip ID, Atalla E, et al. Definitions of sexual dysfunctions in women and men: a consensus statement from the Fourth International Consultation on Sexual Medicine 2015. *J Sex Med*. 2016;13(2):135–143.

McCullough AR, Barada JH, Fawzy A, et al. Achieving treatment optimization with sildenafil citrate (Viagra) in patients with erectile dysfunction. *Urology*. 2002;60:28–38.

McMahon CG. Nonsurgical treatment of cavernosal venous leakage. *Urology*. 1997;49:97–100.

McMahon CG. Topiglan MacroChem. *Curr Opin Investig Drugs*. 2002;3:602–606.

McMahon CG, Samali R, Johnson H. Treatment of intracorporeal injection nonresponse with sildenafil alone or in combination with triple agent intracorporeal injection therapy. *J Urol*. 1999;162:1992–1997.

McMahon CN, Smith CJ, Shabsigh R. Treating erectile dysfunction when PDE5 inhibitors fail. *BMJ*. 2006;332:589–592.

McVary KT, Polepalle S, Riggi S, et al. Topical prostaglandin

E1 SEPA gel for the treatment of erectile dysfunction. *J Urol*. 1999;162:726–730.

Meldrum DR, Gambone JC, Morris MA, et al. Lifestyle and metabolic approaches to maximizing erectile and vascular health. *Int J Impot Res*. 2012;24:61–68.

Metro MJ, Broderick GA. Diabetes and vascular impotence: does insulin dependence increase the relative severity? *Int J Impot Res*. 1999;11:87–89.

Metz P, Bengtsson J. Penile blood pressure. *Scand J Urol Nephrol*. 1981;15:161–164.

Miner M, Seftel AD, Nehra A, et al. Prognostic utility of erectile dysfunction for cardiovascular disease in younger men and those with diabetes. *Am Heart J*. 2012;164:21–28.

Mirone V, Imbimbo C, Fusco F, et al. Androgens and morphologic remodeling at penile and cardiovascular levels: a common piece in complicated puzzles? *Eur Urol*. 2009;56:309–316.

Miyagawa Y, Tsujimura A, Fujita K, et al. Differential brain processing of audiovisual sexual stimuli in men: comparative positron emission tomography study of the initiation and maintenance of penile erection during sexual arousal. *Neuroimage*. 2007;36:830–842.

Moemen MN, Hamed HA, Kamel II, et al. Clinical and sonographic assessment of the side effects of intracavernous injection of vasoactive substances. *Int J Impot Res*. 2004;16:143–145.

Molitch ME. Medication-induced hyperprolactinemia. *Mayo Clin Proc*. 2005;80:1050–1057.

Molitch ME. Drugs and prolactin. *Pituitary*. 2008;11:209–218.

Montague DK, Barada HJ, Belker AM, et al. Clinical guidelines panel on erectile dysfunction: summary report of the treatment of organic erectile dysfunction. The American Urological Association. *J Urol*. 1996;156:2007–2011.

Montague DK, Jarow JP, Broderick GA, et al. Chapter 1: the management of erectile dysfunction: an AUA update. *J Urol*. 2005;174:230–239.

Montorsi F, Althof SE. Partner responses to sildenafil citrate (Viagra) treatment of erectile dysfunction. *Urology*. 2004;63:762–767.

Montorsi F, Brock G, Lee J, et al. Effect of nightly versus on-demand vardenafil on recovery of erectile function in men following bilateral nerve-sparing radical prostatectomy. *Eur Urol*. 2008;54:924–931.

Montorsi F, Perani D, Anchisi D, et al. Apomorphine-induced brain modulation during sexual stimulation: a new look at central phenomena related to erectile dysfunction. *Int J Impot Res*. 2003;15:203–209.

Montorsi P, Briganti A, Salonia A, et al. Impaired vascular reactivity in patients with erectile dysfunction. *J Am Coll Cardiol*. 2004;44:1339–1340.

Morales A, Buvat J, Gooren LJ, et al. Endocrine aspects of sexual dysfunction in men. *J Sex Med*. 2004;1:69–81.

Morales A, Condra M, Heaton JP, et al. Diurnal penile tumescence recording in the etiological diagnosis of erectile dysfunction. *J Urol*. 1994;152:1111–1114.

Morales A, Heaton JP, Johnston B, et al. Oral and topical treatment of erectile dysfunction. Present and future. *Urol Clin North Am*. 1995;22:879–886.

Morales A, Spevack M, Emerson L, et al. Adding to the controversy: pitfalls in the diagnosis of testosterone deficiency syndromes with questionnaires and biochemistry. *Aging Male*. 2007;10:57–65.

Morganroth J, Ilson BE, Shaddinger BC, et al. Evaluation of vardenafil and sildenafil on cardiac repolarization. *Am J Cardiol*. 2004;93:1378–1383.

Morgentaler A, Dobs AS, Kaufman JM. Long acting testosterone undecanoate therapy in men with hypogonadism: results of a pharmacokinetic clinical study. *J Urol*. 2008;180:2307–2313.

Morley JE, Charlton E, Patrick P, et al. Validation of a screening questionnaire for androgen deficiency in aging males. *Metabolism*. 2000;49:1239–1242.

Motiwala HG. Dynamic pharmacocavernosometry: a search for an ideal approach. *Urol Int*. 1993;51:1–8.

Moul JW, McLeod DG. Negative pressure devices in the explanted penile prosthesis population. *J Urol*. 1989;142:729–731.

Mouras H, Stoléru S, Bittoun J, et al. Brain processing of visual sexual stimuli in healthy men: a functional magnetic resonance imaging study. *Neuroimage*. 2003;20:855–869.

Moyad MA, Barada JH, Lue TF, et al. Prevention and treatment of erectile dysfunction using lifestyle changes and dietary supplements: what works and what is worthless, part II. *Urol Clin North Am*. 2004;31:259–273.

Mueller SC, Lue TF. Evaluation of vasculogenic impotence. *Urol Clin North Am*. 1988;15:65–76.

Mueller SC, von Wallenberg-Pachaly H, Voges GE, et al. Comparison of selective internal iliac pharmaco-angiography, penile brachial index and duplex sonography with pulsed Doppler analysis for the evaluation of vasculogenic (arteriogenic) impotence. *J Urol*. 1990;143:928–932.

Mulhall JP, Bivalacqua TJ, Becher EF. Standard operating procedure for the preservation of erectile function outcomes after radical prostatectomy. *J Sex Med*. 2013;10:195–203.

Mulhall JP, King R, Kirby M, et al. Evaluating the sexual experience in men: validation of the sexual experience questionnaire. *J Sex Med*. 2008;5:365–376.

Mydlo JH, Volpe MA, Macchia RJ. Initial results utilizing combination therapy for patients with a suboptimal response to either alprostadil or sildenafil monotherapy. *Eur Urol*. 2000;38:30–34.

Nadig PW, Ware JC, Blumoff R. Noninvasive device to produce and maintain an erection-like state. *Urology*. 1986;27:126–131.

Naroda T, Yamanaka M, Matsushita K, et al. Clinical studies for venogenic impotence with color Doppler ultrasonography—evaluation of resistance index of the cavernous artery. *Nippon Hinyokika Gakkai Zasshi*. 1996;87:1231–1235.

Nehra A. Erectile dysfunction and cardiovascular disease: efficacy and safety of phosphodiesterase type 5 inhibitors in men with both conditions. *Mayo Clin Proc*. 2009;84:139–148.

Nehra A, Blute ML, Barrett DM, et al. Rationale for combination therapy of intraurethral prostaglandin E(1) and sildenafil in the salvage of erectile dysfunction patients desiring noninvasive therapy. *Int J Impot Res*. 2002;14:S38–S42.

Nehra A, Jackson G, Miner M, et al. The Princeton III Consensus recommendations for the management of erectile dysfunction and cardiovascular disease. *Mayo Clin Proc*. 2012;67:766–778.

Nehra A, Jackson G, Miner M, et al. Diagnosis and treatment of erectile dysfunction for reduction of cardiovascular risk. *J Urol*. 2013;189:2031–2038.

Netto Júnior NR, Claro Jde A. The importance of hyperprolactinemia in impotence. *Rev Paul Med*. 1993;111:454–455.

Nicolosi A, Laumann EO, Glasser DB, et al. Sexual behavior and sexual dysfunctions after age 40: the global study of sexual attitudes and behaviors. *Urology*. 2004;64:991–997.

NIH Consensus Statement. *Impotence*. 1992;10:1–33.

Nurnberg HG, Gelenberg A, Hargreave TB, et al. Efficacy of sildenafil citrate for the treatment of erectile dysfunction in men taking serotonin reuptake inhibitors. *Am J Psychiatry*. 2001;158:1926–1928.

O'Connor DB, Lee DM, Corona G, et al. The relationships between sex hormones and sexual function in middle-aged and older European men. *J Clin Endocrinol Metab*. 2011;96(10):E1577–E1587.

O'Leary MP, Fowler FJ, Lenderking WR, et al. A brief male sexual function inventory for urology. *Urology*. 1995;46:697–706.

Owen JA, Saunders F, Harris C, et al. Topical nitroglycerin: a potential treatment for impotence. *J Urol*. 1989;141:546–548.

Padma-Nathan H. Neurologic evaluation of erectile dysfunction. *Urol Clin North Am*. 1988;15:77–80.

Padma-Nathan H, Hellstrom WJ, Kaiser FE, et al. Treatment of men with erectile dysfunction with transurethral alprostadil. Medicated Urethral System for Erection (MUSE) Study Group. *N Engl J Med*. 1997;336:1–7.

Padma-Nathan H, McCullough AR, Levine LA, et al. Randomized, double-blind, placebo-controlled study of postoperative nightly sildenafil citrate for the prevention of erectile dysfunction after bilateral nerve-sparing radical prostatectomy. *Int J Impot Res*. 2008;20:479–486.

Padma-Nathan H, Yeager JL. An integrated analysis of alprostadil topical cream for the treatment of erectile dysfunction in 1732 patients. *Urology*. 2006;68:386–391.

Padmanabhan P, McCullough AR. Penile oxygen saturation in the flaccid and erect penis in men with and without erectile dysfunction. *J Androl*. 2007;28:223–228.

Pagano MJ, Stahl PJ. Variation in penile hemodynamics by anatomic location of cavernosal artery imaging in penile duplex doppler ultrasound. *J Sex Med*. 2015;12(9):1911–1919.

Palmer LS, Valcic M, Melman A, et al. Characterization of cyclic AMP accumulation in cultured human corpus cavernosum smooth muscle cells. *J Urol*. 1994;152:1308–1314.

Park K, Seo JJ, Kang HK, et al. A new potential of blood oxygenation level dependent (BOLD) functional MRI for evaluating cerebral centers of penile erection. *Int J Impot Res*. 2001;13:73–81.

Pavlovich CP, Levinson AW, Su LM, et al. Nightly vs on-demand sildenafil for penile rehabilitation after minimally invasive nerve-sparing radical prostatectomy: results of a randomized double-blind trial with placebo. *BJU Int*. 2013;112:844–851.

Pavone C, Giacalone N, Vella M, et al. Relation between sexual dysfunctions and epilepsy, type of epilepsy, type of antiepileptic drugs: a prospective study. *Urologia*. 2017;84(2):88–92.

Pescatori ES, Hatzichristou DG, Namburi S, et al. A positive intracavernous injection test implies normal veno-occlusive but not necessarily normal arterial function: a hemodynamic study. *J Urol*. 1994;151:1209–1216.

Petak SM, Nankin HR, Spark RF, et al. American Association of Clinical Endocrinologists Medical Guidelines for clinical practice for the evaluation and treatment of hypogonadism in adult male patients—2002 update. *Endocr Pract*. 2002;8:440–456.

Pickard RS, Powell PH, Schofield IS. The clinical application of dorsal penile nerve cerebral-evoked response recording in the investigation of impotence. *Br J Urol*. 1994;74:231–235.

Polinski JM, Kesselheim AS. Where cost, medical necessity, and morality meet: should US government insurance programs pay for erectile dysfunction drugs? *Clin Pharmacol Ther*. 2011;89:17–19.

Porst H. The rationale for prostaglandin E1 in erectile failure: a survey of worldwide experience. *J Urol*. 1996;155:802–815.

Porst H, Giuliano F, Glina S, et al. Evaluation of the efficacy and safety of once-a-day dosing of tadalafil 5mg and 10mg in the treatment of erectile dysfunction: results of a multicenter, randomized, double-blind, placebo-controlled trial. *Eur Urol*. 2006;50:351–359.

Porst H, Burnett A, Brock G, et al. SOP conservative (medical and mechanical) treatment of erectile dysfunction. *J Sex Med*. 2013;10:130–171.

Process of Care Consensus Panel. The process of care model for evaluation and treatment of erectile dysfunction. *Int J Impot Res*. 1999;11:59–70 [discussion 70–54].

Puyau FA, Lewis RW. Corpus cavernosography. Pressure flow and radiography. *Invest Radiol*. 1983;18:517–522.

Qiu X, Lin G, Xin Z, et al. Effects of low-energy shockwave therapy on the erectile function and tissue of a diabetic rat model. *J Sex Med*. 2013;10(3):738–746.

Quam JP, King BF, James EM, et al. Duplex and color Doppler sonographic evaluation of vasculogenic impotence. *AJR Am J Roentgenol*. 1989;153:1141–1147.

Qureshi AA. Alibra (VIVUS). *Curr Opin Investig Drugs*. 2001;2:550–554.

Raina R, Agarwal A, Ausmundson S, et al. Early use of vacuum constriction device following radical prostatectomy facilitates early sexual activity and potentially earlier return of erectile function. *Int J Impot Res*. 2006;18:77–81.

Rajfer J, Rosciszewski A, Mehringer M. Prevalence of corporeal venous leakage in impotent men. *J Urol*. 1988;140:69–71.

Ralph D, McNicholas T. UK management guidelines for erectile dysfunction. *BMJ*. 2000;321:499–503.

Rhee E, Osborn A, Witt M. The correlation of cavernous systolic occlusion pressure with peak velocity flow using color duplex Doppler ultrasound. *J Urol*. 1995;153:358–360.

Rhoden EL, Estrada C, Levine L, et al. The value of pituitary magnetic resonance imaging in men with hypogonadism. *J Urol*. 2003;170:795–798.

Rooney M, Pfister W, Mahoney M, et al. Long-term, multicenter study of the safety and efficacy of topical alprostadil cream in male patients with erectile dysfunction. *J Sex Med*. 2009;6:520–534.

Rosen RC. Psychogenic erectile dysfunction. Classification and management. *Urol Clin North Am*. 2001;28:269–278.

Rosen RC. Evaluation of the patient with erectile dysfunction: history, questionnaires, and physical examination. *Endocrine*. 2004;23:107–111.

Rosen RC, Araujo AB, Connor MK, et al. The NERI Hypogonadism Screener: psychometric validation in male patients and controls. *Clin Endocrinol (Oxf)*. 2011;74:248–256.

Rosen RC, Cappelleri JC, Smith MD, et al. Development and evaluation of an abridged, 5-item version of the International Index of Erectile Function (IIEF-5) as a diagnostic tool for erectile dysfunction. *Int J Impot Res*. 1999;11:319–326.

Rosen RC, Catania J, Pollack L, et al. Male Sexual Health Questionnaire (MSHQ): scale development and psychometric validation. *Urology*. 2004;64:777–782.

Rosen RC, Fisher WA, Eardley I, et al. Men's Attitudes to Life Events and Sexuality (MALES) Study: the multinational Men's Attitudes to Life Events and Sexuality (MALES) study: I. Prevalence of erectile dysfunction and related health concerns in the general population. *Curr Med Res Opin*. 2004;20:607–617.

Rosen RC, Hatzichristou D, Broderick G, et al. Clinical evaluation and symptom scales: sexual dysfunction assessment in men. Lue TF, Basson R, Rosen R, et al. *Sexual medicine: sexual dysfunctions in men and women*. 2004 ed. Health Publications: France; 2004:173–220.

Rosen RC, Lane RM, Menza M. Effects of SSRIs on sexual function: a critical review. *J Clin Psychopharmacol*. 1999;19:67–85.

Rosen RC, Riley A, Wagner G, et al. The international index of erectile function (IIEF): a multidimensional scale for assessment of erectile dysfunction. *Urology*. 1997;49:822–830.

Rowland DL, Thornton JA, Burnett AL. Recognizing the risk of erectile dysfunction in a urology clinic practice. *BJU Int*. 2005;95:1034–1038.

Rudnick J, Bodecker R, Weidner W. Significance of the intracavernosal pharmacological injection test, pharmacocavernosography, artificial erection and cavernosometry in the diagnosis of venous leakage. *Urol Int*. 1991;46:338–343.

Rust J, Golombok S. The GRISS: a psychometric instrument for the assessment of sexual dysfunction. *Arch Sex Behav*. 1986;15:157–165.

Sadovsky R, Brock GB, Gutkin SW, et al. Toward a new ‘EPOCH’: optimising treatment outcomes with phosphodiesterase type 5 inhibitors for erectile dysfunction. *Int J Clin Pract*. 2009;63:1214–1230.

Sáenz de Tejada I, Angulo J, Cellek S, et al. Pathophysiology of erectile dysfunction. *J Sex Med*. 2005;2:26–39.

Safarinejad MR. Oral sildenafil in the treatment of erectile dysfunction in diabetic men: a randomized double-blind and placebo-controlled study. *J Diabetes Complications*. 2004;18:205–210.

Saigal CS, Wessells H, Pace J, et al. Predictors and prevalence of erectile dysfunction in a racially diverse population. *Arch*

Intern Med. 2006;166:207–212.

Sakheim DK, Barlow DH, Abrahamson DJ, et al. Distinguishing between organogenic and psychogenic erectile dysfunction. *Behav Res Ther*. 1987;25:379–390.

Sakhri S, Gooren LJ. Safety aspects of androgen treatment with 5alpha-dihydrotestosterone. *Andrologia*. 2007;39:216–222.

Salonia A, Castagna G, Sacca A, et al. Is erectile dysfunction a reliable proxy of general male health status? The case for the International Index of Erectile Function-Erectile Function domain. *J Sex Med*. 2012;9(10):2708–2715.

Sand M, Fisher WA. Women's endorsement of models of female sexual response: the nurses' sexuality study. *J Sex Med*. 2007;4:708–719.

Sarteschi LM, Montorsi F, Menchini Fabris F, et al. Cavernous arterial and arteriolar circulation in patients with erectile dysfunction: a power Doppler study. *J Urol*. 1998;159:428–432.

Schanz S, Hauck EW, Schmelz HU, et al. Topical treatment of erectile dysfunction with prostaglandin E(1) ethyl ester. *J Dtsch Dermatol Ges*. 2009;7:1055–1059.

Schlesinger N, Radvanski DC, Cheng JQ, et al. Erectile dysfunction is common among patients with gout. *J Rheumatol*. 2015;42(10):1893–1897.

Schrader SM, Breitenstein MJ, Lowe BD. Cutting off the nose to save the penis. *J Sex Med*. 2008;5:1932–1940.

Schwartz AN, Lowe M, Berger RE, et al. Assessment of normal and abnormal erectile function: color Doppler flow sonography versus conventional techniques. *Radiology*. 1991;180:105–109.

Seftel AD. Challenges in oral therapy for erectile dysfunction. *J Androl*. 2002;23:729–736.

Seftel AD, de la Rosette J, Birt J, et al. Coexisting lower urinary tract symptoms and erectile dysfunction: a systematic review of epidemiological data. *Int J Clin Pract*. 2013;67(1):32–45.

Sekine A, Tanabe N, Sugiura T, et al. Polymorphism of the G protein beta3 subunit gene influences the efficacy of sildenafil in patients with pulmonary hypertension. *Intern Med*. 2014;53(4):291–297.

Selvin E, Burnett AL, Platz EA. Prevalence and risk factors for erectile dysfunction in the US. *Am J Med*. 2007;120:151–157.

Shabsigh R, Fishman IJ, Shotland Y, et al. Comparison of penile duplex ultrasonography with nocturnal penile tumescence monitoring for the evaluation of erectile impotence. *J Urol*. 1990;143:924–927.

Shabsigh R, Fishman IJ, Toombs BD, et al. Venous leaks: anatomical and physiological observations. *J Urol*. 1991;146:1260–1265.

Shabsigh R, Donatucci C, Costabile R, et al. Reliability of efficacy in men with erectile dysfunction treated with tadalafil once daily after initial success. *Int J Impot Res*. 2010;22:1–8.

Sharlip ID. Evaluation and nonsurgical management of erectile dysfunction. *Urol Clin North Am*. 1998;25:647–659 [ix].

Shindel AW. 2009 update on phosphodiesterase type 5 inhibitor therapy part 2: updates on optimal utilization for sexual concerns and rare toxicities in this class. *J Sex Med*. 2009;6:2352–2364 [quiz 2365–2356].

Shirai M, Nakamura M, Ishii N, et al. Determination of intrapenial blood volume using 99mTc-labeled autologous red blood cells. *Tohoku J Exp Med*. 1976;120:377–383.

Sidi AA, Becher EF, Zhang G, et al. Patient acceptance of and satisfaction with an external negative pressure device for impotence. *J Urol*. 1990;144:1154–1156.

Sikka SC, Hellstrom WJ, Brock G, et al. Standardization of vascular assessment of erectile dysfunction: standard operating procedures for duplex ultrasound. *J Sex Med*.

2013;10:120–129.

Sironi G, Colombo D, Poggesi E, et al. Effects of intracavernous administration of selective antagonists of alpha(1)-adrenoceptor subtypes on erection in anesthetized rats and dogs. *J Pharmacol Exp Ther*. 2000;292:974–981.

Smith EM, Netto IC, Gladden KH, et al. Role of radionuclide phallogram in therapeutic decision-making for erectile dysfunction. *Urology*. 1998;51:175–178.

Soderdahl DW, Petroski RA, Mode D, et al. The use of an external vacuum device to augment a penile prosthesis. *Tech Urol*. 1997;3:100–102.

Sohn M, Hatzinger M, Goldstein I, et al. Standard operating procedures for vascular surgery in erectile dysfunction: revascularization and venous procedures. *J Sex Med*. 2013;10:172–179.

Solomon H, Man JW, Wierzbicki AS, et al. Relation of erectile dysfunction to angiographic coronary artery disease. *Am J Cardiol*. 2003;91:230–231.

Soran H, Wu FC. Endocrine causes of erectile dysfunction. *Int J Androl*. 2005;28(Suppl 2):28–34.

Speckens AE, Hengeveld MW, Lycklama à Nijeholt G, et al. Psychosexual functioning of partners of men with presumed non-organic erectile dysfunction: cause or consequence of the disorder? *Arch Sex Behav*. 1995;24:157–172.

Speel TG, Bleumer I, Diemont WL, et al. The value of sildenafil as mode of stimulation in pharmaco-penile duplex ultrasonography. *Int J Impot Res*. 2001;13:189–191.

Spitzer M, Basaria S, Travison TG, et al. The effect of testosterone on mood and well-being in men with erectile dysfunction in a randomized, placebo-controlled trial. *Andrology*. 2013;1(3):475–482.

Spitzer M, Basaria S, Travison TG, et al. Effect of testosterone replacement on response to sildenafil citrate in men with erectile dysfunction: a parallel, randomized trial. *Ann Intern Med*. 2012;157(10):681–691.

Spudis EV, Stubbs AJ, Skowronski T. Cerebral-evoked response from stimulation of dorsal nerve in impotent men. *Urology*. 1989;34:370–375.

Stacey D, Legare F, Col NF, et al. Decision aids for people facing health treatment or screening decisions. *Cochrane Database Syst Rev*. 2014;(1) [Cd001431].

Stehling MK, Liu L, Laub G, et al. Gadolinium-enhanced magnetic resonance angiography of the pelvis in patients with erectile impotence. *MAGMA*. 1997;5:247–254.

Stellato RK, Feldman HA, Hamdy O, et al. Testosterone, sex hormone-binding globulin, and the development of type 2 diabetes in middle-aged men: prospective results from the Massachusetts male aging study. *Diabetes Care*. 2000;23:490–494.

Stief CG, Junemann KP, Kellner B, et al. Consensus and progress in corpus cavernosum-EMG (CC-EMG). *Int J Impot Res*. 1994;6:177–182.

Sunagane N, Ogawa T, Uruno T, et al. Mechanism of relaxant action of papaverine. VI. Sodium ion dependence of its effect on 45Ca-efflux in guinea-pig taenia coli. *Jpn J Pharmacol*. 1985;38:133–139.

Teloken C, Rhoden EL, Sogari P, et al. Therapeutic effects of high dose yohimbine hydrochloride on organic erectile dysfunction. *J Urol*. 1998;159:122–124.

Thompson IM, Tangen CM, Goodman PJ, et al. Erectile dysfunction and subsequent cardiovascular disease. *JAMA*. 2005;294:2996–3002.

Tiefer L, Schuetz-Mueller D. Psychological issues in diagnosis and treatment of erectile disorders. *Urol Clin North Am*. 1995;22:767–773.

Tokatli Z, Akand M, Yaman O, et al. Comparison of international index of erectile function with nocturnal penile tumescence and rigidity testing in evaluation of erectile dysfunction. *Int J Impot Res*. 2006;18:186–189.

Traish AM, Guay AT. Are androgens critical for penile erections in humans? Examining the clinical and preclinical evidence. *J Sex Med*. 2006;3:382–404 [discussion 404–387].

Tsujimura A, Matsumiya K, Takao T, et al. Treatment with human chorionic gonadotropin for PADAM: a preliminary report. *Aging Male*. 2005;8:175–179.

Turek SJ, Hastings SM, Sun JK, et al. Sexual dysfunction as a marker of cardiovascular disease in males with 50 or more years of type 1 diabetes. *Diabetes Care*. 2013;36(10):3222–3226.

Turnbull JM, Weinberg PC. Psychological factors involved in impotence. A review of the literature. *J Androl*. 1983;4:59–66.

van Ahlen H, Peskar BA, Sticht G, et al. Pharmacokinetics of vasoactive substances administered into the human corpus cavernosum. *J Urol*. 1994;151:1227–1230.

Vardi Y, Appel B, Jacob G, et al. Can low-intensity extracorporeal shockwave therapy improve erectile function? A 6-month follow-up pilot study in patients with organic erectile dysfunction. *Eur Urol*. 2010;58(2):243–248.

Vardi Y, Dayan L, Apple B, et al. Penile and systemic endothelial function in men with and without erectile dysfunction. *Eur Urol*. 2009;55:979–985.

Vermeulen A, Verdonck L, Kaufman JM. A critical evaluation of simple methods for the estimation of free testosterone in serum. *J Clin Endocrinol Metab*. 1999;84:3666–3672.

Virag R. Intracavernous injection of papaverine for erectile failure. *Lancet*. 1982;2:938.

Virag R, Floresco J, Richard C. Impairment of shear-stress-mediated vasodilation of cavernous arteries in erectile dysfunction. *Int J Impot Res*. 2004;16:39–42.

Vlachopoulos C, Ioakeimidis N, Aznaouridis K, et al. Prediction of cardiovascular events with aortic stiffness in patients with erectile dysfunction. *Hypertension*. 2014;64(3):672–678.

Vodusek DB, Ravnik-Oblak M, Oblak C. Pudendal versus limb nerve electrophysiological abnormalities in diabetics with erectile dysfunction. *Int J Impot Res*. 1993;5:37–42.

Wagner G, Gerstenberg T, Levin RJ. Electrical activity of corpus cavernosum during flaccidity and erection of the human penis: a new diagnostic method? *J Urol*. 1989;142:723–725.

Wald M, Meacham RB, Ross LS, et al. Testosterone replacement therapy for older men. *J Androl*. 2006;27:126–132.

Wang C, Nieschlag E, Swerdloff R, et al. Investigation, treatment, and monitoring of late-onset hypogonadism in males: ISA, ISSAM, EAU, EAA, and ASA recommendations. *J Androl*. 2009;30:1–9.

Wang C, Jackson G, Jones TH, et al. Low testosterone associated with obesity and the metabolic syndrome contributes to sexual dysfunction and cardiovascular disease risk in men with type 2 diabetes. *Diabetes Care*. 2011;34:1669–1675.

Wasserman MD, Pollak CP, Spielman AJ, et al. Theoretical and technical problems in the measurement of nocturnal penile tumescence for the differential diagnosis of impotence. *Psychosom Med*. 1980;42:575–585.

Wespes E, Goes PM, Schiffmann S, et al. Computerized analysis of smooth muscle fibers in potent and impotent patients. *J Urol*. 1991;146:1015–1017.

Wespes E, Moreira de Goes P, Schulman C. Vascular impotence: focal or diffuse penile disease. *J Urol*. 1992;148:1435–1436.

Wessells H, Levine N, Hadley ME, et al. Melanocortin receptor agonists, penile erection, and sexual motivation: human studies with Melanotan II. *Int J Impot Res*. 2000;12(Suppl 4):S74–S79.

Wessells H, Joyce GF, Wise M, et al. Erectile dysfunction. *J Urol*. 2007;177:1675–1681.

Whooley MA, Avins AL, Miranda J, et al. Case-finding instruments for depression. Two questions are as good as many. *J Gen Intern Med*. 1997;12(7):439–445.

Witherington R. Vacuum constriction device for management of erectile impotence. *J Urol*. 1989;141:320–322.

Wolfson B, Pickett S, Scott NE, et al. Intraurethral prostaglandin E-2 cream: a possible alternative treatment for erectile dysfunction. *Urology*. 1993;42:73–75.

Yang Y, Liu H, Lin T, et al. Relationship between erectile dysfunction, comorbidity, and Parkinson's disease: evidence from a population-based longitudinal study. *J Clin Neurol*. 2017;13(3):250–258.

Yurkanin JP, Dean R, Wessells H. Effect of incision and saphenous vein grafting for Peyronie's disease on penile length and sexual satisfaction. *J Urol*. 2001;166:1769–1772 [discussion 1772–1763].

Zeitlin SI, Rajfer J. Hyperprolactinemia and erectile dysfunction. *Rev Urol*. 2000;2:39–42.

Zelefsky MJ, Shasha D, Branco RD, et al. Prophylactic sildenafil citrate improves select aspects of sexual function in men treated with radiotherapy for prostate cancer. *J Urol*. 2014;192(3):868–874.

Zorgniotti AW, Lefleur RS. Auto-injection of the corpus cavernosum with a vasoactive drug combination for vasculogenic impotence. *J Urol*. 1985;133:39–41.

Zumbe J, Porst H, Sommer F, et al. Comparable efficacy of once-daily versus on-demand vardenafil in men with mild-to-moderate erectile dysfunction: findings of the RESTORE study. *Eur Urol*. 2008;54:204–210.

Priapism

Gregory A. Broderick MD

Priapism is a persistent erection arising from dysfunction of the mechanisms regulating penile rigidity and detumescence. A correct diagnosis of priapism is a matter of urgency requiring characterization of the underlying hemodynamics.

Scientific organizations have recommended guidelines for the management of priapism, including the American Urological Association (AUA) in 2003 (http://www.auanet.org), the International Society for Sexual Medicine in 2010 (http://www.issm.info), and the European Association of Urology in 2013 (http://www.uroweb.org). Despite the proliferation of guidelines many urologists express a lack of confidence in the assessment and key steps to emergency management of priapism (Bullock et al., 2018). Guidelines committees have promoted uniform definition for priapism and its subtypes but have provided primarily best practice recommendations rather than evidence-based recommendations. Many of these recommendations were first made in prior editions of this book. The literature on priapism is composed mainly of observational reports, many case reports, and small surgical case series. There are few reports of randomized therapeutic trials. Recent case series have included detailed methodologies: duration of priapism, causes of priapism, medicines and procedures employed in managing priapism, and some erectile function outcomes. The epidemiology, cause, pathophysiology of priapism, and clinical research supporting the most effective treatment strategies are summarized in this chapter.

Defining Priapism

Priapism is a full or partial erection that continues more than 4 hours beyond sexual stimulation and orgasm or is unrelated to sexual stimulation.

Classifying Priapism

Ischemic Priapism (Veno-occlusive, Low-Flow)

Ischemic priapism is a persistent erection marked by rigidity of the corpora cavernosa (CC) and little or no cavernous arterial inflow. In ischemic priapism there are time-dependent changes in the corporal metabolic environment with progressive hypoxia, hypercarbia, and acidosis. The patient typically reports penile pain after 6 to 8 hours, and the examination reveals a rigid erection. The condition is analogous to a muscle compartment syndrome, with initial occlusion of venous outflow and subsequent cessation of arterial inflows. Well-documented histologic changes occur within the corporal smooth muscle as a consequence of prolonged ischemia. **Interventions beyond 36 hours of onset may help relieve erection and pain but have no benefit in preserving potency** (Bennett and Mulhall, 2008). Histologically, by 12 hours corporal specimens show interstitial edema, progressing to destruction of sinusoidal endothelium, exposure of the basement membrane, and thrombocyte adherence at 24 hours. After 48 hours thrombus can be found in the sinusoidal spaces, and smooth muscle necrosis with fibroblast-like cell transformation is evident (Spycher and Hauri, 1986). **Ischemic priapism is an emergency. When left untreated, resolution may take days to weeks, and severe corporal fibrosis and erectile dysfunction (ED) invariably result** (Fig. 70.1).

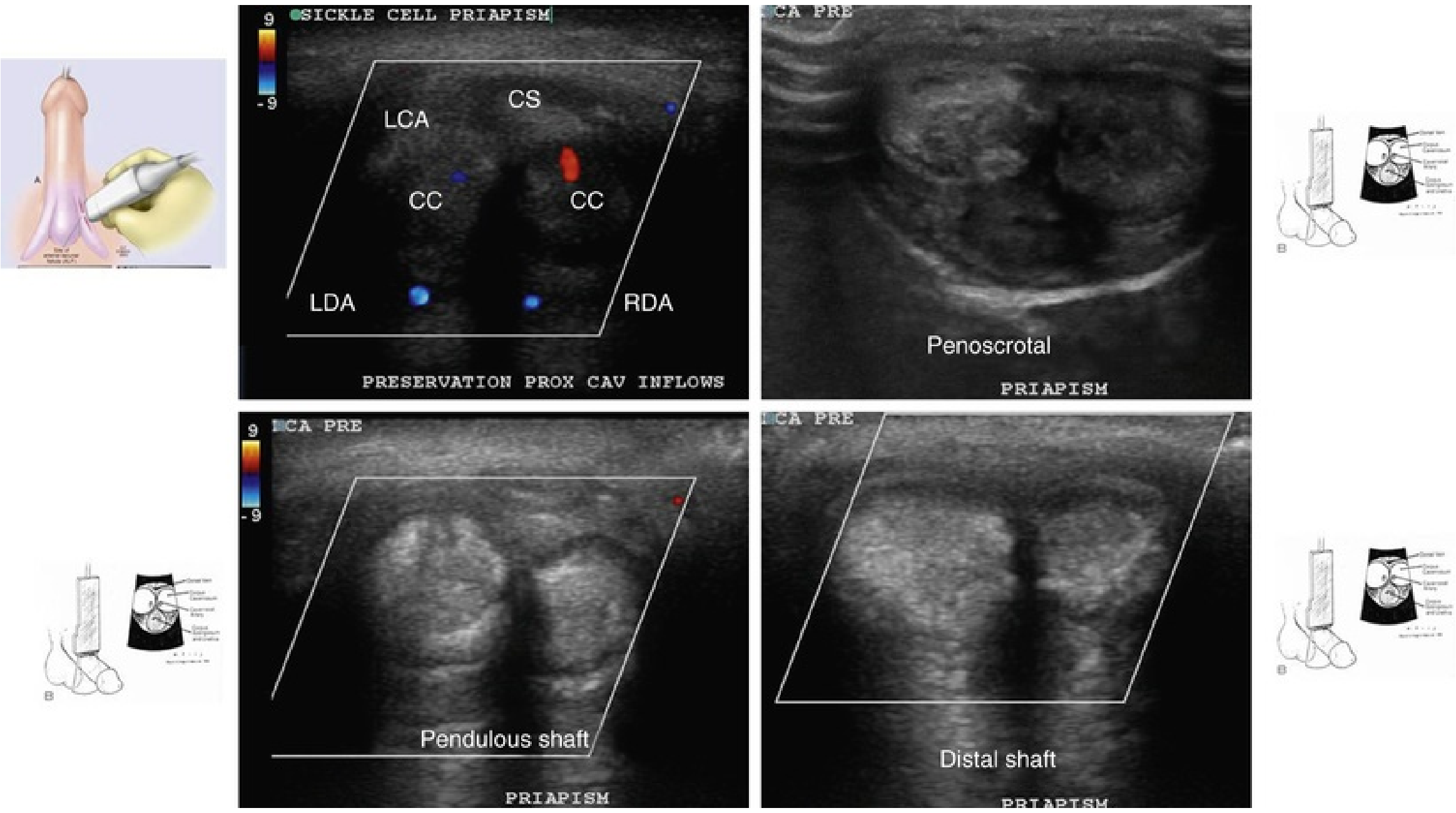
9
SICKLE CELL PRIAPISM
-9
LCA
CS
CC
CC
LDA
RDA
PRESERVATION PROX CAV INFLOWS
CA PRE
Penoscrotal
PRIAPISM
9
CA PRE
-9
Pendulous shaft
PRIAPISM
CA PRE
Distal shaft
PRIAPISM
A
B
B
B

FIG. 70.1 This 21-year-old Nigerian man complained of severe erectile dysfunction after recurrent episodes of sickle cell ischemic priapism. *Top left,* Transperineal imaging with color Doppler shows preservation of cavernous arterial inflow at the crura. *Top right and bottom,* Increasing echogenicity on gray-scale ultrasound of the penile shaft: penoscrotal, pendulous shaft, and distal shaft. These findings are the result of recurring ischemic priapism, which leaves the patient with distal corporal fibrosis. *CC,* Corpus cavernosa; *CS,* corpus spongiosum; *LCA,* left cavernous artery; *LDA,* left dorsal artery; *RDA,* right dorsal artery.

Stuttering Priapism (Intermittent, Recurrent Ischemic Priapism)

Stuttering priapism is characterized by a pattern of recurrence. The term has historically described recurrent unwanted and painful erections in men with sickle cell disease (SCD) (Serjeant et al., 1985). Patients typically awaken with an erection that persists for several hours. Males with SCD may experience stuttering priapism from childhood; in these patients the pattern of stuttering may increase in frequency and duration, leading to a full episode of unrelenting ischemic priapism. Any patient who has experienced an episode of ischemic priapism is also at risk for stuttering priapism (Hoeh and Levine, 2015).

Nonischemic Priapism (Arterial, High Flow)

Nonischemic priapism is a persistent erection caused by unregulated

cavernous arterial inflow. Typically, the corpora are tumescent but not rigid and the penis is not painful. A history of blunt trauma to the perineum or an iatrogenic needle injury is common. Whatever the mechanism of injury, the result is a disruption of the cavernous arterial anatomy creating an arteriolar-sinusoidal fistula. **The cavernous environment does not become ischemic and cavernous blood gases do not show hypoxia, hypercarbia, or acidosis. This type of priapism, once properly diagnosed, does not require emergent intervention.** Beyond the acute trauma, patients do not report pain. Normal erectile function has been reported after recovery from the initial event, despite persistence of nonsexual partial erection (Fig. 70.2).

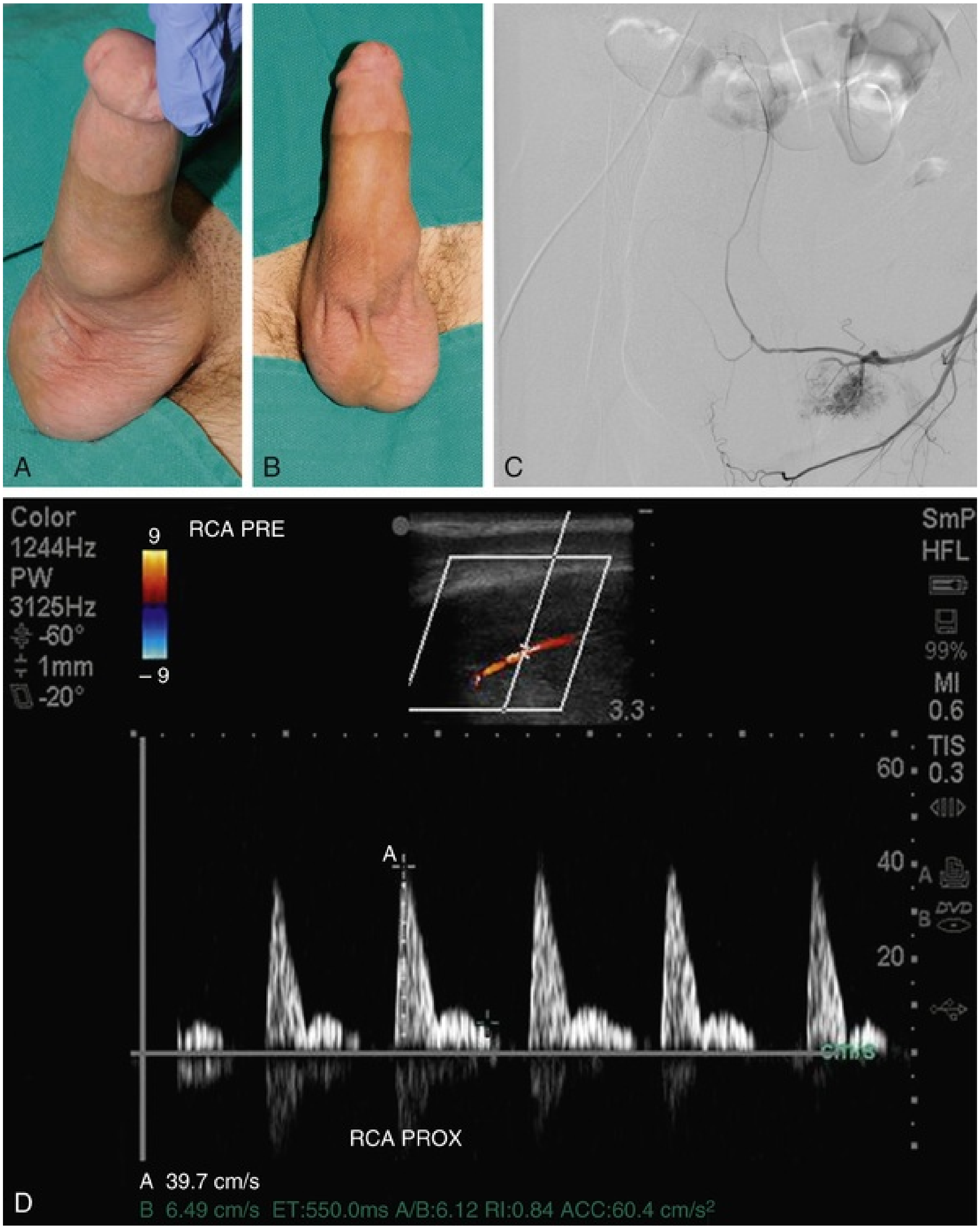
A
B
C
Color
1244Hz
PW
3125Hz
-60°
1mm
-20°
9
– 9
RCA PRE
3.3
SmP
HFL
99%
MI
0.6
TIS
0.3
60
40
20
A
B
A
cm/s
RCA PROX
A 39.7 cm/s
B 6.49 cm/s ET:550.0ms A/B:6.12 RI:0.84 ACC:60.4 cm/s²
D

FIG. 70.2 A 21-year-old man with a history of ischemic priapism after binging with alcohol, marijuana, and energy drinks. Patient had a series of penile shunt procedures performed by different urologists in attempts to reverse ischemic priapism: Winter, Al-Ghorab, and subsequently bilateral corpus cavernosum to corpus spongiosum shunts (note bulging at base of pendulous penis). Six months later he sought evaluation for embarrassing persistent nonpainful partial erection. The history and examination were

consistent with conversion to high-flow state, likely from an arteriolar sinusoidal fistula. (A) Tumescent shaft with glans scar. (B) Penoscrotal bulging at site of cavernospongiosal shunts. (C) Angiogram of fistula originating at the bulbourethral artery. (D) Doppler evaluation without intracavernous vasoactive injection shows a high-flow state: peak systolic velocity of 39 cm/sec and end diastolic flow of 6 cm/sec and resistive index of 84.

Priapism: Historical Perspectives

The term *priapism* has its origin in reference to the Greek god Priapus, who was worshipped as a god of fertility and protector of horticulture. Priapus is memorialized in sculptures for his giant phallus. The first recorded account of priapism in English medical literature appears in the *Lancet* and is attributed to Tripe (1845). Historically, the most commonly cited observation on this condition in North American literature is Frank Hinman Sr.'s landmark article describing the natural history of priapism (Hinman, 1914). Subsequently in 1960 his son, Frank Hinman Jr., postulated that venous stasis, increased blood viscosity, and ischemia were responsible for priapism and emphasized that failure to correct these abnormalities in the penile environment was essentially responsible for treatment nonresponse (Hinman, 1960). Advances in our understanding of the physiology of erection and the pathophysiology of ED substantiated early hypotheses that prolonged veno-occlusion within the corporal bodies is analogous to a compartment syndrome. Hauri et al. (1983) first demonstrated the radiologic differences between veno-occlusive and arterial priapism.

Frank Hinman (1914) first described “acute transitory attacks of priapism” as opposed to persistence or rapid recurrence of a single episode. The actual term *stuttering priapism* is attributed to Emond et al. (1980) in observations of patients with SCD in a Jamaican clinic. Stuttering priapism episodes were seen to increase in frequency and length, leading to major, unrelenting occurrence of ischemic priapism. Attempts to manage SCD patients with stuttering ischemic priapism resulted in the early recommendation for hormonal suppression of nocturnal erections and stuttering with estrogen dosing (Serjeant et al., 1985).

Nonischemic priapism is described far less commonly than ischemic priapism in the urologic literature. **Nonischemic priapism is invariably associated with antecedent perineal or penile trauma.** It was first described in the English literature by Burt et al. (1960). After blunt trauma to the perineum, nonischemic (high-flow) priapism (HFP) is associated with disruption of arteriolar-sinusoidal architecture. At this site a region of unregulated arteriolar flow, commonly referred to as a sinusoidal fistula, develops. **Contemporary literature documents that reversal of ischemic priapism may result in conversion to a high-flow state, secondary to either a post-ischemic hyperemia or direct laceration of a cavernous artery and formation of a high-flow fistula at the**

surgical shunt site (Bertolotto et al., 2009; Lutz et al., 2012; McMahon, 2002, Rodriguez et al., 2006,).

Key Points: Priapism Definitions

- Priapism is a full or partial erection that continues more than 4 hours beyond sexual stimulation and orgasm or is unrelated to sexual stimulation.
- Ischemic (low-flow) priapism is a persistent erection marked by rigidity of the CC with little or no cavernous arterial inflow.
- Nonischemic (arterial, high-flow) priapism is a persistent erection caused by unregulated cavernous arterial inflow. The corpora are tumescent but not rigid, and the erection is not painful.
- Stuttering priapism describes a pattern of recurrence. The term has traditionally described recurrent prolonged and painful erections in men with SCD.

Epidemiology of Priapism

Population-based studies estimate cases per 100,000 person-years (the number of patients with a first episode of priapism divided by the accumulated amount of person-time in the study population). Cases per 100,000 person-years have been calculated in several countries; these data depend on recording of presentations to clinics and hospitals where cases are registered. Kulmala et al. (1995) calculated the cases per 100,000 person-years to be 0.34 to 0.52 from 1975 to 1990 in Finland; Eland et al. (2001) calculated the cases in the Netherlands to be 1.5 per 100,000 person-years; Earle et al. (2003) calculated 0.84 per 100,000 person-years in Australia from 1985 to 2000. These reported incidence rates were significantly affected by the introduction and proliferation of intracavernous vasoactive injections for the management of ED. In Finland during the last 3 years of the study the incidence of priapism doubled to 1.1 cases per 100,000 person-years. These and other reports on the epidemiology and cause of priapism are also greatly influenced by the prevalence of SCD in the populations described. **The lifetime probability of a man with SCD developing ischemic priapism ranges from 29% to 42%** (Emond et al., 1980).

Observation reports in the United States on priapism are evidenced by looking at emergency department data. Two retrospective analyses—the Nationwide Inpatient Sample (NIS) and the Nationwide Emergency Department Sample—provide estimates of the incidence of priapism in the United States. Chrouser et al. (2011) accessed data from the NIS (1998 to 2006). In the sample (4237 hospitalizations), 30% of patients were white, 61.1% were black, and 6.3% were Hispanic; 41.9% of patients had a diagnosis of SCD; and 36.2% of patients required penile surgery. The mean age at time of hospital admission for priapism associated with SCD was 23.8 years and for non-SCD was 40.8 years.

Roghmann et al. (2013) looked at the Nationwide Emergency Department Sample (NEDS). The NEDS includes discharge information on patients, independent of payers. Data were abstracted for the diagnosis of priapism. Between 2006 and 2009 there were 32,462 emergency department visits for priapism. The incidence of priapism in the United States based on this methodology was 5.34 per 100,000 men per year. The incidence of priapism requiring an emergency room visit was 31.4% higher in summer months; 13% of emergency room visits resulted in hospitalizations; 34% of patients were privately insured; 51% were treated in urban teaching hospitals; 13% of adult patients had SCD; 31% of pediatric patients (<18 years old) had SCD. Sickle cell diagnosis was associated with 57% of pediatric admissions and 20% of adult admissions. **This study** (Roghmann et al., 2013) **and others** (Stein et al., 2013) **suggest that in the United States the incidence of priapism is significantly influenced by the prevalence of SCD in a community and that the majority of contemporary cases are being treated in emergency departments as outpatients rather than requiring hospital admissions and presumably surgery.** Sui et al. (2016) looked at readmissions for priapism in the state of New York; they followed a cohort of patients for 12 months after presenting to emergency departments from 2005 to 2014. They found that 24% of patients were re-admitted in 1 year for another episode of priapism; the majority of patients were readmitted within 60 days. Sickle cell disease and an initial hospital stay for priapism were significant risk factors for readmission.

Etiology of Ischemic Priapism (Veno-occlusive, Low-Flow)

Ischemic priapism accounts for the majority of cases described in the literature. The erection of ischemic priapism may begin with sexual stimulation or the administration of pharmacologic agents. **Once an erection persists beyond 4 hours and is not relieved by orgasm or pharmacologic reversal, the pathophysiologic phenomena of ischemic priapism have begun.** Erections lasting up to 4 hours are by consensus defined as “prolonged”; manufacturers of erection-facilitating pharmacotherapies (oral, injectable, and intraurethral) recommend that the patient seek emergent medical consultation for prolonged erection.

Although SCD is a predominant cause of veno-occlusive priapism in the literature, there is a wide variety of reported associations from urinary retention to insect bites (Hoover and Fortenberry, 2004). In 1986 Pohl et al. reported on 230 cases. The cause of priapism was identified as idiopathic in the majority; 21% of cases were associated with alcohol or drug use or abuse, 12% with perineal trauma, and 11% with SCD (Pohl et al., 1986).

Priapism has even been reported after envenomation by arthropods, primarily yellow South American scorpion *Tityus serrulatus* and the Brazilian banana spider, *Phoneutria nigriventer* (Andrade et al., 2008; Nunes et al., 2013; Ravelli et al., 2017; Villanova et al., 2009). The genus *Phoneutria* (from the Greek for “murderess”) has eight species. *P. nigriventer* is known to hide in dark and moist places, wander the jungle floor, and stow away within banana shipments. *P. nigriventer* toxin is a neurotoxin; a variety of mechanisms of action have been implicated: calcium channel–blocking properties, inhibiting glutamate release, sodium channel inactivation, and activation of nitric oxide (NO) synthases. Bites cause intense pain, vascular congestion, loss of muscle control—paralysis, breathing problems—asphyxiation, priapism, and death. Two peptides isolated from the venom of *P. nigriventer* have been directly linked with the induction of persistent and painful erections in mammals (Tx2-5 and Tx2-6) (Leite et al., 2012). The protein has been named *eretina* and has been shown to have a highly specific interference at the molecular level with the NO pathway. Penile erection has been induced in vivo with eretina by direct intraperitoneal injection with a minimum effective dose of 0.006 µg/kg (Andrade et al., 2008). The toxin can induce priapism even in mice after cavernous nerve denervations (Ravelli et al., 2017). One pharmacologic review marvels at the potency of arthropod toxins is entitled *“From the stretcher to the pharmacy's shelf”* (Rates et al., 2011).

Hematologic dyscrasias are a major risk factor for ischemic priapism (Box 70.1). Priapism has been described as a complication of SCD, thalassemia, hereditary spherocytosis, paroxysmal nocturnal hemoglobinuria, glucose-6-phosphate dehydrogenase deficiency, glucose-6-phosphate isomerase deficiency, and congenital dyserythropoietic anemia (Burnett, 2005; Kato, 2012). **Thrombotic disease states have also been cited as precipitants of ischemic priapism;** these conditions include asplenia, erythropoietin use, hemodialysis with heparin use, and cessation of Coumadin therapy. Intracavernous heparin given as a therapy for priapism caused by rebound hypercoagulable states has actually worsened the condition (Bschleipfer et al., 2001; Fassbinder et al., 1976). Lue and Garcia (2013) proposed that postoperative recurrence of priapism may be a thromboembolic event like postoperative thrombosis of vascular grafts; they recommend perioperative anticoagulation be administered to patients having shunt procedures for ischemic priapism.

Box 70.1

Causes of Priapism

α-Adrenergic Receptor Antagonists

Prazosin, terazosin, doxazosin, tamsulosin

Antianxiety Agent

Hydroxyzine

Anticoagulants

Heparin, warfarin

Antidepressants and Antipsychotics

Trazodone, bupropion, fluoxetine, sertraline, lithium, clozapine, risperidone, olanzapine, chlorpromazine, thioridazine, phenothiazines

Antihypertensives

Hydralazine, guanethidine, propranolol

Attention-Deficit/Hyperactivity Disorder Agents

Methylphenidates (Concerta, Daytrana, Focalin, Metadate, Methylin, Quillivant, Ritalin)

Atomoxetine (Strattera)

Recreational Drugs

Alcohol, cocaine (intranasal and topical), crack cocaine, marijuana, synthetic cannabinoids

Genitourinary Conditions

Straddle injury, coital injury, pelvic trauma, kick to penis or perineum, penile bypass surgery, urinary retention

Hematologic Dyscrasias

Sickle cell disease, thalassemia, granulocytic leukemia, myeloid leukemia, lymphocytic leukemia, multiple myeloma, hemoglobin Olmsted variant, fat emboli associated with hyperalimentation, hemodialysis, glucose-6-phosphate dehydrogenase deficiency

Hormones

Gonadotropin-releasing hormone, testosterone

Infectious (Toxin-Mediated) Causes

Scorpion sting, spider bite, rabies, malaria

Metabolic Conditions

Amyloidosis, Fabry disease, gout

Neoplastic Causes (Metastatic or Regional Infiltration)

Prostate, urethra, testis, bladder, rectum, lung, kidney

Neurogenic Conditions

Syphilis, spinal cord injury, cauda equina compression, autonomic neuropathy, lumbar disk herniation, spinal stenosis, cerebral vascular accident, brain tumor, spinal anesthesia, cauda equina syndrome

Vasoactive Erectile Agents

Papaverine, phentolamine, prostaglandin E_1, oral phosphodiesterase type 5 inhibitors, combination intracavernous therapy

Modified from Lue TF: Physiology of penile erection and pathophysiology of erectile dysfunction and priapism. In Walsh PC, Retik AB, Vaughan ED, et al., editors: *Campbell's urology*, Philadelphia, 2002, Saunders, pp 1610–1696.

Priapism may occur in patients with excessive white blood cell (WBC) counts. The incidence of priapism in adult male patients with leukemia is 1% to 5% (Chang et al., 2003). Hyperleukocytosis causes priapism in these patients; it is believed that mechanical pressure on abdominal veins secondary to splenomegaly causes congestion of cavernous outflow and sludging of leukemic cells within the CC. When priapism occurs in the oncology setting, evaluation and management of the predisposing condition must accompany interventions directed at the penis. In hematologic malignancies, leukapheresis and cytotoxic therapy (hydroxyurea, cytosine arabinoside) may reduce the numbers of circulating WBCs (Manuel et al., 2007; Ponniah et al., 2004).

Priapism secondary to metastatic infiltrating solid lesions rather than leukemoid reaction is extremely rare. In most case reports of metastatic priapism, the primary malignancy is genitourinary 69% (Cocci et al., 2016). Cocci et al. (2018) noted that the median cancer-specific survival for patients with penile metastasis was 14 months. Other primary cancers have been described in case reports to metastasize to the penis: testis, kidney, and lung. Metastatic infiltration of the penis may proceed with solid replacement or focal nodules within the CC, glans, and CS. Theoretically, metastatic deposits within the corpora could obstruct venous outflow, resulting in ischemic priapism; metastatic deposits could also disrupt sinusoidal architecture and produce a high flow state. Depending on the status of the patient, metastatic lesions may be managed expectantly, with partial or total penectomy, chemotherapy, or irradiation. These cases are too rarely and poorly described to define best practice recommendations (Broderick et al., 2010; Celma Doménech et al., 2008; Chan et al., 1998; Guvel et al., 2003; Robey and Schellhammer, 1984; Fig. 70.3).

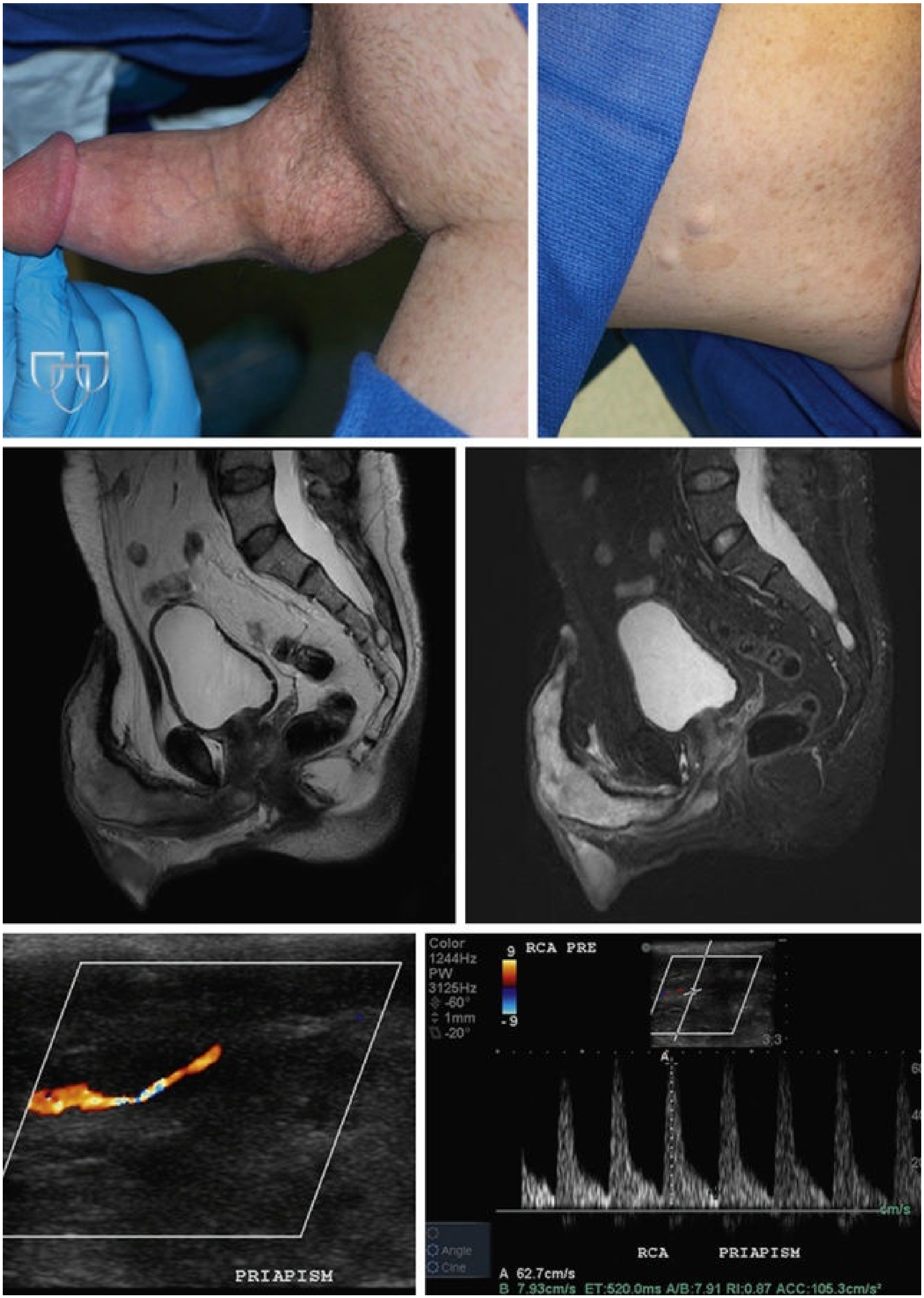
PRIAPISM
Color
1244Hz
PW
3125Hz
-60°
1mm
-20°
9
-9
RCA PRE
3.3
A
cm/s
RCA
PRIAPISM
A 62.7cm/s
B 7.93cm/s ET:520.0ms A/B:7.91 RI:0.87 ACC:105.3cm/s²
Angle
Cine

FIG. 70.3 This is a case of biopsy-proven malignant peripheral nerve sheath tumor (neurofibrosarcoma) arising circumferentially around the base

of the penis in a 60-year-old man with a known history of neurofibromatosis, type I who presented to the urology clinic with a 4-week history of a continuous erection and 4-cm mass. Physical examination demonstrated a 4-cm nodule deforming the base of penis and partial erection. The patient did have pain with deep palpation. Cutaneous neurofibromas are shown on medial thigh. T1 and T2 coronal MRI images show neurofibrosarcoma replacing corpora cavernosa. Penile color Doppler ultrasound was performed establishing high-flow priapism with elevated peak systolic velocities, elevated end diastolic velocities, but no evidence of an arterial sinusoidal fistula.

Sickle Cell Disease

Blood dyscrasias are a risk factor for ischemic priapism. SCD priapism has traditionally been ascribed to stagnation of blood within the sinusoids of the CC during physiologic erection, secondary to obstruction of venous outflow by sickled erythrocytes (Lue, 2002). Nelson and Winter (1977) described a series of cases in which SCD was the primary cause of ischemic priapism in 23% of adults and 63% of children. **Sickle cell hemoglobinopathy accounts for at least one-third of all cases of priapism,** and, indeed, prevalence of ischemic priapism varies significantly within the population of males in a community with SCD. **From Emond et al.'s 1980 observational study comes the most commonly quoted incidence: among 104 men attending an outpatient sickle cell clinic in Kingston, Jamaica, the incidence of priapism in men with homozygous sickle cell disease (SCD) was 42**. In a US clinical series, Tarry et al. (1987) found that 6.4% of male children in an outpatient sickle cell clinic had a history of priapism. Adeyoju et al. (2002), in an international multicenter observational study of SCD, mailed or interviewed 130 patients attending SCD clinics in the United Kingdom and Nigeria. Respondents ranged in age from 4 to 66 years old, with a mean age of 25. The authors cited mean age of onset of priapism as 15 years, with 75% of patients having their first episode before age 20 and rare first-time presentations by the third decade of life. In the questionnaires a clear distinction was made between acute severe prolonged priapism lasting longer than 24 hours requiring emergency attention and stuttering recurrent priapism of shorter and self-limiting duration. In this population the incidence of acute priapism was 35%; of these patients, 72% gave a history of stuttering priapism. The median frequency of occurrence of stuttering priapism was three times per month; the median duration of each episode was 1.2 hours, with the longest being 8 hours. Precipitating events reported from greatest to least were sexual arousal or intercourse, fever, sleep, cold weather, and dehydration. Self-administered regimens were analgesics, drinking water, and exercise. Twenty-one percent of patients reporting a history of priapism also reported ED. Surprisingly only 7% of young men who had not experienced priapism were even aware that priapism was a potential complication of their SCD. On the basis of the World Health Organization global prevalence map of SCD, Aliyu et al. (2008) estimated that 20 to 25 million individuals worldwide have homozygous SCD: 12 to 15 million in sub-Saharan Africa, 5 to 10 million in India, and 3 million in other world regions. They also found that 70,000 patients with SCD live in the United States (Aliyu et al., 2008).

The sickle cell genetic mutation is the result of a single amino acid substitution in the β-globin subunit of hemoglobin S (HbS). The molecular lesion is a point mutation (GAG substituted for GTG) in exon 1 of the β globin gene; this results in substitution of glutamic acid by valine on the β globin polypeptide chain (Ballas et al., 2012)**. Clinical features are seen in homozygous SCD patients: chronic hemolysis, vascular occlusion, tissue ischemia, and end-organ damage.** HbS polymerizes when deoxygenated, injuring the sickle erythrocyte, activating a cascade of hemolysis and vaso-occlusion. Membrane damage results in dense sickling of red cells, causing adhesive interactions among sickle cells, endothelial cells, and leukocytes. Hemolysis releases hemoglobin into the plasma. Free hemoglobin reacts with NO to produce methemoglobin and nitrate. This is a scavenging reaction; the vasodilator NO is oxidized to inert nitrate. Sickled erythrocytes release arginase-I into blood plasma, which converts L-arginine into ornithine, effectively removing substrate for NO synthesis. Oxidant radicals further reduce NO bioavailability. The combined effects of NO scavenging and arginine catabolism result in a state of NO resistance and insufficiency termed *hemolysis-associated endothelial dysfunction* (Aliyu et al., 2008; Kato et al., 2007; Kuypers, 2014; Morris et al., 2005; Rother et al., 2005).

Contemporary science implicates hemolysis and reduced NO in the pathogenesis of pulmonary hypertension, leg ulcers, priapism, and stroke in patients with SCD, whereas increased blood viscosity is believed to be responsible for painful crises, osteonecrosis, and acute chest syndrome (Kato, 2012; Kato et al., 2006). Patients with SCD and priapism have a fivefold greater risk of developing pulmonary hypertension. **SCD priapism is also associated with reduced hemoglobin levels and increased hemolytic**

markers: reticulocyte count, bilirubin, lactate dehydrogenase (LDH), and aspartate aminotransferase. Cerebral vascular accidents are more frequent, close to episodes of full-blown priapism; the ASPEN syndrome (association of SCD, priapism, exchange transfusion, and neurologic events) describes cerebral vascular accidents in patients with SCD who have received exchange transfusions (Merritt et al., 2006; Siegel et al., 1993). One series of 136 adult patients with SCD admitted to the intensive care unit (ICU) noted the most common types of crises were severe pain, acute chest syndrome, and infection; 12% of patients were nonsurvivors; thrombocytopenia is more common than thrombocytosis in severe sickle cell crisis (Shome et al., 2018). Sickle cell trait is considered a benign condition; a few complications have been associated with extreme physical exertion. There have been case reports of sickle cell trait as the predisposing factor to ischemic priapism (Birnbaum and Pinzone, 2008; Larocque and Cosgrove, 1974).

Iatrogenic Priapism: Intracavernous Injections

Prolonged erection is more commonly reported than is priapism after therapeutic or diagnostic injection of intracavernous vasoactive medications (Broderick and Lue, 2002; Coombs et al., 2012). Despite the introduction of effective oral medications for ED in 1998, intracavernous injection (ICI) remains an important therapeutic option for men with severe ED in whom a phosphodiesterase type 5 (PDE5) inhibitor fails or who cannot take PDE5 inhibitors because they require nitrates. In many communities patients receiving intracavernous medications for ED will outnumber patients with SCD. **Priapism after ICI is a problem all urologists will encounter and must be prepared to manage.** In a review of worldwide reports on ICI programs, Junemann et al. (1990) noted that diagnostic injection resulted in 5.3% of men getting ischemic priapism, and 0.4% of men reported priapism after injecting at home. In papaverine-based ICI programs, reports of prolonged erections and priapism are poorly distinguished and range from 0 to 35% (Broderick and Lue, 2002). In worldwide clinical trials of the Alprostadil Study Group, prolonged erection (defined as 4 to 6 hours) was described in 5% of patients, and priapism (longer than 6 hours) in 1% (Porst, 1996). In the United States the approved label and package insert for one product (alprostadil [Caverject]) cites the frequency of prolonged erection (4 to 6 hours) as 4% and frequency of priapism as 0.4%. The label recommends that “to minimize chances of prolonged erection or priapism Caverject should be titrated slowly to the lowest effective dosage.”

Combinations of papaverine/phentolamine/alprostadil commonly referred to as Trimix is the most popular mixture used in ICI programs. In a single-center 5-year retrospective study of 1412 patients, Coombs et al. (2012) noted that 89% of men were using Trimix with significant dropout rates but an overall low rate of priapism (0.5%).

Similar to the clinical trials of Caverject (alprostadil), in clinical trials of Edex (alprostadil) erection lasting longer than 4 hours was reported by 4% of subjects followed for 24 months. Priapism in Edex trials was defined as erection lasting longer than 6 hours; the incidence of priapism was less than 1%. Package inserts approved for marketing Alprostadil injections in the United States contraindicate PGE1 injections for men with sickle cell anemia, sickle cell trait, multiple myeloma, and leukemia.

Injection therapy with alprostadil was first approved in the United States in 1996 and has long since moved out of the spotlight of scientific trials. Neither time nor the introduction of PDE5 inhibitor therapy has completely eclipsed penile injections. Penile injections are the primary alternative offered men who fail or are not satisfied with oral drugs and are the main therapeutic agent offered by men's health clinics. In this author's professional experience the majority of these clinics either fail to do dosage titration in the office or simply “oversell” penile injections, resulting in significantly higher prolonged erection and priapism rates. In a retrospective series from China 214 men were followed for nearly 10 years on alprostadil injections (He et al., 2011). As had been shown in earlier studies dropout rates are significant: 51% of men continue to use treatment for more than 1 year, 6% more than 5 years, 2.9% more than 8 years, and only 1.7% of men were still using penile injectables at 10 years. Major complications identified were pain associated with injection, ecchymosis at injection site, and corporal fibrosis. The authors report that none of the patients in the series required treatment for priapism.

Iatrogenic Priapism: Oral Phosphodiesterase Type 5 Inhibitors, Medications for Attention-Deficit/Hyperactivity Disorder, and Nutritional Supplements for Erectile Dysfunctions

All PDE5 inhibitors have similar side effects related directly to their mode of action, tissue content of substrate, and pharmacologic selectivity for type 5 inhibition versus other phosphodiesterase enzymes. Side effects occurring in 2%

or more of patients include headache, flushing, dyspepsia, rhinitis, light sensitivity, and myalgia. Morales et al. (1998) analyzed data from 4274 men who received double-blind treatment with sildenafil or placebo for up to 6 months and 2199 who received long-term open-label sildenafil for up to 1 year. No cases of priapism (erection lasting longer than 4 hours) were reported. No cases of priapism were reported by Montorsi et al. (2004) in a multicenter, open-label, 24-month extension of 8- or 12-week double-blind, placebo-controlled studies assessing the long-term efficacy, safety, and tolerability of tadalafil in 1173 men with ED. Nonetheless, the **indications and usage section of the US Food and Drug Administration (FDA)–approved product labeling (US prescribing information [USPI]) for PDE5 inhibitors** does contain this warning: **“There have been rare reports of prolonged erection greater than 4 hours and priapism (painful erections >6 hours duration) for this class of compounds.”** The USPI and European Summary of Product Characteristics label information contains warning or precautionary language about the use of these agents in men who have conditions predisposing them to priapism. The FDA approved Cialis (tadalafil) as an oral treatment for ED (2.5 mg, 5 mg, 10 mg, and 20 mg) in 2003. Once-daily tadalafil (2.5 mg and 5 mg) was approved for oral treatment of ED in 2008, and subsequently in 2011 tadalafil (2.5 mg and 5 mg) was approved for the signs and symptoms of benign prostatic hyperplasia (BPH) and treatment of ED. Tadalafil 5 mg daily caused no priapism in a phase 2 clinical study of 281 men with history of lower urinary tract symptoms secondary to BPH for 6 weeks, followed by dosage escalation to 20 mg once daily for 6 weeks (McVary et al., 2007). **The 2013 label for the most recently approved PDE5 inhibitor, Stendra (avanafil 50 mg, 100 mg, 200 mg), contains almost identical precautionary wording as prior labels for as-needed (PRN) oral forms of sildenafil, vardenafil, and tadalafil: “There have been rare reports of prolonged erection greater than 4 hours and priapism (painful erections greater than 6 hours).”**

From 1999 to 2007 there were at least nine case-based reports of oral PDE5 inhibitor use and adult priapism and at least one pediatric patient (Aoyagi et al., 1999; Galatti et al., 2005; Goldmeier, 2002; Kassim et al., 2000; King et al., 2005; Kumar et al., 2005;McMahon, 2003; Sur and Kane, 2000; Wilt and Fink, 2004; Wills et al., 2007). **Most case reports detailing priapism after use of a PDE5 inhibitor reveal histories of increased risk for priapism: SCD, SCI, use of a PDE5 inhibitor recreationally, use of a PDE5 inhibitor in combination with ICI, history of penile trauma, use of psychotropic**

medications, or use of recreational drugs (cocaine). Wills et al. (2007) described a 19-month-old boy weighing 10 kg who accidentally ingested up to six tablets of sildenafil 50 mg. The child had persistent sinus tachycardia and partial erection for 24 hours; the authors presume this was a high-flow priapism (HFP) because the shaft was neither completely rigid nor painful. Erection in the child subsided spontaneously after overnight intravenous hydration and observation.

In 2013 the FDA issued a warning that methylphenidate medications used in the treatment of attention-deficit/hyperactivity disorder (ADHD) may result in prolonged erection or priapism. The FDA also warns that atomoxetine, another ADHD drug, has been linked to reports of priapism in children, teens, and adults. Drug therapy in ADHD is used in children, adolescents, and adults to increase the ability to pay attention and decrease impulsiveness and hyperactivity. The 2012 Summary Health Statistics for US Children: National Health Interview Survey (Bloom et al., 2013) estimated that more than 6.4 million children ages 4 to 17 have been diagnosed with ADHD; this represents a 41% increase over a decade. The Centers for Disease Control and Prevention (CDC, 2013) further estimate that two-thirds of these children are prescribed methylphenidate medications.

Methylphenidate is a central nervous system stimulant; atomoxetine is a selective norepinephrine reuptake inhibitor. The FDA cautions that physicians may be tempted to switch patients from methylphenidate medications to atomoxetine but that priapism is actually more common in patients taking atomoxetine (US Food and Drug Administration, 2013). **The median age of male patients taking methylphenidate who developed priapism (erection lasting longer than 4 hours) was 12½ years.**

Dietary supplements to enhance erectile function or treat erectile dysfunction have become increasingly popular. These are available over-the-counter and through the Internet. Serial investigations by the Food and Drug Administration have identified that these products may contain prescription levels of the drugs Sildenafil the principal ingredient in Viagra or thiosildenafil, the active ingredient in Cialis. These products are marketed as herbal alternatives that are safe and reliable. There is an emerging trend to seek out nutraceuticals as an alternative to prescription medications. The Center for Drug Evaluation and Research (FDA CDER) has tested more than 300 nutraceuticals for male sexual enhancement finding unlabeled active ingredients (sildenafil or thiosildenafil) at varying dosages. Because of poor quality control active drug concentrations were found to vary from pill to pill in one bottle (Ahmed et al., 2017; ElAmrawy et al., 2016; Nounou et al., 2018, US Food and Drug Administration, 2015).

Key Points: Ischemic Priapism as a Complication of Erectile Dysfunction Therapy

- Prolonged erection is more commonly reported than priapism after therapeutic or diagnostic injection of intracavernous vasoactive medications.
- In worldwide clinical trials of alprostadil, prolonged erection (defined as 4 to 6 hours) occurred in 5% of administrations, and priapism (longer than 6 hours) in 1%.
- In clinical practice, ICI of Trimix (papaverine, phentolamine, and alprostadil) results in prolonged erections in 5% to 35% of administrations.
- Few case reports have documented priapism after PDE5 inhibitor therapy. These reports suggest that men were at increased risk for priapism because of SCD, spinal cord injury, use of a PDE5 inhibitor recreationally, use of a PDE5 inhibitor in combination with ICI, history of penile trauma, use of psychotropic medications, or abuse of narcotics.
- Methylphenidate medications and atomoxetine used in the treatment of ADHD may result in prolonged erection or priapism.

Etiology of Stuttering Priapism (Recurrent Ischemic Priapism)

Stuttering (intermittent) priapism describes a pattern of recurrent priapism. The term has traditionally been used to describe recurrent unwanted and painful erections in men with SCD. **Patients typically awaken with an erection that persists up to 4 hours and becomes progressively painful secondary to ischemia. Patients with SCD may experience stuttering priapism from childhood. Any patient who has experienced ischemic priapism is at risk for stuttering priapism. Patients with stuttering priapism will experience repeated painful intermittent attacks up to several hours before remission.** Affected young men suffer embarrassment, sleep deprivation, and performance anxiety with sexual partners (Chow and Payne, 2008). In a study of 130 patients with SCD, Adeyoju et al. (2002) reported that 46 (35%) had a history of priapism and, of these, 33 (72%) had a history of stuttering priapism. In 75% of patients the first episode of stuttering priapism occurred before the age of 20. Two-thirds of males with SCD ischemic priapism at presentation will describe prior stuttering attacks (Jesus and Dekermacher, 2009). **Commonly reported precipitants of full-blown SCD priapism are stuttering nocturnal or early morning erections, dehydration, fever, and exposure to cold** (Broderick, 2012). Sleep-related erections (SREs) take place during REM sleep. SREs are natural phenomena and appeared to be androgen dependent. The exact duration of nocturnal penile tumescence or normal sleep erections is indeterminate. SREs should occur in men who are eugonadal and have physiologically normal penile blood flow. Several others have noted that SCD patients complain of SREs lasting 3 to 4 hours associated with pain but not necessarily other stigmata of sickle cell crisis (Hoeh and Levine, 2015; Rachid-Filho et al., 2009).

Etiology and Pathophysiology of Nonischemic (Arterial, High-Flow) Priapism

HFP is a persistent erection caused by unregulated cavernous arterial inflow. The epidemiologic data on nonischemic priapism is almost exclusively derived from small case series or individual case reports**. Nonischemic priapism is much rarer than ischemic priapism, and the cause is largely attributed to trauma. Forces may be blunt or penetrating, resulting in laceration of the cavernous artery or one of its branches within the corpora. The cause most commonly reported is a straddle injury to the crura. Other mechanisms include coital trauma, kicks to the penis or perineum, pelvic fractures, birth canal trauma to the newborn male, needle lacerations, complications of penile diagnostics, and vascular erosions complicating metastatic infiltration of the corpora** (Brock et al., 1993; Burgu et al., 2007; Dubocq et al., 1998; Jesus and Dekermacher, 2009; Witt et al., 1990). Although accidental blunt trauma is the most common cause, **HFP has been described after iatrogenic injury from cold-knife urethrotomy, Nesbitt corporoplasty, and deep dorsal vein arterialization** (Liguori et al., 2005; Wolf and Lue, 1992). Any mechanism blunt or penetrating that lacerates a cavernous arteriole can produce unregulated pooling of blood in sinusoidal space with consequent erection. Nonischemic priapism is typically delayed in onset compared with the episode of blunt trauma (Ricciardi et al., 1993). **Sustained partial erection may develop 24 hours after**

perineal or penile blunt trauma. It is believed that the hemodynamics of a nocturnal erection disrupts the clot and the damaged artery or arteriole ruptures; the unregulated arterial inflow creates a arteriole-lacunar fistula. As healing progresses with clearing of clot and necrotic smooth muscle tissue, the fistula forms a pseudocapsule. **Formation of a pseudocapsule at the site of fistula may take several weeks to months.**

Contemporary reports suggest that HFP may have a unique subvariety. **Several authors have noted that after either aggressive medical management of ischemic priapism α-adrenergic injection/aspiration protocols or surgical shunting, priapism may rapidly recur with conversion from ischemia to high flow.** HFP has been reported after aspiration and injection of α-adrenergics in the management of ischemic priapism (Bertolotto et al., 2009; McMahon, 2002; Rodriguez et al., 2006). Color Doppler ultrasonography (CDU) has shown formation of an arteriolar-sinusoidal fistula at the site of intervention (needle laceration or shunt site) (see Fig. 70.2). **Secondary HFP should be suspected in patients in whom rapid recurrence, persistence of erection with partial penile rigidity, not associated with pain is evident. Non-fistula type of arterial priapism is the result of dysregulation of cavernous inflows, a post-ischemic hyperemia.** Non-fistula arterial priapism is a rare complication after management of ischemic priapism (Cruz Guerra et al., 2004; Seftel et al., 1998;Wallis et al., 2009). Penile tenderness to palpation is easily confused with the ongoing ache of persistent ischemia. Soft-tissue edema and ecchymosis render the physical examination findings equivocal after medical and surgical maneuvers to alleviate priapism. Dysregulated arterial inflows with or without a fistula can best be distinguished from persistent ischemic priapism by CDU.

Key Points: High-Flow Priapism

- Nonischemic priapism is much rarer than ischemic priapism.
- HFP results from laceration or disruption of a cavernous artery or arteriole.
- The most common cause is a straddle injury to the crura (bicycle accidents in children).
- Other mechanisms include coital trauma, kicks to the penis or perineum, pelvic fractures, birth canal trauma to the male newborn, needle lacerations,

complications of penile diagnostics, and vascular erosions complicating metastatic infiltration of the corpora.

- HFP has been described after iatrogenic trauma from cold-knife urethrotomy, corporoplasty, and penile revascularization procedures.

Priapism in Children

Priapism in children and adolescents is most commonly related to SCD. The literature suggests that the incidence of priapism in pediatric sickle cell clinics is 2% to 6% (Jesus and Dekermacher, 2009; Tarry et al., 1987). Adeyoju et al. (2002) conducted a multicenter study of patients with SCD and found that, among 130 males ages 4 to 66, 35% had experienced priapism and more than 70% had experienced stuttering priapism. Donaldson et al. (2014), in a comprehensive review of priapism in children, estimated that SCD is responsible for 65% of cases, leukemia 10%, and trauma 10%.

In the newborn period, fetal hemoglobin predominates, not HbS (Burgu et al., 2007). SCD phenotypes related to ischemic or occlusive crises are unlikely to be evident while fetal hemoglobin persists. Newborn priapism is an extremely rare phenomenon with only limited case reports and rare application of contemporary diagnostic modalities. Erection is frequently elicited in males during the newborn period. In male newborns, simple tactile stimulation such as diaper changing, bathing, and urethral catheterization may result in erection; the erection quickly subsides after cessation of stimuli. Fewer cases of newborn priapism have been reported in the literature and rarely has the cause been defined. Causes have included polycythemia, blood transfusion, and birth canal trauma (Amlie et al., 1977; Karakaya et al., 2016; Leal et al., 1978; Shapiro, 1979; Walker and Casale, 1997). The majority of cases have been conservatively managed with spontaneous resolution reported from hours to days. Minimally invasive diagnostics (CDU) should be performed (Meijer and Bakker, 2003; Pietras et al., 1979). In children who develop priapism after straddle trauma, every effort should be made to localize the arteriolar-sinusoidal fistula. Hatzichristou et al. (2002) reported that identification of the fistula by Doppler ultrasound coupled with direct manual compression softens the high-flow erection and may speed spontaneous resolution. They suggested that this noninvasive therapy likely works in children and not adults because the perineum has considerably less subcutaneous fat and because crural bodies are more easily compressed. **In children HFP is most commonly reported**

secondary to blunt perineal trauma. A recent case report of cycling trauma causing arterial priapism identified 12 similar cases in the literature (De Rose et al., 2016). De Rose noted that the delay in presentation may be related to the patient's embarrassment and failure to disclose the primary injury and the subsequent priapism to parents. They describe the efficacy of noninvasive color Doppler ultrasonography (CDU) and magnetic resonance angiography in the assessment of children. **Before proceeding to angiographic embolization of high-flow priapism in children, the urologist should give consideration to the reports that HFP may spontaneous resolve and/or respond to the conservative measure of perineal compression and ice.**

Molecular Basis of Ischemic and Stuttering Priapism

Advances in our understanding of the molecular basis of priapism have drawn significantly from in vitro and in vivo experimental studies using animal models. Data on the true inciting mechanisms involved in ischemic priapism are emerging. **Ischemic priapism consists of an imbalance of vasoconstrictive and vasorelaxatory mechanisms predisposing the penis to hypoxia and acidosis. In vitro studies have demonstrated that when corporal smooth muscle strips and cultured corporal smooth muscle cells are exposed to hypoxic conditions, α-adrenergic stimulation fails to induce corporal smooth muscle contraction** (Broderick and Harkaway, 1994; Muneer et al., 2005; Saenz de Tejada et al., 1997). Extended periods of severe anoxia significantly impair corporal smooth muscle contractility and cause significant apoptosis of smooth muscle cells and, ultimately, fibrosis of the CC.

In experimental animal models of ischemic priapism, lipid peroxidation, an indicator of injury induced by reactive oxygen species (ROSs), and increased hemo-oxygenase expression occur in the penis during and after ischemic priapism (Jin et al., 2008; Munarriz et al., 2003). Additional pathophysiologic mechanisms involved in the progression of ischemia-induced fibrosis are the upregulation of hypoxia-induced growth factors. Transforming growth factor-β (TGF-β) is a cytokine that is vital to tissue repair. However, excess amounts may induce tissue damage and scarring. Upregulation of TGF-β occurs during hypoxia and in response to oxidative stress (Jin et al., 2008; Moreland et al., 1995). It is hypothesized that TGF-β may be involved in the progression of the corporal smooth muscle to fibrosis (Bivalacqua et al., 2000; Jeong et al., 2004).

Transgenic mouse models of SCD manifest priapism (Beuzard, 1996; Bivalacqua et al., 2009b). There have been two major discoveries in elucidation of the molecular mechanism of ischemic priapism. Mi et al. (2008) have shown that transgenic sickle cell mice CC have enhanced smooth muscle relaxation to electrical field stimulation. Transgenic sickle cell mice and mice lacking endothelial NO synthase (eNOS) gene expression display supraphysiologic erections and spontaneously phasic priapic activity in vivo (Bivalacqua et al., 2006, 2007).

Endothelial cells actively regulate basal vascular tone and vascular reactivity by responding to mechanical forces and neurohumoral mediators with the release of a variety of relaxing and contracting factors. In the penis the vascular endothelium is a source of vasorelaxing factors such as NO and adenosine, as well as vasoconstrictor factors such as RhoA/Rho-kinase. Recent evidence suggests that in states of priapism there may be aberrant NO and adenosine signaling, thus identifying a potential role for NO/cyclic guanosine monophosphate (cGMP), as well as adenosine and RhoA/Rho-kinase signaling in the pathophysiology of ischemic priapism (Bivalacqua et al., 2009a; Champion et al., 2005; Mi et al., 2008).

eNOS knockout mice have an exaggerated erectile response to cavernous nerve stimulation and have phenotypic changes in erectile function consistent with priapism (Bivalacqua et al., 2006; Champion et al., 2005). Mice lacking the *eNOS* gene manifest a priapism phenotype through mechanisms involving defective PDE5 regulatory function in the penis, resulting from altered endothelial NO/cGMP signaling in the organ (Bivalacqua et al., 2006; Lin et al., 2003). Supporting this hypothesis, PDE5 expression is significantly reduced in corpora cavernosa smooth muscle cells (CCSMCs) grown under anoxic and hypoxic cell culture conditions (Lin et al., 2003). **In the context of molecular dysregulation, the cyclic nucleotide cGMP is produced in low steady-state amounts under the influence of priapism-related destruction of the vascular endothelium and thus reduced endothelial NO activity; this situation downregulates the set point of PDE5 function, secondary to altered cGMP-dependent feedback control mechanisms** (Bivalacqua et al., 2006; Burnett and Bivalacqua, 2007; Champion et al., 2005)**. When NO is neuronally produced in response to natural erectogenic stimuli or with nocturnal erections, cGMP production surges in a manner that leads to excessive erectile tissue relaxation because of basally insufficient PDE5 enzyme to degrade the cyclic nucleotide. In addition, reduced Rho-kinase activity (contractile mediator) may contribute to the susceptibility of corporal tissue to excessive relaxation via two distinct molecular mechanisms. Two distinct molecular mechanisms appear to act in concert to promote stuttering ischemic priapism: enhanced vasorelaxation by uninhibited cGMP and diminished contractile effects of Rho-kinase.** Transgenic sickle cell mice also have significant reductions in penile NO/cGMP signaling leading to deficient PDE5 expression and activity, as well as reduced RhoA/Rho-kinase expression, which causes them to manifest enhanced erectile responses and recurrent priapism (Champion et al., 2005). Another potential cause of enhanced corporal smooth muscle relaxation in SCD-associated priapism is elevated penile adenosine levels, which cause the CC to be in a chronically vasodilated state (Mi et al., 2008). **Taken together, these data suggest that recurrent ischemic priapism results from NO imbalance resulting in aberrant molecular signaling, PDE5 dysregulation, adenosine overproduction, and reductions in Rho-kinase activity, translating into enhanced corporal smooth muscle relaxation and inhibition of vasoconstriction in the penis** (Anele et al., 2015; La Favor et al., 2018).

Key Points: Sickle Cell Disease and Priapism

- Sickle cell hemoglobinopathy accounts for at least a third of all cases of ischemic priapism.
- The sickle cell genetic mutation is the result of a single amino acid substitution in the β-globin subunit of hemoglobin.
- Clinical features are seen in patients with homozygous SCD: chronic hemolysis, vascular occlusion, tissue ischemia, and end-organ damage.
- Hemolysis and reduced NO bioavailability are central in the pathogenesis of pulmonary hypertension, leg ulcers, priapism, and stroke in patients with SCD.
- Increased blood viscosity is responsible for painful crises, osteonecrosis, and acute chest syndrome.
- SCD patients may experience stuttering priapism from childhood.
- SCD patients with stuttering priapism will experience repeated painful intermittent attacks up to several hours before remission.
- Stuttering priapism in SCD is the result of molecular dysregulation with enhanced corporal smooth muscle vasorelaxing forces (secondary to reduced basal levels of PDE5-Inh) and inhibition of vasocontractile forces in the penis.

Evaluation and Diagnosis of Priapism

History

To initiate appropriate management, the physician must determine whether the underlying priapism hemodynamics are ischemic or nonischemic. **Emergency management of ischemic priapism is recommended** (Fig. 70.4). Ischemia should be suspected when the patient has progressive penile pain associated with the duration of erection; has used a known drug associated with priapism; has SCD or another blood dyscrasia; or has a known neurologic condition, especially those affecting the spinal cord. Stuttering priapism history is one of recurrent episodes of prolonged erections, usually nonresolving morning erections. **Nonischemic priapism should be suspected when** there is no pain and the erection duration has not been accompanied by progressive discomfort. There is a history of straddle injury, coital trauma, blunt trauma to the penis or perineum, penile injection, penile surgery, or a diagnostic procedure of the pelvic and penile vessels. The onset of post-traumatic HFP in adults and children may be delayed by hours to several days after the initial injury (Box 70.2).

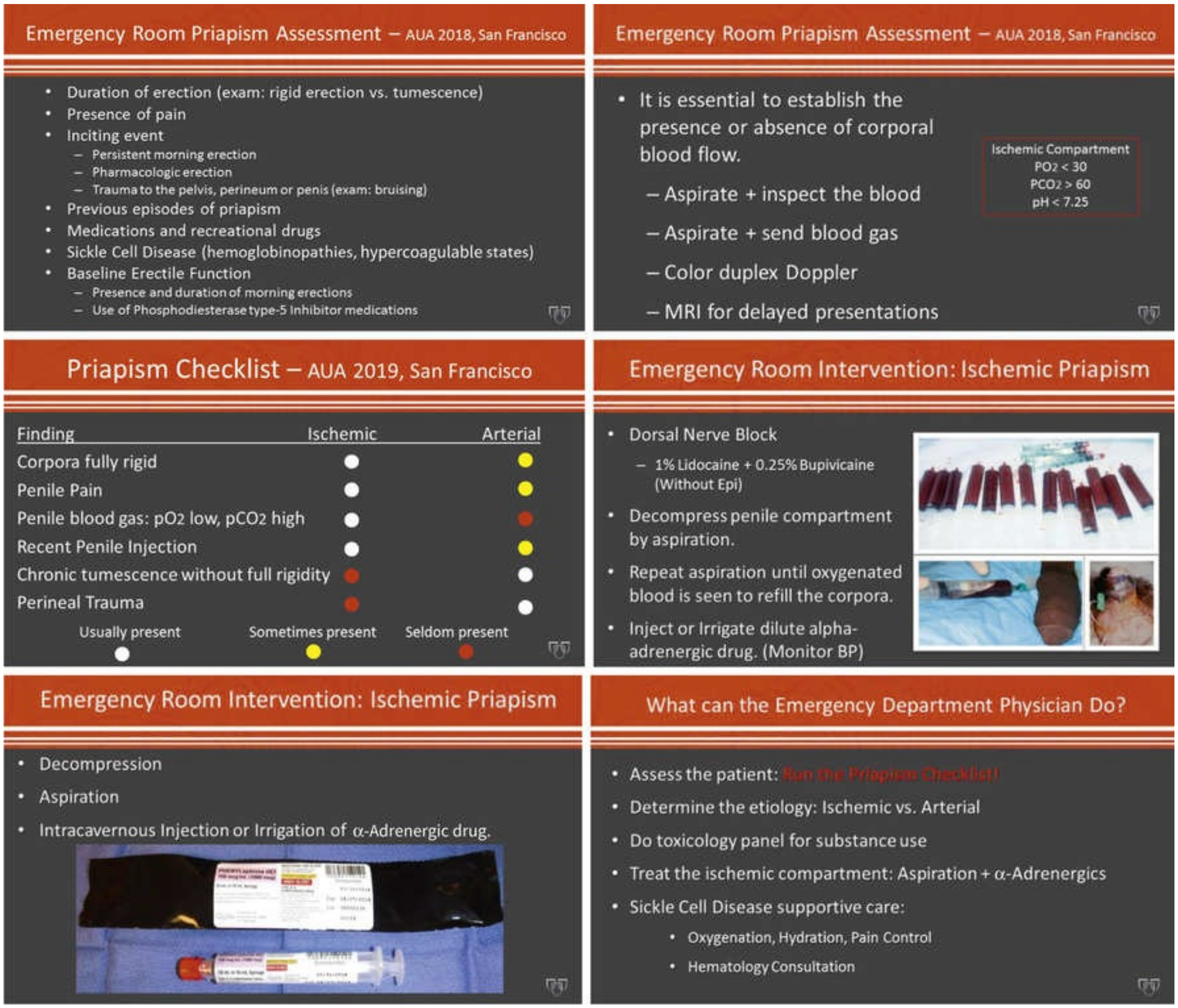

Emergency Room Priapism Assessment – AUA 2018, San Francisco

- Duration of erection (exam: rigid erection vs. tumescence)
- Presence of pain
- Inciting event
  - Persistent morning erection
  - Pharmacologic erection
  - Trauma to the pelvis, perineum or penis (exam: bruising)
- Previous episodes of priapism
- Medications and recreational drugs
- Sickle Cell Disease (hemoglobinopathies, hypercoagulable states)
- Baseline Erectile Function
  - Presence and duration of morning erections
  - Use of Phosphodiesterase type-5 Inhibitor medications

Emergency Room Priapism Assessment – AUA 2018, San Francisco

- It is essential to establish the presence or absence of corporal blood flow.
  - Aspirate + inspect the blood
  - Aspirate + send blood gas
  - Color duplex Doppler
  - MRI for delayed presentations

Ischemic Compartment
$PO_2 < 30$
$PCO_2 > 60$
$pH < 7.25$

Priapism Checklist – AUA 2019, San Francisco

Finding	Ischemic	Arterial
Corpora fully rigid	⚪	🟡
Penile Pain	⚪	🟡
Penile blood gas: pO_2 low, pCO_2 high	⚪	🔴
Recent Penile Injection	⚪	🟡
Chronic tumescence without full rigidity	🔴	⚪
Perineal Trauma	🔴	⚪

Usually present ⚪ Sometimes present 🟡 Seldom present 🔴

Emergency Room Intervention: Ischemic Priapism

- Dorsal Nerve Block
  - 1% Lidocaine + 0.25% Bupivicaine (Without Epi)
- Decompress penile compartment by aspiration.
- Repeat aspiration until oxygenated blood is seen to refill the corpora.
- Inject or Irrigate dilute alpha-adrenergic drug. (Monitor BP)

Emergency Room Intervention: Ischemic Priapism

- Decompression
- Aspiration
- Intracavernous Injection or Irrigation of α-Adrenergic drug.

What can the Emergency Department Physician Do?

- Assess the patient: Run the Priapism Checklist!
- Determine the etiology: Ischemic vs. Arterial
- Do toxicology panel for substance use
- Treat the ischemic compartment: Aspiration + α-Adrenergics
- Sickle Cell Disease supportive care:
  - Oxygenation, Hydration, Pain Control
  - Hematology Consultation

FIG. 70.4 Emergency management of ischemic priapism. (From American Urological Association: Emergency department assessment and management of ischemic priapism: plenary next frontier—panel discussion. *Update on Urologic Emergencies,* San Francisco, 2018, GA Broderick.)

Box 70.2

Elements in Taking the History of Priapism

Duration of erection
Presence of pain
Previous episodes of priapism and method of treatment
Baseline erectile function
Use of any erectogenic therapies (prescription and nutritional supplements)

Medications and recreational drugs
Sickle cell disease, hemoglobinopathies, hypercoagulable states
Trauma to the pelvis, perineum, or penis

Physical Examination

Inspection and palpation of the penis are recommended to determine the extent and degree of tumescence and rigidity; the involvement of the cavernous bodies; the presence of pain; and the evidence of trauma to the perineum. **In ischemic priapism the corporal bodies will be completely rigid; the glans penis and corpus spongiosum are not.** Although malignancies rarely cause priapism, examination of the abdomen, testicles, perineum, rectum, and prostate may help identify a primary cancer. Malignant infiltration of the penis causes indurated nodules within or replacing corporal tissue. The subtle differences in the penile examination findings may be apparent to the experienced urologist but can be overlooked by emergency personnel (Podolej et al., 2017) on initial evaluation (see Fig. 70.4). If physical examination reveals the penis to be nontender, tumescent, or partially erect, nonischemic priapism should be suspected. **In nonischemic priapism the corpora will be tumescent but not completely rigid.** In children and adults with HFP, depending on the location of trauma and time since the traumatic event, there may be residual bruising at the perineum from straddle injury (Table 70.1).

TABLE 70.1

Key Findings in Priapism

FINDINGS	**ISCHEMIC PRIAPISM**	**NONISCHEMIC PRIAPISM**
Perineal trauma	Seldom	Usually
Hematologic abnormalities	Usually	Seldom
Recent intracorporal injection	Sometimes	Sometimes
Corpora cavernosa fully rigid	Usually	Seldom
Penile pain	Usually	Seldom
Abnormal penile blood gas	Usually	Seldom
Cavernous inflow (on Doppler)	Seldom	Usually

Modified from Montague DK, Jarow J, Broderick GA, et al.: American Urological Association guideline on the management of priapism. *J Urol* 170:1318–1324, 2003.

Laboratory Testing

Evaluation should include a complete blood count (CBC), WBC count with blood cell differential, platelet count, and coagulation profile to assess anemia, rule out infection, detect hematologic abnormalities, and ensure that the patient can safely tolerate surgical interventions should initial medical management fail. **In African-Americans, a sickle cell screening should be requested (hemoglobin electrophoresis, reticulocyte count, lactate dehydrogenase).** Other hematologic abnormalities may cause priapism, including leukemia, platelet abnormalities, and thalassemia, and these should be sought if the cause is not evident. An elevated reticulocyte count is nonspecific and may be present in priapism caused by SCD and in thalassemia. Urine and serum toxicology panels should be done if recreational narcotic or prescription psychoactive drugs are suspected from the history. A corporal blood gas by aspiration is recommended in the emergency evaluation of priapism. **The corporal blood aspirate differentiates ischemic from nonischemic priapism. Aspiration may be diagnostic and therapeutic. Visual inspection of the color and consistency of an initial penile aspirate will reveal dark deoxygenated blood with a "crankcase oil" appearance in ischemic priapism. The initial corporal aspirate may be sent for blood gas testing to document pH, P_{O_2}, and P_{CO_2}** (Table 70.2). **CDU should be initiated if the history suggests penile or perineal trauma or if the corporal aspirate reveals well-oxygenated blood** (Fig. 70.5).

TABLE 70.2

Typical Blood Gas Values

SOURCE	P_{O_2} (mm Hg)	P_{CO_2} (mm Hg)	PH
Normal arterial blood (room air)	>90	<40	7.40
Normal mixed venous blood (room air)	40	50	7.35
Ischemic priapism (first corporal aspirate)	<30	>60	<7.25

Modified from Montague DK, Jarow J, Broderick GA, et al.: American Urological Association guideline on the management of priapism. *J Urol* 170:1318–1324, 2003.

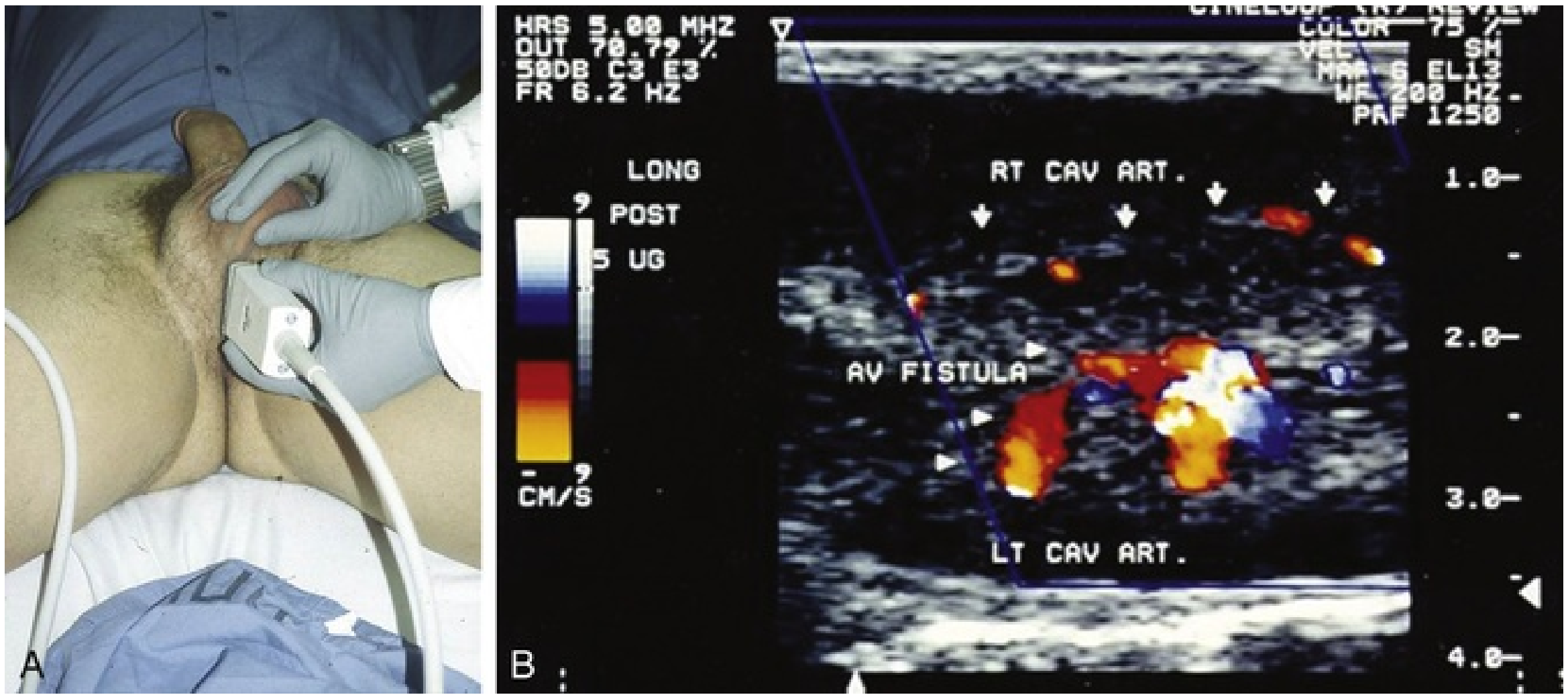

FIG. 70.5 (A) Examination of the crural bodies is required when searching for arterial sinusoidal fistula after straddle injury. (B) Color Doppler image of arterial sinusoidal fistula of left cavernous artery.

Penile Imaging

CDU of the penis and perineum is recommended in the evaluation of priapism. CDU is an adjunct to the corporal aspirate in differentiating ischemic from nonischemic priapism. **Patients with prolonged ischemic priapism will have no blood flow in the cavernous arteries;** the return of the cavernous artery waveform will accompany successful detumescence. **Patients with nonischemic priapism have normal to high blood flow velocities** detectable in the cavernous arteries; an effort should be made to localize the characteristic blush of color emanating from the disrupted cavernous artery or arteriole (Broderick and Lue, 2002). Examination of the entire penile shaft and perineum is recommended; this can be done with the patient supine but frog-legged (see Fig. 70.5). **Penile arteriography should be reserved for the management of HFP, when embolization is planned; arteriography is too invasive as a diagnostic procedure to differentiate ischemic from nonischemic priapism**. **The data from penile blood gas assessments become confusing after interventions. CDU should always be considered in the evaluation of a full or partial erection after treatments for ischemic priapism. The differential diagnosis includes resolved ischemia with penile edema, persistent ischemia, and conversion to high-flow state** (Burnett, 2004; Lutz et al., 2012, McMahon, 2002; Mistry et al., 2017; Rodriguez et al., 2006)**.** Chiou et al. (2009) have recommended that to accurately categorize presentations as nonischemic or ischemic, careful interpretation of CDU hemodynamics must be done in conjunction with the clinical assessment. They describe eight patients with priapism after ICI (duration ≤7 hours), all of whom showed presence of cavernous arterial inflows with varied peak systolic velocities and end-diastolic velocities. They concluded that most patients with priapism after ICI (and duration <7 hours) have a hemodynamic picture of mixed arteriogenic and veno-occlusive priapism. In their series, men with idiopathic ischemic priapism longer than 20 hours showed no detectible cavernous arterial inflows.

There have recently been reports on the use of magnetic resonance imaging (MRI) in priapism. Kirkham et al. (2008) noted that there are **three possible roles for MRI** to help in the assessment of priapism; the primary role would be in the **imaging of a well-established arteriolar-sinusoidal fistula**. The authors acknowledge that a limitation of MRI is resolution; MRI cannot demonstrate small vessels as clearly as high-frequency Doppler sonography or angiography. The second role would be in ischemic priapism to **demonstrate the presence and extent of tissue thrombus and corporal smooth muscle infarction.** Ralph et al. (2009) used MRI to assess 50 patients with refractory ischemic priapism. All patients had priapism lasting from 24 to 72 hours, and each had failed medical and surgical interventions. Patients underwent MRI to characterize the extent of smooth muscle necrosis before placement of penile prosthesis. The third role for MRI would be when imaging the penis for **corporal malignancy or metastasis**. MRI may be useful to identify corporal smooth muscle replaced by malignant tissue with or without true ischemic priapism caused by obstruction of venous outflow. In cases in which the history and physical examination are consistent with penile metastasis and not priapism, whole-body surveillance techniques may be confirmatory (Fig. 70.6).

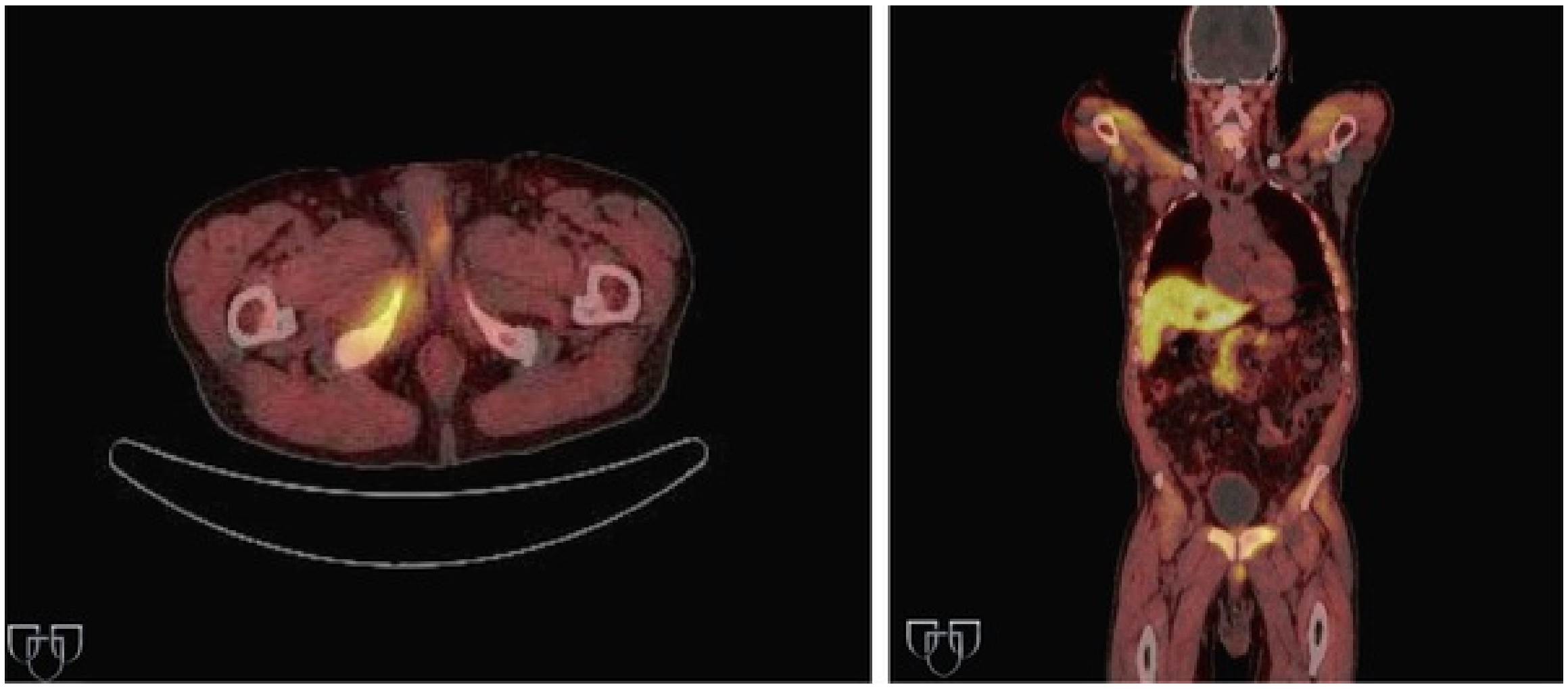

FIG. 70.6 A 76-year-old patient consulted for a penile mass to rule out priapism. His PSA was above 100, and positron emission tomography/computed tomography demonstrated metastatic disease to bone and soft tissue metastasis to the left corpus cavernosum. Metastatic infiltration of the penis must be distinguished from priapism. (Courtesy Dr. Raymond Pak.)

Key Points: Priapism Imaging

- CDU is an adjunct to the corporal aspirate in differentiating ischemic from nonischemic priapism.
- CDU imaging should include corporal shaft and transperineal assessment of the crural bodies when there is a history of penile trauma or straddle injury.
- CDU should always be considered in the evaluation of a persistent or partial erection after treatments for ischemic priapism.
- Penile arteriography is too invasive as a diagnostic procedure to differentiate ischemic from nonischemic priapism.
- MRI has three possible roles: imaging of a well-established arteriolar-sinusoidal fistula, identifying corporal thrombus, and identifying corporal metastasis.

Medical Treatments

Ischemic Priapism

Historically, first aid was applied by the patient or recommended by a health practitioner unfamiliar with the hemodynamics of priapism; these interventions included ejaculation, ice packs, cold baths, and cold water enemas. Each of these remedies was thought to end erection by inducing vasoconstriction. Some historical reports advised voiding and exercise. Oral sympathomimetic drugs (etilefrine, pseudoephedrine, phenylpropanolamine, and terbutaline) have been reported to effectively reverse prolonged erection (<4 hours) initiated by ICI therapies with efficacies of 28% to 36% (Lowe and Jarow, 1993). Lowe and Jarow (1993) compared oral terbutaline with pseudoephedrine or placebo in 75 patients with prolonged erection induced by ICI of alprostadil; they reported detumescence in 38% of cases with terbutaline, 28% with pseudoephedrine, and 12% with placebo. In a follow-up study Priyadarshi (2004) specifically investigated the efficacy of oral terbutaline in the management of prolonged erection after ICI (papaverine/chlorpromazine); he administered oral terbutaline 5 mg or placebo to men with persisting erection for more than 2½ hours. Detumescence was achieved in 42% and 15% of cases, respectively, treated with terbutaline or placebo. Terbutaline treatment was unsuccessful in 58% of cases; all of those patients responded to ICI of an α-adrenergic agent.

Every practice administering diagnostic ICI or teaching ICI must be prepared to manage priapism (Fig. 70.7). In my experience, when a vasoactive injection results in a prolonged erection with duration longer than 1 hour but shorter than 4 hours, aspiration may not be necessary. Phenylephrine (200 µg) injected with an ultrafine needle and 1-mL syringe may reverse the erection. Reversing a prolonged erection will spare the patient and the office staff the complexity of treating full-blown ischemic priapism.

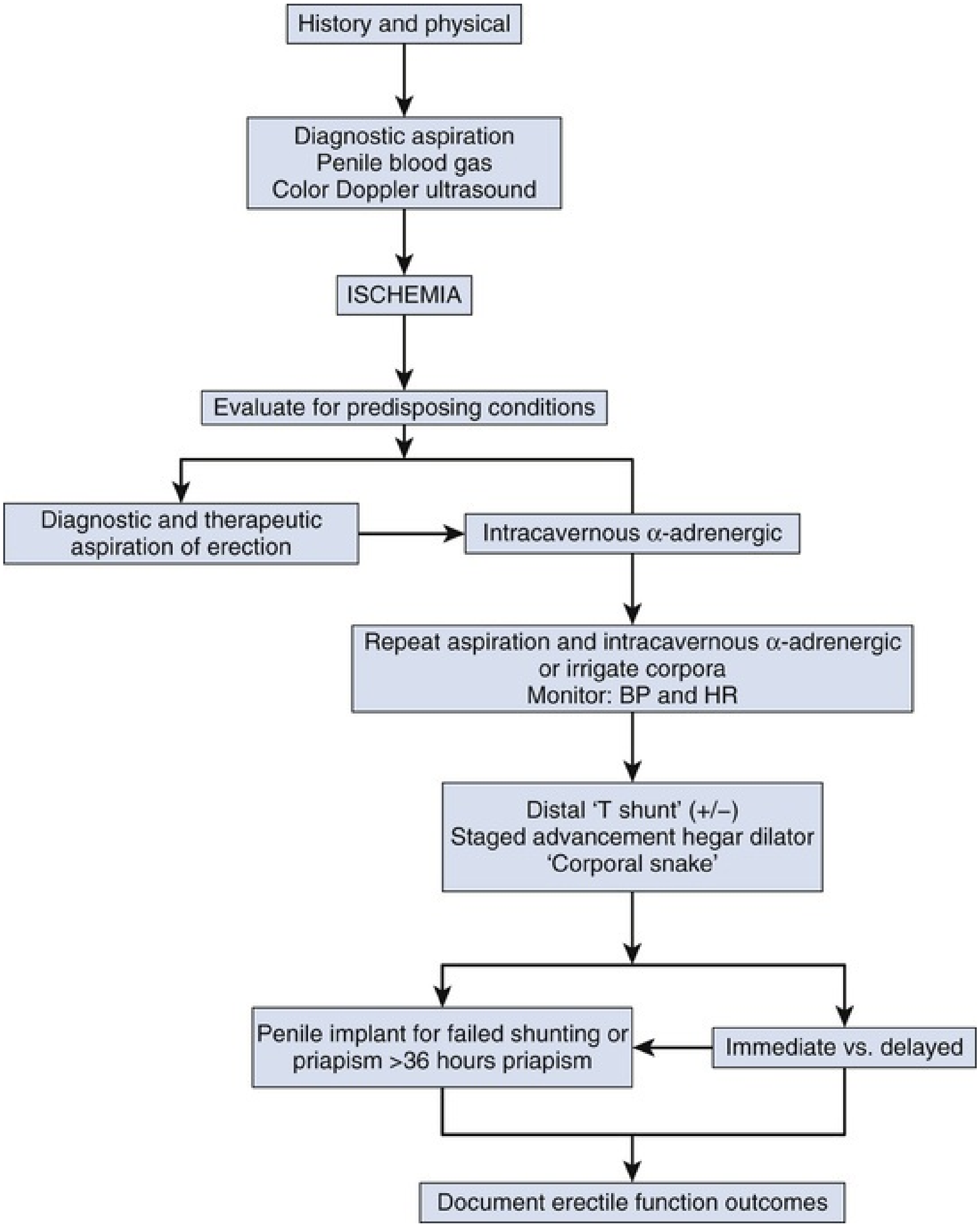
History and physical
Diagnostic aspiration
Penile blood gas
Color Doppler ultrasound
ISCHEMIA
Evaluate for predisposing conditions
Diagnostic and therapeutic aspiration of erection
Intracavernous α-adrenergic
Repeat aspiration and intracavernous α-adrenergic or irrigate corpora
Monitor: BP and HR
Distal 'T shunt' (+/–)
Staged advancement hegar dilator
'Corporal snake'
Penile implant for failed shunting or priapism >36 hours priapism
Immediate vs. delayed
Document erectile function outcomes

FIG. 70.7 Algorithm for managing ischemic priapism. *BP,* Blood pressure; *ECG,* electrocardiogram; *HR,* heart rate.

Oral agents are not recommended in the management of acute ischemic priapism (>4 hours). The recommended initial treatment of ischemic priapism is the decompression of the CC by aspiration. Aspiration will immediately soften the erection and relieve pain. Aspiration alone may relieve priapism in 36% of cases. The AUA Guidelines Panel (2003) advised that there were not sufficient data to conclude that aspiration followed by saline intracorporal irrigation was any more effective than aspiration alone (Montague et al., 2003). Subsequently, Ateyah et al. (2005) reported that a combination of corporal blood aspiration and cold saline irrigation effectively terminated priapism in 66% of cases compared with aspiration alone (24%). **Data to support the efficacy of cold saline are limited. Aspiration should be repeated until no more dark blood can be seen coming out from the corpora and fresh bright red blood is obtained. This process leads to a marked decrease in the intracavernous pressure, relieves pain, and resuscitates the corporal environment, removing anoxic, acidotic, and hypercarbic blood.** A single, large-bore, 19-gauge needle should be inserted at the penoscrotal junction at the 3 or 9 o'clock position to avoid piercing the dorsal neurovascular bundle. The surgeon should compress the penile shaft between the thumb and first digit, just below the 19-gauge needle, aspirating the shaft until it is soft. With the needle left in place, the shaft is permitted to refill. Compression is reapplied and aspiration repeated. These maneuvers may have to be serially repeated. Several small, empty syringes should be available (3-mL to 12-mL syringes) (see Fig. 70.4).

Corporal aspiration, if unsuccessful, should be followed by α-adrenergic injection or irrigation. Aspiration followed by the ICI of sympathomimetic drugs was recommended by the AUA Guidelines Panel in 2003 (Broderick et al., 2010; Montague et al., 2003). Sympathomimetic drugs (phenylephrine, etilefrine, ephedrine, epinephrine, norepinephrine, metaraminol) cause cavernous smooth muscle contraction. In the laboratory, normal cavernous smooth muscle preparations from humans, rabbits, and rodents show concentration-dependent contractions on exposure to phenylephrine if the corporal environment is well oxygenated and has a normal pH (Broderick et al., 1994). In patients, time-dependent changes in the corporeal environment begin within 6 hours of persistent erection (Broderick and Harkaway, 1994). Animal models of ischemic priapism have demonstrated impairment in smooth muscle contraction with progressive acidosis, hypoxia, and glucopenia (Broderick et al., 1994; Muneer et al., 2008; Munnarriz et al., 2006; Saenz de Tejada et al., 1997). Corpus cavernosum specimens from patients with prolonged priapism show no contractions to high-dose phenylephrine in vitro.

Phenylephrine is a relatively selective α_1-adrenergic receptor agonist with minimal β-mediated ionotropic and chronotropic cardiac effects; it is the agent of choice according to AUA consensus recommendation (2003), the International Consultation on Sexual Medicine (2010), and the European

Association of Urology guideline on priapism (2014) (Broderick et al., 2010; Montague et al., 2003; Salonia et al., 2014).

There are no comparative trials of sympathomimetics in the management of priapism, nor are there studies of dosage tolerance to report. In terms of corporal physiology, α-adrenergic agonists are vasoconstrictors of cavernous artery and arterioles. Intracavernous administration of an α-adrenergic agent should contract cavernous smooth muscles, allowing sinusoidal blood to egress from subtunical veins. On the other hand, a β-adrenergic agonist, which would relax cavernous smooth muscle and dilate the cavernous artery and arterioles, could promote oxygenated arteriolar blood to enter the cavernous spaces and wash out deoxygenated blood. Metaraminol is a pure α-adrenergic agent; etilefrine, phenylephrine, and epinephrine are mixed α- and β-adrenergic agonists. Terbutaline is a pure β agonist. Case reports with these agents show varying efficacy from 43% to 81%.

In addition to the specific reversal agent, there is clearly a time-dependent efficacy for pharmacologic reversal of priapism. For acute pharmacologic management of ischemic priapism, the intracavernous administration of dilute solutions of phenylephrine or epinephrine is most commonly described in the United States. In Europe etilefrine is commonly described. Etilefrine is a phenylephrine related β-adrenergic and α-adrenergic agonist. It is available in oral and parenteral formulations internationally (Effortil, ethylandrianol, ethylphenylephrine, phetanol, ethyl noradrianol). Currently, pseudoephedrine, phenylpropanolamine, and ephedrine are the orally active adrenergic agents available in the United States. Pseudoephedrine (Sudafed) is regulated under the Combat Methamphetamine Epidemic Act of 2005, which banned over-the-counter sales of cold medicines containing pseudoephedrine. It is available “behind the counter” without a prescription. Neither Sudafed (pseudoephedrine) nor Sudafed PE (phenylephrine) has been evaluated as an oral agent for the reversal or prevention of priapism in the United States. Phenylephrine is typically diluted in normal saline to a concentration of 100 to 200 µg/mL; it is administered intracavernously as a 1-mL injection every 3 to 5 minutes. Administration should be intermittent over the course of an hour. In my experience, phenylephrine can be concentrated as 200 µg/mL in saline and administered intermittently as 0.5 mL to 1.0 mL every 5 to 10 minutes to a maximum dosage of 1 mg. This will permit up to 10 separate injections of 0.5 mL (100 µg each) or 5 separate injections of 1 mL (200 µg each). The penis is aspirated between successive injections by tightly pinching the shaft at the penoscrotal junction, just below the site of needle insertion. Aspiration should continue until the distal shaft is empty and collapses. This removes deoxygenated acidic blood. Then phenylephrine is injected. Gradually the compression at the penoscrotal junction is released, allowing the shaft to refill with fresh blood. Extremes of age (children vs. elderly), home dosing with pseudoephedrine, and preexisting cardiovascular diseases should be taken into consideration before intracavernous sympathomimetic administration. Serial monitoring of blood pressure and pulse should be performed during and immediately after ICI of sympathomimetic drugs. Potential side effects of intracavernous sympathomimetics include headache, dizziness, hypertension, reflex bradycardia, tachycardia, and irregular cardiac rhythms (Constantine et al., 2017; Sidhu et al., 2018).

Davila et al. (2008) reported subarachnoid hemorrhage in a patient with SCD ischemic priapism. The patient was a 24-year-old African-American man who reported sudden and severe headache immediately after intracorporal administration of phenylephrine 500 μg/mL repeated every 3 minutes for a total of 4 mL (2000 μg = 2 mg). In a retrospective review Ridyard et al. (2016) identified 58 patients presenting to the emergency department with ischemic priapism lasting less than 36 hours. Patients were treated by urology house officers with intracavernous phenylephrine; the protocol resulted in resolution in 86% of patients (Ridyard et al., 2016). Commercially available and compounded phenylephrine HCl (100 mcg/mL) should avoid the risks related to mixing and inadvertently overdosing by emergency personnel (Constantine et al., 2017) (see Fig. 70.4).

SCD and hematologic malignancies are rare but important causes of ischemic priapism. Classically, treatment of SCD-induced ischemic priapism involved analgesics, hydration, oxygen, bicarbonate, and exchange transfusion. Unfortunately, acute neurologic complications may follow exchange transfusions. Hematologists have begun to question the emphasis on intravenous hydration, sodium bicarbonate for alkalinization, and exchange transfusion as first-line therapy for SCD-associated priapism (Kato, 2012). Hydroxycarbamide (hydroxyurea) is a hematologic agent used in the management of vaso-occlusive crises in sickle cell patients (Morrison and Burnett, 2012; Saad et al., 2004). The proposed mechanisms of action are increase in production of hemoglobin F; reduction of leukocytes, platelets, and reticulocytes; and promotion of release of NO. **In the best interests of the patient, the urologist should seek hematologic consultation in the management of boys and men with SCD**

priapism but remain assertive that hematologic therapy alone is not effective management of SCD priapism (Ballas, 2017; Rogers, 2005). A 2006 report suggested that transfusion alone has no effective role in the treatment of sickle cell–induced priapism (Merritt et al., 2006).

Reports from hematology centers suggest high success rates with use of penile aspiration, injection, and irrigation with intracavernous sympathomimetics for SCD priapism (Mantadakis et al., 2000). Mantadakis et al. (2000) conducted a prospective trial for the management of children with SCD with prolonged erection, ages 3 to 18 years (no placebo group). For erections lasting longer than 4 hours and less than 12 hours, emergency department interventions were local anesthetic, cavernous aspiration, and irrigation with 10 mL of a 1 : 1,000,000 solution of epinephrine. If detumescence lasted for 30 minutes, patients were discharged to home. They described 15 patients receiving 39 interventions, of which 37 were successful; 67% required only one aspiration and irrigation treatment. **In the management of SCD pediatric patients with stuttering priapism, several levels of escalating intervention are necessary, with parental and emergency department staff education being the first level.** Gbadoe et al. (2001) described the treatment of 11 patients with SCD (ages 30 months to 15 years) with acute ischemic priapism or stuttering priapism. In their series of cases, if the patient had priapism lasting less than 6 hours, aspiration and injection of 5 mg of etilefrine was given in the emergency department; for stuttering priapism, patients were given oral etilefrine 0.5 mg/kg nightly for 1 month, or 0.25 mg/kg twice daily. Patients (parents) also administered injections at home to reverse painful erection lasting longer than 1 hour. The authors reported no significant hypertension and only one case of "agitation" attributed to daily administration.

Key Points: Medical Management of Ischemic Priapism

- Oral therapy is not recommended for the treatment of acute ischemic priapism.
- The initial treatment of ischemic priapism is decompression by aspiration.
- Aspiration should be repeated until oxygenated blood is seen to refill the corpora.

- Aspiration should be followed by the ICI (or irrigation) of a diluted α-adrenergic drug.
- Worldwide availability of adrenergic agents varies; effective reversal of priapism has been documented with dilute injections of ephedrine, epinephrine, etilefrine, metaraminol, or phenylephrine. Phenylephrine is the agent of choice recommended by AUA, International Consultation on Sexual Medicine, and European Association of Urology guidelines.
- Clinicians are advised to consult their pharmacies and develop clear mixing and dosage protocols for safe administration of adrenergic solutions.
- Phenylephrine is a sympathomimetic drug with selective α_1-adrenergic receptor actions; it has minimal β-mediated ionotropic and chronotropic cardiac effects.
- Phenylephrine should be concentrated as 200 µg/mL in normal saline and administered intracavernously as 0.5 mL to 1 mL. Lower concentrations should be used in children and adults with cardiovascular disease. Administration and aspiration may have to be repeated. No recommendations can be made about maximum safe dosage. Hypertensive stroke has been reported as a complication of cumulative administration of 2 mg.
- Physicians should monitor patients for subjective complaints and objective findings consistent with known undesirable effects: headache, chest discomfort, acute hypertension, reflex bradycardia, tachycardia, palpitations, and cardiac arrhythmia. Patients and parents should be informed about these potential complications.
- Blood pressure monitoring is recommended with repeated sympathomimetic administration. In patients with significant cardiovascular risks, electrocardiogram monitoring is recommended.
- Ischemic priapism associated with SCD requires intracavernous treatment. A hematologist may provide concurrent systemic therapies (oxygen, hydration, transfusion), but the best resolution rates are achieved with therapies directed at the penis.

Stuttering Priapism

Various factors must be considered in treating stuttering priapism. **Although an episode may last less than 4 hours, increasing frequency or duration of**

stuttering episodes may herald a major ischemic priapism. Multiple frequent visits to the emergency department to resolve the priapism are disruptive to the patient's life and embarrassing. If attacks follow sexual activity, patients may become sexually avoidant (Adeyoju et al., 2002; Chow and Payne, 2008). Safety and efficacy of various treatments are poorly characterized in the literature. The side effects of recommended medications should be understood by the patient. Patients on chronic medical therapy to decrease the frequency of stuttering episodes may significantly benefit from performing a single sympathomimetic intracorporal injection at home as part of a personal treatment algorithm (Teloken et al., 2005; Virag et al., 1996). Multiple treatment options have been described: oral and injectable α-adrenergic agonists, terbutaline, digoxin, the antisickling agent hydroxycarbamide (hydroxyurea), estrogens, gonadotropin-releasing hormone (GnRH) analogues, antiandrogens, baclofen, gabapentin, and recently PDE5 inhibitors (Chow and Payne, 2008).

Etilefrine is available as an oral or injectable treatment in some European countries. The maximum oral dosage is 100 mg in 24 hours, given as 50 mg bid (Okpala et al., 2002). Okpala et al. (2002) followed 18 adults (17 SCD patients and 1 with sickle trait), all with a history of stuttering priapism. Patients were given oral etilefrine in escalating doses from 25 mg at bedtime to a maximum of 100 mg each day. Stuttering episodes were reduced in frequency and duration in 72%. A small series of 6 SCD children were followed with administration twice daily with 0.25 mg of etilefrine per kilogram (Gbadoe et al., 2002). **The experience of multiple investigators using oral α-adrenergics in the management of SCD stuttering ischemic priapism suggests that limited daily administration should be considered in the management of stuttering priapism; drug therapy is typically initiated at bedtime. Oral α-adrenergic administration is a preventative strategy for stuttering priapism.**

Hormonal Therapies

The primary action of systemic hormonal therapy in stuttering priapism is the suppression of the androgenic effects on penile erection. Attempts to treat stuttering priapism with hormones have exploited known regulators of male sexual function by targeting the pituitary gland (GnRH agonists), suppressing pituitary function through feedback inhibition (diethylstilbestrol [DES]), blocking androgen receptors (antiandrogens), and reducing testicular and adrenal synthesis (ketoconazole). The common goal of hormonal therapy in the prevention of stuttering priapism is to reduce serum testosterone to hypogonadal levels or block testosterone's effects on the penis. In the only randomized placebo-controlled trial, a synthetic estrogen, **DES,** caused termination of the stuttering episodes in all patients who received treatment (Chinegwundoh and Anie, 2004). However, in more than 50% of patients (5 of 9) priapism recurred after treatment cessation. Similar results have been described by others in case reports (Gbadoe et al., 2002; Shamloul and el Nashaar, 2005). Long-term estrogen therapy is not recommended because of the potential cardiovascular side effects.

GnRH analogues, goserelin acetate and leuprolide acetate, have been described in case reports (Levine and Guss, 1993; Shamloul and el Nashaar, 2005). Chronic therapy with GnRH analogues in combination with penile injection of α-adrenergics as needed has been reported in the management of ischemic stuttering priapism (Steinberg and Eyre, 1995). Discontinuation of GnRH analogues typically leads to stuttering resumption. **Antiandrogens** including flutamide, bicalutamide, and chlormadinone have been used to interrupt stuttering priapism, and their use has been detailed in case reports. Antiandrogens may have benefit to patients over the GnRH analogues because they are orally administered and because some patients continue having sexually stimulated erections (Costabile, 1998; Dahm et al., 2002; Yamashita et al., 2004). Abern and Levine (2009) used nightly administration of the antifungal agent oral ketoconazole and prednisone to suppress nocturnal erections as a preventive strategy for recurrent ischemic priapism in 8 patients followed for 1½ years. The protocol required titrating dosages and monitoring of nocturnal erections and serum testosterone levels; mean testosterone levels fell from a baseline of 475 ng/dL to 275 ng/dL. The fall in testosterone levels appeared to be a surrogate for efficacy in preventing significant episodes of priapism. Ketoconazole (KTZ) inhibits steroidogenesis in the adrenal and gonadal tissues; it has a half-life of 8 hours. KTZ inhibits cortisol production, necessitating concomitant prednisone administration. In the Abern and Levine protocol, men with recurring ischemic priapism were treated with KTZ 200 mg given orally (PO) every 8 hours and prednisone 5 mg at bedtime for 2 weeks, followed by KTZ nightly without prednisone supplementation. In a follow-up study Hoeh and Levine report on 17 patients with recurrent ischemic priapism and SCD treated with KTZ 200 mg three times daily with prednisone 5 mg daily for 2 weeks and then tapered to KTZ 200 mg nightly for 6 months with no prednisone supplementation. The mean number of emergency department visits for recurrent ischemic episodes lasting more than 4 hours before treatment was 6.5 per patient. Sixteen of seventeen patients had resolution of stuttering during the 6 months of treatment (Hoeh and Levine, 2015).

Rachid-Filho et al. (2009) have described the efficacy of oral **5α-reductase inhibitors** (finasteride) in the management of sickle cell stuttering priapism. They administered finasteride to 35 patients over 120 days in doses that decreased monthly from 5 mg/day to 3 mg/day and then 1 mg/day in the final month. This was not a controlled trial, but careful observation of stuttering episodes was made. They found at the beginning of treatment that the mean number of episodes of stuttering priapism per patient was 22.7, and at the end of 4 months the mean number of episodes per patient was 2.1. The optimal effects were found at 5- and 3-mg daily doses. Six of 35 patients in this study developed painless gynecomastia. Finasteride is a 5α-reductase inhibitor approved in the United States for management of symptomatic BPH (Proscar 5 mg) and male pattern alopecia (Propecia 1 mg); finasteride and dutasteride are type II 5α-reductase inhibitors. This class of drugs reduces conversion of testosterone to dihydrotestosterone, which is believed to be many times more potent at the cellular level. Paradoxically, when measured during clinical trials, serum testosterone levels go up in healthy controls and patients administered finasteride or dutasteride. Neither drug is approved for use in patients with stuttering ischemic priapism.

Baclofen

Studies in rats and humans suggest that baclofen inhibits penile erection and ejaculation, through γ-aminobutyric acid (GABA) receptor activity. In rats, stimulation of $GABA_B$ receptors in the lumbosacral spinal cord inhibits erection (Bitran et al., 1988; Paredes and Agmo, 1995; Vaidyanathan et al., 2004). Denys et al. (1998) reported on nine men with multiple sclerosis or spinal cord injuries who were treated for 44 months with intrathecal baclofen for muscle spasticity; eight of nine reported decreased erectile function, which reversed on cessation of baclofen. Rourke et al. (2002) first reported on the use of oral nightly baclofen 40 mg in the management of recurrent priapism in patients with neurologic lesions. D'Aleo et al. (2009) were the first to report on the use of an intrathecal pump to administer baclofen 180 µg daily for the management of skeletal muscle spasm and recurrent priapism in a patient with spinal cord injury; the patient was refractory to treatment with oral administration of 75 mg/day but responded to a test dose of 25 µg intrathecally. The neurologic literature generally fails to categorize these erectile events as ischemic or nonischemic. Triggering events may be tactile nonsexual stimulation causing repeated reflexogenic erections. Better characterization of these unwanted erections in men with upper motor neural lesions is necessary to appreciate hemodynamics, inciting events, duration, and impact on erectile function. There have been reports to the FDA that men with baclofen infusion pumps experience a withdrawal syndrome when those pumps fail. The withdrawal syndrome has been characterized by return of spasticity, agitation, sleeplessness, and priapism. Advanced symptoms resemble autonomic dysreflexia and may include rhabdomyolysis. The syndrome responds to oral baclofen dosing until intrathecal therapy can be resumed. In non-neurogenic patients, daily administration of baclofen is associated with drowsiness, nausea, complaints of fatigue, and ED. Recurrent reflexogenic erections are clearly an unwanted condition associated with muscle spasticity in men with spinal cord lesions and neurologic disease, but it remains to be demonstrated whether the duration and hemodynamics of such erectile events are similar to ischemic stuttering priapism typical in SCD.

Phosphodiesterase Type 5 Inhibitors in the Management of Stuttering Priapism: A Counterintuitive Treatment Strategy

Bialecki and Bridges (2002) first reported on sildenafil having a paradoxic effect in controlling stuttering priapism in three patients with SCD. Although this proposal would immediately seem illogical on the basis of the understanding that PDE5 inhibitors exert erectogenic effects, there is a scientific basis for using these agents to treat priapism.

In a small case series, Burnett et al. (2006a) showed that daily sildenafil or tadalafil therapy reduces ischemic priapism episodes in men with stuttering priapism. **When used in long-term regimens unassociated with erection stimulatory conditions, PDE5 inhibitor therapy alleviates recurrent priapism episodes in men with SCD-associated priapism without affecting normal erectile capacity** (Bivalacqua et al., 2009a; Burnett et al., 2006b). The working theory is that surges of cGMP go unchecked because of downregulated levels of PDE5; this results in stimuli such as nocturnal erection, which causes unchecked corporal smooth muscle relaxation. In initial series, the short-acting PDE5 inhibitor sildenafil citrate was given at a dose of 25 mg oral daily, with escalation to 50 mg daily. Subsequently these investigators reported on tadalafil at a dose of 5 or 10 mg taken orally three times weekly. Unfortunately a phase 1 placebo controlled trial of sildenafil showed no statistical benefit, with the primary outcome goal of a 50% reduction in biweekly priapism episodes from baseline (Burnett et al., 2014). In the phase 2 (open label) there was a reduction in the primary outcome measure and sildenafil treated patients did have fewer visits to the hospital for priapism episodes. Studies remain ongoing.

Key Points: Medical Management of Stuttering Priapism

- The goals of managing a patient with stuttering priapism include prevention of future episodes, preservation of erectile function, and balancing the risks versus benefits of various treatment options.
- Trials of daily oral α-adrenergic therapy have been in the management of patients (adults and children) with stuttering priapism associated with hemoglobinopathies. Efficacy should be monitored through frequency and duration of stuttering episodes, blood pressure, and normal erectile capacity.
- Trials of daily oral sildenafil/tadalafil (PDE5 inhibitor), trials of finasteride (5α-reductase inhibitor), and trials of oral ketoconazole/prednisone have been used in the management of adult patients with SCD stuttering priapism. Efficacy should be monitored through frequency and severity of stuttering episodes, side effects, and normal erectile capacity.
- Trials of GnRH agonists or antiandrogens have been used in the management of adult patients with stuttering priapism. Hormonal agents should not be used in patients who have not achieved full sexual maturation and adult stature. Chronic GnRH or antiandrogen administration in men may affect libido or fertility, cause gynecomastia, cause hot flushes, promote osteoporosis, increase the risks of cardiovascular disease, and worsen sexual function.
- When administered at home for prolonged morning erections, an injection of an intracavernous α-adrenergic agent may avert a full-blown episode of ischemic priapism. ICI of phenylephrine (by the adult patient or parent) should be considered as an adjunct to daily systemic therapies in patients with stuttering priapism.

Surgical Management of Ischemic Priapism

Surgical management of ischemic priapism is indicated after repeated penile aspirations and injections of sympathomimetics have failed or if such an attempt has resulted in a significant cardiovascular side effect. At present there is a paucity of data regarding the timing of surgical intervention following initiation of medical treatment, although the 2004 International Consultation on Sexual Medicine in Paris recommended corporal aspiration and α-adrenergic agonists for at least 1 hour before consideration of shunting (Pryor et al., 2004). **Early surgical intervention may be preferable in patients with malignant or poorly controlled hypertension or for men who are using monoamine oxidase inhibitor medications contraindicating α-adrenergic therapies.** A comprehensive discussion and documentation that includes baseline erectile function, duration of priapism, risks and benefits of the surgery, and ED should be held with the patient or guardian and an informed consent form signed by the patient or guardian.

Shunting

It is generally accepted that the longer an episode of ischemic priapism lasts, the greater the likelihood of compromised erectile function in the future. Early reviews concluded that priapism lasting longer than 24 hours was associated with a 90% ED rate (Pryor and Hehir, 1982). Kulmala et al. (1996) reported 92% erectile function preservation among patients with ischemic priapism reversed in less than 24 hours, but only 22% preservation of erectile function among men with priapism lasting longer than 7 days. Zacharakis et al. (2014a,b) retrospectively identified 45 patients undergoing distal shunting (2009–2102). Using the operative interventions of simultaneous T shunt and intracavernous tunneling all patients with priapism duration less than 24 hours were reversed, but only 30% of those lasting more than 48 hours were successfully reversed. Erectile function outcomes at 6 months were significantly reduced and correlated with the duration of priapism.

Recommendations based on well-documented erectile function outcomes are few. One recent study does document erectile function outcomes by contemporary standards. Bennett and Mulhall (2008) carefully documented 39 patients with SCD priapism who came to their emergency department over 8 years; men were routinely interviewed for erectile function status within 4 weeks of priapism using International Index of Erectile Function (IIEF). Of the 39 African-American men followed, 73% acknowledged prior episodes of stuttering, 85% had previously been diagnosed with SCD, but only 5% had been counseled in SCD clinics or were aware that priapism was a complication of SCD. A standard protocol of aspiration and phenylephrine injection was performed; shunting for failure of medical management was performed in 28%. In patients in whom priapism was reversed, spontaneous erections (with or without use of sildenafil) were reported in 100% of men when priapism was reversed by 12 hours; 78% when reversed by 12 to 24 hours; and 44% when reversed by 24 to 36 hours. In this contemporary series of SCD patients, no men reported the return of spontaneous erections after priapism lasting 36 hours or more. **The International Society for Sexual Medicine Standards Committee (expert opinion) stated that shunting is to be considered for ischemic priapism events lasting 72 hours or less. Consideration should be given to foregoing a shunt in priapism events lasting longer, in particular when cavernous thrombosis is evident and no blood can be aspirated from the corporal bodies** (Mulhall, 2006; Pryor et al., 2004).

The objective of shunt surgery is reoxygenation of the cavernous smooth muscle. The shared principle of shunt procedures is to reestablish corporal inflow by relieving venous outflow obstruction; this requires creation of a fistula between the CC and glans penis, CC and corpus spongiosum, or CC and dorsal or saphenous veins. Shunt procedures are subdivided on the basis of anatomic location on the penis (Lue and Pescatori, 2006; Fig. 70.8).

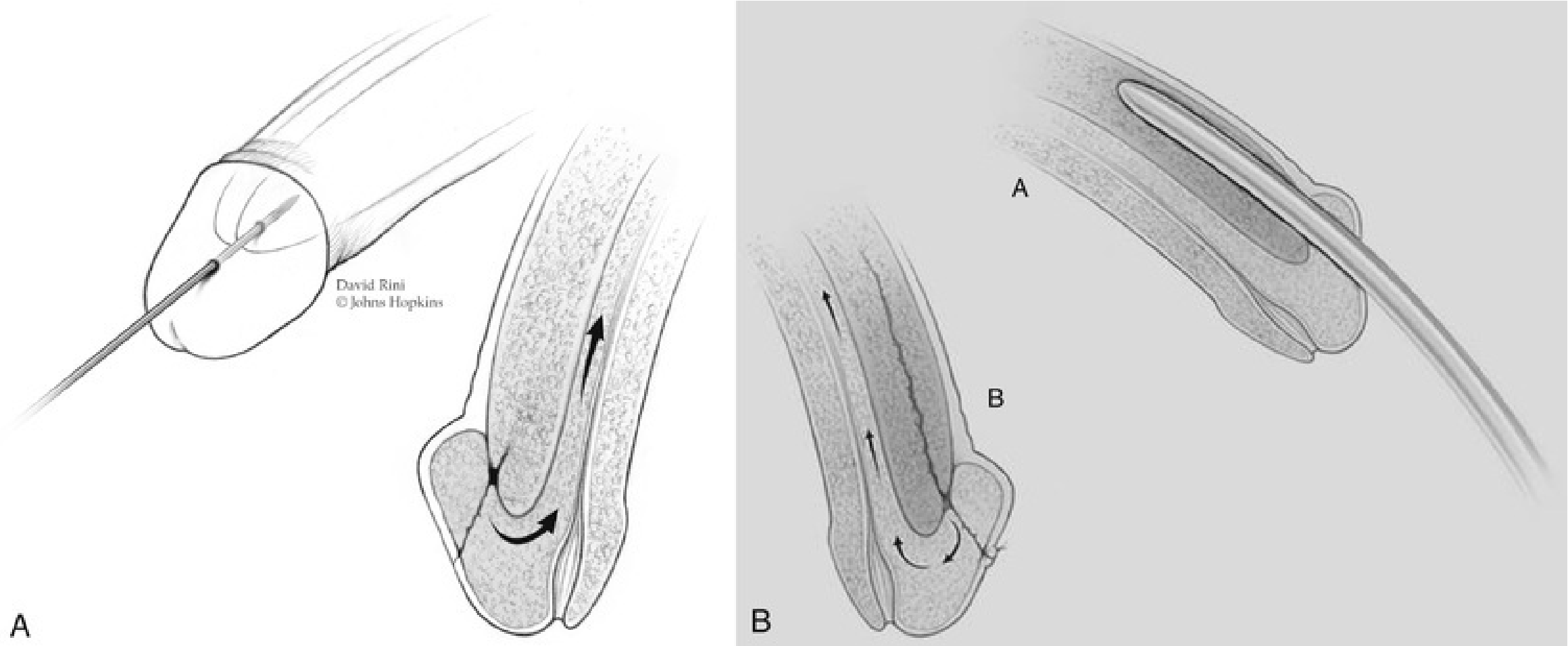

FIG. 70.8 (A) Winter shunt. The distal cavernoglanular shunt procedure is created by transglanular placement of a large-bore needle or angiocatheter into the distal glans and corpus cavernosum. (B) Corporal snake maneuver is a modification of the Al-Ghorab shunt. After excision of a 5-mm circular core of distal tunica albuginea, a 7/8 Hegar dilator is inserted down each corporal body through the tunica window. (B, Copyright Brady Urological Institute. From Burnett AL, Pierorazio PM: Corporal “snake” maneuver: corporoglanular shunt surgical modification for ischemic priapism. *J Sex Med* 6:1171–1176, 2009.)

- Percutaneous distal shunts—Ebbehoj (1974), Winter (1976), or T shunt (Brant et al., 2009)
- Open distal shunt—Al-Ghorab (Borrelli et al., 1983; Hanafy et al., 1976) or corporal snake (Burnett and Pierorazio, 2009)
- Combined T shunt and corporal snake maneuver—Zacharakis et al. (2014b)
- Open proximal shunt—Quackles (1964) or Sacher et al. (1972)
- Saphenous vein—Grayhack et al. (1964)
- Deep dorsal vein shunt—Barry (1976)

A distal cavernoglanular shunt should be the first choice of shunting procedures because it is technically easier to perform than proximal shunting. Percutaneous distal shunting is less invasive than open distal shunting and can be performed with local anesthetic in the emergency department. The most recently described distal shunt (Brant et al., 2009) creates a T-shaped shunt between the CC and glans penis. Brant et al. (2009) describe 13 men with priapism durations longer than 24 hours (in 6 of 13, other distal or proximal shunt procedures had failed). All T shunts were performed after penile anesthetic block; in 12 of 13 patients, the priapism was successfully reversed by initial intervention. In T shunting a No. 10 blade is placed vertically through the glans 4 mm away from the meatus; the blade pierces through the glans to the CC and is rotated 90 degrees away from the urethra and removed (Fig. 70.9). Deoxygenated blood is milked out of the wound. The glans is then sutured with absorbable suture. The authors recommend discharge home if the penis remains flaccid for 15 minutes (Brant et al., 2009). If erection returns or persists, a second T shunt is recommended on the opposite side of the meatus. When ischemic priapism has been present for more than 36 hours, immediate placement of bilateral T shunts is recommended, with passage of 20-Fr dilators into the fistula tract and well into the CC down to the crus. This technique is more traumatic and in my experience requires general anesthesia.

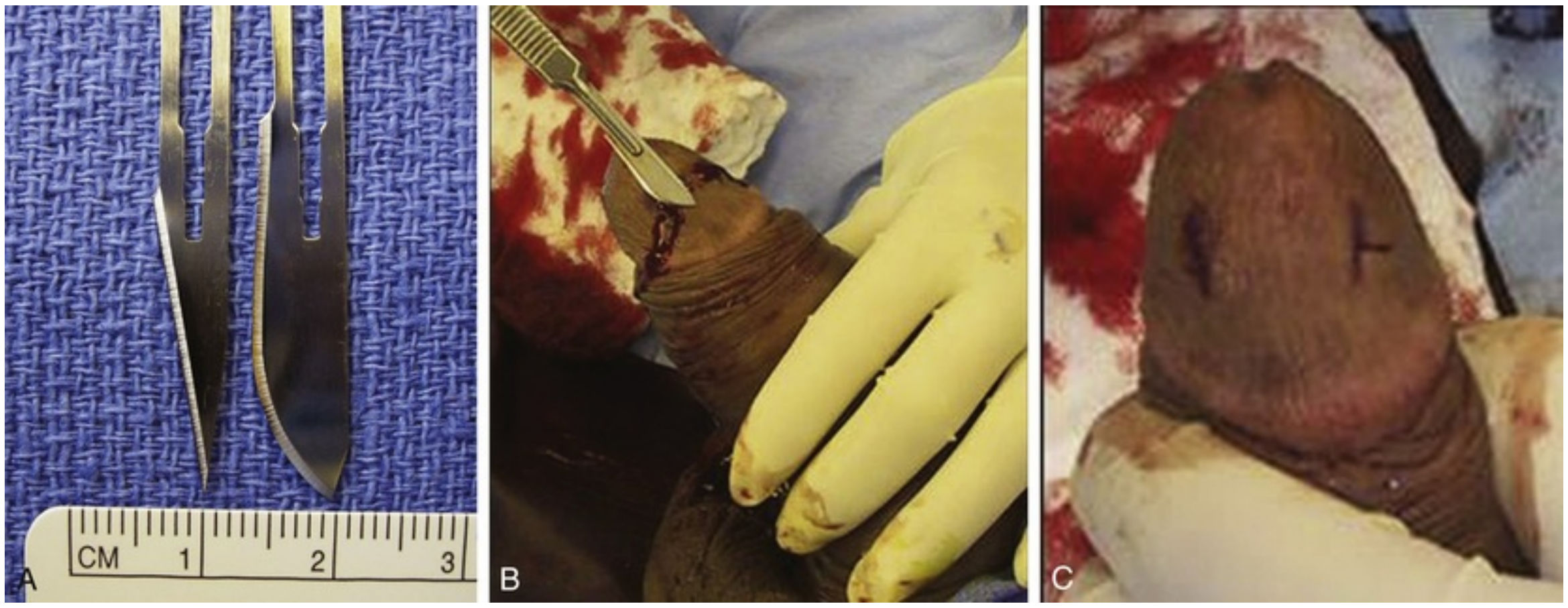

FIG. 70.9 (A) A No. 11 blade is used for an Ebbehoj percutaneous cavernoglanular shunt, and a No. 10 blade is used for a T shunt. (B and C) Note the differences between the Ebbehoj and T shunts. In the Ebbehoj technique the No. 11 blade leaves a straight incision into the glans and corpus cavernosum. In the creation of a T shunt the No. 10 blade is rotated (90 degrees away from the urethra) after insertion and is then withdrawn. In both the percutaneous techniques deoxygenated blood is milked out of the open wounds; once bright red blood is seen, the skin is closed, leaving the deeper incision of the open surgical fistula. In either procedure the maneuver may be repeated on the opposite corpus. (Courtesy Dr. Tom Lue.)

Burnett and Pierorazio (2009) have described a similar technique to resolve ischemic priapism refractory to first-line interventions. Their procedure, known as the *corporal snake*, is a modification of the Al-Ghorab corporoglanular shunt

(Fig. 70.10). With the patient under general anesthesia, a 2-cm transverse incision is made on the glans; the distal tips of the rigid CC are incised and grasped with 2-0 stay sutures or Kocher clamps. Deoxygenated blood is milked out of the CC, but rather than excising a wedge of tunica and underlying CC muscle, a 7/8 Hegar dilator is advanced through each of the tunica windows proximally several centimeters to release blood and thrombus. The penis is made flaccid by repeated manual compression and release; the glans skin is then approximated with 4-0 chromic sutures; a urethral catheter is placed, and lightly compressive dressing is applied to the genitalia (Fig. 70.11).

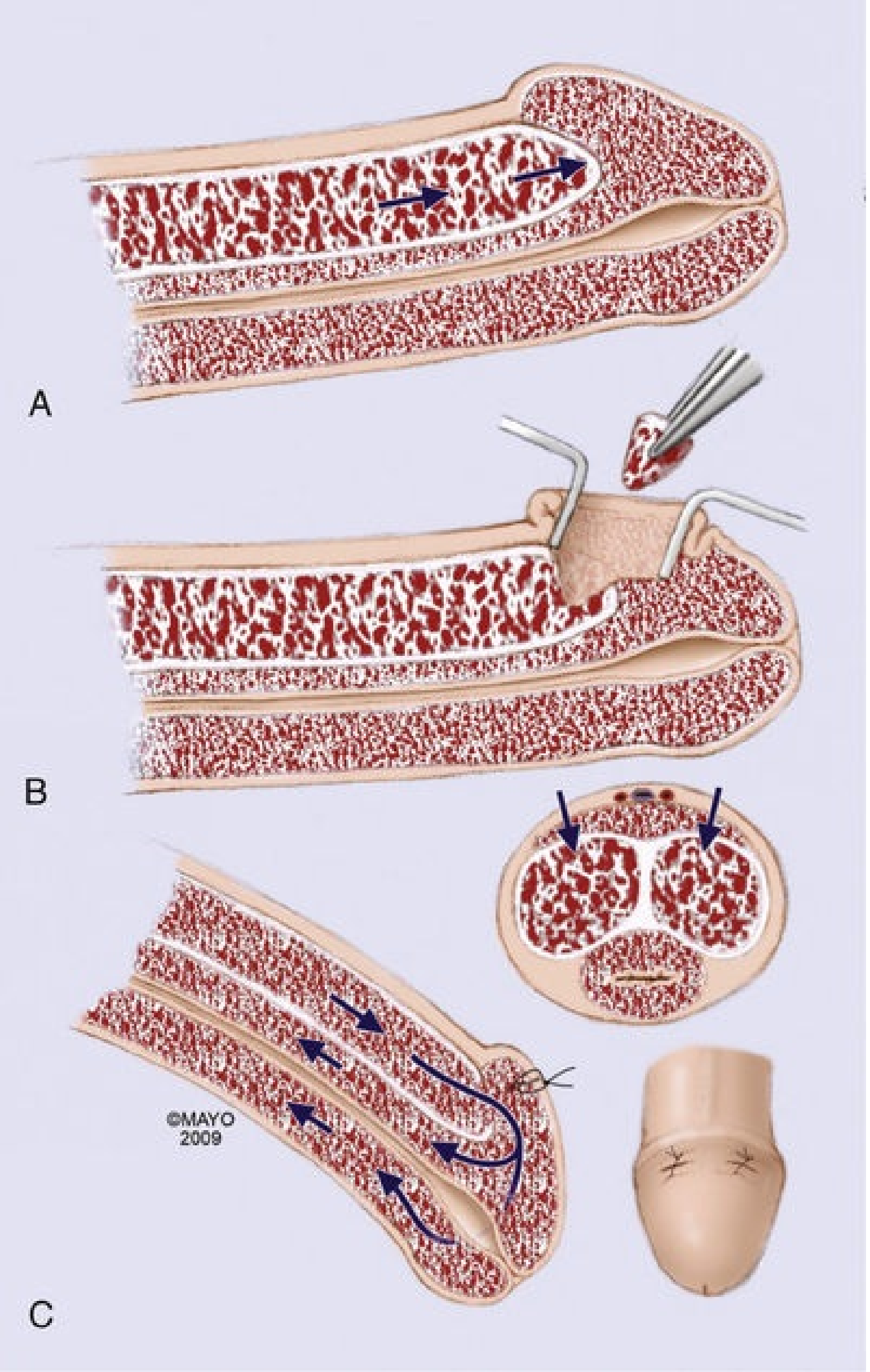

FIG. 70.10 (A to C) The Al-Ghorab shunt requires the excision of circular cone segments of the distal tunica albuginea (5 × 5 mm). (By permission of Mayo Foundation for Medical Education and Research. All rights reserved.)

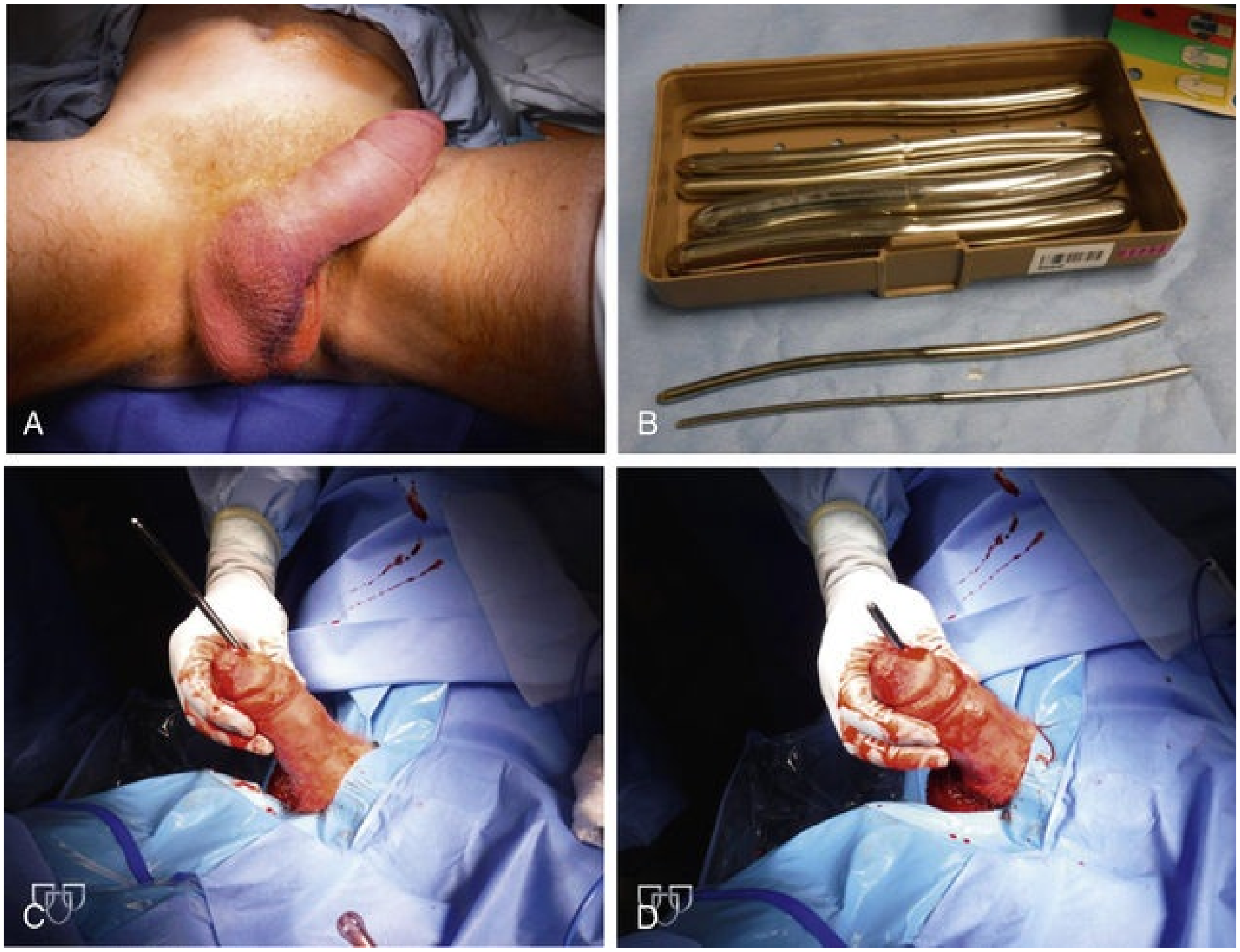

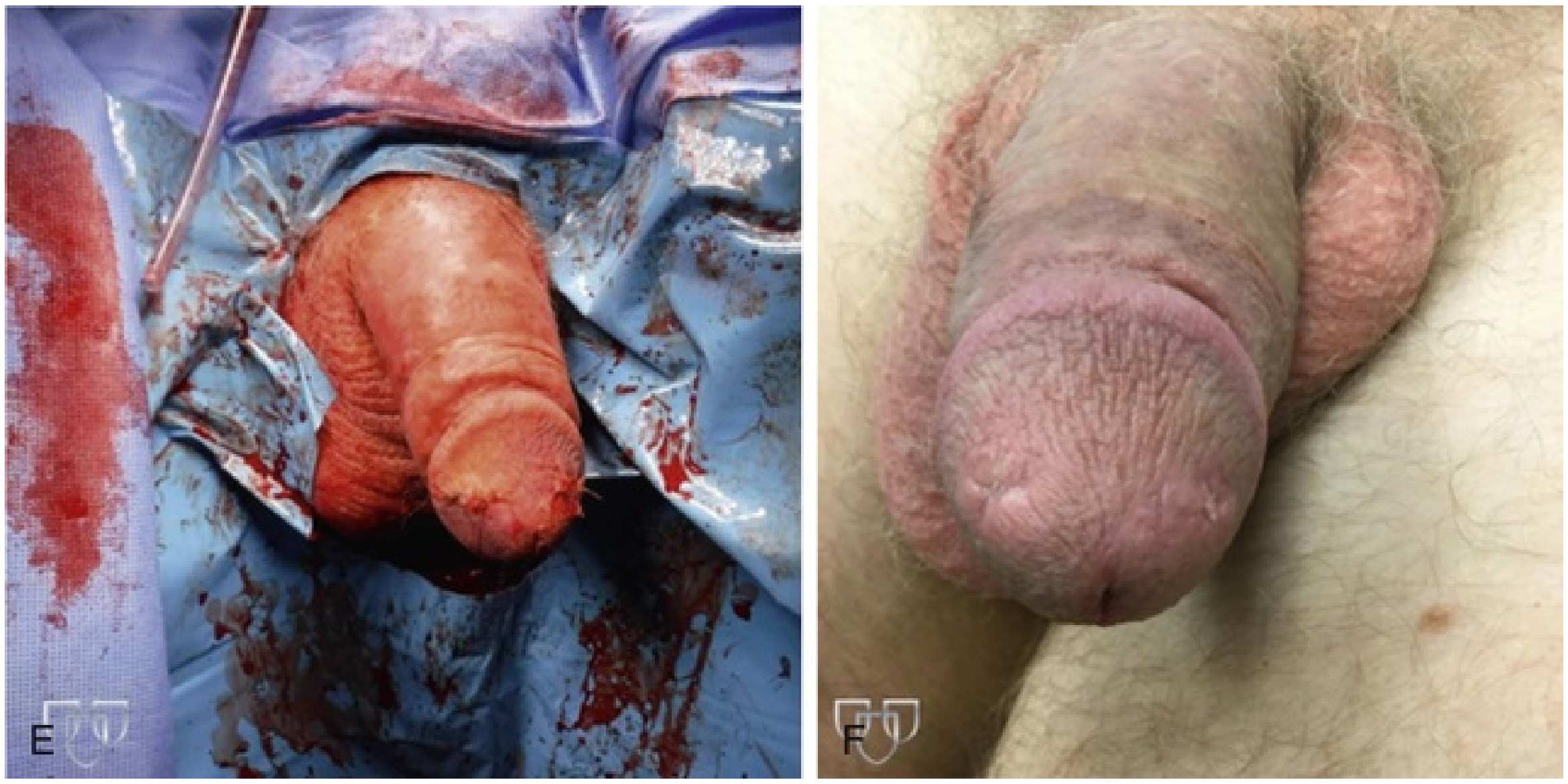

FIG. 70.11 (A) A 54-year-old male who had never been offered a trial of phosphodiesterase type 5 inhibitors before he was started on penile injection therapy by a commercial men's health clinic. He developed priapism after a low-dosage injection of trimix. He failed to respond to prescribed oral Terbutaline and Sudafed. He was treated at 12 to 24 hours in a local emergency department with α-adrenergic irrigations and taken to the operating room (OR) for bilateral distal cavernoglanular shunting with #11 blade. Patient was transferred to Mayo Clinic after more than 48 hours of ischemic priapism, with rigid erection and severe pain. (B) Hegar dilators. (C) Patient was taken to the OR for persistent ischemic priapism and pain. Distal T shunts permitted evacuation of clotting blood, but erection returned while under observation in operating theater. (D) 7/8 French Hegar dilator with staged insertion first distal and then proximal until bright red blood elicited from T shunts. (E) Penis was observed for 5 to 10 minutes in OR with no recurrence of erection; T shunts closed with #3-0 chromic sutures and (F) glans appearance after 3 weeks. The interventions relieved priapism and pain, but patient did develop distal corporal fibrosis and awaits delayed placement of penile prosthesis.

Segal et al. (2013) retrospectively reviewed the Johns Hopkins Hospital experience with the corporal snake maneuver. Ten patients with ischemic priapism with a mean duration of 75 hours (range 24 to 288 hours) refractory to medical intervention and simple distal shunting (Winter or Ebbehoj) were treated surgically with the corporal snake maneuver; in 8 the priapism resolved, and they had no postoperative recurrence during 6-month follow-up. In 2 patients the priapism did not respond; they were treated by insertion of inflatable penile implant at time of presentation. Complication rates were significant (20%); complications included wound infection, penile skin necrosis, and urethrocutaneous fistula. The authors documented sexual health function outcomes in these patients treated for refractory priapism lasting 24 to 288 hours; all had significant complaints of ED at 6 months, with 2 of 8 receiving subsequent penile implants (Segal et al., 2013). Zacharakis et al. (2014b) described the efficacy and outcomes of combining the T shunt (Brant et al., 2009) with the corporal snake maneuver in 45 patients. All were refractory to medical reversal of ischemic priapism. The combined distal surgical technique was successful in resolving the acute priapism if duration was less than 24 hours but had limited efficacy in cases of priapism exceeding 48 hours. Corporal needle biopsies were performed in each patient and documented smooth muscle necrosis, worsening as a function of time and uniform in all men with more than 48 hours of ischemia. At 6 months, erectile function outcomes were assessed by the erectile function domain score from the IIEF-5. T shunt with corporal snake tunneling successfully reversed ischemic priapism in all patients with less than 24 hours' duration, but at 6 months ED was reported by 50% of men. Zacharakis et al. (2014b) concluded that the cutoff for reversing ischemic priapism in the hopes of preserving future erectile function is 48 hours. They advise that management of refractory ischemic priapism of longer than 48 hours' duration should include discussion of immediate insertion of a penile implant.

The key factors determining successful surgical reversal of ischemic priapism are evacuation of thrombus, reestablishing cavernous inflow, and patency of shunt. Theoretically, larger open shunt procedures are likely to result in higher shunt patency rates; there are no data comparing percutaneous and open distal shunts. The surgeon must be guided by familiarity with various techniques: percutaneous shunting, open distal shunting, proximal shunting, and vein shunting. Although distal shunting can be performed with penile block and sedation in the emergency department, open shunting, especially that requiring passage of dilators into the CC, will likely require general anesthesia and an operating room suite. At the completion of the shunt, patency can be verified in the operating room and subsequently the recovery room in a number of ways: bright oxygenated blood should be seen emanating from the corporal bodies; intracavernous pressures should fall; the penis should detumesce and refill with sequential compression and release; and CDU should show resumption of cavernous artery inflow (Chiou et al., 2009; Lue, 2002; Nixon et al., 2003; Box 70.3).

Box 70.3

Assessing Corpora Cavernosa Shunt Patency

Visualization of bright red blood in corporal aspirate
Corporal blood gas
Color Doppler ultrasonography
Measurement of intracavernous pressure
Penile compression maneuver (squeeze and release)

Complications of shunting include penile edema, hematoma, infection, conversion of low-flow to high-flow (iatrogenic laceration of a cavernous artery) urethral fistula, penile necrosis, and pulmonary embolism (Mistry et al., 2017). Distal shunt failures may be the consequence of inadequate size and/or formation of a clot at the site. Distal shunt failure invariably leads to further surgical interventions. Shunts cut through the collagen-rich tunica albuginea; collagen-activated platelets and fibrin form as a reaction to surgical injury and will work to seal off the shunt. Premature thrombosis of the site could lead to shunt failure. Three suggestions have been made to prevent shunt obstruction and subsequent failure: (1) compressive penile dressings should be avoided; (2) the patient should periodically squeeze and release the distal penis to "milk" the shunt maintaining patency; and (3) anticoagulation should be considered with shunting. The literature contains only one such recommendation for perioperative anticoagulation for the prevention of premature shunt obstruction in ischemic priapism. That regimen includes preoperative aspirin 325 mg coupled with subcutaneous heparin 5000 units and postoperative aspirin 81 mg daily for 2 weeks (Lue and Garcia, 2013).

A distal shunt combining the T shunt and the "corporal snake" technique of passing dilators has become my treatment of choice. I perform the two techniques in a staged manner in the operating room for priapism refractory to aspiration/α-adrenergic injection. Beginning with bilateral T shunts and milking out of distal corporal clot, I first observe for full evacuation of old blood and appearance of bright red blood. I close the incisions on the glans with 2-0 chromic and wait and observe for maintained detumescence for up to 10 minutes. If the erection resumes I remove the stitches and initiate the corporal snake maneuver with a 7/8 Hegar. The Hegar can be progressively advanced to the proximal shaft, and the size of the Hegar can be progressively increased. This stepwise progression performs a proximal shunt by disruption corporal sinusoidal architecture without the attendant risks of proximal shunting described later. Using the combination of T shunt and intracavernous tunneling Zacharakis et al. (2014a,b) reported on 45 patients with refractory ischemic priapism. The combined technique resolved priapism in less than 24 hours in all patients but in only 30% of men with priapism lasting more than 48 hours. All of these patients with more than 48 hours of ischemia had necrotic cavernous tissue biopsied at time of shunting, and all eventually had penile implants (Zacharakis et al., 2014a,b).

The most commonly described proximal shunt is the unilateral shunt, described by Quackles in 1964 (Fig. 70.12). Proximal corpus cavernosum to corpus spongiosum (CC-CS) shunt procedures require a trans-scrotal or transperineal approach (Quackles, 1964). There are no data comparing bilateral (Sacher et al., 1972) and unilateral CC-CS shunts (Quackles, 1964). Typically, bilateral shunts are staggered; the right side and left side are separated by a distance of at least 1 cm in an effort to minimize the risk of urethral stricture at the point of CC-CS communication. If proximal shunting fails, some have advocated saphenous vein bypass or deep dorsal vein shunt (Fig. 70.13). A wedge of tunica albuginea is removed, and the vein is anastomosed end to side of CC. There are no comparative trials of vein shunting for ischemic priapism. Authors have described a significant risk of saphenofemoral vein thrombus and pulmonary embolism with vein shunting (Kandel et al., 1968).

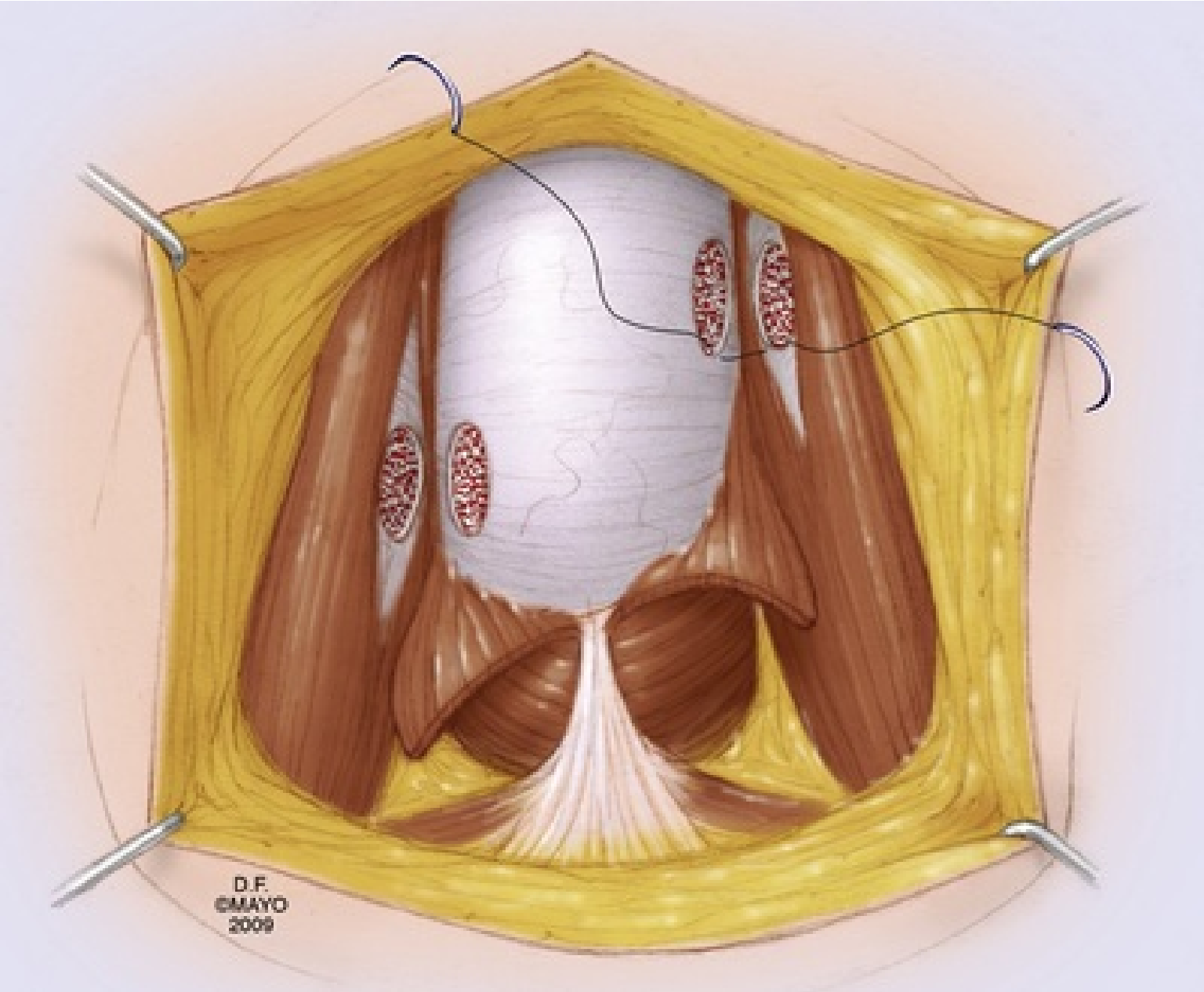

FIG. 70.12 Proximal bilateral shunts are staggered. The right and left sides are separated by a distance of at least 1 cm in an effort to minimize

the risk of urethral stricture at the point of corpus cavernosum to corpus spongiosum communication (Sacher et al., 1972). (By permission of Mayo Foundation for Medical Education and Research. All rights reserved.)

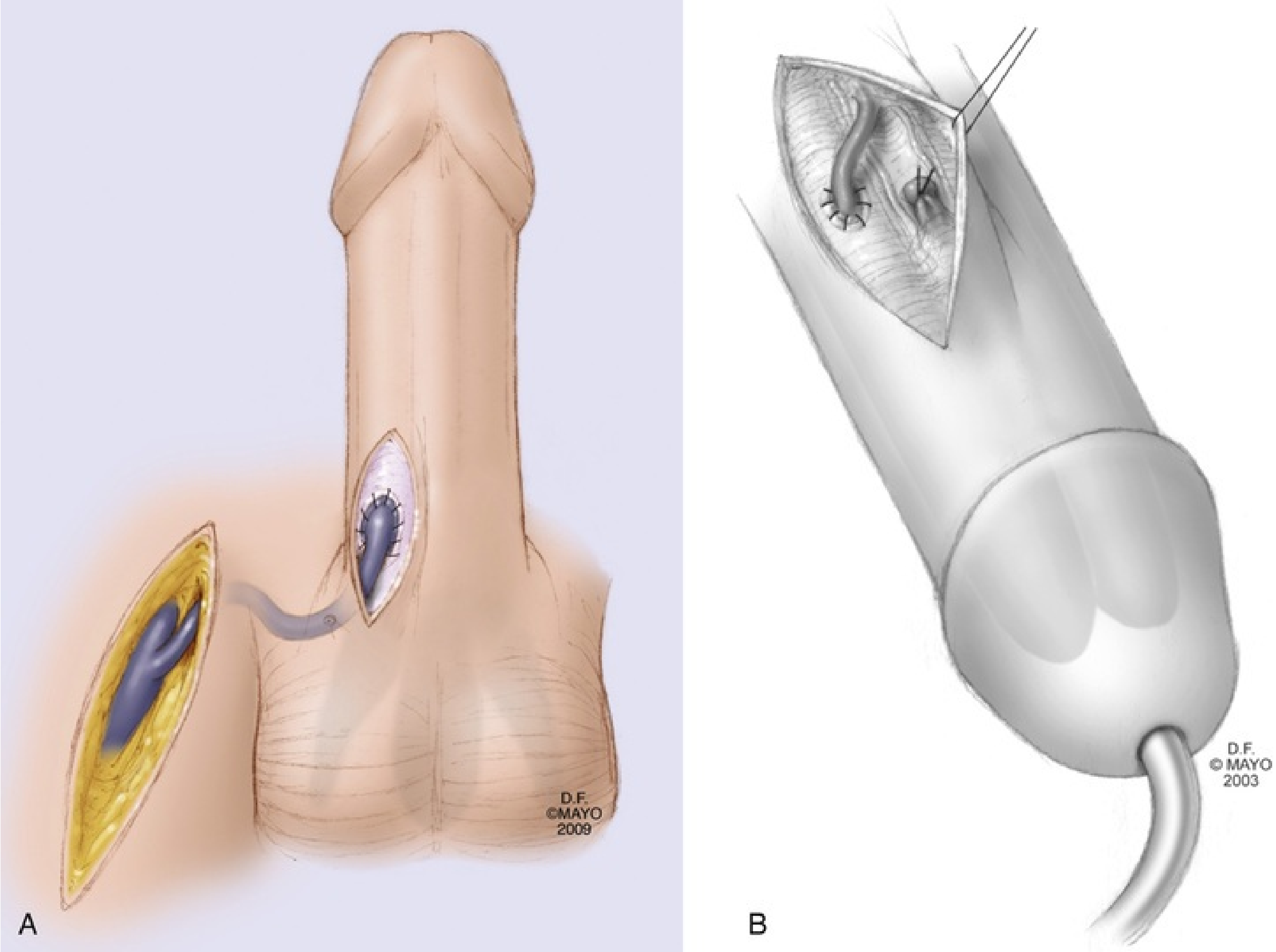

FIG. 70.13 (A) Venous bypass to control ischemic priapism was first described by Grayhack et al. in 1964. The Grayhack shunt mobilizes the saphenous vein below the junction of the femoral vein and anastomoses the vein end to side into the corpus cavernosum. (B) Deep dorsal vein (DDV) shunt with distal ligation of DDV and anastomosis of proximal DDV to corpus cavernosum. A wedge of tunica albuginea is removed. (By permission of Mayo Foundation for Medical Education and Research. All rights reserved.)

Key Points: Surgical Management of Ischemic Priapism

- Shunt surgery should be considered for all patients with ischemic priapism in whom aspiration and ICI of α-adrenergics has failed.

- Patients should be counseled that erectile function outcomes decline significantly when ischemic priapism has lasted longer than 24 hours and that complete ED is anticipated if ischemic priapism persists for longer than 36 hours.
- The objective of shunt surgery is reoxygenation of the cavernous smooth muscle.
- The key factors determining successful surgical reversal of ischemic priapism are evacuation of thrombus, patency of shunt, and resumption of cavernous inflow.
- A distal cavernoglanular shunt should be the first choice of shunting procedures.
- Percutaneous distal shunting is less invasive than open distal shunting and may be performed with local anesthetics.
- There are a number of distal shunting procedures, and the surgeon should be familiar with these procedures and their complications.
- There are no comparative trials of safety, efficacy, or erectile function outcomes for percutaneous versus open distal shunting techniques. There is increasing evidence to support T shunt in combination with “corporal snake” maneuver as the preferred surgical intervention for refractory ischemic priapism.
- Proximal shunting establishes a communication between the CC and CS at the base of the penis. The surgeon must be aware of the unique anatomic relationship between the corpus spongiosum and urethra.
- Shunting may also be accomplished with vein grafting to the CC. Venous shunts have increased the risk of thromboembolism.
- After medical or surgical reversal of ischemic priapism, penile tumescence rather than complete flaccidity may be evident. A phenomenon of conversion from ischemic priapism to HFP has been described. In cases in which the examination findings may be equivocal, CDU or cavernous blood gas is recommended to demonstrate patency of the shunt and restoration of cavernous inflows.
- After shunting, the urologist should follow up with the patient regarding erectile function and any subsequent ED therapies.

Immediate Implantation of Penile Prosthesis

Unfortunately, **the natural history of untreated ischemic priapism or priapism refractory to interventions is severe fibrosis, penile length loss, and complete ED** (see Fig. 70.1). Kelami (1985) described the implantation of the Small-Carrion penile prosthesis through an infrapubic incision in the management of postpriapic ED. Bertram et al. (1985) described six postpriapic cases of penile prosthesis; five of the six men had successful implantation of semirigid prostheses. Both groups described extensive corporal fibrosis and suggested that semirigid implants were preferable because inflatable implants would not overcome the corporal fibrosis sufficiently to erect the penis. Douglas et al. (1990) reported on penile prosthesis in five SCD postpriapic men; they described a surgical technique of tunneling and corporal excavation. Inadvertent damage to the tunica albuginea was common, as was subsequent migration of hardware; 11 additional procedures were required after the initial implants. The average time from priapism to implant in Douglas's series was 4 years.

Monga et al. (1996) described implants in young SCD patients (6 patients, average age 26); inflatable implants were placed to treat ED and circumvent ongoing episodes of stuttering priapism. These researchers suggested that potency and recurrent episodes of ischemic priapism could be managed by "early" implantation (Fig. 70.14).

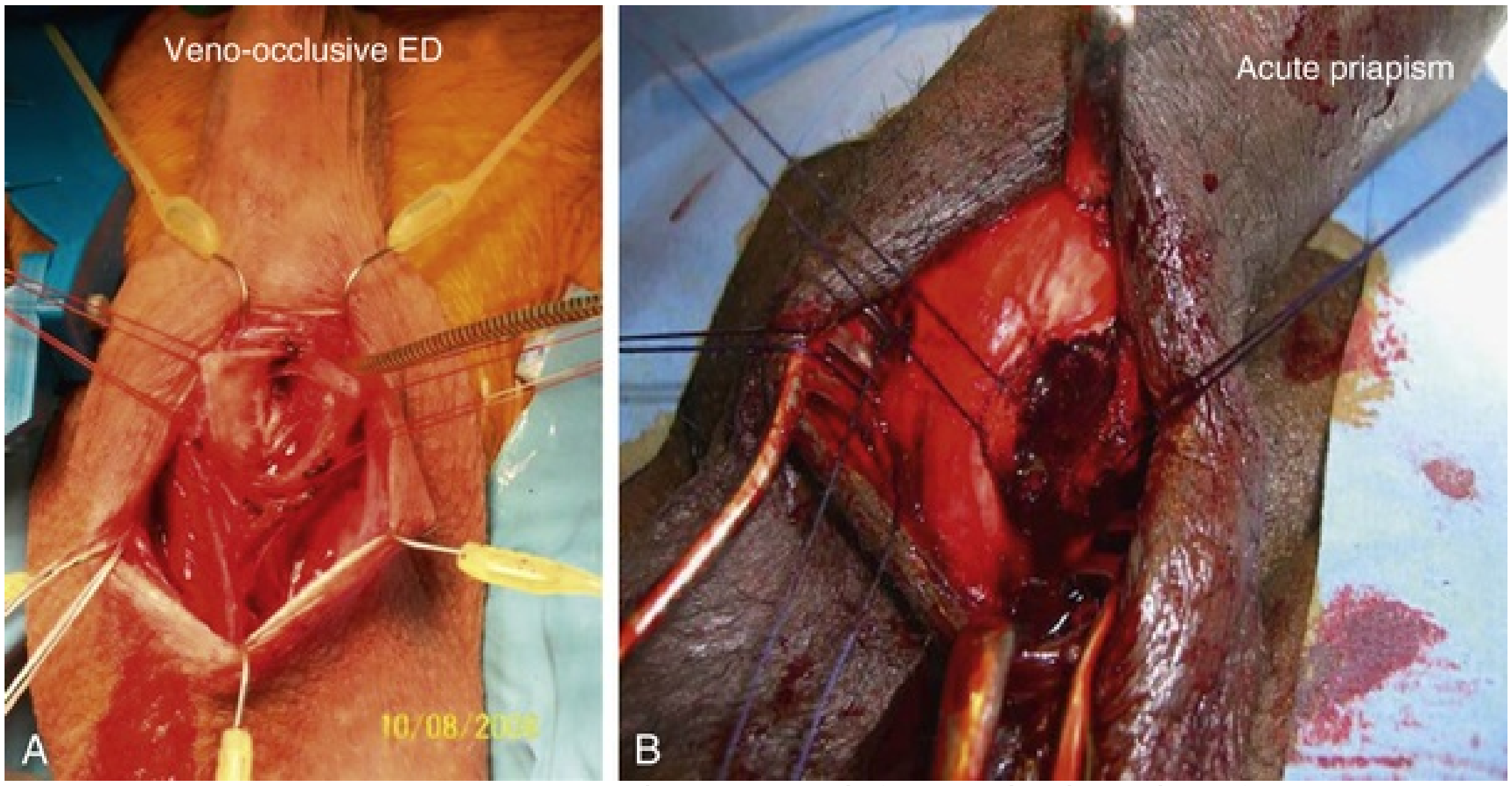

FIG. 70.14 Penoscrotal surgical approach for elective insertion of inflatable penile implant in a white patient with severe veno-occlusive

erectile dysfunction (ED) (A) and a patient with sickle cell disease with acute ischemic priapism refractory to pharmacologic interventions and shunting for 48 hours (B). (B, Courtesy David J. Ralph, MD.)

Some have recommended performing an immediate penile prosthesis procedure in the acute management of ischemic priapism in patients in whom sympathomimetic intracavernous therapies and shunting have both failed (Rees et al., 2002). There are two distinct advantages to immediate implantation: corporal fibrosis is not yet established, and penile length may be preserved. **The exact time point at which prosthetic insertion becomes a reasonable option for managing ischemic priapism is unclear** (see Fig. 70.7). Should medical management of ischemic priapism be followed by distal percutaneous shunt, by open distal shunt, and subsequently by proximal shunting before penile implant? Should men with delayed presentation of ischemic priapism and evident corporal thrombus be triaged to an immediate penile implant procedure? What is clear is that any discussion pertaining to early prosthesis insertion should be documented and should include a comprehensive review of the theoretic advantages and actual risks. **Compared with prosthesis insertion in a typical patient with ED, there are significantly higher rates of complications noted in priapism cases: infection, urethral injury, device migration, device erosion, and need for revision surgeries** (Moore et al., 2017; Reddy et al., 2018). The surgeon must be familiar with the additional technical concerns posed by weaknesses in the tunica albuginea in the region of prior shunts.

The advantages of early penile implantation in the acute management of ischemic priapism are preservation of penile length and technically easier implant insertion. Delayed placement of penile prosthesis is technically challenging because of corporal fibrosis (Stember and Mulhall, 2010). Ralph et al. (2009) reported on 50 patients with ischemic priapism. In all patients, conservative management with the instillation of α-adrenergic agents (200 μg phenylephrine repeated to a maximum dose of 1500 μg) failed. Unsuccessful shunts were performed in 13 of 50 cases (Ralph et al., 2009). Mean duration of priapism was 209 hours (range 24 to 720 hours). All patients had evidence of cavernous thrombus and smooth muscle necrosis on MRI, and all 50 underwent insertion of penile prosthesis in the acute setting of refractory ischemic priapism. Revision rates were significantly high, at 24% (12 of 50 patients). The infection rate of 6% was also notably high and likely related to multiple factors including ischemic tissues and preceding penile interventions. The same surgical group recently compared two cohorts of patients undergoing penile implant for refractory ischemic priapism. An early insertion cohort was operated on at a mean of 7 days after onset of priapism, and the delayed cohort was operated on at a mean of 5 months after priapism. In the early insertion group, satisfaction and ability to have intercourse was 96%; in the delayed group, corporal fibrosis made surgery technically more difficult and overall patient satisfaction was 60% (Zacharakis et al., 2014a). The placement of penile implant in the immediate management of refractory ischemic priapism is controversial. There is good evidence that reversing ischemic priapism beyond 36 to 48 hours will have the same long-term outcome as doing no further procedures: corporal fibrosis and complete ED. A successful intervention at 48 hours will certainly spare the patients several weeks of pain and needed analgesia, but it will not result in the recovery of normal if any erections. Some have suggested logistical considerations balance surgical zeal to "fix the problem early." Elective placement of penile implants in the United States requires prior authorization for those surgical services or contracting with the patient for a cash price. Delaying a penile implant to allow some healing of the distal shunt site for 3 weeks allows for prior authorization of the surgical procedure and should theoretically permit operation while there is still unorganized (liquid) clot in the corporal spaces and not dense fibrosis (Tatem and Kovac, 2017).

Key Points: Surgical Management of Ischemic Priapism With Immediate Penile Implant

- The natural history of untreated ischemic priapism or priapism refractory to interventions is severe fibrosis, penile length loss, and complete ED.
- The advantages of early penile implantation in the acute management of ischemic priapism are preservation of penile length and easier insertion.
- The clinician should document baseline erectile function, duration of priapism, history of stuttering, and prior interventions.
- Penile prosthesis should be considered in the following circumstances:
    - Aspiration and sympathomimetic ICI have failed.
    - Distal and proximal shunting procedures have failed.
    - Ischemia has been present for longer than 36 hours.
- An MRI before surgery or corporal biopsy at the time of implant should be

considered to document corporal smooth muscle necrosis.

- There are higher rates of revision surgery and complications noted in priapism cases resulting from infection, urethral injury, device migration, and device erosion.

Interventional Angiography in the Management of Arterial (Nonischemic, High-Flow) Priapism

Arterial priapism is not an emergency. Spontaneous resolution or response to conservative therapy has been reported in up to 62% of published series (Montague et al., 2003; Pryor et al., 2004). Persistent partial erection from HFP may be evident for months to years without adverse impact on erectile function (Bastuba et al., 1995). Kumar et al. (2006) described a case of HFP in a 24-year-old patient 10 days after straddle injury on a bicycle. The patient had no erection for the first 4 days after injury. Examination revealed a tumescent penis that was compressible. Penile aspiration and blood gas analysis revealed oxygenated corporal blood. CDU of the cavernous artery revealed arteriosinusoidal fistula. Partial erection spontaneously resolved 4 days after diagnostic evaluation, with the patient reporting normal erections 2 weeks later. The authors hypothesized that, in patients with blunt penile and perineal trauma, an arteriolacunar fistula forms; these fistulae, unlike arteriovenous communications, may spontaneously resolve because the less-rigid walls of the lacunae are prone to spontaneous thrombosis. Onset of HFP is typically delayed after injury. The erection is partial, not rigid, and not painful. Although the site of perineal trauma may have hematoma, spreading of the hematoma to the shaft should raise suspicion of rupture of tunica albuginea; this would be highly unusual in blunt perineal (straddle) injury. The pathophysiology of HFP is unregulated arteriolacunar fistula from disruption or crush injury to terminal branches of the cavernous artery. Fistula is typically unilateral. Because there is no restriction of venous outflow, erection is partial and bendable. Patients do report additional engorgement with sexual stimulation with return to partial erection after climax.

There are no comparative outcome studies of intervention versus conservative management in HFP; there are sufficient case descriptions, especially in children, to recommend initial watchful waiting. Initial observation is recommended for this type of priapism. Conservative measures include ice applied to the perineum and site-specific compression. **Cavernous aspiration has only a diagnostic role in HFP. Repeated aspirations, injection, and irrigation with intracavernous sympathomimetics have no role in the**

treatment of nonischemic priapism.

Patients demanding immediate relief can be offered selective arterial embolization. The pathognomonic arteriographic finding is an arteriolacunar fistula; a characteristic intracavernosal cone-shaped blush of contrast is seen at the site of the cavernous artery or arteriole laceration (Fig. 70.15). Selective internal pudendal catheterization and subsequent embolization have been reported with various agents: microcoils, polyvinyl alcohol, *N*-butylcyanoacrylate, gel-foam, and autologous blood clot (Kuefer et al., 2005). Permanent materials pose a greater theoretic risk of ED; many authors recommend use of autologous blood clot and absorbable gels (Kim et al., 2007; Pryor et al., 2004). Autologous blood clot has a low risk of foreign body reaction, or antigenicity; it is a temporary occlusive agent and should permit recanalization of the cavernous artery (Park et al., 2001). **The success rates with selective pudendal artery catheterization followed by embolization are high (89% to 100%), regardless of the embolization material used** (Kuefer et al., 2005; Numan et al., 2008). Similar results have been reported by others (Alexander Tønseth et al., 2006; Savoca et al., 2004). **Normal postembolization erectile function has been reported in 75% to 86% of patients** (Cakan et al., 2006; Numan et al., 2008). **A single treatment of embolization carries a recurrence rate of 30% in some series** (Ciampalani et al., 2002; Gandini et al., 2004; Ozturk et al., 2009). **Although ultimately successful, embolization of HFP may require retreatment**. **The most notable side effect of bilateral arterial embolization is ED.** Recurrence of HPF after embolization may be caused by recanalization of the embolized fistula or unmasking of a fistula in the contralateral cavernous artery. Although it was previously reported that nonpermanent embolization materials cause less ED than permanent ones (5% vs. 39%), reports describing use of the IIEF in evaluation of postembolization erectile function note similar rates of ED—15% and 20% (Alexander Tønseth et al., 2006; Savoca et al., 2004). Older reports show adverse effects including penile gangrene, gluteal ischemia, purulent cavernositis, and abscess of the perineum. These may be due to the less selective embolization techniques (Hakim et al., 1996; Sandock et al., 1996).

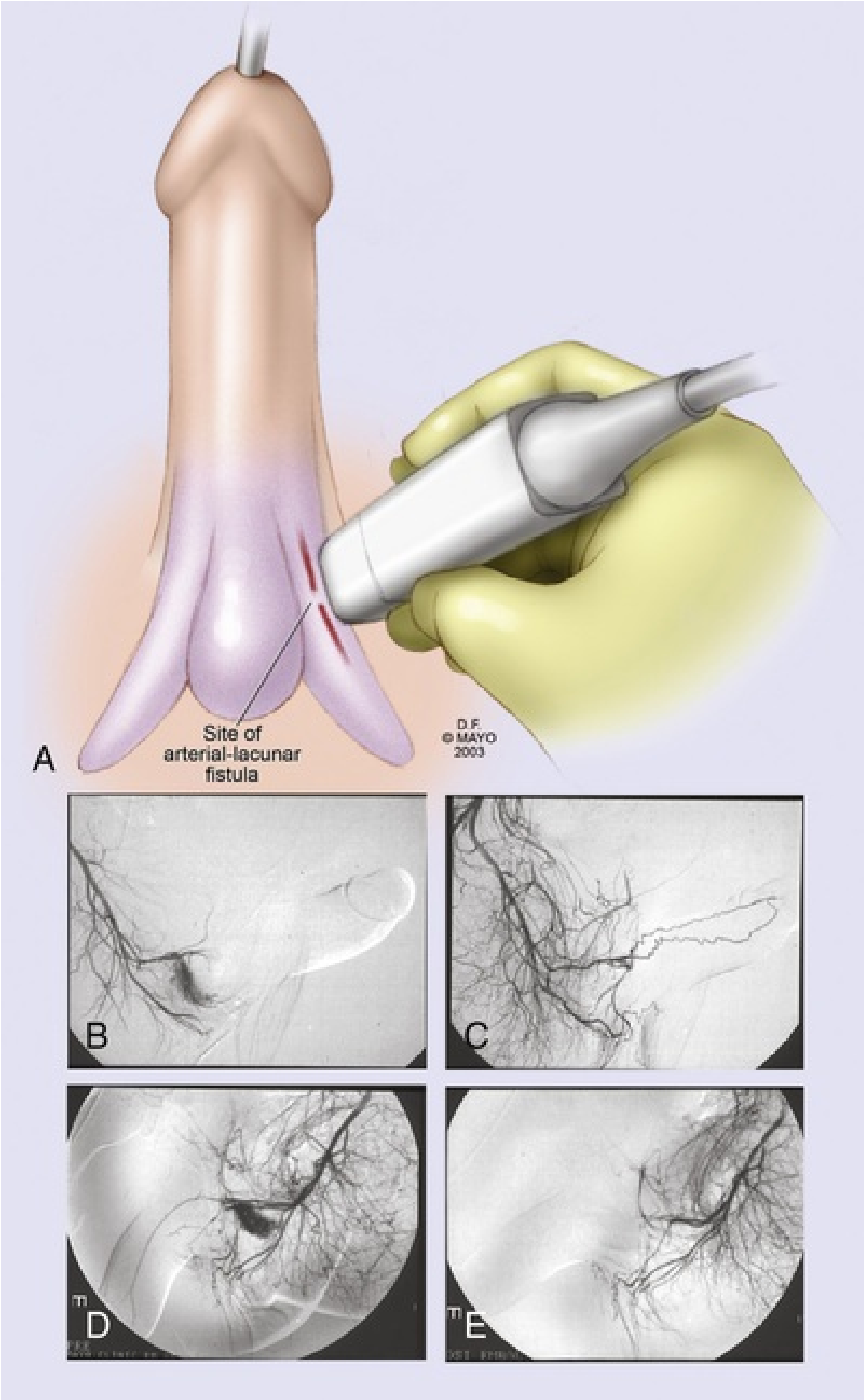

FIG. 70.15 Color Doppler ultrasonography of the penis and perineum is recommended in the evaluation of priapism when the history or examination findings suggest penile trauma (A). Doppler sonography for localization of a fistula correlates well with selective pudendal angiography (B to E); a characteristic fistula blush is shown (B and D), along with normal arteriograms (C and E). (A, By permission of Mayo Foundation for Medical Education and Research. All rights reserved.)

Puppo et al. (1985) compared perineal duplex ultrasound and selective internal pudendal arteriography, showing excellent sensitivity of ultrasound in detecting arteriolacunar fistulae that were seen angiographically (12 of 12 cases). Several reports have described combined ultrasound-guided compression with selective arterial embolization to increase success rates in the treatment of nonischemic priapism (Bartsch et al., 2004; Cakan et al., 2006; Hatzichristou et al., 2002). If the follow-up clinical examination is equivocal for recurrence of HFP, a perineal duplex Doppler ultrasound can determine the need for repeat arteriography and embolization (Kim et al., 2007). In a recent series reviewing 16 patients managed at one center with superselective transcatheter artery embolization, 93% of patients responded to a single embolization and 7% required a second embolization for recurrence or persistence of high-flow arteriosinusoidal fistula. All the patients were adults and 70% reported history of trauma; in the majority the onset of HFP was within 10 days of injury. All patients had superselective embolization into the anterior division of the internal iliac artery with advancement of microguidewire and microcatheter (Terumo, Tokyo, Japan) as close to the fistula as possible. Fourteen of 16 patients had unilateral embolization (all with permanent microcoils), and all had preservation of “premorbid erectile function” (Pei et al., 2018).

Surgical Management of Arterial (Nonischemic, High-Flow) Priapism

Arterial priapism is not a urologic emergency. HFP is painless, and there have been reports of partial erection persisting for years (Nehra, 2006). Any intervention must follow a comprehensive discussion with the patient regarding risks and benefits of any of the procedures advocated by the clinician. **In cases of long-standing arterial priapism in which a pseudocapsule around the fistula has developed, surgical ligation has been reported to be successful. Formation of a pseudocapsule may take weeks to months after trauma. Corporal exploration before the formation of a pseudocapsule** (Fig. 70.16) **may result in ligation of the cavernous artery rather than selective ligation of the fistula.** Currently this intervention is reserved for patients who do not wish to pursue expectant management or who are poor candidates for angioembolization. It is also reserved for patients who refuse the procedure; for patients in places where technology is not available; and for patients in whom angioembolization has failed (Berger et al., 2001; Ji et al., 1994; Mulhall, 2006). The surgical approach is transcorporal. Intraoperative Doppler ultrasound guidance is recommended (Fig. 70.17).

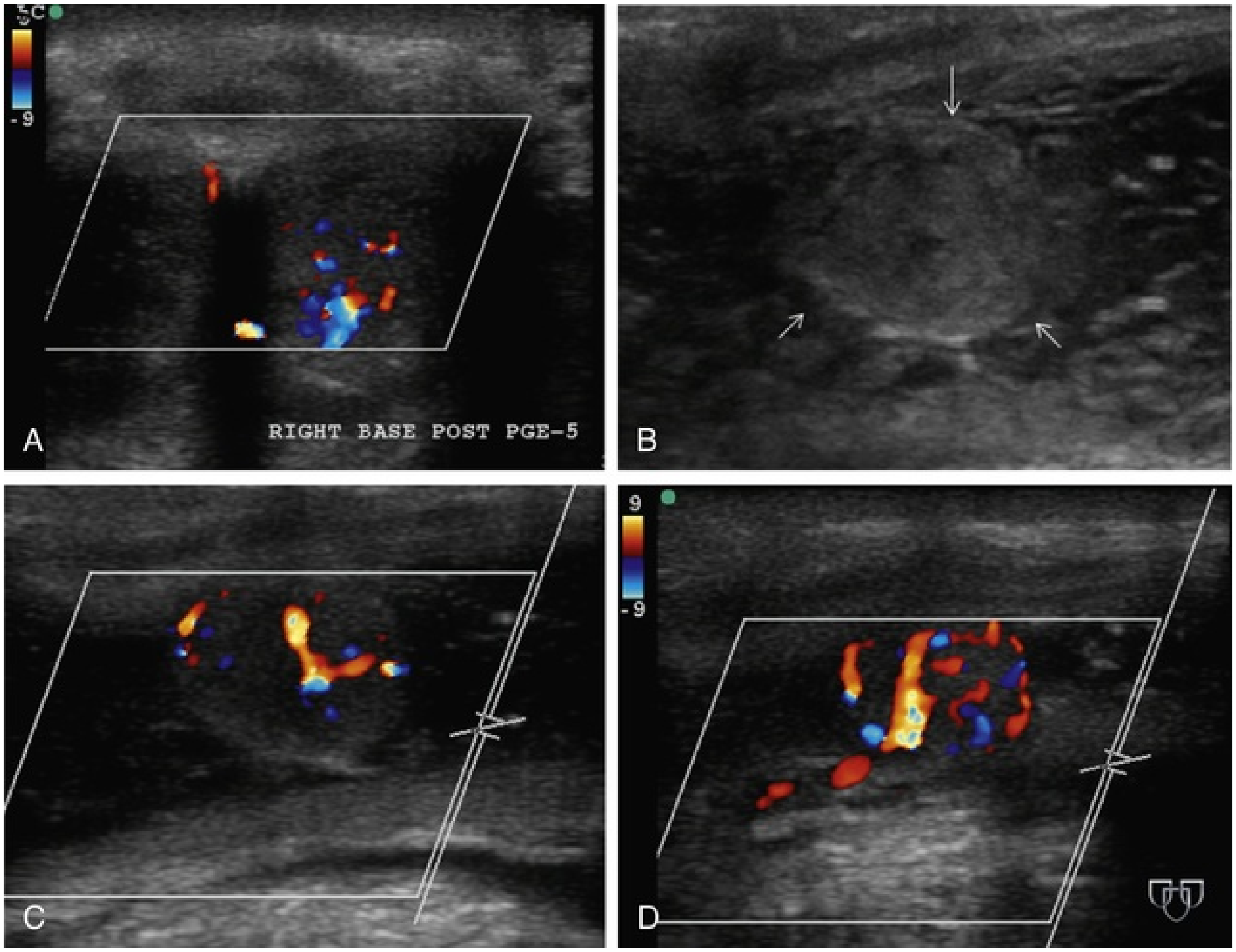

FIG. 70.16 A 60-year-old male presenting more than a year after straddle injury with the complaint of persisting tumescence and no pain. He was unable to achieve rigid erection for sex despite PDE type-5 Inhibitor dosing. (A) Sagittal color Doppler imaging after low dosage alprostadil suggests sinusoidal fistula. (B) Duplex grayscale imaging; *arrows* outline pseudo capsule. (C, D) Coronal images confirm disrupted cavernous arterial and sinusoidal fistula.

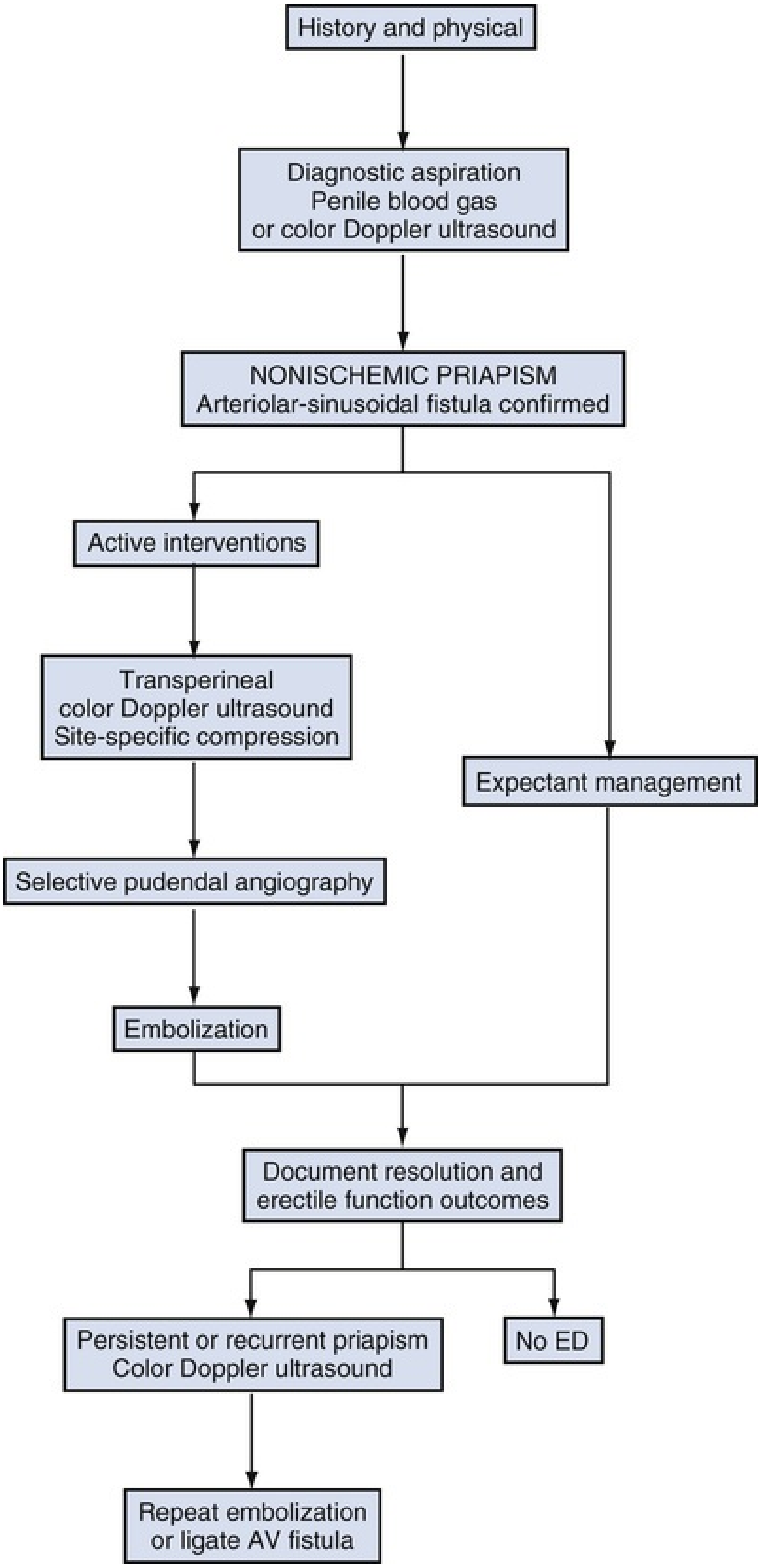
History and physical
Diagnostic aspiration
Penile blood gas
or color Doppler ultrasound
NONISCHEMIC PRIAPISM
Arteriolar-sinusoidal fistula confirmed
Active interventions
Transperineal
color Doppler ultrasound
Site-specific compression
Expectant management
Selective pudendal angiography
Embolization
Document resolution and
erectile function outcomes
Persistent or recurrent priapism
Color Doppler ultrasound
No ED
Repeat embolization
or ligate AV fistula

FIG. 70.17 Algorithm for managing high-flow priapism. *AV,* Arteriovenous; *ED,* erectile dysfunction.

Key Points: Evaluation and Management of High-Flow Priapism

- Arterial priapism is not an emergency and may be managed expectantly.
- Diagnosis of HFP is best made by penile or perineal CDU.
- Penile aspiration and injection of α-adrenergic agents are not recommended for HFP.
- Angioembolization should be preceded by a thorough discussion of chances for spontaneous resolution, risks of treatment-related ED, and lack of significant consequences expected from delaying interventions.
- Overall success rates with embolization are high, although a single treatment carries a variable recurrence rate.
- When angioembolization fails or is contraindicated, surgical ligation is reasonable.
- Formation of a pseudocapsule at the site of a sinusoidal fistula may take weeks to months after trauma.
- CDU guidance is recommended during exploration to locate fistulae.

Summary

Priapism is a full or partial erection that persists more than 4 hours beyond sexual stimulation and orgasm or is unrelated to sexual stimulation. Prompt diagnosis and appropriate management are necessary to spare patients ineffective interventions and optimize erectile function outcomes. Ischemic priapism (veno-occlusive, low-flow) is a persistent painful erection marked by rigidity of the CC. In ischemic priapism there are time-dependent changes in the corpora with progressive hypoxia, hypercarbia, and acidosis. Ischemic priapism is a urologic emergency. Treatment for ischemic priapism is administered in a stepwise manner: decompression of the corpora by needle aspiration, injection and/or irrigation with a dilute sympathomimetic drug (phenylephrine), surgical shunting, and possible consideration of immediate penile implant in refractory cases (see Fig. 70.7). Ischemic priapism is a common pathologic consequence of SCD. Stuttering ischemic priapism describes a pattern of prolonged morning erections that are unwanted and painful in boys and adolescents with SCD. Unfortunately any patient who has experienced an episode of ischemic priapism is also at risk for stuttering priapism. HFP (nonischemic priapism, arterial priapism) is a persistent erection caused by unregulated cavernous arterial inflow. Typically, the corpora are tumescent but not rigid, and the penis is not painful. A history of blunt trauma (a straddle injury) or an iatrogenic needle injury to the penis is common. HFP may follow the primary trauma by several weeks or may be immediate. The cavernous environment in HFP does not become ischemic, and cavernous blood gases do not show hypoxia, hypercarbia, or acidosis. HFP, once properly diagnosed, does not require emergent treatment (see Fig. 70.17).

Urologists intervening to treat priapism should document onset of erection and the presence or absence of pain, trauma, medical history of blood dyscrasias, use of illicit substances, prior prolonged erection events, baseline erectile function, types of interventions, and recovery of erectile function. Physicians should document erectile function outcomes with standardized questionnaires such as Sexual Health Inventory for Men (SHIM) or the International Index of Erectile Function (IIEF). Documenting erectile function outcomes versus the duration of ischemic priapism, time to interventions, and types of interventions will establish evidence-based guidance on how and when to apply those interventions.

Suggested Readings

Bennett N, Mulhall J. Sickle cell disease status and outcomes of African American men presenting with priapism. *J Sex Med*. 2008;5(5):1244–1250.

Bivalacqua TJ, Champion HC, Mason W, et al. Long-term phosphodiesterase type 5 inhibitor therapy reduces priapic activity in transgenic sickle cell mice. *J Urol*. 2006;175:387.

Brant WO, Garcia MM, Bella AJ, et al. T-shaped shunt and intracavernous tunneling for prolonged ischemic priapism. *J Urol*. 2009;181:1699–1705.

Broderick GA. Priapism and sickle-cell anemia: diagnosis and nonsurgical therapy. *J Sex Med*. 2012;9:88–103.

Broderick GA, Kadioglu A, Bivalacqua TJ, et al. Priapism: pathogenesis, epidemiology, and management. *J Sex Med*. 2010;7:476–500.

Burnett AL, Anele UA, Trueheart IN, et al. Randomized controlled trial of sildenafil for preventing recurrent ischemic priapism in sickle cell disease. *Am J Med*. 2014;127(7):664–668.

Chan PTK, Begin LR, Arnold D, et al. Priapism secondary to penile metastasis: a report of two cases and a review of the literature. *J Surg Oncol*. 1998;68(1):51–59.

Chiou RK, Aggarwal H, Chiou C, et al. Colour Doppler ultrasound hemodynamic characteristics of patient with priapism before and after therapeutic interventions. *Can Urol Assoc J*. 2009;3(4):304–311.

Constantine ST, Gopalsami A, Helland G. Recurrent priapism gone wrong: ST-elevation myocardial infarction and cardiogenic shock after penile corporal phenylephrine irrigation. *J Emerg Med*. 2017;52(6):859–862.

Hudnall M, Reed-Maldonado AB, Lue TF. Advances in the understanding of priapism. *Transl Androl Urol*. 2017;6(2):199–206.

Kato GJ. Priapism in sickle-cell disease: a hematologist's perspective. *J Sex Med*. 2012;9:70–78.

La Favor JD, Fu Z, Venkatraman V, et al. Molecular profile of priapism associated with low nitric oxide bioavailability. *J Proteome Res*. 2018;17(3):1031–1040.

Podolej GS, Babcock C. Emergency department management of priapism. *Emerg Med Pract*. 2017;19(1):1–16.

Qi T, Ye L, Chen Z, et al. Efficacy and safety of treatment of high-flow priapism with superselective transcatheter embolization. *Curr Med Sci*. 2018;38(1):101–106.

Ralph DJ, Garaffa G, Muneer A, et al. The immediate insertion of a penile prosthesis for acute ischaemic priapism. *Eur Urol*. 2009;56:1033–1038.

Reed-Maldonado AB, Kim JS, Lue TF. Avoiding complications: surgery for ischemic priapism. *Transl Androl Urol*. 2017;6(4):657–665.

Reddy AG, Alzweri LM, Gabrielson AT, et al. Role of penile prosthesis in priapism: a review. *World J Mens Health*. 2018;36(1):4–14.

Salonia A, Eardley I, Giuliano F, et al. European Association of Urology guidelines on priapism. *Eur Urol*. 2014;65:480–489.

Sidhu AS, Wayne GF, Kim BJ, et al. High-dose intracavernosal phenylephrine for priapism: is it safe? *J Urol*. 2017;197(4 Suppl 1):e1348–e1349.

Zacharakis E, Raheem AA, Freman A, et al. The efficacy of the T-shunt procedure and intracavernous tunneling (snake maneuver) for refractory ischemic priapism. *J Urol*. 2014;191:164–168.

References

Abern MR, Levine LA. Ketoconazole and prednisone to prevent recurrent ischemic priapism. *J Urol*. 2009;182(4):1401–1406.

Adeyoju AB, Olujohungbe AB, Morris J, et al. Priapism in sickle-cell disease; incidence, risk factors and complications —an international multicentre study. *BJU Int*. 2002;90(9):898–902.

Ahmed M, Augustine B, Matthew M, et al. Prognostic factors and outcome of management of ischemic priapism in Zaria, Nigeria. *Niger J Surg*. 2017;23(1):15–19.

Alexander Tønseth K, Egge T, Kolbenstvedt A, et al. Evaluation of patients after treatment of arterial priapism with selective micro-embolization. *Scand J Urol Nephrol*. 2006;40:49–52.

Aliyu ZY, Kato GJ, Taylor J, et al. Sickle cell disease and pulmonary hypertension in Africa: a global perspective and review of epidemiology, pathophysiology, and management. *Am J Hematol*. 2008;83:63–70.

Amlie RN, Borgeois B, Huxtable R. Priapism in preterm infant. *Urology*. 1977;9:558–559.

Andrade E, Villanova F, Borra P, et al. Penile erection induced in vivo by a purified toxin from the Brazilian spider *Phoneutria nigriventer*. *BJU Int*. 2008;120(7):835–837.

Anele UA, Morrison BF, Burnett AL. Molecular pathophysiology of priapism: emerging targets. *Curr Drug Targets*. 2015;16(5):474–483.

Aoyagi T, Hayakawa K, Miyaji K, et al. Sildenafil induced priapism. *Bull Tokyo Dent Coll*. 1999;40(4):215–217.

Ateyah A, Rahman El-Nashar A, Zohdy W, et al. Intracavernosal irrigation by cold saline as a simple method of treating iatrogenic prolonged erection. *J Sex Med*. 2005;2:248–253.

Ballas SK, Kesen MR, Goldberg MF, et al. Beyond the definitions of the phenotypic complications of sickle cell disease: an update on management. *Sci World J*. 2012;2012:949535.

Ballas SK. From total blood exchange to erythrocytapheresis and back to treat complications of sickle cell disease. *Transfusion*. 2017;57(9):2277–2280.

Barry JM. Priapism. Treatment with corpus cavernosum to dorsal vein of penis shunts. *J Urol*. 1976;116:754–756.

Bartsch G Jr, Kuefer R, Engel O, et al. High-flow priapism: colour-Doppler ultrasound-guided supraselective embolization therapy. *World J Urol*. 2004;22:368–370.

Bastuba MD, de Tejada IS, Dinlenc CZ, et al. Arterial priapism: diagnosis, treatment and long-term follow up. *J Urol*. 1995;151:1231–1237.

Bennett N, Mulhall J. Sickle cell disease status and outcomes of African American men presenting with priapism. *J Sex Med*. 2008;5(5):1244–1250.

Berger R, Billups K, Brock G, et al. AFUD thought leader panel on evaluation and treatment of priapism. Report of the American Foundation for Urologic Disease (AFUD) Thought Leader Panel for evaluation and treatment of priapism. *Int J Impot Res*. 2001;13(Suppl 5):S39–S43.

Bertolotto M, Ciampalini S, Martingano P, et al. High flow priapism complicating ischemic priapism following iatrogenic laceration of the dorsal artery during a Winter procedure. *J Clin Ultrasound*. 2009;37(1):61–64.

Bertram RA, Carson CC, Webster GD. Implantation of penile prostheses in patient impotent after priapism. *Urology*. 1985;26(4):325–327.

Beuzard Y. Transgenic mouse models of sickle cell disease. *Curr Opin Hematol*. 1996;3:150–155.

Bialecki ES, Bridges KR. Sildenafil relieves priapism in patients with sickle cell disease. *Am J Med*. 2002;113(3):252.

Birnbaum BF, Pinzone JJ. Sickle cell trait and priapism: a case report and review of the literature. *Cases J*. 2008;1:429.

Bitran D, Miller SA, McQuade DB, et al. Inhibition of sexual reflexes by lumbosacral injection of a GABA-B agonist in the male rat. *Pharmacol Biochem Behav*. 1988;31:657–666.

Bivalacqua TJ, Champion HC, Mason W, et al. Long-term phosphodiesterase type 5 inhibitor therapy reduces priapic activity in transgenic sickle cell mice. *J Urol*. 2006;175:387.

Bivalacqua TJ, Diner EK, Novak TE, et al. A rat model of Peyronie's disease associated with a decrease in erectile activity and an increase in inducible nitric oxide synthase protein expression. *J Urol*. 2000;163:1992–1998.

Bivalacqua TJ, Liu T, Musicki B, et al. Endothelial nitric oxide synthase keeps erection regulatory function balance in the penis. *Eur Urol*. 2007;51:1732–1740.

Bivalacqua TJ, Musicki B, Champion HC, et al. Phosphodiesterase type 5 inhibitor therapy for priapism. Carson CC, Kirby RS, Goldstein I, et al. *Textbook of erectile dysfunction*. 2nd ed. Informa Healthcare: London; 2009:428–433.

Bivalacqua TJ, Musicki B, Hsu LL, et al. Establishment of a transgenic sickle cell mouse model to study the pathophysiology of priapism. *J Sex Med*. 2009;6:2494–2504.

Bloom B, Jones LI, Freeman G. Summary health statistics for U.S. children: National Health Interview Survey, 2012. *Vital Health Stat*. 2013;10:1–81.

Borrelli M, Mitre AI, Alfer Júnior W, et al. Surgical treatment of priapism using Al-Ghorab's technique. *Rev Paul Med*. 1983;101:27 [in Portugese].

Brant WO, Garcia MM, Bella AJ, et al. T-shaped shunt and intracavernous tunneling for prolonged ischemic priapism. *J Urol*. 2009;181:1699–1705.

Brock G, Breza J, Lue TF, et al. High flow priapism: a spectrum of disease. *J Urol*. 1993;150(160):969–971.

Broderick GA, Gordon D, Hypolite J, et al. Anoxia and corporal smooth muscle dysfunction: a model for ischemic priapism. *J Urol*. 1994;151:259–262.

Broderick GA, Harkaway R. Pharmacologic erection: time-dependent changes in the corporal environment. *Int J Impot Res*. 1994;6:9–16.

Broderick GA, Kadioglu A, Bivalacqua TJ, et al. Priapism: pathogenesis, epidemiology, and management. *J Sex Med*. 2010;7:476–500.

Broderick GA, Lue TF. Evaluation and nonsurgical management of erectile dysfunction and priapism. Walsh PC, Retik AB, Vaughan ED, et al. *Campbell's urology*. Saunders: Philadelphia; 2002:1619–1671.

Broderick GA. Priapism and sickle-cell anemia: diagnosis and nonsurgical therapy. *J Sex Med*. 2012;9:88–103.

Bschleipfer TH, Hauck EW, Diemer TH, et al. Heparin-induced priapism. *Int J Impot Res*. 2001;13:357–359.

Bullock N, Steggall M, Brown G. Emergency management of priapism in the United Kingdom: a survey of current practice. *J Sex Med*. 2018;15(4):476–479.

Burgu B, Talas H, Erdeve O, et al. Approach to newborn priapism: a rare entity. *J Pediatr Urol*. 2007;3:509–511.

Burnett AL, Anele UA, Trueheart IN, et al. Randomized controlled trial of sildenafil for preventing recurrent ischemic priapism in sickle cell disease. *Am J Med*. 2014;127(7):664–668.

Burnett AL, Bivalacqua TJ, Champion HC, et al. Feasibility of the use of phosphodiesterase type 5 inhibitors in a pharmacologic prevention program for recurrent priapism. *J Sex Med*. 2006;3:1077–1084.

Burnett AL, Bivalacqua TJ, Champion HC, et al. Long-term oral phosphodiesterase 5 inhibitor therapy alleviates recurrent priapism. *Urology*. 2006;67:1043–1048.

Burnett AL, Bivalacqua TJ. Priapism: current principles and practice. *Urol Clin North Am*. 2007;34:631–642.

Burnett AL, Pierorazio P. Corporal “snake” maneuver: corporoglanular shunt surgical modification for ischemic priapism. *J Sex Med*. 2009;6:1171–1176.

Burnett AL. Priapism. Walsh PC, Retik AB, Vaughan ED, et al. *Campbell's urology*. Saunders: Philadelphia; 2004:839–849.

Burnett AL. Therapy insight: priapism associated with hematologic dyscrasias. *Nat Clin Pract Urol*. 2005;2(9):449–456.

Burt FB, Schimer HK, Scott WW. A new concept in the management of priapism. *J Urol*. 1960;83:60–61.

Cakan M, Altu Gcaron U, Ademir M. Is the combination of superselective transcatheter autologous clot embolization and duplex sonography-guided compression therapy useful treatment option for the patients with high-flow priapism? *Int J Impot Res*. 2006;18:141–145.

Celma Doménech A, Planas Morin J, de Torres Ramírez I, et al. Priapism secondary to penis infiltration of bladder cancer. *Actas Urol Esp*. 2008;32(7):749–751.

Centers for Disease Control and Prevention. *State and local area integrated telephone survey: national survey of children's health*. [(website)] http://www.cdc.gov/nchs/slaits/nsch.htm; 2013.

Champion HC, Bivalacqua TF, Takimoto E, et al. Phosphodiesterase-5A dysregulation in penile erectile tissue is a mechanism of priapism. *Proc Natl Acad Sci USA*. 2005;102:1661–1666.

Chan PT, Bégin LR, Arnold D, et al. Priapism secondary to penile metastasis: a report of two cases and a review of the literature. *J Surg Oncol*. 1998;68(1):51–59.

Chang MW, Tang CC, Chang SS. Priapism: a rare presentation in chronic myeloid leukemia. *Chang Gung Med J*. 2003;26:288–292.

Chinegwundoh FI, Anie KA. Treatments for priapism in boys and men with sickle cell disease. *Cochrane Database Syst Rev*. 2004;(4) [CD004198].

Chiou RK, Aggarwal H, Chiou C, et al. Colour Doppler ultrasound hemodynamic characteristics of patient with priapism before and after therapeutic interventions. *Can Urol Assoc J*. 2009;3(4):304–311.

Chow K, Payne S. The pharmacological management of intermittent priapismic states. *BJU Int*. 2008;102:1515–1521.

Chrouser KL, Onaopemipo AB, Oyetunji TA, et al. Priapism in the United States: the changing role of sickle cell disease. *Am J Surg*. 2011;201:468–474.

Ciampalani S, Savoca G, Buttazi L, et al. High-flow priapism treatment and follow up. *Urology*. 2002;59:110–113.

Cocci A, Gacci M, Cai T, et al. Malignant priapism and non urologic primitive tumors are related with the poorer prognosis in men with penile metastases: results of a systematic review. *J Sex Med*. 2016;2:S222–S223.

Cocci A, Hakenberg OW, Cai T, et al. Prognosis of men with penile metastasis and malignant priapism: a systematic review. *Oncotarget*. 2018;9(2):2923–2930.

Constantine ST, Gopalsami A, Helland G. Recurrent priapism gone wrong: ST-elevation myocardial infarction and cardiogenic shock after penile corporal phenylephrine irrigation. *J Emerg Med*. 2017;52(6):859–862.

Coombs PG, Heck M, Guhring P, et al. A review of outcomes of an intracavernosal injection therapy programme. *BJU Int*. 2012;110(11):1787–1791.

Costabile RA. Successful treatment of stutter priapism with an antiandrogen. *Tech Urol*. 1998;4:167–168.

Cruz Guerra NA, Pozo Mengual B, Perales Céspedes MP, et al. Metachronous recurrence of idiopathic high flow priapism. *Arch Esp Urol*. 2004;57(1):82–84.

D'Aleo G, Rifici C, Kofler M, et al. Favorable response to intrathecal, but not oral, baclofen of priapism in a patient with spinal cord injury. *Spine*. 2009;34(3):E127–E129.

Dahm P, Rao DS, Donatucci CF. Antiandrogens in the treatment of priapism. *Urology*. 2002;59:138.

Davila HH, Parker J, Webster JC, et al. Subarachnoid hemorrhage as complication of phenylephrine injection for the treatment of ischemic priapism in sickle cell disease patient. *J Sex Med*. 2008;5:1025–1028.

De Rose AF, Mantica G, Tosi M, et al. Priapism and glucose-6-phosphate dehydrogenase deficiency: an underestimated correlation? *Arch Ital Urol Androl*. 2016;88(3):235–236.

Denys P, Mane M, Azouvi P, et al. Side effects of chronic intrathecal baclofen on erection and ejaculation in patients with spinal cord lesions. *Arch Phys Med Rehabil*. 1998;79(5):494–496.

Donaldson JF, Rees RW, Steinbrecher HA. Priapism in children: a comprehensive review and clinical guideline. *J Pediatr Urol*. 2014;10(1):11–24.

Douglas L, Fletcher H, Serjeant GR. Penile prostheses in the management of impotence in sickle cell disease. *Br J Urol*. 1990;65(5):533–535.

Dubocq FM, Tefilli MV, Grignon DJ, et al. High flow malignant priapism with isolated metastasis to the corpora cavernosa. *Urology*. 1998;51:324–326.

Earle CM, Stuckey BG, Ching HL, et al. The incidence and management of priapism in western Australia. *Int J Impot Res*. 2003;15(4):272–276.

Ebbehoj J. A new operation for priapism. *Scand J Plast Reconstr Surg*. 1974;8:241–242.

ElAmrawy F, ElAgouri G, Elnoweam O, et al. Adulterated and counterfeit male enhancement nutraceuticals and dietary supplements pose a real threat to the management of erectile dysfunction: a global perspective. *J Diet Suppl*. 2016;13(6):660–693.

Eland IA, van der Lei J, Stricker BH, et al. Incidence of priapism in the general population. *Urology*. 2001;57(5):970–972.

Emond AM, Holman R, Hayes RJ, et al. Priapism and impotence in homozygous sickle cell disease. *Arch Intern Med*. 1980;140:1434–1437.

Fassbinder W, Frei U, Issantier R, et al. Factors predisposing to priapism in haemodialysis patients. *Proc Eur Dial Transplant Assoc*. 1976;12:380–386.

Galatti L, Fioravanti A, Salvo F, et al. Interaction between tadalafil and itraconazole. *Ann Pharmacother*. 2005;39:200.

Gandini A, Spinelli A, Konda D, et al. Superselective embolization in posttraumatic priapism with Glubran 2 acrylic glue. *Cardiovasc Intervent Radiol*. 2004;27:544–548.

Gbadoe AD, Assimadi JK, Segbena YA. Short period of administration of diethylstilbestrol in stuttering priapism in sickle cell anemia. *Am J Hematol*. 2002;69:297–298.

Gbadoe AD, Atakouma Y, Kusiaku K, et al. Management of sickle cell priapism with etilefrine. *Arch Dis Child*. 2001;85:52–53.

Goldmeier D. Prolonged erection produced by dihydrocodeine and sildenafil. *BMJ*. 2002;524:1555.

Grayhack JT, McCullough W, O'Connor VJ, et al. Venous bypass to control priapism. *Invest Urol*. 1964;1:509–513.

Guvel S, Kilinc F, Torun D, et al. Malignant priapism secondary to bladder cancer. *J Androl*. 2003;24(4):499–500.

Hakim LS, Kulaksuzoglu H, Mulligan S, et al. Evolving concepts in the diagnosis and treatment of arterial high-flow

priapism. *J Urol*. 1996;155:541–545.
Hanafy HM, Saad SM, El-Rifaie M, et al. Early Arabian medicine: contribution to urology. *Urology*. 1976;8(1):63–67.
Hatzichristou D, Salpiggidis G, Hatzimouratidis K, et al. Management strategy for arterial priapism: therapeutic dilemmas. *J Urol*. 2002;168:2074–2077.
Hauri D, Spycher M, Brühlmann W. Erection and priapism: a new physiopathological concept. *Urol Int*. 1983;38:138–141.
He L, Wen J, Jiang X, et al. Long-term efficacy and safety of self-intracavernous injection of prostaglandin E1 for treatment of erectile dysfunction in China. *Andrologia*. 2011;43(3):208–212.
Hinman F Jr. Priapism: reasons for failure of therapy. *J Urol*. 1960;83:420–428.
Hinman F. Priapism: report of case in a clinical study of the literature with reference to its pathogenesis and surgical treatments. *Ann Surg*. 1914;60:689–716.
Hoeh MP, Levine LA. Management of recurrent ischemic priapism 2014: a complex condition with devastating consequences. *Sex Med Rev*. 2015;3(1):24–35.
Hoover NG, Fortenberry JD. Use of antivenin to treat priapism after a black widow spider bite. *Pediatrics*. 2004;114:128–129.
Jeong WI, Do SH, Yun HS, et al. Hypoxia potentiates transforming growth factor-beta expression of hepatocyte during the cirrhotic condition in rat liver. *Liver Int*. 2004;24:658–668.
Jesus LE, Dekermacher S. Priapism in children: review of pathophysiology and treatment. *J Pediatr (Rio J)*. 2009;85(3):194–200.
Ji MX, He NS, Wang P, et al. Use of selective embolization of the bilateral cavernous arteries for post-traumatic arterial priapism. *J Urol*. 1994;151:1641.

Jin YC, Gam SC, Jung JH, et al. Expression and activity of heme oxygenase-1 in artificially induced low-flow priapism in rat penile tissues. *J Sex Med*. 2008;5:1876–1882.

Junemann KP, Persson-Junemann C, Alken P. Pathophysiology of erectile dysfunction. *Semin Urol*. 1990;8(2):80–93.

Kandel GL, Bender LI, Grove JS. Pulmonary embolism a complication of corpus saphenous shunt for priapism. *J Urol*. 1968;99:196–197.

Karakaya AE, Koklu E, Ozturk S. A rare entity: idiopathic priapism in a newborn and review of the literature. *J Matern Fetal Neonatal Med*. 2016;29(3):440–442.

Kassim AA, Fabry ME, Nagel RL. Acute priapism associated with the use of sildenafil in a patient with sickle cell trait. Letter to the editor. *Blood*. 2000;95(5):1878–1879.

Kato GJ, Gladwin MT, Steinberg MH. Deconstructing sickle cell disease: reappraisal of the role of hemolysis in the development of clinical subphenotypes. *Blood Rev*. 2007;21:37–47.

Kato GJ, McGowan VR, Machado RF, et al. Lactate dehydrogenase as a biomarker of hemolysis associated nitric oxide resistance, priapism, leg ulceration, pulmonary hypertension and death in patients with sickle cell disease. *Blood*. 2006;107:2279–2285.

Kato GJ. Priapism in sickle-cell disease: a hematologist's perspective. *J Sex Med*. 2012;9:70–78.

Kelami A. Implantation of small-carrion prosthesis in the treatment of erectile impotence after priapism: difficulties and effects. *Urol Int*. 1985;40(6):343–346.

Kim KR, Shin JH, Song HY, et al. Treatment of high-flow priapism with superselective transcatheter embolization in 27 patients: a multicenter study. *J Vasc Interv Radiol*. 2007;18:1222–1226.

King SH, Hallock M, Strote J, et al. Tadalafil associated priapism. *Urology*. 2005;66(2):432.

Kirkham A, Illing RO, Minahas S, et al. MR imaging of nonmalignant penile lesions. *Radiographics*. 2008;28:837–853.

Kuefer R, Bartsch G Jr, Herkommer K, et al. Changing diagnostic and therapeutic concepts in high-flow priapism. *Int J Impot Res*. 2005;17:109–113.

Kulmala RV, Lehtonen TA, Tammela TL. Preservation of potency after treatment for priapism. *Scand J Urol Nephrol*. 1996;30(4):313–316.

Kulmala RV, Lehtonen TA, Tammela TL. Priapism: its incidence and seasonal distribution in Finland. *Scand J Urol Nephrol*. 1995;29(1):93–96.

Kumar R, Jindal L, Seth A. Priapism following oral sildenafil abuse. *Natl Med J India*. 2005;18(1):49.

Kumar R, Shrivastava DN, Seth A. Spontaneous resolution of delayed onset, posttraumatic high-flow priapism. *J Postgrad Med*. 2006;52(4):298–299.

Kuypers FA. Hemoglobin s polymerization and red cell membrane changes. *Hematol Oncol Clin North Am*. 2014;28(2):155–179.

La Favor JD, Fu Z, Venkatraman V, et al. Molecular profile of priapism associated with low nitric oxide bioavailability. *J Proteome Res*. 2018;17(3):1031–1040.

Larocque MA, Cosgrove MD. Priapism: a review of 46 cases. *J Urol*. 1974;112(6):770–772.

Leal J, Walker D, Egan EA. Idiopathic priapism in the newborn. *J Urol*. 1978;120:376.

Leite KR, Andrade E, Ramos AT, et al. Phoneutria nigriventer spider toxin Tx2-6 causes priapism and death: a histopathological investigation in mice. *Toxicon*. 2012;60:797–801.

Levine LA, Guss SP. Gonadotropin releasing hormone analogues in the treatment of sickle cell anemia-associated priapism. *J Urol*. 1993;150:475–477.

Liguori G, Garaffa G, Trombetta C, et al. High flow priapism secondary to Nesbit operation: management by percutaneous embolization and colour Doppler guided compression. *Int J Impot Res*. 2005;17:304–306.

Lin G, Xin ZC, Lue TF, et al. Up and down-regulation of phosphodiesterase-5 as related to tachyphylaxis and priapism. *J Urol*. 2003;170:S15–S19.

Lowe FC, Jarow JP. Placebo-controlled study of oral terbutaline in management of prostaglandin E_1 induced prolonged erections. *J Urol*. 1993;42(1):51–53.

Lue TF, Garcia M. Should perioperative anticoagulation be an integral part of the priapism shunting procedure? *Transl Androl Urol*. 2013;2(4):316–320.

Lue TF, Pescatori ES. Distal cavernosum-glans shunts for ischemic priapism. *J Sex Med*. 2006;3:749–752.

Lue TF. Physiology of penile erection and pathophysiology of erectile dysfunction and priapism. Walsh PC, Retik AB, Vaughan ED, et al. *Campbell's urology*. Saunders: Philadelphia; 2002:1610–1696.

Lutz A, Lacour S, Hellstrom W. Conversion of low-flow to high-flow priapism: a case report and review (CME). *J Sex Med*. 2012;9(4):951–954 [quiz 955].

Mantadakis E, Ewalt DH, Cavender JD, et al. Outpatient penile aspiration and epinephrine irrigation for young patients with sickle cell anemia and prolonged priapism. *Blood*. 2000;95:78–82.

Manuel MB, Leak A, Carroll SA. Priapism in the oncology setting. *Clin J Oncol Nurs*. 2007;11(1):23–25.

McMahon CG. High flow priapism due to an arterial-sinusoidal fistula complicating initial veno-occlusive priapism. *Int J Impot Res*. 2002;14:195–196.

McMahon CG. Priapism associated with concurrent use of phosphodiesterase inhibitor drugs and intracavernous injection therapy. *Int J Impot Res*. 2003;15:383–384.

McVary KT, Roehrborn CG, Kaminetsky JC, et al. Tadalafil relieves lower urinary tract symptoms secondary to benign prostatic hyperplasia. *J Urol*. 2007;177(4):1401–1407.

Meijer B, Bakker HH. Management of priapism in the newborn. *Urology*. 2003;61(1):224.

Merritt AL, Haiman C, Henderson SD. Myth: blood transfusion is effective for sickle cell anemia associated priapism. *CJEM*. 2006;8:119–122.

Mi T, Abbasi S, Zhang H, et al. Excess adenosine in murine penile erectile tissues contributes to priapism via A2B adenosine receptor signaling. *J Clin Invest*. 2008;118:1491–1501.

Mistry NA, Tadros NN, Hedges JC. Conversion of low-flow priapism to high-flow state using t-shunt with tunneling. *Case Rep Urol*. 2017;2017:7394185.

Monga M, Broderick GA, Hellstrom WJ. Priapism in sickle cell disease: the case for early implantation of the penile prosthesis. *Eur Urol*. 1996;30(1):54–59.

Montague DK, Jarow J, Broderick GA, et al. American Urological Association guideline on the management of priapism. *J Urol*. 2003;170:1318–1324.

Montorsi F, Verheyden B, Meuleman E, et al. Long-term safety and tolerability of tadalafil in the treatment of erectile dysfunction. *Eur Urol*. 2004;45:339–345.

Moore J, Whelan TF, Langille GM. The use of penile prostheses in the management of priapism. *Transl Androl Urol*. 2017;S797–S803.

Morales A, Gingell C, Collins M, et al. Clinical safety of oral sildenafil citrate (Viagra) in the treatment of erectile dysfunction. *Int J Impot Res*. 1998;10(2):69–73.

Moreland RB, Traish A, McMillin MA, et al. PGE_1 suppresses the induction of collagen synthesis by transforming growth factor-beta 1 in human corpus cavernosum smooth muscle. *J Urol*. 1995;153:826–834.

Morris CR, Kato GJ, Pojakovic M, et al. Dysregulated arginine metabolism, hemolysis-associated pulmonary hypertension and mortality in sickle cell disease. *J Am Med Assoc*. 2005;294:81–90.

Morrison B, Burnett AL. Stuttering priapism: insights into pathogenesis and management. *Curr Urol Rep*. 2012;13:268–276.

Mulhall J. Priapism—guidelines for surgical management of priapism. Porst H, Buvat J. *Standard practice of sexual medicine*. Blackwell Science: Oxford (UK); 2006:180–190.

Munarriz R, Park K, Huang YH, et al. Reperfusion of ischemic corporal tissue: physiologic and biochemical changes in an animal model of ischemic priapism. *Urology*. 2003;62:760–764.

Muneer A, Cellek S, Dogan A, et al. Investigation of cavernosal smooth muscle dysfunction in low flow priapism using an in vitro model. *Int J Impot Res*. 2005;17:10–18.

Muneer A, Minhas S, Freeman A, et al. Investigating the effects of high-dose phenylephrine in the management of prolonged ischaemic priapism. *J Sex Med*. 2008;5:2152–2159.

Munnarriz R, Wen CC, McAuley I, et al. Management of ischemic priapism with high-dose intracavernosal phenylephrine: from bench to bedside. *J Sex Med*. 2006;3:918–922.

Nehra A. Priapism: pathophysiology and non-surgical management in standard practice. Porst H, Buvat J. *Standard practice of sexual medicine*. Blackwell: Oxford (UK); 2006:174–179.

Nelson JH 3rd, Winter CC. Priapism: evolution of management in 48 patients in a 22 year series. *J Urol*. 1977;117:455–458.

Nixon RG, O'Connor JL, Milam DF. Efficacy of shunt surgery for refractory low flow priapism: a report on the incidence of failed detumescence and erectile dysfunction. *J Urol*. 2003;170:883.

Nounou MI, Ko Y, Helal NA, et al. Adulteration and counterfeiting of online nutraceutical formulations in the United States: time for intervention? *J Diet Suppl*. 2018;15(5):789–804.

Numan F, Cantasdemir M, Ozbayrak M, et al. Posttraumatic nonischemic priapism treated with autologous blood clot embolization. *J Sex Med*. 2008;5:173–179.

Nunes KP, Torres FS, Borges MH, et al. New insights on arthropod toxins that potentiate erectile function. *Toxicon*. 2013;69:152–159.

Okpala I, Westerdale N, Jegede T, et al. Etilefrine for the prevention of priapism in adult sickle cell disease. *Br J Haematol*. 2002;118:918–921.

Ozturk MH, Gumus M, Donme H, et al. Materials in embolotherapy of high-flow priapism: results and long-term follow-up. *Diagn Interv Radiol*. 2009;15(3):215–220.

Paredes RG, Agmo A. The GABA-B antagonist CGP 35348 inhibits the effects of baclofen on sexual behavior and motor coordination. *Brain Res Bull*. 1995;36:495–497.

Park JK, Jeong YB, Han YM. Recanalisation of embolised cavernosal artery: restoring potency in a patient with high-flow priapism. *J Urol*. 2001;165:2002–2003.

Pei R, Yang M, Wang C, et al. Superselective transcatheter artery embolizatoin in patients with non-ischemic priapism. *Cardiovasc Intervent Radiol*. 2018;41(6):867–871.

Pietras JR, Cromie WJ, Duckett JW. Ketamine as a detumescence agent during hypospadias repair. *J Urol*. 1979;121:654.

Podolej GS, Babcock C. Emergency department management of priapism. *Emerg Med Pract*. 2017;19(1):1–16.

Pohl J, Pott B, Kleinhans G. Priapism: a three-phase concept of management according to etiology and prognosis. *Br J Urol*. 1986;58:113.

Ponniah A, Brown CT, Taylor P. Priapism secondary to leukemia; effective management with prompt leukapheresis. *Int J Urol*. 2004;11:809–810.

Porst H. The rationale for prostaglandin E_1 in erectile failure: a survey of worldwide experience. *J Urol*. 1996;155:802–815.

Priyadarshi S. Oral terbutaline in the management of pharmacologically induced prolonged erection. *Int J Impot Res*. 2004;16:424–426.

Pryor J, Akkus E, Alter G, et al. Priapism. *J Sex Med*. 2004;1:16–20.

Pryor JP, Hehir M. The management of priapism. *Br J Urol*. 1982;54:751.

Puppo P, Belgrano E, Germinale F, et al. Angiographic treatment of high-flow priapism. *Eur Urol*. 1985;11:397.

Quackles R. Treatment of a case of priapism by cavernospongious anastomosis. *Acta Urol Belg*. 1964;32:5–13.

Rachid-Filho D, Cavalcanti AG, Favorito LA, et al. Treatment of recurrent priapism in sickle cell anemia with finasteride: a new approach. *Urology*. 2009;74(5):1054–1057.

Ralph DJ, Garaffa G, Muneer A, et al. The immediate insertion of a penile prosthesis for acute ischaemic priapism. *Eur Urol*. 2009;56:1033–1038.

Rates B, Verano-Braga T, Santos DM, et al. From the stretcher to the pharmacy's shelf: drug leads from medically important Brazilian venomous arachnid species. *Inflamm Allergy Drug Targets*. 2011;10(5):411–419.

Ravelli KG, Ramos AT, Goncalves LB, et al. Phoneutria nigriventer spider toxin Tx2-6 induces priapism in mice even after cavernosal denervation. *Toxicon*. 2017;130:29–34.

Rees RW, Kalsi J, Minhas S, et al. The management of low-flow priapism with the immediate insertion of a penile prosthesis. *BJU Int*. 2002;90(9):893–897.

Ricciardi R, Bhatt GM, Cynamon J, et al. Delayed high-flow priapism: pathophysiology and management. *J Urol*. 1993;149:119–121.

Ridyard DG, Phillips EA, Vincent W, et al. Use of high-dose phenylephrine in the treatment of ischemic priapism: five-year experience at a single institution. *J Sex Med*. 2016;13(11):1704–1707.

Robey EL, Schellhammer PF. Four cases of metastases to the penis and a review of the literature. *J Urol*. 1984;132(5):992–994.

Rodriguez J, Cuadrado JM, Frances A, et al. High flow priapism as a complication of veno-occlusive priapism. Two case reports. *Int J Impot Res*. 2006;18:215–217.

Rogers ZR. Priapism in sickle cell disease. *Hematol Oncol Clin North Am*. 2005;19(5):917–928.

Roghmann F, Becker A, Sammon JD, et al. Incidence of priapism in emergency departments in the United States. *J Urol*. 2013;190:1275–1280.

Rother RP, Bell L, Hillmen P, et al. The clinical sequela of intravascular hemolysis and extracellular plasma hemoglobin: a novel mechanism of human disease. *J Am Med Assoc*. 2005;293:1652–1662.

Rourke KF, Fischler AH, Jordan GH. Treatment of recurrent idiopathic priapism with oral baclofen. *J Urol*. 2002;168:2552–2553.

Saad ST, Lajolo C, Gilli S, et al. Follow-up of sickle cell disease patient with priapism treated by hydroxyurea. *Am J Hematol*. 2004;77(1):45–49.

Sacher EC, Sayegh E, Frensilli F, et al. Cavernospongiosum shunt in treatment of priapism. *J Urol*. 1972;108:97–100.

Saenz de Tejada I, Kim NN, Daley JT, et al. Acidosis impairs rabbit trabecular smooth muscle contractility. *J Urol*. 1997;157:722–726.

Salonia A, Eardley I, Giuliano F, et al. European Association of Urology guidelines on priapism. *Eur Urol*. 2014;65:480–489.

Sandock DS, Seftel AD, Herbener TE, et al. Perineal abscess after embolization for high-flow priapism. *Urology*. 1996;308:48.

Savoca G, Pietropaolo F, Scieri F, et al. Sexual function after highly selective embolisation of cavernous artery in patients with high-flow priapism: long-term follow-up. *J Urol*. 2004;172:644–647.

Seftel A, Haas CA, Brown SL, et al. High flow priapism complicating veno-occlusive priapism: pathophysiology of recurrent idiopathic priapism? *J Urol*. 1998;159:1300–1301.

Segal RL, Readal N, Pierorazio PM, et al. Corporal Burnett “Snake” surgical maneuver for the treatment of ischemic priapism: long-term followup. *J Urol*. 2013;189:1025–1029.

Serjeant GR, de Ceulaer K, Maude GH. Stilboestrol and stuttering priapism in homozygous sickle-cell disease. *Lancet*. 1985;2:1274–1276.

Shamloul R, el Nashaar A. Idiopathic stuttering priapism treated successfully with low-dose ethinyl estradiol: a single case report. *J Sex Med*. 2005;2:732–734.

Shapiro SR. Idiopathic priapism in the newborn. *J Urol*. 1979;121:838.

Shome DK, Jaradat A, Mahozi AI, et al. The platelet count and its implications in sickle cell disease patients admitted for intensive care. *Indian J Crit Care Med*. 2018;22(8):585–590.

Sidhu AS, Wayne GF, Kim BJ, et al. The hemodynamic effects of intracavernosal phenylephrine for the treatment of ischemic priapism. *J Sex Med*. 2018;15(7):990–996.

Siegel JF, Rich MA, Brock WA. Association of sickle cell disease, priapism, exchange transfusion and neurological events: ASPEN syndrome. *J Urol*. 1993;150:1480–1482.

Spycher MA, Hauri D. The ultrastructure of the erectile tissue in priapism. *J Urol*. 1986;135:142–147.

Stein DM, Flum AS, Cashy J, et al. Nationwide emergency department visits for priapism in the United States. *J Sex Med*. 2013;10(10):2418–2422.

Steinberg J, Eyre RC. Management of recurrent priapism with epinephrine self-injection and gonadotropin-releasing hormone analogue. *J Urol*. 1995;153:152–153.

Stember DS, Mulhall JP. Ischemic priapism and implant surgery with sharp corporal fibrosis excision. *J Sex Med*. 2010;7(6):1987–1990.

Sui W, Onyeji IC, James MB, et al. Risk factors for priapism readmission. *J Sex Med*. 2016;13(10):1555–1561.

Sur RL, Kane CJ. Sildenafil citrate–associated priapism. *Urology*. 2000;55(6):950.

Tatem A, Kovac JR. Challenges surrounding penile prostheses insertion following acute priapism. *Trans Androl Urol*. 2017;6(Suppl 5):S804–S805.

Tarry WF, Duckett JW, Snyder H. Urological complications of sickle cell disease in a pediatric population. *J Urol*. 1987;138:592.

Teloken C, Ribeiro EP, Chammas M, et al. Intracavernosal etilefrine self-injection therapy for recurrent priapism. *Urology*. 2005;65(5):1002.

Tripe JW. Case of continued priapism. *Lancet*. 1845;2:8.

US Food and Drug Administration. *All natural alternatives for erectile dysfunction: a risky proposition*. [(website)] https://www.fda.gov/ForConsumers/ConsumerUpdates/ucm4 2015.

US Food and Drug Administration. *Methylphenidate ADHD medications: drug safety communication—risk of long-lasting erections*. [(website)] http://www.fda.gov/safety/medwatch/safetyinformation/safety 2013.

Vaidyanathan S, Watt JW, Singh G, et al. Management of recurrent priapism in a cervical spinal cord injury patient with oral baclofen therapy. *Spinal Cord*. 2004;42(2):134–135.

Villanova FE, Andrade E, Leal É, et al. Erection induced by Tx2-6 toxin of *Phoneutria nigriventer* spider: expression profile of genes in the nitric oxide pathway of penile tissue of mice. *Toxicon*. 2009;54(6):793–801.

Virag R, Buchi D, Lee K, et al. Preventive treatment of sickle cell disease with oral and self-administered intracavernous injection of etilefrine. *Urology*. 1996;47(5):777–781.

Walker JR, Casale AJ. Prolonged penile erection in the newborn. *Urology*. 1997;50:796–799.

Wallis CJ, Hoag N, Pommerville PJ, et al. Recurrent idiopathic high-flow priapism treated with selective arterial embolization after repeated initial treatments for low-flow priapism. *Can Urol Assoc J*. 2009;3(1):60–63.

Wills B, Albinson C, Wahl M, et al. Sildenafil citrate ingestion and prolonged priapism and tachycardia in a pediatric patient. *Clin Toxicol*. 2007;45:798–800.

Wilt TJ, Fink HA. Is antidepressant plus sildenafil a recipe for priapism? *Postgrad Med*. 2004;116(6):11–12.

Winter CC. Cure of idiopathic priapism: new procedure for creating fistula between glans penis and corpora cavernosa. *Urology*. 1976;8:389–391.

Witt MA, Goldstein I, Saenz de Tejada I, et al. Traumatic laceration of intracavernosal arteries: the pathophysiology of nonischemic, high flow arterial priapism. *J Urol*. 1990;143:129–132.

Wolf JS, Lue TF. High flow priapism and glans hypervascularization following deep dorsal vein arterialization for vasculogenic impotence. *Urol Int*. 1992;49:227–229.

Yamashita N, Hisasue S, Kato R, et al. Idiopathic stuttering priapism: recovery of detumescence mechanism with temporal use of antiandrogen. *Urology*. 2004;63:1182–1184.

Zacharakis E, Garaffa G, Raheem AA, et al. Penile prosthesis insertion in patients with refractory ischaemic priapism: early vs delayed implantation. *BJU Int*. 2014;114:576–581.

Zacharakis E, Raheem AA, Freman A, et al. The efficacy of the T-shunt procedure and intracavernous tunneling (snake maneuver) for refractory ischemic priapism. *J Urol*. 2014;191:164–168.

71

Disorders of Male Orgasm and Ejaculation

Chris G. McMahon MBBS, FAChSHP

Ejaculatory dysfunction (EjD) is one of the most common male sexual disorders. The spectrum of EjD extends from **premature ejaculation (PE) through delayed ejaculation (DE) to a complete inability to ejaculate (known as anejaculation) and includes retrograde ejaculation (RE), painful ejaculation, ejaculatory anhedonia, and the recently described postorgasmic illness syndrome (POIS).**

The sexual response cycle comprises the four interactive stages of **desire, arousal, orgasm, and resolution.** During sexual activity, increasing levels of sexual arousal reach a threshold that triggers the ejaculatory response, which then typically terminates the sexual episode for the male. The perception of the striated muscle contractions and resulting semen expelled during ejaculation, mediated through sensory neurons in the pelvic region, gives rise to the experience of orgasm, a distinct cortical event, experienced phenomenologically, cognitively, and emotionally.

Ejaculatory latency, the time extending from the onset of penile stimulation to the moment of ejaculation, represents a continuum of time that shows variation across men and, within men, across situations. Although the great majority of men appear to reach ejaculation and orgasm after several minutes of penile vaginal stimulation and are, along with their partners, satisfied with the latency of their ejaculatory response, others report dissatisfaction. Specifically, some men ejaculate very rapidly after, or sometimes even before, penetration and do so with minimal stimulation. Others may ejaculate only with great difficulty or not at all, even after prolonged stimulation (McMahon et al., 2013).

Anatomy and Physiology of the Ejaculatory Response

The ejaculatory reflex comprises sensory receptors and areas, afferent pathways, cerebral sensory areas, cerebral motor centres, spinal motor centers, and efferent pathways (Fig. 71.1). The brain circuitry controlling ejaculation is part of a more global network controlling other aspects of the sexual response. **Neurochemically, this reflex involves a complex interplay between central serotonergic and dopaminergic neurons, with secondary involvement of cholinergic, adrenergic, oxytocinergic, and γ-aminobutyric acid (GABA) neurons.** The peripheral events leading to ejaculation are controlled by synergistic activation of autonomic (sympathetic and parasympathetic) and somatic divisions of the nervous system. In addition, nonadrenergic noncholinergic (NANC) innervation may contribute to the control of ejaculation through modulation of accessory sex gland activity.

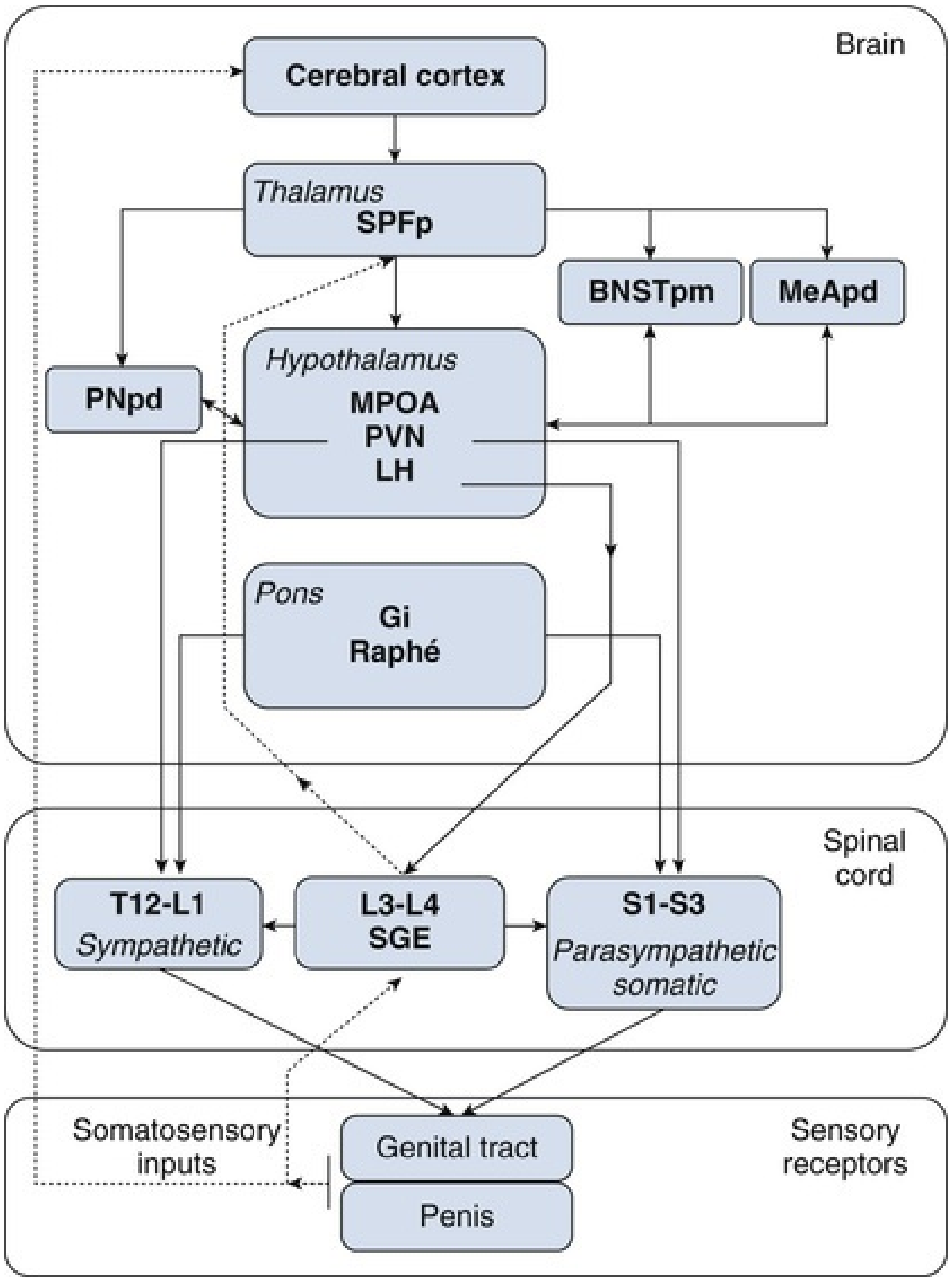
Brain
Cerebral cortex
Thalamus
SPFp
BNSTpm
MeApd
PNpd
Hypothalamus
MPOA
PVN
LH
Pons
Gi
Raphé
Spinal cord
T12-L1
Sympathetic
L3-L4
SGE
S1-S3
Parasympathetic somatic
Somatosensory inputs
Genital tract
Penis
Sensory receptors

FIG. 71.1 Diagram of the central nervous system network controlling ejaculation. Brain nuclei forming the brain circuitry of ejaculation are indicated with their connections to spinal nuclei involved in the control of ejaculation. Somatosensory afferents originating in genitalia and terminating in the CNS are also presented. *BNSTpm,* Posteromedial part of the bed nucleus of the stria terminalis; *Gi,* gigantocellular nuclei; *LH,* lateral hypothalamus; *MeApd,* posterodorsal part of the medial amygdala; *MPOA,* medial preoptic area; *PNpd,* posterodorsal part of the preoptic nucleus; *PVN,* paraventricular nucleus; *SGE,* spinal generator of ejaculation; *SPFp,* parvicellular part of the subparafascicular nucleus. (Clement P, Giuliano F: Physiology and pharmacology of ejaculation. *Basic Clin Pharmacol Toxicol* 119(Suppl 3):18–25, 2016.)

The autonomic and somatic motor efferents originate in five groups of spinal nuclei located in thoracolumbar and lumbosacral segments. Coordinated activation of autonomic and somatic spinal nuclei is controlled by a group of lumbar spinal interneurons (L3-L5) described as the spinal generator of ejaculation. The generator of ejaculation together with the autonomic and somatic spinal nuclei constitutes a spinal network that is under the strong influence of stimulating or inhibiting genital sensory and supraspinal inputs (Clement and Giuliano, 2016).

Several interrelated groups of neurons located in several sensory/integrative, excitatory, and inhibitory areas of the brain form a dedicated neural network for the control of ejaculation. The posteromedial division of the bed nucleus of the stria terminalis, the posterodorsal area of the medial amygdala, the posterodorsal preoptic nucleus, and the parvicellular part of the subparafascicular thalamus contain a group of neurons that are activated during ejaculation (Veening and Coolen, 2014).

Based upon functional, central, and peripheral mediation, the ejaculatory process is typically subdivided into three synchronized phases: **emission, ejection (or penile expulsion), and orgasm.**

Emission consists of contractions of vas deferens, seminal vesicles (SV), and the prostate, with expulsion of sperm and seminal fluid into the posterior urethra and is mediated by synergic activation of sympathetic and parasympathetic pathways (T10-L2) but may also include a cholinergic excitatory mechanism.

Ejection is mediated by somatic nerves (S2 to S4) within the pudendal nerve and involves pulsatile contractions of the bulbospongiosus, ischiocavernosus, and levator ani muscles together with relaxation of the internal urinary sphincter. Ejection also involves a sympathetic spinal cord reflex upon which there is limited voluntary control. The bladder neck (internal urinary sphincter) closes to prevent retrograde flow; the bulbocavernosus, bulbospongiosus, and other pelvic floor muscles contract rhythmically, and the external urinary sphincter relaxes. The external urinary sphincter exhibits intense contractions interrupted by silent periods during ejection of semen.

Orgasm is the result of cerebral processing of pudendal nerve sensory stimuli resulting from increased pressure in the posterior urethra, sensory stimuli arising from the verumontanum, and contraction of the urethral bulb and accessory sexual organs.

Many neurotransmitters are involved in the control of ejaculation, including dopamine, norepinephrine, serotonin, acetylcholine, oxytocin, GABA, and nitric oxide (NO) (McMahon et al., 2004). Of the many studies conducted to investigate the role of the brain in the development and mediation of sexual functioning, dopamine and serotonin have emerged as essential neurochemical factors. **Whereas dopamine promotes seminal emission/ejaculation via D2 receptors, serotonin is inhibitory.** Serotonergic neurons are widely distributed in the brain and spinal cord and are predominantly found in the brainstem, raphe nuclei, and the reticular formation. Currently, multiple serotonin (5-HT) receptors have been characterized (e.g., 5-HT1a, 5-HT1b, 5-HT2a, 5-HT2b) (Peroutka and Snyder, 1979). Stimulation of the 5-HT2c receptor with 5-HT2c agonists results in delay of ejaculation in male rats, whereas stimulation of postsynaptic 5-HT1a receptors results in shortening of ejaculation latency (Ahlenius et al. 1981), leading to the hypothesis that men with PE may have hyposensitivity of 5-HT2c and/or hypersensitivity of the 5-HT1a receptor (Waldinger, 2002; Waldinger and Olivier, 2005).

Premature Ejaculation

Classification of Premature Ejaculation

In 1943 Schapiro proposed classification of PE into two types: types B and A. In 1989 Godpodinoff renamed both types as **lifelong (primary) and acquired (secondary) PE.** Over the years, other attempts to specify subtypes have occurred (e.g., global vs. situational, the effect of a substance).

Lifelong PE is a syndrome characterized by a cluster of core symptoms, including early ejaculation at nearly every intercourse within 30 to 60 seconds in the majority of cases (80%) or between 1 and 2 minutes (20%), with every or nearly every sexual partner and from the first sexual encounters onward (McMahon, 2002; Waldinger et al., 1998).

Acquired PE differs in that sufferers develop early ejaculation at some point in their life, which is often situational, having previously had normal ejaculation experiences. The main distinguishing features between presentations of these two syndromes are the time of onset of symptoms and the reduction in previously normal ejaculatory latency of acquired PE.

Community based normative intravaginal ejaculatory latency time (IELT) research and observational studies of men with PE demonstrated that, although **IELTs of less than 1 minute have a low prevalence of about 2.5% in the general population,** a substantially higher percentage of men with normal IELT complain of PE (Patrick et al., 2005; Waldinger, et al. 2005, 2009). To take account of this diversity, Waldinger and Schweitzer (2006, 2008) proposed a new classification of PE in which **four PE subtypes are distinguished on the basis of the duration of the IELT, frequency of complaints, and course in life. In addition to lifelong PE and acquired PE, this classification includes natural variable PE (or variable PE) and premature-like EjD (or subjective PE).** Men with variable PE occasionally experience an early ejaculation. It should not be regarded as a disorder but as a natural variation of the ejaculation time in men (Waldinger, 2013). On the other hand, men with subjective PE complain of PE while actually having a normal or even extended ejaculation time (Waldinger, 2013). The complaint of PE in these men is probably related to psychological and/or cultural factors. In contrast, the consistent early ejaculations of lifelong PE suggest an underlying neurobiologic functional disturbance, whereas the early ejaculation of acquired PE is more related to underlying medical causes. Serefoglu et al. (2010, 2011) confirmed the existence of these four PE subtypes in a cohort of men in Turkey. Recently, Zhang et al. (2013) and Gao et al. (2013), using a similar methodology, confirmed similar prevalence rates of the four PE subtypes in China to that reported by Serefoglu et al. (2010, 2011). This new classification and continued research into the diverse phenomenology, cause, and pathogenesis of PE is expected to provide a better understanding of the four PE subtypes (Waldinger and Schweitzer, 2008). Although the pathogenesis of lifelong and acquired PE differs, the presence of shared dimensions such as a lack of ejaculatory control and the presence of negative personal consequences suggest a potential for a single unifying definition of lifelong and acquired PE. With continued research into the two other PE subtypes, variable PE and subjective PE, it may be appropriate to expand this unifying definition in the future.

Definition of Premature Ejaculation

Research into the treatment and epidemiology of PE is heavily dependent on how PE is defined. The **medical literature contains several univariate and multivariate operational definitions of PE** (American Psychiatric Association, 1994; Colpi et al., 2004; Jannini et al., 2005; Masters and Johnson, 1970; McMahon et al., 2004, 2008; Metz and McCarthy, 2003; Montague et al., 2004; Waldinger et al., 2005; World Health Organization, 1994; Table 71.1). Each of these definitions characterize men with PE using all or most of the accepted dimensions of this condition: ejaculatory latency, perceived ability to control ejaculation, reduced sexual satisfaction, personal distress, partner distress, and interpersonal or relationship distress. None of these definitions was supported by evidence-based clinical research.

TABLE 71.1

Definitions of Premature Ejaculation (PE)

DEFINITION	SOURCE
PE is a male sexual dysfunction characterized by ejaculation that always or nearly always occurs before or within 1 minute of vaginal penetration (lifelong PE), or, a clinically significant and bothersome reduction in latency time, often to about 3 minutes or less (acquired PE), and the inability to delay ejaculation on all or nearly all vaginal penetrations, and negative personal	International Society of Sexual Medicine, 2014

consequences, such as distress bother, frustration, and/or the avoidance of sexual intimacy	
Lifelong PE is a male sexual dysfunction characterized by ejaculation that always or nearly always occurs before or within 1 minute of vaginal penetration, and the inability to delay ejaculation on all or nearly all vaginal penetrations, and negative personal consequences, such as distress bother, frustration, and/or the avoidance of sexual intimacy	International Society of Sexual Medicine, 2008 (McMahon et al., 2008)
A persistent or recurrent pattern of ejaculation occurring during partnered sexual activity within approximately 1 minute after vaginal penetration and before the individual wishes it. This symptom must have been present for at least 6 months and must be experienced on almost all or all (approximately 75%–100%) occasions of sexual activity. It causes clinically significant distress in the individual.	DSM-V-TR, 2012 (American Psychiatric Association, 2013)
Persistent or recurrent ejaculation with minimal sexual stimulation before, on, or shortly after penetration and before the person wishes it. The condition must also cause marked distress or interpersonal difficulty and cannot be due exclusively to the direct effects of a substance.	DSM-IV-TR, 2000 (American Psychiatric Association, 2000)
For individuals who meet the general criteria for sexual dysfunction, the inability to control ejaculation sufficiently for both partners to enjoy sexual interaction, manifest as either the occurrence of ejaculation before or very soon after the beginning of intercourse (if a time limit is required, before or within 15 seconds) or the occurrence of ejaculation in the absence of sufficient erection to make intercourse possible. The problem is not the result of prolonged absence from sexual activity.	International Statistical Classification of Disease, 10th Edition (ICD-10) 1994 (World Health Organization, 1994)
The inability to control ejaculation for a “sufficient” length of time before vaginal penetration. It does not involve any impairment of fertility when intravaginal ejaculation occurs.	European Association of Urology, Guidelines on Male Sexual Dysfunction: Erectile Dysfunction and Premature Ejaculation (Hatzimouratidis et al., 2010)
Persistent or recurrent ejaculation with minimal stimulation before, on, or shortly after penetration and before the person wishes it, over which the sufferer has little or no voluntary control,	International Consultation on Urological

which causes the sufferer and/or his partner bother or distress	Diseases, 2004 (McMahon et al., 2004)
Ejaculation that occurs sooner than desired, either before or shortly after penetration, causing distress to either one or both partners	American Urological Association Guideline on the Pharmacologic Management of PE, 2004 (Montague et al., 2004)
The man does not have voluntary, conscious control or the ability to choose in most encounters when to ejaculate	Metz and McCarthy, 2003 (Metz and McCarthy, 2003)
The Foundation considers a man a premature ejaculator if he cannot control his ejaculatory process for a sufficient length of time during intravaginal containment to satisfy his partner in at least 50% of their coital connections.	Masters and Johnson, 1970 (Masters and Johnson, 1970)
Men with an IELT of less than 1 minute (belonging to the 0.5 percentile) have “definite” PE, whereas men with IELTs between 1 and 1.5 minutes (between 0.5 and 2.5 percentile) have “probable” PE (see Fig. 71.2). In addition, an additional grading of severity of PE should be defined in terms of associated psychological problems. Thus definite and probable PE require further psychological subclassification in asymptomatic, mild, moderate, and severe PE.	Waldinger et al., 2005b (Waldinger et al., 2005)
PE is diagnosed based on the pathologic IELT, as measured by the stopwatch method, with a feeling of loss of voluntary control and/or distress or relational disturbances, as measured by PRO	Jannini, 2005 (Jannini et al., 2005)

IELT, Intravaginal ejaculatory latency time; *PRO,* patient-related outcome (measures).

Traditional Definitions of Premature Ejaculation

During the period of 1920 to 1960, the absence of any scientific publications proposing a definition of PE reflects the scarcity of prevalence data. Based upon the limited published literature, a man was considered to suffer from PE when he ejaculated within seconds or within about a minute of vaginal penetration (Waldinger, 2006). In the 1970s, despite an absence of any empirical data, Masters and Johnson rejected this ejaculation latency proposal and defined PE as a man's inability to satisfy his female partner on more than 50% of sexual events

(Masters and Johnson 1970). Their rejection of the ejaculation time criterion has led to a debate on “objective criteria” and “subjective criteria” of PE (Waldinger and Schweitzer, 2008). Typical “objective” criteria include the ejaculation latency time and the number of penile thrusts. “Subjective” criteria are measures of self-efficacy including “diminished feelings of control” and “ejaculation at moments without wishing it.”

These opposing constructs have served as the framework for the development of the various definitions proposed in the *Diagnostic and Statistical Manual of Mental Disorders* (DSM) by the American Psychiatric Association (Waldinger and Schweitzer, 2006a, 2006b).

The first official definition of PE was established in 1980 by the American Psychiatric Association (APA) in the DSM-III. PE was defined as “ejaculation that occurs before the individual wishes it, because of recurrent and persistent absence of reasonable voluntary control of ejaculation and orgasm during sexual activity” (American Psychiatric Association, 1980). However, because of disagreement on the criterion of “reasonable voluntary control,” this criterion was removed in the subsequent DSM-III-R and DSM-IV definitions (American Psychiatric Association, 1987, 2000), and replaced by the criterion of a “short ejaculation time.” The DSM-IV-TR defined PE as a

> *persistent or recurrent ejaculation with minimal sexual stimulation before, on, or shortly after penetration and before the person wishes it. The clinician must take into account factors that affect the duration of the excitement phase such as age, novelty of the sexual partner or situation, and recent frequency of sexual activity*

and requires for the diagnosis that “the disturbance causes marked distress or interpersonal difficulty” (American Psychiatric Association, 2000). As such, DSM-III contains the criterion of control but not time, whereas subsequent DSM-III-R, DSM-IV, and DSM-IV-TR definitions contained the criterion of time but not control (Waldinger and Schweitzer, 2006a, 2006b).

The DSM III/IV definitions of PE were largely accepted with little discussion, despite having no evidence-based medical support (St. Lawrence and Madakasira, 1992). After the introduction of evidence-based PE pharmacotherapy, the validity of the DSM definitions was the subject of debate with a substantial polarization of opinion. The inclusion of words such as “persistent,” “recurrent,” “minimal,” and “shortly after” rendered the DSM definitions as vague, multi-interpretable and lacking quantification (Althof and Symonds, 2007; O'Donohue et al., 1993; Waldinger, 2002). Concerns about the validity and application of the DSM-IV-TR definition was also expressed by regulatory agencies such as the United States Food and Drug Administration (FDA), who regarded the lack of evidence-based criteria as a potential obstacle to interpret and assess data from clinical trials of PE investigational drugs.

The World Health Organization (WHO) 1992 ICD-10 defines PE as “the inability to control ejaculation sufficiently for both partners to enjoy sexual interaction” and as “an inability to delay ejaculation sufficiently to enjoy lovemaking, and manifest as either of the following: (1) occurrence of ejaculation before or very soon after the beginning of intercourse (if a time limit is required: before or within 15 seconds of the beginning of intercourse) and (2) ejaculation occurs in the absence of sufficient erection to make intercourse possible” (World Health Organization, 1994). The ICD-10 uses the criteria of “control” and a “very short” ejaculation time and quantifies the ejaculation time to maximally 15 seconds after penetration. Although the ICD-10 provides an objective definition of PE, evidence to support a latency cutoff of 15 seconds was not provided (Waldinger and Schweitzer 2006a, 2006b). Furthermore, the ICD-10 use of the criterion of ejaculation that occurs within 15 seconds restricts the application of the criterion of control (Waldinger and Schweitzer, 2006a, 2006b).

The lack of consensus as to what constitutes PE hampered clinical practice and basic and clinical research into the cause and management of this condition. The results of PE epidemiologic and drug treatment clinical trials are only reliable, interpretable, and capable of being generalized to patients when consistent objective physiologic measures or sensitive, validated outcome assessment instruments are used as study endpoints (McMahon, 2008) in well-defined and consistent populations where lifelong, acquired PE, or PE with comorbid ED are treated as separate PE subgroups.

The absence of a specific ejaculation time cutoff points to operationalize “shortly after penetration or before the person wishes” led to the incorrect application of the DSM definitions in epidemiologic and clinical research (Giuliano et al., 2008; McMahon, 2008; Patrick et al., 2005; Waldinger et al., 1998). Giuliano et al. reported the IELT of men with DSM-IV-TR–diagnosed PE ranged from 0 seconds (antiportal ejaculation) to almost 28 minutes with 44% of subjects having an IELT of at least 2 minutes and 25% of at least 4 minutes. This study demonstrates that a subject with DSM-IV-TR–diagnosed PE has a 44%

risk of not having PE if a PE diagnostic threshold IELT of 2 minutes is used, as suggested by community-based normative IELT trial (Waldinger et al., 2005).

Waldinger et al., in a number of studies in cohorts of heterosexual men with lifelong PE with prospective stopwatch IELT measurement, showed that about **90% of men seeking treatment for lifelong PE ejaculated within 1 minute after penetration, and about 10% ejaculated between 1 and 2 minutes** (Waldinger et al., 1998). These data were confirmed by McMahon in a retrospective questionnaire analysis of a large cohort of men with lifelong PE (McMahon, 2002). These data support the proposal that lifelong PE is characterized by an IELT of less than or about 1 minute after vaginal penetration.

International Society for Sexual Medicine Definition of Premature Ejaculation

In the last decade, substantial progress has been made in the development of evidence-based methodology for PE epidemiologic and drug treatment research using the objective IELT and subjective validated patient-reported outcome (PRO) measures. In October 2007 **the International Society for Sexual Medicine (ISSM) convened an initial meeting of the first Ad Hoc ISSM Committee for the Definition of PE to develop the first contemporary, evidence-based definition of lifelong PE.** Evidence-based definitions seek to limit errors of classification and thereby increase the likelihood that existing and newly developed therapeutic strategies are truly effective in carefully selected dysfunctional populations (Metz and McCarthy, 2003). After critical evaluation of the published data, the committee unanimously agreed that the constructs that are necessary to define lifelong PE are time from penetration to ejaculation, inability to delay ejaculation, and negative personal consequences from PE. They recommended the following definition:

Lifelong PE is a male sexual dysfunction characterized by the presence of all of these criteria: 1) ejaculation that always or nearly always occurs prior to or within about 1 minute of vaginal penetration; 2) the inability to delay ejaculation on all or nearly all vaginal penetrations; and 3) negative personal consequences such as distress, bother, frustration, and/or the avoidance of sexual intimacy

(McMahon et al., 2008). The committee was, however, unable to identify sufficient published objective data to craft an evidence-based definition of acquired PE. The committee anticipated that future studies would generate sufficient data to develop an evidence-based definition for acquired PE.

In April 2013 the International Society for Sexual Medicine (ISSM) convened a second Ad Hoc ISSM Committee for the Definition of PE in Bangalore, India. The brief of the committee was to evaluate the current published data and attempt to develop a contemporary, evidence-based definition of acquired PE and/or a single unifying definition of acquired and lifelong PE. Members unanimously agreed that, although lifelong and acquired PE are distinct and different demographic and etiologic populations, they can be jointly defined, in part, by the constructs of time from penetration to ejaculation, inability to delay ejaculation, and negative personal consequences from PE. The committee agreed that the presence of these mutual constructs was sufficient justification for the development of a single unifying definition of lifelong and acquired PE. Finally, the committee determined that the presence of a clinically significant and bothersome reduction in latency time, often to about 3 minutes or less, was an additional key defining dimension of acquired PE.

The second Ad Hoc ISSM Committee for the Definition of PE (2013) defined PE (lifelong and acquired PE) as a male sexual dysfunction characterized by

- Ejaculation that always or nearly always occurs before or within about 1 minute of vaginal penetration (lifelong PE) or, a clinically significant and bothersome reduction in latency time, often to about 3 minutes or less (acquired PE)
- The inability to delay ejaculation on all or nearly all vaginal penetrations
- Negative personal consequences, such as distress, bother, frustration, and/or the avoidance of sexual intimacy

The unified ISSM definition of lifelong and acquired PE represents the first evidence-based definition for these conditions (Serefoglu et al., 2014). **This definition should form the basis for the office diagnosis of lifelong PE and the design of PE observational and interventional clinical trials. It is limited to men engaging in vaginal intercourse because there are few studies available on PE research in homosexual men or during other forms of**

sexual expression. This definition intentionally includes a degree of diagnostic conservatism and flexibility. The 1-minute IELT cutoff point for lifelong PE should not be applied in the most absolute sense because about 10% of men seeking treatment for lifelong PE have IELTs of 1 to 2 minutes. The phrase “within about 1 minute” must be interpreted as giving the clinician sufficient flexibility to diagnose PE also in men who report an IELT as long as 90 seconds. Similarly, a degree of flexible clinical judgement is key to the recognition and interpretation of a bothersome change in ejaculatory latency with reduction of premorbid latency to 3 minutes or less in men with acquired PE. Men who report these ejaculatory latencies but describe adequate control and no personal negative consequences related to their rapid ejaculation do not merit the diagnosis of PE.

Rationale for ISSM Definition of Lifelong and Acquired Premature Ejaculation.

The multivariate ISSM evidence-based definition of PE captures the **key PE constructs of ejaculatory latency, perceived ejaculatory control, and the presence of negative personal consequences from PE** (McMahon et al., 2008). Although men with lifelong and acquired PE appear to share the dimensions of short ejaculatory latency, reduced or absent perceived ejaculatory control, and the presence of negative personal consequences from PE, they remain distinct and different demographic and etiologic populations (Porst et al., 2010).

Rationale for inclusion of “ejaculation always or nearly always occurs prior to or within about one minute of vaginal penetration IELT less than about 1 minute (lifelong PE), or, a clinically significant and bothersome reduction in latency time, often to about 3 minutes or less (acquired PE)” (McMahon et al., 2008).

Operationalization of PE using **the length of time between penetration and ejaculation, the intravaginal ejaculatory latency time (IELT),** forms the basis of most current clinical studies on PE (Waldinger et al., 1994). Intravaginal ejaculatory latency time can be measured by a stopwatch or estimated. Several authors report that estimated and stopwatch IELT correlate reasonably well or are interchangeable in assigning PE status when estimated IELT is combined with PROs (Althof et al., 1995; Pryor et al., 2005; Rosen et al., 2007).

Several studies suggest that 80% to 90% of men seeking treatment for lifelong PE ejaculate within 1 minute (McMahon, 2002; Waldinger et al., 1998, 2007). Waldinger et al. (1998) reported IELTs less than 30 seconds in 77%

and less than 60 seconds in 90% of 110 men with lifelong PE with only 10% ejaculating between 1 and 2 minutes. These data are consistent with normative community IELT data, support the notion that IELTs of less than 1 minute are statistically abnormal, and confirm that an IELT cutoff of 1 minute will capture 80% to 90% of treatment-seeking men with lifelong PE (Waldinger et al., 2005). Further qualification of this cutoff to “about 1 minute” affords the clinician sufficient flexibility to also diagnose PE in the 10% to 20% of PE treatment-seeking men who ejaculate within 1 to 2 minutes of penetration without unnecessarily stigmatizing the remaining 80% to 90% of men who ejaculate within 1 to 2 minutes of penetration but have no complaints of PE.

Porst et al. reported that the arithmetic (1.1 vs. 0.9 min., $P < 0.001$) and geometric mean IELT (0.9 vs. 0.7 min., $P < 0.001$) was slightly (but significantly) greater for patients with acquired PE (Porst et al., 2010). Several authors have confirmed this preliminary finding by demonstrating that self-estimated IELT is higher in men with acquired PE compared with lifelong PE.

However, a post-hoc analysis of the dapoxetine Phase 3 COUPLE trial data confirms a statistically significant higher IELT in men with acquired PE and comorbid compared with men with lifelong PE with comorbid ED (52.2 years vs. 45.5 years) (Fraschini, 1966; McMahon et al., 2013). Serefoglu et al. (2010) reported that self-estimated IELT was lowest in men with lifelong PE and highest in men with subjective PE (lifelong PE: 20.47±28.90 seconds (2–120 seconds); acquired PE: 57.91±38.72 seconds (90−180 seconds); variable PE: 144.17±22.47 seconds (120–180 seconds); subjective PE:286.67±69.96 seconds (180–420 seconds, $P = 0.001$). Gao et al. (2013) and Zhang et al. (2013) confirmed that self-estimated IELT follows a continuum among the four PE syndromes and reported a mean self-estimated IELT of 1.65±0.82 minutes and 1.84±1.02 minutes, respectively, in acquired PE patients. **These data suggest 3 minutes as a valid cutoff for either self-estimated or stopwatch IELT for the diagnosis of acquired PE.**

Rationale for Inclusion of “The Inability to Delay Ejaculation on All or Nearly All Vaginal Penetrations.”

The ability to prolong sexual intercourse by delaying ejaculation and the subjective feelings of ejaculatory control make up the complex construct of ejaculatory control. **Almost all men report using at least one cognitive or behavioral technique to prolong intercourse and delay ejaculation, with varying degrees of success, and many young men reported using multiple**

different techniques (Grenier and Byers, 1997). Voluntary delay of ejaculation is most likely exerted either before or in the early stages of the emission phase of the reflex but progressively decreases until the point of ejaculatory inevitability (McMahon et al., 2006; Perelman, 2006).

Several authors have suggested that an inability to voluntarily defer ejaculation defines PE (Kaplan et al., 1974; McCarthy, 1988; Vandereycken, 1986; Zilbergeld, 1978). Patrick et al. reported ratings of "very poor" or "poor" for control over ejaculation in 72% of men with PE, compared with 5% in a group of normal controls (Patrick et al., 2005). Lower ratings for control over ejaculation were associated with shorter IELT with "poor" or "very poor" control reported by 67.7%, 10.2%, and 6.7% of subjects with IELT of less than 1 minute, more than 1 minute, and more than 2 minutes, respectively. However, Grenier and Byers (1997, 2001) failed to demonstrate a strong correlation between ejaculatory latency and subjective ejaculatory control. Several authors report that diminished control is not exclusive to men with PE and that some men with a brief IELT report adequate ejaculatory control and vice versa, suggesting that the dimensions of ejaculatory control and latency are distinct concepts (Grenier and Byers, 1997; McMahon et al., 2005; Patrick et al., 2005). Furthermore, there is a greater variability in changes in control compared with IELT in men treated with SSRIs (Waldinger et al., 2004). Contrary to this, several authors have reported a moderate correlation between the IELT and the feeling of ejaculatory control (Giuliano et al., 2008; Rowland et al., 2000; Patrick et al., 2005; Rosen et al., 2007). Rosen et al. reports that control over ejaculation, personal distress, and partner distress was more influential in determining PE status than IELT (Rosen et al., 2007). In addition, the effect of IELT upon satisfaction and distress appears to be mediated via its direct effect upon control (Patrick et al., 2007). However, despite conflicting data on the relationship between control and latency, the balance of evidence supports the notion that the inability to delay ejaculation appears to differentiate men with PE from men without PE (Giuliano et al., 2008; Patrick et al., 2005; Rowland et al., 2004).

Consistent with these findings, **several recent studies reported that the majority of patients with acquired and lifelong PE, regardless of comorbid ED, reported perceived control over ejaculation as "poor" or "very poor"** (Fraschini, 1966; McMahon et al., 2013; Porst et al., 2010).

Rationale for Inclusion of "Negative Personal Consequences, Such as Distress, Bother, Frustration, and/or the Avoidance of Sexual

Intimacy.”

Several authors have reported an **association between lifelong or acquired PE and negative psychological outcomes in men with lifelong or acquired PE** and their female partners (Althof, 2006a, 2006b; Brock et al., 2007; Byers and Grenier, 2003; Dunn et al., 1999; Fraschini, 1966; Giuliano et al., 2008; Hartmann et al., 2005; McCabe, 1997; McMahon et al., 2013; Patrick et al., 2005; Porst et al., 2007; Riley and Riley, 2005; Rosen and Althof, 2008; Rowland et al., 2004, 2007; Symonds et al., 2003). Patrick et al. reported significant differences in men with and without PE in the PRO measures of personal distress (64% vs. 4%) and interpersonal difficulty (31% vs. 1%), suggesting that this personal distress has discriminative validity in diagnosing men with and without PE. **The personal and/or interpersonal distress, bother, frustration, and annoyance that results from PE may affect men's quality of life and partner relationships and their self-esteem and self-confidence; furthermore, it can act as an obstacle to single men forming new partner relationships** (Althof, 2006a, 2006b; Brock et al., 2007; Byers and Grenier, 2003; McCabe, 1997; Dunn et al., 1999; Giuliano et al., 2008; Hartmann et al., 2005; Patrick et al., 2005; Porst et al., 2007; Riley and Riley, 2005; Rosen and Althof, 2008; Rowland et al., 2004, 2007; Symonds et al., 2003). McCabe reported that sexually dysfunctional men, including men with PE, scored lower on all aspects of intimacy (emotional, social, sexual, recreational, and intellectual) and had lower levels of satisfaction compared with sexually functional men ($P < 0.001$ or $P < 0.01$) (McCabe, 1997). Rowland et al. showed that **men with PE had significantly lower overall health-related quality of life, total Self-Esteem and Relationship Questionnaire (SEAR) scores, and lower confidence and self-esteem compared with non-PE groups** (Rowland et al., 2007). PE men rated their overall health-related quality of life lower than men without PE ($P \leq 0.001$).

Rationale for Exclusion of Sexual Satisfaction.

Men with PE report lower levels of sexual satisfaction compared with men with normal ejaculatory latency (Althof, 2006; Brock et al., 2007; Byers and Grenier, 2003; Dunn et al., 1999; Fraschini, 1966; Giuliano et al., 2008, 2013; Hartmann et al., 2005; McCabe, 1997; McMahon et al., 2013; Patrick et al., 2005; Porst et al., 2007, 2010; Riley and Riley, 2005; Rosen and Althof, 2008; Rowland et al., 2004, 2007; Symonds et al., 2003). Patrick et al. reported ratings of “very poor” or “poor” for sexual satisfaction in 31% of subjects with PE compared to 1% in a group of normal controls (Patrick et al., 2005). However, caution should be exercised in assigning lower levels of sexual satisfaction solely to the effect of PE and contributions from other difficult-to-quantify issues such as reduced intimacy, dysfunctional relationships, poor sexual attraction, and poor communication should not be ignored. This is supported by the report of Patrick et al. that, despite reduced ratings for satisfaction with shorter IELTs, a substantial proportion of men with an IELT of less than 1 minute report “good” or very good” satisfaction ratings (43.7%). The current data are limited but suggest that sexual satisfaction is of limited use in differentiating PE subjects from non-PE subjects and was not included in the ISSM definition of PE (Patrick et al., 2005).

Diagnostic and Statistical Manual of Mental Disorders Definition of Premature Ejaculation

Based upon the same data that supported the ISSM definition of lifelong PE, **the recently published DSM-5 definition of PE** (American Psychiatric Association, 2013) now includes an objective ejaculatory latency criterion. DSM-5 defines PE as

> *a persistent or recurrent pattern of ejaculation occurring during partnered sexual activity within approximately 1 minute following vaginal penetration and before the individual wishes it. This symptom must have been present for at least 6 months and must be experienced on almost all or all (approximately 75%–100%) occasions of sexual activity. It causes clinically significant distress in the individual*

(American Psychiatric Association, 2013). The DSM-5 definition of PE requires clinicians to specify PE as either lifelong or acquired and as generalized or situational. In addition, the DSM-5 definition of PE distinguishes between mild PE (ejaculation occurring within approximately 30 seconds to 1 minute of vaginal penetration), moderate PE (ejaculation occurring within approximately 15–30 seconds of vaginal penetration), and severe PE (ejaculation occurring before sexual activity, at the start of sexual activity, or within approximately 15 seconds of vaginal penetration).

Prevalence of Premature Ejaculation

Reliable information on the prevalence of lifelong (L-PE) and acquired (A-PE) premature ejaculation in the general male population is lacking. PE has been estimated to occur in 4% to 39% of men in the general community (Grenier and Byers 1997; Laumann et al., 1999; Nathan, 1986; Porst et al., 2007; Reading and Wiest, 1984; Spector and Boyle, 1986; Spector and Carey, 1990) and is often reported as the most common self-reported male sexual disorder (Jannini and Lenzi, 2005). However, **a substantial disparity exists between the incidence of PE in epidemiologic studies, which rely upon either patient self-report of PE and/or inconsistent and poorly validated definitions of PE** (Giuliano et al., 2008; Laumann et al., 1999; Patrick et al., 2005), and that suggested by community-based stopwatch studies of the IELT, the time interval between penetration and ejaculation (Waldinger et al., 2005). The latter demonstrates that the **distribution of the IELT is positively skewed, with a median IELT of 5.4 minutes (range, 0.55–44.1 minutes), decreases with age and varies between countries,** and supports the notion that IELTs of less than 1 minute are statistically abnormal compared with men in the general western population (Fig. 71.2; Waldinger et al., 2005).

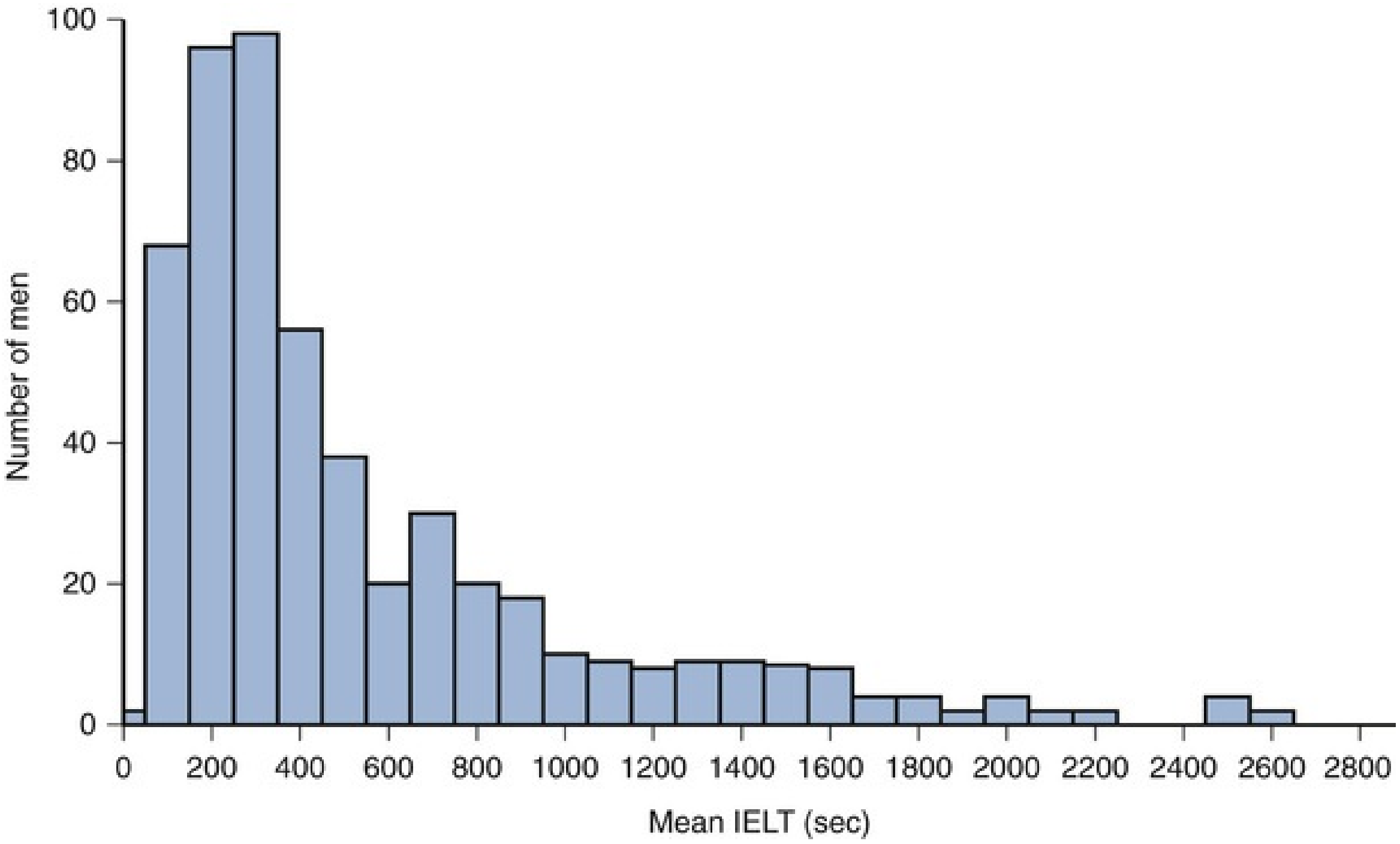

FIG. 71.2 Distribution of intravaginal ejaculatory latency times (IELT) values in a random cohort of 491 men. (Waldinger MD, Quinn P, Dilleen M, et al.: A multinational population survey of intravaginal ejaculation latency time. *J Sex Med* 2[4]:492-497, 2005.)

Prevalence data derived from patient self-report will be appreciably higher than prevalence estimates based on clinician diagnosis using the more conservative ISSM definition of PE. The following studies demonstrate the varying prevalence estimates ranging from 30% to 3%. Data from the Global Study of Sexual Attitudes and Behaviors (GSSAB), an international survey investigating the attitudes, behaviors, beliefs, and sexual satisfaction of 27,500 men and women aged 40 to 80 years, reported the global prevalence of PE (based on subject self-report) to be approximately 30% across all age groups (Nicolosi et al., 2004; Laumann et al., 2005). Perception of “normal” ejaculatory latency varied by country and differed when assessed either by the patient or his partner (Montorsi, 2005). A core limitation of the GSSAB survey stems from the fact that the youngest participants were aged 40 years, an age when the incidence of PE may be different from younger males (Jannini and Lenzi, 2005). Contrary to the GSSAB study, the Premature Ejaculation Prevalence and Attitude Survey found the prevalence of PE among men aged 18 to 70 years to be 22.7% (Porst et al., 2007). The real prevalence of PE is difficult to assess in clinical practice (Jannini and Lenzi, 2005).

Fasalo et al. reported that 2658 of 12,558 men (21.2%) attending a free andrological consultation self-diagnosed PE, the majority describing acquired PE (14.8%) and 4.5% describing lifelong PE (Basile Fasolo et al., 2005). In contrast, Serefoglu et al. (2010) reported that the majority of PE treatment-seeking patients described lifelong PE (62.5%) compared with acquired PE (16.1%). Similar findings were reported by Zhang et al., who found that the majority of 1988 Chinese outpatients described lifelong PE (35.6%) or acquired PE (28.07%). These data provide evidence that lifelong and acquired PE patients make up the majority of the patients who seek treatment for the complaint of ejaculating prematurely. In addition, there appears to be a disparity between the incidence of the various PE subtypes in the general community and in men actively seeking treatment for PE.

Consistent with this notion, **Serefoglu et al.** (2011) **subsequently reported an overall PE prevalence of 19.8% comprising lifelong PE (2.3%), acquired PE (3.9%), variable PE (8.5%), and subjective PE (5.1%).** Using similar research methodology, Gao et al. (2013) reported that 25.80% of 3016 Chinese men complained of PE, with similar prevalence of lifelong PE (3.18%), acquired PE (4.84%), variable PE (11.38%), and subjective PE (6.4%). Of particular interest is the report of Serefoglu et al. (2011) that men with acquired PE are more likely to seek medical treatment than men with lifelong PE (26.53% vs. 12.77%). This finding was confirmed by Gao et al., who demonstrated that acquired PE patients were more likely to seek (17.12% vs. 14.58%) and plan to seek (36.30% vs. 27.08%) treatment for their complaints compared with men with lifelong PE (Gao et al., 2013). These data suggest that the prevalence of acquired PE in the community is approximately around 4% among sexually active adults and that these patients are more likely to seek medical treatment.

Cause of Premature Ejaculation

Historically, attempts to explain the cause of PE have included a diverse range of biologic and psychological theories. Most of these proposed causes are not evidence based and are speculative at best. Although men with lifelong and acquired PE appear to share the dimensions of short ejaculatory latency, reduced or absent perceived ejaculatory control, and the presence of negative personal consequences from PE, they remain distinct and different demographic and etiologic populations (Porst et al., 2010).

Lifelong Premature Ejaculation

Waldinger et al. hypothesized that lifelong early ejaculation in humans may be explained by either a hyposensitivity of the 5-HT2c and/or hypersensitivity of the 5-HT1a receptor (Waldinger, 1998). Recent studies have suggested that **in some men neurobiologic and genetic variations could contribute to the pathophysiology of L-PE,** as defined by the ISSM criteria, and that the condition may be maintained and heightened by psychological/environmental factors (Janssen et al., 2009).

Acquired Premature Ejaculation

Acquired PE is commonly due to **sexual performance anxiety** (Hartmann et al., 2005), psychological or relationship problems (Hartmann et al., 2005), **erectile dysfunction (**ED; Laumann et al., 2005), and occasionally prostatitis (Screponi et al., 2001), hyperthyroidism (Carani et al., 2005), or during withdrawal/detoxification from prescribed (Adson and Kotlyar, 2003) or recreational drugs (Peugh and Belenko, 2001). Consistent with the predominant organic cause of acquired PE, men with this complaint are usually older and have a higher mean BMI and a greater incidence of comorbid disease, including hypertension, sexual desire disorder, diabetes mellitus, chronic prostatitis, and

ED compared with lifelong, variable, and subjective PE (Basile Fasolo et al., 2005; Gao et al., 2013; McMahon et al., 2013; Porst et al., 2010; Serefoglu et al., 2010, 2011; Zhang et al., 2013). An increased prevalence of PE has been reported in men with metabolic syndrome (Bolat et al., 2017). Two extensive systematic analyses of reported data report no significant difference in the incidence of PE between circumcised and uncircumcised men (Morris and Krieger, 2013; Tian et al., 2013).

Premature Ejaculation and Sexual Performance Anxiety, and Psychological or Relationship Problems

Anxiety has been reported as a cause of PE by multiple authors and is entrenched in the folklore of sexual medicine as the most likely cause of PE despite scant empirical research evidence to support any causal role (Janssen et al., 2009; Jern et al., 2007). Several authors have suggested that **anxiety activates the sympathetic nervous system and reduces the ejaculatory threshold as a result of an earlier emission phase of ejaculation** (Janssen et al.. 2009).

Hypoactive sexual desire may lead to PE because of an unconscious desire to abbreviate unwanted penetration. Similarly, diminished sexual desire can be a consequence of chronic and frustrating PE.

Female sexual dysfunctions (such as anorgasmia, hypoactive sexual desire, sexual aversion, sexual arousal disorders, and sexual pain disorders such as vaginismus [Bronner et al., 2015; Dogan and Dogan, 2008]) may also be related to acquired PE.

Premature Ejaculation and Comorbid Erectile Dysfunction

Recent data demonstrate that as many as half of subjects with erectile dysfunction (ED) also experience PE (Fasolo et al., 2005; Laumann et al., 2005; Porst et al., 2007). Subjects with ED may either require higher levels of stimulation to achieve an erection or **intentionally “rush” intercourse to prevent early detumescence of a partial erection,** resulting in ejaculation with a brief latency (Jannini et al., 2005). This may be compounded by the presence of high levels of performance anxiety related to their ED, which only worsens their prematurity. However, caution should be exercised in the diagnosis of comorbid ED in men with PE because 33.3% of potent men with PE confuse the ability to maintain erections before ejaculation and after ejaculation, record contradictory response(s) to some/all questions of the SHIM (especially Q3 and Q4), and receive a false-positive SHIM diagnosis of ED (McMahon, 2009).

Premature Ejaculation and Prostate Disease

Acute and chronic lower urogenital infection, prostatodynia, or chronic pelvic pain syndrome (CPPS) is associated with ED, PE, and painful ejaculation (Donatucci, 2006; Rowland et al., 2010; Waldinger et al., 2005; Zohdy, 2009). **Several studies report PE as the main sexual disorder symptom in men with chronic prostatitis or CPPS with a prevalence of 26% to 77%** (Rowland et al., 2010). The exact pathophysiology of the link between chronic prostatitis, ED, and PE is unknown. It has been hypothesized that prostatic inflammation may result in altered sensation and modulation of the ejaculatory reflex, but evidence is lacking (Donatucci, 2006; Shamloul and el-Nashaar, 2006; Sharlip, 2006). It has been reported that antibiotic treatment of microbiologically confirmed bacterial prostatitis in men with acquired PE resulted in a 2.6-fold increase in IELT and improved ejaculatory control in 83.9% of subjects (El-Nashaar and Shamloul, 2007).

Premature Ejaculation and Hyperthyroidism

The majority of patients with thyroid hormone disorders experience sexual dysfunction. Studies suggest a significant correlation between PE and suppressed TSH values in a selected population of andrological and sexological patients. The 50% prevalence of PE in men with hyperthyroidism fell to 15% after treatment with thyroid hormone normalization (Carani et al., 2005). Although occult thyroid disease has been reported in the elderly hospitalized population, it is uncommon in the population who present for treatment of PE and routine **TSH screening is not indicated unless clinically indicated** (Atkinson et al., 1978).

Evaluation of Men Complaining of Premature Ejaculation

Medical History

Men presenting with self-reported PE should be evaluated with a **full medical/sexual history, a focused physical examination, inventory assessment of erectile function, and any investigations suggested by these**

findings. Inclusion of the partner in the management process is an important but not a mandatory ingredient for treatment success. Some patients may not understand why the clinician wishes to include the partner, and some partners may be reluctant to join the patient in treatment. However, if partners are not involved in treatment, they may be resistant to changing the sexual interaction (Donahey and Miller, 2000). A cooperative partner can enhance the man's self-confidence, skills, self-esteem, sense of masculinity, and more generally assist the man to develop ejaculatory control (Perelman, 2003). This is, in turn, likely to lead to an improvement in the couple's sexual relationship, as well as the broader aspects of their relationship. There are no controlled studies on the impact of involving partners in treating PE. However, a review of treatment studies for ED demonstrated the important role of including a focus on interpersonal factors on treatment success (Mohr and Bentler, 1990).

Patients expect clinicians to inquire about their sexual health (Schein et al., 1988). Often patients are too embarrassed, shy, and uncertain to mention sexual complaints in the health care professional's (HCP's) office (Humphrey and Nazareth, 2001). Inquiry into sexual health gives patients permission to discuss their sexual concerns and also screens for associated health risks (e.g., cardiovascular risk and ED). Table 71.2 lists recommended and optional questions that patients who complain of PE should be asked (Althof et al., 2010; McMahon et al., 2004). The recommended questions establish the diagnosis and direct treatment considerations and the optional questions gather detail for implementing treatment. Finally, the committee recommends that the HCPs take a medical and psychosocial history.

TABLE 71.2

Recommended and Optional Questions to Establish the Diagnosis of Premature Ejaculation (PE) and Direct Treatment

RECOMMENDED QUESTIONS	
	What is the time between penetration and ejaculation (coming)? Can you delay ejaculation? Do you feel bothered, annoyed and/or frustrated by your PE?
OPTIONAL QUESTIONS	
Differentiate lifelong and acquired PE	When did you first experience PE? Have you experienced PE since your first sexual experience on every/almost every attempt and with every partner?
Assess erectile	Is your erection hard enough to penetrate?

function	Do you have difficulty in maintaining your erection until you ejaculate during intercourse? Do you ever rush intercourse to prevent loss of your erection?
Assess relationship impact	How upset is your partner with your PE? Does your partner avoid sexual intercourse? Is your PE affecting your overall relationship?
Previous treatment	Have you received any treatment for you PE previously?
Impact on quality of life	Do you avoid sexual intercourse because of embarrassment? Do you feel anxious, depressed, or embarrassed because of your PE?

From Althof SE, Abdo CH, Dean J, et al.: International Society for Sexual Medicine's guidelines for the diagnosis and treatment of premature ejaculation. *J Sex Med* 7(9):2947–2969, 2010.

Diagnosis of Premature Ejaculation

The ISSM definition of PE should form the basis for the diagnosis of PE. A significant population of men with self-reported PE fails to satisfy the criteria of the ISSM definition of PE. This parallels the substantial disparity between the self-reported incidence of PE in epidemiologic studies (Laumann et al., 1999) and that suggested by community-based normative stopwatch IELT studies (Waldinger et al., 2005). This population has recently been categorized as suffering from either variable PE or subjective PE (Waldinger and Schweitzer, 2006, 2008). Men with subjective PE complain of PE but have a normal ejaculatory latency typically of 2 to 6 minutes but on some occasions as long as 25 minutes. It is characterized by a preoccupation with a subjective but false perception of PE with an IELT within the normal range but often with reduced ejaculatory control.

Determination of Intravaginal Ejaculation Latency Time

Self-estimation by the patient and partner of ejaculatory latency should be used to determine IELT in clinical practice. Stopwatch measures of IELT are widely used in clinical trials and observational studies of PE but have not been recommended for use in routine clinical management of PE. Despite the potential advantage of objective measurement, stopwatch measures have the disadvantage of being intrusive and potentially disruptive of sexual pleasure or spontaneity. More recently, studies have indicated that patient or partner self-report of ejaculatory latency correlate relatively well with objective stopwatch latency and may be useful as a proxy measure of IELT (Althof, 1998; McMahon, 2008; Pryor et al., 2005; Rosen et al., 2007). Because patient self-report is the determining factor in treatment seeking and satisfaction, it is recommended that self-estimation by the patient and partner of ejaculatory latency are accepted as the method for determining IELT in clinical practice.

Patient Reported Outcome Measures

Standardized assessment measures such as validated questionnaires and PRO measures can be used as an adjunct to a full medical/sexual history and self-estimation of ejaculatory latency in the evaluation of men presenting with self-reported PE. These measures are all relatively new and were developed primarily for use as research tools. Some have shown good psychometric properties and are potentially valuable adjuncts for clinical screening and assessment.

Several PE measures have been described in the literature (Althof et al., 2006; Arafa and Shamloul, 2007; Patrick et al., 2008; Serefoglu et al., 2009; Symonds et al., 2007; Yuan et al., 2004), although only a small number have undergone extensive psychometric testing and validation. Five validated questionnaires have been developed and published. Currently, there are two questionnaires that have extensive databases and meet most of the criteria for test development and validation: **the Premature Ejaculation Profile (PEP)** and the **Index of Premature Ejaculation (IPE)** (Althof et al., 2006; Patrick et al., 2008). A third brief diagnostic measure, the **premature ejaculation diagnostic tool (PEDT)** has also been developed, has a modest database, and is available for clinical use (Symonds et al., 2007). Two other measures, the Arabic and Chinese PE Questionnaires, have minimal validation or clinical trial data available and are not recommended for clinical use.

Premature Ejaculation Profile

A four-item, self-report measure of PE has been developed by Patrick et al. (2008). The PEP comprises single-item constructs of: (1) perceived control over ejaculation; (2) satisfaction with sexual intercourse; (3) personal distress related to ejaculation; (4) interpersonal difficulty related to ejaculation; and (5) an index or total score. Each of **the four individual items is assessed on a 5-point scale**, which are averaged to provide an index PE score. The measure has been used in observational studies and clinical trials of PE (Patrick et al., 2005). It has also been recommended for clinical use in evaluating the subjective components of the disorder. Validation studies have been performed in comparison to stopwatch measures of intravaginal latency and other PRO measures of sexual function and distress (Patrick et al., 2005, 2008). The scale has adequate test-retest reliability (total scale = 0.80) and moderate to strong correlations with stopwatch-measured IELT. A major limitation of the scale is the lack of validated cutoff scores, which make it less suitable for use as a diagnostic or clinical screening tool. On the positive side, it is very brief and easy to administer and may be valuable for use in a clinical setting as a measure of treatment responsiveness.

Index of Premature Ejaculation

The IPE was developed by Althof et al. (2006). It is a 10-item, self-administered questionnaire designed to evaluate sexual satisfaction, control, and distress in men with PE. It was developed using four stages: item pool development, initial psychometric analyses, patient interviews, and final psychometric analyses. The IPE contains three factor analytically derived domains: control, sexual satisfaction, and distress. All three domains have shown adequate internal consistency and reliability, as well as known groups validity in comparing men with and without PE. Convergent validity against IELT was also strong for all three domains (control [r = 0.75]; sexual satisfaction [r = 0.60]; and distress [r = 0.68]).

The IPE has the advantages of also being relatively brief and easy to administer, although the measure is not as brief as the PEP. It also assesses clinically relevant domains and has adequate known groups’ validity data. However, similar to the PEP, it lacks norms and diagnostic cutoffs, and has limited value as a diagnostic or screening measure for PE.

Premature Ejaculation Diagnostic Tool

The previous two measures (PEP, IPE) are available for use as treatment change or outcome measures of PE treatment. **The PEDT, in contrast, was developed specifically for use as a screening questionnaire** (Serefoglu et al., 2009; Symonds et al., 2007a, 2007b). This questionnaire is a brief, 5-item measure used to screen men for potential presence of PE based on DSM-IV-TR criteria of lack of control, frequency, minimal stimulation, distress, and interpersonal difficulty.

Depending on the specific need, the PEP or IPE are currently the preferred questionnaire measures for assessing PE, particularly when monitoring responsiveness to treatment. Overall, these measures may serve as useful adjuncts but should not substitute for a detailed sexual history performed by a qualified clinician.

Assessment of Erectile Function

The presence of comorbid ED should be evaluated using a validated instrument such as the International Index of Erectile Function (IIEF) or the IIEF-5 (SHIM). Normal erectile function should be defined as an IIEF EF Domain ≥ 26 or IIEF-5 >21 (Cappelleri et al., 2001; Rosen et al., 1997). Recent data demonstrate that as many as half of subjects with ED also experience PE (Jannini et al., 2005). In the European Premature Ejaculation Prevalence and Attitudes Study, ED present in 31.9% of men with PE compared with 11.8% of non-PE men (Porst et al., 2007). In the Global Study of Sexual Attitudes and Behaviors (GSSAB), the odds ratio for ED in men with PE ranged from was 6.0 in Europe and as high as 11.9 in South America (Laumann et al., 2005). Consistent with this, ED is more prevalent in men with A-PE than L-PE (Basile Fasolo et al., 2005). PE is also more common with increasing severity of ED after adjustment for age (Corona et al., 2004; El-Sakka, 2007; el-Sakka, 2008). Subjects with ED may either require higher levels of stimulation to achieve an erection or intentionally “rush” intercourse to prevent early detumescence of a partial erection, resulting in ejaculation with a brief latency (Jannini et al., 2005). This may be compounded by the presence of high levels of performance anxiety related to their ED, which only worsens their prematurity. However, caution should be exercised in the diagnosis of comorbid ED in men with PE because 33.3% of potent men with PE confuse the ability to maintain erections before ejaculation and after ejaculation, record contradictory response(s) to some or all questions of the SHIM, especially Q3 and Q4, and receive a false-positive SHIM diagnosis of ED (McMahon, 2009).

Physical Examination

Current literature suggests that the diagnosis of L-PE is based purely on the medical history because there are no predictive physical findings or confirmatory investigations (McMahon, 2005). Because differentiation of L-PE and A-PE may be difficult in either young men or men with none or few previous sexual partners and/or limited sexual experience, a physical examination is highly desirable and represents an opportunity for screening for cardiovascular or gender specific diseases. However, **in men with A-PE, a physical examination is mandatory to identify the cause of the PE** and to alleviate its possible cause (Jannini, 2006). The presence of ED should be evaluated either by medical history or with the assistance of a validated instrument. Laboratory or imaging investigations are occasionally required based upon the patient's medical history. A digital prostate examination, routine in an andrological setting for all men over 40, is useful in identifying possible evidence of prostatic inflammation or infection (Jannini, 2006).

Fig. 71.3 is a flow chart for the management of PE (Rowland et al., 2010).

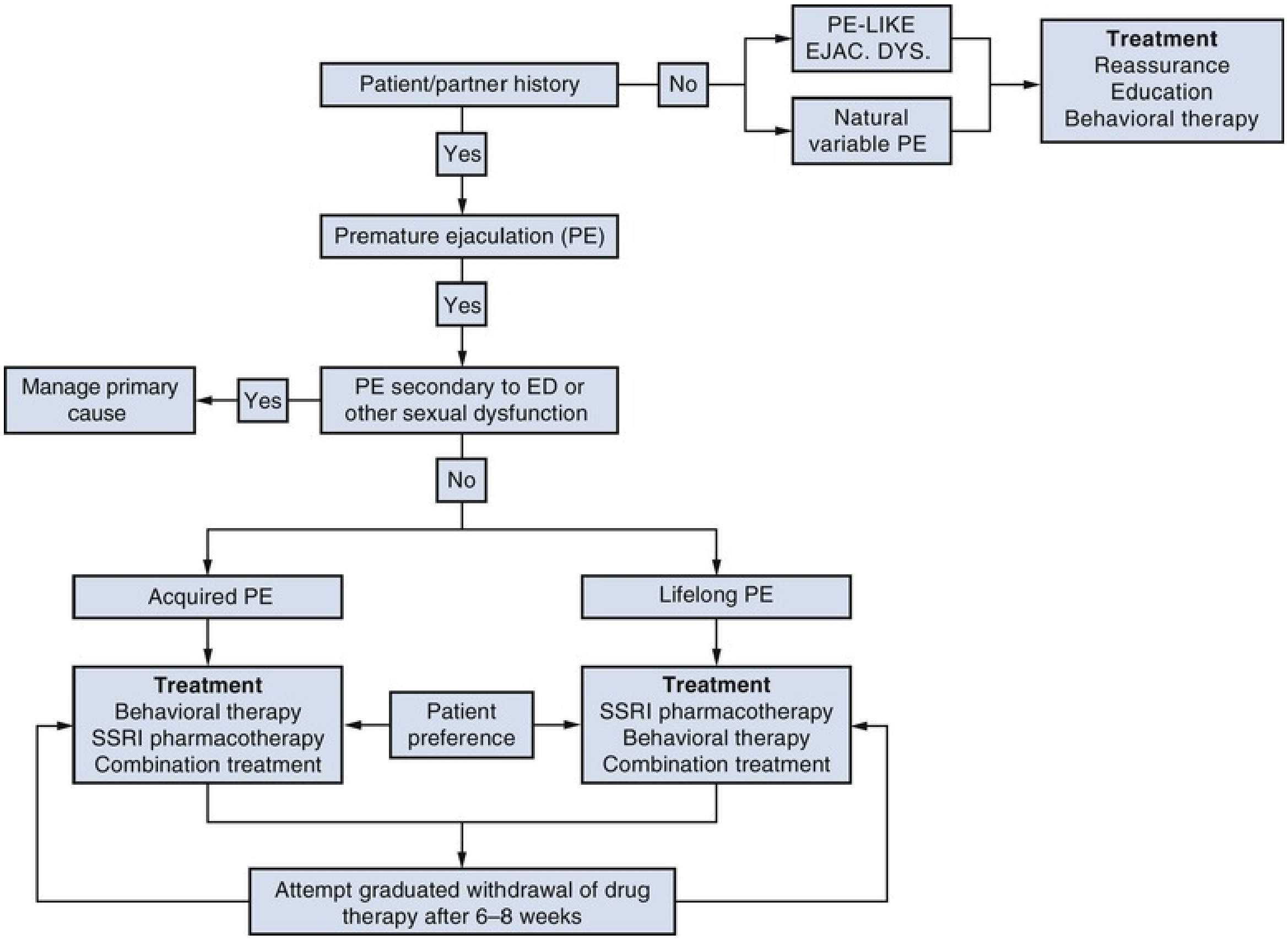
PE-LIKE EJAC. DYS.
Natural variable PE
Treatment
Reassurance
Education
Behavioral therapy
Patient/partner history
No
Yes
Premature ejaculation (PE)
Yes
Manage primary cause
Yes
PE secondary to ED or other sexual dysfunction
No
Acquired PE
Lifelong PE
Treatment
Behavioral therapy
SSRI pharmacotherapy
Combination treatment
Patient preference
Treatment
SSRI pharmacotherapy
Behavioral therapy
Combination treatment
Attempt graduated withdrawal of drug therapy after 6–8 weeks

FIG. 71.3 Algorithm for the office management of premature ejaculation. *ED,* Erectile dysfunction; *SSRI,* selective serotonin reuptake inhibitor.

Treatment of Premature Ejaculation

There are **multiple psychosexual and pharmacologic treatments for PE.** Men with L-PE are best managed with PE pharmacotherapy alone or **in combination with graded levels of patient and couple psychosexual therapy.** Men with A-PE should receive cause-specific treatment (e.g., psychosexual counselling or ED pharmacotherapy), alone or in combination with PE pharmacotherapy. Men with natural variable PE or PE-like ejaculatory dysfunction should be primarily treated with psychosexual education and graded patient and couple psychotherapy. Physicians should recognize the association between PE, comorbid ED, metabolic syndrome, sedentary lifestyle, alcohol consumption, and body mass index and counsel patients to exercise more and improve their overall lifestyle (Kilinc et al., 2018; Ventus and Jern, 2016).

Psychosexual Therapy

All men seeking treatment for PE should receive basic psychosexual education or coaching (Althof 2006, 2007; Perelman 2003, 2006). This may include providing information on the prevalence of PE in the general population and the average range of IELT to dispel myths about PE, information on enjoyable sexual activities to extend the man and his partner’s sexual repertoire, as well as strategies to address avoidance of sexual activity or unwillingness to discuss sex with his partner. These educational strategies are designed to give the man the confidence to try the medical intervention, reduce performance anxiety, and modify his maladaptive sexual scripts.

Graded levels of patient and couple counseling, guidance, and/or relationship therapy, either alone or ideally in combination with PE pharmacotherapy, should be offered as a treatment option for most men with PE. Premature ejaculation exerts a significant psychological burden on men, their partners, the male/partner relationship, and their overall relationship (Rust et al., 1988; Symonds et al., 2003). Men with PE show other negative effects, including a general negative affect associated with sexual situations, and more intense feelings of embarrassment/guilt, worry/tension, and fear of failure (Sotomayor, 2005). Sufferers indicate decreased self-confidence, increased distress, interpersonal difficulty, and mental preoccupation with their condition (Hartmann et al., 2005; Patrick et al., 2005). As partner satisfaction may play a greater role in PE than ED, it is not surprising that relationship dysfunction is reported as the second most common negative effect of PE (Hartmann et al., 2005; Symonds et al., 2003). Not only is PE associated with marital discord (Rust et al., 1988), but the insecurity of men with PE about satisfying the partner also serves as an obstacle to initiating and maintaining new relationships (Sotomayor, 2005; Symonds et al., 2003).

Until recently, treatment options have been limited to behavioral and psychological procedures. Psychological factors such as anxiety and negative affect have frequently been associated with sexual dysfunctions such as PE (Kaplan, 1983, 1989), and treatment addressing such issues has represented a logical approach. Psychological-behavioral strategies for treating PE have been at least moderately successful in alleviating the dysfunction in the short term (Catalan et al., 1986; De Amicis et al., 1984; de Carufel and Trudel, 2006; Golden et al., 1978; Hawton et al., 1986; Levine, 1992).

Psychological interventions are designed to achieve more than simply increasing the IELT. Targeted factors focus on the man, his partner, and their relationship. Psychotherapy and behavioral interventions improve ejaculatory control by helping men/couples to (1) learn techniques to control and/or delay ejaculation, (2) gain confidence in their sexual performance, (3) lessen performance anxiety, (4) modify rigid sexual repertoires, (5) surmount barriers to intimacy, (6) resolve interpersonal issues that precipitate and maintain the dysfunction, (7) increase communication (Althof, 2003; Althof and Wieder, 2004), and (8) come to terms with feelings/thoughts that interfere with sexual function.

Present-day psychotherapy for PE most often represents an integration of behavioral (e.g., the well-known start-stop and pause-squeeze methods) and cognitive approaches within a short-term psychotherapy model (Althof and Wieder, 2004; De Amicis et al., 1984; de Carufel and Trudel, 2006; Golden et al., 1978; Hawton et al., 1986; Levine, 1992). The guiding principles of treatment are to learn to control ejaculation while understanding the meaning of the symptom and the context in which it occurs.

Although the new and often more expedient pharmacologic therapies are overshadowing traditional psychological-behavioral methods in the treatment of PE, the psychological-behavioral approach remains an attractive option for several reasons. The treatment is specific to the problem, is neither harmful nor painful, is less dependent on the man's medical history, produces minimal or no adverse side effects, and encourages open communication about sexuality in the couple, which is likely to lead to a more satisfying sexual relationship (Wincze and Carey, 1991). Once the techniques have been learned and incorporated into lovemaking, men with PE continue to have access to strategies that help them control their ejaculation. The achievement of control of ejaculation may be explained, in part, by the report that the spinal generator of ejaculation in male rats can, like other central pattern generators (CPGs), be trained by daily copulation (Rodriguez-Pena et al., 2017).

At the same time, there are drawbacks to the psychological-behavioral approach: it is time consuming, often requires substantial resources of time and money, lacks immediacy, requires the partner's cooperation, and has mixed (and less well-documented) efficacy. Furthermore, data to support long-term efficacy are lacking.

Combining a medical and psychological approach may be especially useful in men with A-PE, where there is a clear psychosocial precipitant, or L-PE, where the individual or couple's responses to PE are likely to interfere in the medical treatment and ultimate success of therapy (Cooper et al., 2015; Mantovani, 2017). Similarly, in men with PE and comorbid ED combination therapy may also be helpful to manage the psychosocial aspects of these sexual dysfunctions. Once the man's self-confidence and sense of control have improved, it may then be possible to reduce or discontinue the medical intervention (McMahon, 2002).

Pharmacologic Treatment

Several forms of pharmacotherapy have been used in the treatment of PE (Giuliano and Clement, 2012). These include the use of **topical local anesthetics, selective serotonin reuptake inhibitors (SSRIs), tramadol, phosphodiesterase type 5 inhibitors (PDE5Is), and α-adrenergic blockers.** The use of topical local anesthetics (LA), such as lidocaine, prilocaine, or benzocaine, alone or in association, to diminish the sensitivity of the glans penis is the oldest known pharmacologic treatment for PE (Schapiro, 1943). The introduction of the selective serotonin reuptake inhibitors—paroxetine, sertraline, fluoxetine, citalopram and the tricyclic antidepressant (TCA) clomipramine—has revolutionized the treatment of PE. These drugs block axonal reuptake of serotonin from the synaptic cleft of central serotonergic neurons by 5-HT transporters, resulting in enhanced 5-HT neurotransmission and stimulation of postsynaptic membrane 5-HT receptors.

Treatment With Selective Serotonin Reuptake Inhibitors and Tricyclic Antidepressants.

PE can be treated with **on-demand SSRIs such as dapoxetine or off-label clomipramine, paroxetine, sertraline, and fluoxetine, or with daily dosing of off-label paroxetine, clomipramine, sertraline, fluoxetine, or citalopram.**

Dapoxetine.

Dapoxetine has received approval for the treatment of PE in more than 50 countries worldwide. Dapoxetine has not received marketing approval by the US Food and Drug Administration (FDA). It is a **rapid-acting and short half-life SSRI with a pharmacokinetic profile supporting a role as an on-demand treatment for PE** (Pryor et al., 2006). No drug-drug interactions associated with dapoxetine, including phosphodiesterase inhibitor drugs, have been reported. In RCTs, dapoxetine 30 mg or 60 mg taken 1 to 2 hours before intercourse is more effective than placebo from the first dose, resulting in **2.5 and 3.0-fold increases in IELT, increased ejaculatory control, decreased distress, and increased satisfaction.** Dapoxetine was comparably effective in men with L-PE and A-PE (Porst et al., 2010) and was similarly effective and well tolerated in men with PE and comorbid ED treated with PDE5I drugs (McMahon et al., 2013). Treatment-related side effects were uncommon and dose dependent and included nausea, diarrhea, headache, and dizziness (McMahon et al., 2011). They were responsible for study discontinuation in 4% (30 mg) and 10% (60 mg) of subjects. The incidence of treatment-related side effects has been reported to be lower with on-demand dapoxetine compared with daily dosed SSRIs (Verze et al., 2016). There was no indication of an increased risk of suicidal ideation or suicide attempts and little indication of withdrawal symptoms with abrupt dapoxetine cessation (Levine, 2006). Postmarketing experience does, however, report that the discontinuation rate for dapoxetine was high (87% at 12 months) predominantly because of cost and the lack of spontaneity associated with on-demand administration (Park et al., 2017). Jiann et al. reported that 45% of men were satisfied with their response to dapoxetine (30 mg) and that level of satisfaction was closely related to treatment response (Jiann and Huang, 2015).

Off-Label Selective Serotonin Reuptake Inhibitors and Tricyclic Antidepressants.

Daily treatment with off-label paroxetine 10 to 40 mg, clomipramine 12.5 to 50 mg, sertraline 50 to 200 mg, fluoxetine 20 to 40 mg, and citalopram 20 to 40 mg is usually effective in delaying ejaculation. A meta-analysis of published data suggests that **paroxetine exerts the strongest ejaculation delay, increasing IELT approximately 8.8-fold over baseline** (Waldinger et al., 2004).

Ejaculation delay usually occurs within 5 to 10 days of starting treatment, but the full therapeutic effect may require 2 to 3 weeks of treatment and is usually sustained during long-term use (McMahon, 2002). Adverse effects are usually minor, start in the first week of treatment, and may gradually disappear within 2 to 3 weeks. They include **fatigue, yawning, mild nausea, diarrhea, or perspiration.** There are anecdotal reports that decreased libido and ED are less frequently seen in nondepressed PE men treated by SSRIs compared with depressed men treated with SSRIs (Waldinger, 2007). Neurocognitive adverse effects include significant **agitation and hypomania in a small number of patients, and treatment with SSRIs should be avoided in men with a history of bipolar depression** (Marangell et al., 2008).

Platelet serotonin release has an important role in hemostasis (Li et al., 1997), and SSRIs, especially with concurrent use of aspirin and nonsteroidal anti-inflammatory drugs, may be associated with **increased risk of upper gastrointestinal bleeding.** Priapism is a rare adverse effect of SSRIs and requires urgent medical treatment. Long-term SSRI use may be associated with **weight gain and an increased risk of type 2 diabetes mellitus** (Fava et al., 2000). In men with normal semen parameters, **paroxetine has been reported to induce abnormal sperm DNA fragmentation in a significant proportion of subjects, without a measurable effect on semen parameters.** The fertility potential of a substantial number of men on paroxetine may be adversely affected by these changes in sperm DNA integrity (Tanrikut et al., 2010).

Systematic analysis of RCTs of antidepressants (SSRIs and other drug classes) in patients with depressive and/or anxiety disorders indicate **a small increase in the risk of suicidal ideation or suicide attempts in youth but not adults.** In contrast, such risk of suicidal ideation has not been found in trials with SSRIs in nondepressed men with PE. Caution is suggested in prescribing SSRIs to young adolescents with PE aged 18 years or less and to men with PE and a comorbid depressive disorder, particularly when associated with suicidal ideation (Khan et al., 2003). Patients should be advised to **avoid sudden cessation or rapid dose reduction of daily dosed SSRIs, which may be associated with an SSRI withdrawal syndrome** (Black et al., 2000).

On-demand administration of clomipramine, paroxetine, sertraline, and fluoxetine 3 to 6 hours before intercourse is modestly efficacious and well tolerated but is associated with substantially less ejaculatory delay than daily treatment in most studies (Kim and Paick, 1999; McMahon and Touma, 1999; Strassberg et al., 1999; Waldinger et al., 2004). On-demand treatment may be combined with either an initial trial of daily treatment or concomitant low-dose daily treatment (McMahon and Touma, 1999).

Patients are often reluctant to begin off-label treatment of PE with SSRIs.

Salonia et al. reported that 30% of patients refused to begin treatment (paroxetine 10 mg daily for 21 days followed by 20 mg as needed) and another 30% of those that began treatment discontinued it (Salonia et al., 2009). Similarly, Mondaini et al. reported that, in a clinic population, 90% of subjects either refused to begin or discontinued dapoxetine within 12 months of beginning treatment (McMahon, 2002). Reasons given included not wanting to take an antidepressant, treatment effects below expectations, and cost.

The decision to treat PE with either on-demand dosing of dapoxetine (where available) or daily dosing of off-label SSRIs should be based upon the treating physician's assessment of individual patient requirements. Although many men with PE who engage in sexual intercourse infrequently may prefer on-demand treatment, many men in established relationships may prefer the convenience of daily medication. Well-designed preference trials will provide additional insight into the role of on-demand dosing. In some countries, off-label prescribing may present difficulties for the physician as the regulatory authorities strongly advise against prescribing for indications in which a medication is not licensed or approved. Obviously, this complicates treatment in countries where there is no approved medication and the regulatory authorities advise against off-label prescription.

Topical Local Anesthetics.

The use of a topical LA, such as lidocaine and/or prilocaine as a cream, gel, or spray, is well established and is moderately effective in delaying ejaculation. Data suggest that diminishing the glans sensitivity may inhibit the spinal reflex arc responsible for ejaculation (Wieder et al., 2000). Topical anesthetics may be associated with significant penile hypoanesthesia and possible transvaginal absorption, resulting in vaginal numbness and resultant female anorgasmia unless a condom is used (Busato and Galindo, 2004).

PSD502 is a aerosolized eutectic mixture of lidocaine-prilocaine delivered as a metered spray that is designed to optimize tissue penetration and onset of effect (Dinsmore and Wyllie, 2009). The spray only penetrates, and therefore anesthetizes, the mucosa of the glans penis and not the keratinized skin of the shaft. PSD502 has received marketing approval in Europe. The clinical profile of PSD502 is described in one of two double-blind, placebo-controlled, phase III studies.

Dinsmore et al. reported that treatment with PSD502 which is applied to the penis at least 5 minutes before intercourse resulted in a 6.3-fold increase in IELT and associated improvements in PRO measures of control and sexual satisfaction (Dinsmore et al., 2006). In a second prospective multicenter placebo-controlled trial of 256 men with lifelong PE, Carson et al. reported that treatment with PSD502, applied topically to the glans penis 5 minutes before intercourse, increased the geometric mean IELT from a baseline of 0.56 minute and 0.53 minute in the PSD502 and placebo group, respectively, to 2.60 and 0.80 minute (4.6- and 1.5-fold, respectively) (Carson and Wyllie, 2010). There were significantly greater increases in the scores for the IPE domains of ejaculatory control, sexual satisfaction, and distress in the PSD502 group than in the placebo group. There were minimal reports of penile hypoanesthesia and transfer to the partner because of the unique formulation of the compound in both studies.

In 2014 PSD502 (Fortacin) received approval by the European Medicines Agency for the treatment for PE throughout the European Union. The ISSM guidelines for the treatment of PE expert committee identified level 1a evidence to support the efficacy and safety of off-label on-demand label topical anesthetics in the treatment of lifelong PE (Althof et al., 2014). Other topical anesthetics are associated with significant penile hypoanesthesia and possible transvaginal absorption, resulting in vaginal numbness and resultant female anorgasmia unless a condom is used (Busato and Galindo, 2004).

PDE5 Inhibitors.

Off-label on-demand or daily dosing of PDE5Is is not recommended for the treatment of L-PE in men with normal erectile function. ED pharmacotherapy alone or in combination with PE pharmacotherapy is recommended for the treatment of L-PE or A-PE in men with comorbid ED. PDE5Is (sildenafil, tadalafil, and vardenafil) are effective treatments for ED. Several authors have reported experience with PDE5Is alone or in combination with SSRIs as a treatment for PE (Abdel-Hamid et al., 2001; Atan et al., 2006; Aversa et al., 2009; Chen et al., 2003; Chia, 2002; Erenpreiss and Zalkalns, 2002; Jannini et al., 2011; Li et al., 2003; Linn et al., 2002; Lozano, 2003; Mathers et al., 2009; Mattos et al., 2008; Mattos and Lucon, 2005; McMahon et al., 2005; Salonia et al., 2002; Sommer et al., 2005; Sun et al., 2007; Tang et al., 2004; Zhang et al., 2005). The putative role of PDE5Is as a treatment for PE is speculative and based only upon the role of the NO/cGMP transduction system as a central and peripheral mediator of inhibitory nonadrenergic, non-cholinergic nitrergic neurotransmission in the urogenital system (Mamas et al., 2003).

Although systematic reviews of studies on the PDE5I drug treatment of PE has failed to provide robust empirical evidence to support a role of PDE5Is in the treatment of PE with the exception of men with PE and comorbid ED (Asimakopoulos et al., 2012; McMahon et al., 2006), recent well-designed studies do support a potential role for these agents, suggesting a need for further evidence-based research (Aversa et al.. 2009). In a well-designed study of 42 potent men with L-PE, randomized to receive on-demand vardenafil or placebo, Aversa et al. reported a 7.5-fold increase in geometric mean IELT after treatment with vardenafil (4.5±1.1 vs. 0.6±0.3 minute with placebo; $P < 0.01$) and significant improvements in the IPE domains of ejaculatory control, confidence, overall sexual satisfaction, and distress (Aversa et al., 2009). This study suggests that the role of PDE5Is should be further evaluated in additional well-designed studies. Furthermore, a recent meta-analysis of only RCTs found evidence to suggest that PDE5Is are effective compared with placebo and that a PDE5I combined with an SSRI is more effective than an SSRI alone (Martyn-St James et al., 2017).

The ISSM guidelines for the treatment of PE expert committee identified some evidence to support the efficacy and safety of off-label on-demand or daily dosing of PDE5Is in the treatment of L-PE in men with normal erectile function (LOE4D). However, off-label on-demand or daily dosing of PDE5Is is not recommended for the treatment of L-PE in men with normal erectile function (Althof et al., 2014). ED pharmacotherapy alone or in combination with PE pharmacotherapy is recommended for the treatment of L-PE or A-PE in men with comorbid ED (Althof et al., 2014). Further evidence-based research is encouraged to understand conflicting data (Althof et al., 2014).

Table 71.3 is a summary of recommended pharmacologic treatments for PE.

TABLE 71.3

Drug Therapy for Premature Ejaculation (PE)

DRUG	DOSE	DOSING INSTRUCTIONS	INDICATION	COMMENT
Dapoxetine	30–60 mg	On demand, 1–3 hours before intercourse	Lifelong PE Acquired PE	Approved in >50 countries
Paroxetine	10–40 mg	Once daily	Lifelong PE	

			Acquired PE	
Sertraline	50–200 mg	Once daily	Lifelong PE Acquired PE	
Fluoxetine	20–40 mg	Once daily	Lifelong PE Acquired PE	
Citalopram	20–40 mg	Once daily	Lifelong PE Acquired PE	
Clomipramine	12.5–50 µg	Once daily	Lifelong PE Acquired PE	
	12.5–50 µg	On demand, 3–4 hours before intercourse	Lifelong PE Acquired PE	
Tramadol	25–50 mg	On demand, 3–4 hours before intercourse	Lifelong PE Acquired PE	Potential risk of opiate addiction
Topical lignocaine/prilocaine	Patient titrated	On demand, 20–30 minutes before intercourse	Lifelong PE Acquired PE	
Alprostadil	5–20 mcg	Patient administered intracavernosal injection 5 min before intercourse	Lifelong PE Acquired PE	Risk of priapism and corporal fibrosis
PDE5 inhibitors	Sildenafil 25–100 mg Tadalafil 10–20 mg Vardenafil 10–20 mg	On demand, 30–50 minutes before intercourse	Lifelong and acquired PE in men with normal erectile function	
			Lifelong and	? Improved

	Avanafil 50–200 mg	acquired PE in men with ED	efficacy if combined wit SSRI

ED, Erectile dysfunction; *SSRI,* selective serotonin reuptake inhibitor.

On-Demand Treatment With Off-Label Tramadol.

Tramadol is a centrally acting synthetic opioid analgesic with an unclear mode of action, which is thought to include binding of parent and M1 metabolite to μ-opioid receptors and weak inhibition of reuptake of GABA, norepinephrine, and serotonin (Frink et al., 1996). The major metabolite, M1, has a 200-fold increased affinity for the μ-opioid receptor, which likely accounts for the analgesic effects achieved (Frink et al., 1996).

The efficacy of on-demand tramadol in the treatment of PE was recently reported (Alghobary et al., 2010; Bar-Or et al., 2011; Eassa and El-Shazly, 2013; Kaynar et al., 2011; Salem et al., 2008; Xiong et al., 2011). Although the mechanism of action is not completely described, the efficacy of tramadol may be secondary to antinociceptive and anesthetic-like effects, as well as via central nervous system modulation through inhibition of serotonin and noradrenaline reuptake (Frink et al., 1996; Szkutnik-Fiedler et al., 2012). Most studies are poorly designed open-label trials with a wide range of efficacy. The only double-blind trial well-designed study demonstrates superiority to placebo but a mediocre increase in IELT of 2.49, consistent with the weak serotonin reuptake inhibitor activity of tramadol (Bar-Or et al., 2011). In an open-label crossover comparator study of daily paroxetine (20 mg) and on-demand tramadol (50 mg) in 35 subjects with L-PE, superior IELT fold-increases and PRO responses were demonstrated with paroxetine (22-fold vs. 5-fold for tramadol) after 12 weeks of treatment. Although this study was limited by the use of the DSM-IV-TR definition to diagnose PE, 66% of men had an IELT of 1 minute or less at baseline, suggesting that the overall population is reasonably representative of the ISSM definition. A large, international, prospective, randomized, placebo-controlled, double-blind trial of tramadol for the treatment of PE (NCT00983151) was recently stopped prematurely, although no reason has been provided; another similar study (NCT00983736) was stopped because of recruitment difficulties.

A recent meta-analysis (Cepeda et al., 2007) of 11 controlled studies of tramadol in more than 1000 patients with osteoarthritis reported that the most common adverse effects were nausea, vomiting, dizziness, somnolence, tiredness, and headache, and approximately 20% of patients receiving tramadol or tramadol/acetaminophen experienced nonserious AEs. Serotonin syndrome has been reported as an adverse effect of tramadol alone or in combination with SSRI drugs (Garrett, 2004; Mittino et al., 2004; Takeshita and Litzinger, 2009).

There have been four meta-analyses of tramadol that published clinical trial data (Kirby et al., 2015; Martyn-St James et al., 2015; Wu et al., 2012; Yang et al., 2013). All conclude that tramadol appears effective in the treatment of PE but suggest that these findings should be interpreted with caution, given the observed levels of between-trial heterogeneity and the reporting quality of the available evidence. Although the potential for addiction or abuse has not been assessed in men with PE, the risk is regarded as low based upon the use of low intermittent doses and experience in other patient populations. Tramadol is promoted as having a lower risk of dependence than traditional opioids because of the relatively long half-lives and therefore delayed agonist activity of tramadol (6 hours) and the M1 metabolite (9 hours), and its noradrenaline reuptake effects (Cossmann et al., 1997). In clinical practice, dependence does occur but appears minimal (McDiarmid et al., 2005). Adams et al. (2006) reported abuse rates of 0.7% for tramadol compared with 0.5% for nonsteroidal anti-inflammatory drugs and 1.2% for hydrocodone based on application of a dependency algorithm as a measure of persistence of drug use.

The ISSM guidelines for the treatment of PE expert committee believed tramadol may be an effective option for the treatment of PE. However, it may be considered when other therapies have failed because of the risk of addiction and side effects. It should not be combined with an SSRI because of the risk of serotonin syndrome, a potentially fatal outcome. Further well-controlled studies are required to assess the efficacy and safety of tramadol in the treatment of PE patients (LOE2) (Althof et al., 2014).

Daily Treatment With Off-Label α_1-Adrenoceptor Antagonists.

α1-Adrenoceptor antagonists are widely used in the treatment of lower urinary tract symptoms (LUTS) associated with or without BPH (Lepor, 2006), but have some adverse effects, including postural hypotension and EjD (Debruyne, 2000). α_1-Adrenoceptor antagonist-mediated abnormal ejaculation may involve two mechanisms. First, the inhibition of α_{1A}-adrenergic receptor expression in the bladder neck, prostate, and urethra caused by silodosin may relax these organs, resulting in RE (Michel, 2007). Second, α_1-adrenoceptor antagonists inhibit semen emission, which can result in abnormal ejaculation (Hisasue et al., 2006; Kobayashi et al., 2008).

Several researchers have reported their experience with the selective α_1-adrenergic blockers alfuzosin, terazosin, and silodosin in the treatment of PE (Akin et al., 2013; Basar et al., 2005; Cavallini, 1995; Choi et al., 2014; Sato et al., 2012). These drugs are approved only for the treatment of LUTS in men with obstructive benign prostatic hyperplasia (BPH). In a double-blind placebo-controlled study, Cavallini reported that alfuzosin (6 mg/day) and terazosin (5 mg/day) were effective in delaying ejaculation in approximately 50% of the cases (Cavallini, 1995). Similarly, Basar reported that terazosin was effective in 67% of men (2005). However, both studies were limited by the use of subjective study endpoints of patient impression of change and sexual satisfaction, and they did not evaluate actual IELT. Additional controlled studies are required to determine the role of α_1-blockers in the treatment of PE.

In the study by Cavallini (1995) comparing alfuzosin and terazosin with placebo, hypotension was the most common AE leading to discontinuation (4 [4.4%] patients; 2 each with terazosin and alfuzosin). Other AEs included headache (1 patient with alfuzosin) and headache with epigastralgia (1 patient with terazosin), neither of which resulted in discontinuation. In the study by Başar et al. (2005) of terazosin versus placebo daily for 1 month, published safety data were limited to the finding that none of the patients discontinued treatment because of AEs. These data in men with PE are comparable to what has been observed in men with hypertension or BPH. The most common AEs with terazosin include postural hypotension (3.9%), dizziness (9.1%), somnolence (3.6%), nasal congestion/rhinitis (1.9%), and impotence (1.6%) (Hytrin, 2008). With alfuzosin, common AEs in men with BPH include dizziness (5.7%), upper respiratory infections (3.0%), headache (3.0%), and fatigue (2.7%) (Sanofi-Aventis, 2014).

Silodosin is a new highly selective α_{1A}-adrenoceptor antagonist, and clinical trial data demonstrates significant clinical efficacy and safety for LUTS, even in the elderly (Chapple et al., 2011; Kawabe et al., 2006; Yoshida et al., 2011). However, in these studies, abnormal ejaculation was found in a relatively higher percentage of participants (Chapple et al., 2011; Homma et al., 2010; Roehrborn et al., 2011; Yoshida et al., 2011). In a trial to evaluate the superiority of silodosin to placebo and noninferiority to tamsulosin, Chapple et al. (2011)

reported that abnormal ejaculation, the most common AE, occurred more often in the silodosin than in the tamsulosin group (22.3% vs 1.6%). Similarly, Cho and Yoo (2014) reported a reduction or absence of ejaculation in 14% of subjects treated with silodosin compared with tamsulosin (2.1%) and placebo (1.1%). The presence of EjD was associated with significantly more improvement in LUTS. This suppression of ejaculation by silodosin has been confirmed in well-designed studies with control volunteers (Kobayashi et al., 2008, 2009). Sato et al. (2012) evaluated the feasibility of off-label silodosin (4 mg) in 8 patients with PE. The IELT was significantly prolonged (from 3.4 minutes to 10.1 minutes, $P = 0.003$). At study end, all PRO items in the PEP significantly improved, and all subjects rated their PE as at least “better” (Furuya et al., 2005) on the CGIC. Akin et al. (2013) compared silodosin 4 mg, tamsulosin hydrochloride 0.4 mg, alfuzosin 10 mg, terazosin 5 mg, and doxazosin mesylate 4 mg in men with PE and reported that IELT, PEP, and quality of life (QoL) responses were statistically improved for all drugs and that silodosin appeared most effective ($P < 0.05$). Bhat and Shastry (2016) recently reported that silodosin is an effective salvage treatment for men either unresponsive or intolerant of dapoxetine.

These results support the possible use of α_1-adrenoceptor antagonists and in particular silodosin as new treatment options for PE and suggest that a placebo-controlled study assessing its clinical usefulness would be worthwhile.

Intracavernosal Injection of Off-Label Vasoactive Drugs.

Intracavernosal self-injection treatment of PE has been reported but is currently without any evidence-based support for efficacy or safety. In one study, which included 8 PE patients, a mixture of phentolamine mesylate (1.0 mg/mL) and papaverine hydrochloride (30 mg/mL) was injected. All patients reported satisfaction with the results of this treatment, but ejaculation delay was not objectively measured (Fein, 1990). Intracavernosal injection of vasoactive drugs is not recommended for the treatment of PE (LOE4).

Emerging Investigational Drugs

DA-8031.

DA-8031 is a potent SSRI and a potential therapeutic agent in the treatment of PE. Monoamine transporter binding and reuptake inhibition assay demonstrate high affinity and selectivity to the serotonin transporter and low selectivity and affinity to dopamine and norepinephrine transporters (Jeon et al., 2011). In a platelet serotonin uptake study, DA-8031 exhibited significant inhibition at oral doses of 10 and 30 mg/kg in a dose-dependent manner (Kang et al., 2013). DA-8031 is rapidly absorbed and eliminated after oral administration in rats (Kang et al., 2014) DA-8031 has dose-proportional pharmacokinetics with a Tmax of 2 to 3 hours and a terminal half-life of 17-9-28-7 hours after a single dose (Shin et al., 2017).

Several preclinical studies suggest that DA-8031 is a potential candidate treatment for PE. DA-8031 significantly inhibited ejaculation after oral and intravenous administration in para-chloroamphetamine and meta-chlorophenylpiperazine-mediated ejaculation rat models (Jeon et al., 2011). In electrical stimulation of the sensory branch of pudendal nerve (SBPdn) and *para*-chloroamphetamine (PCA)–induced ejaculation models, Kang et al. (2013) demonstrated that DA-8031 administration resulted in inhibition of the expulsion phase of ejaculation by bulbospongiosus muscle activity modulation and impairment of the emission phase by blocking the seminal vesicular pressure rise. Treatment with DA-8031 appears to delay the ejaculation latency time without affecting the initiation of mounting behavior or postejaculatory interval in rats (Kang et al., 2014). The mechanism of action of DA-8031 was confirmed by positron emission tomography (PET) of the rat brain, which demonstrated reduced serotonin transporter (SERT) occupancy by DA-8031 in the midbrain (Park et al., 2014). In vivo micro dialysis showed that administration of DA-8031 produced a dose-dependent increase in extracellular serotonin levels in the dorsal raphe nucleus (33%–81% increase for doses of 10–100 mg/kg) (Park et al., 2014).

Human clinical trials are currently being conducted with DA-8031 as a treatment for PE (NCT01798667, Dong-A ST, Seoul South Korea), but results have not yet been reported.

Oxytocin Antagonists.

Oxytocin is a peptide hormone of nine amino acids that facilitates sexual reproduction in mammals (Carter, 1992). An increasing number of studies report the involvement of central and peripheral oxytocinergic neurotransmission in the ejaculatory process. The effects of oxytocin on male sexual behavior includes a central pathway involved in erection, exerted via oxytocinergic neurons projecting from the paraventricular hypothalamic (PVH) nucleus to the spinal cord, and a peripheral pathway involved in ejaculation, exerted via oxytocin release in the bloodstream (de Jong et al., 2007; de Wied et al., 1993; Hallbeck et

al., 2001).

In human males, plasma oxytocin levels are elevated during penile erection and at the time of orgasm (Carmichael et al., 1987; Uckert et al., 2003). Electrical stimulation of the dorsal penile nerve, produced excitation in about half of the oxytocin cells in the PVH nucleus and hypothalamic supraoptic nucleus (SON) of rats (Honda et al., 1999; Yanagimoto et al., 1996). Systematic administration of oxytocin decreases the number of intromissions required for ejaculation in young adult rats (Stoneham et al., 1985) and reduced ejaculation latencies and post-ejaculation intervals in older, sexually sluggish rats (Arletti et al., 1985, 1990). Because oxytocin cannot easily penetrate the blood-brain barrier, peripherally injected oxytocin's effect on ejaculation is most likely exerted through peripheral oxytocin receptors on the contractility of smooth muscle cells in the testis, epididymis, vas deferens, prostate, and penis of rats and humans (Filippi et al., 2002; Vignozzi et al., 2004). However, because a small proportion of subcutaneously injected oxytocin does cross the blood-brain barrier, some effects of systematically injected oxytocin on ejaculation may be mediated by central oxytocin receptors (Mens et al., 1983).

Several clinical and preclinical studies suggest a potential role for highly selective oxytocin receptor antagonists in the treatment of PE (Gupta et al., 2008). In male rats, Argiolas et al. demonstrated the central administration of a selective oxytocin-receptor antagonist–inhibited ejaculation (Argiolas et al., 1989). Clement et al. reported that in rodents' brains, oxytocin receptors mediate ejaculation elicited by a dopamine agonist, which is dose-dependently inhibited by the intraventricular administration of an oxytocin antagonist, whereas systemic administration of an oxytocin antagonist resulted in no significant change (Clement et al., 2008). In a recent study, the same group demonstrated that a highly selective, nonpeptide oxytocin antagonist (GSK557296) inhibits ejaculation peripherally and centrally (Clement et al., 2013). Several authors report that copulatory behavior/ejaculation activates oxytocin neurons in rodent brain regions (Gil et al., 2011; Witt and Insel, 1994). Furthermore, in oxytocin receptor knockout mice, there is a decreased incidence of ejaculation and a higher stimulatory threshold required to induce sexual arousal compared with wild type mice (Baskerville et al., 2009).

In a randomized, placebo-controlled study of epelsiban in men with PE, Shinghai et al. (2013) demonstrated that 50 mg and 150 mg were well tolerated but did not result in a clinically or statistically significant change in IELT in men with PE, compared with placebo. The baseline (mean) IELT for patient's pretreatment was 0.52, 0.63, and 0.59 minutes for placebo, epelsiban 50 mg, and epelsiban 150 mg, respectively. On-treatment, average geometric least squares means of the median IELT values (mean) were slightly higher in the 50-mg and 150-mg groups (0.72 and 0.69 minutes), respectively, versus the placebo group (0.62 minutes). This study demonstrates that non-CNS penetrant oxytocin receptor antagonists show little effect on ejaculation when given systemically (Shinghal et al., 2013). However, the rodent studies reported above do show that oxytocin antagonists can delay or prevent ejaculation when injected close to the lower thoracic and lower lumbar spinal cord or when injected directly into the cerebral ventricle, strongly supporting the hypothesis that a centrally acting oxytocin receptor antagonist that crosses the blood-brain barrier has the potential to treat PE (Argiolas et al., 1989; Clement et al., 2008, 2013).

Ixchelsis (Sandwich, UK) is developing IX-01, a small-molecule, orally delivered oxytocin receptor antagonist that has demonstrated good CNS penetration in preclinical studies. A phase IIA double-blind, placebo-controlled RCT on the efficacy and safety of flexible dosed IX-01 in men with L-PE demonstrated clinically and statistically significant treatment-related effects in favor of IX-01 for IELT and the patient-reported outcomes of ejaculation control and ejaculation-related distress (McMahon et al., 2017). The geometric mean IELT increased by 1.8-fold for placebo and 3.6-fold for IX-01 over baseline during the last 4 weeks of treatment. At study end, fair or good control of ejaculation was reported by 33% of subjects taking IX-01 and 4% in the control group. Similarly, subjects taking IX-01 reported less ejaculation-related distress compared with both baseline and the control group. At study end, distress rated as “moderate,” “a little bit,” or “not at all” was reported by 46% of subjects with IX-01 and 16% in the control group. The fact that this study has demonstrated efficacy is likely due to the ability of IX-01 to penetrate the blood-brain barrier and enter the CNS. The molecular weight of IX-01 is 419.65 Da and approaches the 400 Da threshold for blood-brain lipid membrane permeation. The post-hoc exploratory analyses that demonstrate a direct dose-response relationship suggest a potential for increased efficacy when larger doses are administered in future studies.

Modafinil.

Modafinil was first identified as a wake-promoting agent and is used for the treatment of narcolepsy. Modafinil's mechanism of action is complex and poorly understood and appears to involve induction of changes in brain activation.

There is evidence for action on brain catecholaminergic and indolaminergic systems, especially dopaminergic pathways and serotonin pathways, as well as gamma-aminobutyric acid (GABA)/glutamate systems, and orexin-containing neurons have been reported (Ballon and Feifel, 2006). It has been shown that dopaminergic D1 and D2 receptors are essential for the arousal effect of modafinil (Qu et al., 2008).

Male sexual behavior in the rat was examined after acute oral administration of d-modafinil in copulation studies with receptive females; d-modafinil (30 mg/kg and 100 mg/kg) produced a significant delay in ejaculation, accompanied by an increase in the number of intromissions without any change in the mount or intromission latency. The greatest delay in ejaculation was observed in animals with shorter baseline ejaculatory latencies (Marson et al., 2010).

d-Modafinil may delay ejaculation via increases in serotonin release in the brain and/or spinal cord or an action upon the dopamine system (Dominguez and Hull, 2005; Ferraro et al., 2000, 2002; Hull et al., 2004). In vivo microdialysis studies demonstrated that d-modafinil induces release of serotonin in the cerebral cortex, central nucleus of amygdala, and dorsal raphe, and at the higher doses, in the medial preoptic area (MPOA) and posterior hypothalamus (Ferraro et al., 2000, 2002). Furthermore, low doses of d-modafinil that normally do not alter serotonergic neurotransmission increased SSRI-induced central serotonin release, suggesting that modafinil works through common pathways that alter mood (Ferraro et al., 2005). Further supporting this hypothesis is a recent study that showed that depressive-like behavior in rats was improved with d-modafinil (Regenthal et al., 2009).

Several in vivo and in vitro studies have suggested that modafinil acts via brain dopamine pathways, and a role for the dopamine transporter and D2 and D1 receptors have been reported. Neurophysiologic studies using brain slices demonstrated that modafinil inhibited dopaminergic neuronal activity via D2 receptors (Korotkova et al., 2007). In D2 receptor knockout mice, modafinil-induced wakefulness was reduced, and D1 and D2 receptor antagonists blocked the modafinil-induced effects, suggesting a role for the D1 and D2 receptors in the arousal effects induced by modafinil (Qu et al., 2008). It is possible that d-modafinil acts by a combination of mechanisms that include a direct inhibition of dopamine, an increase in serotonin release, as well as activation of noradrenaline pathways.

Although these results are promising, caution must be exercised in the application of the results of animal studies of ejaculation to the humans. Tuken et al. (2016), in an uncontrolled pilot study of treatment-naive L-PE sufferers, reported modest twofold changes in self-reported IELT and PROs with treatment with on-demand modafinil. Human trials with careful attention to safety and side effect profile are warranted before consideration of modafinil as a potential treatment for PE.

The short-acting modafinil d-isomer (NH02D, NeuroHealing, Waban, MA) is undergoing preclinical trials as an investigational drug for the on-demand treatment of PE.

Botulinum-A Toxin.

Botulinum toxin is a protein and neurotoxin produced by the bacterium *Clostridium botulinum.* It is a selective blocker of acetylcholine release from nerve endings, which blocks neural transmission when injected into muscle (Simpson, 1981). This drug has been widely used as a cosmetic anti-aging treatment to prevent development of wrinkles by paralyzing facial muscles, and as a medical treatment for a diverse range of conditions including strabismus, benign essential blepharospasm, neurogenic detrusor overactivity, detrusor-sphincter dyssynergia, motor and sensory urge and, more recently, chronic prostatic pain. Worldwide experience demonstrated that this therapeutic agent is safe and effective for such indications.

Serefoglu theorized that the rhythmic contractions of bulbospongiosus and ischiocavernosus muscles during the ejection phase of ejaculation may be inhibited by the injection of botulinum-A toxin (Serefoglu and Silay, 2010). He subsequently demonstrated that percutaneous injection of either 0.5 or 1 unit botulinum toxin A into the bulbospongiosus muscle bilaterally significantly increased ejaculatory latency in male rats (0.5 unit: 314.6 ± 193.1 to 507.6 ± 277.8 seconds, $P = 0.021$; 1 unit: 264.4 ± 129.1 to 598.2 ± 352.5 seconds, $P = 0.008$) in a dose-dependent manner compared with pretreatment latency without affecting their ability to achieve mounts, intromissions, or ejaculation (Serefoglu et al., 2014). Mean ejaculation latency reached its peak 11 days after injection and decreased sharply 14 days after injection at both doses. However, the difference between the post-treatment geometric mean ejaculatory latency for 0.5 or 1 unit of botulinum toxin and saline failed to reach statistical significance possibly because of the small sample size and/or the high variability in ejaculation latency.

Patents have been granted for the local injection of 25 and 50 units of a botulinum-A toxin into the penis, frenulum, prepuce, or glans penis for treating

PE, without any basic or clinical research support (Gaxiola et al., 2012). However, it is probable that botulinum-A toxin injected into the penis would immediately diffuse into the systemic circulation, limiting its local effect. Similarly, injecting botulinum-A toxin into the prepuce or frenulum of the penis will have little effect on ejaculatory latency because botulinum-A toxin does not exhibit any local anesthetic effect.

The current results from these rat studies suggest that botulinum-A toxin injection into the bulbospongiosus muscle may be a safe and effective means to prolong ejaculatory latency without affecting other aspects of sexual behavior. Dose-ranging phase 2 clinical trials of Botox (Allergan, Irvine, CA) as a treatment for PE in humans are currently being conducted.

Acupuncture

One randomized placebo-controlled clinical study compared effectiveness of acupuncture therapy (twice a week) with paroxetine (20 mg/day) and placebo (sham-acupuncture) in the treatment of PE (Sunay et al., 2011). The authors included 90 patients with PE and demonstrated that acupuncture had a significantly stronger ejaculation delaying effect than placebo (65.7 vs. 33.1 seconds), although it was less effective than daily paroxetine (82.7 seconds) (P = 0.001). Similarly, the patient reported outcome measures showed an improvement in the acupuncture and paroxetine groups.

Surgical Neurotomy, Cryoablation, and Neuromodulation of the Dorsal Penile Nerve

Selective dorsal nerve neurotomy or hyaluronic acid gel glans penis augmentation is not recommended for the treatment of PE. Surgery may be associated with permanent loss of sexual function and is contraindicated in the management of PE. Several authors have reported the use of surgically induced penile hypoanesthesia via selective dorsal nerve neurotomy or hyaluronic acid gel glans penis augmentation in the treatment of L-PE refractory to behavioral and/or pharmacologic treatment (Basal et al., 2010; Kim et al., 2004; Kwak et al., 2008; Perelman, 2006; Shi et al., 2008). The role of surgery in the management of PE remains unclear until the results of further studies have been reported.

Key Points: Premature Ejaculation

- PE is a common sexual dysfunction.
- PE is associated with negative psychological consequences, including distress, bother, and frustration, which may affect quality of life, partner relationships, self-esteem, and self-confidence and can act as an obstacle to single men forming new partner relationships.
- The evidence-based ISSM definition of lifelong and acquired PE should form the basis of the office diagnosis of lifelong PE.
- There is limited evidence suggesting that lifelong PE has a genetic basis, and acquired PE is most often due to sexual performance anxiety, psychological or relationship problems, and/or ED.
- Oral SSRI drugs and topical anesthetic drugs are effective and safe treatments for PE.
- Psychosexual CBT has a limited role as a first-line treatment for PE but has an important role as an adjunct to pharmacotherapy, especially in men with acquired PE resulting from sexual performance anxiety.
- Men with acquired PE most secondary to comorbid ED, hyperthyroidism, chronic lower urogenital infection, prostatodynia, or CPPS should receive appropriate cause-specific treatment alone or in combination with an SSRI.

Kate! Delayed Ejaculation, Anejaculation, and Anorgasmia

Any psychological or medical disease or surgical procedure that interferes with either central control of ejaculation or the peripheral sympathetic nerve supply to the vas and bladder neck, the somatic efferent nerve supply to the pelvic floor, or the somatic afferent nerve supply to the penis can result in delayed ejaculation, anejaculation, RE, and/or anorgasmia. As such, the causes of delayed ejaculation, anejaculation, and anorgasmia are manifold.

Definition, Terminology, and Characteristics of Men With Delayed Ejaculation

Delayed (DE), retarded ejaculation (RE), or inhibited ejaculation (IE) are probably the least common, least studied, least reported, and least understood male sexual dysfunctions. Yet their impact is significant in that it typically results in a lack of sexual fulfilment for both the man and his partner, an effect further compounded when procreation is among the couple's goals of sexual intercourse.

Problems with “difficulty” in ejaculating may range from varying delays in the latency to ejaculation to complete inability to ejaculate (anejaculation). Reductions in the volume, force, and sensation of ejaculation may occur as well. At the extremes are anejaculation (time) and RE (direction), but more commonly encountered is DE. A final disorder, anorgasmia, refers to a perceived absence of the orgasm experience or sexual anhedonia, independent of whether any or all the physiologic concomitants of ejaculation have taken place.

Terminology and Definition

RE, DE, inadequate ejaculation, IE, idiopathic anejaculation, primary impotentia ejaculations, and psychogenic anejaculation have been used synonymously to describe a delay or absence of male orgasmic response. If a distinction is to be made, usually inhibited ejaculation is characterized by the complete absence of ejaculation, although no clear consensus exists. Herein, the preferred terminology DE is meant to describe any and all of the ejaculatory disorders resulting in a delay or absence of ejaculation.

The American Psychiatric Association's DSM-5 defines DE as a marked delay or absence of ejaculation on almost all or all occasions (approximately 75%–100%) of partnered sexual activity and without the individual desiring the delay, which causes clinically significant distress in the individual, is not better explained by a nonsexual mental disorder or as a consequence of severe relationship distress or other significant stressors, and is not attributable to the effects of a substance/medication or another medical condition (American Psychiatric Association, 2013). The disturbance may be either lifelong or acquired, generalized or situational, and mild, moderate, or severe. The DSM-5 definition of “delay” does not have precise boundaries, because there is no consensus as to what constitutes a reasonable time to reach orgasm or what is unacceptably long for most men and their sexual partners. Similarly, the 3rd International Consultation on Sexual Dysfunction defines DE as the persistent or recurrent difficulty, delay in, or absence of attaining orgasm after sufficient sexual stimulation, which causes personal distress (Rowland et al., 2010).

There are no clear criteria as to when a man actually meets the conditions for DE, because operationalized criteria do not exist. Given that most sexually functional men ejaculate within about 4 to 10 minutes after intromission (Patrick et al., 2005), a clinician may assume that men with latencies beyond 25 or 30 minutes (21–23 minutes represents about two standard deviations above the mean) who report distress or men who simply cease sexual activity because of exhaustion or irritation qualify for this diagnosis. Such symptoms, together with the fact that a man and/or his partner decide to seek help for the problem, are usually sufficient for a DE diagnosis.

Epidemiology of Delayed Ejaculation

Although EjD contributes to important patient-related outcomes of procreation, general and performance anxiety, and relationship satisfaction, the prevalence of EjD is unclear (Althof, 2012; Paduch et al., 2015; Rowland et al., 2005). Historically, DE has been reported at low rates in the literature, rarely exceeding 3% (Laumann et al., 1999; Simons and Carey, 2001; Spector and Carey, 1990). However, data from a 2003 multinational survey performed in the United States and Europe showed that approximately 40% of men aged 50 to 79 experienced some form of EjD with prevalence as high as ED (Rosen et al., 2003). Epidemiologic population surveys (Rosen et al., 2003) and cross-sectional observational studies (Corona et al., 2006, 2008; Paduch et al., 2012) have reported various demographic and clinical factors that correlate with EjD. The prevalence of DE appears to be moderately and positively related to age, which is not surprising because ejaculatory function tends to diminish as men age. Lindau et al. reported an incidence of DE of 16.2%, 22.7%, and 33.2% of men aged 57 to 65, 65 to 74, and 75 to 85 years, respectively (Lindau et al., 2007). Furthermore, the prevalence of EjD differs between races (Paduch et al., 2012) and is associated with ED, LUTS, low serum testosterone levels, and hyperlipidemia (Corona et al., 2006, 2008; Paduch et al., 2012; Rosen et al., 2003). However, there is little published literature on the demographic and clinical correlates of EjD in community-dwelling populations, and published observational studies have not subdivided various types of ejaculatory disorders (e.g., delayed vs. absent) or evaluated subjects using psychometrically validated scales of EjD.

Although coital anejaculation is frequently the treatment driver especially for extremely religious individuals referred for fertility problems, men also seek treatment when distressed by their inability to achieve orgasm in response to manual, oral, or vaginal stimulation by their partner. Many men with acquired DE can masturbate to orgasm, whereas others, for multiple reasons, will not or cannot. Loss of masturbatory capacity secondary to emotional or physical trauma is also seen. Approximately 75% of one clinical sample (Perelman, 2004) could reach orgasm through masturbation, whereas the remainder either would not or could not.

Men with DE indicate high levels of relationship distress, sexual dissatisfaction, anxiety about their sexual performance, and general health issues—significantly higher than sexually functional men (Althof, 2012; Corona et al., 2006). In addition, along with other sexually dysfunctional counterparts, men with DE typically report lower frequencies of coital activity (Rowland et al., 2005). A distinguishing characteristic of men with DE is the presence of normal erectile function with some men capable of maintaining erections for prolonged periods of time. However, these men often report low levels of subjective sexual arousal compared with sexually functional men (Rowland et al., 2004).

Cause of Delayed Ejaculation/Anejaculation

Delayed ejaculation/anejaculation may be lifelong or acquired, global, or situational. The pathophysiology of DE is complex, and multiple pathophysiologies have been associated with EjD (Table 71.4). These include congenital disorders as well as ones caused by psychological factors, treatment of male pelvic cancers with surgery or radiotherapy, neurologic disease such as multiple sclerosis and Parkinson disease, hypogonadism, hypothyroidism, infection, and treatment for other disorders such as schizophrenia or mood disorders with major tranquilizers or SSRI antidepressants respectively. Psychological factors include performance anxiety, relationship conflict, poor sexual communication, hypoactive sexual desire, and psychological conflict related to fear of fathering a child, fear of harm to either self or partner, or religious belief–induced shame (Althof, 2012; Rowland et al., 2005). Some men habitually use an idiosyncratic style of solitary masturbation, which cannot be replicated during coitus and inadvertently condition themselves to DE or anejaculation (Perelman, 2005).

TABLE 71.4

Causes of Retrograde Ejaculation, Delayed Ejaculation, Anejaculation, and Anorgasmia

Aging male	Degeneration of penile afferent nerves
Psychogenic	Inhibited ejaculation
Congenital	Müllerian duct cyst
	Wolffian duct abnormality
	Prune-belly syndrome
Anatomic causes	Transurethral resection of prostate
	Bladder neck incision
Neurogenic causes	Diabetic autonomic neuropathy
	Multiple sclerosis
	Spinal cord injury
	Radical prostatectomy
	Proctocolectomy
	Bilateral sympathectomy
	Abdominal aortic aneurysmectomy
	Para-aortic lymphadenectomy
Infective	Urethritis
	Genitourinary tuberculosis
	Schistosomiasis
Endocrine	Hypogonadism
	Hypothyroidism

Medication	Alpha-methyldopa
	Thiazide diuretics
	Tricyclic and SSRI antidepressants
	Phenothiazine
	Alcohol abuse

SSRI, Selective serotonin reuptake inhibitor.

The most common causes of DE seen in clinical practice are psychogenic inhibited ejaculation, degeneration of penile afferent nerves and Pacinian corpuscles in the aging male, hypogonadism, diabetic autonomic neuropathy, treatment with SSRI antidepressants and major tranquilizers, radical prostatectomy or other major pelvic surgery, and radiotherapy.

Psychological Delayed Ejaculation

Psychogenic DE, often described as **IE,** is usually related to **sexual performance anxiety, which may draw the man's attention away from erotic cues that normally enhance arousal.** Other psychodynamic explanations emphasize psychosexual development issues and have attributed lifelong DE to a wide range of conditions, including fear, anxiety, hostility, orthodoxy of religious belief, and relationship difficulties (Munjack and Kanno, 1979; Waldinger and Schweitzer, 2005). Although some of these factors may contribute to DE in individual men, no well-controlled studies provide broad support, at this point, for any of the various hypotheses for conditions mentioned above (Waldinger and Schweitzer, 2005).

Masters and Johnson were the first to suggest that DE in some men may be associated with **orthodoxy of religious belief** (Masters and Johnson, 1970). Such beliefs may limit the sexual experience necessary for learning to ejaculate or may result in an inhibition of normal function. Many devoutly religious men have masturbated only minimally or not at all, and for some, guilt and anxiety about “spilling seed” may have led to idiosyncratic masturbatory patterns, which, in turn, resulted in DE. Such men often had little contact with women before marriage and, although they may have dated, were less likely than their secular counterparts to experience orgasm with a partner, especially through intercourse.

Idiosyncratic and vigorous masturbation styles that cannot be replicated during intercourse with a partner, or an “auto sexual” orientation in which men derive greater arousal and enjoyment from masturbation than from intercourse, are risk factors for DE (Perelman 2005; Perelman and Rowland, 2006). These men precondition themselves to possible difficulty attaining orgasm with a partner and, as a result, experience acquired DE. These men appear able to achieve erections sufficient for intercourse despite a relative absence of subjective arousal (Apfelbaum, 1989), and their erections are taken as erroneous evidence by the man and his partner that he was ready for sex and capable of achieving orgasm. Disparity between the reality of sex with the partner and the sexual fantasy used during masturbation may inhibit sexual arousal and thus represent another contributor to DE (Perelman, 2001).

Congenital Disorders

Typical congenital problems include müllerian duct obstruction, caused by failure of complete absorption of müllerian duct remnants in the male; wolffian duct abnormalities, which may compromise vas deferens, ejaculatory duct, and seminal vesicle functioning; and prune-belly syndrome.

Infective Disorders

Sexually transmissible infections such as gonorrhea or nonspecific urethritis can produce cicatrization and obstruction anywhere in the male reproductive tract, especially if treatment is delayed. Urinary infection, especially if complicated by epididymitis, can also produce obstruction that may be situated at ejaculatory duct level. Schistosomiasis is endemic in large parts of Africa and is seen with increasing frequency in tourists returning from Africa who have contracted the disease while enjoying water sports. The disease may occur with hematospermia (McKenna et al., 1997), and fibrosis and calcification may lead to genital obstruction. Genitourinary tuberculosis can cause great damage to the male reproductive tracts, and because healing occurs with calcification, the lesions may be irreparable.

Ejaculatory Duct Obstruction

Ejaculatory duct obstruction may be congenital because of müllerian duct cysts or acquired because of prostatitis, STIs such as chlamydia or other pathogens, or duct obstruction by a calculus (Philip et al., 2007). It is the underlying cause for 1% to 5% of male infertility (Pryor and Hendry, 1991). Men with bilateral obstruction suffer from a very low volume, low pH, low-fructose, fluid low-viscosity azoospermic semen or from aspermia, no semen at all. This is due to the absence of the viscous fructose-rich seminal vesicle secretions, which contribute approximately 80% of seminal volume. This low-volume, low-viscosity azoospermic/oligospermic semen distinguishes ejaculatory duct obstruction from the normal volume semen present in bilateral obstruction of vasa deferens. The persistence of pelvic floor muscle contractions and a sensation of orgasm often with postorgasm pelvic pain distinguishes them from most men with anejaculation. Unilateral or partial obstruction may be associated with pelvic pain and oligospermia (Lawler et al., 2006). Diagnosis of ejaculatory duct obstruction by transrectal ultrasound (TRUS), MRI, or transrectal needle-aspiration of the seminal vesicles has relatively low sensitivity (Engin et al., 2009).

Endocrinopathy

Hypothyroidism is commonly strongly associated with DE whereas hyperthyroidism is rarely associated with PE (Carani et al., 2005; Corona et al., 2006) Similarly, **hypogonadism** and low testosterone are associated with DE or anejaculation (Corona et al., 2008, 2011, 2012). In contrast, Morgentaler et al. (2017) reported that linear regression failed to demonstrate an association between IELT and testosterone in men with self-reported DE. The disparity in the results of these studies highlights the complex relationship between testosterone and ejaculatory function and the multifactorial pathogenesis of DE. **Hyperprolactinemia,** via inhibition of hypothalamic GnRH is associated with low testosterone, reduced sexual desire, ED and delayed ejaculation. The effect of prolactin on ejaculation is possibly mediated via its action on the serotonergic system (Corona et al., 2006, 2009).

Iatrogenic Causes

Any prescribed or recreational drug that changes the levels of neurotransmitters, such as serotonin, dopamine, or oxytocin, which are involved in the central or peripheral neural control of ejaculation, may affect ejaculatory latency.

SSRIs are commonly used for the treatment of depression and are associated with a high incidence of sexual dysfunction, with up to 60% reporting some form of treatment-related sexual dysfunction, most commonly ejaculatory dysfunction (Delgado et al., 2005; Madeo et al., 2008; Montejo et al., 2001). Treatment with **antipsychotics,** probably because of either a direct and/or indirect dopamine antagonism (Hull et al., 2004) or increased prolactin levels (Roke et al., 2012), is also commonly associated with DE and retrograde ejaculation (Madhusoodanan and Brenner, 1996; Raja, 1999). Retrograde ejaculation associated with antipsychotics is thought to be due to antagonistic effects on the α-adrenergic system at the level of the bladder neck (Holtmann et al., 2003).

Treatment of Male Pelvic Cancers

Overall QoL and sexual functioning have evolved as key issues in the management of cancer patients. Because of modern surgical techniques, improved quality of drugs for chemotherapy, and modern radiation techniques, more patients can be successfully treated without largely compromising sexual functioning.

Prostate Cancer

Prostate cancer (CaP) has become the most common non-skin malignancy in men in western countries. External-beam radiotherapy (EBRT) and brachytherapy (BT) are, together with the open or robotic radical prostatectomy (RP/RALP), the most common and effective treatments for localized PC. Despite the introduction of very modern radiotherapy (RT) techniques, sexual functioning after CaP treatment remains problematic for many patients. **After RP/RALP, men no longer ejaculate but maintain a sense of orgasm** that can vary from less to more intense than preoperatively and may experience arousal urinary incontinence or climacturia (i.e., urinary incontinence at orgasm).

Ejaculatory disturbances after RT of CaP were reported in as early as the 1980s (Van Heeringen et al., 1988). More recent studies have evaluated the impact of RT on sexual desire, ejaculation, and orgasm. **After EBRT, a decline in sexual desire was reported by 43% of 64 patients and a decreased frequency of orgasm by 57%; all men reported a decrease in ejaculate volume** (Helgason et al., 1995). Using a validated questionnaire, Borghede and Hedelin (1997) reported a decrease in the ability to ejaculate in 56% of the patients. Good prognostic factors for sexual functioning preservation after RT were low age and higher frequency of intercourse.

Early RT studies also assessed sexual functioning. Herr reported already in

1979 on 51 patients treated with retropubic Iodium-125 seeds, with loss of ejaculate experienced by 6% of the patients. In a later study, dry ejaculation was reported by 16% of the patients after BT (Kwong et al., 1984). In both studies, all patients had previously undergone a transurethral resection of the prostate (TURP). For the first time a discomfort with ejaculation was mentioned in two studies (up to 25% of the patients) (Arterbery et al., 1997; Kleinberg et al., 1994). This result is common in clinical practice after BT because of edema of the prostate possibly reducing the elasticity of the urethra and inducing discomfort with ejaculation. In some patients discomfort with ejaculation did not disappear even 18 to 24 months after BT (Beckendorf et al., 1996). Also, decreased interest in sex, sexual desire, and libido was mentioned in up to 50% of the patients evaluated (Arterbery et al., 1997; Beckendorf et al., 1996; Borghede and Hedelin, 1997; Joly et al., 1998).

Several studies on the cause of post-RT decreased libido and ejaculatory disorders have been reported. Daniell et al (2001) studied retrospectively levels of testosterone (TST) and other hormones after RT of PC. TST was found to be low 3 to 8 years after EBRT with lower levels found in older patients. Although testes are very sensitive to radiation, spermatogenesis is more easily affected than androgen productions. The radiation dose calculated in the testes of men irradiated for PC is only 3% to 8% of the dose that could possibly affect androgen production and explain a decrease in TST. A TURP carries a high incidence of RE because it is thought to disrupt the closure mechanism of the vesical neck; this could explain ejaculatory disturbances in most patients after RT with previous TURP.

Rectal Carcinoma

Not much is known about sexual functioning after RT of rectal carcinoma. Preoperative RT for rectal cancer has been associated with a reduction in the rate of local relapse and possibly an advantage in survival. Preoperative RT with the total mesorectal excision (TME) in low-stage rectal cancer has become a common procedure in Europe. **A sharp dissection of the mesorectum associated with visualization and preservation of the pelvic autonomic nerve leads to excellent results regarding erectile and ejaculatory functioning.** Only one study has specifically studied the effects of preoperative RT for rectal carcinoma on male sexual functioning and concluded that it may impair male sexual functioning (Bonnel et al., 2002). However, numbers were too small to draw final conclusion.

Testicular Cancer

Germ cell tumors of the testis are relatively rare, accounting for about 1% of all male cancers. The long-term survival for early disease approaches 100%. Because testicular cancer affects mainly young men in their sexual and fertile life, sexual functioning and ejaculatory disorders are particularly important. The side effects of retroperitoneal lymph node dissection (RPLND) for residual mass after chemotherapy for nonseminomatous cancer are better documented than sexual sequelae of elective abdominal radiotherapy (RT) for seminoma. **Anejaculation occurs in the majority of the patients in non–nerve-sparing techniques.** As a result of careful anatomic studies, the technique of RPLND has been **modified with nerve sparing so that antegrade ejaculation is now maintained in 80% to 100% of patients** (van Basten et al., 1997). Libido and orgasm seem to be normal in these patients.

After RT, deterioration in sexual functioning has been reported by between 1% and 25% of the patients (Caffo and Amichetti, 1999; Incrocci et al., 2002; Jonker-Pool et al., 1997; Schover et al., 1986; Tinkler et al., 1992). Tinkler et al. (1992) reported on 237 patients after orchiectomy and abdominal RT and compared these data with 402 age-matched controls. In almost all parameters studied including erection, ejaculation, and libido, patients scored less than controls (reduction in orgasm, in libido, and interest in sex). Specifically, there was no difference in the ability to ejaculate during sexual activity, but the RT patients reported a noticeable reduction in the amount of semen compared with before treatment (Tinkler et al., 1992). Caffo and Amichetti (1999) evaluated toxicity and QoL of 143 patients treated for early stage testicular cancer: 23% reported a decreased libido, 27% problems with achieving orgasm, and 38% ejaculation disturbances, including PE. A decrease in sexual desire, in orgasm, and volume or semen was negatively correlated with age (Schover et al., 1986). Jonker-Pool et al. (1997) reported on three groups of patients, after RT, wait and see, and chemotherapy. RT patients reported decreased libido in 22% compared with 12% in the wait-and-see group, and 30% in the chemotherapy group. Decrease of absence of ejaculate was reported in 15%, 7%, and 21% in the three groups, respectively; decreased orgasm in 15%, 12%, and 30%, respectively. Although the differences were not statistically significant, in the RT group ejaculation and orgasm disturbances were higher than in the wait-and-see group. Similar results were reported by Arai et al. (1997). PE was reported in up to half of the patients (Arai et al., 1997; Incrocci et al., 2002), but it was the same as recalled before treatment (Incrocci et al., 2002).

The superior hypogastric plexus is responsible for ejaculation, and it is mediated by the sympathetic system; it is a fenestrated network of fibers anterior to the lower abdominal aorta. The hypogastric nerves exit bilaterally at the inferior pole of the superior hypogastric plexus, and have connections with the S1-S2 roots. Normal emission requires integrity of this system. During RPLND these nerves are difficult to recognize and may be damaged, resulting in decreased semen volume or dry ejaculation. Pathways for ejaculation are included in the RT fields for rectal and prostate carcinomas. Damage of the sympathetic nerves could be caused by radiation, but the dose does not seem enough to completely explain the dysfunction. Orgasm is even more complex than ejaculation because it is also affected by cortical input.

Neurologic Disorders

Degeneration of penile fast conducting afferent nerves and Pacinian corpuscles in the **aging male, diabetic autonomic neuropathy, multiple sclerosis, and spinal cord injury** are often associated with delayed ejaculation/anejaculation.

Spinal Cord Injury

The ability to ejaculate is severely impaired by spinal cord injury (SCI). Bors and Comarr highlighted the impact of the level and completeness of SCI on the postinjury erectile and ejaculatory capacity (Table 71.5) (Bors and Comarr, 1960; Comarr, 1970). **Unlike erectile capacity, the ability to ejaculate increases with descending levels of spinal injury. Less than 5% of patients with complete upper motor neuron lesions retain the ability to ejaculate.** Ejaculation rates are higher (15%) in patients with both lower motor neuron lesions and an intact thoracolumbar sympathetic outflow. Approximately 22% of patients with an incomplete upper motor neuron lesion and almost all men with incomplete lower motor neuron lesions retain the ability to ejaculate. In those patients capable of successful ejaculation, the sensation of orgasm may be absent and RE often occurs.

TABLE 71.5

Correlation of Erection, Ejaculation, and Intercourse With Level and Severity of Spinal Cord Injury

	REFLEXOGENIC	PSYCHOGENIC	SUCCESSFUL	EJACUL

CORD LESION		ERECTIONS (%)	ERECTIONS (%)	COITUS (%)	(%)
Upper motor neuron	Complete	92	9	66	1
	Incomplete	93	48	86	22
Lower motor neuron	Complete	0	24	33	15
	Incomplete	0	1	100	100

From Comarr AE: Sexual function among patients with spinal cord injury. *Urol Int* 25(2):134–168, 1970.

Several techniques for obtaining semen from spinal cord injured men with EjD have been reported. **Vibratory stimulation** is successful in obtaining semen in up to 70% of men with spinal cord injury (Brindley, 1984). The use **of electroejaculation** to obtain semen by electrical stimulation of efferent sympathetic fibers of the hypogastric plexus is an effective and safe method of obtaining semen. Brindley et al. (1986) have reported that 71% of men with spinal cord injury who underwent electroejaculation achieved ejaculation. However, both are associated with **a significantly higher risk of autonomic dysreflexia** than electroejaculation. Pretreatment with a fast-acting vasodilator such as nifedipine minimizes the risk of severe hypertension, should autonomic dysreflexia occur with either form of treatment (Steinberger et al., 1990).

Semen collected from men with spinal cord injury is often initially senescent and of poor quality with a low sperm count and reduced sperm motility but may improve with subsequent ejaculations. This poor semen quality may be due to chronic urinary tract infection, dilution of sperm content with urine, chronic use of various medications, elevated scrotal temperature resulting from prolonged sitting, and stasis of prostatic fluid. Testicular biopsies in spinal cord injured men demonstrate a wide range of testicular dysfunction including hypospermatogenesis, maturation arrest, atrophy of seminiferous tubules, germinal cell hypoplasia, interstitial fibrosis, and Leydig cell hyperplasia. In addition, prostatitis secondary to prolonged catheterization, epididymitis, and epididymo-orchitis can precipitate obstructive ductal lesions and testicular damage. Ohl et al. (1989) reported that sperm density and motility were higher in those with incomplete lesions. In a recent collective analysis of 40 paraplegic patients, 22 successfully produced pregnancies by natural insemination or assisted reproductive techniques (Dahlberg et al., 1995).

Evaluation of Men With Delayed Ejaculation

Evaluation of men presenting with DE or anejaculation (aspermia) should include **a full medical/sexual history, a focused physical examination, determination of serum testosterone levels, and any additional investigations suggested by these findings.**

Assessment begins by determining whether DE is lifelong or acquired, global or situational (Table 71.6). Evaluation includes establishment of how often a man can ejaculate during intercourse and the time elapsed between penetration and ejaculation, IELT. If ejaculation fails to occur, the duration of thrusting before suspension of intercourse, the reasons for suspension of intercourse (e.g., fatigue, loss of erection, a sense of ejaculatory futility, or partner request), and whether ejaculation can occur during postcoital self- or partner-assisted masturbation must be determined. The presence or absence of premonitory ejaculatory sensation during intercourse or masturbation suggests achievement of sufficient arousal to almost attain the ejaculation threshold. Variables that improve or worsen performance are noted. The man's ability to relax, sustain, and heighten arousal and the degree to which he can concentrate on sensations are noted.

TABLE 71.6

Recommended and Optional Questions to Establish the Diagnosis of Delayed Ejaculation and Direct Treatment

RECOMMENDED QUESTIONS	
For diagnosis	• How often can you ejaculate during sexual intercourse? • During intercourse, how long after penetration does it take for you to either ejaculate or stop intercourse?
	• When you cannot ejaculate during sexual intercourse, how often do you feel that you are close to ejaculation? • If you cannot ejaculate, why do you stop intercourse?
	• Do you ever feel that you have ejaculated but fail to release semen? • Do you feel bothered, annoyed, and/or frustrated by your DE?
	• How often can you ejaculate during masturbation by yourself or with your partner?
OPTIONAL QUESTIONS	
Differentiate lifelong and acquired DE	• When did you first experience DE? • Have you experienced DE since your first sexual experience on

	every/almost every attempt and with every partner?
Assess erectile function	• Is your erection hard enough to penetrate? • Do you have difficulty in maintaining your erection during intercourse?
Assess relationship impact	• How upset is your partner with your DE? • Do you or your partner avoid sexual intercourse? • Is your DE affecting your overall relationship?
Previous treatment	• Have you received any treatment for you DE previously?
Impact on quality of life	• Do you feel anxious, depressed, or embarrassed because of your DE?

DE, Delayed ejaculation.

The presence and extent of patient-, partner-, or interpersonal-related negative psychological consequences such as bother, distress, frustration, or the avoidance of sexual contact should be established. The frequency of intercourse and the identity of the initiator of sexual contacts are useful surrogate measures for these negative psychological consequences. The quality of the nonsexual relationship should also be explored.

In men with acquired DE, previous illness, surgery, medications, or life events/circumstances should be reviewed. The events may include a variety of life stressors and other psychological factors (e.g., after his wife's mastectomy, when the man is afraid of hurting her and therefore is only partially aroused). Societal and religious attitudes that may interfere with excitement are noted, such as the “spilling of seed as a sin.”

A focused physical and genital examination to determine whether the testes and epididymes are normal and whether the vasa are present or absent on each side, supported by a screening morning total testosterone level and any other hormonal or imaging investigations indicated by either history or physical examination will identify or exclude organic disease. Digital rectal examination to determine prostate size, anal sphincter tone, and quality of the bulbocavernous reflex (BCR) is indicated in most men except for young men with situational and clear psychogenic inhibited ejaculation. The presence of a neuropathy may require electrophysiologic evaluation of neural pathways controlling ejaculation, pudendal somatosensory and motor-evoked potentials, sacral reflex arc testing, and sympathetic skin responses.

The occurrence of orgasm with either absent or low-volume prograde ejaculation suggests either RE or ejaculatory duct obstruction. The presence of spermatozoa in postmasturbation first-void urine suggests RE, whereas

the presence of azoospermia/oligospermic fluid low-viscosity, low-fructose, low-pH semen on semen analysis suggests ejaculatory duct obstruction. If the cause of DE is unclear, culture of expressed prostatic secretion and urine, urine cytology, and serum prostate-specific antigen will exclude prostatitis and bladder and prostatic cancer. Imaging studies such as transrectal ultrasound (TRUS), MRI, or ultrasound of the testicles and epididymes may define any local disease.

Fig. 71.4 is a flow chart for the management of DE (Rowland et al., 2010).

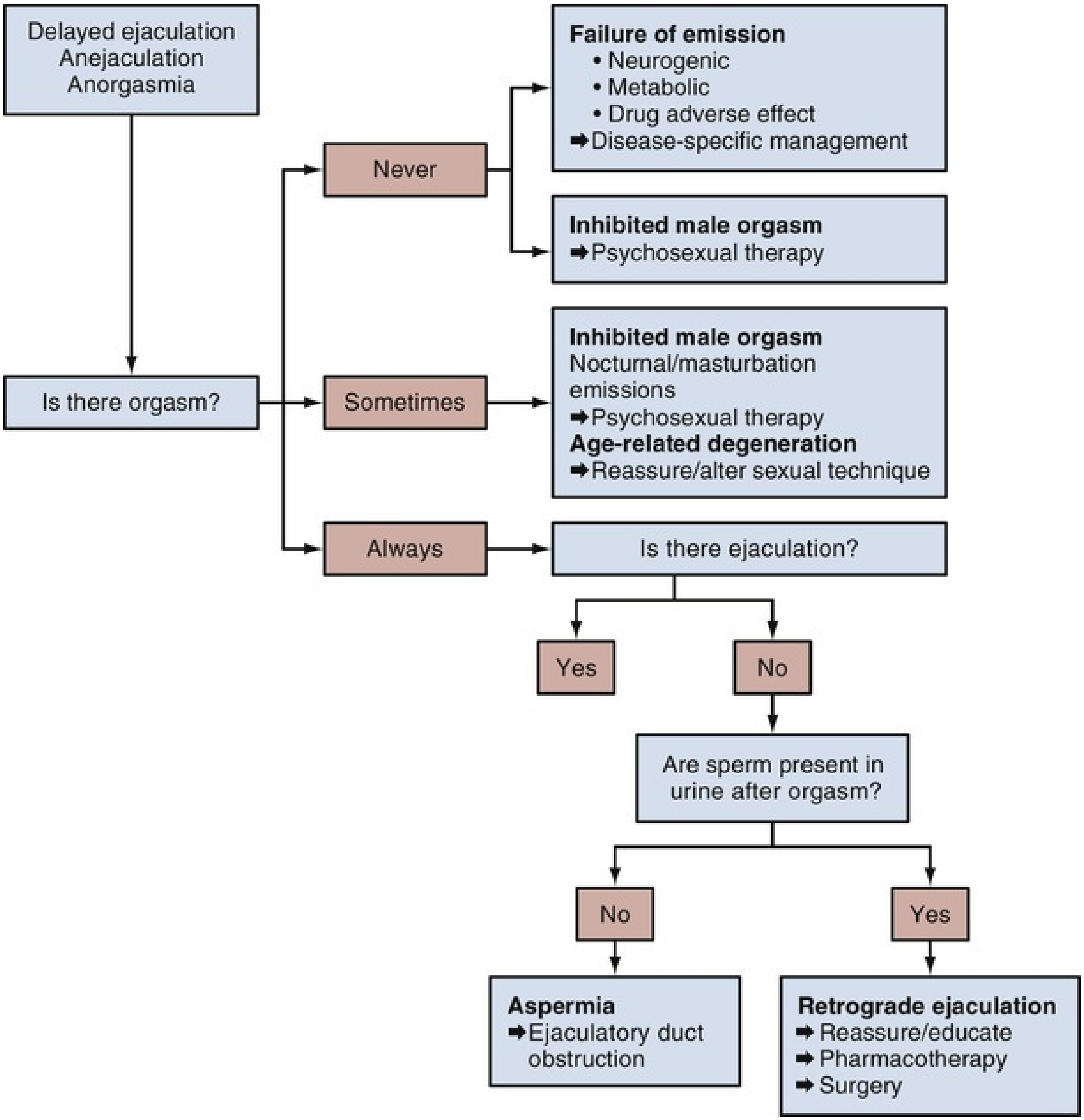

Delayed ejaculation
Anejaculation
Anorgasmia
Is there orgasm?
Never
Sometimes
Always
Failure of emission
• Neurogenic
• Metabolic
• Drug adverse effect
➡Disease-specific management
Inhibited male orgasm
➡Psychosexual therapy
Inhibited male orgasm
Nocturnal/masturbation emissions
➡Psychosexual therapy
Age-related degeneration
➡Reassure/alter sexual technique
Is there ejaculation?
Yes
No
Are sperm present in urine after orgasm?
No
Yes
Aspermia
➡Ejaculatory duct obstruction
Retrograde ejaculation
➡ Reassure/educate
➡ Pharmacotherapy
➡ Surgery

FIG. 71.4 Algorithm for the office management of delayed ejaculation.

Treatment of Men With Delayed Ejaculation/Anejaculation

Treatment should be cause specific, address the issue of infertility in men of a reproductive age and may include **patient/couple psychoeducation and/or psychosexual therapy, pharmacotherapy, or integrated treatment.** Men/partners of reproductive age undergoing pelvic surgery should be informed of the risk of infertility resulting from anejaculation and the availability of sperm harvesting and assisted reproductive techniques.

Whether a clear pathophysiologic cause is present or absent, patients may be counseled to consider **lifestyle changes, including enjoying more time together to achieve greater intimacy, minimizing alcohol consumption, making love when not tired, and practicing techniques that maximize penile stimulation such as pelvic floor training** (Waldinger and Schweitzer, 2005). Neuropathic DE is usually irreversible and therefore the patient may be counseled to seek alternative methods to achieve mutual sexual satisfaction with his partner.

Psychological Strategies in the Treatment of Delayed Ejaculation

If organic and pharmacologic causes have been eliminated, **referral to an expert psychosexual therapist** is usually indicated to evaluate the causative psychological and behavioral issues. Beneficial effects through psychotherapy depend on the severity of the DE and the individual's receptiveness to engage in counseling and adhere to the counselor's recommendations.

The partner and the quality of the relationship warrant exploration. Numerous psychotherapeutic processes are described for the management of delayed or inhibited ejaculation (Apfelbaum 1989; McCarthy 1981), and some appear to be effective, but none has been properly evaluated in large scale samples (McMahon et al., 2006). Among these strategies are (1) sex education; (2) reduction of goal-focused anxiety; (3) increased, more genitally focused stimulation; (4) patient role-playing an exaggerated ejaculatory response on his own and in front of his partner; (5) masturbatory retraining; and (6) realignment of sexual fantasies and arousal strategies.

Most current sex therapy approaches to DE emphasize the importance of masturbation in the treatment of DE, with most of the focus on “masturbatory retraining” integrated into sex therapy (Kaplan, 1995). Typically, self-stimulation techniques incorporating fantasy can be used to achieve incremental increases in arousal that eventually enable orgasm. Fantasy can serve the purpose of increasing arousal and blocking inhibiting thoughts that may otherwise interfere. Once the man's ejaculatory ability is established through masturbation, the same skill set can be incorporated into sex with the partner.

An important component in the treatment of any type of DE is the removal of the “demand” (and thus anxiety-producing) characteristics of the situation (Apfelbaum, 1989). “Ejaculatory performance” anxiety can interfere with the erotic sensations of genital stimulation and may result in levels of sexual excitement insufficient for climax (although they may be more than adequate to maintain an erection). To reduce anxiety, treatment may include recognition of DE men's overeagerness to please their partners, validation of (though not necessarily encouragement of) men's auto sexual orientation, removal of stigmas suggesting hostility or withholding toward their partners, and general anxiety-reduction techniques such as relaxation and desensitization.

The partner also needs to collaborate in the therapeutic process, finding ways to enhance the man's arousal and accepting the use of erotica and various (harmless) sexual fantasies that also may be incorporated into the couple's lovemaking. Furthermore, because interventions used in the treatment of DE may be experienced by the female partner as mechanistic (e.g., using a stepwise program) and insensitive to her sexual needs, the therapeutic challenge is to facilitate the rapport between the partners while maintaining a therapeutic alliance with both partners and simultaneously optimizing his response to her manual, oral, and vaginal stimulation.

The success of treating DE is difficult to assess from the literature (McMahon et al., 2006) because the evidence on the effectiveness of various treatments is limited (Heiman and Meston, 1997), and successful and unsuccessful case reports have been cited (Apfelbaum, 1989).

Pharmacotherapy in the Treatment of Delayed Ejaculation

Drug treatment of delayed or inhibited ejaculation has met with **limited success** (Table 71.7). **These drugs facilitate ejaculation by either a central dopaminergic, antiserotonergic, or oxytocinergic mechanism of action or a peripheral adrenergic mechanism of action.** However, no drugs have been approved by regulatory agencies for this purpose, and most drugs that have been identified for potential use have limited efficacy, impart significant side effects, or are yet considered experimental. **Results are relatively poor in men with psychogenic DE and neuropathic DE.**

TABLE 71.7

Drug Therapy for Delayed Ejaculation and Anejaculation

DRUG	**DOSAGE**	
	AS NEEDED	**DAILY**
Cabergoline		0.5–2.0 mg every 3 days
Pramipexole		0.125–0.25 mg
Amantadine	100–400 mg (for two days before coitus)	100–200 mg bid
Bupropion		150 mg daily or bid
Pseudoephedrine		60–120 mg q6h the day before coitus and then twice on the day of coitus
Reboxetine		4–8 mg
Buspirone		5–15 mg bid
Cyproheptadine	4–12 mg (3–4 h before coitus)	
Oxytocin	24 IU intranasal during coitus	

Cabergoline is a central D2 agonist approved for the treatment of hyperprolactinemia that reduces the ejaculatory latency time and facilitates ejaculation (Kruger et al., 2003). Its use has also been described in men with ejaculatory anhedonia or anorgasmia (Wittstock, et al., 2002). The starting dose is 0.5 mg every 3 days and can be escalated to 2 to 3 mg. Adverse effects include nausea, dizziness, and rarely cardiac valvular, pericardial, pulmonary, and retroperitoneal fibroses. Physicians should be cautious with long-term use, and follow-up echocardiography should be performed every 12 months.

α_1-Adrenergic receptor agonists such as on-demand **precoital pseudoephedrine** (120 mg 1–2 h before intercourse) or the **SNRI antidepressant reboxetine** (4–8 mg daily), which inhibits synaptic noradrenaline reuptake, have limited efficacy. The antihistamines **cyproheptadine and loratadine,** a central serotonin antagonist, is anecdotally associated with the reversal of anorgasmia induced by the SSRI antidepressants, but no controlled studies have been reported (Ashton et al., 1997; Aukst-Margetic and Margetic, 2005; McCormick et al., 1990). These studies suggest an effective cyproheptadine dose range of 2 to 16 mg, with administration on a chronic or "on-demand" basis. However, significant dose-related sedative effects are likely to diminish its overall efficacy.

A variety of other pharmacologic agents including **amantadine, apomorphine, bromocriptine, bupropion, and buspirone** have been anecdotally reported as potential DE pharmacotherapy despite an absence of large-population RCTs. Of interest are the recent reports of the **intracoital administration of intranasal oxytocin** in the treatment of anejaculation and anorgasmia (Burri et al.. 2008; Ishak et al., 2007; MacDonald and Feifel, 2012; Walch et al., 2001). Although both case reports report reduced ejaculatory latency and/or successful treatment of anorgasmia (Ishak et al., 2007; MacDonald and Feifel, 2012), neither RCT demonstrated statistical superiority to placebo (Burri et al,. 2008; Walch et al., 2001). Furthermore, intranasal oxytocin distribution pharmacokinetics demonstrate that despite achieving supraphysiologic levels of oxytocin in peripheral blood with a Cmax of 15 minutes, very little oxytocin entered the CSF with a substantially longer Cmax of up to 75 minutes (Leng and Ludwig, 2016). In addition, there is no correlation between oxytocin plasma and CSF concentrations (Striepens et al., 2013). In the absence of robust RCT data, no conclusion can be drawn until the efficacy of intranasal OT has been evaluated with formal dose-response studies.

Key Points: Delayed Ejaculation

- The causes of DE and anejaculation are manifold.
- Failure of ejaculation can be a lifelong problem (25%) or an acquired problem (75%). It may be global and occur in every sexual encounter or be intermittent or situational.
- Treatment of men with DE should be cause-specific and address the issue of infertility in men of reproductive age.
- Drug treatment of men with DE or anejaculation has limited success.

Retrograde Ejaculation

Antegrade (normal) ejaculation requires a closed bladder neck (and proximal urethra). **Surgical procedures that compromise the bladder neck closure mechanism may result in RE.** Transurethral incision of the prostate (TUIP) results in RE in 5% (Hedlund and Ek, 1985) to 45% (Kelly et al., 1989) of patients and is probably related to whether one or two incisions are made and whether or not the incision includes primarily the bladder neck or extends to the level of the verumontanum. The importance of contraction of the urethral smooth muscle at the level of the verumontanum has been hypothesized to be important in preventing RE (Reiser, 1961). TURP carries a higher incidence of RE than does TUIP. The reported incidence of RE after TURP ranges from 42% (Edwards and Powell, 1982) to 100% (Quinlan et al., 1991). Although these men may have some antegrade ejaculation and usually experience orgasmic sensation, both events may be reduced as part of the changes that occur in the male sexual response as a man ages. Retrograde ejaculation is more common in DM than in age-matched controls ($P < 0.01$), has been reported in 30% of men with DM, and is not statistically associated with duration of DM, BMI, waist circumference, or HgbA1c or total testosterone levels (Waldinger et al., 2005).

Retrograde ejaculation and failure of emission can be distinguished by examination of a postmasturbatory specimen of urine for the presence of spermatozoa and fructose. The finding of greater than 5 to 10 sperm per high-power field in a postejaculation urine specimen confirms the presence of RE. In patients with low-volume ejaculate, the finding of more sperm in the urine than in the antegrade ejaculate indicates a significant component of RE (Sigman and Howards, 1998).

Treatment

Retrograde ejaculation can be surgically treated with bladder neck reconstruction, but results remain consistently poor (Abrahams et al., 1975; Lipshultz et al., 1981). Drug treatment is the most promising approach. As mentioned earlier, α-adrenergic sympathetic nerves mediate bladder neck closure and emission. Several sympathomimetic amine agents have been described as useful with mixed results (Kedia and Markland, 1975; Proctor and Howards, 1983). These drugs include **pseudoephedrine, ephedrine, midocrine, and**

phenylpropanolamine. These agents work by stimulating the release of noradrenaline from the nerve axon terminals but may also directly stimulate α- and β-adrenergic receptors. The most useful is pseudoephedrine, which when administered at a dose of 120 mg every 6 hours on the day before coitus and twice on the day of coitus resulted in prograde ejaculation in 58% of a group of predominantly diabetic men (Shoshany et al., 2017). **The tricyclic antidepressant imipramine, which blocks the reuptake of noradrenaline by the axon from the synaptic cleft, is also occasionally useful** (Ochsenkuhn et al., 1999). The usual dosage is 25 mg twice daily. The current feeling is that long-term treatment with imipramine is likely to be more effective. Preliminary data suggest a potential place for endourethral injection of collagen type 2 in the treatment of RE (Kurbatov et al., 2015).

Key Points: Retrograde Ejaculation

- TURP and diabetic autonomic neuropathy are the most common causes of retrograde ejaculation.
- RE and failure of emission can be distinguished by examination of a postmasturbatory specimen of urine for the presence of spermatozoa and fructose.
- Pharmacotherapy is associated with variable degrees of success and includes agents such as pseudoephedrine, midocrine, and imipramine.

Sperm Retrieval in Men With Anejaculation Pursuing Fertility

Although medical treatment of RE may not always produce normal ejaculation, it may result in some prograde ejaculation. In patients who do not achieve antegrade ejaculation with either surgery or medication, urinary sperm retrieval and artificial insemination using IUI, IVF, or ICSI is an alternative approach with a per-cycle pregnancy rate of 20% to 50% (Nikolettos et al., 1999). The basic method of sperm retrieval involves recovery of previously alkalinized urine by either catheter or voiding after masturbation and then centrifugation and isolation of the sperm.

Penile vibratory stimulation (PVS) and electroejaculation have been used for sperm retrieval in men who are pursuing fertility with psychogenic anejaculation (Wheeler et al., 1988), or EjD secondary to diabetes (Gerig et al., 1997), multiple sclerosis (Previnaire et al., 2014), or SCI (Castle et al., 2014). Application of a medical grade, high-amplitude vibrator to the frenulum activates the afferent nerves of the ejaculatory reflex. In large series, ejaculatory success rate ranged from 65% to 83% (Brackett et al., 1998; Castle et al., 2014; Sonksen et al., 1994). PVS is less effective in SCI below the level of T10, where the nerves of the ejaculatory reflex may be damaged (Sonksen and Ohl, 2002).

Electroejaculation involves the insertion of an electric probe into the rectum adjacent to the prostate gland and delivery of an AC 12- to 24-volt 500 mA current stimulus cycle for 1 to 2 seconds (Denil et al., 1992; Lucas et al., 1991). Ejaculation usually occurs after 2 to 4 stimulus cycles. The stimulus voltage bypasses the reflex arc and applies direct stimulation to the adjacent nerves of the prostate and vas ampulla resulting in contraction of the pelvic floor muscles and ejaculation. Fresh or cryopreserved electroejaculate is subsequently used for IUI, IVF, or ICSI. Ejaculatory success rates range from 80% to 97%, with pregnancy rates ranging from 10% to 12.5% for IUI and 6.3% to 83.3% for IVF or ICSI (Mehta and Sigman, 2015). Electroejaculation pregnancy outcomes appear similar among men with psychogenic anejaculation and men with SCI (Gat et al., 2012), and there appears no significant difference in pregnancy rates with the use of fresh or cryopreserved electroejaculate (Hovav et al., 2002).

It is usually performed under general anesthetic except for men with SCI. It may be associated with rectal mucosal burns with currents more than 500 mA and with autonomic dysreflexia in individuals with a level of spinal cord injury at or above the sixth thoracic vertebral level (T6). Autonomic dysreflexia causes an imbalanced reflex sympathetic discharge, leading to potentially life-threatening hypertension (Sharif and Hou, 2017). Premedication with rapid-acting antihypertensive drugs such as immediate release nifedipine or sublingual or spray nitroglycerine is effective in preventing most AD. Caution should be exercised in older men with coronary artery disease and in men using phosphodiesterase type 5 (PDE5) inhibitors.

Ejaculatory Anhedonia

Sexual anhedonia is also known as “ejaculatory anhedonia” or pleasure dissociative orgasm disorder (PDOD). Sufferers may be male or female, are aware of orgasm and ejaculation but experience little or no pleasure. There is little published in peer-reviewed literature, and our understanding of this uncommon disorder is incomplete. Sexual anhedonia may be associated with depression, fatigue, physical illness, hypoactive sexual desire disorder (HSDD), hypogonadism, hyperprolactinemia, spinal cord injury, multiple sclerosis, or during or after cessation of SSRI antidepressants (Csoka et al., 2008) or antipsychotics (Fortier et al., 2003).

Although there is no clear consensus regarding the pathophysiology of PDOD, it is probably a central neurochemical disorder involving multiple neurotransmitters but predominantly dopamine. The dopaminergic neurons of the mesolimbic pathway project into the nucleus accumbens (NAc) and release dopamine in response to reward stimuli including sexual arousal and orgasm. This disorder is probably due to a defect in either the release of dopamine or the interaction between dopamine and the GABAergic neurons of the NAc. This disorder is commonly associated with chronic depression, and the relationship with depression may be bidirectional. As such, there is invariably a psychogenic component driven by the resultant frustration and negativity from the underlying neurochemical disorder.

As part of assessing these men, androgen studies including total and free testosterone, pituitary gonadotropins, and prolactin levels should be performed. If there is evidence of either hyperprolactinemia or secondary hypogonadism, a pituitary MRI should be conducted. The presence of other sexual disorders, including hypoactive sexual desire, opiate addiction, treatment with psychotropic medication (especially major tranquilizers), or genital sensory neuropathy, should be excluded. These men are typically very resistant to the notion that there is a psychogenic cause or contribution to their disorder and as already indicated they may very well be correct. Sufferers are best managed using an integrated approach with pharmacotherapy and psychotherapy. The former may include the use of central dopamine agonists such as for cabergoline at a dose of 0.5 to 3 mg every 3 days.

Post-SSRI Sexual Dysfunction

Abrupt cessation, interruption, or dose reduction, antidepressant drugs, particularly selective serotonin re-uptake inhibitors (SSRIs) or serotonin–norepinephrine reuptake inhibitors (SNRIs), can result in an antidepressant withdrawal syndrome (Haddad, 2001). Symptoms are mild and transient and include flulike symptoms and disturbances in sleep, movement, mood, and cognition. Post-SSRI sexual dysfunction (PSSD) is a debilitating condition that adversely affects quality of life, may persist for months to years, yet may spontaneously resolve after prolonged presence (Csoka et al., 2008). The prevalence of persistent sexual side effects after discontinuing SSRIs is unknown, although one study reported a 5% to 15% incidence of PSSD (Bahrick, 2006). The symptoms of PSSD can commence as early as after the first SSRI dose (Csoka et al., 2008) or within days or weeks, persist after discontinuing SSRIs, and include genital anesthesia, HSDD, ED, PE, and ejaculatory anhedonia (Waldinger et al., 2015). It is probable that some subjects thought to have PSSD do in fact have HSDD, ED, and EjD because of underlying depression. The cause of PSSD is unknown, and putative theories include dopamine-serotonin interactions, serotonin neurotoxicity, and downregulation of 5-HT-IA receptor (Bala et al., 2018). Diagnosis of PSSD is challenging and involves review of the patient's drug history, onset and type of symptoms, and the patient's premorbid sexual function. Symptoms must be distinguished from those of the actual mental illness symptoms.

There is no definitive treatment for PSSD, and treatment is limited to specific symptom pharmacotherapy such as PDE5I drugs for ED and/or pharmacotherapy for SSRI-induced sexual dysfunction alone or in combination with individual and couple psychotherapy. Waldinger et al. reported improved penile sensitivity but no improvement in EjD and ED after treatment with low-power laser irradiation or phototherapy of the scrotal and penile shaft skin of a male patient with PSSD (Waldinger et al., 2015).

Orgasmic Headache

There are multiple single and case series reporting the abrupt onset of a throbbing or a constant headache during sexual activity and at or around the time of orgasm. Lance (1976) reported two variants of sexual headache. The first developed with escalating sexual excitement and had the characteristics of muscle contraction headache. The second was a severe throbbing, vascular-type headache occurring at the time of orgasm. No structural lesions were found in the majority of patients, although the possibility of intracranial vascular or other lesions must be considered. Risk factors included history of migraine, stress, and fatigue.

Painful Ejaculation

Painful ejaculation or odynorgasmia is a poorly characterized syndrome. It may be associated with **urethritis, BPH, acute or chronic prostatitis, chronic pelvic pain syndrome, seminal vesiculitis, seminal vesicular calculi, or ejaculatory duct obstruction** (Corriere, 1997; Kochakarn et al., 2001; Nickel et al., 2005; Weintraub et al., 1993). Often, no obvious etiologic factor can be found. **Painful ejaculation occurs in 17% to 23% of men with LUTS/BPH (**Brookes et al., 2002; Frankel et al., 1998; Tubaro et al., 2001; Vallancien et al., 2003). Men with BPH and painful ejaculation have more severe LUTS and report greater bother. In addition, they report a higher incidence of ED and a reduced ejaculation volume, compared with men with LUTS only (Rosen et al., 2003). Treatment of men with LUTS with α-blocking drugs may be associated with painful ejaculation. A lower incidence of pain has been reported with the uroselective α_1-blocking drug alfuzosin (van Moorselaar et al., 2005). Management should focus on treatment of the underlying cause.

Postorgasmic Illness Syndrome

POIS is a recently described but poorly characterized “orphan” disease comprising a **collection of symptoms, which include severe myalgia and fatigue associated with a flulike state, which occurs within 30 minutes of orgasm.**

People engage in sexual activity for many reasons. The feelings of calmness, contentment, and sedation after orgasm have been described as inducements for intercourse, particularly in men (Meston and Buss, 2007).

In 2002 Waldinger et al. described a collection of symptoms after orgasm in two males that were qualitatively similar but more extreme and prolonged than the expected state of relaxation and somnolence that would normally occur (Waldinger and Schweitzer, 2002). The symptoms consisted of severe myalgia and fatigue associated with a flulike state after orgasm. The symptoms were severe enough that the individuals avoided ejaculating to try to prevent the symptoms. Waldinger et al. named this cluster of symptoms after ejaculation postorgasmic illness syndrome (POIS). POIS is a rarely described syndrome, and despite having a significant impact on quality of life for individual sufferers, little is known about its epidemiology and cause.

Although POIS may appear an orphan disease, it may be more common than reported in the literature. In the *New York Times* in January 2009, Richard Friedman, a New York City psychiatrist, describes several patients who experience low mood and somatic symptoms after orgasm whose symptoms improved with the use of SSRIs. Evidence of many more undiagnosed sufferers of POIS is seen in the existence of an extremely active Internet forum, in which more than 100 people have self-reported symptoms of POIS.

More recently Waldinger et al. have reported 45 males with suspected POIS in whom symptoms did not occur during sexual contact without ejaculation (Waldinger et al., 2011). POIS symptoms started within 30 minutes after ejaculation in 87% of men. All men reported a gradual intensity peak of symptoms, most of which were experienced on day 2. **Complaints of POIS were categorized in seven clusters of symptoms: (1) a sensation of a flulike state, (2) extreme fatigue or exhaustion, (3) weakness of musculature, (4) experiences of feverishness or perspiration, (5) mood disturbances and/or irritability, (6) memory difficulties, concentration problems, or incoherent speech, and (7) congestion of watery nose or itching eyes.** All symptoms occur immediately (e.g., seconds), soon (e.g., minutes), or within a few hours after ejaculation that is initiated by coitus, masturbation, and/or spontaneously (e.g., during sleep). Symptoms occur always or nearly always (i.e., in more than 90% of ejaculation events). Most of these symptoms last for about 2 to 7 days and disappear spontaneously.

Waldinger et al. proposed **a type 1 hypersensitivity immunogenic mechanism** as local allergic reactions of eyes and nose were reported in 44% and 33% of subjects, 58% had an atopic constitution, and 88% men had a positive skin-prick test with their own semen. He suggested that autologous seminal peptides or peptides released from the disrupted urethral lining cells contact the inner mucosal epithelium of the urethra, are recognized and taken up by dendritic cells in the epithelium and migrate to the T-cell zones of lymph nodes, where contact between the seminal fluid antigen(s) and naive T cells initiate the cascade of events of a hypersensitivity reaction. This may parallel the reports of an alloallergic reaction to specific protein fractions of seminal plasma in female partners of males, in whom symptoms are localized but may include generalized urticaria and rarely anaphylactic shock (Lee et al., 2008; Ohman et al., 1990).

Of particular interest was the observation **that 56% of this POIS study population also suffered from lifelong PE with an IELT of 1 minute or less.** In men with POIS, the relative risk of PE is 22.4-fold higher than healthy individuals. This may be related to forced abstinence of, and therefore low frequency of, sexual activity.

In a third study, two men suffering from POIS with positive autologous semen skin testing underwent **a prolonged hyposensitization program with multiple subcutaneous injections of autologous semen and reported a gradual reduction of complaints resulted in 60% and 90% amelioration of POIS complaints at 31 and 15 months, respectively** (Waldinger, et al., 2011).

Key Points: Postorgasmic Illness Syndrome (POIS)

- The symptoms of POIS occur after ejaculation and comprise severe myalgia, fatigue associated with a flulike state, nasal congestion, and itching eyes.
- POIS symptoms commence within 30 minutes of ejaculation in 87% of men and increase in intensity to a peak on day 2.

- A type 1 hypersensitivity immunogenic reaction has been proposed as the underlying mechanism.
- A prolonged hyposensitization program with multiple subcutaneous injections of autologous semen has been suggested as a possible treatment.

Conclusion

Recent epidemiologic and observational research has provided new insights into PE and the associated negative psychosocial effects of this dysfunction. The recently developed multivariate evidence-based ISSM definition of lifelong and acquired PE provides the clinician a more discriminating diagnostic tool and should form the basis of the official diagnosis of lifelong PE.

Although there is insufficient empirical evidence to unequivocally identify the cause of PE, there is limited evidence to suggest that lifelong PE may have a genetic basis and acquired PE is most often due to sexual performance anxiety, psychological or relationship problems, and/or ED and to a lesser extent, chronic prostatitis, chronic pelvic pain syndrome, or hyperthyroidism.

Current evidence suggests that psychosexual CBT has a limited role in the contemporary management of PE and confirms the efficacy and safety of oral SSRI drugs and topical anesthetic drugs. It is likely that dapoxetine, despite its modest effect upon ejaculatory latency, has a place in the management of PE, which will eventually be determined by market forces once the challenge of regulatory approval has been met. Treatment with tramadol, intracavernosal injection therapy, or alternate methods of drug delivery cannot be recommended until the results of large well-designed RCTs are published in major international peer-reviewed medical journals.

Delayed ejaculation and anejaculation are more common as men age and have manifold organic and psychogenic causes. They have a significant impact upon sexual fulfilment for the man and his partner and may result in infertility. Treatment of men suffering from DE represents one of the most significant challenges in sexual medicine, and outcome results are often disappointing.

Suggested Readings

Althof SE, Abdo CH, Dean J, et al. International Society for Sexual Medicine's guidelines for the diagnosis and treatment of premature ejaculation. *J Sex Med*. 2010;7(9):2947–2969.

Corona G, Mannucci E, Petrone L, et al. Psychobiological correlates of delayed ejaculation in male patients with sexual dysfunctions. *J Androl*. 2006;27(3):453–458.

Janssen PK, Bakker SC, Réthelyi J, et al. Serotonin transporter promoter region (5-HTTLPR) polymorphism is associated with the intravaginal ejaculation latency time in Dutch men with lifelong premature ejaculation. *J Sex Med*. 2009;6(1):276–284.

McMahon CG, Altof SE, Waldinger MD, et al. An evidence-based definition of lifelong premature ejaculation: report of the International Society for Sexual Medicine (ISSM) ad hoc committee for the definition of premature ejaculation. *J Sex Med*. 2008;5(7):1590–1606.

McMahon CG, Jannini E, Waldinger M, et al. Standard operating procedures in disorders of orgasm and ejaculation. *J Sex Med*. 2013;10(1):204–229.

Rowland D, McMahon CG, Abdo C, et al. Disorders of orgasm and ejaculation in men. *J Sex Med*. 2010;7(4 Pt 2):1668–1686.

Waldinger MD, McIntosh J, Schweitzer DH. A five-nation survey to assess the distribution of the intravaginal ejaculatory latency time among the general male population. *J Sex Med*. 2009;6(10):2888–2895.

References

Abdel-Hamid IA, El Naggar EA, El-Gilany A-H. Assessment of as needed use of pharmacotherapy and the pause-squeeze technique in premature ejaculation. *Int J Impot Res*. 2001;13(1):41–45.

Abrahams JI, Solish GI, Boorjian P, et al. The surgical correction of retrograde ejaculation. *J Urol*. 1975;114(6):888–890.

Adams EH, Breiner S, Cicero TJ, et al. A comparison of the abuse liability of tramadol, NSAIDs, and hydrocodone in patients with chronic pain. *J Pain Symptom Manage*. 2006;31(5):465–476.

Adson DE, Kotlyar M. Premature ejaculation associated with citalopram withdrawal. *Ann Pharmacother*. 2003;37(12):1804–1806.

Ahlenius S, Larsson K, Svensson L, et al. Effects of a new type of 5-HT receptor agonist on male rat sexual behavior. *Pharmacol Biochem Behav*. 1981;15(5):785–792.

Akin Y, Gulmez H, Ates M, et al. Comparison of alpha blockers in treatment of premature ejaculation: a pilot clinical trial. *Iran Red Crescent Med J*. 2013;15(10):e13805.

Alghobary M, El-Bayoumy Y, Mostafa Y, et al. Evaluation of tramadol on demand vs. daily paroxetine as a long-term treatment of lifelong premature ejaculation. *J Sex Med*. 2010;7(8):2860–2867.

Althof S. *Therapeutic weaving: the integration of treatment techniques. Handbook of clinical sexuality for mental health professionals. S. Levine, C. Risen and S. Althof*. Bruner-Routledge: New York; 2003:359–376.

Althof S. The psychology of premature ejaculation: therapies and consequences. *J Sex Med*. 2006;3(Suppl 4):324–331.

Althof S. Sex therapy in the age of pharmacotherapy. *Annu Rev Sex Res*. 2006;116–132.

Althof S. *Treatment of rapid ejaculation: psychotherapy, pharmacotherapy, and combined therapy. Principles and practice of sex therapy*. ed 4. Guilford Press: S. Leiblum. New York; 2007.

Althof S, Rosen R, Symonds T, et al. Development and validation of a new questionnaire to assess sexual satisfaction, control and distress associated with premature ejaculation. *J Sex Med*. 2006;3:465–475.

Althof SE. Evidence based assessment of rapid ejaculation. *Int J Impot Res*. 1998;10(Suppl 2):S74–S76 [discussion S77–S79].

Althof SE. Prevalence, characteristics and implications of premature ejaculation/rapid ejaculation. *J Urol*. 2006;175(3 Pt 1):842–848.

Althof SE. Psychological interventions for delayed ejaculation/orgasm. *Int J Impot Res*. 2012;24(4):131–136.

Althof SE, Abdo CH, Dean J, et al. International Society for Sexual Medicine's guidelines for the diagnosis and treatment of premature ejaculation. *J Sex Med*. 2010;7(9):2947–2969.

Althof SE, Levine SB, et al. A double-blind crossover trial of clomipramine for rapid ejaculation in 15 couples. *J Clin Psychiatry*. 1995;56(9):402–407.

Althof SE, McMahon CG, Waldinger MD, et al. An update of the International Society of Sexual Medicine's guidelines for the diagnosis and treatment of premature ejaculation (PE). *J Sex Med*. 2014;11(6):1392–1422.

Althof SE, Symonds T. Patient reported outcomes used in the assessment of premature ejaculation. *Urol Clin North Am*. 2007;34(4):581–589 [vii].

Althof SE, Wieder M. Psychotherapy for erectile dysfunction: now more relevant than ever. *Endocrine*. 2004;23(2–3):131–134.

American Psychiatric Association. *Diagnostic and statistical manual of mental disorders (ed 3) (DSM-III)*. American Psychiatric Association: Washington, DC; 1980.

American Psychiatric Association. *Diagnostic and statistical manual of mental disorders (ed 3, revised) (DSM-III-R)*. American Psychiatric Association: Washington, DC; 1987.

American Psychiatric Association. *Diagnostic and statistical manual of mental disorders, DSM-IV*. ed 4. American Psychiatric Assoaciation; 1994 [Washington, DC].

American Psychiatric Association. *Diagnostic and statistical manual of mental disorders (ed 4, text revision) (DSM-IV-TR)*. American Psychiatric Association: Washington, DC; 2000.

American Psychiatric Association. *Diagnostic and statistical manual of mental disorders, DSM-IV-TR*. ed 4 Revised. American Psychiatric Association; 2000 [Washington, DC].

American Psychiatric Association. *Diagnostic and statistical manual of mental disorders (ed 5) (DSM-5)*. American Psychiatric Association: Washington, DC; 2013.

Apfelbaum B. Retarded ejaculation: a much-misunderstood syndrome. Lieblum SR, Rosen RC. *Principles and practice of sex therapy: update for the 1990's*. ed 2. Guilford Press: New York; 1989:168–206.

Arafa M, Shamloul R. Development and validation of the Arabic Index of Premature Ejaculation (AIPE). *J Sex Med*. 2007;4:1750–1756.

Arai Y, Kawakita M, Osada Y, et al. Sexuality and fertility in long-term survivors of testicular cancer. *J Clin Oncol*. 1997;15:1444–1448.

Argiolas A, Collu M, D'Aquila P, et al. Apomorphine stimulation of male copulatory behavior is prevented by the oxytocin antagonist d(CH2)5 Tyr(Me)-Orn8-vasotocin in rats. *Pharmacol Biochem Behav*. 1989;33(1):81–83.

Arletti R, Bazzani C, Castelli M, et al. Oxytocin improves male copulatory performance in rats. *Horm Behav*. 1985;19(1):14–20.

Arletti R, Benelli A, Bertelini A. Sexual behavior of aging male rats is stimulated by oxytocin. *Eur J Pharmacol*. 1990;179(3):377–381.

Arterbery V, Frazier A, Dalmia P, et al. Quality of life after permanent prostate implant. *Surg Oncol*. 1997;13:461–464.

Ashton K, Hamer R, Rosen R, et al. Serotonin reuptake inhibitor-induced sexual dysfunction and its treatment: a large-scale retrospective study of 596 psychiatric outpatients. *J Sex Marital Ther*. 1997;23(3):165–175.

Asimakopoulos AD, Miano R, Finazzi A, et al. Does current scientific and clinical evidence support the use of phosphodiesterase type 5 inhibitors for the treatment of premature ejaculation? A systematic review and meta-analysis. *J Sex Med*. 2012;9(9):2404–2416.

Atan A, Basar MM, Tuncel A, et al. Comparison of efficacy of sildenafil-only, sildenafil plus topical EMLA cream, and topical EMLA-cream-only in treatment of premature ejaculation. *Urology*. 2006;67(2):388–391.

Atkinson RL, Dahms WT, Fisher DA, et al. Occult thyroid disease in an elderly hospitalized population. *J Gerontol*. 1978;33(3):372–376.

Aukst-Margetic B, Margetic B. An open-label series using loratadine for the treatment of sexual dysfunction associated with selective serotonin reuptake inhibitors. *Prog Neuropsychopharmacol Biol Psychiatry*. 2005;29(5):754–756.

Aversa A, Pili M, Francomano D, et al. Effects of vardenafil administration on intravaginal ejaculatory latency time in men with lifelong premature ejaculation. *Int J Impot Res*. 2009;21(4):221–227.

Bahrick AS. Post SSRI sexual dysfunction. *Am Soc Adv Pharmacother Tablet*. 2006;7:2–3.

Bala A, Nguyen HMT, Hellstrom WJD. Post-SSRI sexual dysfunction: a literature review. *Sex Med Rev*. 2018;6(1):29–34.

Ballon JS, Feifel D. A systematic review of modafinil: potential clinical uses and mechanisms of action. *J Clin Psychiatry*. 2006;67(4):554–566.

Bar-Or D, Salottolo KM, Orlando A, et al. A randomized double-blind, placebo-controlled multicenter study to evaluate the efficacy and safety of two doses of the tramadol orally disintegrating tablet for the treatment of premature ejaculation within less than 2 minutes. *Eur Urol*. 2011;61(4):736–743.

Basal S, Goktas S, Ergin A, et al. A novel treatment modality in patients with premature ejaculation resistant to conventional methods: the neuromodulation of dorsal penile nerves by pulsed radiofrequency. *J Androl*. 2010;31(2):126–130.

Basar MM, Yilmaz E, Ferhat M, et al. Terazosin in the treatment of premature ejaculation: a short-term follow-up. *Int Urol Nephrol*. 2005;37(4):773–777.

Basile Fasolo C, Mirone V, Gentile V, et al. Premature ejaculation: prevalence and associated conditions in a sample of 12,558 men attending the andrology prevention week 2001–a study of the Italian Society of Andrology (SIA). *J Sex Med*. 2005;2(3):376–382.

Baskerville TA, Allard J, Wayman C, et al. Dopamine-oxytocin interactions in penile erection. *Eur J Neurosci*. 2009;30(11):2151–2164.

Beckendorf V, Hay M, Rozan R, et al. Changes in sexual function after radiotherapy treatrment of prostate cancer. *Br J Urol*. 1996;77:118–123.

Bhat GS, Shastry A. Effectiveness of ‘on demand’ silodosin in the treatment of premature ejaculation in patients dissatisfied with dapoxetine: a randomized control study. *Cent European J Urol*. 2016;69(3):280–284.

Black K, Shea CA, Dursun S, et al. Selective serotonin reuptake inhibitor discontinuation syndrome: proposed diagnostic criteria. *J Psychiatry Neuroscience*. 2000;25(3):255–261.

Bolat D, Kocabas GU, Gunlusoy B, et al. The relationship between acquired premature ejaculation and metabolic syndrome: a prospective, comparative study. *Int J Impot Res*. 2017;29(3):105–109.

Bonnel C, Parc YR, Pocard M, et al. Effects of preoperative radiotherapy for primary resectable rectal adenocarcinoma on male sexual and urinary function. *Dis Colon Rectum*. 2002;45:934–939.

Borghede G, Hedelin H. Radiotherapy of localised prostate cancer. Analysis of late treatment complications. A prospective study. *Radiother Oncol*. 1997;43:139–146.

Bors E, Comarr AE. Neurological disturbances of sexcual function with special reference to 529 patients with spional cord injury. *Urol Surv*. 1960;10:191.

Brackett NL, Ferrell SM, Aballa TC, et al. An analysis of 653 trials of penile vibratory stimulation in men with spinal cord injury. *J Urol*. 1998;159(6):1931–1934.

Brindley G. Sexual and reproductive problems of paraplegic men. *Oxf Rev Reprod Biol*. 1986;8:214–222.

Brindley GS. The fertility of men with spinal injuries. *Paraplegia*. 1984;22(6):337–348.

Brock GB, Gajewski J, et al. The prevalence and impact of premature ejaculation in Canada. Proceedings of Annual Meeting of the American Urological Association, Anaheim. *CA*.2007.

Bronner G, Kitrey ND, Uziel N, et al. Correlation between premature ejaculation and female vaginal penetration difficulties. *Int J Impot Res*. 2015;27(4).

Brookes ST, Donovan JL, Peters TJ, et al. Sexual dysfunction in men after treatment for lower urinary tract symptoms: evidence from randomised controlled trial. *BMJ*. 2002;324(7345):1059–1061.

Burri A, Heinrichs M, Schedlowski M, et al. The acute effects of intranasal oxytocin administration on endocrine and sexual function in males. *Psychoneuroendocrinology*. 2008;33(5):591–600.

Busato W, Galindo CC. Topical anaesthetic use for treating premature ejaculation: a double-blind, randomized, placebo-controlled study. *BJU Int*. 2004;93(7):1018–1021.

Byers ES, Grenier G. Premature or rapid ejaculation: heterosexual couples’ perceptions of men's ejaculatory behavior. *Arch Sex Behav*. 2003;32(3):261–270.

Caffo O, Amichetti M. Evaluation of sexual life after orchidectomy followed by radiotherapy for early-stage seminoma of the testis. *BJU Int*. 1999;83:462–468.

Cappelleri JC, Siegel RL, Glasser DB, et al. Relationship between patient self-assessment of erectile dysfunction and the sexual health inventory for men. *Clin Ther*. 2001;23(10):1707–1719.

Carani C, Isidori AM, Granata A, et al. Multicenter study on the prevalence of sexual symptoms in male hypo- and hyperthyroid patients. *J Clin Endocrinol Metab*. 2005;90(12):6472–6479.

Carmichael MS, Humbert R, Dixen J, et al. Plasma oxytocin increases in the human sexual response. *J Clin Endocrinol Metab*. 1987;64(1):27–31.

Carson C, Wyllie M. Improved ejaculatory latency, control and sexual satisfaction when PSD502 is applied topically in men with premature ejaculation: results of a phase III, double-blind, placebo-controlled study. *J Sex Med*. 2010;7(9):3179–

3189.

Carter CS. Oxytocin and sexual behavior. *Neurosci Biobehav Rev*. 1992;16(2):131–144.

Castle SM, Jenkins LC, Ibrahim E, et al. Safety and efficacy of a new device for inducing ejaculation in men with spinal cord injuries. *Spinal Cord*. 2014;52(Suppl 2):S27–S29.

Cavallini G. Alpha-1 blockade pharmacotherapy in primitive psychogenic premature ejaculation resistant to psychotherapy. *Eur Urol*. 1995;28(2):126–130.

Cepeda MS, Camargo F, Zea C, et al. Tramadol for osteoarthritis: a systematic review and metaanalysis. *J Rheumatol*. 2007;34(3):543–555.

Chapple CR, Montorsi F, Tammela TL, et al. Silodosin therapy for lower urinary tract symptoms in men with suspected benign prostatic hyperplasia: results of an international, randomized, double-blind, placebo- and active-controlled clinical trial performed in Europe. *Eur Urol*. 2011;59(3):342–352.

Chen J, Mabjeesh NJ, Matzkin H, et al. Efficacy of sildenafil as adjuvant therapy to selective serotonin reuptake inhibitor in alleviating premature ejaculation. *Urology*. 2003;61(1):197–200.

Chia S. Management of premature ejaculation – a comparison of treatment outcome in patients with and without erectile dysfunction. *Int J Androl*. 2002;25(5):301–305.

Cho HJ, Yoo TK. Silodosin for the treatment of clinical benign prostatic hyperplasia: safety, efficacy, and patient acceptability. *Res Rep Urol*. 2014;6:113–119.

Choi JH, Hwa JS, Kam SC, et al. Effects of tamsulosin on premature ejaculation in men with benign prostatic hyperplasia. *World J Mens Health*. 2014;32(2):99–104.

Clément P, Bernabé J, Compagnie S, et al. Inhibition of ejaculation by the non-peptide oxytocin receptor antagonist

GSK557296: a multi-level site of action. *Br J Pharmacol*. 2013.

Clement P, Giuliano F. Physiology and pharmacology of ejaculation. *Basic Clin Pharmacol Toxicol*. 2016;119(Suppl 3):18–25.

Clement P, Peeters M, Bernabé J, et al. Brain oxytocin receptors mediate ejaculation elicited by 7-hydroxy-2-(di-N-propylamino) tetralin (7-OH-DPAT) in anaesthetized rats. *Br J Pharmacol*. 2008;154(5):1150–1159.

Colpi G, Weidner W, Jungwirth A, et al. EAU guidelines on ejaculatory dysfunction. *Eur Urol*. 2004;46(5):555–558.

Comarr AE. Sexual function among patients with spinal cord injury. *Urol Int*. 1970;25(2):134–168.

Cooper K, Martyn-St James M, Kaltenthaler E, et al. Behavioral therapies for management of premature ejaculation: a systematic review. *Sex Med*. 2015;3(3):174–188.

Corona G, Jannini EA, et al. Different testosterone levels are associated with ejaculatory dysfunction. *J Sex Med*. 2008;5(8):1991–1998.

Corona G, Jannini EA, Lotti F, et al. Premature and delayed ejaculation: two ends of a single continuum influenced by hormonal milieu. *Int J Androl*. 2011;34(1):41–48.

Corona G, Jannini EA, Vignozzi L, et al. The hormonal control of ejaculation. *Nat Rev Urol*. 2012;9(9):508–519.

Corona G, Mannucci E, Jannini EA, et al. Hypoprolactinemia: a new clinical syndrome in patients with sexual dysfunction. *J Sex Med*. 2009;6(5):1457–1466.

Corona G, Mannucci E, Petrone L, et al. Psychobiological correlates of delayed ejaculation in male patients with sexual dysfunctions. *J Androl*. 2006;27(3):453–458.

Corona G, Petrone L, Mannucci E, et al. Psycho-biological correlates of rapid ejaculation in patients attending an andrologic unit for sexual dysfunctions. *Eur Urol*.

2004;46(5):615–622.

Corriere JN Jr. Painful ejaculation due to seminal vesicle calculi. *J Urol*. 1997;157(2):626.

Cossmann M, Kohnen C, Langford R, et al. [Tolerance and safety of tramadol use. Results of international studies and data from drug surveillance]. *Drugs*. 1997;53(Suppl 2):50–62.

Csoka AB, Bahrick A, Mehtonen OP, et al. Persistent sexual dysfunction after discontinuation of selective serotonin reuptake inhibitors. *J Sex Med*. 2008;5(1):227–233.

Dahlberg A, Ruutu M, et al. Pregnancy results from a vibrator application, electroejaculation, and a vas aspiration programme in spinal-cord injured men. *Human Reprod*. 1995;10:2305–2307.

Daniell HW, Clark JC, Pereira SE, et al. Hypogonadism following prostate-bed radiation therapy for prostate carcinoma. *Cancer*. 2001;91:1889–1895.

De Amicis LA, Goldberg DC, LoPiccolo J, et al. Three-year follow-up of couples evaluated for sexual dysfunction. *J Sex Marital Ther*. 1984;10(4):215–228.

de Carufel F, Trudel G. Effects of a new functional-sexological treatment for premature ejaculation. *J Sex Marital Ther*. 2006;32(2):97–114.

de Jong TR, Veening JG, Olivier B, et al. Oxytocin involvement in SSRI-induced delayed ejaculation: a review of animal studies. *J Sex Med*. 2007;4(1):14–28.

de Wied D, Diamant M, Fodor M. Central nervous system effects of the neurohypophyseal hormones and related peptides. *Front Neuroendocrinol*. 1993;14(4):251–302.

Debruyne FM. Alpha blockers: are all created equal? *Urology*. 2000;56(5 Suppl 1):20–22.

Delgado PL, Brannan SK, Mallinckrodt CH, et al. Sexual functioning assessed in 4 double-blind placebo- and paroxetine-controlled trials of duloxetine for major depressive disorder. *J Clin Psychiatry*. 2005;66(6):686–692.

Denil J, Ohl DA, McGuire EJ, et al. Treatment of anejaculation with electroejaculation. *Acta Urol Belg*. 1992;60(3):15–25.

Dinsmore WW, Hackett G, Goldmeier D, et al. Topical eutectic mixture for premature ejaculation (TEMPE): a novel aerosol-delivery form of lidocaine-prilocaine for treating premature ejaculation. *BJU Int*. 2006.

Dinsmore WW, Wyllie MG. PSD502 improves ejaculatory latency, control and sexual satisfaction when applied topically 5 min before intercourse in men with premature ejaculation: results of a phase III, multicentre, double-blind, placebo-controlled study. *BJU Int*. 2009;103(7):940–949.

Dogan S, Dogan M. The frequency of sexual dysfunctions in male partners of women with vaginismus in a Turkish sample. *Int J Impot Res*. 2008;20(2):218–221.

Dominguez JM, Hull EM. Dopamine, the medial preoptic area, and male sexual behavior. *Physiol Behav*. 2005;86(3):356–368.

Donahey K, Miller S. Applying a common factors perspective to sex therapy. *J Sex Ed Ther*. 2000;25:221–230.

Donatucci CF. Etiology of ejaculation and pathophysiology of premature ejaculation. *J Sex Med*. 2006;3(Suppl 4):303–308.

Dunn KM, Croft PR, Hackett GI, et al. Association of sexual problems with social, psychological, and physical problems in men and women: a cross sectional population survey. *J Epidemiol Community Health*. 1999;53(3):144–148.

Eassa BI, El-Shazly MA. Safety and efficacy of tramadol hydrochloride on treatment of premature ejaculation. *Asian J Androl*. 2013;15(1):138–142.

Edwards L, Powell C. An objective comparison of transurethral resection and bladder neck incision in the treatment of prostatic hypertrophy. *J Urol*. 1982;128:325–327.

El-Nashaar A, Shamloul R. Antibiotic treatment can delay ejaculation in patients with premature ejaculation and chronic bacterial prostatitis. *J Sex Med*. 2007;4(2):491–496.

El-Sakka AI. Association of risk factors and medical comorbidities with male sexual dysfunctions. *J Sex Med*. 2007;4(6):1691–1700.

el-Sakka AI. Severity of erectile dysfunction at presentation: effect of premature ejaculation and low desire. *Urology*. 2008;71(1):94–98.

Engin G, Celtik M, Sanli O, et al. Comparison of transrectal ultrasonography and transrectal ultrasonography-guided seminal vesicle aspiration in the diagnosis of the ejaculatory duct obstruction. *Fertil Steril*. 2009;92(3):964–970.

Erenpreiss J, Zalkalns J. Premature ejaculation: comparison of patroxetine alone, paroxetine plus local lidocaine and paroxetine plus sildenafil. *Int J Imp Res*. 2002;14(Suppl 4):S33 [abstract PS-37-34].

Fasolo CB, Mirone V, Gentile V, et al. Premature ejaculation: prevalence and associated conditions in a sample of 12,558 men attending the Andrology Prevention Week 2001——a study of the Italian Society of Andrology (SIA). *J Sex Med*. 2005;2(3):376–382.

Fava M, Judge R, Hoog SL, et al. Fluoxetine versus sertraline and paroxetine in major depressive disorder: changes in weight with long-term treatment. *J Clin Psychiatry*. 2000;61(11):863–867.

Fein RL. Intracavernous medication for treatment of premature ejaculation. *Urology*. 1990;35(4):301–303.

Ferraro L, Fuxe K, Agnati L, et al. Modafinil enhances the increase of extracellular serotonin levels induced by the antidepressant drugs fluoxetine and imipramine: a dual probe microdialysis study in awake rat. *Synapse*. 2005;55(4):230–241.

Ferraro L, Fuxe K, Tanganelli S, et al. Amplification of cortical serotonin release: a further neurochemical action of the vigilance-promoting drug modafinil. *Neuropharmacology*. 2000;39(11):1974–1983.

Ferraro L, Fuxe K, Tanganelli S, et al. Differential enhancement of dialysate serotonin levels in distinct brain regions of the awake rat by modafinil: possible relevance for wakefulness and depression. *J Neurosci Res*. 2002;68(1):107–112.

Filippi S, Vannelli GB, Granchi S, et al. Identification, localization and functional activity of oxytocin receptors in epididymis. *Mol Cell Endocrinol*. 2002;193(1–2):89–100.

Fortier P, Mottard JP, Trudel G, et al. Study of sexuality-related characteristics in young adults with schizophrenia treated with novel neuroleptics and in a comparison group of young adults. *Schizophr Bull*. 2003;29(3):559–572.

Frankel SJ, Donovan JL, Peters TI, et al. Sexual dysfunction in men with lower urinary tract symptoms. *J Clin Epidemiol*. 1998;51(8):677–685.

Fraschini A. Contribution to therapeutics of eiaculatio praecox and of some forms of sexual impotence. *G Gerontol*. 1966;14(12):1205–1207.

Frink MC, Hennies HH, Englberger W, et al. Influence of tramadol on neurotransmitter systems of the rat brain. *Arzneimittelforschung*. 1996;46(11):1029–1036.

Furuya R, Hisasue S, et al. [Ejaculatory disorder by alpha-1 adrenoceptor antagonist in patients with benign prostatic hyperplasia; retrospective comparison between naftopidil and tamsulosin]. *Hinyokika Kiyo*. 2005;51(11):763–766.

Gao J, Zhang X, Su P, et al. Prevalence and factors associated with the complaint of premature ejaculation and the four premature ejaculation syndromes: a large observational study in China. *J Sex Med*. 2013;10(7):1874–1881.

Garrett PM. Tramadol overdose and serotonin syndrome manifesting as acute right heart dysfunction. *Anaesth Intensive Care*. 2004;32(4):575–577.

Gat I, Maman E, et al. Electroejaculation combined with intracytoplasmic sperm injection in patients with psychogenic anejaculation yields comparable results to patients with spinal cord injuries. *Fertil Steril*. 2012;97(5):1056–1060.

Gaxiola GM, Aguilar IE, Paz G. *Method for treating premature ejaculation with a botulinum neurotoxin*. [(website)] https://www.google.com/patents/US8147848?dq=ininventor:%22Gustavo+M.+GAXIOLA%22&hl=en&sa= 2012.

Gerig NE, Meacham RB, et al. Use of electroejaculation in the treatment of ejaculatory failure secondary to diabetes mellitus. *Urology*. 1997;49(2):239–242.

Gil M, Bhatt R, Picotte KB, et al. Oxytocin in the medial preoptic area facilitates male sexual behavior in the rat. *Horm Behav*. 2011;59(4):435–443.

Giuliano F, Clement P. Pharmacology for the treatment of premature ejaculation. *Pharmacol Rev*. 2012;64(3):621–644.

Giuliano F, Patrick DL, Porst H, et al. Premature ejaculation: results from a five-country European observational study. *Eur Urol*. 2008;53(5):1048–1057.

Godpodinoff ML. Premature ejaculation: clinical subgroups and etiology. *J Sex Marital Ther*. 1989;15(2):130–134.

Golden JS, Price S, Heinrich AG, et al. Group vs. couple treatment of sexual dysfunctions. *Arch Sex Behav*. 1978;7(6):593–602.

Grenier G, Byers ES. The relationships among ejaculatory control, ejaculatory latency, and attempts to prolong heterosexual intercourse. *Arch Sex Behav*. 1997;26(1):27–47.

Grenier G, Byers S. Operationalizing premature or rapid ejaculation. *J Sex Res*. 2001;38:369–378.

Gupta J, Russell RJ, Wayman CP, et al. Oxytocin-induced contractions within rat and rabbit ejaculatory tissues are mediated by vasopressin V(1A) receptors and not oxytocin receptors. *Br J Pharmacol*. 2008.

Haddad PM. Antidepressant discontinuation syndromes. *Drug Saf*. 2001;24(3):183–197.

Hallbeck M, Larhammar D, Blomqvist A, et al. Neuropeptide expression in rat paraventricular hypothalamic neurons that project to the spinal cord. *J Comp Neurol*. 2001;433(2):222–238.

Hartmann U, Schedlowski M, Krüger TH, et al. Cognitive and partner-related factors in rapid ejaculation: differences between dysfunctional and functional men. *World J Urol*. 2005;10:10.

Hatzimouratidis K, Amar E, Giuliano F, et al. Guidelines on male sexual dysfunction: erectile dysfunction and premature ejaculation. *Eur Urol*. 2010;57(5):801–814.

Hawton K, Catalan J, Martin P, et al. Long-term outcome of sex therapy. *Behav Res Ther*. 1986;24(6):665–675.

Hedlund H, Ek A. Ejaculation and sexual function after endoscopic bladder neck incision. *Br J Urol*. 1985;57(2):164–167.

Heiman JR, Meston CM. Empirically validated treatment for sexual dysfunction. *Annu Rev Sex Res*. 1997;8:148–194.

Helgason AR, Fredrikson M, Adolffson J, et al. Decreased sexual capacity after external radiation therapy for prostate cancer impairs quality of life. *Int J Radiat Oncol Biol Phys*. 1995;32:33–39.

Herr H. Preservation of sexual potency in prostatic cancer patients after pelvic lymphadenectomy and retropubic I-125 implantation. *J Urol*. 1979;121:621–623.

Hisasue S, Furuya R, Itoh N, et al. Ejaculatory disorder caused by alpha-1 adrenoceptor antagonists is not retrograde ejaculation but a loss of seminal emission. *Int J Urol*.

2006;13(10):1311–1316.

Holtmann M, Gerstner S, Schmidt MH, et al. Risperidone-associated ejaculatory and urinary dysfunction in male adolescents. *J Child Adolesc Psychopharmacol*. 2003;13(1):107–109.

Homma Y, Kawabe K, Takeda M, et al. Ejaculation disorder is associated with increased efficacy of silodosin for benign prostatic hyperplasia. *Urology*. 2010;76(6):1446–1450.

Honda K, Yanagimoto M, Negoro H, et al. Excitation of oxytocin cells in the hypothalamic supraoptic nucleus by electrical stimulation of the dorsal penile nerve and tactile stimulation of the penis in the rat. *Brain Res Bull*. 1999;48(3):309–313.

Hovav Y, Yaffe H, Zentner B, et al. The use of ICSI with fresh and cryopreserved electroejaculates from psychogenic anejaculatory men. *Hum Reprod*. 2002;17(2):390–392.

Hull EM, Muschamp JW, Sato S. Dopamine and serotonin: influences on male sexual behavior. *Physiol Behav*. 2004;83(2):291–307.

Humphrey S, Nazareth I. GP's view on their management of sexual dysfunction. *Fam Pract*. 2001;18:516–518.

Hytrin. *Hytrin (terazosin HCl tablets) [package insert]*. Abbott Laboratories: North Chicago, IL; 2008:2006.

Incrocci L, Hop WCJ, Wijnmaalen A, et al. Treatment outcome, body image, and sexual functioning after orchiectomy and radiotherapy for stage I-II testicular seminoma. *Int J Radiat Oncol Biol Phys*. 2002;53:1165–1173.

Ishak WW, Berman DS, Peters A. Male anorgasmia treated with oxytocin. *J Sex Med*. 2007.

Jannini E, Lenzi A. Epidemiology of premature ejaculation. *Curr Opin Urol*. 2005;15:399–403.

Jannini EA, Carosa E, Pepe M, et al. Update of pathophysiology of premature ejaculation: the bases for new pharmacological treatments. *EAU-EBU Updates*. 2006;Series 4:141–149.

Jannini EA, Lenzi A. Epidemiology of premature ejaculation. *Curr Opin Urol*. 2005;15(6):399–403.

Jannini EA, Lenzi A, Wagner G. Behavioural therapy and counselling. Schill WB, Comhaire FH, Hargreave TB. *Andrology for the clinician*. Springer: Berlin; 2006:598–607.

Jannini EA, Lombardo F, et al. Correlation between ejaculatory and erectile dysfunction. *Int J Androl*. 2005;28(Suppl 2):40–45.

Jannini EA, McMahon C, Chen J, et al. The controversial role of phosphodiesterase type 5 inhibitors in the treatment of premature ejaculation. *J Sex Med*. 2011;8(8):2135–2143.

Janssen PK, Bakker SC, Zwindermann AH, et al. Serotonin transporter promoter region (5-HTTLPR) polymorphism is associated with the intravaginal ejaculation latency time in Dutch men with lifelong premature ejaculation. *J Sex Med*. 2009;6(1):276–284.

Jeon HJ, Kim HS, et al. Candidate molecule for premature ejaculation, DA-8031: in vivo and in vitro characterization of DA-8031. *Urology*. 2011;77(4):1006 [e1017–e1021].

Jern P, Santtila P, Witting K, et al. Premature and delayed ejaculation: genetic and environmental effects in a population-based sample of Finnish twins. *J Sex Med*. 2007;4(6):1739–1749.

Jiann BP, Huang YJ. Assessing satisfaction in men with premature ejaculation after dapoxetine treatment in real-world practice. *Int J Clin Pract*. 2015;69(11):1326–1333.

Joly F, Brune D, Couette JE, et al. Health-related quality of life and sequelae in patients treated with brachytherapy and external beam irradiation for localized prostate cancer. *Ann Oncol*. 1998;9:751–757.

Jonker-Pool G, van Basten JP, Hoeksra HJ, et al. Sexual functioning after treatment for testicular cancer. *Cancer*.

1997;80:454–464.

Kang KK, Ahn GJ, et al. Ejaculatory responses are inhibited by a new chemical entity, DA-8031, in preclinical rodent models of ejaculation. *Urology*. 2013;81(4):920 e913–920 e928.

Kang KK, Sung JH, Kim SH, et al. Effect of DA-8031, a novel oral compound for premature ejaculation, on male rat sexual behavior. *Int J Urol*. 2014;21(3):325–329.

Kaplan H. *The evaluation of sexual disorders: the urologic evaluation of ejaculatory disorders*. Brunner/Mazel: New York; 1983.

Kaplan H. *The evaluation of sexual disorders: psychological and medical aspects*. Brunner/Mazel: New York; 1995.

Kaplan HS. *PE: how to overcome premature ejaculation*. Brunner/Mazel: New York; 1989.

Kaplan HS, Kohl RN, et al. Group treatment of premature ejaculation. *Arch Sex Behav*. 1974;3(5):443–452.

Kawabe K, Yoshida M, Homma Y, et al. Silodosin, a new alpha1A-adrenoceptor-selective antagonist for treating benign prostatic hyperplasia: results of a phase III randomized, placebo-controlled, double-blind study in Japanese men. *BJU Int*. 2006;98(5):1019–1024.

Kaynar M, Kilic O, et al. On-demand tramadol hydrochloride use in premature ejaculation treatment. *Urology*. 2011;79(1):145–149.

Kedia K, Markland C. The effect of pharmacological agents on ejaculation. *J Urol*. 1975;114(4):569–573.

Kelly MJ, Roskamp D, Leach GE, et al. Transurethral incision of the prostate: a preoperative and postoperative analysis of symptoms and urodynamic findings. *J Urol*. 1989;142(6):1507–1509.

Khan A, Khan S, Kolts R, et al. Suicide rates in clinical trials of SSRIs, other antidepressants, and placebo: analysis of FDA reports. *Am J Psychiatr*. 2003;160(4):790–792.

Kilinc MF, Aydogmus Y, Yildiz Y, et al. Impact of physical activity on patient self-reported outcomes of lifelong premature ejaculation patients: results of a prospective, randomised, sham-controlled trial. *Andrologia*. 2018;50(1).

Kim JJ, Kwak TI, Jeon BG, et al. Effects of glans penis augmentation using hyaluronic acid gel for premature ejaculation. *Int J Impot Res*. 2004;16(6):547–551.

Kim SW, Paick JS. Short-term analysis of the effects of as needed use of sertraline at 5 PM for the treatment of premature ejaculation. *Urology*. 1999;54(3):544–547.

Kirby EW, Carson CC, Coward RM, et al. Tramadol for the management of premature ejaculation: a timely systematic review. *Int J Impot Res*. 2015;27(4):121–127.

Kleinberg L, Wallner K, Roy J, et al. Treatment-related symptoms during the first year following transperineal I-125 prostate implantation. *Int J Radiat Oncol Biol Phys*. 1994;28:985–990.

Kobayashi K, Masumori N, Hisasue S, et al. Inhibition of seminal emission is the main cause of anejaculation induced by a new highly selective alpha1A-blocker in normal volunteers. *J Sex Med*. 2008;5(9):2185–2190.

Kobayashi K, Masumori N, Kato R, et al. Orgasm is preserved regardless of ejaculatory dysfunction with selective alpha1A-blocker administration. *Int J Impot Res*. 2009;21(5):306–310.

Kochakarn W, Leenanupunth C, Muangman V, et al. Ejaculatory duct obstruction in the infertile male: experience of 7 cases at Ramathibodi Hospital. *J Med Assoc Thai*. 2001;84(8):1148–1152.

Korotkova TM, Klyuch BP, Ponamarenko AA, et al. Modafinil inhibits rat midbrain dopaminergic neurons through D2-like receptors. *Neuropharmacology*. 2007;52(2):626–633.

Kruger TH, Haake P, Haverkamp J, et al. Effects of acute prolactin manipulation on sexual drive and function in males.

J Endocrinol. 2003;179(3):357–365.

Kurbatov D, Russo GI, Galstyan GR, et al. Correction of retrograde ejaculation in patients with diabetes mellitus using endourethral collagen injection: preliminary results. *J Sex Med*. 2015;12(11):2126–2129.

Kwak TI, Jin MH, Kim JJ, et al. Long-term effects of glans penis augmentation using injectable hyaluronic acid gel for premature ejaculation. *Int J Impot Res*. 2008;20(4):425–428.

Kwong EWH, Huh SH, et al. Intra-operative Iodine-125 prostatic implant following bilateral pelvic lymphadenectomy. *Int J Radiat Oncol Biol Phys*. 1984;10:665–670.

Lance JW. Headaches related to sexual activity. *J Neurol Neurosurg Psychiatry*. 1976;39(12):1226–1230.

Laumann EO, Nicolosi A, Glasser DB, et al. Sexual problems among women and men aged 40-80 y: prevalence and correlates identified in the Global Study of Sexual Attitudes and Behaviors. *Int J Impotence Res*. 2005;17(1):39–57.

Laumann EO, Paik A, Rosen RC, et al. Sexual dysfunction in the United States: prevalence and predictors. *J Am Med Assoc*. 1999;281(6):537–544.

Lawler LP, Cosin O, Jarow JP, et al. Transrectal US-guided seminal vesiculography and ejaculatory duct recanalization and balloon dilation for treatment of chronic pelvic pain. *J Vasc Interv Radiol*. 2006;17(1):169–173.

Lee J, Kim S, Kim M, et al. Anaphylaxis to husband's seminal plasma and treatment by local desensitization. *Clin Mol Allergy*. 2008;6:13.

Leng G, Ludwig M. Intranasal oxytocin: myths and delusions. *Biol Psychiatry*. 2016;79(3):243–250.

Lepor H. The evolution of alpha-blockers for the treatment of benign prostatic hyperplasia. *Rev Urol*. 2006;8(Suppl 4):S3–S9.

Levine L. *Evaluation of Withdrawal Effects with Dapoxetine in the Treatment of Premature Ejaculation (PE)*. [Poster presented at SMSNA] 2006.

Levine S. Helping men to control ejaculation. Levine S. *Sexual life: a clinician's guide. S. Levine*. Plenum Press: New York; 1992:90–106.

Li N, Wallen NH, Ladjevardi M, et al. Effects of serotonin on platelet activation in whole blood. *Blood Coagul Fibrinolysis*. 1997;8(8):517–523.

Li X, Zhang SX, Cheng HM, et al. [Clinical study of sildenafil in the treatment of premature ejaculation complicated by erectile dysfunction]. *Zhonghua Nan Ke Xue*. 2003;9(4):266–269.

Lindau ST, Schumm LP, Laumann EO, et al. A study of sexuality and health among older adults in the United States. *N Engl J Med*. 2007;357(8):762–774.

Linn R, Ginesin Y, et al. Treatment of sildenafil as part of the treatment in premature ejaculation. *Int J Imp Res*. 2002;14(Suppl 4):S39 [abstract P-168].

Lipshultz LI, McConnell J, Benson GS, et al. Current concepts of the mechanisms of ejaculation. Normal and abnormal states. *J Reprod Med*. 1981;26(10):499–507.

Lozano AF. Premature ejaculation. Pharmacological treatment.Three years after. *Int J Imp Res*. 2003;15(Suppl 6):S11 [abstract MP-12-16].

Lucas MG, Hargreave TB, et al. Sperm retrieval by electro-ejaculation. Preliminary experience in patients with secondary anejaculation. *Br J Urol*. 1991;67(2):191–194.

MacDonald K, Feifel D. Dramatic improvement in sexual function induced by intranasal oxytocin. *J Sex Med*. 2012;9(5):1407–1410.

Madeo B, Bettica P, Milleri S, et al. The effects of citalopram and fluoxetine on sexual behavior in healthy men: evidence of delayed ejaculation and unaffected sexual desire. A randomized, placebo-controlled, double-blind, double-dummy, parallel group study. *J Sex Med*. 2008;5(10):2431–2441.

Madhusoodanan S, Brenner R. Risperidone-induced ejaculatory and urinary dysfunction. *J Clin Psychiatry*. 1996;57(11):549–550.

Mamas MA, Reynard JM, et al. Nitric oxide and the lower urinary tract: current concepts, future prospects. *Urology*. 2003;61(6):1079–1085.

Mantovani F. Pharmacological/dynamic rehabilitative behavioural therapy for premature ejaculation: results of a pilot study. *Arch Ital Urol Androl*. 2017;89(2):148–150.

Marangell L, Dennehy E, Wisniewski SR, et al. Case-control analyses of the impact of pharmacotherapy on prospectively observed suicide attempts and completed suicides in bipolar disorder: findings from STEP-BD. *J Clin Psychiatry*. 2008;69:916–922.

Marson L, Yu G, Farber NM. The effects of oral administration of d-modafinil on male rat ejaculatory behavior. *J Sex Med*. 2010;7(1 Pt 1):70–78.

Martyn-St James M, Cooper K, Kaltenthaler E, et al. Tramadol for premature ejaculation: a systematic review and meta-analysis. *BMC Urol*. 2015;15(1):6.

Martyn-St James M, Cooper K, Ren S, et al. Phosphodiesterase type 5 inhibitors for premature ejaculation: a systematic review and meta-analysis. *Eur Urol Focus*. 2017;3(1):119–129.

Masters WH, Johnson VE. *Human sexual inadequacy*. Little Brown: Boston; 1970.

Mathers MJ, Klotz T, Roth S, et al. Safety and efficacy of vardenafil versus sertraline in the treatment of premature ejaculation: a randomised, prospective and crossover study.

Andrologia. 2009;41(3):169–175.

Mattos RM, Lucon AM. Tadalafil and slow-release fluoxetine in premature ejaculation - a prospective study. *J Urol*. 2005;173(4):239–abst.880.

Mattos RM, Marmo Lucon A, Srougi M. Tadalafil and fluoxetine in premature ejaculation: prospective, randomized, double-blind, placebo-controlled study. *Urol Int*. 2008;80(2):162–165.

McMahon C, Abdo C, Incrocci L, et al. *Disorders of orgasm and ejaculation in men. Sexual Medicine: Sexual Dysfunctions in Men and Women (2nd International Consultation on Sexual Dysfunctions)*. [Paris, Health Publications: 409-468] 2004.

McCabe MP. Intimacy and quality of life among sexually dysfunctional men and women. *J Sex Marital Ther*. 1997;23(4):276–290.

McCarthy B. Strategies and techniques for the treatment of ejaculatory inhibition. *J Sex Ed Ther*. 1981;7(2):20–23.

McCarthy B. Cognitive-behavioural strategies and techniques in the treatment of early ejaculation. Leiblum SR, Rosen R, Hargreave TB. *Principles and Practices of Sex Therapy: update for the 1990's*. Guilford Press: New York; 1988:141–167.

McCormick S, Olin J, Brotman AW. Reversal of fluoxetine-induced anorgasmia by cyproheptadine in two patients. *J Clin Psychiatry*. 1990;51(9):383–384.

McDiarmid T, Mackler L, Schneider DM. Clinical inquiries. What is the addiction risk associated with tramadol? *J Fam Pract*. 2005;54(1):72–73.

McKenna G, Schousboe M, Paltridge G. Subjective change in ejaculate as symptom of infection with schistosoma haematobium in travellers. *Br Med J*. 1997;315:1000–1001.

McMahon CG. Long term results of treatment of premature ejaculation with selective serotonin re-uptake inhibitors. *Int.J Impotence Res*. 2002;14(Suppl 3):S19.

McMahon CG. The etiology and management of premature ejaculation. *Nat Clin Pract Urol*. 2005;2(9):426–433.

McMahon CG. Clinical trial methodology in premature ejaculation observational, interventional, and treatment preference studies–part I–defining and selecting the study population. *J Sex Med*. 2008;5(8):1805–1816.

McMahon CG. The DSM-IV-TR definition of premature ejaculation and its impact upon the results of epidemiological studies. *Eur Urol*. 2008;53(5):887–889.

McMahon CG. Screening for erectile dysfunction in men with lifelong premature ejaculation–Is the Sexual Health Inventory for Men (SHIM) reliable? *J Sex Med*. 2009;6(2):567–573.

McMahon CG, Abdo C, Incrocci L, et al. Disorders of orgasm and ejaculation in men. *J Sex Med*. 2004;1(1):58–65.

McMahon CG, Althof S, Waldinger MD, et al. An evidence-based definition of lifelong premature ejaculation: report of the International Society for Sexual Medicine Ad Hoc Committee for the Definition of Premature Ejaculation. *BJU Int*. 2008;102(3):338–350.

McMahon CG, Althof SE, Kaufman JM, et al. Efficacy and safety of dapoxetine for the treatment of premature ejaculation: integrated analysis of results from five phase 3 trials. *J Sex Med*. 2011;8(2):524–539.

McMahon CG, Althof SE, Waldinger MD, et al. An evidence-based definition of lifelong premature ejaculation: report of the International Society for Sexual Medicine (ISSM) ad hoc committee for the definition of premature ejaculation. *J Sex Med*. 2008;5(7):1590–1606.

McMahon CG, Giuliano F, Dean J, et al. Efficacy and safety of dapoxetine in men with premature ejaculation and concomitant erectile dysfunction treated with a phosphodiesterase type 5 inhibitor: randomized, placebo-controlled, phase III study. *J Sex Med*. 2013;10(9):2312–2325.

McMahon CG, Jannini E, et al. Standard operating procedures in the disorders of orgasm and ejaculation. *J Sex Med*. 2013;10(1):204–229.

McMahon CG, McMahon CN, Leow LJ, et al. Efficacy of type-5 phosphodiesterase inhibitors in the drug treatment of premature ejaculation: a systematic review. *BJU Int*. 2006;98(2):259–272.

McMahon CG, Osterloh IH, et al. A phase IIA study to investigate the efficacy and safety of the selective oxytocin receptor antagonist, IX-01, in men with lifelong premature ejaculation. *J Urol*. 2017;1997(4):e1344.

McMahon CG, Stuckey B, Andersen M, et al. Efficacy of Viagra: sildenafil citrate in men with premature ejaculation. *J Sex Med*. 2005;2(3):368–375.

McMahon CG, Touma K. Treatment of premature ejaculation with paroxetine hydrochloride as needed: 2 single-blind placebo controlled crossover studies. *J Urol*. 1999;161(6):1826–1830.

McMahon CG, Waldinger M, et al. *Ejaculatory disorders. Standard practice in sexual medicine*. Blackwell Publishing: Oxford UK; 2006:188–209.

Mehta A, Sigman M. Management of the dry ejaculate: a systematic review of aspermia and retrograde ejaculation. *Fertil Steril*. 2015;104(5):1074–1081.

Mens WB, Witter A, van Wimersma Griedanus TB, et al. Penetration of neurohypophyseal hormones from plasma into cerebrospinal fluid (CSF): half-times of disappearance of these neuropeptides from CSF. *Brain Res*. 1983;262(1):143–149.

Meston CM, Buss DM. Why humans have sex. *Arch Sex Behav*.

2007;36(4):477–507.

Metz M, McCarthy B. *Coping with premature ejaculation: how to overcome PE, please your partner and have great sex*. New Harbinber Publications: Oakland (CA); 2003.

Michel MC. Alpha1-adrenoceptors and ejaculatory function. *Br J Pharmacol*. 2007;152(3):289–290.

Mittino D, Mula M, Monaco F, et al. Serotonin syndrome associated with tramadol-sertraline coadministration. *Clin Neuropharmacol*. 2004;27(3):150–151.

Mohr D, Bentler L. Erectile dysfunction: a review of diagnostic and treatment procedures. *Clin Psychol Rev*. 1990;10:123–150.

Montague DK, Jarow J, Broderick GA, et al. AUA guideline on the pharmacologic management of premature ejaculation. *J Urol*. 2004;172(1):290–294.

Montejo AL, Llorca G, Izquierdo JA, et al. Incidence of sexual dysfunction associated with antidepressant agents: a prospective multicenter study of 1022 outpatients. Spanish Working Group for the Study of Psychotropic-Related Sexual Dysfunction. *J Clin Psychiatry*. 2001;62(Suppl 3):10–21.

Montorsi F. Prevalence of premature ejaculation: a global and regional perspective. *J Sex Med Suppl*. 2005;2.

Morgentaler A, Polzer P, Altof S, et al. Delayed ejaculation and associated complaints: relationship to ejaculation times and serum testosterone levels. *J Sex Med*. 2017;14(9):1116–1124.

Morris BJ, Krieger JN. Does male circumcision affect sexual function, sensitivity, or satisfaction?–a systematic review. *J Sex Med*. 2013;10(11):2644–2657.

Munjack DJ, Kanno PH. Retarded ejaculation: a review. *Arch Sex Behav*. 1979;8(2):139–150.

Nathan SG. The epidemiology of the DSM-III psychosexual dysfunctions. *J Sex Marital Ther*. 1986;12(4):267–281.

Nickel JC, Elhilali M, Vallencien G, et al. Benign prostatic hyperplasia (BPH) and prostatitis: prevalence of painful ejaculation in men with clinical BPH. *BJU Int*. 2005;95(4):571–574.

Nicolosi A, Laumann E, Glasser DB, et al. Global study of sexual attitudes and behaviors investigator's group. Sexual behavior and sexual dysfunctions after age 40: the global study of sexual attitudes and behaviors. *Urology*. 2004;64:991–997.

Nikolettos N, Al-Hasani S, Baukloh V, et al. The outcome of intracytoplasmic sperm injection in patients with retrograde ejaculation. *Hum Reprod*. 1999;14(9):2293–2296.

Ochsenkuhn R, Kamischke A, Nieschlag E. Imipramine for successful treatment of retrograde ejaculation caused by retroperitoneal surgery. *Int J Androl*. 1999;22(3):173–177.

O'Donohue W, Letourneau EJ, et al. *Premature ejaculation*. Simon and Schuster; 1993.

Ohl DA, Bennett CJ, McCabe M, et al. Predictors of success in electroejaculation of spinal cord injured men. *J Urol*. 1989;142(6):1483–1486.

Ohman JL Jr, Malkiel S, Lewis S, et al. Allergy to human seminal fluid: characterization of the allergen and experience with immunotherapy. *J Allergy Clin Immunol*. 1990;85(1 Pt 1):103–107.

Paduch DA, Bolyakov A, Beardsworth A, et al. Factors associated with ejaculatory and orgasmic dysfunction in men with erectile dysfunction: analysis of clinical trials involving the phosphodiesterase type 5 inhibitor tadalafil. *BJU Int*. 2012;109(7):1060–1067.

Paduch DA, Polzer P, Morgentaler A, et al. Clinical and demographic correlates of ejaculatory dysfunctions other than premature ejaculation: a prospective, observational study. *J Sex Med*. 2015;12(12):2276–2286.

Park HJ, Park NC, Kim TN, et al. Discontinuation of dapoxetine treatment in patients with premature ejaculation: a 2-year prospective observational study. *Sex Med*. 2017;5(2):e99–e105.

Park HS, Jung IS, Lim NH, et al. Proof of mechanism study of a novel serotonin transporter blocker, DA-8031, using [11C]DASB positron emission tomography and in vivo microdialysis. *Urology*. 2014;84(1):245 e241–245 e247.

Patrick DL, Althof SE, Pryor JL, et al. Premature ejaculation: an observational study of men and their partners. *J Sex Med*. 2005;2(3):358–367.

Patrick DL, Giuliano F, Ho KF, et al. The premature ejaculation profile: validation of self-reported outcome measures for research and practice. *BJU Int*. 2008;103:358–367.

Patrick DL, Rowland D, et al. Interrelationships among measures of premature ejaculation: the central role of perceived control. *J Sex Med*. 2007;4(3):780–788.

Perelman M. Sildenafil, sex therapy, and retarded ejaculation. *J Sex Educ Ther*. 2001;26(1):13–21.

Perelman M. Sex coaching for physicians: combination treatment for patient and partner. *Int J Impot Res*. 2003;15:S67–S74.

Perelman M. Retarded ejaculation. *Curr Sex Hlth Rep*. 2004;1(3):95–101.

Perelman M. Idiosyncratic masturbation patterns: a key unexplored variable in the treatment of retarded ejaculation by the practicing urologist. *J Urol*. 2005;173(Suppl 3):S340.

Perelman M. A new combination treatment for premature ejaculation. A sex therapist's perspective. *J Sex Med*. 2006;3:1004–1012.

Perelman MA. Sex coaching for physicians: combination treatment for patient and partner. *Int J Impot Res*. 2003;15(Suppl 5):S67–S74.

Perelman MA. A new combination treatment for premature ejaculation: a sex therapist's perspective. *J Sex Med*. 2006;3(6):1004–1012.

Perelman MA, Rowland DL. Retarded ejaculation. *World J Urol*. 2006;24(6):645–652.

Peroutka SJ, Snyder SH. Multiple serotonin receptors: differential binding of [3H]5-hydroxytryptamine, [3H]lysergic acid diethylamide and [3H]spiroperidol. *Mol Pharmacol*. 1979;16(3):687–699.

Peugh J, Belenko S. Alcohol, drugs and sexual function: a review. *J Psychoactive Drugs*. 2001;33(3):223–232.

Philip J, Manikandan R, et al. Ejaculatory-duct calculus causing secondary obstruction and infertility. *Fertil Steril*. 2007;88(3):706 e709–706 e711.

Porst H, McMahon CG, Altoff SE, et al. Baseline characteristics and treatment outcomes for men with acquired or lifelong premature ejaculation with mild or no erectile dysfunction: integrated analyses of two phase 3 dapoxetine trials. *J Sex Med*. 2010;7(6):2231–2242.

Porst H, Montorsi F, Rosen RC, et al. The Premature Ejaculation Prevalence and Attitudes (PEPA) survey: prevalence, comorbidities, and professional help-seeking. *Eur Urol*. 2007;51(3):816–823 [discussion 824].

Previnaire JG, Lecourt G, Soler JM, et al. Sexual disorders in men with multiple sclerosis: evaluation and management. *Ann Phys Rehabil Med*. 2014;57(5):329–336.

Proctor KG, Howards SS. The effect of sympathomimetic drugs on post-lymphadenectomy aspermia. *J Urol*. 1983;129(4):837–838.

Pryor JL, Althof SE, Steidle C, et al. Efficacy and tolerability of dapoxetine in treatment of premature ejaculation: an integrated analysis of two double-blind, randomised controlled trials. *Lancet*. 2006;368(9539):929–937.

Pryor JL, Broderick GA, et al. Comparison of estimated versus measured intravaginal ejaculatory latency time (IELT) in men with and without premature ejaculation (PE). *J Sex Med*. 2005;3(1):54 [abstract 126].

Pryor JL, Broderick GA, et al. Comparison of estimated versus measured intravaginal ejaculatory latency time in men with and without premature ejaculation. *J Sex Med*. 2005;3:54.

Pryor JP, Hendry WF. Ejaculatory duct obstruction in subfertile males: analysis of 87 patients. *Fertil Steril*. 1991;56(4):725–730.

Qu WM, Huang ZL, Xu XH, et al. Dopaminergic D1 and D2 receptors are essential for the arousal effect of modafinil. *J Neurosci*. 2008;28(34):8462–8469.

Quinlan DM, Epstein JI, Carter BS, et al. Sexual function following radical prostatectomy: influence of preservation of neurovascular bundles. *J Urol*. 1991;145:998–1002.

Raja M. Risperidone-induced absence of ejaculation. *Int Clin Psychopharmacol*. 1999;14(5):317–319.

Reading A, Wiest W. An analysis of self-reported sexual behavior in a sample of normal males. *Arch Sex Behav*. 1984;13:69–83.

Regenthal R, Koch H, Koghler C, et al. Depression-like deficits in rats improved by subchronic modafinil. *Psychopharmacology (Berl)*. 2009;204(4):627–639.

Reiser C. The etiology of retrograde ejaculation and a method for insemination. *Fertil Steril*. 1961;12:488–492.

Riley A, Riley E. Premature ejaculation: presentation and associations. An audit of patients attending a sexual problems clinic. *Int J Clin Pract*. 2005;59(12):1482–1487.

Rodriguez-Pena ML, Rodriguez-Manzo G, Carro-Juarez M, et al. Ejaculatory training lengthens the ejaculation latency and facilitates the functioning of the spinal generator for ejaculation of rats with rapid ejaculation. *Int J Impot Res*. 2017;29(1):35–42.

Roehrborn CG, Kaplan SA, Lepor H, et al. Symptomatic and urodynamic responses in patients with reduced or no seminal emission during silodosin treatment for LUTS and BPH. *Prostate Cancer Prostatic Dis*. 2011;14(2):143–148.

Roke Y, van Harten PN, Buitelaar JK, et al. Antipsychotic-induced hyperprolactinemia and testosterone levels in boys. *Horm Res Paediatr*. 2012;77(4):235–240.

Rosen R, Altwein J, Boyle P, et al. Lower urinary tract symptoms and male sexual dysfunction: the multinational survey of the aging male (MSAM-7). *Eur Urol*. 2003;44(6):637–649.

Rosen R, McMahon C, Niederberger C, et al. Correlates to the clinical diagnosis of premature ejaculation: results from a large observational study of men and their partners. *J Urol*. 2007;177:1059–1064.

Rosen RC, Althof S. Impact of premature ejaculation: the psychological, quality of life, and sexual relationship consequences. *J Sex Med*. 2008;5(6):1296–1307.

Rosen RC, Riley A, Wagner G, et al. The international index of erectile function (IIEF): a multidimensional scale for assessment of erectile dysfunction. *Urology*. 1997;49(6):822–830.

Rowland D, McMahon CG, Abdo C, et al. Disorders of orgasm and ejaculation in men. *J Sex Med*. 2010;7(4 Pt 2):1668–1686.

Rowland D, Perelman M, Althof S, et al. Self-reported premature ejaculation and aspects of sexual functioning and satisfaction. *J Sex Med*. 2004;1(2):225–232.

Rowland D, van Diest S, Incrocci L, et al. Psychosexual factors that differentiate men with inhibited ejaculation from men with no dysfunction or another sexual dysfunction. *J Sex Med*. 2005;2(3):383–389.

Rowland DL, Keeney C, Slob AK. Sexual response in men with inhibited or retarded ejaculation. *Int J Impot Res*. 2004;16(3):270–274.

Rowland DL, Patrick DL, Rothman M, et al. The psychological burden of premature ejaculation. *J Urol*. 2007;177(3):1065–1070.

Rowland DL, Strassberg DS, de Gouveia CA, et al. Ejaculatory latency and control in men with premature ejaculation: an analysis across sexual activities using multiple sources of information. *J Psychosom Res*. 2000;48(1):69–77.

Rowland DL, Van Diest S, Incrocci L, et al. Psychosexual factors that differentiate men with inhibited ejaculation from men with no dysfunction or with another dysfunction. *J Sex Med*. 2005;2:383–389.

Rust J, Golombok S, Collier J. Marital problems and sexual dysfunction: how are they related? *Br J Psychiatry*. 1988;152:629–631.

Salem EA, Wilson SK, Bissada NK, et al. Tramadol HCL has promise in on-demand use to treat premature ejaculation. *J Sex Med*. 2008;5(1):188–193.

Salonia A, Maga T, Colombo R, et al. A prospective study comparing paroxetine alone versus paroxetine plus sildenafil in patients with premature ejaculation. *J Urol*. 2002;168(6):2486–2489.

Salonia A, Rocchini L, Sacca A, et al. Acceptance of and discontinuation rate from paroxetine treatment in patients with lifelong premature ejaculation. *J Sex Med*. 2009;6:2868–2877.

Sanofi-Aventis. *Alfuzosin prescribing information*. [(website)] http://products.sanofi.us/uroxatral/uroxatral.html#Patient; 2014.

Sato Y, Tanda H, Nakajima H, et al. Silodosin and its potential for treating premature ejaculation: a preliminary report. *Int J Urol*. 2012;19(3):268–272.

Schapiro B. Premature ejaculation, a review of 1130 cases. *J Urol*. 1943;50:374–379.

Schein M, Zyzanski SJ, Levine S, et al. The frequency of sexual problems among family practice patients. *J Fam Pract Res*. 1988;7(3):122–134.

Schover LR, Gonzales M, von Eschenbach AC, et al. Sexual and marital relationships after radiotherapy for seminoma. *Urology*. 1986;27:117–123.

Screponi E, Carosa E, et al. Prevalence of chronic prostatitis in men with premature ejaculation. *Urology*. 2001;58(2):198–202.

Serefoglu E, Cimen H, et al. Turkish validation of the Premature Ejaculation Diagnostic Tool and its association with intravaginal ejaculatory latency time. *Int J Impot Res*. 2009;21:139–144.

Serefoglu EC, Cimen HI, Atmaca AF, et al. The distribution of patients who seek treatment for the complaint of ejaculating prematurely according to the four premature ejaculation syndromes. *J Sex Med*. 2010;7(2 Pt 1):810–815.

Serefoglu EC, Hawley WR, Lasker GF, et al. Effect of botulinum-A toxin injection into bulbospongiosus muscle on ejaculation latency in male rats. *J Sex Med*. 2014;11(7):1657–1663.

Serefoglu EC, McMahon CG, Waldinger MD, et al. An evidence-based unified definition of lifelong and acquired premature ejaculation: report of the second international society for sexual medicine ad hoc committee for the definition of premature ejaculation. *Sex Med*. 2014;2(2):41–59.

Serefoglu EC, Silay MS. Botulinum toxin-A injection may be beneficial in the treatment of life-long premature ejaculation. *Med Hypotheses*. 2010;74(1):83–84.

Serefoglu EC, Yaman O, Cayan S, et al. Prevalence of the complaint of ejaculating prematurely and the four premature ejaculation syndromes: results from the Turkish Society of Andrology Sexual Health Survey. *J Sex Med*. 2011;8(2):540–548.

Shamloul R, el-Nashaar A. Chronic prostatitis in premature ejaculation: a cohort study in 153 men. *J Sex Med*. 2006;3(1):150–154.

Shapiro B. Premature ejaculation: a review of 1130 cases. *J Urol*. 1943;50:6.

Sharif H, Hou S. Autonomic dysreflexia: a cardiovascular disorder following spinal cord injury. *Neural Regen Res*. 2017;12(9):1390–1400.

Sharlip ID. Guidelines for the diagnosis and management of premature ejaculation. *J Sex Med*. 2006;3(Suppl 4):309–317.

Shi WG, Wang XJ, Liang XQ, et al. [Selective resection of the branches of the two dorsal penile nerves for primary premature ejaculation]. *Zhonghua Nan Ke Xue*. 2008;14(5):436–438.

Shin D, Lee S, et al. Pharmacokinetics and tolerability of DA-8031, a novel selective serotonin reuptake inhibitor for premature ejaculation in healthy male subjects. *Drug Des Devel Ther*. 2017;11:713–723.

Shinghal R, Barnes A, Mahar KM, et al. Safety and efficacy of epelsiban in the treatment of men with premature ejaculation: a randomized, double-blind, placebo-controlled, fixed-dose study. *J Sex Med*. 2013;10(10):2506–2517.

Shoshany O, Abhyankar N, Elyaguov J, et al. Efficacy of treatment with pseudoephedrine in men with retrograde ejaculation. *Andrology*. 2017;5(4):744–748.

Sigman M, Howards SS. Male infertility. Walsh PC, Retik AB, Darracott Vaughan E Jr, et al. *Campbell's urology*. ed 7. WB Saunders Company: Philadelphia; 1998.

Simons JS, Carey MP. Prevalence of sexual dysfunctions:

results from a decade of research. *Arch Sex Behav*. 2001;30(2):177–219.

Simpson LL. The origin, structure, and pharmacological activity of botulinum toxin. *Pharmacol Rev*. 1981;33(3):155–188.

Sommer F, Klotz T, et al. Treatment of premature ejaculation: a comparative vardenafil and SSRI crossover study. *J Urol*. 2005;173(4):202 [abstract 741].

Sonksen J, Biering-Sorensen F, Kiristensen AK, et al. Ejaculation induced by penile vibratory stimulation in men with spinal cord injuries. The importance of the vibratory amplitude. *Paraplegia*. 1994;32(10):651–660.

Sonksen J, Ohl DA. Penile vibratory stimulation and electroejaculation in the treatment of ejaculatory dysfunction. *Int J Androl*. 2002;25(6):324–332.

Sotomayor M. The burden of premature ejaculation: the patient's perspective. *J Sex Med*. 2005;2(Suppl 2):110–114.

Spector IP, Carey M. Incidence and prevalence of the sexual dysfunctions: a critical review of the empirical literature. *Arch Sex Behav*. 1990;19:389.

Spector IP, Carey MP. Incidence and prevalence of the sexual dysfunctions: a critical review of the empirical literature. *Arch Sex Behav*. 1990;19(4):389–408.

Spector KR, Boyle M. The prevalence and perceived aetiology of male sexual problems in a non-clinical sample. *Br J Med Psychol*. 1986;59(Pt 4):351–358.

St Lawrence JS, Madakasira S. Evaluation and treatment of premature ejaculation: a critical review. *Int J Psychiatry Med*. 1992;22(1):77–97.

Steinberger RE, Ohl DA, Bennett CJ, et al. Nifedipine pretreatment for autonomic dysreflexia during electroejaculation. *Urology*. 1990;36(3):228–231.

Stoneham MD, Everitt BJ, Hansen S, et al. Oxytocin and sexual behaviour in the male rat and rabbit. *J Endocrinol*.

1985;107(1):97–106.

Strassberg DS, de Gouveia Brazao CA, Rowland DL, et al. Clomipramine in the treatment of rapid (premature) ejaculation. *J Sex Marital Ther*. 1999;25(2):89–101.

Striepens N, Kendrick KM, Hanking V, et al. Elevated cerebrospinal fluid and blood concentrations of oxytocin following its intranasal administration in humans. *Sci Rep*. 2013;3:3440.

Sun XZ, Deng CH, et al. [A clinical study of sertralin and vardenafil in the treatment of premature ejaculation complicated by erectile dysfunction]. *Zhonghua Nan Ke Xue*. 2007;13(7):610–612.

Sunay D, Sunay M, Aydogmus Y, et al. Acupuncture versus paroxetine for the treatment of premature ejaculation: a randomized, placebo-controlled clinical trial. *Eur Urol*. 2011;59(5):765–771.

Symonds T, Perelman M, Altof S, et al. Further evidence of the reliability and validity of the premature ejaculation diagnostic tool. *Int J Impotence Res*. 2007;19:521–525.

Symonds T, Perelman M, Altof S, et al. Development and validation of a premature ejaculation diagnostic tool. *Eur Urol*. 2007;52:565–573.

Symonds T, Roblin D, Hart K, et al. How does premature ejaculation impact a man's life? *J Sex Marital Ther*. 2003;29(5):361–370.

Szkutnik-Fiedler D, Kus K, Balcerkiewicz M, et al. Concomitant use of tramadol and venlafaxine - evaluation of antidepressant-like activity and other behavioral effects in rats. *Pharmacol Rep*. 2012;64(6):1350–1358.

Takeshita J, Litzinger M. Serotonin syndrome associated with tramadol. Prim Care Companion. *J Clin Psychiary*. 2009;11(5):273.

Tang W, Ma L, Zhou L, et al. [Clinical efficacy of Viagra with behavior therapy against premature ejaculation]. *Zhonghua Nan Ke Xue*. 2004;10(5):366–367 [370].

Tanrikut C, Feldman AS, Altemus M, et al. Adverse effect of paroxetine on sperm. *Fertil Steril*. 2010;94(3):1021–1026.

Tian Y, Liu W, Wang JZ, et al. Effects of circumcision on male sexual functions: a systematic review and meta-analysis. *Asian J Androl*. 2013;15(5):662–666.

Tinkler SD, Howard GC, et al. Sexual morbidity following radiotherapy for germ cell tumors of the testis. *Radiother Oncol*. 1992;25(3):207–212.

Tubaro A, Polito M, Giambroni L, et al. Sexual function in patients with LUTS suggestive of BPH. *Eur Urol*. 2001;40(Suppl 1):19–22.

Tuken M, Kiremit MC, Serefoglu EC, et al. On-demand modafinil improves ejaculation time and patient-reported outcomes in men with lifelong premature ejaculation. *Urology*. 2016;94:139–142.

Uckert S, Becker AJ, Ness BO, et al. Oxytocin plasma levels in the systemic and cavernous blood of healthy males during different penile conditions. *World J Urol*. 2003;20(6):323–326.

Vallancien G, Emberton M, Harving N, et al. Sexual dysfunction in 1,274 European men suffering from lower urinary tract symptoms. *J Urol*. 2003;169(6):2257–2261.

van Basten JP, Jonker-Pool G, Van Driel MF, et al. Sexual functioning after multimodality treatment for disseminated nonseminomatous testicular germ cell tumor. *J Urol*. 1997;158(4):1411–1416.

Van Heeringen C, De Schryver A, et al. Sexual function disorders after local radiotherapy for carcinoma of the prostate. *Radiother Oncol*. 1988;13:47–52.

van Moorselaar RJ, Hartung R, Emberton M, et al. Alfuzosin 10 mg once daily improves sexual function in men with lower urinary tract symptoms and concomitant sexual dysfunction. *BJU Int*. 2005;95(4):603–608.

Vandereycken W. Towards a better delineation of ejaculatory disorders. *Acta Psychiatr Belg*. 1986;86(1):57–63.

Veening JG, Coolen LM. Neural mechanisms of sexual behavior in the male rat: emphasis on ejaculation-related circuits. *Pharmacol Biochem Behav*. 2014;121:170–183.

Ventus D, Jern P. Lifestyle factors and premature ejaculation: are physical exercise, alcohol consumption, and body mass index associated with premature ejaculation and comorbid erectile problems? *J Sex Med*. 2016;13(10):1482–1487.

Verze P, Cai T, Magno C, et al. Comparison of treatment emergent adverse events in men with premature ejaculation treated with dapoxetine and alternate oral treatments: results from a large multinational observational trial. *J Sex Med*. 2016;13(2):194–199.

Vignozzi L, Filippi S, Luconi M, et al. Oxytocin receptor is expressed in the penis and mediates an estrogen-dependent smooth muscle contractility. *Endocrinology*. 2004;145(4):1823–1834.

Walch K, Eder R, Schindler A, et al. The effect of single-dose oxytocin application on time to ejaculation and seminal parameters in men. *J Assist Reprod Genet*. 2001;18(12):655–659.

Waldinger M. The neurobiological approach to premature ejaculation. *J Urol*. 1998;168:2359–2367.

Waldinger M, Hengeveld M, Zwinderman AH, et al. An empirical operationalization of DSM-IV diagnostic criteria for premature ejaculation. *Int J Psychiatry Clin Pract*. 1998;2:287–293.

Waldinger M, Zwinderman A, Schweitzer DH, et al. Relevance of methodological design for the interpretation of efficacy of drug treatment of premature ejaculation: a systematic review and metaanalysis. *Int J Impotence Res*. 2004;1-13.

Waldinger MD. The neurobiological approach to premature ejaculation. *J Urol*. 2002;168(6):2359–2367.

Waldinger MD. The need for a revival of psychoanalytic investigations into premature ejaculation. *J Mens Health Gender*. 2006;3:6.

Waldinger MD. Premature ejaculation: definition and drug treatment. *Drugs*. 2007;67(4):547–568.

Waldinger MD. History of premature ejaculation. McMahon C, Jannini EA, Waldinger MD. *Premature ejaculation: from etiology to diagnosis and treatment*. Springer: New York; 2013:5–24.

Waldinger MD, Hengeveld MW, Zwinderman AH. Paroxetine treatment of premature ejaculation: a double blind, randomized, placebo controlled study. *Am J Psychiatry*. 1994;151(9):1377–1379.

Waldinger MD, Hengeveld MW, Zwinderman AH, et al. An empirical operationalization study of DSM-IV diagnostic criteria for premature ejaculation. *Int J Psychiatry Clin Pract*. 1998;2:6.

Waldinger MD, McIntosh J, Schweitzer DH. A five-nation survey to assess the distribution of the intravaginal ejaculatory latency time among the general male population. *J Sex Med*. 2009;6(10):2888–2895.

Waldinger MD, Meinardi MM, Scweitzer DH. Hyposensitization therapy with autologous semen in two Dutch caucasian males: beneficial effects in Postorgasmic Illness Syndrome (POIS; Part 2). *J Sex Med*. 2011;8(4):1171–1176.

Waldinger MD, Meinardi MM, Zwinderman AH, et al. Postorgasmic Illness Syndrome (POIS) in 45 Dutch caucasian males: clinical characteristics and evidence for an immunogenic pathogenesis (Part 1). *J Sex Med*.

2011;8(4):1164–1170.

Waldinger MD, Olivier B. Animal models of premature and retarded ejaculation. *World J Urol*. 2005;23(2):115–118.

Waldinger MD, Quinn P, Dilleen M, et al. A multinational population survey of intravaginal ejaculation latency time. *J Sex Med*. 2005;2(4):492–497.

Waldinger MD, Schweitzer DH. Postorgasmic illness syndrome: two cases. *J Sex Marital Ther*. 2002;28(3):251–255.

Waldinger MD, Schweitzer DH. Retarded ejaculation in men: an overview of psychological and neurobiological insights. *World J Urol*. 2005;4:4.

Waldinger MD, Schweitzer DH. Changing paradigms from a historical DSM-III and DSM-IV view toward an evidence-based definition of premature ejaculation. Part I–validity of DSM-IV-TR. *J Sex Med*. 2006;3(4):682–692.

Waldinger MD, Schweitzer DH. Changing paradigms from a historical DSM-III and DSM-IV view toward an evidence-based definition of premature ejaculation. Part II–proposals for DSM-V and ICD-11. *J Sex Med*. 2006;3(4):693–705.

Waldinger MD, Schweitzer DH. The use of old and recent DSM definitions of premature ejaculation in observational studies: a contribution to the present debate for a new classification of PE in the DSM-V. *J Sex Med*. 2008;5(5):1079–1087.

Waldinger MD, van Coevorden RS, Schweitzer DH, et al. Penile anesthesia in Post SSRI Sexual Dysfunction (PSSD) responds to low-power laser irradiation: a case study and hypothesis about the role of transient receptor potential (TRP) ion channels. *Eur J Pharmacol*. 2015;753:263–268.

Waldinger MD, Zwinderman AH, Olivier B, et al. On-demand treatment of premature ejaculation with clomipramine and paroxetine: a randomized, double-blind fixed-dose study with stopwatch assessment. *Eur Urol*. 2004;46(4):510–515 [discussion 516].

Waldinger MD, Zwinderman AH, Olivier B, et al. Proposal for a definition of lifelong premature ejaculation based on epidemiological stopwatch data. *J Sex Med*. 2005;2(4):498–507.

Waldinger MD, Zwinderman AH, et al. Thyroid-stimulating hormone assessments in a dutch cohort of 620 men with lifelong premature ejaculation without erectile dysfunction. *J Sex Med*. 2005;2(6):865–870.

Waldinger MD, Zwinderman AH, Olivier B, et al. The majority of men with lifelong premature ejaculation prefer daily drug treatment: an observation study in a consecutive group of Dutch men. *J Sex Med*. 2007;4(4 Pt 1):1028–1037.

Waldinger MD, Zwinderman AH, Schweitzer DH, et al. Relevance of methodological design for the interpretation of efficacy of drug treatment of premature ejaculation: a systematic review and meta-analysis. *Int J Impot Res*. 2004;16(4):369–381.

Weintraub MP, De Mouy E, Hellstrom WJ, et al. Newer modalities in the diagnosis and treatment of ejaculatory duct obstruction. *J Urol*. 1993;150(4):1150–1154.

Wheeler JS Jr, Walter JS, Culkin DJ, et al. Idiopathic anejaculation treated by vibratory stimulation. *Fertil Steril*. 1988;50(2):377–379.

Wieder JA, Brackett NL, Lynne CM, et al. Anesthetic block of the dorsal penile nerve inhibits vibratory-induced ejaculation in men with spinal cord injuries. *Urology*. 2000;55(6):915–917.

Wincze JP, Carey MP. *Sexual dysfunction: a guide for assessment and treatment*. Guilford: New York; 1991.

Witt DM, Insel TR. Increased Fos expression in oxytocin neurons following masculine sexual behavior. *J Neuroendocrinol*. 1994;6(1):13–18.

Wittstock M, Benecke R, Dressler D. Cabergoline can increase penile erections and libido. *Neurology*. 2002;58(5):831.

World Health Organization. *International classification of diseases and related health problems*. ed 10. World Health Organization: Geneva; 1994.

Wu T, Yue X, Duan X, et al. Efficacy and safety of tramadol for premature ejaculation: a systematic review and meta-analysis. *Urology*. 2012;80(3):618–624.

Xiong GG, Wu FH, et al. Safety and efficacy of tramadol hydrochloride with behavioral modification in the treatment of premature ejaculation. *Zhonghua Nan Ke Xue*. 2011;17(6):538–541.

Yanagimoto M, Honda K, Goto Y, et al. Afferents originating from the dorsal penile nerve excite oxytocin cells in the hypothalamic paraventricular nucleus of the rat. *Brain Res*. 1996;733(2):292–296.

Yang L, Qian S, Liu H, et al. Role of tramadol in premature ejaculation: a systematic review and meta-analysis. *Urol Int*. 2013;91(2):197–205.

Yoshida M, Kudoh J, Homma Y, et al. Safety and efficacy of silodosin for the treatment of benign prostatic hyperplasia. *Clin Interv Aging*. 2011;6:161–172.

Yuan Y, Xin ZC, Jiang H, et al. Sexual function of premature ejaculation patients assayed with the Chinese Index of Premature Ejaculation. *Asian J Androl*. 2004;6:121–126.

Zhang X, Gao J, Liu J, et al. Distribution and factors associated with four premature ejaculation syndromes in outpatients complaining of ejaculating prematurely. *J Sex Med*. 2013.

Zhang XS, Wang YX, Huang XY, et al. [Comparison between sildenafil plus sertraline and sertraline alone in the treatment of premature ejaculation]. *Zhonghua Nan Ke Xue*. 2005;11(7):520–522 [525].

Zilbergeld B. *Male sexuality*. Bantam: Toronto; 1978.

Zohdy W. Clinical parameters that predict successful outcome in men with premature ejaculation and inflammatory prostatitis. *J Sex Med*. 2009;6(11):3139–3146.

Surgery for Erectile Dysfunction

Matthew J. Mellon MD, FACS, John J. Mulcahy MD, PhD, FACS

Modern penile implants were marketed for the treatment of erectile dysfunction (ED) almost 50 years ago with the introduction of the three-piece inflatable implant by Dr. Scott and the semirigid rod prosthesis by Dr. Small and Dr. Carrion (Scott et al., 1972; Small, 1978). Before that time there were rudimentary penile stiffeners, which gave variable support to the erection but were inconsistently reliable. At that time these devices were the only effective treatment for ED, but as the years progressed, medical therapies in the form of oral medication, intracorporal injections, intraurethral pellets, and vacuum erection devices (VEDs) were marketed with varying success and acceptance. Penile implants have remained a very effective and satisfying treatment of ED, and improvements in design of the product and surgical placement and repair techniques have increased their longevity and functionality. Although satisfaction rates among patients and partners are 80% to 90% and repairs are seen in about 15% of units at 5 years and 30% at 10 years, they remain a secondary treatment of ED (Carson et al., 2000). They tend to be chosen by men who have a strong motivation to continue with sexual activity and who have failed the less-invasive ED treatments or have found them contraindicated or unacceptable. The current goal-directed approach to the patient with ED outlines the treatments available, offers a trial of each therapy as the patient wishes, and settles on that modality that is effective and appealing (Lue, 1990). The need for extensive testing to determine the exact cause of the dysfunction, as had been done in the past, has been proven to be costly and has not changed the therapeutic outcome. It has been reserved for rare and unusual cases.

Types of Implants Available

When penile implants were introduced in the early 1970s, there were two types: the Scott inflatable and the Small–Carrion sponge-filled semirigid rod. As these devices became popular, improvements in design, introduction of competitive models, and the appearance of other vendors to the marketplace fueled the growth of the field. At one point there were five companies selling penile implants. Throughout the 1980s and early 1990s sales of these devices grew almost exponentially each year and reached an apex in 1996 with about 33,000 units sold worldwide in that year. In the same year preliminary data on the effectiveness of sildenafil citrate (Viagra) in restoring fading erections were presented at various medical meetings, and with the resulting publicity implant sales plummeted to a nadir of 12,000 units the following year (Goldstein et al., 1998). The phosphodiesterase type 5 inhibitor (PDEI5) drugs were not universally effective, and implant sales gradually increased over the ensuing years.

Today there are two vendors of penile implants in the United States: Boston Scientific and Coloplast. Other vendors have exited the marketplace because of diminishing sales or corporate acquisition by larger vendors. Worldwide there are currently approximately 50,000 penile implants placed annually, about 24,000 in the United States. Boston Scientific (Marlborough, MA) and Coloplast (Minneapolis, MN) market their products internationally as well. Some foreign vendors do not distribute their products in the United States. Two of the larger foreign vendors are Zephyr Surgical Instruments (Geneva, Switzerland) and Promedon (Cordoba, Argentina).

There are two categories of penile implants, hydraulic and semirigid rod. The hydraulic group comprises the three-piece inflatable and the two-piece inflatable devices. The three-piece inflatable implant is composed of two cylinders with one placed in each corpus cavernosum. These are connected by tubing to a pump located in the scrotum, which, in turn, is connected to an abdominal reservoir. The function of the pump is to transfer fluid between the reservoir and the cylinders. The cylinders function as inner tubes in a bicycle tire and provide very good firmness to the erection when inflated, because they completely fill the interior of the erectile bodies. Because fluid can be totally evacuated from the cylinders, the penis becomes very loose in the flaccid state. **These two features, alternating exceptional rigidity and flaccidity, make the three-piece**

inflatable group the most popular device among implanting urologists and patients.

Boston Scientific markets three models of the three-piece inflatable device: (1) the AMS 700 LGX (Video 72.1), which expands in girth and may increase in length up to 25% and (2 and 3) the AMS 700 CX and AMS 700 CXR, which increase in girth only (Fig. 72.1). The CXR is a narrower version of the CX. Coloplast sells two versions of a three-piece inflatable implant, the Titan, and a narrower congener, the Titan narrow, which increase in girth only (Fig. 72.2). The two-piece inflatable implant, the Ambicor of Boston Scientific, comprises a scrotal pump and two cylinders, one placed in each corporal body. Pressing the pump pushes fluid from a reservoir chamber located in the proximal portion of each cylinder to the power chamber, the longer distal part of the cylinder (Fig. 72.3). Bending the penis 65 degrees from the horizontal and holding it in that position for 12 seconds transfers fluid back to the reservoir chamber. Only a small amount of fluid is transferred between the reservoir and power portions of the cylinder when alternating between erect and flaccid states, 6 mL in the larger sizes and 2 mL in the smaller sizes. The device is provided in three fixed girth sizes, and the penile rigidity is determined by the firmness of the cylinders, not the bicycle-tire innertube fit of the three-piece inflatable cylinders. The less the dead space around the cylinders in the corporal body, the greater the penile rigidity is. The rigidity and flaccidity afforded by the Ambicor is inferior to that afforded by the three-piece inflatables. It is chosen when a hydraulic device is desired, but placement of a reservoir in the pelvis is not feasible.

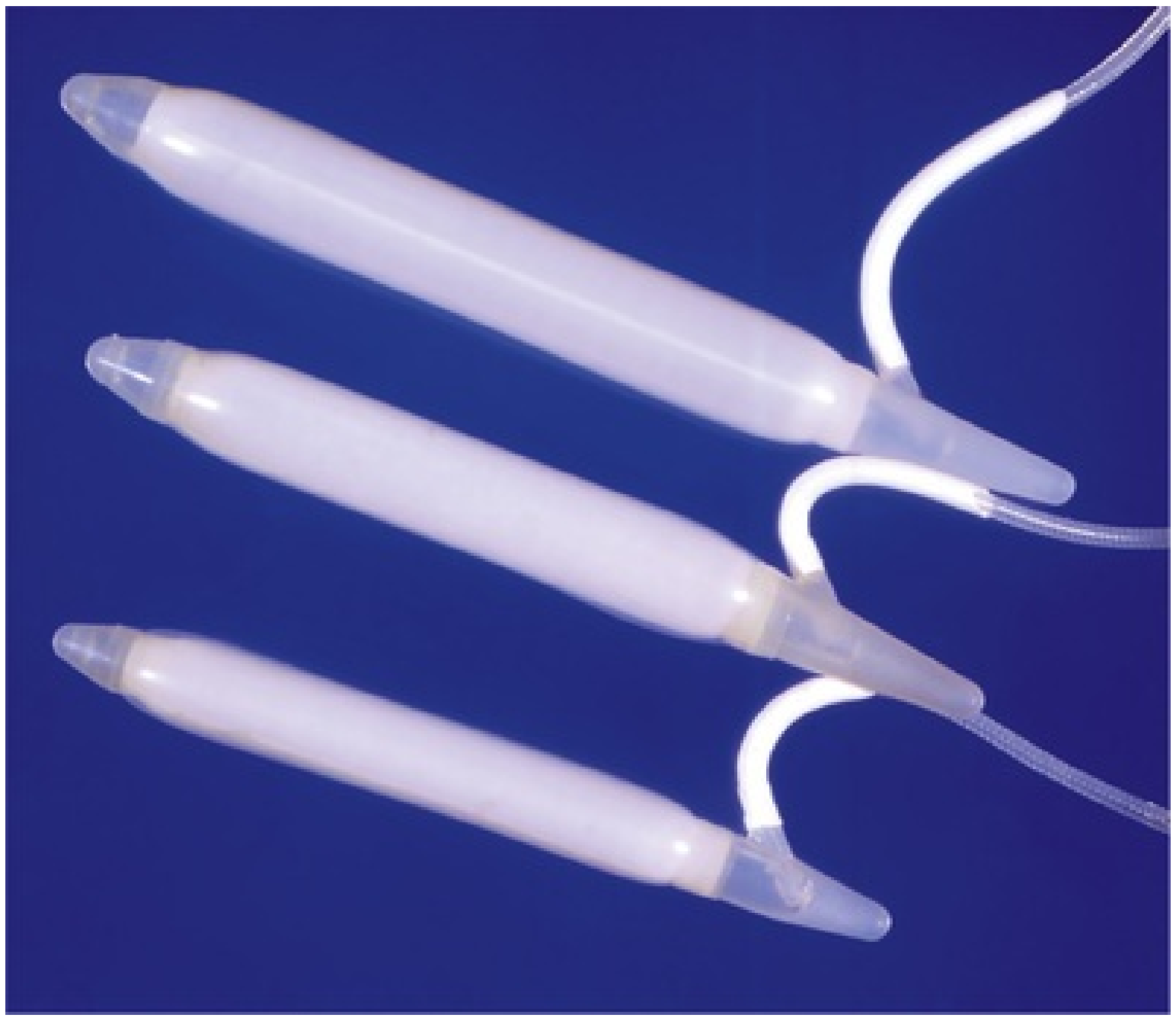

FIG. 72.1 Three AMS 700 18-cm cylinders in full inflation. *Top,* AMS 700 LGX. *Middle,* AMS 700 CX. *Bottom,* AMS 700 CXR.

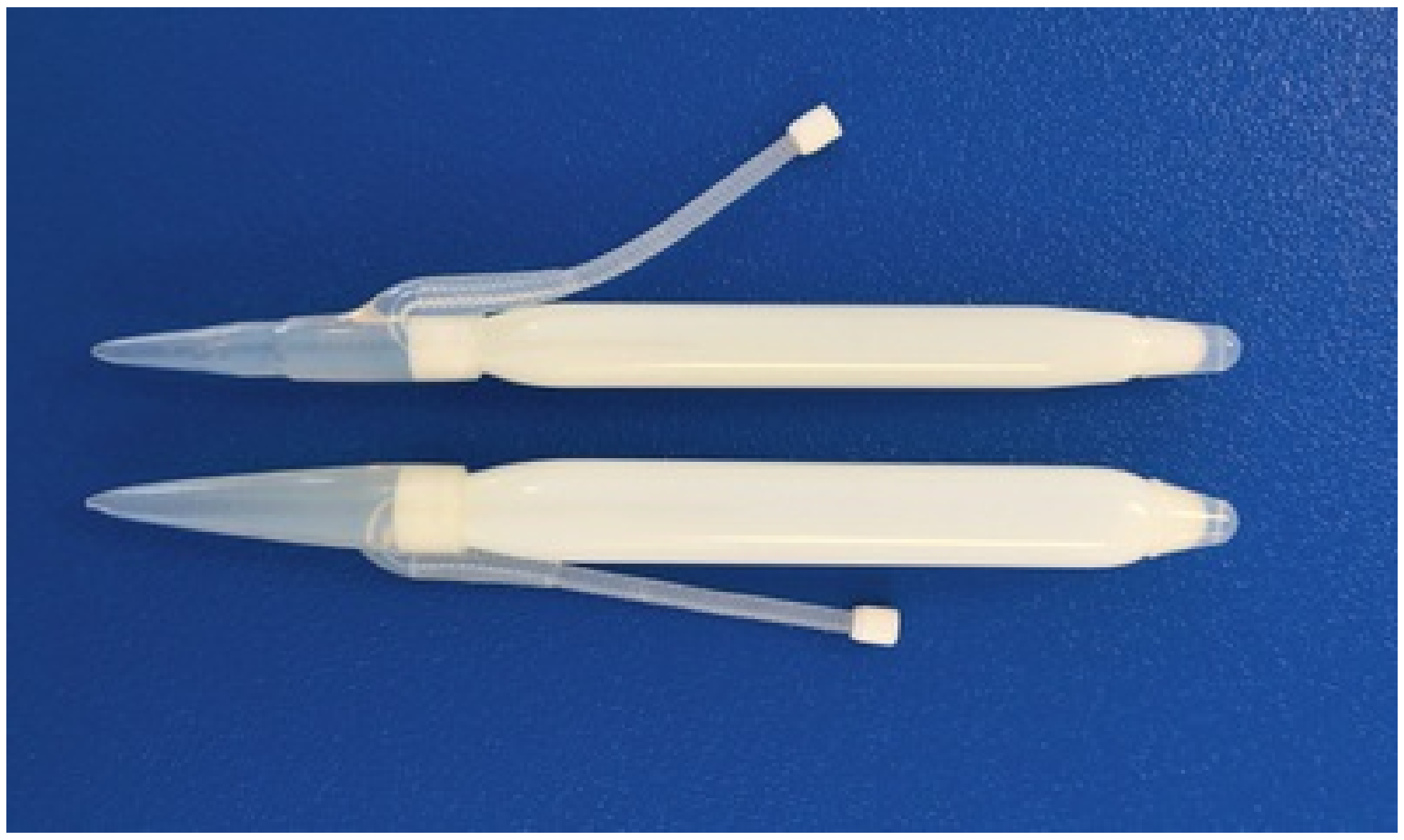

FIG. 72.2 *Top,* Titan Narrow 18-cm inflated cylinder. *Bottom,* Titan 18-cm inflated cylinder.

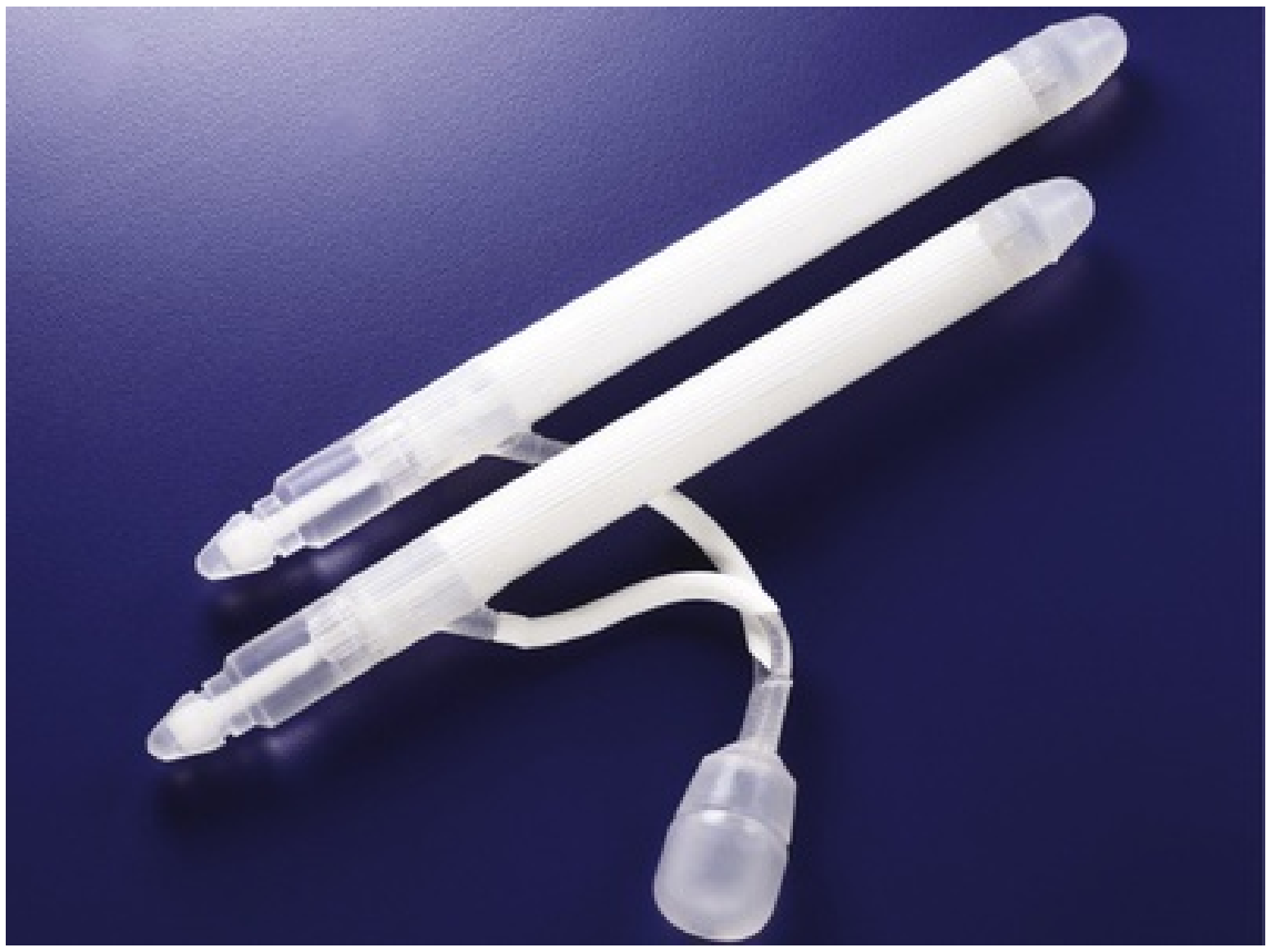

FIG. 72.3 The Ambicor prosthesis.

There are currently two types of malleable semirigid rod implants, the Tactra of Boston Scientific and the Genesis of Coloplast. The Tactra is composed of a nickel-titanium alloy (nitinol) core surrounded by a silicone outer coat (Fig. 72.4). The core of the Genesis is individual braided silver wire strands, and it likewise has a silicone outer cover (Fig. 72.5). Each of these rods bends much like a piece of electric wire. The Tactra replaced the recently discontinued Spectra Implant, a mechanical semirigid rod with articulating high molecular weight polyethylene and titanium segments. Both malleable devices are provided in fixed girth sizes. The firmness of the erection depends on the intrinsic rigidity of the cylinders and the amount of dead space in the erectile chambers surrounding the cylinders. Less dead space provides greater rigidity. Placing semirigid rod cylinders slightly shorter than the measured corporal body length gives easier bendability and less recoil to the penis. Mechanical breakage of these implants has been exceedingly rare. The semirigid rods are recommended for patients with limited mental or manual dexterity, or when repairs of a hydraulic device for mechanical problems would be undesirable. Table 72.1 shows the available sizes and components of the penile implants sold in the United States.

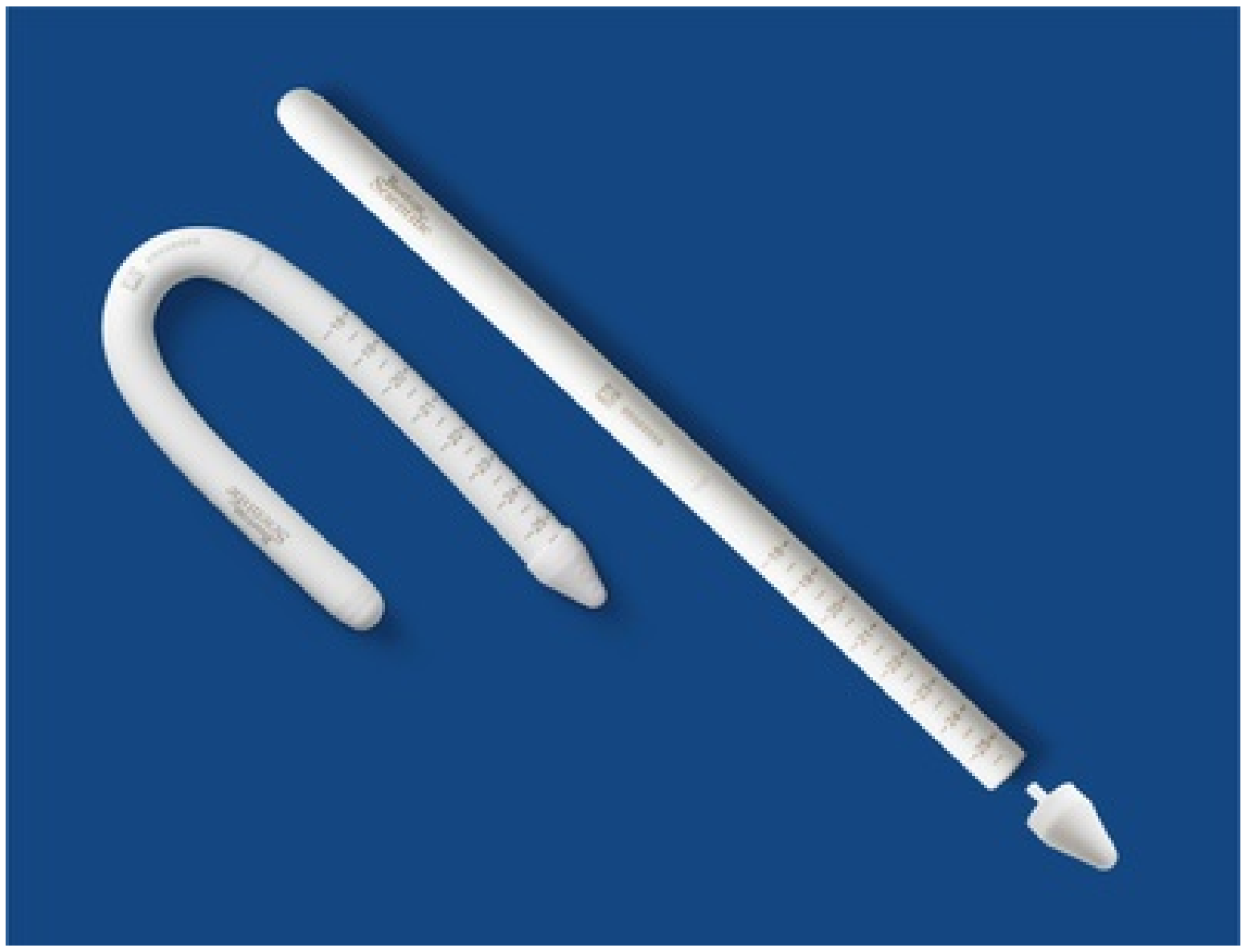

FIG. 72.4 The Tactra malleable semirigid rod implant with trimmable proximal tips and end caps.



FIG. 72.5 The Genesis malleable semirigid rod implant with trimmable proximal tips and end caps.

TABLE 72.1

Sizes and Components of Penile Implants Sold in the United States

	CYLINDER	CYLINDER DIAMETER

IMPLANT	**LENGTH SIZES AVAILABLE (cm)**	**SIZES AVAILABLE OR MAXIMUM EXPANSION (mm)**	**CYLINDER COMPONENTS**
BOSTON SCIENTIFIC CORPORATION			
3-Piece Inflatable			
AMS 700 LGX	12, 15, 18, 21	18	Silicone outer Polyester/spandex middle Silicone inner
AMS 700 CX	12, 15, 18, 21, 24	18	
AMS 700 CXR	10, 12, 14, 16, 18	14	
2-Piece Inflatable			
Ambicor	14, 16, 18	12.5	Silicone outer Polyester middle Silicone inner
Ambicor	16, 18, 20	14	
Ambicor	18, 20, 22	15.5	
Malleable Semirigid Rod			
Tactra	14, 23 16, 25 18, 27	9.5 11 13	Silicone outer Nitinol (nickel titanium alloy) inner core
COLOPLAST CORPORATION			
3-Piece Inflatable			
Titan – Titan Touch	14–28 supplied in even number lengths	19.2–22.1 girth expansion increases with increasing cylinder length	Polyurethane (Bioflex)
Titan Narrow	11, 14, 16, 18	15.2–17.9 girth expansion increases with increasing cylinder length	
Malleable Semirigid Rod			
Genesis	14–23 16–25 18–27	9.5 11 13	Silicone outer covering Braided silver wire inner core

Informed Consent

A thorough explanation of the procedure to the patient and expected results is paramount before the implant is placed. **The greatest disappointment after the surgery is the size of the erection being shorter than what the patient remembers beforehand.** This is due to pseudocapsule scar formation covering all parts of the device and limiting expansion of the cylinders. This apparent size reduction seems to be more apparent in patients with Peyronie disease, in which scar tissue is already present in the tunica albuginea, limiting its expansion. This should be stressed to the patient. These devices are mechanically reliable but not indestructible, and repair may be needed in the future. Tissue problems such as pump migration, erosion and extrusion of parts, and infection may also occur, requiring reoperation. Sensation and climax can be affected as well. Alternative ED treatment options, although usually already tried, should be explained and offered. The more experienced the implanter is, the more extensive the informed consent tends to be. Patients who opt for penile implant placement tend to be highly focused on their genitalia. Disappointed and dissatisfied patients can be litigious. **Many patients have unrealistic expectations of the results of penile implant surgery, and the conversation should confirm that the outcome is a firm penis usable for penetrative intercourse not necessarily accompanied by the feelings, desires, and abilities known to the patient previously.**

Key Points: Informed Consent for Penile Implant Placement

- The size of the erect penis after surgery may be shorter and thinner than preoperatively.
- The goal of implant surgery is to provide a firm penis suitable for intercourse.
- Penile sensation and ejaculation may both be diminished postoperatively.
- There will be varying degrees of postoperative pain.
- Reoperation for a mechanical problem with the implant may be necessary.
- Tissue problems such as infection may necessitate another surgery.

- There are other treatments of ED, such as pills, penile inserts and injections, and VEDs.
- There are a variety of implants, including three-piece and two-piece inflatables and semirigid rods.

Preoperative Preparation

Examination of the skin of the genital region and pelvis may reveal conditions such as phimosis, sebaceous lesions, and fungal infections, which should be attended to and eradicated before surgery. Washing the surgical site with a strong soap at home is reinforced. Shaving of pubic hair is done in the preoperative area or in the operating room so that any nicks in the skin will not develop significant bacterial colonization before the surgical skin preparation. In patients with diabetes mellitus the level of blood glucose at the time of surgery should be under 200 mg/dL. If this level is elevated the morning of surgery, an intravenous line may be started and hourly doses of insulin given in 10-unit boluses until the blood glucose is at an acceptable level. Long-term blood glucose control, as manifested by the HbgA1C level, is not as important in the avoidance of implant infection (Ban et al., 2017; Berrios-Torres et al., 2017; Canguven et al., 2018; Wilson et al., 1998). The urine should not be infected, and anticoagulants including low-dose aspirin should be stopped before surgery. The presence of allergies, especially to antibiotics, should be ascertained; these may be used systemically, in irrigating or dipping solutions or coating the surface of the implant. Prior approval from the patient's insurance company is essential because these procedures are very costly, and some insurance policies do not cover treatment of sexual dysfunction. Cash arrangements, frequently with discounts in price, are available, but relatively few patients opt for this approach.

Incisions

The original Scott three-piece inflatable implant was placed through an infrapubic incision giving easy access to the dorsal surface of the corporal bodies for cylinder placement and the linea alba for reservoir insertion in the space of Retzius. The incision was vertical from the base of the penis extending up toward the umbilicus. Some implanting surgeons adapted a transverse incision as a variation of this approach. Urologists subsequently adapted the penoscrotal incision, which was first made on the scrotal median raphe. Some surgeons prefer a transverse upper scrotal approach, citing better exposure to the proximal crura and the external inguinal ring for reservoir insertion. Today the majority of urologists use the penoscrotal approach for three-piece inflatable implant placement. A Foley catheter should be placed before the incision to identify the location of the corpus spongiosum. The advantages of the penoscrotal approach are secure placement of the pump in a subdartos pouch and a more cosmetic skin incision. During infrapubic placement care should be taken to identify the dorsal neurovascular bundle and to place the corporotomy stay sutures lateral to this structure at the 10 o'clock and 2 o'clock positions. The nerves coursing through this bundle are sensory to the glans penis and distal penile shaft. The fundiform ligament arising from the mid symphysis pubis is a good guide to the midline when identifying this bundle.

There is a recent report of the three-piece inflatable implant being placed through a subcoronal degloving incision (Weinberg et al., 2016). Using this approach the surgeon can place the cylinders via penoscrotal or infrapubic corporotomies, and reconstructive procedures on the penile shaft for straightening the erection can be easily performed (Fig. 72.6). The two-piece inflatable implant, the Ambicor, can only be placed through a penoscrotal incision, because it is supplied with short tubing connecting the pump to the cylinders. The semirigid rod implants are usually inserted via a subcoronal incision with corporotomies created laterally. Disadvantages of this approach are a long distance of corporal dilation proximally, which could be challenging in the presence of corporal scarring, and a limited amount of tissue available to close the incision in multiple layers. Circumcision should be performed simultaneously in the uncircumcised patient to avoid maceration of the suture line or lymphedema of the remnant foreskin. An alternative to the subcoronal approach for semirigid rod implant insertion is the ventral penile incision (Wahle and Mulcahy, 1993). A skin incision is made on the proximal penile shaft over the corpus spongiosum. A vein retractor then draws the foreskin distally to expose corporotomy sites at approximately the same location as via the subcoronal approach. The end of the corporotomy is lifted over the end of the rod with the vein retractor during cylinder insertion, thus avoiding the need to bend the cylinder (Fig. 72.7). The proximal penile incision avoids overlapping the corporotomy and skin incisions and allows the uncircumcised patient to retain his foreskin. The perineal incision, originally described for the Small-Carrion implant, is no longer used.

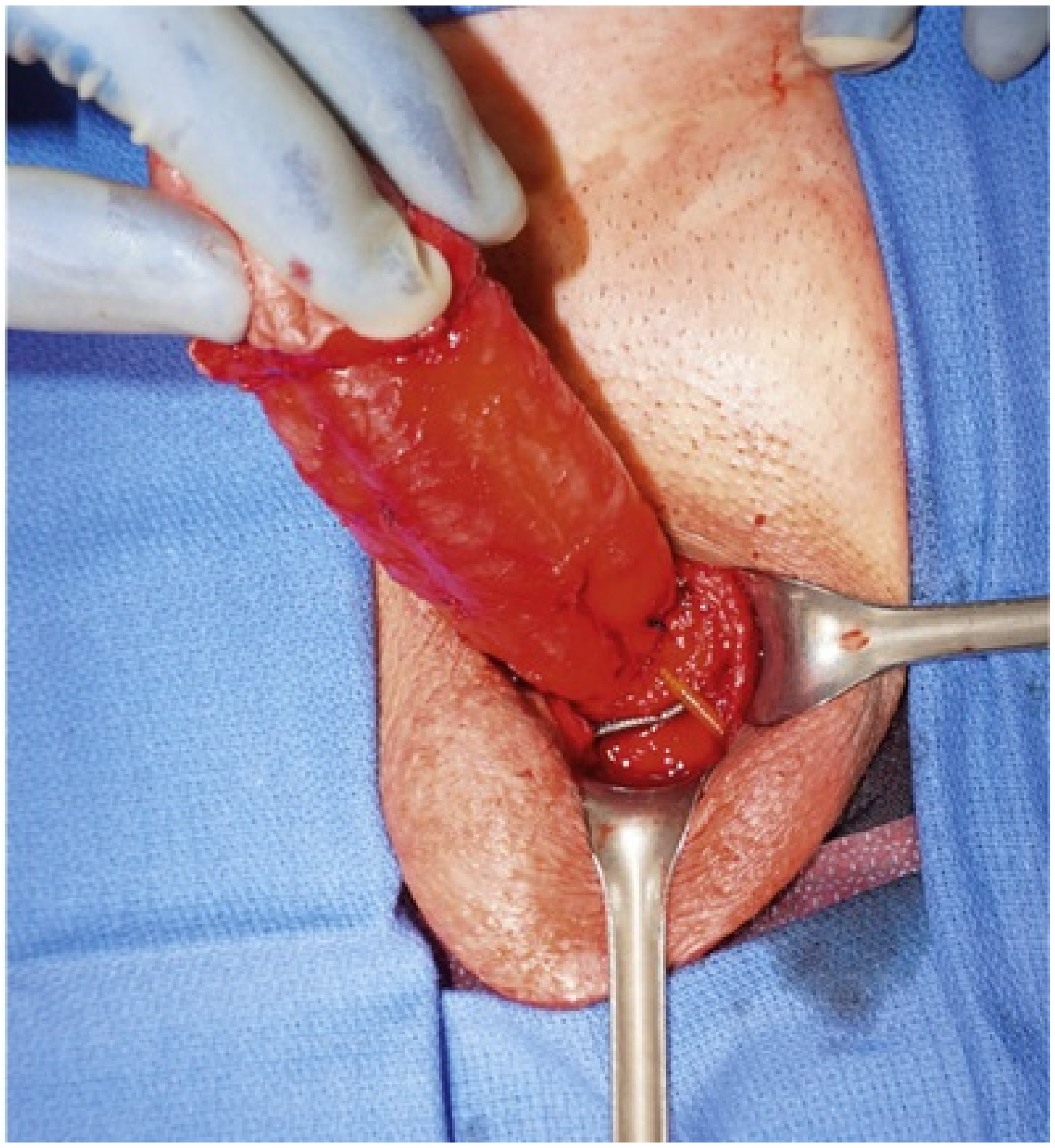

FIG. 72.6 A three-piece inflatable implant placed by the subcoronal approach.

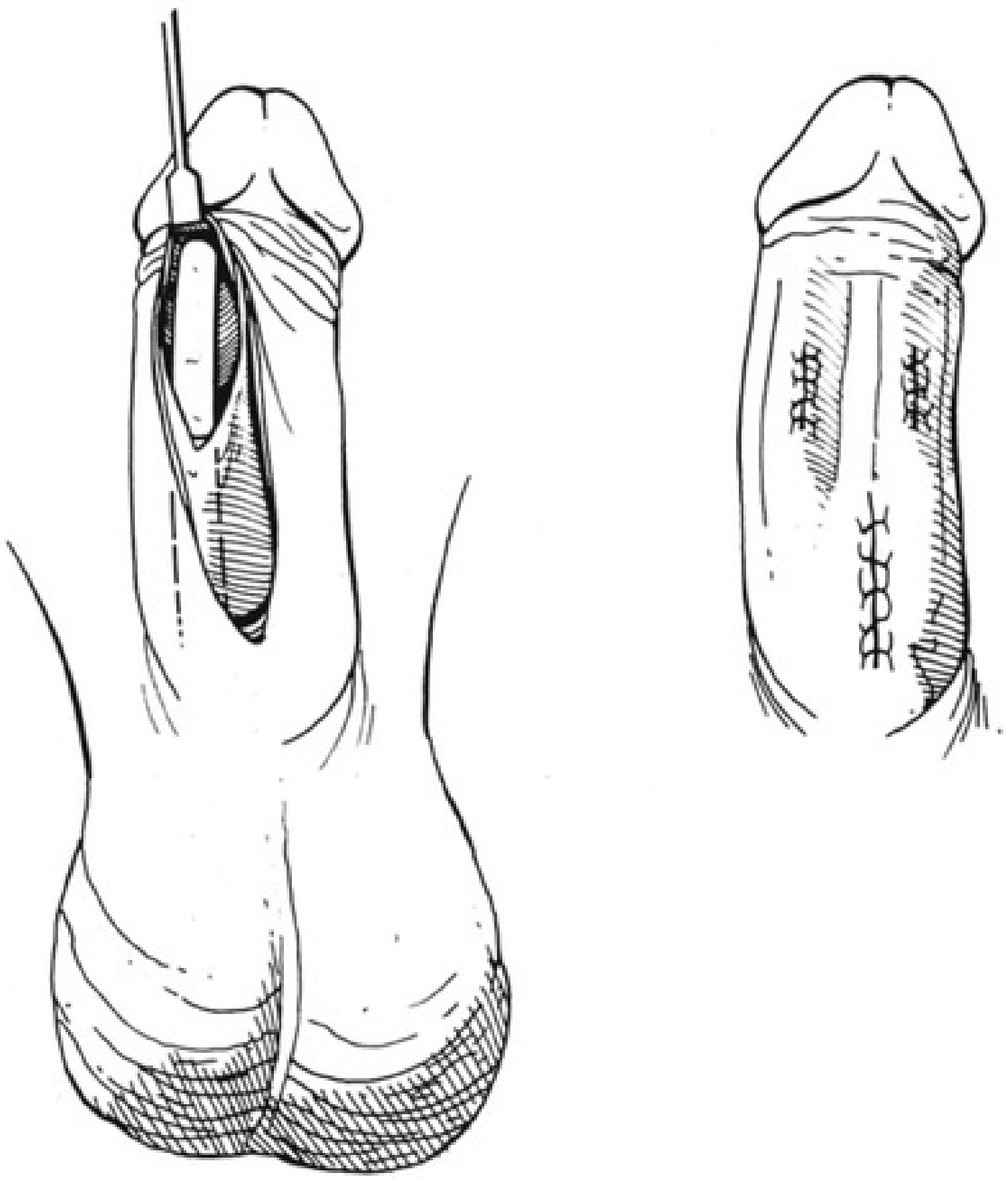

FIG. 72.7 The ventral penile incision for semirigid rod implant placement. The distal end of the corporotomy is lifted over the end of the cylinder with a vein retractor. The midline proximal penile shaft skin incision does not overlap the distal corporotomy incisions.

Technique of Device Placement

Most prosthetic surgeons place patients in the supine position. The bladder is drained with a urinary catheter to ensure safe reservoir placement and avoid inadvertent injury to the urethra. Once the particular surgical approach is selected, the tunica albuginea is exposed and the right and left corporal bodies are skeletonized lateral to the urethra for a penoscrotal approach and lateral to the neurovascular bundles for an infrapubic technique. Two separate 2-0 PDS horizontal mattress sutures are placed approximately 1 cm apart on the respective corporal bodies (Figs. 72.8 and 72.9). These sutures serve as retraction during dilation and also can be used for closure of the incisions once the cylinders are placed. Corporotomies are made between the stay sutures with either electrocautery or a scalpel. These incisions are longitudinal, parallel to the penile shaft, and can be extended as necessary to facilitate device placement. Dilation begins on the proximal then distal corporal bodies with Metzenbaum scissors followed by Hegar or Brooks dilators, beginning with 7 mm and sequentially moving to 13 mm. The initial corporal tunneling is paramount to avoid corporal crossover, crural perforation, or urethral injury. During proximal advancement, the dilators should be passed gently to the ischial tuberosity to avoid perforation at the point of crural insertion. **Distal passage should progress with the points of the instruments directed laterally, especially as the dilator advances toward the glans to avoid perforation into the urethra or through the midline corporal septum, which is relatively thin.** To assess for these complications, the “goalpost” test is employed by placing dilators simultaneously in the left and right corpora cavernosa first proximally, then distally, and noting their symmetry. Occasionally, fibrosis is encountered, requiring cavernotomes to open or remove the corporal scar tissue, especially in cases of postpriapism ED.

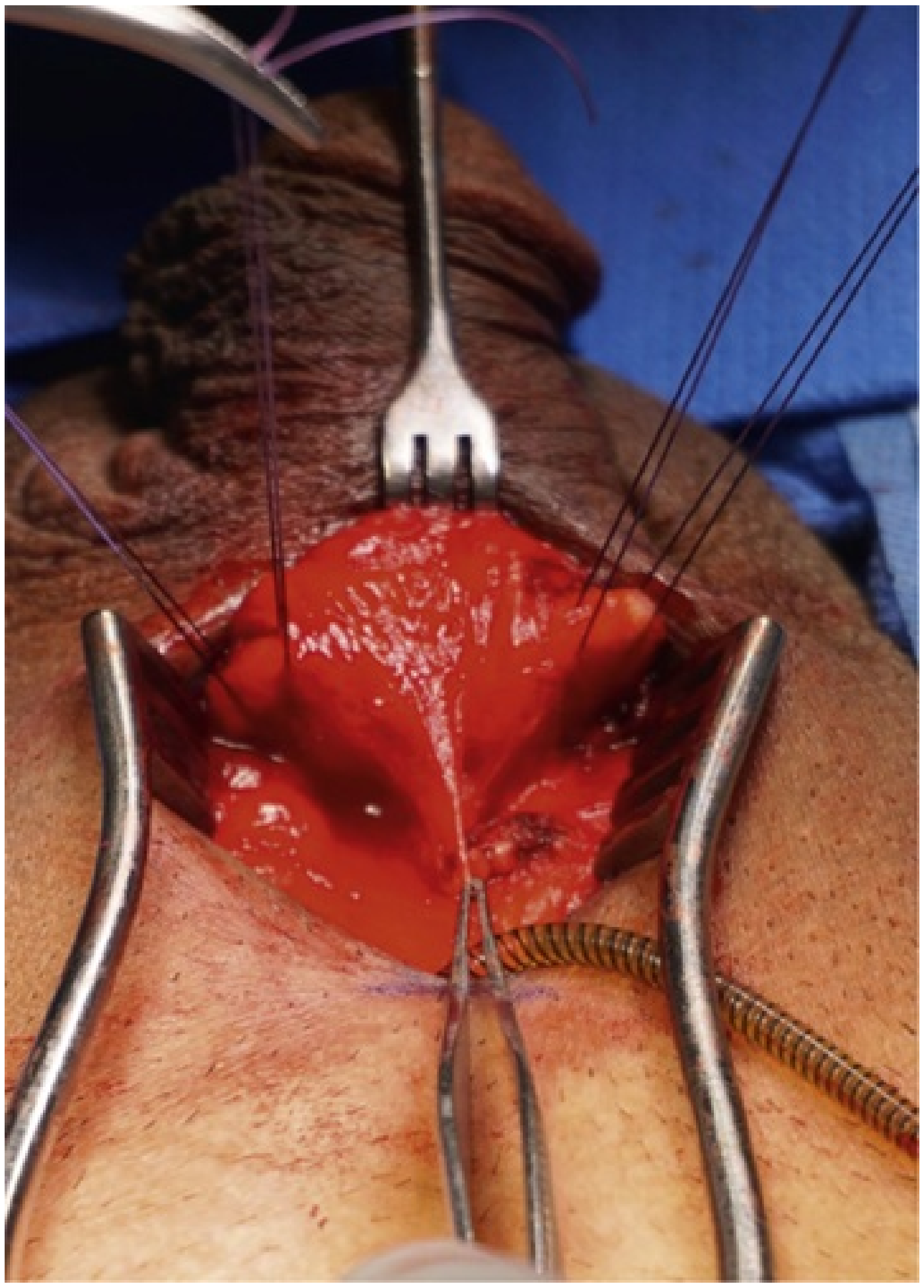

FIG. 72.8 Infrapubic incision for three-piece inflatable implant placement. The corporal stay sutures are placed lateral to the dorsal neurovascular bundle. The Adson forceps is holding the fundiform ligament, a guide to the midline.

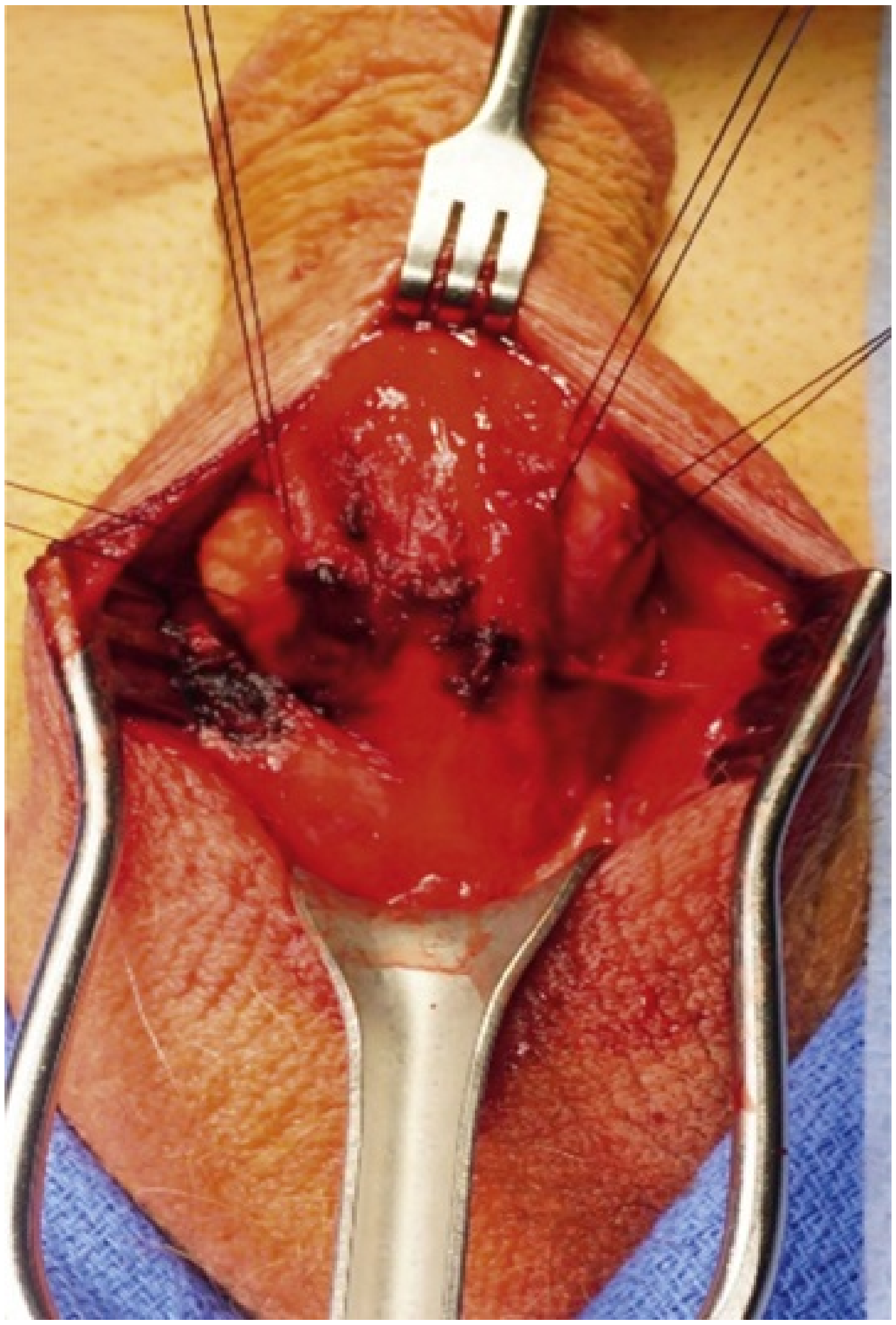

FIG. 72.9 Penoscrotal incision for three-piece inflatable implant placement. Corporal stay sutures are placed lateral to the corpus spongiosum.

Once adequate dilation is accomplished, the corporal length is measured with a Furlow device. With the stay suture used as a reference point, the proximal and distal measurements are added to determine the total corporal length (Fig. 72.10). A cylinder size equal to or slightly shorter (1 cm) than the measured length is generally recommended to avoid intracorporal buckling and creation of an S-shaped cylinder deformity (Wilson et al., 1996). An inflatable cylinder size is selected and length-adjusted using rear tip extenders. For semirigid rod prosthesis placement, downsizing from the total corporal length measurement 0.5 to 1 cm is recommended. These cylinders generally require a longer corporotomy, if placed through a midcorporal incision, and placement of the proximal crural end first is recommended to facilitate proper seating. A vein retractor or similar instrument can be employed to elevate the distal end of the corporal incision for subcoronal semirigid rod placement. Inflatable cylinders are positioned in the corporal bodies using the Furlow introducer with a Keith needle delivering a traction suture through the glans to pull the cylinders into position distally. Once both cylinders are placed and before corporal closure, a test inflation of the device is performed to evaluate for proper seating, crossover, curvature, or inadvertent perforation. During a primary implant placement, where there is little or no scar tissue in the corpora cavernosa, simply passing the measuring tool to assess corporal length followed by placing the cylinders in the standard fashion without further corporal dilation has resulted in patients noting significantly greater penile length and less postoperative pain compared with those patients in whom the cylinders were placed after standard dilation techniques (Moncada et al., 2010).

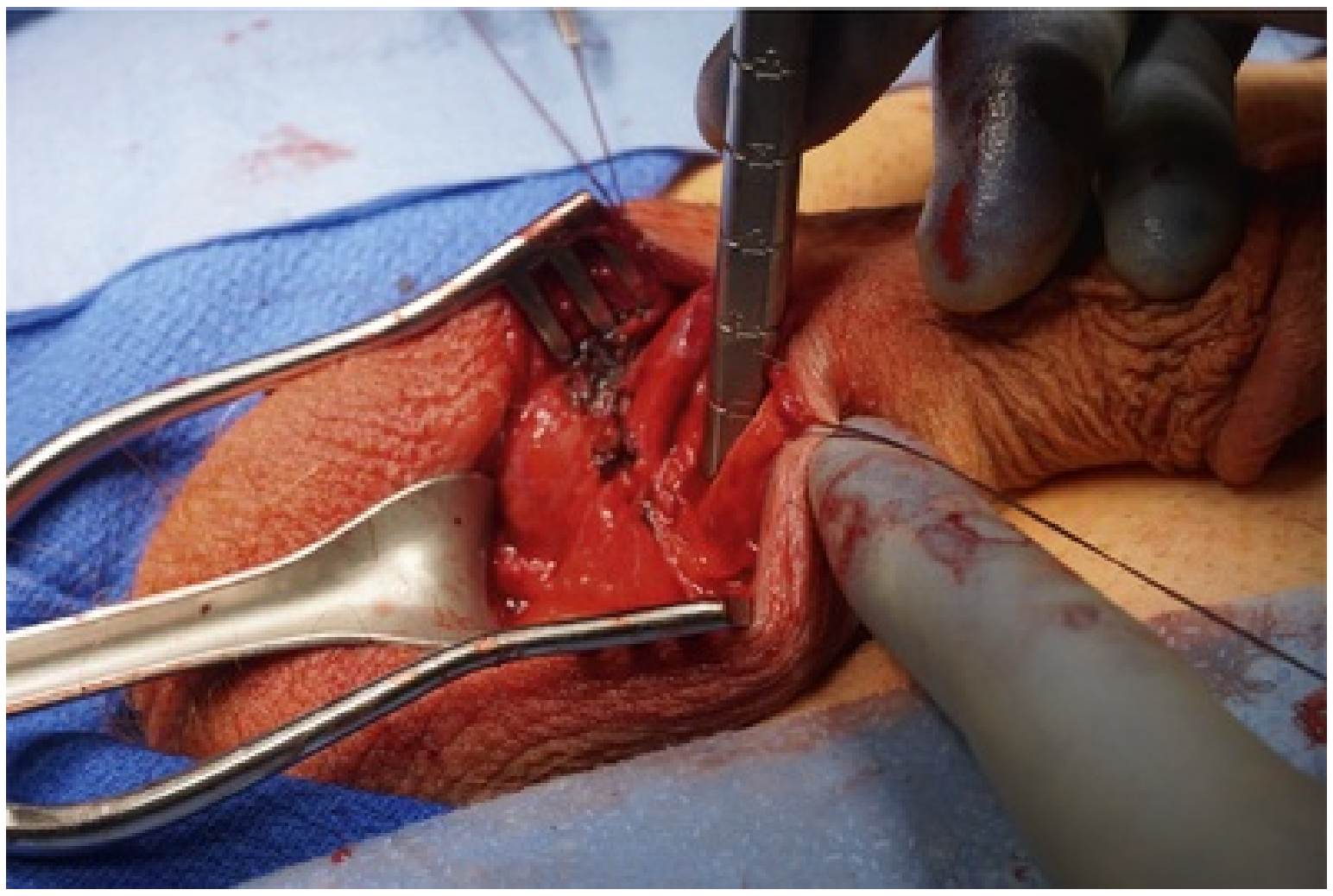

FIG. 72.10 Measuring device indicating an 11-cm proximal corporal measurement. Stay suture used as a reference point.

The corporal incisions are then closed over the cylinders using the previously placed stay sutures. Alternatively, closure can employ interrupted or running sutures with extreme care taken to avoid puncturing the device with the needles. A small malleable or proximal pushing instrument is useful in protecting the cylinder during needle placement. Placing longitudinal traction on the cylinder with the distal traction suture through the glans aids in minimizing cylinder protrusion and incidental puncture. The surgeon should attempt to keep the input tubing of the cylinders in the most proximal position of the corporotomy. After closure, a second test inflation is performed.

Scrotal pump placement is accomplished by creating a sub-dartos pouch in the most dependent portion of the scrotum on the right or left side. Most patients can operate the pump whether it is placed in the right or left hemiscrotum. This pocket is developed anterior and lateral to the testicle using finger, ring clamp, or nasal speculum dissection. The device pump is then placed in the subcutaneous pouch. Occlusive shodded clamps are employed, and all excessive redundant tubing is removed before the creation of the straight pump to reservoir tubing connection. Once the connection is made, the implant is test-inflated a third time to check for malfunction, displacement, fluid leak, and adequate sizing. The scrotal or infrapubic wound is thoroughly irrigated and closed in standard fashion with two separate subcutaneous layers of 3-0 Vicryl and 4-0 Monocryl skin layer.

The Ambicor and semirigid rod cylinders have fixed girths and are supplied in multiple width sizes. Before the packages containing the implants are opened, it is prudent to determine which width cylinder would be the best fit in the corporal bodies. A useful technique to determine the appropriate size would be to place 2 Hegar dilators parallel to each other simultaneously into the corporal bodies. The urologist should try to touch the thumb to the index finger between the dilators (Fig. 72.11). No separation of the dilators would indicate similar girth cylinders would give a tight fit. Slight separation of the dilators indicates an ideal fit, and touching the thumb to the index finger means a loose fit of comparable size cylinders.

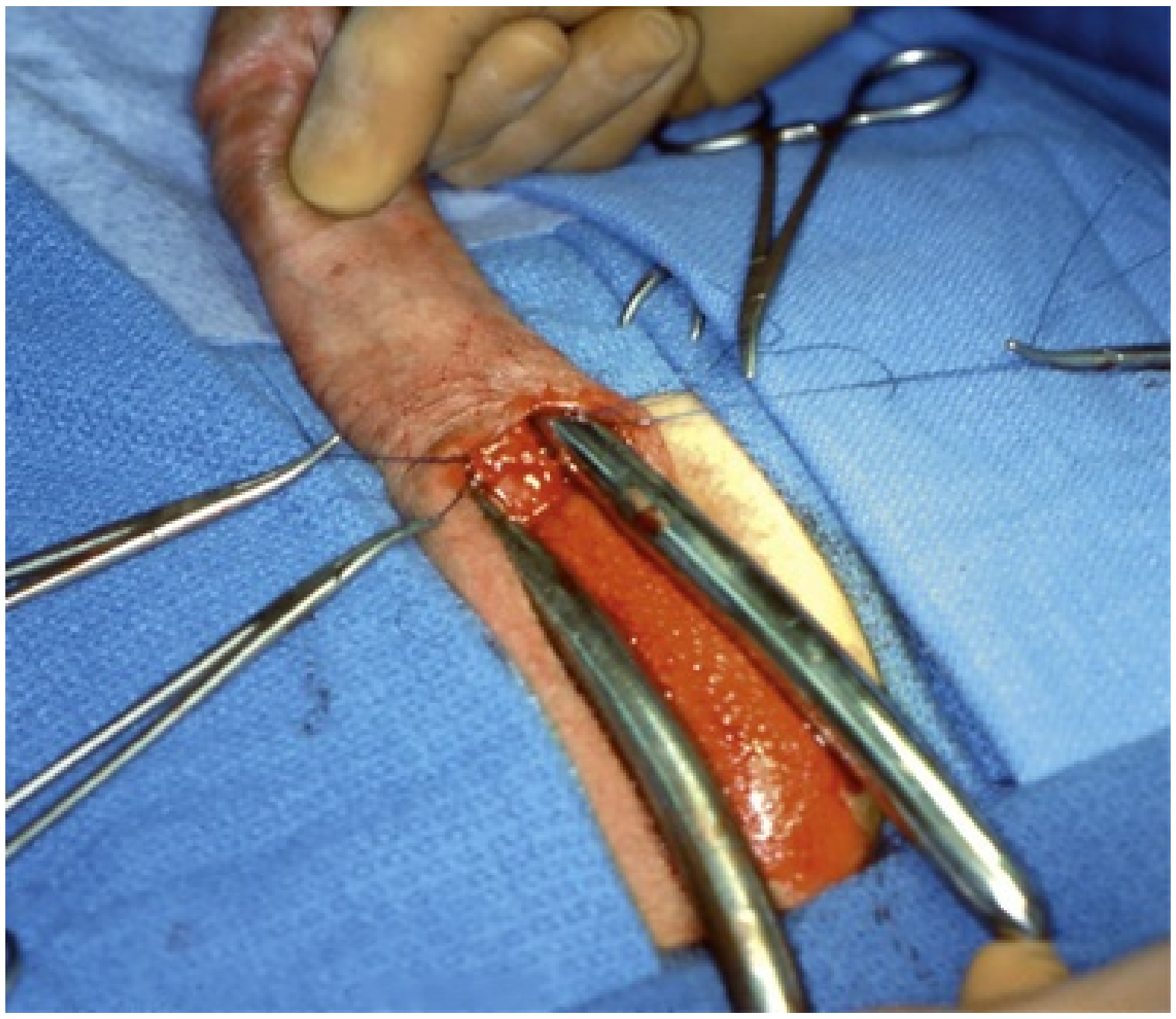

FIG. 72.11 Technique for determining optimal girth size cylinders with Ambicor, Tactra, or Genesis implants.

Reservoir Placement

Boston Scientific supplies two versions of the reservoir, a spherical-shaped balloon in volume sizes of 65 mL and 100 mL and a flat, disk-shaped balloon called the “Conceal,” holding 100 mL of fluid (Fig. 72.12). Coloplast has one shape to the reservoir, resembling a cloverleaf, in two volume sizes, 75 mL and 125 mL (Fig. 72.13). The original reservoirs were placed through the inferior portion of the linea alba, between the rectus muscles in the prevesical space of Retzius. This is still a simple and rapidly accomplished method. With the advent of the penoscrotal incision the reservoirs were advanced via the same incision through the inguinal canal to the side of the bladder. After the bladder is drained and the patient is placed in the Trendelenburg position to reduce the pressure of the bowels on the pelvic structures, a sharp instrument pointing medially pierces the transversalis fascia just above the pubic tubercle, followed by placing the index finger in the fascial defect to ensure location in the space of Retzius. A long nasal speculum is placed beside the finger into the reservoir cavity, the finger is removed, and the reservoir is inserted through the speculum into the space and filled with isotonic saline (Fig. 72.14). The expansion of the reservoir helps to expand the cavity. **The iliac vessels are about 1 inch lateral to the**

reservoir, and if any resistance is encountered in creating this space, it would be wise to choose another location for placing the reservoir (Henry et al., 2014). Prior radiation, a previous perivesical urinoma, and previous surgery in the area may generate adhesions that, when disrupted, could damage the vessels. There have been reports of large-capacity reservoirs compressing the iliac vein with resulting leg edema and other untoward sequelae (Da Justa et al., 2003). Today most radical prostatectomy cases are performed robotically. During this approach, the peritoneal reflection over the pelvis is not replaced, and bowel can migrate to the area of the internal inguinal ring, where it can be fixed by adhesions (Sedeghi-Nejad et al., 2011).



FIG. 72.12 Two types of Boston Scientific reservoirs. *Left,* Disk-shaped "Conceal." *Right,* "Spherical."



FIG. 72.13 Two sizes of the Coloplast “cloverleaf” reservoir.

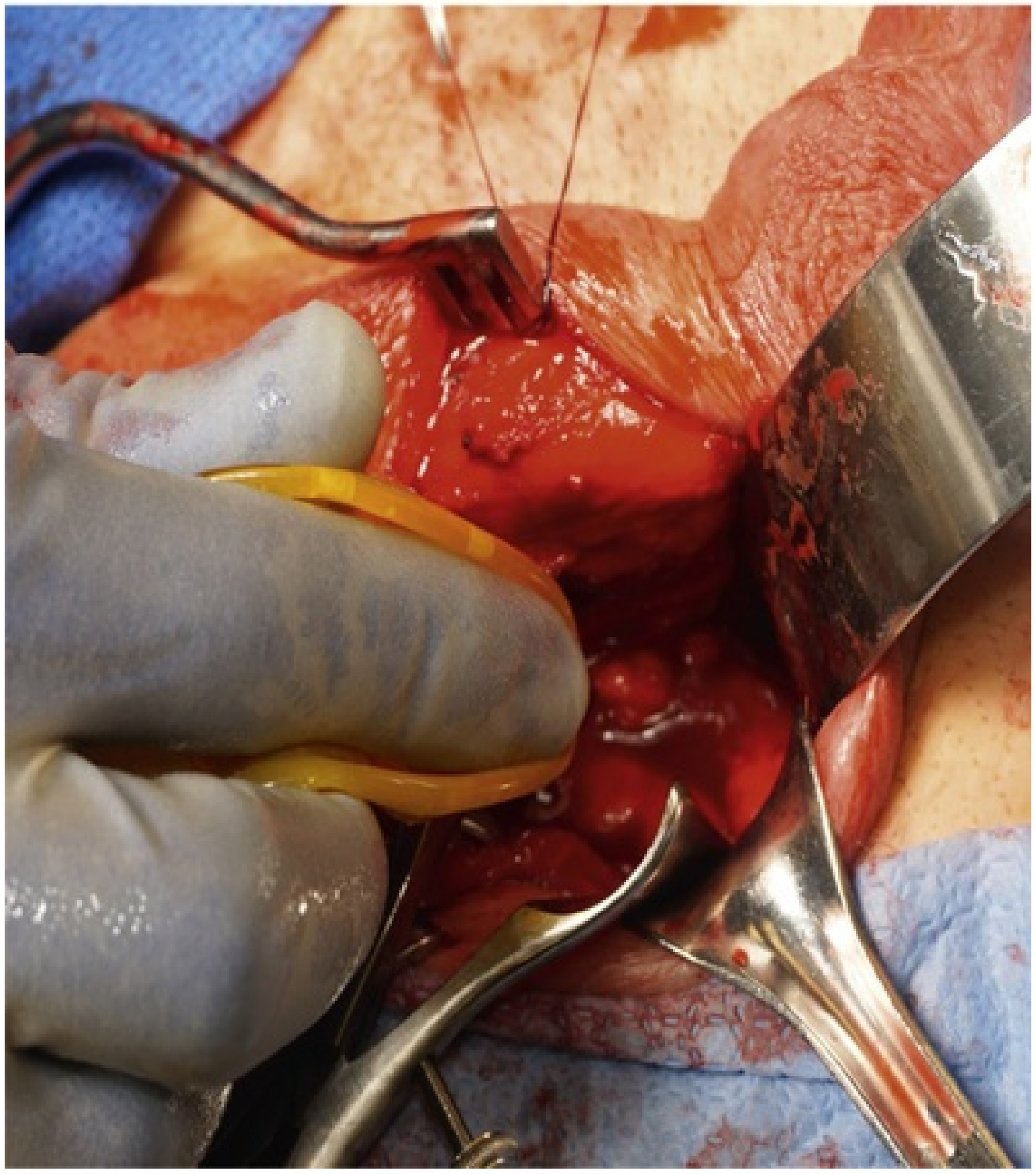

FIG. 72.14 Placing a three-piece inflatable implant reservoir through a long-nosed nasal speculum into the space of Retzius.

Placing the reservoir through the inguinal canal into the space of Retzius in these situations has resulted in bowel being compressed, as the reservoir is inflated, necessitating surgical intervention. Ectopic locations for the reservoir have also been described. The most common is the submuscular suprafascial approach, placing the reservoir between the rectus muscle above and the transversalis fascia below (Morey et al., 2013). A finger is introduced into the inguinal canal, creating a space above the fascia pointing toward the umbilicus. A long nasal speculum is introduced into this space, followed by a long double-hinged clamp or long ring clamp to further develop the cavity about 3 to 4 inches inside the internal inguinal ring (Fig. 72.15). The nipple of the reservoir is grasped with the clamp, driven into the cavity, and held in place while the reservoir is filled with isotonic saline, further expanding the space. Boston Scientific and Coloplast have reservoirs that are flat and will easily rest in this space (Fig. 72.16).The reservoir is under pressure in this location, but both vendors' products have lockout valves preventing fluid from transferring spontaneously from the reservoir to the cylinders. The Boston Scientific lockout valve is located on the pump, whereas the Coloplast lockout valve is positioned at the tubing junction with the reservoir. In the thin patient the reservoir may be visible, and some men report discomfort initially. The location of the reservoir should be checked after placement because these parts have occasionally been found within the peritoneal cavity (Gross et al., 2017).

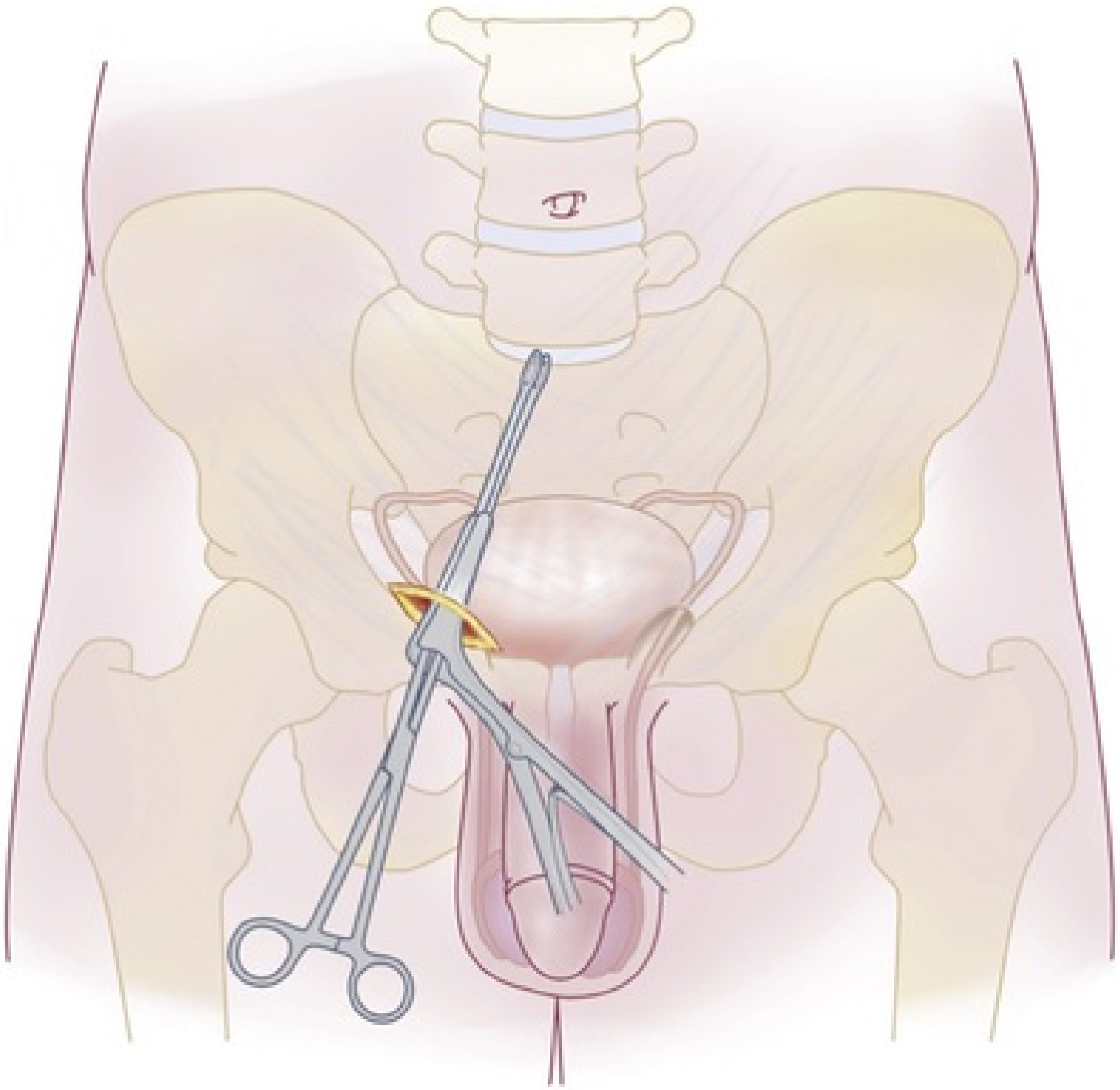

FIG. 72.15 Double-hinged clamp introduced through the inguinal canal pointing toward the umbilicus and developing the submuscular space for reservoir placement.

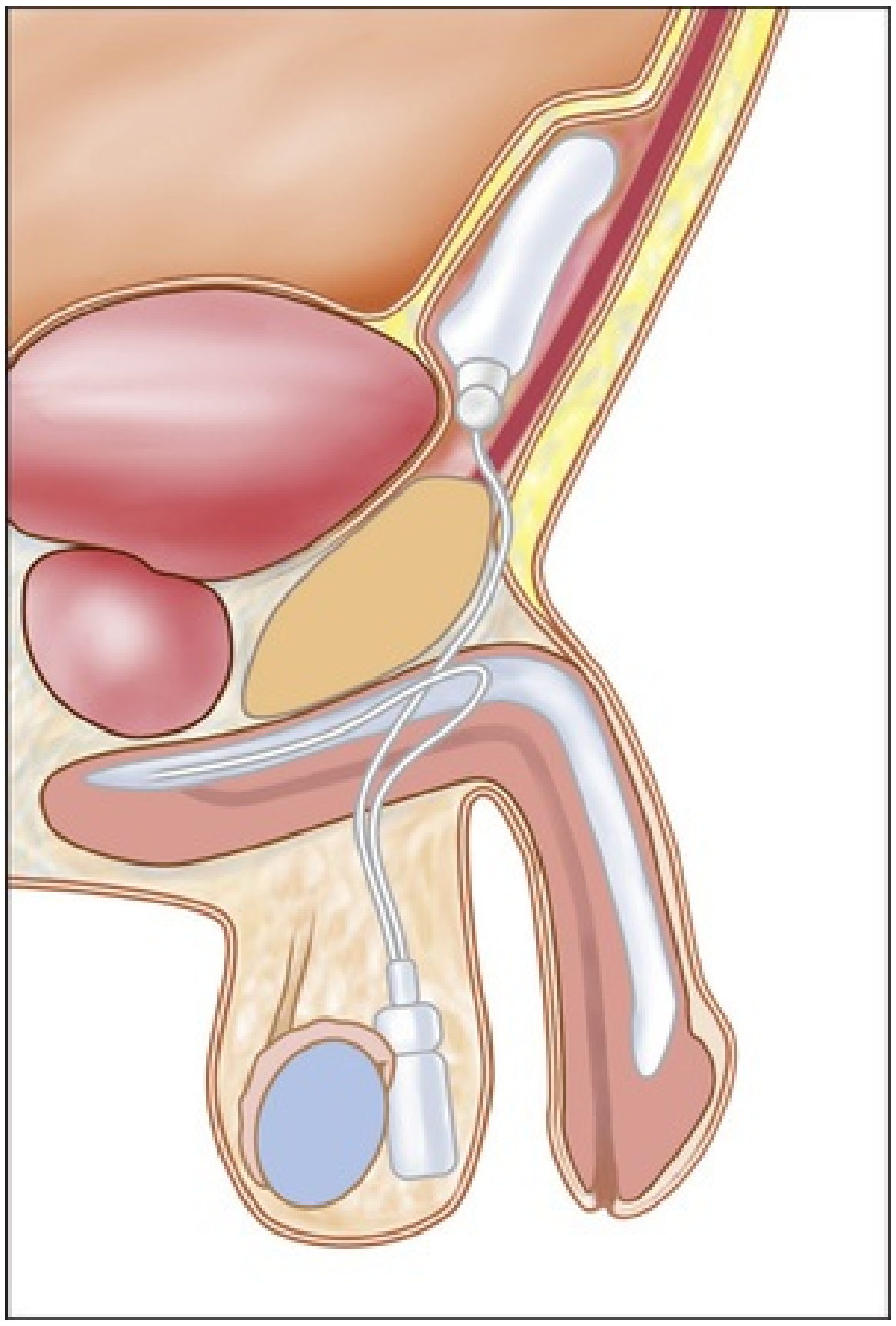

FIG. 72.16 Disk-shaped reservoir positioned below the rectus abdominis muscle and above the transversalis fascia.

The tendency is to fill the reservoir to a volume slightly greater than needed to fill the cylinders, which will be more comfortable and less visible in the patient. However, they should be filled almost to capacity, because a smaller volume will allow the reservoir to migrate out of the inguinal canal during cylinder inflation. When replacing the reservoir at a later date, the urologist should inflate the part, make an incision over it, and remove and replace the reservoir through the incision, rather than progressively incising scar tissue around the reservoir tubing to access it. The latter maneuver could destroy a considerable amount of muscle and be accompanied by significant bleeding.

After cystectomy and urinary diversion, implant reservoirs have been successfully placed in the lateral retropubic space through a separate incision medial to the anterior superior iliac spine (Loh-Doyle et al., 2018). To place the reservoir completely out of the pelvis, the epigastric location is a suitable alternative (Riemenschneider, 1981). A left subcostal incision is made, the aponeurosis of the external oblique muscle is incised, the internal oblique and transversus abdominis muscle fibers are separated, and the reservoir is placed in the epigastric space above the omentum. The reservoir tubing is tunneled through the subcutaneous tissue to the scrotum, where the connection to the appropriate pump tubing is made. This approach is seldom used. In the very obese patient the reservoir has been placed successfully in the fat just above the rectus fascia (Garber and Bickell, 2016). These ectopic locations are especially suitable when there is significant intra-abdominal scarring, such as after a cystectomy and urinary diversion or in the presence of a renal transplant.

Key Points: Technique of Device Placement

- The three-piece inflatable implants give the best rigidity and flaccidity and are by far the most popular among patients and urologists.
- A shorter size to the erection after penile implant placement is the major reason for disappointment after surgery; this should be stressed in the informed consent.
- Patients with limited dexterity should be encouraged to choose a semirigid rod implant to avoid frustration when trying to manipulate the pump of a hydraulic device.

Intraoperative Troubleshooting

Fibrotic Corpora

Dilation of the corporal bodies is usually straightforward and easily accomplished. Pelvic radiation therapy is commonly used in cases of prostate cancer, and patients with this disease are frequently recipients of a penile implant. There is no greater difficulty in placing a penile implant or in the incidence of postoperative complications after pelvic radiation (Golan et al., 2018; Loh-Doyle et al., 2018). In the presence of scar tissue, such as after an episode of acute ischemic priapism or after cylinders had been previously removed because of infection or erosion, creating cavities for the cylinders can be a challenge. Starting such a dilation with a midshaft corporotomy allows the dilators to pass an equal distance in each direction. If one approach is used for the initial implant placement (i.e., penoscrotal), by using the opposite incision (i.e., infrapubic), the surgeon will encounter less scar tissue. **The dilating instruments should always point dorsolaterally away from the corpus spongiosum, be positioned parallel to the penile shaft, and be seen moving against the lateral wall of the penile shaft.** If scissors are used, they should be passed with a spreading motion, not cutting the tissue. Once a channel is created to the distal subglandular area and to the proximal ischial tuberosity, it can be broadened using the Rossello (Coloplast Corporation) or Uramix (Landsdowne, PA) cavernotomes or the Otis urethrotome. The Rossello cavernotome has raised metal cups, which shave the tissue as a wood rasp shaves wood (Fig. 72.17). The Uramix device has a raised metal blade that shaves tissue as the blade is oscillated from side to side (Fig. 72.18). The Otis urethrotome cuts tissue in one plane, and each cut allows one larger-size dilator to be passed easily (Fig. 72.19). The blade of the Otis urethrotome should be pointed away from the urethra, and this blade should be rotated slightly before a subsequent cut is made to avoid cutting through the tunica albuginea. Excising blocks of corporal scar tissue can also be done using a small, sharp knife blade (Montague and Angermeier, 2006). This is especially useful for exposed scar at the corporotomy site. Both vendors have narrow, inflatable cylinders that will fit more comfortably in a corporal cavity restricted by scar tissue and give comparably good rigidity to the standard-size cylinders because they will completely fill the erection chamber. Use of a single cylinder has been attempted, but the result was suboptimal. The erection appears lopsided, and the rigidity is compromised.



FIG. 72.17 Tip of the Rossello cavernotome showing the raised cups, which shave scarred corporal tissue by pulling the metal rod in and out.



FIG. 72.18 Tip of the Uramix cavernotome showing a raised blade that shaves scarred corporal tissue by moving the blade in a back-and-forth, oscillating motion.

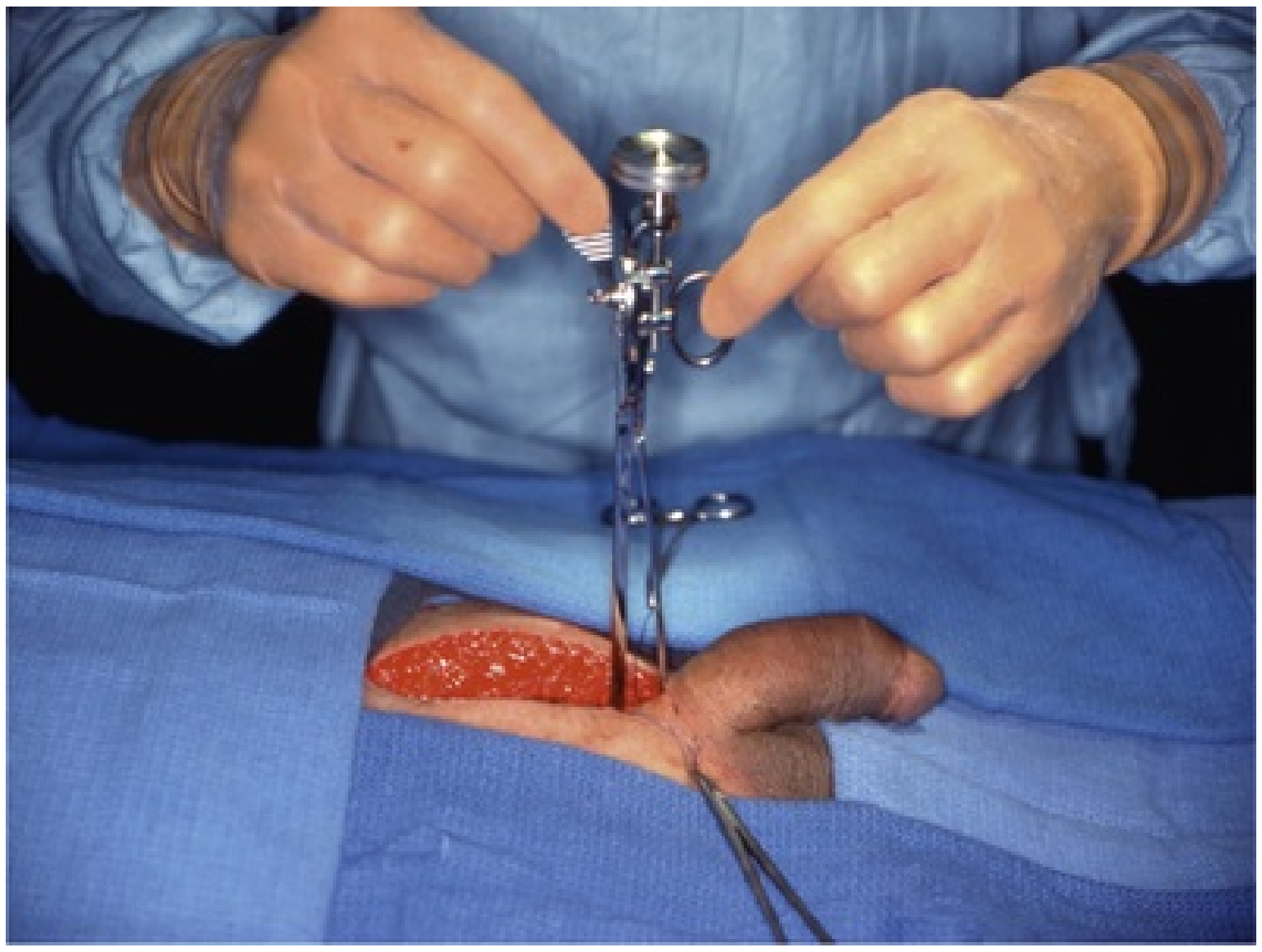

FIG. 72.19 The Otis urethrotome cutting scarred tissue in the proximal crus.

If these measures fail, cavernosal reconstruction can be used. The scarred erectile chamber is incised deeply throughout its length. A cylinder is laid in the cavity and covered by synthetic or natural material as a substitute for native tunica albuginea**. Natural materials used are cadaver pericardium (Tutoplast, Coloplast Corp.)** (Leungwattanakij et al., 2001) **and porcine small intestinal submucosa (Surgisis, Cook Medical, Bloomington, IN)** (Knoll, 2002)**. These grafts are fashioned about 20% larger than the defect to allow for shrinkage and are sewn in place with absorbable suture**. They form a lattice over which the body will form its own scar over a 3-month period. **Synthetic materials used are Dacron (Dupont, Wilmington, DE) and polytetrafluoroethylene (Goretex, Gore Medical, Flagstaff, AZ). A graft the same size as the defect is sewn in place with soft, nonabsorbable sutures**. The natural materials are preferred because they have a lower infection rate. Recently Tachosil (Ethicon, Sommerville, NJ), a hemostatic fibrin sealant and adhesive patch composed of a matrix of equine collagen and marketed for vascular surgery, has been used as a tunical substitute (Patel et al., 2017). This material is fashioned to overlap the tunical edges by about 0.5 cm, applied to the area, and held in place for a short time. No sutures are needed to attach the graft. Cavernosal reconstruction is infrequently used today because urologists have become more proficient at simpler techniques for creating cylinder spaces.

Crural Crossover

The septum between the two erectile chambers is thin and can easily be breached by dilating instruments during cylinder placement. If this occurs and both cylinders wind up on the same side, the erection will look lopsided, the second cylinder will be difficult to place, and corporal length measurements may be significantly different. It is important to recognize and correct this problem during surgery, rather than to have the patient remark at a postoperative visit that the erection looks unusual (Levine and Latchamsetty, 2002). If this problem is identified, both cylinders are removed and a large dilator is placed in the common cavity. The opposite cylinder cavity is redilated with the instruments pointing laterally, and a cylinder is placed into it. The dilator is removed and the second cylinder is placed in the original common cavity. This can be tested by inflating the cylinders and noting that the Foley catheter is in the midline with both inflated cylinders symmetrically located on each side of the catheter. To test for proximal crossover, a dilator is placed in each crus. They should be parallel and of equal height, resembling a football goalpost (Fig. 72.20).

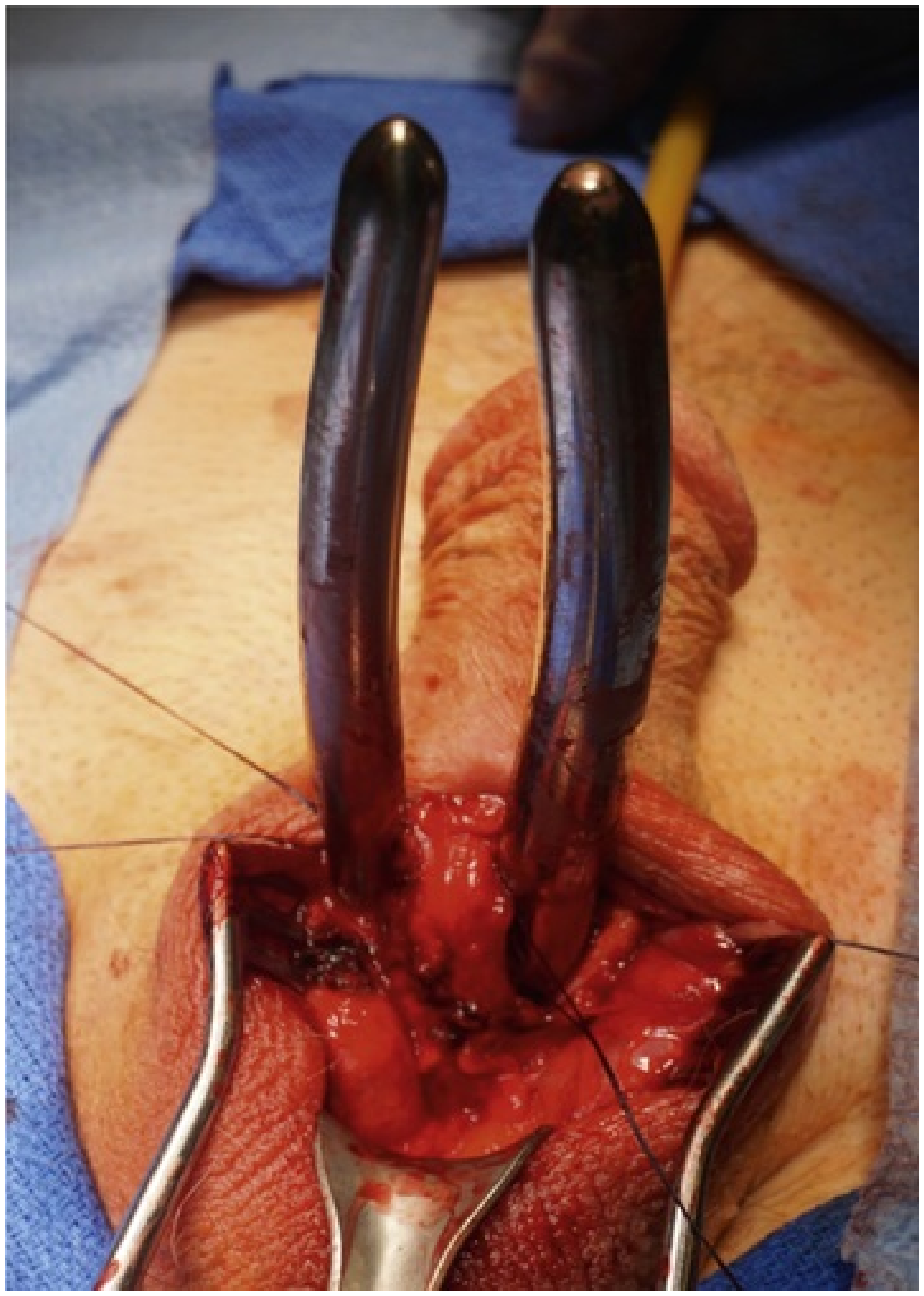

FIG. 72.20 A dilator placed in each proximal crus, parallel and of equal height, indicating no crural crossover or proximal crural perforation, mimicking a football goalpost.

Corporal Perforation

Corporal perforation is unusual and is more commonly seen during secondary cylinder insertion, where corporal scar necessitates aggressive dilation. Proximal perforation through the crus can be suspected if the dilator progresses further inferiorly than its mate and/or corporal measurements differ by more than 1 cm. There is no support, and if pushed to the extreme, the metal rod will be palpable 2 inches lateral to the anus. Formerly a windsock of vascular graft material was fashioned into a cup and placed on the cylinder as a rear tip extender (Steidle and Mulcahy, 1987). The cylinder was introduced into the erection chamber and the synthetic cup sewn to the tunica albuginea, preventing proximal cylinder migration. The foreign material was a possible source of infection and difficult to remove during later implant repair because of ingrowth of body tissues into the fabric.

Currently the suture sling is used for this purpose (Wilson, 2010). A nonabsorbable polypropylene stitch with a needle attached to both ends is placed through the proximal end of the cylinder or through the rear tip extender. The cylinder is placed in the corporal body, the distal insertion string is pulled so that the cylinder rests in the corporal body at the same level as its mate, and then the cylinder is partially inflated. The end of each suture is brought out through each side of the tunica just distal to the input tube exit (Fig. 72.21). The corporotomy is closed, the sling suture is tied firmly over the corporotomy closure, and the knot is cut long so that it can be identified and removed at the time of future cylinder replacement (Fig. 72.22). The defect of a perforation or incision into the urethral lumen at the corporotomy site can be closed securely if easily accessible, the wound copiously irrigated, and a cylinder placed (Anele et al., 2014). If there is any question of closure integrity or complexity of repair, the cylinder placement on that side should be aborted, allowing the defect to completely heal. Distal perforation is usually into the fossa navicularis, and the defect is not amenable to closure because of poor exposure. Blood at the urethral meatus, a visible dilator at the meatus, or fluid exiting the urethra after irrigating through the corporotomy is a sign that this has occurred. The cylinder should be left out to allow the defect to heal spontaneously. Placing a urethral catheter is not necessary because the urinary stream will draw tissue fluid into it, and urine will not enter the defect (Bernoulli principle). A cylinder may be placed in the opposite crus to maintain penile length (Sexton et al., 2018). Cylinder placement in the empty erectile chamber can be performed in 5 to 6 months to allow solid scar to form and avoid the dilator entering the original perforation tract. Recently there was a report of 8 cases of distal perforation, in which the urologist created hypospadias, repaired the perforation defect securely, and placed both cylinders (Perito and Gheiler, 2011). All eight procedures were successful, and four patients requested hypospadias repair at a later date because of spraying of the urinary stream**. It must not be assumed that a urethral injury will heal without closing the defect. Leaving a cylinder in such a situation will likely result in infection.**

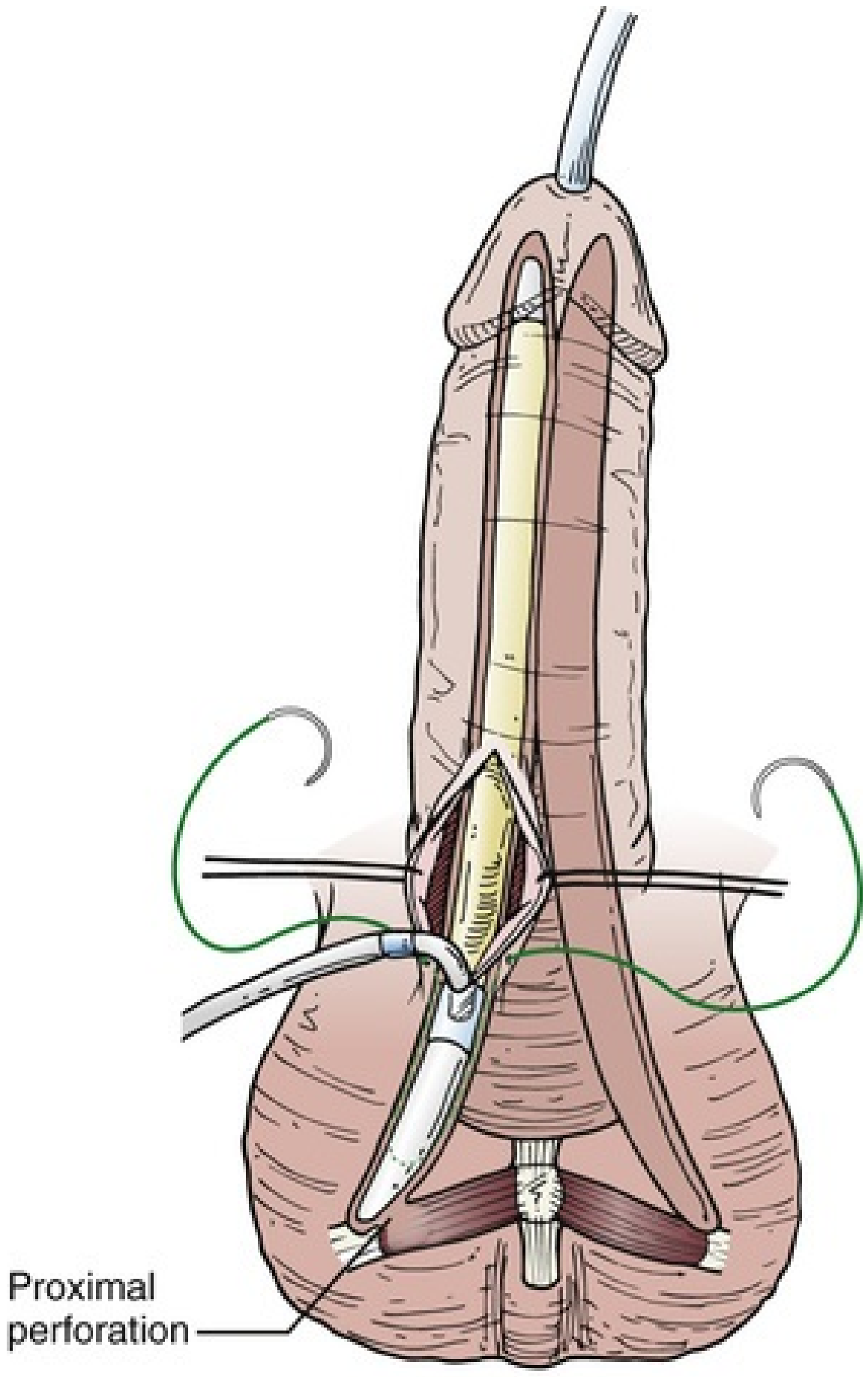
Proximal perforation

FIG. 72.21 A suture sling of proline placed through the proximal end of an implant cylinder or rear tip extender with each end brought out of the corporal body just distal to the input tube.

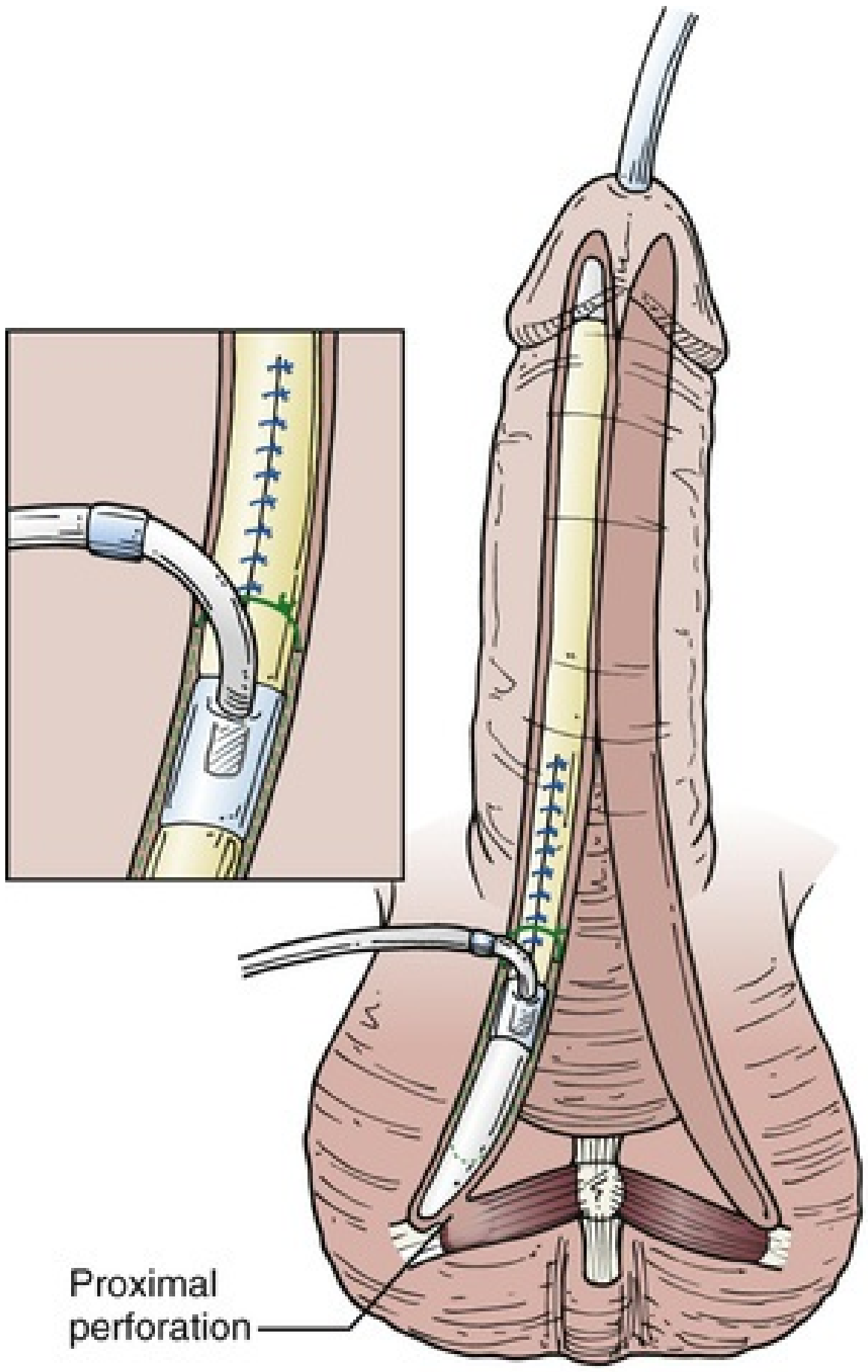

FIG. 72.22 The sling suture *(green)* tied over the closed corporotomy *(blue).*

Hypermobile Glans Penis

Even though the cylinder tips are positioned in the proper distal location, the glans penis may be excessively mobile or floppy, making penetration during intercourse difficult. The mobility may be dorsal, ventral, or in both directions. This appears to be more common in uncircumcised men. Ventral hypermobility is sometimes called the “SST deformity,” mimicking the appearance of the depressed beak of the now-obsolete supersonic transport. If the floppiness is mild, tensing the foreskin toward the scrotum during penetration so that the glans sits more securely on top of the inflated cylinders may be all that is needed. If this is not successful, the problem can be remedied by tacking the glans to the distal tunica albuginea (Ball, 1980; Bickell et al., 2016; Levine and Latchamsetty, 2002). For unidirectional mobility a hemicircumcising incision is made and the glans partially dissected from the distal tunica on either side of the corpus spongiosum or the dorsal neurovascular bundle. A nonabsorbable 3-0 soft suture on an SH needle is driven through the glans substance and then through the tunica albuginea at the level of the inflated cylinder tip (Fig. 72.23). The tunica is grasped in the teeth of an Adson forceps to elevate this tissue from the cylinder and avoid impaling it while placing the needle (Fig. 72.24). The sutures should be placed on both sides before the knot is tied to allow better exposure when placing the second suture. The wound is closed in two layers. Four-quadrant fixation through a complete circumcising incision may be needed for excessive mobility in both directions. **Glans hypermobility and mis-sized cylinders are distinct problems. Cylinders that are too short can be corrected by placing longer cylinders or adding rear tip extenders to the cylinders and should not require glans fixation.**

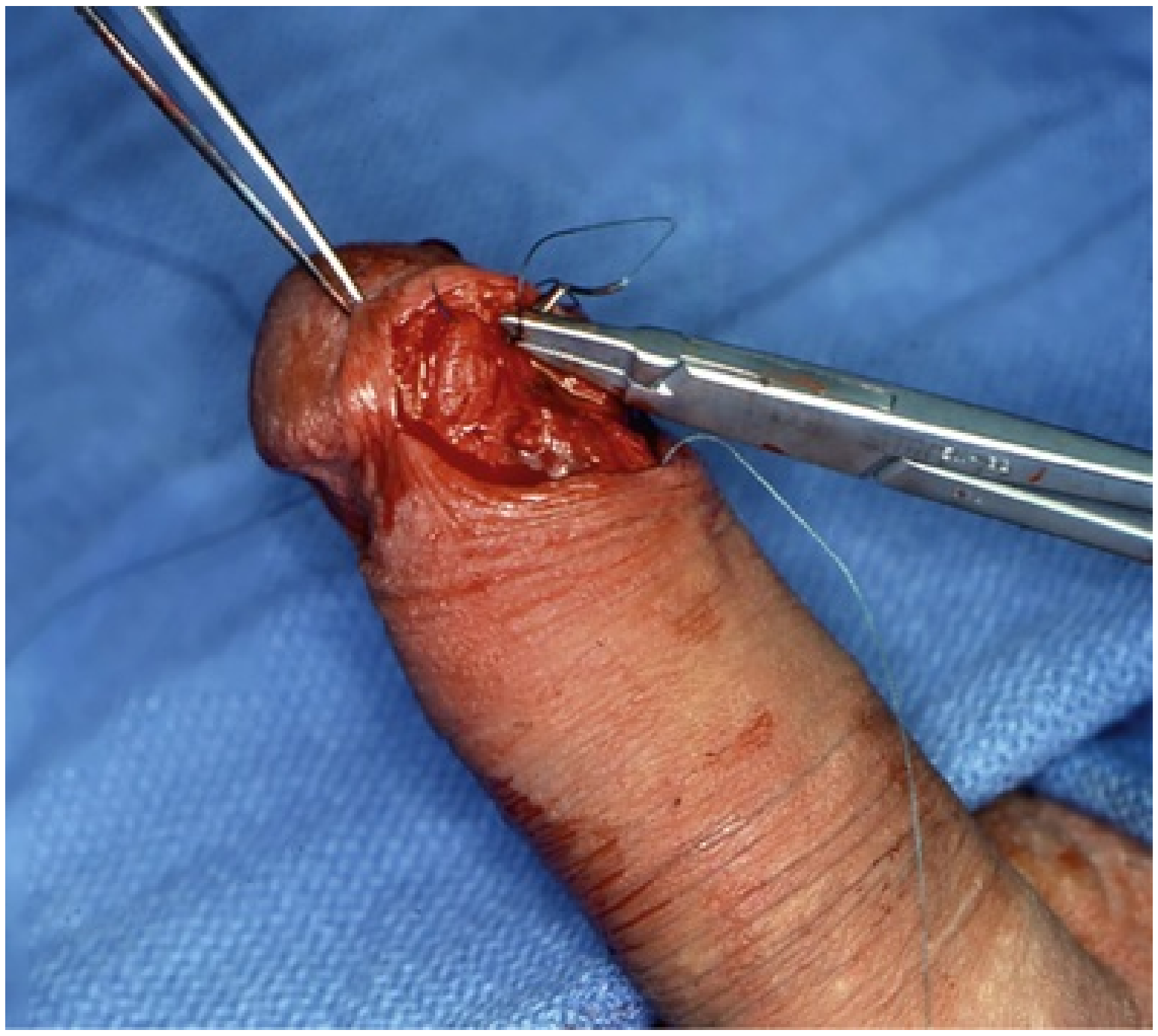

FIG. 72.23 Suture placed through the substance of the glans penis in situation of a hypermobile glans.

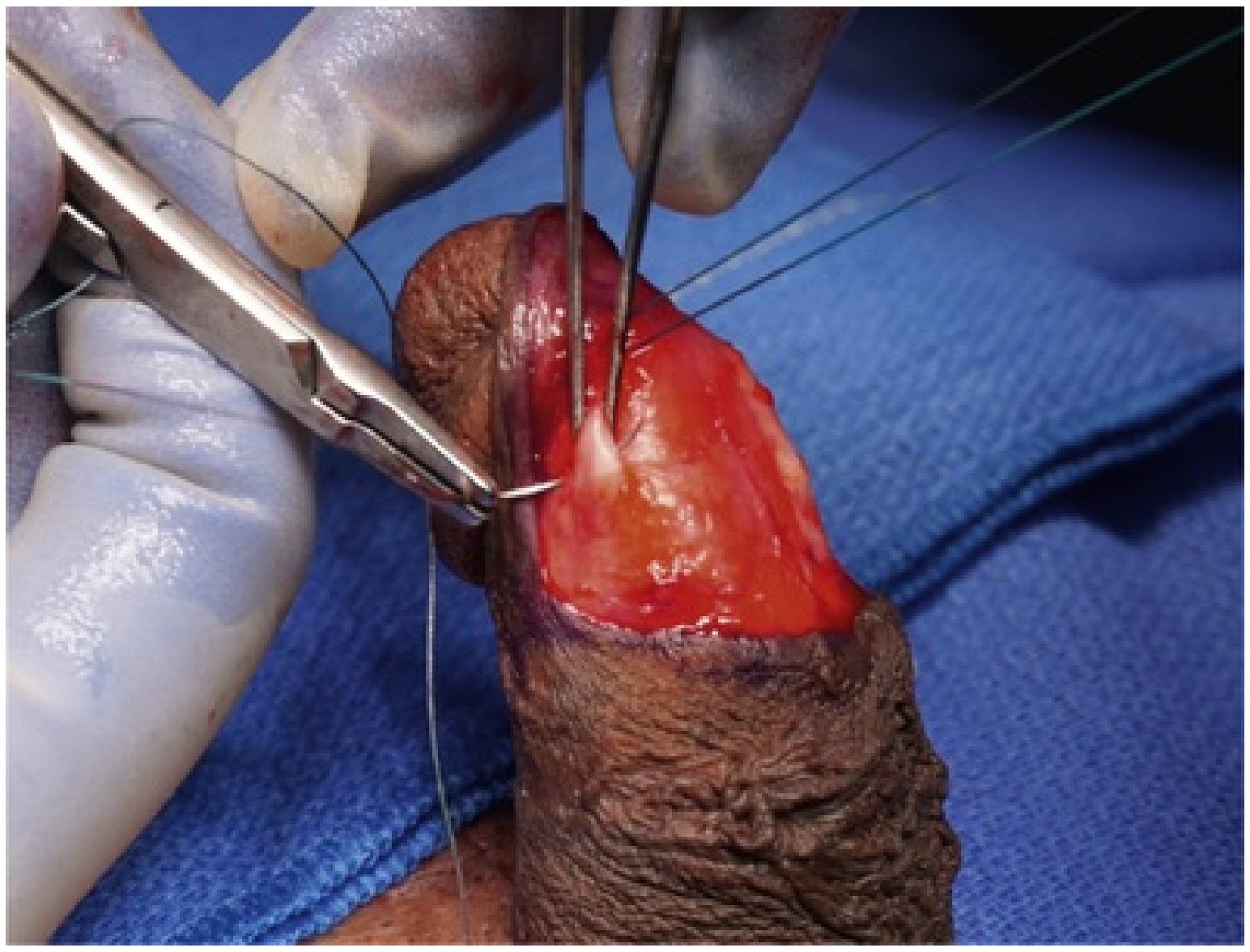

FIG. 72.24 Teeth of an Adson forceps grasping the tunica albuginea over the tip of the underlying implant cylinder as the needle is passed to avoid impaling the cylinder during glans fixation.

Curved Erection After Cylinder Placement

Placing and inflating the implant cylinders usually result in a straight erection because the tunica albuginea expands uniformly. However, in the presence of tunical scar from Peyronie disease, a prolonged pharmacologic injection program, or pelvic trauma, areas of the corpora cavernosa will not stretch uniformly. This results in the erection curving in the direction where the scar tissue limits tunical expansion. The semirigid rod implants can usually be bent to overcome the restriction, but when the scar is extensive and thick, straightening the erection with these devices may be difficult, and maneuvers to repair the tunica may be needed. Of the three-piece inflatable cylinders, the AMS 700 CX and the Titan have the best intrinsic rigidity and are better able to correct the curvature than the distally expanding AMS 700 LGX (Kowalczyk and Mulcahy, 1996). Placing and inflating either of these two devices alone will straighten the erection in the majority of cases. An angle of less than 20 degrees of curvature is acceptable and should enable the patient to successfully penetrate for intercourse. The two-piece Ambicor implant does not straighten well and is not recommended when there is significant tunical scarring.

If inflating the cylinders still leaves a significant curve, the modeling maneuver can be employed (Wilson and Delk, 1994). The inflated cylinders are bent forcefully at a right angle away from the direction of the curve and the position held for 90 seconds after the tubing to the pump has been shod-clamped to protect it from back pressure. If initially unsuccessful, the technique can be repeated. Corporotomy disruption and urethral injury have been seen after modeling and should be ascertained. Modeling is less successful in cases of postimplant removal scarring and works best for untreated Peyronie plaques. The penis should be kept partially erect postoperatively for 3 months to allow for pseudocapsule formation with the cylinders straight. If the cylinders are left deflated, a curved erection may return.

Alternatively, a Nesbit procedure/tunical plication or plaque incision and grafting can also be used in recalcitrant cases (Chung et al., 2014; Garafa et al., 2011; Mulcahy and Rowland, 1987). With use of the former technique, the convex surface of the curve is shortened by removing small tunical ellipses followed by closing the defects with absorbable suture or limiting the tunical expansion by placing plication stitches. When incising the tunica over the Titan bioflex material with electrocautery, a setting less than 35 watts should be used to avoid damaging the material (Hakim et al., 1996). The silicone coating of the Boston Scientific products is not affected by the cautery. Incising through the scar on the concave side of the erection allows the force of the cylinder to straighten the erection. The resulting tunical defect can be covered with graft material as described in the section on cavernosal reconstruction.

Key Points: Intraoperative Troubleshooting

- Injuries between the corpus cavernosum and the exterior should always be closed securely before an implant cylinder is left in place.
- The AMS 700 CX and Titan implants have the best intrinsic rigidity and are better suited to correct curvature associated with tunica albuginea scarring.
- Always keep the distal end of scissors or dilating instruments pointing dorsolaterally and parallel to the penile shaft to avoid crural crossover and urethral injury.

Postoperative Complications

Implant Infection

Numerous precautions to avoid an infection of the implant are taken before, during, and after the surgery. Unfortunately, infections still occur, although the incidence is low, in the range of 1% to 3%. Systemic prophylactic antibiotic usage is recommended by American Urological Association guidelines (Wolf et al., 2008). A combination of vancomycin or a third-generation cephalosporin and gentamicin should be started intravenously 1 hour before the incision and continued up to 24 hours postoperatively or until the wound is sealed (De Chiara et al., 2010). **No antibiotics should be needed beyond that point, although most urologists send the patient home on 5 to 14 days of an oral antibacterial** (Darouiche et al., 2013)**. It has been shown that the explantation rate for infection is the same whether or not oral postoperative antibiotics are used** (Adamsky et al., 2018).

A recent multi-institutional study assessing the organisms found in 156 infected implants discovered that 86% of the microbes isolated were sensitive to the vancomycin-gentamicin combination (Gross et al., 2017). A three-drug combination of vancomycin, an antifungal such as amphotericin or fluconazole, and piperacillin-tazobactam would neutralize 100% of the organisms found in this series. Use of this three-drug regimen may be prudent prophylactically in patients at high risk for developing an infection and in those with a documented infection before wound culture results are known. Caution regarding the duration of treatment and dosage of the antibiotics should be used because there is increasing evidence of nephrotoxicity with combined vancomycin-piperacillin therapy (Watkins and Deresinski, 2017). Copious irrigation with an antibiotic-containing solution should be used throughout the case, although no particular antiseptic agent is currently recommended. The three-piece inflatable devices of both vendors have antibacterial coatings, and the medications will recede into the tissues over several days. The AMS 700 series is covered with a rifampin-minocycline combination called Inhibizone (Fig. 72.25). These antibiotics were chosen because of low allergic potential and their effectiveness against organisms seen in implant infections. The Titan and the Genesis have a hydrophilic coating that absorbs the liquid into its surface when dipped in the antibiotic solution (Fig. 72.26). The common antibiotics used in the dipping solution are rifampin-gentamicin or sulfamethoxazole-trimethoprim. These new vendor modifications have cut the infection rates in half when compared with using noncoated devices (Carson et al., 2011; Serefoglu et al., 2012).

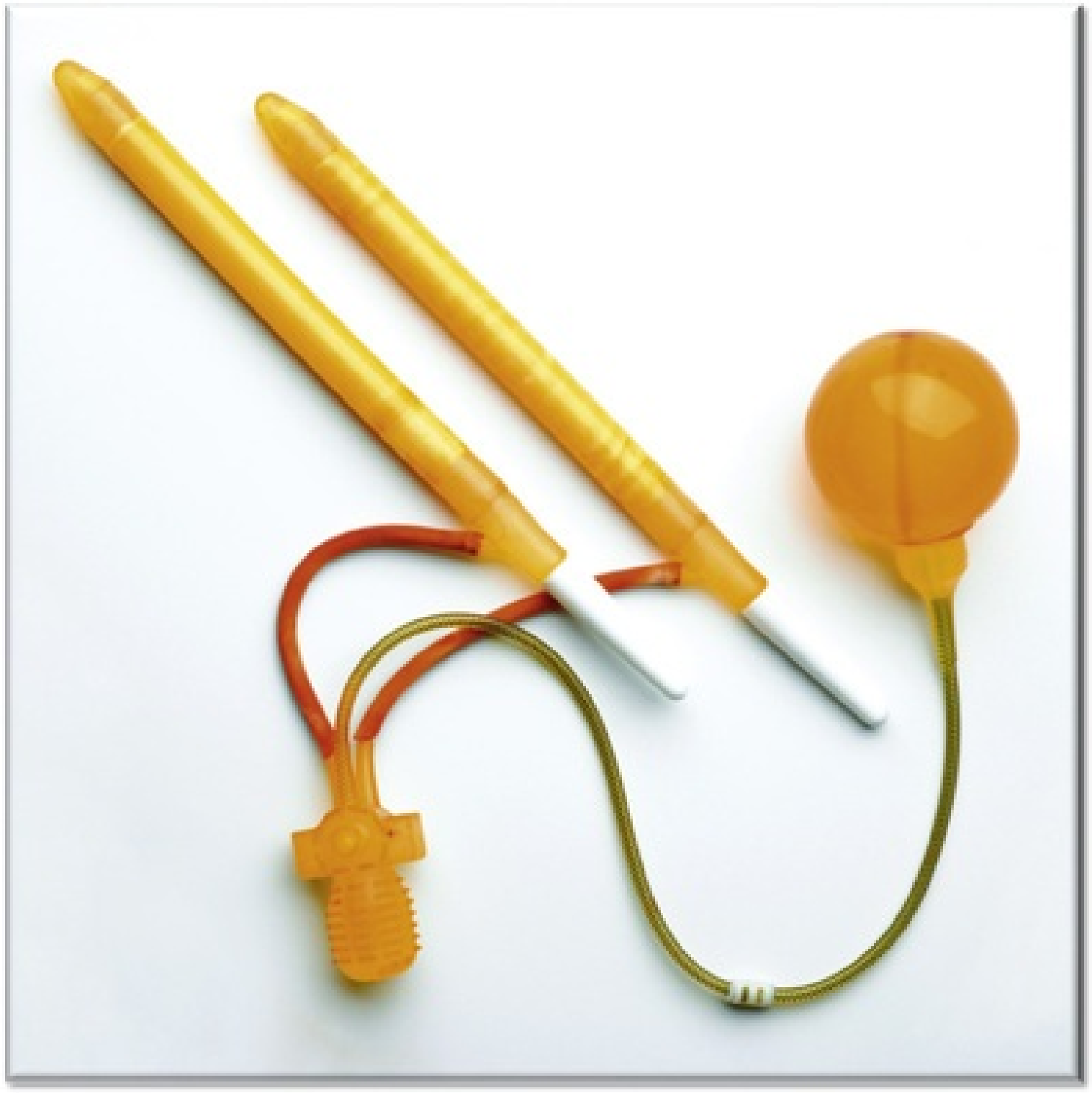

FIG. 72.25 The Inhibizone antibiotic coating of the AMS 700 series implants.

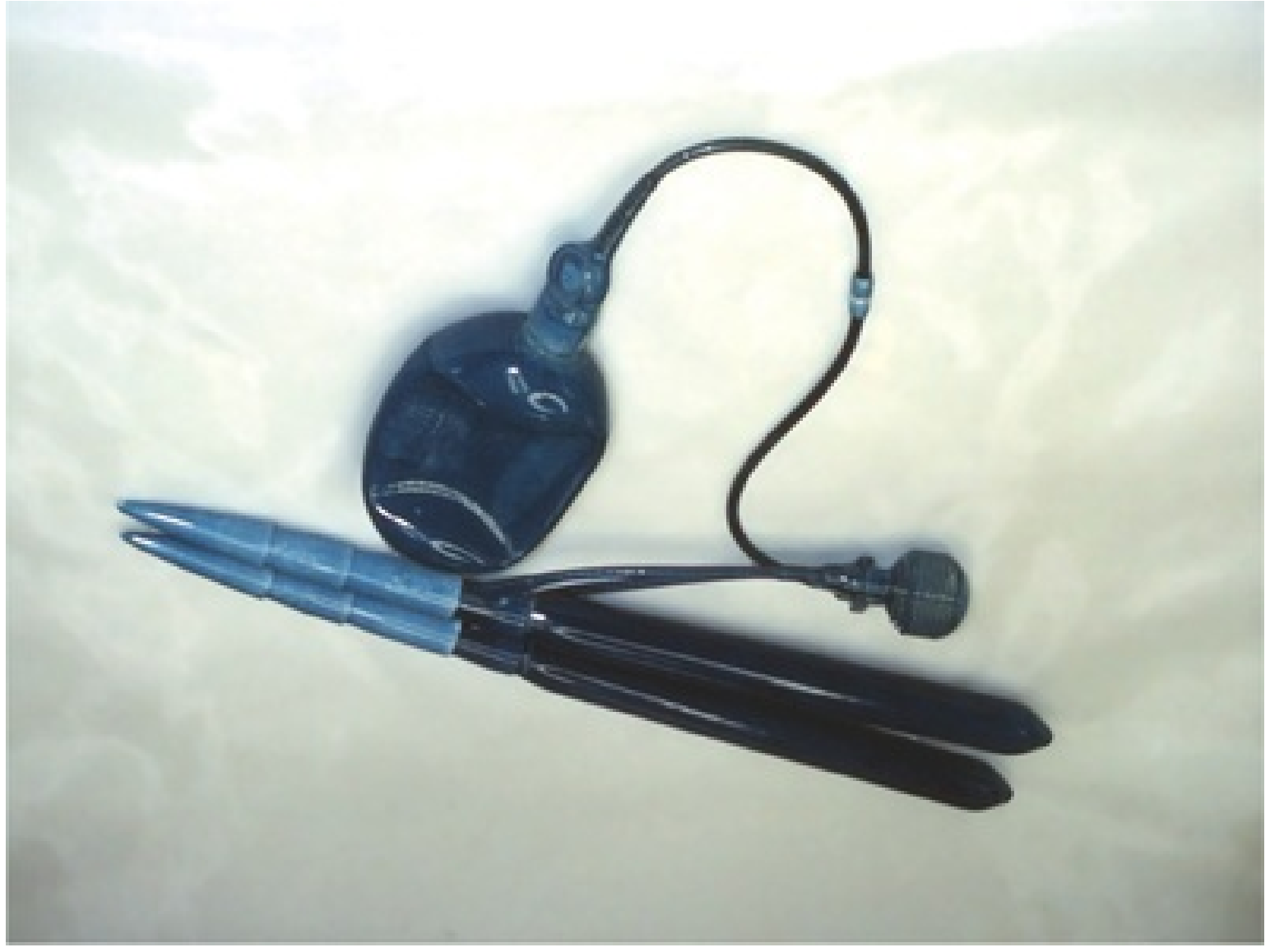

FIG. 72.26 A Titan implant placed in a methylene blue solution showing the solution adhering to the implant surface.

Dr. Eid (2016) has pioneered the “no-touch technique,” in which the skin is completely draped off from the wound and any surgical glove or instrument touching skin is discarded from the operating field. His infection rate in more than 1500 cases was 0.46%. This reinforces the concept that infecting organisms are introduced through the open wound and are not delivered to the surgical site via the bloodstream. A chlorhexidine-alcohol mixture has been shown to be the best preoperative skin prep, showing a 40% lower surgical site infection rate when compared with povidone-iodine (Darouiche et al., 2010).

Twenty-five percent of the population has methicillin-resistant *Staphylococcus aureus* (MRSA) on the skin with greatest concentration in the nasal cavity. Most prosthetic urologists do not screen for MRSA preoperatively. American College of Surgeons Guidelines regarding surgical site infection recommend screening for MRSA in cardiac surgery and orthopedic joint surgery patients. Prosthetic urology patients will likely soon be included among those in whom MRSA screening and decolonization are recommended. If positive MRSA cultures are obtained from the nasal cavity, a decolonization protocol is recommended. This entails chlorhexidine bathing on days 1-3-5 preoperatively and 2% nasal mupirocin (Bactroban) twice a day for 5 days (Ban et al., 2017).

Patients presenting with an infected implant may have the signs and symptoms of fever, chills, and erythema at the incision site, but definitive signs are purulent drainage from the incision, especially when squeezing on the cylinders or pump, visible prosthetic material in the wound, and progressive pain and fixation of the pump to the scrotal wall. **When an infection is present, the incision should be opened and all foreign material removed. Leaving a component behind risks an abscess formation around that part because organisms can migrate along the tubing to remotely located parts of the device.** There are two options after removing the infected device, and these should be thoroughly discussed with the patient before operating. The implant can be left out, irrigation drains placed in each corporal body, and the wound closed (Maatman and Montague, 1984). Solutions containing antibiotics effective against the offending organisms are instilled into each drain every 8 hours for 3 days to eliminate the microbes and prevent a corporal abscess formation. The surgeon can return in 2 to 6 months to replace the implant when the infection has cleared. Placing the cylinders will be difficult because of corporal scarring, and the erection will be noticeably shorter. Using a vacuum erection device for 10 minutes daily to stretch the penis while waiting to replace the implant helps minimize this shortening and keeps the erection straight (Canguven et al., 2017).

Another option, termed a “salvage” or “rescue” procedure, entails removing all foreign material, washing the wound thoroughly with a series of antiseptic solutions, changing the wound drapes and in the original protocol, a series of antiseptic solutions including antibiotics, povidone-iodine, and hydrogen peroxide and pressure washing of the implant cavities were employed with a success rate of 84% (Box 72.1; Mulcahy, 2000). The failures were usually associated with onset of infection within 2 months of implant placement, the presence of aggressive organisms, and accompanied by purulence and cellulitis. In a later series four such aggressive infections were successfully cleared by placing the patients on vancomycin and gentamicin systemically, observing receding cellulitis, and performing the salvage procedure after 3 days (Mulcahy, 2015). The original antiseptic irrigating solutions were chosen empirically, and have not been challenged because of their high success rate. Recent evidence from an extensive review of orthopedic joint infection literature suggests a more appropriate content and use of antiseptic irrigating solutions (Pan et al., 2019). A recent series used semirigid rods rather than the patient's original implant type as the replacement cylinders during a salvage procedure with a 94% success rate (Gross et al., 2016). This avoids placing parts in a macerated scrotum or a remote abdominal cavity and takes less time. One-third of these patients requested conversion to a three-piece inflatable implant at a later date. These salvage techniques highlight the goal of corporal length preservation. Delayed reimplantation of a prosthesis after removal for an infection resulted in a total corporal length loss of 3.7 cm in a recent series (Lopategui et al., 2018). Operations to repair a malfunctioning implant that is clinically uninfected have been associated with a high infection rate, in the range of 10% (Henry et al., 2004). Organisms introduced at the time of the original implant placement form a mucopolysaccharide coating called biofilm, which protects them from the body's defense mechanisms (Wilson and Costerton, 2012). The repair procedure disturbs this environment, and bacteria become active, developing a symptomatic infection. **The infection rate in these repair procedures has been reduced to the acceptable 3% range by using a series of antiseptic irrigations in each of the implant cavities after the old parts have been removed and before placing the new implant. This technique has been called a "revision washout" and is recommended for all secondary prosthetic procedures during which old implant parts are removed** (Henry et al., 2005).

Box 72.1

Antiseptic Washes Used During a Salvage Procedure

- Place dilute povidone–iodine (0.35-3.5%) in implant cavities. Leave in place for 3 minutes.
- Wash out with saline or antibiotic solution.
- Eliminate hydrogen peroxide washes. This substance has no antiseptic advantage over povidone-iodine and can be cytotoxic.
- Chlorhexidine may be more effective than povidone-iodine, but data is insufficient.
- Pressure irrigation is optional.

Cylinder Aneurysm

A bulge stretching the skin at the base of the penis (Figs. 72.27 and 72.28) may have two causes. In the early postoperative period it is usually a disrupted corporotomy with herniation of the cylinder through the defect. Exploring the wound and repairing the defect at the corporotomy site suffice usually without the need for graft material. Years after implant placement a weakness in the cylinder wall may develop as a result of frequent maximal device inflation and aggressive use with resulting bulging of the cylinder wall at the weakened site. If there is a question of an aneurysm, an MRI of the penis will identify the problem, but usually experienced examining fingers can detect the abnormality (Moncada et al., 2004).

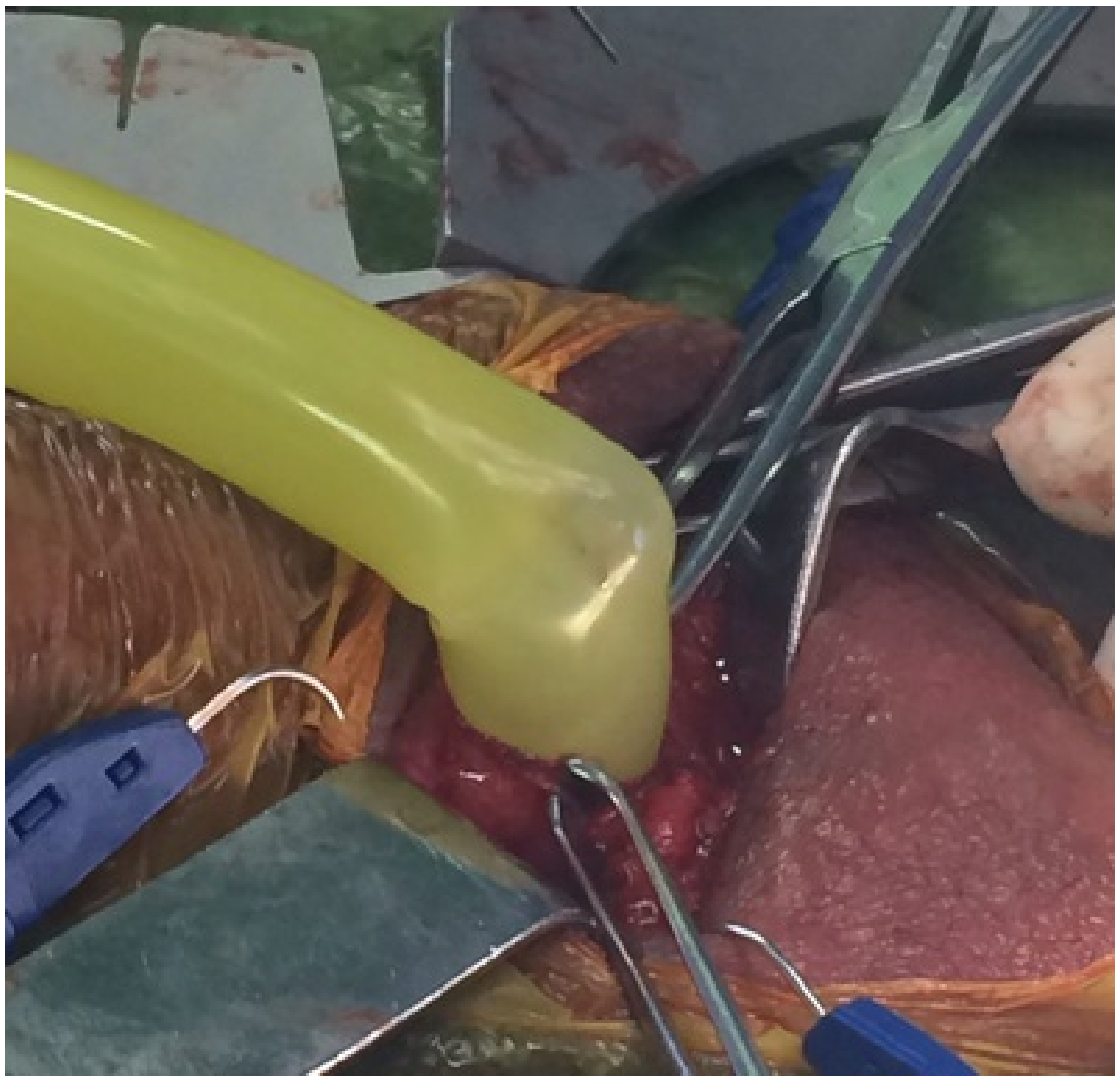

FIG. 72.27 Aneurism of a Titan implant cylinder.

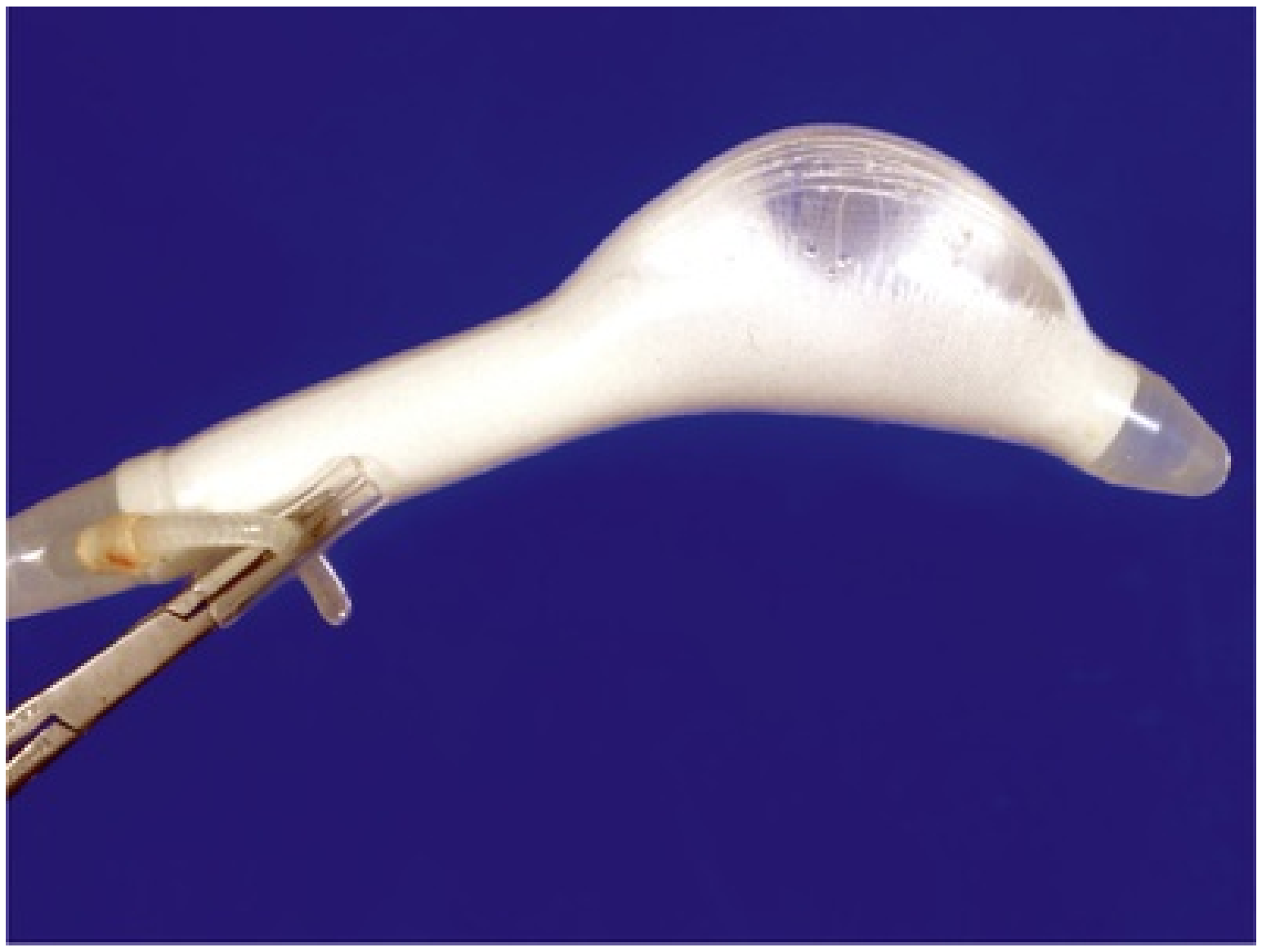

FIG. 72.28 Aneurysm of an AMS 700 cylinder resulting from shredding of the middle fabric layer.

The middle fabric layer of the AMS 700 will shred and the polyurethane material of the Titan will deteriorate with excessive wear. Replacing the cylinders corrects this problem. The tunica albuginea may need tapering, but graft material usually is not required.

Cylinder Extrusion

An implant cylinder may extrude through the tunica at the end of the erection chamber and be palpable under the foreskin on the side of the penis (Fig. 72.29) or protrude prominently into the glans, sometimes manifesting as an impending erosion into the urethra at the meatus (Fig. 72.30). Tunical wear from excessive pressure may be due to damage from forceful dilation, placement of oversized cylinders, or aggressive use of the erection over time. Because the prosthetic components are not externally exposed and infection is absent, the cylinder tip can be reseated in a new plane within the corporal cavity, where the distal tunica is intact, a maneuver termed *distal corporoplasty* (Mulcahy, 1999). A hemicircumcising incision followed by a longitudinal corporotomy is made over the extruded cylinder tip. The tip is removed from the cavity and a suture placed through the end to retract the cylinder inferiorly (Fig. 72.31). The back wall of the pseudocapsule is incised, and a dorsomedial plane is developed in the spongy erectile tissue with the scissors and sequential dilators to create a new cylinder cavity (Fig. 72.32). The traction suture at the cylinder tip is used to introduce the cylinder into this new location (Fig. 72.33), and the corporotomy closed. If the problem was associated with an oversized cylinder, replacement with an appropriately downsized device is performed.

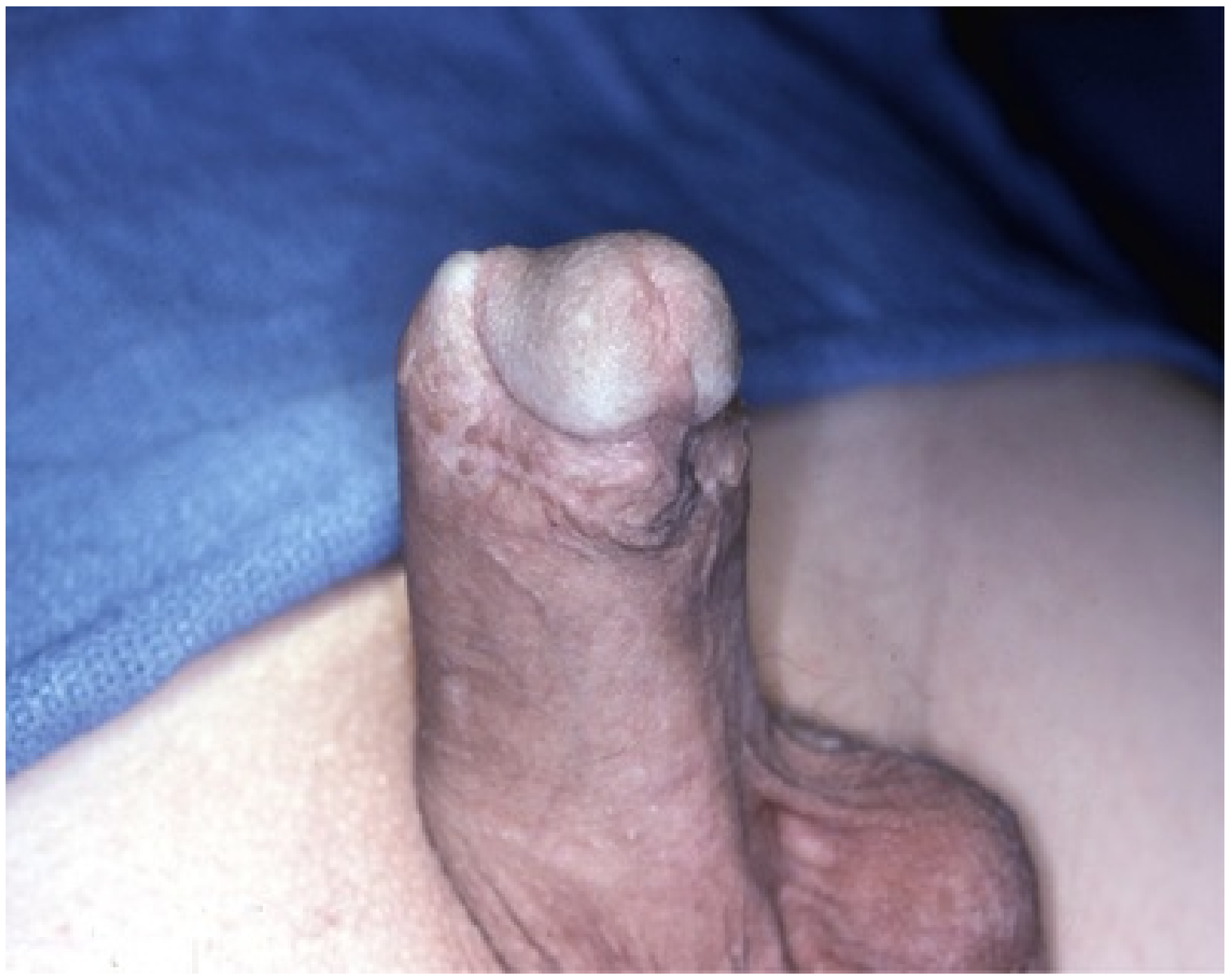

FIG. 72.29 Implant cylinder tip extruding through the distal tunica albuginea.

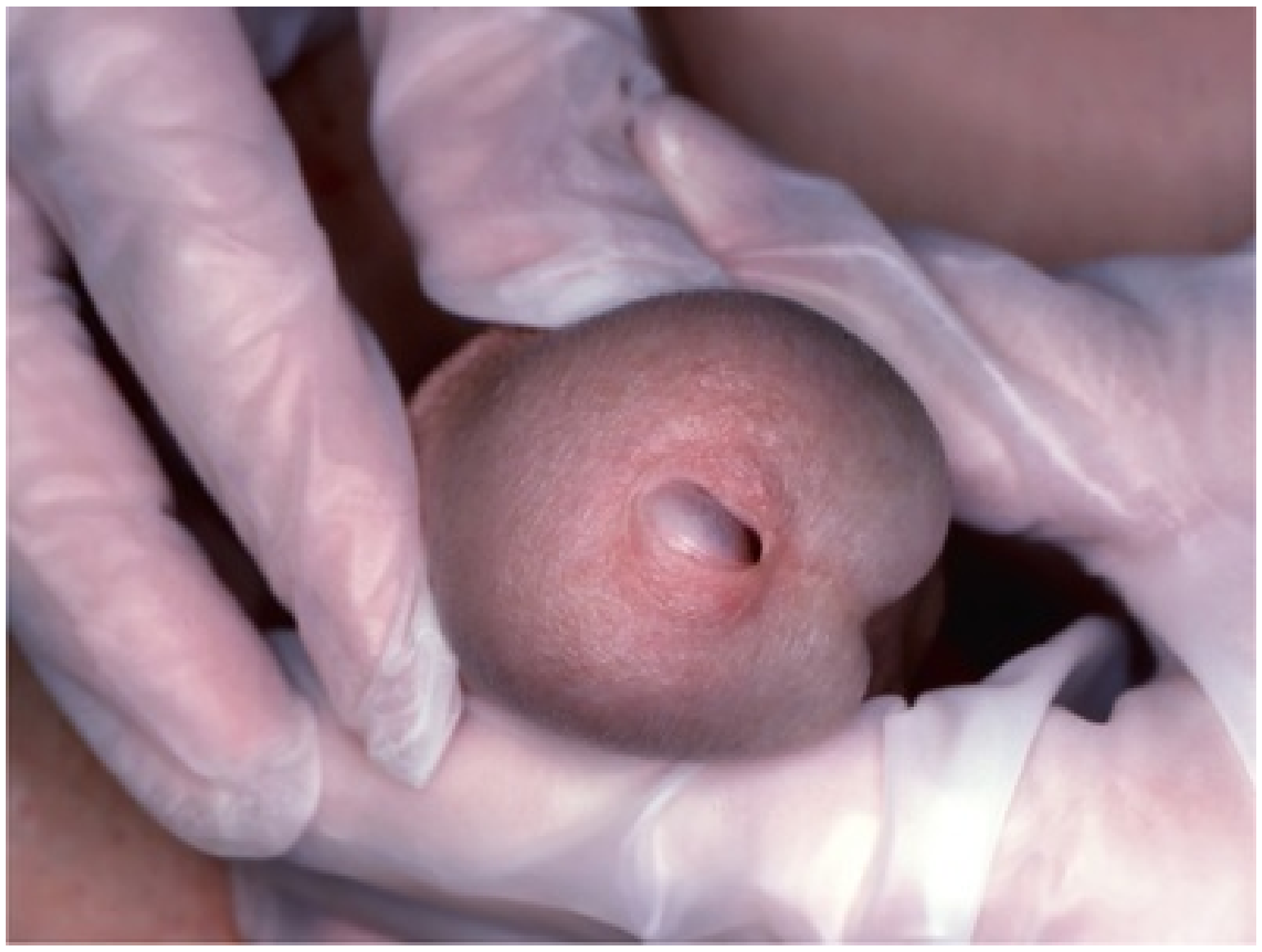

FIG. 72.30 Tip of an implant cylinder protruding into the fossa navicularis.

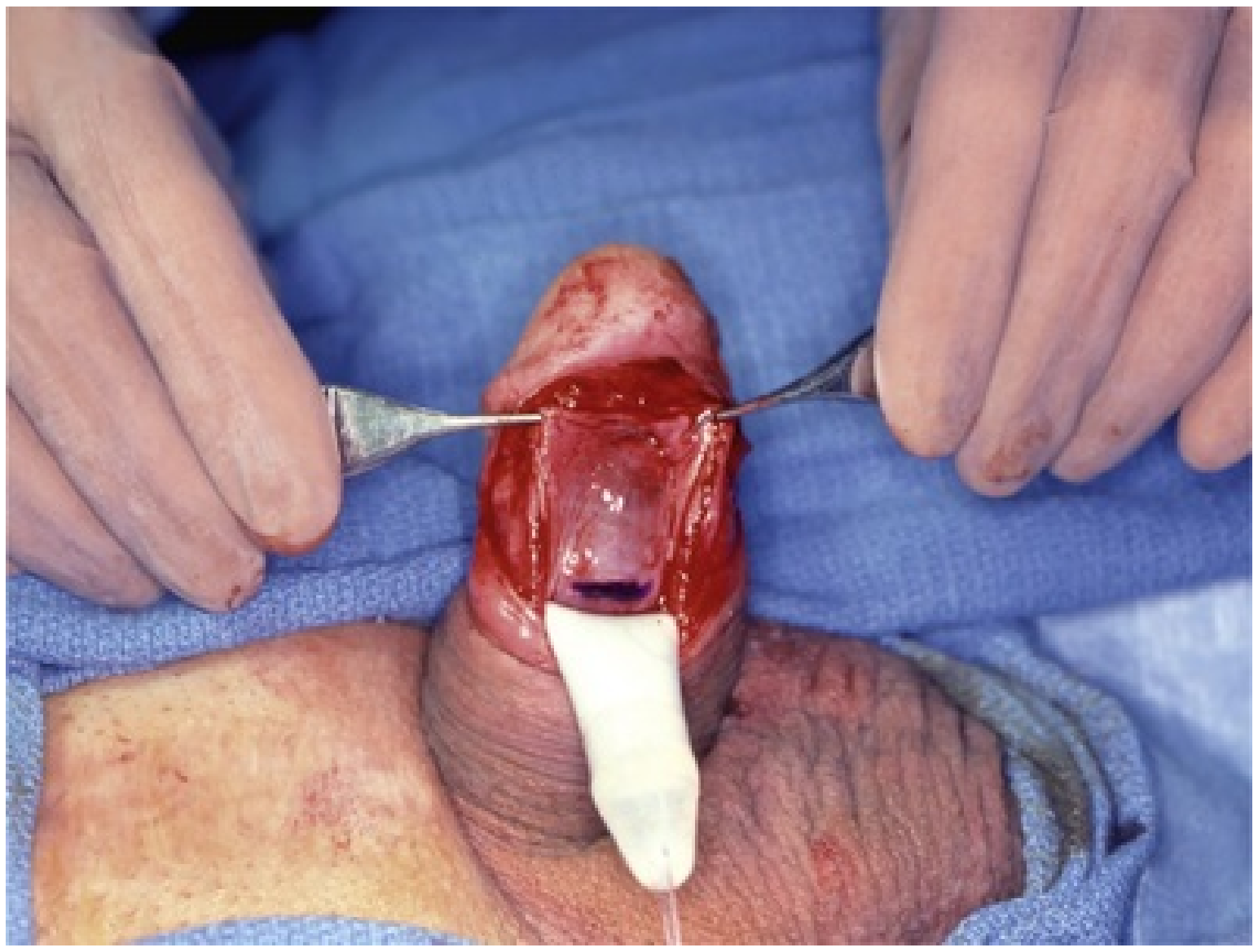

FIG. 72.31 Distal corporoplasty incision into the pseudocapsule surrounding an extruded implant cylinder.

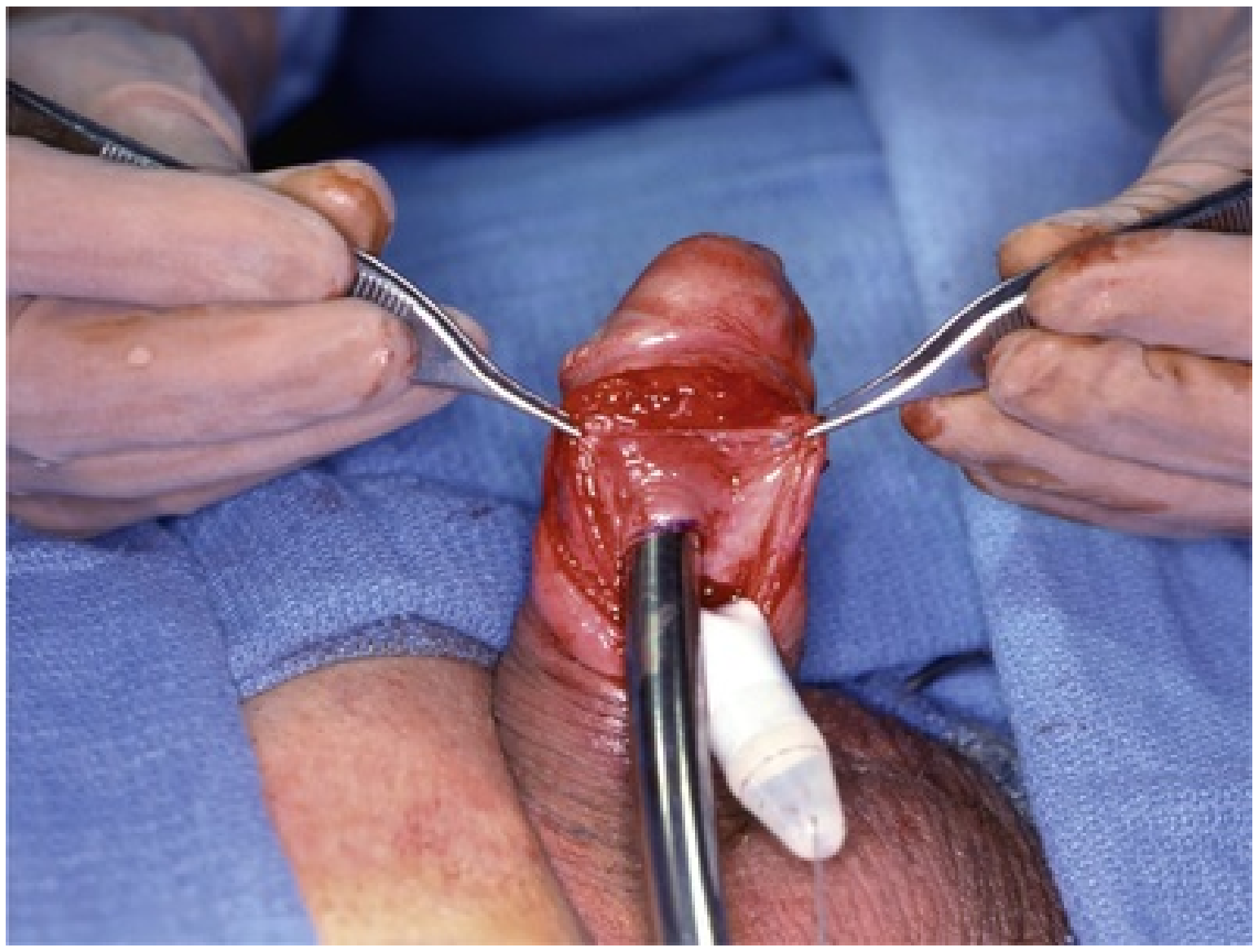

FIG. 72.32 New plane for cylinder placement created behind the pseudocapsule during distal corporoplasty.

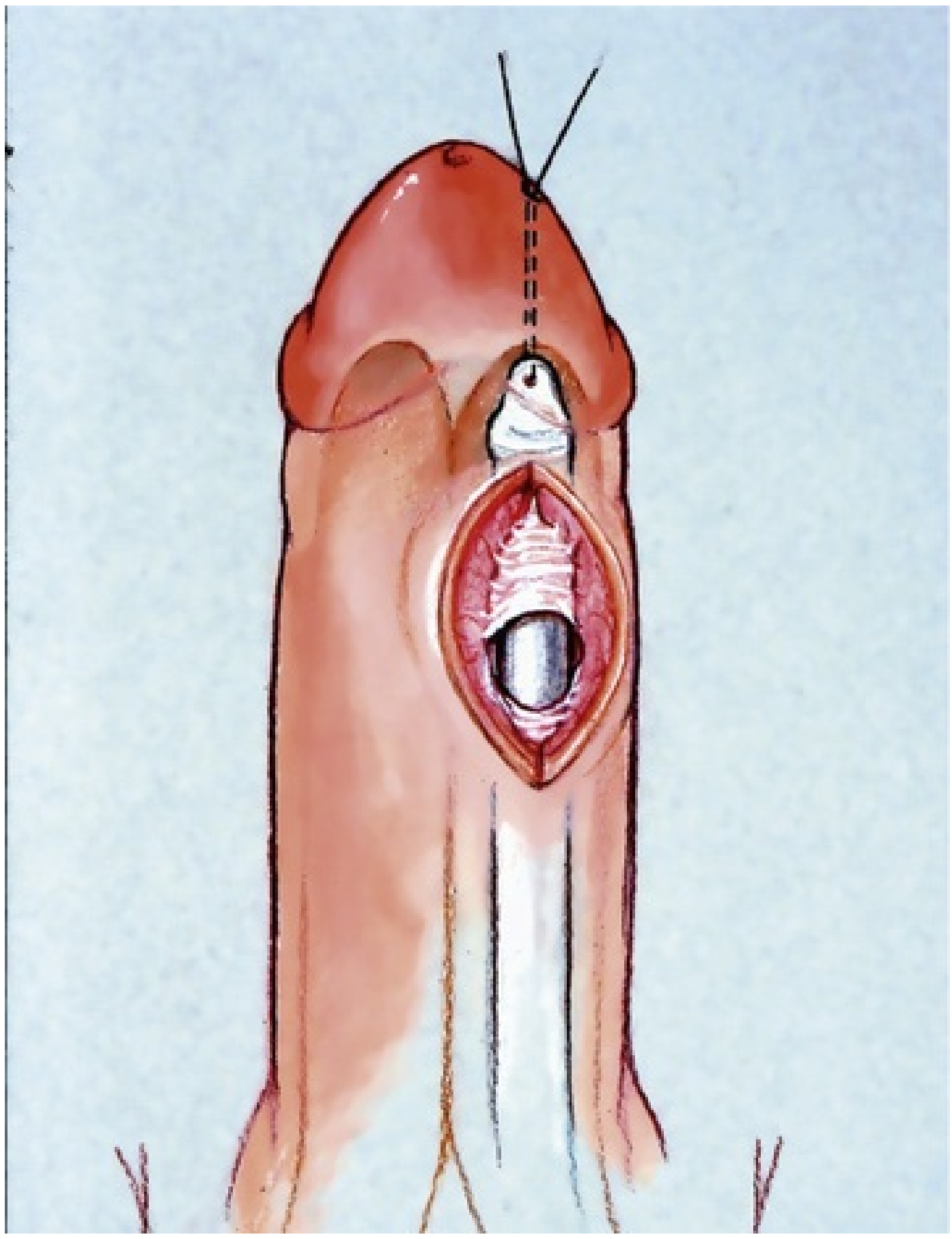

FIG. 72.33 Cylinder placed in new cavity using insertion tool and traction suture during distal corporoplasty.

Cylinder Erosion

Chronic wear at the cylinder tip over time may cause it to extrude from not only inside the protective tunica albuginea but also through the skin or into the urethra (Fig. 72.34). Protrusion of the cylinder tip may be associated with an underlying device infection, excessive pressure from within the corporal cavity, or external friction of repeated catheterization or instrumentation. Chronic catheterization, either indwelling or intermittent, creates friction against the cylinder tip in the fossa navicularis and has been associated with a high incidence of cylinder erosion into the urethra (Steidle and Mulcahy, 1989). Patients with semirigid rod implants who lack penile sensation, such as those with a spinal cord injury, are more prone to cylinder erosion (Zermann et al., 2006). The rod tips are hard and cannot be recessed. **Patients with sensory deficits rub the firm penis against undergarments, creating friction against**

the rod tips. Hydraulic implants should be used in such patients, because they are less prone to erosion. Urethral erosion sites are inaccessible to repair, and therefore the cylinders and other parts of the implant should be removed and the wound washed with antiseptic solutions. The area is contaminated, and organisms can travel via the tubing to other parts of the device. After the wound is cleansed, a spacer cylinder can be placed in the opposite corporal body to maintain its patency and preserve penile length. A cylinder can be replaced on the side of the erosion after 5 to 6 months, when solid scar has formed and obliterated the original erosion tract. If a cylinder erodes laterally, it should be removed and the wound treated the same way as if it had eroded into the urethra. Placing a new cylinder into the corporal body after an erosion combined with antiseptic irrigations and distal corporoplasty has been tried in such cases but usually proven unsuccessful.

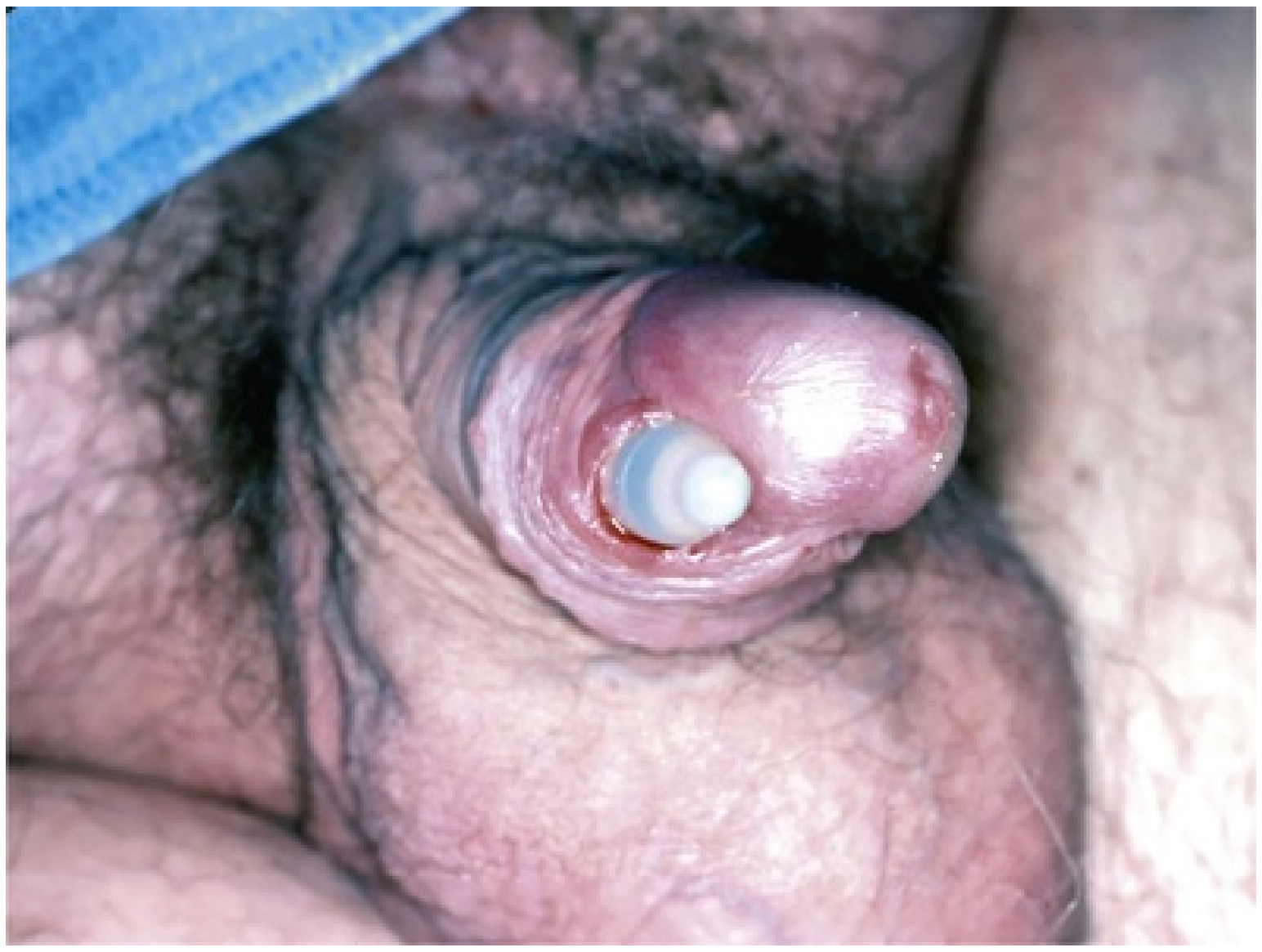

FIG. 72.34 Implant cylinder tip eroding through the skin.

Visceral Erosion of the Reservoir

A very rare occurrence is erosion of the implant reservoir into the urinary bladder or a segment of the bowel. If the reservoir is placed in a restricted perivesical location, the constant pressure of the balloon against the bladder wall will cause the latter to break down, and the reservoir will enter the viscus (Fitch and Roddy, 1986). If a reservoir is placed in a very restricted perivesical cavity and expands during filling with isotonic saline, the bladder wall may be torn. The reservoir may enter the bladder, and scar will quickly form in the defect. When the bladder is opened to remove the reservoir, tubing can be seen exiting through a small hole in the bladder wall scar (Fig. 72.35). The wound and the urine are usually sterile and therefore, after the reservoir is removed, a stitch can be placed in the tubing exit site, the bladder closed, and another reservoir placed elsewhere in a capacious cavity. The area should be thoroughly irrigated with antiseptic solutions.

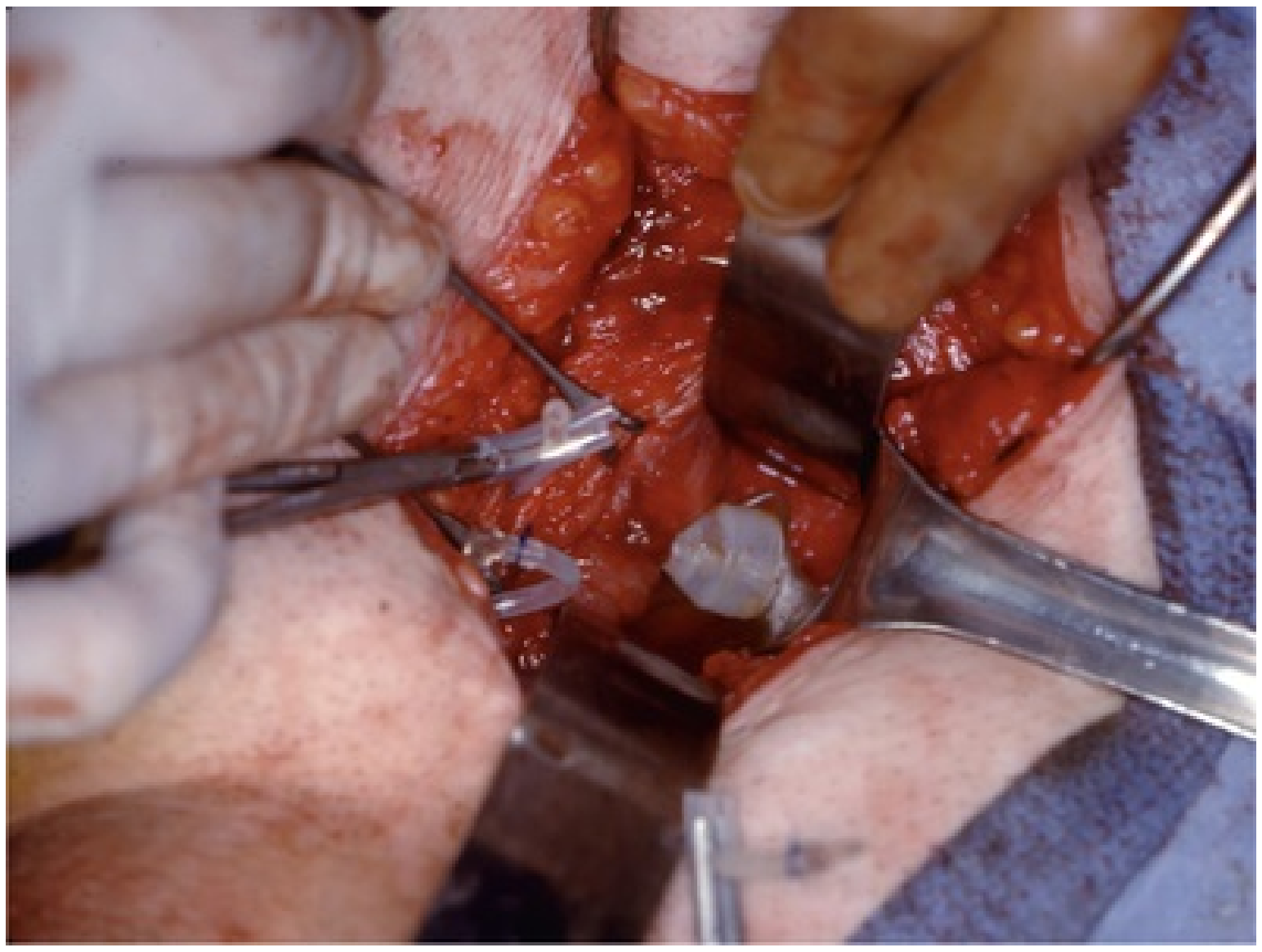

FIG. 72.35 Implant reservoir eroded into the urinary bladder.

Erosion of the reservoir into the bowel is less common than bladder erosion and occurs when the reservoir is placed adjacent to an immobile bowel segment. Expansion of the reservoir, as it is filled, tears a part of the bowel wall (Singh and Godec, 1992). The problem is quickly noticed as succus entericus invades the tissues and causes significant inflammation. The entire implant should be removed and a general surgeon consulted.

Penile Necrosis After Implant Placement

When placing a penile implant and performing procedures on the tunica albuginea to straighten the erection or better seat the cylinders, the urologist must be mindful that the penis is a digit, and nutrient blood flows in a proximal to distal progression. Ischemia to any part of the penis can result in dry gangrene, and the glans, being the most distal structure, is the most susceptible (Fig. 72.36; Wilson et al., 2017). Longitudinal incisions on the foreskin and tunica albuginea, parallel to the shaft, are less likely to interrupt distal blood supply than transverse incisions. Patients with severe cardiovascular disease, diabetes mellitus, chronic smoking, previous prosthetic implants, and prior pelvic radiation to the area should be considered at risk for this complication, especially when two or more of these comorbidities exist. The distal foreskin may be giving significant glans nourishment, and circumcising incisions may contribute to glans necrosis. Incisions in the tunica albuginea to straighten the erection or rearrange the tunical structure in an attempt to lengthen the erection should be attempted with caution in these high-risk patients. Compressive dressings such as the mummy wrap should be applied without excessive pressure, and the glans should always be left exposed to be certain it has good perfusion. When ischemic necrosis is detected, the cylinders should be removed promptly to take pressure off penile parts and hopefully restore better distal blood flow. Conservative debridement of dead tissue should help with future reconstructive procedures.

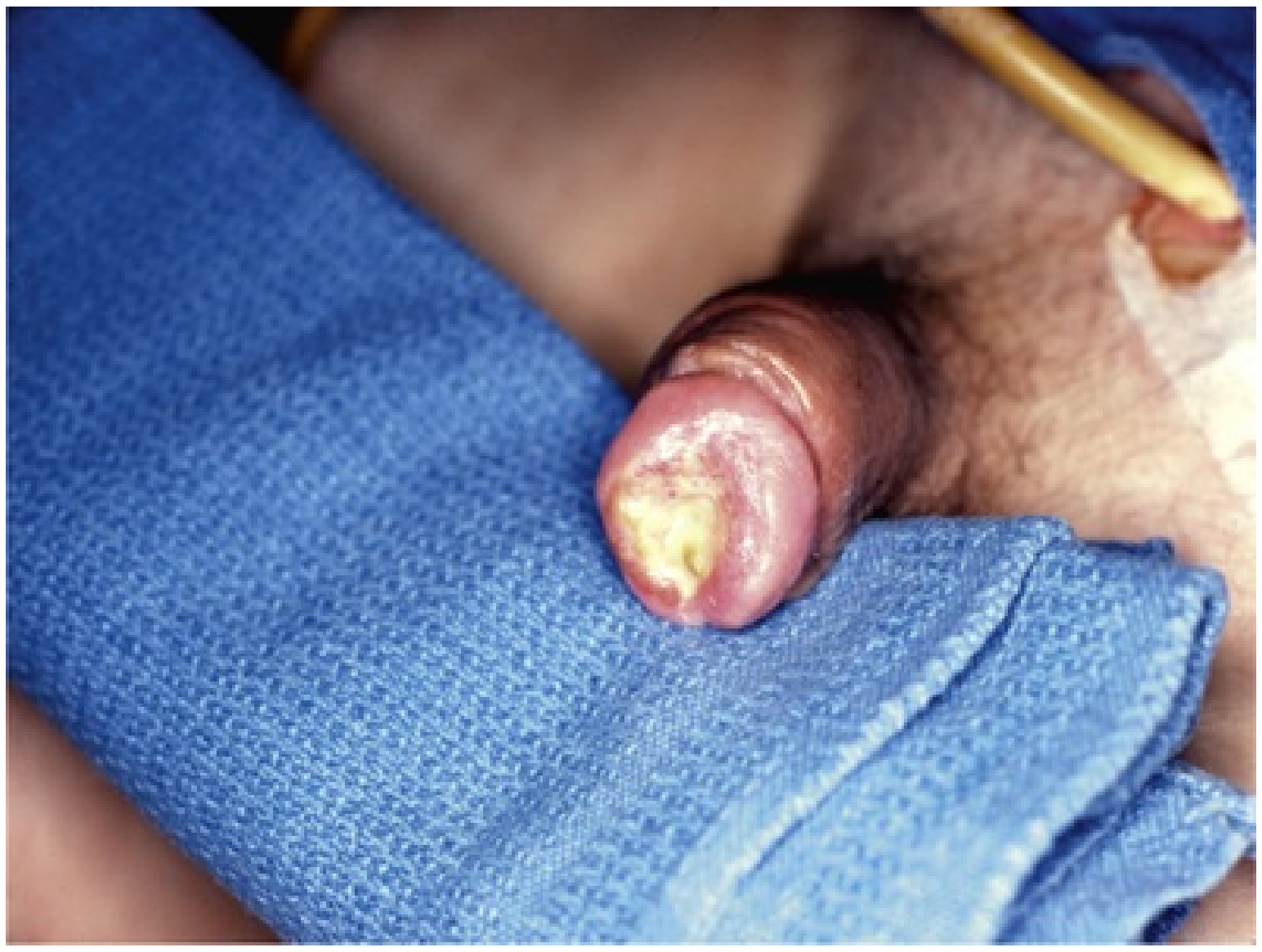

FIG. 72.36 Glans and urethral necrosis after implant placement.

Key Points: Postoperative Complications

- In the presence of a penile implant infection all foreign material should be removed from the wound because remnant parts may harbor microbes that perpetuate the infection.
- Patients at risk for reduced penile vascular perfusion should be counseled preoperatively regarding distal penile necrosis. Aggressive reconstructive procedures should be limited or staged in these patients.
- The implant reservoir should be placed in a capacious cavity to avoid injuring surrounding structures such as bowel or bladder during balloon filling and expansion.

Special Situations

Immunosuppressed Patients

Penile implants have been successfully placed in immunosuppressed patients with renal, cardiac, hepatic, and renal/pancreas transplants (Sidi et al., 1987; Sun et al., 2018). An increased incidence of complications in these patients, including implant infection, has not been seen. The immunosuppressive medications are managed by the transplant specialist along with coordination of the prophylactic antibiotics in conjunction with the urologist. Patients who are human immunodeficiency virus positive and are on antiviral regimens with appropriate CD4 counts have often received penile implants without an increased likelihood of an implant infection developing (Davoudzadeh et al., 2016).

Penile Implants in Ischemic Priapism

Acute ischemic priapism of more than a day's duration will result in completely scarred corporal bodies. Months after the episode had subsided the only successful option in restoring the patient's erections is a penile implant. With the significant fibrosis encountered, creating cavities in which to place the cylinders is difficult, and the resulting erection is significantly shorter. The recent trend has been to place the cylinders at the time of the acute episode (Ralph et al., 2009; Yucel et al., 2018). The corporotomy may help relieve the pain of the compartment syndrome. The cavities are edematous, but solid scar has not yet formed, and most of the erectile length will be preserved. Hydraulic or semirigid rod cylinders can be used, and some documentation of spongy tissue necrosis, such as a biopsy, would be prudent to avoid possible future legal ramifications. The patient likely has had distal corporal shunts; these defects should be closed, and placing the distally expanding AMS 700 LGX cylinders should be avoided. Informed consent is paramount, because these are usually young patients with no prior erectile difficulty who are now told that their natural erection will require prosthetic assistance.

Lax Suspensory Ligament

The crural bodies are attached to the symphysis pubis and ischiopubic rami by the suspensory ligament. This structure supports the erection and prevents proximal migration of the penis during the thrusting motions of intercourse. This ligament can infrequently have laxity (Li et al., 2007). The reason for this is not clear and may be congenital or due to trauma during sexual activity. If penile implant cylinders are placed with a proper fit and filling of the corporal bodies, the erection will tend to buckle with a lax supporting ligament. On examining the penis, a gap or cleft can be felt between the crura and the bone, and the penis can be grasped and easily moved side to side (Fig. 72.37). The situation is easily repaired by placing two or three nonabsorbable interrupted sutures securing the tunica albuginea to the periosteum of the symphysis pubis and the ischiopubic ramus bilaterally (Fig. 72.38).

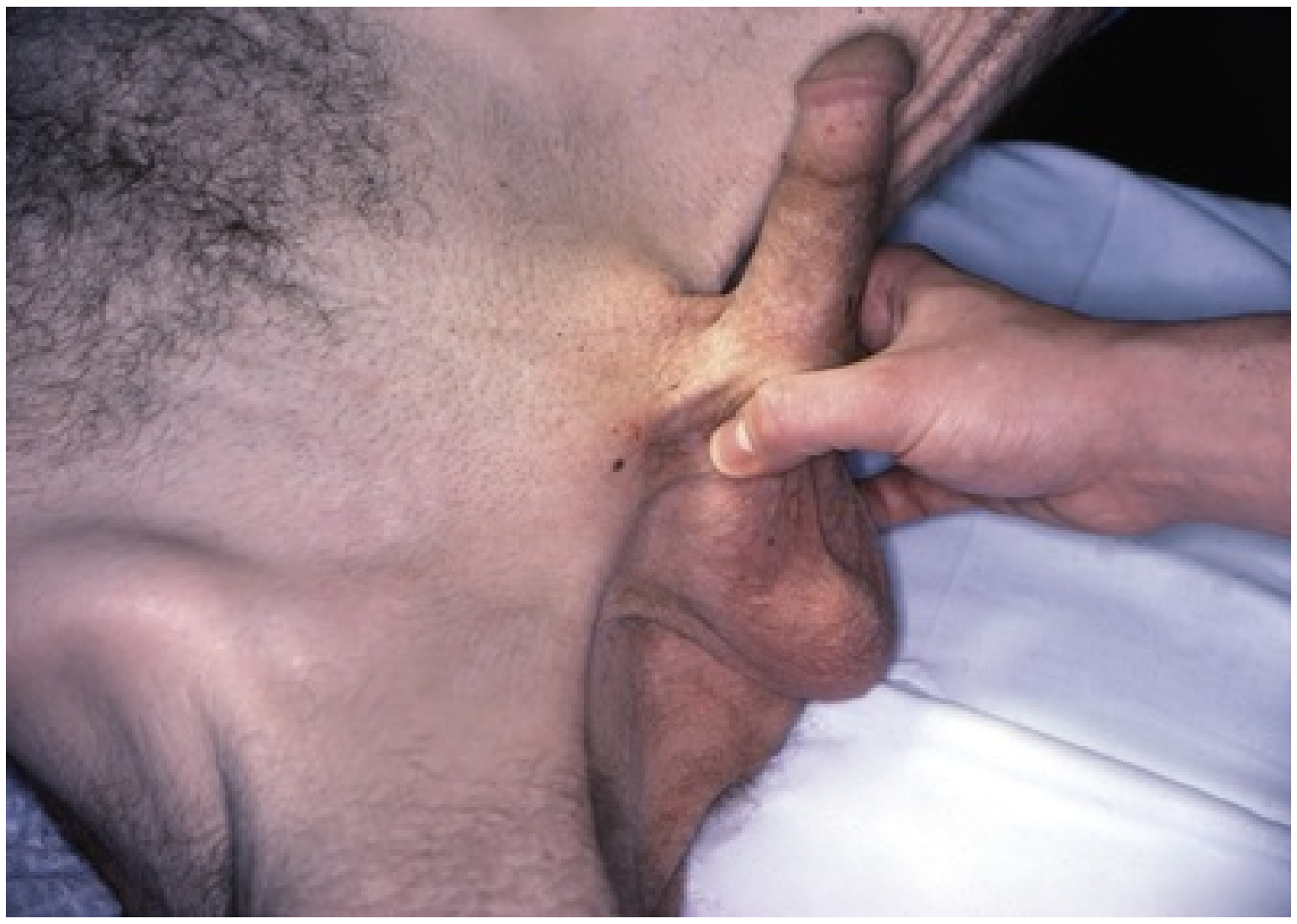

FIG. 72.37 A well-sized penile implant in place providing poor axial rigidity resulting from a lax suspensory ligament. A gap between the crura and the pubic bone is noted, and the crura can easily be moved from side to side.

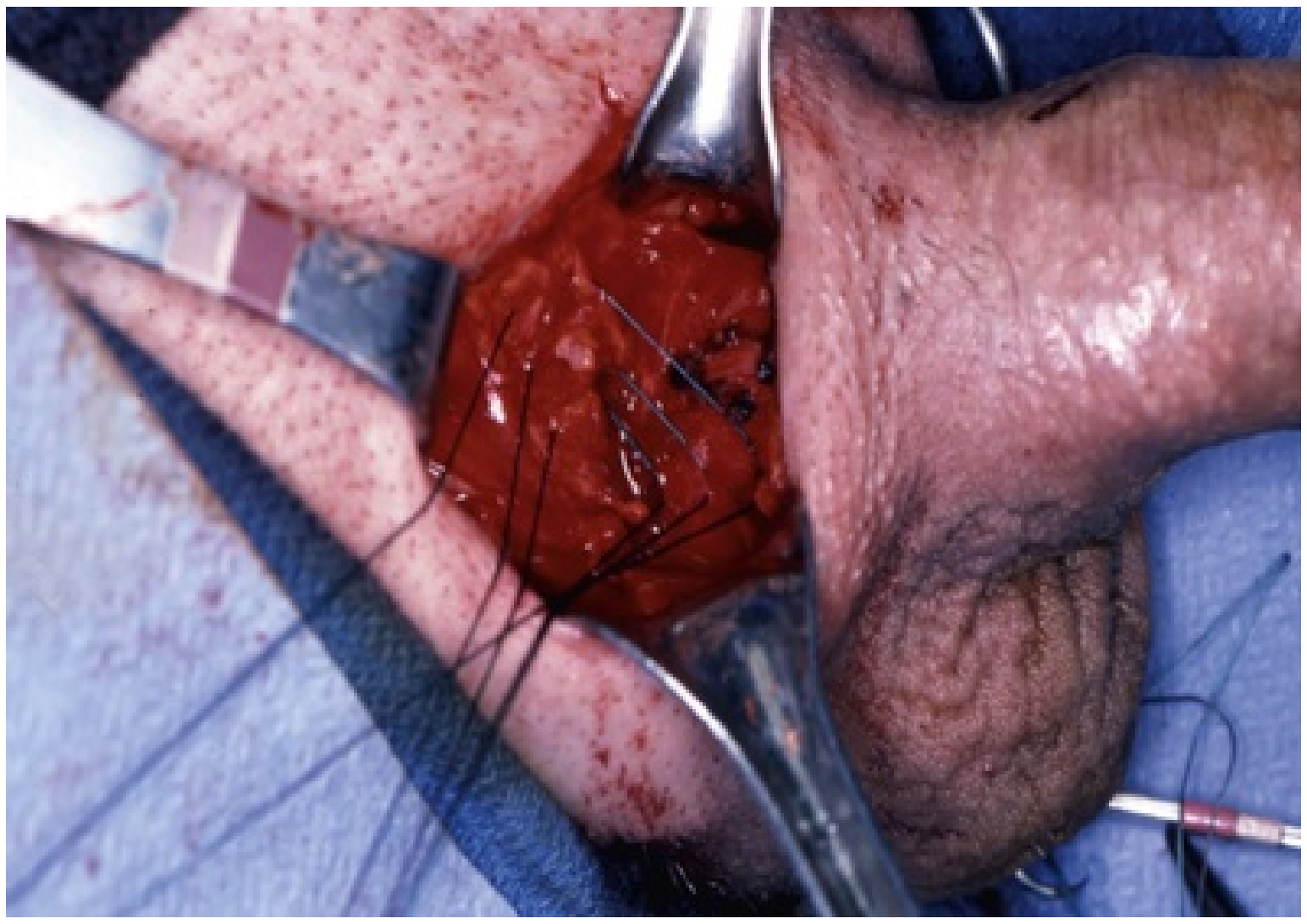

FIG. 72.38 Lax suspensory ligament repaired by three nonabsorbable sutures securing the tunica albuginea to the pubic periosteum bilaterally.

Long-Distance Bicycle Riding

The crural bodies containing the proximal ends of the implant cylinders or rear tip extenders abut against the anterior projecting horn of the standard bicycle seat. In short-distance recreational bicycle riding this will pose no problem for the patient with a penile implant. In the long-distance frequent rider, however, the firm crura will rub against the seat and may cause pain and/or numbness. This has also been associated with the development of urethral strictures (Awad et al., 2018). Substituting a seat with one that has buttock supports only will solve this problem (Fig. 72.39).

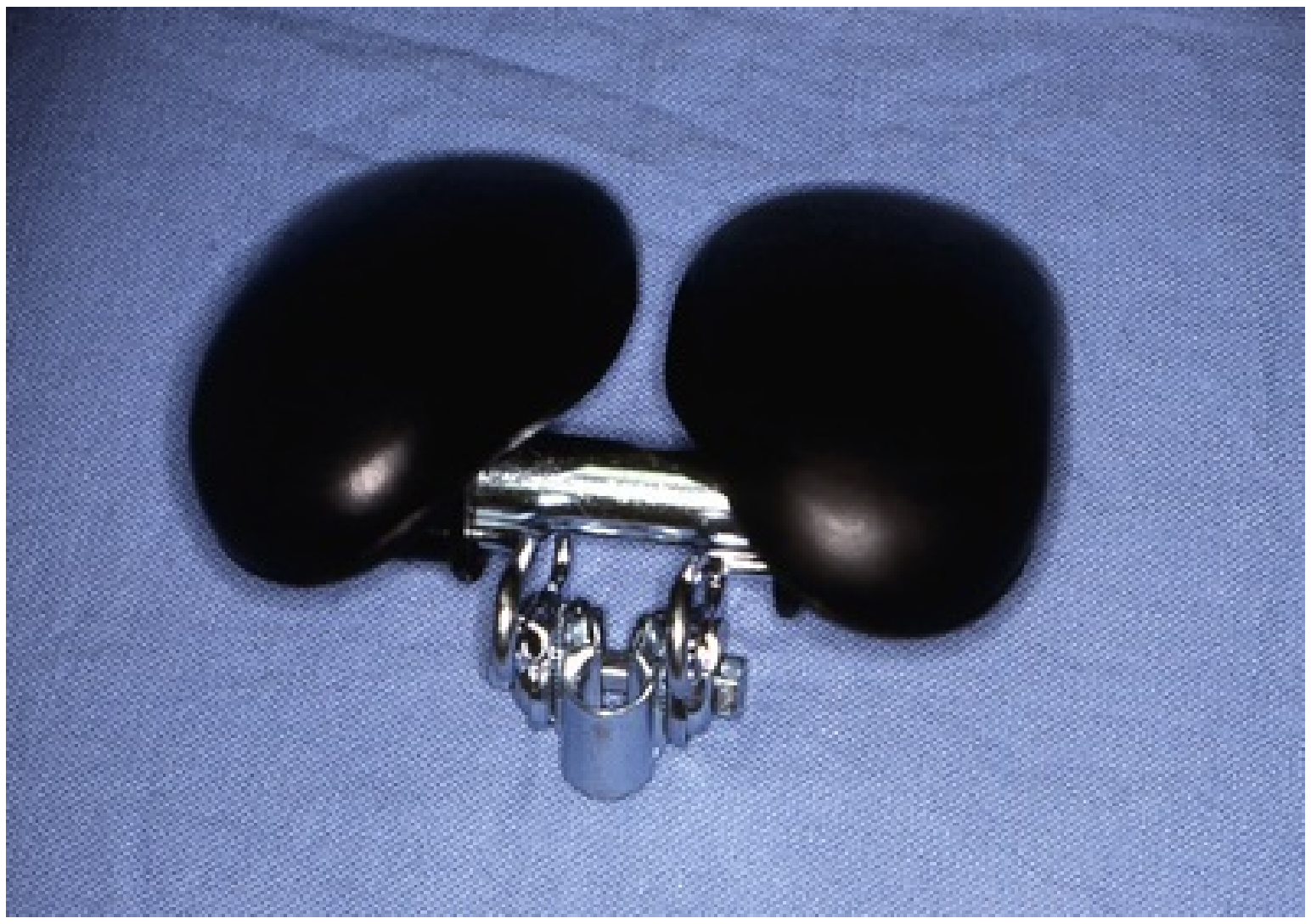

FIG. 72.39 Buttock support bicycle seat used by intense bicycle riders with a penile implant and/or artificial urinary sphincter in place.

Postoperative Care

After surgery most patients can be discharged home the same day. **During placement of inflatable implants it is recommended that the cylinders be left in a partially erect mode. This allows the recently dilated corporal bodies to heal with scar tissue forming around inflated cylinders and prevents the formation of a contracted pseudocapsule surrounding the cylinders, which could limit their expansion.** A compressive “mummy” wrap can be placed for reduction of postoperative bruising and edema (Henry, 2009). Many surgeons routinely use short-term surgical drains to evacuate scrotal blood and avoid hematoma formation (Kramer et al., 2008). Although safe and not proven to lead to increased infection risk, these drains should be routinely removed within 24 hours. All patients are encouraged to wear compressive underwear for 4 to 6 weeks after the procedure and are instructed to keep the penis pointing upward toward the umbilicus to avoid the inadvertent development of a permanent downward angulation to the erection during healing. In addition, men are encouraged to indirectly apply ice to the scrotum as needed. Most individuals require oral narcotics for a week before transitioning to nonsteroidal anti-inflammatory medication.

Infiltration of the dorsal neurovascular bundle with lidocaine and bupivacaine has reduced postoperative pain and the need for analgesics. Bundle injection with Esparel, a long-acting liposomal suspension of lidocaine and bupivacaine, has been found to reduce the postoperative analgesic pill usage threefold compared with standard lidocaine and bupivacaine bundle injection (Reinstatler et al., 2018). Before formal activation of the device, patients are instructed to retract the pump into a dependent position in the scrotum daily after the infrapubic approach. Using the penoscrotal approach, the pump can be secured in the dartos pouch and daily scrotal manipulation is unnecessary. An office visit is scheduled at 4 to 6 weeks once pain has resolved to begin inflation and deflation of the implant. Ideally, partners attend this session to learn how to use the implant as well as provide assistance for pump manipulation. Men are encouraged to cycle their device daily to passively dilate the cylinders and surrounding corporal bodies as well as gain familiarity with the device operation. Most patients begin using the implant for sexual activity 4 to 6 weeks after surgery.

Mechanical Reliability: Repair for Mechanical Defect

Mechanical malfunction continues to remain the most common complication encountered with penile prosthesis surgery. Semirigid implants are associated with few mechanical failures, and the majority of long-term follow-up data are limited to the three-piece inflatable models. Surgeons may encounter aneurysmal dilation of corporal cylinders, pump malfunction, autoinflation, and tube kinking, although device adaptations by Mentor/Coloplast and American Medical Systems/Boston Scientific have reduced their occurrence. A report on 971 patients who underwent placement of the Mentor Alpha-1 prosthesis after its most recent enhancement in 1992 with more than 5 years of follow-up found that the device survival, free from failure, was 92.6% (Wilson et al., 1999). Alternatively, the AMS 700CX/CXM inflatable penile prosthesis was observed to have long-term reliability of 81.3% with almost 10 years of follow-up in 455 patients (Dhar et al., 2006).

Fluid loss remains the most commonly encountered problem. This may be resolved by replacing the individual leaking component, if identified, and usually occurs late in the device's life span. Implants that have been in place for more than 3 years should be removed and entirely replaced because of wear on parts. If during a repair for mechanical failure the urologist decides to leave parts behind, their hydraulic integrity should be ascertained. Although a leak is found in one part, another part may have a defect as well. The parts may be tested by hydraulic distension of each part and observing for fluid leakage, or more accurately by using an ohmmeter to assess electrical continuity (Fig. 72.40; Mulcahy, 2015). To use this technique, an ohmmeter, set on its most sensitive reading, is placed on a nonsterile Mayo stand adjacent to the operating table. The ends of the ohmmeter cables, which have been previously sterilized, are passed off the operating field and connected to the ohmmeter. A 15-gauge blunt metal needle is inserted into the tubing of the part to be tested, and that part is filled with saline. One cable end is placed on the metal needle; the other cable end is placed on a retractor in another part of the wound. If there is a leak in that part, the sodium and chloride ions will travel through the leak site to the retractor and complete the circuit, giving a positive deflection of the needle. If no leak is present in the tested part, there will be no deflection of the needle. If patients note loss of rigidity with a semirigid implant in place, the surgeon must consider potential fracture of the central cylinder wires. Such an event requires explant and replacement.

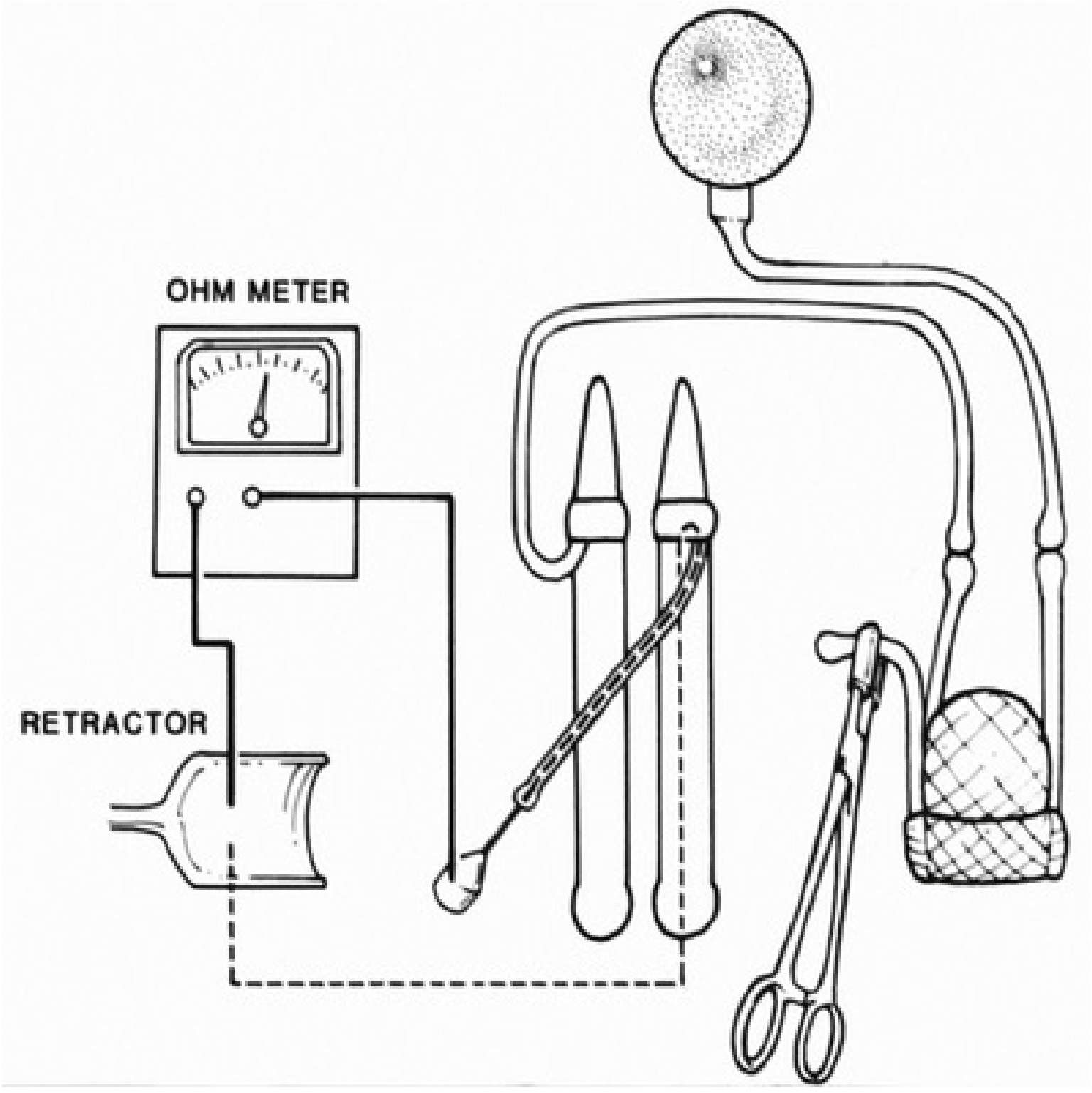
OHM METER
RETRACTOR

FIG. 72.40 Diagram of ohmmeter testing for leakage in a prosthetic part.

Patient and Partner Satisfaction

Although there are many treatment modalities for erectile dysfunction, penile implant placement is associated with high rates of patient satisfaction. A report on 200 patients and 120 sexual partners using AMS 700 three-piece inflatable implants with a mean follow-up of 59 months found that 92% were using the device an average of 1.7 times per week (Montorsi et al., 2000). Ninety-eight percent of patients reported erections as excellent or satisfactory. Importantly, 83% of their partners had similar satisfaction. A more recent study found concurring satisfaction rates, with 97% of patients reporting frequent use of their device (Bettocchi et al., 2010). Only 8% of the 79 patients surveyed were not satisfied with their implant. Complaints of insufficient rigidity and diminished penile length were key drivers of dissatisfaction. In a large series evaluating the satisfaction with the Ambicor implant, 96% of patients and 91% of partners were pleased with the device (Levine et al., 2001). Another large series of 146 men after Ambicor placement reported slightly less satisfaction among patients and partners at 85% and 76%, respectively (Lux et al., 2007). Another group found that 96% of patients and 85% of their partners had a favorable impression of the Spectra mechanical semirigid rod implant (Akdemir, 2017). In a study comparing the satisfaction of patients with the Spectra and the Genesis, 77% were pleased with the former, whereas 76% found the latter appealing (Casabe, 2016).

These studies highlight a small subset of implant patients who may be dissatisfied with these devices. Complaints regarding perceived penile length, chronic pain or coolness, difficulty with mechanical operation, and decreased sensation of the penis do occur. Preoperative counseling and discussion are paramount. Some patients may benefit from preoperative as well as postprocedure sexual counseling. Surgeons should advise potential candidates that prostheses will not replicate normal erections, but rather provide penile support and rigidity adequate for sexual activity. In addition, ejaculatory dysfunction and penile sensitivity changes may occur and should be discussed with patients before implantation.

Video 72.2 ▶ shows prosthetic surgery for erectile dysfunction.

Suggested Readings

Levine LA, Becher E, Bella A, et al. Penile prosthesis surgery: current recommendations from the international consultation on sexual medicine. *J Sex Med*. 2016;13:489–518.

Pineda M, Burnett AL. Penile prosthesis infections— a review of risk factors, prevention, and treatment. *Sex Med Rev*. 2016;4:389–398.

Video Journal of Prosthetic Urology www.vjpu-issm.info. Contains many videos of penile implant placement and management of complications.

References

Adamsky MS, Boysen WR, Cohen AJ, et al. Evaluating the role of postoperative oral antibiotic administration in artificial urinary sphincter and inflatable penile prosthesis explantation: a nationwide analysis. *Urology*. 2018;111:92–98.

Akdemir F, Okule E, Kayigi L. Long term outcomes of AMS Spectra penile prosthesis implantation and satisfaction rate. *Int J Impot Res*. 2017;29:184–188.

Anele UA, Lev BV, Burnett AL. Suprapubic cystostomy for the management of urethral injuries during penile prosthesis implantation. *Sex Med*. 2014;2:178–181.

Awad MA, Gaither TW, Murphy GP, et al. Cycling and male sexual and urinary function: results from a large multinational cross-sectional study. *J Urol*. 2018;199:798–804.

Ball TP. Surgical repair of penile SST deformity. *Urology*. 1980;15:603–604.

Ban KA, Minei JP, Laronga C, et al. American College of Surgeons and Surgical Infection Society: surgical site infection guidelines, 2016 update. *J Am Coll Surg*. 2017;224:59–74.

Berrios-Torres SI, Umscheid CA, Bartzler DW, et al. Centers of Disease Control and prevention guideline for the prevention of surgical site infection, 2017. *JAMA Surg*. 2017;152:784–791.

Bettocchi C, Palumbo F, Spilotros M, et al. Patient and partner satisfaction after AMS inflatable prosthesis implant. *J Sex Med*. 2010;7:304–309.

Bickell M, Minimala N, Parker J, et al. Floppy glans syndrome: pathogenesis and treatment. *Sex Med Rev*. 2016;4:149–156.

Canguven O, Talib RA, Campbell J, et al. Is daily use of vacuum erection device for a month before penile prosthesis implantation beneficial? A random controlled trial. *Andrology*. 2017;5:103–106.

Canguven O, Talib R, El Ansari W, et al. Is Hba1c level of diabetic patients associated with penile prosthesis implantation infections? *Aging Male*. 2018; 10.1080/13685538.2018.1448059.

Carson CC, Mulcahy JJ, Govier FE. Efficacy, safety, and patient satisfaction outcomes with the AMS 700 CX inflatable penile prosthesis: results of a long term multicenter study. *J Urol*. 2000;164:376–380.

Carson CC, Mulcahy JJ, Harsch MR. Long term infection outcomes after original antibiotic impregnated inflatable penile prosthesis implants: up to 7 years follow up. *J Urol*. 2011;185:614–618.

Casabe AR, Sarotto N, Gutirrez C, et al. Satisfaction assessment with the malleable prosthetic implant of Spectra (AMS) and Genesis (Coloplast) models. *Int J Impot Res*. 2016;28:228–233.

Chung PH, Scott JF, Morey AF. High patient satisfaction of inflatable penile prosthesis insertion with synchronous penile plication for erectile dysfunction and Peyronie's Disease. *J Sex Med*. 2014;11:1593–1598.

Da Justa GB, Bianco FJ, Ogle A, et al. Deep venous thrombosis due to compression of external iliac vein by penile prosthesis reservoir. *Urology*. 2003;61:462.

Darouiche RO, Bella AJ, Boone TB, et al. North American consensus document on infection of penile prosthesis. *Urology*. 2013;82:937–942.

Darouiche RO, Wall MJ Jr, Itani KM, et al. Chlorhexidine-alcohol vs. povidone-iodine for surgical site antisepsis. *N Eng J Med*. 2010;362:18–26.

Davoudzadeh N, Stember D, Nagler H. HIV-positive status does not increase risk of penile prosthesis infection. *J Sex Med*. 2016;13(5 Suppl 1):568.

De Chiara S, Chiumello D, Nicolini R, et al. Prolongation of antibiotic prophylaxis after clean and clean contaminated surgery and surgical site infection. *Minerva Anesthesiol*. 2010;76:413–419.

Dhar NB, Angermeier KW, Montague DK. Long term mechanical reliability of AMS 700 CX penile prosthesis. *J Urol*. 2006;176:2599–2601.

Eid JF. Penile implant: review of a no-touch technique. *Sex Med Rev*. 2016;4:294–300.

Fitch WP, Roddy T. Erosion of inflatable penile prosthesis reservoir into bladder. *J Urol*. 1986;136:180.

Garafa G, Minervini A, Christopher NA. The management of residual curvature after penile prosthesis implantation in men with Peyronie's Disease. *BJU Int*. 2011;108:1152–1156.

Garber B, Bickell M. Subcutaneous placement of inflatable penile prosthesis reservoirs. *Urology*. 2016;88:93–96.

Golan R, Sun T, Bernstein A, et al. Effect of radiotherapy on inflatable penile prosthesis complication and reoperation rates. *J Urol*. 2018;199(4S Suppl):e391 [PD18-04].

Goldstein I, Lue TF, Padma-Nathan H, et al. Oral sildenafil in the treatment of erectile dysfunction: sildenafil study group. *N Engl J Med*. 1998;338:1397–1404.

Gross MS, Phillips EA, Allen T, et al. The malleable implant salvage technique: infection outcomes after Mulcahy salvage procedure and replacement of infected inflatable penile prosthesis with malleable prosthesis. *J Urol*. 2016;195:694–698.

Gross MS, Phillips EA, Carrasquillo RJ, et al. Multicenter investigation of the micro-organisms involved in penile prosthesis infection: an analysis of the efficacy of AUA and EUA guidelines for penile prosthesis prophylaxis. *J Sex Med*.

2017;14:455–463.

Gross MS, Stember DS, Garber B, et al. A retrospective analysis of risk factors for IPP reservoir entry into the peritoneum after abdominal wall placement. *Int J Impot Res*. 2017;29:215–218.

Hakim LS, Kulaksizoglu H, Hamill BK, et al. A guide to safe corporotomy incisions in the presence of underlying inflatable penile cylinders. *J Urol*. 1996;155:918–923.

Henry G, Hsaio W, Karpman E, et al. A guide for penile prosthesis reservoir placement: pertinent anatomic measurements in the retropubic space. *J Sex Med*. 2014;11:273–278.

Henry GD, Wilson SK, Delk JR, et al. Penile prosthesis culture during revision surgery: multicenter study. *J Urol*. 2004;172:153–156.

Henry GD, Wilson SK, Delk JR. Revision washout decreases penile prosthesis infection in revision surgery: multicenter study. *J Urol*. 2005;173:89–92.

Henry GD. Surgical technique: the Henry mummy wrap and the Henry finger sweep. *J Sex Med*. 2009;6:619–622.

Knoll LD. Use of porcine small intestinal submucosal graft in the surgical management of tunical deficiencies with penile prosthetic surgery. *Urology*. 2002;59:758–761.

Kowalczyk JJ, Mulcahy JJ. Penile curvature and aneurysmal defects with the ultrex penile prosthesis corrected with inserrion of the AMS 700 CX. *J Urol*. 1996;156:398–401.

Kramer A, Goldmark E, Greenfield J. Is closed suction drainage advantageous for penile implant surgery? *J Sex Med*. 2008;8:601–606.

Leungwattanakij S, Bivalacqua TJ, Reddy S, et al. Long term follow up on use of pericardial graft in the surgical management of Peyronie's Disease. *Int J Impot Res*. 2001;13:183–186.

Levine LA, Estrada CR, Morgentaler A. Mechanical reliability and safety of and patient satisfaction with the Ambicor inflatable penile prosthesis: results of a 2 center study. *J Urol*. 2001;116:932–937.

Levine LA, Latchamsetty KC. Management of intraoperative complications: perforation, hypermobile glans, crural crossover, and penile curvature. *Atlas Urol Clin North Am*. 2002;10:189–201.

Li CY, Agrawal W, Minhas S, et al. Penile suspensory ligament: abnormalities and repair. *BJU Int*. 2007;99:117–120.

Loh-Doyle P, Patil MB, Nakhoda Z, et al. Three-piece inflatable penile prosthesis placement following pelvic radiation: technical considerations and contemporary outcomes. *J Sex Med*. 2018;5(7):1049–1054.

Loh-Doyle J, Patil MB, Sawkar H, et al. 3-Piece inflatable penile prosthesis placement following radical cystoprostatectomy and urinary diversion: technique and outcomes. *J Sex Med*. 2018;15:907–913.

Lopategui DM, Balise RR, Bouzoubaa LA, et al. The impact of immediate salvage surgery on corporeal length preservation in patients presenting with penile implant infections. *J Urol*. 2018;200(1):171–177.

Lue TF. Impotence: a patient's goal directed approach to treatment. *World J Urol*. 1990;8:67–74.

Lux M, Reyes-Vallejo L, Morgentaler A, et al. Outcomes and satisfaction rates for the redesigned 2-piece penile prosthesis. *J Urol*. 2007;177:262–266.

Maatman TJ, Montague DK. Intracorporal drainage after removal of infected penile prosthesis. *Urology*. 1984;23:184–185.

Moncada I, Jara J, Cabello R, et al. Radiologic assessment of penile prosthesis: role of magnetic resonance imaging. *J Urol*. 2004;175:257–258.

Moncada I, Martinez-Salamanca JI, Jara J, et al. Inflatable penile prosthesis implantation without corporeal dilation: a cavernous tissue sparing technique. *J Urol*. 2010;183:1123–1126.

Montague DK, Angermeier KW. Corporal evacuation: new technique for penile prosthesis implantation in men with severe corporal fibrosis. *Urology*. 2006;67:1072–1075.

Montorsi F, Rigatti P, Carmignani G, et al. *AMS three-piece inflatable implants for ED: a long-term multi-institutional study in 200 consecutive patients Eur Urol*. 2000:50–55.

Morey AF, Cefalu CA, Hudak SJ. High submuscular placement of urologic prosthetic balloons and reservoirs via transscrotal approach. *J Sex Med*. 2013;10:603–610.

Mulcahy JJ. Distal corporoplasty for lateral extrusion of penile prosthesis cylinders. *J Urol*. 1999;161:193–195.

Mulcahy JJ. Long-term experience with salvage of infected penile implants. *J Urol*. 2000;163:481–482.

Mulcahy JJ. The prevention and management of non-infectious complications of penile prosthesis. *Sex Med Rev*. 2015;3:203–213.

Mulcahy JJ, Rowland RG. Tunica wedge excision to correct penile curvature associated with the inflatable penile prosthesis. *J Urol*. 1987;138:63–64.

Pan S, Rodriguez D, Thirumavalavan N, et al. The use of antiseptic solutions in the prevention and management of penile prosthesis infections: a review of the cytotoxic and microbiological effects of common irrigation solutions. *J Sex Med*. 2019;16:781–790.

Patel N, McVary K, Gupta N, et al. MP. 56-09 Intermediate outcomes of concurrent Tachosil grafting with inflatable penile prosthesis placement. *J Urol*. 2017;197(4):e757–e758 [suppl.].

Perito P, Gheiler E. Repair of meatal laceration during prosthesis implantation allows preservation of implant. *J Sex Med*. 2011;8(Suppl):p40.

Ralph DJ, Garaffa G, Moneer A, et al. Immediate insertion of a penile prosthesis for acute ischemic priapism. *Eur Urol*. 2009;56:1033–1038.

Reinstatler HW, Shee K, Gross MS. Pain management in penile prosthetic surgery: a review of the literature. *Sex Med Rev*. 2018;6:162–169.

Riemenschneider HW. Epigastric placement of reservoir for inflatable penile prosthesis. *Urology*. 1981;18:79–81.

Scott FB, Bradley WE, Timm GW. Management of erectile impotence: use of implantable inflatable prosthesis. *Urology*. 1972;2:80–82.

Sedeghi-Nejad H, Munarriz R, Shah N. Intra-abdominal reservoir placement during penile prosthesis surgery in post robotically assisted laparoscopic radical prostatectomy patients: a case report and practical considerations. *J Sex Med*. 2011;8:1547–1550.

Serefoglu EC, Mandava SH, Gokce A, et al. Long term revision rate due to infection of hydrophilic-coated inflatable penile prosthesis: 11 year follow up. *J Sex Med*. 2012;9:2182–2186.

Sexton SJ, Granieri MA, Lentz AC. Survey on the contemporary management of intraoperative urethral injuries during penile prosthesis implantation. *J Sex Med*. 2018;15:576–581.

Sidi AA, Peng W, Sanseau C, et al. Penile prosthesis surgery in the treatment of impotence in immunosuppressed man. *J Urol*. 1987;137:681–682.

Singh I, Godec CJ. Asynchronous erosion of inflatable penile prosthesis into small and large bowel. *J Urol*. 1992;147:709–710.

Small MD. Small-Carrion penile prosthesis: report on 160 cases and review of the literature. *J Urol*. 1978;119:365–368.

Steidle CP, Mulcahy JJ. A technique to maintain penile prosthesis position to prevent proximal migration. *J Urol*. 1987;137:294–296.

Steidle CP, Mulcahy JJ. Erosion of penile prosthesis: a complication of urethral catheterization. *J Urol*. 1989;142:736–739.

Sun AY, Babbar P, Gill BC, et al. Penile prosthesis in solid organ transplant patients—a matched cohort study. *Urology*. 2018;117:86–88.

Wahle G, Mulcahy JJ. Ventral penile approach in unitary component penile prosthesis placement. *J Urol*. 1993;149:537–538.

Watkins RR, Deresinski S. Increasing evidence of the nephrotoxicity of piperacillin/tazobactam and vancomycin combination therapy - What is a clinician to do? *Clin Infect Dis*. 2017;65:2137–2143.

Weinberg AC, Pagano MJ, Diebert CR, et al. Sub-coronal inflatable penile prosthesis placement with modified no-touch technique: a step-by-step approach with outcomes. *J Sex Med*. 2016;13:270–276.

Wilson SK. Surgical techniques: rear tip extender sling: a quick and easy repair for crural perforations. *J Sex Med*. 2010;7:1052–1055.

Wilson SK, Carson CC, Cleves MA, et al. Quantifying risk of penile prosthesis infection with elevated glycosylated hemoglobin. *J Urol*. 1998;159:1538–1539.

Wilson SK, Cleves MA, Delk JR. Ultrex cylinders: problems with uncontrolled lengthening: the “S”-shaped deformity. *J Urol*. 1996;155:135–137.

Wilson SK, Cleves MA, Delk JR. Comparison of mechanical reliability of original and enhanced Mentor alpha-1 penile prosthesis. *J Urol*. 1999;162:715–718.

Wilson SK, Costerton JW. Biofilm and penile prosthesis infection: a review. *J Sex Med*. 2012;9:44–53.

Wilson SK, Delk JR. A new treatment for Peyronie's Disease: modeling the penis over an inflatable penile prosthesis. *J Urol*. 1994;152:1121–1123.

Wilson SK, Mora-Esteves C, Egydio P, et al. Glans necrosis following penile prosthesis implantation: prevention and treatment suggestions. *Urology*. 2017;107:144–148.

Wolf JS, Bennett CJ, Dmochowski RR, et al. Best practice policy statement on urologic surgery antimicrobial prophylaxis. *J Urol*. 2008;179:1379–1390.

Yucel OB, Pazir Y, Kadioglu A. Penile prosthesis implantation in priapism. *Sex Med Rev*. 2018;6:310–318.

Zermann DH, Kutzenberger J, Sauerwein D, et al. Penile prosthetic surgery in neurologically impaired patients: long term follow up. *J Urol*. 2006;175:1041–1044.

73

Diagnosis and Management of Peyronie's Disease

Allen D. Seftel MD, Hailiu Yang MD

General Considerations

Peyronie's disease (PD) was first known as *induratio penis plastica*. It was subsequently named after Francois Gigot de la Peyronie because he was the first to describe and offer treatment for it in a paper published in 1743 (de la Peyronie, 1743). But Guilielmus de Saliceto in the 13th century and Gabriele Falloppio in the 15th century had previously reported on this abnormality of the penis (Musitelli et al., 2008).

PD is currently recognized as a wound-healing disorder of the tunica albuginea (Devine and Horton, 1988) **that results in the formation of an exuberant scar, occurring presumably after an injury to the penis activates an abnormal wound-healing response** (Greenfield and Levine, 2005; Levine and Burnett, 2013; Ralph et al., 2010; Van de Water, 1997)**. The resulting scar or plaque is inelastic and therefore results in penile deformity including curvature, indentation, hinge effect, and shortening and is frequently accompanied by erectile dysfunction (ED). One of the most important characteristics of this particular wound-healing disorder is that once the scar has occurred, it does not undergo normal remodeling and therefore the scar and deformity persist** (Del Carlo et al., 2008). Progress with treatment of PD has been limited by an incomplete understanding of its pathophysiology, and this lack of understanding has resulted in an inability to prevent the disease from starting and to prevent progression once it has occurred. This, combined with the fact that there is no known reliable treatment to reverse the scarring process, makes PD a challenging disorder to treat.

Multiple misconceptions have been held for decades about PD. Many of these misconceptions have been carried forward and appear to have compromised the proper assessment and early treatment of men with PD (LaRochelle and Levine, 2007). These include that PD is a rare disorder. **On the contrary, we now know that the prevalence of PD is somewhere between 3% and 20%, and in certain populations such as those with diabetes mellitus and ED the prevalence may be even higher** (Arafa et al., 2007; DiBenedetti et al., 2011; El-Sakka, 2006; La Pera et al., 2001; Lindsay et al., 1991; Mulhall et al., 2004b; Rhoden et al., 2001; Schwarzer et al., 2001; Sommer et al., 2002). Another misconception is that PD has a reasonable likelihood of resolving spontaneously. As a result, men are often told by their physicians that nothing can be done during the acute phase and they should wait 6 months to 1 year before commencing treatment, because there is a “good chance” that the disease process will resolve. **We now know from multiple natural history studies that full spontaneous resolution is extremely rare and that it is more likely that within the first 12 to 18 months after presentation, if no treatment is offered, up to 50% of patients will experience worsening of their deformity** (Mulhall et al., 2006). Another misconception is that PD is a disorder that occurs only in middle-aged men. Multiple studies have demonstrated that it can occur in teenagers to men in their late 70s (Kadioglu et al., 2002; Levine and Dimitriou, 2000; Tal et al., 2012). Why this process occurs more commonly in middle-aged men is unclear, but theories include that the aging tunica is more apt to be injured in men who are susceptible to the disease, which activates the abnormal wound-healing process (Devine and Horton, 1988; Jarow and Lowe, 1997).

PD is a disorder that appears to go through an active phase during which the scar can grow, resulting in progressive deformity and pain. However, once PD has stabilized, there is usually no further progression (Box 73.1).

Box 73.1

Peyronie's Disease Caveats

- Peyronie's disease is not rare.
- It does not have a high likelihood of spontaneous resolution.
- It is not a disease of only middle-aged men.
- It is not a disease of only white men.
- Trauma to the flaccid and erect penis appears to activate the scarring process in susceptible men.
- Erectile dysfunction is frequently found in men with Peyronie's disease.
- Plaque calcification is not an indication of mature, chronic-phase disease.
- **Peyronie's disease is a disorder that appears to go through an active phase during which the scar can grow, resulting in progressive deformity and pain.**
- **Once Peyronie's disease has stabilized, there is usually no further progression.**

Natural History

An understanding of the natural history of PD is critical to counseling patients and selecting treatment options. As noted, there are two phases. **The first is the active (acute) phase, which is commonly associated with painful erections and changing deformity of the penis. This is followed by a stable (chronic) phase, which is characterized by stabilization of the deformity and disappearance of painful erections** (Devine et al., 1997; Jalkut et al., 2003; Kadioglu et al., 2011a; Ralph et al., 2010). It would seem intuitive that once the scarring process has begun, there would be a progressive increase in deformity; but it has been noted that up to 20% of patients will experience a sudden onset of deformity that can be as great as 90 degrees.

It has been reported that PD can completely resolve in some patients, but this is probably a misconception. It is more likely that some men who traumatize their penises develop curvature secondary to the local inflammatory process. In some of these patients, the inflammation resolves before scarring sets in. Thus, the patient who has resolution of his deformity may not have had PD at all, but rather a slow-healing wound that simply takes longer to undergo the proper remodeling found with normal wound healing. **Spontaneous regression has been looked at in several contemporary natural history studies. These data suggest that no more than 13% of patients will have some improvement of their deformity over the first 12 to 18 months after onset of the disease process when not treated** (Kadioglu et al., 2002; Hatzimouratidis et al., 2012; Mulhall et al., 2006; O'Brien et al., 2004). Zigelmann et al. (2017) conducted a survey of 126 men undergoing noninjectional and nonsurgical therapy for PD at a single institution as a surrogate for natural disease course. This study found that, although most patients indicated that their penile pain improved (18%) or resolved (64%), only 16% reported that their curvature resolved. **The key point to remember is that complete spontaneous resolution of PD is a rare occurrence.** Recently, Berookhim et al. (2014) reported on a group of men who elected to have no treatment of their PD. In this study, it appeared that the later in the first year the man sought evaluation after the onset of symptoms, the less likely that he would experience further deformity when left untreated (Berookhim et al., 2014).

Epidemiology

Incidence

The incidence of PD varies widely depending on the population being screened—from 0.39% to 20.3%, with most current estimates of the incidence of PD being between 3% and 9%. The peak age of onset of PD is in the early 50s (Mulhall et al., 2004a; Schwarzer et al., 2001; Stuntz et al., 2016). It was previously held that this was a disorder primarily of white men of northern European descent. **It is now recognized that men of every race can develop PD.** The variation in recognition of and reporting on this disorder in certain populations may be a result of the interest and presence of physicians with expertise in PD, and cultural mores that may make it more or less comfortable for men to share information about changes in their sexual function with a health care provider (Lindsay et al., 1991; Arafa et al., 2007). A recent Japanese study looked at a total of 1090 men undergoing a routine health check and demonstrated the prevalence of PD in healthy men to be quite low at 0.6% (Shiraishi et al., 2012). In a large US web-based survey, 16,000 randomly selected men older than18 years of age were asked to self-report the symptoms, diagnosis, or treatment of PD. In this study, although only 0.5% to 0.8% of respondents had received a diagnosis of or had been treated for PD, 13% of respondents admitted to having symptoms of PD such as penile deformity or palpable plaque (DiBenedetti et al., 2011). A population-based study of 7711 men in the United States similarly found a 0.7% rate of diagnosed PD, and 11% probably had PD based on symptoms without diagnosis by a physician (Stuntz et al., 2016). Both of these population-based studies demonstrate that although PD is widely prevalent, only a small portion of men with this condition are medically diagnosed. The reasons may include lack of bothersome symptoms and/or reluctance to discuss the signs and symptoms of this embarrassing condition with their physician. Therefore, the prevalence of PD seems to be equivalent to if not greater than other important public diseases such as diabetes and urolithiasis, both established to be present in 3% to 4% of the general population (Sommer et al., 2002).

The incidence of symptomatic PD may be increasing, which is perhaps explained by an increasing tendency to obtain medical help, increasing awareness of people seeking information on the Internet, or increasing use

of pharmacologic treatments for ED (e.g., phosphodiesterase inhibitors, intracavernosal injectable agents) (Hellstrom, 2003)**. Phosphodiesterase inhibitors have not been suggested to directly contribute to the development of PD; rather, their associated use in those with medical conditions such as diabetes that contribute to ED is the likely explanation, because these men now experience erections with deformities they would not have realized were previously present.** At this time, there is no suggestion that use of phosphodiesterase type 5 (PDE5) inhibitors should worsen or provoke PD. On the other hand, more recent in vitro and animal model studies have suggested that use of PDE5 inhibitors, as nitric oxide (NO) donors, has an antifibrotic effect that may be beneficial for patients with PD (Valente et al., 2003; Ferrini et al., 2006; Gonzalez-Cadavid and Rajfer, 2009; Chung et al., 2011a). Although treatment for ED, including intracorporeal injection therapy and vacuum devices, has also been implicated as a cause of PD (Carrieri et al., 1998; Jalkut et al., 2003; Bjekic et al., 2006), it seems more likely that these treatments are designed to create a stronger erection, which can then be injured during a sexual encounter, activating the PD disease process in the susceptible individual. Alternatively, as mentioned, these treatments can also unmask unrecognized PD on restoration of erection. To date, there is no evidence that any medicines such as beta-blockers or phenytoin cause PD.

Associated Conditions

Aging

PD is most commonly diagnosed in the fifth decade of life. **A linear increase in prevalence can be seen from 30 to 49 years of age with an exponential increase in prevalence at 50 years of age** upward. (Sommer et al., 2002). Mulhall et al. (2004b) demonstrated an increased PD prevalence of 8.9% in a population being screened for prostate cancer. In this study, the mean patient age was 68 years (Mulhall et al., 2004b). PD may also occur in young men. PD patients younger than 40 years of age tend to present during the acute phase, as there is rapid onset of disease with a penile deformity and pain on erection (Tefekli et al., 2001). Studies have shown that approximately 10% of men with PD are younger than 40 years of age (Levine and Dimitriou, 2000). In addition, Tal et al. (2012) reported on 32 teens diagnosed with PD over a 10-year period with a mean age of 18 (Tal et al., 2012). Sixteen percent reported antecedent trauma, and 37% reported subsequent ED. A high level of distress was reported by 94% of these young men, with 34% seeking treatment for an anxiety or mood disorder (Tal et al., 2012). **The increased prevalence of PD with age is likely a reflection of the increased likelihood of comorbid medical conditions contributing to the development of ED such as hypertension, hyperlipidemia, diabetes, and low testosterone, all of which have been suggested as possible causative factors as the weakened erectile state is associated with PD.** Hypothetically, it could also reflect the reduced tissue elasticity that naturally occurs with aging, predisposing this tissue to stretch-related injury.

Diabetes

One of the more interesting recently studied associations is that of diabetes mellitus and PD. **The prevalence of diabetes in men with PD has been reported to be as high as 33.2%, which is much higher than in the general population** (Bjekic et al., 2006; Cowie et al., 2010; Kadioglu et al., 2002). Further, the prevalence of PD among diabetics has been shown to be increased when compared with the general population, with a reported rate of 8.1% to 20.3% depending on the specific population being screened (Arafa et al., 2007; El-Sakka and Tayeb, 2005; Tefekli et al., 2006). This may reflect particular patient populations, ethnic groups, referral patterns, and expertise of the physicians treating the disorder. Longer duration of diabetes and poor glucose control have also been shown to significantly increase the severity of PD, including duration of PD, deformity, curvature, and erectile function (El-Sakka and Tayeb, 2005; Kendirci et al., 2007). A recent small retrospective study suggested that plaque size and pain may decrease as underlying diabetes is treated (Cavallini and Paulis, 2013).

One theory for the apparent association between PD and diabetes is that men with diabetes are at a higher risk for ED, which may predispose to injury during intercourse because of the less rigid penis pivoting back and forth, potentially resulting in a tissue fatigue–type fracture, activating the scarring disorder (Devine and Horton, 1988) (Fig. 73.1). Another theory suggests that diabetes may lead to decreased compliance of tissues as a result of increased collagen cross-linking (Aronson, 2003). This may make minor injuries less prone to normal remodeling.

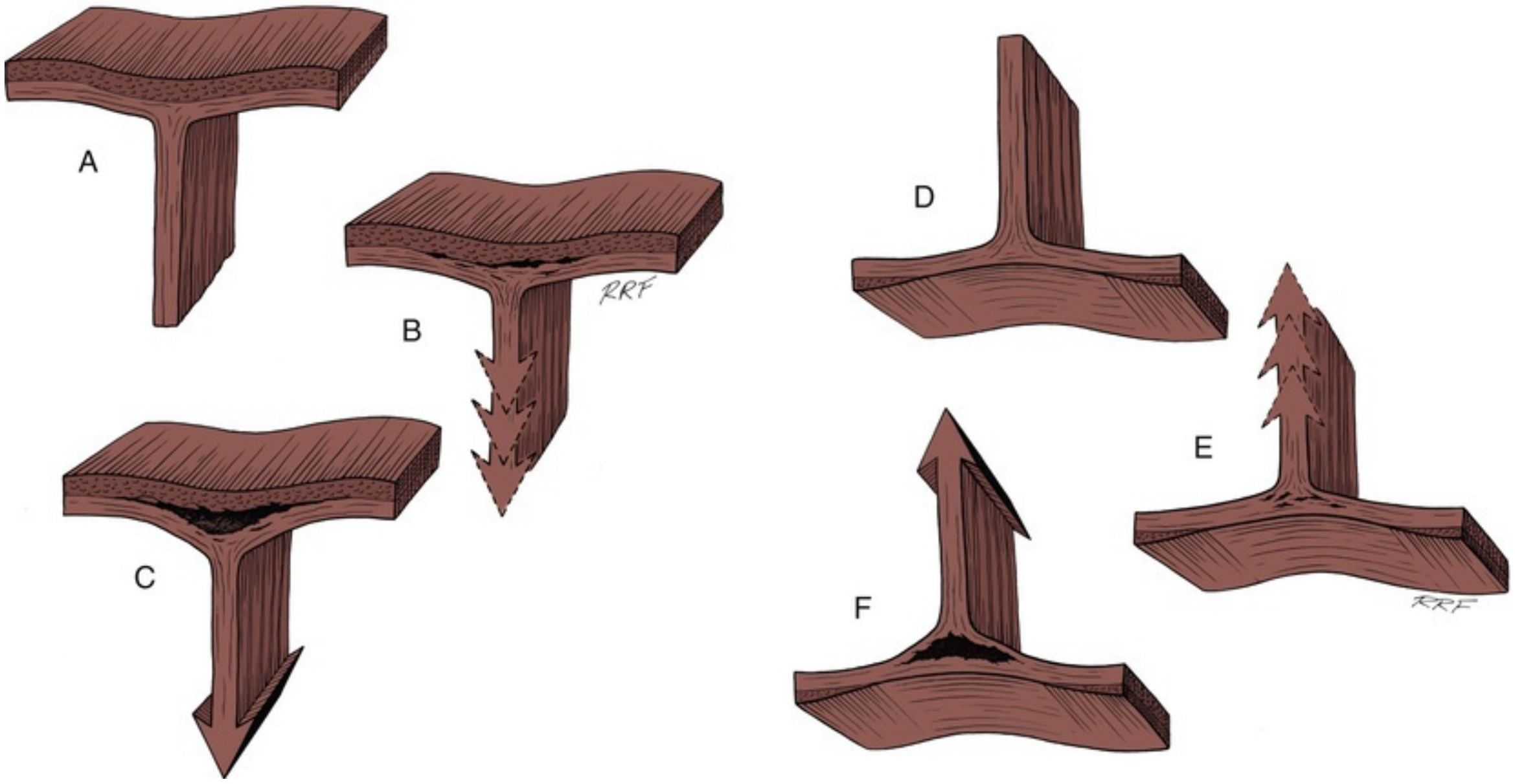

FIG. 73.1 Demonstration of the mechanism of injury during buckling injuries to the penis. (A) Fibers of the septal strands dorsally fan out and are interwoven with the inner circular lamina fibers of the tunica albuginea. The outer lamina consists of longitudinal fibers. (B) In the chronic mechanism of Peyronie's disease, less turgid erections allow flexion of the penis during intercourse, producing elastic tissue fatigue, further reducing elasticity of the tissue and leading to multiple smaller ruptures of the fibers of the tunica with smaller collections of blood, possibly producing multiple scars. (C) In the acute mechanism of Peyronie's disease, bending the erect penis out of column produces tension on the strands of the septum, delaminating the layers of the tunica albuginea. Bleeding occurs, and the space fills with clot. The scar generated by the response of the tissue to this process becomes the Peyronie's disease plaque. (D) Illustration of the situation on the ventrum of the penis, where the bilaminar arrangement of the tunica albuginea becomes thinned, with the midline being monolaminar. The fibers of the septal strands fan out and are interwoven with the inner circular layer. There is no outer circular layer. (E) In the chronic mechanism of Peyronie's disease, less turgid erections allow buckling of the penis as in (B). (F) In the acute mechanism of Peyronie's disease, buckling of the erect penis out of column produces tension on the strands of the septum, causing the septal fibers to tear.

Erectile Dysfunction

ED appears to be more common in men with PD than in the general population (Ralph et al., 2010)**. The prevalence of ED in men with PD has been reported to be 37% to 58%** (Casabé et al., 2011; Chung et al., 2011b; Kadioglu et al., 2002; Usta et al., 2004). In a duplex ultrasound study of 76 men with PD and ED, 36% had evidence of penile arterial insufficiency, and 59% had veno-occlusive disease as the cause of their ED (Lopez and Jarow, 1993).

The prevalence of associated comorbidities is higher in patients with PD and ED than in patients with PD and no ED, which may indicate that hypertension, smoking, hypercholesterolemia, diabetes mellitus, and hyperlipidemia are more likely related to ED than to the pathogenesis of PD (Usta et al., 2004). This may be attributable to changes in penile geometry and/or psychological inhibition, which is difficult to determine even in studies in which duplex ultrasound and cavernosometry are used (Kadioglu et al., 2002; Levine and Coogan, 1996).

Psychological Aspects

PD is not only a physically deforming but also a psychologically devastating disorder. Multiple studies have now demonstrated the frequent association of psychological distress in men with PD including diminished self-esteem, shame, embarrassment, self-disgust, anxiety, loss of sexual confidence, and depression, all of which can compromise the man's relationships at home, at work, and in the bedroom (Gelbard et al., 1990; Jones, 1997; Rosen et al., 2008; Smith et al., 2008a)**. Penile shortening and the inability to have intercourse are the two most common and consistent risk factors for emotional distress and relationship problems associated with PD** (Rosen et al., 2008; Smith et al., 2008a).

Psychosocial stress is reported by 77% to 94% of men with PD (Gelbard et al., 1990; Nelson and Mulhall, 2013; Tal et al., 2012). Contemporary studies using a validated measure of depression (Center for Epidemiologic Studies Depression Scale [CESD]) have **demonstrated moderate to severe depression in 48% of PD patients, with these rates typically increasing with the duration of PD** (Nelson et al., 2008). PD also commonly affects the patient's sexual partner, causing feelings of helplessness and feelings of personal responsibility for the PD caused by trauma during intercourse, and sadness over loss of intimacy (Rosen et al., 2008).

In an effort to develop a valid outcome measure for assessing psychosocial and sexual consequences of PD, Rosen et al. (2008) conducted a study composed of a series of focus groups with 28 PD patients and identified common concerns. These concerns were grouped into four core domains: (1) physical appearance and self-image, (2) sexual function and performance, (3) PD-related pain and discomfort, and (4) social stigmatization and isolation (Rosen et al., 2008). **With these data, a validated Peyronie's Disease Questionnaire (PDQ) was**

developed; patient-reported estimates of penile curvature severity correlated with PDQ domains, whereas objective measures of penile curvature did not. For some patients, even a lesser degree of curvature may be highly bothersome or provoke distress (Hellstrom et al., 2013). This is also evidenced by the fact that self-estimates of penile curvature in men with PD differ from objective measures by an average of 20 degrees, with 54% of patients overestimating their curvature (Bacal et al., 2009). **It is important to remember that despite "successful treatment" that may allow the patient to be sexually functional again, there is often persistent psychological distress, presumably because of residual changes to the patient's pre-PD penile appearance** (Gelbard et al., 1990; Jones, 1997). It is critical that the physician recognize these psychological effects, not only to enhance the trust between the patient and physician, but also to identify more advanced indicators of depression, which should initiate referral to a sex therapist, psychologist, or psychiatrist (Levine, 2013).

Radical Prostatectomy

Both prostate cancer and PD are most prevalent in men after their fifth decade of life. The evidence to support or refute a link between radical prostatectomy and PD is limited. In a study of 1011 post–radical prostatectomy patients, Tal et al. (2010) demonstrated an incidence of PD of 15.9% with a mean time to development of disease of 13.9 months (Tal et al., 2010). Although postoperative erectile function was not a predictor of development of PD, younger age at time of prostatectomy and white race were reported risk factors for developing PD after radical prostatectomy. The authors concluded that prospective controlled studies are needed to elucidate the incidence of PD after radical prostatectomy and determine if radical prostatectomy has a causative role in the pathogenesis of PD (Tal et al., 2010).

Ciancio and Kim (2000) also examined the effects of prostatectomy on penile fibrosis and sexual dysfunction. Eleven percent of all patients undergoing prostatectomy developed fibrotic changes in the penis. This fibrosis led to penile curvature in 93%, "waistband" deformity in 24%, and palpable plaques in 69%. Therefore, it does appear that men undergoing radical prostatectomy by an open or robotic approach have a higher risk for developing PD than the general population. The mechanism responsible for this is not known but may include perioperative penile trauma, neurogenic consequences, or via a local release of cytokines that activate the abnormal wound-healing process in men susceptible to PD.

Hypogonadism

The possibility that low serum testosterone may be associated with PD has also been investigated. Results of studies have varied on this topic. Moreno and Morgentaler (2009) demonstrated that severity of curvature was worse in men with low free and total testosterone. Rhoden et al. could not demonstrate this association and concluded in their study that androgen serum levels and sexual dysfunction had no association to PD (Rhoden et al., 2010).

The presence of hypogonadism in patients with PD has been suggested to exaggerate the severity of PD. Nam et al. (2011) showed in a study of 106 patients with PD that curvature, plaque size, ED, and response to medical therapy were worse in patients with testosterone deficiency. Cavallini et al. (2012) investigated whether testosterone replacement in hypogonadal men with PD would affect treatment with intralesional verapamil injection. In these patients, supplementation with testosterone improved the efficacy of intralesional verapamil compared with those who did not receive testosterone replacement. Plaque area and penile curvature were also more severe in hypogonadal men with PD (Cavallini et al., 2012).

Collagen Disorders

There does appear to be an association of PD with other collagen disorders such as Dupuytren disease (DD). DD is believed to be transmitted in an autosomal dominant manner. The prevalence of DD in different geographic locations is extremely variable (0.2% to 56%), and it is not clear whether this is because of genetic or environmental factors. The literature concerning coexisting DD in patients with PD also demonstrates a very large range (0.01% to 58.8%) (Nugteren et al., 2011). As with PD, the prevalence of DD increases with age, from 7.2% among men in the 45- to 49-year-old age group up to 39.5% in those 70 to 74 years of age (Gudmundsson et al., 2000). Other studies have demonstrated DD in 21% to 22.1% of PD patients and in 6.7% who reported having a first-degree relative with DD (Carrieri et al., 1998; Nugteren et al., 2011). Other associated fibrotic conditions are contracture of the plantar fascia (Ledderhose disease) and tympanosclerosis, both of which are uncommon disorders (Box 73.2).

Box 73.2

Associated Conditions

Aging
Diabetes
Erectile dysfunction
Psychological distress
Radical prostatectomy
Hypogonadism
Collagen disorders

Key Points: Epidemiology

- The incidence of PD varies widely depending on the population being screened and is likely much higher than once thought. Current estimates are between 3% and 9%, and the peak age of onset of PD is the early 50s.
- A linear increase in prevalence can be seen from 30 to 49 years of age, with an exponential increase in prevalence at 50 years of age.
- PDE5 inhibitors have not been suggested to directly contribute to the development of PD; rather, their associated use in those with medical conditions that contribute to ED likely unmasks deformities that would have otherwise gone unrecognized.
- The prevalence of PD among diabetics has been shown to be 8.1% to 20.3% depending on the population screened, which is higher than in the general population. This may reflect particular patient populations, ethnic groups, referral patterns, and expertise of the physicians treating the disorder.
- The prevalence of ED in men with PD has been reported to be 37% to 58%.
- PD is not only a physically deforming but also a psychologically devastating disorder, with 48% of patients showing signs of moderate to severe depression; in general, these rates increase with the duration of PD. Penile shortening and inability to have intercourse are the two most common and consistent risk factors for emotional and relationship problems associated with PD.

- There appears to be an increased incidence of PD in men who have undergone radical prostatectomy, although further prospective studies are required to confirm this association.
- Although hypogonadism may be associated with PD, there is no clear evidence that it is a risk factor. Further study is indicated, and assessment of serum testosterone is recommended.

Penile Anatomy and Peyronie's Disease

The exact cause of PD remains to be determined, as noted earlier. Ongoing studies continue to clarify this disorder on the genetic, molecular, and anatomic level. The corpora cavernosa, the erectile bodies of the penis surrounded by the tunica albuginea, possess the ability to become rigid by becoming engorged with blood. **The tunica albuginea is a multilayered structure predominantly composed of type 1 collagen that is oriented with an inner circular and outer longitudinal layer interlaced with elastin fibers separated by an incomplete septum** (Brock et al., 1997; Gentile et al., 1996; Kelly, 2007). This septum is anchored into the inner circular layer and is key to the structural integrity of the tunica; without it, computer models have demonstrated that the stress generated by a full erection of one contiguous corporeal body would be sufficient to rupture the tunica albuginea (Mohamed et al., 2010). **These anchor sites are susceptible to microvascular trauma and tunical delamination, which may be one of the triggers leading to this disease** (Devine et al., 1997). The structure is further reinforced by intracavernous pillars, which anchor the tunica albuginea across the corpora cavernosa at the 2 to 6 o'clock and 10 to 6 o'clock positions, with finer pillars at the 5 and 7 o'clock positions (Fig. 73.2) (Brock et al., 1997). **It is interesting to note that 60% to 70% of plaques are located on the dorsal aspect of the penis and are usually associated with the septum** (Pryor and Ralph, 2002). It is possible that pressures on the penis during intercourse may cause a delamination between the two layers, activating the abnormal wound-healing process, which is trapped within the tunic, fostering the progressive scarring.

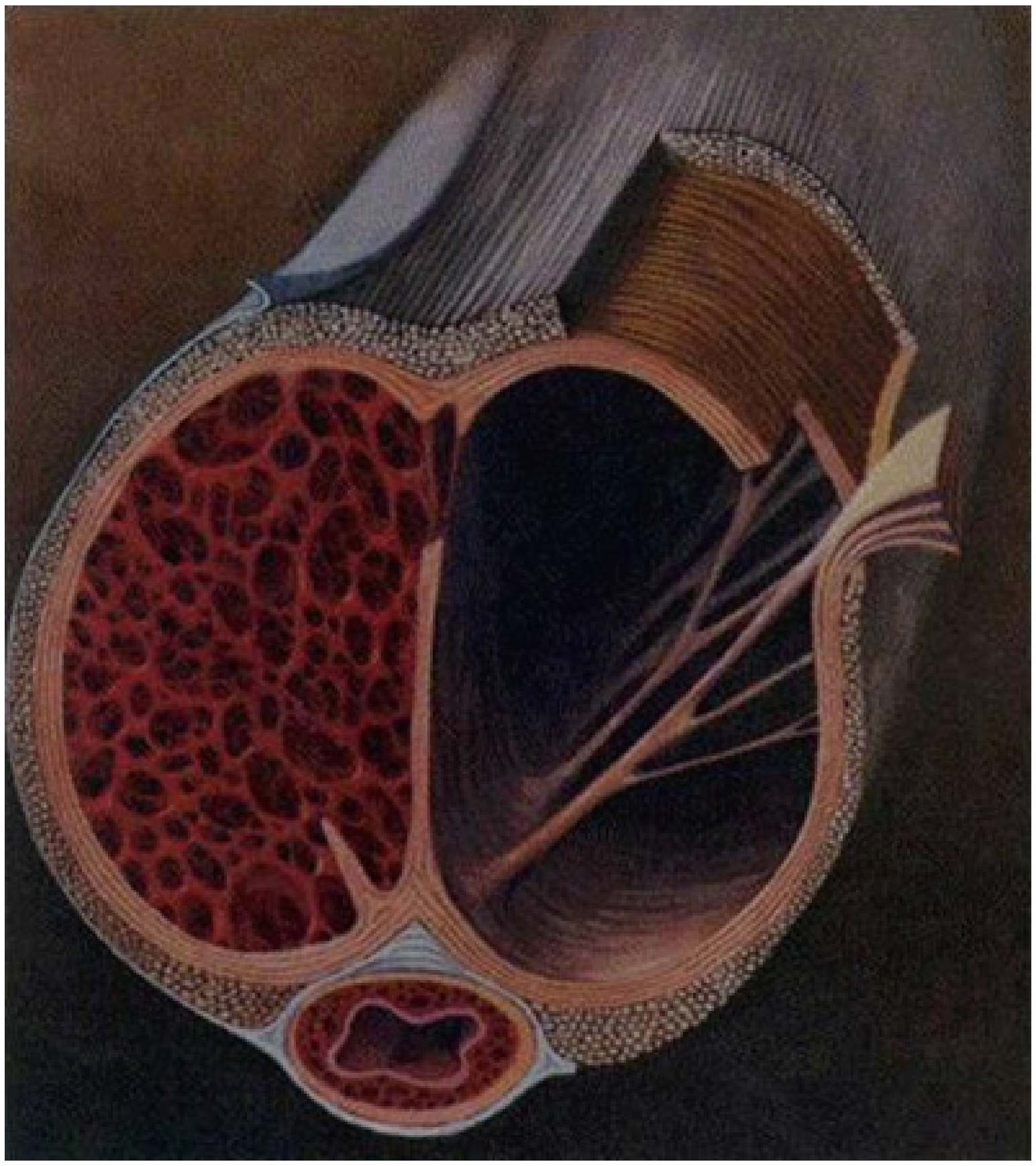

FIG. 73.2 The outer layer bundles, which are coarser and directed in a longitudinal manner, often form an incomplete layer (regions 4 to 5 o'clock, 7 to 8 o'clock, and 11 to 1 o'clock) and condense to form ligament-like structures. Artist's drawing of the penis depicts dorsal and ventral thickening and pillars. (Data from Brock G, Hsu GL, Nunes L, et al. The anatomy of the tunica albuginea in the normal penis and Peyronie's disease. *J Urol* 1997;157:276–81.)

The longitudinal layer of the tunica albuginea is thinnest at the 3 and 9 o'clock positions of the corpora; it is completely absent between the 5 and 7 o'clock positions (Brock et al., 1997)**. This may contribute to greater ease of dorsal buckling and may explain why most PD patients exhibit dorsal curvature** (Border and Ruoslahti, 1992; Brock et al., 1997; Devine et al., 1997; Devine and Horton, 1988; Jarow and Lowe, 1997). In normal tunical tissue, each layer appears to be distinct and is able to slide on the adjacent layer. The normal three-dimensional structure of the tunica affords great flexibility, rigidity, and tissue strength to the penis despite the fact that the tunica albuginea is quite thin —1.5 to 3.0 mm, depending on the position around the circumference. **Normal architecture is essentially lost consequent to this disease, resulting in what is known as a Peyronie's "plaque," which, when examined histologically,**

demonstrates disorganization of collagen fibrils and a decrease in and disorganization of elastin resulting in penile deformity caused by asymmetrical expansion of the corpora (Figs. 73.3 and 73.4) (Akkus et al., 1997; Brock et al., 1997; Costa et al., 2009; Devine et al., 1997). When expansion is limited at one point along the circumference of the corpora by the inelastic scar of the Peyronie's plaque, deviation to that side occurs; a circumferential plaque may lead to an hourglass deformity (Akkus et al., 1997; Devine et al., 1997).

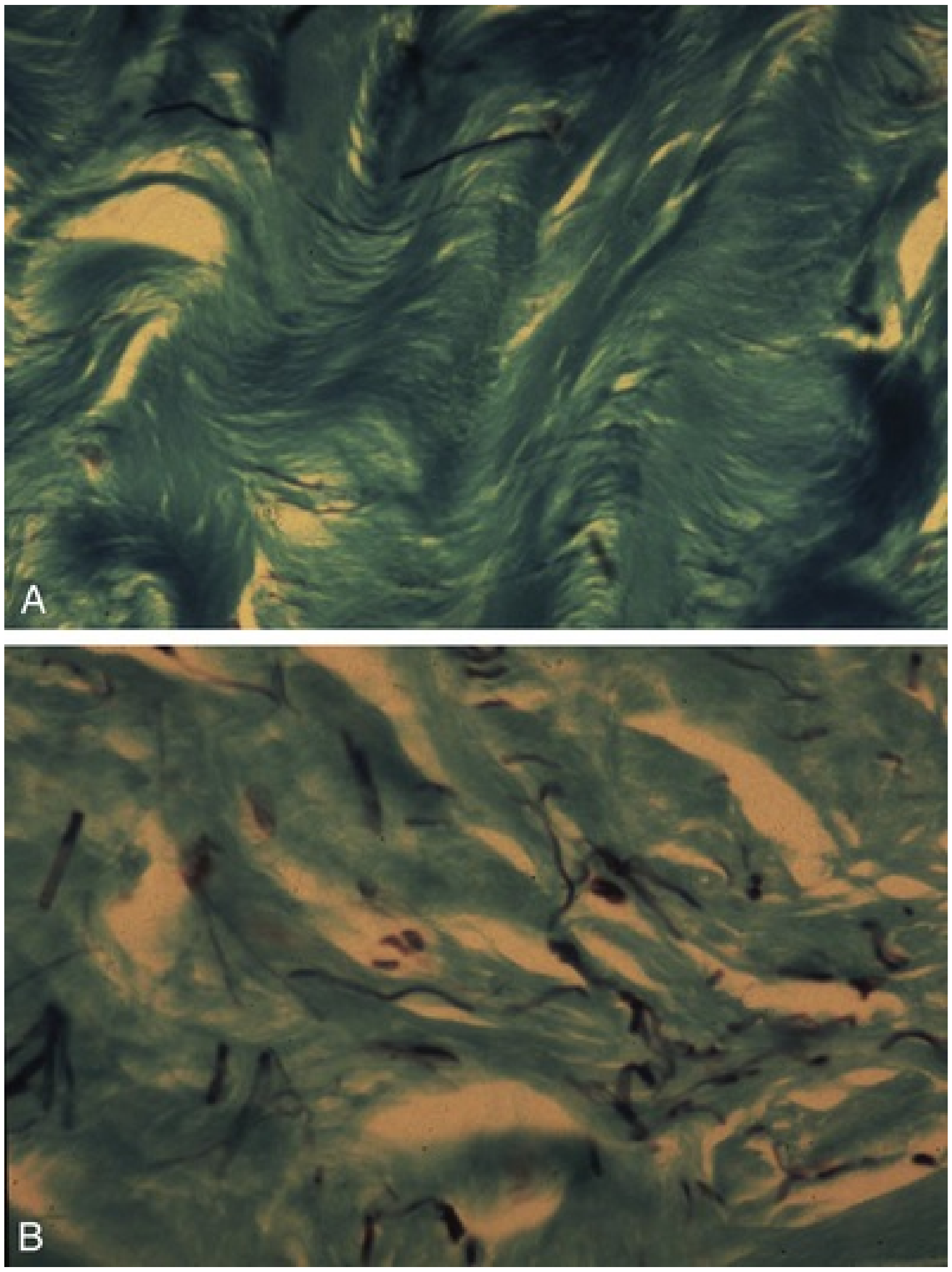

FIG. 73.3 Photomicrographs of the tunica albuginea. (A) Normal tunica albuginea demonstrating the polarized arrangement of collagen. (B) Peyronie's plaque demonstrating the nonpolarized arrangement of collagen and the haphazard arrangement of elastin. Collagen stains green; elastin stains black.

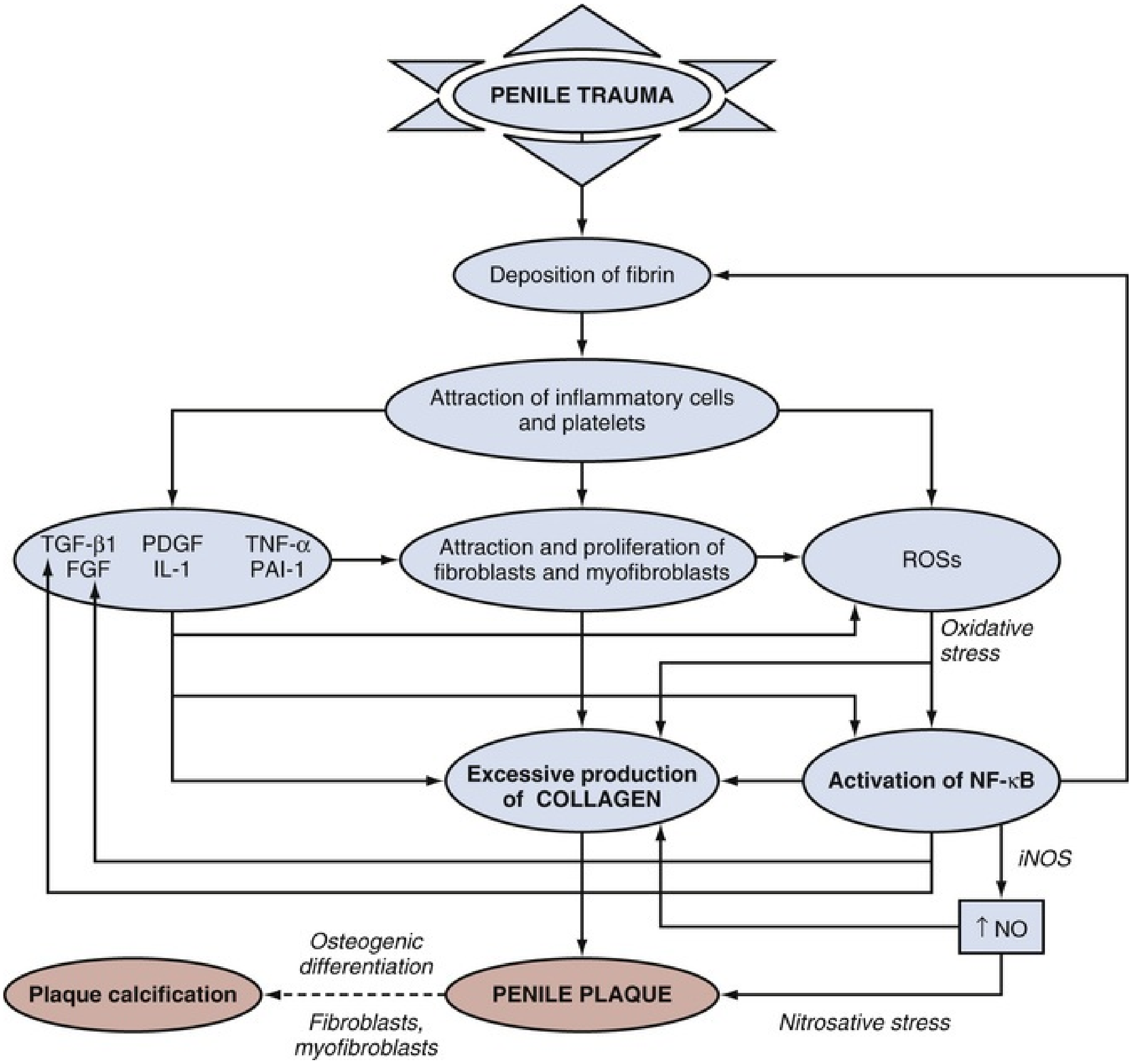
PENILE TRAUMA
Deposition of fibrin
Attraction of inflammatory cells and platelets
TGF-β1 FGF
PDGF IL-1
TNF-α PAI-1
Attraction and proliferation of fibroblasts and myofibroblasts
ROSs
Oxidative stress
Excessive production of COLLAGEN
Activation of NF-κB
iNOS
↑ NO
Osteogenic differentiation
Plaque calcification
PENILE PLAQUE
Fibroblasts, myofibroblasts
Nitrosative stress

FIG. 73.4 Pathogenetic mechanisms of Peyronie's disease. *FGF,* Fibroblast growth factor; *IL,* interleukin; *iNOS,* inducible nitric oxide synthase; *NF-κB,* nuclear factor-κB; *NO,* nitric oxide; *PAI,* plasminogen activator inhibitor; *PDGF,* platelet-derived growth factor; *ROS,* reactive oxygen species; *TGF,* transforming growth factor; *TNF,* tumor necrosis factor. (Data from Paulis G, Brancato T. Inflammatory mechanisms and oxidative stress in Peyronie's disease: therapeutic “rationale” and related emerging treatment strategies. *Inflamm Allergy Drug Targets* 2012;11:48–57.)

Impact of Wound Healing on the Development of Peyronie's Disease

In general, PD has been described as a wound-healing disorder of the tunica albuginea. Recent investigations have focused on the mechanisms of wound healing, fibrosis, and scar formation and have correlated the findings with the PD population. Normal wound healing involves three phases: an acute phase, a proliferative phase, and a remodeling phase. These are not to be confused with the acute and chronic phases of PD previously described. By understanding the wound-healing process, one gains a better understanding of PD, targets for drugs used to treat PD, and the animal models that have been developed for the study of PD. In general, during the **acute phase,** blood vessel injury leads to extravasation of blood and aggregation and activation of platelets that release chemotactic agents that act as promoters in the wound-healing cascade by activating and attracting neutrophils during the first 24 hours after clot formation, macrophages after 48 hours, and finally lymphocytes after 72 hours (DiPietro, 1995). Macrophages phagocytose dead or potentially injurious material and destroy bacteria or other foreign cells via oxygen free radical reactions. In addition, macrophages activate keratinocytes, fibroblasts, and endothelial cells by releasing potent tissue growth factors, particularly transforming growth factor-β (TGF-β), and other mediators such as TGF-α, heparin binding epidermal growth factor, fibroblast growth factor (FGF), and collagenase (DiPietro, 1995; Ravanti and Kahari, 2000).

The next phase of normal wound healing is the **proliferative phase,** which marks the shift toward tissue repair beginning at approximately 72 hours after injury and persisting for approximately 2 weeks. It is characterized by fibroblast and myofibroblast migration in response to TGF-β and platelet-derived growth factor (PDGF), and deposition of newly synthesized extracellular matrix (ECM) composed of type I and type III collagen, hyaluronan, fibronectin, and proteoglycans (Velnar et al., 2009). At this point, fibroblasts are stimulated by TGF-β to change into myofibroblasts, which contain thick actin bundles allowing for wound contraction. TGF-β also signals fibroblasts and myofibroblasts to synthesize types I and III collagen (Tomasek et al., 2002; Gelbard, 2008).

Finally, the **remodeling phase** begins and in the normal situation may last up to 1 or 2 years. The remodeling of an acute wound is tightly regulated by mechanisms that balance the simultaneous degradation and synthesis of collagen and other ECM macromolecules. Any alterations in this process may lead to abnormal wound healing with excessive scarring (Velnar et al., 2009). Matrix metalloproteinases (MMPs) (collagenases), produced by neutrophils, macrophages, and fibroblasts in the wound, are responsible for the degradation of collagen. They are subsequently held in check by inhibitory factors called tissue inhibitors of metalloproteinases (TIMPs). As the activity of TIMPs increases, there is a drop in matrix breakdown by metalloproteinase enzymes, thereby promoting new matrix accumulation (Ravanti and Kahari, 2000). **This balance between TIMPs and MMPs has also been studied in the pathogenesis of PD and is described later in this section.**

Over time, the highly disorganized initial deposition of collagen matrix becomes more oriented and cross-linked during the final stages of the remodeling phase. The process is regulated by a number of factors, with PDGF, TGF-β, and FGF being the most important (Velnar et al., 2009), but also including MMPs, TIMPs, fibrin, or plasminogen activator inhibitor-1 (PAI-1) (Taylor and Levine, 2007; Velnar et al., 2009). **Having accomplished this task, redundant fibroblasts and myofibroblasts are eliminated by apoptosis.** A fundamental understanding of the elements of normal wound healing provides a foundation for understanding which components may go awry in PD. It does appear that most basic science research in this field has focused on the development of the scarring process resulting in the exuberant scar found in men with PD. More recent research has focused on the dysregulation of remodeling that may be responsible for why the fibrosis does not resolve.

Etiology of Peyronie's Disease

The exact cause of PD has not yet been defined, although most would agree that some injurious stimulus is necessary to trigger the cascade of events that leads to PD in the susceptible individual (Bjekic et al., 2006; Carrieri et al., 1998; Devine et al., 1997; Jalkut et al., 2003; Jarow and Lowe, 1997; Nachtsheim and Rearden, 1996). **Trauma may be perceived as a single event experienced by the patient or may take the form of repetitive microtrauma to the penis.** Furey (1957) initially suggested that trauma was the primary cause of PD.

The proposed mechanism is that in the erect state, the pressures inside the penis can get quite high and acutely higher when external forces are placed on the penis during intercourse in particular. These pressures may exceed the elasticity and strength of the tunica tissues, resulting in a microfracture. A commonly held misconception is that the trauma to the penis must occur only when it is erect; however, others have noted that trauma to the flaccid penis may also trigger this process. In a recent review of their database of 228 patients (Levine et al., personal communication) who had recognized trauma to the penis shortly before the onset of PD, 16% reported a traumatic event to the flaccid penis (e.g., motor vehicle accident, sports-related injury). As the scar develops, there may also be an inflammatory response, resulting in the pain that can be present in the flaccid penis or when pressure is placed on the penis. Dorsal and ventral sheer stresses occurring during sexual activity may account for the more common dorsal location of plaques (Devine et al., 1997). Investigators have suggested that repetitive microtrauma to the penis leads to delamination of the tunica albuginea and vessels between the layers of the tunica (Somers and Dawson, 1997). This leads to microhemorrhage and initiates the wound-healing cascade described previously.

Carrieri et al. (1998) **reported a 16-fold increase in PD in those who had undergone prior invasive procedures and a nearly 3-fold increase in PD in patients who had experienced genital and/or perineal trauma** (Carrieri et al., 1998). It is also important to note that although trauma has been considered the most likely trigger activating PD, in our clinical experience no more than 30% of men recall a specific event involving injury to the penis close to the time when the scarring or pain began. Other investigators have reported 16% to 40% of patients having had antecedent trauma (Bjekic et al., 2006; Tal et al., 2012). An injury occurring during sexual activity appears to be the most common recognized event associated with the onset of PD. An association with trauma and position of intercourse has been proposed for some time, based on the assumption that certain positions may be more apt to cause injury. This has not been verified but it does appear from anecdotal experience that the most common sexual position noted to precede the onset of PD is with the partner on top. In this position, a sudden “faux pas de coit” or missed thrust may lead to high intracorporeal pressures (Bitker et al., 1988).

Although trauma undoubtedly plays a pivotal role in the development of disease, it alone cannot explain why some men develop deformity whereas others do not. This is no better illustrated than by a study of 193 penile fracture patients in whom none went on to develop PD (Zargooshi, 2004). Several underlying factors have been considered responsible for PD; genetic predisposition, autoimmune factors, an aberration of localized wound healing, and even infection have been proposed as possible causes (Devine et al., 1991; Jalkut et al., 2003; Mulhall et al., 2002; Ralph et al., 1996; Taylor and Levine, 2007). **Therefore, we should be careful about the medicolegal implications of referring to PD as the result of treatment(s) for ED, trauma to the flaccid penis, or catheterization or endoscopy, which are more likely just providing an opportunity for the forces at hand to activate the abnormal wound-healing response in the “genetically” susceptible man rather than being the cause of PD** (Carrieri et al., 1998; Levine and Latchamsetty, 2002).

The following discussion focuses on specific research into the pathophysiology of PD.

Role of Oxygen Free Radicals and Oxidative Stress

Oxidative stress has a well-documented role in tissue fibrosis and has been studied in the pathogenesis of PD (Gonzalez-Cadavid and Rafjer, 2005). As stated previously, microvascular trauma leads to extravasation of blood, with thrombus formation that leads to deposition of fibronectin and fibrin. Inflammation ensues with accumulation of inflammatory cells and production of reactive oxygen species (ROS). **During the early phase of PD, an increase in oxidative stress in the form of free radicals induces overexpression of fibrogenic cytokines and augmented transcription and synthesis of collagen.** ROS are increased by TGF-β1, which also directly inhibits collagenase and promotes collagen synthesis (Magee et al., 2002). ROS include superoxide anion, hydrogen peroxide, hydroxyl radical, organic hydroperoxide, alkoxy radicals, and peroxy radicals. Although NO seems to play an antifibrotic role, nitrosative stress and oxidative stress can lead to macromolecular damage, cytotoxic effects, lipid peroxidation, DNA fragmentation, collagen accumulation, and cellular dysfunction (Paulis and Brancato, 2012).

Role of Nitric Oxide in Peyronie's Disease

NO is a small reactive free radical that acts as both an intracellular and an extracellular regulatory molecule. Wound cells, including monocytes, macrophages, and fibroblasts, have been shown to synthesize NO through a nuclear factor-κB (NF-κB)–activated inducible NO synthase (iNOS)–dependent mechanism after injury. The iNOS isoform produces NO; it is usually considered a defense mechanism against infection or cancer, is associated with inflammation, and is significantly increased in human and animal PD plaques (Gonzalez-Cadavid, 2009). NO synthesized by iNOS reacts with ROS, thus reducing ROS levels and presumably inhibiting fibrosis. **The antifibrotic effects of NO may be mediated at least in part by the reduction of myofibroblast abundance and may lead to a reduction in collagen I synthesis** (Vernet et al., 2005)**. NO may also play an antifibrotic role by activating guanylyl cyclase, thus producing cyclic guanosine monophosphate (cGMP), which has been suggested to inhibit plaque** formation (Ferrini et al., 2002; Valente et al., 2003).

Role of Myofibroblasts in Peyronie's Disease

The excessive deposition of collagen and ECM accompanied by the loss of functional cells that characterizes tissue fibrosis is caused in some cases by the appearance and accumulation of myofibroblasts (Gonzalez-Cadavid, 2009). Twenty percent of cells cultured from PD tunica albuginea are in fact myofibroblasts, suggesting that they may be one of the primary factors leading to fibrosis in PD (Mulhall et al., 2002). Proposed mechanisms for the presence and persistence of myofibroblasts include a decrease in myofibroblast apoptosis, and stimulation of fibroblast transformation to myofibroblasts by TGF-β and mechanical stress, which has been associated with hypertrophic scarring (Darby and Hewitson, 2007; Gelbard, 2008). **Myofibroblast activation is a key event in the development of fibrosis. Trauma to the tunica albuginea secondary to**

microscopic delamination increases the adherence of fibroblasts to their surroundings, exposing them to changes in ECM tension, and in the presence of appropriate cytokines initiates their differentiation into myofibroblasts (Gelbard, 2008). When tension diminishes, myofibroblasts tend to undergo apoptosis. Gelbard postulated that if myofibroblasts are continuously exposed to tension in the form of rigid corpora during erections, they may fail to undergo apoptosis and subsequently contribute to what appears to be a hallmark of PD—inappropriate and persistent stimulation of the wound-healing process (Gelbard, 2008).

Role of Transforming Growth Factor-β1 in the Etiology of Peyronie's Disease

TGF-β1 has been shown to be significantly associated with PD (El-Sakka et al., 1997)**. TGF-β is a strong activator of myofibroblasts and is known to be a potent fibrotic growth factor by stimulating the deposition of ECM.** TGF-β binds cell surface receptors and, through a signal transduction cascade, leads to the deposition and remodeling of ECM by stimulating cells to simultaneously **(1) increase the synthesis of most matrix proteins** (Ihn, 2002)**; (2) decrease production of matrix-degrading proteases while increasing the production of inhibitors of these proteases** (Knittel et al., 1999)**; and (3) modulate the expression of integrins** (Margadant and Sonnenberg, 2010). The action of TGF-β in tissue repair has been shown to involve an initiation of complex sequences of monocyte chemoattraction, induction of angiogenesis, and control of the production of cytokines and other inflammatory mediators (Border and Ruoslahti, 1992). Moreover, TGF-β stimulates the synthesis of individual matrix components including fibronectin, tenascin, collagens, and proteoglycans while simultaneously blocking matrix degradation by decreasing the synthesis of proteases and increasing levels of protease inhibitors (Balza et al., 1988). All of these events can be beneficial in tissue repair; however, the deposition of ECM at a site of tissue injury can lead to scarring and fibrosis. Furthermore, the ability of TGF-β to induce its own production may be the key to the development of scarring and fibrosis (Border and Ruoslahti, 1992). TGF-β1 is not the only member of the large TGF-β superfamily of growth and differentiation factors (GDFs) that have been implicated as fibrotic agents. Myostatin, also known as *GDF-8*, has been proposed not only as an inhibitor of myofiber formation but also as an inducer of fibrosis. Myostatin is expressed in the normal human tunica albuginea (TA) and is overexpressed in PD plaque. Myostatin stimulates myofibroblast generation and collagen deposition in normal tunic and is upregulated by TGF-β1. Myostatin seems to potentiate the effects of TGF-β1 (Cantini et al., 2008).

Fibrotic Gene Expression in Peyronie's Disease

A variety of profibrotic and antifibrotic factors contribute to the development of PD plaque that leads to deformity (Grazziotin et al., 2004). Qian et al. (2004) performed DNA microarray analysis of PD tissue obtained from patients undergoing surgery for PD. The most highly upregulated gene found in the PD plaque, *PTN* or *OSF1*, codes for a secreted heparin-binding protein thought to stimulate mitogenic growth of fibroblasts and osteoblast recruitment, and is possibly related to plaque ossification. Proteins responsible for cell proliferation, cell cycling, and apoptosis were found to be increased, whereas Id-2, an inhibitor of myofibroblast differentiation, was downregulated. The second most upregulated gene, *MCP-1,* is critical to the inflammatory response and ossification (Graves, 1999; Graves et al., 1999). Genes related to myogenic conversion during wound healing and fibroblast differentiation into myofibroblasts were upregulated, whereas collagenase IV, which is critical for collagen degradation and is decreased in fibrosis, was downregulated (Magee et al., 2002). Qian et al. (2004) performed a study comparing gene-expression profiles of PD patients with those of DD patients. A series of 15 genes were upregulated and none were downregulated in the PD plaque versus the normal TA. Of the genes upregulated, the ones most prominently increased were MMPs involved in collagen breakdown, specifically *MMP-2* or *MMP-9* in one-half of the PD plaques, in addition to genes involved in actin-cytoskeleton interactions required for fibroblasts and myofibroblasts to generate contractile forces (Qian et al., 2004). According to the findings of another study, the lower expression of apoptotic genes may cause the persistence of collagen-producing cells that are upregulated, consequently resulting in plaque formation. Similar expression levels of apoptotic genes in both tunica albuginea and Peyronie's plaques may be caused by the generalized physiopathologic alterations in the tunica albuginea that lead to plaque formation at a vulnerable region subjected to recurrent trauma (Zorba et al., 2012).

Del Carlo et al. (2008) investigated the role of MMPs and TIMPs in the pathogenesis of PD by using harvested plaque from patients who had PD. PD tissue samples were found to have diminished or absent levels of MMP-1, MMP-8, and MMP-13 compared with matched perilesional tunica and non-PD controls. PD fibroblasts were cultured with soluble MMPs and TIMPs after treatment with TGF-β or interleukin-1β (IL-1β). They found that IL-1β stimulation increased the production of MMP-1, MMP-2, MMP-8, MMP-9, MMP-10, and MMP-13 in PD fibroblasts, whereas TGF-β increased the production of only MMP-10 and decreased the production of MMP-13, suggesting that PD fibroblasts can be induced to make MMPs (Del Carlo et al., 2008). Baseline aberrant expression of p53, a cell cycle–regulating protein, has been demonstrated in PD fibroblasts and an absent response to sublethal DNA damage. This suggests a role for an aberration in the p53 pathway in the pathogenesis of this condition (Mulhall et al., 2001).

When all of this information is taken together, it is not hard to understand why there are myriad clinical presentations and treatments for this very complex disease. A variety of alterations may be present in a given patient, which may manifest as fibrosis with penile deformity (see Box 73.2). This has been demonstrated by Qian et al., who found **marked heterogeneity in gene expression profiles among men with PD** (Qian et al., 2004). As suggested by the ensuing section on medical therapy, different medical treatments that target different disease mechanisms may not work uniformly among the PD population (see Fig. 73.4).

Key Points: Anatomy and Etiology

- The longitudinal layer of the tunica albuginea is thinnest at the 3 and 9 o'clock positions of the corpora; it is completely absent between the 5 and 7 o'clock positions. This absence of the longitudinal layer ventrally may contribute to greater ease of dorsal buckling and may explain why most PD patients exhibit dorsal curvature.
- Normal architecture is essentially lost consequent to this disease, resulting in what is known as a Peyronie's plaque, which, when examined histologically, demonstrates disorganization of collagen fibrils and a decrease and disorganization of elastin, resulting in penile deformity caused by asymmetric expansion of the corpora.
- Antecedent trauma has been reported in 16% to 40% of patients; most

would agree that some injurious stimulus is necessary to trigger a cascade of events that lead to PD in the susceptible individual.

- Oxygen free radicals, oxidative stress, NO, myofibroblasts, TGF-β1, and fibrotic gene expression all play a key role in the development of PD and are key avenues for future research to further elucidate the exact mechanism behind the development of PD.

Symptoms

The most frequent presenting symptoms of patients with PD include penile pain, erect deformity, palpable plaque, and ED (Chung et al., 2011a; Pryor and Ralph, 2002; Smith et al., 2008b). Many men who have PD visit the doctor with a self-misdiagnosis of ED. Not all patients experience pain or are able to palpate a plaque, but the shortening, hinge effect, distal softening, and curvature, when present, are readily recognized. Pain, when present in the acute phase, can occur in the flaccid condition with palpation of the plaque, with erection, or during intercourse. Once the disease process is stable, most pain will resolve, but in some men the pain persists with what has been referred to as “torque” pain associated with a pulling sensation on the plaque when a strong erection occurs (Levine and Larsen, 2013). This should not be confused with the inflammatory pain of the acute phase.

Although curvature can be one of the most recognized and distressing deformities associated with PD, many men are capable of sexual activity with curvature up to 60 degrees, particularly if the curvature is dorsal and more gradual along the shaft. Men with ventral or lateral curvatures may have a more difficult time with intromission because of discomfort. Yet, it is not uncommon to hear that the partner does not complain of discomfort during coitus, regardless of the degree or direction of curvature. Patient estimates of curvature are unreliable. One study demonstrated that 50% of patients overestimated their degree of curvature by an average of 20 degrees (Bacal et al., 2009). Classification by degree of curvature was introduced by Kelami (1983). One center reported on the distribution of curvature by the Kelami classification and found that 39.5% of patients had 30 degrees (mild) or less, 35% had 31 to 60 degrees (moderate), and 13.5% had more than 60 degrees of curvature (severe); 12% had no curvature but did experience an hourglass deformity resulting in an unstable erection (Kadioglu et al., 2011b).

The PD plaque can manifest in a variety of configurations including cords; simple nodules; coinlike, irregular dumbbell shapes; or I-beam plaques. It appears that virtually all plaques have a septal component, which supports the concept of delamination of tunical fibers as a result of axial forces on the septum (Jordan, 2007). Pure septal plaques have also been reported and may result in narrowing, shortening, or no recognized deformity at all (Bella et al., 2007).

The orientation of the plaque usually defines the deformity. Therefore,

patients with a simple dorsal plaque are most apt to have dorsal curvature; but if there is transverse or spiraling scarring, which can be partial or circumferential, this could result in varying degrees of indentation including an hourglass deformity, which can result in an unstable penis, or a hinge effect as a result of the inability to tolerate axial forces in the erect condition (Pryor and Ralph, 2002). The distal softening of the shaft beyond the plaque is also difficult to understand, because dynamic infusion cavernosometry and cavernosography (DICC) studies have found that the pressures within the corpora cavernosa are equal, when measured, proximal and distal to the plaque (Jordan and Angermeier, 1993). The cause of distal flaccidity remains speculative and includes local cavernosal fibrosis extending from the involved tunic (Ralph et al., 1992) and site-specific venous leak.

Evaluation of the Patient

As with all medical conditions, a detailed history is a critical part of the evaluation of the patient with PD (Levine and Greenfield, 2003). The intake interview should focus on presenting signs and symptoms such as pain, deformity, and palpable plaque. The assessment should also include whether onset was gradual or sudden and the estimated time that symptoms began; it should be determined if there was any inciting event that may have triggered the process, including direct external penile trauma to the flaccid or erect penis or instrumentation. The patient should be asked whether there is any personal or family history of other fibrotic disorders including DD and Ledderhose disease (Fig. 73.5). **Patients should be carefully queried as to their erectile capacity, but ultimately the question is whether the patient is capable of intromission or incapable because of deformity and/or diminished rigidity. A useful question that has been shown to be an effective predictor of postoperative erectile function is “If your penis was straight with the same quality of rigidity that you have now, do you think it would be adequate for penetrative sexual activity?”** (Levine and Greenfield, 2003; Taylor et al., 2012). Clearly if the patient does not feel his erections would be satisfactory with or without pharmacotherapy, this can help direct the patient to treatment with a penile prosthesis and straightening maneuvers; nonsurgical or other surgical approaches could result in improvement of deformity, but if there is persistent ED, such treatment would likely not give the patient a sexually functional erection.

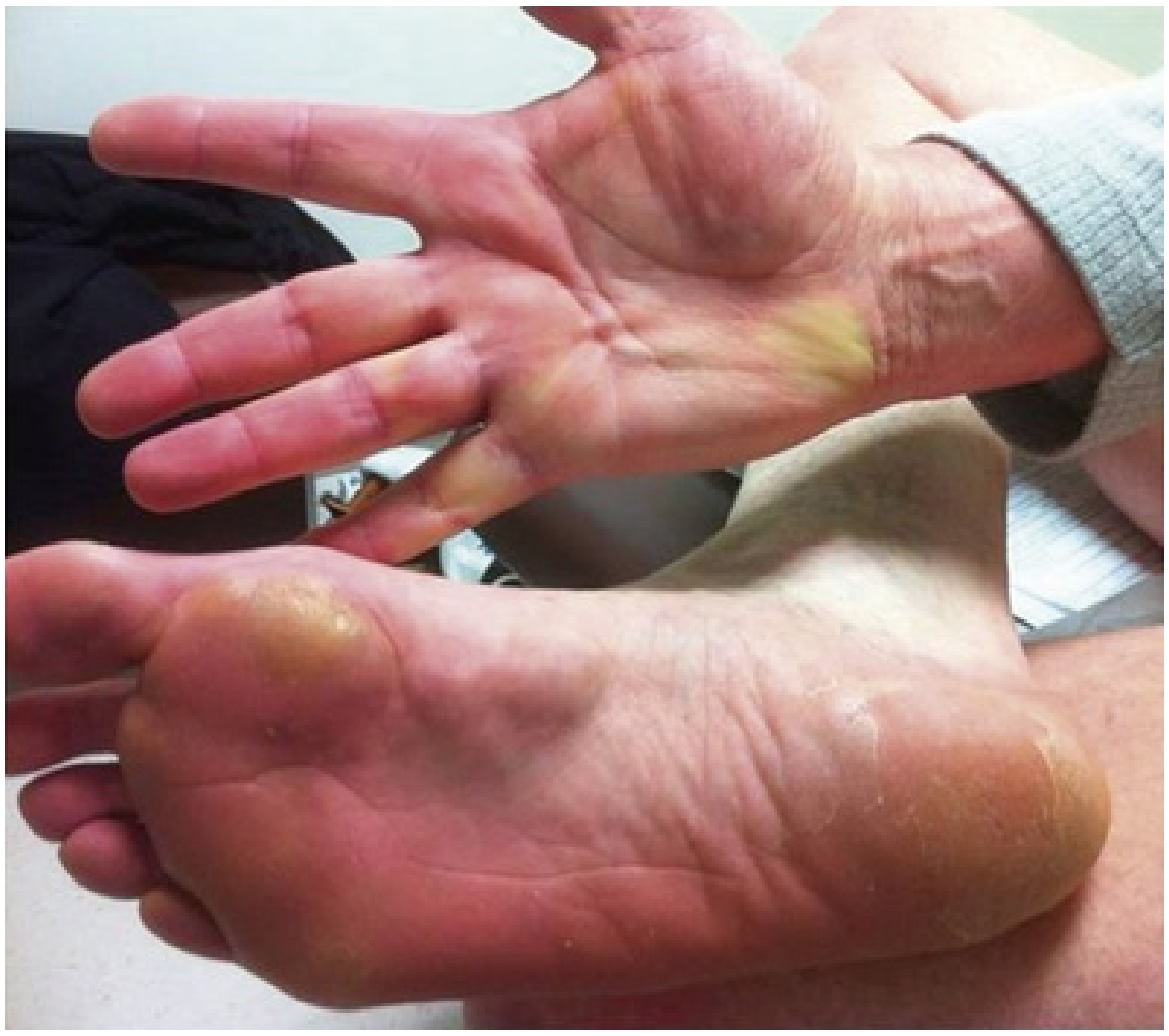

FIG. 73.5 This patient had physical evidence of Dupuytren, Ledderhose, and Peyronie's diseases.

Further information to be obtained from the sexual history will be whether there are any vascular risk factors for ED, including a history of diabetes, hypertension, elevated cholesterol, and smoking. This is also a useful time to determine if there are issues with premature or delayed ejaculation. A list of medications may also indicate underlying medical conditions that may predispose to ED.

The recently validated PD questionnaire (PDQ) (Rosen et al., 2008; Hellstrom et al., 2013) addresses not only the concerns of the patient regarding structural changes of the penis but also how PD affects his overall psychological condition. The current questionnaire has 15 questions assessing three domains, including (1) Peyronie's psychological and physical symptoms (six items), (2) penile pain (three items), and (3) the effects of PD symptoms (six items). Each domain is intended to be an independent measure, and the scores are not summed for a total instrument score. Higher scores indicate a greater negative impact. With further experience, it may prove to be a useful assessment tool for patients making treatment decisions. The PDQ can be downloaded at http://www.endo.com/File%20Library/Products/Other/PDQ_from_Protocol_1-25.pdf.

The value of a photograph taken at home of the erect penis has been controversial because of the inability to adequately represent and measure a

three-dimensional deformity (Bacal et al., 2009; Ohebshalom et al., 2007). At the current time, with the prevalence of smartphones, a photograph can be taken by the patient from above and from the side in the erect state, which can be useful during the initial consultation to get a general impression of the direction and severity of the deformity.

The physical examination should include a general assessment of the femoral pulses, appearance of the flaccid penis, and whether it is circumcised. **To assess the Peyronie's plaque, the penis should be examined on stretch, which allows easier identification of the plaque (Fig. 73.6). The location of the plaque may be useful to record, but measurement of the size of the plaque with any modality has been found to be inaccurate because the plaque is rarely a discrete lesion** (Bacal et al., 2009; Hatzimouratidis et al., 2012; Levine and Burnett, 2013; Ralph et al., 2010). It has irregular borders and often extends into a septal cord (Levine and Greenfield, 2003; Ralph et al., 2010). **Furthermore, there is no evidence that a reduction in plaque size as a result of treatment is associated with improvement of deformity** (Levine and Burnett, 2013)**. The stretched penile length (SPL) is also a critical parameter to measure at the initial consultation. This is performed by placing the penis on stretch by grasping the glans and pulling at a 90-degree angle away from the body** (Wessells et al., 1996). This parameter should be documented, as patient perception of loss of penile length is typically overestimated. It is preferred to measure from the pubis to the corona dorsally, as these are two fixed points and facilitate repeated measurement during the course of treatment and follow-up. The consistency of the plaque may be recorded. A “rock hard” plaque may be an indicator of calcification but will need to be confirmed with some form of imaging, preferably ultrasonography (Fig. 73.7). A calcified plaque is readily identified on ultrasonography because of the hyperdensity of the plaque with shadowing behind it. Computed tomography and magnetic resonance imaging have little value in the evaluation of the patient with PD, but further investigation is ongoing to determine if these modalities can provide prognostic information (Andresen et al., 1998; Hauck et al., 2003).

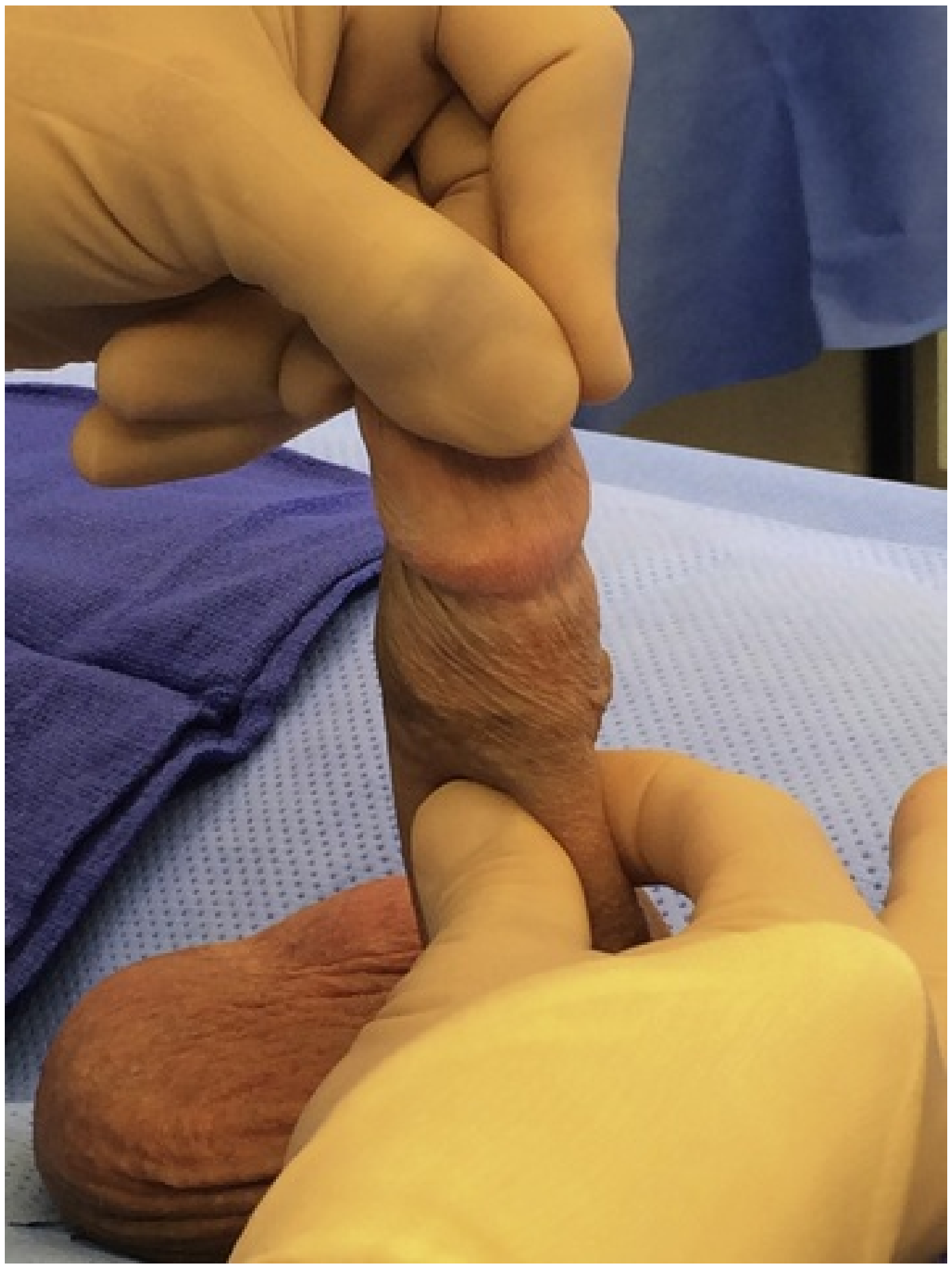

FIG. 73.6 Palpation of the penis on stretch facilitates identification of plaque.

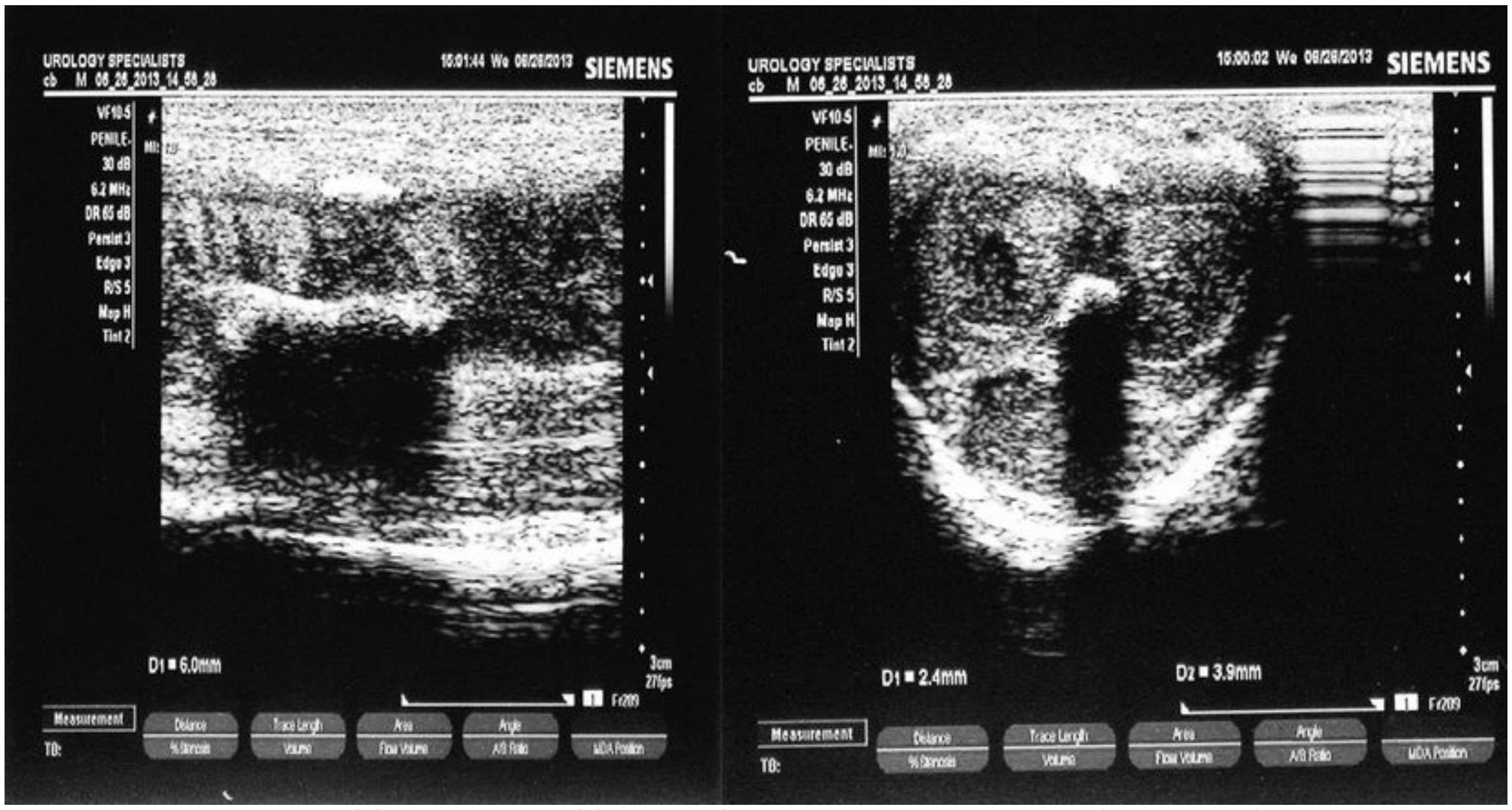

FIG. 73.7 This ultrasound image demonstrates areas of dorsal and ventral calcification. Note shadowing behind calcified plaques.

Only recently has it been recognized that calcification may occur early after the onset of the scarring process, and therefore the previously held notion that calcification is an indication of chronic, severe, and/or mature disease appears untrue (Levine et al., 2013). Calcification is most likely the result of a different genetic subtype of PD in which there is activation of genes involved in osteoblastic activity (Vernet et al., 2005). Why some plaques undergo mineralization and others do not remains unknown, but it does appear that the extent of mineralization may have a bearing on a successful response to nonsurgical therapy; men with more extensive calcification are less likely to benefit from nonsurgical treatment (Chung et al., 2011a). Several investigators have indicated that intralesional injection therapy with verapamil and interferon (IFN) is less likely to be successful in men with significant calcification (Hellstrom et al., 2006; Levine et al., 2002). This is because the drug will not be able to get into or effect change within this mineralized tissue. Furthermore, investigators have also suggested that patients with extensive calcification are more apt to proceed to placement of a penile prosthesis (Breyer et al., 2007; Chung et al., 2012). Recently a calcification grading system was published. The investigators found that patients with grade 3, or the most extensive, calcification (>1.5 cm in any dimension or multiple plaques ≥1.0 cm) were more likely to undergo surgery when they also had satisfactory erectile function. This is in contradistinction to those who had less severe calcification of grade 1 (<0.3

mm) or grade 2 (0.3 to 1.5 cm) or no calcification in whom there was no evidence of an increased likelihood of proceeding to surgery (Levine et al., 2013).

Assessment of penile deformity in the erect state is critical to the evaluation. This has been shown to be most accurately measured after an office vasoactive injection as compared with a home photograph or vacuum-induced erection. As treatment of ED moves toward more invasive treatment, accurate assessment of penile deformity in the erect state is critical. **The AUA 2015 Guideline on Peyronie's Disease now recommends that in-office intracorporeal injection therapy should be performed in every patient before invasive intervention** (Nehra et al., 2015).

The role of vascular testing in the diagnosis of PD has not been clearly defined. In centers that see many patients with this disorder, duplex ultrasound analysis (usually with intracorporeal injection therapy) is routinely performed as part of the initial evaluation, especially for those who are considered surgical candidates (Hatzimouratidis et al., 2012; Levine and Burnett, 2013; Ohebshalom et al., 2007; Ralph et al., 2010). **The benefits of a complete duplex ultrasound assessment include identification of calcification during initial surveillance in the flaccid state, assessment of penile vascular flow parameters after intracavernosal injection of vasoactive agent, observation of the erectile response to the vasoactive injection compared with the patient's sexually induced erection at home, and provision of the best opportunity to objectively assess deformity** (Figs. 73.8 and 73.9; Box 73.3). **These parameters are absolutely critical to the decision process for the patient who is considering surgery (Fig. 73.10).**

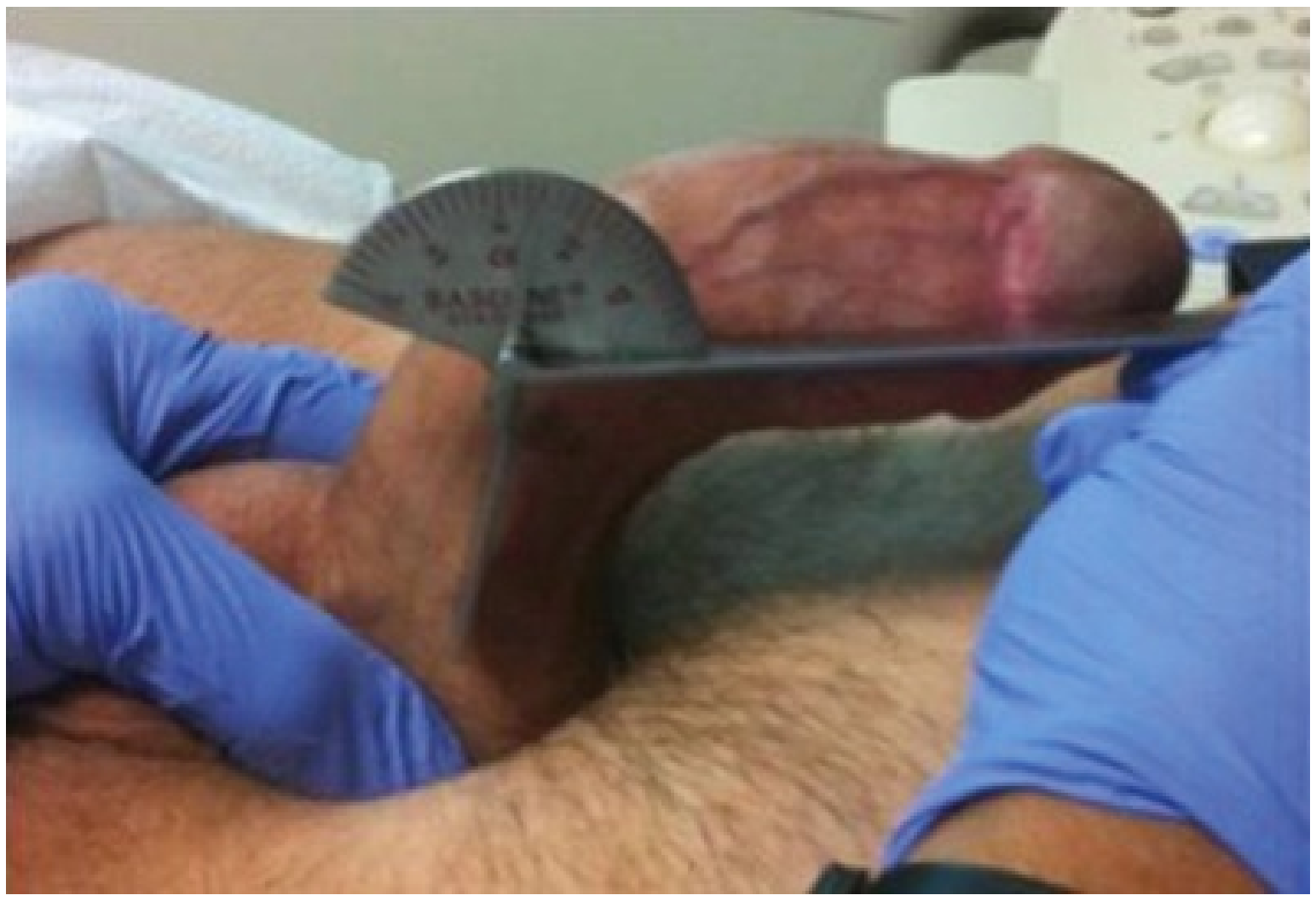

FIG. 73.8 Measurement of curvature with goniometer.

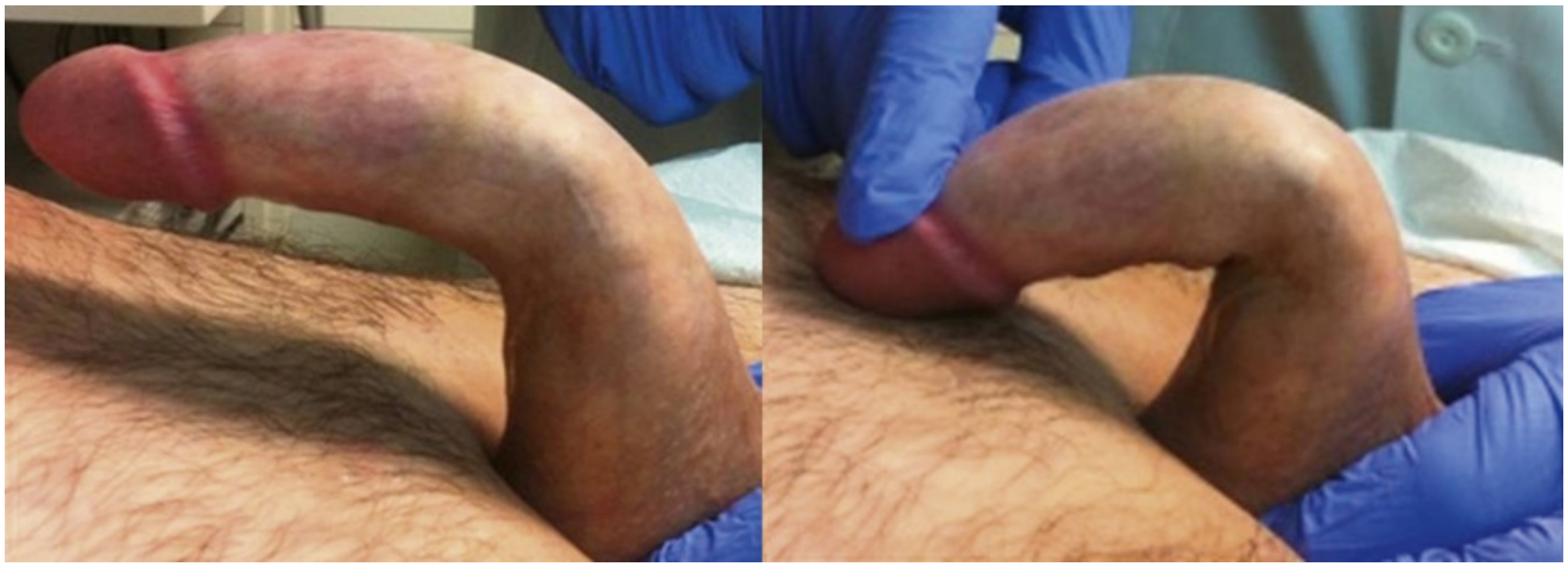

FIG. 73.9 Instability or a hinge effect of the erect penis caused by indentation is demonstrated in this severely dorsally bent penis with application of axial pressure.

Box 73.3

Value of Penile Duplex Ultrasonography for Peyronie's Disease

- Identification and measurement of plaque calcification
- Identification of corporeal fibrosis
- Observation of erectile response to vasoactive intracavernosal injection

- Measurement of penile vascular parameters (peak systolic velocity, end-diastolic velocity, and resistive index)
- Optimum objective measurement of erect penile deformity (curvature, girth irregularities, hinge effect)

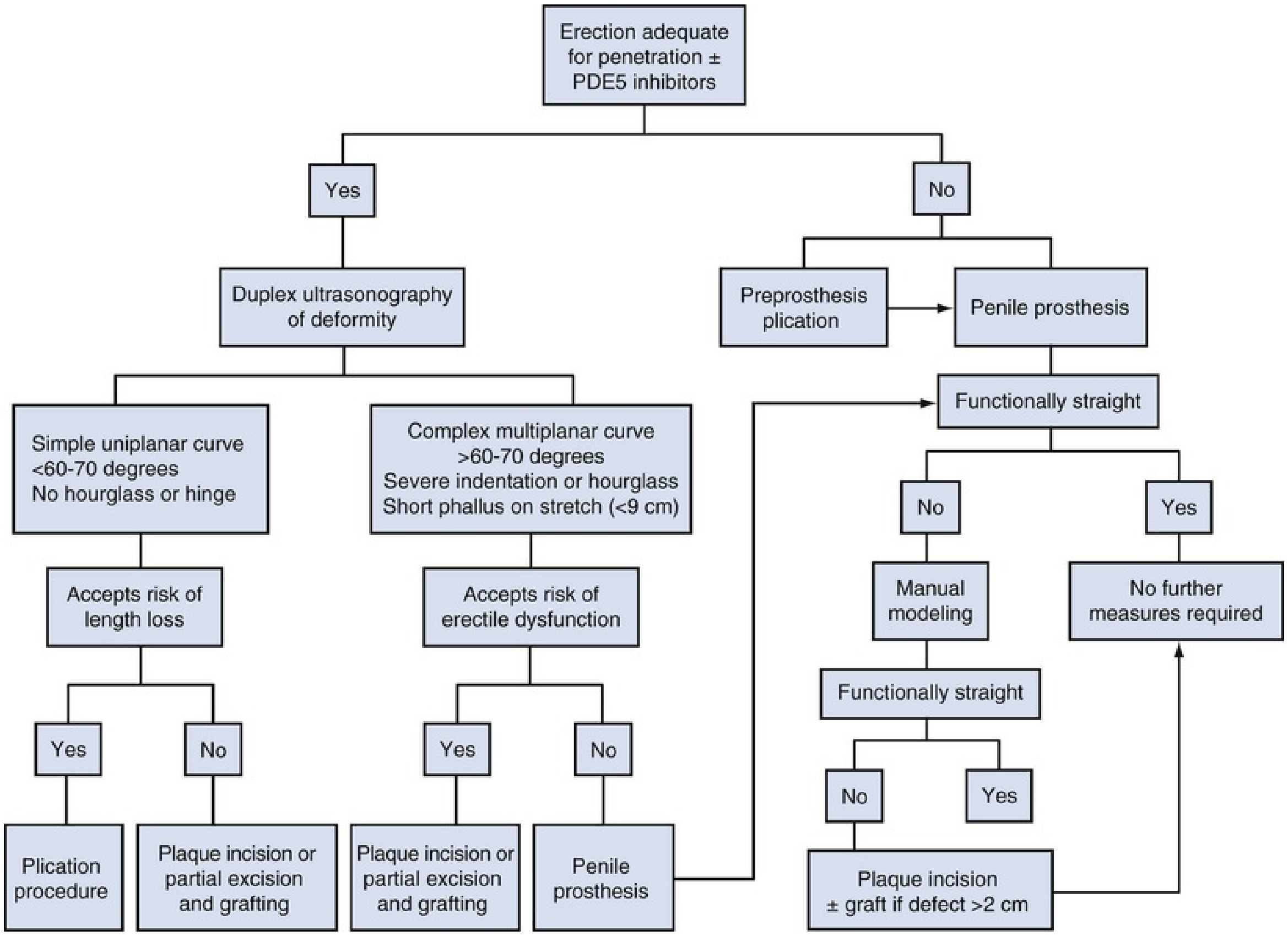
Erection adequate for penetration ± PDE5 inhibitors
Yes
No
Duplex ultrasonography of deformity
Preprosthesis plication
Penile prosthesis
Functionally straight
Simple uniplanar curve <60-70 degrees No hourglass or hinge
Complex multiplanar curve >60-70 degrees Severe indentation or hourglass Short phallus on stretch (<9 cm)
No
Yes
Accepts risk of length loss
Accepts risk of erectile dysfunction
Manual modeling
No further measures required
Functionally straight
Yes
No
Yes
No
No
Yes
Plication procedure
Plaque incision or partial excision and grafting
Plaque incision or partial excision and grafting
Penile prosthesis
Plaque incision ± graft if defect >2 cm

FIG. 73.10 Algorithm for the surgical management of Peyronie's disease. *PDE5,* Phosphodiesterase type 5.

Several studies have demonstrated that preoperative erectile function correlates strongly with postoperative surgical results (Jordan and Angermier, 1993; Levine and Greenfield, 2003; Taylor et al., 2012). In an analysis of the relationship of penile deformity to the vascular status of PD, patients with ventral curvature were most likely to have cavernous veno-occlusive dysfunction, which further confirms the concern about postoperative ED after grafting of ventral curves (Kendirci et al., 2005; Lowsley and Boyce, 1950).

Some authors have reported the use of dynamic infusion cavernosometry (DICC) as a tool to assess penile vascular integrity and, in particular, venous leakage before surgery (Alphs et al., 2010; Jordan, 2007). This test appears to add unnecessary invasiveness and expense and provides little value to the diagnostic evaluation over a well-done dynamic penile duplex ultrasonography. Although no standard evaluation for assessment of penile sexual sensitivity has been established, light touch and biothesiometry can be used (Levine and Burnett, 2013). Biothesiometry has been suggested to be an indirect measure of penile sexual sensation. This is controversial because no definitive controlled studies have been reported (Padma-Nathan, 1988). The assumption is that the vibratory nerves travel with the unique sexual nerves of the penis. Therefore, vibratory appreciation with the index fingers used as the positive control and anterior thighs as the negative control can be a surrogate assessment of sexual sensation, which may be compromised by scar infiltration into the sensory nerves or because of other underlying systemic disorders such as diabetes mellitus. In light of the proposed increased prevalence of hypogonadism with ED, a morning serum total testosterone level during the initial evaluation is recommended for men with ED, as per the recently updated AUA ED guideline, but not for men with PD and no ED (Burnett et al., 2018, Moreno and Morgantaler, 2009).

Key Points: Evaluation

- Detailed history includes onset of symptoms, vascular risk factors for ED, patient-estimated degree of deformity, and patient assessment of quality of erection with respect to rigidity.
- Validated questionnaires include the PDQ to document the degree of effect associated with PD.
- The physical examination focuses on palpability of plaque with the penis on stretch to enhance appreciation of plaque, stretched flaccid penile length, and presence of pain during palpation.
- Penile deformity should be objectively assessed during a vasoactive drug injection–induced erection, especially if surgery is contemplated.

Treatment Protocols

Multiple treatment protocols have been developed and published. It should be recognized that these algorithms serve only as guidelines and that individualization is key to patient success, which depends on specific findings from the history, physical examination, duplex ultrasonography, and patient goals (Bokarica et al., 2005; Hatzimouratidis et al., 2012; Levine and Greenfield, 2003; Levine and Lenting, 1997; Ralph et al., 2010). In an attempt to consolidate guidance to the practicing urologist, the Peyronie's Disease Guideline Panel of the American Urological Association Education and Research was created in 2013. In 2015, the AUA guideline on Peyronie's Disease was published (Nehra et al., 2015).

Nonsurgical Treatment of Peyronie's Disease

Myriad nonsurgical treatments for PD have been offered since the time of de la Peyronie. Medical therapy until very recently has been compromised by suboptimal studies that failed to demonstrate meaningful results because of small numbers of subjects, lack of a control group, lack of randomization, and limited objective measurements (Schaeffer and Burnett, 2012). **In addition, the variety of disease presentations and its poorly understood cause contribute to treatments that have not addressed the underlying pathophysiology of this wound-healing disorder.** As a result, all oral and topical treatments, with the exception of NSAIDs, have been delegated to the “should not offer” status in the 2015 AUA guidelines. In this section, we review the contemporary treatments and focus on placebo-controlled studies when possible.

Some patients require only reassurance, particularly if there is no difficulty or pain for the patient or his partner in accomplishing penetrative sex. Patients should also be reassured that this is not a disorder that will degenerate into a cancer and is therefore not life-threatening.

Oral Medications

Potaba

Potassium para-aminobenzoate (Potaba) is a member of the vitamin B complex. Its mechanism of action has not been studied since 1959, when Zarafonetis and Horrax **demonstrated in fibroblast cell cultures that potassium para-aminobenzoate can reduce the formation of collagen.** According to this in vitro study, it is believed that this drug decreases serotonin levels by increasing monoamine oxidase activity, resulting in enhancement of the endogenous antifibrotic properties of tissues (Zarafonetis and Horrax, 1959).

In a randomized double-blind placebo-controlled trial of 103 treatment-naïve PD patients with noncalcified plaque, 51 patients were assigned to treatment with potassium para-aminobenzoate and 52 to placebo. Mean plaque size decreased in the treatment arm, whereas plaque size remained stable over 12 months of follow-up in the placebo arm. Penile deviation remained stable in those receiving active drug; penile curvature deteriorated significantly in 32.5%

of those receiving placebo. No significant differences concerning decrease in pain could be observed between the two groups. The authors concluded, "**Potassium paraaminobenzoate appears to be useful to stabilize the disorder and prevent progression of penile curvature**" (Weidner et al., 2005). No severe adverse events occurred in the study; however, acute hepatitis associated with administration of potassium para-aminobenzoate for PD has been reported (Roy and Carrier, 2008). **Because there is little evidence of benefit with potassium para-aminobenzoate in placebo-controlled trials and it is expensive and difficult to consume (24 tablets daily), the AUA 2015 PD guideline does not recommend its use.**

Vitamin E

Vitamin E is one of the oldest described oral treatments for the treatment of PD (Scardino and Scott, 1949). Vitamin E, a fat-soluble vitamin metabolized in the liver and excreted in bile, is an antioxidant that **is thought to limit oxidative stress of ROS known to be increased during the acute and proliferative phases of wound healing.** Increased free-radical expression and a prolonged inflammatory phase of wound healing have been demonstrated in PD. **Treatment with vitamin E inactivates circulating free radicals that otherwise would inhibit NO from exerting its positive effects on vascular smooth muscle** (Safarinejad et al., 2007).

Several well-designed studies have demonstrated no significant improvement in pain, curvature, and plaque size when compared with placebo (Ralph et al., 2010). Pryor and Farell (1983) conducted a double-blind, placebo-controlled crossover study evaluating vitamin E for the treatment of PD in 40 subjects. No significant improvements were noted in plaque size or penile curvature (Pryor and Farell, 1983). Gelbard et al. compared treatment with vitamin E with the natural history of PD in 97 subjects with disease duration ranging from 3 months to 8 years; no significant differences were found between the two groups in terms of curvature, pain, or the ability to have intercourse (Gelbard et al., 1990). In a randomized double-blind placebo-controlled study of a total of 236 men with PD, vitamin E failed to show benefit with respect to pain, curvature, or plaque size when compared with placebo (Safarinejad et al., 2007). Although there were no significant observed adverse effects reported in this study, there is evidence that vitamin E may increase the risk for cerebrovascular events (Brown et al., 2001). **Vitamin E is the most frequently recommended oral agent in spite of studies showing no benefit over placebo**

(LaRochelle and Levine, 2007; Shindel et al., 2008)**. The AUA 2015 PD guideline does not recommend its use.**

Tamoxifen

Tamoxifen is a selective estrogen receptor modulator that has both agonist and antagonist effects on target tissues depending on tissue-specific estrogen receptor expression. It has also been demonstrated that tamoxifen can induce the production of TGF-β in an estrogen receptor–independent fashion (Colletta et al., 1990). The use of tamoxifen for the treatment of PD is truly fascinating and underscores how complex the role of TGF-β is in the development of PD. TGF-β released by platelets and activated macrophages plays a central role in the inflammatory response and wound healing. In normal healing, it promotes matrix synthesis by fibroblasts and is self-regulated in an autocrine fashion. However, higher concentrations of TGF-β in the cellular environment inhibit the inflammatory response, causing macrophage deactivation and T-lymphocyte suppression, thus preventing further fibrogenesis (Wahl et al., 1989). This was the initial reasoning for Ralph et al. (1992) to report in a nonrandomized study on the initial use of tamoxifen for the treatment of PD (Ralph et al., 1992).

The initial beneficial effects previously reported were not confirmed in a randomized placebo-controlled trial of 25 patients with PD (Teloken et al., 1999). **The study demonstrated no significant improvement with respect to pain, penile deformity, or plaque size when compared with placebo** (Teloken et al., 1999)**. The AUA 2015 PD guideline does not recommend its use**.

Colchicine

Colchicine has been demonstrated to have several different potential mechanisms of action in the treatment of PD. **By binding to tubulin and causing it to depolymerize, colchicine inhibits cell mitosis, mobility, and adhesion of leukocytes; inhibits transcellular movement of collagen; and stimulates the production of collagenase** (Ehrlich and Bornstein, 1972; El-Sakka et al., 1999; Taylor, 1965).

In a randomized double-blind placebo-controlled study to determine the effectiveness and safety of colchicine, 84 PD patients with noncalcified plaque were randomized to colchicine or placebo. Objective measurements did not demonstrate any difference in plaque size or penile curvature. **There were no substantial differences in response to treatment based on duration of disease**

or within the three Kelami classification groups (Kelami, 1983)**. Significant drug-related adverse effects in the colchicine group included gastrointestinal upset with diarrhea** (Safarinejad, 2004)**. The AUA 2015 PD guideline does not recommend its use.**

Carnitine

Carnitine is a trimethylamine molecule that plays a unique role in cell energy metabolism (Reda et al., 2003). **L-Carnitine is hypothesized to act by increasing mitochondrial respiration and decreasing free radical formation** (Bremer, 1983).

In the same double-blind placebo-controlled study mentioned previously, Safarinejad et al. compared the effects of L-carnitine with placebo (Safarinejad et al., 2007). Fifty-nine PD patients were randomized to receive propionyl-L-carnitine, and 59 were randomized to placebo during the 6-month treatment period. **This study again did not show significant improvement in pain, curvature, or plaque size in patients with PD treated with propionyl-L-carnitine as compared with those treated with placebo. The AUA 2015 PD guideline does not recommend its use.**

Pentoxifylline

Pentoxifylline has been shown to block the TGF-β1–mediated pathway of inflammation and to prevent deposition of collagen type I and is a nonspecific phosphodiesterase inhibitor with combined anti-inflammatory and antifibrogenic properties. In an animal model of PD, pentoxifylline reduced the expression of collagen I, α-smooth muscle actin (ASMA), and plaque size by 95% (Valente et al., 2003). Pentoxifylline inhibits tunica albuginea–derived fibroblast proliferation in vitro and attenuates TGF-β–mediated elastogenesis and collagen type I deposition (Shindel et al., 2010). Elastogenesis is inhibited not by decreasing the amount of elastin produced but by inhibiting its deposition through an α_1-antitrypsin–related mechanism (Lin et al., 2010). **Pentoxifylline has also been shown to downregulate TGF-β and increases fibrinolytic activity** (Raetsch et al., 2002; Schandené et al., 1992). Pentoxifylline has been used successfully for the treatment of experimental autoimmune diseases, the presence of which has been suggested as a cause of PD (Ralph et al., 1996). **Pentoxifylline downregulates the release and the production of the profibrotic cytokine tumor necrosis factor (TNF),**

suppresses the production of platelet-activating factor, and inhibits its action on neutrophils (Safarinejad et al., 2010).

In a randomized double-blind placebo-controlled study, 114 PD patients were randomized to receive pentoxifylline and 114 were randomized to placebo for 6 months. Of patients in the pentoxifylline group, 12 (11%) had disease progression versus 46 (42%) in the placebo group. **Improvement in penile curvature and plaque volume was significantly greater in patients treated with pentoxifylline than with placebo**. **The increase in International Index of Erectile Function (IIEF) total score was significantly higher in the pentoxifylline group.** One patient discontinued the medication because of adverse effects. There were no adverse effects in any of the vital signs or in the laboratory data. Pentoxifylline is a peripheral vasodilator and could induce hypotension; consequently, blood pressure should be monitored during treatment with this drug. The most common side effects include nausea, vomiting, dyspepsia, malaise, flushing, dizziness, and headache (Safarinejad et al., 2010). The AUA PD Guidelines Panel judged that some uncertainty remains regarding the efficacy of pentoxifylline given the limited evidence base; replication in a randomized design is needed before pentoxifylline can be recommended as a PD treatment.

Phosphodiesterase Type 5 Inhibitors

PDE5 inhibitors have been shown to be safe and effective in treating ED in patients with PD (Levine and Latchamsetty, 2002). Recently tadalafil was shown to significantly improve IIEF and quality-of-life (QoL) scores when used in conjunction with penile extracorporeal shock wave therapy (ESWT) as compared with ESWT alone (Palmieri et al., 2012). **There was no advantage with respect to deformity.** (Please note that as per the 2015 AUA PD guideline, clinicians should not use ESWT for the reduction of penile curvature or plaque size).

PDE5 inhibitors have also been suggested as treatment for PD. **By increasing the levels of cGMP, PDE5 inhibitors can inhibit collagen synthesis and induce fibroblast and myofibroblast apoptosis, thus acting as antifibrotic agents by inhibiting scar development** (Gonzalez-Cadavid and Rajfer, 2010; Valente et al., 2003).

In a study by Chung et al., (2011b), **35 men with an isolated septal scar received tadalafil 2.5 mg daily over a 6-month period, after which 24 patients (69%) had resolution of the septal scar. The authors concluded that**

low-dose daily tadalafil is a safe and effective treatment option in septal scar remodeling (Chung et al., 2011a). Although oral PDE5 inhibitors are recommended for the treatment of male erectile dysfunction, they are not recommended for the treatment of Peyronie's disease (Nehra et al., 2015).

Intralesional Injection

Verapamil

Calcium channel blockers were originally found to inhibit the incorporation of proline into ECM protein, thus leading to the conclusions that cellular calcium metabolism appears to regulate ECM production and that hypertrophic disorders of wound healing may respond to therapy with calcium channel antagonist drugs (Lee and Ping, 1990).

Verapamil is a calcium channel blocker that has been shown to significantly affect fibroblast function on several levels, including cell proliferation, ECM protein synthesis and secretion, and collagen degradation. In vitro Peyronie's plaque fibroblast proliferation is inhibited by 65% with verapamil at a concentration of 100 to 1000 mg/mL (Anderson et al., 2000). These changes may allow intralesional verapamil to retard, prevent, or possibly reverse plaque formation and progression of PD (Levine and Estrada, 2002). Recently a study demonstrated the mechanism of action of intralesional verapamil injection versus normal saline in a rat model. After verapamil injection, there were histologic changes and reduced plaque size and penile curvature. Verapamil injection also resulted in decreased collagen and elastin fibers, and reduced ASMA, an indicator of myofibroblast activity (Chung et al., 2013b).

Currently, intralesional verapamil is a popular treatment option for the conservative management of PD despite the fact that some studies have not shown as favorable a response (Shindel et al., 2008).

The first reported use of verapamil for the treatment of PD was by Levine et al. and was the first new intralesional treatment since steroid injection was introduced in 1957 (Furey, 1957; Levine et al., 1994). This was a nonrandomized dose-escalating study in 14 men who received biweekly injections of verapamil for 6 months. Subjectively, there was significant improvement in plaque-associated penile narrowing (100%) and curvature (42%). Objectively, a decreased plaque volume of more than 50% was noted in 30% of the subjects. Plaque softening was noted in all patients, and 83% noticed that plaque-related changes in erectile function had arrested or improved. There was no toxicity, nor did symptoms recur when improvement was noted. This preliminary study suggested that intralesional verapamil may be an economical and sensible nonoperative approach to the treatment of PD warranting further study (Levine et al., 1994). In a larger noncontrolled study, verapamil injection resulted in a reduction of pain in 97% of the patients, an improvement in sexual function in 72%, a subjective reduction of deformity in 86%, an improvement in distal rigidity in 93%, and an objective reduction of curvature in 54% (mean curve reduction of 25 degrees) (Levine, 1997).

Rehman et al. (1998) performed a single-blind study on 14 PD patients who were randomly assigned to injection with verapamil or saline. This study demonstrated a significant improvement in plaque size, plaque-associated penile narrowing, and quality of erection in the verapamil-treated men versus the control group. There was no significant difference with respect to penile curvature. There was no local or systemic toxicity except for an occasional ecchymosis or bruise at the injection site (Rehman et al., 1998). Bennett et al. showed in a shorter 3-month trial of 94 patients improvement in curvature in 18%, no change in 60%, and worsening in 22% and concluded that intralesional verapamil can, at a minimum, stabilize penile deformity (Bennett et al., 2007).

In a recent randomized single-blind placebo-controlled trial, Shirazi et al. (2009) randomized 80 patients to receive intralesional verapamil and 40 patients to receive a local saline injection. This study demonstrated no significant difference with respect to plaque size, pain, curvature, plaque softening, or improvement in sexual dysfunction in the active drug and control groups. This study concluded that although some trials have demonstrated intralesional verapamil to be an effective treatment for PD, further larger-scale studies are warranted given these negative findings to assess the effectiveness of intralesional verapamil for the treatment of PD (Shirazi et al., 2009). Drug concentration has also been evaluated, and although 10 mg/10 mL is the most commonly used dose and volume, Cavallini et al. (2007) showed a greater response to injection when 10 mg of verapamil was diluted with 20 mL of injectable saline (Cavallini et al., 2007). These studies highlight the potential for inconsistent results for men with PD, which may vary because of patient selection, presence of calcification, plaque location, drug administration technique, and sample size. Poor candidates for this treatment include those with extensive calcification, curvature of greater than 90 degrees, or ventral curvature, in which it is difficult to adequately infiltrate the plaque (Levine et al., 2002). Predictors of success with intralesional verapamil include younger age (younger than 40 years of age) and curvature greater than 30 degrees (Moskovic et al., 2011). Currently, the AUA PD guideline states that a physician may offer intralesional verapamil for the treatment of patients with Peyronie's disease but should counsel the patients on potential injection site side effects.

Nicardipine

Nicardipine is a dihydropyridine (DHP) type of calcium channel blocker. An in vitro study has suggested that it is more effective than a non-DHP type, verapamil, in reducing glycosaminoglycan biosynthesis and ECM production (Gürdal et al., 1992). Soh et al. (2010) performed the only study on the effectiveness of nicardipine for the treatment of PD. A total of 74 patients were assigned randomly to nicardipine versus saline. Nicardipine demonstrated a significant reduction of pain, improvement in IIEF-5 score, and reduction of plaque size when compared with placebo. Penile curvature was significantly improved in both the active drug and placebo groups without significant difference. There were no severe side effects, such as hypotension or other cardiovascular events (Soh et al., 2010). Nicardipine currently has no recommendations in the AUA 2015 PD guideline.

Interferon Alfa-2b

IFN alfa-2b was first investigated as a treatment for PD in 1991 in the in vitro studies by Duncan et al. (1991). In fibroblasts derived from Peyronie's plaques, the addition of IFN alfa-2b **decreased their rate of proliferation in a dose-dependent fashion, decreased the production of extracellular collagen, and increased the production of collagenase** (Duncan et al., 1991).

In a single-blind, multicenter, placebo-controlled, parallel study to assess the safety and efficacy of intralesional IFN alfa-2b, Hellstrom et al. (2006) randomized a total of 117 consecutive PD patients to IFN alfa-2b or saline. Improvement in penile curvature, plaque size and density, and pain resolution was significantly greater in patients treated with IFN alfa-2b versus placebo. **The treatment group demonstrated a mean decrease in curvature of 27% or 13.5 degrees versus 9% or 4.5 degrees in the placebo group**. **Although these results were statistically significant, the question arises whether the small difference between the IFN and saline is clinically significant when taking into account the significant cost of the drug and its side-effect profile, which frequently includes flulike symptoms (fever, chills, and arthralgia) and**

minor penile swelling with ecchymosis. All of these symptoms were effectively treated with over-the-counter NSAIDs ingested before the injection procedure, and none lasted longer than 36 hours (Hellstrom et al., 2006). **This study was important because it was the first multicenter randomized placebo-controlled trial of intralesional injection for PD. It also was important because it showed that saline injection had little to no effect on penile deformity.**

Per the AUA 2015 PD guidelines, clinicians may administer intralesional interferon α-2b in patients with PD. However, patients should be counseled on the potential adverse events, including sinusitis, flulike symptoms, and minor penile swelling.

Collagenase Clostridium Histolyticum

The first US Food and Drug Administration (FDA)–approved drug for the treatment of PD, collagenase *Clostridium histolyticum* (CCH), is produced by the bacterium *C. histolyticum* and selectively degrades collagen types I and III in connective tissues despite the presence of TIMPs, which have been shown to be elevated in PD and to increase apoptosis of fibroblasts (Del Carlo et al., 2008; Matsushita et al., 2001; Morales et al., 1983; Syed et al., 2012). The recent flurry of investigation on this drug has come many years after the first time it was examined as a treatment for PD by Gelbard et al. (1982), who demonstrated that CCH significantly reduced the size of PD plaques, whereas elastic fibers, vascular smooth muscle, and axonal sheaths were not affected (Gelbard et al., 1982).

In the first prospective, randomized, double-blind, placebo-controlled study of CCH, 49 men with PD were treated with CCH, resulting in significant improvements in plaque size and penile deformity (Gelbard et al., 1993). All patients with a penile bend of 30 degrees or less and/or palpable plaque less than 2 cm responded ($N = 3$); 36% of patients with a penile bend of 30 to 60 degrees and/or 2 to 4 cm of palpable plaque responded; and 13% of patients with a penile bend of greater than 60 degrees and/or greater than 4 cm of palpable plaque responded. CCH was well tolerated, with no allergic reactions and no significant changes in laboratory parameters (Gelbard et al., 1993). Further investigation was encouraged but took years because of absence of industry support.

In a phase II trial, 25 patients with PD received three intralesional injections of 10,000 units of CCH over 7 to 10 days, with a repeat of

treatment at 3 months to assess change from baseline in penile deviation angle and plaque size (Jordan, 2008). A decrease in deviation angle of at least 25% was achieved in 58% of patients, and 95% of patients experienced a reduction in plaque size (Jordan, 2008). More than 50% of patients in this series were considered “very much improved” or “much improved” at all time points in the study; approximately one-third were considered to show minimal improvement or no change, resulting in an investigator's assessment of “worse.”

Patients receiving CCH and modeling had a significant change in curvature of penis and decrease in the PD symptom effect score compared to placebo and to CCH without modeling (Gelbard et al., 2012)**. Patients receiving CCH and modeling had a significant change in curvature of the penis and decrease in the PD symptom effect score compared with placebo** (Gelbard et al., 2012).

The phase III IMPRESS (Investigation for Maximal Peyronie's Reduction Efficacy and Safety Studies) I and II trials examined the clinical efficacy and safety of CCH intralesional injections in subjects with PD (Gelbard et al., 2013). A total of 417 and 415 subjects, respectively, went through a maximum of four treatment cycles, each separated by 6 weeks. Men received up to eight injections of 0.58 mg CCH, two injections per cycle separated by approximately 24 to 72 hours with the second injection of each followed 24 to 72 hours later by penile plaque modeling. Men were stratified by baseline penile curvature (30 to 60 degrees versus 61 to 90 degrees) and randomized to CCH or placebo 2 : 1 in favor of active drug. Post hoc meta-analysis of IMPRESS I and II data revealed that **men treated with CCH showed a mean 34% improvement in penile curvature, representing a mean change of −17.0 degrees ± 14.8 degrees per subject, compared with a mean 18.2% improvement in placebo-treated men, representing a mean change of −9.3 ± 13.6 degrees per subject ($P < .0001$).** The mean change in PD symptom effect score was significantly improved in treated men versus men on placebo (−2.8 ± 3.8 vs. −1.8 ± 3.5, $P = .0037$). **Patients with extensive calcification, ventral plaques, and disease duration less than 12 months were excluded.** Although serum antibodies to CCH developed in virtually all patients studied, no adverse events were noted as a result. The primary and frequently noted side effect was varying degree of ecchymosis and local penile bruising. Serious adverse events included corporeal rupture in three patients and penile hematoma in three patients. All three corporeal ruptures and one of the three penile hematomas were successfully repaired surgically; another hematoma was successfully drained percutaneously (Gelbard et al., 2013).

The most serious complication of CCH is penile fracture. It is believed that injection weakens the corporal albuginea surrounding the plaque, making it more vulnerable to breaking. The rate of corporal fracture ranges from 0% to 4.9% (Beilan et al., 2018, Jordan 2008, Gelbard et al., 2013, Nguyen et al., 2017). **A pooled analysis of six clinical trials (including the IMPRESS trials) demonstrated that although 85% of patients experienced at least one side effect, most were minor. Only 9 of 1044 patients (0.9%) had a serious side effect, and 4 of 1044 (0.4%) had a penile fracture** (Carson et al., 2015).

There is no consensus treatment protocol for CCH injections. **The current standard of care based on the IMPRESS trials is up to four total treatment sessions consisting of two injections of 0.58 mg of CCH each session (total of 8 injections). However, CCH is expensive, and it is unknown if eight injections are required to achieve an optimal outcome.** There have been several attempts to modify this protocol to achieve maximal benefit while limiting unnecessary treatment. Anaissie et al. (2017) demonstrated that penile curvature improved significantly following the first three cycles but not the fourth cycle. Yang et al. (2016) only administered six 0.58-mg injections over three cycles with an average curvature reduction of 15.4 degrees (32.4%, $P < 0.1$), which is similar to the IMPRESS trials. Raheem et al. (2017) used a modified CCH protocol to three total treatment sessions of 0.9 mg per treatment over the course of 12 weeks. The mean penile curvature decreased an average of 17 degrees or 31% from baseline of 54 degrees, which is similar to the results of the IMPRESS trials. Although CCH is currently FDA-approved for stable disease, Nguyen et al. (2017) demonstrated in a group of 36 acute-phase patients and 126 stable-phase patients that the mean curvature improvement was comparable: 16.7 degrees for acute-phase patients and 15.6 degrees for chronic-phase patients ($P = 0.654$). More studies are indicated to justify use of CCH in acute-phase PD.

Further experience will help make CCH injections more cost-effective and predict which patients will benefit the most. This may depend on direction of curve, size of plaque, prevalence of calcification, and duration of disease, among other factors to be determined. A recent presentation did demonstrate that surgical correction with plication or grafting could be successfully performed after CCH injection without added technical difficulty (Larsen and Levine, 2012). CCH received FDA approval for the treatment of PD in December 2013.

The 2015 AUA PD guideline recommends that physicians may administer CCH in patients with a stable curvature greater than 30 degrees and less than 90 degrees with intact erectile dysfunction (with or without use of medications).

As always, the risk and potential side effects of this treatment should be discussed with the patient before initiating treatment.

Topical Drug Application

Several studies have evaluated the effectiveness of topically applied agents for the treatment of PD. Topical application avoids the pain and trauma of intralesional injection therapy. The first study of topical application of a drug, β-aminopropionitrile, showed no benefit with respect to deformity change (Gelbard et al., 1983).

Topically applied liposomal recombinant human superoxide dismutase (lrhSOD) has also been studied in a randomized placebo-controlled trial (Riedl et al., 2005). This substance is proposed to act as an oxygen free radical scavenger, which might interrupt inflammatory cascades and thereby limit further disease progression. Penile curvature was improved by 5 to 30 degrees in 23% of patients, and pain was significantly reduced as well ($P = .017$) compared with placebo after 4 weeks. The authors concluded that lrhSOD is an easily given, safe, and effective local therapeutic for the painful phase of PD (Riedl et al., 2005). A recent randomized controlled trial showed that the H-100 gel, which contains Nicardipine, SOD, and emu oil, applied daily for 6 months resulted significant decrease in mean curvature (40%, $P = 0.0014$) and increase in mean stretched penile length (22.6%, $P = 0.0002$) (Twidwell and Levine, 2016). However, this study was a pilot study with 22 patients, and larger studies are needed to confirm the efficacy of these topical agents before general use.

Fitch et al. (2007) reported on the use of topical verapamil for the treatment of PD (Fitch et al., 2007). Two simultaneous three-armed, double-blind, placebo-controlled studies were conducted in this pilot study. In this study, topical verapamil improved curvature in 14 of 18 patients (77.8%), with a mean curvature improvement of 43.6%. This study also boasted reduction in plaque size in 100% of participants and improvement in erectile function in 72.7%. This study was originally aimed at comparing verapamil to topical trifluoperazine, **but because of the severity of side effects (anxiety, agitation, blurred vision, insomnia, and depression), topical trifluoperazine was discontinued before**

completion of randomization. The results of this study have been called into question given the small sample size, lack of a true placebo, and absence of objective measures (Levine, 2007). In addition, simple topical administration of verapamil has been shown to be ineffective in achieving tissue levels within the tunica albuginea sufficient for therapeutic effect (Martin et al., 2002). Favilla et al. (2017), in a prospective double-blind randomized study comparing verapamil and hyaluronic acid in the acute setting showed that although both treatments decreased plaque size, neither resulted in a significant decrease in penile curvature.

At this time, no topically applied agent has been established to be effective in the treatment of PD. The AUA 2015 PD Guidelines Panel identified topical therapy for PD as possibly promising but for which insufficient evidence currently exists to support even a conditional recommendation for its use.

Electromotive Drug Administration

Transdermal drug delivery was proposed to be superior to oral or injection therapy because it bypasses hepatic metabolism and minimizes the pain of injection. Unlike topical verapamil gel, electromotive drug administration (EMDA) with verapamil has been found to deliver detectable levels of the drug to the tunica albuginea (Martin et al., 2002; Levine et al., 2003).

A double-blind, placebo-controlled trial to determine the effectiveness of verapamil delivered through EMDA randomized a total of 42 PD patients to verapamil versus saline. Treatments were performed twice weekly for 3 months**. Both verapamil and saline groups demonstrated essentially equivalent reduction of curvature. The study concluded that further research is necessary to determine whether electric current alone may have a role in the treatment of PD** (Greenfield et al., 2007). Overall, EMDA was well tolerated in each group, and it was noted by all patients to be easy and convenient to perform at home. The only adverse event reported by patients was temporary mild erythema at the treatment site (Greenfield et al., 2007).

In another prospective placebo-controlled study with transdermal EMDA, Di Stasi et al. (2004) randomized patients to receive verapamil and dexamethasone versus placebo. Those receiving active drug demonstrated significant decreases in plaque volume and penile curvature from 43 degrees to 21 degrees, which was significant when compared with placebo. Significant pain relief occurred in both groups, transient in the control group and permanent in the study group. All patients experienced temporary erythema at the electrode site. There were no other side effects (Di Stasi et al., 2004). **Although this approach has limited evidence of benefit, it has not been adopted in most centers. The 2015 AUA PD guideline recommends that clinicians should not offer electromotive therapy with verapamil.**

Extracorporeal Shock Wave Therapy

The mechanism of action involved in ESWT for PD is unclear. However, there are two purported hypotheses: (1) Shock waves cause direct damage to the penile plaque, and (2) ESWT increases the vascularity of the targeted area by generating heat, which leads to the induction of an inflammatory reaction, resulting in lysis of the plaque and removal by macrophages (Gholami et al., 2003).

In the first prospective randomized double-blind placebo-controlled clinical trial evaluating ESWT for the treatment of PD, 100 treatment-naïve PD patients with disease duration less than 12 months were randomly allocated to either ESWT (n = 50) or placebo (n = 50). For the placebo group, a nonfunctioning transducer was employed. Patients randomized to ESWT demonstrated improvements in pain, IIEF-5 score, and mean QoL score. **Plaque size and penile curvature were not significantly different in the treatment and placebo groups.** After 24 weeks, the mean IIEF-5 score and mean QoL score were stable in the ESWT group, whereas the mean visual analog scale (VAS) score was significantly lower when compared with baseline in both groups. It is interesting to note that after 24 weeks, mean plaque size and mean curvature degree were significantly worse in the placebo group when compared with both baseline and ESWT values. **This difference was less than 3 degrees, which, although statistically significant, is of no clinical significance** (Palmieri et al., 2012).

Recently, a second placebo-controlled, prospective randomized single-blind study was performed in which 102 PD patients were randomly assigned (n = 51) to ESWT or placebo (Hatzichristodoulou et al., 2013b). Pain decreased in 17 of 20 (85%) patients in the ESWT group and in 12 of 25 (48%) patients in the placebo group. Penile deviation was not reduced by ESWT and worsened in 40% and 24.5% of patients in the ESWT and placebo groups, respectively (P = .133). Change in sexual function and plaque size reduction was not different between the two groups. In addition, plaque size increased in five patients (10.9%) receiving ESWT only. **The authors concluded that despite some potential benefit of ESWT with regard to pain reduction, it should be emphasized that pain usually resolves spontaneously with time. Given this and the fact that deviation may worsen with ESWT, the treatment cannot be recommended.**

The 2015 AUA PD guideline states that clinicians should not use ESWT for the reduction of penile curvature or plaque size. Clinicians may offer ESWT to improve penile pain.

Penile Traction

Controlled stretching of the penis, or "penile traction," by a device that holds the penis in a cradle and subjects it to tension is indicated for treatment of PD patients as a noninvasive, nonsurgical first-option treatment modality.

Traction has been shown in nonpenile tissue models to induce cellular proliferation by several pathways (Ilizarov, 1989; Sun et al., 1996; Molea et al., 1999; Assoian and Klein, 2008; Bueno and Shah, 2008). It can also trigger scar remodeling; it has been shown that tension applied to tissues leads to a reorientation of collagen fibrils parallel to the axis of stress (Molea et al., 1999; Shapiro, 2008). These changes are the result of a process referred to as *mechanotransduction* whereby mechanical stimuli are converted into chemical responses within the cell (Alenghat and Ingber, 2002). Several signaling cascades are activated by tension on the cytoskeleton, which leads to a proliferative response and activation of various genes (Assoian and Klein, 2008). **An in vitro study to determine the cellular effects of traction on PD cells demonstrated a significant decrease in ASMA in the strained compared with nonstrained PD cell cultures, whereas an increase in MMPs involved in collagen degradation was observed.** In contrast, cytokines and proteins involved in fibroblast replication and inflammation such as ASMA, heat shock protein 47 (HSP47), and TGF-β1 receptor were not upregulated (Chung et al., 2013a). Several studies have been performed examining the clinical effects of traction for the treatment of PD, although none have been controlled trials.

Levine et al. (2008) first demonstrated the use of penile traction for the treatment of PD in a pilot study of 10 men. In nearly all subjects (90%), prior medical therapy had failed. Traction was applied as the only treatment for 2 to 8 hours per day for 6 months. All subjects underwent pretreatment and post-treatment physical examination including measurement of stretched flaccid penile length and biothesiometry. Subjectively, all men noted reduced curvature estimated at 10 to 40 degrees, increased penile length (1 to 2.5 cm), and enhanced girth in areas of indentation or narrowing. **Objective measures demonstrated reduced curvature in all 10 men of up to 45 degrees; average reduction for the group was 33%, from 51 degrees to 34 degrees. SPL increased 0.5 to 2.0 cm, and erect girth increased 0.5 to 1.0 cm with correction of hinge effect in four of four men.** It is important to note that results were maintained at 6 months after completion of therapy. The IIEF erectile function domain score increased from 18.3 to 23.6 for the group. There were no adverse events including skin changes, ulcerations, hypoesthesia, or diminished rigidity (Levine et al., 2008).

Gontero et al. (2009) performed a phase II prospective study on 15 PD patients with a curvature not exceeding 50 degrees with mild or no ED. Penile curvature decreased from an average of 31 degrees to 27 degrees at 6 months, which was not statistically significant. Mean stretched and flaccid penile length increased by 1.3 and 0.83 cm, respectively, at 6 months. Results were maintained at 12 months. Overall treatment results were subjectively scored as acceptable in spite of limited curvature improvements, which varied from “no change” to “mild improvement.” **The investigators concluded that the use of a penile extender device provided only minimal improvements in penile curvature but a reasonable level of patient satisfaction, probably attributable to increased penile length. The selection of patients with stabilized disease, many with calcified plaques, and penile curvature not exceeding 50 degrees may have led to outcomes underestimating the potential efficacy of the treatment** (Gontero et al., 2009).

Recently a prospective nonrandomized study was conducted administering traction to PD patients in the acute phase, defined as progressive penile curvature exceeding 15 degrees and/or pain at rest or at erection in the last 12 months (Martínez-Salamanca et al., 2014). A total of 55 patients underwent traction for 6 months and were compared with 41 patients also in the acute phase who did not. Patients were advised to use the device at least 6 hours per day and no more than 9 hours, preventing its use during sleep. Mean duration of use was 4.6 hours per day (3.1 to 9.2 hours). Also, patients were taught to remove the device for at least 30 minutes every 2 hours to prevent glans ischemia. **The mean curvature decreased from 33 degrees at baseline to 15 degrees at 6**

months and 13 degrees at 9 months with a mean decrease of 20 degrees in the traction group. VAS score for **pain decreased from 5.5 to 2.5 after 6 months** (*P* < .05). The percentage of patients who were not able to achieve penetration decreased from 62% to 20% (*P* < .03). Without this intervention, deformity increased significantly, stretched flaccid penile length decreased, VAS score for pain increased, and erection hardness worsened. **Furthermore, the need for surgery was reduced in 40% of patients who would otherwise have been candidates for surgery and simplified the complexity of the surgical procedure (from grafting to plication) in one of three patients.** Treatment-related adverse events included two cases of erythema in the balanopreputial sulcus, which resolved with stopping traction for 24 to 48 hours. Fourteen patients (25.5%) reported some degree of discomfort. Worsening of erectile function over the treatment period was not observed, **and the overall satisfaction rate was 85%** (range 60% to 90%) at 9 months. No case of sensory change after traction was reported (Martínez-Salamanca et al., 2014). **Traction therapy has the potential to be an effective nonsurgical treatment to recover lost length, reduce curvature, and enhance girth.** It is critical that the patient wear the device for 3 or more hours per day to get satisfactory results. There is no recommendation offered by the AUA 2015 PD Guidelines Panel regarding penile traction therapy.

Vacuum Therapy

Application of a penile vacuum device to mechanically straighten the penis has been evaluated in one published noncontrolled study in which subjects wore the vacuum device for 10 minutes twice per day for 12 weeks. This study demonstrated a reduction in the angle of curvature by 5 degrees to 25 degrees in 21 of 31 patients. Three patients' curvature worsened, and in seven the curvature remained unchanged. Fifty-one percent were satisfied with this outcome; the other 49% went on to surgical correction (Raheem et al., 2010). **Although vacuum erection devices are usually considered safe, it would seem that the short-term duration of stretching forces on the penis would not induce the desired physical changes known to occur with mechanotransduction with prolonged stretch therapy.** Several complications such as the development of PD, urethral bleeding, skin necrosis, and penile ecchymosis have been reported with concomitant use of constriction rings and when inappropriately elevated pressures are applied to the penis for an extended period (Kim and Carson, 1993;

Ganem et al., 1998).

There is no recommendation offered by the AUA 2015 PD Guidelines Panel regarding vacuum therapy as monotherapy.

Combination Therapy

One study investigated whether a combination of the mechanical effects of penile traction with the chemical effects of intralesional verapamil and oral medications (pentoxifylline and L-arginine) could have a synergistic effect on the tunica albuginea and Peyronie's plaque (Abern et al., 2012). All patients were given oral pentoxifylline and L-arginine, with 39 electing to undergo traction and 35 choosing not to use traction. Both treatment groups had a statistically significant reduction in erect penile curvature. The traction group had a reduction from a mean of 44.4 degrees (standard deviation [SD] 27.5 degrees) at baseline to a mean of 33.4 degrees (SD 25.3 degrees) after the 24-week protocol ($P = .03$). Patients not using traction had a reduction from a mean of 36.6 degrees at baseline (SD 18.5 degrees) to a mean of 21.5 degrees (SD 19.3 degrees) after treatment ($P < .01$). There were no statistically significant differences in curvature outcomes between the two groups. In patients using traction, SPL increased overall by a mean 0.3 cm (SD 0.9 cm) after treatment, which trended toward statistical significance ($P = .06$), whereas the men not using traction lost an average of 0.7 cm (SD 1.1 cm) of length, which was not statistically different ($P = .46$) (Abern et al., 2012). Unfortunately, this study did not control for duration of traction therapy, and some men included in the traction group applied the device for only 1 to 2 hours per week, whereas others wore it for over 50 hours per week. An analysis of traction duration and deformity change demonstrated that wearing the device on average 3 or more hours per day allowed reliable measured deformity improvement, which occurred in a dose-response fashion.

Another combination study examined the effects of combining verapamil injection and verapamil iontophoresis with or without the use of a combination pill that contained vitamin E, potassium para-aminobenzoate, propolis (as galangin), blueberry anthocyanins, soy isoflavones, *Muira puama*, damiana, and *Persea americana*. Intergroup analysis revealed greater plaque size reduction (−30.8% vs. −18.0%) and greater percentage with reduction of curvature (85% vs. 53.5%) with use of the combination pill (Paulis et al., 2013). There is no recommendation offered by the AUA 2015 PD Guidelines Panel regarding combination therapy.

Radiation Therapy

Radiation therapy has been proposed as a treatment for PD since 1964 (Duggan, 1964). **In vitro studies suggest that low-dose radiation therapy has a potent anti-inflammatory effect, inhibiting leukocyte-endothelium interactions** (Arenas et al., 2012). In recent years, radiation therapy has been proposed as a treatment for pain that was thought to be “abnormally persistent.” In 1975, a retrospective study examined the use of radiation therapy and found it to be no more effective than no treatment (Incrocci et al., 2000). It is the consensus of multiple experts in the field that radiation should be avoided because of potential risk for malignant change and increase in the risk for ED in aging patients (Hatzimouratidis et al., 2012; Mulhall et al., 2012; Ralph et al., 2010). The 2015 AUA PD guideline recommends that clinicians should not use radiotherapy (RT) to treat Peyronie's disease because of the known risks and uncertain benefits.

Conclusion

It appears that the goal of nonsurgical treatment at a minimum should be to prevent progression of deformity during the acute phase. Reducing deformity to improve sexual function and reduce the effects of the scarring is the ultimate goal of all treatment for PD (Tables 73.1 to 73.3).

TABLE 73.1

Oral Agents for Peyronie's Disease

TREATMENT	MECHANISM OF ACTION	STUDY OUTCOMES	ADVERSE EFFECTS
Potaba	Decreases serotonin levels by increasing monoamine oxidase activity, resulting in enhancement of the antifibrotic properties of tissues	Decreased plaque size, no decrease in curvature	Anorexia, nausea, fever, skin rash, hypoglycemia, acute hepatitis
Vitamin E	Antioxidant, limits oxidative stress of reactive oxygen species shown to be increased in PD	No benefit	Possible cerebrovascular events, nausea, vomiting, diarrhea,

			headache, dizziness
Tamoxifen	Induces the production of TGF-β in an estrogen receptor–independent fashion, theoretically causing macrophage deactivation and T-lymphocyte suppression, thus preventing further fibrogenesis	No benefit	Alopecia, retinopathy, thromboembolism, pancytopenia
Colchicine	Microtubule depolymerization; inhibits cell mitosis, mobility, adhesion of leukocytes, and transcellular movement of collagen and stimulates the production of collagenase	No benefit	Myelosuppression, diarrhea, nausea, vomiting
Carnitine	Increases mitochondrial respiration; decreases free radical formation	No benefit	Seizures, diarrhea, nausea, abdominal cramps, vomiting
Pentoxifylline	Blocks the TGF-β1–mediated pathway of inflammation; prevents deposition of collagen type I; is a nonspecific phosphodiesterase inhibitor; decreases platelet-activating factor	Decreased curvature in 33% of patients, mean 23 degrees	Nausea, vomiting, dyspepsia, malaise, flushing, dizziness, and headache

TGF, Transforming growth factor.

TABLE 73.2

Intralesional Agents for Peyronie's Disease

Treatment	MECHANISM OF ACTION	STUDY OUTCOMES	ADVERSE EFFECTS
Verapamil	Calcium channel blocker inhibits fibroblast proliferation, extracellular matrix protein synthesis and secretion; increases collagenase activity.	Reduction of curvature and plaque-associated penile narrowing, improvement in quality of erection	Nausea, lightheadedness, penile pain, ecchymoses
Nicardipine	DHP type of calcium channel blocker. In vitro study demonstrated that it is more effective than a non-DHP	Reduction of pain, improvement in IIEF-5 score, and reduction of plaque size; no benefit in	No severe side effects such as hypotension or other

	type, verapamil, in reducing glycosaminoglycan biosynthesis and production of extracellular matrix, such as collagen.	curvature	cardiovascular events
Interferon alfa-2b	Decreases plaque fibroblast proliferation in a dose-dependent fashion, decreases production of extracellular collagen, and increases production of collagenase.	Decrease in curvature of 27% (13.5 degrees) vs. 9% (4.5 degrees) in the placebo group	Sinusitis, flulike symptoms (fever, chills, and arthralgia), and minor penile swelling with ecchymosis
Clostridial collagenase	Selectively degrades collagen types I and III in connective tissues despite the presence of TIMPs, which have been shown to be elevated in PD and to increase apoptosis of fibroblasts.	Decrease in penile curvature by 34%, mean decrease of 17 degrees vs. 18%, mean decrease 9.3 degrees in placebo; PD symptom bothersomeness score significantly improved vs. placebo	Contusions, ecchymoses, corporeal rupture

DHP, Dihydropyridine; *IIEF,* International Index of Erectile Function; *PD,* Peyronie's disease; *TIMPs,* tissue inhibitors of metalloproteinases.

TABLE 73.3

External Force Application for Peyronie's Disease

TREATMENT	MECHANISM OF ACTION	STUDY OUTCOMES	ADVERSE EFFECTS
Electromotive drug administration	Bypasses hepatic metabolism, increases concentration of drug to target tissues compared with topical application alone	Verapamil alone: no benefit Verapamil + dexamethasone: decreases in plaque volume and penile curvature from 43 to 21 degrees	Temporary erythema at the electrode site
Extracorporeal shock wave therapy	Direct damage to the penile plaque; increases vascularity of the targeted	Improvements in pain, IIEF-5 score, and mean QoL score; no curvature	Local petechiae and ecchymoses

	area inducing an inflammatory reaction, resulting in lysis of the plaque and removal by macrophages	reduction	
Penile traction	Decreases α-smooth muscle actin, increases matrix metalloproteinases involved in collagen degradation	Length increased 0.5–2.0 cm; girth increased 0.5–1.0 cm; curvature mean decrease of 20 degrees; pain decreased; softening or shrinking of plaque; overall satisfaction 85%	Erythema in the balanopreputial sulcus, discomfort
Vacuum therapy	Unknown; mechanical effects similar to traction have been suggested	Reduction in angle of curvature by 5–25 degrees in 21 of 31 patients	Development of PD, urethral bleeding, skin necrosis, and penile ecchymosis
Radiation therapy	Anti-inflammatory effects via functional modulation of the adhesion of white blood cells to activated endothelial cells and modulation of the induction of nitric oxide synthase in activated macrophages	No clinical benefit	Possible malignant change, increased risk for ED in elderly

ED, Erectile dysfunction; *IIEF,* International Index of Erectile Function; *PD,* Peyronie's disease; *QoL,* quality of life.

Key Points: Nonsurgical Treatment of Peyronie's Disease

- Patients who have no pain or difficulty in accomplishing penetrative sex may require only reassurance, because this is not a disorder that will degenerate into cancer and it is not life-threatening.
- A poor understanding of the cause of this wound-healing disorder contributes to the fact that, to date, conservative treatments often yield

inconsistent and clinically insignificant improvements in deformity.

- Currently, no oral agent has been shown in placebo-controlled trials to result in clinically meaningful improvement in curvature. As a result, the only oral medication recommended by the AUA guideline on PD is NSAIDs to reduce pain.
- Topical therapy and ESWT have not been shown to reduce penile deformity.
- Intralesional verapamil and IFN alfa-2b have shown evidence of reduced curvature and improved sexual function. Yet most studies are not controlled trials. These agents at a minimum appear to result in deformity stabilization during the acute phase.
- The first FDA-approved drug for the treatment of PD, CCH (Xiaflex; Endo Pharmaceuticals, Malvern, PA) is produced by the bacterium *C. histolyticum* and selectively degrades collagen types I and III. Mean curvature reduction in the phase III trials in the treatment arm (CCH injection with penile traction) was 34% (17 degrees) versus 18.2% (9.3 degrees) for placebo. The volume of patients seeking treatment for PD may increase over the coming years as public awareness increases with the advent of use of this drug.

Surgical Management

Indications

Surgical reconstruction (▶Video 73.1**) is indicated for men with deformity that precludes satisfactory sexual intercourse or causes pain for themselves or their partner during sexual relations or because of distress as a result of the appearance of the erect penis** (Kadioglu et al., 2006).

Surgery remains the gold standard treatment to most rapidly and reliably correct the deformity associated with PD; for men who also have ED, placement of a penile prosthesis can provide rigidity for penetrative sexual activity. The indications for surgical correction include stable disease, which is defined as disease that is at least 1 year from onset, and at least 6 months of stable deformity. These indications have not been formally studied but appear to be generally accepted by experts in the field (Jordan, 2007; Levine and Burnett, 2013, Nehra et al., 2015; Ralph et al., 2010)**. Other indications include a deformity that compromises or makes impossible the patient's ability to engage in sexual intercourse because of the nature of the deformity and/or inadequate rigidity, and patients in whom conservative therapy has failed (Box 73.4). No single surgical approach is universally defined as the standard of care** (Gur et al., 2011; Kendirci and Hellstrom, 2004) **because there are multiple factors to consider, including severity of curvature, direction of curvature, presence of a hinge effect, erection quality, and patient goals. An algorithm for surgical decision making is presented in Fig. 73.10** (Levine and Larsen, 2013).

Box 73.4

Indications for Surgery

- Stable deformity for at least 6 months from onset of symptoms
- Inability to engage in satisfactory penetrative sexual intercourse because of deformity and/or inadequate rigidity
- Failed conservative treatment
- Desire for most rapid and reliable result

Preoperative consent is critical because patients with PD are distressed and frequently emotionally devastated. It has been reported that men who have undergone treatment for PD are often not satisfied with their results because of their expectation for recovery of their pre-PD penile appearance (Jones, 1997). **It is therefore important to have a frank discussion with the patient so that he understands the limitations of the operation, and to set appropriate expectations regarding outcomes to optimize patient satisfaction** (Ralph et al., 2010)**. The patient should understand that there is a possibility of persistent or recurrent curvature, reduction of penile erect length, diminished rigidity, and decreased sexual sensation (Box 73.5).** Persistent or recurrent curvature is unusual but has been shown in up to 16% of men, the great majority of whom do not require another operation (Ralph et al., 2010; Taylor and Levine, 2007). **The patient should understand that the goal is to make the penis "functionally straight," which expert opinion defines as a residual deformity of 20 degrees or less** (Levine and Burnett, 2013; Ralph et al., 2010). The European Association of Urology (EAU) guidelines committee on PD defines successful curvature correction as 15 degrees or less of residual curvature (Hatzimouratidis et al., 2012). Change (loss) in penile erect length is more likely with plication than with grafting, although all surgical correction procedures have been associated with some length loss. This is extremely important for the patient to understand preoperatively because 70% to 80% of patients initially have loss of length as a result of the fibrotic disease process (Jordan and McCammon, 2007; Pryor and Ralph, 2002; Ralph et al., 2010). Thus, further loss of length can be a major concern. Having stretched flaccid penile length documented preoperatively permits comparison with postoperative length. Diminished rigidity has long been reported after surgery, and studies have demonstrated that up to 50% of men may have some degree of postoperative reduction in rigidity, which may respond to a PDE5 inhibitor. Rigidity will not likely be improved by penile straightening, and therefore in patients who already have significant ED that does not respond to oral medication, placement of a penile prosthesis should be offered (Ralph et al., 2010; Taylor and Levine, 2007). Men who are considering penile straightening procedures without a penile prosthesis should be carefully evaluated for the quality of their preoperative erections, which does appear to be the most reliable predictor of postoperative ED (Flores et al., 2011; Taylor et al., 2012). In some men with PD and ED, correction of the penile geometry resulted in improved rigidity (Pescatori et al., 2003). **Regardless, it is of critical importance that the**

patient understand that any operation done on the penis to correct PD may result in diminished rigidity, and that this may subsequently be treated successfully with oral PDE5 inhibitors, injection therapy, or a vacuum device; and those in whom these approaches fail can have a penile prosthesis implanted with little to no additional difficulty (Chung et al., 2013c; Kendirci and Hellstrom, 2004; Levine et al., 2010). Decreased sexual sensation has been examined and reported on infrequently, but it does appear that approximately 20% of men will describe some reduction in penile sensitivity, rarely interfering with orgasm or ejaculation. During the acute postoperative period, there can be hyperesthesia or hypoesthesia, which tends to resolve and stabilize within 6 to 12 months postoperatively (Taylor and Levine, 2008; Ralph et al., 2010). **The primary determinants for the choice of surgical approach are based on two factors, including quality of the preoperative erection hardness and severity of deformity, including curvature and indentation. In men who have rigidity that is adequate for coital activity with or without pharmacotherapy, tunica plication techniques and plaque incision or partial excision with grafting may be used. Tunica plication techniques are recommended for those who have a simple curvature of less than 70 degrees, those with absence of an hourglass or hinge effect, and those in whom the anticipated loss of length would be less than 20% of the total erect length** (Levine and Lenting, 1997; Mulhall et al., 2005; Ralph and Minhas, 2004)**. The estimated penile length loss can be determined during preoperative testing while the penis is erect by measuring the difference in length between the long and short sides of the penis. Grafting procedures are recommended for those with more complex curves of greater than 60 to 70 degrees and/or a destabilizing hourglass resulting in a hinge effect. This hinge effect results in a buckling or unstable penis, which makes penetrative sex difficult. These men must have strong, sexually induced rigidity to reduce the likelihood of postoperative ED** (Flores et al., 2011; Taylor et al., 2012) **(Table 73.4). For the man who has PD and ED that is refractory to medical therapy, published algorithms have indicated that penile prosthesis placement is the procedure of choice** (Levine and Burnett, 2013; Levine and Dimitriou, 2000; Mulhall et al., 2005; Ralph et al., 2010). This procedure allows for correction of the deformity while also addressing the ED. If curvature is not satisfactorily corrected with the prosthesis inflated during surgery, additional straightening maneuvers may be performed. We recommend manual modeling as the first step as initially reported by Wilson and Delk (1994). If there is residual curvature in excess of 30 degrees after modeling, then a relaxing incision in the tunica albuginea overlying the area of maximum curvature can be made. It is recommended that if the incisional defect is greater than 2 cm, a biograft (i.e., pericardium or small intestine submucosa) should be placed over the defect to prevent cicatrix contracture of the incision or herniation of the prosthesis (Levine and Dimitriou, 2000; Ralph et al., 2010). Plication techniques have been recommended to be performed before placement of the prosthesis to correct curvature in lieu of manual modeling (Dugi and Morey, 2010; Rahman et al., 2004). In this circumstance, if the curvature is dorsal, the erectile deformity can be defined with injection of a vasoactive drug and infusion of saline, then sutures are placed in a Lembert fashion to cause ventral shortening and correction of the curve.

Box 73.5

Preoperative Consent

Set expectations regarding outcome.

- Persistent or recurrent curvature: The goal is “functionally straight” (curvature <20 degrees)
- Change in length: The result is more likely shorter with plication than with grafting.
- Diminished rigidity
  - ≥5% in all studies—grafting more than plication
  - ≥30% if suboptimal preoperative rigidity—dependent on preoperative erectile quality
- Decreased sexual sensation
  - Typically resolves in 1 to 6 months
  - Rarely compromises orgasm or ejaculation

TABLE 73.4

Outcomes for Plaque Excision or Incision and Grafting

GRAFT MATERIAL	AUTHOR AND DATE	PATIENTS *(N)*	MEAN FOLLOW-UP (MONTHS)	STRAIGHT AT LATEST FOLLOW-	ED (%)	SATI RATI

				UP (%)		
Dermal grafts	Wild et al., 1979	10	11	60	6	70
	Levine, 1997	15	11	73	12	70
	Chun et al., 2001	48	19.6	80	25	73
	Kovac and Brock, 2007	50	45	94	NR	NR
	Chung et al., 2011a	6	102	50	NR	35
Saphenous vein grafts	El-Sakka et al., 1998	113	9.72	96	12	92
	Kadioglu et al., 1999	20	13.2	75	5	NR
	Montorsi et al., 2000	50	12	80	6	96
	Akkus et al., 2001	58	16	86	7	92
	Adeniyi et al., 2002	51	32	82	8	88
	Hsu et al., 2003	24	31.2	96	4	100
	Kalsi et al., 2005	113	>60	80	23	60
	Kim et al., 2008	20	>12	85	35	NR
	Wimpissinger et al., 2016	26	156	87	36	73
Buccal mucosa	Shioshvili and Kakonahvili, 2005	26	38	92	8	NR
	Cormio et al., 2009	15	13	100	0	93
	Zucchi et al., 2014	32	43	96.5	3.5	85
Proximal crura	Teloken et al., 2000	7	6	86	0	86
	Schwarzer et al., 2003	31	NR	84	19	94
	Da Ros et al., 2012	27	NR	96	4	70
Tunica vaginalis	Das, 1980	15	4-16	87.5	0	100
	O'Donnell, 1992	25	42.2	88	68	NR
Dura mater	Fallon, 1990	40	12-72	95	25	NR
	Sampaio et al., 2002	40	12-24	95	15	NR
Temporalis fascia	Gelbard and Hayden, 1991	12	NR	100	0	100
Fascia lata	Kalsi et al., 2006	14	31	79	7	93
Small intestinal submucosa (SIS 4-layer)	Breyer et al., 2007	19	15	63	53	Score
	Kovac and Brock, 2007	13	7.8	77	NR	85
	Lee et al., 2008	13	14	100	54	NR
	Staerman et al.,	33	14	67	11	79

	2010					
	Chung et al., 2011b	17	75	77	13	NR
	Valente et al., 2016	28	18	82	17.8	83.2
Bovine pericardium	Egydio et al., 2002	33	19	88	0.0	NR
	Knoll, 2007	162	38	91	21	NR
Tutoplast pericardial graft	Hellstrom and Reddy, 2000	81	58	79	20	78
	Leungwattanakij et al., 2001	19	22	84	16	74
	Usta et al., 2003	11	14	91	NR	NR
	Levine et al., 2003	40	22	98	30	92
	Kovac and Brock, 2007	13	30	100	NR	NR
	Chung et al., 2011a	81	58	91	32	75
	Taylor and Levine, 2008	23	79	87	NR	NR
Acellular dermis	Adamakis et al., 2011	5	6	100	0	100
Synthetic materials	Faerber and Konnak, 1993	9	17.5	100	0	100
TachoSil	Licht and Lewis, 1997	28	22	61	18	30
	Horstmann et al., 2011	43	63	41	9	20
	Yafi et al., 2016	26	20.7	85	0	100
	Hatzichristodoulou, 2018	70	0.2	83.6	NR	NR

ED, Erectile dysfunction; *NR,* not reported.

Tunical Shortening Procedures

Penile plication aims to shorten the longer (or convex) side of the tunica albuginea to match the length to the shorter side (Ralph, 2006; Syed et al., 2003)**. Advantages to these approaches include shorter surgical time, good cosmetic outcomes, minimal effect on rigidity, simple and safe surgery, and effective straightening** (Hatzimouratidis et al., 2012; Hudak et al., 2013)**. Disadvantages include shortening and failure to correct an hourglass or hinge.** A study of failures with the Nesbit procedure identified three factors associated with an unsatisfactory outcome, including impaired preoperative erectile function, penile shortening of greater than 2 cm, and penile deformity greater than 30 degrees (Andrews et al., 2001). Multiple surgical plication techniques have been offered for PD, beginning with the Nesbit procedure (Nesbit, 1965) (Fig. 73.11). This technique uses excision of an elliptical segment of the tunica on the contralateral side of the curvature. In the setting of a ventral curvature, once Buck's fascia has been elevated, small wedges of the dorsal tunica albuginea are excised and then the defect is closed, typically with permanent suture. Multiple variations on this approach have evolved, including the Yachia procedure, which uses the Heineke-Mikulicz technique (Yachia, 1990, 1993). In the setting of a dorsal curvature, a short (0.5 to 1.5 cm), full-thickness vertical incision is made on the ventral shaft tunic, opposite the area of maximum curvature, which is then closed transversely to shorten the ventral aspect and correct the curvature (Fig. 73.12). This approach must be used carefully so that the length of the incision is not too long, such that transverse closure could result in further narrowing of the shaft, possibly resulting in an unstable erection. Several authors have suggested that this approach has a lower risk for perceived penile shortening (Klevmark et al., 1994; Kümmerling and Schubert, 1995; Nooter et al., 1994; Poulson and Kikeby, 1995; Ralph et al., 1995; Savoca et al., 2000, 2004; Sulaiman and Gingell, 1994).

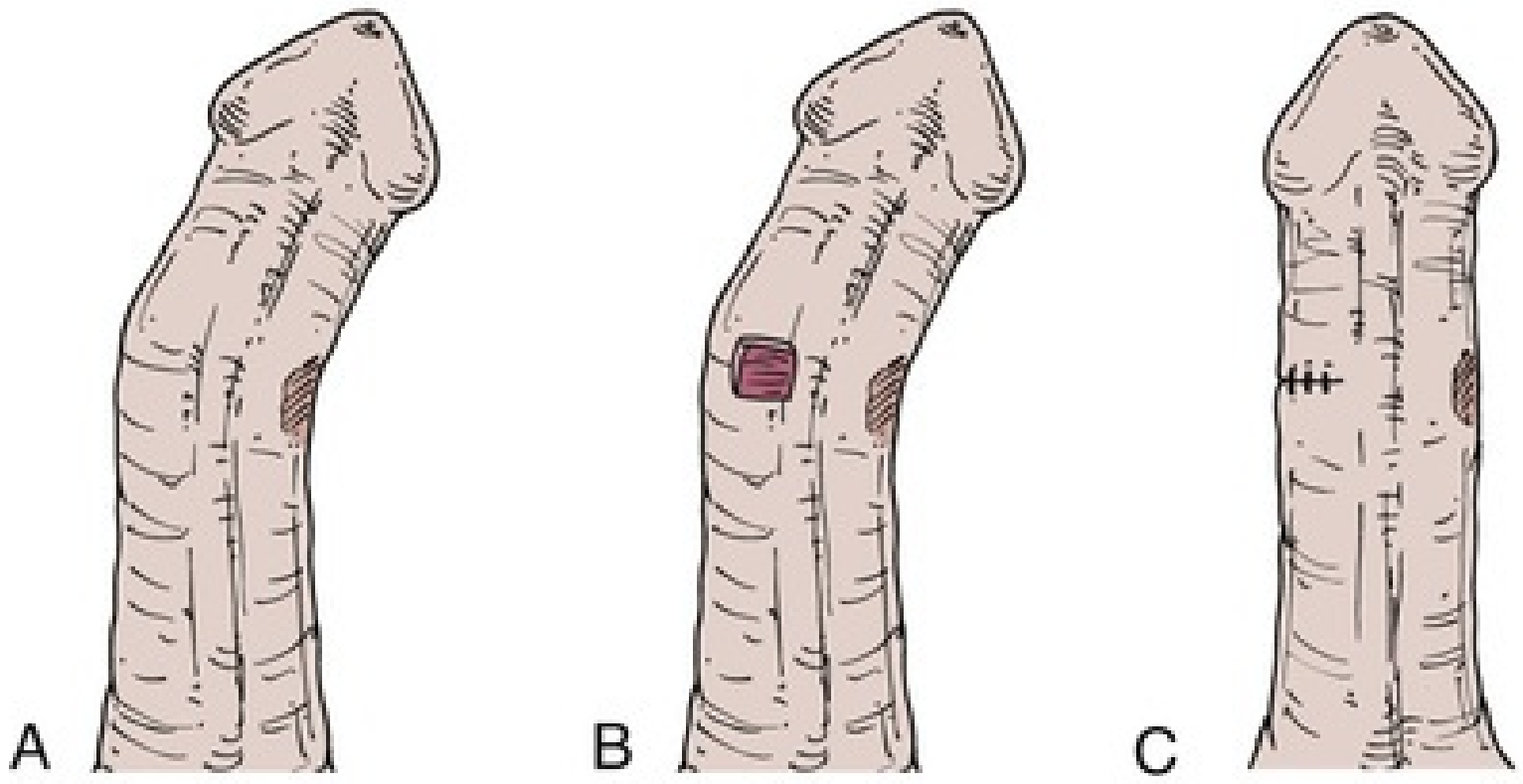

FIG. 73.11 (A) The Nesbit procedure employs a transverse elliptical incision of the tunica albuginea. (B) This is done contralateral to the area of greatest curvature. (C) The defect is closed transversely with permanent suture with or without the addition of absorbable suture.

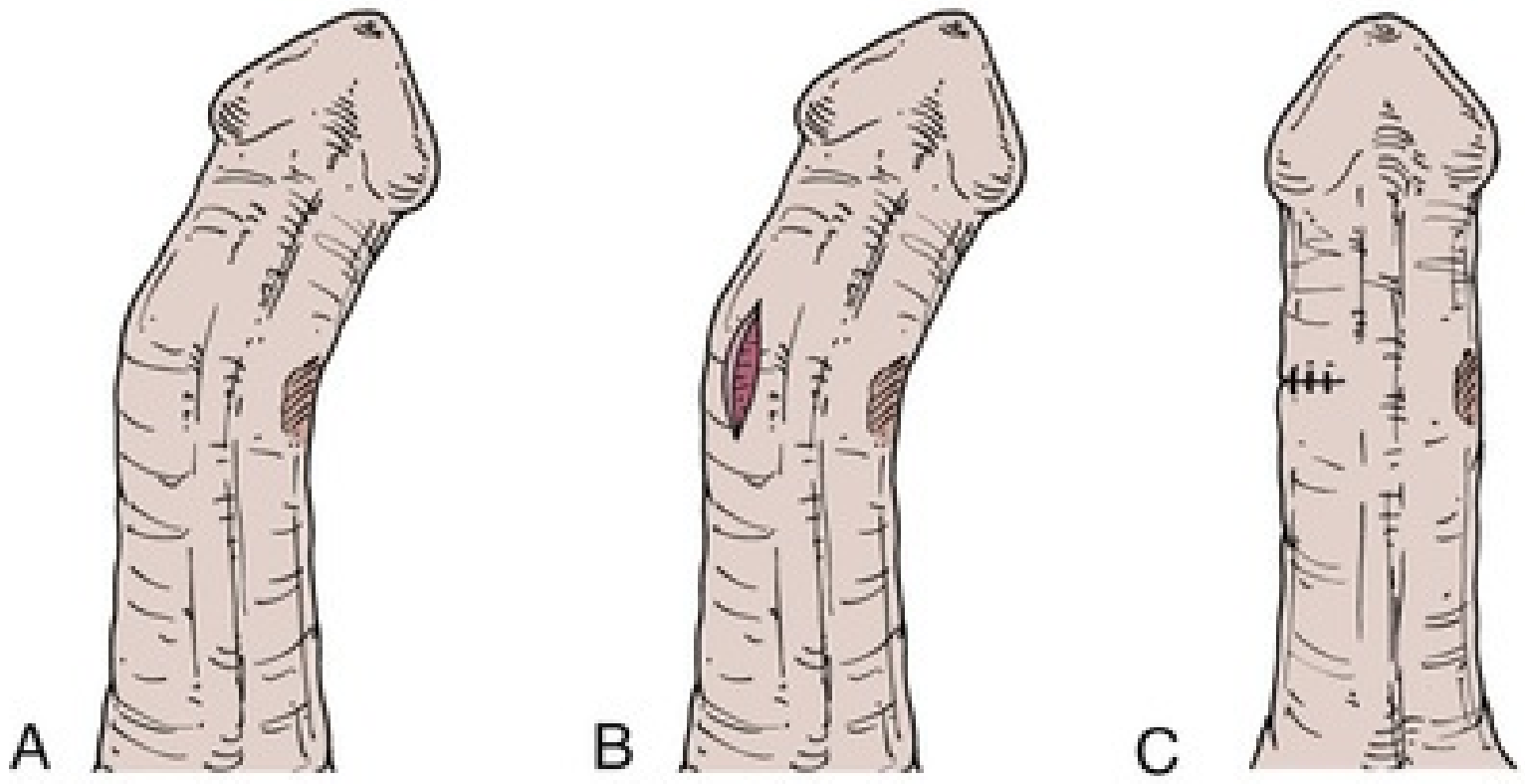

FIG. 73.12 (A) The Yachia procedure employs a full-thickness vertical incision (B) in the tunica albuginea contralateral to the area of greatest curvature and is closed transversely (C) without removal of tunica albuginea.

Imbrication procedures are used to avoid making a full-thickness tunical incision and fold the tunica to correct curvature. The techniques of tunical plication without incision were introduced in 1985 by Essed and Schroeder, who used nonabsorbable sutures placed in a figure-of-eight fashion to enable the knots to be buried (Essed and Schroeder, 1985). Two years later, Ebbehoj and Metz (1987) described their plication technique using multiple rows of sutures to shorten the longer side for congenital curvature (Ebbehoj and Metz, 1987). The 16-dot procedure has become a popular variation of tunical shortening in which there is no incision into the tunic but the tunica albuginea is plicated with permanent suture using an extended Lembert-type suture placement technique (Brant et al., 2007; Gholami and Lue, 2002; Rolle et al., 2005) (Fig. 73.13). Another plication variation is the Levine modification of the Duckett-Baskin tunica albuginea plication (TAP), which was originally used for children with congenital curvature. Here, a partial-thickness incision is made transversely on the contralateral side to the point of maximum curvature (Baskin and Duckett, 1994; Levine, 2006). A pair of transverse parallel incisions 1 to 1.5 cm in length are made through the longitudinal fibers but do not violate the inner circular fibers of the tunic. As a result, the underlying cavernosal tissue is not disturbed, which is thought to reduce the likelihood of postoperative ED. These incisions are separated by 0.5 to 1.0 cm depending on the desired amount of shortening. The longitudinal fibers between the two transverse incisions are excised so as to reduce the bulk of the plication. This procedure is now done with a single central permanent suture (2-0 Tevdek suture, Teleflex Medical, Research Triangle Park, NC, or TiCron suture, Medline, Mundelein, IL) placed in an inverting vertical mattress fashion to bury the knot and then supported with absorbable suture (3-0 polydioxanone [PDS], Ethicon, Somerville, NJ) placed in a Lembert fashion to reduce the palpable nature of the plication and knots (Fig. 73.14).

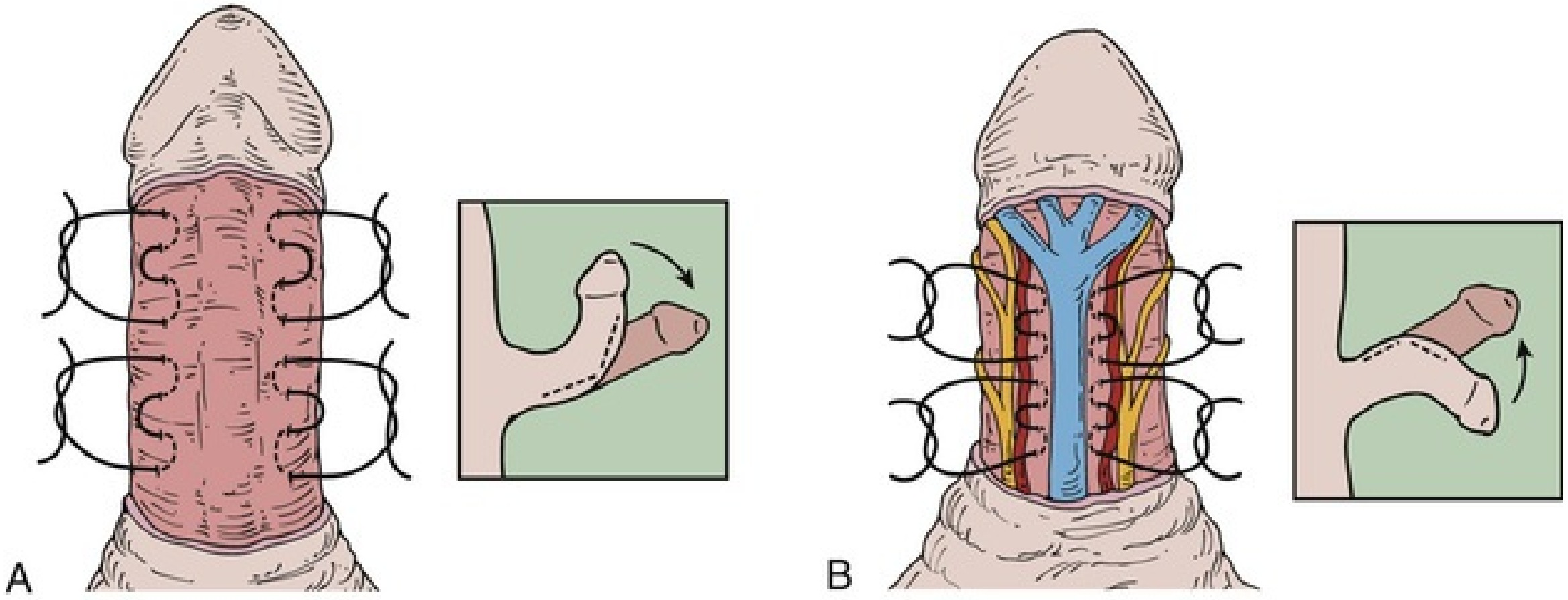

FIG. 73.13 The dot procedure employs no incision. The tunica albuginea is plicated with permanent suture using an extended Lembert-type suture placement following four dots per plication. A, Suture placement for dorsal curve. B, Suture placement for ventral curve.

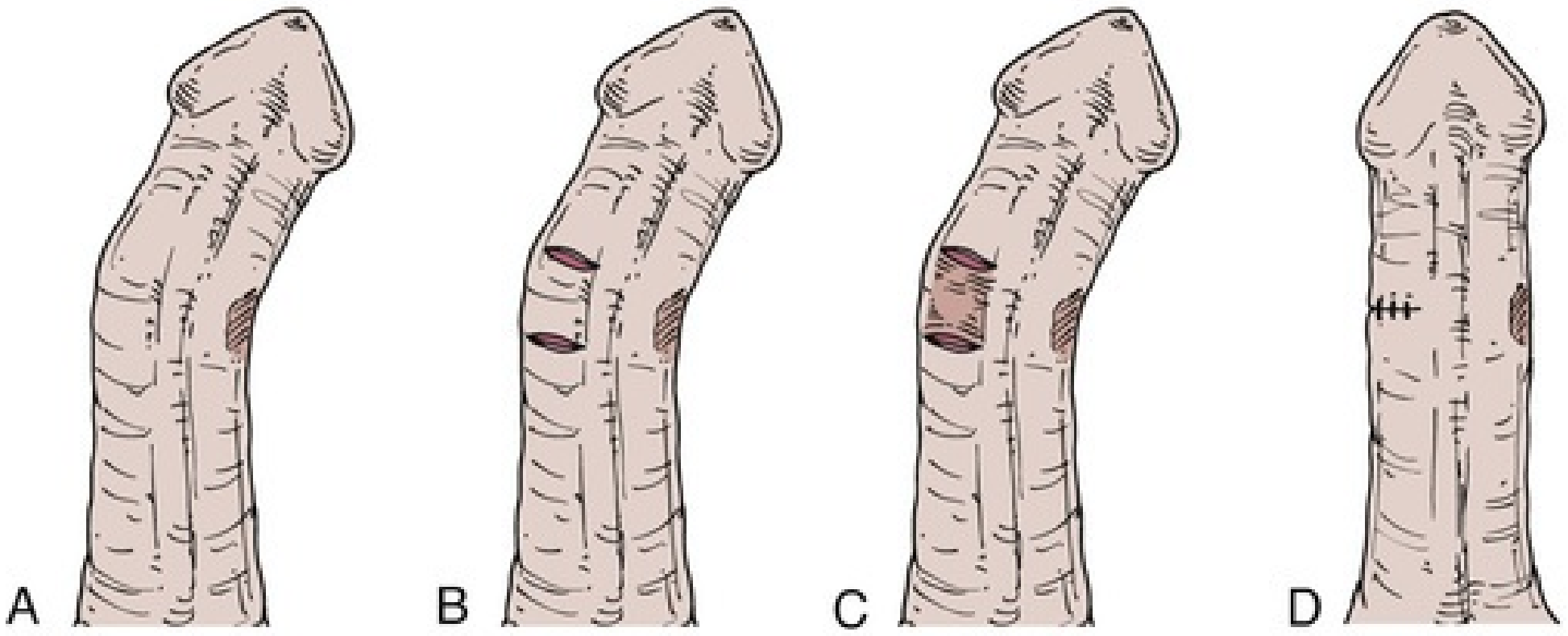

FIG. 73.14 The tunica albuginea plication (TAP) procedure (A) employs a pair of transverse parallel incisions (B) separated by 0.5 to 1.0 cm. The incision is made through the longitudinal fibers but does not violate the inner circular fibers of the tunic. (C) The longitudinal fibers between the two transverse incisions are removed to reduce the bulk of the plication. (D) The defect is then brought together transversely.

The key is that all plication procedures shorten the long side of the penis and therefore can result in loss of length on that aspect of the penis. Studies

have examined the loss of penile length after use of the TAP technique. The expected factors that predicted loss of length included the direction of curvature and the degree of curvature (Greenfield et al., 2006). Greenfield et al. (2006) found that men who had a ventral curvature of greater than 60 degrees tended to have the greatest potential loss of penile length. Preoperative penile length and degree and direction of curvature deformity appear to correlate with postoperative satisfaction (Mulhall et al., 2005; Greenfield et al., 2006).

The drawbacks of any tunica plication procedure for PD are that it does not correct shortening and it potentially may enhance loss of penile shaft length. It does not address hinge or hourglass effect and may exacerbate it, resulting in an unstable penis. The plaque is also left in situ. Penile narrowing or indentation has been reported in up to 17% with these techniques. In addition, there can be pain associated with the knots and suture granulomas (Ralph et al., 2010; Taylor and Levine, 2008; Tornehl and Carson, 2004). Surgical straightening with plication procedures can be expected in 79% to 100% of patients, with a reported satisfaction rate of 65% to 100% (Ding et al., 2010; Larsen and Levine, 2013; Van Der Horst et al., 2004). Recurrence of penile curvature deformity (greater than 30 degrees) has been reported in up to 12% in a limited number of long-term studies (Levine and Burnett, 2013; Taylor and Levine, 2008). The reported risk for new ED ranges from 0% to 38%, and diminished sensation has been reported in 4% to 21% with follow-up of up to 89 months. Other, less common complications include hematoma in up to 9% of patients, urethral injury in less than 2%, and phimosis in up to 5% (Kadioglu et al., 2011b; Larsen and Levine, 2013; Tornehl and Carson, 2004).

A recent International Consultation on Sexual Medicine (ICSM) published recommendations regarding plication procedures in 2010 and reported that there was “no evidence that one surgical approach provides better outcomes over another, but curvature correction can be expected with less risk of new ED” when compared with grafting procedures (Ralph et al., 2010) (Table 73.5 shows a summary of outcomes of tunical shortening procedures).

TABLE 73.5

Outcomes of Tunical Shortening Procedure for Peyronie's Disease

PROCEDURE	AUTHOR AND	PATIENTS *(N)*	MEAN FOLLOW-UP	STRAIGHT AT LATEST	SHORTENING (% OF

	DATE		(MONTHS)	FOLLOW-UP (%)	PATIENTS)
Nesbit	Licht and Lewis, 1997	28	22	79	37
	Schneider et al., 2003	48	25	23	44
	Syed et al., 2003	42	84	91	50
	Savoca et al., 2004	218	89	86.3	17.4
	Bokarica et al., 2005	40	81	88	15,[a] 100[b]
	Ralph, 2006	9	31	NR	NR
Plication	Geertsen et al., 1996	28	34	57	NR
	Levine and Lenting, 1997	22	20	91	9
	Thiounn et al., 1998	29	34	79	NR
	Schultheiss et al., 2000	61	39.8	70.5	45.9
	Chahal et al., 2001	44	49	29	90
	Gholami and Lue, 2002	124	31	85	41
	Van Der Horst et al., 2004	28	30	83	NR
	Paez et al., 2007	76	70	42	NR
	Kim et al., 2008	26	≥12	65	69
	Kadioglu et al., 2008	15	21	87	NR
	Taylor and Levine, 2008	61	72	93	18
	Dugi and	34	6	98	NR

	Morey, 2010				
Yachia	Licht and Lewis, 1997	30	12	100	NR
	Rehman et al., 1997	26	32	92	100
	Daitch et al., 1999	14	24.1	93	57

[a] Patient-perceived shortening.

[b] Objectively measured shortening.

ED, Erectile dysfunction; *NR,* not reported.

Clinicians may offer tunical plication surgery to patients whose rigidity is adequate for coitus (with or without pharmacotherapy and/or vacuum device therapy) to improve penile curvature, as per the 2015 AUA PD guideline.

Tunical Lengthening Procedures (Plaque Incision or Partial Excision and Grafting)

Indications for plaque incision and grafting (PIG) or partial plaque excision and grafting (PEG) for surgical correction of PD includes greater complexity of disease with several (or all) of the following: curvature greater than 60 to 70 degrees, shaft narrowing, hinging, and extensive plaque calcification (Kadioglu et al., 2011b; Kendirci and Hellstrom, 2004; Levine and Burnett, 2013; Levine and Lenting, 1997; Ralph et al., 2010; Yafi et al., 2016)**. Most important, for the patient to be a candidate for PIG or PEG, he must have strong preoperative erections** (Taylor et al., 2012). This can be determined during the patient interview, when he is asked directly, “If your penis was straight, would the quality of rigidity that you currently have allow penetrative sex?” Should the patient hesitate or note suboptimal-quality erections, a grafting procedure should not be performed unless the patient fully understands the risk for more advanced postoperative ED and the possible need for subsequent prosthesis placement to obtain optimal rigidity. Some men simply reject the idea that they need a prosthesis as a first-line surgical treatment. Others who might be considered candidates for tunica plication reject this approach because of fear of penile length loss. These men may be offered a grafting repair with the understanding that a penile prosthesis can be placed with minimal added difficulty at a later time. The advantage of performing the grafting procedure is that it would likely correct curvature and reestablish more normal shaft caliber while increasing the likelihood of some length recovery in the range of 0.5 to 3.0 cm.

Other factors have been reported in the literature as possible predictors of postoperative ED, including age older than 55 years, evidence of corporeal veno-occlusive dysfunction on duplex ultrasound analysis with a resistance index of less than 0.80, large tunica defect and graft size, ventral curvature, and curvature greater than 60 degrees (Leungwattanakij et al., 2001; Levine et al., 2005; Alphs et al., 2010; Flores et al., 2011). These predictors have been suggested as a result of single-center studies, with a limited number of patients in each cohort. Larger-scale studies indicate that the most critical criterion for any grafting procedure is the quality of preoperative erections (Flores et al., 2011; Taylor et al., 2012). **In fact, Jordan and Angermeier found that there was a linear association between preoperative and postoperative ED** (Jordan and Angermeier, 1993)**. Expert opinion has been consistent that patients with ventral deformity do not do well with grafting procedures.** Hellstrom's analysis of the relationship of penile deformity to the vascular status of PD patients showed that men with ventral curvature had the greatest likelihood of having cavernous veno-occlusive dysfunction (Lowsley and Boyce, 1950; Jordan and Angermeier, 1993).

Surgical grafting techniques include PIG and PEG. Historically, total excision of the plaque was practiced to “cut out the disease,” resulting in onlays of large grafts with an unacceptably high rate of ED (Kendirci and Hellstrom, 2004; Kadioglu et al., 2006). Therefore, plaque incision was introduced in which a modified-H or double-Y incision is made in the area of maximum curvature (Gelbard, 1995). This allows the tunic to be expanded in this area, thereby correcting the curvature and shaft caliber but minimizing the underlying exposure of the cavernous tissue and thereby reducing the potential fibrosis of the cavernosal tissue and/or interrupting the delicate veno-occlusive mechanism, which has been considered the most likely contributor to postoperative ED with these grafting procedures (Dalton and Carter, 1991; Hatzimouratidis et al., 2012). Using the modified-H incision allows the correction of the curvature and shaft caliber. Gelbard (1995) has suggested that using multiple incisions and filling them with grafts would result in a smoother correction of curvature and potentially less injury to the underlying cavernosal tissue (Gelbard, 1995).

PEG may be preferable in cases in which the area of maximum deformity is excised, particularly if it is associated with severe indentation. **An increasing number of patients with severe deformity have indentation that if not addressed may result in a straightened penis but with residual narrowing causing instability.** The corners of the defect are darted in a radial fashion to enhance correction of the narrowing in that area (Levine, 2011). Geometric principles have been applied to the grafting technique so as to obtain a properly sized graft with excellent correction of deformity (Egydio et al., 2004). This approach has been considered unnecessarily complex, and there have been reports of a higher rate of postoperative ED when this technique has been used (Flores et al., 2011). **It appears intuitive that to reduce the risk for postoperative ED, the key is to limit trauma to the underlying cavernosal tissue to maintain the veno-occlusive relationship between the cavernosal tissue and the overlying tunica graft.**

Clinicians may offer plaque incision or excision and/or grafting to patients with deformities whose rigidity is adequate for coitus (with or without pharmacotherapy and/or vacuum device therapy) to improve penile curvature, as per the 2015 AUA PD guideline.

Graft Materials

The ideal graft should approximate the strength and elastic characteristics of normal tunica albuginea; should have minimal morbidity and tissue reaction; should be readily available; should not be too thick; should be pliable, easy to size and suture, inexpensive, and resistant to infection; and should preserve erectile capacity (Gur et al., 2011; Kadioglu et al., 2007). Multiple autologous grafts have been used historically, including fat, dermis, tunica vaginalis, dura mater, temporalis fascia, saphenous vein, crura or albuginea, and buccal mucosa (Das, 1980; Devine and Horton, 1974; Hatzichristodoulou et al., 2013a; Kadioglu et al., 2007; Kargi et al., 2004; Leungwattanakij et al., 2003; Liu et al., 2016; Lowsley and Boyce, 1950; Lue and El-Sakka, 1998; Sampaio et al., 2002; Shioshvili and Kakonahvili, 2005; Teloken et al., 2000; Valente et al., 2016; Wimpissinger et al., 2016; Yafi et al., 2016). Although the outcomes of these surgeries are typically good in select patients, they have fallen out of favor because of a need for extended surgery to harvest the graft and a second surgical site, which possesses its own potential complications of healing, scarring, and possible lymphedema. Crural and buccal grafts are compromised by the inability to get enough graft material for large defects (Hatzichristou and Hatzimouratidis, 2002; Schwarzer et al., 2003;

Shioshvili and Kakonahvili, 2005). Synthetic polyethylene terephthalate (PETE, Dacron) and polytetrafluoroethylene (PTFE, Teflon) grafts have been used historically and are not recommended now because of the potential risk for infection, localized inflammatory response, and fibrosis (Brannigan et al., 1998; Devine et al., 1997). Finally, "off-the-shelf" allografts and xenografts have emerged, including processed pericardium from a bovine or human source, porcine intestinal submucosa, and porcine skin. The two most common grafts currently used are Tutoplast (Coloplast US, Minneapolis, MN), processed human and bovine pericardium, and porcine small intestinal submucosa (SIS) grafts (Surgisis ES, Cook Urological, Spencer, IN) (Hellstrom, 1994; Hellstrom and Reddy, 2000; Knoll, 2001; Levine and Estrada, 2003, Valente et al., 2016). These packaged processed grafts are being used with increased frequency because of their ease of use and reduction in operating times. The pericardial grafts are thin, are strong, do not contract, and have no reports of infection or rejection. Chun et al. (2001) performed a comparison of dermal and non-Tutoplast processed human cadaveric pericardial grafts in the modified Horton-Devine procedure. Overall, 92% of patients were able to achieve successful coitus with or without assistance. These researchers reported a 33% overall recurrence rate, with 26% of patients who received dermal grafts and 44% of patients who received pericardial grafts experiencing recurrence. However, this study did not report on the severity of recurrence, and all patients were able to achieve erections suitable for coitus. Satisfaction rates were similar, and those who underwent pericardial grafting had shorter operative times and decreased morbidity associated with the absence of a graft donor site (Chun et al., 2001). The SIS grafts have similar advantages to pericardium, except there have been reports of graft contraction, particularly with one-ply grafts, with associated recurrent curvature in the 37% to 75% range (Breyer et al., 2007; Kovac and Brock, 2007; John et al., 2006; Santucci and Barber, 2005; Taylor and Levine, 2008). Other reported postoperative complications with SIS grafts include subgraft hematoma in 26% and an infection rate of 5% (Breyer et al., 2007). However, a contemporary series showed that of 26 patients, there was 82% patient satisfaction and only 1 of 26 patients had a surgical complication (infected hematoma) (Valente et al., 2016).

Tissue-engineered graft materials have been considered more recently and potentially offer the advantage of having a graft seeded with cellular material, which may enhance the take of the graft and potentially reduce local tissue fibrosis with diminished postoperative ED. Adipose tissue–derived stem cell–

seeded SIS, human acellular matrix tunica albuginea grafts, and autologous tissue–engineered endothelialized tunica albuginea grafts have been investigated for incision and excision procedures (da Silva et al., 2011; Imbeault et al., 2011; Ferretti et al., 2012; Ma et al., 2012; Schultheiss et al., 2004). Imbeault et al. (2011) demonstrated in vitro creation of artificial tunica albuginea using human dermal fibroblast and human endothelial cells. They concluded that this tissue-engineered endothelialized tubular graft was structurally similar to normal tunic with a high burst pressure and adequate mechanical resistance. Furthermore, the autologous property of this model could represent an advantage compared with other available grafts (Imbeault et al., 2011). Such studies may help elucidate future medical treatments for PD using tissue-engineered grafts for the reconstruction of the tunica albuginea. The biomechanical properties, compatibility with the tunica albuginea, and effective neovascularization of the tissue-engineered grafts need to be investigated further before such basic research can be applied in practice.

More recently, several studies have been published on the efficacy of Tachosil (Baxter Healthcare, Deerfield, IL) to cover the tunica defect from plaque partial excision or incision (Hatzichristodoulou, 2018; Hatzichristodoulou et al., 2013a; Lahme et al., 2002; Yafi et al., 2016). Tachosil is a collagen fleece coated with a tissue sealant that adheres to tissue after several minutes of compression. Because no surgical fixation is required, collagen fleece is easy to administer, and may shorten operating time. Lahme et al. (2002) first reported plaque incision/partial excision using a collagen fleece grafting on 19 patients. At a mean follow-up of 25 months, there were no major complications and recurrence was observed in only 16.7%. Yafi et al. used Tachosil on 26 patients undergoing partial excision and grafting for hourglass deformity with no major complications and an 85% success rate with a mean follow-up of 20 months (Yafi et al., 2016). The 2015 AUA PD guideline offers no opinion on choice of graft material.

Grafting Surgical Technique

Once the patient has achieved satisfactory general anesthesia, it is advised that the patient receive a dose of intravenous antibiotics and that the deep venous thrombosis protection apparatus be applied. The dorsal SPL should be measured. An artificial erection is then created by injecting a vasoactive drug (papaverine, Trimix, prostaglandin E_1) via a 21-gauge butterfly needle placed through the glans into the corpus cavernosum. Saline can be infused to create a full rigid erection, which allows visualization and measurement of the deformity, including curvature and areas of indentation with or without hinge effect. The preferred approach for grafting procedures is a circumcising incision made approximately 1.5 to 2 cm proximal to the corona, or through a previous circumcision site. The penis is degloved down to the Buck fascia, at which point hemostasis is obtained with bipolar cautery. It is advisable for the surgeon to use loupe magnification to reduce the likelihood of injury to neurovascular structures. With the shaft exposed, the erection can again be re-created, demonstrating the area of maximum deformity. In the circumstance of a dorsal or dorsal-lateral curvature, the Buck fascia, with the enclosed neurovascular bundle, is elevated by making a pair of parallel incisions just lateral to the urethral ridge, through the Buck fascia to the tunica albuginea. The Buck fascia is carefully elevated off the tunic. Typically this can be done with delicate, sharp dissection, but occasionally, if there is significant adhesion between the Buck fascia and the tunic, bipolar cautery can be used to elevate this with minimal risk for permanent nerve injury. Once the Buck fascia is elevated off the area of maximum deformity, a full erection is re-created. The area of maximum deformity is marked for incision or partial plaque excision. This allows excision and expansion of areas of severe indentation. It should be noted that even with a pure lateral curvature, the tunic to be excised must traverse through the dorsal septum, because this is the anchor point of the scar and if it is not taken, substantial residual curvature will likely remain (Jordan, 2007). When extensive calcification extends beyond the area of partial plaque excision, the calcified component can be removed, leaving the outer lamina intact because the calcification involves the inner circular fibers. Once the rectangular defect is established, the corners are darted in a radial fashion so as to help to recover normal shaft caliber in the area of indentation. Several authors have simplified the geometric principle technique by ensuring that the lateral sides of the defect are of equal length (Egydio et al., 2004; Levine, 2011). In doing this, we create a uniform-sized square or rectangle, which virtually always allows satisfactory correction of lateral and dorsal curvature. Often the proximal transverse length will be longer than the distal transverse length because of distal tapering of the shaft. The penis can now be measured on stretch again; typically there will be increased dorsal length from 0.5 to 3.0 cm. Stay sutures of 4-0 PDS (Ethicon, Somerville, NJ) are placed in the four corners of the defect and at the midpoint transversely, distally, and proximally. With these stay sutures on stretch, the defect can be measured longitudinally and transversely. Our preference is to use a Tutoplast processed pericardial graft (Coloplast, Minneapolis, MN), because there is usually little graft contraction. The graft should be sized no more than 10% larger than the measured defect on stretch. Porcine SIS grafts (Cook Urological, Spencer, IN) need to be oversized by 25%. Once the graft has been cut to size, it is secured in place with the previously placed stay sutures; then, with 4-0 PDS placed in a running fashion, the graft is secured to the defect. If a large defect is created, it may be advisable to place several interrupted 4-0 PDS sutures in the area of the septum to reduce the volume of blood that can accumulate under the graft. An artificial erection is again reestablished; if there is significant residual curvature, this can be addressed with tunica plication. Authors have found that this is necessary in up to 25% of patients. In patients who have a more prolonged curve or in those who have substantial indentation in one area and a more distal curvature, the grafting should be performed in the area of indentation, and plication is used to address any residual dorsal or lateral curve once grafting has been completed. In this circumstance, a single graft can be used, which has not been shown to have a higher rate of postoperative ED than when multiple grafts are used but does have the advantage of shorter operative time. Once satisfactory deformity correction has been accomplished, the Buck fascia is reapproximated with running 4-0 chromic, and the shaft skin is reapproximated to subcoronal skin with interrupted 4-0 chromic in a horizontal mattress fashion. Of note, for those patients who are uncircumcised and do not have any evidence of phimosis, a circumcision is not necessary (Garaffa et al., 2010); but if there is any question of excessive redundant foreskin and/or phimosis, then circumcision should be performed to reduce the likelihood of postoperative paraphimosis (Garaffa et al., 2010). The penis is dressed with Xeroform gauze (3M, St. Paul, MN) placed over the circumcising incision, and then a Coban wrap (3M, St. Paul, MN) is placed distal to proximal, providing gentle compression. Typically the dressing is left in place for 3 days and then removed, at which point the patient may shower. Submersion of the wound is not advised because this may encourage wound separation.

Postoperative Management

The postoperative rehabilitation period is critical to reduce the risk for postoperative ED and length loss and to optimize straight healing. We find it useful to liken the importance of postoperative rehabilitation after penile surgery to the importance of the rehabilitation needed for successful orthopedic joint replacement. Typically, a patient is seen 2 weeks after surgery, at which point massage and stretch therapy are initiated (Horton et al., 1987). The patient is instructed to grasp the penis by the glans and gently stretch it away from the body and then with his other hand to massage the shaft of the penis for 5 minutes twice per day for 2 to 4 weeks. The massage and stretch can be performed by the patient's partner for the second 2 weeks if possible. This will reinitiate the sexual experience for the couple and hopefully diminish the fear of reinjuring the penis, for which the partner may feel responsible. Investigators have recommended the use of nocturnal PDE5 inhibitors to enhance postoperative vasodilation, which may help support graft take, reduce cicatrix contraction, and theoretically preserve cavernosal tissue, thereby reducing postoperative ED (Levine et al., 2005). Finally, external penile traction devices have been encouraged and have been recently shown to reduce length loss postoperatively and can even enhance length gain after both grafting and plication procedures (Levine et al., 2013). In a recent report, SPL in patients who used postoperative traction therapy was shown to increase after plication and PEG procedures by +0.85 cm and +1.48 cm, respectively, versus length changes of −0.53 cm and +0.24 cm in the plication and PEG groups in which postoperative traction was not used. In fact, 50% of the plication and 89% of the PEG patients using postoperative traction had measured length gain. The reported average daily use was 2.5 hours for 4.5 days per week for an average duration of 3.8 months. There was no patient reported with postoperative length loss among those who used postoperative traction therapy, and although not statistically significant, there was a trend of higher satisfaction for erect length in the groups in which postoperative traction was used. Traction is recommended to be used for 3 or more hours per day, beginning 3 to 4 weeks after surgery, once the wound can tolerate the pressures of the stretching device for 3 months (Rybak et al., 2012).

In a review of published reports on grafting for PD over the past 12 years, satisfactory straightening was found in 74% to 100% of patients, but postoperative ED, which does not have a uniform definition in the literature and may include reduced rigidity, compared with preoperative rigidity to complete loss of rigidity has been reported in 5% to 54% of patients. Diminished sensation after grafting has been reported in a few series with a follow-up of less than 5 years (Taylor and Levine, 2008). In the few single-center surgical outcome reviews with 5 or more years of follow-up, ED has been reported in up to 24%, with recurrent or persistent curvature in the 8% to 12% range (Chung et al., 2011a; Kalsi et al., 2005; Montorsi et al., 2004; Usta et al., 2003). See Table 73.4 for a summary of the outcomes for penile straightening with plaque incision or excision and grafting.

The AUA 2015 PD guideline states that, “Clinicians may offer plaque incision or excision and/or grafting to patients with deformities whose rigidity is adequate for coitus (with or without pharmacotherapy and/or vacuum device therapy) to improve penile curvature. (Moderate Recommendation; Evidence Strength Grade C).”

Penile Prosthesis for Men With Peyronie's Disease

Indications

In men with PD and concurrent ED refractory to PDE5 inhibitors, penile prosthesis placement is the procedure of choice (Kendirci and Hellstrom, 2004; Levine and Dimitriou, 2000; Levine and Lenting, 1997; Mulhall et al., 2005; Ralph and Minhas, 2004)**. Additional straightening maneuvers may be necessary, including manual modeling and incising of the tunica albuginea with or without grafting.** Recently, transcorporeal approaches have been used before modeling or relaxing incisions; the plaque is incised or stretched from within the corporeal body (Perito and Wilson, 2013; Shaeer, 2011).

Techniques for Straightening When Placing a Penile Prosthesis for Peyronie's Disease

An inflatable penile prosthesis (IPP) appears to be the preferred surgical implant, as the pressure within the cylinders allows for superior correction of curvature with manual modeling, and improved girth enhancement. Malleable prostheses, when used for PD historically, were associated with narrow, cold, and less than natural erections (Ghanem et al., 1998; Marzi et al., 1997; Montorsi et al., 1993).

Manual modeling via the penoscrotal approach is recommended with a high-pressure inflatable cylinder, but all available three-piece and two-piece devices have been used successfully to correct deformity (Chung et al., 2013c; Levine et al., 2001; Montague et al., 1996; Montorsi et al., 1996; Wilson and Delk, 1994). Our approach is to place the prosthesis cylinders first, followed by closing of the corporotomies. With use of a surrogate reservoir attached to the pump tubing, the prosthesis can be filled to full rigidity, which will allow visualization of the deformity. To protect the pump from the high pressures that may occur during manual modeling, shodded hemostat clamps are applied to the tubing between the pump and the cylinders. The penis is then bent in the contralateral direction to the curvature. It is recommended to try to hold the penis in this position for 60 to 90 seconds, but experience has suggested that approximately 30 seconds may be all that is possible. Once the modeling has been performed, the penis can be reassessed by instilling more fluid, reapplying the hemostats, and then performing the modeling procedure repeatedly until satisfactory curvature correction has been attained. **The modeling technique should be a gradual bending rather than a violent maneuver, because this will reduce the likelihood of inadvertent tearing of the tunic or injury to the overlying neurovascular bundle.** Urethral injuries during performance of this technique as a result of distal extrusion of the prosthetic cylinders at the fossa navicularis have been reported (Wilson and Delk, 1994; Wilson et al., 2001). To reduce the likelihood of this occurring, the bending hand should be placed on the shaft of the penis rather than on the glans, to avoid downward pressure on the tips of the cylinders. The other hand should be grasping the base of the penis with pressure over the corporotomies, which will provide support to this area and reduce the likelihood of disruption of the suture line.

Published reports on the use of modeling have indicated that successful straightening can be expected in 86% to 100% with no higher incidence of device revision; sensory deficit after manual modeling is rare but remains a potential complication that should be discussed with the patient preoperatively (Chung et al., 2013c; Levine et al., 2010; Montague et al., 1996; Wilson and Delk, 1994; Wilson et al., 2001). Although it would appear that for more severe curvature more advanced techniques are necessary, published experience has suggested that manual modeling may be used as first-line therapy for correction of curvature after prosthesis implantation (Chung et al., 2013c; Levine et al., 2010). An alternative to this would be to perform a tunic plication contralateral to the curvature before placement of the prosthesis to correct the curvature (Dugi and Morey, 2010; Rahman et al., 2004). When there is residual curvature of greater than 30 degrees or residual indentation causing the inflated cylinder to buckle, tunical incision is recommended after elevation of the Buck fascia in that area (Levine and Dimitriou, 2000).

The transverse penoscrotal skin incision will allow access to virtually the entire shaft, except when the curvature is distal and dorsal on the shaft, so degloving the penis is not always necessary. The tunical incision is made with the cylinders deflated, using the cautery to release the tunic with an effort to preserve cavernosal tissue over the implant. When Titan cylinders (Coloplast, Minneapolis, MN) are used, the energy should be less than 30 watts to reduce potential cylinder thermal injury (Hakim et al., 1996). Once the incision has been made, the cylinders are reinflated and further modeling can be performed to optimize deformity correction. **Although there is no clearly accepted approach, grafting is recommended when the defect measures greater than 2 cm in any dimension to reduce cicatrix contracture and cylinder herniation** (Carson and Levine, 2014; Levine and Dimitriou, 2000)**. Historically, synthetic grafts were used, but currently biografts of pericardium or porcine SIS are recommended. Use of locally harvested dermal grafts is not recommended, because there is a risk for transferring bacteria to the prosthesis.** Collagen fleece spray has also been reported to cover tunical defects in patients undergoing IPP with favorable results (Hatzichristodoulou, 2018; Yafi et al., 2016).

In patients who have suffered debilitating loss of penile length or girth, the “sliding technique” can be used in conjunction with a penile prosthesis to offer some restoration of length and girth (Egydio and Kuehhas, 2015; Rolle et al., 2012). Details regarding this procedure can be found in Rolle et al. (2012). In a large series of 143 patients undergoing this procedure, the average penile length gain was 3.1 cm. There were no prosthesis infections or any major complications at an average follow-up of 9.7 months. Of the 77 patients who had penile curvature, all were corrected and 89.2% of patients were satisfied with their procedure. At this time, experience with this procedure is limited to a single institution, and most patients in this study received a malleable prosthesis.

There have been limited publications looking at the long-term results with regard to outcomes and satisfaction with inflatable penile prostheses in men with PD and ED. Levine et al. (2010) reported on 90 consecutive men undergoing placement of an IPP, with 4% having satisfactory straightening with prosthesis placement alone, 79% having satisfactory curvature correction with prosthesis and modeling, 4% requiring tunical incision, and 12% having incision and pericardial grafting for correction of curvature. There was no evidence that the additional maneuvers increased the rate of mechanical failure or infection with up to 8 years of follow-up. In the nonvalidated questionnaire used in this study, overall patient satisfaction was 84%, whereas only 73% were satisfied with curvature correction. This may indicate a flaw in the design of the questionnaire, but may also reflect the general disappointment and frustration of patients with PD (Levine et al., 2010). Thus, preoperative counseling and setting appropriate expectations as with any prosthesis placement are critical (Akin-Olugbade et al., 2006). It is recommended that preoperative discussion also be focused on the goal of obtaining “functional straightness,” in which a residual curvature of 20 degrees or less in any direction would likely not compromise sexual activity and may correct in time as a result of tissue expansion caused by the cylinders. A comparison of outcomes between the two three-piece inflatable devices in North America found no significant advantage with respect to device reliability, infection, or patient satisfaction (Chung et al., 2013c).

By far the most common postoperative complaint heard from men who have undergone penile prosthesis placement is length loss (Montague, 2007). Wang et al. objectively evaluated penile length change after prosthesis implantation and demonstrated decreases of 0.8, 0.75, and 0.74 cm at 6 weeks, 6 months, and 1 year after surgery, respectively (Wang et al., 2009). This is of particular concern in the PD population, who often already have loss of penile length. Any additional length loss as a result of the implant may be distressing to the patient and should be addressed preoperatively. For men who cannot tolerate any further length loss, a recent small pilot study using traction therapy before penile prosthesis placement in men with PD and other disorders causing penile shortening (e.g., prosthesis explants, radical prostatectomy) demonstrated that after 3 to 4 months of daily traction for an average of 3 hours or more per day, there was no further loss of length after prosthesis placement, and the majority had gained some length (0.5 to 2.0 cm) compared with the pretraction SPL (Levine and Rybak, 2011). Postoperative prolonged cylinder inflation has been recommended to maintain penile length and decrease residual curvature; the device is kept inflated for 10 to 30 minutes daily for 3 months starting 6 weeks after surgery. See Table 73.6 for a summary on the outcomes of penile straightening with penile prosthesis placement.

TABLE 73.6

Outcomes of Penile Prosthesis Implantation for Peyronie's Disease

AUTHOR AND DATE	PROSTHESIS TYPE	PATIENTS (*N*)	MEAN FOLLOW-UP (MONTHS)	ADDITIONAL STRAIGHTENING MANEUVERS (%)	S F
Garaffa et al., 2011	Inflatable	129	NR	37	8
	Malleable	80	NR	16	7
Levine et al., 2010	Inflatable	90	49	96	8

DiBlasio et al., 2010	Inflatable	79	20	11	N
Wilson and Delk, 1994	Inflatable	138	NR	8	N
Montague, 2007	Inflatable	72	NR	8	6
Chaudhary et al., 2005	Inflatable	46	12	61	9
Rahman et al., 2004	Inflatable	5	22	100	1
Levine and Dimitriou, 2000	Inflatable	46	39	NR	N
Akin-Olugbade et al., 2006	Inflatable	18	≥6	22.2	6
Usta et al., 2003	Inflatable	42	21 (12–48)	30	8
Wilson et al., 2001	Inflatable	104	60	0	9
Carson et al., 2000	Inflatable	63	NR	NR	8
Morganstern, 1997	Inflatable	309	42	NR	N
Montorsi et al., 1996	Inflatable	33	17	40	7
Rolle et al., 2012	Both (sliding technique)	3	13	100[a]	1
Antonini et al., 2018	Inflatable	145	NR	NR	N
Hatzichristodoulou, 2018	Inflatable	15	15.1	100	1
Egydio and Kuehhas, 2015	Both (sliding technique)	143	9.7	100	9

[a] Sliding procedure is by definition a straightening maneuver.

NR, Not reported.

Key Points: Surgical Management

- Surgical correction of PD with or without penile prosthesis placement remains the gold standard to correct deformity and is indicated when deformity or rigidity compromises or prevents penetrative sexual activity.
- Surgical candidates need to undergo a detailed and comprehensive consent process so that the patient will understand the potential limitations of the surgery and will have appropriate personal expectations, thereby improving

postoperative satisfaction.

- For patients with satisfactory preoperative rigidity with curvature less than 60 to 70 degrees without significant indentation, some form of tunica plication is indicated. There does not appear to be any one plication technique that has been demonstrated to be superior to others, as no head-to-head comparative trials have been published.
- Men who have more severe, complex deformity but who have strong preoperative erectile function and no evidence of venous insufficiency on duplex ultrasound analysis should be considered candidates for straightening with plaque incision or PEG.
- Complications associated with all straightening operations include incomplete straightening, recurrent curvature, shaft shortening, diminished penile sexual sensation, and ED.
- It appears that the nature of the graft is less likely the determining factor with respect to postoperative ED. On the other hand, optimum outcomes are most likely a result of proper patient selection with respect to preoperative erectile status and operative technique.
- For men who have inadequate rigidity and PD, penile prosthesis placement with straightening maneuvers as necessary should be considered first-line surgery.
- The AUA 2015 PD guideline recommends the following:
  - Clinicians may offer penile prosthesis surgery to patients with PD with ED and/or penile deformity sufficient to prevent coitus despite pharmacotherapy and/or vacuum device therapy (Moderate Recommendation; Evidence Strength Grade C).
  - Clinicians may perform adjunctive intraoperative procedures, such as modeling, plication, or incision/grafting, when significant penile deformity persists after insertion of the penile prosthesis (Moderate Recommendation; Evidence Strength Grade C).
  - Clinicians should use an inflatable penile prosthesis for the patient undergoing penile prosthetic surgery for treatment of PD.

Conclusion

PD is far more common than previously thought and is a growth area in urology not only for clinical practice, but also for basic science research. The mysteries of this wound-healing disorder need to be clarified, and this will likely yield better treatment options and potential strategies to prevent progression. It should be recognized that there are acute and stable phases and that surgery should be offered only after the scarring process has been stable for 3 to 6 months. Patients with PD should be counseled that complete correction of the deformity, including curvature, indentation, and shortening, is not likely and that the goal is to allow the patient to function sexually again. The devastating psychological impact of this disease is important to recognize, and psychological counseling is occasionally indicated and should be offered. For patients in the acute phase, nonsurgical treatment is limited to oral NSAIDs. When surgery is indicated, the goal is to correct the deformity and prevent worsening of ED so that penetrative sexual activity is possible. The patient must understand that recovery of his pre-PD penile appearance is not likely and that surgery carries the risk for incomplete straightening and recurrent curvature, further shaft shortening, change in sexual sensitivity, and, most important, diminished postoperative rigidity. For men with drug-refractory ED and PD, placement of a penile prosthesis with straightening maneuvers is the best approach to address both problems with one operation.

Suggested Readings

Avant RA, Ziegelmann M, Nehra A, et al. Penile traction therapy and vacuum erection devices in Peyronie's disease. *Sex Med Rev*. 2018 [Epub ahead of print; pii: S2050-0521(18)30019-2].

Eisenberg ML, Smith JF, Shindel AW, et al. Tunica-sparing ossified Peyronie's plaque excision. *BJU Int*. 2011;107(4):622–625.

Goldstein I, Knoll LD, Lipshultz LI, et al. Changes in the effects of Peyronie's disease after treatment with collagenase clostridium histolyticum: male patients and their female partners. *Sex Med*. 2017;5(2):e124–e130.

Gonzalez-Cadavid NF, Rajfer J. Mechanisms of disease: new insights into the cellular and molecular pathology of Peyronie's disease. *Nat Clin Pract Urol*. 2005;2:291–297.

Hatzichristodoulou G, Osmonov D, Kübler H, et al. Contemporary review of grafting techniques for the surgical treatment of Peyronie's disease. *Sex Med Rev*. 2017;5(4):544–552.

Hatzimouratidis K, Eardley I, Giuliano F, et al. European Association of Urology. EAU guidelines on penile curvature. *Eur Urol*. 2012;62(3):543–552.

Levine LA, Burnett AL. Standard operating procedures for Peyronie's disease. *J Sex Med*. 2013;10:230–244.

Lipshultz LI, Goldstein I, Seftel AD, et al. Clinical efficacy of collagenase Clostridium histolyticum in the treatment of Peyronie's disease by subgroup: results from two large, double-blind, randomized, placebo-controlled, phase III studies. *BJU Int*. 2015;116(4):650–656.

Mulhall JP, Schiff J, Guhring P. An analysis of the natural history of Peyronie's disease. *J Urol*. 2006;175(6):2115–2118 [discussion 2118].

Nehra A, Alterowitz R, Culkin DJ, et al. Peyronie's disease: AUA guideline. *J Urol*. 2015;194(3):745–753.

Pagano MJ, Weinberg AC, Deibert CM, et al. Penile intracavernosal pillars: lessons from anatomy and potential implications for penile prosthesis placement. *Int J Impot Res*. 2016;28(3):114–119.

Papagiannopoulos D, Yura E, Levine L. Examining postoperative outcomes after employing a surgical algorithm for management of Peyronie's disease: a single-institution retrospective review. *J Sex Med*. 2015;12(6):1474–1480.

Ralph D, Gonzalez-Cadavid N, Mirone V, et al. The management of Peyronie's disease: evidence-based 2010 guidelines. *J Sex Med*. 2010;7(7):2359–2374.

References

Abern MR, Larsen S, Levine LA. Combination of penile traction, intralesional verapamil, and oral therapies for Peyronie's disease. *J Sex Med*. 2012;9(1):288–295.

Adamakis I, Tyritzis SI, Stravodimos KG, et al. A novel approach for the surgical management of Peyronie's disease using an acellular, human dermis tissue graft: preliminary results. *World J Urol*. 2011;29(3):399–403.

Adeniyi AA, Goorney SR, Pryor JP, et al. The Lue procedure: an analysis of the outcome in Peyronie's disease. *BJU Int*. 2002;89:404.

Akin-Olugbade O, Parker M, Guhring P, et al. Determinants of patients satisfaction following penile prosthesis surgery. *J Sex Med*. 2006;3:743–748.

Akkus E, Carrier S, Baba K, et al. Structural alterations in the tunica albuginea of the penis: impact of Peyronie's disease, ageing and impotence. *Br J Urol*. 1997;79(1):47–53.

Akkus E, Ozkara H, Alici B, et al. Incision and venous patch graft in the surgical treatment of penile curvature in Peyronie's disease. *Eur Urol*. 2001;40:531–536 [discussion 537].

Alenghat FJ, Ingber DE. Mechanotransduction: all signals point to cytoskeleton, matrix, and integrins. *Sci STKE*. 2002;2002(119):pe6.

Alphs HH, Navai N, Kohler TS, et al. Preoperative clinical and diagnostic characteristics of patients who require delayed IPP after primary Peyronie's repair. *J Sex Med*. 2010;7(3):1262–1268.

Anaissie J, Yafi F, Delay K, et al. Impact of number of cycles of collagenase clostridium histoliticum on outcomes in patients with Peyronie's disease. *Urology*. 2017;100:125–130.

Anderson MS, Shankey TV, Lubrano T, et al. Inhibition of Peyronie's plaque fibroblast proliferation by biologic agents. *Int J Impot Res*. 2000;12(Suppl 3):S25–S31.

Andresen R, Wegner HE, Miller K, et al. Imaging modalities in Peyronie's disease. An intrapersonal comparison of ultrasound sonography, x-ray in mammography technique, computerized tomography, and nuclear magnetic resonance in 20 patients. *Eur Urol*. 1998;34(2):128–134.

Andrews HO, Al-Akraa M, Pryor JP, et al. The Nesbit operation for Peyronie's disease: an analysis of the failures. *BJU Int*. 2001;87(7):658–660.

Antonini G, De Beradinis E, Giudice FD, et al. Inflatable penile prosthesis placement, “Scratch technique” and postoperative vacuum therapy as a combined approach in the definitive treatment of patients with Peyronie's disease. *J Urol*. 2018; 10.1016/j.juro.2018.04.060 [Epub ahead of print; pii: S0022-5347(18)43028-5].

Arafa M, Eid H, El-Badry A, et al. The prevalence of Peyronie's disease in diabetic patients with erectile dysfunction. *Int J Impot Res*. 2007;19:213–217.

Arenas M, Sabater S, Hernández V, et al. Anti-inflammatory effects of low-dose radiotherapy. Indications, dose, and radiobiological mechanisms involved. *Strahlenther Onkol*. 2012;188:975–981.

Aronson D. Cross-linking of glycated collagen in the pathogenesis of arterial and myocardial stiffening of aging and diabetes. *J Hypertens*. 2003;21(1):3–12.

Assoian RK, Klein EA. Growth control by intracellular tension and extracellular stiffness. *Trends Cell Biol*. 2008;18:347–352.

Bacal V, Rumohr J, Sturm R, et al. Correlation of degree of penile curvature between patient estimates and objective measures among men with Peyronie's disease. *J Sex Med*.

2009;6(3):862–865.

Balza E, Borsi L, Allemanni G, et al. Transforming growth factor beta regulates the levels of different fibronectin isoforms in normal human cultured fibroblasts. *FEBS Lett*. 1988;228(1):42–44.

Baskin LS, Duckett JW. Dorsal tunica albuginea plication for hypospadias curvature. *J Urol*. 1994;151:1668–1671.

Beilan JA, Wallen JJ, Bumbarten AS, et al. Intralesional injection of collagenase clostridum histolyticum may increase the risk of late onset penile fracture. *Sex Med Rev*. 2018;6:272–278.

Bella AJ, Sener A, Foell K, et al. Nonpalpable scarring of the penile septum as a cause of erectile dysfunction: an atypical form of Peyronie's disease. *J Sex Med*. 2007;4(1):226–230.

Bennett NE, Guhring P, Mulhall JP. Intralesional verapamil prevents the progression of Peyronie's disease. *Urology*. 2007;69(6):1181–1184.

Berookhim BM, Choi J, Alex B, et al. Deformity stabilization and improvement in men with untreated Peyronie's disease. *BJU Int*. 2014;113(1):133–136.

Bitker MO, Belin J, Jardin A, et al. “Faux pas du coit” with associated rupture of corpora cavernosa and urethra. *Urology*. 1988;32(5):447–448.

Bjekic MD, Vlajinac HD, Sipetic SB, et al. Risk factors for Peyronie's disease: a case-control study. *BJU Int*. 2006;97(3):570–574.

Bokarica P, Parazajder J, Mazuran B, et al. Surgical treatment of Peyronie's disease based on penile length and degree of curvature. *Int J Impot Res*. 2005;17:170–174.

Border WA, Ruoslahti E. Transforming growth factor-beta in disease: the dark side of tissue repair. *J Clin Invest*. 1992;90:1–7.

Brannigan RE, Kim ED, Oyasu R, et al. Comparison of tunica albuginea substitutes for the treatment of Peyronie's disease. *J Urol*. 1998;159:1064–1068.

Brant WO, Bella AJ, Lue TF. 16-dot procedure for penile curvature. *J Sex Med*. 2007;2:277–280.

Bremer J. Carnitine—metabolism and functions. *Physiol Rev*. 1983;63:1420.

Breyer BN, Brant WO, Garcia MM, et al. Complications of porcine small intestine submucosa graft for Peyronie's disease. *J Urol*. 2007;177(2):589–591.

Brock G, Hsu GL, Nunes L, et al. The anatomy of the tunica albuginea in the normal penis and Peyronie's disease. *J Urol*. 1997;157:276–281.

Brown BG, Zhao XQ, Chait A, et al. Simvastatin and niacin, antioxidant vitamins, or the combination for the prevention of coronary disease. *N Engl J Med*. 2001;345(22):1583–1592.

Bueno FR, Shah SB. Implications of tensile loading for the tissue engineering of nerves. *Tissue Eng Part B Rev*. 2008;14:219–233.

Burnett AL, Nehra A, Breau RH, et al. Erectile dysfunction: AUA guideline. *J Urol*. 2018; 10.1016/j.juro.2018.05.004 [Epub ahead of print; pii:S0022-5347(18)43100-X].

Cantini LP, Ferrini MG, Vernet D, et al. Profibrotic role of myostatin in Peyronie's disease. *J Sex Med*. 2008;5:1607–1622.

Carrieri MP, Serraino D, Palmiotto F, et al. A case-control study on risk factors for Peyronie's disease. *J Clin Epidemiol*. 1998;51(6):511–515.

Carson CC, Levine LA. Outcomes of surgical treatment of Peyronie's disease. *BJU Int*. 2014;113(5):704–713.

Carson CC, Mulcahy JJ, Govier FE. Efficacy, safety and patient satisfaction outcomes of the AMS 700CX inflatable penile prosthesis: results of a long-term multicenter study. AMS 700CX Study Group. *J Urol*. 2000;164:376–380.

Carson CC, Sadeghi-Nejad H, Tursi J, et al. Analysis of the clinical safety of intralesional injection of collagenase Clostridium histolyticum (CCH) for adults with Peyronie's disease (PD). *BJU Int*. 2015;116:815–822.

Casabé A, Bechara A, Cheliz G, et al. Risk factors of Peyronie's disease. What does our clinical experience show? *J Sex Med*. 2011;8(2):518–523.

Cavallini G, Biagiotti G, Lo Giudice C. Association between Peyronie's disease and low serum testosterone levels: detection and therapeutic considerations. *J Androl*. 2012;33:381–388.

Cavallini G, Modenini F, Vitali G. Open preliminary randomized prospective clinical trial of efficacy and safety of three different verapamil dilutions for intraplaque therapy of Peyronie's disease. *Urology*. 2007;69(5):950–954.

Cavallini G, Paulis G. Improvement of chronic Peyronie's disease symptoms after diabetic compensation: a retrospective study. *Urology*. 2013;81(4):794–798.

Chahal R, Gogoi NK, Sundaram SK, et al. Corporeal plication for penile curvature caused by Peyronie's disease: the patient's perspective. *BJU Int*. 2001;87:352–356.

Chaudhary M, Sheikh N, Asterling S, et al. Peyronie's disease with erectile dysfunction: penile modeling over inflatable penile prostheses. *Urology*. 2005;65(4):760–764.

Chun JL, McGregor A, Krishnan R, et al. A comparison of dermal and cadaveric pericardial grafts in the modified Horton-Devine procedure for Peyronie's disease. *J Urol*. 2001;166(1):185–188.

Chung E, Clendinning E, Lessard L, et al. Five-year follow-up of Peyronie's graft surgery: outcomes and patient satisfaction. *J Sex Med*. 2011;8:594–600.

Chung E, Deyoung L, Brock GB. The role of PDE5 inhibitors in penile septal scar remodeling: assessment of clinical and radiological outcomes. *J Sex Med*. 2011;8:1472–1477.

Chung E, Yan H, De Young L, et al. Penile Doppler sonographic and clinical characteristics in Peyronie's disease and/or erectile dysfunction: an analysis of 1500 men with male sexual dysfunction. *BJU Int*. 2012;110(8):1201–1205.

Chung E, De Young L, Solomon M, et al. Peyronie's disease and mechanotransduction: an in vitro analysis of the cellular changes to Peyronie's disease in a cell-culture strain system. *J Sex Med*. 2013;10(5):1259–1267.

Chung E, Garcia F, Young LD, et al. A comparative study of the efficacy of intralesional verapamil versus normal saline injection in a novel Peyronie's disease animal model: assessment of immunohistopathological changes and erectile function outcome. *J Urol*. 2013;189(1):380–384.

Chung E, Solomon M, Deyoung L, et al. Comparison between AMS 700 CX and Coloplast Titan Inflatable Penile Prosthesis for Peyronie's disease treatment and remodeling: clinical outcomes and patient satisfaction. *J Sex Med*. 2013;10(11):2855–2860.

Ciancio SJ, Kim ED. Penile fibrotic changes after radical retropubic prostatectomy. *BJU Int*. 2000;85(1):101–106.

Colletta AA, Wakefield LM, Howell FV. Anti-oestrogens induce the secretion of active transforming growth factor beta from human fetal fibroblasts. *Brit J Cancer*. 1990;62:405.

Cormio L, Zucchi A, Lorusso F, et al. Surgical treatment of Peyronie's disease by plaque incision and grafting with buccal mucosa. *Eur Urol*. 2009;55:1469–1475.

Costa WS, Rebello SB, Cardoso LE, et al. Stereological and biochemical analysis of muscular and connective tissue components in the penile corpus cavernosum adjacent to the fibrous plaque of Peyronie's disease. *BJU Int*. 2009;103(2):212–216.

Cowie CC, Rust KF, Byrd-Holt DD, et al. Prevalence of diabetes and high risk for diabetes using A1C criteria in the U.S. population in 1988-2006. *Diabetes Care*. 2010;33:562–568.

Da Ros CT, Graziottin TM, Ribeiro E, et al. Long-term follow-up of penile curvature correction utilizing autologous albugineal crural graft. *Int Braz J Urol*. 2012;38(2):242–247 [discussion 248–249].

da Silva FG, Filho AM, Damião R, et al. Human acellular matrix graft of tunica albuginea for penile reconstruction. *J Sex Med*. 2011;8(11):3196–3203.

de la Peyronie F. Sur quelques obstacles qui s'opposent à l'éjaculation naturelle de la semence. *Mém Acad Chir*. 1743;1:425–434.

Daitch JA, Angermeier KW, Montague DK. Modified corporoplasty for penile curvature: long-term results and patient satisfaction. *J Urol*. 1999;162:2006–2009.

Dalton BL, Carter MF. Venogenic impotence following dermal graft repair for Peyronie's disease. *J Urol*. 1991;146:849–851.

Darby IA, Hewitson TD. Fibroblast differentiation in wound healing and fibrosis. *Int Rev Cytol*. 2007;257:143–179.

Das S. Peyronie's disease: excision and autografting with tunica vaginalis. *J Urol*. 1980;124:818–819.

Del Carlo M, Cole AA, Levine LA. Differential calcium independent regulation of matrix metalloproteinases and tissue inhibitors of matrix metalloproteinases by interleukin-1beta and transforming growth factor-beta in Peyronie's plaque fibroblasts. *J Urol*. 2008;179(6):2447–2455.

Devine CJ Jr, Horton CE. Peyronie's disease. *Clin Plast Surg*. 1988;15:405–409.

Devine CJ Jr, Horton CE. The surgical treatment of Peyronie's disease with a dermal graft. *J Urol*. 1974;111:44.

Devine CJ Jr, Somers KD, Jordan GH, et al. Proposal: trauma as the cause of the Peyronie's lesion. *J Urol*. 1997;157:285–290.

Devine CJ Jr, Somers KD, Ladaga LE. Peyronie's disease: pathophysiology. *Prog Clin Biol Res*. 1991;370:355–358.

Di Stasi SM, Giannantoni A, Stephen RL, et al. A prospective, randomized study using transdermal electromotive administration of verapamil and dexamethasone for Peyronie's disease. *J Urol*. 2004;171(4):1605–1608.

DiBenedetti DB, Nguyen D, Zografos L, et al. A population-based study on Peyronie's disease: prevalence and treatment patterns in the United States. *Adv Urol*. 2011;2011:282503; 10.1155/2011/282503 [Epub 2011 Oct 23].

DiBlasio CJ, Kurta JM, Botta S, et al. Peyronie's disease compromises the durability and component-malfunction rates in patients implanted with an inflatable penile prosthesis. *BJU Int*. 2010;106(5):691–694.

Ding S, Lu J, Zhang H, et al. A novel modification of tunical plication by plaque thinning: long-term results in treating penile curvature of Peyronie's disease. *Int Urol Nephrol*. 2010;42:597–602.

DiPietro LA. Wound healing: the role of the macrophage and other immune cells. *Shock*. 1995;4(4):233–240.

Duggan HE. Effect of x-ray therapy on patients with Peyronie's disease. *J Urol*. 1964;91:572–573.

Dugi DD, Morey AF. Penoscrotal plication as a uniform approach to reconstruction of penile curvature. *BJU Int*. 2010;105(10):1440–1444.

Duncan MR, Berman B, Nseyo UO. Regulation of the proliferation and biosynthetic activities of cultured human Peyronie's disease fibroblasts by interferons-alpha, -beta and -gamma. *Scand J Urol Nephrol*. 1991;25:89–94.

Ebbehoj J, Metz P. Congenital penile angulation. *Br J Urol*. 1987;60:264.

Egydio P, Lucon A, Arap S. Treatment of Peyronie's disease by complete circumferential incision of the tunica albuginea and plaque with bovine pericardium graft. *Urology*. 2002;59:570–574.

Egydio PH, Kuehhas FE. Penile lengthening and widening without graft according to a modified “sliding technique”. *BJU Int*. 2015;116:965–972.

Egydio PH, Lucon AM, Arap S. A single relaxing incision to correct different types of penile curvature: surgical technique based on geometrical principles. *BJU Int*. 2004;94(7):1147–1157.

Ehrlich HP, Bornstein P. Microtubules in transcellular movement of procollagen. *Nat New Biol*. 1972;238:257.

El-Sakka AI, Bakircioglu E, Bhatnagar RS, et al. The effects of colchicine on a Peyronie's-like condition in an animal model. *J Urol*. 1999;161:1980–1983.

El-Sakka AI, Hassoba HM, Pillarisetty RJ, et al. Peyronie's disease is associated with an increase in transforming growth factor-β protein expression. *J Urol*. 1997;158:1391–1394.

El-Sakka AI, Rashwan HM, Lue TF. Venous patch graft for Peyronie's disease: II. Outcome analysis [erratum in J Urol 1999;162:809]. *J Urol*. 1998;160:2050–2053.

El-Sakka AI, Tayeb KA. Peyronie's disease in diabetic patients being screened for erectile dysfunction. *J Urol*. 2005;174(3):1026–1030.

El-Sakka AI. Prevalence of Peyronie's disease among patients with erectile dysfunction. *Eur Urol*. 2006;49:564–569.

Essed E, Schroeder FH. New surgical treatment for Peyronie's disease. *Urology*. 1985;25:582–587.

Faerber GJ, Konnak JW. Results of combined Nesbit penile plication with plaque incision and placement of Dacron patch in patients with severe Peyronie's disease. *J Urol*. 1993;149(5 Pt 2):1319–1320.

Fallon B. Cadaveric dura mater graft for correction of penile curvature in Peyronie's disease. *Urol*. 1990;35(2):127–129.

Favilla V, Russo G, Zucchi A, et al. Evaluation of intralesional injection of hyaluronic acid compared with verapamil in Peyronie's disease: preliminary results from a prospective, double-blinded, randomized study. *Andrology*. 2017;5:771–775.

Ferretti L, Giuliani M, Bessede T, et al. Tissue engineering for penile surgery: comparative study of noncellular and cell-seeded synthetic grafts for tunica albuginea replacement. *J Sex Med*. 2012;9:625–631.

Ferrini MG, Kovanecz I, Nolazco G, et al. Effects of long-term vardenafil treatment on the development of fibrotic plaques in a rat model of Peyronie's disease. *BJU Int*. 2006;97(3):625–633.

Ferrini MG, Vernet D, Magee TR, et al. Antifibrotic role of inducible nitric oxide synthase. *Nitric Oxide*. 2002;6:283–294.

Fitch WP 3rd, Easterling WJ, Talbert RL, et al. Topical verapamil HCl, topical trifluoperazine, and topical magnesium sulfate for the treatment of Peyronie's disease—a placebo-controlled pilot study. *J Sex Med*. 2007;4:477–484.

Flores S, Choi J, Alex B, et al. Erectile dysfunction after plaque incision and grafting: short-term assessment of incidence and predictors. *J Sex Med*. 2011;8(7):2031–2037.

Furey CA Jr. Peyronie's disease: treatment by the local injection of meticortelone and hydrocortisone. *J Urol*. 1957;77(2):251–266.

Ganem JP, Lucey DT, Janosko EO, et al. Unusual complications of the vacuum erection device. *Urol*. 1998;51(4):627–631.

Garaffa G, Minervini A, Christopher NA, et al. The management of residual curvature after penile prosthesis implantation in men with Peyronie's disease. *BJU Int*. 2011;108(7):1152–1156.

Garaffa G, Sacca A, Christopher AN, et al. Circumcision is not mandatory in penile surgery. *BJU Int*. 2010;105(2):222–224.

Geertsen UA, Brok KE, Andersen B, et al. Peyronie's curvature treated by plication of the penile fasciae. *Br J Urol*. 1996;77:733–735.

Gelbard M, Goldstein I, Hellstrom WJ, et al. Clinical efficacy, safety and tolerability of collagenase Clostridium histolyticum for the treatment of Peyronie's disease in 2 large double-blind, randomized, placebo controlled phase 3 studies. *J Urol*. 2013;190:199–207.

Gelbard M, Lindner A, Chvapil M, et al. Topical beta-aminopropionitrile in the treatment of Peyronie's disease. *J Urol*. 1983;129(4):746–748.

Gelbard M, Lipshultz LI, Tursi J, et al. Phase 2b study of clinical efficacy and safety of collagenase Clostridium histolyticum in patients with Peyronie's disease. *J Urol*. 2012;187:2268–2274.

Gelbard M. Myofibroblasts and mechanotransduction: do forces in the tunica albuginea contribute to Peyronie's disease? *J Sex Med*. 2008;5(12):2974–2976.

Gelbard MK, Dorey F, James K. The natural history of Peyronie's disease. *J Urol*. 1990;144:1376–1379.

Gelbard MK, Hayden B. Expanding contractures of the tunica albuginea due to Peyronie's disease with temporalis fascia free grafts. *J Urol*. 1991;145(4):772–776.

Gelbard MK, James K, Riach P, et al. Collagenase versus placebo in the treatment of Peyronie's disease: a double-blind study. *J Urol*. 1993;149:56–58.

Gelbard MK, Walsh R, Kaufman J. Collagenase for Peyronie's disease. *Urol Res*. 1982;10:135–140.

Gelbard MK. Relaxing incisions in the correction of penile deformity due to Peyronie's disease. *J Urol*. 1995;154:1457–1460.

Gentile V, Modesti A, La Pera G, et al. Ultrastructural and immunohistochemical characterization of the tunica albuginea in Peyronie's disease and veno-occlusive dysfunction. *J Androl*. 1996;17(2):96–103.

Ghanem HM, Fahmy I, El-Meliegy A. Malleable penile implants without plaque surgery in the treatment of Peyronie's disease. *Int J Impot Res*. 1998;10:171–173.

Gholami SS, Gonzalez-Cadavid NF, Lin CS, et al. Peyronie's disease: a review. *J Urol*. 2003;169:1234–1241.

Gholami SS, Lue TF. Correction of penile curvature using the 16-dot plication technique: a review of 132 patients. *J Urol*. 2002;167:2066–2069.

Gontero P, Di Marco M, Giubilei G, et al. Use of penile extender device in the treatment of penile curvature as a result of Peyronie's disease. Results of a phase II prospective study. *J Sex Med*. 2009;6:558–566.

Gonzalez-Cadavid NF, Rajfer J. Experimental models of Peyronie's disease. Implications for new therapies. *J Sex Med*. 2009;6(2):303–313.

Gonzalez-Cadavid NF, Rajfer J. Mechanisms of disease: new insights into the cellular and molecular pathology of Peyronie's disease. *Nat Clin Pract Urol*. 2005;2:291–297.

Gonzalez-Cadavid NF, Rajfer J. Treatment of Peyronie's disease with PDE5 inhibitors: a fibrotic strategy. *Nat Rev Urol*. 2010;7(4):215–221.

Gonzalez-Cadavid NF. Mechanisms of penile fibrosis. *J Sex Med*. 2009;6(Suppl 3):353–362.

Graves DT, Jiang Y, Valente AJ. The expression of monocyte chemoattractant protein-1 and other chemokines by osteoblasts. *Front Biosci*. 1999;4:D571–D580.

Graves DT. The potential role of chemokines and inflammatory cytokines in periodontal disease progression. *Clin Infect Dis*. 1999;28:482–490.

Grazziotin TM, Da Ros C, Teloken C, et al. Expression of matrix metalloproteinase inhibitors: a new paradigm in Peyronie's disease [abstract 65]. *J Sex Med*. 2004;1(Suppl 1):49.

Greenfield JM, Levine LA. Peyronie's disease: etiology, epidemiology and medical treatment. *Urol Clin North Am*. 2005;32:469–478.

Greenfield JM, Lucas S, Levine LA. Factors affecting the loss of length associated with tunica albuginea plication for correction of curvature. *J Urol*. 2006;175:238–241.

Greenfield JM, Shah SJ, Levine LA. Verapamil versus saline in electromotive drug administration for Peyronie's disease: a double-blind, placebo controlled trial. *J Urol*. 2007;177:972–975.

Gudmundsson KG, Arngrímsson R, Sigfússon N, et al. Epidemiology of Dupuytren's disease: clinical, serological, and social assessment. The Reykjavik Study. *J Clin Epidemiol*. 2000;53(3):291–296.

Gur S, Limin M, Hellstrom WJ. Current status and new developments in Peyronie's disease: medical, minimally invasive and surgical treatment options. *Expert Opin Pharmacother*. 2011;12(6):931–944.

Gürdal H, Sara Y, Tulunay FC. Effects of calcium channel blockers on formalin-induced nociception and inflammation in rats. *Pharmacology*. 1992;44:290–296.

Hakim LS, Kulaksizoglu H, Hamill BK, et al. Guide to safe corporotomy incisions in the presence of underlying inflatable penile cylinders: results of in vitro and in vivo studies. *J Urol*. 1996;155:918–923.

Hatzichristodoulou G. The PICS technique: a novel approach for residual curvature correction during penile prosthesis implantation in patients with severe Peyronie's disease using the collagen fleece TachoSil. *J Sex Med*. 2018;15:416–421.

Hatzichristodoulou G, Gschwend JE, Lahme S. Surgical therapy of Peyronie's disease by partial plaque excision and grafting with collagen fleece: feasibility study of a new technique. *Int J Impor Res*. 2013;25:183–197.

Hatzichristodoulou G, Meisner C, Gschwend JE, et al. Extracorporeal shock wave therapy in Peyronie's disease: results of a placebo-controlled, prospective, randomized, single-blind study. *J Sex Med*. 2013;10(11):2815–2821.

Hatzichristou DG, Hatzimouratidis K, Apostolidis A, et al. Corporoplasty using tunica albuginea free grafts for penile curvature: surgical technique and long-term results. *J Urol*. 2002;167:1367.

Hatzimouratidis K, Eardley I, Giuliano F, et al. European Association of Urology. EAU guidelines on penile curvature. *Eur Urol*. 2012;62(3):543–552.

Hauck EW, Hackstein N, Vosshenrich R, et al. Diagnostic value of magnetic resonance imaging in Peyronie's disease—a comparison both with palpation and ultrasound in the evaluation of plaque formation. *Eur Urol*. 2003;43:293–300.

Hellstrom WJ. The use of prosthetic materials in the surgical management of Peyronie's disease. *Int J Impot Res*. 1994;6(Suppl 2):D32.

Hellstrom WJ. History, epidemiology, and clinical presentation of Peyronie's disease. *Int J Impot Res*. 2003;15(Suppl 5):S91–S92.

Hellstrom WJ, Reddy S. Application of pericardial graft in the surgical management of Peyronie's disease. *J Urol*. 2000;163(5):1445–1447.

Hellstrom WJ, Kendirci M, Matern R, et al. Single-blind, multicenter, placebo controlled, parallel study to assess the safety and efficacy of intralesional interferon alpha-2B for minimally invasive treatment for Peyronie's disease. *J Urol*. 2006;176:394–398.

Hellstrom WJ, Feldman R, Rosen RC, et al. Bother and distress associated with Peyronie's disease: validation of the Peyronie's disease questionnaire. *J Urol*. 2013;190(2):627–634.

Horstmann M, Kwol M, Amend B, et al. A self-reported long-term follow-up of patients operated with either shortening techniques or a TachoSil grafting procedure. *Asian J Androl*. 2011;13:326–331.

Horton CE, Sadove RC, Devine CJ. Peyronie's disease. *Ann Plast Surg*. 1987;18:122–127.

Hsu YS, Huang WJ, Kuo JY, et al. Experience of surgical treatment of Peyronie's disease with deep dorsal venous patch graft in Taiwanese men. *J Chin Med Assoc*. 2003;66:487–491.

Hudak SJ, Morey AF, Adibi M, et al. Favorable patient reported outcomes following penile plication for wide array of Peyronie's deformities. *J Urol*. 2013;189:1019–1024.

Ihn H. Pathogenesis of fibrosis: role of TGF-beta and CTGF. *Curr Opin Rheumatol*. 2002;14(6):681–685.

Ilizarov GA. The tension-stress effect on the genesis and growth of tissues. Part 1. The influence of stability of fixation and soft-tissue preservation. *Clin Orthop Relat Res*. 1989;238:249–281.

Imbeault A, Bernard G, Ouellet G, et al. Surgical option for the correction of Peyronie's disease: an autologous tissue-engineered endothelialized graft. *J Sex Med*. 2011;8(11):3227–3235.

Incrocci L, Wijnmaalen A, Slob AK, et al. Low-dose radiotherapy in 179 patients with Peyronie's disease: treatment outcome and current sexual functioning. *Int J Radiat Oncol Biol Phys*. 2000;47(5):1353–1356.

Jalkut M, Gonzalez-Cadavid N, Rajfer J. Peyronie's disease: a review. *Rev Urol*. 2003;5(3):142–148.

Jarow JP, Lowe FC. Penile trauma: an etiologic factor in

Peyronie's disease and erectile dysfunction. *J Urol*. 1997;158:1388–1390.

John T, Bandi G, Santucci R. Porcine small intestinal submucosa is not an ideal graft material for Peyronie's disease surgery. *J Urol*. 2006;176:1025–1029.

Jones WJ. Counseling men with sexual dysfunction. *AUA Update Series*. 1997;XVI(lesson 23):178–184.

Jordan GH, Angermeier K. Preoperative evaluation of erectile function with dynamic infusion cavernosometry/cavernosography in patients undergoing surgery for Peyronie's disease: correlation with postoperative results. *J Urol*. 1993;150:1138–1142.

Jordan GH. Peyronie's disease. Wein AJ, Kavoussi LR, Novick AC, et al. *Campbell-Walsh urology*. 9th ed. Saunders Elsevier: Philadelphia; 2007:818–838.

Jordan GH. The use of intralesional clostridial collagenase injection therapy for Peyronie's disease: a prospective, single-center, non-placebo-controlled study. *J Sex Med*. 2008;5:180–187.

Kadioglu A, Tefekli A, Usta M, et al. Surgical treatment of Peyronie's disease with incision and venous patch technique. *Int J Impot Res*. 1999;11:75.

Kadioglu A, Tefekli A, Erol B, et al. A retrospective review of 307 men with Peyronie's disease. *J Urol*. 2002;168(3):1075–1079.

Kadioglu A, Akman T, Sanli O, et al. Surgical treatment of Peyronie's disease: a critical analysis. *Eur Urol*. 2006;50:235–248.

Kadioglu A, Sanli O, Akman T, et al. Graft materials in Peyronie's disease surgery: a comprehensive review. *J Sex Med*. 2007;4:581–595.

Kadioglu A, Sanli O, Akman T, et al. Surgical treatment of Peyronie's disease: a single center experience with 145 patients. *Eur Urol*. 2008;53(2):432–439.

Kadioglu A, Kucukdurmaz F, Sanli O. Current status of the surgical management of Peyronie's disease. *Nat Rev Urol*. 2011;8:95–106.

Kadioglu A, Sanli O, Akman T, et al. Factors affecting the degree of penile deformity in Peyronie's disease: an analysis of 1001 patients. *J Androl*. 2011;32(5):502–508.

Kalsi J, Minhas S, Christopher N, et al. The results of plaque incision and venous grafting (Lue procedure) to correct the penile deformity of Peyronie's disease. *BJU Int*. 2005;95(7):1029–1033.

Kalsi JS, Christopher N, Ralph DJ, et al. Plaque incision and fascia lata grafting in the surgical management of Peyronie's disease. *BJU Int*. 2006;98(1):110–114 [discussion 114–115].

Kargi E, Yesilli C, Hosnuter M, et al. Relaxation incision and fascia lata grafting in the surgical correction of penile curvature in Peyronie's disease. *Plast Reconstr Surg*. 2004;113:254–259.

Kelami A. Classification of congenital and acquired penile deviation. *Urol Int*. 1983;38:229–233.

Kelly DA. Penises as variable-volume hydrostatic skeletons. *Ann N Y Acad Sci*. 2007;1101:453–463.

Kendirci M, Hellstrom WJ. Critical analysis of surgery for Peyronie's disease. *Curr Opin Urol*. 2004;14:381–388.

Kendirci M, Nowfar S, Gur S, et al. The relationship between the type of penile deformity and penile vascular status in patients with Peyronie's disease. *J Urol*. 2005;174:632–635.

Kendirci M, Trost L, Sikka SC, et al. Diabetes mellitus is associated with severe Peyronie's disease. *BJU Int*. 2007;99(2):383–386.

Kim DH, Lesser TF, Aboseif SR. Subjective patient-reported experiences after surgery for Peyronie's disease: corporeal plication versus plaque incision with vein graft. *Urology*.

2008;71(4):698–702.

Kim JH, Carson CC 3rd. Development of Peyronie's disease with the use of a vacuum constriction device. *J Urol*. 1993;149(5 Pt 2):1314–1315.

Klevmark B, Andersen M, Schultz A. Congenital and acquired curvature of the penis treated surgically by plication of the tunica albuginea. *Br J Urol*. 1994;74:501–506.

Knittel T, Mehde M, Kobold D, et al. Expression patterns of matrix metalloproteinases and their inhibitors in parenchymal and non-parenchymal cells of rat liver: regulation by TNF-alpha and TGF-beta1. *J Hepatol*. 1999;30(1):48–60.

Knoll LD. Use of porcine small intestinal submucosal graft in the surgical management of Peyronie's disease. *Urol*. 2001;57:753–757.

Knoll LD. Use of small intestinal submucosa graft for the surgical management of Peyronie's disease. *J Urol*. 2007;178:2474–2478.

Kovac JR, Brock GB. Surgical outcomes and patient satisfaction after dermal, pericardial, and small intestinal submucosal grafting for Peyronie's disease. *J Sex Med*. 2007;4:1500–1508.

Kümmerling S, Schubert J. Peyronie's disease. Investigation of staging, erectile failure and operative management. *Int Urol Nephrol*. 1995;27(5):629–637.

La Pera G, Pescatori ES, Calabrese M, et al. Peyronie's disease: prevalence and association with cigarette smoking. A multicenter population-based study in men aged 50-69 years. *Eur Urol*. 2001;40:525–530.

Lahme S, Gotz T, Bichler KH. Collagen Fleece for defect coverage following plaque excision in patients with Peyronie's disease. *Euro Urol*. 2002;41:401–405.

LaRochelle JC, Levine LA. A survey of primary-care physicians and urologists regarding Peyronie's disease. *J Sex Med*.

2007;4(4 Pt 2):1167–1173.

Larsen SM, Levine LA. Review of non-surgical treatment options for Peyronie's disease. *Int J Impot Res*. 2012;24:1–10.

Larsen SM, Levine LA. Surgery for Peyronie's disease. *Asian J Androl*. 2013;15:27–34.

Lee EW, Shindel AW, Brandes SB. Small intestinal submucosa for patch grafting after plaque incision in the treatment of Peyronie's disease. *Int Braz J Urol*. 2008;34:191–196.

Lee RC, Ping JA. Calcium antagonists retard extracellular matrix production in connective tissue equivalent. *J Surg Res*. 1990;49(5):463–466.

Leungwattanakij S, Bivalacqua TJ, Reddy S, et al. Long-term follow-up on use of pericardial graft in the surgical management of Peyronie's disease. *Int J Impot Res*. 2001;12:183–186.

Leungwattanakij S, Bivalacqua TJ, Yang DY, et al. Comparison of cadaveric pericardial, dermal, vein, and synthetic grafts for tunica albuginea substitution using a rat model. *BJU Int*. 2003;92:119–124.

Levine L, Rybak J, Corder C, et al. Peyronie's disease plaque calcification–prevalence, time to identification, and development of a new grading classification. *J Sex Med*. 2013;10(12):3121–3128.

Levine L. Comment on topical verapamil HCL, topical trifluoperazine, and topical magnesium sulfate for the treatment of Peyronie's disease—a placebo-controlled pilot study. *J Sex Med*. 2007;4(4 Pt 1):1081–1082.

Levine LA, Benson JS, Hoover C. Inflatable penile prosthesis placement in men with Peyronie's disease and drug-resistant erectile dysfunction: a single-center study. *J Sex Med*. 2010;7:3775–3783.

Levine LA, Burnett AL. Standard operating procedures for Peyronie's disease. *J Sex Med*. 2013;10:230–244.

Levine LA, Coogan CL. Penile vascular assessment using color duplex sonography in men with Peyronie's disease. *J Urol*. 1996;155(4):1270–1273.

Levine LA, Dimitriou RJ. A surgical algorithm for penile prosthesis placement in men with erectile failure and Peyronie's disease. *Int J Impot Res*. 2000;12:147–151.

Levine LA, Estrada CR, Shou W, et al. Tunica albuginea tissue analysis after electromotive drug administration. *J Urol*. 2003;169:1775–1778.

Levine LA, Estrada CR. Human cadaveric pericardial graft for the surgical correction of Peyronie's disease. *J Urol*. 2003;170:2359–2362.

Levine LA, Estrada CR. Intralesional verapamil for the treatment of Peyronie's disease: a review. *Int J Impot Res*. 2002;14(5):324–328.

Levine LA, Estrada LR, Morgantaler A. Mechanical reliability and safety of, and patient satisfaction with the Ambicor inflatable penile prosthesis: results of a 2 center study. *J Urol*. 2001;166:932–937.

Levine LA, Goldman KE, Greenfield JM. Experience with intraplaque injection of verapamil for Peyronie's disease. *J Urol*. 2002;168(2):621–625 [discussion 625–626].

Levine LA, Greenfield JM, Estrada CR. Erectile dysfunction following surgical correction of Peyronie's disease and a pilot study of the use of sildenafil citrate rehabilitation for postoperative erectile dysfunction. *J Sex Med*. 2005;2(2):241–247.

Levine LA, Greenfield JM. Establishing a standardized evaluation of the man with Peyronie's disease. *Int J Impot Res*. 2003;15(Suppl 5):S103–S112.

Levine LA, Larsen SM. Surgery for Peyronie's disease. *Asian J Androl*. 2013;15(1):27–34.

Levine LA, Latchamsetty KC. Treatment of erectile dysfunction in patients with Peyronie's disease using sildenafil citrate. *Int J Impot Res*. 2002;14:478–482.

Levine LA, Lenting EL. A surgical algorithm for the treatment of Peyronie's disease. *J Urol*. 1997;158:2149–2152.

Levine LA, Merrick PF, Lee RC. Intralesional verapamil injection for the treatment of Peyronie's disease. *J Urol*. 1994;151(6):1522–1524.

Levine LA, Newell M, Taylor FL. Penile traction therapy for treatment of Peyronie's disease: a single-center pilot study. *J Sex Med*. 2008;5(6):1468–1473.

Levine LA, Rybak J. Traction therapy for men with shortened penis prior to penile prosthesis implantation: a pilot study. *J Sex Med*. 2011;8:2112–2117.

Levine LA. Partial plaque excision and grafting (PEG) for Peyronie's disease. *J Sex Med*. 2011;8:1842–1845.

Levine LA. Penile straightening with tunica albuginea plication: TAP procedure. Levine LA. *Peyronie's disease: a guide to clinical management*. Humana Press: Totowa, NJ; 2006:151–160.

Levine LA. The clinical and psychosocial impact of Peyronie's disease. *Am J Manag Care*. 2013;19(4 Suppl):S55–S61.

Levine LA. Treatment of Peyronie's disease with intralesional verapamil injection. *J Urol*. 1997;158(4):1395–1399.

Licht MR, Lewis RW. Modified Nesbit procedure for the treatment of Peyronie's disease: a comparative outcome analysis. *J Urol*. 1997;158:460–463.

Lin G, Shindel AW, Banie L, et al. Pentoxifylline attenuates transforming growth factor-beta1-stimulated elastogenesis in human tunica albuginea–derived fibroblasts: Part 2. Interference in a TGF-beta1/Smad-dependent mechanism and downregulation of AAT1. *J Sex Med*. 2010;7(5):1787–1797.

Lindsay MB, Schain DM, Grambsch P, et al. The incidence of Peyronie's disease in Rochester, Minnesota, 1950 through

1984. *J Urol*. 1991;146(4):1007–1009.

Liu B, Li Q, Cheng G, et al. Surgical Treatment of Peyronie's Disease with autologous tunica vaginalis of testes. *BMC Urol*. 2016;16:1.

Lopez JA, Jarow JP. Penile vascular evaluation of men with Peyronie's disease. *J Urol*. 1993;149(1):53–55.

Lowsley OS, Boyce WH. Further experiences with an operation for the cure of Peyronie's disease. *J Urol*. 1950;63(5):888–902.

Lue TF, El-Sakka AI. Venous patch graft for Peyronie's disease: Part I. Technique. *J Urol*. 1998;160:2047–2049.

Ma L, Yang Y, Sikka SC, et al. Adipose tissue–derived stem cell–seeded small intestinal submucosa for tunica albuginea grafting and reconstruction. *Proc Natl Acad Sci USA*. 2012;109(6):2090–2095.

Magee TR, Qian A, Rajfer J, et al. Gene expression profiles in the Peyronie's disease plaque. *Urology*. 2002;59:451–457.

Margadant C, Sonnenberg A. Integrin-TGF-beta crosstalk in fibrosis, cancer and wound healing. *EMBO Rep*. 2010;11(2):97–105.

Martin DJ, Badwan K, Parker M, et al. Transdermal application of verapamil gel to the penile shaft fails to infiltrate the tunica albuginea. *J Urol*. 2002;168:2483–2485.

Martínez-Salamanca JI, Egui A, Moncada I, et al. Acute phase Peyronie's disease management with traction device: a nonrandomized prospective controlled trial with ultrasound correlation. *J Sex Med*. 2014;11(2):506–515.

Marzi M, Zucchi A, Lombi R, et al. Implant surgery in Peyronie's disease. *Urol Int*. 1997;58:113.

Matsushita O, Koide T, Kobayashi R, et al. Substrate recognition by the collagen-binding domain of Clostridium histolyticum class I collagenase. *J Biol Chem*. 2001;276(12):8761–8770.

Mohamed AM, Erdman AG, Timm GW. The biomechanics of erections: two- versus one-compartment pressurized vessel modeling of the penis. *J Biomech Eng*. 2010;132(12):121004.

Molea G, Schonauer F, Blasi F. Progressive skin extension: clinical and histological evaluation of a modified procedure using Kirschner wires. *Br J Plast Surg*. 1999;52:205–208.

Montague DK, Angermeier KW, Lakin MM, et al. AMS 3-piece inflatable penile prosthesis implantation in men with Peyronie's disease: comparison of CX and Ultrex cylinders. *J Urol*. 1996;156:1633–1635.

Montague DK. Penile prosthesis implantation: size matters. *Eur Urol*. 2007;51:887–888.

Montorsi F, Guazzoni G, Barbieri L, et al. AMS CX inflatable penile implants for Peyronie's disease: functional results, morbidity and patient-partner satisfaction. *Int J Impot Res*. 1996;8:81.

Montorsi F, Guazzoni G, Bergamaschi F, et al. Patient-partner satisfaction with semirigid penile prosthesis for Peyronie's disease: a 5-year follow-up study. *J Urol*. 1993;150:1819–1821.

Montorsi F, Salonia A, Briganti A. Five year follow-up of plaque incision and vein grafting for Peyronie's disease. *J Urol*. 2004;171:331.

Montorsi F, Salonia A, Maga T, et al. Evidence based assessment of long-term results of plaque incision and vein grafting for Peyronie's disease. *J Urol*. 2000;163:1704.

Morales TI, Kuettner KE, Howell DS, et al. Characterization of the metalloproteinase inhibitor produced by bovine articular chondrocyte cultures. *Biochim Biophys Acta*. 1983;760(2):221–229.

Moreno SA, Morgentaler A. Testosterone deficiency and Peyronie's disease: pilot data suggesting treatment of Peyronie's disease. *Tech Urol*. 2009;3:86.

Morganstern SL. Long-term experience with the AMS 700CX inflatable penile prosthesis in the treatment of Peyronie's disease. *Tech Urol*. 1997;3:86–88.

Moskovic DJ, Alex B, Choi JM, et al. Defining predictors of response to intralesional verapamil injection therapy for Peyronie's disease. *BJU Int*. 2011;108:1485–1489.

Mulhall JP, Branch J, Lubrano T, et al. Perturbation of cell cycle regulators in Peyronie's disease fibroblasts. *Int J Impot Res*. 2001;13(Suppl):S21–S28.

Mulhall JP, Anderson MS, Lubrano T, et al. Peyronie's disease cell culture models: phenotypic, genotypic and functional analyses. *Int J Impot Res*. 2002;14(5):397–405.

Mulhall JP, Ahmed P, Anderson M. Penile prosthetic surgery for Peyronie's disease: defining the need for intra-operative adjuvant maneuvers. *J Sex Med*. 2004;1:318.

Mulhall JP, Creech SD, Boorjian SA, et al. Subjective and objective analysis of the prevalence of Peyronie's disease in a population of men presenting for prostate cancer screening. *J Urol*. 2004;171(6 Pt 1):2350–2353.

Mulhall J, Anderson M, Parker M. A surgical algorithm for men with combined Peyronie's disease and erectile dysfunction. Functional and satisfaction outcomes. *J Sex Med*. 2005;2:132–138.

Mulhall JP, Schiff J, Guhring P. An analysis of the natural history of Peyronie's disease. *J Urol*. 2006;175(6):2115–2118 [discussion 2118].

Mulhall JP, Hall M, Broderick GA, et al. Radiation therapy in Peyronie's disease. *J Sex Med*. 2012;9:1435–1441.

Musitelli SI, Bossi M, Jallous H. A brief historical survey of “Peyronie's disease. *J Sex Med*. 2008;5:1737–1746.

Nachtsheim DA, Rearden A. Peyronie's disease is associated with an HLA class II antigen, HLA-DQ5, implying an autoimmune etiology. *J Urol*. 1996;156:1330–1334.

Nam HJ, Park HJ, Park NC. Does testosterone deficiency exaggerate the clinical symptoms of Peyronie's disease? *Int J Urol*. 2011;18(11):796–800.

Nehra A, Alterowitz R, Culkin DJ, et al. Peyronie's disease: AUA guideline. *J Urol*. 2015;194(3):745–753.

Nelson CJ, Diblasio C, Kendirci M, et al. The chronology of depression and distress in men with Peyronie's disease. *J Sex Med*. 2008;5:1985–1990.

Nelson CJ, Mulhall JP. Psychological impact of Peyronie's disease: a review. *J Sex Med*. 2013;10(3):653–660.

Nesbit RM. Congenital curvature of the phallus: report of three cases with description of corrective operation. *J Urol*. 1965;93:230–232.

Nguyen H, Anaissie J, Delay K, et al. Safety and efficacy of Collagenase clostridum histolyticum in the treatment of acute-phase Peyronie's disease. *J Sex Med*. 2017;14:1220–1225.

Nooter RI, Bosch JL, Schröder FH. Peyronie's disease and congenital penile curvature: long-term results of operative treatment with the plication procedure. *Br J Urol*. 1994;74(4):497–500.

Nugteren HM, Nijman JM, de Jong IJ, et al. The association between Peyronie's and Dupuytren's disease. *Int J Impot Res*. 2011;23(4):142–145.

O'Brien K, Parker M, Guhring P, et al. Analysis of the natural history of Peyronie's disease [abstract 69]. *J Sex Med*. 2004;1(Suppl 1):50.

O'Donnell PD. Results of surgical management of Peyronie's disease. *J Urol*. 1992;148:1184–1187.

Ohebshalom M, Mulhall J, Guhring P, et al. Measurement of penile curvature in Peyronie's disease patients: comparison of three methods. *J Sex Med*. 2007;4:199–203.

Padma-Nathan H. Neurologic evaluation of erectile dysfunction.

Urol Clin North Am. 1988;15(1):77–80.

Paez A, Mejias J, Vallejo J, et al. Long-term patient satisfaction after surgical correction of penile curvature via tunical plication. *Int Braz J Urol*. 2007;33:502–507.

Palmieri A, Imbimbo C, Creta M, et al. Tadalafil once daily and extracorporeal shock wave therapy in the management of patients with Peyronie's disease and erectile dysfunction: results from a prospective randomized trial. *Int J Androl*. 2012;35:190–195.

Paulis G, Brancato T. Inflammatory mechanisms and oxidative stress in Peyronie's disease: therapeutic “rationale” and related emerging treatment strategies. *Inflamm Allergy Drug Targets*. 2012;11(1):48–57.

Paulis G, Cavallini G, Brancato T, et al. Peironimev-Plus in the treatment of chronic inflammation of tunica albuginea (Peyronie's disease). Results of a controlled study. *Inflamm Allergy Drug Targets*. 2013;12:61–67.

Perito P, Wilson SK. The Peyronie's plaque “scratch”: an adjunct to modeling. *J Sex Med*. 2013;10:1194–1197.

Pescatori ES, Drei B, Silingardi V. Advanced diagnostics in erectile dysfunction: beyond the concept of hemodynamics. *J Endocrinol Invest*. 2003;26(3 Suppl):125–126.

Poulson J, Kikeby HJ. Treatment of penile curvature—a retrospective study of 175 patients operated with plication or with Nesbit's procedure. *Br J Urol*. 1995;75:370–374.

Pryor JP, Farell CF. Controlled clinical trial of vitamin E in Peyronie's disease. *Prog Reprod Biol*. 1983;9:41–45.

Pryor JP, Ralph DJ. Clinical presentations of Peyronie's disease. *Int J Impot Res*. 2002;14(5):414–417.

Qian A, Meals RA, Rajfer J, et al. Comparison of gene expression profiles between Peyronie's disease and Dupuytren's contracture. *Urology*. 2004;64(2):399.

Raetsch C, Jia JD, Boigk G, et al. Pentoxifylline downregulates profibrogenic cytokines and procollagen I expression in rat secondary biliary fibrosis. *Gut*. 2002;50:241–247.

Raheem AA, Capece M, Kalejaiye O, et al. Safety and effectiveness of collagenase clostridium histolyticum in the treatment of Peyronie's disease using a new modified shortened protocol. *BJU Int*. 2017;120:717–723.

Raheem AA, Garaffa G, Raheem TA, et al. The role of vacuum pump therapy to mechanically straighten the penis in Peyronie's disease. *BJU Int*. 2010;106(8):1178–1180.

Rahman NU, Carrion RE, Bochinski D, et al. Combined penile plication surgery and insertion of penile prosthesis for severe penile curvature and erectile dysfunction. *J Urol*. 2004;171:2346–2349.

Ralph DJ. The surgical treatment of Peyronie's disease. *Eur Urol*. 2006;50(2):196–198.

Ralph DJ, Minhas S. The management of Peyronie's disease. *BJU Int*. 2004;93:208–215.

Ralph DJ, Brooks MD, Bottazzo GF, et al. The treatment of Peyronie's disease with tamoxifen. *Br J Urol*. 1992;70(6):648–651.

Ralph D, Al-Akraa M, Pryor J. The Nesbit operation for Peyronie's disease: 16-year experience. *J Urol*. 1995;154:1362–1363.

Ralph DJ, Mirakian R, Pryor JP, et al. The immunological features of Peyronie's disease. *J Urol*. 1996;155(1):159–162.

Ralph D, Gonzalez-Cadavid N, Mirone V, et al. The management of Peyronie's disease: evidence-based 2010 guidelines. *J Sex Med*. 2010;7(7):2359–2374.

Ravanti L, Kahari VM. Matrix metalloproteinases in wound repair. *Int J Mol Med*. 2000;6:391–407.

Reda E, D'Iddio S, Nicolai R, et al. The carnitine system and body composition. *Acta Diabetol*. 2003;40(Suppl 1):S106–S113.

Rehman J, Benet A, Melman A. Use of intralesional verapamil to dissolve Peyronie's disease plaque: a long-term single-blind study. *Urology*. 1998;51:620–626.

Rehman J, Benet A, Minsky LS, et al. Results of surgical treatment for abnormal penile curvature: Peyronie's disease and congenital deviation by modified Nesbit plication (tunical shaving and plication). *J Urol*. 1997;157:1288–1291.

Rhoden EL, Riedner CE, Fuchs SC, et al. A cross-sectional study for the analysis of clinical, sexual and laboratory conditions associated to Peyronie's disease. *J Sex Med*. 2010;7(4 Pt 1):1529–1537.

Rhoden EL, Teloken C, Ting HY, et al. Prevalence of Peyronie's disease in men over 50-y-old from Southern Brazil. *Int J Impot Res*. 2001;13(5):291–293.

Riedl CR, Sternig P, Gallé G, et al. Liposomal recombinant human superoxide dismutase for the treatment of Peyronie's disease: a randomized placebo-controlled double-blind prospective clinical study. *Eur Urol*. 2005;48:656–661.

Rolle L, Ceruti C, Timpano M, et al. A new, innovative, lengthening surgical procedure for Peyronie's disease by penile prosthesis implantation with double dorsal venral patch graft: the “Sliding technique”. *J Sex Med*. 2012;9:2389–2395.

Rolle L, Tamagnone A, Timpano M, et al. The Nesbit operation for penile curvature: an easy and effective technical modification. *J Urol*. 2005;173:171.

Rosen R, Catania J, Lue T, et al. Impact of Peyronie's disease on sexual and psychosocial functioning: qualitative findings in patients and controls. *J Sex Med*. 2008;5:1977–1984.

Roy J, Carrier S. Acute hepatitis associated with treatment of Peyronie's disease with potassium paraaminobenzoate (Potaba). *J Sex Med*. 2008;5(12):2967–2969.

Rybak J, Papagiannopoulos D, Levine L. A retrospective comparative study of traction therapy vs. no traction following tunica albuginea plication or partial excision and grafting for Peyronie's disease: measured lengths and patient perceptions. *J Sex Med*. 2012;9:2396–2403.

Safarinejad MR, Asgari MA, Hosseini SY, et al. A double-blind placebo-controlled study of the efficacy and safety of pentoxifylline in early chronic Peyronie's disease. *BJU Int*. 2010;106:240–248.

Safarinejad MR, Hosseini SY, Kolahi AA. Comparison of vitamin E and propionyl-l-carnitine, separately or in combination, in patients with early chronic Peyronie's disease: a double-blind, placebo controlled, randomized study. *J Urol*. 2007;178:1398–1403.

Safarinejad MR. Therapeutic effects of colchicine in the management of Peyronie's disease: a randomized double-blind, placebo-controlled study. *Int J Impot Res*. 2004;16:238–243.

Sampaio JS, Passarinho FA, Mendes CJ. Peyronie's disease. Surgical correction of 40 patients with relaxing incision and duramater graft. *Eur Urol*. 2002;41:551–555.

Santucci RA, Barber TD. Resorbable extracellular matrix grafts in urologic reconstruction. *Int Braz J Urol*. 2005;31(3):192–203.

Savoca G, Scieri F, Pietropaolo F, et al. Straightening corporoplasty for Peyronie's disease: a review of 218 patients with median follow-up of 89 months. *Eur Urol*. 2004;46:610.

Savoca G, Trombetta C, Ciampalini S, et al. Long-term results with Nesbit's procedure as treatment of Peyronie's disease. *Int J Impot Res*. 2000;12:289–294.

Scardino PL, Scott WW. The use of tocopherols in the treatment of Peyronie's disease. *Ann N Y Acad Sci*. 1949;52:390.

Schaeffer AJ, Burnett AL. Nonsurgical interventions for Peyronie's disease: 2011 update. *J Androl*. 2012;33:3–14.

Schandené L, Vandenbussche P, Crusiaux A, et al. Differential effects of pentoxifylline on the production of tumour necrosis factor-alpha (TNF-alpha) and interleukin-6 (IL-6) by monocytes and T cells. *Immunology*. 1992;76:30–34.

Schneider T, Sperling H, Schenck M, et al. Treatment of penile curvature—how to combine the advantages of simple plication and the Nesbit-procedure by superficial excision of the tunica albuginea. *World J Urol*. 2003;20(6):350–355.

Schultheiss D, Lorenz RR, Meister R, et al. Functional tissue engineering of autologous tunica albuginea: a possible graft for Peyronie's disease surgery. *Eur Urol*. 2004;45(6):781–786.

Schultheiss D, Meschi MR, Hagemann J, et al. Congenital and acquired penile deviation treated with the Essed plication method. *Eur Urol*. 2000;38:167–171.

Schwarzer JU, Muhlen B, Schukai O. Penile corporoplasty using tunica albuginea free graft from proximal corpus cavernosum: a new technique for treatment of penile curvature in Peyronie's disease. *Eur Urol*. 2003;44(6):720–723.

Schwarzer U, Sommer F, Klotz T, et al. The prevalence of Peyronie's disease: results of a large survey. *BJU Int*. 2001;88(7):727–730.

Shaeer O. Trans-corporeal incision of Peyronie's plaques. *J Sex Med*. 2011;8:589–593.

Shapiro F. Bone development and its relation to fracture repair. The role of mesenchymal osteoblasts and surface osteoblasts. *Eur Cell Mater*. 2008;15:53–76.

Shindel AW, Bullock TL, Brandes S. Urologist practice patterns in the management of Peyronie's disease: a nationwide survey. *J Sex Med*. 2008;5(4):954–964.

Shindel AW, Lin G, Ning H, et al. Pentoxifylline attenuates transforming growth factor-β1–stimulated collagen deposition and elastogenesis in human tunica albuginea–derived fibroblasts: Part 1. Impact on extracellular matrix. *J Sex Med*. 2010;7(6):2077–2085.

Shioshvili TJ, Kakonahvili AP. The surgical treatment of Peyronie's disease: replacement of plaque by free autograft of buccal mucosa. *Eur Urol*. 2005;48:129–135.

Shiraishi K, Shimabukuro T, Matsuyama H. The prevalence of Peyronie's disease in Japan: a study in men undergoing maintenance hemodialysis and routine health checks. *J Sex Med*. 2012;9(10):2716–2723.

Shirazi M, Haghpanah AR, Badiee M, et al. Effect of intralesional verapamil for treatment of Peyronie's disease: a randomized single-blind, placebo-controlled study. *Int Urol Nephrol*. 2009;41:467–471.

Smith JF, Walsh TJ, Conti SL, et al. Risk factors for emotional and relationship problems in Peyronie's disease. *J Sex Med*. 2008;5:2179–2184.

Smith JF, Walsh TJ, Lue TF. Peyronie's disease: a critical appraisal of current diagnosis and treatment. *Int J Impot Res*. 2008;20(5):445–459.

Soh J, Kawauchi A, Kanemitsu N, et al. Nicardipine vs. saline injection as treatment for Peyronie's disease: a prospective, randomized, single-blind trial. *J Sex Med*. 2010;7:3743–3749.

Somers KD, Dawson DM. Fibrin deposition in Peyronie's disease plaque. *J Urol*. 1997;157(1):311–315.

Sommer F, Schwarzer U, Wassmer G, et al. Epidemiology of Peyronie's disease. *Int J Impot Res*. 2002;14(5):379–383.

Staerman F, Pierrevelcin J, Ripert T, et al. Medium-term follow-up of plaque incision and porcine small intestinal submucosal grafting for Peyronie's disease. *Int J Impot Res*. 2010;22(6):343–348.

Stuntz M, Perlaky A, des Vignes F, et al. The prevalence of Peyronie's disease in the United States: a population-based study. *PLoS ONE*. 2016;11(2):e0150157; 10.1371/journal.pone.0150157 [eCollection 2016].

Sulaiman MN, Gingell JC. Nesbit's procedure for curvature of the penis. *J Androl*. 1994;15(Suppl):S54–S56.

Sun JS, Hou SM, Hang YS, et al. Ultrastructural studies on myofibrillogenesis and neogenesis of skeletal muscles after prolonged traction in rabbits. *Histol Histopathol*. 1996;11:285–292.

Syed AH, Abbasi Z, Hargreave TB. Nesbit procedure for disabling Peyronie's curvature: a median follow-up of 84 months. *Urology*. 2003;61:999–1003.

Syed F, Thomas AN, Singh S, et al. In vitro study of novel collagenase (XIAFLEX) on Dupuytren's disease fibroblasts displays unique drug related properties. *PLoS ONE*. 2012;7(2):1–22.

Tal R, Hall MS, Alex B, et al. Peyronie's disease in teenagers. *J Sex Med*. 2012;9(1):302–308.

Tal R, Heck M, Teloken P, et al. Peyronie's disease following radical prostatectomy: incidence and predictors. *J Sex Med*. 2010;7(3):1254–1261.

Taylor EW. The mechanism of colchicine inhibition of mitosis. I. Kinetics of inhibition and the binding of H3 colchicine. *J Cell Biol*. 1965;25:145.

Taylor FL, Abern MR, Levine LA. Predicting erectile dysfunction following surgical correction of Peyronie's disease without inflatable penile prosthesis placement: vascular assessment and preoperative risk factors. *J Sex Med*. 2012;9:296–301.

Taylor FL, Levine LA. Peyronie's disease. *Urol Clin North Am*. 2007;34(4):517–534.

Taylor FL, Levine LA. Surgical correction of Peyronie's disease via tunica albuginea plication or partial plaque excision with pericardial graft: long-term follow up. *J Sex Med*.

2008;5:2221–2228.

Tefekli A, Kandirali E, Erol B, et al. Peyronie's disease: a silent consequence of diabetes mellitus. *Asian J Androl*. 2006;8(1):75–79.

Tefekli A, Kandirali E, Erol H, et al. Peyronie's disease in men under age 40: characteristics and outcome. *Int J Impot Res*. 2001;13(1):18–23.

Teloken C, Grazziotin T, Rhoden E, et al. Penile straightening with crural graft of the corpus cavernosum. *J Urol*. 2000;164:107–108.

Teloken C, Rhoden EL, Grazziotin TM, et al. Tamoxifen versus placebo in the treatment of Peyronie's disease. *J Urol*. 1999;162:2003–2005.

Thiounn N, Missirliu A, Zerbib M, et al. Corporeal plication for surgical correction of penile curvature. Experience with 60 patients. *Eur Urol*. 1998;33:401.

Tomasek JJ, Gabbiani G, Hinz B, et al. Myofibroblasts and mechano-regulation of connective tissue remodelling. *Nat Rev Mol Cell Biol*. 2002;3(5):349–363.

Tornehl CK, Carson CC. Surgical alternatives for treating Peyronie's disease. *BJU Int*. 2004;94:774–783.

Twidwell J, Levine L. Topical treatment for acute phase Peyronie's disease utilizing a new gel, H-100: a randomized, prospective, placebo-controlled pilot study. *Int J Impot Res*. 2016;28:41–45.

Usta MF, Bivalacqua TJ, Jabren GW, et al. Relationship between the severity of penile curvature and the presence of comorbidities in men with Peyronie's disease. *J Urol*. 2004;171(2 Pt 1):775–779.

Usta MF, Bivalacqua TJ, Sanabria J, et al. Patient and partner satisfaction and long-term results after surgical treatment for Peyronie's disease. *Urology*. 2003;62(1):105–109.

Valente EG, Vernet D, Ferrini MG, et al. L-arginine and phosphodiesterase (PDE) inhibitors counteract fibrosis in the Peyronie's fibrotic plaque and related fibroblast cultures. *Nitric Oxide*. 2003;9(4):229–244.

Valente P, Gomes C, Tomada N. Small intestinal submucosa grafting for Peyronie's disease: outcomes and patient satisfaction. *Urology*. 2016;100:117–124.

Van de Water L. Mechanisms by which fibrin and fibronectin appear in healing wounds: implications for Peyronie's disease. *J Urol*. 1997;157:306–310.

Van Der Horst C, Martinez Portillo FJ, Seif C, et al. Treatment of penile curvature with Essed-Schröder tunical plication: aspects of quality of life from the patients’ perspective. *BJU Int*. 2004;93:105–108.

Velnar T, Bailey T, Smrkolj V. The wound healing process: an overview of the cellular and molecular mechanisms. *J Int Med Res*. 2009;37(5):1528–1542.

Vernet D, Nolazco G, Cantini L, et al. Evidence that osteogenic progenitor cells in the human tunica albuginea may originate from stem cells: implications for Peyronie's disease. *Biol Reprod*. 2005;73(6):1199–1210.

Wahl SM, McCartney-Francis N, Mergenhagen SE. Inflammatory and immunomodulatory roles of TGF-β. *Immunol Today*. 1989;10:258–261.

Wang R, Howard GE, Hoang A, et al. Prospective and long-term evaluation of erect penile length obtained with inflatable penile prosthesis to that induced by intracavernosal injection. *Asian J Androl*. 2009;11(4):411–415.

Weidner W, Hauck EW, Schnitker J. Peyronie's Disease Study Group of Andrological Group of German Urologists. Potassium paraaminobenzoate (Potaba) in the treatment of Peyronie's disease: a prospective, placebo-controlled, randomized study. *Eur Urol*. 2005;47:530–535.

Wessells H, Lue T, McAninch J. Penile length in the flaccid and erect states: guidelines for penile augmentation. *J Urol*. 1996;156:995–997.

Wild RM, Devine CJ Jr, Horton CE. Dermal graft repair of Peyronie's disease: survey of 50 patients. *J Urol*. 1979;121(1):47–50.

Wilson SK, Cleves MA, Delk JR 2nd. Long-term follow-up of treatment for Peyronie's disease: modeling the penis over an inflatable penile prosthesis. *J Urol*. 2001;165(3):825–829.

Wilson SK, Delk JR 2nd. A new treatment for Peyronie's disease: modeling the penis over an inflatable penile prosthesis. *J Urol*. 1994;152:1121–1123.

Wimpissinger F, Parnham A, Gutjahr G, et al. 10 years' plaque incision and vein grafting for Peyronie's disease: does time matter? *J Sex Med*. 2016;12:120–128.

Yachia D. Corporeal plication for surgical correction of Peyronie's disease. *J Urol*. 1993;149:869.

Yachia D. Modified corporoplasty for the treatment of penile curvature. *J Urol*. 1990;143:80–82.

Yafi FA, Hatzichristodoulou G, Wang J, et al. Outcomes of surgical management of men with Peyronie's disease with hourglass deformity. *Urology*. 2016;91:119–123.

Yang KK, Bennett N. Peyronie's disease and injectable collagenase clostridium histolyticum. *Urology*. 2016;94:143–147.

Zarafonetis CJ, Horrax TM. Treatment of Peyronie's disease with potassium para-aminobenzoate (Potaba). *J Urol*. 1959;81(6):770–772.

Zargooshi J. Trauma as the cause of Peyronie's disease: penile fracture as a model of trauma. *J Urol*. 2004;172(1):186–188.

Zigelmann M, Bole R, Avant R, et al. Conservatively managed Peyronie's disease—long term survey results from patients undergoing non-surgical and non-injection therapies. *Urology*. 2017;113:99–104.

Zorba OU, Sirma S, Ozgon G, et al. Comparison of apoptotic gene expression profiles between Peyronie's disease plaque and tunica albuginea. *Adv Clin Exp Med*. 2012;21(5):607–614.

Zucchi A, Silvani M, Pastore AL, et al. Corpoplasty using buccal mucosa graft in Peyronie's disease: is it a first choice? *Urology*. 2014;85:679–683.

Sexual Function and Dysfunction in the Female

Ervin Kocjancic MD, Valerio Iacovelli MD, Ömer Acar MD

Anatomy and Physiology of Female Sexual Organs

Accurate examination of the female external and internal genitalia is mandatory to better understand female sexual function and dysfunction.

The *distal vagina* is the site of female sexual response and it is interrelated with the clitoris and the female urethra. Though in anatomic terms these are distinct structures, the distal vagina, clitoris, and urethra *(clitoral complex)* share blood supply and innervation. During sexual activity, these structures, with their overlying highly vascular skin (the vulva), respond as a unit. Therefore, the vulva can be defined as the wrapping overlying the clitoro-urethro-vaginal complex. The female erectile organs include the clitoris and the vestibular bulbs.

The erectile complex is made of specialized vascular tissues that are sexually responsive and consist of two histologically distinct types of vascular tissue. Trabeculated erectile tissue is peculiar of the clitoris and the bulbs and allows for engorgement with blood and volume expansion during sexual arousal. The labia minora and glans clitoris are composed of nonerectile vascular tissue, which also is found surrounding the urethral orifice and within the walls of the vagina. A region of the anterior wall of the vagina overlying the mid-urethra has been identified as the Grafenberg spot (or G-spot), an area that is particularly sensitive to tactile stimulation in some women.

The female sexual reflex is mediated by five components: (1) the receptors of the clitoral complex and vulva; (2) somatic afferents (terminal divisions of pudendal nerves via its dorsal clitoral and perineal branches); (3) spinal cord segments S2–S4; (4) visceral efferents (pelvic parasympathetic fibers) via nervi erigentes running in pelvic ganglia; and (5) effectors (erectile or spongy tissue of the clitoral complex) and secretory responses from sub-bulbar and urethral glands. Parasympathetic stimulation causes dilation of arterioles (dorsal and deep arteries of the clitoris) supplying erectile tissue, which becomes engorged. Erection of the clitoral complex is accompanied by swelling of the vulva with changes to the distal vagina and urethra accompanied by a secretory response of the latter structures.

The female sexual response cycle consists of a sequence of physical and emotional changes that occur as a person becomes sexually aroused and participates in sexually stimulating activities, including intercourse and masturbation. Erotic stimuli initiate a series of physiologic changes that have collectively been termed the *sexual response cycle* and are divided into four distinct phases: (1) *excitement/arousal phase* with subjective pleasure and excitement; (2) *plateau phase* during which there is intensification of the changes in phase 1; (3) *orgasm,* a variable, transient peak sensation of intense pleasure, creating an altered state of consciousness; and (4) *resolution phase*, when sexual excitement declines back to baseline levels.

Brain centers deemed particularly important to the integration of sexual desire and arousal responses for women include the medial amygdala, the stria terminalis, the ventromedial nucleus of the hypothalamus, and the paraventricular nucleus (PVN). The nitric oxide (NO)/cyclic guanosine monophosphate (cGMP) pathway contributes to clitoral erection and vaginal vasodilation with sexual arousal. NO activates guanylate cyclase, which produces cGMP. cGMP activates numerous downstream effectors, the net effect of which is to sequester calcium and to reduce contraction of smooth muscle in the clitoral and vaginal circulation and within the vaginal wall.

Hormone levels in the body affect female sexual function. Estrogens maintain female genital tissue integrity and thickness. Levels of estradiol influence both central and peripheral nerve transmissions and regulate nitric oxide synthase (NOS) expression. Testosterone is also important, being related with sexual arousal, libido, sexual responsiveness, genital sensation, and orgasm.

Although female pelvic anatomy is composed of a continuum of organs and structures interrelated in both structure and function, it is helpful to group them into two categories: **external genitalia** *(vulva)* and **internal genitalia** (*vagina, cervix, uterus, fallopian tubes,* and *ovaries*.) The external genital structures are emphasized, because those are the ones about which most physiologic research has been conducted. Female sexual anatomy, essentially concerning the distal vagina, will be described following the publications of O'Connell et al. (O'Connell et al., 2008).

The ***distal vagina*** is the site of **female sexual response,** and it is interrelated with the **clitoris** and the female **urethra.** Though in anatomic terms these are distinct structures, distal vagina, clitoris, and urethra **share blood supply and innervation.** During sexual activity, these structures, with their overlying highly vascular skin (the vulva), respond as a unit. The distal vagina is made up of several components: the introitus, the walls of the vagina, and its associated exocrine glands.

Vulva

The *vulva* can be defined as the wrapping overlying the **clitoro-urethro-vaginal complex**. The vulva is bound anteriorly by the bony symphysis pubis, posteriorly by the anal sphincter, and laterally by the ischial tuberosities. The **vulva consists** of the **mons pubis**; **clitoris** and its **glands**; **labia majora** and **minora**; **vestibule**; **hymen**; **introitus**; **fourchette**; **perineal body**; urethral orifice; and associated **glandular ducts** (Berman et al., 2000; O'Connell et al., 2008; Standring et al., 2008) (eFig. 74.1).

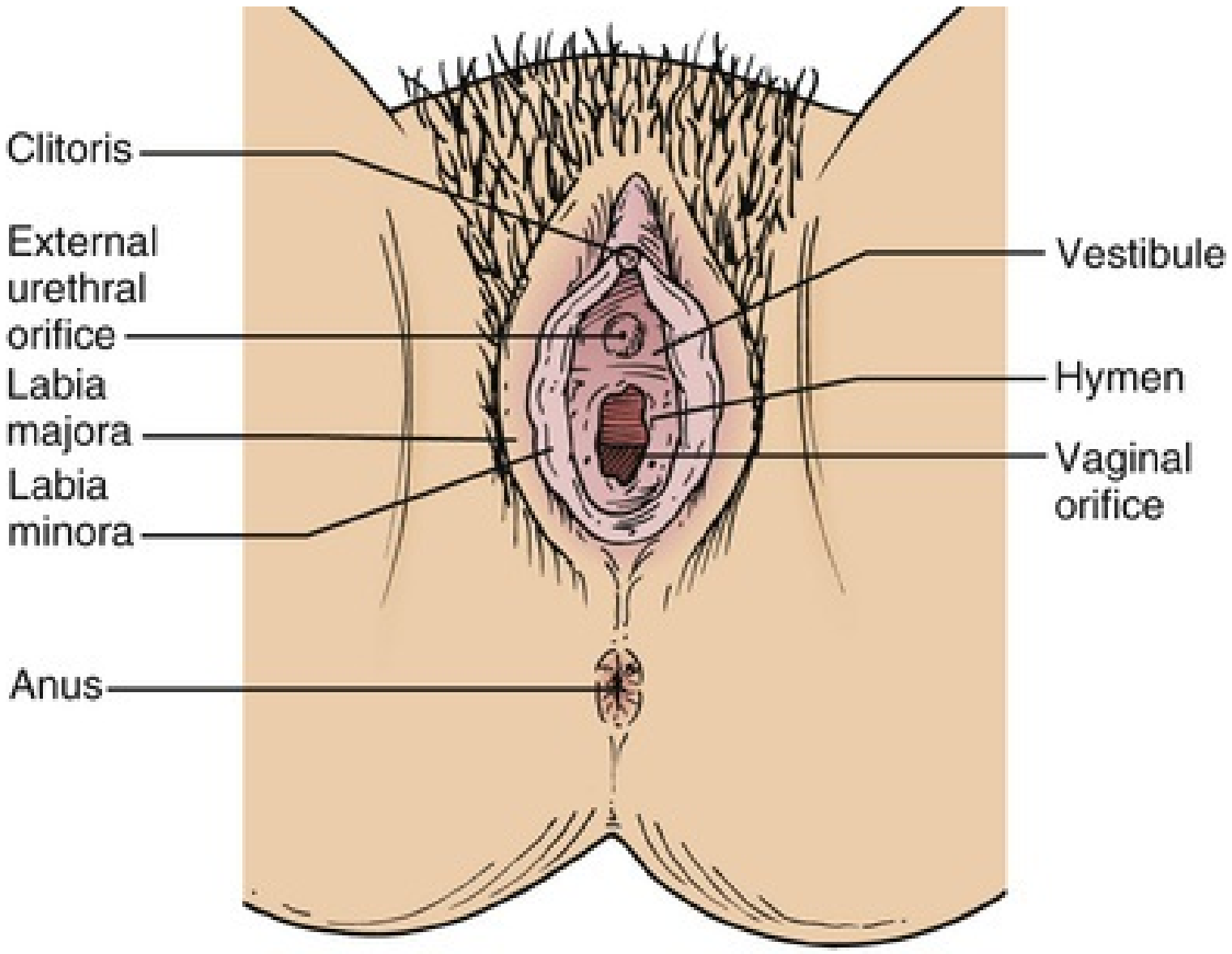

EFIG. 74.1 Clitoro-urethro-vaginal complex.

Mons Pubis

The mons pubis is the rounded eminence that is anterior to the pubic symphysis. It is formed by a mass of **subcutaneous adipose connective tissue.** In adults, the mons is covered by **coarse hair.** This hair is usually limited above by a horizontal boundary. Before adolescence, the mons pubis is relatively flat. During adolescence, coarse hair forms over the mons. After menopause, pubic hair thins. The mons pubis has a **triangle shape with the apex at the glans clitoris**. Mons pubis fascial support to the clitoris and urethra consists of the **suspensory ligaments of the clitoris** (Standring et al., 2008).

Clitoris

The clitoris is an **erectile structure**, homologous with the penis, which lies postero-inferiorly to the anterior commissure. It is partially enclosed by the anterior bifurcated ends of the labia minora. The ***corpus* clitoridis** has **two corpora cavernosa**, which are composed of **erectile tissue** and enclosed in dense fibrous tissue separated medially by an incomplete **fibrous pectiniform septum.** Each corpus cavernosum is **connected to its ischiopubic ramus by a crus**. The paired ***crura*** are called *corpora cavernosa* and are composed of erectile tissue. The ***glans*** of the clitoris is a **small, round tubercle of spongy erectile tissue.** Its epithelium has high cutaneous sensitivity, which is important in sexual responses. The clitoris has a ***suspensory* ligament** and two small muscles, ischiocavernosi, attached to its crura. The clitoris is separated from the urethra, different from the penis. The ***prepuce*** is an inverted "V"-shaped skin fold forming a **hood** over the anterior aspect of the clitoral glans and covering the clitoral body underlying it. The ***frenulum* of the glans** clitoris is a discrete skin fold at the posterior aspect of the clitoral glans (Berman et al., 2000; O'Connell et al., 2008; Strandring et al., 2008).

Labia

The labial formation consists of two pairs of **symmetrically folded skin** designed to provide **protection to the urethral and vaginal orifices** that both open into the vestibule of the vagina. The outer fold, the *labia majora*, is composed of subcutaneous fat that is covered by hair-bearing skin that fuse with each other anteriorly at the ***anterior labial commissure.*** The labia majora are prominent, longitudinal, cutaneous folds extending back from the mons pubis to the perineum. Between these surfaces, there is much loose connective and adipose tissue intermixed with smooth muscle resembling the scrotal dartos muscle, together with vessels, nerves, and glands. The **uterine round ligament** may end in the adipose tissue and skin in the front part of the labium. Posteriorly, labia majora connect to a bridge of skin called the ***posterior labial commissure.*** This overlies the perineal body and is the posterior limit of the vulva. The interval between this and the anus is approximately 2.5 to 3 cm thick and is termed the *gynecologic perineum.*

The thin inner folds, the *labia minora*, consist of fat-free spongy tissue that is punctuated by sebaceous and sweat glands along with many blood vessels and is covered by hairless skin. They extend from the clitoris obliquely down, laterally, and back for approximately 4 cm, flanking the vaginal orifice. In virgins, their posterior ends may be joined by the cutaneous frenulum of the labia minora.

Anteriorly, each labium minus bifurcates. The pinkish medial side of the labia minora is continuous with the vaginal mucosa and contains many sensory nerve endings. The labia minora fuse with each other anteriorly forming the prepuce of the clitoris and fuse with each other posteriorly as the frenulum (Berman et al., 2000; Standring et al., 2008).

Vestibule

The vestibule is the **cavity that lies between the labia minora.** It contains the vaginal and external urethral orifices and the openings of the two greater vestibular glands and those of numerous mucous, lesser vestibular glands. There is a shallow **vestibular fossa** between the vaginal orifice and the frenulum of the labia minora. The greater vestibular glands **(glands of Bartholin)** are homologues of the male bulbourethral glands. They consist of *two small, round or oval reddish-yellow bodies,* flanking the vaginal orifice, in contact with, and often overlapped by, the posterior end of the vestibular bulb. Each opens into the vestibule, by a **duct** of approximately 2 cm, in the groove between the hymen and a labium minus (Standring et al., 2008).

Introitus

The introitus to the vagina varies in appearance with age, being an almost closed structure in childhood and in some pathologic states of adulthood. The introitus is *highly elastic* in nature, as its mucosa is capable of permitting the release of a baby's head without tearing. The vaginal introitus normally returns to a relatively small *resting state of approximately 3 to 4 cm*. The skin overlying the introitus (and the clitoris) is a hairless, moist, squamous epithelium (O'Connell et al., 2008).

Hymen Vaginae

The hymen is a thin fold of mucous membrane situated just within the vaginal orifice on the internal aspect of the introitus. The internal surfaces of the folds are normally in contact each other, and the vaginal orifice appears as a cleft between them. It varies greatly in shape and area. It is *annular and widest posteriorly;* sometimes it is semilunar, concave toward the mons pubis, and occasionally it is cribriform or fringed. It may be absent or form a complete, imperforate hymen. When it is ruptured, small round **carunculae hymenales** (also known as **carunculae myrtiformis**) are its remnants. It has no established function, although the appearance of an *unruptured hymen has extreme sociocultural significance in some societies*, with potentially grave consequences. The appearance of an unruptured hymen is believed by some to demonstrate virginal status. The problem with this assessment is the considerable variation in normal hymenal appearance. This important topic interrelates with the anatomic modification involved in genital mutilation (O'Connell et al 2008; Standring et al., 2008).

Fourchette

The fourchette is the skin of the midline of the posterior margin of the vaginal introitus. It is important for parturition (O'Connell et al., 2008).

Perineal Body

The perineal body is **a pyramidal shaped block of fibromuscular connective** tissue wedged between the vagina and anal canal and is an **extremely elastic zone** at the confluence of the muscles supporting the perineum. This area, although small in the resting state, has the capacity to stretch without tearing to permit the passage of the fetal head (O'Connell et al., 2008).

Female Urethra and Urethral Orifice

The female urethra is about 4 cm long and **begins at the internal urethral orifice of the bladder,** approximately opposite the middle of the symphysis pubis, and **runs anteroinferiorly behind the symphysis pubis, embedded in the anterior wall of the vagina. It crosses the perineal membrane** and ends at the **external urethral orifice** as an anteroposterior slit with rather prominent margins situated directly anterior to the opening of the vagina and approximately 2.5 cm behind the glans clitoridis. It sometimes opens into the anterior vaginal wall. Except during the passage of urine, the anterior and posterior walls of the urethra are in apposition, and the epithelium is thrown into longitudinal folds, one of which, on the posterior wall of the canal, is termed the **urethral crest.** Many small mucous urethral glands and minute pitlike recesses or lacunae open into the urethra. On each side, near the lower end of the urethra, a number of these glands are grouped together and open into a duct, named the **para-urethral duct;** each duct runs down into the submucous tissue and ends in a small aperture on the lateral margin of the external urethral orifice (Berman et al., 2000; O'Connell et al., 2008; Standring et al., 2008).

The mucosa lining the female urethra consists of a **stratified epithelium** and a supporting lamina propria of loose fibroelastic connective tissue. The latter is bulky and wellvascularized, and it contains numerous thin-walled veins. Its abundant **elastic fibers** are orientated both **longitudinally** and **circularly** around the urethra. The lamina propria contains a fine **nerve plexus**, believed to be derived from **sensory branches of the pudendal nerves.** The proximal part of the urethra is lined by urothelium, identical in appearance to that of the bladder neck. Distally, the epithelium changes into a nonkeratinizing stratified squamous type that lines the major portion of the female urethra. This epithelium is keratinized at the external urethral meatus, where it becomes continuous with the skin of the vestibule. The **arterial supply** to the female urethra is from the **urethral artery**, a **branch of the internal pudendal artery**, which in turn is a **branch of the internal iliac artery.** The venous plexus around the urethra drains into the vesical venous plexus around the bladder neck, and into the internal pudendal veins. An erectile plexus of veins along the length of the urethra is continuous with the erectile tissue of the vestibular bulb. The lymphatic drainage of the proximal urethra is into the deep pelvic nodes. The drainage of the distal portion of the urethra is into the inguinal nodes.

A "**hammock" of vaginal tissue** supports the urethra (DeLancey, 1994). The urethral supports, also termed **pubourethral ligaments,** include fascial and muscular attachments to the **arcus tendineus fasciae pelvis and levator ani muscles.** These supports are only present in the distal third of the urethra and fix the urethra to the pubic bone. The **pubovesical muscle** is a separate structure that is an extension of the smooth muscle of the bladder, which extends from the detrusor muscle to the arcus tendineus fasciae pelvis and pubic bone (Strohbehn, 1998). Posteriorly, the urethra is intimately related to the anterior surface of the vagina. The ***periurethral fascia*** is located immediately beneath the vaginal epithelium and is seen as the glistening white layer that surrounds the urethra when an incision is made in the anterior wall of the vagina. *The fascia extends from the meatus to the bladder neck and laterally to where it fuses with the endopelvic fascia at the pubic bone*. The urethra opens into the vestibule approximately 2.5 cm inferiorly to the clitoris and anterior to the vaginal orifice. The **meatus** is usually a short, sagittal cleft with slightly raised margins and is very distensible. It varies in shape, and the aperture may exhibit either rounded, slitlike, crescentic, or stellate forms.

Although not classically described as a sex organ, *the urethra does demonstrate changes in blood flow during arousal* (Levin et al., 2016) and is part of the *clitoral complex* described by O'Connell et al. (2008).

Vulva: Vascularization, Lymphatic Drainage, and Neuroanatomy

The arterial blood supply of the female external genitalia is derived from the **superficial and deep external pudendal branches of the femoral artery** and the **internal pudendal artery** on each side. The blood supply is substantial, and consequently hemorrhage from vulvar injuries may be severe. **Venous drainage of the vulvar skin** is via **external pudendal veins** to the **long saphenous vein. Venous drainage of the clitoris** is via deep **dorsal veins** to the **internal pudendal** vein and **superficial dorsal veins to the external pudendal** and long saphenous veins.

Lymphatic drainage of the vulva is via a meshwork of connecting vessels that emerge into three or four collecting trunks around the mons pubis. They drain **to superficial inguinal nodes**, then **deep femoral nodes, and eventually to pelvic nodes.** The last of the deep femoral nodes lies under the inguinal ligament and is often called Cloquet's node. Lymph vessels in the perineum and lower part of the labia majora drain to the rectal lymphatic plexus. Lymph vessels from the clitoris and labia minora drain to deep inguinal nodes, and direct clitoral efferents may pass to the internal iliac nodes.

The **sensory innervation** of the anterior and posterior parts of the labium majus differs. The anterior third of the labium majus is supplied by the **ilioinguinal nerve (L1).** The posterior two-thirds are supplied by the **labial branches of the perineal nerve (S3).** The lateral aspect of the labium majus also receives innervation from the perineal branch of the **posterior cutaneous nerve of the thigh (S2)** (Standring, 2008).

The Clitoral Complex

The **clitoral complex** comprises the clitoris, distal vagina, and urethra. As mentioned earlier, these structures **respond as a unit during sexual activity with their overlying highly vascular skin.**

The **female erectile organs** include the **clitoris** and the “**vestibular” bulbs.** The bulbs of the vestibule are inappropriately named as they directly relate to the other clitoral components and the urethra. The erectile tissue components are the clitoral body (corpora) giving rise to bilateral crura and separate bulbs that sit posterior to the body clitoral crura, which all unite in the root of the clitoris. The latter is covered by the vestibule of the vulva and relates to the distal urethra and its meatus, its posterior limit being the introitus.

The *erectile complex is made of specialized vascular tissues* that are sexually responsive and consist of two histologically *distinct types of vascular tissue*. Trabeculated erectile tissue is peculiar to the clitoris and the bulbs. The trabecular nature of the erectile tissue allows for engorgement with blood and volume expansion during sexual arousal. On the other hand, the labia minora and glans clitoris are composed of *nonerectile vascular tissue*, in which the blood vessels are dispersed within a fibrous matrix, with a minimal amount of smooth muscle. *Nonerectile, sexually responsive vascular tissue also is found surrounding the urethral orifice and within the walls of the vagina*. These tissues also respond during **sexual arousal** with **increases in blood flow,** but the structure of the tissues does not accommodate vascular engorgement as in the erectile tissues (Levin et al 2016; O'Connell et al., 1998, 2008) (eFig. 74.2).

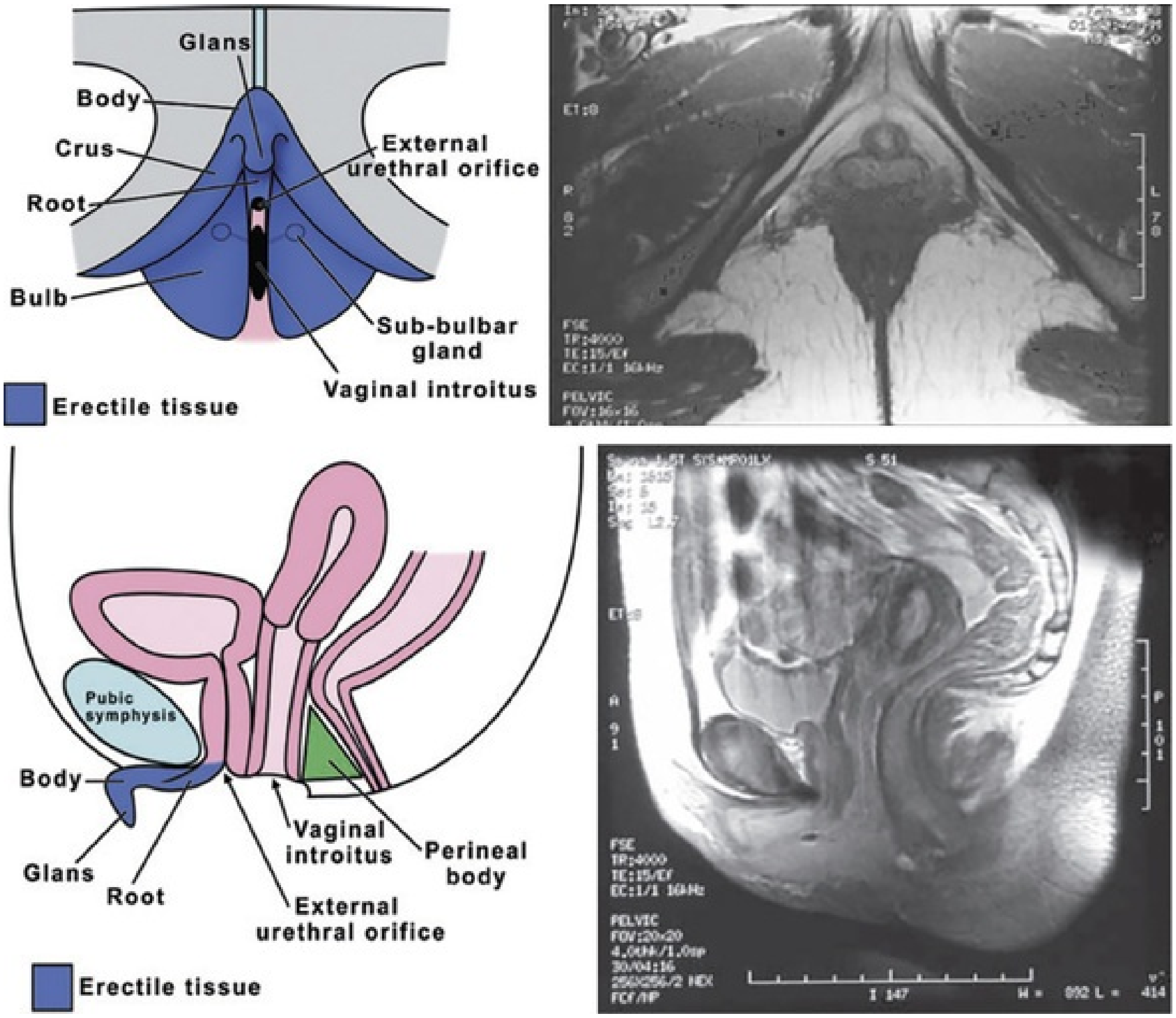
Glans
Body
Crus
Root
Bulb
External urethral orifice
Sub-bulbar gland
Vaginal introitus
Erectile tissue
Pubic symphysis
Body
Glans
Root
Vaginal introitus
Perineal body
External urethral orifice
Erectile tissue

EFIG. 74.2 Female internal and external genital organs and their radiographic correlates.

Immediately deep to the introital skin, anteriorly in the midline, lies the urethra. The urethra can be palpated easily as it pushes out the anterior aspect of the distal vaginal wall. The vaginal mucosa overlying the urethra is moist, hairless, and rugated. The urethra lies surrounded by this *erectile complex* with the body directly anterior to it, flanked superficially by the bulbs and deeply by the crura. Thus, the urethra is a pelvic and perineal conduit embedded in the anterior vaginal wall, but in all other directions it is surrounded by erectile tissue. Thus, dissection or removal of the skin at the urethral orifice reveals the underlying clitoro-urethral relationship. This anatomy is well displayed by magnetic resonance imaging (MRI) studies (O'Connell and DeLancey, 2005; Yang et al., 2005).

The urethra is the source of secretions that occur during high sexual arousal states. In 1880, Skene described the microscopic distal urethral glands as the source of these urethral secretions **(female paraurethral Skene's glands)** (Skene, 1880). *These glands are immunohistochemically positive for the kallikrein protein PSA (prostatic-specific antigen)* (Zaviacic and Ablin, 2000) and considered homologous to the prostate in men. Some papers report women excrete urethral secretions during orgasm *(female ejaculation)*, though there is no firm evidence to support this assertion (Darling et al., 1990; Davidson et al., 1989).

A region of the anterior wall of the vagina overlying the mid-urethra has been identified as the Grafenberg spot (or **G-spot**), an area that, in some women, is particularly sensitive to tactile stimulation. Grafenberg's original article identified the erogenous area as arising from the urethra. Controversy still exists over the possible anatomic structure and site of the G-spot (Hines, 2001; Pan et al., 2015).

Clitoral Complex: Vascularization and Neuroanatomy

The clitoris and related tissues (distal vagina and distal urethra) are supplied and drained from four directions (anterolaterally and posterolaterally on each side), as well as being drained deep in the midline. The external pudendal arteries supply the prepuce, and the erectile tissue is supplied by the dorsal clitoral arteries, perineal arteries, which divide into bulbar and urethral branches, and the deep arteries (centrally in the corpora cavernosa) (Eizenberg et al., 2005).

The erectile tissue of the clitoris is drained via the deep dorsal vein, which passes via the subpubic canal, into the vesical venous plexus within the pelvic cavity. It does not accompany the deep and dorsal arteries of the clitoris. Lymph vessels of the prepuce drain to superficial inguinal nodes, and those of the glans drain directly to deep inguinal nodes. The periphery of the glans is a junctional zone of vascular supply, not only between external and internal pudendal vessels, but also between lymphatics draining to superficial and deep inguinal nodes.

The clitoral complex is supplied by *more than one set of nerves*. The (somatic) pudendal nerve supplies the skin via the "dorsal" nerve of the clitoris, and (visceral) fibers via the cavernous nerves supply arteries to erectile tissue. *Vascular engorgement and associated erection are motor portions of the female sexual reflex* (although it may be augmented or suppressed voluntarily), but it is unique as it involves both somatic and visceral nerves in the reflex arc (cutaneous receptors with somatic afferents and visceral efferents to vascular effectors). **The five components to the reflex arc are as follows:**

1. **The receptors of the clitoral complex and vulva**
2. **Somatic afferents** (terminal divisions of pudendal nerves via its dorsal clitoral and perineal branches)
3. Spinal cord segments **S2–S4**
4. **Visceral efferents** (pelvic parasympathetic fibers) via **nervi erigentes** running in pelvic ganglia
5. **Effectors** (erectile or spongy tissue of the clitoral complex) and secretory responses from sub-bulbar and urethral glands

There may also be visceral afferents from the substance of the clitoral complex heretofore not demonstrated.

Parasympathetic stimulation causes dilation of arterioles (dorsal and deep arteries of the clitoris) **supplying erectile tissue, which becomes engorged.** This is caused by increased inflow of blood in conjunction with restriction of outflow. **Erection of the clitoral complex is accompanied by swelling of the vulva with changes to the distal vagina and urethra accompanied by a secretory response of the latter structures.** During sexual arousal the vulvar components, which are normally hidden by overlying labia minora, become exposed and reddened, making the surface features of the vulva more prominent.

Female Sexual Physiology

A basic understanding of female sexual response is important, as urologic conditions and procedures have the capacity to markedly influence female sexual wellness. The astute urologist will be aware of how sexual function may influence or be influenced by urologic conditions and will address these issues with patients.

Female Sexual Response

Masters and Johnson were among the first to report on the physical aspects of sexual response (Masters and Johnson, 1966). Several female response cycles have been proposed and will be reported in a chronologic order.

The **sexual response cycle** refers to the *sequence of physical and emotional changes that occurs as a person becomes sexually aroused* and participates in sexually stimulating activities, including intercourse and masturbation. Erotic stimuli initiate a series of physiologic changes that have collectively been termed the *sexual response cycle* and are divided into **four distinct phases**: **excitement**, **plateau**, **orgasm,** and **resolution** (EPOR) (Masters and Johnson, 1966).

Sexual response begins with the ***excitement/arousal phase*.** This phase lasts from a few minutes to a few hours and is characterized by **swelling of the clitoris and labia minora, vaginal lubrication and lengthening, nipple erection, increased genital sensitivity, tachycardia, tachypnea, and subjective pleasure and excitement.** The sexual arousal phase is followed by the ***plateau phase*** during which there is an ***intensification of the changes in phase 1*.** The clitoris becomes swollen and highly sensitive, and breathing, heart rate, blood pressure, and muscle tension continue to increase.

Orgasm may follow a variable period of arousal and sexual stimulation. Orgasm ***is a "variable, transient peak sensation of intense pleasure***, creating an altered state of consciousness usually accompanied by **involuntary, rhythmic contraction of the pelvic striated circumvaginal musculature, with concomitant uterine and anal contractions and myotonia, usually with an induction of well-being and contentment"** (Masters and Johnson, 1966; Meston et al., 2004). It is considered the climax of the sexual response cycle and is the shortest phase of it, lasting only a few seconds. Redness or "**sex flush**" may appear over the entire body. Female orgasm has been discussed in the past; for centuries, there was denial that such an entity even existed in healthy women. Many women climax from direct or indirect stimulation of the clitoris; others may experience orgasm during vaginal penetration with or without stimulation of the clitoris or vulva. Some healthy women do not experience orgasm during vaginal penetration under any circumstances (Masters and Johnson, 1966; Wallen and Lloyd, 2011). Anal stimulation may also play a role in attaining orgasm for a minority of women (Herbenick et al., 2010).

After orgasm, there is a ***resolution phase*** as sexual excitement declines back to baseline levels. In women, this involves *reduction in pelvic blood flow, relaxation of nipple erection, and restoration of heart rate to resting levels*. Sexual excitement declines to resting levels; a sense of sexual satiety and lack of desire for additional sexual activity is typical of this phase (Masters and Johnson, 1966). Some women are capable of a rapid return to the orgasm phase with further sexual stimulation and may experience **multiple orgasms.**

In the 1970s, Kaplan added the concept of **sexual *desire*** to the linear response model. Sexual desire was postulated to precede the development of arousal (DPOR) (Kaplan, 1977). A *circular model* was proposed by Whipple and Brash-McGreer with ***four stages:*** **seduction** (encompassing desire), **sensations** (excitement and pleasure), **surrender** (orgasm), and **reflection** (resolution) (Hayes, 2011). Pleasant and satisfying sexual experiences may have a reinforcing effect on a woman, leading to the seduction phase of the next sexual experience. If, during reflection, the sexual experience (phase 4) did not provide pleasure and satisfaction, the woman may not have a desire to repeat the experience. The linear models proposed by Masters and Johnson and by Kaplan may not fit all women, as some may move from sexual arousal to orgasm and satisfaction without any experience of desire or may have desire, arousal, and satisfaction without orgasm. This leads to the *circular models* to be followed soon thereafter by the nonlinear model developed by Basson, who stated that intrinsic, active sexual desire is not an essential component of sexual health for all women. Some women may have a reactive desire that occurs in response to sexual initiation by a partner or by other external stimuli. Receptivity to sexual stimuli allows the woman to move from sexual neutrality to arousal (Basson, 2002a) (eFig. 74.3).

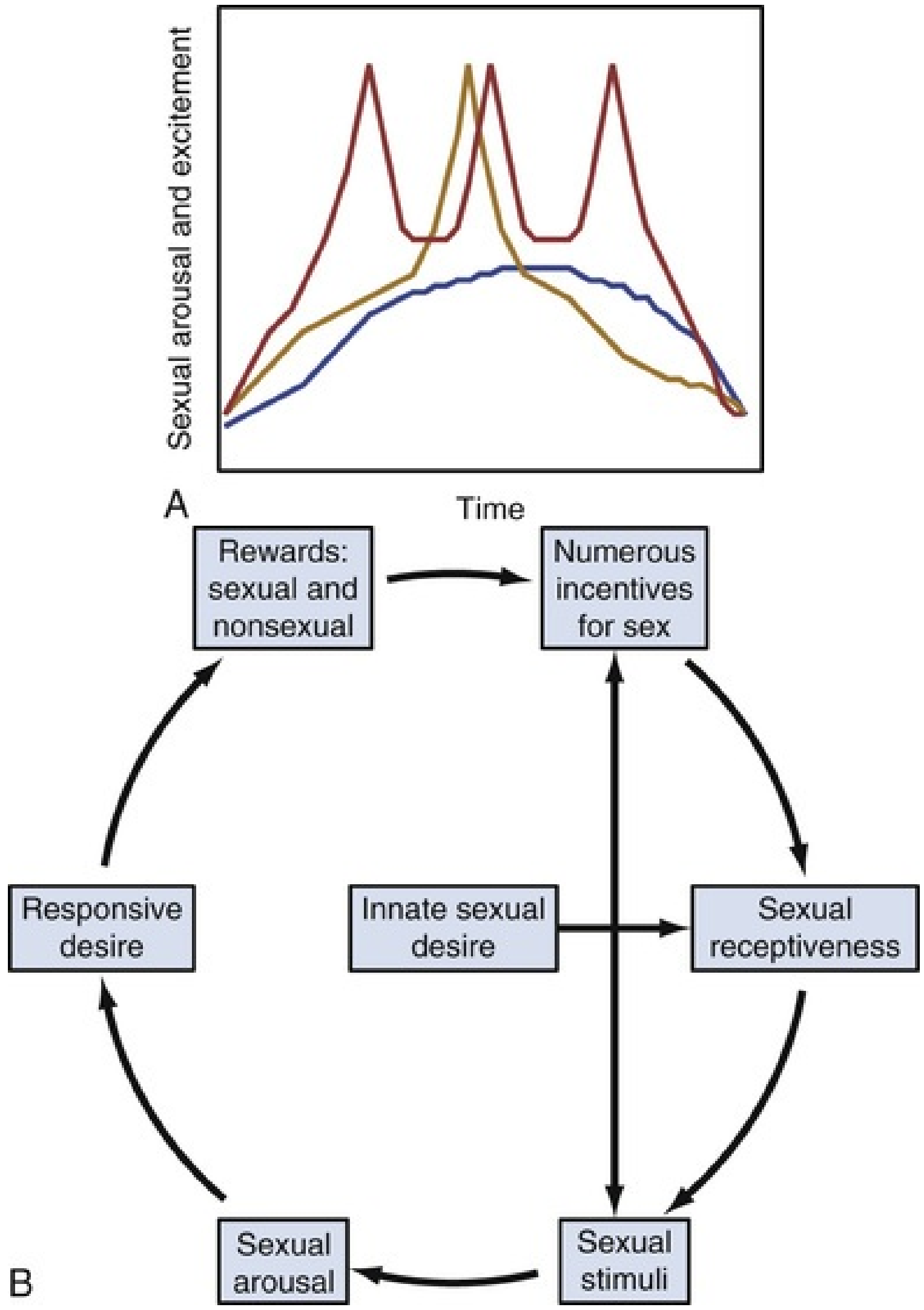
Sexual arousal and excitement
Time
A
Rewards: sexual and nonsexual
Numerous incentives for sex
Responsive desire
Innate sexual desire
Sexual receptiveness
Sexual arousal
Sexual stimuli
B

EFIG. 74.3 A and B, Female sexual response cycle models.

Sexual arousal may lead to an orgasm (or even multiple orgasms) if a sufficient threshold is attained. With orgasm (from the Greek, lustful), a cerebral event, there is activation of sympathetic fibers (primarily derived from T12 and L1) via hypogastric nerves and inferior hypogastric plexus to the uterovaginal plexus. This is accompanied by reflex waves of contraction of skeletal muscle sphincters of the vagina, urethra, and anus mediated by the pudendal nerve, as well as uterine smooth muscle contractions mediated by autonomic nerves.

After sexual arousal (particularly with orgasm), resolution occurs, resulting from sympathetically mediated arterial constriction and pelvic venous decongestion (Masters and Johnson, 1966).

Neurogenic Mediators of the Female Sexual Response

Brain centers deemed particularly important to the integration of sexual desire and arousal responses for women include the medial amygdala, the **stria terminalis,** the **ventromedial nucleus** of the **hypothalamus,** and the **paraventricular nucleus (PVN)** (Veening and Coolen, 1998). Visual sexual stimuli appear to be processed by relays from the vision centers to the **lateral geniculate nucleus** (Schober and Pfaff, 2007). The medial preoptic area is responsible for sexual arousal, mate selection, and excitatory genital response (Giuliano et al., 2001; Whitney, 1986). **Brain centers activated in orgasm** include the ***medial amygdala;*** the ***anterior cingulate;*** the ***frontal, parietal, and insular cortices;*** and the ***cerebellum*** (Komisaruk et al., 2004).

On activation, these centers transmit electrical signals through the parasympathethic and sympathetic nervous system. The neurotransmitters that modulate vaginal and clitoral smooth muscle tone are currently under investigation. **Nitric oxide (NO)** and **phosphodiesterase type 5 (PDE5),** the enzyme responsible for both the degradation of cGMP and NO production, have been identified in clitoral and cavernosal smooth muscle (Burnett et al., 1997; Hilliges et al., 1995). The **nitric oxide (NO)/cyclic guanosine monophosphate (cGMP) pathway** contributes to clitoral erection and vaginal vasodilation with sexual arousal (Burnett et al., 1997; Kim et al., 2003). The cavernous nerves to the clitoris and the vaginal tissues stain positive for neuronal nitric oxide synthase (nNOS) (Burnett et al., 1997). NO activates guanylate cyclase, which produces cGMP. cGMP activates numerous downstream effectors, the net effect of which is to sequester calcium and to reduce contraction of smooth muscle in the clitoral and vaginal circulation and within the vaginal wall. Nitric oxide synthase (NOS) uses the amino acid arginine as a substrate; the enzyme arginase breaks arginine into ornithine and thus reduces the available pool of substrate for NOS. Preliminary data have suggested that **arginase inhibitors** may enhance genital responses in vitro, but in vivo studies are scant (Cama et al., 2003). PDE5 is present in human female genital tissue and is responsible for the breakdown of cGMP. PDE5 inhibitors (PDE5Is) promote vasoconstriction and decreased vaginal blood flow. PDE5Is are active in human female genital tissue and promote vascular engorgement. Side effects of PDE5Is include flushing, congestion, headache, and visual changes (Park et al., 1998). **Published literature supporting the clinical use of PDE5Is for the management of**

sexual arousal problems in women is not robust.

Other studies suggest that vasoactive intestinal polypeptide (VIP) in combination with NO are involved in modulating vaginal relaxation and secretory processes (Park et al., 1998). VIP is a nonadrenergic noncholinergic (NANC) neurotransmitter that enhances vaginal blood flow, lubrication, and secretions and plays a role in clitoral erection (Martin-Alguacil et al., 2006; Ottesen et al., 1987). Prostaglandins and other local tissue effectors (e.g., histamine, tachykinins) play a role in female genital response, particularly with respect to sensation (Martin-Alguacil et al., 2006).

Hormonal Regulators of Female Sexual Response

Hormone levels in the body affect female sexual function (Berman et al., 2000).

Estrogens

Estrogens are the primary “female” sex steroids, and **estradiol** (E) is the most significant of these. Estrogens *act by binding to estrogen receptors (ERs*). The **alpha subtype (ER-α**) is the most common isoform in the genitalia, although the **beta subtype (ER-β**) has also been detected (Hodgins et al., 1998; Saunders et al., 2000). ***Estrogens maintain female genital tissue integrity and thickness*** (Martin-Alguacil et al., 2006). With menopause, there is a marked decline in genital sensitivity, vaginal thickness, collagen content, baseline moisture, and acidity. This may occur because of downregulation of VIP activity in the hypoestrogenic environment (Martin-Alguacil et al., 2006).

Levels of **estradiol influence** both **central** and **peripheral nerve transmissions** (Berman et al., 2000; Ottesen et al., 1982). In animal models, administration of estradiol results in expanded touch receptor zones along the distribution of the pudendal nerve, suggesting that estrogen affects sensory thresholds (Berman et al., 2000; Marson, 1995). Aside from the neurologic effects, **estrogens also have vasoprotective and vasodilatory effects that increase vaginal, clitoral, and urethral arterial flow** (Berman et al., 2000; Natoin et al., 1988). This results in the maintenance of the female sexual response by preventing atherosclerotic compromise to the iliohypogastric arterial bed (Berman et al., 2000).

Estrogen also regulates nitric oxide synthase (NOS) expression, the enzyme responsible for the production of NO. Sarrel et al. reported that a **decline in circulating estrogen levels caused by aging and/or surgical castration results in decreased vaginal NO levels and increased vaginal wall fibrosis.** Therefore, **estrogen replacement therapy** (ERT) restores vaginal mucosa, increases vaginal NO levels, and decreases vaginal mucosal cell death. This suggests a **positive correlation between expression of vaginal NOS, cyclic guanosine monophosphate (cGMP), and estrogen levels.** Animal studies also show that aging and surgical castration result in decreased vaginal NOS levels, vaginal fibrosis, and increased apoptosis, or death of vaginal mucosal and smooth muscle cells. Estrogen replacement restores vaginal mucosa, increases vaginal NOS expression, and decreases vaginal apoptosis (Sarrel, 1998).

Estrogen is important in the maintenance and function of the vaginal epithelium, stromal cells, and smooth muscles of the muscularis as well as the thickness of the vaginal rugae and vaginal lubrication. A decline in the level of estrogen results in thinner vaginal walls that are more easily damaged and a drier, less acidic environment in the vaginal canal. This ultimately results in complaints of FSD such as vaginal dryness and dyspareunia (Berman et al., 1998, 2000).

Women with serum E levels less than 50 pg/mL have a markedly increased risk for vaginal dryness and pain during sexual activity (Sarrel, 2000). Menopausal women who start E hormone replacement (vaginal or systemic) typically report increased sexual interest and enjoyment, less sexual pain, and greater orgasmic potential (Collins et al., 1994; Dennerstein et al., 2005).

Aside from specific sexual dysfunction complaints, menopausal and postmenopausal women have a variety of urogenital complaints including urinary frequency, urgency, dysuria, and incontinence. Furthermore, these symptoms can be exacerbated by sexual intercourse.

Testosterone

Decreased sexual arousal, libido, sexual responsiveness, genital sensation, and orgasm can also be associated with low levels of testosterone (T). Approximately 50% of circulating T in premenopausal women is produced by the adrenal glands, with the remaining 50% produced by the ovaries. Activity of T is influenced by binding to sex hormone–binding globulin (SHBG) and weak binding to albumin. T bound to SHBG tends not to exert biologic effects (Bachmann, 2006). Androgen receptors (ARs) are present in female genital tissues; trinucleotide (CAG) repeats on the AR primer may influence the efficacy of serum T in producing clinically meaningful effects, but evidence is scant (Davison et al., 2011).

Studies show that menopausal women respond better to parenteral estrogen-androgen combinations than estrogen alone with regard to enhanced sexual desire, libido, energy, sexual motivation, and overall sense of well-being (Berman et al., 2000; Sherwin et al., 1985, 1987; Traish et al., 2010). Women on this therapy noted significant improvement in sexual desire, sexual arousal, number of sexual fantasies, enjoyment of sex, and number of orgasms (Davis et al., 2008). **Testosterone treatment with estrogen is also successfully used to treat dyspareunia, vulvovaginal atrophy, or lack of vaginal lubrication in menopausal women** (Witherby et al., 2011)**. Topical testosterone cream** is currently used in treating **vulvar lichen planus.** Potential benefits of this therapy include increased clitoral sensitivity, increased vaginal lubrication, increased libido, and heightened arousal. All androgens carry the risk for inducing virilization in women. Early reversible manifestations include acne, hirsutism, and menstrual irregularities. Long-term side effects such as male-pattern baldness, worsening of the hirsutism, voice changes, and hypertrophy of the clitoris are largely irreversible (Braunstein, 2007a).

Exogenous testosterone is debated for a possible link with cardiovascular diseases. Although long-term safety is needed (White et al., 2012), a 19-year longitudinal study in postmenopausal women did not detect any link between sex hormone levels and cardiovascular mortality (Barrett-Connor et al., 1995). These results aligned with a long-term study in 365 female-to-male (FtM) transgender persons receiving supplemental androgen that did not detect an increase in risk for cardiovascular disease (Asscheman et al., 2011).

However, clinical studies are underway assessing the potential benefits of testosterone for the treatment of FSD.

Mental Aspects of Sexual Response

Recently, several studies have highlighted the significant interaction between psychosocial variables and sexual functioning in women. In particular, mood states, history of trauma, relational factors, and personality variables have been linked to significant impairments in sexual functioning. Numerous biopsychosocial factors, medical and mental health conditions, and medications can interfere with sexual health. Family and cultural beliefs, early sexual experiences, partner relationships, and external stressors also play a strong role. Exploring these issues with patients may reveal modifiable obstacles to sexual fulfillment through better disease management, medication changes, mental health treatment, and discussion around personal and cultural beliefs or counseling.

The **relationship between depression, anxiety, and sexual dysfunction has been documented** (Laurent and Simons, 2009). In one population-based prevalence study in the United States of more than 31,000 respondents, approximately **40% of individuals with sexual arousal disorders also reported having concurrent depression** (Johannes et al., 2009). Women with anxiety disorders reported significantly poorer sexual functioning than those without (Dettore et al., 2013). On the contrary, several studies have highlighted the **facilitative effect of anxiety on sexual response**. In a sample of 606 women, approximately **20% indicated increased sexual interest when anxious** (Lykins et al., 2006).

Daily life stressors are correlated with **self-reported sexual problems** and **lower sexual satisfaction** in women (Hamilton and Julian, 2014). In addition, laboratory studies on stress and sexual functioning have demonstrated significantly lower genital responses during a sexual stimulus in women with higher levels of chronic stress compared with low or average levels of chronic stressors (Hamilton and Meston, 2013). The literature on childhood-adolescent sexual abuse and sexual functioning in adulthood indicates that this early trauma is significantly associated with sexual dysfunction in women (McCabe and Giles, 2012).

Relational conflict, longer relationship duration, general dissatisfaction or distress, desire or sexual script discrepancies, lack of intimacy or trust, incompatibility, poor sexual stimulation, or an otherwise inappropriate or nonoptimal sexual context have been found to relate to sexual arousal problems. Partner variables have included a partner's sexual dysfunction and inadequate sexual knowledge of and/or poor sexual stimulation techniques (Witting et al., 2008). However, the relevant data about this association consist mainly of self-reported and cross-sectional results. Moreover, it does not essentially rely on physiologic measurements of sexual response (Levin, 2006).

An evaluation for possible need for psychotherapy is important, based on the patient's current life stressors, social situation and relationships, history of psychiatric illnesses, and history of sexual trauma.

Key Points: Anatomy, Physiology, and Sexual Response Cycle

- The distal vagina is the site of female sexual response, and it shares blood supply and innervation with the clitoris and urethra.
- The clitoris, distal vagina, and urethra (the clitoral complex) respond as a unit during sexual activity with their overlying highly vascular skin.
- There are two types of sexually responsive vascular tissue in the clitoral complex: erectile and nonerectile.
- The Grafenberg spot (G-spot), which is located in the anterior wall of the vagina overlying the mid-urethra, is particularly sensitive to tactile stimulation in some women.
- The female sexual response cycle refers to the sequence of physical and emotional changes that occur on sexual arousal and engagement in sexually stimulating activities.
- The linear sexual response cycle models (excitement/arousal, plateau, orgasm, and resolution) may not be applicable to all women.

Evaluation of Sexual Wellness

History Taking

Patients are usually reluctant to discuss sexual health–related issues with their physicians. Health care providers should bring up the topic of sexual health because only approximately 18% of women with sexual issues will seek medical advice about sexual dysfunction (Kaplan, 1979). Certain barriers, such as a lack of adequate training and confidence in the topic, a perception that there are few treatment options, a lack of adequate clinical time to obtain a sexual history, patients' hesitancy to initiate the conversation, and the underestimation of the prevalence of sexual dysfunction, can preclude an interactive dialogue about sexual health between the patient and the physician (Bachmann, 2006; Frank et al., 2008).

Clinical conversations should acknowledge the contributions of sexuality, relationships, and sexual behavior to overall health (Latif and Diamond, 2013). By using a "broader, sex-positive, health-focused framework" with patients, physicians can encourage communication about sexuality. Sexual health promotion has become increasingly less stigmatized, and the focus has shifted toward a more holistic view that promotes sexual health as a right for all women and men (American College of Obstetricians and Gynecologists [ACOG], 2017).

Assessment of female sexual (dys)function is best approached using an integrated approach addressing biologic, psychological, sociocultural, and interpersonal factors (Table 74.1) (Bitzer et al., 2013; Fugl-Meyer et al., 2013; Latif and Diamond, 2013).

TABLE 74.1

Biopsychosocial Model of Assessing Sexual (Dys)Function

Biologic factors	Medications Hormonal status Neurobiology Physical health Aging
Psychological factors	Depression Anxiety Self-image

	Substance abuse History of sexual abuse, trauma
Sociocultural factors	Upbringing Cultural norms and expectations Religious influences
Interpersonal factors	Relationship status/quality Partner's sexual function Life stressors

Modified from Bitzer J, Giraldi A, Pfaus J. Sexual desire and hypoactive sexual desire disorder in women. Introduction and overview. Standard operating procedure (SOP Part 1). *J Sex Med* 2013;10(1):36–49; Fugl-Meyer KS, Bohm-Starke N, Damsted Petersen C, et al. Standard operating procedures for female genital sexual pain. *J Sex Med* 2013;10(1):83–93; Latif EZ, Diamond MP. Arriving at the diagnosis of female sexual dysfunction. *Fertil Steril* 2013;100(4):898–904.

When discussing female sexual response, physicians should emphasize the wide range of complex normal experiences. In 1966, Masters and Johnson described female sexual response as a linear model with four phases of response: excitement, plateau, orgasm, and resolution. Basson (2002b) described a “Sexual Response Circle”, which incorporates psychological and social aspects into female sexual function, such as emotional intimacy and emotional satisfaction as well as sexual desire and physical satisfaction. **Therefore, a discussion of sexual responsiveness with a patient should include the importance of not only sexual stimuli, but also factors such as emotional intimacy and relationship satisfaction.**

The PLISSIT Model of Assessment and Treatment

Annon described the PLISSIT model of assessment for female sexual function, which may increase the efficiency of information gathering in the primary health care setting and also incorporates implications for specialized therapeutic approaches to be followed in that particular patient (Annon, 1976). PLISSIT stands for Permission, Limited Information, Specific Suggestions, Intensive Therapy. Permission stands for the discussion with the patient around normalization of sexual behaviors. Limited Information could include information about behaviors that may increase arousal, including foreplay and a discussion of medical conditions or medications that could be contributing to the problem. Specific Suggestions could include use of lubricants, vaginal estrogen, and position changes. Intensive Therapy would be referral to a specialist, such as a sex therapist or couple's counselor, if appropriate (Annon, 1976). Table 74.2

summarizes the steps of the PLISSIT model.

TABLE 74.2

PLISSIT Model of Assessment

STEPS	EXAMPLES OF WHAT TO SAY TO PATIENTS
Permission Give the patient permission to speak about her sexual health and to do what she is already doing sexually (or may want to do).	“This is important. Thank you for sharing. Many postmenopausal women report a decrease in sexual desire.”
Limited information Provide basic accurate sex education (e.g., female sexual response cycle, impact of aging on sexual function, anatomy).	“Sexual desire changes with age. After menopause, you may experience more responsive desire than spontaneous desire.”
Specific suggestions Provide simple suggestions to increase sexual function (e.g., lubricant use, vibrator use, ways to increase emotional intimacy).	“Your responsive sexual desire may benefit from being more planful with sexual activity. Talk with your partner about how to be more intentional sexually.”
Intensive therapy Validate the patient's concerns and refer her to a subspecialist.	“Your sexual health is important. I'd like to refer you to someone with expertise in sexual health.”

Modified from Faubion SS, Rullo JE. Sexual dysfunction in women: a practical approach. *Am Fam Physician* 2015;92(4):281–288.

Assuring the patient that it is not uncommon or abnormal to mention questions or concerns about sexual life might be helpful to initiate the discussion about sexual health issues. Afterwards, simple screening questions may be asked to understand the need for further evaluation. Examples could include the following:

- “Sexuality is such an important part of our overall health. I would like to ask you some questions about that now. Is that okay with you?”
- “Are you currently sexually active?”
- “With men, women, or both?”

- “Do you have any concerns about your sexual health?”

Clinicians can screen all patients, regardless of age, with the help of a validated sex questionnaire or during a routine review of systems. A simple, integrated screening tool to use is the Brief Sexual Symptom Checklist for Women (BSSC-W), created by the International Consultation in Sexual Medicine (Hatzichristou et al., 2010). Although recommended by the ACOG (ACOG, 2017), the BSSC-W is not validated. The questionnaire includes four questions that gather personal information regarding an individual's overall sexual function satisfaction, the problem causing dysfunction, how bothersome the symptoms are, and the willingness to discuss it with her provider (Table 74.3) (Hatzichristou et al., 2016).

TABLE 74.3

Brief Sexual Symptom Checklist for Women

Please answer the following questions about your overall sexual function:
1. Are you satisfied with your sexual function? ____ Yes ___ No If No, please continue
2. How long have you been dissatisfied with your sexual function?
3. The problem(s) with your sexual function is: *(mark one or more)* Problem with little or no interest in sex Problem with decreased genital sensation (feeling) Problem with decreased vaginal lubrication (dryness) Problem reaching orgasm Problem with pain during sex Other:
4. Which problem is most bothersome (circle)?
5. Would you like to talk about it with your doctor?

The use of basic, broad, open-ended, and gender-neutral questions in a routine history gathering can also help the clinician disclose issues that may require further exploration. Furthermore, it will be helpful to discriminate between different types of female sexual dysfunction (FSD). The following are examples of such questions:

- “Are you sexually active?”
- “Are you sexually satisfied?”

- “Do you have questions or concerns about sexual functioning?”
- “Do you think your partner is satisfied?”
- “Do you have orgasms?”
- “Are you satisfied with the frequency of sexual activity?”
- “Does your vagina lubricate enough?”

After the screening questions, further information about the factors (partners, sexual practices, protection from sexually transmitted infections [STIs], past history of STIs, prevention of pregnancy) that might have an influence on female sexual (dys)function can be elaborated via comprehensive history taking (Table 74.4). The precise nature of the sexual concern, any associated symptoms, chronology, presumed or defined trigger events, exacerbating or relieving factors, and previously attempted treatments should be elicited (Kingsberg and Althof, 2009). The ACOG has published recommendations about how to question the patient about these details and how to end the history taking in an interactive and constructive manner (ACOG, 2017). If the clinician does not have training for in-depth discussion of sexuality, an appropriate referral to a specialist should be considered (Goldstein and Alexander, 2005).

TABLE 74.4

ACOG Committee Recommendations for Comprehensive Sexual History Taking

Partners	Are you currently sexually active? (Are you having sex?) • If no, have you ever been sexually active? In recent months, how many sex partners have you had? In the past 12 months, how many sex partners have you had? Are your sex partners men, women, or both? • If a patient answers “both,” repeat the first two questions for each specific gender.
Practices	I am going to be more explicit here about the kind of sex you have had over the past 12 months to better understand if you are at risk for sexually transmitted infections (STIs). What kind of sexual contact do you have or have you had? • Genital (penis in the vagina)? • Anal (penis in the anus)? • Oral (mouth on penis, vagina, or anus)?
Protection	Do you and your partner(s) use any protection against STIs?

from STIs	• If not, could you tell me the reason? • Are you comfortable asking your partner to use condoms? • If so, what kind of protection do you use? • How often do you use this protection? • If “sometimes,” in what situations or with whom do you use protection? Do you have any other questions, or are there other forms of protection from STIs that you would like to discuss today?
Past history of STIs	Have you ever been diagnosed with an STI? • When? • How were you treated? • Have you had any recurring symptoms or diagnoses? Have you ever been tested for human immunodeficiency virus (HIV) or other STIs? Would you like to be tested? Has your current partner or have any former partners ever been diagnosed or treated for an STI? • Were you tested for the same STI(s)? • If yes, when were you tested? • What was the diagnosis? • How was it treated?
Prevention of pregnancy	Are you currently trying to become pregnant? Are you concerned about getting pregnant? Are you using contraception or practicing any form of birth control? Is your partner supportive of your using birth control? Do you need any information on birth control?
COMPLETING THE HISTORY	
What other things about your sexual health and sexual practices should we discuss to help ensure your good health? What other concerns or questions regarding your sexual health or sexual practices would you like to discuss?	

Modified from Committee on Gynecologic Practice. Committee Opinion No. 706. Sexual Health. *Obstet Gynecol* 2017;130(1):e42–e47.

Questionnaires

Validated questionnaires/surveys/scales can be used to assess female sexual functioning. However, it should be noted that survey instruments cannot replace a detailed history and physical examination. In 2000, the Female Sexual Function Index (FSFI) was developed based on the *Diagnostic and Statistical Manual of Mental Disorders (DSM-IV-TR)* definitions (American Psychiatric

Association [APA], 2000) of sexual dysfunction and the Consensus Report of the International Consensus Development Conference on Female Sexual Dysfunction (Basson et al., 2000). It is a brief, 19-item, multidimensional self-report instrument that assesses six domains of sexual function: desire, arousal, lubrication, orgasm, satisfaction, and pain. The target population consists of heterosexual and homosexual women. It is available for premenopausal and postmenopausal women and women with medical and sexual disorders. It refers to the past 4 weeks, and administration time varies between 10 and 15 minutes (Rosen et al., 2000).

Although it is validated for use in research, it is not yet used in clinical practice. However, the questions are quite useful and may be helpful to clinicians in obtaining a more comprehensive sexual history. How to interpret FSFI scores in the clinical setting has yet to be determined, but the individual responses to each question may be very informative when evaluating a sexual complaint. Each domain of FSFI is scored on a scale of 0 to 6 points with the exception of the desire domain (scored from 1.2 to 6) and the satisfaction domain (scored from 0.8 to 6). The instrument thus has a range of 2 to 36, with 36 representing a "perfect" score. The maximum total score is 36, and higher scores indicate better sexual functioning. A total FSFI score of less than 26.55 is considered at risk for sexual dysfunction (Rosen et al., 2000).

An abbreviated version (six items) also has been validated in premenopausal and postmenopausal women and has been proposed as a tool for screening women likely to have FSD (Chedraui et al., 2012; Isidori et al., 2010). The FSFI also has been validated for use in patients with cancer, in whom strong psychometric properties have been reported (Bartula and Sherman, 2015; Baser et al., 2012) in addition to women with chronic pelvic pain (CPP) (Verit and Verit, 2007). A specific cutoff for the diagnosis of hypoactive sexual desire disorder (HSDD) using the two-item desire domain of the FSFI was reported; on a scale of 2 to 10, women with a score of 6 or higher on this domain were unlikely to carry the diagnosis (Gerstenberger et al., 2010).

The Female Sexual Distress Scale (FSDS) is a 12-item scale that assesses subjective distress associated with sexual dysfunction in women (Derogatis et al., 2002). A revised version with an additional 13th question about distress related to low sexual desire was developed to improve discriminative value in women with HSDD (Derogatis et al., 2008). Both versions have been validated and found to be reliable in distinguishing female patients with and without sexual dysfunction (Rosen, 2002). Table 74.5 summarizes selected sexual functioning questionnaires/scales that have been utilized and clinically tested in the context of female sexual (dys)functional assessment (Hatzichristou et al., 2016).

TABLE 74.5

Summary of Selected Questionnaires/Scales Used to Evaluate Female Sexual (Dys)Function

QUESTIONNAIRE/SCALE	TARGET POPULATION	ITEMS	DOMAINS	COMM
Female Sexual Function Index (FSFI) (Rosen et al., 2000)	Premenopausal and postmenopausal women (heterosexual and homosexual)	19 and 6	Desire, arousal, lubrication, orgasm, satisfaction, and pain	• The m extens studie widel • Availa multip langu • Valida abbrev items) also a which used f screen • Valida for us patien cance chroni pain a availa
Profile of Female Sexual Function and Personal Distress Scale (PFSF) (Derogatis et al., 2004)	Postmenopausal women with low sexual desire	37	Desire, arousal, orgasm, sexual pleasure, sexual concerns, sexual responsiveness, sexual self-image	• Specif design measu desire relate in oopho wome libido • Availa

				multip langua be use assess therap chang multic trials
Sexual Function Questionnaire (SFQ) (Quirk et al., 2002)	Women (heterosexual and sexually active during past 4 weeks)	28	Desire, arousal, orgasm, pain, enjoyment, and partner relationship	• Good consis retest and k group for fer arousa and H
Female Sexual Distress Scale-Revised (FSDS-R) (Derogatis et al., 2008)	Women (premenopausal and postmenopausal dissatisfied with their sexual function)	13 and 1	Distress about sexual life (relationship-based)	• Availa multip langua • Single can be screen wome potent sexual distres
Sexual Interest and Desire Inventory (SIDI) (Sills et al., 2005)	Women (premenopausal with low desire)	13	Hypoactive sexual desire disorder	• Availa multip langua • Focus assess severi treatm respo HSD
Pelvic Organ Prolapse/Urinary Incontinence Sexual Questionnaire (PISQ) (Rogers et al., 2001)	Women with pelvic organ prolapse, urinary incontinence, or fecal incontinence	31 and 12	Behavioral and emotive, physical, and partner-related	• Has a revise versio IR) • Only questi develo

				valida addres issues with u incont pelvic prolap
Female Genital Self-Image Scale (FGSIS) Herbenick et al., 2010)	Female genital self-image on sexual function and behavior	4	Feeling and beliefs about genital region	• Desig assess genita image functi behav • Valida studie been c in a na repres sampl wome
Arizona Sexual Experience Scale (ASEX) (McGahuey et al., 2000)	Heterosexual women	5	Desire, arousal, vaginal lubrication, ability to orgasm, satisfaction from orgasm	• Availa both s • Can b screen
Brief Index of Sexual Functioning for Women (BISF-W) (Taylor et al., 1994)	Heterosexual women	22	Sexual thoughts/desires, arousal, frequency of activity, receptivity/initiation, pleasure/orgasm, relationship satisfaction, sexual problems	• Ease admin and s • Suitab in bot and n sampl • Mode retest and in consis needs develo
Golombok Rust Inventory of Sexual Satisfaction (GRISS) (Rust and Golombok, 1986)	Heterosexual women	28	Avoidance, nonsensuality, infrequency, vaginismus,	• Availa both s • Good and v

			anorgasmia, noncommunication, dissatisfaction	• Mainl compa effica differe treatm metho

HSDD, hypoactive sexual desire disorder; *IUGA,* International Urogynecological Association.

Modified from Hatzichristou D, Kirana PS, Banner L, et al. Diagnosing sexual dysfunction in men and women: sexual history taking and the role of symptom scales and questionnaires. *J Sex Med* 2016;13(8):1166–1182.

In addition, the history should focus on systemic comorbidities, medications, and surgeries that may potentially influence neurologic, endocrine, vascular, or psychological function can affect sexual function. There are several correlating factors and conditions that may put some women at an increased risk for sexual dysfunction. Although menopause may seem like a direct risk for sexual dysfunction, there has not been a study with statistically significant results documenting a universal decline in sexual function in menopausal and postmenopausal women (Basson, 2008). Chronic medical conditions, such as diabetes, hypertension, overactive bladder (OAB), multiple sclerosis, spinal cord injury (SCI), and major depressive disorder, can contribute to FSD. Table 74.6 provides a list of possible systemic comorbidities that might potentially influence and/or were found to be associated with the domains of FSD (Clayton and Groth, 2013; Shifren et al., 2008).

TABLE 74.6

Medical Conditions That Can Affect Female Sexual Function

MEDICAL CONDITION	**POSSIBLE IMPACT ON FEMALE SEXUAL FUNCTION**
Coronary artery disease	May affect pelvic perfusion, arousal disorder
Dermatologic conditions (e.g., lichen sclerosus, lichen planus, eczema)	Genital pain, problems with lubrication
Diabetes mellitus	Low desire
Hypertension	Low desire
Hypothyroidism	Problems with lubrication and orgasm
Malignancy and its treatment (breast, anal, colorectal, bladder, gynecologic)	Problems with desire, arousal, orgasm, and genital pain
Neuromuscular disorders, spinal cord injury,	Problems with desire, arousal, orgasm,

multiple sclerosis	and genital pain
Parkinson disease, dementia	Low desire
Urinary incontinence	Desire, arousal and pain domains can be affected.

Modified from Faubion SS, Rullo JE. Sexual dysfunction in women: a practical approach. *Am Fam Physician* 2015;92(4):281–288.

Medications can interfere with sexual function by alteration of mood and libido, such as antidepressants, antipsychotics, and sedatives; by alteration of blood flow to the genitals decreasing arousal and/or lubrication, such as certain antihypertensives or antiestrogens; or by increasing sex hormone–binding globulins (SHBGs) and therefore decreasing free testosterone levels such as with oral contraceptives. Oral contraceptives are another medication group that have been thought to affect sexual function, but the majority of evidence reveals that only a small minority of women actually experience such a side effect. Illicit drug use and alcoholism also are associated with FSD. Excessive tobacco abuse may lead to vascular insufficiency and decreased genital blood flow (Clayton, 2007).

Urogynecologic and obstetric conditions, such as endometriosis, fibroids, infections, pelvic organ prolapse (POP), and previous hysterectomy, are associated with sexual dysfunction. Difficult vaginal delivery, episiotomy, or vaginal surgery may also impair sexual function via genital denervation and/or dyspareunia. Surgical castration, which can be employed for a variety of benign and malignant gynecologic conditions, may affect female sexual function adversely, particularly in premenopausal women (Clayton, 2007; Kammerer-Doak and Rogers, 2008).

Evaluation of the Partner

Involvement of the sexual partner is of utmost importance in the management of FSD. The partner of a woman who has sexual dysfunction is likely to have sexual issues of his or her own (Chedraui et al., 2009; Fisher and Rosen, 2005). There is robust evidence that treatment of erectile dysfunction in the male partner of heterosexual couples leads to positive changes in the female partner's sexual life (Conaglen et al., 2010). Treatment or referral to a specialist should be considered for a partner with sexual health problems.

Physical Examination

A thorough physical examination, including a focused internal and external pelvic examination, is important to identify cause(s) of sexual dysfunction. The pelvic examination is especially important for women with dyspareunia or vaginismus. Relatively more common examination findings in female patients with sexual dysfunction include vaginal atrophy (Fig. 74.4), vaginal dryness, genital tract infection, vulvar dermatoses (Figs. 74.5 and 74.6), pelvic floor muscle (PFM) dysfunction, adnexal/genital masses, or deep pelvic pain (Frank et al., 2008). A normal pelvic examination can also be reassuring and informative to a patient.

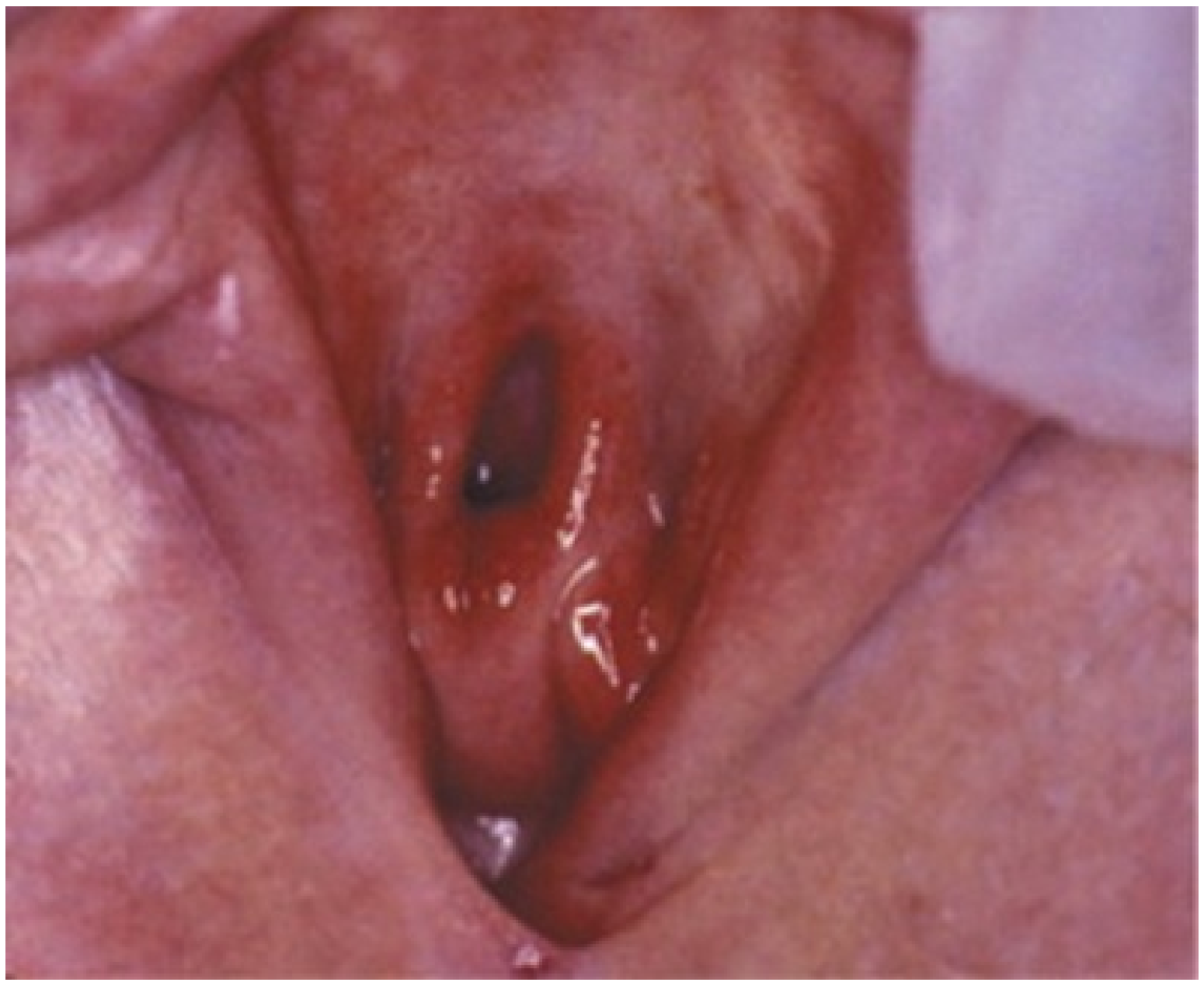

FIG. 74.4 Atrophic vulva. Slightly enlarged clitoris owing to loss of estrogen, with a pale, thin vulvar vestibule. Typical physical examination findings for vaginal atrophy include loss of labial or vulvar fullness, minimal vaginal moisture, pallor of urethra or vagina, narrow introitus, and loss of vaginal rugae. Placing a piece of pH paper on the vaginal wall until it is moistened can test vaginal pH. The pH of an estrogenized vagina ranges from 3.5 to 5.0. A vaginal pH of 4.5 or greater in the absence of infection or recent semen in the vaginal vault can be an indicator of vaginal atrophy caused by estrogen deficiency. (From Apgar BS, Brotzman GL, Spitzer M. Colposcopy: *Principles and practice: An integrated textbook and atlas.* Philadelphia, PA: WB Saunders; 2002).

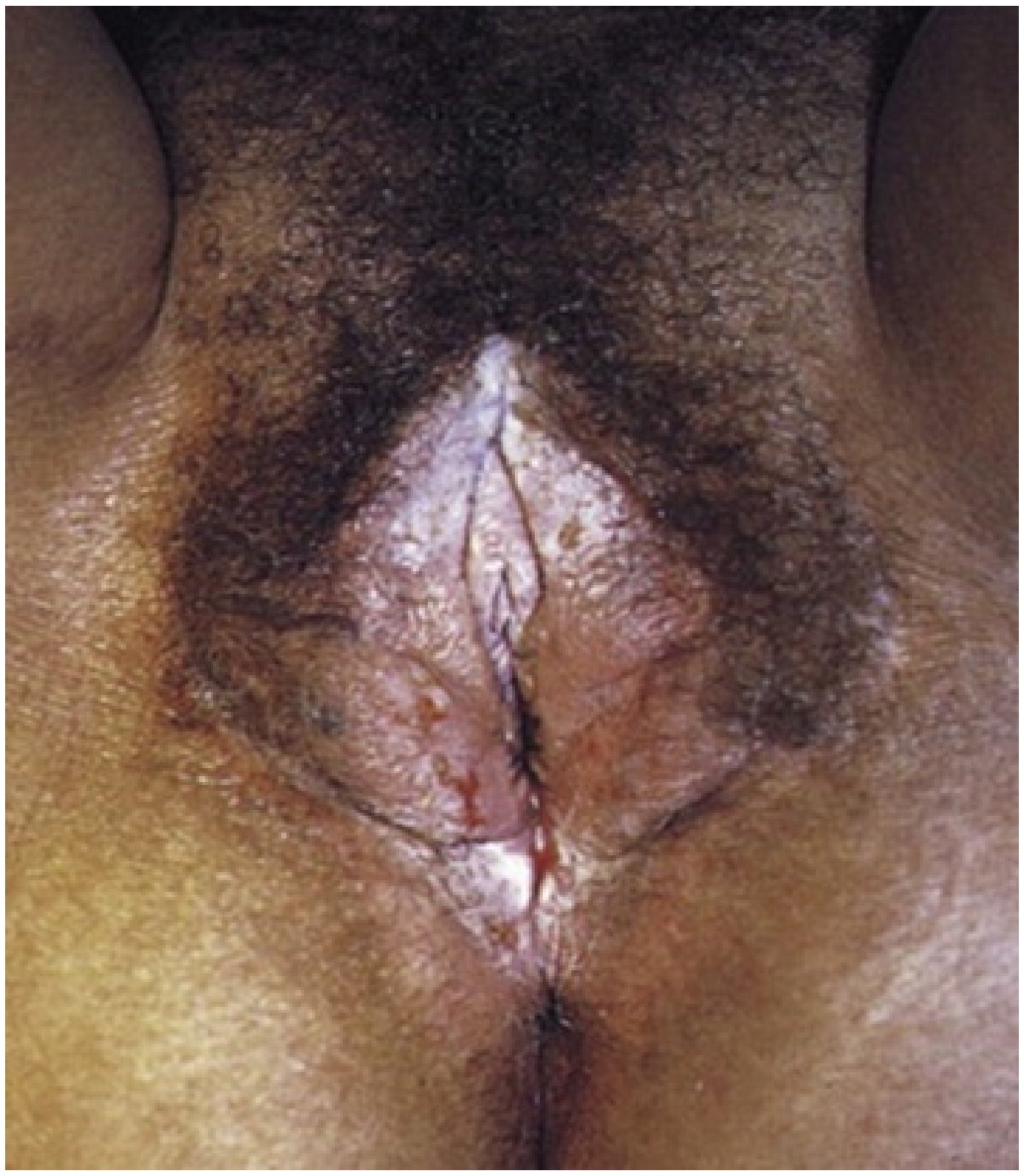

FIG. 74.5 Vulvar lichen sclerosus. Hypertrophic plaques, edema, loss of normal architecture, introital narrowing, and perineal involvement. It is important to evaluate for evidence of vulvar dermatoses when women complain of dyspareunia. Lichen sclerosus is a chronic, progressive inflammatory skin condition of unknown etiology that commonly affects the labia minora and/or labia majora, but can extend to the perineum and around the anus. Dyspareunia is often a late symptom caused by introital stenosis, fissuring, or labial agglutination. (From Moreland A, Kohl P. Genital and dermatologic examination. In: Morse SA, ed. *Atlas of sexually transmitted diseases and AIDS.* 4th ed. Philadelphia, PA: Saunders; 2011:1–23).

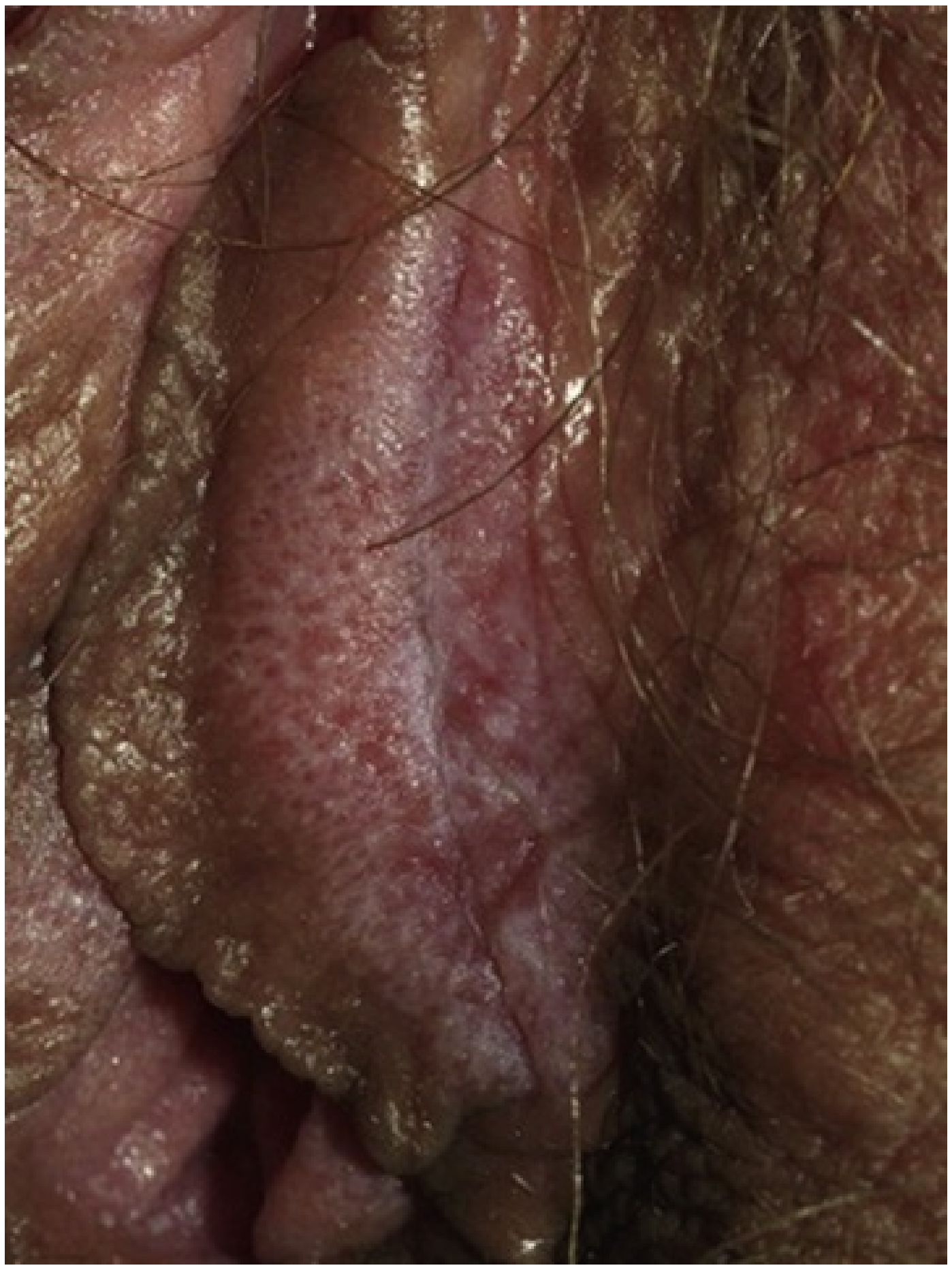

FIG. 74.6 Vulvovaginal lichen planus. Wickham striae is the most classic and only pathognomonic finding of vulvar lichen planus as evident by white, reticulate, lacy papules. This is a chronic, desquamative, erosive dermatitis that can result in severe destruction of the vulvar tissues and stenosis of the vaginal opening. Symptoms most often develop in women 50 to 60 years of age and include severe pruritus or vulvar pain, soreness, or burning. Vulvar lichen planus can involve the labia minor and vestibule. The anus is rarely affected. Lesions can be isolated or diffuse. (From Mirowski GW, Goddard A. Treatment of vulvovaginal lichen planus. *Dermatol Clin* 2010;28[4]:720).

The external pelvic examination begins with visual inspection of the mons pubis, labia majora, labia minora, clitoris, and vulvar vestibule. Often, this is best accomplished gently with a gloved hand and a cotton swab. This inspection may reveal changes in pubic hair distribution, redundancy of the labia, atrophy of the external genitalia, and vulvar skin lesions (see Figs. 74.4 to 74.6). Inspection may also reveal redness and pain typical of vestibulitis, a flattening and pallor of the labia that suggests estrogen deficiency, or POP.

The internal pelvic examination begins with palpation of the PFMs, urethra, and anus. Bimanual examination of the vagina may reveal ovarian mass(es) and/or palpable abnormalities in the adnexal region. The size and flexion of the uterus or tenderness in the vaginal fornix may be indicative of endometriosis (Goldstein and Alexander, 2005). POP and urethral hypermobility should also be assessed by vaginal inspection (with the help of a speculum) and palpation (during resting and straining). The PFMs should voluntarily contract and relax and are not normally tender to palpation.

Neurologic examination of the pelvis will involve evaluation of sensory and motor function of both lower extremities and include a screening lumbosacral neurologic examination. Lumbosacral examination includes assessment of PFM strength, anal sphincter resting tone, voluntary anal contraction, and perineal sensation. If abnormalities are noted in the screening assessment, a complete comprehensive neurologic examination should be performed. Neuropathy involving the genitals can be evaluated by application of heat/cold stimuli, vibration, and/or application of a toothpick or small pin. Considering the association between lower urinary tract symptoms (LUTS) and sexual health issues, a simple assessment for urinary incontinence (UI) (e.g., clinic stress test, Q-tip test) is also warranted.

Sexual function is associated with normal PFM function (Kegel, 1952; Shafik, 2000). The PFMs, particularly the pubococcygeus and iliococcygeus, are responsible for involuntary contractions during orgasm (Kegel, 1952). Women with strong or moderate PFM contractions were found to have higher orgasm and arousal domain scores of the FSFI compared with women with weak PFM contractions (Lowenstein et al., 2010). Orgasm and arousal functions may be associated with PFM strength, with a positive association between pelvic floor strength and sexual activity and function (Kanter et al., 2015; Wehbe et al., 2010).

PFM activity can be categorized as normal, overactive (high tone), underactive (low tone), and nonfunctioning. Normal PFMs are those that can voluntarily and involuntary contract and relax (Haylen et al., 2010; Messelink et al., 2005). Overactive PFMs are those that do not relax and possibly contract during times of relaxation for micturition or defecation. This type of dysfunction can lead to voiding dysfunction, defecatory dysfunction, and dyspareunia (Messelink et al., 2005). Underactive PFMs, which cannot contract voluntarily, may lead to incontinence (urinary and/or fecal) and POP. Nonfunctioning muscles are completely inactive (Messelink et al., 2005).

Digital rectal/vaginal palpation is the most commonly employed method to evaluate PFM tone, squeeze pressure during contraction, symmetry, and relaxation. During the examination, the physician should ask the patient to contract as much as she can to evaluate the maximum strength and sustained contraction for endurance. This assessment can be also done invasively via pressure manometry or dynamometry. There are no validated scales to quantify PFM strength (Messelink et al., 2005). However, certain scales can be used to quantify pelvic floor tenderness. Lukban and Whitmore (2002) described a zero to 4 numbered scale that evaluates tenderness in the pelvic floor: (1) comfortable pressure associated with the examination, (2) uncomfortable pressure associated with the examination, (3) moderate pain associated with the examination that intensifies with contraction, and (4) indicating severe pain with the examination and inability to perform the contraction maneuver because of pain.

Localized vulvodynia can be diagnosed using the Q-tip test, in which pain is “provoked” in the vestibule, interlabial sulci, introitus, or around the clitoris with light touch from a moistened cotton swab (Fig. 74.7). Pain may be prevented or reduced with the use of topical 5% EMLA (2.5% lidocaine + 2.5% prilocaine) cream applied to the painful areas 10 minutes before intercourse (Wright and O'Connor, 2015).

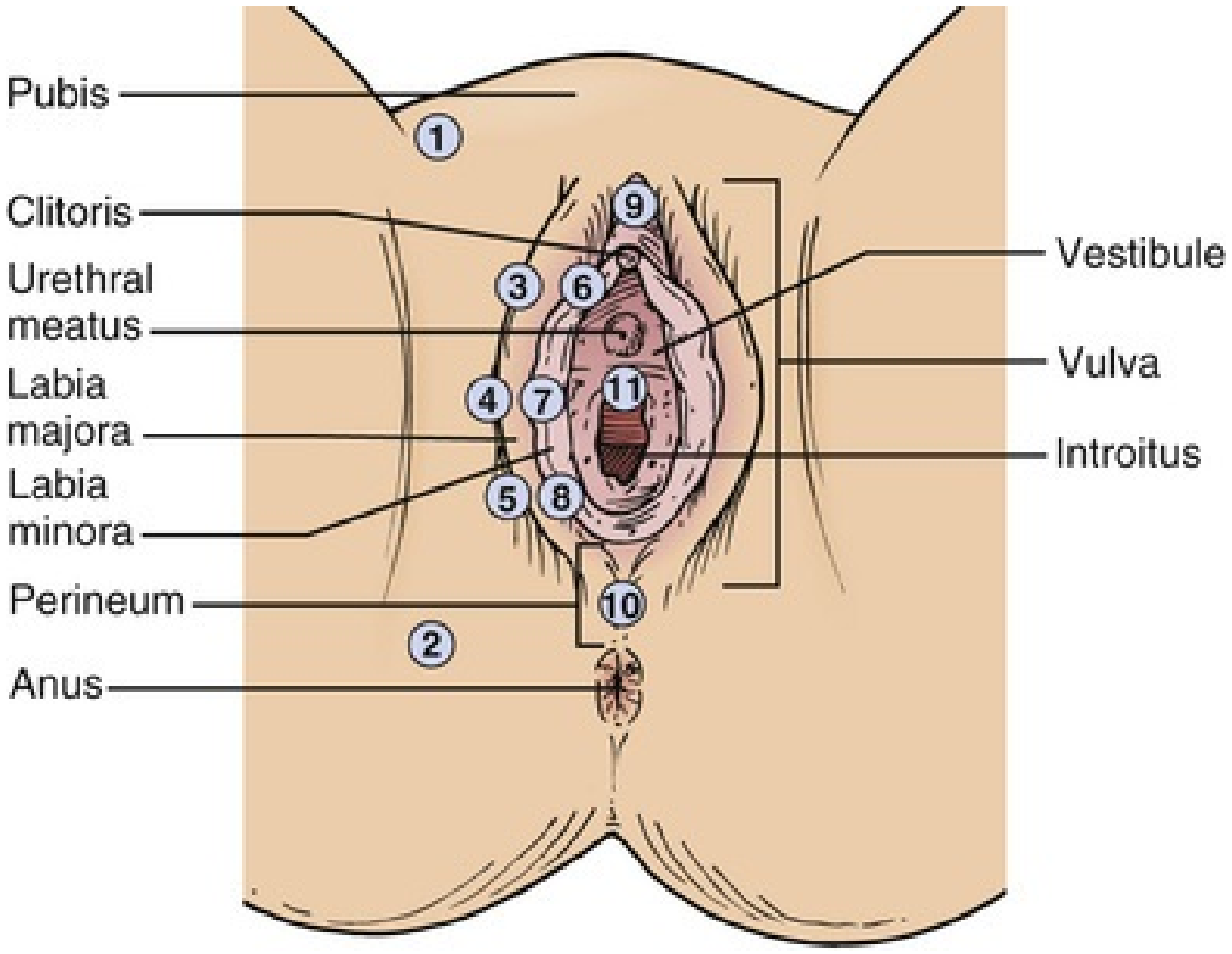

FIG. 74.7 Cotton swab testing for vulvodynia. Check clockwise: *1–2,* inner thigh; *3–5,* labia majora; *6–8,* interlabial sulcus; *9,* clitoris and hood; *10,* perineum; *11,* vestibule. (From Shah M, Hofstetter S. Vulvodynia. *Obstet Gynecol Clin North Am* 2014;41[3]:456.)

Generalized vulvodynia is defined as “unprovoked” stinging, burning, irritation, rawness, or pain anywhere on the vulva that is not explained by another condition. In generalized vulvodynia, physical examination is often normal, or there may be areas of tenderness, hyperesthesia, or hypesthesia (Wright and O'Connor, 2015).

Laboratory Tests

Laboratory evaluation for FSD is rarely indicated unless there is a suspicion for a specific medical condition that might explain the patient's sexual problems. Serum chemistry, lipids, and glycosylated hemoglobin can be assayed, because these are more widely available and might reveal common problems (such as diabetes mellitus) that might potentially influence female sexual function. The normal range of testosterone levels has not been established in women, and testosterone levels do not correlate with libido in females. Therefore, random testosterone measurement is worthless in the evaluation of FSD. Furthermore, there are no data to justify serum testosterone measurement for FSD unless there is a concern about hyperandrogenic/hypoandrogenic state (Meston and Frohlich, 2001; Nappi et al., 2005). If a hormonal abnormality is suspected based on the systemic evaluation of the patient, then a screening blood workup can be done to rule out prolactinoma, thyroid dysfunction, and adrenal disorders. If adrenal insufficiency is suspected, measurement of dehydroepiandrosterone sulfate (DHEA-S) is useful because of isolated adrenal production (Pauls et al., 2005).

There is some suggestion that free testosterone levels less than the lowest quartile may be associated with androgen insufficiency syndrome, which can manifest itself by symptoms of decreased sexual interest and well-being, fatigue, persistent postmenopausal vasomotor symptoms despite estrogen replacement, and lack of motivation (Nappi et al., 2005; Pauls et al., 2005). Despite the fact that estrogen deficiency can lead to urogenital atrophy and vascular insufficiency, both of which can contribute to impairment in female sexual function, routine measurement of estrogen levels within the context of FSD workup was not found to be useful. Likewise, progesterone, measured either alone or in combination with estrogen, has very limited diagnostic/prognostic utility in FSD (Davis et al., 2004; Meston and Frohlich, 2001).

Physiologic Measures of Sexual Function

There are many physiologic monitoring parameters of sexual arousal, which could potentially assist in the diagnosis of organic diseases contributing to sexual dysfunctions (Woodard and Diamond, 2009). Recordings at baseline and after sexual stimulation can determine pathologic changes that occur with arousal (Marthol and Hilz, 2004). Estrogen-dependent vaginal hyperperfusion results in increased vaginal secretions that are important for lubrication. Hypoestrogenism is associated with significant decreases in clitoral, vaginal, and urethral blood flow and histologic changes of thin mucosal layers. Thus, any interference with this process can contribute to FSD (Woodard and Diamond, 2009).

Genital blood flow can be measured with vaginal photoplethysmography, which is the most widely studied and most validated physiologic test used in assessment of female sexual function (Woodard and Diamond, 2009). This method uses a vaginal light source on an acrylic tampon to illuminate the vaginal microcirculation and determine the level of vaginal engorgement. Most studies comparing genital responses of women with and without sexual dysfunction have used vaginal photoplethysmography that measures vaginal pulse amplitude (VPA). In most of these studies, women who met the criteria for sexual dysfunction showed no difference in genital response compared with women without sexual problems (Levin et al., 2016). However, women with medical disorders that are likely to impair sexual response as a result of disease-related neurovascular damage had impaired genital response (lower VPA) in response to sexual stimulation (Levin, 2006).

Diagnostic sensitivity of vaginal photoplethysmography has been variable, although it seems to be most sensitive in patients with arousal disorder (Meston and Frohlich, 2001). However, it lacks an absolute scale, and there are no data regarding normal values. Therefore, it is not possible to decide on genital response abnormality based solely on vaginal photoplethysmography results.

Other methods of assessment of genital blood flow have been used in the research setting, including the use of a radioactive tracer (xenon-133), measures of heat dissipation (the oxygen-temperature method), use of vaginal and labial thermistors for temperature assessment, thermographic photography of the genitals during different phases of the sexual response, duplex Doppler sonography and laser Doppler perfusion imaging of genital blood flow, and magnetic resonance imaging (MRI) (Levin et al., 2016). Table 74.7 provides a summary of the methods that have been tested to assess vulvovaginal perfusion in FSD.

TABLE 74.7

Methods to Assess Vulvovaginal Blood Flow

Oxygen perfusion and heat dissipation in vaginal wall (Levin, 2006)	Heated electrode held by a suction cup onto the vaginal wall; the more blood in the vaginal wall, the greater the amount of oxygen diffusion and heat clearance from the electrode.
Vaginal photoplethysmography (Sintchak and Geer, 1975)	Menstrual tampon-size probe with light source (infrared diode) and photo transistor; diode illuminates vaginal tissue, and photo transistor picks up light that is backscattered from the vaginal wall and the blood circulating within it; the amount of light backscattered is dependent on the volume of blood within the vaginal wall.
Oxygen perfusion in labia minora (Sommer et al., 2001)	Device consisting of heated oxygen electrode attached by a single-sided adhesive ring on minor labia; the more blood present, the greater the amount of perfused oxygen.
Labial photoplethysmography (Prause et al., 2005)	Light source and photo transistor built in a plastic clip that is attached to labia majora.
Thermistor clip (Henson et al., 1978)	Labial temperature is assessed using a thermistor clip attached to labia minora; temperature is assumed to be related to blood flow.
Thermal imaging (Kukkonen et al., 2007)	Human skin emits electrochemical energy, including infrared radiation, which is registered with thermal imaging; genital temperature is assumed to be related to blood flow.
Doppler ultrasonography (Garcia et al., 2005)	Pulse of ultrasound is sent into tissue using ultrasound transducer; sound echoes from parts of the tissue, and the echoes are recorded and displayed as an image.
Laser Doppler imaging (Waxman and Pukall, 2009)	Measures superficial skin blood flow; based on the principle that the frequency of light changes when it interacts with an object in motion (e.g., blood); changes in frequency of light are converted in an electric signal that is processed to an image.
Magnetic resonance imaging (Maravilla and Yang, 2008)	Detects changes in tissue engorgement, which is reflected as increased signal intensity.
Combined clitoral and vaginal photoplethysmography (Gerritsen et al., 2009)	Clitoral photoplethysmograph is built into a silicon shield attached to the lower side of vaginal photoplethysmograph.

Modified from Levin RJ, Both S, Georgiadis J, et al. The physiology of female sexual function and the pathophysiology of female sexual dysfunction (Committee 13A). *J Sex Med* 2016;13(5):733–

759.

Measurement of vaginal lubrication, volume, pressure, and compliance can also be performed. A neurophysiologic examination could evaluate for neurogenic etiologies by measuring the bulbocavernosus reflex and pudendal evoked potentials; genital sympathetic skin response; warm, cold, and vibratory perception thresholds; and pressure and touch sensitivity of the external genitalia (Marthol and Hilz, 2004).

The muscle activity of the pelvic floor can be assessed with electromyography and biofeedback (Woodard and Diamond, 2009). Studies monitoring PFM activity by electromyography have shown some evidence for deviant PFM tone or strength in women with sexual pain disorders. Increased resting electromyography activity and stronger contractile responses to vestibular pressure have been observed (Gentilcore-Saulnier et al., 2010), but some studies have reported lower muscle strength (White et al., 1997).

Many of these methods of physiologic assessment may be beneficial toward our understanding of female sexual physiology and dysfunctions. However, most are invasive, poorly defined, and lack standardization, validity, and reliability. At this time, they are primarily used for research purposes.

Key Points: Evaluation of Sexual Wellness

- Health care providers should bring up the topic of sexual health as female patients are usually reluctant to discuss sexual problems with their physicians.
- The Brief Sexual Symptom Checklist for Women can be used to screen patients for sexual dysfunction.
- The Female Sexual Function Index may be helpful to clinicians in obtaining a more comprehensive sexual history.
- A thorough physical examination is important to identify cause(s) of sexual dysfunction.
- Laboratory evaluation is rarely indicated unless there is a specific concern for a medical condition that might be contributory for the sexual dysfunction.
- Physiologic tests that might be used in assessment of female sexual function

lack standardization, validity, and reliability.

Definitions of Sexual Dysfunctions in Female Patients

The *International Classification of Diseases, 10th Edition (ICD-10-CM)* by the World Health Organization (WHO, 1992) **and the *Diagnostic and Statistical Manual of Mental Disorders (fourth edition with text revision or fifth edition; DSM-1V-TR and DSM-5)* by the APA have been the most widely used systems internationally to define sexual dysfunctions in the female** (Table 74.8) (APA 2000, 2013). Currently, the *DSM-5* and *ICD-10-CM* represent two officially sanctioned systems with international influence. The *ICD-10-CM* is focused on the definition of medical conditions, and the *DSM-5* is a document that primarily defines psychiatric conditions. In the *ICD-10-CM*, disorders are coded as either organic or as nonorganic. The organic FSD codes are vaginismus and dyspareunia of organic etiology. On the other hand, the nonorganic FSD codes include lack of sexual desire, sexual aversion or lack of sexual enjoyment, failure of genital response, orgasmic dysfunction, nonorganic vaginismus, nonorganic dyspareunia, excessive sexual drive, and two nonspecific codes (similar to the “not otherwise specified” codes in the *DSM-IV*).

TABLE 74.8

Definitions of Female Sexual Dysfunction

DSM-IV-TR	*DSM-5*
Sexual desire disorders: ***Hypoactive sexual desire disorder:*** Deficiency or absence of sexual fantasies and desire for sexual activity ***Sexual aversion disorder:*** Aversion to and active avoidance of genital sexual contact with a sexual partner.	**Female sexual interest or arousal disorder:** Lack of or significantly reduced sexual interest or arousal as manifested by three of the following: 1. Absent or reduced interest in sexual activity 2. Absent or reduced sexual or erotic thoughts or fantasies 3. No or reduced initiation of sexual activity and unreceptive
Sexual arousal disorders: ***Female sexual arousal disorder:*** Persistent or recurrent inability to attain or to maintain until completion of the sexual activity, an adequate lubrication-swelling response or sexual	

excitement.	to partner's attempts to initiate 4. Absent or reduced sexual excitement or pleasure during sexual activity in almost all or all (75%–100%) sexual encounters 5. Absent or reduced sexual interest or arousal in response to any internal or external sexual or erotic cues (written, verbal, or visual) 6. Absent or reduced genital or nongenital sensations during sexual activity in almost all or all (75%–100%) sexual encounters
Orgasmic disorder: ***Female orgasmic disorder:*** Persistent or recurrent delay in, or absence of, orgasm after normal sexual excitement.	**Female orgasmic disorder:** Presence of either of the following on all or almost all (75%–100%) occasions of sexual activity: 1. Marked delay in, marked infrequency of, or absence of orgasm 2. Markedly reduced intensity of orgasmic sensations
Sexual pain disorders: ***Dyspareunia:*** Genital pain that is associated with sexual intercourse. ***Vaginismus:*** Recurrent or persistent involuntary contraction of the perineal muscles surrounding the outer third of the vagina when vaginal penetration with a penis, finger, tampon, or speculum is attempted.	Genitopelvic pain or penetration disorder: Persistent or recurrent difficulties with one or more of the following: 1. Vaginal penetration during intercourse 2. Marked vulvovaginal or pelvic pain during intercourse or penetration attempts 3. Marked fear or anxiety about vulvovaginal or pelvic pain in anticipation of, during, or because of vaginal penetration 4. Marked tensing or tightening of pelvic floor muscles during

	attempted vaginal penetration

DSM-5 Definitions of Sexual Dysfunctions in Women

Regarding the *DSM-5* definitions and criteria for sexual dysfunctions in women, all disorders except genito-pelvic pain-penetration disorder require that the symptoms meet the *DSM-5* definition of that condition, have been present for 6 months on at least 75% of sexual occasions, cause clinically significant distress, are not a consequence of a nonsexual mental disorder or of a severe relationship distress or other significant stressors, and are not attributable to the effect of a medication or illness.

Female Sexual Interest–Arousal Disorder

Lack of or significantly decreased sexual interest or arousal is manifested by at least three of the following characteristics: (1) absent or decreased interest in sexual activity; (2) absent or decreased sexual or erotic thoughts or fantasies; (3) no or decreased initiation of sexual activity and typically unreceptive to a partner's attempts to initiate; (4) absent or decreased sexual excitement or pleasure during sexual activity in almost all or all (approximately 75% to 100%) sexual encounters (in identified situational contexts or, if generalized, in all contexts); (5) absent or decreased sexual interest or arousal in response to any internal or external sexual or erotic cues (e.g., written, verbal, or visual); or (6) absent or decreased genital or nongenital sensations during sexual activity in almost all or all (approximately 75% to 100%) sexual encounters (in identified situational contexts or, if generalized, in all contexts).

Female Orgasmic Disorder

This disorder is manifested by either of the following symptoms and experiences on almost all or all (approximately 75% to 100%) occasions of sexual activity (in identified situational contexts or, if generalized, in all contexts): (1) marked delay in, marked infrequency of, or absence of orgasm; or (2) markedly decreased intensity of orgasmic sensations.

Genito-Pelvic Pain-Penetration Disorder

This disorder manifests as persistent or recurrent difficulties with at least one of the following: (1) vaginal penetration during intercourse; (2) marked vulvovaginal or pelvic pain during vaginal intercourse or penetration attempts; (3) marked fear or anxiety about vulvovaginal or pelvic pain in anticipation of, during, or as a result of vaginal penetration; or (4) marked tensing or tightening of the PFMs during attempted vaginal penetration.

International Consultation on Sexual Medicine Definitions of Sexual Dysfunctions in Women

The International Consultation on Sexual Medicine (ICSM), which consists of a large number of international experts in the field of sexual dysfunction, has provided insight for the terminology of FSD that could be applied independent of etiology. The last consultation took place in 2015, and the latest ICSM document focusing on the definitions of sexual dysfunctions in women was published in 2016 (McCabe et al., 2016). The definitions provided in this document represented the synthesis of *DSM-5*, *DSM-1V-TR*, and *ICD-10-CM* explanations and some new definitions developed during the consensus meeting. **It has been highlighted that some of the new definitions were not mature and subject to future revision. Additionally, many definitions were not based on a sufficient level of evidence and represented merely expert clinical opinion; hence it was not possible to assign a reliable grade of recommendation for each.**

Hypoactive Sexual Desire Dysfunction

Hypoactive sexual desire dysfunction manifests as persistent or recurrent deficiency or absence of sexual or erotic thoughts or fantasies and desire for sexual activity.

Female Sexual Arousal Dysfunction

Female sexual arousal dysfunction manifests as persistent or recurrent inability to attain or maintain arousal until completion of the sexual activity.

Female Orgasmic Dysfunction

Female orgasmic dysfunction is characterized by (1) marked delay in, marked frequency of, or absence of orgasm and/or (2) markedly decreased intensity of orgasmic sensation.

Female Genital-Pelvic Pain Dysfunction

This disorder manifests as persistent or recurrent difficulties with at least one of the following: (1) vaginal penetration during intercourse; (2) marked vulvovaginal or pelvic pain during genital contact; (3) marked fear or anxiety about vulvovaginal or pelvic pain in anticipation of, during, or as a result of genital contact; or (4) marked hypertonicity or overactivity of PFMs with or without genital contact.

Persistent Genital Arousal Disorder

Persistent genital arousal disorder manifests as spontaneous, intrusive, and unwanted genital arousal (tingling, throbbing, pulsating) in the absence of sexual interest and desire. Any awareness of subjective arousal is typically, but not invariably, unpleasant. The arousal is unrelieved by at least one orgasm, and the feeling of arousal persists for hours or days.

Postcoital Syndrome (Postorgasmic Illness Syndrome)

This disorder manifests as negative feelings, experiences, and/or physical symptoms such as headache, malaise, fatigue, and other symptoms after sexual activity.

Hypohedonic Orgasm

Hypohedonic orgasm manifests as lifelong or acquired decreased or low level of sexual pleasure with orgasm.

Painful Orgasm

This disorder manifests as the occurrence of genital and/or pelvic pain during or shortly after orgasm.

Epidemiology of Female Sexual Dysfunction

There is limited literature on the prevalence and incidence of FSD. Furthermore, there exists considerable heterogeneity in the methodology of the relevant studies. Available data are difficult to interpret and compare because of differences in the following: (1) the tools used to assess sexual (dys)function (e.g., tick box, diagnostic interviews, nonvalidated assessment measurements, validated assessment measurements); (2) the way information is collected (face-to-face interviews, mail questionnaires, telephone interviews); (3) the definition and classification of sexual dysfunction (3rd, 4th, and 5th edition of *DSM*); (4) the population from which the sample was drawn (e.g., general population, clinical population presenting for treatment of sexual dysfunction, those who have access to the Internet); and (5) terms of the age strata studied, medical history, and socioeconomic and cultural background of the study cohorts.

Burri and Spector found that 5.8% of women reported symptoms consistent with a diagnosis of FSD, and 15.5% of them had lifelong FSD. **Hypoactive sexual desire was the most prevalent sexual complaint (21.4%), followed by problems in arousal (11.4%), satisfaction (10.4%), orgasm (8.8%), and lubrication (8.7%)** (Burri and Spector, 2011). The 5-year incidence study conducted by Kontula and Haavio-Mannila included Finnish women between 18 and 74 years of age. Herein, decreased sexual desire was the most commonly encountered problem, with an incidence of approximately 20% in women younger than 25 years of age and an incidence of 70% to 80% in women 55 to 74 years of age (Kontula et al., 1995). Findings from the Australian Longitudinal Study of Health and Relationships revealed that 36% of women reported at least one new sexual health–related problem during the previous 12 months. Lacking interest in having sex (26%) and taking too long to reach orgasm (11%) were the most common problems. Failure of orgasm (10%), vaginal dryness (9%), not finding sex pleasurable (8%), feeling anxious about the ability to perform sexually (6%), experiencing physical pain during intercourse (5%), and coming to orgasm too quickly (2%) were the other sexual issues having been reported in this patient cohort (Smith et al., 2012).

Interest and Desire

The prevalence of interest and desire-related FSD ranges between 40% and 50% among women older than 65 years of age in most recent studies (McCabe et al., 2016). Laumann et al. investigated the prevalence of sexual dysfunction in the United States. In their cohort of 1749 women between 18 and 59 years of age, the prevalence of lack of interest in sex was in the range of 27% to 32% (Laumann et al., 1999). According to the Global Study of Sexual Attitudes and Behaviors (GSSAB), which included 27,500 individuals, approximately one-half of whom were women 40 to 80 years of age, lack of interest in sex varied from 17% in Northern Europe to 34% in Southeast Asia (Nicolosi et al., 2004). West et al. (2008) conducted a cross-sectional study of 2207 US women 30 to 70 years of age and found that the overall prevalence of HSDD) was 8.3%. In the

Prevalence of Female Sexual Problems Associated with Distress and Determinants of Treatment Seeking [PRESIDE] study, Shifren et al. (2008) reported the overall prevalence of FSD associated with low desire to be 37.7% in a study involving 50.001 US women and 31.531 respondents 18 to 102 years of age who were evaluated by validated questionnaires. In this study, 8.9% of women 18 to 44 years, 12.3% of women 45 to 64 years, and 7.4% of women older than 65 years of age exhibited low desire accompanied by clinically significant distress (HSDD). On the other hand, Hayes et al. (2008) reported a lower overall prevalence, with 16% of Australian women reporting low desire-associated sexual dysfunction in a postal survey that was administered to a random sample of 356 Australian women 20 to 70 years of age. Similarly, the prevalence of low sexual desire was 19% in a large-scale Danish study including women 16 to 67 years of age (Eplov et al., 2007). **In the Women's International Study of Health and Sexuality (WISHeS), Leiblum et al. demonstrated that the prevalence of HSDD ranged from 14% in premenopausal women to 26% in surgically postmenopausal women 20 to 49 years of age.** Furthermore, HSDD was associated with significantly lower sexual and partner satisfaction and significant decrements in general health status, including aspects of mental and physical health (Leiblum et al., 2006).

Arousal

The prevalence of lubrication problems was found to be 12% in the study conducted by Fugl-Meyer et al., who investigated a representative sample of Swedish adults between 18 and 74 years of age (Fugl-Meyer et al., 1999). The rate of female sexual arousal disorder (FSAD) found in the general US population was 5.4% (Shifren et al., 2008). Safarinejad reported a prevalence rate of 30% for arousal disorder among 2626 adult Iranian women 20 to 60 years of age. Furthermore, there was a positive association between the prevalence of arousal disorder and low level of education, low level of physical activity, psychological problems, chronic disease, lower marriage age, and menopausal status (Safarinejad, 2006). In the same study, the significant positive correlation between age and the prevalence of arousal disorder was highlighted (24% in age group 20 to 39 years vs. 35% in age group 50 to 60 years) (Safarinejad, 2006). On the contrary, Laumann et al. (1999) did not detect a relationship between increased age and the prevalence of arousal disorder. Nicolosi et al. (2004) reported the overall prevalence of lubrication difficulties as 16% in the GSSAB. However, in East and Southeast Asia, this ratio increased to 28%. McCool et al.

(2016) published a systematic review of the observational studies assessing the prevalence of FSD in premenopausal women and estimated the prevalence of lubrication difficulties as 20.6%.

Orgasm

The prevalence of orgasmic dysfunction varies between 16% and 25% (Fugl-Meyer et al., 1999; Gruszecki et al., 2005; Laumann et al., 1999; Richters et al., 2003). However, 37% of the patients in the Iranian cohort had orgasmic disorder always or often during sexual intercourse (Safarinejad, 2006). Similarly, Kontula et al. (1995) from Finland reported a relatively high prevalence of orgasmic disorder. In the studies from the United States, Australia, and Iran, older women reported a higher prevalence of orgasmic disorder. In the GSSAB, the inability to reach orgasm was the second most frequent FSD, with the highest prevalence in Southeast Asia (34%) and the lowest in Northern Europe (10%) (Nicolosi et al., 2004). In a large-scale epidemiologic survey including a representative sample of 50,002 US women, orgasmic problems were reported in one-fifth of the respondents (Shifren et al., 2008).

Dyspareunia and Vaginismus

Dyspareunia is relatively uncommon in premenopausal women (approximately 5%). However, its prevalence is known to increase among postmenopausal women, ranging between 12% and 45% (Gregersen et al., 2006). Australian and British studies have reported prevalence rates for dyspareunia as low as 1% to 2% (Barlow et al., 1997; Smith et al., 2003). Other studies found that dyspareunia was present in as many as 14% to 27% of women (Gruszecki et al., 2005; Laumann et al., 1999; Richters et al., 2003). The GSSAB reported pain during sexual intercourse to range from 5% in Northern Europe to 22% in Southeast Asia (Nicolosi et al., 2004). In the Ghanaian study conducted by Amidu et al. (2010), 68.1% of the women were found to have vaginismus. Similarly, Ghanbarzadeh et al. (2013) from Iran reported that 54% of the women felt pain during intercourse.

Key Points: Definitions and Epidemiology

- The *ICD-10* (WHO), *DSM-1V-TR* (APA), and *DSM-5* (APA) are the most widely used systems to define sexual dysfunctions in the female patient.

- There are terminological differences between *ICD* and *DSM* definitions of female sexual dysfunction.
- The ICSM consensus statement about the definitions of female sexual dysfunction represents a synthesis of *ICD* and *DSM* explanations approved by a panel of experts.
- There is significant heterogeneity in the quality of the literature about the epidemiology of female sexual dysfunction.
- Hypoactive sexual desire is the most prevalent type of female sexual dysfunction.

Special Populations

LGBTQ

Over the past decade, transgender and gender-diverse people have gained greater visibility in society, and consequently health care providers are increasingly co-opting with clinical needs for this population. A person's experienced gender is a fundamental and very important aspect of one's sense of self.

The health care needs in the transgender population vary from gender transition–related hormone therapy to surgeries, fertility, and routine urologic and urogynecologic services (Unger, 2015).

The language used and the attention to the pronouns is critical for this vulnerable population. The impact of gendered language is responsible for health disparities experienced by transgender and nonbinary people (Table 74.9). A simple adjustment in the framing and language use can significantly improve the care provided (Daphna et al., 2018).

TABLE 74.9

Basic Terminology Related With Transgender People

Gender identity: The sense of one's own gender as “male,” “female,” “genderqueer,” and so on. Gender identity is not restricted to physical anatomy or lived social roles and refers to the broader sense of gender one has of himself or herself.

Cis Female: Person assigned female at birth who identifies as a woman

Trans Female: Person assigned male at birth who identifies as a woman

Cis Male: Person assigned male at birth who identifies as a man

Trans Male: Person assigned female at birth who identifies as a man

Nonbinary: Person who does not identify as a man or a woman, whose gender identity may not be accurately described using rigid binary gender definitions

Queer: A more flexible, less prescriptive alternative term for one's sexuality that is used over traditional categories such as “gay” or “lesbian”

Bottom surgery: Genital reassignment surgery

Top surgery: Breast reduction or reconstruction surgery

MSM: Man who has sex with a man

WSW: Woman who has sex with a woman

Transgender people compose 0.6% of the adult US population, with rising numbers of younger people identifying as transgender, nonbinary, or gender nonconforming over the past decade. Compared with cis-gender individuals, transgender and gender-nonconforming individuals suffer poorer health outcomes that largely stem from societal discrimination and violence. Nearly 20% of transgender people have reported being refused medical care because of their gender identity. Furthermore, 33% reported a negative experience with a health care provider over the past year, and 23% reported avoiding necessary medical care (such as cervical cancer screening) for fear of discrimination (Grant et al., 2011).

The lack of knowledge of how sexual and gender identities intersect with health care needs may lead to a clinician not being able to fully care for an LGBTQ patient. This unfamiliarity can inhibit the clinician's ability to make appropriate risk assessments for diseases or provide information on the latest available gender therapies for patients. Despite the growing social acceptance, one in five transgender patients seeking health care are still turned away by health care providers (Snowdon et al., 2013).

It is essential to collect accurate sexual orientation and gender identity while taking medical history to identify and address potential health disparities among LGBTQ populations. When these data are not gathered in the everyday clinical practice, there may be missed opportunities to discuss prevention, early detection, and screening for LGBTQ subgroups who may be at an increased risk for certain cancers.

There are some specific conditions more common in the LGBTQ population. For example, gay, lesbian, and bisexual adults and youth are at increased risk for depression, anxiety, suicide, and substance abuse. Lesbian and bisexual women are more likely to be obese than straight women. In addition to these general mental and physical health disparities, the LGBTQ community also has increased risks for some cancers (Table 74.10) (Quinn et al., 2015). Anal cancer disproportionally affects gay and bisexual men as a result of human papillomavirus (HPV) and HIV infection. Breast cancer may affect lesbian and bisexual women at greater rates than heterosexual women. A possible explanation for this higher incidence is the fact that lesbian and bisexual women more commonly experience a variety of breast cancer risk factors such as reduced pregnancy rates, smoking, and obesity. Furthermore, some studies suggest lesbian and bisexual women are less likely to get mammography examinations because of barriers to health care coverage and negative relationships with health care providers (Hart and Bowen, 2009). HPV not only contributes to higher rates of anal cancer among men who have sex with men, but also to higher rates of cervical cancer among lesbian and bisexual women. This health disparity and lack of health education is the reason for an increased risk for cervical cancer in woman who have sex with women and trans men. There is a mistaken belief that they are not at risk for cervical cancer, and therefore they are less prone to undergo Papanicolaou (Pap) testing (Quinn et al., 2015).

TABLE 74.10

Most Common Cancer Types Affecting the LGBTQ Population

Anal
Breast
Cervical
Colorectal
Endometrial
Lung
Prostate

The higher incidence of lung cancer in HIV-infected individuals and the higher prevalence of smoking in LGBTQ individuals are the reasons for the increase in lung cancer compared with the general population.

The lower PSA testing among homosexual African-Americans compared with heterosexual African-Americans might be the reason for a higher incidence of prostate cancer in these subjects (Heslin et al., 2008).

It is unclear whether the incidence of prostatic carcinoma is truly lower in the trans female population, possibly caused by estrogen therapy and androgen suppression, or the screening rates are lower in this population, leading to decreased detection. Research in rodent models exploring the effects of combined exogenous estrogen and testosterone on the prostate has revealed a possible estrogenic link to prostate carcinogenesis and progression of prostate cancer. Estrogen and testosterone treatment regimens were shown to transform human prostate epithelium derived from normal human prostate progenitor cells using a tissue recombinant model, and to drive adenocarcinoma in the tissue graft (Sharif et al., 2017).

Gender Dysphoria and Hormonal Treatment

The two major goals of hormonal therapy are to reduce endogenous sex hormone levels and replace them with the sex hormones consistent with the individual's gender identity in the same fashion as in the hormone replacement treatment of hypogonadal patients. This hormonal "inversion" is the baseline treatment to reduce the secondary sex characteristics of the individual's designated gender and help the development of the sexual characteristics of the gender identity.

In trans males, the hormonal treatment basically follows the general principle of hormone replacement treatment of male hypogonadism. Parenteral or transdermal preparations can be used to achieve testosterone values in the normal male range (typically between 320 and 1000 ng/dL). Similar to androgen therapy in hypogonadal men, testosterone treatment in transgender males results in increased muscle mass and decreased fat mass, increased facial hair and acne, male pattern baldness in those genetically predisposed, and increased sexual desire (Hembree et al., 2017)

In **transgender males,** testosterone will result in clitoromegaly, temporary or permanent decreased fertility, deepening of the voice, cessation of menses (usually), and a significant increase in body hair, particularly on the face, chest, and abdomen.

The hormone regimen for **transgender females** is more complex than the transgender male regimen. The estrogen and antiandrogen treatment induces physical changes within the first 3 to 12 months of the treatment. Trans females experience decreased sexual desire, reduction of spontaneous erections, mild reduction of facial and body hair, increased breast tissue growth, and redistribution of body fat.

Because of the possible side effects and complications of the hormonal suppression and replacement therapy (Table 74.11), a thorough pretreatment screening and appropriate regular follow-up monitoring are recommended for both transgender females and males (Tables 74.12 and 74.13).

TABLE 74.11

Risks Associated With Sex Hormone Treatment

Estrogen

Thromboembolic disease ***(very high risk)***

Cerebrovascular disease, coronary artery disease, breast cancer, hypertriglyceridemia, cholelithiasis ***(moderate risk)***

Testosterone

Erythrocytosis (hematocrit >50%) ***(very high risk)***

Severe liver dysfunction, coronary artery disease, cerebrovascular disease, hypertension, breast or uterine cancer ***(moderate risk)***

TABLE 74.12

Recommended Follow-Up for Trans Male Patients

• Evaluate the patient every 3 months in the first year and then one to two times per year to monitor for appropriate signs of virilization and for development of adverse reactions.
• Measure serum testosterone every 3 months until levels are in the normal physiologic male range.
• Measure hematocrit or hemoglobin at baseline and every 3 months for the first year and then one to two times per year. Monitor weight, blood pressure, and lipids at regular intervals.

TABLE 74.13

Recommended Follow-Up for Trans Female Patients

Measure serum testosterone and estradiol every 3 months.
• Serum testosterone levels should be 50 ng/dL.
• Serum estradiol should not exceed the peak physiologic range: 100–200 pg/mL.
For individuals on spironolactone, serum electrolytes, particularly potassium, should be monitored every 3 months in the first year and annually thereafter.
Routine cancer screening is recommended, as in nontransgender individuals.

The clinical monitoring should include weight, blood pressure, and a systemic physical examination, and it should assess routine health questions such as tobacco use and symptoms of depression. Special attention should be given to the side effects of sex steroids such as deep vein thrombosis and pulmonary embolism.

Fertility in Transgender People

Gender-affirming procedures have a devastating and irreversible effect on the reproductive potential of transgender people. Gender-affirming hormones adversely affect fertility, and gender affirmation surgery may involve the removal of gonads (Martinez, 2017). Thus, fertility preservation options should be discussed with all trans people before medical and surgical transition. Based on recent studies, approximately 47% of transgender individuals desire to have a child to whom they are genetically related (Tornello and Bos, 2017). About 37% of trans men wish to have their gametes preserved before gender-affirmation procedures, and 15% to 51% of trans women seek to have children depending on their sexual orientation (De Sutter et al., 2002; Wierckx et al., 2012). Fertility preservation is best addressed before any hormonal treatment and/or genital-related surgery is undertaken.

A prolonged period on gender-affirming hormones will progressively affect semen quality, with increased frequency of oligozoospermia, asthenozoospermia, teratozoospermia, and azoospermia. Restoration of spermatogenesis is possible after stopping hormonal treatment, but the time to restoration is uncertain, and discontinuing hormone therapy may lead to undesirable effects from increased endogenous testosterone production.

Semen cryopreservation using specimens obtained from masturbation is a standard fertility preservation protocol that has been in use for decades. This is an easy and inexpensive method to collect semen in cis males. However, the ejaculation could cause a major distress in trans women (Hamada et al., 2015). The anti-androgen treatment might also play a role in this distress, making the erections and the ejaculation more troublesome. In these cases, the semen can be obtained with electro-ejaculation or surgically with a direct sperm retrieval from the testicles or epididymis. The testicular sperm extraction (TESE) has been well studied in azoospermic patients postchemotherapy, with a 42% to 65% success rate (Meseguer et al., 2003). Unfortunately, the success rate in azoospermic transgender individuals in unknown.

The quality and quantity of cryopreserved sperm determines the pregnancy outcomes. Also, the assisted reproductive method plays a major role in the pregnancy success rate. If there is a good volume and quality of sperm, a direct intrauterine insemination can be used successfully. Conversely, poor quality and volume of sperm has a better chance of a successful pregnancy with in vitro fertilization (IVF) or intracytoplasmic sperm injection (ICSI).

In trans men, the effect of testosterone on ovaries is inconclusive. The common belief that long-term exposure to testosterone could induce polycystic ovary syndrome (PCOS) was not supported by recent studies (Spinder et al., 1989). In terms of reproduction, androgen therapy does not appear to disturb the ovarian follicular pool.

Malignancies in Female Transgender Patients

Recent studies found gender identity to be relevant to **cancer screening.** Trans men were less likely to be up to date on Pap tests than cis women. Trans men and gender-nonconforming individuals were also shown to have significantly lower proportions of regular Pap tests in an Internet-based convenience sample. **Gender-identity disparities** in cancer screenings persist beyond known sociodemographic and health care factors. It is critical that gender-identity questions are included in cancer and other health-related surveillance systems to create knowledge to better inform health care practitioners and policy makers of appropriate screenings for trans and gender-nonconforming individuals. It was found that, of trans men who do receive Pap tests, they were ten times more likely than cis women to have inadequate tests (i.e., the cell sample taken was insufficient for laboratory testing), which may be associated with increased risk for developing high-grade cervical lesions at a later date.

The current literature is inconclusive about the real **incidence of prostate cancer in trans females,** what the screening and diagnostic pathway should be, and what treatment to recommend in this unique population. According to the sparse literature, the incidence of prostate cancer in trans females is quite rare and is still presented as case reports rather than larger series. In one of the largest European studies on 2306 trans female patients, Gooren and Morgant reported only one case of prostate cancer, for an incidence of 0.04%. This low incidence can be a result of the following:

- Marginalization and lack of access to health care
- Inappropriate screening
- Inconsistent follow-up
- Low level of androgenic hormonal milieu

Because of the prolonged anti-androgen treatment, it is possible that any foci of prostate cancer that might develop will be kept in a quiescent phase for a prolonged period. When these foci become clinically relevant, it presents as castration resistant and as a more aggressive disease.

According to other studies, however, if a low-risk disease is present, this might be driven by estrogenic stimulation. The estrogens can affect prostate cell growth potential. **PSA and diagnosis** of prostate cancer in trans females and in the population under hormonal suppression therapy should be interpreted with caution. Gooren suggests the value of 1 ng/mL as a threshold in subjects who are under prolonged hormone-suppression treatment.

Prostate biopsy is not contraindicated after vaginoplasty. The biopsy can be safely performed through the neovaginal cavity, and the images and technique do not differ much from the traditional transrectal approach used in cis males. **Similarly, radical prostatectomy** is not contraindicated after gender-affirming surgery. Particular attention should be paid during the surgical dissection because the traditional anatomic landmarks may be less clear than usual.

Theoretically, **radiation therapy** is also feasible in transgender patients diagnosed with prostate cancer after vaginoplasty. Caution should be exerted to the target radiation field as the traditional anatomic landmarks might be different from that of the cis male. Patients should be aware of the risk for neovaginal stenosis caused by radiation, from any dose being administered to the neovagina. A more intense vaginal dilation program should be recommended in trans females after pelvic irradiation.

Sexuality and Disability

Sexuality and sexual function are important to people with disabilities just as they are to their able-bodied counterparts. Unfortunately, the knowledge about sexual and reproductive health among people with disabilities is frequently inadequate. Society may still perceive people with disabilities negatively and stereotypically. They could be seen either as asexual or as hypersexual and unable to control their sexual urges (Esmail et al., 2010). Additionally, there is increased reporting of dating violence and sexual abuse and assault of the physically disabled (Jemta et al., 2008).

Adolescents and young adults with physical disabilities are less active socially, and they have difficulties in developing intimate relationships. Thus, despite a greater need for sexual and reproductive health education and service delivery than people without disabilities, dedicated services regarding sexuality and physical disabilities are scantly reported.

Historically, society has ignored or minimized the issue of sexuality in people with disabilities. The physically disabled, especially those with more severe impairments, experience poor body image, lower emotional well-being, and lower sexual self-esteem and satisfaction (McCabe et al., 2003).

Special consideration is needed for females with spinal cord injuries. These patients commonly experience impairment of genital sensation, vaginal lubrication, and orgasm. Also, incontinence, pain, and spasticity are common (Ferreiro-Velasco et al., 2005).

Participants in a UK study on female sexuality after SCI reported a range of physical consequences such as reduced libido, arousal, satisfaction, and orgasm. Also, bladder, bowel, and pelvic floor dysfunction; pain; spasticity; and autonomic dysreflexia were common. Altered vaginal sensation (absent, reduced, fluctuating, or position dependent) was frequently reported. After SCI, some participants reported that sensation improved over time. However, complete vaginal sensory loss was devastating and affected participants' view of intercourse (Thrussell et al., 2018).

According to the National Spinal Cord Injury Statistical Center, there are 270,000 Americans with a spinal cord injury. The majority of the spinal trauma occurs in men (80%). Therefore, literature on FSD after SCI is sparse. Sexuality in women with SCI is treated as a minority of minorities and suffers a total lack of attention.

In her study, Fritz et al. (2015) point out that sexual activity and womanhood continues to be important after a SCI. The study demonstrates that despite the physical limitation caused by the injury, most women desire and engage in relationships and see sex as an important part of their lives.

There are some important changes in the sexual activity after the trauma, such as dissatisfaction with current sexual life, that represent major challenges in female sexual life (Consortium for Spinal Cord Medicine, 2010):

- **Physical barriers** related to SCI could produce lack of bladder and bowel control; pain; weakness; pressure ulcers; and sensory loss.
- **Faster aging process:** Female SCI patients believe that they age faster than able-bodied women.
- **Lack of specific sexual education** such as knowledge of possible positions that could be adopted. The treating physician

should discuss the sexual function and the different available options for sexual activity in subjects with SCI. The sexual education should go beyond merely discussing the possibility of pregnancy or discussing the appropriate birth control.

• **Pregnancy:** Often the SCI occurs at the peak reproductive age. Knowing the possibilities of childbearing is a relevant factor in the "womanhood" of these patients.

• **Sexual confidence:** There is a need to learn how to develop the confidence to pursue intimate relationships and motherhood after SCI (Kreuter et al., 2011).

Key Points: Special Populations

- It is important to question sexual orientation and gender identity during history taking to identify potential health disparities and sexual problems among LGBTQ populations.
- Transgender females and males should be screened and monitored for the possible side effects of cross-sex hormonal therapy.
- As gender-affirming procedures and hormonal therapy may have potentially irreversible effects on their fertility capacity, fertility preservation options should be discussed with transgender patients before proceeding with medical and surgical transition.
- It is not uncommon for females with SCIs to experience problems with genital sensation, vaginal lubrication, and orgasm as well as chronic genital pain and spasticity.
- Despite all the limitations and disabilities that might have been caused, sexual health/functioning of patients with SCI should not be ignored/overlooked.

Female Sexual Interest Disorder

Approximately 40% of women suffer some form of sexual dysfunction in their lifetime (Laumann et al., 1999; Shifren et al., 2008). The most prevalent sexual dysfunction in women across all ages is a lack of sexual desire, which was previously referred to HSDD in the *DSM-IV-TR* (APA, 2000) and female sexual interest and arousal disorder in the *DSM-5* (APA, 2013). The overall prevalence of low sexual desire with distress in premenopausal and postmenopausal women ranged from approximately 8% to 19%. With aging, the intensity of sexual desire generally decreases, whereas the distress associated with low desire decreases. Accordingly, the prevalence of low sexual desire, sexually related personal distress, and HSDD (meeting the diagnostic criteria) were 88%, 15.5%, and 13.6%, respectively, in an Australian cross-sectional study of 1548 women between 65 and 79 years of age (Zeleke et al., 2016).

Associations have also been drawn between distressing low sexual desire and lower health-related quality of life (QoL), as well as psychosocial factors such as dissatisfaction with sex life, partner, or marriage and negative emotional states, including frustration, hopelessness, anger, poor self-esteem, and loss of femininity (Hayes et al., 2007; Leiblum et al., 2006; West et al., 2008). A large-scale survey including more than 2000 US women revealed that those with HSDD had statistically significant decrements in mental aspects of overall health (Leiblum et al., 2006). Biddle et al. showed that postmenopausal women with a lack of sexual desire experienced more health burdens and were more likely to report fatigue, depression, memory problems, back pain, and a lower QoL (Biddle et al., 2009).

Definition

The *ICD-10-CM* defines HSDD as an “absence or marked reduction in desire or motivation to engage in sexual activity as manifested by any of the following: (1) reduced or absent spontaneous desire (sexual thoughts or fantasies); (2) reduced or absent responsive desire to erotic cues and stimulation; or (3) inability to sustain desire or interest during sexual activity. Symptoms are evident over a period of at least several months and are not secondary to a sexual pain disorder. Additionally, sexual symptoms should be associated with clinically significant distress (WHO, 2016).

The International Society for the Study of Women's Sexual Health (ISSWSH) defines HSDD as any of the following for a minimum of 6 months (Parish et al., 2016):

- Lack of motivation for sexual activity as manifested by decreased or absent spontaneous desire (sexual thoughts or fantasies); or decreased or absent responsive desire to erotic cues and stimulation or inability to maintain desire or interest through sexual activity
- Loss of desire to initiate or participate in sexual activity, including behavioral responses such as avoidance of situations that could lead to sexual activity, that is not secondary to sexual pain disorders
- And is combined with clinically significant personal distress that includes frustration, grief, guilt, incompetence, loss, sadness, sorrow, or worry.

HSDD is not secondary to physical and/or emotional abuse, dissatisfaction with the partner, or intrusion of life stressors that can be affected by psychological and/or lifestyle changes. Therefore, relationship issues (e.g., significant relationship conflict) should be ruled out as a primary causative factor before arriving at the diagnosis of HSDD (Goldstein et al., 2017). HSDD may be lifelong or acquired and generalized or situational.

According to the *DSM-IV-TR*, HSDD was defined as “persistently or recurrently deficient (or absent) sexual fantasies and desire for sexual activity that causes marked distress or interpersonal difficulty not related to a medical or psychiatric condition or the use of a substance or medication” (APA, 2000). On the other hand, HSDD and FSAD have been combined into one disorder, now called *female sexual interest/arousal disorder* (FSIAD) in in the *DSM-5* (APA, 2013). This revision was based on data suggesting that sexual response is not always a linear process and that the distinction between desire and arousal may be artificial (Basson, 2001; Binik et al., 2010). Diagnosis requires a minimum duration of approximately 6 months, and loss of desire needs to be associated with personal distress rather than partner or relationship issues.

Pathophysiology

The pathophysiology of low sexual desire is complex and should be considered in the context of the biopsychosocial approach. Biologic factors such as common systemic comorbidities (e.g., hypertension, hypothyroidism, and diabetes mellitus) (Basson and Schultz, 2007) and their treatment modalities (including antihypertensives such as calcium channel blockers and angiotensin-converting enzyme inhibitors) (Finger et al., 1997) have been associated with decreased sexual desire. Pregnancy, breastfeeding, or a postmenopausal state can also be associated with decreased libido.

Aging can have a negative influence on sexual desire. It has been shown that middle-aged women had the highest prevalence of decreased desire with distress (Rosen et al., 2012). Neuroendocrine changes of aging (such as declining testosterone, loss of estrogen) can decrease sexual desire. Although lower testosterone levels have been associated with decreased sexual desire, there is no level of testosterone that can accurately predict HSDD (Davis et al., 2005). Likewise, an association can be drawn between low sexual desire and decreased estradiol levels; however, not all patients with HSDD have low estradiol levels (Goldstein et al., 2017). Furthermore, the intensity and duration of the genital stimulation may need to be higher as a result of the diminished genital sensation that commonly occurs in middle-aged and postmenopausal women (Kingsberg et al., 2015). Hypoestrogenism may induce vulvovaginal atrophy and dyspareunia, which eventually leads to decreased sexual desire (Levine et al., 2008).

Psychiatric conditions (e.g., depression and anxiety) and their treatment (e.g., selective serotonin reuptake inhibitors [SSRIs] and anxiolytics) are also associated with decreased sexual desire. Sexual abuse and trauma in childhood and puberty, perceived stress, distraction, self-focused attention or anxiety, personality disorders, and body image or self-consciousness have all been shown to negatively affect desire (Brotto et al., 2010).

Cultural, social, and religious values and beliefs can negatively influence women's sexual desire, especially in women raised in highly conservative cultures or religions (Kingsberg and Rezaee, 2013). Relationship factors such as conflict or a partner's sexual dysfunction (e.g., erectile dysfunction and premature ejaculation in a male partner) (Rubio-Aurioles et al., 2009), stressors such as financial problems, career-related issues, and familial obligations can also contribute to decreased sexual desire (Kingsberg et al., 2015).

The neurophysiologic background of HSDD has not been completely

unrevealed. Sexual desire is the result of a delicate balance between neuromodulators of excitatory pathways (e.g., dopamine, norepinephrine, melanocortins, oxytocin, vasopressin) and inhibitory pathways (e.g., serotonin, opioids, endocannabinoids, prolactin) (Fig. 74.8). Decreased activity level in the brain regions associated with sexual arousal (e.g., medial orbitofrontal region and periaqueductal gray matter) and a lack of disinhibition of brain regions involved in cognitive processing (e.g., left brain) in women with HSDD can impair vaginal vasocongestion and lubrication and eventually cause orgasmic failure.

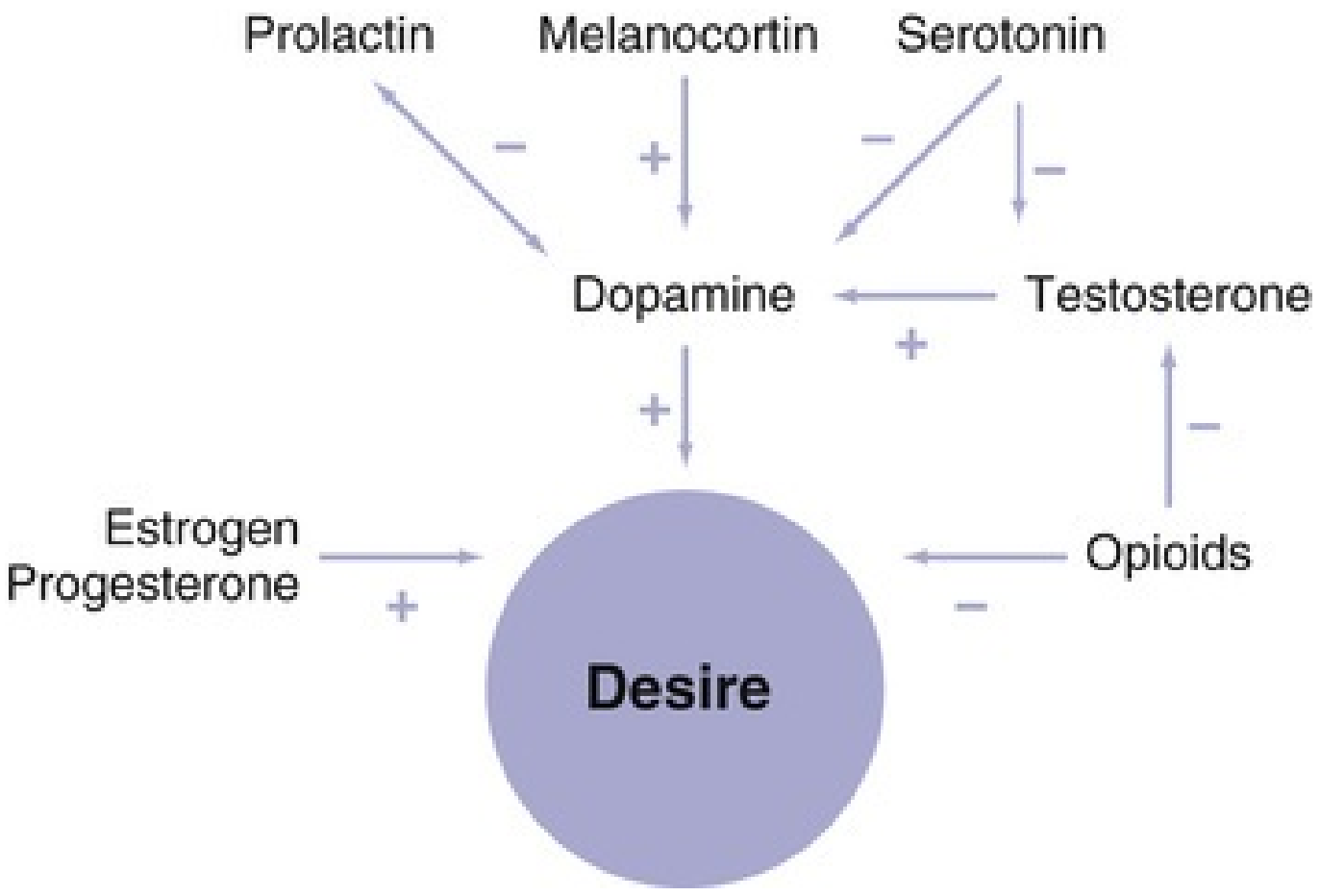

FIG. 74.8 Excitatory and inhibitory effects of neurotransmitters and hormones on sexual desire. (Data from Clayton AH. The pathophysiology of hypoactive sexual desire disorder in women. *Int J Gynaecol Obstet* 2010;110[1]:7–11.)

Evaluation

Health care providers should initiate the general discussion and assessment of sexual concerns because patients are often reluctant to bring up the topic. **It has been shown that 73% of premenopausal women and 81% of postmenopausal women never mentioned their desire problems to a health care provider** according to survey results including 450 premenopausal and postmenopausal women with self-reported low sexual desire (Kingsberg, 2014).

A variety of screening instruments can be used to help identify women who suffer from low desire. **In particular, the Decreased Sexual Desire Screener is a validated, five-question, self-administered survey that helps identify**

generalized acquired HSDD in both premenopausal and postmenopausal women (Table 74.14). This screener is a useful adjunct to the patient history and physical examination in the diagnosis of HSDD (Clayton and Balon, 2009). It was found to be easy to use by clinicians who are not specialized in sexual medicine and had greater accuracy when compared with an expert clinician interview (Goldfischer et al., 2008). Because the *DSM-5* diagnostic category of FSIAD combines the prior *DSM-IV-TR* disorders of HSDD and FSAD, screening and assessment should also include inquiry of difficulties with genital and nongenital excitement and arousal.

TABLE 74.14

Decreased Sexual Desire Screener

1. In the past, was your level of sexual desire or interest good and satisfying to you?	○ Yes	○ No
2. Has there been a decrease in your level of sexual desire or interest?	○ Yes	○ No
3. Are you bothered by your decreased level of sexual desire or interest?	○ Yes	○ No
4. Would you like your level of sexual desire or interest to increase?	○ Yes	○ No
5. Please check all the factors that you feel may be contributing to your current decrease in sexual desire or interest:		
a. An operation, depression, injuries, or other medical conditions	○ Yes	○ No
b. Medications, drugs, or alcohol you are currently taking	○ Yes	○ No
c. Pregnancy, recent childbirth, menopausal symptoms	○ Yes	○ No
d. Other sexual issues you may be having (pain, decreased arousal, or orgasms)	○ Yes	○ No
e. Your partner's sexual problems	○ Yes	○ No
f. Dissatisfaction with your relationship or partner	○ Yes	○ No
g. Stress or fatigue	○ Yes	○ No
• If the patient answers *no* to any of the questions 1–4, then she does not qualify for the diagnosis of generalized acquired hypoactive sexual desire disorder (HSDD).		

• If the patient answers *yes* to all of the questions 1–4, and your review confirms *no* answers to all of the factors in question 5, then she does qualify for the diagnosis of generalized acquired HSDD.		
• If the patient answers *yes* to all of the questions 1–4 and *yes* to any of the factors in question 5, then decide whether the answers to question 5 indicate a primary diagnosis other than generalized acquired HSDD. Comorbid conditions such as arousal or orgasmic disorder do not rule out a concurrent diagnosis of HSDD.		

Reprinted with permission from *J Sex Med*

Data from Clayton AH, Goldfischer ER, Goldstein I, et al. Validation of the decreased sexual desire screener (DSDS): a brief diagnostic instrument for generalized acquired female hypoactive sexual desire disorder (HSDD). *J Sex Med* 2009;6(3):730–738; Goldfischer ER, Clayton AH, Goldstein I, et al. Decreased sexual desire screener (DSDS) for diagnosis of hypoactive sexual desire disorder in women. *Obstet Gynecol* 2008;111:109.

Women indicate yes/no responses to the five questions. The purpose of questions 1 to 4 is to determine the presence/absence of HSDD. If the patient responds yes to all the questions, this is consistent with generalized acquired HSDD. The purpose of question 5 is to help determine whether the etiology of HSDD is primary or secondary. If screening suggests the presence of HSDD, the next steps should include gathering more information about patient's experience of low desire, including onset, duration, behavioral adaptation and avoidance, and level of distress.

A complete medical history is essential to identify contributing factors that may reveal the cause of low sexual desire. A variety of systemic comorbidities and urogynecologic problems might interfere with sexual desire (Table 74.15). Psychiatric conditions should be identified, as relatively more prevalent ones such as depression and anxiety disorder have been associated with HSDD. Presence of depression increases the risk for sexual dysfunction in the range of 50% to 70%. On the other hand, problems related to sexual function are associated with a 130% to 210% increased risk for depression (Atlantis and Sullivan, 2012). **Given this significant bidirectional relationship, every patient with HSDD should be screened for depressive symptoms.**

TABLE 74.15

Conditions That Are Associated With Low Sexual Desire

Hypertension
Diabetes mellitus (type 1 and type 2) (Pontiroli et al., 2013)

Metabolic syndrome (Trompeter et al., 2016)

Hypothyroidism, hyperthyroidism (Krysiak et al., 2016; Atis et al., 2011)

Hyperprolactinemia (Kadioglu et al., 2005)

Renal failure

- Spinal cord injury (Hajiaghababaei et al., 2014)
- Multiple sclerosis (Mohammadi et al., 2013)
- Neuromuscular disorders
- Parkinson disease
- Dementia

Vulvar dermatoses

Postmenopausal status

Polycystic ovary syndrome (Janssen et al., 2008)

Malignancy (breast cancer and its treatment) (Panjari et al., 2011; Fobair and Spiegel, 2009)

Depression

Medications should be noted, because certain classes of drugs (e.g., SSRIs, antipsychotics, antihypertensives) may negatively influence desire (Table 74.16). Other examples include medications that lower testosterone production (combined hormonal contraceptives); chemical ovarian suppression by gonadotropin-releasing hormone analogues and exogenous glucocorticoids; drugs with antiandrogenic activity (spironolactone, cyproterone acetate, flutamide, and finasteride); drugs that increase SHBG levels, and hence lowering free testosterone levels (oral estrogens, combined hormonal contraceptive, tamoxifen, and thyroxine); and drugs that increase serum prolactin levels (antipsychotics).

TABLE 74.16

Classes and Examples of Medications That Might Be Associated With Low Sexual Desire

Anticonvulsants	Carbamazepine Phenytoin Primidone
Cardiovascular medications	Angiotensin-converting enzyme inhibitors Amiodarone

	Beta-blockers (atenolol, metoprolol, propranolol) Calcium channel blockers Clonidine Digoxin Diuretics (hydrochlorothiazide, spironolactone) Lipid-lowering agents
Hormones	Antiandrogens (flutamide) Gonadotropin-releasing hormone agonists Oral contraceptives
Analgesics	Nonsteroidal anti-inflammatory drugs Opiates
Psychotropic medications	Antipsychotics Anxiolytics (alprazolam, diazepam) Selective serotonin reuptake inhibitors Serotonin norepinephrine reuptake inhibitors Tricyclic antidepressants
Illicit drugs	Amphetamine Cocaine Heroin Marijuana
Others	Histamine receptor antagonists Alcohol Indomethacin Ketoconazole Chemotherapeutic agents

Modified from Clayton AH, Kingsberg SA, Goldstein I. Evaluation and management of hypoactive sexual desire disorder. *Sex Med* 2018;6(2):59–74.

Overlap of female sexual disorders is not uncommon, and concurrent sexual problems might exacerbate low desire, such as HSDD impairing arousal that impairs orgasm or may lead to pain (e.g., attempting penetrative intercourse without adequate lubrication caused by lack of interest and/or orgasmic failure) or hypoestrogenism-related vaginal dryness leading to persistent dyspareunia, which eventually interferes with sexual desire. A temporal relationship between the onset of sexual complaints might provide an idea about the primary versus secondary nature of low sexual desire. Lifelong versus acquired HSDD should be discriminated as well as situational versus generalized (occurs in all settings with all partners) forms of the disorder. Prior sexual function and relationship/interpersonal issues should also be sought. Urogynecologic history should cover information about conditions that might influence a woman's willingness to engage in sexual activity such as menstrual cycles in premenopausal women, menopausal vasomotor symptoms, STIs, LUTS, UI, fecal incontinence, POP, and high-tone pelvic floor dysfunction (Clayton et al., 2018a).

Many women will ask whether their form of contraception, especially combined oral contraceptives (COCs), may be contributing. COCs may decrease libido as a result of antiandrogenic effects and a decrease in lubrication, whereas decreased fear of pregnancy and improvement in certain gynecologic conditions, such as dysmenorrhea, menorrhagia, or endometriosis, might augment sexual desire. The use of oral contraceptives and low sexual desire has been a matter of debate for a long time, with some studies supporting an association (Bitzer et al., 2003; Wallwiener et al., 2010) and others failing to identify any cause-effect relationship (Burrows et al., 2012; Pastor et al., 2013). The presence of menstrual irregularities may give a clue about possible hormonal disorders (e.g., hyperprolactinemia and hypothyroidism) that interfere with sexual desire.

A history of pelvic surgery (such as bilateral salpingo-oophorectomy before natural menopause), pelvic trauma, or radiotherapy involving pelvic organs may point to an anatomic source because these factors may be associated with pelvic pain and altered ovarian function.

Physical examination is not necessary to arrive at the diagnosis of HSDD. However, it can provide valuable information to discover the factors that may be contributing to diminished sexual interest. Signs of hormonal insufficiency, such as vulvovaginal atrophy, may result in dyspareunia and negatively affect sexual desire. Genital sensory changes (sensitivity to pressure with a cotton swab around the vestibule in vulvodynia); macroscopic signs of vulvar dermatoses (e.g., lichen sclerosus, lichen planus); abnormal neurologic examination findings (tenderness at ischial spine suggestive of pudendal nerve disorder or changes in anal sphincter tone/bulbocavernosus reflex latency suggestive of lumbosacral spinal pathology); PFM overactivity/tenderness; urethral hypermobility; positive cough stress test; and POP are some of the important physical examination findings that might shed light to the underlying cause and possible treatment pathway of low sexual desire (Kingsberg et al., 2005).

Laboratory evaluation is rarely helpful in the workup of low sexual desire. There are no biomarkers that can reliably confirm or exclude HSDD. Laboratory tests may only be considered in patients who exhibit signs and symptoms of hormonal dysregulation. Women with physical findings suggestive of hyperprolactinemia or thyroid disease should have prolactin levels and thyroid function tests measured, respectively. Androgen levels have not been shown to correlate with sexual function (Davis et al., 2005; Santoro et al., 2005). Furthermore, currently available testosterone assays are unreliable at the lower levels usually seen in women. As a result, measuring serum testosterone levels in women presenting with low sexual desire will not provide meaningful clinical guidance.

Treatment

The treatment of HSDD involves psychosocial and biologic approaches. It is recommended to sequence treatment that gives priority to the most distressing aspect of the problem (Brotto et al., 2016). An office-based incremental counseling may be helpful using the PLISSIT model, which is basically a stepped approach specifically designed for health care providers in the primary setting (Annon, 1976). According to this incremental model, women are given permission (P) to discuss their problems and emotions. Then, the practitioner provides limited information (LI), which includes basic sexual function education and/or resources, and specific suggestions (SS) for addressing the problem in the form of directives and advice. If the individual needs more intensive treatment (IT) for HSDD, then the practitioner can refer her for individual or couple's therapy.

Initially, modifiable factors that are thought to be playing a role in HSDD should be addressed. Taking control over these conditions (e.g., disease states, medications) will have a positive influence regarding the amelioration of sexual dysfunction. If HSDD persists despite correction of modifiable factors, further treatment can be applied in the form of psychological therapy and medications that exert their effect through central nervous system (CNS) or hormonal pathways (Fig. 74.9).

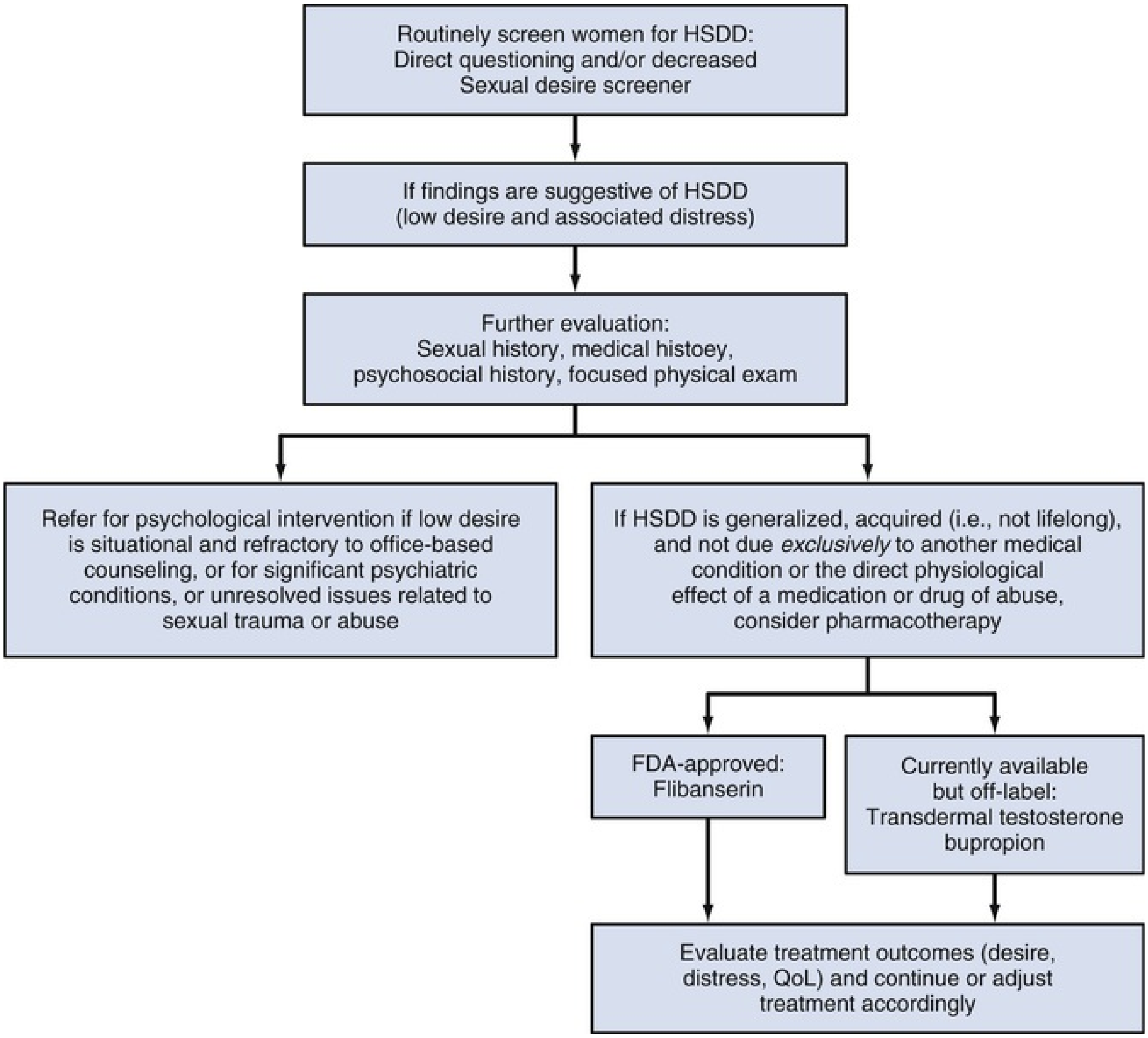
Routinely screen women for HSDD:
Direct questioning and/or decreased
Sexual desire screener
If findings are suggestive of HSDD
(low desire and associated distress)
Further evaluation:
Sexual history, medical histoey,
psychosocial history, focused physical exam
Refer for psychological intervention if low desire
is situational and refractory to office-based
counseling, or for significant psychiatric
conditions, or unresolved issues related to
sexual trauma or abuse
If HSDD is generalized, acquired (i.e., not lifelong),
and not due *exclusively* to another medical
condition or the direct physiological
effect of a medication or drug of abuse,
consider pharmacotherapy
FDA-approved:
Flibanserin
Currently available
but off-label:
Transdermal testosterone
bupropion
Evaluate treatment outcomes (desire,
distress, QoL) and continue or adjust
treatment accordingly

FIG. 74.9 Treatment algorithm for hypoactive sexual desire disorder. (Data from Clayton AH, Kingsberg SA, Goldstein I. Evaluation and management of hypoactive sexual desire disorder. *Sex Med* 2018b;6[2]:59–74.)

Psychological Treatment

The most commonly employed psychological interventions that are used to treat HSDD are behavioral therapy, cognitive behavioral therapy (CBT), and mindfulness therapy. Modifying thoughts, beliefs, behaviors, and emotions that interfere with desire represent the common target of each psychological modality. Behavior therapy utilizes education, communication skills training, and sensate focus exercises to tackle sexual complaints (Sarwer and Durlak, 1997). Questions during the assessment address cognitive function, sexual behavior, and skills of the couple (Brotto et al., 2016). Sensate focus therapy involves sensual touching exercises and aims to reduce anxiety and avoidance of sexual activity, improve sexual communication between partners, and improve intimacy by reintroducing sexual activity in an incremental way. It is more effective when HSDD is associated with penetration-related anxiety and associated behavioral avoidance (Masters and Johnson, 1970).

CBT aims to modify thoughts and behaviors that inhibit sexual thoughts in a sexual situation (Meston and Bradford, 2007). Through this process, patients learn to identify and challenge the unrealistic beliefs that keep them away from sexual activity. McCabe (2001) reported that CBT was effective in 44.4% of women with sexual health concerns. Likewise, Trudel et al. (2001) found that 74% of women with HSDD were improved with CBT, and this benefit was durable in 64% at 1-year follow-up.

The goal of mindfulness therapy is to encourage participants to connect and engage with their sexuality by learning and practicing a variety of mindfulness exercises (Brotto et al., 2014). It has been shown to help decrease cognitive distraction during sexual activity and increase awareness of pleasurable sensations when used in the setting of HSDD (Brotto et al., 2008b).

Medical Treatment

Flibanserin is currently the only U.S. Food and Drug Administration (FDA)-approved medication that can be used for the management of premenopausal women with low sexual desire. All of the other medical treatment options that can be applied in patients diagnosed with HSDD are used off-label. Several other drugs are currently under clinical development and may enter the HSDD armamentarium in the future.

Hormones

The increase in FSD during menopause is partly a result of decreasing levels of estrogens, which have been associated with vulvovaginal atrophy. Replacing estrogens via exogenous sources is the most straightforward approach to ameliorate hypoestrogenism-related sexual issues (Clayton and Hamilton, 2010). A meta-analysis covering 192 randomized controlled trials, related with estrogen replacement therapy (ERT) in postmenopausal women, showed that estrogens, alone or in a combination form, remain an effective therapy for relieving the symptoms associated with sexual dysfunction (Nelson et al., 2007), especially pain with sexual activity. Vestergaard et al. demonstrated that long-term (5 years) ERT significantly improved libido and dyspareunia (Vestergaard et al., 2003). Ospemifene is a novel selective estrogen receptor modulator with indication for the treatment of vulvovaginal atrophy and dyspareunia in postmenopausal women. A daily dose of 60 mg has been shown to be safe and effective in the treatment of women who have low sexual desire secondary to vaginal atrophy and dyspareunia (Cui et al., 2014; Goldstein et al., 2014). However, the International Society of Sexual Medicine Consensus concluded that, although topical vaginal estrogen is currently the first-line therapy for vulvovaginal atrophy, available evidence does not support the use of systemic estrogen therapy for FSD (e.g., HSDD) (Santoro et al., 2016).

Substantial evidence suggests that testosterone therapy positively influences overall sexual wellness in postmenopausal women with low desire with improvement in the number of sexual events reported as satisfactory, sexual desire, pleasure, arousal, and frequency of orgasm as well as a reduction in personal distress (Braunstein, 2007b; Davis et al., 2008; Somboonporn et al., 2005). In their randomized placebo-controlled study, Braunstein et al. (2005) showed that statistically significant increases in sexual desire and frequency of satisfying sexual encounters were achieved among the group of women who received the 300-μg/day dose. Similarly, positive results were reported by Buster et al., who assessed the efficacy and safety of the 300-μg/day testosterone patch during 24 weeks of administration in surgically menopausal women with HSDD who were already on estrogen therapy. In this study, testosterone treatment significantly increased the number of satisfying sexual events and sexual desire, and decreased sexually related personal distress (Buster et al., 2005). A recent systematic review and meta-analysis of seven randomized placebo-controlled studies enrolling over 3000 postmenopausal women with HSDD revealed that transdermal testosterone (with or without concomitant estrogen therapy) treatment led to significant increases in sexual desire, sexual activity, satisfying sexual events, and orgasms and a significant decrease in personal distress (Achilli et al., 2017).

While being approved for use in postmenopausal women in the European Union, concerns about long-term safety have precluded FDA approval of testosterone treatment in postmenopausal women with low sexual desire (Snabes and Simes, 2009). Peripheral conversion of exogenously administered testosterone by endogenous aromatases to estrogen and the resultant causal possibility of cardiovascular adverse events and development/progression of breast cancer represented the main issues that are being questioned with regard to the safety of long-term testosterone use in women (Brand et al., 2009; Laughlin et al., 2010). The Nurses' Health Study suggested that methyltestosterone users may be at increased risk for breast cancer (Ness et al., 2009), whereas other studies denied such an association (Davis, 2011). A phase III long-term study showed that testosterone transdermal gel did not increase cardiovascular events or breast cancer, even in high-risk women (White et al., 2012).

Oral formulations are not recommended as they are subject to significant intraindividual/interindividual variations in absorption, which might lead to supraphysiologic levels and consequently negative effects on lipid metabolism and hepatotoxicity. Transdermal administration avoids first-pass liver effects; hence it does not lead to alterations in lipid metabolism (Davis et al., 2012). The most common formulation used is a transdermal 1% testosterone cream (0.5 g cream, 5 mg testosterone daily) applied to skin of the arms, abdomen, or legs. Testosterone patches and gels that are originally formulated for men should be used with extreme caution in women, because accurate dosing is difficult. Likewise, testosterone injections and implants are also available but may lead to adverse effects as a result of irreversibly high, supraphysiologic serum testosterone levels. Women prescribed off-label testosterone therapy should be cautiously monitored for potential side effects; lipids and liver function should be regularly assessed (Kingsberg et al., 2015) during the course of treatment. It should also be noted that efficacy may not emerge for several weeks, and treatment should not be continued beyond 6 months in the absence of any clinical benefit (Davis et al., 2016).

The potential side effects of exogenous testosterone administration include signs of virilization, such as development of acne, hirsutism, deepening of the voice, and androgenic alopecia (ACOG, 2011). However, these effects are dose-related and can be avoided if hormone levels are kept in the female physiologic range. In the long-term safety study including women with surgically induced menopause, the most common side effects of transdermal testosterone treatment were application site reactions and unwanted hair growth (Nachtigall et al., 2011).

Tibolone is a synthetic steroid sex hormone with estrogenic, androgenic, and progestogenic effects. Wu et al. randomized 48 postmenopausal women to tibolone versus estrogen-progesterone hormone replacement therapy (HRT) for 12 weeks. As a result, tibolone was found to be superior to HRT in improving sexual parameters, including general sexual satisfaction, sexual interest, sexual fantasies, sexual arousal, and orgasm, with decreased frequency of vaginal dryness and dyspareunia (Wu et al., 2001). Another study compared tibolone to transdermal estradiol (E_2)/norethisterone (NETA) in naturally postmenopausal women with FSD. Both treatment modalities increased the frequency of sexual events and reduced sexuality-related personal distress. However, the increase in total FSFI score was more profound in the tibolone group when compared with that achieved in the E_2/NETA group (Nijland et al., 2008).

Regarding oral dehydroepiandrosterone (DHEA), systematic reviews and meta-analyses have found no statistically significant benefit of its systemic administration within the context of FSD (Elraiyah et al., 2014).

Bupropion

Bupropion is a dopamine and norepinephrine reuptake inhibitor and nicotinic acetylcholine receptor antagonist that is used as an antidepressant and smoking-cessation aid. It is also used as an off-label medical treatment for HSDD. **It has been found superior to placebo in improving sexual desire and decreasing distress in nondepressed premenopausal women with HSDD** (Modell et al., 2000; Segraves et al., 2001). In the randomized, double-blind, placebo-controlled study including 232 premenopausal women with depression, significant increase in sexual desire and decrease in distress were achieved with bupropion (150 mg/day) treatment (Safarinejad et al., 2010). **Bupropion has also been shown to be effective in reversing SSRI-induced sexual dysfunction in premenopausal women, as statistical improvements in desire have been achieved with bupropion SR 300 to 400 mg/day** (Clayton et al., 2004). A Cochrane review supports the addition of bupropion in higher dosages (150 mg twice daily) for the treatment of antidepressant-induced sexual dysfunction in women (Taylor et al., 2013).

The most common adverse effects of bupropion in placebo-controlled clinical trials for major depression or smoking cessation were tremor (13.5%), agitation (9.7%), dry mouth (9.2%), constipation (8.7%), excessive sweating (7.7%), dizziness (6.1%), and nausea/vomiting (4%). Treatment discontinuation rate caused by adverse events was approximately 10% (GlaxoSmithKline, 2016).

Buspirone

Buspirone is a 5-HT_{1A} partial agonist that is approved as an anxiolytic for the management of generalized anxiety disorder and for the short-term relief of symptoms of anxiety. It is one of the off-label treatment alternatives for HSDD. **It has been shown that buspirone minimized the negative effect of selective serotonin reuptake inhibition on sexual function when it was coadministered with SSRIs for the treatment of depression.** Fifty-eight percent of individuals treated with buspirone (20 to 60 mg/day) reported an improvement in sexual function compared with 30% treated with placebo (Landén et al., 1999).

Similar to bupropion, specific safety data of buspirone in women with HSDD is lacking. The most common adverse events in placebo-controlled anxiety disorder trials were dizziness (9%), nervousness (4%), nausea (3%), and headache (3%). Approximately 1 in 10 patients discontinued buspirone because of adverse effects.

Flibanserin

Flibanserin (Valeant Pharmaceuticals North America LLC, Bridgewater, NJ), dosed at 100 mg PO once daily at bedtime, is a nonhormonal, centrally acting, postsynaptic 5-HT$_{1A}$ receptor agonist and 5-HT$_{2A}$ receptor antagonist that results in a decrease in serotonin activity and an increase in dopamine and norepinephrine activity. It is believed to enhance sexual desire by stimulating excitatory elements of brain function and diminishing the inhibitory response to sexual cues (Kingsberg and Woodard, 2015). Approximately 50% of women with HSDD respond to flibanserin, and it may take up to 8 weeks for efficacy to emerge. **Flibanserin is currently the only FDA-approved treatment for acquired, generalized HSDD in premenopausal women.** Phase III trials have demonstrated that flibanserin was significantly superior to placebo with regard to the improvement in sexual desire, decrease in sexually related distress, and increase in the number of satisfying sexual events (Katz et al., 2013; Valeant Pharmaceuticals, 2015). **In the pivotal clinical trials of flibanserin in premenopausal women with HSDD, results of which led to FDA approval, the rate of subjective improvement in sexual desire was significantly higher (54% to 58% in the flibanserin group vs. 40% to 48% in the placebo group) in the treatment arm when compared with the placebo arm.** Although similar results have been obtained in postmenopausal women, flibanserin has not yet been approved for the treatment of HSDD in this population (Simon et al., 2014).

Regarding its safety profile, the most common adverse events in premenopausal women were dizziness (9.2%), somnolence (8.3%), nausea (6.5%), and fatigue (3.7%). Most of the side effects were transient or episodic and were mild to moderate in severity. The discontinuation rate caused by adverse effects was 13% and 6% in patients treated with flibanserin and placebo, respectively (Flibanserin Advisory Committee. https://www.fda.gov/media/93087/download. Katz et al., 2013; Simon et al., 2014; Flibanserin Medication Guide, 2015).

Because somnolence and dizziness were the most common adverse events having been reported in flibanserin clinical trials, safety concerns related to alcohol consumption have been raised during the FDA review process, and several additional investigations had to be carried out to clarify the potential hazards of this possible interaction. Incidence of hypotension- and syncope-related adverse events in flibanserin-treated patients was low for self-reported alcohol users (0.7%) and alcohol nonusers (0.3%) in the post hoc analysis of five randomized, placebo-controlled flibanserin trials. Alcohol use did not increase the rate of adverse events in the three pivotal clinical trials. Furthermore, ethanol ingestion did not have a significant effect on somnolence, drowsiness, orthostatic blood pressure changes, vertigo, hypotension, or syncope in an alcohol interaction study that was carried out after FDA approval (Fisher and Pyke, 2017), **Nevertheless, because of ongoing concerns about the risk for hypotension and/or syncope caused by flibanserin-alcohol interaction, the flibanserin package insert indicates that alcohol use is contraindicated in women taking flibanserin** (Valeant Pharmaceuticals, 2016**). Risk Evaluation and Mitigation Strategy (REMS) (https://www.addyirems.com/AddyiUI/rems/home.action) was deemed necessary for the prescription of flibanserin.** According to REMS, health care providers must review the drug's prescribing information, review a Prescriber and Pharmacy Training Program, complete a Knowledge Assessment Form, and submit the Prescriber Enrollment Form online before prescribing flibanserin. A similar certification and enrollment process is necessary for the pharmacies that are to dispense flibanserin (Valeant Pharmaceuticals, 2016).

The potential interaction between flibanserin and combined oral contraceptive pills has also been studied since flibanserin was FDA-approved in the premenopausal setting. Flibanserin was not found to cause clinically significant alterations in the pharmacokinetic properties of a combination of ethinyl estradiol and levonorgestrel in a study including healthy premenopausal women (Noll et al., 2016).

Others

The combination of sublingual testosterone with a phosphodiesterase type 5 inhibitor (PDE5I) (Emotional Brain BV, Almere, The Netherlands) or a 5HT$_{1A}$ receptor agonist (Emotional Brain BV) have also been tested for the medical treatment of low sexual desire in women. Both are proposed to increase sexual motivation through testosterone; however, the addition of the PDE5I is thought to increase vascular response (Poels et al., 2013), whereas addition of a 5HT$_{1A}$ receptor agonist is thought to act centrally by releasing sexual inhibition (van Rooij et al., 2013).

Bremelanotide (AMAG Pharmaceuticals, Inc, Waltham, MA), a melanocortin receptor agonist formulated as a subcutaneous injection, is another agent that is being investigated for the treatment of low desire and is also postulated to work through CNS mechanisms (Portman et al., 2014). Bremelanotide (1.25 and 1.75 mg) was found to demonstrate significantly superior clinical efficacy when compared with placebo in a randomized study of women with HSDD and/or FSAD in terms of the measures of sexual desire and arousal and in the number of satisfying sexual events. The most common adverse events were nausea (22% to 24%), flushing (14% to 17%), and headache (9% to 14%) (Clayton et al., 2016). Phase III clinical trials in premenopausal women with HSDD have demonstrated significant improvement in desire domain score of FSFI with bremelanotide treatment (1.75 mg, administered subcutaneously through an auto-injector before anticipated sexual activity) (Clayton et al., 2017; Derogatis et al., 2017).

Key Points: Hypoactive Sexual Desire Disorder

- Pathophysiology of low sexual desire involves biologic, psychological, and social elements.
- The Decreased Sexual Desire Screener can be utilized to identify generalized acquired HSDD.
- Concurrent sexual problems involving other aspects of sexual function might exacerbate low desire.
- A variety of systemic comorbidities and urogynecologic problems might interfere with sexual desire.

- Flibanserin is currently the only FDA-approved treatment for acquired, generalized HSDD in premenopausal women.
- All of the other medical treatment options for HSDD (including hormones) are used off-label.

Female Orgasmic Disorder

Female orgasmic disorder (FOD) is defined by a marked delay in orgasm, infrequency or absence of orgasm, or less intense orgasm for at least 6 months in 75% to 100% of sexual interactions (APA, 2013). FOD can be lifelong (primary) or acquired (secondary), generalized or situational, psychological or combined.

FOD is the second most common sexual dysfunction among women, closely following HSDD. Reported prevalence rates of FOD range from 16% to 28% in the United States, Europe, and Central/South America to 30% to 46% in Asia. **FOD can be diagnosed concurrently with at least one other sexual dysfunction** (Lewis et al., 2010). **It has been estimated that among women with FOD, 31% also report difficulties with sexual arousal, 18% with lubrication, 14% with desire, 12% with pain, and 0.9% with vaginismus** (Nobre et al., 2006).

The *DSM-5* definition of FOD does not contain the *DSM-IV-TR* criterion requiring that difficulty with orgasm occur despite “a normal excitement phase.” This revision was based on the fact that FOD can occur despite intact arousal. Another difference between the *DSM-5* and *DSM-IV-TR* with regard to the definition of FOD is that the *DSM-5* considers the intensity of orgasm in addition to the frequency and latency aspects of the problem, which were already included in *DSM-IV-TR* (Basson et al., 2003).

To arrive at the diagnosis of FOD, it is necessary to rule out medical conditions, pharmacologic interventions (SSRIs, other psychotropic medications), and psychosocial issues (e.g., severe interpersonal distress, life stressors) that might cause orgasmic difficulties (APA, 2013; Carey, 2006). Moreover, insufficient stimulation must also be ruled out before assigning the diagnosis of FOD. A woman whose sexual partner suffers from erectile dysfunction and/or premature ejaculation, thus depriving her of sufficient stimulation to reach orgasm, cannot be assigned an FOD diagnosis. About one-half of women who do not consistently reach orgasm during sexual activity do not report distress (Shifren et al., 2008). However, for orgasmic problems to be named as FOD, it must cause significant distress and interpersonal difficulty.

Subjective experiences of orgasm and the type and intensity of tactile stimulation that is required to provoke an orgasm can show significant variation. Orgasm triggered by clitoral stimulation has been accepted as a normal variation in sexual response (Harris et al., 2008). Furthermore, although most women can reach orgasm through masturbation, orgasm during partnered sexual activity is less frequent (Garcia et al., 2014) as many women might need additional manual stimulation to orgasm during coitus. Therefore, FOD should not be diagnosed solely on the basis of a failure to experience orgasm during sexual intercourse in the absence of additional clitoral stimulation FOD (APA, 2013; Laan et al., 2013; Meston et al., 2004).

Assessment

A comprehensive sexual history is essential to diagnose and characterize FOD. The nature and onset of the problem should be carefully assessed as well as the other aspects of female sexual function, because FOD often accompanies problems with interest and arousal. Women with lifelong generalized anorgasmia tend to be younger and have never experienced orgasm in any context. Lifelong anorgasmia may suggest that the patient is unfamiliar or uncomfortable with self-stimulation or sexual interaction with her partner, or lacks adequate sex education (Laan et al., 2013). On the other hand, in women with acquired anorgasmia, who have achieved orgasm in the past but have a distressing current inability to reach orgasm, inadequate stimulation, contextual factors, or physiologic factors are usually the cause of orgasmic dysfunction (Kingsberg et al., 2017). In the generalized subtype, FOD occurs with all stimulations, situations, and partners, whereas in the situational subtype, it only occurs within specific conditions. Psychological subtype denotes specific cognitive, affective, or relational factors that are implicated with orgasmic difficulties, in the absence of medical conditions or substance contributors. For the combined subtype, psychological factors together with medical conditions or substance abuse contribute to the development of orgasmic problems.

It is also crucial to understand the degree of bother and distress associated with FOD. Frequency of orgasm during partnered sexual activity has been accepted as a significant predictor of overall sexual satisfaction (Philippsohn et al., 2009).

During clinical evaluation, certain conditions that might increase the risk for FOD should be kept in mind and sought for. Among the risk factors for anorgasmia are lower socioeconomic status; lower educational level; poorer physical health status (de Lucena and Abdo, 2014); cognitive/affective factors such as anxiety disorder (Bradford and Meston, 2006); depression (Shifren et al., 2008); body image misbeliefs (Sanchez and Kiefer, 2007); negative thinking styles (Nobre et al., 2008); relationship adjustment issues such as conflicts, dissatisfaction, and sexual communication (Kelly et al., 2006) or intimacy problems (Burri and Spector, 2011); being exposed to restrictive and conservative attitudes (because of religious or cultural misbeliefs) about sexuality (Kelly et al., 1990); history of sexual abuse or childhood maltreatment (Rellini and Meston, 2007); feeling guilty about sex; sexual inexperience; and the absence or deficiency of sex education during childhood or adolescence (de Lucena and Abdo, 2014).

Certain medical conditions (Bitzer et al., 2013; Kingsberg et al., 2013) including hypothyroidism, arthritis, hypertension, chronic pain, asthma, diabetes, coronary heart disease, malignancies (breast, colorectal, gynecologic), neuromuscular disorders, SCIs, and multiple sclerosis, might also have a negative impact on orgasmic functioning. Additionally, medications such as amphetamines, digoxin, antiandrogens, narcotics, antipsychotics, barbiturates, lithium, SSRIs (Montejo-Gonzalez et al., 1997), tricyclic antidepressants, chemotherapeutics, and antihypertensives (Clayton et al., 2009), can have a similar negative effect. It is often unclear whether it is the medical condition per se, the treatment, or the psychological side effects of such conditions that impair orgasmic response. Likewise, the factors associated with the indications for medication usage (e.g., nerve damage, anxiety, and depression) also affect orgasmic function. Therefore, it is not always possible to realize the actual impact of drugs on FOD.

Validated questionnaires that contain orgasm domains or orgasm-specific items (FSFI, Changes in Sexual Functioning Questionnaire, Brief Index of Sexual Function for Women), can also be used while evaluating patients who experience orgasmic problems. **Questionnaires alone are not sufficient to diagnose FOD. However, they can be used to track progress of the orgasmic function and monitor treatment response.**

Psychosocial Treatment

Several psychosocial treatment strategies for FOD, mainly in the form of cognitive and behavioral psychotherapies, have been evaluated in clinical trials.

The majority of the relevant literature dates back to the 1980s. A recent systematic review has supported the efficacy of psychosocial interventions in the treatment of FOD (Frühauf et al., 2013).

It has been recommended that the partner should be actively involved in the assessment and treatment process in cases in which the orgasm problems are acquired or happen only during partnered sex (Laan et al., 2013). The PLISSIT modeled approach can be used while addressing orgasmic disorder. Primary care providers can apply this approach to provide initial support to uncomplicated cases of sexual dysfunction caused mainly by lack of education or need for permission to overcome fears or myths (Haeberle, 2010).

Education

Education is the hallmark of any treatment modality addressing FOD. Informing the patient and/or the partner about female sexual anatomy, physiology, and response as well as how orgasm can be climaxed via different stimulation techniques constitutes the first step of treatment (Kilmann et al., 1983).

Directed Masturbation and Sensate Focus

Directed masturbation is a behavioral technique involving self-awareness and exploration home exercises that are conducted in a progressive fashion (4 to 16 weekly therapy sessions) and aim to make the patient familiarize herself with her genitals and other erotic areas of her body. It has shown well-established efficacy when administered in a variety of modalities: group, individual, couples therapy, and bibliotherapy. Eventually, patients become more aware of sexually arousing stimuli and utilize self-knowledge to masturbate and reach orgasm (Heiman and LoPiccolo, 1988). It has been evaluated in clinical trials and was found to be effective in relieving the symptoms and distress associated with FOD (Andersen, 1981; Morokoff and LoPiccolo, 1986). The success rates for directed masturbation training in women with primary anorgasmia are usually high and show some variation depending on the type of orgasm-triggering stimulation: 60% to 90% with masturbation, and 33% to 85% with partnered sexual activity (Heiman, 2002). CBT can be combined with directed masturbation training in an effort to increase clinical efficacy. Riley and Riley (1978) demonstrated that the percentage of patients achieving the ability to orgasm was significantly higher in the group of patients who received CBT (sensate focus and supportive psychotherapy) plus directed masturbation when compared with those who were treated with conventional CBT only (90% vs. 53%).

Sensate focus consists of graded exposure from nonsexual to sexual touching to acquaint sexual pleasure with trust and effective communication between the couple. It can also be applied within the context of FOD. Similarly, it involves home exercises and active participation of the patient (Kingsberg et al., 2017). Directed masturbation training plus sensate focus was shown to be more effective than directed masturbation training alone (Heiman and Meston, 1997).

Mindfulness and Yoga

Mindfulness and yoga practice may be considered as possible adjuncts to directed masturbation and sensate focus. Herein, attentional focus is directed to “being in the moment without judgment.” In their study that utilized the FSFI as the assessment tool, Dhikav et al. (2010) showed that younger women with sexual health–related issues improved maximally in terms of their quality of orgasm and satisfaction with 12 weeks of yoga.

Coital Alignment Technique

The coital alignment technique focuses on maximizing glans clitoris stimulation and aims to increase the frequency of the woman achieving orgasm simultaneously with her male partner during vaginal intercourse. Herein, the male partner is taught about ways to augment clitoral stimulation during the act of penetrative vaginal sexual intercourse (Eichel et al., 1988). In this coital position, the man positions his pelvis above the pubic bone of his partner. The woman stretches her legs and folds them around his. Penetration of the penis is less deep but the glans clitoris is more strongly stimulated with each thrust than with conventional intercourse. Clinical trials, which have included patients with primary anorgasmia, have shown that this technique was more effective than a waiting list control group and as effective as directed masturbation (Eichel et al., 1988; Hurlbert and Apt, 1995).

Sexual Enhancement Products

Modifying the type and intensity of physical and psychological sexual stimulation via sexual enhancement products can be an effective way of addressing FOD. Vibrators and sexually explicit media represent the most commonly utilized methods under this heading. These tools can also be used during directed masturbation sessions. A common concern about the use of vibrators is that the woman will be dependent on this type of stimulation to reach orgasm, and eventually avoid partnered sexual intercourse (Marcus, 2011). However, vibrator use has been associated with higher scores on sexual function domains. Additionally, a vibrator can be used during partnered penetrative sexual intercourse (Herbenick et al., 2010).

Medical Treatment

Medical treatment of FOD can be divided into two main categories: treatment of orgasmic disorder in the context of desire and arousal disorders and the treatment of orgasmic disorder in women without desire or arousal disorder.

Women With Female Orgasmic Disorder Together With Desire and Arousal Problems

When an improvement has been achieved in desire and arousal, this will translate into an enhancement in orgasmic function. Medications, which can be used in this context, act via increasing the intensity of the sexual stimulus and/or augmenting the sensitivity of the receptive areas to sexual stimuli. Alternatively, cholinergic activation and/or stimulation of the guanosine monophosphate pathway can be targeted to treat FOD in an indirect fashion. Furthermore, sexual enhancement products (vibrators, erotica) can be utilized in this subset of patients. Vibrators have been widely available in many countries through drug stores, websites, and erotica shops. However, there is only one FDA cleared-to-market device available to treat FSD (EROS Therapy device; UroMetrics, Inc, St Paul, MN). The EROS device is a small battery-powered handheld vacuum device applied gently and directly over the clitoris, causing the clitoris and labia to engorge with blood. Whereas vibrators do not require a prescription and come in a variety of prices, the Eros Therapy device does require a prescription. Billups et al. demonstrated that the EROS Therapy device was successful in terms of increasing the ability to reach orgasm in more than 50% of their patient cohort who had problems related with arousal and satisfaction (Billups et al., 2001).

Phosphodiesterase Type 5 Inhibitors

These drugs inhibit the enzyme (PDE5) responsible for the breakdown of cyclic guanosine monophosphate. The end result is increased blood flow to the vulva and vagina through smooth muscle relaxation and vasodilation. Caruso et al. (2003) demonstrated that sildenafil has a positive impact on arousal and orgasmic function in their randomized double-blind placebo-controlled study. Nurnberg et al. assessed the efficacy of sildenafil in treating antidepressant-associated FSD in a randomized controlled setting and reported beneficial effects of sildenafil on adverse side effects of SSRI use on orgasmic function (Nurnberg et al., 2008.)

Hormones

Systemic testosterone treatment (either alone or in combination with systemic/intravaginal estrogens) and tibolone (Nijland et al., 2008), (a synthetic steroid available in Europe that provides a mixture of estrogenic, progestonic, and androgenic actions), have a positive influence on all aspects of female sexual response (desire, arousal, and orgasm) in postmenopausal women with low testosterone/low estrogen levels. They achieve this therapeutic effect via CNS-related mechanisms (testosterone's excitatory effect on the limbic system) and changing the hormonal milieu of the vulvovaginal complex (Wierman et al., 2014). In their systematic review, which was conducted in 2014 and focused on testosterone treatment in HSDD, Reis et al. (2014) concluded that androgenic supplementation with transdermal testosterone (patch, gel) was effective in terms of increasing the level of sexual desire, the ability to experience orgasm, and eventually the degree of satisfaction.

Treatment with local or systemic estrogen also has positive effects for orgasmic dysfunction. Increased cellularity of the vaginal epithelium, augmented genital blood flow, and enhanced lubrication provide improvement in all four domains of FSD. Addressing dyspareunia and arousal problems with intravaginal estrogen might also have an indirect beneficial effect on orgasmic issues (Cappelletti and Wallen, 2016).

However, it should be noted that more research is warranted about the safety and efficacy of hormonal treatment in women with FOD as the primary complaint. The majority of available data originate from studies actually concentrating on other aspects of female sexual response and reporting indirect, secondary outcome about orgasmic function.

Women With Female Orgasmic Disorder Who Report Subjectively Sufficient Arousal

The goal of any medical treatment in this context would be to increase the arousal stimulation in intensity and frequency. Sexual enhancement products (vibrators, erotica) can also be used for this purpose.

Oxytocin

Oxytocin can be used on-demand in patients with intact arousal but orgasmic failure. It is a short-acting drug and exerts its effect via working synergistically with sex hormones to facilitate muscle contractions during orgasm. Oxytocin, which can be considered as a facilitator of arousal and orgasm, is normally secreted into the bloodstream from the paraventricular nucleus of the hypothalamus during arousal and orgasm (Magon et al., 2011).

Medication-Induced Female Orgasmic Disorder

SSRIs, which represent the cornerstone of pharmacotherapy for depression, have the potential to adversely affect various aspects of the female sexual response cycle, including desire, arousal, and/or orgasm, with estimates of 30% to 70% of patients on SSRIs reporting some degree of sexual dysfunction (Serretti and Chiesa, 2009). First, it is important to investigate the onset of a patient's sexual dysfunction. Depression itself may lead to sexual dysfunction, and treatment with an SSRI may actually be helpful, although this may take weeks of therapy. On the other hand, if sexual side effects are detected, it is recommended to wait for tolerance to develop, provided that the SSRI is successfully treating the depressive symptoms (Laan et al., 2013). Tolerance usually occurs within 14 to 120 days. After the development of tolerance, some patients will experience spontaneous resolution or marked improvement in their orgasmic complaints, and others will keep having distressing orgasmic delays or failures (Haberfellner and Rittmannsberger, 2004). Regarding the women who have persistent orgasmic dysfunction beyond 3 to 6 months, additional approaches such as reducing the dose of SSRI or switching to another antidepressant medication can be considered. Switching to medications with positive noradrenergic effects, such as serotonin-norepinephrine reuptake inhibitors, or to medications such as buproprion or mirtazapine may reduce sexual side effects (Serretti et al., 2009).

Key Points: Female Orgasmic Disorder

- Medical conditions, pharmacologic interventions, and psychosocial issues, which might cause orgasmic difficulties, should be ruled out before arriving at the diagnosis of FOD.
- A comprehensive sexual history (involving details about the nature and onset of the problem) is essential to diagnose and characterize FOD.
- FOD often accompanies problems with interest and arousal.
- Education (about sexual anatomy, physiology, and wellness) is the hallmark of any treatment modality addressing FOD.
- Directed masturbation and sensate focus, coital alignment, and mindfulness techniques represent the psychosocial treatment options for FOD.
- More research is warranted about the safety and efficacy of hormonal treatment in women with FOD.

Female Sexual Arousal Disorder

In 2017, the ICSM Committee focused on the distressing complaints of hypoactive sexual desire, impaired arousal, and orgasmic problems (Kingsberg et al., 2017). The Committee chose to use the *DSM-IV-TR* (APA, 2000) classifications of female sexual disorders (FSD) instead of those from the *DSM-5* (APA, 2013). This is consistent with the recommendations of the ICSM Committee on Definitions (McCabe et al., 2016) and a recent article on nomenclature by the ISSWSH (Parish et al., 2016). The Committee suggested that separating desire and arousal allows an easier way to characterize the assessment and treatment of each dysfunction, rather than combining them as seen in the new and controversial diagnosis of FSIAD (APA, 2013). We will follow this approach and acknowledge that there is often significant overlap and comorbidity among all *DSM-IV-TR* diagnoses. However, treatment is typically focused on the primary disorder identified by the woman.

The ICSM definition for FSAD is *a persistent or recurrent inability to attain or maintain arousal until completion of the sexual activity, an adequate subjective assessment of her genital response (clinical principle)* (McCabe et al., 2016). As mentioned earlier, FSAD was merged with HSDD in the *DSM-5* (APA, 2013) and is now known as FSIAD (Sungur et al., 2014). On one hand, neither version of the *DSM* categories and their criteria appears to fully correspond with women's subjective experience; on the other hand, experts in the field have not reached a consensus on FSIAD (Kingsberg et al., 2017).

Female sexual arousal has been described since the 1970s. This is a debated topic given the lack of concordance between subjective sexual arousal and genital arousal. A woman's perception about her genital responses is defined as subjective sexual arousal, whereas genital arousal refers to the physiologic activation such as vaginal lubrication and vasocongestion. Lack of concordance leads to a weak relation between subjective and objective sexual responses (Kingsberg et al., 2017). Recent strategies focused on the external genitalia (and, to a lesser extent, on the central processing of sex stimuli) have suggested that the various components composing female sexual arousal might be processed differently in women's appraisal of sexual arousal.

Interview Assessment of Sexual Arousal

Understanding of a woman's subjective experience is crucial in identifying a problem with sexual arousal. During the initial assessment, a semistructured interview could be helpful to define the patient's concepts of sexual arousal, including erotic mental images, emotions of sexual excitement, pleasurable genital sensations, and noticing physical changes such as vaginal lubrication. Table 74.17 presents examples of helpful questions as suggested by the Female Sexual Dysfunction—Medical and Psychological Treatments Committee (Kingsberg et al., 2017).

TABLE 74.17

Examples of Helpful Questions as Suggested by the Female Sexual Dysfunction–Medical and Psychological Treatments Committee

How often do you notice yourself feeling sexually excited?
What situations help you feel excited (e.g., seeing an attractive person, engaging in sexual caressing, viewing erotic images, or reading an erotic story)? It might be useful to note that Ogi Ogas and Sari Gadam analyzed Internet usage of men and women. In their book, *A Billion Wicked Thoughts: What the Internet Tells Us About Sexual Relationships* (New York, NY: Dutton, Penguin Group; 2011), they described a gender difference. Women are more easily aroused by narrative stories, whereas men look for visual images.
Do you sometimes have sexual fantasies?
Is there a particular type of scenario in a fantasy or story that arouses you?
How easy is it to get aroused with your current sexual partner? (Partner-specific problems can signal relationship issues rather than a generalized sexual problem.)
What sensations do you notice in your genital area when you feel excited (e.g., warmth, tingling, pleasure, increased wetness)?
Do you ever have erotic dreams?
Do you believe that your sexual excitement is healthy? (Guilt about sex can inhibit arousal. Some women, raised in a culture with a strong double standard restricting female sexuality, might rarely or never have felt sexually aroused [Laan et al., 1994]. Women who had a sexually traumatic experience in childhood also might have difficulty feeling sexual excitement [Wylie et al., 2006]).
If you used to get aroused more easily, what do you think is interfering now?

Modified from Kingsberg SA, Althof S, Simon JA, et al. Female Sexual

Dysfunction—Medical And Psychological Treatments, Committee 14. *J Sex Med* 2017;14(12):1463–1491.

Potential Treatments for the Psychosocial Aspects of Female Sexual Arousal Disorder

Following the ICSM Committee (Kingsberg et al., 2017), a careful clinical evaluation is mandatory to create a proper treatment plan for a woman with difficulty getting or staying subjectively aroused during sexual situations. Investigation of the cause should focus on at least one of the following factors:

1. Are cultural or religious factors causing sex guilt and inhibition?
2. Is the problem with arousal specific to the partner and associated with problems in a dyadic relationship?
3. Does the woman have many distracting cognitions during sex, and what kinds of thoughts interfere (insecurity about attractiveness or ability to please the partner sexually, memories of past sexual trauma, or other issues)?
4. Is the woman under high levels of stress, and/or does she have poor stress management skills?
5. Does the woman tend to focus on negative affect that might be related to her genetic disposition or her developmental attachment issues?
6. If the woman is older than 40 years of age, does she lack a sexual partner or have a partner whose ill health or erectile dysfunction limits sexual activity and pleasure?

Women's sexuality could be affected by cultural or religious concerns. However, there is no treatment to lessen women's guilt and negative views of sexuality. Christensen et al. described how using online role-playing games may be helpful in identifying a potential role of a member of the clergy or of a local community leader having a moderate stance on sexual pleasure who might be more effective in decreasing guilt than a mental health professional from outside the community (Christensen et al., 2013).

Incorporating mindfulness training into sex CBT approaches (Brotto and Basson, 2014; Brotto et al., 2008a) may improve attention during sex. Learning to focus on pleasurable sensations while avoiding distractions by negative thoughts and feelings during sex can improve satisfaction. Indeed, asking each partner to focus on his or her own bodily sensations while noticing any negative thoughts and refocusing attention on physical feelings could be viewed as training mindfulness.

Mindfulness meditation can help women in stress management, although data are scarce. Improved nutrition and exercise, if applicable, also may have a positive influence on women's sexual function because of enhanced well-being, increased feelings of attractiveness, and decreased distraction from negative thoughts about body image during sex. Depression or anxiety disorders have often been regarded as poor prognostic factors for sex therapy. Although studies on this topic are scarce, treating attachment and mood disorders may play a role in FSAD.

Pharmacotherapy for Female Sexual Arousal Disorder

Hormonal Therapy

Testosterone and Selective Tissue Estrogenic Activity Regulator

In 2012, Davis et al. demonstrated that transdermal testosterone patch therapy can improve sexual desire and arousal (level of evidence 1) (Davis et al., 2012; Kingsberg et al., 2017). These results were aligned with the study performed by Tuiten et al. (2000) that demonstrated an enhanced genital arousal in hypogonadotropic hypogonadal women after a treatment with testosterone undecanoate 40 mg/day orally during an 8-week period. Testosterone seems to act independently from the estrogens (Pessina et al., 2006) and has a direct effect on the vagina and genital structures.

Tibolone is a selective tissue estrogenic activity regulator and acts differently in multiple organs because of the dissimilar steroid properties of its metabolites (Nappi and Cucinella, 2015). It has been used in postmenopausal women and it enhanced mood and libido, but further research is needed (Biglia et al., 2010; Davis, 2002).

Nonhormonal Therapy

Phosphodiesterase Type 5 Inhibitors

The use of vasoactive drugs such as PDE5Is in women is based on the notion that an increase in blood flow to the clitoris and vagina might improve sexual function like that seen in men with erectile dysfunction (Chivers and Rosen, 2010). The data for PDE5Is from clinical randomized controlled trials for FSAD have been reviewed and found to be contradictory and ultimately lacking in efficacy (Nappi and Cucinella, 2015; Chivers and Rosen, 2010).

In 2004, Pfizer (New York, NY) ended its program of testing sildenafil in women, perhaps resulting from the conflicting findings in medically healthy women (Major, 2004). However, data suggest a potential therapeutic role for these vasoactive agents in well-established medical conditions interfering with genital neurovascular substrates such as type 1 diabetes, SCI, multiple sclerosis, and FSAD secondary to SSRI use (level of evidence 2) (Kingsberg et al., 2017).

Prostaglandins

Topical alprostadil (prostaglandin E_1) is a vasodilatory agent that acts on smooth muscle relaxation. Indeed, prostaglandins enhancing the activity of sensory afferent nerves, improve sensation. Kielbasa and Daniel did not identify consistent or reproducible results of beneficial effects (Kielbasa and Daniel, 2006).

l-Arginine

L-arginine is the nitric oxide precursor. Its combination with yohimbine, an adrenergic antagonist, in women with FSAD could significantly increase physiologic measures of sexual arousal (vaginal photoplethysmography) but had no effect on subjective measures of arousal or affect (Meston and Worcel, 2002).

Dopamine Agonists

Dopaminergic drugs have a direct effect on the brain and therefore could have a positive influence on sexual arousal and desire. Apomorphine is a nonselective dopamine agonist that acts on D_1 and D_2 receptors. Caruso et al. (2004) reported significant improvement of sexual function in a group of premenopausal women with FSAD after sublingual apomorphine. Furthermore, Bechara et al. (2004) showed that the use of apomorphine before and after vibrator use significantly improved arousal and lubrication but did not improve orgasm.

Bupropion

Bupropion is an antidepressant with dopamine and norepinephrine reuptake inhibition; it has no serotonergic effect and has been shown to have prosexual effects, with improvement in all domains of sexual dysfunction compared with placebo (Levin, 2014; Segraves et al., 2004).

In a Cochrane Database Systematic Review of management of SSRI-induced sexual dysfunction, five high-quality randomized trials, including 579 participants, found improvement in sexual rating scores with the use of bupropion 150 mg twice daily (level of evidence 2) (Kingsberg et al., 2017; Taylor et al., 2013).

Oxytocin

Oxytocin is a neuropeptide involved in parturition and lactation, but it seems to have a potential role as an agent of arousal and orgasm. Behavioral studies have demonstrated that it might be responsible for prosocial behaviors in humans such as positive physical contact and communication methods with a partner (Grewen et al., 2005).

Female Persistent Genital Arousal Disorder

The ICSM definition for female persistent genital arousal disorder (FPGAD) is a spontaneous, intrusive, and unwanted genital arousal (i.e., tingling, throbbing, pulsating) in the absence of sexual interest and desire. Any awareness of subjective arousal is typically, but not invariably, unpleasant. The arousal is unrelieved by at least one orgasm, and the feeling of arousal persists for hours or days (McCabe et al., 2016*)* In 2001, Leiblum and Nathan defined this syndrome according to the following criteria reported in Table 74.18.

TABLE 74.18

Leiblum and Nathan Criteria for Female Persistent Genital Arousal Disorder in Women

Physiologic sexual arousal (genital and breast vasocongestion and sensitivity) persists for an extended period (from hours to days) and does not remit on its own.
The signs of physiologic sexual arousal do not remit with ordinary orgasmic experience.
The signs of physiologic sexual arousal are experienced in the absence of subjective feelings of sexual desire and arousal.
The symptoms of sexual arousal can be triggered by sexual-related stimulus but also by nonsexual cues or no stimulus at all.
These symptoms are perceived as intrusive and unwanted, leading at least to some degree of distress.

PGAD must be distinguished from hypersexuality (Kafka, 2010) (a symptomatic cluster characterized by out-of-control sexual thoughts and behaviors, accompanied by subjective feelings of sexual desire) and clitoral priapism (engorgement of the clitoris that is experienced with significant pain) (Goldmeier et al., 2009).

Psychosocial Characterization and Etiologic Factors

Characterization of women with PGAD is complicated, and evidence is limited (Kingsberg et al., 2017). Psychologically, women with PGAD present a negative appraisal of genital sensations (Leiblum and Seehuus, 2009) and are more likely to be depressed and to have panic attacks, or to present a history of sexual victimization (Leiblum et al., 2007). Furthermore, patients with PGAD seem to be associated with a sexually conservative thinking style accompanied by a maladaptive cognitive and emotional functioning during sexual activity (Carvalho et al., 2013). Scores on the FSFI showed that women with PGAD are not sexually dysfunctional but lack a satisfactory sexual life (Leiblum and Seehuus, 2009).

Data on the etiology of PGAD are poor. Studies on the biologic underpinnings of PGAD underline the role of physical defects such as the presence of a periclitoral mass (Bedell et al. 2014), pelvic varices (Thorne and Stuckey, 2008), or Tarlov cysts (Komisaruk and Lee, 2012). Use of venlafaxine or the discontinuation of an SSRI (Leiblum and Goldmeier, 2008; Mahoney and Zarate, 2007) could be involved in the PGAD etiology.

Biologic versus psychological factors may lead to different subsets of cases and variants. However, the exact proportion in which this happens is unknown.

Treatment Targets

Improvement of PGAD symptoms has been described in case series with duloxetine (Philippsohn et al., 2012), pregabalin, and varenicline. Electroconvulsive therapy also has been successfully applied (Korda et al., 2009) and reported in some small studies. CBT targeting anxiety management, response prevention, and dyadic issues has been shown to improve sexual and emotional symptoms (Hiller and Hekster, 2007).

Key Points: Female Sexual Arousal Disorder

- FSAD is a persistent or recurrent inability to attain or maintain arousal until completion of the sexual activity.
- In the *DSM-5*, FSAD is merged with HSDD and is called *female sexual interest/arousal disorder (FSIAD).*

- Defining the patient's concepts of sexual arousal should be the first step while assessing FSAD.
- Testosterone therapy, which has a direct effect on genital structures, can improve sexual desire and arousal.
- Treatment with PDE5Is can be considered in patients whose arousal disorder is associated with medical conditions interfering with genital neurovascular supply.
- Leiblum criteria should be used while defining FPGAD.

Genitopelvic Pain and Penetration Disorder

Pain and Sex

Sexual pain is common and can have many repercussions for women and their partners. Vaginal and vulvar pain is a commonly neglected health problem in women. These conditions are frequently ignored by health care providers, poorly understood, and often mismanaged. Pain during sexual intercourse might originate from any dysfunction of the vulva, vagina, cervix, uterus, adnexa, PFMs, and the nerves that innervate these structures. The following list provides descriptions of the common genitopelvic pain and penetration disorders.

- **Dyspareunia:** pain during intercourse
- **Vaginismus:** involuntary contraction of the musculature of the vagina that interferes with intercourse
- **Vulvodynia:** vulvar discomfort, described as burning pain, occurring in the absence of relevant visible findings (Moyal-Barracco and Lynch, 2004)
- **Localized vulvodynia:** pain localized in a particular part of the vulva (e.g., vestibule, vaginal entrance)
- **Generalized vulvodynia:** pain affecting the entire vulvar region
- **Provoked vulvodynia:** pain triggered by an external stimulation
- **Unprovoked vulvodynia:** spontaneous pain, unrelated to any specific stimulation

The most common type of vulvodynia is localized to the vestibulum and is related to sexual intercourse. This type of provoked vulvodynia leads to dyspareunia (painful intercourse). According to the International Society for the Study of Vulvovaginal Disease (ISSVD) terminology classification, this common subtype of vulvodynia is called *provoked vestibulodynia (PVD)*. It is estimated that 12% of women in the general population are affected by this condition (Goldstein et al., 2009). PVD is frequently associated with other pain syndromes. Frequently documented comorbidities are irritable bowel syndrome

(IBS) and fibromyalgia (Arnold et al., 2006).

Provoked Vestibulodynia

Primary

Primary PVD is pain experienced since the first attempt of any type of vaginal penetration (e.g., tampons or sexual activity). This condition has an early onset, the duration of the pain is longer, and the women are less likely to have had children. These patients also have a positive family history of the same condition. Frequently there is also an association with enuresis and dysmenorrhea (Bornstein et al., 2001). The presence of local signs of inflammation is less common.

Secondary

Secondary PVD is pain experienced after a certain period pertaining to vaginal penetrative activities that previously were pain free. This condition is typically acquired and has a late onset. Larger areas of vestibule are involved in the pain process. The clitoral hood is the area with the most severe pain (Bornstein et al., 2001). Secondary PVD appears to be more frequent than primary PVD (65% vs. 35%) (Nguyen et al., 2015), and primary PVD appears to be more frequent in Hispanic women (Bornstein et al., 2001).

Pathogenesis

The cause of PVD is multifactorial in nature and not completely understood. Vaginal secretions seem to play an important role in at least some of these conditions (Jayaram et al., 2015). According to some studies, it appears that human epididymis protein 4 (HE-4) and secretory leukocyte protease inhibitor (SLPI) are reduced in women with PVD compared with control women (Jayaram et al., 2015). Further, the subgroup of patients who experienced constant vulvar pain had markedly lower levels of HE-4 and SLPI compared with the subgroup who experienced pain only during sexual intercourse. These findings play an important role in our understanding of the protease-activated receptor 2 (PAR-2) pathway's influence on pain sensitization in women with PVD. The same pathway is also known to be activated in pain sensitization in cancer patients. Specifically, unopposed protease activity, which can result in decreased ability to inhibit PAR-2 activation, coupled with nerve fiber density changes at the level of the vulvar vestibule may be explanatory for the pain sensitization occurring in women with PVD.

An important difference between primary and secondary PVD is in the nerve fiber density and the presence of inflammation. Primary PVD patients appeared to have greater nerve fiber density and a thicker vulvar vestibule compared with the secondary group. Thus, this subgroup of patients presents with a greater peripheral and central involvement. One potential explanation for the increased nongenital sensitivity found in women with PVD in general, and in women with primary PVD in particular, could be that women with primary PVD are genetically predisposed to factors that contribute to an increased generalized pain response (Lam and Schmidt, 2010).

Additionally, **hypertonicity of PFMs appears to be highly prevalent in patients with PVD** (Morin et al., 2014; Pukall et al., 2016). Pelvic muscle dysfunction in patients with PVD can present with decreased muscular strength and reduced speed of contraction, coordination, and endurance.

Brain activity is also associated with recurrent and chronic pain. Pain is multidimensional involving physical sensations, thoughts, and emotions. Brain regions thought to influence the motivational aspects of pain include the anterior cingulate gyrus (ACC), an area that provides an interface between emotions and rational cognitions. The anterior insula, an area involved in many conscious behaviors, is also involved in the motivational aspects of pain. Somatosensory areas (SI, SII) and the posterior insula process pain's sensory components. The prefrontal cortex (PFC) and amygdala, both involved in processing affect and negative emotions, process the emotional aspects of pain. Specific areas in the brainstem, the periaqueductal gray (PAG), and the medulla are thought to integrate descending signals from the brain to the dorsal horn cells of the spinal cord (Tracey and Mantyh, 2007).

Patients with PVD might develop changes of **central sensitization** in the CNS (Foster et al., 2005). This phenomenon is characterized by higher excitability of the central nociceptive circuits in a number of chronic pain syndromes and could maintain chronicity or even be the main etiologic factor.

Clitoris and Clitorodynia

One possible presenting sign of vestibulodynia might originate from the clitoris (Lam and Schmidt, 2010). Clitoral pain is greatly underdiagnosed and undertreated (Parada et al., 2015). Many health care providers completely neglect the physical examination of the clitoris. In gynecology training programs, physical examination of the clitoris is uncommon and not routinely taught. Interestingly, urology residency programs routinely teach physical examination of the male genitalia, specifically the penis and foreskin, but the examination of the clitoris is totally neglected. The foreskin and clitoral hood have basically the same function and very similar pathologic changes. Clitoral adhesions can reduce an adequate drainage of keratinaceous desquamation. Smegma and squamous cells can accumulate underneath the prepuce, resulting in smegmatic pseudocysts and/or keratin pearls with a subsequent irritation. Erythematous changes and infection of the clitoris is a common cause of pain known as *clitorodynia*. Besides pain, clitoral adhesions could represent a risk factor associated with yeast infection, urinary tract infection, genital trauma, and lichen sclerosus. According to Aerts, of 1265 patients examined in their clinic who underwent a vulvoscopy, 23% presented with some degree of clitoral adhesions (Aerts et al., 2018).

Clinical Presentation (Fig. 74.10)

Menopause and Dyspareunia

Menopause induces changes in vaginal epithelium and is commonly associated with atrophy. Between 10% and 40% of postmenopausal women experience discomfort caused by vulvovaginal atrophy that requires treatment, and approximately 40% of women with vaginal atrophy report dyspareunia (North American Menopause Society [NAMS], 2013).

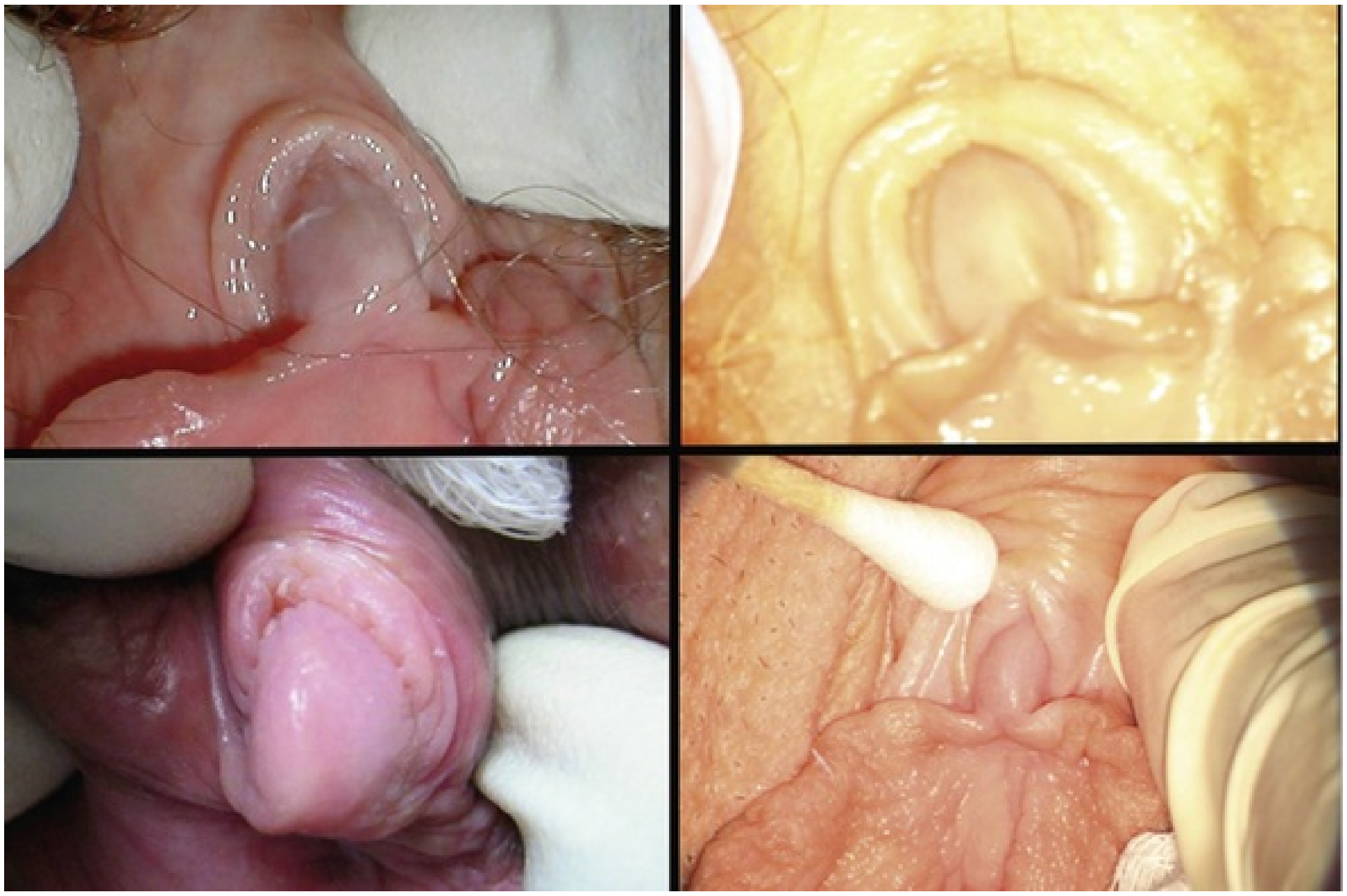

FIG. 74.10 Absent clitoral glans adhesions when the prepuce was retracted to the balanopreputial sulcus and full visualization of the corona. (Aerts L, Rubin RS, Randazzo M, et al. Retrospective study of the prevalence and risk factors of clitoral adhesions: women' s health providers should routinely examine the glans clitoris. *Sex Med* 2018;6[2]:115–122.)

Sexual activity in menopausal women is not insignificant. A literature review showed that 22% of married women 70 to 79 years of age report that they still have sexual intercourse (Schneidewind-Skibbe et al., 2008).

Vaginal atrophy may present with some or all symptoms of: dryness, burning and sexual symptoms of lack of lubrication, discomfort or pain, and impaired function. Urinary symptoms of urgency, dysuria, and recurrent urinary tract infections can also be observed. According to current terminology, this condition should be referred as genitourinary syndrome of menopause (GSM) (Portman and Gass, 2014).

Murina et al. (2016) stated that many menopausal women with complaints of dyspareunia have vestibular tenderness with more pronounced atrophic changes in this region rather than in the vagina.

Previous Genitourinary Surgery

The use of synthetic mesh in POP surgery is being closely scrutinized

because of serious concerns regarding life-changing complications such as erosion, pain, infection, bleeding, dyspareunia, organ perforation, and urinary problems (de Mattos Lourenco et al., 2019)**. Mesh complications can occur several years after the procedure** (Arsene et al., 2015)**. Most randomized trials evaluating POP surgery using synthetic mesh failed to report on clinically important outcomes and to evaluate medium- and long-term efficacy and safety.**

The sexually active women in the study were relatively satisfied. Interestingly, it was observed that women with a mesh complication, although not statistically significant, appeared to be more satisfied with their sex life. A possible explanation might be that after recovery of a complication, the mere fact of being able to have sexual intercourse again or the absence of pain might be a big relief. Women with a mesh complication were more frequently sexually active. An explanation may be that more sexual activity increases the risk for exposure, as friction is a risk factor for exposure. Further research is needed to investigate whether this observation is a real phenomenon or related to low numbers.

According to a cross-sectional study of 128 women who had vaginal mesh surgery, the sexually active women were relatively more satisfied with their sex life despite mesh-related complications compared with the group of non–sexually active patients (Kowalik et al., 2019). Also, women with a mesh complication were more frequently sexually active. The authors are hypothesizing that more sexual activity increases the risk for exposure, as friction is a risk factor for exposure.

Energy-based devices using radiofrequency and laser technologies have gained popularity as therapies for vaginal atrophy, UI, and vaginal prolapse. The technology is used by both medical and surgical specialties including dermatology, plastic surgery, gynecology, and genitourinary specialties. More recently, **cosmetic or “rejuvenating” nonsurgical procedures** using these same radiofrequency and laser technologies are growing in popularity. Vaginal “rejuvenation” is a descriptive nonscientific term used by the medical device and cosmetic industries for nonsurgical vaginal cosmetic procedures or therapies. It is used to treat symptoms related to menopause or UI, or to improve sexual function (FDA, 2018). Complications such as vaginal burns, scarring, dryness, infection, altered sensation, dyspareunia, adhesions, scarring, recurrent pain, or vaginal stenosis may occur over time. These could cause sexual dysfunction or worsening QoL as a result of radiofrequency and laser vaginal procedures for vaginal rejuvenation (ACOG, 2007).

In July 2018, the FDA issued a public notification regarding significant risks related to devices marketed for use in medical procedures for vaginal rejuvenation. There is a growing number of manufacturers marketing vaginal rejuvenation devices to women and claiming these procedures will treat conditions and symptoms related to menopause, UI, or sexual function. The procedures use lasers and other energy-based devices to destroy or reshape vaginal tissue. These products have serious risks and do not have adequate evidence to support their use for these purposes. Additionally, these procedures are also being marketed for cancer patients who experience an early menopause, eluding the possibility of treating this condition. According to the FDA, this is a dangerous procedure and without a proven benefit in a vulnerable population.

Laser vaginal rejuvenation can produce vaginal burns, scarring, dyspareunia, and CPP. These procedures may be particularly appealing to women who are not candidates for conventional FDA-approved treatments to relieve vaginal dryness and are thus seeking alternative nonhormonal options. Women considering treatment for vaginal symptoms should speak to their doctor about the potential and known benefits and risks of all available treatment options.

Treatment

Education

Discussions with patients related to vulvar hygiene habits, avoidance of irritants, behavior modification, stress-decreasing techniques, and education about sexual function and pain pathophysiology appear to have a relevant role. According to Fowler (2000), an emphasis on the patient's education resulted in a positive response in 21% of patients with PVD and an improvement in pain scores in 56% of the study cohort after 6 to 36 months of treatment.

Biofeedback

PVD has been shown to present heightened PFM tone, which encompasses an active (contractile) component and a passive (viscoelastic) component. The assistance of visual feedback of muscle activity is particularly relevant in women with pain because more than 50% of women without symptoms have difficulty achieving an adequate PFM contraction with only verbal instructions. Glazer et al. were first to develop an electromyographic (EMG) biofeedback protocol for women with vulvar pain and showed that 52% of the sample reported pain-free sexual intercourse after 16 weeks of treatment in a prospective study (Bo et al., 1990).

Dilators and Insertion Techniques

The use of vaginal dilators can help women with dyspareunia to control their fear of pain and promote pelvic floor relaxation during insertion (Idama and Pring, 2000). Little is known about treatment duration and the possible benefit of using dilators in conjunction with other treatments.

Electrical Stimulation

Electrical stimulation is a therapeutic modality widely used in physical therapy and pain management. The stimulation improves muscle proprioception, local blood circulation, and decreases nociceptive signal flows. Additionally, there is an increase in secretion of endorphins. Two prospective studies showed a significant improvement in dyspareunia and sexual function in women with PVD after domiciliary electrical stimulation and in-clinic electrical stimulation combined with home PFM exercises (Nappi et al., 2003; Vallinga et al., 2015).

Manual Therapy

Manual therapy is typically considered the cornerstone of physical therapy. This consists of stretching, massage, and myofascial techniques (Rosenbaum et al, 2008). The aim of this therapy is to facilitate muscle relaxation, release tensions and trigger points, improve blood circulation and mobility in the pelvic-perineal region, adjust postural imbalances, and increase the vaginal opening and desensitize the area.

Multimodal Physical Therapy

Multimodal interventions represent current practice in physical therapy in women with PVD and consist of a combination of manual therapy, stretching, PFM control exercises with or without biofeedback, and education (Hartmann et al., 2007).

Topical Therapy

According to the NAMS, nonhormonal lubricants and moisturizers in combination with regular sexual activity should be considered first-line therapies, but women often find these products inadequate (NAMS, 2013). Estrogen is known to affect inflammatory neuropeptides involved in chronic pain, in which the lack of estrogen is associated with an increased density of sympathetic, parasympathetic, and sensory nerve fibers in the vulva. Acute or chronic estrogen administration may decrease the total and sympathetic fiber numbers. Topical therapy is more effective than systemic therapy in reducing the density of vaginal autonomic and sensory nerve fibers (Griebling et al., 2012). Apparently, estrogen replacement targeted to the vestibule appears to be more effective in reducing the sensitivity compared with vaginal application (Murina et al., 2016).

Surgery

Vestibulectomy is a surgical procedure that can be used to treat PVD and specifically in case of vestibulodynia. According to Goetsch (2007), 79% of participants who underwent vestibulectomy had a significant decrease of pain compared with only 48% for those who received nonsurgical treatments and 12% who did not receive any treatment (eFig. 74.11).

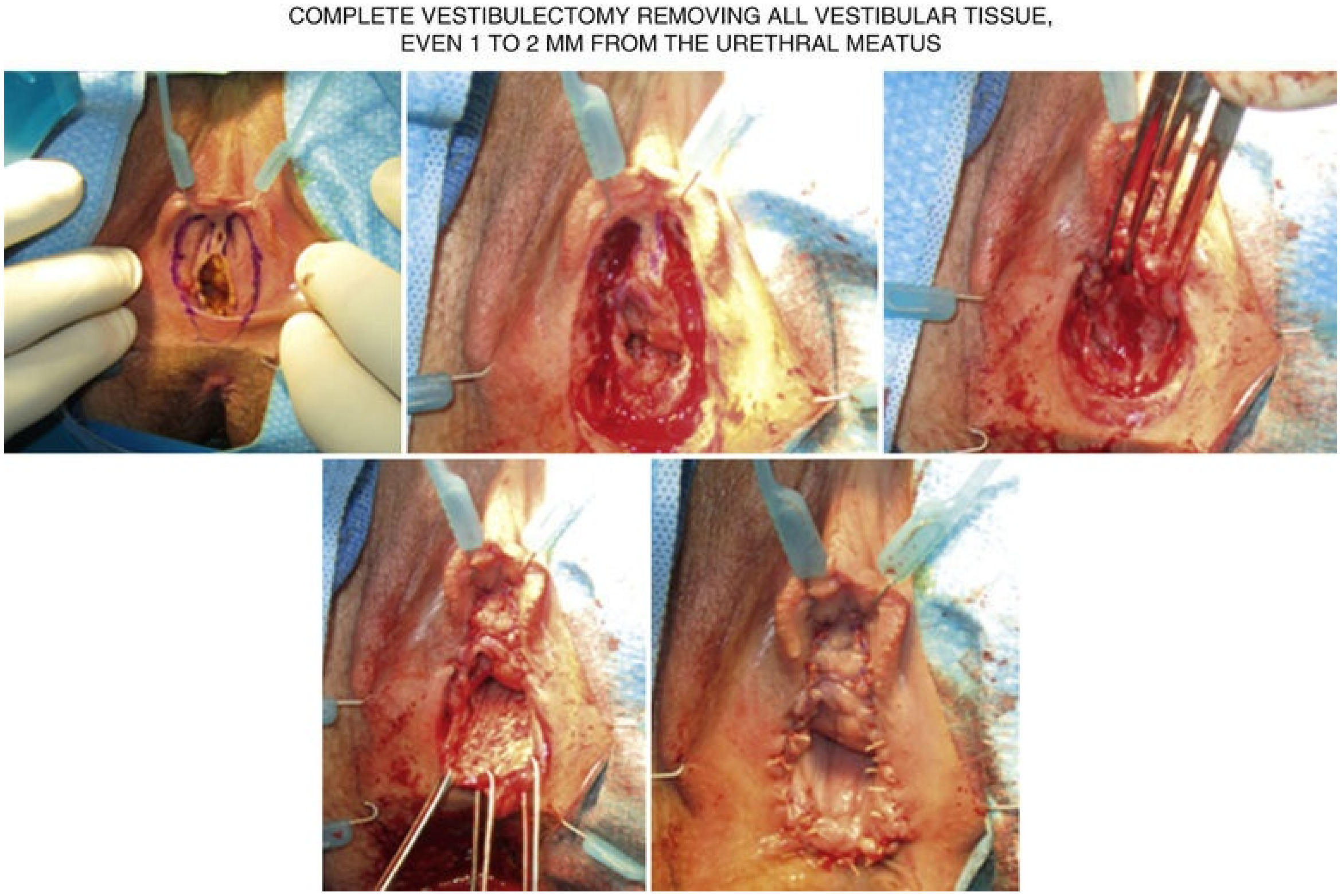
COMPLETE VESTIBULECTOMY REMOVING ALL VESTIBULAR TISSUE,
EVEN 1 TO 2 MM FROM THE URETHRAL MEATUS

EFIG. 74.11 Complete vestibulectomy for neuroproliferative vestibulodynia.

Multidisciplinary and Multimodality Approaches

Because of the multifactorial nature of PVD, multidisciplinary and multimodality approaches have been increasingly proposed to deal with chronic vulvar pain conditions (Goldstein et al., 2016). Thus, a combined approach would better address all factors contributing to the pain and associated psychosexual and relational difficulties and provide greater benefit to patients.

Key Points: Genitopelvic Pain and Penetration Disorder

- Pain during sexual intercourse can originate from any dysfunction of internal/external genital organs, PFMs, or the nerves that innervate these structures.
- Approximately 10% of the women are affected by PVD, which is frequently

associated with other pain syndromes such as irritable bowel syndrome and fibromyalgia.

- Postmenopausal atrophic changes in the vagina lead to dyspareunia.
- Biofeedback can be utilized to treat vulvodynia, especially in patients with hypertonic pelvic floor overactivity.
- Multimodal physical therapy, which consists of manual therapy, stretching, pelvic floor exercises, biofeedback, and education, represents the mainstay treatment in women with PVD.
- Optimal treatment of chronic vulvar pain conditions requires the integrated effort of various medical/surgical disciplines.

Lower Urinary Tract Dysfunction and Female Sexual Dysfunction

LUTS are the subjective indicator of a disease or change in condition as perceived by the patient, caretaker, or partner and may lead him or her to seek help from health care professionals (Abrams et al., 2002).

In 2017, the International Consultation on Incontinence-Research Society (ICI-RS), a multidisciplinary group of health care professionals, took part in a think tank questioning on how LUTS affect sexual function in men and women (Apostolidis et al., 2017; Rantell et al., 2017). Following this think tank, we will discuss the effect of LUTS on sexual dysfunction in the female population. In 2012, the 5th International Consultation on Incontinence estimated that, of the world's population, 46% of adults (older than 20 years of age) experience LUTS, 11.8% complain of OAB symptoms, 8% suffer from some type of urinary incontinence (UI), and 4% are estimated to have severe stress urinary incontinence (SUI) (Abrams et al., 2013).

Sexual Lifestyle and Communication

Sexual health is a state of physical, emotional, mental, and social well-being in relation to sexuality; it is not merely the absence of disease, dysfunction, or infirmity (WHO, 2006). Over the past 30 years, three National Surveys of Sexual Attitudes and Lifestyles demonstrated that sexual lifestyles and practices have significantly changed (Mercer et al., 2013). In women, age is related to a reduction in sexual frequency and range of practices. Furthermore, certain sexual behaviors and lifestyles have become increasingly more common, such as sexual experience with a same-sex partner and having anal sex (Table 74.19).

TABLE 74.19

Change in Sexual Practices Over the Past 30 Years

Sexual Behavior	1990	2010
Number of partners over lifetime	3.7	7.7
Number of occasions of SA in the past month	6.1	4.8
Vaginal sex in the past month	76.3%	69.6%
Given or received oral sex in past month	65.6%	75.1%

Anal sex in the past year	6.5%	15.1%
Sexual experience with same sex partner	3.7%	16%
Masturbated in past 4/52	n/a	32.9%

Modified from Rantell A, Apostolidis A, Anding R, et al. How does lower urinary tract dysfunction affect sexual function in men and women? ICI-RS 2015-Part 1. *Neurourol Urodyn* 2017;36(4):949–952.

Communication about sexual function and LUTS has always been problematic (Rantel et al., 2017). Relief rather than embarrassment is achieved after health care professionals inquire (Penson et al., 2000). An American obstetrician and gynecologist survey reported that 63% of clinicians ask if the patient is sexually active, but only 40% routinely inquire about sexual problems (Sobecki et al., 2012). Indeed, women seem to prefer to discuss sexual problems with a nurse rather than with a physician (Farrell and Belza, 2012). Dyer and das Nair (2013) reported several common themes on why health care professionals do not talk about sex: “opens a can of worms,” lack of time/resources/training, concern about knowledge and ability, worry that it will cause offense, personal discomfort, lack of awareness about sexual issues, and opposite gender/race/age concerns.

Epidemiology

Following the 2017 International Urogynecological Association (IUGA) and International Continence Society (ICS) Joint Report, it is reported that more than 40% of women will experience a sexual problem over the course of their lifetime (Rogers et al., 2018). A sexual complaint could lead to personal distress or interpersonal difficulties reaching a level of a diagnosable sexual disorder. Recent epidemiologic surveys place the prevalence of diagnosable sexual disorders at approximately 8% to 12% (Shifren et al., 2008).

The effects of pelvic floor disorders (PFDs) including UI and POP on sexual function remain debatable (Fashokun et al., 2013; Handa et al., 2008; Rogers, 2013). This variability can be attributed partly to the heterogeneity of the populations studied and the methodology and type of questionnaires used, and can also be attributed partly to the complexity of human sexual function, which is subject to a host of influences. Despite conflicting published data, **in general most PFDs are thought to negatively affect sexual health. Handa et al.** (2008) **showed that dyspareunia, low sexual arousal, and infrequent orgasm are associated with pelvic floor symptoms. Up to 45% of the women with UI and/or LUTS complain of sexual dysfunction, with 34% reporting**

hypoactive sexual desire, 23% reporting sexual arousal disorder, 11% reporting orgasmic deficiency, and 44% reporting sexual pain disorders (dyspareunia or noncoital genital pain) (Salonia et al., 2004). Lowenstein et al. reported that sexual function is related to women's self-perceived body image and degree of bother from POP, especially in women with stage 2 or greater POP (Jelovsek and Barber, 2006; Lowenstein et al., 2009a; Zielinski et al., 2012) and particularly in the domains of sexual desire and satisfaction. CPP may cause dyspareunia in 16% to 25% of women, often leading to sexual avoidance (Kingsberg and Knudson, 2011). In women with PFDs, there is a positive association between pelvic floor strength and sexual activity and function (Kanter et al., 2015), highlighting that high PFM tone and sexual dysfunction are related (Bortolami et al., 2015). Resolution of symptoms after successful treatment of PFDs often improves sexual function and/or women's well-being as measured on pelvic floor condition specific measures.

Etiology and Classification

Multiple systemic aspects such as endocrine, neurologic, cardiovascular, dermatologic, and psychiatric disorders; surgical and medical complications; and cancer may lead to central and peripheral changes in cell-to-cell communication, changes in endocrine milieu, disruption in the homeostasis of neurotransmitters and signal molecules, tissue damage, organ damage, vascular changes, and neurologic changes that predispose to FSD (Rantell et al., 2017). The IUGA/ICS 2017 Joint Report disclosed a list of symptoms either volunteered by or elicited from the individual, or described by the individual's caregiver (Haylen et al., 2010). Sexual symptoms may occur in combination with other pelvic floor symptoms such as UI or POP or with pelvic pain. We will discuss the FSD symptoms related with LUTS, POP, and pain.

Lower urinary tract sexual dysfunction symptoms:

1. Coital UI: UI occurring during or after vaginal intercourse
2. Orgasmic UI: UI at orgasm
3. Penetration UI: UI at penetration (penile, manual, or sexual device)
4. Coital urinary urgency: feeling of urgency to void during vaginal intercourse
5. Postcoital LUTS: worsened urinary frequency or urgency, dysuria, suprapubic tenderness
6. Receptive urethral intercourse: having a penis penetrating one's urethra

(urethral coitus)

Prolapse-specific symptoms:

1. Abstinence as a result of POP: nonengagement in sexual activity resulting from prolapse or associated symptoms
2. Vaginal wind (flatus): Passage of air from the vagina (usually accompanied by sound)
3. Vaginal laxity: feeling of vaginal looseness
4. Obstructed intercourse: vaginal intercourse is difficult or not possible because of obstruction by genital prolapse or shortened vagina, or pathologic conditions such as lichen planus or lichen sclerosus

Pain symptoms:

1. Dyspareunia: complaint of persistent or recurrent pain or discomfort associated with attempted or complete vaginal penetration (Haylen et al., 2010)
2. Superficial (introital) dyspareunia: complaint of pain or discomfort on vaginal entry or at the vaginal introitus
3. Deep dyspareunia: complaint of pain or discomfort on deeper penetration (mid- or upper vagina)
4. Vaginismus: recurrent or persistent spasm of vaginal musculature that interferes with vaginal penetration
5. Dyspareunia with penile vaginal movement: pain that is caused by and is dependent on penile movement
6. Vaginal dryness: complaint of reduced vaginal lubrication or lack of adequate moisture in the vagina
7. Hypertonic PFM: A general increase in muscle tone that can be associated with either elevated contractile activity and/or passive stiffness in the muscle (Basson et al., 2004; Raina et al., 2007)
8. Noncoital sexual pain: pain induced by noncoital stimulation
9. Postcoital pain: pain after intercourse such as vaginal burning sensation or pelvic pain
10. Vulvodynia: vulvar pain of at least 3 months duration, without a clear identifiable cause, which may have potentially associated factors (Bornstein et al., 2016; Di Biase et al., 2016).

Clinical Signs and Investigations

The genital examination is often informative and in women with sexual dysfunction could have a therapeutic effect. A focused genital examination is highly recommended in the presence of dyspareunia, vaginismus, neurologic disease, genital arousal disorders, history of pelvic trauma, or acquired or lifelong orgasmic disorder (Haylen et al., 2011). The internal examinations are generally best performed with the woman's bladder empty (Haylen et al., 2010). Examination should be performed and described including vaginal length, caliber, and mobility; presence of scarring and/or pain and estrogenization; and whether or not there is vaginal or labial agglutination. The location of any vaginal pain should be noted. POP should be evaluated as it may affect body image and vaginal symptoms during sexual activity (Toozs-Hobson et al., 2012). If the patient has had an operation in which a synthetic mesh is utilized, then mesh may be felt in the vagina that may or may not be associated with symptoms (Haylen et al., 2011). Bimanual examination may reveal a pelvic mass or unusual tenderness by vaginal examination together with suprapubic palpation. PFM examination may elicit signs pertaining to FSD. If dyspareunia, vaginismus, or history of pelvic trauma are present, completing internal examinations is difficult and may be impossible. Assessing for the presence of vulvar pain via a gentle, introital palpation, or performing a “Q-tip touch test” of the introitus is recommended before any internal examination.

Measurement of sexual activity and function is largely limited to self-reporting and the use of sexual diaries or event logs, clinician-administered interviews, or questionnaires. A daily log of sexual thoughts and activities is helpful to evaluate sexual function (Rogers et al., 2018). Record individual sexual events or activities classifying them as a “sexually satisfying event (SSE)” or not (Rogers et al., 2018).

Physical examinations aim to evaluate different causes of sexual dysfunction and should include vascular, neurologic, musculoskeletal, and hormonal systems investigations.

Lower Urinary Tract Symptoms and Female Sexual Dysfunction: Links and Treatments

Urinary Incontinence and Overactive Bladder

Women with UI have a prevalence of FSD estimated to range between 26% and 47% (Geiss et al., 2003; Nusbaum and Gamble, 2001; Ozel et al., 2006; Sacco and Tienforti, 2013). All forms of UI are associated with FSD of all phases of the sexual cycle affecting all the individual domains of sexual function and satisfaction (Aslan et al., 2005; Cohen et al., 2008; Norton and Brubaker, 2006; Sen et al., 2007). **The loss of urine significantly impairs the QoL of women, who are forced to organize exhausting strategies to prevent or mask stains and/or odors causing a generalized apathy, feelings of guilt, and depressive attitude** (Simonelli et al., 2008). Thus, several studies showed a correlation between UI and major depression, which has a three-times higher incidence in incontinent patients than in continent patients (Ko et al., 2005). Specifically, women with UI feel threatened in their femininity, expressing feelings of shame, inadequacy, and reduced self-esteem (Melville et al., 2005) and subsequently a communicative and emotional inability with a strong sense of isolation (Salloum, 2005). **The lack of libido and reduced level of self-esteem because of a fear of uncontrolled leakage are the main factors in women with UI and FSD** (Brubaker et al., 2009)**. The presence of severe UI doubled the odds for reduced libido, vaginal dryness, and dyspareunia** (WHO, 1992) **compared with nonincontinent women.**

As reported by the ICI-RS, large epidemiologic studies, such as the EpiLUTS study, suggest associations between OAB and sexual dysfunctions (Apostolidis et al., 2017; Coyne et al., 2011;). However, the literature is partially contradictory. In a large treatment outcomes study, only 37% of the female participants claimed a negative sexual and relationship impact of OAB in their lives. Moreover, in a multivariate analysis, OAB was not a predictor of loss of interest in sex in female participants as opposed to male participants. Improvement of OAB symptoms was followed by a similar improvement in sex lives only in 19% of the patients, with another 11% reporting a deterioration (Sand et al., 2006). By contrast, in other published studies in which the subjects used tolterodine, there were beneficial effects of both the immediate-release (IR) and extended-release (ER) formulations on sexual health outcomes. Sexual desire, arousal, vaginal lubrication, orgasm, and orgasm satisfaction improved for up to 6 months of treatment (Hajebrahimi et al., 2008; Rogers et al., 2008, 2009).

Nilsson et al. (2011) evaluated women with UI and/or urinary urgency (the key symptom of OAB) and their partners and reported that 22% of men and 43% of women stated that the female urinary symptoms impaired their sexual life. Salonia et al. (2004) found that 47% of patients who reported a hypoactive sexual desire had SUI, and 46% of those who reported orgasm problems also had significant symptoms of OAB with urgency urinary incontinence (UUI). Yip et al. (2003) found that patients with SUI or OAB have a decreased QoL measured with King's Health Questionnaire (KHQ) (Kelleher et al., 1997), less sexual satisfaction, and poorer marital relations than controls (Yip et al., 2003). Sacco et al. (2012) reported that, among women with UI and/or OAB, those with UUI and mixed urinary incontinence (MUI) reported worse FSD as compared with those with SUI or with dry OAB. Women with urodynamically proven detrusor overactivity incontinence appeared in this and other studies to have the worst female sexual function (Barber et al., 2002; Kim et al., 2005; Yip et al., 2003). Mechanisms associated with the impact of OAB on female sexual function can be the fear of leakage during stimulation and intercourse, coital UI during orgasm, the need to interrupt intercourse to void, urgency and frequency after coitus, dyspareunia, and pelvic floor dysfunction.

The 11% to 45% of patients with UI suffered the fear of urine leakage during intercourse (Rogers et al., 2001). **Moran et al.** (1999) **found that 11% of 2153 women had UI during intercourse.** A questionnaire was helpful in detecting this symptom. **Specifically, 70% reported urine leakage during penetration, 20% only during orgasm, and 11% during both penetration and orgasm. A SUI was present in 80% of women with UI during penetration, in 93% of women with UI during orgasm, and in 92% of women with UI during both phases.** The pathophysiology leading to UI during intercourse is not clear (Sacco and Tienforti, 2013). A hypothesis is that during penetration, the displacement of the anterior wall of the vagina and bladder neck or increase of the intra-abdominal pressure loss can cause SUI. Detrusorial simultaneous contractions and urethral relaxation were demonstrated in urodynamic studies during orgasm (Vierhout and Gianotten, 1993).

Although SUI surgery is thought to improve sexual function (Brubaker et al., 2009; De Souza et al., 2012; Vierhout and Gianotten, 1993), data reporting sexual function after surgical repair are limited and conflicting (Srikrishna et al., 2010). A recent meta-analysis showed that in two studies, women who underwent retropubic and transobturator sling intervention and completed the Pelvic Organ Prolapse Urinary Incontinence Sexual Questionnaire (PISQ-12) showed an increase in sexual function of 2.40 points after transobturator compared with retropubic sling intervention (95% CI, –2.48 to –2.32; I2 = 35%, $P < .00001$). However, two other studies composed of 183 women comparing the same techniques, but using the FSFI, did not show a statistically significant difference (95% CI, –1.77 to 3.78; I2 = 0%, $P = .48$). The authors concluded that the impact of UI surgery on sexual function is uncertain because of the imprecision of the effect and inconsistency among studies. Only limited evidence on the impact of the transobturator versus the retropubic sling was found (Bicudo-Fürst et al., 2018).

However, it is important to underline that vaginal sling procedures may have a potential negative effect on FSF as a result of damage to vascular and/or neural genital structures or de novo dyspareunia (Sacco and Tienforti, 2013; Serati et al., 2009). Baessler et al. reported that dyspareunia was a severe indication for removing the posterior intravaginal synthetic sling (Serati et al., 2009). Bekker et al. (2012) described the autonomic and somatic pathways in relationship to sling surgery in 14 adult female dissected hemipelves after tension-free vaginal tape (TVT) or transobturator tape (TOT) procedures were performed. They concluded that the dorsal nerve of the clitoris was not disturbed during placement of the TOT, but the autonomic innervation of the vaginal wall was disrupted by the TVT procedure, which could lead to an altered lubrication-swelling response.

In a meta-analysis performed by Jha et al. (2012), sexual function was unchanged in 55.5% of women, improved in 31.9%, and deteriorated in 13.1% after surgery for SUI. The resolution of coital incontinence is closely correlated to a patient's degree of sexual satisfaction, and preoperative coital incontinence has been suggested as a prognostic factor for improvement of sexual function after surgery (Lonnee-Hoffmann et al., 2013).

As reported by the ICI-RS, improvements in women's sexual function after successful treatment of either OAB/UI or SUI suggest indirect effects of lower urinary tract dysfunction (LUTD) on sexual function (Apostolidis et al., 2017). Improvement of secondary parameters as a result of OAB/UI (leakage during intercourse, intercourse interruption caused by urgency, pain during intercourse) and of factors that have a negative effect on the satisfaction of the sexual relationships and on patients' self-image (embarrassment associated with OAB/UI, fear of leakage during stimulation and intercourse, postcoital worsening of OAB) may also result in improvement of FSD (Coyne et al., 2007; Hajebrahimi et al., 2008). In the case of SUI, surgical or conservative restoration of continence is commonly associated with improvement of sexual function as demonstrated by most prospective studies (Filocamo et al., 2011; Glavind et al., 2014; Kamalak et al., 2014; Narin et al., 2014; Serati et al., 2015), literature reviews (Fatton et al., 2014), and meta-analyses (Jha et al., 2012). **The cure of coital incontinence, achieved in 90% of surgically treated cases, is thought to be a major predictor of sexual improvement** (Fatton et al., 2014; Glavind et al., 2014; Kamalak et al., 2014)**, with improvements in coital pain** (Kamalak et al., 2014) **and in partner-related aspects** (Narin et al., 2014; Roos et al., 2014) **also reported to be associated with postsurgery sexual function beneficial effects.**

The use of neuromodulation to treat refractory LUTD could shed some light in the mechanisms connecting LUTD to FSD. Almost all studies show that sacral neuromodulation (SNM) improves LUTS and sexual function irrespective of the cause of LUTD (Gaziev et al., 2013; Gill et al., 2011; Pauls et al., 2007; Signorello et al., 2011). Their findings suggest that **neural and vascular changes may be common in LUTD and FSD.** In this respect, women with refractory OAB and nonobstructive urinary retention were found to have abnormal pudendal nerve function, which showed a trend toward improvement after SNM (Parnell et al., 2015). Neurally augmented sexual function was achieved by percutaneous epidural spinal cord space stimulation, resulting in reproducible pleasurable genital stimulation, increased frequency of sexual activity and lubrication, and improved orgasmic function (Meloy and Southern, 2006). Active neurostimulation could also increase the vaginal pulse amplitude with both erotic and nonerotic stimuli (van Voskuilen et al., 2012). Whether neurovascular changes proposed in the four-theory complex to explain associations between male LUTS and ED also apply for LUTD and FSD needs be further researched (Kohler and McVary, 2009).

Pelvic Organ Prolapse

POP is associated with different LUTS such as SUI, UI, urgency, and frequency that are present in 40%, 34%, 29%, and 30% of women, respectively (Swift et al., 2005). Women with prolapse may present with a wide range of LUTS such as SUI, UI, urgency, frequency, and urge incontinence have been reported in 40%, 34%, 29%, and 30% of women with POP, respectively (De Boer et al., 2011; Grody, 1998). Understanding the relationship between POP and pelvic floor symptoms is a crucial step in the management of patients. The symptoms are largely subjective in nature (Ghoniem et al., 2008). Contradictory results have been reported regarding the association of POP with LUTS and sexual dysfunction (Broekhuis et al., 2010; Burrows et al., 2004; Ellerkmann et al., 2001; Ghetti et al., 2005; Gutman et al., 2008; Salvatore et al., 2011).

Cetinkaya et al. (2013) demonstrated that there is no significant correlation between POP stages and the PISQ-12. In a recent cross-sectional observational study, Athanasiou et al. (2012) evaluated the effect of POP on FSF in 101 women compared with 70 women without POP, and found that female sexual function was poorer in the POP group than in the control group, but did not correlate with an increasing grade of POP. Handa et al. (2004) found that POP was not associated with any sexual complaint. Weber et al. (1995) reported that women with POP and/or UI have a similar sexual function as women without these PFDs. On the other hand, Novi et al. (2005) **compared sexual function of women with POP to that of women without POP using the PISQ, and reported that mean PISQ scores in sexually active women with POP were significantly lower compared with controls, with significant difference in satisfaction with sexual relationship, actual frequency of intercourse, and ability to achieve orgasm with masturbation, but no difference in the desired frequency of intercourse, initiation of sexual activity, rate of anorgasmia, or subjective assessment of partner satisfaction.** Digesu et al. (2005) observed that FSD was related to uterine displacement, likely leading the cervix to obstruct penile penetration.

Options for prolapse repair include abdominal versus vaginal approaches and native tissue versus grafted repairs. A native tissue repair is one that uses a patient's own structures to repair the vaginal defect. These surgeries most commonly include anterior and posterior repairs (colporrhaphy), uterosacral vault suspensions, and sacrospinous fixations (Thompson and Rogers, 2016). For most women, native tissue repairs result in improved or unchanged sexual function (Azar et al., 2008; Jha et al., 2015; Komesu et al., 2007). A 2014 meta-analysis of the impact of native tissue repair on sexual function using standardized questionnaires included nine studies that showed improvement in sexual function after prolapse repair (Jha et al., 2015). Eight studies evaluating dyspareunia showed that women were 4.8 times more likely to have improvement in pain or unchanged symptoms than increased pain postoperatively (Jha et al., 2015). A systematic review of anterior repair comparing native tissue with biologic graft and polypropylene mesh included 12 randomized trials (Maher et al., 2013). Anterior native tissue repair versus biologic graft showed no difference in dyspareunia rates postoperatively, but the repairs with a graft showed lower recurrent prolapse rates (Thompson and Rogers, 2016). Repair of the posterior compartment of the vagina has been associated with increased concern for postoperative dyspareunia (Thompson and Rogers, 2016). A systematic review comparing posterior native tissue repair with biologic grafting showed no difference in the rate of dyspareunia (Maher et al., 2013)

Grafts can be used for the repair of POP. Graft repairs for anterior, posterior, and apical descent can use vaginal and abdominal approaches. Polypropylene mesh has gained favor in prolapse repair for its durability and low-risk profile. Conversely, biologic grafts have fallen out of favor because of their higher risk for recurrent prolapse. Many surgeons consider sacrocolpopexy the gold standard for surgery addressing apical prolapse (Thompson and Rogers, 2016). Sexual function after sacrocolpopexy can remain unchanged or can be improved after surgery (Geller et al., 2011; Handa et al., 2004; Price et al., 2011; Sarlos et al., 2008). The Society of Gynecologic Surgeons performed a systematic review on adverse events after vaginal prolapse repair using graft materials from 1950 through 2010. From the 70 articles reporting on dyspareunia after transvaginal mesh placement for prolapse, the incidence was 9.1% (Abed et al., 2011). The incidence was similar regardless of whether synthetic and biologic grafts were used for repairs. This systematic review is limited because most studies did not measure preoperative rates of dyspareunia and did not consistently use validated measurements (Thompson and Rogers, 2016).

Bladder Pain Syndrome/Interstitial Cystitis

Sexual dysfunction issues have been reported among women with BPS/IC and can contribute to reduced QoL in these patients (Sacco and Tienforti, 2013). Pelvic pain caused by inflammation of the bladder wall and neuropathic dysfunction, dyspareunia, and fear of pain during intercourse are particularly frequent among these patients and may cause resistance to penetration and consequent pelvic floor overactivity, vulvodynia, and vaginismus (Peters et al.,

2008).

Sacco et al. (2012) showed that women with BPS reported the greatest adverse impact on FSF, mostly as a result of sexual pain, followed by those with urodynamic DO, clinical diagnosis of UUI, MUI and SUI; dry OAB; and voiding-phase LUTS. These results were aligned with those of Peters et al. (2007). CPP is significantly associated with FSD (Ottem et al., 2007; Verit et al., 2006) in terms of HSDD, sexual arousal disorder, orgasmic disorder, and sexual pain disorder.

Self-Image/Body Image Connected to Female Sexual Dysfunction and Lower Urinary Tract Symptoms

The ICI-RS reported that body image problems could be associated with sexual problems. Sparse data are available on correlations between self-image and SD in women with LUTS. Sexual function was found to be affected by body image perception in women with POP (Lowenstein et al., 2009a). In neurourologic patients, the presence of an indwelling catheter had a negative impact on female sexuality and QoL. Urinary tract reconstruction restored QoL and markedly improved sexual function by improving self-image, self-esteem, and the ability to cope (Watanabe et al., 1996). In women undergoing surgery for SUI, the goals of improving sexuality and body image are predictors of post-treatment sexual function improvement (Lonne-Hoffman et al., 2013), but there is still no available literature on the impact of urgency or MUI on patients' self-image and its possible associations with sexual function. The impact of using pads and diapers on patients' self-image and sexual function also has not been studied.

Key Points: Lower Urinary Tract Dysfunction and Female Sexual Dysfunction

- Almost one-half of the women with UI and/or LUTS suffer from various types of sexual dysfunction.
- Sexual symptoms may occur in combination with other pelvic floor symptoms such as UI, POP, or pelvic pain.
- UI negatively affects sexual function via interfering with libido and self-esteem.
- Mid-urethral sling procedures can lead to FSD via neurovascular insult affecting the genital organs or postoperative de novo dyspareunia.
- Resolution of UI after medical and/or surgical treatment may also have a significant positive effect on various domains of female sexual wellness.

- Sexually active women with POP can have problems with sexual satisfaction, decreased frequency of intercourse, and inability to achieve orgasm with masturbation.

Conclusion

Female sexual function and dysfunction are important aspects of urologic practice. Urologists should be aware of the urologic ramifications of sexual issues and vice versa. Appropriate treatment (or referral) of women with sexual concerns will improve patient satisfaction and treatment compliance.

References

Abed H, Rahn DD, Lowenstein L, Systematic Review Group of the Society of Gynecologic Surgeons, et al. Incidence and management of graft erosion, wound granulation, and dyspareunia following vaginal prolapse repair with graft materials: a systematic review. *Int Urogynecol J*. 2011;22(7):789.

Abrams P, Cardozo L, Fall M, et al. The standardisation of terminology of lower urinary tract function: report from the standardisation subcommittee of the international continence society. *Am J Obstet Gynecol*. 2002;187(1):116–126.

Abrams P, Cardozo L, Khoury S, et al. *Incontinence*. ed 4. Health Publications Ltd: Plymouth, UK; 2013.

Achilli C, Pundir J, Ramanathan P, et al. Efficacy and safety of transdermal testosterone in postmenopausal women with hypoactive sexual desire disorder: a systematic review and meta-analysis. *Fertil Steril*. 2017;107(2) [475.e15–482.e15].

Aerts L, Rubin RS, Randazzo M, et al. Retrospective study of the prevalence and risk factors of clitoral adhesions: women's health providers should routinely examine the glans clitoris. *Sex Med*. 2018;6(2):115–122.

American College of Obstetricians and Gynecologists. Committee on Gynecologic Practice. Committee Opinion No. 378: "Vaginal rejuvenation" and cosmetic vaginal procedures. *Obstet Gynecol*. 2007;110(3):737–738.

American College of Obstetricians and Gynecologists. Committee on Gynecologic Practice. Committee Opinion No. 706. Sexual health. *Obstet Gynecol*. 2017;130(1):e42–e47.

American College of Obstetricians and Gynecologists. Committee on Gynecologic Practice. Female sexual dysfunction. Practice Bulletin No. 119. *Obstet Gynecol*.

2011;117(4):996–1007.

American Psychiatric Association. *American Psychiatric Association Task Force on DSM-IV. Diagnostic and statistical manual of mental disorders: DSM-IV-TR*. ed 4. American Psychiatric Association: Washington, DC; 2000.

American Psychiatric Association. *American Psychiatric Association DSM-5 Task Force. Diagnostic and statistical manual of mental disorders: DSM-5*. ed 5. American Psychiatric Association: Washington, DC; 2013.

Amidu N, Owiredu WK, Woode E, et al. Incidence of sexual dysfunction: a prospective survey in Ghanaian females. *Reprod Biol Endocrinol*. 2010;8:106.

Andersen BL. A comparison of systematic desensitization and directed masturbation in the treatment of primary orgasmic dysfunction in females. *J Consult Clin Psychol*. 1981;49(4):568–570.

Annon JS. The PLISSIT model: a proposed conceptual scheme for the behavioral treatment of sexual problems. *J Sex Educ Ther*. 1976;2(2):1–15.

Apostolidis A, Rantell A, Anding R, et al. How does lower urinary tract dysfunction (LUTD) affect sexual function in men and women? ICI-RS 2015-Part 2. *Neurourol Urodyn*. 2017;36(4):869–875.

Arnold LD, Bachmann GA, Rosen R, et al. Vulvodynia: characteristics and associations with comorbidities and quality of life. *Obstet Gynecol*. 2006;107(3):617–624.

Arsene E, Giraudet G, Lucot JP, et al. Sacral colpopexy: long-term mesh complications requiring reoperation(s). *Int Urogynecol J*. 2015;26(3):353–358.

Aslan G, Köseoğlu H, Sadik O, et al. Sexual function in women with urinary incontinence. *Int J Impot Res*. 2005;17(3):248–251.

Asscheman H, Giltay EJ, Megens JA, et al. A long-term follow-up study of mortality in transsexuals receiving treatment with cross-sex hormones. *Eur J Endocrinol*. 2011;164(4):635–642.

Athanasiou S, Grigoriadis T, Chalabalaki A, et al. Pelvic organ prolapse contributes to sexual dysfunction: a cross-sectional study. *Acta Obstet Gynecol Scand*. 2012;91(6):704–709.

Atis G, Dalkilinc A, Altuntas Y, et al. Hyperthyroidism: a risk factor for female sexual dysfunction. *J Sex Med*. 2011;8(8):2327–2333.

Atlantis E, Sullivan T. Bidirectional association between depression and sexual dysfunction: a systematic review andmeta-analysis. *J Sex Med*. 2012;9(6):1497–1507.

Azar M, Noohi S, Radfar S, et al. Sexual function in women after surgery for pelvic organ prolapse. *Int Urogynecol J Pelvic Floor Dysfunct*. 2008;19(1):53–57.

Bachmann G. Female sexuality and sexual dysfunction: are we stuck on the learning curve? *J Sex Med*. 2006;3(4):639–645.

Barber MD, Visco AG, Wyman JF, et al. Sexual function in women with urinary incontinence and pelvic organ prolapse. *Obstet Gynecol*. 2002;99(2):281–289.

Barlow DH, Cardozo LD, Francis RM, et al. Urogenital ageing and its effect on sexual health in older British women. *Br J Obstet Gynaecol*. 1997;104(1):87–91.

Barrett-Connor E, Goodman-Gruen D. Prospective study of endogenous sex hormones and fatal cardiovascular disease in postmenopausal women. *BMJ*. 1995;311(7014):1193–1196.

Bartula I, Sherman KA. The Female Sexual Functioning Index (FSFI): evaluation of acceptability, reliability, and validity in women with breast cancer. *Support Care Cancer*. 2015;23(9):2633–2641.

Baser RE, Li Y, Carter J. Psychometric validation of the Female Sexual Function Index (FSFI) in cancer survivors. *Cancer*. 2012;118(18):4606–4618.

Basson R. Human sex-response cycles. *J Sex Marital Ther*.

2001;27(1):33–43.

Basson R. A model of women's sexual arousal. *J Sex Marital Ther*. 2002;28(1):1–10.

Basson R. Are our definitions of women's desire, arousal and sexual pain disorders too broad and our definition of orgasmic disorder too narrow. *J Sex Marital Ther*. 2002;28(4):289–300.

Basson R. Women's sexual function and dysfunction: current uncertainties, future directions. *Int J Impot Res*. 2008;20(5):466–478.

Basson R, Schultz WW. Sexual sequelae of general medical disorders. *Lancet*. 2007;369(9559):409–424.

Basson R, Berman J, Burnett A, et al. Report of the international consensus development conference on female sexual dysfunction: definitions and classifications. *J Urol*. 2000;163(3):888–893.

Basson R, Leiblum S, Brotto L, et al. Definitions of women's sexual dysfunction reconsidered: advocating expansion and revision. *J Psychosom Obstet Gynaecol*. 2003;24(4):221–229.

Basson R, Leiblum S, Brotto L, et al. Revised definitions of women's sexual dysfunction. *J Sex Med*. 2004;1(1):40–48.

Bechara A, Bertolino MV, Casabe A, et al. A double-blind randomized placebo control study comparing the objective and subjective changes in female sexual response using sublingual apomorphine. *J Sex Med*. 2004;1(2):209–214.

Bedell S, Goldstein AT, Burrows L. A periclitoral mass as a cause of persistent genital arousal disorder. *J Sex Med*. 2014;11(1):136–139.

Bekker MD, Hogewoning CR, Wallner C. The somatic and autonomic innervation of the clitoris; preliminary evidence of sexual dysfunction after minimally invasive slings. *J Sex Med*. 2012;9(6):1566–1578.

Berman J, McCarthy M, Kyprianou N. Effect of estrogen withdrawal on nitric oxide synthase expression and apoptosis in the rat vagina. *Urology*. 1998;51(4):650–656.

Berman JR, Adhikari SP, Goldstein I. Anatomy and physiology of female sexual function and dysfunction: classification, evaluation and treatment options. *Eur Urol*. 2000;38(1):20–29.

Bicudo-Fürst MC, Borba Leite PH, Araújo Glina FP, et al. Female sexual function following surgical treatment of stress urinary incontinence: systematic review and meta-analysis. *Sex Med Rev*. 2018;6(2):224–233.

Biddle AK, West SL, D'Aloisio AA, et al. Hypoactive sexual desire disorder in postmenopausal women: quality of life and health burden. *Value Health*. 2009;12:763–772.

Biglia N, Maffei S, Lello S, et al. Tibolone in postmenopausal women: a review based on recent randomised controlled clinical trials. *Gynecol Endocrinol*. 2010;26:804–814.

Billups KL, Berman L, Berman J, et al. A new nonpharmacological vacuum therapy for female sexual dysfunction. *J Sex Marital Ther*. 2001;27(5):435–441.

Binik YM, Brotto LA, Graham CA, et al. Response of the DSM-V Sexual Dysfunctions subworkgroup to commentaries published in JSM. *J Sex Med*. 2010;7(7):2382–2387.

Bitzer J, Tschudin S, Meier-Burgoa J, et al. Effects on the quality of life of a new oral contraceptive containing 30 mcg EE and 3 mg drospirenone (Yasmin). *Praxis (Bern 1994)*. 2003;92(25–26):1177–1184.

Bitzer J, Giraldi A, Pfaus J. Sexual desire and hypoactive sexual desire disorder in women. Introduction and overview. Standard operating procedure (SOP Part 1). *J Sex Med*. 2013;10(1):36–49.

Bo K, Kvarstein B, Hagen R, et al. Pelvic floor muscle exercises for the treatment of female stress urinary incontinence: II. Validity of vaginal pressure measurements of pelvic floor muscle strength and the necessity of supplementary methods for control of correct contraction. *Neurourol Urodyn*. 1990;9(5):479–487.

Bornstein J, Maman M, Abramovici H. “Primary” vs “secondary” vulvar vestibulitis: one disease, two variants. *Am J Obstet Gynecol*. 2001;184(2):28–31.

Bornstein J, Goldstein AT, Stockdale CK, et al. 2015 ISSVD, ISSWSH, and IPPS consensus terminology and classification of persistent vulvar pain and vulvodynia. *J Sex Med*. 2016;13(4):607–612.

Bortolami A, Vanti C, Banchelli F, et al. Relationship between female pelvic floor dysfunction and sexual dysfunction: an observational study. *J Sex Med*. 2015;12(5):1233–1241.

Bradford A, Meston CM. The impact of anxiety on sexual arousal in women. *Behav Res Ther*. 2006;44(8):1067–1077.

Braunstein GD. Management of female sexual dysfunction in postmenopausal women by testosterone administration: safety issues and controversies. *J Sex Med*. 2007;4(4 Pt 1):859–866.

Braunstein GD. Safety of testosterone treatment in postmenopausal women. *Fertil Steril*. 2007;88(1):1–17.

Braunstein GD, Sundwall DA, Katz M, et al. Safety and efficacy of a testosterone patch for the treatment of hypoactive sexual desire disorder in surgically menopausal women: a randomized, placebo-controlled trial. *Arch Intern Med*. 2005;165(14):1582–1589.

Broekhuis SR, Hendriks JCM, Futterer JJ, et al. Perineal descent and patients’ symptoms of anorectal dysfunction, pelvic organ prolapse, and urinary incontinence. *Int Urogynecol J*. 2010;21(6):721–729.

Brotto LA, Basson R. Group mindfulness-based therapy significantly improves sexual desire in women. *Behav Res Ther*. 2014;57:43–54.

Brotto LA, Basson R, Luria M. A mindfulness-based group psychoeducational intervention targeting sexual arousal disorder in women. *J Sex Med*. 2008;5(7):1646–1659.

Brotto LA, Krychman M, Jacobson P. Eastern approaches for enhancing women's sexuality: mindfulness, acupuncture, and yoga (CME). *J Sex Med*. 2008;5(12):2741–2748.

Brotto LA, Bitzer J, Laan E, et al. Women's sexual desire and arousal disorders. *J Sex Med*. 2010;7(1 Pt 2):586–614.

Brotto L, Atallah S, Johnson-Agbakwu C, et al. Psychological and interpersonal dimensions of sexual function and dysfunction. *J Sex Med*. 2016;13(4):538–571.

Brubaker L, Chiang S, Zyczynski H, Urinary Incontinence Treatment Network, et al. The impact of stress incontinence surgery on female sexual function. *Am J Obstet Gynecol*. 2009;200(5):562.e1–562.e7.

Burnett AL, Calvin DC, Silver RI, et al. Immunohistochemical description of nitric oxide synthase isoforms in human clitoris. *J Urol*. 1997;158(1):75–78.

Burri A, Spector T. Recent and lifelong sexual dysfunction in a female UK population sample: prevalence and risk factors. *J Sex Med*. 2011;8(9):2420–2430.

Burrows LJ, Meyn LA, Walters MD, et al. Pelvic symptoms in women with pelvic organ prolapse. *Obstet Gynecol*. 2004;104(5 Pt 1):982–988.

Burrows LJ, Basha M, Goldstein AT. The effects of hormonal contraceptives on female sexuality: a review. *J Sex Med*. 2012;9(9):2213–2223.

Buster JE, Kingsberg SA, Aguirre O, et al. Testosterone patch for low sexual desire in surgically menopausal women: a randomized trial. *Obstet Gynecol*. 2005;105(5 Pt 1):944–952.

Cama E, Colleluori DM, Emig FA, et al. Human arginase II: crystal structure and physiological role in male and female sexual arousal. *Biochemistry*. 2003;42(28):8445–8451.

Cappelletti M, Wallen K. Increasing women's sexual desire: the comparative effectiveness of estrogens and androgens. *Horm Behav*. 2016;78:178–193.

Carey JC. Pharmacological effects on sexual function. *Obstet Gynecol Clin North Am*. 2006;33(4):599–620.

Caruso S, Intelisano G, Farina M, et al. The function of sildenafil on female sexual pathways: a double-blind, crossover, placebo-controlled study. *Eur J Obstet Gynecol Reprod Biol*. 2003;110(2):201–206.

Caruso S, Agnello C, Intelisano G, et al. Placebo-controlled study on efficacy and safety of daily apomorphine SL intake in premenopausal women affected by hypoactive sexual desire disorder and sexual arousal disorder. *Urology*. 2004;63(5):955–959.

Carvalho J, Verissimo A, Nobre PJ. Cognitive and emotional determinants characterizing women with persistent genital arousal disorder. *J Sex Med*. 2013;10(6):1549–1558.

Cetinkaya SE, Dokmeci F, Dai O. Correlation of pelvic organ prolapse staging with lower urinary tract symptoms, sexual dysfunction, and quality of life. *Int Urogynecol J*. 2013;24(10):1645–1650.

Chedraui P, Perez-Lopez FR, San Miguel G, et al. Assessment of sexuality among middle-aged women using the Female Sexual Function Index. *Climacteric*. 2009;12(3):213–221.

Chedraui P, Perez-Lopez FR, Sanchez H, et al. Assessment of sexual function of mid-aged Ecuadorian women with the 6-item Female Sexual Function Index. *Maturitas*. 2012;71(4):407–441.

Chivers ML, Rosen RC. Phosphodiesterase type 5 inhibitor and female sexual response: faulty protocols or paradigms? *J Sex Med*. 2010;7(2 Pt 2):858–872.

Christensen JL, Miller LC, Appleby PR, et al. Reducing shame in a game that predicts HIV risk reduction for young adult

MSM: a randomized trial delivered nationally over the Web. *J Int AIDS Soc*. 2013;16(3 Suppl 2):18716.

Clayton AH. Epidemiology and neurobiology of female sexual dysfunction. *J Sex Med*. 2007;4(Suppl 4):260–268.

Clayton AH, Balon R. The impact of mental illness and psychotropic medications on sexual functioning: the evidence and management. *J Sex Med*. 2009;6(5):1200–1211 [quiz 1212–1213].

Clayton AH, Hamilton DV. Female sexual dysfunction. *Psychiatr Clin North Am*. 2010;33(2):323–338.

Clayton AH, Groth J. Etiology of female sexual dysfunction. *Womens Health (Lond)*. 2013;9(2):135–137.

Clayton AH, Warnock JK, Kornstein SG, et al. A placebo-controlled trial of bupropion SR as an antidote for selective serotonin reuptake inhibitor–induced sexual dysfunction. *J Clin Psychiatry*. 2004;65(1):62–67.

Clayton AH, Goldfischer ER, Goldstein I, et al. Validation of the decreased sexual desire screener (DSDS): a brief diagnostic instrument for generalized acquired female hypoactive sexual desire disorder (HSDD). *J Sex Med*. 2009;6(3):730–738.

Clayton AH, Althof SE, Kingsberg S, et al. Bremelanotide for female sexual dysfunctions in premenopausal women: a randomized, placebo-controlled dose-finding trial. *Womens Health (Lond)*. 2016;12(3):325–337.

Clayton AH, Kingsberg SA, Jordan E: Efficacy of the investigational drug bremelanotide for hypoactive sexual desire disorder (HSDD): results from the RECONNECT study; Presented at: Annual Meeting of the American Society of Clinical Psychopharmacology; May 30, 2017. 2017; Miami, FL, USA.

Clayton AH, Goldstein I, Kim NN, et al. The International Society for the Study of Women's Sexual Health process of care for management of hypoactive sexual desire disorder in women. *Mayo Clin Proc*. 2018;93(4):467–487.

Clayton AH, Kingsberg SA, Goldstein I. Evaluation and management of hypoactive sexual desire disorder. *Sex Med*. 2018;6(2):59–74.

Cohen BL, Barboglio P, Gousse A. The impact of lower urinary tract symptoms and urinary incontinence on female sexual dysfunction using a validated instrument. *J Sex Med*. 2008;5(6):1418–1423.

Collins A, Landgren BM. Reproductive health, use of estrogen and experience of symptoms in perimenopausal women: a population-based study. *Maturitas*. 1994;20(2–3):101–111.

Conaglen HM, O'Connor EJ, McCabe MP, et al. An investigation of sexual dysfunction in female partners of men with erectile dysfunction: how interviews expand on questionnaire responses. *Int J Impot Res*. 2010;22(6):355–362.

Consortium for Spinal Cord Medicine. Sexuality and reproductive health in adults with spinal cord injury: a clinical practice guideline for health-care professionals. *J Spinal Cord Med*. 2010;33(3):281–336.

Coyne KS, Margolis MK, Jumadilova Z, et al. Overactive bladder and women's sexual health: what is the impact? *J Sex Med*. 2007;4(3):656–666.

Coyne KS, Sexton CC, Thompson C, et al. The impact of OAB on sexual health in men and women: results from EpiLUTS. *J Sex Med*. 2011;8(6):1603–1615.

Cui Y, Zong H, Yan H, et al. The efficacy and safety of ospemifene in treating dyspareunia associated with postmenopausal vulvar and vaginal atrophy: a systematic review and meta-analysis. *J Sex Med*. 2014;11(2):487–497.

Darling C, Davidson J, Conway-Welch C. Female ejaculation: perceived origins, the Grafenberg spot/area, and sexual responsiveness. *Arch Sex Behav*. 1990;19(1):29–47.

Davidson J, Darling C, Conway-Welch C. The role of the Grafenberg spot and female ejaculation in the female orgasmic response: an empirical analysis. *J Sex Marital Ther*. 1989;15(2):102–120.

Davis SR. The effects of tibolone on mood and libido. *Menopause*. 2002;9(3):162–170.

Davis SR. Cardiovascular and cancer safety of testosterone in women. *Curr Opin Endocrinol Diabetes Obes*. 2011;18(3):198–203.

Davis SR, Guay AT, Shifren JL, et al. Endocrine aspects of female sexual dysfunction. *J Sex Med*. 2004;1(1):82–86.

Davis SR, Davison SL, Donath S, et al. Circulating androgen levels and self-reported sexual function in women. *JAMA*. 2005;294(1):91–96.

Davis SR, Moreau M, Kroll R, APHRODITE Study Team, et al. Testosterone for low libido in postmenopausal women not taking estrogen. *N Engl J Med*. 2008;359(19):2005–2017.

Davis SR, Braunstein GD. Efficacy and safety of testosterone in the management of hypoactive sexual desire disorder in postmenopausal women. *J Sex Med*. 2012;9(4):1134–1148.

Davis SR, Worsley R, Miller KK, et al. Androgens and female sexual function and dysfunction: findings from the Fourth International Consultation of Sexual Medicine. *J Sex Med*. 2016;13(2):168–178.

Davison SL, Davis SR. Androgenic hormones and aging–the link with female sexual function. *Horm Behav*. 2011;59(5):745–753.

De Boer TA, Slieker-ten Hove MC, Burger CW, et al. The prevalence and risk factors of overactive bladder symptoms and its relation to pelvic organ prolapse symptoms in a general female population. *Int Urogynecol J*. 2011;22(5):569–575.

de Lucena BB, Abdo CH. Personal factors that contribute to or impair women's ability to achieve orgasm. *Int J Impot Res*. 2014;26(5):177–181.

de Mattos Lourenco TR, Pergialiotis V, Duffy JMN, et al. A systematic Review on reporting outcomes and outcome. Measures in trials on synthetic mesh procedures for pelvic organ prolapse: urgent action is needed to improve quality of research. *Neurourol Urodyn*. 2019;38(2):509–524.

De Souza A, Dwyer PL, Rosamilia A, et al. Sexual functioning following retropubic TV and transobturator Monarc sling in women with intrinsic sphincter deficiency: a multicenter prospective study. *Int Urogynecol J*. 2012;23(2):153–158.

De Sutter P, Kira K, Verschoor A, et al. The desire to have children and the preservation of fertility in transsexual women: a survey. *Int J Transgend*. 2002;6(3):215–221.

DeLancey JO. Structural support of the urethra as it relates to stress urinary incontinence: the hammock hypothesis. *Am J Obstet Gynecol*. 1994;170(6):1713–1720 [discussion 1720–1723].

Dennerstein L, Lehert P, Burger H. The relative effects of hormones and relationship factors on sexual function of women through the natural menopausal transition. *Fertil Steril*. 2005;84(1):174–180.

Derogatis LR, Rosen R, Leiblum S, et al. The female sexual distress scale (FSDS): initial validation of a standardized scale for assessment of sexually related personal distress in women. *J Sex Marital Ther*. 2002;28(4):317–330.

Derogatis L, Rust J, Golombok S, et al. Validation of the profile of female sexual function (PFSF) in surgically and naturally menopausal women. *J Sex Marital Ther*. 2004;30(1):25–36.

Derogatis L, Clayton A, Lewis-D'Agostino D, et al. Validation of the female sexual distress scale-revised for assessing distress in women with hypoactive sexual desire disorder. *J*

Sex Med. 2008;5(2):357–364.

Derogatis L, Althof S, Clayton A, et al: Changes in arousal and desire in bremelanotide RECONNECT study. Presented at: Annual Meeting of the International Society for the Study of Women's Sexual Health (ISSWSH); February 23–26, 2017; Atlanta, GA, USA.

Dettore D, Pucciarelli M, Santarnecchi E. Anxiety and female sexual functioning: an empirical study. *J Sex Marital Ther*. 2013;39(3):216–240.

Dhikav V, Karmarkar G, Gupta R, et al. Yoga in female sexual functions. *J Sex Med*. 2010;7(2 Pt 2):964–970.

Di Biase M, Iacovelli V, Kocjancic E. Vulvodynia: current etiology, diagnosis, and treatment. *Curr Bladder Dysfunct Rep*. 2016;11(3):248–257.

Digesu GA, Chaliha C, Salvatore S. The relationship of vaginal prolapse severity to symptoms and quality of life. *BJOG*. 2005;112(7):971–976.

Dyer K, das Nair R. Why don't healthcare professionals talk about sex? A systematic review of recent qualitative studies conducted in the United Kingdom. *J Sex Med*. 2013;10(11):2658–2670.

Eichel EW, Eichel JD, Kule S. The technique of coital alignment and its relation to female orgasmic response and simultaneous orgasm. *J Sex Marital Ther*. 1988;14(2):129–141.

Eizenberg N, Briggs C, Barker P, et al. *Anatomedia "A new approach to medical education: Developments in Anatomy Pelvis McGraw-Hill."*. [CD-ROM ISBN: 0 7340 2729 X; Available at] http://www.anatomedia.com; 2005 [Images are to be acknowledged as follows: Images Copyright Anatomedia Pty Ltd; Available at] http://www.anatomedia.com.

Ellerkmann RM, Cundiff GW, Melick CF, et al. Correlation of symptoms with location and severity of pelvic organ prolapse. *Am J Obstet Gynecol*. 2001;185(6):1332–1337 [discussion 1337–1338].

Elraiyah T, Sonbol MB, Wang Z, et al. The benefits and harms of systemic dehydroepiandrosterone (DHEA) in postmenopausal women with normal adrenal function: a systematic review and meta-analysis. *J Clin Endocrinol Metab*. 2014;99(10):3536–3542.

Eplov L, Giraldi A, Davidsen M, et al. Sexual desire in a nationally representative Danish population. *J Sex Med*. 2007;4(1):47–56.

Esmail S, Darry K, Walter A, et al. Attitudes and perceptions towards disability and sexuality. *Disabil Rehabil*. 2010;32(14):1148–1155.

Farrell J, Belza B. Are older patients comfortable discussing sexual health with nurses? *Nurs Res*. 2012;61(1):51–57.

Fashokun TB, Harvie HS, Schimpf MO, et al. Sexual activity and function in women with and without pelvic floor disorders. *Int Urogynecol J*. 2013;24(1):91–97.

Fatton B, de Tayrac R, Costa P. Stress urinary incontinence and LUTS in women-effects on sexual function. *Nat Rev Urol*. 2014;11(10):565–578.

Faubion SS, Rullo JE. Sexual dysfunction in women: a practical approach. *Am Fam Physician*. 2015;92(4):281–288.

Ferreiro-Velasco ME, Barca-Buyo A, de la Barrera SS, et al. Sexual issues in a sample of women with spinal cord injury. *Spinal Cord*. 2005;43(1):51–55.

Filocamo MT, Serati M, Frumenzio E, et al. The impact of midurethral slings for the treatment of urodynamic stress incontinence on female sexual function: a multicenter prospective study. *J Sex Med*. 2011;8(7):2002–2008.

Finger WW, Lund M, Slagle MA. Medications that may contribute to sexual disorders. A guide to assessment and treatment in family practice. *J Fam Pract*. 1997;44(1):33–43.

Fisher WA, Rosen RC, Eardley I, et al. Sexual experience of female partners of men with erectile dysfunction: the female experience of men's attitudes to life events and sexuality (FEMALES) study. *J Sex Med*. 2005;2(5):675–684.

Fisher WA, Pyke RE. Flibanserin efficacy and safety in premenopausal women with generalized acquired hypoactive sexual desire disorder. *Sex Med Rev*. 2017;5(4):445–460.

Flibanserin Advisory Committee. *Flibanserin for the treatment of hypoactive sexual desire disorder in premenopausal women: Flibanserin Advisory Committee briefing document*. [Available at] http://www.fda.gov/downloads/advisorycommittees/committe

Fobair P, Spiegel D. Concerns about sexuality after breast cancer. *Cancer J*. 2009;15(1):19–26.

Foster DC, Dworkin RH, Wood RW. Effects of intradermal foot and forearm capsaicin injections in normal and vulvodynia-afflicted women. *Pain*. 2005;117(1–2):128–136.

Fowler SR. Vulvar vestibulitis: response to hypocontactant vulvar therapy. *J Low Genit Tract Dis*. 2000;4:200–203.

Frank FE, Mistretta PM, Will J. Diagnosis and treatment of female sexual dysfunction. *Am Fam Physician*. 2008;77(5):635–642.

Fritz HA, Dillaway H, Lysack CL. “Don't think paralysis takes away your womanhood”: sexual intimacy after spinal cord injury. *Am J Occup Ther*. 2015;69(2) [6902260030p1-10].

Frühauf S, Gerger H, Schmidt HM, et al. Efficacy of psychological interventions for sexual dysfunction: a systematic review and meta-analysis. *Arch Sex Behav*. 2013;42(6):915–933.

Fugl-Meyer AR, Fugl-Meyer KS. Sexual disabilities, problems, and satisfaction in 18-74 year old Swedes. *Scand J Sexol*. 1999;2:79–105.

Fugl-Meyer KS, Bohm-Starke N, Damsted Petersen C, et al. Standard operating procedures for female genital sexual pain. *J Sex Med*. 2013;10(1):83–93.

Garcia JR, Lloyd EA, Wallen K, et al. Variation in orgasm occurrence by sexual orientation in a sample of U.S. singles. *J Sex Med*. 2014;11(11):2645–2652.

Garcia S, Talakoub L, Maitland S, et al. Genital duplex Doppler ultrasonography before and after sexual stimulation in women with sexual dysfunction: gray scale, volumetric, and hemodynamic findings. *Fertil Steril*. 2005;83(4):995–999.

Gaziev G, Topazio L, Iacovelli V, et al. Percutaneous Tibial Nerve Stimulation (PTNS) efficacy in the treatment of lower urinary tract dysfunctions: a systematic review. *BMC Urol*. 2013;13:61.

Geiss IM, Umek WH, Dungl A, et al. Prevalence of female sexual dysfunction in gynecologic and urogynecologic patients according to the international consensus classification. *Urology*. 2003;62(3):514–518.

Geller EJ, Parnell BA, Dunivan GC. Pelvic floor function before and after robotic sacrocolpopexy: one-year outcomes. *J Minim Invasive Gynecol*. 2011;18(3):322–327.

Gentilcore-Saulnier E, McLean L, Goldfinger C, et al. Pelvic floor muscle assessment outcomes in women with and without provoked vestibulodynia and the impact of a physical therapy program. *J Sex Med*. 2010;7(2 Pt 2):1003–1022.

Gerritsen J, van der Made F, Bloemers J, et al. The clitoral photoplethysmograph: a new way of assessing genital arousal in women. *J Sex Med*. 2009;6(6):1678–1687.

Gerstenberger EP, Rosen RC, Brewer JV, et al. Sexual desire and the female sexual function index (FSFI): a sexual desire cutpoint for clinical interpretation of the FSFI in women with and without hypoactive sexual desire disorder. *J Sex Med*. 2010;7(9):3096–3103.

Ghanbarzadeh N, Nadjafi-Semnani M, Ghanbarzadeh M-R, et al. Female sexual dysfunction in Iran: study of prevalence and risk factors. *Arch Gynecol Obstet*. 2013;287(3):533–539.

Ghetti C, Gregory WT, Edwards SR, et al. Pelvic organ descent and symptoms of pelvic floor disorders. *Am J Obstet Gynecol*. 2005;193(1):53–57.

Ghoniem G, Stanford E, Kenton K, et al. Evaluation and outcome measures in the treatment female urinary stress incontinence: International Urogynecological Association (IUGA) guidelines for research and clinical practice. *Int Urogynecol J*. 2008;19(1):5–33.

Gill BC, Swartz MA, Firoozi F, et al. Improved sexual and urinary function in women with sacral nerve stimulation. *Neuromodulation*. 2011;14(5):436–443 [discussion 43].

Giuliano F, Allard J, Compagnie S, et al. Vaginal physiological changes in a model of sexual arousal in anesthetized rats. *Am J Physiol Regul Integr Comp Physiol*. 2001;281(1):R140–R149.

Glavind K, Larsen T, Lindquist AS. Sexual function in women before and after tension-free vaginal tape operation for stress urinary incontinence. *Acta Obstet Gynecol Scand*. 2014;93(10):986–990.

GlaxoSmithKline. *Bupropion [prescribing information]*. [Research Triangle Park, NC: GlaxoSmithKline; Available at] https://www.gsksource.com/pharma/content/dam/GlaxoSmith TABLETS-PI-MG.PDF [Revised August 2017].

Glazer HI, Rodke G, Swencionis C, et al. Treatment of vulvar vestibulitis syndrome with electromyographic biofeedback of pelvic floor musculature. *J Reprod Med*. 1995;40(4):283–290.

Goetsch MF. Surgery combined with muscle therapy for dyspareunia from vulvar vestibulitis: an observational study. *J Reprod Med*. 2007;52(7):597–603.

Goldfischer ER, Clayton AH, Goldstein I, et al. Decreased sexual desire screener (DSDS) for diagnosis of hypoactive sexual desire disorder in women. *Obstet Gynecol*. 2008;111:109.

Goldmeier D, Mears A, Hiller J, et al. Persistent genital arousal disorder: a review of the literature and recommendations for management. *Int J STD AIDS*. 2009;20(6):373–377.

Goldstein I, Alexander JL. Practical aspects in the management of vaginal atrophy and sexual dysfunction in perimenopausal and postmenopausal women. *J Sex Med*. 2005;2(Suppl 3):154–165.

Goldstein AT, Pukall CF, Goldstein I. *Female sexual pain disorders: evaluation and management*. Blackwell Publishing: Oxford, England; 2009:76.

Goldstein SR, Bachmann GA, Koninckx PR, et al. Ospemifene 12-month safety and efficacy in postmenopausal women with vulvar and vaginal atrophy. *Climacteric*. 2014;17(2):173–182.

Goldstein AT, Pukall CF, Brown C, et al. Vulvodynia: assessment and treatment. *J Sex Med*. 2016;13(4):572–590.

Goldstein I, Kim NN, Clayton AH, et al. Hypoactive sexual desire disorder. International Society for the Study of Women's Sexual Health (ISSWSH) expert consensus panel review. *Mayo Clin Proc*. 2017;92(1):114–128.

Gooren L, Morgentaler A. Prostate cancer incidence in orchidectomised male-to-female transsexual persons treated with oestrogens. *Andrologia*. 2014;46(10):1156–1160; 10.1111/and.12208.

Grafenberg E. The role of urethra in female orgasm. *Int J Sexol*. 1950;3:145–148.

Grant JM, Mottet LA, Tanis J, et al. *Injustice at every turn: a Report of the National Transgender Discrimination Survey*. The National Center for Transgender Equality and National

Gay and Lesbian Task Force: Washington, DC; 2011.

Gregersen N, Jensen PT, Giraldi AGE. Sexual dysfunction in the peri- and postmenopause. Status of incidence, pharmacological treatment and possible risks. A secondary publication. *Dan Med Bull*. 2006;53(3):349–353.

Grewen KM, Girdler SS, Amico J, et al. Effects of partner support on resting oxytocin, cortisol, norepinephrine, and blood pressure before and after warm partner contact. *Psychosom Med*. 2005;67(4):531–538.

Griebling TL, Liao Z, Smith PG. Systemic and topical hormone therapies reduce vaginal innervation density in postmenopausal women. *Menopause*. 2012;19(6):630–635.

Grody MH. Urinary incontinence and concomitant prolapse. *Clin Obstet Gynecol*. 1998;41(3):777–785.

Gruszecki L, Forchuk C, Fisher WA. Factors associated with common sexual concerns in women: new findings from the Canadian Contraception Study. *Can J Hum Sex*. 2005;14(1):1–13.

Gutman RE, Ford DE, Quiroz LH, et al. Is there a pelvic organ prolapse threshold that predicts pelvic floor symptoms? *Am J Obstet Gynecol*. 2008;199(6):683.e1–683.e7.

Haberfellner EM, Rittmannsberger H. Spontaneous remission of SSRI-induced orgasm delay. *Pharmacopsychiatry*. 2004;37(3):127–130.

Haeberle EJ. *The “Classic” Dysfunctions—the PLISSIT model of sex therapy (explanation): The treatment of sexual dysfunctions—sex therapy*. [Magnus Hirschfeld Archive for Sexology] 2010.

Hajebrahimi S, Azaripour A, Sadeghi-Bazargani H. Tolterodine immediate release improves sexual function in women with overactive bladder. *J Sex Med*. 2008;5(12):2880–2885.

Hajiaghababaei M, Javidan AN, Saberi H, et al. Female sexual dysfunction in patients with spinal cord injury: a study from

Iran. *Spinal Cord*. 2014;52(8):646–649.

Hamada A, Kingsberg S, Wierckx K, et al. Semen characteristics of transwomen referred for sperm banking before sex transition: a case series. *Andrologia*. 2015;47(7):832–838.

Hamilton LD, Meston CM. Chronic stress and sexual function in women. *J Sex Med*. 2013;10(10):2443–2454.

Hamilton LD, Julian AM. The relationship between daily hassles and sexual function in men and women. *J Sex Marital Ther*. 2014;40(5):379–395.

Handa VL, Garrett E, Hendrix S, et al. Progression and remission of pelvic organ prolapse: a longitudinal study of menopausal women. *Am J Obstet Gynecol*. 2004;190(1):27–32.

Handa VL, Harvey L, Cundiff GW, et al. Sexual function among women with urinary incontinence and pelvic organ prolapse. *Am J Obstet Gynecol*. 2004;191(3):751–756.

Handa VL, Cundiff G, Chang HH, et al. Female sexual function and pelvic floor disorders. *Obstet Gynecol*. 2008;111(5):1045–1052.

Harris JM, Cherkas LF, Kato BS, et al. Normal variations in personality are associated with coital orgasmic infrequency in heterosexual women: a population-based study. *J Sex Med*. 2008;5(5):1177–1183.

Hart SL, Bowen DJ. Sexual orientation and intentions to obtain breast cancer screening. *J Womens Health*. 2009;18(2):177–185.

Hartmann D, Strauhal MJ, Nelson CA. Treatment of women in the United States with localized, provoked vulvodynia: practice survey of women's health physical therapists. *J Reprod Med*. 2007;52(1):48–52.

Hatzichristou D, Rosen RC, Derogatis LR, et al. Recommendations for the clinical evaluation of men and women with sexual dysfunction. *J Sex Med*. 2010;7(1 Pt 2):337–348.

Hatzichristou D, Kirana PS, Banner L, et al. Diagnosing sexual dysfunction in men and women: sexual history taking and the role of symptom scales and questionnaires. *J Sex Med*. 2016;13(8):1166–1182.

Hayes RD. Circular and linear modeling of female sexual desire and arousal. *J Sex Res*. 2011;48(2–3):130–141.

Hayes RD, Dennerstein L, Bennett CM, et al. Relationship between hypoactive sexual desire disorder and aging. *Fertil Steril*. 2007;87(1):107–112.

Hayes RD, Dennerstein L, Bennett CM, et al. What is the “true” prevalence of female sexual dysfunctions and does the way we assess these conditions have an impact? *J Sex Med*. 2008;5(4):777–787.

Haylen BT, de Ridder D, Freeman RM, et al. An International Urogynecological Association (IUGA)/International Continence Society (ICS) joint report on the terminology for female pelvic floor dysfunction. *Neurourol Urodyn*. 2010;29(1):4–20.

Haylen BT, Freeman RM, Swift SE, et al. An International Urogynecological Association (IUGA)/international continence society (ICS) joint terminology and classification of the complications related directly to the insertion of protheses (meshes, implants, tapes) and grafts in female pelvic floor surgery. *Int Urogynecol J*. 2011;30(1):2–12.

Heiman JR. Psychologic treatments for female sexual dysfunction: are they effective and do we need them? *Arch Sex Behav*. 2002;31(5):445–450.

Heiman JR, LoPiccolo J. *Becoming orgasmic: a sexual and personal growth program for women (revised and expanded edition)*. Simon & Schuster: New York; 1988.

Heiman JR, Meston CM. Empirically validated treatment for sexual dysfunction. *Annu Rev Sex Res*. 1997;8:148–194.

Hembree WC, et al. Endocrine treatment of gender-dysphoric/gender-incongruent persons: an endocrine society clinical practice guideline. *J Clin Endocrinol Metab*. 2017;102(11):3869–3903.

Henson DE, Rubin HB, Henson C. Consistency of the labial temperature change measure of human female eroticism. *Behav Res Ther*. 1978;16(2):125–129.

Herbenick D, Reece M, Sanders SA, et al. Women's vibrator use in sexual partnerships: results from a nationally representative survey in the United States. *J Sex Marital Ther*. 2010;36(1):49–65.

Herbenick D, Reece M. Development and validation of the female genital self-image scale. *J Sex Med*. 2010;7(5):1822–1830.

Heslin KC, Gore JL, King WD, et al. Sexual orientation and testing for prostate and colorectal cancers among men in California. *Med Care*. 2008;46(12):1240–1248.

Hiller J, Hekster B. Couple therapy with cognitive behavioural techniques for persistent sexual arousal syndrome. *Sex Relation Ther*. 2007;22:91–96.

Hilliges M, Falconer C, Ekman-Ordeberg G, et al. Innervation of the human vaginal mucosa as revealed by PGP 9.5 immunohistochemistry. *Acta Anat (Basel)*. 1995;153(2):119–126.

Hines TM. The G-spot: a modern gynecologic myth. *Am J Obstet Gynecol*. 2001;185(2):359–362.

Hodgins MB, Spike RC, Mackie RM, et al. An immunohistochemical study of androgen, oestrogen and progesterone receptors in the vulva and vagina. *Br J Obstet Gynaecol*. 1998;105(2):216–222.

Hurlbert DF, Apt C. The coital alignment technique and directed masturbation: a comparative study on female orgasm. *J Sex*

Marital Ther. 1995;21(1):21–29.
Idama TO, Pring DW. Vaginal dilator therapy—an outpatient gynaecological option in the management of dyspareunia. *J Obstet Gynaecol*. 2000;20(3):303–305.
Isidori AM, Pozza C, Esposito K, et al. Development and validation of a 6-item version of the female sexual function index (FSFI) as a diagnostic tool for female sexual dysfunction. *J Sex Med*. 2010;7(3):1139–1146.
Janssen OE, Hahn S, Tan S, et al. Mood and sexual function in polycystic ovary syndrome. *Semin Reprod Med*. 2008;26(1):45–52.
Jayaram A, Esbrand F, Dulaveris G, et al. Decreased concentration of protease inhibitors: possible contributors to allodynia and hyperalgesia in women with vestibulodynia. *Am J Obstet Gynecol*. 2015;212(2):184.e1–184.e4.
Jelovsek JE, Barber MD. Women seeking treatment for advanced pelvic organ prolapse have decreased body image and quality of life. *Am J Obstet Gynecol*. 2006;194(5):1455–1461.
Jemta L, Fugl-Meyer KS, Oberg K. On intimacy, sexual activities and exposure to sexual abuse among children and adolescents with mobility impairment. *Acta Paediatr*. 2008;97(5):641–646.
Jha S, Ammenbal M, Metwally M. Impact of incontinence surgery on sexual function: a systematic review and meta-analysis. *J Sex Med*. 2012;9(1):34–43.
Jha S, Gray T. A systematic review and meta-analysis of the impact of native tissue repair for pelvic organ prolapse on sexual function. *Int Urogynecol J*. 2015;26(3):321–327.
Johannes CB, Clayton AH, Odom DM, et al. Distressing sexual problems in United States women revisited: prevalence after accounting for depression. *J Clin Psychiatry*. 2009;70(12):1698–1706.

Kadioglu P, Yalin AS, Tiryakioglu O, et al. Sexual dysfunction in women with hyperprolactinemia: a pilot study report. *J Urol*. 2005;174(5):1921–1925.

Kafka MP. Hypersexual disorder: a proposed diagnosis for DSM-V. *Arch Sex Behav*. 2010;39(2):377–400.

Kamalak Z, Kosus A, Hizli F, et al. Does quality of female sexual function improve after a transobturator tape procedure? *J Obstet Gynaecol*. 2014;34(6):512–514.

Kammerer-Doak D, Rogers RG. Female sexual function and dysfunction. *Obstet Gynecol Clin North Am*. 2008;35(2):169–183.

Kanter G, Rogers RG, Pauls RN, et al. A strong pelvic floor is associated with higher rates of sexual activity in women with pelvic floor disorders. *Int Urogynecol J*. 2015;26(7):991–996.

Kaplan HS. Hypoactive sexual desire. *J Sex Marital Ther*. 1977;3(1):3–9.

Kaplan H. *Disorders of sexual desire and other new concepts and techniques in sex therapy*. Brunner/Hazel Publications: New York; 1979.

Katz M, Derogatis LR, Ackerman R, et al. Efficacy of flibanserin in women with hypoactive sexual desire disorder: results from the BEGONIA trial. *J Sex Med*. 2013;10(7):1807–1815.

Kegel A. Sexual functions of the pubococcygeus muscle. *West J Surg Obstet Gynecol*. 1952;60(10):521–524.

Kelleher CJ, Cardozo LD, Khullar V, et al. A new questionnaire to assess the quality of life of urinary incontinent women. *Br J Obstet Gynaecol*. 1997;104(12):1374–1379.

Kelly MP, Strassberg DS, Kircher JR. Attitudinal and experiential correlates of anorgasmia. *Arch Sex Behav*. 1990;19(2):165–177.

Kelly MP, Strassberg DS, Turner CM. Behavioral assessment of couples' communication in female orgasmic disorder. *J Sex*

Marital Ther. 2006;32(2):81–95.

Kielbasa LA, Daniel KL. Topical alprostadil treatment of female sexual arousal disorder. *Ann Pharmacother*. 2006;40(7–8):1369–1376.

Kilmann PR, Mills KH, Bella B, et al. The effects of sex education on women with secondary orgasmic dysfunction. *J Sex Marital Ther*. 1983;9(1):79–87.

Kim SW, Jeong SJ, Munarriz R, et al. Role of the nitric oxide-cyclic GMP pathway in regulation of vaginal blood flow. *Int J Impot Res*. 2003;15(5):355–361.

Kim YH, Seo JT, Yoon H. The effect of overactive bladder syndrome on the sexual quality of life in Korean young and middle aged women. *Int J Impot Res*. 2005;17(2):158–163.

Kingsberg SA. Attitudinal survey of women living with low sexual desire. *J Womens Health (Larchmt)*. 2014;23(10):817–823.

Kingsberg S, Althof SE. Evaluation and treatment of female sexual dis- orders. *Int Urogynecol J Pelvic Floor Dysfunct*. 2009;20(Suppl 1):S33–S43.

Kingsberg SA, Knudson G. Female sexual disorders: assessment, diagnosis, and treatment. *CNS Spectr*. 2011;16(2):49–62.

Kingsberg SA, Rezaee RL. Hypoactive sexual desire in women. *Menopause*. 2013;20(12):1284–1300.

Kingsberg SA, Woodard T. Female sexual dysfunction: focus on low desire. *Obstet Gynecol*. 2015;125(2):477–486.

Kingsberg SA, Clayton AH, Pfaus JG. The female sexual response: current models, neurobiological underpinnings and agents currently approved or under investigation for the treatment of hypoactive sexual desire disorder. *CNS Drugs*. 2015;29(11):915–933.

Kingsberg SA, Althof S, Simon JA, et al. Female sexual dysfunction—Medical and psychological treatments, Committee 14. *J Sex Med*. 2017;14(12):1463–1491.

Ko Y, Lin SJ, Salmon JW, et al. The impact of urinary incontinence on quality of life of the elderly. *Am J Manag Care*. 2005;11(4 Suppl):103–111.

Kohler TS, McVary KT. The relationship between erectile dysfunction and lower urinary tract symptoms and the role of phosphodiesterase type 5 inhibitors. *Eur Urol*. 2009;55(1):38–48.

Komesu YM, Rogers RG, Kammerer-Doak DN, et al. Posterior repair and sexual function. *Am J Obstet Gynecol*. 2007;197(1):101.e1–101.e6.

Komisaruk BR, Lee HJ. Prevalence of sacral spinal (Tarlov) cysts in persistent genital arousal disorder. *J Sex Med*. 2012;9(8):2047–2056.

Komisaruk BR, Whipple B, Crawford A, et al. Brain activation during vaginocervical self-stimulation and orgasm in women with complete spinal cord injury: fMRI evidence of mediation by the vagus nerves. *Brain Res*. 2004;1024(1–2):77–88.

Kontula O, Haavio-Mannila E. *Sexual pleasures. Enhancement of sex life in Finland*. Dartmouth: Aldershot; 1995:1971–1992.

Korda JB, Pfaus JG, Goldstein I. Persistent genital arousal disorder: a case report in a woman with lifelong PGAD where serendipitous administration of varenicline tartrate resulted in symptomatic improvement. *J Sex Med*. 2009;6(5):1479–1486.

Kowalik CR, Lakeman MME, de Kraker AT, et al. Effects of mesh-related complications in vaginal surgery on quality of life. *Int Urogynecol J*. 2019;30(7):1083–1089.

Kreuter M, et al. Women's sexual functioning and sex life after spinal cord injury. *Spinal Cord*. 2011;49:154–160.

Krysiak R, Drosdzol-Cop A, Skrzypulec-Plinta V, et al. Sexual function and depressive symptoms in young women with thyroid autoimmunity and subclinical hypothyroidism. *Clin Endocrinol (Oxf)*. 2016;84(6):925–931.

Kukkonen TM, Binik YM, Amsel R, et al. Thermography as a physiological measure of sexual arousal in both men and women. *J Sex Med*. 2007;4(1):93–105.

Laan E, Everaerd W, van Bellen G, et al. Women's sexual and emotional responses to male- and female-produced erotica. *Arch Sex Behav*. 1994;23(2):153–169.

Laan E, Rellini AH, Barnes T. International Society for Sexual Medicine. Standard operating procedures for female orgasmic disorder: consensus of the International Society for Sexual Medicine. *J Sex Med*. 2013;10(1):74–82.

Lam DK, Schmidt BL. Serine proteases and protease activated receptor 2-dependent allodynia: a novel cancer pain pathway. *Pain*. 2010;149(2):263–272.

Landén M, Eriksson E, Agren H, et al. Effect of buspirone on sexual dysfunction in depressed patients treated with selective serotonin reuptake inhibitors. *J Clin Psychopharmacol*. 1999;19(3):268–271.

Latif EZ, Diamond MP. Arriving at the diagnosis of female sexual dysfunction. *Fertil Steril*. 2013;100(4):898–904.

Laughlin GA, Goodell V, Barrett-Connor E. Extremes of endogenous testosterone are associated with increased risk of incident coronary events in older women. *J Clin Endocrinol Metab*. 2010;95(2):740–747.

Laumann EO, Paik A, Rosen RC. Sexual dysfunction in the United States: prevalence and predictors. *JAMA*. 1999;281(6):537–544.

Laurent SM, Simons AD. Sexual dysfunction in depression and anxiety: conceptualizing sexual dysfunction as part of an internalizing dimension. *Clin Psychol Rev*. 2009;29(7):573–585.

Leiblum SR, Nathan SG. Persistent sexual arousal syndrome: a newly discovered pattern of female sexuality. *J Sex Marital Ther*. 2001;27(4):365–380.

Leiblum SR, Goldmeier D. Persistent genital arousal disorder in women: case reports of association with anti-depressant usage and withdrawal. *J Sex Marital Ther*. 2008;34(2):150–159.

Leiblum SR, Seehuus M. FSFI scores of women with persistent genital arousal disorder compared with published scores of women with female sexual arousal disorder and healthy controls. *J Sex Med*. 2009;6(2):469–473.

Leiblum SR, Koochaki PE, Rodenberg CA, et al. Hypoactive sexual desire disorder in postmenopausal women: US results from the Women's International Study of Health and Sexuality (WISHeS). *Menopause*. 2006;13(1):46–56.

Leiblum S, Seehuus M, Goldmeier D, et al. Psychological, medical, and pharmacological correlates of persistent genital arousal disorder. *J Sex Med*. 2007;4(5):1358–1366.

Levin RJ. Blood flow: heated electrodes. Goldstein I, Meston CM, Davis SR, et al. *Women's sexual function and dysfunction, study, diagnosis, and treatment*. Taylor & Francis: London; 2006:391–398.

Levin RJ. The pharmacology of the human female orgasm—its biological and physiological backgrounds. *Pharmacol Biochem Behav*. 2014;121:62–70.

Levin RJ, Both S, Georgiadis J, et al. The physiology of female sexual function and the pathophysiology of female sexual dysfunction (Committee 13A). *J Sex Med*. 2016;13(5):733–759.

Levine KB, Williams RE, Hartmann KE. Vulvovaginal atrophy is strongly associated with female sexual dysfunction among sexually active postmenopausal women. *Menopause*. 2008;15(4 Pt 1):661–666.

Lewis RW, Fugl-Meyer KS, Corona G, et al.

Definitions/epidemiology/risk factors for sexual dysfunction. *J Sex Med*. 2010;7(4 Pt 2):1598–1607.

Lonnee-Hoffmann RA, Salvesen O, Morkved S, et al. What predicts improvement of sexual function after pelvic floor surgery? A follow-up study. *Acta Obstet Gynecol Scand*. 2013;92(11):1304–1312.

Lowenstein L, Gamble T, Sanses TV, et al. Sexual function is related to body image perception in women with pelvic organ prolapse. *J Sex Med*. 2009;6(8):2286–2291.

Lowenstein L, Pierce K, Pauls R. Urogynecology and sexual function research. How are we doing? *J Sex Med*. 2009;6(1):199–204.

Lowenstein L, Gruenwald I, Gartman I, et al. Can stronger pelvic muscle floor improve sexual function? *Int Urogynecol J*. 2010;21(5):553–556.

Lukban JC, Whitmore KE. Pelvic floor muscle re-education treatment of the overactive bladder and painful bladder syndrome. *Clin Obstet Gynecol*. 2002;45(1):273–285.

Lykins AD, Janssen E, Graham CA. The relationship between negative mood and sexuality in heterosexual college woman and men. *J Sex Res*. 2006;43(2):136–143.

Magon N, Kalra S. The orgasmic history of oxytocin: love, lust, and labor. *Indian J Endocrinol Metab*. 2011;15(Suppl 3):S156–S161.

Maher C, Feiner B, Baessler K, et al. Surgical management of pelvic organ prolapse in women. *Cochrane Database Syst Rev*. 2013;(4) [CD004014].

Mahoney S, Zarate C. Persistent sexual arousal syndrome: a case report and review of the literature. *J Sex Marital Ther*. 2007;33(1):65–71.

Major S. Pfizer will not apply for a license for sildenafil for women. *BMJ*. 2004;382:542.

Maravilla KR, Yang CC. Magnetic resonance imaging and the female sexual response: overview of techniques, results, and future directions. *J Sex Med*. 2008;5(7):1559–1571.

Marcus BS. Changes in a woman's sexual experience and expectations following the introduction of electric vibrator assistance. *J Sex Med*. 2011;8(12):3398–3406.

Marson L. Central nervous system neurons identified after injection of pseudorabies virus into the rat clitoris. *Neurosci Lett*. 1995;190(1):41–44.

Marthol H, Hilz MJ. Female sexual dysfunction: a systematic overview of classification, pathophysiology, diagnosis, and treatment. *Fortschr Neurol Psychiatr*. 2004;72(3):121–135.

Martin-Alguacil N, Schober J, Kow LM, et al. Arousing properties of the vulvar epithelium. *J Urol*. 2006;176(2):456–462.

Martinez F. International Society for Fertility Preservation EAEWG. Update on fertility preservation from the Barcelona International Society for Fertility Preservation-ESHRE-ASRM 2015 expert meeting: indications, results and future perspectives. *Fertil Steril*. 2017;108(3) [407.e11–415.e11].

Masters WH, Johnson VE. *Human sexual response*. Little Brown & Company: Boston, MA; 1966.

Masters Q, Johnson VE. *Human sexual inadequacy*. Little Brown & Company: Boston, MA; 1970.

Mayor S. Pfizer will not apply for a license for sildenafil for women. *BMJ*. 2004;328(7439):542.

McCabe MP. Evaluation of cognitive behavior therapy program for people with sexual dysfunction. *J Sex Marital Ther*. 2001;27(3):259–271.

McCabe MP, Taleporos G. Sexual esteem, sexual satisfaction, and sexual behavior among people with physical disability. *Arch Sex Behav*. 2003;32(4):359–369.

McCabe MP, Giles K. Differences between sexually functional and dysfunctional women in childhood experiences and individual and relationship domains. *Int J Sex Health*. 2012;24:181–194.

McCabe MP, Sharlip ID, Atalla E, et al. Definitions of sexual dysfunctions in women and men: a consensus statement from the Fourth International Consultation on Sexual Medicine 2015. *J Sex Med*. 2016;13(2):135–143.

McCool ME, Zuelke A, Theurich MA, et al. Prevalence of female sexual dysfunction among premenopausal women: a systematic review and meta-analysis of observational studies. *Sex Med Rev*. 2016;4(3):197–212.

McGahuey CA, Gelenberg AJ, Laukes CA, et al. The Arizona Sexual Experience Scale (ASEX): reliability and validity. *J Sex Marital Ther*. 2000;26(1):25–40.

Meloy TS, Southern JP. Neurally augmented sexual function in human females: a preliminary investigation. *Neuromodulation*. 2006;9(1):34–40.

Melville JL, Delaney K, Newton K, et al. Incontinence severity and major depression in incontinent women. *Obstet Gynecol*. 2005;106(3):585–592.

Mercer C, Tanton C, Prah P, et al. Changes in sexual attitudes and lifestyles in Britain through the life course and over time: findings from the National Surveys of Sexual Attitudes and Lifestyles (NATSAL). *Lancet*. 2013;382(9907):1781–1794.

Meseguer M, Garrido N, Remohi J, et al. Testicular sperm extraction (TESE) and ICSI in patients with permanent azoospermia after chemotherapy. *Hum Reprod*. 2003;18(6):1281–1285.

Messelink B, Benson T, Berghmans B, et al. Standardization of terminology of pelvic floor muscle function and dysfunction: report from the pelvic floor clinical assessment group of the International Continence Society. *Neurourol Urodyn*. 2005;24(4):374–380.

Meston CM, Frohlich PF. Update on female sexual function.

Curr Opin Urol. 2001;11:603–609.

Meston CM, Worcel M. The effects of yohimbine plus L-arginine glutamate on sexual arousal in postmenopausal women with sexual arousal disorder. *Arch Sex Behav*. 2002;31(4):323–332.

Meston CM, Bradford A. Sexual dysfunctions in women. *Annu Rev Clin Psychol*. 2007;3:233–256.

Meston CM, Hull E, Levin RJ, et al. Disorders of orgasm in women. *J Sex Med*. 2004;1(1):66–68.

Modell JG, May RS, Katholi CR. Effect of bupropion-SR on orgasmic dysfunction in nondepressed subjects: a pilot study. *J Sex Marital Ther*. 2000;26(3):231–240.

Mohammadi K, Rahnama P, Mohseni SM, et al. Determinants of sexual dysfunction in women with multiple sclerosis. *BMC Neurol*. 2013;13:83.

Montejo-Gonzalez AL, Llorca G, Izquierdo JA, et al. SSRI induced sexual dysfunction: fluoxetine, paroxetine, sertraline, and fluvoxamine in a prospective, multicenter, and descriptive clinical study of 344 patients. *J Sex Marital Ther*. 1997;23(3):176–194.

Moran PA, Dwyer PL, Ziccone SP. Urinary leakage during coitus in women. *J Obstet Gynaecol*. 1999;19(3):286–288.

Morin M, Bergeron S, Khalife S, et al. Morphometry of the pelvic floor muscles in women with and without provoked vestibulodynia using 4D ultrasound. *J Sex Med*. 2014;11(3):776–785.

Morokoff PJ, LoPiccolo J. A comparative evaluation of minimal therapist contact and 15-session treatment for female orgasmic dysfunction. *J Consult Clin Psychol*. 1986;54(3):294–300.

Moyal-Barracco M, Lynch PJ. 2003 terminology and classification of vulvodynia: a historical perspective. *J Reprod Med*. 2004;49(10):772–777.

Murina F, Graziottin A, Felice R, et al. Coital pain in the elderly: could a low dose estriol gel thrill the vulvar vestibule? *Eur J Obstet Gynecol Reprod Biol*. 2016;207:121–124.

Nachtigall L, Casson P, Lucas J, et al. Safety and tolerability of testosterone patch therapy for up to 4 years in surgically menopausal women receiving oral or transdermal oestrogen. *Gynecol Endocrinol*. 2011;27(1):39–48.

Nappi RE, Cucinella L. Advances in pharmacotherapy for treating female sexual dysfunction. *Expert Opin Pharmacother*. 2015;16(6):875–887.

Nappi RE, Ferdeghini F, Abbiati I, et al. Electrical stimulation (ES) in the management of sexual pain disorders. *J Sex Marital Ther*. 2003;29(Suppl 1):103–110.

Nappi R, Salonia A, Traish AM, et al. Clinical biologic pathophysiologies of women's sexual dysfunction. *J Sex Med*. 2005;2(1):4–25.

Narin R, Attar R, Narin MA, et al. Impact of transobturator tape procedure on female and their partner sexual function: it improves sexual function of couples. *Arch Gynecol Obstet*. 2014;290(5):913–917.

Natoin B, Maclusky NJ, Leranth CZ. The cellular effects of estrogens on neuroendocrine tissues. *J Steroid Biochem*. 1988;30(1–6):195–207.

Nelson H, Haney H, Miller J, et al. *Management of menopause-related symptoms: summary*. [Evidence Rep Technology Assessment No. 120. AHQR Publication No. 05-E016-1. Rockville, MD: Agency for Healthcare Research and Quality. As cited by Petersen M. In: Tepper MS, Owens AF, eds. Menopause and sexuality in sexual health. Westport, CT: Praeger Press] 2007.

Ness RB, Albano JD, McTiernan A, et al. Influence of estrogen plus testosterone supplementation on breast cancer. *Arch*

Intern Med. 2009;169(1):41–46.

Nguyen R, Mathur C, Wynings E, et al. Remission of vulvar pain among women with primary vulvodynia. *J Low Genit Tract Dis*. 2015;19(1):62–67.

Nicolosi A, Laumann EO, Glasser DB, Global Study of Sexual Attitudes and Behaviors Investigators’ Group, et al. Sexual behavior and sexual dysfunctions after age 40: the global study of sexual attitudes and behaviors. *Urology*. 2004;64(5):991–997.

Nijland EA, Weijmar Schultz WC, Nathorst-Boos J, et al. Tibolone and transdermal E2/NETA for the treatment of female sexual dysfunction in naturally menopausal women: results of a randomized active-controlled trial. *J Sex Med*. 2008;5(3):646–656.

Nilsson M, Lalos O, Lindkvist H, et al. Impact of female urinary incontinence and urgency on women's and their partners’ sexual life. *Neurourol Urodyn*. 2011;30(7):1276–1280.

Nobre PJ, Pinto-Gouveia J, Gomes FA. Prevalence and comorbidity of sexual dysfunctions in a Portuguese clinical sample. *J Sex Marital Ther*. 2006;32(2):173–182.

Nobre PJ, Pinto-Gouveia J. Cognitive and emotional predictors of female sexual dysfunctions: preliminary findings. *J Sex Marital Ther*. 2008;34(4):325–342.

Noll J, Brown L, Yuan J, et al: Effect of flibanserin on the pharmacokinetics of a combined ethinylestradiol/levonorgestrel oral contraceptive in healthy premenopausal women. Presented at: 24th Annual Congress of Women's Health; April 14–17, 2016; Washington, DC, USA.

North American Menopause Society. Management of symptomatic vulvovaginal atrophy: 2013 position statement of the North American Menopause Society. *Menopause*.

2013;20(9):888–902.

Norton P, Brubaker L. Urinary incontinence in women. *Lancet*. 2006;367(9504):57–67.

Novi JM, Jeronis S, Morgan MA, et al. Sexual function in women with pelvic organ prolapse compared to women without pelvic organ prolapse. *J Urol*. 2005;173(5):1669–1672.

Nurnberg HG, Hensley PL, Heiman JR, et al. Sildenafil treatment of women with antidepressant associated sexual dysfunction: a randomized controlled trial. *JAMA*. 2008;300(4):395–404.

Nusbaum MR, Gamble G. The prevalence and importance of sexual concerns among female military beneficiaries. *Mil Med*. 2001;166(3):208–210.

O'Connell H, DeLancey J. Clitoral anatomy in nulliparous, healthy, premenopausal volunteers using unenhanced magnetic resonance imaging. *J Urol*. 2005;173(6):2060–2063.

O'Connell HE, Hutson JM, Plenter RJ, et al. Anatomical relationship between urethra and clitoris. *J Urol*. 1998;159(6):1892–1897.

O'Connell HE, Eizenberg N, Rahman M, et al. The anatomy of the distal vagina: towards unity. *J Sex Med*. 2008;5(8):1883–1891.

Ottem DP, Carr LK, Perks AE, et al. Interstitial cystitis and female sexual dysfunction. *Urology*. 2007;69(4):608–610.

Ottesen B, Ulrichsen H, Frahenkrug J, et al. Vasoactive intestinal polypeptide and the female genital tract: relationship to reproductive phase and delivery. *Am J Obstet Gynecol*. 1982;143(4):414–420.

Ottesen B, Pedersen B, Nielesen J, et al. Vasoactive intestinal polypeptide provokes vaginal lubrication in normal women. *Peptides*. 1987;8(5):797–800.

Ozel B, White T, Urwitz-Lane R, et al. The impact of pelvic organ prolapse on sexual function in women with urinary incontinence. *Int Urogynecol J Pelvic Floor Dysfunct*. 2006;17(1):14–17.
Pan S, Leung C, Shah J, et al. Clinical anatomy of the G-spot. *Clin Anat*. 2015;28(3):363–367.
Panjari M, Bell RJ, Davis SR. Sexual function after breast cancer. *J Sex Med*. 2011;8(1):294–302.
Parada M, D'Amours T, Amsel R, et al. Clitorodynia: a descriptive study of clitoral pain. *J Sex Med*. 2015;12(8):1772–1780.
Parish SJ, Goldstein AT, Goldstein SW, et al. Toward a more evidence-based nosology and nomenclature for female sexual dysfunctions part II. *J Sex Med*. 2016;13(12):1888–1906.
Park K, Moreland RB, Goldstein I, et al. Sildenafil inhibits phosphodiesterase type 5 in human clitoral corpus cavernosum smooth muscle. *Biochem Biophys Res Commun*. 1998;249(3):612–617.
Parnell BA, Howard JF Jr, Geller EJ. The effect of sacral neuromodulation on pudendal nerve function and female sexual function. *Neurourol Urodyn*. 2015;34(5):456–460.
Pastor Z, Holla K, Chmel R. The influence of combined oral contraceptives on female sexual desire: a systematic review. *Eur J Contracept Reprod Health Care*. 2013;18(1):27–43.
Pauls RN, Kleeman SD, Karram MM. Female sexual dysfunction: principles of diagnosis and therapy. *Obstet Gynecol Surv*. 2005;60(3):196–205.
Pauls RN, Marinkovic SP, Silva WA, et al. Effects of sacral neuromodulation on female sexual function. *Int Urogynecol J Pelvic Floor Dysfunct*. 2007;18(4):391–395.
Penson R, Gallagher J, Gioiella ME, et al. Sexuality and cancer: conversation comfort zone. *Oncologist*. 2000;5(4):336–344.
Pessina MA, Hoyt RF Jr, Goldstein I, et al. Differential effects

of estradiol, progesterone, and testosterone on vaginal structural integrity. *Endocrinology*. 2006;147(1):61–69.

Peters KM, Killinger KA, Carrico DJ, et al. Sexual function and sexual distress in women with interstitial cystitis: a case-control study. *Urology*. 2007;70(3):543–547.

Peters KM, Carrico DJ, Diokno AC. Characterization of a clinical cohort of 87 women with interstitial cystitis/painful bladder syndrome. *Urology*. 2008;71(4):634–640.

Philippsohn S, Hartmann U. Determinants of sexual satisfaction in a sample of German women. *J Sex Med*. 2009;6(4):1001–1010.

Philippsohn S, Kruger TH. Persistent genital arousal disorder: successful treatment with duloxetine and pregabalin in two cases. *J Sex Med*. 2012;9(1):213–217.

Poels S, Bloemers J, van Rooij K, et al. Toward personalized sexual medicine (part 2): testosterone combined with a PDE5 inhibitor increases sexual satisfaction in women with HSDD and FSAD, and a low sensitive system for sexual cues. *J Sex Med*. 2013;10(3):810–823.

Pontiroli AE, Cortelazzi D, Morabito A. Female sexual dysfunction and diabetes: a systematic review and meta-analysis. *J Sex Med*. 2013;10(4):1044–1051.

Portman DJ, Gass MLS. Genitourinary syndrome of menopause: new terminology for vulvovaginal atrophy from the International Society for the Study of Women's Sexual Health and The North American Menopause Society. *Maturitas*. 2014;79(3):349–354.

Portman DJ, Edelson J, Jordan R, et al. Bremelanotide for hypoactive sexual desire disorder: analyses from a phase 2B dose-ranging study. *Obstet Gynecol*. 2014;123(Suppl 1):31S.

Prause N, Cerny J, Janssen E. The labial photoplethysmograph: a new instrument for assessing genital hemodynamic changes in women. *J Sex Med*. 2005;2(1):58–65.

Price N, Slack A, Jackson SR. Laparoscopic sacrocolpopexy: an observational study of functional and anatomical outcomes. *Int Urogynecol J*. 2011;22(1):77–82.

Pukall CF, Goldstein AT, Bergeron S, et al. Vulvodynia: definition, prevalence, impact, and pathophysiological factors. *J Sex Med*. 2016;13(3):291–304.

Quinn GP, Sanchez JA, Sutton SK, et al. Cancer and lesbian, gay, bisexual, transgender/transsexual, and queer/questioning (LGBTQ) populations. *CA Cancer J Clin*. 2015;65(5):384–400.

Quirk FH, Heiman JR, Rosen RC, et al. Development of a sexual function questionnaire for clinical trials of female sexual dysfunction. *J Womens Health Gend Based Med*. 2002;11(3):277–289.

Raina R, Pahlajani G, Khan S, et al. Female sexual dysfunction: classification, pathophysiology, and management. *Fertil Steril*. 2007;88(5):1273–1284.

Rantell A, Apostolidis A, Anding R, et al. How does lower urinary tract dysfunction affect sexual function in men and women? ICI-RS 2015-Part 1. *Neurourol Urodyn*. 2017;36(4):949–952.

Reis SL, Abdo CH. Benefits and risks of testosterone treatment for hypoactive sexual desire disorder in women: a critical review of studies published in the decades preceding and succeeding the advent of phosphodiesterase type 5 inhibitors. *Clinics (Sao Paulo)*. 2014;69(4):294–303.

Rellini A, Meston C. Sexual function and satisfaction in adults based on the definition of child sexual abuse. *J Sex Med*. 2007;4(5):1312–1321.

Richters J, Grulich AE, de Visser RO, et al. Sex in Australia: sexual difficulties in a representative sample of adults. *Aust N Z J Public Health*. 2003;27(2):164–170.

Riley AJ, Riley EJ. A controlled study to evaluate directed masturbation in the management of primary orgasmic failure in women. *Br J Psychiatry*. 1978;133:404–409.

Rogers RG. Sexual function in women with pelvic floor disorders. *Can Urol Assoc J*. 2013;7(9–10 Suppl 4):S199–S201.

Rogers RG, Kammerer-Doak D, Villarreal A, et al. A new instrument to measure sexual function in women with urinary incontinence or pelvic organ prolapse. *Am J Obstet Gynecol*. 2001;184(4):552–558.

Rogers GR, Villarreal A, Kammerer-Doak D, et al. Sexual function in women with and without urinary incontinence and/or pelvic organ prolapse. *Int Urogynecol J Pelvic Floor Dysfunct*. 2001;12(6):361–365.

Rogers R, Bachmann G, Jumadilova Z, et al. Efficacy of tolterodine on overactive bladder symptoms and sexual and emotional quality of life in sexually active women. *Int Urogynecol J Pelvic Floor Dysfunct*. 2008;19(11):1551–1557.

Rogers RG, Omotosho T, Bachmann G, et al. Continued symptom improvement in sexually active women with overactive bladder and urgency urinary incontinence treated with tolterodine ER for 6 months. *Int Urogynecol J Pelvic Floor Dysfunct*. 2009;20(4):381–385.

Rogers RG, Pauls RN, Thakar R, et al. An International Urogynecological Association (IUGA)/International Continence Society (ICS) joint report on the terminology for the assessment of sexual health of women with pelvic floor dysfunction. *Neurourol Urodyn*. 2018;37(4):1220–1240.

Roos AM, Thakar R, Sultan AH, et al. The impact of pelvic floor surgery on female sexual function: a mixed quantitative and qualitative study. *BJOG*. 2014;121:92–101 [discussion 1].

Rosen RC. Assessment of female sexual dysfunction: review of validated methods. *Fertil Steril*. 2002;77(Suppl 4):S89–S93.

Rosen R, Brown C, Heiman J, et al. The Female Sexual Function Index (FSFI): a multidimensional self-report instrument for the assessment of female sexual function. *J Sex Marital Ther*. 2000;26(2):191–208.

Rosen RC, Connor MK, Miyasato G, et al. Sexual desire problems in women seeking healthcare: a novel study design for ascertaining prevalence of hypoactive sexual desire disorder in clinic-based samples of U.S. women. *J Womens Health (Larchmt)*. 2012;21(5):505–515.

Rosenbaum TY, Owens A. The role of pelvic floor physical therapy in the treatment of pelvic and genital pain-related sexual dysfunction (CME). *J Sex Med*. 2008;5(3):513–523 [quiz 524–525].

Rubio-Aurioles E, Kim ED, Rosen RC, et al. Impact on erectile function and sexual quality of life of couples: a double-blind, randomized, placebo-controlled trial of tadalafil taken once daily. *J Sex Med*. 2009;6:1314–1323.

Rust J, Golombok S. The GRISS: a psychometric instrument for the assessment of sexual dysfunction. *Arch Sex Behav*. 1986;15(2):157–165.

Sacco E, Tienforti D. Female sexual dysfunctions and urogynecological disorders. *Eur Med J Urol*. 2013;1:92–99.

Sacco E, D'Addessi A, Racioppi M, et al. Bladder pain syndrome associated with highest impact on sexual function among women with lower urinary tract symptoms. *Int J Gynaecol Obstet*. 2012;117(2):168–172.

Safarinejad MR. Female sexual dysfunction in a population-based study in Iran: prevalence and associated risk factors. *Int J Impot Res*. 2006;18(4):382–395.

Safarinejad MR, Hosseini SY, Asgari MA, et al. A randomized, double-blind, placebo-controlled study of the efficacy and safety of bupropion for treating hypoactive sexual desire disorder in ovulating women. *BJU Int*. 2010;106(6):832–839.

Salloum M. Self-esteem disturbance in patients with urinary diversions: assessing the void. *Ostomy Wound Manage*. 2005;51(12):64–69.

Salonia A, Zanni G, Nappi RE, et al. Sexual dysfunction is common in women with lower urinary tract symptoms and urinary incontinence: results of a cross-sectional study. *Eur Urol*. 2004;45(5):642–648 [discussion 648].

Salvatore S, Serati M, Siesto G, et al. Correlation between anatomical findings and symptoms in women with pelvic organ prolapse using an artificial neural network analysis. *Int Urogynecol J*. 2011;22(4):453–459.

Sanchez DT, Kiefer AK. Body concerns in and out of the bedroom: implications for sexual pleasure and problems. *Arch Sex Behav*. 2007;36(6):808–820.

Sand PK, Goldberg RP, Dmochowski RR, et al. The impact of the overactive bladder syndrome on sexual function: a preliminary report from the Multicenter Assessment of Transdermal Therapy in Overactive Bladder with Oxybutynin trial. *Am J Obstet Gynecol*. 2006;195(6):1730–1735.

Santoro N, Torrens J, Crawford S, et al. Correlates of circulating androgens in mid-life women: the study of women's health across the nation. *J Clin Endocrinol Metab*. 2005;90(8):4836–4845.

Santoro N, Worsley R, Miller KK, et al. Role of estrogens and estrogen-like compounds in female sexual function and dysfunction. *J Sex Med*. 2016;13(3):305–316.

Sarlos D, Brandner S, Kots L, et al. Laparoscopic sacrocolpopexy for uterine and post-hysterectomy prolapse: anatomical results, quality of life and perioperative outcome—a prospective study with 101 cases. *Int Urogynecol J Pelvic Floor Dysfunct*. 2008;19(10):1415–1422.

Sarrel PM. Ovarian hormones and vaginal blood flow using laser Doppler velocimetry to measure effects in a clinical trial of postmenopausal women. *Int J Impot Res*. 1998;10(Suppl 2):S91–S93 [discussion S98–S101].

Sarrel PM. Effects of hormone replacement therapy on sexual psychophysiology and behavior in postmenopause. *J Womens Health Gend Based Med*. 2000;9(Suppl 1):S25–S32.

Sarwer DB, Durlak JA. A field trial of the effectiveness of behavioral treatment for sexual dysfunctions. *J Sex Marital Ther*. 1997;23(2):87–97.

Saunders PT, Millar MR, Williams K, et al. Differential expression of estrogen receptor-alpha and -beta and androgen receptor in the ovaries of marmosets and humans. *Biol Reprod*. 2000;63:1098–1105.

Schneidewind-Skibbe A, Hayes RD, Koochaki PE, et al. The frequency of sexual intercourse reported by women: a review of community-based studies and factors limiting their conclusions. *J Sex Med*. 2008;5(2):301–335.

Schober JM, Pfaff D. The neurophysiology of sexual arousal. *Best Pract Res Clin Endocrinol Metab*. 2007;21(3):445–461.

Segraves RT, Croft H, Kavoussi R, et al. Bupropion sustained release (SR) for the treatment of hypoactive sexual desire disorder (HSDD) in nondepressed women. *J Sex Marital Ther*. 2001;27(3):303–316.

Segraves RT, Clayton A, Croft H, et al. Bupropion sustained release for the treatment of hypoactive sexual desire disorder in premenopausal women. *J Clin Psychopharmacol*. 2004;24(3):339–342.

Sen I, Onaran M, Tan MO, et al. Evaluation of sexual function in women with overactive bladder syndrome. *Urol Int*. 2007;78(2):112–115.

Serati M, Salvatore S, Uccella S, et al. The impact of the mid-urethral slings for the treatment of stress urinary incontinence on female sexuality. *J Sex Med*. 2009;6(6):1534–1542.

Serati M, Braga A, Di Dedda MC, et al. Benefit of pelvic floor muscle therapy in improving sexual function in women with stress urinary incontinence: a pretest-posttest intervention study. *J Sex Marital Ther*. 2015;41(3):254–261.

Serretti A, Chiesa A. Treatment-emergent sexual dysfunction related to antidepressants: a meta-analysis. *J Clin Psychopharmacol*. 2009;29(3):259–266.

Shafik A. The Role of the levator ani muscle in evacuation, sexual performance and pelvic floor disorders. *Int Urogynecol J*. 2000;11(6):361–376.

Sharif A, Malhotra NR, Acosta AM. The development of prostate adenocarcinoma in a transgender male to female patient: could estrogen therapy have played a role? *Prostate*. 2017;77(8):824–828.

Sherwin BB, Gelfand MM. Differential symptom response to parental estrogen and androgen in the surgical menopause. *Am J Obstet Gynecol*. 1985;151(2):153–160.

Sherwin BB, Gelfand MM. The role of androgen in the maintenance of sexual functioning in oophorectomized women. *Psychosom Med*. 1987;49(4):397–409.

Shifren JL, Monz BU, Russo PA, et al. Sexual problems and distress in United States women: prevalence and correlates. *Obstet Gynecol*. 2008;112(5):970–978.

Signorello D, Seitz CC, Berner L, et al. Impact of sacral neuromodulation on female sexual function and his correlation with clinical outcome and quality of life indexes: a monocentric experience. *J Sex Med*. 2011;8(4):1147–1155.

Sills T, Wunderlich G, Pyke R, et al. The Sexual Interest and Desire Inventory-Female (SIDI-F): item response analyses of data from women diagnosed with hypoactive sexual desire disorder. *J Sex Med*. 2005;2(6):801–818.

Simon JA, Kingsberg SA, Shumel B, et al. Efficacy and safety of flibanserin in postmenopausal women with hypoactive sexual desire disorder: results of the SNOWDROP trial. *Menopause*. 2014;21(6):633–640.

Simonelli C, Tripodi F, Vizzari V, et al. Psychorelational aspects of urinary incontinence in female sexuality. *Urologia*. 2008;75(1):14–19.

Sintchak G, Geer JH. A vaginal plethysmograph system. *Psychophysiology*. 1975;12(1):113–115.

Skene A. The anatomy and pathology of two important glands of the female urethra. *Am J Obstet Gynecol*. 1880;13:265–270.

Smith AMA, Rissel CE, Richters J, et al. Sex in Australia: the rationale and methods and rationale of the Australian Study of Health and Relationships. *Aust N Z J Public Health*. 2003;27(2):106–117.

Smith AMA, Lyons A, Ferris JA, et al. Incidence and persistence/recurrence of women's sexual difficulties: findings from the Australian Longitudinal Study of Health and Relationships. *J Sex Marital Ther*. 2012;38(4):378–393.

Snabes MC, Simes SM. Approved hormonal treatments for HSDD: an unmet medical need. *J Sex Med*. 2009;6(7):1846–1849.

Snowdon S. *Healthcare Equality Index 2013: Promoting Equitable and Inclusive Care for Lesbian, Gay, Bisexual, and Transgender Patients and Their Families*. [Human Rights Campaign: Washington, DC, USA] 2013.

Sobecki JN, Curlin FA, Rasinski KA, et al. What we don't talk about when we don't talk about sex1: results of a national survey of United States Obstetrician/Gynecologists. *J Sex Med*. 2012;9(5):1285–1294.

Somboonporn W, Davis S, Seif MW, et al. Testosterone for peri- and postmenopausal women. *Cochrane Database Syst Rev*. 2005;(4) [CD004509].

Sommer F, Caspers HP, Esders K, et al. Measurement of vaginal and minor labial oxygen tension for the evaluation of female sexual function. *J Urol*. 2001;165(4):1181–1184.

Spinder T, Spijkstra JJ, van den Tweel JG, et al. The effects of long term testosterone administration on pulsatile luteinizing hormone secretion and on ovarian histology in eugonadal female to male transsexual subjects. *J Clin Endocrinol Metab*. 1989;69(1):151–157.

Srikrishna S, Robinson D, Cardozo L, et al. Can sex survive pelvic floor surgery? *Int Urogynecol J*. 2010;21(11):1313–1319.

Standring S. Gray's anatomy. [Chapter 68] *The anatomical basis of clinical practice*. ed 40. Elsevier Churchill Livingstone: London; 2008.

Strohbehn K. Normal pelvic floor anatomy. *Obstet Gynecol Clin North Am*. 1998;25(4):683–705.

Stroumsa D, Wu JP. Welcoming transgender and non-binary patients: expanding the language of “women's health”. *Am J Obstet Gynecol*. 2018;219(6):585.e1–585.e5.

Sungur MZ, Gunduz A. A comparison of DSM-IV-TR and DSM-5 definitions for sexual dysfunctions: critiques and challenges. *J Sex Med*. 2014;11(2):364–373.

Swift S, Woodman P, O'Boyle A, et al. Pelvic Organ Support Study (POSST): the distribution, clinical definition, and epidemiologic condition of pelvic organ support defects. *Am J Obstet Gynecol*. 2005;192(3):795–806.

Taylor JF, Rosen RC, Leiblum SR. Self-report assessment of female sexual function: psychometric evaluation of the Brief Index of Sexual Functioning for Women. *Arch Sex Behav*. 1994;23(6):627–643.

Taylor MJ, Rudkin L, Bullemor-Day P, et al. Strategies for managing sexual dysfunction induced by antidepressant medication. *Cochrane Database Syst Rev*. 2013;(5) [CD003382].

Thompson JC, Rogers RG. Surgical management for pelvic organ prolapse and its impact on sexual function. *Sex Med Rev*. 2016;4(3):213–220.

Thorne C, Stuckey B. Pelvic congestion syndrome presenting as persistent genital arousal: a case report. *J Sex Med*. 2008;5(2):504–508.

Thrussell H, Coggrave M, Graham A, et al. Women's experiences of sexuality after spinal cord injury: a UK perspective. *Spinal Cord*. 2018;56(11):1084–1094.

Toozs-Hobson P, Freeman R, Barber M. An International Urogynecological Association (IUGA)/International Continence Society (ICS) Joint Report on the terminology for reporting outcomes of surgical procedures for pelvic organ prolapse. *Int Urogynecol J*. 2012;23(5):527–535.

Tornello SL, Bos H. Parenting intentions among transgender individuals. *LGBT Health*. 2017;4(2):115–120.

Tracey I, Mantyh PW. The cerebral signature for pain perception and its modulation. *Neuron*. 2007;55(3):377–391.

Traish AM, Botchevar E, Kim NN. Biochemical factors modulating female genital sexual arousal physiology. *J Sex Med*. 2010;7(9):2925–2946.

Trompeter SE, Bettencourt R, Barrett-Connor E. Metabolic syndrome and sexual function in postmenopausal women. *Am J Med*. 2016;129(12) [1270.e1–1277.e1].

Trudel G, Marchand A, Ravart M, et al. The effect of a cognitive-behavioral group treatment program on hypoactive sexual desire in women. *Sex Relation Ther*. 2001;16(2):145–164.

Tuiten A, Van Honk J, Koppeschaar H, et al. Time course of effects of testosterone administration on sexual arousal in women. *Arch Gen Psychiatry*. 2000;57(2):149–153.

Unger CA. Care of the transgender patient: a survey of gynecologists’ current knowledge and practice. *J Womens*

Health (Larchmt). 2015;24(2):114–118.

U.S Food and Drug Administration. *FDA warns against use of energy-based devices to perform vaginal "rejuvenation" or vaginal cosmetic procedures: FDA Safety Communication*. [Available at] https://www.fda.gov/MedicalDevices/Safety/AlertsandNotice 2018.

Valeant Pharmaceuticals. *Flibanserin [prescribing information]*. [Bridgewater, NJ: Valeant Pharmaceuticals; Available at] http://www.accessdata.fda.gov/drugsatfda_docs/label/2015/0

Vallinga MS, Spoelstra SK, Hemel IL, et al. Transcutaneous electrical nerve stimulation as an additional treatment for women suffering from therapy-resistant provoked vestibulodynia: a feasibility study. *J Sex Med*. 2015;12(1):228–237.

van Rooij K, Poels S, Bloemers J, et al. Toward personalized sexual medicine (part 3): testosterone combined with a Serotonin1A receptor agonist increases sexual satisfaction in women with HSDD and FSAD, and dysfunctional activation. *J Sex Med*. 2013;10(3):824–837.

van Voskuilen AC, Oerlemans DJ, Gielen N, et al. Sexual response in patients treated with sacral neuromodulation for lower urinary tract symptoms or fecal incontinence. *Urol Int*. 2012;88(4):423–430.

Vasey PL, Abild M. A billion wicked thoughts: what the internet tells us about sexual relationships. *Arch Sex Behav*. 2013;42(6):1101.

Veening JG, Coolen LM. Neural activation following sexual behavior in the male and female rat brain. *Behav Brain Res*. 1998;92(2):181–193.

Verit FF, Verit A. Validation of the female sexual function index in women with chronic pelvic pain. *J Sex Med*. 2007;4(6):1635–1641.

Verit FF, Verit A, Yeni E. The prevalence of sexual dysfunction and associated risk factors in women with chronic pelvic pain: a cross-sectional study. *Arch Gynecol Obstet*. 2006;274(5):297–302.

Vestergaard P, Hermann AP, Stilgren L, et al. Effects of 5 years of hormonal replacement therapy on menopausal symptoms and blood pressure—a randomized controlled study. *Maturitas*. 2003;46(2):123–132.

Vierhout ME, Gianotten WL. Mechanisms of urine loss during sexual activity. *Eur J Obstet Gynecol Reprod Biol*. 1993;52(1):45–47.

Wallen K, Lloyd EA. Female sexual arousal: genital anatomy and orgasm in intercourse. *Horm Behav*. 2011;59(5):780–792.

Wallwiener CW, Wallwiener LM, Seeger H, et al. Prevalence of sexual dysfunction and impact of contraception in female German medical students. *J Sex Med*. 2010;7(6):2139–2148.

Watanabe T, Rivas DA, Smith R, et al. The effect of urinary tract reconstruction on neurologically impaired women previously treated with an indwelling urethral catheter. *J Urol*. 1996;156(6):1926–1928.

Waxman SE, Pukall CF. Laser Doppler imaging of genital blood flow: a direct measure of female sexual arousal. *J Sex Med*. 2009;6(8):2278–2285.

Weber AM, Walters MD, Schover LR, et al. Sexual function in women with uterovaginal prolapse and urinary incontinence. *Obstet Gynecol*. 1995;85(4):483–487.

Wehbe SA, Kellogg-Spadt S, Whitmore K. Urogenital complaints and female sexual dysfunction. Part 2. *J Sex Med*. 2010;7(7):2304–2317.

West SL, D'Aloisio AA, Agans RP, et al. Prevalence of low sexual desire and hypoactive sexual desire disorder in a nationally representative sample of US women. *Arch Intern*

Med. 2008;168(13):1441–1449.

White G, Jantos M, Glazer H. Establishing the diagnosis of vulvar vestibulitis. *J Reprod Med*. 1997;42(3):157–160.

White WB, Grady D, Giudice LC, et al. A cardiovascular safety study of LibiGel (testosterone gel) in postmenopausal women with elevated cardiovascular risk and hypoactive sexual desire disorder. *Am Heart J*. 2012;163(1):27–32.

Whitney JF. Effect of medial preoptic lesions on sexual behavior of female rats is determined by test situation. *Behav Neurosci*. 1986;100(2):230–235.

Wierckx K, Stuyver I, Weyers S, et al. Sperm freezing in transsexual women. *Arch Sex Behav*. 2012;41(5):1069–1071.

Wierckx K, Van Caenegem E, Schreiner T, et al. Cross-sex hormone therapy in trans persons is safe and effective at short-time follow-up: results from the European network for the investigation of gender incongruence. *J Sex Med*. 2014;11(8):1999–2011.

Wierman ME, Arlt W, Basson R, et al. Androgen therapy in women: a reappraisal: an Endocrine Society clinical practice guideline. *J Clin Endocrinol Metab*. 2014;99(10):3489–3510.

Witherby S, Johnson J, Demers L, et al. Topical testosterone for breast cancer patients with vaginal atrophy related to aromatase inhibitors: a phase I/II study. *Oncologist*. 2011;16(4):424–431.

Witting K, Santtila P, Varjonen M, et al. Female sexual dysfunction, sexual distress, and compatibility with partner. *J Sex Med*. 2008;5(11):2587–2599.

Woodard TL, Diamond MP. Physiologic measures of sexual function in women: a review. *Fertil Steril*. 2009;92(1):19–34.

World Health Organization. *International statistical classification of diseases and related health problems*. ed 10. World Health Organization: Geneva, Switzerland; 1992.

World Health Organization. *Defining sexual health. Report of a* *technical consultation on sexual health, WHO*. WHO: Geneva, Switzerland; 2006.

World Health Organization. *11th revision of the International Classification of Diseases, beta draft*. [Published; Available at] https://icd.who.int/en/; 2016.

Wright JJ, O'Connor KM. Female sexual dysfunction. *Med Clin North Am*. 2015;99(3):607–628.

Wu MH, Pan HA, Wang ST, et al. Quality of life and sexuality changes in postmenopausal women receiving tibolone therapy. *Climacteric*. 2001;4(4):314–319.

Wylie K, Levin R, Hallam-Jones R, et al. Sleep exacerbation of persistent sexual arousal syndrome in a postmenopausal woman. *J Sex Med*. 2006;3(2):296–302.

Yang C, Cold C, Yilmaz U, et al. Sexually responsive vascular tissue of the vulva. *BJU Int*. 2005;97(4):766–772.

Yip SK, Chan A, Pang S, et al. The impact of urodynamic stress incontinence and detrusor overactivity on marital relationship and sexual function. *Am J Obstet Gynecol*. 2003;188(5):1244–1248.

Zaviacic M, Ablin F. The female prostate and prostate-specific antigen. Immunohistochemical localization, implications for this prostate marker in women, and reasons for using the term “prostate” in the human female. *Histol Histopathol*. 2000;15(1):131–142.

Zeleke BM, Bell RJ, Billah B, et al. Hypoactive sexual desire dysfunction in community-dwelling older women. *Menopause*. 2016;24(4):391–399.

Zielinski R, Miller J, Low LK, et al. The relationship between pelvic organ prolapse, genital body image, and sexual health. *Neurourol Urodyn*. 2012;31(7):1145–1148.

PART VII
Male Genitalia

OUTLINE

75 Surgical, Radiographic, and Endoscopic Anatomy of the Retroperitoneum
76 Neoplasms of the Testis
77 Surgery of Testicular Tumors
78 Laparoscopic and Robotic-Assisted Retroperitoneal Lymphadenectomy for Testicular Tumors
79 Tumors of the Penis
80 Tumors of the Urethra
81 Inguinal Node Dissection
82 Surgery for Benign Disorders of the Penis and Urethra
83 Surgery of the Scrotum and Seminal Vesicles

75

Surgical, Radiographic, and Endoscopic Anatomy of the Retroperitoneum

---

Drew A. Palmer MD, Alireza Moinzadeh MD

Anatomic knowledge of the retroperitoneum is critical for urologists in the clinic and the operating room. This chapter provides a thorough description of retroperitoneal anatomy, including the genitourinary organs, musculature, bony structures, fasciae, vessels, lymphatics, neural structures, and gastrointestinal viscera. See Table 75.1 for a review of the anatomic and surgical history of the retroperitoneum.

TABLE 75.1

Anatomic and Surgical History of the Retroperitoneum

Morgagni	1761	Described retroperitoneal lipoma found at autopsy
Cloquet	1817	Studied perirenal fascia
Bogros	1823	Studied surgical anatomy of iliac area
Lobstein	1829	First use of term *retroperitoneal tumor*
Broca	1850	Discovered retroperitoneal tumors at autopsy
Moynier	1850	Discovered retroperitoneal tumors at autopsy
Treitz	1853	Stated theory of “absorption”; described retroduodenopancreatic fascia
Dickinson	1871	Described teratomatous tumor similar to dermoid teratomas commonly found in the ovary
Toldt	1879, 1893	Theory of conjoined visceral fasciae
Zuckerkandl	1883	Described posterior renal fascia
Bassini	1889	Described retroperitoneal cystadenoma that resembled pseudomucinous cystadenoma of ovary
Rogie	1894	Described retroperitoneal anatomy
Gerota	1895	Described anterior renal fascia

Poirer et al.	1923	Studied lobulation of adipose tissue in pararenal and perirenal areas
Drouet	1941	Studied subperitoneal area
Baumann	1945	Described embryology of renal area
Altmeir and Alexander	1961	Described extraperitoneal compartments above pelvic brim
Stevenson and Ozeran	1969	Subdivided anatomy of extraperitoneal pelvis into posterior, anterior, inferior, and superior spaces
Meyers et al.	1972	Descriptions of anterior and posterior pararenal and perirenal spaces
Wickham	1979	Operated in a pneumoretroperitoneum for endoscopic removal of ureteric stone
Hureau et al.	1990, 1991	CT study of extraperitoneal spaces
Korobkin et al.	1992	Used CT to study anatomy and fluid collections in retroperitoneal space
Gaur	1992	Performed retroperitoneal videoscopic renal surgery
McDougall et al.	1994	Performed retroperitoneal videoscopic renal surgery

CT, Computed tomography.

Data from Skandalakis JE, Colborn GL: *Skandalakis' surgical anatomy: the embryological and anatomic basis of modern surgery,* Athens, Greece, 2004, Paschalides Medical Publications.

The retroperitoneum can be described as the entirety of the structures contained anteriorly by the posterior reflection of the peritoneum, posteriorly by the abdominal wall, cranially by the diaphragm, and caudally by the extraperitoneal pelvic structures (Fig. 75.1). The last term must be distinguished from *extraperitoneal space*, which includes the retroperitoneum and the space that circumferentially surrounds the abdominal cavity (Miralis and Skandalakis, 2009, 2010a-d).

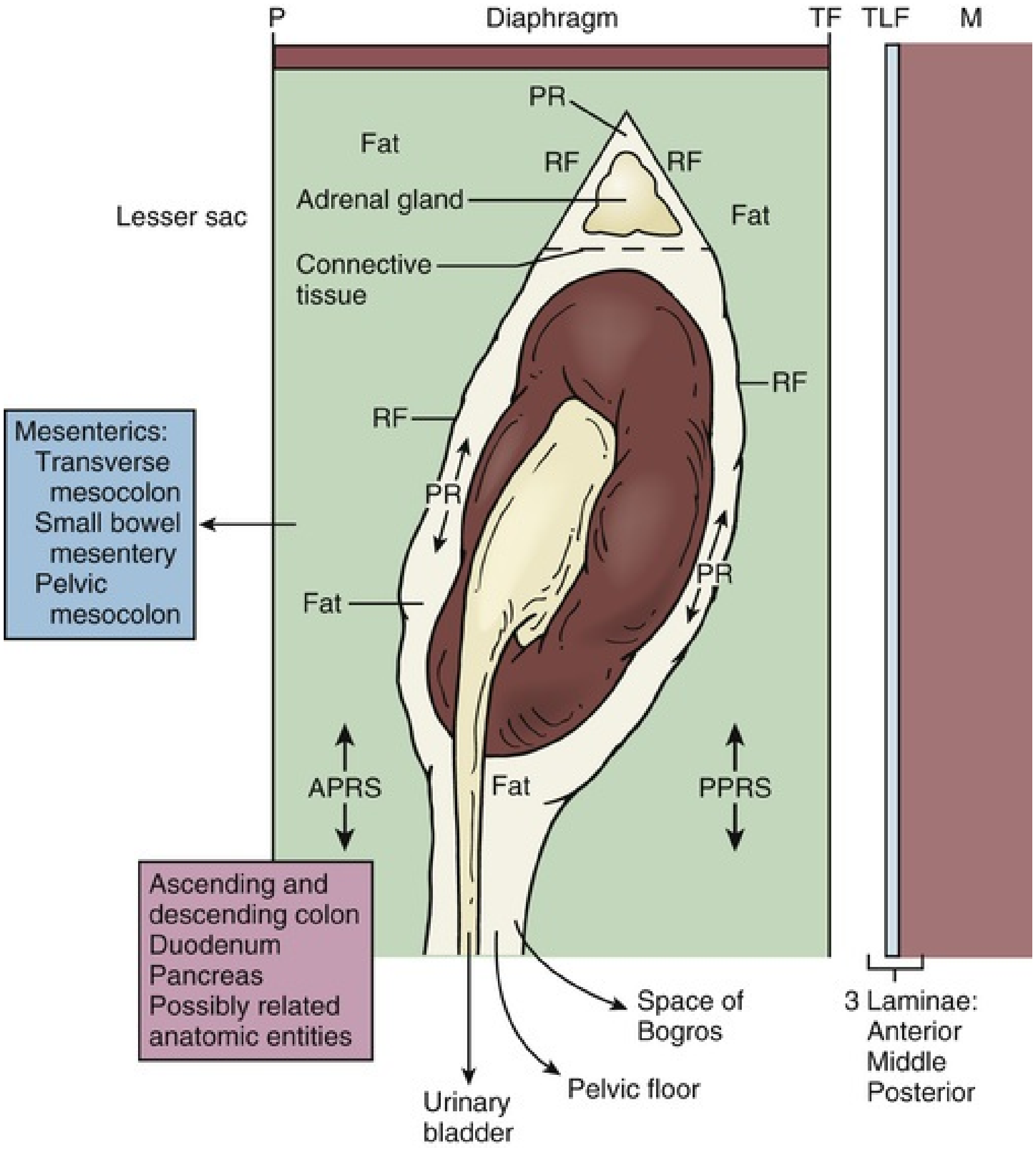
P
Diaphragm
TF
TLF
M
PR
Fat
RF
RF
Adrenal gland
Fat
Lesser sac
Connective tissue
RF
RF
Mesenterics:
Transverse mesocolon
Small bowel mesentery
Pelvic mesocolon
PR
PR
Fat
APRS
Fat
PPRS
Ascending and descending colon
Duodenum
Pancreas
Possibly related anatomic entities
Space of Bogros
3 Laminae:
Anterior
Middle
Posterior
Pelvic floor
Urinary bladder

FIG. 75.1 Diagram of retroperitoneal spaces. *APRS,* Anterior pararenal space; *M,* muscles; *P,* peritoneum; *PPRS,* posterior pararenal space; *PR,* perirenal space; *RF,* renal fascia (Gerota fascia); *TF,* transversalis fascia; *TLF,* thoracolumbar fascia. (Modified from Skandalakis JE, Colborn GL: *Skandalakis' surgical anatomy: the embryological and anatomic basis of modern surgery*, Athens, Greece, 2004, Paschalides Medical Publications, p 155.)

The contents of the retroperitoneum include the **kidneys, ureters, adrenals, pancreas, portions of the duodenum, ascending colon, descending colon, mesentery, arterial structures including the aorta and its branches, venous structures including the inferior vena cava (IVC) and its tributaries, lymphatics, lymph nodes, sympathetic trunk, and lumbosacral plexus** (Fig. 75.2 and Box 75.1; also see Fig. 75.1).

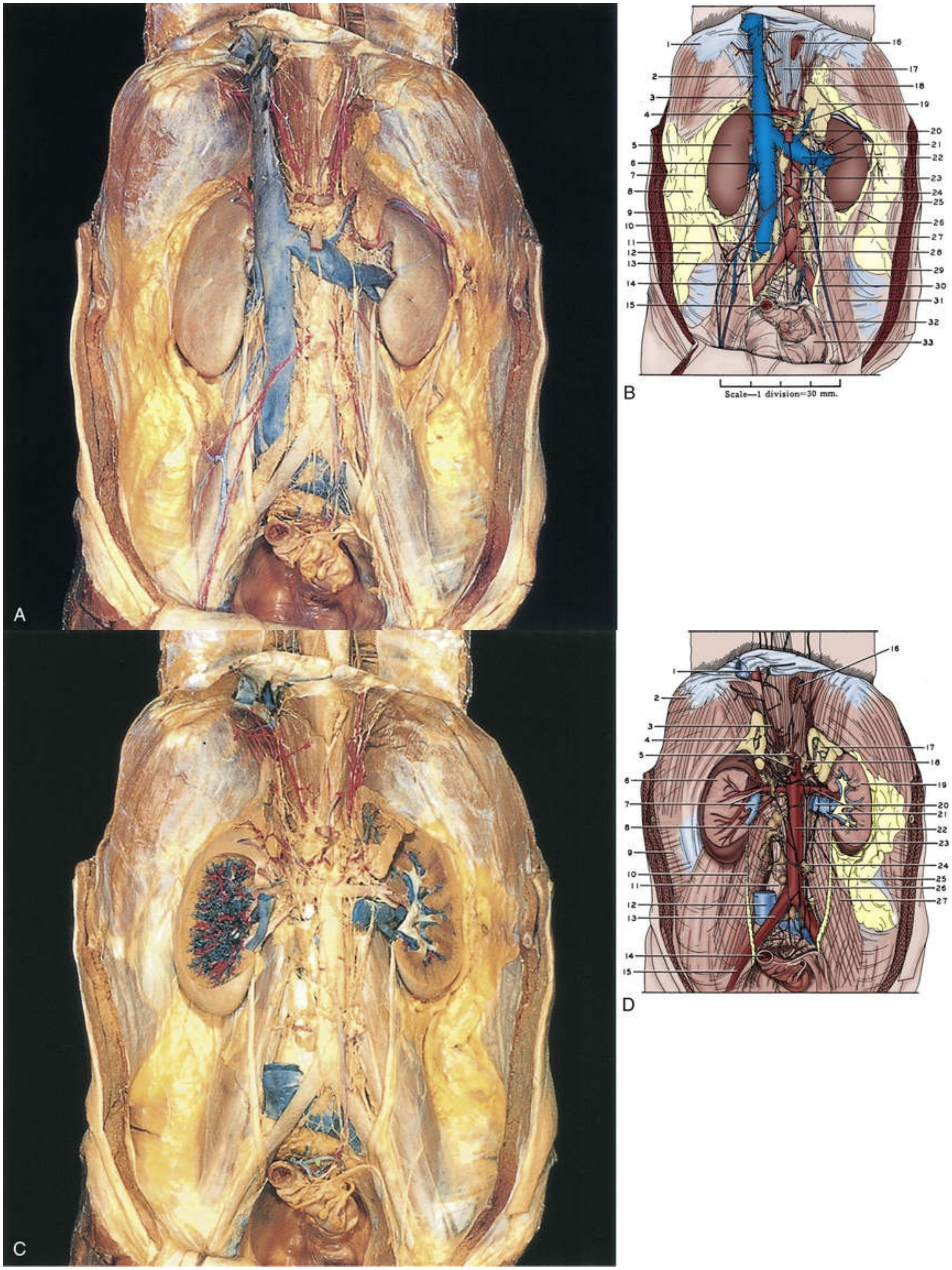
A
B
1
2
3
4
5
6
7
8
9
10
11
12
13
14
15
16
17
18
19
20
21
22
23
24
25
26
27
28
29
30
31
32
33
Scale—1 division=30 mm.
C
D
1
2
3
4
5
6
7
8
9
10
11
12
13
14
15
16
17
18
19
20
21
22
23
24
25
26
27

FIG. 75.2 (A) Dissected retroperitoneum. The anterior perirenal (Gerota) fascia has been removed. (B) *1,* Diaphragm. *2,* Inferior vena cava. *3,* Right adrenal gland. *4,* Upper pointer, celiac artery; lower pointer, celiac autonomic nervous plexus. *5,* Right kidney. *6,* Right renal vein. *7,* Gerota fascia. *8,* Pararenal retroperitoneal fat. *9,* Perinephric fat. *10,* Upper pointer, right gonadal vein; lower pointer, right gonadal artery. *11,* Lumbar lymph nodes. *12,* Retroperitoneal fat. *13,* Right common iliac artery. *14,* Right ureter. *15,* Sigmoid colon (cut). *16,* Esophagus (cut). *17,* Right crus of diaphragm. *18,* Left inferior phrenic artery. *19,* Upper pointer, left adrenal gland; lower pointer, left adrenal vein. *20,* Upper pointer, superior mesenteric artery; lower pointer, left renal artery. *21,* Left kidney. *22,* Upper pointer, left renal vein; lower pointer, left gonadal vein. *23,* Aorta. *24,* Perinephric fat. *25,* Aortic autonomic nervous plexus. *26,* Upper pointer, Gerota fascia; lower pointer, inferior mesenteric ganglion. *27,* Inferior mesenteric artery. *28,* Aortic bifurcation into common iliac arteries. *29,* Left gonadal artery and vein. *30,* Left ureter. *31,* Psoas major muscle covered by psoas sheath. *32,* Cut edge of peritoneum. *33,* Pelvic cavity. (Reproduced from the Bassett anatomic collection, with permission from Dr. Robert A. Chase.) (C) Dissected retroperitoneum. The kidneys and adrenal glands have been sectioned, and the inferior vena cava has been excised over most of its intra-abdominal course. (D) *1,* Inferior vena cava (cut). *2,* Diaphragm. *3,* Right inferior phrenic artery. *4,* Right adrenal gland. *5,* Upper pointer, celiac artery; lower pointer, superior mesenteric artery. *6,* Right kidney. *7,* Upper pointer, right renal artery; lower pointer, right renal vein (cut). *8,* Lumbar lymph node. *9,* Transversus abdominis muscle covered with transversalis fascia. *10,* Right ureter. *11,* Anterior spinous ligament. *12,* Inferior vena cava (cut). *13,* Right common iliac artery. *14,* Sigmoid colon (cut). *15,* Right external iliac artery. *16,* Esophagus (cut). *17,* Left adrenal gland. *18,* Celiac ganglion. *19,* Left kidney. *20,* Upper pointer, left renal artery; lower pointer, left renal vein (cut). *21,* Left renal pelvis. *22,* Aorta. *23,* Aortic autonomic nervous plexus. *24,* Inferior mesenteric ganglion. *25,* Left ureter. *26,* Inferior mesenteric artery. *27,* Psoas major muscle covered by psoas sheath. (Reproduced from the Bassett anatomic collection, with permission from Dr. Robert A. Chase.)

Box 75.1

Organs and Structures of the Retroperitoneum

Organs

Kidneys (PR)
Ureters (PR)
Adrenal glands (PR)
Portions of the duodenum (SR)
Ascending colon (SR)
Descending colon (SR)

Pancreas (SR)

Vessels and Lymphatics

Abdominal aorta (and its branches)
Inferior vena cava (and its tributaries)
Ascending lumbar veins
Portal vein
Lumbar lymph nodes
Lumbar lymphatic trunks
Cisterna chyli

Nerves

Branches of the lumbosacral plexus
Sympathetic trunk
Autonomic plexuses
Autonomic ganglia

PR, Primarily retroperitoneal; *SR*, secondarily retroperitoneal.

Data from Miralis P, Skandalakis JE: Surgical anatomy of the retroperitoneal spaces—part I: embryogenesis and anatomy. *Am Surg* 75(11):1091–1097, 2009.

Body Surface Landmarks

The ability to identify abdominal organs using physical examination is useful for clinical diagnosis and operative planning. The location of the kidneys can be estimated based on their relationship to the bony structures of the posterior abdominal wall (Fig. 75.3). The upper pole of the left kidney is typically located at the level of the 11th rib. The right kidney lies lower than the left, with its upper pole at the level of the 12th rib. The lower poles of the kidneys are between the L3 and L4 vertebrae, and **the renal hila are approximately at the level of L1.**

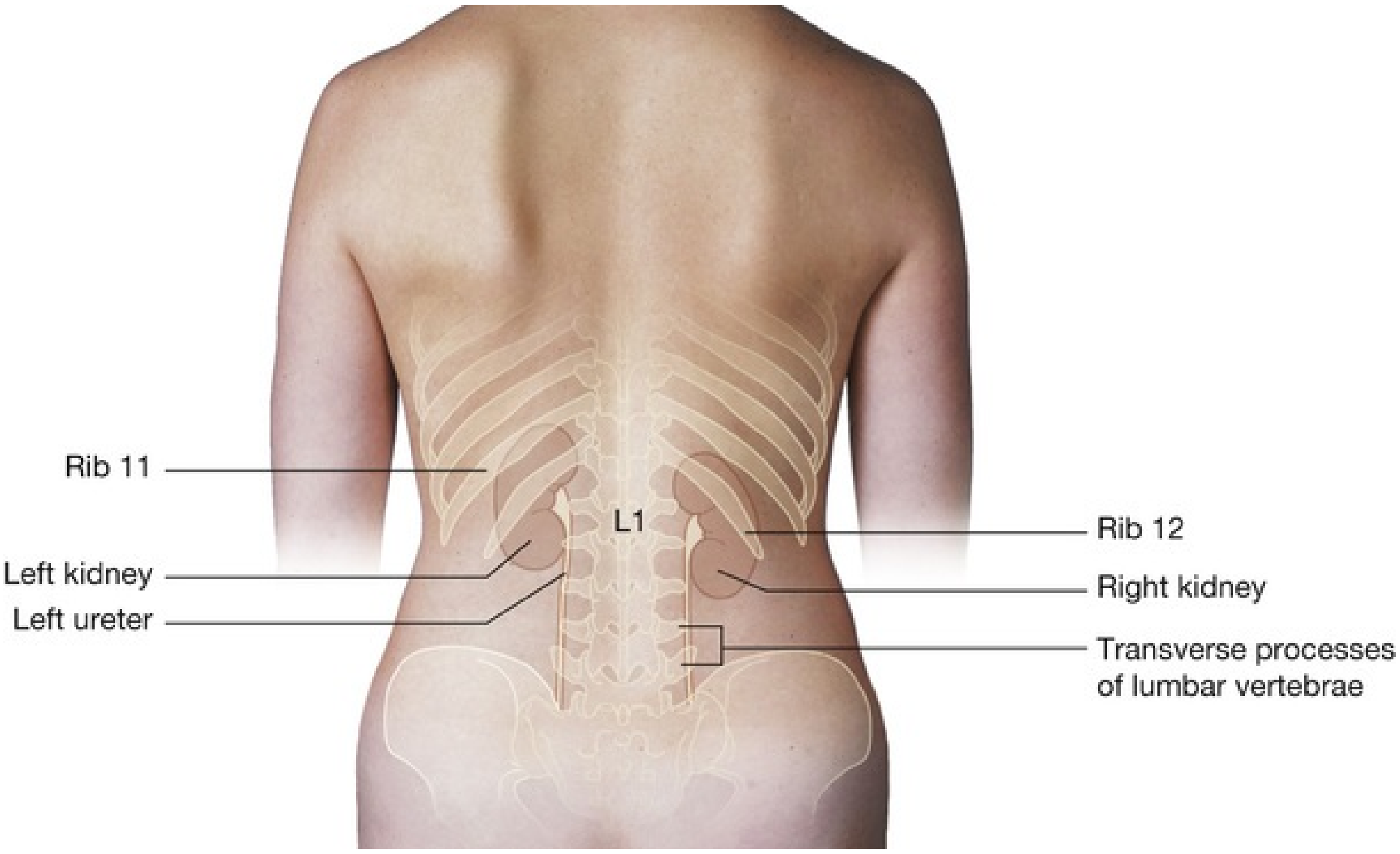
Rib 11
Left kidney
Left ureter
L1
Rib 12
Right kidney
Transverse processes of lumbar vertebrae

FIG. 75.3 Posterior view of the abdominal region of a woman with projections of the kidneys and ureters. (From Drake RL, Vogl AW, Mitchell AWM: *Gray's anatomy for students,* ed 2, Philadelphia, 2010. Churchill Livingstone.)

Posterior Abdominal Wall

Flank Muscles (Figs. 75.4 to 75.7 and Table 75.2)

The most superficial of the flank muscles is the **external oblique,** which lies beneath the subcutaneous fascia. It originates from ribs 5 through 12, and its muscle fibers travel inferomedially inserting at the iliac crest and ending in the midline at the linea alba. **The inferior border of the aponeurosis of the external oblique forms the inguinal ligament.** Deep to the external oblique lies the **internal oblique,** which originates from the lumbodorsal fascia and the iliac crest. It travels superomedially, inserting at the lower ribs and linea alba. Each of these muscle layers is invested in a layer of fascia. The **transversus abdominis** muscle, named because of the *transverse* direction of its muscle fibers, lies deep to the internal oblique. Deep to the transversus abdominis muscle lies the **transversalis fascia,** which crosses the midline anteriorly and fuses with the lumbodorsal fascia posteriorly. These flank muscles function to flex, extend, and rotate the trunk and provide compression of the abdominal contents.

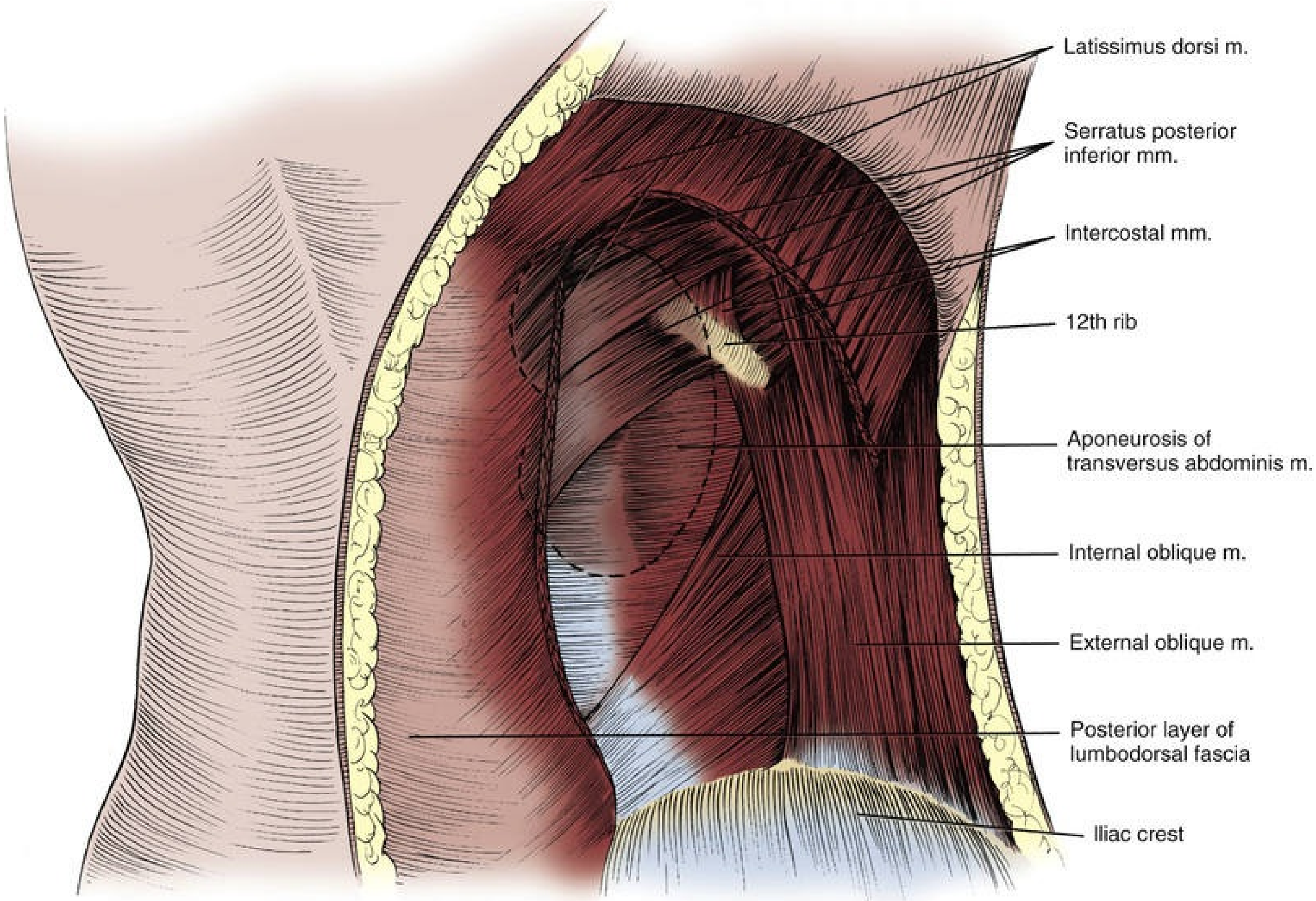
Latissimus dorsi m.
Serratus posterior inferior mm.
Intercostal mm.
12th rib
Aponeurosis of transversus abdominis m.
Internal oblique m.
External oblique m.
Posterior layer of lumbodorsal fascia
Iliac crest

FIG. 75.4 Posterior abdominal wall musculature, superficial dissection. A section of the latissimus dorsi muscle has been removed. The location of the right kidney within the retroperitoneum is shown by the *dashed outline*.

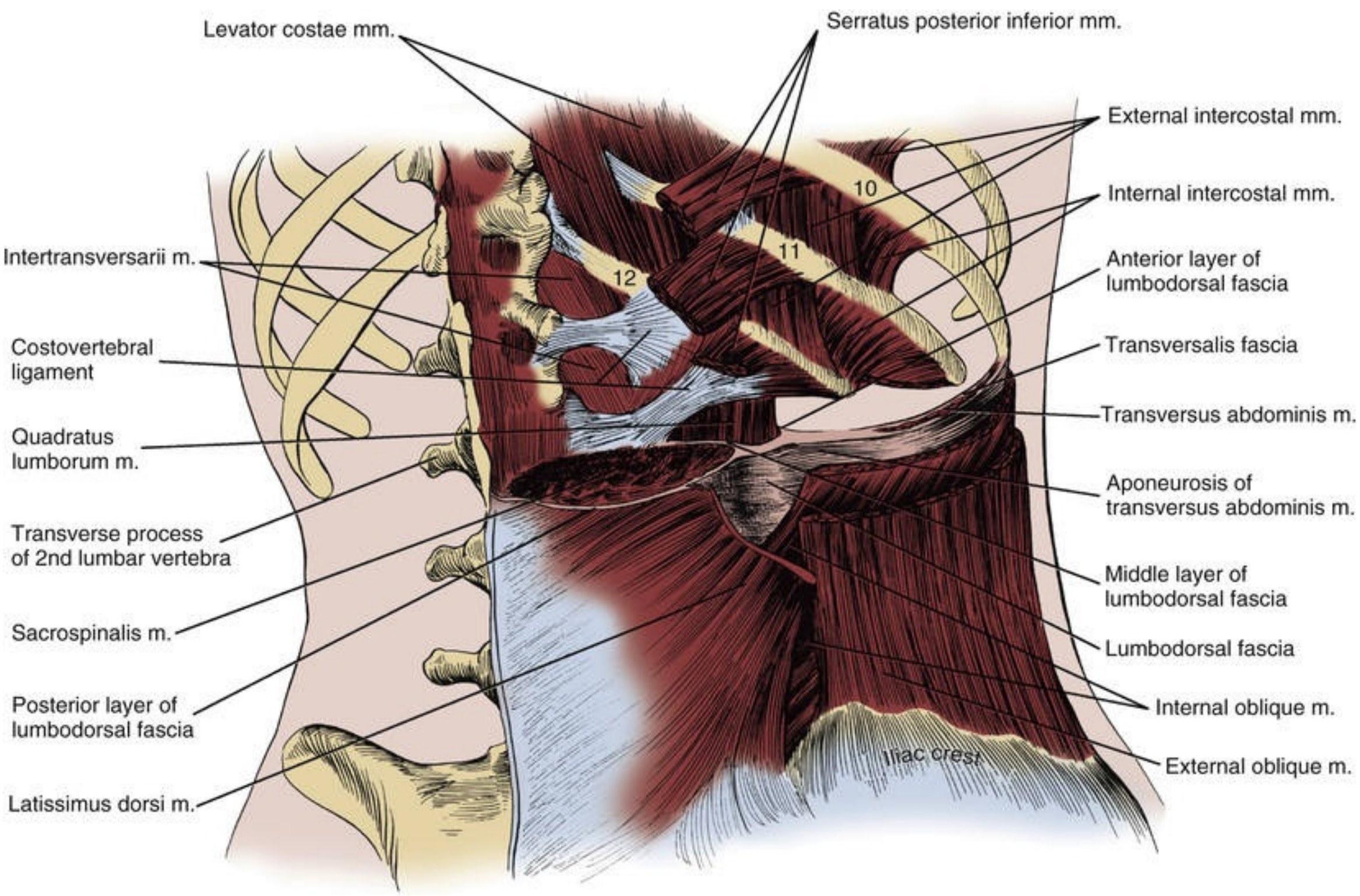
Levator costae mm.
Serratus posterior inferior mm.
External intercostal mm.
Internal intercostal mm.
Anterior layer of lumbodorsal fascia
Transversalis fascia
Transversus abdominis m.
Aponeurosis of transversus abdominis m.
Middle layer of lumbodorsal fascia
Lumbodorsal fascia
Internal oblique m.
External oblique m.
Intertransversarii m.
Costovertebral ligament
Quadratus lumborum m.
Transverse process of 2nd lumbar vertebra
Sacrospinalis m.
Posterior layer of lumbodorsal fascia
Latissimus dorsi m.
10
11
12
Iliac crest

FIG. 75.5 Posterior abdominal wall musculature, intermediate dissection. The sacrospinalis muscle and three anterolateral flank muscle layers are seen in cut section, and the three layers of the lumbodorsal fascia posteriorly can be appreciated.

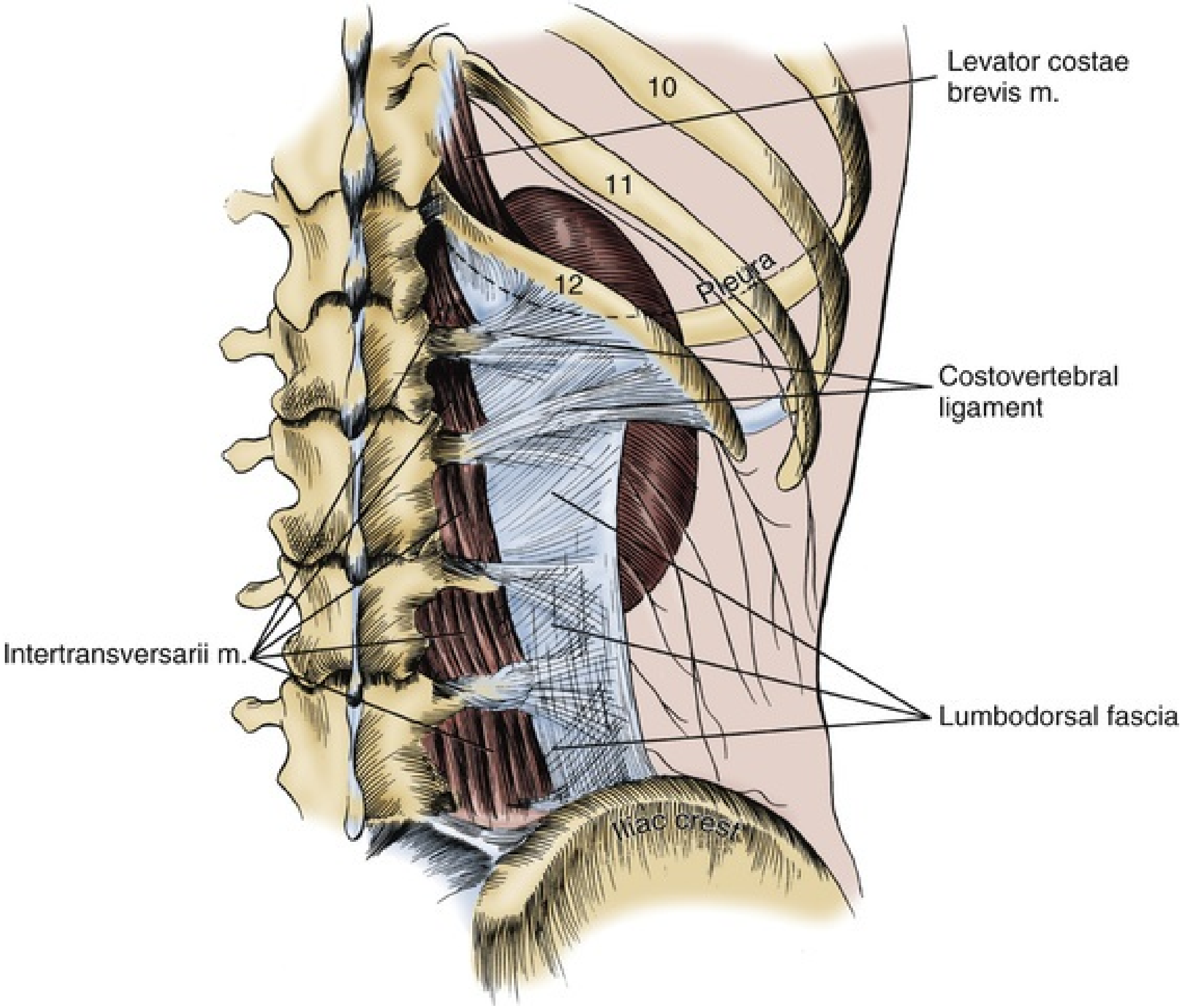
10
11
12
Pleura
Levator costae brevis m.
Costovertebral ligament
Intertransversarii m.
Lumbodorsal fascia
Iliac crest

FIG. 75.6 Posterior abdominal wall musculature, deep dissection. The lumbodorsal fascia and costovertebral ligament are visualized arising from the transverse processes of the lumbar vertebrae. The relationship of the kidney and pleura is also shown.

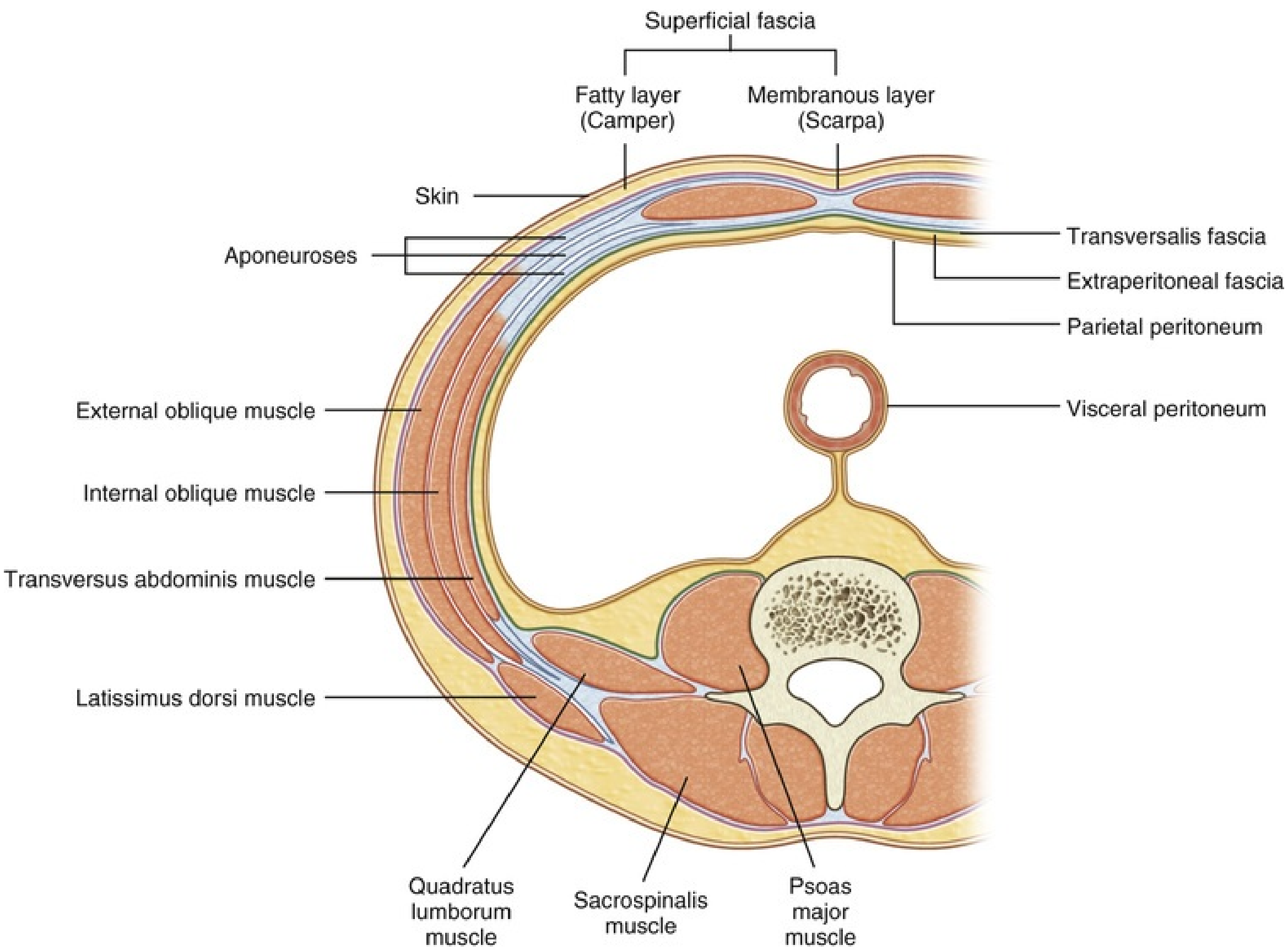
Superficial fascia
Fatty layer (Camper)
Membranous layer (Scarpa)
Skin
Aponeuroses
Transversalis fascia
Extraperitoneal fascia
Parietal peritoneum
Visceral peritoneum
External oblique muscle
Internal oblique muscle
Transversus abdominis muscle
Latissimus dorsi muscle
Quadratus lumborum muscle
Sacrospinalis muscle
Psoas major muscle

FIG. 75.7 Transverse section showing layers of the lateral flank musculature. (From Drake RL, Vogl AW, Mitchell AWM: *Gray's anatomy for students,* ed 2, Philadelphia, 2010, Churchill Livingstone.)

TABLE 75.2

Musculature of the Posterior and Lateral Abdominal Wall

MUSCLE	ORIGIN	INSERTION	FUNCTION
Erector spinae	Sacrum and vertebrae	Lower ribs and vertebrae	Extension of spine
External oblique	Ribs 5–12	Lateral lip of iliac crest, aponeurosis ending in linea alba	Compress abdominal contents, flexion of trunk
Internal oblique	Lumbodorsal fascia, iliac crest, inguinal ligament	Lower four ribs, aponeurosis ending in linea alba, pubic crest	Compress abdominal contents, flexion of trunk
Transversus abdominis	Lumbodorsal fascia, medial lip of iliac crest, ribs 7–12	Aponeurosis ending in linea alba, pubic crest	Compress abdominal contents

Psoas major	T12-L5 vertebrae	Lesser trochanter of femur	Flexion of hip
Psoas minor	T12 and L1 vertebrae	Pelvic brim, iliopubic eminence	Weak flexion of lumbar vertebral column
Iliacus	Iliac fossa, sacrum	Lesser trochanter of femur	Flexion of the hip
Quadratus lumborum	5th lumbar vertebra, iliac crest	L1-L4 vertebrae, 12th rib	Depress and stabilize 12th rib, lateral bending of trunk

Modified from Drake RL, Vogl AW, Mitchell AWM: *Gray's anatomy for students,* Philadelphia, 2005, Churchill Livingstone.

Psoas, Iliacus, Quadratus Lumborum, and Erector Spinae (Fig. 75.8; also see Figs. 75.4 to 75.7 and Table 75.2)

The **psoas major** muscle arises from the 12th thoracic vertebra to the 5th lumbar vertebra to attach to the lesser trochanter of the femur after traveling along the pelvic brim posterior to the inguinal ligament. The psoas minor muscle, which may be absent in some individuals, originates at T12 and L1 and inserts at the pelvic brim and iliopubic eminence. The psoas major functions in flexion of the thigh at the hip joint and is innervated by the anterior rami of L1, L2, and L3. The **iliacus** muscle originates at the caudal aspect of the iliac fossa and the lateral sacrum to insert at the lesser trochanter of the femur. It functions in flexion of the thigh at the hip joint along with the psoas major. The **quadratus lumborum** lies posterior and medial to the psoas muscle and assists with lateral bending of the trunk and stabilization of the 12th rib. Its origin is at L5 and the iliac fossa, and it attaches to the inferior border of the 12th rib and the transverse processes of L1-L4. The **erector spinae (sacrospinalis)** is a large group of back muscles that function to extend the spine.

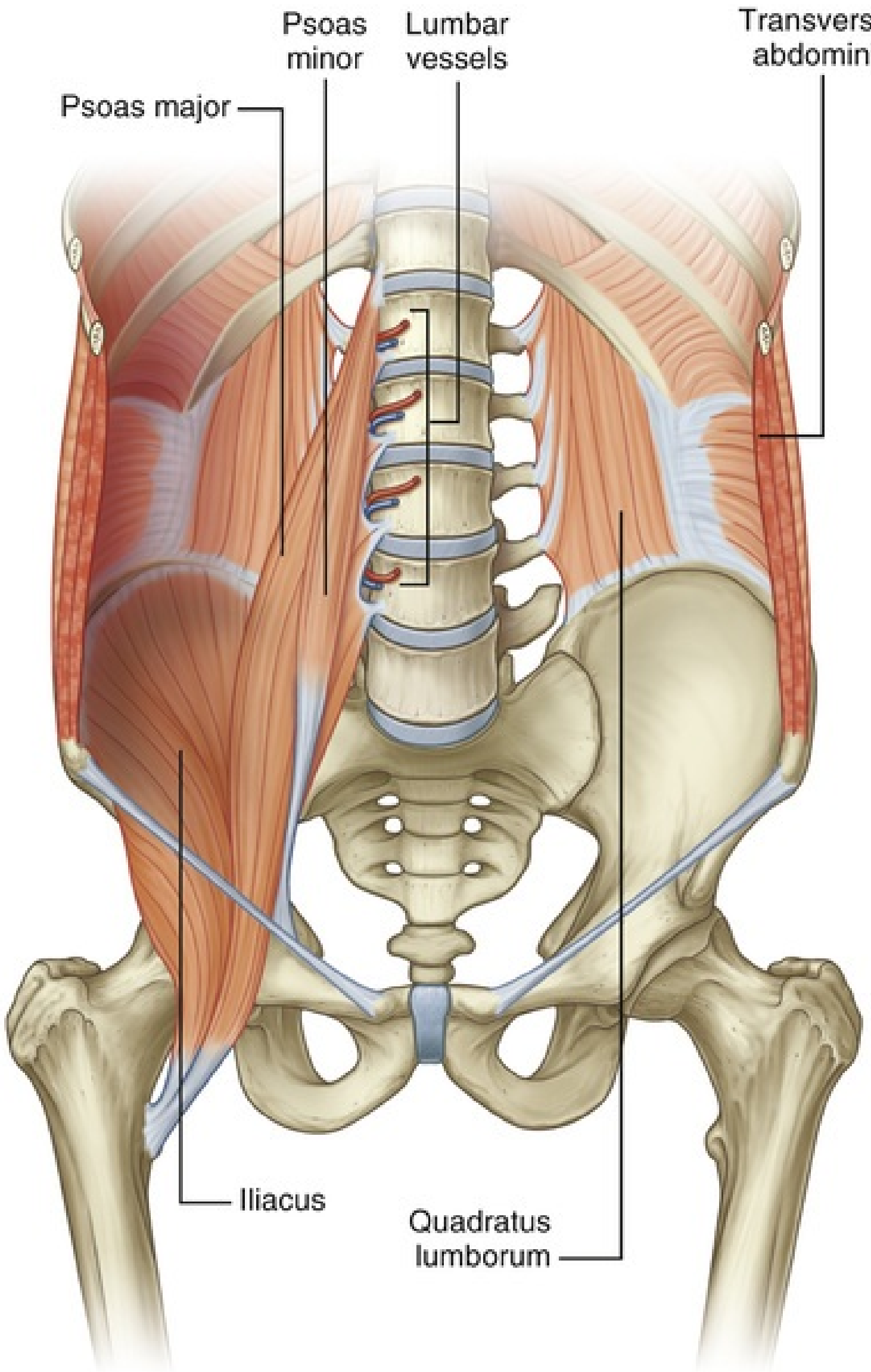
Psoas minor
Lumbar vessels
Transversus abdominis
Psoas major
Iliacus
Quadratus lumborum

FIG. 75.8 Muscles of the posterior abdominal wall. (From Drake RL, Vogl AW, Mitchell AWM: *Gray's anatomy for students,* ed 2, Philadelphia, 2010, Churchill Livingstone.)

Spine

The spine consists of 7 cervical vertebrae, 12 thoracic vertebrae, 5 lumbar vertebrae, the sacrum, and the coccyx. Each vertebra has a large weight-bearing area called the **vertebral body** and a posterior and lateral arch that forms the vertebral foramen (eFig. 75.9 on ExpertConsult.com). The **spinous process** projects posteroinferiorly, and the **transverse processes** project posterolaterally.

The lumbar vertebrae are the most clinically significant in regard to the retroperitoneum. They are larger than the other vertebrae with generally long, thin transverse processes.

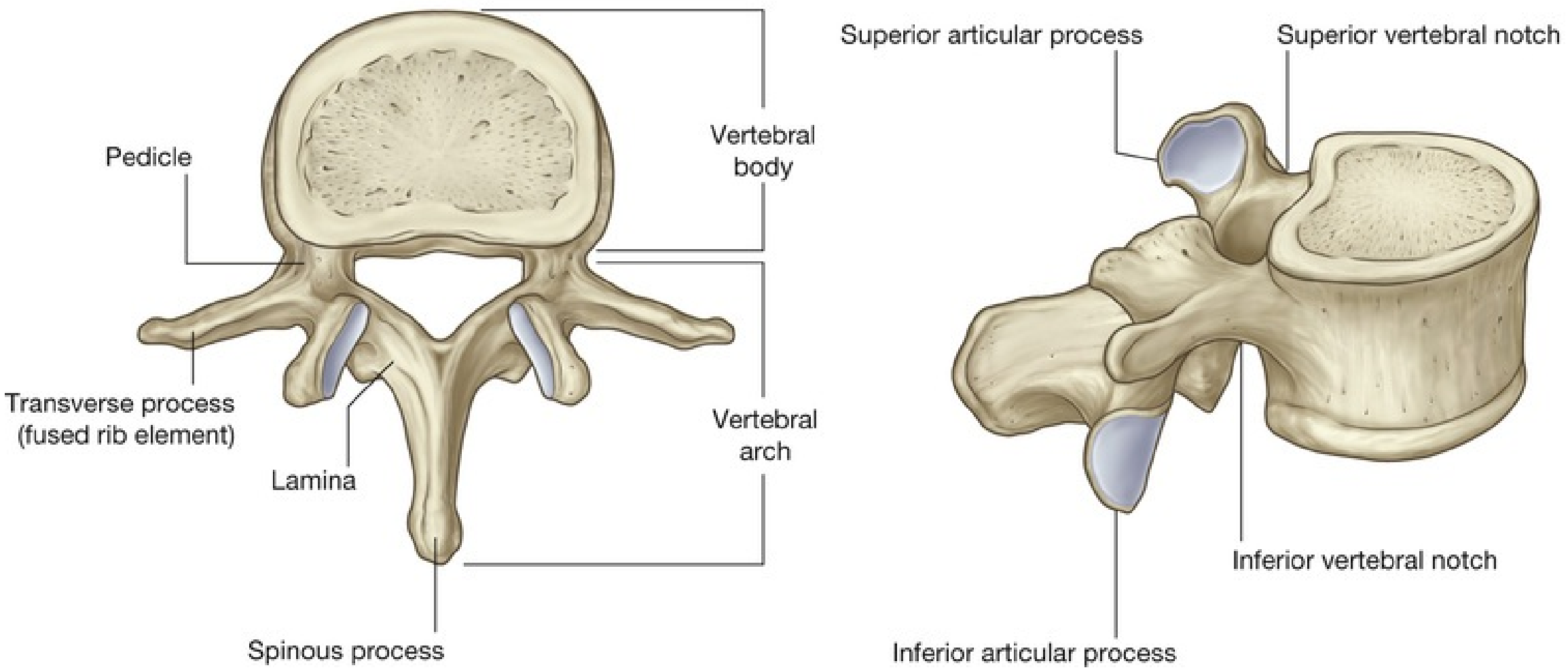
Pedicle
Vertebral body
Transverse process (fused rib element)
Lamina
Vertebral arch
Spinous process
Superior articular process
Superior vertebral notch
Inferior vertebral notch
Inferior articular process

EFIG. 75.9 Typical vertebrae. (From Drake RL, Vogl AW, Mitchell AWM: *Gray's anatomy for students*, ed 2, Philadelphia, 2010, Churchill Livingstone.)

The vertebral column levels have different relationships with the spinal cord segmental levels at different locations within the spinal column. For example, the sacral spinal cord segmental levels typically begin between vertebral column level T12 and L1 in adults. Discussions of spinal cord injury must specify vertebral column level versus spinal segmental level.

10th, 11th, and 12th Ribs

The lower ribs protect the retroperitoneal structures from traumatic injury. **Fracture of these lower ribs should lead to a high clinical suspicion for injury to the retroperitoneal structures** (eFig. 75.10 on ExpertConsult.com). The lower ribs differ from the upper ribs given their shorter length with less pronounced angulation. The 10th rib articulates with the body of the vertebra at its head and the transverse process at its neck. The 11th rib lacks a neck and does not articulate with the transverse process. The angle of the 11th rib is less pronounced than that of the upper ribs. The 12th rib has no angle and is shorter than the other ribs. **Its inferior border is attached to the transverse processes of L1 and L2 by the costovertebral (lumbocostal) ligament, which can be**

incised to allow for increased mobility for greater exposure of the upper retroperitoneum during posterior approaches. **Similar increased mobility may be achieved by dividing a thick, fibrous band known as the intercostal ligament found between other ribs.**

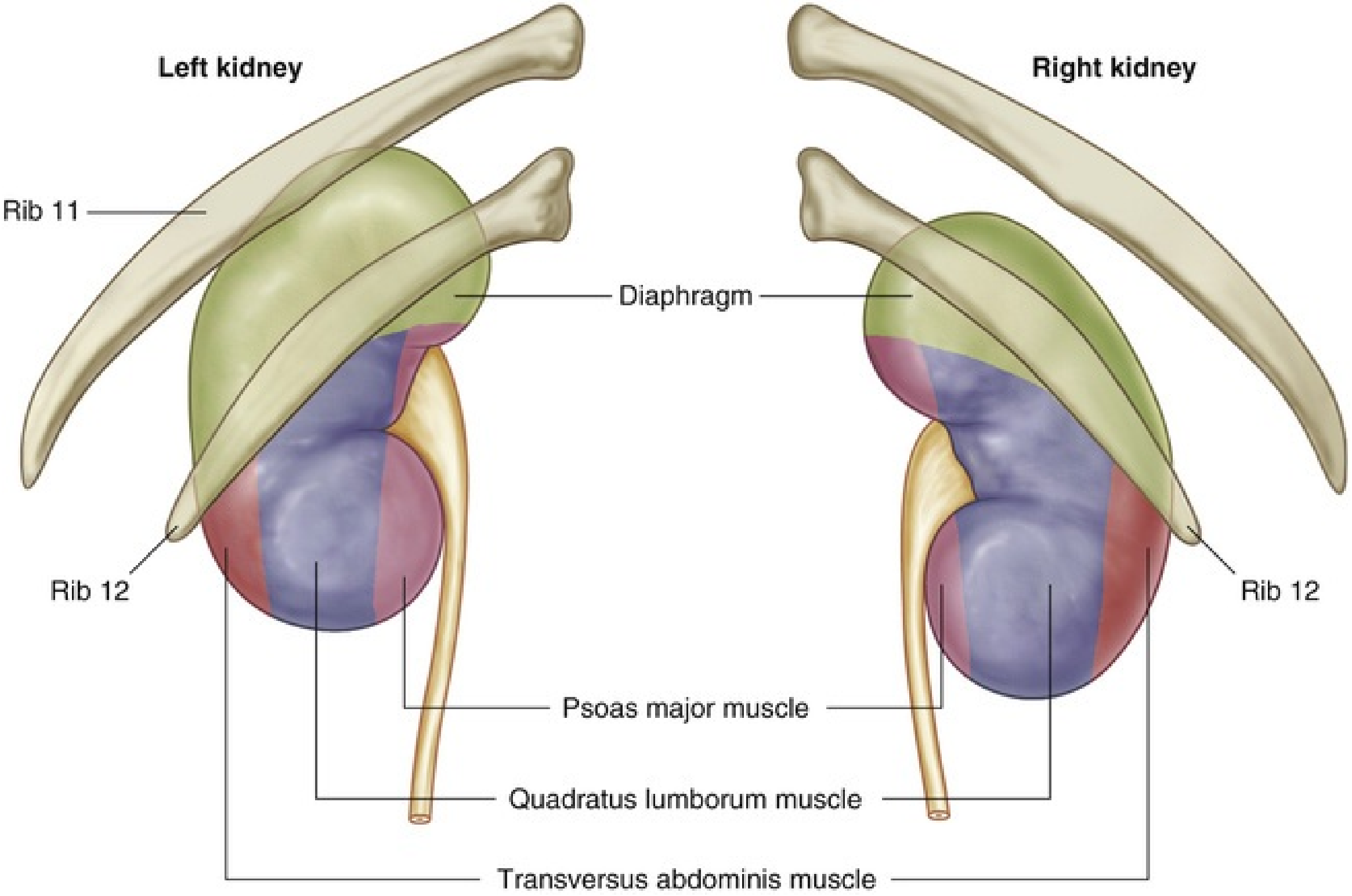
Left kidney
Right kidney
Rib 11
Diaphragm
Rib 12
Rib 12
Psoas major muscle
Quadratus lumborum muscle
Transversus abdominis muscle

EFIG. 75.10 Structures related to the posterior surface of the kidney. (From Drake RL, Vogl AW, Mitchell AWM: *Gray's anatomy for students,* ed 2, Philadelphia, 2010, Churchill Livingstone.)

The 11th and 12th ribs must be distinguished from the other ribs because they have no anterior connection with the sternum and are often referred to as *floating ribs*. These ribs are of clinical significance during palpation for the marking of a surgical incision.

The intercostal vessels and nerves travel between the internal intercostal and innermost intercostal muscles within the costal groove on the caudal margin of the superior rib (Fig. 75.11). The vein is the most superior structure with the artery running inferior to it. The intercostal nerve is the most inferior of the three structures and is often not protected by the costal groove.

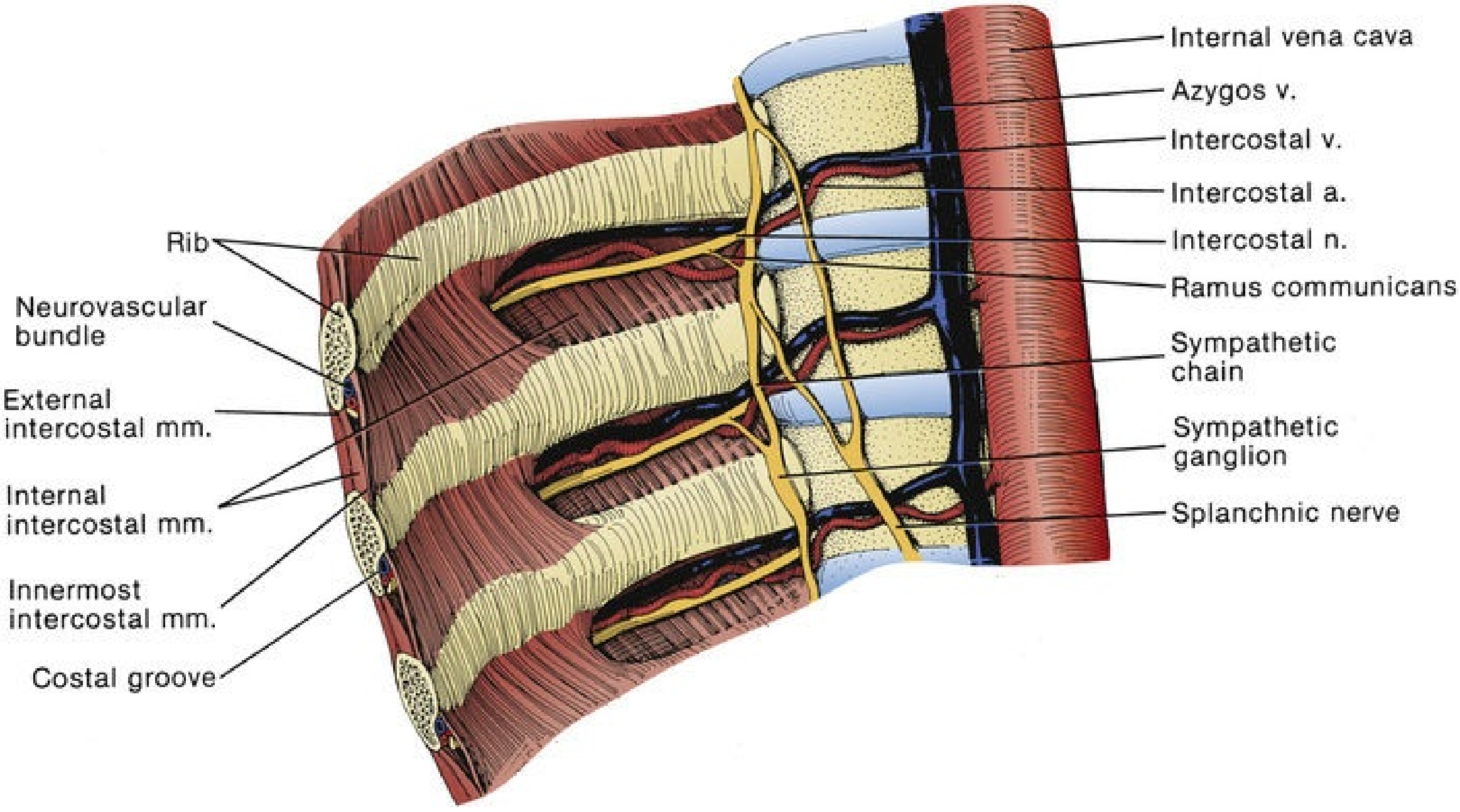
Internal vena cava
Azygos v.
Intercostal v.
Intercostal a.
Intercostal n.
Ramus communicans
Sympathetic chain
Sympathetic ganglion
Splanchnic nerve
Rib
Neurovascular bundle
External intercostal mm.
Internal intercostal mm.
Innermost intercostal mm.
Costal groove

FIG. 75.11 Intercostal neurovascular bundle. (From MacLennan GT: *Hinman's atlas of urosurgical anatomy,* ed 2, Philadelphia, 2012, Saunders.)

Lumbodorsal Fascia

The **lumbodorsal (thoracolumbar) fascia** is composed of three distinct layers that invest the posterior abdominal wall musculature (Fig. 75.12). **These three layers merge into one as they travel laterally. A common access point to the retroperitoneum is near the tip of the 12th rib, where all layers have merged into one.** This single layer of lumbodorsal fascia merges with the aponeurosis of the transversus abdominis muscle anterolaterally. The **posterior lamella** originates medially from the spinous process of the lumbar vertebrae and covers the erector spinae muscles. The **middle lamella** separates these erector spinae muscles from quadratus lumborum. The anterior lamella covers the ventral surface of quadratus lumborum. Extending medially, the **anterior lamella** attaches to the vertebral transverse process and is continuous with the fascia that invests the psoas muscle.

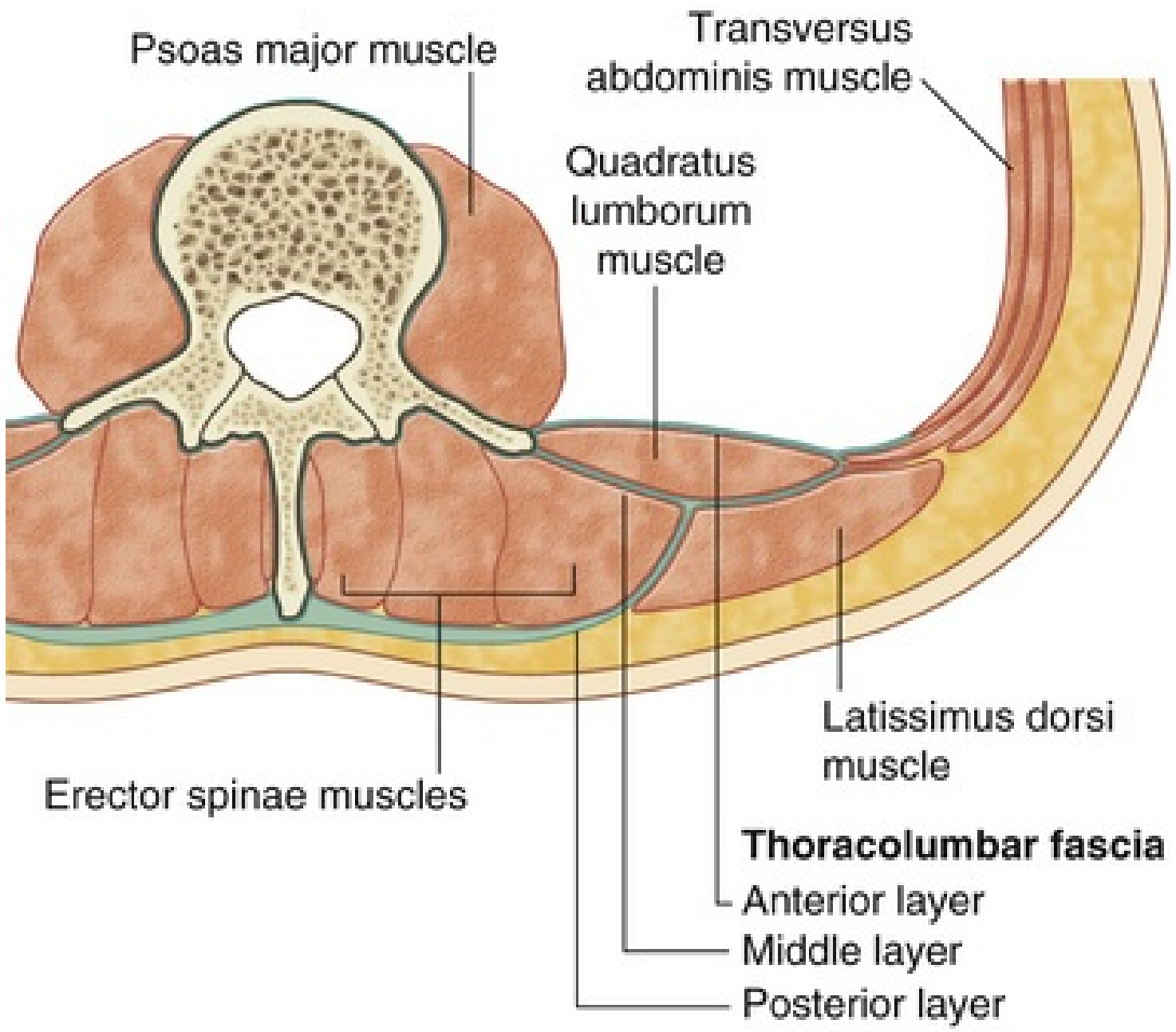
Psoas major muscle
Transversus abdominis muscle
Quadratus lumborum muscle
Latissimus dorsi muscle
Erector spinae muscles
Thoracolumbar fascia
Anterior layer
Middle layer
Posterior layer

FIG. 75.12 Lumbodorsal fascia and the deep back muscle. (From Drake RL, Vogl AW, Mitchell AWM: *Gray's anatomy for students,* ed 2, Philadelphia, 2010, Churchill Livingstone.)

The retroperitoneum can be entered without incising muscle using a dorsal lumbotomy incision (Fig. 75.13). This approach uses a vertical incision through the lumbodorsal fascia lateral to the erector spinae and quadratus lumborum muscles (eFig. 75.14 on ExpertConsult.com).

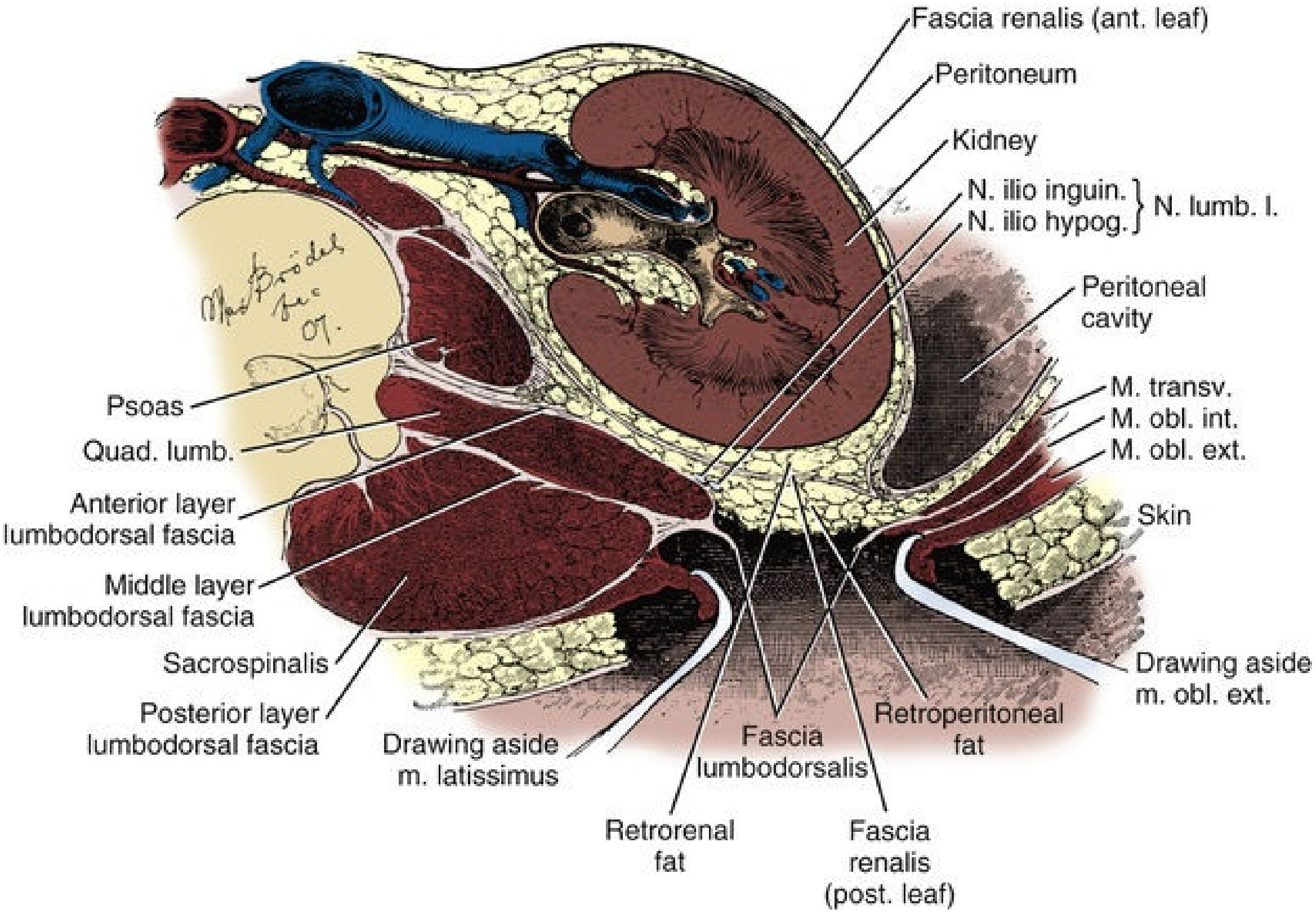
Fascia renalis (ant. leaf)
Peritoneum
Kidney
N. ilio inguin.
N. ilio hypog.
N. lumb. I.
Peritoneal cavity
M. transv.
M. obl. int.
M. obl. ext.
Skin
Drawing aside m. obl. ext.
Retroperitoneal fat
Fascia renalis (post. leaf)
Fascia lumbodorsalis
Retrorenal fat
Drawing aside m. latissimus
Posterior layer lumbodorsal fascia
Sacrospinalis
Middle layer lumbodorsal fascia
Anterior layer lumbodorsal fascia
Quad. lumb.
Psoas
Max Brödel fec. 07.

FIG. 75.13 Transverse section through the kidney and posterior abdominal wall showing the lumbodorsal fascia incised. Through such a lumbodorsal incision, the kidney can be reached without incising muscle. (From McVay C: *Anson & McVay surgical anatomy,* ed 6, Philadelphia, 1994, Saunders.)

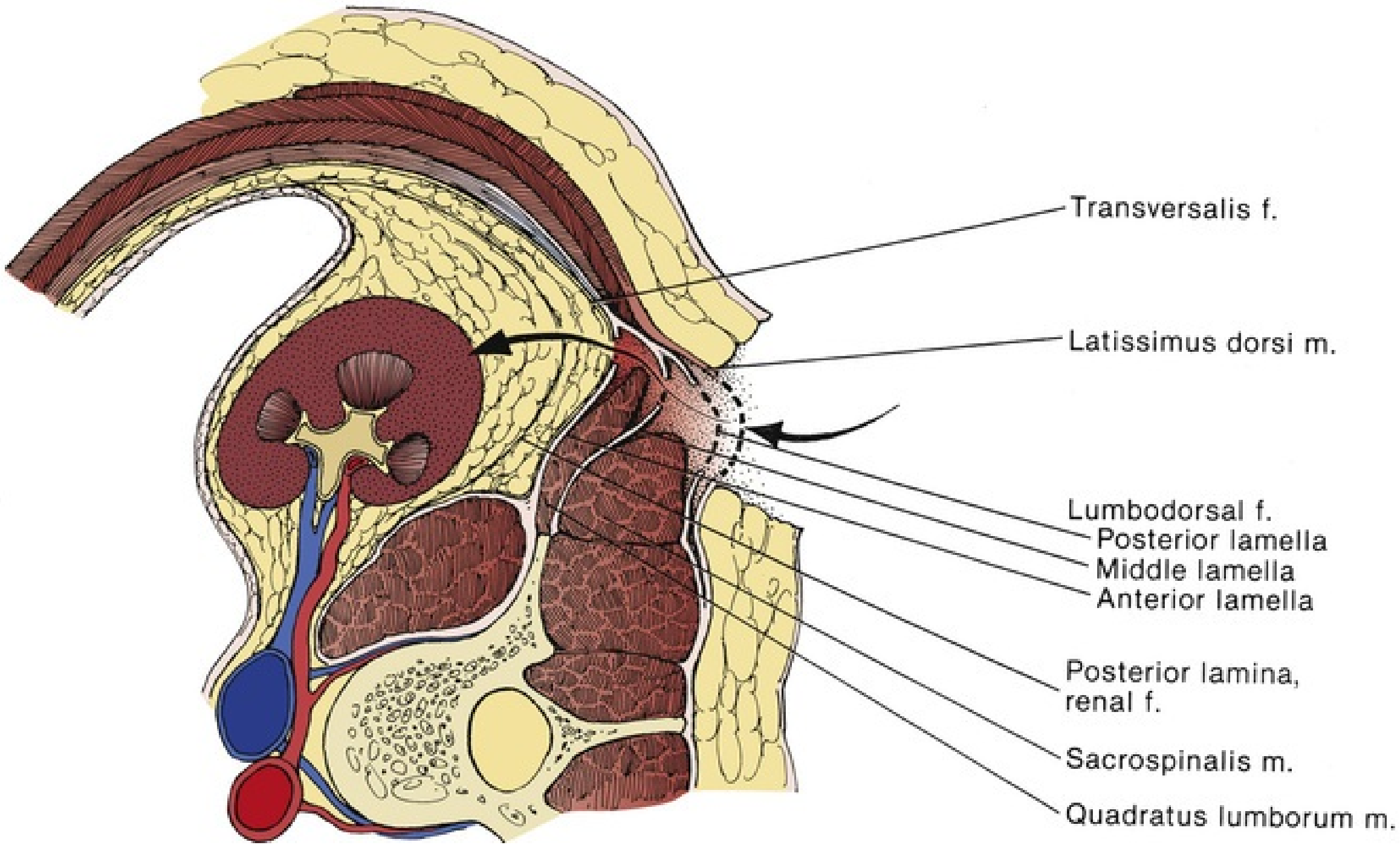
Transversalis f.
Latissimus dorsi m.
Lumbodorsal f.
Posterior lamella
Middle lamella
Anterior lamella
Posterior lamina, renal f.
Sacrospinalis m.
Quadratus lumborum m.

EFIG. 75.14 Posterior approach to the kidney through the lumbodorsal fascia. (From MacLennan GT: *Hinman's atlas of urosurgical anatomy,* ed 2, Philadelphia, 2012, Saunders.)

Key Points: Organs and Boundaries of the Retroperitoneum

- Retroperitoneal contents include the kidneys, ureters, adrenals, pancreas, portions of the duodenum, ascending colon, descending colon, mesentery, vasculature, lymphatics, and nervous structures.
- The retroperitoneum is contained anteriorly by the posterior reflection of the peritoneum and posteriorly by the abdominal wall.
- It is contained cranially and caudally by the diaphragm and the extraperitoneal pelvic structures, respectively.
- The intercostal vessels and nerves travel between the internal intercostal and innermost intercostal muscles within the costal groove on the caudal margin of the superior rib.
- The lumbodorsal fascia merges anterolaterally with the transversus abdominis muscle and is composed of three layers that cover the posterior abdominal wall musculature.

Retroperitoneal Fasciae and Spaces

Derived from the mesoderm, the primitive mesenchyme differentiates to form a subcutaneous layer, a body layer, and a retroperitoneal layer. The retroperitoneal layer forms three strata in late fetal development: the outer stratum, intermediate stratum, and inner stratum (eFig. 75.15 on ExpertConsult.com). Historically, the retroperitoneum has been divided embryologically based on these three strata (Tobin, 1944). The **outer stratum** covers the epimysium of the abdominal wall muscles and becomes the transversalis fascia. The **intermediate stratum** is associated with the genitourinary organs, and the **inner stratum** is associated with the gastrointestinal organs (MacLennan, 2012). The aim is not to have the reader memorize what each embryologic stratum becomes during development. **Rather, these embryologic strata categorize the retroperitoneal fasciae, which compartmentalize various spaces within the retroperitoneum.**

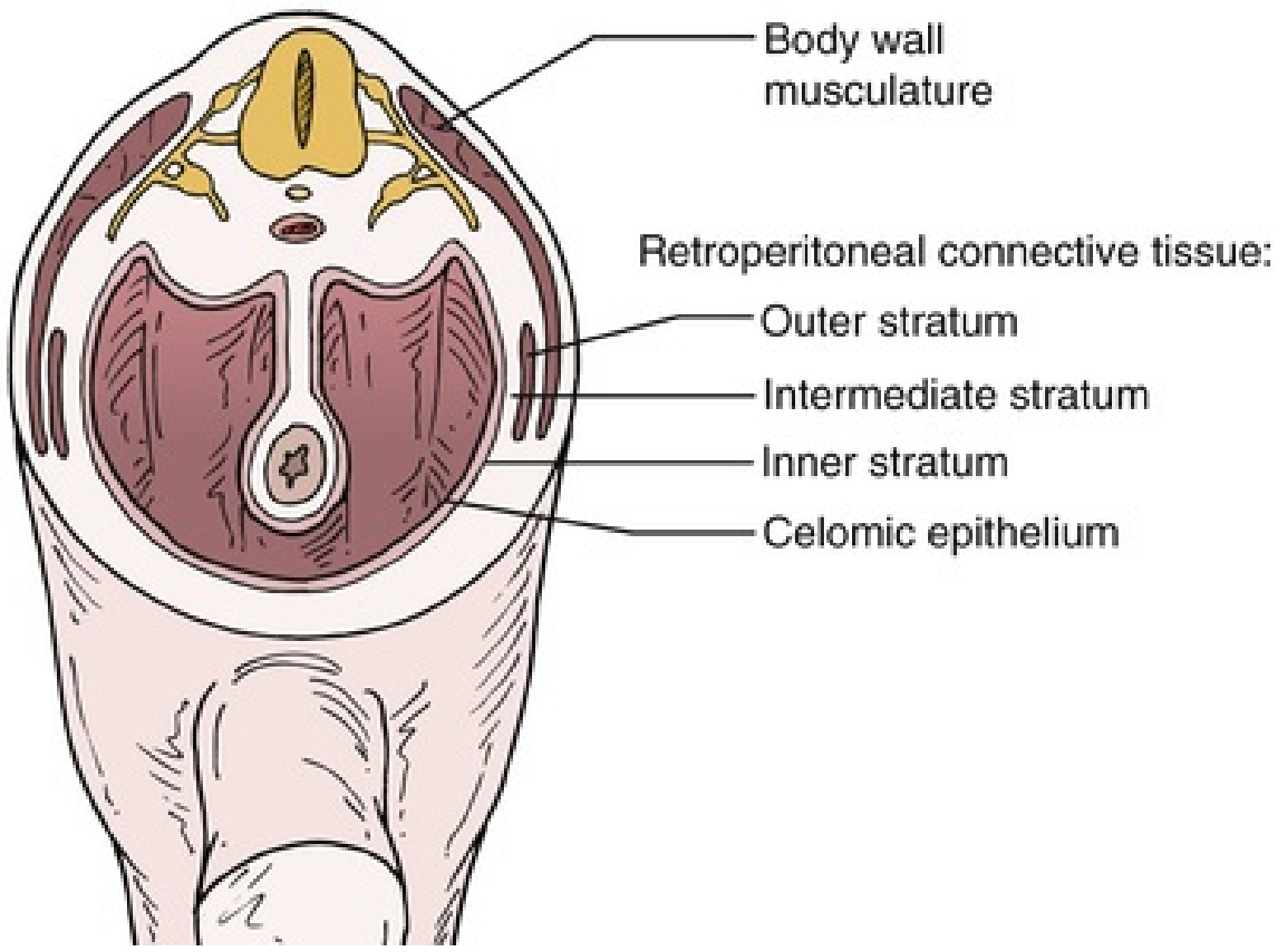

EFIG. 75.15 Retroperitoneal fascial development at 5 weeks. (Modified from Skandalakis JE, Colborn GL: *Skandalakis' surgical anatomy: the embryological and anatomic basis of modern surgery,* Athens, Greece, 2004, Paschalides Medical Publications.)

Transversalis Fascia and Posterior Pararenal

Space

The outer stratum forms the **transversalis fascia,** which lies deep to the transversus abdominis muscle and superficial to the preperitoneal fat and peritoneum. Posterior to the kidney, the transversalis fascia remains anterior to the fascia surrounding the quadratus lumborum and psoas muscle (Fig. 75.16). **It may fuse medially with the posterior lamina of Gerota fascia, which is of clinical significance during retroperitoneal dissection because this fascia must be incised to allow access to the renal hilum.** This fusion creates the medial boundary of the **posterior pararenal space.** The anterior boundary is formed by the posterior lamina of Gerota fascia, and the posterior and lateral boundaries are formed by the transversalis fascia (Tobin, 1944).

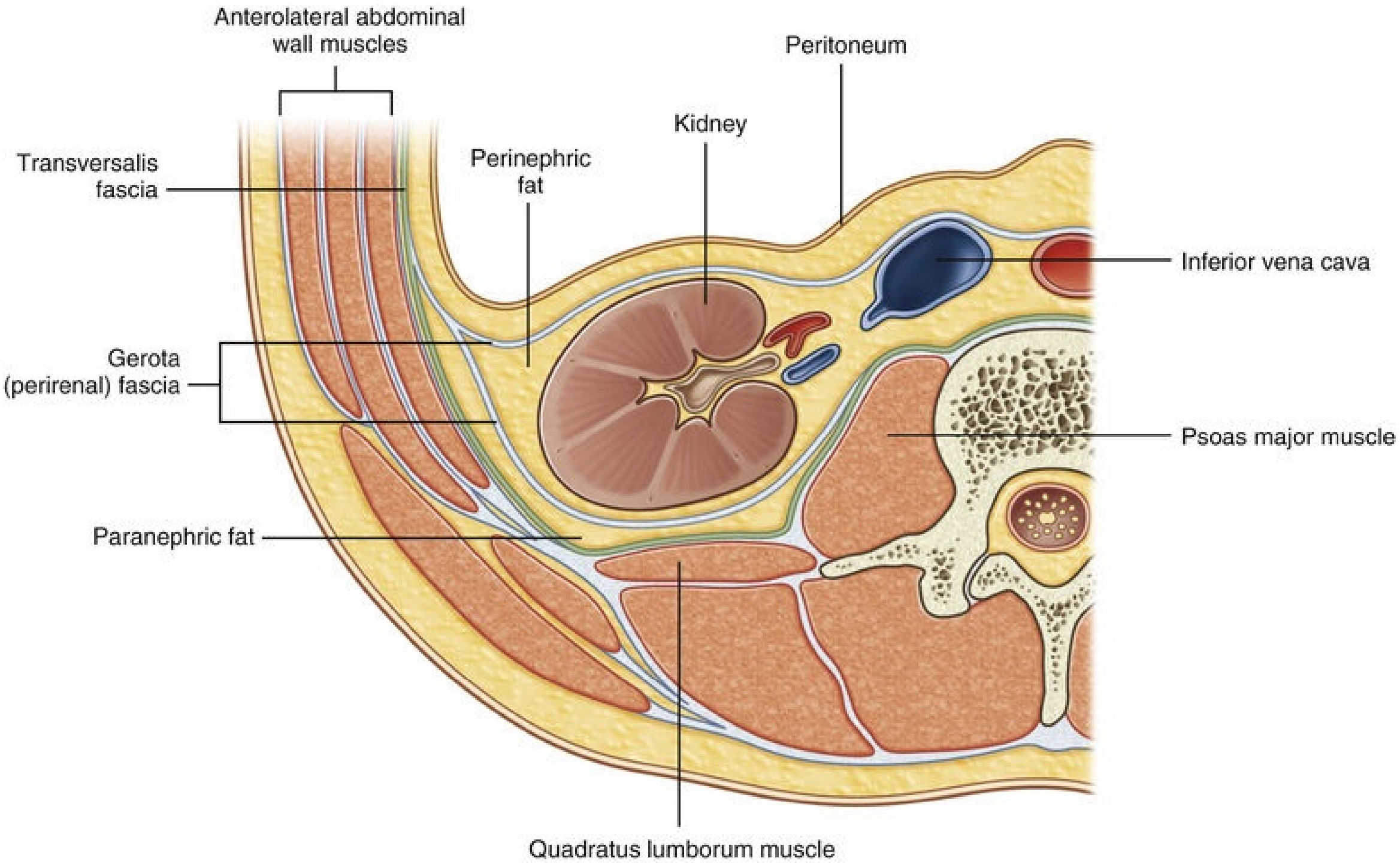
Anterolateral abdominal wall muscles
Peritoneum
Kidney
Transversalis fascia
Perinephric fat
Inferior vena cava
Gerota (perirenal) fascia
Psoas major muscle
Paranephric fat
Quadratus lumborum muscle

FIG. 75.16 Organization of the fasciae and fat surrounding the kidney. (From Drake RL, Vogl AW, Mitchell AWM: *Gray's anatomy for students,* ed 2, Philadelphia, 2010, Churchill Livingstone.)

Gerota Fascia (Renal Fascia) and Perirenal Space

The **anterior lamina** (fascia of Toldt or prerenal fascia) and the **posterior lamina** (fascia of Zuckerkandl or retrorenal fascia) of the renal fascia are derived from the intermediate stratum, which embeds the genitourinary organs. **They help to form the boundaries of the retroperitoneal spaces: the posterior pararenal space, perirenal space, and anterior pararenal space** (Figs. 75.17 and 75.18; also see 75.16). The two laminae together form the **renal fascia,** eponymously named *Gerota fascia*, after the Romanian anatomist Dimitrie D. Gerota (1867–1939). The **perirenal space** contains the adrenal, kidney, ureter, perirenal fat, renal vascular pedicle, and gonadal vessels. The perirenal fat is finer and lighter yellow than the coarser yellow-orange pararenal fat. This color distinction can be helpful during colon mobilization for retroperitoneal surgery. The anatomy of the adrenal, kidney, and ureter is discussed in detail in their respective chapters.

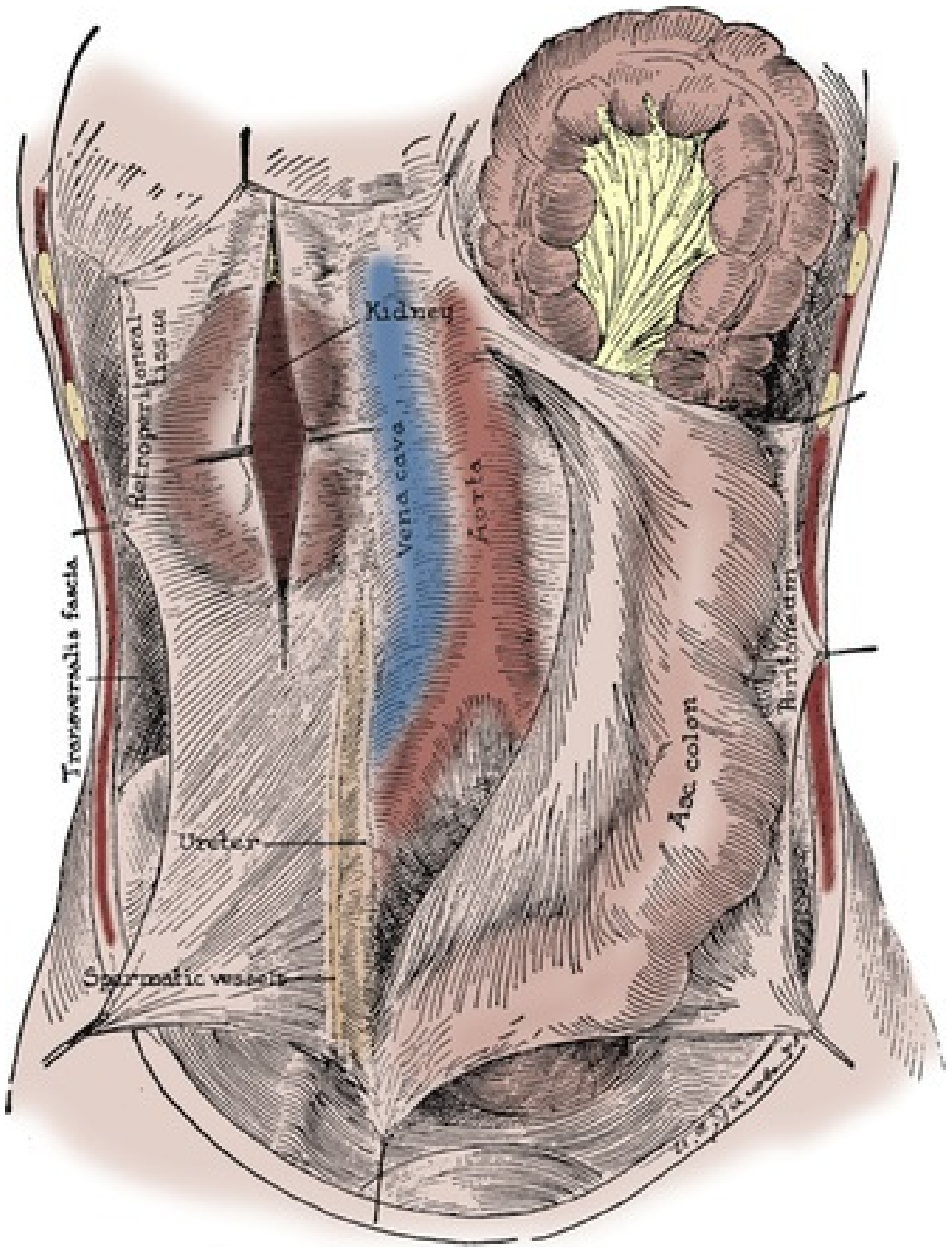

FIG. 75.17 Anterior view of Gerota fascia on the right side, split over the right kidney (which it contains) and showing inferior extension enveloping the ureter and gonadal vessels. The ascending colon and overlying peritoneum have been reflected medially. (From Tobin CE: The renal fascia and its relation to the transversalis fascia. *Anat Rec* 89:295–311, 1944.)

al., 1998).

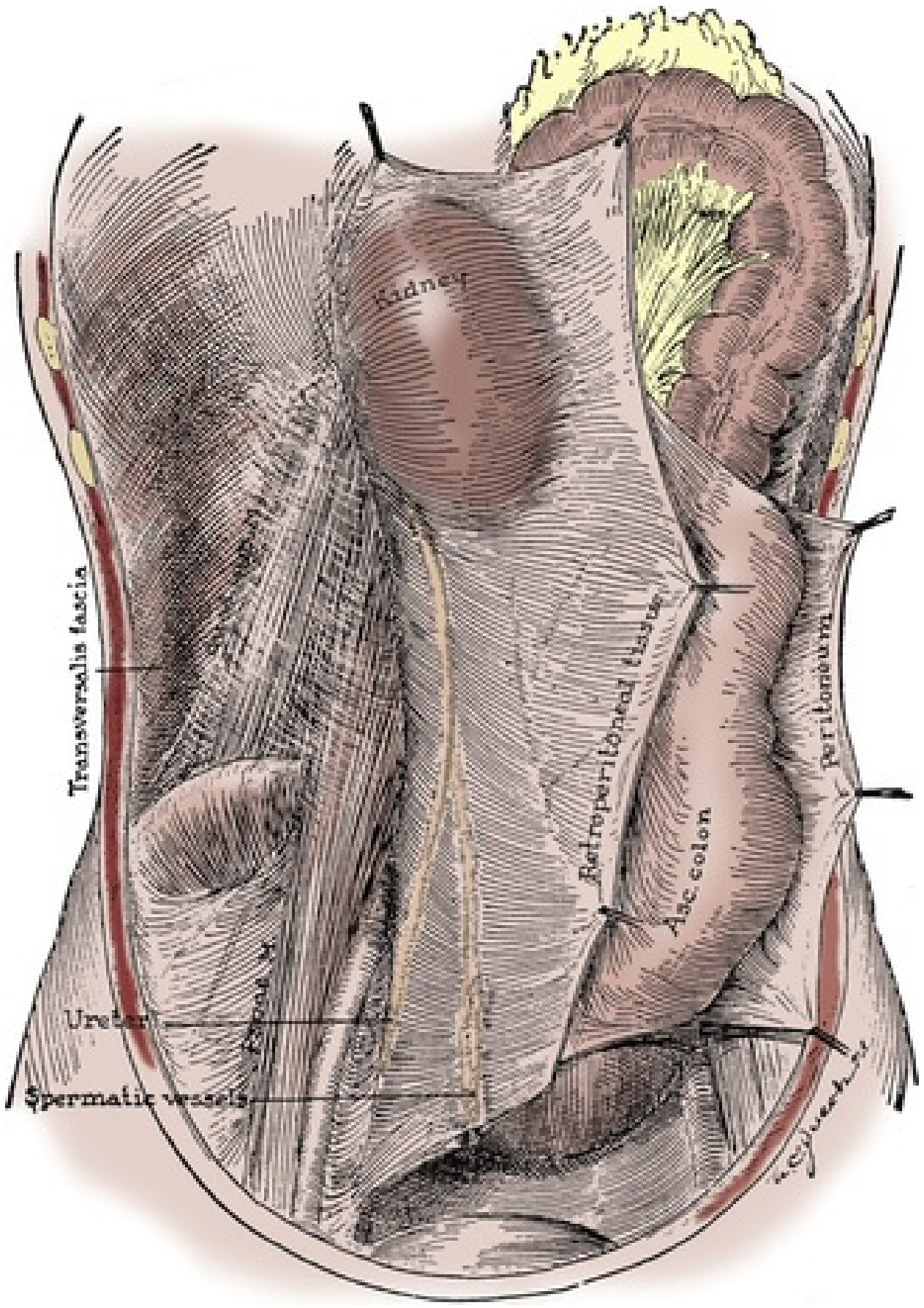

FIG. 75.18 Posterior view of Gerota fascia on the right side, rotated medially with the contained kidney, ureter, and gonadal vessels, exposing the muscular posterior body wall covered by the transversalis fascia. (From Tobin CE: The renal fascia and its relation to the transversalis fascia. *Anat Rec* 89:295–311, 1944.)

The posterior lamina of Gerota fascia is thicker and more frequently visualized radiographically than the anterior lamina. These two layers merge laterally to form the **lateroconal fascia,** which separates the anterior and posterior pararenal spaces and continues anterolaterally deep to the transversalis fascia. There is some controversy regarding the medial and inferior extents of the perirenal space. Historically, it was assumed that there was no communication between the right and left perirenal spaces. However, based on in vivo cases and cadaveric injection studies, **there may be some communication across the midline below the level of the renal hilum** (Lim et al., 1998).

In addition, there has been no consensus on the patency and caudal extent of the perirenal space. Previously, it was suggested that the perirenal space is closed inferiorly by the fusion of Gerota fascia. However, in vivo cases and cadaveric injection studies demonstrated that the **perirenal space has a conelike shape that is open at its inferior extent in the extraperitoneal pelvis** (Lim et al., 1998). These boundaries are of clinical significance in the pathology of urologic disease because they function to contain perinephric fluid collections, which include urine (traumatic or iatrogenic urinary extravasation, obstructive uropathy with calyceal rupture), blood (traumatic or iatrogenic perinephric hematoma, ruptured aneurysm), or purulence (perinephric abscess or infected urinoma).

Anterior Pararenal Space and Inner Stratum

The **anterior pararenal space** is formed by the anterior lamina of the renal fascia posteriorly and the posterior layer of parietal peritoneum anteriorly (eFig. 75.19 on ExpertConsult.com). Clinically, this space is significant because it can be developed to gain access to the kidney anteriorly when followed medially from the **white line of Toldt.** This classic landmark is created during embryogenesis when the inner stratum forms a multilayer fusion fascia with the primary dorsal peritoneum during the rotation and posterior attachment of the gastrointestinal viscera (eFig. 75.20 on ExpertConsult.com). **During this event, the white line of Toldt is formed at the lateral border of the fusion of the colonic mesentery with the posterior peritoneum.**

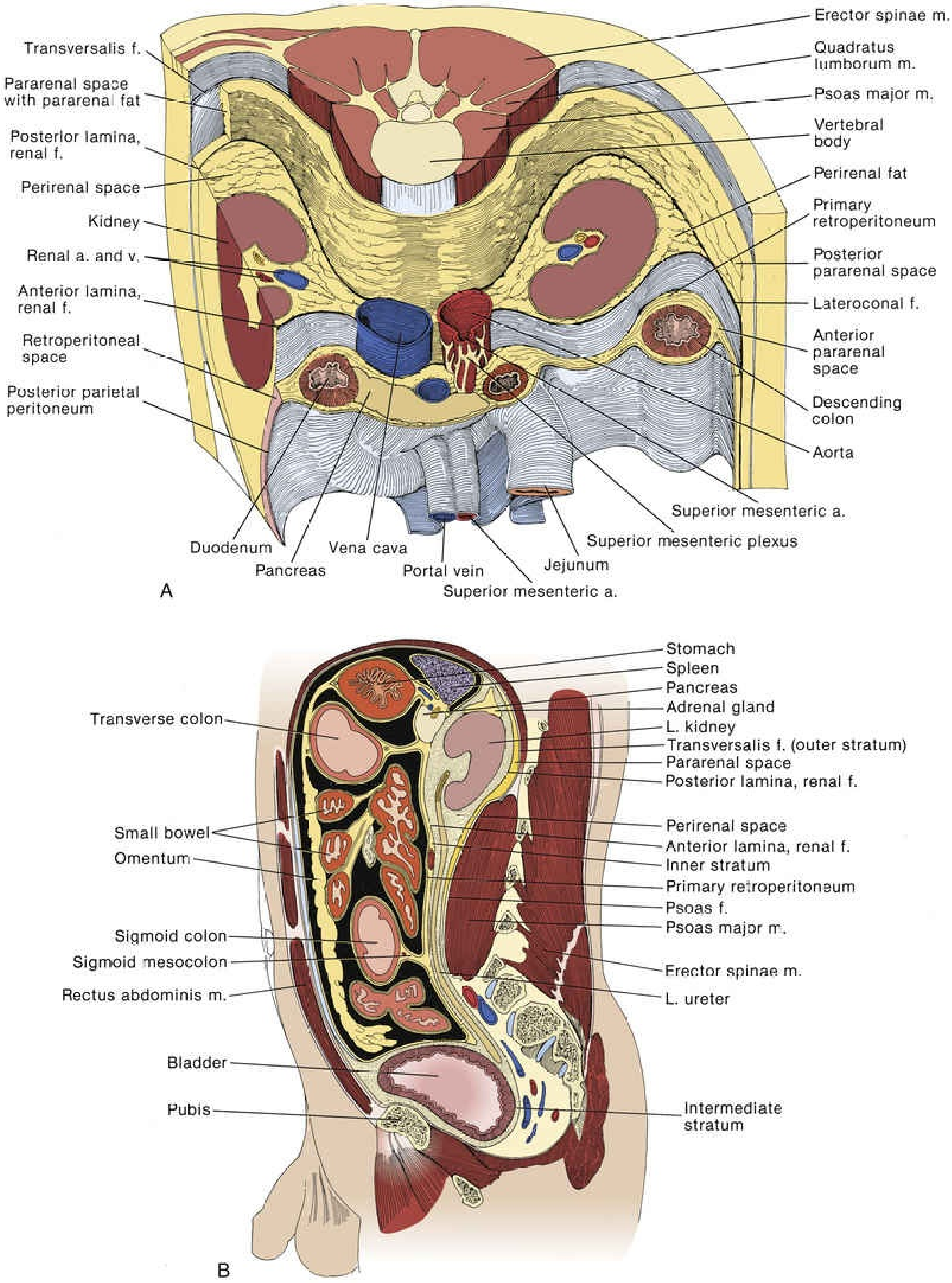
Transversalis f.
Pararenal space with pararenal fat
Posterior lamina, renal f.
Perirenal space
Kidney
Renal a. and v.
Anterior lamina, renal f.
Retroperitoneal space
Posterior parietal peritoneum
Erector spinae m.
Quadratus lumborum m.
Psoas major m.
Vertebral body
Perirenal fat
Primary retroperitoneum
Posterior pararenal space
Lateroconal f.
Anterior pararenal space
Descending colon
Aorta
Superior mesenteric a.
Superior mesenteric plexus
Jejunum
Duodenum
Pancreas
Vena cava
Portal vein
Superior mesenteric a.
A
Stomach
Spleen
Pancreas
Adrenal gland
L. kidney
Transversalis f. (outer stratum)
Pararenal space
Posterior lamina, renal f.
Transverse colon
Perirenal space
Anterior lamina, renal f.
Inner stratum
Primary retroperitoneum
Psoas f.
Psoas major m.
Small bowel
Omentum
Sigmoid colon
Sigmoid mesocolon
Rectus abdominis m.
Erector spinae m.
L. ureter
Bladder
Pubis
Intermediate stratum
B

EFIG. 75.19 Retroperitoneal spaces. (A) Transverse-oblique view. (B) Sagittal view. (From MacLennan GT: *Hinman's atlas of urosurgical* *anatomy*, ed 2, Philadelphia, 2012, Saunders.)

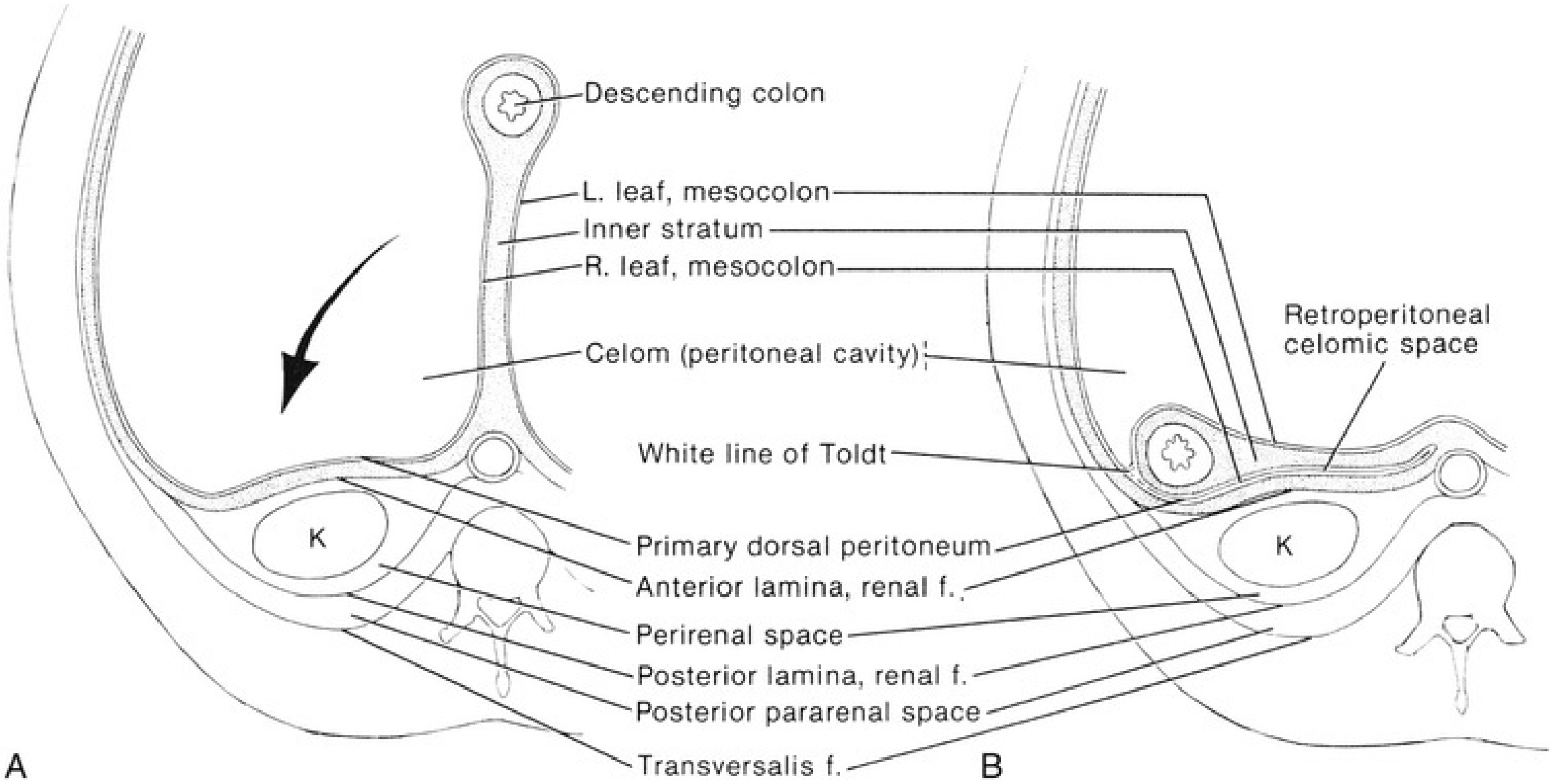
Descending colon
L. leaf, mesocolon
Inner stratum
R. leaf, mesocolon
Celom (peritoneal cavity)
Retroperitoneal celomic space
White line of Toldt
K
Primary dorsal peritoneum
Anterior lamina, renal f.
Perirenal space
Posterior lamina, renal f.
Posterior pararenal space
Transversalis f.
K
A
B

EFIG. 75.20 (A and B) Colonic rotation and formation of the white line of Toldt. *K,* Kidney. (From MacLennan GT: *Hinman's atlas of urosurgical anatomy,* ed 2, Philadelphia, 2012, Saunders.)

The anterior pararenal space contains the secondarily retroperitoneal organs: the ascending and descending colon, pancreas, and second and third portions of the duodenum. These organs are intraperitoneal at one point during embryogenesis; however, they become retroperitoneal secondarily as they attach to the posterior abdominal wall when the inner stratum fuses with the primary dorsal peritoneum.

Key Points: Retroperitoneal Fasciae and Spaces

- The boundaries of the posterior pararenal space are the posterior lamina of Gerota fascia anteriorly and the transversalis fascia posteriorly and laterally.
- The anterior and posterior laminae of Gerota fascia form the boundaries of the perirenal space, which has a conelike shape that is open caudally in the extraperitoneal pelvis.
- Perinephric fluid collections can expand caudally because of the opening in

the perirenal space.

- The white line of Toldt represents the lateral border of the fusion of the colonic mesentery with the posterior peritoneum.

Gastrointestinal Viscera and Mesentery

The nonurologic structures within the retroperitoneum include the pancreas and parts of the duodenum and the colon (Figs. 75.21 and 75.22). The **pancreas** consists of four parts and has endocrine and exocrine functions. The head lies anterior to the IVC and is surrounded by the second portion of the duodenum. This portion is of concern for potential injury during right kidney procedures. The neck connects the head to the body, which crosses the abdomen anterior to the aorta and the origin of the superior mesenteric artery (SMA). **The tail of the pancreas is closely associated with the spleen and must be accounted for during left retroperitoneal surgery because of its proximity to the upper pole of the left kidney and left adrenal.** In addition, the stomach is anterior to the upper pole of the left kidney and must be accounted for during transperitoneal left renal surgery (eFig. 75.23 on ExpertConsult.com).

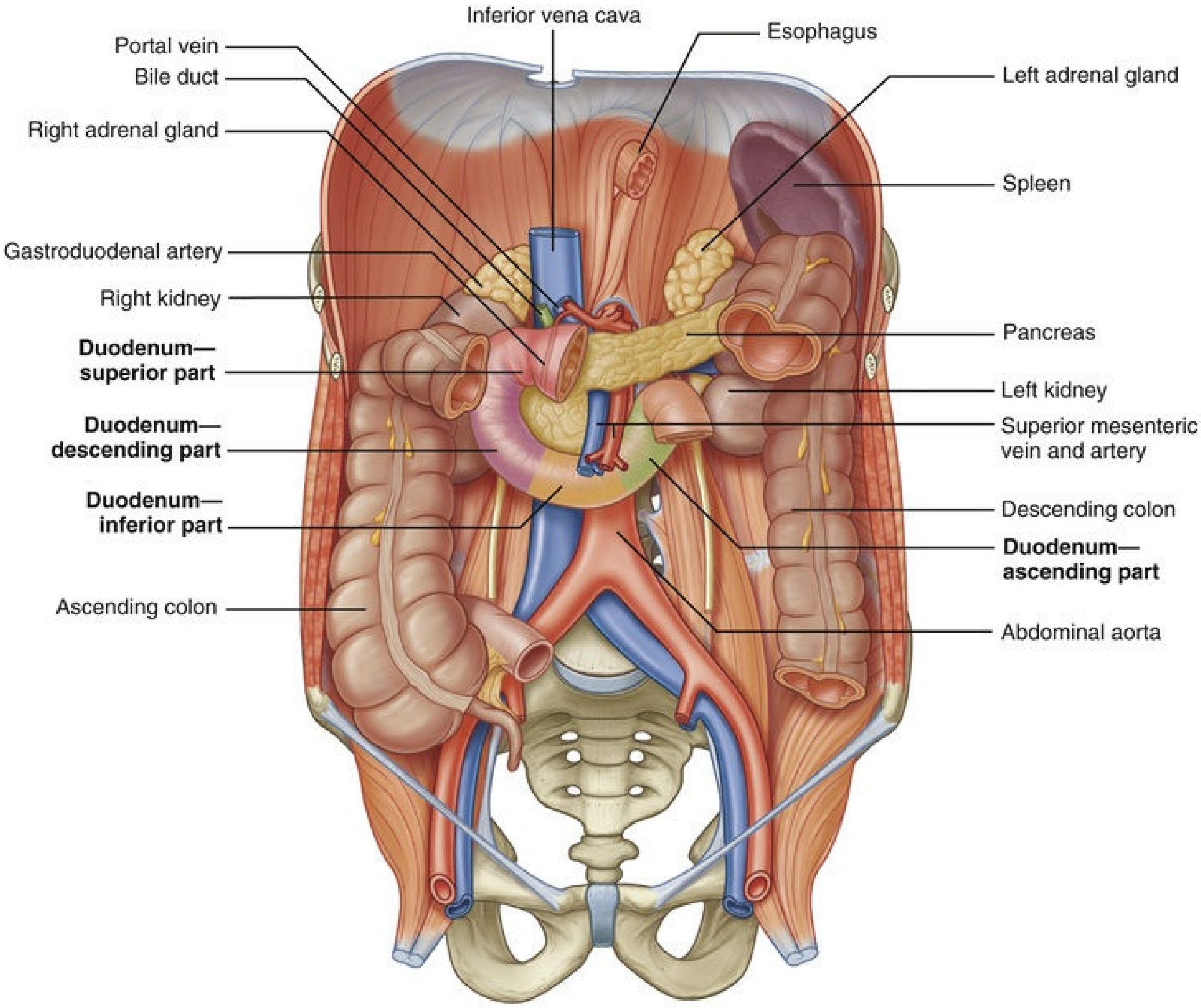
Inferior vena cava
Portal vein
Bile duct
Esophagus
Left adrenal gland
Right adrenal gland
Spleen
Gastroduodenal artery
Right kidney
Pancreas
Duodenum—
superior part
Left kidney
Duodenum—
descending part
Superior mesenteric
vein and artery
Duodenum—
inferior part
Descending colon
Duodenum—
ascending part
Ascending colon
Abdominal aorta

FIG. 75.21 Colon, duodenum, and pancreas within the retroperitoneum. (From Drake RL, Vogl AW, Mitchell AWM: *Gray's anatomy for students,* ed 2, Philadelphia, 2010, Churchill Livingstone.)

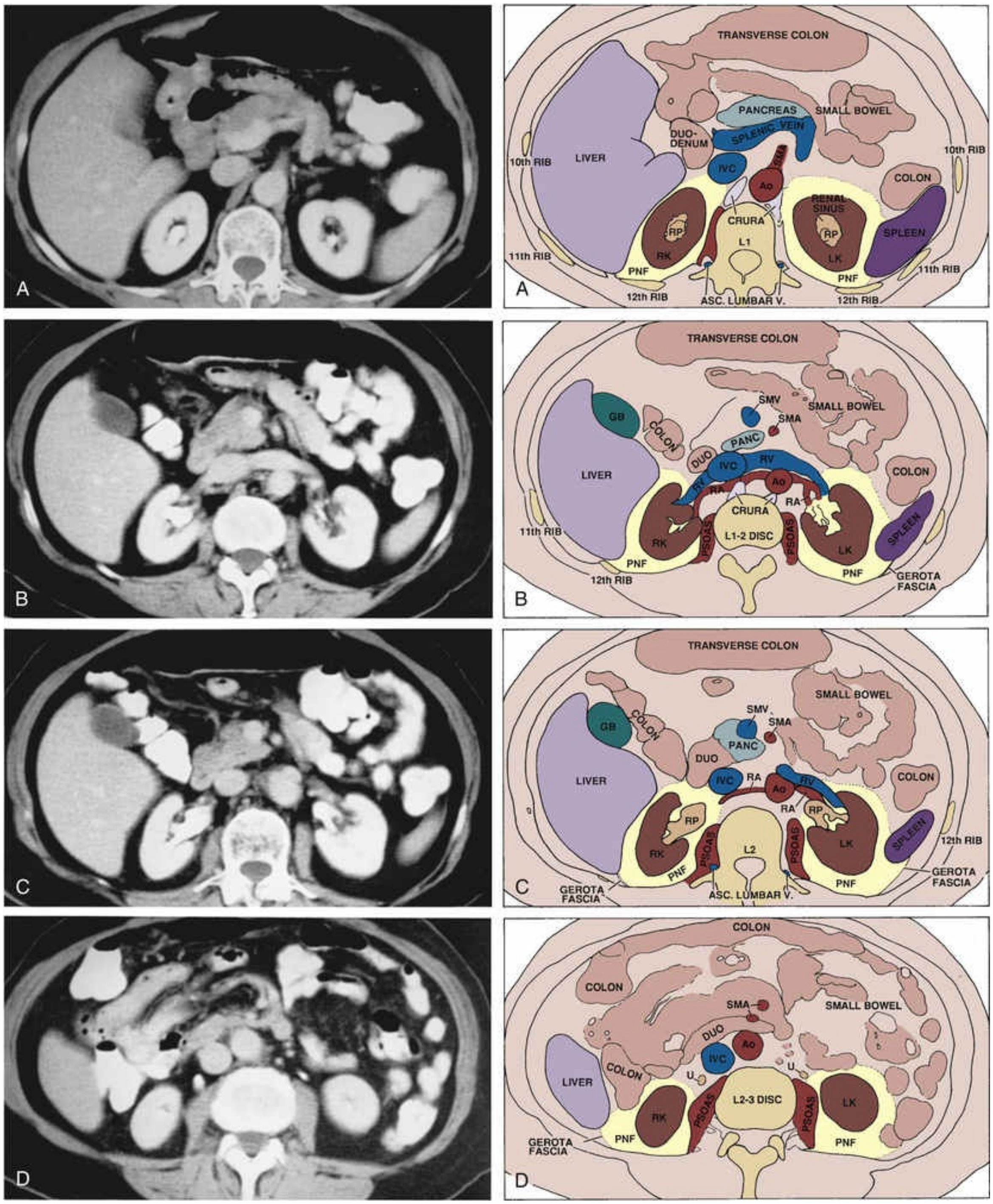
A
TRANSVERSE COLON
PANCREAS
SMALL BOWEL
SPLENIC VEIN
DUO-DENUM
SMA
10th RIB
LIVER
IVC
Ao
10th RIB
COLON
RENAL SINUS
CRURA
RP
RP
SPLEEN
L1
RK
LK
11th RIB
11th RIB
PNF
PNF
12th RIB
ASC. LUMBAR V.
12th RIB
B
TRANSVERSE COLON
SMV
SMALL BOWEL
SMA
GB
COLON
PANC
DUO
RV
LIVER
IVC
Ao
COLON
RV
RA
RA
CRURA
11th RIB
L1-2 DISC
PSOAS
PSOAS
SPLEEN
RK
LK
PNF
PNF
12th RIB
GEROTA FASCIA
C
TRANSVERSE COLON
SMALL BOWEL
SMV
SMA
GB
COLON
PANC
DUO
LIVER
IVC
RA
RV
COLON
Ao
RA
RP
RP
LK
SPLEEN
12th RIB
L2
PSOAS
PSOAS
RK
PNF
PNF
GEROTA FASCIA
GEROTA FASCIA
ASC. LUMBAR V.
D
COLON
COLON
SMA
SMALL BOWEL
DUO
Ao
IVC
COLON
U
U
LIVER
L2-3 DISC
LK
RK
PSOAS
PSOAS
PNF
PNF
GEROTA FASCIA

FIG. 75.22 Cross-sectional anatomy of the upper abdomen at the level of the kidneys demonstrated with transverse sections obtained by computed tomography. Sections are arranged from most cephalic to caudal. (A) Section through the upper poles of the kidneys, superior to the renal vascular pedicles. (B) Section through the level of the renal arteries and veins. (C) Slightly more inferior section showing the renal pelves and relationship of the duodenum to the right renal hilum. (D) Section through

the lower poles of the kidneys showing the upper ureters. *Ao,* Aorta; *DUO,* duodenum; *GB,* gallbladder; *IVC,* inferior vena cava; *LK,* left kidney; *PANC,* pancreas; *PNF,* perinephric fat; *RA,* renal artery; *RK,* right kidney; *RP,* renal pelvis; *RV,* renal vein; *SMA,* superior mesenteric artery; *SMV,* superior mesenteric vein; *U,* ureter.

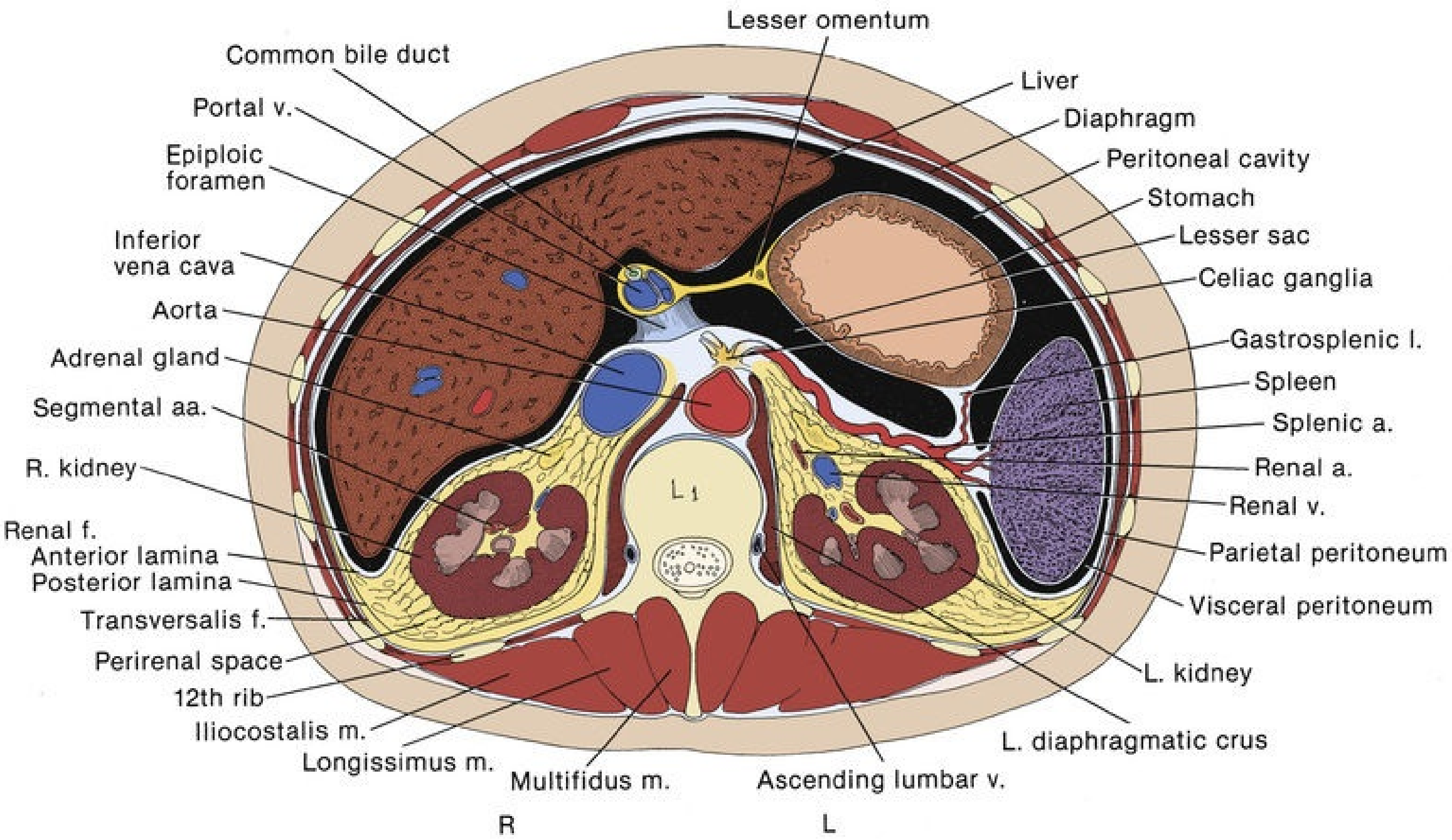
Lesser omentum
Common bile duct
Portal v.
Epiploic foramen
Inferior vena cava
Aorta
Adrenal gland
Segmental aa.
R. kidney
Renal f.
Anterior lamina
Posterior lamina
Transversalis f.
Perirenal space
12th rib
Iliocostalis m.
Longissimus m.
Multifidus m.
Liver
Diaphragm
Peritoneal cavity
Stomach
Lesser sac
Celiac ganglia
Gastrosplenic l.
Spleen
Splenic a.
Renal a.
Renal v.
Parietal peritoneum
Visceral peritoneum
L. kidney
L. diaphragmatic crus
Ascending lumbar v.
L1
R
L

EFIG. 75.23 Transverse section at L1. (From MacLennan GT: *Hinman's atlas of urosurgical anatomy*, ed 2, Philadelphia, 2012, Saunders.)

The **duodenum** is 20 cm to 25 cm in length and can be divided into four distinct parts. The first (superior) portion is intraperitoneal and extends from the pylorus to the neck of the gallbladder. The second (descending) and third (horizontal or inferior) portions of the duodenum are contained within the retroperitoneum. **The second, descending portion of the duodenum is critical to the urologist because of its proximity to the right renal hilum. The duodenum may be mobilized medially using a *Kocher maneuver* to expose these right-sided retroperitoneal structures.** During left-sided retroperitoneal surgery, as the colon is reflected medially the mesentery thins and the duodenum can be encountered. The common bile duct and the main pancreatic duct combine to enter the second portion of the duodenum at the ampulla of Vater (hepatopancreatic ampulla). The third portion of the duodenum crosses the body from right to left and lies posterior to the SMA and anterior to the aorta. The fourth and final portion ascends and becomes intraperitoneal as it transitions into the jejunum.

As with the duodenum, portions of the colon are secondarily retroperitoneal because they developed intraperitoneally but fused with the posterior abdominal wall during embryogenesis. The **ascending colon** and hepatic flexure overlie the right-sided retroperitoneal structures, and the splenic flexure and **descending colon** cover the left-sided retroperitoneal structures. To gain access to the kidneys transperitoneally, the ipsilateral colon must be reflected medially in most instances. This can be performed by mobilizing the colon at the white line of Toldt, which visually represents the transition from the colonic visceral peritoneum to the posterior parietal peritoneum. **Care must be taken to divide the hepatocolic and splenocolic ligaments sharply when necessary to avoid iatrogenic injury to the liver and spleen, which is often due to excessive retraction during attempts to obtain adequate exposure.**

Recent investigations have begun to classify the mesentery as a distinct organ that has intestinal, vascular, immunologic, and endocrine function. Initial early depictions of the mesentery by Leonardo Da Vinci showed a continuous structure from the small bowel to the colon. However, in the late 1800s, a fragmented mesenteric model was adopted with no mesentery associated with the ascending or descending colon (Coffey and O'Leary, 2016). **Continuity of the mesentery from the ileocecal level to the rectosigmoid level was established in an observational cohort study of patients undergoing total abdominal colectomy for colon cancer** (Culligan et al., 2012).

The function of the mesentery is linked with its physiology and anatomy. It acts as a scaffolding for the small and large intestines, suspending these structures from the posterior abdominal wall. As the mesentery is the first barrier between the intestines and the body, it also acts as a sampling reservoir for systemic immune responses. **Mesenteric nodes regulate the cell-mediated immune response with the adjacent intestinal mucosa.** Although the mesenteric component of the enteric nervous system is poorly understood at this time, it houses the postganglionic nerves from the main abdominal ganglia (Coffey and O'Leary, 2016).

Several mesenteric disease processes are of important clinical significance to the practicing urologist. **Internal herniation resulting from surgically created mesenteric defects can cause a potentially life-threatening postoperative complication.** After bowel segment isolation, it is imperative that small defects in the mesentery are closed primarily because the risk of herniation is higher in these cases. Vascular mesenteropathies are also of clinical significance as vascular compromise of the mesenteric arteries can result in loss of an intestinal segment used for urinary diversion, ureteral interposition, or bladder augmentation (Coffey and O'Leary, 2016).

Vasculature

Arterial System

Arterial structures have three layers: the tunica intima (intima), tunica media (media), and tunica externa (tunica adventitia or adventitia) as shown in eFig. 75.24 on ExpertConsult.com. The **intima** consists of a layer of endothelial cells surrounded by subendothelial connective tissue. The **media** layer contains vascular smooth muscle cells and elastic connective tissue that control the caliber of the vessel. This layer is surrounded by the internal and external elastic laminae. The **adventitia** is the connective tissue sheath surrounding the vessel. It contains the nerves that control vasomotor tone and the *vasa vasorum* (Latin, "vessels of the vessels"), which are smaller vessels that supply the walls of larger vessels.

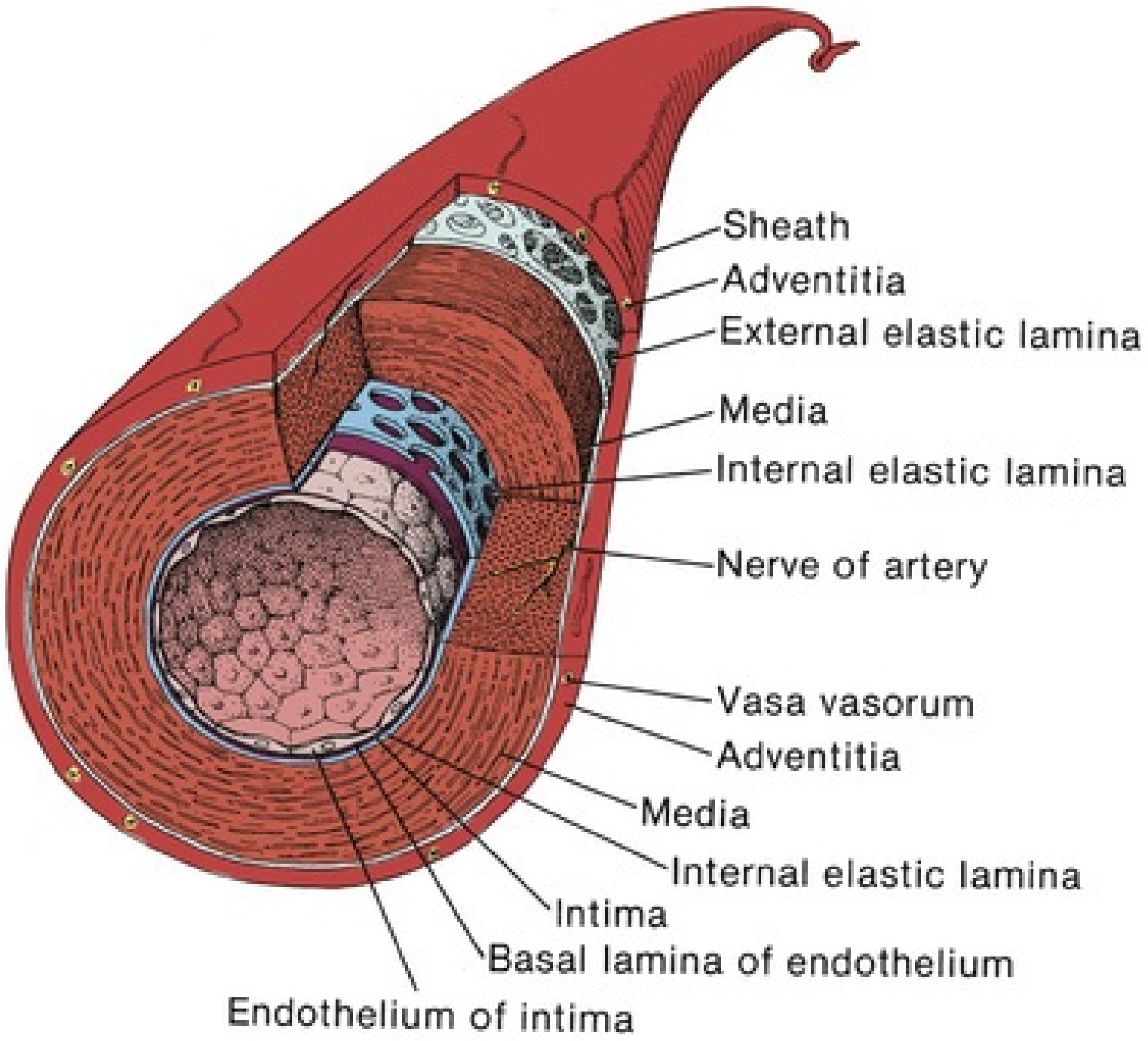
Sheath
Adventitia
External elastic lamina
Media
Internal elastic lamina
Nerve of artery
Vasa vasorum
Adventitia
Media
Internal elastic lamina
Intima
Basal lamina of endothelium
Endothelium of intima

EFIG. 75.24 Structure of the arterial wall. (From MacLennan GT: *Hinman's atlas of urosurgical anatomy,* ed 2, Philadelphia, 2012, Saunders.)

The major arterial structures of the retroperitoneum include the abdominal aorta (eFig. 75.25 on ExpertConsult.com and Fig. 75.26) and its branches (Fig.

75.27 and Table 75.3). Entering the abdomen through the aortic hiatus of the diaphragm at the level of T12, the **abdominal aorta** courses centrally and to the left of the IVC. The first branches are the paired **inferior phrenic arteries,** which supply the inferior surface of the diaphragm (eFig. 75.28 on ExpertConsult.com). The **superior adrenal artery** branches from the inferior phrenic artery and supplies the ipsilateral adrenal gland. **The superior arterial blood supply to the adrenal is constant; however, the middle and inferior arteries to the adrenal are variable. These arteries vary in number and location with the most common variant being the middle adrenal artery arising from the aorta and the inferior adrenal arising from the renal artery.**

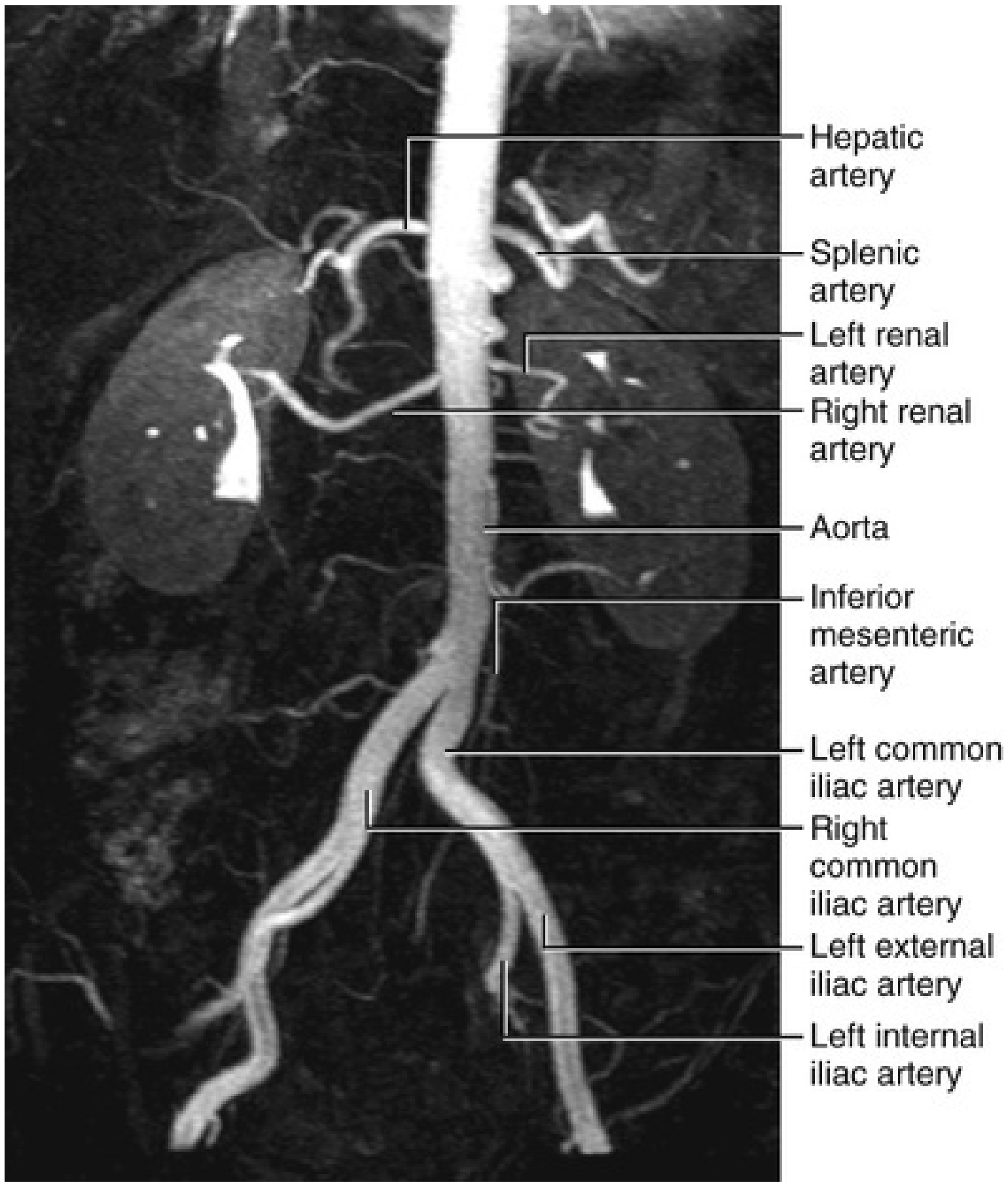
Hepatic artery
Splenic artery
Left renal artery
Right renal artery
Aorta
Inferior mesenteric artery
Left common iliac artery
Right common iliac artery
Left external iliac artery
Left internal iliac artery

FIG. 75.26 Computed tomography angiogram of the abdominal aorta and its branches. (From MacLennan GT: *Hinman's atlas of urosurgical anatomy,* ed 2, Philadelphia, 2012, Saunders.)

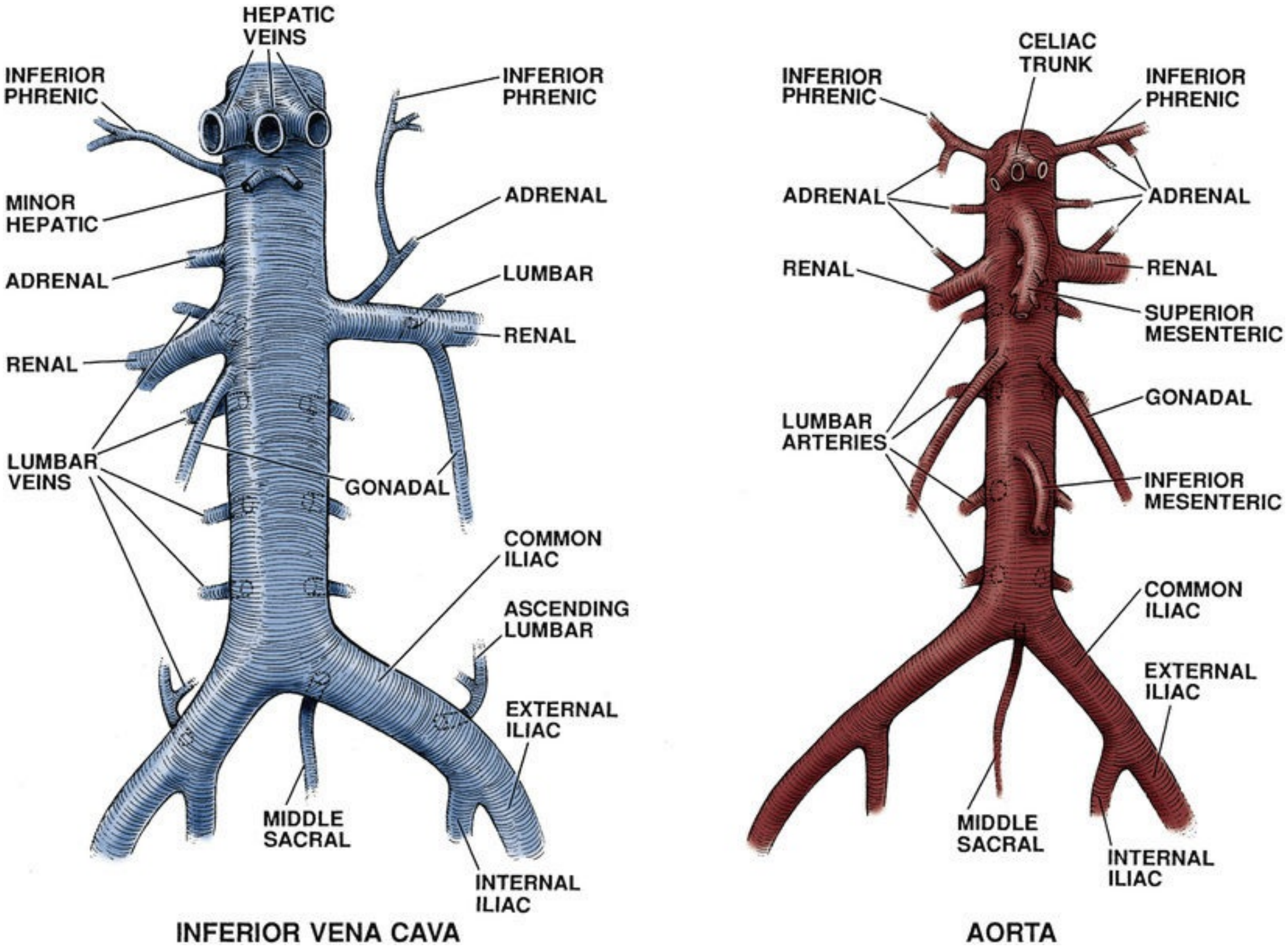
HEPATIC VEINS
INFERIOR PHRENIC
INFERIOR PHRENIC
MINOR HEPATIC
ADRENAL
ADRENAL
LUMBAR
RENAL
RENAL
LUMBAR VEINS
GONADAL
COMMON ILIAC
ASCENDING LUMBAR
EXTERNAL ILIAC
MIDDLE SACRAL
INTERNAL ILIAC
INFERIOR VENA CAVA
CELIAC TRUNK
INFERIOR PHRENIC
INFERIOR PHRENIC
ADRENAL
ADRENAL
RENAL
RENAL
SUPERIOR MESENTERIC
LUMBAR ARTERIES
GONADAL
INFERIOR MESENTERIC
COMMON ILIAC
EXTERNAL ILIAC
MIDDLE SACRAL
INTERNAL ILIAC
AORTA

FIG. 75.27 Inferior vena cava and its tributaries and abdominal aorta and its branches.

TABLE 75.3

Branches of the Abdominal Aorta

ARTERY	BRANCH	ORIGIN	SUPPLIES
Celiac trunk	Anterior	Immediately inferior to aortic hiatus of diaphragm	Abdominal foregut
Superior mesenteric artery	Anterior	Immediately inferior to celiac trunk	Abdominal midgut
Inferior mesenteric artery	Anterior	Inferior to renal arteries	Abdominal hindgut
Middle adrenal arteries	Lateral	Immediately superior to renal arteries	Adrenal glands
Renal	Lateral	Immediately inferior to superior	Kidneys

arteries		mesenteric artery	
Testicular or ovarian arteries	Paired anterior	Inferior to renal arteries	Testes in male and ovaries in female
Inferior phrenic arteries	Paired lateral	Immediately inferior to aortic hiatus	Diaphragm
Lumbar arteries	Posterior	Usually four pairs	Posterior abdominal wall and spinal cord
Median sacral arteries	Posterior	Just superior to aortic bifurcation, pass inferiorly across lumbar vertebrae, sacrum, and coccyx	
Common iliac arteries	Terminal	Bifurcation usually occurs at level of L4 vertebra	

Modified from Drake RL, Vogl AW, Mitchell AWM: *Gray's anatomy for students*, Philadelphia, 2005, Churchill Livingstone, p 331.

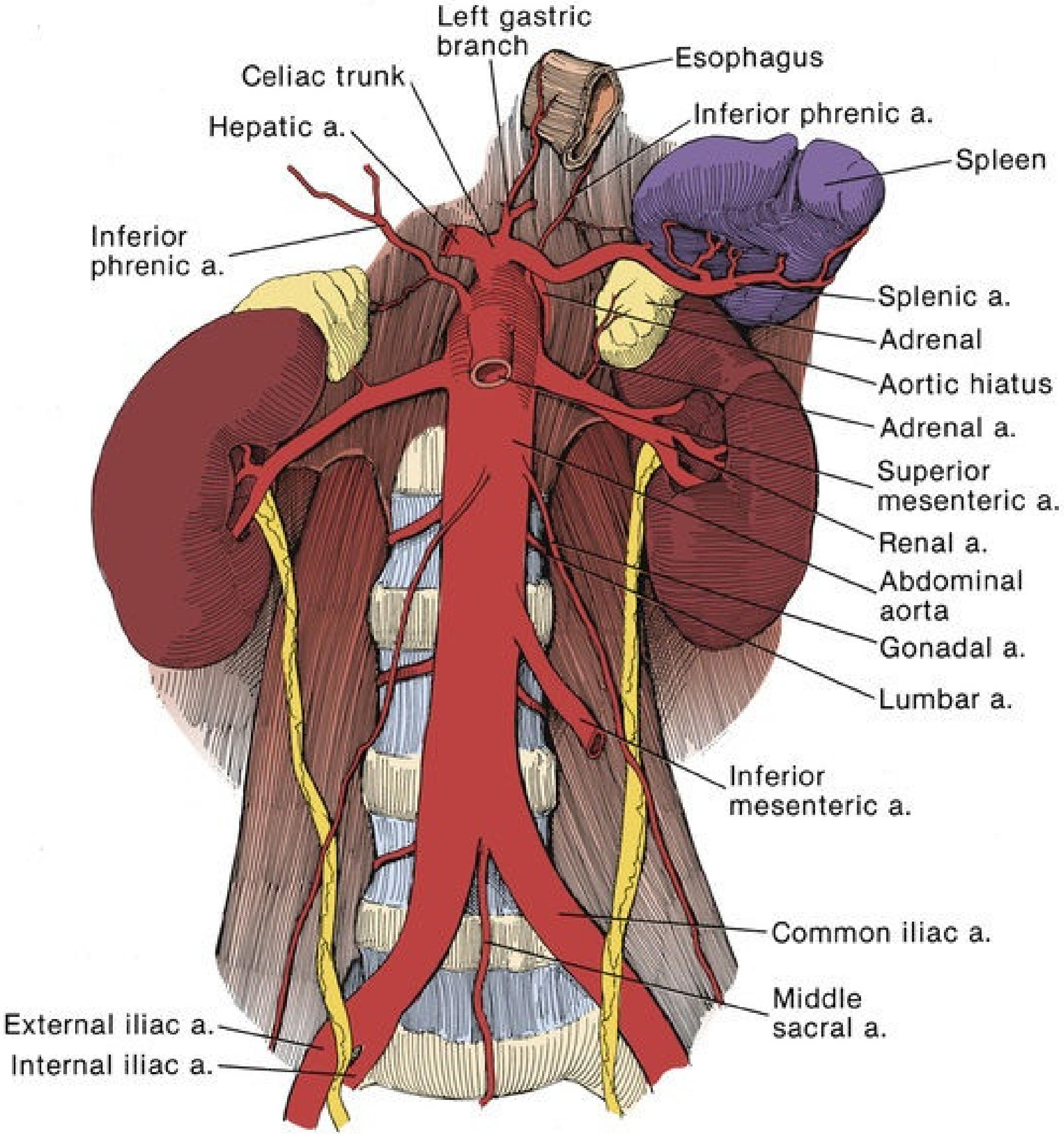
Left gastric branch
Esophagus
Celiac trunk
Hepatic a.
Inferior phrenic a.
Spleen
Inferior phrenic a.
Splenic a.
Adrenal
Aortic hiatus
Adrenal a.
Superior mesenteric a.
Renal a.
Abdominal aorta
Gonadal a.
Lumbar a.
Inferior mesenteric a.
Common iliac a.
Middle sacral a.
External iliac a.
Internal iliac a.

EFIG. 75.25 Abdominal aorta and its branches. (From MacLennan GT: *Hinman's atlas of urosurgical anatomy,* ed 2, Philadelphia, 2012, Saunders.)

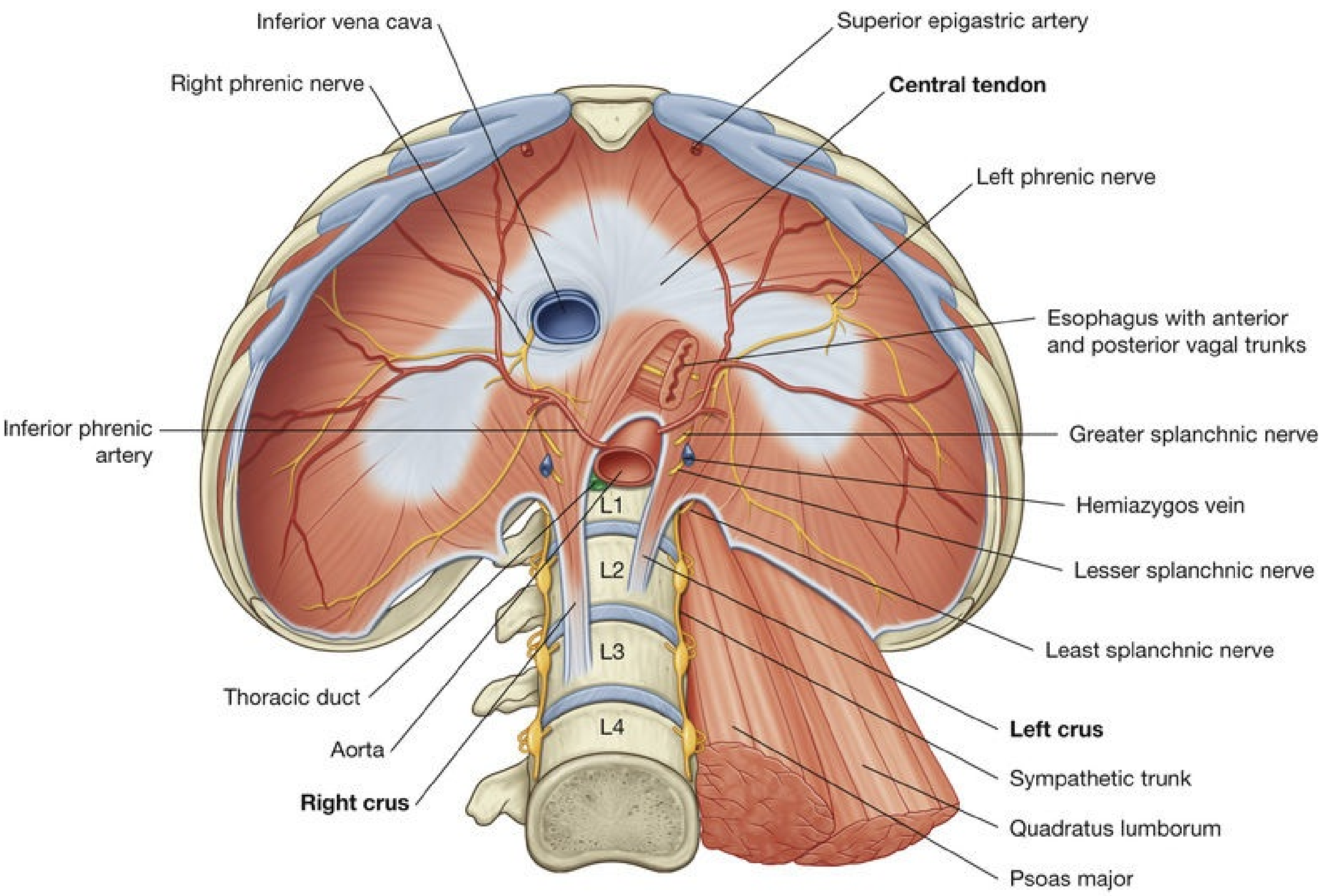
Inferior vena cava
Superior epigastric artery
Right phrenic nerve
Central tendon
Left phrenic nerve
Esophagus with anterior and posterior vagal trunks
Inferior phrenic artery
Greater splanchnic nerve
Hemiazygos vein
Lesser splanchnic nerve
Least splanchnic nerve
L1
L2
L3
L4
Thoracic duct
Aorta
Right crus
Left crus
Sympathetic trunk
Quadratus lumborum
Psoas major

EFIG. 75.28 The abdominal surface of the diaphragm. (From Drake RL, Vogl AW, Mitchell AWM: *Gray's anatomy for students,* ed 2, Philadelphia, 2010, Churchill Livingstone.)

The next branch of the abdominal aorta is the **celiac artery** (celiac trunk or truncus coeliacus), which is a short, unpaired artery that arises anteriorly at the midline at the level of T12. It gives origin to the left gastric, splenic, and common hepatic arteries, which supply the abdominal esophagus, stomach, duodenum, spleen, liver, and pancreas. Of surgical anatomic significance, the splenic vessels course on the cephalad aspect of the body and tail of the pancreas. When the inferior pancreatic edge is mobilized off the anterior renal fascia during adrenal or renal transperitoneal surgery, knowledge of the anatomic relationship between the splenic vessels and the pancreas is important to prevent vascular injury. The next branches are the paired middle adrenal arteries, which supply the ipsilateral adrenal gland as noted earlier.

The **superior mesenteric artery (SMA)** branches next off the aorta, arising anteriorly in the midline at approximately the level of the middle adrenal arteries at L1-L2. It supplies the pancreas (inferior pancreaticoduodenal artery), small intestine, and most of the large intestine (ileocolic, right colic, and middle colic arteries). **The middle colic artery anastomoses with the left colic artery off the inferior mesenteric artery (IMA) via the marginal artery of Drummond.**

This anastomosis forms an important SMA-to-IMA collateral circulation that allows for the IMA to be sacrificed without colonic ischemia (Walker, 2009). However, despite the presence of this collateral circulation, injury to the SMA during left-sided retroperitoneal surgery may lead to severe bowel ischemia.

The paired **renal arteries** are the next branch of the aorta (eFig. 75.29 on ExpertConsult.com). These classically arise at the L1-L2 vertebral levels. The inferior adrenal arteries branch off the renal arteries to supply the ipsilateral adrenal gland. There is considerable variation in the location, size, and number of renal arteries, with at least one quarter of cases manifesting with supernumerary renal arteries. There is no clear consensus on whether supernumerary arteries are more common on the right or the left. In a study out of India examining 37 cadavers, 23 (62.2%) were found to have supernumerary renal arteries on the right with 21 (56.8%) on the left (Budhiraja et al., 2013). There are variations between genders as well, with renal arteries in female patients being approximately 5 mm smaller on average than male patients based on CT angiographic studies (Turba et al., 2009). The specific anatomic variations are discussed in depth in Chapter 84.

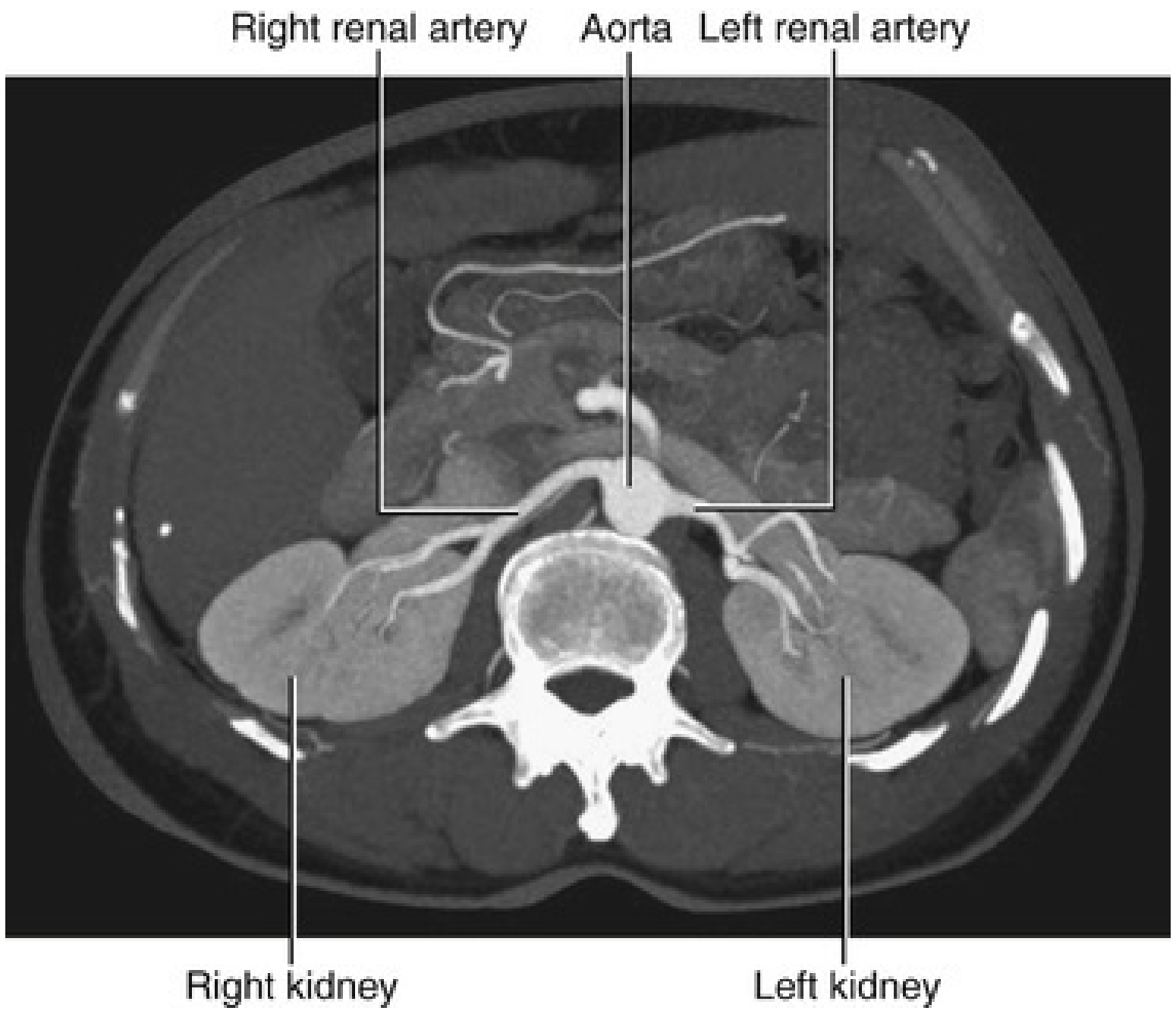

EFIG. 75.29 Magnetic resonance angiogram, transverse section, right and left renal arteries arising from the aorta and supplying the kidneys. (From MacLennan GT: *Hinman's atlas of urosurgical anatomy,* ed 2, Philadelphia, 2012, Saunders.)

The **gonadal arteries** are the next paired branch of the aorta, typically arising anterolaterally from the aorta below the renal arteries. They may emerge from the renal artery in some variations, in which case they course with the gonadal vein. In males, the gonadal arteries are called the **testicular arteries,** and in females, they are called the **ovarian arteries.** The testicular arteries typically run anterior to the psoas, IVC, genitofemoral nerve, and ipsilateral ureter as they travel toward the internal inguinal ring.

The ovarian arteries arise from the anterolateral aspect of the aorta below the renal arteries. They travel anterior to the ureter and course medially as they pass through the infundibulopelvic ligament (suspensory ligament of the ovary) to the ovary. **There are extensive collaterals to the gonads in both sexes, allowing for ligation of the testicular and ovarian arteries without gonadal ischemia.**

The paired **lumbar arteries** arise posteriorly, adjacent to the bodies of the upper four lumbar vertebrae. They supply the posterior body wall and spine. In some instances, a fifth pair of lumbar arteries is present, arising from the middle sacral artery.

The **inferior mesenteric artery (IMA)** arises from the anterior aorta in the midline at the level of L3-L4 and supplies the colon from the splenic flexure to the upper rectum. The branches of the IMA are the left colic, sigmoid, and superior hemorrhoidal (rectal) arteries. The **sigmoid artery** branches into two to three inferior left colic arteries. As previously mentioned, the colonic branches of the IMA anastomose with the SMA via the marginal artery of Drummond and preclude colonic ischemia with IMA ligation. **The superior hemorrhoidal artery has collateral circulation with the inferior and middle hemorrhoidal arteries, which branch off the internal iliac arteries. These collaterals provide blood supply to the rectum and prevent ischemia during IMA ligation.**

Before bifurcation, the **median sacral** (middle sacral) artery arises from the posterior aspect of the aorta and courses over the fifth lumbar vertebra and sacrum. This vessel may be sacrificed if necessary without end-organ ischemia. At the fourth lumbar vertebra, the aorta bifurcates to form the **common iliac arteries.** No named branches are given off as these arteries enter the pelvis and divide to form the internal and external iliac arteries.

The ureter has a variable arterial supply that changes proximally and distally. **Most often, the renal artery supplies the proximal ureter, and the internal iliac artery, including its branches, the superior and inferior vesical arteries,**

supply the distal ureter. The middle ureter is typically supplied by the aorta; however, it may also be supplied by the common iliac, gonadal, uterine, middle rectal, and vaginal arteries. In general, the abdominal (proximal) ureter receives its blood supply medially, and the pelvic (distal) ureter receives its blood supply from a lateral direction.

Venous System

Although not as well defined, the layers of the venous system are similar to that of the arterial system. The layers from innermost to outermost are the intima, internal elastic lamina, media, external elastic lamina, and adventitia. As in the arterial system, the intima is composed of a layer of endothelial cells with subendothelial connective tissue. In the venous system, the internal and external elastic laminae are often poorly defined even in larger caliber vessels. The media layer of veins is significantly smaller than that of arteries and contains less vascular smooth muscle. Conversely, the venous adventitia is larger than the venous media and functions similar to the adventitia of the arterial system.

The venous system also differs from the arterial system with the presence of valves that prevent retrograde flow. These valves are typically bicuspid, and they function to maintain the full venous blood flow toward the heart.

The major retroperitoneal venous structure is the **inferior vena cava (IVC),** formed from the confluence of the **common iliac veins,** inferior and to the right of the aortic bifurcation (see Fig. 75.27). The IVC ascends anterior to the vertebral bodies and to the right of the aorta through the retroperitoneum (eFigs. 75.30 and 75.31 on ExpertConsult.com). The infrarenal portion runs parallel and inferior to the aorta. On its ascent, the IVC becomes more anterior, and at the level of the diaphragm the great vessels are separated by the right crus of the diaphragm. **The IVC then enters the thorax through the central tendon of the diaphragm at the level of T8 and drains into the inferior aspect of the right atrium.**

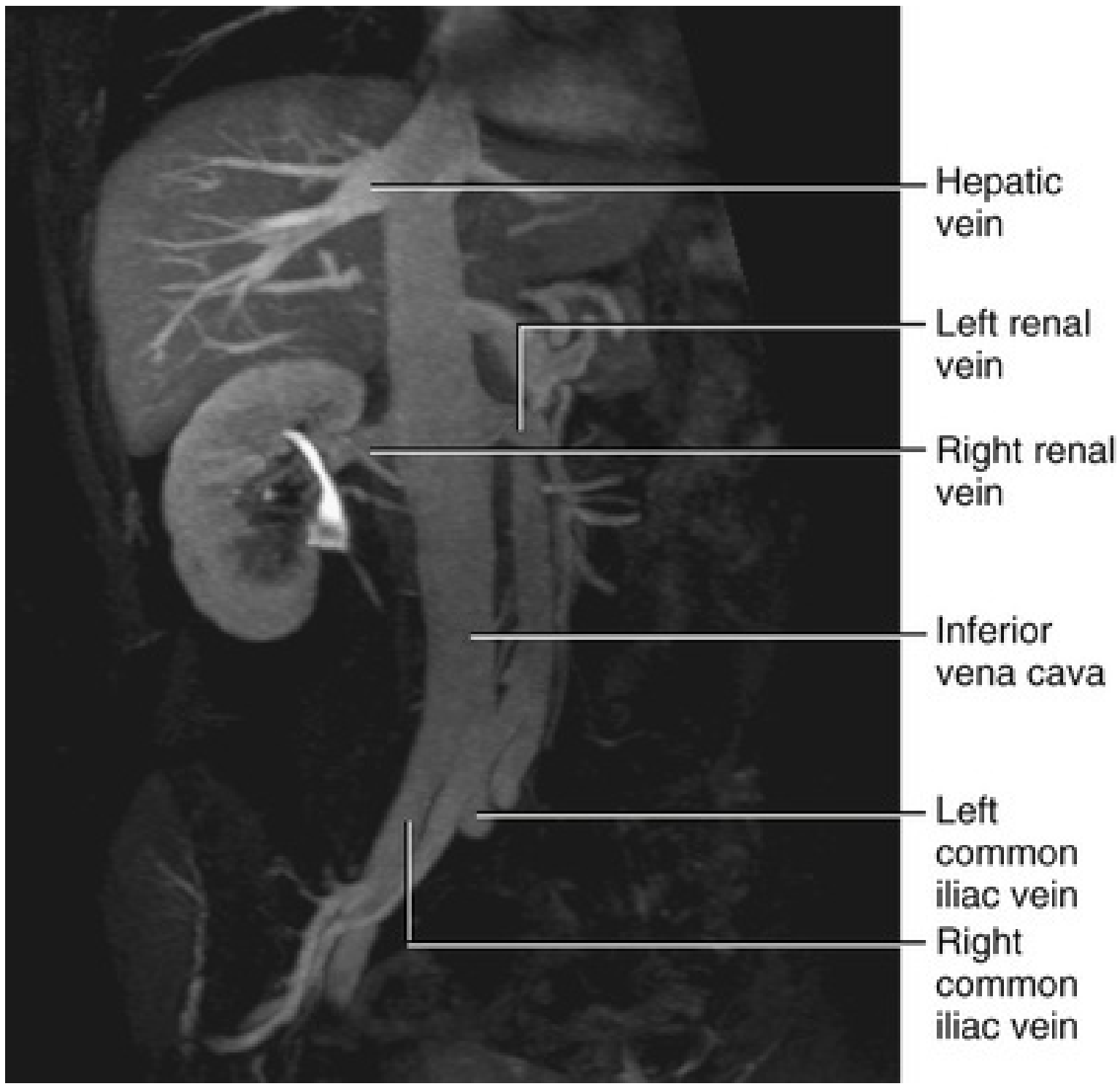
Hepatic vein
Left renal vein
Right renal vein
Inferior vena cava
Left common iliac vein
Right common iliac vein

EFIG. 75.30 Radiograph showing inferior vena cava and its tributaries. (From MacLennan GT: *Hinman's atlas of urosurgical anatomy,* ed 2, Philadelphia, 2012, Saunders.)

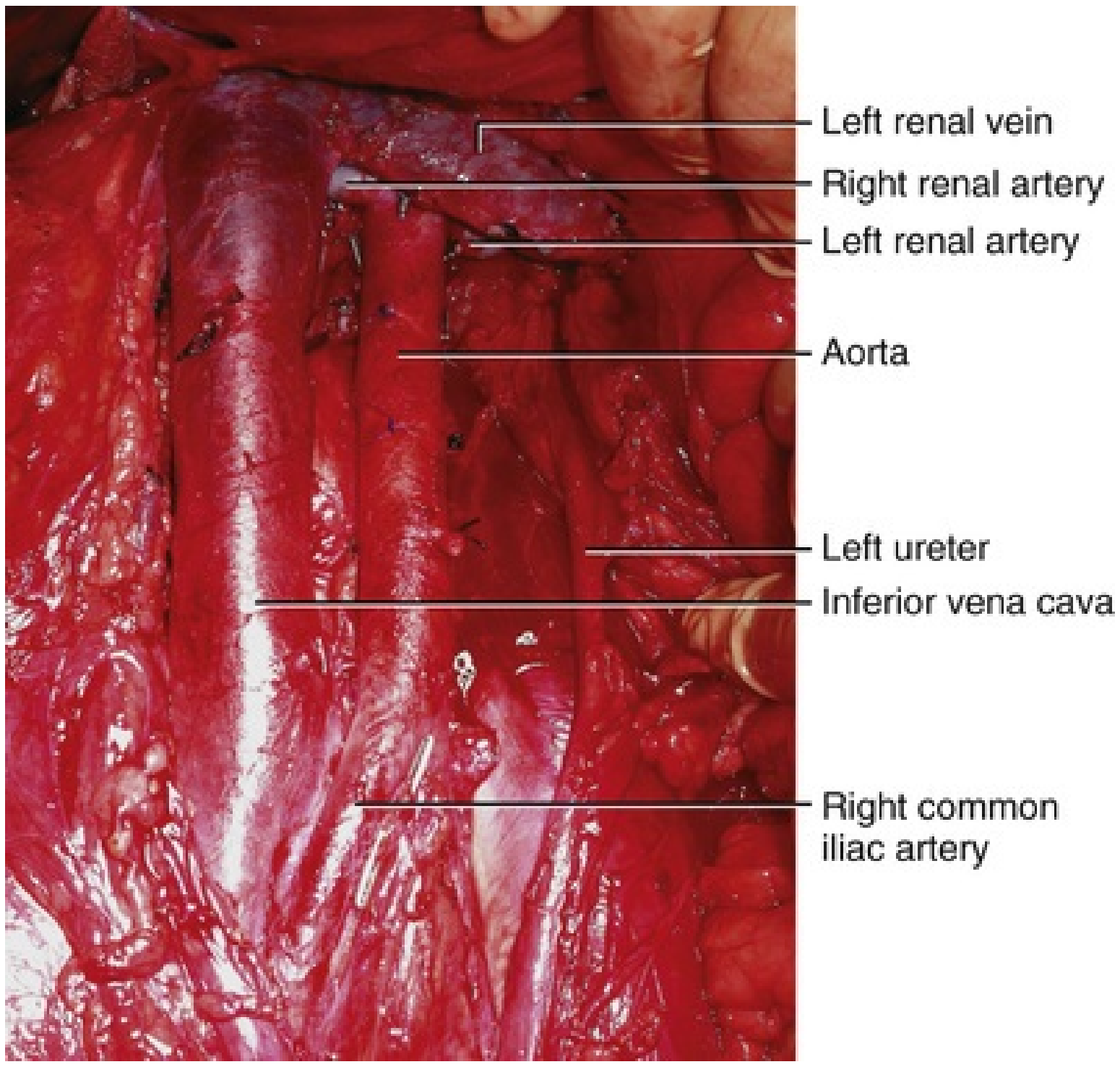
Left renal vein
Right renal artery
Left renal artery
Aorta
Left ureter
Inferior vena cava
Right common iliac artery

EFIG. 75.31 Intraoperative photograph of inferior vena cava and its tributaries. (From MacLennan GT: *Hinman's atlas of urosurgical anatomy,* ed 2, Philadelphia, 2012, Saunders.)

The venous system is more variable than the arterial system; however, many venous structures run parallel with their arterial equivalent. The **median (middle) sacral vein** runs with its respective artery and typically drains into the left common iliac vein; however, it may enter into the angle created by convergence of the two common iliac veins. Avoiding these veins during fixation of the proximal limb of mesh during sacral colpopexy procedures is critical.

The **ascending lumbar veins** drain the posterior abdominal wall and run posterior to the psoas muscle and lateral to the spinal column (eFig. 75.32 on ExpertConsult.com). They connect with the ipsilateral **lumbar veins,** which are variable in number and location compared with their arterial equivalents. These veins may assume a plexiform arrangement anterior to the vertebral bodies. **As the ascending lumbar veins enter the thorax, they become the hemiazygos vein on the left and the azygos vein on the right.**

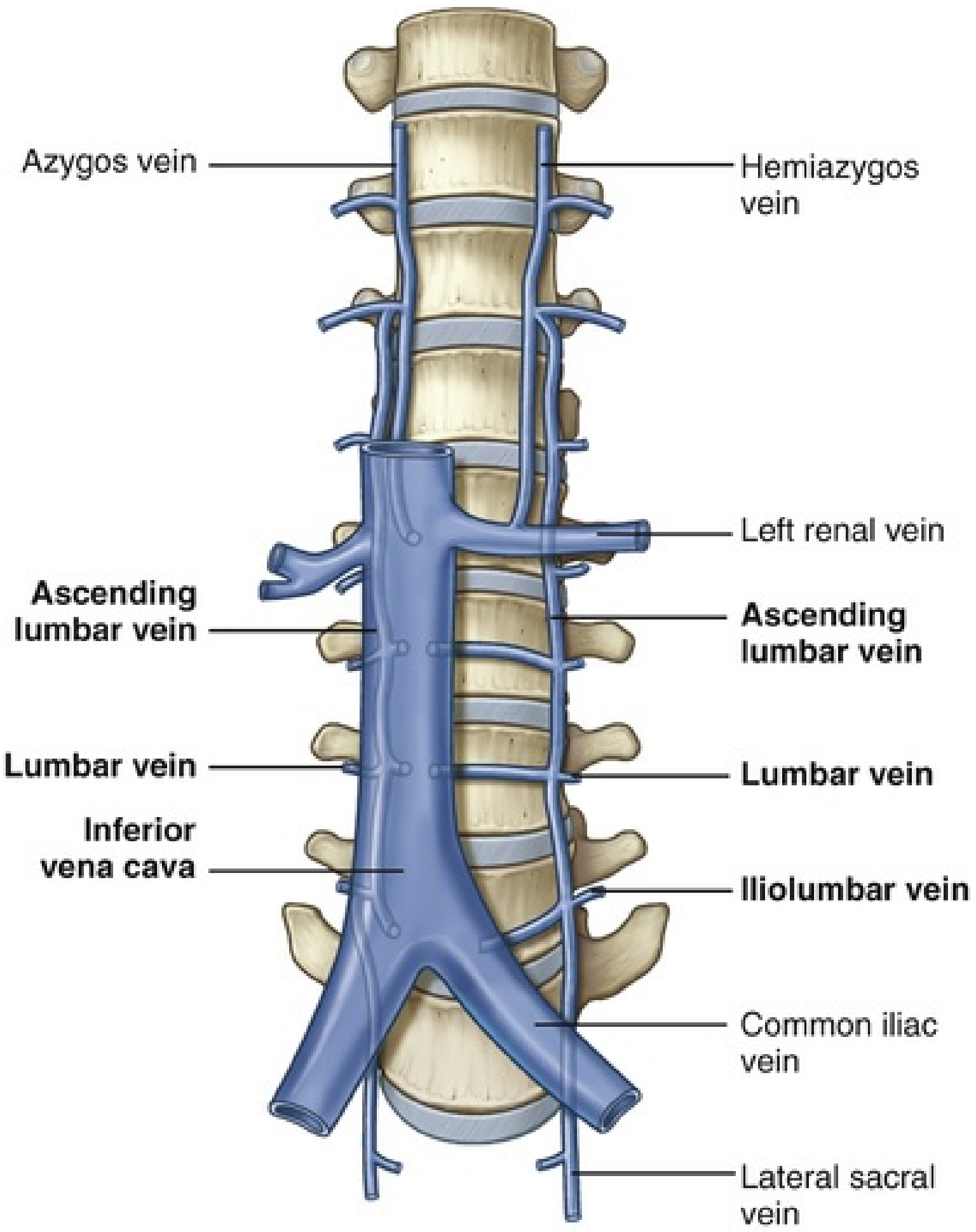
Azygos vein
Hemiazygos vein
Left renal vein
Ascending lumbar vein
Ascending lumbar vein
Lumbar vein
Lumbar vein
Inferior vena cava
Iliolumbar vein
Common iliac vein
Lateral sacral vein

EFIG. 75.32 Lumbar, azygos, and hemiazygos veins. (From Drake RL, Vogl AW, Mitchell AWM: *Gray's anatomy for students,* ed 2, Philadelphia, 2010, Churchill Livingstone.)

In males, the **gonadal veins (testicular veins)** receive drainage from the pampiniform plexus, which is the venous complex that emerges from the testes. The testicular veins ascend through the retroperitoneum medially, running lateral to the respective artery and anterior to the ipsilateral ureter. The left testicular vein typically enters the inferior aspect of the left renal vein at a right angle; however, it may enter the IVC directly. The right testicular vein typically enters into the right anterolateral aspect of the IVC; however, it may enter into the right renal vein in up to 10% of cases. **These anatomic differences have clinical significance because the increased length and perpendicular entry of the left testicular vein into the left renal vein may account for the increased incidence of left-sided varicoceles.** This anatomic configuration may result in some element of increased back pressure in the left testicular vein compared with the right side. With the relative rarity of unilateral right-sided varicocele, a sudden-onset right varicocele should increase suspicion for a renal or retroperitoneal malignancy causing obstruction and poor venous outflow (e.g., right side renal cell cancer with venous thrombus). This clinical scenario should warrant retroperitoneal imaging to rule out malignancy. Further clinical significance exists with this anatomic distinction after mobilization of the colon in transperitoneal retroperitoneal surgery. During the identification of the ureter on the right, the plane is developed lateral to the gonadal, which leaves the gonadal vein in a medial position. If the plane medial to the gonadal vein is developed, there is a risk of injury to the IVC and with elevation of the kidney avulsion of the gonadal may occur.

The **ovarian veins** receive drainage from the pampiniform plexus adjacent to the ovarian hilum and travel through the infundibulopelvic ligament. As with the gonadal veins in males, the left ovarian vein enters the left renal vein, and the right ovarian vein empties into the anterolateral wall of the vena cava.

The **renal veins** course anteriorly to the renal arteries and empty into the lateral aspects of the vena cava at the level of L1. The right and left renal veins differ in length and tributaries with the right being shorter and typically having no tributaries. In rare cases, the right gonadal vein or a lumbar vein may empty into the right renal vein. In one-sixth of cases, the renal vein is duplicated on the right side. The left renal vein is longer and typically receives the left gonadal vein at its caudal margin. At least one lumbar vein enters the left renal vein at or near the ostia of the gonadal vein. **The left adrenal vein is situated at the superior margin of the renal vein and, in most patients, inserts into the renal vein just medial to the gonadal vein.** The left adrenal vein occasionally is joined by the left inferior phrenic vein. The **right adrenal vein** is short, is single, has no tributaries, and drains directly into the posterolateral aspect of the vena cava. Although variable, the right inferior phrenic vein also typically drains into the superior portion of the IVC.

The gastrointestinal venous drainage does not mirror the arterial system as directly as the aforementioned venous structures. **The portal venous system receives venous blood from the bowel, spleen, pancreas, and gallbladder to be emptied into the liver** (Fig. 75.33). The **superior mesenteric vein (SMV)** receives venous drainage from the small intestine and the large intestine proximal to the splenic flexure. Tributaries of the SMV include the right gastroepiploic, anterior and posterior inferior pancreaticoduodenal, jejunal, ileal, ileocolic, right colic, and middle colic veins. The SMV is joined by the splenic vein to form the **portal vein.** The tributaries of the **splenic vein** are the inferior mesenteric, short gastric, left gastroepiploic, and pancreatic veins. The **inferior mesenteric vein** (IMV) drains into the SMV instead of the splenic vein in 40% of cases (Feller and Woodburne, 1961). The IMV receives the venous drainage from the colon distal to the splenic flexure. When the colon is reflected medially for left-sided retroperitoneal surgery, the IMV can often be identified within the mesocolon. Also during re-operative retroperitoneal procedures, the IMV can potentially be mistaken for the gonadal vein during colon mobilization as the mesentery may be adherent to the Gerota fascia.

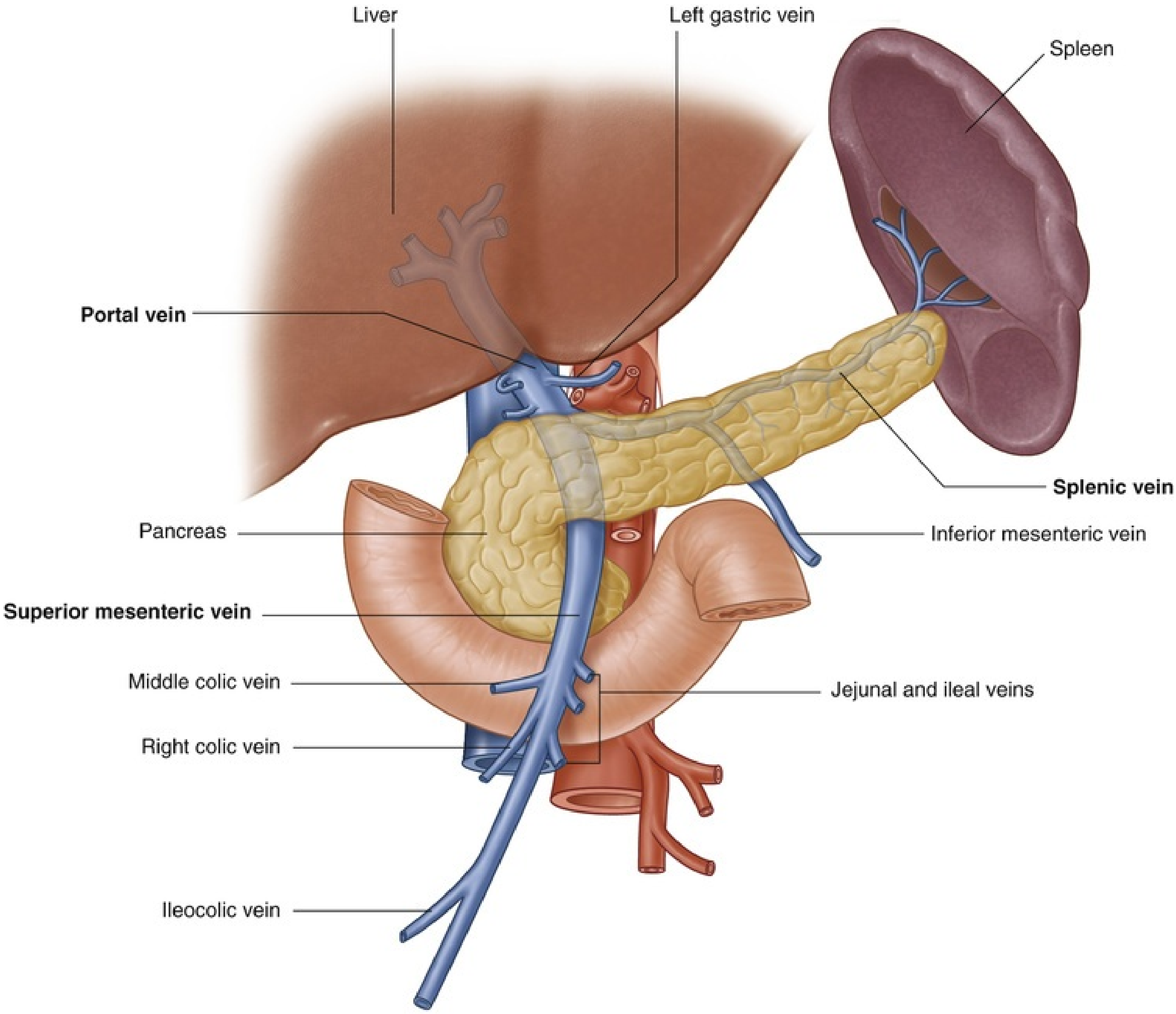
Liver
Left gastric vein
Spleen
Portal vein
Splenic vein
Pancreas
Inferior mesenteric vein
Superior mesenteric vein
Middle colic vein
Jejunal and ileal veins
Right colic vein
Ileocolic vein

FIG. 75.33 Portal vein and its tributaries. (From Drake RL, Vogl AW, Mitchell AWM: *Gray's anatomy for students,* ed 2, Philadelphia, 2010, Churchill Livingstone.)

The portal vein splits into right and left branches, and the venous blood enters the endothelial lined hepatic sinusoids. After passing through these sinusoids, the venous blood leaves the liver through the hepatic veins, which enter the anterior aspect of the IVC before it crosses the diaphragm into the thorax. There are two groups of hepatic veins: the upper group, typically larger in caliber, and the lower group, which are typically smaller. **Occlusion of these hepatic veins can lead to Budd-Chiari syndrome, which is a form of progressive liver failure that often manifests rapidly with jaundice, ascites, abdominal pain, and hepatomegaly.**

Key Points: Retroperitoneal Vasculature

- The blood supply to the adrenal artery arises from the inferior phrenic artery, the aorta, and the renal artery.
- The renal hila are at the level of L1, and the renal veins are anterior to the renal arteries.
- The paired gonadal arteries typically arising anterolaterally from the aorta below the renal arteries.
- The SMA to IMA collateral circulation occurs via the marginal artery of Drummond, which allows the IMA to be sacrificed without colonic ischemia.
- In general, the proximal ureter receives its blood supply medially, and the distal ureter receives its blood supply from a lateral direction.
- The left gonadal vein enters left renal vein at a right angle and the right gonadal vein enters into the IVC directly; this anatomic distinction results in higher rates of varicoceles on the left.

Lymphatic System

The lymphatic channels line tissue spaces and transport lymph to specialized areas of lymphoid tissue called lymph nodes. **The nodes typically have multiple afferent lymphatics and a single efferent lymphatic that drains into larger lymphatic vessels. Lymph generally flows cephalad from right to left until it returns to the venous circulation at the left innominate (brachiocephalic) vein.** Lymphatic fluid from the head, neck, right thorax, right arm, and right heart drains into the right innominate vein.

The lymphatic fluid from the pelvis and lower extremities drains into the internal iliac, external iliac, common iliac, obturator, and sacral nodes. These nodal regions then drain cephalad toward the lumbar nodes, whose efferent lymphatics form the lumbar trunks (Parker, 1935). The lumbar nodes are of considerable interest to the urologist because they provide the primary lymphatic drainage for structures supplied by lateral aortic arterial branches: the kidneys, adrenals, ureters, and gonads (Fig. 75.34). **For anatomic classification, three groups of lumbar nodes can be defined: left lumbar (aortic), interaortocaval (interaorticovenous), and right lumbar (caval) nodal groups.**

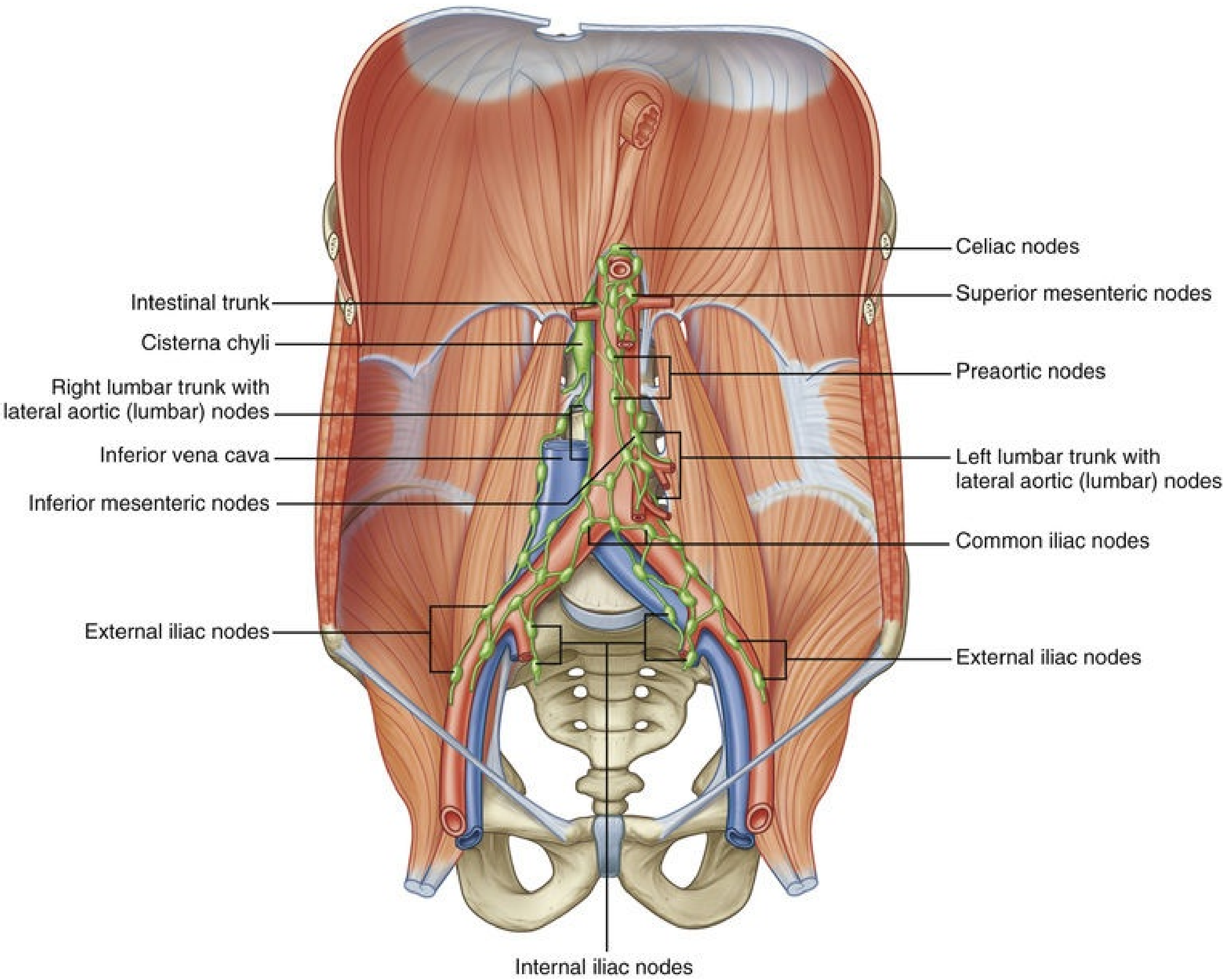
Celiac nodes
Intestinal trunk
Superior mesenteric nodes
Cisterna chyli
Preaortic nodes
Right lumbar trunk with lateral aortic (lumbar) nodes
Inferior vena cava
Left lumbar trunk with lateral aortic (lumbar) nodes
Inferior mesenteric nodes
Common iliac nodes
External iliac nodes
External iliac nodes
Internal iliac nodes

FIG. 75.34 Retroperitoneal lymphatics. (From Drake RL, Vogl AW, Mitchell AWM: *Gray's anatomy for students,* ed 2, Philadelphia, 2010, Churchill Livingstone.)

The left lumbar group includes the preaortic, left para-aortic (periaortic), and retroaortic nodes. The preaortic nodes are located anterior to the abdominal aorta, around the major anterior arterial branches that supply the gastrointestinal tract. The celiac, superior mesenteric, and inferior mesenteric nodes receive lymphatic drainage based on the anatomy of the similarly named arteries that supply the corresponding abdominal viscera. The efferents of these lymphatics coalesce to form the intestinal trunk. The left para-aortic region includes the nodes lateral to the midline of the aorta and medial to the left ureter. The retroaortic nodes are variably present and located between the aorta and vertebrae. The interaortocaval nodal group extends from the midline of the IVC to the midline of the aorta.

The right lumbar group includes the precaval, right paracaval, and retrocaval nodes. The precaval nodes are located on the anterior wall of the IVC. The right paracaval region includes the area lateral to the midline of the IVC, extending to the right ureter. The retrocaval nodes are present between the vena cava and the psoas muscle.

The testes are significant because they are embryologically retroperitoneal and have retroperitoneal blood supply and primary lymphatic drainage. In a practical discussion of testis malignancy, the three significant nodal regions are the left para-aortic, interaortocaval, and right paracaval. Elegant studies of early metastasis demonstrated the drainage pattern of the testes. **The left testis drains to the left para-aortic nodes with some drainage to the interaortocaval nodes.** There is no significant drainage to the right paracaval nodes, which is consistent with the general direction of lymphatic flow from right to left. **The right testis drains primarily to the interaortocaval nodes with some drainage to the right paracaval nodes. The left para-aortic region receives a small but appreciable amount of lymphatic drainage from the right testis, consistent with the aforementioned right-to-left flow.**

The efferent lymphatics of the lateral lumbar nodes coalesce to form the right and left lumbar trunks. Posterior to the right side of the abdominal aorta and anterior to the L1 and L2 vertebrae, these trunks come together at a saccular dilated structure known as the **cisterna chyli.** This marks the beginning of the **thoracic duct,** which runs cephalad posterior to the aorta and empties into the left innominate vein.

Key Points: Retroperitoneal Lymphatic System

- Testes are embryologically retroperitoneal and have retroperitoneal blood supply and primary lymphatic drainage.
- The lymph of the left testis drains to the left para-aortic nodes with some drainage to the interaortocaval nodes.
- The right testis drains primarily to the interaortocaval nodes with some to the right paracaval nodes and a small amount to the left para-aortic region.
- The lymphatic drainage of the testicles is consistent with global lymphatic flow from right to left.

Nervous Structures

The nervous structures of the retroperitoneum can be divided into the autonomic nervous system and the somatic nervous system. The autonomic system supplies efferent and afferent innervation to the abdominal viscera, blood vessels, and smooth muscle. The somatic system supplies efferent and afferent innervation to skeletal muscle, skin, and peritoneum.

Autonomic Nervous System

The general structure of the **autonomic nervous system** consists of two nerves with two cell bodies. The **preganglionic neuron** has a cell body within the central nervous system and an axon that extends into the peripheral nervous system, synapsing with another neuron within a ganglion. The second neuron is referred to as a **postganglionic neuron,** and its axon enters the structure in which it provides innervation. One caveat to this general structure is the neural anatomy of the adrenal gland. **The preganglionic fibers synapse directly with the cells of the adrenal medulla, resulting in release of catecholamines. The adrenal can be considered a specialized ganglion of the autonomic nervous system.**

The autonomic system can be divided further into the parasympathetic and sympathetic nervous systems. The **parasympathetic nervous system** has craniosacral outflow because the preganglionic fibers originate from cranial nerves III, VII, IX, and X and from the ventral rami of the second, third, and fourth sacral nerves. The preganglionic fibers from S2-S4 form the pelvic splanchnic nerves, which provide parasympathetic innervation to the pelvic and abdominal viscera, which often contain the postganglionic parasympathetic fibers within their walls. The vagus nerve (cranial nerve X) also provides preganglionic parasympathetic fibers to the thoracic, abdominal, and pelvic viscera.

In contrast to the parasympathetic system, the preganglionic fibers of the **sympathetic nervous system** originate between the first thoracic and the second lumbar vertebral levels. These fibers exit the spinal cord from T1 to L2 through the ventral root and course through the corresponding spinal nerve and anterior rami into the ipsilateral sympathetic trunk (Fig. 75.35). The fibers then run medial to the psoas muscle along the anterolateral aspect of the spine. **The**

paired sympathetic trunks are in close proximity to the lumbar arteries and veins, which cross them perpendicularly. The preganglionic fibers can synapse within the ganglia of the sympathetic trunk and send forth postganglionic fibers to the body wall and lower extremities. The preganglionic fibers also may leave the trunk as splanchnic nerves to synapse with the ganglia of the autonomic plexuses of the aorta (Fig. 75.36).

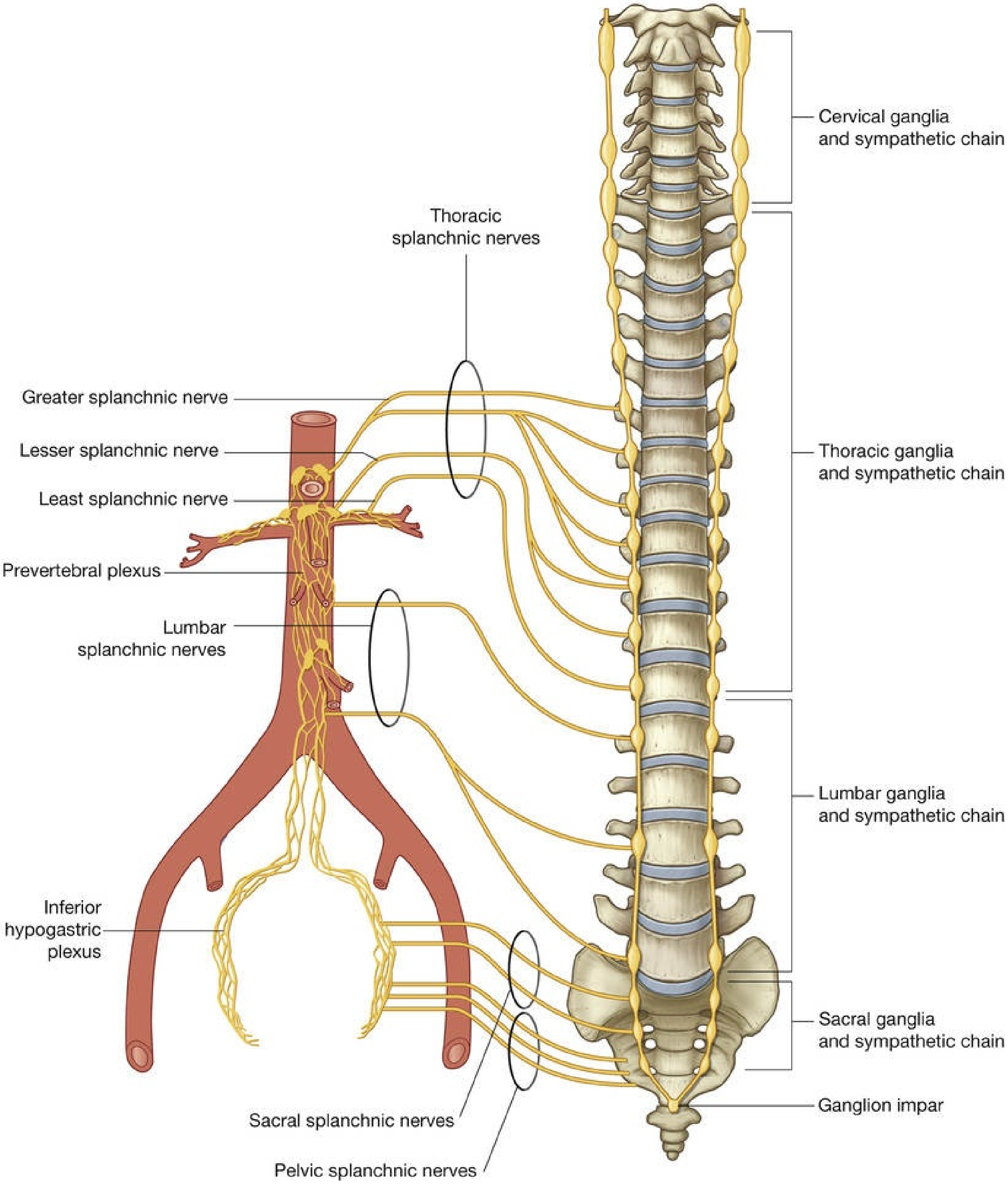
Cervical ganglia and sympathetic chain
Thoracic splanchnic nerves
Greater splanchnic nerve
Lesser splanchnic nerve
Least splanchnic nerve
Thoracic ganglia and sympathetic chain
Prevertebral plexus
Lumbar splanchnic nerves
Lumbar ganglia and sympathetic chain
Inferior hypogastric plexus
Sacral ganglia and sympathetic chain
Ganglion impar
Sacral splanchnic nerves
Pelvic splanchnic nerves

FIG. 75.35 Sympathetic chain and splanchnic nerves. (From Drake RL, Vogl AW, Mitchell AWM: *Gray's anatomy for students,* ed 2, Philadelphia, 2010, Churchill Livingstone.)

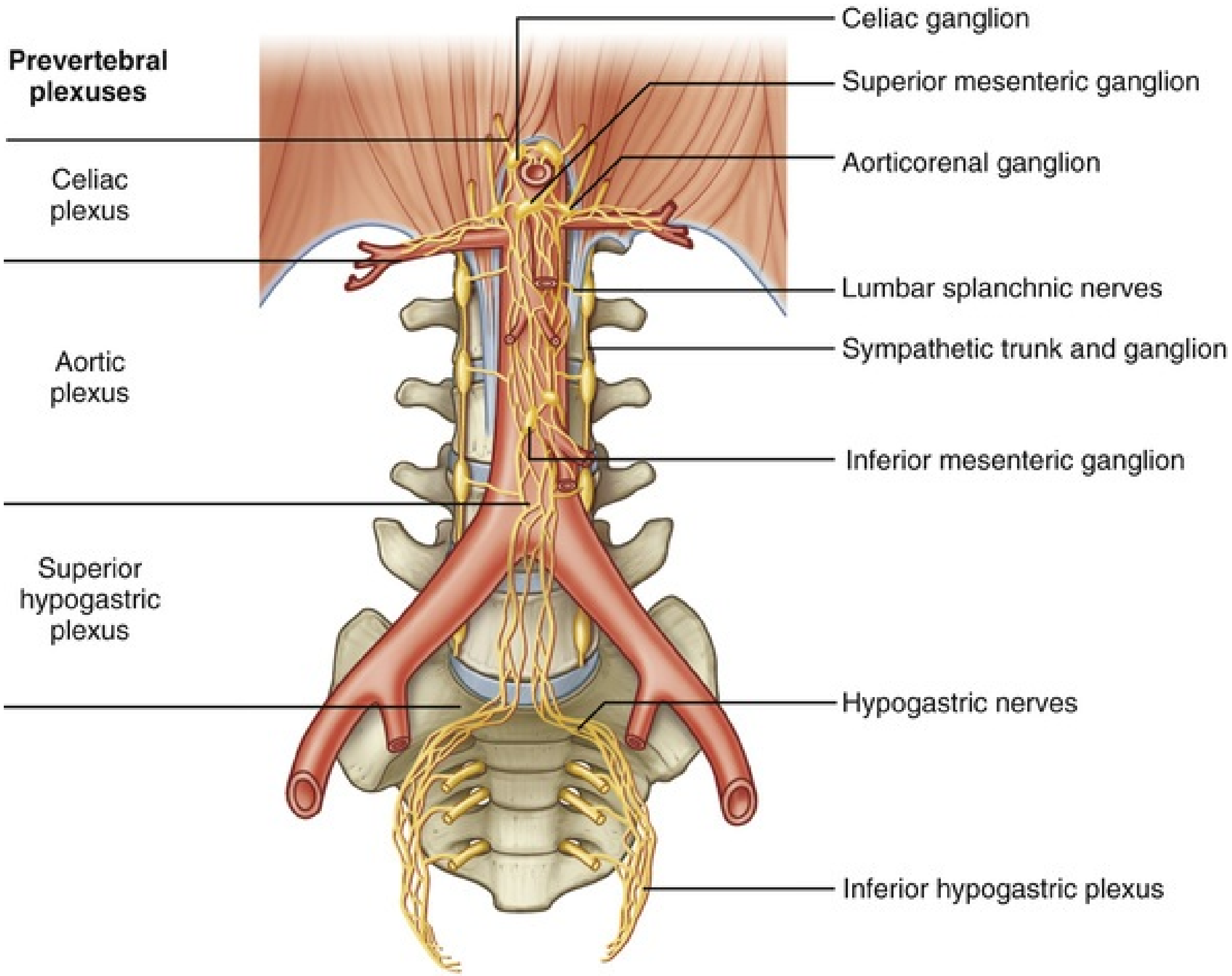
Prevertebral plexuses
Celiac plexus
Aortic plexus
Superior hypogastric plexus
Celiac ganglion
Superior mesenteric ganglion
Aorticorenal ganglion
Lumbar splanchnic nerves
Sympathetic trunk and ganglion
Inferior mesenteric ganglion
Hypogastric nerves
Inferior hypogastric plexus

FIG. 75.36 Autonomic plexuses associated with branches of the aorta. (From Drake RL, Vogl AW, Mitchell AWM: *Gray's anatomy for students,* ed 2, Philadelphia, 2010, Churchill Livingstone.)

The first and largest of these plexuses is the celiac plexus, which contains paired ganglia that lie lateral to the celiac artery. Much of the autonomic innervation to the kidney, adrenal, renal pelvis, and ureter runs through this plexus. Some of the autonomic innervation for the testes passes through this plexus and travels caudally with the testicular artery. The renal autonomic plexus is continuous with the celiac plexus and forms adjacent to the renal arteries. It contains the aorticorenal ganglion, which is an inferior extension of the celiac ganglion.

Much of the sympathetic innervation to the pelvic viscera travels through the superior and inferior hypogastric plexuses, which are contiguous. The superior hypogastric plexus originates at the caudal extent of the abdominal aorta and extends to the anterior surface of the fifth lumbar vertebra. **Extensive retroperitoneal dissection that causes disruption of these plexuses may result in loss of seminal vesicle emission or failure of bladder neck closure,**

resulting in retrograde ejaculation.

Confusion may arise with the term *splanchnic* used for nerves of the parasympathetic and the sympathetic systems (see Fig. 75.35). For clarification, the thoracic splanchnics (greater, lesser, and least), lumbar splanchnics, and sacral splanchnics carry sympathetic fibers from the paired sympathetic trunks to the autonomic plexuses, whereas the pelvic splanchnics carry parasympathetic fibers from the sacral outflow.

Somatic Nervous System

The somatic sensory and motor nerves of the lower abdomen and lower extremities originate in the retroperitoneum. They form the lumbosacral plexus from the anterior rami of the lumbar and sacral nerves along with T12 (eFig. 75.37 on ExpertConsult.com). The nerves arising from this plexus are close to the psoas muscle, with the superior nerves piercing the muscle, whereas the inferior nerves travel medial to the muscle body (Fig. 75.38). This plexus provides the cutaneous sensory innervation to the lower extremities (Fig. 75.39 and Table 75.4).

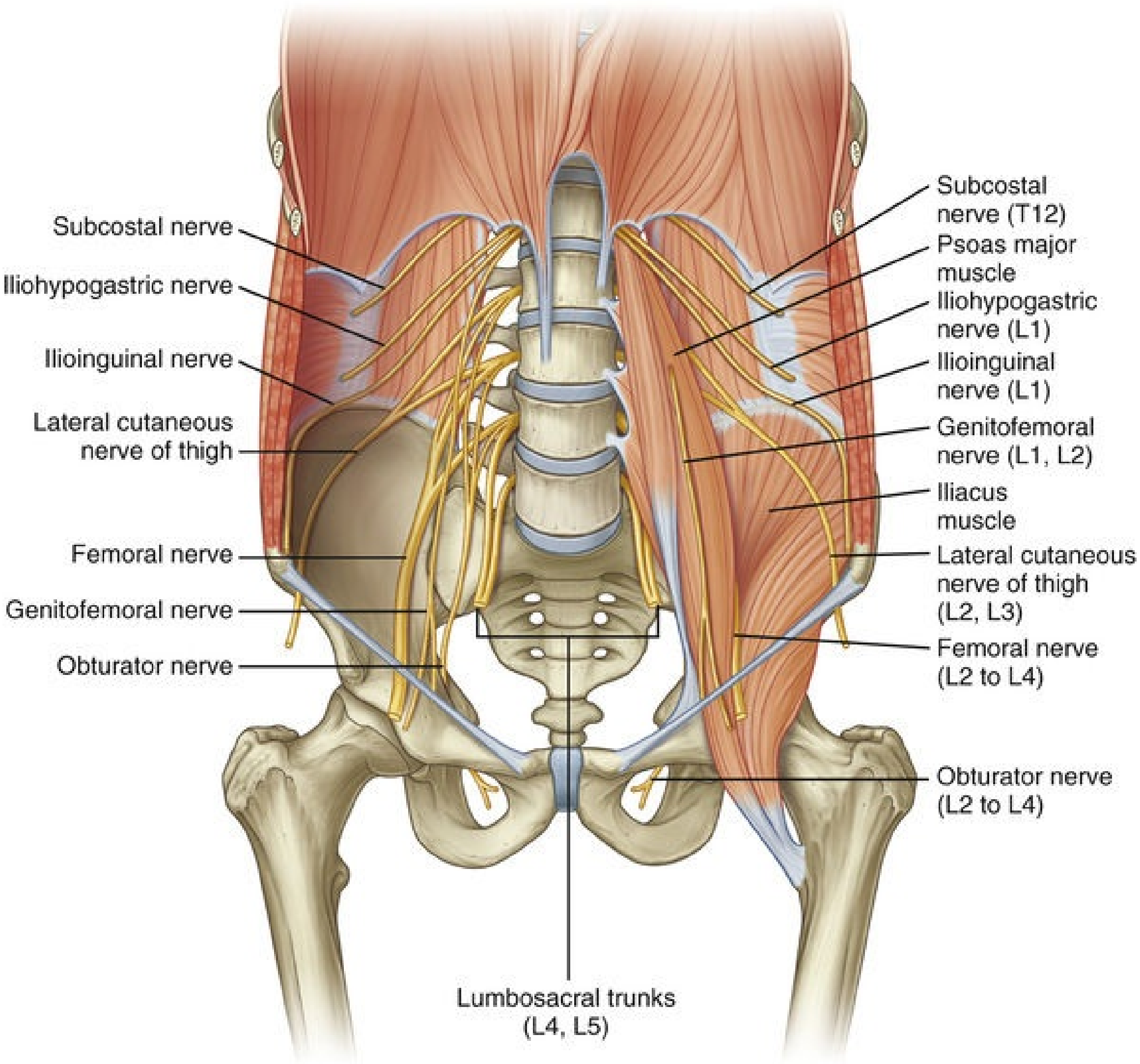
Subcostal nerve
Iliohypogastric nerve
Ilioinguinal nerve
Lateral cutaneous nerve of thigh
Femoral nerve
Genitofemoral nerve
Obturator nerve
Subcostal nerve (T12)
Psoas major muscle
Iliohypogastric nerve (L1)
Ilioinguinal nerve (L1)
Genitofemoral nerve (L1, L2)
Iliacus muscle
Lateral cutaneous nerve of thigh (L2, L3)
Femoral nerve (L2 to L4)
Obturator nerve (L2 to L4)
Lumbosacral trunks (L4, L5)

FIG. 75.38 Lumbar plexus in the posterior abdominal region. (From Drake RL, Vogl AW, Mitchell AWM: *Gray's anatomy for students,* ed 2, Philadelphia, 2010, Churchill Livingstone.)

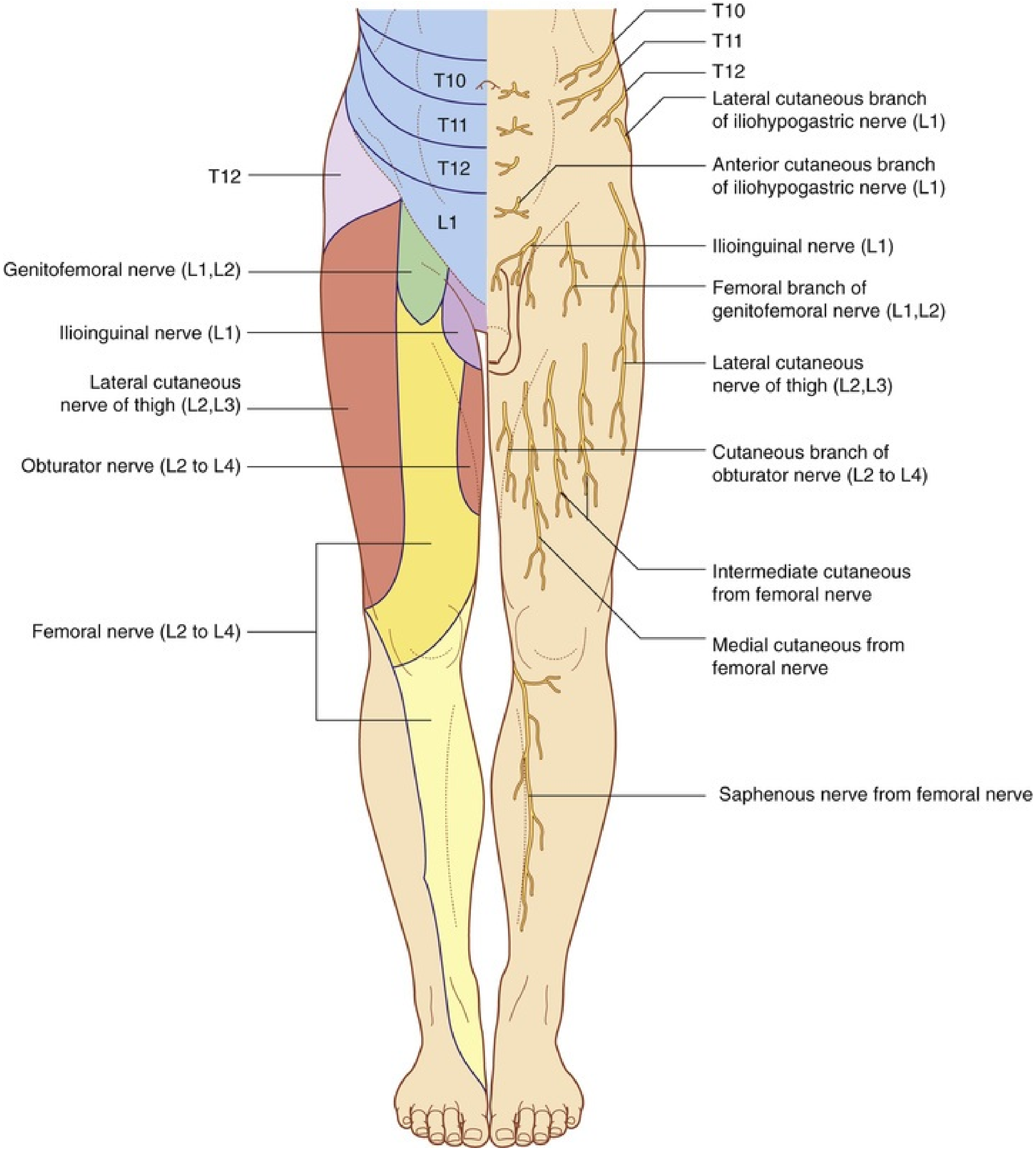
T10
T11
T12
Lateral cutaneous branch of iliohypogastric nerve (L1)
T10
T11
T12
T12
Anterior cutaneous branch of iliohypogastric nerve (L1)
L1
Ilioinguinal nerve (L1)
Genitofemoral nerve (L1,L2)
Femoral branch of genitofemoral nerve (L1,L2)
Ilioinguinal nerve (L1)
Lateral cutaneous nerve of thigh (L2,L3)
Lateral cutaneous nerve of thigh (L2,L3)
Cutaneous branch of obturator nerve (L2 to L4)
Obturator nerve (L2 to L4)
Intermediate cutaneous from femoral nerve
Femoral nerve (L2 to L4)
Medial cutaneous from femoral nerve
Saphenous nerve from femoral nerve

FIG. 75.39 Cutaneous distribution of the nerves from the lumbar plexus. (From Drake RL, Vogl AW, Mitchell AWM: *Gray's anatomy for students,* ed 2, Philadelphia, 2010, Churchill Livingstone.)

TABLE 75.4

Branches of the Lumbosacral Plexus

BRANCH	ORIGIN	SPINAL SEGMENTS	MOTOR FUNCTION	SENSORY FUNCTION

Subcostal	Anterior ramus T12	T12	Muscles of abdominal wall	Skin over hip
Iliohypogastric	Anterior ramus L1	L1	Internal oblique and transversus abdominis	Posterolateral gluteal skin and skin in pubic region
Ilioinguinal	Anterior ramus L1	L1	Internal oblique and transversus abdominis	Skin in upper medial thigh and the skin over either the root of the penis and anterior scrotum or the mons pubis and labium majus
Genitofemoral	Anterior rami L1 and L2	L1, L2	Genital branch: male cremasteric muscle	Genital branch: skin of anterior scrotum or skin of mons pubis and labium majus
				Femoral branch: skin of upper anterior thigh
Lateral cutaneous nerve of the thigh	Anterior rami L2 and L3	L2, L3	None	Skin on anterior and lateral thigh to the knee
Obturator	Anterior rami L2-L4	L2-L4	Obturator externus, pectineus, and muscles in medial compartment of thigh	Skin on medial aspect of thigh
Femoral	Anterior rami L2-L4	L2-L4	Iliacus, pectineus, and muscles in anterior compartment of thigh	Skin on anterior thigh and medial surface of leg

Modified from Drake RL, Vogl AW, Mitchell AWM: *Gray's anatomy for students*, Philadelphia, 2005, Churchill Livingstone.

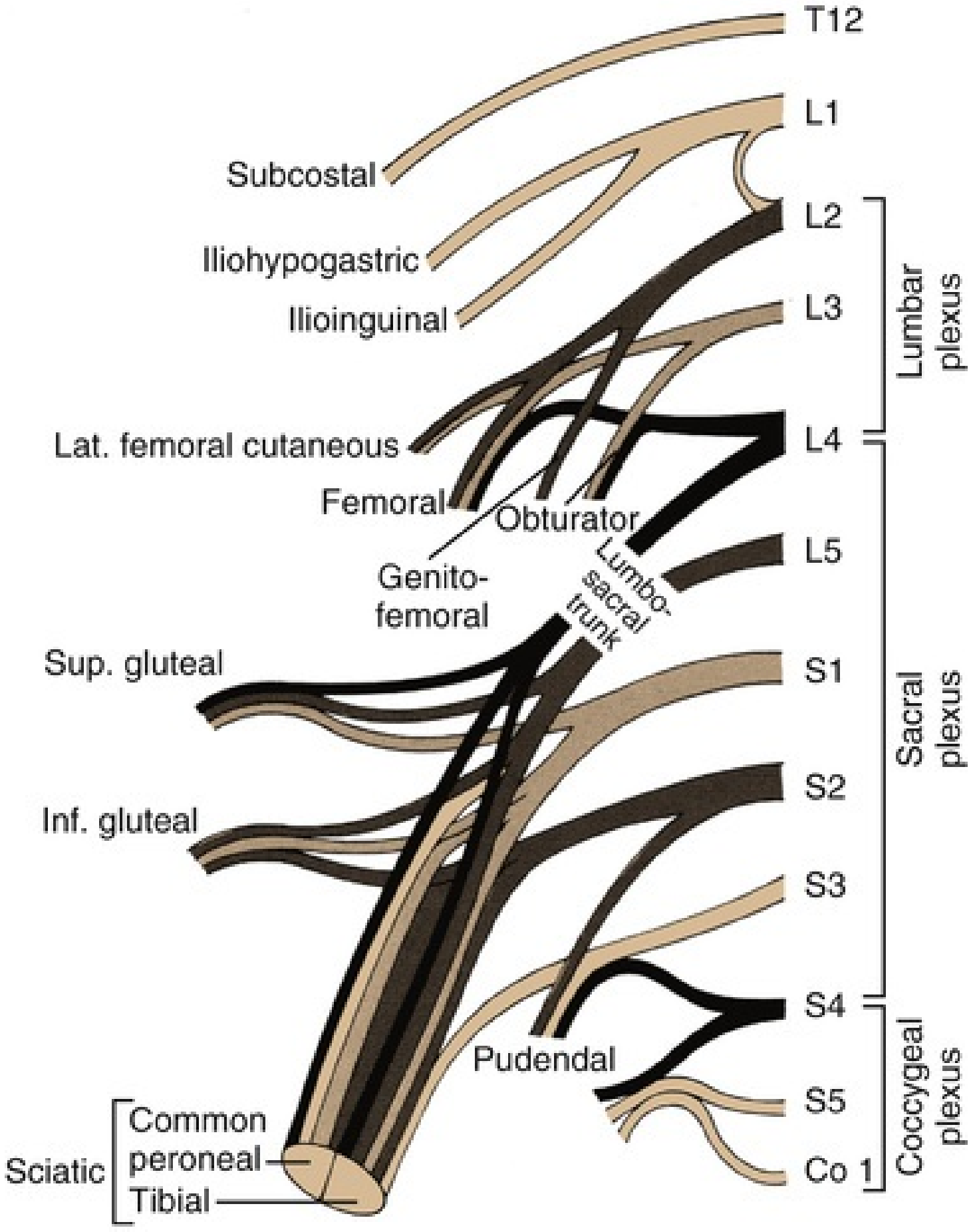
T12
L1
Subcostal
L2
Iliohypogastric
Ilioinguinal
L3
Lumbar plexus
Lat. femoral cutaneous
L4
Femoral
Obturator
Genito-femoral
Lumbo-sacral trunk
L5
Sup. gluteal
S1
Sacral plexus
S2
Inf. gluteal
S3
S4
Pudendal
Coccygeal plexus
S5
Common peroneal
Sciatic
Tibial
Co 1

EFIG. 75.37 Diagrammatic representation of the lumbosacral nervous plexus.

The **subcostal nerve** is an extension of the 12th thoracic nerve and runs inferior to the 12th rib. The **ilioinguinal and iliohypogastric nerves** arise from the anterior ramus of L1. These three nerves run laterally over the anterior aspect of the quadratus lumborum and travel through the transversus abdominis to run deep to the internal oblique muscle. They provide innervation to the muscles of the abdominal wall and sensory innervation to the posterolateral gluteal skin, upper medial thigh, and genitalia.

The **genitofemoral nerve** originates from L1 and L2 and courses anterior and parallel to the psoas muscle. The nerve typically divides near the level of the inguinal ligament. The **femoral branch** passes under the inguinal ligament and enters the femoral sheath to supply sensation to the upper anterior thigh. The **genital branch** enters the inguinal canal at the deep internal ring to provide motor innervation to the cremaster muscle. This motor component allows for contraction of the muscle during the cremasteric reflex. In addition to the motor component, the genital branch supplies sensation to the anterior scrotum in males and the mons pubis and labium majus in females. The genitofemoral nerve may be injured during a psoas hitch procedure (suture placement) and laparoscopic varicocelectomy (ligation). The **lateral cutaneous nerve of the thigh** (lateral femoral cutaneous nerve) arises from L2 and L3 and provides sensory innervation to the anterior and lateral thigh.

The **obturator nerve** originates from the anterior rami of L2-L4 posterior to the psoas muscle and courses inferiorly to the obturator canal. **The function of the obturator nerve includes hip adduction via motor innervation to the medial thigh compartment, which is of clinical significance during lateral transurethral resection and pelvic lymph node dissection.** Electrocautery employed during a transurethral resection of bladder tumor (TURBT) procedure may result in obturator nerve stimulation with subsequent rapid, forceful hip adduction. If this potential event is not anticipated and accounted for, severe bladder perforation may occur.

With its origin from the anterior rami of L2-L4, the **femoral nerve** provides efferent motor input to the muscles of the anterior thigh as well as the iliacus and pectineus, which are responsible for knee extension and hip flexion, respectively. The femoral nerve also gives sensory innervation to the skin over the anterior medial lower extremity. Compression of the femoral nerve may occur intraoperatively with placement of retractor blades inferolaterally against the inguinal ligament. Compression injury may result in a motor palsy to the quadriceps muscle, impairing extension at the knee. In addition, a stretch injury to the femoral nerve may occur with prolonged hip flexion in low lithotomy position used during minimally invasive pelvic surgery.

The **sciatic nerve** receives input from L4-S3 and provides the bulk of motor and sensory input to the lower extremities, including motor innervation to the posterior thigh compartment and all muscles in the leg and foot. Injury to this nerve may occur secondary to prolonged hip hyperflexion used during a high lithotomy position for vaginal and urethral procedures.

See ExpertConsult.com for Videos 75.1▶, 75.2▶, 75.3▶, and 75.4▶, which show procedures related to this chapter.

Key Points: Nervous Structures

- The parasympathetic autonomic nervous system has craniosacral outflow, and the postganglionic fibers are often contained within the walls of the innervated viscera.

- The preganglionic sympathetic nervous system fibers exit from the spinal cord from T1 to L2 and may synapse within the sympathetic trunk or within the autonomic plexuses.
- The somatic nervous system provides sensory and motor innervation to the pelvis and lower extremities through the lumbosacral plexus.

Suggested Readings

Drake RL, Vogl AW, Mitchell AWM. *Gray's anatomy for students*. 2nd ed. Churchill Livingstone: Philadelphia; 2010.

MacLennan GT. *Hinman's atlas of urosurgical anatomy*. 2nd ed. Saunders: Philadelphia; 2012.

Smith JA, Howards SS, Preminger GM. *Hinman's atlas of urologic surgery*. 3rd ed. Saunders: Philadelphia; 2012.

References

Budhiraja V, Rastogi R, Anjankar V, et al. Supernumerary renal arteries and their embryological and clinical correlation: a cadaveric study from North India. *ISRN Anat*. 2013;405712.

Coffey JC, O'Leary DP. The mesentery: structure, function, and role in disease. *Lancet Gastroenterol Hepatol*. 2016;1(3):238–247.

Culligan K, Coffey JC, Kiran RP, et al. The mesocolon: a prospective observational study. *Colorectal Dis*. 2012;14:421–428.

Feller I, Woodburne RT. Surgical anatomy of the abdominal aorta. *Ann Surg*. 1961;154(Suppl 6):239–252.

Lim JH, Kim B, Auh YH. Anatomical communications of the perirenal space. *Br J Radiol*. 1998;71(844):450–456.

MacLennan GT. *Hinman's atlas of urosurgical anatomy*. 2nd ed. Saunders: Philadelphia; 2012.

Miralis P, Skandalakis JE. Surgical anatomy of the retroperitoneal spaces—part I: embryogenesis and anatomy. *Am Surg*. 2009;75(11):1091–1097.

Miralis P, Skandalakis JE. Surgical anatomy of the retroperitoneal spaces—part II: the architecture of the retroperitoneal space. *Am Surg*. 2010;76(1):33–42.

Miralis P, Skandalakis JE. Surgical anatomy of the retroperitoneal spaces—part III: retroperitoneal blood vessels and lymphatics. *Am Surg*. 2010;76(2):139–144.

Miralis P, Skandalakis JE. Surgical anatomy of the retroperitoneal spaces—part IV: retroperitoneal nerves. *Am Surg*. 2010;76(3):253–262.

Miralis P, Skandalakis JE. Surgical anatomy of the retroperitoneal spaces—part V: surgical applications and complications. *Am Surg*. 2010;76(4):358–364.

Parker AE. Studies on the main posterior lymph channels of the abdomen and their connections with the lymphatics of the genitourinary system. *Am J Anat*. 1935;56:409–443.
Tobin CE. The renal fascia and its relation to the transversalis fascia. *Anat Rec*. 1944;89:295–311.
Turba UC, Uflacker R, Bozlar U, et al. Normal renal arterial anatomy assessed by multidetector CT angiography: are there differences between men and women? *Clin Anat*. 2009;22(2):236–242.
Walker TG. Mesenteric vasculature and collateral pathways. *Semin Intervent Radiol*. 2009;26(3):167–174.

Neoplasms of the Testis

Andrew J. Stephenson MD, MBA, FRCSC, FACS, Timothy D. Gilligan MD, MS, FASCO

Neoplasms of the testis comprise a morphologically and clinically diverse group of tumors, more than 95% of which are germ cell tumors (GCTs). GCTs are broadly categorized as seminoma and nonseminoma (NSGCT) because of differences in natural history and treatment. GCT is a relatively rare malignancy, accounting for 1% to 2% of cancers among adult males in the United States. Approximately 95% of GCTs arise in the testis, and 5% are extragondal in origin. With the development of cisplatin-based chemotherapy and the integration of surgery, GCTs have become a model of a curable neoplasm and serve as a paradigm for the multidisciplinary treatment of cancer (Einhorn, 1981). In the era before cisplatin, the cure rate for patients with advanced GCT was 5% to 10%. Currently, the long-term survival for men with metastatic GCT is 80% to 90%. With the successful cure of patients, an important treatment objective is minimizing treatment-related toxicity without compromising curability. Mortality from GCT is due to inherent resistance to platin chemotherapy and the failure to fully eradicate residual disease elements in the early course of therapy.

Non-GCT tumors of the testis are rare and include sex cord-stromal tumors, lymphoid and hematopoietic tumors, tumors of the collecting duct and rete testis, and tumors of the testicular adnexa. A classification of testis neoplasms is outlined in Table 76.1.

TABLE 76.1

2016 World Health Organization Classification of Testis Neoplasms

GERM CELL TUMORS OF THE TESTIS
Germ cell tumors derived from germ cell neoplasia in situ
Noninvasive germ cell neoplasia
Germ cell neoplasia in situ

  - Specific forms of intratubular germ cell neoplasia
  - Seminomatous tumors of a single histologic type (pure seminoma)
  - Seminoma
  - Seminoma with syncytiotrophoblast cells
  - Nonseminomatous germ cell tumors of a single histologic type
  - Embryonal carcinoma
  - Yolk sac tumor, postpubertal type
  - Trophoblastic tumors
  - Choriocarcinoma
  - Nonchoriocinomatous trophoblastic tumors
  - Placental site trophoblastic tumor
  - Epithelioid trophoblastic tumor
  - Cystic trophoblastic tumor
  - Teratoma, postpubertal type
  - Teratoma with somatic-type malignancy
  - Nonseminomatous germ cell tumors of more than one histologic type
  - Mixed germ cell tumors
  - Germ cell tumors of unknown type
  - Regressed germ cell tumors
- Germ cell tumors unrelated to germ cell neoplasia in situ
  - Spermatocytic tumor
  - Teratoma, prepubertal type
  - Dermoid cyst
  - Epidermoid cyst
  - Well-differentiated neuroendocrine tumor (monodermal teratoma)
  - Mixed teratoma and yolk sac tumor, prepubertal type
  - Yolk sac tumor, prepubertal type

SEX CORD-STROMAL TUMORS OF THE TESTIS

- Pure tumors
- Leydig cell tumor
- Malignant Leydig cell tumor
- Sertoli cell tumor
- Malignant Sertoli cell tumor
- Large cell calcifying Sertoli cell tumor
- Intratubular hyalinizing Sertoli cell neoplasia
- Granulosa cell tumor
- Adult granulosa cell tumor
- Juvenile granulosa cell tumor
- Tumors in the fibroma-thecoma group
- Mixed and unclassified sex cord-stromal tumors
- Mixed sex cord-stromal tumor
- Unclassified sex cord-stromal tumor

Data from Williamson SR, Delahunt B, Magi-Galluzzi C, et al.: The World Health Organization 2016 classification of testicular germ cell tumours: a review and update from the International Society of Urological Pathology Testis Consultation Panel. *Histopathology* 70:335–346, 2017.

Germ Cell Tumors

Epidemiology

In 2018 an estimated 9310 men were diagnosed with testis cancer in the United States, and 400 will die from this disease (Siegel et al., 2018). **In the United States, testis cancer is the most common malignancy among men aged 20 to 40 years and the second most common cancer after leukemia among males aged 15 to 19 years** (Howlader et al., 2017). Testis tumors are most common between the ages of 15 and 55. The incidence rate rises rapidly after puberty, peaking at ages 25 to 35, and then slowly declines such that men aged 50 to 54 years have the same incidence as males aged 15 to 19. **The incidence of bilateral GCT is approximately 2%** (Fossa et al., 2005). The majority of bilateral GCTs are metachronous and occur over an average interval of 5 years. Discordant histology between primary tumors occurs in 30% to 50% of patients (Kopp et al., 2017).

The incidence of testis cancer varies significantly according to geographic region; **rates are highest in Scandinavia, Western Europe, and Australia-New Zealand, intermediate in the United States and United Kingdom, and lowest in Africa and Asia** (Trabert et al., 2015). **The incidence of testis cancer in the United States in non-Hispanic whites is 3.6 times higher than the incidence in blacks, 2.5 times higher than the incidence in Asians and similar to but slightly higher than in Hispanics** (Howlader et al., 2017).

The incidence of GCT appears to be increasing worldwide (Huyghe et al., 2003; Rosen et al., 2011; Shanmugalingam et al., 2013; Znaor et al., 2014). In the United States, the age-adjusted incidence rate has increased from 3.73 per 100,000 in 1975 to 6.35 per 100,000 in 2014 (Howlader et al., 2017). Incidence has increased for seminomas and nonseminomas (Bray et al., 2006a; Trabert et al., 2015). **A stage migration of GCT has been observed in several countries partially because of an increased awareness and earlier diagnosis.** Between 1973 and 2014, the percentage of tumors diagnosed at a localized stage increased from 55% to 68% in the United States. **Only about 13% of men are seen initially with distant metastatic disease.**

Risk Factors

There are five well-established risk factors for testis cancer: white race, cryptorchidism, family history of testis cancer, a personal history of testis cancer, and germ cell neoplasia in situ (GCNIS), also referred to as intratubular germ cell neoplasia (ITGCN) (Stevenson and Lowrance, 2015). Infertile and subfertile men also have a higher incidence of testis cancer (Doria-Rose et al., 2005; Hanson et al., 2016). **Numerous studies have reported that recent increases in testis cancer incidence can be largely attributed to birth-cohort effects, which implies that diet and/or other environmental factors play a major role in GCT carcinogenesis** (Bray et al., 2006a,b; Huyghe et al., 2003; Liu et al., 1999; McGlynn et al., 2003; McKiernan et al., 1999; Richiardi et al., 2004; Verhoeven et al., 1970). **Specific environmental factors have not been definitively identified but there is evidence of an association between early exposure to endocrine-disrupting chemicals and an increased risk of testicular germ cell tumors** (Bonde et al., 2016; Giannandrea and Fargnoli, 2017).

Men with cryptorchidism are 4 to 6 times more likely to be diagnosed with testis cancer in the affected gonad, but the relative risk falls to 2 to 3 if orchidopexy is performed before puberty (Dieckmann and Pichlmeier, 2004; Wood and Elder, 2009). **A meta-analysis of cryptorchidism studies reported that the contralateral descended testis is also at slightly increased risk** (RR 1.74 [95% CI, 1.01–2.98]) (Akre et al., 2008). Men with a first-degree relative with testis cancer have a substantially increased risk of testis cancer, and the median age at diagnosis in these men is 2 to 3 years younger than in the general population (Mai et al., 2009). An individual's relative risk for testis cancer is 8 to 12 with an affected brother compared with 2 to 4 in those with an affected father (Hemminki and Chen, 2006; Sonneveld et al., 1999; Westergaard et al., 1996). Men with a history of testis cancer are at a 12-fold increased risk of developing GCT in the contralateral testis, but the 15-year cumulative incidence is only 2% (Fossa et al., 2005).

Most GCTs arise from a precursor lesion called GCNIS (Williamson et al., 2017). **Exceptions to this are prepubertal germ cell tumors (which can rarely occur after puberty), ovarian cystic teratomas, dermoid cysts, and spermatocytic tumors (previously referred to as spermatocytic seminomas)** (Cheng et al., 2017; Williamson et al., 2017). **GCNIS is present in adjacent testicular parenchyma in 80% to 90% cases of invasive GCT and is associated with a 50% risk of GCT within 5 years and 70% within 7 years** (Dieckmann and Skakkebaek, 1999; Montironi, 2002; Skakkebaek et al., 1982).

Between 5% and 9% of patients with GCT have GCNIS within the unaffected contralateral testis, although the incidence of contralateral GCNIS increases to about 36% in men with testicular atrophy or cryptorchidism (Dieckmann and Loy, 1996; Dieckmann and Skakkebaek, 1999). Gene expression profile analysis indicates that GCNIS develops before birth from an arrested gonocyte (Hussain et al., 2008; Sonne et al., 2009). In men with a history of GCT, the finding of testicular microlithiasis on ultrasound of the contralateral testis is associated with an increased risk of GCNIS (Karellas et al., 2007). **However, the significance of microlithiasis in the general population is unclear;** a study of 1500 army volunteers found a 5.6% prevalence of microlithiasis, yet fewer than 2% of those with microlithiasis developed GCT within 5 years (DeCastro et al., 2008).

Pathogenesis and Biology

The carcinogenesis of GCTs is poorly understood (Looijenga et al., 2011; Sheikine et al., 2012; Turnbull and Rahman, 2011). As noted earlier, testicular GCTs develop from a precursor lesion, GCNIS, which in turn appears to develop from arrested primordial germ cells or gonocytes that failed to differentiate into prespermatogonia (Hussain et al., 2008; Looijenga et al., 2011; Rajpert-de Meyts and Hoei-Hansen, 2007). These transformed primordial germ cells are thought to then lay dormant until after puberty when they are stimulated by increased testosterone levels.

The increased incidence of testis cancer that started in the first half of the 20th century has been accompanied by an increased incidence of other male reproductive disorders such as hypospadias, cryptorchidism, and subfertility (Rajpert-de Meyts and Hoei-Hansen, 2007; Sonne et al., 2008). These findings led to the hypothesis that testis cancer and these other disorders resulted from a testicular dysgenesis syndrome, which in turn resulted from environmental and/or lifestyle factors and genetic susceptibility (Akre and Richiardi, 2009; Xing and Bai, 2018). Although this hypothesis remains controversial, the increasing incidence of testis cancer supports the presence of environmental and/or lifestyle risk factors. The strongest epidemiologic evidence supports a role for prenatal exposure but there is no strong evidence identifying specific chemicals (Bonde et al., 2016). Increased prenatal estrogen exposure has been hypothesized as a risk factor but this is controversial (Martin et al., 2008). Similarly, mothers of testis cancer patients have been reported to have higher blood levels of polychlorinated biphenyls and other persistent organic pollutants (Hardell et al., 2003, 2006). Epidemiologic studies have also reported associations between testis cancer and prior exposure to organochloride pesticides as well as to firefighting and aircraft maintenance occupations (McGlynn and Trabert, 2012; McGlynn et al., 2008; Purdue et al., 2009). There is stronger evidence that reduction in androgen activity can result in features of testicular dysgenesis syndrome, including cryptorchidism, hypospadias, and impaired spermatogenesis, but a direct link between reduced androgen signaling and GCNIS remains hypothetical (Hu et al., 2009; Sonne et al., 2008).

Evidence of environmental and lifestyle factors contributing to testis cancer includes the rapid rise in its incidence as well as findings that second-generation immigrants' risk is similar to their country of birth. In addition, mothers of children with testis cancer (but not the testis cancer patients themselves) have been found to have higher blood levels of certain organic pollutants compared with other mothers (Sonne et al., 2008). Evidence for genetic factors includes the clustering of testis cancer in some families, the extreme difference in the rate of testis cancer in black and white Americans, and the finding of susceptibility loci on chromosomes 5, 6, and 12 in case-control studies (Mai et al., 2009). In addition, specific polymorphisms of certain genes, including the gene encoding c-KIT ligand, have been associated with an increased risk of testis cancer (Blomberg Jensen et al., 2008; Kanetsky et al., 2009; Sheikine et al., 2012; Turnbull and Rahman, 2011). Gonocytes depend on KIT ligand for survival and the gene for this protein is located on the short arm of chromosome 12. **An increased number of copies of genetic material from the short arm of chromosome 12 is a universal finding in postpubertal testicular and extragonadal germ cell tumors except for spermatocytic tumors** (Cheng et al., 2017)**.** Between 70% and 80% of GCTs have an extra copy of chromosome 12 in the form of an isochromosome 12p (i[12p]), whereas the remainder show gain of 12p sequences detectable with fluorescence in situ hybridization (Mayer et al., 2003). Thus a connection between mutations or polymorphisms in c-KIT ligand and GCT has biologic plausibility.

One of the most striking features of GCTs is their sensitivity to cisplatin-based chemotherapy, which enables cure in the vast majority of patients with widely metastatic disease. The specific biologic basis of this acute vulnerability to chemotherapy remains incompletely understood but is thought to derive from the close relationship between GCTs and embryonal stem cells and gonocytes, which have a low threshold for undergoing apoptosis in response to DNA damage (Mayer et al., 2003; Schmelz et al., 2010). Gene expression analysis has found an upregulation of numerous genes that facilitate apoptosis, including *FasL*, *TRAIL*, and *Bax* while *BCL-2* is downregulated (Schmelz et al., 2010). Expression patterns of genes controlling the G1/S-phase checkpoint in GCTs appear to promote induction of apoptosis (Schmelz et al., 2010). In addition, GCTs lack transporters to export cisplatin from the cell and have a reduced ability to repair cisplatin-induced DNA damage (Mayer et al., 2003). GCTs have high intrinsic levels of wild-type p53 protein (which plays a role in mediating cell cycle arrest and apoptosis), and p53 mutations in GCTs are rare, yet differences have not been consistently found in p53 status when comparing chemo-sensitive and chemo-resistant germ cell tumors (Burger et al., 1998; Houldsworth et al., 1998). Similarly, expression of the anti-apoptotic protein BCL-2 is low in germ cell tumors but BCL-2 levels do not distinguish chemo-sensitive and chemo-resistant cell lines (Mayer et al., 2003). A small fraction of GCTs are resistant to chemotherapy, and the basis of that resistance remains obscure (Veenstra and Vaughn, 2011). Impaired DNA mismatch repair and activating *BRAF* mutations have been associated with treatment failure (Honecker et al., 2009; Looijenga et al., 2011; Sheikine et al., 2012; Veenstra and Vaughn, 2011).

Approximately 5% of postpubertal GCTs are extragondal in origin, and most develop in midline anatomic locations (retroperitoneum and mediastinum are most common). There are two main competing theories regarding the pathogenesis of extragonadal GCTs. The first hypothesizes that they originate from germ cells that mis-migrated along the genital ridge and were able to survive in an extragonadal environment. The second theory proposes a reverse migration from the testis to extragonadal locations (Chaganti and Houldsworth, 2000).

Primary mediastinal NSGCTs differ in several ways from those originating in the testis or retroperitoneum (Moran and Suster, 1997a,b, 1998; Moran et al., 1997a). First, they are less sensitive to chemotherapy and have a poor prognosis with a 5-year overall survival of about 45% (Bokemeyer et al., 2002). Mediastinal NSGCTs are more likely to have yolk-sac-tumor components and thus to be associated with elevations in serum α-fetoprotein (AFP) (Bokemeyer et al., 2002; Kesler et al., 2008; Moran et al., 1997a). They are also associated with Klinefelter syndrome and with hematologic malignancies that carry extra copies of the short arm of chromosome 12, as seen in adult GCT (Bokemeyer et al., 2002; McKenney et al., 2007). **In contrast, mediastinal**

seminomas carry a similar prognosis to testicular seminomas, and mature teratomas of the mediastinum have low metastatic potential and can generally be cured surgically (Allen, 2002; Horner et al., 2009; International Germ Cell Cancer Collaborative Group, 1997). **Primary retroperitoneal GCTs are indistinguishable biologically from testicular GCTs and carry the same prognosis**.

Histologic Classification

The histologic classification of postpubertal GCT is outlined in Table 76.1 (Williamson et al., 2017). **GCTs are broadly classified as GCNIS-derived and non-GCNIS–derived. The majority of postpubertal GCTs are GCNIS derived. For clinical purposes, GCNIS-derived GCTs are divided into seminoma and NSGCT, and the relative distribution of each is 52% to 56% and 44% to 48%, respectively** (McGlynn et al., 2005; Powles et al., 2005)**. NSGCTs include embryonal carcinoma (EC), yolk sac tumor, teratoma, and choriocarcinoma subtypes, either alone as pure forms or in combination as mixed GCT with or without seminoma.** Most NSGCTs are mixed tumors composed of two or more GCT subtypes. GCTs that contain both NSGCT subtypes and seminoma are classified as NSGCT even if the NSGCT component represents a tiny proportion of the tumor.

Germ Cell Tumor Neoplasia in Situ

With the exception of spermatocytic tumor, postpubertal invasive GCTs arise from GCNIS. GCNIS consists of undifferentiated germ cells that have the appearance of seminoma that are located basally within the seminiferous tubules. The tubule usually shows decreased or absent spermatogenesis and normal constituents are replaced by GCNIS. The presence of GCNIS in an orchiectomy specimen in men with testis cancer does not carry any prognostic implications with regard to the risk of relapse (von Eyben et al., 2004). GCNIS is much less frequent in pediatric GCTs (Cheville, 1999).

Seminoma

Seminoma is the most common type of GCT. On average, seminomas occur at an older average age than NSGCT, with most cases diagnosed in the fourth or fifth decade of life (Cheville, 1999). Grossly, seminoma is a soft tan to white diffuse or multinodular mass (Fig. 76.1A). Necrosis may be present but is usually focal and not as prominent as other GCTs. Seminomas consist of a sheet-like arrangement of cells with polygonal nuclei and clear cytoplasm, with the cells divided into nests by fibrovascular septae that contain lymphocytes (Fig. 76.1B) (Ulbright, 2005). Syncytiotrophoblasts, which stain positive for human chorionic gonadotropin (HCG), can be identified in about 15% of cases but are of no clear prognostic significance (Cheville, 1999). Lymphocytic infiltrates and granulomatous reactions are often seen, and seminomas appear to be associated with an increased incidence of sarcoidosis (Rayson et al., 1998; Tjan-Heijnen et al., 1998). Seminomas may be confused with solid-pattern EC, yolk sac tumor, or Sertoli cell tumors (Ulbright and Young, 2008). Although immunohistochemical staining plays a limited role in diagnosing GCTs, seminomas are typically negative for CD30, positive for CD117, and strongly positive for placental alkaline phosphatase (PLAP). Anaplastic seminoma was a previously recognized subtype of seminoma, but this distinction is of no clear biologic or clinical significance and is no longer recognized. Seminoma arises from GCNIS and is considered to be the common precursor for the other NSGCT subtypes (Ulbright, 2004). This ability of seminoma to transform into NSGCT elements has important therapeutic implications for the management of seminoma (discussed later) (Ulbright, 2004).

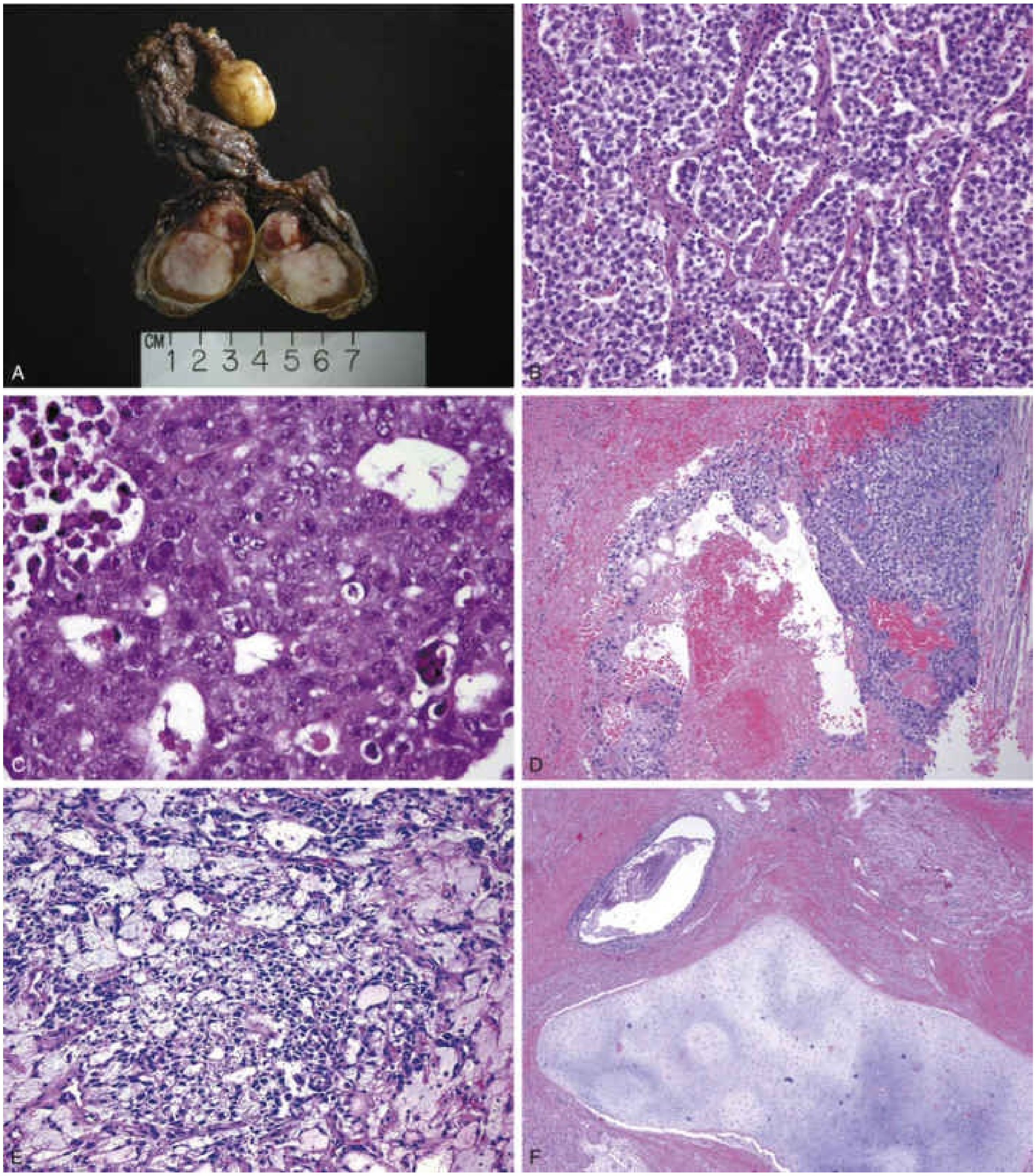

FIG. 76.1 (A) Gross section of testis containing seminoma. (B) Seminoma (H&E stain). (C) Embryonal carcinoma (H&E stain). (D) Choriocarcinoma (H&E stain). (E) Yolk sac tumor (H&E stain). (F) Teratoma (H&E stain).

Spermatocytic Tumor

Spermatocytic tumor (previously referred to as spermatocytic seminoma) used to be classified as a subtype of seminoma but is now considered a distinct entity from seminoma and other GCTs. It is rare and accounts for less than 1% of

GCTs. Unlike other GCTs, spermatocytic tumor does not arise from GCNIS, is not associated with a history of cryptorchidism or bilaterality, does not demonstrate i(12p), and does not occur as part of mixed GCTs (Ulbright, 2005). The lack of association of spermatocytic tumors with GSNIS is similar to juvenile YST and teratoma. Histopathologically, they differ from seminoma in that they do not stain for OCT 3/4, PLAP, or glycogen (PAS stain), nuclei are round, minimal lymphocytic infiltration is present, and three distinct cell types are present, including small lymphocyte-like cells, medium-size cells with dense eosinophilic cytoplasm and a round nucleus, and large mono- or multi-nucleated cells (Aggarwal and Parwani, 2009). The peak incidence is the sixth decade of life (Chung et al., 2004; Eble, 1994). It is a benign tumor (only three documented cases of metastases) and is almost always cured with orchiectomy (Chung et al., 2004; Horn et al., 2011). An exception to this rule are the rare cases of “spermatocytic tumor with sarcoma,” which exhibit elements of sarcomatous differentiation, and an anaplastic variant, both of which are associated with widely metastatic chemotherapy-resistant disease and poor prognosis (Dundr et al., 2007; Narang et al., 2012; Wetherell et al., 2013).

Embryonal Carcinoma

EC consists of undifferentiated malignant cells resembling primitive epithelial cells from early stage embryos with crowded pleomorphic nuclei (Ulbright, 2005). Grossly, EC is a tan to yellow neoplasm that often exhibits large areas of hemorrhage and necrosis. The microscopic appearance of these tumors varies considerably, and they may grow in solid sheets or in papillary, glandular-alveolar, or tubular patterns (Fig. 76.1C). In some cases, syncytiotrophoblasts are identified. EC is an aggressive tumor associated with a high rate of metastasis, often in the context of normal serum tumor markers. **EC is the most undifferentiated cell type of NSGCT, with totipotential capacity to differentiate to other NSGCT cell types (including teratoma) within the primary tumor or at metastatic sites.** As discussed later, the presence and proportion of EC has been associated an increased risk of occult metastases in clinical stage (CS) I NSGCT. EC typically stains for AE1/AE3, PLAP, and OCT3/4 and do not stain for c-Kit.

Choriocarcinoma

Choriocarcinoma is a rare and aggressive tumor that typically is seen with extremely highly elevated serum HCG levels and disseminated disease. They are typically poor-risk (stage IIIC) at diagnosis because of the serum HCG level and/or nonpulmonary organ metastases (Alvarado-Cabrero et al., 2014). **Choriocarcinoma commonly spreads by hematogenous routes,** and common sites of metastases include lungs, liver, and brain (Allen, 2002; Alvarado-Cabrero et al., 2014; Osada et al., 2004; Tinkle et al., 2001; Yokoi et al., 2008). Microscopically, the tumor is composed of syncytiotrophoblasts and cytotrophoblasts, and the former stain positively for HCG (Fig. 76.1D; Cheville, 1999). Seminoma and EC may also contain syncytiotrophoblasts. Areas of hemorrhage and necrosis are prominent. As in gestational trophoblastic disease, testicular choriocarcinoma is prone to hemorrhage, sometimes spontaneously and immediately after chemotherapy is initiated; such bleeding can be catastrophic, particularly when it occurs in the lungs or brain (Kandori et al., 2010; Motzer et al., 1987; Yokoi et al., 2008). In addition, choriocarcinomas are associated with hormonal disturbances, most likely because of highly elevated serum HCG. Stimulation of receptors for thyroid stimulating hormone and luteinizing hormone (LH) by HCG (which shares an identical alpha-subunit) can result in hyperthyroidism and elevated androgen production (Ulbright, 2005). Hyperprolactinemia has also been reported.

Yolk Sac Tumor

Pure yolk sac tumors (sometimes called endodermal sinus tumors) represent a very small fraction of adult gonadal and retroperitoneal GCTs but are more common in mediastinal and pediatric GCTs (Cao and Humphrey, 2011; Moran and Suster, 1997b; Moran et al., 1997a; Rossen et al., 2009; Ulbright, 2005). Mixed GCTs often include elements of yolk sac tumor, which consists of a reticular network of medium-sized cuboidal cells with cytoplasmic and extra-cytoplasmic eosinophilic, hyaline-like globules (Epstein, 2010). Yolk sac tumors may grow in a glandular, papillary, or micro-cystic pattern. A characteristic feature is the Schiller-Duval body, which resembles endodermal sinuses, and is seen in roughly half of cases (Fig. 76.1E). Cytoplasmic and extracellular eosinophilic hyaline globules are another characteristic histologic feature and are present in up to 84% of cases. **Yolk sac tumors almost always produce AFP but not HCG.**

Teratoma

Teratomas are tumors that contain well or incompletely differentiated elements of at least two of the three germ cell layers: endoderm, mesoderm, and ectoderm. Characteristically, all components are intermixed. Well-differentiated tumors are labeled mature teratomas, whereas those that are incompletely differentiated (i.e., similar to fetal or embryonal tissue) are called immature teratomas. **In adolescent and adult males, there is no clinical significance to the distinction between mature and immature teratomas, and histopathologists do not typically distinguish between the two entities** (Williamson et al., 2017). Mature teratomas may include elements of mature bone, cartilage, teeth, hair, and squamous epithelium, a fact that most likely explains the name *teratoma,* which roughly means "monster tumor," in Greek (Fig. 76.1F). The gross appearance of teratoma depends largely on the elements within it; most tumors have solid and cystic areas. **Teratomas are generally associated with normal serum tumor markers, but they may cause mildly elevated serum AFP levels.** Approximately 47% of adult mixed GCTs contain teratoma, but pure teratomas are uncommon (Geldart et al., 2002; Leibovitch et al., 1995).

In men, teratomas have a histologically benign appearance but are frequently found at metastatic sites in patients with advanced NSGCT. **Teratoma is resistant to chemotherapy**. Thus, given its frequent presence at metastatic sites in advanced NSGCT, patients with residual masses after chemotherapy require consolidative surgical resection. The inherent chemo-resistance of teratoma is a limitation to treatment strategies for NSGCT that use chemotherapy alone.

Despite their benign histologic appearance, teratomas contain many genetic abnormalities frequently found in malignant GCT elements, including aneuploidy, isochrome 12p (i[12p]), and widely variable proliferative capacity (Castedo et al., 1989; Sella et al., 1991). Studies have also shown that cystic fluid from teratoma frequently contains HCG and AFP, confirming its malignant potential (Beck et al., 2004; Sella et al., 1991). The genetic instability of teratoma has important clinical implications. **Teratomas may grow uncontrollably, invade surrounding structures, and become unresectable** (Logothetis et al., 1982). **On rare occasions, teratoma may transform into a somatic malignancy such as rhabdomyosarcoma, adenocarcinoma, or primitive neuroectodermal tumor** (Comiter et al., 1998; Little et al., 1994; Motzer et al., 1998). These tumors are called "teratoma with somatic-type malignancy" or "teratoma with malignant transformation." These tumors frequently have abnormalities of chromosome 12 or i(12p), indicating their origin from GCT. Malignant transformation is highly aggressive, resistant to conventional chemotherapy, and associated with a poor prognosis (Comiter et al., 1998; El Mesbahi et al., 2007). Only 4% of teratoma with somatic-type malignancy arise within the testis. The majority arise at metastatic sites, usually within 3 to 4 years after completion of chemotherapy as a consequence of unresected teratoma (Magers et al., 2014; Rice et al., 2014). Last, unresected teratoma in patients with advanced NSGCT may result in late relapse (Sheinfeld, 2003). All of these events may have lethal consequences.

Accurate characterization of GCTs is essential for successful treatment and consideration for expert pathology review may be considered. A study of orchiectomy specimens reviewed at Indiana University from outside institutions revealed a 31% discrepancy in histologic subtype and a change in lymphovascular invasion (LVI) status in 22% of cases (Harari et al., 2017). These differences in pathological assessment between expert and community pathologists may have important treatment implications.

Key Points: Germ Cell Tumors

- GCT is the most common solid malignancy among males age 20 to 40 years.
- Bilateral GCT occurs in 2% of men. Metachronous lesion is the most common presentation.
- Incidence of GCT is highest in Caucasians and lowest in African-Americans.
- Cryptorchidism, personal or family history of GCT, and GCNIS are the known risk factors for GCT.
- Orchidopexy for cryptorchidism performed before puberty is associated with a decreased risk of GCT.
- Postpubertal GCTs other than spermatocytic tumors universally contain extra copies of genetic material from the small arm of chromosome 12. In 70% to 80% of cases, this consists of an extra copy of the short arm of 12 appearing as an isochromosome (i[12p]), whereas in the remaining cases, this genetic material can be demonstrated with fluorescent in situ hybridization. This genetic marker may be used in the diagnosis of GCT (e.g., for carcinomas of unknown primary) and non-GCT somatic malignancy arising from malignant transformation of teratoma.

- Approximately 5% of GCT originate at extragonadal sites, most commonly mediastinum and retroperitoneum. Primary mediastinal NSGCTs are associated with poor prognosis.
- Teratoma is histologically benign. Teratoma at metastatic sites is believed to arise from differentiation of metastatic non-teratoma GCT elements.
- Teratoma is resistant to chemotherapy.
- Teratoma is histologically benign but genetically unstable. Thus it has unpredictable biology. Although uncommon, teratoma has the capacity to grow rapidly or undergo malignant transformation of its ectodermal, mesodermal, and/or endodermal elements to form a non-GCT somatic malignancy.

Initial Presentation

Signs and Symptoms

The most common presentation of testis cancer is a painless testis mass. Acute testicular pain is less common and is caused by rapid expansion of the testis resulting from intra-tumor hemorrhage or infarction caused by rapid tumor growth. Pain is more commonly associated with NSGCT; these tumors tend to be more vascular and exhibit more rapid growth compared with seminomas. Patients frequently report a history of testicular trauma, although incidental trauma is likely responsible for bringing the testis mass to the patient's attention for the first time. Patients may also complain of vague scrotal discomfort or heaviness. **Regional or distant metastasis at diagnosis is present in approximately two-thirds of NSGCTs and 15% of pure seminomas, and symptoms related to metastatic disease are the presenting complaint in 10% to 20% of patients.** Bulky retroperitoneal metastasis may cause a palpable mass, abdominal pain, flank pain resulting from ureteral obstruction, back pain because of involvement of the psoas muscle or nerve roots, lower extremity swelling resulting from compression of the inferior vena cava, or gastrointestinal (GI) symptoms. Pulmonary metastasis may present with dyspnea, chest pain, cough, or hemoptysis. Metastasis to supraclavicular lymph nodes may be seen as a neck mass. **Approximately 2% of men have gynecomastia,** resulting from either elevated serum HCG levels, decreased androgen production, or increased estrogen levels (most commonly seen in men with Leydig cell tumors). **Although approximately two-thirds of men with GCT have diminished**

fertility, it is an uncommon initial presentation.

Physical Examination

The physician should carefully examine the affected and the normal contralateral testis, noting their relative size and consistency and palpating for any testicular or extra-testicular masses. Atrophy of the affected or contralateral testis is common, particularly in patients with a history of cryptorchidism. Any firm area within the testis should be considered suspicious for malignancy and should prompt further investigations. A hydrocele may accompany a testis cancer and impair the examiner's ability to evaluate the testis. In this case, a scrotal ultrasound to evaluate the testis is warranted. The patient should also be examined for any evidence of palpable abdominal mass or pain, inguinal lymphadenopathy (particularly if he has had prior inguinal or scrotal surgery), gynecomastia, and supraclavicular lymphadenopathy, and auscultation of the chest for intrathoracic disease.

Differential Diagnosis

The differential diagnosis of a testis mass includes epididymo-orchitis, torsion, hematoma, or para-testicular neoplasm (benign or malignant). Other diagnostic possibilities include hernia, varicocele, or spermatocele, although these usually can be distinguished from a testis mass by physical examination. **A firm intratesticular mass should be considered cancer until proven otherwise and should be evaluated further with a scrotal ultrasound. In patients with a presumptive diagnosis of epididymo-orchitis, patients should be re-evaluated within 2 to 4 weeks of completion of an appropriate course of oral antibiotics.** A persistent mass or pain should be evaluated further with a scrotal ultrasound.

Diagnostic Delay

Diagnostic delay is a well-recognized phenomenon of this disease, with patients and physicians contributing to this delay. Testis cancer patients are typically young and may be less inclined to seek medical evaluation for symptoms because of denial, ignorance, or limited access. **Prior studies show that up to one-third of testis tumors are initially misdiagnosed as epididymitis or hydrocele** (Bosl et al., 1981). For patients with signs or symptoms from metastatic GCT, these may become the focus of the treating physician, resulting in the failure to diagnose GCT. These patients may be subjected to inappropriate treatment, diagnostic tests, and unnecessary surgery with subsequent delays in definitive therapy. Case reports describe patients undergoing exploratory laparotomy, neck dissection, or mastectomy for unsuspected metastatic GCT. The interval of delay is associated with advanced clinical stage, suboptimal response to chemotherapy, and diminished survival. Moul et al. (1990) reported a decrease in survival in GCT patients treated from 1970 to 1987 with a diagnostic delay greater than 16 weeks, though a significant survival difference was not observed among patients treated in the cisplatin era. Stephenson et al. (2004) reported a higher proportion of men requiring intensive chemotherapy (multiple regimens, high-dose, and salvage chemotherapy) among those with a treatment delay greater than 30 days resulting from unnecessary exploratory laparotomy.

Diagnostic delay can be avoided by efforts to improve patient and physician education. Physicians must consider the diagnosis of GCT in any male age 15 to 50 years with a firm testis mass, midline retroperitoneal mass, or mass in the left supraclavicular fossa.

Diagnostic Testing and Initial Management

Scrotal Ultrasound

In men with a testis mass, hydrocele, or unexplained scrotal symptoms or signs, **scrotal ultrasonography should be considered an extension of the physical examination because it widely available, inexpensive, and noninvasive.** With high-frequency transducers (5–10 MHz), intratesticular lesions as small as a few millimeters can be identified and readily distinguished from extra-testicular pathology. On ultrasound, the typical GCT is hypoechoic and two or more discrete lesions may be identified (Fig. 76.2). Heterogeneous echotexture within a lesion is more commonly associated with NSGCT, because seminomas usually have a homogenous echotexture. The presence of increased flow within the lesion on color Doppler sonography is suggestive of malignancy, although its absence does not exclude GCT. The association between testicular microlithiasis and GCT is not clearly defined, and this finding alone should not prompt further evaluation (DeCastro et al., 2008). **Given the 2% incidence of bilateral GCT, both testes should be evaluated sonographically, although bilateral tumors at diagnosis is a rare (0.5% of all GCT) and metachronous presentation is more common** (Fossa et al., 2005).

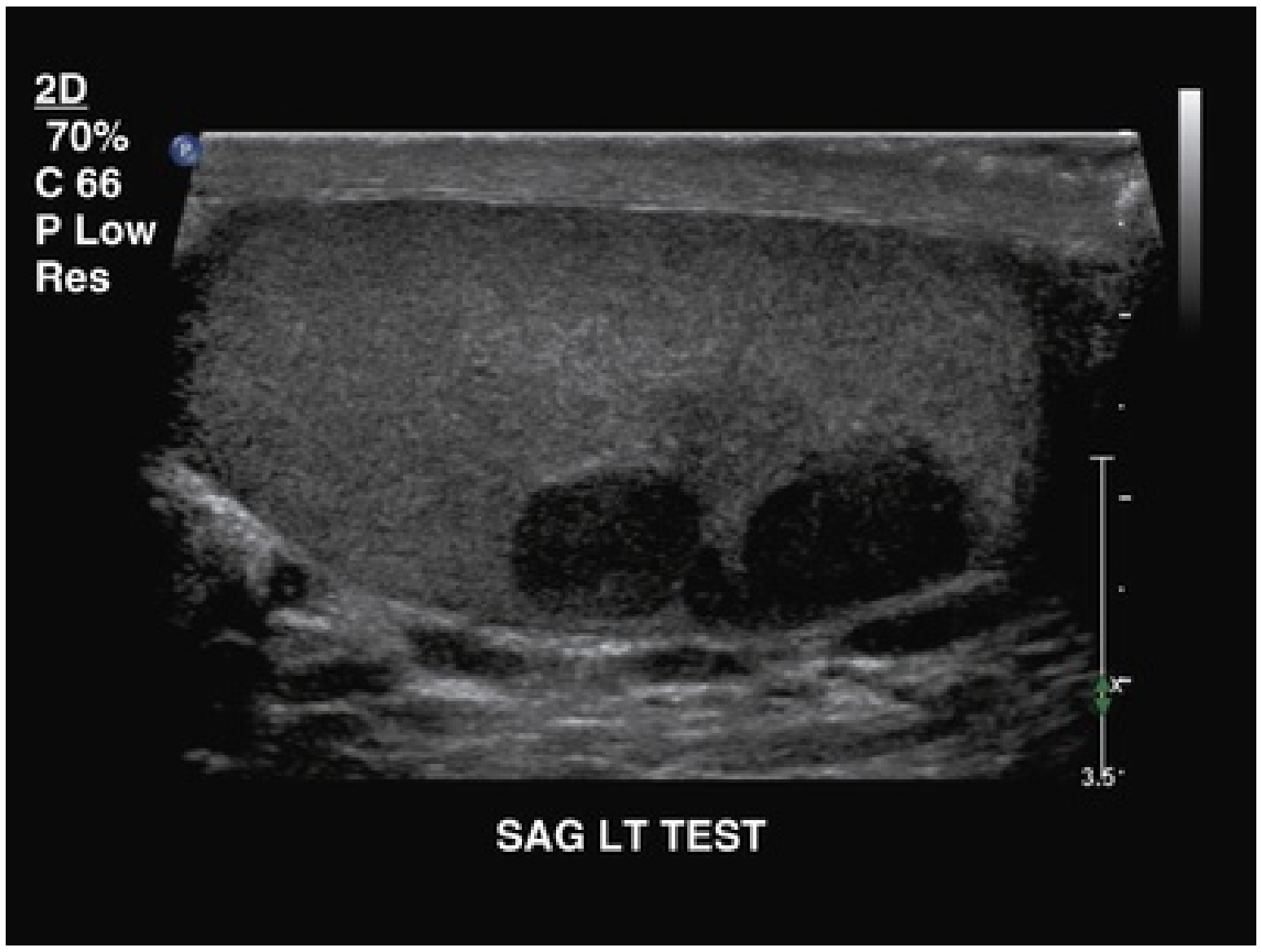

FIG. 76.2 Sagittal view of left testis showing multinodular hypoechoic intratesticular lesion confirmed to be pure seminoma at orchiectomy.

In men with advanced GCT and a normal testicular examination, scrotal ultrasonography should be performed to rule out the presence of a small, impalpable scar or calcification, indicating a “burned-out” primary testis tumor. GCTs are one of the most common neoplasms to undergo spontaneous regression; seminoma is the most frequent subtype (Balzer and Ulbright, 2006). Radical orchiectomy should be performed in those patients with sonographic evidence of intratesticular lesions (discrete nodule, stellate scar, coarse calcification) because GCNIS and residual teratoma are frequently encountered. Men with advanced GCT with normal testes on physical examination and sonographic evaluation are considered to have primary extragondal GCT.

The presence of small (<10 mm), impalpable intratesticular lesions in the absence of disseminated GCT or elevated serum tumor markers represents a diagnostic dilemma. The majority of these lesions are benign (testicular cysts, small infarcts, Leydig cell nodules, or small Leydig cell or Sertoli cell tumors), although up to 20% to 50% may represent small GCT (usually seminoma) (Connolly et al., 2006; Hindley et al., 2003; Muller et al., 2006; Shilo et al., 2012). The risk of malignancy increases with the size of the lesion, from 50% for lesions smaller than 1 cm to 80% or more for lesions 1 to 2 cm (Carmignani et al., 2005). Management options include inguinal orchiectomy, testis-sparing surgery involving inguinal exploration and excision (with frozen section analysis to rule out GCT), and close observation with serial sonographic evaluation (with exploration of growing lesions). Intraoperative ultrasonography is useful during surgical exploration of the testis to locate the lesion.

Magnetic Resonance Imaging

In cases in which the sonographic findings are equivocal or suboptimal, magnetic resonance imaging (MRI) with enhancement is a helpful tool to distinguish between testicular versus extratesticular lesions and neoplastic versus non-neoplastic entities (Park et al., 2011).

Serum Tumor Markers

Testis cancer is one of the few malignancies associated with serum tumor markers (lactate dehydrogenase [LDH], AFP, and HCG) that are essential in its diagnosis and management. Serum tumor marker levels should be obtained at diagnosis, after orchiectomy, to monitor for response to chemotherapy, and to monitor for relapse in patients on surveillance and after completion of therapy.

At diagnosis, AFP levels are elevated in 50% to 70% of low-stage (CS I, IIA, IIB) NSGCTs and 60% to 80% of advanced (CS IIC, III) NSGCTs. EC and yolk sac tumors secrete AFP. Choriocarcinomas and seminomas do not produce AFP. Patients with pure seminoma in the primary tumor with an elevated serum AFP are considered to have NSGCT. The half-life of AFP is 5 to 7 days. AFP levels may also be raised in patients with hepatocellular carcinoma, cancers of the stomach, pancreas, biliary tract and lung, non-malignant liver disease (infectious, drug-induced, alcohol-induced, autoimmune), ataxic telangiectasia, and hereditary tyrosinemia.

HCG levels are elevated in 20% to 40% of low-stage NSGCTs and 40% to 60% of advanced NSGCTs. Approximately 15% of seminomas secrete HCG. HCG is also secreted by choriocarcinoma and EC. Levels above 5000 IU/L are usually associated with NSGCT. The half-life of HCG is 24 to 36 hours. HCG levels may be elevated in cancers of the liver, biliary tract, pancreas, stomach, lung, breast, kidney, and bladder. The alpha-subunit of HCG is common to several pituitary tumors, thus **immunoassays for HCG are directed at the beta-subunit. Cross-reactivity of the HCG assay with LH may cause false-positive HCG elevations in patients with primary hypogonadism.** Elevated serum HCG results caused by hypogonadism will normalize within 48 to 72 hours after the administration of testosterone, and this can be done to distinguish between true- and false-positive HCG results. Marijuana use may also cause false-positive HCG results.

LDH levels are elevated in approximately 20% of low-stage GCT and 20% to 60% of advanced GCT. LDH is expressed in smooth, cardiac, and skeletal muscle. Lymphoma may also cause elevated LDH levels. Of the five isoenzymes of LDH, LDH-1 is the most frequently elevated isoenzyme in GCT. LDH-1 levels are correlated with the chromosome arm 12p copy number, which is frequently amplified in GCT. The magnitude of LDH elevation correlates with the bulk of disease. As a nonspecific marker for GCT, its main use is in the prognostic assessment of GCT at diagnosis. The serum half-life of LDH is 24 hours.

Patients suspected of having a GCT should have blood drawn for serum AFP, HCG, and LDH before orchiectomy to aid in the diagnosis and to help interpret post-orchiectomy tumor marker levels. For staging purposes, it is relevant to know whether pre-orchiectomy serum tumor marker levels are declining after orchiectomy and, if so, how quickly. The results of serum tumor marker assays should not be used to guide decision-making about whether to perform a radical orchiectomy, because AFP or HCG levels in the normal range do not rule out GCT. A significantly elevated serum AFP can establish the diagnosis of NSGCT in a patient whose histopathological diagnosis is pure seminoma because seminomas do not produce AFP. However, borderline-elevated values should be interpreted cautiously. **In rare patients who are seen initially with a testis, retroperitoneal, or mediastinal primary tumor and whose disease burden has resulted in a need to start treatment very urgently, substantially elevated serum AFP and/or HCG may be considered sufficient for diagnosis of GCT.** For such rare, medically unstable patients, treatment need not be delayed until histology results permit a tissue diagnosis. However, these patients should undergo radical orchiectomy after the completion of chemotherapy because the testis is a sanctuary site for malignant GCT because of the blood-testis barrier, and the testis frequently contains residual invasive GCT, teratoma, and/or GCNIS (Geldart et al., 2002).

Radical Inguinal Orchiectomy

Patients suspected of having a testicular neoplasm should undergo a radical inguinal orchiectomy with removal of the tumor-bearing testicle and spermatic cord to the level of the internal inguinal ring. **A transscrotal orchiectomy or biopsy is contraindicated because it leaves the inguinal portion of the spermatic cord intact and may alter the lymphatic drainage of the testis, increasing the risk of local recurrence and pelvic or inguinal lymph node**

metastasis. Because of the rapid growth of GCT, orchiectomy should be performed in a timely manner, and delays greater than 1 to 2 weeks should be avoided.

Radical orchiectomy establishes the histologic diagnosis and primary T stage, provides important prognostic information from the tumor histology, and is curative in 80% to 85% and 70% to 80% of CS I seminoma and CS I NSGCT, respectively.

Histopathological examination of the testis should identify the histologic type of the tumor (see Table 76.1; Williamson et al., 2017), tumor size, multifocality, local tumor invasion (rete testis, tunica albuginea, tunica vaginalis, epididymis, spermatic cord, scrotum), primary T stage (Table 76.2; Amin et al., 2017), presence of GCNIS, invasion of blood or lymphatic vessels (termed lymphovascular invasion [LVI]), and the surgical margin status. For patients with mixed GCT, each individual tumor subtype should be identified, including its relative proportion. Because of the relative rarity of GCT and the importance of primary tumor histology for treatment decision making, review of primary tumor specimens by experienced pathologists is recommended (Krege et al., 2008a). One high-volume GCT center reported that among 221 consecutive second-opinion reviews of orchiectomy cases, the pathological stage was changed in 23%, mostly because of changes in whether lymphovascular and/or spermatic cord invasion were present (Harari et al., 2017). Most significantly, 23% of stage T2 and 35% of T3 tumors were downstaged. In addition, 31% had changes in histologic subtype.

TABLE 76.2

TNM Staging of Testicular Tumor: American Joint Committee on Cancer and Union Internationale Contre le Cancer

PRIMARY TUMOR (T)[a]	
The extent of primary tumor is usually classified after radical orchiectomy and, for this reason, a *pathological* stage is assigned.	
pTx	Primary tumor cannot be assessed
pT0	No evidence of primary tumor (e.g., histologic scar in testis)
pTis	Intratubular germ cell neoplasia (carcinoma in situ)
pT1	Tumor limited to testis and epididymis without vascular/lymphatic invasion; tumor may invade into tunica albuginea but not tunica vaginalis
pT2	Tumor limited to testis and epididymis with vascular/lymphatic invasion or tumor

	extending through tunica albuginea with involvement of tunica vaginalis
pT3	Tumor invades spermatic cord with or without vascular/lymphatic invasion
pT4	Tumor invades scrotum with or without vascular/lymphatic invasion
REGIONAL LYMPH NODES (N)	
Clinical (as Determined by Noninvasive Staging)	
NX	Regional lymph nodes cannot be assessed
N0	No regional lymph node metastasis
N1	Metastasis with lymph node mass ≤2 cm in greatest dimension; or multiple lymph nodes, none more than 2 cm in greatest dimension
N2	Metastasis with lymph node mass, >2 cm, but not more than 5 cm in greatest dimension; or multiple lymph nodes, any one mass >2 cm but not more than 5 cm in greatest dimension
N3	Metastasis with lymph node mass >5 cm in greatest dimension
Pathologic (pN) (as Determined by Pathologic Findings of RPLND Without Prior Chemotherapy or Radiotherapy)	
pNX	Regional lymph nodes cannot be assessed
pN0	No regional lymph node metastasis
pN1	Metastasis with lymph node mass ≤2 cm in greatest dimension and ≤5 nodes positive, none more than 2 cm in greatest dimension
pN2	Metastasis with lymph node mass >2 cm but not more than 5 cm in greatest dimension; or >5 nodes positive, none more than 5 cm; or evidence of extranodal extension of tumor
pN3	Metastasis with lymph node mass >5 cm in greatest dimension
DISTANT METASTASIS (M)	
MX	Distant metastasis cannot be assessed
M0	No distant metastasis
M1	Distant metastasis
M1a	Nonregional nodal or pulmonary metastasis
M1b	Distant metastasis at site other than nonregional lymph nodes or lung
SERUM TUMOR MARKERS (S)	
SX	Marker studies unavailable or not performed
S0	Marker study levels within normal limits
S1	LDH <1.5 × N[b] *and*
	HCG (MIU/mL) <5000 *and*
	AFP (ng/mL) <1000
S2	LDH 1.5-10 × N *or*
	HCG (MIU/mL) 5000–50,000 *or*
	AFP (ng/mL) 1000–10,000
S3	LDH >10 × N *or*
	HCG (MIU/mL) >50,000 *or*

	AFP (ng/mL) >10,000
STAGE GROUPING	

GROUP	**T**	**N**	**M**	**S (SERUM TUMOR MARKERS)**
Stage 0	pTis	N0	M0	S0
Stage I	pT1-4	N0	M0	SX
Stage IA	pT1	N0	M0	S0
Stage IB	pT2	N0	M0	S0
	pT3	N0	M0	S0
	pT4	N0	M0	S0
Stage IS	Any pT/Tx	N0	M0	S1-3
Stage II	Any pT/Tx	N1-3	M0	SX
Stage IIA	Any pT/Tx	N1	M0	S0
	Any pT/Tx	N1	M0	S1
Stage IIB	Any pT/Tx	N2	M0	S0
	Any pT/Tx	N2	M0	S1
Stage IIC	Any pT/Tx	N3	M0	S0
	Any pT/Tx	N3	M0	S1
Stage III	Any pT/Tx	Any N	M1	SX
Stage IIIA	Any pT/Tx	Any N	M1a	S0
	Any pT/Tx	Any N	M1a	S1
Stage IIIB	Any pT/Tx	N1-3	M0	S2
	Any pT/Tx	Any N	M1a	S2
Stage IIIC	Any pT/Tx	N1-3	M0	S3
	Any pT/Tx	Any N	M1a	S3
	Any pT/Tx	Any N	M1b	Any S

[a] Except for pTis and pT4, extent of primary tumor is classified by radical orchiectomy. Tx may be used for other categories in the absence of radical orchiectomy.

[b] N indicates the upper limit of normal for the LDH assay.

AFP, α-Fetoprotein; *HCG,* human chorionic gonadotropin; *LDH,* lactate dehydrogenase; *RPLND,* retroperitoneal lymph node dissection.

Data from AJCC: Testis. In Edge SE, Byrd DR, Compton CC, editors: *AJCC Cancer Staging Manual,* ed 7, New York, 2010, Springer, pp 469–473.

Testis-Sparing Surgery

Testis-sparing surgery (or partial orchiectomy) is highly controversial and has no role in the patient suspected of having a testicular neoplasm with a normal contralateral testis. However, it may be considered for organ-confined tumors smaller than 2 to 3 cm (up to 30% of testicular volume) in

patients with synchronous bilateral tumors or tumor in a solitary testis with sufficient testicular androgen production. It may also be considered for suspected benign tumor or indeterminate lesion. Benign histology may be encountered in up to 80% of testicular lesions smaller than 3 cm with a long duration of symptoms (>6 months) (Giannarini et al., 2010). Testis-sparing surgery is seldom feasible for larger tumors (>3 cm) because a complete excision frequently leaves insufficient residual testicular parenchyma for preservation. **When testis-sparing surgery is performed, intraoperative frozen section analysis can distinguish between benign and malignant histology in the vast majority of cases** (Elert et al., 2002; Tokuc et al., 1992)**. Biopsies of the adjacent testicular parenchyma should be performed to rule out the presence of GCNIS. For patients with GCNIS, adjuvant radiotherapy to the residual testis using doses of at least 20 Gy is usually sufficient to prevent the development of a GCT while preserving Leydig cell function (and thereby testicular androgen production).** Radiation at these doses causes permanent sterility of the treated testis. Leydig cell function may decline over time, and up to 40% will require supplemental testosterone (Petersen et al., 2002). The German Testicular Cancer Study Group reported no cases of local recurrence over a median follow-up of 91 months in 46 patients with small, organ-confined tumors who underwent testis-sparing surgery and received adjuvant radiotherapy for GCNIS (Heidenreich et al., 2001). In contrast, recurrent testis cancer developed in 4 of 5 men who did not receive adjuvant radiotherapy. Adjuvant radiotherapy may be delayed after testis-sparing surgery if fathering a child is desired, although close follow-up is mandatory (Giannarini et al., 2010).

Contralateral Testis Biopsy

Between 5% and 9% of patients with GCT have GCNIS in the normal contralateral testis (Dieckmann and Skakkebaek, 1999). In patients with an atrophic testis, history of cryptorchidism, or age less than 40 years, the risk of GCNIS in the contralateral testis has been reported in up to 36% (Dieckmann and Loy, 1996). Thus an open inguinal biopsy of the contralateral testis may be considered in patients with risk factors for GCNIS or those with suspicious lesions on preoperative ultrasound (Motzer et al., 2006).

Suspected Extragonadal Germ Cell Tumor

Approximately 5% of GCTs are extragonadal (Bokemeyer et al., 2002). Thus GCT should be considered in any male with a midline mass and a normal testicular examination. Of the patients with metastatic GCT without a testis mass, only one-third definitively have a primary extragonadal GCT. The majority of these cases represent a “burned-out” primary testicular tumor that has undergone spontaneous regression as 30% to 50% have evidence of GCNIS in the testis and one-third have sonographic evidence of a “burned-out” tumor on the basis of a scar or coarse calcification (Scholz et al., 2002; Ulbright and Young, 2014). GCT should be considered in any young male with a midline mass. The presence of elevated serum AFP and/or HCG with a normal testicular evaluation is sufficient for the diagnosis of GCT, and histologic confirmation by biopsy is not necessary before starting treatment. In cases of normal serum tumor markers, biopsy of the mass should be performed to confirm the diagnosis of GCT before commencing treatment. A biopsy showing poorly differentiated carcinoma represents a diagnostic dilemma if a primary tumor site cannot be confirmed. In this scenario, the diagnosis of extragonadal GCT with malignant transformation may be considered and supported by the expression of i(12p) in biopsy specimens.

Patients with suspected extragonadal GCT should undergo inguinal orchiectomy at some point during their treatment course if the pattern of metastasis is consistent with a right- or left-sided testicular primary or if there is sonographic evidence of a “burned-out” primary tumor.

Key Points: Diagnosis and Work-Up

- A solid intratesticular mass in a postpubertal male should be considered a GCT until proven otherwise.
- With rare exceptions, inguinal orchiectomy with high ligation of the spermatic cord should be performed in men suspected of having GCT. Trans-scrotal orchiectomy or biopsy are to be condemned.
- Testis-sparing surgery for GCT is a consideration in highly select patients who have a small tumor in either a solitary testis or synchronous bilateral testis masses, where preservation of the affected testis will provide the patient with sufficient testicular androgen production.
- Diagnostic delay is common in GCT, and approximately one-third of cases

are initially misdiagnosed.

- If elevated before orchiectomy, serum tumor marker levels should be measured after orchiectomy to determine if levels are declining, stable, or rising. Preorchiectomy serum tumor marker levels should not be used in management decisions.

Clinical Staging

The prognosis of GCT and initial management decisions are dictated by the clinical stage of the disease, which is based on the histopathological findings and pathological stage of the primary tumor, post-orchiectomy serum tumor marker levels, and the presence and extent of metastatic disease as determined by physical examination and staging imaging studies. In 1997 an international consensus classification for GCT was developed by the American Joint Committee on Cancer (AJCC) and Union Internationale Contre le Cancer (UICC) (see Table 76.2). The AJCC and UICC staging systems for GCT are unique because, for the first time, a serum tumor marker category (S) based on post-orchiectomy AFP, HCG, and LDH levels is used to supplement the prognostic stages as defined by anatomic extent of disease. **The AJCC and UICC staging systems were updated in 2002, and the new systems consider the presence of LVI in the primary as pT2 in an otherwise organ-confined tumor. CS I** is defined as disease clinically confined to the testis, **CS II** indicates the presence of regional (retroperitoneal) lymph node metastasis, and **CS III** represents non-regional lymph node and/or visceral metastasis.

Staging Imaging Studies

GCT follows a predictable pattern of metastatic spread that has contributed to its successful management. **With the exception of choriocarcinoma, the most common route of disease dissemination is via lymphatic channels from the primary tumor to the retroperitoneal lymph nodes and subsequently to distant sites. Choriocarcinoma has a propensity for hematogenous dissemination. The retroperitoneum is the initial site of metastatic spread in 70% to 80% of patients with GCT.** Detailed mapping studies from retroperitoneal lymph node dissection (RPLND) series have increased our understanding of the testicular lymphatic drainage and identified the most likely sites of metastatic spread (Sheinfeld, 1994). **For right testis tumors, the primary drainage site is the inter-aortocaval lymph nodes inferior to the**

renal vessels, followed by the paracaval and para-aortic (PA) nodes. The primary "landing zone" for left testis tumors is the PA lymph nodes, followed by the interaortocaval nodes (Donohue et al., 1982)**. The pattern of lymph drainage in the retroperitoneum is from right to left.** Thus contralateral spread from the primary "landing zone" is common with right-sided tumors but is rarely seen with left-sided tumors and usually is associated with bulky disease. **More caudal deposits of metastatic disease usually reflect retrograde spread to distal iliac and inguinal lymph nodes secondary to large volume disease and, more rarely, aberrant testicular lymphatic drainage. Retroperitoneal lymphatics drain into the cisterna chyli behind the right renal artery and right crus of the diaphragm.** Thus retrocrural lymph node metastasis may be visible in patients with retroperitoneal disease. From there, lymphatic spread occurs via the thoracic duct to the posterior mediastinum and left supraclavicular fossa.

Clinical Staging of the Abdomen and Pelvis

All patients with GCT should undergo staging imaging studies of the abdomen and pelvis. Computed tomography (CT) imaging with oral and intravenous contrast is the most effective, noninvasive means of staging the retroperitoneum and pelvis. CT imaging also provides a detailed anatomic assessment of the retroperitoneum to identify anatomic anomalies that may complicate subsequent RPLND, such as a circum-aortic or retro-aortic left renal vein, lower pole renal artery, or retrocaval right ureter. MRI is an alternative to CT, although it is associated with longer examination times, higher cost, and less availability.

Enlarged retroperitoneal lymph nodes are found on CT in approximately 10% to 20% of seminomas and 60% to 70% of NSGCT. The retroperitoneum continues to be the most difficult area to accurately stage clinically. **A consistent 25% to 35% rate of pathologically involved retroperitoneal lymph nodes has been a "normal" CT scan. A size cutoff of 10 mm is frequently used to identify enlarged lymph reported for CS I NSGCT in the presence of a "normal" CT scan despite the improvements in CT imaging over the last 4 decades** (Fernandez et al., 1994)**.** There is no consensus regarding size criteria for retroperitoneal lymph nodes that constitutes nodes, but false-negative rates up to 63% have been reported when this size criterion is used. Among patients with CS IIA and IIB disease, clinical overstaging by CT (i.e., pathologically negative lymph nodes at RPLND despite enlarged lymph nodes on CT) is reported in 12% to 40% of patients.

An understanding of the primary drainage sites for left- and right-sided tumors has led to efforts to increase the sensitivity of abdominal-pelvic CT imaging by decreasing the size criteria for clinically positive lymph nodes in the primary landing zone. Leibovitch et al. (1995) showed that using a size cutoff of 4 mm in the primary landing zone and 10 mm outside this region was associated with a sensitivity and specificity for pathologic stage II disease of 91% and 50%, respectively. In a similar study, Hilton et al. (1997) reported a sensitivity and specificity of 93% and 58%, respectively using a cutoff of 4 mm for lymph nodes in the primary landing zone that were anterior to a horizontal line bisecting the aorta. **Based on this evidence, retroperitoneal lymph nodes 5 to 9 mm in size in the primary landing zone should be viewed with suspicion for regional lymph node metastasis, particularly if they are anterior to the great vessels on transaxial images (Fig. 76.3).** Because of the rapid growth of GCT, it is advisable to base management decision on CT imaging studies performed within 4 weeks of the initiation of treatment.

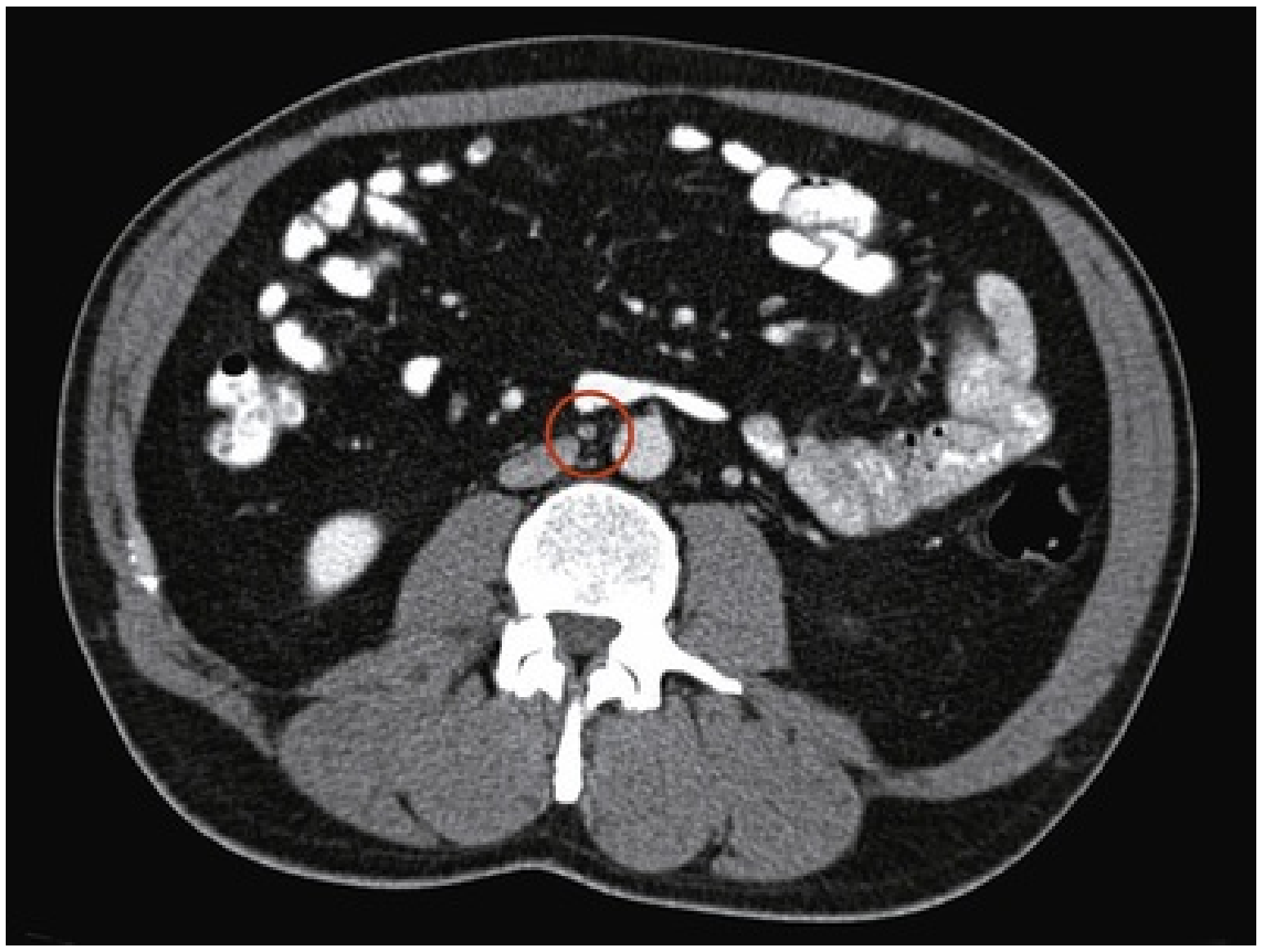

FIG. 76.3 Postorchiectomy computed tomography image of abdomen-pelvis in a patient with right testicular nonseminoma germ cell tumor showing 7-mm lymph node in primary landing zone. The lymph node was involved with teratoma at retroperitoneal lymph node dissection.

Malignant GCT accumulate fluorodeoxyglucose (FDG) and several studies have investigated positron emission tomography (FDG-PET) in the staging of GCT at diagnosis and assessing response after chemotherapy. Several small pilot studies suggested that FDG-PET can identify retroperitoneal metastasis in low-stage seminoma and NSGCT more precisely than CT (Albers et al., 1999). In a prospective trial of centrally reviewed FDG-PET studies in 111 contemporary patients with CS I NSGCT on surveillance, relapse was observed in 33 of 87 patients who were PET-negative with an estimated relapse-free rate of 63% (Huddart et al., 2007). The investigators concluded the FDG-PET is not sufficiently sensitive to accurately stage CS I NSGCT. De Wit et al. (2008) also reported that FDG-PET yielded only slightly better results than CT as a primary staging tool for low-stage NSGCT. **Thus there is currently no role for FDG-PET in the routine evaluation of NSGCT and seminoma at the time of diagnosis.**

CS II disease is subclassified based on the size of regional lymph node(s) as determined by abdominal-pelvic imaging into IIA (enlarged retroperitoneal lymph nodes ≤ 2 cm), IIB (enlarged retroperitoneal lymph nodes > 2 cm but ≤ 5 cm), and IIC (enlarged lymph nodes > 5 cm).

Pathological Staging of the Abdomen and Pelvis

In select European centers performing open RPLND and most laparoscopic RPLND series, RPLND is performed in patients with CS I or IIA NSGCT, largely as a staging procedure without curative intent, to identify the presence of regional lymph nodes and determine the need for subsequent chemotherapy (Albers et al., 2003, 2008; Bhayani et al., 2003; Janetschek et al., 2000; Nelson et al., 1999, 2007; Nielsen et al., 2007). Pathological N stage differs from clinical N stage in that the former considers the number of lymph nodes involved:

pN0: no regional lymph node metastasis
pN1: ≤5 lymph nodes involved, none > 2 cm
pN2: >5 lymph nodes involved and/or any lymph node 2–5 cm
pN3: any lymph node > 5 cm

In patients with pathological stage II disease (pTany, pN1-3, M0), the risk of occult metastases (and relapse after RPLND) is closely related to the burden of regional lymph node metastasis (10%–30% of pN1 vs. 50%–80% for pN2-3). The pathological N stage cannot be applied to RPLND specimens from patients who have received prior chemotherapy.

Chest Imaging

All patients with GCT should undergo chest imaging before management decisions. Thoracic metastasis in the absence of retroperitoneal disease and/or elevated serum tumor markers is uncommon, particularly for seminoma. Thus routine chest CT imaging may be associated with a high rate of false-positive findings, which may complicate subsequent therapy (Horan et al., 2007). Thus it is reasonable to obtain chest radiographs at the time of diagnosis as an initial staging study and CT should be performed in patients with elevated post-orchiectomy serum tumor markers, evidence of metastatic disease by physical examination or abdominal-pelvic CT imaging, or abnormal or equivocal findings on chest x-ray (CXR). It may be reasonable to perform chest CT imaging in patients with CS I NSGCT with evidence of LVI or EC predominance because some studies have reported a high rate of hematogenous metastasis to the lung in the setting of a negative CT for retroperitoneal metastasis (Hermans et al., 2000; Sweeney et al., 2000). Mediastinal or hilar lymphadenopathy in the absence of retroperitoneal disease should raise the index of suspicion of non-GCT cause such as lymphoma or sarcoidosis, and histologic confirmation of GCT by mediastinoscopy and biopsy should be performed before initiating systemic therapy (Hunt et al., 2009).

Visceral metastasis to bone and brain is uncommon in GCT in the absence of symptoms or other clinical indicators of disease. As such, there is no role for routine bone scintigraphy or brain CT imaging at the time of diagnosis. A notable exception to this is brain CT imaging for patients with a highly elevated HCG (>10,000 mU/mL) because these levels are often associated with metastatic choriocarcinoma, which has a propensity for brain metastases.

Serum Tumor Markers

Post-orchiectomy AFP, HCG, and LDH levels are important for staging, prognosis, and treatment selection. Thus all patients should have serum tumor markers drawn after orchiectomy to assess for appropriate decline according to half-life in those with elevated levels before orchiectomy. The presence of newly elevated and/or rising serum tumor marker levels after orchiectomy indicates the presence of metastatic disease, and these patients should receive induction chemotherapy. In setting of a negative metastatic evaluation and slowly declining markers (i.e., not according to half-life), patients should be monitored closely and have levels checked periodically until levels normalize or begin to rise. Stable AFP or HCG levels slightly above the normal range should be interpreted cautiously, and other causes for serum tumor marker elevation should be ruled out before management decisions are made. As with staging imaging studies, management decisions should be based on serum tumor marker levels measured within 4 weeks of the initiation of treatment.

Prognostic Classification of Advanced Germ Cell Tumor

An international, retrospective pooled analysis of 5202 patients with advanced NSGCT treated between 1975 and 1990 with platin-containing chemotherapy regimens (cisplatin or carboplatin) identified AFP, HCG, and LDH levels at the initiation of chemotherapy, the presence of nonpulmonary visceral metastasis, and primary mediastinal NSGCT as significant and independent prognostic factors for progression and survival (International Germ Cell Cancer Collaborative Group, 1997). In 660 patients with advanced seminoma, only the presence of nonpulmonary visceral metastasis was an important predictor of progression and survival (International Germ Cell Cancer Collaborative Group, 1997).

Based on these analyses, the International Germ Cell Cancer Collaborative Group (IGCCCG) risk classification for advanced GCT was developed (Table 76.3) (International Germ Cell Cancer Collaborative Group, 1997). **The IGCCCG risk group should be determined for each patient with metastatic GCT, and this should be used to guide treatment decision making on the choice of chemotherapy (discussed later).** It should be emphasized that this classification applies only to advanced GCT patients at the time of diagnosis and is not applicable to patients with relapsed GCT. It is also based on the post-orchiectomy serum tumor marker levels at the start of chemotherapy, not pre-orchiectomy levels.

TABLE 76.3

International Germ Cell Cancer Collaborative Group Risk Classification for Advanced Germ Cell Tumor

NONSEMINOMA	SEMINOMA
GOOD PROGNOSIS	
Testicular/retroperitoneal primary	Any primary site
and	*and*
No nonpulmonary visceral metastases	No nonpulmonary visceral metastases
and	*and*
Good markers—all of:	Normal AFP, any HCG, any LDH

AFP <1000 ng/mL *and*	
HCG <5000 IU/L (1000 ng/mL) *and*	
LDH <1.5 × *upper limit of normal (N)*	
56% of nonseminomas	90% of seminomas
5-year PFS 89%	5-year PFS 82%
5-year survival 92%	5-year survival 86%
INTERMEDIATE PROGNOSIS	
Testicular/retroperitoneal primary	Any primary site
and	*and*
No nonpulmonary visceral metastases	Nonpulmonary visceral metastases
and	*and*
Intermediate markers—any of:	Normal AFP, any HCG, any LDH
AFP ≥1000–10,000 ng/mL and ≤10,000 ng/mL *or*	
HCG ≥5000–50,000 IU/L and ≤50,000 IU/L *or*	
LDH ≥1.5 × N and ≤10 × N	
28% of nonseminomas	10% of seminomas
5-year PFS 75%	5-year PFS 67%
5-year survival 80%	5-year survival 72%
POOR PROGNOSIS	
Mediastinal primary	No patients classified as poor prognosis
or	
Nonpulmonary visceral metastases	
or	
Poor serum markers—any of:	
AFP >10,000 ng/mL *or*	
HCG >50,000 IU/L (10,000 ng/mL) *or*	
LDH >10 × *upper limit of normal*	
16% of nonseminomas	
5-year PFS 41%	
5-year survival 48%	

AFP, α-Fetoprotein; *HCG,* human chorionic gonadotropin; *LDH,* lactate dehydrogenase; *PFS,* progression-free survival.

Data from International Germ Cell Consensus Classification: a prognostic factor-based staging system for metastatic germ cell cancers. International Germ Cell Cancer Collaborative Group. *J Clin Oncol* 15:594–603, 1997.

Approximately 56%, 28%, and 16% of advanced NSGCT patients are classified as good-, intermediate-, and poor-risk by IGCCCG criteria, and the 5-year progression-free and overall survival rates for these patients are 89% and 92%, 75% and 80%, and 41% and 48%, respectively. There is no poor-risk category for seminoma. Approximately 90% and 10% of advanced seminoma patients are classified as good- and intermediate-risk by IGCCCG criteria, and the 5-year progression-free and overall survival rates for these patients is 82% and 86%, and 67% and 72%, respectively. Van Dijk et al. (2006) recently published a meta-analysis of 10 studies of 1775 NSGCT patients treated after 1989 and reported pooled 5-year survival estimates of 94%, 83% and 71% for good-, intermediate-, and poor-risk patients by IGCCCG criteria. These results represent a significantly improved survival compared with the original study (particularly for those classified as poor-risk) and are attributed to more effective therapy and more experience in treating NSGCT patients.

The TNM system does incorporate marker levels (S0-3) and nonpulmonary visceral metastasis in the staging of testis cancer. However, this system does not consider the differences in prognosis between seminomas and NSGCT with nonpulmonary visceral metastasis. In the TNM, these would be classified as stage IIIC but IGCCCG would classify the former as intermediate risk and the latter as poor risk. As such, the IGCCCG system is preferentially used for prognostic assessment and the selection of chemotherapy.

Sperm Cryopreservation

Although infertility is an uncommon presentation for GCT, up to 52% of men have oligospermia at diagnosis and 10% are azoospermic (Williams et al., 2009). The germinal epithelium is exquisitely sensitive to platin-based chemotherapy and radiation therapy. **Almost all patients will become azoospermic after chemotherapy, and 50% and 80% of patients with normal semen parameters at diagnosis will return to these levels within 2 and 5 years, respectively** (Bokemeyer et al., 1996; Feldman et al., 2008)**. Recovery of spermatogenesis after radiation therapy for seminoma may take to 2 to 3 years or more** (Fossa et al., 1999). Retroperitoneal lymph node dissection may result in ejaculatory dysfunction in 80% or more of patients undergoing a full, bilateral template dissection without nerve sparing. **Given the impact of treatments for testis cancer on fertility, men who are undecided or are planning future paternity are recommended to undergo sperm cryopreservation before treatment is initiated.** Sperm banking can be done before or after radical orchiectomy.

Key Points: Staging

- Testicular GCT follows a predictable pattern of spread from the primary tumor to retroperitoneal lymph nodes and then to distant metastatic sites.
- The primary landing zone for left-sided tumors is the para-aortic and left renal hilar lymph nodes and for right-sided tumors is the inter-aortocaval and paracaval lymph nodes.
- CT imaging is the optimal modality for staging the retroperitoneum, although false-negatives occur in 25% to 35% and 14% to 20% of patients with CS I NSGCT and seminoma, respectively, when a 1-cm cutoff is used.
- Chest x-ray and CT chest are acceptable staging modalities in the absence of retroperitoneal lymphadenopathy or elevated serum tumor marker levels. If serum tumor markers are persistently elevated or CT abdomen and pelvis shows evidence of metastatic disease, then a chest CT should be performed.
- Rising post-orchiectomy serum tumor marker levels indicate the presence of metastatic GCT and these patients should receive chemotherapy.
- The IGCCCG risk classification is used to evaluate the prognosis of patients with metastatic GCT and dictates the selection of chemotherapy. For NSGCT, IGCCCG risk is assigned based on the post-orchiectomy serum tumor marker levels, mediastinal primary tumor, and the presence of nonpulmonary visceral metastases. For seminoma, IGCCCG risk is assigned based on the presence of nonpulmonary visceral metastases only.
- Sperm cryopreservation should be offered to all patients before RPLND, chemotherapy, or radiation therapy because of the potential effects of these treatments on fertility.

Treatment

Therapeutic Principles

The management of GCTs is governed by the potential for rapid growth and for cure in almost all patients. **This translates into a need for rapid diagnosis and staging and expeditious application of appropriate treatment so as not to have patients die unnecessarily or suffer side effects from treatment that would not have been required with earlier diagnosis and proper management.** After orchiectomy, staging imaging studies, serum tumor marker status, and treatment plans should be performed/developed as rapidly as can be reasonably accomplished.

The probability of cure even in the presence of metastatic disease has also led to an aggressive approach with regard to the administration of chemotherapy and the performance of post-chemotherapy surgery to resect residual masses. Chemotherapy is generally administered regardless of low white blood cell counts or thrombocytopenia, and nephrotoxic chemotherapy (cisplatin) is often administered even in the presence of moderate-to-severe renal insufficiency (Bajorin et al., 1993; Bokemeyer et al., 1996; de Wit et al., 2001; Einhorn et al., 1989; Loehrer et al., 1995; Nichols et al., 1998; Williams et al., 1987). Similarly, an aggressive surgical approach is taken to resect all sites of residual disease after chemotherapy for NSGCT, even if this involves multiple anatomic sites. The young age and generally good health of GCT patients permits an aggressive treatment approach if needed.

Serum tumor markers strongly influence the management of GCTs, particularly NSGCT. As discussed, **elevated serum AFP or HCG after orchiectomy indicates the presence of metastatic disease and these patients are preferentially given chemotherapy.** For patients receiving chemotherapy, rising serum tumor markers levels during or after therapy generally indicates refractory or relapsed disease, respectively. As discussed, serum AFP, HCG, and LDH levels at the initiation of chemotherapy are important prognostic factors and influence the selection and duration of chemotherapy regimens (International Germ Cell Cancer Collaborative Group, 1997).

Testis cancer is a relatively rare disease and general urologists and general oncologists do not typically treat a large volume of GCT patients. In addition, the treatment algorithms are relatively complex and nuanced and the data supporting certain treatments, such as RPLND, are based on data from a relatively small number of surgeons who have performed a large number of these operations (Donohue et al., 1993, 1995; Heidenreich et al., 2003; Stephenson et al., 2005b; Williams et al., 2009). The majority of urology residents in the United States complete their training having performed 2 or fewer RPLND procedures (Lowrance et al., 2007). Several studies have reported improved survival when the treatment was provided at high-volume institutions (Aass et al., 1991; Collette et al., 1999; Harding et al., 1993; Feuer et al., 1994; Joudi and Konety, 2005; Suzumura et al., 2008). Therefore, whenever possible, GCT patients should be treated at a high-volume centers and RPLND should be performed by surgeons who are experienced with this operation.

Contrasting Seminoma and Nonseminoma Germ Cell

Tumor

For treatment purposes, the distinction between seminoma and NSGCT holds great importance. Compared with NSGCT, seminoma has a relatively favorable natural history. In general, seminoma tends to be less aggressive, to be diagnosed at an earlier stage, and to spread predictably along lymphatic channels to the retroperitoneum before spreading hematogenously to the lungs or other organs. **At diagnosis, the proportion of patients with CS I, II, and III disease is 85%, 10%, and 5%, respectively, for seminoma and approximately 33%, 33%, and 33% for NSGCT** (Powles et al., 2005)**. Seminoma is also associated with a lower incidence of occult metastasis among patients with CS I (10%–15% vs. 25%–35% for NSGCT) and a lower risk of systemic relapse after treatment of the retroperitoneum (1%–4% after radiotherapy for seminoma vs. 10% after RPLND for NSGCT),** which has important implications for the use of chemotherapy. Seminoma is less likely to have elevated serum tumor markers and does not range as high as in NSGCT. Serum tumor markers are also not used in the IGCCCG risk classification of seminoma.

Compared with NSGCT, **seminoma is exquisitely sensitive to radiation therapy and platin-based chemotherapy.** Regarding the former aspect, substantially lower radiation doses are required to eradicate seminoma compared to other solid tumors. As such, **radiation therapy is a standard treatment option for CS I and IIA-B seminoma but has no role in NSGCT,** with the exception of treatment for brain metastases. Seminoma only accounts for 10% of advanced GCT cases despite the fact it accounts for 52% to 56% of all GCTs. A poor prognosis IGCCCG risk category does not exist for advanced seminoma and more than 90% of metastatic cases are classified as good risk (compared with 56% for NSGCT) (International Germ Cell Cancer Collaborative Group, 1997). **The risk of teratoma at metastatic sites is generally not a consideration for advanced seminoma, which has important implications for the management of residual masses after chemotherapy**. **However, the potential for seminoma to transform into NSGCT elements is an important consideration in the management of patients who fail to respond to chemotherapy or who relapse after radiation therapy. Of patients with metastatic seminoma who relapse after treatment, approximately 10% to 15% have NSGCT elements at the site(s) of relapse. An autopsy study has shown that 30% of patients who die from seminoma have NSGCT elements at metastatic sites** (Bredael et al., 1982)**.**

The risk of teratoma at metastatic sites has a substantial effect on treatment algorithms for NSGCT and necessitates the frequent use of post-chemotherapy surgery (PCS) in patients with advanced disease. The risk of teratoma in the retroperitoneum in low-stage NSGCT has also influenced many clinicians to favor RPLND over chemotherapy in situations in which the risk of occult distant metastases is low. As discussed, teratoma is not sensitive to chemotherapy and the outcome of patients with metastatic teratoma is related to the completeness of surgical resection.

Because GCTs are almost always cured, numerous clinical trials have been conducted in an attempt to minimize treatment and avoid any unnecessary therapies in an effort to reduce short- and particularly long-term side effects and toxicity. One such approach has been to limit the number of patients who receive two interventions (“double-therapy”): either surgery or chemotherapy and not both. **However, because NSGCTs are usually mixed tumors and teratoma often exists at metastatic sites with other GCT elements, “cure” often requires chemotherapy to kill the chemosensitive components and surgery to remove teratomatous components.** It is widely accepted that the successful integration of systemic therapy and post-chemotherapy surgery is a major contributing factor to the improved cure rates for metastatic GCT seen over the past several decades. Although minimizing unnecessary treatment is an important goal, chemotherapy, radiation therapy, and CT imaging are associated with an increased lifetime risk of secondary malignant neoplasms (SMN) and/or cardiovascular disease (Brenner and Hall, 2007; Meinardi et al., 2000; Tarin et al., 2009; van den Belt-Dusebout et al., 2007; Zagars et al., 2004). In contrast, RPLND is associated with a substantially more favorable long-term toxicity profile when performed by experienced surgeons.

Key Points: Seminoma vs. Nonseminoma

- Compared with NSGCT, seminoma is associated with an indolent natural history with a lower incidence of metastatic disease and lower rates of occult retroperitoneal and distant metastases in patients with CS I and IIA-B, respectively.
- No poor-risk prognostic category exists for metastatic seminoma, and substantially more patients are classified as good-risk by IGCCCG criteria compared with NSGCT.

- Seminoma is associated with increased sensitivity to radiation therapy and platin-based chemotherapy compared with NSGCT.
- Serum HCG is elevated in only 15% of patients with metastatic seminoma, and serum tumor marker levels are not used to guide treatment decisions.
- Teratoma at metastatic sites is less of a concern for seminoma compared with NSGCT but should be considered in patients who fail to respond to conventional therapy.

Germ Cell Neoplasia in Situ

GCNIS is diagnosed by testicular biopsy performed for the investigation of infertility, contralateral testis biopsy in patient with GCT, or within the affected testis in a patient undergoing testis-sparing surgery. The rationale for treatment of GCNIS is based on the high risk of developing invasive GCT (Dieckmann and Skakkebaek, 1999; Skakkebaek et al., 1982). Treatment options include orchiectomy, low-dose radiotherapy, and close observation. The choice of therapy should be individualized based on the patient's desire for future paternity, the presence or absence of a normal contralateral testis, and the patient's desire to avoid testosterone replacement therapy. **Radical orchiectomy is the most definitive, although low-dose radiotherapy (≥ 20 Gy) is associated with similar rates of local control with the prospect of preserving testicular endocrine because of the relative radio-resistance of Leydig cells compared with germinal epithelium** (Dieckmann et al., 2003; Heidenreich et al., 2001; Montironi, 2002)**. However, testosterone replacement therapy is ultimately required in up to 40% of patients, and patients should be monitored after radiotherapy for adequate testicular androgen production** (Heidenreich et al., 2001; Petersen et al., 2002). To preserve testicular endocrine function, dose reductions less than 20 Gy have been investigated, but cases of recurrent GCNIS have been observed (Classen et al., 2003; Dieckmann et al., 2003). For patients with a normal contralateral testis who desire future paternity, radical orchiectomy is preferred as scatter to the contralateral testis from radiotherapy may impair spermatogenesis. For patients with abnormal semen parameters but sufficient for assisted reproductive techniques, close surveillance with periodic sonographic evaluation of the testis is a reasonable strategy with deferred therapy until successful pregnancy and/or GCT. Another option for these patients is testis exploration, sperm harvesting, and cryopreservation for assisted reproductive techniques, and radical orchiectomy followed by testosterone replacement therapy.

Patients with GCNIS scheduled to receive cisplatin-based chemotherapy represent a unique circumstance because chemotherapy may reduce (but not eliminate) the risk of GCT. A recent study estimated the risk of testicular GCT after chemotherapy in a patient with GCNIS to be 21% and 45% and 5 and 10 years, respectively (Christensen et al., 1998). These patients may be treated by low-dose radiotherapy after completion of chemotherapy or they may undergo testis biopsy 2 years or more after chemotherapy with therapy reserved for patients with evidence of GCNIS (Krege et al., 2008a).

Key Points: Germ Cell Neoplasia in Situ

- GCNIS is a precursor lesion for GCT and is associated with a 50% risk of developing an invasive GCT within 5 years.
- Radical orchiectomy or low-dose (≥ 20 Gy) radiation therapy is an effective treatment option for GCNIS.

Nonseminoma Germ Cell Tumor

Clinical Stage I Nonseminoma Germ Cell Tumor

Approximately one-third of NSGCT patients have CS I with normal post-orchiectomy serum tumor markers. **The optimal management of these patients continues to generate controversy as the long-term survival associated with surveillance, RPLND, and primary chemotherapy approaches 100%.** Contributing to the controversy is the fact that occult metastases in the retroperitoneum or at distant sites are present in only 20% to 30% of patients overall. Thus any intervention after orchiectomy, with the potential for short- and long-term morbidity, represents overtreatment for the 70% to 80% of patients with disease limited to the testis. Most centers employ a risk-adapted approach based on the probability of occult metastatic, although surveillance is the preferred approach at select centers, regardless of a man's risk.

Risk Assessment.

Numerous studies have attempted to identify histopathological factors within the primary tumor that predict for the presence of occult metastasis. **The most**

commonly identified risk factors for occult metastasis are LVI and a predominant component of EC. The definition of EC predominance in the literature varies from 45% to 90%. **The reported rate of occult metastasis (based on observed relapses on surveillance or lymph node metastasis at RPLND) with LVI and EC predominance varies from 45% to 90% and 30% to 80%, respectively** (Albers et al., 2003; Alexandre et al., 2001; Heidenreich et al., 1998; Hermans et al., 2000; Nicolai et al., 2004; Roeleveld et al., 2001; Sogani et al., 1998; Stephenson et al., 2005a; Sweeney et al., 2000; Vergouwe et al., 2003). **In the absence of these two risk factors, the risk of occult metastasis is less than 20%.** Other identified risk factors include advanced pT stage, absence of mature teratoma, absence of yolk sac tumor, presence of EC (regardless of the percent composition), percentage of MIB-1 staining, tumor size, and patient age. In a pooled analysis of 23 studies assessing predictors of occult metastasis in CS I NSGCT, Vergouwe et al. identified LVI (odds ratio [OR] 5.2), MIB-1 staining > 70% (OR 4.7), and EC predominance (OR 2.8) as the strongest predictors, and these factors were present in 36%, 55%, and 51% of patients, respectively (Vergouwe et al., 2003).

As discussed previously, the results of abdominal-pelvic CT imaging should be considered when formulating treatment recommendations because a size cutoff of 1 cm is associated with a high false-negative rate. Retroperitoneal lymph nodes greater than 5 to 9 mm in the primary landing zone should be viewed with suspicion for regional lymph node metastasis.

Numerous risk groups and prognostic indices have been proposed based on the presence/absence of several of these risk factors, most commonly on the basis of LVI and EC predominance (Albers et al., 2003; Alexandre et al., 2001; Freedman et al., 1987; Heidenreich et al., 1998; Hermans et al., 2000; Nicolai et al., 2004; Read et al., 1992; Sogani et al., 1998; Stephenson et al., 2005a). **Patients classified as low- vs. high-risk based on LVI and EC predominance applies to the risk of occult metastatic disease in patients with CS I and should not be confused with the IGCCCG risk classification for metastatic NSGCT** (discussed previously). Only one of these prognostic models has been prospectively validated, and none have considered the results of staging CT imaging (Freedman et al., 1987; Read et al., 1992). Four recent prospective studies suggest that LVI and EC predominance is associated with risks of occult metastasis between 35% and 55%, which are substantially lower than the risks reported in older series (Kollmannsberger et al., 2015). A contemporary surveillance series from Princess Margaret Hospital reported a relapse rate of

52% among patients with LVI and/or pure EC (Sturgeon et al., 2011). Similarly, a series from British Columbia and Portland, Oregon, reported that LVI was associated with a relapse rate of 50%, whereas the relapse rate associated with EC predominance was 33% (Kollmannsberger et al., 2010). Likewise, a population-based surveillance study from Scandinavia reported a 42% relapse rate in patients with LVI (Tandstad et al., 2009). Last, only 18% of CS I NSGCT patients treated by RPLND in a randomized trial had retroperitoneal lymph node metastasis despite the fact that 42% had evidence of LVI in the primary tumor (Albers et al., 2008). This lower-than-expected rate of occult metastasis may be due to greater scrutiny of staging CT imaging for abnormal lymph nodes and/or stage migration.

Surveillance.

The rationale for surveillance is based on the fact that 70% to 80% of patients with CS I NSGCT are cured by orchiectomy alone and the ability to salvage virtually all relapsing patients with chemotherapy based on the long-term cure rates achieved for chemotherapy for good-risk metastatic NSGCT (International Germ Cell Cancer Collaborative Group, 1997). Surveillance offers the potential of reducing treatment-related toxicity by restricting treatment to those with a proven need for it. Surveillance series have reported overall and disease-specific survival rates indistinguishable from those seen with RPLND and primary chemotherapy. As a result, initial surveillance is regarded as a standard treatment option for CS I NSGCT. The disadvantages of surveillance are that it is associated with the highest risk of relapse, the need for long-term (>5 years) surveillance, the potential for SMN because of intensive surveillance CT imaging (Brenner and Hall, 2007; Tarin et al., 2009), and the more intensive therapy required to treat patients at the time of relapse than if they had received treatment at diagnosis. In the National Cancer Database between 2004 and 2013, surveillance was the most frequently employed treatment approach for NSGCT patients with CS IA (75%) and CS IB (48%) (Weiner et al., 2017).

Published surveillance series have reported results on more than 3000 men, with a mean relapse risk of 28% and 1.2% cancer-specific mortality. The 11 largest series are summarized in Table 76.4 (Colls et al., 1999; Daugaard et al., 2003; Francis et al., 2000; Freedman et al., 1987; Gels et al., 1995; Hao et al., 1998; Kollmannsberger et al., 2010; Read et al., 1992; Sogani et al., 1998; Sharir et al., 1999; Sturgeon et al., 2011; Tandstad et al., 2009, 2010). More than 90% of relapses occur within the first 2 years, but late relapses (>5 years) are seen in up to 1% of patients (as many as 5% in some reports) (Daugaard et al., 2003; Sturgeon et al., 2011). In more contemporary series, 65% to 75% of relapses are contained in the retroperitoneum, with or without elevated serum tumor markers (Sturgeon et al., 2011; Tandstad et al., 2009). Induction chemotherapy is the most common treatment used for relapsing patients because most will have bulky (>3 cm) retroperitoneal lymphadenopathy, elevated serum tumor markers, or distant metastasis. However, patients with normal serum tumor markers and relapses limited to non-bulky (< 3 cm) retroperitoneal lymphadenopathy may be managed initially with RPLND (Stephenson et al., 2007).

TABLE 76.4

Surveillance Series for Clinical Stage I Nonseminoma Germ Cell Tumor

STUDY	PATIENTS	RELAPSES (%)	MEDIAN FOLLOW-UP (MONTHS)	MEDIAN TIME TO RELAPSE (MONTHS)	% SYSTEMIC RELAPSE[a]
Freedman et al., 1987	259	70 (32)	30	NR	61%
Read et al., 1992	373	100 (27)	60	3 (1.5–20)	39%
Gels et al., 1995	154	42 (27)	72	4 (2–24)	71%
Sogani et al., 1998	105	27 (26)	136	5 (2–24)	37%
Sharir et al., 1999	170	48 (28)	76	7 (2–21)	79%
Colls et al., 1999	248	70 (28)	53	NR	73%
Francis et al., 2000	183	52 (28)	70	6 (1–12)	54%
Daugaard et al., 2003	301	86 (29)	60	5 (1–171)	66%
Ernst et al., 2005; Hao et al., 1998	197	58 (29)	54	6 (2–135)	22%
Kollmannsberger et al., 2010b	223	59 (26)	52	NR	NR
Sturgeon et al., 2011	371	104	76	7	33
Tandstad et al.,	350	44 (13)	56	8	27%

2009 (97% were LVI negative and thus low risk)						
Tandstad et al., 2010 (96% were LVI negative and thus low risk)	129	19 (15)	123	8	37%	(

[a] Systemic relapse defined as relapse with elevated serum tumor markers and/or relapse in tissue other than retroperitoneal lymph nodes.

LVI, Lymphovascular invasion.

The surveillance schedule employed in published series is highly variable, and no schedule has been demonstrated superior to another in terms of survival. Given that the vast majority of relapses will occur within the first 2 years, surveillance imaging and testing is intense in years 0 to 2, with less frequent testing in years 3 to 5. The risk of late relapse mandates surveillance beyond 5 years, but whether such surveillance should include CT scans is controversial. The frequency of abdominal-pelvic CT imaging varies across multiple series from 2 to 13 or more scans within the first 5 years of follow-up. A randomized trial of 2 vs. 5 CT scans in years 1 to 2 reported no significant differences in survival, IGCCCG risk category at relapse, or clinical stage at relapse (Rustin et al., 2007). Noncompliance with the prescribed surveillance schedule has been reported in 35% to 80% of patients in published series (Hao et al., 1998; Howard et al., 1995).

The majority of relapses will be detected by CT imaging or by elevated STM. CXR and physical examination rarely detect relapses and may be of limited clinical utility. Patients with lymphovascular invasion are more likely to have elevated STM at relapse compared with those without lymphovascular invasion (61% vs. 38%), whereas the latter are more likely to have relapses detected by surveillance CT imaging (48% vs. 41%) (Kollmannsberger et al., 2015). Although late relapses occur in a small proportion of patients, the treatment of these relapses with chemotherapy, surgery, or a combination of the two appears to be as successful as those with early relapses (Rice et al., 2014).

Retroperitoneal Lymph Node Dissection.

The rationale for RPLND for CS I NSGCT is based on several factors: (1) the retroperitoneum is the most common site of occult metastatic disease and the risk of associated systemic disease is low, (2) 15% to 25% incidence of retroperitoneal teratoma (which is resistant to chemotherapy) in those with occult metastasis, (3) low risk of abdominal-pelvic recurrence after full, bilateral template RPLND, thereby obviating the need for routine surveillance CT imaging, (4) high cure rates after RPLND alone for patients with low-volume (pN1) retroperitoneal malignancy and teratoma (pN1-3), (5) avoidance of chemotherapy in more than 75% of more of patients if adjuvant chemotherapy is restricted to those with extensive retroperitoneal malignancy (pN2-3), (6) high salvage rate of relapses with good-risk, induction chemotherapy, (7) low short- and long-term morbidity when a nerve-sparing RPLND is performed by experienced surgeons**. In low-stage NSGCT, the therapeutic focus is the retroperitoneum, for which RPLND provides most the effective control with the lowest rates of serious long-term morbidity. The disadvantages of RPLND are that all patients undergo major abdominal surgery, it requires the availability of experienced surgeons and thus may not be deliverable to all patients, and it is associated with the highest rate of double therapy.** In recent years, rates of RPLND have decreased nationally for CS IA (14%) and CS IB (16%) (Weiner et al., 2017).

A summary of the 7 largest RPLND series for CS I NSGCT are listed in Table 76.5 (Albers et al., 2008; Donohue et al., 1993; Hermans et al., 2000; Nicolai et al., 2004; Richie, 1990; Stephenson et al., 2005b; Williams et al., 2009). The rate of pathological stage II in these series ranges from 19% to 28% and an estimated 66% to 81% of these patients were cured after RPLND alone (Al-Ahmadie et al., 2013; Donohue et al., 1993; Hermans et al., 2000; Nicolai et al., 2004; Rabbani et al., 2001; Stephenson et al., 2005a; Sweeney et al., 2000). **The long-term cancer-specific survival with RPLND (+/- adjuvant chemotherapy) approaches 100%, and the risk of late relapse is negligible. Most RPLND series have reported retroperitoneal recurrences in less than 2% of patients, demonstrating its efficacy for control of the retroperitoneum** (Donohue et al., 1993; Hermans et al., 2000; Stephenson et al., 2005b). Rates of relapse after RPLND for retroperitoneal teratoma are low regardless of pathological stage, and adjuvant chemotherapy is not recommended (Liu et al., 2015).

TABLE 76.5

Summary of Published Series of Retroperitoneal Lymph Node Dissection for Clinical Stage I Nonseminoma Germ Cell Tumor

	PS	% TERATOMA IN	%	%	%

	PATIENTS	II (%)	RETROPERITONEUM	RELAPSE, PS I	RELAPSE, PS II	C
Donohue et al. (Donohue et al., 1993).	378	113 (30)	15%	12%	34%	13
Hermans et al. (Hermans et al., 2000).	292	67 (23)	NR	10%	22%	12
Nicolai et al. (Nicolai et al., 2004).	322	61 (19)	NR	NR	27%	N
Stephenson et al. (Stephenson et al., 2005b).	297	83 (28)	15%	6%	19%	15
Williams et al. (Williams et al., 2009).	76	37 (49)	NR	5%	11%	N
Albers et al. (Albers et al., 2008).	173	31 (19)	NR	9%	***	19
Richie et al. (Richie, 1990).	99	35 (35)	NR	6%	15%	15

GCT, Germ cell tumor; *NR,* not reported; *PS,* pathologic stage.

A full, bilateral template dissection is associated with the lowest risk of abdominal-pelvic recurrence (<2%) and the highest rate of antegrade ejaculation (>90%) when nerve-sparing techniques are employed (Donohue and Foster, 1998; Eggener et al., 2007; Jewett, 1990; Stephenson et al., 2005b; Subramanian et al., 2010). For this reason, it is now considered by many to be the standard of care for primary RPLND (Stephenson et al., 2011). A recent randomized trial of primary RPLND (+ adjuvant BEPx2 for pathological stage II) vs. BEPx1 chemotherapy for CS I NSGCT showed a significant improvement in 2-year progression-free survival with chemotherapy (99% vs. 92%), although no GCT deaths were observed in either arm (Albers et al., 2008). The local recurrence rate was 11% in patients with histologically negative retroperitoneal lymph nodes at RPLND, which was substantially higher than the local recurrence rate among all patients from experienced centers. The 191 patients undergoing RPLND in this trial were treated in 1 of 61 centers in Germany. Thus the relative inexperience of surgeons and unilateral templates likely contributed to these poor results. **Thus patients who opt for RPLND should have this procedure performed by experienced surgeon with a full, bilateral template dissection. Otherwise, patients should go on surveillance or receive primary chemotherapy.**

RPLND is a curative procedure in 60% to 90% of patients with pN1 disease and up to 100% of patients with teratoma only (regardless of the extent of lymph node involvement) (Pizzocaro and Monfardini, 1984; Rabbani et al., 2001; Richie and Kantoff, 1991; Sheinfeld et al., 2003; Stephenson et al., 2005; Williams et al., 1987). The risk of relapse in patients with pN2-3 disease is greater than 50% (Socinski et al., 1988; Stephenson et al., 2005b; Vogelzang et al., 1983; Williams et al., 1987). With 2 cycles of adjuvant chemotherapy (most commonly BEPx2 or EPx2), relapses are reduced to 1% or less (Albers et al., 2003; Behnia et al., 2000; Kondagunta et al., 2004). **A randomized trial of adjuvant chemotherapy vs. observation after RPLND for pathological stage II showed a significant reduction in the risk of relapse (6% vs. 49%), but no difference in overall survival** (Williams et al., 1987)**.** Adjuvant chemotherapy and observation are acceptable treatment options for patients with pathological stage II disease, and patients should be informed of the risk of relapse after RPLND and the potential benefits and risks of these approaches.

Primary Chemotherapy.

In contradistinction to adjuvant chemotherapy given for pathological stage II disease after RPLND, primary chemotherapy refers to treatment administered to men with CS I NSGCT after orchiectomy. The goal of primary chemotherapy is to minimize the risk of relapse and to allow men to avoid RPLND and induction chemotherapy (for those who relapse on surveillance). The rationale for primary chemotherapy is based on the efficacy of 2 cycles of chemotherapy to eradicate micrometastatic disease when given as adjuvant therapy after RPLND and the 20% to 25% need for chemotherapy despite RPLND (either as adjuvant or for treatment of relapse) (Behnia et al., 2000; Hermans et al., 2000; Kondagunta and Motzer, 2007; Nicolai et al., 2004; Stephenson et al., 2005). Primary chemotherapy offers patients the greatest chance of being relapse free with any single treatment modality, and it can be delivered at community-based institutions (Tandstad et al., 2009, 2010). The disadvantages of primary chemotherapy are (1) it does not treat retroperitoneal teratoma and thus exposes patients to the potential for chemo-resistant and/or late relapse (discussed later), (2) long-term surveillance CT imaging of the retroperitoneum is required, and (3) all patients are exposed to chemotherapy and the potential risk of late toxicity (cardiovascular disease and secondary malignancies among others). The risk of late toxicity from 1 or 2 cycles of chemotherapy is poorly defined, although there appears to be no safe lower limit. Rates of primary chemotherapy in the United States for CS IA (13%) and CS IB (37%) NSGCT are substantially lower than in Europe (Weiner et al., 2017).

Primary chemotherapy has been investigated in more than a dozen published series, including five that used BEPx1 (Table 76.6; Abratt et al., 1994; Albers et al., 2008; Amato et al., 2004; Bohlen et al., 1999; Chevreau et al., 2004; Cullen et al., 1996; Dearnaley et al., 2005; Gilbert et al., 2006; Huddart and Reid, 2018; Huddart et al., 2017; Oliver et al., 2004; Ondrus et al., 1998; Pont et al., 1996; Tandstad et al., 2009, 2010). In men with LVI and/or EC predominance, it is possible to reduce the recurrence rate from 30% to 60% down to about 2% to 3%. A total of 1551 subjects were included in the 14 series summarized in Table 76.6, and a total of 38 relapses and 7 deaths were reported. The overall relapse rate was thus 2.4% and the overall mortality rate was 0.45%, but 18% of relapsing patients died. **Primary chemotherapy is thus associated with the lowest risk of relapse, but these relapses are less amenable to salvage therapy because they are chemo-resistant, particularly if they have received a regimen other than standard dose BEP. In contrast, patients who relapse after RPLND or on surveillance are chemotherapy naïve and are cured with chemotherapy in virtually all cases. However, the overall cure rate (>99%) is similar with both approaches.** Although relapses are uncommon with primary chemotherapy, almost all occur in the retroperitoneum. This mandates the use of surveillance CT abdominal-pelvis imaging in the follow-up of these patients. Many European institutions prefer primary chemotherapy with BEP to RPLND, as the latter is primarily used as a staging procedure performed without curative intent (Honecker et al., 2018; Krege et al., 2008a).

TABLE 76.6

Published Series of Primary Chemotherapy for Clinical Stage I

Nonseminoma Germ Cell Tumor

	PATIENTS	REGIMEN	MEDIAN FOLLOW-UP (MONTHS)	RELAPSES (%)	TIME TO RELAPSE (MONTHS)
Abratt et al., 1994	20	BEPx2 (E 360)	31	0	-
Cullen et al., 1996	114	BEPx2 (E 360)	48	2 (1.8)	7,18
Pont et al., 1996	29	BEPx2 (E 500)	79	2 (2.7)	8,27
Ondrus et al., 1998	18	BEPx2 (E 360)	36	0	-
Amato et al., 2004	68	CEBx2 (E 360)	38	1 (1.5)	21
Bohlen et al., 1999	58	BEPx2 (E 360) PVBx2 (20 pts)	93	2 (3.4)	22, 90
Chevreau et al., 2004	40	BEPx2 (E 360)	113	0	-
Oliver et al., 2004	148	BEPx1 (n=28); BEPx2 (n=46), BOPx2 (n=74).(E: 360)	33	6 (4.1)	Not reported
Dearnaley et al., 2005	115	BOPx2	70	3 (1.7)	3, 6, 26
Gilbert et al., 2006	22	BEPx1	120	1	-
Albers et al., 2008	191	BEPx1 (E 500)	56	2 (1.0)	15, 60
Tandstad et al., 2009	382	BEPx1 (n=312), BEPx2 (n=70) (E	56	7 (1.8)	Range: 8–36

		500)			
Tandstad et al., 2010	100	PVBx1 (n=40) or PVBx2 (n=60)	116	5	1, 9, 10, 27, 126
Huddart et al., 2017	246	BEPx1	39	7 (2.8)	5, 7, 8, 10, 12, 13, 27

E 360 refers to an etoposide dose of 360 mg/m (Siegel et al., 2018)/cycle, E 500 refers to an etoposide dose of 500 mg/m (Siegel et al., 2018)/cycle.

For men undergoing primary chemotherapy, major guidelines now recommend BEPx1 (Gilligan et al., 2018; Honecker et al., 2018). Series investing BEPx1 have accrued over 1000 patients and have reported a relapse rate of 2.3% and a mortality rate of 0.2% (n = 2), which is not appreciably different from the rate seen with BEPx2 (Huddart and Reid, 2018).

Treatment Selection for Clinical Stage I Nonseminoma Germ Cell Tumor.

There are no randomized trials that compare the standard treatment approaches for CS I NSGCT. A recent phase III, randomized trial compared BEPx1 with unilateral, modified-template RPLND (with BEPx2 for patients with pathological stage II disease) (Albers et al., 2008). Although a statistically significantly reduced risk of relapse was reported with BEPx1 (HR 0.13; 95% CI 0.02–0.55), no cancer-specific deaths were reported in either arm. This trial has been criticized as it compared two non-standard treatment approaches for CS I NSGCT (Sheinfeld and Motzer, 2008).

Given the excellent long-term survival with surveillance, RPLND, and primary chemotherapy, it is inappropriate to recommend any specific treatment option because there are relative advantages and disadvantages of each approach in terms of treatment-related toxicity, the need for subsequent treatment, and intensity of surveillance testing and imaging. Likewise, patient preferences may vary and should be considered. **Several clinical practice guidelines for CS I NSGCT have been published, and surveillance is generally recommended to low-risk patients and either surveillance, RPLND, or primary chemotherapy to those at high-risk** (Albers et al., 2005; Honecker et al., 2018; Hotte et al., 2008; Krege et al., 2008a; Motzer et al., 2006; Stephenson et al., 2011). Recently, Nguyen et al. (2010) developed a decision-analysis model that considered cancer outcomes, treatment-related toxicity, and patient preferences for important post-treatment outcomes to define the optimal treatment for CS I NSGCT. Surveillance is associated with the highest quality-adjusted survival when the estimated risk of relapse is less than 33% to 37%, and active treatment (RPLND or primary chemotherapy) is favored when the risk of relapse is greater than 46% to 54% (Nguyen et al., 2010).

Clinical Stage IS Nonseminoma Germ Cell Tumor

CS IS defined as the presence of elevated post-orchiectomy serum tumor markers without clinical or radiographic evidence of metastatic disease. Studies of primary RPLND for CS IS NSGCT have reported that 37% to 100% of patients subsequently required chemotherapy for retroperitoneal metastasis, persistently elevated serum tumor markers, or relapse (Davis et al., 1994; Saxman et al., 1996). **There is consensus that these patients should be treated similar to those with CS IIC-III and receive induction chemotherapy.** The cancer-specific survival after chemotherapy for CS IS is greater than 90% (Culine et al., 1996; International Germ Cell Cancer Collaborative Group, 1997). Slightly elevated and stable serum tumor marker levels after orchiectomy in patients without clinical evidence of disease should be interpreted cautiously as they may represent false positives for disseminated NSGCT.

Clinical Stage IIA and IIB Nonseminoma Germ Cell Tumor

The optimal management of CS IIA-B NSGCT is controversial. **RPLND (+/- adjuvant chemotherapy) and induction chemotherapy (+/- post-chemotherapy RPLND) are accepted treatment options with survival rates exceeding 95%.** There are no randomized trials comparing these treatment approaches. In a prospective, multi-center, non-randomized trial of RPLND and 2 cycles of adjuvant chemotherapy versus induction chemotherapy, no significant differences in recurrence (7% for RPLND vs. 11% for chemotherapy) or overall survival were observed (Weissbach et al., 2000). A single-institution, non-randomized, retrospective comparison of RPLND (and 2 cycles of adjuvant chemotherapy for pathological stage II) and induction chemotherapy reported a significant reduction in the risk of recurrence with induction chemotherapy (98% vs. 79%), but cancer-specific approached 100% with both modalities (100% vs. 98%), RPLND patients received fewer cycles of chemotherapy (mean 4.2 vs. 1.4), and 51% of RPLND patients avoided chemotherapy (Stephenson et al., 2007).

The arguments in favor of RPLND for CS IIA-B are (1) 13% to 35% of patients have pathologically negative lymph nodes and thus avoid chemotherapy (Donohue et al., 1995; Pizzocaro, 1987; Stephenson et al., 2007; Weissbach et al., 2000), (2) approximately 30% have retroperitoneal teratoma that is resistant to chemotherapy (Foster et al., 1996; Stephenson et al., 2007), (3) long-term cancer-specific survival is 98% to 100% with RPLND +/- adjuvant chemotherapy (Donohue et al., 1995; Pizzocaro, 1987; Stephenson et al., 2007; Weissbach et al., 2000), (4) 10% to 52% avoid any chemotherapy (Donohue et al., 1995; Pizzocaro, 1987; Stephenson et al., 2007; Weissbach et al., 2000), and (5) ejaculatory function is preserved in 70% to 90% of patients (Donohue et al., 1995; Richie and Kantoff, 1991; Weissbach et al., 2000). **The disadvantages of RPLND are** (1) additional therapy is required in 48% or more of patients, (2) 13% to 15% have persistence of disease after RPLND and require a full induction chemotherapy regimen, and (3) high-quality RPLND may not be deliverable at all institutions (Stephenson et al., 2007; Weissbach et al., 2000).

The arguments in favor of induction chemotherapy are (1) 60% to 78% of patients achieve a complete response and avoid post-chemotherapy surgery, (2) treatment can be delivered at community-based institutions, and (3) cancer-specific survival is 96% to 100% (Culine et al., 1997; Debono et al., 1997; Horwich et al., 1994; Lerner et al., 1995; Logothetis et al., 1987; Ondrus et al., 1992; Peckham and Hendry, 1985; Socinski et al., 1988; Stephenson et al., 2007; Weissbach et al., 2000). **The disadvantages of chemotherapy are** (1) all patients are exposed to the risk of long-term toxicity of chemotherapy and (2) those who do not undergo post-chemotherapy RPNLD are at risk of relapse with chemorefractory GCT.

Given that 13% to 35% of patients with CS IIA NSGCT have pathologically negative lymph nodes (thus a false-positive CT result), patients with indeterminate lesions on staging abdominal-pelvic CT imaging who are at otherwise low-risk for metastatic disease may be observed closely initially to clarify subsequent treatment decisions.

Treatment considerations for CS IIA-B NSGCT include the risk of occult systemic disease, risk of retroperitoneal teratoma, short- and long-term treatment-related morbidity, and the need for double-therapy. The latter consideration is of least importance but has strongly influenced opinion regarding the optimal treatment of these patients. As discussed earlier, because metastatic NSGCT frequently exists as chemo-sensitive malignant GCT and chemoresistant teratoma, “cure” often requires the combination of chemotherapy and surgery.

Experience with primary RPLND in low-stage NSGCT for over the last 2 decades has identified parameters associated with systemic relapse. As with CS IS NSGCT, the presence of elevated post-orchiectomy AFP and HCG is associated with an increased risk of systemic relapse after RPLND. Rabbani et al. (2001) reported relapses after RPLND in 4 of 5 patients (80%) with elevated post-orchiectomy AFP or HCG compared with 7 of 45 (16%) with normal serum tumor markers. Stephenson et al. identified the presence of elevated serum tumor markers (HR 5.6, $P < 0.001$) and retroperitoneal lymphadenopathy >3 cm (HR 12.3, $P < 0.001$) as significant predictors of systemic relapse after RPLND (Stephenson et al., 2005b). **Thus there is consensus that CS IIA-B NSGCT patients with elevated AFP or HCG or bulky lymph nodes (>3 cm) should receive induction chemotherapy.**

The presence of retroperitoneal teratoma is a limitation to any strategy for metastatic NSGCT that uses chemotherapy alone as it is resistant to chemotherapy. Overall, approximately 20% of CS IIA-B patients have retroperitoneal teratoma, and this increases to 30% to 35% in those with teratoma in the primary tumor (Donohue et al., 1995; Foster et al., 1996; Stephenson et al., 2005b). Residual microscopic teratoma may remain dormant and clinically silent throughout a patient's lifetime. It may also exhibit slow growth, which can be detected on surveillance CT imaging and be amenable to cure by surgical resection. However, growing teratoma syndrome, malignant transformation, and late relapse are the most serious (although rare) sequelae of unresected teratoma. **Thus RPLND is preferred as initial therapy in those patients at risk for retroperitoneal teratoma who are at otherwise low risk for systemic disease (normal serum tumor markers, lymphadenopathy <3 cm).**

Clinical Stage IIC and III Nonseminoma Germ Cell Tumor

Induction chemotherapy with cisplatin-based regimens is the initial approach used for the treatment of CS IIC and III NSGCT. As discussed previously, induction chemotherapy is also the preferred approach for CS IS and CS IIA-B with elevated post-orchiectomy AFP and HCG. The specific regimen and number of cycles is based on the IGCCCG risk stratification (see Table 76.3) (International Germ Cell Cancer Collaborative Group, 1997).

The development of cisplatin-based chemotherapy represents the most important advancement in the treatment of GCT. Before the identification of cisplatin, complete responses to chemotherapy were achieved in 10% to 20% of patients, and the cure rate was only 5% to 10% (Einhorn, 1990). Long-term cure is now anticipated in 80% to 90% of patients with metastatic GCT. Randomized trials have evaluated the efficacy and safety of various drug combinations to determine the optimal regimen based on the IGCCCG risk (Debono et al., 1997).

The initial landmark study was conducted at Indiana University using cisplatin-vinblastine-bleomycin (PVBx4) in the 1970s and reported complete responses in 74% of patients and more than 70% of long-term survivors (Beck et al., 2005). When it was demonstrated that etoposide could cure some patients with relapse after PVB chemotherapy, PVBx4 was compared with bleomycin-etoposide-cisplatin (BEPx4) in a multi-center randomized trial. No significant difference in overall survival was seen between the two regimens (2-year survival 80%, $P = 0.11$), but BEPx4 was associated with less neuromuscular toxicity and was subsequently adopted as the standard regimen (Williams et al., 1987).

Chemotherapy for Good-Risk Nonseminoma Germ Cell Tumor.

After BEPx4 became the standard regimen for advanced GCT, subsequent trials focused on reducing toxicity for patients with good-risk features and improving outcomes for those with intermediate- and poor-risk disease. **For good-risk patients, two randomized trials have shown that BEPx3 is not inferior to BEPx4** (de Wit et al., 2001; Einhorn et al., 1989; Saxman et al., 1998)**.** With 184 patients enrolled in the US study, 92% of patients were continuously disease free in each arm with a minimum follow-up of 1 year, and 4 deaths in each arm at 10 years were reported in a later analysis (Einhorn et al., 1989; Saxman et al., 1998). Similarly, an international European trial comparing BEPx3 with BEPx4 in more than 800 IGCCG good-risk patients reported similar outcomes with respect to 2-year progression-free (90% vs. 89%) and overall survival (97% in each arm) (de Wit et al., 2001). With these studies, BEPx3 became the standard regimen for good-risk GCT.

To reduce toxicity, investigators have studied the effect of omitting bleomycin and substituting carboplatin for cisplatin. **All of the randomized trials in which a cisplatin regimen has been compared with a carboplatin regimen have reported superior outcomes with cisplatin** (Bajorin et al., 1993; Bokemeyer et al., 1996, 2004; Horwich et al., 1997, 2000)**. The issue of whether bleomycin can be safely omitted from cisplatin-based regimens in good-risk patients is much less clear and is one of the few remaining controversies in the**

management of advanced GCT. The rationale for omitting bleomycin is based on the risk of pulmonary complications (including pulmonary fibrosis) and Raynaud phenomenon. All of these studies have shown a trend toward superiority for the bleomycin-containing regimen, although no significant survival advantage has been shown in any of the trials (Bosl et al., 1988; Levi et al., 1993). EPx3 is inferior to BEPx3 (Loehrer et al., 1995). A European randomized trial comparing BEPx4 with EPx4 (with reduced doses of etoposide) reported a significantly higher complete response rate (95% vs. 87%, $P = 0.008$) with BEPx3, but no difference in overall survival (de Wit et al., 1997). Most recently, a French randomized trial comparing BEPx3 with EPx4 (using conventional doses of etoposide) failed to show a statistically significant difference in the risk of relapse or survival between the two regimens (Culine et al., 2007). **Thus BEPx3 and EPx4 are accepted regimens for advanced GCT patients with good-risk features by IGCCCG criteria, and the 5-year overall survival is 91% to 94%** (International Germ Cell Cancer Collaborative Group, 1997; van Dijk et al., 2006).

Chemotherapy for Intermediate- and Poor-Risk Nonseminoma Germ Cell Tumor.

BEPx4 has been the standard regimen for advanced GCT with intermediate- and poor-risk features since 1987 and the corresponding 5-year survival rate was 79% and 48%, respectively, at the time these risk categories were defined in the 1990s (International Germ Cell Cancer Collaborative Group, 1997). More recent data from an analysis of 10 trials enrolling 1775 patients with disseminated NSGCT suggest that survival in these groups has increased to 83% and 71%, respectively (van Dijk et al., 2006). Ifosfamide-based regimens using either etoposide-ifosfamide-cisplatin (VIPx4) and vinblastine-ifosfamide-cisplatin (VeIPx4) have been investigated in randomized trials compared with BEPx4 (de Wit et al., 1998; Hinton et al., 2003; Nichols et al., 1998). The multi-center US trial reported results on nearly 300 men with advanced GCT, with 13%, 23%, and 64% classified as good-, intermediate-, and poor-risk by IGCCCG criteria, respectively (Hinton et al., 2003; Nichols et al., 1998). Comparing BEPx4 with VIPx4, the 2-year survival was 71% vs. 74% and the 5-year survival was 57% vs. 62%, neither of which was significantly different statistically (Nichols et al., 1998). The European study closed prematurely because the results of the US study became available. Nevertheless, with 84 patients enrolled and over 7 years median follow-up, progression-free survival was similar (85% with VIP and 83% with BEP), and overall survival at 5 years exceeded 80 percent (de Wit et al., 1998). **Because VIPx4 resulted in more high-grade hematologic and urologic toxicity, BEPx4 has remained the standard regimen for intermediate- and poor-risk GCT. However, these trials** showed that comparable cancer outcomes could be achieved when ifosfamide is substituted for bleomycin. **Thus VIPx4 may be substituted for BEPx4 in patients with compromised pulmonary function and to patients in whom extensive chest surgery will likely be performed to remove residual disease after chemotherapy** (Kesler et al., 2008).

High-dose chemotherapy (HDCT) using carboplatin-etoposide–based regimens with autologous stem cell support (also termed stem-cell rescue) has been investigated as an alternative to BEPx4 in patients with poor prognosis GCT. The rationale for HDCT is hypothesis that increasing dosage may overcome chemotherapy resistance. The most widely studied regimens have included carboplatin-etoposide alone or in combination with cyclophosphamide, ifosfamide, paclitaxel, or thiotepa (Beyer et al., 1996; Bokemeyer et al., 2002; Einhorn et al., 2007; Kondagunta et al., 2007; Kollmannsberger et al., 2009; Lorch et al., 2007). Carboplatin is used in HDCT regimens because of dose-limiting nephrotoxicity and neuropathy with cisplatin. A randomized trial in 219 patients with intermediate- (21%) and poor-risk (79%) GCT randomized to BEPx4 vs. BEPx2 followed by 2 cycles of high-dose carboplatin-etoposide-cyclophosphamide and autologous stem cell support showed no significant difference in the 1-year durable complete responses rate (48% vs. 52%, $P = 0.5$) or overall survival (Motzer et al., 2007). The 2-year and 5-year survival for patients in both arms was 83% and 71%, respectively. However, toxicity was more severe for patients receiving HDCT. A smaller randomized trial also failed to demonstrate an improved survival with HDCT compared with standard-dose regimens as first-line therapy for patients with poor-prognosis metastatic GCT (Droz et al., 2007).

More recently, investigators have studied whether outcomes can be improved through intensification of chemotherapy in patients with a prolonged time-to-normalization of serum AFP and/or BHCG during the first 6 weeks of chemotherapy (Fizazi et al., 2014). Longer time to normalization and longer half-life of AFP and BHCG have been shown to be adverse prognostic markers in studies (Fizazi et al., 2004; Massard et al., 2013). A randomized controlled trial enrolled 263 patients and 254 had tumor marker assessment. Of these, 203 (80%) prolonged time-to-normalization of at least one of the markers after one cycle of BEP and were randomly assigned to either standard care with three more cycles of BEP or a dose-dense regimen using two cycles of paclitaxel, bleomycin, etoposide, cisplatin, and oxaliplatin followed by two cycles of cisplatin, ifosfamide, and bleomycin. Three-year progression-free survival was longer in the dose-dense arm (59% vs. 48%, HR = 0.66, 95% CI = 0.44–1.00, $P = 0.05$), but there was no significant difference in overall survival ($P = 0.34$). **As a result, BEPx4 remains the standard first-line regimen in patients with intermediate- and poor-risk disease.**

Management of Post-Chemotherapy Residual Masses in Nonseminoma Germ Cell Tumor.

To assess the response to first-line, cisplatin-based chemotherapy, patients are re-staged with serum tumor markers and imaging studies of the chest-abdomen-pelvis (including other sites of disease if present before chemotherapy). **Patients are classified into the following categories based on their response to chemotherapy:** (1) complete response (CR), defined by normalization of serum tumor markers and resolution of radiographic disease (usually defined as residual masses ≤1 cm); (2) normalization of serum tumor markers with persistent radiographic tumor (partial remission–marker negative); (3) partial remission–marker positive; and (4) disease progression. **Approximately 5% to 15% of patients fall into categories 3 and 4 and are typically managed with second-line (also termed salvage) chemotherapy** (de Wit et al., 1997; Debono et al., 1997; Einhorn et al., 1989; Mead et al., 1992). **Between 38% and 68% of patients have residual masses larger than 1 cm after first-line chemotherapy, and there is clear consensus that they should undergo post-chemotherapy surgery (PCS)** (Albers et al., 2005; Honecker et al., 2018; Krege et al., 2008b; Motzer et al., 2006)**.** The management of patients with complete serologic and radiographic response is controversial, with some guidelines advocating close observation and others recommending PCS if pre-chemotherapy mass size is greater than 3 cm (Albers et al., 2005; Honecker et al., 2018; Krege et al., 2008b).

The role of PCS for residual masses in metastatic NSGCT is well established, and its rationale is based on several factors. **Multiple large series of patients undergoing PCS for residual masses after first-line chemotherapy have consistently reported evidence of persistent GCT elements in the resected specimens in 50% or more. On average, histology of resected specimens will demonstrate necrosis, teratoma, and viable malignancy (with or without**

teratoma) in 40%, 45%, and 15% of cases respectively (**Table 76.7**) (Albers et al., 2004; Carver et al., 2007; Debono et al., 1997; de Wit et al., 1997; Gerl et al., 1995; Hartmann et al., 1997; Hendry et al., 2002; Sonneveld et al., 1998; Spiess et al., 2006; Stenning et al., 1998; Steyerberg et al., 1995, 1998; Toner et al., 1990). For primary mediastinal NSGCT, residual masses after first-line chemotherapy contain viable malignancy in up to 53% of cases (Sarkaria et al., 2011). The 5-year overall survival of patients with complete resection of viable malignancy (with or without further chemotherapy) ranges from 45% to 77% (Carver et al., 2007; Donohue et al., 1998; Fizazi et al., 2001, 2008; Fox et al., 1993; Gerl et al., 1995; Hartmann et al., 1997; Spiess et al., 2006; Stenning et al., 1998; Toner et al., 1990). In contrast, if left unresected, residual viable malignancy is destined to relapse and only 25% to 35% of patients will achieve durable remissions to second-line chemotherapy.

TABLE 76.7

Histology of Post-chemotherapy Residual Masses

STUDY	PATIENTS	NECROSIS	VIABLE MALIGNANCY +/− TERATOMA	TERATOMA ONLY
Steyerberg et al., 1995	556	45%	13%	42%
Carver et al., 2007	504	49%	11%	39%
Hendry et al., 2002	330	25%	9%	66%
Debono et al., 1997	295	25%	7%	67%
Spiess et al., 2006	236	41%	17%	42%
Albers et al., 2004	232	35%	31%	34%
Toner et al., 1990	185	47%	16%	37%
Steyerberg et al., 1998	172	45%	13%	42%
Stenning et al., 1998	153	29%	15%	55%
deWit et al., 1997	127	35%	9%	56%

Oechsle et al., 2008	121	45%	21%	34%
Sonneveld et al., 1998	113	46%	9%	45%
Gerl et al., 1995	111	47%	12%	41%
Hartmann et al., 1997	109	52%	21%	27%

As discussed earlier, teratoma is resistant to chemotherapy and is present at metastatic sites in 15% of more of patients with disseminated NSGCT. The presence of metastatic teratoma is a limitation to any strategy for NSGCT that uses chemotherapy alone and necessitates the integration of chemotherapy and PCS in the majority of patients with metastatic GCT. Unresected teratoma has the potential to exhibit rapid growth (growing teratoma syndrome), undergo malignant transformation, or cause late relapse, all of which may have lethal consequences. **The outcome of metastatic teratoma is related to the completeness of surgical resection, and long-term survival is reported in 75% to 90% of patients who undergo PCS for residual teratoma** (Carver et al., 2007; Hartmann et al., 1997; Sonneveld et al., 1998; Stenning et al., 1998; Toner et al., 1990). Last, infield retroperitoneal relapse occurs in fewer than 2% of patients after a full, bilateral template RPLND, largely eliminating the need for radiographic surveillance of the abdomen and pelvis (Carver et al., 2007).

Approximately 6% to 8% of PCS specimens contain evidence of non–germ cell tumor malignancy, arising from malignant transformation of teratoma (Carver et al., 2007; Little et al., 1994; Toner et al., 1990). The most common histology is rhabdomyosarcoma, and the presence of i(12p) or abnormalities of chromosome 12 in most specimens confirms its origin from GCT (Motzer et al., 1998). **As with teratoma, the outcome of patients with malignant transformation is related to the completeness of surgical resection because they are generally resistant to GCT-specific chemotherapy regimens.** With complete resection, approximately 50% to 66% of patients will survive, whereas the vast majority of patients with incomplete resection will experience rapid progression and death from GCT (Carver et al., 2007; Comiter et al., 1998; Little et al., 1994; Lutke Holzik et al., 2003; Motzer et al., 1998). Chemotherapy specific to the transformed histology (e.g., sarcoma-specific regimen) has been investigated in two small series in select patients with measurable disease limited to one histology. Partial responses are observed in a total of 11 of 24 patients, 6 of whom are alive (Donadio et al., 2003; El Mesbahi et al., 2007).

Patients with necrosis only in the PCS specimens have a favorable prognosis, with relapse rates of 10% or less reported in most series (Carver et al., 2007; Hartmann et al., 1997; Mano et al., 2017; Stenning et al., 1998; Toner et al., 1990). Investigators have sought to identify factors that reliably predict for a high probability of necrosis to obviate the need for PCS in all patients with residual masses. In an early study, Donohue et al. (1987) reported that 0 of 15 patients without teratoma in the primary tumor and who achieved a 90% or greater reduction in the size of the residual mass with chemotherapy had no evidence of viable malignancy or teratoma at PCS. In contrast, 7 of 9 patients (78%) with teratoma in the primary tumor experiencing a similar reduction in the size of the metastasis with chemotherapy had evidence of viable malignancy and/or teratoma (Donohue et al., 1987). **The absence of teratoma in the primary tumor, the percentage reduction in the retroperitoneal mass with chemotherapy, and the size of the residual mass have consistently been identified as predictors of necrosis in PCS specimens** (Albers et al., 2004; Fossa et al., 1992; Stomper et al., 1991; Steyerberg et al., 1995, 1998; Toner et al., 1990)**.** However, despite statistical modeling using these and other factors, a consistent false-negative rate for necrosis of 20% has been reported (Steyerberg et al., 1995, 1998; Vergouwe et al., 2001). **Thus the presence of necrosis only in the retroperitoneum cannot be predicted with sufficient accuracy to safely obviate the need for PCS in patients with residual masses. An important concept is that the absence of teratoma in the primary tumor does not reliably exclude its presence in the retroperitoneum** (Beck et al., 2002; Toner et al., 1990). Investigators have also investigated the utility of FDG-PET in the prediction of the histology of residual masses after first-line chemotherapy. The utility of FDG-PET in the prediction of retroperitoneal histology for NSGCT is limited by the fact that teratoma is not FDG-avid. In a prospective study of 121 patients with residual masses after induction chemotherapy, the predictive accuracy of FDG-PET (56%) for viable malignancy or teratoma was no better than CT (55%) or post-chemotherapy serum tumor markers (56%) (Oechsle et al., 2008). **Thus FDG-PET has no role in the assessment of NSGCT patients with residual masses after chemotherapy.**

Approximately 26% to 62% of patients will experience a serologic and radiographic complete response to first-line chemotherapy (Dearnaley et al., 1991; Debono et al., 1997; Ehrlich et al., 2010; Einhorn et al., 1989; Kollmannsberger et al., 2010a; Mead et al., 1992; Stenning et al., 1998). **The optimal management of these patients is controversial.** Advocates of PCS for these patients argue that residual mass size (or percentage reduction with chemotherapy) cannot be used to reliably exclude the presence of residual disease within the retroperitoneum. **Numerous studies have demonstrated that, on average, patients with residual masses 20 mm or smaller have a 30% and 6% incidence of teratoma and viable malignancy, respectively** (**Table 76.8;** Beck et al., 2002; Fossa et al., 1989, 1992; Oldenburg et al., 2003; Toner et al., 1990; Stephenson et al., 2007; Steyerberg et al., 1995; Stomper et al., 1991). In an analysis of 295 patients with GCT managed at Indiana University after induction chemotherapy, 77 (26%) experienced a complete serologic and radiographic response to chemotherapy and 92% were alive at 5 to 10 years with an observational strategy (Debono et al., 1997). This result highlights the therapeutic benefit of PCS for patients with residual masses. **However, it should be emphasized that patients with complete serologic and radiographic response after induction chemotherapy represent a small minority of the overall population, indicating that observation is a reasonable option for only a select group of patients.** Recently, two studies have confirmed the low risk of relapse (4% to 10%) and 97% to 100% cancer-specific survival in patients with residual masses smaller than 1 cm who were observed without PCS (Ehrlich et al., 2010; Kollmannsberger et al., 2010). However, the majority of these patients were good risk by IGCCCG criteria and did not have teratoma in the primary tumor, highlighting their select nature.

TABLE 76.8

Histology of Post-Chemotherapy Residual Masses Less Than 20 mm

STUDY	PATIENTS	SIZE	NECROSIS	VIABLE MALIGNANCY +/− TERATOMA	TERATOMA ONLY
Steyerberg et al., 1995	275	≤20 mm	65%	5%	30%
Steyerberg et al., 1995	162	≤10 mm	72%	4%	24%
Oldenburg et al., 2003	87	≤20 mm	67%	7%	26%

Fossa et al., 1992	78	<20 mm	68%	4%	29%
Fossa et al., 1989	37	≤10 mm	67%	3%	30%
Stephenson et al., 2007	36	≤5 mm	69%	6%	25%
Toner et al., 1990	21	≤15 mm	81%	7%	12%
Stomper et al., 1991	14	≤20 mm	36%	14%	50%

Approximately one-third of patients have residual masses at multiple anatomic sites (the retroperitoneum, chest, and left supraclavicular fossa are the most common), and these patients should undergo resection of all sites of measurable residual disease (Gerl et al., 1994; Hartmann et al., 1997; McGuire et al., 2003; Toner et al., 1990). Although some centers have described performing simultaneous RPLND, thoracotomy, and/or neck dissection, our practice is to perform infradiaphragmatic and supradiaphragmatic resections as separate procedures. **Discordant histology between anatomic sites is reported in 22% to 46% of cases** (Masterson et al., 2012; Toner et al., 1990). In general, the histology of PCS specimens from non-retroperitoneal sites is more likely to show necrosis (60%) and less likely to show viable malignancy (10%) and teratoma (30%) (Gerl et al., 1994; Hartmann et al., 1997; Steyerberg et al., 1997; Toner et al., 1990). In addition to the size of residual masses and the number of anatomic sites, the presence of necrosis in post-chemotherapy RPLND specimens is highly predictive of necrosis at other sites (Steyerberg et al., 1997). Of patients undergoing PCS for residual masses at different sites, only 33 of 245 (13%) who had necrosis in the RPLND specimen had either viable malignancy or teratoma at other sites (Brenner et al., 1996; Gerl et al., 1994; Masterson et al., 2012; McGuire et al., 2003; Steyerberg et al., 1997; Tiffany et al., 1986; Tognoni et al., 1998). **Thus RPLND should be performed before PCS at other sites because the probability of residual disease in the retroperitoneum is highest and RPLND histology is a strong predictor of histology at other sites. Observation of small residual masses at other sites is a reasonable option if the histology of the RPLND specimen is necrosis.**

As mentioned, the 5-year survival for patients with viable malignancy in PCS specimens is 45% to 77%. The role of postoperative chemotherapy in this setting is controversial. Fox et al. (1993) reported that 14 of 27 patients (70%) undergoing PCS for viable malignancy were free of recurrence with adjuvant chemotherapy versus 0 of 7 patients who were observed. In an international pooled analysis of 238 patients with viable malignancy in PCS specimens, Fizazi et al. (2001) identified pre chemotherapy IGCCCG intermediate- and poor-risk disease, incomplete resection, and greater than 10% viable malignancy in PCS specimens as important prognostic factors. Patients with 0, 1, and 2 to 3 risk factors had a 5-year overall survival of 100%, 83%, and 51%, respectively. Overall, a significant improvement in 5-year relapse-free survival was observed with postoperative chemotherapy (73% vs. 64%, $P < 0.001$), but no difference in 5-year overall survival (74% vs. 70%, $P = 0.7$). In a subset analysis, patients with 1 risk factor had an improved 5-year survival with postoperative chemotherapy (88% vs. 56%, $P = 0.02$), but those with 0 (100% survival, with or without chemotherapy) and 2 to 3 risk factors (55% vs. 60%) did not. In a confirmatory study, this prognostic index was validated for relapse-free and overall survival, and no significant difference in these endpoints was observed among the patients who did and did not receive postoperative chemotherapy (Fizazi et al., 2008). **A complete resection of residual masses is the most critical determinant of outcome for patients with viable malignancy in PCS specimens after first-line chemotherapy. Immediate postoperative chemotherapy or surveillance may be reasonable options depending on the completeness of resection, IGCCCG risk group, and percent of viable cells.** There is no consensus on the appropriate chemotherapy regimen and the number of cycles that should be used in this setting.

The importance of PCS was highlighted in a randomized trial of BEPx3 vs. EPx4 in 257 men with good-risk metastatic NSGCT (Culine et al., 2007). As part of this trial, PCS was not dictated by protocol and only 52% underwent PCS, which frequently involved resection of residual mass only. Overall, 14 of 20 (70%) relapsing patients and 7 of 14 (50%) of those who died from GCT either did not undergo PCS or relapsed in the retroperitoneum after an inadequate RPLND. **These results suggest a substantial proportion of deaths from GCT may be prevented by the appropriate integration of chemotherapy and surgery.**

Relapsed Nonseminoma Germ Cell Tumor

The treatment of relapsing NSGCTs depends upon what treatment the patient has previously received and, in certain cases, the location of the relapse. Patients who have never received chemotherapy have a much more favorable prognosis than patients who have already been treated with chemotherapy for disseminated disease.

Chemotherapy-Naïve Nonseminoma Germ Cell Tumor Relapse.

Chemotherapy-naïve relapses occur in men with CS I NSGCT managed with either surveillance or RPLND and in the men with CS IIA-B NSGCT treated with RPLND alone. Serum tumor markers are elevated 60% to 75% of the time in CS I patients who relapse on surveillance (Alexandre et al., 2001; Gels et al., 1995; Read et al., 1992; Sharir et al., 1999). **In general, these patients are treated with induction chemotherapy, with the specific regimen and duration of therapy determined by IGCCCG risk, and cure rates exceed 95%. Select CS I patients on surveillance who relapse in the retroperitoneum with non-bulky (<3 cm) and normal serum tumor markers may be treated by induction chemotherapy or RPLND (particularly if teratoma were present in the primary tumor)** (Stephenson et al., 2007). The rationale for RPLND is to avoid or minimize the toxicity of chemotherapy, and long-term cure rates approach 100% with RPLND with or without adjuvant chemotherapy (Stephenson et al., 2007). CS I, IIA, and IIB patients who relapse after RPLND will usually do so in the lungs or mediastinum. Almost all of these patients are cured with first-line chemotherapy. The majority of relapses during surveillance or after RPLND occur within the first 2 years (Albers et al., 1995, 2008; Colls et al., 1999; Daugaard et al., 2003; Francis et al., 2000; Freedman et al., 1987; Gels et al., 1995; Kollmannsberger et al., 2010a; McLeod et al., 1991; Read et al., 1992; Sharir et al., 1999; Sogani et al., 1998; Stephenson et al., 2005b; Williams et al., 2009; Zuniga et al., 2009). For the rare patient relapsing more than 2 years after orchiectomy or RPLND with normal tumor markers, biopsy or surgical resection should be strongly considered because of the likelihood of teratoma (Michael et al., 2000; Oldenburg et al., 2006). **Although the time-to-relapse is an important determinant of outcome in relapsing patients who have received prior chemotherapy, chemotherapy-naïve patients who relapse more than 2 years after initial treatment have a similar prognosis to those who relapse earlier.**

Post-Chemotherapy Nonseminoma Germ Cell Tumor Relapse—Early.

Men who relapse after previously receiving first-line chemotherapy are treated with second-line (also termed salvage) chemotherapy. **The majority of relapses occur within 2 years of completing initial treatment, and these are classified**

as early relapse (Culine et al., 2007; de Wit et al., 1998; Michael et al., 2000; Motzer et al., 2007; Nichols et al., 1998)**. Relapses occurring more than 2 years after the completion of initial therapy are classified as late relapse and differ substantially in terms of prognosis and therapy (discussed later).** A subset of early relapsing patients who appear to have a particularly unfavorable prognosis are those who fail to achieve a complete response to first-line therapy or who relapse within 6 months of achieving a complete response; these patients are frequently termed incomplete responders (Fossa et al., 1999). **In an international pooled analysis of 1984 patients from 38 centers with relapse after first-line chemotherapy who received second-line chemotherapy, median progression-free and overall survival were 10 months and 41 months, respectively** (Lorch et al., 2010)**. Incomplete response to induction chemotherapy (HR 1.4–1.9), primary mediastinal NSGCT (HR 3.0), nonpulmonary visceral metastasis (HR 1.3), and elevated AFP (HR 1.3–2.0) and HCG (HR 1.5) were associated with increased risk of progression with second-line chemotherapy.**

As discussed earlier, etoposide and ifosfamide were demonstrated to have substantial activity in patients with relapse after first-line chemotherapy, and this led to the investigation of VIPx4 as a second-line regimen for relapse GCT after PVBx4 (Einhorn, 1990; Loehrer et al., 1986). VeIPx4 was also studied as a second-line regimen in men who had received prior etoposide from BEP regimens (Loehrer et al., 1998). Studies of VIPx4 and VeIPx4 reported long-term remission rates of 23% to 35% and overall survival rates of 32% to 53% (Loehrer et al., 1998; McCaffrey et al., 1997; Pico et al., 2005). Studies of paclitaxel in the early 1990s showed activity in relapsed GCT. This led to the development of the TIP regimen (paclitaxel, ifosfamide, and cisplatin), and relapse-free survival has been reported in 36% to 47% of patients (Kondagunta et al., 2005; Mardiak et al., 2005; Mead et al., 2005). **TIPx4, VIPx4, and VeIPx4 have never been compared in a randomized trial, and all are considered standard second-line regimens.**

HDCT has also been investigated as a second-line (and third-line) regimen in patients with GCT relapse, although its role as second-line therapy is controversial. Indiana University has amassed the largest, single-institution series involving 184 consecutive patients with metastatic GCT that progressed after first- (73%) or second-line chemotherapy (27%), 94% of whom received 2 or more courses of HDCT (Einhorn et al., 2007). Over a median follow-up of 4 years, 63% of patients were continuously disease free, including 70% and 45%

of patients who received HDCT as second- and third-line therapy, respectively. An international matched-pair analysis comparing 74 patients treated at a single institution who received 2 to 3 cycles of VIP followed by 1 cycle of HDCT using carboplatin-etoposide-ifosfamide to 119 patients treated at multiple centers throughout Europe who received standard-dose, second-line chemotherapy using a variety of regimens, reported a 10% improvement in event-free and overall survival with HDCT (Beyer et al., 2002). HDCT was compared with standard-dose, second-line chemotherapy in a randomized controlled trial enrolling 280 patients from 43 institutions. Patients in the standard-dose arm received VIPx4 or VeIPx4, depending on whether they received prior etoposide during first-line therapy. Patients in the HDCT arm received VIP/VeIPx3 followed by 1 cycle of high-dose carboplatin-etoposide-cyclophosphamide (Pico et al., 2005). Over a median follow-up of 45 months, there were no significant differences in complete and partial response rates (56% in both arms) or the 3-year event-free (35% vs. 42%, $P = 0.16$) and overall survival (53% in both arms).

There are several potential explanations for the lack of benefit of HDCT in the randomized trial despite the favorable results reported in the two non-randomized studies. First, the results from single-arm trials may be subject to selection bias from differences in case-mix. In addition, the results achieved at high-volume institutions with unique experience with HDCT may not be reproducible at other institutions. Alternatively, the treatment strategy employed in the randomized trial may have been suboptimal in that 3 cycles of standard-dose chemotherapy and only 1 cycle of HDCT were given. The treatment philosophy at Indiana University is to take patients to HDCT as quickly as possible, limit the number of cycles of standard-dose chemotherapy so that patients are able to better tolerate HDCT, and to give 2 cycles of HDCT. In the randomized trial, only 73% of patients assigned HDCT were able to receive it, and toxic deaths on the HDCT arm were twice as common as the standard-dose arm (7% vs. 3%). In the Indiana University series, 94% of patients were able to receive 2 cycles of HDCT, and the treatment-related death rate was 2.7%. **Although HDCT as second-line therapy can cure a significant number of patients, the failure to demonstrate an improvement in survival compared with standard-dose regimens in 3 randomized trials (2 as first-line therapy and 1 as second-line therapy) suggests it should not be considered a standard approach.** Currently, HDCT should only be offered at specialized centers with extensive experience.

Treatment options for high-risk patients with relapse (e.g., incomplete responders) include standard-dose, second-line chemotherapy or HDCT (if administered at a specialized, high-volume institution). Standard-dose, second-line chemotherapy is the preferred approach for patients who relapse more than 6 months after first-line chemotherapy. **Special mention is made of patients with declining or normalized serum tumor markers during first-line chemotherapy with enlarging (usually cystic) masses. These patients are considered to have growing teratoma syndrome. In these rare cases, chemotherapy is temporarily interrupted and patients are taken for surgical resection. With complete surgical resection, the long-term prognosis for these patients is favorable** (Andre et al., 2000; Logothetis et al., 1982; Spiess et al., 2007).

For patients relapsing after second-line chemotherapy, subsequent options include HDCT (if not given previously) and regimens including various combinations of the following agents: gemcitabine, paclitaxel, oxaliplatin, and irinotecan (Bokemeyer et al., 2008; De Giorgi et al., 2006; Nicolai et al., 2009; Oechsle et al., 2011; Pectasides et al., 2004; Veenstra and Vaughn, 2011).

Management of Post-Salvage Chemotherapy Residual Masses.

Patients with serologic complete response to second-line chemotherapy with residual masses should undergo post-salvage chemotherapy surgical resection (PSCS). Patients undergoing PSCS differ from those undergoing PCS of residual masses after first-line chemotherapy in several ways. A complete resection of residual masses is feasible in only 56% to 72% of patients (compared with 85% or more after first-line therapy) (Cary et al., 2015; Debono et al., 1997; Eggener et al., 2007; Fox et al., 1993; Hartmann et al., 1997; Stenning et al., 1998). The histology of PSCS specimens is characterized by higher rates of viable malignancy (38%–53%) and lower rates of necrosis (26%) and teratoma (21%–34%) compared with those after first-line chemotherapy. The long-term survival of patients is also substantially poorer with 5-year survival rates of 44% to 61% in most series (Donohue et al., 1998; Fox et al., 1993; Hartmann et al., 1997; Stenning et al., 1998). **Patients with viable malignancy in PCSC specimens have a particularly poor prognosis, and their survival is not improved with the use of postoperative chemotherapy.**

Desperation Surgery.

The majority of patients with progressive disease despite first- and second-line chemotherapy have a dismal prognosis. **However, a highly select group of**

patients with rising serum tumor markers who are deemed to have resectable disease limited to a single site (usually the retroperitoneum) may be candidates for salvage surgery, commonly referred to as "desperation surgery." Although published studies are limited to small, single-institution case series, 47% to 60% will have normalization of serum tumor markers postoperatively, and long-term survival is reported in 33% to 57% of patients after desperation surgery with or without postoperative chemotherapy (Albers et al., 2000; Beck et al., 2005; Eastham et al., 1994; Murphy et al., 1993; Wood et al., 1992). Up to 50% of patients undergoing "desperation surgery" have necrosis or teratoma on final pathology.

Post-Chemotherapy Nonseminoma Germ Cell Tumor Relapse—Late.

Late relapse after chemotherapy is defined as that occurring more than 2 years after treatment. Roughly 3% of NSGCT patients experience a late relapse (Oldenburg et al., 2006; Ronnen et al., 2005). Because late relapse is rare, a biopsy should be performed to confirm the diagnosis, particularly when serum AFP and HCG are normal. **Late relapses can be divided into three histopathological categories: viable malignancy (54%–88%; yolk sac tumor most common), teratoma (12%–28%), and malignant transformation (10%–20%; adenocarcinoma most common)** (Baniel et al., 1995; George et al., 2003; Gerl et al., 1997; Michael et al., 2000; Sharp et al., 2008).

Risk factors for late relapse have not been definitively identified, but a history of prior relapse and presence teratoma in PCS specimens (potentially for incomplete resection) are associated with an increased risk (Gerl et al., 1997; Shahidi et al., 2002). Most men with a late relapse have only one site of disease. The majority of late relapses occur in the retroperitoneum (50%–72%), 17% occur in the lungs, 9% in the mediastinum, 7% in the neck, and 4% in the pelvis (Baniel et al., 1995; Dieckmann et al., 2005; George et al., 2003; Gerl et al., 1997; Oldenburg et al., 2006; Sharp et al., 2008). **Thus failure to control the retroperitoneum in the initial treatment phase is a major risk factor for late relapse.** Serum AFP and HCG are elevated in about 50% and 25% of late relapses (Oldenburg et al., 2006). Patients with elevated serum tumor markers as the only manifestation of late relapse should be monitored closely until there is measurable disease (George et al., 2003).

Until recently, late relapse has been associated with a worse prognosis than early relapses, although contemporary data suggest these patients may have a similar probability of cure. **In general, late relapse is resistant to**

chemotherapy and the outcome is related to the ability to render patients disease free by complete surgical resection (Dieckmann et al., 2005; George et al., 2003; Gerl et al., 1997; Oldenburg et al., 2006; Shahidi et al., 2002; Sharp et al., 2008)**.**

The importance of surgery is related to the fact that teratoma and malignant transformation are inherently chemo-insensitive, and viable malignancy is usually present in the setting of prior chemotherapy (thereby, platin resistant). Of 32 patients with late relapse at Indiana University who received chemotherapy, only 6 (19%) achieved a complete response. Of the 49 patients treated initially with surgery, 45 (92%) were rendered free of disease (22 [45%] by surgery alone) and 29 (59%) are in complete remission. Overall, 69 (85%) patients achieved a disease-free state, and 58% are disease-free over a median follow-up of 25 months (George et al., 2003). In the Memorial Sloan-Kettering experience, the 5-year cancer-specific survival was 60% and patients who had a complete surgical resection at the time of late relapse (60%) and a significantly improved survival compared with those without complete resection (40%) (79% vs. 36%, $P < 0.001$) (Sharp et al., 2008). The presence of symptoms and multifocal disease at late relapse were associated with inferior survival. In a German study of 72 patients with NSGCT and late relapse, 35 (49%) were in complete remission at last follow-up, most of whom were treated with a combination of chemotherapy and surgery (Dieckmann et al., 2005). The most favorable chemotherapy results for late relapse are with the TIP regimen (Kondagunta et al., 2005). **An aggressive surgical approach to resect all disease is appropriate either as the primary treatment or, in the setting of unresectable disease, after chemotherapy.**

Key Points

- The optimal management of CS I NSGCT is controversial. Surveillance, primary RPLND, and primary chemotherapy with BEPx2 are accepted treatment options with long-term survival rates approaching 100% for each.
- A risk-adapted approach based on the presence of LVI and EC predominance is recommended. Surveillance is recommended to patients without these risk factors and active treatment (RPLND or BEPx2) is recommended to those with LVI and/or EC predominance. A non–risk-adapted approach is employed at some centers, whereby surveillance is the

recommended approach for all patients.

- Surveillance is not recommended to patients who are anticipated to be poorly compliant with follow-up imaging and clinical evaluation. The standard treatment approach to patients who relapse on surveillance is induction chemotherapy based on the IGCCCG risk. However, select patients with normal serum tumor marker levels and non-bulky (<3 cm) retroperitoneal adenopathy may also be managed by RPLND.
- BEPx1 is the standard regimen used for patients with CS I NSGCT who choose to receive chemotherapy.
- A full, bilateral template with nerve sparing is the recommended approach for primary RPLND. Attempts at preserving ejaculatory function should not compromise oncologic efficacy. RPLND should be performed only by surgeons experienced with the procedure.
- Adjuvant chemotherapy after primary RPLND for pathological stage II disease is associated with a substantial reduction in the risk of relapse but no difference in long-term survival compared with an observational strategy with induction chemotherapy at the time of relapse. Adjuvant chemotherapy is usually recommended to patients with extensive retroperitoneal metastasis (pN2-3) and those anticipated to be noncompliant with postoperative cancer surveillance imaging and testing.
- Induction chemotherapy and primary RPLND are accepted treatment options for patients with CS IIA-B NSGCT, with long-term cure in 95% or more. Induction chemotherapy is favored in patients with a high risk of occult metastasis disease on the basis of elevated post-orchiectomy serum tumor markers and/or bulky (>3 cm) retroperitoneal lymphadenopathy.
- The management of patients with CS IS, IIC, and III NSGCT is induction cisplatin-based chemotherapy. The specific regimen and number of cycles is dictated by IGCCCG risk criteria. Patients with good-risk disease should receive BEPx3 or EPx4, and those with intermediate- and poor-risk disease should receive BEPx4. With risk-appropriate chemotherapy and post-chemotherapy surgery, the survival of patients with good-, intermediate- and poor-risk disease is 89%–94%, 75%–83%, and 41%–71%, respectively.
- Post-chemotherapy resection of all residual masses is based on the incidence of residual cancer (either viable malignancy or teratoma) in 50% or more of patients.
- The use of adjuvant chemotherapy is controversial in patients with viable

malignancy in residual masses after first-line chemotherapy.

Seminoma

Clinical Stage I Seminoma

Approximately 80% of patients with seminoma are CS I, and this is the most common presentation of testis cancer. **The management of these patients has undergone substantial changes over the past 2 decades, and surveillance, primary radiotherapy, and primary chemotherapy with single-agent carboplatin are now accepted treatment options.** Recent efforts have focused on reducing the therapeutic burden. **Platin-based chemotherapy and infradiaphragmatic radiotherapy are associated with an increased risk of late cardiovascular toxicity and secondary malignant neoplasms (SMN)** (Travis et al., 2005; van den Belt-Dusebout et al., 2007; Zagars et al., 2004). Minimizing target volume and dose have been investigated to reduce the toxicity of radiotherapy. Carboplatin is associated with less neurotoxicity, ototoxicity, and nephrotoxicity compared with cisplatin, but the risks of cardiovascular disease and SMN are largely unknown. In many instances, the short-term efficacy and safety of these approaches has been validated by randomized trials. **The long-term cancer control with each of these modalities approaches 100%.**

Primary Radiotherapy.

Until the turn of the century, the mainstay of treatment for CS I seminoma had been primary radiotherapy to the retroperitoneum and ipsilateral pelvis, termed dog-leg (DL) configuration. Published series of radiotherapy for CS I are listed in Table 76.9 (Classen et al., 2004; Fossa et al., 1989, 1999; Jones et al., 2005; Oliver et al., 2005; Tandstad et al., 2011; Warde et al., 1995, 2005). **The optimal radiation dose has not been defined and most centers use 25 to 35 Gy in 15 to 20 daily fractions** (Fossa et al., 1989, 1999; Warde et al., 1995). Long-term cancer-specific survival approaches 100%, and progression-free probability between 95% and 97% is reported (Fossa et al., 1989, 1999; Kollmannsberger et al., 2010; Tandstad et al., 2011; Warde et al., 1995, 2005). **In-field recurrence after DL radiotherapy is less than 1%,** obviating the need for routine surveillance abdominal-pelvic CT imaging. Inguinal metastases are uncommon in those without prior inguinal or scrotal surgery. **The most common sites of recurrence are the thorax and left supraclavicular fossa. Virtually all recurrences are cured with first-line chemotherapy.** Select patients with isolated inguinal relapse may be salvaged with radiotherapy or surgical resection. **The surveillance of patients after DL radiotherapy consists of regular clinical assessment, chest x-ray, and serum tumor markers.**

TABLE 76.9

Summary of Radiation Therapy Series for Clinical Stage I Seminoma

	PATIENTS	MEDIAN FOLLOW-UP	TARGET VOLUME	MEDIAN DOSE (GY)	GCT DEATHS (%)	RE (%)
Fossa et al., 1989	365	109 months	Dogleg	40	4 (1)	13 (
Warde et al., 1995	194	97 months	Dogleg	25	0	11 (
Warde et al., 2005	282	106 months	Dogleg	25	0	14 (
Fossa et al., 1999	242	54 months	Dogleg	30	0	9 (4
Fossa et al., 1999	236	54 months	Para-Aortic	30	1	9 (4
Classen et al., 2004	721	61 months	Para-Aortic	26	2 (0.3)	26 (
Jones et al., 2005	313	61 months	Para-Aortic	30	1 (0.3)	10 (
Jones et al., 2005	312	61 months	Para-Aortic	20	0	11 (
Oliver et al., 2005, 2011	904	78 months	Para-Aortic	20-30	1 (0.1)	32 (
Tandstad et al., 2011	481	73 months	Dogleg	25	0	4 (1
Kollmannsberger et al., 2010	159	65 months	Para-Aortic	25	0	4 (2

Most patients experience some acute side effects with adjuvant radiotherapy, which typically include transient nausea, vomiting, and diarrhea, which are usually mild and self-limited. Acute grade II to IV hematologic toxicity occurs in 5% to 15% (Fossa et al., 1999). Moderate and severe late gastrointestinal (GI) toxicity (usually chronic dyspepsia or peptic ulcer disease) is reported in 5% and less than 2% of patients, respectively. The testicular germinal epithelium is exquisitely sensitive to ionizing radiation, and scatter dose to the contralateral testis may be significant despite protective shielding. After DL radiotherapy, persistent oligospermia is reported in 8% (Fossa et al., 1999). The issue of late cardiac toxicity and SMN is particularly germane for these patients given the long anticipated life expectancy. **The actuarial risk of developing SMN is estimated to be 18% at 25 years after radiotherapy for seminoma** (Travis et al., 2005). Secondary leukemia is linked with radiotherapy and chemotherapy, whereas an excess of the upper GI tract, bladder, and possibly pancreas cancers is associated with radiotherapy.

To reduce the toxicity of radiotherapy, efforts to minimize the target volume and dose have been evaluated in randomized trials. The Medical Research Council (MRC; United Kingdom) conducted a randomized trial of DL vs. para-aortic (PA) radiotherapy for CS I seminoma (Fossa et al., 1999). The rationale for omitting radiotherapy to the ipsilateral pelvis is based on the low rate (1%–3%) of pelvic lymph node involvement in patients without prior inguinal or scrotal surgery. Restricting radiotherapy to the PA strip may reduce the risk of SMN and improve the recovery of spermatogenesis. The 3-year relapse-free survival (96% vs. 97%) and overall survival (99% vs. 100%) in the PA vs. DL arms were similar, but patients receiving PA radiotherapy had an improved short-term recovery of spermatogenesis (although no difference was seen at 3 years). However, the PA arm experienced a significant increase in the rate of pelvic recurrence (2% vs. 0, $P = 0.04$). The small but significant risk of pelvic recurrence necessitates the use of routine surveillance pelvic CT imaging with the associated increased cost and radiation exposure (Brenner and Hall, 2007).

The MRC and the European Organisation for the Research and Treatment of Cancer (EORTC) also conducted a randomized trial of 20 vs. 30 Gy PA radiotherapy for CS I seminoma (Jones et al., 2005). The 5-year relapse-free survival (96% vs. 97%) and overall survival (99.6% vs. 100%) were similar, but patients receiving 20 Gy experienced less acute GI toxicity, leukopenia, and lethargy (though results were similar at 12 weeks). Further follow-up is necessary to assess the durability of these results.

Surveillance.

Given the potential for late toxicity with DL radiotherapy, the 80% to 85% cure rate after orchiectomy, and the more than 90% cure rates achieved with platin-based chemotherapy for advanced seminoma, surveillance has been evaluated at several centers. **Compared with NSGCT, surveillance for CS I seminoma is complicated by the limited utility of serum tumor markers to detect relapse**

and the need for long-term surveillance CT imaging because 10% to 20% of relapses occur 4 years or more after diagnosis (Chung et al., 2002). In the National Cancer Database, the majority of contemporary CS I seminoma patients (60%) are placed on surveillance (Matulewicz et al., 2016).

The largest surveillance series for CS I seminoma are listed in Table 76.10 (Aparicio et al., 2003, 2005; Choo et al., 2005; Daugaard et al., 2003; Horwich et al., 1992; Kollmannsberger et al., 2010c; Tandstad et al., 2011; von der Maase et al., 1993; Warde et al., 1995, 2005). **The 5-year relapse-free survival ranges from 80% to 86%, and cancer-specific survival approaches 100%**. **Eighty-four to 100% of patients relapse in the retroperitoneum, and 18% to 24% of patients have bulky retroperitoneal disease and/or distant metastases at the time of recurrence** (Aparicio et al., 2003; Choo et al., 2005; Horwich et al., 1992; von der Maase et al., 1993; Warde et al., 1995). DL radiotherapy is employed for treatment of relapse in 73% to 88% of patients, and cure rates of 70% to 90% are reported. Almost all patients who relapse outside the retroperitoneum are cured with first-line chemotherapy. Compared with NSGCT, the median time to relapse is longer for CS I seminoma (14 months vs. 4–8 months.), and a greater proportion of patients will relapse 5 years or more after diagnosis (Kollmannsberger et al., 2015).

TABLE 76.10

Summary of Surveillance Series for Clinical Stage I Seminoma

STUDY	PATIENTS	MEDIAN FOLLOW-UP	GCT DEATHS (%)	RELAPSE (%)	RPN RELAPSE (%)	CS IIC RELA (%)
Daugaard et al., 2003	394	—	0	69 (17)	—	—
Warde et al., 2005	348	106 months	1 (0.3)	55 (16)	—	—
Warde et al., 1995	172	50 months	1 (0.6)	27 (16)	24 (89)	5 (19)
von der Maase et al., 1993	261	48 months	1 (0.4)	49 (19)	46 (94)	12 (24
Aparacio et al., 2003	143[a]	52 months	0	23 (16)	19 (84)	—
Horwich et al., 1992	103	62 months	0	17 (17)	17 (100)	3 (18)
Choo et al., 2005	88	145 months	0	17 (19)	15 (88)	3 (18)

Aparacio et al., 2005	100[b]	34 months	0	6 (7)	6 (100)	—
Tandstad et al., 2011	512	60 months	0	65 (14)	65 (100)	—
Kollmannsberger et al., 2010	313	34 months	0	47 (19)	—	—

[a] Patients with lymphovascular invasion or clinical stage ≥ T2 excluded

[b] Patients with tumor size > 4 cm or rete testis invasion excluded

CS, Clinical stage; *GCT,* germ cell tumor; *RPN,* retroperitoneal.

To detect and treat recurrences at an early stage, patients on surveillance should be followed with clinical assessment, chest x-ray, serum tumor markers, and CT abdominal-pelvic imaging. Surveillance schedules employ assessments every 2 to 4 months in years 1 to 3, every 6 months in years 4 to 7, then annually thereafter. The necessary frequency of CT imaging is poorly defined, and centers obtain this every 4 to 6 months in years 1 to 3, every 6 months in years 4 to 7, then annually thereafter. A recent MRC trial suggested that the frequency of surveillance CT imaging in low-risk CS I NSGCT in years 0 to 2 may be safely reduced from 5 to 2 without affecting survival or burden of therapy (Rustin et al., 2007). It is unclear whether these findings can be safely applied to surveillance for seminoma. Long-term follow-up is mandatory given the higher incidence of relapse after 5 years compared with NSGCT (Chung et al., 2002). Surveillance CT imaging detects the majority of relapses among CS I seminoma patients (>85%), less than 5% of relapses are detected by elevated HCG levels, and almost no relapses are detected by chest x-ray or physical assessment (Kollmannsberger et al., 2015).

To better select patients for active treatment, investigators have endeavored to identify prognostic factors for occult metastasis. **In a pooled analysis of 3 large surveillance series from the 1980s, tumor size larger than 4 cm and rete testis invasion were significant predictors of relapse in multivariable analysis** (Warde et al., 2002)**. Unlike NSGCT, LVI has not been identified as a significant predictor of relapse for CS I seminoma.** The 5-year relapse rate for patients with 0, 1, and 2 risk factors was 12%, 16%, and 32%, respectively. Twenty-one percent of patients in this cohort had rete testis invasion and tumor size greater than 4 cm. Primary radiotherapy or carboplatin for all “high-risk” patients would still expose two-thirds of CS I seminoma patients (who are cured by orchiectomy) to unnecessary therapy. However, prospective validation of these risk factors is currently lacking.

Primary Chemotherapy With Single-Agent Carboplatin.

Primary chemotherapy with 1 to 2 cycles of single-agent carboplatin has also been investigated as an alternative to primary radiotherapy with the potential for reduced late toxicity. The rationale for single-agent carboplatin is based on the 65% to 90% reported complete response rates observed among patients with advanced seminoma (Horwich et al., 2000), and its reduced toxicity compared with cisplatin. Oliver et al. (1994) first described the use of 1 to 2 cycles of carboplatin in 78 patients and reported only 2 relapses and no deaths (Oliver et al., 1994). The published studies of carboplatin in CS I seminoma are listed in Table 76.11 (Aparicio et al., 2003, 2005, 2011; Dieckmann et al., 2000; Kollmannsberger et al., 2010c; Reiter et al., 2001; Steiner et al., 2002; Tandstad et al., 2011). No deaths from seminoma have been observed, and 3- to 5-year relapse-free rates are 91% to 100%.

TABLE 76.11

Summary of Adjuvant Chemotherapy Series for Clinical Stage I Seminoma

	PATIENTS	MEDIAN FOLLOW-UP	NO. CYCLES	GCT DEATHS (%)	RELAPSE (%)
Oliver et al., 2011	573	78 months	1	0	27 (5)
Steiner et al., 2002	108	60 months	2	0	2 (2)
Reiter et al., 2001	107	74 months	2	0	0
Dieckmann et al., 2000	93	48 months	1	0	8 (9)
Dieckmann et al., 2000	32	48 months	2	0	0
Oliver et al., 1994	78	51 months	2[a]	0	2 (2)
Aparacio et al., 2003	60	52 months	2	0	2 (3.3)
Aparacio et al., 2005	214	34 months	2	0	7 (4)
Tandstad et al., 2011	188	62 months	1	0	7 (4)
Kollmannsberger et al., 2010	73	33 months	1-2	0	1 (2)

[a] 33% of patients received 1 cycle of carboplatin.

GCT, Germ cell tumor.

The MRC and EORTC conducted a randomized, phase III clinical trial of 1 cycle of carboplatin vs. 20 to 30 Gy PA radiotherapy in 1477 patients with CS I seminoma (Oliver et al., 2005, 2011). Over a median follow-up of 6½ years, the 5-year relapse-free survival was similar (94.7% vs. 96%), and only 1 death was observed in the PA radiotherapy arm. In this trial, patients receiving carboplatin experienced less lethargy and time away from work than those receiving radiotherapy, and acute grade III to IV hematologic toxicity was observed in 4% of patients. Since this study was completed, a pooled analysis of 185 patients who relapsed after adjuvant carboplatin reported 5-year disease-free survival of 82% and 5-year overall survival of 98%, indicating that these patients are salvageable and do not have an unexpected rate of chemotherapy-resistant disease at relapse (Fischer et al., 2017). Fifteen percent of relapses occurred after 3 years, so a minimum of 5 years of surveillance is recommended.

A concern with one cycle of carboplatin is the potential for inadequate dosing, leading to an increased risk of relapse. A higher relapse rate with 1 vs. 2 cycles has been seen when comparing different studies, and a higher risk of relapse was reported among patients receiving an inadequate dose of carboplatin in the MRC/EORTC trial (Dieckmann et al., 2000; Oliver et al., 2008). More recently, a SWENOTECA study of 1118 men reported that a single dose of carboplatin reduced the risk of relapse in men with risk factors by only about 50% (Tandstad et al., 2016). In men with tumors larger than 4 cm, the risk of relapse was 19% with surveillance and 9.7% with a single dose of carboplatin, whereas the figures were 13.6% and 9.1% for men with rete testis invasion. A German study similarly reported only a 50% reduction in risk of relapse for men with large tumors when one cycle of carboplatin was administered (Dieckmann et al., 2016). Overall, the risk of relapse in this study was 5% with one cycle of carboplatin and 1.5% with two cycles. As a result of these and other studies, guidelines are divided on whether one or two cycles of carboplatin should be administered to men receiving primary chemotherapy for CS I seminomas (Dieckmann and Anheuser, 2016; Gilligan et al., 2018; Honecker et al., 2018). Moreover, the relatively small benefit seen with a single dose of carboplatin has led some to question this agent's use altogether for stage I disease (van de Wetering et al., 2018). Regardless of the number of cycles, the optimal dosing of carboplatin is calculated by the formula

$$7 \times (\text{Glomerular filtration rate [GFR, mL/min]} + 25)\ \text{mg}$$

(Calvert and Egorin, 2002). **Carboplatin dosing should not be based on estimated GFR. Thus it is recommended to base 1 cycle of carboplatin dosing on the results of radioisotope renal scans or administer 2 cycles of therapy.**

Given the low overall risk of relapse with CS I seminoma, the lack of prospectively validated markers to identify a high-risk population, and the potential for late toxicity with radiotherapy and carboplatin, many clinical practice guidelines now recommend surveillance as the preferred approach (Gilligan et al., 2018; Honecker et al., 2018; Krege et al., 2008a). Surveillance enables 80% to 85% of patients to avoid treatment-related toxicity, and relapses are effectively salvaged with DL radiotherapy in most cases. However, surveillance must be continued more than 5 years, and frequent CT imaging is required. **For noncompliant patients or those unwilling to accept surveillance, primary radiotherapy or primary chemotherapy with 2 cycles of carboplatin are recommended.**

Clinical Stage IIA and IIB Seminoma

Approximately 15% to 20% of seminoma patients have CS II disease, 70% of whom have CS IIA-B. DL radiotherapy using 25 to 30 Gy (including a 5 to 10 Gy boost to involved areas) is employed at most centers. The higher radiation doses administered to CS IIA-B patients is generally well tolerated with acute grade III to IV GI toxicity reported in 8% to 10% (Classen et al., 2003). Prophylactic radiation to the left supraclavicular fossa is no longer practiced because less than 3% of patients are likely to benefit (Chung et al., 2003; Zagars and Pollack, 2001). Long-term disease-free survival rates of 92% to 100% for CS IIA and 87% to 90% for CS IIB have been reported, with in-field recurrences reported in 0 to 2% and 0 to 7% of cases, respectively (Chung et al., 2004; Classen et al., 2003; Zagars and Pollack, 2001). Adding single-agent carboplatin to 30 Gy DL radiotherapy reduced the relapse rate from 30% to 6% in one series, although further data are required to assess the utility of this approach (Patterson et al., 2001). **Relapses are cured in almost all cases with first-line chemotherapy, and disease-specific survival approaches 100%. Routine surveillance CT imaging is not necessary after complete resolution of disease.**

Induction chemotherapy using first-line regimens (BEPx3 or EPx4) is an accepted alternative to DL radiotherapy. The Spanish Germ Cell Cancer Study Group recently reported on the use of BEPx3 or EPx4 in 72 patients with CS IIA-B seminoma (Garcia-del-Muro et al., 2008). Overall, 83% of patients achieved a serologic and radiographic complete response, and only 1 (1.3%) had residual mass larger than 3 cm, and the 2 patients who underwent PCS for residual masses had necrosis only in the resected specimens. Overall, the 5-year relapse-free and overall survival was 90% and 95%, respectively. The SWENOTECA group similarly reported that there were no relapses among 73 CSIIA/B patients treated with cisplatin-based chemotherapy, whereas there were 3 relapses (10%) among 29 patients treated with radiotherapy. **Induction chemotherapy is preferentially given to patients with bulky (>3 cm) and/or multiple retroperitoneal masses as the risk of relapse is lower than DL radiotherapy** (Chung et al., 2004; Garcia-del-Muro et al., 2008; Patterson et al., 2001).

Primary RPLND is an accepted intervention for NSGCT patients with CS IIA and IIB disease who have negative serum tumor markers. RPLND has not been accepted as a standard treatment for CS IIA and IIB seminoma for largely historical reasons. With recognition of the late toxicity of primary chemotherapy and radiotherapy, there is renewed interest in defining the role of primary RPLND for these patients. The rationale for RPLND is further supported by the recognition that metastatic disease is usually limited to the retroperitoneum in the majority of patients with CS IIA (>90%) and IIB (>85%) seminoma, suggesting RPLND alone may cure these patient without the need for systemic therapy. Two prospective trials in the United States and Germany are investigating the role of primary RPLND as treatment for CS IIA with or without IIB seminoma or as treatment for isolated retroperitoneal relapses for CS I seminoma patients on surveillance or after carboplatin primary chemotherapy.

Clinical Stage IIC and III Seminoma

As with NSGCT, patients with CS IIC and III seminoma are treated with induction chemotherapy, with the regimen and number of cycles determined by the IGCCCG risk. Ninety percent of patients with advanced seminoma are classified as good-risk and should receive either BEPx3 or EPx4 chemotherapy. Complete radiographic responses are reported in 70% to 90% of patients, and the 5-year overall is 91% (Gholam et al., 2003; International Germ Cell Cancer Collaborative Group, 1997; Loehrer et al., 1987; Mencel et al., 1994). Only 10% of advanced seminomas have nonpulmonary visceral metastasis (classified as intermediate-risk by IGCCCG criteria). With BEPx4 chemotherapy, the 5-year overall and progression-free survival is 79% and 75%, respectively (International Germ Cell Cancer Collaborative Group, 1997). Single-agent carboplatin in advanced seminoma is associated with inferior survival compared to cisplatin-based regimens (Bokemeyer et al., 2004).

Management of Post-Chemotherapy Residual Masses.

After first-line chemotherapy, 58% to 80% of patients have radiologically detectable residual masses (De Santis et al., 2004; Duchesne et al., 1997; Flechon et al., 2002; Fossa et al., 1997; Herr et al., 1997; Motzer et al., 1987; Puc et al., 1996). **Spontaneous resolution of these masses is reported in 50% to 66% of cases (30%–50% for masses >3 cm), and the median time to resolution is 12 to 18 months** (De Santis et al., 2004; Flechon et al., 2002). **The histology of residual masses is necrosis and viable malignancy in 90% and 10% of cases, respectively** (De Santis et al., 2004; Flechon et al., 2002; Herr et al., 1997; Puc et al., 1996; Ravi et al., 1999). **PCS for seminoma is technically difficult (and frequently not feasible) because of the desmoplastic reaction that occurs after chemotherapy with resultant increased perioperative morbidity** (Mosharafa et al., 2003). Surgical complete resections in post-chemotherapy seminoma are reported in only 58% to 74% of patients (compared with 85% or more after first-line chemotherapy for NSGCT) (De Santis et al., 2004; Flechon et al., 2002; Herr et al., 1997; Puc et al., 1996; Ravi et al., 1999). Adjunctive procedures such as nephrectomy are required in 38% to 51% of patients. **Teratoma and malignant transformation are much less of a concern with advanced seminoma.** As such, the management of post-chemotherapy residual masses differences substantially for seminoma compared with NSGCT.

Investigators have endeavored to identify factors associated with a high risk of viable malignancy to justify PCS. **Post-chemotherapy radiotherapy has no role in the management of residual masses** (Duchesne et al., 1997)**. The size of residual masses is an important predictor of viable malignancy; 13% to 55% of discrete residual masses larger than 3 cm contain viable malignancy compared with 0 to 4% for masses less than 3 cm** (De Santis et al., 2004; Flechon et al., 2002; Herr et al., 1997; Puc et al., 1996). **Recently, FDG-PET has been found to be a useful adjunct to CT imaging to select patients for PCS** (De Santis et al., 2004). In a prospective study, the specificity and sensitivity of a positive FDG-PET for masses greater than 3 cm was 100% and 80%, respectively. Recently, rates of false-positive FDG-PET results have been reported in 22% to 78% of patients; the accuracy of a negative FDG-PET result remains high. The risk of a false-positive FDG-PET result is higher if the study is completed within 4 to 6 weeks after completion of chemotherapy because of inflammation or residual nonviable malignancy. Thus FDG-PET should be delayed until at least 6 weeks after completion of chemotherapy. **There is consensus that patients with discrete residual masses greater than 3 cm should be evaluated further with FDG-PET at least 6 weeks after completion of chemotherapy, and those who are PET-negative and those with masses smaller than 3 cm should be observed.**

There is controversy regarding the appropriate management of patients with FDG-positive residual masses larger than 3 cm given the reported rates of false-positive FDG-PET imaging. Close observation with repeat FDG-PET imaging in 6 to 8 weeks has been advocated by some, although its role is unproven. Close observation with delayed intervention for growing masses has also been advocated because only 14% to 20% of these patients will relapse with most identified within 4 to 6 months of completion of chemotherapy. In the Indiana University experience, this approach of observation with delayed intervention was associated with durable disease control in only 9 of 36 patients with a 72% relapse rate after PC-RPLND (Rice et al., 2014). Although a survival advantage associated with PCS for metastatic seminoma has yet to be definitely proven, there is a therapeutic benefit to upfront PC-RPLND: it enables an immediate assessment of tumor response and further chemotherapy can be administered in a timely fashion. PCS is also therapeutic for the rare advanced seminoma patient with metastatic teratoma, which is reported to be present in up to one-third of residual masses larger than 3 cm after chemotherapy. In the study by Herr et al. (1997), all 6 patients who had complete resection of viable malignancy were disease free over a median follow-up of 45 months. In contrast, 4 of 6 patients with unresected viable malignancy died of seminoma despite additional chemotherapy and/or radiotherapy (Herr et al., 1997). **For patients with FDG-PET positive residual masses larger than 3 cm, strong consideration should be given for PC-RPLND, particularly those with residual masses after second-line chemotherapy.**

Historically, resection of the residual mass only was advocated rather than completion of a full, bilateral RPLND. In the Indiana University experience, this approach was associated with a 33% local relapse rate (Rice et al., 2014). As such, consideration should be given to performing a full, bilateral, or accepted modified template dissection (as is used at PC-RPLND NSGCT) if it is technically feasible to do so.

Relapsed Seminoma

Chemotherapy-Naïve Seminoma Relapse.

Chemotherapy-naïve relapse occurs in men with CS I seminoma on surveillance and in those with CS I-IIB seminoma treated with primary radiotherapy. **For the former patients, DL radiotherapy is employed for treatment of relapse in 73% to 88% of patients and cure rates of 70% to 90% are reported. Patients with bulky (>3 cm) retroperitoneal masses and systemic relapse should receive first-line chemotherapy and salvage rates approach 100%. First-line chemotherapy cures virtually all patients who relapse outside the retroperitoneum after primary radiotherapy**. Patients who relapse after single-agent carboplatin are considered to have chemotherapy-naïve relapse and should receive first-line cisplatin-base chemotherapy.

Post-Chemotherapy Seminoma Relapse—Early.

An estimated 15% to 20% of advanced seminoma patients relapse after induction chemotherapy, including 10% who achieve an initial complete response (International Germ Cell Cancer Collaborative Group, 1997; Loehrer et al., 1987; Mencel et al., 1994). In general, patients with incomplete response to first-line chemotherapy or relapse after an initial major clinical response have a poor prognosis with long-term survival rates of 20% to 50% (Gholam et al., 2003; Miller et al., 1997; Vuky et al., 2002). The small number of patients with seminoma who require second-line chemotherapy has limited the evaluation of unique treatment strategies and relapsing patients are treated on regimens that were largely developed for NSGCT relapse. In two small studies, the efficacy of VeIPx4 as second-line chemotherapy was evaluated in 36 patients with relapsed seminoma. Overall, 30 patients (83%) achieved a complete response to chemotherapy (with or without PCS) and 21 (53%) were continuously free of recurrence over a median follow-up of 72 to 84 months (Miller et al., 1997; Vuky et al., 2002). Vuky et al. (2002) also evaluated HDCT in 12 advanced seminoma patients with an incomplete response to first-line chemotherapy and 6 patients (50%) achieving a complete response have remained free of recurrence. **An important consideration for advanced seminoma patients who relapse after first-line chemotherapy is the potential for teratoma at the site of relapse. Thus patients with normal serum tumor markers should undergo**

biopsy before starting second-line chemotherapy.

Post-Chemotherapy Seminoma Relapse—Late.

In most published series, pure seminoma accounts for fewer than 8% of late relapse events (Baniel et al., 1995; George et al., 2003; Ronnen et al., 2005; Sharp et al., 2008). However, Dieckmann et al. recently (2005) reported a series of 122 patients with late relapse, of whom 50 (41%) had pure seminoma at diagnosis. Only 6 (12%) of these patients had received prior first-line chemotherapy and the majority had received single-agent carboplatin or radiation therapy at diagnosis. Long-term cancer control was achieved in 88% of patients. **Thus late relapse of seminoma may have a favorable prognosis, particularly among patients without prior exposure to cisplatin.**

Key Points

- The optimal management of CS I seminoma is controversial. Surveillance, primary radiotherapy (20–30 Gy to the para-aortic region +/− ipsilateral pelvis), and primary chemotherapy with carboplatin (1–2 cycles) are accepted treatment options with long-term survival rates approaching 100% for each.
- Prognostic factors for occult metastases in CS I seminoma are not as well developed as for NSGCT. Given the overall low-risk of occult metastases (15%–20%), the inability to identify a high-risk population on the basis of histopathological factors in the primary tumor, and the potential for late toxicity with primary radiotherapy, surveillance has become the recommended treatment approach for CS I seminoma.
- Surveillance is not recommended to patients who are anticipated to be poorly compliant with follow-up imaging and clinical evaluation. The standard treatment approach to patients who relapse on surveillance is DL radiotherapy (25–35 Gy), although patients with bulky retroperitoneal lymphadenopathy or distant metastases should receive IGCCCG risk-appropriate first-line chemotherapy.
- Primary radiotherapy and primary chemotherapy with single-agent carboplatin are associated with similar rates of cure and survival. PA radiotherapy and carboplatin require periodic CT imaging in the

surveillance of recurrent disease after treatment; this is not required for DL radiotherapy.

- DL radiotherapy (25–35 Gy) and first-line chemotherapy (BEPx3 or EPx4) are accepted treatment options for CS IIA-B seminoma patients with non-bulky (<3 cm) retroperitoneal lymph node metastasis. First-line chemotherapy (BEPx3 or EPx4) is recommended for bulky (>3 cm) and/or multifocal retroperitoneal metastases.
- The treatment of patients with CS IIC and III seminoma is first-line cisplatin-based chemotherapy and the specific regimen and number of cycles is dictated by IGCCCG risk criteria. Patients with good-risk disease should receive BEPx3 or EPx4, and those with intermediate-risk disease should receive BEPx4.
- Patients with discrete, residual masses larger than 3 cm after first-line chemotherapy should undergo further evaluation with FDG-PET imaging. Patients with PET-positive residual masses should undergo post-chemotherapy surgical resection. Residual masses that are PET-negative or less than 3 cm can be safely observed after chemotherapy.

Brain Metastases

About 1% of men with disseminated GCT have brain metastases detected before initiating chemotherapy and between 0.4% and 3% will develop brain metastases after first-line chemotherapy (Fossa SD et al., 1999; International Germ Cell Cancer Collaborative Group, 1997; Raina et al., 1993). **Brain metastases are associated with choriocarcinoma and should be suspected in any patient with a very high serum HCG level** (Fossa et al., 1999; Gremmer et al., 2008; Kollmannsberger et al., 2000; Nonomura et al., 2009; Salvati et al., 2006). **Choriocarcinomas are highly vascular and tend to hemorrhage during chemotherapy and death rates of 4% to 10% resulting from intracranial hemorrhage have been reported** (Kollmannsberger et al., 2000; Nonomura et al., 2009). Management of these patients must consider this risk and neurologic changes must be evaluated expeditiously.

The 5-year overall survival in patients with brain metastases is 33% and 57% for those with disseminated NSGCT and seminoma, respectively (International Germ Cell Cancer Collaborative Group, 1997). **Men who relapse in the brain after achieving a complete response to chemotherapy appear to have a worse prognosis than those with brain involvement at diagnosis**, with overall survival rates of 39% to 44% for isolated brain metastases and 2% to 26% for those with brain metastases in association with other sites of disease (Fossa et al., 1999; Gremmer et al., 2008; Hartmann et al., 1607; Kollmannsberger et al., 2000; Nonomura et al., 2009; Salvati et al., 2006). Case studies and pooled analyses of GCT patients with brain metastases have reported outcomes with various treatment strategies, but there are no randomized trials to clearly define optimal management (Fossa et al., 1999; Gremmer et al., 2008; Hartmann et al., 1607; Kollmannsberger et al., 2000; Nonomura et al., 2009; Salvati et al., 2006; Spears et al., 1992). Treatment strategies have included chemotherapy, surgical resection, whole-brain radiation therapy, and stereotactic radiosurgery, with most patients receiving multi-modal therapy. **Patients with brain metastases at diagnosis should receive BEPx4 chemotherapy followed by resection of residual masses.** The benefit of radiation therapy in this setting is unclear (Fossa et al., 1999; Hartmann et al., 1607; Kollmannsberger et al., 2000). At our institution, radiation therapy is only considered for patients with unresectable residual lesions not amenable to stereotactic radiosurgery because of the concerns of radiation-induced neurotoxicity (Doyle and Einhorn, 2008). **Patients who relapse in the brain after first-line chemotherapy should be treated with second-line chemotherapy followed by resection and/or radiation therapy** (Fossa et al., 1999; Hartmann et al., 1607).

Key Point: Brain Metastases

- Brain metastases are associated with choriocarcinoma and should be suspected in any patient with a very high serum HCG level. Choriocarcinomas are highly vascular, and there is a risk of hemorrhage during chemotherapy. Patients with metastatic choriocarcinoma to the brain are at risk of intracranial hemorrhage and should be monitored for such when chemotherapy is started.

Treatment Sequelae

Testis cancer treatment sequelae can be divided into late and early complications. Complications from orchiectomy and retroperitoneal lymph node dissection will not be reviewed here except to note that the main issues after RPLND are midline scar, ejaculatory dysfunction, small bowel obstruction, and perioperative complications. There also is an increased incidence of hypogonadism after orchiectomy for GCT.

Early Toxicity

Cisplatin-based chemotherapy is associated with numerous early complications and side effects, including fatigue, myelosuppression, infection, peripheral neuropathy, hearing loss, diminished renal function, and death. The toxic death rate has ranged from 0 to 2.4% during chemotherapy for good-risk disease and from 3% to 4.4% during standard first-line chemotherapy for intermediate- and poor-risk disease (Culine et al., 2007, 2008; de Wit et al., 1998, 2001; Nichols et al., 1998; Toner et al., 2001). The impact of chemotherapy and radiation therapy on spermatogenesis has been discussed previously. Most men are able to father children after treatment for GCT, but paternity rates are lower for men treated with radiation therapy and/or chemotherapy (Brydoy et al., 2005; Huyghe et al., 2004). Early complications of radiation therapy include fatigue, nausea and vomiting, leukopenia, and dyspepsia (Fossa et al., 1999; Jones et al., 2005; Oliver et al., 2005).

Late Toxicity

Numerous long-term sequelae have been reported in GCT survivors, including peripheral neuropathy, Raynaud phenomenon, hearing loss, hypogonadism, infertility, secondary malignant neoplasms, and cardiovascular disease (Brydoy et al., 2009; Fossa et al., 2009; Rossen et al., 2009). Symptoms of Raynaud phenomenon and peripheral neuropathy have been reported in 20% to 45% and 14% to 43% (Brydoy et al., 2009; Rossen et al., 2009). Significant hearing loss and/or tinnitus after cisplatin-based chemotherapy is reported in 20% to 40% of patients and can be documented via audiometry in 30% to 75%. Hypogonadism has been documented in about 10% to 20% of patients treated with orchiectomy alone, 15% to 40% of patients treated with radiation therapy, and 20% to 25% of men treated with first-line chemotherapy regimens (Lackner et al., 2009; Nord et al., 2003).

Large population-based studies of GCT survivors have reported an increased risk of death from GI and cardiovascular diseases after radiation therapy and an increased risk of death from infections, cardiovascular, and pulmonary diseases after chemotherapy (Fossa et al., 2007). Patients treated with both radiation and chemotherapy have the highest risk of death from nonmalignant causes. The increased cardiovascular disease incidence and mortality in GCT survivors is particularly well documented (Fossa et al., 2007; 2009; Huddart et al., 2003; Meinardi et al., 2000; van den Belt-Dusebout et al., 2007). The causes of these cardiovascular complications are not well understood, but putative contributing factors are radiation- or chemotherapy-induced vascular injury, chemotherapy-induced cardiac injury, and metabolic syndrome (Altena et al., 2009; Nuver et al., 2005).

The risk of second malignant neoplasms is a particular concern. The incidence of non–germ cell malignancies is 60% to 100% higher in GCT survivors treated with cisplatin-based chemotherapy or radiation therapy compared with the general population and 200% higher in patients who received both radiation and chemotherapy (Richiardi et al., 2007; Travis et al., 2005). The risk of death from non–germ cell malignancies in GCT survivors treated with radiation or chemotherapy is less well defined but appears to be doubled compared with the general population (Fossa et al., 2004). The frequent use of body CT imaging in the surveillance of patients after therapy is another source of radiation that may increase the risk of secondary malignant neoplasms (Brenner and Hall, 2007; Chamie et al., 2008; Tarin et al., 2009).

Key Point: Late Effects

- All treatments for GCT (surgery, radiotherapy, and chemotherapy) are associated with risks of early and late toxicity. The most concerning late complications are cardiovascular disease and SMNs. With the successful cure of patients (even those with advanced disease), an important treatment objective is minimizing treatment-related toxicity without compromising curability.

Non–Germ Cell Tumors

Sex Cord-Stromal Tumors

Sex cord-stromal tumors are rare, making up approximately 0.4% to 4% of testis neoplasms, and the term refers to neoplasms containing Leydig cells, Sertoli cells, granulosa cells, or thecal cells (Banerji et al., 2016). **Approximately 90% of these tumors are benign and 10% are malignant.** Histologic criteria have been developed to help distinguish between benign and malignant histology and include tumor size larger than 5 cm, necrosis, vascular invasion, nuclear atypia, high mitotic index, increased MIB-1 expression, infiltrative margins, extension beyond the testicular parenchyma, and DNA ploidy (Cheville et al., 1998; Kim et al., 1985). Most malignant cases are associated with at least 2 of these features. **However, the presence of metastatic disease is the only reliable criteria for making this distinction.**

Leydig Cell Tumors

Leydig cell tumors account for 75% to 80% of sex cord-stromal tumors. There is no association with cryptorchidism. Most of these tumors occur in adult males between 30 and 60 years, although approximately one-fourth occur in children. Adults may initially be seen with painless testis mass, testicular pain, gynecomastia (as a result of androgen excess and peripheral estrogen conversion), impotence, decreased libido, and infertility. Children usually have a testis mass and isosexual precocious puberty (prominent external genitalia, pubic hair growth, and masculine voice).

Diagnostic workup should include serum tumor markers and testicular ultrasound. The sonographic appearance of these tumors is variable and is indistinguishable from GCT. In the presence of gynecomastia, infertility, depressed libido, or precocious puberty, LH, FSH, testosterone, estrogen, and estradiol should also be drawn (these should be measured after orchiectomy if the diagnosis is not suspected preoperatively). Once the diagnosis is confirmed, patients should undergo CT chest-abdomen-pelvis for staging purposes.

In the past, radical inguinal orchiectomy was the initial treatment of choice. If the diagnosis is suspected preoperatively, testis-sparing surgery may be considered for lesions smaller than 3 cm with intraoperative frozen section histologic confirmation given the 90% incidence of benign histology

(Carmignani et al., 2006, 2007). **Completion orchiectomy should be performed if GCT histology is seen (either on intraoperative frozen section or final pathology) or if malignant features (listed earlier) are present on final pathological examination of the resected tumor.** Testis-sparing surgery for small tumors without malignant histologic risk factors is associated with similar survival and a low risk of local recurrence that may be successfully treated with completion orchiectomy (Laclergerie et al., 2018; Nicolai et al., 2015; Paffenholz et al., 2018). Given the rarity of these tumors, they are often not suspected preoperatively, and most patients undergo radical orchiectomy. Benign lesions are usually small, yellow to brown, well circumscribed, without areas of necrosis of hemorrhage. Histologically, the tumors consist of uniform, polygonal cells with round nuclei. Reinke crystals are present in 25% to 40% of cases and appear as densely eosinophilic needle-like or rhomboid structures within the cytoplasm. These tumors must be distinguished from Leydig cell hyperplasia that occur in atrophic testes and adjacent to GCTs, in which Leydig cells infiltrate between seminiferous tubules without displacing or obliterating them. Malignant behavior has not been reported in a prepubertal patient. Older patients are more likely to have malignant tumors.

The most frequent metastatic sites are the retroperitoneum and the lung. Patients with CS I disease with at least 1 malignant histologic feature may be safely observed. Those with 2 or more malignant features or retroperitoneal metastases should undergo RPLND, although high rates of progression are observed in those with pathologically involved nodes (Mosharafa et al., 2003; Nicolai et al., 2015; Silberstein et al., 2014). **Metastatic Leydig cell tumors are resistant to chemotherapy and radiation therapy, and survival is poor** (Mosharafa et al., 2003). Ortho-para-DDD, a potent inhibitor of steroidogenesis, may produce partial responses in metastatic patients with excess androgen production, but cure is not possible (Schwarzman et al., 1989). Surveillance is recommended for those without clinical or pathological features suggestive of malignancy. There are no widely accepted criteria for follow-up, but patients should be monitored at regular intervals with clinical assessment, hormonal profile (including LH, follicle-stimulating hormone [FSH], testosterone, estrogen, estradiol), and CT imaging of the chest-abdomen-pelvis for 2 years. Persistent Leydig cell dysfunction and hypogonadism may occur after excision of the primary tumor, and up to 40% of men may require testosterone supplementation postoperatively (Conkey et al., 2005).

Sertoli Cell Tumor

These tumors constitute less than 1% of testis neoplasms. The median age at diagnosis is 45 years, but rare cases in children have been reported. In rare cases, these tumors are associated with Peutz-Jeghers syndrome and androgen insensitivity syndrome and are frequently bilateral (either synchronous or metachronous). There is no association with cryptorchidism. Gynecomastia is evident in up to one-third of patients. **As for Leydig cell tumors, testis-sparing surgery can be considered for tumors smaller than 3 cm given the high incidence of benign histology (90%). For tumors larger than 3 cm or if intraoperative frozen section or final pathological analysis reveals germ cell tumor or malignant features, radical inguinal orchiectomy should be performed.** The tumors are well circumscribed, yellow-white or tan, with uniform consistency. Microscopically, the tumors contain epithelial elements resembling Sertoli cells with varying amounts of stroma organized into tubules. These tumors may be misinterpreted as seminomas leading to errors in the selection of treatment. **Diagnostic workup, staging studies and criteria for treatment, surveillance, and follow-up are similar to that for Leydig cell tumors with similar outcomes** (Nicolai et al., 2015; Silberstein et al., 2014).

Granulosa Cell Tumors

Granulosa cell tumors of the testis are exceedingly rare. The juvenile type is benign and is the most frequent congenital testis tumor (most frequently occurring in infants younger than 6 months of age), accounting for 7% of all prepubertal testicular neoplasms. The adult-type resembles granulosa cell tumors of the ovary. Gynecomastia and increased estrogen secretion are common. Testis-sparing surgery may be considered for tumors smaller than 3 cm if the diagnosis is suspected preoperatively. Otherwise, radical inguinal orchiectomy is recommended. Treatment of the primary tumor is curative as these tumors appear to have limited metastatic potential.

Gonadoblastoma

Gonadoblastoma is a mixed germ cell-sex cord-stromal tumor composed of seminoma-like germ cells and sex cord cells showing Sertoli differentiation. They occur almost exclusively in patients with dysgenic gonads and intersex syndromes. Eighty percent of affected individuals are phenotypic females, usually with primary amenorrhea. The remainder of patients are phenotypic males, almost always with cryptorchidism (with the dysgenic gonad in the inguinal or abdominal location), hypospadias, and some form of female internal genitalia. **These tumors should be considered an in situ form of malignant GCT; approximately 50% will develop an invasive GCT (usually seminoma, although yolk sac tumor and EC can occur)** (Ulbright, 2004). Gonadoblastomas do not metastasize but the malignant GCT elements may. **Bilateral orchiectomy is required because of the risk of bilateral tumors (40%)** (Scully, 1970). For patients with malignant GCT, subsequent workup for metastatic disease and appropriate treatment should be initiated.

Miscellaneous Testis Neoplasms

Dermoid and Epidermoid Cyst

These rare benign neoplasms that are thought to arise from benign germ cells with retrained embryonic properties or from displaced metaplastic mesothelial cells (Ye and Ulbright, 2012). Grossly, they are well-circumscribed, unilocular cystic masses filled with keratinized debris that may have a laminated appearance that gives them the characteristic “onion peel” or target appearance on ultrasound. They are typically smaller than 3 cm and do not exhibit flow or enhancement on Doppler US and MRI, respectively. Dermoid cysts are differentiated from epidermoid cysts by the presence of adnexal structures such as glandular elements, adipose tissue, and cartilage. Dermoid and epidermoid cysts are distinguished from teratoma by the absence of GCNIS in the adjacent testis. **Enucleation or partial orchiectomy may be performed, although the lesion should be thoroughly sampled by a pathologist to rule out GCT or GCNIS.**

Adenocarcinoma of the Rete Testis

Adenocarcinoma of the rete testis is a rare but highly malignant neoplasm arising from the collecting system of the testis. The usual presentation is a painless testis mass with hydrocele. More than 50% of patients have metastatic disease, and the overall median survival is 1 year. RPLND may be curative in patients with limited retroperitoneal lymph node metastasis. Chemotherapy and radiation therapy are ineffective.

Testicular “Tumor” of the Adrenogenital Syndrome.

This non-neoplastic entity is derived from hyperplasia of remnant adrenal steroid cells that migrate to the scrotum during descent of the testis in utero or from pluripotent stem cells within the testis. The hyperplasia occurs as a consequences of ACTH stimulation in response to deficiency of cortisol or aldosterone in patients with C-21- hydroxylase (90%) or C-11-hydroxylase deficiency. Increased LH production at puberty can also stimulate the growth of these cells. The median age at presentation is 22 years; one-third are children. It may be the initial presentation in up to 18% of patients. Bilateral testicular masses are present in 83% of cases and typically develop near the testicular hilum. Corticosteroid therapy typically induces regression or stabilization of these masses. Surgical intervention may be necessary for persistent symptoms and/or evidence of testicular damage because of chronic obstruction (Ozisik et al., 2017; Ulbright and Young, 2014).

Secondary Tumors of the Testis

Lymphoma

Primary testicular non-Hodgkin lymphoma (NHL) is a rare tumor and represents only 1% to 2% of all cases of lymphoma. Most commonly, lymphoma involves the testis through dissemination from extratesticular sites (Ulbright, 2004). Eighty-five percent of cases occur in men over age 60. **NHL is the most common testicular neoplasm in men over age 50. Bilateral testicular involvement occurs in 35% of cases.** It usually is seen as a painless testicular mass in an older male. Approximately 25% of men have systemic symptoms (fever, night sweats, weight loss). Central nervous system involvement at diagnosis is reported in 10% of men. The initial treatment is radical inguinal orchiectomy. Men with testicular NHL should be referred to hematology-oncology for staging investigations and subsequent therapy. Most cases are associated with systemic disease and the overall prognosis is poor.

Leukemic Infiltration

The testis is a frequent site of relapse in boys with acute lymphocytic leukemia. The majority of boys are in complete remission at the time of testicular enlargement. **The diagnosis can usually be made by biopsy, and orchiectomy is unnecessary. Local control can be achieved with low-dose radiotherapy (20 Gy), and treatment should include the contralateral testis**

because of the frequent risk of bilateral involvement. Overall, the prognosis is poor because most have associated systemic disease.

Metastases

Metastases to the testis are rare. Bilateral involvement occurs in 15% of patients. The most common primary tumors are prostate, lung, melanoma, colon, and kidney cancer. Although treatment is largely dictated by the primary tumor, orchiectomy may be considered for palliative reasons.

Tumors of the Testicular Adnexa

Paratesticular tumors are rare and account for approximately 5% of intrascrotal neoplasms, roughly 75% of which arise from the spermatic cord.

Adenomatoid Tumor

Adenomatoid tumor is of mesothelial origin and is the most common paratesticular tumor, 75% of which involve the epididymis (although these tumors may also arise within the testicular tunics or the spermatic cord). The most common presentation is a small (0.5–5 cm), painless paratesticular mass detected on routine examination in a male in their third or fourth decade. **These tumors are benign and managed by inguinal exploration and surgical excision.** On microscopic examination, these tumors are composed of epithelial-like cells, which contain vacuoles and fibrous stroma.

Cystadenoma

Cystadenoma of the epididymis corresponds to benign epithelial hyperplasia. The lesions are usually multicystic, the walls of which are studded with nodules of epithelial cells arranged in a glandular or papillary configuration. **Approximately one-third of cases, which are usually bilateral, occur in patients with von Hippel-Lindau syndrome.** The lesions are usually small and painless and are detected on routine examination in a young adult.

Mesothelioma

Paratesticular mesothelioma arises from the tunica vaginalis and usually is seen as a painless paratesticular mass or tunical vegetations in association with a hydrocele. These tumors most commonly occur in older adults but may be encountered in any age group. **Benign and malignant mesothelioma have been described, with the distinction based on atypia, mitotic activity, and invasion** (Ulbright, 2004). Well-differentiated papillary mesotheliomas are usually solitary exophytic nodules distinguished from malignant cases by a focal exophytic papillary growth without evidence of invasion. Malignant cases may be associated with asbestos exposure and represent less than 5% of all malignant mesothelioma cases. Metastatic spread is typically lymphatic to inguinal, pelvic, and retroperitoneal lymph nodes. **Treatment is radical inguinal orchiectomy and hemiscrotectomy.** Retroperitoneal, pelvic, and inguinal lymph node dissection may be considered in patients with malignant tumors without widespread metastatic disease. The role of chemotherapy for these tumors is poorly defined. Overall, prognosis of malignant cases is poor with a median survival less than 2 years (Recabal et al., 2017).

Sarcoma

Sarcomas of the spermatic cord, epididymis, and testis are the most common genitourinary sarcomas in adults. **Liposarcoma is the most common histologic subtype in adults**, followed by leiomyosarcoma, malignant fibrous histiocytoma, rhabdomyosarcoma, and fibrosarcoma (Coleman et al., 2003; Dotan et al., 2006; Rodriguez et al., 2014; Ulbright, 2004). **Embryonal rhabdomyosarcoma is the most common histologic subtype in men under age 30.** Sarcomas most commonly arise from the spermatic cord and are located in the intrascrotal region; primary mesenchymal tumors of the testis are exceedingly rare. These tumors usually present as a painless, palpable mass and most are large (>5 cm) (Dotan et al., 2006). Ultrasonography will demonstrate a solid mass, although it cannot distinguish between benign and malignant pathology. **As such, any solid mass in the scrotum external to the tunica albuginea should be explored through an inguinal approach and biopsy performed.** Liposarcomas of the spermatic cord in the inguinal canal may be mistaken for inguinal hernia or lipoma, and CT or MRI is helpful to distinguish between these entities.

The majority of patients have localized disease at diagnosis. **Sarcomas should be managed initially through an inguinal approach with wide excision of the spermatic cord and testis with high ligation. Patients with an initial incomplete resection should under repeat wide excision** (Coleman et al., 2003). **The primary pattern of failure is local, particularly for liposarcoma** (Ballo et al., 2001; Khandekar et al., 2013; Montgomery and Fisher, 2003). **As such, some have advocated for postoperative radiation therapy for all paratesticular sarcomas, particularly for liposarcomas and for those tumors where the adequacy of local control is in doubt** (Ballo et al., 2001; Hazariwala et al., 2013). **However, the efficacy of this approach is debated** (Coleman et al., 2003; Fagundes et al., 1996; Khandekar et al., 2013). Systemic chemotherapy should be given to patients with evidence of retroperitoneal or distant metastases. **In the presence of a normal metastatic evaluation,**

patients with sarcomas other than liposarcoma should undergo RPLND and postoperative chemotherapy should be given to patients with retroperitoneal lymph node metastasis (Dang et al., 2013). Given that the lymphatic drainage of the spermatic cord includes the ipsilateral pelvis, inguinal, and retroperitoneal lymph nodes, consideration should be given to treat these areas with lymphadenectomy or radiation therapy. The long-term survival of men with paratesticular sarcoma is approximately 50%, with liposarcoma having the most favorable prognosis and malignant fibrous histiocytoma and leiomyosarcoma having the least favorable prognosis (Coleman et al., 2003; Rodriguez et al., 2014).

Suggested Readings

Albers P, Siener R, Krege S, et al. Randomized phase III trial comparing retroperitoneal lymph node dissection with one course of bleomycin and etoposide plus cisplatin chemotherapy in the adjuvant treatment of clinical stage I Nonseminomatous testicular germ cell tumors: AUO trial AH 01/94 by the German Testicular Cancer Study Group. *J Clin Oncol*. 2008;26:2966–2972.

Albers P, Weissbach L, Krege S, et al. Prediction of necrosis after chemotherapy of advanced germ cell tumors: results of a prospective multicenter trial of the German Testicular Cancer Study Group. *J Urol*. 2004;171:1835–1838.

Beck SD, Foster RS, Bihrle R, et al. Long-term outcome for patients with high volume retroperitoneal teratoma undergoing post-chemotherapy surgery. *J Urol*. 2009;181:2526–2532.

Calaway AC, Einhorn LH, Masterson TA, et al. Adverse surgical outcomes associated with robotic retroperitoneal lymph node dissection among patients with testicular cancer. *Eur Urol*. 2019.

Carver BS, Shayegan B, Serio A, et al. Long-term clinical outcome after postchemotherapy retroperitoneal lymph node dissection in men with residual teratoma. *J Clin Oncol*. 2007;25:1033–1037.

Fizazi K, Oldenburg J, Dunant A, et al. Assessing prognosis and optimizing treatment in patients with postchemotherapy viable nonseminomatous germ-cell tumors (NSGCT): results of the sCR2 international study. *Ann Oncol*. 2008;19:259–264.

Fossa SD, Gilbert E, Dores GM, et al. Noncancer causes of death in survivors of testicular cancer. *J Natl Cancer Inst*.

2007;99:533–544.

Gilligan T, Beard C, Carneiro B, et al. *NCCN Guidelines Version 2.2018 Testicular Cancer*. [In] nccn.org; 2018 [National Comprehensive Cancer Network].

Gilligan TD, Seidenfeld J, Basch EM, American Society of Clinical Oncology, et al. American Society of Clinical Oncology Clinical Practice Guideline on uses of serum tumor markers in adult males with germ cell tumors. *J Clin Oncol*. 2010;28:3388–3404.

Hanna NH, Einhorn LH. Testicular cancer—discoveries and updates. *N Engl J Med*. 2014;371:2005–2016.

Harari SE, Sassoon DJ, Priemer DS, et al. Testicular cancer: the usage of central review for pathology diagnosis of orchiectomy specimens. *Urol Oncol*. 2017;35:605.e9–605.e16.

Honecker F, Aparicio J, Berney D, et al. ESMO Consensus Conference on testicular germ cell cancer: diagnosis, treatment and follow-up. *Ann Oncol*. 2018;29:1658–1686.

Huddart RA, Reid AM. Adjuvant therapy for stage IB germ cell tumors: one versus two cycles of BEP. *Adv Urol*. 2018;2018:8781698.

International Germ Cell Consensus Classification: a prognostic factor-based staging system for metastatic germ cell cancers. International Germ Cell Cancer Collaborative Group. *J Clin Oncol*. 1997;15:594–603.

Kvammen O, Myklebust TA, Solberg A, et al. Long-term relative survival after diagnosis of testicular germ cell tumor. *Cancer Epidemiol Biomarkers Prev*. 2016;25:773–779.

Motzer RJ, Amsterdam A, Prieto V, et al. Teratoma with malignant transformation: diverse malignant histologies arising in men with germ cell tumors. *J Urol*. 1998;159:133–138.

Oldenburg J, Aparicio J, Beyer J, et al. Personalizing, not patronizing: the case for patient autonomy by unbiased presentation of management options in stage I testicular cancer. [On behalf of; SWENOTECA (Swedish Norwegian Testicular Cancer group), the Italian Germ Cell Cancer Group (IGG), Spanish Germ Cell Cancer Group (SGCCG)] *Ann Oncol*. 2015;26:833–838.

Oliver RT, Mead GM, Rustin GJ, et al. Randomized trial of carboplatin versus radiotherapy for stage I seminoma: mature results on relapse and contralateral testis cancer rates in MRC TE19/EORTC 30982 study (ISRCTN27163214). *J Clin Oncol*. 2011;29:957–962.

Rabbani F, Farivar-Mohseni H, Leon A, et al. Clinical outcome after retroperitoneal lymphadenectomy of patients with pure testicular teratoma. *Urology*. 2003;62:1092–1096.

Spiess PE, Kassouf W, Brown GA, et al. Surgical management of growing teratoma syndrome: the M. D. Anderson cancer center experience. *J Urol*. 2007;177:1330–1334 [discussion 34].

Stephenson A, Eggener SE, Bass EB, et al. Diagnosis and treatment of early stage testicular cancer: AUA guideline. *J Urol*. 2019;202:272–281.

Stephenson AJ, Bosl GJ, Motzer RJ, et al. Retroperitoneal lymph node dissection for nonseminomatous germ cell testicular cancer: impact of patient selection factors on outcome. *J Clin Oncol*. 2005;23:2781–2788.

Trabert B, Chen J, Devesa SS, et al. International patterns and trends in testicular cancer incidence, overall and by histologic subtype, 1973-2007. *Andrology*. 2015;3:4–12.

Travis LB, Fossa SD, Schonfeld SJ, et al. Second cancers among 40,576 testicular cancer patients: focus on long-term survivors. *J Natl Cancer Inst*. 2005;97:1354–1365.

Treglia G, Sadeghi R, Annunziata S, et al. Diagnostic performance of fluorine-18-fluorodeoxyglucose positron emission tomography in the postchemotherapy management of patients with seminoma: systematic review and meta-analysis. *Biomed Res Int*. 2014;2014:852681.

Verrill C, Yilmaz A, Srigley JR, Members of the International Society of Urological Pathology Testicular Tumor Panel, et al. Reporting and staging of testicular germ cell tumors: the International Society of Urological Pathology (ISUP) testicular cancer consultation conference recommendations. *Am J Surg Pathol*. 2017;41:e22–e32.

Williamson SR, Delahunt B, Magi-Galluzzi C, Members of the ISUP Testicular Tumour Panel, et al. The World Health Organization 2016 classification of testicular germ cell tumours: a review and update from the International Society of Urological Pathology Testis Consultation Panel. *Histopathology*. 2017;70:335–346.

References

Aass N, Fossa SD, Theodorsen L, et al. Prediction of long-term gonadal toxicity after standard treatment for testicular cancer. *Eur J Cancer*. 1991;27:1087–1091.

Abratt RP, Pontin AR, Barnes RD, et al. Adjuvant chemotherapy for stage I non-seminomatous testicular cancer. *S Afr Med J*. 1994;84:605–607.

Aggarwal N, Parwani AV. Spermatocytic seminoma. *Arch Pathol Lab Med*. 2009;133:1985–1988.

Akre O, Richiardi L. Does a testicular dysgenesis syndrome exist? *Hum Reprod*. 2009;24:2053–2060.

Akre O, Pettersson A, Richiardi L. Risk of contralateral testicular cancer among men with unilaterally undescended testis: a meta analysis. *Int J Cancer*. 2008.

Al-Ahmadie HA, Carver BS, Cronin AM, et al. Primary retroperitoneal lymph node dissection in low-stage testicular germ cell tumors: a detailed pathologic study with clinical outcome analysis with special emphasis on patients who did not receive adjuvant therapy. *Urology*. 2013;82:1341–1346.

Albers P, Miller GA, Orazi A, et al. Immunohistochemical assessment of tumor proliferation and volume of embryonal carcinoma identify patients with clinical stage A nonseminomatous testicular germ cell tumor at low risk for occult metastasis. *Cancer*. 1995;75:844–850.

Albers P, Bender H, Yilmaz H, et al. Positron emission tomography in the clinical staging of patients with Stage I and II testicular germ cell tumors. *Urology*. 1999;53:808–811.

Albers P, Ganz A, Hannig E, et al. Salvage surgery of chemorefractory germ cell tumors with elevated tumor markers. *J Urol*. 2000;164:381–384.

Albers P, Siener R, Kliesch S, et al. Risk factors for relapse in clinical stage I nonseminomatous testicular germ cell tumors: results of the German Testicular Cancer Study Group Trial. *J Clin Oncol*. 2003;21:1505–1512.

Albers P, Weissbach L, Krege S, et al. Prediction of necrosis after chemotherapy of advanced germ cell tumors: results of a prospective multicenter trial of the German Testicular Cancer Study Group. *J Urol*. 2004;171:1835–1838.

Albers P, Albrecht W, Algaba F, et al. Guidelines on testicular cancer. *Eur Urol*. 2005;48:885–894.

Albers P, Siener R, Krege S, et al. Randomized phase III trial comparing retroperitoneal lymph node dissection with one course of bleomycin and etoposide plus cisplatin chemotherapy in the adjuvant treatment of clinical stage I Nonseminomatous testicular germ cell tumors: AUO trial AH 01/94 by the German Testicular Cancer Study Group. *J Clin Oncol*. 2008;26:2966–2972.

Alexandre J, Fizazi K, Mahe C, et al. Stage I non-seminomatous germ-cell tumours of the testis: identification of a subgroup of patients with a very low risk of relapse. *Eur J Cancer*. 2001;37:576–582.

Allen MS. Presentation and management of benign mediastinal teratomas. *Chest Surg Clin N Am*. 2002;12:659–664 [vi].

Altena R, de Haas EC, Nuver J, et al. Evaluation of sub-acute changes in cardiac function after cisplatin-based combination chemotherapy for testicular cancer. *Br J Cancer*. 2009;100:1861–1866.

Alvarado-Cabrero I, Hernandez-Toriz N, Paner GP. Clinicopathologic analysis of choriocarcinoma as a pure or predominant component of germ cell tumor of the testis. *Am J Surg Pathol*. 2014;38:111–118.

Amato RJ, Ro JY, Ayala AG, et al. Risk-adapted treatment for patients with clinical stage I nonseminomatous germ cell tumor of the testis. *Urology*. 2004;63:144–148 [discussion 148–149].

Amin MB, American Joint Committee on Cancer, American Cancer Society. *AJCC cancer staging manual*. [(ed Eight edition / editor-in-chief, Mahul B. Amin, MD, FCAP; editors, Stephen B. Edge, MD, FACS and 16 others; Donna M. Gress, RHIT, CTR - Technical editor; Laura R. Meyer, CAPM - Managing editor.)] American Joint Committee on Cancer, Springer: Chicago IL; 2017.

Andre F, Fizazi K, Culine S, et al. The growing teratoma syndrome: results of therapy and long-term follow-up of 33 patients. *Eur J Cancer*. 2000;36:1389–1394.

Aparicio J, Garcia del Muro X, Maroto P, et al. Multicenter study evaluating a dual policy of postorchiectomy surveillance and selective adjuvant single-agent carboplatin for patients with clinical stage I seminoma. *Ann Oncol*. 2003;14:867–872.

Aparicio J, Germa JR, Garcia del Muro X, et al. Risk-adapted management for patients with clinical stage I seminoma: the Second Spanish Germ Cell Cancer Cooperative Group study. *J Clin Oncol*. 2005;23:8717–8723.

Aparicio J, Maroto P, Garcia Del Muro X, et al. Risk-adapted treatment in clinical stage I testicular seminoma: the third Spanish Germ Cell Cancer Group Study. *J Clin Oncol*. 2011.

Bajorin DF, Sarosdy MF, Pfister DG, et al. Randomized trial of etoposide and cisplatin versus etoposide and carboplatin in patients with good-risk germ cell tumors: a multiinstitutional study. *J Clin Oncol*. 1993;11:598–606.

Ballo MT, Zagars GK, Pisters PW, et al. Spermatic cord sarcoma: outcome, patterns of failure and management. *J Urol*. 2001;166:1306–1310.

Balzer BL, Ulbright TM. Spontaneous regression of testicular germ cell tumors: an analysis of 42 cases. *Am J Surg Pathol*.

2006;30:858–865.

Banerji JS, Odem-Davis K, Wolff EM, et al. Patterns of care and survival outcomes for malignant sex cord stromal testicular cancer: results from the National Cancer Data Base. *J Urol*. 2016;196:1117–1122.

Baniel J, Foster RS, Gonin R, et al. Late relapse of testicular cancer. *J Clin Oncol*. 1995;13:1170–1176.

Beck SD, Foster RS, Bihrle R, et al. Teratoma in the orchiectomy specimen and volume of metastasis are predictors of retroperitoneal teratoma in post-chemotherapy nonseminomatous testis cancer. *J Urol*. 2002;168:1402–1404.

Beck SD, Patel MI, Sheinfeld J. Tumor marker levels in post-chemotherapy cystic masses: clinical implications for patients with germ cell tumors. *J Urol*. 2004;171:168–171.

Beck SD, Foster RS, Bihrle R, et al. Outcome analysis for patients with elevated serum tumor markers at postchemotherapy retroperitoneal lymph node dissection. *J Clin Oncol*. 2005;23:6149–6156.

Behnia M, Foster R, Einhorn LH, et al. Adjuvant bleomycin, etoposide and cisplatin in pathological stage II non-seminomatous testicular cancer: the Indiana University experience. *Eur J Cancer*. 2000;36:472–475.

Beyer J, Kramar A, Mandanas R, et al. High-dose chemotherapy as salvage treatment in germ cell tumors: a multivariate analysis of prognostic variables. *J Clin Oncol*. 1996;14:2638–2645.

Beyer J, Stenning S, Gerl A, et al. High-dose versus conventional-dose chemotherapy as first-salvage treatment in patients with non-seminomatous germ-cell tumors: a matched-pair analysis. *Ann Oncol*. 2002;13:599–605.

Bhayani SB, Ong A, Oh WK, et al. Laparoscopic retroperitoneal lymph node dissection for clinical stage I nonseminomatous germ cell testicular cancer: a long-term update. *Urology*. 2003;62:324–327.

Blomberg Jensen M, Leffers H, Petersen JH, et al. Association of the polymorphism of the CAG repeat in the mitochondrial DNA polymerase gamma gene (POLG) with testicular germ-cell cancer. *Ann Oncol*. 2008;19:1910–1914.

Bohlen D, Borner M, Sonntag RW, et al. Long-term results following adjuvant chemotherapy in patients with clinical stage I testicular nonseminomatous malignant germ cell tumors with high risk factors. *J Urol*. 1999;161:1148–1152.

Bokemeyer C, Berger CC, Kuczyk MA, et al. Evaluation of long-term toxicity after chemotherapy for testicular cancer. *J Clin Oncol*. 1996;14:2923–2932.

Bokemeyer C, Kohrmann O, Tischler J, et al. A randomized trial of cisplatin, etoposide and bleomycin (PEB) versus carboplatin, etoposide and bleomycin (CEB) for patients with ‘good-risk’ metastatic non-seminomatous germ cell tumors. *Ann Oncol*. 1996;7:1015–1021.

Bokemeyer C, Kollmannsberger C, Flechon A, et al. Pronostic factors in patients (pts) with advanced metastatic seminoma (SEM) treated with either single agent carboplatin (CP) or cisplatin-based (DDP) combination chemotherapy (CTX): a meta-analysis of prospective European trials. *Proc Am Soc Clin Oncol*. 2002;21 [abstract 740].

Bokemeyer C, Nichols CR, Droz JP, et al. Extragonadal germ cell tumors of the mediastinum and retroperitoneum: results from an international analysis. *J Clin Oncol*. 2002;20:1864–1873.

Bokemeyer C, Kollmannsberger C, Stenning S, et al. Metastatic seminoma treated with either single agent carboplatin or cisplatin-based combination chemotherapy: a pooled analysis of two randomised trials. *Br J Cancer*. 2004;91:683–687.

Bokemeyer C, Oechsle K, Honecker F, et al. Combination chemotherapy with gemcitabine, oxaliplatin, and paclitaxel in patients with cisplatin-refractory or multiply relapsed germ-cell tumors: a study of the German Testicular Cancer Study Group. *Ann Oncol*. 2008;19:448–453.

Bonde JP, Flachs EM, Rimborg S, et al. The epidemiologic evidence linking prenatal and postnatal exposure to endocrine disrupting chemicals with male reproductive disorders: a systematic review and meta-analysis. *Hum Reprod Update*. 2016;23:104–125.

Bosl GJ, Vogelzang NJ, Goldman A, et al. Impact of delay in diagnosis on clinical stage of testicular cancer. *Lancet*. 1981;2:970–973.

Bosl GJ, Geller NL, Bajorin D, et al. A randomized trial of etoposide + cisplatin versus vinblastine + bleomycin + cisplatin + cyclophosphamide + dactinomycin in patients with good-prognosis germ cell tumors. *J Clin Oncol*. 1988;6:1231–1238.

Bray F, Ferlay J, Devesa SS, et al. Interpreting the international trends in testicular seminoma and nonseminoma incidence. *Nat Clin Pract Urol*. 2006;3:532–543.

Bray F, Richiardi L, Ekbom A, et al. Trends in testicular cancer incidence and mortality in 22 European countries: continuing increases in incidence and declines in mortality. *Int J Cancer*. 2006.

Bredael JJ, Vugrin D, Whitmore WF Jr. Autopsy findings in 154 patients with germ cell tumors of the testis. *Cancer*. 1982;50:548–551.

Brenner DJ, Hall EJ. Computed tomography–an increasing source of radiation exposure. *N Engl J Med*. 2007;357:2277–2284.

Brenner PC, Herr HW, Morse MJ, et al. Simultaneous retroperitoneal, thoracic, and cervical resection of postchemotherapy residual masses in patients with metastatic nonseminomatous germ cell tumors of the testis. *J Clin*

Oncol. 1996;14:1765–1769.

Brydoy M, Fossa SD, Klepp O, et al. Paternity following treatment for testicular cancer. *J Natl Cancer Inst*. 2005;97:1580–1588.

Brydoy M, Oldenburg J, Klepp O, et al. Observational study of prevalence of long-term Raynaud-like phenomena and neurological side effects in testicular cancer survivors. *J Natl Cancer Inst*. 2009;101:1682–1695.

Burger H, Nooter K, Boersma AW, et al. Expression of p53, Bcl-2 and Bax in cisplatin-induced apoptosis in testicular germ cell tumour cell lines. *Br J Cancer*. 1998;77:1562–1567.

Calvert AH, Egorin MJ. Carboplatin dosing formulae: gender bias and the use of creatinine-based methodologies. *Eur J Cancer*. 2002;38:11–16.

Cao D, Humphrey PA. Yolk sac tumor of the testis. *J Urol*. 2011;186:1475–1476.

Carmignani L, Morabito A, Gadda F, et al. Prognostic parameters in adult impalpable ultrasonographic lesions of the testicle. *J Urol*. 2005;174:1035–1038.

Carmignani L, Salvioni R, Gadda F, et al. Long-term followup and clinical characteristics of testicular Leydig cell tumor: experience with 24 cases. *J Urol*. 2006;176:2040–2043 [discussion 2043].

Carmignani L, Colombo R, Gadda F, et al. Conservative surgical therapy for Leydig cell tumor. *J Urol*. 2007;178:507–511 [discussion 511].

Carver BS, Serio AM, Bajorin D, et al. Improved clinical outcome in recent years for men with metastatic nonseminomatous germ cell tumors. *J Clin Oncol*. 2007;25:5603–5608.

Carver BS, Shayegan B, Eggener S, et al. Incidence of metastatic nonseminomatous germ cell tumor outside the boundaries of a modified postchemotherapy retroperitoneal lymph node dissection. *J Clin Oncol*. 2007;25:4365–4369.

Carver BS, Shayegan B, Serio A, et al. Long-term clinical outcome after postchemotherapy retroperitoneal lymph node dissection in men with residual teratoma. *J Clin Oncol*. 2007;25:1033–1037.

Cary C, Pedrosa JA, Jacob J, et al. Outcomes of postchemotherapy retroperitoneal lymph node dissection following high-dose chemotherapy with stem cell transplantation. *Cancer*. 2015;121:4369–4375.

Castedo SM, de Jong B, Oosterhuis JW, et al. Chromosomal changes in human primary testicular nonseminomatous germ cell tumors. *Cancer Res*. 1989;49:5696–5701.

Chaganti RS, Houldsworth J. Genetics and biology of adult human male germ cell tumors. *Cancer Res*. 2000;60:1475–1482.

Chamie K, Kurzrock EA, Romero V, et al. Increased risk of secondary malignancy in patients on surveillance for NSGCT. *J Urol*. 2008;179:172–173 [abstract 492].

Cheng L, Lyu B, Roth LM. Perspectives on testicular germ cell neoplasms. *Hum Pathol*. 2017;59:10–25.

Cheville JC. Classification and pathology of testicular germ cell and sex cord-stromal tumors. *Urol Clin North Am*. 1999;26:595–609.

Cheville JC, Sebo TJ, Lager DJ, et al. Leydig cell tumor of the testis: a clinicopathologic, DNA content, and MIB-1 comparison of nonmetastasizing and metastasizing tumors. *Am J Surg Pathol*. 1998;22:1361–1367.

Chevreau C, Mazerolles C, Soulie M, et al. Long-term efficacy of two cycles of BEP regimen in high-risk stage I nonseminomatous testicular germ cell tumors with embryonal carcinoma and/or vascular invasion. *Eur Urol*. 2004;46:209–214 [discussion 214–215].

Choo R, Thomas G, Woo T, et al. Long-term outcome of postorchiectomy surveillance for Stage I testicular seminoma. *Int J Radiat Oncol Biol Phys*. 2005;61:736–740.

Christensen TB, Daugaard G, Geertsen PF, et al. Effect of chemotherapy on carcinoma in situ of the testis. *Ann Oncol*. 1998;9:657–660.

Chung P, Parker C, Panzarella T, et al. Surveillance in stage I testicular seminoma - risk of late relapse. *Can J Urol*. 2002;9:1637–1640.

Chung PW, Warde PR, Panzarella T, et al. Appropriate radiation volume for stage IIA/B testicular seminoma. *Int J Radiat Oncol Biol Phys*. 2003;56:746–748.

Chung PW, Bayley AJ, Sweet J, et al. Spermatocytic seminoma: a review. *Eur Urol*. 2004;45:495–498.

Chung PW, Gospodarowicz MK, Panzarella T, et al. Stage II testicular seminoma: patterns of recurrence and outcome of treatment. *Eur Urol*. 2004;45:754–759 [discussion 759–760].

Classen J, Dieckmann K, Bamberg M, et al. Radiotherapy with 16 Gy may fail to eradicate testicular intraepithelial neoplasia: preliminary communication of a dose-reduction trial of the German Testicular Cancer Study Group. *Br J Cancer*. 2003;88:828–831.

Classen J, Schmidberger H, Meisner C, et al. Radiotherapy for stages IIA/B testicular seminoma: final report of a prospective multicenter clinical trial. *J Clin Oncol*. 2003;21:1101–1106.

Classen J, Schmidberger H, Meisner C, et al. Para-aortic irradiation for stage I testicular seminoma: results of a prospective study in 675 patients. A trial of the German testicular cancer study group (GTCSG). *Br J Cancer*. 2004;90:2305–2311.

Coleman J, Brennan MF, Alektiar K, et al. Adult spermatic cord sarcomas: management and results. *Ann Surg Oncol*.

2003;10:669–675.

Collette L, Sylvester RJ, Stenning SP, et al. Impact of the treating institution on survival of patients with “poor-prognosis” metastatic nonseminoma. European Organization for Research and Treatment of Cancer Genito-Urinary Tract Cancer Collaborative Group and the Medical Research Council Testicular Cancer Working Party. *J Natl Cancer Inst*. 1999;91:839–846.

Colls BM, Harvey VJ, Skelton L, et al. Late results of surveillance of clinical stage I nonseminoma germ cell testicular tumours: 17 years’ experience in a national study in New Zealand. *BJU Int*. 1999;83:76–82.

Comiter CV, Kibel AS, Richie JP, et al. Prognostic features of teratomas with malignant transformation: a clinicopathological study of 21 cases. *J Urol*. 1998;159:859–863.

Conkey DS, Howard GC, Grigor KM, et al. Testicular sex cord-stromal tumours: the Edinburgh experience 1988-2002, and a review of the literature. *Clin Oncol (R Coll Radiol)*. 2005;17:322–327.

Connolly SS, D'Arcy FT, Gough N, et al. Carefully selected intratesticular lesions can be safely managed with serial ultrasonography. *BJU Int*. 2006;98:1005–1007 [discussion 1007].

Culine S, Theodore C, Terrier-Lacombe MJ, et al. Primary chemotherapy in patients with nonseminomatous germ cell tumors of the testis and biological disease only after orchiectomy. *J Urol*. 1996;155:1296–1298.

Culine S, Theodore C, Court BH, et al. Evaluation of primary standard cisplatin-based chemotherapy for clinical stage II non-seminomatous germ cell tumours of the testis. *Br J Urol*. 1997;79:258–262.

Culine S, Kerbrat P, Kramar A, et al. Refining the optimal chemotherapy regimen for good-risk metastatic nonseminomatous germ-cell tumors: a randomized trial of the Genito-Urinary Group of the French Federation of Cancer Centers (GETUG T93BP). *Ann Oncol*. 2007;18:917–924.

Culine S, Kramar A, Theodore C, et al. Randomized trial comparing bleomycin/etoposide/cisplatin with alternating cisplatin/cyclophosphamide/doxorubicin and vinblastine/bleomycin regimens of chemotherapy for patients with intermediate- and poor-risk metastatic nonseminomatous germ cell tumors: genito-urinary group of the French Federation of Cancer Centers Trial T93MP. *J Clin Oncol*. 2008;26:421–427.

Cullen MH, Stenning SP, Parkinson MC, et al. Short-course adjuvant chemotherapy in high-risk stage I nonseminomatous germ cell tumors of the testis: a Medical Research Council report. *J Clin Oncol*. 1996;14:1106–1113.

de Wit M, Brenner W, Hartmann M, et al. [18F]-FDG-PET in clinical stage I/II non-seminomatous germ cell tumours: results of the German multicentre trial. *Ann Oncol*. 2008;19:1619–1623.

de Wit R, Stoter G, Kaye SB, et al. Importance of bleomycin in combination chemotherapy for good-prognosis testicular nonseminoma: a randomized study of the European Organization for Research and Treatment of Cancer Genitourinary Tract Cancer Cooperative Group. *J Clin Oncol*. 1997;15:1837–1843.

de Wit R, Stoter G, Sleijfer DT, et al. Four cycles of BEP vs four cycles of VIP in patients with intermediate-prognosis metastatic testicular non-seminoma: a randomized study of the EORTC Genitourinary Tract Cancer Cooperative Group. European Organization for Research and Treatment of Cancer. *Br J Cancer*. 1998;78:828–832.

de Wit R, Roberts JT, Wilkinson PM, et al. Equivalence of three or four cycles of bleomycin, etoposide, and cisplatin chemotherapy and of a 3- or 5-day schedule in good-prognosis germ cell cancer: a randomized study of the European Organization for Research and Treatment of Cancer Genitourinary Tract Cancer Cooperative Group and the Medical Research Council. *J Clin Oncol*. 2001;19:1629–1640.

Dang ND, Dang PT, Samuelian J, et al. Lymph node management in patients with paratesticular rhabdomyosarcoma: a population-based analysis. *Cancer*. 2013;119:3228–3233.

Daugaard G, Petersen PM, Rorth M. Surveillance in stage I testicular cancer. *APMIS*. 2003;111:76–83 [discussion 83–85].

Davis BE, Herr HW, Fair WR, et al. The management of patients with nonseminomatous germ cell tumors of the testis with serologic disease only after orchiectomy. *J Urol*. 1994;152:111–113 [discussion 114].

De Giorgi U, Rosti G, Aieta M, et al. Phase II study of oxaliplatin and gemcitabine salvage chemotherapy in patients with cisplatin-refractory nonseminomatous germ cell tumor. *Eur Urol*. 2006;50:1032–1038 [discussion 1038–1039].

De Santis M, Becherer A, Bokemeyer C, et al. 2-18fluoro-deoxy-D-glucose positron emission tomography is a reliable predictor for viable tumor in postchemotherapy seminoma: an update of the prospective multicentric SEMPET trial. *J Clin Oncol*. 2004;22:1034–1039.

Dearnaley DP, Horwich A, A'Hern R, et al. Combination chemotherapy with bleomycin, etoposide and cisplatin (BEP) for metastatic testicular teratoma: long-term follow-up. *Eur J Cancer*. 1991;27:684–691.

Dearnaley DP, Fossa SD, Kaye SB, et al. Adjuvant bleomycin, vincristine and cisplatin (BOP) for high-risk stage I nonseminomatous germ cell tumours: a prospective trial (MRC TE17). *Br J Cancer*. 2005;92:2107–2113.

Debono DJ, Heilman DK, Einhorn LH, et al. Decision analysis for avoiding postchemotherapy surgery in patients with disseminated nonseminomatous germ cell tumors. *J Clin Oncol*. 1997;15:1455–1464.

DeCastro BJ, Peterson AC, Costabile RA. A 5-year followup study of asymptomatic men with testicular microlithiasis. *J Urol*. 2008;179:1420–1423 [discussion 1423].

Dieckmann KP, Anheuser P. The challenge to one-course carboplatin in seminoma clinical stage 1. *Ann Oncol*. 2016;27:1648–1649.

Dieckmann KP, Loy V. Prevalence of contralateral testicular intraepithelial neoplasia in patients with testicular germ cell neoplasms. *J Clin Oncol*. 1996;14:3126–3132.

Dieckmann KP, Pichlmeier U. Clinical epidemiology of testicular germ cell tumors. *World J Urol*. 2004;22:2–14.

Dieckmann KP, Skakkebaek NE. Carcinoma in situ of the testis: review of biological and clinical features. *Int J Cancer*. 1999;83:815–822.

Dieckmann KP, Bruggeboes B, Pichlmeier U, et al. Adjuvant treatment of clinical stage I seminoma: is a single course of carboplatin sufficient? *Urology*. 2000;55:102–106.

Dieckmann KP, Classen J, Loy V. Diagnosis and management of testicular intraepithelial neoplasia (carcinoma in situ)–surgical aspects. *APMIS*. 2003;111:64–68 [discussion 68–69].

Dieckmann KP, Albers P, Classen J, et al. Late relapse of testicular germ cell neoplasms: a descriptive analysis of 122 cases. *J Urol*. 2005;173:824–829.

Dieckmann KP, Dralle-Filiz I, Matthies C, et al. Testicular seminoma clinical stage 1: treatment outcome on a routine care level. *J Cancer Res Clin Oncol*. 2016;142:1599–1607.

Donadio AC, Motzer RJ, Bajorin DF, et al. Chemotherapy for teratoma with malignant transformation. *J Clin Oncol*. 2003;21:4285–4291.

Donohue JP, Foster RS. Retroperitoneal lymphadenectomy in staging and treatment. The development of nerve-sparing techniques. *Urol Clin North Am*. 1998;25:461–468.

Donohue JP, Zachary JM, Maynard BR. Distribution of nodal metastases in nonseminomatous testis cancer. *J Urol*. 1982;128:315–320.

Donohue JP, Rowland RG, Kopecky K, et al. Correlation of computerized tomographic changes and histological findings in 80 patients having radical retroperitoneal lymph node dissection after chemotherapy for testis cancer. *J Urol*. 1987;137:1176–1179.

Donohue JP, Thornhill JA, Foster RS, et al. Retroperitoneal lymphadenectomy for clinical stage A testis cancer (1965 to 1989): modifications of technique and impact on ejaculation. *J Urol*. 1993;149:237–243.

Donohue JP, Thornhill JA, Foster RS, et al. Clinical stage B non-seminomatous germ cell testis cancer: the Indiana University experience (1965-1989) using routine primary retroperitoneal lymph node dissection. *Eur J Cancer*. 1995;31A:1599–1604.

Donohue JP, Leviovitch I, Foster RS, et al. Integration of surgery and systemic therapy: results and principles of integration. *Semin Urol Oncol*. 1998;16:65–71.

Doria-Rose VP, Biggs ML, Weiss NS. Subfertility and the risk of testicular germ cell tumors (United States). *Cancer Causes Control*. 2005;16:651–656.

Dotan ZA, Tal R, Golijanin D, et al. Adult genitourinary sarcoma: the 25-year Memorial Sloan-Kettering experience. *J Urol*. 2006;176:2033–2038 [discussion 2038–2039].

Doyle DM, Einhorn LH. Delayed effects of whole brain radiotherapy in germ cell tumor patients with central nervous system metastases. *Int J Radiat Oncol Biol Phys*. 2008;70:1361–1364.

Droz JP, Kramar A, Biron P, et al. Failure of high-dose cyclophosphamide and etoposide combined with double-dose cisplatin and bone marrow support in patients with high-volume metastatic nonseminomatous germ-cell tumours: mature results of a randomised trial. *Eur Urol*. 2007;51:739–746 [discussion 747–748].

Duchesne GM, Stenning SP, Aass N, et al. Radiotherapy after chemotherapy for metastatic seminoma–a diminishing role. MRC Testicular Tumour Working Party. *Eur J Cancer*. 1997;33:829–835.

Dundr P, Pesl M, Povysil C, et al. Anaplastic variant of spermatocytic seminoma. *Pathol Res Pract*. 2007;203:621–624.

Eastham JA, Wilson TG, Russell C, et al. Surgical resection in patients with nonseminomatous germ cell tumor who fail to normalize serum tumor markers after chemotherapy. *Urology*. 1994;43:74–80.

Eble JN. Spermatocytic seminoma. *Hum Pathol*. 1994;25:1035–1042.

Eggener SE, Carver BS, Loeb S, et al. Pathologic findings and clinical outcome of patients undergoing retroperitoneal lymph node dissection after multiple chemotherapy regimens for metastatic testicular germ cell tumors. *Cancer*. 2007;109:528–535.

Eggener SE, Carver BS, Sharp DS, et al. Incidence of disease outside modified retroperitoneal lymph node dissection templates in clinical stage I or IIA nonseminomatous germ cell testicular cancer. *J Urol*. 2007;177:937–943.

Ehrlich Y, Brames MJ, Beck SD, et al. Long-term follow-up of cisplatin combination chemotherapy in patients with disseminated nonseminomatous germ cell tumors: is a postchemotherapy retroperitoneal lymph node dissection needed after complete remission? *J Clin Oncol*. 2010;28:531–536.

Einhorn LH. Testicular cancer as a model for a curable neoplasm: the Richard and Hinda Rosenthal Foundation Award Lecture. *Cancer Res*. 1981;41:3275–3280.

Einhorn LH. Treatment of testicular cancer: a new and improved model. *J Clin Oncol*. 1990;8:1777–1781.

Einhorn LH, Williams SD, Loehrer PJ, et al. Evaluation of optimal duration of chemotherapy in favorable-prognosis disseminated germ cell tumors: a Southeastern Cancer Study Group protocol. *J Clin Oncol*. 1989;7:387–391.

Einhorn LH, Williams SD, Chamness A, et al. High-dose chemotherapy and stem-cell rescue for metastatic germ-cell tumors. *N Engl J Med*. 2007;357:340–348.

El Mesbahi O, Terrier-Lacombe MJ, Rebischung C, et al. Chemotherapy in patients with teratoma with malignant transformation. *Eur Urol*. 2007;51:1306–1311 [discussion 1311–1312].

Elert A, Olbert P, Hegele A, et al. Accuracy of frozen section examination of testicular tumors of uncertain origin. *Eur Urol*. 2002;41:290–293.

Epstein JI. The lower urinary tract and male genital system. Kumar V, Abbas AK, Fausto N, et al. *Robbins and cotran pathologic basis of disease, professional edition*. ed 8. Elsevier: Philadelphia; 2010.

Ernst DS, Brasher P, Venner PM, et al. Compliance and outcome of patients with stage 1 non-seminomatous germ cell tumors (NSGCT) managed with surveillance programs in seven Canadian centres. *Can J Urol*. 2005;12(2):2575–2580.

Fagundes MA, Zietman AL, Althausen AF, et al. The management of spermatic cord sarcoma. *Cancer*. 1996;77:1873–1876.

Feldman DR, Bosl GJ, Sheinfeld J, et al. Medical treatment of advanced testicular cancer. *J Am Med Assoc*. 2008;299:672–684.

Fernandez EB, Moul JW, Foley JP, et al. Retroperitoneal imaging with third and fourth generation computed axial tomography in clinical stage I nonseminomatous germ cell tumors. *Urology*. 1994;44:548–552.

Feuer EJ, Frey CM, Brawley OW, et al. After a treatment breakthrough: a comparison of trial and population-based data for advanced testicular cancer. *J Clin Oncol*. 1994;12:368–377.

Fischer S, Tandstad T, Wheater M, et al. Outcome of men with relapse after adjuvant carboplatin for clinical stage I seminoma. *J Clin Oncol*. 2017;35:194–200.

Fizazi K, Tjulandin S, Salvioni R, et al. Viable malignant cells after primary chemotherapy for disseminated nonseminomatous germ cell tumors: prognostic factors and role of postsurgery chemotherapy–results from an international study group. *J Clin Oncol*. 2001;19:2647–2657.

Fizazi K, Culine S, Kramar A, et al. Early predicted time to normalization of tumor markers predicts outcome in poor-prognosis nonseminomatous germ cell tumors.[see comment]. *J Clin Oncol*. 2004;22:3868–3876.

Fizazi K, Oldenburg J, Dunant A, et al. Assessing prognosis and optimizing treatment in patients with postchemotherapy viable nonseminomatous germ-cell tumors (NSGCT): results of the sCR2 international study. *Ann Oncol*. 2008;19:259–264.

Fizazi K, Pagliaro L, Laplanche A, et al. Personalised chemotherapy based on tumour marker decline in poor prognosis germ-cell tumours (GETUG 13): a phase 3, multicentre, randomised trial. *Lancet Oncol*. 2014;15:1442–1450.

Flechon A, Bompas E, Biron P, et al. Management of post-chemotherapy residual masses in advanced seminoma. *J Urol*. 2002;168:1975–1979.

Fossa SD, Aass N, Kaalhus O. Radiotherapy for testicular seminoma stage I: treatment results and long-term post-irradiation morbidity in 365 patients. *Int J Radiat Oncol Biol Phys*. 1989;16:383–388.

Fossa SD, Ous S, Lien HH, et al. Post-chemotherapy lymph node histology in radiologically normal patients with metastatic nonseminomatous testicular cancer. *J Urol*. 1989;141:557–559.

Fossa SD, Qvist H, Stenwig AE, et al. Is postchemotherapy retroperitoneal surgery necessary in patients with nonseminomatous testicular cancer and minimal residual tumor masses? *J Clin Oncol*. 1992;10:569–573.

Fossa SD, Oliver RT, Stenning SP, et al. Prognostic factors for patients with advanced seminoma treated with platinum-based chemotherapy. *Eur J Cancer*. 1997;33:1380–1387.

Fossa SD, Bokemeyer C, Gerl A, et al. Treatment outcome of patients with brain metastases from malignant germ cell tumors. *Cancer*. 1999;85:988–997.

Fossa SD, Horwich A, Russell JM, et al. Optimal planning target volume for stage I testicular seminoma: a Medical Research Council randomized trial. Medical Research Council Testicular Tumor Working Group. *J Clin Oncol*. 1999;17:1146.

Fossa SD, Stenning SP, Gerl A, et al. Prognostic factors in patients progressing after cisplatin-based chemotherapy for malignant non-seminomatous germ cell tumours. *Br J Cancer*. 1999;80:1392–1399.

Fossa SD, Aass N, Harvei S, et al. Increased mortality rates in young and middle-aged patients with malignant germ cell tumours. *Br J Cancer*. 2004;90:607–612.

Fossa SD, Chen J, Schonfeld SJ, et al. Risk of contralateral testicular cancer: a population-based study of 29,515 U.S. men. *J Natl Cancer Inst*. 2005;97:1056–1066.

Fossa SD, Gilbert E, Dores GM, et al. Noncancer causes of death in survivors of testicular cancer. *J Natl Cancer Inst*. 2007;99:533–544.

Fossa SD, Oldenburg J, Dahl AA. Short- and long-term morbidity after treatment for testicular cancer. *BJU Int*. 2009;104:1418–1422.

Foster RS, Baniel J, Leibovitch I, et al. Teratoma in the orchiectomy specimen and volume of metastasis are predictors of retroperitoneal teratoma in low stage nonseminomatous testis cancer. *J Urol*. 1996;155:1943–1945.

Fox EP, Weathers TD, Williams SD, et al. Outcome analysis for patients with persistent nonteratomatous germ cell tumor in postchemotherapy retroperitoneal lymph node dissections. *J Clin Oncol*. 1993;11:1294–1299.

Francis R, Bower M, Brunstrom G, et al. Surveillance for stage I testicular germ cell tumours: results and cost benefit analysis of management options. *Eur J Cancer*. 2000;36:1925–1932.

Freedman LS, Parkinson MC, Jones WG, et al. Histopathology in the prediction of relapse of patients with stage I testicular teratoma treated by orchidectomy alone. *Lancet*. 1987;2:294–298.

Garcia-del-Muro X, Maroto P, Guma J, et al. Chemotherapy as an alternative to radiotherapy in the treatment of stage IIA and IIB testicular seminoma: a Spanish Germ Cell Cancer Group Study. *J Clin Oncol*. 2008;26:5416–5421.

Geldart TR, Simmonds PD, Mead GM. Orchidectomy after chemotherapy for patients with metastatic testicular germ cell cancer. *BJU Int*. 2002;90:451–455.

Gels ME, Hoekstra HJ, Sleijfer DT, et al. Detection of recurrence in patients with clinical stage I nonseminomatous testicular germ cell tumors and consequences for further follow-up: a single-center 10-year experience. *J Clin Oncol*. 1995;13:1188–1194.

George DW, Foster RS, Hromas RA, et al. Update on late relapse of germ cell tumor: a clinical and molecular analysis. *J Clin Oncol*. 2003;21:113–122.

Gerl A, Clemm C, Schmeller N, et al. Sequential resection of residual abdominal and thoracic masses after chemotherapy for metastatic non-seminomatous germ cell tumours. *Br J Cancer*. 1994;70:960–965.

Gerl A, Clemm C, Schmeller N, et al. Outcome analysis after post-chemotherapy surgery in patients with non-seminomatous germ cell tumours. *Ann Oncol*. 1995;6:483–488.

Gerl A, Clemm C, Schmeller N, et al. Late relapse of germ cell tumors after cisplatin-based chemotherapy. *Ann Oncol*. 1997;8:41–47.

Gholam D, Fizazi K, Terrier-Lacombe MJ, et al. Advanced seminoma–treatment results and prognostic factors for survival after first-line, cisplatin-based chemotherapy and for patients with recurrent disease: a single-institution experience in 145 patients. *Cancer*. 2003;98:745–752.

Giannandrea F, Fargnoli S. Environmental factors affecting growth and occurrence of testicular cancer in childhood: an overview of the current epidemiological evidence. *Children (Basel)*. 2017;4.

Giannarini G, Dieckmann KP, Albers P, et al. Organ-sparing surgery for adult testicular tumours: a systematic review of the literature. *Eur Urol*. 2010;57:780–790.

Gilbert DC, Norman AR, Nicholl J, et al. Treating stage I nonseminomatous germ cell tumours with a single cycle of chemotherapy. *BJU Int*. 2006;98:67–69.

Gilligan T, Beard C, Carneiro B, et al. *NCCN Guidelines Version 2.2018 Testicular Cancer. NCCN. nccn.org*. [National Comprehensive Cancer Network] 2018.

Gremmer R, Schroder ML, Ten Huinink WW, et al. Successful management of brain metastasis from malignant germ cell tumours with standard induction chemotherapy. *J Neurooncol*. 2008;90:335–339.

Hanson HA, Anderson RE, Aston KI, et al. Subfertility increases risk of testicular cancer: evidence from population-based semen samples. *Fertil Steril*. 2016;105:322–328.e1.

Hao D, Seidel J, Brant R, et al. Compliance of clinical stage I nonseminomatous germ cell tumor patients with surveillance. *J Urol*. 1998;160:768–771.

Harari SE, Sassoon DJ, Priemer DS, et al. Testicular cancer: the usage of central review for pathology diagnosis of orchiectomy specimens. *Urol Oncol*. 2017;35:605.e9–605.e16.

Hardell L, van Bavel B, Lindstrom G, et al. Increased concentrations of polychlorinated biphenyls, hexachlorobenzene, and chlordanes in mothers of men with testicular cancer. *Environ Health Perspect*. 2003;111:930–934.

Hardell L, Bavel B, Lindstrom G, et al. In utero exposure to persistent organic pollutants in relation to testicular cancer risk. *Int J Androl*. 2006;29:228–234.

Harding MJ, Paul J, Gillis CR, et al. Management of malignant teratoma: does referral to a specialist unit matter? *Lancet*. 1993;341:999–1002.

Hartmann JT, Bamberg M, Albers P, et al. Multidisciplinary treatment and prognosis of patients (pts) with central nervous system metastases (CNS) from testicular germ cell tumor (GCT) origin. *Proc Am Soc Clin Oncol*. 2003;22 [Abst 1607].

Hartmann JT, Candelaria M, Kuczyk MA, et al. Comparison of histological results from the resection of residual masses at different sites after chemotherapy for metastatic non-seminomatous germ cell tumours. *Eur J Cancer*. 1997;33:843–847.

Hartmann JT, Schmoll HJ, Kuczyk MA, et al. Postchemotherapy resections of residual masses from metastatic non-seminomatous testicular germ cell tumors. *Ann Oncol*. 1997;8:531–538.

Hazariwala R, Morris CG, Gilbert S, et al. Radiotherapy for spermatic cord sarcoma. *Am J Clin Oncol*. 2013;36:392–394.

Heidenreich A, Sesterhenn IA, Mostofi FK, et al. Prognostic risk factors that identify patients with clinical stage I nonseminomatous germ cell tumors at low risk and high risk for metastasis. *Cancer*. 1998;83:1002–1011.

Heidenreich A, Weissbach L, Holtl W, et al. Organ sparing surgery for malignant germ cell tumor of the testis. *J Urol*. 2001;166:2161–2165.

Heidenreich A, Albers P, Hartmann M, et al. Complications of primary nerve sparing retroperitoneal lymph node dissection for clinical stage I nonseminomatous germ cell tumors of the testis: experience of the German Testicular Cancer Study Group. *J Urol*. 2003;169:1710–1714.

Hemminki K, Chen B. Familial risks in testicular cancer as aetiological clues. *Int J Androl*. 2006;29:205–210.

Hendry WF, Norman AR, Dearnaley DP, et al. Metastatic nonseminomatous germ cell tumors of the testis: results of elective and salvage surgery for patients with residual retroperitoneal masses. *Cancer*. 2002;94:1668–1676.

Hermans BP, Sweeney CJ, Foster RS, et al. Risk of systemic metastases in clinical stage I nonseminoma germ cell testis tumor managed by retroperitoneal lymph node dissection. *J Urol*. 2000;163:1721–1724.

Herr HW, Sheinfeld J, Puc HS, et al. Surgery for a post-chemotherapy residual mass in seminoma. *J Urol*. 1997;157:860–862.

Hilton S, Herr HW, Teitcher JB, et al. CT detection of retroperitoneal lymph node metastases in patients with clinical stage I testicular nonseminomatous germ cell cancer: assessment of size and distribution criteria. *AJR Am J Roentgenol*. 1997;169:521–525.

Hindley RG, Chandra A, Saunders A, et al. Impalpable testis cancer. *BJU Int*. 2003;92:572–574.

Hinton S, Catalano PJ, Einhorn LH, et al. Cisplatin, etoposide and either bleomycin or ifosfamide in the treatment of disseminated germ cell tumors: final analysis of an intergroup trial. *Cancer*. 2003;97:1869–1875.

Honecker F, Wermann H, Mayer F, et al. Microsatellite instability, mismatch repair deficiency, and BRAF mutation in treatment-resistant germ cell tumors. *J Clin Oncol*. 2009;27:2129–2136.

Honecker F, Aparicio J, Berney D, et al. ESMO Consensus Conference on testicular germ cell cancer: diagnosis, treatment and follow-up. *Ann Oncol*. 2018;29:1658–1686.

Horan G, Rafique A, Robson J, et al. CT of the chest can hinder the management of seminoma of the testis; it detects irrelevant abnormalities. *Br J Cancer*. 2007;96:882–885.

Horn T, Schulz S, Maurer T, et al. Poor efficacy of BEP polychemotherapy in metastatic spermatocytic seminoma. *Med Oncol*. 2011;28(Suppl 1):S423–S425.

Horner MJ, Ries LAG, Krapcho M, et al. *SEER cancer statistics review, 1975-2006*. National Cancer Institute: Bethesda, MD; 2009.

Horwich A, Alsanjari N, A'Hern R, et al. Surveillance following orchidectomy for stage I testicular seminoma. *Br J Cancer*. 1992;65:775–778.

Horwich A, Norman A, Fisher C, et al. Primary chemotherapy for stage II nonseminomatous germ cell tumors of the testis. *J Urol*. 1994;151:72–77 [discussion 77–78].

Horwich A, Sleijfer DT, Fossa SD, et al. Randomized trial of bleomycin, etoposide, and cisplatin compared with bleomycin, etoposide, and carboplatin in good-prognosis metastatic nonseminomatous germ cell cancer: a Multiinstitutional Medical Research Council/European Organization for Research and Treatment of Cancer Trial. *J Clin Oncol*. 1997;15:1844–1852.

Horwich A, Oliver RT, Wilkinson PM, et al. A medical research council randomized trial of single agent carboplatin versus etoposide and cisplatin for advanced metastatic seminoma. MRC Testicular Tumour Working Party. *Br J Cancer*. 2000;83:1623–1629.

Hotte S, Mayhew LA, Jewett M, et al. *Management of stage I nonseminomatous testicular cancer: guideline recommendations. Care CCOPiE-B*. [(website)] http://www.cancercare.on.ca/toolbox/qualityguidelines/diseasebs/; 2008.

Houldsworth J, Xiao H, Murty VV, et al. Human male germ cell tumor resistance to cisplatin is linked to TP53 gene mutation. *Oncogene*. 1998;16:2345–2349.

Howard GC, Clarke K, Elia MH, et al. A Scottish national audit of current patterns of management for patients with testicular non-seminomatous germ-cell tumours. The Scottish Radiological Society and the Scottish Committee of the Royal College of Radiologists. *Br J Cancer*. 1995;72:1303–1306.

Howlader N, Noone AM, Krapcho M, et al. *SEER cancer statistics review, 1975-2014*. National Cancer Institute: Bethesda, MD; 2017.

Hu GX, Lian QQ, Ge RS, et al. Phthalate-induced testicular dysgenesis syndrome: leydig cell influence. *Trends*

Endocrinol Metab. 2009;20:139–145.

Huddart RA, Reid AM. Adjuvant therapy for stage IB germ cell tumors: one versus two cycles of BEP. *Adv Urol*. 2018;2018:8781698.

Huddart RA, Norman A, Shahidi M, et al. Cardiovascular disease as a long-term complication of treatment for testicular cancer. *J Clin Oncol*. 2003;21:1513–1523.

Huddart RA, O'Doherty MJ, Padhani A, et al. 18fluorodeoxyglucose positron emission tomography in the prediction of relapse in patients with high-risk, clinical stage I nonseminomatous germ cell tumors: preliminary report of MRC Trial TE22–the NCRI Testis Tumour Clinical Study Group. *J Clin Oncol*. 2007;25:3090–3095.

Huddart RA, Joffe JK, White JD, et al. 111: a single-arm trial evaluating one cycle of BEP as adjuvant chemotherapy in high-risk, stage 1 non-seminomatous or combined germ cell tumors of the testis (NSGCTT). *J Clin Oncol*. 2017;35:400.

Hunt BM, Vallieres E, Buduhan G, et al. Sarcoidosis as a benign cause of lymphadenopathy in cancer patients. *Am J Surg*. 2009;197:629–632 [discussion 632].

Hussain SA, Ma YT, Palmer DH, et al. Biology of testicular germ cell tumors. *Expert Rev Anticancer Ther*. 2008;8:1659–1673.

Huyghe E, Matsuda T, Thonneau P. Increasing incidence of testicular cancer worldwide: a review. *J Urol*. 2003;170:5–11.

Huyghe E, Matsuda T, Daudin M, et al. Fertility after testicular cancer treatments: results of a large multicenter study. *Cancer*. 2004;100:732–737.

International Germ Cell Consensus Classification. A prognostic factor-based staging system for metastatic germ cell cancers. International Germ Cell Cancer Collaborative Group. *J Clin Oncol*. 1997;15:594–603.

Janetschek G, Hobisch A, Peschel R, et al. Laparoscopic retroperitoneal lymph node dissection for clinical stage I nonseminomatous testicular carcinoma: long-term outcome. *J Urol*. 2000;163:1793–1796.

Jewett MA. Nerve-sparing technique for retroperitoneal lymphadenectomy in testis cancer. *Urol Clin North Am*. 1990;17:449–456.

Jones WG, Fossa SD, Mead GM, et al. Randomized trial of 30 versus 20 Gy in the adjuvant treatment of stage I Testicular Seminoma: a report on Medical Research Council Trial TE18, European Organisation for the Research and Treatment of Cancer Trial 30942 (ISRCTN18525328). *J Clin Oncol*. 2005;23:1200–1208.

Joudi FN, Konety BR. The impact of provider volume on outcomes from urological cancer therapy. *J Urol*. 2005;174:432–438.

Kandori S, Kawai K, Fukuhara Y, et al. A case of metastatic testicular cancer complicated by pulmonary hemorrhage due to choriocarcinoma syndrome. *Int J Clin Oncol*. 2010;15:611–614.

Kanetsky PA, Mitra N, Vardhanabhuti S, et al. Common variation in KITLG and at 5q31.3 predisposes to testicular germ cell cancer. *Nat Genet*. 2009;41:811–815.

Karellas ME, Damjanov I, Holzbeierlein JM. ITGCN of the testis, contralateral testicular biopsy and bilateral testicular cancer. *Urol Clin North Am*. 2007;34:119–125 [abstract vii].

Kesler KA, Rieger KM, Hammoud ZT, et al. A 25-year single institution experience with surgery for primary mediastinal nonseminomatous germ cell tumors. *Ann Thorac Surg*. 2008;85:371–378.

Khandekar MJ, Raut CP, Hornick JL, et al. Paratesticular liposarcoma: unusual patterns of recurrence and importance of margins. *Ann Surg Oncol*. 2013;20:2148–2155.

Kim I, Young RH, Scully RE. Leydig cell tumors of the testis. A clinicopathological analysis of 40 cases and review of the literature. *Am J Surg Pathol*. 1985;9:177–192.

Kollmannsberger C, Nichols C, Bamberg M, et al. First-line high-dose chemotherapy +/- radiation therapy in patients with metastatic germ-cell cancer and brain metastases. *Ann Oncol*. 2000;11:553–559.

Kollmannsberger C, Beyer J, Bokemeyer C. High-dose chemotherapy in nonseminomatous germ cell cancer. *BJU Int*. 2009;104:1398–1403.

Kollmannsberger C, Daneshmand S, So A, et al. Management of disseminated nonseminomatous germ cell tumors with risk-based chemotherapy followed by response-guided postchemotherapy surgery. *J Clin Oncol*. 2010;28:537–542.

Kollmannsberger C, Moore C, Chi KN, et al. Non-risk-adapted surveillance for patients with stage I nonseminomatous testicular germ-cell tumors: diminishing treatment-related morbidity while maintaining efficacy. *Ann Oncol*. 2010;21:1296–1301.

Kollmannsberger C, Tyldesley S, Moore C, et al. Evolution in management of testicular seminoma: population-based outcomes with selective utilization of active therapies. *Ann Oncol*. 2010;22:808–814.

Kollmannsberger C, Tandstad T, Bedard PL, et al. Patterns of relapse in patients with clinical stage I testicular cancer managed with active surveillance. *J Clin Oncol*. 2015;33:51–57.

Kondagunta GV, Sheinfeld J, Mazumdar M, et al. Relapse-free and overall survival in patients with pathologic stage II nonseminomatous germ cell cancer treated with etoposide and cisplatin adjuvant chemotherapy. *J Clin Oncol*. 2004;22:464–467.

Kondagunta GV, Bacik J, Donadio A, et al. Combination of paclitaxel, ifosfamide, and cisplatin is an effective second-line therapy for patients with relapsed testicular germ cell tumors. *J Clin Oncol*. 2005;23:6549–6555.

Kondagunta GV, Bacik J, Sheinfeld J, et al. Paclitaxel plus Ifosfamide followed by high-dose carboplatin plus etoposide in previously treated germ cell tumors. *J Clin Oncol*. 2007;25:85–90.

Kondagunta GV, Motzer RJ. Adjuvant chemotherapy for stage II nonseminomatous germ cell tumors. *Urol Clin North Am*. 2007;34:179–185.

Kopp RP, Chevinsky M, Bernstein M, et al. Bilateral testicular germ cell tumors in the era of multimodal therapy. *Urology*. 2017;103:154–160.

Krege S, Beyer J, Souchon R, et al. European Consensus Conference on Diagnosis and Treatment of Germ Cell Cancer: a report of the second meeting of the European Germ Cell Cancer Consensus Group (EGCCCG): Part I. *Eur Urol*. 2008;53:478–496.

Krege S, Beyer J, Souchon R, et al. European Consensus Conference on Diagnosis and Treatment of Germ Cell Cancer: a report of the second meeting of the European Germ Cell Cancer Consensus Group (EGCCCG): Part II. *Eur Urol*. 2008;53:497–513.

Lackner JE, Koller A, Schatzl G, et al. Androgen deficiency symptoms in testicular cancer survivors are associated with sexual problems but not with serum testosterone or therapy. *Urology*. 2009;74:825–829.

Laclergerie F, Mouillet G, Frontczak A, et al. Testicle-sparing surgery versus radical orchiectomy in the management of Leydig cell tumors: results from a multicenter study. *World J Urol*. 2018;36:427–433.

Leibovitch L, Foster RS, Kopecky KK, et al. Improved accuracy of computerized tomography based clinical staging in low stage nonseminomatous germ cell cancer using size criteria of retroperitoneal lymph nodes. *J Urol*. 1995;154:1759–1763.

Lerner SE, Mann BS, Blute ML, et al. Primary chemotherapy for clinical stage II nonseminomatous germ cell testicular tumors: selection criteria and long-term results. *Mayo Clin Proc*. 1995;70:821–828.

Levi JA, Raghavan D, Harvey V, et al. The importance of bleomycin in combination chemotherapy for good-prognosis germ cell carcinoma. Australasian Germ Cell Trial Group. *J Clin Oncol*. 1993;11:1300–1305.

Little JS Jr, Foster RS, Ulbright TM, et al. Unusual neoplasms detected in testis cancer patients undergoing post-chemotherapy retroperitoneal lymphadenectomy. *J Urol*. 1994;152:1144–1149.

Liu NW, Cary C, Strine AC, et al. Risk of Recurrence for clinical stage I and II patients with teratoma only at primary retroperitoneal lymph node dissection. *Urology*. 2015;86:981–984.

Liu S, Wen SW, Mao Y, et al. Birth cohort effects underlying the increasing testicular cancer incidence in Canada. *Can J Public Health*. 1999;90:176–180.

Loehrer PJ Sr, Einhorn LH, Williams SD. VP-16 plus ifosfamide plus cisplatin as salvage therapy in refractory germ cell cancer. *J Clin Oncol*. 1986;4:528–536.

Loehrer PJ Sr, Birch R, Williams SD, et al. Chemotherapy of metastatic seminoma: the Southeastern Cancer Study Group experience. *J Clin Oncol*. 1987;5:1212–1220.

Loehrer PJ Sr, Johnson D, Elson P, et al. Importance of bleomycin in favorable-prognosis disseminated germ cell tumors: an Eastern Cooperative Oncology Group trial. *J Clin Oncol*. 1995;13:470–476.

Loehrer PJ Sr, Gonin R, Nichols CR, et al. Vinblastine plus ifosfamide plus cisplatin as initial salvage therapy in recurrent germ cell tumor. *J Clin Oncol*. 1998;16:2500–2504.

Logothetis CJ, Samuels ML, Trindade A, et al. The growing teratoma syndrome. *Cancer*. 1982;50:1629–1635.

Logothetis CJ, Swanson DA, Dexeus F, et al. Primary chemotherapy for clinical stage II nonseminomatous germ cell tumors of the testis: a follow-up of 50 patients. *J Clin Oncol*. 1987;5:906–911.

Looijenga LH, Gillis AJ, Stoop H, et al. Dissecting the molecular pathways of (testicular) germ cell tumour pathogenesis; from initiation to treatment-resistance. *Int J Androl*. 2011;34:e234–e251.

Lorch A, Kollmannsberger C, Hartmann JT, et al. Single versus sequential high-dose chemotherapy in patients with relapsed or refractory germ cell tumors: a prospective randomized multicenter trial of the German Testicular Cancer Study Group. *J Clin Oncol*. 2007;25:2778–2784.

Lorch A, Beyer J, Bascoul-Mollevi C, et al. Prognostic factors in patients with metastatic germ cell tumors who experienced treatment failure with cisplatin-based first-line chemotherapy. *J Clin Oncol*. 2010;28:4906–4911.

Lowrance WT, Cookson MS, Clark PE, et al. Assessing retroperitoneal lymphadenectomy experience in United States urological residency programs. *J Urol*. 2007;178:500–503 [discussion 503].

Lutke Holzik MF, Hoekstra HJ, Mulder NH, et al. Non-germ cell malignancy in residual or recurrent mass after chemotherapy for nonseminomatous testicular germ cell tumor. *Ann Surg Oncol*. 2003;10:131–135.

Magers MJ, Kao CS, Cole CD, et al. “Somatic-type” malignancies arising from testicular germ cell tumors: a clinicopathologic study of 124 cases with emphasis on glandular tumors supporting frequent yolk sac tumor origin. *Am J Surg Pathol*. 2014;38:1396–1409.

Mai PL, Chen BE, Tucker K, et al. Younger age-at-diagnosis for familial malignant testicular germ cell tumor. *Fam Cancer*. 2009.

Mano R, Becerra MF, Carver BS, et al. Clinical outcome of patients with fibrosis/necrosis at post-chemotherapy retroperitoneal lymph node dissection for advanced germ cell tumors. *J Urol*. 2017;197:391–397.

Mardiak J, Salek T, Sycova-Mila Z, et al. Gemcitabine plus cisplatine and paclitaxel (GCP) in second-line treatment of germ cell tumors (GCT): a phase II study. *Neoplasma*. 2005;52:243–247.

Martin OV, Shialis T, Lester JN, et al. Testicular dysgenesis syndrome and the estrogen hypothesis: a quantitative meta-analysis. *Environ Health Perspect*. 2008;116:149–157.

Massard C, Kramar A, Beyer J, et al. Tumor marker kinetics predict outcome in patients with relapsed disseminated non-seminomatous germ-cell tumors. *Ann Oncol*. 2013;24:322–328.

Masterson TA, Carver BS, Shayegan B, et al. Outcomes in patients with clinical stage III NSGCT who achieve complete clinical response to chemotherapy at extraretroperitoneal disease site. *Urology*. 2012;79:1079–1084.

Masterson TA, Shayegan B, Carver BS, et al. Clinical impact of residual extraretroperitoneal masses in patients with advanced nonseminomatous germ cell testicular cancer. *Urology*. 2012;79:156–159.

Matulewicz RS, Oberlin DT, Sheinfeld J, et al. The evolving management of patients with clinical stage I seminoma. *Urology*. 2016;98:113–119.

Mayer F, Stoop H, Scheffer GL, et al. Molecular determinants of treatment response in human germ cell tumors. *Clin Cancer Res*. 2003;9:767–773.

McCaffrey JA, Mazumdar M, Bajorin DF, et al. Ifosfamide- and cisplatin-containing chemotherapy as first-line salvage therapy in germ cell tumors: response and survival. *J Clin Oncol*. 1997;15:2559–2563.

McGlynn KA, Trabert B. Adolescent and adult risk factors for testicular cancer. *Nat Rev Urol*. 2012;9:339–349.

McGlynn KA, Devesa SS, Sigurdson AJ, et al. Trends in the incidence of testicular germ cell tumors in the United States. *Cancer*. 2003;97:63–70.

McGlynn KA, Devesa SS, Graubard BI, et al. Increasing incidence of testicular germ cell tumors among black men in the United States. *J Clin Oncol*. 2005;23:5757–5761.

McGlynn KA, Quraishi SM, Graubard BI, et al. Persistent organochlorine pesticides and risk of testicular germ cell tumors. *J Natl Cancer Inst*. 2008;100:663–671.

McGuire MS, Rabbani F, Mohseni H, et al. The role of thoracotomy in managing postchemotherapy residual thoracic masses in patients with nonseminomatous germ cell tumours. *BJU Int*. 2003;91:469–473.

McKenney JK, Heerema-McKenney A, Rouse RV. Extragonadal germ cell tumors: a review with emphasis on pathologic features, clinical prognostic variables, and differential diagnostic considerations. *Adv Anat Pathol*. 2007;14:69–92.

McKiernan JM, Goluboff ET, Liberson GL, et al. Rising risk of testicular cancer by birth cohort in the United States from 1973 to 1995. *J Urol*. 1999;162:361–363.

McLeod DG, Weiss RB, Stablein DM, et al. Staging relationships and outcome in early stage testicular cancer: a report from the Testicular Cancer Intergroup Study. *J Urol*. 1991;145:1178–1183 [discussion 1182–1183].

Mead GM, Stenning SP, Parkinson MC, et al. The Second Medical Research Council study of prognostic factors in nonseminomatous germ cell tumors. Medical Research

Council Testicular Tumour Working Party. *J Clin Oncol*. 1992;10:85–94.

Mead GM, Cullen MH, Huddart R, et al. A phase II trial of TIP (paclitaxel, ifosfamide and cisplatin) given as second-line (post-BEP) salvage chemotherapy for patients with metastatic germ cell cancer: a medical research council trial. *Br J Cancer*. 2005;93:178–184.

Meinardi MT, Gietema JA, van der Graaf WT, et al. Cardiovascular morbidity in long-term survivors of metastatic testicular cancer. *J Clin Oncol*. 2000;18:1725–1732.

Mencel PJ, Motzer RJ, Mazumdar M, et al. Advanced seminoma: treatment results, survival, and prognostic factors in 142 patients. *J Clin Oncol*. 1994;12:120–126.

Michael H, Lucia J, Foster RS, et al. The pathology of late recurrence of testicular germ cell tumors. *Am J Surg Pathol*. 2000;24:257–273.

Miller KD, Loehrer PJ, Gonin R, et al. Salvage chemotherapy with vinblastine, ifosfamide, and cisplatin in recurrent seminoma. *J Clin Oncol*. 1997;15:1427–1431.

Montgomery E, Fisher C. Paratesticular liposarcoma: a clinicopathologic study. *Am J Surg Pathol*. 2003;27:40–47.

Montironi R. Intratubular germ cell neoplasia of the testis: testicular intraepithelial neoplasia. *Eur Urol*. 2002;41:651–654.

Moran CA, Suster S. Primary mediastinal choriocarcinomas: a clinicopathologic and immunohistochemical study of eight cases. *Am J Surg Pathol*. 1997;21:1007–1012.

Moran CA, Suster S. Primary germ cell tumors of the mediastinum: I. Analysis of 322 cases with special emphasis on teratomatous lesions and a proposal for histopathologic classification and clinical staging. *Cancer*. 1997;80:681–690.

Moran CA, Suster S. Germ-cell tumors of the mediastinum. *Adv Anat Pathol*. 1998;5:1–15.

Moran CA, Suster S, Koss MN. Primary germ cell tumors of the mediastinum: III. Yolk sac tumor, embryonal carcinoma, choriocarcinoma, and combined nonteratomatous germ cell tumors of the mediastinum–a clinicopathologic and immunohistochemical study of 64 cases. *Cancer*. 1997;80:699–707.

Moran CA, Suster S, Przygodzki RM, et al. Primary germ cell tumors of the mediastinum: II. Mediastinal seminomas–a clinicopathologic and immunohistochemical study of 120 cases. *Cancer*. 1997;80:691–698.

Mosharafa AA, Foster RS, Leibovich BC, et al. Is post-chemotherapy resection of seminomatous elements associated with higher acute morbidity? *J Urol*. 2003;169:2126–2128.

Motzer R, Bosl G, Heelan R, et al. Residual mass: an indication for further therapy in patients with advanced seminoma following systemic chemotherapy. *J Clin Oncol*. 1987;5:1064–1070.

Motzer RJ, Amsterdam A, Prieto V, et al. Teratoma with malignant transformation: diverse malignant histologies arising in men with germ cell tumors. *J Urol*. 1998;159:133–138.

Motzer RJ, Bolger GB, Boston B, et al. Testicular cancer. Clinical practice guidelines in oncology. *J Natl Compr Canc Netw*. 2006;4:1038–1058.

Motzer RJ, Nichols CJ, Margolin KA, et al. Phase III randomized trial of conventional-dose chemotherapy with or without high-dose chemotherapy and autologous hematopoietic stem-cell rescue as first-line treatment for patients with poor-prognosis metastatic germ cell tumors. *J Clin Oncol*. 2007;25:247–256.

Moul JW, Paulson DF, Dodge RK, et al. Delay in diagnosis and survival in testicular cancer: impact of effective therapy and changes during 18 years. *J Urol*. 1990;143:520–523.

Muller T, Gozzi C, Akkad T, et al. Management of incidental impalpable intratesticular masses of < or = 5 mm in diameter. *BJU Int*. 2006;98:1001–1004.

Murphy BR, Breeden ES, Donohue JP, et al. Surgical salvage of chemorefractory germ cell tumors. *J Clin Oncol*. 1993;11:324–329.

Narang V, Gupta K, Gupta A, et al. Rhabdomyosarcomatous differentiation in a spermatocytic seminoma with review of literature. *Indian J Urol*. 2012;28:430–433.

Nelson JB, Chen RN, Bishoff JT, et al. Laparoscopic retroperitoneal lymph node dissection for clinical stage I nonseminomatous germ cell testicular tumors. *Urology*. 1999;54:1064–1067.

Nguyen CT, Fu AZ, Gilligan TD, et al. Defining the optimal treatment for clinical stage I nonseminomatous germ cell testicular cancer using decision analysis. *J Clin Oncol*. 2010;28:119–125.

Nichols CR, Catalano PJ, Crawford ED, et al. Randomized comparison of cisplatin and etoposide and either bleomycin or ifosfamide in treatment of advanced disseminated germ cell tumors: an Eastern Cooperative Oncology Group, Southwest Oncology Group, and Cancer and Leukemia Group B Study. *J Clin Oncol*. 1998;16:1287–1293.

Nicolai N, Miceli R, Artusi R, et al. A simple model for predicting nodal metastasis in patients with clinical stage I nonseminomatous germ cell testicular tumors undergoing retroperitoneal lymph node dissection only. *J Urol*. 2004;171:172–176.

Nicolai N, Necchi A, Gianni L, et al. Long-term results of a combination of paclitaxel, cisplatin and gemcitabine for salvage therapy in male germ-cell tumours. *BJU Int*. 2009.

Nicolai N, Necchi A, Raggi D, et al. Clinical outcome in testicular sex cord stromal tumors: testis sparing vs. radical orchiectomy and management of advanced disease. *Urology*. 2015;85:402–406.

Nielsen ME, Lima G, Schaeffer EM, et al. Oncologic efficacy of laparoscopic RPLND in treatment of clinical stage I nonseminomatous germ cell testicular cancer. *Urology*. 2007;70:1168–1172.

Nonomura N, Nagahara A, Oka D, et al. Brain metastases from testicular germ cell tumors: a retrospective analysis. *Int J Urol*. 2009;16:887–893.

Nord C, Bjoro T, Ellingsen D, et al. Gonadal hormones in long-term survivors 10 years after treatment for unilateral testicular cancer. *Eur Urol*. 2003;44:322–328.

Nuver J, Smit AJ, Wolffenbuttel BHR, et al. The metabolic syndrome and disturbances in hormone levels in long-term survivors of disseminated testicular cancer.[see comment]. *J Clin Oncol*. 2005;23:3718–3725.

Oechsle K, Hartmann M, Brenner W, et al. [18F]Fluorodeoxyglucose positron emission tomography in nonseminomatous germ cell tumors after chemotherapy: the German multicenter positron emission tomography study group. *J Clin Oncol*. 2008;26:5930–5935.

Oechsle K, Kollmannsberger C, Honecker F, et al. Long-term survival after treatment with gemcitabine and oxaliplatin with and without paclitaxel plus secondary surgery in patients with cisplatin-refractory and/or multiply relapsed germ cell tumors. *Eur Urol*. 2011;60:850–855.

Oldenburg J, Alfsen GC, Lien HH, et al. Postchemotherapy retroperitoneal surgery remains necessary in patients with nonseminomatous testicular cancer and minimal residual tumor masses. *J Clin Oncol*. 2003;21:3310–3317.

Oldenburg J, Alfsen GC, Waehre H, et al. Late recurrences of germ cell malignancies: a population-based experience over three decades. *Br J Cancer*. 2006;94:820–827.

Oliver RT, Edmonds PM, Ong JY, et al. Pilot studies of 2 and 1 course carboplatin as adjuvant for stage I seminoma: should it be tested in a randomized trial against radiotherapy? *Int J Radiat Oncol Biol Phys*. 1994;29:3–8.

Oliver RT, Ong J, Shamash J, et al. Long-term follow-up of Anglian Germ Cell Cancer Group surveillance versus patients with Stage 1 nonseminoma treated with adjuvant chemotherapy. *Urology*. 2004;63:556–561.

Oliver RT, Mason MD, Mead GM, et al. Radiotherapy versus single-dose carboplatin in adjuvant treatment of stage I seminoma: a randomised trial. *Lancet*. 2005;366:293–300.

Oliver RT, Mead GM, Fogarty PJ, et al. Radiotherapy versus carboplatin for stage I seminoma: updated analysis of the MRC/EORTC randomized trial (ISRCTN27163214). *J Clin Oncol*. 2008;26:5s [abstract 1].

Oliver RT, Mead GM, Rustin GJ, et al. Randomized trial of carboplatin versus radiotherapy for stage I seminoma: mature results on relapse and contralateral testis cancer rates in MRC TE19/EORTC 30982 study (ISRCTN27163214). *J Clin Oncol*. 2011;29:957–962.

Ondrus D, Hornak M, Matoska J, et al. Primary chemotherapy in the management of low stage (IIA and IIB) non-seminomatous germ cell testicular tumours. *Int Urol Nephrol*. 1992;24:299–304.

Ondrus D, Matoska J, Belan V, et al. Prognostic factors in clinical stage I nonseminomatous germ cell testicular tumors: rationale for different risk-adapted treatment. *Eur Urol*. 1998;33:562–566.

Osada K, Iijima H, Imasawa M, et al. Metastatic uveal tumor secondary to testicular choriocarcinoma. *Jpn J Ophthalmol*. 2004;48:85–87.

Ozisik H, Yurekli BS, Simsir IY, et al. Testicular Adrenal Rest Tumor (TART) in congenital adrenal hyperplasia. *Eur J Med*

Genet. 2017;60:489–493.

Paffenholz P, Held L, Loosen SH, et al. Testis-sparing surgery for benign testicular masses - diagnostics and therapeutic approaches. *J Urol*. 2018.

Park SB, Lee WC, Kim JK, et al. Imaging features of benign solid testicular and paratesticular lesions. *Eur Radiol*. 2011;21:2226–2234.

Patterson H, Norman AR, Mitra SS, et al. Combination carboplatin and radiotherapy in the management of stage II testicular seminoma: comparison with radiotherapy treatment alone. *Radiother Oncol*. 2001;59:5–11.

Peckham MJ, Hendry WF. Clinical stage II non-seminomatous germ cell testicular tumours. Results of management by primary chemotherapy. *Br J Urol*. 1985;57:763–768.

Pectasides D, Pectasides M, Farmakis D, et al. Oxaliplatin and irinotecan plus granulocyte-colony stimulating factor as third-line treatment in relapsed or cisplatin-refractory germ-cell tumor patients: a phase II study. *Eur Urol*. 2004;46:216–221.

Petersen PM, Giwercman A, Daugaard G, et al. Effect of graded testicular doses of radiotherapy in patients treated for carcinoma-in-situ in the testis. *J Clin Oncol*. 2002;20:1537–1543.

Pico JL, Rosti G, Kramar A, et al. A randomised trial of high-dose chemotherapy in the salvage treatment of patients failing first-line platinum chemotherapy for advanced germ cell tumours. *Ann Oncol*. 2005;16:1152–1159.

Pizzocaro G. Retroperitoneal lymph node dissection in clinical stage IIA and IIB nonseminomatous germ cell tumours of the testis. *Int J Androl*. 1987;10:269–275.

Pizzocaro G, Monfardini S. No adjuvant chemotherapy in selected patients with pathologic stage II nonseminomatous germ cell tumors of the testis. *J Urol*. 1984;131:677–680.

Pont J, Albrecht W, Postner G, et al. Adjuvant chemotherapy for high-risk clinical stage I nonseminomatous testicular germ cell cancer: long-term results of a prospective trial. *J Clin Oncol*. 1996;14:441–448.

Powles TB, Bhardwa J, Shamash J, et al. The changing presentation of germ cell tumours of the testis between 1983 and 2002. *BJU Int*. 2005;95:1197–1200.

Puc HS, Heelan R, Mazumdar M, et al. Management of residual mass in advanced seminoma: results and recommendations from the Memorial Sloan-Kettering Cancer Center. *J Clin Oncol*. 1996;14:454–460.

Purdue MP, Engel LS, Langseth H, et al. Prediagnostic serum concentrations of organochlorine compounds and risk of testicular germ cell tumors. *Environ Health Perspect*. 2009;117:1514–1519.

Rabbani F, Sheinfeld J, Farivar-Mohseni H, et al. Low-volume nodal metastases detected at retroperitoneal lymphadenectomy for testicular cancer: pattern and prognostic factors for relapse. *J Clin Oncol*. 2001;19:2020–2025.

Raina V, Singh SP, Kamble N, et al. Brain metastasis as the site of relapse in germ cell tumor of testis. *Cancer*. 1993;72:2182–2185.

Rajpert-de Meyts E, Hoei-Hansen CE. From gonocytes to testicular cancer: the role of impaired gonadal development. *Ann N Y Acad Sci*. 2007;1120:168–180.

Ravi R, Ong J, Oliver RT, et al. The management of residual masses after chemotherapy in metastatic seminoma. *BJU Int*. 1999;83:649–653.

Rayson D, Burch PA, Richardson RL. Sarcoidosis and testicular carcinoma. *Cancer*. 1998;83:337–343.

Read G, Stenning SP, Cullen MH, et al. Medical Research Council prospective study of surveillance for stage I testicular teratoma. Medical Research Council Testicular Tumors

Working Party. *J Clin Oncol*. 1992;10:1762–1768.

Recabal P, Rosenzweig B, Bazzi WM, et al. Malignant mesothelioma of the tunica vaginalis testis: outcomes following surgical management beyond radical orchiectomy. *Urology*. 2017;107:166–170.

Reiter WJ, Brodowicz T, Alavi S, et al. Twelve-year experience with two courses of adjuvant single-agent carboplatin therapy for clinical stage I seminoma. *J Clin Oncol*. 2001;19:101–104.

Rice KR, Beck SD, Bihrle R, et al. Survival analysis of pure seminoma at post-chemotherapy retroperitoneal lymph node dissection. *J Urol*. 2014;192:1397–1402.

Rice KR, Beck SD, Pedrosa JA, et al. Surgical management of late relapse on surveillance in patients presenting with clinical stage I testicular cancer. *Urology*. 2014;84:886–890.

Rice KR, Magers MJ, Beck SD, et al. Management of germ cell tumors with somatic type malignancy: pathological features, prognostic factors and survival outcomes. *J Urol*. 2014;192:1403–1409.

Richiardi L, Akre O, Montgomery SM, et al. Fecundity and twinning rates as measures of fertility before diagnosis of germ-cell testicular cancer. *J Natl Cancer Inst*. 2004;96:145–147.

Richiardi L, Scelo G, Boffetta P, et al. Second malignancies among survivors of germ-cell testicular cancer: a pooled analysis between 13 cancer registries. *Int J Cancer*. 2007;120:623–631.

Richie JP. Clinical stage 1 testicular cancer: the role of modified retroperitoneal lymphadenectomy. *J Urol*. 1990;144:1160–1163.

Richie JP, Kantoff PW. Is adjuvant chemotherapy necessary for patients with stage B1 testicular cancer? *J Clin Oncol*. 1991;9:1393–1396.

Rodriguez D, Barrisford GW, Sanchez A, et al. Primary spermatic cord tumors: disease characteristics, prognostic factors, and treatment outcomes. *Urol Oncol*. 2014;32:52.e19–52.e25.

Roeleveld TA, Horenblas S, Meinhardt W, et al. Surveillance can be the standard of care for stage I nonseminomatous testicular tumors and even high risk patients. *J Urol*. 2001;166:2166–2170.

Ronnen EA, Kondagunta GV, Bacik J, et al. Incidence of late-relapse germ cell tumor and outcome to salvage chemotherapy. *J Clin Oncol*. 2005;23:6999–7004.

Rosen A, Jayram G, Drazer M, et al. Global trends in testicular cancer incidence and mortality. *Eur Urol*. 2011;60:374–379.

Rossen PB, Pedersen AF, Zachariae R, et al. Health-related quality of life in long-term survivors of testicular cancer. *J Clin Oncol*. 2009;27:5993–5999.

Rustin GJ, Mead GM, Stenning SP, et al. Randomized trial of two or five computed tomography scans in the surveillance of patients with stage I nonseminomatous germ cell tumors of the testis: Medical Research Council Trial TE08, ISRCTN56475197–the National Cancer Research Institute Testis Cancer Clinical Studies Group. *J Clin Oncol*. 2007;25:1310–1315.

Salvati M, Piccirilli M, Raco A, et al. Brain metastasis from non-seminomatous germ cell tumors of the testis: indications for aggressive treatment. *Neurosurg Rev*. 2006;29:130–137.

Sarkaria IS, Bains MS, Sood S, et al. Resection of primary mediastinal non-seminomatous germ cell tumors: a 28-year experience at Memorial Sloan-Kettering Cancer Center. *J Thorac Oncol*. 2011;6:1236–1241.

Saxman SB, Nichols CR, Foster RS, et al. The management of patients with clinical stage I nonseminomatous testicular tumors and persistently elevated serologic markers. *J Urol*.

1996;155:587–589.

Saxman SB, Finch D, Gonin R, et al. Long-term follow-up of a phase III study of three versus four cycles of bleomycin, etoposide, and cisplatin in favorable-prognosis germ-cell tumors: the Indian University experience. *J Clin Oncol*. 1998;16:702–706.

Schmelz HU, Port M, Stockinger M, et al. Testis cancer cells have a genetic determination for a high sensitivity to apoptosis inducing stimuli. *Urol Oncol*. 2010;28:49–58.

Scholz M, Zehender M, Thalmann GN, et al. Extragonadal retroperitoneal germ cell tumor: evidence of origin in the testis. *Ann Oncol*. 2002;13:121–124.

Schwarzman MI, Russo P, Bosl GJ, et al. Hormone-secreting metastatic interstitial cell tumor of the testis. *J Urol*. 1989;141:620–622.

Scully RE. Gonadoblastoma. A review of 74 cases. *Cancer*. 1970;25:1340–1356.

Sella A, el Naggar A, Ro JY, et al. Evidence of malignant features in histologically mature teratoma. *J Urol*. 1991;146:1025–1028.

Shahidi M, Norman AR, Dearnaley DP, et al. Late recurrence in 1263 men with testicular germ cell tumors. Multivariate analysis of risk factors and implications for management. *Cancer*. 2002;95:520–530.

Shanmugalingam T, Soultati A, Chowdhury S, et al. Global incidence and outcome of testicular cancer. *Clin Epidemiol*. 2013;5:417–427.

Sharir S, Jewett MA, Sturgeon JF, et al. Progression detection of stage I nonseminomatous testis cancer on surveillance: implications for the followup protocol. *J Urol*. 1999;161:472–475 [discussion 475–476].

Sharp DS, Carver BS, Eggener SE, et al. Clinical outcome and predictors of survival in late relapse of germ cell tumor. *J*

Clin Oncol. 2008;26:5524–5529.

Sheikine Y, Genega E, Melamed J, et al. Molecular genetics of testicular germ cell tumors. *Am J Cancer Res*. 2012;2:153–167.

Sheinfeld J. Nonseminomatous germ cell tumors of the testis: current concepts and controversies. *Urology*. 1994;44:2–14.

Sheinfeld J. Risks of the uncontrolled retroperitoneum. *Ann Surg Oncol*. 2003;10:100–101.

Sheinfeld J, Motzer RJ. Stage I testicular cancer management and necessity for surgical expertise. *J Clin Oncol*. 2008;26:2934–2936.

Sheinfeld J, Motzer RJ, Rabbani F, et al. Incidence and clinical outcome of patients with teratoma in the retroperitoneum following primary retroperitoneal lymph node dissection for clinical stages I and IIA nonseminomatous germ cell tumors. *J Urol*. 2003;170:1159–1162.

Shilo Y, Zisman A, Lindner A, et al. The predominance of benign histology in small testicular masses. *Urol Oncol*. 2012;30:719–722.

Siegel RL, Miller KD, Jemal A. Cancer statistics, 2018. *CA Cancer J Clin*. 2018;68:7–30.

Silberstein JL, Bazzi WM, Vertosick E, et al. Clinical outcomes of local and metastatic testicular sex cord-stromal tumors. *J Urol*. 2014;192:415–419.

Skakkebaek NE, Berthelsen JG, Muller J. Carcinoma-in-situ of the undescended testis. *Urol Clin North Am*. 1982;9:377–385.

Socinski MA, Garnick MB, Stomper PC, et al. Stage II nonseminomatous germ cell tumors of the testis: an analysis of treatment options in patients with low volume retroperitoneal disease. *J Urol*. 1988;140:1437–1441.

Sogani PC, Perrotti M, Herr HW, et al. Clinical stage I testis cancer: long-term outcome of patients on surveillance. *J Urol*. 1998;159:855–858.

Sonne SB, Kristensen DM, Novotny GW, et al. Testicular dysgenesis syndrome and the origin of carcinoma in situ testis. *Int J Androl*. 2008;31:275–287.

Sonne SB, Almstrup K, Dalgaard M, et al. Analysis of gene expression profiles of microdissected cell populations indicates that testicular carcinoma in situ is an arrested gonocyte. *Cancer Res*. 2009;69:5241–5250.

Sonneveld DJ, Sleijfer DT, Koops HS, et al. Mature teratoma identified after postchemotherapy surgery in patients with disseminated nonseminomatous testicular germ cell tumors: a plea for an aggressive surgical approach. *Cancer*. 1998;82:1343–1351.

Sonneveld DJ, Sleijfer DT, Schrafford Koops H, et al. Familial testicular cancer in a single-centre population. *Eur J Cancer*. 1999;35:1368–1373.

Spears WT, Morphis JG 2nd, Lester SG, et al. Brain metastases and testicular tumors: long-term survival. *Int J Radiat Oncol Biol Phys*. 1992;22:17–22.

Spiess PE, Brown GA, Liu P, et al. Predictors of outcome in patients undergoing postchemotherapy retroperitoneal lymph node dissection for testicular cancer. *Cancer*. 2006;107:1483–1490.

Spiess PE, Brown GA, Pisters LL, et al. Viable malignant germ cell tumor in the postchemotherapy retroperitoneal lymph node dissection specimen: can it be predicted using clinical parameters? *Cancer*. 2006;107:1503–1510.

Spiess PE, Kassouf W, Brown GA, et al. Surgical management of growing teratoma syndrome: the M. D. Anderson cancer center experience. *J Urol*. 2007;177:1330–1334 [discussion 1334].

Steiner H, Holtl L, Wirtenberger W, et al. Long-term experience with carboplatin monotherapy for clinical stage I seminoma: a retrospective single-center study. *Urology*. 2002;60:324–

328.

Stenning SP, Parkinson MC, Fisher C, et al. Postchemotherapy residual masses in germ cell tumor patients: content, clinical features, and prognosis. Medical Research Council Testicular Tumour Working Party. *Cancer*. 1998;83:1409–1419.

Stephenson AJ, Russo P, Kaplinsky R, et al. Impact of unnecessary exploratory laparotomy on the treatment of patients with metastatic germ cell tumor. *J Urol*. 2004;171:1474–1477.

Stephenson AJ, Bosl GJ, Bajorin DF, et al. Retroperitoneal lymph node dissection in patients with low stage testicular cancer with embryonal carcinoma predominance and/or lymphovascular invasion. *J Urol*. 2005;174:557–560.

Stephenson AJ, Bosl GJ, Motzer RJ, et al. Retroperitoneal lymph node dissection for nonseminomatous germ cell testicular cancer: impact of patient selection factors on outcome. *J Clin Oncol*. 2005;23:2781–2788.

Stephenson AJ, Bosl GJ, Motzer RJ, et al. Nonrandomized comparison of primary chemotherapy and retroperitoneal lymph node dissection for clinical stage IIA and IIB nonseminomatous germ cell testicular cancer. *J Clin Oncol*. 2007;25:5597–5602.

Stephenson AJ, Aprikian AG, Gilligan TD, et al. Management of low-stage nonseminomatous germ cell tumors of testis: SIU/ICUD Consensus Meeting on Germ Cell Tumors (GCT), Shanghai 2009. *Urology*. 2011;78(4 Suppl):S444–S455.

Stevenson SM, Lowrance WT. Epidemiology and diagnosis of testis cancer. *Urol Clin North Am*. 2015;42:269–275.

Steyerberg EW, Keizer HJ, Fossa SD, et al. Prediction of residual retroperitoneal mass histology after chemotherapy for metastatic nonseminomatous germ cell tumor: multivariate analysis of individual patient data from six study groups. *J Clin Oncol*. 1995;13:1177–1187.

Steyerberg EW, Keizer HJ, Messemer JE, et al. Residual pulmonary masses after chemotherapy for metastatic nonseminomatous germ cell tumor. Prediction of histology. ReHiT Study Group. *Cancer*. 1997;79:345–355.

Steyerberg EW, Gerl A, Fossa SD, et al. Validity of predictions of residual retroperitoneal mass histology in nonseminomatous testicular cancer. *J Clin Oncol*. 1998;16:269–274.

Stomper PC, Kalish LA, Garnick MB, et al. CT and pathologic predictive features of residual mass histologic findings after chemotherapy for nonseminomatous germ cell tumors: can residual malignancy or teratoma be excluded? *Radiology*. 1991;180:711–714.

Sturgeon JF, Moore MJ, Kakiashvili DM, et al. Non-risk-adapted surveillance in clinical stage I nonseminomatous germ cell tumors: the Princess Margaret Hospital's experience. *Eur Urol*. 2011;59:556–562.

Subramanian VS, Nguyen CT, Stephenson AJ, et al. Complications of open primary and post-chemotherapy retroperitoneal lymph node dissection for testicular cancer. *Urol Oncol*. 2010;28:504–509.

Suzumura S, Ioka A, Nakayama T, et al. Hospital procedure volume and prognosis with respect to testicular cancer patients: a population-based study in Osaka, Japan. *Cancer Sci*. 2008;99:2260–2263.

Sweeney CJ, Hermans BP, Heilman DK, et al. Results and outcome of retroperitoneal lymph node dissection for clinical stage I embryonal carcinoma–predominant testis cancer. *J Clin Oncol*. 2000;18:358–362.

Tandstad T, Dahl O, Cohn-Cedermark G, et al. Risk-adapted treatment in clinical stage I nonseminomatous germ cell testicular cancer: the SWENOTECA management program. *J Clin Oncol*. 2009;27:2122–2128.

Tandstad T, Cohn-Cedermark G, Dahl O, et al. Long-term follow-up after risk-adapted treatment in clinical stage 1 (CS1) nonseminomatous germ-cell testicular cancer (NSGCT) implementing adjuvant CVB chemotherapy. A SWENOTECA study. *Ann Oncol*. 2010;21:1858–1863.

Tandstad T, Smaaland R, Solberg A, et al. Management of seminomatous testicular cancer: a binational prospective population-based study from the Swedish norwegian testicular cancer study group. *J Clin Oncol*. 2011;29:719–725.

Tandstad T, Stahl O, Dahl O, et al. Treatment of stage I seminoma, with one course of adjuvant carboplatin or surveillance, risk-adapted recommendations implementing patient autonomy: a report from the Swedish and Norwegian Testicular Cancer Group (SWENOTECA). *Ann Oncol*. 2016;27:1299–1304.

Tarin TV, Sonn G, Shinghal R. Estimating the risk of cancer associated with imaging related radiation during surveillance for stage I testicular cancer using computerized tomography. *J Urol*. 2009;181:627–632 [discussion 632–633].

Tiffany P, Morse MJ, Bosl G, et al. Sequential excision of residual thoracic and retroperitoneal masses after chemotherapy for stage III germ cell tumors. *Cancer*. 1986;57:978–983.

Tinkle LL, Graham BS, Spillane TJ, et al. Testicular choriocarcinoma metastatic to the skin: an additional case and literature review. *Cutis*. 2001;67:117–120.

Tjan-Heijnen VC, Vlasveld LT, Pernet FP, et al. Coincidence of seminoma and sarcoidosis: a myth or fact? *Ann Oncol*. 1998;9:321–325.

Tognoni PG, Foster RS, McGraw P, et al. Combined post-chemotherapy retroperitoneal lymph node dissection and resection of chest tumor under the same anesthetic is appropriate based on morbidity and tumor pathology. *J Urol*. 1998;159:1833–1835.

Tokuc R, Sakr W, Pontes JE, et al. Accuracy of frozen section examination of testicular tumors. *Urology*. 1992;40:512–516.

Toner GC, Panicek DM, Heelan RT, et al. Adjunctive surgery after chemotherapy for nonseminomatous germ cell tumors: recommendations for patient selection. *J Clin Oncol*. 1990;8:1683–1694.

Toner GC, Stockler MR, Boyer MJ, et al. Comparison of two standard chemotherapy regimens for good-prognosis germ-cell tumours: a randomised trial. Australian and New Zealand Germ Cell Trial Group. *Lancet*. 2001;357:739–745.

Trabert B, Chen J, Devesa SS, et al. International patterns and trends in testicular cancer incidence, overall and by histologic subtype, 1973-2007. *Andrology*. 2015;3:4–12.

Travis LB, Fossa SD, Schonfeld SJ, et al. Second cancers among 40,576 testicular cancer patients: focus on long-term survivors. *J Natl Cancer Inst*. 2005;97:1354–1365.

Turnbull C, Rahman N. Genome-wide association studies provide new insights into the genetic basis of testicular germ-cell tumour. *Int J Androl*. 2011;34:e86–e96 [discussion e96–e97].

Ulbright TM. Germ cell tumors of the gonads: a selective review emphasizing problems in differential diagnosis, newly appreciated, and controversial issues. *Mod Pathol*. 2005;18(Suppl 2):S61–S79.

Ulbright TM, Young RH. Metastatic carcinoma to the testis: a clinicopathologic analysis of 26 nonincidental cases with emphasis on deceptive features. *Am J Surg Pathol*. 2008;32:1683–1693.

Ulbright TM, Young RH. Testicular and paratesticular tumors and tumor-like lesions in the first 2 decades. *Semin Diagn Pathol*. 2014;31:323–381.

Ulbright TM. Testicular and paratesticular tumors. Mills SE, Greenson JK, Oberman HA, et al. *Sternberg's diagnostic surgical pathology*. ed 4. Lippincott, Williams and Wilkins: Philadelphia; 2004:2168–2190.

van de Wetering RAW, Sleijfer S, Feldman DR, et al. Controversies in the management of clinical stage I seminoma: carboplatin a decade in-time to start backing out. *J Clin Oncol*. 2018;36:837–840.

van den Belt-Dusebout AW, de Wit R, Gietema JA, et al. Treatment-specific risks of second malignancies and cardiovascular disease in 5-year survivors of testicular cancer. *J Clin Oncol*. 2007;25:4370–4378.

van Dijk MR, Steyerberg EW, Habbema JD. Survival of non-seminomatous germ cell cancer patients according to the IGCC classification: an update based on meta-analysis. *Eur J Cancer*. 2006;42:820–826.

Veenstra CM, Vaughn DJ. Third-line chemotherapy and novel agents for metastatic germ cell tumors. *Hematol Oncol Clin North Am*. 2011;25:577–591.

Vergouwe Y, Steyerberg EW, Foster RS, et al. Validation of a prediction model and its predictors for the histology of residual masses in nonseminomatous testicular cancer. *J Urol*. 2001;165:84–88 [discussion 88].

Vergouwe Y, Steyerberg EW, Eijkemans MJ, et al. Predictors of occult metastasis in clinical stage I nonseminoma: a systematic review. *J Clin Oncol*. 2003;21:4092–4099.

Verhoeven R, Houterman S, Kiemeney B, et al. Testicular cancer: marked birth cohort effects on incidence and a decline in mortality in southern Netherlands since 1970. *Int J Cancer*. 2008;122:639–642.

Vogelzang NJ, Fraley EE, Lange PH, et al. Stage II nonseminomatous testicular cancer: a 10-year experience. *J Clin Oncol*. 1983;1:171–178.

von der Maase H, Specht L, Jacobsen GK, et al. Surveillance following orchidectomy for stage I seminoma of the testis. *Eur J Cancer*. 1993;29A:1931–1934.

von Eyben FE, Jacobsen GK, Rorth M, et al. Microinvasive germ cell tumour (MGCT) adjacent to testicular germ cell tumours. *Histopathology*. 2004;44:547–554.

Vuky J, Tickoo SK, Sheinfeld J, et al. Salvage chemotherapy for patients with advanced pure seminoma. *J Clin Oncol*. 2002;20:297–301.

Warde P, Gospodarowicz MK, Panzarella T, et al. Stage I testicular seminoma: results of adjuvant irradiation and surveillance. *J Clin Oncol*. 1995;13:2255–2262.

Warde P, Specht L, Horwich A, et al. Prognostic factors for relapse in stage I seminoma managed by surveillance: a pooled analysis. *J Clin Oncol*. 2002;20:4448–4452.

Warde P, Gospodarowicz M, Panzarella T, et al. Outcome in stage I seminoma managed by radiation therapy and surveillance. *J Urol*. 2005;4(Suppl):196 [abstract 719].

Weiner AB, Pearce SM, Eggener SE. Management trends for men with early-stage nonseminomatous germ cell tumors of the testicle: an analysis of the National Cancer Database. *Cancer*. 2017;123:245–252.

Weissbach L, Bussar-Maatz R, Flechtner H, et al. RPLND or primary chemotherapy in clinical stage IIA/B nonseminomatous germ cell tumors? Results of a prospective multicenter trial including quality of life assessment. *Eur Urol*. 2000;37:582–594.

Westergaard T, Olsen JH, Frisch M, et al. Cancer risk in fathers and brothers of testicular cancer patients in Denmark. A population-based study. *Int J Cancer*. 1996;66:627–631.

Wetherell D, Lawrentschuk N, Gyomber D. Spermatocytic seminoma with sarcoma: an indication for adjuvant chemotherapy in localized disease. *Korean J Urol*.

2013;54:884–887.

Williams DH, Karpman E, Sander JC, et al. Pretreatment semen parameters in men with cancer. *J Urol*. 2009;181:736–740.

Williams SB, McDermott DW, Dock W, et al. Retroperitoneal lymph node dissection in patients with high risk testicular cancer. *J Urol*. 2009;181:2097–2101 [discussion 2101–2102].

Williams SD, Birch R, Einhorn LH, et al. Treatment of disseminated germ-cell tumors with cisplatin, bleomycin, and either vinblastine or etoposide. *N Engl J Med*. 1987;316:1435–1440.

Williams SD, Stablein DM, Einhorn LH, et al. Immediate adjuvant chemotherapy versus observation with treatment at relapse in pathological stage II testicular cancer. *N Engl J Med*. 1987;317:1433–1438.

Williamson SR, Delahunt B, Magi-Galluzzi C, et al. The World Health Organization 2016 classification of testicular germ cell tumours: a review and update from the International Society of Urological Pathology Testis Consultation Panel. *Histopathology*. 2017;70:335–346.

Wood DP Jr, Herr HW, Motzer RJ, et al. Surgical resection of solitary metastases after chemotherapy in patients with nonseminomatous germ cell tumors and elevated serum tumor markers. *Cancer*. 1992;70:2354–2357.

Wood HM, Elder JS. Cryptorchidism and testicular cancer: separating fact from fiction. *J Urol*. 2009;181:452–461.

Xing JS, Bai ZM. Is testicular dysgenesis syndrome a genetic, endocrine, or environmental disease, or an unexplained reproductive disorder? *Life Sci*. 2018;194:120–129.

Ye H, Ulbright TM. Difficult differential diagnoses in testicular pathology. *Arch Pathol Lab Med*. 2012;136:435–446.

Yokoi K, Tanaka N, Furukawa K, et al. Male choriocarcinoma with metastasis to the jejunum: a case report and review of the literature. *J Nippon Med Sch*. 2008;75:116–121.

Zagars GK, Pollack A. Radiotherapy for stage II testicular seminoma. *Int J Radiat Oncol Biol Phys*. 2001;51:643–649.

Zagars GK, Ballo MT, Lee AK, et al. Mortality after cure of testicular seminoma. *J Clin Oncol*. 2004;22:640–647.

Znaor A, Lortet-Tieulent J, Jemal A, et al. International variations and trends in testicular cancer incidence and mortality. *Eur Urol*. 2014;65:1095–1106.

Zuniga A, Kakiashvili D, Jewett MA. Surveillance in stage I nonseminomatous germ cell tumours of the testis. *BJU Int*. 2009;104:1351–1356.

77

Surgery of Testicular Tumors

Stephen Riggs MD, Kris Gaston MD, Peter E. Clark MD

Testicular cancer is a model of success in the treatment of solid tumor malignancies. It is highly chemosensitive in addition to being one of the most surgically curable malignancies. In the modern era, surveillance after orchiectomy for clinical stage I nonseminomatous germ cell tumor (NSGCT) results in cure rates of up to 88% (Daugaar et al., 2014). Patients with low volume pathologic stage II NSCGCT enjoy a 60% to 80% disease-free survival with primary retroperitoneal lymph node dissection (RPLND) alone (Donohue et al., 1993; Stephenson et al., 2007). Even those patients deemed to have refractory disease after primary chemotherapy can achieve durable long-term cure rates of around 45% with various salvage chemotherapy regimens (Petrelli et al., 2017). What is paramount in the treatment of this disease is an active collaboration and multimodal approach that includes surgeons, medical personnel, and radiation oncologists. In this chapter, we describe the management and decision-making process, operative techniques, and outcomes for testicular cancer surgery. This chapter should provide the urologist with a foundation regarding the role of surgery in primary and advanced testicular cancer from orchiectomy, to primary or post-chemotherapy RPLND (PC-RPLND).

Management of Testis Mass

History and Physical Examination, Ultrasonography, and Preorchiectomy Evaluation

Any man with a testicular mass should undergo a prompt and complete evaluation, particularly younger men in the age group most susceptible to testicular cancer. The critical components to that evaluation include a detailed history focused particularly on the growth rate of the lesion and any associated symptoms, a careful physical examination, ultrasound of the scrotal contents, and appropriate serologic studies (Bosl et al., 1981; Honig et al., 1994; Jacobsen et al., 2000; Petersen et al., 1999; Richie, 1993; Robson et al., 1965; Sandeman, 1979; Simon et al., 2001; Thornhill et al., 1987). Because testis cancer is often rapidly progressive, timely diagnosis and management is critical to minimizing the intensity and morbidity of therapy necessary to effect a cure (Chapple et al., 2004; Gascoigne et al., 1999; Oliver, 1985; Moul, 2007; Post and Belis, 1980). The physical examination should include examination of the supraclavicular lymph nodes, the breasts, abdomen, and, in particular, focus on the scrotal contents and characterization of the mass. Although an ultrasound of the testicles is not mandatory, it can more fully characterize the mass and radiographically document its laterality (Goddi et al., 2012; Horstman et al., 1992; Shah et al., 2010). Perhaps the most important role for ultrasound, however, is to document the characteristics of the contralateral testicle, because the incidence of bilateral synchronous testicular masses is approximately 1% of patients (Bokemeyer et al., 1993; Che et al., 2002: Coogan et al., 1998; Fossa et al., 2005; Hentrich et al., 2005; Holzbeierlein et al., 2003; Pamenter et al., 2003). Serum tumor markers should be obtained because these can further bolster the diagnosis of a germ cell tumor, provide important staging information, and will serve as a baseline for follow-up after orchiectomy. Placement of a testicular prosthesis can be considered and should be discussed in advance of surgery (Clifford et al., 2018; Dieckmann et al., 2015; Yossepowitch et al., 2011).

Radical Orchiectomy

In patients in whom a testicular malignancy is suspected, radical

orchiectomy is the diagnostic and therapeutic treatment of choice. The approach is via an inguinal incision, allowing for early control of the spermatic cord and complete removal of the ipsilateral testis, epididymis, and spermatic cord to the level of the internal inguinal ring.

Technique

After adequate anesthesia, the patient is positioned supine on the operating room table. Skin preparation should include at a minimum the abdomen to a level cranial to the umbilicus, inferiorly to the mid-thigh bilaterally, and the genitalia posteriorly to the level of the perineum. The patient should be sterilely draped so that the scrotum, ipsilateral anterior superior iliac spine, and pubic tubercle are all adequately exposed. Examination under anesthesia can typically locate the external inguinal ring, which facilitates identification of the medial-most aspect of the inguinal canal.

A 3- to 5-cm incision is made in a transverse orientation over the inguinal canal following Langer lines. This size incision is typically adequate for delivery of the mass; however, if this is inadequate, the incision can be extended over the scrotum. This can be done in a hockey-stick fashion, or the original incision can be rotated in a more caudally directed orientation aiming toward the scrotum from the outset. The subcutaneous tissues are now separated, exposing the external oblique fascia and external inguinal ring. The external oblique fascia is now incised along the course of the inguinal canal for approximately 4 cm. If needed, self-retaining instruments such as a Weitlaner or Gelpi forceps can be used to aid with exposure. Once the fascia is incised, the ilioinguinal nerve should be prospectively identified and preserved as it courses over the anterior aspect of the spermatic cord within the inguinal canal. Once the nerve is displaced, the spermatic cord can be mobilized at approximately the level of the pubic tubercle and encircled with a Penrose drain. The external spermatic fascia and cremasteric fibers that surround the spermatic cord should be divided and traction applied to deliver the testicle/testicular mass superiorly into the incision. This can be facilitated by upward pressure on the ipsilateral hemiscrotum. With the testicle/testicular mass delivered into the operative field the gubernaculum is divided and the spermatic cord dissected superiorly to the level of the peritoneal reflection at the internal inguinal ring. The vas deferens should be separated from the remainder of the gonadal vessels at this level, and both structures should be ligated and divided separately. Nonabsorbable sutures are preferred for ligation with a 1- to 2-cm suture tail to facilitate later identification and excision of the gonadal vessel stump during RPLND. Some surgeons make a specific effort to drop the ligated stump of the spermatic cord into the preperitoneal space deep to the internal inguinal ring to facilitate subsequent dissection at the time of RPLND. Separating the vas deferens from the remaining gonadal vessels is also helpful in this regard because the vas deferens does not have to be removed at the time of RPLND.

After the spermatic cord has been divided, the wound is irrigated and carefully inspected for hemostasis. The ilioinguinal nerve should be positioned safely in the bed of the inguinal canal and external oblique aponeurosis then reapproximated. The subcutaneous tissues should be closed in one to two layers followed by skin closure. Sterile dressings are then applied and often a scrotal support with fluff dressings is added, which aids in reducing scrotal swelling and hematoma formation for the first 2 to 3 days postoperatively.

Partial Orchiectomy

With the success of therapy for testis cancer and the high probability of long-term survival there has been increasing focus on minimizing long-term treatment related side effects while not compromising treatment efficacy (Carmignani et al., 2004; Haas et al., 1986; Jacobsen et al., 1981; Klein et al., 1985; Kressel et al., 1988; Robertson, 1995; Skakkebaek, 1975). **In highly select patients, partial orchiectomy can be considered in cases in which the tumor is polar, measures 2 cm or less, and in which the contralateral testicle is compromised or absent.** If the malignant nature of a testicular mass is not clear, an inguinal exploration with early control of the spermatic cord and excisional biopsy with or without frozen section analysis can be performed. However, this should only be considered in patients for whom the risks of being anorchic outweigh the risks of increased local tumor recurrence. In general, for patients with a normal contralateral testicle attempts at elective testis-sparing surgery should not be made.

Technique

The initial approach to a partial orchiectomy is identical to a radical operation. Once the testicle/testicular mass is delivered into the operative field, the testicle should be isolated from the wound with sterile towels. Intraoperative ultrasonography can be used if necessary to localize the mass. The potential need for hypothermia has been raised by some investigators but can likely be omitted as long as resection times are minimized to less than 30 minutes (Giannarini et al., 2010). After the mass is localized, the tunica albuginea is sharply incised with a scalpel. The approach will vary depending on the mass's location. A vertical incision along the long axis of the testicle is generally preferred for an approach from the ventral midline, whereas incisions medial or lateral to the ventral midline ideally should be oriented horizontally, minimizing injury to the segmental arteries that course just deep to the tunica albuginea.

The mass should then be excised, ideally including a small rim of normal seminiferous tubules to facilitate a negative surgical margin. There is some debate on how to manage the remnant testicle if a germ cell tumor (GCT) is confirmed and the surrounding parenchyma demonstrates intratubular germ cell neoplasia. Many advocate proceeding to radical orchiectomy with these findings, whereas others would recommend only routine adjuvant radiation therapy to the remnant testicle to reduce the risk of local recurrence. The individual surgeon's assessment of this risk will in part dictate whether a frozen section analysis is done to direct whether to preserve the testicle. If the testicle is preserved, then the tunica albuginea is closed with absorbable sutures and the testicle fixed in the dependent aspect of the scrotum at three points, typically including the gubernaculum and scrotal septum.

Traditionally patients who underwent partial orchiectomy for a histologically confirmed GCT underwent 18 to 20 Gy of adjuvant radiotherapy to reduce the risk of local tumor recurrence (Giannarini et al., 2010; Heidenreich et al., 2001; Krege et al., 2008). Thus in patients with a solitary testicle, the main benefit of organ sparing was the preservation of Leydig cell function because spermatogenesis will be permanently compromised. More recently, however, a small series of 27 men who underwent partial orchiectomy, 17 (63%) of which were shown to have GCT, suggested that select patients can be observed with a low risk of recurrence, even in the face of carcinoma in situ (Lawrentschuk et al., 2011). Thus it may be that, in the future, more patients with partial orchiectomy for GCT may be observed. This is an area that requires more investigation. **What is not debated is that any patient who develops ipsilateral local recurrence of GCT should undergo completion radical orchiectomy regardless of prior adjuvant therapy or residual testicular function.**

Delayed Orchiectomy

The majority of cases of testicular cancer are diagnosed via radical orchiectomy**. However, a minority of cases may present with diffuse metastatic and/or symptomatic GCT that requires early initiation of systemic chemotherapy** (Ondrus et al., 2001)**. In these circumstances, diagnosis may be pursued via biopsy of a metastatic site or even made presumptively based on the clinical features with or without serologic studies. For such cases, a delayed radical orchiectomy is recommended for all patients regardless of response to therapy in the retroperitoneum or elsewhere resulting from the discordant response rates to chemotherapy between the testis and other sites (**Leibovitch et al., 1996; Miller et al., 2013; Ondrus et al., 2001; Simmonds et al. 1995; Snow et al., 1983).

The role of delayed orchiectomy for patients with an apparent retroperitoneal/extragonadal primary GCT is more controversial. Studies have biopsied the testicle in such patients and demonstrated intratubular germ cell neoplasia in up to 42% (Daugaard et al., 1992). If such patients are observed after chemotherapy, there is approximately a 5% rate of metachronous testicular cancer during follow-up (Hartmann et al., 2001). **For patients in whom the retroperitoneal disease lateralizes with a distribution strongly suggestive of a testicular primary, a radical orchiectomy on that side has been advocated.** This is based at least in part on a small cohort series of patients with presumed extragonadal GCT who underwent delayed orchiectomy after completing chemotherapy (Brown et al., 2008); 71% of the specimens demonstrated histologic evidence of teratoma or necrotic tissue suggestive of a “burned-out primary” or a complete response to therapy. Should observation be chosen for patients with an apparent extragonadal GCT, follow-up should include careful, regular monthly testicular self-examination and regular practitioner physical examination.

Postorchiectomy Evaluation

After orchiectomy, the clinical stage is determined based on the pathologic findings combined with radiographic and serologic studies. Typically contrast-enhanced computed tomography (CT) with intravenous and oral contrast is used to image the retroperitoneum, although in some cases magnetic resonance imaging (MRI) can be an alternative approach. In general, neither fluorodeoxyglucose-labeled positron emission tomography (PET) nor lymphoangiography play an important role in the initial diagnosis and staging of

GCTs. Assessment of serum tumor markers (α-fetoprotein, beta human chorionic gonadotropin, and lactate dehydrogenase) should be repeated after surgery, and the trend in values also aids in guiding subsequent management.

Key Points: Management of the Testis Mass

- Radical orchiectomy, including early control of the spermatic cord and complete removal of the ipsilateral testis, epididymis, and spermatic cord to the level of the internal inguinal ring, is the diagnostic and therapeutic treatment of choice in patients in whom a testicular malignancy is suspected.
- In highly select patients, partial orchiectomy can be considered in cases in which the tumor is polar, measures 2 cm or less, and in which the contralateral testicle is compromised or absent.
- For the rare patient with diffuse metastatic and/or symptomatic GCT requiring early initiation of systemic chemotherapy, diagnosis may be pursued via biopsy of a metastatic site or even made presumptively based on the clinical features and/or serologic studies. For such cases, a delayed radical orchiectomy is recommended for all patients regardless of response to therapy in the retroperitoneum.

Retroperitoneal Lymph Node Dissection

Testicular cancer has a predilection for spread to the retroperitoneal lymph nodes in a predictable fashion. The landing sites for right- or left-sided primary tumors are illustrated in Fig. 77.1 (Beveridge et al., 2016; Donohue et al., 1982; Ray et al., 1974; Weissbach and Boedefeld. 1987). RPLND is an important part of the management of testicular tumors in several clinical settings, which are discussed across this chapter. However, the technical aspects of the surgery are very similar no matter what the disease state. The following is a list of terms used to describe RPLND based on the timing and whether primary systemic therapy has been used.

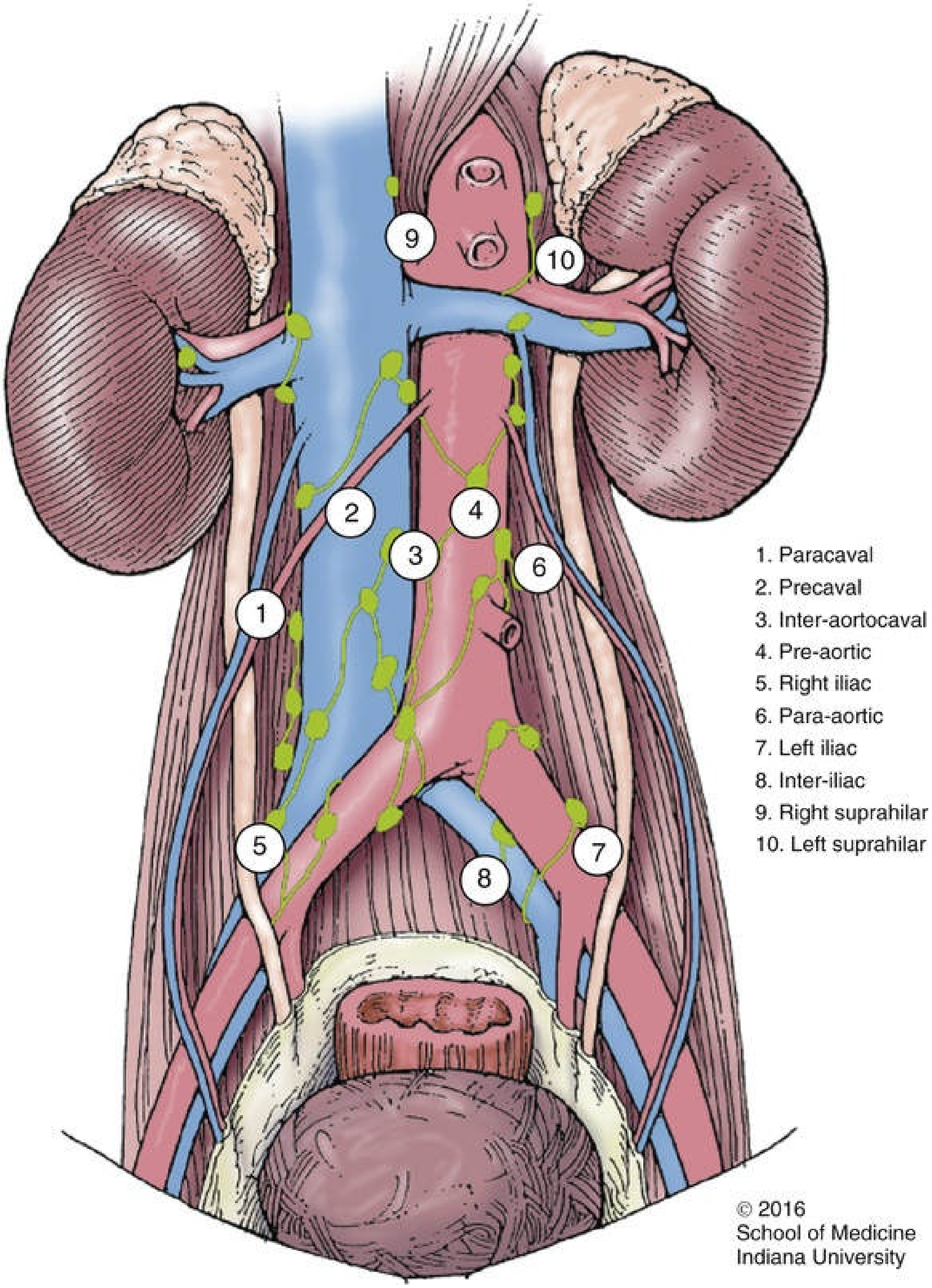
9
10
2
4
3
6
1
5
8
7
1. Paracaval
2. Precaval
3. Inter-aortocaval
4. Pre-aortic
5. Right iliac
6. Para-aortic
7. Left iliac
8. Inter-iliac
9. Right suprahilar
10. Left suprahilar

© 2016
School of Medicine
Indiana University

FIG. 77.1 Retroperitoneal lymph node regions. (Copyright 2016 Section of Medical Illustration in the Office of Visual Media at the Indiana University School of Medicine. Published by Elsevier Inc. All rights reserved.)

- Primary RPLND: After orchiectomy for high-risk clinical stage (CS) 1 or low-volume CS II (N1) NSGCT with normal STMs
- PC-RPLND: Refers to an RPLND performed after induction chemotherapy. Although there remains some debate (see later discussion), this is often performed when there is a residual mass > 1 cm in the retroperitoneum and the STMs post-chemotherapy are normal.
- Salvage PC-RPLND: RPLND performed after both induction and salvage chemotherapy
- Desperation PC-RPLND: RPLND performed after chemotherapy where there is elevated STMs
- Reoperative RPLND: RPLND performed after a prior RPLND
- Resection of late relapse: RPLND performed for relapse of disease > 24 months after a complete response (CR) from primary chemotherapy

Preoperative Planning

The urologic surgeon must review the patient's abdominal CT scan for the location of any retroperitoneal (RP) masses as well as delineating the patient's RP anatomy (e.g., duplicated renal vessels). Careful review of the films helps avoid unplanned intraoperative consultation of other surgical services. We prefer a scan within 6 weeks of surgery and STMs within 7 to 10 days. No preoperative bowel preparation is required. Preoperative sperm banking should be offered and recommended to all patients who desire future paternity. Pulmonary toxicity occurs in approximately 11% of patients who received first-line chemotherapy with bleomycin as compared with 1.7% in those receiving non–bleomycin-based regimens. In addition, the probability of grade 3 or grade 4 toxicity is fivefold higher for those receiving bleomycin (Necchi et al., 2017). **Therefore special attention should be given to these patients. Pulmonary function tests should be obtained preoperatively, and if any deficits are noted, these patients should be referred to a pulmonologist for evaluation before proceeding to surgery. Equally as important, the anesthesia team should be alerted, and this should clearly be communicated to all personnel for pre-, intra-, and postoperative management.** Specific recommendations for intraoperative management include (1) low fraction of inspired oxygen (FiO_2) and (2) conservative fluid replacement. We have found that there is no substitute for direct communication at the time of the surgical time-out to ensure the surgical plan and nuances are understood by all who are involved in the operative team.

Preoperative chest CT should be performed in all patients with prior lung lesions as well as those planning to undergo simultaneous lung resection. In addition, identification of inferior vena cava (IVC) thrombus is important because total occlusion can be managed with resection of the IVC (Beck and Lalka, 1998) and incomplete occlusion with allograft reconstruction as needed.

Surgical Technique

For an open RPLND the patient is placed in the supine position with the arms in a T position slightly below a 90-degree angle. An orogastric tube is almost always adequate for gastric decompression. A midline incision is carried from the level of the xyphoid to a couple of centimeters below the umbilicus. For the more traditional intraperitoneal approach, the peritoneal cavity is entered sharply and the round ligament is divided, and the falciform toward the superior IVC is released to avoid hepatic injury from retraction. More recently an extraperitoneal approach for select patients has been advocated (Kim et al., 2012; Syan-Bhanvadia et al., 2017). For this approach, a similar incision is used with care taken to release the peritoneum from the fascia starting at the infraumbilical portion of the incision. Proponents of the latter approach suggest it offers length of stay (LOS) and earlier return of bowel function.

Exposure of the Retroperitoneum

Once the peritoneum is entered, a self-retaining retractor is placed to aid exposure. An incision is started from the tip of the cecum to the medial aspect of the inferior mesenteric vein (Fig. 77.2, *green dotted line*). If full mobilization of the bowels is desired, followed by placement of the bowels on the chest, then the peritoneal reflection (white line of Toldt) is incised up the ascending colon to the level of the foramen of Winslow (see Fig. 77.2, *right purple dotted line*). In cases with large left-sided tumors, the inferior mesenteric vein can be divided to aid in exposure of the left retroperitoneum (see Fig. 77.2, *left purple dotted line*). If a modified left sided approach is being performed, then the peritoneal reflection (white line of Toldt) of the descending colon is incised.

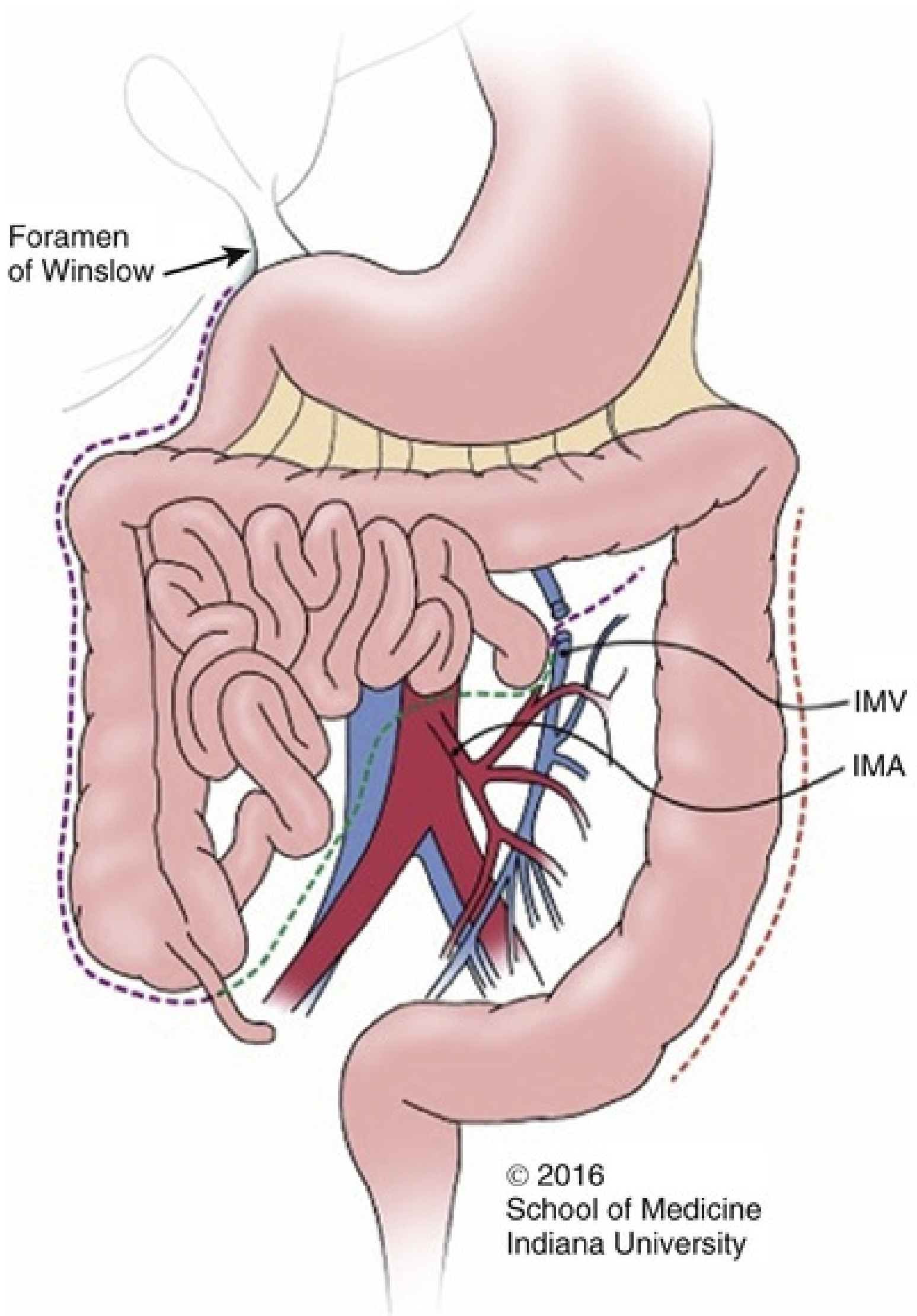

FIG. 77.2 Exposure of the retroperitoneum. *IMA,* Inferior mesenteric artery; *IMV,* inferior mesenteric vein. (Copyright 2016 Section of Medical Illustration in the Office of Visual Media at the Indiana University School of Medicine. Published by Elsevier Inc. All rights reserved.)

The plane between the mesentery and retroperitoneal fat is developed. Identification of the plane may be facilitated by identification of the gonadal vein and ureter and staying anterior to these structures. The duodenum and inferior surface of the pancreas are freed from the anterior surface of the renal vessels, IVC, and aorta. Liberal use of clips in this area helps reduce the chance of a postoperative chylous leak.

Split and Roll Technique (Video 77.1)

We prefer to start over the left renal vein or vena cava at this level in a top-down approach. The cephalad end of the lymphatics at the level of the renal veins should be ligated. Understanding retroperitoneal anatomy and landmarks is crucial, and although we tend to start on the aorta, the size of the mass and ease of dissection often dictates the flow of the case. If the surgeon does come down the aorta, the postganglionic sympathetic nerves should be accounted for on the anterior surface of the aorta in addition to the superior hypogastric plexus. One advantage of starting on the aorta may be the ability to use the postganglionic sympathetic nerves emanating from the right side to identify the superior hypogastric plexus. The goal is to identify this plexus and avoid injury. The split is started at the 12 o'clock position on the aorta just below the left renal vein, and this plane is continued caudally to identify the IMA (Fig. 77.3). In nerve-sparing techniques it is vitally important to identify and preserve the postganglionic nerves at the level of IMA (or sooner) before proceeding caudally.

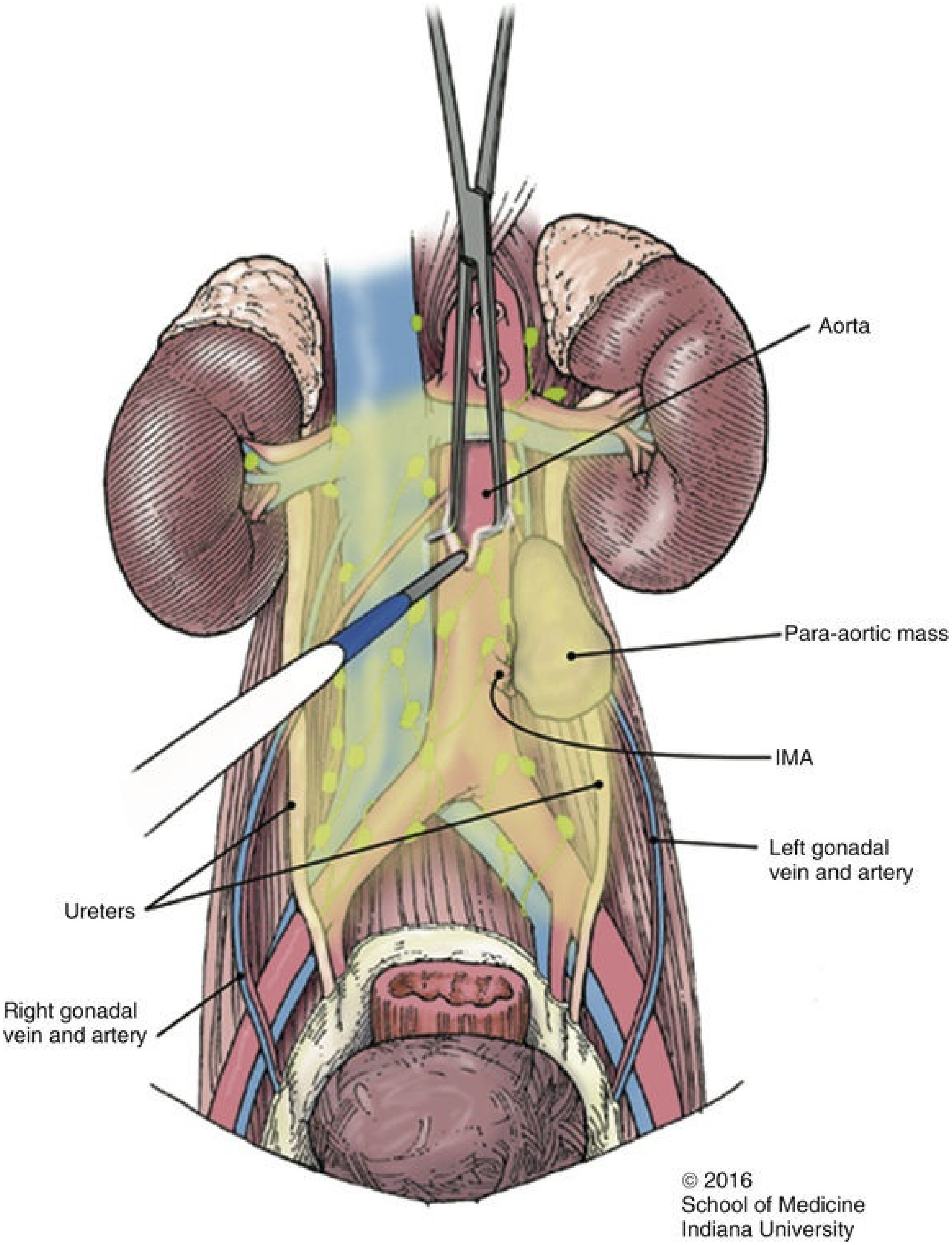
Aorta
Para-aortic mass
IMA
Left gonadal vein and artery
Ureters
Right gonadal vein and artery
© 2016 School of Medicine Indiana University

FIG. 77.3 The split-and-roll technique. *IMA,* Inferior mesenteric artery. (Copyright 2016 Section of Medical Illustration in the Office of Visual Media at the Indiana University School of Medicine. Published by Elsevier Inc. All rights reserved.)

Left Para-Aortic Packet

Dissection of the left para-aortic lymphatic packet in a template dissection is facilitated by rolling the descending colon medially (through division of the white line of Toldt). In a bilateral dissection with the small bowels pushed cephalad or placed on the chest, the dissection moves through the mesenteric root. The left gonadal vein is divided, where it crosses the ureter or it is moved medially. A small retractor can be used to pull the ureter laterally to help avoid injury. The anterior split along the aorta and iliac vessels proceeds caudally to the crossing of the ureter, which will include about one-half of the left common iliac artery. The tissue is then rolled laterally, and the lumbar arteries up to the renal hilum are doubly ligated. There are usually three pairs of lumbar arteries in equal distance from the hilum to the common iliac vessels. Importantly, the second pair usually comes off at the level of the IMA, thus acting as a landmark to facilitate localization (Beveridge et al., 2016).

Interaortocaval Packet

In a right-sided nerve-sparing procedure, the next step is a split-and-roll on the anterior surface of the IVC including ligation of the gonadal vein. If a non–nerve-sparing procedure is performed and if one starts on the aorta first, then the medial side of the aorta can be controlled before proceeding to the IVC side of the dissection. Dissection should proceed caudally along the IVC until the bifurcation of the iliac vessels and then the right common iliac artery is followed up until the crossing of the right ureter is reached. As with the left side, the gonadal vein on the right can be ligated at the level of its crossing of the ureter and the ureter placed gently in a retractor and held laterally to reduce risk of injury. Dissection should now be performed with the goal of controlling the medial and lateral lumbar veins, which are variable in number and location. A clear knowledge of the anatomy during this portion is critical to safety and efficiency as well as to the ability to spare the nerves. Usually there are two or three lumbar veins. A superior right lumbar vein should be looked for just below or posterior to the renal veins. A common lumbar vein is usually centrally located (between superior and inferior lumbar veins) and is the largest tributary. It can often cross under the aorta to the contralateral side, so it may require additional para-aortic ligation. Equally important is the spatial relationship of the IMA, common lumbar vein, and postganglionic sympathetic nerves. The common lumbar vein can usually be found adjacent to the level of the IMA, and the postganglionic parasympathetic nerve (second-infrarenal lumbar splanchnic nerve) usually crosses to the anterior surface of the aorta at this level. It is important therefore that this is prospectively identified and carefully dissected away in a nerve-sparing procedure (Beveridge et al., 2016).

After control of the medial aspect of the IVC, the medial aspect of the aorta is controlled and the tissue is rotated medially in the interaortocaval space. This requires identification and ligation of the three medial lumbar arteries (Fig. 77.4). At this point the anterior and lateral attachments of the desired lymph node packet are fully released. The tissue is now ready to be pulled caudal by release of the lymphatics toward the crus of the diaphragm and anterior spinous ligament in the interaortocaval space at the level of the right renal artery and vein. Care should be taken to ligate the cephalad level of the lymphatics at this point to prevent a postoperative chylous leak. The surgery continues to proceed caudally, exposing the anterior spinous ligament to the level of the left common iliac vein. The surgeon must pay attention to entry and re-entry of lumbar vessels into the body wall as well as clear identification of the right renal artery and any accessory renal arteries.

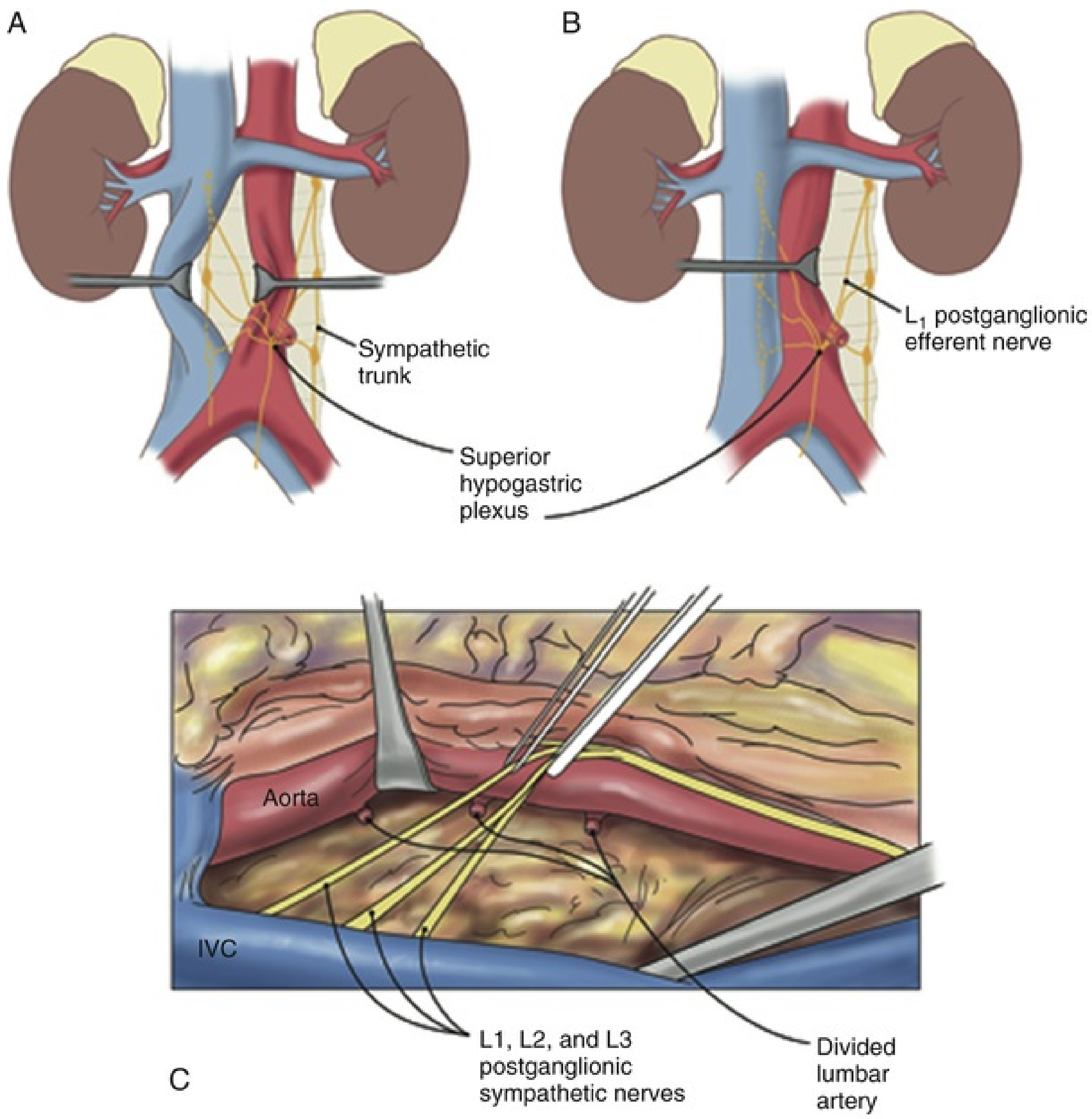
A
B
Sympathetic trunk
Superior hypogastric plexus
L_1 postganglionic efferent nerve
Aorta
IVC
C
L1, L2, and L3 postganglionic sympathetic nerves
Divided lumbar artery

© 2016
School of Medicine
Indiana University

FIG. 77.4 Nerve-sparing technique. (A) Location of right-sided postganglionic sympathetic nerves. (B) Location of left-sided postganglionic sympathetic nerves. (C) Right-sided nerve-sparing technique with ligated lumbar arteries. *IVC,* Inferior vena cava. (Copyright 2016 Section of Medical Illustration in the Office of Visual Media at the Indiana University School of Medicine. Published by Elsevier Inc. All rights reserved.)

Right Paracaval Packet

The right paracaval packet is often the smallest and easiest to remove. If a bilateral dissection is performed in a split and roll maneuver, it is often fruitful to release the packet at the level of the right renal artery to allow it to begin passing medially underneath the vena cava en-bloc with the interaortocaval packet. The packet often tapers down to essentially nothing at the level of the right renal vessels. The packet is then released from the psoas muscle, avoiding injury to the genitofemoral nerve to the level of the right common iliac vessel and ureteral crossing. The urologist must take care to identify the right parasympathetic trunk that usually sits posterior and lateral to the IVC. It is often mistaken for lymphatic tissue or vessels but should be preserved, particularly in a nerve-sparing RPLND.

Gonadal Vein

To remove the residual gonadal vein to the previously removed testicle, the peritoneum overlying it should be incised. In addition, the ureter (which is often previously freed) should be swept off from its posterior location. A left gonadal vein that is identified through the mesentery must be passed under the sigmoid before moving toward the inguinal canal. After mobilization of either vein, gentle traction facilitates resection down to the internal ring, where the suture from the previous orchiectomy should be encountered.

Nerve Sparing

The anatomy of the four postganglionic efferent sympathetic fibers (L1 through L4) involved in antegrade ejaculation are variable. From a surgical perspective some of the nerve fibers are often fused, creating essentially three efferent fibers exiting the right sympathetic chain underneath the IVC as well as three para-aortic fibers exiting the left parasympathetic chain. Both course toward and along the anterior surface of the aorta (Fig. 77.5).

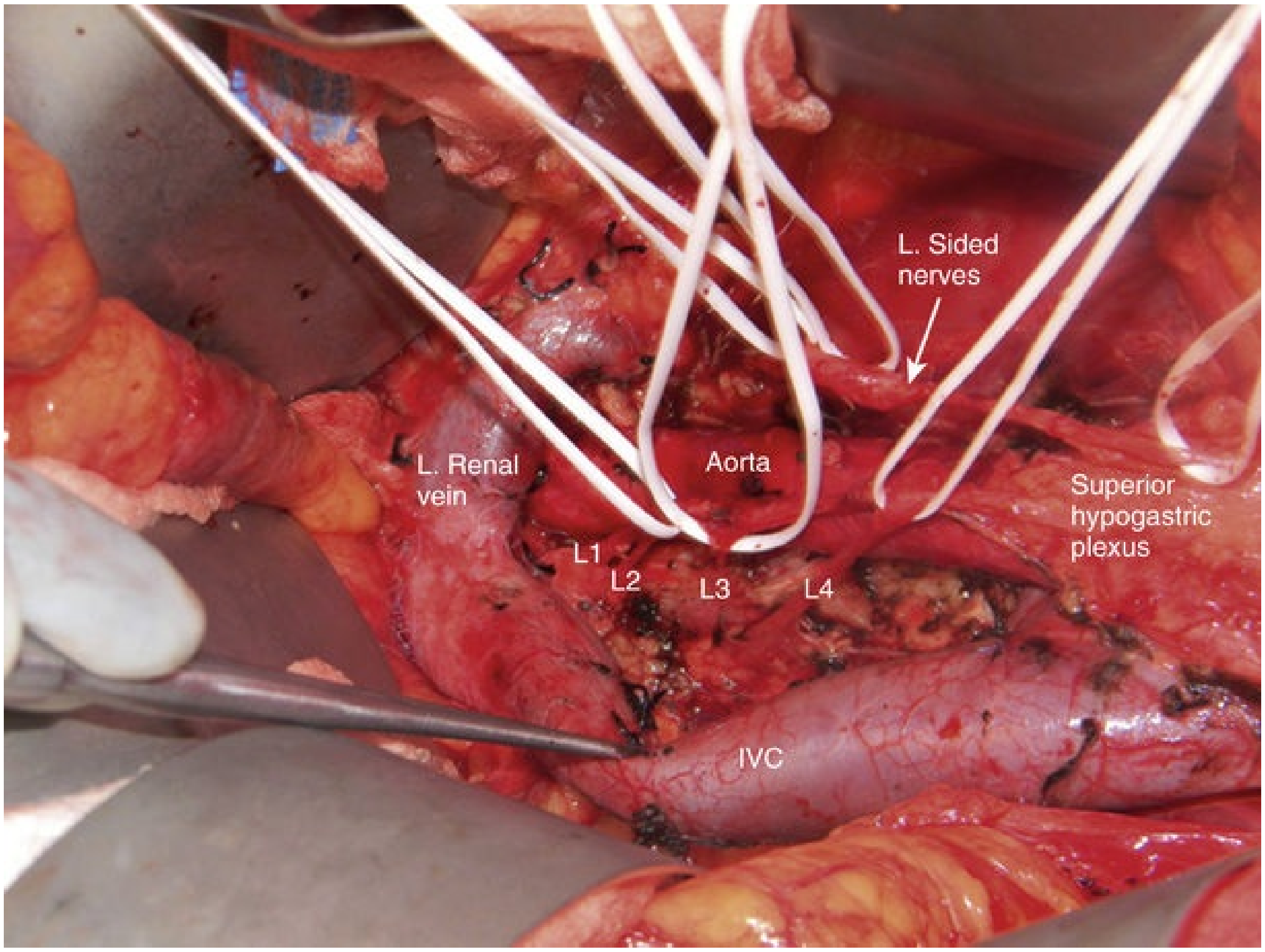

FIG. 77.5 Bilateral nerve-sparing technique. *IVC,* Inferior vena cava; *L.,* left; *L1 through L4,* right-sided postganglionic sympathetic nerves.

The left-sided postganglionic nerves can be identified at the lateral border of the aorta, emanating from underneath the left renal vein, and around the left common iliac artery. The relationship of the nerves posterior to the left renal vein and first lumbar artery are important. In addition, the more inferior nerves usually are located around the left gonadal artery and move toward the IMA (Beveridge et al., 2016). Sharp or blunt dissection helps to sweep the tissue away from these nerves as they course anteriorly on the aorta toward the hypogastric plexus. Fibers can be tagged with vessel loops to facilitate dissection if desired.

Right-sided postganglionic nerve fibers are best identified during dissection of the precaval tissue and medial isolation of the lumbar veins. The postganglionic fibers course from beneath the IVC obliquely toward the superior hypogastric plexus (see Figs. 77.4A and 77.5). Sharp and blunt dissection can facilitate separation from the lymph node packet. Attention should be given to the right superior lumbar vein because the nerve often courses beside this as well as the common lumbar trunk. Care must be taken when ligating these vessels to avoid concomitant injury to the right-sided nerves (Beveridge et al., 2016).

Once all fibers have been isolated the lymph node packet must be sequentially passed around the web of postganglionic fibers as it is released from the body wall. Care must be taken during this portion of the procedure to avoid inadvertent injury.

Closure and Postoperative Care

After completion of the RPLND, the resection bed should be inspected for any residual lymphatic tissue, lymph leak, and hemostasis. Any lymph leaks that are encountered can be clipped or suture ligated with fine suture. Irrigation of the wound with warm irrigation is performed to facilitate identification of any bleeding vessels in spasm. Some advocate reapproximation of the posterior parietal peritoneum to prevent bowel adhesion to the great vessels and retroperitoneum. Consideration can also be given to reapproximation of the root of the mesentery that some feel may decrease the risk of volvulus. No matter how the urologist deals with the peritoneum and root of the mesentery, the bowel should be inspected for inadvertent injury in addition to inspection of the liver, stomach, and pancreas.

We do not routinely leave a surgical drain, but it should be considered in large-volume retroperitoneal, retrocrural, or bowel resection. In these cases, because of the propensity for large-volume third-spacing, a nonsuction drain is left in place and removed when the output has remained serous and less than 100 mL/24 hours on a regular diet.

In the absence of complicating factors, the patients are left without a nasogastric tube and given clear liquids beginning the evening of surgery. The patients are advanced as tolerated to regular low-fat diet through postoperative days 1 and 2. Transition to oral narcotics and use of non-narcotic analgesia (Toradol, Tylenol, gabapentin) is aggressively pursued to reduce narcotic use and ileus. Ambulation is mandatory day 1 along with significant time spent out of bed in a chair. Patients are typically discharged 3 to 5 days after surgery with a target discharge of day 3 depending on their ability to tolerate oral intake and manage their pain. Of course, with any surgery, patients with larger, more complex surgery tend to have a protracted course, and individualization of the postoperative care plan should always trump enhanced any standardized postoperative recovery algorithm.

Auxiliary Procedures

Auxiliary procedures typically occur in the post-chemotherapy setting and should rarely be required during primary RPLND. The incidence of auxiliary procedures at the time of PC-RPLND ranges from 23% to 45% in the literature (Beck et al., 2009; Heidenreich et al., 2009; Winter et al., 2012). **The most common auxiliary procedure is nephrectomy followed by vascular interventions. The larger the volume of the residual retroperitoneal mass, the greater the need for possible auxiliary procedures.**

Nephrectomy

Nephrectomy is the most common auxiliary procedure, ranging from 5% to 31% (Table 77.1). Renal salvage can be an important issue in advanced RPLND cases because of the primary lymphatic drainage of the testes being in the location of the great vessels near the renal hilum**. Left-sided metastatic testes cancer cases particularly put the left kidney at risk because of its primary lymphatic drainage being at the para-aortic/left renal hilum.** Nephrectomy may have a particularly higher risk in settings such as salvage RPLND, desperation RPLND, and reoperative RPLND. The incidence of concomitant nephrectomy in the setting of retroperitoneal node dissection has been decreasing over the last 3 decades. According to a database review at Indiana University from 1980 to 2007, the overall incidence of nephrectomy was 14.8% (Cary et al., 2013). In this review the authors stratified their data finding the incidence from 1980 to 1988 was 17%, 1989 to 1997 was 19%, 1998 to 2002 was 14%, and 2002 to 2007 was 8%. Histologic stratification of the results of RPLND requiring nephrectomy found it was needed in 10% of cases with fibrosis, 15% with teratoma, and 20% for cases with residual viable cancer. Overall the authors found the strongest predictor of nephrectomy was a residual post-chemotherapy retroperitoneal mass greater than 10 cm (OR 9.30, 95% CI 3.8–22.7). These findings were consistent when compared with a privately insured national US cohort of patients who underwent RPLND between 2007 and 2012, in whom the adjunctive nephrectomy rate was 10% (Macleod et al., 2016). Daneshmand et al. reported the University of Southern California experience with RPLND between 2004 and 2010 and found a 14% adjunctive nephrectomy rate (83% of which were on the left vs. 17% right) (Djaladat et al., 2012). Major risk factors for nephrectomy include bulky disease, especially in cases of a left-sided, greater-than-10-cm residual mass post-chemotherapy, salvage RPLND, desperation RPLND, and repeat RPLND. A major concern with nephrectomy is the possible need for adjuvant/salvage platinum–based salvage chemotherapy in the setting of residual/recurrent disease. With patients in this setting potentially receiving 4 to 8 cycles of cisplatin (primary/salvage chemotherapy), nephrectomy can lead to late-stage chronic kidney disease, which may limit options for future systemic therapy. However, because of the typically young age of this patient population, the renal reserve is typically more than adequate to avoid renal replacement therapy.

TABLE 77.1

Risk Factors and Indications for Nephrectomy at Postchemotherapy Retroperitoneal Lymph Node Dissection[a]

STUDY	PATIENTS UNDERGOING NX, N (INCIDENCE %)	TIME PERIOD	INDICATIONS/RISK FACTORS
Macleod et al., 2016	20 (10)	2007–2012	Older age
			Year of surgery
			Comorbidities
Cary et al., 2013	265 (14.8)	1980–1997	RP mass size
			Year of surgery
			Primary tumor site
			Salvage chemotherapy
			Elevated markers
Djaladat et al., 2012	12 (14.1)	2004–2010	Left-sided hilar mass
Heidenreich et al., 2009	7 (4.6)	1999–2007	Encasement of renal vessels/ureter
Stephenson, 2006	32 (5)	1989–2002	Salvage RPLND
			Desperation RPLND
			Redo RPLND
			Late relapse
Nash et al., 1998	162 (19)	1974–1994	Involvement of renal structures
			Venous thrombus
			Poor renal function
			Combination of above

[a] Not all studies performed formal statistical analyses for predictive risk factors because of small

sample size.

Nx, Nephrectomy*; RP,* retroperitoneal; *RPLND,* retroperitoneal lymph node dissection.

Major Vascular Reconstruction

When performing PC-RPLND, surgical planning must always include the need for vascular reconstruction because there can be extensive post-chemotherapy fibrosis involving the great vessels. Unintentional subadventitial aortic injury can lead to life-threatening hemorrhage and possible intraoperative death. Therefore surgical planning for the need for vascular control and possible intervention with vascular replacement is imperative. According to data from the University of Southern California, 15% of patients needed vascular procedures, of which 40% required aortic resection, 30% requiring cavotomy/caval resection, 20% requiring iliac resection, and 10% required renovascular resection with repair (Djaladat et al., 2012). Retrospective data out of a high-volume German Center found that out of 185 patients who underwent PC-RPLND, 16 (8.6%) underwent vascular surgery, including aortic resection and replacement, complete or partial resection of the IVC with thrombectomy, and resection and replacement of the iliac vessels (Heidenreich et al., 2017). With adequate expertise, small vessel wall injuries may be repaired with bovine/porcine pericardial patches/grafts, mitigating the need for bypass or replacement of the vessel. However, if complete vessel resection is required, a polytetrafluoroethylene (PTFE) or Dacron graft can be used (Fig. 77.6).

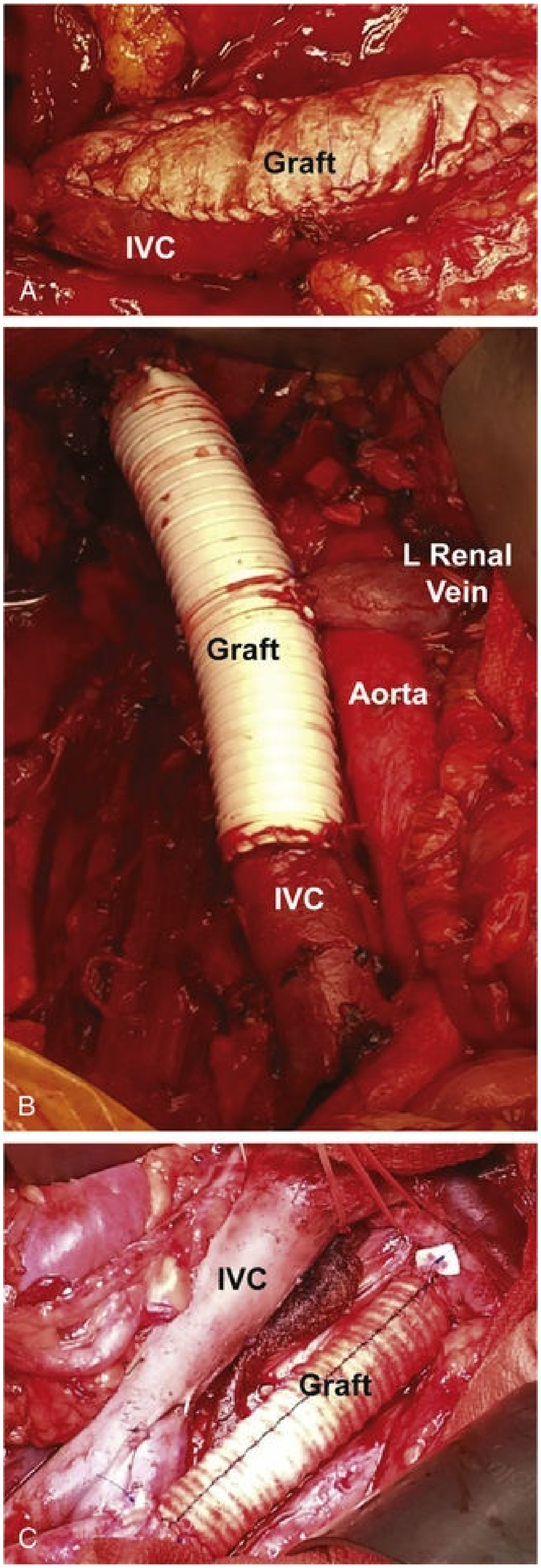
Graft
IVC
A
L Renal Vein
Graft
Aorta
IVC
B
IVC
Graft
C

FIG. 77.6 Examples of vascular reconstruction at the time of PC-RPLND. (A) Autologous patch graft of the inferior vena cava (IVC). (B) Synthetic graft replacing a segment of the IVC with anastomosis of the left renal vein. (C) Synthetic graft replacing a portion of the aorta.

Testes cancer, in addition to displaying post-chemotherapy fibrosis requiring venal caval resection/replacement, can directly invade the wall of the vessel with venous and arterial thrombus formation. According to a database review from Indiana University from 1990 to 2010, about 6% of patients at the time of PC-RPLND have intraluminal thrombus (Johnston et al., 2013). Of these patients, nearly all were involving the vena cava and/or renal vein. However, there was one aortic thrombus that required resection and grafting.

Inferior Vena Cava Resection

Vena caval repair after planned and unplanned venotomy can be performed by interposition bypass replacement, patch venoplasty, or lateral venorrhaphy and primary repair. **When possible, primary repair of the vena cava is preferred because of the low-pressure nature of the IVC with an increased risk of thrombosis compared with the arterial high-pressure system** (see Fig. 77.6). Primary repair can be performed in selected cases in which this does not cause significant venous obstruction from intraluminal narrowing (Mansukhani et al., 2017). Obviously in the unstable patient with life-threatening bleeding, caval ligation or lateral venorrhaphy should be considered. Historically 5% to 10% of PC-RPLND cases require resection of the vena caval wall or entire abdominal vena cava resulting from fibrosis, direct invasion, and/or tumor thrombus. A German experience with post-chemotherapy RPLND identified 30 patients that underwent IVC reconstruction, 23 of which were complete IVC resections with only 4 patients undergoing IVC reconstruction using a PTFE graft. On multivariable analysis, retroperitoneal size and International Germ Cell Consensus Classification Group (IGCCCG) intermediate/poor risk group were associated with the need for an IVC intervention. According to their study, masses greater than 5 cm had a 20% IVC intervention rate compared with only 2.7% for those masses less than 5 cm (Winter et al., 2012). At Indiana University for many years the standard protocol with IVC resection was ligation. Data in 65 patients with IVC resection and ligation found that at long-term follow-up only 1 patient had chronic venous sequelae (Beck and Lalka, 1998). Retrospective data from the University of Southern California identified 47 patients who underwent

IVC reconstruction in which 27 underwent PTFE grafting and the remainder underwent primary repair or patch venoplasty (Quinones-Baldrich et al., 2012). At a mean follow-up of 3½ years only one IVC went on to develop thrombosis. Vena caval repair/reconstruction is safe and effective at reducing lower extremity edema compared with acute ligation; however, there generally also appears to be no significant long-term effects from ligation in this young population. If possible, because of lack of complications and less operative time required, a primary repair or lateral venorrhaphy is preferred if less than 25% narrowing is expected. If more than 25% narrowing is expected, patch venoplasty or interposition graft should be considered (see Fig. 77.6). Patch venoplasty is particularly useful if the circumferential wall does not have to be completely resected to remove tumor. Most commonly commercially available substances for patch venoplasty consist of bovine and porcine pericardium. Also, if xenografts are not desired, cadaveric donor vein can be used.

Aortic Reconstruction

Aorta dissection in PC-RPLND, especially with seminomatous disease, can be life-threatening if vascular principles are not followed. Small injuries to the aorta can be repaired with primary repair. Unlike venous reconstructive options that can include ligation and resection without reconstruction, significant aortic injury almost always requires grafting**. It is imperative to have a multidisciplinary surgical team immediately available for possible intervention. The most common injuries occur with subadventitial dissection of densely adherent masses, which required aortic replacement with a polytetrafluoroethylene (PTFE) or Dacron graft** (see Fig. 77.6). Any long duodenal serosal injury with aortic injury should be considered for grafting to reduce the risk of delayed aortoduodenal fistula (Donohue and Foster, 1994).

Beck et al. reported their experience at Indiana University over a 30-year span involving 1200 patients and found that approximately 1% required aortic replacement (Beck et al., 2001). Nearly two-thirds of these patients had salvage chemotherapy or were undergoing desperation RPLND with elevated tumor markers at the time of surgery. In this high-risk setting, 33% were disease free at a mean follow-up of 34 months, and there were no graft-related complications. Therefore, especially in the high-risk setting for relapse with little systemic chemotherapeutic options available, aortic resection can be used to obtain complete resection if needed and maximize the patient's opportunity to be cured of their disease.

Hepatic Resections

According to the 1997 IGCCCG nonpulmonary visceral metastases are considered poor risk with a 48% 5-year survival. It is estimated that about 6% of advanced metastatic testes cancer patients have liver metastases (International Germ Cell Consensus Classification, 1997). RPLND of poor risk nonpulmonary liver disease is usually considered after primary, salvage, or third-line chemotherapy. Therefore RPLND requires all disease resection, including residual liver disease identified by cross-sectional imaging.

Unfortunately, liver histology at the time of liver resection can be discordant with retroperitoneal histology. A database review at Indiana University found 59 cases of hepatic resection, and of these cases, the overall rate of histologic discordance between retroperitoneal and liver histology was 51%, with 73% of all liver specimens containing necrosis only. Retroperitoneal necrosis is highly predictive of hepatic necrosis (94%) (Jacobsen et al., 2010). This discordance was also characterized from another high-volume center, who reviewed their database from 1990 to 2015 and concluded that residual liver masses in the absence of marker positive disease should undergo resection or ablation (Pietzak et al., 2018). Data from the Memorial Sloan Kettering Cancer Center (MSKCC) identified 36 patients, of which 29 (81%) presented with a liver mass at initial diagnosis and 17 (47%) received salvage chemotherapy before surgery. Teratoma and viable GCT was found in 8 (22%) and 5 (14%) of PC-RPLND specimens, respectively. For the liver resection specimens, this was 5 (14%) and 4 (11%), respectively. Among patients who had either teratoma or viable GCT on PC-RPLND, 29% (95% CI 0.10–0.56) had teratoma or viable GCT on liver resection as well. The rate of benign versus malignant histologic discordance was 21% (95% CI 0.06–0.46), with 4 of 19 patients having either teratoma or viable GCT on liver resection when only fibrosis/necrosis was found in their PC-RPLND. At some hepatobiliary centers of excellence, liver biopsy with intraoperative open microwave ablation may be performed if liver masses are present, in which resection would lead to undue morbidity. Multi-institutional data from four high-volume centers comparing liver resection to ablation found more morbidity with resection but no difference with respect to recurrence, except for a higher recurrence rate in percutaneous liver-ablated patients (Groeschl et al., 2014). Therefore if the residual liver lesion is less than 3 cm and not amenable to safe resection, open microwave ablation at the time of RPLND may be a safe alternative. However, there are no studies with a large cohort of GCT patients to recommend this as an alternative to extirpation except in cases of undue morbidity with liver resection. Of course, management in the post-chemotherapy and salvage setting must be individualized because some smaller lesions in difficult locations may have to be biopsied and observed.

Pelvic Resections

Pelvic disease in metastatic testes cancer is rarely observed outside of prior groin surgery, repeat RPLND, or late relapsed disease. Data from Indiana University from 1990 to 2009 identified 2722 patients who underwent RPLND, of which 134 had pelvic disease: 14% had prior groin surgery, 98% had prior chemotherapy, 19.4% underwent prior RPLND, and 24% had late-stage relapse (Jacob et al., 2017). Surgical intervention included pelvic excision alone in 27.6%, pelvic excision with primary RPLND in 1.5%, or pelvic excision with PC-RPLND in 70.9%. Median pelvic mass size was 6.5 cm. Histology was 55% teratoma, residual germ cell in 21%, sarcomatous transformation in 6%, and necrosis in 16.5%. The fibrosis rate at pelvic excision is less than 50% compared with PC-RPLND specimens alone; therefore complete resection should be undertaken whenever feasible.

Similar data from MSKCC were found when they reviewed 2186 patients who underwent RPLND between 1989 and 2011, 44 (2%) of whom underwent pelvic excision at the time of RPLND (Alanee et al., 2016). Median size on imaging was 4 cm. Histology revealed teratoma in 15/44 (34%) and viable tumor in 5/44 (11%) patients. At a median follow-up of 46 months, 40/44 (91%) patients were living without disease recurrence. Thus, although patients in both of these series tended to present with higher-volume disease, surgery was curative in the majority of patients after chemotherapy.

Management of Supradiaphragmatic Disease

Approximately 10% to 20% of patients with a diagnosis of testes cancer have evidence of supradiaphragmatic disease at presentation or go on to intrathoracic spread at some point during their illness. Thoracic disease can be the result of hematogenous spread leading to pulmonary metastases or by lymphangitic spread to the mediastinal and cervical lymph nodes. Approximately 80% of mediastinal metastases are in the lower to middle mediastinum (Kesler et al., 2011). Anterior mediastinal disease is worrisome for a primary GCT of the mediastinum. **Multiple studies have looked at the concordance in histology between retroperitoneal and thoracic disease and, as is the case with liver disease, there is substantial discordance ranging from 25% to 50%** (Besse et al., 2009; Gels et al., 1997; Gerl et al., 1994; Steyerberg et al., 1997). Retrospective data from Indiana University regarding metastatic testes patients with thoracic spread of testes cancer from 1980 to 2006 identified 431 patients who underwent 640 post-chemotherapy surgical procedures to remove lung (n = 159), mediastinal (n = 136), and lung and mediastinal (n = 136) disease within 2 years of chemotherapy (Kesler et al., 2011). The overall median survival was 23.4 years, with 295 (68%) patients alive and well after an average follow-up of 5.6 years. There was no survival difference in patients who underwent removal of lung or mediastinal metastases. Pathologic categories of resected residual disease were necrosis (21.5%), teratoma (52.7%), persistent NSGCT (15.0%), and degenerative non–germ cell cancer (10.1%). Multivariable analysis identified older age at time of diagnosis ($P = 0.001$), non–germ cell cancer in testes specimen ($P = 0.004$), and pathology of residual disease ($P < 0.001$) as significant predictors of survival. **Extrapolating from this data it is generally recommended to resect any residual disease greater than 1 cm.**

Steyerberg et al. in a multi-institutional study identified 215 patients undergoing thoracotomy for residual thoracic masses after platinum-based chemotherapy for testes cancer (Steyerberg et al., 1997). Necrosis was found in 116 patients (54%), mature teratoma in 70 (33%), and residual viable GCT in 29 (13%). Necrosis was found at thoracotomy in 89% of those patients with necrosis found in the RPLND specimen. **Therefore, in general, thoracic management should be deferred until after RPLND because, if fibrosis is found in the retroperitoneum, observation of the mediastinal masses may be warranted as a result of the high rate of concordant fibrosis with the lungs in that circumstance. For these reasons, a multidisciplinary team of specialists should be involved in the care of these complex patients.**

Resection of Retrocrural Disease

Resection of retrocrural disease can be extremely challenging from a traditional midline incision. For this reason, other options include a thoracoabdominal approach, left thoracotomy approach, and thorascopic dissection with or without the assistance of robotics. Depending on level of expertise, any of these options can be used to resect retrocrural disease. Without advanced laparoscopy/robotics, a thoracotomy can be used to resect residual retrocrural disease. However, thoracotomy has substantial morbidity and convalescence; therefore efforts to have a combined thoracoabdominal approach avoiding thoracotomy have been employed.

Fadel et al. (2000) reported on 18 patients who had simultaneous resection of retroperitoneal and posterior mediastinal masses using this approach between 1993 and 1999. After standard retroperitoneal lymph node dissection through a midline laparotomy, an incision parallel to the right crus of the diaphragm was made and extended anteriorly through the muscular portion. Excellent exposure of the lower posterior mediastinum was obtained. Masses located higher than vertebra T8 were resected by extending this incision anteriorly and performing a partial sternal division. A complete median sternotomy can be done to allow subcarinal dissection, as well as pulmonary or anterior mediastinal mass resection. There were no perioperative deaths; 3 patients had minor postoperative complications. After a median follow-up of 3.2 years, the overall 5-year survival rate was 92%, and the 5-year disease-free survival rate was 87% (Fadel et al., 2000). Kessler et al. at Indiana have used a transdiaphragmatic approach on 60 patients with a low complication rate (Fig. 77.7). **Deciding to do a retrocrural dissection at the same time as RPLND may be less morbid to the patient; however, if more extensive thoracic resection is required (i.e., pulmonary metastectomy, mediastinal resection), the consideration should be made for a staged procedure because of prolonged anesthesia and potential increased risk of complications with a single-stage approach.**

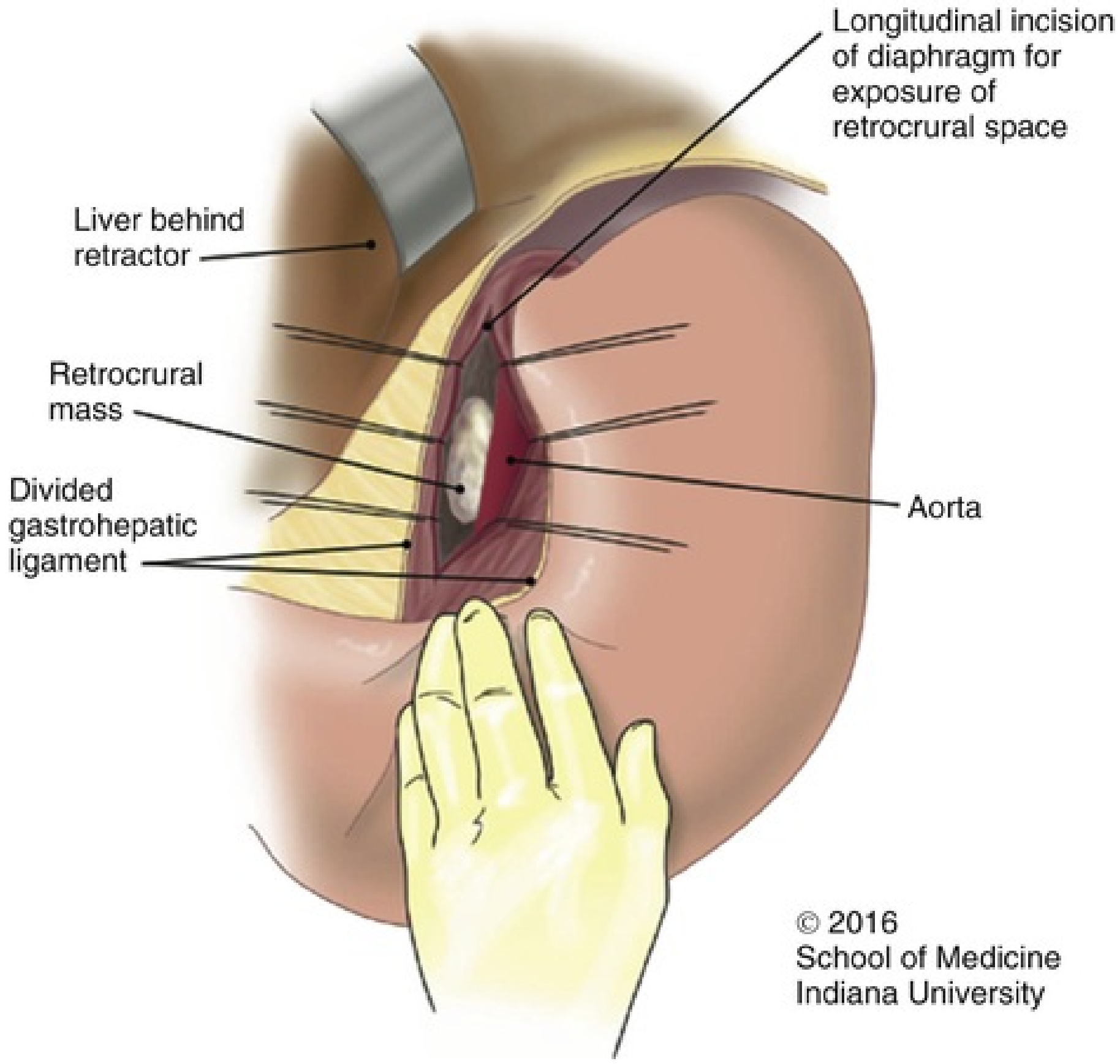
Longitudinal incision of diaphragm for exposure of retrocrural space
Liver behind retractor
Retrocrural mass
Divided gastrohepatic ligament
Aorta
© 2016 School of Medicine Indiana University

FIG. 77.7 Transabdominal, transdiaphragmatic approach to retrocrural mass. (Copyright 2016 Section of Medical Illustration in the Office of Visual Media at the Indiana University School of Medicine. Published by Elsevier Inc. All rights reserved.)

Key Points: Auxiliary Procedures

- The most common auxiliary procedure during RPLND is nephrectomy, particularly for left-sided or larger masses in the post-chemotherapy or other higher risk settings.
- Surgical planning is critical to success or RPLND in high-risk settings such as after systemic chemotherapy. This is particularly critical for those who may require an en-bloc aortic replacement.
- When possible, primary reconstruction of the IVC is preferred to grafting when a venotomy or partial excision is required.
- Histologic discordance between the liver and retroperitoneum is common,

and the decision to perform hepatic resection should be individualized using a multidisciplinary care team.

- There is frequent histologic discordance between disease in the thoracic cavity and retroperitoneum. In general, thoracic masses should be managed after RPLND is completed, and masses greater than 1 cm should be considered for resection unless the retroperitoneum harbored only fibrosis.
- Retrocrural dissection may be a consideration at the time of RPLND; however, if more extensive thoracic resection is required, a stage approach may be preferable.

Surgical Decision Making

This section focuses on the controversies and decision-making process for RPLND in the primary and post-chemotherapy setting and the role for adjuvant chemotherapy after RPLND. The indications for primary RPLND, including its advantages and disadvantages compared with other management strategies, are addressed in another chapter and are not discussed here.

Management of Clinical Complete Remission to Induction Chemotherapy

Roughly 70% of patients who are treated with cisplatin-based chemotherapy for clinical stage II or higher GCT achieve a complete radiographic (defined as no residual mass > 1 cm) and serologic remission. The management for these patients remains controversial, but the fundamental options are observation or performing PC-RPLND.

Those who favor observation for a patient with a complete response to chemotherapy point out the excellent long-term overall and recurrence-free survival for patients who are managed by surveillance (Ravi et al., 2014). For example, a study of 141 men, most of whom were IGCCCG good risk, with a clinically complete response to chemotherapy managed with observation found a 15-year recurrence-free survival (RFS) rate of 90% and cancer-specific survival (CSS) of 97% (Ehrlich et al., 2010). Another similar study of 161 patients with a shorter, median 4½-year follow-up also reported excellent oncologic outcomes with surveillance alone after chemotherapy with RFS of 93.8% and CSS of 100% (Kollmannsberger et al., 2010). Because of these excellent results, investigators at Indiana University and many other major centers observe men who achieve a radiologic (residual mass <1 cm) and serologically complete response after cisplatin-based chemotherapy for stage II or higher disease.

Those who favor performing PC-RPLND in all patients with a history of retroperitoneal metastases regardless of response to chemotherapy point to a risk of harboring residual viable disease even with small residual masses. For example, in a report of 532 patients undergoing PC-RPLND at MSKCC, 154 had a residual mass 1 cm or less on cross-sectional imaging after chemotherapy (Carver et al., 2006). In this group of men with a clinically complete response to chemotherapy, 22%, 1%, and 5% had teratoma, teratoma/GCT, and GCT, respectively, in their final pathologic specimen at the time of surgery.

The debate continues in large part because the natural history of microscopic residual teratoma after cisplatin chemotherapy remains unknown. Proponents of PC-RPLND despite a clinical CR argue microscopic teratoma residing in the retroperitoneum may eventually lead to growing teratoma syndrome, late disease relapse, or malignant transformation that is typically chemotherapy resistant and difficult to salvage. Conversely, those who favor observation would argue that microscopic teratoma behaves in an indolent fashion in the majority of cases. The debate is further complicated by the observation that retrospective studies examining either approach (Table 77.2) appear to have similar excellent results, suggesting both can be successful provided patients are appropriately selected (Carver et al., 2006, Ehrlich et al., 2010, Kollmannsberger et al., 2010). The debate will therefore likely continue until it can be demonstrated **(1) whether performing PC-RPLND can prevent cancer-related deaths for patients after a clinically complete response to chemotherapy and (2) if the number needed to treat to prevent one death is sufficiently low to justify the potential morbidity of PC-RPLND.**

TABLE 77.2

Management of Patients Experiencing a Clinical Complete Remission to Induction Chemotherapy

	EHRLICH ET AL., 2010	KOLLMANNSBERGER ET AL., 2010	KARELLAS ET AL., 2007
Management	Observation	Observation	PC-RPLND
No. patients	141	161	147
Follow-up (yr)	15.5	4.3	3
Good risk (%)	77	94	98
DFS (%)	91	94	97
CSS (%)	97	100	NR

CSS, Cancer-specific survival; *DFS,* disease-free survival; *NR,* not reported; *PC-RPLND,* post-chemotherapy retroperitoneal lymph node dissection.

Use of Modified Templates in Primary

Retroperitoneal Lymph Node Dissection

Historically RPLND included the removal of all the lymphatic tissue included within the bounds of contemporary bilateral infrahilar templates plus resection of the tissue in the interiliac region inferiorly to the level of the bifurcation of the common iliac arteries (Ray et al., 1974), often with the addition of the suprahilar tissue bilaterally (Donohue et al., 1982). The dissection often was done through a thoracoabdominal incision and was associated with significant perioperative morbidity, and the majority of patients were rendered anejaculatory (Donohue and Rowland, 1981). Despite the morbidity, the scale of the dissection was thought necessary to offer the optimal opportunity to cure the patient in an era in which curative chemotherapy for GCT was not yet available.

Beginning in the 1970s and continuing through the 1980s, the advent of curative cisplatin-based chemotherapy (Einhorn and Donohue, 1977)**, the recognition of the distinct patterns of lymphatic spread of right-sided versus left-sided disease** (Donohue et al., 1982; Ray et al., 1974; Weissbach and Boedefeld, 1987)**, and the development of surgical techniques to spare the postganglionic sympathetic nerve fibers responsible for ejaculatory function** (Colleselli et al., 1990; Donohue et al., 1990; Jewett et al., 1988) **revolutionized the management of GCT and the approach to RPLND.** Increasingly the surgical approach to RPLND focused on decreasing the morbidity associated with the operation while maintaining its oncologic efficacy. An important advance in this regard was the development of modifications to the historically wide dissections before these interventions.

The first such attempts at detailing alternative templated modifications to traditional RPLND were pioneered by Ray et al. (1974). This report of 283 patients who underwent RPLND at MSKCC over three decades detailed a transition from full bilateral dissections to modifications that included a focus on the primary landing zones for right- versus left-sided tumors. **This seminal work set the stage for subsequent work and refinement of the modified templates still in use today.**

In 1982 an important pathologic mapping study by Donohue et al. (1982) on 104 patients with pathologically positive lymph nodes at the time of primary RPLND was able to identify a relatively predictable pattern to lymphatic spread of GCT in the retroperitoneum. These included the observation that left-sided tumors typically metastasize to the left para-aortic region, whereas the primary “landing zone” for right-sided tumors was the interaortocaval and precaval spaces. Although spread to the contralateral area and the suprahilar regions was rare, the incidence increased as the bulk of retroperitoneal disease increased. Spread to the interiliac region was very rare. This study provided further confirmation of the modified template concept proposed earlier by Ray et al. (1974) on patients who did not have bulky disease in the retroperitoneum. These findings were further reinforced by a study from Weissbach and Boedefeld in 1987 on 214 patients with nonbulky pathologic stage II disease in which a reduced template of the para-aortic and preaortic regions in left-sided tumors was proposed, with intraoperative frozen section used to identify those patients who should go on to a more formal full template dissection.

The sum of these and other template-based studies was the adoption of a less morbid and more efficient approach to RPLND using modified templates. Examples of the boundaries of full bilateral compared with a modified template dissection are shown in Fig. 77.8. **Most authors now agree that the interiliac region and the suprahilar regions can generally be omitted in the absence of bulky retroperitoneal disease.** Omission of the suprahilar dissection reduces the risk of chylous ascites, renal injury, and pancreatic and/or duodenal injuries. The omission of the interiliac region, when combined with the omission of the contralateral retroperitoneal space, can help preserve antegrade ejaculatory function in the majority of men. **However, the omission of the contralateral retroperitoneal space remains controversial.**

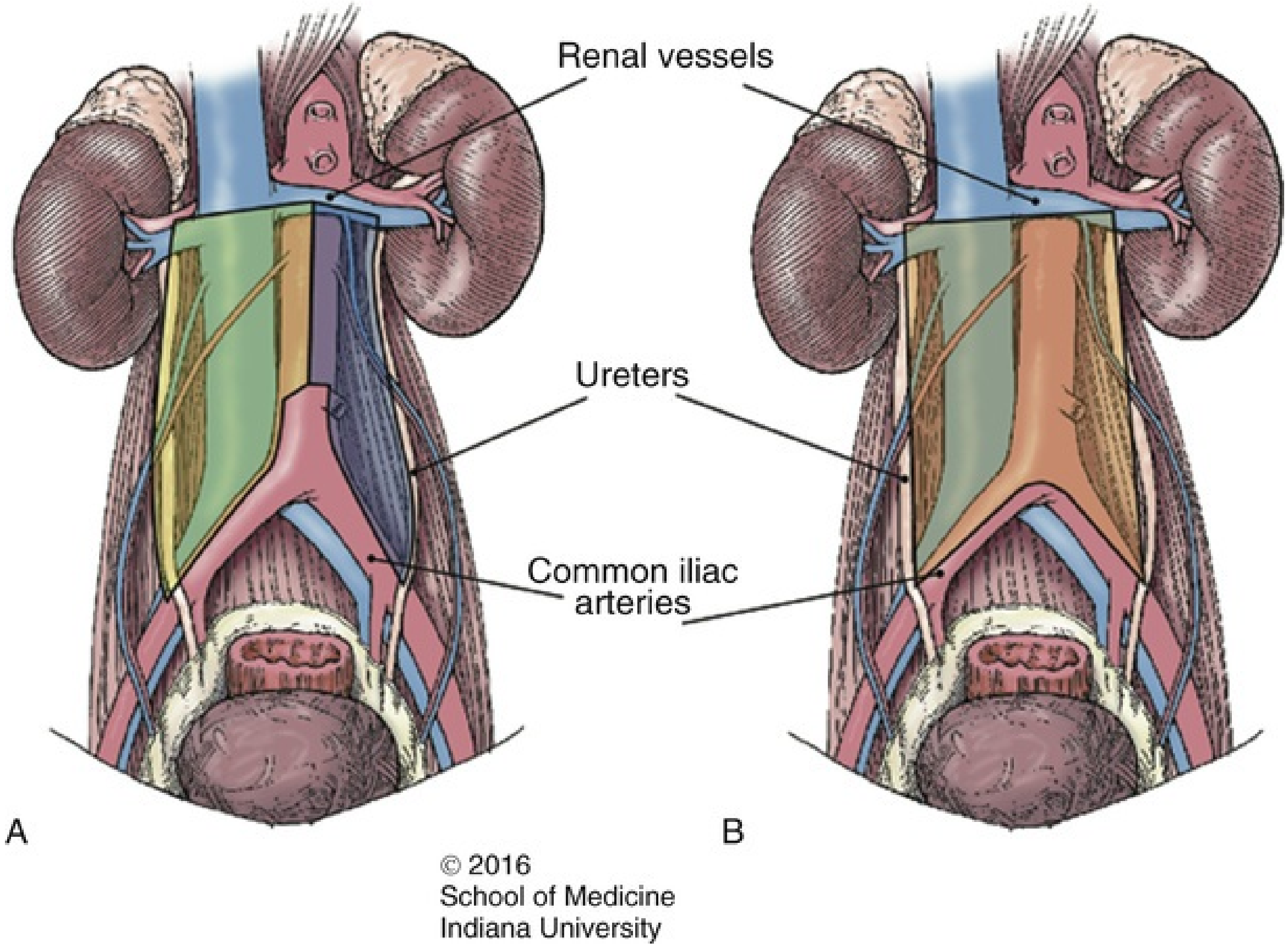

FIG. 77.8 Retroperitoneal lymph node dissection templates. (A) Modified unilateral templates—right-sided shaded in yellow, left-sided shaded in purple. (B) Modified bilateral template—shaded area. (Copyright 2016 Section of Medical Illustration in the Office of Visual Media at the Indiana University School of Medicine. Published by Elsevier Inc. All rights reserved.)

Data that argue against the use of modified unilateral templates include a report by Eggener et al. (2007) from MSKCC, who presented data from a series of 500 patients who underwent primary RPLND for clinical stage I or IIA GCT. Suprahilar dissection was generally omitted in this series, but a full template was otherwise applied across all patients. There were 191 patients (38%) who had pathologic stage II disease. The authors analyzed the anatomic location of the positive nodes in these patients relative to varying modified templates that have been published and noted that 3% to 23% of patients would have had a positive node that would not have been resected, depending on which modified template was analyzed. This extra-template node positivity was more prevalent for right-sided than left-sided tumors. On the basis of this and similar data, the authors recommended that a full bilateral infrahilar nerve-sparing RPLND be the standard for all patients with clinical stage I or IIA GCT.

The most ideal method to resolve the debate between modified/unilateral template versus full bilateral templated dissections for primary RPLND for clinical stage I or IIA disease would be a prospective randomized trial, but no such trial has been completed. Published results of both approaches have shown excellent results with overall and cause specific survival rates approaching 100% (Table 77.3; Donohue et al., 1993; Hermans et al., 2000; Nicolai et al., 2004; Stephenson et al., 2005). Therefore proving a substantive difference between approaches would be difficult. Attempts to compare across series is complicated not only by the usual caveats of such an approach but also varying approaches to the use of adjuvant chemotherapy for those patients who ultimately are found to have pathologically positive nodes. For example, in a series by MSKCC that showed a high proportion of patients being cured by surgery (Stephenson et al., 2005), a high proportion of patients with pN2 disease were treated with adjuvant chemotherapy. In one of the studies from Indiana University (Donohue et al., 1993), most of the patients with node-positive disease were randomized on study to observation or adjuvant chemotherapy. However, in a different study from the same institution (Hermans et al., 2000), all pN1 and most patients pN2 patients were observed, while chemotherapy was confined to those patients at relapse or who harbored pN3 disease at the time of surgery. These challenges therefore preclude a definitive “one-size-fits-all” approach to template selection in primary RPLND. From the work summarized here it is clear that with appropriate patient selection, excellent surgical technique, and the judicious use of adjuvant chemotherapy excellent results can be expected for the majority of patients. **Whether it should be mandatory to use either a full bilateral template or a modified/unilateral template to achieve such results remains unclear.**

TABLE 77.3

Selected Primary RPLND Series

STUDY	NO. PATIENTS	NO. pN+ (%)	RECURRENCE RATE FOR pN0 (%)	RECURRENCE RATE FOR pN+ MANAGED WITH RPLND ALONE (%)	FOLLOW-UP (YR)	CSS (%)
Donohue et al., 1993a	378	112 (29.6)	31 (12)	22 (34)	6.2	99.2

Stephenson et al., 2005	308	91 (29.5)	NR (7)	NR (34)	4.9	99.7
Hermans et al., 2000	292	66 (22.4)	23 (10.2)	7 (22.6)	3.8	100.
Nicolai et al., 2004	322	60 (20)	NR	NR	7.2	98.8

CSS, Cancer-specific survival; *NR,* not reported; *pN+,* histologically positive lymph nodes; *pN0,* histologically negative lymph nodes; *RPLND,* retroperitoneal lymph node dissection.

Use of Modified Templates in Retroperitoneal Lymph Node Dissection After Chemotherapy

Unlike primary RPLND, for patients undergoing PC-RPLND the standard of care in most instances is a resection of the residual mass and a full bilateral infrahilar RPLND. This has been the standard since the first reported experience with PC-RPLND by Donohue et al. in 1982. Although the majority of the viable GCT and/or teratoma was located in the appropriate primary landing zone, given the frequent contralateral crossover in the setting of bulky initial disease and the difficulty of detecting viable residual neoplasm intraoperatively, the authors emphasized the importance of a complete resection (Donohue et al., 1982). **This has remained the standard of care because it provided excellent control of the retroperitoneum, albeit at the cost of significant potential morbidity and frequent ejaculatory dysfunction in patients for whom a nerve-sparing approach was not feasible.**

Because of the potential morbidity of PC-RPLND, a number of groups have explored the potential to apply modified unilateral templates to PC-RPLND in a manner analogous to the primary setting (Beck et al., 2007; Carver et al., 2007; Ehrlich et al., 2006; Heidenreich et al., 2009; Herr, 1997; Rabbani et al., 1998; Steiner et al., 2008; Wood et al., 1992). A summary of the results is shown in Table 77.4 demonstrating that this approach, if appropriately applied, can be done safely with encouraging oncologic results. Despite a high degree of variability in the reported rates of positive nodes outside of a standard full bilateral template the in-field and out-of-field retroperitoneal recurrences rates remained low and, in all but one report, the CSS was 98% to 100% (when reported). Nevertheless, **the application of modified unilateral templates in the setting of PC-RPLND is critically reliant on proper patient selection. Although no universal consensus exists, based on the reports to date**

patients who are potential candidates for modified template PC-RPLND should probably meet the following criteria:

TABLE 77.4

Studies Evaluating the Use of Modified Unilateral Templates in Post-Chemotherapy Retroperitoneal Lymph Node Dissection

---

STUDY	NO. PATIENTS	N+ OUTSIDE TEMPLATE (%)	N+ OUTSIDE TEMPLATE & MACROSCOPIC DISEASE	IN-FIELD RP RECURRENCE AFTER B/L RPLND (%)	IN-FIE RECU AFTE RPLN
Wood et al., 1992	113	14 (21.4)	9 (8)	NA	NA
Herr, 1997	62	NR	NR	1 (4)	1 (2.7)
Rabbani et al., 1998	50	12 (24)	1 (2.6)	1 (2.6)	1* (9.1
Ehrlich et al., 2006	50	9 (18)	1 (2)	0	0
Beck et al., 2007	100	NA	NA	NA	0
Steiner et al., 2008	102	NA	NA	NA	1(1)
Carver et al., 2007a	269	20–86 (7-32)	50 (18.6)	NR	NR
Heidenreich et al., 2009	152	NA	NA	1 (1.9)	0
Cho et al., 2017	100	7	7	0	0

*Occurred in patient who underwent tumorectomy only.

B/L, Bilateral; *CSS,* cancer-specific survival; *NA,* not applicable; *N+,* histologically positive lymph nodes; *NR,* not reported; *RP,* retroperitoneal; *RPLND,* retroperitoneal lymph node dissection; *U/L,* unilateral.

1. Well-defined lesion measuring 5 cm or less confined to the primary landing zone of the primary tumor on imaging before and after chemotherapy (Fig. 77.9 shows representative CT examples)

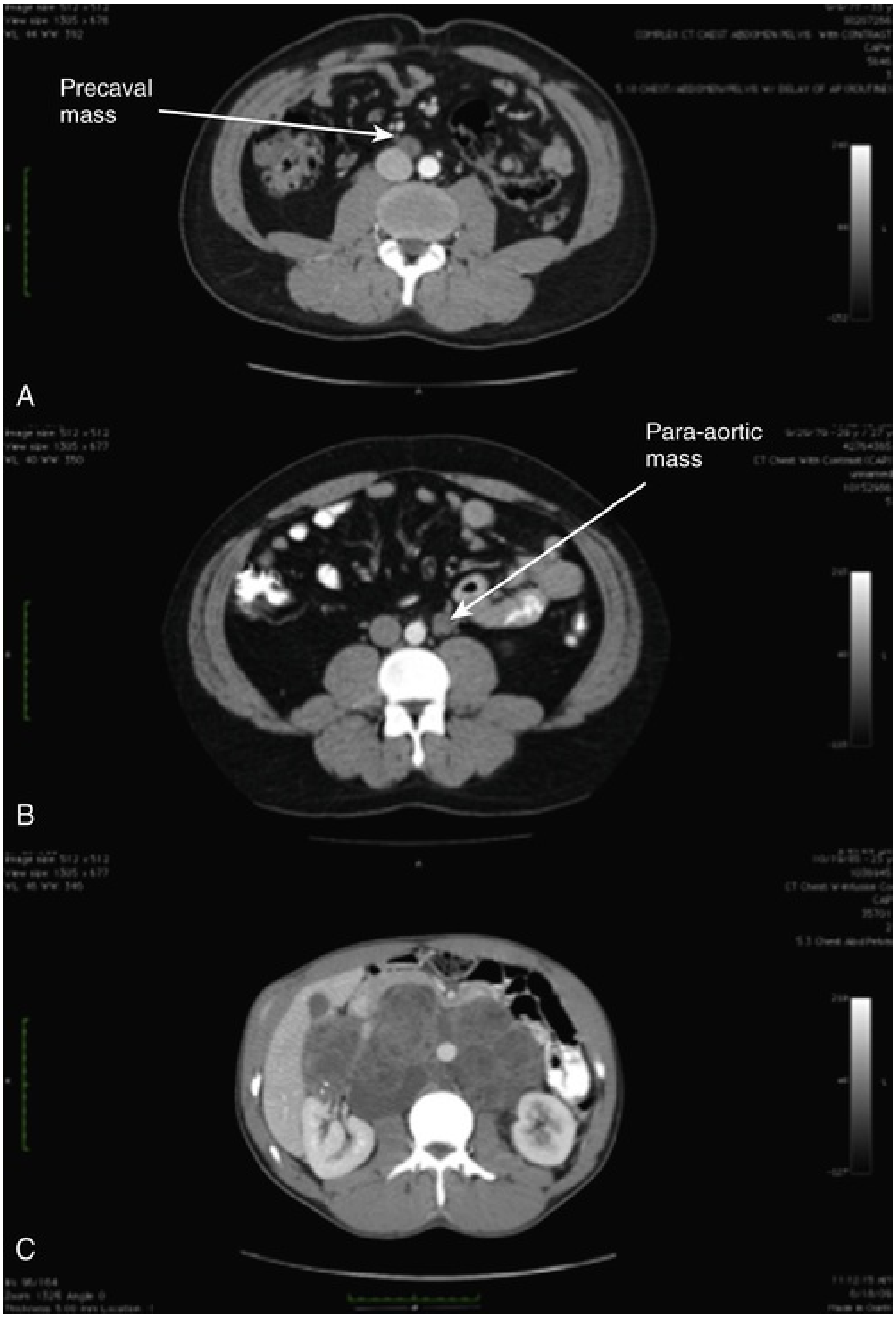

FIG. 77.9 Computed tomography images of post-chemotherapy residual retroperitoneal masses. (A) This patient could be considered a candidate for modified right template post-chemotherapy retroperitoneal lymph node dissection (PC-RPLND). (B) This patient could be considered a candidate for modified left template PC-RPLND. (C) This patient would require an extensive bilateral PC-RPLND.

2. Normal post-chemotherapy STMs
3. IGCCCG good/intermediate risk

After selection criteria, such as those outlined, have been reported in PC-RPLND with excellent local control, including in-field retroperitoneal recurrence rates of 0 to 1% and CSS rates of 98% to 100% at a follow-up of 2.6 to 10.4 years antegrade ejaculation was maintained in more than 85% of men (Beck et al., 2007; Cho et al., 2017; Heidenreich et al., 2009; Steiner et al., 2008). Such excellent results are encouraging and warrant further study. However, as is the case with primary RPLND, **there have been no prospective, randomized comparative studies of full bilateral versus modified unilateral template approaches to PC-RPLND. Strict adherence to the criteria described is critical for patient selection and, in general, full, bilateral infrahilar dissection with resection of the residual mass remains the standard of care for the majority of PC-RPLNDs.**

Adjuvant Chemotherapy for Pathologic Stage II Disease at Primary Retroperitoneal Lymph Node Dissection

Patients who have no lymph node metastases at the time of primary RPLND can be safely observed without additional therapy. However, there is less consensus on the role for adjuvant chemotherapy for those patients with pathologically positive lymph nodes at the time of surgery. On the one hand, it has been demonstrated that roughly 70% of patients with pN1 or pN2 disease can be cured with surgery alone and, even for those patients who recur, the majority can be successfully salvaged with chemotherapy if they relapse (Donohue et al., 1993, 1995; Nicolai et al., 2004; Stephenson et al., 2005). However, for those patients who do relapse, the salvage chemotherapy required is more intensive, typically at least one more cycle of bleomycin, etoposide, and cisplatin or two more cycles of etoposide and cisplatin, than if the therapy were given in an adjuvant setting. Conversely, adjuvant chemotherapy has been shown to virtually eliminate the risk of disease relapse for patients with pN1 or pN2 disease after primary RPLND (Behnia et al., 2000, Kondagunta et al., 2004; Williams et al., 1987). However, its universal application across all such men would subject 70% of them “unnecessarily” to the potential toxicity of chemotherapy. The ideal, then, would be if clinicians could accurately predict which patients were at the highest risk for subsequent relapse and confine adjuvant chemotherapy to that high-risk group.

Attempts to accurately define a high-risk group for disease relapse in the setting of positive nodal metastases after primary RPLND have met with mixed results. The most obvious potential predictor of relapse would be the bulk of nodal involvement. There have been some early studies suggesting that microscopic lymph node disease involvement had a lower recurrence rate than macroscopic disease (Fraley et al., 1985; Vugrin et al., 1981). In a prospective, randomized trial of adjuvant chemotherapy, analysis of the observation arm demonstrated patients with microscopic nodal disease had a recurrence rate of 40%, those with macroscopic nodal disease less than 2 cm recurred at a 53% rate, whereas those with disease greater than 2 cm recurred at a rate of 60% (Williams et al., 1987). Although these results were not significant (likely because of relatively small sample size), they remain intriguing. At least two retrospective reports on patients with clinical stage II NSGCT managed with RPLND alone reported that larger lymph node metastatic burden was associated with higher recurrence rates (Donohue et al., 1995; Weissbach et al., 2000). Conversely, several other studies that have compared outcomes between pathologic stages IIA and IIB disease for patients managed with observation have not found a difference in recurrence rates (Al-Ahmadie et al., 2013; Donohue et al., 1993; Nicolai et al., 2010; Pizzocaro and Monfardini, 1984). These conflicting results may be, at least in part, due to differences in patient selection for adjuvant therapy and other potential unmeasured confounders inherent in retrospective studies.

There have been a variety of other histologic variables tested for their prognostic ability to predict disease recurrence. These include such parameters as the number of positive nodes as a proportion of the number removed (Al-Ahmadie et al., 2013; Beck et al., 2005), the histologic type of GCT in the metastases (Al-Ahmadie et al., 2013; Beck et al., 2005), and the presence or absence of extranodal extension (Al-Ahmadie et al., 2013; Beck et al., 2007). **None of these have proven reliable enough that they can accurately predict those who are at high risk for recurrence and warrant up-front adjuvant therapy. The one exception is that the finding of only teratoma in the retroperitoneum is associated with very low relapse rates, and therefore additional therapy other than observation is not warranted** (Liu et al., 2015).

Given the absence of a reproducible and reliable predictor for disease recurrence, most centers rely on the nodal staging to determine the approach to adjuvant chemotherapy. **There is relatively broad consensus that many patients with pN1 disease at primary RPLND who are reliable can be safely managed with observation. The management of pN2 disease is more controversial with some centers advocating two cycles of adjuvant chemotherapy** (Kondagunta and Motzer, 2007)**, whereas others would manage many of these patients with observation** (Beck and Foster, 2006; Jacobsen et al., 2007).

Key Points: Surgical Decision Making

- Although there remains some debate in the literature, in general, patients who have a complete response to chemotherapy should be observed.
- Modified templates can be used for primary RPLND in select patients who have low-stage, low-volume retroperitoneal disease.
- In general, the standard of care for PC-RPLND is a full, bilateral infrahilar retroperitoneal dissection with nerve sparing where technically feasible.
- The use of modified templates in the post-chemotherapy setting should be confined to the fraction of patients who meet highly strict selection criteria.
- Patients who are found to have only teratoma at the time of RPLND have a very low risk for subsequent relapse and likely do not require adjuvant chemotherapy.
- The use of adjuvant chemotherapy for patients found to have pN+ at RPLND is controversial, but in general pN1 disease can often be observed, while the use of adjuvant chemotherapy for those with pN2 should be individualized.

Histologic Findings at Post-Chemotherapy Retroperitoneal Lymph Node Dissection and Survival Outcomes

The three major histologic findings (fibrosis/necrosis, teratoma, and viable GCT) and their frequencies at the time of RPNLD have been reported in multiple series. Although there has been some evolution over time because of refinement in chemotherapy regimens resulting in a decreasing frequency of viable GCT at PC-RPLND**, the current relative frequencies of fibrosis, teratoma, and viable GCT are generally around 40%, 45%, and 15%, respectively** (Albers et al., 2004; Carver et al., 2006; Donohue et al., 1998; Hendry et al., 2002; Spiess et al., 2007; Steyerberg et al., 1995).

Outcomes by Histology

The outcomes after PC-RPLND vary depending on the type of histology encountered. The CSS outcomes after the finding of teratoma or fibrosis in the modern era are excellent, with the group of biggest concern being those with a finding of viable GCT (Table 77.5). There has been some debate on the distribution of histology after BEP × 3 or EP × 4 for good risk disease, but, in general, the long-term survival after PC-RPLND has been similar (Cary et al., 2015; Kundu et al., 2015). The variability in reported histology and outcomes likely is a product of era of treatment, pretreatment risk stratification, and length of follow-up.

TABLE 77.5

Survival Outcomes by Histologic Findings at Post-Chemotherapy Retroperitoneal Lymph Node Dissection

STUDY	NO. PATIENTS	FOLLOW-UP (YR)	RFS	CSS
Fibrosis				
Donohue and Foster, 1994	150	>2	NR	93
Eggener et al., 2007a[a]	36	4.3	NR	85
Carver et al., 2007c	113	NR	95	NR
Maroni et al., 2008	184	4	92.1	NR

Teratoma				
Loehrer et al., 1986	51	NR	61	82.3
Jansen et al., 1991	26	7.7	88.5	88.5
Donohue and Foster, 1994	273	>2	NR	93.4
Eggener et al., 2007[a]	15	4.3	NR	77
Carver et al., 2006	210	3	85.4	94
Beck et al., 2009	99	3.5	76.8	98
Viable Malignancy				
Jansen et al., 1991	23	7.9	54.5	64
Fox et al., 1993	133	3	30.8	42.8
Donohue et al., 1998	122	9	39	51.5
Fizazi et al., 2001	238	7.2	64	73
Eggener et al., 2007a[a]	10	4.3	NR	56
Spiess et al., 2007	41	3.9	50	71
Kundu et al., 2010	90	NR	62	71

[a] All patients received salvage chemotherapy before post-chemotherapy retroperitoneal lymph node dissection.

CSS, Cancer-specific survival; *NR,* not reported; *RFS,* recurrence-free survival.

Fibrosis/Necrosis

The finding of necrosis/fibrosis only at PC-RPLND portends an excellent prognosis with CSS and RFS approaching 95% (Carver et al., 2007; Donohue and Foster, 1994; Maroni et al., 2008). It can be inferred from this finding that systemic chemotherapy has rendered all malignant cells nonviable and that most likely all other subclinical metastatic deposits have been likely cleared with a low likelihood of subsequent disease recurrence.

Teratoma

Contemporary studies also suggest excellent outcomes after a histologic finding of teratoma after PC-RPLND with expected RFS rates of 80% to 90% and CSS of 85% to 95% (Carver et al., 2006; Donohue and Foster, 1994; Jansen et al., 1991; Liu et al., 2015). In this setting somatic type malignancy and mediastinal primaries are associated with an increased risk of recurrence (Carver et al., 2007; Jansen et al., 1991; Loehrer et al., 1986).

Viable Malignancy

Persistent disease at the time of PC-RPLND suggests primary resistance to

systemic treatment. This finding is associated with 50% to 70% long-term survival rate, which is reduced as compared with the finding of fibrosis or teratoma (Donohue et al., 1998; Fizazi et al., 2001, 2008; Jansen et al., 1991; Kundu et al., 2010; Spiess et al., 2007).

In a multi-institutional review of 238 patients with viable malignancy at PC-RPLND, Fizazi et al. (2001, 2008) **determined three factors associated with worse prognosis: (1) incomplete resection, (2) 10% or greater viable malignancy, and (3) IGCCCG intermediate/poor risk group stratification at initial diagnosis.** Patients in the favorable risk group (i.e., none of the factors mentioned earlier) demonstrated a 90% 5-year progression-free survival (PFS) and 100% 5-year OS. Those patients with one risk factor were deemed "intermediate risk" (5-year PFS 76%, 5-year OS 83%), and those with two or three risk factors were deemed "poor risk" (5-year PFS 38%, 5-year OS 51%). **Unfortunately, these factors and risk group stratification on follow-up analysis** (Fizazi et al., 2008) **did not predict response to chemotherapy and thus remain only prognostic.**

Adjuvant Chemotherapy

The use of adjuvant chemotherapy after the finding of viable malignancy at PC-RPLND remains an area of debate. Historically the use of adjuvant chemotherapy has been recommended; however, the exact regimen has been variable with a duration that usually consists of two cycles. **Fizazi et al.** (2001, 2008) **found that adjuvant chemotherapy was associated with a statistically superior PFS but not OS.** As noted above, the indices of complete resection, less than 10% viable tumor, and IGCCCG risk group status are associated with PFS and OS but do not predict response to chemotherapy. **Recommendations for the use of adjuvant chemotherapy should remain individualized considering original IGCCCG risk group stratification, pathology, and extent of surgical resection.** Adjuvant chemotherapy in the NCCN guidelines is currently recommended for incomplete resection as well as intermediate and poor risk disease (Motzer et al., 2015). Similarly, the European Association of Urology guidelines advocate adjuvant chemotherapy after incomplete resection but not in IGCCCG good risk disease where there is less than 10% viable tumor (Albers et al., 2015). However, because of the lack of randomization, firm data to support the use of adjuvant chemotherapy after single-line chemotherapy are lacking. Finally, use of two cycles of adjuvant chemotherapy after second-line or salvage chemotherapy is not recommended because it does not appear to improve outcomes (Fox et al., 1993; Kundu et al., 2010).

Key Points: Histologic Findings at Post-Chemotherapy Retroperitoneal Lymph Node Dissection and Outcomes

- Approximately 90% long-term survival can be expected among patients with fibrosis and/or teratoma only at PC-RPLND. This number is reduced to 50% to 70% for patients demonstrating viable GCT at PC-RPLND.
- Recommendations for adjuvant chemotherapy in patients with residual viable GCT should be individualized, considering original IGCCCG risk group stratification, completeness of resection. and percentage of viable tumor remaining at PC-RPLND.
- Adjuvant chemotherapy is not needed for patients with either fibrosis/necrosis or teratoma on final pathology after PC-RPLND.

Post-Chemotherapy Retroperitoneal Lymph Node Dissection in High-Risk Populations

Salvage Retroperitoneal Node Dissection

Salvage node dissection occurs in a subset of particularly high-risk metastatic testes cancer patients who have demonstrated some degree of platinum resistance and have typically undergone at least 7 to 8 cycles of chemotherapy with first- and second-line chemotherapy to achieve testes serum tumor marker resolution. Classically, histology after RPLND after first-line chemotherapy demonstrates viable malignancy in about 20% of cases. **In the salvage setting the rate of viable GCT can be at least double the rate seen after primary chemotherapy with worse overall survival** (Table 77.6). In a study of 16 patients who underwent salvage RPLND, histopathology from the retroperitoneum demonstrated necrosis in 25% of cases, 31% of cases had teratoma, and 44% of cases harbored residual viable tumor (Alqasem et al., 2016). The OS after salvage RPLND ranges from 60% to 75% (Donohue et al., 1998; Eggener et al., 2007; Fox et al., 1993).

TABLE 77.6

Post-Chemotherapy Retroperitoneal Lymph Node Dissection in High-Risk Populations

STUDY	NO. PATIENTS	TERATOMA (%)	FIBROSIS (%)	VIABLE MALIGNACNY (%)	FOLLOW-UP (YR)	
SALVAGE						
Fox et al., 1993	163	NR	NR	55	5	3
Donohue et al., 1998	166	NR	NR	NR	9.7	6
Eggener et al., 2007a	71	21	51	28	5	7
HDCT						
Rick et al.,	57	16	38	46	7.3	6

2004						
Cary et al., 2011	77	33.8	27.3	39	4.2	7
DESPERATION						
Donohue et al., 1998	150	NR	NR	NR	9.7	6
Ravi et al., 1998	30	26.7	27.6	46.7	4.8	5
Albers et al., 2000	30	11	25	64	11	5
Beck et al., 2005c	114	34.2	12.3	53.5	6	5
Ong et al., 2008	45	25	17	58	4.3	6
REDO						
McKiernan et al., 2003	56	37.5	28.6	33.9	4.1[b] 2.4[c]	5
Sexton et al., 2003	21	67	24	24	4.7	6
Heidenreich et al., 2003	18	33.3	44.4	22.2	1.9	8
Willis et al., 2007	54	35	9	56	5	9
Pedrosa et al., 2014	203	34	14.8	51.2	5	6
LATE RELAPSE						
Baniel et al., 1995a	81	19	0	81	4.8	5
George et al., 2003	83	71	0	78	2.4	7
Dieckmann et al., 2005	72	NR	NR	NR	NR	5
Sharp et al., 2008	75	19	3	78	4.5	6

[a] Includes only patients with viable malignancy in the survival analysis.

[b] Follow-up for post-chemotherapy retroperitoneal lymph node dissection.

[c] Follow-up for primary retroperitoneal lymph node dissection.

CSS, Cancer-specific survival; *HDCT,* high-dose chemotherapy; *NR,* not reported; *OS,* overall survival.

RPLND after third-line chemotherapy is extremely rare. Indiana University has the greatest experience in this setting reporting on 92 patients that underwent PC-RPLND after high-dose chemotherapy and stem cell transplantation (Cary et al., 2015). Histology at the time of PC-RPLND was necrosis in 26%, teratoma in 34%, and residual viable cancer in 38%. At a mean follow-up of 80 months, the 5-year OS was 70%. Obviously, such results require great care in patient selection and emphasize the need for treatment decision making in a multidisciplinary fashion because RPLND can still have a significant role for such high-risk patients (Albany et al., 2018).

Desperation Retroperitoneal Node Dissection

In general, one of the main indications for RPLND after first-, second-, or third-line chemotherapy is the normalization of serum tumor markers. **Desperation RPLND occurs in a special limited setting of persistently elevated STMs despite chemotherapy and should never be undertaken outside of a multidisciplinary setting because this subset of patients are at a particularly high risk of relapse and progression** (Albany et al., 2018). Histology in the studies of patients who underwent desperation RPLND are listed in Table 77.6. Beck et al. reported the outcomes of 116 patients who underwent desperation RPLND with a median follow-up of 6 years, and the 5-year OS was 53.9% (Beck et al., 2005). In this report, on multivariate analysis poor OS was independently associated with patients who underwent desperation RPLND after salvage chemotherapy, patients with an elevated beta hCG before surgery, and patients undergoing repeat RPLND. On the contrary, patients with initially declining STMs after first-line chemotherapy but subsequently plateaus at a detectable level had a greater than 75% chance of having fibrosis or teratoma in the specimen. In this setting, however, fibrosis in the RPLND specimen may portend a worse prognosis because this could indicate the patient has elevated tumor markers resulting from disease outside the retroperitoneum (Ong et al., 2008). Normalization of tumor markers after RPLND was the only variable linked to increased OS in this setting. Who should undergo desperation RPLND? It should generally never be done in the setting of rising tumor markers with rapid doubling times or progressive metastatic disease in multiple sites because this is clearly an indication for salvage chemotherapy or third-line high-dose chemotherapy.

Multi-institutional outcomes of desperation RPLND are in Table 77.6. **Desperation RPLND should be done in patients with limited metastatic**

disease sites (optimally only retroperitoneal but may include thoracic or liver sites) that are completely resectable at the time of RPLND (non-staged), declining/plateauing serum tumor markers, and patients with elevated tumor markers who have exhausted all chemotherapeutic options with resectable disease.

Reoperative Retroperitoneal Node Dissection

Reoperative or “redo” RPLND is usually performed because of technical failure of the first operation leaving behind residual disease at primary staging RPLND or PC-RPLND. This is the main reason RPLND should be performed by experienced high-volume surgeons and, if done minimally invasively by a laparoscopic or robotic approach, the rules of complete dissection must be the same as in the open setting. Despite the preponderance of data demonstrating superior outcomes by high-volume surgeons, data from the American Board of Urology recertification process shows that most RPLNDs are performed by urologists who have performed only one RPLND (Flum et al., 2014). Urologists who performed more than two RPLNDs per year were in the top 25% and 3 RPLNDs per year were in the top 10%. This lack of volume and experience may be one of the factors that contribute to inadequate RPLND.

The largest contemporary series identified 203 patients at a single institution undergoing reoperative RPLND for recurrent retroperitoneal GCT after initial retroperitoneal lymph node dissection with local relapse (Pedrosa et al., 2014). On multivariate analysis, two factors highly associated with local recurrence were incomplete lumbar vessel division at initial resection ($P < 0.01$) and teratoma histology in the reoperative specimen ($P = 0.01$). Only active cancer at reoperation ($P < 0.01$), M1b stage ($P = 0.01$) and salvage chemotherapy before reoperation ($P = 0.02$) were associated worse oncologic outcomes. Several other studies have supported that incomplete surgical control of the retroperitoneum is the main cause of relapse as most recurrences are within the primary landing zone (Heidenreich et al., 2005; McKiernan et al., 2003). Willis et al. (2007), in a series of reoperative RPLND, found 46% of recurrences were retroaortic or retrocaval and omitted at the time of RPLND. Reoperative RPLND can be technically challenging with higher complications and worse overall cancer specific outcomes (see Table 77.6). There is a higher incidence of residual viable GCT with somatic-type malignancies in 15% to 20% of the specimens. **Reoperative RPLND can lead to poor oncologic outcomes and greater**

surgical complications; therefore thorough dissection of the retroperitoneum and complete mobilization of the great vessels at the time of RPLND is mandatory and cannot be overemphasized.

Late Relapse

Late relapse is defined as a recurrence outside the setting of observation occurring 24 months or more after primary management of GCT with initial complete response. Such recurrence after CR is rare and only occurs in 2% to 4% of patients (Baniel et al., 1995; Gerl et al., 1997). The retroperitoneum is the most common site of late relapse (Baniel et al., 1995). Greater than 80% of late relapses have GCT with yolk sac as the dominant histology and additionally a higher incidence of somatic-type malignancy (Baniel et al., 1995; George et al., 2003; Michael et al., 2000; Sharp et al., 2008). **For these reasons, if the recurrent disease is deemed resectable, RPLND should be undertaken as first choice because the dominant histology is usually resistant to chemotherapy. Chemotherapy should be reserved for patients with widespread metastatic or unresectable disease in an attempt to decrease tumor burden and make the disease resectable.** Reported OS is nearly 60% and should be performed in highly select cases. Based upon reported series, factors negatively affecting OS after late relapse PC-RPLND include viable GCT, somatic-type mutation, having received prior salvage chemotherapy, and undergoing incomplete resection of the specimen (Baniel et al., 1995; Michael et al., 2000; Sharp et al., 2008).

Key Points: Post-Chemotherapy Retroperitoneal Lymph Node Dissection in High-Risk Populations

- In the salvage setting the rate of viable GCT at PC-RPLND can be at least double of what is seen after primary chemotherapy with worse overall survival. Although PC-RPLND can still play a role in this setting, it should be done after multidisciplinary decision making.
- Desperation RPLND should never be undertaken outside of a multidisciplinary setting because this subset of patients are at a particularly high risk of relapse and progression.

- Desperation RPLND should be done in patients with limited metastatic disease sites that are completely resectable at the time of RPLND, declining/plateauing serum tumor markers, and patients with elevated tumor markers that have exhausted all chemotherapeutic options with resectable disease.
- Reoperative RPLND is associated with poor oncologic outcomes and greater surgical complications; thorough dissection of the retroperitoneum and complete mobilization of the great vessels at RPLND is mandatory and cannot be overemphasized.

Surgical Outcomes, Functional Considerations, and Complications of Retroperitoneal Lymph Node Dissection

Lymph Node Counts

Lymph node counts have been proposed as a measure of surgical quality and shown to be associated with oncologic outcomes in a number of malignancies (Herr et al., 2002; Le Voyer et al., 2003; Schwarz and Smith, 2006, 2007; Stein et al., 2003). A similar concept has been proposed for RPLND but has met with mixed results. One study out of MSKCC has suggested that increased lymph node counts are associated with increased node positivity for primary RPLND (Thompson et al., 2010). However, in other reports there was no significant association between lymph node counts and node positivity (Liberman et al., 2010; Nayan et al., 2015; Risk et al., 2010). In many such reports there is a wide variability in the reported number of nodes removed. In a number of disease states it is well recognized that multiple factors can influence the nodal count at surgery, including how the tissue is submitted, processed, and analyzed by pathology that have little to do with surgical quality.

Retroperitoneal Lymph Node Dissection and Fertility

Fertility in Patients Undergoing Retroperitoneal Lymph Node Dissection

Because testicular cancer predominantly affects young men, the issue of fertility after therapy can be particularly important. Although RPLND does not affect testicular function or spermatogenesis, subfertility is a common finding in men with testicular cancer. When taking into consideration all stages, abnormal semen parameters have been reported in as high as 40% to 60% of newly diagnosed men (Fossa et al., 1985; Foster et al., 1994; Hansen et al., 1991; Lange et al., 1987). This is important to keep in mind when attempting to report paternity rates for men after therapy for GCT. With these caveats in mind, the rates of live birth in a small cohort of men after therapy for GCT managed with orchiectomy and primary RPLND was reported as 36% (Ping et al., 2014).

Ejaculatory Dysfunction and Retroperitoneal Lymph Node Dissection

Antegrade ejaculation of semen is a complex physiologic process that requires coordinated neurologic input. In particular, **the smooth muscle contraction of the vas deferentia, seminal vesicles, and prostate that results in seminal emission and prostate glandular secretion as well as the subsequent closure of the bladder neck preventing retrograde ejaculation is critically reliant on input from the postganglionic sympathetic fibers that emanate from L1 to L4. These fibers then coalesce at or below the IMA in the hypogastric plexus before traveling caudally in the interiliac space at the sacral promontory** (Donohue et al., 1990).

Because the L1-L4 postganglionic sympathetic fibers course through the retroperitoneum, they were frequently surgically removed, thereby rendering the man anejaculatory at the time of RPLND before the advent of template modification and prospective nerve preservation (Donohue et al., 1991). With a goal of improving ejaculatory function several key modifications to RPLND were made. **The first was a recognition that in carefully selected patients, as discussed previously, a modified unilateral template dissection could be performed that preserved the sympathetic fibers in the majority of men without significantly compromising oncologic outcomes** (Pizzocaro et al., 1985; Weissbach et al., 1985). Early studies in which modified unilateral template RPLND was performed without prospective nerve-sparing demonstrated between 75% and 87% preservation of antegrade ejaculation (Fossa et al., 1985; Pizzocaro et al., 1985; Weissbach et al., 1985). A more recent study shows that with further surgical refinement a 97% rate of antegrade ejaculation in patients after modified, unilateral RPLND without nerve sparing can be achieved (Beck et al., 2010).

The second modification to RPLND that significantly improved postoperative ejaculatory function was a series of studies that demonstrated the postganglionic fibers could be prospectively identified and preserved during RPLND (Jewett and Torbey, 1988). Since the early studies these nerve sparing techniques have been further refined such that current series report preservation of antegrade ejaculation with meticulous prospective sympathetic nerve sparing at 90% to 100% (Beck et al., 2010; Donohue et al., 1990; Heidenreich et al., 2003; Jewett and Torbey, 1988). The initial studies by Jewett and Torbey (1988) reported an anejaculatory period in the immediate postoperative period that subsequently resolved. Later studies have shown that with further refinement the period of transient postoperative anejaculation is no longer apparent (Donohue, 1993), possibly by avoiding undue traction on the nerves and subsequent neuropraxia.

With the development of modified unilateral templates and prospective nerve preservation, ejaculatory function can now be preserved in more than 90% of men undergoing RPLND, particularly in the primary setting. **Indeed paternity rates for men who underwent a nerve-sparing, primary RPLND have been reported as high as 75%** (Beck et al., 2010). Because of the significant and prolonged effect of chemotherapy on spermatogenesis and fertility, the rates of paternity in the PC-RPLND setting have not been well established (Lampe et al., 1997). **Importantly, these approaches to preserving ejaculatory function have not lead to any appreciable decrement in oncologic control.** With follow-up between 10 months and 5 years, only one retroperitoneal recurrence has been reported in the series highlighted here (Beck et al., 2010; Donohue et al., 1990, 1993; Fossa et al., 1985; Heidenreich et al., 2003; Jewett and Torbey, 1988; Pizzocaro et al., 1985; Weissbach et al., 1985).

Complications of Retroperitoneal Lymph Node Dissection

The overall complication rate for primary RPLND has been reported to range from 10.6% to 24% (Baniel et al., 1994; Heidenreich et al., 2003; Subramanian et al., 2010). Historically, complication rates after PC-RPLND appear to occur more frequently in the range of 20% to 30% (Baniel et al., 199; Subramanian et al. 2010; Wells et al., 2017) but may be less common at more experienced centers (Cary et al., 2015). Variability in reported data and expected outcomes is highlighted by the finding that the mean number of RPLNDs performed annually by board-certified urologists is 1 (Flum et al., 2014). Table 77.7 summarizes reported complications for primary and PC-RPLND.

TABLE 77.7

Complications of Retroperitoneal Lymph Node Dissection

	PRIMARY RPLND	PC-RPLND
	BANIEL	**BANIEL**

	ET AL., 1994	HEIDENREICH ET AL., 2003	SUBRAMANIAN ET AL., 2010	ET AL., 1995B	SUBRAMA ET AL., 201
No. patients	478	239	112	603	96
Overall complications (%)	10.6	19.7	24	20.7	32
Major complications (%)	8.2	5.4	3	NS	8
Mortality (%)	0	0	0	0.8	1
Major pulmonary (%)	1.9	0.8	0.9	5.1	3.1
Minor pulmonary (%)	0.2	0.4	3.6	5.1	3.1
Chylous ascites (%)	0.2	2.1	2	2	2
Symptomatic lymphocele (%)	0.2	1.7	0	1.7	1
Ileus (%)	NR	2.1	17.9	2.2	20.8
Wound infection (%)	4.8	5.4	0.9	4.8	4
Pulmonary embolism (%)	0	0.8	0.9	0.1	3.1
Ureteral injury (%)	0.2	0.4	0.9	0.9	0
Small bowel obstruction (%)	2.3	0.4	2.7	2.3	1.8
Postoperative hemorrhage (%)	0	0.8	0	0.3	1

NR, Not reported; *NS,* not studied; *PC-RPLND,* post-chemotherapy retroperitoneal lymph node dissection; *RPLND,* retroperitoneal lymph node dissection.

Pulmonary Complications

Major pulmonary complications after primary RPLND are rare. However, in PC-

RPLND pulmonary complications have been reported to occur in 3% to 5% but may be decreasing with time as surgical teams become aware of the use of bleomycin and its associated risk of pulmonary toxicity (Baniel et al., 1994, 1995; Cary et al., 2015; Heidenreich et al., 2003; Subramanian et al., 2010). **It cannot be overstated that patients treated with bleomycin-containing regimens for induction chemotherapy are at increased risk for acute respiratory distress syndrome and prolonged postoperative ventilation. The incidence of bleomycin-related perioperative pulmonary complications can be minimized by avoiding aggressive intraoperative and postoperative intravenous fluid resuscitation and keeping the FiO_2 as low as safely possible.** As stated previously, the anesthesia team must be notified and skilled in managing patients receiving prior bleomycin. In addition, the postoperative team, including the nursing staff in the PACU and surgical ward must be notified that tachycardia is common after RPLND and that it should not be used as an isolated indicator for fluid management. Finally, nasal cannula O_2 should be used judiciously with tolerance for lower FiO_2 levels (i.e., S02 88-90).

Ileus

The reported rates of postoperative paralytic ileus vary widely but can occur up to 21% of the time in primary or PC-RPLND. Use of an extraperitoneal approach may significantly decrease this possibility (Syan-Bhanvadia et al., 2017). We do not advocate routine use of a nasogastric tube and, unless there are extenuating circumstances, always provide some enteric feeding on postoperative day 1.

Lymphocele

The exact rates of lymphoceles after RPLND is unknown because most are subclinical. Symptomatic lymphoceles are very rare and have been reported to occur in up to 1.7% of cases (Baniel et al., 1994, 1995; Heidenreich et al. 2003; Subramanian et al., 2010). Presenting symptoms are usually characterized by a sense of abdominal fullness or flank pain secondary to ureteral compression. Cross-sectional imaging demonstrates a thin-walled cystic lesion located within the resection bed. Air within the lymphocele and/or a rim of enhancement should raise concern for an infection. Treatment for symptomatic or infected lymphoceles is carried out by percutaneous drainage. Antibiotics should be reserved for those who are perceived to be infected, and in this case consideration should also be given to leaving a drain. **Prevention of lymphocele occurs through meticulous surgery with care to clip or ligate lymphatic channels as noted previously.**

Chylous Ascites

Chylous ascites is the accumulation of lipid-rich lymph fluid within the peritoneal cavity. It has been reported to occur in 0.2% to 2.1% of patients undergoing primary RPLND and 2% to 7% of patients undergoing PC-RPLND with lower rates in more recent series (Baniel et al., 1994, 1995; Cary et al., 2015; Evans et al., 2006; Heidenreich et al., 2003; Subramanian et al., 2010). The most common presenting symptoms are an increase in abdominal girth, fullness, anorexia, and weight gain. If the ascites is large, the patients may complain of dyspnea secondary to diaphragmatic restriction. **Diagnosis is usually made through clinical suspicion and cross-sectional imaging such as a CT scan. The fluid is classically a milky color when paracentesis is performed. In addition, it usually has a high protein content (>3 g/dL) as well as a triglyceride level that is two-eight times that of serum.**

Suprahilar resections are thought to carry a higher risk for chylous ascites because of disruption of the cisterna chyli and its contributing lymphatics. The location of the cisterna chyli is variable but generally lies at the level of the L1-L2 vertebral bodies at or just above the level of the renal vessels. Most consistently it has been reported to be located posterior to the aorta behind the left crus of the diaphragm, but a distinct cisterna chyli is believed to be present only about half of the time (Leibovitch et al., 2002).

Patients presenting with symptomatic chylous ascites should first undergo paracentesis without leaving a drain. If rapid accumulation occurs, we leave a drain and cap it off for interval release. In addition, the patient should be given a very low-fat, high-protein diet with replacement of medium chain triglycerides and use of intramuscular octreotide. Octreotide has not been shown in the urologic literature to reduce lymph fluid, but it has demonstrated efficacy-reducing chylous leaks after hepaticopancreaticobiliary surgery (Kuboki et al., 2013; Shapiro et al., 1996). Persistent high-volume leak is rare. If initial dietary modifications fail to adequately address the leak, then the next step is to make the patient NPO and institute parenteral nutrition. If after this the chylous drainage remains significant, then options for management include continued observation or attempted invasive intervention. The latter includes lymphangiogram/lymphoscintigraphy with consideration to percutaneous embolization, peritoneovenous shunt, and surgical exploration. The consideration of invasive options should be reserved as a last resort in high-volume leaks that have not improved over several days to weeks or when electrolyte abnormalities and protein loss are unmanageable with conservative efforts. After resolution of chylous ascites, a low-fat diet should be continued for at least 4 weeks after resolution with gradual reinstitution of a regular diet.

Venous Thromboembolism

The incidence of venous thromboembolism (VTE) after RPLND, although not known with great precision, is thought to be low. Most likely this is secondary to the young, otherwise healthy population who usually undergo RPLND. After primary RPLND, VTE complications have been reported to occur in less than 1% of cases (Baniel et al., 1994; Heidenreich et al., 2003; Subramanian et al., 2010). After PC-RPLND the rates range from 0.1% to 3.1% (Baniel et al., 1995, Cary et al., 2015; Subramanian et al., 2010).

Patients undergoing RPLND should receive sequential compression devices in the preoperative holding area. Early ambulation on postoperative day 0 should be encouraged along with significant periods of time out of bed to chair. The specific use of prophylactic subcutaneous low-dose unfractionated heparin or low-molecular-weight heparin has not been studied after RPLND. However, it has been well documented to reduce VTE rates in patients undergoing surgery in general (Collins et al., 1988; Kakkar et al., 1993). In addition, contemporary reports on patients receiving first-line bleomycin chemotherapy have a deep venous thrombosis (DVT) rate of 12.7%, suggesting that post-chemotherapy patients may have an increased risk (Gizzi et al., 2016). We advocate for pharmacologic thromboprophylaxis in patients undergoing RPLND, especially those with a history of VTE, hypercoagulable conditions, obesity, and prior chemotherapy (particularly those who have received bleomycin).

Neurologic Complications

Peripheral nerve injury has been reported, albeit rarely (Baniel et al., 1995, Cary et al., 2015). All cases are presumed to be secondary to patient positioning or potentially secondary to retractor position (femoral neuropraxia). Careful positioning and discussion with the operative team is important to minimize the possibility of this complication. Post-chemotherapy patients with bulky mediastinal or RP disease may have an increased risk of paraplegia (Kesler et al.,

2003).

Mortality

Morality after primary RPLND is excessively rare (Baniel et al., 1994; Capitanio et al., 2009; Heidenreich et al., 2003, Subramanian et al., 2010). In addition, mortality after PC-RPLND is also rare, reported to be less than 1% and, when reported, most often secondary to pulmonary embolism, duodenal fistula, myocardial infarction, and chylous ascites (Baniel et al., 1995; Capitanio et al., 2009; Cary et al., 2015; Subramanian et al., 2010).

Key Points: Surgical Outcomes, Functional Considerations, and Complications of Retroperitoneal Lymph Node Dissection

- Through the use of modified templates and bilateral nerve-sparing techniques, preservation of antegrade ejaculation should be expected in most patients undergoing primary RPLND. These techniques can be used during PC-RPLND with similar outcomes, although this is not always possible in cases of large retroperitoneal masses.
- Although major complications are rare following primary RPLND, bleomycin related pulmonary toxicity should always be considered in those undergoing PC-RPLND. Perioperative attention to FiO_2, judicious fluid management, and communication with anesthesia is critical to minimize the potential for respiratory distress syndrome
- Although rare, chylous ascites can be a challenging complication to manage. Careful attention to retroperitoneal lymphatic anatomy with ligation of lymphatic channels is thought to minimize the risk of this complication

Retroperitoneal Lymph Node Dissection in Unique Situations

Post-Chemotherapy Retroperitoneal Node Dissection for Seminoma

Pure seminoma is an exquisitely chemosensitive cancer that has been shown to have complete response rates from 70% to 90% with platinum-based chemotherapy even in widely metastatic disease (Loehrer, Birch et al. 1987, 1997, Gholam, Fizazi et al. 2003). **Therefore, it is rare to have residual retroperitoneal masses after chemotherapy. Retroperitoneal node dissection in this setting can be extremely difficult due to dense desmoplastic fibrosis with viable tumor found in only 10% of cases (Herr, Sheinfeld et al., 1997; Ravi, Ong et al., 1999; Flechon, Bompas et al., 2002).** The desmoplastic fibrosis in post-chemotherapy RPLND for seminoma has been well demonstrated to cause more operative complications compared with RPLND for nonseminomatous disease (Fossa et al., 1987; Friedman et al., 1985; Mosharafa et al., 2003). **RPLND in the pure seminoma post-chemotherapy patient must be carefully selected because of the low incidence of viable cancer, absence of teratoma that can be seen in nonseminomatous disease, and high fibrosis rate resulting in difficult and potentially morbid surgery.**

In a study from MSKCC, 55 patients who had pure seminoma underwent post-chemotherapy RPLND or biopsy obtaining tissue for correlation and found that for masses larger than 3 cm only 30% had viable cancer or teratoma (Herr et al., 1997). On the contrary, all patients had fibrosis on tissue obtained from masses smaller than 3 cm. From this data, the standard of care is now to observe all masses less than 3 cm in patients treated with platinum-based chemotherapy for pure seminoma. It was also recommended that all patients with masses greater than 3 cm undergo PC-RPLND. Unfortunately, 70% of patients with residual masses larger than 3 cm have fibrosis in the PC-RPLND setting and still undergo a potentially morbid procedure. Data from Indiana University regarding observation of residual masses in 21 patients post-chemotherapy for pure seminoma found that there was no correlation with residual masses size and disease relapse/progression. The authors recommended observing all masses unless they demonstrated serologic or radiographic progression. Given the controversy, alternatives have been sought that could better identify which patients may be harboring residual viable GCT. **It is in this setting in which FDG-PET scans have been shown to play a role in testes cancer decision making, specifically on whether RPLND is indicated on post-chemotherapy retroperitoneal masses greater than 3 cm in the setting of pure seminoma after chemotherapy.** DeSantis et al. (2004) studied the role of PET in such residual masses and correlated the findings by histology or radiographic/serologic progression. Out of 51 patients with residual masses, all 19 masses larger than 3 cm and 35 (95%) of 37 with residual lesions of 3 cm or smaller were correctly predicted by FDG-PET. For masses larger than 3 cm, the specificity was 100%, sensitivity 80%, positive predictive value 100%, and negative predictive value was 96%. For masses smaller than 3 cm, the specificity was 74%, sensitivity 70%, positive predictive value 37%, and negative predictive value were 92%. **Residual masses less than 3 cm have a fibrosis rate that is nearly 100% historically and with a low negative predictive value on PET scan, there is little to no role for PET imaging of masses smaller than 3 cm. However, for masses greater than 3 cm, PET is a useful adjunct in the clinical decision to obverse versus surgically treat. Some oncology guidelines have added PET scan for pure seminoma post-chemotherapy masses greater than 3 cm and observation for masses less than 3 cm** (Motzer et al., 2015) **or as a general tool for suspicious retroperitoneal masses after chemotherapy** (Albers et al., 2015)**. Masses greater than 3 cm that are PET avid should be treated by PC-RPLND, salvage chemotherapy, or high-dose chemotherapy (HDCT) with stem cell transplantation.** There is some controversy as to whether patients with a residual PET-avid retroperitoneal mass after chemotherapy for pure seminoma should undergo RPLND versus salvage chemotherapy because residual seminoma in the PC-RPLND specimen is an ominous prognosis. Rice et al. reported the Indiana University experience with 36 patients who underwent PC-RPLND after primary or salvage chemotherapy for pure seminoma and found there was a 54% 5-year cancer specific survival with a mean time from PC-RPLND to death of 6.9 months (Rice et al., 2014). Only 9 of 36 patients remained continuously free of disease. HDCT has demonstrated a 92% overall survival in the second line setting and 64% in the third- or fourth-line setting with pure seminoma and in this subset should be considered as an alternative to consolidative surgery (Agarwala et al., 2011). In general, PC-RPLND in the pure seminoma setting should only be performed for PET-avid masses that are easily resectable in very limited select cases that could spare the morbidity of HDCT or in patients who are chemotherapy ineligible.

Post-Chemotherapy Retroperitoneal Node Dissection for Sex Cord Stromal Tumors

Sex cord stromal tumors (SCSTs) are exceedingly rare, accounting for less than 5% of testes neoplasm. SCST consists of Leydig cell, Sertoli cell, and granulosa cell tumors in pure or mixed histology. Because these are rare tumors, challenges in management exist because there are few large case series to extrapolate data. Adult granulosa cell tumors are the rarest tumor of the testes with less than 50 cases reported in the literature. From a clinicopathologic standpoint, outside of metastatic disease it can be challenging to appropriately diagnose a malignant sex cord stromal tumor. Generally, malignant behavior is correlated with older age of diagnosis, tumor size greater than 4 cm, necrosis, mitotic rate greater than 3–5/10 high-powered fields, moderate to severe nuclear atypia, infiltrative tumor margins/invasion of adjacent structures, and lymphovascular invasion (Dilworth et al., 1991; Kim et al., 1985; Kratzer et al., 1997; Rove et al., 2015; Young et al., 1998). Multiple factors may be present or one or two (Kim et al., 1985; Rove et al., 2015; Young et al., 1998). Some authors suggest, if two or more pathologic variables are present, to categorize such tumors as malignant (Kratzer et al., 1997; Silberstein et al., 2014). **However, in general, prospectively classifying a given tumor as benign or malignant histologically remains challenging.**

Behavior of Sertoli cell and Leydig cell tumors can be difficult to categorize because few centers have any high-volume experience in this subset of patients. For example, Banerji et al. (2016) reviewed a national cancer registry from 1998 to 2011 and out of 79,120 cases of testicular cancer, found a total of 315 (0.39%) Sertoli cell and Leydig cell tumors (Banerji et al., 2016), demonstrating how exceedingly rare these tumors are found. Osbun et al. (2017) used SEER data between 2004 and 2012 to better characterize Sertoli cell and Leydig cell tumors. According to this SEER data only 0.6% of testes tumors had Sertoli cell (n = 31) or Leydig cell (n = 76) histology. Only 3% of germ cell neoplasm patients were African-American, whereas 23% of Sertoli cell and 24% of Leydig cell tumor patients were African-American. Sertoli cell and Leydig cell tumor patients were typically older compared with GCT. Leydig cell tumors most commonly presented with stage I disease (98.5%), whereas patients with Sertoli cell tumors presented at higher stages (35% with stage II/III). Cancer-specific mortality was the highest in the Sertoli cell tumors (32%) compared with the Leydig cell (2%) and GCT in general (7%). This data and others consistently show that Sertoli cell tumors can have aggressive behavior.

Because of low incidence of SCST, the role of RPLND in this subgroup is not well established. As discussed previously, according to SEER data, Leydig cell tumors are predominantly early stage compared with 35% of Sertoli cell tumors presenting at a more advanced stage and generally portending a worse prognosis (Osbun et al., 2017). **It has been difficult to determine if RPLND can treat limited metastatic spread for SCSTs.** Mosharafa et al. (2003) reported data from Indiana University on RPLND for SCSTs in 17 patients. Eight patients had stage II to III disease, of whom 6 (75%) died from metastatic disease despite additional therapies (Mosharafa et al., 2003). Yuh et al. (2017) presented data from the California cancer registry that identified 67 patients with SCST. Nine patients underwent RPLND. Data on outcomes demonstrated that, in patients with stage II disease, the cancer-specific and overall survival was only 30%. Presence of metastatic disease was the only predictor of survival. **In summary, there is no conclusive evidence in the literature that RPLND affects survival in the metastatic setting regarding malignant SCSTs, and therefore it likely plays only a limited role in this subset of germ cell neoplasms.**

Key Points: Retroperitoneal Lymph Node Dissection in Unique Situations

- Patients with a residual retroperitoneal mass less than 3 cm in size after chemotherapy for pure seminoma should be observed as the probability of viable GCT is very low.
- An FDG-PET scan is indicated to assess for viable GCT in post-chemotherapy residual retroperitoneal masses more than 3 cm in patients with pure seminoma.
- An FDG-PET–avid retroperitoneal mass greater that 3 cm after chemotherapy for seminoma should be treated by PC-RPLND, salvage chemotherapy, or HDCT with stem cell transplantation.
- The role for RPLND for malignant SCSTs remains unknown because it does not appear to improve survival for these neoplasms.

Conclusion

The management of testicular cancer has evolved and now represents one of the great success stories in oncology. With modern therapeutic approaches, cure can now be expected in more than 90% of men diagnosed with testis cancer. Although much of this success is due to the advent of cisplatin based multiagent chemotherapy, surgery retains a central and critical role in the management of this disease. The urologist is typically the physician who first diagnoses testis cancer and often is the one who helps shepherd patients through their cancer journey. It is vital that the urologic surgeon understand the nuances of testis cancer management and work within the framework of a multidisciplinary team to ensure the best care for the patient. Indeed, success is now measured not only by the survival of the patient, but also by accomplishment of this with the least morbidity and treatment burden necessary. Thus refinements in surgery have sought to improve the quality of life and to avoid long-term sequelae while maintaining oncologic efficacy. The urologist therefore remains a key element in the management of testicular malignancies, and surgery (including RPNLND) retains a central role in the successful management of this disease.

References

Agarwala AK, Perkins SM, Abonour R, et al. Salvage chemotherapy with high-dose carboplatin and etoposide with peripheral blood stem cell transplant in patients with relapsed pure seminoma. *Am J Clin Oncol*. 2011;34(3):286–288.

Al-Ahmadie HA, Carver BS, Cronin AM, et al. Primary retroperitoneal lymph node dissection in low-stage testicular germ cell tumors: a detailed pathologic study with clinical outcome analysis with special emphasis on patients who did not receive adjuvant therapy. *Urology*. 2013;82(6):1341–1346.

Alanee SR, Carver BS, Feldman DR, et al. Pelvic lymph node dissection in patients treated for testis cancer: the Memorial Sloan Kettering Cancer Center Experience. *Urology*. 2016;95:128–131.

Albany C, Adra N, Snavely AC, et al. Multidisciplinary clinic approach improves overall survival outcomes of patients with metastatic germ-cell tumors. *Ann Oncol*. 2018;29(2):341–346.

Albers P, et al. Salvage surgery of chemorefractory germ cell tumors with elevated tumor markers. *J Urol*. 2000;164(2):381–384.

Albers P, Weissbach L, Krege S, G. German Testicular Cancer Study, et al. Prediction of necrosis after chemotherapy of advanced germ cell tumors: results of a prospective multicenter trial of the German Testicular Cancer Study Group. *J Urol*. 2004;171(5):1835–1838.

Albers P, Albrecht W, Algaba F, U. European Association of, et al. Guidelines on testicular cancer: 2015 update. *Eur Urol*. 2015;68(6):1054–1068.

Alqasem K, Abukhiran I, Jasser J, et al. Clinico-pathological outcomes of post- primary and salvage chemotherapy retroperitoneal lymph node dissection for mixed germ cell tumors, King Hussein Cancer Center experience. *Turk J Urol*. 2016;42(4):256–260.

Banerji JS, Odem-Davis K, Wolff EM, et al. Patterns of care and survival outcomes for malignant sex cord stromal testicular cancer: results from the national cancer data base. *J Urol*. 2016;196(4):1117–1122.

Baniel J, Foster RS, Rowland RG, et al. Complications of primary retroperitoneal lymph node dissection. *J Urol*. 1994;152(2 Pt 1):424–427.

Baniel J, Foster RS, Rowland RG, et al. Complications of post-chemotherapy retroperitoneal lymph node dissection. *J Urol*. 1995;153(3 Pt 2):976–980.

Baniel J, Foster RS, Gonin R, et al. Late relapse of testicular cancer. *J Clin Oncol*. 1995;13(5):1170–1176.

Beck SD, et al. Impact of the number of positive lymph nodes on disease-free survival in patients with pathological stage B1 nonseminomatous germ cell tumor. *J Urol*. 2005;174(1):143–145.

Beck SD, Foster RS. Long-term outcome of retroperitoneal lymph node dissection in the management of testis cancer. *World J Urol*. 2006;24(3):267–272.

Beck SD, Lalka SG. Long-term results after inferior vena caval resection during retroperitoneal lymphadenectomy for metastatic germ cell cancer. *J Vasc Surg*. 1998;28(5):808–814.

Beck SD, Bey AL, Bihrle R, et al. Ejaculatory status and fertility rates after primary retroperitoneal lymph node dissection. *J Urol*. 2010;184(5):2078–2080.

Beck SD, Cheng L, Bihrle R, et al. Does the presence of extranodal extension in pathological stage B1 nonseminomatous germ cell tumor necessitate adjuvant chemotherapy? *J Urol*. 2007;177(3):944–946.

Beck SD, Foster RS, Bihrle R, et al. Is full bilateral retroperitoneal lymph node dissection always necessary for postchemotherapy residual tumor? *Cancer*. 2007;110(6):1235–1240.

Beck SD, Foster RS, Bihrle R, et al. Does the histology of nodal metastasis predict systemic relapse after retroperitoneal lymph node dissection in pathological stage B1 germ cell tumors? *J Urol*. 2005;174(4 Pt 1):1287–1290 [discussion 1290].

Beck SD, Foster RS, Bihrle R, et al. Outcome analysis for patients with elevated serum tumor markers at postchemotherapy retroperitoneal lymph node dissection. *J Clin Oncol*. 2005;23(25):6149–6156.

Beck SD, Foster RS, Bihrle R, et al. Long-term outcome for patients with high volume retroperitoneal teratoma undergoing post-chemotherapy surgery. *J Urol*. 2009;181(6):2526–2532.

Beck SD, Foster RS, Bihrle R, et al. Aortic replacement during post-chemotherapy retroperitoneal lymph node dissection. *J Urol*. 2001;165(5):1517–1520.

Behnia M, Foster R, Einhorn LH, et al. Adjuvant bleomycin, etoposide and cisplatin in pathological stage II non-seminomatous testicular cancer. the Indiana University experience. *Eur J Cancer*. 2000;36(4):472–475.

Besse B, Grunenwald D, Flechon A, et al. Nonseminomatous germ cell tumors: assessing the need for postchemotherapy contralateral pulmonary resection in patients with ipsilateral complete necrosis. *J Thorac Cardiovasc Surg*. 2009;137(2):448–452.

Beveridge TS, Allman BL, Johnson M, et al. Retroperitoneal lymph node dissection: anatomical and technical considerations from a cadaveric study. *J Urol*.

2016;196(6):1764–1771.

Bokemeyer C, Schmoll HJ, Schoffski P, et al. Bilateral testicular tumours: prevalence and clinical implications. *Eur J Cancer*. 1993;29A(6):874–876.

Bosl GJ, Vogelzang NJ, Goldman A, et al. Impact of delay in diagnosis on clinical stage of testicular cancer. *Lancet*. 1981;2(8253):970–973.

Brown JA, Bihrle R, Foster RS. Delayed orchiectomy at postchemotherapy retroperitoneal lymph node dissection due to laterality of retroperitoneal metastatic pattern consistent with testicular primary: assessment of pathologic findings. *Urology*. 2008;71(5):911–914.

Capitanio U, Jeldres C, Perrotte P, et al. Population-based study of perioperative mortality after retroperitoneal lymphadenectomy for nonseminomatous testicular germ cell tumors. *Urology*. 2009;74(2):373–377.

Carmignani L, Gadda F, Bozzini G. Impalpable testis cancer. *BJU Int*. 2004;93(6):887–888.

Carver BS, Shayegan B, Serio A, et al. Long-term clinical outcome after postchemotherapy retroperitoneal lymph node dissection in men with residual teratoma. *J Clin Oncol*. 2007;25(9):1033–1037.

Carver BS, Shayegan B, Eggener S, et al. Incidence of metastatic nonseminomatous germ cell tumor outside the boundaries of a modified postchemotherapy retroperitoneal lymph node dissection. *J Clin Oncol*. 2007;25(28):4365–4369.

Carver BS, Bajorin D, Motzer RJ, et al. Improved clinical outcome for men with fibrosis at post chemotherapy retroperitoneal lymph node dissection for metastatic non-seminomatous germ cell tumors. *J Urol*. 2007;177:330.

Carver BS, Bianco FJ Jr, Shayegan B, et al. Predicting teratoma in the retroperitoneum in men undergoing post-chemotherapy retroperitoneal lymph node dissection. *J Urol*. 2006;176(1):100–103 [discussion 103–104].

Cary KC, Beck SD, Bihrle R, et al. Outcomes of post-chemotherapy retroperitoneal lymph node dissection following high-dose chemotherapy with stem cell transplant. *J Urol*. 2011;185:e237.

Cary C, Pedrosa JA, Jacob J, et al. Outcomes of postchemotherapy retroperitoneal lymph node dissection following high-dose chemotherapy with stem cell transplantation. *Cancer*. 2015;121(24):4369–4375.

Cary C, Masterson TA, Bihrle R, et al. Contemporary trends in postchemotherapy retroperitoneal lymph node dissection: additional procedures and perioperative complications. *Urol Oncol*. 2015;33(9):389 [e315–e321].

Cary KC, Pedrosa JA, Kaimakliotis HZ, et al. The impact of bleomycin on retroperitoneal histology at post-chemotherapy retroperitoneal lymph node dissection of good risk germ cell tumors. *J Urol*. 2015;193(2):507–512.

Cary KC, Beck SD, Bihrle R, et al. Clinical and pathological features predictive of nephrectomy at post-chemotherapy retroperitoneal lymph node dissection. *J Urol*. 2013;189(3):812–817.

Chapple A, Ziebland S, McPherson A. Qualitative study of men's perceptions of why treatment delays occur in the UK for those with testicular cancer. *Br J Gen Pract*. 2004;54(498):25–32.

Che M, Tamboli P, Ro JY, et al. Bilateral testicular germ cell tumors: twenty-year experience at M. D. Anderson Cancer Center. *Cancer*. 2002;95(6):1228–1233.

Cho JS, Kaimakliotis HZ, Cary C, et al. Modified retroperitoneal lymph node dissection for post-chemotherapy residual tumour: a long-term update. *BJU Int*. 2017;120(1):104–108.

Clifford TG, Burg ML, Hu B, et al. Satisfaction with testicular prosthesis after radical orchiectomy. *Urology*. 2018;114:128–132.

Colleselli K, Poisel S, Schachtner W, et al. Nerve-preserving bilateral retroperitoneal lymphadenectomy: anatomical study and operative approach. *J Urol*. 1990;144(2 Pt 1):293–297 [discussion 297–298].

Collins R, Scrimgeour A, Yusuf S, et al. Reduction in fatal pulmonary embolism and venous thrombosis by perioperative administration of subcutaneous heparin. Overview of results of randomized trials in general, orthopedic, and urologic surgery. *N Engl J Med*. 1988;318(18):1162–1173.

Coogan CL, Foster RS, Simmons GR, et al. Bilateral testicular tumors: management and outcome in 21 patients. *Cancer*. 1998;83(3):547–552.

Daugaard G, Gundgaard MG, Mortensen MS, et al. Surveillance for stage I nonseminoma testicular cancer: outcomes and long-term follow-up in a population-based cohort. *J Clin Oncol*. 2014;32(34):3817–3823.

Daugaard G, Rorth M, von der Maase H, et al. Management of extragonadal germ-cell tumors and the significance of bilateral testicular biopsies. *Ann Oncol*. 1992;3(4):283–289.

De Santis M, Becherer A, Bokemeyer C, et al. 2-18fluoro-deoxy-D-glucose positron emission tomography is a reliable predictor for viable tumor in postchemotherapy seminoma: an update of the prospective multicentric SEMPET trial. *J Clin Oncol*. 2004;22(6):1034–1039.

Dieckmann KP, Anheuser P, Schmidt S, et al. Testicular prostheses in patients with testicular cancer—acceptance rate and patient satisfaction. *BMC Urol*. 2015;15:16.

Dilworth JP, Farrow GM, Oesterling JE. Non-germ cell tumors of testis. *Urology*. 1991;37(5):399–417.

Djaladat H, Nichols C, Daneshmand S. Adjuvant surgery in testicular cancer patients undergoing postchemotherapy retroperitoneal lymph node dissection. *Ann Surg Oncol*. 2012;19(7):2388–2393.

Donohue JP. Nerve-sparing retroperitoneal lymphadenectomy for testis cancer. Evolution of surgical templates for low-stage disease. *Eur Urol*. 1993;23(Suppl 2):44–46.

Donohue JP, Rowland RG. Complications of retroperitoneal lymph node dissection. *J Urol*. 1981;125(3):338–340.

Donohue JP, Foster RS. Management of retroperitoneal recurrences. Seminoma and nonseminoma. *Urol Clin North Am*. 1994;21(4):761–772.

Donohue JP, Leviovitch I, Foster RS, et al. Integration of surgery and systemic therapy: results and principles of integration. *Semin Urol Oncol*. 1998;16(2):65–71.

Donohue JP, Thornhill JA, Foster RS, et al. Resection of the inferior vena cava or intraluminal vena caval tumor thrombectomy during retroperitoneal lymph node dissection for metastatic germ cell cancer: indications and results. *J Urol*. 1991;146(2):346–349.

Donohue JP, Thornhill JA, Foster RS, et al. Primary retroperitoneal lymph node dissection in clinical stage A non-seminomatous germ cell testis cancer. Review of the Indiana University experience 1965-1989. *Br J Urol*. 1993;71(3):326–335.

Donohue JP, Thornhill JA, Foster RS, et al. Retroperitoneal lymphadenectomy for clinical stage A testis cancer (1965 to 1989): modifications of technique and impact on ejaculation. *J Urol*. 1993;149(2):237–243.

Donohue JP, Thornhill JA, Foster RS, et al. Clinical stage B non-seminomatous germ cell testis cancer: the Indiana University experience (1965-1989) using routine primary retroperitoneal lymph node dissection. *Eur J Cancer*. 1995;31A(10):1599–1604.

Donohue JP, Zachary JM, Maynard BR. Distribution of nodal metastases in nonseminomatous testis cancer. *J Urol*. 1982;128(2):315–320.

Donohue JP, Roth LM, Zachary JM, et al. Cytoreductive surgery for metastatic testis cancer: tissue analysis of retroperitoneal masses after chemotherapy. *J Urol*. 1982;127(6):1111–1114.

Donohue JP, Foster RS, Rowland RG, et al. Nerve-sparing retroperitoneal lymphadenectomy with preservation of ejaculation. *J Urol*. 1990;144(2 Pt 1):287–291 [discussion 291–282].

Eggener SE, Carver BS, Sharp DS, et al. Incidence of disease outside modified retroperitoneal lymph node dissection templates in clinical stage I or IIA nonseminomatous germ cell testicular cancer. *J Urol*. 2007;177(3):937–942 [discussion 942–943].

Eggener SE, Carver BS, Loeb S, et al. Pathologic findings and clinical outcome of patients undergoing retroperitoneal lymph node dissection after multiple chemotherapy regimens for metastatic testicular germ cell tumors. *Cancer*. 2007;109(3):528–535.

Ehrlich Y, Brames MJ, Beck SD, et al. Long-term follow-up of Cisplatin combination chemotherapy in patients with disseminated nonseminomatous germ cell tumors: is a postchemotherapy retroperitoneal lymph node dissection needed after complete remission? *J Clin Oncol*. 2010;28(4):531–536.

Ehrlich Y, Yossepowitch O, Kedar D, et al. Distribution of nodal metastases after chemotherapy in nonseminomatous testis cancer: a possible indication for limited dissection. *BJU Int*. 2006;97(6):1221–1224.

Einhorn LH, Donohue J. Cis-diamminedichloroplatinum, vinblastine, and bleomycin combination chemotherapy in disseminated testicular cancer. *Ann Intern Med*. 1977;87(3):293–298.

Evans JG, Spiess PE, Kamat AM, et al. Chylous ascites after post-chemotherapy retroperitoneal lymph node dissection: review of the M. D. Anderson experience. *J Urol*. 2006;176(4 Pt 1):1463–1467.

Fadel E, Court B, Chapelier AR, et al. One-stage approach for retroperitoneal and mediastinal metastatic testicular tumor resection. *Ann Thorac Surg*. 2000;69(6):1717–1721.

Fizazi K, Oldenburg J, Dunant A, et al. Assessing prognosis and optimizing treatment in patients with postchemotherapy viable nonseminomatous germ-cell tumors (NSGCT): results of the sCR2 international study. *Ann Oncol*. 2008;19(2):259–264.

Fizazi K, Tjulandin S, Salvioni R, et al. Viable malignant cells after primary chemotherapy for disseminated nonseminomatous germ cell tumors: prognostic factors and role of postsurgery chemotherapy–results from an international study group. *J Clin Oncol*. 2001;19(10):2647–2657.

Flechon A, Bompas E, Biron P, et al. Management of post-chemotherapy residual masses in advanced seminoma. *J Urol*. 2002;168(5):1975–1979.

Flum AS, Bachrach L, Jovanovic BD, et al. Patterns of performance of retroperitoneal lymph node dissections by American urologists: most retroperitoneal lymph node dissections in the United States are performed by low-volume surgeons. *Urology*. 2014;84(6):1325–1328.

Fossa SD, Chen J, Schonfeld SJ, et al. Risk of contralateral testicular cancer: a population-based study of 29,515 U.S. men. *J Natl Cancer Inst*. 2005;97(14):1056–1066.

Fossa SD, Borge L, Aass N, et al. The treatment of advanced metastatic seminoma: experience in 55 cases. *J Clin Oncol*.

1987;5(7):1071–1077.

Fossa SD, Ous S, Abyholm T, et al. Post-treatment fertility in patients with testicular cancer. I. Influence of retroperitoneal lymph node dissection on ejaculatory potency. *Br J Urol*. 1985;57(2):204–209.

Foster RS, McNulty A, Rubin LR, et al. The fertility of patients with clinical stage I testis cancer managed by nerve sparing retroperitoneal lymph node dissection. *J Urol*. 1994;152(4):1139–1142 [discussion 1142–1143].

Fox EP, Weathers TD, Williams SD, et al. Outcome analysis for patients with persistent nonteratomatous germ cell tumor in postchemotherapy retroperitoneal lymph node dissections. *J Clin Oncol*. 1993;11(7):1294–1299.

Fraley EE, Narayan P, Vogelzang NJ, et al. Surgical treatment of patients with stages I and II nonseminomatous testicular cancer. *J Urol*. 1985;134(1):70–73.

Friedman EL, Garnick MB, Stomper PC, et al. Therapeutic guidelines and results in advanced seminoma. *J Clin Oncol*. 1985;3(10):1325–1332.

Gascoigne P, Mason MD, Roberts E. Factors affecting presentation and delay in patients with testicular cancer: results of a qualitative study. *Psychooncology*. 1999;8(2):144–154.

Gels ME, Hoekstra HJ, Sleijfer DT, et al. Thoracotomy for postchemotherapy resection of pulmonary residual tumor mass in patients with nonseminomatous testicular germ cell tumors: aggressive surgical resection is justified. *Chest*. 1997;112(4):967–973.

George DW, Foster RS, Hromas RA, et al. Update on late relapse of germ cell tumor: a clinical and molecular analysis. *J Clin Oncol*. 2003;21(1):113–122.

Gerl A, Clemm C, Schmeller N, et al. Sequential resection of residual abdominal and thoracic masses after chemotherapy for metastatic non-seminomatous germ cell tumours. *Br J Cancer*. 1994;70(5):960–965.

Gerl A, Clemm C, Schmeller N, et al. Late relapse of germ cell tumors after cisplatin-based chemotherapy. *Ann Oncol*. 1997;8(1):41–47.

Gholam D, Fizazi K, Terrier-Lacombe MJ, et al. Advanced seminoma–treatment results and prognostic factors for survival after first-line, cisplatin-based chemotherapy and for patients with recurrent disease: a single-institution experience in 145 patients. *Cancer*. 2003;98(4):745–752.

Giannarini G, Dieckmann KP, Albers P, et al. Organ-sparing surgery for adult testicular tumours: a systematic review of the literature. *Eur Urol*. 2010;57(5):780–790.

Gizzi M, Oberic L, Massard C, et al. Predicting and preventing thromboembolic events in patients receiving cisplatin-based chemotherapy for germ cell tumours. *Eur J Cancer*. 2016;69:151–157.

Goddi A, Sacchi A, Magistretti G, et al. Real-time tissue elastography for testicular lesion assessment. *Eur Radiol*. 2012;22(4):721–730.

Groeschl RT, Pilgrim CH, Hanna EM, et al. Microwave ablation for hepatic malignancies: a multiinstitutional analysis. *Ann Surg*. 2014;259(6):1195–1200.

Haas GP, Shumaker BP, Cerny JC. The high incidence of benign testicular tumors. *J Urol*. 1986;136(6):1219–1220.

Hansen PV, Glavind K, Panduro J, et al. Paternity in patients with testicular germ cell cancer: pretreatment and post-treatment findings. *Eur J Cancer*. 1991;27(11):1385–1389.

Hartmann JT, Fossa SD, Nichols CR, et al. Incidence of metachronous testicular cancer in patients with extragonadal germ cell tumors. *J Natl Cancer Inst*. 2001;93(22):1733–1738.

Heidenreich A, Ohlmann C, Hegele A, et al. Repeat retroperitoneal lymphadenectomy in advanced testicular cancer. *Eur Urol*. 2005;47(1):64–71.

Heidenreich A, Pfister D, Witthuhn R, et al. Postchemotherapy retroperitoneal lymph node dissection in advanced testicular cancer: radical or modified template resection. *Eur Urol*. 2009;55(1):217–224.

Heidenreich A, Haidl F, Paffenholz P, et al. Surgical management of complex residual masses following systemic chemotherapy for metastatic testicular germ cell tumours. *Ann Oncol*. 2017;28(2):362–367.

Heidenreich A, Weissbach L, Holtl W, G. German Testicular Cancer Study, et al. Organ sparing surgery for malignant germ cell tumor of the testis. *J Urol*. 2001;166(6):2161–2165.

Heidenreich A, Albers P, Hartmann M, G. German Testicular Cancer Study, et al. Complications of primary nerve sparing retroperitoneal lymph node dissection for clinical stage I nonseminomatous germ cell tumors of the testis: experience of the German Testicular Cancer Study Group. *J Urol*. 2003;169(5):1710–1714.

Hendry WF, Norman AR, Dearnaley DP, et al. Metastatic nonseminomatous germ cell tumors of the testis: results of elective and salvage surgery for patients with residual retroperitoneal masses. *Cancer*. 2002;94(6):1668–1676.

Hentrich M, Weber N, Bergsdorf T, et al. Management and outcome of bilateral testicular germ cell tumors: twenty-five year experience in Munich. *Acta Oncol*. 2005;44(6):529–536.

Hermans BP, Sweeney CJ, Foster RS, et al. Risk of systemic metastases in clinical stage I nonseminoma germ cell testis tumor managed by retroperitoneal lymph node dissection. *J Urol*. 2000;163(6):1721–1724.

Herr HW. Does necrosis on frozen-section analysis of a mass after chemotherapy justify a limited retroperitoneal resection in patients with advanced testis cancer? *Br J Urol*.

1997;80(4):653–657.

Herr HW, Bochner BH, Dalbagni G, et al. Impact of the number of lymph nodes retrieved on outcome in patients with muscle invasive bladder cancer. *J Urol*. 2002;167(3):1295–1298.

Herr HW, Sheinfeld J, Puc HS, et al. Surgery for a post-chemotherapy residual mass in seminoma. *J Urol*. 1997;157(3):860–862.

Holzbeierlein JM, Sogani PC, Sheinfeld J. Histology and clinical outcomes in patients with bilateral testicular germ cell tumors: the Memorial Sloan Kettering Cancer Center experience 1950 to 2001. *J Urol*. 2003;169(6):2122–2125.

Honig SC, Lipshultz LI, Jarow J. Significant medical pathology uncovered by a comprehensive male infertility evaluation. *Fertil Steril*. 1994;62(5):1028–1034.

Horstman WG, Melson GL, Middleton WD, et al. Testicular tumors: findings with color Doppler US. *Radiology*. 1992;185(3):733–737.

1997. International Germ Cell Consensus Classification: a prognostic factor-based staging system for metastatic germ cell cancers. International Germ Cell Cancer Collaborative Group. *J Clin Oncol*. 1997;15(2):594–603.

Jacob JM, Mehan R, Beck SD, et al. Management of pelvic metastases in patients with testicular cancer. *Urology*. 2017;102:159–163.

Jacobsen GK, Henriksen OB, von der Maase H. Carcinoma in situ of testicular tissue adjacent to malignant germ-cell tumors: a study of 105 cases. *Cancer*. 1981;47(11):2660–2662.

Jacobsen NE, Foster RS, Donohue JP. Retroperitoneal lymph node dissection in testicular cancer. *Surg Oncol Clin N Am*. 2007;16(1):199–220.

Jacobsen NE, Beck SD, Jacobson LE, et al. Is retroperitoneal histology predictive of liver histology at concurrent post-chemotherapy retroperitoneal lymph node dissection and hepatic resection? *J Urol*. 2010;184(3):949–953.

Jacobsen R, Bostofte E, Engholm G, et al. Risk of testicular cancer in men with abnormal semen characteristics: cohort study. *BMJ*. 2000;321(7264):789–792.

Jansen RL, Sylvester R, Sleyfer DT, et al. Long-term follow-up of non-seminomatous testicular cancer patients with mature teratoma or carcinoma at postchemotherapy surgery. EORTC Genitourinary Tract Cancer Cooperative Group (EORTC GU Group). *Eur J Cancer*. 1991;27(6):695–698.

Jewett MA, Torbey C. Nerve-sparing techniques in retroperitoneal lymphadenectomy in patients with low-stage testicular cancer. *Semin Urol*. 1988;6(3):233–237.

Jewett MA, Kong YS, Goldberg SD, et al. Retroperitoneal lymphadenectomy for testis tumor with nerve sparing for ejaculation. *J Urol*. 1988;139(6):1220–1224.

Johnston P, Beck SD, Cheng L, et al. Incidence, histology and management of intraluminal thrombus at post-chemotherapy retroperitoneal lymph node dissection. *J Urol*. 2013;190(3):874–877.

Kakkar VV, Cohen AT, Edmonson RA, et al. Low molecular weight versus standard heparin for prevention of venous thromboembolism after major abdominal surgery. The Thromboprophylaxis Collaborative Group. *Lancet*. 1993;341(8840):259–265.

Karellas MK, Carver BS, Stasi J, et al. *Clinical outcome following postchemotherapy retroperitoneal lymph node dissection for men with CII non-seminomatous germ cell tumors and a radiographically normal retroperitoneum*. [Paper presented at: American Urologic Association Annual Meeting] 2007 [May 19-24; Anaheim (CA)].

Kesler KA, Brooks JA, Rieger KM, et al. Mediastinal metastases from testicular nonseminomatous germ cell tumors: patterns of dissemination and predictors of long-term survival with surgery. *J Thorac Cardiovasc Surg*. 2003;125(4):913–923.

Kesler KA, Kruter LE, Perkins SM, et al. Survival after resection for metastatic testicular nonseminomatous germ cell cancer to the lung or mediastinum. *Ann Thorac Surg*. 2011;91(4):1085–1093 [discussion 1093].

Kim I, Young RH, Scully RE. Leydig cell tumors of the testis. A clinicopathological analysis of 40 cases and review of the literature. *Am J Surg Pathol*. 1985;9(3):177–192.

Kim P, Syan-Bhanvadia S, Djaladat H, et al. Midline extraperitoneal approach for retroperitoneal lymph node dissection for testicular germ cell tumor. *Urology*. 2012;80(4):941–945.

Klein FA, Melamed MR, Whitmore WF Jr. Intratubular malignant germ cells (carcinoma in situ) accompanying invasive testicular germ cell tumors. *J Urol*. 1985;133(3):413–415.

Kollmannsberger C, Daneshmand S, So A, et al. Management of disseminated nonseminomatous germ cell tumors with risk-based chemotherapy followed by response-guided postchemotherapy surgery. *J Clin Oncol*. 2010;28(4):537–542.

Kondagunta GV, Motzer RJ. Adjuvant chemotherapy for stage II nonseminomatous germ cell tumors. *Urol Clin North Am*. 2007;34(2):179–185 [abstract ix].

Kondagunta GV, Sheinfeld J, Mazumdar M, et al. Relapse-free and overall survival in patients with pathologic stage II nonseminomatous germ cell cancer treated with etoposide and cisplatin adjuvant chemotherapy. *J Clin Oncol*. 2004;22(3):464–467.

Kratzer SS, Ulbright TM, Talerman A, et al. Large cell calcifying Sertoli cell tumor of the testis: contrasting features of six malignant and six benign tumors and a review of the literature. *Am J Surg Pathol*. 1997;21(11):1271–1280.

Krege S, Beyer J, Souchon R, et al. European consensus conference on diagnosis and treatment of germ cell cancer: a report of the second meeting of the European Germ Cell Cancer Consensus group (EGCCCG): part I. *Eur Urol*. 2008;53(3):478–496.

Kressel K, Schnell D, Thon WF, et al. Benign testicular tumors: a case for testis preservation? *Eur Urol*. 1988;15(3–4):200–204.

Kuboki S, Shimizu H, Yoshidome H, et al. Chylous ascites after hepatopancreatobiliary surgery. *Br J Surg*. 2013;100(4):522–527.

Kundu SD, Feldman DR, Carver BS, et al. Rates of teratoma and viable cancer at post-chemotherapy retroperitoneal lymph node dissection after induction chemotherapy for good risk nonseminomatous germ cell tumors. *J Urol*. 2015;193(2):513–518.

Kundu S, Carver BS, Karanikolas N, et al. Outcomes in patients with viable cancer at post-chemotherapy retroperitoneal lymph node dissection. *J Urol*. 2010;183(4):220.

Lampe H, Horwich A, Norman A, et al. Fertility after chemotherapy for testicular germ cell cancers. *J Clin Oncol*. 1997;15(1):239–245.

Lange PH, Chang WY, Fraley EE. Fertility issues in the therapy of nonseminomatous testicular tumors. *Urol Clin North Am*. 1987;14(4):731–747.

Lawrentschuk N, Zuniga A, Grabowksi AC, et al. Partial orchiectomy for presumed malignancy in patients with a solitary testis due to a prior germ cell tumor: a large North American experience. *J Urol*. 2011;185(2):508–513.

Le Voyer TE, Sigurdson ER, Hanlon AL, et al. Colon cancer survival is associated with increasing number of lymph nodes analyzed: a secondary survey of intergroup trial INT-0089. *J Clin Oncol*. 2003;21(15):2912–2919.

Leibovitch I, Little JS Jr, Foster RS, et al. Delayed orchiectomy after chemotherapy for metastatic nonseminomatous germ cell tumors. *J Urol*. 1996;155(3):952–954.

Leibovitch I, Mor Y, Golomb J, et al. The diagnosis and management of postoperative chylous ascites. *J Urol*. 2002;167(2 Pt 1):449–457.

Liberman D, Lughezzani G, Badaus L, et al. Lymph node yield and number of positive lymph nodes after RPLND does not predict cancer-specific survival in patients with nonseminomatous germ cell tumors of the testis. *J Urol*. 2010;183(4):222.

Liu NW, Cary C, Strine AC, et al. Risk of recurrence for clinical stage I and II patients with teratoma only at primary retroperitoneal lymph node dissection. *Urology*. 2015;86(5):981–984.

Loehrer PJ Sr, Birch R, Williams SD, et al. Chemotherapy of metastatic seminoma: the Southeastern Cancer Study Group experience. *J Clin Oncol*. 1987;5(8):1212–1220.

Loehrer PJ Sr, Hui S, Clark S, et al. Teratoma following cisplatin-based combination chemotherapy for nonseminomatous germ cell tumors: a clinicopathological correlation. *J Urol*. 1986;135(6):1183–1189.

Macleod LC, Rajanahally S, Nayak JG, et al. Characterizing the morbidity of postchemotherapy retroperitoneal lymph node dissection for testis cancer in a national cohort of privately insured patients. *Urology*. 2016;91:70–76.

Mansukhani NA, Havelka GE, Helenowski IB, et al. The enduring patency of primary inferior vena cava repair. *Surgery*. 2017;161(5):1414–1422.

Maroni PD, Beck SD, Rosenbaum DH, et al. Recurrence pattern in patients with necrosis only at post chemotherapy retroperitoneal lymph node dissection (PCRPLND). *J Urol*. 2008;179(4):270.

McKiernan JM, Motzer RJ, Bajorin DF, et al. Reoperative retroperitoneal surgery for nonseminomatous germ cell tumor: clinical presentation, patterns of recurrence, and outcome. *Urology*. 2003;62(4):732–736.

Michael H, Lucia J, Foster RS, et al. The pathology of late recurrence of testicular germ cell tumors. *Am J Surg Pathol*. 2000;24(2):257–273.

Miller RE, Dudderidge T, Huddart R, et al. Pathological findings after primary chemotherapy in patients undergoing simultaneous orchidectomy and retroperitoneal lymph node dissection for advanced germ cell tumours. *BJU Int*. 2013;111(4 Pt B):E152–E157.

Mosharafa AA, Foster RS, Leibovich BC, et al. Is post-chemotherapy resection of seminomatous elements associated with higher acute morbidity? *J Urol*. 2003;169(6):2126–2128.

Mosharafa AA, Foster RS, Bihrle R, et al. Does retroperitoneal lymph node dissection have a curative role for patients with sex cord-stromal testicular tumors? *Cancer*. 2003;98(4):753–757.

Motzer RJ, Jonasch E, Agarwal N, et al. Testicular cancer, version 2.2015. *J Natl Compr Canc Netw*. 2015;13(6):772–799.

Moul JW. Timely diagnosis of testicular cancer. *Urol Clin North Am*. 2007;34(2):109–117 [abstract vii].

Nash PA, et al. En bloc nephrectomy in patients undergoing post-chemotherapy retroperitoneal lymph node dissection for nonseminomatous testis cancer: indications, implications and outcomes. *J Urol*. 1998;159(3):707–710.

Nayan M, Jewett MA, Sweet J, et al. Lymph node yield in primary retroperitoneal lymph node dissection for nonseminoma germ cell tumors. *J Urol*. 2015;194(2):386–391.

Necchi A, Miceli R, Oualla K, et al. Effect of bleomycin administration on the development of pulmonary toxicity in patients with metastatic germ cell tumors receiving first-line chemotherapy: a meta-analysis of randomized studies. *Clin Genitourin Cancer*. 2017;15(2):213–220 [e215].

Nicolai N, Miceli R, Necchi A, et al. Retroperitoneal lymph node dissection with no adjuvant chemotherapy in clinical stage I nonseminomatous germ cell tumours: long-term outcome and analysis of risk factors of recurrence. *Eur Urol*. 2010;58(6):912–918.

Nicolai N, Miceli R, Artusi R, et al. A simple model for predicting nodal metastasis in patients with clinical stage I nonseminomatous germ cell testicular tumors undergoing retroperitoneal lymph node dissection only. *J Urol*. 2004;171(1):172–176.

Oliver RT. Factors contributing to delay in diagnosis of testicular tumours. *Br Med J (Clin Res Ed)*. 1985;290(6465):356.

Ondrus D, Hornak M, Breza J, et al. Delayed orchiectomy after chemotherapy in patients with advanced testicular cancer. *Int Urol Nephrol*. 2001;32(4):665–667.

Ong TA, Winkler MH, Savage PM, et al. Retroperitoneal lymph node dissection after chemotherapy in patients with elevated tumour markers: indications, histopathology and outcome. *BJU Int*. 2008;102(2):198–202.

Osbun N, Winters B, Holt SK, et al. Characteristics of patients with Sertoli and Leydig cell testis neoplasms from a national population-based registry. *Clin Genitourin Cancer*. 2017;15(2):e263–e266.

Pamenter B, De Bono JS, Brown IL, et al. Bilateral testicular cancer: a preventable problem? Experience from a large cancer centre. *BJU Int*. 2003;92(1):43–46.

Pedrosa JA, Masterson TA, Rice KR, et al. Reoperative retroperitoneal lymph node dissection for metastatic germ cell tumors: analysis of local recurrence and predictors of survival. *J Urol*. 2014;191(6):1777–1782.

Petersen PM, Skakkebaek NE, Vistisen K, et al. Semen quality and reproductive hormones before orchiectomy in men with testicular cancer. *J Clin Oncol*. 1999;17(3):941–947.

Petrelli F, Coinu A, Rosti G, et al. Salvage treatment for testicular cancer with standard- or high-dose chemotherapy: a systematic review of 59 studies. *Med Oncol*. 2017;34(8):133.

Pietzak EJ, Assel M, Becerra MF, et al. Histologic and oncologic outcomes following liver mass resection with retroperitoneal lymph node dissection in patients with nonseminomatous germ cell tumor. *Urology*. 2018;118:114–118.

Ping P, Gu BH, Li P, et al. Fertility outcome of patients with testicular tumor: before and after treatment. *Asian J Androl*. 2014;16(1):107–111.

Pizzocaro G, Monfardini S. No adjuvant chemotherapy in selected patients with pathologic stage II nonseminomatous germ cell tumors of the testis. *J Urol*. 1984;131(4):677–680.

Pizzocaro G, Salvioni R, Zanoni F. Unilateral lymphadenectomy in intraoperative stage I nonseminomatous germinal testis cancer. *J Urol*. 1985;134(3):485–489.

Post GJ, Belis JA. Delayed presentation of testicular tumors. *South Med J*. 1980;73(1):33–35.

Quinones-Baldrich W, Alktaifi A, Eilber F, et al. Inferior vena cava resection and reconstruction for retroperitoneal tumor excision. *J Vasc Surg*. 2012;55(5):1386–1393 [discussion 1393].

Rabbani F, Goldenberg SL, Gleave ME, et al. Retroperitoneal lymphadenectomy for post-chemotherapy residual masses: is a modified dissection and resection of residual masses sufficient? *Br J Urol*. 1998;81(2):295–300.

Ravi P, Gray KP, O'Donnell EK, et al. A meta-analysis of patient outcomes with subcentimeter disease after chemotherapy for metastatic non-seminomatous germ cell tumor. *Ann Oncol*. 2014;25(2):331–338.

Ravi R, Ong J, Oliver RT, et al. The management of residual masses after chemotherapy in metastatic seminoma. *BJU Int*. 1999;83(6):649–653.

Ray B, Hajdu SI, Whitmore WF Jr. Proceedings: distribution of retroperitoneal lymph node metastases in testicular germinal tumors. *Cancer*. 1974;33(2):340–348.

Rice KR, Beck SD, Bihrle R, et al. Survival analysis of pure seminoma at post-chemotherapy retroperitoneal lymph node dissection. *J Urol*. 2014;192(5):1397–1402.

Richie JP. Advances in the diagnosis and treatment of testicular cancer. *Cancer Invest*. 1993;11(6):670–675.

Rick O, et al. Residual tumor resection after high-dose chemotherapy in patients with relapsed or refractory germ cell cancer. *J Clin Oncol*. 2004;22(18):3713–3719.

Risk M, Beck SD, Bihrle R, et al. Quantitative analysis of lymph node number resected at primary retroperitoneal lymph node dissection (RPLND). *J Urol*. 2010;183(4):221–222.

Robertson GS. Radical orchidectomy and benign testicular conditions. *Br J Surg*. 1995;82(3):342–345.

Robson CJ, Bruce AW, Charbonneau J. Testicular tumors: a collective review from the Canadian Academy of Urological Surgeons. *J Urol*. 1965;94(4):440–444.

Rove KO, Maroni PD, Cost CR, et al. Pathologic risk factors in pediatric and adolescent patients with clinical stage I testicular stromal tumors. *J Pediatr Hematol Oncol*. 2015;37(8):e441–e446.

Sandeman TF. Symptoms and early management of germinal tumours of the testis. *Med J Aust*. 1979;2(6):281–284.

Schwarz RE, Smith DD. Extent of lymph node retrieval and pancreatic cancer survival: information from a large US population database. *Ann Surg Oncol*. 2006;13(9):1189–1200.

Schwarz RE, Smith DD. Clinical impact of lymphadenectomy extent in resectable gastric cancer of advanced stage. *Ann Surg Oncol*. 2007;14(2):317–328.

Sexton WJ, Wood CG, Kim R, et al. Repeat retroperitoneal lymph node dissection for metastatic testis cancer. *J Urol*. 2003;169:1353–1356.

Shah A, Lung PF, Clarke JL, et al. Re: new ultrasound techniques for imaging of the indeterminate testicular lesion may avoid surgery completely. *Clin Radiol*. 2010;65(6):496–497.

Shapiro AM V, Bain G, Sigalet DL, et al. Rapid resolution of chylous ascites after liver transplantation using somatostatin analog and total parenteral nutrition. *Transplantation*. 1996;61(9):1410–1411.

Sharp DS, Carver BS, Eggener SE, et al. Clinical outcome and predictors of survival in late relapse of germ cell tumor. *J Clin Oncol*. 2008;26(34):5524–5529.

Silberstein JL, Bazzi WM, Vertosick E, et al. Clinical outcomes of local and metastatic testicular sex cord-stromal tumors. *J Urol*. 2014;192(2):415–419.

Simmonds PD, Mead GM, Lee AH, et al. Orchiectomy after chemotherapy in patients with metastatic testicular cancer. Is it indicated? *Cancer*. 1995;75(4):1018–1024.

Simon SD, Lee RD, Mulhall JP. Should all infertile males undergo urologic evaluation before assisted reproductive technologies? Two cases of testicular cancer presenting with infertility. *Fertil Steril*. 2001;75(6):1226–1227.

Skakkebaek NE. Atypical germ cells in the adjacent “normal” tissue of testicular tumours. *Acta Pathol Microbiol Scand [A]*. 1975;83(1):127–130.

Snow BW, Rowland RG, Donohue JP, et al. Review of delayed orchiectomy in patients with disseminated testis tumors. *J Urol*. 1983;129(3):522–523.

Spiess PE, Tannir NM, Tu SM, et al. Viable germ cell tumor at postchemotherapy retroperitoneal lymph node dissection: can we predict patients at risk of disease progression? *Cancer*. 2007;110(12):2700–2708.

Stein JP, Cai J, Groshen S, et al. Risk factors for patients with pelvic lymph node metastases following radical cystectomy with en bloc pelvic lymphadenectomy: concept of lymph node density. *J Urol*. 2003;170(1):35–41.

Steiner H, Peschel R, Bartsch G. Retroperitoneal lymph node dissection after chemotherapy for germ cell tumours: is a full bilateral template always necessary? *BJU Int*. 2008;102(3):310–314.

Stephenson AJ, et al. Adjunctive nephrectomy at post-chemotherapy retroperitoneal lymph node dissection for nonseminomatous germ cell testicular cancer. *J Urol*. 2006;176(5):1996–1999 [discussion 1999].

Stephenson AJ, Bosl GJ, Motzer RJ, et al. Nonrandomized comparison of primary chemotherapy and retroperitoneal lymph node dissection for clinical stage IIA and IIB nonseminomatous germ cell testicular cancer. *J Clin Oncol*. 2007;25(35):5597–5602.

Stephenson AJ, Bosl GJ, Motzer RJ, et al. Retroperitoneal lymph node dissection for nonseminomatous germ cell testicular cancer: impact of patient selection factors on outcome. *J Clin Oncol*. 2005;23(12):2781–2788.

Steyerberg EW, Keizer HJ, Messemer JE, et al. Residual pulmonary masses after chemotherapy for metastatic nonseminomatous germ cell tumor. Prediction of histology.

ReHiT Study Group. *Cancer*. 1997;79(2):345–355.

Steyerberg EW, Keizer HJ, Fossa SD, et al. Prediction of residual retroperitoneal mass histology after chemotherapy for metastatic nonseminomatous germ cell tumor: multivariate analysis of individual patient data from six study groups. *J Clin Oncol*. 1995;13(5):1177–1187.

Subramanian VS, Nguyen CT, Stephenson AJ, et al. Complications of open primary and post-chemotherapy retroperitoneal lymph node dissection for testicular cancer. *Urol Oncol*. 2010;28(5):504–509.

Syan-Bhanvadia S, Bazargani ST, Clifford TG, et al. Midline extraperitoneal approach to retroperitoneal lymph node dissection in testicular cancer: minimizing surgical morbidity. *Eur Urol*. 2017;72(5):814–820.

Thompson RH, Carver BS, Bosl GJ, et al. Evaluation of lymph node counts in primary retroperitoneal lymph node dissection. *Cancer*. 2010;116(22):5243–5250.

Thornhill JA, Fennelly JJ, Kelly DG, et al. Patients’ delay in the presentation of testis cancer in Ireland. *Br J Urol*. 1987;59(5):447–451.

Vugrin D, Whitmore WF, Cvitkovic E, et al. Adjuvant chemotherapy combination of vinblastine, actinomycin D, Bleomycin, and Chlorambucil following retroperitoneal lymph node dissection for stage II testis tumor. *Cancer*. 1981;47(5):840–844.

Weissbach L, Boedefeld EA. Localization of solitary and multiple metastases in stage II nonseminomatous testis tumor as basis for a modified staging lymph node dissection in stage I. *J Urol*. 1987;138(1):77–82.

Weissbach L, Boedefeld EA, Oberdorster W. Modified RLND as a means to preserve ejaculation. *Prog Clin Biol Res*. 1985;203:323–334.

Weissbach L, Bussar-Maatz R, Flechtner H, et al. RPLND or primary chemotherapy in clinical stage IIA/B nonseminomatous germ cell tumors? Results of a prospective multicenter trial including quality of life assessment. *Eur Urol*. 2000;37(5):582–594.

Wells H, Hayes MC, O'Brien T, et al. Contemporary retroperitoneal lymph node dissection (RPLND) for testis cancer in the UK - a national study. *BJU Int*. 2017;119(1):91–99.

Williams SD, Stablein DM, Einhorn LH, et al. Immediate adjuvant chemotherapy versus observation with treatment at relapse in pathological stage II testicular cancer. *N Engl J Med*. 1987;317(23):1433–1438.

Willis SF, Winkler M, Savage P, et al. Repeat retroperitoneal lymph-node dissection after chemotherapy for metastatic testicular germ cell tumour. *BJU Int*. 2007;100(4):809–812.

Winter C, Pfister D, Busch J, et al. Residual tumor size and IGCCCG risk classification predict additional vascular procedures in patients with germ cell tumors and residual tumor resection: a multicenter analysis of the German Testicular Cancer Study Group. *Eur Urol*. 2012;61(2):403–409.

Wood DP Jr, Herr HW, Heller G, et al. Distribution of retroperitoneal metastases after chemotherapy in patients with nonseminomatous germ cell tumors. *J Urol*. 1992;148(6):1812–1815 [discussion 1815–1816].

Yossepowitch O, Aviv D, Wainchwaig L, et al. Testicular prostheses for testis cancer survivors: patient perspectives and predictors of long-term satisfaction. *J Urol*. 2011;186(6):2249–2252.

Young RH, Koelliker DD, Scully RE. Sertoli cell tumors of the testis, not otherwise specified: a clinicopathologic analysis of 60 cases. *Am J Surg Pathol*. 1998;22(6):709–721.

Yuh LM, Primo NL, Wagenaar RM, et al. A contemporary population-based study of testicular sex cord stromal tumours: presentation, treatment patterns, and predictors of outcome. *Can Urol Assoc J*. 2017;11(9):344–349.

Laparoscopic and Robotic-Assisted Retroperitoneal Lymphadenectomy for Testicular Tumors

Mohamad E. Allaf MD, Louis R. Kavoussi MD, MBA

Germ cell tumors (GCTs) are the most common malignancy in men between the ages of 15 and 35 years old (Carver and Sheinfeld, 2005). Testicular cancer is also one of the most curable solid-organ neoplasms, primarily because of an excellent multimodal treatment paradigm that includes effective platinum-based chemotherapy and surgery (Einhorn, 1981). **Although contemporary survival rates for GCTs are more than 90%, cure rates and patient morbidity depend on selection of the management options.** Retroperitoneal lymph node dissection (RPLND) plays a major role in the management of patients with GCTs. The role of surgery continues to evolve because of advances in chemotherapy regimens, clinical staging modalities, and continued surgical innovation (Albers et al., 2008; Allaf et al., 2005; Sheinfeld and Herr, 1998).

Primary chemotherapy is favored in Europe, whereas RPLND traditionally has been the management strategy of choice in the United States for high-risk patients with clinical stage I nonseminomatous germ cell tumor (NSGCT). RPLND can accurately stage the retroperitoneum and positively identify patients harboring metastases. In addition, patients with pathologic stage I disease are spared the toxicity and morbidity of any additional therapy because 90% or more experience long-term disease-free survival with surgery alone. Patients with pathologic stage II disease can learn more about the extent of their disease and make informed decisions regarding further therapy after RPLND. For patients in this group who harbor small-volume retroperitoneal disease (pN1), a properly performed RPLND can be curative in approximately 70% of men, so chemotherapy also can be avoided in this setting (Donohue et al., 1993; Rabbani et al., 2001; Richie and Kantoff, 1991). Because the retroperitoneum is the most frequent site of chemoresistant malignant GCT and teratoma, both of these processes are minimized with RPLND (Baniel et al., 1995). Some groups advocate RPLND as the treatment of choice for all men with clinical stage I NSGCT with teratoma in the orchiectomy specimen given the increased propensity of harboring teratoma in the retroperitoneum (Sheinfeld et al., 2003). RPLND eliminates these chemoresistant elements and maximizes therapeutic efficacy.

Traditionally, RPLND for GCTs has been performed via an open transabdominal or thoracoabdominal approach. Over the past two decades, minimally invasive approaches for the treatment of various malignancies have emerged and become popular. Since the early 1990s, retroperitoneal laparoscopic surgery has been used with proven benefits related to reducing perioperative morbidity, improving cosmesis, and shortening convalescence without compromising oncologic efficacy (Allaf et al., 2004; Cadeddu et al., 1998; Permpongkosol et al., 2005). Laparoscopic RPLND (L-RPLND) and more recently robotic-assisted RPLND (RA-RPLND) are technically demanding procedures that are increasingly being performed by experienced surgeons aiming to minimize morbidity while duplicating the open technique. **Given that untreated retroperitoneal disease and late relapses in the retroperitoneum are fatal and can be chemorefractory, it is paramount that, as in open RPLND, a complete “cleanout” of lymph nodes is performed** (Baniel et al., 1995; Borge et al., 1988; Carver et al., 2005; Whitmore, 1979).

In this chapter, the evolution of L-RPLND and RA-RPLND is summarized. Controversies surrounding their use, surgical techniques, outcomes, and associated complications are discussed. The focus is on the management of low-stage NSGCTs and the role of these minimally invasive approaches after chemotherapy.

Rationale and Evolution

In an effort to decrease the morbidity associated with open RPLND, shortly after the introduction of laparoscopic renal surgery in 1991, several reports emerged documenting the feasibility of L-RPLND in the management of clinical stage I NSGCT (Klotz, 1994; Rukstalis and Chodak, 1992; Stone et al., 1993). Larger retrospective series followed, suggesting decreased blood loss, shorter hospital stays, and faster return to normal activity compared with open RPLND, with preservation of antegrade ejaculation in more than 95% of patients (Gerber et al., 1994; Janetschek et al., 1994, 1996). An early multi-institutional retrospective analysis demonstrated preservation of antegrade ejaculation in all patients, short hospital stays (<3 days), and return to normal activity at 2 to 3 weeks postoperatively (Gerber et al., 1994). **The abbreviated convalescence allows patients who are candidates to receive chemotherapy with minimal delay.** These attractive early results encouraged others to investigate L-RPLND as a viable treatment option for low-stage NSGCT.

Staging Laparoscopic Retroperitoneal Lymph Node Dissection and Controversy

Of all laparoscopic applications to surgical urology, L-RPLND has caused the most controversy. This controversy is due to the technical difficulty of RPLND in general, the limited number of cases, and lack of interest at traditional centers of excellence. Laparoscopy is an access technique with the internal procedure being performed the same as with an open incision. Experience drives an equivalent dissection. In all early series and some contemporary studies, L-RPLND was used as a staging procedure (Bianchi et al., 1998; Janetschek et al., 2000). Patients not harboring occult metastases were identified and spared exposure to chemotherapy without undergoing open RPLND. In this form, L-RPLND was performed without retrocaval or retroaortic dissection, and chemotherapy was given to all patients harboring metastatic disease (including patients with pN1 disease). The decision to omit dissection behind the great vessels was based on the belief of a lack of isolated positive lymph nodes in this area (Holtl et al., 2002). Within this paradigm, the procedure was routinely aborted if positive lymph nodes were encountered, and chemotherapy was instituted in these cases (Bianchi et al., 1998; Nelson et al., 1999). **In contemporary series, this approach has been abandoned, and L-RPLND has evolved into a therapeutic procedure duplicating the open approach in its intent** (Allaf et al., 2005; Hyams et al., 2012; Steiner et al., 2008).

The use of restrictive template boundaries coupled with the universal use of chemotherapy in men harboring pathologic stage II disease generated criticism of published L-RPLND series. The controversy regarding the use of “staging” L-RPLND hinges on mapping studies demonstrating increased multifocality and contralateral disease in the presence of positive retroperitoneal nodes (Donohue et al., 1982; Eggener et al., 2007; Ray et al., 1974; Weissbach and Boedefeld, 1987). Critics argue that the liberal use of chemotherapy would not prevent relapses and compensate for incomplete resection.

Duplication of Open Retroperitoneal Lymph Node Dissection

At centers with experienced staff, an exact replication of the open template is performed on all patients with NSGCT undergoing L-RPLND with wide templates and complete excision of retroaortic and retrocaval tissue, rendering the procedure a staging and a therapeutic operation. Some groups perform a bilateral dissection on all patients, whereas others reserve bilateral dissection for patients with lymph node involvement (Allaf et al., 2005; Steiner et al., 2008).

Development of Robotic-Assisted Retroperitoneal Lymph Node Dissection

Robotic technology has become ubiquitous within the urologic oncology community, and it is believed to have facilitated a minimally invasive approach to complex urologic operations such as radical prostatectomy and partial nephrectomy. Robotic technology has been shown to increase use of partial nephrectomy, likely because of perceived ease in facility of this complex laparoscopic procedure (Patel et al., 2013). Given the wide range of robotic procedures performed by urologists and given that L-RPLND requires a complex laparoscopic skill set, small case series of RA-RPLND have emerged demonstrating safety and feasibility (Davol et al., 2006; Pearce et al., 2017; Williams et al., 2011).

Surgical Technique

L-RPLND and RA-RPLND are technically challenging procedures associated with a steep learning curve and should be undertaken by experienced surgeons who are comfortable and adept with advanced vascular techniques and open surgery in case of conversion. The indications for primary L-RPLND and RA-RPLND are identical to the indications for open RPLND and include clinical stage I or IIA disease, negative serum tumor markers, and the absence of comorbidities that would preclude safe surgery. In the postchemotherapeutic setting, these procedures have been limited mainly to small-volume residual disease; however, experienced surgeons have excised bulky tumors. **The surgical template for the procedure is dictated by laterality and intraoperative findings. Surgical margins should not be compromised to minimize morbidity or to preserve ejaculation or because of technical constraints. The extent of the node dissection can be expanded based on intraoperative findings.**

Preoperative Patient Preparation and Technical Considerations

All patients considered candidates for L-RPLND and RA-RPLND must be fully informed of all treatment options, including open RPLND, chemotherapy, and surveillance. All potential complications should be discussed, including bleeding requiring blood transfusion; injury to adjacent organs (liver, bowel, gallbladder, kidney, ureter, pancreas, major vascular structures); and orthopedic, neurologic, or pulmonary complications as well as conversion to open surgery because of complications or incomplete resection (Allaf et al., 2005; Winfield, 1998). Patients interested in future fertility are educated regarding preoperative sperm banking. Some surgeons advocate a low-fat diet 1 to 2 weeks before surgery to reduce the risk of chylous ascites, but data regarding this practice are not definitive. Patients undergo a mechanical bowel preparation the afternoon before surgery and take only clear liquids until midnight to decompress the bowels. Preoperative antibiotics are given before surgery, and antiembolism devices are placed on the lower extremities to minimize deep vein thrombosis.

Laparoscopic Approach

Standard laparoscopic instruments are used throughout this procedure (e.g., atraumatic graspers, scissors, clip appliers, irrigation/suction device, and laparoscopic paddle retractor). Radiolucent polypropylene clips (Hem-o-lok, Weck Closure Systems, Triangle Park, NC) may minimize artifact on postoperative imaging of the retroperitoneum. In addition, a needle driver loaded with suture and adjunct hemostatic agents such as gelatin matrix (FloSeal Matrix Hemostatic Sealant, Fusion Medical Technologies, Fremont, CA) or oxidized cellulose (Surgicel, Ethicon, Piscataway, NJ) should be readily available in case of vascular injury. Sealing devices such as ultrasonic shears and bipolar devices should be used with caution and can be unreliable in sealing large lymphatic channels. A laparoscopic retractor is particularly useful for medial retraction of the bowel and alleviates the need to position the patient in a modified flank position. A gauze sponge placed in the abdomen can be helpful in tamponading bleeding.

Although some surgeons use an extraperitoneal approach (Hara et al., 2004; Hsu et al., 2003), most prefer a transperitoneal approach because of the larger and more familiar working space. **In addition, a transperitoneal approach facilitates bilateral dissection when warranted by allowing access to all four quadrants.**

Patient Positioning and Port Placement for Laparoscopic Retroperitoneal Lymph Node Dissection

After general anesthesia is induced, an orogastric tube and Foley catheter are inserted. The patient may be placed in the modified flank position (45 degrees) with the side of dissection elevated, but we prefer the supine position because it makes transitioning to a bilateral dissection less cumbersome and does not require patient repositioning (Fig. 78.1 and Video 78.1). Great care is taken to pad all pressure points to minimize the risk of nerve injury or rhabdomyolysis because these surgeries may require a longer time than their open counterpart. The patient must be secured to the operating table because tilt is needed to use gravity to help shift the bowel out of the operative field.

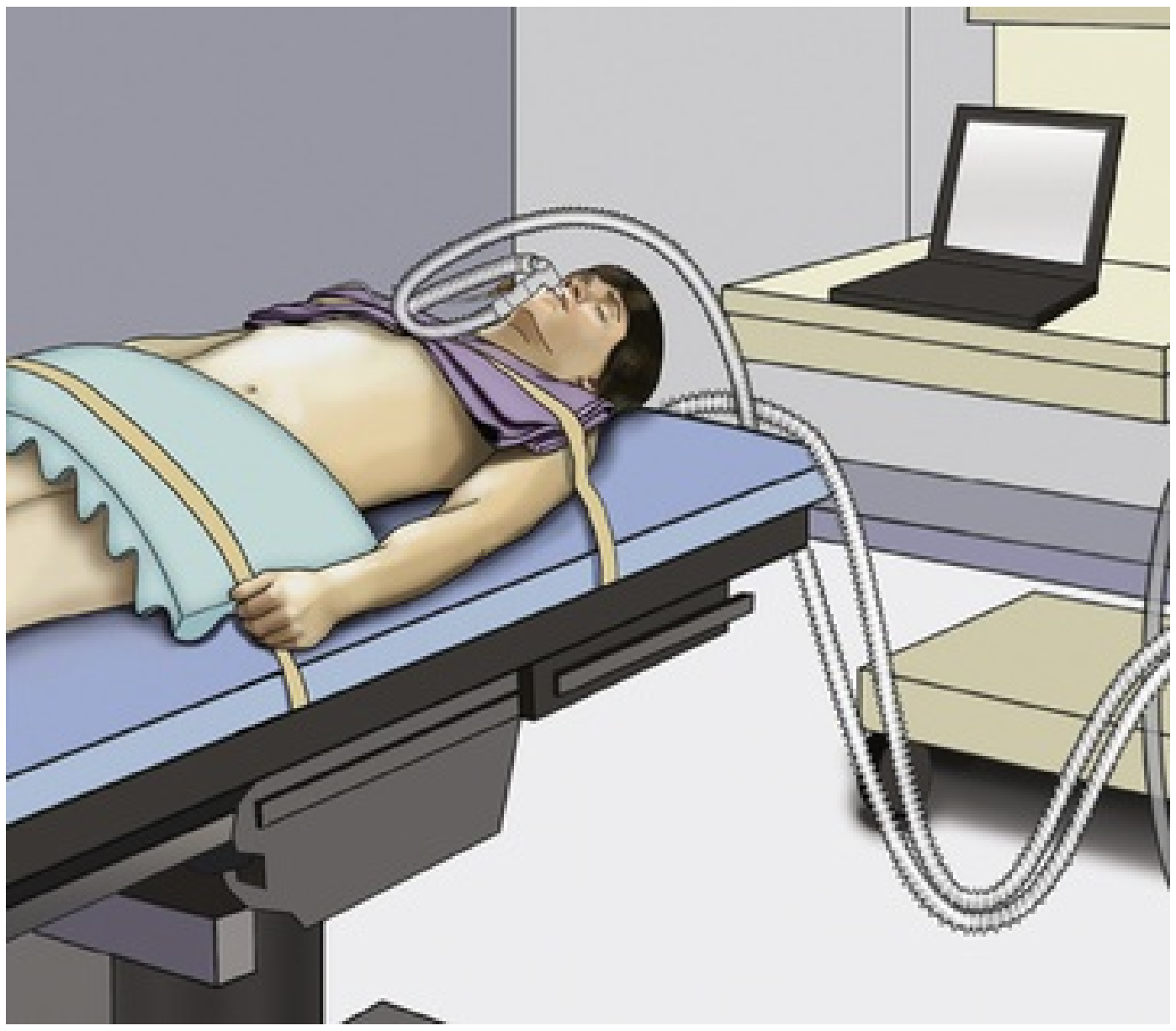

FIG. 78.1 Patient positioning during laparoscopic retroperitoneal lymph node dissection. The arms are tucked, and the patient is padded and secured in a relatively supine position.

After intraperitoneal access is achieved (via a Veress needle or Hasson technique), four equally spaced, 12 mm trocar (10 mm inner working diameter) laparoscopic ports are placed in the midline beginning 1 cm below the xiphoid process (Fig. 78.2). The umbilicus may not be incorporated as a port site. The large port size is essential to allow for the convenient introduction of larger (10/12-mm) instruments from varying angles. An additional 5-mm port may be placed in the midaxillary line midway between the iliac crest and ribs for additional retraction if needed. The bed is rotated maximally to allow optimal medialization of the bowel away from the operative field.

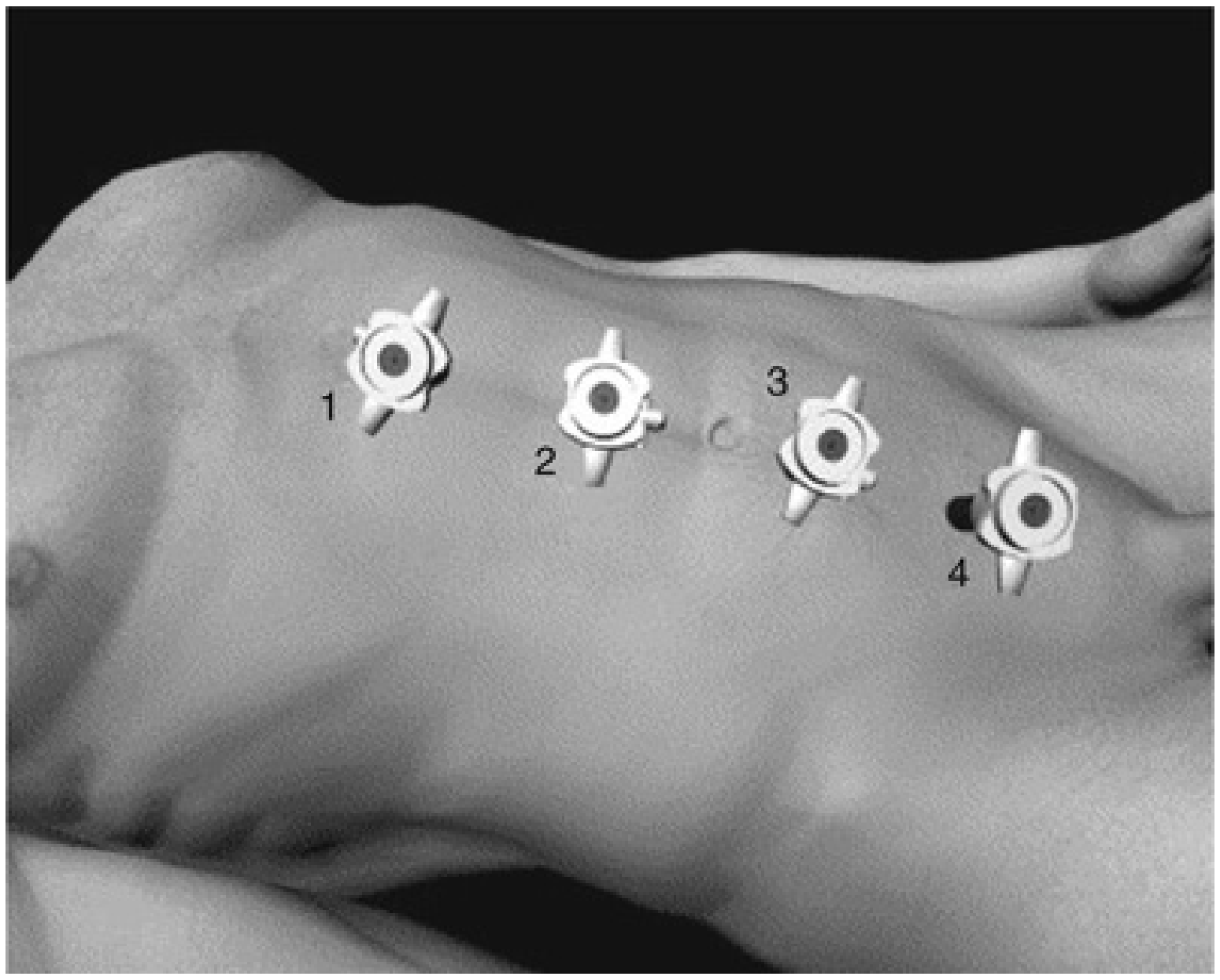

FIG. 78.2 Port placement for laparoscopic retroperitoneal lymph node dissection. Four 10/12-mm, equally spaced trocars are placed in the midline.

Right-Sided Dissection

The ascending colon is mobilized by incising the white line of Toldt from the pelvis and around the hepatic flexure. The second portion of the duodenum is identified and kocherized, providing exposure of the retroperitoneum including the medial para-aortic space on the left.

Spermatic Cord Dissection

The camera is moved to the second-from-the-bottom trocar (trocar 3 in Fig. 78.2) to facilitate visualization during dissection of the spermatic cord stump. The peritoneum medial to the spermatic cord is incised, and the vas deferens is transected. The peritoneum is incised circumferentially around the inguinal ring (Fig. 78.3). With gentle traction on the cord, fibrous attachments and scar are incised until the suture on the spermatic cord is identified. The attachments are cut, and the cord is followed proximally along with surrounding nodal and fibroadipose tissue to the inferior vena cava (IVC). The ureter must be identified at all times to prevent inadvertent thermal injury. The spermatic vein and artery are ligated proximally and transected. The specimen is placed in an endobag and dropped on the contralateral side of the abdomen.

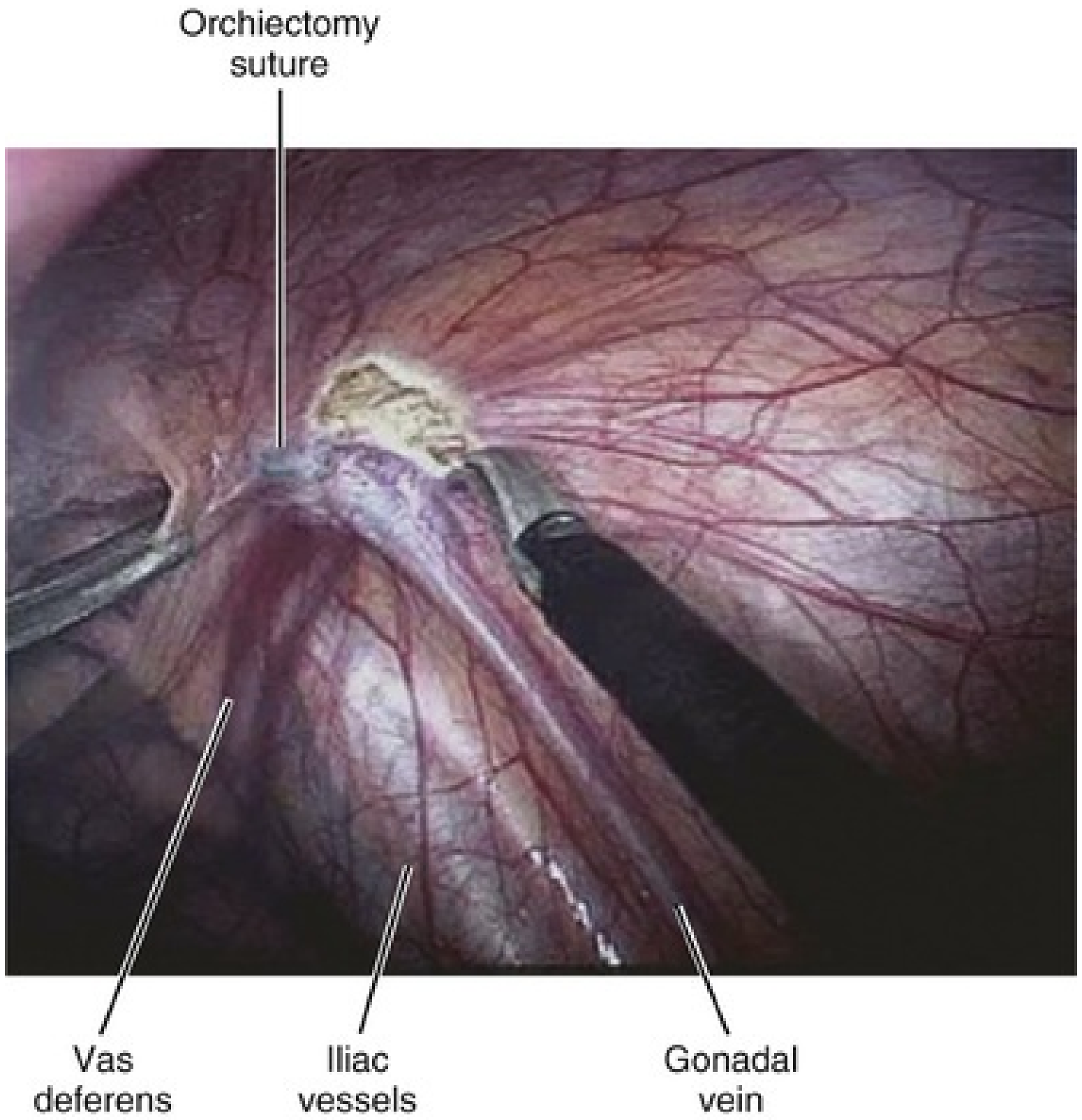

FIG. 78.3 Incision of posterior peritoneum circumferentially around the inguinal ring.

Lymphadenectomy

Although templates should be individualized to each case, we advocate removal of the right common iliac, paracaval, interaortocaval, preaortic, and medial para-aortic nodes (Fig. 78.4). Occasionally in obese patients (or during a full bilateral dissection), the leftmost border of the dissection must be performed after rotating the table contralaterally to optimize exposure. The camera should be moved to the port second from the top. A paddle retractor is placed in the lowest trocar to protect and sweep the bowel medially.

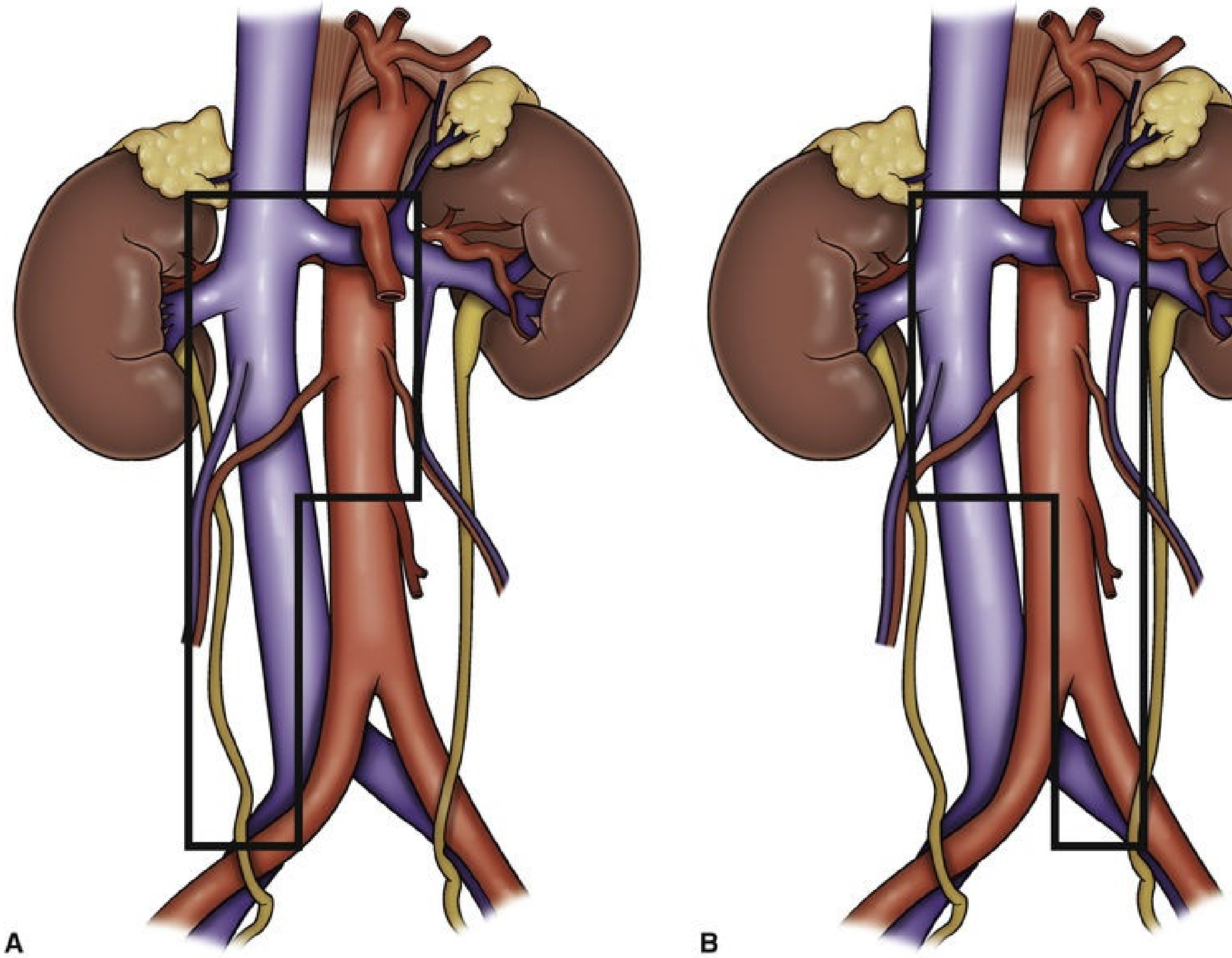

FIG. 78.4 Suggested templates for right (A) and left (B) therapeutic laparoscopic retroperitoneal lymph node dissection. These templates can be expanded or contracted based on each patient's tumor.

The testicular vein stump is identified and minimally manipulated to prevent pseudoaneurysm formation with subsequent rupture. The tissues overlying the IVC are gently lifted and carefully incised longitudinally (Fig. 78.5). It is swept off the IVC in a “split-and-roll” fashion. Blunt dissection aids in further separating these lymphatic tissues toward and overlying the common iliac vessels inferiorly and renal hilum superiorly. Care must be taken to avoid injury of lower pole renal arteries, which are present in approximately 20% of cases, and accessory vessels crossing anterior to the IVC. The renal hilum is dissected to separate all fibroadipose tissue from the renal vein and artery as far under the IVC as possible. Next, the ureter is traced to its crossing over the common iliac vessels, and the lymphatic packet is separated from both of these structures. The “split” tissue along the IVC is “rolled” medially to expose the retrocaval space. Lumbar vessels are identified, clipped, and divided to allow splitting of the posterior lymphatic tissues (Fig. 78.6). After this splitting is accomplished, the tissues are released from their attachment to the spine and delivered laterally.

Great care is taken to separate the lymph nodes from the sympathetic chain and postganglionic nerve fibers. The aorta is identified next, and the tissues overlying it are similarly split to the level of the inferior mesenteric artery and rolled medially to enter the retroaortic space. The lumbar arteries may be controlled if additional mobility is needed to mobilize the interaortocaval packet posteriorly. The aorta can be medially retracted, facilitating para-aortic node excision with careful preservation of the sympathetic chain laterally. The interaortocaval nodes finally are removed to complete the dissection.

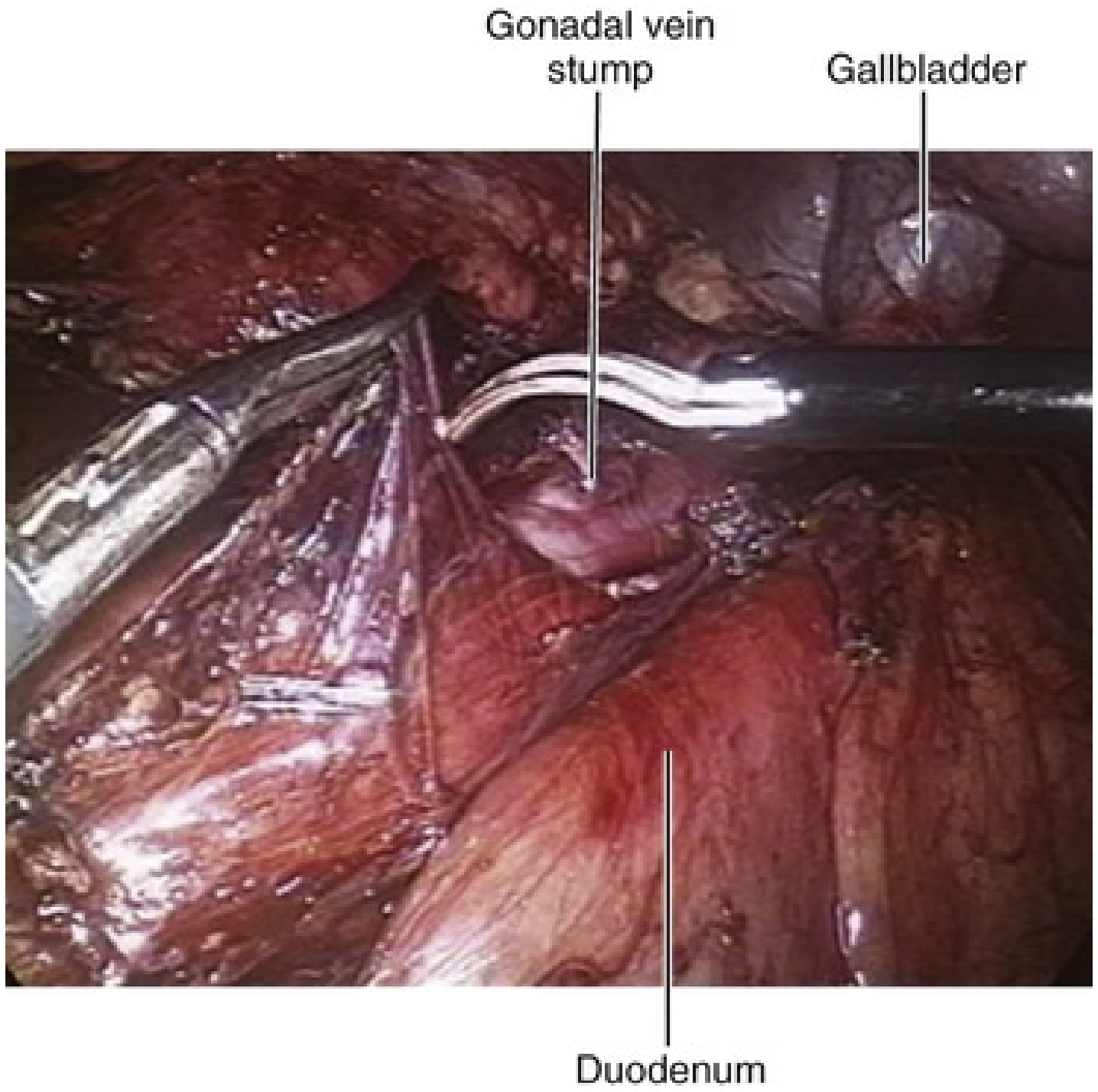

FIG. 78.5 Fibrofatty tissue overlying the inferior vena cava being incised to initiate the "split-and-roll" technique. The duodenum has been reflected medially, and the spermatic vein stump has been clipped and divided.

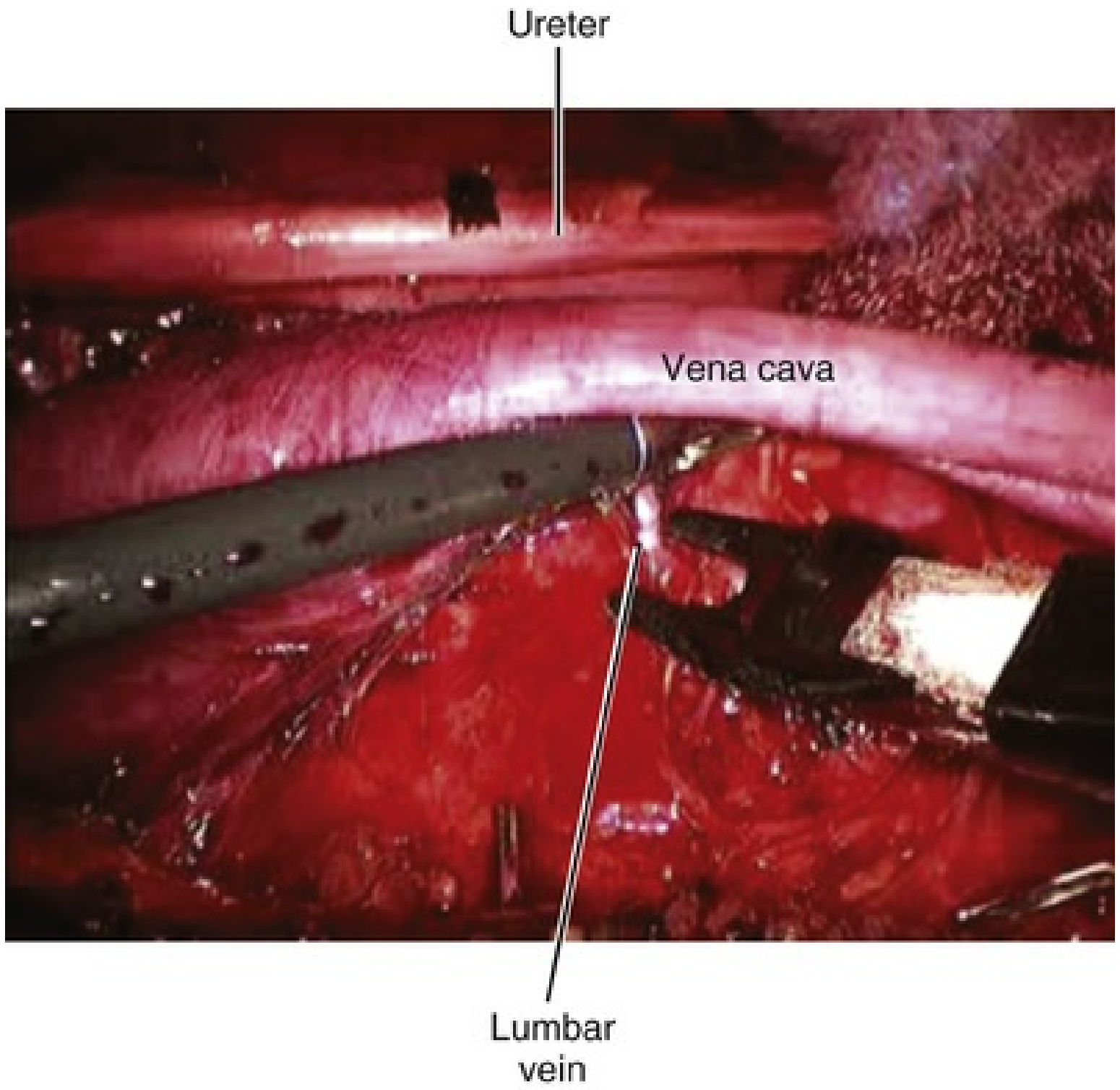

FIG. 78.6 The inferior vena cava is retracted to allow for lumbar vein ligation. Paracaval and precaval lymph nodes have been cleared.

An important technical point is to leave a long stump on the aorta/vena cava side when ligating lumbar vessels so that they can be grasped and controlled in the event a clip dislodges. Lumbar vessels that retract into the iliopsoas uncontrolled usually can be managed with pressure or a figure-of-eight suture placed deep into the muscle. Lacerations of the IVC and aorta may occur during this operation but in most cases do not mandate open conversion. Direct pressure usually prevents excessive hemorrhage and can achieve hemostasis without the need for additional maneuvers. Adjunct hemostatic agents also can be used successfully in this circumstance. If the bleeding persists or in the case of arterial bleeding, direct pressure can be used temporarily before definitive repair is undertaken with intracorporeal suturing.

Left-Sided Dissection

The peritoneum is incised lateral to the descending colon and along the splenic flexure. The colorenal ligaments are severed, and the bowel is bluntly dissected medially. The lateral attachments of the spleen are incised, and the tail of the pancreas is swept medially to ensure wide exposure of the retroperitoneum, including the medial paracaval space.

Spermatic Cord Dissection

Analogous to what is done on the right side, the spermatic cord stump suture is identified after circumscribing the peritoneum at the inguinal ring. The spermatic vein along with adjacent lymph nodes is traced proximally to the renal vein and the artery to the aorta, where they are ligated and cut. The cord is placed in an endobag for removal at the conclusion of the procedure.

Lymphadenectomy

We advocate removal of the left common iliac, para-aortic, preaortic, interaortocaval, and medial paracaval lymph nodes (see Fig. 78.4). The dissection can be expanded as needed. Lumbar veins draining into the renal vein are clipped and divided to allow full dissection of the renal hilum. The vein is cleaned off medially to the junction of the vena cava. A paddle retractor in the lowest trocar aids in dissection. The renal artery is completely freed of all lymphatic tissues. Clips are generously used to avoid postoperative leakage of lymph. The tissues overlying the aorta are split from the renal hilum to the level of the inferior mesenteric artery. Care should be taken to identify the right spermatic artery to avoid avulsion. In contrast to the tissues overlying the vena cava, the preaortic space may include postganglionic sympathetic nerves; care must be taken to separate the nodal tissue while preserving these nerves (Fig. 78.7). The ureter and common iliac vessels are separated from all fibroadipose tissue. The preaortic tissues are rolled medially down to the lumbar arteries. The lumbar vessels are controlled and cut, allowing excision of the retroaortic lymph nodes. The vena cava is identified, and with use of a “split-and-roll” approach, the paracaval, precaval, and interaortocaval lymph nodes are removed in the same manner as for a right-sided dissection. Care should be taken to identify any right-sided renal arteries to avoid inadvertent ligation. In patients who have had chemotherapy, it may be necessary to ligate and transect the inferior mesenteric artery. If suspect nodes are detected, the node dissection can be expanded to perform a complete bilateral dissection; this can be performed from the same side using retraction.

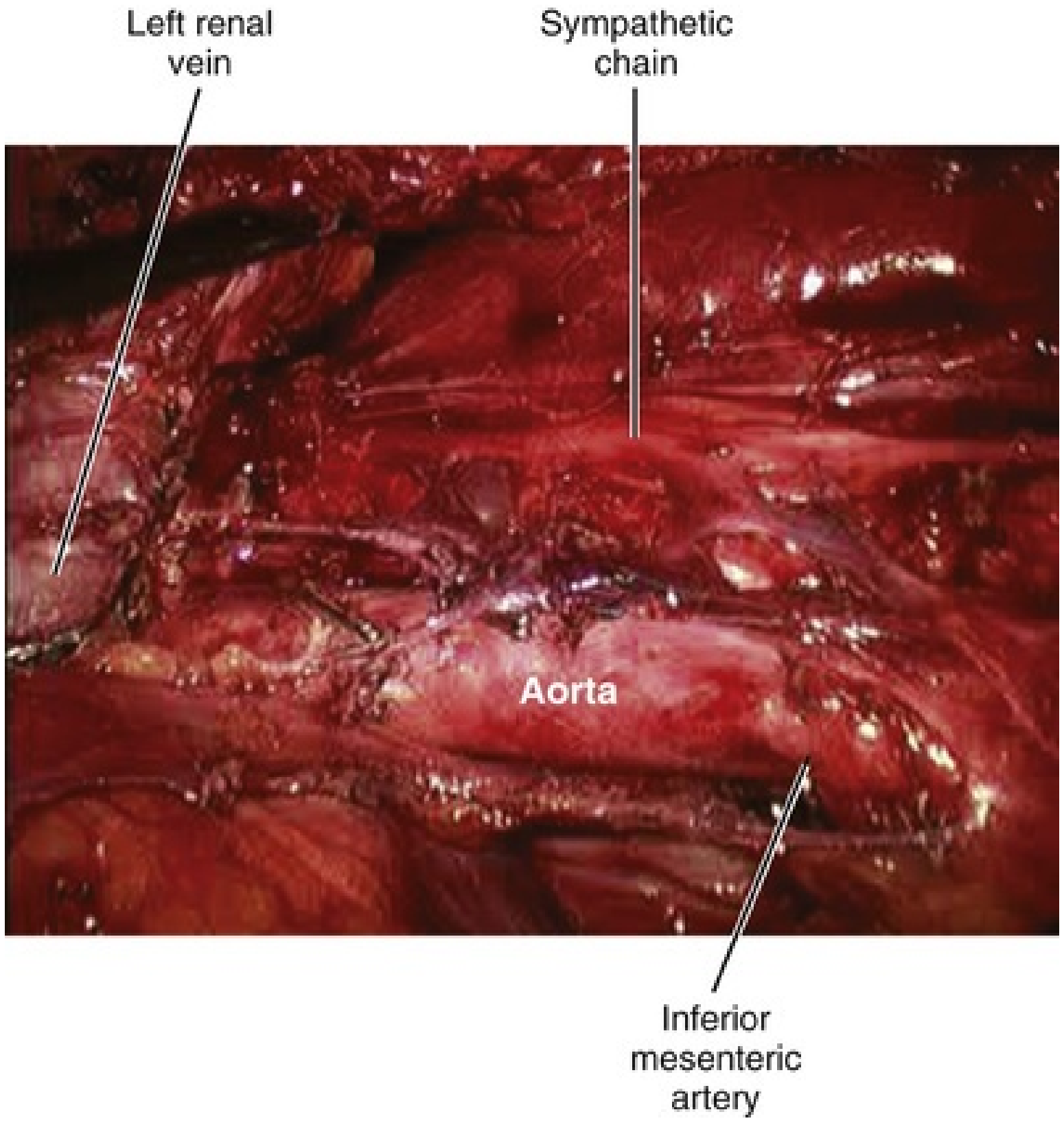

FIG. 78.7 The sympathetic chain and efferent nerves are seen spared, whereas para-aortic and preaortic lymph nodes have been removed.

At the conclusion of the operation, the lymph nodes are placed in an endobag and extracted. Each packet should be placed in a separate sac during dissection to help increase yield of nodal evaluation and count. The retroperitoneum is irrigated with warm water, and lymphostasis and hemostasis are ensured. The bowel and adjacent organs (liver, gallbladder, kidneys, ureters, pancreas, and spleen) are inspected carefully for injury. The trocar sites are closed with fascial sutures. A drain is not routinely used.

Bilateral Laparoscopic Retroperitoneal Lymph Node Dissection

Bilateral dissections may be performed when necessary and usually can be undertaken without a change in patient positioning. When the side of primary tumor is completed with the templates described, a small amount of tissue is left just medial to the contralateral ureter and inferiorly toward the common iliac vessels. These tissues are dissected free, and a bilateral dissection is completed. It is easier to approach a bilateral dissection from the right side.

Robotic-Assisted Retroperitoneal Lymph Node Dissection Port Placement and Technique

For RA-RPLND, we place the patient in a modified flank position, and the port locations are similar to the locations used in robotic renal surgery, with the ports shifted slightly caudally to assist in the iliac nodal dissection (Fig. 78.8). Use of the robotic fourth arm is preferred for improved retraction, leaving the surgeon two working instruments. The newer-generation robotic systems allow for improved multiquadrant access, facilitating wider dissection templates. One or two 12-mm assistant ports may be used, depending on surgeon preference. The general steps of the operation mirror the open and laparoscopic techniques. The robotic clip applier allows the surgeon to articulate the instrument while placing clips and can be particularly helpful in securing select lumbar vessels. Depending on body habitus, dissection of the spermatic cord to the orchiectomy suture may require re-docking of the robotic arms and triangulating them toward the inguinal ring for a more direct approach to this area, although this rarely is required.

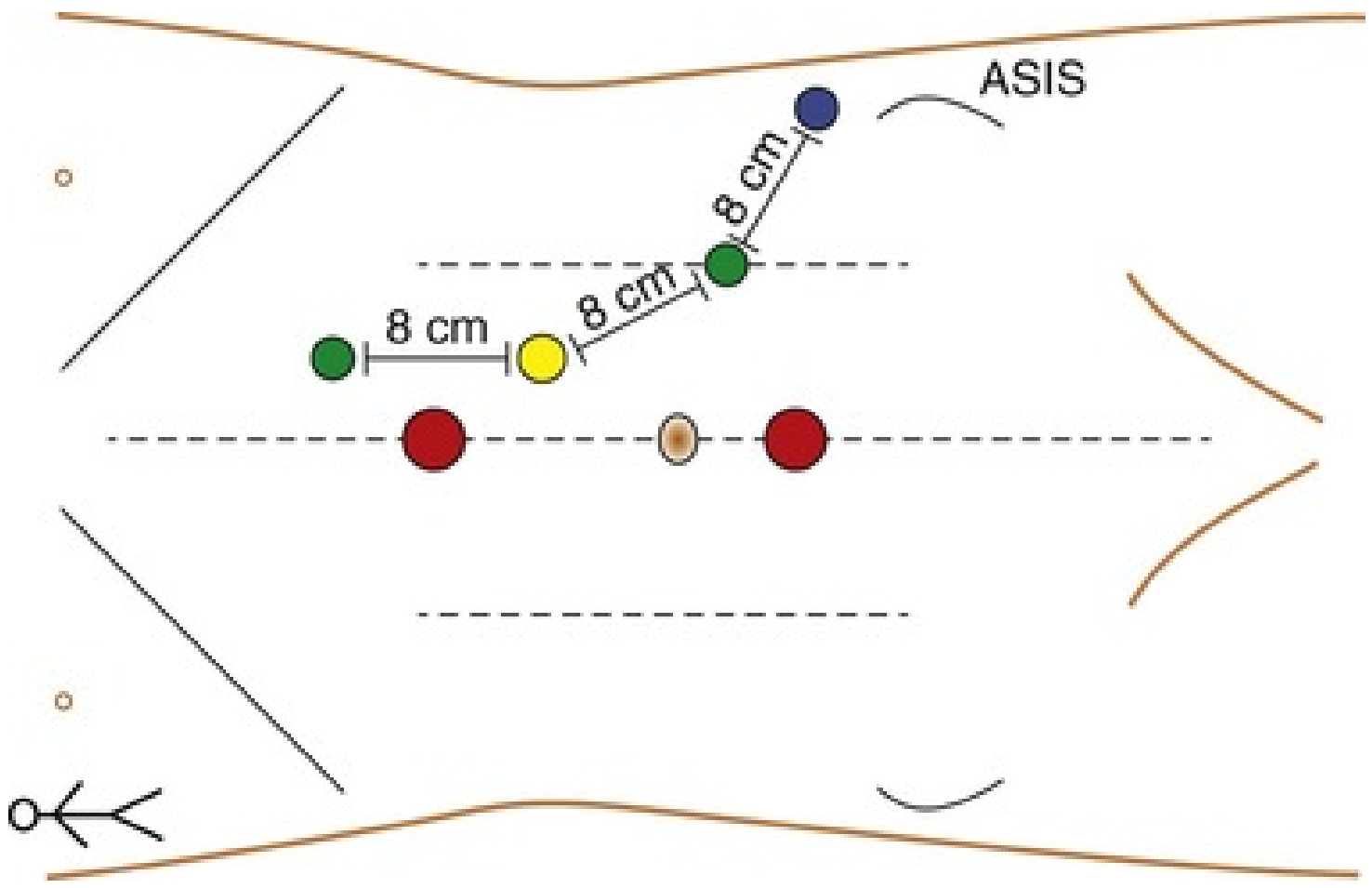

FIG. 78.8 Port placement for robotic-assisted retroperitoneal lymph node dissection. *Yellow* indicates camera port, *green* indicates 8-mm robotic ports, and *red* indicates 12-mm assistant ports. *ASIS,* Anterior superior iliac spine.

An alternative technique has been described and entails placement of the patient supine and in a steep Trendelenburg supine position with the robot docking from the patient's head (de Cobelli et al., 2013). The ports are placed in positions similar to robotic-assisted radical prostatectomy, but the field of dissection is reversed (toward the head). This allows access to the entire retoperitoneum without changing patient position or challenging the limitations of the working envelope of the robotic arms (Stepanian et al., 2017).

Postoperative Care

Patients are extubated and transferred to the recovery area without nasogastric tube drainage. The patient may ambulate and resume a liquid diet the night of surgery. **Postoperative tachycardia may occur secondary to sympathetic stimulation** (Bahnson et al., 1989). Most patients can be discharged on postoperative day 1. Some surgeons advocate consumption of a low-fat diet for 1 to 2 weeks postoperatively.

Prospective Nerve-Sparing Techniques

As in open RPLND, nerve-sparing techniques involve prospectively identifying, dissecting, and preserving the sympathetic chains, hypogastric plexus, and postganglionic fibers. With experience, these tissues can be readily identified as more fibrous compared with lymphatic tissue. On the right side, the postganglionic sympathetic fibers are most easily identified behind the IVC as they cross anterior to the aorta to insert in the hypogastric plexus. Their takeoff from the sympathetic chains is always near lumbar veins, so great care should be taken when clipping lumbar vessels. On the left side, it is easiest to identify the postganglionic sympathetic nerves at the ganglia as they leave the sympathetic chain and dissect them prospectively as they course anterior to the aorta before joining the hypogastric plexus. Care should be taken to avoid energy sources such as electrocautery when dissecting nerve fibers (Abdel-Aziz et al., 2006; Bhayani et al., 2003; Peschel et al., 2002; Steiner et al., 2008).

Complications

The most common reason for conversion to an open procedure is uncontrollable bleeding, and vascular injury is cited as the most common intraoperative complication (Abdel-Aziz et al., 2006; Bhayani et al., 2003; Kenney and Tuerk, 2008; Neyer et al., 2007). Although bleeding and open conversion occurred frequently in older series, it is less common in more recent series. **In most contemporary series, the open conversion rate is less than 5%, but it has been reported to be as high as 11.8%** (Cresswell et al., 2008; Neyer et al., 2007; Nielsen et al., 2007; Rassweiler et al., 2000; Skolarus et al., 2008). **Conversion to an open procedure should never be viewed as a failure, and surgeons should be familiar with open RPLND should it be required.** Injury to major abdominal viscera also has been reported but appears to be a rare event (Kenney and Tuerk, 2008; Neyer et al., 2007).

Postoperative complication rates of 9% to 25% have been reported in contemporary series (Albqami and Janetschek, 2005; Cresswell et al., 2008; Neyer et al., 2007; Nielsen et al., 2007; Skolarus et al., 2008). Reported complications include chylous ascites, ileus, lymphocele, nerve injury, pulmonary embolus, *Clostridium difficile* colitis, retroperitoneal hematoma, and ureteral injury (Kenney and Tuerk, 2008). Retrograde ejaculation is a potential long-term source of morbidity for patients undergoing open RPLND and L-RPLND. **The rates of retrograde ejaculation have been consistently low with the laparoscopic approach and range from 0 to 14%** (Albqami and Janetschek, 2005; Cresswell et al., 2008; Neyer et al., 2007; Nielsen et al., 2007; Skolarus et al., 2008; Steiner et al., 2008). **With meticulous ligation of lymphatic channels, the incidence of chylous ascites should be less than 2%.** A summary of the morbidity of L-RPLND in the management of clinical stage I NSGCT is provided in Table 78.1. Although it is difficult to compare these data retrospectively with published open RPLND series, they appear to compare favorably. In one study of open primary RPLND, a 6% transfusion rate with a mean length of stay of 6 days was reported (Subramanian et al., 2010). Similar to L-RPLND, vascular injury was the most common intraoperative complication (4.5% of cases); 2 patients developed chylous ascites (1.8%) and 14 (12.5%) had an ileus. Antegrade ejaculation in this group of patients was 80%, and 7 patients (6.3%) required reoperation (for small bowel obstruction [2 patients], incisional hernia repair [4 patients], and ureteral reconstruction [1 patient]); 2 patients required nephrectomy, 1 for a dysplastic kidney and the other for oncologic reasons.

TABLE 78.1

Perioperative and Morbidity Outcomes of L-RPLND for Clinical Stage I NSGCT

STUDY	NO. PATIENTS	OR TIME (MEAN, MIN)	OPEN CONVERSION	EBL (ML)	LENGTH OF STAY (DAYS)	MAJOR INTRAOPER COMPLICAT
Hyams et al., 2012	91	NA	4	200	2.1	7
Steiner et al., 2008	42[a]	323	0	125	4.8	0
Skolarus et al., 2008	19	250	0	145	1.5	0
Cresswell et al., 2008	79	177	1	NR	6	1 (bleeding wit conversion)
Albqami and Janetschek, 2005	103	217	3	144	3.6	3 (bleeding wit conversion)
Bhayani et al., 2003	29	258	2	389	2.6	2 (bleeding wit conversion)
LeBlanc et al., 2001	20	230	0	<50	1.2	0

[a] Data include 21 patients with clinical stage II disease.

[b] Ejaculation data given only as percentage of all patients (included are 7 patients with nonclinical stage I disease).

EBL, Estimated blood loss; *L-RPLND,* laparoscopic retroperitoneal lymph node dissection; *NA,* not available; *NR,* not reported; *NSGCT,* nonseminomatous germ cell tumor; *OR,* operating room.

The morbidity and open conversion rate of L-RPLND after chemotherapy is higher and seems to depend on surgeon experience level as well. Early series cited major complication rates of more than 50% (Palese et al., 2002) and high conversion rates (Rassweiler et al., 1996). However, similar to primary L-

RPLND, more recent series from experienced centers show improvement in these parameters (Permpongkosol et al., 2007; Steiner et al., 2004). Steiner et al. (2004) reported on 68 L-RPLND procedures performed after chemotherapy and reported no open conversions. In another more limited report including 17 patients who underwent L-RPLND after chemotherapy, the authors reported no complications, transfusions, or open conversions (Maldonado-Valadez et al., 2007). Studies report preservation of antegrade ejaculation with experience (Albqami and Janetschek, 2005; Corvin et al., 2005; LeBlanc et al., 2001).

Results and Current Status

There are no randomized trials comparing open RPLND and L-RPLND. Retrospective assessments suggest that patients undergoing L-RPLND have a significantly shorter hospital stay, decreased blood loss, greater quality-of-life scores, and faster return to normal activities (Abdel-Aziz et al., 2006; Janetschek et al., 1996; Poulakis et al., 2006). Results of RA-RPLND are limited to early reports demonstrating feasibility. Early comparative data comparing RA-RPLND and L-RPLND suggest parity between these approaches in terms of safety, perioperative complications, and nodal yields (Harris et al., 2015; Tselos, 2018).

Laparoscopic Retroperitoneal Lymph Node Dissection for Clinical Stage I Disease

Published reports of L-RPLND with long-term follow-up suggest that it is an effective treatment option for patients with low-stage NSGCTs (Table 78.2). The staging accuracy of L-RPLND has been documented and consistent with open series in that 25% to 30% of men with clinical stage I NSGCT are found to harbor occult nodal disease. **A study with a mean follow-up of 7 years included 87 patients with clinical stage I disease and revealed a 9% and 0 relapse rate for patients with pN0 and pN+ disease, respectively, with all patients alive and free of disease at last follow-up** (Cresswell et al., 2008). The two retroperitoneal recurrences (2.5%) in this series occurred outside the dissection template, and all patients with pN+ disease were administered adjuvant chemotherapy. Examination of other large L-RPLND series confirms these findings, and recurrence rates and their patterns in this patient population are comparable with those of open RPLND series. The recurrence rate of patients found to have negative lymph nodes at L-RPLND is reported between 0 and 10%, which compares favorably with open RPLND series (Donohue et al., 1993; Hermans et al., 2000).

TABLE 78.2

Oncologic Outcomes of Published L-RPLND Series for Patients With Clinical Stage I NSGCT

STUDY	NO. PATIENTS	FOLLOW-UP (MEAN, MONTHS)	NODE YIELD	N0/N+	NO. PN+ RECEIVING ADJUVANT CHEMOTHERAPY	NO. RECUR
Hyams et al, 2012	91	38	26.1	N0: 63	21 (75%)	N0: (2 P distant)
				N1: 21		N+: 0
				N2: 7		
Steiner et al, 2008	21	17	22	N0: 16	0 (0%)	N0: 1 (P
				N+: 5		N+: 0
Skolarus et al, 2008	19	23.7	23.8	N0: 13	5 (83.3%)	N0: 0
				N1: 6		N+: 0
Cresswell et al, 2008	79	84	14	N0: 60	19 (100%)	N0: 8 (3 1 PS, 1
				N+: 19		N+: 0
Albqami and Janetschek, 2005	103	62	NR	N0: 77	26 (100%)	N0: 5 (3 1 BC)
				N+: 26		N+: 0
Bhayani et al, 2003	29	72	20	N0: 17	10 (83.3%)	N0: 2 (P
				N+: 12		N+: 1 (
LeBlanc et al, 2001	20	15	9.8 (Rt)	N0: 14	6 (100%)	N0: 0
			17.7 (Lt)	N+: 6		N+: 0

[a]Recurrences: *BC,* isolated biochemical; *PS,* port site; *PU,* pulmonary; *RP,* retroperitoneal, outside of template.

L-RPLND, Laparoscopic retroperitoneal lymph node dissection; *Lt,* left; *NSGCT,* nonseminomatous germ cell tumor; *pN+,* histologically positive lymph nodes; *Rt,* right.

Despite the favorable long-term outcomes, the practice of universal chemotherapy in the adjuvant setting in patients with clinical stage I disease who are also harboring metastatic disease at L-RPLND has been the focus of critics who question the therapeutic efficacy of the technique. Approximately 70% of men found to have pN1 disease and who undergo a properly performed RPLND are cured and can avoid chemotherapy (Donohue et al., 1993; Rabbani et al., 2001; Richie and Kantoff, 1991). However, patients found to have pN1 disease can opt to receive two cycles of chemotherapy in the adjuvant setting with excellent long-term results rather than risk receiving three or four cycles of chemotherapy should they experience relapse. The decision to administer chemotherapy to patients with pN1 disease is a matter of preference and factors in the philosophy of the urologist and medical oncologist as well as the patient.

A report of 120 patients undergoing L-RPLND at one of four institutions in the United States included 10 patients with pathologic stage II disease who underwent surveillance (Nielsen et al., 2007). At a mean follow-up of 34.8 months, none of the patients had experienced a retroperitoneal recurrence. **Additional reports omitting chemotherapy for patients with pN1 disease who underwent L-RPLND support its therapeutic efficacy, but further studies and follow-up are required** (Nicolai et al., 2018; Skolarus et al., 2008; Steiner et al., 2008).

The adequacy of L-RPLND also can be evaluated by examining patients found to have pathologic stage I disease. If L-RPLND were inadequate, certain patients with pathologic stage II disease would be mislabeled as having pathologic stage I disease, and a retroperitoneal recurrence would result. This supposition has not occurred because no retroperitoneal recurrence has resulted in a series of therapeutic L-RPLND where a full dissection has been performed (Bhayani et al., 2003; Nielsen et al., 2007; Porter and Lange, 2003; Skolarus et al., 2008; Steiner et al., 2008). The therapeutic efficacy of L-RPLND will continue to be tested as more patients found to have pathologic stage II disease are choosing observation after this technique with good results (Nicolai et al., 2017).

Laparoscopic Retroperitoneal Lymph Node Dissection for Clinical Stage II

Fewer reports exist examining the role of L-RPLND for patients with clinical stage II NSGCTs as a primary modality or in the postchemotherapeutic setting. Data regarding the use of primary L-RPLND in patients with clinical stage IIA disease are limited. Several authors have reported on the use of L-RPLND in the postchemotherapeutic setting (see Table 78.2). Albqami and Janetschek (2005) reported their experience with 59 patients with stage IIB or IIC disease who underwent L-RPLND after chemotherapy: of the 43 patients with preoperative stage IIB disease with a mean follow-up of 53 months, one experienced a recurrence 24 months postoperatively along the external iliac nodes, outside the original template. Another group (Maldonado-Valadez et al., 2007) reported on 17 patients and demonstrated the feasibility of L-RPLND after chemotherapy: viable tumor was found in 3 patients, 2 of whom experienced retroperitoneal recurrences. Full bilateral RPLND, which is typically recommended in this setting, was not performed in these series (Stephenson and Sheinfeld, 2004).

Keeping in line with the goals of open RPLND performed after chemotherapy, Steiner et al. (2008) performed bilateral nerve-sparing L-RPLND on 19 postchemotherapy patients with stage IIB disease. The authors found teratoma in 4 patients, necrosis/fibrosis in 14 patients, and active tumor in 1 patient. This study included 2 patients with clinical stage IIA disease who underwent L-RPLND without adjuvant chemotherapy. No retroperitoneal recurrences were noted in either group at 17 months of follow-up.

Summary

L-RPLND and RA-RPLND have been demonstrated to be feasible, safe, and effective treatment options for men with clinical stage I NSGCT when performed at large-volume institutions by experienced surgeons. These approaches have evolved into therapeutic operations duplicating the open procedure, with reports demonstrating efficacy and minimal morbidity. Data regarding these procedures for clinical stage II disease and for patients who have received chemotherapy are limited and associated with a longer learning curve.

Key Points

- L-RPLND and RA-RPLND aim to decrease operative morbidity while duplicating the open approach.
- The most common reason for conversion to an open procedure is bleeding, although this is a rare complication (<5%).
- L-RPLND and RA-RPLND are effective treatment options for patients with low-stage NSGCTs.
- Reports omitting chemotherapy for patients with N1 disease who underwent L-RPLND and RA-RPLND support its therapeutic efficacy.
- Traditional centers of excellence should consider offering minimally invasive node dissection to provide patient-focused modern care.

Suggested Readings

Allaf ME, Bhayani SB, Link RE, et al. Laparoscopic retroperitoneal lymph node dissection: duplication of open technique. *Urology*. 2005;65:575–577.

Nicolai N, Tarabelloni N2, Gasperoni F, et al. Laparoscopic retroperitoneal lymph node dissection for clinical stage I nonseminomatous germ cell tumors of the testis: safety and efficacy analyses at a high volume center. *J Urol*. 2018;199:741–747.

Nielsen ME, Lima G, Schaeffer EM, et al. Oncologic efficacy of laparoscopic RPLND in treatment of clinical stage I nonseminomatous germ cell testicular cancer. *Urology*. 2007;70:1168–1172.

Steiner H, Zangerl F, Stohr B, et al. Results of bilateral nerve sparing laparoscopic retroperitoneal lymph node dissection for testicular cancer. *J Urol*. 2008;180:1348–1352 [discussion 1352–1353].

Stepanian S, Patel M, Porter J. Robot-assisted laparoscopic retroperitoneal lymph node dissection for testicular cancer: evolution of the technique. *Eur Urol*. 2017;70(4):661–667.

References

Abdel-Aziz KF, Anderson JK, Svatek R, et al. Laparoscopic and open retroperitoneal lymph-node dissection for clinical stage I nonseminomatous germ-cell testis tumors. *J Endourol*. 2006;20:627–631.

Albers P, Siener R, Krege S, et al. Randomized phase III trial comparing retroperitoneal lymph node dissection with one course of bleomycin and etoposide plus cisplatin chemotherapy in the adjuvant treatment of clinical stage I nonseminomatous testicular germ cell tumors: AUO trial AH 01/94 by the German Testicular Cancer Study Group. *J Clin Oncol*. 2008;26:2966–2972.

Albqami N, Janetschek G. Laparoscopic retroperitoneal lymph-node dissection in the management of clinical stage I and II testicular cancer. *J Endourol*. 2005;19:683–692 [discussion 692].

Allaf ME, Bhayani SB, Link RE, et al. Laparoscopic retroperitoneal lymph node dissection: duplication of open technique. *Urology*. 2005;65:575–577.

Allaf ME, Bhayani SB, Rogers C, et al. Laparoscopic partial nephrectomy: evaluation of long-term oncological outcome. *J Urol*. 2004;172:871–873.

Bahnson RR, Andriole GL, Clayman RV, et al. Catecholamine excess: probable cause of postoperative tachycardia following retroperitoneal lymph node dissection (RPLND) for testicular carcinoma. *J Surg Oncol*. 1989;42:132–135.

Baniel J, Foster RS, Gonin R, et al. Late relapse of testicular cancer. *J Clin Oncol*. 1995;13:1170–1176.

Bhayani SB, Ong A, Oh WK, et al. Laparoscopic retroperitoneal lymph node dissection for clinical stage I nonseminomatous germ cell testicular cancer: a long-term update. *Urology*. 2003;62:324–327.

Bianchi G, Beltrami P, Giusti G, et al. Unilateral laparoscopic retroperitoneal lymph node dissection for clinical stage I nonseminomatous germ cell testicular neoplasm. *Eur Urol*. 1998;33:190–194.

Borge N, Fossa SD, Ous S, et al. Late recurrence of testicular cancer. *J Clin Oncol*. 1988;6:1248–1253.

Cadeddu JA, Ono Y, Clayman RV, et al. Laparoscopic nephrectomy for renal cell cancer: evaluation of efficacy and safety: a multicenter experience. *Urology*. 1998;52:773–777.

Carver BS, Motzer RJ, Kondagunta GV, et al. Late relapse of testicular germ cell tumors. *Urol Oncol*. 2005;23:441–445.

Carver BS, Sheinfeld J. Germ cell tumors of the testis. *Ann Surg Oncol*. 2005;12:871–880.

Corvin S, Sturm W, Schlatter E, et al. Laparoscopic retroperitoneal lymph-node dissection with the waterjet is technically feasible and safe in testis-cancer patient. *J Endourol*. 2005;19:823–826.

Cresswell J, Scheitlin W, Gozen A, et al. Laparoscopic retroperitoneal lymph node dissection combined with adjuvant chemotherapy for pathological stage II disease in nonseminomatous germ cell tumours: a 15-year experience. *BJU Int*. 2008;102:844–848.

Davol P, Sumfest J, Rukstalis D, et al. Robotic-assisted-laparoscopic retroperitoneal lymph node dissection. *Urology*. 2006;67:199.

de Cobelli O, Brescia A, Mazzoleni F, et al. A novel “intuitive” surgical technique for right robot-assisted retroperitoneal lymph node dissection for stage I testicular NSGCT. *World J Urol*. 2013;31(3):435–439.

Donohue JP, Thornhill JA, Foster RS, et al. Retroperitoneal lymphadenectomy for clinical stage A testis cancer (1965 to 1989): modifications of technique and impact on ejaculation.

J Urol. 1993;149:237–243.

Donohue JP, Zachary JM, Maynard BR. Distribution of nodal metastases in nonseminomatous testis cancer. *J Urol*. 1982;128:315–320.

Eggener SE, Carver BS, Sharp DS, et al. Incidence of disease outside modified retroperitoneal lymph node dissection templates in clinical stage I or IIA nonseminomatous germ cell testicular cancer. *J Urol*. 2007;177:937–942 [discussion 942–943].

Einhorn LH. Testicular cancer as a model for a curable neoplasm: the Richard and Hinda Rosenthal Foundation Award Lecture. *Cancer Res*. 1981;41:3275–3280.

Gerber GS, Bissada NK, Hulbert JC, et al. Laparoscopic retroperitoneal lymphadenectomy: multi-institutional analysis. *J Urol*. 1994;152:1188–1191 [discussion 1191–1192].

Hara I, Kawabata G, Yamada Y, et al. Extraperitoneal laparoscopic retroperitoneal lymph node dissection in supine position after chemotherapy for advanced testicular carcinoma. *Int J Urol*. 2004;11:934–939.

Harris KT, Gorin MA, Ball MW, et al. A comparative analysis of robotic vs laparoscopic retroperitoneal lymph node dissection for testicular cancer. *BJU Int*. 2015;116(6):920–923.

Hermans BP, Sweeney CJ, Foster RS, et al. Risk of systemic metastases in clinical stage I nonseminoma germ cell testis tumor managed by retroperitoneal lymph node dissection. *J Urol*. 2000;163:1721–1724.

Holtl L, Peschel R, Knapp R, et al. Primary lymphatic metastatic spread in testicular cancer occurs ventral to the lumbar vessels. *Urology*. 2002;59:114–118.

Hsu TH, Su LM, Ong A. Anterior extraperitoneal approach to laparoscopic retroperitoneal lymph node dissection: a novel technique. *J Urol*. 2003;169:258–260.

Hyams ES, Pierorazio P, Proteek O, et al. Laparoscopic retroperitoneal lymph node dissection for clinical stage I nonseminomatous germ cell tumor: a large single institution experience. *J Urol*. 2012;187(2):487–492.

Janetschek G, Hobisch A, Holtl L, et al. Retroperitoneal lymphadenectomy for clinical stage I nonseminomatous testicular tumor: laparoscopy versus open surgery and impact of learning curve. *J Urol*. 1996;156:89–93 [discussion 94].

Janetschek G, Hobisch A, Peschel R, et al. Laparoscopic retroperitoneal lymph node dissection for clinical stage I nonseminomatous testicular carcinoma: long-term outcome. *J Urol*. 2000;163:1793–1796.

Janetschek G, Reissigl A, Peschel R, et al. Laparoscopic retroperitoneal lymph node dissection for clinical stage I nonseminomatous testicular tumor. *Urology*. 1994;44:382–391.

Kenney PA, Tuerk IA. Complications of laparoscopic retroperitoneal lymph node dissection in testicular cancer. *World J Urol*. 2008;26:561–569.

Klotz L. Laparoscopic retroperitoneal lymphadenectomy for high-risk stage 1 nonseminomatous germ cell tumor: report of four cases. *Urology*. 1994;43:752–756.

LeBlanc E, Caty A, Dargent D, et al. Extraperitoneal laparoscopic para-aortic lymph node dissection for early stage nonseminomatous germ cell tumors of the testis with introduction of a nerve sparing technique: description and results. *J Urol*. 2001;165:89–92.

Maldonado-Valadez R, Schilling D, Anastasiadis AG, et al. Post-chemotherapy laparoscopic retroperitoneal lymph-node dissection in testis cancer patients. *J Endourol*. 2007;21:1501–1504.

Nelson JB, Chen RN, Bishoff JT, et al. Laparoscopic retroperitoneal lymph node dissection for clinical stage I nonseminomatous germ cell testicular tumors. *Urology*. 1999;54:1064–1067.

Neyer M, Peschel R, Akkad T, et al. Long-term results of laparoscopic retroperitoneal lymph-node dissection for clinical stage I nonseminomatous germ-cell testicular cancer. *J Endourol*. 2007;21:180–183.

Nicolai N, Tarabelloni N, Gasperoni F, et al. Laparoscopic retroperitoneal lymph node dissection for clinical stage I nonseminomatous germ cell tumors of the testis: safety and efficacy analyses at a high volume center. *J Urol*. 2018;199:741–747.

Nielsen ME, Lima G, Schaeffer EM, et al. Oncologic efficacy of laparoscopic RPLND in treatment of clinical stage I nonseminomatous germ cell testicular cancer. *Urology*. 2007;70:1168–1172.

Palese MA, Su LM, Kavoussi LR. Laparoscopic retroperitoneal lymph node dissection after chemotherapy. *Urology*. 2002;60:130–134.

Patel HD, Mullins JK, Pieorazio PM, et al. Trends in renal surgery: robotic technology is associated with increased use of partial nephrectomy. *J Urol*. 2013;189(4):1229–1235.

Pearce SM, Golan S, Gorin MA, et al. Safety and early oncologic effectiveness of primary robotic retroperitoneal lymph node dissection for nonseminomatous germ cell testicular cancer. *Eur Urol*. 2017;71(3):476–482.

Permpongkosol S, Chan DY, Link RE, et al. Long-term survival analysis after laparoscopic radical nephrectomy. *J Urol*. 2005;174:1222–1225.

Permpongkosol S, Lima GC, Warlick CA, et al. Postchemotherapy laparoscopic retroperitoneal lymph node dissection: evaluation of complications. *Urology*. 2007;69:361–365.

Peschel R, Gettman MT, Neururer R, et al. Laparoscopic retroperitoneal lymph node dissection: description of the nerve-sparing technique. *Urology*. 2002;60:339–343 [discussion 343].

Porter J, Lange P. Laparoscopic retroperitoneal lymph node dissection for stage I NSGCT. *J Urol*. 2003;169(Suppl):78.

Poulakis V, Skriapas K, de Vries R, et al. Quality of life after laparoscopic and open retroperitoneal lymph node dissection in clinical stage I nonseminomatous germ cell tumor: a comparison study. *Urology*. 2006;68:154–160.

Rabbani F, Sheinfeld J, Farivar-Mohseni H, et al. Low-volume nodal metastases detected at retroperitoneal lymphadenectomy for testicular cancer: pattern and prognostic factors for relapse. *J Clin Oncol*. 2001;19:2020–2025.

Rassweiler JJ, Frede T, Lenz E, et al. Long-term experience with laparoscopic retroperitoneal lymph node dissection in the management of low-stage testis cancer. *Eur Urol*. 2000;37:251–260.

Rassweiler JJ, Seemann O, Henkel TO, et al. Laparoscopic retroperitoneal lymph node dissection for nonseminomatous germ cell tumors: indications and limitations. *J Urol*. 1996;156:1108–1113.

Ray B, Hajdu SI, Whitmore WF Jr. Proceedings: distribution of retroperitoneal lymph node metastases in testicular germinal tumors. *Cancer*. 1974;33:340–348.

Richie JP, Kantoff PW. Is adjuvant chemotherapy necessary for patients with stage B1 testicular cancer? *J Clin Oncol*. 1991;9:1393–1396.

Rukstalis DB, Chodak GW. Laparoscopic retroperitoneal lymph node dissection in a patient with stage 1 testicular carcinoma. *J Urol*. 1992;148:1907–1909 [discussion 1909–1910].

Sheinfeld J, Herr HW. Role of surgery in management of germ cell tumor. *Semin Oncol*. 1998;25:203–209.

Sheinfeld J, Motzer RJ, Rabbani F, et al. Incidence and clinical outcome of patients with teratoma in the retroperitoneum following primary retroperitoneal lymph node dissection for clinical stages I and IIA nonseminomatous germ cell tumors. *J Urol*. 2003;170:1159–1162.

Skolarus TA, Bhayani SB, Chiang HC, et al. Laparoscopic retroperitoneal lymph node dissection for low-stage testicular cancer. *J Endourol*. 2008;22:1485–1489.

Steiner H, Peschel R, Janetschek G, et al. Long-term results of laparoscopic retroperitoneal lymph node dissection: a single-center 10-year experience. *Urology*. 2004;63:550–555.

Steiner H, Zangerl F, Stohr B, et al. Results of bilateral nerve sparing laparoscopic retroperitoneal lymph node dissection for testicular cancer. *J Urol*. 2008;180:1348–1352 [discussion 1352–1353].

Stepanian S, Patel M, Porter J. Robot-assisted laparoscopic retroperitoneal lymph node dissection for testicular cancer: evolution of the technique. *Eur Urol*. 2017;70(4):661–667.

Stephenson AJ, Sheinfeld J. The role of retroperitoneal lymph node dissection in the management of testicular cancer. *Urol Oncol*. 2004;22:225–233 [discussion 234–235].

Stone NN, Schlussel RN, Waterhouse RL, et al. Laparoscopic retroperitoneal lymph node dissection in stage A nonseminomatous testis cancer. *Urology*. 1993;42:610–614.

Subramanian VS, Nguyen CT, Stephenson AJ, et al. Complications of open primary and post-chemotherapy retroperitoneal lymph node dissection for testicular cancer. *Urol Oncol*. 2010;28:504–509.

Tselos A, Moris D, Tsilimigras DI, et al. Robot-assisted retroperitoneal lymphadenectomy in testicular cancer treatment: a systematic review. *J Laparoendosc Adv Surg Tech A*. 2018; 10.1089/lap.2017.0672 [Epub ahead of print].

Weissbach L, Boedefeld EA. Localization of solitary and multiple metastases in stage II nonseminomatous testis tumor as basis for a modified staging lymph node dissection in stage I. *J Urol*. 1987;138:77–82.

Whitmore WF Jr. Surgical treatment of adult germinal testis tumors. *Semin Oncol*. 1979;6:55–68.

Williams SB, Lau CS, Josephson DY. Initial series of robot-assisted laparoscopic retroperitoneal lymph node dissection for clinical stage 1 nonseminomatous germ cell testicular cancer. *Eur Urol*. 2011;60:1299–1302.

Winfield HN. Laparoscopic retroperitoneal lymphadenectomy for cancer of the testis. *Urol Clin North Am*. 1998;25:469–478.

79

Tumors of the Penis

Curtis A. Pettaway Sr., MD, Juanita M. Crook MD, FRCPC, Lance C. Pagliaro MD

Cancers of the penis are uncommon tumors that are often devastating for the patient and frequently diagnostically and therapeutically challenging for the urologist. Although rare in North America and Europe, penile malignant neoplasms constitute a substantial health concern in many African, South American, and Asian countries.

Any discussion of penile cancers must begin by addressing premalignant and malignant tumors of the penis. A description of these lesions establishes their anatomic, etiologic, and histologic relationship to squamous cell carcinoma, which is the most common malignant tumor of the penis, as well as to other malignant neoplasms that involve the penis. Developments in the causes of various premalignant and malignant penile tumors are reviewed in this chapter.

In this chapter, we review the epidemiology, cause, and natural history of squamous carcinoma and its contemporary management. **Reports have confirmed the importance of pathologic stage and histologic features of the primary tumor as well as the presence and extent of lymph node metastasis in determining prognosis and treatment planning for penile squamous carcinoma** (McDougal, 1995; Pizzocaro et al., 1997; Ravi, 1993a; Slaton et al., 2001; Theodorescu et al., 1996). In addition, developments in staging of the disease, including novel imaging modalities and the use of dynamic sentinel node biopsy (DSNB), and modified surgical approaches to improve staging accuracy and reduce potential morbidities are presented. The selection of patients for organ-preserving surgical strategies is discussed.

The role of radiation therapy as a primary treatment and a palliative measure is reviewed. Contemporary developments in chemotherapy as well as in combination therapy with multiple therapeutic modalities are also discussed. A contemporary scheme for the management of the inguinal region, based on histologic and clinical features, is presented.

Finally, the various nonsquamous malignant neoplasms that may involve the penis are reviewed and discussed.

Premalignant Cutaneous Lesions

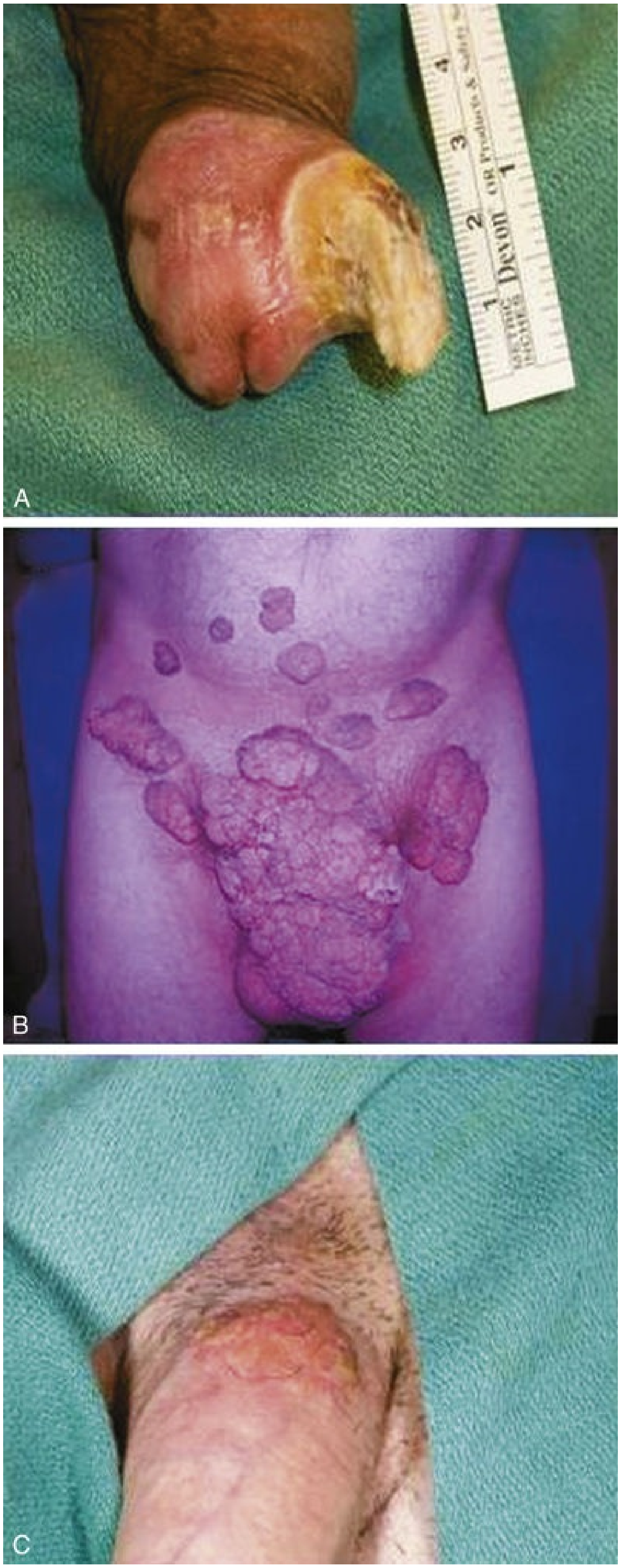
A
METRIC
INCHES
Devon
OR Products & Safety
1
2
3
4
1
B
C

EFIG. 79.1 (A) Cutaneous horn with underlying well-differentiated squamous cell carcinoma. (B) Buschke-Löwenstein tumor. (C) Bowen disease involving penile shaft skin.

- When in doubt, biopsy of penile lesions should be considered to establish a diagnosis.
- Lesions associated with the development of penile carcinoma that require treatment or close follow-up include cutaneous horn, balanitis xerotica obliterans, and pseudoepitheliomatous keratotic and micaceous balanitis.

Some histologically benign penile lesions have been recognized as having malignant potential or close association with the development of squamous carcinoma. In one large series, 42% of patients with squamous cell cancer had a history of preexisting penile lesions (Bouchot et al., 1989). Although the incidence of progression of these lesions to squamous cell carcinoma is not known, all have been associated with the disease. Premalignant penile lesions have now been divided into two broad categories based on their potential causation by human papillomavirus (HPV) or inflammatory pathways (reviewed in Shabbir et al., 2011b).

Non–Human Papillomavirus–Related Penile Premalignant Lesions

Cutaneous Horn

The penile cutaneous horn is a rare skin lesion with fewer than 100 cases reported. It usually develops over a preexisting skin lesion. Predisposing factors include chronic inflammation, trauma, poor hygiene, viral infection, and tumor, including squamous cell carcinoma or rarely basal cell carcinoma or Kaposi sarcoma. The horn resembles that of an animal and is characterized by overgrowth and cornification of the epithelium, which forms a solid protuberance (see eFig. 79.1A). On microscopic examination, extreme hyperkeratosis, dyskeratosis, and acanthosis are noted. The clinically important issue is not the actual horn but the underlying lesion, which could be benign (seborrheic keratosis, viral warts, others), premalignant (solar keratosis, Bowen disease), or malignant (squamous cell carcinoma, basal cell carcinoma, Kaposi sarcoma, others). Among the latter category squamous carcinomas are noted in up to 33% of penile horns (Gupta et al., 2014).

Treatment consists of surgical excision with a margin of normal tissue about the base of the horn. If malignancy is found at the base, resection appropriate to provide complete removal with a negative surgical margin should be performed. These lesions may recur and may demonstrate malignant change on subsequent biopsy, even when initial histologic appearance was benign (Fields et al., 1987). **Because this tumor may evolve into a carcinoma or may develop as a result of an underlying carcinoma, careful histologic evaluation of the base and close follow-up of the excision site are essential** (Hassan et al., 1967; Pressman et al., 1962; Solivan et al., 1990).

Pseudoepitheliomatous Keratotic and Micaceous Balanitis

Pseudoepitheliomatous keratotic and micaceous balanitis (PKMB) is a rare lesion that manifests as a hyperkeratotic scaly, micaceous growth on the surface of the glans penis. Microscopic features of the tumor include marked hyperkeratosis and parakeratosis in addition to pseudo epitheliomatous hyperplasia. The differential diagnosis of these lesions includes verrucous carcinoma, squamous cell carcinoma, giant condyloma, penile horn, and keratoacanthoma (Das et al., 2014). PKMB occurs in four stages, including (1) initial plaque, (2) late tumor stage, (3) verrucous carcinoma, and (4) invasive squamous cell carcinoma (Krunic et al., 1996). Treatment is based upon stage at presentation and can include topical 5-flourouracil, surgical excision, laser ablation, or cryotherapy. However, PKMB tends to recur as a frank carcinoma when less invasive treatment occurs and therefore requires close follow-up and prompt excision (Gray and Ansell, 1990).

Male Lichen Sclerosus (Balanitis Xerotica Obliterans)

Male lichen sclerosus (LS) (balanitis xerotica obliterans), a genital variation of lichen sclerosus et atrophicus, manifests as a whitish patch on the prepuce or glans, often involving the meatus and sometimes extending into the fossa navicularis. The lesions may be multiple and may assume a mosaic appearance. The meatus may appear white, indurated, and edematous. Glanular erosions, fissures, and meatal stenosis may occur. The disorder is most common in uncircumcised men and occurs most commonly in middle-aged men, but it does occur in boys (McKay et al., 1975). Symptoms include pain, dyspareunia, pruritus, painful erections, and urinary obstruction (Bainbridge et al., 1971).

On histologic examination, these lesions show an atrophic epidermis with loss of the rete pegs and homogenization of collagen on the upper third of the dermis combined with a zone of lymphocytic and histiocytic infiltration. They resemble the lesions of lichen sclerosus et atrophicus found elsewhere (Laymon and Freeman, 1944). **There are reports documenting the association of male LS with squamous cell carcinoma as well as with the development of carcinoma long after a lesion of LS has been treated** (Bart and Kopf, 1978; Dore et al., 1990; Jamieson et al., 1986; Kumaran and Kanwar, 2004; Laymon and Freeman, 1944; Simonart et al., 1998; Velazquez and Cubilla, 2003). It is a frequent finding in conjunction with squamous penile cancer, noted in 28% to 50% of patients. Penile cancer was subsequently diagnosed in 2.3% to 5.8% of men with LS in two different series (Depasquale et al., 2000; Nasca et al., 1999; Pietrzak et al., 2006; Powell and Wojnarowska et al., 1999). Cubilla et al. (2004) describe a well-differentiated nonverruciform variant of squamous cell carcinoma associated with lichen sclerosus et atrophicus that preferentially involves the prepuce. The cause of male LS is unknown; however, a recent study identified *Borrelia burgdorferi* infection in affected tissues in the early course of the disease. Floating microscopy was used to examine specimens from 60 patients with LS, and *B. burgdorferi* species were identified in 63% of the LS tissues and none of the controls (Eisendle et al., 2008). Whether this organism is causative is unproven at this time and requires additional study.

Other potential etiologic factors include autoimmunity, genetic factors in addition to trauma, and chronic inflammation. The latter is interesting in that LS almost never occurs in males circumcised at birth, thus implicating the closed, moist preputial environment as potentially being permissive for the disease (Fistarol et al., 2013).

Treatment involves clobetasol propionate cream for 2 to 3 months (Pugliese et al., 2007). Meatal stenosis is a common problem often requiring repeated dilations, corticosteroid injection, or even formal reconstructive surgery (Poynter and Levy, 1967). Close follow-up is essential, with biopsy if a change in appearance or behavior occurs.

Virus-Related Penile Lesions

There is increasing evidence to suggest that a number of penile lesions share viral causes. **Condyloma acuminatum and bowenoid papulosis appear to be related to infection with HPV. Human herpesvirus 8, also known as *Kaposi sarcoma–associated herpesvirus,* is strongly suspected of being the causative agent of epidemic (acquired immunodeficiency syndrome [AIDS]–related) Kaposi sarcoma** (Dianzani et al., 2004; Jaffe and Pellett, 1999; Miller et al., 1996; Simpson et al., 1996).

Human Papillomavirus in Malignant Transformation

Condylomata acuminata are soft, papillomatous growths typically considered benign. Also known as *genital warts* or *venereal warts,* they have a predilection for the moist, glabrous areas of the body and the mucocutaneous surfaces of the perineal and genital areas. The lesions are soft and friable and may occur singly on a pedicle or in a moruloid cluster on a broad base. These lesions are rare before puberty (Copulsky et al., 1975; Redman and Meacham, 1973) and when encountered may suggest sexual abuse (Handly et al., 1993).

In the male, condylomata occur most commonly on the glans, the penile shaft, and the prepuce. The meatus should also be carefully inspected. Lesions recur frequently in new and in previously treated sites. Approximately 5% of patients demonstrate urethral involvement, which may extend to the prostatic urethra. Rarely, extreme involvement of the urethra may require urethroplasty (Feneley et al., 1992). Bladder involvement, although rare, is extremely difficult to treat effectively (Bissada et al., 1974).

On microscopic examination, condylomata acuminata demonstrate an outer layer of keratinized tissue covering papillary fronds, which are supported by connective tissue stroma. The epithelial layer consists of well-ordered rows of squamous cells. A dermal lymphocytic infiltrate is usually present.

Interest in genital condylomata has increased dramatically, stimulated by an increased understanding of the relationship between HPV infection and certain human cancers. The terms *genital condyloma*, *venereal warts*, *genital warts,* and *genital HPV infection* all refer to a sexually transmitted disease caused by HPV. Although HPV is not a reportable sexually transmitted disease, a current estimate puts the number of new infections at 500,000 to 1 million annually (Stone, 1989). A study of 463 men aged 18 to 40 years analyzed samples from the glans and corona, penile shaft, scrotum, urethra, perianal area, anal canal, and semen and detected HPV in 51.2% (Nielson et al., 2007). Giuliano et al. (2009) found the prevalence of HPV in US males to be 51.7%, in Brazilian men to be 69.4%, and in Mexican men to be 56.1%. In a study of 379 adult heterosexual males, HPV infection was localized to the penile shaft (52%), scrotum (40%), glans or corona (32%), urine (10%), and semen (6%) (Hernandez et al., 2008). In a cohort of 379 adult heterosexual males, the overall incidence of HPV infection was 52%, with 60% of the uncircumcised and 50% of the circumcised males found to have HPV infection. There was a higher prevalence of oncogenic HPV in the uncircumcised group (Hernandez et al., 2008). **Factors associated with higher rates of infection with HPV include presence of foreskin, increasing numbers of sexual partners, lack of condom use, and smoking** (Giuliano et al., 2009).

The overall prevalence of HPV in females was found to be 26.8% among US females aged 14 to 59 years and highest among women aged 20 to 24 years (44.8%) (Dunne et al., 2007). **HPV is recognized as the principal causative agent in cervical dysplasia and cervical cancer** (Alani and Munger, 1998; Gross and Pfister, 2004; Lancaster et al., 1986). Significant numbers of male partners of women with cervical condylomata have lesions not identified on simple inspection and may not be aware that they are infected or have the potential to infect others (Sedlacek et al., 1986).

On histologic examination, the koilocyte—a cell characterized by an empty cavity surrounding an atypical nucleus—is pathognomonic for HPV infection (Schneider, 1989). DNA hybridization techniques have been used to identify and classify HPV infections, and 118 genotypes of HPV virus have been identified, of which about 40 involve the genital tract (de Sanjose et al., 2010; Nielson et al., 2007). **Virus types 6, 11, and 42 to 44 are associated with gross condylomata and low-grade dysplasia. Types 16, 18, 31, 33, 35, 39, 45, 51, 52, 58, and 59 have a higher association with malignant disease** (de Sanjose et al., 2010; Smotkin, 1989). **Data suggest that tumor virus transforming proteins from HPV types 16 and 18, particularly the E6 and E7 proteins, may target tumor suppressor gene products pRB and TP53** (Griffiths and Mellon, 1999; Levi et al., 1998). E6 appears to bind to cellular tumor suppressor protein TP53, leading to its rapid degradation, resulting in chromosome instability, DNA mutations, and aneuploidy. E7 binds to and phosphorylates the pRB retinoblastoma protein, leading to the release of transcription factor E2Fand upregulates p16$^{\mathrm{INK4a}}$, which drives cell cycle progression (Doorbar, 2006; zur Hausen, 1996). In fact, in human penile cancer infection with high risk, HPV is correlated with p16$^{\mathrm{INK4A}}$ protein expression, implicating pRB phosphorylation in HPV-induced carcinogenesis with little or no correlation of p53 with HPV-induced penile cancer (Stankiewicz et al., 2011). Human immunodeficiency virus (HIV) infection may predispose affected patients to rapid development of squamous carcinoma from preexisting condyloma infection (Sanders, 1997). The most recent estimate based upon a meta-analysis suggests that about 47% of all penile cancers are caused by HPV (Backes et al., 2009).

Subclinical disease may be detected by the application of 5% acetic acid solution to the penis, followed by inspection with a magnifying glass. Lesions will turn white, and flat lesions often invisible on regular inspection may be detected. These acetowhite lesions are not always caused by HPV, and biopsy must be performed to confirm the diagnosis (Krebs and Schneider, 1987). Careful inspection of the base of the shaft, the scrotum, and the inguinal folds is essential. The meatus should be examined; if lesions are present, urethroscopy should be performed (Barrasso et al., 1987).

A variety of treatments for genital warts are available, but none has been proven to reduce transmission to sexual partners nor to prevent progression to dysplasia or cancer. In addition, recurrence after treatment is common. The more commonly used treatments include (1) podophyllotoxin 0.5% solution or gel *(used historically)*, (2) trichloroacetic acid 35% to 85%, (3) cryotherapy with liquid nitrogen, (4) electrofulguration, (5) CO_2 laser therapy, and (6) imiquimod 5% cream (Buechner, 2002; Dupin, 2004; Kinghorn et al., 1993).

The goal of surgical therapies is to either remove or ablate condylomata. Circumcision will remove preputial lesions, gain exposure for treatment, and allow post-treatment monitoring. Fulguration and excision may be advisable to avoid large areas of maceration, ulceration, and secondary infection.

Surgical therapy with use of a pediatric resectoscope may be helpful in debulking large intraurethral lesions. The lowest power required to resect the lesions should be used, and electrocautery should be minimized to avoid the development of urethral stricture. Whether laser therapy, electrocautery, or cryotherapy is used, significant rates of recurrence have been noted. **Imiquimod cream (5%) has become the topical treatment of choice for condyloma. Imiquimod is an immune modulator that enhances natural killer cell activity** (Buechner, 2002; Sanchez-Ortiz and Pettaway, 2003). Immune modulators and antiviral agents have the potential to affect the viral load.

Various interferons have been used in condyloma treatment (Geffen et al., 1984). A randomized study has shown that short-term intralesional interferon alfa-2b has activity against condyloma (Eron et al., 1986). The outcome of studies using other interferons has been less clear (Zouboulis et al., 1991). Interferon therapy continues to be reserved for extensive and recalcitrant lesions

(Ferenczy, 1990; Krebs, 1989a, 1989b).

Another recent antiviral agent shown to have activity against HPV includes (*S*)-1-(3-hydroxy-2-phosphonylmethoxypropyl) cytosine (cidofovir), an acyclic nucleoside phosphonate with broad-spectrum antiviral activity against DNA viruses. A 1% gel preparation of cidofovir applied daily every other week for six cycles was shown to be superior to placebo in a double-blind, placebo-controlled trial, with a complete response of 47% in treated patients (Snoeck et al., 2001).

Intraurethral lesions may be extremely difficult to treat. 5-Fluorouracil cream applied weekly for 3 weeks has been successful in eliminating urethral lesions (Bissada et al., 1974; Boxer and Skinner, 1977; Dretler and Klein, 1975). Care must be taken to work the cream down the urethra and to avoid exposure of the scrotal skin. Use of a scrotal support or zinc oxide cream may be helpful. The addition of 5-fluorouracil cream to laser therapy did not improve the success rate in one study (Carpiniello et al., 1987).

Buschke-Löwenstein Tumor (Giant Condyloma Acuminatum)

The Buschke-Löwenstein tumor was initially described by Buschke and Löwenstein in 1925 and later by Löwenstein in 1939 in the United States (eFig. 79.1B).

The Buschke-Löwenstein tumor differs from condyloma acuminatum in that condylomata, regardless of size, always remain superficial and never invade adjacent tissue. Buschke-Löwenstein tumor displaces, invades, and destroys adjacent structures by compression. Aside from this unrestrained local growth, it does not metastasize. On microscopic examination, the tumor forms a luxuriant mass composed of broad, rounded rete pegs, often extending far into underlying tissue. The pegs are composed of well-differentiated squamous cells that show no cellular anaplasia. These epithelial pegs are characteristically surrounded by a dense band of acute and chronic inflammatory cells. As with condyloma acuminata, DNA from HPV types 6 and 11 has been identified in these tumors (Boshart and zur Hausen, 1986; Braga et al., 2012).

Either excisional biopsy or multiple deep biopsies are required to distinguish the lesion from true penile carcinoma. In the perianal region 30% to 56% have been associated with an existing carcinoma with a mortaliy of about 20% (Chu et al., 1994). Optimal treatment consists of complete surgical excision. In extensive cases skin graft reconstruction may be required (Hasid and Papadopoulos, 2017). Recurrence is common, and close follow-up is essential.

Topical therapy with either podophyllin or 5-fluorouracil has been unsuccessful, probably because the characteristic thickened stratum corneum is impervious to the medication (Bruns et al., 1975). Likewise, radiation therapy has also been shown to be ineffective (Lepor and Leffler, 1960). Successful treatment of a Buschke-Löwenstein tumor with systemic interferon therapy combined with Nd:YAG laser therapy has been reported in lower-volume disease involving the penis (Gilbert and Beckert, 1990).

HPV infection is common and, as noted earlier, potentially carcinogenic. Condylomata have been associated with squamous cell carcinoma of the penis (Beggs and Spratt, 1964; Rhatigan et al., 1972). Malignant transformation of condyloma to squamous cell carcinoma has been reported (Boxer and Skinner, 1977; Coetzee, 1977; Malek et al., 1993). Condylomata acuminata located in the perianal, scrotal, and oral areas have also demonstrated malignant degeneration (Burmer et al., 1993). An increased incidence of penile intraepithelial neoplasia has been found in the male partners of women with cervical intraepithelial neoplasia (Barrasso et al., 1987; Iversen et al., 1997). Thus preventive strategies are relevant. A quadrivalent vaccine (Gardasil, approved by the US Food and Drug Administration [FDA], June 2006) that protects against HPV types 5, 11, 16, and 18 in women ages 9 to 26 years was approved (Watson et al., 2008). Subsequently in 2010 the same vaccine was approved for use in males ages 9 to 26 for the prevention of anal and genital lesions. In one study the efficacy of preventing HPV-related genital lesions was 65% (Giuliano et al., 2011).

More recently a nanovalent HPV vaccine has become available that extends the coverage of the quadrivalent vaccine to HPV genotypes 31, 33, 45, 52, and 58 (Petrosky et al., 2015). This current HPV vaccine requires only two doses among immunocompetent subjects vaccinated before age 15. Approximately 49.5% of US females and 37.5% of males were up to date using the two-dose criteria (Walker et al., 2017).

Carcinoma in situ (Penile Intraepithelial Neoplasia)

Carcinoma in situ of the penis (penile intraepithelial neoplasia, also known as PEIN or PIN) has been well recognized since its first description by Queyrat in 1911. **Carcinoma in situ (CIS) of the penis is called *erythroplasia of Queyrat* (EQ) by urologists and dermatologists if it involves the glans penis and prepuce or Bowen disease (BD) if it involves the penile shaft or the**

remainder of the genitalia or perineal region. Kopf and Bart described a third entity, bowenoid papulosis (BP), a condition having a histologic appearance similar to that of carcinoma in situ but a benign course, in 1977. These three lesions fall under the category of penile intraepithelial neoplasia (i.e., PeIN or PIN) but have distinct clinical presentations and characteristics (Porter et al., 2002). The incidence of HPV infection in two small series of penile dysplasia or carcinoma in situ was approximately 90% (Krusrup et al., 2009; Rubin et al., 2001).

BP manifests as multiple papules on the penile skin or female vulva, usually during the second or third decade of life. The lesions are usually pigmented and range from 0.2 to 3.0 cm in diameter, and smaller lesions may coalesce into larger ones (Patterson et al., 1986). Pigmented lesions occur on the penile skin, whereas glanular lesions tend to be flat papules (Gross et al., 1985). Diagnosis is confirmed by biopsy (Peters and Perry, 1981). These lesions meet all the histologic criteria of carcinoma in situ but display differing growth patterns relative to flat, endophytic, or exophytic clinical appearance (Bhojwani et al., 1997; Gross et al., 1985; Patterson et al., 1986; Peters and Perry, 1981; Wade et al., 1978). DNA sequences suggestive of HPV-16 have been found in specimens of BP, and a causative role for HPV is likely (Endo et al., 2003; Gross et al., 1985). **Whereas histologically this condition is a CIS, the clinical course of BP is invariably benign** (Su and Shipley, 1997). Treatment has included electrodesiccation, cryotherapy, laser fulguration, topical 5-fluorouracil cream, and excision with skin grafting.

EQ originally described by Queyrat in 1911 consists of a red, velvety, well-marginated lesion of the glans penis or, less frequently, the prepuce of the uncircumcised man (Aragona et al., 1985). It may ulcerate and may be associated with discharge and pain. On histologic examination the normal mucosa is replaced by atypical hyperplastic cells characterized by disorientation, vacuolation, multiple hyperchromatic nuclei, and mitotic figures at all levels. The epithelial rete extends into the submucosa and appears elongated, broadened, and bulbous. The submucosa shows capillary proliferation and ectasia with a surrounding inflammatory infiltrate that is usually rich in plasma cells. These microscopic features distinguish EQ from chronic localized balanitis. Progression to invasive carcinoma can occur in 10% to 33% of patients (Bleeker et al., 2009; Buechner, 2002).

In 1912 Bowen described an intraepithelial neoplasm of the skin associated with a high occurrence of subsequent internal malignant disease as a distinct entity. BD, BP, and EQ are histologically similar (Graham and Helwig, 1973) (see eFig. 79.1C on ExpertConsult.com). All three lesions are characterized by the noninvasive changes of CIS. **Visceral malignant disease is not associated with EQ, and subsequent case-control studies have shown no association of BD with internal malignant tumors** (Anderson et al., 1973). Thus penile CIS does not warrant a specific search for internal malignant tumors.

BD is characterized by sharply defined plaques of scaly erythema on the penile shaft. Crusted or ulcerated variants can occur. The appearance can be confused with BP, nummular eczema, psoriasis, and superficial basal cell carcinoma. If it is not treated, then invasive carcinoma may arise in about 5% of patients (Buechner, 2002)**. When all cases of CIS are considered, metastasis is extremely rare but has been reported** (Eng et al., 1995).

Treatment is based on proper histopathologic confirmation of malignancy with multiple biopsies of adequate depth to rule out invasion. When lesions are located on the foreskin, circumcision or excision with a 5-mm margin is adequate for local control (Bissada, 1992). In this regard, lesions on the glans penis are more difficult to treat by excisional strategies while maintaining normal penile anatomy. Recently several groups have described the technique of glans resurfacing for penile squamous carcinoma of the glans penis. In this technique the epithelium and subepithelial tissue of the glans penis are completely dissected off the underlying spongiosal tissue. The resulting defect is then closed with a skin graft. Early follow-up reveals very low rates of local recurrence (Hadway et al., 2006; Shabbir et al., 2011b). Alternative strategies include topical 5-fluorouracil cream (Goette, 1974; Graham and Helwig, 1973; Lewis and Bendl, 1971), 5% imiquimod cream (Danielson et al., 2003), and ablation with Nd:YAG (Frimberger et al., 2002a; Landthaler et al., 1986), potassium titanyl phosphate (KTP) 532-nm, or carbon dioxide lasers (Rosemberg and Fuller, 1980; Tietjen and Malek, 1998; van Bezooijen et al., 2001). Such strategies have been shown to produce excellent cosmetic and functional results. Historically radiation therapy has be used to treat tumors that were resistant to topical treatment, especially among patients who are not surgical candidates (Grabstald and Kelley, 1980; Kelley et al., 1974; Mazeron et al., 1984; McLean et al., 1993).

Kaposi Sarcoma

Kaposi sarcoma, first described in 1972, is a tumor of the reticuloendothelial system (Kaposi, 1982). It appears as a cutaneous neovascular lesion, a raised, painful, bleeding papule or ulcer with bluish discoloration. On histologic examination the tumor is vasoformative with endothelial proliferation and spindle cell formation.

Initially, Kaposi sarcoma occurred rarely in Europe and North America. It was characterized by a slowly progressive tumor affecting the lower extremities of older men, usually of Eastern European Jewish or Italian descent. Kaposi sarcoma was also found in young black African men and patients receiving immunosuppressive therapy. The disease is now closely linked with patients who have AIDS and takes a much more aggressive clinical course in this group.

Kaposi sarcoma is now subcategorized as follows: (1) classic Kaposi sarcoma, which occurs in patients without known immunodeficiency and has an indolent and rarely fatal course; (2) immunosuppressive treatment–related Kaposi sarcoma, which occurs in patients undergoing immunosuppressive therapy for organ transplantation or other indications and is often reversed with dosage modification of the immunosuppressive agents; (3) African Kaposi sarcoma, which occurs in young men and may be indolent or aggressive in course; and (4) epidemic or HIV-related Kaposi sarcoma, which occurs in the patient with AIDS.

The classic and immunosuppressive forms of the disease are considered nonepidemic. Nonepidemic Kaposi sarcoma limited to penile involvement should be aggressively treated because it is rarely associated with diffuse organ involvement. Localized surgical excision or small-field external-beam or electron beam radiation has been effective (Lands et al., 1992). With wider areas of involvement, partial penectomy is indicated. In the immunosuppressed patient Kaposi sarcoma often regresses with the discontinuation of immunosuppressive therapy. If regression does not occur, local excision or radiation should be considered. Systemic management for multisystem involvement has employed interferon and cytotoxic therapy (National Cancer Institute Position Statement, 1990).

In the patient with AIDS, the underlying immunodeficiency predisposes the host to Kaposi sarcoma by a factor of 7000 (Miles, 1994). The first case of HIV-related epidemic Kaposi sarcoma was reported in 1981 (Friedman-Kien, 1981) and the first with penile involvement in 1986 (Seftel et al., 1986). Subsequently, Kaposi sarcoma of the penis has become a relatively common lesion in the patient with AIDS. Penile involvement is more common in homosexual men than in others with AIDS. In the first 1000 cases of AIDS reported by the Centers for Disease Control and Prevention, incidence of penile Kaposi sarcoma was 44% in homosexual and bisexual patients compared with only 16% in intravenous drug abusers with AIDS and 0 hemophiliac patients with AIDS (Bayne and Wise, 1988; Jaffe et al., 1983). **Several reports suggest a strong relationship between infection with human herpesvirus 8, also known as *Kaposi sarcoma–related herpesvirus,* and the development of Kaposi sarcoma lesions in patients with HIV infection** (Jaffe and Pellett, 1999; Sitas et al., 1999). Some studies have found epidemic Kaposi sarcoma in patients who are HIV negative, which suggests that certain sexual practices and a separate sexually transmitted agent may be responsible for this form of the disease (Chitale et al., 2002; Miles, 1994). Human herpesvirus 8 has been isolated from penile Kaposi lesions in patients who were HIV negative, which supports the notion that this disease may be sexually transmitted potentially via homosexual practices (Morelli et al., 2003).

Whereas Kaposi sarcoma may be the presenting sign of the disease in many patients with AIDS, early involvement of the penis is rare in this group (Grunwald et al., 1994). Treatment is directed toward palliation (Lowe et al., 1989). Glans penis or corpus spongiosum involvement may produce urethral obstruction, necessitating proximal urethrostomy. This usually allows voiding in the upright position. With large lesions involving the penis, partial or total penectomy may be necessary. Radiation therapy and use of the neodymium:yttrium-aluminum-garnet (Nd:YAG) laser to alleviate distal urethral obstruction have also been reported (Ruszczak et al., 1996; Wishnow and Johnson, 1988).

Key Points: Virus-Related Dermatologic Lesions

- HPV infection among men is associated with penile carcinoma as well as with cervical dysplasia and carcinoma among female partners.
- Imiquimod cream is now the standard topical treatment of choice for condyloma.
- Giant condyloma of Buschke Lowenstein are locally progressive HPV-related tumors that are nonmetastatic but require complete excision and follow-up. The potential for co-existing or malignant degeneration to squamous carcinoma has been shown.
- Penile carcinoma in situ (CIS) is an intraepithelial malignant process

manifesting as three differing clinical entities, including bowenoid papulosis, Bowen disease, and erythroplasia of Queryrat.

  - Bowenoid papulosis occurs on the shaft of young men in most cases and does not progress to invasive disease.
  - Progression to invasive carcinoma in men with BD and EQ may occur in 5% to 33% of patients, respectively, if it is not treated.
  - Metastasis has rarely occurred.
  - Cancer eradication with organ-preserving strategies is the goal of therapy.

- A diagnosis of penile Kaposi sarcoma is often associated with human herpesvirus 8 and should prompt an investigation into whether the patient is also infected with HIV or otherwise immunosuppressed.

Squamous Cell Carcinoma

Invasive Carcinoma

Penile carcinoma accounts for 0.4% to 0.6% of all malignant neoplasms among men in the United States and Europe; it may represent up to 10% of malignant neoplasms in men in some Asian, African, and South American countries (Gloeckler-Ries et al., 1990). **Trends in penile cancer incidence have suggested differing patterns with decreasing rates in many countries, including Finland, the United States, India, and other Asian countries** (Frisch et al., 1995; Maiche, 1992; Yeole and Jussawalla, 1997). However more recently in Denmark, the Netherlands, and the United Kingdom rates have actually increased. In the latter countries increasing exposure to human papillomavirus and decreasing rates of childhood circumcision were suggested as potential factors (Arya et al., 2013; Baldur-Felskov et al., 2012; Graafland et al., 2011a).

Penile cancer is a disease of older men, with an abrupt increase in incidence in the sixth decade of life (Persky, 1977). In two studies the mean ages were 58 years (Gursel et al., 1973) and 55 years (Derrick et al., 1973). The tumor is not unusual in younger men; in one large series, 22% of patients were younger than 40 years and 7% were younger than 30 years (Dean, 1935); the disease has also been reported in children (Kini, 1944; Narasimharao et al., 1985). The Surveillance, Epidemiology, and End Results (SEER) database reveals the age standardized incidence rate of penile cancer between the years of 2000 and 2004 among US white, black, and Hispanic men to be 0.8, 0.9, and 1.1 per 100,000, respectively. However, this same rate was substantially higher among Puerto Rican Hispanic men at 2.8 per 100,000 (Colon-Lopez et al., 2012).

Two studies suggest that mortality in penile cancer may differ in part in relation to race and ethnicity. Rippentrop et al. (2004) found factors independently predictive of worsened survival in penile cancer to be higher stage at diagnosis, age older than 65 years, African-American ethnicity, and disease within lymph nodes. These researchers demonstrated a statistically significant disease-specific risk of death that was 2.2-fold higher in African-American patients than in white patients. Another more recent study using data from the Puerto Rico Cancer Registry and SEER data showed that when compared with US whites, US Hispanics, and African Americans, Puerto Rican men exhibited

1.8 to 3 times higher penile cancer mortality (Colon-Lopez et al., 2012). The reasons for these disparities are unknown but could include differences in cancer biology, health care access, or treatment. Such differences deserve further study.

Etiology

The incidence of carcinoma of the penis varies according to circumcision practice, hygienic standards, phimosis, number of sexual partners, HPV infection, exposure to tobacco products, and other factors (Barrasso et al., 1987; Maden et al., 1993; Maiche, 1992; Misra et al., 2004).

Neonatal circumcision has been well established as a prophylactic measure that virtually eliminates the occurrence of penile carcinoma because it eliminates the closed preputial environment where penile carcinoma develops. The chronic irritative effects of smegma, a byproduct of bacterial action on desquamated cells that are within the preputial sac, have been proposed as a causative agent. Although definitive evidence that human smegma itself is a carcinogen has not been established (Reddy and Baruah, 1963), its relationship to the development of penile carcinoma has been widely observed. Improper hygiene can lead to buildup of smegma beneath the preputial foreskin, with resulting inflammation. Healing by fibrosis leads to phimosis of the preputial skin, which tends to perpetuate the cycle. Phimosis is found in 25% to 75% of patients described in most large series. Reddy et al. (1984) studied the foreskins of 26 men undergoing circumcision because of phimosis and found epithelial atypia in one-third of the specimens.

Carcinoma of the penis is rare among the Jewish population, for whom neonatal circumcision is a universal practice (Licklider, 1961). Similarly, in the United States, where neonatal circumcision is widely practiced, penile cancer represents less than 1% of male malignant neoplasms. Among noncircumcising tribes of Africa and within Asian cultures in which circumcision is not practiced, penile cancer may amount to 10% to 20% of all male malignant neoplasms (Dodge, 1965; Narayana et al., 1982). Data from most large series show that penile cancer is rare among neonatally circumcised individuals but more frequent when circumcision is delayed until puberty (Frew et al., 1967; Gursel et al., 1973; Johnson et al., 1973). Adult circumcision appears to offer little or no protection from subsequent development of the disease (Maden et al., 1993). **These data suggest that the critical period of exposure to certain causative agents may have already occurred at puberty and certainly by adulthood,**

rendering later circumcision relatively ineffective as a prophylactic tool for penile cancer.

Population-based data reveal that although neonatal circumcision is highly protective for invasive penile cancer, it does not afford the same level of protection for CIS. Schoen et al. (2000) evaluated the incidence of invasive penile cancer or CIS during a 10-year period and found only 2 cases of 89 (2.3%) occurring among neonatally circumcised men, whereas of 118 men with CIS, 16 cases were noted among 102 men who were circumcised at birth for an incidence of 15.7%. In consideration that the protective effects of circumcision on invasive penile cancer are likely to be mediated by avoidance of phimosis, it is noteworthy that another study associated phimosis with the development of invasive penile cancer but not CIS (Hung-fu et al., 2001).

Male circumcision has also been shown to be effective against HIV type 1 (HIV-1) infection. This effect was shown to be specific by Reynolds et al. (2004). There was no protective effect of circumcision for other sexually transmitted diseases, such as herpes simplex virus type 2 infection, syphilis, or gonorrhea.

HPV infection and exposure to tobacco products are associated with development of penile cancer. Epidemiologic data provided the first clues to a relationship between a sexually transmitted agent and cancer by demonstrating that the wives or ex-wives of men with penile cancer had a threefold higher risk of cervical carcinoma (Graham et al., 1979). Further investigation revealed that the male partners of women with cervical intraepithelial neoplasia had a significantly higher incidence of penile intraepithelial neoplasia (Barrasso et al., 1987). These same male patients were also found to have a greater incidence of HPV infection.

Polymerase chain reaction and in situ hybridization have provided increased evidence for a causative role of HPV by identifying specific DNA sequences from different HPV types in primary penile lesions (malignant and benign) but not in normal foreskins (Iwasawa et al., 1993; Varma et al., 1991). More than 40 types of HPV infect genital sites. HPV types 6 and 11 are most commonly associated with nondysplastic lesions such as genital warts, but these are also noted in nonmetastatic verrucous carcinomas. In contrast, HPV types 16, 18, 31, 33, 45, 52, 58 are the more common types associated with in situ and invasive carcinomas (Petrosky et al., 2015). **HPV-16 appears to be the most frequently detected type in primary carcinomas and has also been detected in metastatic lesions** (Iwasawa et al., 1993; Varma et al., 1991; Wiener and

Walther, 1995). As noted previously, the HPV genome encodes oncoprotein E6, which complexes with the tumor suppressor protein TP53, and oncoprotein E7, which binds the retinoblastoma (RB) protein, thus affecting cell cycle regulation (Griffiths and Mellon, 1999; Levi et al., 1998; Munger et al., 1989; zur Hausen, 1996) via the p14ARF/MDM2/p53 and p15INK4a/cyclin D/Rb pathways (Bleeker et al, 2009). Maden et al. (1993) **found that the incidence of HPV infection directly correlated with the number of lifetime sexual partners, which was also related to risk of penile cancer.** Another recent study found that HIV infection was a risk factor for HPV infection (Olesen et al., 2017).

Poblet et al. (1999) reported on two patients with coexisting HIV-1 and HPV infection and postulated that HIV-1 could synergize with HPV to increase the progression of HPV penile lesions into penile carcinoma. Although there is evidence supporting this effect in cervical and anal neoplasia, definitive proof for penile cancer awaits further study (Northfelt, 1994).

Although HPV infection is probably an important factor in the development of penile cancer, its presence is not invariable (31% to 63% of patients with penile carcinoma test positive) (Backes et al., 2009; Wiener and Walther, 1995), **indicating that additional factors may be involved in the development of the disease or its subtypes.** Additional evidence includes a study by Rubin et al. (2001) who noted that overall, 42% of penile carcinomas were HPV positive and varied by pathologic subtype. Only 34.9% and 33.3% of keratinizing and verrucous carcinomas, respectively, were positive, whereas 80% and 100% of basaloid and warty tumor subtypes, respectively, exhibited HPV DNA. Other non–HPV-dependent molecular events leading to penile carcinogenesis have been described, including silencing of the CDK2NA locus via promoter hypermethylation, the expression of genes that target the INK4a/ARF locus, other gene mutations affecting TP53, and p14ARF, and MDM2 overexpression (reviewed in Bleeker et al, 2009; Ferreux et al., 2003).

Four studies have shown a significant association between exposure to cigarette smoke and development of penile cancer (Daling et al., 1992; Harish and Ravi, 1995; Hellberg et al., 1987; Maden et al., 1993). Hellberg et al. (1987) studied the smoking history of 244 men with penile cancer and matched controls. They found a significantly increased odds ratio for penile cancer based on whether an individual had smoked, and the risk increased with the number of cigarettes smoked. This observation held even when the presence of phimosis was controlled. **Harish and Ravi** (1995) **extended these observations by showing that all forms of tobacco products, including cigarettes, chewing**

tobacco, and snuff, were significantly and independently related to the incidence of penile cancer subsequent to multivariate regression analysis. It has been hypothesized that tobacco products can act in the presence of HPV infection or bacteria associated with chronic inflammation to promote malignant transformation. These same risk factors are also common to other anogenital carcinomas (Daling et al., 1992; Maden et al., 1993).

Penile trauma may be another risk factor for penile cancer. The development of carcinoma in the scarred penile shaft after mutilating circumcision has been reported as a distinct entity (Bissada et al., 1986). Furthermore, Maden et al. (1993) found a greater than threefold risk of penile cancer in men with penile tears and rashes. A case-control study also revealed an odds ratio of 18 : 1 for the development of penile cancer for those men reporting a penile injury 2 years before the onset of the disease (Hung-fu et al., 2001).

Lichen sclerosus (also known as balanitis xerotica obliterans) is a risk factor for the development of penile cancer. **Studies have shown the incidence of subsequent cancer with long-term follow-up to be between 2.3% and 9% of men with LS** (Depasquale et al., 2000; Micali et al., 2001). Velazquez and Cubilla (2003) studied LS occurring in association with penile cancer and noted its presence distinctly among the subset of penile carcinomas that were not associated with HPV.

Larger studies performed in areas where the disease is endemic, incorporating the many risk factors for penile cancer into a multivariate analysis, are clearly needed to define which factors independently confer risk. Thus far, no convincing evidence has been found linking penile cancer to other factors such as occupation, other venereal diseases (gonorrhea, syphilis, and herpes), marijuana use, or alcohol intake (Maden et al., 1993).

Prevention

The role of routine neonatal circumcision as a preventive strategy for penile cancer has been, to say the least, a controversial topic. The position of the American Academy of Pediatrics has changed over time with accumulating evidence from one of denial of any medical benefits (Schoen et al., 1989) to the more moderate position stating, **“There are potential medical benefits of newborn circumcision”** (Shapiro, 1999), to the most recent statement published in August 2012, which states, “Evaluation of current evidence indicates that the health benefits of newborn male circumcision outweigh the risks and that the procedure's benefits justify access to this procedure for families who choose it." Specific benefits in their data review included prevention of urinary tract infections, penile cancer, and transmission of sexually transmitted infections, including HIV (American Academy of Pediatrics Task Force on Circumcision, 2012).

Any argument against circumcision must consider that penile carcinoma represents the only neoplasm for which there exists a predictable and simple means of prophylaxis to spare the organ at risk (Dagher et al., 1973). Although circumcision can obviate the disease, especially where facilities for daily hygiene may be lacking, it may not be as important in countries where good hygiene is practiced. Frisch et al. (1995) reported a falling incidence of penile cancer (from 1.15 per 100,000 men to 0.82 per 100,000 men) in the Danish population, which has a circumcision rate of only 1.6%. They attributed this trend to improved hygiene because the incidence of dwellings having a bath facility increased from 35% in the 1940s to 90% in the 1990s. Thus considering the benefits of circumcision (including the prevention of infections, HIV infection and its transmission, and penile and cervical cancer), enhanced education about the potential benefits of circumcision, especially in developing countries, seems rational (Kinkade et al., 2005; Reynolds et al., 2004; Schoen et al., 1989).

Although neonatal circumcision and good hygiene to prevent the occurrence of phimosis represent important penile cancer prevention strategies, additional efforts to prevent malignant transformation include avoidance of HPV infection, and avoidance of tobacco products. Thus modifiable behaviors can potentially prevent penile cancer (Bleeker et al., 2009; Griffiths and Mellon, 1999; Harish and Ravi, 1995; Levi et al., 1998; Maden et al., 1993; Munger et al., 1989).

As mentioned previously, HPV vaccination should play an emerging role in the future with respect to preventing transmission of HPV between males and females and, potentially, penile cancer. Three prophylactic HPV vaccines are available (HPV 16/18 vaccine Cervarix [GlaxoSmithKline], the quadrivalent HPV 16/18/6/11 vaccine Gardasil, and Gardasil 9 HPV 16/18/6/11/31/33/45/52/58 [Merck Sharp & Dohme]), and the efficacy of preventing HPV infection among HPV-negative young women and men has been demonstrated (Bleeker et al., 2009; Block et al., 2006; Giuliano et al., 2011, Harper et al., 2004; Petrosky et al., 2015; Villa et al., 2005). Future efforts should focus on gaining more widespread use of such vaccines to prevent HPV-related disease.

Key Points: Epidemiology, Etiology, and Prevention

- Penile cancer is rare in developed countries and varies worldwide with age, circumcision, HPV exposure, and lifestyle/hygiene practices.
- Recent epidemiologic data from the United States suggest a disparity in incidence and outcome of penile cancer for Puerto Rican Hispanic men.
- Risk factors for development of penile cancer include lack of neonatal circumcision, phimosis, HPV infection, exposure to tobacco products, penile LS, and, potentially, penile trauma.
- Penile cancer represents a preventable disease in most cases via neonatal circumcision, HPV vaccination, and/or behavior modification.

Natural History

Carcinoma of the penis usually begins with a small lesion that gradually extends to involve the entire glans, shaft, and corpora. The lesion may be papillary and exophytic or flat and ulcerative; if it is untreated, penile autoamputation may occur as a late result. The rates of growth of the papillary and ulcerative lesions are similar, but the flat, ulcerative tumor has a tendency toward earlier nodal metastasis and is associated with poorer 5-year survival rates (Dean, 1935; Marcial et al., 1962; Ornellas et al., 1994). Lesions larger than 5 cm (Beggs and Spratt, 1964) and those extending over 75% of the shaft (Staubitz et al., 1955) are also associated with an increased incidence of metastases and a decreased survival rate. However, others have not found a consistent relationship among lesion sizes, presence of metastases, and decreased survival (Ekstrom and Edsmyr, 1958; Puras et al., 1978).

Buck fascia acts as a temporary natural barrier to local extension of the tumor, protecting the corporeal bodies from invasion. Penetration of Buck fascia and the tunica albuginea permits invasion of the vascular corpora and establishes the potential for vascular dissemination.

The earliest route of dissemination from penile carcinoma is metastasis to the regional femoral and iliac nodes. A detailed description of lymphatic drainage of the penis is found elsewhere in this text and is well documented in the literature

(Dewire and Lepor, 1992). Briefly, the lymphatics of the prepuce form a connecting network that joins with the lymphatics from the skin of the shaft. These tributaries drain into the superficial inguinal nodes (the nodes external to the fascia lata). The lymphatics of the glans join the lymphatics draining the corporeal bodies, and they form a collar of connecting channels at the base of the penis that drain by way of the superficial nodes. The superficial nodes drain to the deep inguinal nodes (those deep to the fascia lata). From there, drainage is to the pelvic nodes (external iliac, internal iliac, and obturator). Penile lymphangiographic studies demonstrate a consistent pattern of drainage that proceeds from superficial inguinal to deep inguinal to pelvic node sites without evidence of ipsilateral drainage (Cabanas, 1977, 1992). Multiple cross-connections exist at all levels of drainage so that penile lymphatic drainage is bilateral to both inguinal areas.

Metastatic enlargement of the regional nodes eventually leads to skin necrosis, chronic infection, and death from inanition, sepsis, or hemorrhage secondary to erosion into the femoral vessels. Clinically detectable distant metastatic lesions to the lung, liver, bone, or brain are uncommon and are reported to occur in 1% to 10% of patients in most large series (Beggs and Spratt, 1964; Derrick et al., 1973; Johnson et al., 1973; Kossow et al., 1973; Puras et al., 1978, reviewed in Pettaway et al., 2010; Staubitz et al., 1955). Such metastases usually occur late in the course of the disease after the local lesion has been treated. Distant metastases in the absence of regional node metastases are unusual.

Carcinoma of the penis is characterized by a relentless progressive course, causing death for the majority of untreated patients within 2 years (Beggs and Spratt, 1964; Derrick et al., 1973; Skinner et al., 1972). Rarely, long-term survival occurs, even with advanced local disease and regional node metastases (Beggs and Spratt, 1964; Furlong and Uhle, 1953). No report of spontaneous remission of carcinoma of the penis is known; 5% to 15% of patients have been reported to develop a second primary neoplasm (Beggs and Spratt, 1964; Buddington et al., 1963; Gursel et al., 1973), and one series reported secondary carcinoma in 17% of patients (Hubbell et al., 1988).

Modes of Presentation

Signs

It is the penile lesion itself that usually alerts the patient to the presence of penile cancer. The presentation ranges from a relatively subtle induration or

small excrescence to a small papule, pustule, warty growth, or more luxuriant exophytic lesion. It may appear as a shallow erosion or as a deeply excavated ulcer with elevated or rolled-in edges. Phimosis may obscure a lesion and allow a tumor to progress silently. Eventually, erosion through the prepuce, foul preputial odor, and discharge with or without bleeding call attention to the disease.

Penile tumors may arise anywhere on the penis but occur most commonly on the glans (48%) and prepuce (21%). Other tumors involve the glans and prepuce (9%), the coronal sulcus (6%), or the shaft (<2%) (Sufrin and Huben, 1991). This distribution of lesions may be the result of constant exposure of the glans, coronal sulcus, and interior prepuce to irritants (e.g., smegma, HPV infection) within the preputial sac, whereas the shaft is relatively spared.

Rarely, a mass, ulceration, suppuration, or hemorrhage in the inguinal area may be caused by nodal metastases from a lesion concealed within a phimotic foreskin. Urinary retention or urethral fistula from local corporeal involvement is a rare presenting sign.

Symptoms

Pain does not develop in proportion to the extent of the local destructive process and usually is not a presenting complaint. Weakness, weight loss, fatigue, and systemic malaise occur secondary to chronic suppuration. On occasion, significant blood loss from the penile lesion, the nodal lesion, or both may occur. Because local disease and regional disease are usually far advanced by the time distant metastases occur, presenting symptoms referable to such metastases are rare.

Diagnosis

Delay

Patients with cancer of the penis, more than patients with other types of cancer, seem to delay seeking medical attention (Lynch and Krush, 1969). In large series, 15% to 50% of patients delayed medical care for more than a year (Buddington et al., 1963; Dean, 1935; Gursel et al., 1973; Hardner et al., 1972). Explanations include embarrassment, guilt, fear, ignorance, and personal neglect. This level of denial is substantial, given that the penis is observed and handled on a daily basis.

Delay on the part of the physician in initiating diagnosis and treatment may also be considerable. In some instances patients have been given prolonged courses of antibiotics or topical antifungal preparations before being referred for biopsy. Although some studies show that the difference in survival rates between patients with early presentation and those with later presentation is negligible (Ekstrom and Edsmyr, 1958; Johnson et al., 1973), other series show decreased survival with longer delay (Hardner et al., 1972). It appears logical that earlier diagnosis and treatment should improve outcome.

Examination

At presentation most lesions are confined to the penis (Derrick et al., 1973; Johnson et al., 1973; Skinner et al., 1972). The penile lesion is assessed with regard to size, location, fixation, and involvement of the corporeal bodies. Inspection of the base of the penis and scrotum is necessary to rule out extension into these areas. Rectal and bimanual examination provides information about perineal body involvement and presence of a pelvic mass. Careful bilateral palpation of the inguinal area for adenopathy is extremely important.

Key Points: Natural History and Presentation

- Penile cancer often begins on the surface of the glans penis or in the preputial area, where it progressively enlarges.
- Delay in seeking medical attention and then in subsequent definitive biopsy is common.
- Examination of the penile primary tumor and the inguinal region is critical to treatment planning.
- Metastasis occurs by embolization of tumor deposits from the penile tumor through penile lymphatics to the inguinal lymph nodes.
- Distant metastases occur late in the history of the disease.

Biopsy

Confirmation of the diagnosis of carcinoma of the penis and assessment of the depth of invasion, the presence of vascular invasion, and the histologic grade of the lesion by microscopic examination of a biopsy specimen are mandatory before the initiation of any therapy. This provides insight into the therapeutic options for treatment of the primary lesion as well as the likelihood of nodal metastases in patients with no palpable adenopathy (Lopes et al., 1996; McDougal, 1995; Theodorescu et al., 1996).

Biopsy may be a separate procedure from definitive surgical treatment. A dorsal slit is frequently necessary to gain adequate exposure of the lesion for satisfactory biopsy. An alternative approach to treatment is biopsy with frozen-section confirmation followed by definitive resection or ablation. Velazquez et al. (2004) demonstrated the shortcomings of superficial diagnostic biopsies in a study evaluating specimens from 57 patients. There was difficulty in delineating the extent of depth in 91% of patients, discordance with the histologic grade in 30% of patients (specifically with verrucous and mixed histologic patterns), and failure to detect any cancer in 3.5% of patients with well-differentiated cancers. The importance of obtaining an adequate biopsy specimen cannot be overemphasized.

Histologic Features

Most tumors of the penis are squamous cell carcinomas demonstrating keratinization, epithelial pearl formation, and various degrees of mitotic activity. The normal rete pegs are disrupted. Invasive lesions penetrate the basement membrane and the surrounding structures. Subsequent to review of 61 cases from Memorial Sloan Kettering Cancer Center, Cubilla et al. (2001) classified the histologic types as follows: usual type, 59% of cases; papillary, 15%; basaloid, 10%; warty (condylomatous), 10%; verrucous, 3%; and sarcomatoid, 3%. Both of the basaloid and sarcomatous types were associated with aggressive behavior; 5 of 7 patients with these histologic patterns exhibited metastasis, and 5 of 8 (63%) died. In contrast, the verruciform histologic patterns were more favorable (1 patient with metastasis and no deaths). The typical squamous histologic type was intermediate in biologic potential; 14 of 26 patients exhibited metastases, and 13 of 36 (36%) died.

The basaloid variant, in addition to its aggressive behavior as noted previously, is associated with HPV expression in approximately 80% of cases (Cubilla et al., 1998, 2001; Gregoire et al., 1995; Rubin et al., 2001).

More recently HPV expression has been used to classify penile cancers into morphologically and molecularly distinct subtypes that include HPV-related (basaloid, warty, warty-basaloid, papillary basaloid, clear cell, lymphoepithelioma-like) and non–HPV-related (usual, verrucous, papillary [not otherwise specified], cuniculatum, pseudoglandular, pseudoglandularhyperplastic, adenosquamous, sarcomatoid). This new classification system has subsequently been adopted by the World Health Organization. The classification allows HPV-associated penile cancer to be recognized not only by the demonstration of p16, but also by its associated histologic features (Moch et al., 2016; Sanchez et al., 2015).

Squamous cell carcinomas have classically been graded using the Broders classification to define the level of differentiation on the basis of keratinization, nuclear pleomorphism, number of mitoses, and several other features (Broders, 1921; Lucia and Miller, 1992). This grading system was originally designed for squamous carcinoma of the skin and has been adapted by pathologists for penile squamous carcinoma. Four grades were originally described, but it is common for authors to modify this to a three-grade system by combining grades (Maiche et al., 1991). Low-grade lesions (grade 1 and grade 2) constitute 70% to 80% of the reported cases at diagnosis, whether a three- or four-grade system is used (Maiche et al., 1991). These well-differentiated lesions show cords of atypical squamous cells projecting downward from a hyperkeratotic epidermis. The lower-grade carcinomas typically demonstrate keratin, prominent intercellular bridges, and keratin pearls, characteristics that are absent in high-grade tumors. Almost half the tumors originating in the shaft are poorly differentiated (grade 3 and grade 4, depending on scale), whereas only 10% of tumors located in the prepuce are high-grade tumors (Maiche et al., 1991). Thus grade and stage are often correlated.

Several studies have emphasized the association of high-grade disease with regional nodal metastases (Fraley et al., 1989; Heyns et al., 1997; McDougal, 1995; Ravi, 1993a; Theodorescu et al., 1996). Overall, there is a significant body of agreement as to the histologic features that characterize high tumor grade (grade 3 and grade 4) and its correlation with nodal metastasis. However, as noted previously, most tumors are of lower grades. Histologic features that would better stratify the prognosis for patients with invasive, low- to intermediate-grade penile cancers would be of value for management of patients.

Slaton et al. (2001) found that describing the percentage of poorly differentiated cancer in the primary penile tumor specimen correlated with lymph node metastasis. In this study, a semiquantitative system that estimated the amount of high-grade cancer (i.e., ≤50% vs. >50%) was significantly associated with nodal metastases and was more predictive than the Broders three-grade system in stratifying those with or without nodal metastasis.

However, Chaux et al. (2009) questioned these findings as they examined 117 specimens among patients undergoing primary tumor therapy and lymph node dissection. More than 50% of the tumors were actually heterogeneous with respect to grade, and among these tumors any proportion of grade 3 cancer was associated with lymph node metastasis. These disparate findings point to at least three problems with respect to grading and prognosis, including (1) lack of a uniform system, (2) reproducibility of interpretation, and (3) intratumoral heterogeneity of tumor components.

Vascular invasion by tumor cells has significant prognostic importance but may not be specifically mentioned in pathology reports. When vascular invasion is present, it provides valuable information. Four studies have assessed its presence or absence, and it was an important predictor of nodal metastasis in all the reports (Fraley et al., 1989; Heyns et al., 1997; Lopes et al., 1996; Slaton et al., 2001). **Thus the pathologist should specifically comment on the presence or absence of vascular invasion in the surgical specimen.**

Perineural invasion was recently found to be present in 36% of cases analyzed in a multi-institutional data set of 134 patients and was a strong predictor of lymph node metastasis (Velazquez et al., 2008).

Key Points: Biopsy and Histologic Features

- Adequate tumor biopsy is essential to diagnosis and treatment planning.
- Squamous carcinoma histologic subtypes has recently been classified into two major groups by their relationship to HPV and show distinct morphologic features and clinical behavior.
- Pathologic description of anatomic structures invaded (i.e., stage), the grade, and the status of vascular and perineural invasion provide important information to assess the risk of metastasis.

Laboratory Studies

The results of laboratory tests in patients with penile cancer are often normal. Anemia, leukocytosis, and hypoalbuminemia may be present in patients with chronic illness, malnutrition, and extensive suppuration at the area of the primary and inguinal metastatic sites. Azotemia may develop secondary to urethral or ureteral obstruction.

Hypercalcemia without detectable osseous metastases has been associated

with penile cancer (Anderson and Glenn, 1965; Rudd et al., 1972). In a review from Memorial Sloan Kettering Cancer Center (Sklaroff and Yagoda, 1982), 17 of 81 patients (20.9%) were hypercalcemic. Hypercalcemia seems to be largely a function of the bulk of the disease. It is often associated with inguinal metastases and may resolve after excision of involved inguinal nodes (Block et al., 1973). **Parathyroid hormone and related substances may be produced by tumor and metastases that activate osteoclastic bone resorption** (Malakoff and Schmidt, 1975). Medical treatment of hypercalcemia includes aggressive saline hydration to restore the extracellular fluid volume and to promote sodium and calcium excretion. The administration of diuretics is performed if volume overload is suspected. Bisphosphonates (e.g., pamidronate, etidronate, and zoledronic acid) have become first-line therapy because they possess demonstrated efficacy as antiresorptive agents and are relatively safer than mithramycin, an older agent (Morton and Lipton, 2000; Videtic et al., 1997). For severe hypercalcemia associated with neurologic manifestations, the antiresorptive bisphosphonates can be combined with an agent that produces calciuria, such as calcitonin, to rapidly lower serum calcium levels.

Radiologic Studies

Primary Penile Tumor.

In patients with penile cancer the primary tumor and the inguinal lymph nodes are readily assessed by palpation. However, Horenblas et al. (1991) found that physical examination incorrectly established the actual pathologic stage in 26% of cases, with understaging in 10% and overstaging in 16%. It is clear that more accurate means of staging for penile tumors is needed.

Penile ultrasonography was performed on 16 patients referred for primary therapy by Horenblas et al. (1994). With use of a 7.5-MHz linear array small parts transducer they found that the ultrasound appearance of cancer was invariably hypoechoic. However, ultrasound examination often underestimated the thickness of tumors and could not delineate invasion into the subepithelial connective tissue of the glans penis from corpus spongiosum involvement (i.e., glanular stage T1 vs. glanular stage T2). However, the tunica albuginea separating the corpus cavernosum from the glans was easily identified in all patients, and the sensitivity for detecting corpus cavernosum invasion was 100%. This study confirmed the value of ultrasonography in assessing the primary tumor, as reported by others (Dorak et al., 1992; Yamashita and Ogawa, 1989).

Several studies have assessed the role of magnetic resonance imaging (MRI) in evaluating the normal penis and its involvement by cancer. Vapnek et al. (1992) described the MRI appearance of the normal corpus cavernosum, corpus spongiosum, tunica albuginea, and Buck fascia. Of six patients with urethral cancer, the disease was accurately staged in five (83%). De Kerviler et al. (1995) used gadolinium contrast-enhanced MRI to compare clinical and MRI findings with tumor pathologic stage. Clinical examination correctly staged six of nine tumors: MRI was correct in seven of nine cases but was not useful for clinical T1 lesions. Compared with MRI and ultrasonography, computed tomography (CT) has poor soft-tissue resolution and has not been useful for imaging the extent of the primary tumor (Vapnek et al., 1992).

Lont et al. (2003) directly compared physical examination with ultrasonography and MRI to assess their ability to determine the tumor stage. They evaluated 33 patients with penile squamous cell carcinoma, all of whom underwent ultrasound examination, MRI, and physical examination of the primary tumor. Findings were correlated with histologic evaluation of the specimens obtained at surgery with a focus on determining the invasion of the corpus cavernosum. The respective positive predictive value, sensitivity, and specificity for the study were as follows—physical examination: 100%, 86%, 100%; ultrasound examination: 67%, 57%, 91%; and MRI: 75%, 100%, 91%. This comparative study concluded that physical examination is reliable in determining corporeal invasion and that additional tests are mainly of value when physical examination cannot be properly performed.

The technique of artificial erection (by intracorporeal injection of prostaglandin E_1) may augment the use of contrast-enhanced MRI in staging of the primary tumor. A study by the European Institute of Oncology evaluated nine patients to compare clinical, pathologic, and MRI staging (Scardino et al., 2004). MRI aided by artificial erection and contrast enhancement was shown to be of value because it correlated with pathologic stage in eight of nine cases, whereas physical examination correlated with only five of nine cases. Another recent study from the UK supports these findings among a cohort of 100 men with penile cancer where the sensitivity and specificity of detecting tumor invasion of the tunica albuginea was 82% and 79%, respectively (Hanchanale et al., 2016). These data suggest that this novel MRI approach could be beneficial in staging of glanular tumors, specifically when physical examination findings are equivocal. **Thus, for small-volume glanular lesions, imaging studies add virtually no additional information to palpation in most patients. However,**

for lesions thought to invade the corpus cavernosum, contrast-enhanced MRI (perhaps augmented with artificial erection) may provide unique information, especially when physical examination findings are equivocal and organ-sparing techniques are being considered.

Inguinal and Pelvic Region

Current Imaging Strategies Among Clinical Node-Negative Patients.

The ability to noninvasively determine the presence or absence of inguinal and pelvic metastases in patients with penile cancer remains problematic because physical examination exhibits varying reliability based on the grade and stage of the primary tumor as well as body habitus of the patient. CT and MRI techniques have depended on lymph node enlargement for detection of metastases but are unable to define the internal architecture of normal-sized nodes. Because CT and MRI have similar accuracy in determining lymphadenopathy in other cancers, CT has often been the imaging modality chosen in penile cancer to examine the inguinal and pelvic areas as well as to rule out more distant metastases.

Horenblas et al. (1991) compared the ability of physical examination, CT, and lymphangiography to assess the inguinal region in patients who were surgically staged or had prolonged follow-up. In 102 patients with a 39% prevalence of positive nodes, the sensitivity and specificity of physical examination were 82% and 79%, respectively. CT and lymphangiography were performed in patients who were thought to have metastases. The sensitivity of lymphangiography was only 31%, but there were no false-positive results. Similarly, the sensitivity and specificity of CT were 36% and 100%, respectively. The combination of CT and lymphangiography performed simultaneously demonstrated equally poor sensitivity. Only one-fifth of patients had positive nodes detected with either test. **On the basis of these data the authors concluded that CT and lymphangiography offer no useful additional information over physical examination, especially in patients with no palpable adenopathy.** An important caveat is that CT may have a role in examination of the inguinal region in obese patients or in those who have had prior inguinal surgery, in whom the physical examination may be unreliable.

Insights in the field of nanoparticle technology have been applied to imaging of genitourinary malignant neoplasms to enhance detection of microscopic metastases. Ferumoxtran-10 particles (size, 35 nm), administered at a dose of 2.6 mg of iron per kilogram of body weight intravenously combined with MRI, were capable of imaging microscopic metastasis in lymph nodes that were less than or equal to 1 cm. Tabatabaei et al. (2005) evaluated lymphotropic nanoparticle-enhanced MRI (LNMRI) in seven patients with penile cancer who subsequently underwent groin dissection. Five of seven patients had no palpable adenopathy. LNMRI was highly sensitive and detected positive nodes in all five of these patients. The size range of the metastases was less than 1 cm in four patients. Unfortunately, no confirmatory studies were performed using this agent, and the compound is not currently available for routine use.

Squamous carcinoma was shown to take up the radiopharmaceutical fluorodeoxyglucose (FDG) and to be amenable to detection using combination positron emission tomography (PET) and CT. Scher et al. (2005) evaluated PET/CT among 13 patients with penile cancer who received injections of FDG. Five of the 13 patients had metastatic disease, and FDG-PET/CT detected it in 4 of them (80% sensitivity). However, in a follow-up study from the Netherlands, PET/CT was used in patients who were clinically node negative to determine the sensitivity among patients scheduled to undergo inguinal staging procedures. Among 5 patients with proven nodal metastasis, PET/CT was positive in only 1 (i.e., sensitivity of 20%) (Leijte et al., 2009a).

Among a similar cohort reported from this same group, ultrasound-guided needle aspiration was also shown to have limited sensitivity as well, detecting only 9 of 23 patients with proven metastases (sensitivity of 39%; Kroon et al., 2005a). Thus, among clinically node-negative patients, no current imaging modality has been shown to be sufficiently sensitive to detect microscopic metastases.

Current Imaging Strategies Among Clinical Node-Positive Patients.

Recent data among patients with proven inguinal metastases suggest that additional imaging may be of value in determining those patients with advanced disease who may do poorly when treated with surgery alone or could in fact exhibit occult distant metastases.

Graafland et al. (2011) evaluated the CT scan findings among a cohort of biopsy-proven patients with metastatic inguinal adenopathy to define if scan parameters could determine those with poor prognostic features subsequent to lymphadenectomy. They found that central necrosis or an irregular nodal border was highly sensitive and specific for any of the poor prognostic features including three or more positive nodes, extranodal extension (ENE) of cancer, or positive pelvic nodes.

In contrast to the clinically node-negative disease setting, one study has shown the potential value of PET/CT among patients with proven inguinal metastases. Graafland et al. (2009) studied PET/CT among 18 patients with biopsy-proven inguinal metastases and found PET/CT to have a sensitivity and specificity of 91% and 100%, respectively, for detecting pelvic lymph node metastases. In that study, PET/CT also identified several patients with distant metastases that were unsuspected. Thus, if confirmed, PET/CT may become an important study for detecting pelvic and distant metastasis.

In general, distant metastases occur late in the course of the disease, usually in patients with recognized significant inguinal and pelvic adenopathy. The most common metastatic sites are the lung, bone, and liver. Currently, in addition to chest, abdominal, and pelvic CT, radionuclide bone scintigraphy may be indicated to stage the extent of disease in patients thought to have widespread metastases (Vapnek et al., 1992).

Key Points: Radiologic Studies

- Soft-tissue detail of penile tumors is best imaged by MRI.
- Physical examination provides the most reliable staging information for small distal lesions.
- Penile MRI especially performed in combination with artificial erection may provide unique staging information when physical examination findings are equivocal.
- Physical examination of the inguinal region remains the clinical gold standard for evaluating the presence of metastasis in the nonobese patient.
- CT or MRI can be useful in evaluating the inguinal region of obese patients and in those who have had prior inguinal surgery.
- Among patients with proven inguinal metastases, CT scan of the abdomen and pelvis may help to determine those patients with poor prognostic features for cure with surgery alone.
- PET/CT may be useful among patients with clinically detected inguinal metastases to define the presence of pelvic or distant metastasis.

Penile Cancer Staging

Eighth Edition TNM Penile Staging System.

The seventh edition of the American Joint Committee on Cancer (AJCC) and Union for International Cancer Control (UICC) TNM staging system was published in 2010 and was the consensus method for staging penile cancer (Edge et al., 2010) until the recent publication of the eighth edition TNM staging system (Table 79.1 and Fig. 79.2) (Pettaway et al., 2017). The eighth edition retains clinical and pathologic components for staging but further refines categories defined in the seventh edition. Table 79.2 provides changes incorporated into the eighth edition TNM staging based upon recent evidence (Pettaway et al., 2017).

TABLE 79.1

Definition of Primary Tumor

T CATEGORY	**T CRITERIA**
TX	Primary tumor cannot be assessed
T0	No evidence of primary tumor
Tis	Carcinoma in situ (penile intraepithelial neoplasia)
Ta	Noninvasive localized squamous cell carcinoma
T1	Glans: Tumor invades lamina propria Foreskin: Tumor invades dermis, lamina propria, or dartos fascia Shaft: Tumor invades connective tissue between epidermis and corpora regardless of location All sites with or without lymphovascular invasion or perineural invasion and is or is not high grade
T1a	Tumor is without lymphovascular invasion or perineural invasion and is not high grade (i.e., grade 3 or sarcomatoid)
T1b	Tumor exhibits lymphovascular invasion and/or perineural invasion or is high grade (i.e., grade 3 or sarcomatoid)
T2	Tumor invades into corpus spongiosum (either glans or ventral shaft) with or without urethra invasion
T3	Tumor invades into corpora cavernosum (including tunica albuginea) with or without urethral invasion
T4	Tumor invades into adjacent structures (i.e., scrotum, prostate, pubic bone)
CLINICAL N (cN)	
cN CATERGORY	**cN CRITERIA**

cNX	Regional lymph nodes cannot be assessed
cN0	No palpable or visibly enlarged inguinal lymph nodes
cN1	Palpable mobile or unilateral inguinal lymph node
cN2	Palpable mobile or bilateral inguinal lymph nodes
cN3	Palpable fixed inguinal nodal mass or pelvic lymphadenopathy unilateral or bilateral

PATHOLOGIC N (pN)

pN CATEGORY	**pN CRITERIA**
pNX	Lymph node metastasis cannot be established
pN0	No lymph node metastasis
pN1	≤2 unilateral inguinal metastases, no extranodal extension
pN2	≥3 unilateral inguinal metastases or bilateral metastases
pN3	Extranodal extension of lymph node metastases or pelvic lymph node metastases

DEFINITON OF DISTANCE MESTATSIS (M)

M CATEGORY	**M CRITERIA**
M0	No distant metastasis
M1	Distant metastasis present

AJCC PROGNOSTIC STATE GROUPS

WHEN T IS …	**AND N IS …**	**AND M IS …**	**THEN THE STAGE GROUP IS …**
Tis	N0	M0	0is
Ta	N0	M0	0a
T1a	N0	M0	I
T1b	N0	M0	IIA
T2	N0	M0	IIA
T3	N0	M0	IIB
T1-3	N1	M0	IIIA
T1-3	N2	M0	IIIB
T4	Any N	M0	IV
Any T	N3	M0	IV
Any T	Any N	M1	IV

Modified from Pettaway CA, Srigley JR, Brookland RK et al: Penis. In Amin MB, Edge SB, Greene FL, et al, editors: *AJCC cancer staging manual*, 8th ed, New York, 2017, Springer, pp 699–712.

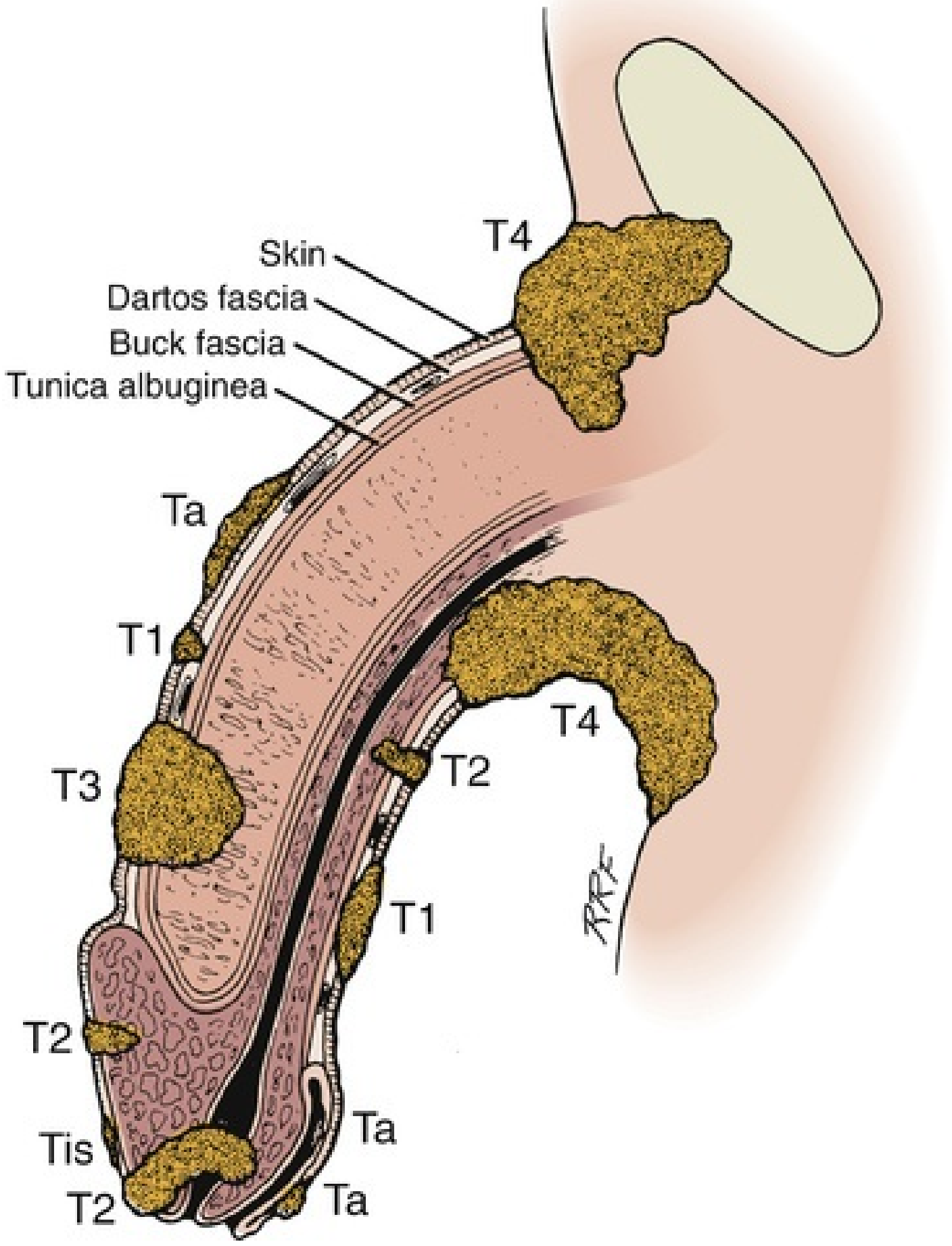

FIG. 79.2 Because treatment decisions for inguinal node dissections are based in part on the pathologic characteristics of the primary lesion (see section on treatment of inguinal nodes), determining the anatomic structure invaded is required. This diagram illustrates primary tumor (T) staging using the eighth edition TNM system.

TABLE 79.2

Eighth Edition American Joint Committee on Cancer: Summary of Penile Cancer Staging Revisions to the Seventh Edition

CHANGE	DETAILS OF CHANGE	LEVEL OF EVIDENCE
Histologic Grade (G)	The three-tiered World Health Organization (WHO)/International Society of Urological Pathology (ISUP) grading system has been adopted. Any proportion of anaplastic cells is sufficient to categorize a tumor as grade 3.	III
Definition	Ta definition is now broadened to include noninvasive	II

of Primary Tumor (T)	localized squamous carcinoma.	
Definition of Primary Tumor (T)	T1a and T1b have been separated by an additional prognostic indicator (the presence or absence or perineural invasion).	III
Definition of Primary Tumor (T)	T1a or T1b are described by the site where they occur on the penis and are designated glans, foreskin, or shaft. Anatomic layers invaded are described for the three locations.	I
Definition of Primary Tumor (T)	T2 definition includes corpus spongiosum invasion.	II
Definition of Primary Tumor (T)	T3 definition now involves corpora cavernosum invasion.	II
Definition of Regional Lymph Nodes (N)	pN1 is defined as ≤2 unilateral inguinal metastases, no extranodal extension.	II
Definition of Regional Lymph Nodes (N)	pN2 is defined as ≥3 unilateral inguinal metastases or bilateral metastases.	II

Modified from Pettaway CA, Srigley JR, Brookland RK et al: Penis. In Amin MB, Edge SB, Greene FL, et al, editors: *AJCC cancer staging manual*, 8th ed, New York, 2017, Springer, pp 699–712.

Tumor Grading.

Incorporation of the WHO/International Society of Urologic Pathology Grading System. Tumor grade has traditionally been based on modifications of the Broder's grading system and consists of either a 3- or 4-grade system, in which grade 1 means well differentiated, grade 2 means moderately differentiated, grade 3 means poorly differentiated, and grade 4 means undifferentiated (Cubilla et al., 2016; Edge et al., 2010). The World Health Organization (WHO) has recently adopted the 3-tiered WHO/International Society of Urological Pathology (ISUP) grading system. Using this classification any proportion of anaplastic cells is sufficient to categorize a tumor as grade 3 (Cubilla et al., 2016).

Definition of the Primary Tumor

Stage Ta Definition.

In the seventh edition TNM category Ta referred to “non-invasive verrucous carcinoma.” This term was misleading to some pathologists who thought this would apply to all cases of verrucous carcinoma. The great majority of verrucous carcinomas are destructive, but the invading front is smooth and pushing with the depth of invasion often difficult to assess. In the current classification, the Ta category is expanded and applies to (1) pure (well or completely sampled) verrucous carcinomas with no overt destructive invasion and (2) noninvasive papillary, warty, basaloid, or mixed carcinomas. These rare, noninvasive surface-based tumors are somewhat analogous to noninvasive (pTa) papillary urothelial neoplasms.

Stage T1 Definition: Anatomic Detail.

In the seventh edition structures between the epidermis and the tunica albuginea were designated by the term “subepithelial connective tissue. In the eighth edition the specific layers are designated according to where the tumor is located (i.e., glans penis, foreskin, or shaft).

Stage T1 Definition: Inclusion of Perineural Invasion.

Recent data have validated the seventh edition TNM primary tumor pathologic designations stage T1a and T1b as having different capacities for metastasis to inguinal nodes. In a series reported by Sun et al. (2015) including two cohorts, the incidence of inguinal metastases was 10.5% to 18.1% for pT1a tumors versus 33.3% to 50% for pT1b tumors. In addition to lymphovascular space involvement and high tumor grade, the presence of perineural invasion has also been shown to be significantly associated with inguinal lymph node metastasis and is now included as a criterion to define pT1b (Velazquez et al., 2008).

Stage T2-T4 Definition Changes.

In the seventh edition TNM corpora spongiosum and cavernosum were grouped as T2 tumors. However, recent studies provide a justification for the separation of tumors invading the corpus spongiosum (CS) from those invading the corpora cavernosa (CC) as pT2 and pT3 tumors, respectively. In two cohorts invasion into the CS versus CC was associated with improved disease-specific survival (77.7% vs. 52.6%, respectively) and a lower incidence of inguinal lymph node metastasis (33%–35% vs. 48.6%–52.5%, respectively) (Leijte et al., 2008a; Sun et al, 2015). Urethral invasion previously designated as stage T3 does not appear to have prognostic significance independent of CS or CC involvement (Leijte et al., 2008) and had been removed from the eighth edition primary tumor staging.

Extensive tumors invading adjacent structures such as the scrotum, prostate, or pubic bone are designated as stage T4 and are less common but may require major amputative procedures, neoadjuvant chemotherapy before surgery, or palliative radiotherapy if unresectable.

Pathologic Stage N1-N2 Definitions.

Recent series have suggested refinements to the seventh edition AJCC TNM lymph node definitions to better stratify the prognosis of patients with inguinal lymph node metastasis (Li et al., 2015; Sun et al., 2015). Data from Li et al. revealed that the 3-year disease-specific survival of patients with 1 to 2 unilateral inguinal metastases with no ENE as similar to patients with a single node of the same characteristics (89% to 90%). By migrating patients with 1 to 2 nodes into the pN1 category, this places more patients into a low-risk category and avoids the need for adjuvant chemotherapy recommended for pN2 patients according to the EAU guidelines (Hakenberg et al., 2015).

Alternatively, patients with more than 3 positive unilateral inguinal nodes or bilateral metastasis (pN2) have distinctly worse 3-year disease-specific survival compared with those with 2 or fewer unilateral inguinal nodes (60% pN2 vs. approximately 90% pN1) (Li et al., 2015).

Based upon two series the pN3 category remains defined as the presence of ENE or positive pelvic nodes. This group has an ominous 3-year cancer-specific or relapse-free survival ranging from 32% to 33% (Li et al., 2015; Zhu et al., 2011). In this scenario adjuvant chemotherapy is a strong consideration according to the EAU guidelines (Hakenberg et al., 2015).

Considering that the pathologic status of inguinal nodes is the driving factor determining survival, stage groupings (i.e., stage 0 to stage IV; see Table 79.1) in the eighth edition TNM use the extent of nodal involvement as the major consideration. Thus the strength of the unified AJCC-UICC eighth edition TNM system (2017) is that it provides not only an accurate assessment of the primary tumor based on clinical staging (examination, biopsy) but also clinical and improved pathologic descriptors of lymph node status to predict outcome.

In the TNM staging system the primary tumor stage is assigned by biopsy (or even more reliably by complete resection) and additional prognostic factors within the primary tumor now included in the TNM system (i.e., tumor grade, the presence of vascular or perineural invasion, corpora cavernosum involvement). In most cases, the presence of palpable adenopathy, along with the histologic features of the primary tumor, determines the need for additional imaging studies. Positive fine-needle aspiration of palpably enlarged inguinal nodes or fine-needle biopsy of pelvic adenopathy identified by CT can assist in assigning nodal stage before therapy. In patients requiring surgical staging (palpable lymph nodes or those with adverse primary tumor histologic features), pathologic nodal status assigned according to eighth edition TNM stage provides valuable prognostic information. The suggested diagnostic criteria for current TNM staging are listed in Table 79.3.

TABLE 79.3

Carcinoma of Penis: Suggested Diagnostic Procedures to Assign TNM Stage

---

PRIMARY TUMOR (T)
Clinical examination
Incisional-excisional biopsy of lesion (or complete resection) and histologic examination for grade, anatomic structure invaded, and presence of vascular or perineural invasion
REGIONAL AND JUXTAREGIONAL LYMPH NODES (N)
Clinical examination
CT, if inguinal adenopathy is palpable[a]
CT/PET may be considered for bulky inguinal adenopathy[b]
Superficial inguinal node dissection or dynamic sentinel node biopsy (as indicated for high grade, vascular or perineural invasion, or invasive histologic pattern)
Aspiration cytology (as indicated)
DISTANT METASTASES (M)
Clinical examination
Biochemical determinations (liver functions, calcium)
CT scan of the chest, abdomen, pelvis; bone scintigraphy; or CT/PET scan (as indicated)

[a] CT should also be performed in obese patients and those who have had prior inguinal surgery, whose physical examination findings may be unreliable.

[b] CT/PET scans coregistered to correlate uptake with anatomic location.

CT, Computed tomography; *PET,* positron emission tomography.

Key Points: Staging

- Clinical and pathologic factors related to the presence and extent of lymph node involvement determine survival and should be recorded.

- The current, eighth edition unified TNM staging system represents a consensus document that includes clinical and pathologic descriptors that provide important prognostic information.

Differential Diagnosis

A number of penile lesions must be considered in the differential diagnosis of penile carcinoma. They include condyloma acuminatum, Buschke-Löwenstein tumor, and balanitis xerotica obliterans, as well as a number of infectious lesions (e.g., chancre, chancroid, herpes, lymphopathia venereum, granuloma inguinale, tuberculosis). These diseases can be identified by appropriate skin tests, tissue studies, serologic examinations, cultures, or specialized staining techniques.

Surgical Management of the Primary Tumor

Organ Preservation

Surgical amputation of the primary tumor remains the oncologic gold standard for rapid definitive treatment of the penile primary tumor; local recurrence rates range from 0 to 8% (de Kernion et al., 1973; Horenblas et al., 1992; McDougal et al., 1986). Whereas amputation is often necessary for bulky stage T2 to T4 tumors, it has been shown to decrease sexual quality of life (Opjordsmoen and Fossa, 1994). This is relevant because approximately 55% of penile cancer patients are 60 years of age or younger and 30% are 55 years of age or younger (Narayana et al., 1982).

It is generally accepted that patients with penile primary tumors exhibiting favorable histologic features (stages Tis, Ta, T1; grade 1 and grade 2 tumors) are at a lower risk for metastases. These patients are also best suited for organ-sparing or glans-sparing procedures (Solsona et al., 2004). The goal of treatment is to preserve glans sensation where possible or at least to maximize penile shaft length. Such approaches include topical treatments (5-fluorouracil or imiquimod cream for Tis only), radiation therapy, Mohs surgery, limited excision strategies, and laser ablation (Alnajjar et al., 2012; Crook et al., 2009; Minhas et al., 2005; Sanchez-Ortiz and Pettaway, 2003; Solsona et al., 2004). This section focuses on novel insights into surgical strategies to achieve organ preservation. Radiation-based strategies are discussed later in the section on radiation therapy for the primary lesion.

Circumcision and Limited Excision Strategies

Circumcision, limited excisions of the glans, and glans removal with sparing of the penile shaft represent surgical strategies to maintain function and penile length. Historically, data on circumcision and limited excision of glanular lesions have been associated with recurrence rates from 11% to 50% (McDougal et al., 1986; Skinner et al., 1972). However, the grade, size, and exact location of the lesion and the status of surgical margins were often unavailable in such reports.

Recent reports have suggested that conservative surgery may be

performed safely in well-selected patients with discrete tumors by intraoperative frozen-section analysis (Bissada et al., 2003; Davis et al., 1999; Minhas et al., 2005; Pietrzak et al., 2004). **In addition, several studies have challenged the dictum establishing that a 2-cm surgical margin is required for all patients undergoing partial penectomy** (Agrawal et al., 2000; Hoffman et al., 1999). After performing a prospective histologic analysis of 64 penectomy specimens, Agrawal et al. (2000) concluded that tumor grade highly correlated with microscopic tumor spread. The maximum proximal histologic extent was 5 mm for grade 1 and grade 2 tumors and 10 mm for grade 3 tumors. Furthermore, “skip” lesions were not encountered. After performing a retrospective pathologic review of 12 penectomy specimens, Hoffman et al. (1999) also found 7 patients with disease of pathologic stage T1 or greater with microscopic margins measuring less than 10 mm. None of these patients had disease recurrence at a mean follow-up of 32.4 months. Pietrzak et al. (2004) documented the use of various techniques in a series of 39 patients to excise the tumor and to reconstruct or graft the glans and distal penis. With a mean follow-up of 16 months, only 1 patient (2.5%) who underwent a partial glans resection had a local recurrence. There were two early complications with grafts and two late complications with graft overgrowth intruding on the urethral meatus. Minhas et al. (2005) similarly performed either wide local excision or glans penis removal in 51 patients with margins of 0 to 10 mm in 48% and less than 2 cm in 98% of patients. With a median follow-up of 26 months, a local recurrence rate of 4% to 6% was noted. Limitations of this approach include proximal and distal deeply invasive tumors, high-grade tumors, and patients with poor health status who would not be candidates for salvage procedures if they experienced recurrence. A follow-up series from this same group that included 179 patients having undergone a variety of organ-sparing procedures including glansectomy, excisions, and distal corporectomy was recently reported (Philippou et al., 2012). With a mean follow-up of 43 months, the incidence of recurrence was 8.9% (16 patients). Local relapse did not affect disease-specific survival. These results seem to suggest that a 2-cm margin may not be necessary for small tumors of lower grade in the presence of a negative frozen section. However, patients managed with limited excision techniques should be considered to be at a higher risk for local recurrence until longer-term follow-up and additional surgical series are available.

Another recent technique used in the surgical management of carcinoma in situ of the glans penis is *glans resurfacing,* also known as *glans stripping.* In this technique, subdermal dissection of the skin and subepithelial connective tissue off the underlying corpora spongiosa is performed. Shabbir et al. (2011a) described this procedure in 25 patients with clinical carcinoma in situ of the glans; they performed either a total or partial removal of all the glans surface tissue. Positive surgical margins were noted in 48% of patients overall but in only 20% of those having total removal. At a mean of 29 months, 5 patients underwent re-excision for unexpected invasive disease at the margin. One of 25 patients exhibited a clinical recurrence. Topical therapy was used for isolated positive margins with CIS. Important considerations for this procedure are to document the absence of invasive cancer, to use topical therapy as an adjunct in the case of residual CIS at a margin, and to perform careful follow-up.

Mohs Micrographic Surgery

Mohs microsurgery has historically had a positive impact on the management of penile CIS and small, superficially invasive tumors. As originally described by Mohs et al. (1985), it involves layer-by-layer complete excision of the penile lesion in multiple sessions (fixed tissue technique), with microscopic examination of the undersurface of each layer. Its sequential microscopic guidance offers improved precision and control of the negative margin while maximizing organ preservation. In a series of 29 consecutive cases of penile squamous cell carcinoma, the primary tumor was eradicated in 23 (92%) of 25 patients available for follow-up. Local recurrences were highly associated with tumor size (3 cm), advanced stage, and failure of previous definitive therapy (Mohs et al., 1992). These excellent results using a fixed tissue technique have not been reproduced with the currently used frozen-section methodology. Shindel et al. (2007) treated 33 patients with stage Tis (26 patients), T1 (4 patients), T2 (7 patients), and T3 (4 patients) penile cancer. Five procedures were terminated with positive margins. Of 25 patients with mean follow-up of 58 months, 8 (32%) developed recurrence. However, 7 of 8 were retreated successfully with Mohs surgery. One patient who had progression of his disease died from it. **Thus Mohs microsurgery, as currently performed, may offer no additional benefit over surgical excision with intraoperative frozen-section assessment of margin status.**

Laser Ablation

The four most widely used laser energy sources are the CO_2, argon, Nd:YAG, and KTP lasers (Carpiniello et al., 1987; Malloy et al., 1988; von Eschenbach et al., 1991). Although the CO_2 laser has been widely used previously, the superficial depth of penetration (limited to 0.1 mm) makes it less than optimal for the treatment of penile CIS or small T1 tumors. When the CO_2 laser is used, local recurrence rates have been shown to be as high as 50% (Bandieramonte et al., 1988; van Bezooijen et al., 2001). Conversely, the Nd:YAG laser results in protein denaturation at a depth of up to 6 mm by emitting at a wavelength of 1060 nm. Overall recurrence rates after laser ablation have been reported to be 7.7% for penile CIS and have ranged from 10% to 25% for T1 lesions (Malloy et al., 1988; Tietjen and Malek, 1998; Windahl and Hellsten, 1995), but results from more contemporary series using the Nd:YAG laser exclusively have been more encouraging. **Frimberger et al.** (2002a) **treated 29 men with CIS and stage T1 tumors, combining Nd:YAG laser ablation with tumor base biopsies to ensure negative surgical margins. Only two recurrences (6.9%) were reported at a mean follow-up of 46.7 months, which is comparable to recurrence rates after partial penectomy.** In an effort to reduce the incidence of positive surgical margins, Frimberger et al. (2002b) have proposed the use of autofluorescence and 5-aminolevulinic acid–induced fluorescence for targeting of frozen-section biopsy specimens.

Laser ablation is feasible and may achieve results equivalent to those of extirpative surgery, especially when it is performed in well-selected patients in conjunction with frozen-section biopsies. In addition, laser ablation has been associated with high rates of resumption of sexual activity (75%) and overall satisfaction (78%) (Windahl et al., 2004). However, until additional long-term studies become available, laser ablation should be performed with the understanding that local recurrences may develop and that close surveillance and patient self-examination are necessary for early detection. Although well-selected patients who develop small recurrent lesions may be candidates for repeated laser ablation, recurrences are best treated with wide local excision or partial amputation.

Contemporary Penile Amputation

Penile amputation remains the standard therapy for patients with deeply invasive or high-grade cancers. **Partial (**Video 79.1**) or total penectomy should be considered in patients exhibiting adverse features for cure by organ-preservation strategies. These are consistently associated with tumors of size**

4 cm or more, grade 3 lesions, and those invading deeply into the glans urethra or corpora cavernosa (Gotsadze et al., 2000; Kiltie et al., 2000; Mohs et al., 1992). Because recurrence rates are higher with organ-preserving strategies, compliance with follow-up is also a consideration in recommending organ preservation versus amputation. Fortunately, the survival of most patients with recurrences that are detected and treated early is not adversely affected (Lont et al., 2006).

On the basis of contemporary results, organ preservation strategies should be discussed with patients exhibiting optimal tumor characteristics (stages Tis, Ta, T1; grade 1 and grade 2 tumors) to assist them in making informed decisions about therapy. (See Table 79.4 for treatment modalities for the primary penile tumor.)

TABLE 79.4

Treatment of the Primary Penile Tumor

STAGE	TREATMENT
Tis (glans)	Laser therapy, glans resurfacing; alternative: topical therapy
Ta, Tis (foreskin, shaft skin)	Surgical excision to achieve negative margin; alternatives: laser therapy, topical therapy (Tis only)
Ta, T1 grade 1-3 (glans)	Therapy based on size and position of lesion as well as potential side effects, excision, glans resurfacing procedures, glansectomy, radiotherapy (not indicated for Ta)
Ta, Tl grade 1-3 (foreskin, shaft)	Complete surgical excision to achieve negative margin
T2 (glans) without gross cavernosum involvement	Total glansectomy with or without corpora cavernosa transection to achieve negative surgical margins, partial penectomy, radiotherapy
T2 (corporeal invasion), T3	Partial or total penectomy
T4 (adjacent structures)	Consider neoadjuvant chemotherapy with surgical consolidation for responding patients if baseline resectability is a concern
Local disease recurrence after conservative therapy	Complete surgical excision to achieve negative surgical margins; may require partial or total penectomy; select patients with superficial low-grade recurrences may be candidates for repeat penile-conserving procedure
Radiotherapy	Select patients with T1-T2 tumors involving glans, coronal sulcus <4 cm

Key Points: Surgical Treatment of the Primary Tumor

- Patients with small lesions of low grade and stage (Tis, Ta, T1; grade 1 and grade 2) are the optimal candidates for organ preservation to maintain sexual quality of life.
- The goals of organ preservation are to maintain glanular tissue for sensory purposes when possible and/or to maintain penile length when glans penis preservation is not possible.
- Surgical modalities include limited excision strategies, Mohs surgery, and laser ablation.
- Local recurrence rates overall after organ preservation are higher than with traditional amputation; however, when local recurrences are detected and treated, early survival does not appear to be adversely affected.
- Amputation remains the standard for large or deeply invasive lesions, to gain rapid tumor control.

Treatment of the Inguinal Nodes

The presence and the extent of metastasis to the inguinal region are the most important prognostic factors for survival in patients with squamous penile cancer. These findings affect the prognosis of the disease more than do tumor grade, gross appearance, and morphologic or microscopic patterns of the primary tumor.

Unlike with many other genitourinary tumors, which mandate systemic therapeutic strategies once metastasis has occurred, lymphadenectomy alone can be curative and should be performed. The biology of squamous penile cancer is such that it exhibits a prolonged locoregional phase before distant dissemination, providing a rationale for the therapeutic value of lymphadenectomy.

However, because of the morbidity of traditional lymphadenectomy, especially among patients with clinically negative groins, contemporary controversial issues include (1) the selection of patients for lymphadenectomy versus careful observation; (2) the types of procedures to correctly stage the inguinal region with low morbidity; and (3) multimodal strategies to improve survival among patients with bulky inguinal metastases.

In this rare disease, prospective randomized trials have not been performed to answer many of these questions. However, with the use of retrospective and prospective clinicopathologic data from several centers, treatment strategies are presented using the available data.

Contemporary Indications for Inguinal Lymphadenectomy

Prognostic Significance of the Presence and Extent of Metastatic Disease

Table 79.5 reveals data collected from 24 surgical series during a 37-year period. Patients proved to have no evidence of inguinal metastases on the basis of histologic examination of the inguinal nodes or repeated normal examination findings over time; the average 5-year survival rate was 73% (46% to 100%). In patients with resected inguinal metastases the 5-year survival averaged 60% (0 to 86%), but this varied widely and was directly attributable to the extent of nodal metastasis (see Table 79.5). This point is illustrated in several series shown in Tables 79.5 and 79.6. Patients with minimal nodal metastases (usually two or less) exhibited 5-year survivals that ranged from 72% to 88% compared with 0 to 50% when a greater degree of nodal involvement was present (see Table 79.6).

TABLE 79.5

Carcinoma of the Penis: Prognostic Indicators for Survival

SERIES	NO. OF PATIENTS	CLINICAL AND PATHOLOGIC CHARACTERISTICS OF INGUINAL ADENOPATHY			5-Y RA
		PERCENTAGE WITH PALPABLE NODES	PERCENTAGE CLINICALLY FALSE POSITIVE (NODES PALPABLE, HISTOLOGIC FINDINGS NORMAL)	PERCENTAGE CLINICALLY FALSE NEGATIVE (NODES NONPALPABLE, HISTOLOGIC FINDINGS ABNORMAL)	ING NO NE
Ekstrom and Edsmyer, 1958	229	33	48	—	80[c]
Beggs and Spratt, 1964	88	35	36	20	72.
Thomas and Small, 1968	190	—	64	20	—
Edwards and Sawyers, 1968	77	—	—	0	68
Hanash et al., 1970	169	—	58[d]	2[d]	77[e]
Kuruvilla et al., 1971	153	39	63	10	69
Hardner et al., 1972	100	42	41[d]	16[d]	—
Gursel et al., 1973	64	53	60[d]	—	58
Skinner et al., 1972	34	29	40	—	75 87[f]

de Kernion et al., 1973	48	54	38[d]	—	84[g]
Derrick et al., 1973	87	29	52	—	53 76[f]
Johnson et al., 1973	153	—	—	—	64.4
Kossow et al., 1973	100	51	49	25	—
Puras et al., 1978	576	82	47	38[b]	89
Cabanas, 1977	80	96	65	100	90
Fossa et al., 1987	79	—	—	13	90
Srinivas et al., 1987	199	63	14[p]	18	74
McDougal et al., 1986	65	—	—	66	100
Young et al., 1991	34	24	27	42	77
Horenblas et al., 1993	110	36	26	40	100
Ravi, 1993a	201	53	8	16	95
Ornellas et al., 1994	414	50	51[aa]	39	87
Theodorescu et al., 1996	40	70	35	—	46
Puras-Baez et al., 1995	272	—	—	—	89

[a] On histologic or repeated physical examination.

[b] On histologic examination of adenectomy specimen.

[c] Majority of patients received prophylactic or preoperative radiation therapy to inguinal area.

[d] Histologic classification based on node biopsy, not node dissection.

[e] Corrected 5-year survival (i.e., patients dying before 5 years without evidence of disease are excluded).

[f] Patients dying free of cancer before 5 years are considered surgical cures.

[g] Three-year survival.

[h] Omitted.

[i] Positive findings in inguinofemoral nodes.

[j] Positive findings in inguinofemoral and pelvic nodes.

[k] Single inguinal node with positive findings.

[l] More than one inguinal node with positive findings.

[m] Three-year survival with positive findings in inguinal and pelvic nodes.

[n] N1-2.

[o] N3.

[p] After antibiotic therapy.

[q] One node positive.

[r] One to six nodes positive.

[s] More than six nodes positive.

[t] Bilateral nodes positive.

[u] Adjunctive adenectomy.

[v] Immediate therapeutic adenectomy.

[w] Delayed therapeutic adenectomy.

[x] One to three positive nodes.

[y] More than three positive nodes.

[z] Unilateral.

[aa] Some lymph node dissection done without antibiotic pretreatment.

TABLE 79.6

Five-Year Survival (%) Related to Extent of Nodal Metastasis

SERIES	NO. OF PATIENTS	NO. OF POSITIVE NODES	
		≤2	>2
Fraley et al., 1989	31	88%	7%
Johnson and Lo, 1984a	22	85%[a]	13%
Srinivas et al., 1987	119	82%	20%

			54%[b]
Graafland et al., 2010	152	73%	27%
Ravi, 1993b	21	81%[c]	50%[d]
Pandey et al., 2006	102	76%[c]	8%[e] 0%[f]

[a] Approximate.

[b] A subset with one to six positive nodes.

[c] One to three positive nodes.

[d] More than three positive nodes.

[e] Four to five positive lymph nodes.

[f] More than five positive lymph nodes.

The extent of cancer in a lymph node was also of prognostic significance. Ravi (1993a) noted ENE of cancer in lymph nodes 4 cm in size, and only 1 of 17 patients (6%) undergoing lymphadenectomy survived 5 years. Finally, pelvic lymph node involvement has been a particularly ominous finding with respect to long-term survival; the combined results of several small series reveal an average 5-year survival of 14% when pelvic nodal metastases are present (Table 79.7). **Taken together, these data suggest that the pathologic criteria associated with long-term survival after attempted curative surgical resection of inguinal metastases (i.e., 80% 5-year survival) include minimal nodal disease (up to two involved nodes in most series), unilateral involvement, no evidence of ENE of cancer, and absence of pelvic nodal metastases.**

TABLE 79.7

Five-Year Survival Related to Pelvic Node Metastases

AUTHOR	NO. OF PATIENTS WITH POSITIVE NODES	5-YEAR SURVIVAL NO. (%)
de Kernion et al., 1973	2	1 (50)
Horenblas et al., 1993	2	0 (0)
Srinivas et al., 1987	11	0 (0)
Pow-Sang et al., 1990	3	2 (66)

Kamat et al., 1993	6	2 (33)
Ravi, 1993a	30	0 (0)
Lopes et al., 2000	13	5 (38)
Lont et al., 2007	25	4 (16)
Zhu et al., 2008	16	1 (6)
Total	108	15 (14)

Presence of Palpable Adenopathy as a Selection Factor for Inguinal Dissection

One can conclude from these data that it is advantageous to find and to treat nodal metastasis at the earliest possible opportunity. Data in Table 79.5 suggest that the presence of palpable adenopathy is associated with proven nodal metastasis in about 43% of cases on average (range 8% to 64%). In the remainder, lymph node enlargement is secondary to inflammation. Persistent adenopathy after treatment of the primary lesion and 4 to 6 weeks of antibiotic therapy is most often the consequence of metastatic disease. Similarly, the development of new adenopathy during follow-up is much more likely to be caused by tumor than inflammatory response. Thus historically a course of antibiotics was recommended for patients with suspicious nodes to potentially discern metastasis from cancer (Srinivas et al., 1987).

However, several authors have raised the issue that this causes a significant delay and could affect survival, especially among patients who are likely to be truly positive because of the stage or grade of the primary tumor (Kroon et al., 2005b; Pettaway et al., 2007). An alternative approach for such patients is to perform fine-needle aspiration cytology of palpable nodes either at the time of or immediately after treatment of the primary tumor. In the case of a positive result, definite therapy can be planned without a 4- to 6-week delay. Saisorn et al. (2006) reported a 93% sensitivity and a 91% specificity in 16 patients with palpable adenopathy (mean size 1.47 cm) undergoing fine-needle aspiration before lymphadenectomy. The recommendation for this procedure among patients with palpable nodes was also incorporated in the European Association of Urology (EAU) Penile Cancer Guidelines. **Thus, although treatment of the primary tumor and a period of antibiotics are useful to help sterilize the inguinal region, this practice is no longer advocated as a tool to select patients who either should or should not undergo lymphadenectomy.** Should the fine-needle aspiration result be negative, depending on clinical suspicion, close observation, repeat aspiration, or excisional biopsy is performed because the false-negative rate of fine-needle aspiration cytology was 20% to 30% in two other, older series (Horenblas et al., 1991; Scappini et al., 1986).

Evolving Indications for Lymphadenectomy in Patients Without Palpable Adenopathy

Immediate Versus Delayed Surgery

Considering the value of early detection and treatment of metastasis, **should inguinal lymphadenectomy (ILND) be routinely performed in patients with clinically normal groin examination findings at the time of presentation of the primary lesion?** This was the most controversial issue in the management of patients with squamous penile cancer previously; however, the pendulum has moved toward earlier lymphadenectomy in selected patients with penile cancer. As noted, the cure rate with ILND when nodes are positive for malignancy may be as high as 80%. A cure rate of this magnitude with surgery in the face of regional nodal metastases parallels the urologist's experience with testicular cancer, in which retroperitoneal lymphadenectomy provides cure in many patients with minimal nodal metastasis. In contrast, for other common genitourinary malignant neoplasms—bladder, prostate, and kidney—surgical cure in the presence of regional nodal metastases is rare. Given that node dissection can cure metastatic penile cancer, why is there debate about whether the procedure should be performed, especially given that regional node dissections are often advocated in other malignant neoplasms when evidence of their efficacy is marginal at best?

Morbidity Versus Benefit

The reluctance to advocate automatic ilioinguinal lymphadenectomy (IILND) in all patients with penile cancer stems from the substantial morbidity the procedure can produce, as opposed to the relatively limited postoperative morbidity of pelvic or retroperitoneal lymphadenectomies. Early complications of phlebitis, pulmonary embolism, wound infection, flap necrosis, and permanent and disabling lymphedema of the scrotum and lower limbs were frequent after inguinal and ilioinguinal node dissections (Fraley et al., 1989; Johnson and Lo, 1984a; McDougal et al., 1986; Skinner et al., 1972). **Postoperative complications have been reduced by improved preoperative and postoperative care; advances in surgical technique; plastic surgical**

consultation for myocutaneous flap coverage; and preservation of the dermis, Scarpa fascia, and saphenous vein, as well as modification of the extent of the dissection (Bevan-Thomas et al., 2002; Catalona, 1988; Coblentz and Theodorescu, 2002; Colberg et al., 1997; Nelson et al., 2004). In the University of Texas MD Anderson Cancer Center experience, the incidence and severity of lymphedema and skin edge necrosis were significantly decreased (Table 79.8; Fig. 79.3; Bevan-Thomas et al., 2002).

TABLE 79.8

Lymphadenectomy Complications in Four Surgical Series

	JOHNSON AND LO (1984b)	RAVI (1993b)	ORNELLAS ET AL. (1994)	BEVAN-THOMAS ET AL. (2002)
No. of dissections	101	405	200	106
Period	1948–1983	1962–1990	1972–1987	1989–1998
COMPLICATIONS (%)				
Skin edge necrosis	50	62	45	8[a]
Lymphedema	50	27	23	23[b]
Wound infection	14	17	15[c]	10
Seroma formation	16	7	6	10
Death	0	1.3	Not stated	1.8

[a] Significantly lower than in the three other reported series (all $P = 0.0001$).

[b] Significantly lower than in the series of Johnson and Lo ($P = 0.0001$).

[c] Incidence among 85 lymphadenectomies performed by Gibson-type incision.

Modified from Bevan-Thomas R, Slaton JW, Pettaway CA: Contemporary morbidity from lymphadenectomy for penile squamous cell carcinoma: the MD Anderson Cancer Center experience. *J Urol* 167:1638–1642, 2002.

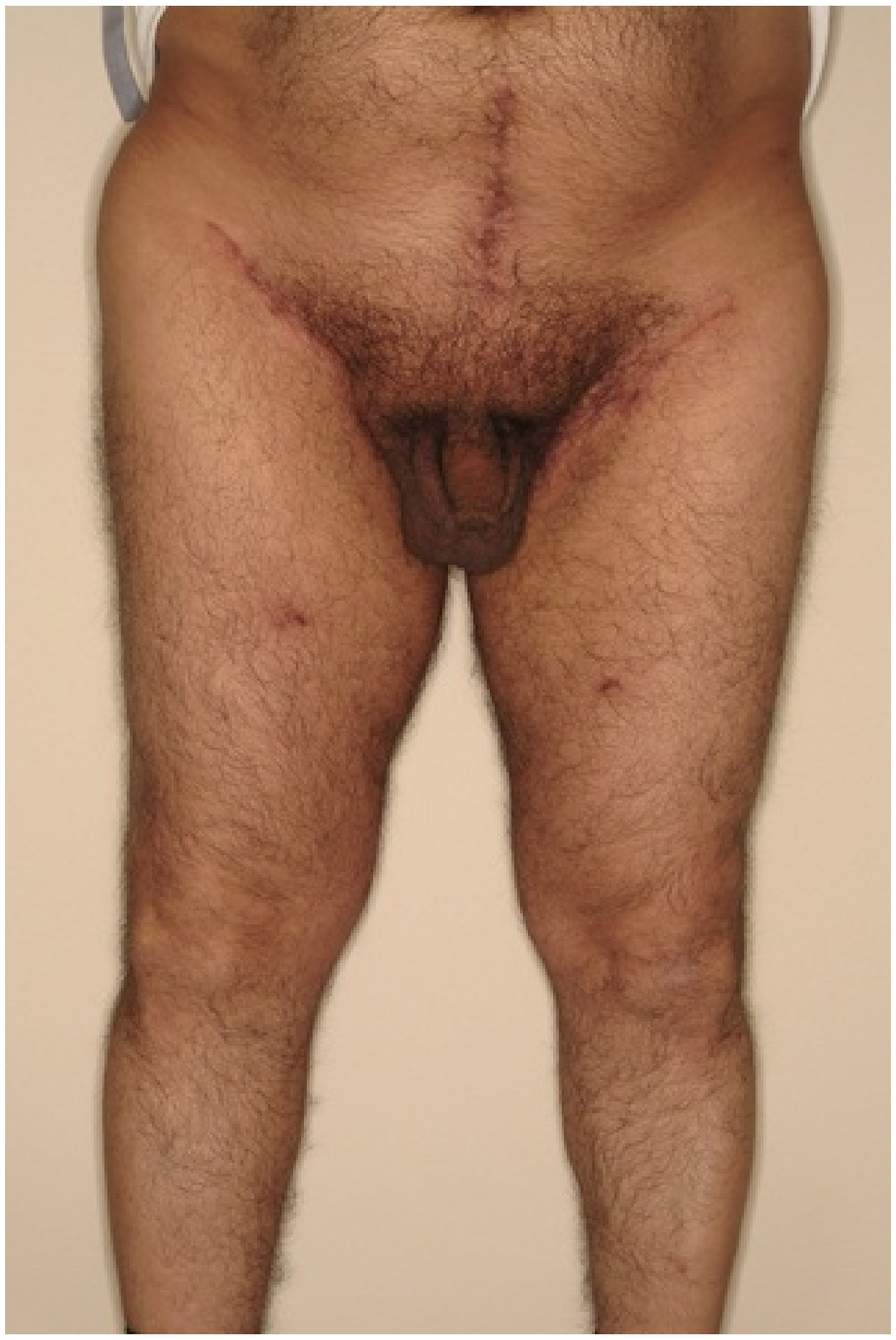

FIG. 79.3 Postoperative appearance after contemporary lymphadenectomy. The patient's status is after right ilioinguinal lymphadenectomy and left superficial inguinal dissection for stage T2N1M0 squamous penile cancer. Mild edema is visible on the left 10 months after surgery. Patient remains without disease at 9 years.

Furthermore, experience has suggested that lymphadenectomy in the setting of microscopic disease may be less likely to produce complications than node dissection in the presence of bulky nodal metastases (Coblentz and Theodorescu, 2002; Fraley et al., 1989; Ornellas et al., 1994). This is presumably because of the reduced amount of lymphatic tissue removed, preservation of venous drainage, and less blood supply compromised. Together these factors affect the viability of skin flaps and lymphatic flow.

Mortality after ILND has been reported in association with surgery performed concomitantly with penectomy and after palliative inguinal dissection. In both scenarios it was related to sepsis (Bevan-Thomas et al., 2002). An operative mortality of 3.3% was reported in earlier series (Beggs and Spratt, 1964). However, Johnson and Lo (1984a) and others (Coblentz and Theodorescu, 2002;

Nelson et al., 2004; Ornellas et al., 1994; Ravi, 1993b) have reported no mortality in more recent series. Appropriate selection of patients along with routine preoperative antibiotic therapy and wound care to avoid septic complications has minimized this event.

Clearly, lymphadenectomy is not a trivial concern, even though morbidity appears to be decreasing. If a policy of routine lymphadenectomy were adopted in all patients with clinically negative lymph nodes, the average risk of false-negative examination findings (metastasis is actually present) would be approximately 29%, with wide-ranging variation (see Table 79.5). Stated another way, an average of 70% of patients could be subjected to the morbidity of ILND with no benefit. Potential reasons for false-negative examination findings include obesity, preexisting edema, and changes from prior therapy (radiation, inguinal surgery).

One alternative to immediate lymphadenectomy for all patients has been to observe patients with normal findings on inguinal examination. Lymphadenectomy is subsequently reserved for those patients who develop palpable lymph nodes. **The relevant question then becomes this: Can a delayed therapeutic dissection effectively salvage patients who have inguinal recurrence?**

Several studies have analyzed the survival of men undergoing early versus delayed lymphadenectomy according to pathologic evaluation of nodal status. McDougal et al. (1986) reported a series of 23 patients with invasive primary lesions and nonpalpable nodes; 9 patients were treated with immediate adjunctive lymph node dissection (6 had positive findings), and 14 were treated with surveillance and delayed lymph node dissection. The 5-year survival in the node-positive immediate adjunctive lymphadenectomy group was 83% (5 of 6 patients), whereas in the surveillance group the 5-year survival was 36% (5 of 14 patients). However, only 1 patient in the surveillance group had a node dissection. Presumably, the other 9 patients had progressed to inoperable local tumor or distant disease before presentation, emphasizing the role of careful, frequent follow-up and the difficulty of enforcing it. A third subset in this series had palpable nodes at presentation and had immediate therapeutic lymph node dissection, with 10 of 15 patients (66%) surviving 5 years (McDougal et al., 1986). The best results were from immediate adjunctive lymph node dissection (83%), with the next best from immediate therapeutic lymphadenectomy (66%). The worst results were from the surveillance and delayed lymphadenectomy group (36%), in whom dissection was delayed until palpable nodes developed.

The interval of opportunity for cure in this third group appears to have been lost.

Similarly, Fraley et al. (1989) reported that immediate adjunctive lymphadenectomy resulted in a 5-year disease-free survival in 6 of 8 node-positive patients (75%) compared with 1 of 12 patients (8%) who had been observed and then treated with delayed lymphadenectomy when nodal enlargement occurred. Six other patients in that series also had unresectable adenopathy after initial surveillance, and all died of their disease. Although only 2 of 6 patients who had immediate lymphadenectomy had more than 2 positive nodes, all the patients treated by delayed lymph node dissection had 3 or more positive nodes.

Three other series suggest that early lymphadenectomy for varying degrees of “suspicious” or clinically positive nodes improves survival compared with the “surveillance” or delayed intervention approach in patients with clinically negative nodes (Johnson and Lo, 1984b; Kroon et al., 2005b; Ornellas et al., 1994). A series from the University of Texas MD Anderson Cancer Center compared 5-year disease-free survival of 14 patients undergoing early lymphadenectomy for clinically suspicious and histologically node-positive disease with that of 8 patients who were observed and later underwent lymphadenectomy when clinical nodal enlargement was undisputed (Johnson and Lo, 1984b). The primary tumors were of similar stage. The 5-year disease-free survival was 57% for early lymphadenectomy compared with 13% for delayed node dissection. The number of involved nodes in the immediate lymphadenectomy group (median, 2) was half that of the delayed lymphadenectomy group (median, 4), and no patient with more than 2 positive nodes survived more than 5 years.

Kroon et al. (2005b) from the Netherlands Cancer Institute compared survival of 20 patients found to have positive lymph nodes subsequent to prophylactic DSNB with that of 20 patients who underwent delayed inguinal dissection after proven nodal metastasis. The 3-year survival for patients detected during close surveillance was only 35% compared with 84% ($P = 0.0017$) for those undergoing early dissection. Pathologic evaluation of involved lymph nodes revealed ENE of cancer among 19 of 20 patients in the delayed group versus only 4 of 20 patients ($P = 0.001$) in the early group. Thus, despite careful follow-up, survival was adversely affected by the extent of cancer in involved lymph nodes.

A single large study from India disputes the magnitude of the value of early prophylactic dissection. Ravi (1993b) performed early prophylactic dissection in

113 patients with invasive penile cancer and compared the 5-year survival with that of 258 similarly staged patients who were initially observed. In the “early” group, 20 patients (18%) were found to have metastases, and all patients survived 5 years. The recurrence rate in the observed group was only 8% (21 patients). However, the 5-year survival in the patients who experienced recurrence was only 76% (compared with 100% in the early lymphadenectomy group). The enhanced survival of patients undergoing surveillance in India compared with other countries is probably attributable to patient selection factors, strict adherence to follow-up schedules, and aggressive treatment approach for recurrent disease (a combination of radiation and surgical resection) (Ravi, 1993a).

Thus six series reveal an improvement in survival for patients undergoing early therapeutic versus delayed therapeutic dissection. Furthermore, five of the six series show that delayed therapeutic dissection can rarely salvage patients who experience recurrence. Taken together, these data suggest that a policy of immediate adjunctive or early lymphadenectomy gives greater assurance that surgical intervention will occur when tumor volume is small (see Table 79.4) (Fossa et al., 1987; Fraley et al., 1989; Johnson and Lo, 1984a; Kroon et al., 2005b; Ravi, 1993b; Srinivas et al., 1987).

Impact of Primary Tumor Histologic Features on Predicting Occult Nodal Metastasis

Although early lymphadenectomy improves survival in patients with inguinal metastases, the challenge remains to identify those patients who are truly lymph node negative to avoid the morbidity of traditional lymphadenectomy. **Data gained from analysis of a variety of histopathologic variables within the primary penile tumor allow the classification of patients into higher and lower risk groups for lymph node metastasis** (Ficarra et al., 2006; Lopes et al., 1996; McDougal, 1995; Solsona et al., 2001; Theodorescu et al., 1996).

Patients with primary tumors exhibiting CIS or verrucous carcinoma have little or no risk for metastasis. Only 2 cases of metastasis in association with CIS have been reported, and none of 47 cases of penile verrucous carcinoma have been shown to metastasize (Avrach and Christensen, 1976; Eng et al., 1995; Johnson et al., 1985; Seixas et al., 1994). Thus patients with both Tis and Ta penile cancer are included in the low-risk group for inguinal metastases (Solsona et al., 2001, 2004).

In contrast, patients with corporeal invasion (stage pT2) in the penile tumor exhibit a high risk for metastasis. The average risk for inguinal metastasis among 225 patients in 7 different series was 59% (Table 79.9). **The risk for metastasis among patients exhibiting corporeal invasion was similar regardless of whether palpable adenopathy was present.**

TABLE 79.9

Penile Carcinoma: Corporeal Invasion and Incidence of Lymph Node Metastasis

STUDY	NO. OF PATIENTS	NO. OF POSITIVE NODES (%)	CLINICAL N STAGE
McDougal et al., 1986	23	11 (48)	N0
Fraley et al., 1989	29	26 (90)	N0
Theodorescu et al., 1996	18	12 (67)	N0
Villavicencio et al., 1997	37	14 (38)	N0
Lopes et al., 1996	44	28 (64)	NS
Heyns et al., 1997	32	15 (47)	NS
Solsona et al., 1992	42	27 (64)	NS

N, Node; *NS,* not specified.

Stage T1 penile cancers exhibit involvement of the subepithelial connective tissue only and lack involvement of the corpus spongiosum, corpora cavernosa, or urethra (Edge et al., 2010). Similarly staged tumors historically have been associated with a 4% to 14% incidence of nodal metastasis (Hall et al, 1998; Solsona et al., 1992; Villavicencio et al., 1997). Theodorescu et al. (1996) noted one exception to this relatively low rate of metastatic disease; 58% of patients (14 of 24) with pT1 primary tumors and initially negative nodes on clinical assessment subsequently developed inguinal nodal metastases. These data suggest that other variables present within the penile cancers of the cohort of patients studied (i.e., tumor grade and presence of vascular invasion) may have modified the effect of tumor stage on metastasis.

Several authors have evaluated the risk of nodal metastasis for stage T1 lesions according to tumor grade (Table 79.10). Among 73 patients with T1 grade 1 or grade 2 primary tumors, metastasis occurred in only 5 patients (7%). Recent data from Naumann et al. (2008), however, suggested that among T1 grade 2 tumors specifically, the risk of metastases could be higher than previously described. Among four series reporting specifically on the T1 grade 2 subset, in 129 initially node-negative patients, metastases occurred in 18 (14%) (see Table 79.8). However, 5 patients in this subset also exhibited either lymphatic or venous invasion (an adverse prognostic feature, see later). Ficarra et al. (2006) developed the first penile cancer nomogram using data from 175 patients. Based on tumor thickness and growth pattern, patients with T1 grade 2 tumors exhibited metastatic rates of 5% to 20%. Thus grade 2 tumors represent a heterogeneous group in which the histologic criteria used to describe grade 2 and the presence or absence of other poor prognostic features ultimately determine prognosis (Cubilla, 2009). In this regard the EAU guidelines assigned patients with T1 grade 2 tumors to the intermediate-risk category in which the risk of lymph node metastasis is greater than 16% (low risk) and less than 68% (high risk) (Pizzocaro et al., 2010; Solsona et al., 2004).

TABLE 79.10

Penile Carcinoma: Incidence of Nodal Metastasis for Stage T1, Grade 1, and Grade 2 Primary Tumors

AUTHOR	STAGE AND GRADE	NO. OF PATIENTS	NO. OF PATIENTS WITH METASTASIS (%)
Theodorescu et al., 1996	T1, G1	8	2 (25)
Solsona et al., 1992	T1, G1	19	0 (0)
McDougal, 1995	T1, G1-G2	24	1 (4)
Heyns et al., 1997	T1, G1-G2	9	1 (11)
Hungerhuber et al., 2006	T1, G1-G2	13	1 (8)
Total		73	5 (7)
Solsona et al., 1992	T1, G2	4	1 (25)
Solsona et al., 2001	T1, G2	4	1 (25)
Naumann et al., 2008[a]	T1, G2	16	7 (44)
Hughes et al., 2010	T1, G2	105	9 (9)

TOTAL		129	18 (14)

[a] Five tumors in node-positive group had lymphatic or venous invasion.

The presence of vascular invasion as a prognostic indicator of inguinal lymph node metastasis in squamous penile cancer is now evident (Ficarra et al., 2005; Fraley et al., 1989; Heyns et al., 1997; Lopes et al., 1996; Slaton et al., 2001). Lopes et al. (1996) studied the prognostic value of lymphatic invasion in 146 patients with penile cancer. In a univariate analysis, clinical nodal stage, tumor thickness, lymphatic and venous embolization, and urethral infiltration were associated with lymph node metastasis. However, subsequent to multivariate analysis, only venous and lymphatic invasion remained significant predictors for positive lymph nodes. Data from the University of Texas MD Anderson Cancer Center revealed that vascular invasion was absent in all patients with T1 tumors (Slaton et al., 2001). These patients were also lymph node negative at surgery. In contrast, patients with stage pT2 primary tumors exhibited nodal metastasis in 75% of cases (15 of 20) when vascular invasion was present but in only 25% of cases (3 of 12) when it was absent.

Ficarra et al. (2005, 2006) developed a nomogram predicting inguinal lymph node involvement including the variables of tumor thickness, growth pattern, grade, venous or lymphatic invasion, corpus spongiosum or cavernosum involvement, urethral involvement, and palpable lymph nodes. The most important variables were venous or lymphatic invasion and the presence of palpable nodes in multivariate analysis. The concordance index of the nomogram was very good at 0.876. Zhu et al. (2010) also developed a nomogram to predict inguinal lymph node metastasis among 110 patients with clinically negative lymph nodes from 1990 to 2008. The variables included in their model were T stage, grade, lymphovascular invasion (LVI), and tumor p53 expression. Similar to Ficarra et al. LVI was the only variable that showed independent prognostic value. This nomogram exhibited a concordance index of 0.79 and actually provided superior ability to stratify patients when compared with the European Association of Urology risk classification system. However, neither of these nomograms has been externally validated, and they are not in routine use. This is likely due to the complexity of the nomogram variables included.

The presence of perineural invasion (Velazquez et al., 2008) and the microscopic front pattern of invasion (Guimares et al., 2006) have also been shown in recent studies to provide independent information with which to stratify a patient's risk of lymph node metastasis. In fact the variable perineural invasion is has now been added to the eighth edition TNM staging system (Pettaway et al., 2017).

Molecular Prognostic Markers

Analysis of gene expression in penile cancer will likely have future practical implications with respect to the prediction of lymph node metastasis or survival. A review by Muneer et al. (2009) described the status of several genes evaluated in tissue or serum that could have future prognostic implications with respect to predicting lymph node status or survival (Table 79.11).

TABLE 79.11

Prognostic Molecular Markers of Lymph Node Status and Survival in Penile Cancer: Current Status

MARKER	ROLE	LYMPH NODE STATUS	SURVIVAL
Human papillomavirus (HPV) p16^{INK4a}	High-risk (HR) types affect TP53 and RB function Increased expression with HR-HPV	Contradictory studies	Increased survival[a] Increased survival, decreased recurrence[b]
TP53	Altered or mutated expression, increased proliferation, altered apoptosis, dedifferentiation	Preliminary data correlated with increased metastasis	Correlated with decreased survival[c]
CDKN2A	Inhibits RB function, enhancing proliferation	Not established	Not established
Squamous cell carcinoma antigen (TA-4)	Serum marker function unknown	Correlates with grossly evident metastases	No role
Ki-67	Nuclear protein associated with cycling cells	Predicts increased risk	No role
E-cadherin	Epithelial cell adhesion molecule lost in progression	Low expression associated with nodal metastasis	Low expression predicts worse survival
MMP-9	Matrix metalloproteinase family facilitates invasion	No role	High expression predicts

			recurrence

[a] Djajadiningrat RS, Jordanova ES, Kroon BK, et al.: Human papillomavirus prevalence in invasive penile cancer and association with clinical outcome. *J Urol* 193:526–531, 2015.

[b] Gunia S, Erbersdobler A, Hakenberg OW, et al.: p16(INK4a) is a marker of good prognosis for primary invasive penile squamous cell carcinoma: a multi-institutional study. *J Urol* 187(3):899–907, 2012.

[c] Ferrandiz-Pulido C, Masferrer E, Toll A, et al.: mTOR signaling pathway in penile squamous cell carcinoma: pmTOR and peIF4E over expression correlate with aggressive tumor behavior. *J Urol* 190 (6):2288–2295, 2013.

RB, Retinoblastoma.

Modified from Muneer A, Kayes O, Ahmed HU, et al.: Molecular prognostic factors in penile cancer. *World J Urol* 27:161–167, 2009. With additional references below:

Several genetic pathways have been associated with the development of SCC of the penis, including p16 and p53 (Poetsch et al., 2011,Yanagawa et al., 2008).

The p16 gene encodes the protein p16INK4A, and increased expression of this protein has been seen as a late event after HPV infection and causes inactivation of the cell cycle cascade. In cervical carcinoma, increased expression of p16INK4A has been associated with malignant transformation in HPV-positive cancers (Doorbar, 2006).

The tumor suppressor gene p53 encodes a transcription factor that normally blocks cell cycle progression. When altered by deletion or mutation, it results in a loss of inhibition and malignant growth. Further characterizations of the mechanisms involved are needed.

Recently other pathways involved in penile cancer progression and correlated with adverse outcomes include epithelial-mesenchymal transition (with molecular markers such as increased expression of vimentin, matrix metalloproteinases, and loss of E-cadherin), increased expression of CD44, and the mammalian target of rapamycin (MTOR) (da Cunha et al., 2011; Ferrandiz-Pulido et al., 2013; Minardi et al., 2012; Muneer et al., 2009). Although routine evaluation of many of these molecular markers is currently not indicated because of lack of validation, there is a growing evidence that determining the HPV/p16 status of tumors may be useful for prognostic purposes. In recent studies the expression of high-risk HPV and p16 have been correlated with enhanced disease-specific survival (Djajadiningrat et al., 2015; Gunia et al., 2012). This is especially the case for assessing p16 status in tumors via immunohistochemistry, which is routinely available and is highly correlated with high-risk HPV positive tumors (Stankiewicz et al., 2011). In addition, counseling for female partners of males with HPV-associated penile cancers may be indicated.

Standardization of methodologies for assessment of gene expression and the lack of large tissue banks with well-annotated clinical data for validation studies hamper efforts to rigorously evaluate the potential usefulness of such biomarkers. Prospective multi-institutional studies analyzing pathologic and molecular features are needed to further validate which pathologic and molecular variables best stratify a patient's risk for metastasis and survival.

Evolving Indications for Expectant Management of the Inguinal Region

Data reviewed in the preceding paragraphs along with consensus guidelines demonstrate that patients with primary tumors exhibiting CIS, verrucous carcinoma (Ta), and stage T1, grade 1 tumors exhibit a relatively low incidence of positive lymph nodes overall (0 to 16%) and are optimal candidates for watchful waiting strategies (Pizzocaro et al., 2010; Pompeo et al., 2009).

Recommendations for the management of T1 grade 2 tumors varied based on quoted rates of subsequent metastases (see Table 79.10). The former EAU guideline (Solsona et al., 2004), although classifying such cases in the intermediate-risk group, recommended observation for T1 grade 2 tumors that lacked vascular invasion and exhibited a superficial growth pattern (i.e., absence of any other adverse features). This guideline was recently modified to recommend an inguinal staging procedure for this group of patients (Hakenberg et al., 2015; Pizzocaro et al., 2010). Given the low rate of metastases of 9% overall in a recent study among 105 patients, we agree with the Société Internationale d'Urologie/International Consultation on Urological Diseases (ICUD) recommendation that these patients may also be considered for observation (Hughes et al., 2010; Pompeo et al., 2009; see Table 79.10). The T1 grade 2 grouping should correspond to the AJCC TNM seventh edition stage T1a classification (Edge et al., 2010, Hakenberg et al., 2015). These tumors lacked LVI and were not poorly differentiated. In two series consisting of 183 total patients the rates of metastases were 10.5% and 18% (Sun et al., 2015). Given that the eighth edition TNM T1a tumor staging definition excludes any tumors with perineural invasion or any proportion of anaplastic cells we anticipate that the eighth edition T1a classification (Pettaway et al., 2017) would represent an even lower-risk group of patient harboring micrometastatic disease.

The incidence of metastases among patients with AJCC stage T1b or greater tumors (see Table 79.1) as a group ranged from 33% to more than 50% in two recent collected series (Sun et al., 2014), so an inguinal staging procedure appears warranted. In addition, noncompliant patients with invasive primary tumors should be offered an inguinal staging procedure versus observation. Table 79.12 provides a guideline for more intensive follow-up of high-risk patients, especially within the first 2 years. **It is imperative for the patient and the physician to adhere to such follow-up agreements and to be willing to intervene immediately if initial inguinal parameters change. Leijte et al. (2008) have documented that only one-third of patients who were initially node negative but who subsequently develop an inguinal recurrence survive 5 years.**

TABLE 79.12

Penile Carcinoma: Suggested Follow-Up for Patients With No Evidence of Inguinal Adenopathy Who Do Not Undergo Initial Lymphadenectomy

YEAR	INTERVAL	
	LOW-RISK GROUP[a]	HIGH-RISK GROUP[b]
1–2	3 months	2 months
3	6 months	4 months
4	6 months	6 months
5+	Annually	Annually

[a] Primary tumor stage Tis, Ta, and T1a.

[b] Primary tumor stage T1b or greater.

Indications for Modified and Traditional Inguinal Procedures

Modified Procedures

In patients with no evidence of palpable adenopathy who are selected to undergo inguinal procedures by virtue of adverse prognostic factors within the primary tumor, the goal is to define whether metastases exist with minimal morbidity for the patient. A variety of treatment options for this purpose have been reported and include fine-needle aspiration cytology, node biopsy, sentinel lymph node biopsy, extended sentinel lymph node dissection, dynamic sentinel lymph node biopsy, superficial dissection, and modified complete dissection. The technical aspects of many of these procedures are beyond the scope of this chapter but may be found in the references by Horenblas et al. (2000) and Spiess et al. (2009).

Fine-Needle Aspiration Cytology.

The experience with aspiration of clinically negative inguinal nodes guided by either lymphangiography or ultrasonography is limited. Scappini et al. (1986) performed fine-needle aspiration cytology under pedal or penile lymphangiography for nodal localization in 29 patients. Of 20 patients who had lymphadenectomy for histologic confirmation, there was complete agreement between aspiration cytology and histologic results. However, 2 of 9 patients whose cytologic analysis was negative subsequently died of metastatic disease, a presumptive 20% false-negative result. A series from Horenblas et al. (1991) also found that the sensitivity of fine-needle aspiration cytology was approximately 71% in 18 patients with clinically negative lymph nodes. This finding and the technical difficulty with lymphangiography make aspiration less practical as a staging technique for patients with no palpable lymph nodes. Kroon et al. (2005a) described fine-needle aspiration cytology guided by ultrasonography as a preliminary study to surgical staging with DSNB. Thirty-four groins in 27 patients with clinically negative groins were found to have suspicious nodes by ultrasound examination and were aspirated. However, the sensitivity of the technique was only 39% subsequent to surgical staging. **Thus, at present, fine-needle aspiration cytology of clinically negative groins does not exhibit high enough sensitivity to be relied on as a staging modality.** However, direct aspiration of palpable inguinal nodes is easily performed, exhibited a sensitivity of 93%, and, if positive, provides immediate information with which to advise patients about further treatment (Saisorn et al., 2006).

Sentinel Lymph Node Biopsy, Extended Sentinel Lymph Node Dissection, and Node Biopsy.

The concept of sentinel lymph node biopsy as described by Cabanas (1977) is predicated on detailed penile lymphangiographic studies that have demonstrated consistent drainage of the penile lymphatics into a sentinel node or group of nodes located superomedial to the junction of the saphenous and femoral veins in the area of the superficial epigastric vein. In this series, when this sentinel node was negative for tumor, metastases to other ilioinguinal lymph nodes did not occur. Metastases to this node indicated the need for a complete superficial and deep inguinal dissection.

The accuracy of the sentinel node histology to identify inguinal node metastases was, however, questioned by a number of reports (Fowler, 1984; Perinetti et al., 1980; Wespes et al., 1986). Because nodal metastases became palpable within 1 year of sentinel node biopsy with normal findings in some patients in these series, a false-negative biopsy result must be presumed. In one large series, 5 of 41 patients (12%) with normal findings on sentinel node biopsy subsequently developed inguinal node metastases (Fossa et al., 1987). In Cabanas's series (1992), 3 of 31 patients with negative sentinel nodes died of disease, suggesting a false-negative rate for identifying metastases of 10%. McDougal et al. (1986) reported a 50% false-negative rate with inguinal node biopsy. A report by Pettaway et al. (1995), in which additional nodes around the sentinel node area were also removed, revealed that even this extended dissection was associated with a false-negative rate of 25%. The authors hypothesized that false-negative inguinal node biopsies were the result of anatomic variation in the position of the sentinel node within the inguinal field. **Thus biopsies directed to a specific anatomic area can be unreliable in identifying microscopic metastasis and are no longer recommended.**

Dynamic Sentinel Node Biopsy.

DSNB offers the potential for precise localization of the sentinel node with the lowest morbidity of any surgical staging technique (Kroon et al., 2005c). The goal of DSNB is to define where in the inguinal lymph node field the sentinel lymph node resides through use of a combination of visual (vital blue dyes) or gamma emission (hand-held gamma probe) techniques at the time of surgery.

The technique has been studied in patients with malignant melanoma and breast and vulvar carcinomas who required evaluation of the regional lymph nodes (Albertini et al., 1996; Gershenwald et al., 1999; Levenback et al., 1994; Morton et al., 1992). The technique involves intradermal injection of a vital blue dye (isosulfan blue or patent blue dyes) or technetium-labeled colloid adjacent to the lesion. The dye (or radioactive tracer) is transported by the afferent lymphatics to a specific node in the regional nodal basin. This node is designated the sentinel lymph node.

Several studies evaluating the results of DSNB as a staging tool in penile cancer are now available. Kroon et al. (2004) updated the Netherlands Cancer

Institute experience, describing their experience using the combination of preoperative lymphoscintigraphy and intraoperative intradermally injected blue dye in 123 patients with penile cancer. They identified a sentinel node in 98% of patients, for a sensitivity rate of 82% and a false-negative rate of 18% (6 patients). Four of the 6 patients subsequently died of disease progression. Spiess et al. (2007) also noted a false-negative rate of 25% among 31 patients undergoing DSNB. The Netherlands Cancer Institute group subsequently instituted several changes, including (1) routine serial sectioning of the involved lymph nodes along with cytokeratin immunohistochemistry, (2) routine exploration of groins with low or no signal subsequent to preoperative or intraoperative studies, and (3) inguinal ultrasonography with fine-needle aspiration to detect subtle architectural changes (nonpalpable) in positive lymph nodes that could result in the redistribution of lymphatic flow (Kroon et al., 2005a).

In a multicenter update that included patients assessed with the modified DSNB protocol from two high-volume centers (the Netherlands Cancer Institute and St. George's Hospital in London) the false-negative rate was 7% (6 patients) among 323 patients (Leijte et al., 2009b). Three of 6 patients with recurrence (50%) either died or developed distant metastases. **Thus DSNB, when performed at high-volume centers using a standardized protocol, has an acceptable sensitivity, but deaths from penile cancer among initially node-negative patients still occurred.** This limits the applicability of this strategy to larger centers with experienced surgeons and nuclear medicine specialists.

Superficial and Modified Complete Inguinal Dissection.

Superficial inguinal and modified complete dissections have been proposed as staging tools for the patient without palpable inguinal lymphadenopathy. Superficial node dissection involves removal of those nodes superficial to the fascia lata. A complete IILND (removal of those nodes deep to the fascia lata contained within the femoral triangle as well as the pelvic nodes) is then performed if the superficial nodes are positive at surgery by frozen-section analysis. The rationale for superficial dissection is that two series have shown no positive nodes deep to the fascia lata unless superficial nodes were also positive (Pompeo et al., 1995; Puras-Baez et al., 1995). Furthermore, Spiess et al. (2007) showed that among the lymph node–negative cohort of patients undergoing DSNB followed by completion superficial dissection, no patient with a negative superficial dissection experienced recurrence, with more than 3 years of follow-up. A complete modified inguinal dissection was originally proposed by Catalona (1988) and involves smaller skin incision, limited field of inguinal dissection, preservation of the saphenous vein, and thicker skin flaps. This technique also avoids having to transpose the sartorius muscle to cover exposed femoral vessels. Unlike in superficial dissection, deep nodes within the fossa ovalis are also removed. Two reports involving 21 patients have confirmed the value of this technique, when it is properly performed, for identifying microscopic metastases with minimal morbidity (Colberg et al., 1997; Parra, 1996).

Thus either superficial or complete modified inguinal dissection should adequately identify microscopic metastases in patients with clinically normal inguinal examination findings, without the need for a pelvic dissection if the inguinal nodes are negative. The disadvantage of the modified dissections is the higher overall complication rate (12% to 35%) when compared with DSNB (5% to 7%) (Kroon et al., 2005c; Spiess et al., 2009).

Limited dissections have the following advantages: more information is provided than by biopsy of a single node or group of nodes; the possibility of not identifying the sentinel node is limited by removal of all potential first-echelon nodes; and the dissection is readily performed by any surgeon experienced in inguinal surgery without the need for specialized equipment.

Minimally Invasive Inguinal Lymphadenectomy Using Laparoscopy or Robotic Techniques.

The laparoscopic and robotic approaches to the inguinal region offer the potential for removing all of the inguinal lymph nodes at risk for disease while minimizing complications. The technical details of the contemporary procedure and early results have been described (Matin et al., 2013; Sotelo et al., 2007; Tobias-Machado et al., 2007). The results of laparoscopic and robotic ILND have been comparable with those of open inguinal lymph dissection with comparable node counts achieved in both. A single case of inguinal recurrence reported at 12 to 33 months of follow-up and minor complications in about 20% of patients have been reported (Sotelo et al., 2009). However, in one study using a laparoscopic approach with more than 600 days of follow-up, Master et al. (2012) noted minor complications in 27% of patients, with major complications noted in 14.6%. These were mainly infectious in nature and were managed with intravenous antibiotics or incision and drainage. Among 41 dissections there was only a single case of skin edge necrosis. Matin et al. (2013), using a robotic-assisted approach, noted in a phase 1 pilot study that inguinal dissection appeared equivalent to an open approach in 18 of 19 (94.7%) patients when verified by a second surgeon using an open incision to inspect the same groin. Another recent study compared the complication rates and outcomes among 35 patients undergoing open inguinal lymph node dissection versus the robotic approach (n = 33 patients [Kumar and Sethia, 2017]). They also found that lymph node yields were similar for both approaches; however, the wound complication rate was much higher in the open group when compared with the robotic group (68% versus 6%, respectively). There were no local recurrences in either group; however, the open group follow-up was 71 months versus only 16 for the robotic group. Minimally invasive approaches are promising as inguinal staging procedures and appear reasonable in experienced hands for staging clinically negative groins. However, further validation with larger patient numbers and longer follow-up to better determine efficacy among node positive patients are required to determine whether this is an acceptable oncologic procedure. Among those patients who are clinically node negative, data on complication rates compared with traditional approaches or DSNB will help to better determine its place as a staging tool.

Traditional Inguinal and Ilioinguinal Lymphadenectomy

In patients with resectable metastatic adenopathy, the potential therapeutic value of lymphadenectomy justifies the morbidity of treatment. The goals are to eradicate all obvious cancer, to provide coverage for exposed vasculature, and to provide rapid wound healing (primary closure or myocutaneous flap coverage). Several issues remain with respect to surgical decision making.

Should ILND be bilateral rather than unilateral for patients with unilateral adenopathy at initial presentation of the primary tumor? The answer to this question is yes. The anatomic crossover of penile lymphatics is well established, and bilateral drainage is the rule. In 43 of 54 patients (79%) undergoing intraoperative lymph node mapping at the Netherlands Cancer Institute, lymphatic drainage from the penis was bilateral (Horenblas et al., 2000). The contralateral node dissection may be limited to the area superficial to the fascia lata if no histologic evidence of positive superficial nodes is found at surgery by frozen-section analysis. Clinical support for a bilateral procedure is based on the finding of contralateral metastases in more than 50% of patients so treated, even if the contralateral nodal region was normal on palpation (Ekstrom and Edsmyr, 1958).

Should bilateral ILND be performed in patients with unilateral lymphadenopathy some time after the initial presentation and treatment of the primary tumor? It is generally believed that bilateral node dissection in this setting is not necessary. The recommendation of unilateral rather than bilateral node dissection with delayed presentation of unilateral lymphadenopathy is supported by the elapsed disease-free interval of observation on the normal side. If one assumes that nodal metastases will enlarge at the same rate, the clinical palpation of nodal metastases, if present in both groins, should appear at approximately the same time. The absence of clinical adenopathy on one side despite prolonged observation suggests freedom from disease on that side (Ekstrom and Edsmyr, 1958). However, this concept may not apply to all patients with delayed recurrence. Horenblas et al. (2000) noted that in patients with two or more unilateral metastases, contralateral occult metastases were noted in 30% of cases. Thus, in patients with a bulky unilateral recurrence, a contralateral inguinal staging procedure should be considered. With the current treatment recommendations for bilateral inguinal staging procedures in men at high risk for metastasis and the definition of low-risk groups for metastasis by use of available prognostic markers, this scenario should rarely occur.

Should pelvic lymphadenectomy (PLND) be performed in all patients with inguinal metastases, considering its potential for added morbidity and relatively low therapeutic value? This issue remains controversial, but recent data suggest that PLND may be omitted in select patients with limited inguinal metastases (Lont et al., 2007; Pizzocaro et al., 2010; Zhu et al., 2008). Patients with inguinal nodal metastases are at increased risk for spread to the pelvic nodes. Ravi (1993b) found no pelvic nodal metastases when inguinal nodes were negative but found positive pelvic nodes in 17 of 75 patients (22%) with one to three positive inguinal nodes and in 13 of 23 patients (57%) with more than three positive inguinal nodes. Srinivas et al. (1987) also found a similar correlation. Horenblas et al. (1993) showed that among patients with a single inguinal lymph node involved without extracapsular extension, the incidence of pelvic metastases was rare; they recommended avoiding pelvic dissection in such patients. Zhu et al. (2008) found that the sensitivity of CT for pelvic lymph node metastasis was only 37.5%. Use of the Cloquet node in predicting a positive pelvic node was only about 30% sensitive as well. Important predictors were the number of positive nodes and lymph node size. Two contemporary studies addressing this issue have found a 0 to 12% incidence of pelvic lymph node metastasis when patients exhibited only one or two positive inguinal nodes, especially when extracapsular extension was absent and/or size was less than 3.5 cm (Lont et al., 2007; Zhu et al., 2008). Additional factors noted in these studies included the grade of the nodal metastasis and its TP53 status. Thus patients with only a single small lymph node metastasis discovered at the time of inguinal dissection (i.e., no extracapsular extension, not high grade) may be at very low risk for pelvic metastasis and are potentially the optimal candidates in whom PLND can be avoided.

With respect to efficacy, the 5-year survival for patients with positive pelvic nodes averages around 14% (see Table 79.6). However, data from some of the smaller series suggest that in selected instances 5-year survival can occur in patients treated with surgery alone. In the series reported by Ravi (1993b), however, patients with even a single positive pelvic node did not survive 5 years (0 of 8 patients). The difficulty in determining the potential independent value of PLND as a therapeutic procedure is related to the small numbers of patients reported, the coexisting extensive inguinal adenopathy in patients with resectable pelvic nodes, and the failure to specify sites of relapse in patients undergoing IILND (i.e., inguinal versus pelvic versus distant site).

Thus, for patients undergoing ILND for curative intent (i.e., in whom preoperative studies reveal no pelvic adenopathy), PLND should routinely be considered in patients with two or more positive inguinal lymph nodes or when extracapsular nodal extension is present. PLND in this setting serves as an effective staging tool for identifying those patients at increased risk for pelvic metastases in whom adjunctive therapy should be considered (Lont et al., 2007; Pizzocaro et al., 2010). Given the aforementioned indications, PLND can be performed simultaneously with ILND in the setting of higher-volume inguinal metastases or as a secondary procedure after inguinal pathology is available. Alternatively, if pelvic nodal metastases are proven before lymphadenectomy (based on clinical findings), consideration should be given to neoadjuvant chemotherapeutic strategies followed by surgery or clinical trial enrollment (Leijte et al., 2007; National Comprehensive Cancer Network [NCCN], 2018; Pagliaro et al., 2010).

Key Points: Treatment of the Inguinal Nodes

- The presence and extent of inguinal metastases determine survival in penile cancer.

- Patients with persistent palpable inguinal adenopathy should undergo an ultrasound or CT-guided inguinal biopsy followed by management appropriate for the clinical scenario.
- On the basis of the histologic features of the primary tumor, the risk of lymph node metastases can be assessed in patients with no palpable adenopathy based upon the TNM staging system. DSNB, superficial ILND, or close follow-up can be recommended based on TNM stage and other histologic features.
- Factors associated with a high cure rate in surgically treated patients include no more than two inguinal metastases, unilateral involvement, no ENE of cancer, and the absence of pelvic metastases. Patients with higher volumes of disease should be considered for adjuvant or neoadjuvant therapy.
- Morbidity of lymphadenectomy is decreasing in contemporary series.
- Superficial ILND reliably determines the presence of microscopic inguinal metastases without the need for specialized facilities but can have significant morbidity.
- Modified DSNB techniques to determine microscopic inguinal disease exhibit low morbidity, have been validated externally in higher-volume centers, and are now a recommended procedure in such centers.
- Laparoscopic and robotic ILND obtains lymph node yields that are comparable with those of open techniques when used in selected patients and are an appropriate staging procedure in clinically lymph node negative patients. Additional studies with larger patient numbers and longer follow-up are required before routine adoption into clinical practice among patients with clinically positive inguinal lymph nodes.
- PLND is now recommended when more than one inguinal lymph node exhibits metastasis or when ENE of cancer is present.

Risk-Based Management of the Inguinal Region

A contemporary schema for management of the inguinal region is presented in Fig. 79.4. Assumptions for these guidelines are that the primary tumor has been adequately controlled, the pathologic stage of the primary tumor is available, and an inguinal examination has been performed. CT of the abdomen and pelvis as well as chest radiography or other imaging studies should also be performed as clinically indicated.

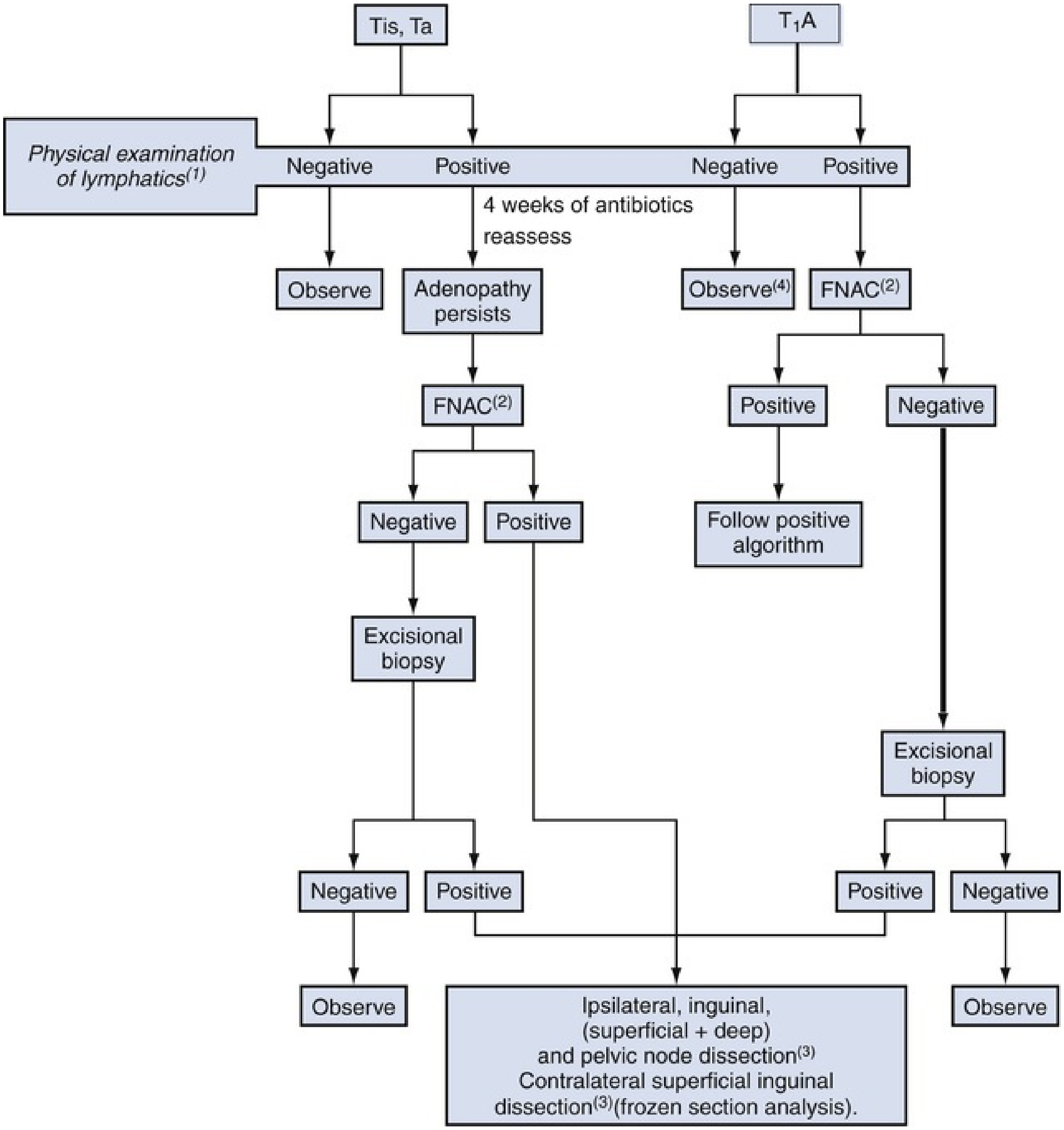
Tis, Ta
T1A
Physical examination of lymphatics(1)
Negative
Positive
Negative
Positive
4 weeks of antibiotics reassess
Observe
Adenopathy persists
Observe(4)
FNAC(2)
Positive
Negative
FNAC(2)
Negative
Positive
Follow positive algorithm
Excisional biopsy
Excisional biopsy
Negative
Positive
Positive
Negative
Observe
Ipsilateral, inguinal, (superficial + deep) and pelvic node dissection(3) Contralateral superficial inguinal dissection(3)(frozen section analysis).
Observe

A

1) Includes physical examination and/or imaging studies.
2) Fine-needle aspiration cytology.
3) If 2 or more positive ipsilateral inguinal nodes or extranodal extension found.
4) Alternative DSNB at experienced centers, superficial dissection if noncompliant patient.

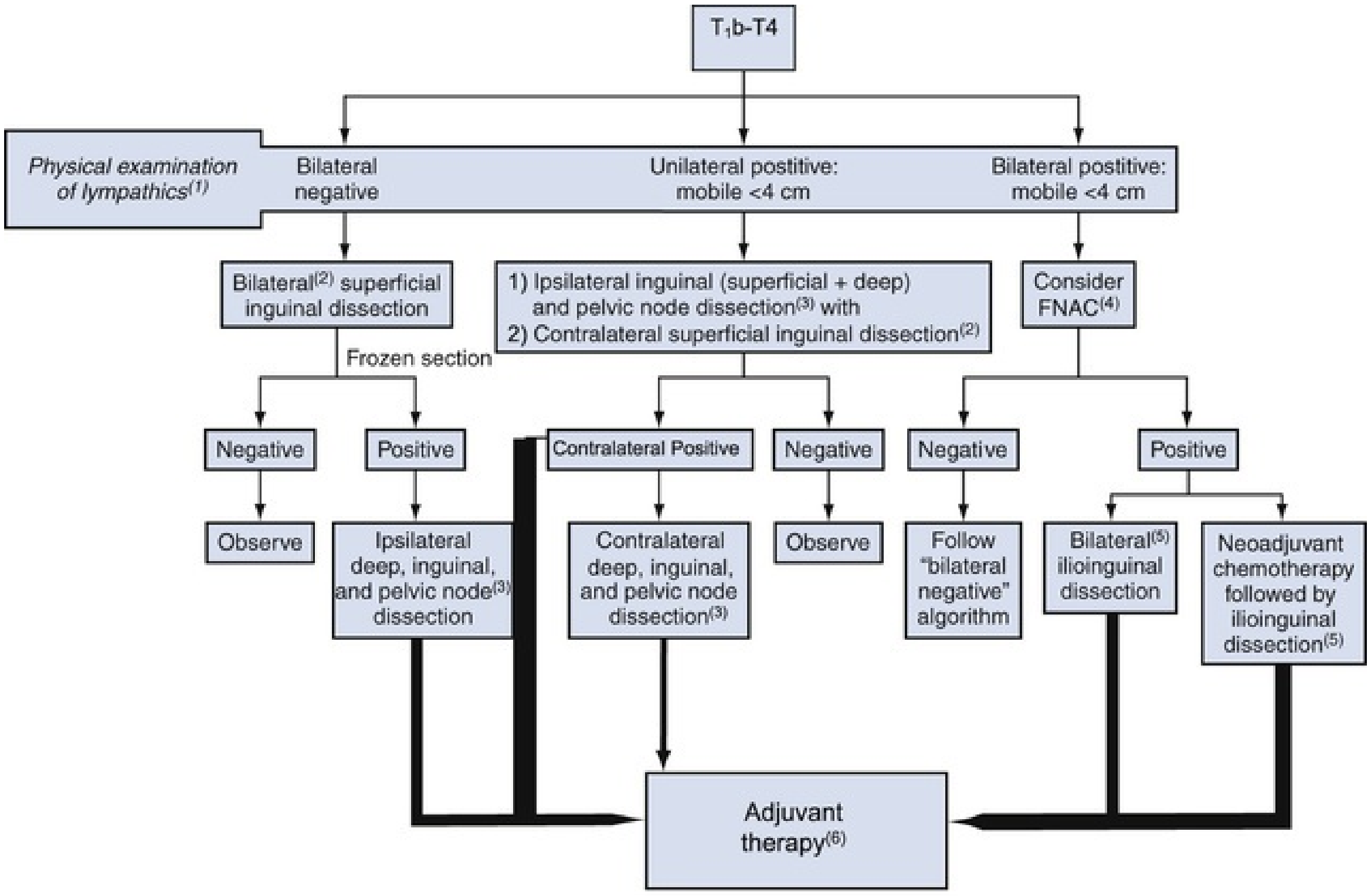
T1b-T4
Physical examination of lympathics(1)
Bilateral negative
Unilateral postitive: mobile <4 cm
Bilateral postitive: mobile <4 cm
Bilateral(2) superficial inguinal dissection
Frozen section
1) Ipsilateral inguinal (superficial + deep) and pelvic node dissection(3) with
2) Contralateral superficial inguinal dissection(2)
Consider FNAC(4)
Negative
Positive
Contralateral Positive
Negative
Negative
Positive
Observe
Ipsilateral deep, inguinal, and pelvic node(3) dissection
Contralateral deep, inguinal, and pelvic node dissection(3)
Observe
Follow "bilateral negative" algorithm
Bilateral(5) ilioinguinal dissection
Neoadjuvant chemotherapy followed by ilioinguinal dissection(5)
Adjuvant therapy(6)

B

1) Includes physical examination and/or imaging studies.
2) Complete modified dissection and dynamic sentinel node biopsy (DSNB, experienced centers) acceptable.
3) If >2 positive inguinal nodes or extranodal extension of cancer.
4) Fine-needle aspiration cytology.
5) Either approach is acceptable.
6) Consider if >2 positive lymph nodes, or bilateral metastases, extranodal extension of cancer or positive pelvic lymph nodes.

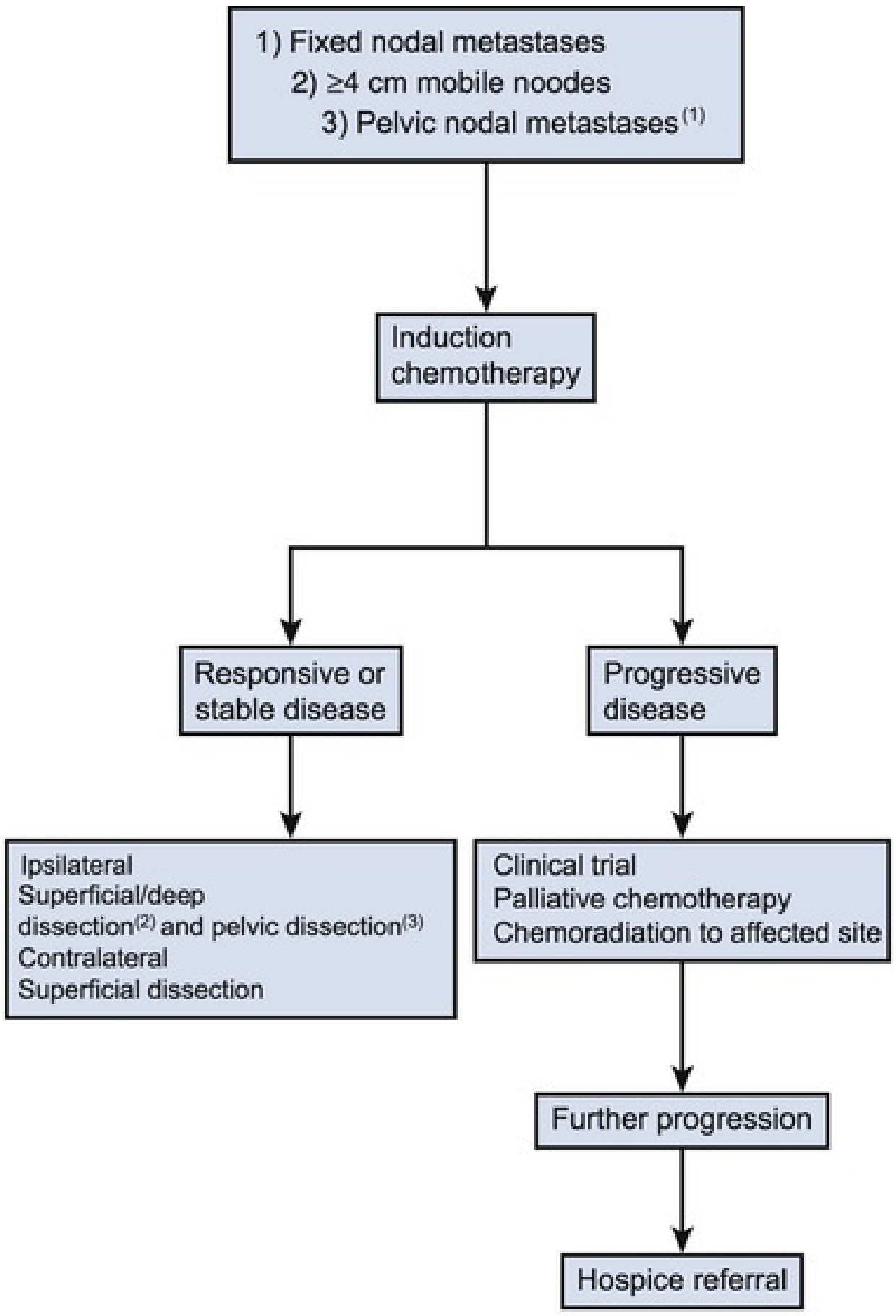
1) Fixed nodal metastases
2) ≥4 cm mobile noodes
3) Pelvic nodal metastases (1)
Induction chemotherapy
Responsive or stable disease
Progressive disease
Ipsilateral Superficial/deep dissection(2) and pelvic dissection(3) Contralateral Superficial dissection
Clinical trial
Palliative chemotherapy
Chemoradiation to affected site
Further progression
Hospice referral
C

(1) Subsequent to preoperative imaging studies.
(2) May require resection skin, fascia, or muscle.
(3) Postoperative adjuvant chemoradiation ≥ positive inguinal nodes, bilateral positive comma nodes or pelvic nodes.

FIG. 79.4 Management of regional disease. (A) Very low risk (left side) and low-intermediate risk (right side). (B) High-risk and lower-volume metastatic patients. (C) Bulky metastatic and distant disease.

Very Low-Risk Patients

Because the incidence of inguinal metastasis is anecdotal at best for patients with stage Tis or Ta primary tumors, observation is reasonable for those patients with normal inguinal examination findings (see Fig. 79.4A, *left*). For patients with palpable adenopathy, a course of antibiotics should reveal those whose adenopathy is related to infection versus metastasis. A persistently palpable node should undergo fine-needle aspiration cytology; if the result is negative, an excisional biopsy is recommended. If the biopsy finding is abnormal, ipsilateral inguinal dissection with contralateral superficial or modified complete dissection is performed. DSNB is an option in experienced centers.

Low- to Intermediate-Risk Patients (American Joint Committee on Cancer Stage T1a)

Several earlier series have combined patients with stage T1 grade 1 and grade 2 tumors and have found them to exhibit less than a 10% incidence of inguinal metastasis (see Fig. 79.4A, *right*; see also Table 79.10). However, the incidence of metastasis among strictly T1 grade 2 tumors (25% to 44%) may be higher, and variable recommendations have been made. The recent EAU guidelines recommend inguinal staging for T1 grade 2 tumors (also stage T1a) among patients with clinically negative lymph nodes (Hakenberg et al., 2015). However, observation is also an option for compliant patients in this setting (ICUD penile cancer guidelines found in Pompeo et al., 2009; NCCN penile cancer guidelines, 2018). Similar patients with palpable nodes on initial presentation should undergo fine-needle aspiration cytology. If the nodes are positive, the patients then undergo lymphadenectomy, as in Fig. 79.4A. If they are negative, then either excisional biopsy and/or planned lymphadenectomy are reasonable options.

High-Risk Patients (American Joint Committee on Cancer Stage T1b or Higher)

For the high-risk cohort, the incidence of inguinal metastasis ranges from 30% to approximately 70% (see Fig. 79.4B). According to the recent guidelines, there is consensus that patients with poorly differentiated tumors, lymphovascular or perineural invasion, or pT2 or greater tumors should undergo an inguinal staging procedure (Hakenberg et al., 2015; NCCN penile cancer guidelines, 2018). The surgical approach depicted in Fig. 79.4B is designed to maximize detection and treatment for those with proven nodal metastasis while limiting the morbidity of those with negative lymph nodes at surgery. Thus surgical staging is indicated even in those patients with clinically normal inguinal examination findings. **In this setting, antibiotic use minimizes the risk of inguinal wound infections or septic complications after control of an infected primary tumor, rather than influencing the decision for surgical staging.**

Patients with normal inguinal examination findings are offered bilateral superficial dissection, complete modified dissection, or DSNB (with the last offered in experienced centers). If frozen-section results reveal no metastasis, the procedure is concluded. For DSNB the results are based on permanent sections; thus further therapy is planned at a second setting if needed. If either side is positive, an ipsilateral inguinal dissection is performed. Pelvic dissection in the setting of a patient with no palpable adenopathy who is discovered to have positive inguinal metastasis at frozen section is optional and based on pathologic findings (Lont et al., 2007; Zhu et al., 2008). Patients with unilateral resectable adenopathy that is strongly suggestive of metastasis should undergo an ipsilateral ilioinguinal dissection and a contralateral superficial or complete modified dissection. Frozen-section analysis then determines if deep inguinal or pelvic nodes should be excised. DSNB is another option in managing the contralateral node-negative side. Palpable adenopathy of less than 4 cm was arbitrarily selected as a cutoff point for surgery as monotherapy because nodal metastases larger than 4 cm are associated with ENE of cancer (Ravi, 1993a).

For patients with bilateral palpable nodes that are strongly suggestive of metastasis, preoperative fine-needle aspiration cytology can be helpful for counseling of the patient as to the likelihood of the extent of surgery. For patients with negative results of fine-needle aspiration cytology, a staged surgical approach starting with superficial dissection is performed. Subsequent procedures in this setting depend on the results of frozen-section analysis. For patients requiring IILND because of metastases, adjuvant chemotherapy should be considered for those exhibiting more than two positive lymph nodes, ENE of cancer, or pelvic nodal metastasis (Hakenberg et al., 2015). An alternative approach to consider among patients with bilateral metastases is neoadjuvant chemotherapy followed by surgical resection as described by Pagliaro et al. (2010) and recently incorporated into the NCCN Penile Cancer Guidelines 2018.

Bulky Adenopathy and Fixed Nodal Metastasis

Survival in patients with bulky adenopathy and fixed nodal metastasis is related to complete eradication of extensive disease (see Fig. 79.4C). **This task is difficult to achieve with surgery, chemotherapy, or radiation therapy alone. The combination of surgery and chemotherapy has shown some benefit in advanced penile carcinoma** (Bermejo et al., 2007; Corral et al., 1998; Dickstein et al., 2016; Leijte et al., 2007; Pagliaro et al., 2010; Pizzocaro et al., 1997). The optimal integration and timing of such therapy are unknown. A reasonable approach in this cohort of patients is to use neoadjuvant chemotherapy followed by an aggressive surgical resection for patients demonstrating either response to therapy or stable disease. The neoadjuvant approach could improve surgical resectability and avoid obstacles in the administration of chemotherapy resulting from delays in postoperative healing.

The prognosis is poor in patients exhibiting progression while they are receiving chemotherapy. Palliative groin dissection is a consideration but rarely provides significant palliation (Leijte et al., 2007, Wang et al., 2015). Hemipelvectomy in patients without distant metastases was reported before the development of effective chemotherapy (Block et al., 1973) and is no longer used. Endoluminal vascular stents have also been reported to have transient success in preventing vascular erosion by tumor (Link et al., 2004). Clinical trials of novel systemic strategies and radiation therapy to affected areas provide the next level of care. With further progression, supportive care provided by hospice services can provide valuable support to patients with end-stage disease.

Radiation Therapy

Radiation Therapy for the Primary Lesion

Primary radiation therapy has curative potential and may permit preservation of penile form and function. If local control is not achieved, salvage surgery may still be curative, and therefore in a subset of men with penile cancer, initial radiation represents a reasonable treatment strategy. External-beam radiotherapy and interstitial brachytherapy can be used to treat the primary penile tumor. Before radiation therapy, circumcision is necessary to expose the lesion, to allow resolution of any surface infection, and to prevent preputial edema and subsequent phimosis. In many cases, circumcision may also significantly debulk the primary tumor.

External-Beam Radiotherapy

External-beam radiotherapy has several advantages. It is widely available, delivers a homogeneous dose, and does not require the same interventional technical skills required for delivery of effective brachytherapy. In a review, Crook et al. described contemporary dose- fractionation ranging from 60 Gy in 25 fractions over 5 weeks to 74 Gy in 37 fractions over 7.5 weeks (Crook et al., 2009). This contrasts with the lower doses of 50 to 55 Gy cited in older series (McLean et al., 1993; Neave et al., 1993). One of the challenges of external-beam radiotherapy is to position the penis consistently for treatment so that it is accessible by the radiation beam while not implicating adjacent normal tissues and structures. This can be achieved by positioning the patient supine on the treatment couch and encasing the penis in a vertical position in a block of wax or Perspex with a central cylindric chamber. The block is bivalved for ease of application and air gaps should be minimal. If penile edema develops during treatment, a larger chamber size may have to be selected. The second consideration involves the physical nature of megavoltage radiation beams, which relatively spare the skin surface and deliver the prescribed radiation dose at a depth in tissue. Penile cancer is of cutaneous origin and requires full treatment of the skin surface. Wax and Perspex are tissue-equivalent materials, so the choice of these in fabricating an immobilization device effectively boluses the penis and brings the full dose to the skin surface.

Table 79.13 is adapted from Crook et al. (2009) and describes the efficacy of external-beam radiotherapy and interstitial brachytherapy with respect to local control, cause-specific survival, complications, and penile preservation. The data represent retrospective reviews of single institution series collected over many years, during which time staging systems and treatment techniques evolved. The data often represent a range of doses and fractionation schemes, which permits only limited conclusions regarding optimal dose and fractionation. **Five-year local control rates among patients treated using a variety of techniques ranged from 55% to 70% with penile preservation rates of 39% to 66%. Thus primary external-beam radiotherapy affords at least a 50% chance to control the primary tumor and avoid penile amputation.** Furthermore, surgical salvage, when necessary, can be achieved in most cases by partial or total amputation. Cause-specific survival ranged from 58% to 96% depending on primary tumor stage and lymph node status.

TABLE 79.13

Selected Series of Studies Reporting Local Control (LC) of Disease, Cancer-Specific Survival (CSS), Complications, and Penile Preservation for Men Treated With External-Beam Radiation Therapy (Xrt) or Brachytherapy (BT) as Primary Treatment for Penile Cancer

STUDY	#	TYPE	DOSE Gy/fr	F/U (mo)	LC 5y	CSS 5y	COMPLICATION
EXTERNAL BEAM							
McLean et al., 1993	26	XRT	35/10–60/25	116 (84–168)	62%	69%	7/26 unspecified
Neave et al., 1993	20	XRT	50–55	36 mo min	70%	58%	10% stenosis
Sarin et al., 1997	59	XRT	60/30	62 (2–264)	55%	66%	3% necrosis 15% stenosis
Gotsadze et al., 2000	155	XRT	40–60	40	65%	86%	1 necrosis 5 stenoses
Zouhair et al., 2001	23	XRT	45–74 @ 1.8–2 Gy	70	57%	—	10% stenosis
Ozsahin et al., 2006	33	XRT/BT	52	62 (2–454)	44%	—	10% stenosis
Azrif et	41	XRT	50–52 /16	54	62%	96%	8% necrosis

al., 2006							29% stenosis
Mistry et al., 2007	18	XRT	55/16–50/20	62	63%	75%	2 necroses 1 stenosis
BRACHYTHERAPY							
Mazeron et al., 1984	50	BT: LDR	60–70	(36–96)	78% crude		3 necroses 19% stenosis
Delannes et al., 1992	51	BT: LDR	50–65	65 (12–144)	86% crude	85%	23% necrosis 45% stenosis
Rozan et al., 1995	184	BT: LDR	63	139	85%	88%	21% necrosis 30% stenosis
Soria et al., 1997	102	BT: LDR	61–70	111	77%	72%	
Chaudhary et al., 1999	23	BT: LDR	50	21 (4–117)	70% (8 years)		0 necrosis 9% stenosis
Kiltie et al., 2000	31	BT: LDR	63.5	61.5	81%	85%	8 necroses 44% stenosis
Crook et al., 2009	67	BT: LDR	60	48 (4–194)	88%	84%	12% necrosis 9% stenosis
de Crevoisier et al., 2009	144	BT: LDR	65	68(6–348)	80% 10-yr	92% 10-yr	26% necroses 29% stenoses
Pimenta et al., 2015	25	BT: LDR	60–65	110 (0–228)	1@ 4 mo	91%	8% necroses 43% stenoses
Kamsu-Kom et al., 2015	27	BT: PDR	60–70	33(6–64)	88% 3-yr	NS	9% necroses 22% stenoses
Seibold et al., 2016	13	BT:PDR		54(13–155)	88%	78%	30% necroses 15% stenoses
Petera et al., 2011	10	BT: HDR	3 Gy bid 42–45	20	100%	100%	0 necrosis 0 stenosis
Sharma et al., 2014	14	BT: HDR	3 Gy bid 51	22 (6–40)	12/14	83% 3-yr	0 necrosis 0 stenosis
Rouscoff et al., 2014	12	BT: HDR	4–4.3 bid 36–39	27(5–83)	11/12	100%	1 necrosis 1 stenosis

Kellas-Sleczka, et al., 2015	55	BT: HDR	3–3.5 bid 30-54	55(8–154)	73%	NS	0 necrosis 0 stenosis

bid, Twice daily; *F/U,* follow-up; *HDR,* high-dose rate; *LDR,* low-dose rate; PDR, pulse-dose rate; *RT,* radiation therapy.

Prognostic factors for improved local control among patients treated with external-beam radiotherapy include dose above 60 Gy, treatment time not exceeding 45 days, and daily fraction size of 2 Gy. Lower control rates are seen with stage T3 tumors, those more than 4 cm in diameter, and high-grade lesions (Crook et al., 2009; Gotsadze et al., 2000; Sarin et al., 1997). This suggests that the minimum tumor dose should be at least 66 Gy in 2-Gy fractions over a period of 6.5 weeks (45 days). Hypofractionated courses (fraction size >2 Gy) may be associated with increased toxicity.

External beam radiotherapy is most frequently considered in patients who are not surgical candidates by virtue of age or comorbidities, or those presenting with locoregionally advanced disease in which the primary region would be treated in contiguity with the nodal regions, including both groins and the pelvis.

Brachytherapy

Interstitial brachytherapy using the isotope iridium-192 is as an alternative to external-beam radiotherapy. Penile brachytherapy involves a temporary implantation of interstitial needles in a parallel array through and around the tumor (Video 79.2▶). These can then be either manually loaded with iridium-192 wire or seeds to deliver a classic low-dose rate (LDR; 50–60 cGy/h) treatment or connected to an automated afterloader with a high-activity iridium-192 source for pulse dose rate (PDR) brachytherapy. This delivers an hourly pulse equivalent to the hourly dose rate of LDR brachytherapy. High-dose rate (HDR) brachytherapy is evolving as an option because of the wider availability of HDR equipment and increased convenience.

Low-Dose Rate Brachytherapy.

Gerbaulet and Lambin reported successful local control in 82% of 109 patients, with long-term survival rates of 75% to 80% in those with tumor-free regional lymph nodes (Gerbaulet and Lambin, 1992). Rozan et al. (1995) reviewed 184 patients from multiple centers, with 5- and 10-year disease-free survival rates of 78% and 67%, respectively. Although 22% of patients required a prior circumcision or local excision, only 4% underwent total penectomy. The most frequent late side effects were soft tissue ulceration (22%) or meatal stenosis (30%). Factors predicting for late side effects were dose greater than 60 Gy, volume greater than 30 cc, and an implant with more than 2 planes of needles.

Crook et al. reported on 67 patients treated between 1989 and 2007 with iridium-192 delivered by 17- to 19.5-gauge steel needles held in a three-dimensional parallel array by predrilled acrylic plastic templates (Crook et al., 2009). In the early years of the experience, manually afterloaded iridium-192 wires were used but in later years PDR brachytherapy has been preferred because of advantages in radiation safety and protection with radiobiological equivalence to the traditional iridium-192 wires. A median of six needles (range 2–9) were arranged in 2 parallel planes and delivered a prescribed dose of 60 Gy over 4 to 5 days. With a median follow-up of 4 years (range 0.2 to 16.2), the 10-year actuarial cause-specific survival was 84%. Five- and 10-year penile preservation rates were 88% and 67% (Fig. 79.5). Of 8 local failures, 5 occurred before 2 years and 3 were late, observed at 42, 64, and 90 months. Penectomy was performed for these 8 recurrences as well as 2 necroses; partial penectomy was adequate for 8 patients, whereas 2 required a total penectomy because of insufficient penile length.

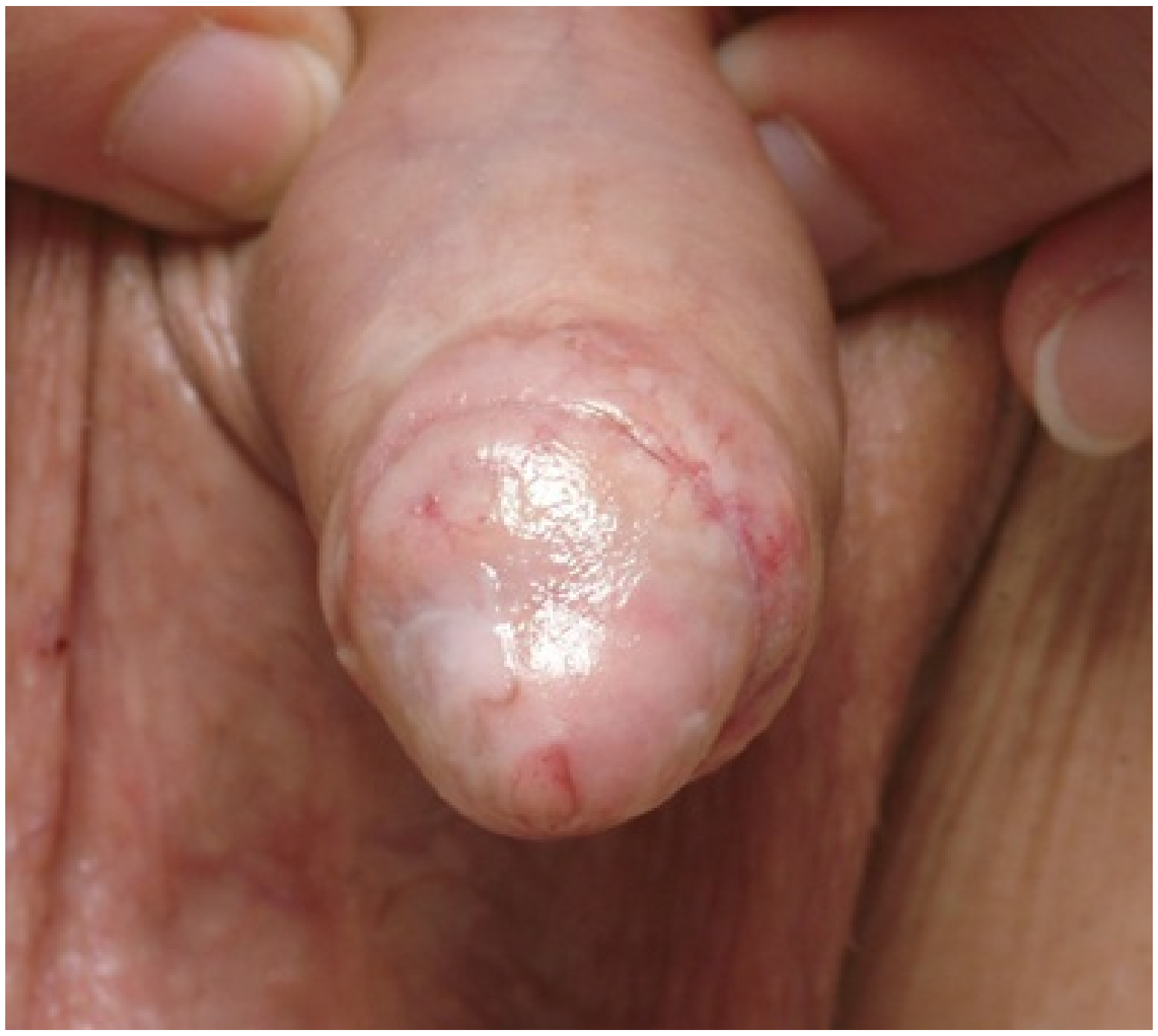

FIG. 79.5 Penile appearance 8 years after low-dose rate brachytherapy for T2N1 squamous cell carcinoma penis. Brachytherapy performed concurrently with inguinal node dissection. 60 Gy delivered over 5 days.

Hypopigmented scar at site of original tumor. Minor telangiectasia on glans.

Inguinal lymph node status remains an important prognostic factor, even when nonsurgical management of the primary tumor is being considered. Before 2002, prophylactic lymph node dissections were not part of the management algorithm (Crook et al., 2002). Crook et al. reported that 50% of moderately or poorly differentiated tumors treated with brachytherapy recurred regionally or distantly. Subsequently, inguinal lymph nodes have been managed with the same indications as for patients undergoing primary surgery (Hakenberg et al., 2015; NCCN Penile Cancer Guidelines, 2018). Biopsy information provides the required evidence on tumor grade and the presence of lymphovascular invasion.

Overall, in reviewing the literature, **local control** (see Table 79.13) **provided by interstitial brachytherapy appears superior to that provided by external-beam radiotherapy, with 5-year local control rates of 77% to 88%, and 70 to 80% at 10 years. Penile preservation rates are 74% to 88% at 5 years, and 67% to 70% at 8 to 10 years.** Crook et al. (2009) found that a predictor of local failure was needle spacing, with an increase in spacing (range 12 to 18 mm) resulting in decreased local recurrence because of the wider lateral margin achieved. With this consideration, larger tumor size did not predict for local recurrence, although others have reported an increase in local failure in tumors larger than 4 cm and with invasion of the corpora (Kiltie et al., 2000; Mazeron et al., 1984; Soria et al., 1997).

Brachytherapy: High-Dose Rate Interstitial.

Manually afterloaded sources such as iridium-192 wires are no longer widely available because of concerns around staff exposure and radiation safety. However, HDR brachytherapy is increasingly common for malignancies such as breast and prostate and is an essential component of curative treatment of cervical cancer. The technique of HDR brachytherapy for penile cancer is similar to that for LDR brachytherapy. Recent publications indicate that 3 Gy given twice daily, a minimum of 6 hours apart, appears safe and effective for total doses of 45 to 51 Gy delivered over 7½ to 8½ days (Petera et al., 2011; Sharma et al., 2014). Although long-term follow-up is still lacking, penile preservation rates are reported between 80% and 100%. The largest report with the most mature follow-up is from Kellas-Slezka et al. (2015), who describe 55 patients with a median follow-up of 4½ years. Treatments were 3.0 to 3.5 Gy twice daily to a median total dose of 49 Gy after biopsy or 36 Gy after previous total gross excision. At 5 years (8–152 months), 22% had local failure, 22% regional, and 5% distant. Penile preservation was achieved in 80%. Although promising, HDR brachytherapy for penile cancer must still be considered to be in evolution; optimal fractionation and homogeneity parameters are yet to be established (Crook et al., 2016; Rouscoff et al., 2014; Fig. 79.6).

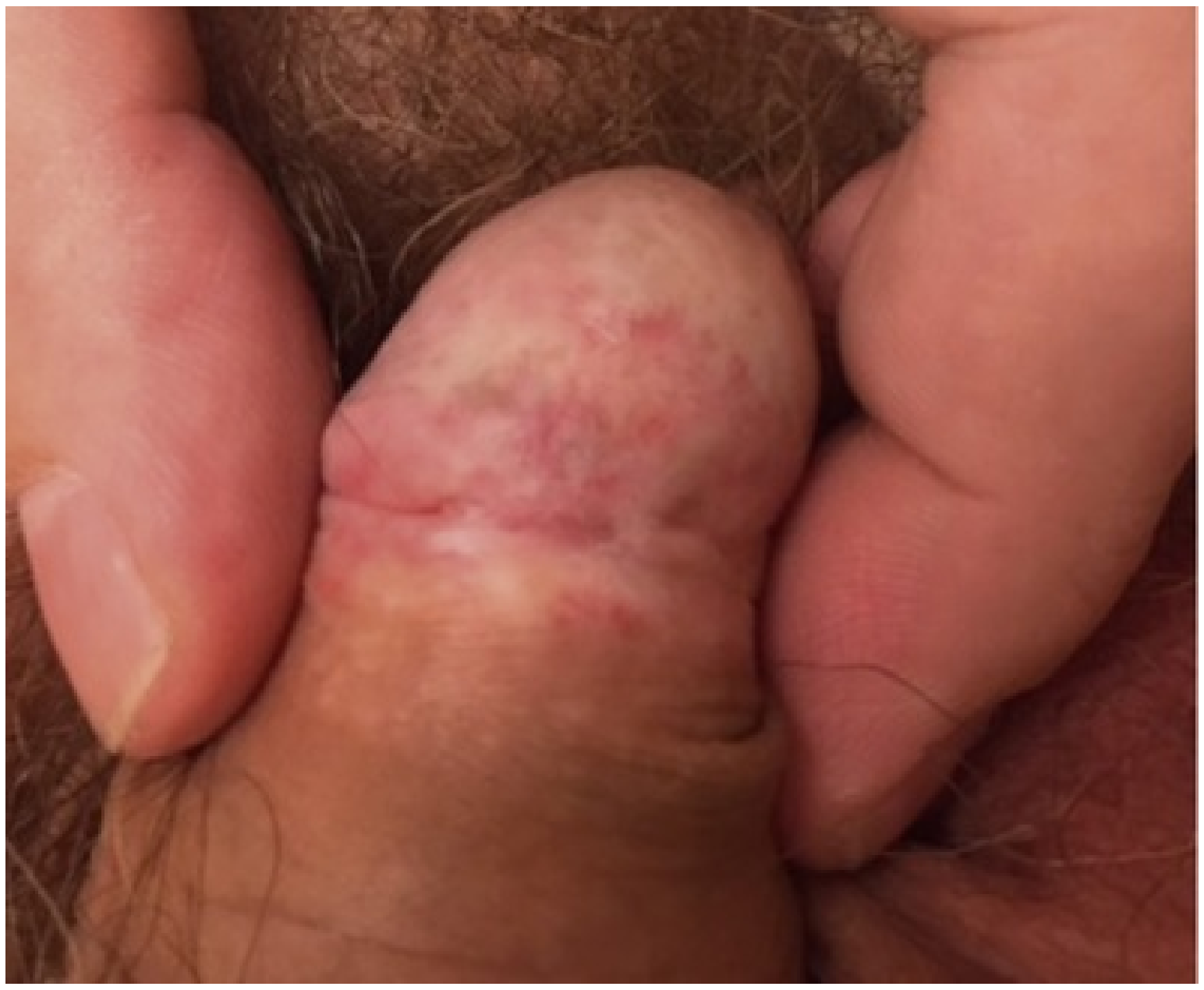

FIG. 79.6 Penile appearnce 5 years after high-dose rate penile brachytherapy, 38.4 Gy in twice daily fractions of 3.2 Gy for 6 days after circumcision and local excision of primary with positive margins (T1 well to moderately differentiated, 8-mm invasion).

Brachytherapy: Surface Mold

For noninvasive or very superficial tumors, a surface mold containing iridium-192 wires can be constructed. Originally reported in the LDR era, the plastic mold is worn in close apposition to the penile shaft for several hours per day for a period of 7 to 10 days for an adequate surface dose of 60 Gy with rapid fall-off at a depth (Akimoto et al., 1997; el-Demiry et al., 1984). Because the depth of tumor invasion can be difficult to ascertain by clinical examination or imaging, and because a dose margin (comparable with the required surgical margin) is advisable beyond visible disease, patients must be carefully selected.

The availability of HDR afterloading has renewed interest in surface mold plesiotherapy. Custom molds can be produced with 3D printing (Helou et al., 2015; Matys et al., 2011). The typical dose is 40 Gy over 5 days with two fractions of 4 Gy per day. The sources are embedded in the mold or applicator to maintain a distance from the skin surface and thus limit the skin dose to tolerable levels while still achieving an appropriate treatment depth. This may be especially suitable for recurrence after laser surgery or topical therapy. The reaction tends to peak at about 3 weeks and takes 6 to 10 weeks to heal (Fig. 79.7). There are no long-term results reported yet.

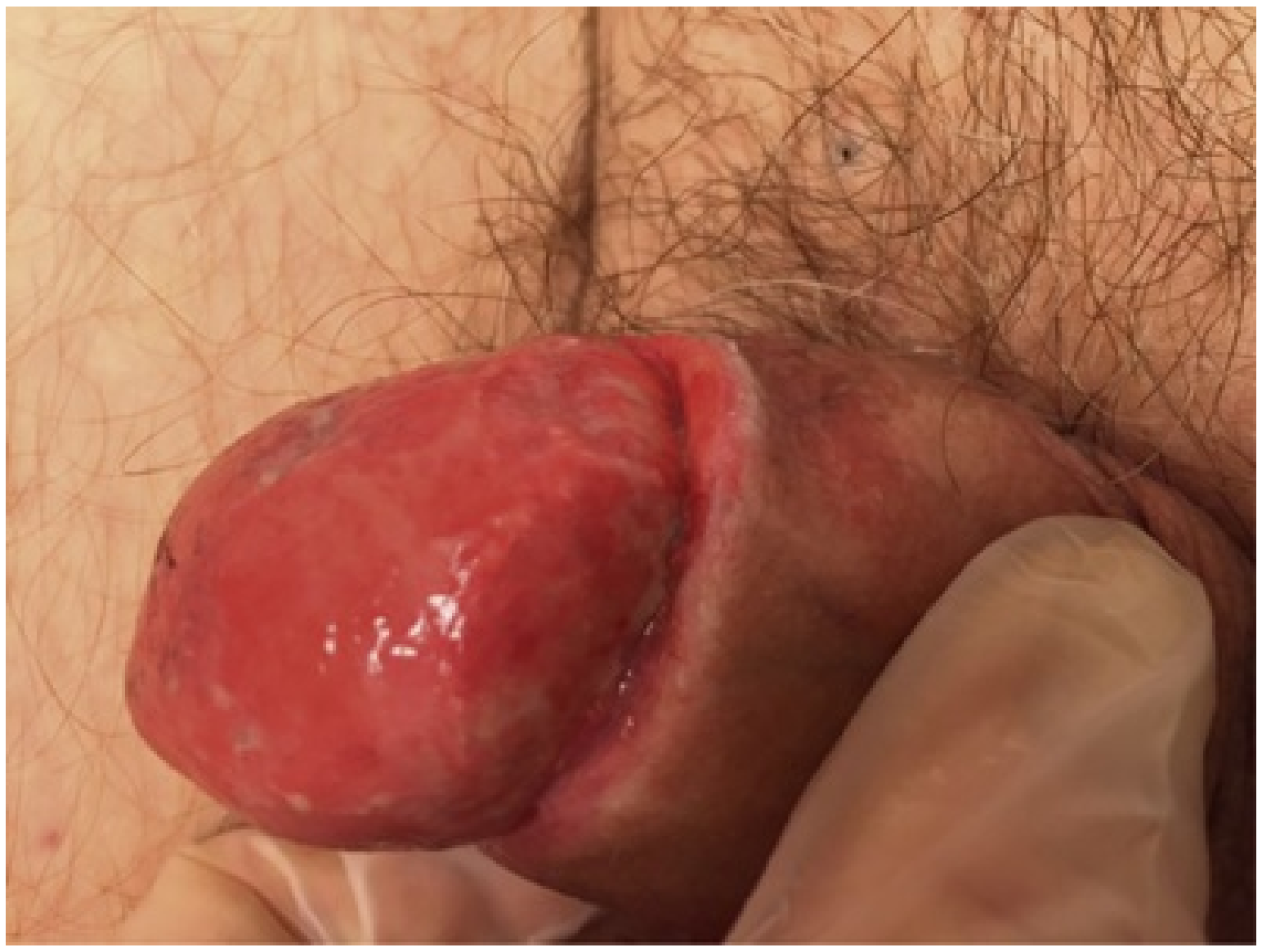

FIG. 79.7 Acute moist desquamation 3 weeks after high-dose rate surface mold brachytherapy for squamous cell carcinoma in situ. 40 Gy over 5 days in twice daily fractions of 4 Gy.

Adverse Effects Associated With Radiotherapy

Acutely, after radiotherapy or brachytherapy moist desquamation can be expected at the treated site. This will be more extensive after external-beam radiotherapy because of the larger treatment volume. Re-epithelialization occurs in 4 to 8 weeks. Saline soaks and hygiene are important. Intercourse can be resumed when the patient is comfortable, but the use of additional water-based lubrication is recommended.

The two most common late side effects associated with radiotherapy are meatal stenosis and soft-tissue ulceration. Soft-tissue ulceration overall is reported in 0 to 8% after external beam radiotherapy and 0 to 26% of after interstitial radiotherapy (see Table 79.13). Persistent ulceration may raise concerns about recurrent cancer. A biopsy may be indicated, but in general, ulceration is flat and superficial, with no raised or exophytic component. The majority will heal over several weeks with conservative management, but healing is slower in patients with diabetes and in those cases that were originally more deeply invasive. Close follow-up and treatment with antibiotics, vitamin E, and steroid creams are recommended. For cases resistant to these measures, hyperbaric oxygen is often effective (Crook et al., 2009; Gomez-Iturriaga et al., 2011).

Meatal stenosis is reported in 10% to 45% of patients and may be related to increased dose per fraction in those treated with external-beam radiotherapy or closer needle spacing and proximity to the meatus after brachytherapy. Meatal stenosis occurs later in follow-up (18 to 24 months) and may be preceded by reports of a weak, deviated, or divided urinary stream. Self-dilatation with a meatal dilator will improve the urinary stream and help to prevent subsequent unyielding fibrotic stenosis. Otherwise, urethral stricture may develop and require a more formal dilation or, in very rare cases, urethroplasty.

The benefits of avoiding a mutilating surgical procedure are clear; penile-sparing options are encouraged whenever appropriate. The side effects of radiation on sexual quality of life would appear modest. Delaunay et al. (2013) approached 21 French patients treated with penile brachytherapy between 1992 and 2009. The response rate to a validated questionnaire was more than 90%. At a median follow-up of 80 months, sexual function was maintained in 59% of those sexually active before brachytherapy. The age of the patient and his partner determined frequency of intercourse. Erections were maintained in 17 of 18 men potent before brachytherapy, although 52% noticed some change in glans sensitivity. A report from Gustave Roussy Institute assessed 39 men with a minimum of 3-year follow-up after brachytherapy (Gambachidze et al., 2017). The response rate to the survey was 60%, median age 63, and median follow-up 5.9 years. Seventy percent maintained sexual activity and erectile dysfunction was mild.

Because brachytherapy irradiates much less of the penile shaft, erectile function is more likely to be preserved than after external-beam radiotherapy. However, for the elderly in whom sexual function is not an issue, partial penectomy may be acceptable, offering a prompt treatment with more rapid healing, conducive to less limitation of activity in the postoperative period.

The organ-sparing benefits of radiation can be compared with surgical choices such as laser therapy, Mohs micrographic surgery, and reconstructive surgery, all of which can provide organ-sparing while minimizing functional loss. This emphasizes the need for multidisciplinary assessment and referral to tertiary-care centers where all options are available. Radiation may be the only solution for a patient with significant comorbidities who is not a surgical candidate.

Finally, as with any organ-sparing approach, extended follow-up is essential and should be emphasized at the time of the original treatment decision. Teaching self-examination and prompt reporting of concerns is also important. Local recurrence can be salvaged surgically without jeopardizing survival. Long-term follow-up is essential because recurrences may be delayed, with up to 1 in 5 local recurrences occurring after 5 years (Crook et al., 2009; Mazeron et al., 1984). Because brachytherapy is a more focal treatment than external beam radiotherapy, salvage options are more likely to result in a partial rather than a total penectomy.

In summary, T1 and T2 tumors smaller than 4 cm with no or minimal extension beyond the coronal sulcus are appropriate for radiotherapy, and with careful planning, complications can be minimized (de Crevoisier et al., 2009). Brachytherapy can provide better local control and penile preservation with faster dose delivery (4 to 5 days rather than 6 to 7 weeks) compared with external beam radiotherapy. For the patient who is an appropriate candidate for a radiation-based approach, the selection of external beam versus brachytherapy may depend on the skill and experience of the radiation oncology team.

The treatment of locally advanced disease is clearly associated with a higher metastatic rate, and the treatment approach must encompass regional nodes. For a locally advanced penile tumor, brachytherapy is not an option. Combined chemoradiotherapy with weekly cisplatin as a radiation sensitizer is standard management in vulvar and cervical squamous carcinoma and is associated with excellent response rates. Chemoradiation may convert a patient with inoperable disease into a surgical candidate or, alternatively, may be used as definitive management, as in cervical cancer (Rose, 2002). Neoadjuvant chemoradiotherapy is being studied in a cooperative international trial, InPACT (International Penile Advanced Cancer Trial) run through ECOG-ACRIN (EA8134; NCT02305654), for patients with clinically positive groin nodes.

Radiation Therapy for the Inguinal Areas

The presence and extent of lymph node involvement is such a key prognostic factor in the management of penile cancer that surgical evaluation of the inguinal regions is recommended for patients selected as per the EAU and NCCN penile cancer guidelines (Hakenberg et al., 2015; NCCN, 2018). Surgical evaluation of high-risk, clinically node-negative patients is recommended so that additional treatment can be tailored to the actual pathology, rather than offering "prophylactic" radiation to the inguinal nodes. A surgical approach to resectable adenopathy is also preferable to obtain the prognostic information of number of involved nodes and presence of extranodal disease. For high-risk groin pathology, consideration should be given to a prophylactic pelvic nodal dissection. InPACT (EA 8134; NCT02305654) will randomize such patients between pelvic node dissection and pelvic chemoradiotherapy.

Preoperative radiation for lymph node metastases from penile cancer has been reported to reduce the incidence of ENE compared with surgery alone (8% vs. 33%; $P < 0.01$) and is associated with a decrease in subsequent groin recurrence (3% vs. 19% $P < 0.03$) in a small series of 33 patients (Ravi, 1993; Ravi et al., 1994). This is consistent with the benefit of radiotherapy used together with surgery or chemotherapy in other squamous malignancies such as vulvar, cervical, or anal carcinomas (Bartelink et al., 1997; Montana et al., 2000; Stehman et al., 2007). Furthermore, there are case reports of remarkable efficacy of chemoradiation for inoperable nodal disease in advanced penile cancer cases (Chhabra et al., 2014; Lapierre et al., 2017; Fig. 79.8A-C). The sequencing of surgery, neoadjuvant chemotherapy and chemoradiation, and the benefits of neoadjuvant treatment, are being investigated for node-positive penile cancer in InPACT (EA 8134; NCT02305654). Four hundred patients with node-positive penile squamous cell cancer will be randomized in the United Kingdom and North America over the next 5 years (http://ecog-acrin.org/clinical-trials/ea8134-educational-materials).

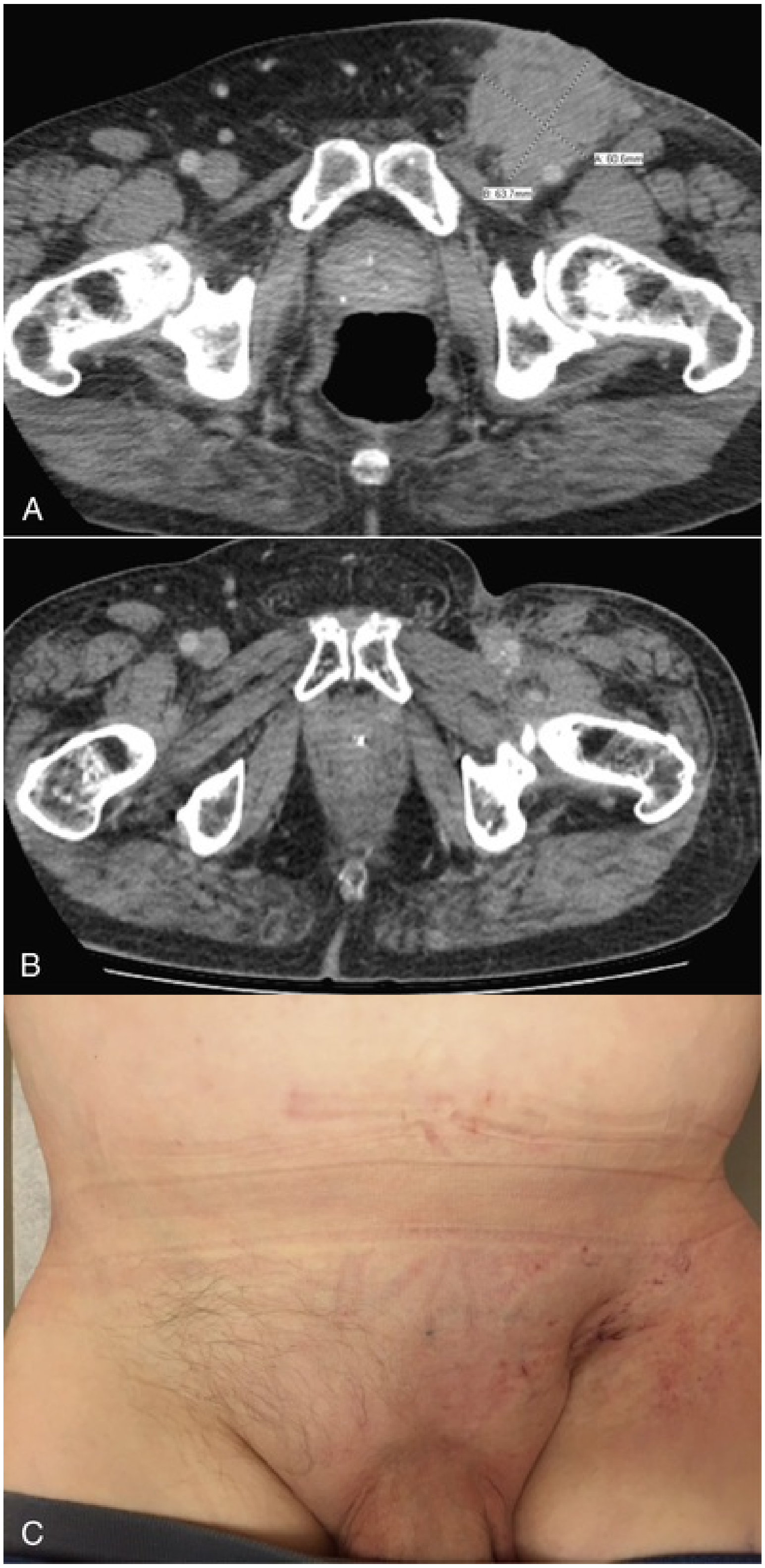

FIG. 79.8 (A) A 70-year-old patient presented with inoperable left inguinal adenopathy from squamous cell carcinoma penis. Treated with concurrent weekly cisplatin chemotherapy (40 mg/m^2) and volumetric modulated arc therapy radiotherapy 45 Gy/25 fractions to pelvic nodes and 63 Gy/35

fractions to left groin. PET-CT clear 4 months post-treatment. (B) CT scan 2 years after treatment. (C) Appearance of groin 2 years post-treatment. No leg edema.

Palliative radiation ameliorates symptoms in a significant proportion of patients with painful bony metastases, or spinal cord compression, but a standard short course of 5 to 10 fractions is not highly effective for bulky or fixed groin nodes. Although these patients may be elderly and frail, consideration should be given to combined platinum and radiotherapy provided kidney function is adequate with a GFR exceeding 50 mL/min.

Adjuvant radiation has an important role to play for surgically treated pN+ patients. In a review of the National Cancer Data Base from 1998 to 2012, Winters et al. (2017) found 589 patients who underwent inguinal lymph node dissection for stage III penile cancer. The use of adjuvant radiotherapy improved overall survival (HR 0.58, 95% CI 0.39–0.86). Similarly, data were collected from 4 tertiary referral centers on patients undergoing lymph node dissection from 1980 to 2013 (Tang et al., 2017). Adjuvant pelvic radiation was received by 43% of patients after a positive pelvic node dissection. On multivariate analysis, those without adjuvant pelvic radiotherapy had worse overall survival (HR 1.7; 95% CI 1.01–2.9, $P = 0.04$) and disease-specific survival (HR 1.9; 95% CI 1.09–3.236; $P = 0.02$). Extrapolating from the published literature on vulvar cancer, adjuvant radiotherapy 4500 cGy in 25 fractions over 5 weeks to the ipsilateral groin should be considered for patients with two or more positive nodes and for those with ENE (Hyde et al., 2007). If the pelvic nodes are known to be clear, then the pelvis does not have to be included, but if pelvic node dissection has not been performed, then the radiation volume should extend to include the pelvis. As is the case in vulvar cancer (Lee et al., 2016), HPV-positive patients may derive greater benefit from radiotherapy or chemoradiation for locoregional control.

In summary, inguinal radiotherapy is not recommended as prophylaxis for patients at high risk for inguinal node metastases unless the patient is not a surgical candidate. It should, however, be considered as adjuvant treatment for those with multiple positive nodes or ENE. Chemoradiotherapy may render inoperable disease resectable or can be used definitively. Radiation as a part of a multimodal approach with chemotherapy and surgery among patients with advanced penile cancer is being evaluated in an international prospective randomized trial (InPACT: EA 8134; NCT02305654).

Key Points: Radiation Therapy

- Radiation provides an effective penile-preserving approach for T1-T2 squamous cell carcinomas smaller than 4 cm using either external-beam radiotherapy or brachytherapy.
- Because 20% of recurrences occur after 5 years, continued follow-up is required as salvage penectomy for persistent or recurrent disease may be curative.
- The criteria for surgical staging of inguinal lymph nodes are the same whether patients undergo primary radiation or primary surgical management.
- Unresectable lymph nodes may be rendered operable by neoadjuvant chemotherapy or chemoradiation.
- Integration of radiation, surgery, and chemotherapy in advanced disease is being investigated in a prospective international randomized trial (InPACT: EA 8134).
- Palliative radiotherapy may be beneficial for metastatic disease.

Chemotherapy

Active Single Agents, Combination Strategies, and Post-Chemotherapy Surgery

Advanced penile cancer presenting as either bulky or unresectable regional disease or visceral metastases at initial presentation or disease recurrence is highly lethal; it is incurable in most cases with either surgery or radiotherapy alone (Hegarty et al., 2006; Ornellas et al., 1994; Ravi et al., 1994). Experience with single-agent or multiagent chemotherapy in this setting is limited: there are few phase II clinical trials and no randomized clinical trials. Several regimens have produced clinically meaningful responses that have occasionally resulted in clearance of disease or facilitated surgical resection.

Single-Agent Chemotherapy

Gagliano et al. (1989) from the Southwest Oncology Group treated 26 patients with low-dose (50 mg/m^2) cisplatin and observed responses in 15% and a median overall survival of 4.7 months. In a study from Memorial Sloan-Kettering Cancer Center, 13 patients with extensive disease and either prior radiotherapy or chemotherapy were treated with cisplatin 70 to 120 mg/m^2 every 21 days. Three of 12 evaluable patients (25%) demonstrated responses (one complete and two partial; duration = 2–8 months) (Ahmed et al., 1984).

Initial favorable reports from Japan suggested that bleomycin appeared to be effective in the treatment of penile and scrotal cancer. Ichikawa et al. (1969; 1977) reported a 50% response in 24 previously untreated patients with squamous carcinoma of the penis. A similar report from Uganda documented partial or complete tumor regression in 45% of treated patients (Kyalwazi et al., 1974). A review of 90 patients from the world literature demonstrated similar responses (Eisenberger, 1992). In the study by Ahmed et al. (1984) 14 patients were evaluable for response to single-agent bleomycin. There was one complete response (CR), but the patient died from bleomycin pulmonary toxicity. There were also two partial responses (PRs), for an overall response rate (ORR) of 21%. The median response duration was only 3 months (range 2–4).

Methotrexate produced responses in 8 of 13 patients (61%) treated at Memorial Sloan-Kettering Cancer Center (Ahmed et al., 1984) with one CR.

However, median response duration even with the high response rate was 3 months (2–31 months), and one patient died from treatment-related sepsis. Methotrexate had been shown to be active in other reports (Garnick et al., 1979; Mills, 1972). Based on the Ahmed study in which cisplatin, bleomycin, and methotrexate were given sequentially, there did not appear to be any obvious cross-resistance to the three agents. Subsequently a three-drug trial using combination bleomycin, methotrexate, and cisplatin (BMP) was developed.

Combination Chemotherapy

The Southwest Oncology Group reported a phase II study using a modified regimen that reduced the total dose of BMP. Haas et al. (1999) enrolled 45 patients with locally advanced or metastatic penile cancer, including distant metastases. There were five complete and eight PRs among 40 evaluable patients (32.5% response rate). The median duration of response was 16 weeks with an overall survival of 28 weeks (Haas et al., 1999). Although the response rate appeared encouraging, it was still within the 95% confidence intervals previously reported for single agent cisplatin; moreover, there were 5 treatment-related deaths on the study (one from infection and four from pulmonary complications) (Ahmed et al., 1984; Gagliano et al., 1989; Haas et al., 1999). Thus this study failed to confirm the initial high response rate of single agent methotrexate, did not establish superiority of BMP to single agent cisplatin, and found that bleomycin pulmonary toxicity was significant (Haas et al., 1999).

Three additional trials, all employing cisplatin, reveal significant activity while omitting the bleomycin and methotrexate (Table 79.14). Theodore et al. (2008) reported the results of an EORTC phase II study (30992) in which 28 patients with locally advanced or metastatic disease (T3, T4, N1-N3, or M1) received combination cisplatin and irinotecan. Patients were treated in either the neoadjuvant setting for 4 cycles before surgery (T3, N1-N2) or up to 8 cycles (T4, N3, M1 disease). Toxicity was acceptable with no treatment-related deaths. Eight responses were noted (2 complete, 6 partial) for an objective response rate of 30.8% (80% CI 0.188–0.45). Three patients taken to surgery in the neoadjuvant setting were found to have no evidence of residual disease. The authors reported the trial as negative, however, as it was powered to show an ORR not less than 30% by confidence interval.

TABLE 79.14

Safety and Efficacy of Multidrug Penile Cancer Regimens Without Bleomycin

CHEMOTHERAPY		RESPONSE RATE	TREATMENT-RELATED DEATH	MEDIAN OVERALL SURVIVAL (mo)
Di Lorenzo et al., 2012[a]	Fluorouracil, 800–1000 mg/m^2/day, days 1–4 continuous infusion Cisplatin, 70–80 mg/m^2, day 1; cycle q3wk	32%	0/25	8
Pagliaro et al., 2010	Paclitaxel, 175 mg/m^2, day 1 Ifosfamide, 1200 mg/m^2, days 1–3 Cisplatin, 25 mg/m^2, days 1–3; cycle q3wk	50%	0/30	17.1[b]
Theodore et al., 2008	Irinotecan, 60 mg/m^2, days 1, 8, 15 Cisplatin, 80 mg/m^2, day 1; cycle q4wk	30.8%	0/28	4.7
Nicholson et al., 2013	Docetaxel, 75 mg/m^2, day 1 Cisplatin, 60 mg/m^2, day 1 Fluorouracil, 750 mg/m^2/day, days 1–5; cycle q3wk	38.5%	0/28	13.9

[a] Retrospective study.

[b] Neoadjuvant setting (N2-3, M0).

A phase II clinical trial of neoadjuvant paclitaxel, ifosfamide, and cisplatin (TIP) was conducted at the University of Texas MD Anderson Cancer Center (Pagliaro et al., 2010). Eligible patients exhibited clinical N2-N3 lymph node metastases, no evidence of distant metastases (M0), and no prior chemotherapy. Treatment consisted of 4 courses of TIP followed by bilateral inguinal lymph node dissections, unilateral or bilateral pelvic lymph node dissections, and surgical control of the primary tumor when appropriate. The ORR was 50% and the pathologic CR rate was 10%; 23 of 30 eligible patients completed 4 courses of TIP and 22 of those underwent surgery; 9 patients (30% for the trial, 40.9% of those completing treatment) were alive and disease free at a median follow-up of 34 months; 19 deaths occurred as a result of progressive disease and 2 from unrelated causes. Toxicity was acceptable and no treatment-related deaths occurred (Pagliaro et al., 2010). These data suggest that the TIP regimen has a response rate significantly higher than single-agent cisplatin and is better tolerated than older regimens containing bleomycin or methotrexate. Table 79.13 provides safety and efficacy of cisplatin-containing chemotherapy regimens reported.

A third prospective trial evaluated the combination of docetaxel, cisplatin, and 5-fluorouracil (TPF) in patients with locally advanced or metastatic penile cancer (Nicholson et al., 2013). The response rate was 38.5% (10 of 26 evaluable patients), and 65.5% of patients experienced at least a grade 3 or grade 4 event. The predetermined target response rate of 60% was not reached, and the authors concluded that similar results could be achieved with 5-FU/cisplatin and that the addition of docetaxel resulted in toxicity. By comparison, the objective response rate to 5-FU/cisplatin in one retrospective series was 32% (8 of 25 patients) (Di Lorenzo et al., 2012).

Data from the earlier-mentioned three prospective trials and one retrospective series suggest that patients with advanced, unresectable primary tumors or metastatic disease can benefit from cisplatin-based chemotherapy, and selected patients with bulky regional lymph node metastases appeared to benefit from post-chemotherapy lymphadenectomy. Negative pathology in lymph nodes was seen after neoadjuvant treatment with TIP (3/30 patients) and irinotecan/cisplatin (3/7 patients). For patients with initially unresectable primary tumors or bulky regional lymph node metastases, neoadjuvant treatment with a cisplatin-containing regimen may be effective and allow curative resection.

Adjuvant Chemotherapy

Historically, combination vincristine, bleomycin, and methotrexate therapy was administered in 12 weekly courses to 17 patients in the postoperative setting (12) or neoadjuvant setting (5) at the Milan National Tumor Institute. The patients treated were at high risk for recurrence with surgery alone; 9 showed extranodal tumor growth, 5 had pelvic nodal involvement, and 5 had bilateral metastases. At follow-up ranging between 18 and 102 months, only 1 relapse had occurred (Pizzocaro and Piva, 1988). Later, reports from this center further confirmed the value of adjuvant chemotherapy. Of 56 node-positive patients, 82% of the 25 patients receiving adjuvant vincristine, bleomycin, and methotrexate (VBM) therapy survived 5 years, compared with 37% of 31 patients treated with surgery alone (Pizzocaro et al., 1995, 1997). In the neoadjuvant treatment group, PRs were noted in 3 of 5 patients with extremely large (6 to 11 cm) nodal metastases. These 3 patients subsequently were completely resected and were free of tumor at intervals ranging from 20 to 72 months. These data have yet to be confirmed and will probably not be further studied given the potential toxicities of bleomycin and methotrexate. A recent contemporary study suggested a potential benefit for the use of adjuvant chemotherapy among penile cancer patients with proven pelvic nodal metastases postsurgery. Sharma et al. (2015) retrospectively studied a multi-institutional cohort of 84 patients (collected from 1978–2013) with pelvic nodal metastases who either did or did not receive adjuvant chemotherapy with published regimens including TIP, TPF (used in later years), and BMP or VBM (used in earlier years). A subset of patients also received adjuvant pelvic radiotherapy. A total of 36 patients received adjuvant chemotherapy (ACT). When compared with the 48 that did not, the ACT cohort was younger, had a lower likelihood of receiving groin or pelvic radiotherapy, were more likely to exhibit inguinal extranodal extension of cancer but had a lower incidence of bilateral metastases. ACT was significantly associated with an 11.6-month survival advantage (21.7 vs. 10.1 months, $P = 0.048$) and was independently associated with reduced all-cause mortality subsequent to multivariate analysis. Thus there is a positive signal that adjuvant chemotherapy may be beneficial at least in the subset of patients with pelvic nodal metastases postsurgery. However, this remains to be confirmed prospectively.

Post-Chemotherapy Surgical Consolidation

Corral et al. (1998) reported on the long-term follow-up of a prospective group of patients treated with BMP. Among the cohort, 21 patients had penile carcinoma with 10/21 (48%) having either N3 or M1 disease. The remainder had either N1 or N2 nodal metastases. Objective responses were noted in 12 patients (57%), and 6 patients in the group (28.5%) eventually achieved disease-free status after chemotherapy alone (2) or followed by surgery (3) or radiotherapy (1). The median survival for patients who were free of disease was 27.8 months and was significantly longer than that of those not achieving disease-free status (6.7 months, $P = 0.004$), suggesting that a multidisciplinary approach to achieve disease-free status could prolong survival. Subsequently Leijte et al. (2007) from the Netherlands Cancer Institute reviewed their experience with neoadjuvant chemotherapy in patients with initially “unresectable” penile cancer. The series included 20 patients treated with 5 different regimens, including (1) single-agent bleomycin, (2) bleomycin, vincristine, methotrexate, (3) cisplatin and 5-fluorouracil, (4) BMP, and (5) cisplatin and irinotecan. The objective responses were evaluable in 19 (one patient died as a result of bleomycin toxicity after 2 weeks) with 12 responses (63%, 2 complete, 10 partial). Surgical procedures included treatment of the primary tumor as well as inguinal and pelvic dissections. Additional soft-tissue resection including bone was sometimes required. Vascularized tissue flaps were used for inguinal reconstruction. Among 12 responders only 9 went to surgery; 2 died of bleomycin-related complications, and the third was deemed unfit for surgery. Eight of 9 responding patients taken to surgery (two were pT0) were free of disease with a median follow-up of 20.4 months. This is in contrast to 3 nonresponders who went to surgery for palliative intent. All 3 died within 4 to 8 months because of locoregional recurrence. The implications from this study were that a response to chemotherapy together with an aggressive surgical procedure provides the optimal scenario for significant palliation or potentially cure.

In a separate study, Bermejo et al. (2007) described the surgical considerations and complications among 10 patients who had either a response or stable disease after combination chemotherapy. The regimens used included (1) BMP, (2) TIP, or paclitaxel and carboplatin. This cohort of patients exhibited bulky inguinal or pelvic metastases before chemotherapy, with the only exclusions being patients with fixed pelvic masses or complete encasement of the femoral vessels. In addition to ilioinguinal lymphadenectomy, resection of the inguinal ligament, the inferior aspect of the rectus abdominis or external and internal oblique muscles, the spermatic cord and ipsilateral testicle, and segments of the femoral artery and vein (with subsequent patch or bypass grafting) were performed to achieve negative margins. Plastic surgery consultation was obtained for wound coverage, including the insertion of monofilament polypropylene mesh for abdominal wall defects and myocutaneous flaps of the sartorius, rectus abdominus, serratus anterior, and latissimus dorsi muscles. Among 5 patients with an objective response to preoperative chemotherapy, 3 were alive and disease free at 48, 50, and 73 months postoperative. Among the 5 patients with stable disease as their best response to chemotherapy, 4 were dead within 7 to 8 months. A single patient treated with paclitaxel and carboplatin achieving only stable disease was alive and disease free at 84 months. These data appear to reinforce the concept that response to preoperative chemotherapy enhances the chance for long-term survival among those undergoing surgical resection. All three pT0 responses at surgery were among patients treated with TIP. Finally, in the prospective phase II study of neoadjuvant TIP for patients with clinical N2-N3 nodal disease (Pagliaro et al., 2010), the patients with an objective response (CR or PR) to neoadjuvant TIP had significantly better overall survival ($P = 0.001$) and time to progression ($P < 0.001$) compared with those who did not. This experience was updated to include a total of 61 patients with 90% of patients receiving the TIP regimen (Dickstein et al., 2016). In all, 39 patients (65%) had either a partial or complete response to chemotherapy. The 5-year survival varied significantly ($P = 0.045$–0.001) among patients achieving a CR/PR (50%), stable disease (25%), and progression (7.7%). In all, 10 patients (16.4%) were rendered pN0 with combined therapy, and 20 patients (33%) were alive and disease free at a median follow-up of 67 months, whereas 32 (52%) died from disease. Long-term survival was associated with response to chemotherapy and favorable pathologic findings after resection.

Taken together these data provide evidence that response to chemotherapy improves resectability and survival. Surgery among patients who do not respond to chemotherapy may occasionally be associated with long-term survival but is more often associated with death resulting from either rapidly occurring locoregional recurrence or distant metastases (Bermejo et al., 2007; Dickstein et al., 2016; Leijte et al., 2007; Pagliaro et al., 2010).

Key Points: Chemotherapy

- Neoadjuvant chemotherapy with a cisplatin-containing regimen should be considered for patients with lymph node metastases, as responses in this setting may facilitate curative resection. In the absence of level 1 evidence, the optimal or standard multimodal strategy remains undefined.
- The use of bleomycin in the treatment of men with metastatic penile cancer was associated with an unacceptable level of toxicity and is discouraged.
- Surgical consolidation to achieve disease-free status or palliation should be considered in fit patients with a proven objective response to systemic chemotherapy.

- Among patients who progress through chemotherapy, surgery is not recommended.

Nonsquamous Penile Malignant Neoplasms

Nonsquamous penile malignant neoplasms are extremely rare. Pathologic descriptions and local and regional treatment options are available; however, outcomes and comparisons are limited to case reports and small retrospective series. Most reports establish the following features: (1) incidence of disease, (2) distinguishing pathologic features, (3) treatment recommendations, and (4) parallels (or lack thereof) to the same carcinoma in nongenital locations.

Basal Cell Carcinoma

Although basal cell carcinoma is frequently encountered on other sun-exposed cutaneous surfaces, it is rare on the penis (Fig. 79.9A). Fewer than 30 cases have been well documented (Goldminz et al., 1989; Ladocsi et al., 1998; Nguyen et al., 2006). The lesion can be seen anywhere on the penis but is commonly on the penile shaft. It is slow growing, and delay in diagnosis in one series ranged from 2 months to 50 years (Kim et al., 1994). **Treatment is by local excision, which is virtually always curative** (Goldminz et al., 1989; Hall et al., 1968). Only one case report describes what the authors believe to be the only reported case of metastatic penile basal cell carcinoma (Jones et al., 2000). Nguyen et al. (2006) reported two cases of basal cell carcinoma treated by Mohs surgery.

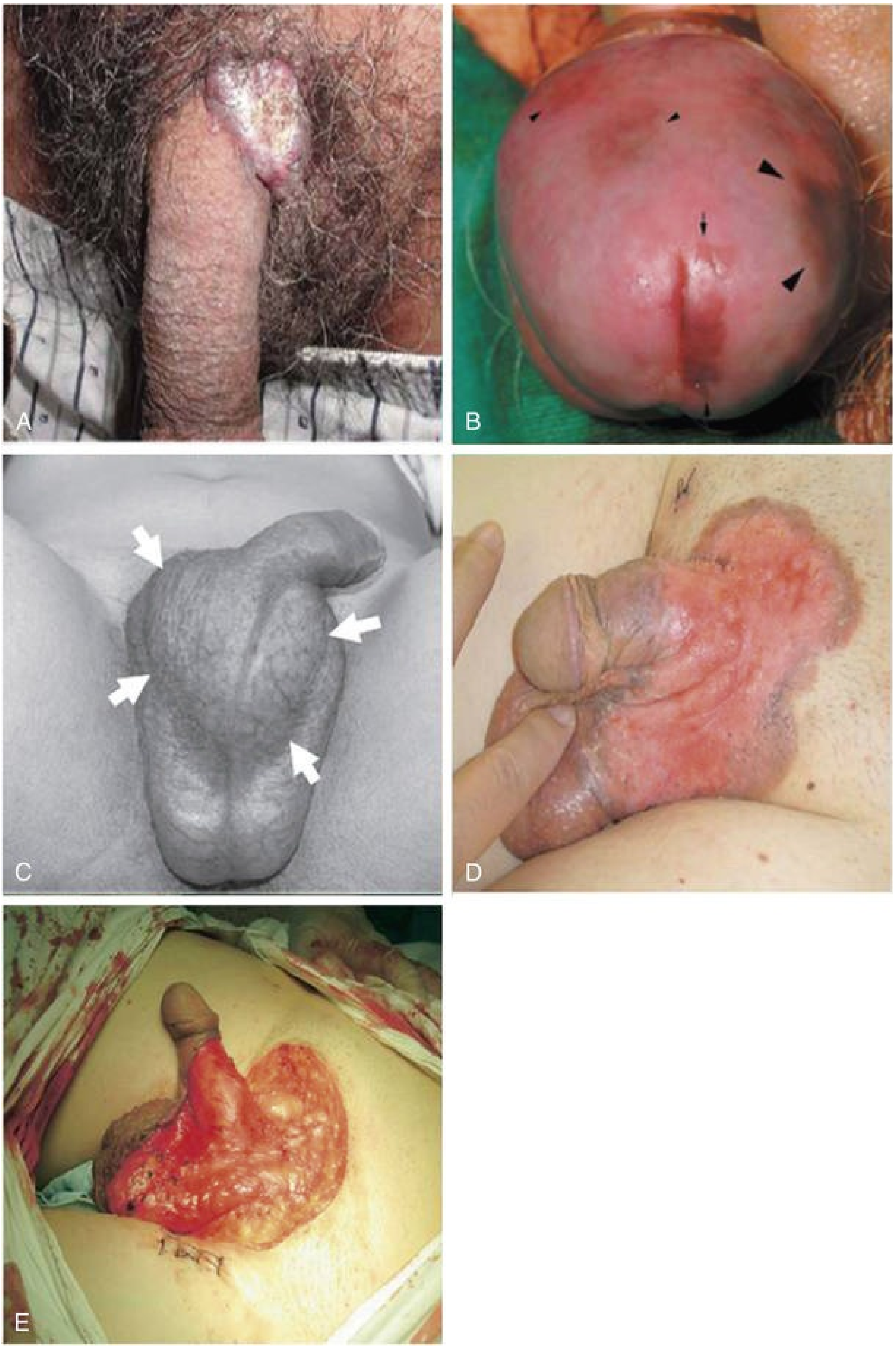
A
B
C
D
E

FIG. 79.9 Clinical examination findings from nonsquamous involving the penis. (A) Basal cell carcinoma. (B) Melanoma-superficial spreading type *(large arrowheads),* melanoma in situ *(arrow),* and two areas of possible melanosis *(small arrowheads).* (C) Leiomyosarcoma involving base of penis *(arrows).* (D) Paget disease involving penile, suprapubic, and left scrotal skin. (E) Surgical defect after Paget disease resection.

A benign variant of basal cell carcinoma, the premalignant fibroepithelioma of Pinkus, has been reported to occur on the penile shaft (Heymann et al., 1983). Diagnosis is made at excisional biopsy. Excision has been uniformly curative.

Melanoma and basal cell carcinoma rarely occur on the penis, presumably because the organ's skin is protected from exposure to the sun. Malignant neoplasms arising from the supporting structures of the penis are also rare and include any combination of tumors of smooth or striated muscle or of fibrous, fatty, or vascular tissue. Information about appropriate treatment of these malignant neoplasms is derived from the review of single case reports and small series (Belville and Cohen, 1992).

Melanoma

More than 150 cases of melanoma of the penis have been reported (Fig. 79.9B). Of 1200 melanomas treated at Memorial Sloan Kettering Cancer Center, only 2 were of penile origin (Das Gupta and Grabstald, 1965). At the University of Texas MD Anderson Cancer Center, less than 1% of all primary penile cancers were malignant melanomas (de Bree et al., 1997; Johnson and Ayala, 1973).

Melanoma manifests as a blue-black or reddish brown pigmented papule, plaque, or ulceration on the glans penis. It occurs on the prepuce less frequently. Diagnosis is made by histologic examination of biopsy specimens, which demonstrate atypical junctional cell activity with displacement of pigmented cells into the dermis.

Prognostic characteristics that have been found significant for melanoma in other sites, such as depth of invasion (Clark staging) and thickness of the tumor (Breslow classification), have not been prospectively applied to penile lesions because experience with these lesions is limited. Sanchez-Ortiz et al. (2005) used the AJCC system for classifying cutaneous melanomas in the largest report on melanoma of the penis. This system incorporates elements of the Clark and Breslow staging systems. When this information is favorable, local excision is feasible. Distant metastatic spread has been found in 60% of patients studied

(Abeshouse, 1958; de Bree et al., 1997; Johnson et al., 1973) in older series. However, Sanchez-Ortiz found that patients with early stage melanomas had excellent outcomes if primary tumors were of low stage and regional lymph nodes were negative. Hematogenous metastases occur by means of the vascular structures of the corporeal bodies; lymphatic spread to the regional inguinal and pelvic nodes occurs by lymphatic permeation.

Surgery is the primary mode of treatment; radiation therapy and chemotherapy are of only adjunctive or palliative benefit. For stage I melanoma (localized lesion without metastases) and stage II melanoma (metastases confined to one regional area), adequate excision of the primary tumor by partial or total penile amputation together with en bloc bilateral ilioinguinal node dissection has historically been advocated (Bracken and Diokno, 1974; Johnson et al., 1973; Manivel and Fraley, 1988). In reviewing the University of Texas MD Anderson Cancer Center experience plus the literature to date, Sanchez-Ortiz et al. (2005) proposed a treatment algorithm for management of the primary tumor and inguinal lymph nodes. For tumors of the foreskin, circumcision may be adequate. For glans tumors, a partial penectomy was recommended; and for glans-shaft tumors, a partial or total penectomy can be performed. The authors recommend bilateral modified inguinal lymph node dissections in all patients with lesions that are Breslow depth 1 mm or greater, with ulceration, or with Clark level IV or V involvement. Although dynamic sentinel lymph node biopsy techniques are increasingly used in more common sites of melanoma, their use in penile melanoma is unproven as yet. This is likely because of the rarity of the disease (Sanchez-Ortiz et al., 2006).

The prognosis for patients with penile melanoma clearly depends on stage of the primary tumor and the presence or absence of inguinal metastases. Contemporary staging and prognostic factors were reviewed by Sanchez-Ortiz et al. (2005). A report from the Netherlands (van Geel et al., 2007) focused on the concept of mucosal site penile melanomas—glans, meatus, fossa navicularis, and distal urethral. These lesions may appear more aggressive than cutaneous lesions, but greater delay in diagnosis may be a factor. In a pooled, retrospective analysis of 66 cases, the recurrence outcomes were similar for cutaneous melanomas of comparable tumor thickness. Among patients with recurrent or metastatic melanoma, effective immunotherapy based upon immune checkpoint blockade has revolutionized management. A recent study documented a 12-month recurrence-free survival of 70% among patients with resected advanced stage melanoma (stage IIIb-IV) when treated with adjuvant nivolumab (Weber et

al., 2017).

Sarcomas

Primary mesenchymal tumors of the penis are rare. A thorough review of 46 such tumors from the Armed Forces Institute of Pathology revealed an equal number of benign and malignant lesions (Dehner and Smith, 1970). The patients ranged in age from newborn to the eighth decade of life. The presenting signs and symptoms of subcutaneous mass, penile pain and enlargement, priapism, and urinary obstruction were the same for benign and malignant lesions. A sarcoma has been reported to masquerade as a Peyronie plaque (Moore et al., 1975).

Malignant lesions were found more frequently on the proximal shaft (Fig. 79.9C); **benign lesions were more often located distally. The most common malignant lesions were those of vascular origin (hemangioepithelioma), followed in frequency by those of neural, myogenic, and fibrous origin** (Ashley and Edwards, 1957). Single case reports of sarcomatous lesions have been published—for example, malignant fibrous histiocytoma (Parsons and Fox, 1988), angiosarcoma (Rasbridge and Parry, 1989), leiomyosarcoma (Planz et al., 1998), epithelioid sarcoma (Leviav et al., 1988), hemangioendothelioma (Kamat et al., 2004), and osteosarcoma (Sacker et al., 1994).

Sarcomas have been classified as superficial when they arise from the integumentary supporting structures and as deep when they develop from the corporeal body supporting structures (Pratt and Ross, 1969). Wide, local surface excision and partial penile amputation for the superficial tumors have been suggested and used successfully in isolated case reports (Dalkin and Zaontz, 1989; Pak et al., 1986). Total penile amputation has been reserved for tumors of deep corporeal origin. **However, local recurrences are characteristic of sarcomas** (Dehner and Smith, 1970). Fetsch et al. (2004), from the Armed Forces Institute of Pathology, have updated their series of 14 cases of leiomyosarcoma with review of the literature. They concluded that small lesions (smaller than 2 cm) were best managed with local resection, whereas deeper-seated tumor often necessitates partial or total amputation. Deep lesions at the base of the penis have the worst prognosis.

Regional metastases are rare. Unless adenopathy is palpable, node dissections are not recommended (Hutcheson et al., 1969). Distant metastases have also been unusual (Dehner and Smith, 1970). This supports aggressive local treatment in anticipation of cure. Radiation therapy and chemotherapy have not been used extensively enough for comment on their efficacy (Fetsch et al., 2004).

Extramammary Paget Disease

Extramammary Paget disease (EMPD) of the penis is rare; however, more recently several large series have been reported from China and Korea (Wang et al., 2008; Yang et al., 2005). EMPD appears grossly as an erythematous, eczematoid, well-demarcated area that cannot be clinically distinguished from EQ, BD, or CIS of the penis. Clinical presentation includes local discomfort, pruritus, and occasionally a serosanguineous discharge involving the penis, the scrotum, the perianal area and the axilla (Figs. 79.9D and E). EMPD in these sites is directly related to the presence of apocrine sweat glands. On microscopic examination, identification is clearly made by the presence of large, round or oval, clear-staining hydropic cells with hypochromatic nuclei (i.e., Paget cells). The cells often stain positively for cytokeratin 7 in addition to carcinoembryonic antigen and show gross cystic fluid protein but are S-100 protein negative (O'Connor et al., 2003). The tumor behaves as a slow-growing intraepithelial adenocarcinoma with cells derived from apocrine glands. With time the cells may become invasive with dermal tumor deposits metastasizing to regional lymph nodes via dermal lymphatics (Hegarty et al., 2011; Park et al., 2001). Penoscrotal EMPD may be associated with other malignancies of the genitourinary tract, such as prostate, bladder, and renal malignancies (Allan et al., 1998; Chanda, 1985; Koh, 1995; Ojeda et al., 1987) and should be evaluated for their presence. In a recent series from MD Anderson Cancer Center among 20 reported patients, 9 (45%) had at least one other malignancy including prostate, bladder, renal, skin, esophageal, and rectal sites. Notably, 8 of the 9 patients were diagnosed with the other cancer before their diagnosis of EMPD.

Two reports from the Far East have added to the case series in the literature: 130 cases of penoscrotal Paget disease from China (Wang et al., 2008) and 36 from South Korea (Yang et al., 2005). In most cases only the skin and dermis must be resected with a gross margin of up to 3 cm. Positive margins may still occur, and frozen sections are recommended to guide the extent of resection (Park et al., 2017; Pettaway, 2017b). However, false-negative frozen-section reports are not uncommon especially in a settings where specialized expertise (i.e., dermatopathologists) is not available to review the cases. Outpatient mapping biopsies may be helpful in determining the approximate tumor-free margin before major resection and can be helpful to the pathologist by providing formalin-fixed paraffin-embedded tissue with which to examine margins before actual resection. In this setting peripheral biopsies away from the obvious tumor are performed sequentially in the outpatient setting until all the margins are negative. In this setting Park et al. (2017) compared EMPD surgical outcomes among cohorts of patients that underwent resection alone versus prior mapping biopsies subsequent to surgical resection. They found that the mapping biopsy cohort exhibited lower rates of positive margins at frozen and permanent section, and this translated into lower 5-year tumor-free rates. Mapping biopsies were independently associated with lower local recurrence rates. Patients with a positive surgical margin are at a higher risk for recurrence, and additional resection is advised. In the series from Hegarty et al. (2011), no recurrences were noted among patients with intraepidermal EMPD with negative surgical margins. Local skin or scrotal flaps (Wang et al., 2008) can be used to cover the defects.

In a minority of cases the tumor may invade deeper structures, necessitating more extensive resection and reconstruction, as reported in case series (Fujisawa et al., 2008; Hatoko et al., 2002). If inguinal adenopathy is present, radical node dissection is advised (Hagan et al., 1975), but prognosis is poor (Yang et al., 2005). Hegarty et al. (2011) described the use of neoadjuvant docetaxel and carboplatin chemotherapy and surgical resection in two patients. One patient was alive with disease at 40 months, and the other had no evidence of disease at 13 months.

Adenosquamous Carcinoma

Adenosquamous carcinoma is a rare tumor characterized by glandular and squamous histologic elements that are independent of the urethral glands. It manifests as a large (5 to 9 cm), firm, and grayish white granular exophytic mass involving the distal shaft or glans. On microscopic examination the glands contain mucin and are positive for carcinoembryonic antigen. In one reported case, the tumor was metastatic to a single inguinal node. This patient was managed with local excision of the primary tumor and a limited inguinal node dissection and lived 9 years after treatment. Other tumors were managed with local excision and surveillance (Cubilla et al., 1996). In only the seventh reported case (Romero et al., 2006), a patient with a bulky primary mass and inguinal lymph nodes underwent total penectomy and delayed ILND and PLND with a final pathologic stage of pT2N3M0 and was free of disease at 5-year follow-up.

Lymphoreticular Malignant Neoplasm

Primary lymphoreticular malignant neoplasms rarely occurs on the penis (Dehner and Smith, 1970). This term is likely a misnomer and when it occurs the penile findings almost always represent an early manifestation of a more systemic process (Chu et al., 2013). **Leukemia may infiltrate the corpora, resulting in priapism** (Pochedly et al., 1974). Given the absence of lymphoid tissue in the penis, **a thorough search for systemic disease is necessary when lymphomatous infiltration of the penis is diagnosed. In a recent report 48 case reports of lymphomatous involvement of the penis were analyzed** (Chu et al., 2013)**. The most common type of lymphoma was the diffuse large B cell type with the most common symptoms being a lump on the penis or priapism. Involved additional sites have included lymph nodes, lung, liver, and occasionally the brain thus a search for systemic disease is mandatory.** If the penile lesion is indeed the only identified site, systemic directed toward the disease entity should still be administered. In the case of lymphomatous involvement this included rituxumab-cyclophosphamide, doxorubicin, vincristine, and prednisone as the most common regimen used. A systemic approach is effective therapy for local disease, for potential occult deposits that may exist elsewhere, and for preservation of form and function (Chu et al., 2013; Marks et al., 1988).

Metastases

Metastatic lesions to the penis are relatively rare. Up to the year 2011 approximately 437 cases had been reported (Chaux et al., 2011). Their infrequency is somewhat puzzling when one considers the rich blood and lymphatic supply to the organ and its proximity to the bladder, prostate, and rectal areas frequently involved with neoplasm. It is from these three organs that the majority of metastatic penile lesions originate (Abeshouse and Abeshouse, 1961). The most likely routes of spread are by direct extension, retrograde venous and lymphatic transport, and arterial embolism. Other sources of penile metastases emanate from the gastrointestinal tract, testis, and kidney (Belville and Cohen, 1992).

The most frequent sign of penile metastasis is priapism; penile swelling,

nodularity, and ulceration have also been reported (Abeshouse and Abeshouse, 1961; McCrea and Tobias, 1958; Weitzner, 1971). Urinary obstruction and hematuria may occur. The most common histologic feature of penile invasion by metastatic lesions is the replacement of one or both corpora cavernosa, which explains the frequent occurrence of priapism. Solitary cutaneous, preputial, and glandular deposits are less common.

The differential diagnosis includes idiopathic priapism; venereal or other infectious ulcerations; tuberculosis; Peyronie plaque; and primary, benign, or malignant tumors.

Penile metastases represent an advanced form of virulent disease and usually appear rather rapidly after recognition and during treatment of the primary tumor site (Abeshouse and Abeshouse, 1961; Chaux et al., 2011; Hayes and Young, 1967; Mukamel et al., 1987). On rare occasions a long period may elapse between the treatment of the primary lesion and the appearance of penile metastases (Abeshouse and Abeshouse, 1961), or the penile lesion may occur as the initial and only site of metastasis. In one report of 17 patients with penile metastases, 14 patients died of disseminated disease, with a median survival of 5 months after the diagnosis of penile metastases (Chaux et al., 2011).

Because of the association of a penile metastatic lesion with advanced disease, survival after its presentation is limited, and the majority of patients die within 1 year (Chaux et al., 2011; Mukamel et al., 1987; Robey and Schellhammer, 1984). Successful palliative treatment may occasionally be possible in the case of solitary nodules or localized distal penile involvement if complete excision by partial or total amputation succeeds in removing the entire area of malignant infiltration (Spaulding and Whitmore, 1978). The prospect for surgical cure is minimal if proximal corporeal invasion is present. Penectomy is occasionally indicated after failure of other modalities to palliate intractable pain (Mukamel et al., 1987). In such cases obtaining an MRI of the penis to determine the proximal extent of the tumor and the presence of discontinuous tumor satellites can assist in determining the feasibility of surgery and the extent of resection (Gupta and Rajesh, 2014). Pain can also be managed by dorsal nerve section (Hill and Khalid, 1988) along with suprapubic cystostomy diversion used to optimize bladder emptying. In general, radiation therapy has been unsuccessful. Salvage systemic therapy strategies, clinical trials directed toward the primary histology or hospice care represent options to consider in this patient cohort with an overall poor prognosis.

Key Points: Nonsquamous Malignant Neoplasms

- Basal cell carcinoma represents a highly curable variant with a relatively low metastatic potential.
- Sarcomas are prone to local recurrence; regional and distant metastases are rare. Superficial lesions can be treated with less radical procedures.
- Melanoma is an aggressive form of cancer but can be cured if diagnosed and treated with the appropriate surgical procedure at an early stage. Novel immunotherapy strategies may improve survival in recurrent or advanced disease.
- EMPD disseminates by intraepidermal spread initially. Wide local excision to achieve negative margins is the therapy of choice. Invasive EMPD can be lethal.
- Penile metastases most often represent spread from a clinically obvious existing primary tumor. Prognosis is poor, and therapy should be directed toward the primary tumor site histology and local palliation.

References

Abeshouse BS. Primary and secondary melanoma of the genitourinary tract. *South Med J*. 1958;51:994–1006.

Abeshouse BS, Abeshouse GA. Metastatic tumors of the penis: a review of the literature and a report of two cases. *J Urol*. 1961;86:99–112.

Agrawal A, Pai D, Ananthakrishnan N, et al. The histological extent of the local spread of carcinoma of the penis and its therapeutic implications. *BJU Int*. 2000;85:299–301.

Ahmed T, Sharloff R, Yagoda A. Sequential trials of methotrexate, cisplatin, bleomycin for penile cancer. *J Urol*. 1984;132:465–468.

Akimoto T, Mitsuhashi N, Takahashi I, et al. Brachytherapy for penile cancer using silicon mold. *Oncology*. 1997;54:23–27.

Alani RM, Munger K. Human papillomaviruses and associated malignancies. *J Clin Oncol*. 1998;16:330–337.

Albertini JJ, Lyman GH, Cox C, et al. Lymphatic mapping and sentinel node biopsy in the patient with breast cancer. *J Am Med Assoc*. 1996;276:1818–1822.

Allan SJR, McLaren K, Aldridge RD. Paget's disease of the scrotum: a case exhibiting positive prostate-specific antigen staining and associated with prostatic adenocarcinoma. *Br J Dermatol*. 1998;138:689–691.

Alnajjar HM, Lam W, Bolgeri M, et al. Treatment of carcinoma in situ of the glans penis with topical chemotherapy agents. *Eur Urol*. 2012;62(5):923–928.

Anderson EE, Glenn JF. Penile malignancy and hypercalcemia. *J Am Med Assoc*. 1965;192:328–329.

Anderson SL, Nielson A, Reymann F. Relationship between Bowen disease and internal malignant tumors. *Arch Dermatol*. 1973;108:367.

Aragona F, Serretta V, Marconi A, et al. Queyrat's erythroplasia of the prepuce: a case-report. *Acta Chir Belg*. 1985;85:303–304.

Arya M, Li R, Pegler K, et al. Long-term trends in incidence, survival and mortality of primary penile cancer in England. *Cancer Causes Control*. 2013;24(12):2169–2176.

Ashley DJ, Edwards EC. Leiomyosarcoma of the penis: report of a case with a review of the literature of sarcoma of the penis. *Br J Surg*. 1957;45:170–179.

Avrach WW, Christensen HE. Metastasizing erythroplasia of Queyrat. Report of a case. *Acta Derm Venereol*. 1976;56:409–412.

Azrif M, Logue JP, Swindell R, et al. External-beam radiotherapy in T1-2 N0 penile carcinoma. *Clin Oncol (R Coll Radiol)*. 2006;18:320–325.

Backes DM, Kurman RJ, Pimenta JM, et al. Systematic review of human papillomavirus prevalence in invasive penile cancer. *Cancer Causes Control*. 2009;20(4):449–457.

Bainbridge DR, Whitaker RH, Shepheard BGF. Balanitis xerotica obliterans and urinary obstruction. *Br J Urol*. 1971;43:487–491.

Baldur-Felsov BB, Hannibal CG, Munk C, et al. Increased incidence of penile cancer and high-grade penile intraepithelial neoplasia in Denmark 1978-2008: a nationwide population-based study. *Cancer Causes Control*. 2012;23(2):273–280.

Bandieramonte G, Santoro O, Boracchi P, et al. Total resection of glans penis surface by CO2 laser microsurgery. *Acta Oncol*. 1988;27:575–578.

Barrasso R, DeBrux J, Croissant O, et al. High prevalence of papillomavirus-associated penile intraepithelial neoplasia in sexual partners of women with cervical intraepithelial neoplasia. *N Engl J Med*. 1987;317:916–923.

Bart RS, Kopf AW. Tumor Conference No. 18: squamous cell carcinoma arising in balanitis xerotica obliterans. *J Dermatol Surg Oncol*. 1978;4:556–558.

Bartelink H, Roelofsen F, Eschwege F, et al. Concomitant radiotherapy and chemotherapy is superior to radiotherapy alone in the treatment of locally advanced anal cancer: results of a phase III randomized trial of the European Organization for Research and Treatment of Cancer Radiotherapy and Gastrointestinal Cooperative Groups. *J Clin Oncol*. 1997;15:2040–2049.

Bayne D, Wise GJ. Kaposi sarcoma of penis and genitalia: a disease of our times. *Urology*. 1988;31:22–25.

Beggs JH, Spratt JS. Epidermoid carcinoma of the penis. *J Urol*. 1964;91:166.

Belville WD, Cohen JA. Secondary penile malignancies: the spectrum of presentation. *J Surg Oncol*. 1992;51:134–137.

Bermejo C, Busby JE, Spiess PE, et al. Neoadjuvant chemotherapy followed by aggressive surgical consolidation for metastatic penile squamous cell carcinoma. *J Urol*. 2007;177:1335–1338.

Bevan-Thomas R, Slaton JW, Pettaway CA. Contemporary morbidity from lymphadenectomy for penile squamous cell carcinoma: the M. D. Anderson Cancer Center experience. *J Urol*. 2002;167:1638–1642.

Bhojwani A, Biyani CS, Nicol A, et al. Bowenoid papulosis of the penis. *Br J Urol*. 1997;80:508.

Bissada NK. Conservative extirpative treatment of cancer of the penis. *Urol Clin North Am*. 1992;19:283.

Bissada NK, Cole AT, Fried FA. Extensive condylomas acuminata of the entire male urethra and the bladder. *J Urol*. 1974;112:201–203.

Bissada NK, Morcos RR, El-Senoussi M. Post-circumcision carcinoma of the penis. I. Clinical aspects. *J Urol*.

1986;135:283–287.

Bissada NK, Yakout HH, Fahmy WE, et al. Multi-institutional long-term experience with conservative surgery for invasive penile carcinoma. *J Urol*. 2003;169:500–502.

Bleeker MCG, Heideman DAM, Snijders PJF, et al. Penile cancer: epidemiology, pathogenesis, and prevention. *World J Urol*. 2009;27:141–150.

Block SL, Nolan T, Sattler C, et al. Comparison of the immunogenicity and reactivity of a prophylactic human papillovirus (types 6,11,16,18) L1 virus-like particle vaccine in male and female adolescents and young women. *Pediatrics*. 2006;118:2135–2145.

Block NL, Rosen P, Whitmore WF Jr. Hemipelvectomy for advanced penile cancer. *J Urol*. 1973;110:703–707.

Boshart M, zur Hausen H. Human papillomaviruses (HPV) in Buschke-Löwenstein tumors: physical state of the DNA and identification of a tandem duplication in the non-coding region of a human papillomavirus 6 subtype. *J Virol*. 1986;58:963–966.

Bouchot O, Auvigne J, Peuvrel P, et al. Management of regional lymph nodes in carcinoma of the penis. *Eur Urol*. 1989;16:410–415.

Boxer RJ, Skinner DG. Condylomata acuminata and squamous cell carcinoma. *Urology*. 1977;9:72–78.

Bracken RB, Diokno AC. Melanoma of the penis and the urethra: 2 case reports and review of the literature. *J Urol*. 1974;111:198–201.

Braga JCT, Stiepcich M, Muller H, et al. Buschke- Lowenstein tumor: identification of HPV type 6 and 11. *An Bras Dermatol*. 2012;87(1):131–134.

Broders AC. Squamous cell epithelioma of the skin. *Ann Surg*. 1921;73:141–143.

Bruns TNC, Lauvetz RJ, Kerr ES, et al. Buschke-Löwenstein giant condylomas: pitfalls in management. *Urology*. 1975;5:773–776.

Buddington WT, Kickham CJ, Smith WE. An assessment of malignant disease of the penis. *J Urol*. 1963;89:442–449.

Buechner SA. Common skin disorders of the penis. *BJU Int*. 2002;90:498–506.

Burmer GC, True LD, Krieger JN. Squamous cell carcinoma of the scrotum associated with human papillomaviruses. *J Urol*. 1993;149:374–377.

Buschke A, Löwenstein L. Über carcinomahnliche Condylomata acuminata des Penis. *Klin Wochenschr*. 1925;4:1726–1728.

Cabanas R. An approach to the treatment of penile carcinoma. *Cancer*. 1977;39:456–466.

Cabanas RM. Anatomy and biopsy of the sentinel lymph nodes. *Urol Clin North Am*. 1992;19:267–276.

Carpiniello VL, Zderic SA, Malloy TR, et al. Carbon dioxide laser therapy of subclinical condyloma found by magnified penile surface scanning. *Urology*. 1987;29:608–610.

Catalona WJ. Modified inguinal lymphadenectomy for carcinoma of the penis with preservation of saphenous veins: technique and preliminary results. *J Urol*. 1988;140:306–310.

Chanda JJ. Extramammary Paget's disease: prognosis and relationship to internal malignancy. *J Am Acad Dermatol*. 1985;13:1009–1014.

Chaudhary AJ, Ghosh S, Bhalavat RL, et al. Interstitial brachytherapy in carcinoma of the penis. *Strahlenther Onkol*. 1999;175:17–20.

Chaux A, Torres J, Pfannl R, et al. Histologic grade in penile squamous cell carcinoma: visual estimation versus digital measurement of proportions grades, adverse prognosis with any proportion of grade 3 and correlation of a Gleason-like system with nodal metastasis. *Am J Surg Pathol*.

2009;33:1042–1048.

Chaux A, Amin M, Cubilla AL, et al. Metastatic tumors to the penis: a report of 17 cases and review of the literature. *Int J Surg Pathol*. 2011;19(5):597–606.

Chhabra A, Schwartz D, Leaf A, et al. Neoadjuvant concurrent chemoradiation for curative treatment of penile squamous cell carcinoma. *Case Rep Oncol Med*. 2014;2014:479376.

Chitale SV, Peat D, Meaden JD, et al. Kaposi's sarcoma of the glans penis in an HIV negative patient. *Int Urol Nephrol*. 2002;34:251–253.

Chu QD, Vezeridis MP, Libbey NP, et al. Giant condyloma acuminatum (Buschke-Lowenstein tumor) of the anorectal and perianal regions. Analysis of 42 cases. *Dis Colon Rectum*. 1994;37(9):950–957.

Chu L, Mao W, Vikramsingh KC, et al. Primary malignant lymphoma of the glans penis: a rare case report and review of the literature. *Asian J Androl*. 2013;15(4):571–572.

Coblentz TR, Theodorescu D. Morbidity of modified prophylactic inguinal lymphadenectomy for squamous cell carcinoma of the penis. *J Urol*. 2002;168(Pt 1):1386–1389.

Coetzee T. Condyloma acuminatum. *S Afr J Surg*. 1977;15:75–80.

Colberg JW, Andriole GL, Catalona WJ. Long-term follow-up of men undergoing modified inguinal lymphadenectomy for carcinoma of the penis. *Br J Urol*. 1997;79:54–57.

Colon-Lopez V, Ortiz AP, Soto-Salgado M, et al. Penile cancer disparities in Puerto Rican men as compared to the United States population. *Int Braz J Urol*. 2012;38(6):728–738.

Copulsky J, Whitehead ED, Orkin LA. Condyloma acuminata in a three-year-old boy. *Urology*. 1975;5:372–373.

Corral DA, Sella A, Pettaway CA, et al. Combination chemotherapy for metastatic or locally advanced genitourinary squamous cell carcinoma: a phase II study of methotrexate, cisplatin and bleomycin. *J Urol*. 1998;160:1770–1774.

Crook J, Grimard L, Tsihlias J, et al. Interstitial brachytherapy for penile cancer: an alternative to amputation. *J Urol*. 2002;167:506–511.

Crook J, Ma C, Grimard L. Radiation therapy in the management of the primary penile tumor: an update. *World J Urol*. 2009;27:189–196.

Crook JM, Keyes M, Dubai R, et al. Lessons learned in converting from a Low Dose Rate to High Dose Rate penile brachytherapy program. *Brachytherapy*. 2016;16.

Cubilla AL. The role of pathologic prognostic factors in squamous cell carcinoma of the penis. *World J Urol*. 2009;27:169–177.

Cubilla AL, Ayala MT, Barreto JE, et al. Surface adenosquamous carcinoma of the penis: a report of three cases. *Am J Surg Pathol*. 1996;20:156–160.

Cubilla AL, Reuter V, Gregoire L, et al. Basaloid squamous cell carcinoma: a distinctive human papilloma virus–related penile neoplasm: a report of 20 cases. *Am J Surg Pathol*. 1998;22:755–761.

Cubilla AL, Reuter V, Velazquez E, et al. Histologic classification of penile carcinoma and its relation to outcome in 61 patients with primary resection. *Int J Surg Pathol*. 2001;9:111–120.

Cubilla AL, Velazquez EF, Young RH. Pseudohyperplasia squamous cell carcinoma of the penis associated with lichen sclerosus: an extremely well differentiated, nonverruciform neoplasm that preferentially affects the foreskin and is frequently misdiagnosed: a report of 10 cases of a distinctive clinicopathologic entity. *Am J Surg Pathol*. 2004;28:895–900.

Cubilla AL, Amin MB, Ayala A, et al. Malignant epithelial tumors. Moch H, Humphrey PA, Ulbright TM, et al. *World*

Health Organization classification of tumours of the urinary system and male genital organs. 4th ed. IARC Press: Lyon; 2016:260–276.

Da Cunha IW, Souza MJL, da Costa H, et al. Epithelial-mesenchymal transition (EMT) phenotype at invasion front of squamous cell carcinoma of the penis influences oncological outcomes. *Urol Oncol*. 2016;34:433.e19–433.e26.

Dagher R, Selzer ML, Lapides J. Carcinoma of the penis and the anti-circumcision crusade. *J Urol*. 1973;110:79–80.

Daling JR, Sherman KJ, Hislop TG, et al. Cigarette smoking and the risk of anogenital cancer. *Am J Epidemiol*. 1992;135:180–189.

Dalkin B, Zaontz MR. Rhabdomyosarcoma of the penis in children. *J Urol*. 1989;141:908–909.

Danielson AG, Sand C, Weisman K. Treatment of Bowen's disease of the penis with 5% imiquimod cream. *Clin Exp Dermatol*. 2003;28(Suppl 1):7–9.

Das Gupta T, Grabstald H. Melanoma of the genitourinary tract. *J Urol*. 1965;93:607–614.

Das S, Ghoshal L. Pseudoepitheliomatous keratotic and micaceous balanitis of Civatte. *Indian Dermatol Online J*. 2014;5(2):148–149.

Davis JW, Schellhammer PF, Schlossberg SM. Conservative surgical therapy for penile and urethral carcinoma. *Urology*. 1999;53:386–392.

Dean AL Jr. Epithelioma of the penis. *J Urol*. 1935;33:252–283.

de Bree E, Sanidas E, Tzardi M, et al. Malignant melanoma of the penis. *Eur J Surg Oncol*. 1997;23:277–279.

de Crevoisier R, Slimane K, Sanfilippo N, et al. Long-term results of brachytherapy for carcinoma of the penis confined to the glans (N- or NX). *Int J Radiat Oncol Biol Phys*. 2009;74(4):1150–1156.

Dehner LP, Smith BH. Soft tissue tumors of the penis. *Cancer*. 1970;25:1431–1447.

de Kernion JB, Tynberg P, Persky L, et al. Proceedings: carcinoma of the penis. *Cancer*. 1973;32:1256–1262.

de Kerviler E, Ollier P, Desgrandchamps F, et al. Magnetic resonance imaging in patients with penile carcinoma. *Br J Radiol*. 1995;68:704–711.

Delannes M, Malavaud B, Douchez J, et al. Iridium-192 interstitial therapy for squamous cell carcinoma of the penis. *Int J Radiat Oncol Biol Phys*. 1992;24:479–483.

Delaunay B, Soh PN, Delannes M, et al. Brachytherapy for penile cancer: efficacy and impact on sexual function. *Brachytherapy*. 2014;13(4):380–387.

Depasquale L, Park AJ, Bracka A. The treatment of balanitis xerotica obliterans. *BJU Int*. 2000;86:459–465.

Derrick FC, Lynch KM, Kretkowski RC, et al. Epidermoid carcinoma of the penis: computer analysis of 87 cases. *J Urol*. 1973;110:303–305.

de Sanjose S, Quint WGV, Alemany L, et al. Human papillomavirus genotype attribution in invasive cervical cancer: a retrospective cross-sectional worldwide study. *Lancet Oncol*. 2010;11:1048–1056.

Dewire D, Lepor H. Anatomic considerations of the penis and its lymphatic drainage. *Urol Clin North Am*. 1992;19:211–219.

Dianzani C, Calvieri S, Pierangeli A, et al. Identification of human papilloma viruses in male dysplastic genital lesions. *New Microbiol*. 2004;27:65–69.

Dickstein RJ, Munsell MF, Pagliaro LC, et al. Prognostic factors influencing survival from regionally advanced squamous cell carcinoma of the penis after preoperative chemotherapy. *BJU Int*. 2016;117(1):118–125.

Di Lorenzo G, Buonerba C, Federico P, et al. Cisplatin and 5-

fluorouracil in inoperable, stage IV squamous cell carcinoma of the penis. *BJU Int*. 2012;110(11 Pt B):E661–E666.

Djajadiningrat RS, Jordanova ES, Kroon BK, et al. Human papillomavirus prevalence in invasive penile cancer and association with clinical outcome. *J Urol*. 2015;193:526–531.

Dodge OG. Carcinoma of the penis in East Africans. *Br J Urol*. 1965;37:223–226.

Doorbar J. Molecular biology of human papillomavirus infection and cervical cancer. *Clin Sci*. 2006;110(5):525–541.

Dorak AC, Ozkan GA, Tamac NI, et al. Ultrasonography in the recognition of penile cancer. *J Clin Ultrasound*. 1992;20:624–626.

Dore B, Irani J, Aubert J. Carcinoma of the penis in lichen sclerosus atrophicus: a case report. *Eur Urol*. 1990;18:153–155.

Dretler SP, Klein LA. The eradication of intraurethral condyloma acuminata with 5 percent fluorouracil cream. *J Urol*. 1975;113:195–198.

Dunne EF, Unger ER, Sternberg M, et al. Prevalence of HPV infection among females in the United States. *J Am Med Assoc*. 2007;297(8):813–819.

Dupin N. Genital warts. *Clin Dermatol*. 2004;22:481–486.

Edge SB, Byrd DR, Compton CC, et al. Penis. *AJCC Cancer staging manual*. ed 7. Springer: New York; 2010.

Edwards RH, Sawyers JL. The management of carcinoma of the penis. *South Med J*. 1968;61:843–845.

Eisenberger MA. Chemotherapy for carcinomas of the penis and urethra. *Urol Clin North Am*. 1992;19:333–338.

Eisendle K, Grabner T, Kutzner H, et al. Possible role of Borrelia burgdorferi sensu lato infection in lichen sclerosis. *Arch Dermatol*. 2008;144(5):591–598.

Ekstrom T, Edsmyr F. Cancer of the penis: a clinical study of 229 cases. *Acta Chir Scand*. 1958;115:25–45.

El-Demiry MI, Oliver RT, Hope-Stone HF, et al. Reappraisal of the role of radiotherapy and surgery in the management of carcinoma of the penis. *Br J Urol*. 1984;56:724–728.

Endo M, Yamashita T, Jin HY, et al. Detection of human papillomavirus type 16 in bowenoid papulosis and nonbowenoid tissues. *Int J Dermatol*. 2003;42:474–476.

Eng TY, Petersen JP, Stack RS, et al. Lymph node metastasis from carcinoma in situ of the penis: a case report. *J Urol*. 1995;153:432–434.

Eron LJ, Judson F, Tucker S, et al. Interferon therapy for condylomata acuminata. *N Engl J Med*. 1986;315:1059–1064.

Feneley MR, Liu S, Miller PD, et al. Urethroplasty for condylomata acuminata throughout the urethra. *Br J Urol*. 1992;69:218–219.

Ferenczy A. Strategies to eradicate genital HPV infection in men. *Contemp Urol*. 1990;2:19.

Ferrandiz-Pulido C, Masferrer E, Toll A, et al. mTOR signaling pathway in penile squamous cell carcinoma: pmTOR and peIF4E over expression correlate with aggressive tumor behavior. *J Urol*. 2013;190(6):2288–2295.

Ferreux E, Lont A, Horenblas S, et al. Evidence for at least three alternative mechanisms targeting the p16(INK4A)/CyclinD/Rb Pathway in penile carcinoma, one of which is mediated by high-risk human papillomavirus. *J Pathol*. 2003;201(1):109–118.

Fetsch JF, Davis CJ, Miettinen M, et al. Leiomyosarcoma of the penis: a clinicopathologic study of 14 cases with review of the literature and discussion of the differential diagnosis. *Am J Surg Pathol*. 2004;28(1):115–125.

Ficarra V, Zattoni F, Cunico SC, et al. Lymphatic and vascular embolizations are independent predictive variables of inguinal lymph node involvement in patients with squamous cell carcinoma of the penis. Gruppo Uro-Oncologico del Nord Est (Northeast Uro-Oncological Group) Penile Cancer data base. *Cancer*. 2005;103:2507–2516.

Ficarra V, Zattoni F, Artibani W, et al. Nomogram predictive of pathological inguinal lymph node involvement in patients with squamous cell carcinoma of the penis. [and the; G.U.O.N.E. Penile Cancer Project Members] *J Urol*. 2006;175:1700–1705.

Fields T, Drylie D, Wilson J. Malignant evolution of penile horn. *Urology*. 1987;30:65–66.

Fistarol SK, Itin PH. Diagnosis and treatment of lichen sclerosis. An Update. *Am J Clin Dermatol*. 2013;14:27–47.

Fossa SD, Hall KS, Johannessen MB, et al. Cancer of the penis: experience at the Norwegian Radium Hospital 1974–85. *Eur Urol*. 1987;13:372–377.

Fowler JE. Sentinel lymph node biopsy for staging penile cancer. *Urology*. 1984;23:352–353.

Fraley EE, Zhang G, Manivel C, et al. The role of ilioinguinal lymphadenectomy and significance of histological differentiation in treatment of carcinoma of the penis. *J Urol*. 1989;142:1478–1482.

Frew IDO, Jefferies JD, Swiney J. Carcinoma of penis. *Br J Urol*. 1967;39:398–404.

Friedman-Kien AE. Disseminated Kaposi's sarcoma syndrome in young homosexual men. *J Am Acad Dermatol*. 1981;5:468–471.

Frimberger D, Hungerhuber E, Zaak D, et al. Penile carcinoma: is Nd:YAG laser therapy radical enough? *J Urol*. 2002;168:2418–2421 [discussion 2421].

Frimberger D, Schneede P, Hungerhuber E, et al. Autofluorescence and 5-aminolevulinic acid induced fluorescence diagnosis of penile carcinoma—new techniques to monitor Nd:YAG laser therapy. *Urol Res*. 2002;30:295–

300.

Frisch M, Friis S, Kjaer SK, et al. Falling incidence of penis cancer in an uncircumcised population (Denmark 1943–90). *BMJ*. 1995;311:1471.

Fujisawa Y, Nakamura Y, Takahashi T, et al. Penile preservation surgery in a case of extramammary Paget's disease involving the glans penis and distal urethra. *Dermatol Surg*. 2008;34:823–831.

Furlong JH, Uhle CAW. Cancer of penis: a report of eighty-eight cases. *J Urol*. 1953;60:550–555.

Gagliano RG, Blumenstein BA, Crawford ED, et al. Cis-Diamminedichloroplatinum in the treatment of advanced epidermoid carcinoma of the penis: a Southwest Oncology Group Study. *J Urol*. 1989;141:66–67.

Gambachidze D, Lebacle C, Maroun P, et al. Long-term evaluation of urinary, sexual, and quality of life outcomes after brachytherapy for penile carcinoma. *Brachytherapy*. 2017;17(1):221–226.

Garnick MB, Skarin AT, Steele GD. Metastatic carcinoma of the penis: complete remission after high dose methotrexate chemotherapy. *J Urol*. 1979;122:265–266.

Geffen JR, Klein RJ, Friedman-Kien AE. Intralesional administration of large doses of human leukocyte interferon for the treatment of condylomata acuminata. *J Infect Dis*. 1984;150:612–615.

Gerbaulet A, Lambin P. Radiation therapy of cancer of the penis. *Urol Clin North Am*. 1992;19:325–332.

Gershenwald GE, Thompson W, Mansfield PF, et al. Multi-institutional melanoma lymphatic mapping experience: the prognostic value of sentinel lymph node status in 612 stage I or II melanoma patients. *J Clin Oncol*. 1999;17:976–983.

Gilbert P, Beckert R. Combination therapy for penile giant Buschke-Löwenstein condyloma. *Urol Int*. 1990;45:122–124.

Giuliano AR, Lazcano E, Lina Villa L, et al. Circumcision and sexual behavior: factors independently associated with human papillomavirus detection among men in the HIM study. *Int J Cancer*. 2009;124:1251–1257.

Giuliano AR, Palefsky JM, Goldstone S, et al. Efficacy of quadrivalent HPV vaccine against HPV Infection and disease in males. *N Engl J Med*. 2011;364(5):401–411.

Gloeckler-Ries LA, Hankey BF, Edwards BK. *Cancer statistics review 1973–1987. National Cancer Institute, National Institutes of Health Publication No. 90-2789*. [ed; Bethesda, MD: National Institutes of Health] 1990.

Goette DK. Erythroplasia of Queyrat. *Arch Dermatol*. 1974;110:271–273.

Goldminz D, Scott G, Klaus S. Penile basal cell carcinoma: report of a case and review of the literature. *J Am Acad Dermatol*. 1989;20:1094–1097.

Gomez-Iturriaga A, Crook J, Evans W, et al. The efficacy of Hyperbaric Oxygen Therapy in the treatment of medically refractory soft tissue necrosis after penile brachytherapy. *Brachytherapy*. 2011;10(6):491–497.

Gotsadze D, Matveev B, Zak B, et al. Is conservative organ-sparing treatment of penile carcinoma justified? *Eur Urol*. 2000;38:306–312.

Grabstald H, Kelley CD. Radiation therapy of penile cancer. *Urology*. 1980;15:575–576.

Graafland NM, Verhoeven RHA, Coebergh JW, et al. Incidence trends and survival of penile squamous cell carcinoma in the Netherlands. *Int J Cancer*. 2011;128(2):426–432.

Graafland NM, Teertstra HJ, Besnard PE, et al. Identification of high risk pathological node positive penile carcinoma: value of preoperative computerized tomography imaging. *J Urol*. 2011;185(3):881–887.

Graafland NM, Leijte JAP, Valdes Olmos RA, et al. Scanning with 18F-FDG-PET/CT for detection of pelvic nodal involvement in inguinal node-positive penile carcinoma. *Eur Urol*. 2009;56(2):339–345.

Graham JH, Helwig EB. Erythroplasia of Queyrat. *Cancer*. 1973;32:1396–1414.

Graham S, Priore R, Graham M, et al. Genital cancer in wives of penile cancer patients. *Cancer*. 1979;44:1870–1874.

Gray MR, Ansell ID. Pseudo-epitheliomatous hyperkeratotic and micaceous balanitis: evidence for regarding it as premalignant. *Br J Urol*. 1990;66:103–104.

Gregoire L, Cubilla AL, Reuter VE, et al. Preferential association of human papillomavirus with high-grade histologic variants of penile invasive squamous cell carcinoma. *J Natl Cancer Inst*. 1995;87:1705–1709.

Griffiths TR, Mellon JK. Human papillomavirus and urological tumours. I. Basic science and role in penile cancer. *BJU Int*. 1999;84:579–586.

Gross G, Pfister H. Role of human papillomavirus in penile cancer, penile intraepithelial squamous cell neoplasias and in genital warts. *Med Microbiol Immunol (Berl)*. 2004;193:35–44.

Gross G, Hagedorn M, Ikenberg H, et al. Bowenoid papulosis: presence of human papillomavirus (HPV) structural antigens and of HPV 16–related DNA sequences. *Arch Dermatol*. 1985;121:858–863.

Grunwald MH, Amichai B, Halevy S. Purplish penile papule as a presenting sign of Kaposi's sarcoma. *Br J Urol*. 1994;74:517.

Guimares G, Lopez A, Campos RS, et al. Front pattern of invasion in squamous cell carcinoma of the penis; new prognostic factor for predcting risk of lymph node metastasis. *Urology*. 2006;68:148–153.

Gunia S, Erbersdobler A, Hakenberg OW, et al. p16(INK4a) is a marker of good prognosis for primary invasive penile squamous cell carcinoma: a multi-institutional study. *J Urol*. 2012;187(3):899–907.

Gupta V, Chopra V, Verma S. A large cutaneous horn of the glans penis: a rare presentation. *Indian J Surg*. 2014;76(2):143–144.

Gupta S, Rajesh A. Magnetic resonance imaging of penile cancer. *Magn Reson Imaging Clin N Am*. 2014;22(2):191–199.

Gursel EO, Georgountzos C, Uson AC, et al. Penile cancer. *Urology*. 1973;1:569–578.

Haas GP, Blumenstein BA, Gagliano RG, et al. Cisplatin, methotrexate, and bleomycin for the treatment of carcinoma of the penis: a Southwest Oncology Group study. *J Urol*. 1999;161:1823–1825.

Hadway P, et al. Total glans resurfacing for premalignant lesions of the penis: initial outcome data. *BJU Int*. 2006;98(3):532–536.

Hagan KW, Braren V, Viner NA, et al. Extramammary Paget's disease in the scrotal and inguinal areas. *J Urol*. 1975;114:154–156.

Hakenberg OW, Comperat EM, Minhas S, et al. EAU guidelines on penile cancer: 2014 update. *Eur Urol*. 2015;67(1):142–150.

Hall MC, Sanders JS, Vuitch F, et al. Deoxyribonucleic acid flow cytometry and traditional pathologic variables in invasive penile carcinoma: assessment of prognostic significance. *Urology*. 1998;52:111–116.

Hall TC, Britt DB, Woodhead DM. Basal cell carcinoma of the penis. *J Urol*. 1968;99:314–315.

Hanchanale V, Yeo L, Subedi N, et al. The accuracy of Magnetic Resonance Imaging (MRI) in predicting the invasion of the tunica albuginea and the urethra during the

primary staging of penile cancer. *BJU Int*. 2016;117:439–443.
Handly J, Dinsmore W, Maw R, et al. Condyloma lesions in children. *Int J STD AIDS*. 1993;4:271–279.
Hardner GJ, Bhanalaph T, Murphy GP, et al. Carcinoma of the penis: analysis of therapy in 100 consecutive cases. *J Urol*. 1972;108:428–430.
Harish K, Ravi R. The role of tobacco in penile carcinoma. *Br J Urol*. 1995;75:375–377.
Harper DM, Franco EL, Wheeler C, et al. Efficacy of a bivalent L1 virus-like particle vaccine in prevention of infection with human papillovirus types 16 and 18 in young women: a randomised controlled trial. *Lancet*. 2004;364(9447):1757–1765.
Hassan AA, Orteza AM, Milam DF. Penile horn: review of literature with 3 case reports. *J Urol*. 1967;97:315–317.
Hasid VJ, Papadopoulos JN. Penile squamous cell carcinoma masquerading as giant condyloma. *Plast Reconstr Surg Glob Open*. 2017;5(3):e1269.
Hatoko M, Kuwahara M, Tanaka A, et al. Penile reconstruction for extramammary Paget's disease. *Ann Plast Surg*. 2002;48:672–675.
Hayes WT, Young JM. Metastatic carcinoma of the penis. *J Chronic Dis*. 1967;20:891–895.
Hegarty PK, Kayes O, Freeman A, et al. A prospective study of 100 cases of penile cancer managed according to European Association of Urology guidelines. *BJU Int*. 2006;98:526–531.
Hegarty PK, Suh J, Fisher M, et al. Penoscrotal extramammary Paget's disease: the University of Texas M. D. Anderson Cancer Center contemporary experience. *J Urol*. 2011;186:97–102.
Hellberg D, Valentin J, Eklund T, et al. Penile cancer: is there an epidemiological role for smoking and sexual behavior? *BMJ*.

1987;295:1306–1308.

Helou J, Morton G, Easton H, et al. Customized penile plesiobrachytherapy using latest stereolithography techniques. *Brachytherapy*. 2015;14:599.

Hernandez BY, Wilkens LR, Zhu X, et al. Circumcision and human papillomavirus infection in men: a site-specific comparision. *J Infect Dis*. 2008;197(6):787–794.

Heymann WR, Soifer I, Burk PG. Penile premalignant fibroepithelioma of Pinkus. *Cutis*. 1983;31:519–521.

Heyns CF, van Vollenhoven P, Steenkamp JW, et al. Carcinoma of the penis—appraisal of a modified tumor-staging system. *Br J Urol*. 1997;80:307–312.

Hill JT, Khalid MA. Penile denervation. *Br J Urol*. 1988;61:167.

Hoffman MA, Renshaw AA, Loughlin KR. Squamous cell carcinoma of the penis and microscopic pathologic margins: how much margin is needed for local cure? *Cancer*. 1999;85:1565–1568.

Horenblas S, van Tinteren H. Squamous cell carcinoma of the penis. IV. Prognostic factors of survival: analysis of tumor, nodes and metastasis classification system. *J Urol*. 1994;151:1239–1243.

Horenblas S, van Tinteren H, Delemarre JF, et al. Squamous cell carcinoma of the penis: accuracy of tumor, nodes and metastases classification system and role of lymphangiography, computerized tomography scan, and fine needle aspiration cytology. *J Urol*. 1991;146:1279–1283.

Horenblas S, van Tinteren H, Delemarre JF, et al. Squamous cell carcinoma of the penis. II. Treatment of the primary tumor. *J Urol*. 1992;147:1533–1538.

Horenblas S, van Tinteren H, Delemarre JF, et al. Squamous cell carcinoma of the penis. III. Treatment of regional lymph nodes. *J Urol*. 1993;149:492–497.

Horenblas S, Jansen L, Meinhardt W, et al. Detection of occult metastasis in squamous cell carcinoma of the penis using a dynamic sentinel node procedure. *J Urol*. 2000;163:100–104.

Hubbell CR, Rabin VR, Mora RG. Cancer of the skin in blacks. V. A review of 175 black patients with squamous cell carcinoma of the penis. *J Am Acad Dermatol*. 1988;18(Pt 1):292–298.

Hughes BE, Leijte JAP, Kroon BK, et al. Lymph node metastasis in intermediate-risk penile squamous cell cancer: a two-centre experience. *Eur Urol*. 2010;57:688.

Hungerhuber E, Schlenker B, Karl A, et al. Risk stratification in penile carcinoma: 25-year experience with surgical inguinal lymph node staging. *Urology*. 2006;68:621–625.

Hung-fu T, Morganstern H, Mack T, et al. Risk factors for penile cancer: results of a population-based case-control study in Los Angeles County. *Cancer Causes Control*. 2001;12:267–277.

Hutcheson JB, Wittaker WW, Fronstin MH. Leiomyosarcoma of the penis: case report and review of literature. *J Urol*. 1969;101:874–875.

Hyde SE, Valmadre S, Hacker NF, et al. Squamous cell carcinoma of the vulva with bulky positive groin nodes-nodal debulking versus full groin dissection prior to radiation therapy. *Int J Gynecol Cancer*. 2007;17:154–158.

Ichikawa T. Chemotherapy of penis carcinoma. *Recent Results Cancer Res*. 1977;60:140–156.

Ichikawa T, Nakano I, Hirokawa I. Bleomycin treatment of the tumors of penis and scrotum. *J Urol*. 1969;102:699–707.

Iversen T, Tretli S, Johansen AA, et al. Squamous cell carcinoma of the penis and of the cervix, vulva, and vagina in spouses: is there any relationship? An epidemiological study from Norway, 1960–92. *Br J Cancer*. 1997;76:658–660.

Iwasawa A, Kumamoto Y, Fujinaga K. Detection of human papillomavirus deoxyribonucleic acid in penile carcinoma by polymerase chain reaction and in situ hybridization. *J Urol*. 1993;149:59–63.

Jaffe HW, Pellett PE. Human herpesvirus 8 and Kaposi's sarcoma—some answers, more questions. *N Engl J Med*. 1999;340:1912–1913.

Jaffe HW, Bregman DJ, Selik RM. Acquired immunodeficiency syndrome in the United States: the first 1,000 cases. *J Infect Dis*. 1983;148:339–345.

Jamieson NV, Bullock KN, Barker TH. Adenosquamous carcinoma of the penis associated with balanitis xerotica obliterans. *J Urol*. 1986;58:730–731.

Johnson DE, Ayala AG. Primary melanoma of penis. *Urology*. 1973;2:174–177.

Johnson DE, Lo RK. Management of regional lymph nodes in penile carcinoma: five-year results following therapeutic groin dissections. *Urology*. 1984;24:308–311.

Johnson DE, Lo RK. Complications of groin dissection in penile cancer: experience with 101 lymphadenectomies. *Urology*. 1984;24:312–314.

Johnson DE, Fuerst DE, Ayala AG. Carcinoma of the penis: experience in 153 cases. *Urology*. 1973;1:404–408.

Johnson DE, Lo RK, Srigley J, et al. Verrucous carcinoma of the penis. *J Urol*. 1985;133:216–218.

Jones VS, Chandra S, Smile SR, et al. A unique case of metastatic penile basal cell carcinoma. *Indian J Pathol Microbiol*. 2000;43:465–466.

Kamat AM, Plager C, Tamboli P, et al. Metastatic epithelioid hemangioendothelioma of the penis managed with surgery and interferon alpha. *J Urol*. 2004;171:1886–1887.

Kamat MR, Kulkarni JN, Tongaonkar HB. Carcinoma of the penis: the Indian experience. *J Surg Oncol*. 1993;52:50–55.

Kamsu-Kom L, Bidault F, Mazeron R, et al. Clinical experience with pulse dose rate brachytherapy for conservative treatment of penile carcinoma and comparison with historical data of low dose rate brachytherapy. *Clin Oncol (R Coll Radiol)*. 2015;27:387–393.

Kaposi M. Idiopathic multiple pigmented sarcoma of the skin. *Arch Dermatol Syph*. 1982;32:342–347.

Kellas-Sleczka S, Bialis B, Fijalkowski M, et al. Interstital HDR brachytherapy for penile cancer: a 13 year follow up of 55 patients. *Brachytherapy*. 2015;14:S33.

Kelley CD, Arthur K, Rogoff E, et al. Radiation therapy of penile cancer. *Urology*. 1974;4:571–573.

Kiltie AE, Elwell C, Close HJ, et al. Iridium-192 implantation for node-negative carcinoma of the penis: the Cookridge Hospital experience. *Clin Oncol*. 2000;12:25–31.

Kim ED, Kroft S, Dalton DP. Basal cell carcinoma of the penis: case report and review of the literature. *J Urol*. 1994;152:1557–1559.

Kinghorn GR, McMillan A, Mulcahy F, et al. An open comparative study of the efficacy of 0.5% podophyllotoxin lotion and 25% podophyllotoxin solution in the treatment of condylomata acuminata in males and females. *Int J STD AIDS*. 1993;4:194–199.

Kini MG. Cancer of penis in a child, aged two years. *Ind Med Gaz*. 1944;79:66–68.

Kinkade S, Meadows S, Gracia-Trujillo J. Clinical inquiries: does neonatal circumcision decrease morbidity? *J Fam Pract*. 2005;54:81–82.

Koh KBH, Nazarina AR. Paget's disease of the scrotum: report of a case with underlying carcinoma of the prostate. *Br J Dermatol*. 1995;133:306–307.

Kossow JH, Hotchkiss RS, Morales PA. Carcinoma of penis treated surgically: analysis of 100 cases. *Urology*. 1973;2:169–172.

Krebs HB. Genital HPV infections in men. *Clin Obstet Gynecol*. 1989;32:180–190.

Krebs HB. Genital human papillomavirus infection—management strategies. *Clin Obstet Gynecol*. 1989;32:200–213.

Krebs HB, Schneider V. Human papillomavirus–associated lesions of the penis: colposcopy, cytology, and histology. *Obstet Gynecol*. 1987;70:299–304.

Kroon BK, Horenblas S, Deurloo EE, et al. Ultrasonography-guided fine-needle aspiration cytology before sentinel node biopsy in patients with penile carcinoma. *BJU Int*. 2005;95:517–521.

Kroon BK, Horenblas S, Estourgie SH, et al. How to avoid false-negative dynamic sentinel node procedures in penile carcinoma. *J Urol*. 2004;171(Pt 1):2191–2194.

Kroon BK, Horenblas S, Lont AP, et al. Patients with penile carcinoma benefit from immediate resection of clinically occult lymph node metastases. *J Urol*. 2005;173:816–819.

Kroon BK, Lont AP, Valdes Olmos RA, et al. Morbidity of dynamic sentinel node biopsy in penile carcinoma [see comment]. *J Urol*. 2005;173:813–815.

Krunic AL, Djerdj K, Starcevic-Bozovic A, et al. Pseudoepitheliomatous, keratotic, and micaceous balanitis. *Urol Int*. 1996;56:125–128.

Krusrup DK, Jensen HL, van den Brute AJC, et al. Histological characteristics of human papilloma-virus-positive and -negative invasive and in situ squamous cell tumours of the penis. *Int J Exp Pathol*. 2009;90(2):182–189.

Kumar V, Sethia KK. Prospective study compring video-endoscopic rdical inguinal lymph node dissection (VEILND) with open radical ILND(OILND) for penile cancer over an 8-year period. *BJU Int*. 2017;119:530–534.

Kumaran MS, Kanwar AJ. Squamous cell carcinoma in untreated lichen sclerosus of the penis: a rare complication. *J Dermatol*. 2004;31(3):239–241.

Kuruvilla JT, Garlick FH, Mammen KE. Results of surgical treatment of carcinoma of the penis. *Aust N Z J Surg*. 1971;41:157–159.

Kyalwazi SK, Bhama D, Harrison NW. Carcinoma of the penis and bleomycin chemotherapy in Uganda. *Br J Urol*. 1974;46:689–696.

Ladocsi LT, Siebert CF, Rickert RR, et al. Basal cell carcinoma of the penis. *Cutis*. 1998;61:25–27.

Lancaster WD, Castellano C, Santos C, et al. Human papillomavirus deoxyribonucleic acid in cervical carcinoma from primary and metastatic sites. *Am J Obstet Gynecol*. 1986;154:115–119.

Lands RH, Ange D, Hartman DL. Radiation therapy for classic Kaposi's sarcoma presenting only on the glans penis. *J Urol*. 1992;147:468–470.

Landthaler M, Haina D, Brunner R, et al. Laser therapy of bowenoid papulosis and Bowen's disease. *J Dermatol Surg Oncol*. 1986;12:1253–1257.

Lapierre A, Riou O, Flechon A, et al. Advanced penile cancer with iliac lymph node involvement treated with radiation and concurrent gemcitabine. *Cancer Radiother*. 2017;21:134–137.

Laymon CW, Freeman C. Relationship of balanitis xerotica obliterans to lichen sclerosus et atrophicus. *Arch Dermatol Syph*. 1944;49:57–59.

Lee LJ, Howitt B, Catalano P, et al. Prognostic importance of human papillomavirus (HPV) and p16 positivity in squamous cell carcinoma of the vulva treated with radiotherapy. *Gynecol Oncol*. 2016.

Leijte JAP, Gallee M, Antonini N, et al. Evaluation of current TNM classification of penile carcinoma. *J Urol*.

2008;180:933–938.

Leijte JAP, Kirrander P, Antonini N, et al. Recurrence patterns of squamous cell carcinoma of the penis: recommendations for follow-up based on a two-centre analysis of 700 patients. *Eur Urol*. 2008;54:161–169.

Leijte JAP, Hughes B, Graafland NM, et al. Two-center evaluation of dynamic sentinel node biopsy for squamous cell carcinoma of the penis. *J Clin Oncol*. 2009;27(20):3325–3329.

Leijte JAP, Graafland NM, Olmos RAV, et al. Prospective evaluation of hybrid 18F-fluorodeoxyglucose positron emission tomography/computed tomography in staging clinically node-negative patients with penile carcinoma. *BJU Int*. 2009;104(5):640–644.

Leijte JAP, Kerst JM, Bais E, et al. Neoadjuvant chemotherapy in advanced penile carcinoma. *Eur Urol*. 2007;52(2):448–494.

Lepor H, Leffler N. Giant condylomata acuminata (Buschke-Löwenstein tumor): report of two cases. *J Urol*. 1960;83:853–858.

Levenback C, Burke TW, Gershenson DM, et al. Intraoperative lymphatic mapping for vulvar cancer. *Obstet Gynecol*. 1994;163–167.

Levi JE, Rahal P, Sarkis AS, et al. Human papillomavirus DNA and p53 status in penile carcinomas. *Int J Cancer*. 1998;76:779–783.

Leviav A, Devine PC, Schellhammer PF, et al. Epithelioid sarcoma of the penis. *Clin Plast Surg*. 1988;15:489–492.

Lewis RJ, Bendl BJ. Erythroplasia of Queyrat: report of a patient successfully treated with topical 5-fluorouracil. *Can Med Assoc J*. 1971;104:148–149.

Li Z-S, Yao K, Chen P, et al. Modification of N staging systems for penile cancer: a more precise prediction of prognosis. *Br J*

Cancer. 2015;112:1766–1771.

Licklider S. Jewish penile carcinoma. *J Urol*. 1961;86:98.

Link RE, Soltes GD, Coburn M. Treatment of acute inguinal hemorrhage from metastatic penile carcinoma using an endovascular stent graft. *J Urol*. 2004;173:1878–1879.

Lont AP, Besnard AP, Gallee MP, et al. A comparison of physical examination and imaging in determining the extent of primary penile carcinoma. *BJU Int*. 2003;91:493–495.

Lont AP, Kroon BK, Gallee MP, et al. Pelvic lymph node dissection for penile carcinoma: extent of inguinal lymph node involvement as an indicator for pelvic lymph node involvement and survival. *J Urol*. 2007;177:947.

Lont AP, Gallee MP, Meinhardt W, et al. Penis conserving treatment for T1 and T2 penile carcinoma: clinical implications of a local recurrence. *J Urol*. 2006;176:575–580.

Lopes A, Hidalgo GS, Kowalski LP, et al. Prognostic factors in carcinoma of the penis: multivariate analysis of 145 patients treated with amputation and lymphadenectomy. *J Urol*. 1996;156:1637–1642.

Lopes A, Bezerra AL, Serrano SV, et al. Iliac nodal metastases from carcinoma of the penis treated surgically. *BJU Int*. 2000;86:690–693.

Lowe FC, Lattimer DG, Metroka CE. Kaposi's sarcoma of the penis in patients with acquired immunodeficiency syndrome. *J Urol*. 1989;142:1475–1477.

Lucia MS, Miller GJ. Histopathology of malignant lesions of the penis. *Urol Clin North Am*. 1992;19:227–246.

Lynch HT, Krush AJ. Delay factors in detection of cancer of the penis. *Nebr State Med J*. 1969;54:360.

Maden C, Sherman KJ, Beckman AM, et al. History of circumcision, medical conditions, and sexual activity and risk of penile cancer. *J Natl Cancer Inst*. 1993;85:19–24.

Maiche AG. Epidemiological aspects of cancer of the penis in

Finland. *Eur J Cancer Prev*. 1992;1:153–158.

Maiche AG, Pyrhonen S. Karkinem M: histological grading of squamous cell carcinoma of the penis: a new scoring system. *Br J Urol*. 1991;67:522–526.

Malakoff AF, Schmidt JD. Metastatic carcinoma of penis complicated by hypercalcemia. *Urology*. 1975;5:510–513.

Malek RS, Goellner JR, Smith TF, et al. Human papillomavirus infection and intraepithelial, in situ, and invasive carcinoma of the penis. *Urology*. 1993;42(2):159–170.

Malloy TR, Wein AJ, Carpiniello VL. Carcinoma of the penis treated with neodymium YAG laser. *Urology*. 1988;31:26–29.

Manivel JC, Fraley EE. Malignant melanoma of the penis and male urethra: 4 case reports and literature review. *J Urol*. 1988;139:813–816.

Marcial VA, Figueroa-Colen J, Marcial-Rojas RA, et al. Carcinoma of the penis. *Radiology*. 1962;79:209–220.

Marks D, Crosthwaite A, Varigos G, et al. Therapy of primary diffuse large cell lymphoma of the penis with preservation of function. *J Urol*. 1988;139:1057–1058.

Master VA, Mohammad S, Jafri A, et al. Minimally invasive inguinal lymphadenectomy via endoscopic groin dissection: comprehensive assessment of immediate and long-term complications. *J Urol*. 2012;188:1176–1180.

Matin SF, Cormier JN, Ward JF, et al. Phase 1 prospective evaluation of the oncological adequacy of robotic assisted video-endoscopic inguinal lymphadenectomy in patients with penile carcinoma. *BJU Int*. 2013;111(7):1068–1074.

Matys R, Kubicka-Mendak I, Lyczek J, et al. Penile cancer brachytherapy HDR mould technique used at the Holycross Cancer Center. *J Contemp Brachytherapy*. 2011;3:224–229.

Mazeron JJ, Langlois D, Lobo PA, et al. Interstitial radiation therapy for carcinoma of the penis using iridium 192 wires: the Henri Mondor experience (1970–79). *Int J Radiat Oncol*

Biol Phys. 1984;10:1891–1895.

McCrea LW, Tobias GL. Metastatic disease of the penis. *J Urol*. 1958;80:489–500.

McDougal WS. Carcinoma of the penis: improved survival by early regional lymphadenectomy based on the histological grade and depth of invasion of the primary lesion. *J Urol*. 1995;154:1364–1366.

McDougal WS, Kirchner FK Jr, Edwards RH, et al. Treatment of carcinoma of the penis: the case of primary lymphadenectomy. *J Urol*. 1986;136:38–41.

McKay DL Jr, Fuqua F, Weinberg AG. Balanitis xerotica obliterans in children. *J Urol*. 1975;114:773–775.

McLean M, Akl AM, Warde P, et al. The results of primary radiation therapy in the management of squamous cell carcinoma of the penis. *Int J Radiat Oncol Biol Phys*. 1993;25:623–628.

Micali G, Nasca MR, Innocenzi D. Lichen sclerosus of the glans is significantly associated with penile carcinoma. *Sex Transm Infect*. 2001;77:229.

Miles SA. Pathogenesis of HIV-related Kaposi's sarcoma. *Curr Opin Oncol*. 1994;6:497–502.

Miller G, Rigsby MO, Heston L, et al. Antibodies to butyrate-inducible antigens of Kaposi's sarcoma–associated herpesvirus in patients with HIV-1 infection. *N Engl J Med*. 1996;334:1292–1297.

Mills EE. Intermittent intravenous methotrexate in the treatment of advanced epidermoid carcinoma. *S Afr Med J*. 1972;46:398–401.

Minardi D, Lucarini G, Filosa A, et al. Prognostic value of CD44 expression in penile squamous cell carcinoma: a pilot study. *Cell Oncol*. 2012;35(5):377–384.

Minhas S, Kayes O, Hegarty P, et al. What surgical resection margins are required to achieve oncological control in men with primary penile cancer? *BJU Int*. 2005;96:1040–1043.

Misra S, Chaturvedi A, Misra NC. Penile carcinoma: a challenge for the developing world. *Lancet Oncol*. 2004;5:240–247.

Mistry T, Jones RWA, Dannatt E, et al. A 10-year retrospective audit of penile cancer management in the UK. *BJU Int*. 2007;100:1277–1281.

Moch H, Cubilla AL, Humphrey PA, et al. The 2016 WHO Classification of tumours of the urinary system and male genital organs-part a: renal, penile, and testicular tumours. *Eur Urol*. 2016;70(1):93–105.

Mohs FE, Snow SN, Messing EM, et al. Microscopically controlled surgery in the treatment of carcinoma of the penis. *J Urol*. 1985;133:961–966.

Mohs FE, Snow SN, Larson PO. Mohs micrographic surgery for penile tumors. *Urol Clin North Am*. 1992;19:291–304.

Montana GS, Thomas GM, Moore DH, et al. Preoperative chemo-radiation for carcinoma of the vulva with N2/N3 nodes: a gynecologic oncology group study. *Int J Radiat Oncol Biol Phys*. 2000;48(4):1007–1013.

Moore SW, Wheeler JE, Hefter LG. Epithelioid sarcoma masquerading as Peyronie's disease. *Cancer*. 1975;35:1706–1710.

Morelli I, Pusiol T, Pisioli F, et al. Herpesvirus 8-associated penile Kaposi's sarcoma in an HIV-negative patient. *Am J Dermatopathol*. 2003;25(1):28–31.

Morton DL, Wen DR, Wong JH, et al. Technical details of intraoperative lymphatic mapping for early stage melanoma. *Arch Surg*. 1992;127:392–399.

Morton RA, Lipton A. Hypercalcemia. Abeloff MD, Armitage JO, Lichter AS, et al. *Clinical oncology*. ed 2. Churchill Livingstone: Philadelphia; 2000:719–735.

Mukamel E, Farrer J, Smith RB, et al. Metastatic carcinoma for penis: when is total penectomy indicated? *Urology*. 1987;29:15–18.

Muneer A, Kayes O, Ahmed HU, et al. Molecular prognostic factors in penile cancer. *World J Urol*. 2009;27:161–167.

Munger K, Phelps WC, Bubb V, et al. The E6 and E7 genes of the human papillomavirus type 16 together are necessary and sufficient for transformation of primary human keratinocytes. *J Virol*. 1989;63:4417–4421.

Narasimharao KL, Chatterjee H, Veliath AJ. Penile carcinoma in the first decade of life. *Br J Urol*. 1985;57:358.

Narayana AS, Olney LE, Loening SA, et al. Carcinoma of the penis: analysis of 219 cases. *Cancer*. 1982;49:2185–2191.

Nasca MR, Innocenzi D, Micali G. Penile cancer among patients with genital lichen sclerosus. *J Am Acad Dermatol*. 1999;41:911–914.

National Cancer Institute Position Statement. *National Cancer Institute position statement: Kaposi's sarcoma*. [August 21] Physician Data Query (database). 1990 [August 21, 1990.1-11].

Naumann CM, Alkatout I, Al-Najar A, et al. Lymph node metastasis in intermediate-risk squamous cell carcinoma of the penis. *BJU Int*. 2008;102:1102–1106.

NCCN Clinical Practice Guidelines in Oncology. *Penile Cancer Ver 2.2018*. [National Comprehensive Cancer Network] NCCN.org; 2018.

Neave F, Neal AJ, Hoskin PJ, et al. Carcinoma of the penis: a retrospective review of treatment with iridium mold and extenal beam irradiation. *Clin Oncol*. 1993;5:207–210.

Nelson BA, Cookson MS, Smith JA Jr, et al. Complications of inguinal and pelvic lymphadenectomy for squamous cell carcinoma of the penis: a contemporary series. *J Urol*. 2004;172:494–497.

Nguyen H, Saadat P, Bennett RG. Penile basal cell carcinoma:

two cases treated with Mohs micrographic surgery and remarks on pathogenesis. *Dermatol Surg*. 2006;32:135–144.

Nicholson S, Hall E, Harland SJ, et al. Phase II trial of docetaxel, cisplatin and 5FU chemotherapy in locally advanced and metastatic penis cancer (CRUK/09/001). *Br J Cancer*. 2013;109(10):2554–2559.

Nielson CM, Flores R, Harris RB, et al. Human papillomavirus prevalence and type distribution in male anogenital sites and semen. *Cancer Epidemiol Biomarkers Prev*. 2007;16(6):1107–1114.

Northfelt DW. Cervical and anal neoplasia and HPV infection in persons with HIV infection. *Oncology (Williston Park)*. 1994;8:33.

O'Connor WJ, Lim KK, Zalla MJ, et al. Comparison of Mohs micrographical surgery and wide excision for extrammary Paget's disease. *Dermatol Surg*. 2003;29:723–727.

Ojeda VJ, Heenan PJ, Watson SH. Paget's disease of the groin associated with adenocarcinoma of the urinary bladder. *J Cutan Pathol*. 1987;14:227–231.

Olesen TB, Mwaiselage J, Iftner T, et al. Risk factors for genital human papillomavirus among men in Tanzania. *J Med Virol*. 2017;89(2):345–351.

Opjordsmoen S, Fossa SD. Quality of life in patients treated for penile cancer: a follow-up study. *Br J Urol*. 1994;74:652–657.

Ornellas AA, Seixas AL, Marota A, et al. Surgical treatment of invasive squamous cell carcinoma of the penis: retrospective analysis of 350 cases. *J Urol*. 1994;151:1244–1249.

Ozsahin M, Jichlinski P, Weber DC, et al. Treatment of penile carcinoma: to cut or not to cut? *Int J Radiat Oncol Biol Phys*. 2006;66(3):674–679.

Pak K, Sakaguchi N, Takayama H, et al. Rhabdomyosarcoma of the penis. *J Urol*. 1986;136:438–439.

Pagliaro LC, Williams DL, Daliani D, et al. Neoadjuvant paclitaxel, ifosfamide, and cisplatin chemotherapy for metastatic penile cancer: a phase II study. *J Clin Oncol*. 2010;28(24):3851–3857.

Park S, Grossfeld GD, McAninch JW, et al. Extramammary Paget's disease of the penis and scrotum: excision, reconstruction and evaluation of occult malignancy. *J Urol*. 2001;166:2112–2117.

Park SO, Ha JH, Hong KY, et al. Usefulness of mapping biopsy in the treatment of penoscrotal extramammary Paget's disease. *Ann Surg Oncol*. 2017;24(11):3229–3236.

Parra RO. Accurate staging of carcinoma of the penis in men with nonpalpable inguinal lymph nodes by modified inguinal lymphadenectomy. *J Urol*. 1996;155:560–563.

Parsons MA, Fox M. Malignant fibrous histiocytoma of the penis. *Eur Urol*. 1988;14:75–76.

Patterson JW, Kao GF, Graham JH, et al. Bowenoid papulosis: a clinicopathologic study with ultrastructural observations. *Cancer*. 1986;57:823–836.

Perinetti E, Crane DB, Catalona WJ. Unreliability of sentinel lymph node biopsy for staging penile carcinoma. *J Urol*. 1980;124:734–735.

Persky L. Epidemiology of cancer of the penis. *Recent Results Cancer Res*. 1977;60:97–109.

Petera J, Sirak I, Kasaova L, et al. High-dose rate brachytherapy in the treatment of penile carcinoma–first experience. *Brachytherapy*. 2011;10:136–140.

Peters MS, Perry HO. Bowenoid papules of the penis. *J Urol*. 1981;126:482–484.

Petrosky E, Bocchini JA, Hariri S, et al. Use of 9-valent human papillomavirus (HPV) vaccine: updated HPV vaccination recommendations of the advisory committee on immunization practices. *MMWR Morb Mortal Wkly Rep*.

2015;64:300–304.

Pettaway CA, Pisters LL, Dinney CP, et al. Sentinel lymph node biopsy for penile squamous carcinoma: the M.D. Anderson Cancer Center experience. *J Urol*. 1995;154:1999–2003.

Pettaway CA, Lynch D, Davis J, et al. Tumors of the penis. Wein AJ, Kavoussi LR, Novick AC. *Campbell-Walsh urology*. ed 9. WB Saunders: Philadelphia; 2007:959.

Pettaway CA, Pagliaro LC, Theodore C, et al. Treatment of visceral, unresectable, or bulky/unresectable regional metastases of penile cancer. *Urology*. 2010;76(2):S58–S65.

Pettaway CA, Srigley JR, Brookland RK, et al. Penis. Amin MB, Edge SB, Greene FL. *AJCC cancer staging manual*. ed 8. Springer: New York; 2017:699–712.

Pettaway CA. Usefulness of mapping biopsy in the treatment of penoscrotal extramammary Paget's Disease. *Ann Surg Oncol*. 2017;24(11):3115.

Philippou P, Shabbir M, Malone P, et al. Conservative surgery for squamous cell carcinoma of the penis: resection margins and long-term oncological control. *J Urol*. 2012;188(3):803–808.

Pietrzak P, Corbishley C, Watkin N. Organ-sparing surgery for invasive penile cancer: early follow-up data. *BJU Int*. 2004;94:1253–1257.

Pietrzak P, Hadway P, Corbishley CM, et al. Is the association between bala- nitis xerotica obliterans and penile carcinoma under- estimated? *BJU Int*. 2006;98:74–76.

Pimenta A, Gutierrez C, Mosquera D, et al. Penile brachytherapy-Retrospective review of a single institution. *Brachytherapy*. 2015;14:525–530.

Pizzocaro G, Piva L. Adjuvant and neoadjuvant vincristine, bleomycin, and methotrexate for inguinal metastases from squamous cell carcinoma of the penis. *Acta Oncol*. 1988;27:823–824.

Pizzocaro G, Piva L, Bandieramonte G, et al. Up-to-date management of carcinoma of the penis. *Eur Urol*. 1997;32:5–15.

Pizzocaro G, Piva L, Nicolai N. Improved management of nodal metastases of squamous cell carcinoma (SCC) of the penis. *J Urol*. 1995;153:246a.

Pizzocaro G, Algaba F, Horenblas S, et al. EAU penile cancer guidelines 2009. *Eur Urol*. 2010;57:1002–1012.

Planz B, Brunner K, Kalem T, et al. Primary leiomyosarcoma of the epididymis and late recurrence on the penis. *J Urol*. 1998;159:508.

Poblet E, Alfaro L, Fernander-Segoviano P, et al. Human papillomavirus–associated penile squamous cell carcinoma in HIV positive patients. *Am J Surg Pathol*. 1999;23:1119–1126.

Pochedly C, Mehta A, Feingold E. Priapism with hyperacute stem-cell leukemia. *N Y State J Med*. 1974;74:540–541.

Poetsch M, Hemmerich M, Kakies C, et al. Alterations in the tumor suppressor gene p16(INK4A) are associated with aggressive behavior of penile carcinomas. *Virchows Arch*. 2011;458:221.

Pompeo AC, Mesquita JL, Junior WA, et al. Staged inguinal lymphadenectomy (SIL) for carcinoma of the penis (CP): 13 years prospective study of 50 patients. *J Urol*. 1995;153:246a.

Pompeo ACL, Heyns CF, Abrams P. *Penile cancer: international consultation on penile cancer, Santiago, Chile, November 2008*. [Montreal: Société Internationale d'Urologie (SIU)] 2009.

Porter WM, Francis N, Hawkins D, et al. Penile intraepithelial neoplasia: clinical spectrum and treatment of 35 cases. *Br J Dermatol*. 2002;147(6):1159–1165.

Pow-Sang JE, Benavente V, Pow-Sang JM, et al. Bilateral ilioinguinal lymph node dissection in the management of cancer of the penis. *Semin Surg Oncol*. 1990;6:241–242.

Powell J, Wojnarowska F. Lichen sclerosus. *Lancet*. 1999;353:1777–1783.

Poynter JH, Levy J. Balanitis xerotica obliterans: effective treatment with topical and sublesional steroids. *Br J Urol*. 1967;39:420–425.

Pratt RM, Ross RTA. Leiomyosarcoma of the penis. *Br J Surg*. 1969;56:870–872.

Pressman D, Rolnick D, Turbow B. Penile horn. *Am J Surg*. 1962;104:640–641.

Pugliese JM, Morey AF, Peterson AC. Lichen sclerosus: review of the literature and current recommendations for management. *J Urol*. 2007;178:2268–2276.

Puras A, Gonzalez-Flores B, Fortuno R, et al. Treatment of carcinoma of the penis. *Proc Kimbrough Urol Semin*. 1978;12:143.

Puras-Baez A, Rivera-Herrera J, Miranda G, et al. Role of superficial inguinal lymphadenectomy in carcinoma of the penis. *J Urol*. 1995;153:246a.

Rasbridge SA, Parry JR. Angiosarcoma of the penis. *Br J Urol*. 1989;63:440–441.

Ravi R. Prophylactic lymphadenectomy vs observation vs inguinal biopsy in node-negative patients with invasive carcinoma of the penis. *Jpn J Clin Oncol*. 1993;23:53–58.

Ravi R. Correlation between the extent of nodal involvement and survival following groin dissection for carcinoma of the penis. *Br J Urol*. 1993;72:817–819.

Ravi R, Chaturvedi HK, Sastry DV. Role of radiation therapy in the treatment of carcinoma of the penis. *Br J Urol*. 1994;74:646–651.

Reddy CR, Devendranath V, Pratap S. Carcinoma of penis—role of phimosis. *Urology*. 1984;24:85–88.

Reddy DG, Baruah IK. Carcinogenic action of human smegma.

Arch Pathol. 1963;75:414–420.

Redman JF, Meacham KR. Condyloma acuminata of the urethral meatus in children. *J Pediatr Surg*. 1973;8:939–941.

Reynolds SJ, Shepherd ME, Risbud AR, et al. Male circumcision and risk of HIV-1 and other sexually transmitted infections in India. *Lancet*. 2004;363:1039–1040.

Rhatigan RM, Jimenez S, Chopskie EJ. Condyloma acuminatum and carcinoma of the penis. *South Med J*. 1972;65:423–428.

Rippentrop JM, Joslyn SA, Konety BR. Squamous cell carcinoma of the penis: evaluation of data from the Surveillance, Epidemiology, and End Results Program. *Cancer*. 2004;101:1357–1363.

Robey EL, Schellhammer PF. Four cases of metastases to the penis and a review of the literature. *J Urol*. 1984;132:992–994.

Romero FR, de Castro MG, Garcia CR, et al. Adenosquamous carcinoma of the penis. *Clinics (São Paulo)*. 2006;61(4):363–364.

Rose PG. Chemoradiotherapy for cervical cancer. *Eur J Cancer*. 2002;38(2):270–278.

Rosemberg SK, Fuller TA. Carbon dioxide rapid superpulsed laser treatment of erythroplasia of Queyrat. *Urology*. 1980;16:181–182.

Rouscoff Y, Falk AT, Durand M, et al. High-dose rate brachytherapy in localized penile cancer: short-term clinical outcome analysis. *Radiat Oncol*. 2014;9 [142-717X-9-142].

Rozan R, Albuisson E, Giraud B, et al. Interstitial brachytherapy for penile carcinoma: a multicentric survey (259 patients). *Radiother Oncol*. 1995;36:85–93.

Rubin MA, Kleter B, Zhou M, et al. Detection and typing of human papillomavirus DNA in penile carcinoma. *Am J Pathol*. 2001;59:1211–1218.

Rudd FV, Rott RK, Skoglund RW Jr, et al. Tumor-induced hypercalcemia. *J Urol*. 1972;107:986–989.

Ruszczak Z, Stadler R, Schwartz RA. Kaposi's sarcoma limited to penis treated with cobalt-60 radiotherapy. *J Med*. 1996;27:211–220.

Sacker AR, Oyama KK, Kessler S. Primary osteosarcoma of the penis. *Am J Dermatopathol*. 1994;16:285–287.

Saisorn I, Lawrentschuk N, Leewansangtong S, et al. Fine-needle aspiration cytology predicts inguinal lymph node metastasis without antibiotic pretreatment in penile carcinoma. *BJU Int*. 2006;97:1225–1228.

Sanchez DF, Canete S, Fernandez-Nestosa MJF, et al. HPV- and non-HPV-related subtypes of penile squamous cell carcinoma (SCC): morphological features and differential diagnosis according to the new WHO classification 2015. *Semin Diagn Pathol*. 2015;32:198–221.

Sanchez-Ortiz RF, Pettaway CA. Natural history, management, and surveillance of recurrent penile squamous cell carcinoma: a risk-based approach. *Urol Clin North Am*. 2003;30:853–867.

Sanchez-Ortiz R, Huang SF, Tamboli P, et al. Melanoma of the penis, scrotum and male urethra: a 40-year single institution experience. *J Urol*. 2005;173:1958–1965.

Sanchez-Ortiz R, Huang SF, Tamboli P, et al. Letters to the Editor. Reply by Authors: melanoma of the penis, scrotum and male urethra: a 40-year single institution experience. *J Urol*. 2006;175(4):1574–1576.

Sanders CJG. Condylomata acuminata of the penis progressing rapidly to invasive squamous cell carcinoma. *Genitourin Med*. 1997;73:402–403.

Sarin R, Norman AR, Steel GG, et al. Treatment results and prognostic factors in 101 men treated for squamous carcinoma of the penis. *Int J Radiat Oncol Biol Phys*.

1997;38:713–722.

Scappini P, Piscioli F, Pusiol T, et al. Penile cancer: aspiration biopsy cytology for staging. *Cancer*. 1986;58:1526–1533.

Scardino E, Villa G, Bonomo G, et al. Magnetic resonance imaging combined with artificial erection for local staging of penile cancer. *Urology*. 2004;63:1158–1162.

Scher M, Seitz M, Reiser M, et al. 18F-FDG PET/CT for staging of penile cancer. *J Nucl Med*. 2005;46:1460.

Schneider V. Microscopic diagnosis of HPV infection. *Clin Obstet Gynecol*. 1989;32:148–156.

Schoen EJ, Anderson G, Bohon C, et al. Task force on circumcision, report of the task force on circumcision. *Pediatrics*. 1989;84:388–391.

Schoen EJ, Oehrli M, Colby C, et al. The highly protective effect of newborn circumcision against invasive penile cancer. *Pediatrics*. 2000;105:E36.

Sedlacek TV, Cunnane M, Carpiniello V. Colposcopy in the diagnosis of penile condyloma. *Am J Obstet Gynecol*. 1986;154:494–496.

Seftel AD, Sadick NS, Waldbaum RS. Kaposi's sarcoma of the penis in a patient with the acquired immune deficiency syndrome. *J Urol*. 1986;136:673–675.

Seibold J, Strnad V, Fietkau R. Organ-sparing treatment of penile cancer with interstitial pulsed-dose-rate brachytherapy. *Strahlenther Onkol*. 2016;192:467–472.

Seixas ALC, Ornellas AA, Marota A, et al. Verrucous carcinoma of the penis: retrospective analysis of 32 cases. *J Urol*. 1994;152:1476–1479.

Shabbir M, Minhas S, Muneer A. Diagnosis and management of premalignant penile lesions. *Ther Adv Urol*. 2011;3(3):151–158.

Shabbir M, Muneer A, Kalsi J, et al. Glans resurfacing for the treatment of carcinoma in situ of the penis: surgical technique and outcomes. *Eur Urol*. 2011;59(1):142–147.

Shapiro E. American Academy of Pediatrics policy statements on circumcision and urinary tract infection. *Rev Urol*. 1999;1:154–156.

Sharma DN, Joshi NP, Gandhi AK, et al. High-dose-rate interstitial brachytherapy for T1-T2-stage penile carcinoma: short-term results. *Brachytherapy*. 2014;13:481–487.

Sharma P, Djajadiningrat R, Zargar-Shoshtari K, et al. Adjuvant chemotherapy is associated with improved overall survival in pelvic node-positive penile cancer after lymph node dissection: a multi-institutional study. *Urol Oncol*. 2015;33(11):496.e17–496.e23.

Shindel AW, Mann MW, Lev RY, et al. Mohs micrographic surgery for penile cancer: management and long-term followup. *J Urol*. 2007;178:1980–1985.

Simonart T, Noel JC, De Dobbeleer G, et al. Carcinoma of the glans penis arising 20 years after lichen sclerosus. *Dermatology*. 1998;196:337–338.

Simpson GR, Schulz TF, Whitby D, et al. Prevalence of Kaposi's sarcoma associated herpesvirus infection measured by antibodies to recombinant capsid protein and latent immunofluorescence antigen. *Lancet*. 1996;348:1133–1138.

Sitas F, Carrara H, Beral V, et al. Antibodies against human herpesvirus-8 in black South African patients with cancer. *N Engl J Med*. 1999;340:1863–1871.

Skinner DG, Leadbetter WF, Kelley SB. The surgical management of squamous cell carcinoma of the penis. *J Urol*. 1972;107:273–277.

Sklaroff RB, Yagoda A. Penile cancer: natural history and therapy. Spiers ASD. *Chemotherapy and urological malignancy*. Springer-Verlag: New York; 1982:98–105.

Slaton JW, Morgenstern N, Levy DA, et al. Tumor stage, vascular invasion and the percentage of poorly differentiated cancer: independent prognosticators for inguinal lymph node metastasis in penile squamous cancer. *J Urol*. 2001;165:1138–1142.

Smotkin D. Virology of human papillomavirus. *Clin Obstet Gynecol*. 1989;32:117–126.

Snoeck R, Bossens M, Parent D, et al. Phase II double-blind placebo-controlled study of the safety and efficacy of cidofovir topical gel for the treatment of patients with human papillomavirus infection. *Clin Infect Dis*. 2001;33:597–602.

Solivan GA, Smith KJ, James WD. Cutaneous horn of the penis: its association with squamous cell carcinoma and HPV-16 infection. *J Am Acad Dermatol*. 1990;23(Pt 2):969–972.

Solsona E, Iborra I, Ricos JV, et al. Corpus cavernosum invasion and tumor grade in the prediction of lymph node condition in penile carcinoma. *Eur Urol*. 1992;22:115–118.

Solsona E, Iborra I, Rubio J, et al. Prospective validation of the association of local tumor stage and grade as a predictive factor for occult lymph node micrometastasis in patients with penile carcinoma and clinically negative inguinal lymph nodes. *J Urol*. 2001;165(5):1506–1509.

Solsona E, Algaba F, Horenblas S, et al. EAU guidelines on penile cancer. *Eur Urol*. 2004;46:1–18.

Soria JC, Fizazi K, Kramar A, et al. Squamous cell carcinoma of the penis: multivariate analysis of prognostic factors and natural history in a monocentric study with a conservative policy. *Ann Oncol*. 1997;8:1089.

Sotelo R, Sanchez-Salas R, Carmano O, et al. Endoscopic lymphadenectomy for penile carcinoma. *J Endourol*. 2007;21:364–367.

Sotelo R, Sanchez-Salas R, Clavijo R. Endoscopic inguinal lymph node dissection for penile carcinoma: the development of a novel technique. *World J Urol*. 2009;27:213–219.

Spaulding JT, Whitmore WF Jr. Extended total excision of prostatic adenocarcinoma. *J Urol*. 1978;120:188–190.

Spiess PE, Izawa JI, Bassett R, et al. Pre-operative lymphoscintigraphy and dynamic sentinel node biopsy in staging penile cancer: results with pathologic correlation. *J Urol*. 2007;177(6):2157–2161.

Spiess PE, Hernandez MS, Pettaway CA. Contemporary inguinal node dissection: minimizing complications. *World J Urol*. 2009;27:205–212.

Srinivas V, Morse MJ, Herr HW, et al. Penile cancer: relation of extent of nodal metastasis to survival. *J Urol*. 1987;137:880–882.

Stankiewicz E, Prowse DM, Ktori E, et al. The retinoblastoma protein/p16 INK4A pathway but not p53 is disrupted by human papillomavirus in penile squamous cell carcinoma. *Histopathology*. 2011;58(3):433–439.

Staubitz WJ, Melbourne HL, Oberkircher OJ. Carcinoma of the penis. *Cancer*. 1955;8:371–378.

Stehman FB, Ali S, Keys HM, et al. Radiation therapy with or without weekly cisplatin for bulky stage 1B cervical carcinoma: follow-up of a Gynecologic Oncology Group trial. *Am J Obstet Gynecol*. 2007;197:503.e1–503.e6.

Stone KM. Epidemiologic aspects of genital HPV infection. *Clin Obstet Gynecol*. 1989;32:112–116.

Su CK, Shipley WU. Bowenoid papulosis: a benign lesion of the shaft of the penis misdiagnosed as squamous carcinoma. *J Urol*. 1997;157:1361–1362.

Sufrin G, Huben R. Benign and malignant lesions of the penis. Gillenwater JY. *Adult and pediatric urology*. ed 2. Year Book: Chicago; 1991:1997–2042.

Sun M, Djajadiningrat RS, Alnajar HM, et al. Development and external validation of a prognostic tool for prediction of cancer –specific mortality after complete loco-regional pathological staging for squamous cell carcinoma of the penis. BJU International. *Eur Urol*. 2015;67:142–150; 10.1111/bju.12677.

Tabatabaei S, Harisinghani M, McDougal WS. Regional lymph node staging using lymphotropic nanoparticle enhanced magnetic resonance imaging with ferumoxtran-10 in patients with penile cancer. *J Urol*. 2005;174:925.

Tang DH, Djajadiningrat R, Diorio G, et al. Adjuvant pelvic radiation is associated with improved survival and decreased disease recurrence in pelvic node-positive penile cancer after lymph node dissection: a multi-institutional study. *Urol Oncol*. 2017;35:605.e17–605.e23.

Task Force On Circumcision, American Academy of Pediatrics. Circumcision policy statement. *Pediatrics*. 2012;130:585.

Theodore C, Skoneczna I, Bodrogi I, et al. A phase II multicentre study of irinotecan (CPT 11) in combination with cisplatin (CDDP) in metastatic or locally advanced penile carcinoma (EORTC PROTOCOL 30992). *Ann Oncol*. 2008;19:1304.

Theodorescu D, Russo P, Zhang ZF, et al. Outcomes of initial surveillance of invasive squamous cell carcinoma of the penis and negative nodes. *J Urol*. 1996;155:1626–1631.

Thomas JA, Small CS. Carcinoma of the penis in Southern India. *J Urol*. 1968;100(4):520–526.

Tietjen DN, Malek RS. Laser therapy of squamous cell dysplasia and carcinoma of the penis. *Urology*. 1998;52:559–565.

Tobias-Machado M, Tavares A, Ornellas AA, et al. Video endoscopic inguinal lymphadenectomy: a new minimally invasive procedure for radical management of inguinal nodes in patients with penile squamous cell carcinoma. *J Urol*. 2007;177:953–957.

van Bezooijen BP, Horenblas S, Meinhardt W, et al. Laser therapy for carcinoma in situ of the penis. *J Urol*.

2001;166:1670–1671.

van Geel AN, den Bakker MA, Kirkels W, et al. Prognosis of primary mucosal penile melanoma: a series of 19 Dutch patients and 47 patients from the literature. *Urology*. 2007;70:1437.

Vapnek JM, Hricak H, Carroll PR. Recent advances in imaging studies for staging of penile and urethral carcinoma. *Urol Clin North Am*. 1992;19:257–266.

Varma VA, Sanchez-Lanier M, Unger ER, et al. Association of human papillomavirus with penile carcinoma: a study using polymerase chain reaction and in situ hybridization. *Hum Pathol*. 1991;22:908–913.

Velazquez EF, Ayala G, Liu H, et al. Histologic grade and perineural invasion are more important than tumor thickness as predictor of nodal metastasis in penile squamous cell carcinoma invading 5 to 10 mm. *Am J Pathol*. 2008;32(7):974–979.

Velazquez EF, Barreto JE, Rodriguez I, et al. Limitations in the interpretation of biopsies in patients with penile squamous cell carcinoma. *Int J Surg Pathol*. 2004;12:139–146.

Velazquez EF, Cubilla A. Lichen sclerosus in 68 patients with squamous cell carcinoma of the penis: frequent atypias and correlation with special carcinoma variants suggests a precancerous role. *Am J Surg Pathol*. 2003;27:1448–1453.

Videtic GMM, Ago CT, Winquist EW. Hypercalcemia and carcinoma of the penis. *Med Pediatr Oncol*. 1997;29:576–577.

Villa LL, Costa RL, Petta CA, et al. Prophylactic quadrivalent human papillovirus (types 6,11,16,18) L1 virus-like particle vaccine in young women: a randomized double-blind placebo-controlled multicentre phase II efficacy trial. *Lancet Oncol*. 2005;6(5):271–278.

Villavicencio H, Rubio-Briones J, Regalado R, et al. Grade, local stage and growth pattern as prognostic factors in carcinoma of the penis. *Eur Urol*. 1997;32:442–447.

von Eschenbach AC, Johnson DE, Wishnow KI, et al. Results of laser therapy for carcinoma of the penis: organ preservation. *Prog Clin Biol Res*. 1991;370:407–412.

Wade TR, Kopf AW, Ackerman AB. Bowenoid papulosis of the penis. *Cancer*. 1978;42:1890–1903.

Walker TY, Elam-Evans LD, Singleton JA, et al. National, regional, state, and selected local area vaccination coverage among adolescents aged 13-17 years - United States, 2016. *MMWR Morb Mortal Wkly Rep*. 2017;66(33):874–882.

Wang J, Pettaway CA, Pagliaro LC. Treatment for metastatic penile cancer after first-line chemotherapy failure: analysis of response and survival outcomes. *Urology*. 2015;85(5):1104–1110.

Wang Z, Lu M, Dong GQ, et al. Penile and scrotal Paget's disease: 130 Chinese patients with long-term follow-up. *BJU Int*. 2008;102:485–488.

Watson M, Saraiya M, Ahmed F, et al. Using population-based cancer registry data to assess the burden of human papillomavirus-associated cancers in the United States: overview of methods. *Cancer*. 2008;113(10 Suppl):2941–2954.

Weber J, Mandala M, Delvecchio M, et al. Adjuvant nivolumab versus ipilimumab in resected stage III or IV melanoma. *N Engl J Med*. 2017;377:1824–1834.

Weitzner S. Secondary carcinoma in the penis: report of three cases and literature review. *Am Surg*. 1971;37:563–567.

Wespes E, Simon J, Schulman CC. Cabanas approach: is sentinel node biopsy reliable for staging of penile carcinoma? *Urology*. 1986;28:278–279.

Wiener JS, Walther PJ. The association of oncogenic human papillo-maviruses with urologic malignancy. *Surg Oncol Clin*

North Am. 1995;4:257–276.

Windahl T, Hellsten S. Laser treatment of localized squamous cell carcinoma of the penis. *J Urol*. 1995;154:1020–1223.

Windahl T, Skeppner E, Andersson SO, et al. Sexual function and satisfaction in men after LASER treatment for penile carcinoma. *J Urol*. 2004;172:648–651.

Winters BR, Kearns JT, Holt SK, et al. Is there a benefit to adjuvant radiation in stage III penile cancer after lymph node dissection? Findings from the National Cancer Database. *Urol Oncol*. 2017.

Wishnow KI, Johnson DE. Effective outpatient treatment of Kaposi's sarcoma of the urethral meatus using the neodymium:YAG laser. *Lasers Surg Med*. 1988;8:428–432.

Yang WJ, Kim DS, Im YJ, et al. Extramammary Paget's disease of penis and scrotum. *Urology*. 2005;65:972–975.

Yamashita T, Ogawa A. Ultrasound in penile cancer. *Urol Radiol*. 1989;11:174–187.

Yanagawa N, Osakabe M, Hayashi M, et al. Detection of HPV-DNA, p53 alterations, and methylation in penile squamous cell carcinoma in Japanese men. *Pathol Int*. 2008;58:477.

Yeole BB, Jussawalla DJ. Descriptive epidemiology of the cancers of male genital organs in greater Bombay. *Indian J Cancer*. 1997;34:30–39.

Young MJ, Reda DJ, Waters WB. Penile carcinoma: a twenty-five year experience. *Urology*. 1991;38(6):529–532.

Zhu Y, Zhang SH, Ye DW, et al. Predicting pelvic lymph node metastasis in penile cancer patients: a comparison of computed tomography, Cloquets's node, and disease burden of the inguinal lymph nodes. *Onkologie*. 2008;31:37–41.

Zhu Y, Zhang HL, Yao XD, et al. Development and evaluation of a nomogram to predict inguinal lymph node metastasis in patients with penile cancer and clinically negative lymph nodes. *J Urol*. 2010;184(2):539–545.

Zhu Y, Ye D, Yao XD, et al. New N staging system of penile cancer provides a better reflection of prognosis. *J Urol*. 2011;186(2):518–523.

Zouboulis CC, Stadler R, Ikenberg H, et al. Short-term systemic recombinant interferon-gamma treatment is ineffective in recalcitrant condylomata acuminata. *J Am Acad Dermatol*. 1991;24:302–303.

Zouhair A, Coucke PA, Jeanneret W, et al. Radiation therapy alone or combined surgery and radiation therapy in squamous-cell carcinoma of the penis? *Eur J Cancer*. 2001;37:198–203.

zur Hausen H. Roots and perspectives of contemporary papillomavirus research. *J Cancer Res Clin Oncol*. 1996;122:3–13.

Tumors of the Urethra

Christopher B. Anderson MD, MPH, James M. McKiernan MD

Benign Urethral Tumors

Benign tumors of the urethra are rare and generally only described in small case reports. Leiomyoma, hemangioma, and fibroepithelial polyp are most frequently reported. Female urethral prolapse and urethral caruncles are benign lesions that can mimic tumors, which will be discussed elsewhere (Fletcher and Lemack, 2008).

Leiomyoma

Leiomyomas are mesenchymal tumors that arise from urethral or paraurethral smooth muscle and are most commonly seen in reproductive-aged women (Pahwa et al., 2012). These tumors often are accompanied by obstructive voiding symptoms, dyspareunia or hematuria, and occasionally are diagnosed incidentally (Cornella et al., 1997). On physical examination they are generally firm, smooth, nontender masses in the anterior vaginal wall or that protrude from the urethral meatus. Cystoscopically they appear as suburothelial lesions without ulceration that often displace or obstruct the urethral lumen. These tumors can grow during pregnancy and regress postpartum, suggesting they are hormonally sensitive (Fry et al., 1988; Kato et al., 2004). They can occur anywhere along the urethra but most commonly arise within the posterior wall (Cicilet et al., 2016). Urethral leiomyomas are hypoechoic with internal vascularity on ultrasound. On magnetic resonance imaging (MRI) they are well-circumscribed tumors that can displace the urethra and vaginal wall. They enhance with contrast and are isointense to muscle on T1 and hypointense on T2, similar to uterine leiomyomas (Del Gaizo et al., 2013; Verma et al., 2014). Surgical excision is curative in nearly all cases and can be accomplished transvaginally or transurethrally depending on size and location. Pathologically, these tumors demonstrate fascicles of smooth muscle cells with uniform, spindle-shaped nuclei that lack atypia or mitotic figures (Goldman et al., 2007).

Hemangioma

Urethral hemangiomas are benign vascular tumors that are thought to arise from angioblastic cells within the urethra. They tend to be more common in men, although there are several reports of female urethral hemangiomas (Manuel et al., 1977; Ongun et al., 2014). There is no obvious age predilection, they can occur as solitary or multiple lesions, and they can grow anywhere along the length of the urethra (Roberts and Devine, 1983). Urinary tract hemangiomas may be associated with the presence of cutaneous hemangiomas or congenital disorders such as Klippel-Trenaunay-Weber syndrome (Terada et al., 2007). The most common symptoms of a urethral hemangioma are intermittent hematuria and bloody urethral discharge (Parshad et al., 2001). They are normally painless, although they can cause pain if they become thrombosed (Tabibian and Ginsberg, 2003). Posterior urethral hemangiomas in males are typically located between the verumontanum and external sphincter and can cause hematospermia and postejaculatory hematuria (Han et al., 2015; Saito, 2008).

The diagnosis of a urethral hemangioma is made by cystoscopy and biopsy. The most common appearance is that of a bluish sessile lesion with associated varicosities, with pathology demonstrating cavernous hemangioma in most cases (Jahn and Nissen, 1991). Because they can sometimes be more extensive than they appear, MRI scans can be used to delineate the extent of the lesion and demonstrates a high signal on T2 similar to hepatic hemangiomas (Hayashi et al., 1997; Jahn and Nissen, 1991). Smaller hemangiomas are treated with transurethral fulguration or laser ablation (Saito, 2008). However, an incompletely ablated or resected hemangioma can recur (Manuel et al., 1977; Uchida et al., 2001). When a hemangioma is more extensive, open excision with urethral reconstruction may be required (Parshad et al., 2001; Roberts and Devine, 1983). Selective embolization has also been used (Murray et al., 1986).

Fibroepithelial Polyp

Urethral fibroepithelial polyps (FEPs) are rare benign tumors of mesodermal origin most commonly found in males (Kumar et al., 2008). Urethral FEPs are usually found in children but can also occur in adults (Kumar et al., 2008; Tsuzuki and Epstein, 2005). Most male FEPs arise within the bulbar and posterior urethra, and the most common clinical presentation in adults is obstructive urinary symptoms, hematuria, dysuria, and rarely urinary retention (Kumar et al., 2008; Tsuzuki and Epstein, 2005). They may protrude from the urethral meatus in women (Aita et al., 2005; Yamashita et al., 2004). Retrograde urethrography and voiding cystourethrography demonstrate a smooth, cylindrical urethral filling defect. On cystoscopy, they usually appear as smooth pink or tan tumors that are connected to the urethra on a stalk.

Transurethral resection of urethral FEPs is usually curative (Kumar et al., 2008). Pathologic examination is required to confirm the diagnosis and rule out a urothelial papilloma. Microscopically they have a fibrovascular core that is surrounded by normal urothelium (Tsuzuki and Epstein, 2005).

Male Urethral Cancer

Epidemiology, Etiology, and Clinical Presentation

Male primary urethral cancer (PUC) is a rare disease that usually manifests after the sixth decade of life and is more common in African Americans than Caucasians (Dalbagni et al., 1999; Rabbani, 2011; Sui et al., 2017; Swartz et al., 2006; Thyavihally et al., 2006; Visser et al., 2012). Based on national cancer registry data, it is estimated that there are 1.3 to 4.3 cases of urethral cancer for every million men (Swartz et al., 2006; Visser et al., 2012). **Most patients with anterior PUC have a history of chronic urethral inflammation with urethral stricture disease being the most common risk factor.** Preexisting stricture disease is present in at least 50% of patients with PUC (Dalbagni et al., 1999; Kaplan et al., 1967). Other risk factors for anterior PUC include sexually transmitted diseases, lichen sclerosis, urethritis, pelvic radiation, trauma, and instrumentation (Agrawal et al., 2017; Anderson and McAninch, 1984; Dalbagni et al., 1999; Gakis et al., 2013; Smith et al., 2007; Thyavihally et al., 2006). Human papillomavirus 16 has been detected in some urethral cancers and may play a role in pathogenesis (Cupp et al., 1996). Arsenic exposure has also been reported to increase the risk of urethral cancer (Tsai et al., 2005).

Presenting symptoms for PUC most commonly include obstructive voiding symptoms, hematuria or bloody urethral discharge, and penile or perineal mass (Dalbagni et al., 1999; Dinney et al., 1994; Kent et al., 2015; Thyavihally et al., 2006). Nearly all patients are symptomatic at the time of presentation (Dalbagni et al., 1999). The onset of malignant change in a patient with chronic urethral stricture disease may be insidious, and a high index of clinical suspicion is required to diagnose these tumors.

Pathology

The male urethra is approximately 20 cm long and consists of the anterior and posterior urethra. **The anterior urethra includes the bulbar urethra, pendulous urethra, and fossa navicularis, whereas the posterior urethra consists of the prostatic and membranous urethra. The anterior urethra is lined by stratified and pseudostratified columnar epithelium, which**

transitions to stratified squamous epithelium in the very distal urethra (Fig. 80.1; Reuter, 2014). **The posterior urethra is lined by urothelium.** Paired bulbourethral glands, or Cowper glands, drain into the bulbar urethra, and several periurethral glands, or glands of Littre, reside along the length of the anterior urethra.

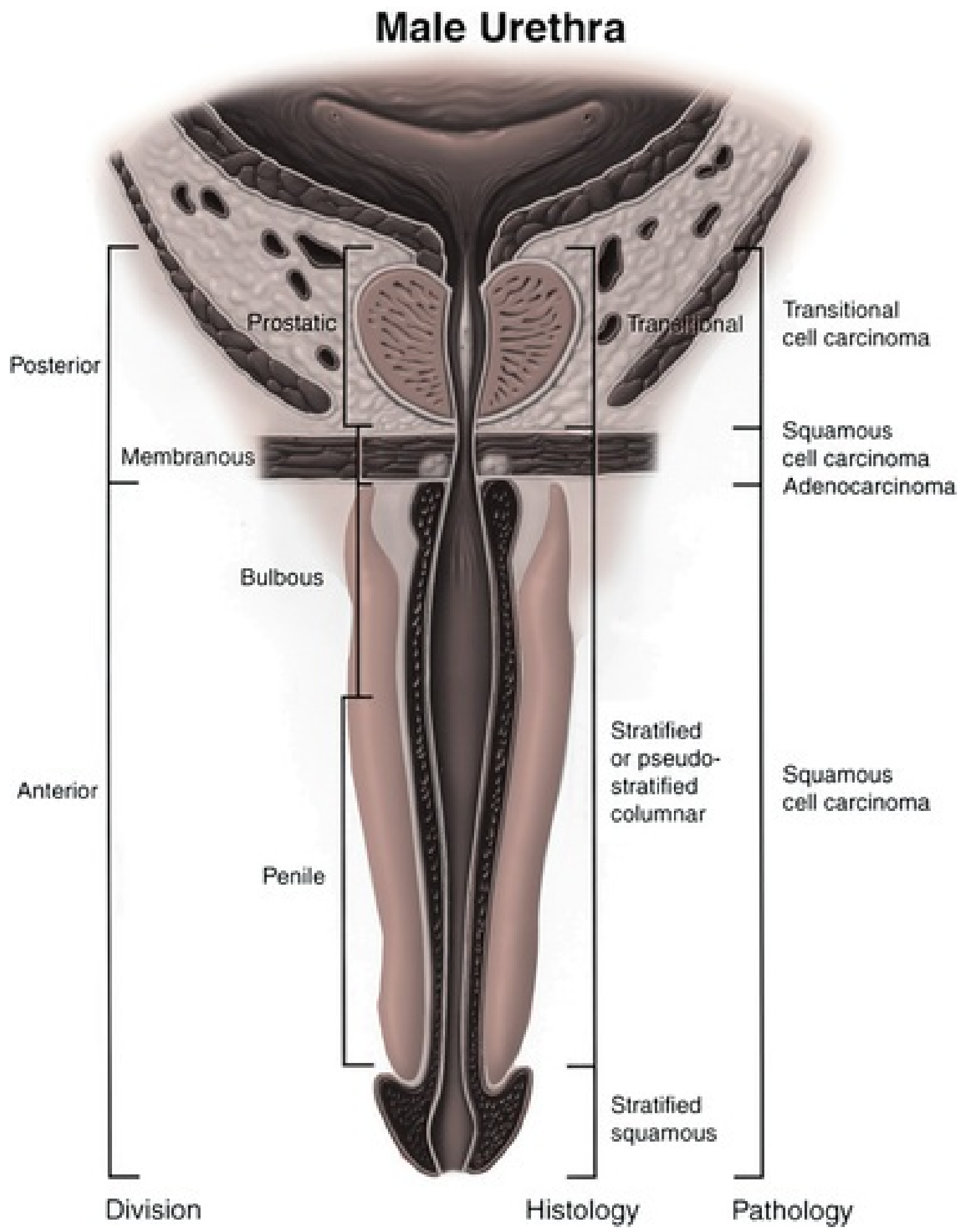
Male Urethra
Posterior
Prostatic
Membranous
Bulbous
Anterior
Penile
Transitional
Stratified or pseudo-stratified columnar
Stratified squamous
Transitional cell carcinoma
Squamous cell carcinoma
Adenocarcinoma
Squamous cell carcinoma
Division
Histology
Pathology

FIG. 80.1 Anatomy of the male urethra with corresponding histology and pathology.

Carcinoma of the male urethra is categorized according to location and histology. Because there is a change in cell type along the length of the urethra, male PUCs vary by site of origin. **Among urethral cancers described in population-level studies, 50% to 80% are urothelial carcinomas, 10% to 30% are squamous cell carcinomas, and 5% to 10% are adenocarcinomas** (Gakis et al., 2016; Rabbani, 2011; Sui et al., 2017; Visser et al., 2012). These large datasets may overestimate the true proportion of urothelial PUCs due to misclassification or miscoding because this histologic class comprises the minority of PUCs in institutional data sets (Dalbagni et al., 1999; Dinney et al., 1994). Other rare cancer types include melanoma and sarcoma (Gakis et al., 2016).

Urothelial carcinomas are graded as either low or high, whereas squamous cell carcinoma and adenocarcinoma are graded as well, moderately, and poorly differentiated (Table 80.1; Hansel et al., 2017). The majority of posterior urethral cancers are urothelial carcinomas, whereas more than 80% of anterior urethral cancers are squamous cell carcinomas (Dalbagni et al., 1999; Dinney et al., 1994; Kaplan et al., 1967; Thyavihally et al., 2006). Adenocarcinoma tends to be more common in the bulbar urethra (Kaplan et al., 1967; Tsai et al., 2005). **Among anterior urethral tumors, 60% are located in the bulbar urethra and 30% are in the pendulous urethra** (Dalbagni et al., 1999; Kaplan et al., 1967; Thyavihally et al., 2006).

TABLE 80.1

Grading System for Primary Urethral Carcinoma

G	DEFINITION
UROTHELIAL CARCINOMA	
LG	Low grade
HG	High grade
SQUAMOUS CELL CARCINOMA, ADENOCARCINOMA	
Gx	Grade cannot be assessed
G1	Well differentiated
G2	Moderately differentiated
G3	Poorly differentiated

Data from Hansel D, Reuter VE, Bochner B, et al.: Urethra. In Amin MB, editor: *AJCC Cancer Staging Manual*, ed 8, New York, 2017, Springer.

Male PUC can spread by direct extension to adjacent structures, including the corpus spongiosum and the periurethral tissues, or it can metastasize through lymphatic spread to regional lymph nodes. **The lymphatics from the anterior urethra drain into the inguinal lymph nodes, although the bulbar urethral can occasionally drain into the external iliac lymph nodes**. **The posterior urethra drains into the pelvic lymph nodes**. Palpable inguinal lymph nodes occur in approximately 20% to 30% of cases and almost always represents metastatic disease in contrast to penile cancer, in which palpable inguinal nodes can be inflammatory (Dalbagni et al., 1999; Dayyani et al., 2014; Gakis et al., 2016; Rabbani, 2011).

Evaluation and Staging

The tumor, node, metastases (TNM) staging classification is based on depth of invasion of the primary tumor, and presence or absence of regional lymph node involvement and distant metastasis (Table 80.2). Examination under anesthesia with cystoscopy and bimanual palpation of the external genitalia, urethra, rectum, perineum, and inguinal lymph nodes is required to evaluate the extent of local tumor involvement and establish clinical staging. Transurethral or percutaneous needle biopsy of the primary lesion is necessary for a tissue diagnosis. Urine cytology has little utility in diagnosing PUC given its poor sensitivity (Touijer and Dalbagni, 2004). If rectal involvement is suspected, an evaluation of the lower colon with flexible sigmoidoscopy is recommended. **MRI provides superior soft-tissue resolution and is the optimal imaging modality to characterize the local extent of disease** (Fig. 80.2; Stewart et al., 2010). The presence of metastatic disease is best evaluated by a computed tomography (CT) scan or MRI of the abdomen and pelvis. Chest imaging with CT may also be required.

TABLE 80.2

The American Joint Committee on Cancer (AJCC) Urethral Cancer Tumor, Node, Metastases (TNM) Staging System

---

PRIMARY TUMOR (T) (MALE AND FEMALE)	
TX	Primary tumor cannot be assessed
T0	No evidence of primary tumor
Ta	Noninvasive papillary carcinoma
Tis	Carcinoma in situ
T1	Tumor invades subepithelial connective tissue
T2	Tumor invades any of the following: corpus spongiosum, periurethral muscle
T3	Tumor invades any of the following: corpus cavernosum, anterior vagina
T4	Tumor invades other adjacent organs (e.g., bladder)
TRANSITIONAL CELL CARCINOMA OF THE PROSTATE	
Tis	Carcinoma in situ, involvement of the prostatic urethra or periurethral prostatic ducts without stromal invasion
T1	Tumor invades urethral subepithelial connective tissue immediately underlying the

	urothelium
T2	Tumor invades the prostatic stroma surrounding ducts either by direct extension from the urothelial surface or by invasion from prostatic ducts
T3	Tumor invades the periprostatic fat
T4	Tumor invades other adjacent organs (e.g., bladder, rectum)
REGIONAL LYMPH NODES (N)	
NX	Regional lymph nodes cannot be assessed
N0	No regional lymph node metastasis
N1	Single regional lymph node metastasis in the inguinal region or true pelvis (perivesical, obturator, internal [hypogastric] and external iliac), or presacral lymph node
N2	Multiple regional lymph node metastasis in the inguinal region or true pelvis (perivesical, obturator, internal [hypogastric] and external iliac), or presacral lymph node
DISTANT METASTASIS (M)	
M0	No distant metastasis
M1	Distant metastasis

Data from Hansel D, Reuter VE, Bochner B, et al.: Urethra. In Amin MB, editor: *AJCC Cancer Staging Manual,* ed 8, New York, 2017, Springer.

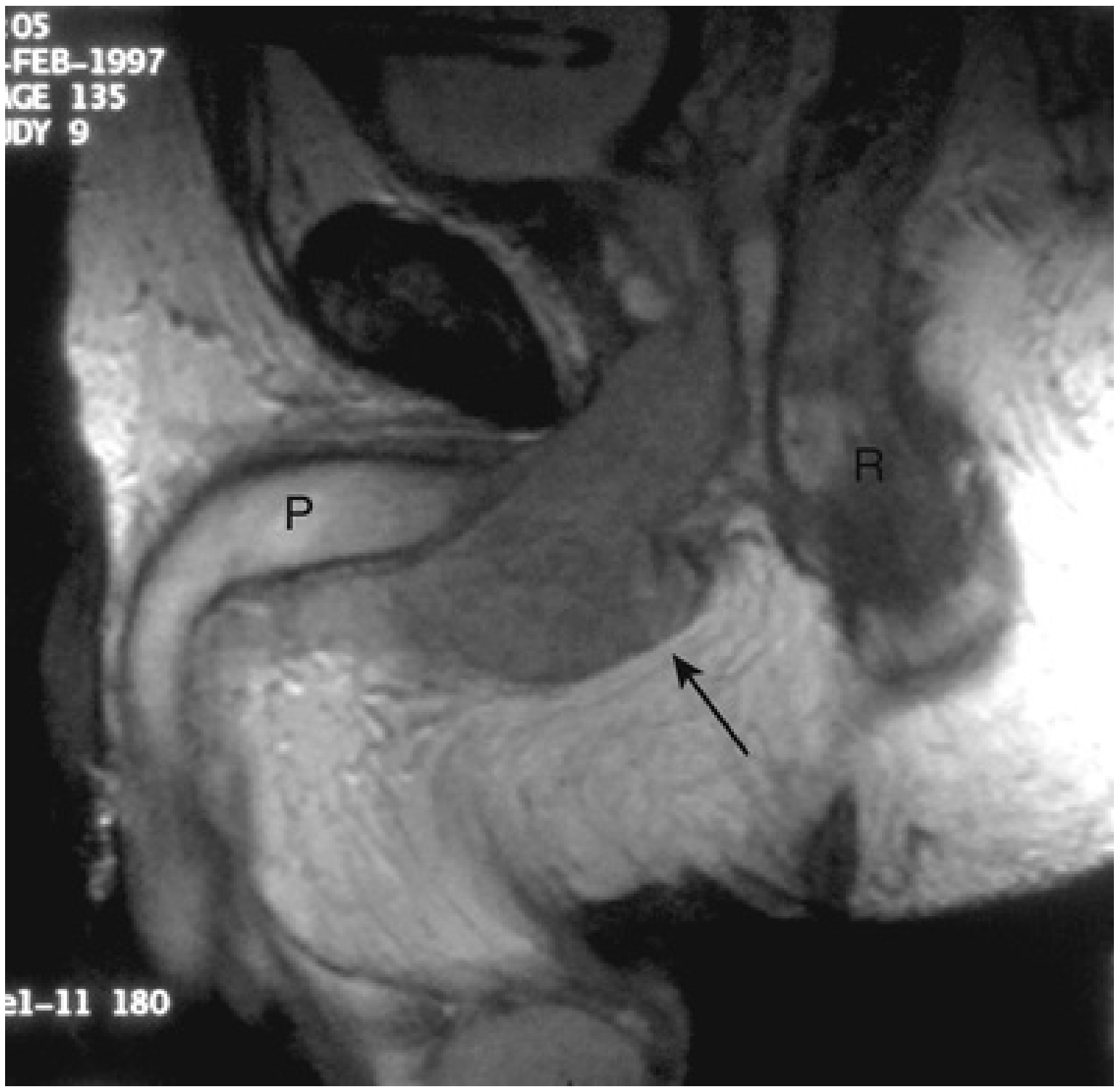

FIG. 80.2 Magnetic resonance image demonstrating a large proximal anterior urethral cancer *(arrow). P,* Penis; *R,* rectum.

Male Anterior Urethral Cancer

Prognosis

The prognosis of male anterior PUC is variable and is strongly tied to tumor aggressiveness. The 5-year cancer-specific and overall survival for all men with PUC is between 50% and 70%, and 40% and 50%, respectively (Dalbagni et al., 1999; Kent et al., 2015; Rabbani, 2011; Sui et al., 2017; Thyavihally et al., 2006; Visser et al., 2012). Several tumor characteristics are associated with survival, including grade, stage, location, and histology (Gakis et al., 2016; Sui et al., 2017). **Whereas distal urethral tumors are often curable, bulbar tumors have survival rates as low as 20% to 30%** (Dalbagni et al., 1999; Dinney et al., 1994; Thyavihally et al., 2006)**.** One large series reported overall survival rates of 83% for low-stage tumors, 36% for high-stage tumors, 69% for pendulous tumors, and 26% for bulbar tumors (Dalbagni et al., 1999). Similarly, among 29 patients with PUC the 5-year overall survival rates were 67% for low-stage disease, 33% for high-stage, 72% for distal tumors, and 36% for proximal tumors (Thyavihally et al., 2006). **Tumors arising from the proximal urethra tend to be found at more advanced stages** (Gheiler et al., 1998), **although tumor stage is independently associated with survival after controlling for location** (Thyavihally et al., 2006). Tumor grade and location are strongly correlated with stage, which ultimately dictates prognosis. Finally, men with adenocarcinoma may have a more favorable prognosis than other histologic subtypes (Rabbani, 2011; Sui et al., 2017).

Treatment

Aggressive local control is paramount in the management of localized PUC. The optimal method varies according to tumor location; however, there is growing interest in multimodal treatment for patients with advanced-stage disease (Table 80.3).

TABLE 80.3

Summary of 2018 National Comprehensive Cancer Network (NCCN) Clinical Practice Guidelines on Primary Urethral Cancer of the Male Anterior and Female Urethra

STAGE		**FIRST-LINE TREATMENT OPTIONS**	**ADJUVANT THERAPY**
Tis, Ta, T1		Repeat TUR ± intraurethral BCG or chemotherapy	
Male T2	Pendulous urethra	Partial urethrectomy ± penectomy[a]	If positive margin: Chemoradiotherapy OR Additional surgery OR Chemotherapy
	Bulbar urethra	Urethrectomy ± radical cystectomy[a]	If ≥ pT3 or N+: Chemotherapy OR Chemoradiotherapy
Female T2		Radical cystectomy[a] OR Chemoradiotherapy	
≥ T3	N0	Chemoradiotherapy ± consolidative surgery OR Neoadjuvant chemotherapy with consolidative surgery or radiation OR Radiotherapy	
	N+	Chemoradiotherapy ± consolidative surgery OR Systemic therapy	

[a] Consider neoadjuvant chemotherapy.

BCG, Bacille Calmette-Guérin; *TUR*, transurethral resection.

Data from Bladder Cancer, *NCCN Clinical Practice Guidelines in Oncology,* 2018 (website): https://www.nccn.org/professionals/physician_gls/default.aspx.

Carcinoma of the Pendulous Urethra

Tumors of the pendulous urethra and fossa navicularis are usually amenable to surgical resection. Transurethral resection, distal urethrectomy with or without partial penectomy, and total urethrectomy with perineal urethrostomy with or without total penectomy are acceptable treatment options in patients with distal urethral tumors depending on tumor size, location, and stage (Bladder cancer, 2018; Gakis et al., 2013).

Based on a limited number of small case series, surgical monotherapy for patients with distal tumors can successfully achieve local control (Anderson and McAninch, 1984; Gheiler et al., 1998; Kaplan et al., 1967). One series described successful treatment of three patients with low-stage fossa navicularis tumors with distal urethrectomy (Dinney et al., 1994). The same report described 10 patients with pendulous urethral tumors, among whom partial or radical penectomy provided local control in nearly all patients, although the risk of systemic relapse was higher than with tumors originating in the fossa navicularis.

The treatment for distal urethral tumors historically included urethral resection with radical or partial penectomy. **More recently, tumor excision with penile preservation has emerged as an option for select patients** (Gakis et al., 2013). The largest series on penile preservation for patients with distal PUC includes 18 men, most of whom had invasive squamous cell carcinoma and 6 had positive lymph nodes (Smith et al., 2007). Depending on the location and stage of the tumor, treatments included creation of a distal hypospadias with topical 5-fluorouracil (5-FU), distal urethrectomy with two-staged urethroplasty, glansectomy with skin graft reconstruction, and anterior urethrectomy with perineal urethrostomy. Patients with positive margins were treated with additional surgery or adjuvant radiation and no patient experienced a local recurrence. Squamous cell carcinoma in situ (CIS) of the perimeatal glans can extend into the distal urethra (Fig. 80.3) and has been successfully treated with partial glansectomy and distal urethrectomy with urethral reconstruction or penile urethrectomy (Fig. 80.4; Nash et al., 1996).

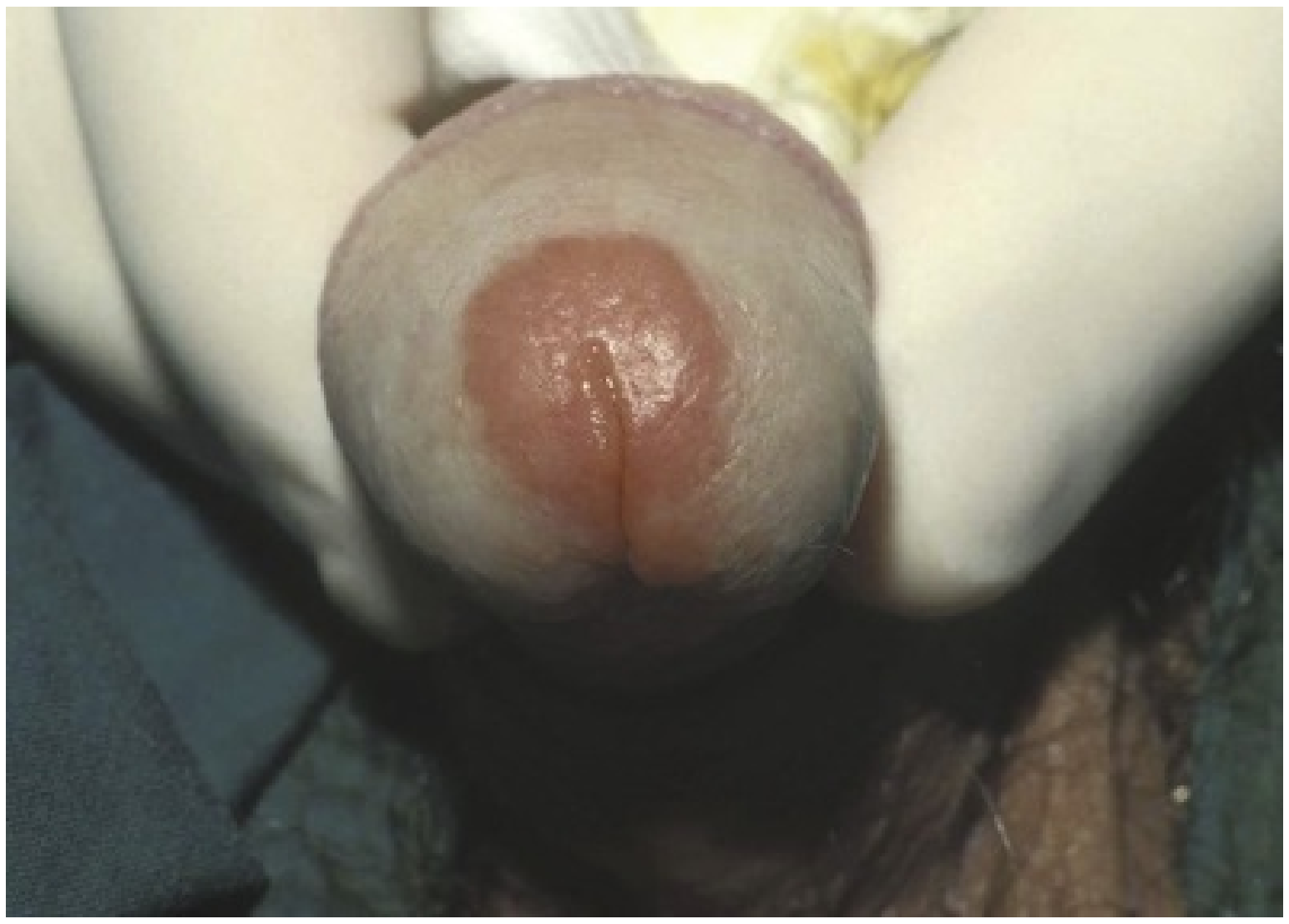

FIG. 80.3 Squamous cell carcinoma in situ of the perimeatal glans extending into the distal urethra.

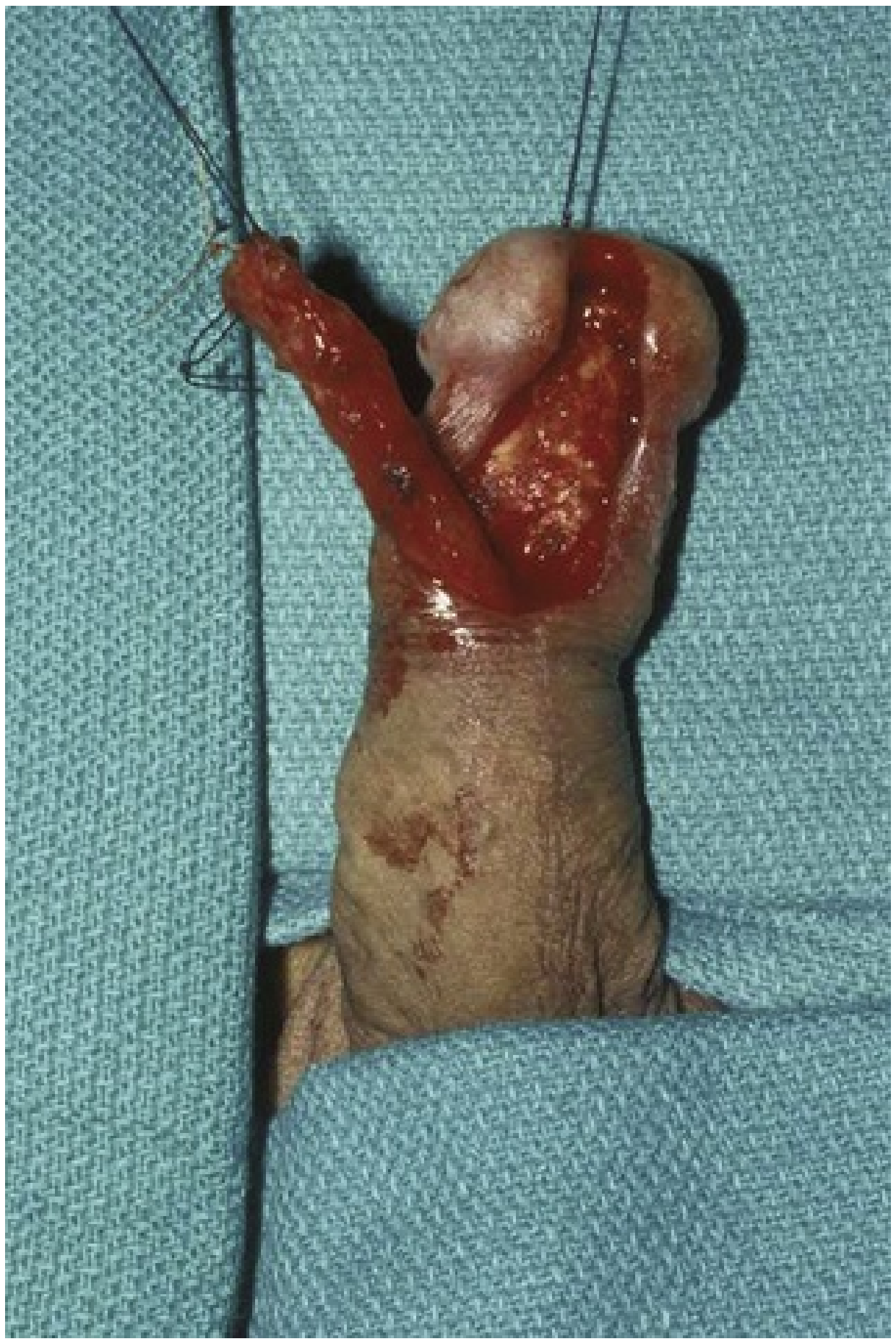

FIG. 80.4 Partial glansectomy and distal urethrectomy (same patient as

Fig. 80.3). After a negative margin was obtained, a penile urethrostomy was performed.

Partial penectomy with a 1-cm negative margin has been the traditional recommendation for invasive tumors localized to the distal urethra, but excision with a 5-mm negative margin has shown to produce excellent local control (Karnes et al., 2010; Smith et al., 2007). If invasive disease extends to or involves the proximal penile urethra, total urethrectomy, with or without penectomy, may be required to obtain a negative margin (Fig. 80.5). The proximal extent of disease must be carefully evaluated if partial urethrectomy is being considered. The risk of local recurrence after resection of a distal urethral tumor is low, but ongoing surveillance is necessary (Kaplan et al., 1967).

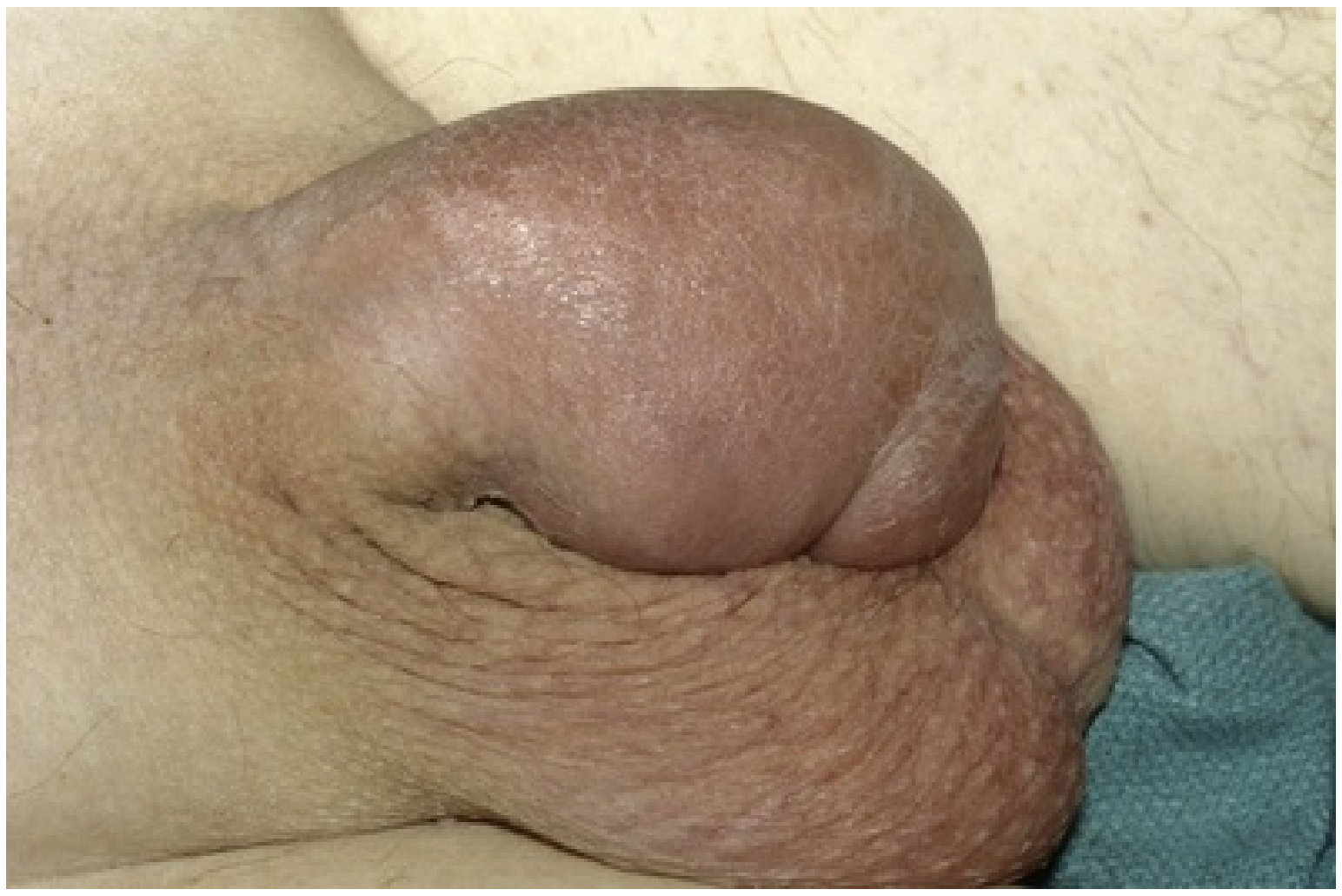

FIG. 80.5 A large penile mass in a patient with urothelial carcinoma of the pendulous urethra.

As opposed to patients with penile cancer, it is unclear if there is a survival benefit to prophylactic inguinal lymph node dissection in patients with anterior PUC without palpable inguinal lymph nodes. Some institutions have used inguinal sentinel lymph node biopsy to identify patients with low-volume inguinal metastasis, and performed an inguinal lymphadenectomy, if the biopsy is positive (Bracken et al., 1980; Dinney et al., 1994; Smith et al., 2007). Patients with low-volume inguinal lymph node metastasis can be rendered disease free with inguinal lymphadenectomy, providing rationale for aggressive management of inguinal node metastases (Bracken et al., 1980). Certain groups have advocated for prophylactic inguinal lymphadenectomy for advanced stage pendulous PUC with clinically negative inguinal lymph nodes; however, this remains controversial (Karnes et al., 2010; Traboulsi et al., 2016). Prophylactic radiation to the reginal nodal basins should be strongly considered for patients with clinically negative lymph nodes whose primary lesions are being managed with radiotherapy (Bladder cancer, 2018).

Chemoradiation with or without surgical consolidation has emerged as an alternative to surgical resection of advanced urethral tumors (Baskin and Turzan, 1992). The largest series on chemoradiation for male PUC included 29 patients treated with 45 to 55 Gy of external beam radiotherapy combined with systemic 5-FU and mitomycin C (MMC), 12 of whom had squamous cell carcinoma of the pendulous urethra (Kent et al., 2015). Most patients were clinical stage T3 or lymph node positive (N+) and 79% (N = 19) demonstrated a complete response to treatment, including some who were clinically node positive. The 5-year disease-specific survival was 68%, and 6 of 19 complete responders experienced a local recurrence, some of whom could not be salvaged with surgery. **The role of surgical consolidation after a complete response to chemoradiation is unclear at this time, although all patients who responded to primary chemoradiation developed a urethral stricture, often requiring complex urethral reconstruction.** Patients who did not respond to chemoradiation died of disease. The authors recommended surgery for low-stage distal PUC.

Primary radiation therapy has been reserved for patients with early stage lesions of the anterior urethra who refuse surgery. A commonly used technique consists of parallel opposed fields with the penis suspended vertically by a urethral catheter (Heysek et al., 1985). Radiation therapy has the advantage of potentially preserving the penis, but it may result in skin ulceration and necrosis, urethral stricture, and chronic edema. The long-term results of radiotherapy are difficult to evaluate because few reports are available of male patients treated with this modality (Forman and Lichter, 1992; Koontz and Lee, 2010; Raghavaiah, 1978).

Because some patients with distal PUCs will have locally advanced or clinically node-positive disease, surgery with or without systemic therapy has been used with variable success (Dinney et al., 1994; Kaplan et al., 1967). Cases of cure with limited nodal disease have been reported; therefore systemic therapy followed by inguinal lymphadenectomy should be considered in the presence of palpable inguinal lymph nodes. Chemoradiation is also an option for clinically positive inguinal lymph nodes. Control of inguinal nodal disease may also help prevent complications from local invasion such as skin breakdown, wound drainage, and vascular erosion.

Carcinoma of the Bulbar Urethra

Some low-stage lesions of the proximal anterior urethra may be treated by transurethral resection or segmental excision with an end-to-end anastomosis. Patients treated with transurethral resection should be considered for repeat transurethral resection to ensure accurate staging and a complete resection (Bladder cancer, 2018). Unfortunately, there are relatively few patients eligible for limited resection because PUC of the bulbar urethra tends to present at an advanced stage and local control can be difficult (Dinney et al., 1994). **The standard and most aggressive surgical management for advanced-stage bulbar urethral cancer is radical cystoprostatectomy, pelvic lymphadenectomy, and total penectomy.** Depending on the extent of disease, this may require resection of the pubic rami and the adjacent urogenital diaphragm (Dinney et al., 1994). Bladder preservation with urethrectomy and perineal urethrostomy or bladder neck closure and creation of a continent catheterizable stoma may also be an option in select cases (Christopher et al., 2002; Hakenberg et al., 2001). Patients with positive margins or local recurrences should be managed with radiation, with or without chemotherapy. The benefit of more conservative surgical approaches must be weighed against the probability of local relapse or dissemination of disease.

In a cohort of 46 men with PUC treated primarily with surgery alone, the 5-year overall survival for patients with posterior tumors was 26%, and only 4 of 28 patients were free of disease (Dalbagni et al., 1999). This observation led the authors to conclude that surgery alone is inadequate for advanced PUC. Patients with bulbar tumors treated with more aggressive surgical resection may have a more favorable prognosis (Dayyani et al., 2014). Those with involvement of the pelvic lymph nodes have a high risk of recurrence and death (Dinney et al., 1994).

Radical cystectomy with total penectomy is performed with the patient in the dorsal lithotomy position to allow perineal access. Standard transabdominal mobilization of the bladder is completed, except for preservation of the endopelvic fascia and the anterior pubic attachments. A modified λ or inverted U-shaped perineal incision is performed with the apex in the midperineum. The inferior skin flap is mobilized by sharply dividing the intervening subcutaneous tissue and rectourethral muscle. The superior flap is mobilized by sharply incising the subcutaneous tissue to the superficial Colles fascia and then continuing bilaterally to the adductor musculature at the inferior pubic rami. The ischiorectal fossa are developed as in perineal prostatectomy, and a tunnel is bluntly dissected anterior to the rectum, extending from one fossa to the other. Circumferential incision of the skin and dartos fascia at the penoscrotal junction is performed, and the corporeal bodies are mobilized for a short distance proximally from the superior aspect of the symphysis pubis to allow subsequent inferior pubectomy if needed. Care must be taken not to carry this dissection too far proximally to avoid breaching the anterior aspect of a locally advanced tumor. The penis is passed downward through the perineal incision. Wider exposure may be gained by dividing the scrotum in the midline, although the testicles can usually be preserved. The specimen should be delivered en bloc (Fig. 80.6).

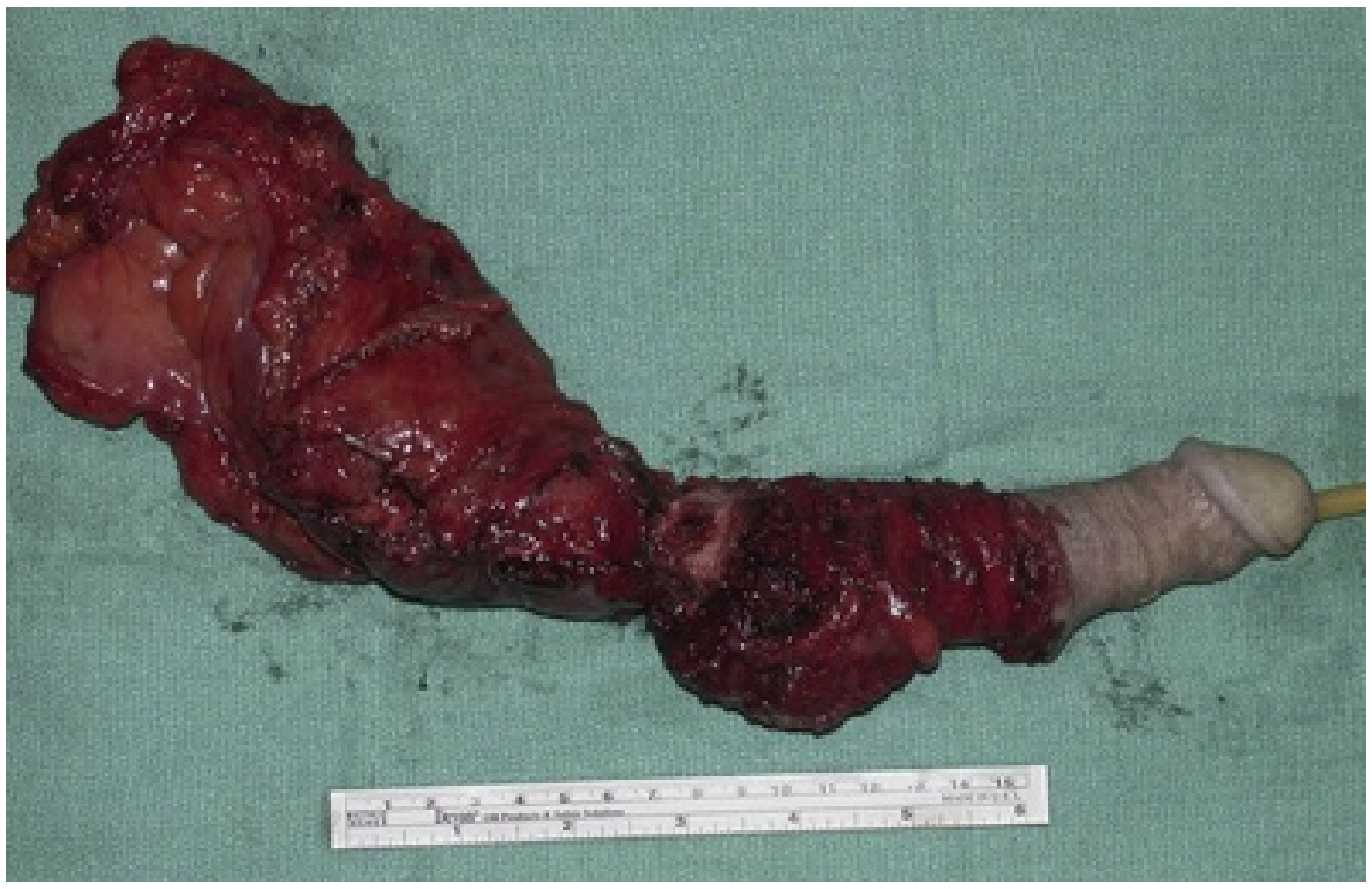

FIG. 80.6 Surgical specimen after radical cystoprostatectomy, urethrectomy, penectomy, and inferior pubectomy for a large bulbomembranous squamous cell carcinoma.

Advanced proximal male PUCs, although rare, may require an extensive operation to achieve complete resection with a negative margin. This may include resection of the testicles, inferior pubic rami, and pelvic floor musculature (Fig. 80.7). Reconstruction of the pelvic floor soft tissue defects may require myocutaneous vascularized pedicle flaps. Such resections requires collaboration with orthopedic and plastic surgeons.

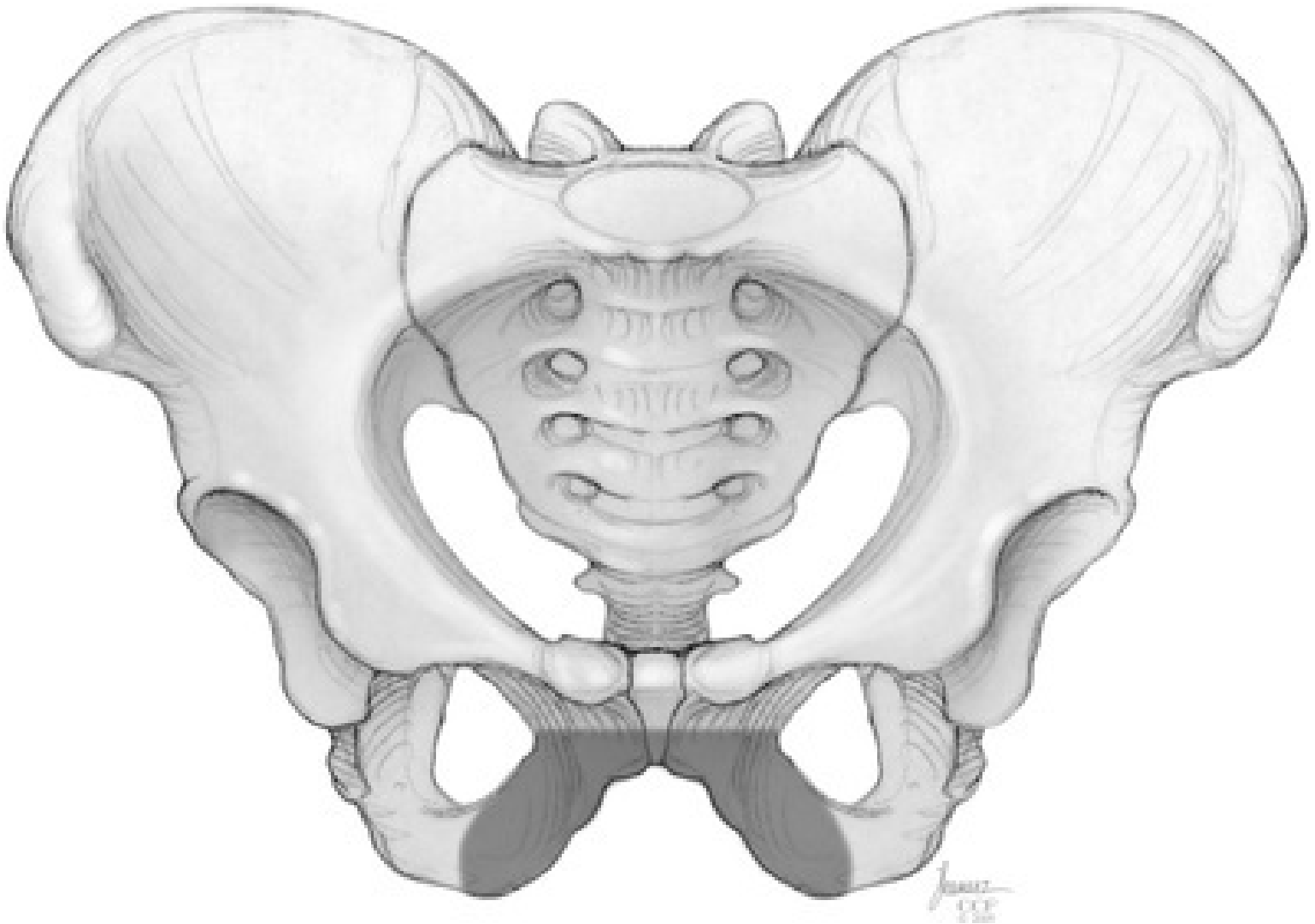

FIG. 80.7 Shaded area outlines the portions of the ischiopubic rami excised at the time of inferior pubectomy during radical excision of bulbomembranous urethral cancer. (Reprinted with permission, Cleveland Clinic Center for Medical Art and Photography. Copyright 2003–2010. All rights reserved.)

Because of the poor outcomes after surgery alone for advanced tumors of the urethra, surgical monotherapy has been deemed inadequate for advanced-stage PUC, particularly of the bulbar urethra, leading to increased interest in multimodal therapy (Bladder cancer, 2018; Dalbagni et al., 1999; Gakis et al., 2013). One option is the use of perioperative chemotherapy. Approximately 30% of patients with PUC in contemporary cohorts are treated with perioperative chemotherapy (Gakis et al., 2016). One retrospective study observed that 25% to 33% of patients treated with primarily cisplatin-based neoadjuvant chemotherapy or chemoradiation before surgery had a complete or partial response, and prognosis was highly correlated with response to chemotherapy (Gakis et al., 2015). Chemotherapy before surgery or radiation was associated with better survival for patients with advanced disease compared with surgery alone or surgery plus adjuvant chemotherapy. All patients with locally advanced or clinically node-positive disease treated with neoadjuvant chemotherapy or chemoradiation in this series were alive at 5 years.

A retrospective review of 44 patients with advanced PUC referred for medical oncology evaluation examined the role of cisplatin-based chemotherapy (Dayyani et al., 2013). The study included 28 (64%) females, and squamous cell carcinoma and adenocarcinoma were the most common histologies. All patients but one had at least T3 disease, 43% were N+ and 16% had metastatic disease

(M1). Thirty-six patients received one of four platinum-based chemotherapy regimens depending on histologic subtype. Five (14%) were complete responders and 72% of patients achieved a complete or partial response. Surgical consolidation with either urethrectomy or radical cystectomy (RC) was performed in 21 patients. The median overall survival of the entire cohort was 31.7 months, which was higher for the surgical group (46.9 months) compared with the group that did not have surgery (21.7 months). Nine patients initially presented with lymph node–positive disease, four of whom were free of disease after neoadjuvant chemotherapy followed by surgery, although the postchemotherapy pathologic nodal stage was not reported. The authors concluded that neoadjuvant cisplatin-based chemotherapy is a reasonable option for patients with high-risk and locally advanced PUC, which is supported by professional guidelines (Bladder cancer, 2018; Gakis et al., 2013). Adjuvant systemic therapy is an option for patients with locally advanced disease after surgery (Bladder cancer, 2018).

As previously mentioned, chemoradiation therapy with external beam radiation to the external genitalia, perineum, and inguinal lymph nodes with 5-FU plus MMC is an effective treatment option for patients with advanced PUC (Cohen et al., 2008). Patients treated with chemoradiation therapy have similar rates of complete response in the proximal and distal urethra. One group commonly performed consolidative surgery after chemoradiation and found that 7 of 8 patients were ypT0 at surgery (Gheiler et al., 1998). **Given the morbidity of surgery for patients with advanced stage bulbar PUC, chemoradiation is a reasonable alternative for some patients** (Bladder cancer, 2018; Gakis et al., 2013). Surgical consolidation after chemoradiation is recommended by some (Dalbagni et al., 1999). Radiation monotherapy is considered ineffective for bulbar PUC (Bracken et al., 1980; Kaplan et al., 1967).

Professional guidelines recommend radical surgery with or without perioperative chemotherapy, chemoradiation, or radiation monotherapy as treatment options for nonmetastatic bulbar PUC (Bladder cancer, 2018)**. Patients with clinically positive lymph should have chemoradiation or chemotherapy followed by surgical consolidation.** There is no high-quality comparative effectiveness research on treatment options for male PUC.

The condition of at least half of patients with advanced disease treated with perioperative chemotherapy will recur (Gakis et al., 2015). After resection of an invasive urethral cancer, there remains a risk of local and/or systemic recurrence at high as 50%, necessitating regular urethral, inguinal, and systemic surveillance (Gakis et al., 2016).

Approximately 10% to 20% of men with PUC have clinically positive lymph nodes, and 5% to 20% have distant metastasis, most commonly to nonregional lymph nodes, liver, lungs, and bone (Dayyani et al., 2014; Gakis et al., 2016; Rabbani, 2011; Sui et al., 2017; Thyavihally et al., 2006). One retrospective cohort observed long-term survival in four of eight patients who presented with metastatic urethral carcinoma that were treated with cisplatin-based chemotherapy and surgical excision of the primary tumor (Dinney et al., 1994).

Male Posterior Urethral Cancer

Prostatic urethral carcinoma is commonly found in patients with a history of bladder cancer. Approximately 20% to 40% of patients with aggressive bladder cancer have synchronous involvement of the prostate at the time of RC, and up to 39% of patients with high-risk non–muscle-invasive bladder cancer (NMIBC) can have recurring problems in the prostate after intravesical therapy (Bruins et al., 2013; Herr and Donat, 1999; Patel et al., 2009). Prostatic urethral biopsies are not consistently performed at the time of transurethral resection of bladder tumor (TURBT), thus the reported range of synchronous prostatic involvement for patients with NMIBC varies widely between 3% and 30% (Bretton et al., 1989; Canda et al., 2004; Gofrit et al., 2009; Orihuela et al., 1989; Palou et al., 1996; Rikken et al., 1987; Schellhammer et al., 1995). However, primary prostatic urethral carcinoma without a history of bladder cancer is rare (Rikken et al., 1987) and comprises fewer than 4% of all prostate cancers (Ende et al., 1963; Tannenbaum, 1975). **Given the rarity of primary prostatic urethral carcinoma, any patients found to have urothelial carcinoma in the prostate should be thoroughly evaluated for coexisting urothelial carcinoma of the bladder and upper tracts.**

Urothelial carcinoma of the prostate can involve the prostatic urothelium, ducts, acini, or stroma and is diagnosed through transurethral resection of the prostate (TURP). Primary posterior male PUC is staged according to the TNM system outlined in Table 80.2. Prostatic urothelial carcinoma commonly presents in the form of carcinoma in situ (CIS) (Schellhammer et al., 1995). Cross-sectional imaging with computed tomography (CT) or MRI is required to evaluate the local extent of disease and to rule out metastasis. Whereas patients with superficial or ductal involvement have a 5-year survival rate between 67% and 74%, the 5-year survival rate for bladder cancer patients with stromal involvement drops to 36% (Cheville et al., 1998; Esrig et al., 1996). The prognosis of patients with stromal invasion is related to the primary bladder tumor stage, such that patients with T1 bladder tumors had a 61% 5-year survival rate, and those with muscle invasive or locally advanced bladder tumors had a less than 30% 5-year survival rate (Esrig et al., 1996).

The management of male primary posterior urethral cancer is largely based on the treatment of patients with bladder cancer who have synchronous or metachronous prostatic involvement (Table 80.4**).** Patients with prostatic urethral involvement were previously classified as stage T4 and historically managed with radical cystectomy (Palou et al., 2013). It was eventually understood that not all patients with prostatic involvement had a poor prognosis, and many could be managed with less aggressive measures (Esrig et al., 1996; Orihuela et al., 1989). **Those with high-grade superficial disease treated with bacille Calmette-Guérin (BCG) can have prostatic response rates of at least 70%** (Bladder cancer, 2018; Canda et al., 2004; Gakis et al., 2013; Gofrit et al., 2009; Orihuela et al., 1989; Palou et al., 2013; Schellhammer et al., 1995). **An extensive TURP before treatment with BCG removes the majority of cancerous urothelium and likely improves exposure of prostatic tissue to BCG and increases response rates** (Gofrit et al., 2009; Orihuela et al., 1989). Although BCG without TURP is an option (Palou et al., 1996). In one study of 23 patients with prostatic urethral involvement who were treated with extensive endoscopic resection and intravesical BCG, there was a 56% complete response rate but a 44% rate of progression, with 7 patients requiring a radical cystectomy (Bretton et al., 1989). However, no progression events occurred within the prostate.

TABLE 80.4

Summary of 2018 National Comprehensive Cancer Network (NCCN) Clinical Practice Guidelines on Localized Prostatic Urethral Cancer

TYPE	FIRST-LINE TREATMENT OPTIONS
Mucosal	TURP and BCG
Ductal or acinar	TURP and BCG OR Radical cystectomy ± urethrectomy
Stromal invasion	Radical cystectomy ± urethrectomy[a]

[a] Consider neoadjuvant chemotherapy.

Data from Bladder Cancer, *NCCN Clinical Practice Guidelines in Oncology,* 2018 (website): https://www.nccn.org/professionals/physician_gls/default.aspx.

Prostatic ductal involvement has been an indication for cystectomy for some and remains an option in professional guidelines (Bladder cancer, 2018; Orihuela et al., 1989; Taylor et al., 2007). **However, these patients can also be effectively managed with transurethral resection of the prostate (TURP) and BCG, and their prognosis is similar to those with superficial prostatic involvement** (Bladder cancer, 2018; Esrig et al., 1996; Schellhammer et al., 1995). One retrospective series of 11 men with NMIBC and prostatic ductal involvement who were treated with BCG demonstrated a complete response in the prostate of 82% at a median follow-up of 40 months (Palou Redorta et al., 2006). However, there is a risk of progression and understaging mandating close follow-up with repeat prostatic biopsies. **Patients with prostatic urothelial carcinoma invasive into the stroma should be managed with radical cystectomy and pelvic lymphadenectomy with or without perioperative chemotherapy** (Bladder cancer, 2018). Previous studies have evaluated the role of neoadjuvant chemotherapy in patients with advanced-stage disease. A regimen including methotrexate, vinblastine, doxorubicin, and cisplatin (MVAC) has had activity against urothelial carcinoma but not against other histologic types (Scher et al., 1988).

Key Points: Male Urethral Cancer

- This prognosis of distal anterior male PUC is better than that of proximal anterior PUC, which is often associated with local invasion and distant metastasis.
- Multimodal therapy should be considered for advanced urethral tumors given the poor outcomes after surgery and radiation alone.
- The benefit from prophylactic inguinal lymph node dissection has not been demonstrated in anterior urethral cancer.
- Primary posterior urethral carcinoma is rare, and noninvasive tumors can be effectively managed with TURP and BCG.

Female Urethral Cancer

Epidemiology, Etiology, and Clinical Presentation

Female PUC is a rare malignancy with fewer than 100 cases diagnosed in the United States every year and an estimated annual incidence of 1.5 cases per million women (Champ et al., 2012; Sui et al., 2017; Swartz et al., 2006). One study identified 869 women in the National Cancer Database who were diagnosed with PUC from 2004 to 2013 (Sui et al., 2017). Approximately two-thirds of these patients were older than 60, one-third were black, and PUC was less commonly diagnosed in women than in men. Studies using the Surveillance, Epidemiology, and End Results (SEER) registry found that female PUC is more common in African-American women, and the incidence may be decreasing over time (Swartz et al., 2006). Data from European cancer registries confirm the rare nature of female PUC, its presentation at an advanced age, and a higher incidence of PUC in men (Derksen et al., 2013; Visser et al., 2012).

Given the rarity of the disease, there is relatively little known about the underlying causes of female PUC. Proposed risk factors include leukoplakia, glandular metaplasia, chronic irritation, stricture disease, recurrent urinary infections, caruncles, and human papillomavirus infection (Dalbagni et al., 1998; Fletcher and Lemack, 2008; Milosevic et al., 2000; Murphy et al., 1999; Thyavihally et al., 2005; Wiener et al., 1994). **Female urethral diverticula also may predispose a patient to PUC, with 6% of urethral diverticula harboring a malignancy** (Thomas et al., 2008).

Nearly all women with a PUC present symptomatically (Dalbagni et al., 1998; Dimarco et al., 2004; Johnson and O'Connell 1983; Moinuddin Ali et al., 1988). Common symptoms include hematuria or vaginal spotting, lower urinary tract symptoms, and a vaginal or urethral mass.

Anatomy and Pathology

Knowledge of female urethral anatomy is essential for disease management. The female urethra is approximately 4 cm long (Reuter, 2014). **The proximal third is lined by urothelium and the distal two-thirds are lined by nonkeratinizing stratified squamous epithelium** (Fig. 80.8). Paraurethral (Skene) glands, which are the female homologue of the prostate, surround the urethra and drain via ducts located near the meatus. **The female urethra is divided into an anterior segment (distal one-third) and a posterior segment (proximal two-thirds). This distinction is critical as the distal third can be excised without compromising urinary continence.** The lymphatic drainage differs along the course of the female urethra. **Lymphatics from the posterior urethra generally drain to the pelvic lymph nodes, whereas the anterior urethra drains to the inguinal lymph nodes** (Bracken et al., 1976).

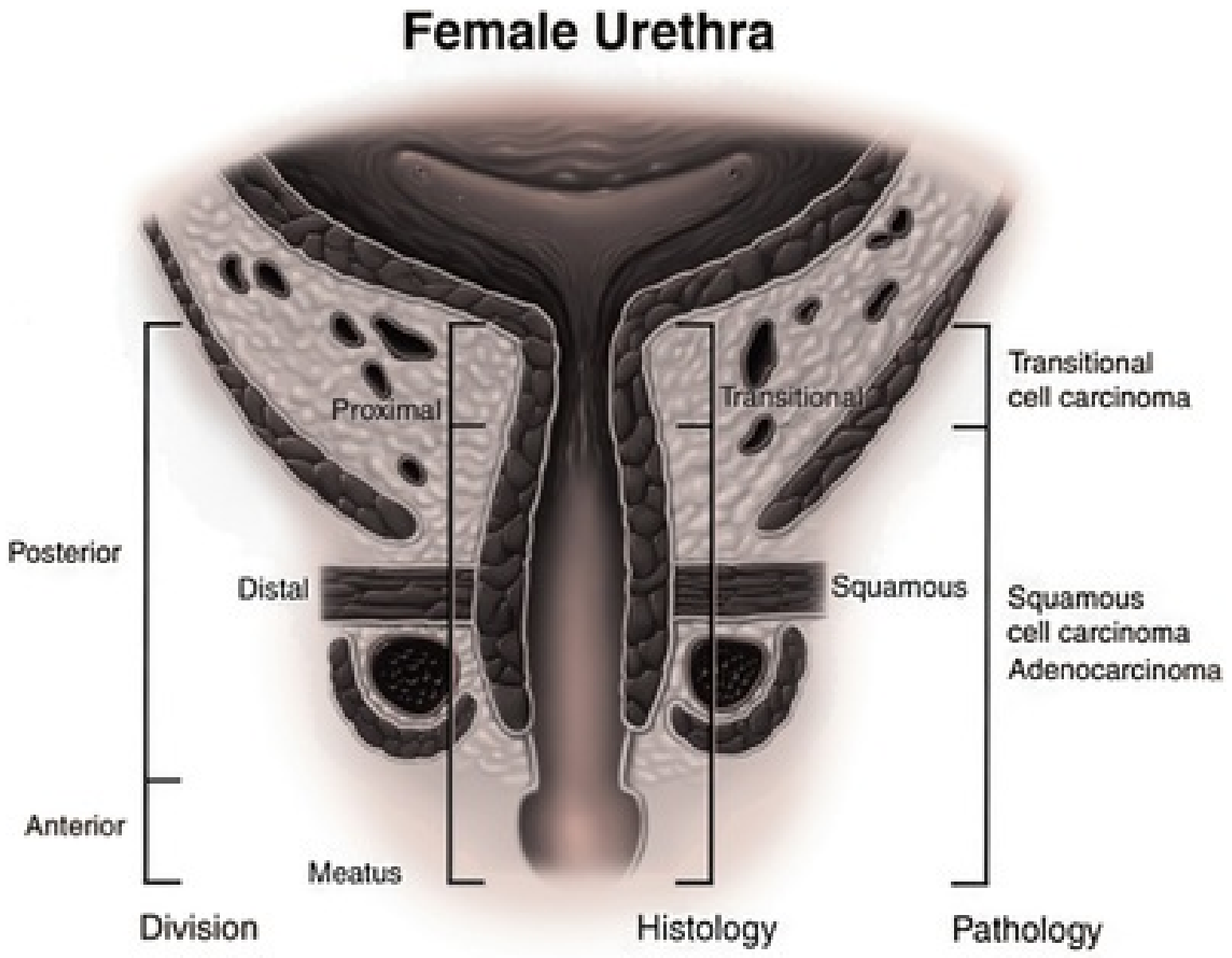
Female Urethra
Proximal
Transitional
Transitional cell carcinoma
Posterior
Distal
Squamous
Squamous cell carcinoma
Adenocarcinoma
Anterior
Meatus
Division
Histology
Pathology

FIG. 80.8 Anatomy of the female urethra with corresponding histology and pathology.

The histology of PUC depends primarily on the site of origin within the urethra. **From population-based studies, there are similar numbers of women with urothelial carcinoma (28%–45%), squamous cell carcinoma (19%–29%), and adenocarcinoma (28%–38%)** (Champ et al., 2012; Derksen et al., 2013; Sui et al., 2017). Adenocarcinoma is more likely to occur in women than in men, may be particularly prevalent in African American women, and is the predominant form of cancer found in urethral diverticula (Garden et al., 1993; Sui et al., 2017; Thomas et al., 2008). There are two predominant forms of female urethral adenocarcinoma: mucinous and clear cell (Murphy et al., 1999; Reis et al., 2011). Mucinous adenocarcinoma is more common, can appear microscopically similar to colonic or cervical adenocarcinoma, and may produce carcinoembryonic antigen (Dell'Atti et al., 2018; Kato et al., 1998; Murphy et al., 1999). Clear cell adenocarcinoma is microscopically similar to clear cell carcinomas of the female genital tract, can secrete prostate-specific antigen, and is more commonly found in urethral diverticula (Dodson et al., 1994; Murphy et al., 1999). Some female urethral adenocarcinomas are microscopically similar to prostate adenocarcinoma (Pongtippan et al., 2004).

Female urethral adenocarcinoma likely originates from the Skene gland, perhaps with the mucinous subtype arising from the proximal gland and the clear cell subtype from the distal gland (Dell'Atti and Galosi, 2018). Others have proposed that female urethral adenocarcinoma can arise from more than one type of urethral tissue, including glandular metaplasia, urothelium, nephrogenic adenoma, and residual müllerian tissue (Alexiev and Tavora, 2013; Murphy et al., 1999). Rare histologic types of female PUC include melanoma, sarcoma, lymphoma, and small cell carcinoma (DiMarco et al., 2004; Grabstald et al., 1966; Grigsby and Corn, 1992).

Evaluation and Staging

The evaluation of women with suspected urethral carcinoma includes a thorough bimanual and pelvic examination to evaluate the clinical extent of disease, with careful attention to potential involvement of the vaginal wall and vulva. The groin should be assessed for adenopathy. Patients should have cystourethroscopy and examination under anesthesia with tumor biopsy, although percutaneous or transvaginal biopsies are alternatives. Cross-sectional imaging is critical to assess the local extent of disease. MRI has superior soft-tissue contrast and gives the best anatomic detail of the pelvis and urethra (Del Gaizo et al., 2013; Surabhi et al., 2013). In addition, MRI can assess local extension and lymph node involvement. Determining the location of the tumor through clinical examination and imaging is critical for treatment decision making. **Approximately one-third of patients have a distal tumor, and the remainder have proximal or pan-urethral tumors** (Dalbagni et al., 1998; Foens et al., 1991; Grabstald et al., 1966; Grigsby, 1998; Johnson and O'Connell, 1983; Kang et al., 2015). Chest radiograph or CT is appropriate to rule out distant metastases. Bone scan may be performed if there is clinical suspicion for bony involvement. Elevated serum prostate-specific antigen has been found in a small number of females with adenocarcinoma and may normalize after successful treatment (Dodson et al., 1994; Pongtippan et al., 2004).

The staging for female urethral cancer is similar to that for male urethral cancer (see Table 80.2). **Approximately 30% to 50% of females with PUC**

present with locally advanced disease (Champ et al., 2012; Foens et al., 1991; Grigsby, 1998; Kang et al., 2015; Sui et al., 2017). As compared with men, women tend to present with higher stage and higher grade tumors (Sui et al., 2017). Roughly 20% of women with PUC have clinically enlarged inguinal lymph nodes, which are usually cancerous, and 10% to 20% have metastases to pelvic lymph nodes or distant sites (Bracken et al., 1976; Champ et al., 2012; Derksen et al., 2013; Garden et al., 1993; Milosevic et al., 2000; Sui et al., 2017). Patients with squamous cell carcinoma may be particularly at risk for synchronous or metachronous nodal involvement (Garden et al., 1993). Distant metastatic disease at presentation is rare (Grigsby, 1998).

Prognosis

Female PUC is an aggressive disease with 5-year survival rates of 40% to 60% (Champ et al., 2012; Dalbagni et al., 1998; Dimarco et al., 2004; Grigsby, 1998; Kang et al., 2015; Sui et al., 2017). However, females with PUC do not appear to have an independently increased risk of death compared with males with PUC (Sui et al., 2017). There are several disease characteristics that affect prognosis. In one of the earliest reports of female PUC it was observed that “survival is determined chiefly by the extent of neoplasm,” (Grabstald et al., 1966) and **tumor stage has since been strongly associated with survival in numerous studies** (Bracken et al., 1976; Dalbagni et al., 1998; Dimarco et al., 2004; Foens et al., 1991; Kang et al., 2015; Thyavihally et al., 2005). Data from the National Cancer Registry of the Netherlands evaluated 91 females with PUC and reported 5-year overall survival rates of 67%, 53%, and 17% for stage II or less, III, and IV, respectively (Derksen et al., 2013). A retrospective cohort study observed that 5-year overall survival for low- versus high-stage tumors was 78% and 22%, respectively, and high-stage, positive nodal status and pan-urethral location were all negatively associated with survival (Dalbagni et al., 1998). Among the 869 women in a large retrospective cohort from the United States, higher tumor stage and the presence of positive lymph nodes were independently associated with worse survival on multivariate analysis (Sui et al., 2017). Finally, a retrospective cohort study using the SEER dataset identified 722 women with PUC between 1983 and 2008, of whom 359 who could be assessed for cancer survival outcomes (Champ et al., 2012). The observed 5-year overall and disease-specific survival rates were 43% and 53%, respectively, and multivariate analysis revealed that black race, increased age, stage, nodal status, and nonsquamous histology were associated with worse cancer-specific survival. Importantly, when interpreting prognostic factors from the existing literature on female PUC, many case series included patients treated before cross-sectional imaging, in which case they were incompletely staged (Foens et al., 1991).

Tumor location has been shown to affect prognosis, as proximal and pan-urethral cancers have lower survival than distal cancers. Five-year disease-specific survival is 71% for distal, 48% for proximal, and 24% for pan-urethral lesions (Dalbagni et al., 1998), and proximal and pan-urethral involvement are independently associated with worse survival (Dalbagni et al., 1998; Dimarco et al., 2004). **However, it has been noted that proximal and pan-urethral tumors are more likely to be higher stage** (Bracken et al., 1976; Thyavihally et al., 2005).

Several reports have also noted that tumor size is strongly associated with survival. A retrospective study of 44 females with PUC observed 5-year overall survival of 89%, 36%, and 19% for tumors smaller than 2 cm, 2 to 4 cm, and more than 4 cm, respectively (Grigsby, 1998). This study found that size was independently associated with survival, although tumor stage was not included in the model. Similar to tumor location, tumor size is also associated with stage so that lager tumors are more often in a proximal location and have a higher stage (Milosevic et al., 2000). Tumor stage is strongly correlated with grade, size, location, and nodal status; however, given the small study sizes, multivariate analyses have not always been possible and the independent effects of stage have not been consistently proven.

There is conflicting evidence about the impact of histologic subtype. Several studies have failed to detect any differences in survival based on histologic subtype, recommending similar treatment regardless of histology (Dimarco et al., 2004; Foens et al., 1991). However, two large population-based studies observed that females with squamous cell carcinoma have a lower risk of death compared with nonsquamous histologies (Champ et al., 2012; Sui et al., 2017). Another retrospective cohort study reported 5-year overall survival rates of 64%, 61%, and 31% for squamous cell carcinoma, urothelial carcinoma, and adenocarcinoma, respectively (Derksen et al., 2013). Urethral melanoma, however, does have a poor prognosis (DiMarco et al., 2004).

Treatment

Given the rarity of female PUC, the majority of information on treatment comes from small institutional cohorts or case reports, and there are limited data on the preferred method of treatment or standardized treatment algorithms. Treatment options include surgery, radiation therapy, and chemotherapy, alone or in combination (see Table 80.3). **As with male PUC, there is increasing interest in multimodal therapy for female PUC** (Dayyani et al., 2013; Derksen et al., 2013; Sui et al., 2017)**, and the types of operations used vary according to the location and stage of the primary tumor**. Roughly 40% of women with PUC are treated with radiation in some form (Champ et al., 2012). Local excision may be sufficient for the small, low-stage, anterior urethral tumors, whereas proximal and advanced urethral tumors require a more aggressive approach.

Tumors in the **anterior urethra** tend to be low stage, and at least 70% can be cured with local excision alone (Grabstald et al., 1966). Small, noninvasive tumors of the urethra can be managed with endoscopic resection or laser fulguration, with or without adjuvant BCG (Bladder cancer, 2018; Staehler et al., 1985). Anterior urethral tumors not amenable to endoscopic treatment can be treated with surgical resection or radiation (Gakis et al., 2013). **Small, exophytic tumors of the anterior urethra can be surgically excised along with a portion of the anterior vaginal wall via a transvaginal approach.** Frozen section of the proximal urethra should be obtained to ensure a negative margin. In a report from the Mayo Clinic, 26 women with PUC were managed with local resection, the majority of whom had T2 lesions or less in the anterior urethra, and some were also given radiation (Dimarco et al., 2004). The 5-year disease-specific survival for patients who had a partial urethrectomy or endoscopic resection was 81%, but 21% experienced a local recurrence and many could not be salvaged. Small case-series have also observed that many patients selected for partial urethrectomy can be cured with surgery alone (Grabstald et al., 1966; Moinuddin Ali et al., 1988).

Partial urethrectomy is not without the risk of complications, most notably urinary incontinence. Although a portion of the female urethra can be safely excised without sacrificing continence, one series reported that 42% of patients had new or worsening stress incontinence after partial urethrectomy (Dimarco et al., 2004). The risk of meatal stenosis can be minimized by performing a wide spatulation of the urethra.

In select patients with advanced staged anterior tumors, bladder-sparing strategies have been employed. Radical urethrectomy with bladder neck closure and creation of a catheterizable stoma or ileovesicostomy may be an option if a negative margin can be achieved (Dimarco et al., 2004). Radical urethrectomy includes wide resection of all periurethral tissue laterally to the bulbocavernosal muscles, anteriorly to the pubic symphysis, and superiorly to the bladder neck, including the anterior vaginal wall.

Radiation monotherapy is also an effective option for low-stage anterior tumors and is an alternative when urethral preservation is desired and surgical resection would negatively affect functional outcomes (Koontz and Lee, 2010). Radiation can be delivered as external beam, brachytherapy, or combined therapy, using doses between 55 and 70 Gy (Weghaupt et al., 1984). One series of 97 women with PUC treated with radiation therapy included 34 women with invasive tumors of the distal urethra and 13 who had their tumors completely resected before radiation (Garden et al., 1993). Most patients with distal tumors were treated with brachytherapy alone at a median of 60 Gy, and the 5-year survival was 74% if only part of the urethra was involved. The extent of urethral involvement by the primary tumor was the only variable that predicted local control. In another retrospective series of 62 patients treated with combined external and brachytherapy, 68% of patients had an anterior tumor and their 5-year overall survival was 71% (Weghaupt et al., 1984). Finally, in a cohort of 34 women with PUC who were treated with radiation, 9 of whom first had a local tumor resection, the 7-year cancer-specific survival and relapse-free rate were 71% and 85%, respectively, for the 14 patients with distal tumors (Milosevic et al., 2000).

Complication rates after radiation have ranged from 20% to 50%, including urethral stricture, necrosis, fistula, and cystitis (Forman and Lichter, 1992; Garden et al., 1993; Milosevic et al., 2000). Although a higher cumulative dose of radiation increases the risk of complications, the complication rate is less with contemporary radiation techniques (Forman and Lichter, 1992; Garden et al., 1993).

Given the lymphatic drainage of the urethra, patients with anterior PUC are at risk for synchronous or metachronous **inguinal lymph node metastasis.** Up to one-third of patients have or develop inguinal adenopathy at some point during the course of disease (Grabstald et al., 1966; Weghaupt et al., 1984). **Similar to male PUC, there is no clear role for prophylactic inguinal lymphadenectomy for patients with high-risk anterior tumors that have clinically negative inguinal lymph nodes.** However, given the frequent use of prophylactic inguinal lymphadenectomy for vulvar squamous cell carcinoma (Dellinger et al., 2017), there is precedent for such treatment of female urogenital cancers and further study of prophylactic inguinal lymphadenectomy has been advocated (Karnes et al., 2010). **Unlike penile and vulvar cancer, there are no known prognostic factors for the development of inguinal lymph node metastases for PUC.**

Prophylactic groin radiation should be considered for patients being treated with primary radiation (Garden et al., 1993). One study suggested prophylactic groin radiation decreased inguinal recurrences; however, recurrences can still occur despite the use of prophylactic radiation (Foens et al., 1991; Milosevic et al., 2000).

Up to 20% of patients experience a recurrence in the inguinal lymph nodes, usually within 2 years of diagnosis (Grabstald et al., 1966; Milosevic et al., 2000). **Patients with clinically palpable inguinal lymph nodes require aggressive treatment because these usually represent metastatic disease, and some of these patients can be cured** (Milosevic et al., 2000; Weghaupt et al., 1984). Treatment options for inguinal lymph node metastases endorsed by professional guidelines include chemoradiation, chemotherapy alone, inguinal lymphadenectomy, and chemoradiation followed by consolidative surgery (Bladder cancer, 2018; Gakis et al., 2013). The technique for inguinal lymphadenectomy is identical to that used for men with penile cancer. Patients with pelvic adenopathy have a poor prognosis and usually die from disease (Grabstald et al., 1966). It is unclear if there is any benefit to pelvic lymphadenectomy for patients with clinically positive pelvic lymph nodes.

Posterior female PUC is more likely to be high stage, involve the entire urethra, and may invade surrounding structures, including the bladder, vagina, and external genitalia (Milosevic et al., 2000). **Despite aggressive treatment with surgery or radiation, the 5-year metastasis-free survival for posterior female PUC is only 24% to 48%** (Dalbagni et al., 1998). **Surgical management usually requires anterior pelvic exenteration.** Anterior exenteration when used alone is associated with low cure rates and a significant risk of local recurrence. In one cohort, 15 of 21 women with posterior or pan-urethral PUC treated with radical surgery died of disease (Grabstald et al., 1966), and a separate group of 26 females with PUC treated with radical cystectomy had a median survival of only 36 months (Dalbagni et al., 1998). Another cohort of 27 women with advanced-stage PUC who were treated with radical surgery alone had a 5-year disease-specific and recurrence-free survival of 52% and 43%, respectively, and a third experienced a pelvic recurrence (Dimarco et al., 2004). Patients that recur in the pelvis have a poor prognosis and usually die of disease (Dimarco et al., 2004).

Anterior exenteration includes radical cystectomy and urethrectomy along with hysterectomy, oophorectomy, extended pelvic lymph node dissection, and wide or complete vaginal excision, which may be required to obtain negative margins. If the lesion extends into the external genitalia, partial vulvectomy or labial excision may be necessary. Anterior exenteration is performed in a similar fashion to that performed for bladder cancer, with a more extensive perineal portion of the procedure to provide wide urethral margins. The perineal portion is performed by making an inverted U-shaped incision to widely encircle the urethral meatus. This incision can be extended onto the posterior vaginal wall, the labia minora, and continued anteriorly to include the clitoris. En bloc resection of the pubic symphysis and inferior pubic rami may be necessary if obtaining a negative margin at the pubis is not possible (Klein et al., 1983), although intraoperative irradiation may be an alternative to pubic bone resection (Dalbagni et al., 2001).

Radiation monotherapy for proximal urethral carcinoma has yielded similarly poor local control, with 5-year survival rates of 0 to 57% and a median survival of less than 3 years (Dalbagni et al., 1998; Garden et al., 1993; Grabstald et al., 1966; Grigsby, 1998; Narayan and Konety, 1992). In one series, patients with proximal urethral tumors treated with radiation monotherapy experienced a 7-year relapse-free rate of 37% and cancer-specific survival of 20% (Milosevic et al., 2000). Several studies have observed that combined external beam radiation and brachytherapy are more effective at achieving local control for posterior tumors than external beam therapy alone (Foens et al., 1991; Milosevic et al., 2000). This may, in part, be due to dose escalation. After treatment with radiation monotherapy for proximal PUC, up to 50% of women experience a local failure and the length of urethra involved significantly affects local control (Foens et al., 1991; Garden et al., 1993; Milosevic et al., 2000). Almost all failures occur within 2 years of treatment and salvage may not be possible (Bracken et al., 1976; Garden et al., 1993).

Because surgery and radiation have similarly low rates of local control and poor survival outcomes when used alone, there is growing interest in use of multimodal therapy for advanced-stage female PUC (Dalbagni et al., 1998, 2001; Foens et al., 1991; Garden et al., 1993). At least 20% of women with PUC receive a combination of surgery and radiation, which has been increasing over time (Derksen et al., 2013). Neoadjuvant radiation followed by surgery may provide better local control than surgery or radiation alone (Dalbagni et al., 1998; Narayan and Konety, 1992). One small case series of 6 women with advanced-stage PUC were treated with pelvic exenteration with intraoperative radiation therapy as well as postoperative external beam radiation and perioperative chemotherapy (Dalbagni et al., 2001). Two of 6 patients were cured, but 2 experienced a local recurrence, and 4 ultimately died of disease. There are several case reports of excellent cancer control with use of multimodal therapy for female PUC (Awakura et al., 2003; Hara et al., 2004; Licht et al., 1995; Nicholson et al., 2008).

Professional guidelines and several expert groups recommend that women with advanced-stage PUC should be treated with multimodal therapy, including systemic chemotherapy with consolidative radiation, surgery, or radiation followed by surgery (Bladder cancer, 2018; Dalbagni et al., 1998; Garden et al., 1993; Grabstald et al., 1966). The type of chemotherapy should be dictated by the tumor histology. The ideal perioperative systemic therapy for squamous cell carcinoma should be cisplatin based, with regimens including CGI and TIP (Dayyani et al., 2013). Adenocarcinoma has been treated with Gem-FLP, and either M-VAC or GC can be used for urothelial carcinoma. Patients treated with chemoradiation can be given systemic cisplatin, 5-FU, and MMC, alone or in combination, as radiosensitizers. Systemic chemotherapy should be used for metastatic disease. The most common sites of distant metastases are lung, bone, and brain (Grabstald et al., 1966).

Given the poor quality of evidence to support treatment recommendations for female PUC and the inherent confounding by treatment indication present in the literature, treatment should be individualized. However, multimodal treatment should be strongly considered given the aggressive nature of advanced female PUC.

Key Points: Female Urethral Cancer

- The three most common histologies for female urethral cancer are urothelial carcinoma, squamous cell carcinoma, and adenocarcinoma.
- Compared with anterior urethral cancers, posterior cancers are found at a more advanced stage and are associated with worse survival.
- Radiation and surgical excision are options for low-stage anterior tumors, each with high cure rates.
- Surgery and radiation therapy for proximal female urethral tumors have poor outcomes when used alone; therefore multimodal therapy is recommended.

Urethral Recurrence After Radical Cystectomy

Male Urethra

After radical cystectomy (RC) there is a risk of recurrence in the remnant urothelium of the urethra and upper urinary tracts. Urothelial recurrence is due to either growth of cancer along the urothelium as an extension of the primary tumor or metachronous tumor development resulting from a field defect (Clark and Hall, 2005; Hardeman and Soloway, 1990). During the early experience with RC, patients often had a prophylactic urethrectomy to eliminate the possibility of a urethral recurrence (UR) (Schellhammer and Whitmore, 1976). However, 64% to 100% of prophylactically removed urethras had no evidence of disease (Lopez-Almansa et al., 1988; Raz et al., 1978; Schellhammer and Whitmore 1976; Spiess et al., 2006; Stockle et al., 1990; Tobisu et al., 1991, 1997; Tongaonkar et al., 1993; Zabbo and Montie, 1984), and when disease was present it was most commonly in the form of CIS (Spiess et al., 2006; Stockle et al., 1990). Over time, surgeons came to understand that the patients with synchronous urethral involvement usually had specific risk factors (Tobisu et al., 1991). Still, the majority of at-risk patients had negative pathology at the time of prophylactic urethrectomy (Tobisu et al., 1991). **Given the low prevalence of synchronous unrecognized urethral involvement, the added morbidity of a urethrectomy to RC, and the growing use of orthotopic urinary diversions, there has been a shift toward urethral preservation** (Beahrs et al., 1984; Tomic and Sjodin, 1992; Zabbo et al., 1984).

The risk of UR after RC ranges from 1% to 15%, with larger series reporting rates near 5% (Table 80.5)**. Most URs occur within 2 years of RC, although 11% occur after 5 years, and they can rarely present as late as 15 years postoperatively** (Clark et al., 2004; Huguet et al., 2008; Sakai et al., 1999). There are several risk factors for UR, including bladder tumor multifocality, presence of CIS, a history of NMIBC, involvement of the prostate with urothelial carcinoma, a positive urethral margin, and a cutaneous diversion (Balci et al 2015; Baron et al., 1989; Donat et al., 2001; Hardeman and Soloway, 1990; Huguet et al., 2003, 2008; Tobisu et al., 1991; Varol et al., 2004). Patients with more risk factors tend to have an increased risk of UR (Tobisu et al., 1991;

Tongaonkar et al., 1993). However, using these multiple criteria to select patients for urethrectomy would eliminate as many as 70% of RC patients from orthotopic neobladder (ONB) eligibility (Freeman et al., 1996). Because UR is a rare event, only the highest risk patients should be subjected to a prophylactic urethrectomy.

TABLE 80.5

Male Urethral Recurrences After Radical Cystectomy

STUDY	YEARS	NUMBER	URETHRAL RECURRENCES	TIME TO RECURRENCE	COMMENTS
Beahrs et al., 1984	1965–1974	349	8%		
Zabbo and Montie, 1984	1960–1979	119	6.4%	1–5 yr	
Lopez-Almansa et al., 1988	1975–1984	110	3.8%		
Baron et al., 1989	1977–1987	140	9.1%	Mean 26 mo	
Hardeman and Soloway, 1990	1975–1987	86	15%	Mean 12 mo	
Stockle et al., 1990	1967–1987	273	9.2%		
Tobisu et al., 1991	1963–1987	169	10.6%		
Tongaonkar et al., 1993	1981–1996	177	9%	Mean 13 mo	
Erckert et al., 1996	1969–1994	910	7.4%	Median 17.9 mo	
Nieder et al.,2004	1992–2003	226	3.7%	Mean 12.8 mo	
Donat et al., 2001	1989–1997	246	6.4%	15.2 mo	
Boorjian et al., 2011	1980–2000	1,506	5.6%	Median 13.3 mo	
Hassan et	1995–	290	1.7%	66 mo	ONB only

al., 2004	2001				
Yoshida et al., 2006	1993–2004	77	5%	6–45 mo	ONB only
Huguet et al., 2008	1978–2003	729	4.7%	Median 13.9 mo	
Cho et al., 2009	1986–2004	294	4.4%	Median 17 mo	
Taylor et al., 2010	1980–2004	259	2.3%	Mean 2.3 yrs	ONB only
Mitra et al., 2014	1971–2005	2,029	2.7%	Median 25.3 mo	
Giannarini et al., 2010	1985–2009	479	5%		ONB only
Gaya et al., 2014	1990–2010	234	1.1%		
Balci et al., 2015	1991–2013	287	3.8%	28 mo	
Pichler et al., 2017	2006–2015	177	6.8%		
Perlis et al., 2013	1992–2008	503	3.6%	Median 18 mo	

ONB, Orthotopic neobladder.

Prostatic involvement is a strong risk factor for UR. The prostate is involved by urothelial carcinoma in 17% to 40% of RC specimens, most commonly in the prostatic urethra or ducts, but disease can also invade into the prostatic stroma (Donat et al., 2001; Freeman et al., 1996; Hardeman and Soloway, 1990; Huguet et al., 2008; Mazzucchelli et al., 2009; von Rundstedt et al., 2015). Patients with recurrent tumors, tumors located at the trigone or bladder neck, and multifocal tumors are more likely to have prostatic involvement (Mazzucchelli et al., 2009). Stein reported a 5% UR rate among patients with no prostatic involvement but a 15% rate among patients with prostatic involvement (Stein et al., 2005). In this cohort, neither multifocality nor CIS were predictive of UR on multivariate analysis. Another group similarly found that prostatic urethral involvement was significantly associated with risk of UR and recommend against ONB for patients with prostatic involvement (Cho et al., 2009).

Preoperative prostatic biopsy has been studied to identify prostatic involvement before RC and select patients for prophylactic urethrectomy. In a cohort of 234 RC patients, a preoperative transurethral prostatic biopsy had a sensitivity of 80.6% and a negative predictive value of 93% for prostatic involvement on final pathology (Gaya et al., 2014). These findings suggested that patients with a negative preoperative biopsy can safely proceed to ONB without additional intraoperative frozen section. Although preoperative prostatic urethral biopies are reasonably good at diagnosing prostatic involvement, they correlate poorly with the final urethral margin (Kassouf et al., 2008; Lebret et al., 1998; von Rundstedt et al., 2015). **Preoperative prostatic biopsies to determine ONB eligibility have largely been abandoned in favor of intraoperative frozen section** (Donat et al., 2001; Kassouf et al., 2008).

A positive urethral margin is seen in fewer than 7% of RC specimens but is also a strong risk factor for UR (Boorjian et al., 2011; Cho et al., 2009; Donat et al., 2001; Kassouf et al., 2008; Mitra et al., 2014). Among 294 RC patients who experienced 13 URs (4.4%), a positive urethral margin (HR 18.3, 95% confidence interval (CI) 4.6–71.7, $P < 0.001$) was the strongest risk factor for UR after controlling for prostatic involvement and tumor stage (Cho et al., 2009). Still, many URs occur in the absence of a positive apical margin, suggesting additional factors contribute (Donat et al., 2001; Taylor et al., 2010).

Given the low incidence of urethral recurrence, most surgeons feel comfortable proceeding with ONB as long as the frozen-section biopsy of the distal prostatic urethral margin is normal at the time of RC (Freeman et al., 1996; Hassan et al., 2004; Kassouf et al., 2008; Nieder et al., 2004; Stein et al., 2005). Intraoperative frozen section can accurately evaluate the final urethral margin, and up to half of positive margins on frozen section can be converted to negative margins with additional sections (Gaya et al., 2014; Kassouf et al., 2008; Kates et al., 2016). However, if there is concern about the ability of obtaining a negative margin, an ONB should not be performed.

Patients with ONBs have a lower risk of UR than patients with cutaneous diversions. Although this may reflect differences in selection criteria for urinary diversion, some theorize that ONBs are protective against UR because of changes in the local immune response, the antineoplastic effects of ileum, or the continued exposure of the urethra to urine (Freeman et al., 1996; Gakis et al., 2017). When comparing 397 ONB patients with 371 patients with cutaneous diversions, the estimated 5-year risk of UR was 5% and 9%, respectively, equating to a 50% decreased relative risk ($P = 0.035$) (Stein et al., 2005). Diversion type and prostatic involvement were the only two prognostic factors for UR on multivariate analysis. A large retrospective cohort study of 1506 RC patients found that ONB (0.34, 95% CI 0.13–0.86; $P = 0.02$), prostatic involvement (HR 4.89, 95% CI 3.0–7.9; $P < 0.0001$), and bladder tumor multifocality (HR 2.34, 95% CI 1.4–3.9; $P = 0.001$) were significantly associated with UR after adjusting for stage and presence of CIS (Boorjian et al., 2011). Two percent of patients with ONB had a UR, whereas 6% of patients with an ileal conduit had a UR.

Although prior groups have advocated prophylactic urethrectomy in the presence of several risk factors for UR, including multifocal bladder tumors, upper urinary tract tumors, diffuse CIS, involvement of the prostatic urethra, and involvement of the bladder neck, **the strongest indications for prophylactic urethrectomy are a positive urethral margin or gross urethral involvement** (Gaya et al., 2014; Lopez-Almansa et al., 1988; Stockle et al., 1990; Van Poppel and Sorgeloose, 2003; Zabbo and Montie, 1984). A urologist may determine that a patient is at sufficiently high risk to recommend a prophylactic urethrectomy. A staged urethrectomy after RC has similar outcomes compared with a planned urethrectomy at the time of RC (Nelles et al., 2008; Spiess et al., 2006). Still, total urethrectomy after RC with cutaneous diversion can be challenging, particularly with regard to completely excising the proximal urethra from the pelvic floor. The proximal urethra is at risk for positive margins, and incomplete resection can lead to retropubic relapses that are difficult to manage.

Patients who experience a urethral recurrence often have urethral bloody discharge or a palpable mass (Beahrs et al., 1984). Recurrences tend to be proximal but can occur anywhere along the length of the urethra (Stockle et al., 1990; Tongaonkar et al., 1993). Several groups have investigated whether screening for asymptomatic recurrences with urethral cytology improves outcomes for patients with a UR. Cytology is either obtained from a voided sample with an ONB or a catheterized urethral barbotage from patients with a cutaneous diversion. Among 1054 RC patients who had regular urethral cytology assessments, one study found no difference in survival between the 24 patients who presented symptomatically compared with the 13 detected asymptomatically with urine cytology (Clark et al., 2004). Another study similarly found no survival difference between 17 URs detected on cytology compared with 7 who presented symptomatically (Lin et al., 2003). However, a third study found that although patients who presented asymptomatically had a similar time to diagnosis to those with symptoms, an asymptomatic UR tended to be a lower stage and had improved 5-year cancer specific survival compared with a symptomatic recurrence (80% vs. 41%) (Boorjian et al., 2011).

Patients who have a positive cytology or symptoms of urethral bleeding, discharge, or palpable mass require evaluation with urethroscopy and biopsy. There is a risk of false-positive cytology emphasizing the importance confirming a UR with a biopsy before initiating treatment (Lin et al., 2003). Pelvic CT or MRI is necessary to assess the local extent of disease and search for metastasis. The most definitive treatment of a UR is total urethrectomy (Video 80.1). The entire urethra should be removed because incomplete removal of the distal urethra leaves patients at risk for a distal recurrence (Baron et al., 1989; Schellhammer and Whitmore, 1976).

Urethrectomy in patients with a cutaneous diversion can be difficult, with a risk of positive margins proximally given the difficulty of removing the urethral stump from the scarred pelvic floor (Stockle et al., 1990). After an orthotopic diversion radical urethrectomy generally requires conversion to a cutaneous diversion, although subtotal urethrectomy with perineal urethrostomy has been described (Clark et al., 2004).

Patients with noninvasive URs can be managed successfully with endoscopic resection and topical therapy (Erckert et al., 1996; Huguet et al., 2003; Miller and Benson, 1996; Yossepowitch et al., 2003). Intraurethral BCG, although cumbersome to administer, has had high response rates when used for patients with urethral CIS, but not for those with papillary or invasive disease (Giannarini et al., 2010; Huguet et al., 2003; Varol et al., 2004). There is a significant risk of a second UR after endoscopic management necessitating continued surveillance (Yoshida et al., 2006). Radiation therapy has also been used for treatment of UR (Chakrabarti et al., 2013).

Patients who experience an isolated noninvasive UR generally have a favorable prognosis and can usually be salvaged (Beahrs et al., 1984; Clark et al., 2004; Taylor et al., 2010; Tongaonkar et al., 1993; Varol et al., 2004). Patients with invasive URs often have an aggressive disease course with a median survival of 17 months (Baron et al., 1989; Clark et al., 2004). At least one-third of patients with URs have concomitant pelvic or distant recurrences in which case the prognosis is poor (Gakis et al., 2017).

Total Urethrectomy After Cutaneous Diversion

The high lithotomy position provides optimal exposure for total urethrectomy, with the hips and knees gently flexed and the lower limbs abducted in stirrups. A urethral catheter can be placed to assist with urethral dissection. Through a modified λ or midline perineal incision (Fig. 80.9), the subcutaneous tissue and bulbospongiosus muscle are divided in the midline and retracted to expose the corpus spongiosum. The corpus spongiosum is mobilized circumferentially at the level of the bulbar urethra, and traction is applied to facilitate sharp dissection of the urethra distally, thus separating the corpus spongiosum from the adjacent corpora cavernosa. As dissection proceeds distally, the penis becomes inverted, the corpora cavernosa become bowed, and the glans recedes into the phallus. The penis is essentially turned inside out onto the perineum, and the dissection is completed to the base of the glans. To excise the meatus and glandular urethra, the penis is replaced in its anatomic position, and an incision is made around the meatus and extended on each side down the ventral aspect of the glans. The distal urethra is then freed from its investments within the glans, and the isolated pendulous urethra is delivered onto the perineum. The deep spongiosum of the glans penis is reapproximated with 4-0 polydioxanone sutures, and the surface layer is closed with interrupted 4-0 chromic sutures.

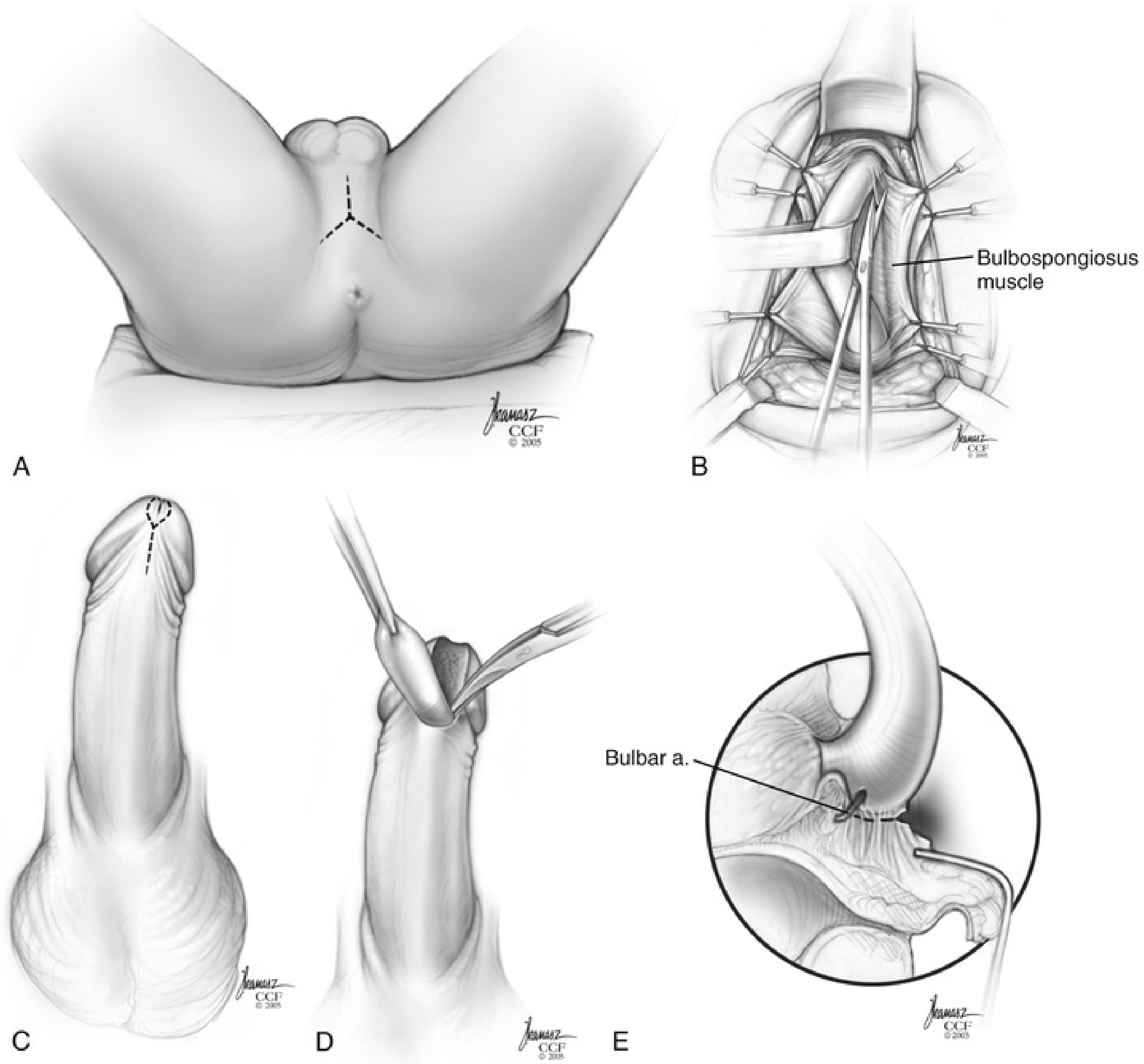

FIG. 80.9 Total urethrectomy after previous cystoprostatectomy. (A) Perineal incision. (B) Division of bulbospongiosus muscle to expose the bulb of the corpus spongiosum and initial dissection of the urethra off of the corporeal bodies. (C) Distal incision circumscribing the urethral meatus. (D) Distal urethral dissection, which then connects to the proximal dissection at the level of the distal shaft. (E) Sagittal view demonstrating posterior bulb dissection and location of the bulbar artery. (Reprinted with permission, Cleveland Clinic Center for Medical Art and Photography. Copyright 2003–2010. All rights reserved.)

Proximal sharp dissection of the urethral bulb is carried out posteriorly and laterally, staying close to the bulb but avoiding entry. Care must be taken with posteriolateral dissection because this is where the bulbar arteries are located. Bothersome bleeding will result if these vessels are not controlled, generally with electrocautery or suture ligature. The urethra is detached from the corporeal bodies anteriorly to the level of the departure of the urethra from the bulb, leaving the specimen attached only by the membranous urethra. Care must be exercised in completing the proximal dissection given the possibility of bowel adhesions to the superior surface of the urogenital diaphragm in patients with cutaneous diversions. This should be done under direct vision, and exposure can be aided by separating the crura of the corporeal bodies in the midline to open the intracrural space. All that remains of the membranous urethra proximally is an ill-defined fibrotic band, which should be completely excised. Frozen-section analysis of this region adds some assurance that a negative proximal margin has been attained. A small suction drain is placed in the urethral bed and brought out through the perineum. The bulbospongiosus muscle, subcutaneous tissue, and skin are closed with interrupted absorbable sutures, and a light pressure dressing is applied. Superficial hematoma, edema along the penile shaft, and infection are uncommon complications.

Total Urethrectomy After Orthotopic Diversion

Total urethrectomy after orthotopic urinary diversion and conversion to a cutaneous diversion is performed through an abdominoperineal approach. The patient is placed in lithotomy position with stirrups that can be adjusted during the procedure. A catheter is placed into the neobladder. Urethrectomy is carried out in a similar fashion to the level of the membranous urethra. Abdominal exploration with lysis of adhesions and mobilization of the orthotopic neobladder is done to the level of the urethral anastomosis. Working from above and below, the urethroneovesical anastomosis is dissected free. A circular area of the pouch adjacent to the anastomosis is excised with the urethra to ensure an adequate margin, and the specimen is delivered through the perineum. Bleeding from the musculature within the tunnel developed during excision of the membranous urethra can be bothersome and is best controlled with suture ligatures or electrocautery.

In most situations, urinary diversion is accomplished with an ileal conduit. This often can be carried out with use of bowel from the ONB, which may be reconfigured when necessary, with care taken to incise the bowel along visible lines of previous closure with preservation of the mesenteric blood supply. The remaining portions of the pouch are excised. If the existing orthotopic diversion has an afferent limb, this segment can be used to construct the conduit without the need for reimplantation of the ureters (Bissada et al., 2004). Conversion to a continent cutaneous diversion may also be possible, depending on intra-abdominal anatomy and the motivation of the patient (Bartoletti et al., 1999;

Taylor et al., 2010).

Female Urethra

Urethrectomy at the time of a female RC is relatively easy to perform and has traditionally been a standard part of surgery. However, with the improved understanding of the female continence mechanism and the low rate of urethral involvement at RC, preservation of the urethra and construction of ONBs in women have gained popularity. **Synchronous urethral involvement at the time of radical cystectomy in females is seen in 8% to 13% of patients** (Chen et al., 1997; Stein et al., 1995)**. The main risk factor for female urethral involvement is bladder neck involvement, which is seen in up to 25% of female cystectomy specimens** (Stein et al., 1995). Although nearly all urethral tumors have bladder neck involvement, only 30% to 50% of patients with bladder neck involvement have urethral tumors, suggesting that bladder neck involvement is not an absolute contraindication to urethral preservation (Chen et al., 1997; Stein et al., 1995). Anterior vaginal wall involvement may also increase the risk of urethral involvement, although many patients with vaginal wall invasion also have bladder neck involvement (Maralani et al., 1997; Stein et al., 1995). Direct extension of bladder tumors into the urethra is the most likely cause of urethral involvement, but skip lesions are possible (Chen et al., 1997; Maralani et al., 1997).

There have been several criteria proposed to select women for ONB, including absence of bladder neck, urethral, and anterior vaginal wall involvement, and a negative intraoperative frozen section (Stein et al., 1995, 2007). Intraoperative frozen-section analysis of the urethral stump is an accurate method for determining the presence of cancer, and a positive frozen section can often be converted to negative with additional resection (Jentzmik et al., 2012; Stein et al., 1998). **Most surgeons would consider a negative intraoperative frozen section essential to ONB eligibility** (Stein et al., 2007). Patients with trigonal involvement and positive lymph nodes may still be candidates for ONB as long as the urethral frozen section is negative (Gakis et al., 2015).

A urethral recurrence after ONB in females is a rare event, seen in fewer than 5% of patients (Ali-El-Dein, 2009; Gakis et al., 2015; Pichler et al., 2013; Stein et al., 2008; Stenzl and Holtl, 2003). This is likely due to less at-risk urothelium given shorter female urethral length and the cephalad extension of squamous epithelium after menopause (Stenzl and Holtl, 2003). Urethral recurrences can present with symptoms of obstruction, hematuria, and pain and most commonly occur in the proximal urethra (Gakis et al., 2015; Hrbacek et al., 2015). **Most studies find that URs occur 2 to 4 years postoperatively, although a recent report observed 12 URs that occurred at a median 8 months after RC** (Ali-El-Dein et al., 2004; Gakis et al., 2015; Hrbacek et al., 2015; Pichler et al., 2013; Stein et al., 2008).

One large retrospective cohort study of 180 women who had RC and ONB, approximately 60% of whom had squamous cell carcinoma, demonstrated two URs (1.4%) (Ali-El-Dein, 2009). This highly select group excluded patients having an ONB with trigonal, bladder neck, or vaginal wall involvement and those with a positive intraoperative frozen section. Another large retrospective multi-institutional cohort of 297 highly selected women who had RC and ONB observed seven URs (2.4%) at a median 30 months postoperatively (Gakis et al., 2015). Interestingly, only one UR had a positive final margin at RC, suggesting most recurrences were from skip lesions. Five of the seven URs also had distant or local recurrences, and the 3-year overall survival for all patients with a UR was 25%.

Treatment for local URs most commonly involves urethrectomy and conversion to a cutaneous diversion, although there have been reports on use of BCG (Hrbacek et al., 2015; Jones et al., 2000; Pichler et al., 2013; Stein et al., 2008). Patients with an isolated UR have a good prognosis with curative treatment (Stein et al., 2008). However, many patients with URs also have synchronous pelvic recurrences, distant metastasis, or locally advanced disease, in which case the prognosis is dismal (Hrbacek et al., 2015; Jones et al., 2000).

Key Points: Urethral Recurrence After Radical Cystectomy

- Male urethral recurrence after radical cystectomy is rare, but more common with prostatic involvement, a positive urethral margin, and cutaneous diversions.
- The primary risk factors for female urethral recurrences are bladder neck involvement and a positive urethral margin.
- Most surgeons will proceed with ONB if an intraoperative frozen section of the urethral margin is negative.

- After urethrectomy in patients with ONBs, bowel from the neobladder can often be reconfigured and used for a cutaneous diversion.

Acknowledgments

Thanks to Dr. Kenneth W. Angermeier and Dr. David S. Sharp, who authored this chapter previously.

References

Agrawal S, Lacy JM, Bagga H, et al. Secondary urethral malignancies following prostate brachytherapy. *Urology*. 2017;110:172–176.

Aita GA, Begliomini H, Mattos D Jr. Fibroepithelial polyp of the urethra. *Int Braz J Urol*. 2005;31(2):155–156.

Alexiev BA, Tavora F. Histology and immunohistochemistry of clear cell adenocarcinoma of the urethra: histogenesis and diagnostic problems. *Virchows Arch*. 2013;462(2):193–201.

Ali-El-Dein B. Oncological outcome after radical cystectomy and orthotopic bladder substitution in women. *Eur J Surg Oncol*. 2009;35(3):320–325.

Ali-el-Dein B, Abdel-Latif M, Ashamallah A, et al. Local urethral recurrence after radical cystectomy and orthotopic bladder substitution in women: a prospective study. *J Urol*. 2004;171(1):275–278.

Anderson KA, McAninch JW. Primary squamous cell carcinoma of the anterior male urethra. *Urology*. 1984;23(2):134–140.

Awakura Y, Nonomura M, Itoh N, et al. Adenocarcinoma of the female urethral diverticulum treated by multimodality therapy. *Int J Urol*. 2003;10(5):281–283.

Balci U, Dogantekin E, Ozer K, et al. Patterns, risks and outcomes of urethral recurrence after radical cystectomy for urothelial cancer; over 20 year single center experience. *Int J Surg*. 2015;13:148–151.

Baron JC, Gibod LB, Steg A. Management of the urethra in patients undergoing radical cystectomy for bladder carcinoma. *Eur Urol*. 1989;16(4):283–285.

Bartoletti R, Natali A, Gacci M, et al. Urethral carcinoma recurrence in ileal orthotopic neobladder: urethrectomy and conversion in a continent pouch with abdominal stoma. *Urol Int*. 1999;62(4):213–216.

Baskin LS, Turzan C. Carcinoma of male urethra: management of locally advanced disease with combined chemotherapy, radiotherapy, and penile-preserving surgery. *Urology*. 1992;39(1):21–25.

Beahrs JR, Fleming TR, Zincke H. Risk of local urethral recurrence after radical cystectomy for bladder cancer. *J Urol*. 1984;131(2):264–266.

Bissada NK, Herschorn S, Elzawahri A, et al. Urinary conduit formation using retubularized bowel from continent urinary diversion or intestinal augmentations: I. A multi-institutional experience. *Urology*. 2004;64(3):485–487 [discussion 487].

Bladder cancer. [*NCCN Clinical Practice Guidelines in Oncology*] https://www.nccn.org/professionals/physician_gls/default.asp 2018.

Boorjian SA, Kim SP, Weight CJ, et al. Risk factors and outcomes of urethral recurrence following radical cystectomy. *Eur Urol*. 2011;60(6):1266–1272.

Bracken RB, Henry R, Ordonez N. Primary carcinoma of the male urethra. *South Med J*. 1980;73(8):1003–1005.

Bracken RB, Johnson DE, Miller LS, et al. Primary carcinoma of the female urethra. *J Urol*. 1976;116(2):188–192.

Bretton PR, Herr HW, Whitmore WF Jr, et al. Intravesical bacillus Calmette-Guerin therapy for in situ transitional cell carcinoma involving the prostatic urethra. *J Urol*. 1989;141(4):853–856.

Bruins HM, Djaladat H, Ahmadi H, et al. Incidental prostate cancer in patients with bladder urothelial carcinoma: comprehensive analysis of 1,476 radical cystoprostatectomy specimens. *J Urol*. 2013;190(5):1704–1709.

Canda AE, Tuzel E, Mungan MU, et al. Conservative management of mucosal prostatic urethral involvement in patients with superficial transitional cell carcinoma of the bladder. *Eur Urol*. 2004;45(4):465–469 [discussion 469–470].

Chakrabarti B, Ghorai S, Ray SB, et al. Intraluminal urethral brachytherapy for recurrence of transitional cell carcinoma of urinary bladder in urethral stump. *J Contemp Brachytherapy*. 2013;5(1):42–44.

Champ CE, Hegarty SE, Shen X, et al. Prognostic factors and outcomes after definitive treatment of female urethral cancer: a population-based analysis. *Urology*. 2012;80(2):374–381.

Chen ME, Pisters LL, Malpica A, et al. Risk of urethral, vaginal and cervical involvement in patients undergoing radical cystectomy for bladder cancer: results of a contemporary cystectomy series from M. D. Anderson Cancer Center. *J Urol*. 1997;157(6):2120–2123.

Cheville JC, Dundore PA, Bostwick DG, et al. Transitional cell carcinoma of the prostate: clinicopathologic study of 50 cases. *Cancer*. 1998;82(4):703–707.

Cho KS, Seo JW, Park SJ, et al. The risk factor for urethral recurrence after radical cystectomy in patients with transitional cell carcinoma of the bladder. *Urol Int*. 2009;82(3):306–311.

Christopher N, Arya M, Brown RS, et al. Penile preservation in squamous cell carcinoma of the bulbomembranous urethra. *BJU Int*. 2002;89(4):464–465.

Cicilet S, Joseph T, Furruqh F, et al. Urethral leiomyoma: a rare case of voiding difficulty. *BMJ Case Rep*. 2016;2016.

Clark PE, Hall MC. Contemporary management of the urethra in patients after radical cystectomy for bladder cancer. *Urol Clin North Am*. 2005;32(2):199–206.

Clark PE, Stein JP, Groshen SG, et al. The management of urethral transitional cell carcinoma after radical cystectomy for invasive bladder cancer. *J Urol*. 2004;172(4 Pt 1):1342–1347.

Cohen MS, Triaca V, Billmeyer B, et al. Coordinated chemoradiation therapy with genital preservation for the treatment of primary invasive carcinoma of the male urethra. *J Urol*. 2008;179(2):536–541 [discussion 541].

Cornella JL, Larson TR, Lee RA, et al. Leiomyoma of the female urethra and bladder: report of twenty-three patients and review of the literature. *Am J Obstet Gynecol*. 1997;176(6):1278–1285.

Cupp MR, Malek RS, Goellner JR, et al. Detection of human papillomavirus DNA in primary squamous cell carcinoma of the male urethra. *Urology*. 1996;48(4):551–555.

Dalbagni G, Donat SM, Eschwege P, et al. Results of high dose rate brachytherapy, anterior pelvic exenteration and external beam radiotherapy for carcinoma of the female urethra. *J Urol*. 2001;166(5):1759–1761.

Dalbagni G, Zhang ZF, Lacombe L, et al. Female urethral carcinoma: an analysis of treatment outcome and a plea for a standardized management strategy. *Br J Urol*. 1998;82(6):835–841.

Dalbagni G, Zhang ZF, Lacombe L, et al. Male urethral carcinoma: analysis of treatment outcome. *Urology*. 1999;53(6):1126–1132.

Dayyani F, Hoffman K, Eifel P, et al. Management of advanced primary urethral carcinomas. *BJU Int*. 2014;114(1):25–31.

Dayyani F, Pettaway CA, Kamat AM, et al. Retrospective analysis of survival outcomes and the role of cisplatin-based chemotherapy in patients with urethral carcinomas referred to medical oncologists. *Urol Oncol*. 2013;31(7):1171–1177.

Del Gaizo A, Silva AC, Lam-Himlin DM, et al. Magnetic resonance imaging of solid urethral and peri-urethral lesions. *Insights Imaging*. 2013;4(4):461–469.

Dell'Atti L, Galosi AB. Female urethra adenocarcinoma. *Clin Genitourin Cancer*. 2018;16(2):e263–e267.

Dellinger TH, Hakim AA, Lee SJ, et al. Surgical management of vulvar cancer. *J Natl Compr Canc Netw*. 2017;15(1):121–128.

Derksen JW, Visser O, de la Riviere GB, et al. Primary urethral carcinoma in females: an epidemiologic study on demographical factors, histological types, tumour stage and survival. *World J Urol*. 2013;31(1):147–153.

DiMarco DS, DiMarco CS, Zincke H, et al. Outcome of surgical treatment for primary malignant melanoma of the female urethra. *J Urol*. 2004;171(2 Pt 1):765–767.

Dimarco DS, Dimarco CS, Zincke H, et al. Surgical treatment for local control of female urethral carcinoma. *Urol Oncol*. 2004;22(5):404–409.

Dinney CP, Johnson DE, Swanson DA, et al. Therapy and prognosis for male anterior urethral carcinoma: an update. *Urology*. 1994;43(4):506–514.

Dodson MK, Cliby WA, Keeney GL, et al. Skene's gland adenocarcinoma with increased serum level of prostate-specific antigen. *Gynecol Oncol*. 1994;55(2):304–307.

Donat SM, Wei DC, McGuire MS, et al. The efficacy of transurethral biopsy for predicting the long-term clinical impact of prostatic invasive bladder cancer. *J Urol*. 2001;165(5):1580–1584.

Ende N, Woods LP, Shelley HS. Carcinoma originating in ducts surrounding the prostatic urethra. *Am J Clin Pathol*. 1963;40:183–189.

Erckert M, Stenzl A, Falk M, et al. Incidence of urethral tumor involvement in 910 men with bladder cancer. *World J Urol*. 1996;14(1):3–8.

Esrig D, Freeman JA, Elmajian DA, et al. Transitional cell carcinoma involving the prostate with a proposed staging classification for stromal invasion. *J Urol*. 1996;156(3):1071–1076.

Fletcher SG, Lemack GE. Benign masses of the female periurethral tissues and anterior vaginal wall. *Curr Urol Rep*. 2008;9(5):389–396.

Foens CS, Hussey DH, Staples JJ, et al. A comparison of the roles of surgery and radiation therapy in the management of carcinoma of the female urethra. *Int J Radiat Oncol Biol Phys*. 1991;21(4):961–968.

Forman JD, Lichter AS. The role of radiation therapy in the management of carcinoma of the male and female urethra. *Urol Clin North Am*. 1992;19(2):383–389.

Freeman JA, Tarter TA, Esrig D, et al. Urethral recurrence in patients with orthotopic ileal neobladders. *J Urol*. 1996;156(5):1615–1619.

Fry M, Wheeler JS Jr, Mata JA, et al. Leiomyoma of the female urethra. *J Urol*. 1988;140(3):613–614.

Gakis G, Ali-El-Dein B, Babjuk M, et al. Urethral recurrence in women with orthotopic bladder substitutes: a multi-institutional study. *Urol Oncol*. 2015;33(5):204.e17–204.e23.

Gakis G, Black PC, Bochner BH, et al. Systematic review on the fate of the remnant urothelium after radical cystectomy. *Eur Urol*. 2017;71(4):545–557.

Gakis G, Morgan TM, Daneshmand S, et al. Impact of perioperative chemotherapy on survival in patients with advanced primary urethral cancer: results of the international collaboration on primary urethral carcinoma. *Ann Oncol*. 2015;26(8):1754–1759.

Gakis G, Morgan TM, Efstathiou JA, et al. Prognostic factors and outcomes in primary urethral cancer: results from the international collaboration on primary urethral carcinoma. *World J Urol*. 2016;34(1):97–103.

Gakis G, Witjes JA, Comperat E, et al. EAU guidelines on primary urethral carcinoma. *Eur Urol*. 2013;64(5):823–830.

Garden AS, Zagars GK, Delclos L. Primary carcinoma of the female urethra. Results of radiation therapy. *Cancer*. 1993;71(10):3102–3108.

Gaya JM, Matulay J, Badalato GM, et al. The role of preoperative prostatic urethral biopsy in clinical decision-making at the time of radical cystectomy. *Can J Urol*. 2014;21(2):7228–7233.

Gheiler EL, Tefilli MV, Tiguert R, et al. Management of primary urethral cancer. *Urology*. 1998;52(3):487–493.

Giannarini G, Kessler TM, Thoeny HC, et al. Do patients benefit from routine follow-up to detect recurrences after radical cystectomy and ileal orthotopic bladder substitution? *Eur Urol*. 2010;58(4):486–494.

Gofrit ON, Pode D, Pizov G, et al. Prostatic urothelial carcinoma: is transurethral prostatectomy necessary before bacillus Calmette-Guerin immunotherapy? *BJU Int*. 2009;103(7):905–908.

Goldman HB, McAchran SE, MacLennan GT. Leiomyoma of the urethra and bladder. *J Urol*. 2007;177(5):1890.

Grabstald H, Hilaris B, Henschke U, et al. Cancer of the female urethra. *J Am Med Assoc*. 1966;197(11):835–842.

Grigsby PW. Carcinoma of the urethra in women. *Int J Radiat Oncol Biol Phys*. 1998;41(3):535–541.

Grigsby PW, Corn BW. Localized urethral tumors in women: indications for conservative versus exenterative therapies. *J Urol*. 1992;147(6):1516–1520.

Hakenberg OW, Franke HJ, Froehner M, et al. The treatment of primary urethral carcinoma–the dilemmas of a rare condition: experience with partial urethrectomy and adjuvant chemotherapy. *Onkologie*. 2001;24(1):48–52.

Han H, Zhou XG, Fan DD, et al. An unusual etiology for hematospermia and treatments that were successful. *Urology*.

2015;86(4):740–743.

Hansel D, Reuter VE, Bochner B, et al. Urethra. Amin MB. *AJCC cancer staging manual*. ed 8. Springer: New York; 2017.

Hara I, Hikosaka S, Eto H, et al. Successful treatment for squamous cell carcinoma of the female urethra with combined radio- and chemotherapy. *Int J Urol*. 2004;11(8):678–682.

Hardeman SW, Soloway MS. Urethral recurrence following radical cystectomy. *J Urol*. 1990;144(3):666–669.

Hassan JM, Cookson MS, Smith JA Jr, et al. Urethral recurrence in patients following orthotopic urinary diversion. *J Urol*. 2004;172(4 Pt 1):1338–1341.

Hayashi T, Igarashi K, Sekine H. Urethral hemangioma: case report. *J Urol*. 1997;158(2):539–540.

Herr HW, Donat SM. Prostatic tumor relapse in patients with superficial bladder tumors: 15-year outcome. *J Urol*. 1999;161(6):1854–1857.

Heysek RV, Parsons JT, Drylie DM, et al. Carcinoma of the male urethra. *J Urol*. 1985;134(4):753–755.

Hrbacek J, Macek P, Ali-El-Dein B, et al. Treatment and outcomes of urethral recurrence of urinary bladder cancer in women after radical cystectomy and orthotopic neobladder: a series of 12 cases. *Urol Int*. 2015;94(1):45–49.

Huguet J, Monllau V, Sabate S, et al. Diagnosis, risk factors, and outcome of urethral recurrences following radical cystectomy for bladder cancer in 729 male patients. *Eur Urol*. 2008;53(4):785–792 [discussion 792–783].

Huguet J, Palou J, Serrallach M, et al. Management of urethral recurrence in patients with Studer ileal neobladder. *Eur Urol*. 2003;43(5):495–498.

Jahn H, Nissen HM. Haemangioma of the urinary tract: review of the literature. *Br J Urol*. 1991;68(2):113–117.

Jentzmik F, Schrader AJ, de Petriconi R, et al. The ileal neobladder in female patients with bladder cancer: long-term clinical, functional, and oncological outcome. *World J Urol*. 2012;30(6):733–739.

Johnson DE, O'Connell JR. Primary carcinoma of female urethra. *Urology*. 1983;21(1):42–45.

Jones J, Melchior SW, Gillitzer R, et al. Urethral recurrence of transitional cell carcinoma in a female patient after cystectomy and orthotopic ileal neobladder. *J Urol*. 2000;164(5):1646.

Kang M, Jeong CW, Kwak C, et al. Survival outcomes and predictive factors for female urethral cancer: long-term experience with Korean patients. *J Korean Med Sci*. 2015;30(8):1143–1149.

Kaplan GW, Bulkey GJ, Grayhack JT. Carcinoma of the male urethra. *J Urol*. 1967;98(3):365–371.

Karnes RJ, Breau RH, Lightner DJ. Surgery for urethral cancer. *Urol Clin North Am*. 2010;37(3):445–457.

Kassouf W, Spiess PE, Brown GA, et al. Prostatic urethral biopsy has limited usefulness in counseling patients regarding final urethral margin status during orthotopic neobladder reconstruction. *J Urol*. 2008;180(1):164–167 [discussion 167].

Kates M, Ball MW, Chappidi MR, et al. Accuracy of urethral frozen section during radical cystectomy for bladder cancer. *Urol Oncol*. 2016;34(12):532.e1–532.e6.

Kato H, Ogihara S, Kobayashi Y, et al. Carcinoembryonic antigen positive adenocarcinoma of a female urethral diverticulum: case report and review of the literature. *Int J Urol*. 1998;5(3):291–293.

Kato T, Kobayashi T, Ikeda R, et al. Urethral leiomyoma expressing estrogen receptors. *Int J Urol*. 2004;11(7):573–575.

Kent M, Zinman L, Girshovich L, et al. Combined chemoradiation as primary treatment for invasive male urethral cancer. *J Urol*. 2015;193(2):532–537.

Klein FA, Whitmore WF Jr, Herr HW, et al. Inferior pubic rami resection with en bloc radical excision for invasive proximal urethral carcinoma. *Cancer*. 1983;51(7):1238–1242.

Koontz BF, Lee WR. Carcinoma of the urethra: radiation oncology. *Urol Clin North Am*. 2010;37(3):459–466.

Kumar A, Das SK, Trivedi S, et al. Genito-urinary polyps: summary of the 10-year experiences of a single institute. *Int Urol Nephrol*. 2008;40(4):901–907.

Lebret T, Herve JM, Barre P, et al. Urethral recurrence of transitional cell carcinoma of the bladder. Predictive value of preoperative latero-montanal biopsies and urethral frozen sections during prostatocystectomy. *Eur Urol*. 1998;33(2):170–174.

Licht MR, Klein EA, Bukowski R, et al. Combination radiation and chemotherapy for the treatment of squamous cell carcinoma of the male and female urethra. *J Urol*. 1995;153(6):1918–1920.

Lin DW, Herr HW, Dalbagni G. Value of urethral wash cytology in the retained male urethra after radical cystoprostatectomy. *J Urol*. 2003;169(3):961–963.

Lopez-Almansa M, Molina R, Huben RP. Transitional cell carcinoma of the urethra in men after radical cystectomy for bladder cancer. Is prophylactic urethrectomy indicated? *Br J Urol*. 1988;61(6):507–509.

Manuel ES, Seery WH, Cole AT. Capillary hemangioma of the male urethra: case report with literature review. *J Urol*. 1977;117(6):804.

Maralani S, Wood DP Jr, Grignon D, et al. Incidence of urethral involvement in female bladder cancer: an anatomic pathologic study. *Urology*. 1997;50(4):537–541.

Mazzucchelli R, Barbisan F, Santinelli A, et al. Prediction of prostatic involvement by urothelial carcinoma in radical cystoprostatectomy for bladder cancer. *Urology*. 2009;74(2):385–390.

Miller MI, Benson MC. Management of urethral recurrence after radical cystectomy and neobladder creation by urethroscopic resection and fulguration. *J Urol*. 1996;156(5):1768.

Milosevic MF, Warde PR, Banerjee D, et al. Urethral carcinoma in women: results of treatment with primary radiotherapy. *Radiother Oncol*. 2000;56(1):29–35.

Mitra AP, Alemozaffar M, Harris BN, et al. Outcomes after urothelial recurrence in bladder cancer patients undergoing radical cystectomy. *Urology*. 2014;84(6):1420–1426.

Moinuddin Ali M, Klein FA, Hazra TA. Primary female urethral carcinoma. A retrospective comparison of different treatment techniques. *Cancer*. 1988;62(1):54–57.

Murphy DP, Pantuck AJ, Amenta PS, et al. Female urethral adenocarcinoma: immunohistochemical evidence of more than 1 tissue of origin. *J Urol*. 1999;161(6):1881–1884.

Murray WJ, Fletcher MS, Walters HL, et al. Treatment of urethral hemangioma by selective arterial embolization. *J Urol*. 1986;136(6):1304–1306.

Narayan P, Konety B. Surgical treatment of female urethral carcinoma. *Urol Clin North Am*. 1992;19(2):373–382.

Nash PA, Bihrle R, Gleason PE, et al. Mohs' micrographic surgery and distal urethrectomy with immediate urethral reconstruction for glanular carcinoma in situ with significant urethral extension. *Urology*. 1996;47(1):108–110.

Nelles JL, Konety BR, Saigal C, Urologic Diseases in America Project, et al. Urethrectomy following cystectomy for bladder cancer in men: practice patterns and impact on survival. *J Urol*. 2008;180(5):1933–1936 [discussion 1936–1937].

Nicholson S, Tsang D, Summerton D. Aggressive combined-modality therapy for squamous cell carcinoma of the female urethra. *Nat Clin Pract Urol*. 2008;5(10):574–577.

Nieder AM, Sved PD, Gomez P, et al. Urethral recurrence after cystoprostatectomy: implications for urinary diversion and monitoring. *Urology*. 2004;64(5):950–954.

Ongun S, Celik S, Aslan G, et al. Cavernous hemangioma of the female urethra: a rare case report. *Urol J*. 2014;11(2):1521–1523.

Orihuela E, Herr HW, Whitmore WF Jr. Conservative treatment of superficial transitional cell carcinoma of prostatic urethra with intravesical BCG. *Urology*. 1989;34(5):231–237.

Pahwa M, Saifee Y, Pahwa AR, et al. Leiomyoma of the female urethra-a rare tumor: case report and review of the literature. *Case Rep Urol*. 2012;2012 [280816].

Palou J, Wood D, Bochner BH, et al. ICUD-EAU International Consultation on Bladder Cancer 2012: urothelial carcinoma of the prostate. *Eur Urol*. 2013;63(1):81–87.

Palou J, Xavier B, Laguna P, et al. In situ transitional cell carcinoma involvement of prostatic urethra: bacillus Calmette-Guerin therapy without previous transurethral resection of the prostate. *Urology*. 1996;47(4):482–484.

Palou Redorta J, Schatteman P, Huguet Perez J, et al. Intravesical instillations with bacillus calmette-guerin for the treatment of carcinoma in situ involving prostatic ducts. *Eur Urol*. 2006;49(5):834–838.

Parshad S, Yadav SP, Arora B. Urethral hemangioma. An unusual cause of hematuria. *Urol Int*. 2001;66(1):43–45.

Patel SG, Cookson MS, Barocas DA, et al. Risk factors for urothelial carcinoma of the prostate in patients undergoing radical cystoprostatectomy for bladder cancer. *BJU Int*. 2009;104(7):934–937.

Perlis N, Turker P, Bostrom PJ, et al. Upper urinary tract and urethral recurrences following radical cystectomy: review of risk factors and outcomes between centres with different follow-up protocols. *World J Urol*. 2013;31(1):161–167.

Pichler R, Tulchiner G, Oberaigner W, et al. Effect of urinary cytology for detecting recurrence in remnant urothelium after radical cystectomy: insights from a 10-year cytology database. *Clin Genitourin Cancer*. 2017;15(5):e783–e791.

Pichler R, Zangerl F, Leonhartsberger N, et al. Orthotopic bladder replacement in women: focus on functional results of a retrospective, single-centre study. *Scand J Urol*. 2013;47(4):295–301.

Pongtippan A, Malpica A, Levenback C, et al. Skene's gland adenocarcinoma resembling prostatic adenocarcinoma. *Int J Gynecol Pathol*. 2004;23(1):71–74.

Rabbani F. Prognostic factors in male urethral cancer. *Cancer*. 2011;117(11):2426–2434.

Raghavaiah NV. Radiotherapy in the treatment of carcinoma of the male urethra. *Cancer*. 1978;41(4):1313–1316.

Raz S, McLorie G, Johnson S, et al. Management of the urethra in patients undergoing radical cystectomy for bladder carcinoma. *J Urol*. 1978;120(3):298–300.

Reis LO, Billis A, Ferreira FT, et al. Female urethral carcinoma: evidences to origin from Skene's glands. *Urol Oncol*. 2011;29(2):218–223.

Reuter VE. Urethra. Bostwick DG, Cheng L. *Urologic surgical pathology*. 3rd ed. Elsevier/Saunders: Philadelphia; 2014:542–558.

Rikken CH, van Helsdingen PJ, Kazzaz BA. Are biopsies from the prostatic urethra useful in patients with superficial bladder carcinoma? *Br J Urol*. 1987;59(2):145–147.

Roberts JW, Devine CJ Jr. Urethral hemangioma: treatment by total excision and grafting. *J Urol*. 1983;129(5):1053–1054.

Saito S. Posterior urethral hemangioma: one of the unknown causes of hematuria and/or hematospermia. *Urology*. 2008;71(1):168.e11–168.e14.

Sakai N, Yamada T, Asao T, et al. A case of urethral recurrence found 15 years after radical cystectomy. *Int J Urol*. 1999;6(11):578–580.

Schellhammer P, Ladaga L, Moriarty RP. Intravesical bacillus Calmette-Guerin for treatment of superficial transitional cell carcinoma of the prostatic urethra in association with carcinoma of the bladder. *J Urol*. 1995;153:53–56.

Schellhammer PF, Whitmore WF Jr. Transitional cell carcinoma of the urethra in men having cystectomy for bladder cancer. *J Urol*. 1976;115(1):56–60.

Scher HI, Yagoda A, Herr HW, et al. Neoadjuvant M-VAC (methotrexate, vinblastine, doxorubicin and cisplatin) for extravesical urinary tract tumors. *J Urol*. 1988;139(3):475–477.

Smith Y, Hadway P, Ahmed S, et al. Penile-preserving surgery for male distal urethral carcinoma. *BJU Int*. 2007;100(1):82–87.

Spiess PE, Kassouf W, Brown G, et al. Immediate versus staged urethrectomy in patients at high risk of urethral recurrence: is there a benefit to either approach? *Urology*. 2006;67(3):466–471.

Staehler G, Chaussy C, Jocham D, et al. The use of neodymium-YAG lasers in urology: indications, technique and critical assessment. *J Urol*. 1985;134(6):1155–1160.

Stein JP, Clark P, Miranda G, et al. Urethral tumor recurrence following cystectomy and urinary diversion: clinical and pathological characteristics in 768 male patients. *J Urol*. 2005;173(4):1163–1168.

Stein JP, Cote RJ, Freeman JA, et al. Indications for lower urinary tract reconstruction in women after cystectomy for bladder cancer: a pathological review of female cystectomy specimens. *J Urol*. 1995;154(4):1329–1333.

Stein JP, Esrig D, Freeman JA, et al. Prospective pathologic analysis of female cystectomy specimens: risk factors for orthotopic diversion in women. *Urology*. 1998;51(6):951–955.

Stein JP, Hertz J, Nichols PW. Urethral recurrence in a woman after continent orthotopic urinary diversion for bladder cancer. *Urology*. 2008;71(4):755.e1–755.e2.

Stein JP, Penson DF, Wu SD, et al. Pathological guidelines for orthotopic urinary diversion in women with bladder cancer: a review of the literature. *J Urol*. 2007;178(3 Pt 1):756–760.

Stenzl A, Holtl L. Orthotopic bladder reconstruction in women–what we have learned over the last decade. *Crit Rev Oncol Hematol*. 2003;47(2):147–154.

Stewart SB, Leder RA, Inman BA. Imaging tumors of the penis and urethra. *Urol Clin North Am*. 2010;37(3):353–367.

Stockle M, Gokcebay E, Riedmiller H, et al. Urethral tumor recurrences after radical cystoprostatectomy: the case for primary cystoprostatourethrectomy? *J Urol*. 1990;143(1):41–42 [discussion 43].

Sui W, RoyChoudhury A, Wenske S, et al. Outcomes and prognostic factors of primary urethral cancer. *Urology*. 2017;100:180–186.

Surabhi VR, Menias CO, George V, et al. Magnetic resonance imaging of female urethral and periurethral disorders. *Radiol Clin North Am*. 2013;51(6):941–953.

Swartz MA, Porter MP, Lin DW, et al. Incidence of primary urethral carcinoma in the United States. *Urology*. 2006;68(6):1164–1168.

Tabibian L, Ginsberg DA. Thrombosed urethral hemangioma. *J Urol*. 2003;170(5):1942.

Tannenbaum M. Transitional cell carcinoma of prostate. *Urology*. 1975;5(5):674–678.

Taylor JH, Davis J, Schellhammer P. Long-term follow-up of intravesical bacillus Calmette-Guerin treatment for superficial transitional-cell carcinoma of the bladder involving the prostatic urethra. *Clin Genitourin Cancer*. 2007;5(6):386–389.

Taylor JM, Spiess PE, Kassouf W, et al. Management of urethral recurrence after orthotopic urinary diversion. *BJU Int*. 2010;106(1):56–61.

Terada N, Arakaki R, Okada Y, et al. Management of urethral hemangiomas associated with Klippel-Trenaunay-Weber syndrome by endoscopic sclerotherapy. *Int J Urol*. 2007;14(7):658–660.

Thomas AA, Rackley RR, Lee U, et al. Urethral diverticula in 90 female patients: a study with emphasis on neoplastic alterations. *J Urol*. 2008;180(6):2463–2467.

Thyavihally YB, Tongaonkar HB, Srivastava SK, et al. Raibhattanavar SG. Clinical outcome of 36 male patients with primary urethral carcinoma: a single center experience. *Int J Urol*. 2006;13(6):716–720.

Thyavihally YB, Wuntkal R, Bakshi G, et al. Primary carcinoma of the female urethra: single center experience of 18 cases. *Jpn J Clin Oncol*. 2005;35(2):84–87.

Tobisu K, Kanai Y, Sakamoto M, et al. Involvement of the anterior urethra in male patients with transitional cell-carcinoma of the bladder undergoing radical cystectomy with simultaneous urethrectomy. *Jpn J Clin Oncol*. 1997;27(6):406–409.

Tobisu K, Tanaka Y, Mizutani T, et al. Transitional cell carcinoma of the urethra in men following cystectomy for bladder cancer: multivariate analysis for risk factors. *J Urol*. 1991;146(6):1551–1553 [discussion 1553–1554].

Tomic R, Sjodin JG. Sexual function in men after radical cystectomy with or without urethrectomy. *Scand J Urol*

Nephrol. 1992;26(2):127–129.

Tongaonkar HB, Dalal AV, Kulkarni JN, et al. Urethral recurrences following radical cystectomy for invasive transitional cell carcinoma of the bladder. *Br J Urol*. 1993;72(6):910–914.

Touijer AK, Dalbagni G. Role of voided urine cytology in diagnosing primary urethral carcinoma. *Urology*. 2004;63(1):33–35.

Traboulsi SL, Witjes JA, Kassouf W. Contemporary management of primary distal urethral cancer. *Urol Clin North Am*. 2016;43(4):493–503.

Tsai YS, Yang WH, Tong YC, et al. Experience with primary urethral carcinoma from the blackfoot disease-endemic area of South Taiwan: increased frequency of bulbomembranous adenocarcinoma? *Urol Int*. 2005;74(3):229–234.

Tsuzuki T, Epstein JI. Fibroepithelial polyp of the lower urinary tract in adults. *Am J Surg Pathol*. 2005;29(4):460–466.

Uchida K, Fukuta F, Ando M, et al. Female urethral hemangioma. *J Urol*. 2001;166(3):1008.

Van Poppel H, Sorgeloose T. Radical cystectomy with or without urethrectomy? *Crit Rev Oncol Hematol*. 2003;47(2):141–145.

Varol C, Thalmann GN, Burkhard FC, et al. Treatment of urethral recurrence following radical cystectomy and ileal bladder substitution. *J Urol*. 2004;172(3):937–942.

Verma R, Mehra S, Garga UC, et al. Imaging diagnosis of urethral leiomyoma, usual tumour at an unusual location. *J Clin Diagn Res*. 2014;8(11):RD4–RD6.

Visser O, Adolfsson J, Rossi S, et al. Incidence and survival of rare urogenital cancers in Europe. *Eur J Cancer*. 2012;48(4):456–464.

von Rundstedt FC, Lerner SP, Godoy G, et al. Usefulness of transurethral biopsy for staging the prostatic urethra before radical cystectomy. *J Urol*. 2015;193(1):58–63.

Weghaupt K, Gerstner GJ, Kucera H. Radiation therapy for primary carcinoma of the female urethra: a survey over 25 years. *Gynecol Oncol*. 1984;17(1):58–63.

Wiener JS, Walther PJ. A high association of oncogenic human papillomaviruses with carcinomas of the female urethra: polymerase chain reaction-based analysis of multiple histological types. *J Urol*. 1994;151(1):49–53.

Yamashita T, Masuda H, Yano M, et al. Female urethral fibroepithelial polyp with stricture. *J Urol*. 2004;171(1):357.

Yoshida K, Nishiyama H, Kinoshita H, et al. Surgical treatment for urethral recurrence after ileal neobladder reconstruction in patients with bladder cancer. *BJU Int*. 2006;98(5):1008–1011.

Yossepowitch O, Dalbagni G, Golijanin D, et al. Orthotopic urinary diversion after cystectomy for bladder cancer: implications for cancer control and patterns of disease recurrence. *J Urol*. 2003;169(1):177–181.

Zabbo A, Montie JE. Management of the urethra in men undergoing radical cystectomy for bladder cancer. *J Urol*. 1984;131(2):267–268.

81

Inguinal Node Dissection

Rene Sotelo MD, Luis G. Medina MD, Marcos Tobias Machado MD, PhD

Introduction

Inguinal lymph nodes (ILNs) are the primary site for metastasis of invasive penile squamous cell carcinoma (SCC). Despite growing experience in managing penile cancer over the years, surgery remains a cornerstone of treatment. The most important prognostic factor is the involvement of the lymphatics located at the inguinal region (Ornellas et al., 1994; Pettaway et al., 1995; Pizzocaro et al., 2010).

The National Comprehensive Cancer Network (NCCN) recommends bilateral inguinal lymph node dissection (ILND) for all patients, after management of the primary lesions, who are staged as intermediate (T1b) and high-risk (T2 and T3) tumors. Nonpalpable lymph nodes with low-risk primary disease can undergo observation (NCCN, 2018). Additionally, any patient with a positive lymph node on dynamic sentinel node biopsy (DSNB), discussed later in this chapter, should undergo ILND. This recommendation, based on a study by Slaton et al., concluded that patients with T2 disease carry an increased risk for metastasis (42% to 80%) when lymphovascular invasion is present or greater than 50% poorly differentiated cancer is identified in the pathology examination of the primary lesion. However, despite evidence that survival of patients undergoing ILND had a survival benefit (HR 0.79; CI 0.74–0.84, P <0.001), partial adherence to the guidelines has been described, possibly caused by concerns of overtreatment (Slaton et al., 2001; Correa et al., 2018; Pizzocaro et al., 2010).

For patients with a nonpalpable ILN, careful evaluation of prognostic factors for higher risk for inguinal metastasis is crucial. When these factors are present, performing surgical resection of the ILN has been shown to increase survival (Kroon et al., 2005b). On the other hand, for patients with a palpable and resectable ILN, complete cure is possible with or without adjuvant chemotherapy (McDougal et al., 1986; Pizzocaro et al., 2010).

When nodal ulceration or local skin invasion is noted, surgery can be performed for symptom palliation or to avoid death caused by femoral bleeding (Puras-Baez et al., 1995; Ornellas et al., 2008).

In this chapter, we review and discuss the most significant and compelling data regarding anatomy, evaluation, and management of ILNs for penile cancer.

Anatomic Background

Penile Lymphatics

As a rule, penile carcinoma spreads initially to the ILNs before development of distant metastatic disease (Wood and Angermeier, 2010). Lymphatic spread of disease follows the normal route for penile lymphatic drainage.

Penile lymphatics drain to the superficial and then deep ILNs, and subsequently to the iliac nodes (Pompeo, 2005; Riveros et al., 1967). It is worth mentioning that only anecdotal observations suggested that penile lymphatics may drain directly to the external iliac nodes (Lopes et al., 2000).

The prepuce and skin of the penile shaft drain to the superficial lymphatic system. This consists of a network of vessels that converge dorsally and then divide at the base of the penis to drain into the right and left superficial ILNs, respectively. The glans and frenulum drain into the deep lymphatic system, which consists of large trunks that circle the corona to merge with those from the other side on the dorsum of the penile shaft. They traverse the penis toward the base within Buck fascia, draining through presymphyseal lymphatics into the nodes of the femoral triangle. **It is possible for penile cancer to metastasize to the contralateral ILNs because of crossover in the symphyseal region. This fact is critical and guides the surgical approach when considering bilateral inguinal dissection.** However, it is accepted that although micrometastases can be found in the contralateral inguinal area, the drainage does not skip levels and usually follows the path from superficial to deep ILNs and from deep ILNs to pelvic lymphatic systems.

Although penile carcinoma metastases to the ILNs confers a poorer prognosis overall, aggressive lymphadenectomy is associated with improved long-term survival and potential cure when lymphatic metastases are present (Horenblas and van Tinteren, 1994; McDougal et al., 1986). Additionally, immediate resection of clinically occult lymph node metastases is associated with improved 5-year survival rates (85% vs. 35%) when compared with delayed resection of involved nodes at the time of clinical detection (Kroon et al., 2005a). Nonetheless, if the tumor has spread to the pelvic nodes, long-term survival is less than 10% (Lapierre et al., 2017).

Urethral Lymphatics

Urethral lymphatic drainage runs parallel to the urethra and is located within the mucosal layer and submucosa (Spirin, 1963). This network is most dense in the area of the fossa navicularis, and these branches join the lymphatics of the glans at the prepuce. The lymphatics of the penile urethra course laterally around the corpora cavernosa to join the vessels proceeding from the glans penis. Bulbar urethral drainage is more variable and may occur along the bulbar artery toward the medial retrofemoral node or may course under the pubis toward the anterior bladder wall, terminating in the retrofemoral and medial external iliac nodes (Wood and Angermeier, 2010).

Inguinal Anatomy

The femoral triangle is bounded by the inguinal ligament superiorly, the sartorius muscle laterally, and the adductor longus muscle medially. The floor of the triangle is composed of the pectineus muscle medially and the iliopsoas laterally. The location of the saphenofemoral junction is estimated to be two fingerbreadths lateral and two inferiors from the pubic tubercle.

The ILNs are divided into superficial and deep groups, which are anatomically separated by the fascia lata. The superficial group is composed of 4 to 25 lymph nodes that are settled in the deep membranous layer. The superficial ILNs have been divided into five anatomic groups (Daseler et al., 1948): (1) central nodes around the saphenofemoral junction, (2) superolateral nodes around the superficial circumflex vein, (3) inferolateral nodes around the lateral femoral cutaneous and superficial circumflex veins, (4) superomedial nodes around the superficial external pudendal and superficial epigastric veins, and (5) inferomedial nodes around the greater saphenous vein (Fig. 81.1). **Superficial nodes are the first to be affected and therefore play a factor in the selection of the template for the dissection.**

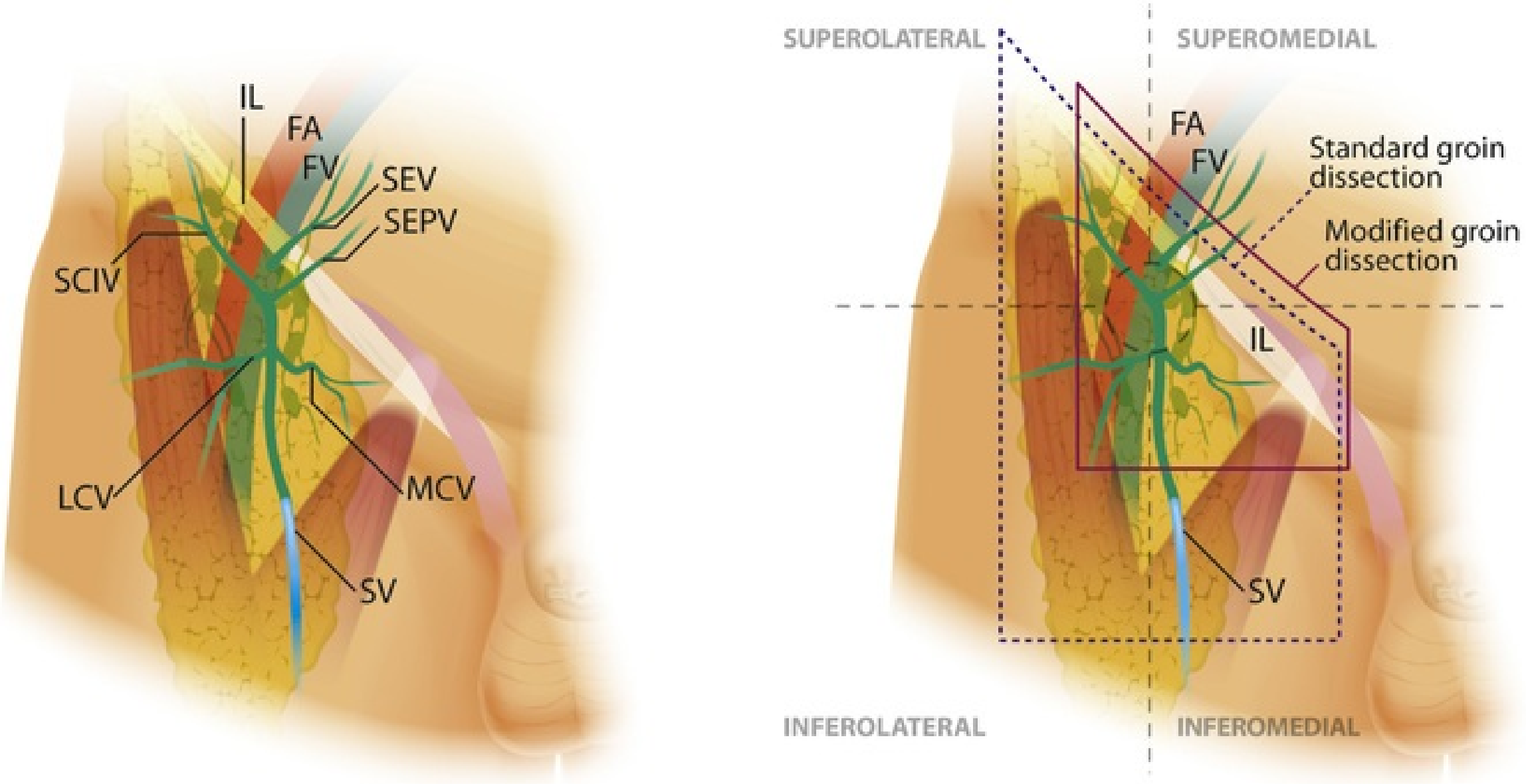

FIG. 81.1 Topographic anatomy plus limits of the standard and modified inguinal lymph node dissections. *IL,* inguinal ligament; *FA,* femoral artery; *FV,* femoral vein; *SEV,* superficial epigastric vein; *SEPV,* superficial

external pudendal vein; *MCV,* medial cutaneous vein; *LCV,* lateral cutaneous vein; *SCIV,* superficial circumflex iliac vein.

The deep ILNs are fewer in number than in the superficial package (1 to 3) and are located medial to the femoral vein in the femoral canal. The node of Cloquet is the most cephalad of this deep group and is situated between the femoral vein and the lacunar ligament. The external iliac lymph nodes receive drainage from the deep inguinal, obturator, and hypogastric groups. The drainage then proceeds on to the common iliac and para-aortic nodes.

The blood supply to the skin of the inguinal region derives from branches of the common femoral artery—the superficial external pudendal, superficial circumflex iliac, and superficial epigastric arteries. Conventional open INLD sacrificed these branches. **Viability of the skin flaps raised during the dissection depends on anastomotic vessels in the superficial fatty layer of Camper fascia that course from lateral to medial along the natural skin lines.** Because lymphatic drainage of the penis to the groin runs beneath Camper fascia, this layer can be preserved and left attached to the overlying skin when the superior and inferior skin flaps are created. Based on this anatomy, a transverse skin incision would compromise this blood supply the least, and serious skin sloughing is prevented in a majority of patients. The femoral nerve lies deep to the iliacus fascia and supplies motor function to the pectineus, quadriceps femoris, and sartorius muscles. In addition, this nerve provides cutaneous sensation to the anterior thigh and should be preserved. Some of the sensory branches of inguinal skin, however, are commonly sacrificed in the regional node dissection.

Endoscopic Anatomy of Inguinal Area

Video-endoscopic inguinal surgery has been described as a viable option in patients with low-volume inguinal disease. The most routinely utilized technique is retrograde dissection, initiating at the vertex of the femoral triangle distally and progressing toward the inguinal ligament proximally (Sotelo et al., 2007; Tobias-Machado et al., 2006). To perform this surgery with good results, it is essential to know and understand aspects of endoscopic anatomy.

The first significant anatomic landmarks to identify are the limits of skin, Camper, and Scarpa fascia using a small incision. After that, digital maneuvers are performed to place the trocars.

Insufflation with CO_2 gas and blunt optic dissection allows proper separation of the skin from the lymphatic and vascular elements located beneath it.

The lateral limit of superficial femoral triangle is the fascia of the sartorius muscle, and the medial border is the adductor longus fascia. Both fascias are externally palpable and easily identified endoscopically. Crossing the medial limit, the Saphena Magna, the great saphenous vein, is identified. In most patients with nonpalpable lymph nodes, it is possible to spare the saphenous vein. Progressive proximal dissection will lead to the fossa ovalis, also referred to as the *saphenous hiatus,* and identification of the accessory saphenous vein and other tributaries of the saphena.

Most nodes are located above the fascia lata, specifically medial to the saphenous-femoral junction, and can be identified by their brown or green coloration. One must be careful to include all areolar tissue between the skin, inguinal cord, and saphenous vein. Preoperative ultrasonographic (US) guidance may be useful to mark the skin above the most prominent nodes. If fluorescence is available, minimally invasive resection can aid to remove suspicious nodes.

Sectioning the fascia lata over the pulse of femoral artery is needed to access the deep node compartment where the deep ILNs lie. This includes all nodal and areolar tissue medial to the femoral vein and lateral to the adductor longus muscle. This resection is continued until Cloquet node (more proximal node located inside the femoral channel) is identified. After this resection has been completed, the most critical structures of femoral triangle are identified.

Imaging Evaluation of Inguinal Area

Ultrasonography With Fine-Needle Aspiration Cytology

US of the ILNs can be used to identify neoplastic nodes. Lymph nodes that appear hypoechoic or heterogeneous on US are suspicious of harboring metastases. Some experts can discern better when the normal node architecture is replaced by neoplastic tissue (Goldberg et al., 2005; Clément and Luciani, 2004; Bude, 2004).

Some studies have suggested that in men with penile cancer, fine-needle aspiration cytology (FNAC) of suspicious nodes should be the first investigation in clinically node-negative patients at high risk for occult metastasis. FNAC could also be used in patients with clinically palpable nodes. FNAC is currently performed under US or computed tomography (CT) control. Contemporary studies report a false-negative rate of 20% to 30% (Horenblas et al., 1991).

Although the sensitivity of US-guided FNAC has varied from 50% to 100%, the specificity varies from 90% to 100%. If a tumor is confirmed, therapeutic ILND can be performed instead of DSNB (Saisorn et al., 2006; Kroon et al., 2005b; Van Rijk et al., 2006; Serpa Neto et al., 2011). If the FNAC is positive, ILND should be performed, and overlying skin and tissues containing the needle tract should be removed with the nodal tissue. If FNAC is negative, it can be repeated if suspicion of lymph node involvement remains.

Computed Tomography and Magnetic Resonance Imaging

Computed tomography (CT) and conventional magnetic resonance imaging (MRI) are unreliable in staging nonpalpable regional lymph nodes as microscopic involvement of lymph node cannot be identified on these studies.

Appropriate staging imaging, including CT of chest, abdomen, and pelvis is recommended in patients with ILN involvement or in patients with clinically suspected pelvic lymph nodes (Horenblas, 2001a, 2001b).

Magnetic Resonance Imaging With

Nanotechnology

Preliminary evidence using MRI with iron nanoparticles demonstrated that this imaging modality could detect inguinal metastasis in more than 90% of patients with positive ILN disease. Iron nanoparticles are phagocyted by tumor-associated macrophages, promoting a negative signal in T1 MRI sequences inside the positive nodes (Tabatabaei et al., 2005).

Other studies have suggested that lymphotropic nanoparticle–enhanced MRI (LNMRI) cannot reliably detect micrometastases (Hughes et al., 2009). Furthermore, nanoparticle contrast is rarely available in clinical practice nowadays because of safety concerns such as skin thickening, joint stiffness, and swelling after administration of the contrast (Hughes et al., 2009).

Positron Emission Tomography

Experienced centers have shown that positron emission tomography (PET) has better accuracy over other image methods routinely used such as CT or MRI (Ottenhof and Vegt, 2017; Zhang et al., 2016).

The accuracy of PET/CT for lymph node staging seems to be higher when compared with CT. In groins with normal physical examination, the sensitivity is only 57%. In groins with palpable or enlarged lymph nodes, the sensitivity of PET/CT reaches 96% (Ottenhof and Vegt, 2017). For pelvic lymph nodes and distant metastases, PET/CT is more accurate if inguinal metastases are present. However, these results are based on a very limited number of studies (Ottenhof and Vegt, 2017; Zhang et al., 2016).

In clinical practice today, PET scan is not currently recommended routinely for penile cancer staging.

Penile Cancer: Surgical Management of Regional Lymph Nodes

In the following sections of this chapter, we will describe the minimally invasive and open techniques for ILND in clinically negative and positive lymph nodes, respectively. It is important to highlight that either technique can be used in each of these clinical scenarios.

Penile Cancer: Nonpalpable Inguinal Adenopathy

Approximately 25% of patients with nonpalpable lymph nodes will have lymphatic metastases (Slaton et al., 2001). For nonpalpable lymph nodes, ILND is indicated for intermediate (T1b), and high-risk tumors (T2 and T3) (NCCN, 2018) (Box 81.1). Moreover, there is evidence that **delays in the treatment of the ILNs of more than 12 weeks will negatively impact a patient's chances of survival significantly** (5-year disease specific survival of 64.1% vs. 39.5%) (Chipollini et al., 2017). Lymph node metastases are the most important single predictor for survival in patients with penile cancer; the overall 5-year survival rate for patients with one to three positive ILNs after inguinal lymphadenectomy is about 75.6%, whereas with four to five positive nodes it is 8.4% (Pandey et al., 2006).

Box 81.1

Indications for Inguinal Lymph Node Dissection in Penile Cancer

- Nonpalpable lymph nodes: intermediate (T1b) and high-risk tumors (T2 and T3)
- Palpable lymph nodes: Lymph nodes less than 4 cm in size with low-risk primary lesions that are positive after fine-needle aspiration or high-risk primary lesions (T1 with high-grade and/or lymphovascular invasion and/or greater than 50% poorly undifferentiated/T2/T3)

Therefore, the standard for both staging and treatment with penile cancer has been ILND, even in patients with no clinical suspicion of lymph node involvement. This procedure, however, has been linked to high rates of morbidity, with complication rates of approximately 55.4% (Gopman et al., 2015). On the other hand, treating all patients with nonpalpable ILNs will result in considerable overtreatment in more than 70% of these cases (Slaton et al., 2001).

Several approaches are being proposed to enhance the patient selection process for ILND, selectively limiting the number of patients to undergo this surgery to those with a higher likelihood of lymph node metastases. (Cabanas, 1977; Pettaway et al., 1995; Leijte et al., 2007; Kumar and Ananthakrishnan, 1998).

Studies assessing predictor factors of lymph node metastasis in patients with penile cancer identified tumor stage, tumor grading, p53 mutation expression, and lymphovascular invasion (Zhu et al., 2010). Other reports in the literature have included molecular factors such as Ki-67, epithelial cadherin, and matrix metalloproteinase, as playing a role in predicting lymph nodes metastasis (Zhu et al., 2007).

Several nomograms have been developed based on these factors to predict lymph node metastasis in an effort to recognize lymph node involvement without performing ILND (Ficarra et al., 2006; Zhu et al., 2007).

Sentinel Lymph Node Biopsy

Physical examination is not reliable when trying to identify ILN metastasis. Using previous experiences reported for melanoma or breast cancer, Cabanas was first to introduce **sentinel lymph node biopsy,** suggesting that lymph node involvement is a stepwise process (Cabanas, 1977). In this technique, he sampled a single node superomedial to the saphenofemoral junction located two fingerbreadths lateral and inferior to the pubic tubercle. He reported that 4% of patients with no clinical suspicion for micrometastasis, were positive for metastasis on SNB. However, even when initial results were encouraging, this approach lost favor after the publication of false-negatives in other experiences throughout the literature (Cabanas, 1977; Catalona, 1980; Perinetti et al., 1980; Srinivas et al., 1991; Wespes et al., 1986).

One of the reasons SNB did not achieve the expected results is the fact that the lymphatic anatomy for penile cancer is not static, and it varies among patients. There is also the possibility that improper pathologic sectioning could be the reason other studies were not able to reproduce Cabanas’ results. Subsequently, a **standard extended SN dissection** was suggested (Pettaway et al., 1995). In this modification of the initial SNB technique, all tissue to be resected is located in the area enclosed by the inguinal ligament superiorly, the superior external pudendal vein inferiorly, and the saphenous vein laterally. However, discouraging results for this approach include a false-negative rate of

25% in 20 patients who underwent extended SN dissection, hampering its widespread use (Pettaway et al., 1995).

Furthermore, Kumar and Ananthakrishnan developed another modification of Cabanas’ lymph node resection called the **medial inguinal node dissection** in which they resected the most medial node to the groin, but lateral to the pubic tubercle false-negative reported was 8.7%. Yet, the sensitivity was not significantly different when compared with DSNB (Kumar and Ananthakrishnan, 1998).

Dynamic Sentinel Lymph Node Biopsy

Based on our experience with sentinel node biopsies, acknowledging the limitation of the sensitivity of preoperative imaging is important when deciding whether or not ILND surgery should be performed. Advances and improvements in lymphoscintigraphy driven by the work of Morton et al. in melanoma, DSNB was proposed as an alternative method to identify patients who are potentially harboring micrometastasis without clinically palpable nodes (Morton et al., 2006; Leijte et al., 2007).

The pioneers on this area were the Netherlands Group in 1994. The study used radiotracers, such as Technetium-99m nanocolloid, and blue dye injection around the tumor/resection site, and further imaging guidance with lymphoscintigraphy to identify the sentinel lymph node. This technique addresses the previously discussed sentinel node resection criticism that the inguinal lymphatic anatomy is not static. This procedure individualizes the location of the sentinel lymph node, providing an enhanced option for identification and assessment for metastases. Still, misidentification of nodes can still happen when DSNB is performed (4.8% to 19.2%) (Leijte et al., 2007).

The technique has undergone several modifications from its start to the present day. One of these modifications is inclusion of the use of US before the procedure together with fine-needle aspiration of suspicious nodes. Characteristics of suspicious nodes include the presence of necrosis, increased size, abnormal vascularity on Doppler US, a longitudinal/transverse diameter ratio less than 2, and a lack of echogenicity of the hilum of the lymph, with the latter two having relatively high specificity for metastatic nodes (Lam et al., 2008). The introduction of US has overcome the limitation identified by Riveros et al., that some lymph channels can appear deformed as a result of a shift of lymphatic fluid as a consequence of an obstructed node by tumor or necrosis. As a result, the lymph nodes are not visible with other imaging techniques because there is no uptake of contrast material. Ultrasound evaluation of the groin is included in the EAU guidelines for the diagnosis, evaluation, and staging of penile cancer (Leijte et al., 2007; Pizzocaro et al., 2010; Riveros et al., 1967).

There have also been modifications to the sectioning of the pathology slides. In the present day, serial slices (150 micrometers) are done of the entire lymph node to support a more accurate pathologic analysis of the resected node. Since this technique was started, the centers of expertise have been able to develop and finesse their learning curves. This is a critical point of discussion because some centers have not been able to replicate these results. Neto et al. reported that the false-negative rate started to decrease after the first 50 patients, mirroring the findings of other studies like the ALMANAC study for sentinel node biopsy in breast cancer. In that study, they found that 40 patients were required to evidence the value of the sentinel node in for that malignancy. Therefore, achieving proficiency for DSNB in penile cancer can be limited because of the low incidence of this disease, even more in developed countries. As a result, the widespread use of this procedure has been limited to specific centers of expertise. **NCCN guidelines for penile cancer included a recommendation for DSNB only in expert hands** (Leijte et al., 2007; NCCN, 2018; Serpa Neto et al., 2011).

A systematic review and cumulative analysis demonstrated encouraging results regarding this technique for the detection of micrometastasis, as well with a pooled cumulative sensitivity of 84.4% and specificity of 99.4% (Serpa Neto et al., 2011). In expert centers, the false-negative and complication rates have been reported to be 4.8% and 5.7%, respectively (Leijte et al., 2007). These results highlight the importance of expertise in performing this procedure, as other studies have a false-negative rate as high as 22% (Tanis et al., 2002).

Technique

The technique consists of first performing a groin ultrasound. If suspicious nodes are found, FNAC should be performed. If this cytology is positive for malignancy, a bilateral ILND should be performed.

If the cytology is negative or the patient had no suspicious nodes, lymphoscintigraphy is performed. The day before or 4 hours before the start of the procedure, 0.3 to 0.4 mL of technetium nanocolloid (Tc-99m) is injected around the tumor or the base of the penis, and then lymphoscintigraphy is performed. Immediate, dynamic, and static images are obtained with a gamma camera to obtain anterior and lateral views of the sentinel lymph node, which is subsequently marked on the skin surface.

Then, 1 mL of blue dye is injected at the time of the biopsy, intradermally and in a circumferential fashion around the proximal area of the penile shaft. After this, small inguinal incisions are made, and the sentinel lymph node is found using the gamma probe as a guide. The node is resected, and analyzed by the pathologist after paraffin embedding of the entire node. If the results of the pathologic analysis is positive for malignancy, the patient should undergo ILND. Finally, intraoperative palpation of the groin is done to identify nodes that did not have contrast uptake.

Follow-Up

Normally, the follow-up after a DSNB is one follow-up appointment every 2 months for the first 2 years, every 3 months for the third year, and every 6 months up to the fifth year of follow-up. **Ordinarily, most recurrences occur within the first 2 years** (local recurrences: 66.2%, regional recurrences: 86.1%, and distant recurrences: 100%) (Leijte et al., 2008).

In 2007, the Netherlands Cancer Institute reported that after an initial false-negative rate of 19.2%, they were able to decrease it to 4.8% after addition of intraoperative exploration of the groin, fine-needle biopsy, a more extensive pathologic review, and US exploration. However, they were not able to discern what percentage of this was caused by the learning curve of the institution because the study compared one cohort to a historical series (Leijte et al., 2009).

The false-negative rate was associated with lymph vessels rerouting to another ganglion or low uptake of the tracer by the nodes. A meta-analysis by Sadeghi et al. showed that the use of both blue dye and radiotracer improves the detection rate from 88.3% to 90.1% (Sadeghi et al., 2012).

Although the use of the DSNB technique has not been standardized, the EAU guidelines include it in the diagnosis algorithm for evaluation of patients with penile cancer with clinically negative nodes (Pizzocaro et al., 2010). This technique can provide critical information in patient management and surgical decision making. If the DSNB yields positive for malignancy, ILND should be performed.

Superficial Inguinal Lymph Node Dissection

(SILND)

For a more accurate assessment of the ILNs, while avoiding high rates of morbidity, a superficial ILN dissection can be considered. This technique consists of removal of the ILNs that are located above the fascia lata with the same template of dissection as the modified ILND (see Modified Inguinal Node Dissection later in the chapter). These nodes are evaluated intraoperatively with frozen section, and if positive for malignancy, a deep ILN dissection is performed.

The rationale is that if the lymph nodes in the superficial compartment are negative, there should be no involvement of the deep package. Pompeo et al. in a prospective study of 50 patients found no cases of deep compartment invasion without positive lymph nodes in the superficial package (Pompeo, 2005). Spiess et al. reported a series of 31 patients with invasive penile cancer who underwent SILND; from those, no recurrences at 3-year follow-up was found in patients without involvement of the superficial compartment (Spiess et al., 2007).

There is debate on the extent of the ILND template (see Modified Inguinal Lymph Node Dissection later in the chapter) and the accuracy of the frozen section to detect malignancy in the nodes. Chipollini et al. in 2018 was the first to evaluate the use of frozen section in penile cancer. In an analysis of 84 patients, they found that frozen section has high specificity (100%), however, the sensitivity is lower (74%). Most false-negative results occurred as a consequence of sampling errors by the pathologist/surgeon, surgeon-related technique, and time limitations. Of note, the rate of accuracy of frozen section is similar when compared with its use in other clinical settings, such as in breast cancer or melanoma (Alperovich et al., 2016; Ariyan et al., 2004). This study also found that a higher body mass index (BMI) is associated with frozen-section false-negatives. Even though it is the only evidence available, this study has some limitations to sample size, the retrospective nature of the study, and the heterogeneity among operators (Chipollini et al., 2018).

Modified Inguinal Lymph Node Dissection

In 1988, Catalona proposed a modified inguinal lymphadenectomy to provide proper diagnostic and therapeutic benefit while decreasing morbidity. In this technique, using a smaller incision, he proposed preservation of the saphenous vein, suggesting that this would decrease lymphatic complications. This modified ILND also excludes the areas lateral to the femoral artery and caudal to the fossa ovalis from the dissection template. It also eliminates the sartorius interposition. **The limits of the modified inguinal lymphadenectomy are the abductor longus muscle medially, the femoral artery laterally, and the inguinal ligament with the fossa ovalis as superior, and inferior limits, respectively** (Catalona, 1988) (see Fig. 81.1).

Since Catalona's implementation of this modified technique, he reported only one case of lymphocele formation and mild lymphedema in all six patients (Catalona, 1988). Several subsequent studies have reported morbidity results using this technique, which include infection (0% to 9.1%), skin necrosis (0% to 8.3%), lymphedema (0% to 100%), seroma (0% to 26.3%), and lymphocele (0% to 22.7%) (Bevan-Thomas et al., 2002; Catalona, 1988; Coblentz and Theodorescu, 2002; d'Ancona et al., 2004; Parra, 1996).

In terms of oncologic outcomes, Lopes et al. reported a 15% recurrence rate when using modified ILND in a 13-patient cohort with 13.2 months of follow-up. This may be in part caused by the lymph nodes with metastatic involvement located in the left lateral quadrant, which should not be eliminated from the template (Lopes et al., 1996). Other studies have shown a false-negative rate between 0% and 5.5% (Bouchot et al., 2004; Coblentz and Theodorescu, 2002; d'Ancona et al., 2004; Parra, 1996).

Endoscopic and Robotic Inguinal Lymphadenectomy

Background

Endoscopic inguinal lymphadenectomy is a more recent technique with the potential for thorough excision of ILNs with decreased morbidity. Bishoff et al. were the first to report the use of endoscopic ILN dissection (Bishoff et al., 2003). In 2006, Tobias-Machado et al. reported 10 patients who underwent bilateral lymphadenectomy for nonpalpable ILNs. Standard open lymphadenectomy was performed on one side, and endoscopic lymphadenectomy on the other. Nodal counts were similar ($P = 0.4$), with a 20% complication rate on the endoscopic side compared with a 70% rate on the open surgery side ($P = 0.01$) (Tobias-Machado et al., 2008). Sotelo et al. reported the outcomes after 14 inguinal endoscopic lymphadenectomies in eight patients with clinical stage T2 SCC of the penis with a median operative time of 91 minutes and an average node yield of 9. Ultrasonic energy is used for the lymph vessel sealing, and postoperatively three lymphoceles were reported but no wound-related complications occurred (Sotelo et al., 2007). In 2011, Tobias-Machado et al. described the single-site video-endoscopic ILND. This consists of a three-port technique for trocar placement (with minimal skin separation between trocars), with the aim to decrease cutaneous complications associated with ILND (Tobias-Machado et al., 2011). This technique raised some concern regarding excessive crowding and clashing of the instruments. In 2011, a detailed analysis of immediate and long-term complications using the Clavien classification system in 29 patients who underwent 41 endoscopic inguinal lymphadenectomy procedures revealed minor complications in 27% (superficial wound infections, seroma, lymphocele, skin edge necrosis, mild-moderate lymphedema), and major complications in 14.6% (death, sepsis, flap necrosis, severe lymphedema, secondary procedure, venous thromboembolism, readmission) (Master et al., 2012). There were no perioperative deaths. Similar experiences have been reported in other series, demonstrating an operative time between 87.86 to 150 minutes, a lymph node yield of 3 to 16 lymph nodes per groin, and a 20% to 73% overall complication rate (Chaudhari et al., 2016; Cui et al., 2016; Pahwa et al., 2013; Pompeo et al., 2013; Yuan et al., 2015; Zhou et al., 2013).

In 2009, the first staged bilateral endoscopic operation performed robotically was reported with the Si DaVinci platform (Josephson et al., 2009). Pathologic examination revealed no metastatic involvement in six superficial and four deep lymph nodes. The contralateral dissection occurred 3 weeks later, and pathologic examination revealed five superficial and four deep negative nodes. There was no wound complication or lower-extremity edema. Sotelo et al. reported performing a concurrent bilateral procedure without repositioning of the robot, which had been identified as a limitation in previous experiences. Metastatic nodes were present bilaterally, with a yield of 19 lymph nodes on the right and 14 on the left (Sotelo et al., 2013). Matin et al. performed a thorough evaluation of the adequacy of a robotic ILN dissection by subsequently opening the incision and having a second surgical oncologist look for residual nodal tissue in 10 patients. The verifying surgeon's role was to inspect the surgical field to ensure that no additional superficial ILNs (above the fascia lata of the thigh) remained within the operative field. If additional tissue was identified at that time, it was removed and sent for pathologic analysis to determine if it was nodal in origin and if it contained metastasis. In one of these groins, two residual lymph nodes were recovered from below Scarpa fascia along the superficial aspect of the inguinal field near the spermatic cord. No metastases were detected in these additional nodes. Among all patients undergoing robotic dissection, 18 of 19 fields (94.7%) were adequately dissected (Matin et al., 2013).

In summary, there is evidence to suggest that the morbidity of an endoscopic ILN dissection is lower than what has been previously reported for the open contemporary series with a similar number of lymph nodes being removed. The applicability of the robot is a more recent development and will need continued prospective evaluation in comparison with standard laparoscopic endoscopic procedures.

Surgical Technique

The patient is positioned on low lithotomy position to allow bilateral groin dissection without repositioning the robot. The assistant stands lateral to the right leg for a right-sided dissection and between the legs for the left side. A Foley catheter is inserted in a sterile fashion, after the inguinal and groin areas have been prepared and draped. Bony and soft tissue landmarks are marked on the skin surface, creating an inverted triangle in which the base is a line connecting the anterior superior iliac spine to the pubic tubercle, along the course of the inguinal ligament. The lateral boundary is the sartorius muscle angling toward the apex. The medial boundary is the adductor longus muscle, again extending toward the apex. These marks aid in correct trocar placement and in delineating the extent of dissection.

A 2-cm incision is made 3 cm below the inferior aspect of the femoral triangle, approximately 25 cm below the inguinal ligament. A white subcutaneous layer is identified, which corresponds to Scarpa fascia. Sweeping finger dissection is used to dissect the potential space beneath the Scarpa fascia to develop the skin flaps at the apex of the triangle in both directions and allow for two additional 8-mm ports to be placed. These two primary robotic 8-mm ports are placed with finger-guided techniques laterally and medially (Fig. 81.2A). A subcutaneous workspace is extended with the endoscope by sweeping with the lens itself (see Fig. 81.2B). The aim of this step is to create a superficial subcutaneous flap under the Scarpa fascia. Alternatively, after the initial finger dissection, a 12-mm Origin balloon port trocar may be used (Origin Medsystems, Menlo Park, CA). Insufflation is set at 25 mm Hg for 10 minutes to create the working space (Master et al., 2012); after that, CO_2 insufflation pressure is lowered to 15 mm Hg. A 0-degree 10-mm lens is inserted, and one additional 10-mm assistant port is placed between the camera and primary 8-mm working port on the assistant side. The robot is positioned at 45 degrees contralateral to the first procedure (right side) and ipsilateral to the patient in the second procedure (left side) (see Fig. 81.2C,D).

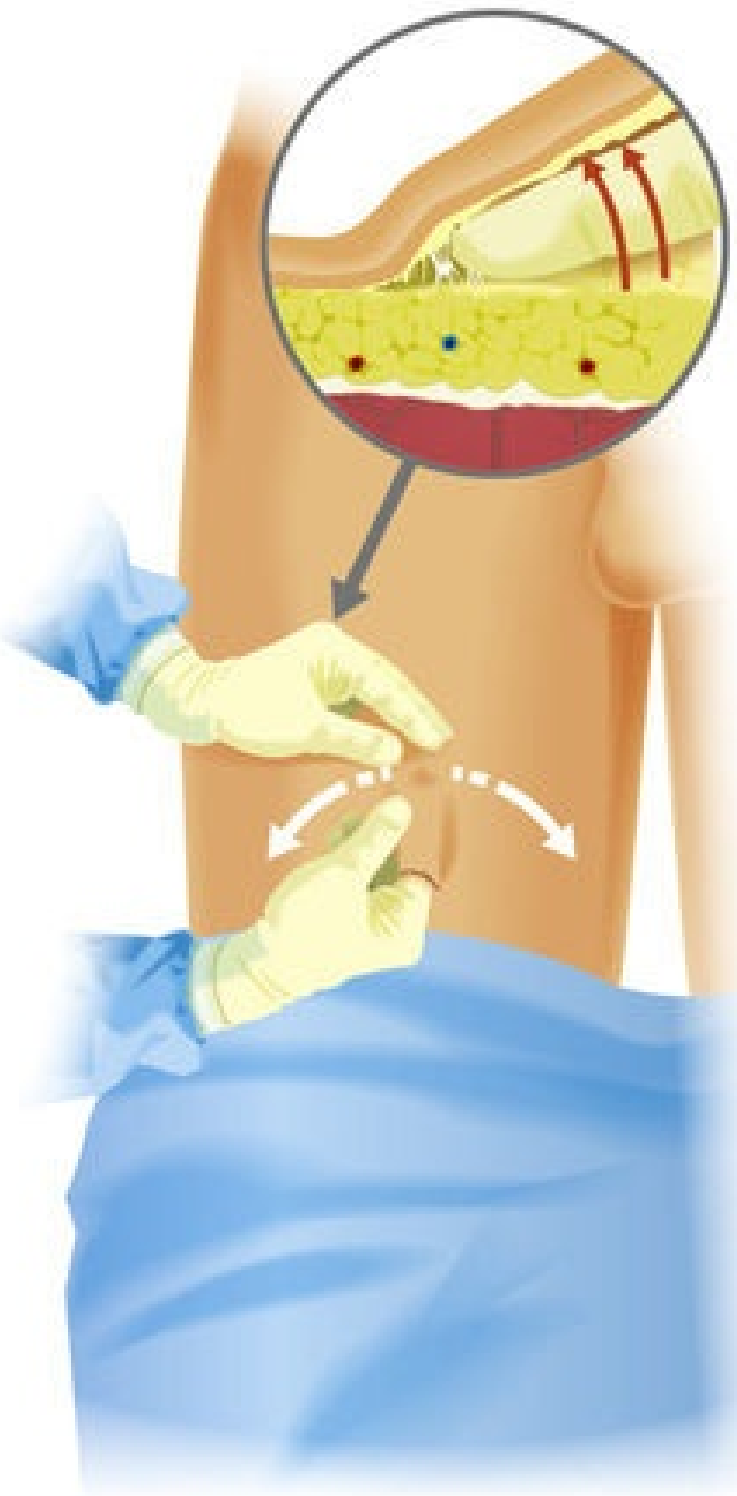

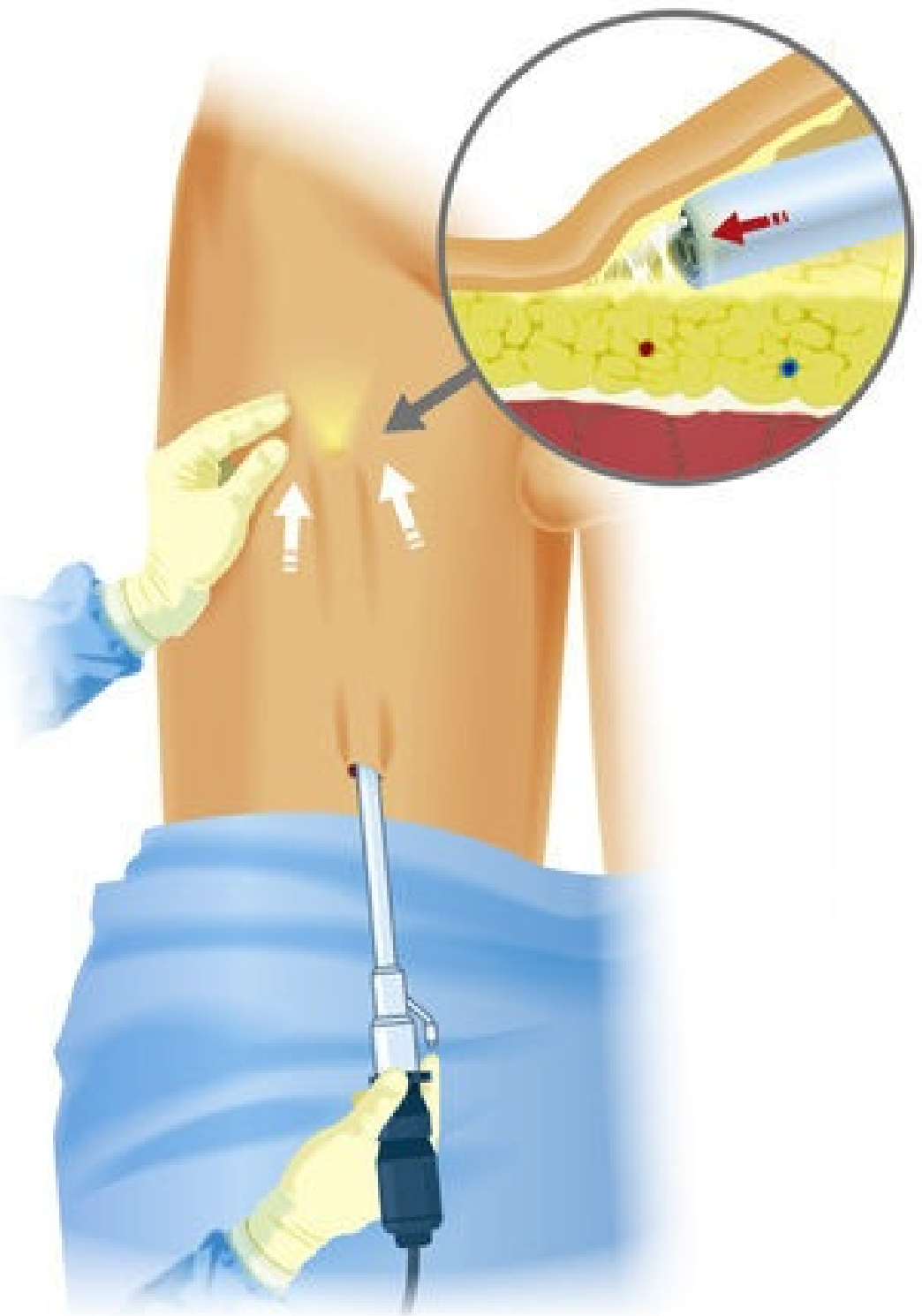

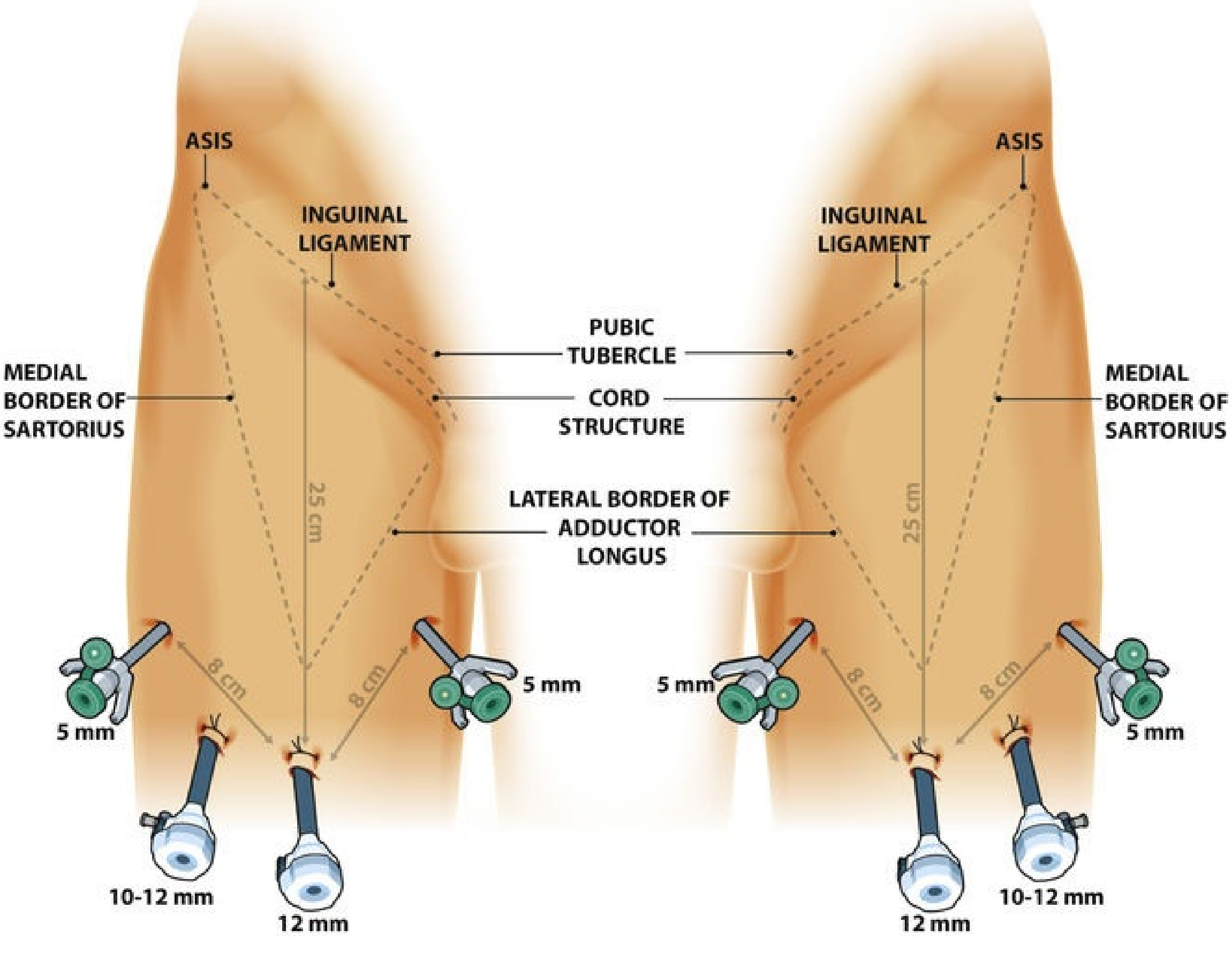
ASIS
INGUINAL LIGAMENT
INGUINAL LIGAMENT
ASIS
PUBIC TUBERCLE
MEDIAL BORDER OF SARTORIUS
CORD STRUCTURE
MEDIAL BORDER OF SARTORIUS
25 cm
LATERAL BORDER OF ADDUCTOR LONGUS
25 cm
8 cm
8 cm
5 mm
5 mm
8 cm
8 cm
5 mm
5 mm
10-12 mm
12 mm
12 mm
10-12 mm

FIG. 81.2 Creation of the working space and trocar placement: *Top left,* Dissection is created by sweeping the finger to find the space below the scarpa at the apex of the dissection. *Top right,* Further extension of the space is done using sweeping movements with the scope. *Bottom left,* Trocar placement for the right side. *Bottom right,* Trocar placement for the left side.

Instruments that can be used include a bipolar Maryland, or PK forceps (Olympus, Hamburg, Germany) in the left robotic arm, and monopolar scissors or robotic ultrasonic instruments in the right arm to dissect the membranous and lymphatic tissue beneath Camper fascia. Every effort is made to completely develop the anterior working space to the inguinal ligament, which is usually identified at the end of this dissection as being a transverse structure with white fibers, marking the superior limit of the dissection. The boundaries of the dissection extend from the inguinal ligament superiorly, sartorius muscle laterally, and adductor longus muscle medially (Fig. 81.3A). One will be able to spare the saphenous vein in most patients, while the smaller branches of the femoral artery and vein may be clipped and divided. Identification of the adductor longus and sartorius muscles is facilitated by identifying the fascia of the respective muscles and correlating this to the previously made skin markings. The spermatic cord is seen medially. Inadvertent dissection deep to the fascia lata is apparent when reddish muscular fibers are seen.

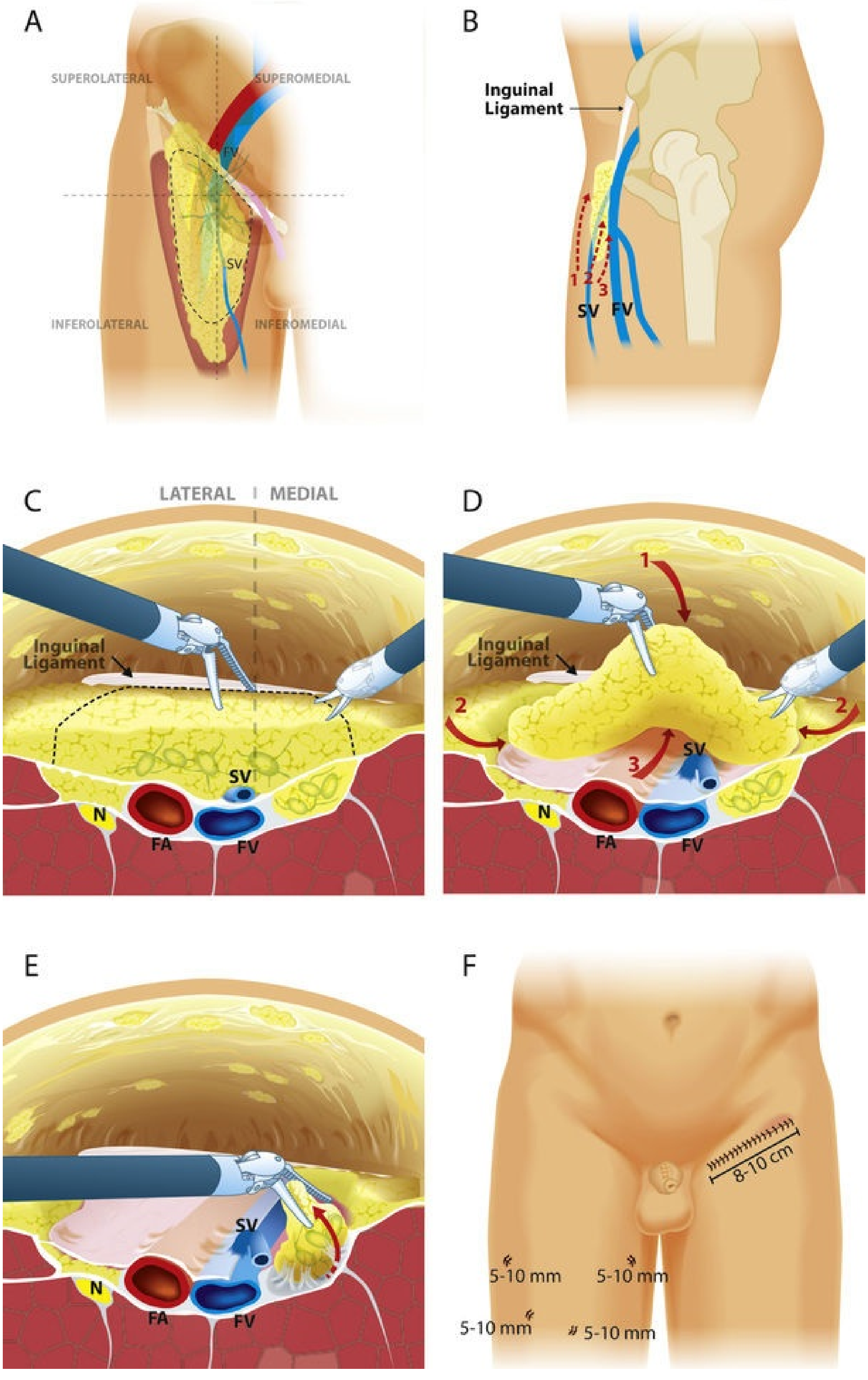
A
SUPEROLATERAL
SUPEROMEDIAL
FV
SV
INFEROLATERAL
INFEROMEDIAL
B
Inguinal Ligament
1
2
3
SV
FV
C
LATERAL | MEDIAL
Inguinal Ligament
SV
N
FA
FV
D
1
Inguinal Ligament
2
2
3
SV
N
FA
FV
E
SV
N
FA
FV
F
8-10 cm
5-10 mm
5-10 mm
5-10 mm
5-10 mm

FIG. 81.3 (A) Limits of the endoscopic inguinal lymph node dissection. (B) Lateral view of the steps to perform a nodal inguinal node dissection. (C) Superficial lymph node dissection. (D) Superficial package being removed along with saphenous vein preservation. (E) Deep lymph node dissection resection. (F) Graphic representation of the surgical wounds after open inguinal lymph node dissection *(right)* and inguinal lymph node dissection *(left). 1,* Superficial package. *2,* Management/dissection around the saphenous vein. *3,* Deep inguinal package resection. *FA,* femoral artery; *FV,* femoral vein; *N,* femoral nerve; *SV,* saphenous vein.

With blunt dissection, the nodal tissue can be rolled inward on both sides. This maneuver is continued inferiorly as much as possible from both sides to define the inferior apex of the nodal packet. The saphenous vein will be identified as it crosses the internal border of the dissection near the apex of the femoral triangle, and following the vein leads the surgeon to the saphenous arch until its junction with the superficial femoral vein at the fossa ovalis. The dissection continues superiorly, where the packet is dissected off the fascia lata with a combination of sharp and blunt dissection. Typically, the nondominant hand lifts the packet, and the monopolar scissors in the dominant hand advance the dissection. After the fossa ovalis is encountered, the packet is dissected away at its superolateral and superomedial limits, thereby narrowing the packet and pulling it away from the inguinal ligament. At this point, the superficial and deep plane of dissection join and separate the package from the inguinal ligament (see Fig. 81.3B–D).

With the nodal packet circumferentially dissected except for its attachments to the saphenous arch, venous tributaries are clipped. Characteristic pulsations of the femoral artery serve as a nearby landmark. If possible, the packet will be released from the saphenous vein. If not, the vein can be ligated in the saphenous arch with Weck clips (Teleflex, Wayne, Pennsylvania). One must always attempt to preserve the saphenous vein whenever possible, to reduce the risk for postoperative lymphedema (Zhang et al., 2007).

The specimen is removed in a specimen-retrieval bag after extension of the camera trocar incision. Frozen-section results determine whether a deep ipsilateral dissection will be required. While waiting for pathology results, you can begin to create the working space in the contralateral leg.

For the deep ILN dissection, the pneumoperitoneum is reestablished. The fascia lata medial to the saphenous arch is opened to expose the saphenofemoral junction. Inferomedial dissection around the femoral vein enables resection of the deep ILNs (Master et al., 2012) (see Fig. 81.3E). This should be continued to the level of the femoral canal until the pectineus muscle is seen to ensure complete nodal retrieval.

Insufflation pressure is then decreased to 5 mm Hg to confirm hemostasis. It is of great importance that meticulous control of lymphatics and excellent hemostasis be established to reduce the risk for lymphocele and hematoma formation, which could potentially become infected. A closed suction drain is positioned in the most dependent (caudal) portion of the lymphadenectomy field, as the fluid will drain dependently toward the drain when the patient is upright. Trocar incisions are closed in the standard fashion (see Fig. 81.3F). The patient is allowed to ambulate the day of surgery and is given a regular diet. Discharge is planned for the first postoperative day. A compressive elastic girdle, as used for liposuction patients, is used to provide bilateral compression of the groins. In addition, elastic compression stockings are worn simultaneously and are used for 3 months after surgery. Broad-spectrum antibiotics are continued until after the drains have been removed. Drains typically stay in place until the output is less than 50 mL per 24-hour period. All patients receive venous thromboembolism prophylaxis using fractionated or low-molecular-weight heparin.

There are no studies comparing robotic versus laparoscopic techniques to date. There has been no advantage demonstrated of one technique over the other. Theoretically, the ergonomics and the tridimensional view can be an advantage. Additionally, the ability to use indocyanine green (ICG) during groin dissection on the robotic platform, can enhance the surgeon's ability to identify lymphatics and potentially avoid complications (Bjurlin et al., 2017).

For the robotic ILND, the creation of the working space is performed in the same fashion as the one described in the endoscopic technique, however, the size of the ports is different because robotic and assistant ports are 8 and 5 mm in size, respectively. Another shared technical aspect of both techniques is that the ultrasonic instruments available for the laparoscopic and robotic systems do not articulate. Hence, both work in a linear fashion, and this can be cumbersome when different angulations are needed during lymph vessel sealing.

The Xi robotic platform offers several advantages over the Si system, specifically in the capacity of repositioning without modifications of the operative room setting (Fig. 81.4). In addition, the Xi system allows for intraoperative rotation of the camera up and down from the surgeon's console, and the ability to use the camera from any port, which can be beneficial if instrument collisions occur during the dissection. The new Single Port robotic platform can also offer some advantages for this surgery that should be assessed once experience on this system is developed, such as an additional reduction of skin complications without increasing the difficulty of the procedure.

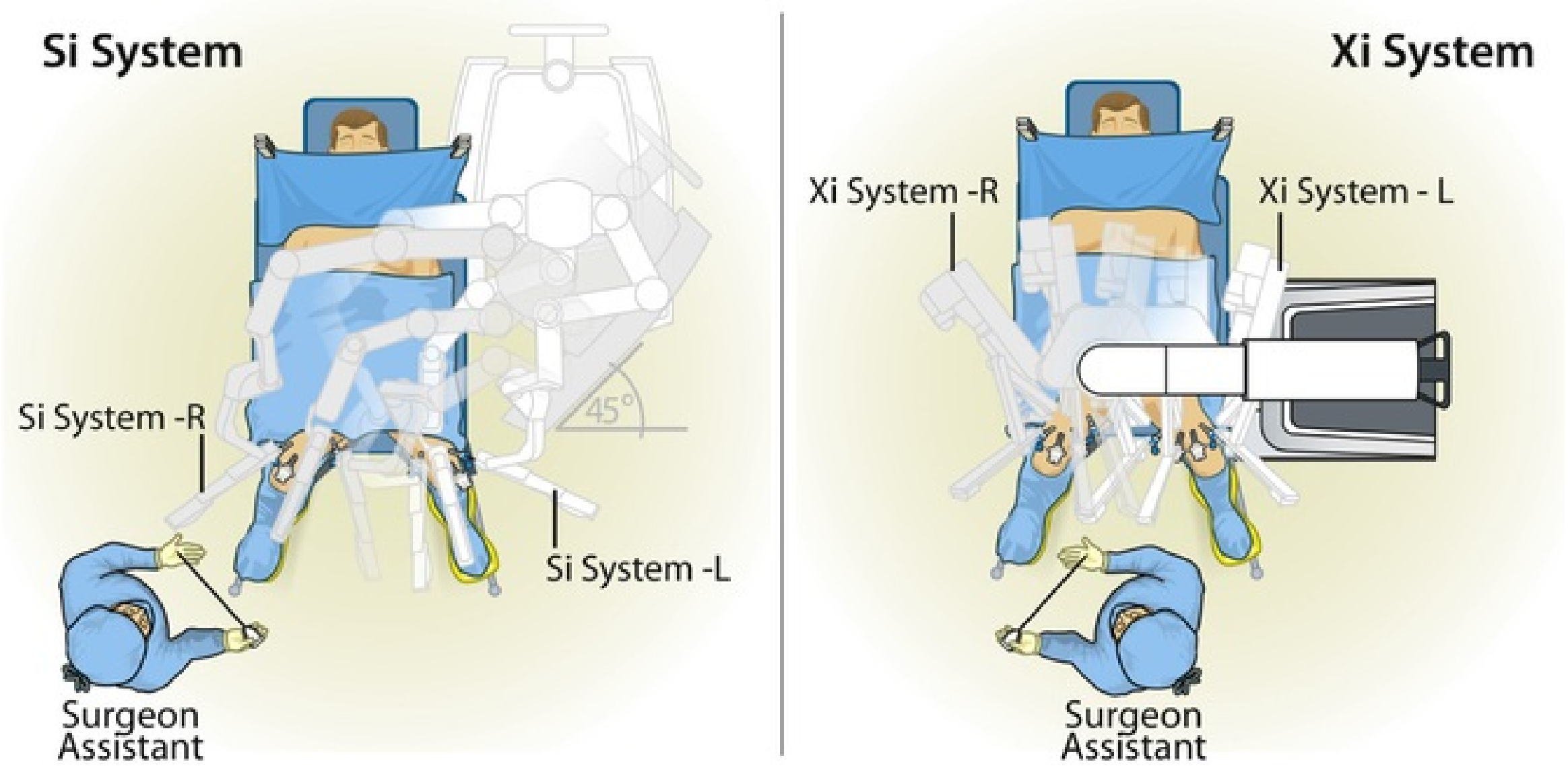
Si System
Xi System
Xi System -R
Xi System - L
Si System -R
45°
Si System -L
Surgeon
Assistant
Surgeon
Assistant

FIG. 81.4 Assistant and robotic dock positioning for robotic inguinal lymph node dissection for the robotic SI system *(left)* and Xi system *(right).*

Penile Cancer: Palpable Inguinal Adenopathy or Positive Inguinal Lymph Nodes

Primary ILND for patients with palpable nodes is indicated for lymph nodes less than 4 cm, with a low-risk primary lesion, that are positive after FNA/excisional biopsy, or that are high-risk primary lesions. It is also indicated for lymph nodes greater than 4 cm that are mobile and positive for malignancy after percutaneous biopsy (neoadjuvant chemotherapy is an option for this group as well) (NCCN, 2018) (see Box 81.1).

Surgery for Curative Purposes

Radical ILND is indicated for patients with palpable positive nodes and may be curative if disease is limited to ILNs. However, a “therapeutic curative window” exists, and it is mainly associated with the volume of inguinal metastases. Patients who have unilateral limited metastases without extranodal extension of cancer or pelvic metastases are potentially curable (Johnson and Lo, 1984a, 1984b; Spratt, 2000; Srinivas et al., 1987).

Radical Inguinal Lymph Node Dissection

The patient is positioned with the thigh abducted and externally rotated with support under the flexed knee.

The dissection is limited superiorly by a line drawn from margin of the external ring to the anterior superior iliac spine, laterally, by a line drawn from the anterior superior iliac spine extending 20 cm inferiorly, and medially by a line drawn from the pubic tubercle 15 cm down the medial thigh.

The most utilized incision is an oblique 2-cm section below and parallel to the inguinal ligament extending from the lateral to the medial limit of the dissection. If an area of the overlying skin is involved by the disease or adherent to a palpable node, an elliptical incision is made around the involved skin and then extended medially and laterally (Fig. 81.5). Alternatively, in this case, the incision may be extended superiorly from the lateral border of the ellipse and inferiorly from the medial border to make a single S-shaped incision for concomitant iliac and inguinal dissections. Superior and inferior skin flaps are developed in the plane just below Scarpa fascia. The superior flap is elevated 3 cm cephalad above the inguinal ligament and the inferior flap to the limit of the dissection.

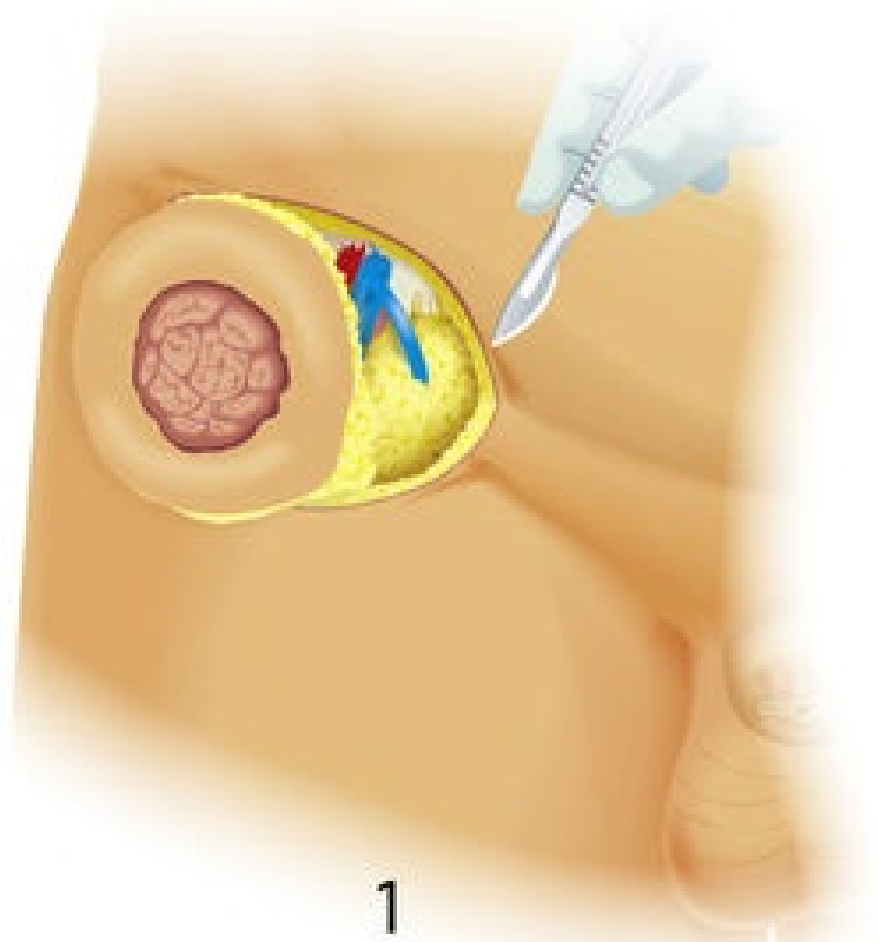

1

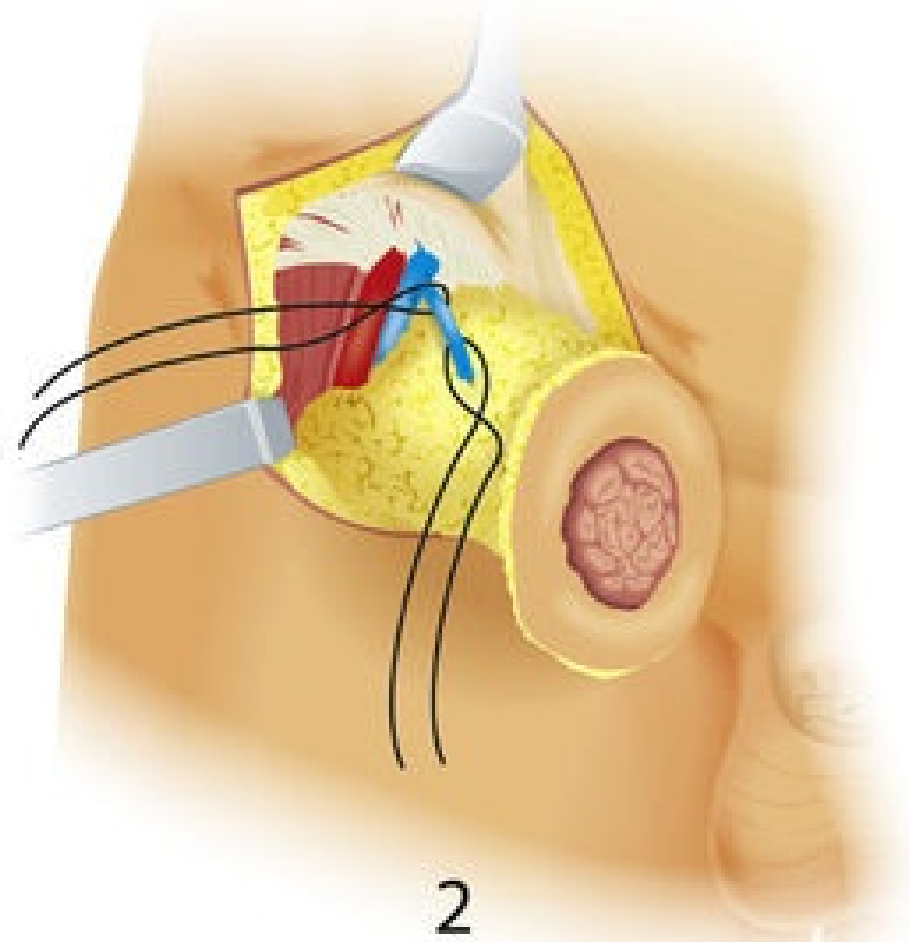

2

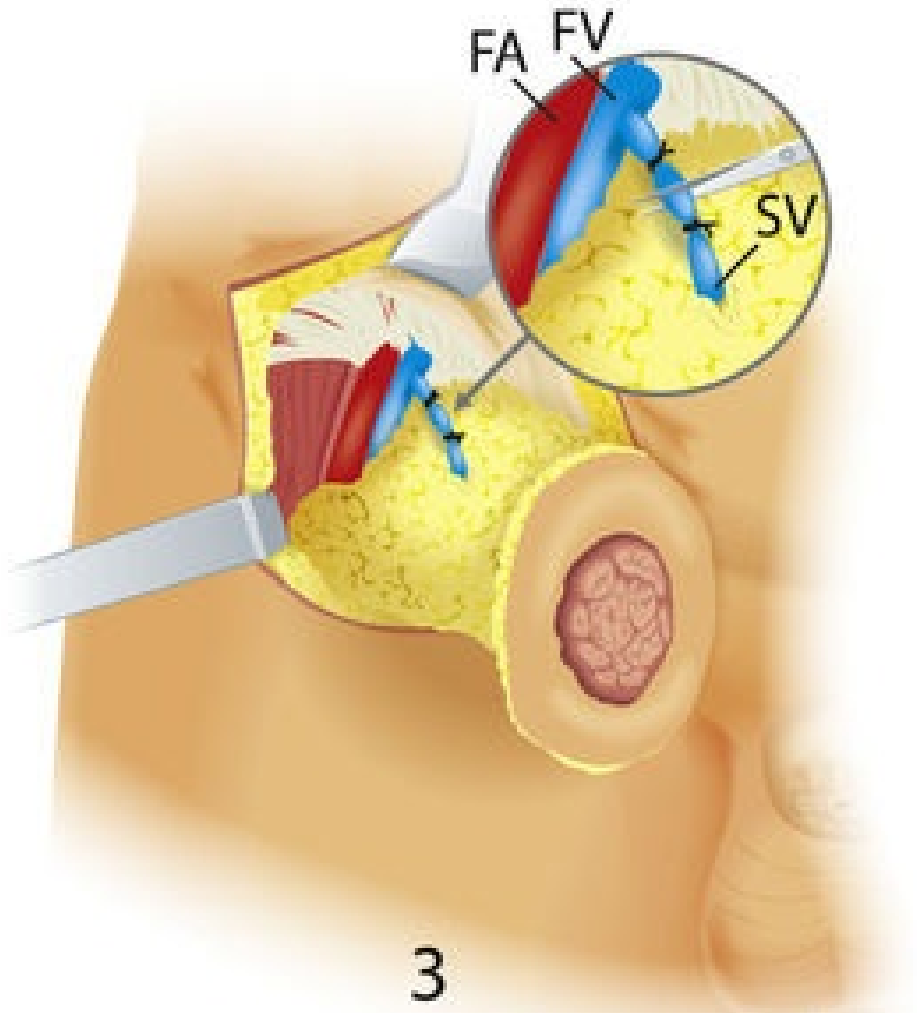

3

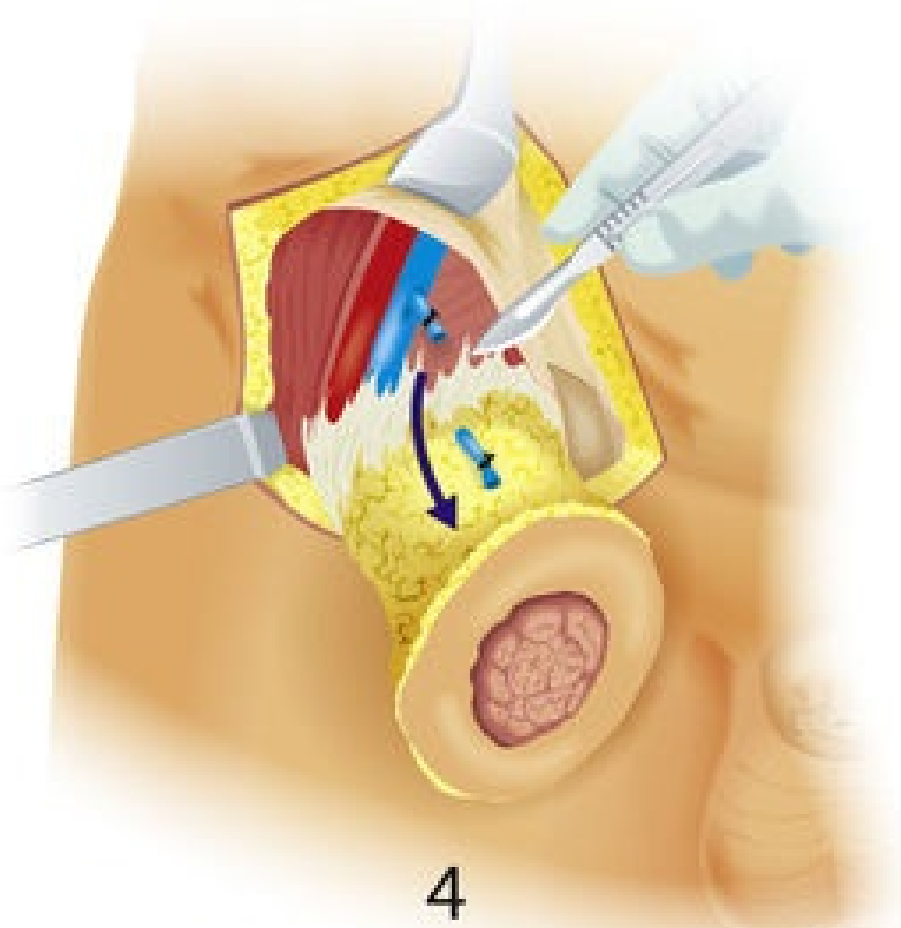

4

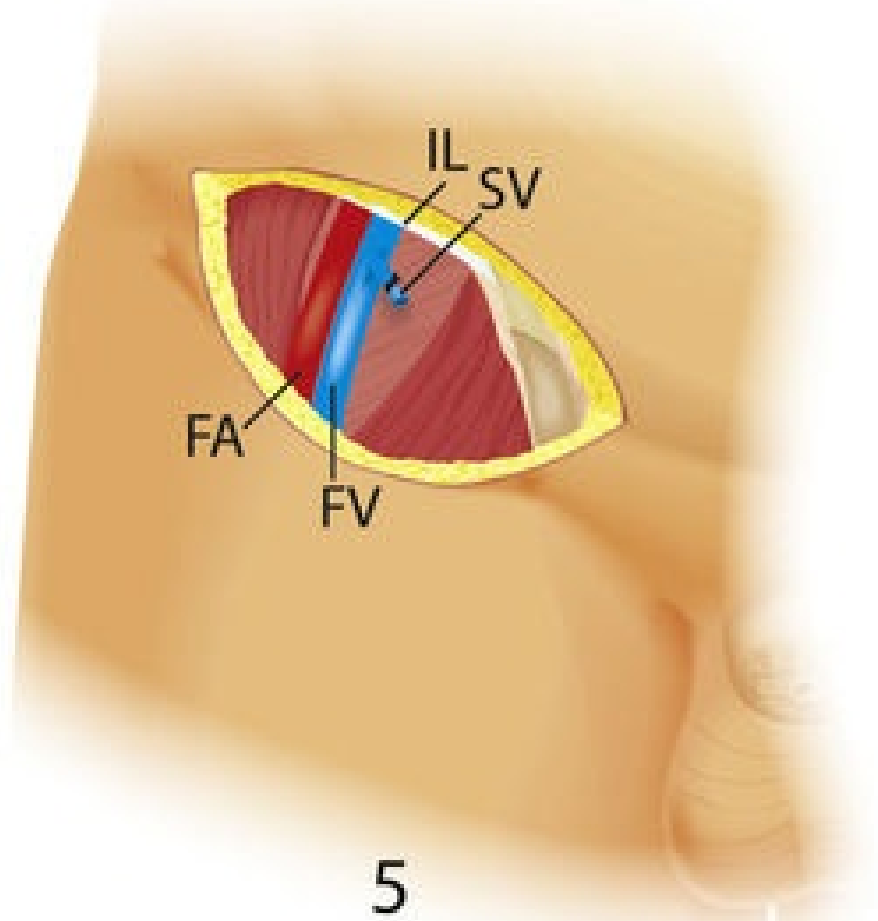

5

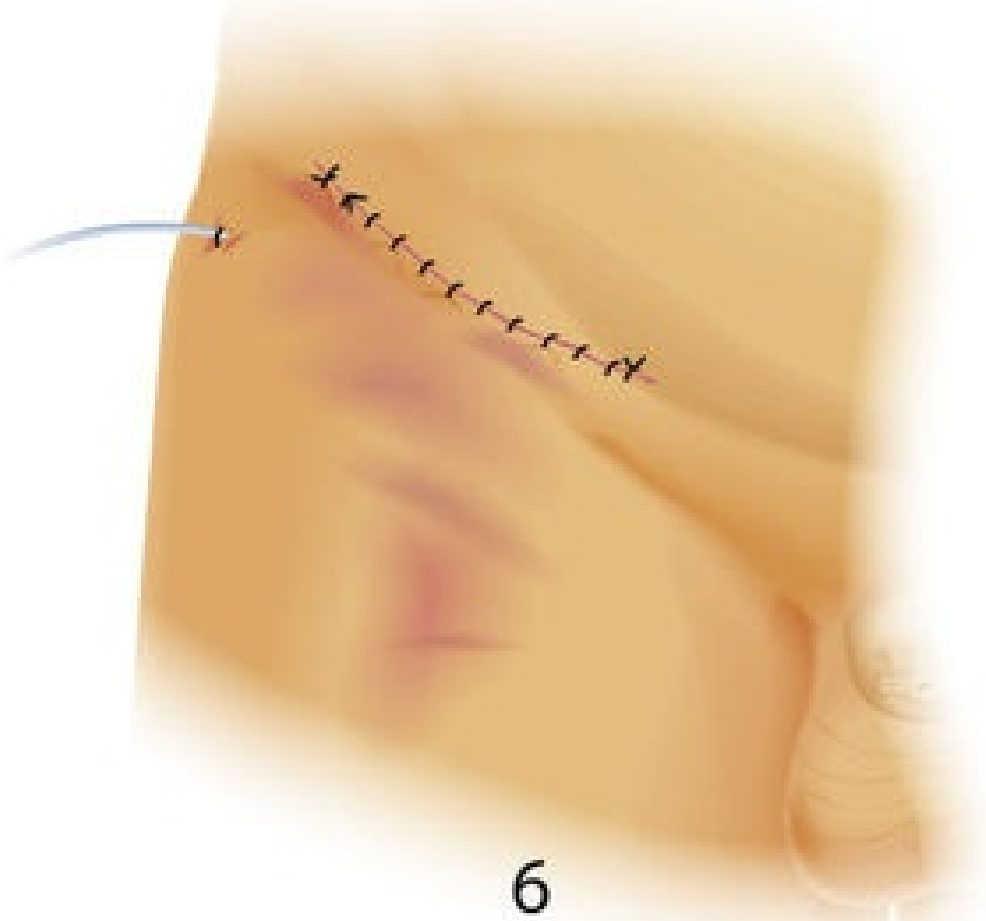

6

FIG. 81.5 Graphic representation of an inguinal lymph node dissection plus resection of an inguinal metastasis. *1,* Incision is made marking the borders of the metastatic lesion. *2,* Saphenous vein is detected. *3,* Saphenous vein is ligated. *4,* Skin along with the metastatic lesion and the lymph nodes is removed en bloc. *5,* Final setup of the anatomy after resection. *6,* Wound is closed in a traditional aseptic fashion.

Another option, described by Ornellas et al. in 1991, is to make a large Gibson incision and dissect inferiorly (Ornellas et al., 1991). The advantages reported are minimized skin devascularization, because the superior border of incision remains intact, and this permits easy access to concomitant iliac dissection if necessary.

The fat and areolar tissues are dissected from the external oblique aponeurosis and the spermatic cord to the inferior border of the inguinal ligament, forming the superior boundary of the lymph node packet. The inferior angle is the apex of the femoral triangle, where the long saphenous vein is identified and divided. In patients with minimal metastatic disease, it may be feasible and beneficial to spare the saphenous vein. Dissection is deepened through the fascia lata overlying the sartorius muscle laterally and the fascia covering the adductor longus muscle medially. At the apex of the femoral triangle, the femoral artery and vein are identified, and the dissection is continued superiorly along the femoral vessels. Cutaneous perforating arteries are ligated as they are encountered on the surface of the femoral artery. The saphenous vein is divided at the saphenofemoral junction, and the dissection is continued superiorly to include the deep ILNs medial and lateral to the femoral vein until the femoral canal (see Fig. 81.5). The anterior aspects of the femoral vessels are dissected, but lateral surface of the femoral artery is not exposed. This avoids injury to the femoral nerve and the deep femoral artery.

After the femoral triangle is dissected, the sartorius muscle is mobilized from its origin at the anterior superior iliac spine and either transposed or rolled 180 degrees medially to cover the femoral vessels (Barofsky maneuver). The muscle is sutured to the inguinal ligament superiorly, and its margins are sutured to the muscles of the thigh immediately adjacent to the femoral vessels. The femoral canal can be closed by suturing the shelving edge of the inguinal ligament to Cooper ligament, being careful not to compromise the lumen of the external iliac vein or to injure the inferior epigastric vessels in the process. Primary closure of the dissection is usually possible with minimal or no further mobilization of the excision margins. When circumstances demand a large area of skin resection, a primary closure may be performed using scrotal skin rotation flaps (Skinner, 1974), an abdominal wall advancement flap (Tabatabaei and McDougal, 2003), or a myocutaneous flap based on the rectus abdominis or tensor fascia lata (Airhart et al., 1982) (Fig. 81.6). Closed-suction drains are placed under the subcutaneous tissue. During closure, the skin flaps are sutured to the surface of the exposed musculature to decrease dead space. The skin is closed with absorbable subcutaneous sutures or staples (see Fig. 81.3F).

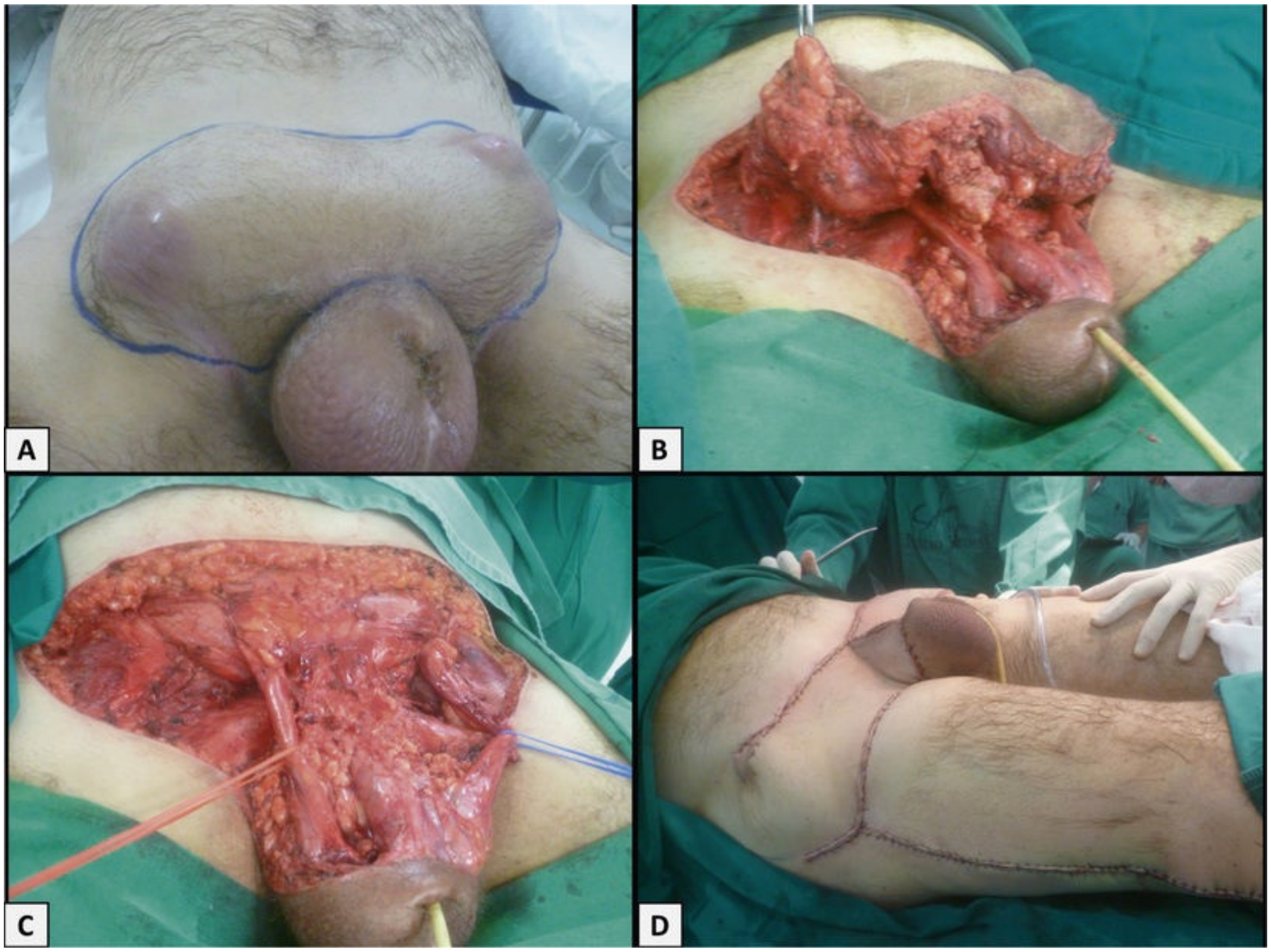

FIG. 81.6 (A) Area to be resected is delineated. (B) Incision including skin and ulcerated nodes plus dissection of the area with inguinal cord and femoral vessels skeletonized. (C) Further incision and removal en bloc of the piece is made. (D) Further vertical incision in lateral position of legs bilaterally to skin muscular fascia lata flap to cover the defect. Final aspect.

In contemporary series, early minor complications have been reported in about 50% of radical dissections (Bevan-Thomas et al., 2002; Bouchot et al., 2004; Nelson et al., 2004; Spiess et al., 2009). These consist primarily of lymphocele, wound infection or necrosis, and lymphedema. Major complications, such as debilitating lymphedema, flap necrosis, and lymphocele requiring intervention, occur in 5% to 20% of patients (Bevan-Thomas et al., 2002; Nelson et al., 2004). Deep venous thrombosis (DVT) or pulmonary embolism (PE) has been reported in 5% of patients (Johnson and Lo, 1984a, 1984b; Ravi, 1993; Spiess et al., 2009). Efforts to minimize lower-extremity lymphedema include early use of compression stockings and saphenous vein preservation when feasible.

Adjuvant Chemotherapy

A study of more than 200 patients with penile cancer reported a relapse rate of 45% in patients treated with surgery versus 16% in those who received adjuvant chemotherapy after surgery (Pizzocaro et al., 1996). The authors concluded that adjuvant chemotherapy can improve the results of radical surgery significantly. However, most of the patients in need of adjuvant treatment, such as patients with bilateral metastases or pelvic involvement, had poorer outcomes.

In a study of 13 patients with radically resected node metastases treated with adjuvant chemotherapy, 3 of 8 patients were cured, 4 progressed, and 1 died from chemotherapy-related pulmonary toxicity. The authors concluded that **adjuvant chemotherapy can increase survival compared with surgery alone but that the risk for toxicity is high** (Hakenberg et al., 2006).

A literature review demonstrated that, after ILND, the 5-year survival rate for men is 90% to 100% with negative ILNs, 80% for those with one positive node or unilaterally positive nodes, 50% for two or more unilaterally positive nodes, and 10% for bilaterally positive nodes, extranodal extension, or positive pelvic nodes (Pow-Sang et al., 1979; Srinivas et al., 1987).

It has been suggested that adjuvant therapy is advisable when there are two or more positive nodes, extranodal extension of cancer, or pelvic node metastasis (Solsona et al., 2004).

Surgery for Palliative Purposes

Infiltrative or coalescent inguinal disease left untreated can result in significant local complications such as infection, abscess, foul-smelling drainage, and life-threatening vascular hemorrhage (Koifman et al., 2013).

Palliative surgery can offer a better short-term quality of life by removing infected and painful disease, however, cure is rarely achieved. One study included 24 patients who underwent a palliative dissection, of whom 21%, 8%, and 4% survived 1, 2, and 3 years, respectively (Srinivas et al., 1987).

In very select cases, an extra-anatomical arterial bypass can be performed to prevent femoral hemorrhage or death (Ferreira et al., 2008).

Considering surgery as monotherapy for this disease stage is inadequate because it only addresses the genital and inguinal area, thereby, distant metastases are not being treated. Several series have described multimodal approaches utilizing systemic chemotherapy and surgery in patients with bulky inguinal metastases. The available data are limited to retrospective reviews, and in most of these cases, patients had either initial or recurrent bulky metastases treated with systemic chemotherapy and then subsequently underwent a surgical procedure (Ornellas et al., 2008; Pizzocaro and Piva, 1988).

The feasibility of performing aggressive surgical resection and reconstruction in the postchemotherapy setting has been described and with no perioperative deaths (Chen et al., 2004). In a series from MD Anderson Cancer Center, the incidence of complications was greater among those undergoing a palliative dissection (67%) when compared with prophylactic (35%) or therapeutic (36%) dissections (Bevan-Thomas et al., 2002).

The available literature suggests that the optimal candidates for postchemotherapy surgical consolidation in advanced penile cancer are those with a significant response to therapy, who are fit for surgery, and whose inguinal disease is free from infection (Ornellas et al., 2008).

Preparation of the Patient Before Surgery

Antibiotics

Antibiotic therapy for at least 4 weeks after treatment of the primary lesion of the penis has been advised to allow complete resolution of septic lymphadenitis (Catalona, 1980; Crawford and Daneshgari, 1992).

Some authors recommend prophylactic antibiotics considering this surgery as a contaminated procedure and the inflammatory reaction in the lymph nodes (Horenblas, 2001a, 2001b).

It has been said that, for palpable disease, **30% to 50% of these nodes are secondary to associated inflammatory conditions and not to metastases.** Traditionally, it was stated that the timing to differentiate between infection and metastasis was 6 weeks of antibiotic treatment. However, recent evidence from Chipollini et al. revealed that **late ILND and positive node disease are significant factors for recurrence and decreased survival** (Chipollini et al., 2017). Precaution must be taken in this regard; percutaneous biopsy may be an option for these cases or antibiotic therapy if an overlying infection is confirmed.

The most frequent microorganisms isolated in inguinal wounds include gram-negative, *Staphylococcus*, diphtheroids, and *Peptostreptococcus*. It has been suggested that proper sterilization of the surgical field before the procedure would decrease wound colonization and therefore decrease the risk for postoperative wound infection. The most utilized broad-spectrum antibiotics have been ampicillin with an aminoglycoside or ciprofloxacin. In patients with preoperative cellulitis or infection of the inguinal region, bacterial cultures should be obtained, and culture-specific–guided oral antibiotics should be given before surgical management (Spiess et al., 2009).

Anticoagulation

Heparin may increase the risk for wound hematoma and serous wound drainage because of continued extravasation of lymph (Tomic et al., 1994). In one study on patients who underwent ILND for melanoma, heparin did not reduce the DVT incidence. However, the total volume and duration of wound drainage was significantly greater in the group treated with low-dose heparin (Arbeit et al., 1981).

However, some authors still advocate using routine low-molecular-weight heparin, starting the evening before surgery and continuing while the patient is on bed rest. Early ambulation is highly recommended as well (Spiess et al., 2009).

In patients with a recent history of DVT or pulmonary embolism (PE), a therapeutic dose of low-molecular-weight heparin followed by oral anticoagulants should be restarted (Spiess et al., 2009).

The use of intermittent compression devices or compression stockings immediately before anesthetic induction to prevent venous stasis has also been recommended (Crawford and Daneshgari, 1992).

Bowel Cleansing

It has been suggested that a low-residue diet and a cleansing enema the day before surgery can minimize the risk for wound contamination. However, there is no evidence for the benefit for bowel preparation, and it is not routinely recommended (Spratt, 2000).

Postoperative Care of Patients After Inguinal Lymphadenectomy

Bed Rest

Past literature suggested that after ILND, the patient should be maintained on bed rest for 7 days, with both legs elevated (Crawford, 1984; Ekstrom and Edsmyr, 1958). Lymph flow increases with motion in the lower limb, whereas immobilization permits the regeneration of lymphatics or the opening of anastomotic lymphatics (Dewire and Lepor, 1992). More recent papers recommend early or immediate ambulation after ILND (Milathianakis et al., 2005; Spiess et al., 2009; Tobias-Machado et al., 2007). If a myocutaneous flap has been used, mobilization should be restricted in the early postoperative period (48 to 72 hours) to avoid compromising the blood supply to the flap (Thomas et al., 1995).

Dietary Considerations

There are no dietary restrictions for patients. Patients who present with high drainage of lymph fluid should be recommended restricted fluid intake and decreased saturated fat consumption (Lv et al., 2017).

Antibiotics

Prophylactic antibiotics should be continued for 1 week after surgery, or until all wound drains have been removed (Loughlin, 2006).

Anticoagulation (see Preparation of the Patient Before Surgery)

Compressive Dressings and Stockings

It has been suggested that the wound should be made as airtight as possible, suction drains can be used routinely, and the application of pressure by heavy dressings on the thin flaps is to be avoided (Master et al., 2012; Tobias-Machado et al., 2008). Efforts to minimize lower-extremity lymphedema include early ambulation, and the use of elastic stockings and sequential compression devices. It is advised that individually fitted elastic stockings be worn for at least 6 months after surgery (Leone et al., 2017; Rabe et al., 2018).

Drainage

It has been suggested that lymphorrhea and seroma can be prevented by postoperative suction drainage and that the drains should be removed when the 24-hour output becomes less than 50 mL, usually between 3 to 15 days postoperatively (Loughlin, 2006; Tobias-Machado et al., 2006). Colonization and spread of bacteria along these drains may increase the risk for infection if the drains stay in place for an extended period (Chintamani et al., 2005).

There is a theoretical risk that the presence of a suction drain may prolong and intensify the inflammatory phase and may also prevent leaking lymphatics from closing, thus facilitating seroma formation (Jain et al., 2004).

Complications of Inguinal Lymphadenectomy

ILND carries an overall high complication rate when compared with other surgical procedures, however, most of these complications are not severe or life-threatening. Regardless, the burden of mental distress, cost, and morbidity is considerably high, and some may argue unnecessary. This is why patient selection is critical, and extensive evaluation of the patient for micrometastasis assessment is recommended for all patients with penile cancer.

The complication reports of this procedure vary as there is no standard method for reporting these in the literature. This leads to different nomenclatures for the same complications, limiting accurate analysis and development of preventative and management strategies. Overall, the complication rate is 55.4%, of which 65.7% of complications are classified as minor using the Clavien-Dindo classification system. Number of lymph nodes removed has been shown to be a predictive factor for overall and major complication rate (Gopman et al., 2015).

The wound complications reported are largely wound infections, cellulitis, necrosis of the graft, or wound breakdown. Wound-related issues compose 0.6% to 43% of complications in some series (Gopman et al., 2015; Koifman et al., 2013; Stuvier, 2013). Antibiotics that target gram-negative rods, *Staphylococcus* group, *Diphteroids*, or *Peptostreptococcus* are recommended (ampicillin/gentamycin or ampicillin/ciprofloxacin). As previously mentioned, the type of incision, reservation of the fatty tissue within the Camper fascia, and proper preoperative care is important to prevent wound complications. The use of anticoagulants has been discussed previously (see Postoperative Care of Patients After Inguinal Lymphadenectomy).

An attempt to reduce wound complications with the introduction of endoscopic techniques has also been performed. The last prospective comparison study published by Kumar and Sethia showed that with endoscopic procedures there are a higher mean number of nodes retrieved (9.36 vs. 7.1), increased mean number of nodes involved (1.24 vs. 0.57), and fewer major complications (5% vs. 68%). However, concern was raised because of the heterogeneity between the groups compared (Heyns, 2009; Kumar and Sethia, 2017).

It has been suggested that the main advantage of minimally invasive techniques is a decreased rate of wound complications as a result of a smaller surgical incision size. Care must be taken on accomplishing the central surgical principle of preserving Camper fascia as well avoiding ischemic complications of the skin. Gopman et al. lead a multicenter study including more than 300 patients undergoing ILND and found, after a multivariate logistic regression analysis, that the sartorius flap transposition was a predictor of wound complications. Age was also reported to increase the likelihood of major infection complications (Gopman et al., 2015).

Lymphatic complications and seromas contribute significantly to the morbidity associated with the procedure. They are reported throughout the literature as lymphorrhea, lymphedema, or lymphoceles (2.4% to 26.5%) (Gopman et al., 2015; Koifman et al., 2013). The question has been raised whether drainage with or without suctioning systems should be used, although no difference as been found on this matter. However, there is a theoretical rationale to believe that suctioning systems may prolong and intensify the inflammatory phase postoperatively and prevent lymphatics from closing, resulting in more lymphatic complications. Saphenous preservation has been proposed as one mechanism by which lymphatic complications can be reduced, as preserving the saphenous vein can improve the circulation of the region. A study of vulvar carcinoma reported that this sparing technique could avoid 30% of the overall complication rate (Zhang et al., 2000). Cui et al. in 2016 published a randomized comparison of patients undergoing saphenous vein sparing and ligation. In this study, the authors report that short- and long-term lymphedema were reduced significantly by more than 25% (Cui et al., 2016; Heyns, 2009).

In addition, the type of mechanism used for management of lymph vessels intraoperatively has been extensively evaluated. Some studies advocate the use of electrocautery, and others argue that ultrasonic energy may be superior. In an experiment carried out by Gallo et al., they found that ultrasonic energy was strong enough to obliterate the thoracic duct in cases of chylous ascites, and this is the reason it has been used in other series (Gallo et al., 2002; Sotelo et al., 2009).

A clinical trial presented by Adwani and Ebbs (2006) showed no benefit between ultrasonic energy and regular coagulation. Fibrin sealant was also proposed with the intention of sealing leaking capillaries and obliterating dead space where accumulation of fluids can occur and develop into a lymphocele and seroma. A meta-analysis based on clinical trials on this subject for breast cancer found no difference in the formation of collections, drainage volume, or length of stay (Carless and Henry, 2006)

Mobilization and the use of compressive techniques have been previously discussed in this chapter. Other complications such as DVT, thrombophlebitis, myocardial infarction, and neuropraxias have also been reported in the literature (Adwani and Ebbs, 2006; Heyns, 2009).

Oncologic Results and Follow-Up After Surgery

Oncologic Control

In SCC of the penis with no ILN metastases, the reported 5-year survival rate varies from 40% to 100%, with an average survival rate of approximately 75% (Djajadiningrat et al., 2014). In patients with lymph node metastases that were removed surgically, the reported 5-year survival rate varies from 0% to 80%, with an average rate of 60% (Djajadiningrat et al., 2014). This wide variation depends on the extent of nodal metastases. In men with minimal node metastases (one to two nodes) the reported 5-year survival rate varies from 75% to 90%, compared with an average of approximately 25% (7% to 50%) in those with more than two involved nodes, and 5% to 10% in those with extranodal extension of cancer, lymph nodes larger than 4 cm in diameter, or pelvic node metastases (Johnson and Lo, 1984a, 1984b; Spratt, 2000) (Table 81.1).

TABLE 81.1

Survival of Men With Squamous Cell Carcinoma of the Penis After Inguinal Lymph Node Dissection

	MONTHLY INTERVAL			
	YEARS 1–2	**YEAR 3**	**YEAR 4**	**YEAR 5**
Low-risk primary lesion: G1–2, Tis, Ta, T1, no vascular invasion	3	4	6	12
High-risk primary lesion: G3, T2–3, vascular invasion	2	3	6	12
Penile preserving treatment	3	6		
Partial penectomy	6	12		
Pathologically N0 (at SNB)	4	6	12	12
Pathologically N1 (at SNB)	3[a]	4[a]	6[a]	12[a]

[a] Includes ultrasonography with fine-needle aspiration cytology, computed tomography, and chest radiograph.

SNB, sentinel node biopsy.

The data demonstrates that in node-positive patients, ILND may be curative in approximately 20% to 60% of cases. However, it is also clear that even in node-negative men, ILND does not guarantee 5-year survival, with treatment failure varying from 5% to 20% (Johnson and Lo, 1984a, 1984b).

Follow-Up

Previous studies noted that recurrences mainly occur within the first 2 years after treatment of the primary penile lesion (66.2% to 100%) (Leijte et al., 2008).

Based on other proposed follow-up protocols in the literature, the following protocol is suggested (Table 81.2):

TABLE 81.2

Follow-Up Protocol for Men With Penile Squamous Cell Carcinoma

AUTHOR	YEAR	5-YEAR OVERALL SURVIVAL (%)	5-YEAR OVERALL SURVIVAL (%)
		NODE-NEGATIVE	NODE-POSITIVE
Beggs and Spratt	1964	72.5%	19.3%
Johnson and Lo	1984	74%	–
Srinivas et al.	1987	85%	32%
Pow-Sang et al.	1979	80%	62.5%
Ornellas et al.	1991	87%	29%
Ravi	1993	95%	53%
Lopes et al.	1996	–	40.3%
Pandey et al.	2006	95.7%	51.1%

Despite all the evidence presented, some physicians are reluctant to proceed with immediate ILND because of concerns over the high complication rate of this surgical procedure. In a recent report on 454 patients registered between 2000 and 2003 in the National Penile Cancer Register in Sweden, ILND was performed in only 50% of those considered at high risk for inguinal metastases according to EAU guidelines (G2–3 pT1 primary tumor) (Persson et al., 2007).

Selecting patients for ILND according to risk groups may be useful in guiding decision making, but it has its limitations. Leijte et al. reported that in the low-risk group (G1T1), the incidence of node metastases was only 6%. However, in the intermediate-risk group (G2T1) the incidence was 54%, and in the high-risk groups (G3T1, G1–3T2–3) it was only 37%, suggesting that 46% to 63% of these patients do not have ILN metastases (Leijte et al., 2007). Other recent studies have shown that the current EAU risk stratification guidelines have a low accuracy for predicting lymph node involvement, with the result that up to 82% of patients may undergo unnecessary prophylactic lymphadenectomy (Hegarty et al., 2006; Novara et al., 2008).

Key Points

- The most important independent prognostic factor related to cancer-specific survival in SCC of the penis is lymph node metastasis.
- Immediate ILND is associated with improved survival compared with salvage surgery for clinically detectable disease.
- For centers of excellence with expertise in penile cancer and ILND, DSNB can be performed with a false-negative rate of less than 5%.
- Superficial and modified ILNDs are options in the initial management of the inguinal region in patients with nonpalpable disease. These techniques have less morbidity than radical ILND.
- Endoscopic inguinal lymphadenectomy has been demonstrated to have less morbidity than open ILND and remove a comparable number of lymph nodes.
- Radical ILND is indicated for palpable disease, with potential for cure in inguinal-only disease, and for palliation of pain, infection, or hemorrhage in selected patients.
- Adjuvant chemotherapy can aid in more favorable outcomes in patients with positive inguinal disease.
- Pelvic metastasis do not occur in patients with negative ILNs.

References

Adwani A, Ebbs SR. Ultracision reduces acute blood loss but not seroma formation after mastectomy and axillary dissection: a pilot study. *Int J Clin Pract*. 2006;60(5):562–564.

Airhart RA, de Kernion JB, Guillermo EO. Tensor fascia lata myocutaneous flap for coverage of skin defect after radical groin dissection for metastatic penile carcinoma. *J Urol*. 1982;128:599–601.

Alperovich M, Choi M, Karp NS, et al. Nipple-sparing mastectomy and sub-areolar biopsy: to freeze or not to freeze? Evaluating the role of sub-areolar intraoperative frozen section. *Breast J*. 2016;22(1):18–23.

Arbeit JM, Lowry SF, Line BR, et al. Deep venous thromboembolism in patients undergoing inguinal lymph node dissection for melanoma. *Ann Surg*. 1981;194(5):648–655.

Ariyan S, Ariyan C, Farber LR, et al. Reliability of identification of 655 sentinel lymph nodes in 263 consecutive patients with malignant melanoma. *J Am Coll Surg*. 2004;198(6):924–932.

Beggs JH, Spratt JS. Epidermoid carcinoma of the penis. *J Urol*. 1964;91:166–172.

Bevan-Thomas R, Slaton JW, Pettaway CA. Contemporary morbidity from lymphadenectomy for penile squamous cell carcinoma: the M.D. Anderson Cancer Center experience. *J Urol*. 2002;167:1638–1642.

Bishoff JT, Basler JW, Teichman JM, et al. Endoscopic subcutaneous modified inguinal lymph node dissection (ESMIL) for squamous cell carcinoma of the penis. *J Urol*. 2003;169:78A.

Bjurlin MA, Zhao LC, Kenigsberg AP, et al. Novel use of fluorescence lymphangiography during robotic groin dissection for penile cancer. *Urology*. 2017;107:267.

Bouchot O, Rigaud J, Maillet F, et al. Morbidity of inguinal lymphadenectomy for invasive penile carcinoma. *Eur Urol*. 2004;45:761–765.

Bude R. Does contrast-enhanced US have potential for sentinel lymph node detection. *Radiology*. 2004;230(3):603–604.

Cabanas RM. An approach for the treatment of penile carcinoma. *Cancer*. 1977;39(2):456–466.

Carless PA, Henry DA. Systematic review and meta-analysis of the use of fibrin sealant to prevent seroma formation after breast cancer surgery. *Br J Surg*. 2006;93(7):810–819.

Catalona WJ. Modified inguinal lymphadenectomy for carcinoma of the penis with preservation of saphenous veins: technique and preliminary results. *J Urol*. 1988;140(2):306–310.

Catalona WJ. Role of lymphadenectomy in carcinoma of the penis. *Urol Clin North Am*. 1980;7(3):785–792.

Chaudhari R, Khant SR, Patel D. Video endoscopic inguinal lymphadenectomy for radical management of inguinal nodes in patients with penile squamous cell carcinoma. *Urol Ann*. 2016;8(3):281–285.

Chen MF, Chen WC, Wu CT, et al. Contemporary management of penile cancer including surgery and adjuvant radiotherapy: an experience in Taiwan. *World J Urol*. 2004;22(1):60–66.

Chintamani, Singhal V, Singh J, et al. Half versus full vacuum suction drainage after modified radical mastectomyfor breast cancer—a prospective randomized clinical trial (ISRCTN24484328). *BMC Cancer*. 2005;27(5):11.

Chipollini J, Tang DH, Gilbert SM, et al. Delay to inguinal lymph node dissection greater than 3 months predicts poorer recurrence-free survival for patients with penile cancer. *J*

Urol. 2017;198(6):1346–1352.

Chipollini J, Tang DH, Manimala N, et al. Evaluating the accuracy of intraoperative frozen section during inguinal lymph node dissection in penile cancer. *Urol Oncol*. 2018;36(1):14e1–14e5.

Clément O, Luciani A. Imaging the lymphatic system: possibilities and clinical applications. *Eur Radiol*. 2004;14(8):1498–1507.

Coblentz TR, Theodorescu D. Morbidity of modified prophylactic inguinal lymphadenectomy for squamous cell carcinoma of the penis. *J Urol*. 2002;168(4 Pt 1):1386–1389.

Correa AF, Handorf E, Joshi SS, et al. Differences in survival by receipt of lymph node dissection in patients with invasive penile cancer: results from NCDB. *J Urol*. 2018;199(5):1238–1244.

Crawford ED, Daneshgari F. Management of regional lymphatic drainage in carcinoma of the penis. *Urol Clin North Am*. 1992;19(2):305–317.

Crawford ED. Radical ilioinguinal lymphadenectomy. *Urol Clin North Am*. 1984;11(3):543–552.

Cui Y, Chen H, Liu L, et al. Saphenous vein sparing during laparoscopic bilateral inguinal lymphadenectomy for penile carcinoma patients. *Int Urol Nephrol*. 2016;48(3):363–366.

d'Ancona CA, de Lucena RG, Querne FA, et al. Long-term followup of penile carcinoma treated with penectomy and bilateral modified inguinal lymphadenectomy. *J Urol*. 2004;172(2):498–501.

Daseler EH, Barry JA, Reimann AF. Radical excision of the inguinal and iliac lymph glands (a study based upon 450 anatomical dissections and upon supportive clinical observation). *Surg Gynecol Obstet*. 1948;87:679–694.

Dewire D, Lepor H. Anatomic considerations of the penis and its lymphatic drainage. *Urol Clin North Am*. 1992;19(2):211–

219.

Djajadiningrat RS, Graafland NM, van Werkhoven E, et al. Contemporary management of regional nodes in penile cancer—improvement in survival? *J Urol*. 2014;191:68–73.

Ekstrom T, Edsmyr F. Cancer of the penis: a clinical study of 229 cases. *Acta Chir Scand*. 1958;115(1–2):25–45.

Ferreira U, Reis LO, Ikari LY, et al. Extra-anatomical transobturator bypass graft for femoral artery involvement by metastatic carcinoma of the penis: report of five patients. *World J Urol*. 2008;26(5):487–491.

Ficarra V, Zattoni F, Artibani W, et al. Nomogram predictive of pathological inguinal lymph node involvement in patients with squamous cell carcinoma of the penis. *J Urol*. 2006;175(5):1700–1704.

Gallo Rolania FJ, Beneitez Alvarez ME, Izquierdo García FM, et al. The role of inguinal lymphadenectomy in epidermoid carcinoma of the penis. Use of Ligasure and analysis of the results. *Arch Esp Urol*. 2002;55(5):535–538.

Goldberg B, Merton D, Liu J, et al. Contrast-enhanced sonographic imaging of lymphatic channels and sentinel lymph nodes. *J Ultrasound Med*. 2005;24(7):953–965.

Gopman JM, Djajadiningrat RS, Baumgarten AS, et al. Predicting postoperative complications of inguinal lymph node dissection for penile cancer in an international multicentre cohort. *BJU Int*. 2015;116(2):196–201.

Hakenberg OW, Nippgen JB, Froehner M, et al. Cisplatin, methotrexate and bleomycin for treating advanced penile carcinoma. *BJU Int*. 2006;98(6):1225–1227.

Hegarty PK, Kayes O, Freeman A, et al. A prospective study of 100 cases of penile cancer managed according to European Association of Urology guidelines. *BJU Int*. 2006;98(3):526–531.

Heyns CF. Management of the lymph nodes in penile cancer.

Pompeo AC, Heyns CF, Abrams P. *Penile cancer*. ed 1. Societe Internationale d' Urologie: Santiago, Chile; 2009:133–175.

Horenblas S, Van Tinteren H, Delemarre JF, et al. Squamous cell carcinoma of the penis: accuracy of tumor, nodes and metastasis classification system, and role of lymphangiography, computerized tomography scan and fine needle aspiration cytology. *J Urol*. 1991;146(5):1279–1283.

Horenblas S, van Tinteren H. Squamous cell carcinoma of the penis. IV. Prognostic factors of survival: analysis of tumor, nodes and metastasis classification system. *J Urol*. 1994;151:1239–1243.

Horenblas S. Lymphadenectomy for squamous cell carcinoma of the penis. Part 1: diagnosis of lymph node metastasis. *BJU Int*. 2001;88(5):467–472.

Horenblas S. Lymphadenectomy for squamous cell carcinoma of the penis. Part 2: the role and technique of lymph node dissection. *BJU Int*. 2001;88(5):473–483.

Hughes B, Leijte J, Shabbir M, et al. Non-invasive and minimally invasive staging of regional lymph nodes in penile cancer. *World J Urol*. 2009;27(2):197–203.

Jain PK, Sowdi R, Anderson AD, et al. Randomized clinical trial investigating the use of drains and fibrin following surgery for breast cancer. *Br J Surg*. 2004;91(1):54–60.

Johnson DE, Lo RK. Complications of groin dissection in penile cancer. Experience with 101 lymphadenectomies. *Urology*. 1984;24:312–314.

Johnson DE, Lo RK. Management of regional lymph nodes in penile carcinoma. Five-year results following therapeutic groin dissections. *Urology*. 1984;24(4):308–311.

Josephson DY, Jacobsohn KM, Link BA, et al. Robotic-assisted endoscopic inguinal lymphadenectomy. *Urology*. 2009;73:167–170.

Koifman L, Hampl D, Koifman N, et al. Radical open inguinal lymphadenectomy for penile carcinoma: surgical technique, early complications and late outcomes. *J Urol*. 2013;190(6):2086–2092.

Kroon BK, Horenblas S, Deurloo EE, et al. Ultrasonography-guided fine-needle aspiration cytology before sentinel node biopsy in patients with penile carcinoma. *BJU Int*. 2005;95(4):517–521.

Kroon BK, Horenblas S, Lont AP, et al. Patients with penile carcinoma benefit from immediate resection of clinically occult lymph node metastases. *J Urol*. 2005;173:816–819.

Kumar S, Ananthakrishnan P. Predicting regional lymph node metastasis in carcinoma of the penis: a comparison between fine-needle aspiration cytology, sentinel lymph node biopsy and medial inguinal lymph node biopsy. *BJU Int*. 1998;81:453–457.

Kumar V, Sethia KK. Prospective study comparing video-endoscopic radical inguinal lymph node dissection (VEILND) with open radical ILND (OILND) for penile cancer over an 8-year period. *BJU Int*. 2017;119(4):530–534.

Lam W, Alnajjar H, La-Touche S, et al. Dynamic sentinel lymph node biopsy in patients with invasive squamous cell carcinoma of the penis: a prospective study of the long-term outcome of 500 inguinal basins assessed at a single institution. *Eur Urol*. 2008;63(4):657–663.

Lapierre A, Riou O, Flechon A, et al. Advanced penile cancer with iliac lymph node involvement treated with radiation and concurrent gemcitabine. *Cancer Radiother*. 2017;21(2):134–137.

Leijte JA, Kroon BK, Valdés Olmos RA, et al. Reliability and safety of current dynamic sentinel node biopsy for penile carcinoma. *Eur Urol*. 2007;52(1):170–177.

Leijte JA, Hughes B, Graafland NM, et al. Two-center evaluation of dynamic sentinel node biopsy for squamous cell carcinoma of the penis. *J Clin Oncol*. 2009;27(20):3325–3329.

Leijte JA, Kirrander P, Antonini N, et al. Recurrence patterns of squamous cell carcinoma of the penis: recommendations for follow-up based on a two centre analysis of 700 patients. *Eur Urol*. 2008;54(1):161–169.

Leone A, Diorio GJ, Pettaway C, et al. Contemporary management of patients with penile cancer and lymph node metastasis. *Nat Rev Urol*. 2017;14(6):335–347.

Lopes A, Bezerra AL, Serrano SV, et al. Iliac nodal metastases from carcinoma of the penis treated surgically. *BJU Int*. 2000;86(6):690–693.

Lopes A, Rossi BM, Fonseca FP, et al. Unreliability of modified inguinal lymphadenectomy for clinical staging of penile carcinoma. *Cancer*. 1996;77(10):2099–2102.

Loughlin KR. Surgical atlas. Surgical management of penile carcinoma: the inguinal nodes. *BJU Int*. 2006;97(5):1125–1134.

Lv S, Wang Q, Zhao W, et al. A review of the postoperative lymphatic leakage. *Oncotarget*. 2017;8(40):69062–69075.

Master VA, Jafri SM, Moses KA, et al. Minimally invasive inguinal lymphadenectomy via endoscopic groin dissection: comprehensive assessment of immediate and long-term complications. *J Urol*. 2012;188:1176–1180.

Matin SF, Cormier JN, Ward JF, et al. Phase 1 prospective evaluation of the oncological adequacy of robotic assisted video-endoscopic inguinal lymphadenectomy in patients with penile carcinoma. *BJU Int*. 2013;111:1068–1074.

McDougal WS, Kirchner FK, Edwards RH, et al. Treatment of carcinoma of the penis: the case for primary lymphadenectomy. *J Urol*. 1986;136:38–41.

Milathianakis C, Bogdanos J, Karamanolakis D. Morbidity of prophylactic inguinal lymphadenectomy with saphenous vein preservation for squamous cell penile carcinoma. *Int J Urol*. 2005;12(8):776–778.

Morton DL, Thompson JF, Cochran AJ, et al. Sentinel-node biopsy or nodal observation in melanoma. *N Engl J Med*. 2006;355(13):1307–1317.

Nelson BA, Cookson MS, Smith JA Jr, et al. Complications of inguinal and pelvic lymphadenectomy for squamous cell carcinoma of the penis: a contemporary series. *J Urol*. 2004;172(2):494–497.

Novara G, Artibani W, Cunico SC, et al. GUONE Penile Cancer Project. How accurately do Solsona and European Association of Urology risk groups predict for risk of lymph node metastases in patients with squamous cell carcinoma of the penis? *Urology*. 2008;71(2):328–333.

Ornellas AA, Kinchin EW, Nóbrega BL, et al. Surgical treatment of invasive squamous cell carcinoma of the penis: Brazilian National Cancer Institute long-term experience. *J Surg Oncol*. 2008;97(6):487–495.

Ornellas AA, Seixas AL, de Moraes JR. Analyses of 200 lymphadenectomies in patients with penile carcinoma. *J Urol*. 1991;146(2):330–332.

Ornellas AA, Seixas AL, Marota A, et al. Surgical treatment of invasive squamous cell carcinoma of the penis: retrospective analysis of 350 cases. *J Urol*. 1994;151(5):1244–1249.

Ottenhof SR, Vegt E. The role of PET/CT imaging in penile cancer. *Transl Androl Urol*. 2017;6(5):833–838.

Pahwa HS, Misra S, Kumar A, et al. Video endoscopic inguinal lymphadenectomy (VEIL)—a prospective assessment of feasibility and morbidity with points of technique in penile carcinoma. *World J Surg Oncol*. 2013;11:42.

Pandey D, Mahajan V, Kannan RR. Prognostic factors in node-positive carcinoma of the penis. *J Surg Oncol*.

2006;93(2):133–138.

Parra RO. Accurate staging of carcinoma of the penis in men with nonpalpable inguinal lymph nodes by modified inguinal lymphadenectomy. *J Urol*. 1996;155(2):560–563.

Perinetti E, Crane DB, Catalona WJ. Unreliability of sentinel lymph node biopsy for staging penile carcinoma. *J Urol*. 1980;124(5):734–735.

Persson B, Sjödin JG, Holmberg L, et al. Steering committee of the national penile cancer register in Sweden. The national penile cancer register in Sweden 2000-2003. *Scand J Urol Nephrol*. 2007;41(4):278–282.

Pettaway CA, Pisters LL, Dinney CP, et al. Sentinel lymph node dissection for penile carcinoma: the M.D. Anderson Cancer Center experience. *J Urol*. 1995;154:1999–2003.

Pizzocaro G, Algaba F, Horenblas S, et al. EAU penile cancer guidelines 2009. *Eur Urol*. 2010;57:1002–1012.

Pizzocaro G, Piva L, Nicolai N. Treatment of lymphatic metastasis of squamous cell carcinoma of the penis: experience at the National Tumor Institute of Milan. *Arch Ital Urol Androl*. 1996;68(3):169–172.

Pizzocaro G, Piva L. Adjuvant and neoadjuvant vincristine, bleomycin, and methotrexate for inguinal metastases from squamous cell carcinoma of the penis. *Acta Oncol*. 1988;27(6b):823–824.

Pompeo A, Tobias-Machado M, Molina WR, et al. Extending boundaries in minimally invasive procedures with simultaneous bilateral video endoscopic inguinal lymphadenectomy (veil) for penile cancer: initial Denver health medical center and ABC school of medicine experience and surgical considerations. *Int Braz J Urol*. 2013;39(4):587–592.

Pompeo AC. Extended lymphadenectomy in penile cancer. *Can J Urol*. 2005;12(Suppl 1):30–36.

Pow-Sang J, Ojeda J, Ramirez G, et al. Carcinoma of the penis: analysis of 192 consecutive cases at the Instituto Nacional de Enfermedades Neoplasicas. *Int Adv Surg Oncol*. 1979;2:201–221.

Puras-Baez A, Rivera-Herrera J, Miranda G, et al. Role of superficial inguinal lymphadenectomy in carcinoma of the penis. *J Urol*. 1995;153:246A.

Rabe E, Partsch H, Hafner J, et al. Indications for medical compression stockings in venous and lymphatic disorders: an evidence-based consensus statement. *Phlebology*. 2018;33(3):163–184.

Ravi R. Correlation between the extent of nodal involvement and survival following groin dissection for carcinoma of the penis. *Br J Urol*. 1993;72(5 Pt 2):817–819.

Riveros M, Garcia R, Cabanas R. Lymphadenography of the dorsal lymphatics of the penis. *Cancer*. 1967;20:2026–2031.

Sadeghi R, Gholami H, Zakavi SR, et al. Accuracy of sentinel lymph node biopsy for inguinal lymph node staging of penile squamous cell carcinoma: systematic review and meta-analysis of the literature. *J Urol*. 2012;187(1):25–31.

Saisorn I, Lawrentschuk N, Leewansangtong S, et al. Fine-needle aspiration cytology predicts inguinal lymph node metastasis without antibiotic pretreatment in penile carcinoma. *BJU Int*. 2006;97(6):1225–1228.

Serpa Neto A, Tobias-Machado M, Ficarra V, et al. Dynamic sentinel node biopsy for inguinal lymph node staging in patients with penile cancer: a systematic review and cumulative analysis of the literature. *Ann Surg Oncol*. 2011;18(7):2026–2034.

Skinner DG. Management of extensive, localized neoplasms of lower abdominal wall. Pubectomy and scrotal skin transfer technique. *Urology*. 1974;3:34–37.

Slaton JW, Morgenstern N, Levy DA, et al. Tumor stage, vascular invasion and the percentage of poorly differentiated cancer: independent prognosticators for inguinal lymph node metastasis in penile squamous cancer. *J Urol*. 2001;165(4):1138–1142.

Solsona E, Algaba F, Horenblas S, et al. EAU guidelines on penile cancer. *Eur Urol*. 2004;46:1–8.

Sotelo R, Cabrera M, Carmona O, et al. Robotic bilateral inguinal lymphadenectomy in penile cancer, development of a technique without robot repositioning: a case report. *Ecancermedicalscience*. 2013;7:356.

Sotelo R, Sanchez-Salas R, Carmona O, et al. Endoscopic lymphadenectomy for penile carcinoma. *J Endourol*. 2007;21:364–367.

Sotelo R, Sanchez-Salas R, Clavijo R. Endoscopic inguinal lymph node dissection for penile carcinoma: the developing of a novel technique. *World J Urol*. 2009;27(2):213–219.

Spiess PE, Hernandez MS, Pettaway CA. Contemporary inguinal lymph node dissection: minimizing complications. *World J Urol*. 2009;27:205–212.

Spiess PE, Izawa JI, Basset R, et al. Preoperative lymphoscintigraphy and dynamic sentinel node biopsy for staging penile cancer: results with pathological correlation. *J Urol*. 2007;177(6):2157–2161.

Spirin BA. Internal lymphatic system of the penis. *Arkh Anat Gistol Embriol*. 1963;44(3):159–167.

Spratt J. Groin dissection. *J Surg Oncol*. 2000;73(4):243–262.

Srinivas V, Joshi A, Agarwal B, et al. Penile cancer—the sentinel lymph node controversy. *Urol Int*. 1991;47(2):108–109.

Srinivas V, Morse MJ, Herr HW, et al. Penile cancer: relation of extent of nodal metastasis to survival. *J Urol*. 1987;137(5):880–882.

Tabatabaei S, Harisinghani M, McDougal WS. Regional lymph node staging using lymphotropic nanoparticle enhanced magnetic resonance imaging with ferumoxtran-10 in patients with penile cancer. *J Urol*. 2005;174(3):923–927.

Tabatabaei S, McDougal WS. Primary skin closure of large groin defects after inguinal lymphadenectomy for penile cancer using an abdominal cutaneous advancement flap. *J Urol*. 2003;169:118–120.

Tanis PJ, Lont AP, Meinhardt W, et al. Dynamic sentinel node biopsy for penile cancer: reliability of a staging technique. *J Urol*. 2002;168(1):76–80.

Thomas JA, Matanhelia SS, Dickson WA, et al. Use of the rectus abdominis myocutaneous flap in treating advanced carcinomas of the penis. *Br J Urol*. 1995;75(2):214–219.

Tobias-Machado M, Correa WF, Reis LO, et al. Single-site video endoscopic inguinal lymphadenectomy: initial report. *J Endourol*. 2011;25(4):607–610.

Tobias-Machado M, Tavares A, Molina WR, et al. Video endoscopic inguinal lymphadenectomy (VEIL): minimally invasive resection of inguinal lymph nodes. *Int Braz J Urol*. 2006;32:316–321.

Tobias-Machado M, Tavares A, Ornellas AA, et al. Video endoscopic inguinal lymphadenectomy: a new minimally invasive procedure for radical management of inguinal nodes in patients with penile squamous cell carcinoma. *J Urol*. 2007;177(3):953–957.

Tobias-Machado M, Tavares A, Silva MN, et al. Can video endoscopic inguinal lymphadenectomy achieve a lower morbidity than open lymph node dissection in penile cancer patients? *J Endourol*. 2008;22(8):1687–1691.

Tomic R, Granfors T, Sjodin JG, et al. Lymph leakage after staging pelvic lymphadenectomy for prostatic carcinoma with and without heparin prophylaxis. *Scand J Urol Nephrol*. 1994;28(3):273–275.

Van Rijk MC, Teertstra HJ, Peterse JL, et al. Ultrasonography and fine-needle aspiration cytology in the preoperative evaluation of melanoma patients eligible for sentinel node biopsy. *Ann Surg Oncol*. 2006;13(11):1511–1516.

Wespes E, Simon J, Schulman CC. Cabanas approach: is sentinel node biopsy reliable for staging penile carcinoma? *Urology*. 1986;28(4):278–279.

Wood HM, Angermeier KW. Anatomic considerations of the penis, lymphatic drainage, and biopsy of the sentinel node. *Urol Clin North Am*. 2010;37:327–334.

Yuan JB, Chen MF, Qi L, et al. Preservation of the saphenous vein during laparoendoscopic single-site inguinal lymphadenectomy: comparison with the conventional laparoscopic technique. *BJU Int*. 2015;115(4):613–618.

Zhang S, Li W, Liang F. Clinical value of fluorine-18 2-fluoro-2-deoxy-D-glucose positron emission tomography/computed tomography in penile cancer. *Oncotarget*. 2016;7(30):48600–48606.

Zhang SH, Sood AK, Sorosky JI, et al. Preservation of the saphenous vein during inguinal lymphadenectomy decreases morbidity in patients with carcinoma of the vulva. *Cancer*. 2000;89(7):1520–1525.

Zhang X, Sheng X, Niu J, et al. Sparing of saphenous vein during inguinal lymphadenectomy for vulval malignancies. *Gynecol Oncol*. 2007;105:722–726.

Zhou XL, Zhang JF, Zhang JF, et al. Endoscopic inguinal lymphadenectomy for penile carcinoma and genital malignancy: a preliminary report. *J Endourol*. 2013;27:657–661.

Zhu Y, Zhang HL, Yao XD, et al. Development and evaluation of a nomogram to predict inguinal lymph node metastasis in patients with penile cancer and clinically negative lymph nodes. *J Urol*. 2010;184(2):539–545.

Zhu Y, Zhou XY, Yao XD, et al. The prognostic significance of p53, Ki-67, epithelial cadherin and matrix metalloproteinase-9 in penile squamous cell carcinoma treated with surgery. *BJU Int*. 2007;100(1):204–208.

Surgery for Benign Disorders of the Penis and Urethra

Ramón Virasoro MD, Gerald H. Jordan MD, FACS, FAAP (Hon), FRCS (Hon), Kurt A. McCammon MD, FACS

Improvements in microsurgery, tissue transfer techniques, and tissue handling have expanded the repertoire of the urologic surgeon and, in particular, the genitourinary reconstructive surgeon. Urologists are now able to reconstruct congenital and acquired genitourinary abnormalities with greater facility. Microvascular and microneurosurgical techniques have made it possible to construct a phallus that allows a patient to void while standing and to enjoy erotic sensibility. Because the phallus has erotic sensibility and protective sensation, the patient can eventually have a prosthetic implantation that allows an acceptable sexual life. This chapter discusses the general principles of male genital reconstructive surgery; specifics include male urethral surgery, surgery for congenital and traumatic penile lesions, and complex fistula and obliterative issues associated with the posterior urethra.

Generalities of Reconstructive Surgical Techniques

With any surgical procedure, including reconstructive procedures of the external genitalia, there are basic rules and surgeons' biases regarding the best way to perform a certain operation. In this section, the differences are highlighted.

Reconstructive surgery is performed with all efforts aimed at minimizing tissue injury and promoting healing. Adequate visualization is essential. Surgical loupes are used by almost all surgeons performing adult and pediatric reconstructive genital reconstructive surgery. A headlight or suction with attached light often adds to visualization, especially in deep perineal surgery. **In penile cases, such as reconstruction of the fossa navicularis or correction of penile curvature, bipolar cautery is commonly used.** With cautery, the electrical charge is grounded either to a pad (monopolar) or to the opposite tong of the forceps (bipolar). In most instances, the field effects of the electricity are more confined with bipolar cautery. Because electricity is dissipated by conductors (in the case of human tissue, vessels, and nerves), there is a possibility of damage to these delicate structures. In other cases, monopolar cautery can be used in the superficial structures, but bipolar cautery is better during dissection around the corpus spongiosum, elevation of penile and scrotal flaps, division of the perineal intracorporal space, and dissection of the dorsal neurovascular structures. The same principles apply when harvesting oral mucosal grafts for the purpose of genitourinary reconstruction.

Appropriate instruments for genitourinary reconstructive surgery can commonly be found in a plastic surgery tray or on the peripheral vascular tray in the typical operating room. Some examples are fine tenotomy scissors, fine forceps, various skin hooks, and delicate needle holders. Sharp scissors that cut with minimal collateral trauma are essential. These instruments minimize tissue injury from manipulation and permit more precise dissection. For urethral surgery, a set of bougie à boule sizers is essential to check the caliber of the urethral lumen. McCrea urethral sounds are a good addition to the typical van Buren sounds available in the usual operating room. For calibration, sounds do not replace the need for bougie à boule calibrators. For posterior urethral reconstruction, a sound to pass through the cystostomy tract and prostate to find the proximal end for the reconstruction is often helpful; we currently use a

Haygrove sound. Some centers use the cystoscope for this purpose, and often it suffices. Some centers use a hollow Haygrove (Gelman Urethral Sound, CS Surgical, Slidell, LA), which allows the passage of the flexible cystoscope to better visualize the bladder neck (Gelman and Wisenbaugh, 2015).

The choice of suture material evolves on the basis of the surgeon's experience and bias. However, there are some common principles with which most surgeons would agree. **First, in urethral surgery, absorbable suture is the rule.** Typical choices for most surgeons are braided absorbable sutures or the family of monofilament absorbable sutures. Chromic suture is rarely used because the choices of other absorbable sutures seem superior. The caliber of suture should be the smallest possible to align the tissue tension free. There is no reason to use suture that is stronger than the tissue. For a flap or graft repair, 4-0 to 6-0 suture is usually adequate. For primary anastomosis of the corpus spongiosum and urethra or for a posterior urethral reconstruction, 3-0 and 4-0 suture may be appropriate. The needle should be tapered if possible except when, as in urethroplasty, for example, severe spongiofibrosis or scarring is present. Some typical choices are taper needles, such as RB-1, TF, and SH-1, and cutting needles, such as P-3 and PC-3. The UR-6 half-circle taper needle that is often used in radical prostatectomy can be helpful for deep perineal anastomosis of the urethra.

Surgical position and retraction are critical to attaining good results. If possible, procedures are done with the patient supine or prone. Many procedures previously done with the patient in the lithotomy position can be done with the patient in the frog-leg or split-leg position. For penile surgery, a Scott retractor with stay hooks (Lone Star Medical Products, Houston, TX), the Jordan-Bookwalter perineal retractor set (CS Surgical, Slidell, LA; J. Hugh Knight Instrument Company, New Orleans, LA), or the Omni-Tract perineal retractor (Omni-Tract Surgical, Division of Minnesota Scientific, St. Paul, MN) is helpful. Lithotomy or exaggerated lithotomy position is used only for the minimal time necessary. With appropriate padding for the foot and positioning without pressure on the back of the leg, complications in the low-lithotomy position are minimal. When the patient is in the supine, split-leg, and low-lithotomy positions, venous compression stockings can be used. The controversy in positioning revolves around the use of the exaggerated lithotomy position. We prefer to use this position for all bulbar and posterior urethral reconstructions. Other surgeons use a lower lithotomy position. We find the more exaggerated position to be safe and believe it provides unequaled access to the deep perineal structures (Angermeier and Jordan, 1994). Details of positioning, as we do it, are described later. To minimize the patient's time in the exaggerated position, all graft harvesting or flap elevation is done with the patient in the flat supine position.

In addition to proper diagnosis and planning, the surgical technique is important for the overall success of reconstructive surgery. In contrast to the results of extirpative surgery, the results of reconstructive surgery depend on methods that minimize tissue damage and maximize wound healing. The key ingredients are adequate visualization, appropriate choice of suture, delicate tissue handling, appropriate positioning, and adequate retraction.

Key Points: Reconstructive Surgical Techniques

- Reconstructive surgery is performed with all efforts aimed at minimizing tissue injury and promoting healing. Loupe magnification is used by almost all surgeons performing adult and pediatric reconstructive surgery. For deep exposure, a headlight or lighted suction is advantageous. Instruments must be delicate because reconstructive surgery employs small sutures and small needles.
- The choice of suture material evolves on the basis of the surgeon's experience. However, absorbable materials are the rule, and the caliber of sutures should be the smallest possible to align the tissue tension free.
- The choice of surgical positioning is the surgeon's preference.
- Proper diagnosis and planning of the surgical technique are important for the success of reconstructive surgery.

Principles of Reconstructive Surgery

Many techniques in reconstructive surgery require the transfer of tissue. Skin is one of those tissues, and **its properties vary from individual to individual and from place to place on the same individual.** Variable characteristics such as color, texture, thickness, extensibility, innate skin tension, and blood supply can be useful in various situations. Mucosa from different sources have been used in genitourinary reconstructive surgery with excellent results. Different anatomic sites have inherent characteristics.

The term *tissue transfer* implies the movement of tissue for purposes of reconstruction. In contrast to extirpative surgery, **the transfer of tissue for reconstruction requires an intimate knowledge of the anatomy of the donor and the recipient sites as well as of the principles that allow the tissue to survive after it is transferred.**

The skin can be used as a model. The superficial layer of the skin is termed the *epidermis* (thickness 0.8 to 1 mm). The deep layer of the skin is termed the *dermis*. The dermis has two layers: a superficial layer, the adventitial dermis (also called the papillary or periadnexal dermis, depending on the anatomy), and a deep layer, the reticular dermis. For genitourinary reconstruction, skin without adnexal structures is often used. Other tissues commonly transferred for genitourinary reconstruction include bladder and oral mucosa as well as rectal. The bladder epithelium is the superficial layer of the bladder; the deep layer of the bladder is termed the *lamina propria,* with superficial and deep layers. The oral mucosa is the superficial layer of much of the oral cavity, which also has a deeper layer termed the *lamina propria,* again with superficial and deep layers.

All tissue has physical characteristics: extensibility, inherent tension, and the viscoelastic properties of stress relaxation and creep. The physical characteristics of a transferred unit are primarily a function of the helical arrangement of collagen along with the elastin cross-linkages. The collagen-elastin structure is suspended in a mucopolysaccharide matrix that influences the viscoelastic properties.

The epidermal (or epithelial) layer is a covering—the barrier to the “outside”—and is adjacent to the superficial dermis, or superficial lamina. At approximately this interface is the superficial plexus. In the case of skin, the plexus is the intradermal plexus. There are some lymphatics in the superficial dermal or tunica layer. On the undersurface of the deep dermal layer or deep lamina is the deep plexus. In the case of skin, this is the subdermal plexus. The deep dermis contains most of the lymphatics and greater collagen content than found in the superficial dermal layer. The deep, or reticular, dermis is generally thought to account for the physical characteristics of the tissue.

Grafts

Tissue can be transferred as a graft (Fig. 82.1). **The term *graft* implies that tissue has been excised and transferred to a graft host bed, where a new blood supply develops by a process termed *take*. Take requires approximately 96 hours and occurs in two phases. The initial phase, imbibition, requires about 48 hours.** During that phase, the graft survives by “drinking” nutrients from the adjacent graft host bed, and the temperature of the graft is less than the core body temperature. **The second phase, inosculation, also requires about 48 hours and is the phase in which true microcirculation is reestablished in the graft.** During that phase, the temperature of the graft increases to core body temperature. The process of take is influenced by the nature of the grafted tissue and the conditions of the graft host bed. Processes that interfere with the vascularity of the graft host bed interfere with graft take.

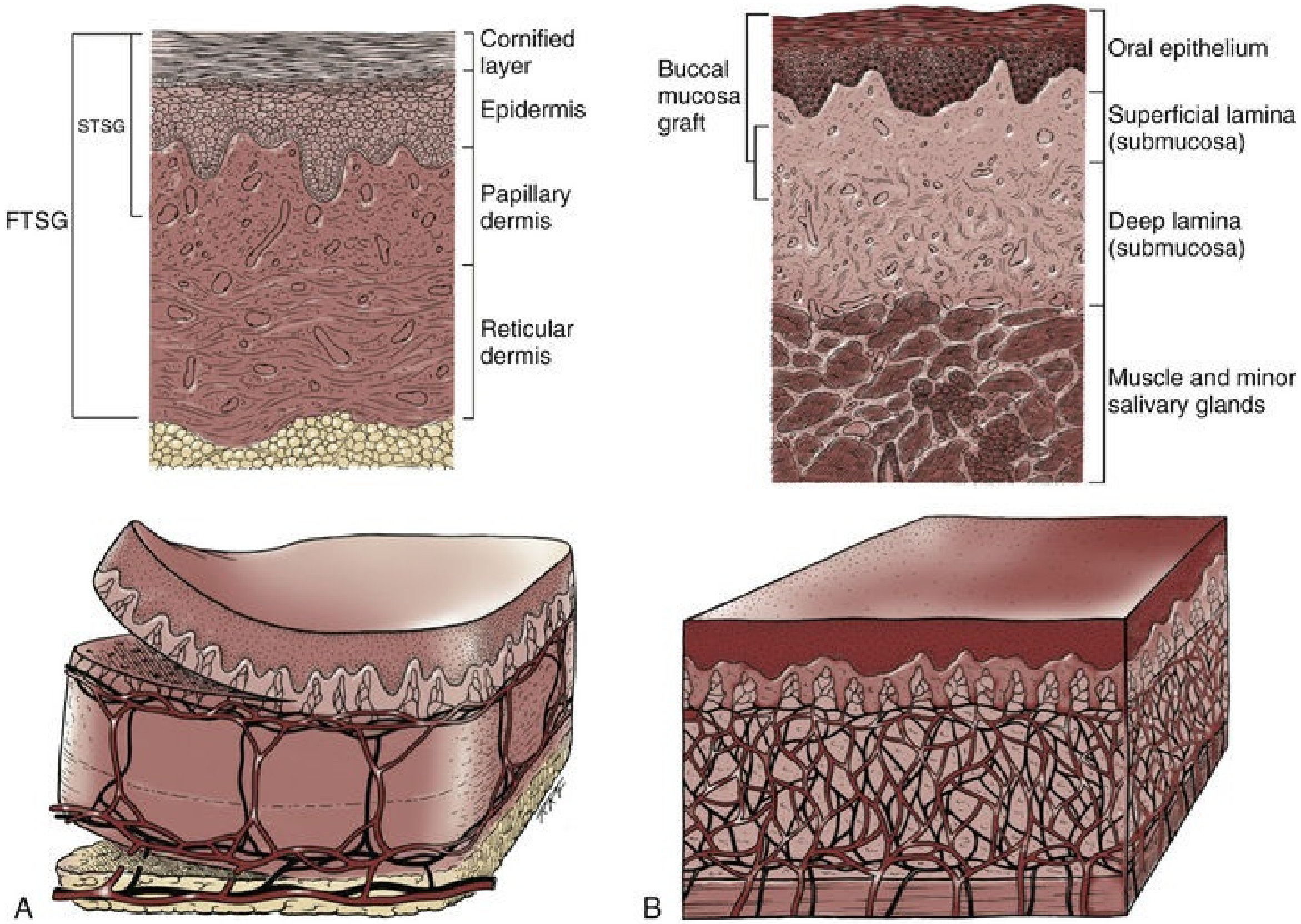
FTSG
STSG
Cornified layer
Epidermis
Papillary dermis
Reticular dermis
Buccal mucosa graft
Oral epithelium
Superficial lamina (submucosa)
Deep lamina (submucosa)
Muscle and minor salivary glands
A
B

FIG. 82.1 Cross-sectional diagrams (histologic appearance above, microvasculature below) of the skin. (A) Cross-sectional diagrams of skin. (B) Cross-sectional diagrams of oral mucosa. *FTSG,* Full-thickness skin graft; *STSG,* split-thickness skin graft. (From Jordan GH, Schlossberg SM: Using tissue transfer for urethral reconstruction. *Contemp Urol* 13:23, 1993.)

Split-Thickness Skin Graft

If a graft is a split-thickness skin graft (STSG) unit, it carries the epidermis or the covering. The graft also exposes the superficial dermal (intradermal or intralaminar) plexus. In most grafts, the superficial plexus comprises small but numerous vessels, which **convey favorable vascular characteristics to a split-thickness unit.** The unit has few lymphatics, and **the physical characteristics are not carried, which accounts for the tendency of split-thickness units to be brittle and less durable.** The reticular dermis is not carried with the split-thickness unit (Jordan, 1993).

A mesh graft is usually an application of the split-thickness graft. After the harvest of a sheet graft, the sheet is placed on a carrier that cuts systematically placed slits in the graft. These slits can expand the graft by various ratios (i.e., 1.5 : 1, 2 : 1, 3 : 1). For most genital reconstructive surgery, the slits are not for expansion but rather to allow subgraft collections to escape; in some cases, the slits allow the graft to conform better to irregular graft host beds (e.g., the testes in STSG scrotal construction). It has also been proposed that mesh grafts take readily because of increased levels of growth factors, possibly as a function of the slits. In general, full-thickness skin grafts (FTSGs) are not meshed (Jordan, 1993; Schreiter and Koncz, 1983).

Full-Thickness Skin Graft

If a graft is a FTSG unit, it carries the covering and the superficial dermis or lamina with all the characteristics attributable to that layer. However, it also carries the deep dermis or deep lamina. In skin, the subdermal plexus is exposed. In most cases, **the plexus is composed of larger vessels that are more sparsely distributed. The graft is fastidious in its vascular characteristics.** A full-thickness unit carries most of the lymphatics, and the physical characteristics are likewise carried with the transferred tissue (Devine et al., 1976; Jordan, 1993; Wessels and McAninch, 1996). Comparing the grafts that are most commonly used in genitourinary reconstructive surgery, **the STSG has favorable vascular characteristics but tends to contract** and be brittle when mature. **The FTSG tends to have more fastidious vascular characteristics, but it does not contract as much and is more durable when mature** (see Fig. 82.1A).

There is a difference between genital full-thickness skin (penile and preputial skin grafts) and extragenital full-thickness skin. This is probably a reflection of the increased mass of the graft in extragenital skin grafts. This increased mass makes the graft more fastidious, and the poor results reported with urethral reconstruction with extragenital FTSGs are probably due to poor or ischemic take (Jordan, 1993; Webster, 1987; Webster et al., 1984). The posterior auricular graft (Wolfe graft) is an exception to the rule concerning extragenital skin. The postauricular skin is thin and overlies the temporalis fascia and is thought to be carried on numerous perforators. The subdermal plexus of this graft mimics the characteristics of the intradermal plexus, and the total mass of the graft is more like that of the split-thickness unit.

Dermal Graft

The dermal graft has been used for years to augment the tunica albuginea

of the corpora cavernosa. When it is harvested, the graft exposes the intradermal plexus and the deep dermal plexus. The dermal graft takes readily (is not fastidious) and has the physical characteristics of normal skin. When it is properly prepared, the tunica vaginalis graft is essentially peritoneum. The tendency of peritoneum to take readily is well documented in the literature that examines adhesion formation and in the urology literature concerning the application of peritoneal grafts for reconstruction of the urinary tract. The literature fails to define accurately what the surgeon can expect regarding physical characteristics (Jordan, 1993).

Oral Mucosa Grafts

Oral mucosal grafts (OMGs) consist of nonkeratinized mucosa and are thought to have optimal vascular characteristics (Humby, 1941; Memmelaar, 1947). **OMGs have a panlaminar plexus. The OMG can be thinned, provided that a sufficient amount of deep lamina is carried to preserve the physical characteristics and not affect the vascular characteristics** (see Fig. 82.1B).

According to dental terminology, there are three types of OMG: buccal mucosal graft (BMG), overlying the buccinator muscle in the cheeks; the labial mucosa graft, overlying the mandible; and the lingual mucosa graft, overlying the caudal aspect of the tongue. The lingual, labial, and buccal grafts vary in thickness and in substance.

The enthusiasm for the BMG seems well founded: it is easy to harvest and handle, is resilient to infections, and is accustomed to a wet environment. The fact that the graft has a “wet epithelial” surface is likewise thought to be a favorable characteristic for many cases of urethral reconstructive surgery. Over the last decade, OMGs have become the new recommended source for urethral reconstruction (Bhargava and Chapple, 2004).

A systematic review of the literature regarding the use of oral mucosa in the reconstruction of urethral defects associated with stricture and hypospadias/epispadias by Markiewicz et al. (2007) revealed a total of 22 studies using OMG only for the reconstruction of urethral defects attributed to stricture, with an overall success rate of 76.4%. A total of 17 studies have assessed OMG in a strictly hypospadias/epispadias population, with an average success rate of 66.5%.

A series by Fichtner et al. (2004) reporting the use of “buccal mucosal” onlay grafts with midterm and long-term results seems to suggest durability for these grafts. In that series, 67 patients were described, all with follow-up exceeding 5 years and some with 10 years of follow-up. All failures occurred within 12 months of the original procedure. More recent studies showed equal results with buccal and lingular grafts (Sharma et al., 2013).

Because the labial mucosal grafts are thin, some surgeons prefer that donor site for reconstruction of the fossa navicularis (Jordan, 1993).

Vein Grafts

As described in the urologic literature, vein grafts are perhaps not true grafts according to the terminology used in this chapter. Vein patches are widely used in vascular surgery. The premise is that the vein survives by endothelial direct perfusion and re-establishment of vein wall blood flow by perfusion of the vasa vasorum. At the present time, vein “grafts” are being widely used for replacement of defects of the tunica albuginea of the corpora cavernosa. The pertinent points with regard to the transfer of vein patches to the corpora cavernosa and their long-term behavior have been inferred from the current vascular literature. Dermal grafts have been tried for urethral reconstruction, also with generally poor results.

Other Grafts

In the bladder epithelial graft, there is a superficial and a deep plexus; however, the plexuses are connected by many more perforators. **Bladder epithelial grafts tend to have more favorable vascular characteristics.**

Rectal mucosal grafts also have been proposed for urethral reconstruction, but little is known about their graft take. In general, the vascularity of the bowel mucosa is based on the vascularity of the underlying muscle, with the mucosa carried on perforators. Little is found in the literature regarding the process of take of these grafts.

Tunica vaginalis grafts have proven useful for small defects of the tunica albuginea of the corpora cavernosa, but aneurysmal dilation tends to develop when they are used for larger defects. Tunica vaginalis grafts have been tried for urethral reconstruction with uniformly poor results.

Flaps

Tissue can be transferred as a flap. **The term *flap* implies that the tissue is excised and transferred with the blood supply either preserved or surgically**

reestablished at the recipient site. Flaps can be classified by numerous criteria. Flaps can be classified on the basis of their vascularity and characterized as either random flaps (Fig. 82.2) **or axial flaps** (Fig. 82.3).

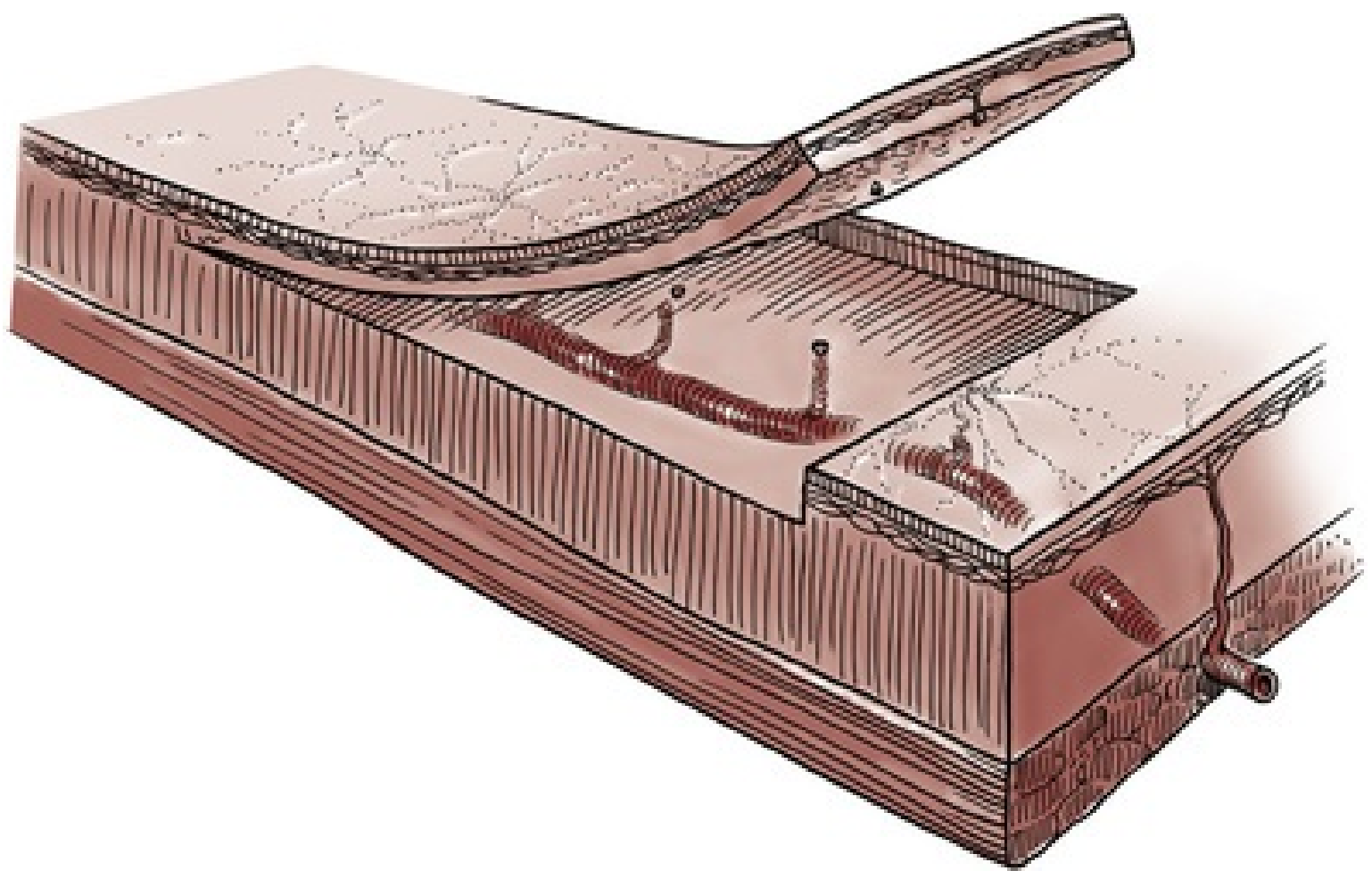

FIG. 82.2 Random flap. The arterial perforators have been interrupted, and flap survival depends on the intradermal and subdermal plexuses.

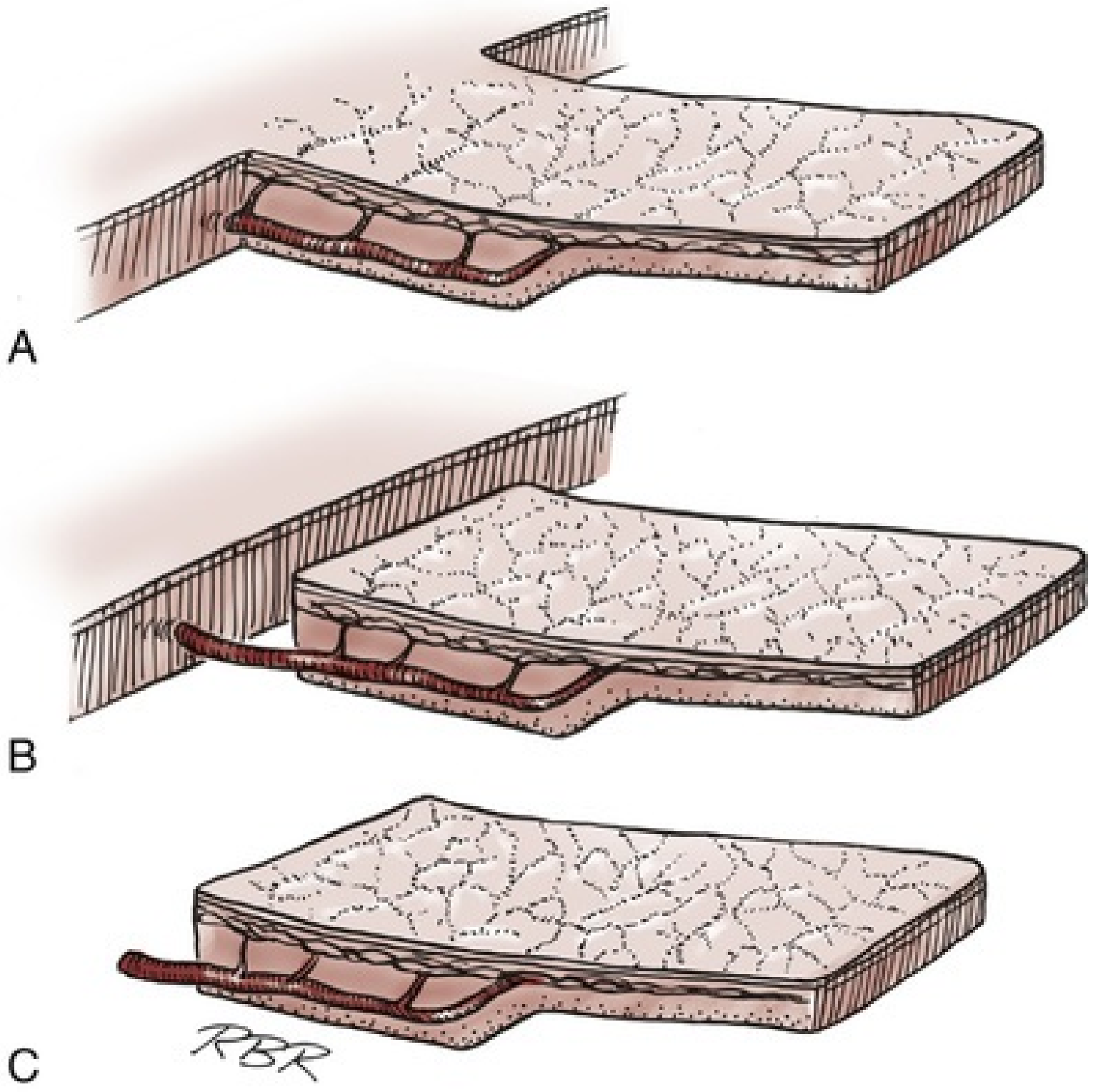

FIG. 82.3 Axial flaps. Large vessels enter the base of the flaps. Survival

depends on these vessels and on the random distal vascularity. (A) Peninsula flap. The vascular continuity and the cutaneous continuity in the flap base are intact. (B) Island flap. The vascular pedicle is intact; the cuticular continuity has been divided. These axial vessels are unsupported (dangling). (C) Microvascular free-transfer flap. The free-flap cuticular and vascular connections are interrupted at the base of the flap. Vascular continuity is reconstituted in the recipient area by a microsurgical anastomosis. (From Jordan GH, McCraw JB: Tissue transfer techniques for genitourinary reconstructive surgery. *AUA Update Series* 7:lesson 10, 1988.)

Random Flaps

A *random flap* is a flap without a defined cuticular vascular territory. The flap is carried on the dermal or laminar plexuses; the dimensions of random flaps can vary widely from individual to individual and from body site to body site.

Axial Flaps

The term *axial flap* means that there is a defined vessel in the base of the flap. There are three types of axial flaps. The direct cuticular axial flap is a flap based on a vessel superficial to the superficial layer of the deep body wall fascia (see Fig. 82.3A). The classic example of a direct cuticular flap is the groin flap. A musculocutaneous flap (Fig. 82.4A) is based on the vascularity to the muscle. **The overlying skin paddle is carried on perforators.** If the muscle alone is carried as a flap, the overlying skin survives as a random unit. **The fasciocutaneous system of vascularity (Fig. 82.4B) is similar to the musculocutaneous system.** However, the deep blood supply is carried on the fascia (deep and superficial layers), and the overlying skin paddle is based again on perforators. One can transfer a fascial flap based on the deep blood supply associated with the flap; the overlying skin, if it is not carried with the flap, remains as a random unit (Cormack and Lamberty, 1984; Ponten, 1981; Tolhurst and Haeseker, 1982). It has been argued that fascia is relatively avascular and cannot serve as the “blood supply” to the fasciocutaneous unit. Actually, the fascial layer acts as a trellis: the vessels are carried much like the limbs of a vine (Jordan, 1993).

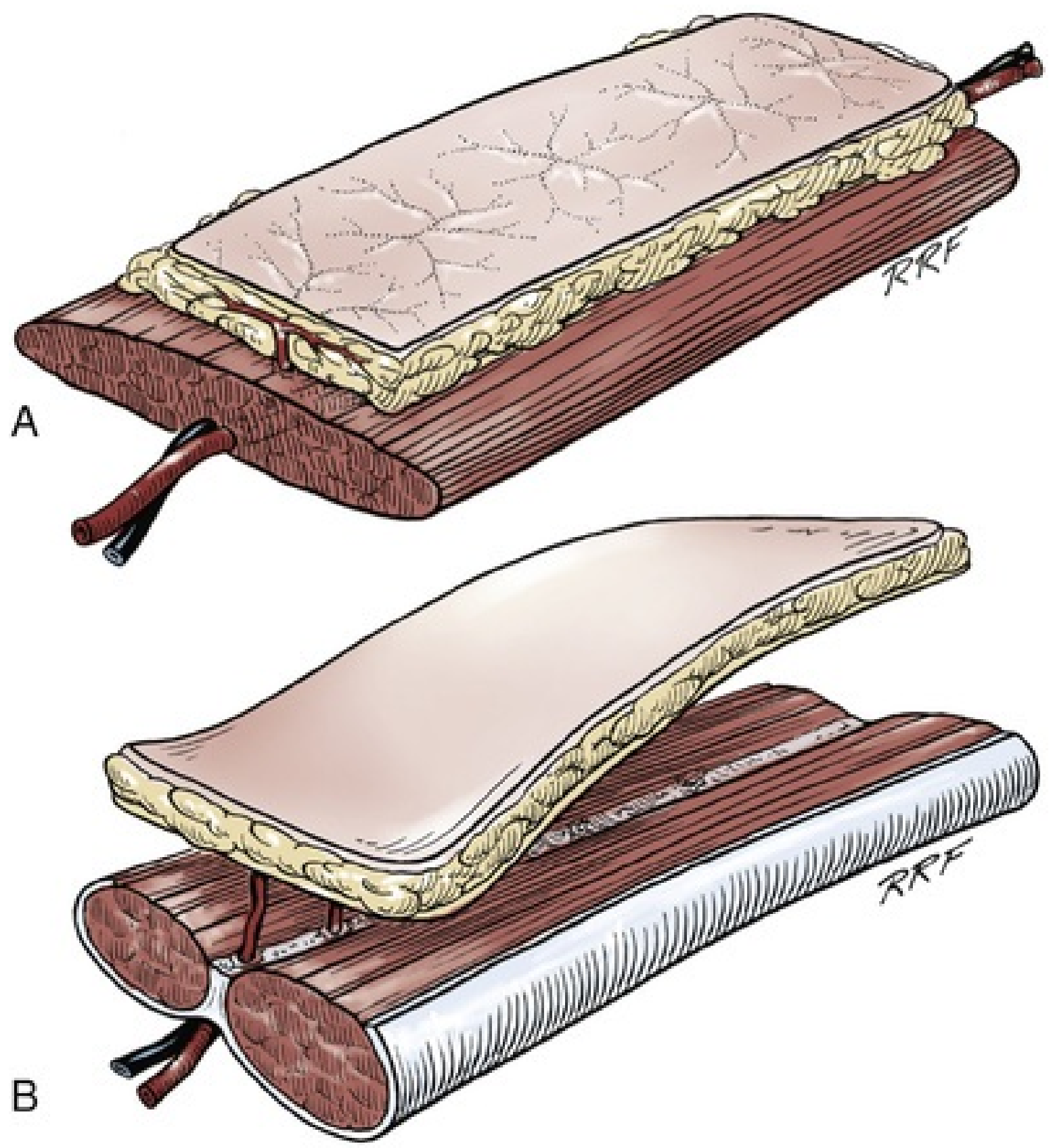

FIG. 82.4 (A) Musculocutaneous flap. Musculocutaneous perforators from the artery to a muscle vascularize the skin and overlying subcutaneous fat. They may be transferred as free flaps but are usually transferred locally, left attached to the vascular pedicle. (B) Fasciocutaneous flap. Perforating blood vessels from rich plexuses on the superficial and deep aspects of the fascia connect to perforator vessels that communicate with the microvasculature of the overlying paddle. In genital reconstruction, these flaps are based on the dartos fascia of the penis or are free flaps from the forearm. (From Jordan GH, McCraw JB: Tissue transfer techniques for genitourinary reconstructive surgery. *AUA Update Series* 7:lesson 10, 1988.)

Peninsular Flap

A flap also can be classified by the elevation technique. A peninsular flap is a flap in which the vascular continuity and the cutaneous continuity of the flap base are left intact (see Figs. 82.2 and 82.3A).

Island Flap

An island flap (see Fig. 82.3B) **is a flap in which the vascular continuity is maintained; however, the cuticular continuity is divided. A true island flap**

is elevated on dangling vessels. The microvascular free-transfer flap (free flap) (see Fig. 82.3C) **has the vascular continuity and the cuticular continuity interrupted. The vascular continuity is then reestablished at the recipient site.**

The terminology is confusing. In genitourinary reconstructive surgical procedures, we tend to use the term *island flap*. As already mentioned, a true island flap is elevated on dangling vessels. However, the usual case is that a skin island or paddle is elevated either on the muscle, as in the gracilis musculocutaneous flap, or on the fascia, as in local genital skin flaps. The term *island flap* is not synonymous with the terms *skin island* and *skin paddle*. The usefulness of these flaps and grafts is illustrated in the discussion of surgical techniques later in this chapter. There is continued interest in the use of tissue-cultured grafts or "manufactured" grafts. The likelihood of someday being able to use off-the-shelf grafts or sheets of cultured material successfully is not far in the future (Atala, 2002; Bhargava et al., 2004; Chen et al., 1999; El-Kassaby et al., 2003; Rotariu et al., 2002).

Key Points: Principles of Reconstructive Surgery

- Many of the techniques in reconstructive surgery require the transfer of tissue. Tissue transfer implies the movement of tissue for purposes of reconstruction. All tissue has extensibility, inherent tension, and the viscoelastic properties of stress relaxation and creep. These physical characteristics are important in predicting the behavior of transferred tissue.
- A graft is tissue that has been excised and transferred to a graft host bed, where a new blood supply develops by a process termed *take*. A flap is tissue that has been excised and transferred with the blood supply preserved or surgically re-established at the recipient site. Grafts that have been successfully used for primary urethral reconstruction are the FTSG, the OMG, the bladder epithelial graft, and the rectal mucosal graft. The OMG has numerous vascular properties that make it desirable for urethral reconstruction. The issue of desiccation and hypertrophic growth, in the case of the bladder epithelial graft, has limited its use in the distal urethra.
- FTSGs and STSGs have been used for penile reconstruction. The results with STSGs are so good that FTSGs are rarely used for coverage of the

penis. In complex cases, microvascular free-transfer technology has become a mainstay. For urethral reconstruction, skin islands based on the dartos fascia or tunica dartos have been effectively used. The dermal graft has been used for years to augment the tunica albuginea of the corpora cavernosa.

- The behavior of almost all forms of transfer can be predicted by examining histologic features and recognizing which layers provide which characteristics to the tissue.

Surgical Anatomy of the Penis and Male Perineum

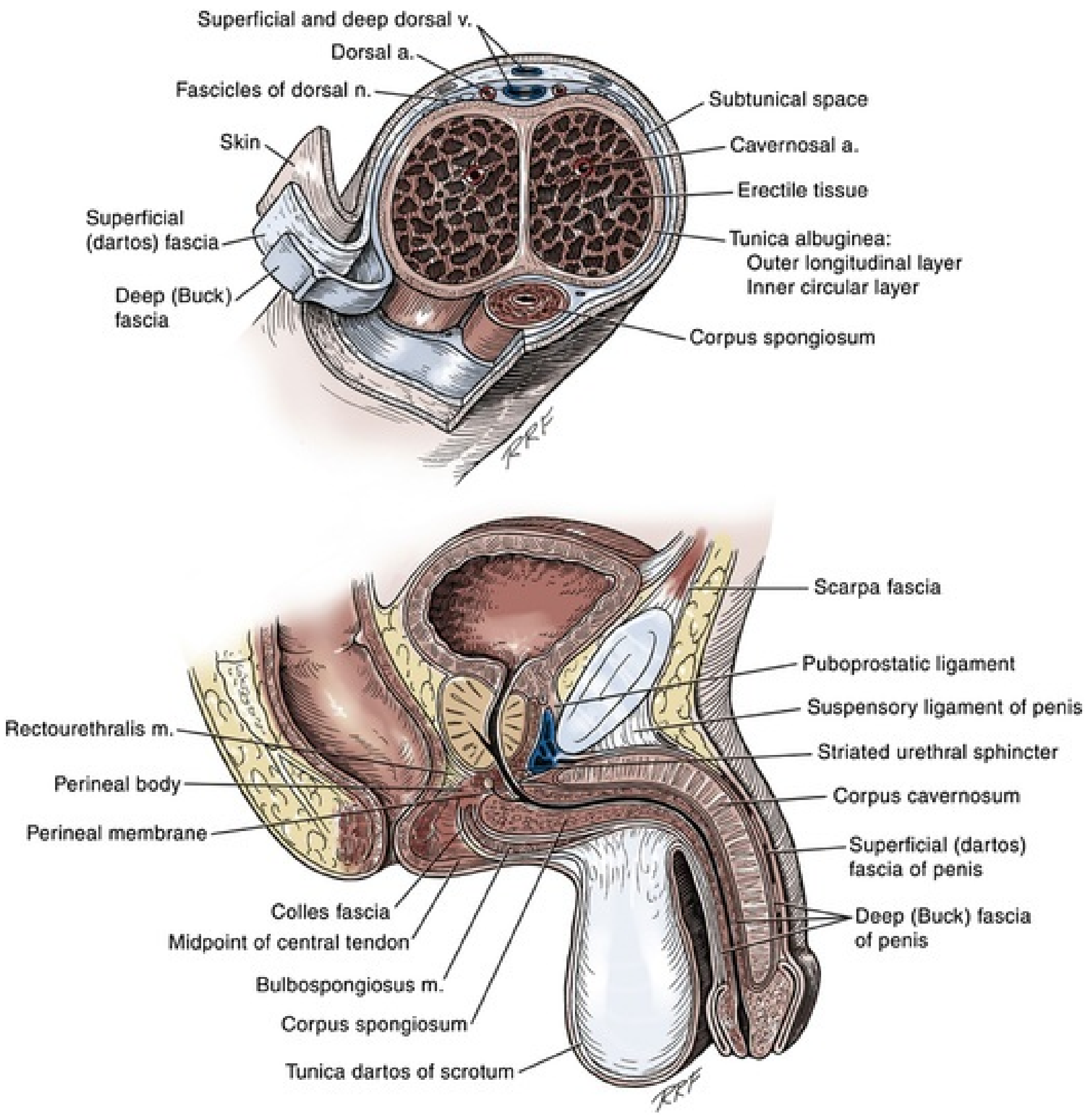
Superficial and deep dorsal v.
Dorsal a.
Fascicles of dorsal n.
Skin
Superficial (dartos) fascia
Deep (Buck) fascia
Subtunical space
Cavernosal a.
Erectile tissue
Tunica albuginea:
Outer longitudinal layer
Inner circular layer
Corpus spongiosum
RRF
Scarpa fascia
Puboprostatic ligament
Suspensory ligament of penis
Striated urethral sphincter
Corpus cavernosum
Superficial (dartos) fascia of penis
Deep (Buck) fascia of penis
Rectourethralis m.
Perineal body
Perineal membrane
Colles fascia
Midpoint of central tendon
Bulbospongiosus m.
Corpus spongiosum
Tunica dartos of scrotum
RRF

EFIG. 82.5 *Top,* Cross section of the penis at the junction of its middle and distal thirds. The septum is correctly illustrated as strands that interweave with the tunica albuginea ventrally and dorsally. *Bottom,* Diagram of a sagittal section of the penis and perineum illustrating the fascial layers. *a.,* Artery; *m.,* muscle; *n.,* nerve; *v.,* vein.

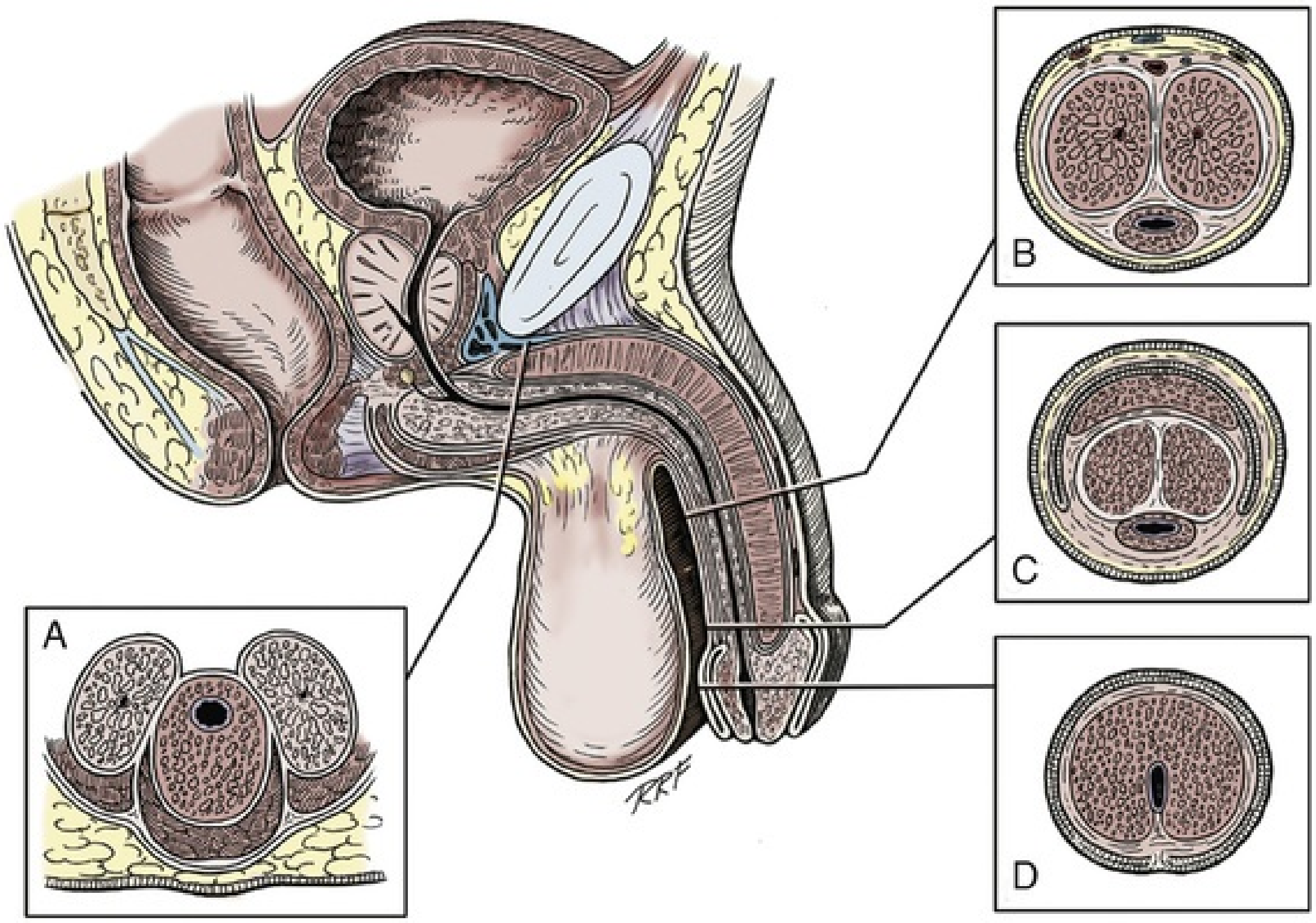

EFIG. 82.6 Diagrammatic cross sections of the anterior urethra. (A) The bulbous urethra. The urethra is eccentrically placed in the corpus spongiosum. Proximally, the corpora cavernosa have split into individual crura, with the urethra lying against the triangular ligament. (B) In the shaft of the penis, the urethra is more centrally placed in relation to the corpus spongiosum, and the corpora cavernosa are intimately fused, separated only by septal fibers. (C) At the coronal margin, the urethra remains relatively centrally placed, and the corpora cavernosa are fused, again separated by septal fibers. The spongy tissue of the corpus spongiosum has become incorporated as the deep tissues of the glans. (D) The fossa navicularis widens in caliber and is totally surrounded by the spongy erectile tissue of the glans penis. The urethra here is relatively ventrally placed in relation to the body of the corpus spongiosum. (From Jordan GH: Complications of interventional techniques of urethral stricture disease: direct visual internal urethrotomy, stents and laser. In Carson C, editor: *Topics in clinical urology: complications of interventional techniques,* New York, 1996, Igaku-Shoin, pp 86–94.)

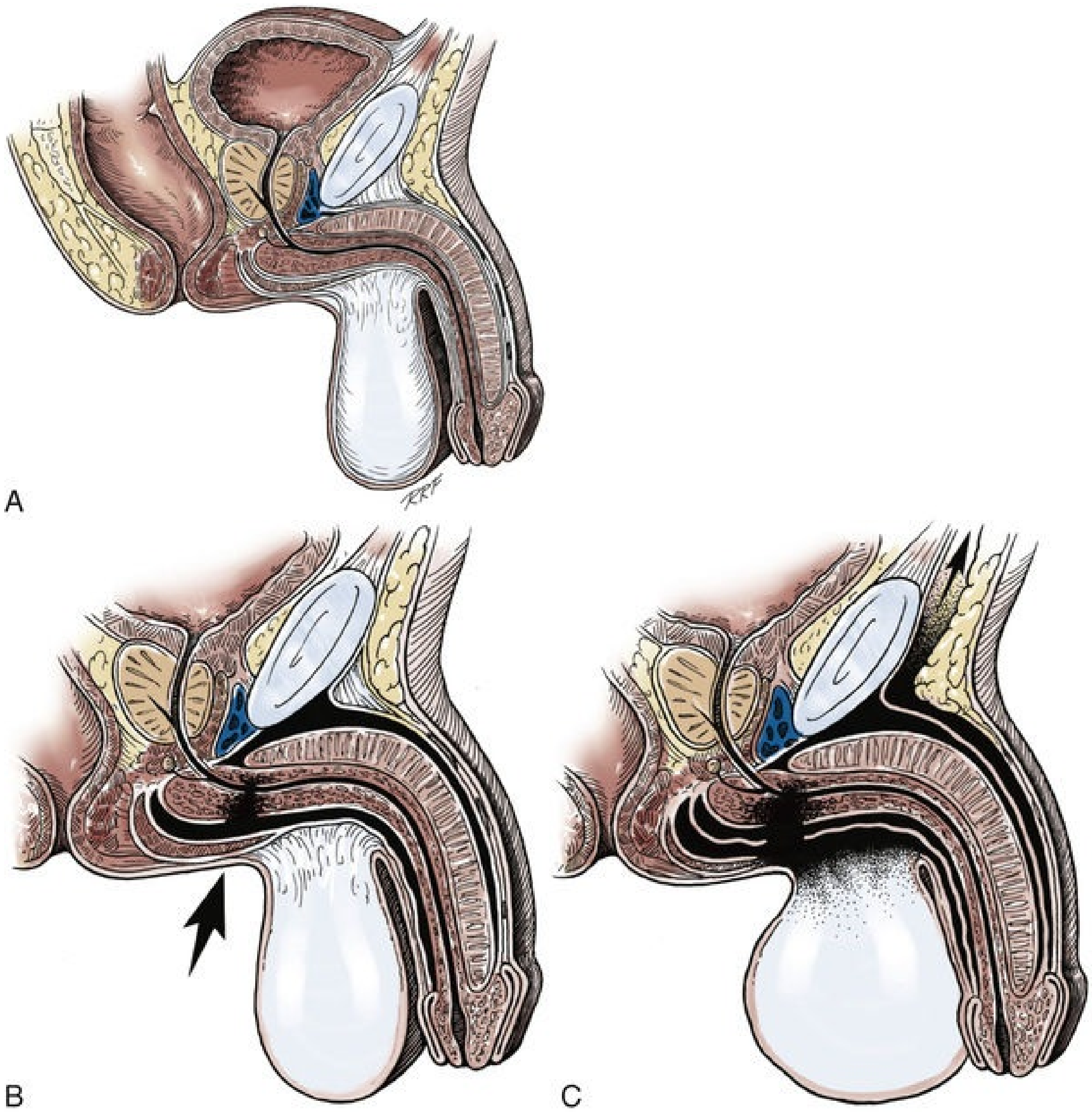

EFIG. 82.7 Cross sections of the pelvis. (A) The normal attachment of the fasciae enveloping the penile structures. The dartos fascia is contiguous with the Scarpa fascia onto the abdomen, with the tunica dartos of the scrotum, with the Colles fascia on the perineum, and over the thigh—eventually to insert at the fascia lata. (B) With trauma to the pelvis or perineum, the corpus spongiosum is injured; however, the hematoma is confined by the attachment of the Buck fascia. (C) With trauma to the perineum or pelvis, the corpus spongiosum is injured, and the Buck fascia is violated; the hematoma can spread throughout the confines of the extended dartos fascia–tunica dartos system.

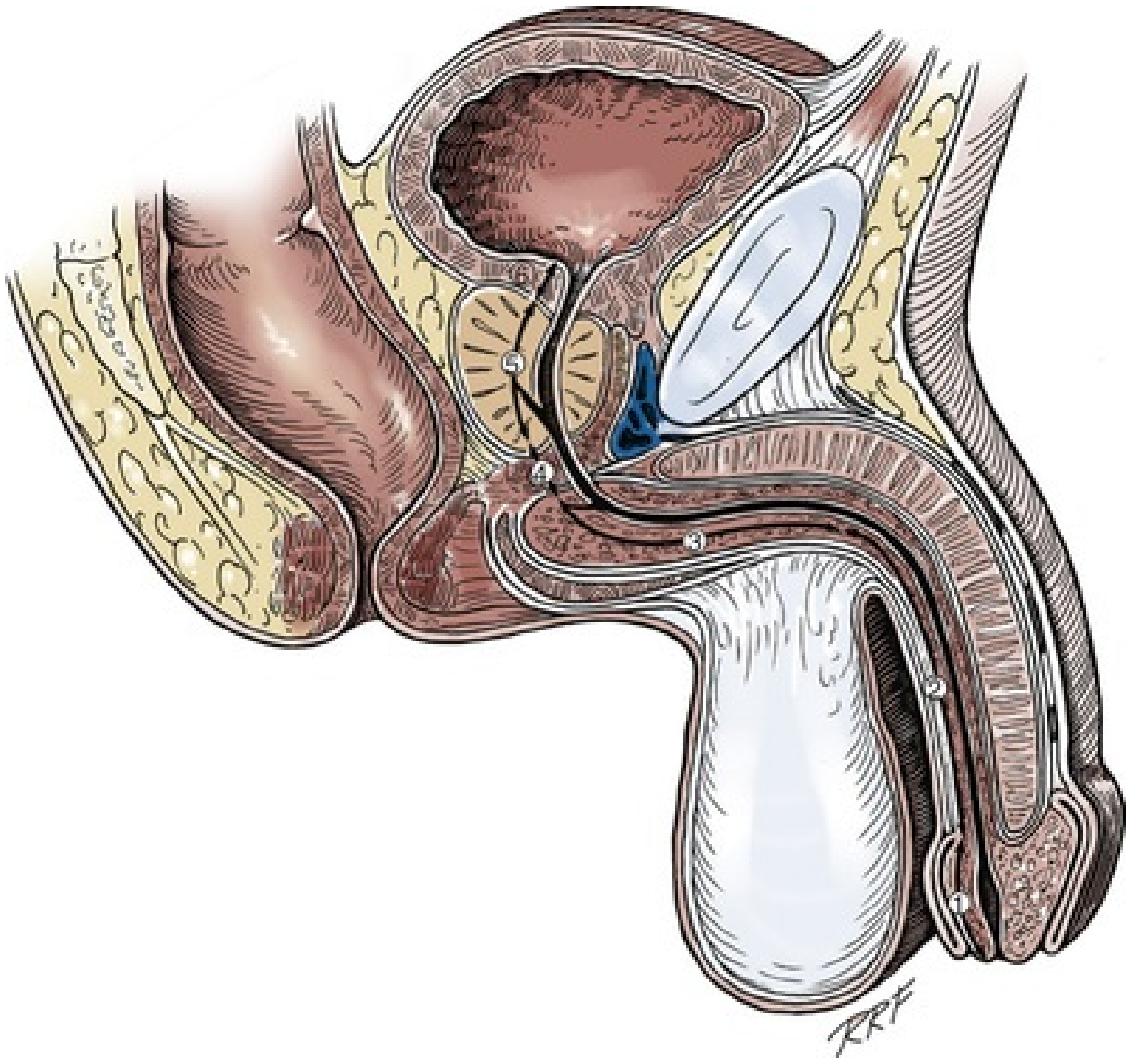

EFIG. 82.8 Sagittal section of the pelvis. The urethra is subdivided into the following sections: *1,* fossa navicularis; *2,* pendulous or penile urethra; *3,* bulbous urethra; *4,* membranous urethra; *5,* prostatic urethra; and *6,* bladder neck. By common usage, the divisions of the fossa navicularis, pendulous urethra, and bulbous urethra compose the anterior urethra, and the divisions of the membranous urethra, prostatic urethra, and bladder neck compose the posterior urethra. (Modified from Devine CJ Jr, Angermeier KW: Anatomy of the penis and male perineum. *AUA Update Series* 8:11, 1994.)

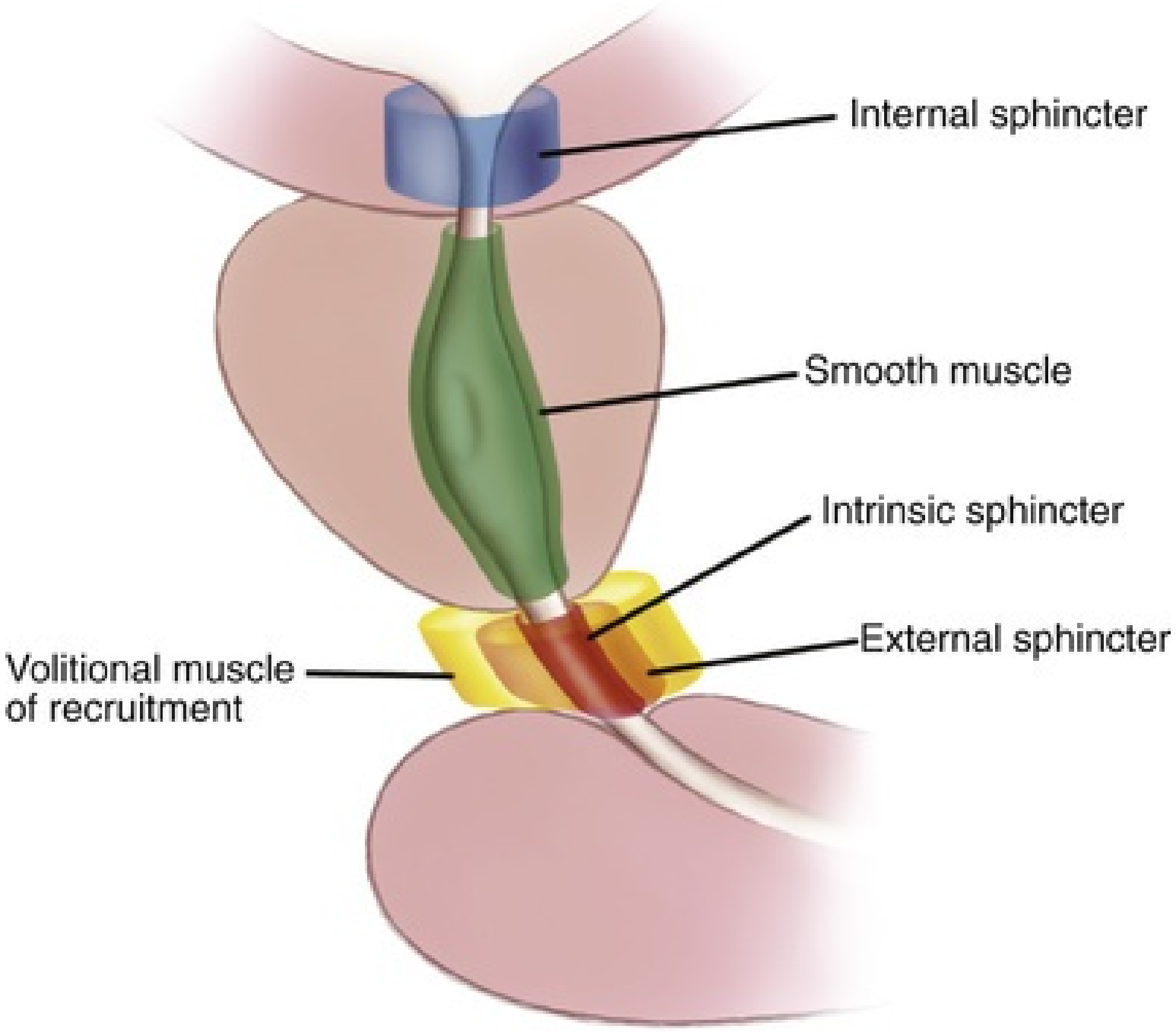
Internal sphincter
Smooth muscle
Intrinsic sphincter
External sphincter
Volitional muscle of recruitment

EFIG. 82.9 Diagrammatic representation of the sphincters surrounding the male posterior urethra.

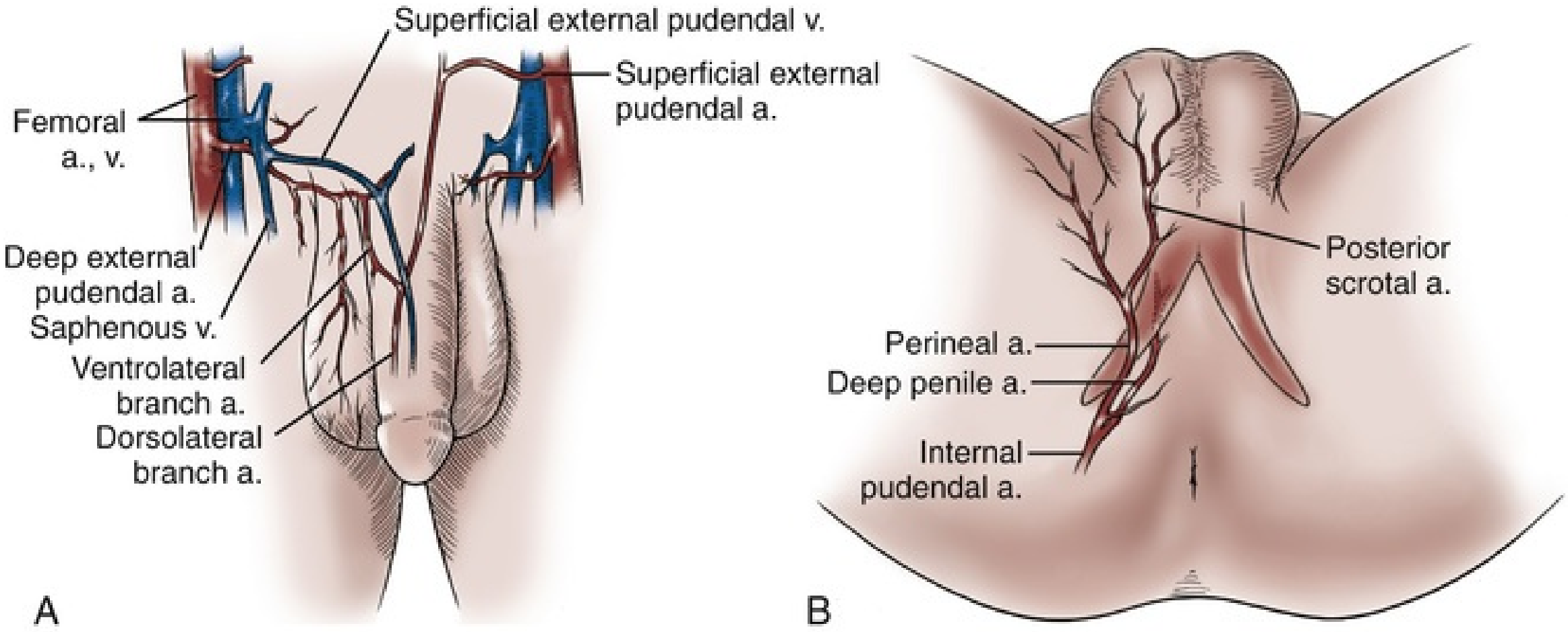
Superficial external pudendal v.
Superficial external pudendal a.
Femoral a., v.
Deep external pudendal a.
Saphenous v.
Ventrolateral branch a.
Dorsolateral branch a.
A
Posterior scrotal a.
Perineal a.
Deep penile a.
Internal pudendal a.
B

EFIG. 82.10 The vasculature to the genital skin. (A) The superficial external pudendal vessels arborize to become the fascial blood supply contained in the dartos fascia of the penis. (B) The scrotal artery is a terminal branch of the deep internal pudendal artery. This artery is thought to arborize in the tunica dartos of the scrotum and Colles fascia of the perineum. The perineal artery continues lateral to the groin crease onto the thigh and extends toward the groin. *a.,* Artery; *v.,* vein.

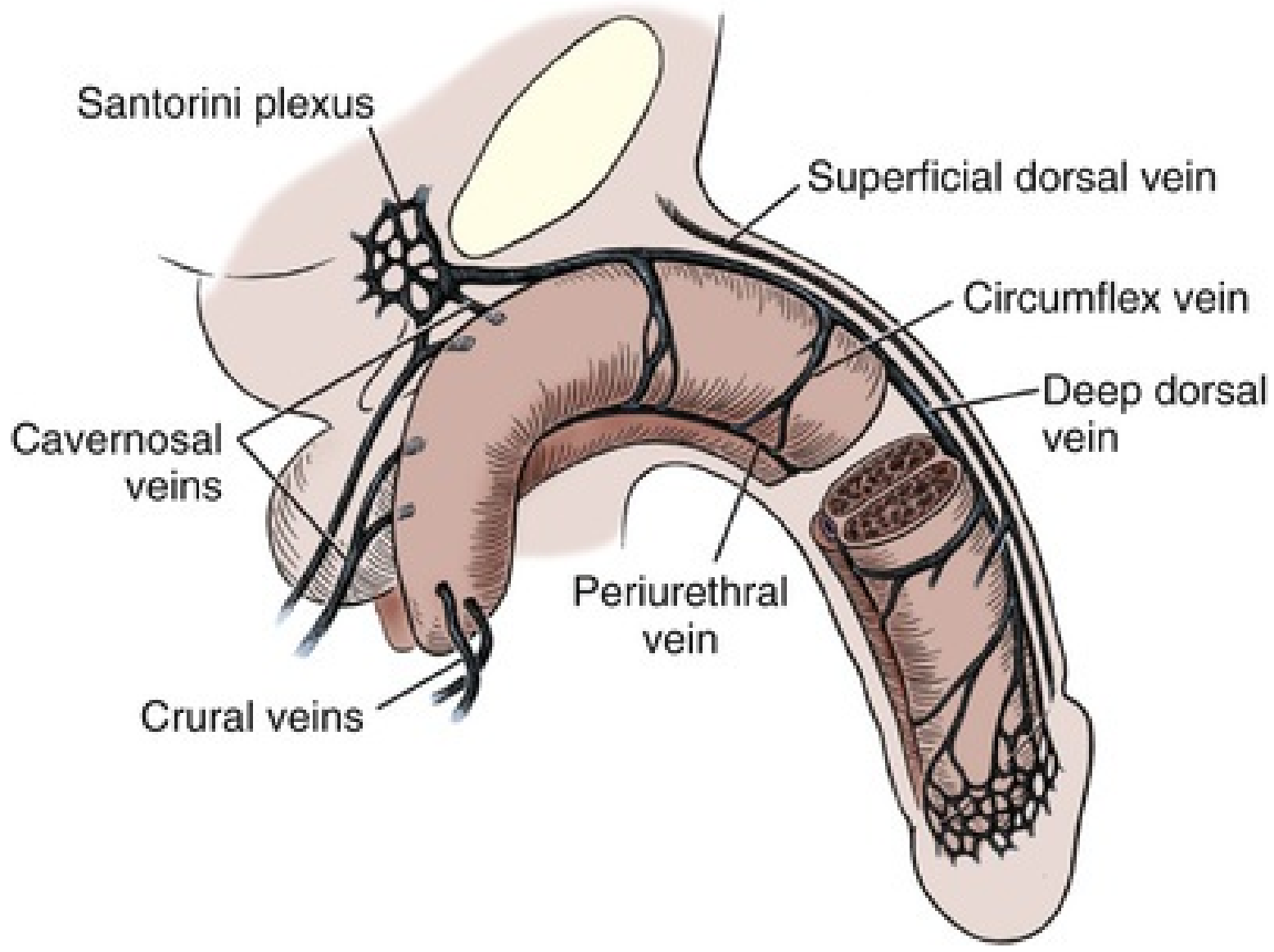
Santorini plexus
Superficial dorsal vein
Circumflex vein
Deep dorsal vein
Cavernosal veins
Periurethral vein
Crural veins

EFIG. 82.11 The venous drainage of the deep structures of the penis. (From Horton CE, Stecker JF, Jordan GH: Management of erectile dysfunction, genital reconstruction following trauma and transsexualism. In McCarthy JG, editor: *Plastic surgery,* vol 6, Philadelphia, 1990, Saunders pp 4213–4245.)

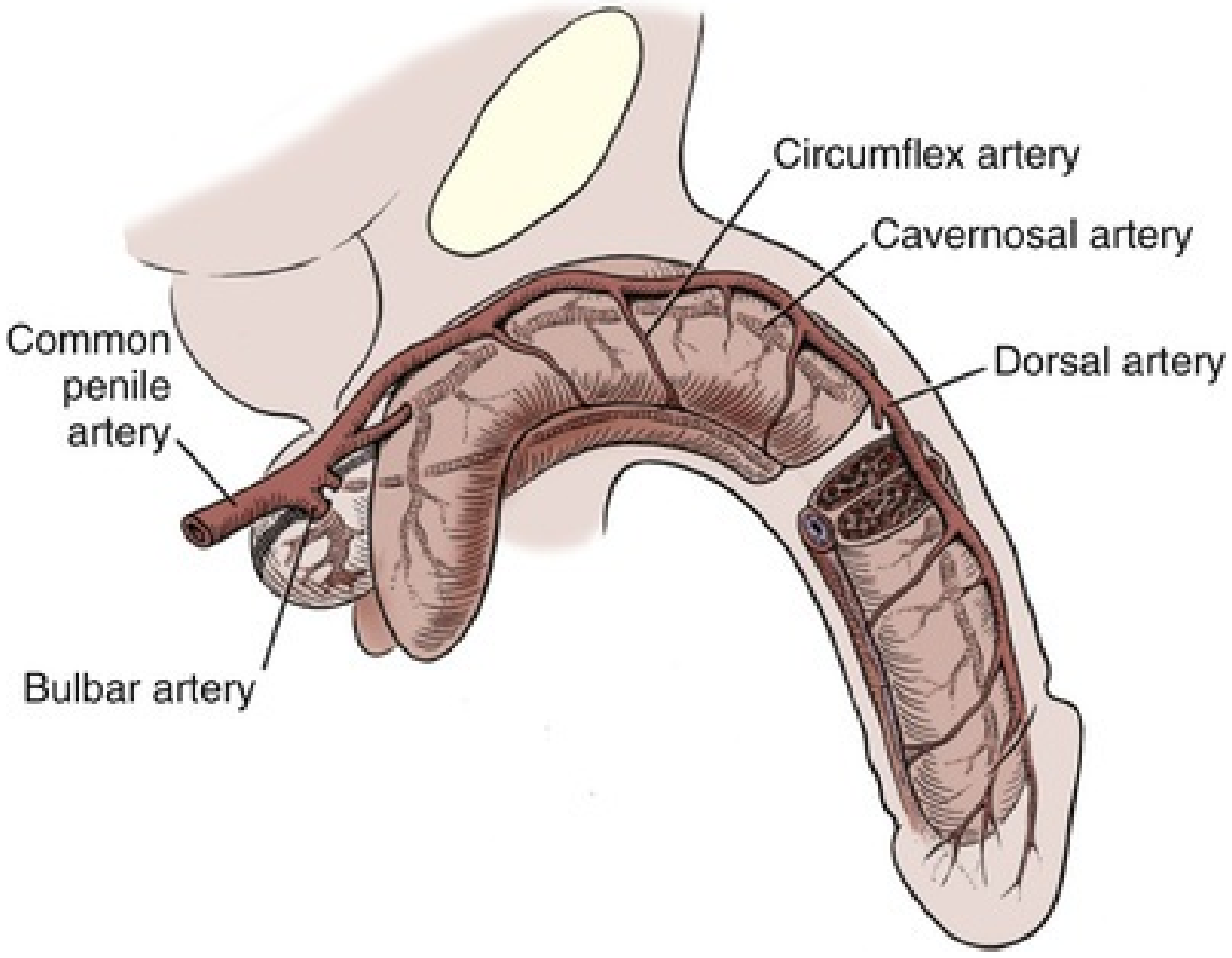
Circumflex artery
Cavernosal artery
Dorsal artery
Common penile artery
Bulbar artery

EFIG. 82.12 The arterial supply to the deep structures of the penis. (From Horton CE, Stecker JF, Jordan GH: Management of erectile dysfunction, genital reconstruction following trauma and transsexualism. In McCarthy JG, editor: *Plastic surgery,* vol 6, Philadelphia, 1990, Saunders, pp 4213–4245.)

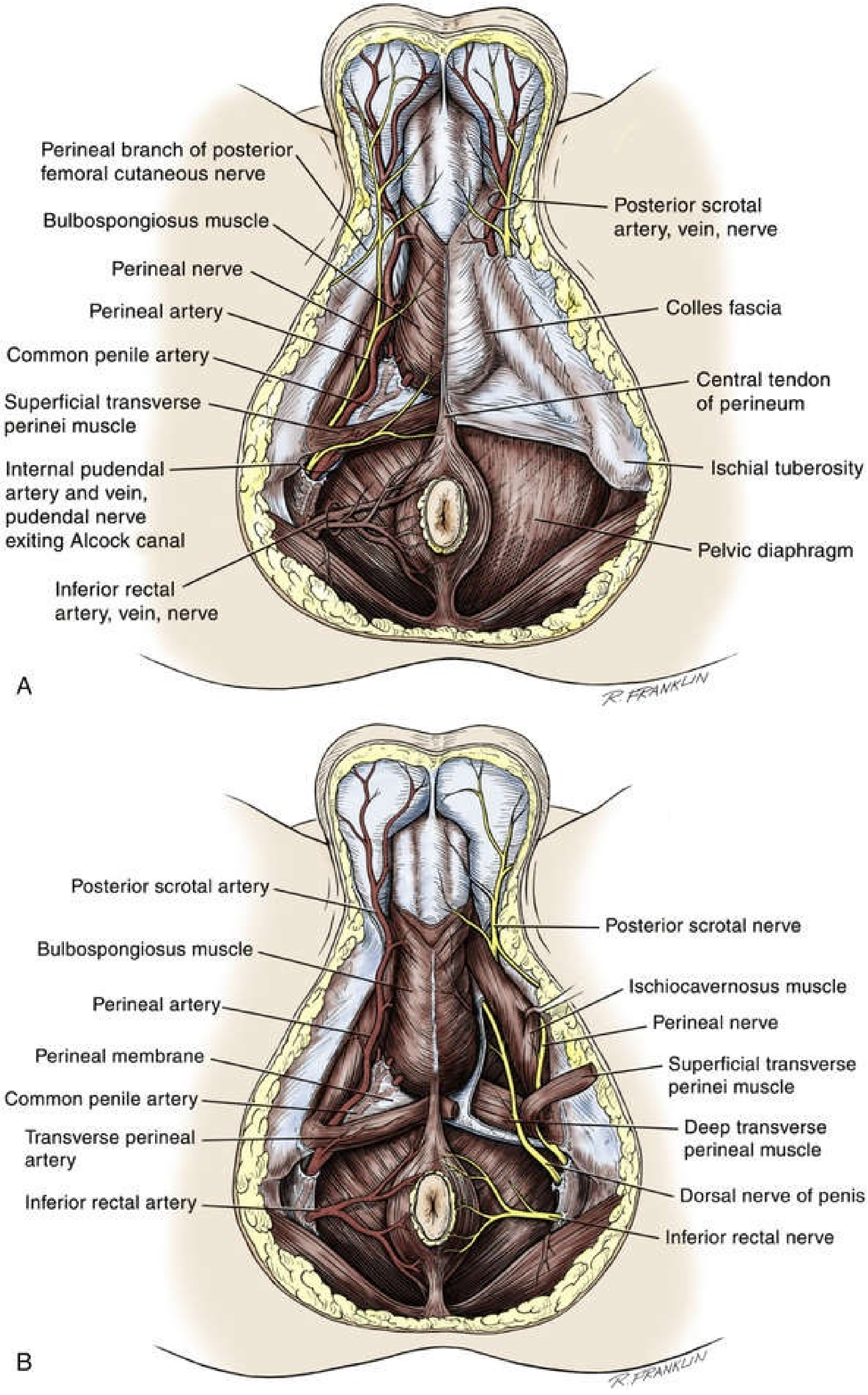
Perineal branch of posterior femoral cutaneous nerve
Bulbospongiosus muscle
Perineal nerve
Perineal artery
Common penile artery
Superficial transverse perinei muscle
Internal pudendal artery and vein, pudendal nerve exiting Alcock canal
Inferior rectal artery, vein, nerve
Posterior scrotal artery, vein, nerve
Colles fascia
Central tendon of perineum
Ischial tuberosity
Pelvic diaphragm
A
R. FRANKLIN
Posterior scrotal artery
Bulbospongiosus muscle
Perineal artery
Perineal membrane
Common penile artery
Transverse perineal artery
Inferior rectal artery
Posterior scrotal nerve
Ischiocavernosus muscle
Perineal nerve
Superficial transverse perinei muscle
Deep transverse perineal muscle
Dorsal nerve of penis
Inferior rectal nerve
B
R. FRANKLIN

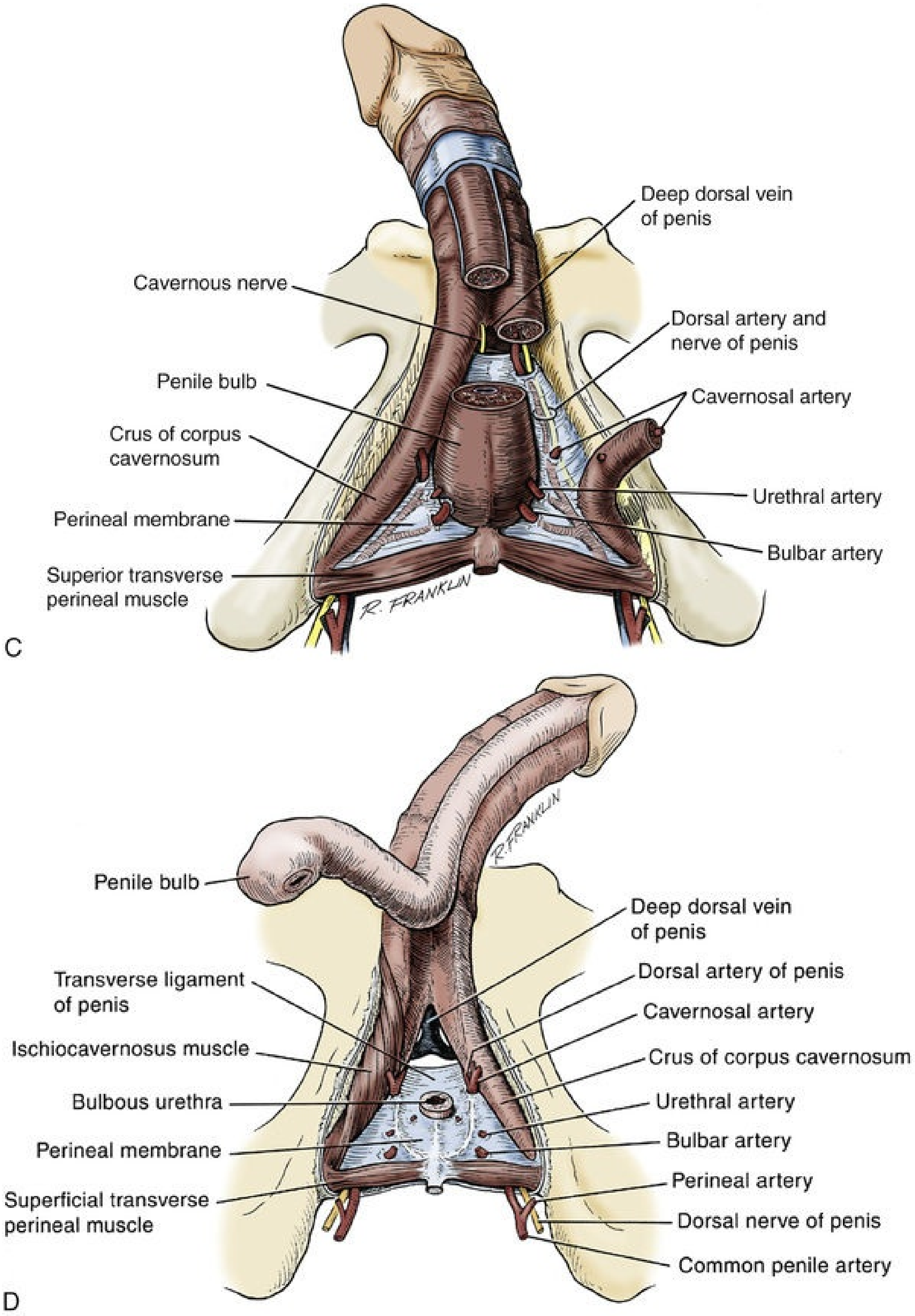
Deep dorsal vein of penis
Cavernous nerve
Dorsal artery and nerve of penis
Penile bulb
Cavernosal artery
Crus of corpus cavernosum
Urethral artery
Perineal membrane
Bulbar artery
Superior transverse perineal muscle
R. FRANKLIN
C
R. FRANKLIN
Penile bulb
Deep dorsal vein of penis
Transverse ligament of penis
Dorsal artery of penis
Cavernosal artery
Ischiocavernosus muscle
Crus of corpus cavernosum
Bulbous urethra
Urethral artery
Perineal membrane
Bulbar artery
Perineal artery
Superficial transverse perineal muscle
Dorsal nerve of penis
Common penile artery
D

EFIG. 82.13 “Peel-away” diagrams of the anatomy of the perineum. (A) The skin and subcuticular tissues have been removed. (B) In the anterior perineal triangle, Colles fascia has been removed. In the posterior anal triangle, the pelvic diaphragm has been removed. Note the division of the superficial transverse perineal muscle, exposing the deep transverse perineal muscle. (C) The anterior perineal triangle has been dissected to expose the erectile bodies. (D) The corpus spongiosum has been divided at the departure of the urethra from the penile bulb. The intracrural space is exposed. (From Devine CJ Jr, Angermeier KW: Anatomy of the pelvis and male perineum. *AUA Update Series* 13:1015, 1994.)

Discussion of the anatomic relationships of the male genitourinary structures in the penis and male perineum must precede discussion of specific reconstructive surgical techniques; for a complete anatomic description, please see Chapters 21 and 68.

Penile Anatomy

The penile shaft (eFig. 82.5) comprises three erectile bodies, the two corpora cavernosa and the corpus spongiosum containing the urethra, along with their enveloping fascial layers, nerves, and vessels, all covered by skin. All of these structures continue into the perineum. The corpora cavernosa contain erectile tissue within a dense elastic sheath of connective tissue called the tunica albuginea. The corpora cavernosa are not separate structures but constitute a single space with free communication through an incompetent midline septum that becomes more complete toward the base of the penis. This erectile tissue contains arteries, nerves, muscle fibers, and venous sinuses lined with flat endothelial cells, and these features fill the corpora cavernosa, making its cut surface look like a sponge. This tissue is separated from the tunica albuginea by a thin layer of areolar connective tissue.

The third erectile body, the corpus spongiosum, lies in the ventral groove between the two corpora cavernosa. The tunica albuginea (adventitia) of the corpus spongiosum is thinner than the tunica albuginea of the corpora cavernosa, and the corpus spongiosum contains less erectile tissue than the corpora cavernosa. The urethra traverses the length of the penis within the corpus spongiosum. At its distal end, the corpus spongiosum expands to form the glans penis. The urethral meatus is slitlike, lying slightly on the ventral aspect of the tip of the glans, with its long axis oriented vertically. **At its base, the penis is supported by two ligaments, composed primarily of elastic fibers that are continuous with the fascia of the penis.** Posterior to this attachment, the right and left corpora cavernosa diverge, and the corpus spongiosum broadens between the two crura to form the bulbospongiosus (bulb) (eFig. 82.6).

In the penis, the erectile bodies are surrounded by Buck fascia, dartos fascia, and skin. Buck fascia is the tough, elastic layer immediately adjacent to the tunica albuginea (see eFig. 82.5). On the superior aspect of the corpora cavernosa, the deep dorsal vein, paired dorsal arteries, and multiple branches of the dorsal nerves are contained within the envelope of Buck fascia. In the midline groove on the underside of the corpora cavernosa, Buck fascia splits to surround the corpus spongiosum. Consolidation of the fascial layers (eFig. 82.7), lateral to the corpus spongiosum, attaches it to the tunica albuginea of the corpora cavernosa. Attached distally to the undersurface of the glans penis at the corona, Buck fascia extends into the perineum, enclosing each crus of the corpora cavernosa and the bulb of the corpus spongiosum and firmly fixing these structures to the pubis, ischium, and inferior fascia of the perineal membrane (urogenital diaphragm).

Distally, the skin of the penis is confluent with the glabrous skin covering the glans. At the corona, it is folded on itself to form the foreskin (prepuce) that overlies the glans. The dartos fascia, a layer of areolar tissue remarkable for its lack of fat, separates these two layers of skin and continues into the perineum, where it fuses with the layers of the superficial perineal (Colles) fascia. In the penis, the dartos fascia is loosely attached to the skin and the deeper layer of Buck fascia and contains the superficial arteries, veins, and nerves of the penis.

Urethral Anatomy

In relation to trauma and reconstruction, the **consensus opinion of the International Consultation on Urological Diseases held in Morocco in 2010 is that the common use of the terms *anterior urethra* and *posterior urethra* be put aside and that the urethra be subdivided into seven separate areas** (Latini et al., 2014). These portions of the urethra are illustrated in eFig. 82.8 and described as follows:

1. The urethral meatus is a slitlike opening located at the tip of the glans penis slightly ventrally, with its long axis oriented vertically. It is the termination of the urethra at the distal end of the penis.
2. The **fossa navicularis** is contained within the spongy erectile tissue of the glans penis and terminates at the junction of the urethral epithelium with the skin of the glans. This portion of the urethra is lined with stratified squamous epithelium.

3. The **penile urethra** lies distal to the investment of the ischiocavernosus musculature but is invested by the corpus spongiosum and maintains a constant lumen size roughly centered in the corpus spongiosum. The penile urethra is lined with simple squamous epithelium.
4. The **bulbar urethra** is covered by the midline fusion of the ischiocavernosus musculature and is invested by the bulbospongiosus of the corpus spongiosum. It becomes larger and lies closer to the dorsal aspect of the corpus spongiosum, exiting from its dorsal surface before the posterior attachment of the bulbospongiosus to the perineal body. The bulbous urethra is lined distally with squamous epithelium that gradually changes to the transitional epithelium found in the membranous urethra as it swings upward (Devine and Horton, 1977).
5. The **membranous urethra** is the portion that traverses the perineal pouch and is surrounded by the external urethral sphincter. This segment of the urethra is unattached to fixed structures, has the distinction of being the only portion of the male urethra that is not invested by another structure, and is lined with a delicate transitional epithelium.
6. The **prostatic urethra** is the portion of the urethra that is proximal to the membranous urethra and is mostly surrounded by the prostatic stromal and glandular tissue. Its epithelium is continuous with the epithelium of the trigone and bladder.
7. The **bladder neck** is the location of the bladder neck musculature, variably surrounded by intravesical protrusion of the prostate. Its epithelium is contiguous with the epithelium of the trigone and bladder.

Sphincteric Anatomy

Five “sphincters” are recognized (eFig. 82.9):

1. If one begins proximally, the bladder neck is first.
2. The prostate is composed of a muscular stroma.
3. The prostate muscle continues into the membranous urethra as the external smooth muscle sphincter.
4. The external rhabdosphincter is often referred to as the external sphincter.
5. In the area of the membranous urethra are the muscles of recruitment, which are not true sphincters but provide aid with volitional continence.

Blood Supply

Blood is supplied to the skin of the penis by the left and right superficial external pudendal vessels (eFig. 82.10A), which arise from the first portion of the femoral artery, cross the upper medial portion of the femoral triangle, and divide into two main branches, running dorsolaterally and ventrolaterally in the shaft of the penis, with collateralization across the midline. At intervals, fine branches split off to the skin, forming a rich subdermal vascular plexus that can sustain the skin after its underlying dartos fascia has been mobilized. The arteries are accompanied by venous tributaries that are more prominent and more easily seen than the arteries. Because of its remarkable thinness and mobility and the character of its vascular supply, the skin covering the penis is an ideal substitute—in some cases, for urethral reconstruction. **The blood supply to the scrotal wall and ventral penile skin is based on the posterior scrotal artery, a superficial vessel from the deep internal pudendal artery** (eFig. 82.10B). As with the superficial external pudendal tributaries, the posterior scrotal system provides a series of tributaries carried within the tunica dartos.

Venous Drainage.

The penis is drained by three venous systems: superficial, intermediate, and deep (eFig. 82.11) (Aboseif et al., 1989).

a. **The superficial veins contained in the dartos fascia on the dorsolateral aspects of the penis unite** at its base to form a single superficial dorsal vein. The superficial dorsal vein usually drains into the left saphenous vein (rarely into the right) and occasionally forms two trunks that drain into both. Veins from more superficial tissue may drain into the external superficial pudendal veins.

b. **The intermediate system contains the deep dorsal and circumflex veins, lying within and beneath Buck fascia.** Emissary veins begin within the erectile space of the corpora cavernosa and, following a perpendicular or oblique course through the tunica albuginea, emerge from the lateral and dorsal surfaces of the corpora cavernosa to empty into the circumflex veins or the deep dorsal vein. The circumflex veins are channels, usually more prominently present in the distal two-thirds of the penile shaft. They arise from the corpus spongiosum, on the ventrum of the penis, and often receive the emissary veins as they travel around the lateral aspect of the corpora cavernosa, passing beneath the dorsal arteries and nerves to empty into the deep dorsal vein. The circumflex veins can also become confluent ventrally, forming periurethral veins on each side. These may become important in the treatment of impotence caused by veno-occlusive incompetence.

c. **The deep dorsal vein is formed by five to eight small veins emerging from the glans penis to form the retrocoronal plexus,** which drains into the deep dorsal vein that may consist of more than one vein lying in the midline groove between the corporal bodies. In many patients, there is a connection between the superficial and deep dorsal veins. The vein gathers blood from the emissary and circumflex veins, and, passing beneath the pubis at the level of the suspensory ligament, it leaves the shaft of the penis at the crus and drains into the periprostatic plexus.

The deep drainage system consists of the crural and cavernosal veins. The crural veins arise in the midline, in the space between the crura. Normally, they are small and almost indiscernible, joining the deep dorsal vein or the periprostatic plexus. If the deep dorsal vein has been ligated or obliterated after trauma, striking development of these veins can be noted as the intracrural space is entered during the perineal dissection for urethral repair. Emissary veins in the proximal third of the crura, near their attachment to the ischial tuberosities, join to form several thin-walled trunks on the dorsomedial surface of each corpus cavernosum. Some pass medially, joining the dorsal or crural veins, or, extending proximally, enter the periprostatic plexus. Most consolidate into one or

> two cavernosal veins on each side. Running in the penile hilum, deep and medial to the cavernosal arteries and nerves, they join to form a large venous channel that drains into the internal pudendal vein. Three or four small cavernosal veins emerge from the dorsolateral surface of each crus and course laterally between the bulbospongiosus and the crus of the penis for 2 to 3 cm before draining into the internal pudendal veins. These usually insignificant vessels become larger and can be noted more readily in patients with veno-occlusive erectile dysfunction. The internal pudendal veins (usually two) run together with the internal pudendal artery and nerve in the Alcock canal to empty into the internal iliac vein.

Arterial System.

The blood supply to the deep structures of the penis is derived from the common penile artery, which is a continuation of the internal pudendal artery after it gives off the perineal branch (eFig. 82.12). From that point, the artery is termed the *common penile artery* and travels along the medial margin of the inferior pubic ramus. As it nears the urethral bulb, the artery divides into its three terminal branches, the bulbourethral artery, dorsal artery, and cavernosal artery.

The bulbourethral artery is a short artery or arteries of relatively large caliber that pierce the Buck fascia to enter the bulbospongiosus. These arteries are oriented almost parallel to the path of the membranous urethra.

The dorsal artery generally travels along the dorsum of the penis between the deep dorsal vein medially and the dorsal nerves laterally, with a coiled rather than a straight configuration. The artery uncoils as the penis elongates with erection, allowing flow to be maintained. Along its course, it gives off 3 to 10 circumflex branches (the circumflex cavernosal arteries) that accompany the circumflex veins around the lateral surface of the corpora cavernosa and provide vascularity to the corpus spongiosum. Its terminal branches arborize in the glans penis. In many patients, branches penetrate the tunica and connect to the cavernosal arteries. The functional significance of these perforators varies from individual to individual.

The cavernosal artery, usually a single artery, arises on each side as the terminal branch of the penile artery. It enters the corpus cavernosum at the hilum and runs the length of the penile shaft, splitting off the many helicine arteries that constitute the arterial portion of the erectile apparatus. The arteries frequently branch before entering the corporal body. Sometimes a branch enters the opposite corpus cavernosum, and occasionally a single artery branches in the penile shaft to supply both sides.

Lymphatics

Lymph drainage from the glans penis collects in large trunks in the area of the frenulum. The lymph vessels circle to the dorsal aspect of the corona, where they unite with vessels from the other side. The vessels traverse the penis beneath Buck fascia, terminating mostly in the deep inguinal lymph nodes of the femoral triangle. Some drainage is to the presymphyseal lymph nodes and by way of these to the lateral lymph nodes of the external iliac group.

Nerve Supply

The nerves of the penis are derived from the pudendal and cavernosal nerves. The pudendal nerves supply somatic motor and sensory innervation to the penis. The cavernosal nerves are a combination of the parasympathetic and visceral afferent fibers and constitute the autonomic nerves of the penis. These provide the nerve supply to the erectile apparatus.

The pudendal nerves enter the perineum with the internal pudendal vessels through the lesser sciatic notch at the posterior border of the ischiorectal fossa. They run in the fibrofascial pudendal Alcock canal to the edge of the urogenital diaphragm. Each dorsal nerve of the penis arises in the Alcock canal as the first branch of the pudendal nerve. Traveling ventral to the main pudendal trunk above the internal obturator and under the levator ani, the dorsal nerves perforate the transverse perineal muscles to arrive on the dorsum of the penis and continue distally along the respective dorsolateral penile surface lateral to the dorsal artery. On the shaft, their fascicles fan out to supply proprioceptive and sensory nerve terminals in the tunica of the corpora cavernosa and sensory terminals in the skin. These nerves terminate in the glans penis.

Perineum

The perineum is the diamond-shaped outlet bounded anteriorly by the pubic arch and the arcuate ligaments of the pubis, posteriorly by the tip of the coccyx and laterally by the inferior rami of the pubis and ischium. A transverse line between the ischial tuberosities divides the perineum into an anterior triangle containing the external urogenital organs and a posterior anal triangle (eFigs. 82.13A and B).

Colles Fascia

In the anterior triangle, Colles fascia (see eFig. 82.13A) attaches at its posterior margin to the perineal body at the posteroinferior margin of the urogenital diaphragm. The fascia curves below the superficial transverse perineal muscles and projects forward as two layers attached laterally to the ischium and the inferior ramus of the pelvis. The loose superficial layer is fatty and is continuous with the more substantial dartos fascia (tunica dartos) of the scrotum. In the scrotum, the dartos fascial layer contains muscle fibers that cause the rugose appearance of the scrotum. The fascia also projects (but without muscle fibers) into the midline to form the septum between the halves of the scrotum. The median raphe in the skin delineates the separation of the halves of the scrotum and is continued anteriorly as a dark-colored streak in the ventral midline of the penis and posteriorly as the median raphe of the perineum terminating at the anus.

The deep membranous layer of Colles fascia is a more substantial layer that forms a roof over the scrotal cavity, separating it from the superficial perineal pouch. At the anterior aspect of the scrotum, Colles fascia joins with the dartos fascia (tunica dartos) of the scrotum, and a fold of this fascia projects backward beneath the fibers of the midline fusion of the ischiocavernosus muscle (bulbospongiosus muscle). At the base of the penis, it is continuous with the dartos fascia of the penis. Thickenings of the fascia at this level form the two suspensory ligaments of the penis. First, the outer fundiform ligament, which is continuous with the lower end of the linea alba, splits into laminae that surround the body of the penis and unite beneath it. Second, the inner triangular suspensory ligament is attached to the anterior aspect of the symphysis pubis and blends with the dartos fascia of the penis below it.

Anteriorly, Colles fascia fuses and becomes continuous with the membranous layer of the subcutaneous connective tissue of the anterior abdominal wall (Scarpa fascia). Laterally, Colles fascia fuses to the pubic arch and with the fascia lata. Posteriorly, Colles fascia sweeps beneath the transverse perineal muscles, fusing with the posterior aspect of the perineal membrane. The space beneath the continuous plane formed by these fascial attachments is the superficial perineal pouch, in which infections or extravasation of urine and collections of blood (after trauma to the urethra) may be confined (see eFig. 82.9).

Superficial Perineal Space

In males, **the superficial perineal space contains the continuation of the corpora cavernosa, the proximal part of the corpus spongiosum and urethra, the muscles associated with them, and the branches of the internal pudendal vessels and pudendal nerves** (see eFig. 82.13B). **The ischiocavernosus muscles cover the crura of the corpora cavernosa.** They attach to the inner surfaces of the ischium and ischial tuberosities on each side and insert at the midline into Buck fascia, surrounding the crura at their junction below the arcuate ligament of the penis. **The midline fusion of the ischiocavernosus muscles and bulbospongiosus muscles is in the midline of the perineum.** They are attached to the perineal body posteriorly and to each other in the midline as they encompass the bulbospongiosus and crura of the corpora cavernosa at the base of the penis. These muscles are confluent with the ischiocavernosus muscles laterally and at their insertion into Buck fascia, covering the dorsal vessels and nerves at the base of the penis.

Central Perineal Tendon (Perineal Body).

Lying just anterior to the anus, as a part of the plane separating the anterior and posterior perineal triangles, the **perineal body is formed by the interconnection of eight muscles of the perineum** (see eFigs. 82.13A and B). **The perineal body receives fibers from the anterior portion of the anal sphincter and is the central point of insertion of the superficial transverse perineal muscles that arise at the ischial tuberosities.** The bulbospongiosus muscle (midline fusion of the ischiocavernosus muscle) is fixed to the perineal body by its most posterior fibers. The deep transverse perineal muscles and fibers from the anterior portions of the levator ani muscles attach to the deep aspect of the perineal body.

Deep Perineal Space.

The urogenital diaphragm constitutes the deep perineal space (see eFigs. 82.13C and D). **It is contained within two layers of fascia and incompletely**

covers the outlet of the pelvis anterior to the deep layer of the perineal body. The deep layer of fascia is an indistinct structure—the continuation of the endopelvic obturator fascia. The superficial fascia attaches laterally to the ischial rami and the inferior ramus of the pubis. This fascia blends with the deep layer behind the perineal body and anteriorly, where it terminates with a thickened edge, the transverse perineal ligament. A space between this ligament and the arcuate ligament of the pubis accommodates the deep dorsal vein of the penis.

The deep perineal pouch (see eFig. 82.13D) **contains the deep transverse perineal muscles, the external sphincter of the urethra, the bulbourethral (Cowper) glands, and the blood vessels and nerves associated with the structures within it.** The sphincter urethral muscle fibers arise from the medial surface of the inferior pubic rami and pass medially toward the urethra, where they meet the fibers from the opposite side. In males, the muscle encircles the membranous urethra to function as the somatic sphincter of the urethra (Haertsch, 1981).

Key Points: Anatomy of the Penis and Male Perineum

- An understanding of the anatomy is of utmost importance to the surgeon. The penile shaft is composed of three erectile bodies: the paired corpora cavernosa and the corpus spongiosum. The corpus spongiosum invests the anterior urethra.
- By consensus, the urethra has been subdivided into seven separate areas: the meatus, the fossa navicularis, the penile urethra, the bulbar urethra, the membranous urethra, the prostatic urethra, and the bladder neck.
- In the male, five urethral "sphincters" are recognized. If one begins proximally, there is the bladder neck. The prostate is composed of a muscular stroma. The prostatic muscle continues into the membranous urethra as the external smooth muscle sphincter. The external rhabdosphincter is often referred to as the external sphincter, and in the area of the membranous urethra are the muscles of recruitment that are not true sphincters.
- Buck fascia is devoted to the deep structures of the penis. The more areolar and superficial fascia, the dartos fascia, is related more to the skin and its vasculature.

- The blood supply to the deep structures of the penis is based on the common penile artery, which is the extension of the deep internal pudendal artery. The blood supply to the skin of the genitalia is based on the perineal branch–scrotal branch of the deep internal pudendal artery and the superficial external pudendal vessels, branches of the femoral arteries. The penis is drained by three systems: the superficial, intermediate, and deep venous systems.
- The nerves to the penis are derived from the pudendal and the cavernosal nerves. The pudendal nerve supplies somatic motor and sensory innervation to the penis. The cavernosal nerves are a combination of the parasympathetic and the visceral afferent fibers and constitute the autonomic nerves to the penis.
- The perineum is a diamond-shaped outlet bounded anteriorly by the pubic arch and the circuate ligaments of the pubis, posteriorly by the tip of the coccyx, and laterally by the inferior rami of the pubis and ischium. A transverse line between the ischial tuberosities divides the perineum into an anterior triangle containing the external urogenital organs and a posterior anal triangle.

Selected Processes

Urethral Hemangioma

Although **urethral hemangioma is a rare condition, it is usually persistent** and offers a challenge to the surgeon when excision is deemed necessary. Patients typically present with hematuria or a bloody urethral discharge and occasionally with obstructive symptoms. The lesions may be single or multiple, and the urethral meatus is a common location. Although the diagnosis is often made with cystoscopy, which readily visualizes the dilated blood vessels, the lesion often extends beyond the point at which it is seen with cystoscopy.

Because all reported cases of urethral hemangioma have been benign, management depends on the size and location of the lesion. Asymptomatic lesions do not require treatment and should be observed because hemangiomas can regress spontaneously. Symptomatic lesions that require treatment must be completely excised to prevent recurrence.

Although electrofulguration has been reported as a possible treatment of urethral hemangioma, it should be used only to control an acute episode. For smaller lesions, laser treatment has been successful and produces less scarring. Lasers that are used for this purpose include argon, potassium titanyl phosphate (KTP) (532 nm), and neodymium:yttrium-aluminum garnet (Nd:YAG). The preferred treatment of larger lesions is open excision and urethral reconstruction; in some cases, this means circumferential reconstruction. Tubed graft reconstruction should be avoided; tubed flap reconstruction or tubed construction with mixed tissue transfer could be considered, although staged reconstruction is probably preferable. In addition, good initial success has been reported with polidocanol as a sclerosing agent for extensive urethral hemangiomas.

Reactive Arthritis/Reiter Syndrome

Reactive arthritis is characterized by a classic triad of arthritis, conjunctivitis, and urethritis. In addition, **some patients have had an episode of diarrhea that preceded the development of arthritis.** However, the classic triad is not present in most cases, and patients present with only arthritis affecting the knees, ankles, and feet in an asymmetrical distribution. The history of urethritis is obtained on detailed questioning.

Urethral involvement is usually mild and self-limited and constitutes a minor portion of the disease. In approximately 10% to 20% of patients, a glanular lesion is present. Referred to as **circinate balanitis,** this lesion **is diagnostic of reactive arthritis** and typically appears as a shallow, painless ulcer with gray borders. Occasionally, the lesion appears as small, red macules, 1 to 2 mm in diameter. When the urethritis is mild and self-limited, no treatment is necessary.

In rare cases, urethritis causes severe inflammation with necrosis of the mucosa, producing uncompromising stricture disease. We have been unsuccessful in excision and replacement of the urethra in these cases. Alternatively, we perform a perineal urethrostomy (PU) and excise the entire distal urethra. This approach may decrease the rheumatic manifestations associated with reactive arthritis.

Lichen Sclerosus

Lichen sclerosus (LS), previously known as balanitis xerotica obliterans (BXO), is a chronic inflammatory, hypomelanotic, lymphocyte-mediated skin disorder, which, in men, involves the prepuce and glans and frequently leads to phimosis, meatal stenosis, and urethralstrictures (Stewart et al., 2014).

The reported incidence of LS in the western population is 1 per 300 persons; however, the worldwide prevalence may be substantially different (Datta et al., 1993; Dogliotti et al., 1974; Jacyk and Isaac, 1979; Wallace, 1971). A recent publication showed the incidences in black and Hispanic male populations to be double the incidence among white males (Kizer et al., 2003). In men, LS seems to peak between ages 30 and 50; however, LS has been described in people of all ages, from infants to elderly adults (Kizer et al., 2003; Tasker and Wojnarowska, 2003). LS is commonly found at the time of circumcision when performed after the neonatal period (Garat et al., 1986; Ledwig and Weigland, 1989; McKay et al., 1975; Meuli et al., 1994; Rickwood et al., 1980). **LS is the most common cause of meatal stenosis and appears as a whitish plaque that may involve the prepuce, glans penis, urethral meatus, and fossa navicularis. If only the foreskin is involved, circumcision may be curative** (Akporiaye et al., 1997). In our experience, LS usually begins as a meatal or perimeatal process in a circumcised patient, but it may involve other areas of the preputial space in uncircumcised patients. In uncircumcised men, the prepuce becomes edematous and thickened and often may be adherent to the glans (Bainbridge et al., 1971). Diagnosis of LS remains primarily clinical and histologic, although an assay for circulating autoantibodies to extracellular matrix protein 1 (ECM-1) was recently shown to be a possible indicator of disease severity (Oyama et al., 2004). Several reports have suggested an association with chronic infection by a spirochete, *Borrelia burgdorferi* (Dillon and Ghassan, 1995; Shelley et al., 1999; Tuffanelli, 1987).

The first report of what was probably LS was published by Weir in 1875. He described a case of vulvar and oral "ichthyosis" (Weir, 1875). The term *balanitis xerotica obliterans* was first applied by Stühmer in 1928. Freeman and Laymon showed that BXO and LS were probably the same process (Freeman and Laymon, 1941; Laymon and Freeman, 1944). In 1976 the International Society for the Study of Vulvar Disease devised a new classification system unifying the nomenclature and proposed the term *lichen sclerosus* (Friedrich, 1976).

The SIU/ICUD Consultation on Urethral Stricture convened in Morocco in 2010 recommended that the accepted term for this condition is LS and the term *balanitis xerotica obliterans* should no longer be used (Level A) (Stewart et al., 2014).

The cause of LS has not been defined. Many mechanisms have been proposed. Koebner phenomenon relates the development of LS to trauma to an affected area (Lee and Phillips, 1994). A proposed mechanism is an autoimmune event. Autoantibodies to ECM-1 were detected in the serum of 67% of patients with LS and only 7% of control subjects, which would imply an autoimmune process (Oyama et al., 2003). Reports of LS associated with vitiligo, alopecia areata, thyroid disease, and diabetes mellitus also suggest a possible autoimmune basis. Reported oxidative damage of lipids, DNA, and protein in patients with LS may explain the mechanism of sclerosus, autoimmunity, and carcinogenesis of LS (Sander et al., 2004).

An infectious cause was previously implicated (Ross et al., 1990; Tuffanelli, 1987), but a more recent case-control series found no association (Edmonds and Bunker, 2010). It has also been proposed that LS has a genetic origin, based on the observation of a familial distribution of cases (Marren et al., 1995). There have been reports of concomitant existence of the disease in identical twins (Fallic et al., 1997; Thomas and Kennedy, 1986) and nonidentical twins (Cox et al., 1986), with coexistence of dermatosis. The disease also has been seen in mothers and daughters (Shirer and Ray, 1987). Studies on the human leukocyte antigen (HLA) have suggested a genetic component in patients with LS (Marren et al., 1995).

The combination of topical steroids and antibiotics may help stabilize the inflammatory process. Conservative therapy may be warranted in patients whose meatus can easily be maintained at 14 to 16 Fr (Staff, 1970). In these cases, intermittent catheterization with lubrication of the catheter and meatal dilator with 0.05% clobetasol (Temovate) may be adequate treatment. Long-term antibiotic therapy may also be helpful to improve inflammation because secondary infection of the inflamed tissue may occur. We have typically used tetracycline, but a trial of long-term penicillin or advanced-generation erythromycin therapy may be warranted (Shelley et al., 1999). This nonsurgical approach to treatment is used in patients who are not good surgical candidates for other medical reasons or in older patients and in younger patients who demonstrate stable disease. Secrest et al. (2008) proposed a link between hypogonadism and LS in male patients. These authors consistently showed diminished testosterone levels in patients with LS and analyzed whether replacement androgen therapy would be helpful.

Surgery is indicated in young patients with severe meatal stenosis. Because patients with long-standing meatal stenosis often have severe proximal urethral stricture disease, retrograde urethrography should be performed before therapy is initiated. A simple meatotomy is generally ineffective in patients with LS. Morey et al. (2007) showed that an extended meatotomy in patients with refractory stenosis was successful in 14 of 16 patients (87%). Malone (2004) described a ventral/dorsal meatotomy with an inverted V-shaped relaxing incision with the apex of the V close to the proximal limit of the dorsal meatotomy.

The cause of stricture disease associated with LS is unclear. Possible causes include iatrogenic stricture resulting from repeated instrumentation and pressure voiding associated with meatal stenosis, causing secondary intravasation of urine into the glands of Littre (Fig. 82.14). In cases of early LS with only meatal involvement resulting in stenosis of the fossa navicularis, prompt reconstruction seems to be successful in the long term and seems to avoid the sequelae of panurethral stricture disease. Most surgeons believe that because LS is a disease of genital skin, better tissue for reconstruction is the oral mucosa; techniques are discussed later (Bracka, 1999; Mundy, 1994). Long-standing cases with a long length of urethral stricture are amenable to techniques of reconstruction but are challenging. Except in the case of urethral stricture disease confined only to the meatus and fossa navicularis, staged oral graft reconstruction, at least in the short term to midterm, seems to provide superior durable results. This may also be true in cases confined to the meatus and fossa navicularis, because an analysis of patients reconstructed with the ventral transverse skin island technique showed a 50% recurrence rate even in those patients. The weakness of this analysis is that the data did not include biopsy proof that all patients had LS (Virasoro et al., 2007).

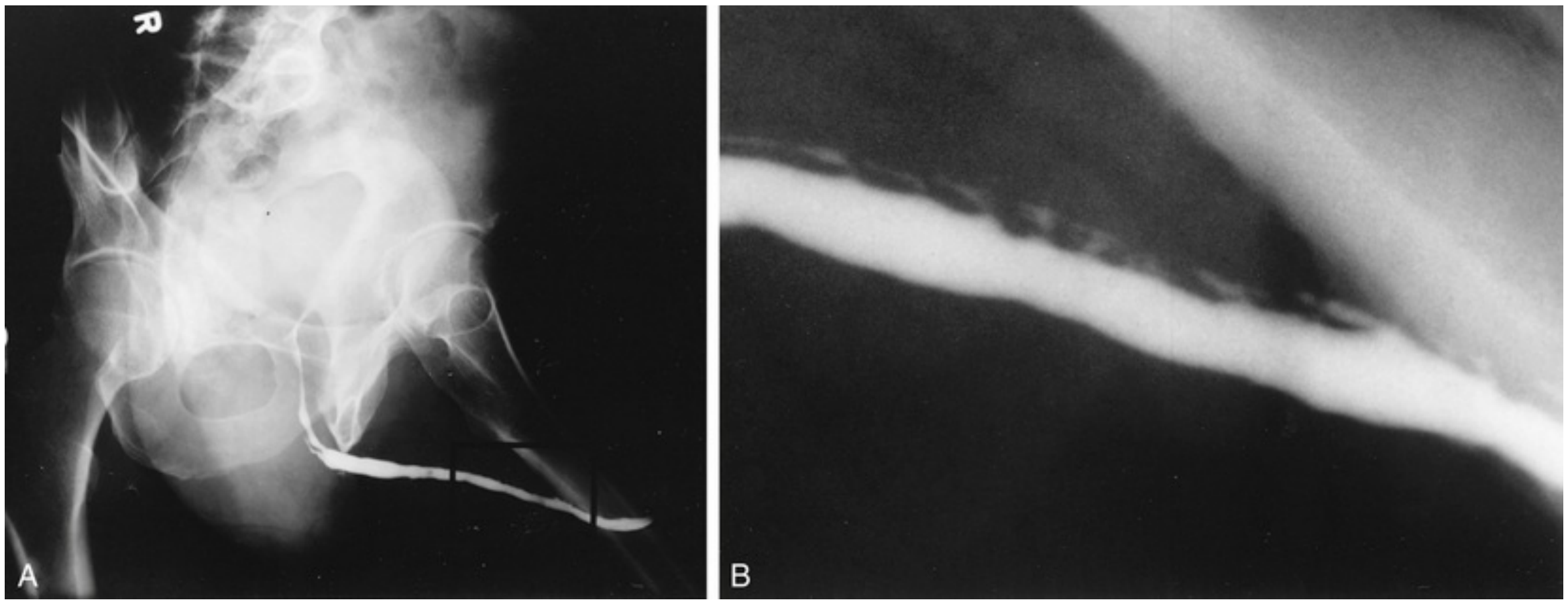

FIG. 82.14 (A and B) Urethrography in a patient with urethral stricture disease associated with lichen sclerosus. The intravasation of contrast material into the dilated glands of Littre during voiding is illustrated. (From Jordan GH: Management of membranous urethral strictures via the perineal approach. In McAninch J, Carroll P, Jordan GH, editors: *Traumatic and reconstructive urology,* Philadelphia, 1996, Saunders.)

We also see patients with a buried penis. This phenomenon occurs when the skin of the penile shaft has been lost because of severe inflammation, and the penis is trapped in the penopubic and scrotal area. These patients are often profoundly overweight, and many are diabetic; they have often had prior surgical procedures. Management of these patients is complex and ultimately determined by their desire and need for functional reconstruction. In some patients with severe urethral stricture disease, we have completely reconstructed the urethra; in others, we have simply performed a perineal urethrostomy. Perineal urethrostomy is usually technically straightforward because the rule in most patients with LS is to spare the proximal anterior urethra. We have proposed that, in many cases, the sparing of the proximal anterior urethra demonstrates the distribution of the glands of Littre for a given patient. Younger patients have requested mobilization and release of the penis with placement of an STSG. However, because the inflammation involves the glans penis (which is not removed), the secondary inflammation may also involve the skin graft. Lifelong monitoring of these patients for the secondary effects of inflammation is necessary.

Finally, **several reports have suggested the development of squamous cell carcinoma in patients with a long history of LS** (Doré et al., 1990; Pride et al., 1993).

Amyloidosis

Amyloidosis of the urethra, although a rare disease, should be considered in the evaluation of any patient with a urethral mass. Patients may present with hematuria, dysuria, or urethral obstruction. Because the differential diagnosis includes urethral neoplasm, cystoscopy with transurethral biopsy is indicated. When the diagnosis is made, treatment should be based only on symptoms. Most patients can be observed expectantly and do not require aggressive treatment. Some patients require treatment for urethral stricture. Progression and recurrence are rare (Crook et al., 2002; Dounis et al., 1985; Walzer et al., 1983).

Urethrocutaneous Fistula

A urethrocutaneous fistula is a tract lined with epithelium that leads from the urethra to the skin. The size of a fistula can vary from pinpoint to large. **Urethral fistula may be a complication of urethral surgery or develop secondary to periurethral infection associated with inflammatory strictures or treatment of a urethral growth** (condyloma or papillary tumor)**. Treatment of a urethral fistula must be directed not only to the defect but also to the underlying process that led to its development.** Treatment varies according to the cause of the fistula. In cases of urethral reconstruction, especially reconstruction for hypospadias, fistula often occurs or recurs because of distal obstruction and high-pressure voiding. In addition, in some cases in which multiple attempts at fistula closure have been attempted and failed, the tissues adjacent to the fistula are so scarred that staged reconstruction is needed to import “better tissue.”

After urethral surgery, fistulae can develop immediately or as delayed complications. An early fistula is the result of poor local healing, possibly secondary to hematoma, infection, or tension with closure. In addition, breakdown of the urethra or overlying skin closure, or both, could occur. Occasionally, with aggressive local care and continued urinary diversion, the fistula closes spontaneously.

Several techniques are used for fistula closure. Endoscopic and radiographic evaluation of the urethra must be performed before the repair in all cases. If the fistula is small and closure of the hole does not decrease the lumen of the urethra, a button of skin is removed from around the fistula, and its edges are cut flush with the urethral wall. The urethra is closed with small (6-0 or 7-0) absorbable sutures, inverting the epithelial edge, and the repair is tested to ensure that it is watertight. We prefer either polyglycolic acid (Vicryl) or polydioxanone suture. Subsequent layers are designed and closed to avoid superimposed suture lines. Without question, the safest diversion is a suprapubic catheter. However, in many cases, a silicone stent that reduces pressure during voiding for 7 to 14 days suffices. The operating microscope can be useful for the closure of small fistulae, allowing the use of 8-0 polyglycolic acid suture and limiting the size of the associated skin incision.

If the fistula is so large that simple closure would compromise the lumen of the urethra, local flaps often are required. However, if the adjacent tissues are thin and poorly visualized, closure of the fistula may become a staged urethral reconstruction as mentioned earlier. For larger fistulae, a suprapubic tube for diversion is probably prudent. Mobilization of flaps, such as the tunica dartos flap, may be necessary to secure adequate tissue interposition and avoidance of superimposed suture lines.

Fistulae associated with inflammatory strictures occur as periurethral tracts and develop secondary to high-pressure voiding of infected urine. As multiple tracts develop, this problem becomes what is known as a “watering pot perineum.” Repair requires suprapubic drainage, and treatment of the infection requires incision and drainage of any abscesses present. We widely excise the fistula tracts and associated inflammatory tissue and wait 4 to 6 months before repairing the underlying stricture. Flap reconstruction, if donor tissues are available, may be used. However, a staged graft procedure (discussed later) is also an excellent choice. Caution is warranted in a patient with urethral fistulae but without a history of chronic obstructive voiding symptoms. In many cases, fistula or periurethral abscess may be the hallmark symptom of urethral carcinoma.

Urethral Diverticulum: Male

A congenital diverticulum is a transitional cell epithelium–lined pouch that is the result of either a distention of a segment of the urethra or the attachment of a structure to the urethra by a narrow neck (i.e., a müllerian remnant)**. In male patients, a congenital anterior urethral diverticulum may result from incomplete development of the urethra,** with a defect in only the ventral wall and subsequent distention of this segment by the hydraulic force of the voiding stream (Bedos and Cibert, 1989; Ozgok et al., 1994; Valdivia et al., 1986). The downstream lip of the defect may serve as a valvular obstruction, increasing the pressure in the lumen, and subsequently the diverticulum enlarges. **Another possible cause is injury of the urethra, which may cause an intraspongiosal hematoma.** This hematoma could create a paraurethral space and subsequent diverticulum or fistula. These defects can also be associated with urethral strictures (Bryden and Gough, 1999). It has also been suggested that congenital diverticula may represent giant cystic dilation of Cowper ducts (Gil-Vernet, 1977; Jiminez Cruz and Rioja Sanz, 1993). We do not favor this proposed cause because the diverticula seem to be slightly more distal than the expected location of Cowper ducts, and in our experience with reconstruction of a considerable number of these diverticula, no proximal limb of the ducts seems to exist in them. In many cases, endoscopic unroofing of the diverticulum remedies the voiding symptoms; although after unroofing, the patient commonly may note postvoid dribbling. Open repair essentially excises the redundancy of the urethra associated with the diverticulum. If the lumen is compromised, dorsal onlay by either graft or flap can be useful.

A congenital diverticulum in the prostatic urethra may be a large remnant of the müllerian duct associated with defects of diminished virilization. However, it often occurs in proximal hypospadias and represents an enlarged utricle (Devine et al., 1980)**. These diverticula may not be demonstrated with voiding urethrography but are demonstrated with cystoscopy or retrograde urethrography.** The tip of a urethral catheter tends to catch in this opening, necessitating the use of something to direct the catheter tip toward the true lumen. Other than necessitating caution during evaluation, these diverticula do not usually cause problems or require treatment unless they are very large.

Large utricles can accumulate urine with voiding and then decompress after voiding. If they are large enough, the stasis of urine can be associated with recurrent urinary tract infection or difficult-to-manage “incontinence.” A surgical approach to small lesions can be through a suprapubic incision, possibly opening the bladder to go through the center of the trigone. However, large diverticula can be approached trans-sacrally (Peña and Devries, 1982). Although this is a complex procedure, it is associated with much less morbidity than an abdominal or a perineal approach and provides superior exposure. We excise the diverticulum after exposing and dissecting its communication with the urethra. After ensuring that there is no distal obstruction to interfere with healing, we close the urethra.

Diverticula of the female urethra are covered in Chapter 90.

Paraphimosis, Balanitis, and Phimosis

Paraphimosis, or painful swelling of the foreskin distal to a phimotic ring, occurs if the foreskin remains retracted for a prolonged time. Swelling is sufficient to make reduction of the foreskin over the glans difficult. **In a very young child, paraphimosis is often seen after the foreskin has been traumatically reduced during an examination or sometimes by overzealous parental attempts at hygiene.** Traumatic, sudden reduction of a tight foreskin should be avoided in all ages and circumstances. To reduce a paraphimosis, gentle steady pressure must be applied to the foreskin to decrease the swelling; with a child, this is best accomplished in a quiet room by a parent squeezing it in the hand. Elastic wrap may be helpful in some cases. Putting an ice pack on the area for a short time before gentle compression is helpful as an analgesic. When the swelling has been reduced, the surgeon can push against the glans with the thumbs, pulling on the foreskin with the fingers. Because paraphimosis tends to recur, a dorsal slit at a minimum or a circumcision should be carried out as an elective procedure at a later date. Occasionally a patient has acute paraphimosis that has been present for many hours to days; this is typically seen in an adolescent who is reluctant to reveal the problem to his parents. In these cases, reduction may be impossible, and paraphimosis should be dealt with by emergency dorsal slit or circumcision. Considerable postoperative edema is the rule in these cases.

Balanitis, or inflammation of the glans, can occur as a result of poor hygiene from failure to retract and clean under the foreskin. The subsequent swelling makes cleaning more difficult, but the inflammation usually responds to local care and antibiotic ointment. Oral antibiotic therapy occasionally may be necessary. Balanoposthitis is a severe form of balanitis and occurs when the phimotic band is tight enough to retain inflammatory secretions, creating a preputial cavity abscess. Occasionally, an emergent dorsal slit is required.

Phimosis, or the inability to retract the foreskin, can result from repeated episodes of balanitis. In older patients, balanitis may be a presenting sign of diabetes. In these cases, circumcision may be warranted.

Urethral Meatal Stenosis

A small urethral meatus in a newborn probably would not be called to a urologist's attention unless the stenosis is associated with other congenital deformities (e.g., hypospadias) or causes voiding difficulties or urinary tract infection (Allen and Summers, 1974). If the urethral meatus of a boy appears exceptionally narrow and there are associated symptoms, a meatotomy should be considered. For this decision to be made, voiding should be observed to note that the meatus opens as a full, forceful stream is passed. If the stream is narrow and excessively forceful, stenosis is probably present. The occluding skin is generally a thin layer that sometimes can be seen to pouch out, with the meatus opening at the dorsal lip as the child voids. **Meatal stenosis in a boy appears to be a consequence of circumcision that then allows subsequent ammoniacal meatitis.** If the child is seen with ammoniacal meatitis, we usually start meatal dilation with 0.05% clobetasol cream. Within a week, the process seems to abate. Anecdotally, the fusion of the ventral-meatal skin that causes meatal stenosis can be avoided. Parents must be counseled about the cause—that is, a wet diaper pressing for prolonged periods against the tip of the glans.

A ventral urethral meatotomy sometimes can be accomplished with the use of local anesthesia. In a young child, general anesthesia is the preferred approach, avoiding trauma to the child, the parents, and the urologist. It is important to insert the anesthetic needle into the skin fold from the underside so that the tip of the needle can be observed and controlled. If insertion is from the outside, the needle passes through both layers of the fold, and a wheal cannot be raised because of leakage of the anesthetic solution. After the meatotomy, the edges of the cut seal together unless they are kept open. The tip of a meatal dilator is the best instrument for this purpose. The child's parents are instructed to separate the edges gently with the tip of the dilator three times a day for 7 to 10 days. The surgeon should observe the parents carry out this procedure. Pediatric meatal dilators (see later product reference) are available; however, the tip of an ophthalmic antibiotic tube also works well, and the antibiotic ointment can be used as the lubricant.

Meatal stenosis occurs in adults after inflammation, specific or nonspecific urethral infection, and trauma (especially in association with indwelling catheters, urethral instrumentation, or radical prostatectomy in some cases). It also may be the result of the failure of a previous hypospadias repair. To perform a ventral meatotomy in a normally developed penis in adolescents and adults, it is often necessary to place sutures to approximate the urethral mucosal edge to control bleeding. This step usually requires three sutures: one at the apex and one on either side. We have found a dilator made by Cook Urological (Spencer, IN; Catalog No. 073406, adult 6 to 34 Fr; No. 073403, pediatric 6 to 10 Fr) to be helpful in keeping the meatus open. In some cases, it may be necessary to perform a dorsal rather than a ventral meatotomy. This procedure can be accomplished as a Y-V-plasty after the excision of any scarred ridge of neourethra. Dorsal meatotomy, although effective in opening the meatus, often creates a cosmetically suboptimal shape of the meatus. In an adult, it is unusual for the meatal stenosis to be an isolated finding. The stricture process usually involves the fossa navicularis to some extent as well.

Circumcision

Controversy continues regarding whether neonatal circumcision should or should not be performed (Poland, 1990; Schoen, 1990). Much attention has been focused on this issue, but despite this, many boys in the United States are circumcised. Ritual circumcision will continue; however, in ritual circumcision, it is not necessary to remove the skin but only to draw blood. **It is important not to circumcise any boy with a penile abnormality (e.g., hypospadias, chordee) that may require the foreskin during repair. Circumcision is indicated in a young boy who has had recurrent urinary tract infections thought to be associated with the redundant preputial skin.**

Most circumcisions performed just after birth are done with the Gomco clamp or one of the plastic disposable devices made for this purpose. Care should be taken to free the foreskin from the glans completely and to apply appropriate tension when the foreskin is pulled into the clamp. To prevent either a too generous or an inadequate circumcision, we find it useful to mark the foreskin carefully so that the correct level is ascertained. At our center, we perform neonatal circumcision with a penile block for anesthesia.

The most common complication is bleeding as a result of inadequate control with vascular compression. Application of an epinephrine-soaked sponge may help in controlling minimal venous bleeding. Infection can also occur and responds to local care. Any resulting skin separation should be repaired after the inflammation resolves. Minimal separation may be amenable to healing by secondary intention. Sometimes too much skin is removed, or the urethra is included in the clamp, resulting in a fistula. In many, if not most, cases in which excess skin is removed, closure can still be accomplished with aggressive frenuloplasty along with remaining skin closure by transposition of the remaining skin. If the entire penis is "scalped," it may be best managed with an STSG or with reapplication of the excised foreskin after it is prepared properly as a graft. In complicated cases, burying the penis in the scrotum and repairing it at a later date may be prudent. **Monopolar electrocautery should be avoided in a neonatal circumcision because penile loss from the field distribution of the current can occur. The use of monopolar cautery with a Gomco or similar clamping device must be avoided because devastating loss of tissue can occur.**

A newborn who lost his penis because of a circumcision mishap should not be gender reassigned. Our experience with phallic construction includes many children and youths who had been converted to a female after a circumcision accident. As they passed through puberty, they realized that this sexual assignment was wrong. Most of these boys could undergo reconstruction in such a manner as to preserve reproductive function.

In adults, circumcision can be done with local anesthesia, by blocking the dorsal nerves at the base of the penis and circumferentially infiltrating the superficial layers of the penile base. In men and older boys, we favor a sleeve circumcision. With the foreskin in its retracted position, a marking pen outlines an incision, leaving a small preputial cuff. This mark should go straight across the base of the frenulum. This incision is made and carried through the dartos fascia to the superficial lamina of the Buck fascia. The foreskin is reduced, and a second incision is marked, following the outlines of the coronal margin and the V of the frenulum on the ventral side. The frenulum usually retracts into a V. In some cases, the frenulum can be lengthened by closing the edges of the V in a longitudinal orientation for a short length (frenuloplasty). If frenuloplasty is done, the proximal incision does not have to follow the V of the retracted frenulum because the ventral skin is straight. We make the skin incision and fulgurate bleeding vessels with bipolar cautery as the incision is deepened and the skin edge is mobilized. In older boys and men, the vessels are more substantial and not easily sealed by compression, no matter how vigorous. Circumcision clamps can be ineffective and are not recommended even though larger sizes are available. After the sleeve of preputial skin has been removed, hemostasis is obtained, and the skin edges are reapproximated.

In younger boys, some surgeons may consider this sleeve procedure to be tedious and difficult. If this is the case, after the skin is marked, a dorsal slit is made through both layers of the prepuce back to the level of the corona. After the marks, the two layers of the preputial skin are incised. Bleeders are controlled, and the skin edges are reapproximated.

Complications are uncommon. Most patients develop some hyperesthesia of the glans, which resolves. A hematoma is probably the most common immediate complication. Some patients notice minor cosmetic imperfections that are functionally insignificant. One of the most distressing problems we see is a patient who complains that the surgeon has removed too much skin. To avoid this occurrence, a circumcision should be done precisely, and, whatever the procedure to be carried out, the incisions should first be marked with the skin lying undistorted on the shaft. Adults requesting circumcision must be carefully evaluated from a psychosexual standpoint because many of these patients who are the most persistent in requesting circumcision become the most dissatisfied after the surgery.

Circumcision has been shown in numerous studies to provide protection for men in areas where human immunodeficiency virus (HIV) is very prevalent (Auvert et al., 2005; Bailey et al., 2007; Gray et al., 2007). Circumcision has consistently been shown in well-conducted, randomized controlled trials to reduce the risk of HIV acquisition in heterosexual African men by 50% to 60%. Similar prospective trials have not been performed in developed countries; however, retrospective data among heterosexual men in the United States showed a similar approximately 50% reduction in HIV prevalence among men with known exposure, suggesting the data may be extrapolated to this population. In addition, male circumcision has been shown to reduce the risk for acquisition of herpes simplex virus type 2, human papillomavirus, genital ulcer disease, and some sexually transmitted bacterial infections (Tobian et al., 2014).

There is a biologic rationale for reduction in the spread of sexually transmitted infections, particularly HIV, with circumcision. Superficial Langerhans cells, CD4+ T cells, and CD8+ T cells are rich and less well protected by keratin on the inner aspect of the male foreskin and frenulum. When the foreskin is retracted during intercourse, this large and susceptible surface area is exposed allowing contact with HIV-infected secretions and subsequent risk for infection. Uncircumcised men have also been shown to have an increased frequency of genital ulcers and increased frequency of microtears during intercourse, both of which increase HIV transmission.

Despite the well-demonstrated benefit of circumcision in heterosexual men, the same benefit has not been shown for men who have sex with men (MSM). A large meta-analysis of more than 53,000 MSM did not demonstrate a statistically significant protection against HIV (Millett et al., 2008). Subgroup analysis demonstrated a trend toward reduced prevalence of HIV among MSM performing predominantly insertive rather than receptive anal intercourse, and others have corroborated these findings.

Transitional Urologic Care for the Patient With Failed Hypospadias and Epispadias Repair

Failed Hypospadias Repair

In treatment of a patient in whom hypospadias repair has failed, it is important to obtain all available records to help determine what may have contributed to his complications. **A hypospadias repair may fail because of an inadequate correction of chordee or an inadequate urethra, with a stricture, fistula, or diverticulum** (Winslow et al., 1986)**. It is often readily apparent from the records that not all aspects of the hypospadias deformity** (i.e., ventrally displaced meatus, ventral chordee, and some expression of inadequacy of ventral tissue fusion) **were addressed in the previous repairs.** Adults with urethral strictures who have had hypospadias surgery as children are often seen. Depending on the age of the patient and the preference of the treating urologist, a variety of different techniques may have been used to repair the original hypospadias. Many of these patients have persistent chordee and a subcoronal meatus. Adults also have been seen who have had long-standing evidence of urethral fistula. In addition, some patients may have clinical findings not related to hypospadias that should have been recognized previously, especially when hypospadias is part of an overlying intersex problem. In the past, problems associated with previous failures were caused by errors in design, technique, or postoperative care (Devine et al., 1978). **With more modern techniques available and with most hypospadias treated by surgeons with considerable**

experience, failures often are associated with perioperative infections or other factors that adversely affect wound healing. At the present time, complex hypospadias repair failures are encountered with much less frequency, and most that are encountered are in patients who had previous procedures more than 15 to 20 years ago. Complications in these patients resulted not from poorly designed surgery at the time but rather from the “state of the art” at the time.

Evaluation of a failed hypospadias repair includes retrograde urethrography, voiding cystourethrography, and cystoscopy. In an older patient, a reliable preoperative assessment of residual chordee can be made on the basis of the history and photographs taken at home. In younger patients, complete evaluation of more complex situations with use of anesthesia may be necessary.

In an adult patient, a detailed discussion must occur regarding the positive and negative aspects of the various approaches. Patients who were initially operated on before the late 1970s probably underwent either a graft or some form of repair using almost exclusively ventral tissue. Some of these patients still have the remnants of a dorsal hood or enough dorsal skin for a dorsal transverse penile skin island type of reconstruction to be performed.

We believe that surgical correction of complex cases requires an aggressive approach by the surgeon (Secrest et al., 1993). However, with the advent and very common use of the tubed incised plate repair, initially described by Snodgrass (1999), the nature of failures is different, and the approaches also are remarkably different. Based on our observations, the number of failed surgeries is less, the nature of graft salvage techniques is remarkably different, and the method of addressing residual curvature is different. It is possible to reincise the “urethral plate” and tubularize it if the plate is not scarred and possible to graft the plate dorsally if it is; if the tissues are badly scarred, many surgeons revert to staged reconstruction (Snodgrass et al., 2009). The use of flaps has a place in corrective procedures, and the excision of scarred tissues causing residual curvature likewise has its place. However, plication or corporoplasty techniques for correction of residual curvature have, for the most part, become the standard of care. Graft techniques for correction of curvature are used but with far less frequency than in years past.

Failed Epispadias Repair

Residual genital defects in men who have had exstrophy/epispadias repaired

as children can cause functional, aesthetic, and psychologic problems. The effects of these problems are compounded in men who have undergone urinary diversion and who must wear stomal appliances, although with the improvement of continent diversions, this is less of a factor. Successful reconstruction is possible except in the most severe forms of bladder exstrophy or cloacal exstrophy—when the penis or the halves of the bifid penis are truly inadequate. Even then, if normal testes are present, the success of newer techniques of phallic construction (see subsequent discussion) should lend support to considering the option of raising such a child as a boy, possibly preserving his reproductive potential through puberty. In these very difficult cases, we think that the parents must be presented with both options, gender reassignment versus eventual phalloplasty. Remarkable progress has been made in the treatment of difficult cases (Gearhart et al., 1994; Hendren, 1979; Jeffs, 1979; Johnston, 1975; Mitchell and Bagli, 1996; Perovic et al., 1992; Snyder, 1990) and in techniques of primary closure. However, many patients need further genital surgery because they experience the hypertrophic growth spurt of the penis associated with puberty.

The goals of reconstructive surgery in male patients with exstrophy or epispadias are to produce a dangling penis with erectile bodies of satisfactory length and shape to allow sexual function and to construct a urethra that serves as a conduit for the passage of urine and ejaculate. However, experience has shown that in a patient with a diverted exstrophy and only a bladder remnant, construction of a urethra that is essentially defunctionalized is difficult. These urethras eventually seem to fibrose and stenose. The bladder neck remnant becomes a cyst that is often colonized. Bouts of virulent epididymitis or the formation of what is really a bladder neck remnant abscess begin to occur. We have seen two patients who developed carcinoma of the prostate in a bladder neck remnant. The diagnosis in these patients was difficult, and the resultant surgery was even more difficult. Neither patient did well from the standpoint of treatment of the carcinoma. Both were seen before the aggressive use and better understanding of prostate-specific antigen.

Many patients who have undergone surgery as children do not present for correction of inadequacies of the external genitalia until after they have completed puberty and realize that their situation has not improved and is not likely to improve. Some have been in sexual situations and have encountered problems. We employ a systematic approach to accomplish the reconstruction necessary to correct the anatomic defects in these patients (Devine et al., 1980; Winslow et al., 1988). Sequential surgery is undertaken beginning with the simplest procedure that would achieve the desired functional result.

Lower abdominal wall scarring can be corrected or defects can be closed by fashioning peripenile flaps that are shaped like a W. In many patients, there may be wide diastasis recti that is really a ventral hernia. Anchoring of meshes or Gore-Tex can be difficult, and we have resorted to a fibular bone microvascular free transfer in several cases to reconstruct the continuity of the pubis, allowing effective closure of the abdominal hernia.

With more effective contemporary primary closure techniques, the adult reconstructive surgeon's place is primarily in the correction of hernia or in the patient who has an inadequate penis because of deformity, scarring, or improper gender reassignment.

Key Points: Selected Processes

- Urethral hemangioma is a rare condition that is usually persistent. It can present a significant challenge to the surgeon. All reported cases of urethral hemangioma have been benign, and management depends on the size and location of the lesion.
- Reactive arthritis is characterized by a classic triad of arthritis, conjunctivitis, and urethritis. Urethral involvement is usually mild, self-limited, and a minor portion of the disease.
- LS previously was referred to as balanitis xerotica obliterans. Diagnosis is made through biopsy. LS is thought to be possibly premalignant for the development of squamous cell carcinoma of the glans. It is the most common cause of meatal stenosis. Management of patients with LS-related stricture is complex, and results are suboptimal. The management is determined by the desire of the patient and the need for functional reconstruction.
- Amyloidosis is a rare disease of the urethra and should be considered in the evaluation of any patient with a urethral mass. Patients present with hematuria, dysuria, or urethral obstruction.
- A urethrocutaneous fistula is a tract lined with epithelium that leads from the urethra to the skin. It may be a complication of urethral surgery or develop

secondary to periurethral infection associated with inflammatory strictures or treatment of a urethral growth. Treatment of the urethral fistula must be directed not only to the defect but also to the underlying process that led to its development.

- A congenital urethral diverticulum is a transitional cell epithelium–lined pouch that is the result of either a distention of a segment of the urethra or the attachment of a structure to the urethra by a narrow neck. In male patients, “congenital” anterior urethral diverticulum may result from incomplete development of the urethra or possibly may be the result of straddle trauma that led to an intracorporeal spongiosal hematoma. Congenital diverticulum in the prostatic urethra is a remnant of the müllerian duct.
- Paraphimosis is a painful swelling of the foreskin distal to a phimotic ring. It occurs when the foreskin has been retracted and not reduced. Edema forms in the distal skin.
- Urethral meatal stenosis in a young boy appears to be a consequence of circumcision. The circumcision allows the development of ammoniacal meatitis, which can heal with a membrane across the ventral portion of the meatus. Controversy continues regarding whether neonatal circumcision should or should not be performed. If it is going to be performed, the circumcision must be adequate. The most common complication of neonatal circumcision, in our opinion, is when it is inadequately done.
- A patient with failed hypospadias repair can be complex. Many are victims of the technology of the time when they had their initial reconstruction. All patients with urethral involvement should be evaluated as if they have urethral stricture disease.
- Advanced techniques for the reconstruction of the exstrophy-epispadias complex have led to much better functional results and less need for secondary exstrophy reconstruction. Secondary exstrophy reconstruction is aimed at the area of the escutcheon, the dorsal base of the penis, the penile shaft, the urethra, and the penoscrotal junction.

Urethral Stricture Disease

The term *urethral stricture* refers to fixed anatomic narrowing of the urethra so that the lumen will not accommodate instrumentation without disruption of the urethral mucosal lining. A stricture involving the urethra that is surrounded by the corpus spongiosum is considered an anterior urethral stricture, and the associated scarring may be associated with a scarring process involving the spongy erectile tissue of the corpus spongiosum (spongiofibrosis) (Fig. 82.15). The spongy erectile tissue of the corpus spongiosum underlies the urethral epithelium, and the scarring process extends through the tissues of the corpus spongiosum in some cases and into adjacent tissues. **Contraction of this scar reduces the urethral lumen.** For example, if a normal urethra measures 30 Fr, its diameter is 10 mm, and the area of the lumen is approximately 78 mm^2. If scarring has resulted in a urethra that measures 15 Fr, the lumen is only 55 mm^2, or 29% reduced. It is evident that scar contraction caused by urethral stricture disease can be asymptomatic for a while, but because the lumen is further reduced, it can be associated with marked voiding symptoms.

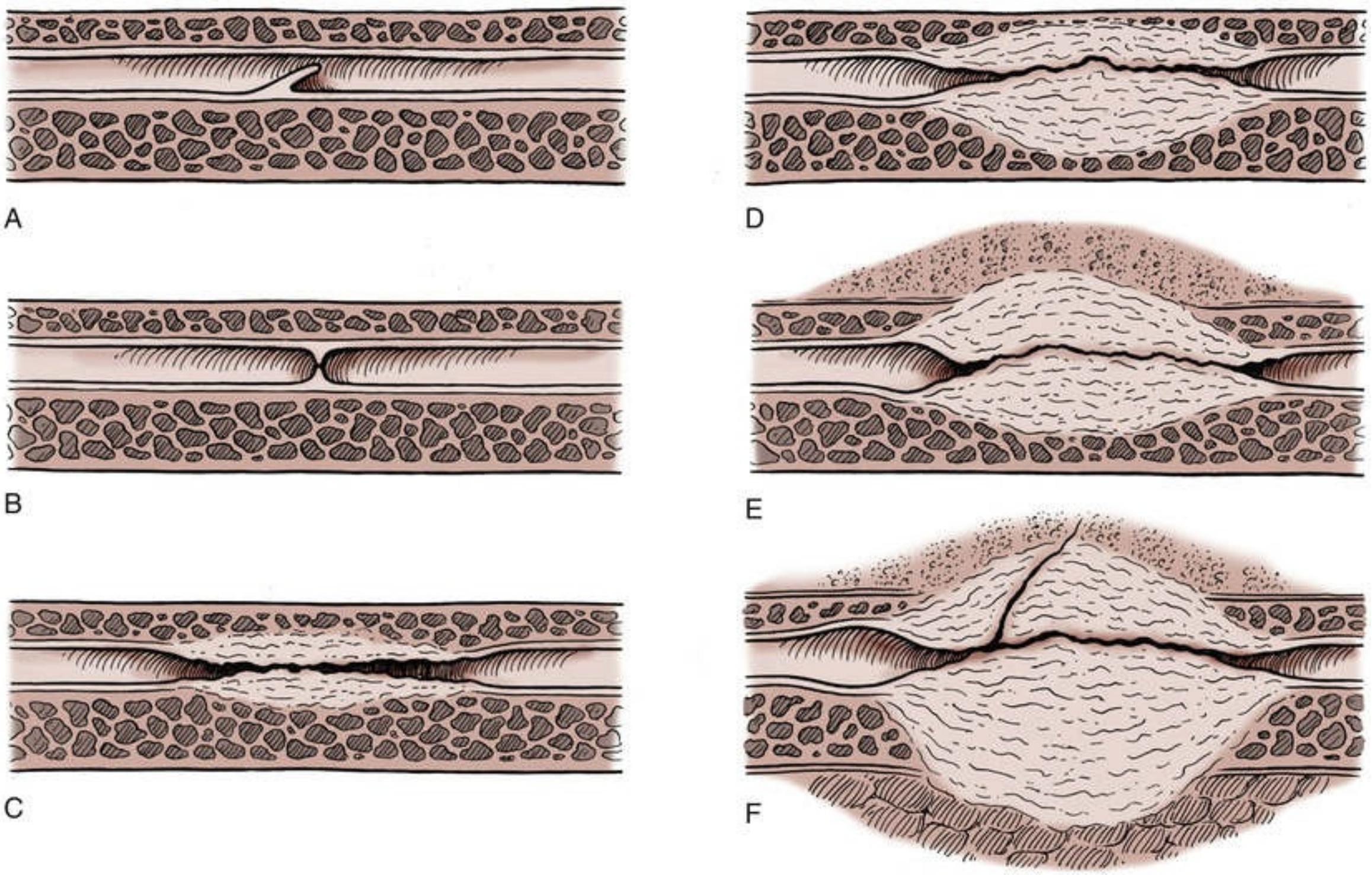

FIG. 82.15 The anatomy of anterior urethral strictures includes, in most cases, underlying spongiofibrosis. (A) Mucosal fold. (B) Iris constriction. (C) Full-thickness involvement with minimal fibrosis in the spongy tissue. (D) Full-thickness spongiofibrosis. (E) Inflammation and fibrosis involving tissues outside the corpus spongiosum. (F) Complex stricture complicated by a fistula. This can proceed to the formation of an abscess, or the fistula may open to the skin or the rectum. (From Jordan GH: Management of anterior urethral stricture disease. *Probl Urol* 1:199–225, 1987.)

In contrast, posterior urethral "strictures" are not included in the common definition of urethral stricture. *Posterior urethral injury* (PUI) and *posterior urethral stenosis* are more appropriate terms, according to the last International Consultation of Urologic Diseases in Urethral Stricture, held in Marrakesh in 2010 (Gómez et al., 2014; Latini et al., 2014)**. Posterior urethral stenosis is an obliterative process in the posterior urethra that has resulted in fibrosis and is generally the effect of distraction in that area caused by either trauma or radical prostatectomy.** Although the distraction defect can be lengthy in some cases, the actual process involving the tissues of the urethra is usually confined. By consensus of the World Health Organization (WHO) conference in 2004 and later by International Consultation on Urological Diseases (ICUD) in 2010, the term *stricture* is limited to the anterior urethra. Distraction defects are processes of the membranous urethra associated with pelvic fracture. Other narrowings of the posterior urethra are termed *urethral* *contractures* or *stenosis* (Bhargava et al., 2004; Herschorn et al., 2014).

Urethral Anatomy

Although urethral anatomy is described in the earlier section on anatomy, it is useful to re-emphasize key anatomic points. **The bulbous urethra is eccentrically placed in relation to the corpus spongiosum and is much closer to the dorsum of the penile structures** (see eFig. 82.6). As one moves distally, the pendulous or penile urethra becomes more centrally placed within the corpus spongiosum.

The genital skin has a dual (proximal and distal) and bilateral blood supply, forming a fasciocutaneous system (see eFig. 82.10)**. The corpus spongiosum receives blood from the common penile artery, the terminal branch of the internal pudendal artery** (see eFig. 82.12)**. The corpus spongiosum also has a dual blood supply: a proximal blood supply and a retrograde blood supply through the dorsal arteries as they arborize in the glans penis.**

Etiology

Any process that injures the urethral epithelium or the underlying corpus spongiosum to the point that healing results in a scar can cause a urethral stricture.

Latini et al. (2014) **proposed a broad categorization of urethral stricture disease into iatrogenic, traumatic, inflammatory, and idiopathic causes. A recent meta-analysis of etiology found that most common causes are idiopathic (33%) and iatrogenic (33%), followed by post-traumatic (19%) and inflammatory (15%)** (Fenton et al., 2005).

Iatrogenic

Iatrogenic urethral strictures can be the result of urethral instrumentation, either diagnostic or therapeutic. Diagnostic cystoscopy and urethral dilation are common causes of urethral stricture. Transurethral procedures such as transurethral resection of bladder tumors (TURBTs) and transurethral resection of the prostate (TURP) also cause strictures of the urethra either by direct insult of the frail mucosa or from inflammation and subsequent ischemia related to the technique, the caliber of the instruments, and the

time of the procedure. In addition, the perioperative catheter may play a role in the cause of potential strictures in those settings (Jørgensen et al., 1986)**. The material, insertion technique, and time of indwelling catheters are closely associated with urethral stricture development. Again, the mechanism of injury may be due to injury, pressure necrosis, or inflammation/infection. In our experience, catheter-related urethral stricture disease is very prevalent in low- and middle-income countries (LMIC)** (McCammon and Virasoro, personal communication)**. The use of silicone catheters and hydrophilic coating for intermittent catheterization may help in reducing this empirical cause.**

Traumatic

Urethral strictures can be the result of blunt or penetrating trauma. With straddle and deceleration trauma, the corpus spongiosum is crushed against the inferior rami of the pubis. This trauma to the urethra often goes unrecognized until the patient experiences voiding symptoms resulting from the obstruction of the stricture or scar. In most cases of straddle trauma, reconstruction of the bulbar urethral injury is possible (Park and McAninch, 2004). Finally, posterior urethral injuries, traumatic by definition, result in obliterative or near-obliterative defects that are associated with extensive fibrosis interposed between the distracted ends of the urethra. Another cause of posterior urethral stenosis is prostate cancer treatment.

Inflammatory

Inflammatory strictures associated with gonorrhea were the most commonly seen in the past and are less common now. With the advent of prompt and effective antibiotic treatment, gonococcal urethritis progresses less often to gonococcal urethral strictures. The place of *Chlamydia* and *Ureaplasma urealyticum* (i.e., nonspecific urethritis) in the development of anterior urethral strictures is unclear. No clear association between nonspecific urethritis and the development of anterior urethral stricture has been established.

As mentioned earlier, there is a definite association between the development of an inflammatory stricture and LS. LS usually begins with inflammation of the glans and inevitably causes meatal stenosis, if not a true stricture of the fossa navicularis. The cause of this distal penile skin and urethral inflammation is unknown. Some evidence suggests that the progression of the stricture eventually to involve the anterior urethra extensively may be due to high-pressure voiding that causes intravasation of urine into the glands of Littre, inflammation of these glands, and, perhaps, microabscesses and deep spongiofibrosis. Whether the urethral changes and eventual fibrosis are also related to bacterial injury has not been well defined. Although the use of antibiotics seems to limit obstructive voiding symptoms in these patients, to our knowledge the literature does not show resolution of the stricture process with the use of antibiotics.

Idiopathic

Iatrogenic trauma to the urethra still exists, but with the development of small endoscopes and the limitation of indications for cystoscopy in boys, we see fewer iatrogenic strictures today than in the past. The place of idiopathic urethrorrhagia with regard to strictures in children is unclear; some question whether it may be a cause of strictures in young boys regardless of whether the child underwent an endoscopic procedure (Rourke et al., 2003). No specific inciting factor has been identified as causing idiopathic urethrorrhagia. Histologic results from a patient of ours with resolving urethrorrhagia showed portions of tissues covered in part by squamous epithelium; other parts were covered by transitional epithelium; there were several areas of denuded epithelium with acute hemorrhage and neutrophilic infiltration; a few foci of microcalcification were shown; several mucus glands were found within the submucosal connective tissue as well as a few collections of amorphous material, likely mucin. These areas stained negatively with a special stain for amyloid. There was no evidence of viral cytopathic effect or malignancy. We did not see evidence of bacterial infection or viral inclusions. However, we have seen an increase in strictures associated with LS, and those strictures clearly behave much more like inflammatory strictures than traumatically induced isolated scars.

Congenital

The entity known as a congenital stricture is difficult to understand. In embryologic development, if a stricture is found at a natural place where a fusion of structures occurs (i.e., the posterior and anterior urethra), a congenital stricture may be a reasonable assumption. However, the term *congenital stricture* is used by some authors to define a stricture for which there is no identifiable cause. We propose that it is reasonable to define a stricture as congenital only if it is not an inflammatory stricture, it is a short-length stricture, and it is not associated with a history of or potential for urethral trauma. These criteria limit the term *congenital stricture* to strictures of the anterior urethra found in infants before they attempt erect ambulation. So defined, congenital strictures are the rarest encountered.

Diagnosis and Evaluation

Patients who have urethral strictures most often have obstructive voiding symptoms or urinary tract infections such as prostatitis and epididymitis. Some patients also experience urinary retention. However, on close inquiry, most of these patients are found to have tolerated notable voiding obstructive symptoms for a long time before progressing to complete obstruction.

When a patient cannot void, an attempt commonly is made to pass a urethral catheter. If the catheter does not pass, the nature of the obstruction is determined by dynamic retrograde urethrography. Most cases are managed with acute dilation, but there are many instances in which this is not the best course for the patient. When there is doubt, we determine the nature of the stricture, when possible, and selectively place a suprapubic cystostomy catheter to treat the acute situation and allow time for a more appropriate treatment plan to be devised. The practice of blind passage of filiforms and blind dilation without knowledge of the anatomy of the urethral stricture is condemned. Although detailed imaging is not always available, flexible endoscopy is almost universally available in the United States. The stricture can be visualized, and guidewire placement under direct vision can be attempted.

For an appropriate treatment plan to be devised, it is important to determine the location, length, depth, and density of the stricture (spongiofibrosis). The length and location of the stricture can be determined with radiography, urethroscopy, and ultrasonography. The depth and density of the scar in the spongy tissue can be deduced from the physical examination, the appearance of the urethra in contrast-enhanced studies, and the amount of elasticity noted on urethroscopy. The depth and density of fibrosis are difficult to determine objectively. The absolute length of spongiofibrosis may not be evident on ultrasound evaluation. **Ultrasound examination can augment contrast-enhanced studies and is accurate in determining the length of narrow-caliber annularity** (Morey and McAninch, 1996b). Contrast studies of the urethra are best carried out by or under the direct supervision of the surgeon responsible for treatment of the patient.

McCallum and Colapinto (1979a, 1979b) described the use of dynamic radiographic studies and emphasized the need for these studies to be dynamic as opposed to static (Fig. 82.16). At our center, imaging includes dynamic studies that are performed during retrograde injection of contrast material and while the patient is voiding. Even with gentle technique, extravasation during retrograde urethrography is possible in patients in whom the urethra is markedly inflamed. For this reason, contrast studies should be carried out with contrast material that is suitable for intravenous injection and used either directly from the bottle or diluted according to the manufacturer's guidelines. Contrast materials that have been thickened with lubricating jelly or anesthetic gels can be a source of problems and offer little with regard to enhancement of radiographic studies, and they do not make the studies more comfortable. Real-time ultrasound evaluation of the urethra after it has been filled with a lubricating jelly or saline has been described by Morey and McAninch (1996a, 1996b). However, it is a misconception that ultrasonography always directly visualizes the spongiofibrosis. Morey and McAninch (1996a, 1996b) believed that ultrasonography of the bulbous urethra possibly more accurately determines the length of the stricture, which could be important in considering an anastomotic repair. If the patient is not in steep lateral oblique position for retrograde urethrography, the length of the stricture will be underestimated. Finally, during contrast-enhanced urethrography, more than one projection may be necessary to visualize the stricture. Magnetic resonance imaging (MRI) is also being explored as an adjunct to the evaluation of urethral stricture and pelvic fracture urethral injuries (PFUIs). In our experience, the use of MRI for routine strictures or pelvic fracture urethral distraction defects is not beneficial. In the case of urethral tumors, we have found MRI to be invaluable. The experience of others is commensurate with ours (Pavlica et al., 2003). In a pelvic fracture urethral distraction defect, the alignment of the two urethral ends can be defined clearly.

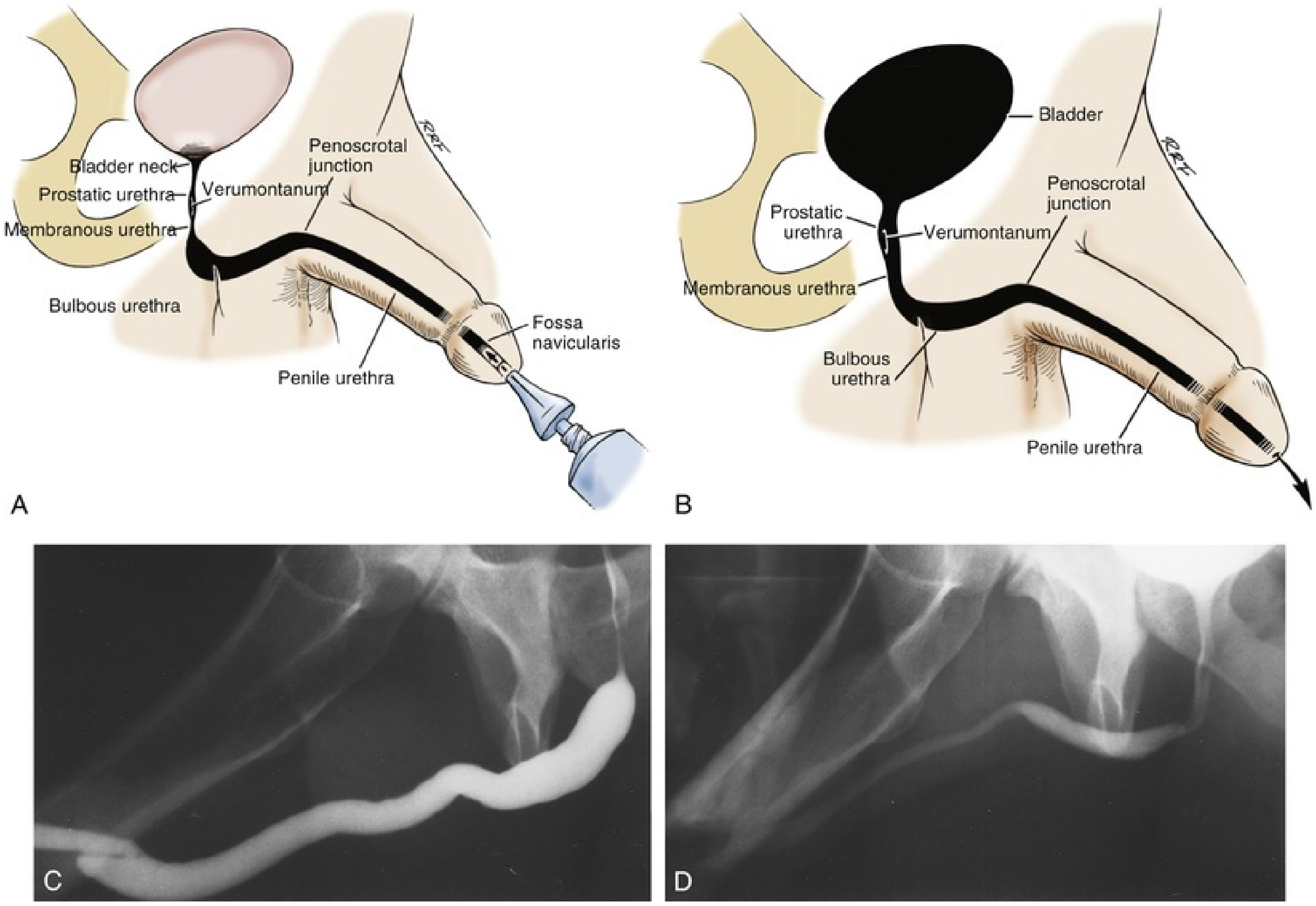
Bladder neck
Prostatic urethra
Membranous urethra
Bulbous urethra
Verumontanum
Penoscrotal junction
Penile urethra
Fossa navicularis
RRF
A
Bladder
Penoscrotal junction
Prostatic urethra
Verumontanum
Membranous urethra
Bulbous urethra
Penile urethra
RRF
B
C
D

FIG. 82.16 (A) Representation of a dynamic retrograde urethrogram with the criteria of McCallum illustrated. (B) Representation of a dynamic voiding urethrogram with the criteria of McCallum illustrated. (C) Normal retrograde urethrogram. (D) Normal voiding urethrogram. (A and B, Modified from McCallum RW: The adult male urethra. *Radiol Clin North Am* 17:227–244, 1979.)

Endoscopic examination may be necessary after contrast studies. The flexible cystoscope has simplified this evaluation, and when local anesthesia is used, there is little discomfort associated with it. The scope can be passed to the stricture, and it often is unnecessary to pass it beyond that level. In addition, it is not always necessary, and usually not beneficial, to dilate the stricture at the time of the initial endoscopic evaluation. Pediatric endoscopic equipment has proven to be extremely valuable for examination of the urethra proximal to a narrow-caliber area without the need to dilate the narrowest area. In a patient who cannot void and has a suprapubic tube, combined contrast studies with endoscopy are helpful in defining the stricture anatomy (Fig. 82.17).

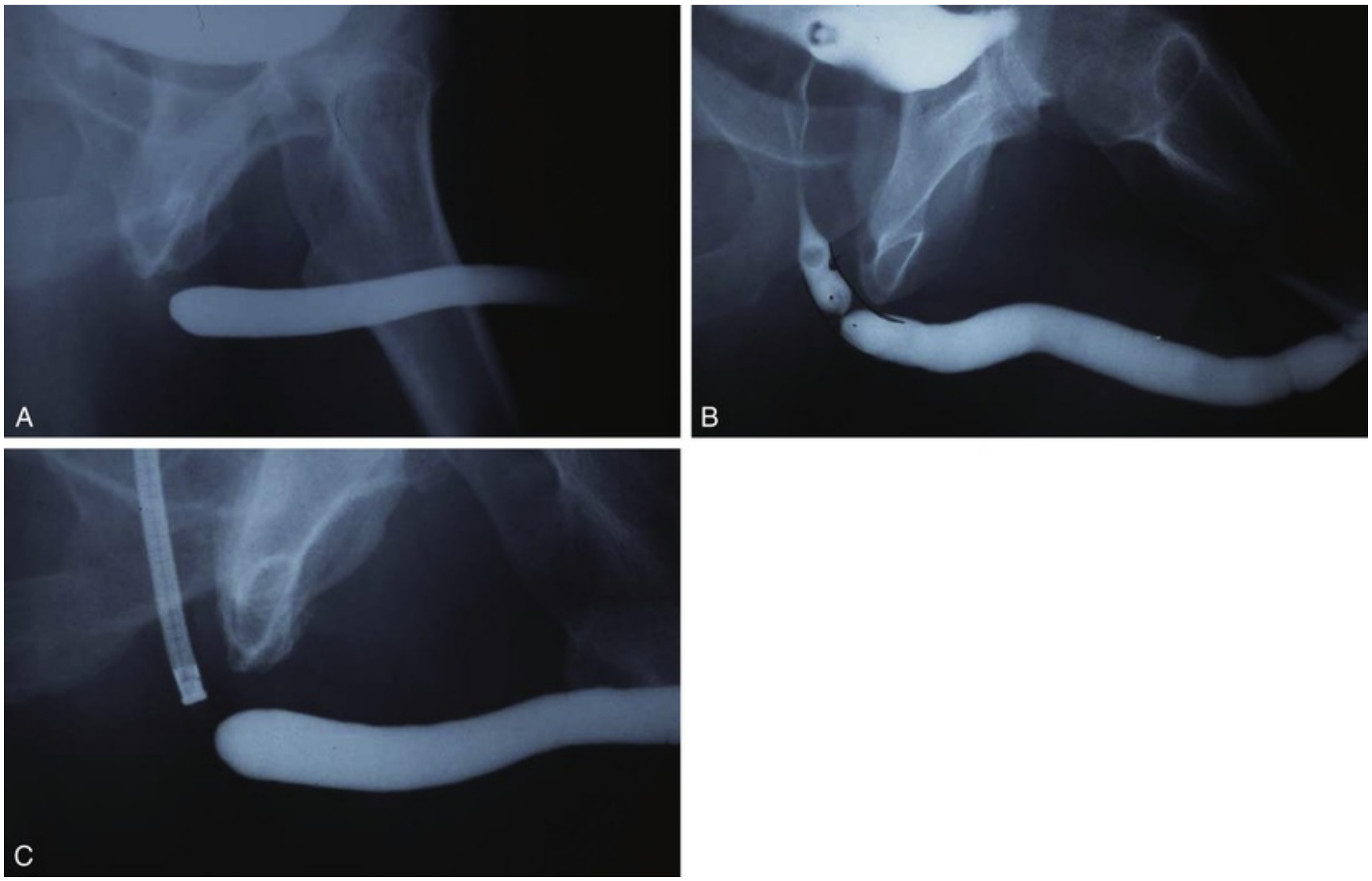

FIG. 82.17 Series of radiographs demonstrating the usefulness of the combination of contrast enhancement with endoscopy. (A) A retrograde urethrogram shows a totally obliterative process involving the proximal bulbous urethra. (B) The patient was successful in relaxing to void; however, there is suggestion of a wide-caliber annular area proximal to the obliterative process of the bulbous urethra. (C) Endoscopy through the suprapubic cystostomy tube clarifies the anatomy of the proximal urethra and demonstrates the length of the obliterative process.

It is imperative to evaluate the urethra completely proximal and distal to the stricture with endoscopy and bougienage during surgery to ensure that all the involved urethra is included in the reconstruction. Although hydraulic pressure generated by voiding may keep segments proximal to the stricture patent, unless these segments are included in the repair, they are at risk for contraction after obstruction of the narrow-caliber segment is relieved with reconstruction. For this reason, any abnormal areas of the urethra that are proximal to a narrow-caliber segment of the stricture must be treated with suspicion. If the lumen does not appear to demonstrate evidence of diminished compliance, we presume that area to be uninvolved in active stricture disease. However, coning down of the urethra suggests its involvement in the scar.

In some patients, the urethra proximal to a narrow area may remain confusing with regard to its potential for continued constriction after reconstruction. In select patients, we have found it useful to place a suprapubic tube to defunctionalize the urethra. After 6 to 8 weeks, if there is to be constriction of an area that was hydrodilated with voiding, the tendency for that constriction to occur should become apparent.

Decision Making

Once the stricture and patient specifics have been evaluated, the next step in the decision-making algorithm is determining if treatment is to be palliative or curative. The assessment and decision-making algorithm in urethral stricture surgery is predicated upon several main factors. First, the surgeon should have a good understanding of the role of radiologic and endoscopic evaluations to fully characterize the anatomy of the stricture. Second, he or she should be familiar with the available techniques and their uses and limitations. Last, patient and surgeon should agree upon a desired outcome of any intervention and understand the long-term goals and expectations. Curative procedures should be attempted when possible and desired. Palliative procedures are acceptable if that is the recognized goal of treatment.

Treatment

Although the treatment of urethral stricture disease dates to the foundations of urology, significant progress made during the last 50 years allows many of the most complex strictures to be reliably reconstructed in one stage. In the past, a concept known as the reconstructive ladder was used as a treatment guideline for urethral strictures. That concept was based on the principle that the simplest procedure should always be attempted first, and sometimes repeated after failure, before moving on to more complex approaches. This approach is considered archaic in modern urethral reconstruction.

The patient and the physician must have a good understanding of the goal of treatment before the treatment choice is made. Treatment options should be discussed with the patient, with care taken to emphasize the anticipated outcome with regard to potential cure. Some patients may prefer stricture management and choose to have periodic dilations in the office, at home, or in the hospital rather than undergo technically detailed open surgery. Others may have cure as a goal and choose surgical management. Many surgical procedures today have short-term and midterm results approaching long-term success rates of more than 90% to 95% for many strictures.

Dilation

Urethral dilation is the oldest and simplest treatment of urethral stricture disease, and for a patient with an epithelial stricture without spongiofibrosis, it may be curative. **The goal of this treatment, a concept that is frequently forgotten, is to stretch the scar without producing more scarring.** If bleeding occurs during dilation, the stricture has been torn rather than stretched, possibly further injuring the involved area.

The least traumatic method to stretch the urethra is to use soft techniques over multiple treatment sessions. We believe that the safest method of urethral dilation currently available involves the use of urethral balloon-dilating catheters. These catheters may be attached to a filiform tip or passed over a guidewire or may come with an integral coudé tip. For initial dilation, we favor the use of balloons placed over wires that have been passed through the stricture under endoscopic control.

Dilation can be curative and, in the literature, in correctly selected patients, has short-term and midterm efficacy rates equal to internal urethrotomy. Selection criteria are discussed in the following section on internal urethrotomy. The literature does not compare internal urethrotomy and dilation in randomized selection, and we do not have a true comparison but rather comparison by retrospective analysis (Steenkamp et al., 1997).

Internal Urethrotomy

Internal urethrotomy refers to any procedure that opens the stricture by incising it transurethrally. The urethrotomy procedure involves incision through the scar to healthy tissue to allow the scar to expand (release of scar contracture) and the lumen to heal enlarged. The goal is for the resultant larger luminal caliber to be maintained after healing.

With epithelial apposition, wound healing occurs by primary intention. Internal urethrotomy does not provide an epithelial approximation but rather aims to separate the scarred epithelium so that healing occurs by secondary intention. In healing by secondary intention, epithelialization progresses from the wound edges. As it progresses from the wound edge, epithelialization slows. In an effort to aid epithelialization, nature invokes the forces of wound contraction, not to be confused with scar contraction. Wound contraction closes the wound defect and limits the size of the area that requires epithelialization, hastening the healing of the surface defect. However, in the case of internal urethrotomy, wound contraction merely tries to reapproximate the edges of the scar, putting a race into effect. If epithelialization progresses completely before wound contraction significantly narrows the lumen, the internal urethrotomy may be a success. If wound contraction significantly narrows the lumen before completion of epithelialization, the stricture has recurred. Dubey et al. (2005) showed the extent of luminal narrowing to be a predictor of success with internal urethrotomy: the narrower the percent of narrowing, the worse the outcome, with a cutoff of 74% narrowing.

Many surgeons have learned to perform internal urethrotomy by making a single incision at the 12 o'clock position. However, this location may be questioned on the basis of the location of the urethra within the corpus spongiosum. Examination of a cross section of the corpus spongiosum demonstrates that the thinnest portion of the anterior aspect is from 10 o'clock to 2 o'clock. The distance between the anterior wall of the urethra and the corpora cavernosa is likewise short in the bulbous urethra, and a single incision at 12 o'clock could rapidly penetrate the corpus spongiosum and extend into the triangular ligament. Although it may not enter the corpora cavernosa, a deep cut could enter the intracrural space. Distally, although the anterior aspect of the corpus spongiosum is thicker, a deep incision in the more distal aspects of the anterior urethra would enter the corpora cavernosa, and these incisions have been associated with erectile dysfunction (ED) thought to be due to local cavernosal veno-occlusive dysfunction. Vigorous incisions at 10 o'clock and 2 o'clock in the bulbous urethra risk the same problem. If deep spongiofibrosis is present, stricture cure is impossible by internal urethrotomy, and these deep incisions are unnecessary.

The most common complication of internal urethrotomy is recurrence of stricture. Less commonly noted complications of internal urethrotomy include bleeding (almost always associated with erections immediately after the procedure) and extravasation of irrigation fluid into the perispongiosal tissues. These complications are rare today because of the less frequent use of aggressive internal urethrotomy as a treatment modality for urethral strictures. Normal saline should be used as the irrigant when direct visual internal urethrotomy is performed. In addition, with the use of deep urethrotomy incisions, another complication can be creation of a fistula between the corpus spongiosum and the corpora cavernosa and cavernosal veno-occlusive dysfunction.

A major problem with assessing the success rates of internal urethrotomy is that the nature of the strictures that have been treated with internal urethrotomy has been poorly reported. In addition, the literature is unclear regarding the goal of internal urethrotomy. For many, an internal urethrotomy is successful if it offers temporary relief. In many cases, internal urethrotomy has been reported as successful despite the fact that it has been associated with eventual stricture recurrence. Rosen et al. (1994) and later Santucci et al. (2001) showed that actuarial curative success rate of internal urethrotomy is approximately 20%. Evaluations by Pansadoro and Emiliozzi (1996) et al. showed the curative success rate of direct visual internal urethrotomy to be approximately 30% to 35%. Their analysis also showed that there is virtually no increase in success rate with a second internal urethrotomy. **The data show that strictures at the bulbous urethra that are less than 1.5 cm in length and not associated with dense, deep spongiofibrosis (i.e., straddle injuries) can be managed with internal urethrotomy, with a 74% moderately long-term success rate.** The study by Pansadoro and Emiliozzi (1996) did not have any long-term successes for treated strictures outside the bulbous urethra. The variables associated with success of internal urethrotomy have been verified by other studies (Heyns et al., 1998). Many studies have shown that the success of reconstruction is diminished by multiple prior urethral dilations and internal urethrotomy (Albers et al., 1996; Boccon-Gibod, personal communication, 2005; Heyns et al., 1998 Stone et al., 1983). Success rates with internal urethrotomy are not equal to success rates of open urethral reconstruction (Mandhani et al., 2005). Numerous analyses have sought to compare the cost effectiveness of the practice of internal urethrotomy initially before consideration of open reconstruction. The analyses differ in method and in findings (Rourke and Jordan, 2005; Wessells, 2009; Wright et al., 2006).

Several techniques have been employed to oppose the process of wound contraction and to prevent stricture recurrence. One method is to leave an indwelling Foley catheter for 6 weeks after urethrotomy in the hope that the urethra will mold around the catheter as it heals. However, studies have shown that the failure rate of long-term catheterization after internal urethrotomy is similar to that seen with 3 to 7 days of catheterization, and even 6 weeks is insufficient time to oppose the forces of wound contraction.

Another technique used to oppose the forces of wound contraction after internal urethrotomy is home self-catheterization or home urethral obturation. After internal urethrotomy, patients generally have an indwelling catheter placed for 3 to 5 days. When the catheter is removed, the patient is started on a urethral obturation regimen. Most regimens require more frequent catheterizations early in the recovery period, with a tapering schedule during the next 3 to 6 months. Anecdotally, many surgeons have reported an improved cure rate with self-catheterization combined with internal urethrotomy. However, it has been our experience that the stricture inevitably recurs when the patient stops self-obturation, regardless of how long it has been used. That being understood, this approach can effectively manage the problems when it is combined with a urethral dilating regimen in a properly motivated patient. Colchicine, because it binds tubulin, has been used along with internal urethrotomy (Carney et al., 2007). Initial findings in a nonrandomized study also suggest that, perhaps by pharmacologically blocking tubulin and possibly wound contracture, the results of internal urethrotomy may be better. Mitomycin C with its antifibroblast and anticollagen activity when injected submucosally has been shown to decrease the risk of recurrence after a urethrotomy (Mazdak et al., 2007).

Lasers

Types of lasers that have been used for the treatment of urethral stricture disease include carbon dioxide (CO_2), argon, KTP, Nd:YAG, holmium:YAG, and excimer lasers. The ideal laser for use in the treatment of urethral stricture disease is one that totally vaporizes tissue, exhibits negligible peripheral tissue destruction, is not absorbed by water, and is easily propagated along a fiber. Although the CO_2 laser appears to be ideally suited, it must be used with a gas cystoscope, which carries the potential threat of a CO_2 embolus.

For the argon and the Nd:YAG lasers, the predominant mode of action is thermal necrosis, which leads to a significant potential for peripheral tissue injury rather than vaporization. The Nd:YAG laser has also been used with a bare fiber in the contact mode. A bare fiber carries with it a risk of forward scatter. When it is used in the contact mode, the YAG energy is transferred to a sapphire tip. Advocates of the use of a contact laser suggest that it obliterates the scar by vaporization; however, results with use of these fibers are no better than results with direct cold-knife visual internal urethrotomy.

A KTP laser is essentially an Nd:YAG laser that has passed through a KTP crystal, resulting in a reduced depth of penetration. A KTP laser urethrotomy is accomplished by passing the fiber over the scar tissue to make urethrotomy cuts. The holmium:YAG laser has properties similar to the KTP laser, and, similar to the KTP laser, it provides direct contact cutting and vaporization with minimal forward scatter. Experience with the holmium:YAG laser is accumulating; anecdotally, it may have a place in the management of some strictures, in particular, strictures that are relatively isolated and short.

The excimer laser is a true vaporizing laser that has little forward scatter or peripheral tissue necrosis associated with it. Little experience with this laser has been reported, but future investigation is warranted.

The results of laser urethrotomy are mixed. However, with the advent of new lasers and experience with them, future data may show better results.

Stents

Urethral stents (removable or permanently implantable) are another modality used in opposing the forces of wound contraction after internal urethrotomy or dilation. Removable urethral stents are designed to prevent the process of epithelialization from incorporating the stent into the urethral wall and are left in place for 6 months to 1 year before they are removed. The greatest experience with these removable stents comes from Israel (Yachia and Beyar, 1991), where success in small series is reported. The Memokath stent is not currently available in the United States. It is a removable stent made of nitinol with varying success rates.

Most experience with permanently implantable stents comes from Europe and the United Kingdom. Milroy (1993) reported a success rate of 84% at 4½ years with use of the permanently implantable UroLume (Ashken et al., 1991; Badlani et al., 1995; Brandes and McAninch, 1998; Jordan, 1997; Krah et al., 1992; Milroy and Allen, 1996; Milroy et al., 1988, 1989; Rousseau et al., 1987; Sarramon et al., 1990; Shah et al., 2003; Sigwart et al., 1987; Sneller and Bosch, 1992; Tillem et al., 1997; Verhamme et al., 1993). The UroLume, made of an alloy, is designed to be incorporated into the wall of the urethra and corpus spongiosum. Available data show that the stent is best employed for relatively short strictures of the bulbous urethra associated with minimal spongiofibrosis. However, these are the strictures that are most successfully reconstructed with open techniques that offer better long-term success rates. The North American Study Group 11-year data showed that of 179 patients originally enrolled in the North American Study, 24 patients completed 11 years of follow-up. The overall success rate for all patients enrolled at 11 years is less than 30% (Shah et al., 2003). A 10-year follow-up study from the Netherlands (De Vocht et al., 2003) reported results thought to “weaken the optimistic early results”; of 15 patients implanted, only 2 were satisfied with their stent at 10 years.

Permanently implantable stents are associated with unique complications. The stents must be **placed only in the bulbous urethra,** and when placed beyond the area of the scrotal urethra, placement has been associated with pain on sitting and intercourse. Some patients (particularly young patients) **complain of perineal pain,** often with vigorous activity, even after implantation of the stent in the deep bulbous urethra. In addition, **longer bulbous strictures require two stents that are overlapped.** These **stents can migrate** away from each other, leaving a gap between them where recurrence of stricture is inevitable. When this occurs, the stricture recurrence is excised, and a third stent is placed to span the gap.

The UroLume stent has been taken off the market and is currently not available for implantation. However, many patients still have UroLume stents, and many of these will need treatment.

Open Reconstruction

If curative techniques are to be employed, then consideration must be given to anastomotic urethroplasty and substitution urethroplasty techniques. There is currently no clear evidence as to which procedure is best for all strictures; however, if stratified by stricture length, cause and site of stricture several recommendation are clear.

Excision and Reanastomosis.

The most dependable technique of anterior urethral reconstruction is the complete excision of the area of fibrosis, with a primary reanastomosis of the normal ends of the anterior urethra (Fig. 82.18; Russell, 1914). The best results are achieved when **the following technical points are observed: the area of fibrosis is totally excised; the urethral anastomosis is widely spatulated, creating a large ovoid anastomosis; and the anastomosis is tension free.**

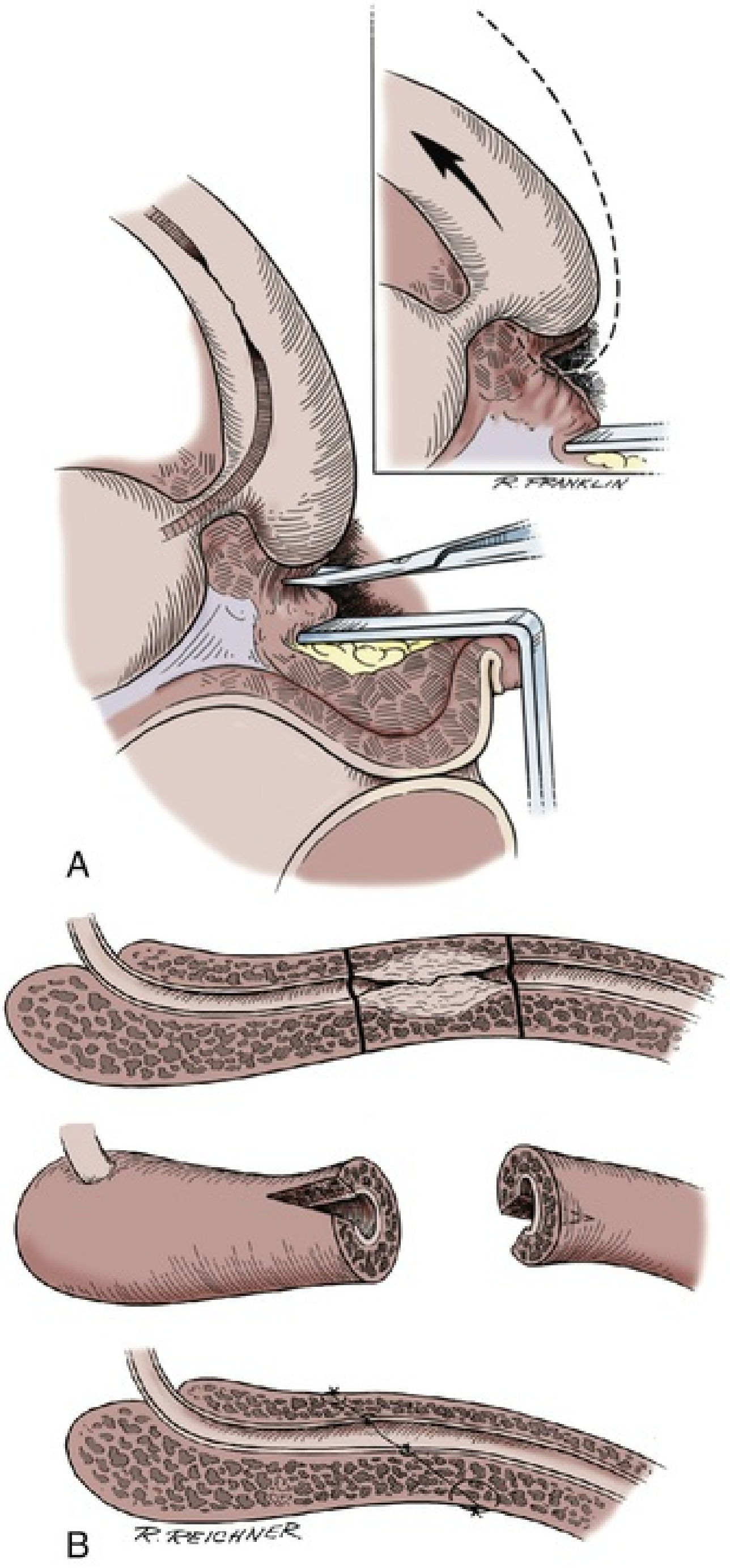

FIG. 82.18 Techniques for excision and primary reanastomosis of anterior urethral stricture. (A) The bulbospongiosus is released from its attachment to the perineal body. The arteries to the bulb are not divided. This technique allows the urethra to be mobilized distally. This technique combined with development of the intracrural space can shorten the path of the urethra by approximately 1 to 1.5 cm. (B) Technique of a primary spatulated anastomosis after excision of an anterior urethral stricture. (From Jordan GH: Principles of plastic surgery. In Droller MJ, editor: *Surgical management of urologic disease: an anatomic approach,*

Philadelphia, 1992, Mosby, pp 1218–1237.)

The success of this procedure relies on vigorous mobilization of the corpus spongiosum. With vigorous mobilization, dissection of Buck fascia to improve compliance, development of the intracrural space, and detachment of the bulbospongiosus from the perineal body, significant lengths of stricture can be excised and reanastomosed. Strictures of 1 to 2 cm are generally easily excised with reanastomosis. In some cases, strictures 3 to 5 cm can be totally excised, and a primary reanastomosis of the anterior urethra can be performed. For very proximal short-length bulbous strictures, tension-free anastomosis can be facilitated by the dissection of the membranous urethra (Fig. 82.19). As a rule, the closer the stricture is to the membranous urethra, the longer it can be and still be reconstructed with anastomotic techniques. For many proximal strictures, a single-layer anastomosis is preferable. When the length of stricture precludes total excision of fibrosis with primary anastomosis, tissue transfer is required. Morey and Kizer (2006) studied a series of patients who had stricture excision with anastomosis for strictures up to 5 cm and pointed out that younger patients have more compliant tissue, allowing the limits to be stretched.

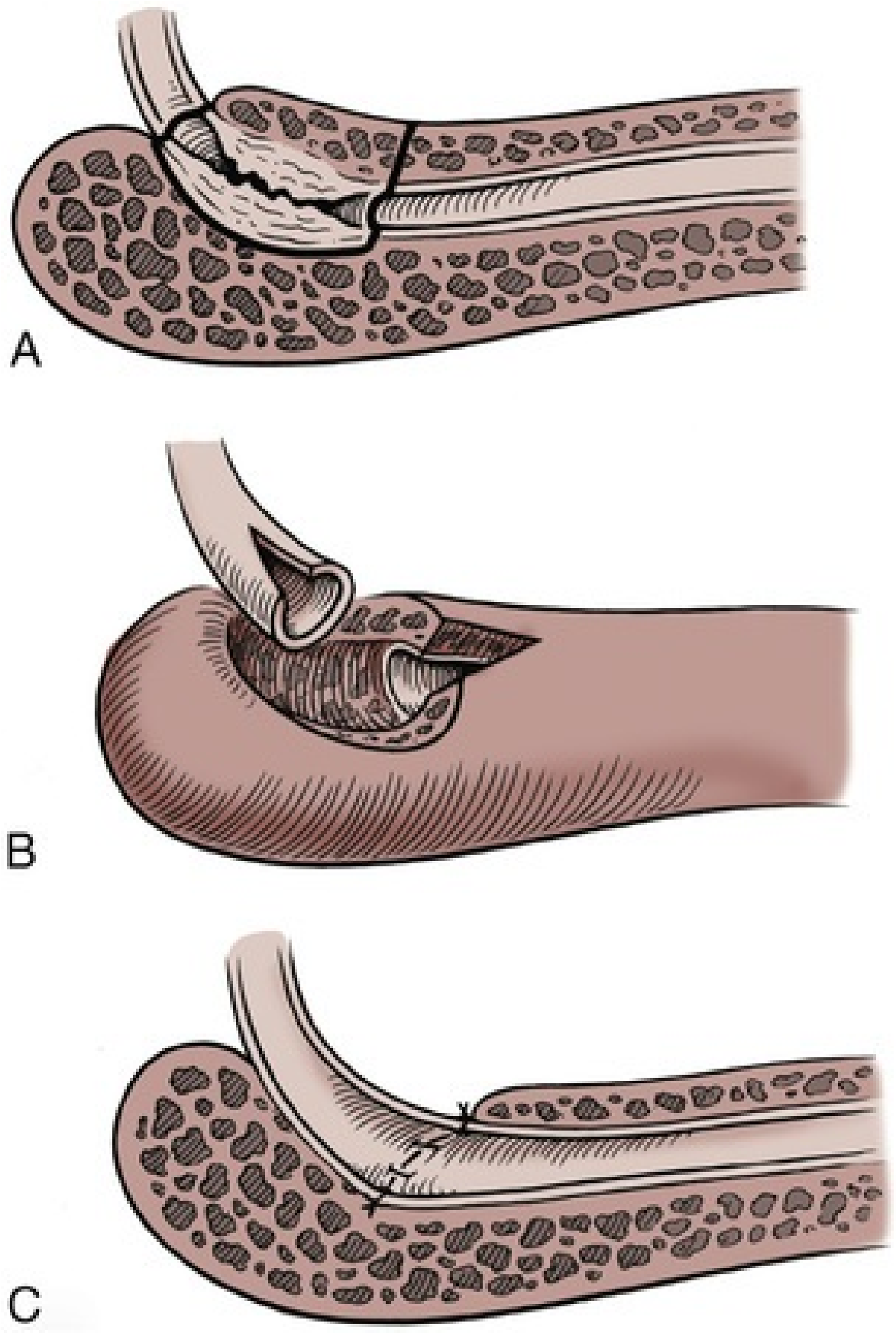

FIG. 82.19 Technique of excision of very proximal bulbous urethral stricture with reanastomosis. This technique is facilitated by dissection of the membranous urethra. (A) The area of the stricture is defined for excision. (B) The stricture is excised, and both ends of the urethra are spatulated on the dorsal aspect. (C) The anastomosis is complete.

DeCastro et al. (2002) reported an interesting variant of excision with anastomosis for anterior stricture. In that case report, a patient had two independent areas of stricture apparently separated by totally normal urethra and corpus spongiosum. The authors excised both areas of stricture independently with respective anastomosis of each site. Although this case was successful, we think that the authors' considerable experience allowed them to achieve a successful result, and a safer reconstruction with use of onlay or augmented onlay may have been better.

Vessel-Sparing Technique.

Jordan et al. (2007) first reported the use of a vessel-sparing excision and reanastomosis of the bulbar urethra. The dissection is similar to the standard excision and reanastomosis (Fig. 82.20): the triangular ligament is divided, and the intracrural space is developed, the space between the membranous urethra and the proximal vasculature is developed, and these vessels are preserved (Fig. 82.21). The urethra is divided with the stenotic segment excised, the ends are spatulated, and the reanastomosis is performed. Andrich and Mundy (2012) described an alternative vessel-sparing technique for proximal strictures in which a longitudinal dorsal stricturotomy is performed and the stricture is excised from within the urethra without disrupting the spongiosum. After stricture excision, the ventral urethra is reapproximated primarily, and the longitudinal dorsal stricturotomy is closed horizontally, preserving the vasculature. Preserving the proximal blood supply to the bulbar urethra is advantageous in patients whose distal blood supply is compromised by trauma, previous surgery, or hypospadias. Another theoretical advantage would be a decrease in the risk of ED and potential decreased risk for erosion if subsequent artificial sphincter implantation were probable.

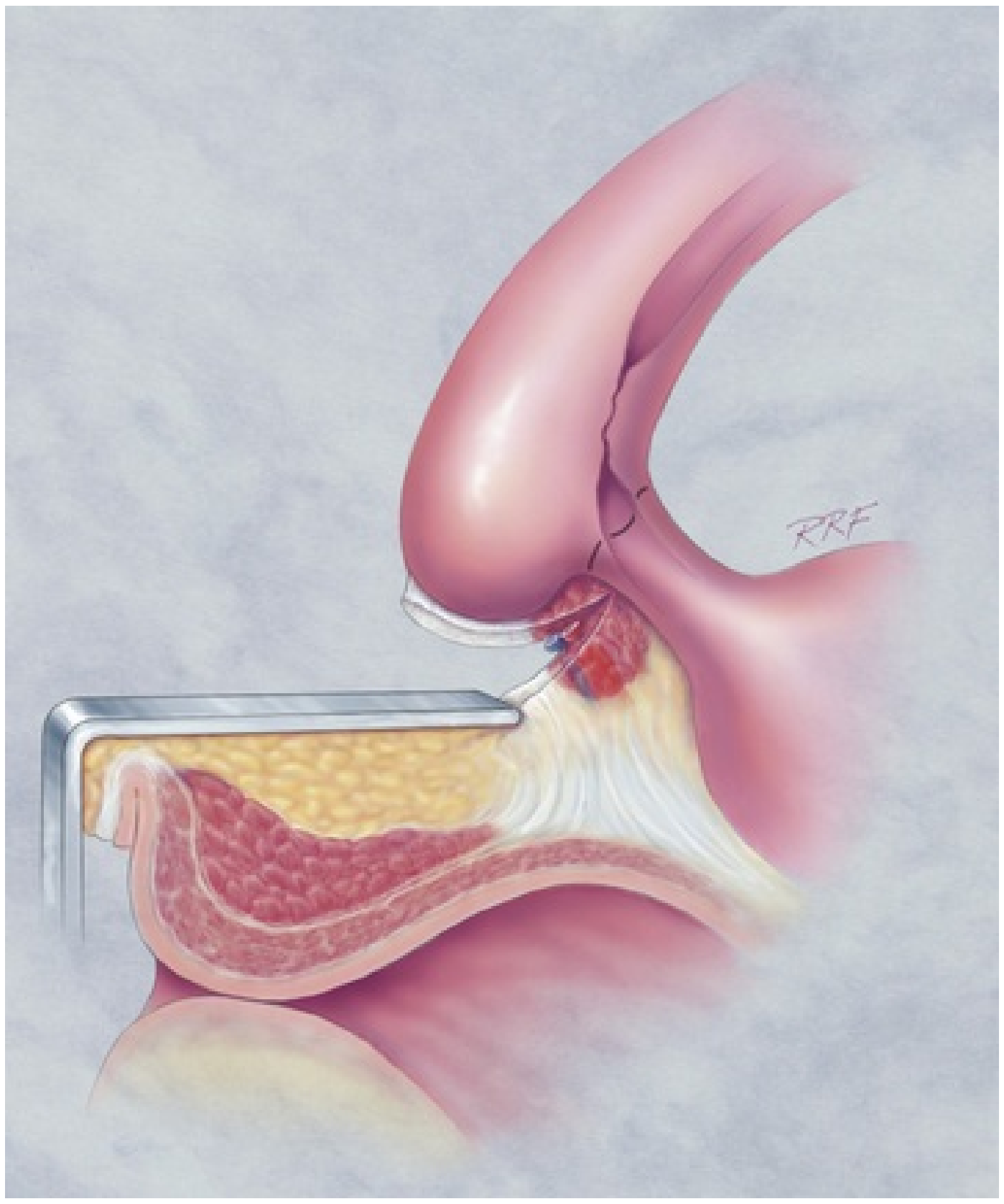

FIG. 82.20 Diagrammatic representation of the dissection of the proximal corpus spongiosum, bulbospongiosum, and membranous urethra. The customary technique for dividing the urethra through the juncture of the membranous urethra with the proximal bulbous urethra—to perform an

excision of stricture with a primary anastomosis. In this illustration, the proximal vasculature has been ligated and divided. The urethra can then be divided at the distal-most limits of the membranous urethra.

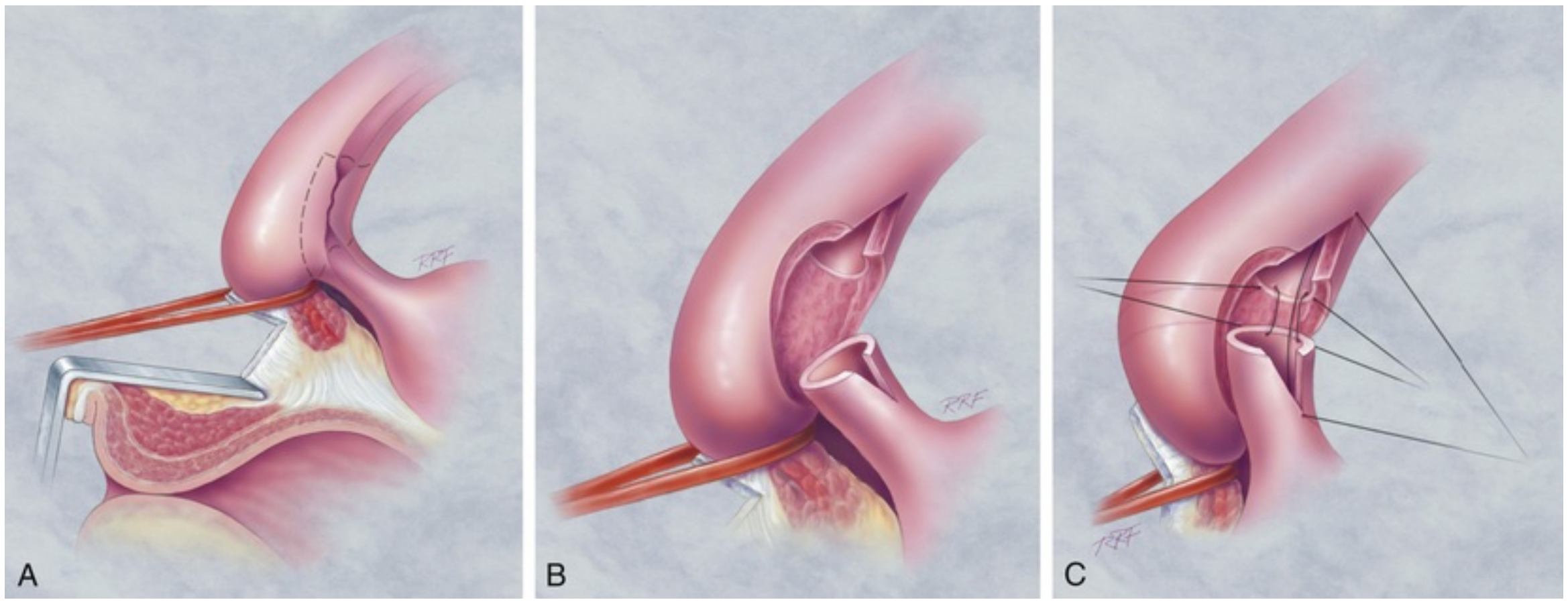

FIG. 82.21 Technique of vessel-sparing excision with primary anastomosis. The proximal corpus spongiosum, bulbospongiosum, and area of the proximal vessels and membranous urethra have been dissected. (A) Dissection of the space between the proximal vasculature and the membranous urethra is illustrated. In this technique, the arteries to the bulb can be preserved, and the membranous urethra can be divided at its juncture with the bulbous urethra. The area of proximal stricture can be excised. (B) The stricture has been excised before placement of the anastomotic sutures. (C) Anastomotic sutures are placed to effect the spatulated anastomosis. At this center, customarily we alternate polydioxanone sutures with Monocryl; however, any acceptable absorbable suture can be used. The membranous urethra is spatulated on the dorsum as is the proximal bulbous urethra.

Further studies must be done to confirm the initial excellent results with the vessel-sparing technique and prove the theoretical advantages (Andrich and Mundy, 2012; Gur and Jordan, 2008; Jordan et al., 2007; Virasoro et al., 2015).

Graft Onlay.

Four grafts that have been successfully used for primary urethral reconstruction are the FTSG, bladder epithelial graft, OMG, and rectal mucosal graft. OMGs, as mentioned earlier, can be taken from the cheek (buccal), the lip (labial), and the undersurface of the tongue (lingual). STSGs have been used for staged anterior urethral reconstruction (Burger et al., 1992; Devine et al., 1976; El-Kassaby et al., 1996; Hendren and Crooks, 1980; Hendren and Reda, 1986; Humby, 1941; Jordan, 1993; Memmelaar, 1947;

Pressman and Greenfield, 1953; Ransley et al., 1987; Schreiter and Koncz, 1983; Webster et al., 1984; Wessels and McAninch, 1996). The characteristics and microvascularity of some of the grafts were discussed earlier in Principles of Reconstructive Surgery.

Graft reconstruction of the urethra was almost abandoned in favor of flap reconstruction techniques. However, since the late 1990s, there has been a resurgence of interest in the use of grafts (Wessells and McAninch, 1996) and, specifically, the use of BMGs (Barbagli et al., 2003; Bhargava and Chapple, 2004; Bhargava et al., 2004; Dubey et al., 2005; Elliott et al., 2003; Hellstrom et al., 1996; Kellner et al., 2004; Weinberg et al., 2002; Xu et al., 2004). **Grafts have been employed most successfully in the area of the bulbous urethra, where the urethra is invested by the bulk of the ischiocavernosus muscles. However, the use of grafts other than in the area of the bulbous urethra and, in some cases, the use of tubed reconstruction are reported in increasing numbers.** The grafts can be applied to the ventrum of the urethra; however, a ventral urethrotomy seems to be advantageous only if use of the spongioplasty maneuver is contemplated (Fig. 82.22). The spongioplasty procedure requires that the corpus spongiosum adjacent to the area of the stricture be relatively normal and free of fibrosis. Data support the superiority of results with the dorsal onlay technique and other reports showing no difference in success. In the past, we preferred to use lateral graft onlay (see Fig. 82.22B) or dorsal graft onlay (see Fig. 82.22C). Placement of the urethrostomy laterally allows exposure of the urethra while cutting through the corpus spongiosum, where it is relatively thinner, limiting bleeding and maximizing exposure. In addition, in the bulbous urethra, the graft can be sutured to the underlying muscle bed in the hope of improving graft–host bed immobilization and approximation.

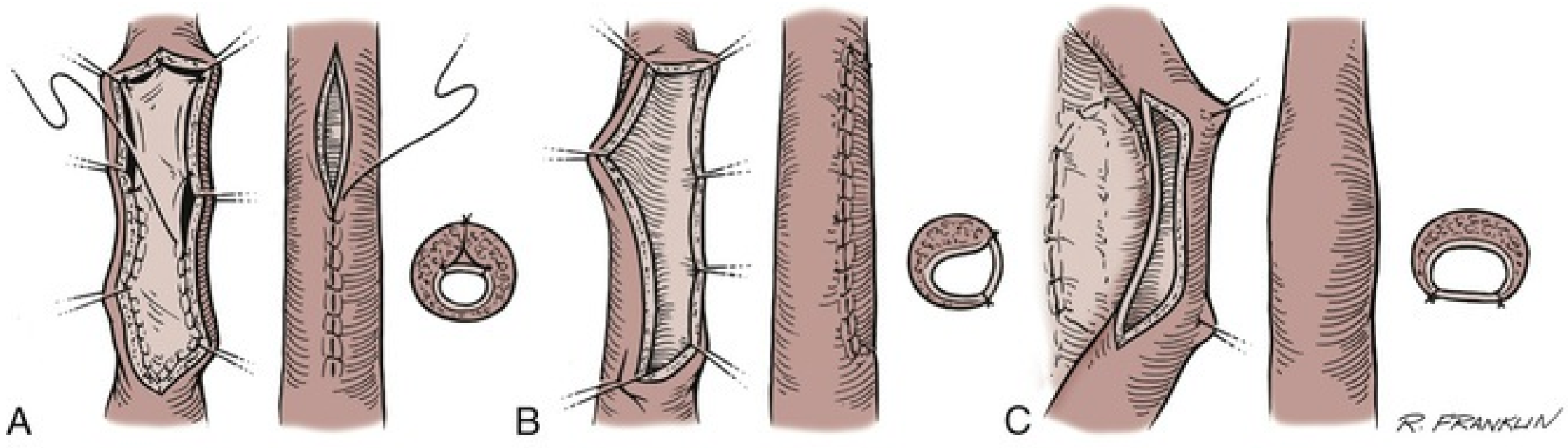

FIG. 82.22 Various techniques of graft onlay. (A) Ventral onlay with spongioplasty. (B) Lateral onlay with quilting to the ischiocavernosus

muscle. (C) Dorsal onlay with spread fixation of the graft.

The Monseur urethral reconstruction was applied in only a few select centers (Monseur, 1980). In this technique, the urethrostomy was made through the stricture on the dorsal wall. The edges of the stricture were sutured open to the underlying triangular ligament or corpora cavernosa, or both. Barbagli et al. (1995) subsequently modified the Monseur technique (Fig. 82.23). In their modification, the urethrostomy is performed through the stricture on the dorsal wall. In the area of the urethrostomy, a graft is applied and spread fixed to the triangular ligament or corpora cavernosa, or to both. The edges of the stricturotomy are sutured to the edges of the graft and to the adjacent structures. The results of this technique are excellent. The ventral and dorsal graft onlay techniques can be used with stricture excision and strip anastomosis (augmented anastomotic procedure) (Fig. 82.24). For proximal strictures, the vessel-sparing technique of augmented anastomosis depends on the surgeon's ability to excise the scarred epithelium and underlying corpus spongiosum tissue without the need to divide the corpus spongiosum completely.

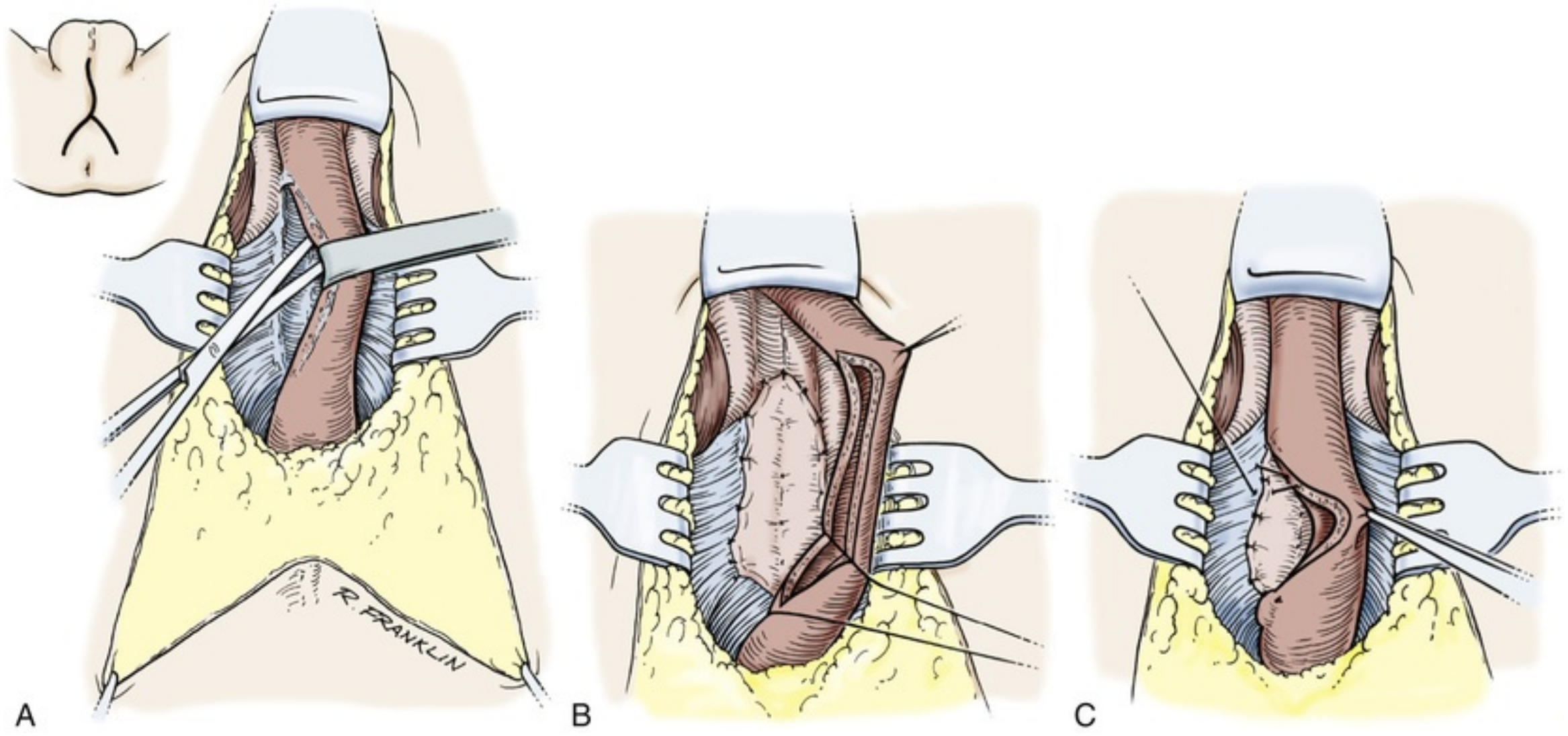

FIG. 82.23 Technique of dorsal graft onlay popularized by Barbagli. (A) The corpus spongiosum is detached from the triangular ligament and corpora cavernosa. (B) A dorsal urethrostomy is performed. The graft is spread fixed to the corpora cavernosa. Note the pie-crusting incision. (C) The edges of the stricturotomy are sutured to the graft and to the corpora cavernosa.

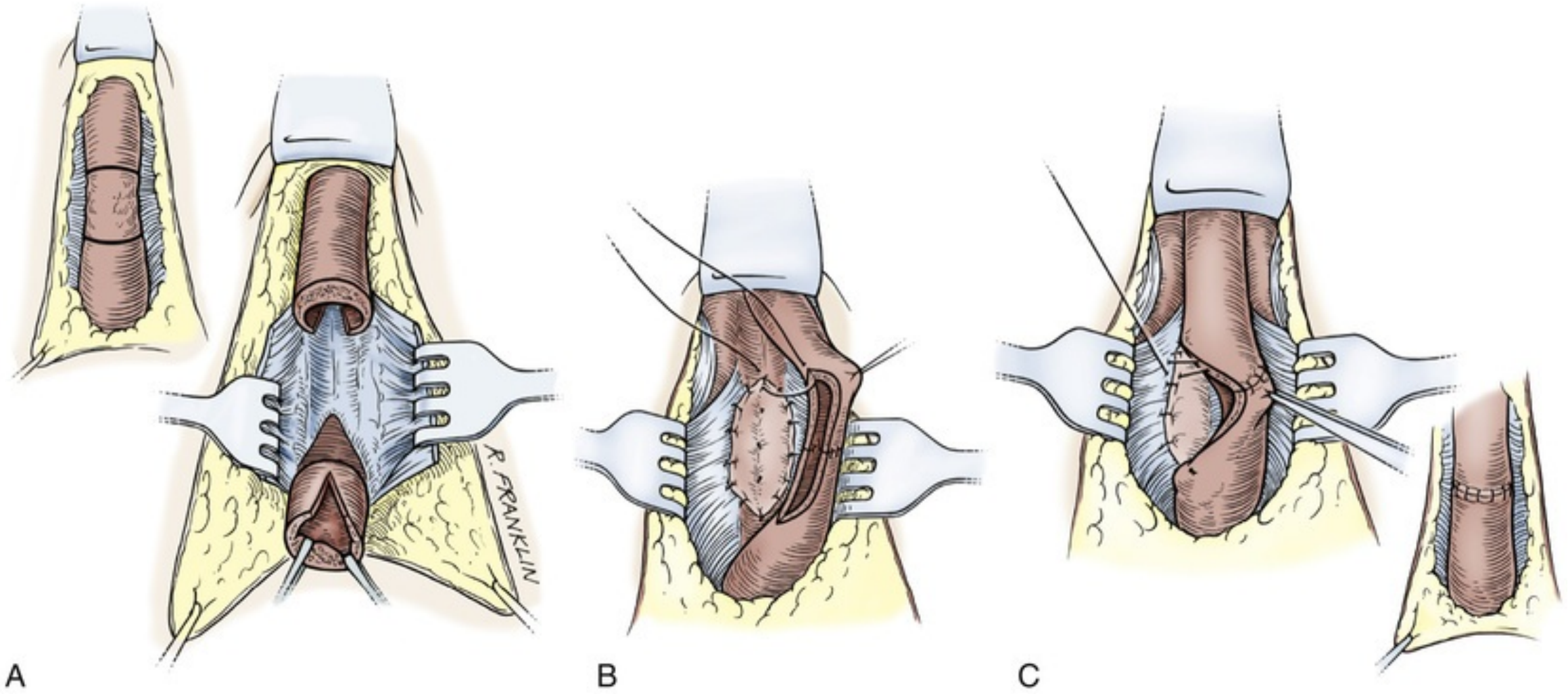

FIG. 82.24 Technique of augmented anastomosis with graft onlay. (A) The corpus spongiosum is detached from the triangular ligament and the corpora cavernosa. The area of spongiofibrosis is identified and marked, and the area of the narrowest caliber stricture is excised. The urethral ends are spatulated on the dorsum. (B) A two-layer floor strip anastomosis is performed, and the graft is spread fixed to the corpora cavernosa. Note the pie-crusting incisions and the mattress sutures. (C) The edges of the stricturotomy are sutured to the graft and to the corpora cavernosa.

Another option is the two-staged application of a mesh STSG, BMG, or posterior auricular FTSG. In the first stage of the staged graft procedure, a medium-thickness STSG, a BMG, or a Wolfe graft is placed over the dartos fascia. If the graft is placed immediately onto the tunica albuginea or corpora cavernosa, the inability to mobilize the graft makes second-stage tubularization difficult. However, there is an advantage to having at least a midline strip of the graft adherent to the corpora cavernosa. At a later date, second-stage surgery is performed to tubularize the graft. Although Schreiter and Noll (1989), who first described the procedure of mesh STSG, often proceeded to the second stage within 3 to 4 months, we wait 12 months between the first-stage and second-stage surgeries if an STSG is used. According to studies in the United States and Europe, this procedure has been determined useful for select cases. In the United States, its use has mostly been confined to the most difficult cases, with single-stage reconstruction still applied to most cases. As already mentioned, staged graft techniques have been used effectively in complicated patients with hypospadias. Staged buccal graft operations have been successful in patients with LS with midterm follow-up. In addition, in complicated patients with hypospadias, staged buccal grafts and posterior auricular skin grafts have been successfully employed (Fig. 82.25).

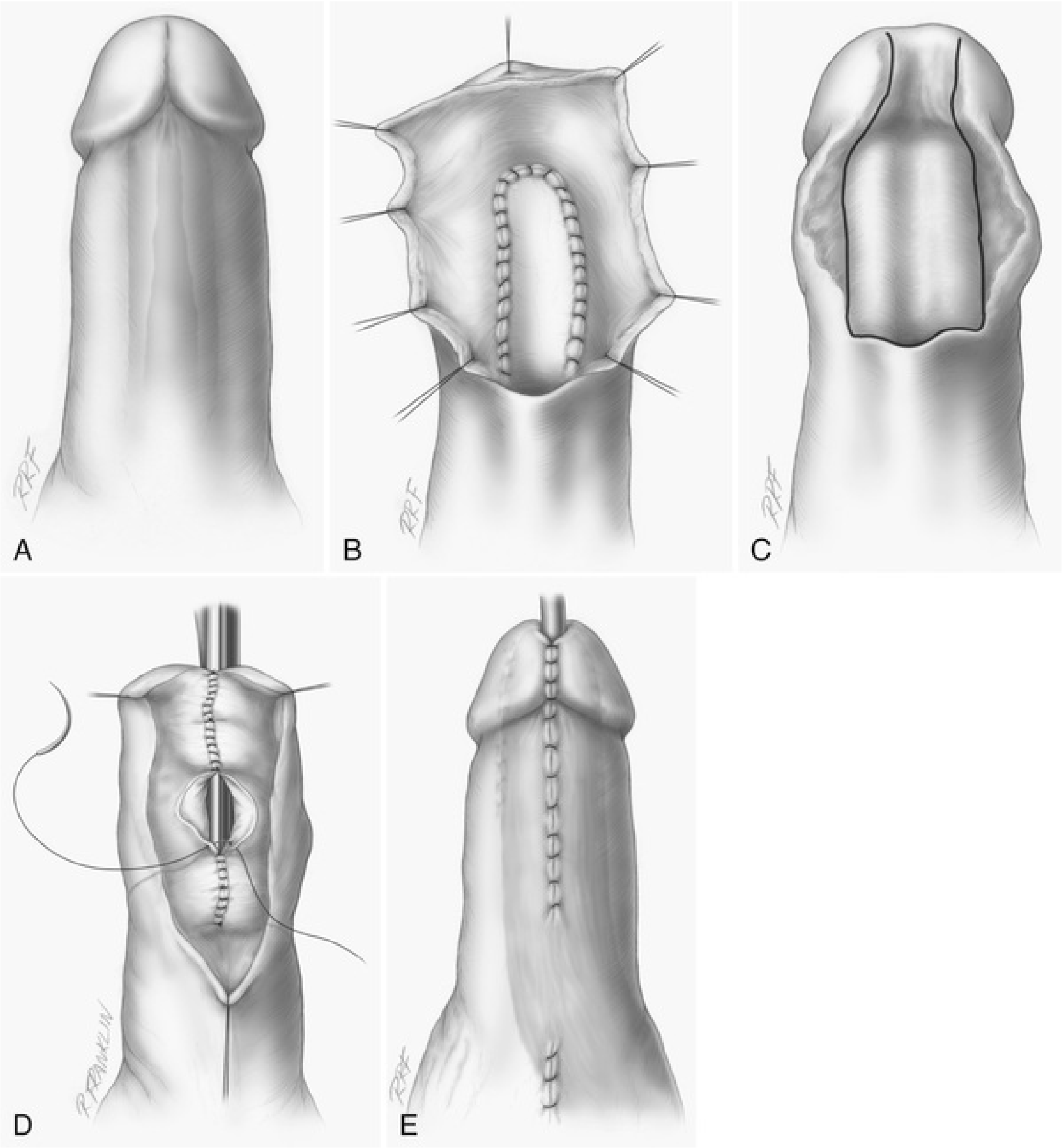

FIG. 82.25 Staged reconstruction of a distal anterior urethral stricture. (A) The appearance of the penis with the urethra (shaded area shows the location of a tight stenosis of the fossa navicularis that extends into the distal pendulous urethra). (B) The distal narrow stricture of the fossa navicularis has been excised, and stricturotomy into the normal urethra proximal to the excised tissue has been performed. A buccal graft has been applied to the defect, but the bolster dressing has not yet been applied. (C) After 6 months, the graft is mature. The illustration shows a Tiersch tube ready for closure. (D) The Tiersch tube is closed with a watertight suture line. The distal urethra is usually calibrated to create a urethral lumen of approximately 28 Fr. (E) Glans reconstruction and closure of the distal shaft has been performed (shaded area shows the tunica dartos flap that carries a parietal tunica vaginalis island). The flap is mobilized in this case

from left hemiscrotum and transposed to cover the entire area of the urethral reconstruction.

Flap Onlay.

Numerous applications of genital skin islands, mobilized on either the dartos fascia of the penis or the tunica dartos of the scrotum, have been proposed for the repair of urethral stricture disease. In the past, these “flap operations” were considered separate procedures. We suggest that all these procedures are different applications of a single concept, as proposed by the microinjection studies of Quartey (1983). Skin islands can be viewed as passengers on fascial flaps, and the design of flaps for urethral reconstruction can be paralleled to the design of flaps for reconstruction in general.

There are **three important considerations for the use of flaps in urethral reconstruction: the nature of the flap tissue, the vasculature of the flap, and the mechanics of flap transfer.** The skin must be nonhirsute for urethral reconstruction. **In addition, for donor site consideration, it is most convenient to use the areas of redundant nonhirsute genital skin.**

If the redundancy is dorsal, the skin island can be oriented transversely and mobilized on the dorsal dartos fascia after the techniques described by Duckett and Standoli in 1984 (Fig. 82.26) (Duckett, 1984, 1992; Duckett et al., 1993; El-Kassaby et al., 1986). If there is redundancy of the ventral skin, the skin island can be mobilized as a ventral longitudinal island. These islands can be either vigorously mobilized on a ventrolaterally oriented dartos fascial flap for transposition to the perineum or less vigorously mobilized and transposed and inverted into a pendulous urethral stricture defect (Fig. 82.27; Orandi, 1972). Ventral islands can be oriented transversely (Fig. 82.28) and longitudinally. Longer skin islands can be mobilized by orienting the island ventrally and transversely at the distal extent. This “hockey stick” orientation allows islands 7 to 9 cm (Fig. 82.29). For distal strictures of the anterior urethra, including the fossa and meatus and the pendulous urethra, the islands can be advanced to reconstruct to the level of the meatus by either developing glans wings or elevating the ventral glans.

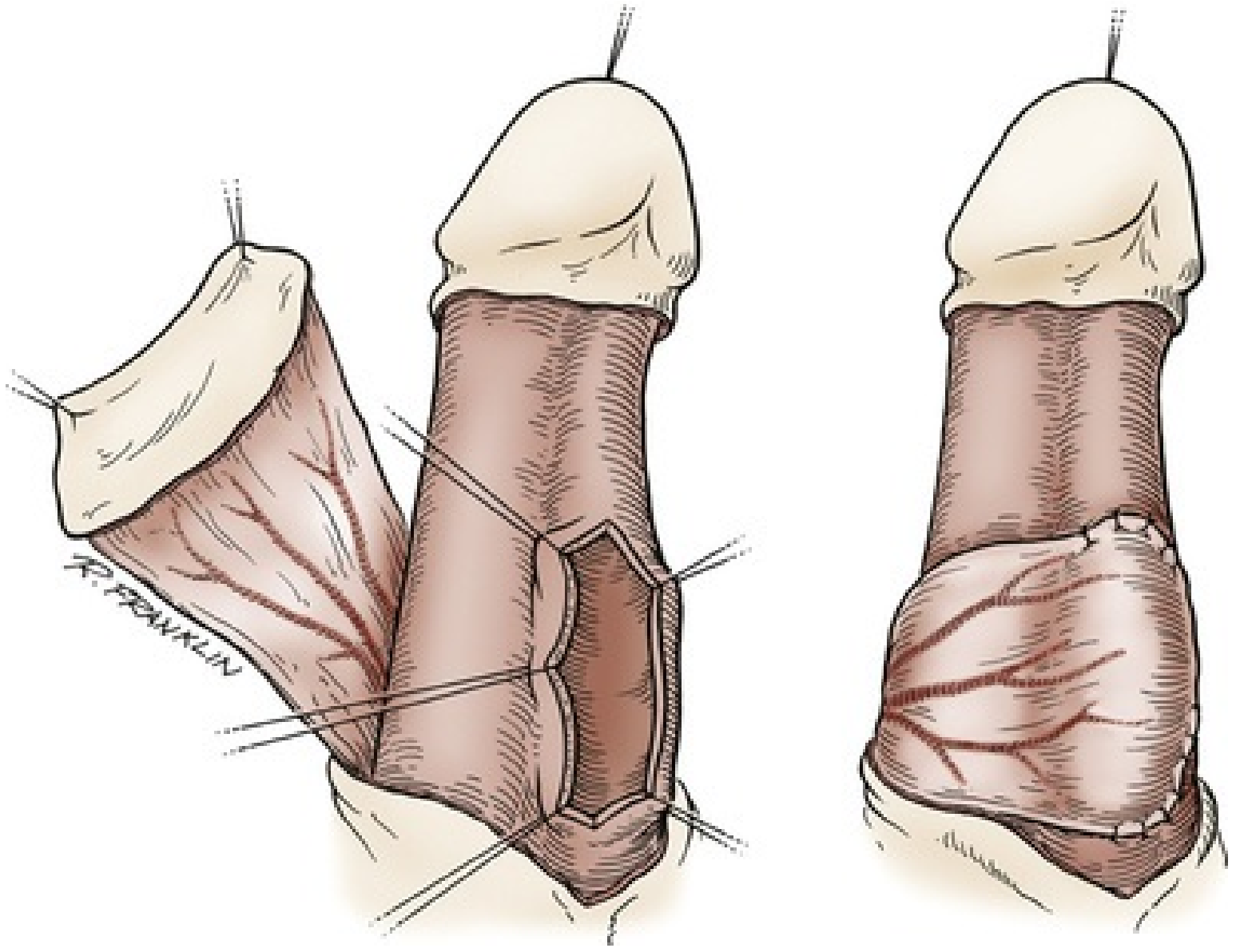

FIG. 82.26 A dorsal transverse island of penile skin applied to a stricture of the urethra. The flap has been elevated on the dartos fascia, and a lateral incision into the urethra has been made. The flap is secured in place *(right)*. (From Jordan GH: Management of anterior urethral stricture disease. In Webster GD, editor: *Problems in urology,* Philadelphia, 1987, Lippincott, p 217.)

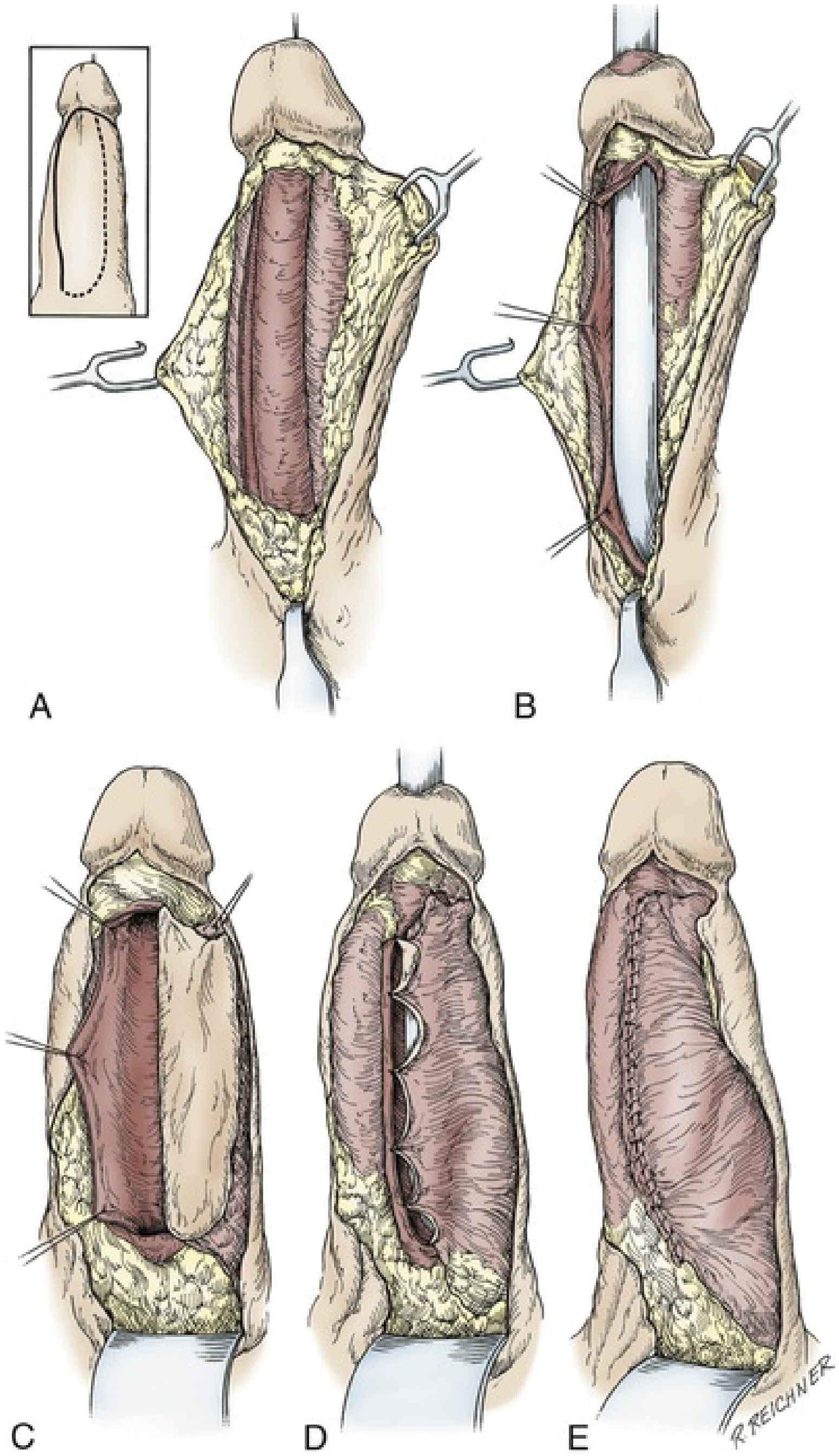

FIG. 82.27 Penile longitudinal skin island. The incisions to be made to mobilize the flap are demonstrated in the *inset*. The heavy line is the primary incision made full thickness through the dartos fascia and superficial Buck fascia lateral to the corpus spongiosum. (A) Dissection elevates the dartos fascial flap well past the corpus spongiosum in the midline. (B) A lateral urethrostomy placed to face the flap has opened the entire length of the stricture. (C) The skin paddle of the flap has been developed by making the incision outlined by the dotted line *(inset)* and undermining the skin lateral to it. The medial edge of the flap has been fixed to the edge of the stricturotomy. (D) The flap is inverted into the

defect. (E) A watertight subepithelial suture line has been completed with a running absorbable monofilament suture. The skin will be closed with subcutaneous sutures and interrupted cutaneous sutures. (From Jordan GH: Management of anterior urethral stricture disease. In Webster GD, editor: *Problems in urology,* Philadelphia, 1987, Lippincott, p 214.)

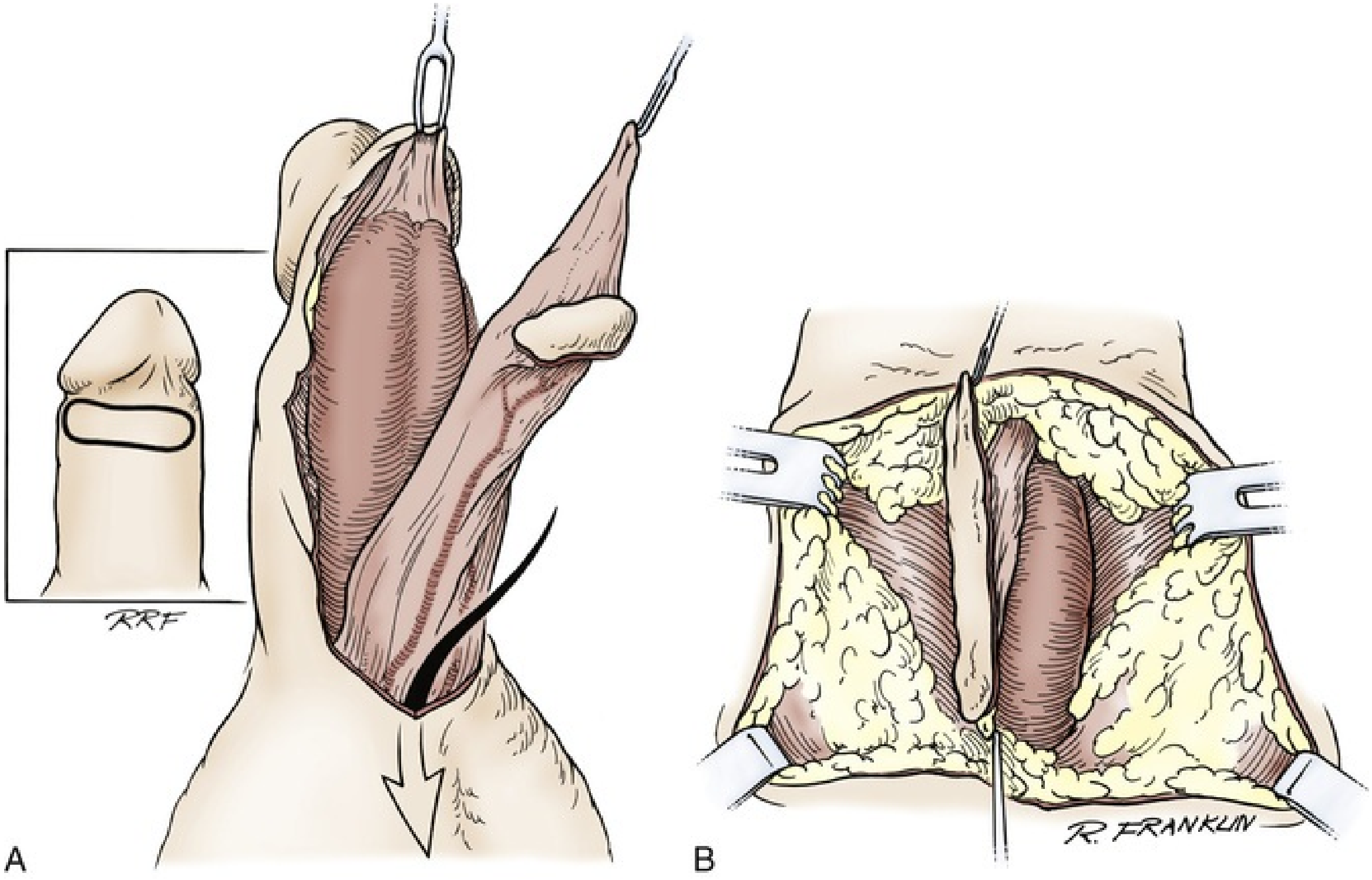

FIG. 82.28 A ventral transverse skin island is elevated on the penile dartos fascia, inverted to the area of the perineum where flap onlay is accomplished. (A) The skin island is elevated on the dartos fascia. (B) The appearance of the flap transposed to the area of the perineum for onlay in a proximal bulbous urethral stricture.

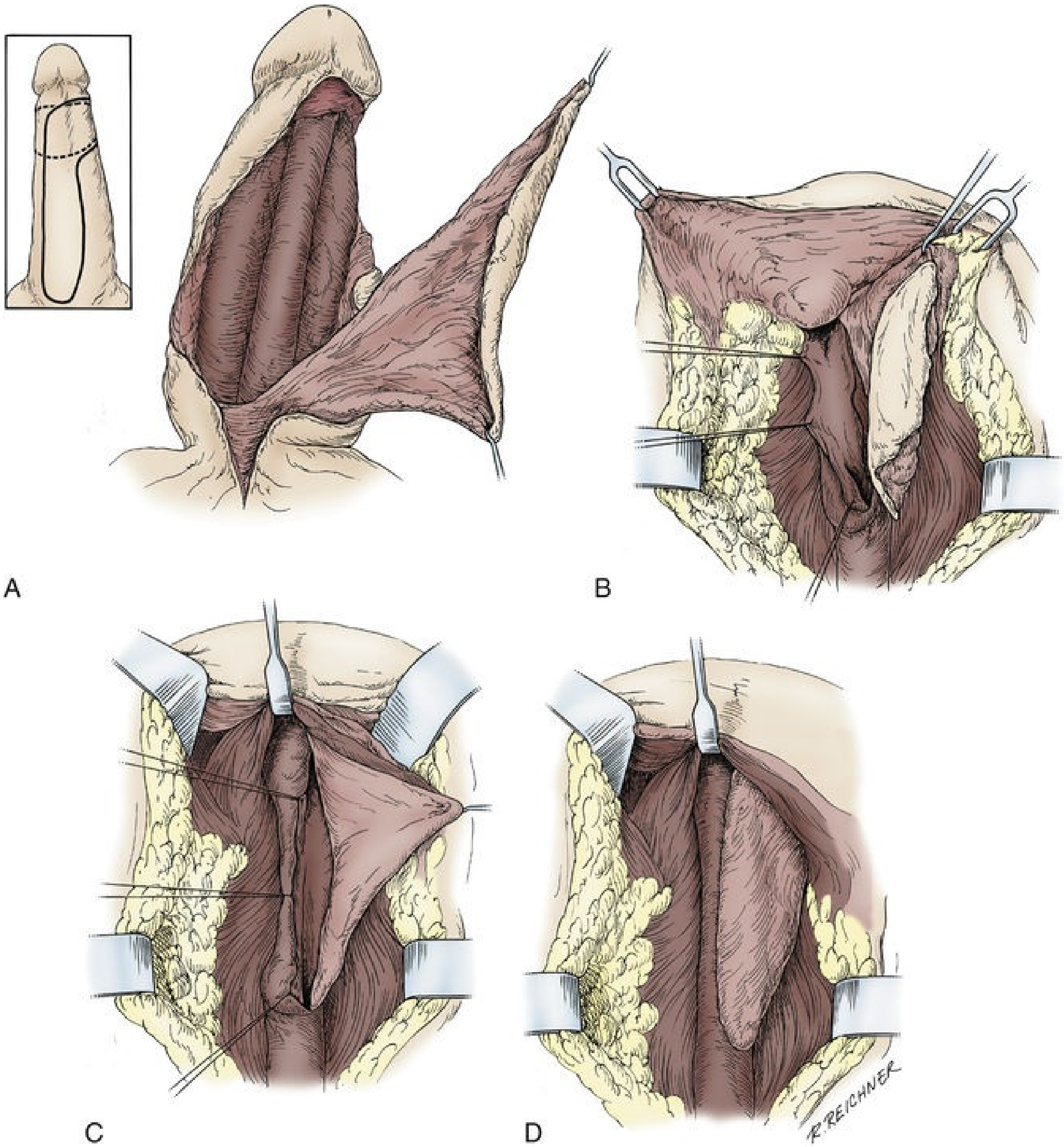

FIG. 82.29 Ventral skin island for long bulbous stricture. The skin paddle of the flap is developed on the ventral midline of the penis and can be extended around the penile shaft at its distal end. (A) The paddle of the flap has been incised, and its pedicle has been elevated. This pedicle includes Buck fascia and dartos fascia, denuding the tunica of the corpus spongiosum and the corpora cavernosa. The pedicle (the dartos fascia bilaterally) is based on the superficial external pudendal vessels and the internal pudendal vessels in the scrotum. Development of this pedicle allows the flap to be moved to any area of the urethra. (B) The flap has been passed through a tunnel beneath the scrotum developed by dissection along the corpus spongiosum. A laterally placed urethrostomy has opened the urethral stricture. (C) The deep edge of the flap is secured by the suture techniques previously described. (D) Anastomosis of the flap

has been completed. The pedicle can be seen extending beneath the scrotum. (From Jordan GH, McCraw JB: Tissue transfer techniques for genitourinary surgery, part III. *AUA Update Series* 7:lesson 11, 1988.)

Where there is general redundancy to the penile skin, the islands can be oriented circumferentially. These “circular skin islands” are mobilized on the entire penile dartos fascia, and the mechanics of transposition suggest that they are most efficient when they are ventrally based, with the pedicle split dorsally. In some cases, circular skin islands 15 cm can be obtained (El-Kassaby et al., 1986; McAninch, 1993; Miller and McAninch, 1993). The so-called Q flap circular island design can provide even longer islands, sometimes necessary for complex long-length anterior urethral reconstruction (Morey et al., 2000).

Augmented Anastomosis.

It is often beneficial to combine the excision of the stricture with a skin island onlay (Fig. 82.30) **or a graft onlay in an augmented anastomosis** (see Fig. 82.24). We have found that **segments of very narrow caliber (nearly or totally obliterating) are difficult.** These segments can often be completely excised; a roof or floor strip anastomosis of the urethra is performed, and the remaining urethrotomy defect is filled with either a graft or a skin island onlay. In some patients, there are relatively large nonhirsute areas of the scrotal skin that can be elevated on the tunica dartos of the scrotum. This flap has been maligned in the literature in the past. However, we and others have extensive experience with these flaps and, in select cases, have had very good results. The fascial flap must be based laterally, and so oriented, these flaps have been shown to be extremely reliable. Because the tunica dartos has a significant muscle component, the skin island must be carefully tailored. If these skin islands are correctly tailored at the outset, they are not attended with diverticular development as was sometimes believed in the past. Scrotal skin islands are not our first choice; however, for difficult cases, they remain a reasonable option.

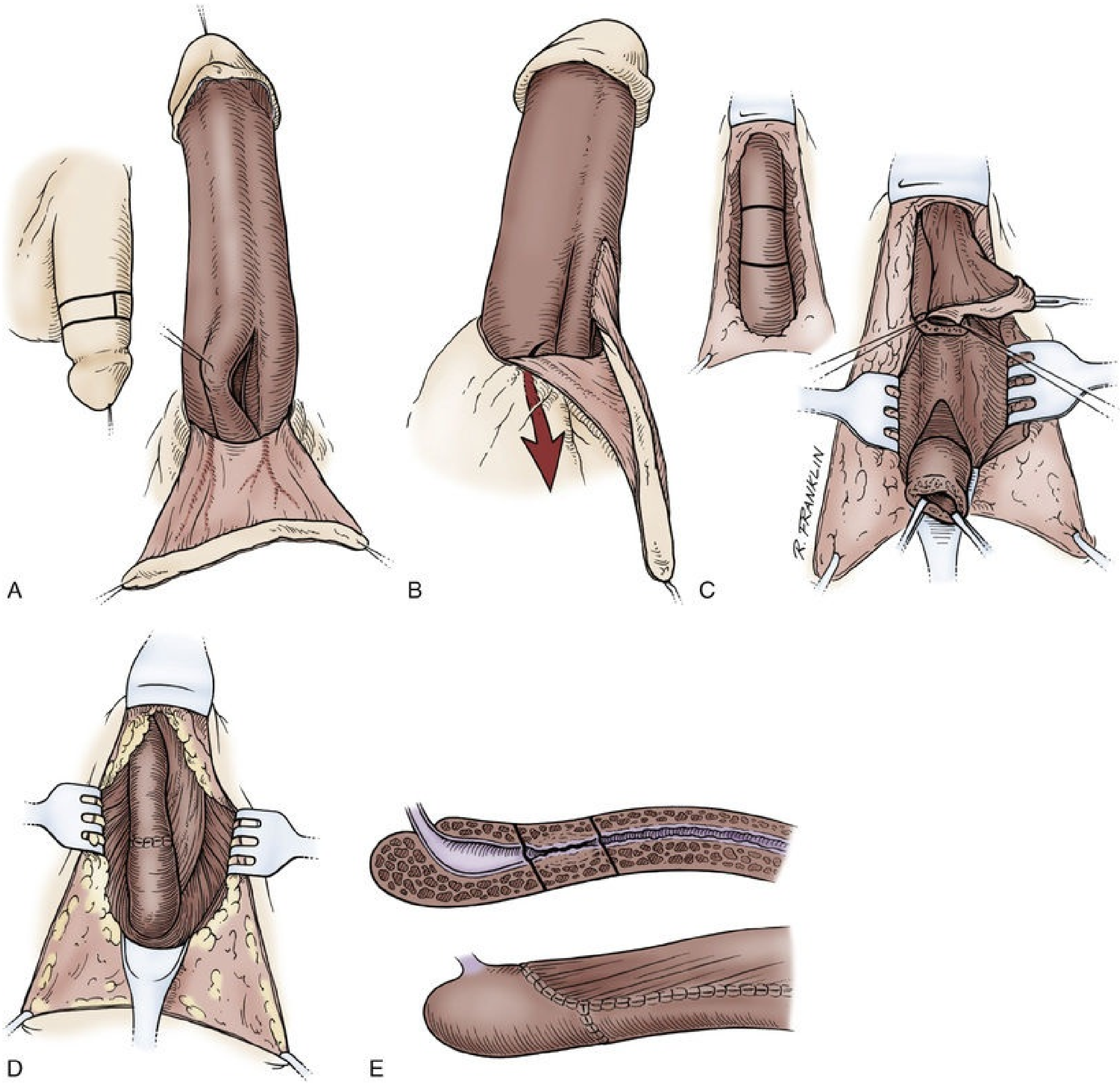

FIG. 82.30 Reconstruction in a patient with a long anterior urethral stricture with a relatively short narrow-caliber section (technique of augmented anastomosis with circular skin island). (A) A circular skin island is elevated on the dartos fascia. The patient is positioned flat on the table. (B) The skin island onlay is begun, the rest of the flap is placed into the perineal dissection, and the penis is closed; the patient is then repositioned in the lithotomy position. (C) The flap is retrieved through the perineal dissection. The narrow-caliber section is excised, and the urethra is spatulated on the dorsum. (D) The onlay is completed, and the floor strip anastomosis is closed. (E) Schematic of the surgery. (From Stack RS, Schlossberg SM, Jordan GH: Reconstruction of anterior urethral strictures by the technique of excision and primary anastomosis. *Atlas Urol Clin North Am* 5:11–21, 1997.)

These procedures using skin islands oriented on the penile dartos fascia have also been useful for reconstruction of the fossa navicularis (Armenakas et al., 1998; Blandy and Tresidder, 1967; Brannen, 1976; Cohney, 1963; De Sy, 1984; Jordan, 1987). In the past, meatal strictures and strictures of the fossa navicularis were managed with repeated dilations or sequential meatotomies. Because these meatotomies were seldom successful in the long term, techniques were developed that allowed the spatulation of random penile skin flaps into the meatotomy defects. These procedures functionally improved the results; however, the cosmetic appearance of the penis was suboptimal. With the use of skin islands elevated on the dartos fascia, excellent functional and cosmetic results became the norm. The design of these islands must take into consideration the location of hair on the shaft of the penis and the mechanics of flap transfer (i.e., transposition vs. advancement) (Figs. 82.31 and 82.32). In addition, full-thickness skin has been used to reconstruct the fossa navicularis; however, when they can be avoided, skin grafts are not considered appropriate for reconstruction in cases of LS. As already mentioned, there is question about the use of skin islands in general in patients with LS.

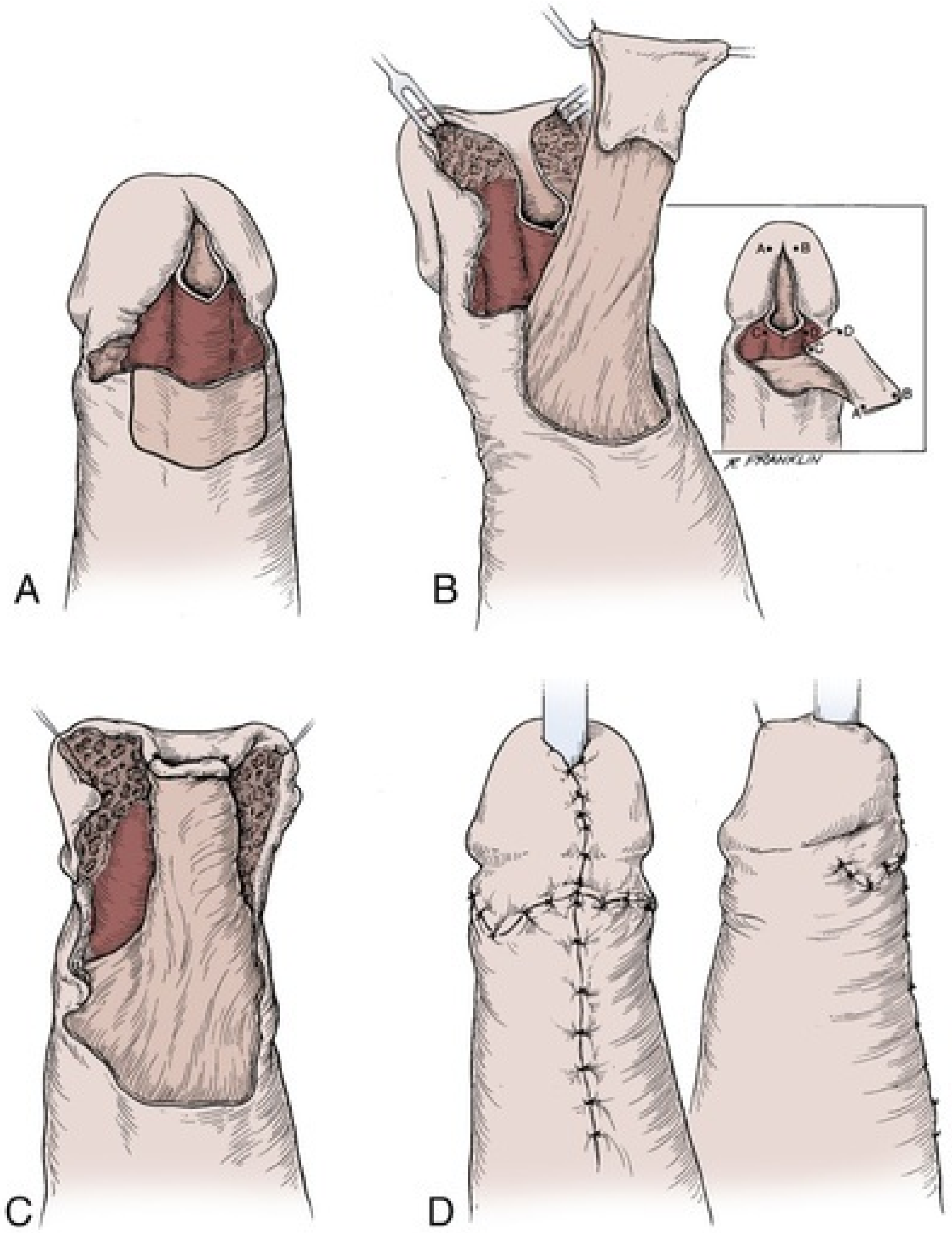

FIG. 82.31 Technique of reconstruction of the fossa navicularis after Jordan. (A) The ventral corpus spongiosum is exposed, and the urethra is opened ventrally through the area of stenosis. A transverse ventral skin island is outlined on the distal penile skin. (B) The skin island is elevated on the ventral dartos fascia. (C) The skin island is transposed and inverted into the meatotomy defect *(inset, B)*. (D) Appearance of the penis closed after the procedure. (A to C, From Jordan GH: Reconstruction of the fossa navicularis. *J Urol* 138:1210, 2987. D, From Jordan GH: Reconstruction of the meatus–fossa navicularis using flap techniques. In Schreiter F, editor: *Plastic-reconstructive surgery in urology,* Stuttgart, 1999, Georg Thieme pp 338–344.)

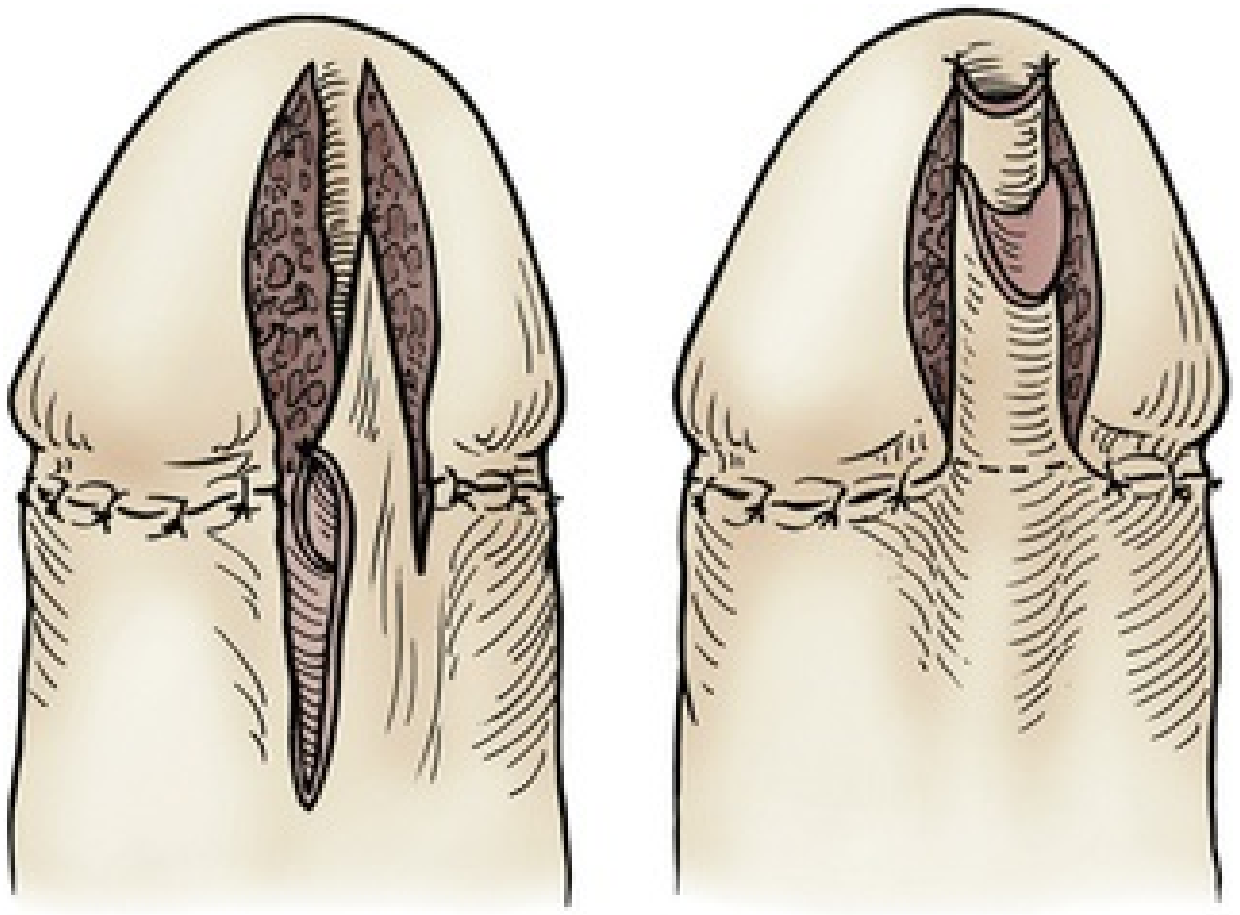

FIG. 82.32 Technique after De Sy, in which a ventral longitudinal skin island is advanced into the meatotomy defect. The skin island is developed by de-epithelialization of a portion of the longitudinal flap. (From Jordan GH: Management of anterior urethral stricture disease. *Probl Urol* 1:199–225, 1987.)

The literature is clear that onlay procedures (graft or flap) are associated with a higher success rate than tubularized grafts or tubularized skin islands (Hendren and Crooks, 1980). **Tubularized grafts and skin islands should be avoided, if possible. When tubularized segments cannot be avoided, the length of these segments can be limited by combining aggressive mobilization and excision. Without question, tubularized flaps provide better results than tubularized grafts.** Where extremely long segments of the anterior urethra require reconstruction, a flap can be used distally and augmented by graft onlay proximally (Wessells et al., 1997). Where tubed reconstruction is required, in a small series with only short follow-up, the combination of a graft spread fixed to reestablish the “urethral plate” with flap onlay seems perhaps to be better than tubed flap reconstruction, even when it is employed in the onlay-tube-onlay configuration (Morey, 2001).

More recently, Kulkarni et al. (2012) published their approach to a single-stage panurethral reconstruction. Through a perineal incision and invaginating the penis, they described using a dorsal graft from the proximal bulbar urethra to the meatus. The mean stricture length was 14 cm, and mean follow-up was 59 months. The overall success rate was 83.7%; for primary repairs, the success rate was 86.5% compared with 61.5% in patients who failed a previous urethroplasty. Most of the recurrences the authors described were proximal.

A flap procedure that can be used as an alternative to STSGs when nonhirsute skin is unavailable is the epilated midline genital skin island. Similar to a STSG, this procedure must be viewed as a staged procedure, with the epilations being the initial stage or stages. Epilation can be accomplished with either a narrow-gauge needle and monopolar cautery or epilation needles and machines. The interval between the epilations must be 6 to 8 weeks, and urethral reconstruction cannot be accomplished until 10 to 12 weeks after the last epilation. The actual stricture repair involves elevation of the midline skin island, based on the dartos fascia of the penis and the tunica dartos of the scrotum. As with nonhirsute scrotal skin islands in general, the importance of meticulous tailoring of the scrotal portion of the island cannot be overemphasized.

Mundy (1994) **analyzed a large series of urethral reconstructions. His data showed that when follow-up is limited to 1 year, the success rate with tissue transfer clusters is about 95%. However, with longer follow-up, there is deterioration over time. With excision and primary anastomosis, the success seen at 1 year seems to be more durable and does not appear to deteriorate at the same rate with time.** We have reported our long-term data for excision and primary anastomosis with anterior urethral stenosis in 220 patients with a mean follow-up of 44 months; three recurrences were noted, two within the first 6 months and a third at 4 years. The rate of postoperative ED is 2%, with patients with severe straddle injuries being at increased risk. **In a meta-analysis of graft onlay procedures compared with flap procedures, Wessells and McAninch** (1998) **showed equivalent results for graft operations and flap procedures,** and graft onlay procedures are technically far easier to perform. There are some cases in which flap reconstruction would be expected to provide superior results (i.e., radiation strictures, patients with multiple operations, pendulous strictures). However, with the increased knowledge gained by the enthusiastic application of graft reconstruction, a paradigm for anterior reconstruction has been redefined. Although grafts have been used successfully for all segments of the anterior urethra, many authors think that, all other variables being equivalent, flaps are best suited for distal reconstruction, and grafts are best for proximal reconstruction (Greenwell et al., 1999).

Postoperative ED is an important issue. Our rates for anterior urethral anastomotic reconstruction were quoted earlier. **In an analysis by Coursey et al.** (2001)**, 200 patients who underwent urethroplasty were studied. Overall, the rate of ED after urethroplasty was approximately equal to the rate after circumcision. Longer-segment reconstructions were associated with a higher risk of postoperative ED, although the patient's erectile function improved**

over time in many cases.

Special mention is needed regarding reconstruction for strictures associated with LS. With the advent of flap techniques, many centers embraced these techniques for these strictures. However, analysis of results from patients with LS treated at several large centers showed a very high recurrence rate. Consequently, these centers adjusted the techniques by applying staged graft techniques (see Fig. 82.25). Staged graft techniques using skin grafts also had a very high recurrence rate in many analyses. **Theoretically, because LS is a skin condition, the use of skin as a flap, single-stage graft, or staged graft does not preclude involvement of the skin with the inflammatory process** (Akporiaye et al., 1997; Lee and Phillips, 1994). **Surgeons at numerous centers believe that staged oral graft techniques should be employed for reconstruction of strictures associated with LS.** Short-term follow-up results suggest better success with this approach. Long-term follow-up results are unavailable. In a review of our experience in patients with a fossa navicularis stricture and LS, we noted a 50% recurrence in the stricture with a ventral transverse skin island (Virasoro et al., 2007).

Perineal Urethrostomy.

Complex urethral strictures resulting from LS, previous failed reconstructions, or failed hypospadias repairs are among the most challenging problems, requiring surgical expertise and good clinical judgment to select the appropriate intervention (Myers et al., 2011). These patients usually have a long history of multiple urethral instrumentations, urethral reconstructions or both. Particularly those patients with multiple failed hypospadias repairs or LS can be emotionally devastated; sexual function is diminished and quality of life is negatively affected (Barbagli et al., 2010; Kulkarni et al., 2009). Referral to reconstructive centers often occurs after many options have been exhausted, and appropriate procedure selection is paramount. Pananterior urethral reconstruction with multiple grafts, in one or more stages, is technically feasible and has fair success rates but may not be the optimal solution for these patients (Dubey et al., 2005). In addition, in elderly patients with significant comorbidities and high surgical risk, a complex and prolonged reconstructive surgery may not be indicated. Even for healthy and/or young patients, staged reconstruction may not represent the best option, because success rates are decreased in this group with multiple failed urethroplasties (Myers et al., 2011). For those patients a simpler and more effective urethral procedure such as perineal urethrostomy (PU) may be appropriate. The creation of a perineal urinary diversion is simple and effective (Myers and McAninch, 2011). Challenging cases are those patients who have stricture disease that continues into the proximal bulbar and/or the membranous urethra. In these instances, traditional PU cannot be successfully performed. In addition, patients with prior pelvic radiation and history of LS have a higher rate of restricture at the PU (Levine et al., 2007; Myers et al., 2011). PU creation using BMG is an alternative for these patients. This technique allows the surgeon to bring the urethrostomy to the surface of the perineum instead of burying the skin to the urethral opening. In addition, by inserting tissue into the neomeatus, it decreases the probability of circumferential scarring of the urethrostomy (Kamat, 2008). Our group, in abstract form, previously described this method (Davies et al., 2008), and more recently a combined series was published (DeLong et al., 2017).

The patient is repositioned into high lithotomy. The lower abdomen, genitalia, and perineum are prepped with betadine solution and draped in the usual fashion. An inverted U incision is created and deepened, and the bulbospongiosus muscle is identified and divided in the midline. Corpus spongiosum is freed from the triangular ligament proximally and from the corpora cavernosa distally. Once the necessary mobilization is achieved, the corpus spongiosum is transected transversely and a dorsal urethrotomy is made until healthy mucosa is encountered.

Adequate mobilization allows a healthy ventral urethra to be brought out to perineal skin rather than creating a channel comprising inwardly mobilized skin. Normal urethral mucosa is visualized, and proximal calibration of the lumen is determined with bougie à boule to 30 Fr. The distal urethra is closed and allowed to retract.

At our most recent series (Delong et al., 2017) a total of 44 patients met inclusion criteria. Mean patient age was 60 (range 44–81) years. All strictures were panurethral. Causes were unknown in 16 patients (36%), failed hypospadias repair in 6 (14%), LS in 10 (23%), iatrogenic in 7 (16%), Fournier in 3 (7%), urethral cancer in 1 (2%), and penile cancer in 1 (2%). Mean follow-up was 45 (range 6–136) months. Overall success was 80%; 9 patients recurred, of which 4 had a successful revision, 2 are awaiting potential revision, and 3 are being managed with periodic dilations.

Complex anterior urethral strictures involving the proximal bulbous urethra represent a challenging problem. BMG perineal urethrostomy is a reproducible, viable alternative in appropriately selected patients with encouraging midterm results.

Key Points: Urethral Stricture

- The term *urethral stricture* refers to anterior urethral disease and is a scarring process that involves the epithelium and the spongy erectile tissue of the corpus spongiosum. Contraction of the scar reduces the urethral lumen. Posterior urethral strictures are more correctly referred to as PFUIs; strictures of the prostatic urethra or bladder neck are properly referred to as contractures or stenoses.
- The anterior urethra is invested by the corpus spongiosum, and, as it proceeds proximally, it is eccentrically placed in relation to the corpus spongiosum. The genital skin has a dual and bilateral blood supply, forming a fasciocutaneous vascular system. The vascularity of the corpus spongiosum is based on the common penile artery.
- In general, most anterior urethral strictures are the result of trauma. Inflammatory strictures associated with gonorrhea are rarely seen; however, strictures associated with LS have behavior similar to inflammatory strictures.
- Patients who have urethral strictures most often have obstructive voiding symptoms or urinary tract infections such as prostatitis and epididymitis. Patients with urinary retention, on close inquiry, have tolerated notable voiding obstructive symptoms for a long time.
- To devise an appropriate treatment plan, it is important to determine the length, location, depth, and density of the spongiofibrosis. This determination can be done with a combination of contrast-enhanced studies, endoscopy, and selective ultrasonography. It is imperative to evaluate the urethra completely proximal and distal to the stricture with endoscopy. A pediatric cystoscope is useful.

Key Points: Treatment of Urethral Stricture

- In the treatment of urethral stricture disease, the patient and the physician must have a good understanding of the goals of treatment before the treatment choice is made.

- Urethral dilation is the oldest and simplest treatment of urethral stricture disease. However, the goal of dilation is to stretch the scar atraumatically. Dilation is seldom used curatively.
- Internal urethrotomy refers to any procedure that opens the stricture by incising it transurethrally. The factors that contribute to success of internal urethrotomy have been defined as follows: internal urethrotomy should be reserved for strictures of the bulbous urethra; the stricture should be less than 1.5 cm in length; and the stricture should not be associated with dense deep spongiofibrosis. Many studies have shown that repeated dilation and internal urethrotomies diminish the success rate of eventual open urethral reconstruction.
- Numerous lasers have been used for anterior urethral strictures. The results of laser urethrotomy are mixed.
- Excision with primary anastomosis has proven to be the gold standard for repair of anterior urethral strictures. Previously, excision with primary anastomosis was thought to be a relatively limited procedure and applicable only for strictures smaller than 1.5 to 2 cm. However, with better understanding of the anatomy, longer strictures have been successfully addressed with excision and primary anastomosis.
- Some strictures require tissue transfer, and grafts and flaps have been successfully employed. A meta-analysis by Wessells and McAninch (1998) showed that the results of graft reconstruction and flap reconstruction are equivalent. The complexity of flap procedures is greater than that of graft procedures. The concept of augmented anastomosis can be used with graft and flap onlay and is thought to provide better results than just pure onlay in many cases. When flaps are employed for urethral reconstruction, conceptually all become one operation with multidimensional application.
- Perineal urethrostomy is a viable option in selected patients, and the addition of BMG may be useful in those with very proximal bulbar strictures.

Pelvic Fracture Urethral Injuries

PFUIs are the result of blunt pelvic trauma and accompany about 10% of pelvic fracture injuries. Although total disruption of the urethra is possible with a straddle injury, these injuries most commonly involve only the bulbous urethra. However, the ensuing spongiofibrosis can be associated with complete obliteration of the urethra. **Distraction injuries are unique to the membranous urethra.** Pelvic fracture distraction injuries of the membranous urethra have been compared with plucking an apple (prostate) off its stem (the membranous urethra). This analogy implies that the injury most frequently occurs at the apex of the prostate. However, experience shows that this is not the case, and the most frequent point of distraction is at the departure of the bulbous urethra from the membranous urethra (Andrich and Mundy, 2001; Mouraviev and Santucci, 2005). The distraction can involve all or any portion of the membranous urethra between the departure of the bulbous urethra and the apex of the prostate. In postpubescent male patients, the injury seldom involves the prostatic urethra. In prepubescent male patients in whom the prostatic urethra is more fragile, the injury can extend into that area.

Total distraction of the entire circumference of the urethra appears not to occur with many injuries. Instead, a strip of epithelium is left intact. In these patients, the placement of an aligning catheter may allow the urethra to heal virtually unscarred or with an easily managed stenosis. Because of flexible endoscopy equipment, the placement of an aligning catheter is straightforward. If distraction is complete, the catheter aligns the obliterated urethral ends, and reconstruction is facilitated. Because of the ready availability of flexible cystoscopes, some centers acutely evaluate these injuries only with endoscopy. Clinicians who are enthusiastic for this approach believe that not only can the injury be completely evaluated but also the entire process, including the placement of an aligning catheter, is expedited (Kielb et al., 2001). **Aligning catheters are just what the name implies—a guide, not a mechanism for placing traction on the bladder and prostate.** Aligning catheters also seem to act as a drain as the pelvic hematoma liquefies, and perhaps the presence of the catheter may allow more rapid and complete resolution of the process (Cohen et al., 1991; Herschorn et al., 1992; Mouraviev et al., 2005; Rehman et al., 1998). Close follow-up after a voiding trial is essential because many of these patients experience stricture formation after removal of the aligning catheter and require definitive repair (Leddy et al., 2012). Some patients who have undergone primary endoscopic realignment have delayed surgical repair and increased unsuccessful endoscopic treatments, which has led some to recommend against its routine use (Tausch et al., 2014).

Evaluation

As with the repair of any stricture or stenosis, it is important to define the precise anatomy of the pelvic fracture injury before treatment is undertaken (McCallum and Colapinto, 1979a, 1979b)**; this includes the depth, density, length, and location. In pelvic fracture urethral distraction defects, the depth and density of fibrosis are predictable. Although the location of the distraction injury has been shown to be an important factor in continence after reconstruction, this information should be a factor only in counseling of patients before the reconstruction and not in the treatment approach. The length of the defect is an important consideration and must be determined as precisely as possible.**

Contrast studies are a first-line tool for the evaluation of PFUI. A cystogram outlines the bladder and provides information about rostral displacement of the proximal urethra. A lack of contrast material in the posterior urethra gives some information, albeit inconclusive, about the integrity of the bladder neck.

When the patient is successful in relaxing to void and the cystogram outlines the posterior urethra, a simultaneous retrograde urethrogram outlines the length of the injury defect. However, this situation is the exception rather than the rule, and retrograde urethrography is most useful for determining whether the anterior urethra is normal. If the anterior urethra is normal, **a successful anastomotic repair is ensured, from our experience and that of others.** A primary anastomosis has been demonstrated possible even with some involvement of the anterior urethra. Even in cases of prior failed posterior urethral reconstruction, primary anastomotic repair is often feasible, although the failure rate is slightly higher in these cases (Chapple and Pang, 1999; Flynn et al., 2003; Koraitim, 2003; Shenfeld et al., 2004). **Primary anastomosis is unquestionably the goal in all patients until it is proven impossible to perform.**

When the proximal urethra is not visualized on a simultaneous cystogram with urethrogram, endoscopy through the suprapubic tract in combination with retrograde urethrography can be used to outline the defect. After the endoscopic appearance of the bladder neck is assessed, the flexible endoscope can be advanced through the bladder neck and into the posterior urethra to the level of the obstruction. **The appearance of the bladder neck on contrast studies or on antegrade endoscopy does not accurately predict the ultimate function of the bladder neck after urethral reconstruction** (Iselin and Webster, 1999). A simultaneous retrograde urethrogram outlines the anterior urethra, with the space not visualized representing the injury defect.

Some authors have advocated MRI for the evaluation of patients with PFUIs. We have had little experience with MRI for that purpose; however, we have found the information obtained on the few studies that we have done to be useful. In these cases, there was the question of bone interposition into the injury defect, and MRI outlined this. We evaluated a case in which the prostatic urethra appeared obliterated. On MRI, one could easily see that the prostate was not only distracted from the membranous urethra but also distracted from the bladder. This information was essential to planning of subsequent reconstruction in this case. It would seem intuitively obvious that knowing the length of distraction would be helpful in determining the precise approach and steps necessary for reconstruction. However, the literature is unclear on this matter (Andrich et al., 2003; Koraitim, 2004), and the surgeon must be prepared to exercise all options of reconstruction in almost all such cases (McCallum and Colapinto, 1979a, 1979b).

Repair

The timetable for the reconstruction of PFUIs is determined by the type and extent of associated injuries. If possible, it is desirable to proceed within 3 to 6 months after trauma. However, orthopedic injuries of the lower extremities often necessitate a delay in proceeding with urethral reconstruction (Brandes and Borrelli, 2001; Follis et al., 1992; Mundy, 1991).

In most cases, PFUIs are not long, and the resultant obliteration is amenable to a technically straightforward mobilization of the corpus spongiosum with a primary anastomotic technique. The classic reconstruction consists of a spatulated anastomosis of the proximal anterior urethra to the apical prostatic urethra. However, experience has demonstrated that anastomosis of the proximal anterior urethra to any segment of the posterior urethra (apical, prostatic, or below) **can be successfully accomplished by a widely spatulated anastomosis in which**

optimal epithelial apposition is achieved. About 10% of PFUIs are associated with more complex injuries and can be associated with fistulae (most commonly urethral rectal fistulae). Reconstruction of these injuries is technically more demanding.

Several series support the concept that the bulk of PFUIs, even the most difficult cases, can be managed by the perineal approach (Flynn et al, 2003; Koraitim, 1985, 1997; Morey et al., 1996; Webster and Sihelnik, 1985; Webster et al., 1983, 1990). A transpubic or an abdominal-perineal approach, as pioneered by Waterhouse et al. (1973), in our experience, is unnecessary for the reconstruction of distraction injuries. In addition, pubectomy can be associated with long-term sequelae, including shortening of the penis, destabilization of erection, and destabilization of the pelvis, resulting in a chronic pain syndrome with exercise. However, some surgeons continue to rely heavily on the transpubic approach (Das et al., 2004; Koraitim, 1997).

Alternatively, the above-and-below approach has merit when concomitant surgery is planned in the region of the bladder neck. We have found, and Iselin and Webster (1999) reported, that the competence of the bladder neck is difficult to assess accurately before the reestablishment of urethral continuity. In the past, great reliance was placed on whether the bladder neck was closed or open on cystography. However, contrast material may opacify the prostatic urethra when the bladder neck is more than adequately competent for continence. Similarly, confidence has been placed in the appearance of the bladder neck on endoscopic examination through the suprapubic tube. Again, even when an obvious scar is noted to involve the bladder neck, follow-up of these patients after urethral reconstruction establishes continuity of the urethra and finds many patients with more than adequate continence. Other patients are believed to have incontinence secondary to scar incarceration of the bladder neck, caused by the extensive fibrosis left behind by resolution of the hematoma. However, in our experience, this is an infrequent occurrence, and the appearance of the bladder neck by any modality available is not predictive of continence. It is currently our practice to reestablish the continuity of the urethra and, when there are concerns about continence, to forewarn the patient before the urethral reconstruction. If these patients find that they experience inadequate continence postoperatively, the problem is addressed in a subsequent procedure (Bhargava et al., 2004).

At the time of reconstruction, before the patient is placed in the lithotomy position, endoscopy is performed through the meatus and again through the suprapubic tube sinus. Endoscopy on the table is designed to ensure that there is no concomitant vesicolithiasis. The endoscopy is performed with a rigid endoscope, which is manipulated through the suprapubic tube sinus and the bladder neck and positioned against the area of total obliteration. On gentle manipulation of the endoscope, if the impulse of the endoscope tip is felt on the patient's perineum, the impulse is palpable when the perineum is opened, and an instrument is manipulated through the bladder neck during reconstruction. If the impulse is not palpable perineally at this time, it may not be palpable during dissection. If unable to pass the sound easily, the creation of a temporary vesicostomy allows the surgeon to position an instrument reliably through the bladder neck, because it allows the surgeon to identify the bladder neck palpably before instrumentation of the posterior urethra. This maneuver has eliminated the occurrence of false passages with use of a sound such as the Haygrove staff through the suprapubic site and has eliminated the occurrence of anastomosis to false passage.

As we mentioned previously, some centers use the cystoscope for this purpose, and often it suffices well, and even some centers use a hollow Haygrove (Gelman Urethral Sound, CS Surgical) that allows the passage of the flexible cystoscope through to better visualize the bladder neck (Gelman and Wisenbaugh, 2015).

We prefer the use of the exaggerated lithotomy position for the perineal approach (Fig. 82.33). This position is safe and provides optimal exposure to the area of the membranous and apical prostatic urethra (Angermeier and Jordan, 1994). The legs are carefully positioned in Allen-style or Guardian-style stirrups. Care is taken to avoid pressure on the lateral aspects of the lower extremities and calf muscles. The patient's hips are elevated into position by raising the buttocks portion of the operating table. The boots are positioned to avoid stretch injuries of the common peroneal nerves (see Fig. 82.33).

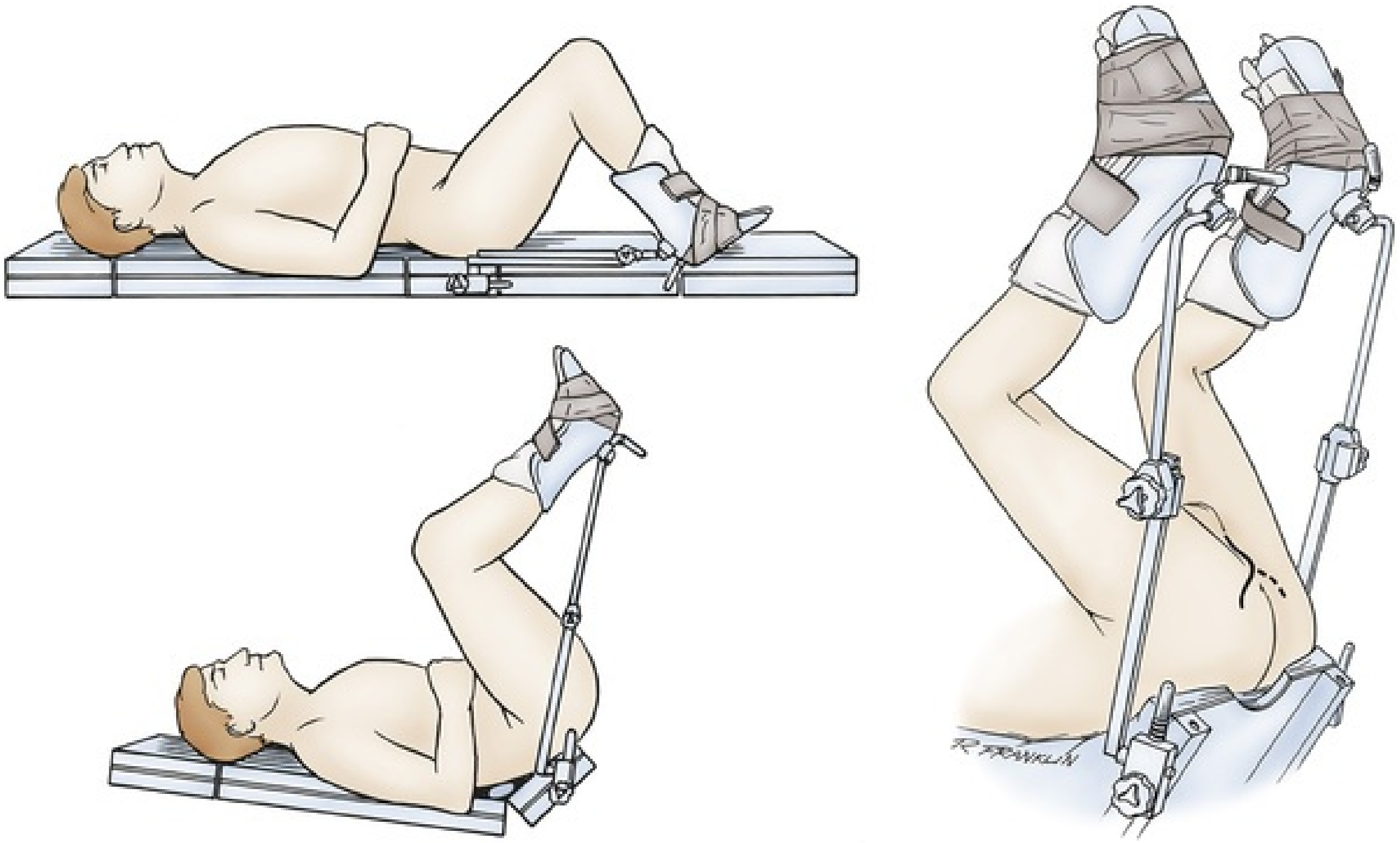

FIG. 82.33 Patient placed in an exaggerated lithotomy position. The hips have been rotated into position by elevation of the buttocks portion of a specially modified table. The legs are suspended from boot-style stirrups with as little flexion of the hips and knees as allowed by the design of the stirrups. (From Angermeier KW, Jordan GH: Complications of the exaggerated lithotomy position: a review of 177 cases. *J Urol* 151:866–868, 1994.)

After the patient is correctly positioned, the perineal approach to reconstruction begins with an incision and dissection anterior to the transverse perineal musculature (anterior perineal triangle). This is in contrast to the approach posterior to the transverse perineal musculature (posterior anal triangle), which is useful for perineal prostatectomy. We use a λ-shaped incision (Fig. 82.34) that is carried sharply down to the midline fusion of the ischiocavernosus musculature (see Fig. 82.34A), then beneath the scrotum, to expose the uninvested portion of the corpus spongiosum. We then place a self-retaining ring retractor.

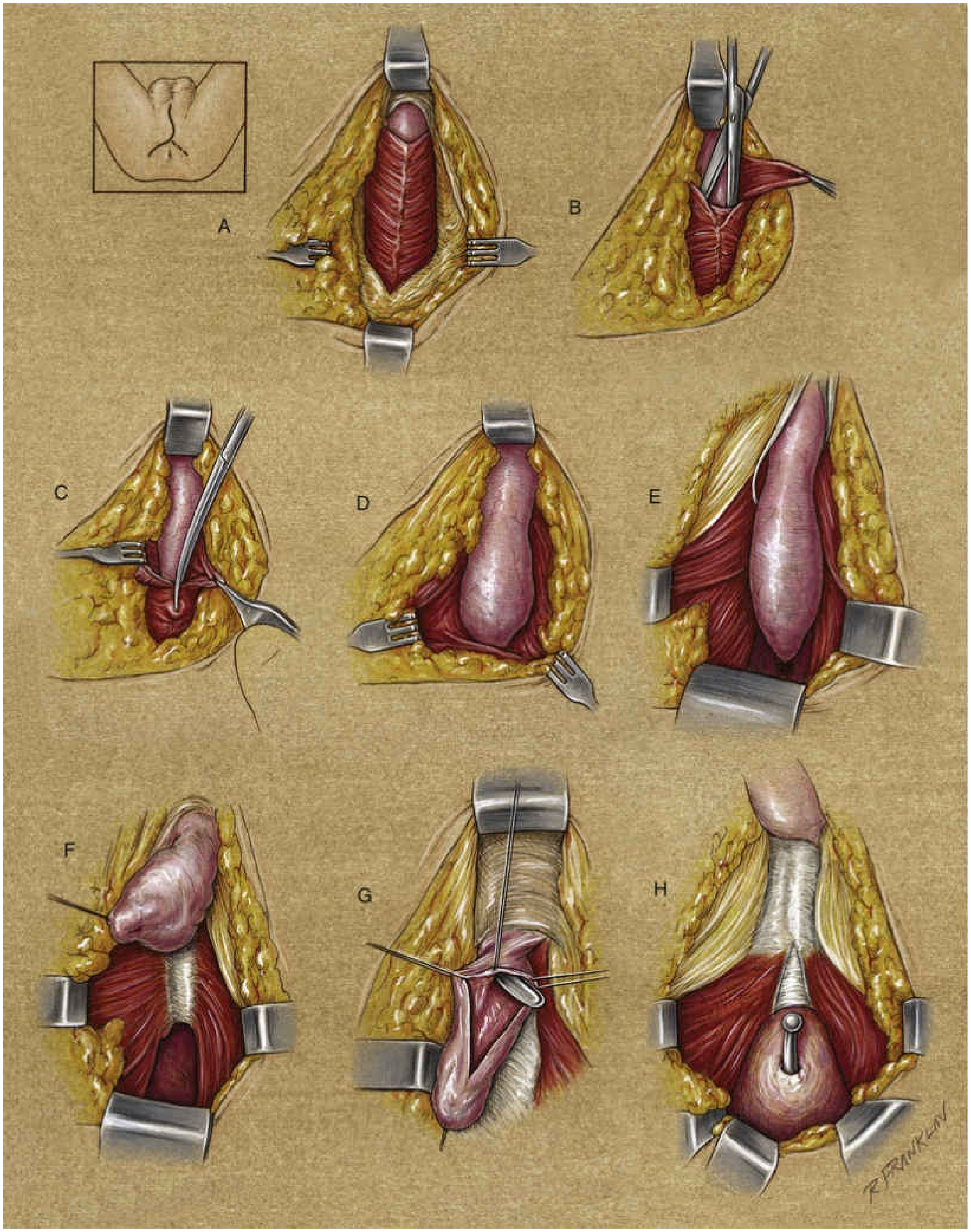

FIG. 82.34 Perineal repair of a membranous urethral stricture. A λ-shaped incision extends from the midline of the scrotum to the ischial tuberosities. (A) Colles fascia has been opened to expose the midline fusion of the ischiocavernosus muscles and the tunica of the corpus spongiosum distal to the edge of the muscles. (B) The scissors are introduced to develop the

space between the muscle and the bulb of the urethra. (C) An incision is made in the midline with the scissors, exposing the length of the bulb. (D) The ischiocavernosus muscle is retracted to expose the full length of the bulb. (E) The self-retaining retractor is placed to expose the inferior fascia of the genitourinary diaphragm. The bulb of the corpus spongiosum (bulbospongiosum) can be mobilized to gain access to the fibrosed area of the urethra. (F) The fibrosed urethra is incised, freeing the bulb. (G) The anterior urethra is opened to make an adequate lumen. (H) The Haygrove staff has been passed through the suprapubic cystostomy. Resection of the fibrotic distraction defect has allowed it to pass into the perineum.

The fusion of the ischiocavernosus musculature is divided, and the musculature is cleanly dissected from the corpus spongiosum and bulbospongiosum (see Fig. 82.34B to D). The corpus spongiosum is detached from the triangular ligament and corpora cavernosa (see Fig. 82.34E), the bulbospongiosum is detached from the perineal body, and the dissection is carried farther down to the infrapubic space. Posterior detachment of the bulbospongiosum is carried anteriorly, and the dissection is eventually carried through the area of fibrosis (see Fig. 82.34F).

In some cases, the proximal blood supply is encountered and must be controlled. We have found that these arteries are easily controlled with a sharp-tipped hemostat and monopolar cautery. Suture ligature should be avoided in the arteries to the bulbospongiosum because of their proximity to the nerves as they are coursing into the corpora cavernosa. Recently, vessel sparing repair of a PFUI has been described with good result (Gomez et al., 2016).

We divide the triangular ligament and vigorously develop the intracrural space down to the pubis (Fig. 82.35). If the dorsal vein is encountered, it is ligated and divided. It is important to ensure that the arteries were not rolled into the intracrural space if the tissues were dislocated during trauma. The penetration of the cavernosal arteries or the dorsal arteries, or both, into this space is commonly seen. If there is doubt about the nature of the vessels encountered, Doppler sonography should be performed. When the pubis is exposed, the periosteal elevator can be gently introduced onto the retropubic surface, releasing and allowing the descent of the tissues from beneath the pubis.

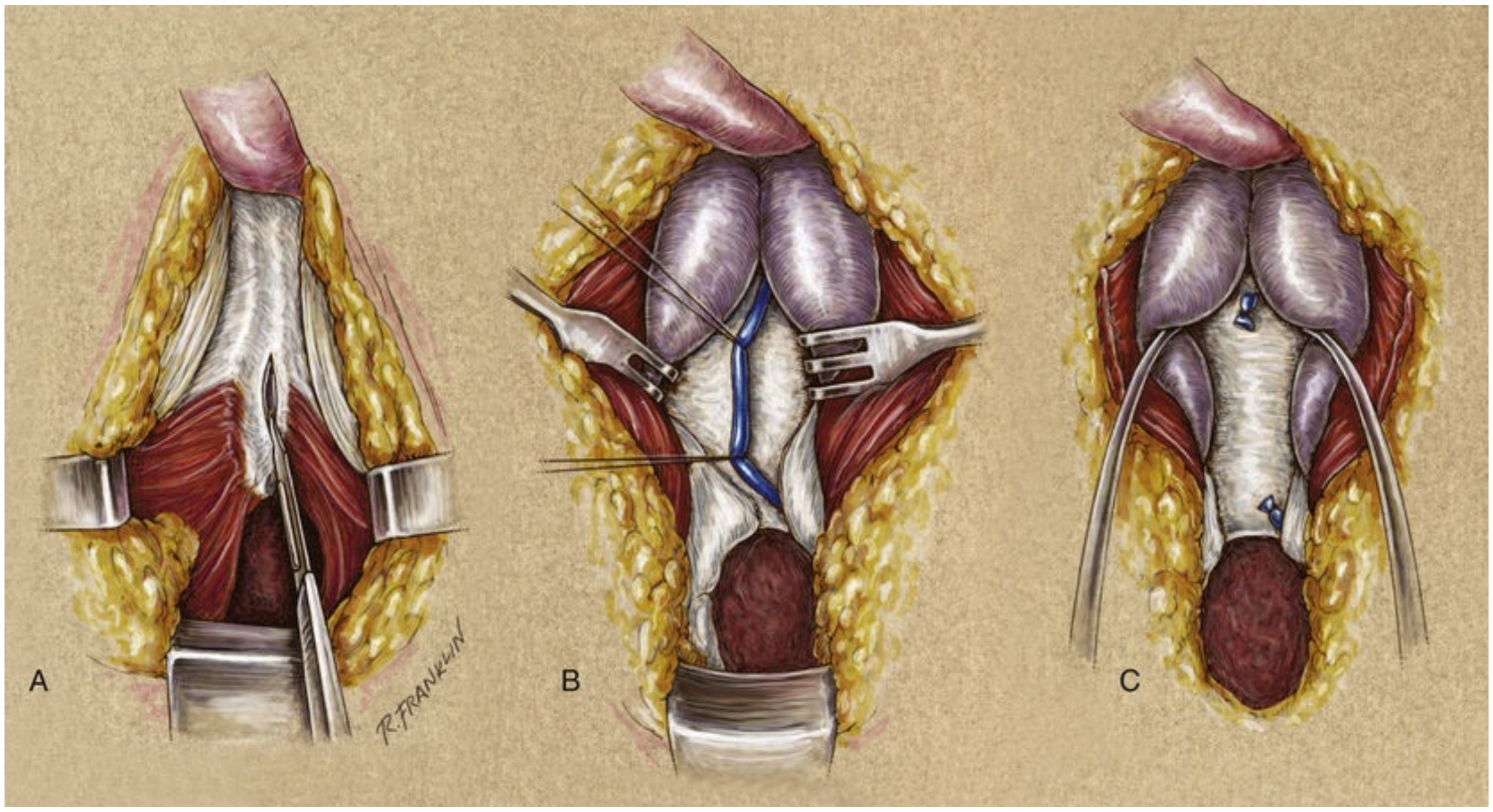

FIG. 82.35 Division of the triangular ligament and development of the intracrural space. (A) When the prostatic urethra is displaced and the arc that the urethra must traverse must be shortened, that length can be shortened by incision of the triangular ligament. (B) Incision and mobilization of the perichondrium and periosteum of the symphysis pubis to allow placement of retractors without trauma to the erectile bodies. Lateral displacement of the crura exposes the dorsal vein of the penis; after careful identification, the vein can be ligated and divided. (C) Completion of the dissection affords additional exposure for resection of the fibrosis that surrounds the apex of the prostate and the proximal end of the disrupted urethra. (From Jordan GH: Reconstruction of the meatus–fossa navicularis using flap techniques. In Schreiter F, editor: *Plastic-reconstructive surgery in urology*, Stuttgart, 1999, Georg Thieme, pp 338–344.)

We introduce a Haygrove staff into the suprapubic sinus and through the bladder neck to the distal limits of the posterior urethra (see Figs. 82.34G and H). The impulse is palpated, and the fibrosis is resected until normal tissue planes are encountered. The tissue is submitted for histologic examination. The tip of the Haygrove staff is eventually concealed only by the normal urethral epithelium, at which point we open the epithelium and control it with either a skin hook or a stitch. We perform endoscopy to ensure that the urethrotomy is at the distal limits of the posterior urethra. If a tension-free anastomosis is determined impossible, we mobilize the corpus spongiosum beneath the scrotum from its attachment to the corpora cavernosa. Aggressive mobilization of the corpus spongiosum is the last maneuver undertaken because it is thought to have possible ill effects on the retrograde blood supply, which, in a patient with pelvic fracture, may be tenuous. Meticulous detachment of the investment of Buck fascia from the corpus spongiosum increases the compliance of the corpus and limits the need for aggressive mobilization.

The surgeon should try to avoid the creation of chordee during the repair of a distraction injury. To prevent chordee, the attachment cannot be carried beyond the area of the penoscrotal attachment. However, it is warranted in some cases to counsel patients preoperatively that they may have some chordee after aggressive mobilization that results in a primary anastomotic repair. Primary anastomotic repairs have success rates in the high 90% range. If a technique of tissue transfer is needed, the long-term cure rates may eventually be only in the mid-80% range. Most of these patients are young. Successful, durable reconstruction is paramount. If chordee results, it is most often mild and not disabling sexually; it is probably a fair trade for optimizing the urethral reconstruction. Development of the intracrural space—mobilization of the corpus spongiosum, infrapubectomy, and, if needed, rerouting of the corpus spongiosum—shortens the course that the corpus spongiosum must traverse and allows reconstruction without attendant chordee.

The proximal urethrotomy is spatulated so that it accepts at least a 32-Fr bougie à boule, and 10 to 12 anastomotic sutures are placed and tagged to allow identification of their position in the proximal anastomosis. We have used a combination of 3-0 Monocryl and 3-0 polydioxanone sutures for this purpose. No special needles are required for the placement of these sutures. However, a Heaney needle driver and a Ravitch needle driver can be useful in difficult cases. After spatulation of the proximal urethrotomy and placement of the sutures, we spatulate the proximal portion of the anterior urethra. The spatulation is continued until the urethrotomy accepts a 30-Fr to 32-Fr bougie à boule and the anastomotic sutures are placed in their respective locations. Before seating the anastomosis, we introduce a soft silicone (Silastic) ribbed urethral stenting catheter through the anastomosis under direct vision. The wound is copiously irrigated to reduce the clot around the area of the anastomosis, and the anastomosis is seated.

Next, we reattach the corpus spongiosum to the corpora cavernosa and the bulbospongiosum to the perineal body. We place a small suction drain deep to the closure of the ischiocavernosus musculature and Colles fascia and a second one superficial to that closure and beneath the subcutaneous closure.

In cases in which the proximal urethra is significantly distracted in a rostral direction, the surgeon must be prepared to perform infrapubectomy (Fig. 82.36) or corporal rerouting, or both (Fig. 82.37). Performance of the infrapubectomy, along with the development of the intercrural space, allows exposure of the apical prostatic urethra. When the prostatic urethra remains rostrally displaced, the impulse of the sound or instrument placed through the cystostomy tract into the bladder neck is often not readily apparent. In these situations, it is reassuring to be able to palpate the bladder neck and the properly placed sound before embarking on a dissection beneath the pubis. In addition, if the rostral distraction is significant, the path of the anterior urethra over the hilum of the penis into the infrapubectomy often does not allow a tension-free anastomosis, and the infrapubectomy can be continued beneath one side of the corpora cavernosa, allowing rerouting of the corpus spongiosum (see Fig. 82.37).

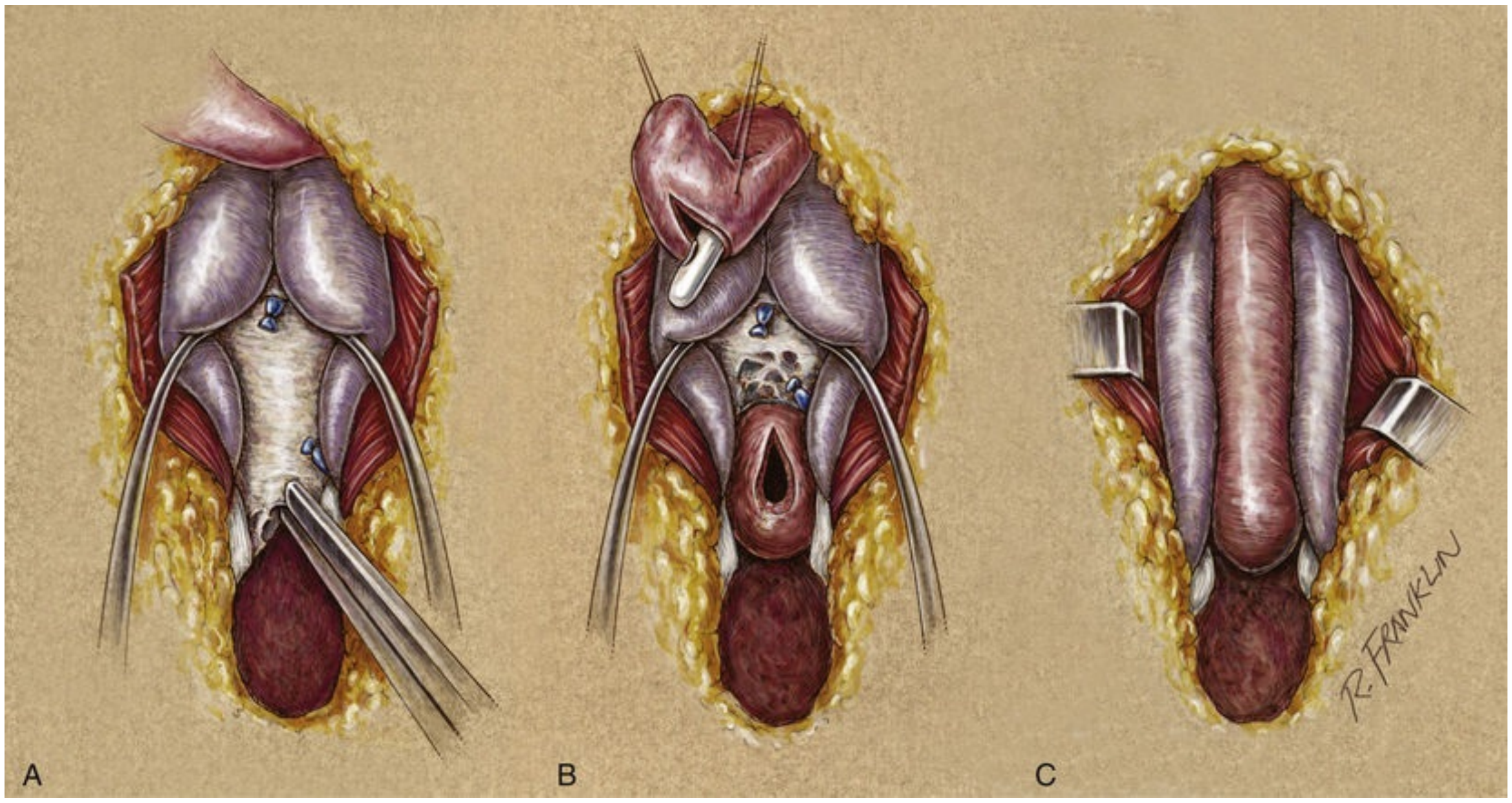

FIG. 82.36 Infrapubectomy. If the prostate is elevated behind the symphysis pubis (A), the inferior aspect of the symphysis is resected with a Kerrison rongeur. As much of the bone can be removed as necessary (B) to afford a simple approximation of the ends of the urethra (C).

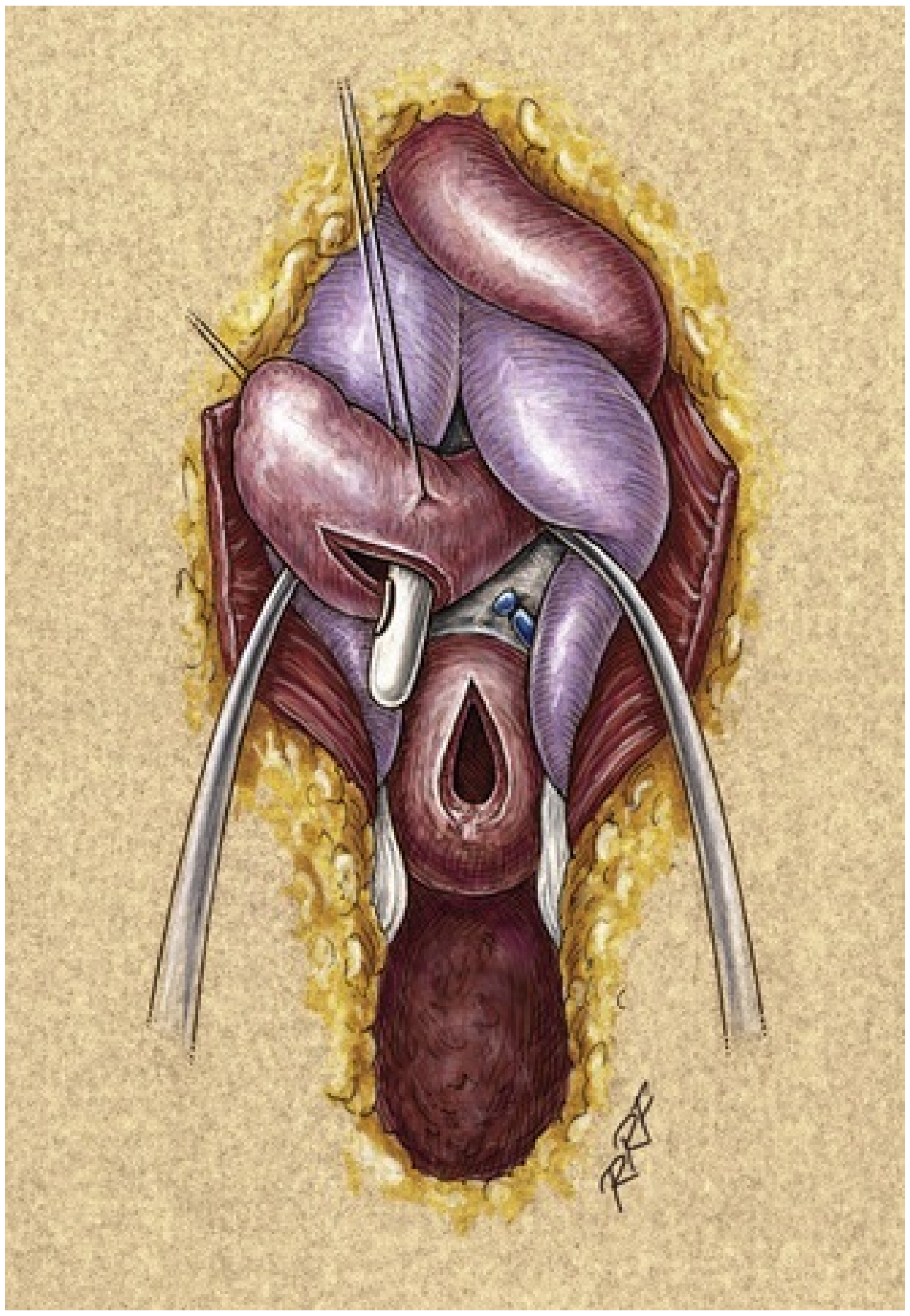

FIG. 82.37 Resection of the pubis and rerouting of the urethra around the crus. When the prostate is markedly displaced, it may be necessary to expand the infrapubectomy. Sometimes, despite separation of the crura to the full extent possible, the two ends of the urethra do not meet when they are brought directly through the crus. It is necessary to bring the urethra lateral to one of the crura to make up this length.

Postoperative Management

We use a small soft silicone (Silastic) stenting catheter. Urine is diverted via the suprapubic cystostomy, and the urethral catheter is plugged and serves as a stent only. After the reconstruction, patients are initially kept in the hospital for 24 to 48 hours and then ambulated and discharged. Patients are discharged on a regimen of oxybutynin and a suppressive antibiotic only if the preoperative urine culture was positive.

A voiding trial with contrast material is performed between 21 and 28 days postoperatively. Patients are directed to stop taking oxybutynin 24 hours before the voiding trial. In anastomoses that are technically straightforward, the trial is performed at 21 days, and in cases with more rostral distraction of the proximal urethra, the trial is delayed for 3 to 5 days longer. The trial involves removing the urethral catheter, filling the patient's bladder with contrast material, and instructing him to void. We do not use pericatheter retrograde urethrography to evaluate patients who have undergone urethral reconstruction. The voiding film is examined to ensure that there is no extravasation and that the reanastomosis appears widely patent. A urine culture specimen is also obtained. Approximately 6 months postoperatively the patients are evaluated with flexible endoscopy. At that time, we consider the reconstruction to be mature, and it should be widely patent.

We have almost completely replaced postoperative retrograde studies with flexible endoscopy.

With the use of the techniques discussed or similar techniques, curative rates for reconstruction of posterior PFUIs are in the high 90% range. In large centers, failures are not due to technical problems (i.e., anastomotic restenosis). In general, failures are indicative of ischemia of the proximal corpus spongiosum with ensuing stenosis of the mobilized corpus spongiosum. This occurs because, with mobilization, the corpus spongiosum, in essence, becomes a flap with the vascular pedicle being the retrograde vascularity from the arborization of the dorsal arteries through the glans (Fig. 82.38).

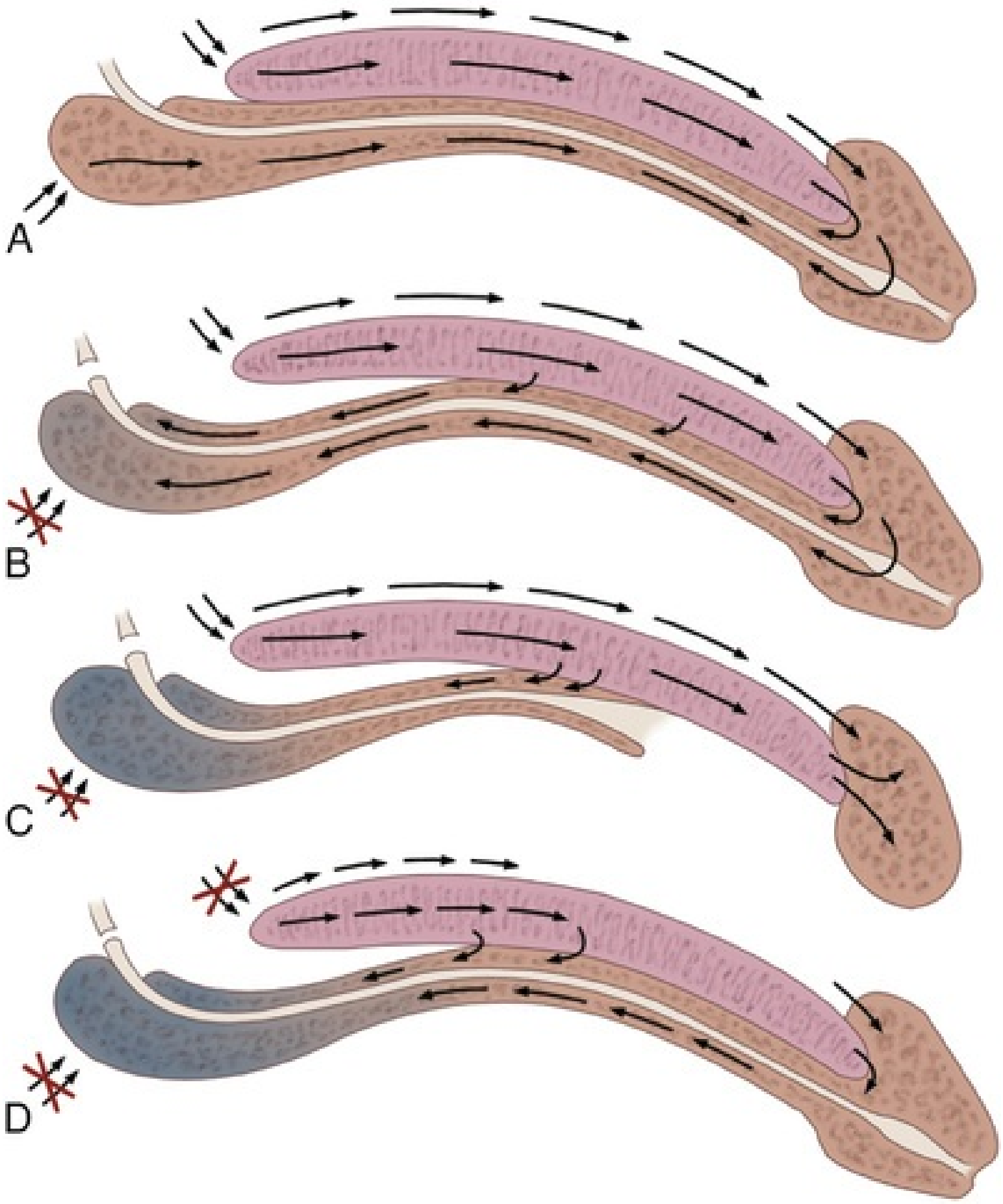

FIG. 82.38 Diagrammatic representation of the deep vasculature of the penis. (A) In the normal situation, through the common penile artery, flow is directed to the tip of the penis with arborization into the spongy erectile tissue of the glans penis. This provides retrograde flow into the corpus spongiosum. If the arteries of the bulb are intact, there is also antegrade arterial flow to the corpus spongiosum. (B) With interruption of the arteries to the bulb and mobilization of the corpus spongiosum, all flow to the corpus spongiosum is retrograde through the common penile arterial system. (C) In hypospadias, the distal corpus spongiosum may have been interrupted, with proximal mobilization of the corpus spongiosum and division of the arteries to the bulb. Even if the common penile circulation is intact to the tip of the penis, it may not adequately provide retrograde vascularity to the corpus spongiosum; ischemic stenosis can ensue. (D) In the case of injury to the common penile artery, with elevation of the proximal corpus spongiosum and division of the arteries to the bulb, blood flow to the proximal corpus spongiosum may be inadequate, leading to ischemic necrosis or ischemic stenosis.

We have studied this phenomenon in trauma patients and have arrived at conclusions that we believe allow us to predict the patients at risk for this ischemic atrophy phenomenon. Initially, we used pudendal angiography to study all trauma patients who seemed to be at risk for bilateral deep internal pudendal artery injury at the time of trauma. These were patients who had evidence of injury to the dorsal penile nerves, patients in whom reconstruction had failed at other centers, patients with lateral impact pelvic fractures, and patients whose pelvic fractures were of the “windswept” variety (Brandes and Borrelli, 2001). We found that many patients had evidence of either unilateral or bilateral pudendal artery lesions, but that most had evidence of vascular reconstitution. **Patients with an intact pudendal artery on one side often were potent and were reliably cured with reconstruction. Patients with only reconstituted vessels, either unilateral or bilateral, never were potent but were reliably reconstructed.** We found that these patients were optimal candidates for penile arterial revascularization to improve potency. Because we noted this relationship to potency, we began evaluating patients with duplex ultrasonography. We found that patients with normal unilateral or bilateral pudendal arteries demonstrated normal arterial parameters on duplex evaluation. Patients with only reconstituted bilateral or unilateral arteries never had normal arterial parameters on duplex ultrasonography.

This information allows us to proceed to pudendal angiography only in patients with abnormal arterial parameters on duplex ultrasonography; patients with normal findings on ultrasonography predictably do well with reconstruction. Our data also show that patients do well with reconstruction if they have at least one side that is reconstituted, and the only patients at risk for ischemic stenosis are patients with bilateral complete obstruction of the internal pudendal vessels. In such patients, we perform penile arterial revascularization to augment the vascularity and, with that accomplished, proceed to urethral reconstruction (Davies et al., 2009; Jordan, 2005; Zuckerman et al., 2012). In many cases of pelvic fracture urethral distraction defects, ED is a consequence of the injury, although ED clearly results from the reconstructive surgery in some patients. We think that the incidence of injury to the pudendal arteries is drastically under-reported and under-recognized. We and others believe that in many of these cases, the cause of ED is vascular (Brandes and Borrelli, 2001). However, there are at least a portion of patients with neurogenic ED after PFUI; some men experiencing ED after PFUI have normal arterial inflow (Metze et al., 2007; Shenfeld et al., 2003).

Summary

Using the maneuvers outlined, we have found that almost all distraction injuries can be reconstructed through a perineal approach with an anastomotic technique. Although the above-and-below approach is used when concomitant bladder neck surgery is performed, the inability to identify these patients accurately has led us to perform bladder neck surgery at a second setting. We have abandoned a transpubic approach as applied to posterior urethral distraction injuries.

Although we favor primary reconstruction of posterior urethral distraction injuries, other authors choose to manage these injuries endoscopically (Barry, 1989). We have found that the endoscopic management of PFUIs is not a simple procedure and must be undertaken only by a skilled and experienced surgeon. Many of these procedures can be categorized as a “cut-for-light” procedure. Although some surgeons report success, most cut-for-light procedures are not done with sufficient precision to allow adequate realignment of the urethra. We have seen many disasters that have resulted from these procedures and in most cases condemn the use of these modalities. In addition, no cut-for-light series compares favorably, with regard to long-term success rates, with series from large centers that use primary anastomotic techniques (Levine and Wessells, 2001).

In 1989 Marshall described his method of using stereotactic techniques for endoscopic alignment of the ends of the urethra. He emphasized the length of time it takes to obtain precise alignment before undertaking the endoscopic portion of the procedure. In his procedure, he passed a wire through the aligned ends of the urethra, minimally dilating the channel and widening it with transurethral resection. The scar is stabilized by a period of self-catheterization. Although technically feasible, this approach has limited applicability for most patients. Patients whose medical condition, age, or concomitant orthopedic injury prevents them from being placed in the exaggerated lithotomy position or reconstructed using a transpubic approach may be managed with this technique.

In children, the goals of surgery are the same as in adults. In our experience, most children can undergo reconstruction by the same perineal exposure as used in adults. Exposure is more difficult, but nonetheless perineal anastomosis can be done (Hafez et al., 2005). However, the posterior, sagittal transsphincteric approach has been proposed as a better approach in children (Mathews et al., 1998; Peña and Hong, 2004). We agree that the posterior approach is an elegant method of exposure; however, with this approach, we have observed that surgeons tend to resort to techniques of substitution reconstruction where primary anastomosis could be done and, in our opinion, is superior. With our growing experience using the vessel-sparing approach to anterior urethral reconstruction—primary anastomosis and augmented anastomosis—we have extended the technique to select patients with pelvic fracture urethral reconstruction and have found the approach feasible with good results in a small number of patients. However, the advantage has not been proven.

Key Points: Distraction Injuries of the Urethra

- Urethral distraction injuries are the result of blunt pelvic trauma and accompany about 10% of pelvic fracture injuries. In many injuries, there does not appear to be total distraction of the entire circumference of the urethra; instead, a strip of epithelium may be left behind.
- The use of aligning catheters acutely is controversial, but most clinicians would agree that the aligning catheter, at the very worst, facilitates subsequent reconstruction and, at best, often leaves the patient with an endoscopically manageable stenosis.
- As with any stricture, it is important to define the precise anatomy. The combination of contrast-enhanced studies with endoscopy and selective MRI is useful. The appearance of the bladder neck on contrast-enhanced studies or on antegrade endoscopy is not predictive of ultimate function of the bladder neck. Simultaneous reconstruction of the bladder neck and the posterior urethra is usually not undertaken at the present time.

Vesicourethral Distraction Defects (Vesicourethral Stenosis)

Enthusiastic use of radical prostatectomy has led to increasing experience with patients who have had total obliteration of vesicourethral anastomosis. In some patients, there is distraction of the vesicourethral anastomosis with either a totally obliterating distraction defect or severe anastomotic stenosis. With increased use of robotic-assisted laparoscopic techniques we have seen a decrease in the number of significant anastomotic stenoses, and other authors have shown this as well (Breyer et al., 2010). This improvement may be secondary to reduction in anastomotic urine leaks, better mucosal apposition, and the running anastomosis allowed with the magnification and dexterity using the robotic approach.

As with other defects, it is important to determine the length of the defect accurately. This can be accomplished by simultaneous cystography with retrograde urethrography, simultaneous retrograde urethrography, and antegrade endoscopy through the suprapubic tube, or both.

Numerous options are available for the management of these complex patients. Many of these patients have other medical problems, and it has been our observation that many have thick and small bladders, possibly contributing to the difficulty with the initial surgery. The ever-present issue of body habitus also must be considered and, in our opinion, contributes to problems with the initial anastomosis. An indwelling suprapubic tube must always be considered an option. In a patient who is significantly overweight, the results of aggressive reconstruction have not been good. The place for endoscopic techniques is covered later in this section; however, in the case of short-length distractions, we have had success with aggressive incisions at the 3 o'clock and 9 o'clock positions followed in approximately 3 weeks with repeated incisions. Whether the holmium laser is better than the cold knife can be debated; the hot knife is unnecessary. If the urologist must “core through” to establish continuity, endoscopic procedures are not appropriate, in our opinion, except as discussed later. Vanni et al. (2011) published their experience with radial urethrotomy and intralesional injection of mitomycin C. They had an initial success rate of 72% in patients with recalcitrant strictures.

In some cases, a continent catheterizable bladder augmentation may be a better operation than aggressive functional reconstruction; in an obese patient, construction of a functional catheter channel can be difficult. Diversion must also be entertained, and in patients in whom functional reconstruction is not an obvious choice, it becomes a primary option.

If functional reconstruction is deemed possible, we think it is a reasonable choice, and our technique is as follows. We place the patient in a low-lithotomy position and use an abdominal-perineal combined approach. We make a lower midline incision, exposing the bladder and dissecting it from the lateral sidewall and further mobilizing the anterior bladder from beneath the pubis as aggressively as can be safely undertaken from above. We then open the peritoneum and develop the retrovesical space, again taking care to complete the dissection as safely as can be accomplished from above.

A second surgeon begins the perineal dissection by a curvilinear perineal incision similar to that used for a radical perineal prostatectomy. The dissection is posterior to the transverse perineal musculature (posterior anal triangle) and carried along the anterior rectal wall to the area where fibrosis is encountered from the prior radical prostatectomy dissection. The impulse of the perineal surgeon's finger can usually be felt adjacent and lateral to the area of fibrosis and distraction at this point. In addition, the abdominal surgeon places a finger at the limits of the retrovesical dissection from above to provide another palpable landmark and to ensure a safe dissection anterior to the rectal wall and posterior to the bladder and trigone. The perineal dissection is joined to the abdominal dissection, and the rectal wall is completely peeled off the area of fibrosis associated with the distraction defect. We place drains between the rectum and the distraction defect, encircling the area of fibrosis.

The dissection beneath the pubis is made easier by the excision of an ellipse of the rim of the superior pubic ramus. Total pubectomy is not required. Partial pubectomy can be performed with the reciprocating attachment of the Aesculap surgical drilling device (Aesculap, Tuttlingen, Germany); this makes placement of the sutures technically straightforward and improves the exposure for the dissection and resection of the distraction fibrosis.

At this point, the bladder is opened, and the area of the bladder neck is determined. A sound is placed and advanced to the area of obliteration; this allows us to resect the well-defined area of fibrosis completely. The urethral stump is exposed and opened, and the site of the neobladder neck, having been identified, is opened. We marsupialize the bladder epithelium as described by Eggleston and Walsh (1985), place anastomotic sutures in the urethral stump, and pass a stenting catheter.

Before the vesicourethral anastomosis is seated, the omentum is mobilized and placed between the posterior wall of the anastomosis and the anterior rectal wall. We seat the anastomosis and wrap the omentum around the area of anastomosis, tagging it into place. The lateral vesical spaces are drained with closed suction drains, and a suprapubic tube is left in place when the vesicostomy is closed. More recently we have been doing this procedure purely perineally with similar outcomes.

Postoperative care is the same as for a radical prostatectomy. Patients are discharged when their drainage and ambulation allow and their diet has been resumed. We evaluate patients 4 to 6 weeks postoperatively, with the stenting urethral catheter removed and the bladder filled by way of the suprapubic tube.

Our series continues to grow, and we continue to have excellent success in reconstruction. We have some patients who deem their continence adequate for their lifestyle; in the others, we have been successful with the placement of an artificial sphincter.

Complex Fistula of the Posterior Urethra

The increase in the performance of radical prostatectomy has also led to an increased incidence of vesicorectal or vesicourethrorectal fistulae. In most cases, these are small and managed by a transperineal, transanal-transsphincteric, or posterior approach. However, some cases are complex, with the fistulae associated with large granulated cavities. The problem is magnified when radiation (brachytherapy, external beam therapy, or both) is part of the equation. With radiation fistulae, surgeons at many centers use diversion with ileal conduit or bowel pouch instead of functional reconstruction. These cases have also been managed with the approach described earlier for vesicourethral distraction problems. However, the omentum serves an even more important purpose in these cases. In addition, with the increasing application of “minimally invasive” modalities for carcinoma of the prostate (i.e., brachytherapy, combined brachytherapy with external beam irradiation, higher dose external beam irradiation, and cryotherapy), the magnitude of complexity of these problems of prostatic urethral fistulae, granulated cavities, and severe rectal injury continues to increase. We have tried to approach these problems aggressively, with preservation of function where possible.

In many of these cases, salvage prostatectomy can be combined with rectosigmoid resection. In some cases, we have successfully reanastomosed the bladder to the membranous urethra. Preservation of continence has been mixed. In cases in which vesicourethral anastomosis is impossible, a urachal-peritoneal flap combined with a rectus abdominis muscle flap is used to bolster the closed bladder neck and to keep the closed bladder neck from sticking to the back of the pubis. The bladder is augmented, and a continent catheterizable channel is developed. In some cases, the continuity of the colon cannot be reestablished, and a colostomy is performed as distally on the descending portion of the colon as possible. Whenever continuity of the colon can be reestablished, a J-pouch coloanal anastomosis is done. Omentum is used to envelop the rectal closure or to separate the rectal closure from the vesicourethral anastomosis. The combined abdominal-perineal approach that was previously described provides excellent safe exposure for management of these complex situations. The morbidity associated with this approach has been acceptable.

Zinman reported a 10-year experience with the management of rectourethral fistulae (Vanni et al., 2009). The series comprised 33 patients who had fistulae and who had not undergone irradiation and 33 patients who had undergone irradiation. Mean follow-up for the entire series was about 20 months. The review was a retrospective review taken from office records and hospital records. All fistulae were repaired by an anterior transperineal approach using gracilis muscle interposition flaps and in some cases with a buccal graft. In this series, 100% of the nonirradiated fistulae were successfully closed with a mean follow-up of 20 months, 85% of the irradiated fistulae were closed in a single stage, and 12% required an additional procedure, with an ultimate closure rate of about 97%. In the nonirradiated group, there were no urethral strictures noted with long-term follow-up; five recurrent strictures were noted in the irradiated group. In the nonirradiated group, 91% of the patients had their bowel undiverted. In the irradiated group, 39% had long-term bowel diversion. Zinman believes that the use of muscle interposition flaps are integral to achieving good results, and the use of buccal mucosal grafts, where needed to augment the closure of the urinary tract, was also believed to be invaluable (Vanni et al., 2009). An estimation of ultimate urinary and bowel function is integral to the determination of the plan for reconstruction or diversion, or both. Also, the surgical approach chosen facilitates and limits options (i.e., of the bowel, the urethra, or tissue interposition) (Lane et al., 2006).

Key Points: Vesicourethral Distraction Defects and Complex Fistulae of the Posterior Urethra

- Vesicourethral distraction defects are a complication of radical prostatectomy.
- There are many options for management of these complex patients. An indwelling suprapubic tube must always be considered a long-term option. Likewise, in some cases, a continent catheterizable bladder augmentation may be a better operation than aggressive functional reconstruction. If functional reconstruction is deemed reasonable, we have employed an above-and-below technique, in which laparotomy is combined with a posterior perineal triangle dissection.
- The interposition of omentum has been used for distraction defects and for complex fistulae. This approach allows safe mobilization of the rectum from the area of the distraction scar or from the fistula site.

- When radiation is added, the complexity of reconstruction is magnified. The effects of radiation must be allowed to settle; tissue interposition is the rule, and functional reconstruction is impossible in many cases. Some think that diversion, in the case of patients who have received radiation, is the safest and best option.
- Careful consideration of ultimate urinary and bowel function is integral to proper planning of surgery.

Curvatures of the Penis

Normal elasticity and compliance of all tissue layers of the penis are critical for erectile function, tumescence, and rigidity. Tissues must expand in all dimensions as the penis engorges with blood; eventually, the tissues of the tunica albuginea and the septal fibers of the corpora cavernosa are stretched to the limits of their compliance, and tumescence is converted to rigidity. In the normal penis, the tissues are symmetrically elastic, and the erection is straight. In curvature of the penis, there is relative asymmetry of one aspect of the erect penis. In some cases, this condition arises from diminished compliance of one aspect of the tunica albuginea or outright foreshortening of one aspect of the erectile bodies.

The term *chordee* means curvature, but it is commonly used as if it refers to the tissues causing the curvature. This misuse of the term is seen in the statement "the chordee was resected"; properly phrased, the statement should be "the chordee can be corrected by resecting the inelastic tissues that are causing the chordee."

Curvatures of the penis can be congenital or acquired. Some confusion also exists in common usage of the term *congenital curvature of the penis*. The terms *congenital curvature of the penis* and *chordee without hypospadias* have often been used interchangeably. We prefer to reserve the term *chordee without hypospadias* for patients in whom the meatus is properly located on the tip of the glans penis; a ventral curvature is associated with abnormalities of the ventral fascial tissues or corpus spongiosum, or both. It has long been recognized that hypospadias is a condition that is associated in some patients with either a diminutive penis or a micropenis. Although a small penis is not diagnostic of hypospadias, it is highly unusual for a patient with hypospadias to have an exceptionally large erect penis. In contrast, other congenital curvatures of the penis (ventral, lateral, or dorsal) are inevitably associated with the finding of a large erect penis. Because **the trauma that results in acquired curvature is virtually always associated with intercourse, the occurrence of acquired curvature is nil before the onset of puberty.** We have seen some patients in whom there was a history of trauma during vigorous masturbation, but these patients are the exception. Similar to congenital curvatures of the penis, acquired curvatures may be dorsal, lateral, ventral, or complex.

Types of Congenital Curvature of the Penis

The urethra begins as an epithelial groove in the midline of the ventral surface of the developing penis. As the groove extends, it deepens, with the edges eventually meeting to fuse into a tube. Fusion begins proximally and progresses distally. During normal development, the fusion of the urethral tube eventually reaches the tip of the glans penis. Proliferating mesenchyma surrounds the tube, separating it from the skin, and differentiates to form the corpus spongiosum, Buck fascia, dartos fascia, and overlying ventral skin of the penis. Fetal development of the penis is regulated by testosterone, produced by the fetal testis, which is converted by 5α-reductase to dihydrotestosterone. Dihydrotestosterone acts directly on cells with androgen receptors and on all layers of the male external genitalia. This embryologic process explains the development of the anterior urethra that is unique to males.

Maturation of these tissues into normal structures depends on the same growth factors that control the formation of the urethra. Although urethral development has progressed normally, mesenchymal tissue development in the penis may be deficient or abnormal and results in dysgenetic and inelastic fascial layers. In 1973 Devine and Horton proposed a typing classification for the various congenital curvatures. In type I congenital curvature, the urethral meatus is at the tip of the glans. However, none of the surrounding layers are normally formed, and the epithelial urethra is associated with malfusion of the corpus spongiosum and all the tissues superficial to the urethra. Skin coverage of the epithelial tube is present. In type II, a dysgenetic band of fibrous tissue thought to be derived from the mesenchyma, which would have produced the Buck fascia and the dartos fascia, lies beneath and lateral to the urethra. However, the urethra is contained within a normally developed and fused corpus spongiosum.

In type III, the urethra, corpus spongiosum, and Buck fascia are normally developed and ventrally fused. However, there is a short area of inelastic tissue in the dartos layer of the penis that causes a relatively sharp bend. Abnormal development of the dartos fascia is frequently associated with complex curvatures. With extensive involvement, the inelastic dartos can be sufficient to restrain the penis and conceal the penile shaft. In many of these cases, there appears to be abnormal prominence of the mons fat pad. These stigmata are thought to be associated with an abnormality in the proper progression of virilization during fetal development.

In type IV, although the urethra, corpus spongiosum, and fascial layers are normally developed, there is relative shortness or inelasticity of one aspect of the tunica albuginea of the corpora cavernosa. Experience has shown that most patients whose congenital curvature is type IV seem to demonstrate evidence of a hypercompliance of the tunica albuginea. In these patients, the flaccid penis is normal in size and not impressively large, whereas the erect penis is large. The tunica albuginea of the corpora cavernosa is required to expand through a wide range, and if there is asymmetry in the compliance of the tunica, curvature occurs. Patients with type IV curvature commonly notice curvature before puberty; as puberty progresses, an increase in the curvature is noted because of the penile hypertrophic growth spurt that occurs during this time.

Type V congenital curvature is also known as congenital short urethra. This term implies that there has been correct fusion of all elements of the penis (i.e., tunica albuginea, urethral epithelium, corpus spongiosum, Buck fascia, dartos fascia, and ventral skin). However, during erection, the correctly fused urethra and corpus spongiosum are not long or compliant enough to match the compliance of the other ventral tissue layers.

If type V congenital curvature exists at all, it occurs so rarely that when it is encountered, one should doubt the findings. Although discussion of the condition in the past has centered on the best location to “cut the urethra” during the repair, on the rare occasions when this condition is encountered, it should be diagnosed and treated only by the most experienced surgeons. In general, if the urethral meatus has developed to the tip of the glans, the urethra should not be divided to correct ventral curvature of the penis. Although there will be extremely rare exceptions to this bold statement, if those exceptions are encountered, their existence should still be questioned.

Congenital curvature types I, II, and III represent forms of the hypospadias anomaly, and we prefer to refer to them collectively under the term *chordee without hypospadias*. This term implies that, although the meatus is not improperly placed, curvature is due to inappropriate fetal development of the ventral penile structures. We prefer to refer to the type IV anomaly as congenital curvature of the penis. If a patient has findings of hypercompliance of the corpora cavernosa and a ventral curvature, the diagnosis is congenital ventral curvature of the penis; if the hypercompliance causes a lateral curvature, it is referred to as congenital lateral curvature of the penis (left or right). Although, as mentioned, **the type V anomaly is so rarely encountered that it deserves its own diagnosis, we believe its correction is best discussed with types I, II, and III, in the category of chordee without**

hypospadias.

Chordee Without Hypospadias in Young Men

Patients with chordee without hypospadias usually present with either ventral curvature or ventral curvature associated with torsion (complex curvature). These young men do not typically have a greater-than-average stretched penile length (13.1 cm) (Schonfeld and Beebe, 1942) and will have noted curvature throughout life. If prepubescent, they have obvious curvature with erection; if postpubescent, they may offer a history of increasing curvature as they pass through puberty.

In many cases, there are abnormalities of the ventral penile skin. These abnormalities may consist of either an element of hooded preputial skin or a high insertion of the penoscrotal junction. Although patients have fusion of the preputial skin, there is also often a wrinkled appearance dorsally that we now recognize to be a form of the classic hooded preputial skin. In addition, in many cases, the tissues on the ventrum of the penis seem inelastic as the patient's penis is examined on stretch. This palpable inelasticity on the ventral penis consists of dysgenetic tissue, which can replace the Buck and dartos fascia layers; in some cases, there is an element of inelasticity of the tunica.

During surgical exploration, Devine and Pepe (unpublished data) obtained tissue from patients for evaluation of 5α-reductase levels. Their data suggested a deficiency of the enzyme in the ventral dysgenetic tissue. Similarly, Silva et al. (2013) found reduced levels of androgen receptors in the urethral mucosa in patients with hypospadias compared with control subjects. El-Galley et al. (1997) also looked for growth factor deficiency in tissues of male patients with hypospadias and found a correlation. However, to our knowledge, a growth factor analysis has not been undertaken in patients with chordee without hypospadias.

An important part of the preoperative evaluation is the submission of photographs of the erect penis, taken by the patient, documenting the curvature. The photographs are especially helpful in differentiating between the patients we refer to as having chordee without hypospadias and patients with congenital curvatures of the penis. In a patient who has chordee without hypospadias, the photograph reveals an erect penis commensurate with the size of the detumesced penis, whereas in a patient with congenital curvature, the erect penis is noticeably large. It is important to address the psychologic aspects of the condition as an integral part of the treatment. Corrective surgery for chordee without hypospadias is highly successful, and an effective correction can be accomplished in almost all cases with a single operation (Devine et al., 1991). In some cases, the penis has been straightened by excision of all the dysgenetic tissues from the ventral side of the penis and wide mobilization of the corpus spongiosum from the glans penis into the perineum.

Even in patients with obvious abnormalities of the corpus spongiosum (i.e., poor ventral fusion or frank bifid corpus spongiosum), wide mobilization usually reveals that it is not the corpus spongiosum that remains as the ventral limiting factor. In most patients, the penis remains curved because of the inelasticity of the ventral aspect of the corpora cavernosa. Occasionally in a patient, the corpus spongiosum becomes atretic distal on the shaft, and the urethra is only an epithelium-lined tube. Even in these patients, with wide mobilization of the epithelial distal portion and elevation of the proximal corpus spongiosum, it is unusual to find the corpus spongiosum or the epithelial tube limiting the ventral erection. If the epithelial tube has served as an adequate urethra (i.e., it is not stenotic), the morbidity of urethral division and subsequent need for urethral reconstruction must be considered before such a procedure is undertaken. Because the evolution of hypospadias repairs accomplished by wide mobilization of the corpus spongiosum and epithelial and corpus spongiosal elements distal to the meatus has allowed onlay procedures, the morbidities of urethral division must be strongly considered and, we believe, usually avoided.

In children, after mobilization and excision of the dysgenetic tissues, the residual chordee can usually be corrected by making a longitudinal incision, with a sharp blade, in the ventral midline of the corpora cavernosa while an artificial erection is maintained. The incision (midline ventral septotomy) often can be extended between the corporal bodies for a significant distance, allowing the edges of the ventral tunica to move laterally. The penis noticeably straightens with erection.

If this maneuver is insufficient, the dorsal neurovascular structures can be mobilized in concert with Buck fascia, and a small ellipse or ellipses of dorsal tunica albuginea can be excised and closed with watertight plicating sutures. Caution is important when the dorsal neurovascular structures are mobilized; with poor development of the ventral structures, which occurs in some patients, the arborization of the dorsal arteries provides the dominant vascularity to the glans.

Congenital Curvatures of the Penis

Patients with congenital curvature of the penis can have ventral, lateral (which is most often to the left), or, unusually, dorsal curvature. Photographs of the erect penis demonstrate a smooth curvature that generally involves the entire pendulous portion of the penile shaft.

Patients are usually otherwise healthy young men between the ages of 18 and 30 years. Many of these patients have noticed curvature before passing through puberty but have presumed it to be normal. However, with puberty, they discover that the curvature is not normal; or they become sexually active and discover that the curvature impedes their efforts; or they notice increasing curvature as they pass through puberty, and this, in their minds, clearly would preclude sexual intercourse. Occasionally, a patient waits until he is older than 30 years to deal with the anomaly; even less often, a younger adolescent may discuss his genitalia with his parents.

In circumcised patients, we make an incision through the circumcision scar, which in many cases is displaced well down on the penile shaft. However, even with relatively significant displacement of the circumcision scar on the shaft of the penis, the reincision should be through the circumcision scar. The penis is degloved by dissection of the layer immediately superficial to the superficial lamina of Buck fascia.

An artificial erection is obtained with normal saline infusion or pharmacologic agents. We do not routinely recommend a tourniquet device because constricting devices can conceal the proximal limits of the curvature; this is of most significance in cases of ventral curvatures, which frequently extend proximally. Occasionally, some element of perineal pressure is initially required, but these are patients with normal erectile function, and venous occlusive function is normal. The artificial erection demonstrates the character of the curvature and the location of maximal curvature. In patients with ventral curvature, there may be some illusion of thickening of the dartos and Buck fascia, and in these patients, the fibrous tissue is mobilized and completely excised. The corpus spongiosum is detached from the corpora cavernosa and mobilized from the glans to the penoscrotal junction.

After these tissues are excised, the artificial erection is repeated, and occasionally a patient has complete straightening. However, most patients experience a differential elasticity between the dorsal and the ventral aspects of the corporeal bodies, and although the curvature may have been lessened, it persists unless further procedures are done to straighten the penis.

In an adult patient with persistent curvature, there are two options for surgical correction: (1) to lengthen the ventral aspect of the penis by making transverse incisions in the ventral tunica and placing an autologous tissue graft (we currently use the small intestinal submucosal graft at our institution), and (2) to shorten the dorsal aspect of the penis by elevating the neurovascular bundle, excising an ellipse or ellipses from the dorsum of the tunica albuginea, and closing the defects in watertight fashion (Nesbit procedure [Nesbit, 1965]). **Because the size of the erect penis is usually not a problem in these cases of congenital curvature, we have chosen the second option and strenuously discourage ventral grafting in these patients.** The recovery period after this procedure is much shorter, and the variabilities of graft take do not have to be considered. In addition, when a graft is used, there is always the possibility, although uncommon, of the development of graft-induced veno-occlusive dysfunction. **In a 2000 consensus conference sanctioned by the WHO, the committee on Peyronie disease and congenital curvature of the penis agreed that most, if not all, cases in men with the classic finding of congenital curvature of the penis were best managed with plication or corporoplasty techniques but not grafting techniques** (Jardin et al., 1999; Lue, 2004). This consensus was reiterated at the next WHO conference. It is preferable to shorten the longer aspect of the penis in patients with congenital curvature. However, **if the patient falls into the category of chordee without hypospadias and shortness of the penis is an issue, we selectively use incisions with grafts to correct the curvature** (Devine and Horton, 1975).

After the decision has been made to proceed with excisions of ellipses of dorsal tunica, Buck fascia can be elevated in concert with the dorsal neurovascular structures by beginning just lateral to the corpus spongiosum and carrying the dissection dorsally across the midline. Alternatively, the tunica can be exposed by excising the deep dorsal vein of the penis and opening the inner lamina of Buck fascia. Elevation of the neurovascular structures is done by dissecting from the dorsal midline laterally around to the corpus spongiosum and from the coronal margin to the penopubic junction, limiting the effects of stretching the dorsal structures with exposure of the dorsum of the penis.

An artificial erection is obtained to plan the proposed ellipse excisions. We prefer to use several small ellipses rather than try to correct the curvature with one large ellipse. The first ellipse is usually positioned at the point of maximal concavity. The edges of the planned ellipse are apposed with a Prolene suture.

The artificial erection is repeated to assess the effects of that excision. If there is good straightening in that area of the shaft, the incisions are again well marked, the plicating sutures are removed, and the ellipses of tunica are made with a sharp scalpel blade. By dissection in the space of Smith and removal of only an ellipse of tunica, the ellipses are carefully excised to avoid damage to the underlying erectile tissue or can be merely closed under the reapproximated edge of the defect in the tunica albuginea. The edge of the ellipse is reapproximated with a combination of interrupted 4-0 polydioxanone sutures and a watertight running 4-0 polydioxanone suture.

After closure, we repeat the artificial erection to assess the results of the first ellipse with the others. A final artificial erection should demonstrate the penis to be perfectly straight. In cases of ventral curvature or when complex curvatures are associated with an element of ventral curvature, a minimal degree of dorsal curvature after correction is acceptable. In most cases, as the sutures dissolve, the penis either remains minimally dorsiflexed or becomes perfectly straight.

The Buck fascia is closed. Two small suction drains are placed superficial to the Buck fascia but deep to the dartos fascia. We replace the skin sleeve, with its edges apposed with interrupted small Vicryl or Monocryl sutures. In all patients, we place a small Foley catheter and a small suction drain, and both are removed on the first postoperative day. Depending on the amount of edema and drainage, patients are discharged from the hospital on the evening of the first postoperative day or early the second postoperative day.

A congenital lateral curvature of the penis is often associated with some complexity of curvature; patients frequently notice lateral curvature in association with a ventral or, less commonly, a dorsal curvature. However, some patients present with only lateral curvature, with the right side larger than the left, and curvature to the left.

In some cases, a repair of the lateral curvature can be approached through a small incision at the point of maximal curvature. Laterally placed incisions on the penile shaft are not cosmetically optimal. We prefer a degloving incision after exposure of the deep penile structures; the point of maximal concavity is then marked. Prolene sutures are placed, and an artificial erection is performed again. The size of the ellipse is assessed, and the ellipse is excised and closed as discussed earlier.

As mentioned, most cases of lateral curvature are associated with complex curvatures. In these patients, the correction of the curvature is similar to that described for patients with ventral curvature, with incision through the circumcision scar with the skin reflected. In contrast to a ventral curvature, with a lateral curvature, the entire dorsal neurovascular bundle does not have to be reflected; it is seldom required and it is not considered beneficial to excise the deep dorsal vein in approaching the dorsum of the penis. The postoperative care is the same as described for a ventral curvature. Uncommonly a patient has a congenital dorsal curvature of the penis; for this, the repair is best accomplished by mobilizing the lateral aspect of the corpus spongiosum to allow small ellipses lateral to the midline to be positioned on the ventrum of the penis, by the technique described before.

Although described as a method for plication for curvature associated with Peyronie disease, corporoplasty, a procedure described by Yachia (1993), is also useful for the correction of congenital curvatures. The procedure consists of longitudinal incisions in the tunica albuginea with transverse closure. The “long side” is plicated without the need for excision; however, the plication is durable in that the tunica is opened and closed with a resulting scar, rather than reliance only on the strength of sutures as originally described by Nesbit (1965). With this technique, closure is done with absorbable monofilament suture.

Acquired Curvatures of the Penis

Acquired curvatures of the penis inevitably follow trauma to the penis. Many of these cases are associated with Peyronie disease, also believed to be associated with trauma to the penis during intercourse (Bella et al., 2007). Patients occasionally have had vigorous internal urethrotomy, with the incision extended outside the urethra and corpus spongiosum and involving the tunica of the corporal bodies, causing scarring that is significant enough to be associated with curvature.

Acquired Curvatures of the Penis From Causes Other Than Peyronie Disease

When a young man presents with an acquired curvature of the penis, one must always consider Peyronie disease. However, many men do not have true Peyronie disease. These patients, on close questioning, reveal a history of minimal lateral curvature of the penis and a clear memory of a lateral buckling injury that occurred during intercourse. In some cases, the patient remembers hearing a “snap” and notices immediate detumescence and significant ecchymosis of the penis. These patients are often referred with a diagnosis of Peyronie disease, but a diagnosis of curvature secondary to penile fracture is more accurate. Because of the noticeable events associated with fracture of the penis, many patients are seen with an acute injury, and reconstruction can be accomplished at that time.

Occasionally, a patient or his primary care physician ignores the stigmata of the trauma (often described as “minimal” by patients), and the patient has a noticeable lateral scar that causes indentation of the lateral aspect of the penis and, in some cases, curvature. Patients who had preexisting lateral curvature may notice that their penis has been straightened by the trauma, but they are disturbed by the concavity caused by the scar. In others, the small linear scar causes a significant lateral curvature.

Another group of patients seek medical attention after a similar buckling trauma to the penis but without associated detumescence or ecchymosis. These patients report noticing that their erections were painful for a period after the trauma, and then a nodule developed in the lateral aspect of the penis. Eventually, they develop a lateral linear scar that has led to curvature and indentation at the site. We refer to this injury as a subclinical fracture of the penis.

The lesion of a subclinical fracture of the penis is believed to be due to the disruption of the outer longitudinal layer of the tunica albuginea during the buckling trauma. The inner, circular layer is not disrupted and maintains the blood-tight continuity of the corpus spongiosum. Another possible scenario is that both layers of the tunica albuginea are disrupted, but the overlying Buck fascia maintains its integrity. Some patients notice a pop with intercourse and a period of pain with erections, followed by curvature of the penis—usually dorsal. These patients probably tear the septal insertion completely. These patients have a similar presentation to patients with Peyronie disease.

Patients usually have normal erectile function after subclinical or clinical fracture of the penis; there does not appear to be an association with concomitant global cavernosal veno-occlusive dysfunction. However, the association of cavernosal veno-occlusive dysfunction and trauma of the penis continues to be seen, and some patients have significant problems with erectile dysfunction after fracture-type injuries of the penis. These injuries are not associated with shortening of the penis. In most cases, the lack of erectile dysfunction and penile shortening help distinguish these patients from patients with Peyronie disease. If a detailed history leads one to suspect blighted erectile function, erectile function should be evaluated before proceeding with surgery. We evaluate these patients with duplex ultrasonography and selectively with dynamic infusion cavernosometry and cavernosography.

Although foreshortening of the penis is a characteristic of neither the injury nor the resulting scar in either of these injuries, these patients are not ideal candidates for contralateral plication procedures. This treatment would result in bilateral scars, which would cause bilateral indentations of the penis. Although the penis would have been straightened by the correction, most patients are upset by the cosmetic and functional result of a near-circumferential indentation of the penis. Instead, we excise the scar and place a graft to replace the corporotomy defect caused by the scar excision. Because these scars are on the lateral aspect of the penis, minimal mobilization of Buck fascia, associated dorsal neurovascular structures, and corpus spongiosum is required at the site.

The results of the surgical correction described have been extremely effective. Successful correction with a single operation has been achieved in all patients treated at our institution.

Key Points: Curvatures of the Penis

- Curvatures of the penis can be acquired or congenital. Congenital curvatures of the penis can be categorized as chordee without hypospadias or congenital curvature of the penis.
- In general, chordee without hypospadias is a forme fruste of hypospadias. Although the meatus may not be abnormally placed, these patients usually have findings suggestive of hypospadias (i.e., malformation of the ventral structures of the penis). These patients are not characterized by large erect penises. In contrast, patients with congenital curvature of the penis seem to have exceptionally large erect penises.
- The entity of congenital curvature of the penis seems to be related to nonsymmetrical expansion of the erectile bodies, which must expand significantly during tumescence. Reconstruction in these patients generally is best accomplished by excision with plicating closure or pure plication techniques. The use of grafts is not recommended because of the unusual but real occurrence of graft-induced veno-occlusive dysfunction in certain

patients.

Penile Transplantation

General

The principal techniques of penile reconstruction were originally developed for treatment of trauma patients, and these patients were often victims of war injuries. In 1936 Bogaraz described a technique for phallic construction in a series of war-injured patients, and in 1944 Frumkin followed with a series from the Soviet Union. Aware of the work in the Soviet Union, Gillies and Harrison (1948) reported on a series of patients in whom they had accomplished penile reconstruction while stationed at a major hospital in the outskirts of London during World War II. In this series, numerous patients had a complete absence of the penis.

Initially, all procedures for phallic construction involved delayed formation and transfer of tubed abdominal flaps. These tubes were produced from random flaps of skin and because of their size were based on a tenuous blood supply. To allow new vascular patterns to become established in the transferred tissue, they were formed in stages, with a “delay” between the stages. In the “tube-within-a-tube” design, the inner tube allowed the placement of a baculum during intercourse, and the outer tube provided skin coverage. Patients voided through a proximal urethrostomy. This approach continued to be the “state-of-the-art” phallic construction and penile reconstruction until 1972, when Orticochea described total reconstruction of the penis using the gracilis musculocutaneous flap. In 1978 Puckett and Montie reported a series in which they constructed the penis with a tubed groin flap. In the early cases in this series, the flap was transferred in delayed fashion to the area of the penile stump. Later in the series, a microvascular free-transfer technique was employed.

In 1984 Chang and Hwang popularized the forearm flap, based on the radial artery, for phallic construction. Biemer (1988) reported a modification of the forearm flap, which was also based on the radial artery; in 1990, Farrow et al. reported their “cricket bat” modification of the radial forearm flap. **At the present time, forearm flaps are the most commonly employed method for total phallic construction and penile reconstruction.**

The forearm flap is usually harvested from the nondominant forearm. Preoperatively, the Allen test is used to screen patients carefully for arterial insufficiency. This test involves palpation of the radial and ulnar arteries in the wrist, with the patient making a tight fist to express blood from his hand. As he opens his hand, the fingers are pale, but if palmar circulation is normal and both arteries are patent, the fingers turn pink when one of the arteries is released. On the basis of either the Allen test or the patient's history, if there is any doubt about the integrity of the radial and ulnar arteries or the palmar arch, upper extremity angiography is performed.

As described, the forearm flap is a fasciocutaneous flap vascularized by the radial artery; however, the ulnar artery also vascularizes the forearm fascia and most of the forearm skin. The radial artery arises as a continuation of the brachial artery and proximally lies beneath the belly of the brachioradialis muscle, becoming more superficial at the wrist. The ulnar artery is also a continuation of the brachial artery and vascularizes a similar area of skin and underlying adipose tissue. The vascularity of the overlying skin is achieved by way of the underlying (antebrachial) fascia, which is the superficial fascia investing the musculature of the forearm.

The forearm flap can be elevated and transferred on the superficial fascia. The lateral and medial antebrachial cutaneous nerves appear proximally beneath the fascia. The cephalic, basilic, and medial antebrachial veins are also included in the flap and constitute a portion of the venous drainage. In some patients, the vena comitans is the dominant venous drainage system. At the time of flap transfer, it is imperative to assess the vena comitans and the superficial veins to determine which is the dominant system in the individual patient.

The various modifications of the forearm flap do not represent changes in the technique of flap elevation; rather, they are modifications in the design of the skin island and the relative position of the urethral paddle in relation to the skin that eventually becomes shaft coverage. Each of these modifications has advantages in different situations.

In the forearm flap as described by Chang and Hwang (1984), the shaft is covered with the radial aspect of the skin paddle. A de-epithelialized strip is made, and a second skin island, on the ulnar aspect of the skin paddle, is tubed to form the urethra. The urethral tube is rolled within the tube of skin to form a tube-within-a-tube design. In the white population, this flap has demonstrated a tendency to lead to ischemic stenosis of the lateral paddle, where the urethra is constructed.

In the cricket bat modification, the urethral tube extends distally, closely overlying either the radial or the ulnar artery. We have experience with elevation of the cricket bat modification on both arteries. Proximal to the urethral strip, a broader portion of the skin paddle provides coverage of the shaft. The urethral portion is tubed and transposed by inverting it into the center of the shaft portion of the skin paddle. The advantage of this modification lies in centering the urethral portion over the respective artery, in contrast to the Chinese design, in which the ulnar aspect is far distal from the radial artery, with the potential for ischemic stenosis or loss of that portion. The cricket bat modification has been useful in trauma patients, particularly in patients who have a significant stump of erectile bodies and urethra left after the injury.

The modification by Biemer (1988) also centers the urethral portion of the flap over the artery. As described by Biemer, the flap is elevated on the radial artery and includes a vascularized piece of the radial bone intended to provide rigidity to the new penis. However, the inclusion of cartilage and bone has not been universally successful, and rigidity in these flaps is obtainable by the use of either an externally applied or an internally implanted prosthesis. If the bone is not elevated, the Biemer flap design can be elevated on either the radial or the ulnar artery. At our center, we most often elevate the flap on the ulnar artery, in a modification of the Biemer design.

Modifications of the Biemer design also include the glans construction technique that was originally described by Puckett and Montie (1978). In the original Biemer design, a central strip becomes the urethra, and lateral to that strip, two de-epithelialized portions and two lateral islands (lateral aspects of that skin paddle) are fused dorsally and ventrally to cover the shaft. With the modification of Puckett et al. (1982), a large island is left distally and flared back over the tip of the tubed flaps, creating the illusion of a glans penis. The Biemer design, especially when it is combined with Puckett's design for glanular construction, offers the best cosmetic results (Fig. 82.39).

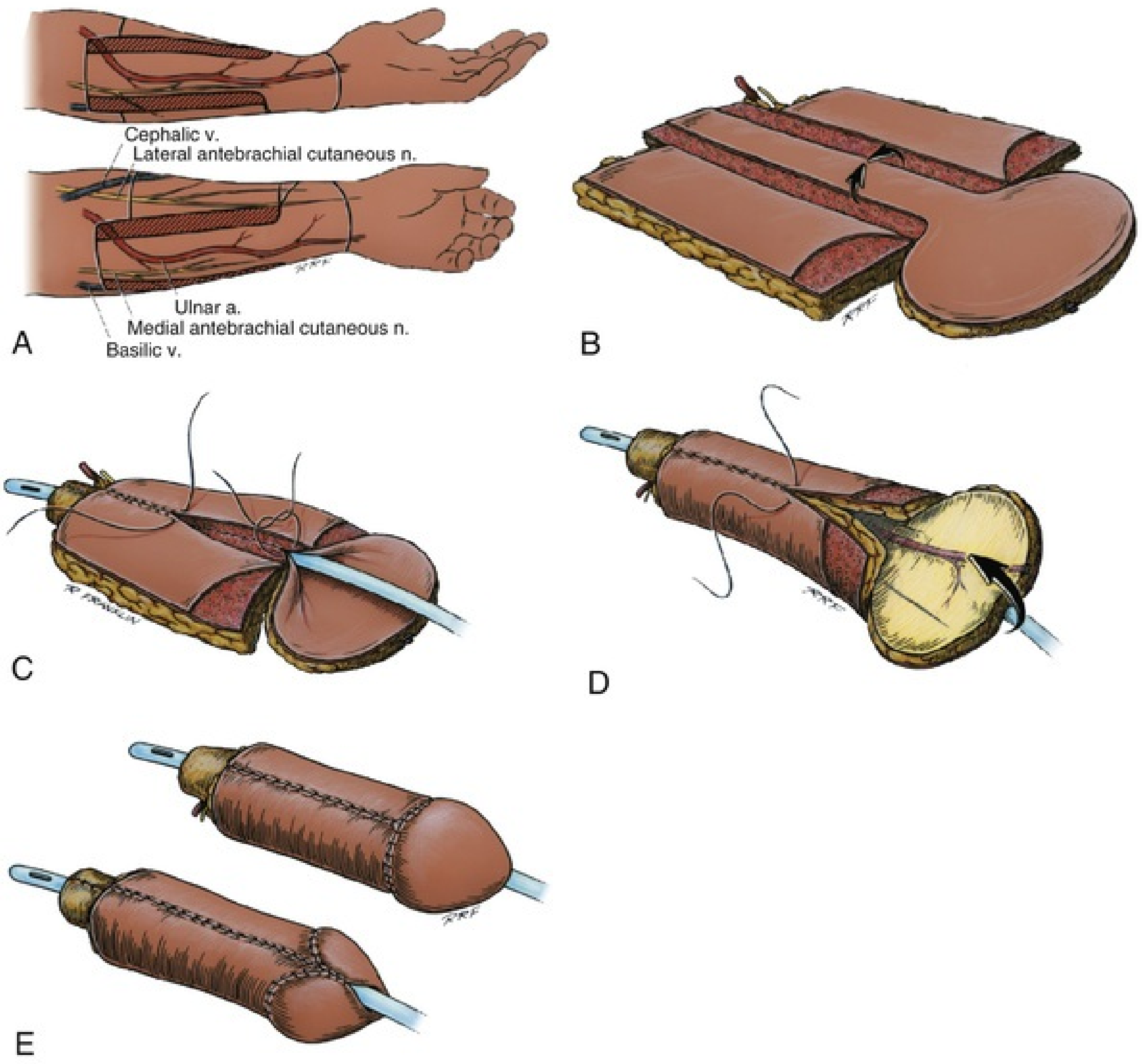
Cephalic v.
Lateral antebrachial cutaneous n.
Ulnar a.
Medial antebrachial cutaneous n.
Basilic v.
A
B
C
D
E

FIG. 82.39 (A) Schematic diagram of an ulnar forearm flap, modified Biemer design, on the patient's left (usually nondominant) forearm. (B) Schematic of the elevated flap. The flap has been divided into skin islands by de-epithelializing the strips. Laterally are the shaft skin islands, medially is the urethral skin island, and distally is the integral glans after the design of Puckett. (C) Schematic of the configuration of the flap. Notice the urethral skin island has been tubularized to the level of the neomeatus. The lateral shaft skin islands are now in the process of being tubularized over the tubularized urethra. (D) Schematic of the phallic flap as it is further configured. This view is of the dorsum. The ventral skin island has been closed over the urethra, and the dorsal skin islands are being collected. The integral glans will then be reflected over the dorsum of the flap. (E) The appearance of the phallus after it is totally configured and transposed to the area of the “penis.” *a.,* Artery; *n.,* nerve; *v.,* vein.

There are several disadvantages to the use of a forearm flap for phallic construction. The major disadvantage of forearm flaps is the obvious donor

site deformity. We have reconstructed the donor site with FTSGs taken from the area of the inguinal crease or buttock, and the cosmetic result is far superior to that obtained when the donor site is reconstructed with STSG (even thick split-thickness skin). In addition, morbidity can be reduced with mobilization of the intact forearm skin to reduce the grafting requirement and attempts to minimize the step between the skin and muscle bed. A second disadvantage lies in the **possibility of the development of cold intolerance in the hand of the donor side.** Early in our experience with the forearm flap, we reconstructed the radial artery with an interposition vein graft. We have since abandoned this procedure in most of our series and have not seen cold intolerance in our patients. Another disadvantage occurs in male and virilized transgender patients **when the forearm skin is hirsute, because the hair can be problematic** if it is included in the portion of the flap used for urethral construction. In such patients, we try to identify the potential for the problem and refer them for epilation before surgery.

McRoberts and Sadove (2002) proposed the use of the fibular osteocutaneous flap for phallic construction. The fibula is elevated on the periosteal vessel along with the overlying skin paddle. As they described, urethral reconstruction is by tubed graft techniques, and their procedure had a 100% urethral complication rate. Kim et al. (2009) used a radial forearm osteocutaneous flap in 40 patients with reasonable results, although for many patients the incorporation of bone did not provide sufficient rigidity for sexual function over time. For patients who need vascularized tissue only to cover the shaft of the penis, we have used the upper lateral arm flap. This is a fasciocutaneous flap, and its cutaneous vascular territory is centered on the radial collateral artery. The skin of the lateral upper arm is thin, with little subcutaneous adiposity. To mark the location of the lateral intramuscular septum and the course of the superior radial collateral artery, we draw a line joining the insertion of the deltoid with the lateral epicondyle. We begin the dissection posteriorly, elevating the superficial fascia until the posterior lateral portion of the intramuscular septum has been identified. A potential disadvantage of this flap lies in the fact that the entire venous drainage depends on the vena comitans, and although superficial veins do traverse the flap, none of them seems to provide significant venous drainage. We have found the flap to be completely reliable so far, with no losses secondary to venous insufficiency.

This flap has also been used for total phallic construction. For this purpose, the flap is expanded by tissue expander and elevated across the elbow, and the distal flap is elevated on the recurrent radial artery. As with the forearm flap, the donor site of an upper lateral arm flap can be disfiguring. However, because the scar is on the upper arm, it is more easily concealed beneath a shirtsleeve than a scar in the forearm. All the flaps described allow microneurosurgical coaptation of the flap cutaneous nerves with recipient nerves. With total phallic construction, the cutaneous nerves can be attached either to the dorsal nerves of the penis or to the dorsal nerves of the clitoris in a transsexual patient. When these nerves are unavailable, the nerves can be coapted to the pudendal nerve, which in most patients requires an interposition graft. These nerves are thought to provide the best restoration of erogenous cutaneous sensibility. We have also coapted the flap's cutaneous nerves to the ilioinguinal nerves, which provides sensation to the inner aspect of the thigh and the lateral aspect of the scrotum, and have achieved a reasonable degree of erogenous sensibility. The ilioinguinal nerve is also thought to provide a better degree of protective sensation (albeit less erogenous sensation) compared with the dorsal nerves (Monstrey et al., 2009).

In most patients, the deep inferior epigastric vessels are the recipient vasculature for flap transfer. These vessels are medial branches of the iliac system and lie on the dorsal (deep) aspect of the rectus abdominis muscle. The artery usually remains deep to the muscle, although an early penetration of the artery into the muscle can be observed in some patients. The artery classically bifurcates at the level of the umbilicus and is generally accompanied by two or more venae comitantes. These vessels have been elevated by several methods, and Lund et al. (1995) described their elevation for penile revascularization with laparoscopic techniques. When the deep inferior epigastric vessels are used, it is often necessary to include a saphenous vein for further venous runoff.

In some patients, these vessels are unavailable, and we have used a saphenous interposition graft to the superficial femoral artery. With use of this technique, we mobilize the saphenous vein well down the upper aspect of the thigh and then attach the vein to the femoral artery, making a temporary arteriovenous fistula. The fistula is divided, with the saphenous vein becoming the venous runoff and the interposition graft providing the arterial inflow. This system of recipient vessels is greatly inferior to a direct arterial anastomosis; because of this, in a few patients we have divided the profunda femoris vessel and vigorously dissected it from its other branches. We have then performed an end-to-end (artery-to-artery) anastomosis of the ulnar artery to the profunda femoris. However, the long-term consequences to the patient of dividing the profunda femoris are unclear. Immediate reconstruction of the profunda does not appear to be advantageous because the dissection required to mobilize the profunda femoris to become a recipient vessel requires the division of numerous proximal branches, and these would not be reconstructed with an immediate reconstruction of the profunda femoris. Mention of this as a potential means of “creating” recipient vessels is not to recommend the procedure because the procedure may yet have unacceptable long-term consequences. Another option in extreme cases is to use the superficial femoral vein, which could be reconstructed with a vein interposition. When the “classic” recipient vessels are unavailable, these other methods may be acceptable. However, we strenuously caution concerning their use because the long-term consequences are unknown. We believe that division of the superficial femoral artery with immediate reconstruction is the preferable choice.

In the latter part of our series, we included the routine transfer of gracilis muscle to cover the area of the urethral anastomosis, increasing the vascularity to that area and significantly altering the incidence of anastomotic fistula and stricture formation. We also elevated a bipedicled flap from the area of the penile shaft base, which is transposed beneath the phallic flap. This flap provides increased bulk and some modicum of scrotal construction, and when it is combined with the gracilis muscle, its thickness provides excellent coverage for the juncture of the flap with the base of the neoscrotum. Mobilization of a tunica dartos flap with tunica vaginalis pedicle, or a Martius flap in a transgender patient, may obviate the necessity to elevate and transpose a gracilis muscle flap.

During the phallic construction procedure, urine is diverted by means of a suprapubic cystostomy tube, and the urethra is stented with a No. 14 soft silicone (Silastic) catheter. A voiding study is usually performed between the third and fourth postoperative week.

Outcomes after forearm free-flap phalloplasty have now been reported from several centers. Even in centers of excellence for phallic construction, complications and reoperations seem to be the rule rather than the exception. Monstrey et al. (2009) reported the largest single-stage radial forearm phalloplasty series with 289 patients over 15 years. Urologic complications were seen in 41% of patients, the most common being fistula in 25%, stricture in 8.7%, and both in 9% of patients. Stricture treatment in this series required a multitude of procedures to achieve a patent urethra; however, fistulae healed spontaneously in most cases. Tactile sensation was achieved in all patients, and many were sexually active.

Similarly, Garaffa et al. (2010) published a series from the United Kingdom on 112 patients undergoing total phallic construction with a radial forearm free flap. Reconstructions at this center are performed in stages rather than a single stage. The urethral anastomosis is deferred until several months after the flap has demonstrated stability. At a median 26 months of follow-up, 99% of patients who had achieved urethral continuity were voiding anatomically through the phallus. Despite staging the procedure, strictures still developed in 10% and fistulae in 24% of patients. Most patients (71.5%) developed phallus sensation.

Vascular complications and graft loss are the most feared morbidities associated with free-flap phalloplasty. These are rare events with rates of total flap loss ranging from 0.6% to 5% and higher rate of partial loss or limited skin necrosis (Garaffa et al., 2010; Leriche et al., 2008; Monstrey et al., 2009). Occasionally, minimal loss of the phallus is amenable to local wound care, but more often these cases require debridement and split-thickness skin grafting for coverage.

Rigidity for intercourse in a patient with phallic construction is usually achieved by either an externally applied or a permanently implanted prosthesis. Prosthetic implantation is never undertaken until 1 year after phallic construction because protective sensibility must be demonstrated in the flap. When the flap is transferred, it is, by definition, rendered insensate. At about 3 to 4 months after reconstruction, as nerve regeneration occurs, sensation becomes noticeable. In addition, the urethra must be patent and proved to be durable before prosthetic implantation is undertaken.

At our center, we have a large series of patients with internally implanted devices. We have implanted hydraulic and articulated prostheses encased in Gore-Tex neocorpora. These devices are anchored to the ischial tuberosity and the pubis by anchoring the neocorpora to these bone structures. In most patients, we implant two cylinders or rods. Early in our series, we had problems with hematoma and seroma formation and subsequent infection. However, since modifying our antibiotic regimen and including the routine use of suction drains with the implant procedure, we have had excellent success with implantation. At the present time, we place the antibiotic-coated (Inhibizone) AMS 700CXR (American Medical Systems, Minnetonka, MN). The Titan prosthesis (Coloplast, Humlebaek, Denmark) with hydrophilic coating and narrow base has also been used.

The largest published series describing the use of a mechanical prosthesis in a neophallus is from Belgium, where a variety of prostheses have been put in 129 patients from 1996 through 2007 (Hoebeke et al., 2010). The proximal prosthesis was fixed to the pubic rami using either a Dacron sheath or permanent stitches through a rear tip extender. At a mean 30 months of follow-up, 41.1% of patients needed revision or explant for infection (11.9%), malfunction (13%), erosion/malposition (22.7%), or leak (9.2%). Complications are higher than seen for implants into normal corpora, which would be expected given that the neophallus has had extensive prior surgery, is not as well vascularized, and the device may be used more frequently in this traditionally young patient population.

We also have implanted testicular prostheses in many patients. In patients in whom we have used a hydraulic device, we have implanted the pump in one neohemiscrotum and a testicular prosthesis in the opposite one.

Other options for phallic construction include the use of latissimus dorsi flap. This flap's characteristics allow for adequate size of the phallus as well as allows for good urethral reconstruction and ease of penile implant. A free sensate osteocutaneous fibula flap was initially described in 1993 and has been well accepted and has been shown to have good cosmetic as well as functional outcomes.

With the increase in vascularized composite allotransplantation (VCA) penile transplantation has become a concept that must be explored. There have been a number of reported successful transplants and certainly more will follow. Obviously, there are many issues to consider with regard to penile transplantation. Not only the medical concerns associated with VCAs but religious, personal, emotional, and cultural issues will have to be researched and considered as penile transplantation becomes more of a mainstay.

Reconstruction After Trauma

In many ways, the problems of trauma patients are more challenging to solve than the problems of patients who require total phallic construction. We have treated a large number of patients who have had devastating injuries to the penis after complicated prosthetic surgery or surgery to correct penile curvatures of Peyronie disease. The goal in these patients is to preserve the penile structures and function as much as possible and correct the deficiencies that are imposed on the patient by the trauma.

Acutely, urine must be diverted, necrotic tissue must be carefully debrided, and any foreign bodies that may have been implanted must be removed. Vigorous acute wound management stabilizes the wounds and allows active granulation to progress. In all trauma patients, an attempt should be made to save as many of the penile structures as possible.

Approximately 3 to 6 weeks after trauma, primary reconstruction can be undertaken, although we have elected to wait 4 to 6 months in some patients, depending on the situation. When significant adjacent tissue loss has occurred, the adjacent areas must be well reconstructed before proceeding with either phallic construction or penile reconstruction.

In a trauma patient, well-vascularized tissues must be eventually transposed to the adjacent area, and reconstruction of these areas can be accomplished with numerous flaps. For groin reconstruction, the tensor fascia lata flap has been useful. The rectus femoris flap, characteristically long and large, can be transposed to the area of the lower abdomen and has been an extremely useful flap for inguinal and lower abdominal reconstruction. The gracilis muscle is an excellent flap for reconstruction of the perineum and the groin. Alternatively, the posterior thigh flap can be used for reconstruction of the groin and perineum and, in some cases, transposed to the lowermost portion of the lower abdomen. The rectus abdominis flap is a useful flap and can be elevated with a vertical or transverse skin paddle. In addition, the flap can be transposed to either the ipsilateral or the contralateral side. Care must be taken in a patient who has had lower abdominal external beam irradiation.

Variations of the flap designs described for complete phallic construction have been successfully applied in select patients for penile reconstruction. An example is one patient who sustained an injury to his penis from a shotgun blast. The blast injured a large portion of the patient's right corpus cavernosum, and most of the penile skin was either destroyed or used for urethral reconstruction. In this patient, a flap based on the Chinese design was elevated. However, because the urethral reconstruction was accomplished with a penile skin island, the ulnar portion of the flap was not needed for that purpose. The ulnar portion was de-epithelialized and tubularized to form bulk and a new right corporeal body. This patient is now sexually active, and the bulk of the tube's dermal section gives adequate support to his penis for intercourse.

Another patient required only distal urethral construction and glans reconstruction. For this patient, we based a flap on the Biemer design to construct a glans. The proximal portions of the flap were de-epithelialized, allowing fixation of the neoglans on the tips of the corporeal bodies, and an excellent functional and cosmetic result was achieved for this patient. The versatility of free-flap technology allows the solution of complex issues with reasonably acceptable functional and cosmetic results.

Female-to-Male Transgender

Female-to-male transgender patients present a unique challenge, and no patient should be considered for definitive reassignment surgery without having undergone complex screening and evaluation by a team consisting of mental health professionals as well as surgeons who are skilled in undertaking transgender surgery. It is imperative that an ongoing, stable, therapeutic relationship be established between the patient and a mental health professional at the time of definitive gender reassignment surgery. At our institution, the Harry Benjamin criteria (Ramsey, 1996) are strictly adhered to, and surgery is accomplished by a team of urologists, plastic surgeons, and gynecologists.

In most patients, the first stage of female-to-male transgender surgery consists of bilateral salpingo-oophorectomy, hysterectomy, vaginectomy, and urethral lengthening with colpocleisis. Even in virginal patients, our surgeons have become skilled at accomplishing a hysterectomy and bilateral salpingo-oophorectomy by way of transvaginal surgery. We perform a vaginectomy at the same operation, leaving the anterior vaginal wall to be transposed as a random flap to lengthen the female urethra and allow colpocleisis. Lengthening of the female urethra brings the base of the native urethra up to what will be the base of the phallic flap; along with the transfer of gracilis muscle, it has significantly altered our surgical results with regard to urethral anastomotic fistula and stricture. Urine is diverted with a suprapubic tube, and a voiding trial is performed in approximately 21 days. Patients are generally in the hospital for 2 to 3 days and return 3 to 4 months later for phallic construction.

For phallic construction in a transgender patient, we elevate a bipedicled flap of skin, as already described, from the area where the phallic structure will be implanted and transpose it to the undersurface of the neopenis. The patient is generally in the hospital for 10 to 14 days after total phallic construction, and a voiding trial with contrast material is done at about 28 days postoperatively. After 1 year, when erogenous sensibility is demonstrated and the urethra is proved to be durable, prosthetic implantation is considered.

Key Points: Total Penile Reconstruction and Female-to-Male Transgender

- The principal techniques of penile reconstruction originally were developed for treatment of victims of war injuries. Initially, all of the procedures involved delayed tissue transfer. In 1978 Puckett and Montie reported a series of phallic reconstructions in which a groin flap was transferred by microvascular free-transfer techniques to the area of the penis. The phallus was insensible, but this represented the first free-flap reconstruction for phallic construction. In 1984 Chang and Hwang popularized use of the forearm flap. This flap has been modified by numerous individuals.
- We prefer to use an ulnar forearm flap with a combined Puckett modification of the flap and Biemer modification of the glans. These flaps allow sensible phallic construction that lets the patient stand to void and permits eventual prosthetic implantation because the phallus has protective and erogenous sensibility.
- The techniques employed in transgender patients are not different from techniques employed in trauma patients. The shapes of the skin paddles often must be tailored to the individual patient.

Suggested Readings

Aboseif SR, Breza J, Lue TF, et al. Penile venous drainage in erectile dysfunction: anatomical, radiological and functional considerations. *Br J Urol*. 1989;64:183–190.

Akporiaye LE, Jordan GH, Devine CJ Jr. Balanitis xerotica obliterans (BXO). *AUA Update Series*. 1997;16:166–167.

Chapple C, Barbagli G, Jordan G, et al. Consensus statement on urethral trauma. *BJU Int*. 2004;93:1195–1202.

Chapple CR, Pang D. Contemporary management of urethral trauma and the post-traumatic stricture. *Curr Opin Urol*. 1999;9:253–260.

Coursey JW, Morey AF, McAninch JW, et al. Erectile function after anterior urethroplasty. *J Urol*. 2001;166:2273–2276.

Devine CJ Jr, Blackley SK, Horton CE, et al. The surgical treatment of chordee without hypospadias in men. *J Urol*. 1991;146:325–329.

Fichtner J, Filipas D, Fisch M, et al. Long-term outcome of ventral buccal mucosa onlay graft urethroplasty for urethral stricture repair. *Urology*. 2004;64:648–650.

Heyns CF, Steenkamp JW, de Kock ML, et al. Treatment of male urethral strictures: is repeated dilation or internal urethrotomy useful? *J Urol*. 1998;160:356–358.

Iselin CE, Webster GD. The significance of the open bladder neck associated with pelvic fracture urethral distraction defects. *J Urol*. 1999;162:34–51.

Jordan GH. The application of tissue transfer techniques in urologic surgery. Webster G, Kirby R, King L, et al. *Reconstructive urology*. Blackwell Scientific: Oxford, UK; 1993:143–169.

Levine J, Wessells H. Comparison of open and endoscopic treatment of posttraumatic posterior urethral strictures. *World*

J Surg. 2001;25:1597–1601.

McCallum RW, Colapinto V. The role of urethrography in urethral disease. Part I. Accurate radiological localization of the membranous urethra and distal sphincters in normal male subjects. *J Urol*. 1979;122:607–611.

McCallum RW, Colapinto V. The role of urethrography in urethral disease. Part II. Indications for transsphincter urethroplasty in patients with primary bulbous strictures. *J Urol*. 1979;122:612–618.

McRoberts JW, Chapman WH, Answell JS. Primary anastomosis of the traumatically amputated penis: case report and summary of literature. *J Urol*. 1968;100:751–754.

Morey AF, Metro MJ, Carney KJ, et al. Consensus on genitourinary trauma: external genitalia. *BJU Int*. 2004;94:507–515.

Pansadoro V, Emiliozzi P. Internal urethrotomy in the management of anterior urethral strictures: long-term followup. *J Urol*. 1996;156:73–75.

Quartey JK. One stage penile/preputial cutaneous island flap urethroplasty for urethral stricture: a preliminary report. *J Urol*. 1983;129:284–287.

Rourke KF, McCammon KA, Sumfest JM, et al. Open reconstruction of pediatric and adolescent urethral strictures: long-term follow-up. *J Urol*. 2003;169:1818–1821 [discussion 1821].

Webster GD, Mathes GL, Selli C. Prostatomembranous urethral injuries: a review of the literature and a rational approach to their management. *J Urol*. 1983;130:898–902.

References

Aboseif SR, Breza J, Lue TF, et al. Penile venous drainage in erectile dysfunction: anatomical, radiological and functional considerations. *Br J Urol*. 1989;64:183–190.

Akporiaye LE, Jordan GH, Devine CJ Jr. Balanitis xerotica obliterans (BXO). *AUA Update Series*. 1997;16:166–167.

Albers P, Fichtner J, Bruhl P, et al. Long-term results of internal urethrotomy. *J Urol*. 1996;156:1611–1614.

Allen JS, Summers JL. Meatal stenosis in children. *J Urol*. 1974;112:526–527.

Andrich DE, Mundy AR. Non-transecting anastomotic bulbar urethroplasty: a preliminary report. *BJU Int*. 2012;109:1090–1094.

Andrich DE, Mundy AR. The nature of urethral injury in cases of pelvic fracture urethral trauma. *J Urol*. 2001;165:1492–1495.

Andrich DE, O'Malley KJ, Summerton DJ, et al. The type of urethroplasty for a pelvic fracture urethral distraction defect cannot be predicted preoperatively. *J Urol*. 2003;170(Pt 1):464–467.

Angermeier KW, Jordan GH. Complications of the exaggerated lithotomy position: a review of 177 cases. *J Urol*. 1994;151:866–868.

Armenakas NA, Morey AF, McAninch JW. Reconstruction of resistant strictures of the fossa navicularis and meatus. *J Urol*. 1998;160:359–363.

Ashken MH, Coulange C, Milroy EJ, et al. European experience with the urethral Wallstent for urethral strictures. *Eur Urol*. 1991;1:181.

Atala A. Experimental and clinical experience with tissue engineering techniques for urethral reconstruction. *Urol Clin*

North Am. 2002;29:485–492.

Auvert B, Taljaard D, Lagarde E, et al. Randomized, controlled intervention trial of male circumcision for reduction of HIV infection risk: the ANRS 1265 Trial. *PLoS Med*. 2005;2:e298.

Badlani GH, Press SM, Defalco A, et al. UroLume endourethral prosthesis for the treatment of urethral stricture disease. Long-term results of the North American Multicenter UroLume Trial. *Urology*. 1995;45:846–856.

Bailey RC, Moses S, Parker CB, et al. Male circumcision for HIV prevention in young men in Kisumu, Kenya: a randomised controlled trial. *Lancet*. 2007;369:643–656.

Bainbridge DR, Whitaker RH, Shepheard BG. Balanitis xerotica obliterans and urinary obstruction. *Br J Urol*. 1971;43:487–491.

Barbagli G, Menghetti I, Azzaro F. A new urethroplasty for bulbous urethral strictures. *Acta Urol Ital*. 1995;9:313–317.

Barbagli G, Palminteri E, Lazzeri M, et al. One-stage circumferential buccal mucosa graft urethroplasty for bulbous stricture repair. *Urology*. 2003;61:452–455.

Barbagli G, Perovic S, Djinovic R, et al. Retrospective descriptive analysis of 1,176 patients with failed hypospadias repair. *J Urol*. 2010;183:207–211.

Barry JM. Visual urethrotomy in the management of the obliterated membranous urethra. *Urol Clin North Am*. 1989;16:319–324.

Bedos F, Cibert J. *Urologia. La térapeutica y sus bases*. Espaxs: Barcelona; 1989:1122–1125.

Bella AJ, Sener A, Foell K, et al. Nonpalpable scarring of the penile septum as a cause of erectile dysfunction: an atypical form of Peyronie's disease. *J Sex Med*. 2007;4:226–230.

Bhargava S, Chapple CR, Bullock AJ, et al. Tissue-engineered buccal mucosa for substitution urethroplasty. *BJU Int*. 2004;93:807–811.

Bhargava S, Chapple CR. Buccal mucosal urethroplasty: is it the new gold standard? *BJU Int*. 2004;93:1191–1193.

Biemer E. Penile construction by the radial arm flap. *Clin Plast Surg*. 1988;15:425–430.

Blandy JP, Tresidder GC. Meatoplasty. *Br J Urol*. 1967;39:633.

Bogaraz NA. Plastic restoration of the penis. *Sovet Khir*. 1936;8:303–307.

Bracka A. Letter to the editor. Re: reconstruction of resistant strictures of the fossa navicularis and meatus. *J Urol*. 1999;162:1389.

Brandes S, Borrelli J Jr. Pelvic fracture and associated urologic injuries. *World J Surg*. 2001;25:1578–1587.

Brandes SB, McAninch JW. Predictive factor for penile fasciocutaneous flap urethroplasty re-stricture. *Urology*. 1998;9:54 [abstract].

Brannen GE. Meatal reconstruction. *J Urol*. 1976;116:319–321.

Breyer BN, Davis CB, Cowan JE, et al. Incidence of bladder neck contracture after robot-assisted laparoscopic and open radical prostatectomy. *BJU Int*. 2010;106:1734–1738.

Bryden AA, Gough DC. Traumatic urethral diverticula. *BJU Int*. 1999;84:885–886.

Burger RA, Muller SC, El Damanhoury H, et al. The buccal mucosal graft for urethral reconstruction: a preliminary report. *J Urol*. 1992;147:662–664.

Carney KJ, House J, Tillett J. Effects of DVIU and colchicine combination therapy on recurrent anterior urethral strictures. *J Urol*. 2007;177(4):14 [abstract 38].

Chang TS, Hwang WY. Forearm flap in one-stage reconstruction of the penis. *Plast Reconstr Surg*. 1984;74:251–258.

Chapple CR, Pang D. Contemporary management of urethral trauma and the post-traumatic stricture. *Curr Opin Urol*. 1999;9:253–260.

Chen F, Yoo JJ, Atala A. Acellular collagen matrix as a possible "off the shelf" biomaterial for urethral repair. *Urology*. 1999;54:407–410.

Cohen JK, Berg G, Carl GH, et al. Primary endoscopic realignment following posterior urethral disruption. *J Urol*. 1991;146:1548–1550.

Cohney BC. A penile flap procedure for the relief of meatal stricture. *Br J Urol*. 1963;35:182–183.

Cormack GC, Lamberty BG. A classification of fascio-cutaneous flaps according to their patterns of vascularization. *Br J Plast Surg*. 1984;37:80–87.

Coursey JW, Morey AF, McAninch JW, et al. Erectile function after anterior urethroplasty. *J Urol*. 2001;166:2273–2276.

Cox NH, Mitchell JNS, Morley WN. Lichen sclerosus et atrophicus in non-identical female twins. *Br J Dermatol*. 1986;115:743–746.

Crook TJ, Koslowski M, Dyer JP, et al. A case of amyloid of the urethra and review of this rare diagnosis, its natural history and management, with reference to the literature. *Scand J Urol Nephrol*. 2002;36:481–486.

Das K, Charles AR, Alladi A, et al. Traumatic posterior urethral disruptions in boys: experience with the perineal/perineal-transpubic approach in ten cases. *Pediatr Surg Int*. 2004;20:449–454.

Datta C, Dutta SK, Chaudhuri A. Histopathological and immunological studies in a cohort of balanitis xerotica obliterans. *J Indian Med Assoc*. 1993;9:146–148.

Davies TO, Bepple JL, Roseman T, et al. Perineal urethrostomy with buccal mucosal graft: a novel technique. *J Urol*. 2008;179(Suppl 4):282.

Davies TO, Colen LB, Cowan N, et al. Preoperative vascular evaluation of patients with pelvic fracture urethral distraction defects (PFUDD). *J Urol*. 2009;181(4):29 [abstract 79].

De Sy WA. Aesthetic repair of meatal stricture. *J Urol*. 1984;132:678–679.

De Vocht TF, van Venrooij GE, Boon TA. Self-expanding stent insertion for urethral strictures: a 10-year follow-up. *BJU Int*. 2003;91:627–630.

DeCastro BJ, Anderson SB, Morey AF. End-to-end reconstruction of synchronous urethral strictures. *J Urol*. 2002;167:1389.

DeLong J, McCammon K, Capiel L, et al. Augmented perineal urethrostomy using a dorsal buccal mucosal graft, bi-institutional study. *World J Urol*. 2017;35(8):1285–1290.

Devine CJ Jr, Blackley SK, Horton CE, et al. The surgical treatment of chordee without hypospadias in men. *J Urol*. 1991;146:325–329.

Devine CJ Jr, Franz JP, Horton CE. Evaluation and treatment of patients with failed hypospadias repair. *J Urol*. 1978;119:223–226.

Devine CJ Jr, Gonzales-Serva L, Stecker JF Jr, et al. Utricular configuration in hypospadias and intersex. *J Urol*. 1980;123:407–411.

Devine CJ Jr, Horton CE. Chordee without hypospadias. *J Urol*. 1973;110:264–271.

Devine CJ Jr, Horton CE. Use of dermal graft to correct chordee. *J Urol*. 1975;113:56–58.

Devine PC, Fallon B, Devine CJ Jr. Free full thickness skin graft urethroplasty. *J Urol*. 1976;116:444–446.

Devine PC, Horton CE. Strictures of the male urethra. 2nd ed. Saunders: Philadelphia; 1977:3883–3895. Converse JM. *Reconstructive plastic surgery*. vol 7.

Dillon WI, Ghassan MS. *Borrelia burgdorferi* DNA is undetectable by polymerase chain reaction in skin lesions of morphea, scleroderma, or lichen sclerosus et atrophicus of patients from North America. *J Am Acad Dermatol*.

1995;33:617–620.

Dogliotti M, Bentley-Phillips CV, Schmaman A. Lichen sclerosus et atrophicus in the Bantu. *Br J Dermatol*. 1974;91:81–85.

Doré B, Irani J, Aubert J. Carcinoma of the penis in lichen sclerosus atrophicus: a case report. *Eur Urol*. 1990;18:153–155.

Dounis A, Bourounis M, Mitropoulos D. Primary localized amyloidosis of the urethra. *Eur Urol*. 1985;11:344–345.

Dubey D, Kumar A, Mandhani A, et al. Buccal mucosal urethroplasty: a versatile technique for all urethral segments. *BJU Int*. 2005;95:625–629.

Dubey D, Sehgal A, Srivastava A, et al. Buccal mucosal urethroplasty for balanitis xerotica obliterans related urethral strictures: the outcome of 1 and 2-stage techniques. *J Urol*. 2005;173:463–466.

Duckett JW, Baskin L, Uedio K, et al. The onlay island flap hypospadias repair: extended indications. *J Urol*. 1993;149(Suppl):334.

Duckett JW. Hypospadias techniques—update 1984. Standoli L. *Advances in hypospadias*. Acta Medica Edizione e Congressi: Rome; 1986:131–148 [symposium].

Duckett JW. Hypospadias. 6th ed. Saunders: Philadelphia; 1992:1914. Walsh PC. *Campbell's urology*. vol 2.

Edmonds EV, Bunker CB. Nuclear magnetic resonance spectroscopy of urine in male genital lichen sclerosus. *Br J Dermatol*. 2010;163:1355–1356.

Eggleston JC, Walsh PC. Radical prostatectomy with preservation of sexual function: pathological findings in the first 100 cases. *J Urol*. 1985;134:1146.

El-Galley RE, Smith E, Cohen C, et al. Epidermal growth factor (EGF) and EGF receptor in hypospadias. *Br J Urol*. 1997;79:116–119.

El-Kassaby AW, Alla MF, Noweir A, et al. One stage anterior urethroplasty. *J Urol*. 1996;156:975–978.

El-Kassaby AW, El-Bialy MH, El-Halaby MR, et al. Urethroplasty using transverse penile island flap for hypospadias. *J Urol*. 1986;136:643–644.

El-Kassaby AW, Retik AB, Yoo JJ, et al. Urethral stricture repair with an off-the-shelf collagen matrix. *J Urol*. 2003;169:170–173 [discussion 173].

Elliott S, Metro M, McAninch J. Long-term followup of the ventrally placed buccal mucosa onlay graft in bulbar urethral reconstruction. *J Urol*. 2003;169:1754–1757.

Fallic ML, Faller G, Klauber GT. Balanitis xerotica obliterans in monozygotic twins. *Br J Urol*. 1997;79:810.

Fenton AS, Morey AF, Aviles R, et al. Anterior urethral strictures: etiology and characteristics. *Urology*. 2005;65:1055–1058.

Fichtner J, Filipas D, Fisch M, et al. Long-term outcome of ventral buccal mucosa onlay graft urethroplasty for urethral stricture repair. *Urology*. 2004;64:648–650.

Flynn BJ, Delvecchio FC, Webster GD. Perineal repair of pelvic fracture urethral distraction defects: experience in 120 patients during the last 10 years. *J Urol*. 2003;170:1877–1880.

Follis HW, Koch MO, McDougal WS. Immediate management of prostatomembranous urethral disruptions. *J Urol*. 1992;147:1259–1262.

Freeman C, Laymon CW. Balanitis xerotica obliterans. *Arch Dermatol Syphilol*. 1941;44:547–561.

Friedrich EG. New nomenclature for vulvar disease. *Obstet Gynecol*. 1976;47:122–124.

Frumkin AP. Reconstruction of male genitalia. *Am Rev Soviet Med*. 1944;2:14–21.

Garaffa G, Christopher NA, Ralph DJ. Total phallic reconstruction in female-to-male transsexuals. *Eur Urol*. 2010;57:715–722.

Garat JM, Chechile G, Algaba F, et al. Balanitis xerotica obliterans in children. *J Urol*. 1986;136:436–437.

Gearhart JP, Leonard MP, Burgers JK, et al. The Cantwell-Ransley technique for repair of epispadias. *J Urol*. 1994;15:457–459.

Gelman J, Wisenbaugh ES. Posterior urethral strictures. *Adv Urol*. 2015;2015; 10.1155/2015/628107 [Article ID 628107].

Gillies HD, Harrison RH. Congenital absence of the penis. *Br J Plast Surg*. 1948;1:8–28.

Gil-Vernet S. Diverticulos bulbouretrals y reflujo vesicoureteral. *Arch Esp Urol*. 1977;30:325.

Gomez RG, Campos RA, Velarde LG. Reconstruction of pelvic fracture urethral injuries with sparing of the bulbar arteries. *Urology*. 2016;88:207–212.

Gómez RG, Mundy T, Dubey D, et al. SIU/ICUD Consultation on Urethral Strictures: pelvic fracture urethral injuries. *Urology*. 2014;83(3 Suppl):S48–S58; 10.1016/j.urology.2013.09.023 [Epub 2013 Nov 8].

Gray RH, Kigozi G, Serwadda D, et al. Male circumcision for HIV prevention in men in Rakai, Uganda: a randomised trial. *Lancet*. 2007;369:657–666.

Greenwell TJ, Venn SN, Mundy AR. Changing practice in anterior urethroplasty. *BJU Int*. 1999;83:631–635.

Gur U, Jordan GH. Vessel-sparing excision and primary anastomosis (for proximal bulbar urethral strictures). *BJU Int*. 2008;101(9):1183–1195.

Haertsch PA. The blood supply to the skin of the leg: a post-mortem investigation. *Br J Plast Surg*. 1981;34:470–477.

Hafez AT, El-Assmy A, Sarhan O, et al. Perineal anastomotic urethroplasty for managing post-traumatic urethral strictures in children: the long-term outcome. *BJU Int*. 2005;95:403–

406.

Hellstrom WJ, Monga M, Cote D, et al. Reconstruction of a total anterior urethral defect using buccal mucosa. *South Med J*. 1996;89:1088–1091.

Hendren WH, Crooks KK. Tubed free skin graft for construction of male urethra. *J Urol*. 1980;123:858–861.

Hendren WH, Reda EF. Bladder mucosa graft for construction of male urethra. *J Pediatr Surg*. 1986;21:189–192.

Hendren WH. Penile lengthening after previous repair of epispadias. *J Urol*. 1979;121:527–534.

Herschorn S, Elliott S, Coburn M, et al. SIU/ICUD Consultation on urethral strictures: posterior urethral stenosis after treatment of prostate cancer. *Urology*. 2014;83(3 Suppl):S59–S70; 10.1016/j.urology.2013.08.036 [Epub 2013 Dec 20].

Herschorn S, Thijssen A, Radomski SB. The value of immediate or early catheterization of the traumatized posterior urethra. *J Urol*. 1992;148:1428–1431.

Heyns CF, Steenkamp JW, de Kock ML, et al. Treatment of male urethral strictures: is repeated dilation or internal urethrotomy useful? *J Urol*. 1998;160:356–358.

Hoebeke PB, Decaestecker K, Beysens M, et al. Erectile implants in female-to-male transsexuals: our experience in 129 patients. *Eur Urol*. 2010;57:334–340.

Humby G. One-stage operation for hypospadias. *Br J Surg*. 1941;29:84–92.

Iselin CE, Webster GD. The significance of the open bladder neck associated with pelvic fracture urethral distraction defects. *J Urol*. 1999;162:34–51.

Jacyk WK, Isaac F. Lichen sclerosus et atrophicus in Nigerians. *J Natl Med Assoc*. 1979;71:387–388.

Jardin A, Wagner G, Khoury S, et al. Erectile dysfunction. *First International Consultation on Erectile Dysfunction, Co-sponsored by World Health Organization, International*

Society for Impotence Research, and Société Internationale d'Urologie; 1999 July 1-3. Health Publications: Paris. London; 2000.

Jeffs RD. Exstrophy. Harrison JH, Gittes RF, Perlmutter A, et al. *Campbell's urology*. 4th ed. Saunders: Philadelphia; 1979.

Jimenez Cruz JF, Rioja Sanz LA. *Tratado de urologia*. JR Prous: Barcelona; 1993:1538.

Johnston JH. The genital aspects of exstrophy. *J Urol*. 1975;113:701–705.

Jordan GH, Eltahawy EA, Virasoro R. The technique of vessel sparing excision and primary anastomosis for proximal bulbous urethral reconstruction. *J Urol*. 2007;177:1799–1802.

Jordan GH. Guest editor. Reconstruction for urethral stricture. *Atlas Urol Clin North Am*. 1997;5.

Jordan GH. *Penile revascularization [abstract]*. [Presented at: American Association of Genitourinary Reconstructive Surgeons] 2005 [Laguna Nigel, CA].

Jordan GH. Reconstruction of the fossa navicularis. *J Urol*. 1987;138:102–104.

Jordan GH. The application of tissue transfer techniques in urologic surgery. Webster G, Kirby R, King L, et al. *Reconstructive urology*. Blackwell Scientific: Oxford (UK; 1993:143–169.

Jørgensen PE, Weis N, Bruun E. Etiology of urethral stricture following transurethral prostatectomy. A retrospective study. *Scand J Urol Nephrol*. 1986;20:253–255.

Kamat N. Perineal urethrostomy stenosis repair with buccal mucosa: description of technique and report of 4 cases. *Urology*. 2008;72:1153–1155.

Kellner DS, Fracchia JA, Armenakas NA. Ventral onlay buccal mucosal grafts for anterior urethral stricture: long-term followup. *J Urol*. 2004;171(Pt 1):726–729.

Kielb SJ, Voeltz ZL, Wolf JS. Evaluation and management of traumatic posterior urethral disruption with flexible cystourethroscopy. *J Trauma*. 2001;50:36–40.

Kim SK, Lee KC, Kwon YS, et al. Phalloplasty using radial forearm osteocutaneous free flaps in female-to-male transsexuals. *J Plast Reconstr Aesthet Surg*. 2009;62:309–317.

Kizer WS, Prarie T, Morey AF. Balanitis xerotica obliterans: epidemiologic distribution in an equal access health care system. *South Med J*. 2003;96:9–11.

Koraitim M. Experience with 170 cases of posterior urethral stricture during 7 years. *J Urol*. 1985;133:408–410.

Koraitim M. Failed posterior urethroplasty: lessons learned. *Urology*. 2003;62:719–722.

Koraitim M. Posttraumatic posterior urethral strictures in children: a 20-year experience. *J Urol*. 1997;157:641–645.

Koraitim M. Post-traumatic posterior urethral strictures: preoperative decision making. *Urology*. 2004;64:228–231.

Krah H, Djamilian M, Seabert J, et al. Significant obliteration of the urethral lumen after Wallstent implantation. *J Urol*. 1992;148:1901–1902.

Kulkarni S, Barbagli G, Kirpekar D, et al. Lichen sclerosus of the male genitalia and urethra: surgical options and results in a multicenter international experience with 215 patients. *Eur Urol*. 2009;55:945–995.

Kulkarni SB, Joshi PM, Venkatesan K. Management of panurethral stricture disease in India. *J Urol*. 2012;188:824–830.

Lane BR, Stein DE, Remzi FH, et al. Management of radiotherapy induced rectourethral fistula. *J Urol*. 2006;175:1382–1387.

Latini JM, McAninch JW, Brandes SB, et al. IU/ICUD Consultation on urethral strictures: epidemiology, etiology, anatomy, and nomenclature of urethral stenoses, strictures, and pelvic fracture urethral disruption injuries. *Urology*. 2014;83(3A Suppl):S2–S7.

Laymon CW, Freeman C. Relationship of balanitis xerotica obliterans to lichen sclerosus et atrophicus. *Arch Dermatol Syph*. 1944;49:57–59.

Leddy LS, Vanni AJ, Wessells H, et al. Outcomes of endoscopic realignment of pelvic fracture associated urethral injuries at a level 1 trauma center. *J Urol*. 2012;188:174–178.

Ledwig PA, Weigland DA. Late circumcision and lichen sclerosus et atrophicus of the penis. *J Am Acad Dermatol*. 1989;20:211–214.

Lee SJ, Phillips SM. Recurrent lichen sclerosus et atrophicus in urethroplasties from multiple skin grafts. *Br J Urol*. 1994;74:802–803.

Leriche A, Timsit MO, Morel-Journel N, et al. Long-term outcome of forearm flee-flap phalloplasty in the treatment of transsexualism. *BJU Int*. 2008;101:1297–1300.

Levine J, Wessells H. Comparison of open and endoscopic treatment of posttraumatic posterior urethral strictures. *World J Surg*. 2001;25:1597–1601.

Levine LA, Strom KH, Lux MM. Buccal mucosa graft urethroplasty for urethral stricture repair: evaluation of the impact of stricture location and lichen sclerosus on surgical outcome. *J Urol*. 2007;178:2011–2015.

Lue TF. Sexual medicine, sexual dysfunctions in men and women. *Second International Consultation on Sexual Dysfunctions, Co-sponsored by International Consultation on Urological Diseases, International Society of Urology, and International Society for Sexual and Impotence Research*. Health Publications: Paris; 2004.

Lund GO, Winfield HN, Donovan JF. Laparoscopically assisted penile revascularization for vasculogenic impotence. *J Urol*.

1995;153:1923–1926.

Malone P. A new technique for meatal stenosis in patients with lichen sclerosus. *J Urol*. 2004;172:949–952.

Mandhani A, Chaudhury H, Kapoor R, et al. Can outcome of internal urethrotomy for short segment bulbar urethral stricture be predicted? *J Urol*. 2005;173:1595–1597.

Markiewicz MR, Lukose MA, Margarone JE, et al. The oral mucosa graft: a systematic review. *J Urol*. 2007;178:387–394.

Marren P, Yell J, Charnock FM, et al. The association between lichen sclerosus and antigens of the HLA system. *Br J Dermatol*. 1995;132:197–203.

Marshall FF. Endoscopic reconstruction of traumatic urethral transections. *Urol Clin North Am*. 1989;16:313–318.

Mathews R, Silver RI, Paidas C, et al. Posterior sagittal approach for management of a traumatic urethral stricture. *J Urol*. 1998;160:1475–1476.

Mazdak H, Meshki I, Ghassami F. Effect of mitomycin C on anterior urethral stricture recurrence after internal urethrotomy. *Eur Urol*. 2007;51:1089–1092.

McAninch JW. Reconstruction of extensive urethral strictures: circular fasciocutaneous penile flap. *J Urol*. 1993;149:488.

McCallum RW, Colapinto V. The role of urethrography in urethral disease. Part I. Accurate radiological localization of the membranous urethra and distal sphincters in normal male subjects. *J Urol*. 1979;122:607–611.

McCallum RW, Colapinto V. The role of urethrography in urethral disease. Part II. Indications for transsphincter urethroplasty in patients with primary bulbous strictures. *J Urol*. 1979;122:612–618.

McKay DL Jr, Fuqua F, Weinberg AG. Balanitis xerotica obliterans in children. *J Urol*. 1975;114:773–775.

McRoberts JW, Sadove RC. Penile reconstruction with a free sensate osteocutaneous fibular flap in the surgical management of the intersex patient. *Adv Exp Med Biol*. 2002;511:283–287.

Memmelaar J. Use of bladder mucosa in a one stage repair of hypospadias. *J Urol*. 1947;58:68–73.

Metze M, Tiemann AH, Josten C. Male sexual dysfunction after pelvic fracture. *J Trauma*. 2007;63:394–401.

Meuli M, Briner J, Hanimann B, et al. Lichen sclerosus et atrophicus causing phimosis in boys: a prospective study with 5-year follow-up after complete circumcision. *J Urol*. 1994;152:987–989.

Miller KS, McAninch JW. Circular fasciocutaneous flap urethroplasty. *J Urol*. 1993;149:505A.

Millett GA, Flores SA, Marks G, et al. Circumcision status and risk of HIV and sexually transmitted infections among men who have sex with men: a meta-analysis. *J Am Med Assoc*. 2008;300:1674–1684.

Milroy E, Allen A. Long-term results of UroLume urethral stent for recurrent urethral strictures. *J Urol*. 1996;155:904.

Milroy E, Chapple CR, Cooper JE, et al. A new treatment for urethral strictures. *Lancet*. 1988;1:1424.

Milroy E. Treatment of sphincter strictures using permanent UroLume stent. *J Urol*. 1993;150:1729–1733.

Milroy EJ, Chapple CR, Eldin A, et al. A new stent for the treatment of urethral strictures: preliminary report. *Br J Urol*. 1989;63:392.

Mitchell ME, Bagli DJ. Complete penile disassembly for epispadias repair: the Mitchell technique. *J Urol*. 1996;155:300–304.

Monseur J. Widening of the urethra using the supra-urethral layer [Author's trans. *J Urol*. 1980;86:439–449.

Monstrey S, Hoebeke P, Selvaggi G, et al. Penile reconstruction: is the radial forearm flap really the standard technique? *Plast*

Reconstr Surg. 2009;124:510–518.

Morey AF, Bruce JE, McAninch JW. Reconstruction of traumatic posterior urethral strictures: outcome analysis in 82 patients. *J Urol*. 1996;155:503A [abstract 768].

Morey AF, Kizer WS. Proximal bulbar urethroplasty via extended anastomotic approach—what are the limits? *J Urol*. 2006;175:2145–2149.

Morey AF, Lin HC, DeRosa CA, et al. Fossa navicularis reconstruction: impact of stricture length on outcomes and assessment of extended meatotomy (first stage Johanson) maneuver. *J Urol*. 2007;177:184–187.

Morey AF, McAninch JW. Buccal mucosa grafts in reconstruction of bulbar urethral strictures. *J Urol*. 1996;155:502A [abstract 767].

Morey AF, McAninch JW. Ultrasound evaluation of the male urethra for assessment of urethral stricture. *J Clin Ultrasound*. 1996;24:473–479.

Morey AF, Tran LK, Zinman LM. Q-flap reconstruction of panurethral strictures. *BJU Int*. 2000;86:1039–1042.

Morey AF. Urethral plate salvage with dorsal graft promotes successful penile flap onlay reconstruction of severe pendulous strictures. *J Urol*. 2001;166:1376–1378.

Mouraviev VB, Coburn M, Santucci RA. The treatment of posterior urethral disruption associated with pelvic fractures: comparative experience of early realignment versus delayed urethroplasty. *J Urol*. 2005;173:873–876.

Mouraviev VB, Santucci RA. Cadaveric anatomy of pelvic fracture urethral distraction injury: most injuries are distal to the external urinary sphincter. *J Urol*. 2005;173:869–872.

Mundy AR. *A comparison of urethral reconstruction techniques*. [Presented at: Society of Genitourinary Reconstructive Surgery (GURS)] 1994 [Jun 21; London, England].

Mundy AR. The role of delayed primary repair in the acute management of pelvic fracture injuries of the urethra. *Br J Urol*. 1991;68:273–276.

Myers JB, McAninch JW. Perineal urethrostomy. *BJU Int*. 2011;107(5):856–865.

Myers JB, Porten SP, McAninch JW. The outcomes of perineal urethrostomy with preservation of the dorsal urethral plate and urethral blood supply. *Urology*. 2011;77:1123–1227.

Nesbit RM. Congenital curvature of the phallus. Report of three cases with description of corrective operation. *J Urol*. 1965;93:230–232.

Orandi A. One stage urethroplasty: 4 year follow up. *J Urol*. 1972;107:977–980.

Orticochea M. The musculo-cutaneous flap method: an immediate and heroic substitute for the method of delay. *Br J Plast Surg*. 1972;25:106–110.

Oyama N, Chan I, Neill SM, et al. Development of antigen-specific ELISA for circulating autoantibodies to extracellular matrix protein 1 in lichen sclerosus. *J Clin Invest*. 2004;113:1550–1559.

Oyama N, Chan I, Neill SM, et al. Autoantibodies to extracellular matrix protein 1 in lichen sclerosus. *Lancet*. 2003;362:118–123.

Ozgok Y, Seckin B, Demirci S, et al. Surgical treatment of urethral diverticula in men. *Scand J Urol Nephrol*. 1994;28:207.

Pansadoro V, Emiliozzi P. Internal urethrotomy in the management of anterior urethral strictures: long-term followup. *J Urol*. 1996;156:73–75.

Park S, McAninch JW. Straddle injuries to the bulbar urethra: management and outcomes in 78 patients. *J Urol*. 2004;171(Pt 1):722–725.

Pavlica P, Barozzi L, Menchi I. Imaging of male urethra. *Eur*

Radiol. 2003;13:1583–1596.

Peña A, Devries PA. Posterior sagittal anorectoplasty. Important technical considerations and new applications. *J Pediatr Surg*. 1982;17:796–811.

Peña A, Hong A. The posterior sagittal trans-sphincteric approach. *Acta Chir Iugosl*. 2004;51:11–21.

Perovic S, Scepanovic D, Sremcevic D, et al. Epispadias surgery—Belgrade experience. *Br J Urol*. 1992;70:674–677.

Poland RL. The question of routine neonatal circumcision. *N Engl J Med*. 1990;322:1312–1315.

Ponten B. The fasciocutaneous flap: its use in soft tissue defects of the lower leg. *Br J Plast Surg*. 1981;34:215–220.

Pressman D, Greenfield DL. Reconstruction of the perineal urethra with a free full thickness skin graft from the prepuce. *J Urol*. 1953;69:677–680.

Pride HB, Miller OF 3rd, Tyler WB. Penile squamous cell carcinoma arising from balanitis xerotica obliterans. *J Am Acad Dermatol*. 1993;29:469–473.

Puckett CL, Montie JE. Construction of male genitalia in the transsexual, using a tubed groin flap for the penis and a hydraulic inflation device. *Plast Reconstr Surg*. 1978;61:523–530.

Puckett CL, Reinisch JF, Montie JE. Free flap phalloplasty. *J Urol*. 1982;128:294–297.

Quartey JK. One stage penile/preputial cutaneous island flap urethroplasty for urethral stricture: a preliminary report. *J Urol*. 1983;129:284–287.

Ramsey G. Appendix B: standards of care: the hormonal and surgical sex reassignment of gender dysphoric persons. Ramsey G. *Transsexuals: candid answers to private questions*. Crossing Press: Freedom (CA); 1996:155–168.

Ransley PG, Duffy PG, Oesch IL, et al. The use of bladder mucosa and combined bladder mucosa/preputial skin grafts for urethral reconstruction. *J Urol*. 1987;138:1096–1098.

Rehman J, Samadi D, Ricciardi R Jr, et al. Early endoscopic realignment as primary therapy for complete posterior urethral disruptions. *J Endourol*. 1998;12:283–289.

Rickwood AM, Hemalatha V, Batcup G, et al. Phimosis in boys. *Br J Urol*. 1980;52:147–150.

Rosen MA, Nash PA, Bruce JE, et al. The actuarial success rate of surgical treatment of urethral strictures. *J Urol*. 1994;151:370 [meeting abstract].

Ross SA, Sanchez JL, Taboas JO. Spirochetal forms in the dermal lesions of morphea and lichen sclerosus et atrophicus. *Am J Dermatopathol*. 1990;12:357–362.

Rotariu P, Yohannes P, Alexianu M, et al. Reconstruction of rabbit urethra with Surgisis small intestinal submucosa. *J Endourol*. 2002;16:617–620.

Rourke KF, Jordan GH. Primary urethral reconstruction: the cost minimized approach to the bulbous urethral stricture. *J Urol*. 2005;173:1206–1210.

Rourke KF, McCammon KA, Sumfest JM, et al. Open reconstruction of pediatric and adolescent urethral strictures: long-term follow-up. *J Urol*. 2003;169:1818–1821 [discussion 1821].

Rousseau H, Puel J, Joffre F, et al. Self-expanding endovascular prosthesis: an experimental study. *Am J Radiol*. 1987;164:709.

Russell RH. The treatment of urethral stricture by excision. *Br J Surg*. 1914;2:375.

Sander CS, Ali I, Dean D, et al. Oxidative stress is implicated in the pathogenesis of lichen sclerosus. *Br J Dermatol*. 2004;151:627–635.

Santucci RA, McAninch JW. Actuarial success rates of open urethral stricture repair in 369 patients. *J Urol*. 2001;165(Suppl):13 [abstract 54].

Sarramon JP, Joffre F, Rischmann P, et al. Use of the Wallstent endourethral prosthesis in the treatment of recurrent urethral strictures. *Eur Urol*. 1990;18:281.

Schoen EJ. The status of circumcision of newborns. *N Engl J Med*. 1990;322:1308–1312.

Schonfeld WA, Beebe GW. Normal growth and variation in the male genitalia from birth to maturity. *J Urol*. 1942;48:759–777.

Schreiter F, Koncz PM. Traitement des stenoses uretrales compliquees par suture uretrale bout-a-bout et ureteroplastie par greffe libre du prepuce. Les implant cutanes dans la reparation de stenoses uretrales. *J Urologiques de l'Hopital Necker*. 1983;34–41.

Schreiter F, Noll F. Mesh graft urethroplasty using split thickness skin graft or foreskin. *J Urol*. 1989;142:1223–1226.

Secrest CL, Jordan GH, Winslow BH, et al. Repair of the complications of hypospadias surgery. *J Urol*. 1993;150:1415–1418.

Secrest CL, Rollins R, Hardin B. A breakthrough in the treatment of balanitis xerotica obliterans. *J Urol*. 2008;179:258–259.

Shah DK, Paul EM, Badlani GH. North American Study Group: 11-year outcome analysis of endourethral prosthesis for the treatment of recurrent bulbar urethral stricture. *J Urol*. 2003;170(Pt 1):1255–1258.

Sharma AK, Chandrashekar R, Keshavamurthy R, et al. Lingual versus buccal mucosa graft urethroplasty for anterior urethral stricture: a prospective comparative analysis. *Int J Urol*. 2013;20:1199–1203.

Shelley WB, Shelley ED, Grunenwald MA, et al. Long-term antibiotic therapy for balanitis xerotica obliterans. *J Am Acad Dermatol*. 1999;40:69–72.

Shenfeld OZ, Gofrit ON, Gdor Y, et al. Anastomotic urethroplasty for failed previously treated membranous urethral rupture. *Urology*. 2004;63:837–840.

Shenfeld OZ, Kiselforf D, Gofrit ON, et al. The incidence and causes of erectile dysfunction after pelvic fractures associated with posterior urethral disruption. *J Urol*. 2003;169:2173–2176.

Shirer JA, Ray MC. Familial occurrence of lichen sclerosus et atrophicus. *Arch Dermatol*. 1987;123:485–488.

Sigwart U, Puel J, Miarkovitch V, et al. Intravascular stents to prevent occlusion and restenosis after transluminal angioplasty. *N Engl J Med*. 1987;316:701.

Silva TS, Richeti F, Cunha DP, et al. Androgen receptor mRNA measured by quantitative real time PCR is decreased in the urethral mucosa of patients with middle idiopathic hypospadias. *Horm Metab Res*. 2013;45:495–500.

Sneller ZW, Bosch RJ. Restenosis of the urethra despite indwelling Wallstent. *J Urol*. 1992;148:145.

Snodgrass WT, Bush N, Cost N. Algorithm for comprehensive approach to hypospadias reoperation using 3 techniques. *J Urol*. 2009;182:2885–2891.

Snodgrass WT. Tubularized plate hypospadias repair: indications, technique, and complications. *Urology*. 1999;54:6–11.

Snyder H. The surgery of bladder exstrophy and epispadias. Frank JD, Johnston JH. *Operative paediatric urology*. Churchill Livingstone: London; 1990:153–185.

Staff WG. Urethral involvement in balanitis xerotica obliterans. *Br J Urol*. 1970;42:234–239.

Steenkamp JW, Heyns CF, de Kock ML. Outpatient treatment for male urethral strictures—dilatation versus internal urethrotomy. *S Afr J Surg*. 1997;35(3):125–130.

Stewart L, McCammon K, Metro M, et al. SIU/ICUD Consultation on Urethral Strictures: anterior urethra-lichen sclerosus. *Urology*. 2014;83(Suppl):S27.

Stone AR, Randall JR, Shorrock K, et al. Optical urethrotomy—a 3-year experience. *Br J Urol*. 1983;55:701–704.

Stühmer A. Balanitis xerotica obliterans (post operationem) und ihre beziehungem zur Kraurosis glandis et preaeputii. *Penis Arch Derm Syph (Berlin)*. 1928;156:613–623.

Tasker GL, Wojnarowska F. Lichen sclerosus. *Clin Exp Dermatol*. 2003;28:128–133.

Tausch TJ, Morey AF, Scott JF, et al. Unintended negative consequences of primary endoscopic realignment for men with pelvic fracture urethral injuries. *J Urol*. 2014;192:1720–1724.

Thomas RHM, Kennedy CT. The development of lichen sclerosus et atrophicus in monozygotic twin girls. *Br J Dermatol*. 1986;114:277–279.

Tillem SM, Press SM, Badlani GH. Use of multiple UroLume endourethral prostheses in complex bulbar urethral strictures. *J Urol*. 1997;157:1665.

Tobian AA, Kacker S, Quinn TC. Male circumcision: a globally relevant but under-utilized method for the prevention of HIV and other sexually transmitted infections. *Annu Rev Med*. 2014;65:293–306.

Tolhurst DE, Haeseker B. Fasciocutaneous flaps in the axillary region. *Br J Plast Surg*. 1982;35:430–435.

Tuffanelli D. Do some patients with morphea and lichen sclerosus et atrophicus have a *Borrelia* infection? *Am J Dermatopathol*. 1987;9:371–373.

Valdivia JG, Lopez JA, Arende JM, et al. Diverticulos bulbouretrales. *Arch Esp Urol*. 1986;39:117.

Vanni A, Buckley J, Zinman L. Contemporary management of rectourethral fistulas: 10-year experience. *J Urol*. 2009;181:421–422.

Vanni AJ, Zinman LN, Buckley JC. Radial urethrotomy and intralesional mitomycin C for the management of recurrent bladder neck contractures. *J Urol*. 2011;186:156–160.

Verhamme L, Van Poppe CH, Van DeVoorde W, et al. Total fibrotic obliteration of urethral stent. *Br J Urol*. 1993;72:389.

Virasoro R, Eltahawy EA, Jordan GH. Long-term follow-up for reconstruction of strictures of the fossa navicularis with a single technique. *BJU Int*. 2007;100:1143–1145.

Virasoro R, Zuckerman JM, McCammon KA, et al. International multi-institutional experience with the vessel-sparing technique to reconstruct the proximal bulbar urethra: mid-term results. *World J Urol*. 2015;33(12):2153–2157.

Wallace HJ. Lichen sclerosus et atrophicus. *Trans St John's Dermatol Soc*. 1971;57:9–30.

Walzer Y, Bear R, Colapinto V, et al. Localized amyloidosis of urethra. *Urology*. 1983;21:406–407.

Waterhouse K, Abrahams JI, Gruber H, et al. The transpubic approach to the lower urinary tract. *J Urol*. 1973;109:486–490.

Webster GD, Brown MW, Koefoot RB, et al. Suboptimal results in full thickness skin graft urethroplasty using an extrapenile skin donor site. *J Urol*. 1984;131:1082–1083.

Webster GD. *Problems in urology*. Lippincott: Philadelphia; 1987:214.

Webster GD, Mathes GL, Selli C. Prostatomembranous urethral injuries: a review of the literature and a rational approach to their management. *J Urol*. 1983;130:898–902.

Webster GD, Ramon J, Kreder KJ. Salvage posterior urethroplasty after failed initial repair of pelvic fracture membranous urethral defects. *J Urol*. 1990;144:1370–1372.

Webster GD, Sihelnik S. The management of strictures of the membranous urethra. *J Urol*. 1985;134:469–473.

Weinberg G, Williot P, Leonard M. The utility of buccal mucosa graft in salvage urethroplasty. *Can J Urol*. 2002;9:1641–

1645.

Weir RF. Icthyosis of the tongue and vulva. *N Y State J Med*. 1875;21:246–248.

Wessells H, McAninch JW. Current controversies in anterior urethral stricture repair: free-graft versus pedicled skin-flap reconstruction. *World J Urol*. 1998;16:175–180.

Wessells H, McAninch JW. Use of free grafts in urethral stricture reconstruction. *J Urol*. 1996;155:1912–1915.

Wessells H, Morey AF, McAninch JW. Single stage reconstruction of complex anterior urethral strictures: combined tissue transfer techniques. *J Urol*. 1997;157:1271–1274.

Wessells H. Cost-effective approach to short bulbar urethral strictures supports single internal urethrotomy before urethroplasty. *J Urol*. 2009;181:954–955.

Winslow BH, Horton CE, Gilbert DA, et al. Epispadias and exstrophy of the bladder. Mustarde JC, Jackson IT. *Plastic surgery in infancy and childhood*. 3rd ed. Churchill Livingstone: New York; 1988:511–527.

Winslow BH, Vorstman B, Devine CJ Jr. Complications of hypospadias surgery. Marshall FF. *Urologic complications, medical and surgical, adult and pediatric*. Year Book: Chicago; 1986:411–426.

Wright JL, Wessells H, Nathens AB, et al. What is the most cost-effective treatment for 1 to 2-cm bulbar urethral strictures: societal approach using decision analysis. *Urology*. 2006;67:889–893.

Xu YM, Qiao Y, Sa YL, et al. 1-stage urethral reconstruction using colonic mucosa graft for the treatment of a long complex urethral stricture. *J Urol*. 2004;171:220–223 [discussion 223].

Yachia D, Beyar M. Temporarily implanted urethral coil stent for the treatment of recurrent urethral stricture: a preliminary report. *J Urol*. 1991;146:1001–1004.

Yachia D. Corporeal plication for surgical correction of Peyronie's disease. *J Urol*. 1993;149:869.

Zuckerman JM, McCammon KA, Tisdale BE, et al. Outcome of penile revascularization for arteriogenic erectile dysfunction after pelvic fracture urethral injuries. *Urology*. 2012;80:1369–1373.

83

Surgery of the Scrotum and Seminal Vesicles

Dorota J. Hawksworth MD, MBA, Mohit Khera MD, MBA, MPH, Amin S. Herati MD

Surgical Anatomy of the Scrotum

Scrotal Wall

A detailed understanding of the scrotal anatomy is critical in the operative planning of scrotal and pelvic surgeries. Knowledge of scrotal wall anatomy enables safer access into the scrotum for common scrotal procedures, facilitates identification of surgical planes during surgical debridement, and allows for multilayer closures.

The scrotal skin is rugated because of its underlying attachment to the dartos muscle, deeply pigmented, and hair-bearing. In contrast with other parts of the body, the scrotum is elastic and highly-temperature regulated to enable spermatogenesis.

Scrotal Contents

Scrotal contents are maintained in their position within the scrotal cavity by the spermatic cord and gubernacular attachments. The testicle is intimately encased by the tunica albuginea, and protected by the layers of tunica vaginalis, internal and external spermatic fascia (separated by a layer of cremasteric muscle), and ultimately covered by the dartos layer and scrotal skin. **The dartos fascial layer acts as a barrier to the spread of necrotizing fasciitis to deeper structures in the scrotum (Figs. 83.1 and 83.2).** The epididymis originates from the efferent ducts of the rete testis in mediastinum testis. It is located along the posterolateral aspect of the testis, with its head (caput) located superiorly, the body (corpus) along the longitudinal axis of the testis, and the tail (cauda) at the inferior testicular pole. The vas deferens begins as continuation of the cauda epididymis, travels along the spermatic cord into the pelvis, where it becomes ampulla of the vas, joins with seminal vesicles (SVs), and forms the proximal ejaculatory duct. Two nonfunctional, vestigial structures may be encountered in the scrotum: the appendix testis over the upper pole of the testis and the appendix epididymis attached to the head of the epididymis.

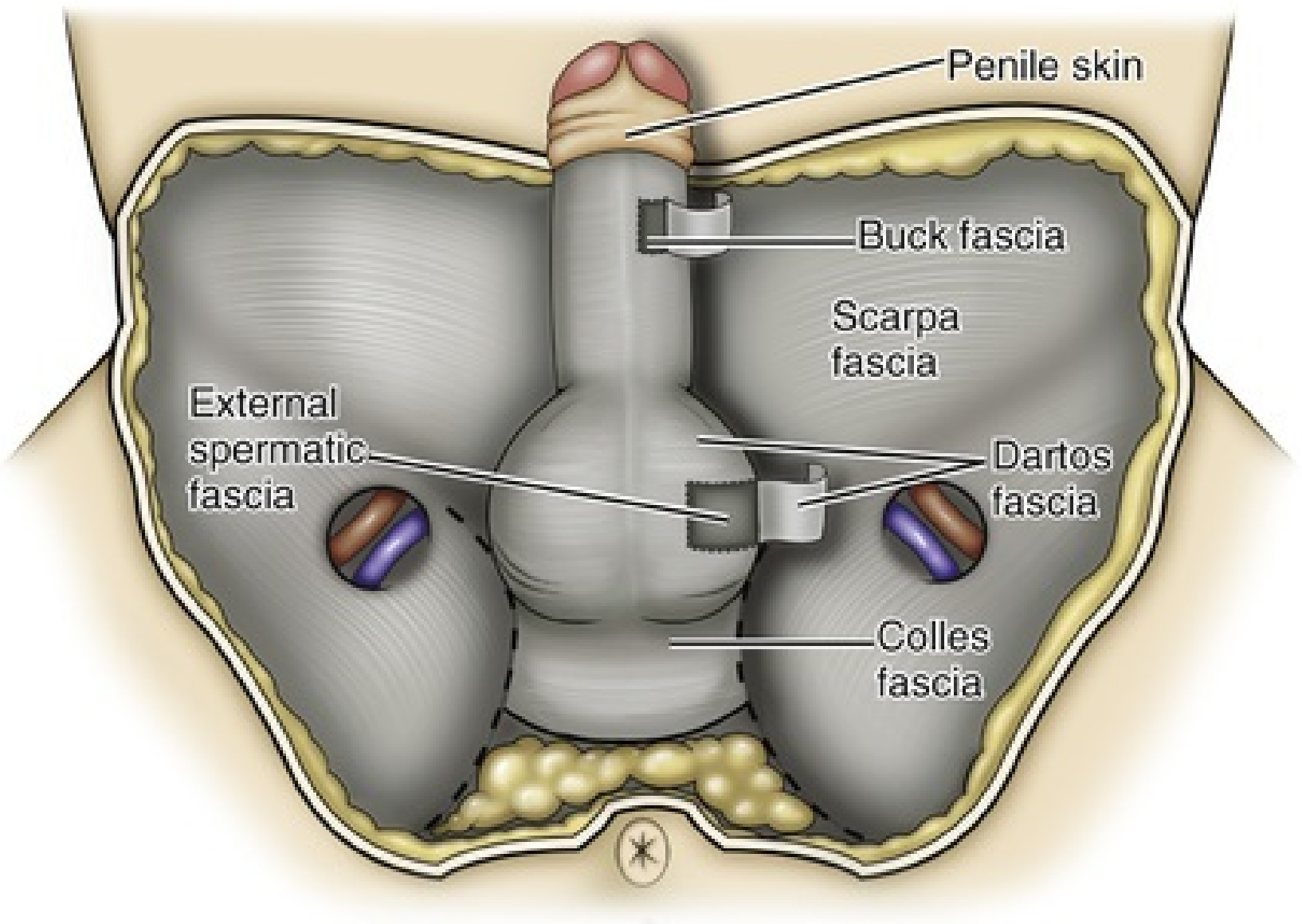
Penile skin
Buck fascia
Scarpa fascia
External spermatic fascia
Dartos fascia
Colles fascia

FIG. 83.1 Anatomic barriers to the spread of infection. (Modified from Kavoussi PK, Costabile RA. Disorders of scrotal contents: orchitis, epididymitis, testicular torsion, torsion of the appendages, and Fournier gangrene. In: Chapple CR, Steers WD, eds. *Practical urology: essential principles and practice.* London: Springer-Verlag; 2011.)

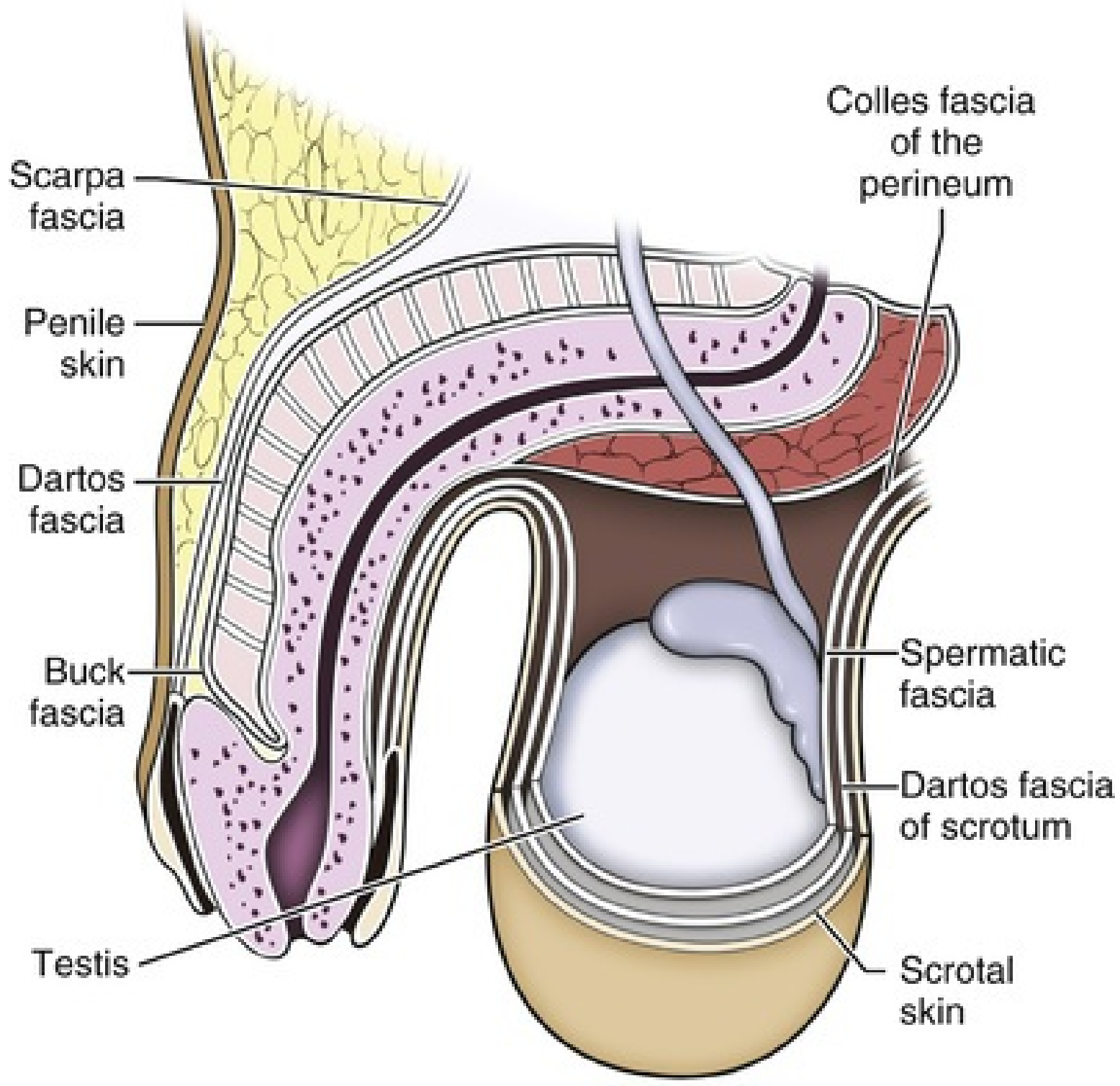
Scarpa fascia
Penile skin
Dartos fascia
Buck fascia
Testis
Colles fascia of the perineum
Spermatic fascia
Dartos fascia of scrotum
Scrotal skin

FIG. 83.2 Sagittal view of anatomic barriers to the spread of infection.

(Modified from Kavoussi PK, Costabile RA. Disorders of scrotal contents: orchitis, epididymitis, testicular torsion, torsion of the appendages, and Fournier gangrene. In: Chapple CR, Steers WD, eds. Practical urology: essential principles and practice. London: Springer-Verlag; 2011.)

Vasculature

The scrotum is highly vascularized, with blood supply provided anteriorly from the superficial external pudendal artery and deep external pudendal artery, and posteriorly from the posterior scrotal artery. Venous drainage follows the arterial supply draining into the external pudendal vein and posterior scrotal vein, which empty into the great saphenous vein and to the internal iliac veins, respectively.

In addition to temperature regulation, the thin, highly vascular nature of the scrotal skin allows increased transdermal medication absorption, up to 40 times the absorption of other parts of the body (Nieschlag and Behre, 2010). This absorptive quality of the scrotal skin was utilized in testosterone supplementation; however, the necessity of frequent scrotal hair clipping made continued application of scrotal testosterone patches cumbersome for patients, and this formulation of testosterone is no longer available. Additionally, the scrotal skin is high in 5α-reductase enzyme, and as result, high dihydrotestosterone levels were seen with scrotal transdermal testosterone therapy (Ahmed et al., 1988).

The blood supply to the testis arises from the aorta as the testicular artery, from the internal iliac artery as the artery to the ductus deferens, and from the external iliac artery as the cremasteric artery. The epididymis is nurtured by the superior epididymal artery from the testicular artery and from the inferior epididymal artery, arising as branches off the deferential artery and distal branches of the testicular artery. Although the majority of the blood supply (~84%) to the epididymis comes from the superior epididymal artery, **the superior epididymal artery can be sacrificed to gain additional testicular mobilization during vasectomy reversal because of the vascular anastomoses between the superior and inferior epididymal artery** (Strittmatter and Konrad, 1989). Understanding the blood supply to the epididymides is important in the surgical treatment of epididymal disease.

Important anastomoses are also present cranial and caudal to the testis. Cranially, thin-caliber anastomoses are often present in the spermatic cord between the testicular artery and the deferential artery approximately 10 cm above the testis (Strittmatter and Konrad, 1989). At the level of the cauda of the epididymis, anastomoses form between the testicular artery, deferential artery, and cremasteric artery. **This redundancy of blood supply to the testis allows viability of the testis if one or two of the arteries are injured or ligated.**

Innervation

The scrotum is innervated by autonomic and somatic nerve fibers. Three groups of converging autonomic nerve fibers contribute to the autonomic innervation of the testes: (1) superior spermatic nerves, from the renal and mesenteric plexi, which follow the testicular artery, (2) middle spermatic nerves, from the superior hypogastric plexus, which travel adjacent to the vas as it enters the internal spermatic ring, and (3) inferior spermatic nerves, which originate from the inferior hypogastric plexus (Patel, 2017). The inferior spermatic nerve fibers fuse with the middle spermatic nerve fibers at the prostate-vesical junction, run within the spermatic cord along the vas deferens, and ultimately penetrate the epididymis and testis (Sosa et al., 2009; Patel, 2017). In addition to the sensory fibers contained in the autonomic spermatic nerves, afferent fibers of these nerves are also important in the endocrine control of the testis. Sosa et al. demonstrated the endocrine control over testis function by modulating androgen release in adult male rats via exposure of autonomic ganglia to adrenoreceptor agonists and antagonists (Sosa et al., 2009). Exposure of the inferior mesenteric plexus ganglia to noradrenaline resulted in significantly higher serum testosterone levels compared with untreated ganglia in the control male rats; however, noradrenaline exposure to the superior mesenteric ganglia did not influence testosterone concentrations.

The scrotum is also innervated by somatic nerves, including ilioinguinal and genitofemoral nerves. The genital branch of the genital femoral nerve is positioned on the inferolateral aspect of the spermatic cord and innervates the anterolateral scrotal skin, the tunica vaginalis, and the cremaster muscles (Ducic and Dellon, 2004; Zorn et al., 1994). In contrast, the ilioinguinal nerve sits on the anterior of the cremasteric muscles and innervates the anterior scrotal skin (Wijsmuller et al., 2007). An understanding of the course of these nerves is important in scrotal denervation procedures, which are discussed later in this chapter.

Preoperative Considerations

Hair removal from the surgical field facilitates exposure, reduces surgical site infection, enables suturing, and eases the application of wound dressing (Alexander et al., 1983; World Health Organization, 2016). The methods of epilation include clippers and razors. Although most hospitals encourage the use of clippers, Grober et al. (2013) showed a lower rate of skin trauma and improved shave quality of razors over clippers ($P < 0.05$). **Scrotal hair should be removed using a disposable razor on the day of surgery.**

The scrotal skin is cleansed of bacteria using an antiseptic such as iodine solutions and chlorhexidine gluconate. Although a 2015 Cochrane review showed lower infection rates with a chlorhexidine scrub compared with alcohol-based povidone iodine paint, the studies analyzed were of small sample sizes and of poor methodologic quality (Dumville et al., 2015). The choice of antiseptic product should be based on cost and patient allergy profile.

According to the American Urological Association (AUA) Best Practice Statement on Urologic Surgery Antimicrobial Prophylaxis, genital surgical procedures should be prophylaxed with a single dose of intravenous cephalosporin or clindamycin for patients who possess risk factors for infection, such as advanced age, anatomic abnormalities of the urinary tract, poor nutritional status, smoking, chronic corticosteroid use, immunodeficiency, externalized catheters, colonized endogenous/exogenous material, distant coexistent infection, and prolonged hospitalization (Wolf et al., 2008).

The choice of anesthetics can include local, regional, spinal, and/or general anesthetics. The combination of spermatic cord block and local infiltration of anesthetic allows for the successful in-office completion of a number of scrotal procedures (Alom et al., 2017; Fuchs, 1982; Magoha, 1998). Regardless of whether the scrotal surgery is performed in the operating theater or in an office setting, preincisional injection of a local anesthetic with 0.5% lidocaine without epinephrine is recommended to control postprocedural pain (Leach, 1996).

Surgical Approaches to Scrotal Contents

Access Into the Scrotum

The approach to scrotal surgery depends on the etiology. Benign diseases of the scrotum are approached through a scrotal incision, whereas possible malignant conditions are approached through an inguinal incision. To prevent tumor seeding during the inguinal approach, the spermatic cord is isolated and clamped with noncrushing clamps until frozen-section biopsies confirm the presence of neoplasia. Scrotal hypothermia can be utilized once the spermatic cord is clamped; however, animal models show impaired testicular function and greater testicular histopathologic change associated with cold ischemia compared with warm ischemia over a 5-week period (Goldstein and Waterhouse, 1983; McNamara et al., 2014). If no malignancy is detected on frozen section, then the testis and spermatic cord can be spared and the remainder of the surgery can be performed.

Access into the scrotum can be obtained with either a transverse or a median raphe scrotal incision. Common to all techniques, dissection must be performed with attention to obtain hemostasis when the tunica vaginalis is bluntly taken off of the scrotal wall and to not injure the testis, epididymis, or other cord structures when making the incision into the tunica vaginalis to access intrascrotal contents. Obstructive azoospermia can result from injuries to the epididymis and/or vas deferens during hydrocelectomy, thus great care should be taken to avoid these structures opening and excising the hydrocele sac (Ross and Flom, 1991).

Surgeries of the Scrotum

Scrotal Wall

Cyst/Tumor Excision

Scrotal sebaceous cysts and epidermal inclusion cysts, like any other skin cystic lesions, are either managed conservatively or with surgical resection, if not infected. The standard ellipsoid resection yields excellent outcomes and with good cosmetic results (Noel et al., 2006). If the scrotal lesion has any signs of infection, it is either managed solely with a course of antibiotics or with incision and drainage (I&D) in addition to systemic therapy. This can be easily performed in a clinic or emergency room setting with minimal analgesia and morbidity. Once the infection resolves, patients often require surgical excision, as recurrence is quite high.

Partial/Total Scrotectomy

Partial scrotectomy is performed uncommonly and is mostly required in an infectious process caused by Fournier gangrene (FG). Urgent surgical debridement is of essence as tissue gangrene can spread as quickly as 2 to 3 cm/hour, and delay can result in significant increase in patient mortality (Paty and Smith, 1992). Repeat debridement should be performed every 24 to 48 hours as all visibly necrotic tissue must be removed (Fig. 83.3A). On average, patients require up to 4 repeat debridement procedures (Norton et al., 2002). Treatment of patients with FG requires a multidisciplinary approach, to include trauma, general, and colorectal surgeons, and intensive care and infectious disease specialists. Extension of gangrene to the anorectal region may necessitate fecal diversion with a colostomy and is an important consideration in the preoperative planning of FG patients.

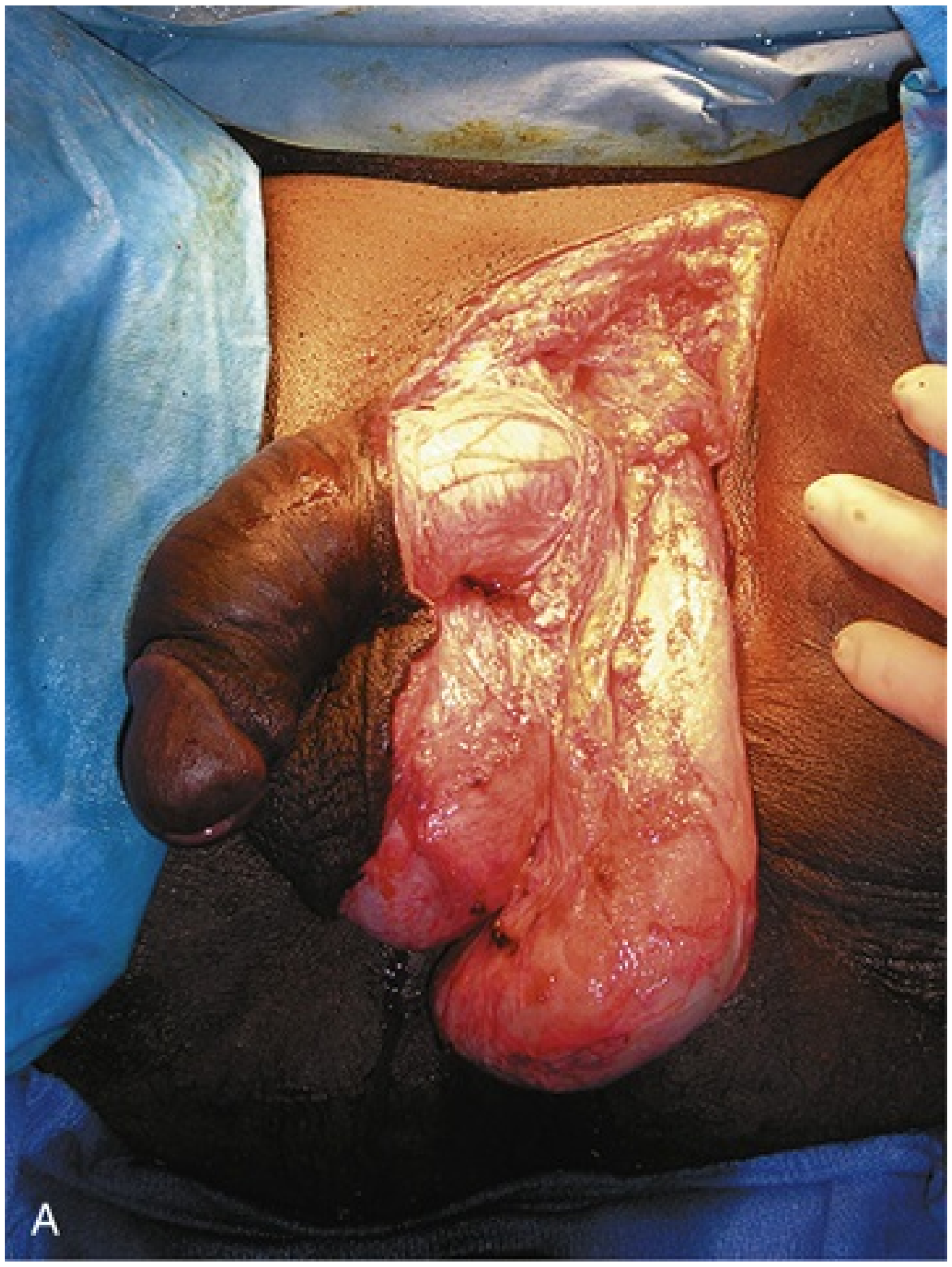
A

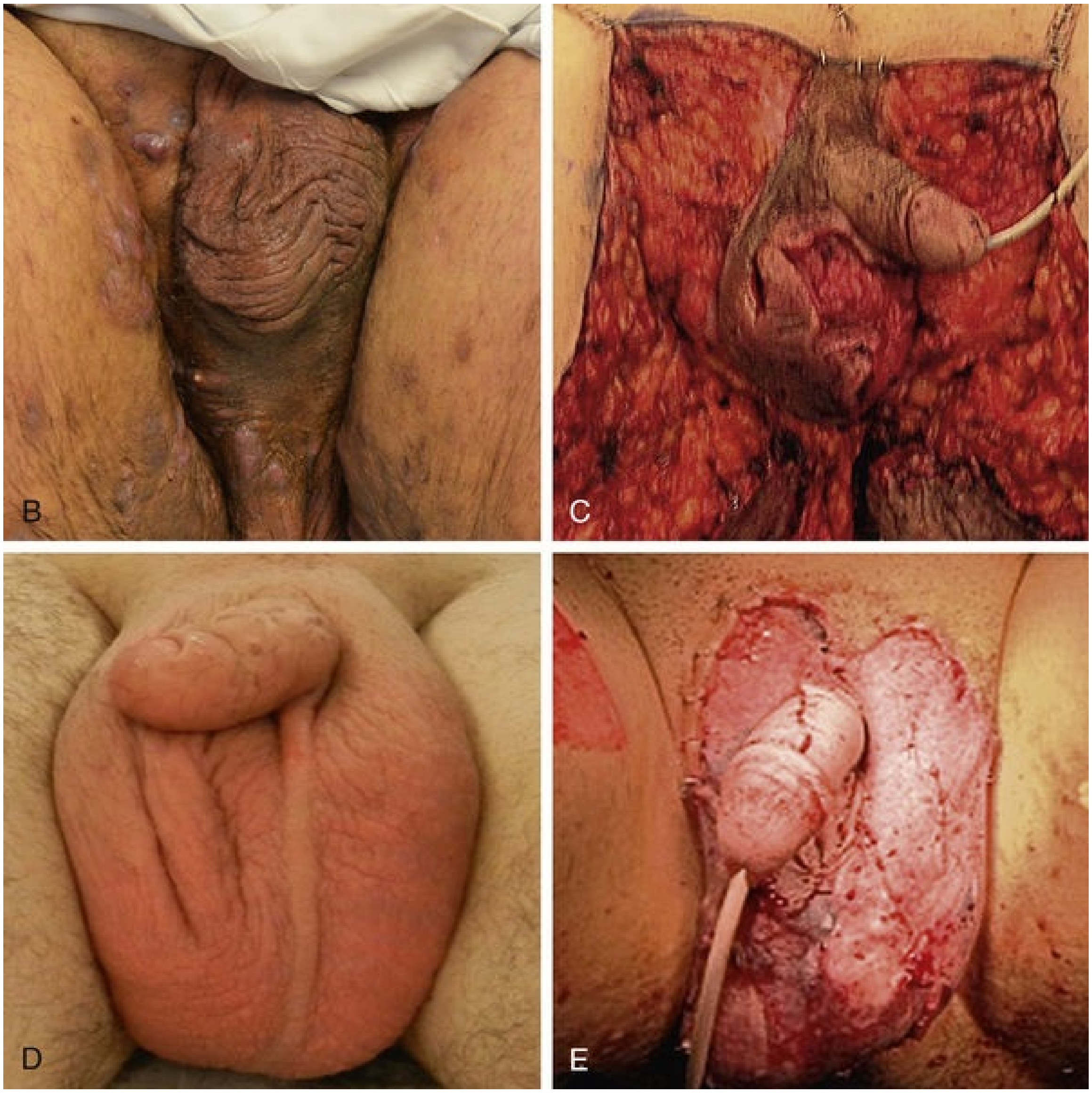

FIG. 83.3 (A) Aggressive debridement of Fournier gangrene. (B to E) Wide excision of hidradenitis suppurativa of the perineum. (B) Before. (C) After. Use of excision and split-thickness skin graft for lymphedema of the penis and scrotum. (D) Before. (E) After. (A, From Kavoussi PK, Costabile RA. Disorders of scrotal contents: orchitis, epididymitis, testicular torsion, torsion of the appendages, and Fournier gangrene. In: Chapple CR, Steers WD, eds. *Practical urology: essential principles and practice*. London: Springer-Verlag; 2011.)

Partial scrotectomy is also required in patients who had an inadvertent scrotal violation during an evaluation and/or treatment of a nonseminomatous germ cell tumor of the testis. To prevent tumor contamination and local recurrence, partial scrotectomy is required following a trans-scrotal tumor aspiration, biopsy, exploration, and/or orchiectomy.

Other scrotal nonmalignant conditions (such as hidradenitis suppurativa, postradiation lymphedema, penoscrotal Paget disease, and primary lymphangitis) may also require extensive surgical excision. Finally, partial scrotectomy can also be performed for cosmesis to reduce the level of scrotal descent.

Total scrotectomy is less commonly performed than partial scrotectomy. It is often required when there is extensive involvement of scrotal skin with FD, in malignant processes, and in extensive trauma-related damage. If an extensive amount of scrotal skin is removed and an immediate reconstruction is not performed, the testes are placed into medial thigh pockets with loose wound approximation until the scrotum can be reconstructed.

Scrotal Reconstruction

Reconstruction of the scrotum depends on the extent of the defect and on the availability of suitable local tissue. Following surgical debridement, patients can be left with significant scrotal defects. Small scrotal defects can be successfully treated with wet-to-dry dressing changes. Larger scrotal defects are managed with negative-pressure wound therapy with a vacuum-assisted closure (VAC) device (VAC KCI, San Antonio, TX). Negative-pressure therapy hastens recovery by evacuating bacteria and edema, improving angiogenesis, and promoting granulation of the wound bed. These changes hasten recovery time, reduce the surface area of the wound, and improve the likelihood of skin graft take (Scherer et al., 2002; Silberstein et al., 2008).

Scrotal wound closure for FG depends on the wound size and spread of gangrene beyond the scrotum (Fig. 83.3B–E). Small defects, involving less than one-half of the scrotum, can heal by secondary intention. This process can be potentially further facilitated by loose approximation of skin edges with nonabsorbable monofilament suture and VAC therapy. Larger defects, involving more than one-half of the scrotum, can be closed with local advancement flaps with either use of remaining scrotum or thigh tissues. The remaining scrotal skin and dartos can be undermined and stretched to cover much larger defects (Por et al., 2003). It has been reported that defects up to 96 cm^2 can be replaced with the remaining scrotal skin (Silberstein et al., 2008). If scrotal flaps are impossible to perform because of lack of local tissue, fasciocutaneous flaps obtained either from the superomedial or anterolateral thigh have been described and can be used with good cosmetic results (Lin et al., 2016; Mello and Helene Júnior, 2018; Oufkir et al., 2013). Meshed split-thickness skin grafts can also be used for coverage of scrotal defects, although they are inferior to thigh flaps, as more significant contracture-related effects occur with their application (Karian et al., 2015) (Fig. 83.4).

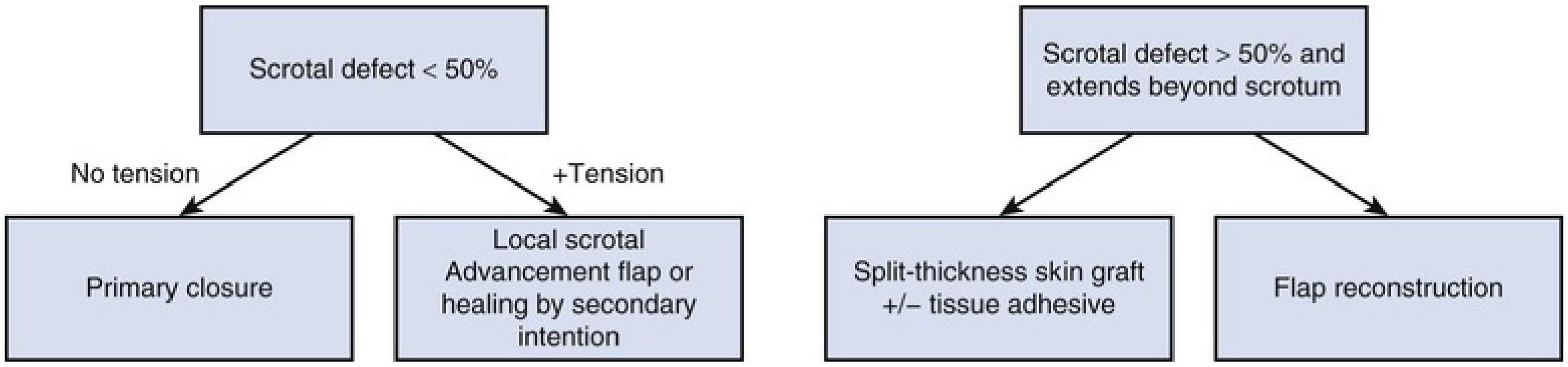
Scrotal defect < 50%
No tension
+Tension
Primary closure
Local scrotal Advancement flap or healing by secondary intention
Scrotal defect > 50% and extends beyond scrotum
Split-thickness skin graft +/– tissue adhesive
Flap reconstruction

FIG. 83.4 Algorithm for the management of scrotal reconstruction following scrotal debridement. (Modified from Karian LS, Chung SY, Lee ES. Reconstruction of defects after Fournier gangrene: a systematic review. *Eplasty.* 2015;15:e18. eCollection 2015.)

Testis

Hydrocelectomy

Hydroceles arise from the accumulation of fluid between the parietal and visceral layers of the tunica vaginalis. Congenital hydroceles arise from persistent drainage of peritoneal fluid through a patent processus vaginalis (communicating hydrocele), with a higher prevalence of congenital hydrocele among preterm neonates. The processus vaginalis, which arises embryologically from the peritoneum, normally closes by the second year of life, with 80% of congenital hydroceles spontaneously resolving by 18 months of age (Osifo and Osaigbovo, 2008). In contrast, acquired hydroceles form as a result of an imbalance between the production and reabsorption of fluid within the tunica vaginalis. Acquired hydroceles are among the most common benign scrotal conditions affecting adult men older than 40 years of age. In an ultrasound study of 40 asymptomatic men, 86% of the hemiscrotums evaluated had at least a minimal amount of peritesticular fluid (Leung et al., 1984). This fluid can consist of peritoneal fluid, lymph fluid, abscess, blood, bile, cerebrospinal fluid, or urine (Dagur et al., 2017).

Hydroceles generally present as a painless bulge in the groin and may extend along the spermatic cord and into the inguinal canal. They do not require treatment unless there is associated discomfort, cosmetic concerns, or an underlying malignancy. Urgent treatment may be necessary in the setting of a pyocele with associated clinical symptoms of infection. High-resolution B-mode ultrasonography and color Doppler ultrasonography play important roles in distinguishing among the various causes of fluid accumulation and often guide the surgical approach.

Various approaches are available for performing the hydrocelectomy including excisional and plication techniques. **In general, excisional techniques are associated with the lowest rates of recurrence and should be reserved for chronic, large, multiloculated and thick-walled hydroceles** (Rodriguez et al., 1981). Excisional techniques include the Jaboulay technique, the bottleneck procedure, the window operation, and the simple excision technique.

Lord Plication.

Thin-walled and smaller volume hydroceles are often amenable to a plication procedure. The Lord plication technique involves opening the hydrocele sac along its anterior surface, extruding the testis through the aperture, and plicating the sac using interrupted, radially placed chromic sutures in a circumferential fashion (Fig. 83.5) (Lord, 1964). As no excision is performed, this technique carries the lowest risk for hematoma postoperatively and does not benefit from drain placement.

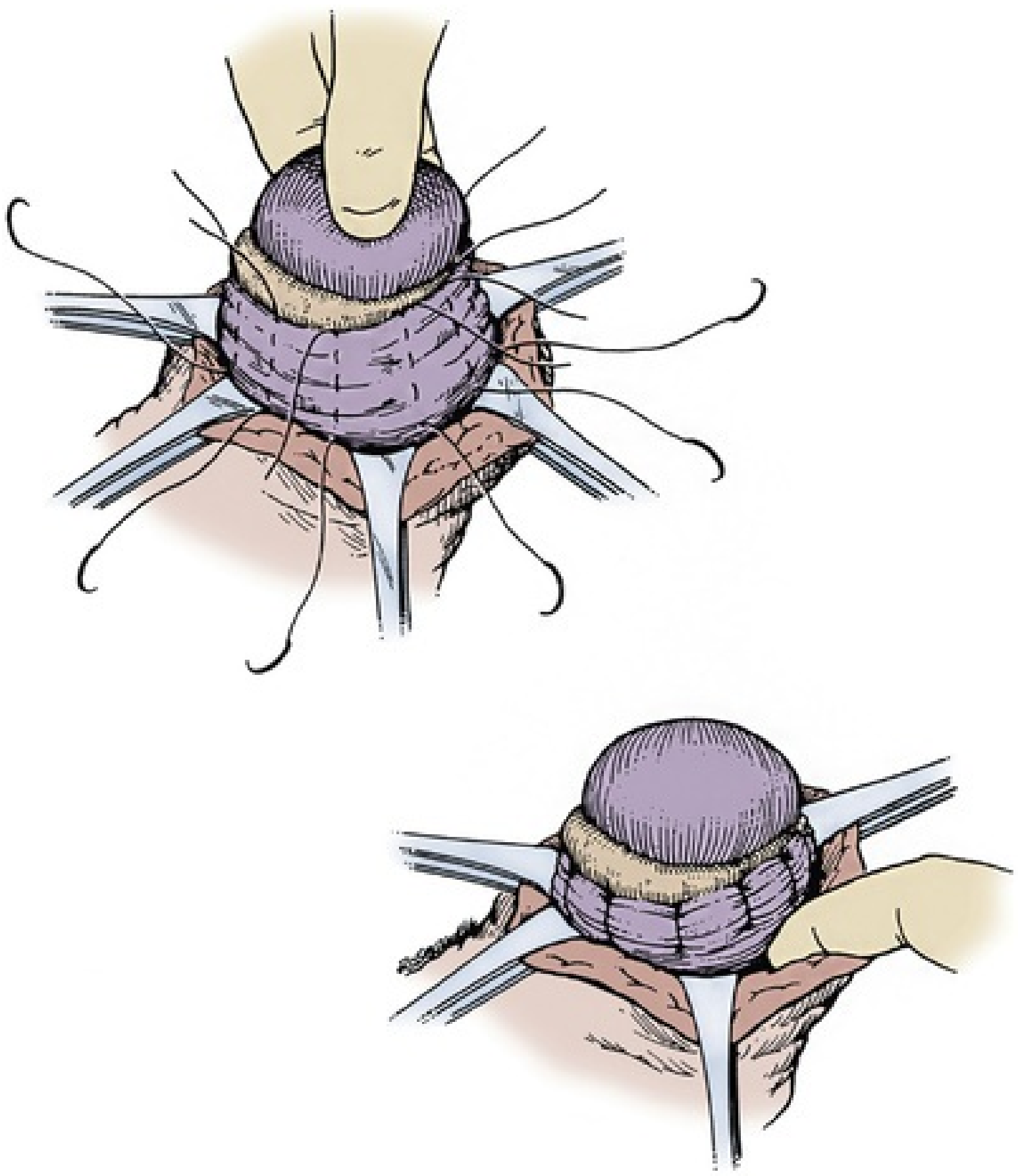

FIG. 83.5 Lord plication technique.

Jaboulay (Winkelman) Technique.

The Jaboulay technique involves resecting a portion of the parietal tunica albuginea, everting the parietal layer of the tunica behind the testis, and approximating the opposing parietal tunical edges to each other without compressing the spermatic cord. Alternatively, once the excess tunica vaginalis is excised and the bleeding edges have been cauterized, the cut edges can be oversewn with a 3-0 chromic suture (Fig. 83.6).

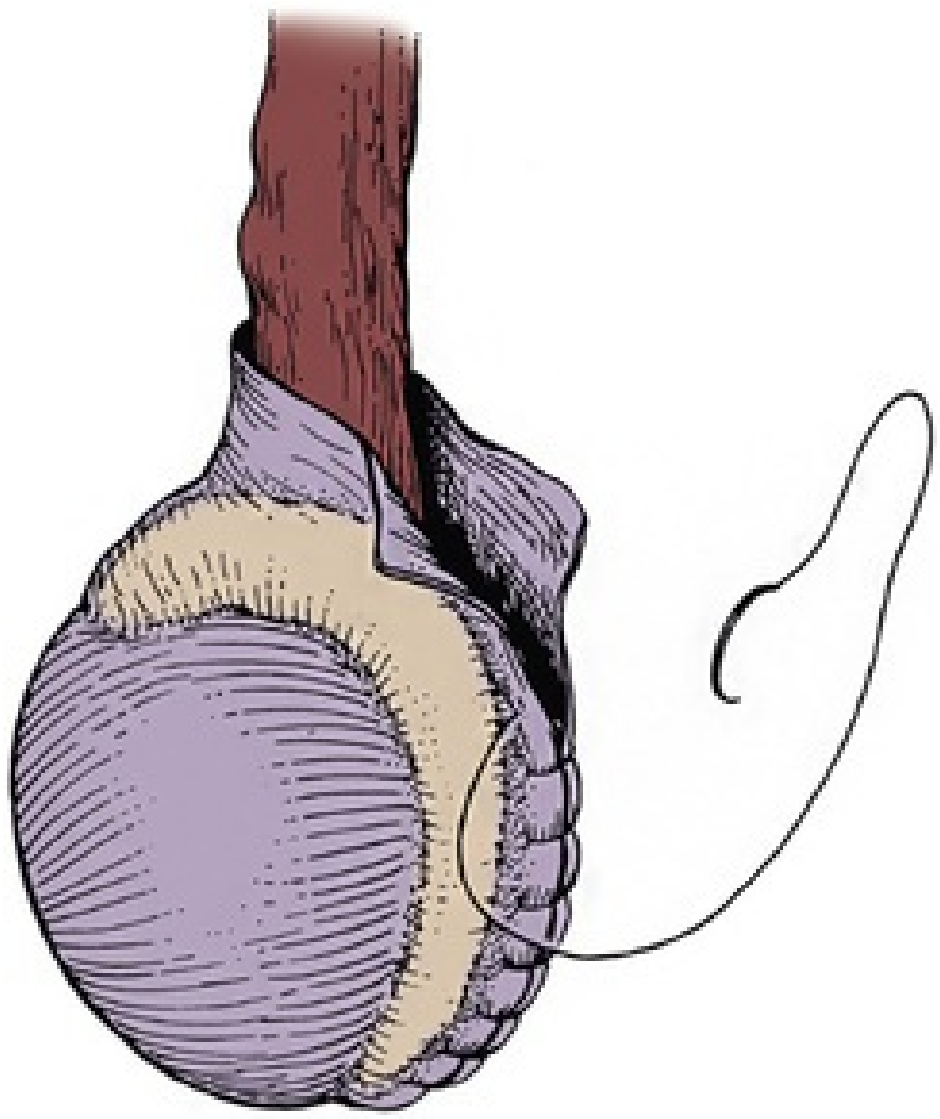

FIG. 83.6 Jaboulay technique for excision of thin, floppy sacs.

Bottleneck Technique.

The bottleneck procedure entails trimming all but a 2-cm circumferential segment of tunica around the testis and cord structures and tacking the tunical edges to each other, leaving the sac open (Fig. 83.7).

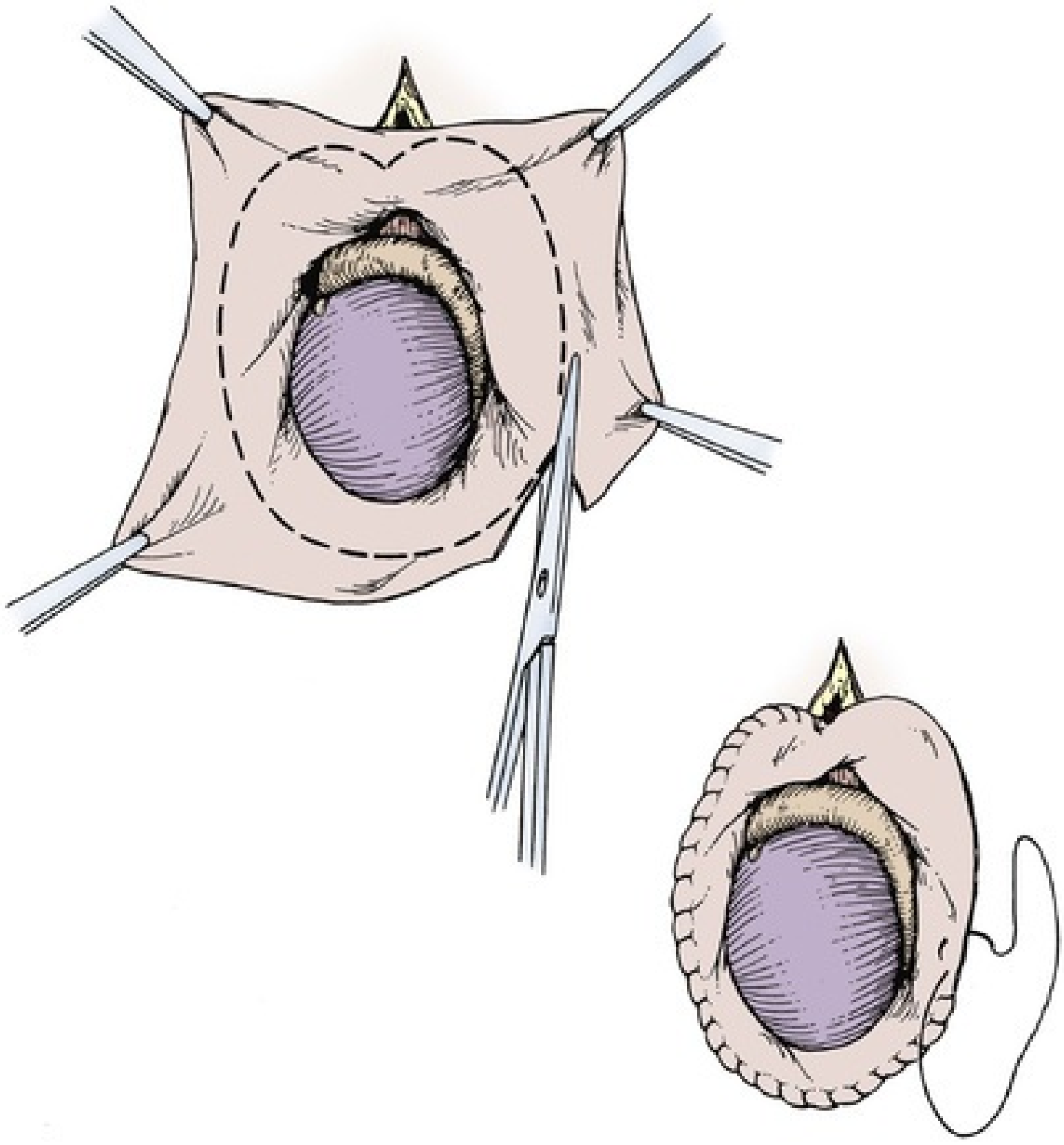

FIG. 83.7 Simple excision of the thick-walled hydrocele sac and oversewn edges.

Window Technique.

A less commonly used approach involves a 4-cm anterior scrotal wall incision to reach the parietal layer of the tunica vaginalis. Blunt dissection is performed to separate the tissue overlying the parietal layer away from the tunica vaginalis. Following a stab incision into the tunica to drain the hydrocele fluid, a 2.5 × 2.5-cm cruciate incision, or a “window,” is made into the parietal layer of the tunica vaginalis (Nigam, 1984). The flaps of the cruciate incision are everted and stitched with a 2-0 chromic suture.

Aspiration and Sclerotherapy

William of Saliceto first described the instillation of sclerosing agents into the scrotum using sugar and ginger in the thirteenth century (Bullock and Thurston, 1987). Sclerosing agents re-emerged in 1975 as a cost-effective, office-based alternative to hydrocelectomy and spermatocelectomy, and aspiration and sclerotherapy (AS) of hydroceles and spermatoceles remains a viable option for nonsurgical patients (Moloney, 1975). **Because of the high recurrence rate (78% to 86%) associated with aspiration alone, a sclerosing agent should be used to reduce the risk for hydrocele recurrence** (Lund et al., 2014; Roosen et al., 1991). Various sclerotherapy agents have been reported in the literature including doxycycline, tetracycline, alcohol, polidocanol, ethanolamine oleate, and sodium tetradecylsulfate (STDS) (Beiko et al., 2003; Braslis and Moss, 1996; Daehlin et al., 1997; Francis and Levine, 2013; Jahnson et al., 2011; Lund et al., 2014; Shan et al., 2011; Shokeir et al., 1994; Tammela et al., 1992). **Single-procedure success rates vary with the various sclerosing agents and can range from 33% to 85%; however, the best success rates are associated with the use of tetracycline and polidocanol** (see Table 83.1 for comparisons of success rates using various sclerosing agents).

TABLE 83.1

Sclerosants With Associated Single-Procedure and Retreatment Success Rates

SCLEROSANT	SINGLE-PROCEDURE SUCCESS RATE	RETREATMENT SUCCESS RATE	REFERENCE
Polidocanol	54%–67%	83%–89%	(Jahnson et al., 2011; Lund et al., 2014; Sigurdsson et al., 1994)
Tetracycline	57%–85%	57%–90%	(Bullock and Thurston, 1987; Daehlin et al., 1997; Levine and DeWolf, 1988; Shokeir et al., 1994)
Doxycyline	84%	88%	(Francis and Levine, 2013)
Sodium tetradecylsulfate	62%–76%	94%–96%	(Beiko et al., 2003; Braslis and Moss, 1996; Khaniya et al., 2009; Rencken et al., 1990)
99.5% Alcohol	76%	98%	(Shan et al., 2011)
5% Ethanolamine oleate	68%	98%	(Tammela et al., 1992)

Technique

To perform AS, the affected hemiscrotum is cleansed and prepped with chlorhexidine. Local anesthetic is injected to the site of aspiration and the spermatic cord blocked before aspiration with a mix of 1% lidocaine and 0.25% bupivacaine. Once the skin and spermatic cord are adequately anesthetized, a 16- to 19-gauge angiocatheter is inserted into the sac in either the lateral or anterior and superior aspects of the scrotum. Plastic cannulas are less likely to slip out of the sac and are preferred. The angiocatheter is preconnected to a 60-cc Luer-Lock syringe with connector tubing to maintain a closed system. The fluid is analyzed microscopically to determine if sperm are present. Fluid should also be sent for culture or cytology if clinical suspicion is present for infection or malignancy. Once all the fluid is drained and the volume recorded, sclerotherapy can be performed by injecting the sclerosing agent into the collapsed sac and massaging it. If recurrence occurs in the weeks following AS, the procedure can be repeated or the patient can proceed to hydrocelectomy.

Limitations of AS include pain, multiple treatments necessary for cure, and diminished efficacy for multiloculated hydrocele sacs and large hydrocele sacs (>750 cc) (Francis and Levine, 2013). Comparisons of AS with hydrocelectomy correction confirm the lower success rates (76% vs. 84%, respectively) and lower satisfaction rates (75% vs. 87.5%, respectively) for AS, a first-line option (Beiko et al., 2003). However, complications and costs are less with AS compared with open repair, and repeat treatments may improve the success rate up to 94% (Beiko et al., 2003; Braslis and Moss, 1996; Khaniya et al., 2009).

Simple Orchiectomy

Bilateral simple orchiectomy continues to be a treatment option for patients with hormonally-responsive metastatic prostate cancer who would like to avoid medical androgen deprivation therapy (ADT). From 1991 to 1998, orchiectomy procedures for ADT decreased by 10.2%, and use of gonadotropin-releasing hormone (GnRH) agonist increased 29.6% over the same period (Shahinian et al., 2005). However, with a threefold increase in overall economic burden of cancer treatment over the last two decades, which has partly been driven by the rising cost of medical castration, decreasing reimbursement, and survival advantage conferred with orchiectomy over medical castration, surgical castration is regaining its foothold as a viable treatment option in the setting of advanced prostate cancer (Elkin and Bach, 2010; Elliott et al., 2010; Krahn et al., 2014; Lin et al., 2011; Weight et al., 2008). In a retrospective review of patients with locally advanced and metastatic prostate cancer who were treated with either a luteinizing hormone–releasing hormone (LHRH) agonist or simple orchiectomy, surgical castration was associated with a lower rate of PSA rebound ($P = 0.02$), tumor progression-free survival ($P < 0.001$), and overall survival rate ($P < 0.001$) (Lin et al., 2011). In addition to the cost savings of surgical over medical castration, Potosky et al. showed a lower rate of gynecomastia (LHRH agonist, 24.9% vs. orchiectomy, 9.7%; $P < 0.01$) and higher quality of life because of less physical discomfort and anxiety regarding their prostate cancer in surgically castrated men than in men treated with an LHRH agonist (Potosky et al., 2001). Nevertheless, patients must be counseled on the potential negative impact on self-image associated with orchiectomy procedures (Anderson et al., 2008; Saylor and Smith, 2009).

Several options are available to maintain the esthetics of patients undergoing bilateral orchiectomy for androgen deprivation, including the placement of testicular prostheses and an epididymal-sparing orchiectomy (both of which are described later in this chapter). Epididymal-sparing orchiectomy with epididymoplasty in one study compared patient satisfaction scores between conventional orchiectomy and subepididymal orchiectomy, with significantly higher satisfaction associated with the subepididymal approach (Bapat et al., 2011).

Unilateral simple orchiectomy can also be performed in patients with severe testis trauma or prolonged ischemia caused by testicular torsion, when testis salvage is impossible. Much less commonly, orchiectomy can also be performed in patients with chronic orchalgia. This indication however, lacks level-one evidence and should be utilized only in patients who have failed all other available conservative treatments.

Technique

The simple orchiectomy procedure can be performed through a scrotal incision or through an inguinal incision for patients with orchalgia**. An inguinal approach is associated with better pain-related outcomes in patients with orchalgia.** The improved pain-control arises from resection of more proximal segments of the ilioinguinal, iliohypogastric, and genitofemoral nerves along with the other cord structures to maximize the likelihood of pain relief (Fig. 83.8). In a small retrospective review of 24 patients with orchalgia, Davis et al. showed better pain control with a higher rate of cure associated with an inguinal approach (Davis et al., 1990). The authors showed a 73% cure rate of orchalgia and a 27% rate of improved pain when orchiectomy is performed via an inguinal incision compared with a 55% cure and a 33% improved rate associated with scrotal orchiectomy. Yamamoto et al. demonstrated a similar cure rate of 75% albeit in a smaller cohort of four patients (Yamamoto et al., 1995).

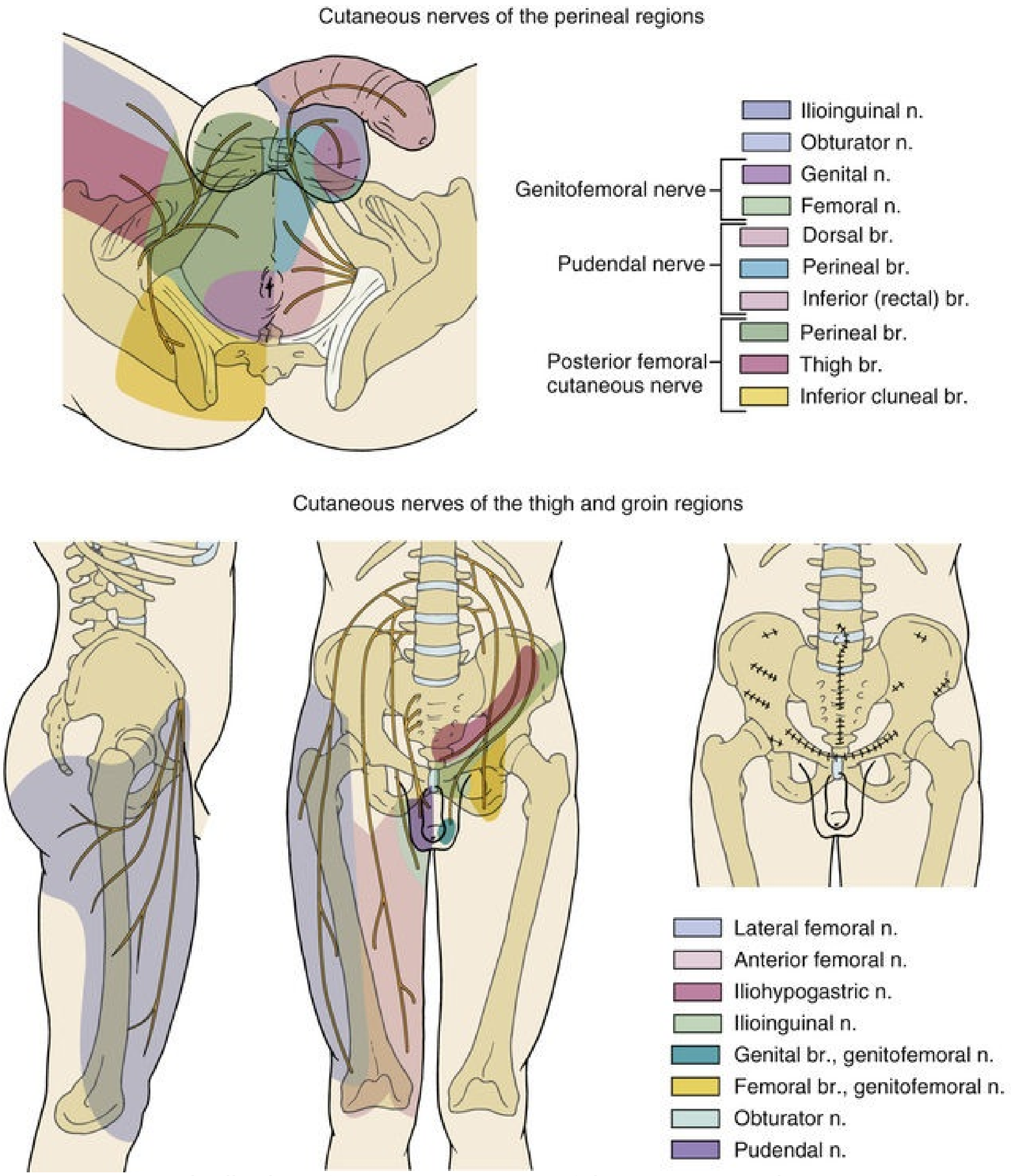
Cutaneous nerves of the perineal regions
Ilioinguinal n.
Obturator n.
Genitofemoral nerve
Genital n.
Femoral n.
Pudendal nerve
Dorsal br.
Perineal br.
Inferior (rectal) br.
Posterior femoral cutaneous nerve
Perineal br.
Thigh br.
Inferior cluneal br.
Cutaneous nerves of the thigh and groin regions
Lateral femoral n.
Anterior femoral n.
Iliohypogastric n.
Ilioinguinal n.
Genital br., genitofemoral n.
Femoral br., genitofemoral n.
Obturator n.
Pudendal n.

FIG. 83.8 Distribution of cutaneous nerves of the scrotum, perineum, thigh, and groin regions. (Courtesy A. Lee Dellon, MD, PhD, from Dellon.com.)

If a scrotal approach is used, a single vertical midline incision in the median raphe or bilateral transverse incisions can be used to access the scrotum. Once all the fascial and tunical layers have been opened, the spermatic cord is divided into two bundles that are double-clamped proximally and distally. The spermatic cord is divided between the two clamps, and the proximal stump is suture-ligated with 2-0 vicryl ties.

If the patient elects epididymis-sparing orchiectomy, rather than dividing the spermatic cord, the testis is sharply dissected off the epididymis using an operating microscope. Attention must be paid to locate and suture-ligate the superior, middle, and inferior epididymal arteries that perforate the testis. To obtain additional hemostasis, the longitudinal epididymal edges are approximated with a 4-0 chromic suture; however, the ends of the suture should be left untied. The caput and cauda of the epididymis are then adjoined by tying the free ends of the 4-0 chromic suture together (Issa et al., 2005).

Testicular Prosthesis Placement

Because of the psychological effects of an empty scrotum following an orchiectomy or as a consequence of testicular atrophy secondary to a maldescended testis, consideration should be given to the insertion of a testicular prosthesis. Although early testicular prostheses were composed of the alloy Vitalium (Girsdansky and Newman, 1941), lucite (Rea, 1943), and glass (Hazzard, 1953), the only FDA-approved testicular prosthesis is a silicone implant called the Coloplast Torosa (Coloplast, Minneapolis, MN). The Torosa (Fig. 83.9) comes in sizes ranging from extra-small to large and are inflatable with sodium chloride U.S.P. solution, which can be injected into the prosthetic via an injection port. However, the injection port should not be pierced more than five times intraoperatively and should be accessed postoperatively.



FIG. 83.9 Testicular prostheses. (Image obtained from https://www.coloplastmd.com/products/torosa-testicular-implants/).

Similar to other prosthetic implantation surgeries, strict antiseptic technique is critical during testicular prosthesis insertion. The prosthetics can be inserted via an inguinal, high-scrotal or trans-scrotal incision. The choice of approach often depends on the indication of the orchiectomy, with an inguinal insertion most commonly performed simultaneous to radical orchiectomy and for pediatric patients who have thin scrotal walls (Kogan, 2014; Zaontz et al., 1990). In the absence of malignancy or compromised scrotum, the decision to perform a high-scrotal or scrotal incision depends on surgeon preference; however, the high-scrotal incision into a subdartos pouch carries a lower risk for infection, erosion, and pain secondary to reduced contact between the prosthetic and the suture line (Libman et al., 2006). The prosthesis can also be placed via a trans-scrotal incision into a suba dartos pouch or into the tunica vaginalis if performed concurrently with a simple orchiectomy for nonsalvageable testicular torsion or during simple orchiectomy for ADT (Bush and Bagrodia, 2012; Lucas et al., 2017).

Epididymis

Excision of Epididymal Cysts and Spermatoceles

Epididymal cysts and spermatoceles arise from the cystic accumulations of semen in the epididymal tubules, rete testes, or efferent ductuli. Although most spermatoceles form idiopathically, some can arise from infectious or traumatic processes resulting in inflammation. Similar to the indications for hydrocele repair, spermatoceles and epididymal cysts should only be surgically treated if there is discomfort, infection, disability caused by size, or infertility (Kauffman et al., 2011; Rioja et al., 2011). Epididymal cysts and spermatoceles are common benign findings on scrotal sonography. Leung et al. identified epididymal cystic lesions in approximately 31% of 20- to 39-year-old men and up to 43% of asymptomatic 40- to 59-year-old men (Leung et al., 1984). **Men of reproductive age should be counseled on the risk for obstructive azoospermia associated with epididymal cyst surgery, particularly if the epididymal cyst is located in the corpora or cauda of the epididymis** (Sheynkin et al., 1998).

The preoperative considerations and surgical approach to epididymal cyst excision and spermatocelectomy are similar to that of hydrocelectomy. The most common approach is via a trans-scrotal incision and dissection to the level of the tunica vaginalis. **Once the tunica vaginalis is sharply opened and the epididymal cyst or spermatocele is exposed, an attempt should be made to dissect the cyst or spermatocele down to its stalk and to ligate it with a 5-0 or 6-0 absorbable suture** (Kauffman et al., 2011). If the epididymal cyst or spermatocele cannot be completely dissected off the testis, a portion of the cyst wall can be unroofed and the tunic of the epididymis should be reapproximated with a 4-0 absorbable suture to cover the defect (Rioja et al., 2011). Hemostasis should be obtained with bipolar cautery.

Epididymal Tumor Excision

In contrast with epididymal cystic diseases, tumors of the epididymis with malignant potential should be approached via an inguinal incision to avoid disruption of the natural lymphatic drainage patterns. The spermatic cord is isolated and clamped with noncrushing clamps until frozen-section biopsies confirm the presence of neoplasia (Ting et al., 2018). If preoperative percutaneous biopsy confirms that an epididymal mass is benign, the epididymal tumor can be removed via a trans-scrotal approach. A microsurgical approach with 10× to 25× magnification is recommended to avoid injury to the testicular blood supply (Kauffman et al., 2011; Ting et al., 2018).

Key Points: Surgery of the Scrotal Contents

- High-resolution ultrasonography is used to evaluate scrotal fluid collection as it may identify intratesticular malignancy and thus guide surgical approach.
- Excisional hydrocelectomy techniques are associated with the lowest recurrence rates.

Vas Deferens

Vasectomy

Vasectomy is a safe, effective, and permanent method of male contraception. In 2015, approximately 520,000 men in the United States underwent a vasectomy (Ostrowski et al., 2018). Worldwide, usage of vasectomy varies by country and can exceed 10% of men in countries such as Australia, Bhutan, Canada, the Netherlands, New Zealand, the Republic of Korea, Great Britain, and the United States (Pile and Barone, 2009). **Contemporary analysis of vasectomy trends demonstrates that >80% of vasectomies are performed on 25- to 44-year-old men, in an office setting, and by a urologist** (Ostrowski et al., 2018).

Despite the simplicity and efficacy of vasectomy, significant gender gaps remain between the prevalence of male vasectomy and female tubal ligation. Anderson et al. analyzed the 2006–2008 National Survey of Family Growth data and found a 13.1% (95% confidence interval [CI] 0.104–0.163) reported rate of vasectomy compared with a 21.1% (95% CI 0.178–0.249) reported rate of tubal ligation (Anderson et al., 2012). This disparity in contraceptive methods likely reflects differing family-planning priorities, insurance with lower Medicaid coverage of vasectomies, and marital status, with more unmarried women undergoing tubal ligation than unmarried men undergoing vasectomy (Eeckhaut, 2015; Pile and Barone, 2009; White et al., 2014).

Although the majority of vasectomies are performed in an outpatient clinic setting, the same approach to preoperative planning should be undertaken as for any other surgical procedure performed in an operating theater. **Before the vasectomy, initial in-person or telephonic preoperative consultation should be conducted and should include a review of medical and surgical history, physical examination, and genitourinary examination**. Patients should also be counseled on the potential need for repeat vasectomy if the postvasectomy semen analysis (PVSA) demonstrates persistent live sperm, the potential for recanalization of the two vasal ends resulting in pregnancy, and the 1% to 2% risk for chronic scrotal pain that can ensue. Following the discussion of procedure risks, benefits, and vasectomy alternatives, an informed consent form should be signed preoperatively.

Vasectomy is performed with local anesthesia with or without oral sedation. If the patient declines local anesthesia or if the surgeon believes that local anesthesia will not be adequate for a particular patient, then vasectomy may be performed with intravenous sedation or general anesthesia (Sharlip et al., 2012). The choice of local anesthesia is based on surgeon preference and formulation availability and may include 1% or 2% lidocaine without epinephrine, or a mixture of either with bupivacaine as a 50-50 mix. More recent availability of long-acting anesthetics such as EXPAREL (Pacira Pharmaceuticals Inc, Parsippany, NJ) have also been used, providing significant short- and long-term pain relief, although they may be cost-prohibitive (Alom et al., 2017). The smallest available needle should be used for injection of the local anesthetic, and the AUA Panel recommends that smaller gauge needles (25- to 32-gauge) cause less injection site–related pain and that topical anesthetic cream should not be used as a sole source of anesthesia (Sharlip et al., 2012).

Vasectomy consists of two key surgical steps, and these include vas isolation and its occlusion. With many approaches to both, it is important to emphasize that the surgeon should perform a vasectomy according to his or her established and trained technique, which should be readjusted when and if a significantly higher than expected failure rate is encountered.

Methods of Vas Isolation

Methods of vas isolation consist of conventional vasectomy (CV) and minimally invasive vasectomy (MIV), which includes a no-scalpel vasectomy (NSV), and are related to procedure-associated risk for infection, bleeding, and pain. It is recommended that vas isolation is performed using one of the MIV techniques, as data indicate less procedure-associated discomfort and fewer complications (Sokal et al., 1999).

CV may be still used in patients with a history of prior scrotal surgery or trauma or with a challenging anatomy such as thick, tight scrotal skin, associated varicocele, hydrocele, or spermatocele or under any other conditions when vas isolation with use of MIV cannot be safely performed.

Conventional Vasectomy

This technique implies that the area of scrotal dissection is much larger than with any of the MIV techniques. Depending on surgeon preference, a 1.5- to 3-cm single vertical, median raphe incision or bilateral paramedian scrotal incisions are made. Although there are no studies demonstrating the advantage over a single incision versus bilateral incisions, the single incision seems to carry fewer side effects and is associated with decreased procedure time. Despite this, many surgeons advocate bilateral incisions, as this helps them avoid potential for grasping and transecting the same vas deferens twice. When performing a vasectomy through a single incision, a gentle tug on the vas during its isolation will move the ipsilateral testis, and this will ensure that one vas is not occluded twice. When using a single midline scrotal incision, the skin opening should be performed at the level of penoscrotal junction or between the penoscrotal junction and the top of the testis. When performing bilateral scrotal incisions, they should be placed at the level of the penoscrotal junction or higher, to access the straight aspect of the vas deferens. Making skin openings in lower locations provides access to smaller-diameter convoluted vas, which is overall much more difficult to manipulate during the vasectomy and in the future, during a potential vasectomy reversal.

After infiltration of adequate anesthesia, the vas is firmly grasped and trapped between the surgeon's thumb, index, and middle fingers using a three-finger grasp. The same hand is used to isolate the bilateral vasa. To ease the initial identification of the vas, a few drops of fluid over the scrotal skin may be used for lubrication. Additional anesthetic can be administered after identification of the vas, assuring proper analgesia over the precise location of the planned skin incision. Anesthetic usually takes effect within a few seconds, but testing appropriate analgesia can be easily performed by grasping the skin with an Adson pickup. The patient should be informed that the sensation of tugging and touch is expected, but sharp pain should not be experienced. Additional anesthetic medication should be injected subcutaneously if the patient reports sharp pain and/or appears in significant discomfort.

The skin incision is made over the vasal sheath, longitudinally, down to the vas. During CV, there are no special instruments used, and the vas is usually grasped with a towel clamp or an Allis forceps. While pulling the vas out of the wound, use of a few overlapping clamps may be helpful to avoid its falling back into the scrotum. Adjacent structures should be avoided, and only vas deferens should be occluded. A small segment of vas is removed, and the remaining free vasal ends are occluded. After inspection and assurance that there is no bleeding, the vas ends are dropped back into the scrotum. The methods of vasal occlusion, with or without tissue interposition, are discussed later in this section.

The same procedure is performed on the contralateral side. The skin incisions are closed with an absorbable suture, especially with larger skin openings, as skin edges commonly bleed and cause undue concern to patients.

Minimally Invasive Vasectomy

The term *MIV* describes any vasectomy technique that utilizes a small (≤10 mm) skin opening and minimal vasal dissection. Minimally invasive vasectomy is performed with the use of special vas dissecting instruments (Fig. 83.10) and/or ring-tipped vas clamps (Fig. 83.11). The initial approach is the same as described earlier for CV (however, the size of the incision is limited to <10 mm). The vas is isolated by elevating it to the level of the anterior scrotal skin with manual pressure using the three-finger grasping method.

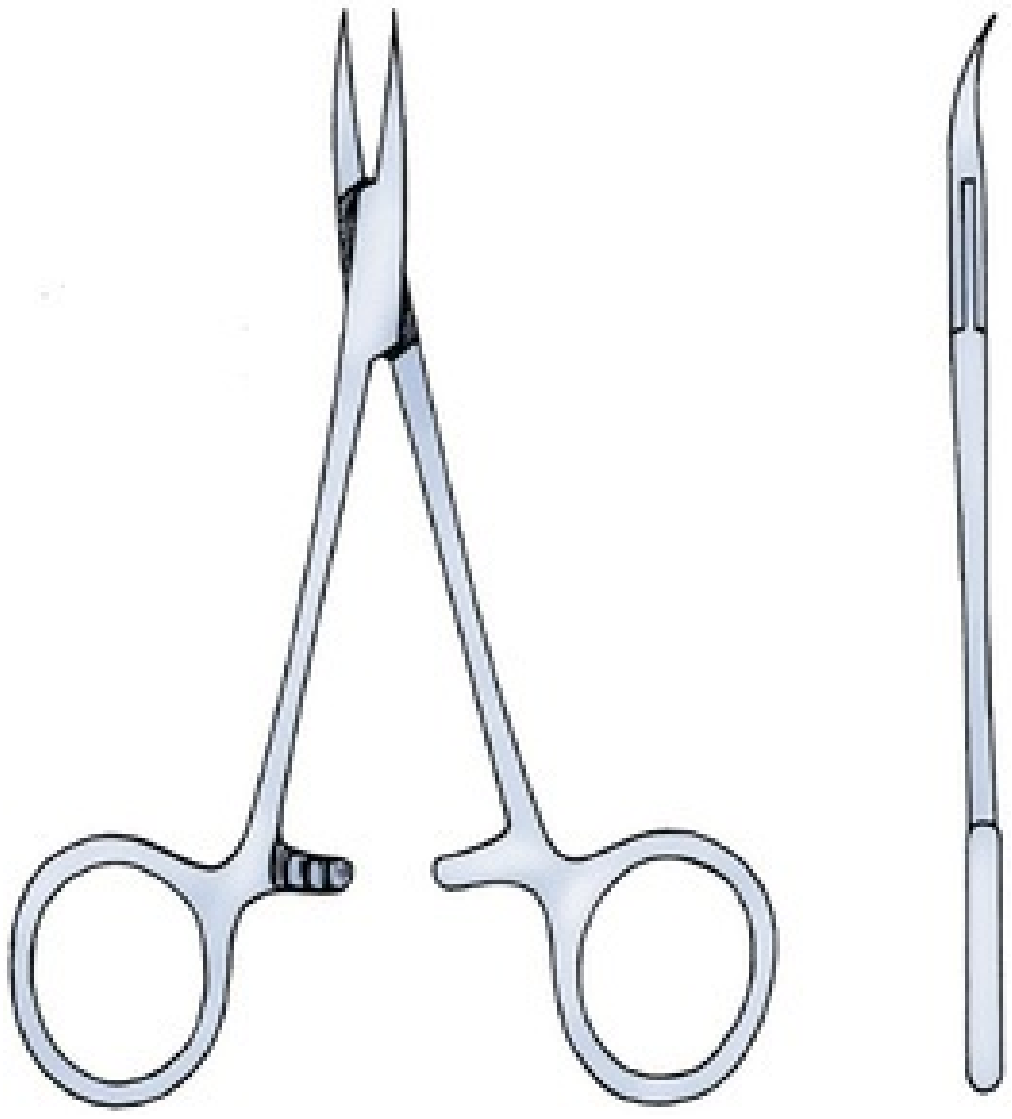

FIG. 83.10 Sharp, curved mosquito hemostat. (From Li S, Goldstein M, Zhu J, et al. The no-scalpel vasectomy. *J Urol* 1991;145:341–344.)

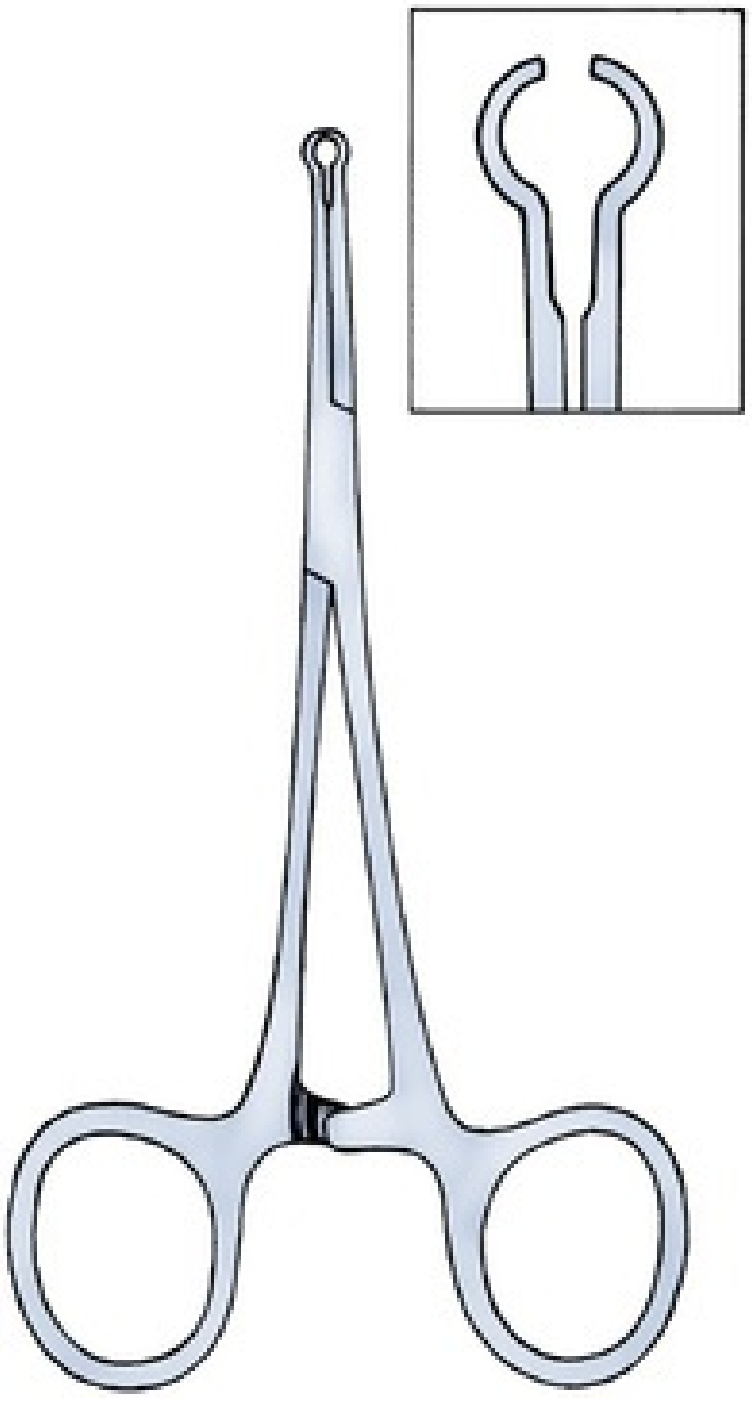

FIG. 83.11 Ring-tipped vas deferens fixation clamp. The cantilevered design prevents injury. (From Li S, Goldstein M, Zhu J, et al. The no-scalpel vasectomy. *J Urol* 1991;145:341–344.)

The MIV technique can be performed using an open- or closed-access approach. In the open approach, just like in the CV, a small skin incision is made with a scalpel, the perivasal tissues are minimally dissected, and then vas is grasped with a clamp. In the closed approach, the vas is grasped with a vas clamp before making an incision. Once this is done, the surgeon can release the vas and use his or her nondominant hand to manipulate the clamp. The incision is made afterward, and the remainder of the procedure is the same as for all approaches. The MIV incisions may be left open, as they are much smaller and carry less bleeding risk.

No-Scalpel Vasectomy

The NSV is the initial MIV technique, developed in China in 1974 and described by Dr. Shunqiang Li (Li et al., 1991). **It is important to emphasize that NSV represents strictly a vas isolation technique and does not specify the vas occlusion method.** The vas is grasped with the ring-tipped vas clamp and after a proper anesthesia, the skin overlying the vas is punctured and spread with a sharp, curved mosquito hemostat (Figs. 83.12 and 83.13). This spreading maneuver is continued until the vas is encountered, at which point the anterior vasal wall is pierced with the hemostat and lifted through the skin opening (Figs. 83.14 and 83.15). The partially transected vas is regrasped with the ring clamp, and its posterior wall is dissected and divided to strip the vas of its sheath (see Figs. 83.13 and 83.14). After vas occlusion, the ends are dropped back into the scrotum. The skin perforation(s) can be closed with an absorbable suture or may be left open as the puncture openings are <10 mm.

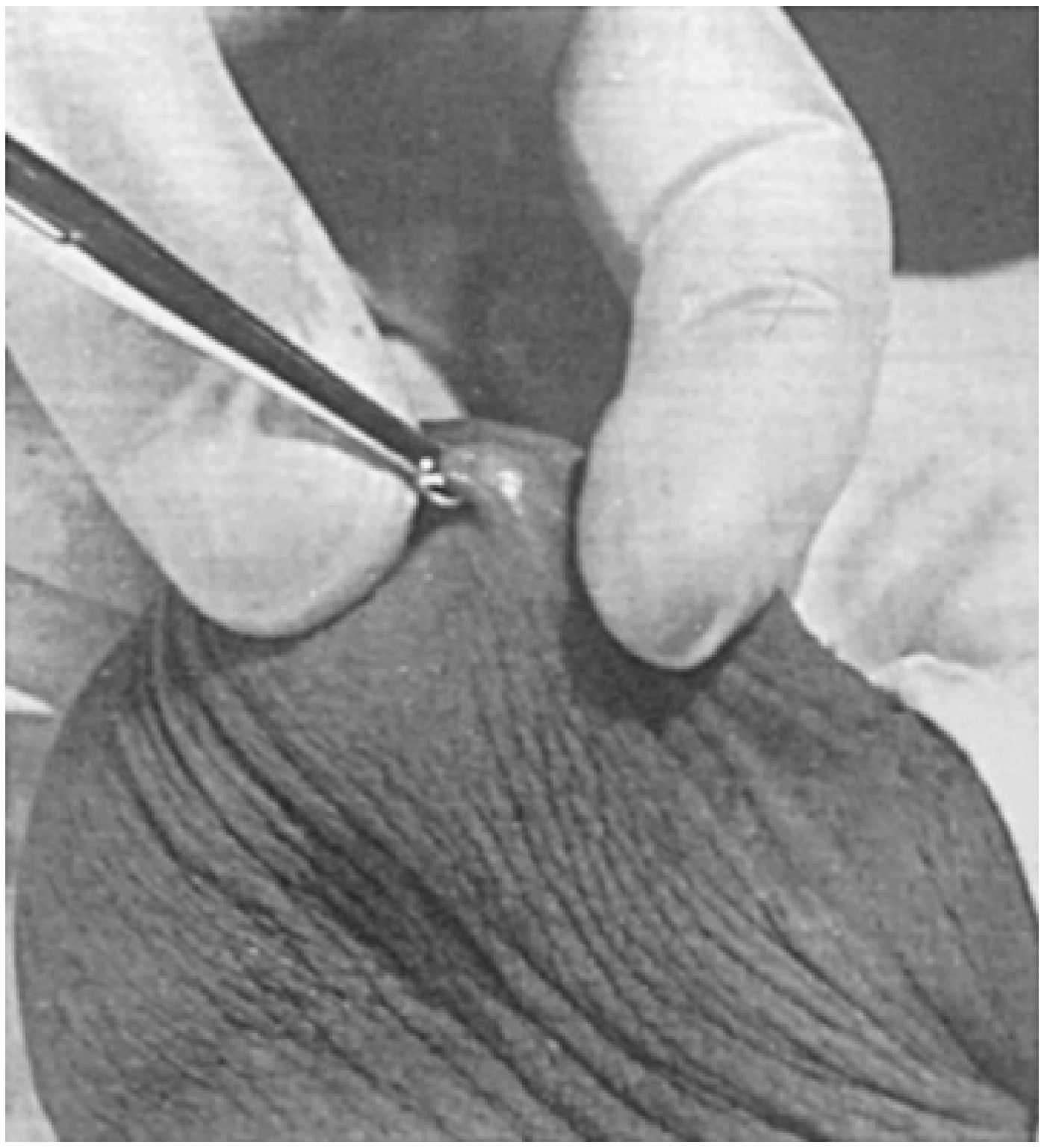

FIG. 83.12 Vas fixed in the ring clamp. The scrotal skin is tightly stretched over the most prominent portion of the vas. (From Li S, Goldstein M, Zhu J, et al. The no-scalpel vasectomy. *J Urol* 1991;145:341–344.)

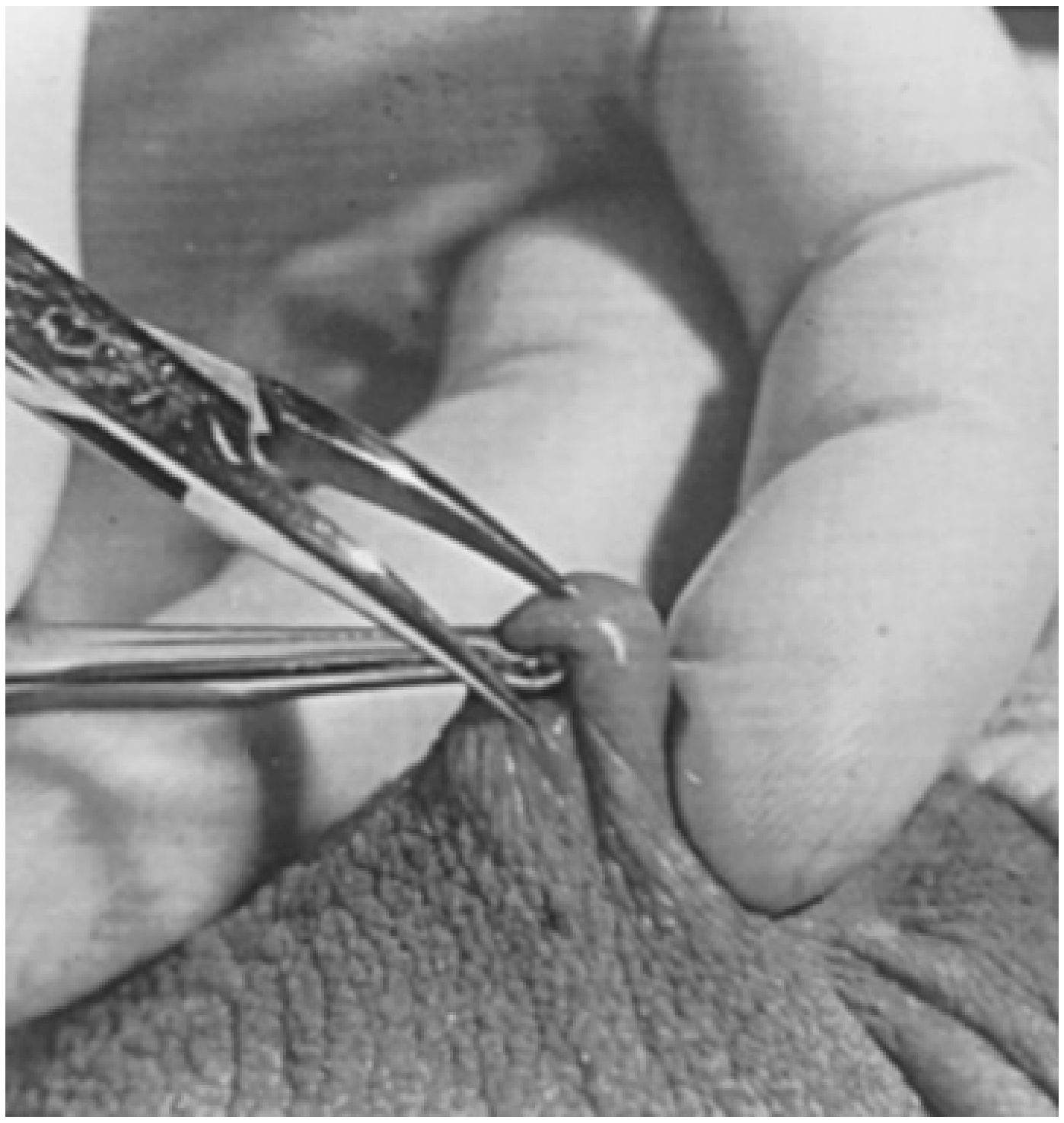

FIG. 83.13 Puncture of the skin, vas sheath, and wall into the lumen. (From Li S, Goldstein M, Zhu J, et al. The no-scalpel vasectomy. *J Urol* 1991;145:341–344.)

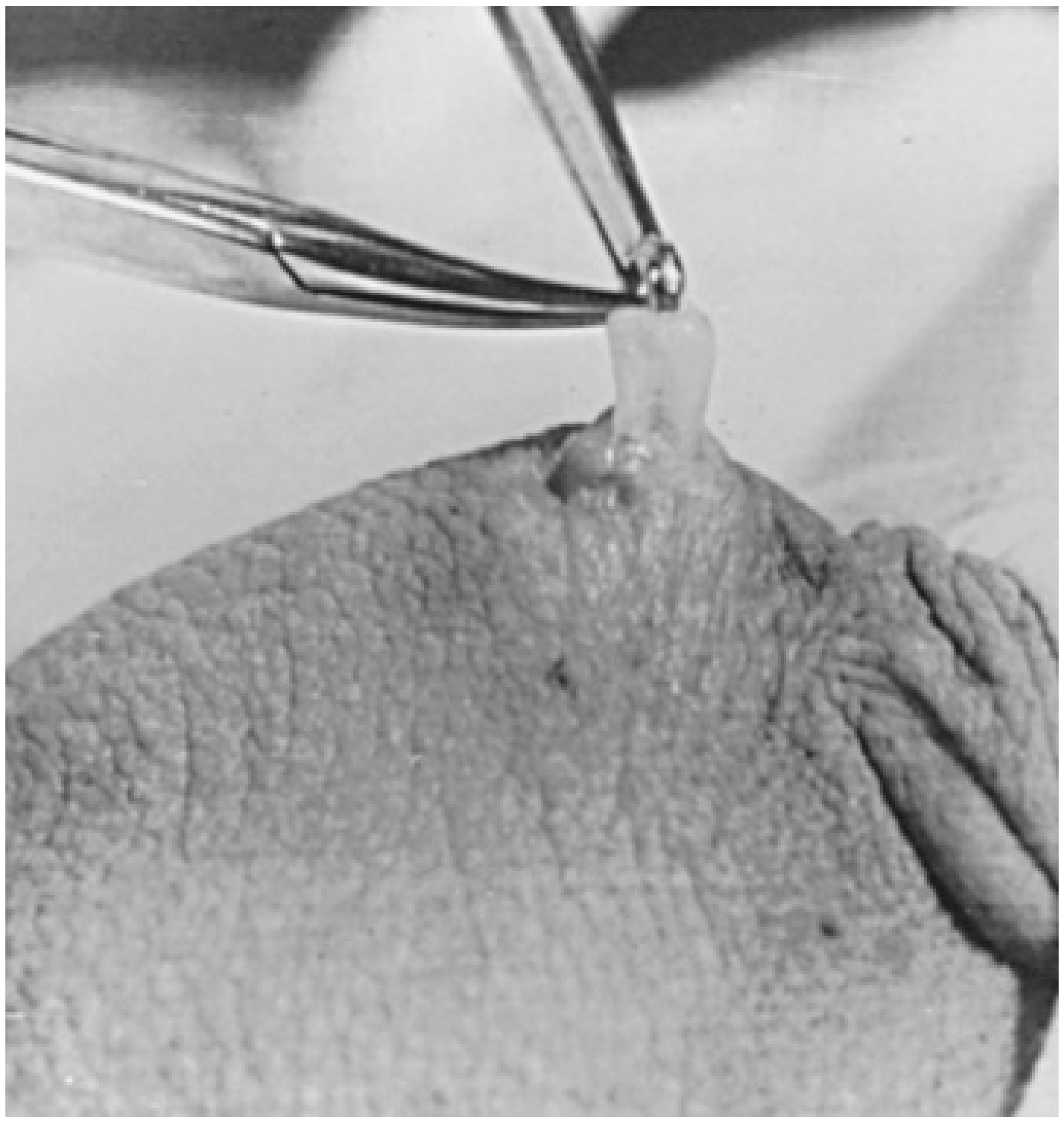

FIG. 83.14 Delivery of the clean vas. (From Li S, Goldstein M, Zhu J, et al. The no-scalpel vasectomy. *J Urol* 1991;145:341–344.)

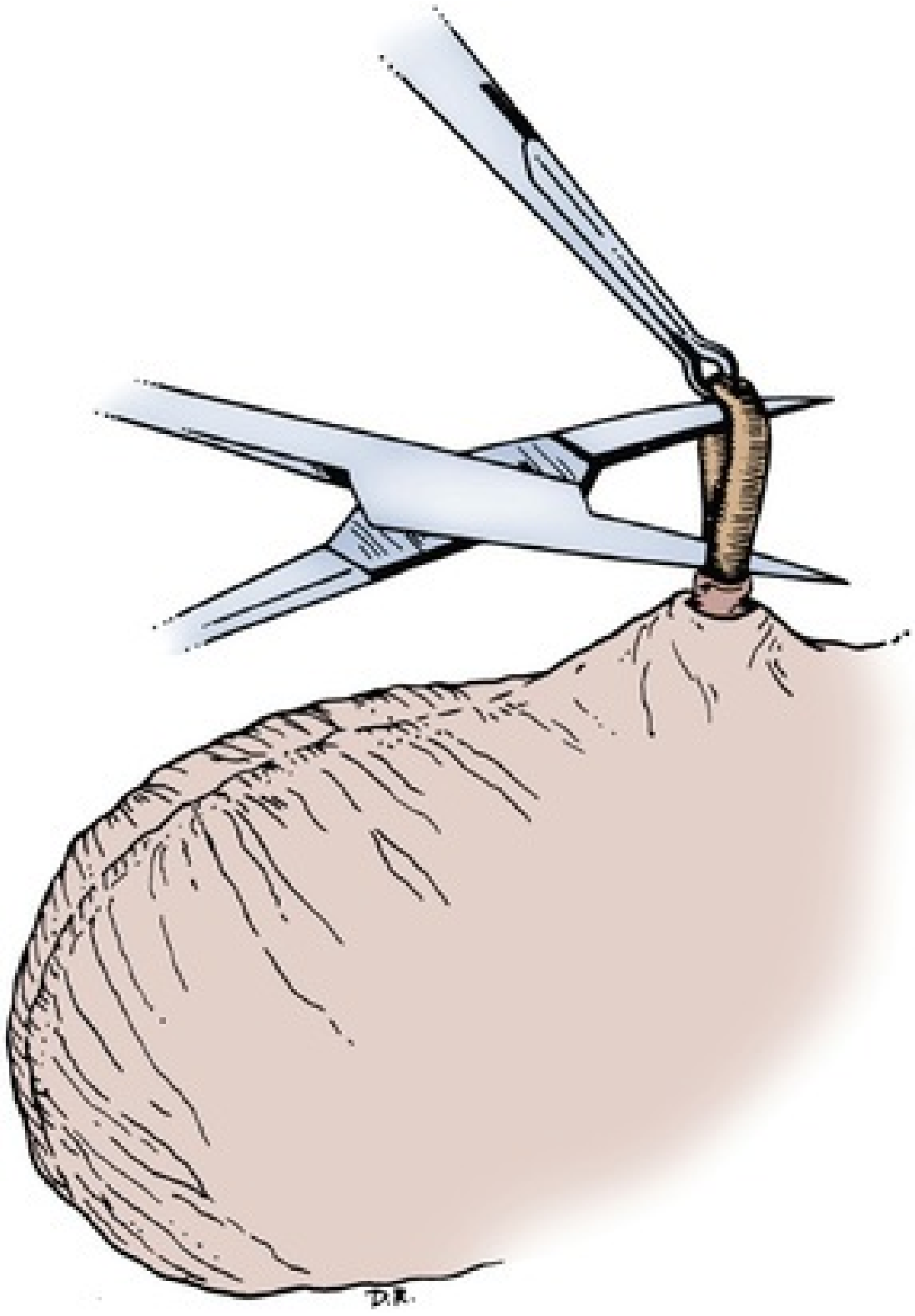

FIG. 83.15 Dissection of the testicular artery away from the vas deferens.

There are many methods of vas occlusion, and vasectomy success and ultimately failure rates are directly related to the choice of occlusion technique.

In the United States, complete division of the vas with or without excision of its segment is used. Following the vas division, its free ends may be separated by one of many techniques used alone or in combination, including fascial interposition (FI), suture ligation, vas clipping or folding, and mucosal cauterization (MC). **Fascial interposition uses a layer of the internal spermatic fascia to cover one of the vas ends and is usually used in combination with one of the other occlusion techniques.**

Suture ligation is usually applied to both vasal ends. One to three ligating sutures about 1 cm away from the cut edge are usually placed. Clips may be used instead of the suture material to ligate the free vas edges. The vas folding-back technique is utilized at times to prevent the free edges from facing each other and thus possibly recanalizing. MC involves direct application of thermal or electrical cautery to the vas lumen and edge for about a few millimeters to 1.5 cm.

A partial ligation (open-ended) technique may also be used when the abdominal vas is ligated by one of the techniques described earlier, while the testicular vas is left open, and both are separated by FI. This technique is believed to limit the postvasectomy pain likely resulting from epididymal back pressure. This approach may also improve the chances of potential future vasectomy reversal, as presence of sperm granuloma forming at the open vasal end has been associated with improved reversal outcomes (Errey and Edwards, 1986).

The only nondivisional extended cautery technique of vas occlusion (Marie Stopes International technique) does not use vas division and is not commonly used in the United States. This technique involves a 2.5- to 3-cm electrocoagulation of the anterior vas full- thickness and posterior vas partial-thickness. This technique was developed in the United Kingdom as a vasectomy technique that could be easily utilized in Third World conditions (Black et al., 1989).

The current AUA guidelines recommend one of the four methods of vas occlusion that, in large numbers of patients and performed by different surgeons, consistently produce occlusive failure rates (OFR) ≤1%. The following three vas division methods, in addition to the nondivisional approach with extended cautery (OFR = 0.64%), are recommended: (1) MC with FI and without clips or ligatures (OFR = 0.0% to 0.55%); (2) MC without FI and without ligatures/clips (OFR = 0.0% to 0.60%); and (3) open-end vasectomy with the unoccluded testicular end while the abdominal end is occluded with MC and FI (OFR = 0.0% to 0.50%) (Sharlip et al., 2012).

Routine excision of the vasal segment is performed by the majority of surgeons, but, depending on personal preference, training, and outcomes, its excision is not absolutely necessary. It is recommended, that, if excision is performed, a segment of 1.0 cm in length should be adequate.

It is recommended that fresh semen specimen should be tested 8 to 16 weeks postoperatively, with the ultimate choice of proper timing of the initial test left to the surgeon. Before this testing, patients should perform at least 10 to 20 ejaculations, keeping in mind that older men have been found to have lower and slower rates of sperm clearance (Griffin et al., 2005). **If the initial PVSA has persistent motile sperm, a repeat testing is recommended in 6 months. If this trend continues at the 6 month PVSA, the procedure is considered a failure,**

and arrangements for a repeat procedure should be made (Sharlip et al., 2012).

Need for use of an alternative contraceptive method until confirmation of procedure success should be emphasized at time of prevasectomy counseling and later, during the discussion of postprocedure instructions. Couples may stop using other contraceptive methods once the PVSA demonstrates azoospermia or only rare nonmotile sperm (RNMS or ≤100,000 nonmotile sperm/mL). **Despite an initial negative PVSA, recanalization can occur and pregnancy rates following a successful vasectomy are at a rate of 0.05%** (Philp et al., 1984a).

Vasectomy Reversal

Vasectomy reversal, performed microscopically is currently a standard of practice and is offered to patients who had a vasectomy in the past and wish to proceed with a natural conception again. A detailed discussion of this topic is provided in a separate chapter.

Key Points: Vasectomy

- There is no one vasectomy technique that is 100% effective.
- Before the vasectomy, initial in-person or telephonic preoperative consultation should be conducted and include review of medical and surgical history, physical examination, and genitourinary examination.
- Vasectomy success is directly related to the choice of occlusion technique.
- Complete division of the vas with or without excision of its segment should be utilized.
- It is recommended that if excision of the vasal end is performed, a segment of 1.0 cm in length should be adequate.
- Partial ligation (open-ended) technique may improve the chances of potential future vasectomy reversal.
- Couples may stop using other contraceptive methods once the PVSA demonstrates azoospermia or only rare nonmotile sperm (RNMS or ≤100,000 nonmotile sperm/mL).

Surgical Management of Chronic Scrotal Pain

Pain is a subjective sensation that originates from noxious stimuli activating nociceptors that transmit ascending signals from the peripheral nervous system toward the central nervous system. Scrotal pain is multifactorial, and its cause often cannot be determined. Chronic scrotal pain is defined as constant or intermittent pain that lasts longer than 3 months and interferes with activities of daily living, and it accounts for up to 4.8% of urologic clinic visits (Ciftci et al., 2010; Sigalos and Pastuszak, 2017). An understanding of the diseases that cause pain in the scrotum, knowledge of the nerve locations in the scrotum, and a systematic approach to the patient with chronic scrotal pain can identify patients who will respond favorably to a surgical approach.

Chronic scrotal pain can originate from the testis, epididymis, pampiniform plexus, sperm extravasation following vasectomy, hematoma following a surgical procedure, or proximal injuries to the ilioinguinal, iliohypogastric, genitofemoral, pudendal, and/or sympathetic nerves (Masarani and Cox, 2003). Scrotal pain can also be referred from the pelvic floor, prostate, or other visceral organs that share nerve pathways with the ilioinguinal, genitofemoral, pudendal, and sympathetic nerves (Tan and Levine, 2017). A comprehensive review of the common causes and treatment of all etiologies of chronic scrotal pain is beyond the scope of this chapter. Rather, the surgical management of intrascrotal abnormalities is discussed. Multiple algorithms are available for patients with chronic scrotal pain (Fig. 83.16).

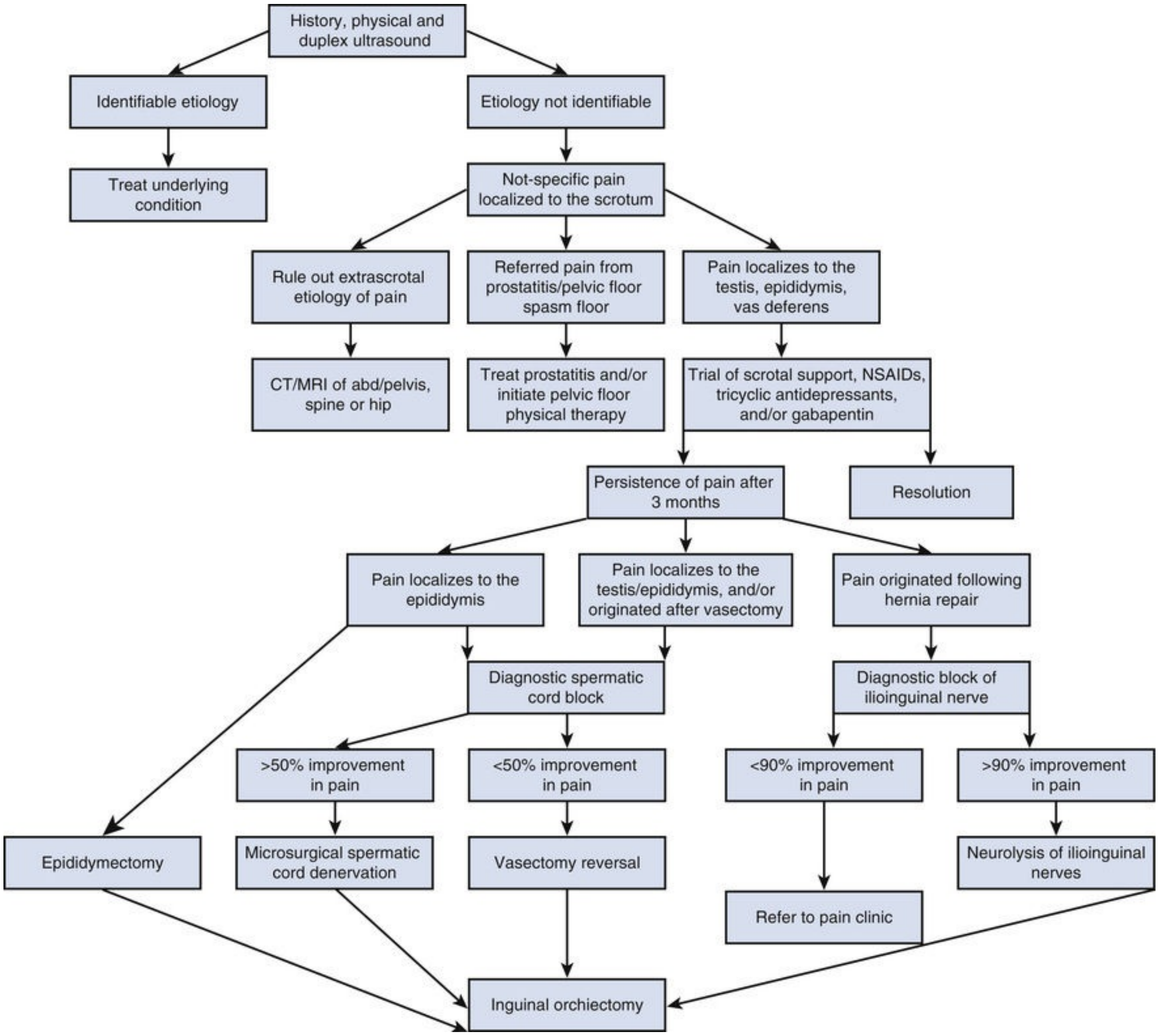
History, physical and duplex ultrasound
Identifiable etiology
Etiology not identifiable
Treat underlying condition
Not-specific pain localized to the scrotum
Rule out extrascrotal etiology of pain
Referred pain from prostatitis/pelvic floor spasm floor
Pain localizes to the testis, epididymis, vas deferens
CT/MRI of abd/pelvis, spine or hip
Treat prostatitis and/or initiate pelvic floor physical therapy
Trial of scrotal support, NSAIDs, tricyclic antidepressants, and/or gabapentin
Persistence of pain after 3 months
Resolution
Pain localizes to the epididymis
Pain localizes to the testis/epididymis, and/or originated after vasectomy
Pain originated following hernia repair
Diagnostic spermatic cord block
Diagnostic block of ilioinguinal nerve
>50% improvement in pain
<50% improvement in pain
<90% improvement in pain
>90% improvement in pain
Epididymectomy
Microsurgical spermatic cord denervation
Vasectomy reversal
Neurolysis of ilioinguinal nerves
Refer to pain clinic
Inguinal orchiectomy

FIG. 83.16 Algorithm of chronic orchalgia evaluation and management. (Modified from Tan WP, Levine LA. What can we do for chronic scrotal content pain? *World J Mens Health* 2017;35(3):146–155).

Surgical Management of Intrascrotal Pain

Acute and Chronic Epididymitis

Most cases of acute epididymitis resolve with conservative measures (rest, scrotal support, elevation, and ice packs), antibiotics, and/or nonsteroidal anti-inflammatory drugs (NSAIDs). Rarely, acute bacterial infections of the epididymis may present as local softening (malacia) of the epididymis suggesting an abscess (Banyra and Shulyak, 2012). Epididymal abscesses that do not respond to antimicrobial therapy should be drained or surgically debrided.

Some patients develop chronic epididymitis despite adequate therapy. Chronic epididymitis is defined as epididymitis that lasts longer than 6 weeks. **Although surgical resection is a treatment option, epididymitis patients treated with epididymectomy often have poor outcomes with persistence of pain, thus surgical management should be considered as a last resort option** (Padmore et al., 1996; Sweeney et al., 1998).

Following a failed trial of medical therapy, the indications for surgical treatment of epididymal disease with partial or total epididymectomy include postvasectomy epididymal engorgement, intractable epididymal pain, severe acute or chronic epididymitis, and symptomatic epididymal cysts. The likelihood of pain control is significantly improved if a palpable abnormality, such as a mass, cyst, or granuloma, is present in the epididymis (Tan and Levine, 2017). **If epididymectomy is performed for epididymitis, patients should be counseled preoperatively on the low likelihood of complete cure of their pain and the potential need for orchiectomy.**

Epididymectomy for Palpable Abnormalities of the Epididymis

In contrast with the poor surgical outcomes of epididymectomy for epididymitis, outcomes are more favorable for patients who have palpable abnormalities of the epididymis, such as epididymal cyst, and undergo partial or complete epididymectomy (Calleary et al., 2009). Epididymectomy performed for cystic dilation, granulomatous, or tender swollen epididymides can be performed by ligating the efferent tubules draining into the caput of the epididymis. The corpora and cauda of the epididymis are sharply dissected from the testis. If a partial epididymectomy is performed, then the remaining proximal and distal stumps of the epididymis are suture-ligated to reduce extravasation of sperm.

Microsurgical Spermatic Cord Denervation

For nonspecific chronic scrotal pain that localizes to the testis and/or epididymis or pain that originates after a vasectomy, a spermatic cord block can identify patients who will respond favorably to microsurgical denervation of the spermatic cord (MDSC) (Benson et al., 2013). **Moreover, the degree of pain relief following a spermatic cord block correlates with the degree of pain relief from MDSC.** Microsurgical denervation of the spermatic cord can be performed via a 4-cm incision over the external inguinal ring. Once the spermatic cord is isolated at the level of the external inguinal ring, the ilioinguinal nerve is isolated and suture ligated with a 4-0 silk suture (Tan et al., 2018). The genital branch of the genitofemoral nerve can also be identified and ligated at this level. Using an operative microscope with 4× to 20× magnification and a micro-Doppler to distinguish arterial pulsations, arteries of the cremaster muscle and spermatic cord are isolated. Lymphatic vessels are also spared to avoid hydrocele formation. All remaining spermatic cord structures, including pampiniform vessels, vas deferens, and cremaster muscle fibers are subsequently divided with electrocautery.

Denervation can also be performed via a vertical paramedian scrotal incision to isolate the spermatic cord. Similar to the subinguinal approach, lymphatic vessels and arteries of the cremaster and spermatic cord are spared. Parekattil et al. demonstrated a reproducible pattern of scrotal nerve distribution in 56 patients (Parekattil et al., 2013). In decreasing order of nerve density, nerves were located in the cremasteric muscle fibers (mean 19.1 nerves per patient), perivasal tissue and vasal sheath (mean 9.4 nerves per patient), and posterior periarterial/lipoma (mean 3.3 nerves per patient) (Fig. 83.17). In another nerve distribution study by Oka et al., immunohistochemical staining for nerve markers isolated sensory and sympathetic nerves to the perivasal sheath and spermatic fascia (Oka et al., 2016). **Therefore, if a scrotal approach to spermatic cord denervation is utilized, the posterior periarterial/cord lipoma should also be transected to improve the likelihood of pain control (Fig. 83.18).**

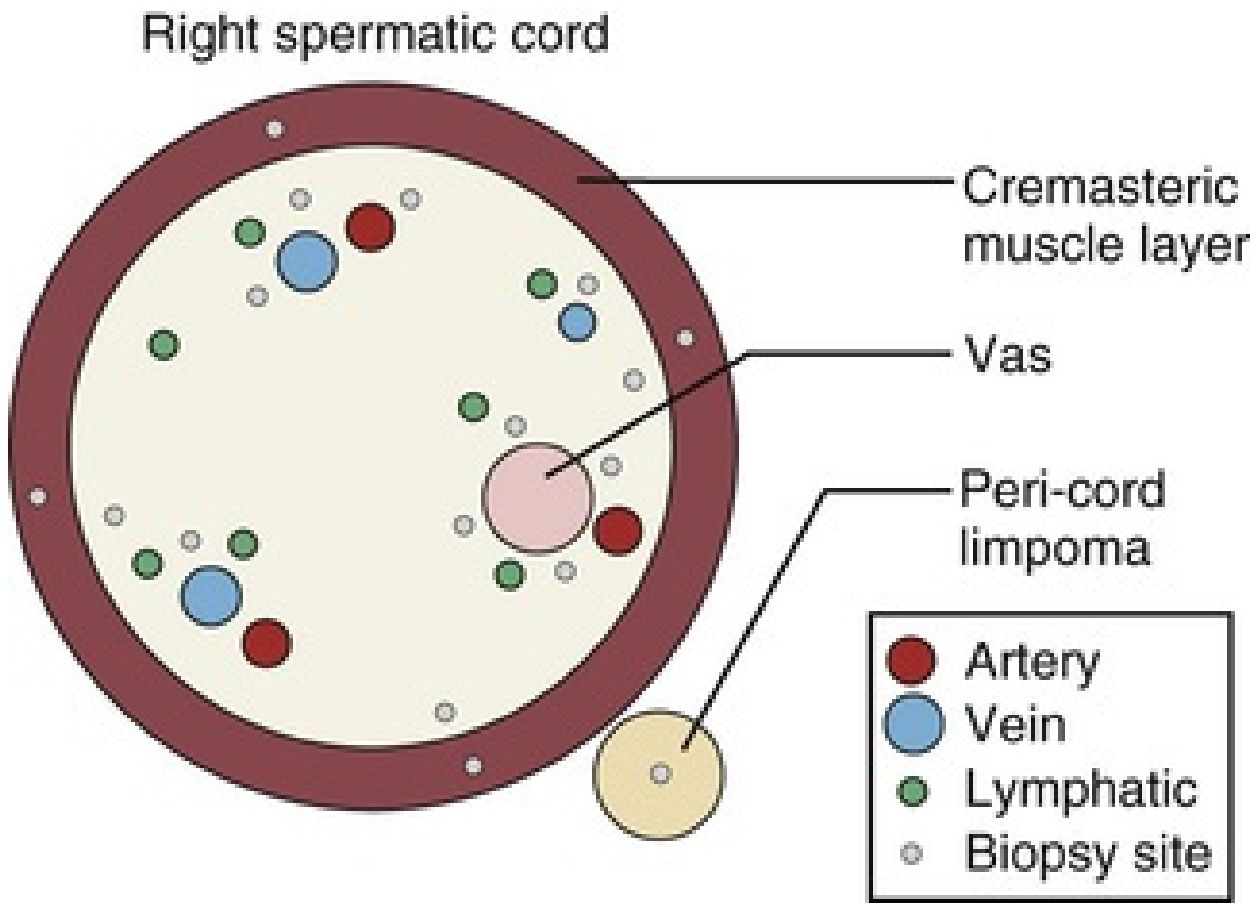

FIG. 83.17 Spermatic cord neural anatomy. (From Parekattil SJ, Gudeloglu A, Brahmbhatt JV, et al. Trifecta nerve complex: potential anatomical basis for microsurgical denervation of the spermatic cord for chronic orchialgia. *J Urol* 2013;190:265–270).

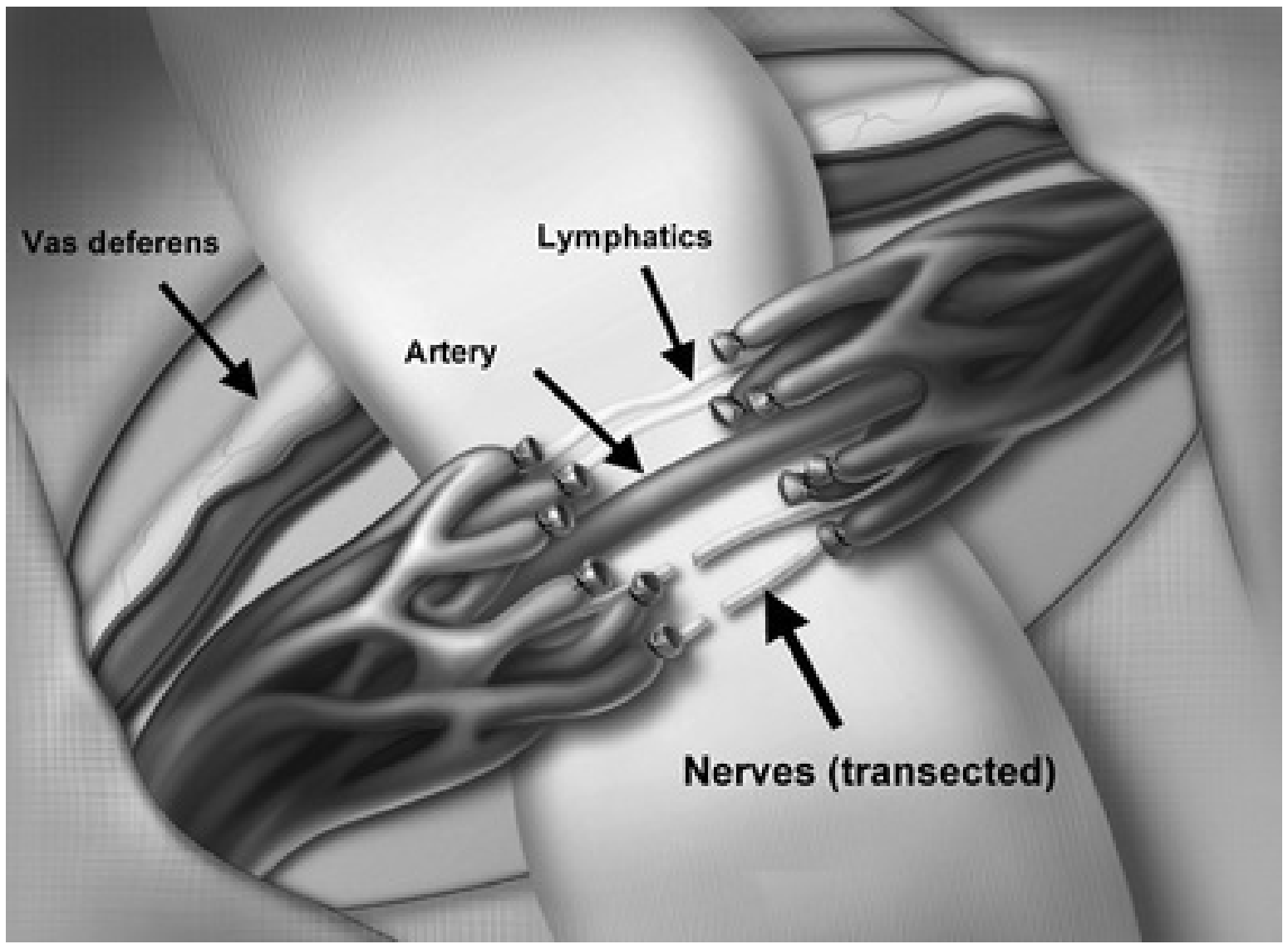

FIG. 83.18 Microsurgical denervation. The goal is to transect all branches of the genitofemoral nerve while preserving the vas deferens, vasal vessels, testicular artery, and lymphatics.

Varicocelectomy

Clinical and subclinical varicocele veins are a common physical examination and sonographic finding and are present in 15% of the general male population (Meacham et al., 1994). Despite their ubiquity in the general male population, varicocele veins should remain high in the differential for orchalgia (Peterson et al., 1998). In a review of varicocelectomy procedures performed for orchalgia, Shridharani et al. showed complete resolution of pain in 85% of men and partial resolution of pain in 6% of men who underwent microsurgical repair (Shridharani et al., 2012). In contrast, nonmicrosurgical repair of varicocele veins was associated with a 76.5% rate of complete resolution of pain and a 13% partial resolution of pain.

Retractile Testis and Intermittent Testicular Torsion

Ascent of one or both testes is a rare phenomenon beyond puberty, but it can occur and can be associated with pain and male infertility (Caucci et al., 1997). Equally rare, but a consideration in the differential for testicular pain is the presence of intermittent testicular torsion (ITT). **ITT is characterized by acute, short-duration (<2 hours) scrotal pain with rapid, spontaneous resolution of pain** (Creagh et al., 1988; Eaton et al., 2005). **Nausea and vomiting may be present in one-fourth of patients with ITT**.

Orchiopexy is recommended for retractile testes and ITT given the low morbidity of surgical treatment, excellent outcomes in pain relief, and reduction in risk for testicular infarction (Eaton et al., 2005; Hayn et al., 2008; Pogorelic et al., 2013). Several approaches to orchiopexy are available, including suture fixation of the tunica, albuginea of the testis to the tunica vaginalis, and placement of the testis in an extravaginal dartos pouch (Benson and Lotfi, 1967; Frank and O'Brien, 2002; Ritchey and Bloom, 1995).

Technique

Testicular Fixation With Suture.

Testicular fixation is performed by accessing the testis and spermatic cord via a midline or transverse incision and dissecting down to the tunica vaginalis. Once the parietal layer of the tunica vaginalis pouch is opened to expose the testis and spermatic cord, the testis is fixed by suturing the tunica albuginea to the dartos muscle with an absorbable 3-0 suture.

Dartos Pouch Procedure.

The dartos pouch procedure is carried out by accessing the cranial aspect of the hemiscrotum through a transverse incision. Dissection is carried down to the tunica vaginalis. The parietal layer is opened to externalize the spermatic cord and testis. A subdartos tunnel is developed between the dartos and external spermatic fascia with blunt dissection caudally toward the dependent portion of the scrotum. The testis is then positioned in the pouch and secured in place via a purse-string suture around the spermatic cord as it exits the cremaster window (Redman and Barthold, 1995).

Testicular fixation with suture is not without risk. Recurrent torsion may occur after a successful testicular fixation with suture, despite the use of nonabsorbable suture. **In a retrospective review by Mor et al.** (2006)**, ipsilateral intravaginal torsion occurred at a rate of 2.2% following prior fixation with suture** (Mor et al., 2006). Repeat torsion occurred in the orchiopexied testis 4 to 17 years subsequent to repair. **Segmental or complete infarction of the testis can occur by entrapping the intratesticular arteries at the lower pole of the testis**

(Jarow, 1991). Furthermore, animal studies examining the impact of transparenchymal suture fixation have shown an inflammatory reaction and impaired spermatogenesis in rat and hamster testes fixed with chromic and nylon suture (Bellinger et al., 1989; Dixon et al., 1993; Lotan et al., 2005). Bellinger et al. identified intratesticular abscess formation in 76% of rat testes orchiopexed with catgut suture; 88% had tubular necrosis, and 82% had no spermatogonia (Bellinger et al., 1989). In contrast, 94% of testes fixed with a dartos pouch had normal spermatogenesis. The negative impact on spermatogenesis may be diminished by placement of the testis in a dartos pouch or fixation with polytetrafluoroethylene (PTFE) suture (Steinbecker et al., 1999). There is currently no consensus on the ideal fixation method; however, based on animal data, we recommend dartos pouch placement for patients who wish to preserve fertility.

Key Points: Surgery of the Scrotal Contents

- Patients with chronic orchalgia have better pain-related outcomes when their simple orchiectomy is performed via an inguinal approach.
- Men of reproductive age should be counseled on the infertility risks before undergoing an epididymal surgery.
- Epididymectomy performed for chronic epididymitis should be performed as a last resort option, as it has poor outcomes and is associated with persistence of pain.

Complications of Scrotal Surgery

Bleeding and Postoperative Hematoma

Postoperative bleeding is the main complication of scrotal surgery. This complication is most commonly self-limiting, and the accumulated hematoma should be drained only if it is very large, is infected, or continues to enlarge. The continued bleeding is most commonly caused by incomplete ligation of the spermatic artery and can be controlled via a small subinguinal incision. Through this few-centimeter subinguinal incision, the cord can be pulled up and re-ligated. Retroperitoneal hemorrhage in this setting is very rare but potentially lethal and should be promptly recognized and addressed, especially if significant decrease in patient's hematocrit is noted in a setting of an expanding hematoma. If the spermatic cord is retracted into the retroperitoneum, the subinguinal incision may not suffice and should be extended into the retroperitoneum.

Chronic Scrotal Pain

Risk for chronic scrotal pain following vasectomy and affecting a patient's quality of life is reported to be about 2% (Choe and Kirkemo, 1996; Leslie et al., 2007). The reports however, are of poor quality and variable definitions, and only few men ultimately require surgical treatment of their chronic scrotal pain.

Early/Late Vasectomy Failure

Vasectomy failure is defined as either occurrence of pregnancy or failure to achieve azoospermia or RNMS following vasectomy. Early vasectomy failure is usually caused by technical failure, where only one vas has been occluded properly.

If the initial PVSA met success criteria and the patient subsequently is noted to have motile sperm and/or reported conception, this failure usually occurs later and oftentimes is associated with recanalization, and it may occur in approximately 1 in 2000 vasectomies (Davies et al., 1990; Philp et al., 1984a, 1984b).

Epididymal/Vasal Injury or Ligation With

Resulting Infertility

Although injury to the epididymis and vasa differentia are known complications of hydrocele and spermatocele correction, few studies have examined the short- and long-term sequelae of hydrocelectomy and aspiration and sclerotherapy (AS). Shan et al. evaluated the impact of AS on the change in semen parameters at 6 and 12 months postinterventionally. The authors found deterioration of sperm concentration, motility, and morphology at 6 months, but return to baseline levels at 12 months (Shan et al. 2011).

Hydrocele Recurrence

Hydrocele recurrence after successful repair ranges from 0% to 2%, regardless of a choice of operative technique (Ku et al., 2001; Rodriguez et al., 1981). Resolution of hydrocele following AS is reported to be 85% to 96%, although repeat procedures may be required to achieve higher success rates.

Infection

Infection commonly results from the pre-existing hematoma. This may be either treated conservatively with antibiotics or with more aggressive wound exploration, irrigation, and hematoma evacuation. If the initial incision is reopened, it should be left open to allow maximal drainage and healing via secondary intention.

Sperm Granuloma

The inflammatory nodule at site of vasectomy is common and not considered a complication of surgery. Initially, for up to 3 months, the nodule may be symptomatic, and treatment with anti-inflammatory analgesics on an as-needed basis in addition to patient reassurance should suffice. The incidence rate of the persisting symptomatic nodule has been reported at rates <5% (Sharlip et al., 2012). In cases of prolonged postprocedural pain localized to the terminal ends of the transected vasa, repeat vasectomy or excision of the vasal edges may be offered with successful outcomes.

Anatomy and Embryology of Seminal Vesicles

SV anatomy was first described by Gabriele Fallopius in 1561 with a further, more detailed study and description continued in the late 19th century (Brewster, 1985).

The SVs are paired male reproductive organs that produce about 60% of the seminal fluid (Ndovi et al., 2007). The organs are located posteriorly to the prostate and fuse with the ampulla of the vas deferens to form the ejaculatory ducts that empty into the prostatic urethra via the verumontanum (Fig. 83.19). The arterial supply to the SVs originates from the vesiculodeferential artery, a branch off the umbilical artery (Braithwaite, 1952; Clegg, 1955).

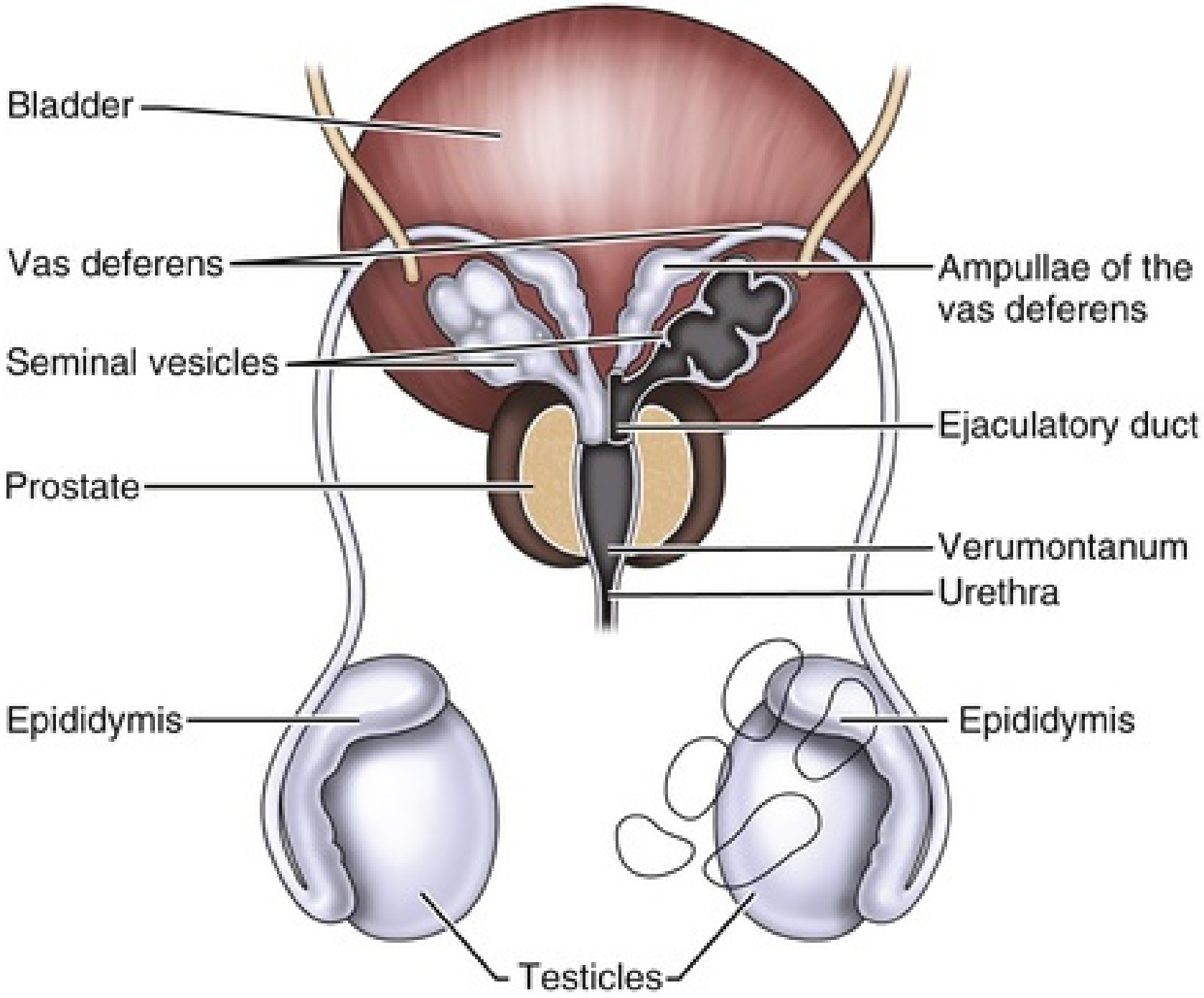
Bladder
Vas deferens
Seminal vesicles
Prostate
Epididymis
Ampullae of the vas deferens
Ejaculatory duct
Verumontanum
Urethra
Epididymis
Testicles

FIG. 83.19 Posterior view of seminal vesicle anatomy in relation to the lower genitourinary tract (bivalved areas in dark gray).

Developmentally, the SVs begin as bilateral dorsolateral bulbous dilations of the distal mesonephric ducts at about 12 weeks' gestation, and continue to form multiple diverticula by the end of 16 weeks (Fig. 83.20A–C). Subsequently, the vesicles elongate, develop multiple diverticula, and become highly convoluted. The seminal epithelium differentiates into the principal (secretory) and basal cells at birth, with the latter decreasing in numbers until 18 years of age.

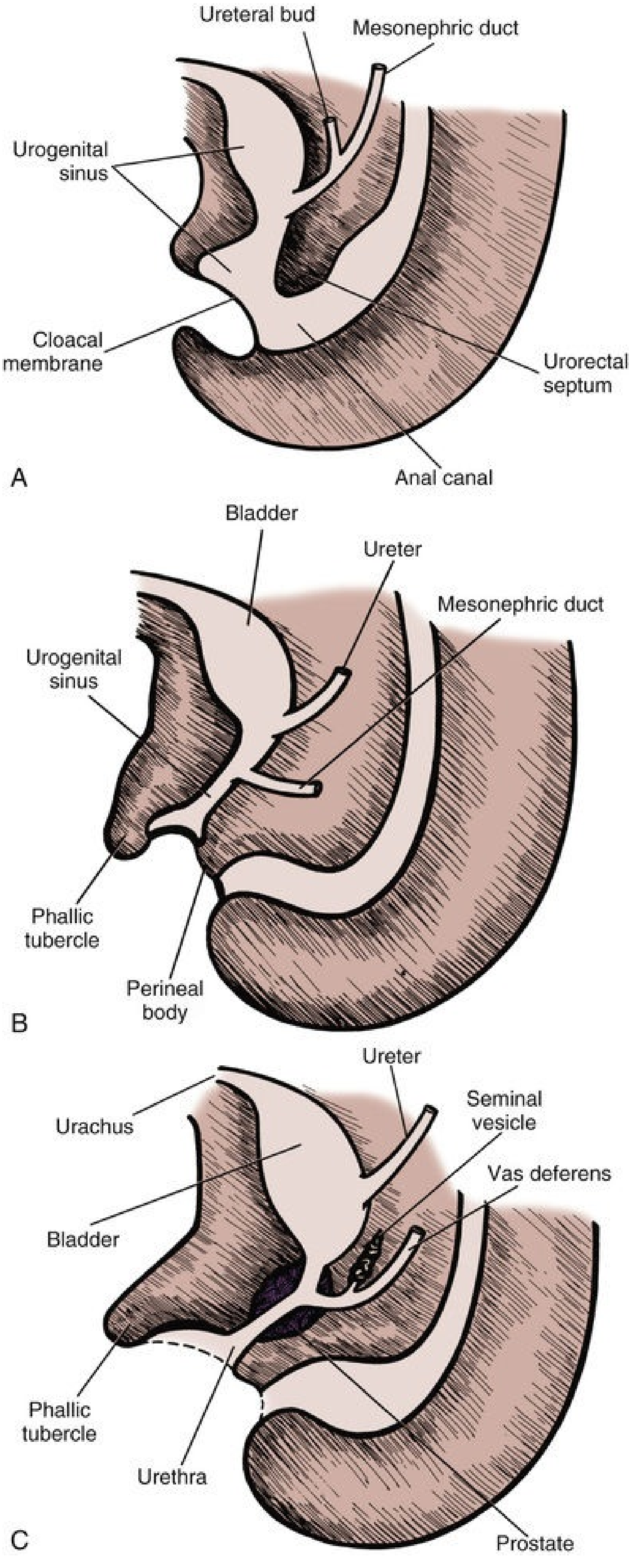
Ureteral bud
Mesonephric duct
Urogenital sinus
Cloacal membrane
Urorectal septum
Anal canal
A
Bladder
Ureter
Mesonephric duct
Urogenital sinus
Phallic tubercle
Perineal body
B
Ureter
Urachus
Seminal vesicle
Vas deferens
Bladder
Phallic tubercle
Urethra
Prostate
C

FIG. 83.20 Intrauterine (fetal) development of the seminal vesicles. (A) Week 5. (B) Week 8. (C) Week 13. (Redrawn from Langman J. *Medical embryology*. 4th ed. Baltimore, MD: Williams & Wilkins; 1981:242–243.)

The size of the SVs varies with age and has been assessed historically with autopsy studies, transrectal ultrasonography (TRUS) (Fig. 83.21AB), and more recently cross-sectional imaging (Figs. 83.22 and 83.23AB) and prostatectomy pathology specimens (Mann, 1974). Rosenberg et al. assessed the SV length, width, and volume from pathology specimens of men who underwent transperitoneal robotic-assisted laparoscopic radical prostatectomy (Rosenberg et al., 2009). The authors found the average SV to be 31 ± 10.3 mm long with an average volume 7.1 ± 5.2 mL. Moreover, statistically significant size discrepancy was noted, with the right SV more often larger than the left SV (P = 0.0003).

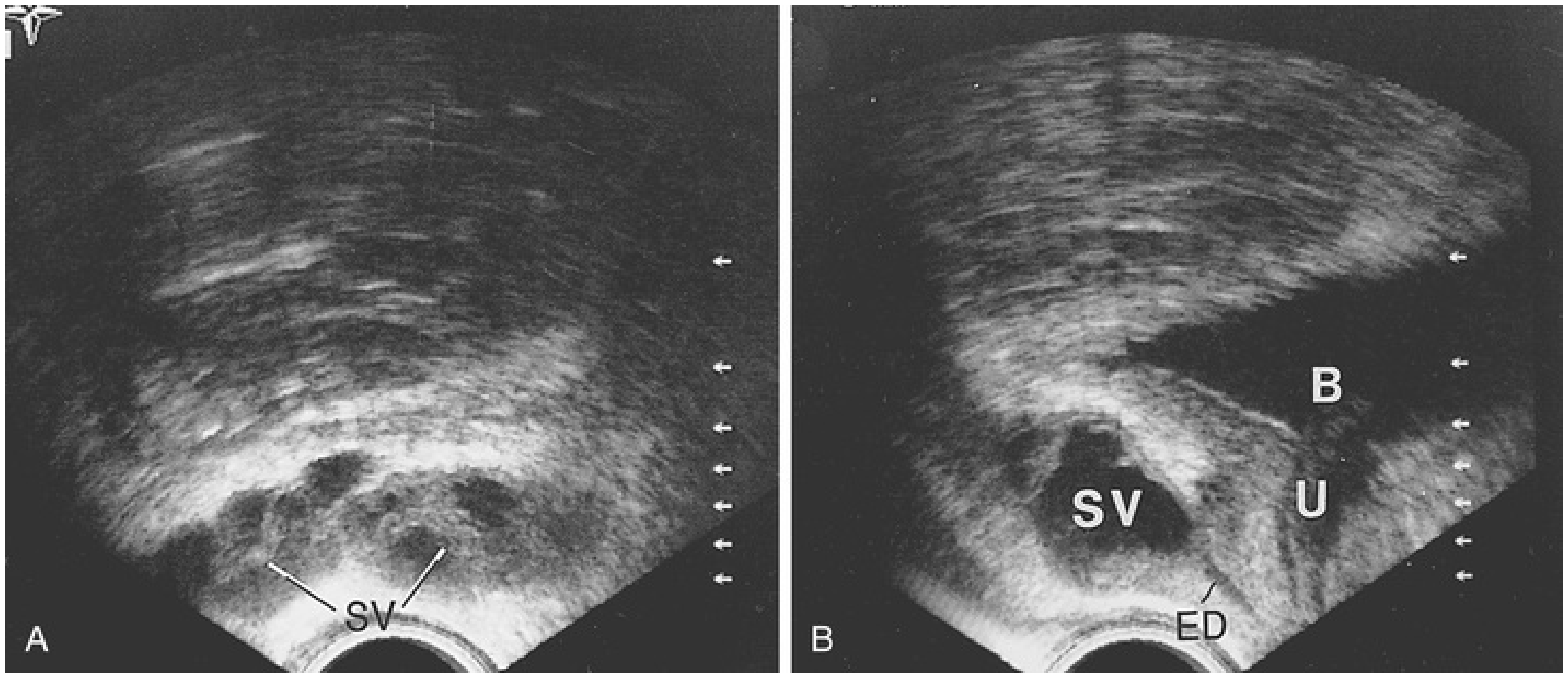

FIG. 83.21 Transrectal ultrasound examination of normal seminal vesicles. (A) Transverse view. (B) Sagittal view. *B,* bladder; *ED,* ejaculatory duct; *SV,* seminal vesicle; *U,* urethra.

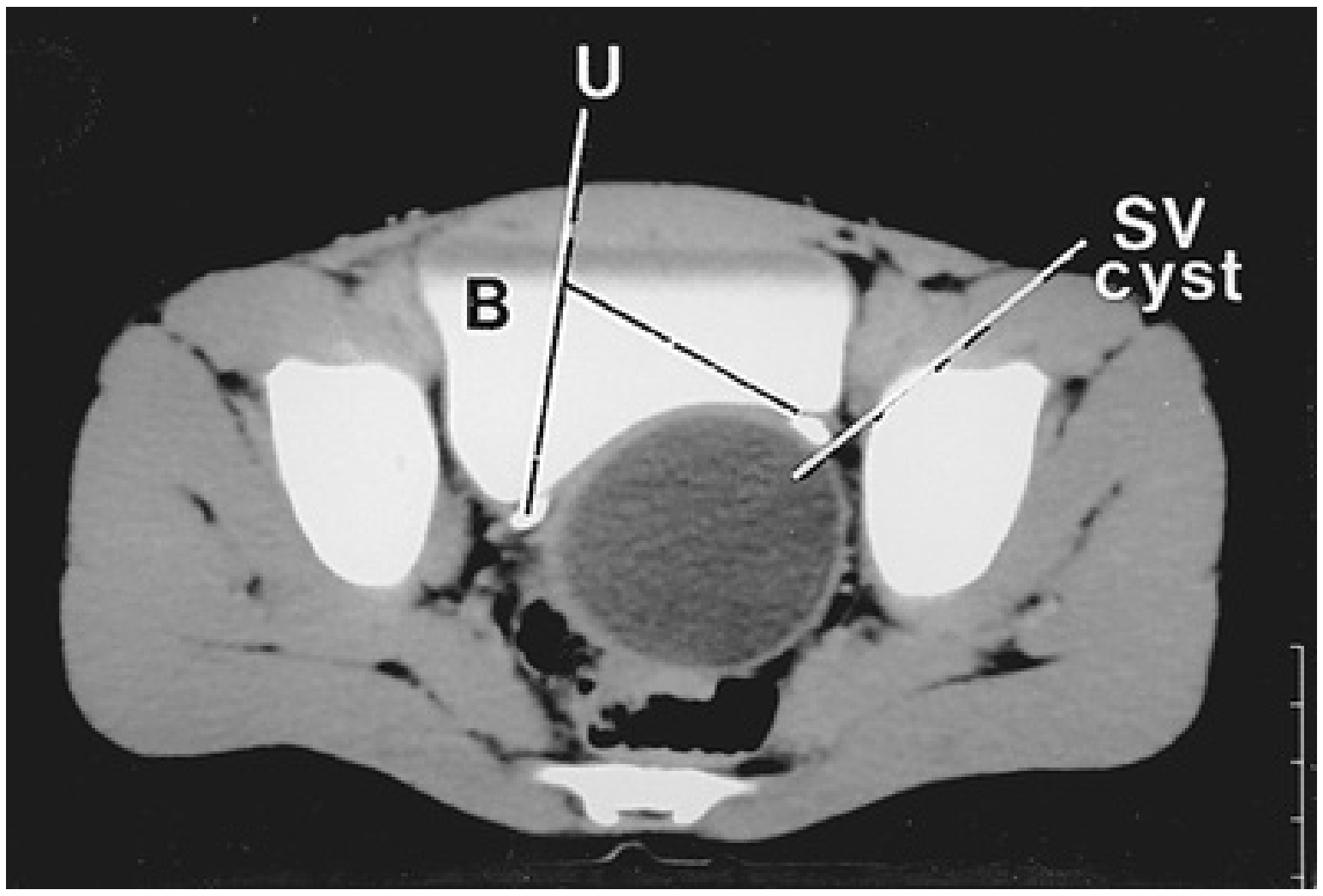

FIG. 83.22 Computed tomography scan of seminal vesicle *(SV)* cyst. *B,* bladder; *U,* ureters.

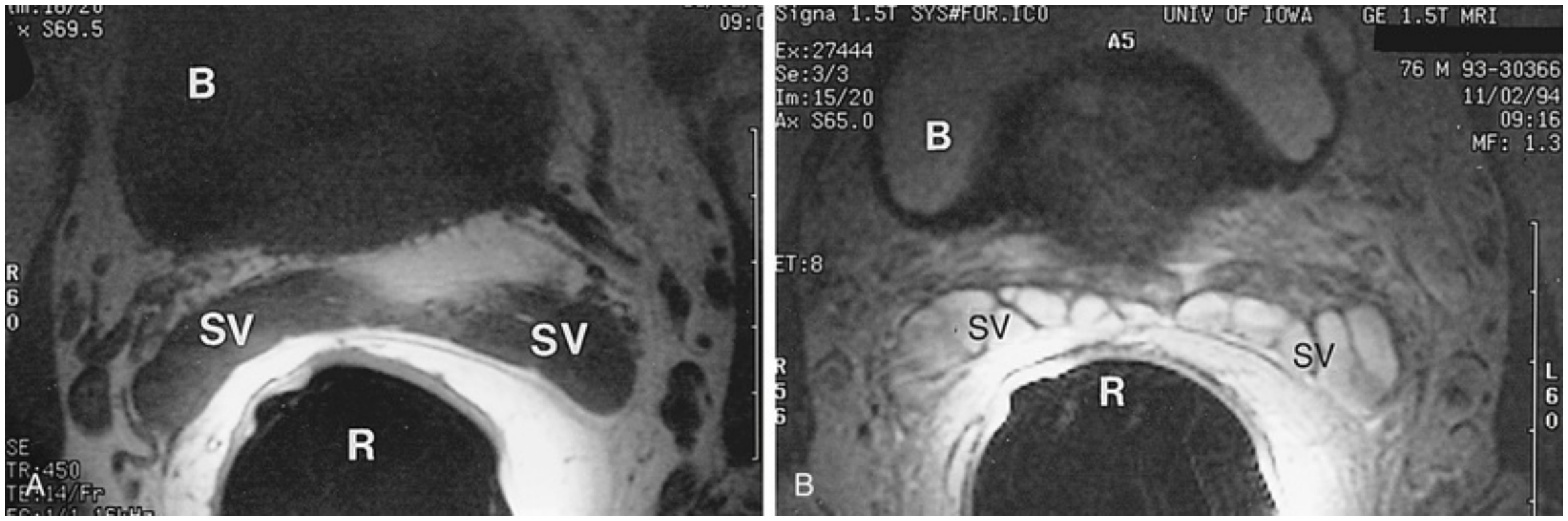
× S69.5
09:0
B
R
6
0
SV
SV
R
SE
TR:450
A
Signa 1.5T SYS#FOR.ICO
UNIV OF IOWA
GE 1.5T MRI
A5
Ex:27444
Se:3/3
Im:15/20
Ax S65.0
76 M 93-30366
11/02/94
09:16
MF: 1.3
B
ET:8
SV
SV
R
R
5
6
L
6
0
B

FIG. 83.23 Transaxial magnetic resonance imaging of normal seminal vesicles (SV) with endorectal coli. (A) T1-weighted image. (B) T2-weighted image. *B,* Bladder; *R,* rectum.

Surgical Approaches to Seminal Vesicles

The majority of procedures on SVs are performed in conjunction with radical cystectomy or prostatectomy. As a result, traditional approaches to unilateral or bilateral SV surgery have mirrored those for pelvic neoplasms.

Anterior

The transvesical transtrigonal anterior approach has been traditionally utilized when large benign SV masses or cysts are present or when an ectopic ureteral drainage is established into an SV cyst (Politano et al., 1975) (Fig. 83.24AB).

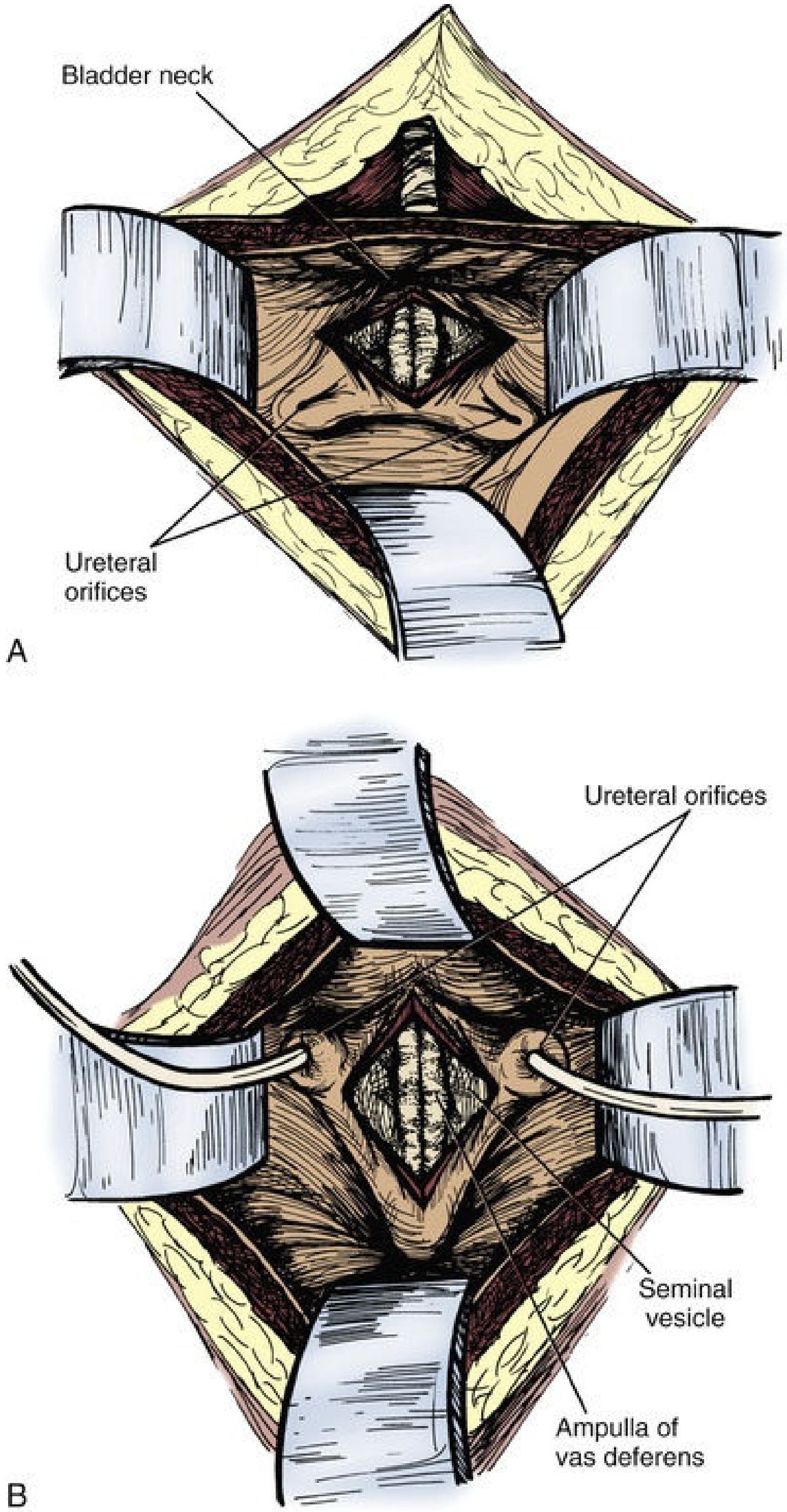
Bladder neck
Ureteral orifices
A
Ureteral orifices
Seminal vesicle
Ampulla of vas deferens
B

FIG. 83.24 Transvesical approach to seminal vesiculectomy. (A) Vertical incision between the ureteral orifices. (B) Transverse incision 2 cm superior to the bladder neck below the ureteral orifices. (Redrawn from Hinman F Jr. *Atlas of urologic surgery.* Philadelphia, PA: Saunders; 1989.)

This is the most direct approach to the SVs. Following an infraumbilical midline incision and entry into the space of Retzius, the anterior bladder wall is entered via a vertical/longitudinal incision. Self-retaining retractor is placed to expose the posterior bladder wall. **Ureteral catheters or feeding tubes should be placed bilaterally to easily identify and avoid potential ureteral injury.** A longitudinal incision in the trigone, avoiding the bladder neck is made. Stay sutures may be placed into the cut edges of the posterior bladder wall to aid with further exposure. Once the muscular bladder wall is transected, the ampullae of the vas deferens will be visible below the level of the bladder neck. The SV may be removed where it joins with the vas deferens, or it may be removed together with the ampulla of the vas (Hinman, 1998). Pulling the vas medially helps identify the ipsilateral SV. Once resection is completed, the posterior bladder wall should be closed with a two-layer closure, with a 2-0 or 3-0 vicryl suture to the muscularis and a smaller, 4-0 vicryl to the bladder mucosa. The anterior bladder wall should be closed in a similar fashion. A closed suction pelvic drain should be placed and Foley catheter should be maintained postoperatively. Ureteral stent(s) may be placed if there is suspicion of ureteral injury; however, stent placement is not the standard of practice on uncomplicated cases.

The perivesical anterior approach is useful in pediatric patients with a large SV cyst, and especially when a nephroureterectomy is planned at time of seminal vesiculectomy. A midline or Pfannenstiel incision is utilized for exposure. The bladder is dissected off of the lateral sidewall on the side ipsilateral to the SV cyst. When an SV cyst is identified, the SV needs to be completely dissected all the way down to the junction with the prostate. It can be ligated with a 2-0 absorbable suture and a ligating clip, carefully avoiding the ureter superiorly and the vas deferens, which runs superior and medial to the SV. Once the SV is removed, a standard abdominal closure can be completed. A closed suction pelvic drain and a Foley catheter can be maintained for the next 24 hours postoperatively and safely removed afterwards, provided there was no bladder injury at time of surgery and/or no excessive drain output has been observed.

Transperitoneal anterior approach can be performed either via an open or laparoscopic/robotic approach. This approach is useful for bilateral SV cysts or benign masses. Following a standard entry into the pelvis, a transverse incision is made through the retroperitoneum, where the retroperitoneum joins the bladder wall in the cul-de-sac. The space between the bladder and the rectum is gently developed (Fig. 83.25AC). The SVs and the ampullae of the vas deferens are identified over the posterior bladder wall. The SVs are then dissected off of the bladder, ligated and resected.

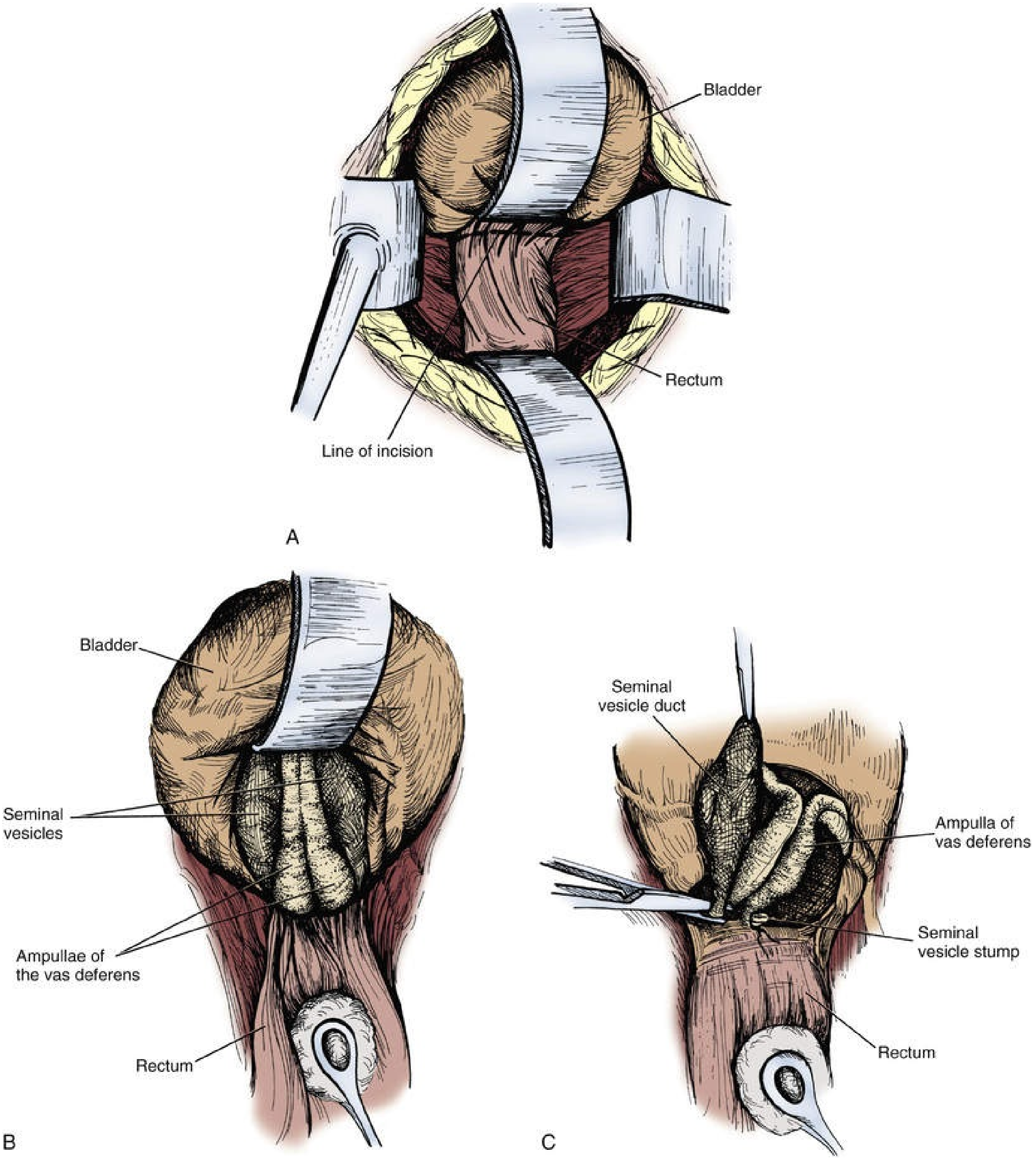
Bladder
Rectum
Line of incision
A
Bladder
Seminal vesicles
Ampullae of the vas deferens
Rectum
B
Seminal vesicle duct
Ampulla of vas deferens
Seminal vesicle stump
Rectum
C

FIG. 83.25 Retrovesical approach to seminal vesiculectomy. (A) Incision line between base of bladder and peritoneal reflection over the rectum. (B) Caudal dissection reveals the ampullae of the vas deferens on the midline and seminal vesicles immediately lateral to them. (C) The duct of the seminal vesicle is ligated and transected. (Redrawn from Hinman F Jr. *Atlas of urologic surgery.* Philadelphia, PA: Saunders; 1989.)

The transperitoneal/laparoscopic approach was initially described by Kavoussi in conjunction with the perineal prostatectomy at time of the laparoscopic pelvic lymph node dissection (Kavoussi et al., 1993). Although awaiting the results of frozen section on the lymph nodes, the SVs and ampullae of the vasa deferentia are dissected free. If the frozen pathology section shows no evidence of nodal involvement, the patient is repositioned and perineal prostatectomy is performed. This procedure was further modified for use during the transperitoneal/robotic approach (Fig. 83.26AC), which has increased in utilization with the advent of robotic surgery. Nowadays, the majority of pelvic urologic surgeries are performed via this approach.

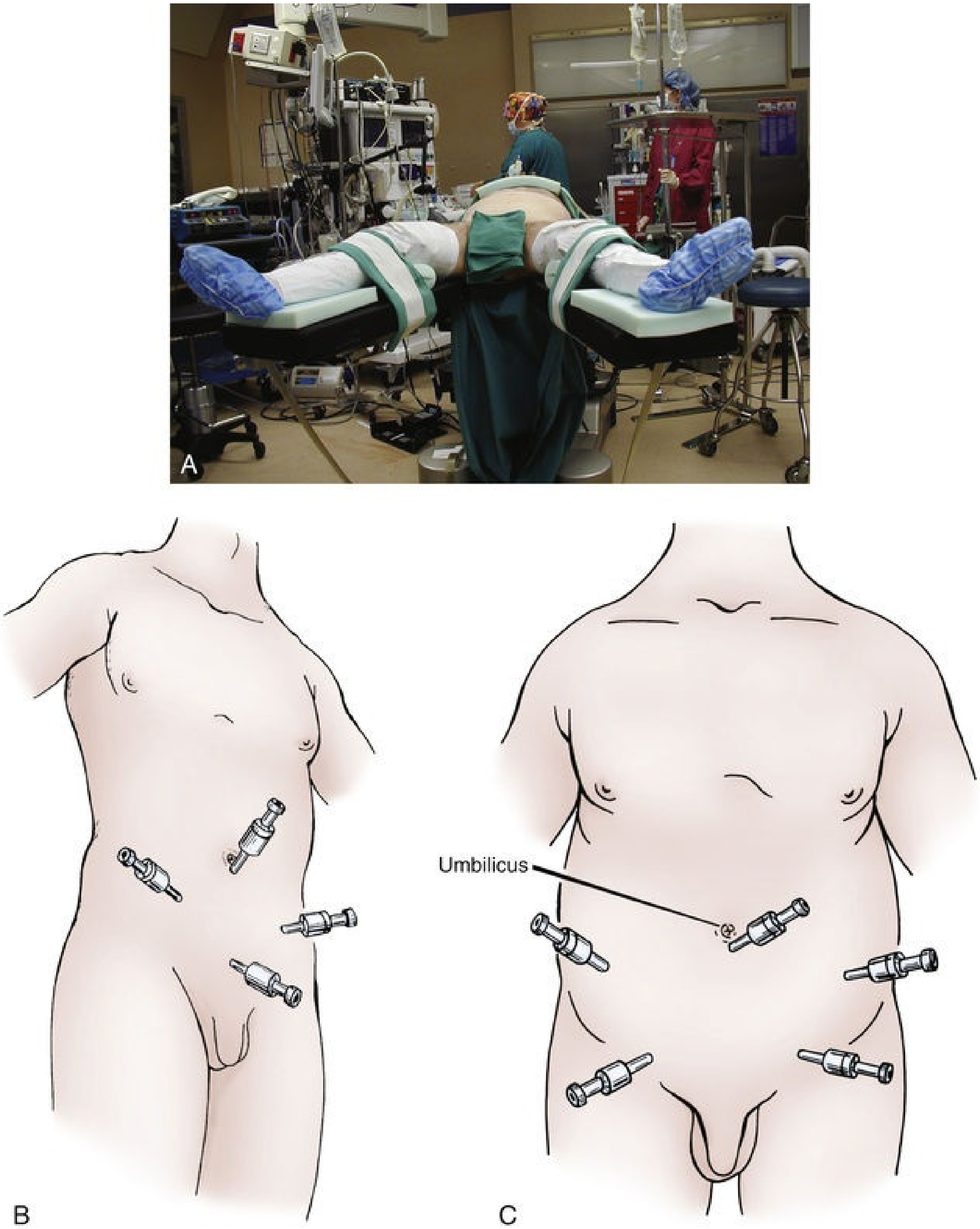

FIG. 83.26 (A) Positioning of the patient for laparoscopic seminal vesicle dissection. (B) Diamond configuration of laparoscopic ports. (C) Inverted U-shaped configuration of laparoscopic ports in obese patients. (From Winifield HN. Laparoscopic pelvic lymph node dissection for urological pelvic malignancies. *Atlas Urol Clin North Am* 1993;1:33–47.)

Perineal

This approach is most commonly utilized at the time of the perineal radical prostatectomy. The perineal approach is limited in the incision size, possibly making the dissection of the ampulla of the vasa deferentia and SVs difficult. The limited visibility may result in injury to the neurovascular bundles or in incomplete removal of the SVs. The risk for injury to the neurovascular bundle can be minimized by maintaining the plane of dissection as close to the midline as possible. In an effort to facilitate the approach to the SVs, the laparoscopic seminal vesical dissection has been described.

Posterior

The transcoccygeal approach (Fig. 83.27A–D) is the least used approach and the least familiar to urologists, however it may be useful in patients who have had previous suprapubic or perineal surgeries or for those who may not tolerate supine or lithotomy positioning.

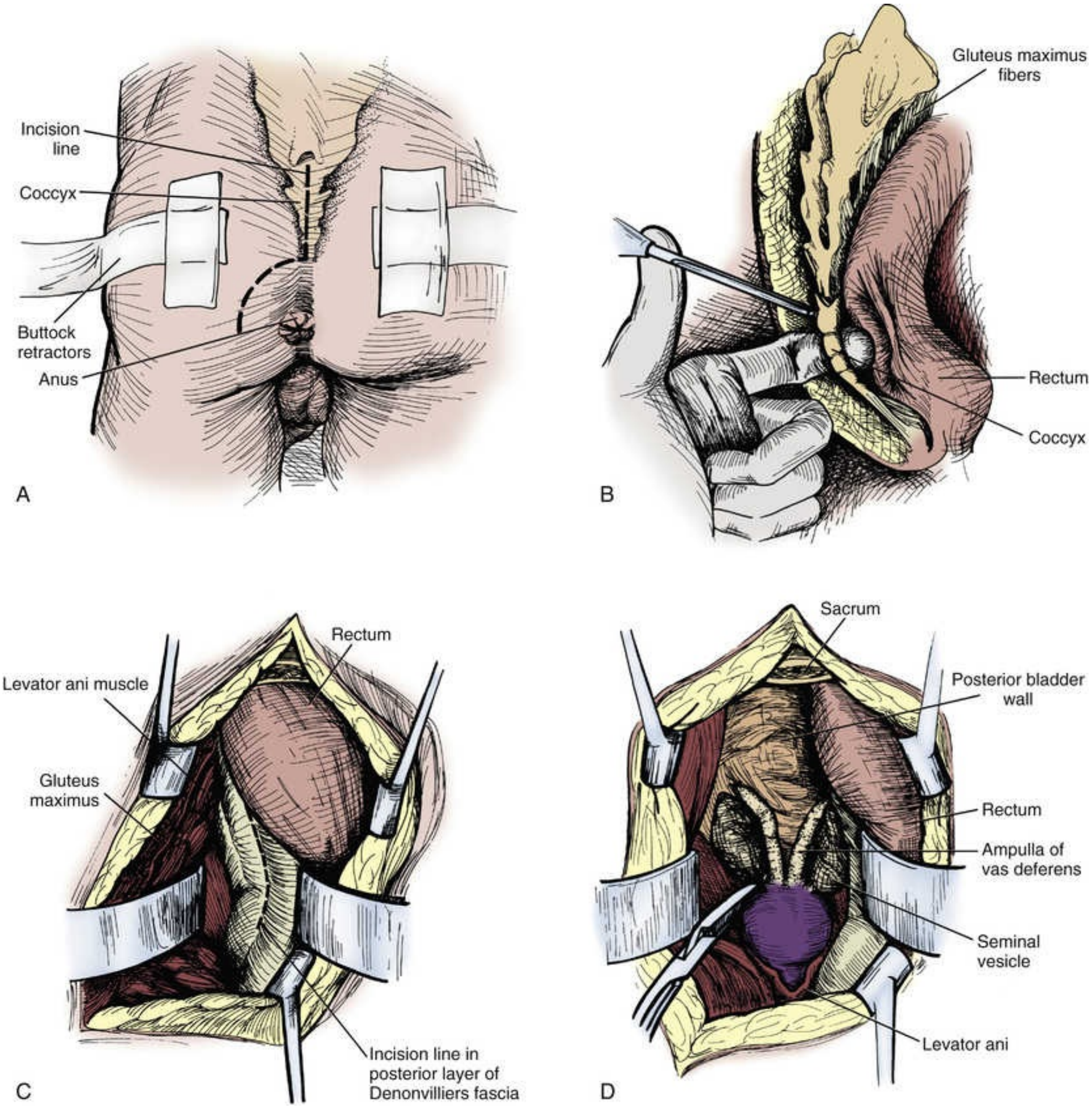
Incision line
Coccyx
Buttock retractors
Anus
A
Gluteus maximus fibers
Rectum
Coccyx
B
Rectum
Levator ani muscle
Gluteus maximus
Incision line in posterior layer of Denonvilliers fascia
C
Sacrum
Posterior bladder wall
Rectum
Ampulla of vas deferens
Seminal vesicle
Levator ani
D

FIG. 83.27 Transcoccygeal seminal vesiculectomy. (A) Incision line over the lower sacrum on coccyx surrounding the anus. (B) Dissection of the coccyx. (C) Incision of Denonvilliers fascia after the rectum has been displaced. (D) Exposure of the prostate and seminal vesicles. (Redrawn from Hinman F Jr. *Atlas of urologic surgery.* Philadelphia, PA: Saunders; 1989.)

In preparation for this approach, the patient is positioned in the prone jackknife position (Kreager and Jordan, 1965). The skin incision is made in an L-shape fashion, proceeding vertically from mid-sacrum and turning down at the tip of the coccyx toward the gluteal cleft, 3 cm away from the rectum. The deeper tissues are dissected down to the lateral side of the coccyx, and once the gluteus maximus muscle fibers are identified and moved over to the side, the rectosigmoid is encountered and carefully dissected off of the sacrum. The lateral rectal wall ipsilateral to the side of the SV lesion is dissected free and moved over medially until prostate is encountered. Next, superiomedial dissection should reveal the ampulla of the vas in midline and the SV lateral to it.

At completion of surgery, a Penrose drain is placed into the resection area and brought out through a separate skin incision. If no significant drainage is observed over the next 2 to 3 days, it should be removed postoperatively. The rectum should be carefully inspected for injury and imbricated in two layers if such injury is encountered. Once the rectum is placed back into its anatomic position, the incision should be closed in layers.

Surgeries of the Seminal Vesicles

Seminal Vesicle Cyst Management

Seminal vesicle cysts (SVCs) are rare lesions, with a prevalence of about 0.005% in men, and they can have either a congenital or acquired etiology (Sheih et al., 1990). Congenital SVCs are commonly related to abnormalities of the mesonephric (Wolffian) duct, and the acquired cysts usually result from ejaculatory duct obstruction as further sequelae of infection, urethral inflammation, or ejaculatory duct stones. The vast majority of SVCs are asymptomatic. Symptoms associated with SVCs include hematospermia, terminal hematuria, lower abdominal or lumbosacral pain, and testicular and perineal discomfort. Symptomatic cysts may also result in obstruction-related hydronephrosis and problems with urination or defecation. They are usually associated with ipsilateral renal agenesis and ectopic ureter and require surgical management.

The management of SVCs depends mainly on their size and clinical symptoms. The vast majority of cases involving small cysts and those that are asymptomatic or cause only mild symptoms are usually treated conservatively, with only occasional percutaneous drainage or transrectal or transurethral cyst aspiration.

Surgical excision is generally indicated for the treatment of large SVCs associated with significant clinical symptoms. The first case of symptomatic SVC surgical removal was reported in 1914, when Zinner described their association with other anomalous developments along with their open surgical resection (Zinner, 1914). Currently, SVC excision is either performed laparoscopically or with use of robotic-assisted technology. Both techniques significantly reduce rates of morbidity and hospital stay, and they allow for more accurate dissection of surrounding structures (McDougall et al., 2001; Scarcia et al., 2016).

Transurethral Endoscopic Treatments

Transurethral treatment constitutes the preferred approach to SVCs, persistent hematospermia, or ejaculatory duct obstruction and/or stones, as it is much less invasive, faster, and associated with fewer complications.

Li et al. (1991) demonstrated that transurethral endoscopic unroofing can be safely performed with use of a standard resectoscope. A 1-cm-long, 1-cm-wide, and 1-cm-deep tissue can be resected from the bladder neck to the verumontanum. Once the SVC is unroofed in such fashion, it can be irrigated with saline and cauterized with a loop electrode. This approach was reported to provide easy access to the cyst with very little overall trauma and bleeding. Furthermore, it was associated with few complications and rapid recovery (Wang et al., 2015).

Transurethral seminal vesiculoscopy has been reported for evaluation and treatment of ejaculatory duct and SV disease. The majority of these cases were performed with a semirigid ureteroscope following dilation with a ureteral serial dilator. Holmium laser was shown to be safe and effective in incision of obstructed ejaculatory ducts, coagulation of hemorrhagic mucosa, and fragmentation of the ejaculatory duct or SV stones (Oh and Seo, 2016). When performed during infertility workup and treatment, vesiculoscopy was associated with initial detection of sperm in 66% of patients. This, however, significantly decreased after 6 months, proving that the reobstruction rate was high in this patient population either because of their underlying etiology or secondary to the procedure risks (Li et al., 2013; Tang et al., 2016).

Transrectal Ultrasound–Guided Aspiration

SVs with a width greater than 1.5 cm and an ejaculatory duct diameter greater than 2.3 mm on transrectal ultrasound (TRUS) are suggestive of obstruction (Smith et al., 2008). However, TRUS findings must be interpreted with caution as dilated SV on TRUS does not necessarily demonstrate ejaculatory duct obstruction, and patients with ejaculatory duct obstruction do not always have dilated SVs (Smith et al., 2008). Further investigation is often needed with SV aspiration to confirm obstruction.

Seminal Vesicle Tumor Excision

Primary SV tumors are extremely rare. Both benign and malignant tumors can appear as complex solid cystic retrovesical masses and oftentimes are asymptomatic. If symptoms occur, they are similar to those resulting from other pathologic SV entities (i.e., SVCs, stones, inflammatory disease, metastatic lesions) and are thus difficult to differentiate. Thorough preoperative evaluation with abdominal and pelvic imaging is the initial step in evaluation. Because of its multiplanar technology and excellent tissue contrast, MRI is the most accurate tool currently used (Kim et al., 2009). When imaging is inconclusive or unspecific, TRUS-guided biopsy should be performed to obtain a more precise histopathologic description of the suspicious lesion. Preoperatively, the benign nature of the SV lesion should be distinguished from the malignancy, as the latter can potentially require more radical treatment approaches (Monica et al., 2008).

The benign tumors of SV include cystadenomas, hydatid cysts, papillary adenomas, and amyloid depositions, and malignant primary SV lesions include mixed epithelial-stromal tumors (MESTs), also known as phyllodes tumors, adenocarcinomas, sarcomas, carcinoids, and primary seminomas (Lorber et al., 2011).

All SV tumors are resected either using open or laparoscopic surgery. Over the years, as described earlier in this chapter, open approaches became replaced by laparoscopic and robotic ones, specifically because of the lower risk for complications and shorter hospital stays. The open surgical approach most commonly applied is transvesical, as this enables full exposure to SVs without damaging the pelvic nervous plexus and blood supply to the bladder and rectum (Takayasu et al., 2015). The laparoscopic approach has been previously described in the management of SV cysts, and it is currently applied in the treatment of SV solid tumors (Kavoussi et al., 1993; Zhang et al., 2013; Zhu et al., 2013). Furthermore, with the advent of robotic-assisted technology, nerve-sparing vesiculectomy has been demonstrated to achieve safe and optimal perioperative and oncologic outcomes (Campi et al., 2015).

Primary adenocarcinoma of the SV has been reported in about 60 cases worldwide, and because of its rarity, standard treatment guidelines are not available (Sollini et al., 2014).

A multimodal approach is utilized in the management of this malignant tumor, with radical surgical excision as a mainstay of treatment. The majority of cases present late, with local metastatic disease, mainly to the bladder and prostate. As a result of this late presentation, with metastatic disease, most publications describe radical excision (radical prostatectomy, radical cystoprostatectomy, partial cystectomy, total pelvic exenteration with ileal conduit for urinary diversion, and sigmoid colostomy) with bilateral lymphadenectomy followed by various adjuvant therapies to include hormonal manipulation, radiotherapy, and chemotherapeutic agents (Katafigiotis et al., 2016).

Another extremely rare but highly malignant lesion of the SVs is the yolk sac tumor. Currently, only two case reports of this rare malignant cause of hematospermia have been described. The multimodal approach of chemotherapy, radiotherapy, and radical surgical removal have been described, but because of its rarity, it has not been accepted as a standard of care (Benson et al., 1978; Gill et al., 2015).

Key Points: Surgery of the Seminal Vesicles

- SVs produce about 60% of the ejaculate fluid.
- Surgical approaches to unilateral or bilateral seminal vesicles mirror those for pelvic neoplasms.
- Symptomatic SV cysts may be associated with ipsilateral renal agenesis and ectopic ureter.
- Transrectal ultrasound-guided aspiration of an SV must be performed to confirm ejaculatory duct obstruction, as the SV may be dilated from a nonobstructive cause.
- Benign and malignant tumors of SVs are very rare.
- MRI provides the most accurate radiographic evaluation of SV lesions.

Complications of Seminal Vesicle Surgery

SV surgery mimics surgical approaches to the prostate, and thus carries potential for similar complications.

Bladder Injury

Anterior dissection of the SVs carries a small risk for bladder injury. When recognized, this can be easily closed with absorbable sutures in two layers (mucosal and muscular), and, with prolonged bladder drainage, they heal without significant consequences.

The transvesical approach to the SV places patients at a higher risk for urinary leak, as the bladder sustains two planned transverse incisions, both to the anterior and posterior bladder wall. Prolonged catheterization and consideration of pelvic drain placement is strongly advised in these cases.

Endoscopic Surgery Complications

Potential complications associated with the endoscopic approach to SVs may result in epididymitis and postvoid dribbling caused by urinary reflux and urinary tract infection (Goluboff et al., 1995).

Laparoscopic/Robotic Surgery Complications

Injuries inherent to laparoscopic and robotic surgical approaches, although uncommon these days, can be devastating when they occur and may rapidly result in case termination or conversion to an open one. These include but are not limited to: trocar injury to blood vessel/bowel, abdominal wall bleeding, extraperitoneal insufflation, and gas embolism.

Neurovascular Bundle Injury

Neurovascular bundles (NVBs) run immediately lateral to the tips of SVs, and thus any surgical approach will place them at risk for injury. The NVB may result in transient or permanent erectile dysfunction, thus cautious dissection in this area should be performed.

Rectal Injury

Rectal injury is very rare, but when it happens, the same repair principles as for an injury sustained at time of radical prostatectomy should be applied. In the absence of gross fecal spillage, primary repair is acceptable. Debridement of any devitalized tissue, followed by a double-layer repair (mucosal and muscular) is recommended. For larger injuries, gross fecal spillage, or if the surgeon is concerned about viability of the rectal repair, temporary diverting colostomy in addition to the rectal defect repair is strongly advised. This risk can be minimized by approaching the SVs from an anterior approach.

Ureteral Injury

In general, ureters enter the posterior bladder wall, anterolateral to the tips of the SVs and cross to the midline above the trigone. If ureteral injury is suspected during posterior dissection of the SVs, intravenous indigo carmine or on-the-table retrograde ureterogram may be performed to confirm it. Once the injury is confirmed, the ureteroneocystostomy should be performed in the standard fashion. The cut end of the ureter should be pulled into the bladder, spatulated, and sutured into the bladder mucosa. If tension on the anastomosis is encountered, a Boari flap or a psoas hitch may be further used to ease the tension. Stent placement is advised following reconstruction.

Suggested Readings

Oesterling JE. Scrotal surgery: a reliable method for the prevention of postoperative hematoma and edema. *J Urol*. 1990;143:1201–1202.

Parekattil SJ, Gudeloglu A, Brahmbhatt JV, et al. Trifecta nerve complex: potential anatomical basis for microsurgical denervation of the spermatic cord for chronic orchialgia. *J Urol*. 2013;190:265–270.

Schlegel PN, Goldstein M. No-scalpel vasectomy. *Semin Urol*. 1992;10:252–256.

Tan WP, Levine LA. What can we do for chronic scrotal content pain? *World J Mens Health*. 2017;35:146–155.

Weinberg AE, Liu JJ, Sandelien M, et al. Epididymal sparing bilateral simple orchiectomy: cost-effectiveness and aesthetic preservation for men with metastatic prostate cancer. *Urol Pract*. 2016;3:112–117.

References

Ahmed SR, Boucher AE, Manni A, et al. Transdermal testosterone therapy in the treatment of male hypogonadism. *J Clin Endocrinol Metab*. 1988;66:546–551.

Alexander JW, Fischer JE, Boyajian M, et al. The influence of hair-removal methods on wound infections. *Arch Surg*. 1983;118:347–352.

Alom M, Ziegelmann M, Savage J, et al. Office-based andrology and male infertility procedures—a cost-effective alternative. *Transl Androl Urol*. 2017;6:761–772.

Anderson J, Abrahamsson PA, Crawford D, et al. Management of advanced prostate cancer: can we improve on androgen deprivation therapy? *BJU Int*. 2008;101:1497–1501.

Anderson JE, Jamieson DJ, Warner L, et al. Contraceptive sterilization among married adults: national data on who chooses vasectomy and tubal sterilization. *Contraception*. 2012;85:552–557.

Banyra O, Shulyak A. Acute epididymo-orchitis: staging and treatment. *Cent European J Urol*. 2012;65:139–143.

Bapat S, Mahajan PM, Bhave AA, et al. Prospective randomised controlled trial comparing sub-epididymal orchiectomy versus conventional orchiectomy in metastatic carcinoma of prostate. *Indian J Surg*. 2011;73:175–177.

Beiko DT, Kim D, Morales A. Aspiration and sclerotherapy versus hydrocelectomy for treatment of hydroceles. *Urology*. 2003;61:708–712.

Bellinger MF, Abromowitz H, Brantley S, et al. Orchiopexy: an experimental study of the effect of surgical technique on testicular histology. *J Urol*. 1989;142:553–555 [discussion 572].

Benson CD, Lotfi MW. The pouch technique in the surgical correction of cryptorchidism in infants and children. *Surgery*. 1967;62:967–973.

Benson JS, Abern MR, Larsen S, et al. Does a positive response to spermatic cord block predict response to microdenervation of the spermatic cord for chronic scrotal content pain? *J Sex Med*. 2013;10:876–882.

Benson RC Jr, Segura JW, Carney JA. Primary yolk-sac (endodermal sinus) tumor of the prostate. *Cancer*. 1978;41:1395–1398.

Black TR, Gates DS, Lavely K, et al. The percutaneous electrocoagulation vasectomy technique—a comparative trial with the standard incision technique at Marie Stopes House, London. *Contraception*. 1989;39:359–368.

Braithwaite JL. The arterial supply of the male urinary bladder. *Br J Urol*. 1952;24:64–71.

Braslis KG, Moss DI. Long-term experience with sclerotherapy for treatment of epididymal cyst and hydrocele. *Aust N Z J Surg*. 1996;66:222–224.

Brewster SF. The development and differentiation of human seminal vesicles. *J Anat*. 1985;143:45–55.

Bullock N, Thurston AV. Tetracycline sclerotherapy for hydroceles and epididymal cysts. *Br J Urol*. 1987;59:340–342.

Bush NC, Bagrodia A. Initial results for combined orchiectomy and prosthesis exchange for unsalvageable testicular torsion in adolescents: description of intravaginal prosthesis placement at orchiectomy. *J Urol*. 2012;188:1424–1428.

Calleary JG, Masood J, Hill JT. Chronic epididymitis: is epididymectomy a valid surgical treatment? *Int J Androl*. 2009;32:468–472.

Campi R, Serni S, Raspollini MR, et al. Robot-assisted laparoscopic vesiculectomy for large seminal vesicle cystadenoma: a case report and review of the literature. *Clin*

Genitourin Cancer. 2015;13:e369–e373.

Caucci M, Barbatelli G, Cinti S. The retractile testis can be a cause of adult infertility. *Fertil Steril*. 1997;68:1051–1058.

Choe JM, Kirkemo AK. Questionnaire-based outcomes study of nononcological post-vasectomy complications. *J Urol*. 1996;155:1284–1286.

Ciftci H, Savas M, Yeni E, et al. Chronic orchialgia and associated diseases. *Curr Urol*. 2010;4:67–70.

Clegg EJ. The arterial supply of the human prostate and seminal vesicles. *J Anat*. 1955;89:209–216.

Creagh TA, McDermott TE, McLean PA, et al. Intermittent torsion of the testis. *BMJ*. 1988;297:525–526.

Daehlin L, Tonder B, Kapstad L. Comparison of polidocanol and tetracycline in the sclerotherapy of testicular hydrocele and epididymal cyst. *Br J Urol*. 1997;80:468–471.

Dagur G, Gandhi J, Suh Y, et al. Classifying hydroceles of the pelvis and groin: an overview of etiology, secondary complications, evaluation, and management. *Curr Urol*. 2017;10:1–14.

Davies AH, Sharp RJ, Cranston D, et al. The long-term outcome following “special clearance” after vasectomy. *Br J Urol*. 1990;66:211–212.

Davis BE, Noble MJ, Weigel JW, et al. Analysis and management of chronic testicular pain. *J Urol*. 1990;143:936–939.

Dixon TK, Ritchey ML, Boykin W, et al. Transparenchymal suture fixation and testicular histology in a prepubertal rat model. *J Urol*. 1993;149:1116–1118.

Ducic I, Dellon AL. Testicular pain after inguinal hernia repair: an approach to resection of the genital branch of genitofemoral nerve. *J Am Coll Surg*. 2004;198:181–184.

Dumville JC, McFarlane E, Edwards P, et al. Preoperative skin antiseptics for preventing surgical wound infections after clean surgery. *Cochrane Database Syst Rev*. 2015;(4) [CD003949].

Eaton SH, Cendron MA, Estrada CR, et al. Intermittent testicular torsion: diagnostic features and management outcomes. *J Urol*. 2005;174:1532–1535 [discussion 1535].

Eeckhaut MC. Marital status and female and male contraceptive sterilization in the United States. *Fertil Steril*. 2015;103:1509–1515.

Elkin EB, Bach PB. Cancer's next frontier: addressing high and increasing costs. *JAMA*. 2010;303:1086–1087.

Elliott SP, Jarosek SL, Wilt TJ, et al. Reduction in physician reimbursement and use of hormone therapy in prostate cancer. *J Natl Cancer Inst*. 2010;102:1826–1834.

Errey BB, Edwards IS. Open-ended vasectomy: an assessment. *Fertil Steril*. 1986;45:843–846.

Francis JJ, Levine LA. Aspiration and sclerotherapy: a nonsurgical treatment option for hydroceles. *J Urol*. 2013;189:1725–1729.

Frank JD, O'Brien M. Fixation of the testis. *BJU Int*. 2002;89:331–333.

Fuchs EF. Cord block anesthesia for scrotal surgery. *J Urol*. 1982;128:718–719.

Gill JD, Bhattarai S, Patel CN, et al. Yolk sac tumor of the seminal vesicles: a rare malignant cause of hematospermia. *Urol Ann*. 2015;7:107–108.

Girsdansky J, Newman HF. Use of a Vitallium testicular implant. *Am J Surg*. 1941;53:514.

Goldstein M, Waterhouse K. When to use the Chevassu maneuver during exploration of intrascrotal masses. *J Urol*. 1983;130:1199–1200.

Goluboff ET, Kaplan SA, Fisch H. Seminal vesicle urinary reflux as a complication of transurethral resection of ejaculatory ducts. *J Urol*. 1995;153:1234–1235.

Griffin T, Tooher R, Nowakowski K, et al. How little is enough? The evidence for post-vasectomy testing. *J Urol*. 2005;174:29–36.

Grober ED, Domes T, Fanipour M, et al. Preoperative hair removal on the male genitalia: clippers vs. razors. *J Sex Med*. 2013;10:589–594.

Hayn MH, Herz DB, Bellinger MF, et al. Intermittent torsion of the spermatic cord portends an increased risk of acute testicular infarction. *J Urol*. 2008;180:1729–1732.

Hazzard CT. The development of a new testicular prosthesis. *J Urol*. 1953;70:959–960.

Hinman FJ. *Seminal vesiculectomy. An atlas of urologic surgery*. Saunders: Philadelphia, PA; 1998:481–484.

Issa MM, Lendvay TS, Bouet R, et al. Epididymal sparing bilateral simple orchiectomy with epididymoplasty: preservation of esthetics and body image. *J Urol*. 2005;174:893–897.

Jahnson S, Sandblom D, Holmang S. A randomized trial comparing 2 doses of polidocanol sclerotherapy for hydrocele or spermatocele. *J Urol*. 2011;186:1319–1323.

Jarow JP. Clinical significance of intratesticular arterial anatomy. *J Urol*. 1991;145:777–779.

Karian LS, Chung SY, Lee ES. Reconstruction of defects after Fournier gangrene: a systematic review. *Eplasty*. 2015;15:e18.

Katafigiotis I, Sfoungaristos S, Duvdevani M, et al. Primary adenocarcinoma of the seminal vesicles. A review of the literature. *Arch Ital Urol Androl*. 2016;88:47–51.

Kauffman EC, Kim HH, Tanrikut C, et al. Microsurgical spermatocelectomy: technique and outcomes of a novel surgical approach. *J Urol*. 2011;185:238–242.

Kavoussi LR, Schuessler WW, Vancaillie TG, et al. Laparoscopic approach to the seminal vesicles. *J Urol*.

1993;150:417–419.

Khaniya S, Agrawal CS, Koirala R, et al. Comparison of aspiration-sclerotherapy with hydrocelectomy in the management of hydrocele: a prospective randomized study. *Int J Surg*. 2009;7:392–395.

Kim B, Kawashima A, Ryu JA, et al. Imaging of the seminal vesicle and vas deferens. *Radiographics*. 2009;29:1105–1121.

Kogan S. The clinical utility of testicular prosthesis placement in children with genital and testicular disorders. *Transl Androl Urol*. 2014;3:391–397.

Krahn MD, Bremner KE, Luo J, et al. Health care costs for prostate cancer patients receiving androgen deprivation therapy: treatment and adverse events. *Curr Oncol*. 2014;21:e457–e465.

Kreager JA Jr, Jordan WP Jr. Transcoccygeal approach to the seminal vesicles. *Am Surg*. 1965;31:126–127.

Ku JH, Kim ME, Lee NK, et al. The excisional, plication and internal drainage techniques: a comparison of the results for idiopathic hydrocele. *BJU Int*. 2001;87:82–84.

Leach GE. Local anesthesia for urologic procedures. *Urology*. 1996;48:284–288.

Leslie TA, Illing RO, Cranston DW, et al. The incidence of chronic scrotal pain after vasectomy: a prospective audit. *BJU Int*. 2007;100:1330–1333.

Leung ML, Gooding GA, Williams RD. High-resolution sonography of scrotal contents in asymptomatic subjects. *Am J Roentgenol*. 1984;143:161–164.

Levine LA, DeWolf WC. Aspiration and tetracycline sclerotherapy of hydroceles. *J Urol*. 1988;139:959–960.

Li BJ, Zhang C, Li K, et al. Clinical analysis of the characterization of magnetic resonance imaging in 102 cases of refractory haematospermia. *Andrology*. 2013;1:948–956.

Li SQ, Goldstein M, Zhu J, et al. The no-scalpel vasectomy. *J*

Urol. 1991;145:341–344.

Libman JL, Pippi-Salle JL, Chan PT. The use of a suprascrotal or “wink” incision for placing a testicular prosthesis. *BJU Int*. 2006;98:1051–1053.

Lin CT, Chang SC, Chen SG, et al. Reconstruction of perineoscrotal defects in Fournier's gangrene with pedicle anterolateral thigh perforator flap. *ANZ J Surg*. 2016;86:1052–1055.

Lin YH, Chen CL, Hou CP, et al. A comparison of androgen deprivation therapy versus surgical castration for patients with advanced prostatic carcinoma. *Acta Pharmacol Sin*. 2011;32:537–542.

Lorber G, Pizov G, Gofrit ON, et al. Seminal vesicle cystadenoma: a rare clinical perspective. *Eur Urol*. 2011;60:388–391.

Lord PH. A bloodless operation for the radical cure of idiopathic hydrocele. *Br J Surg*. 1964;51:914–916.

Lotan G, Golan R, Efrati Y, et al. An experimental study of the effect of two distinct surgical techniques of orchiopexy on spermatogenesis and testicular damage in cryptorchid testes. *Fertil Steril*. 2005;84:749–755.

Lucas JW, Lester KM, Chen A, et al. Scrotal reconstruction and testicular prosthetics. *Transl Androl Urol*. 2017;6:710–721.

Lund L, Kloster A, Cao T. The long-term efficacy of hydrocele treatment with aspiration and sclerotherapy with polidocanol compared to placebo: a prospective, double-blind, randomized study. *J Urol*. 2014;191:1347–1350.

Magoha GA. Local infiltration and spermatic cord block for inguinal, scrotal and testicular surgery. *East Afr Med J*. 1998;75:579–581.

Mann T. Secretory function of the prostate, seminal vesicle and other male accessory organs of reproduction. *J Reprod Fertil*. 1974;37:179–188.

Masarani M, Cox R. The aetiology, pathophysiology and management of chronic orchialgia. *BJU Int*. 2003;91:435–437.

McDougall EM, Afane JS, Dunn MD, et al. Laparoscopic management of retrovesical cystic disease: Washington University experience and review of the literature. *J Endourol*. 2001;15:815–819.

McNamara ER, Madden-Fuentes RJ, Routh JC, et al. Evaluation of cold ischemia for preservation of testicular function during partial orchiectomy in the rat model. *J Pediatr Urol*. 2014;10:593–597.

Meacham RB, Townsend RR, Rademacher D, et al. The incidence of varicoceles in the general population when evaluated by physical examination, gray scale sonography and color Doppler sonography. *J Urol*. 1994;151:1535–1538.

Mello DF, Helene Júnior A. Scrotal reconstruction with superomedial fasciocutaneous thigh flap. *Rev Col Bras Cir*. 2018;45:e1389.

Moloney GE. Comparison of results of treatment of hydrocele and epididymal cysts by surgery and injection. *Br Med J*. 1975;3:478–479.

Monica B, Larosa M, Facchini F, et al. Low grade epithelial stromal tumour of the seminal vesicle. *World J Surg Oncol*. 2008;6:101.

Mor Y, Pinthus JH, Nadu A, et al. Testicular fixation following torsion of the spermatic cord—does it guarantee prevention of recurrent torsion events? *J Urol*. 2006;175:171–173 [discussion 173–174].

Ndovi TT, Parsons T, Choi L, et al. A new method to estimate quantitatively seminal vesicle and prostate gland contributions to ejaculate. *Br J Clin Pharmacol*. 2007;63:404–420.

Nieschlag E, Behre HM. Testosterone therapy. Nieschlag E, Behre HM, Nieschlag S. *Andrology: male reproductive health and dysfunction*. ed 3. Springer-Verlag: New York; 2010:437–453.

Nigam VK. Window operation: new technique for hydrocele. *Urology*. 1984;24:481–482.

Noel B, Bron C, Kunzle N, et al. Multiple nodules of the scrotum: histopathological findings and surgical procedure. A study of five cases. *J Eur Acad Dermatol Venereol*. 2006;20:707–710.

Norton KS, Johnson LW, Perry T, et al. Management of Fournier's gangrene: an eleven year retrospective analysis of early recognition, diagnosis, and treatment. *Am Surg*. 2002;68:709–713.

Oh TH, Seo IY. Endoscopic treatment for persistent hematospermia: a novel technique using a holmium laser. *Scand J Surg*. 2016;105:174–177.

Oka S, Shiraishi K, Matsuyama H. Microsurgical anatomy of the spermatic cord and spermatic fascia: distribution of lymphatics, and sensory and autonomic nerves. *J Urol*. 2016;195:1841–1847.

Osifo OD, Osaigbovo EO. Congenital hydrocele: prevalence and outcome among male children who underwent neonatal circumcision in Benin City, Nigeria. *J Pediatr Urol*. 2008;4:178–182.

Ostrowski KA, Holt SK, Haynes B, et al. Evaluation of vasectomy trends in the United States. *Urology*. 2018;118:76–79.

Oufkir AA, Tazi MF, El Alami MN. The superomedial thigh flap in scrotal reconstruction: technical steps to improve cosmetic results. *Indian J Urol*. 2013;29:360–362.

Padmore DE, Norman RW, Millard OH. Analyses of indications for and outcomes of epididymectomy. *J Urol*. 1996;156:95–96.

Parekattil SJ, Gudeloglu A, Brahmbhatt JV, et al. Trifecta nerve complex: potential anatomical basis for microsurgical denervation of the spermatic cord for chronic orchialgia. *J Urol*. 2013;190:265–270.

Patel AP. Anatomy and physiology of chronic scrotal pain. *Transl Androl Urol*. 2017;6:S51–S56.

Paty R, Smith AD. Gangrene and Fournier's gangrene. *Urol Clin North Am*. 1992;19:149–162.

Peterson AC, Lance RS, Ruiz HE. Outcomes of varicocele ligation done for pain. *J Urol*. 1998;159:1565–1567.

Philp T, Guillebaud J, Budd D. Complications of vasectomy: review of 16,000 patients. *Br J Urol*. 1984;56:745–748.

Philp T, Guillebaud J, Budd D. Late failure of vasectomy after two documented analyses showing azoospermic semen. *Br Med J (Clin Res Ed)*. 1984;289:77–79.

Pile JM, Barone MA. Demographics of vasectomy—USA and international. *Urol Clin North Am*. 2009;36:295–305.

Pogorelic Z, Mrklic I, Juric I. Do not forget to include testicular torsion in differential diagnosis of lower acute abdominal pain in young males. *J Pediatr Urol*. 2013;9:1161–1165.

Politano VA, Lankford RW, Susaeta R. A transvesical approach to total seminal vesiculectomy: a case report. *J Urol*. 1975;113:385–388.

Por YC, Tan BK, Hong SW, et al. Use of the scrotal remnant as a tissue-expanding musculocutaneous flap for scrotal reconstruction in Paget's disease. *Ann Plast Surg*. 2003;51:155–160.

Potosky AL, Knopf K, Clegg LX, et al. Quality-of-life outcomes after primary androgen deprivation therapy: results from the Prostate Cancer Outcomes Study. *J Clin Oncol*. 2001;19:3750–3757.

Rea CE. The use of a testicular prosthesis made of lucite: with a note concerning the size of the testis at different ages. *J Urol*.

1943;49:727.

Redman JF, Barthold JS. A technique for atraumatic scrotal pouch orchiopexy in the management of testicular torsion. *J Urol*. 1995;154:1511–1512.

Rencken RK, Bornman MS, Reif S, et al. Sclerotherapy for hydroceles. *J Urol*. 1990;143(5):940–943.

Rioja J, Sanchez-Margallo FM, Uson J, et al. Adult hydrocele and spermatocele. *BJU Int*. 2011;107:1852–1864.

Ritchey ML, Bloom DA. Modified dartos pouch orchiopexy. *Urology*. 1995;45:136–138.

Rodriguez WC, Rodriguez DD, Fortuno RF. The operative treatment of hydrocele: a comparison of 4 basic techniques. *J Urol*. 1981;125:804–805.

Roosen JU, Larsen T, Iversen E, et al. A comparison of aspiration, antazoline sclerotherapy and surgery in the treatment of hydrocele. *Br J Urol*. 1991;68:404–406.

Rosenberg S, Pode D, Shapiro A, et al. The fate of the seminal vesicle remnant after proximal transection or ligation: an animal model. *J Urol*. 2009;181:1483–1486.

Ross LS, Flom LS. Azoospermia: a complication of hydrocele repair in a fertile population. *J Urol*. 1991;146:852–853.

Saylor PJ, Smith MR. Metabolic complications of androgen deprivation therapy for prostate cancer. *J Urol*. 2009;181:1998–2006 [discussion 2007-1998].

Scarcia M, Maselli FP, Cardo G, et al. Robot-assisted excision of seminal vesicle cyst associated with ipsilateral renal agenesis. *Arch Ital Urol Androl*. 2016;87:325–326.

Scherer LA, Shiver S, Chang M, et al. The vacuum assisted closure device: a method of securing skin grafts and improving graft survival. *Arch Surg*. 2002;137:930–933 [discussion 933–934].

Shahinian VB, Kuo YF, Freeman JL, et al. Increasing use of gonadotropin-releasing hormone agonists for the treatment of localized prostate carcinoma. *Cancer*. 2005;103:1615–1624.

Shan CJ, Lucon AM, Pagani R, et al. Sclerotherapy of hydroceles and spermatoceles with alcohol: results and effects on the semen analysis. *Int Braz J Urol*. 2011;37:307–312 [discussion 312–333].

Sharlip ID, Belker AM, Honig S, American Urological Association, et al. Vasectomy: AUA guideline. *J Urol*. 2012;188:2482–2491.

Sheih CP, Hung CS, Wei CF, et al. Cystic dilatations within the pelvis in patients with ipsilateral renal agenesis or dysplasia. *J Urol*. 1990;144:324–327.

Sheynkin YR, Hendin BN, Schlegel PN, et al. Microsurgical repair of iatrogenic injury to the vas deferens. *J Urol*. 1998;159:139–141.

Shokeir AA, Eraky I, Hassan N, et al. Tetracycline sclerotherapy for testicular hydroceles in renal transplant recipients. *Urology*. 1994;44:96–99.

Shridharani A, Lockwood G, Sandlow J. Varicocelectomy in the treatment of testicular pain: a review. *Curr Opin Urol*. 2012;22:499–506.

Sigalos JT, Pastuszak AW. Chronic orchialgia: epidemiology, diagnosis and evaluation. *Transl Androl Urol*. 2017;6:S37–S43.

Sigurdsson T, Johansson JE, Jahnson S, et al. Polidocanol sclerotherapy for hydroceles and epididymal cysts. *J Urol*. 1994;151:898–901.

Silberstein J, Grabowski J, Parsons JK. Use of a vacuum-assisted device for Fournier's gangrene: a new paradigm. *Rev Urol*. 2008;10:76–80.

Smith JF, Walsh TJ, Turek PJ. Ejaculatory duct obstruction. *Urol Clin North Am*. 2008;35:221–227 [viii].

Sokal D, McMullen S, Gates D, et al. A comparative study of the no scalpel and standard incision approaches to vasectomy in 5 countries. The Male Sterilization Investigator Team. *J Urol*. 1999;162:1621–1625.

Sollini M, Silvotti M, Casali M, et al. The role of imaging in the diagnosis of recurrence of primary seminal vesicle adenocarcinoma. *World J Mens Health*. 2014;32:61–65.

Sosa ZY, Palmada MN, Foscolo MR, et al. Administration of noradrenaline in the autonomic ganglia modifies the testosterone release from the testis using an ex vivo system. *Int J Androl*. 2009;32:391–398.

Steinbecker KM, Teague JL, Wiltfong DB, et al. Testicular histology after transparenchymal fixation using polytetrefluoroethylene suture: an animal model. *J Pediatr Surg*. 1999;34:1822–1825.

Strittmatter T, Konrad G. Testicular blood supply with a view to surgical treatment. Rübben H, Jocham D, Jacobi GH. *Investigative urology 3*. Springer: Berlin, Heidelberg; 1989:47–52.

Sweeney P, Tan J, Butler MR, et al. Epididymectomy in the management of intrascrotal disease: a critical reappraisal. *Br J Urol*. 1998;81:753–755.

Takayasu K, Harada J, Kawa G, et al. Transvesical removal of seminal vesicle cystadenoma]. *Hinyokika Kiyo*. 2015;61:299–303.

Tammela TL, Hellstrom PA, Mattila SI, et al. Ethanolamine oleate sclerotherapy for hydroceles and spermatoceles: a survey of 158 patients with ultrasound followup. *J Urol*. 1992;147:1551–1553.

Tan WP, Levine LA. What can we do for chronic scrotal content pain? *World J Mens Health*. 2017;35:146–155.

Tan WP, Tsambarlis PN, Levine LA. Microdenervation of the spermatic cord for post-vasectomy pain syndrome. *BJU Int*. 2018;121:667–673.

Tang SX, Zhou HL, Ding YL. Effectiveness of transurethral seminal vesiculoscopy in the treatment of persistent hematospermia, and oligoasthenozoospermia and azoospermia from ejaculatory duct obstruction]. *Zhonghua Yi Xue Za Zhi*. 2016;96:2872–2875.

Ting J, Jin Q, Biles M, et al. Xanthogranuloma of the epididymis. *Urol Case Rep*. 2018;17:50–52.

Wang MS, Li BJ, Huang ZM, et al. Transurethral endoscopic treatment of seminal vesicle cysts (report of seven cases). *Int Urol Nephrol*. 2015;47:717–721.

Weight CJ, Klein EA, Jones JS. Androgen deprivation falls as orchiectomy rates rise after changes in reimbursement in the US Medicare population. *Cancer*. 2008;112:2195–2201.

White K, Potter JE, Hopkins K, et al. Variation in postpartum contraceptive method use: results from the Pregnancy Risk Assessment Monitoring System (PRAMS). *Contraception*. 2014;89:57–62.

Wijsmuller AR, Lange JF, Kleinrensink GJ, et al. Nerve-identifying inguinal hernia repair: a surgical anatomical study. *World J Surg*. 2007;31:414–420 [discussion 421-412].

Wolf JS Jr, Bennett CJ, Dmochowski RR, Urologic Surgery Antimicrobial Prophylaxis Best Practice Policy Panel, et al. Best practice policy statement on urologic surgery antimicrobial prophylaxis. *J Urol*. 2008;179:1379–1390.

World Health Organization. *Global guidelines for the prevention of surgical site infection*. World Health Organization: Geneva, Switzerland; 2016.

Yamamoto M, Hibi H, Katsuno S, et al. Management of chronic orchialgia of unknown etiology. *Int J Urol*. 1995;2:47–49.

Zaontz MR, Ritchie EL, Maizels M, et al. Insertion of testicular prosthesis: use of vaginal speculum. *Urology*. 1990;35:130–132.

Zhang DX, Li Y, Li XG, et al. Transperitoneal laparoscopic excision of primary seminal vesicle benign tumors: surgical techniques and follow-up outcomes. *Urology*. 2013;82:237–241.

Zhu JG, Chen WH, Xu SX, et al. Cystadenoma in a seminal vesicle is cured by laparoscopic ablation. *Asian J Androl*. 2013;15:697–698.

Zinner A. Ein fall von intravesikaler Samenblasenzyste. *Wien Med Wochenschr*. 1914;64:605.

Zorn BH, Watson LR, Steers WD. Nerves from pelvic plexus contribute to chronic orchidalgia. *Lancet*. 1994;343:1161.

PART VIII
Renal Physiology and Pathophysiology

OUTLINE

84 Surgical, Radiologic, and Endoscopic Anatomy of the Kidney and Ureter
85 Physiology and Pharmacology of the Renal Pelvis and Ureter
86 Renal Physiology and Pathophysiology Including Renovascular Hypertension
87 Renal Insufficiency and Ischemic Nephropathy
88 Urologic Complications of Renal Transplantation

Surgical, Radiologic, and Endoscopic Anatomy of the Kidney and Ureter

Mohamed Aly Elkoushy MD, MSc, PhD, Sero Andonian MD, MSc, FRCS(C), FACS

> *Anatomy of course does not change, but our understanding of anatomy and its clinical significance does change.*
>
> *– Frank H. Netter, MD*

Anatomy provides a roadmap for surgical procedures. This chapter presents the normal anatomy of the kidney and ureter. To make it more interesting for urologists, we provide clinical, radiologic, surgical, and endoscopic correlations. Of course, the human body never ceases to amaze explorers with its variations from the “normal.” With modern imaging technology, it has become possible to create three-dimensional (3D) virtual reality of each patient before surgical procedures. However, the surgeon is advised to be cautious of the minute anomalies not appreciated on perioperative imaging studies.

Kidneys

Surface Anatomy and Relationships

The kidneys are paired ovoid, reddish-brown retroperitoneal organs situated in the posterior part of the abdomen on each side of the vertebral column. The kidneys lie on the psoas muscles; thus the **longitudinal axes** of the kidneys are oblique *(arrows*, eFig. 84.1 on the Expert Consult website), with the upper poles more medial and posterior than the inferior poles. Therefore, during percutaneous renal access, the lower pole of the kidney lies laterally and anteriorly relative to the upper pole. In addition, the medial aspect of each kidney is rotated anteriorly at an angle of approximately 30 degrees. The exact **position** of the kidney within the retroperitoneum varies during different phases of respiration, body position, and presence of anatomic anomalies. For example, the kidneys move inferiorly approximately 3 cm (one vertebral body) during inspiration and during changing body position from supine to the erect position. The position of the kidneys in the supine end-expiration is described here. Because of the inferior displacement of the right kidney by the liver, the right kidney sits 1 to 2 cm lower than the left kidney. Therefore the right kidney resides in the space between the top of the 1st lumbar vertebra to the bottom of the 3rd lumbar vertebra, whereas the left kidney occupies a space between the 12th thoracic vertebra and the 3rd lumbar vertebra.

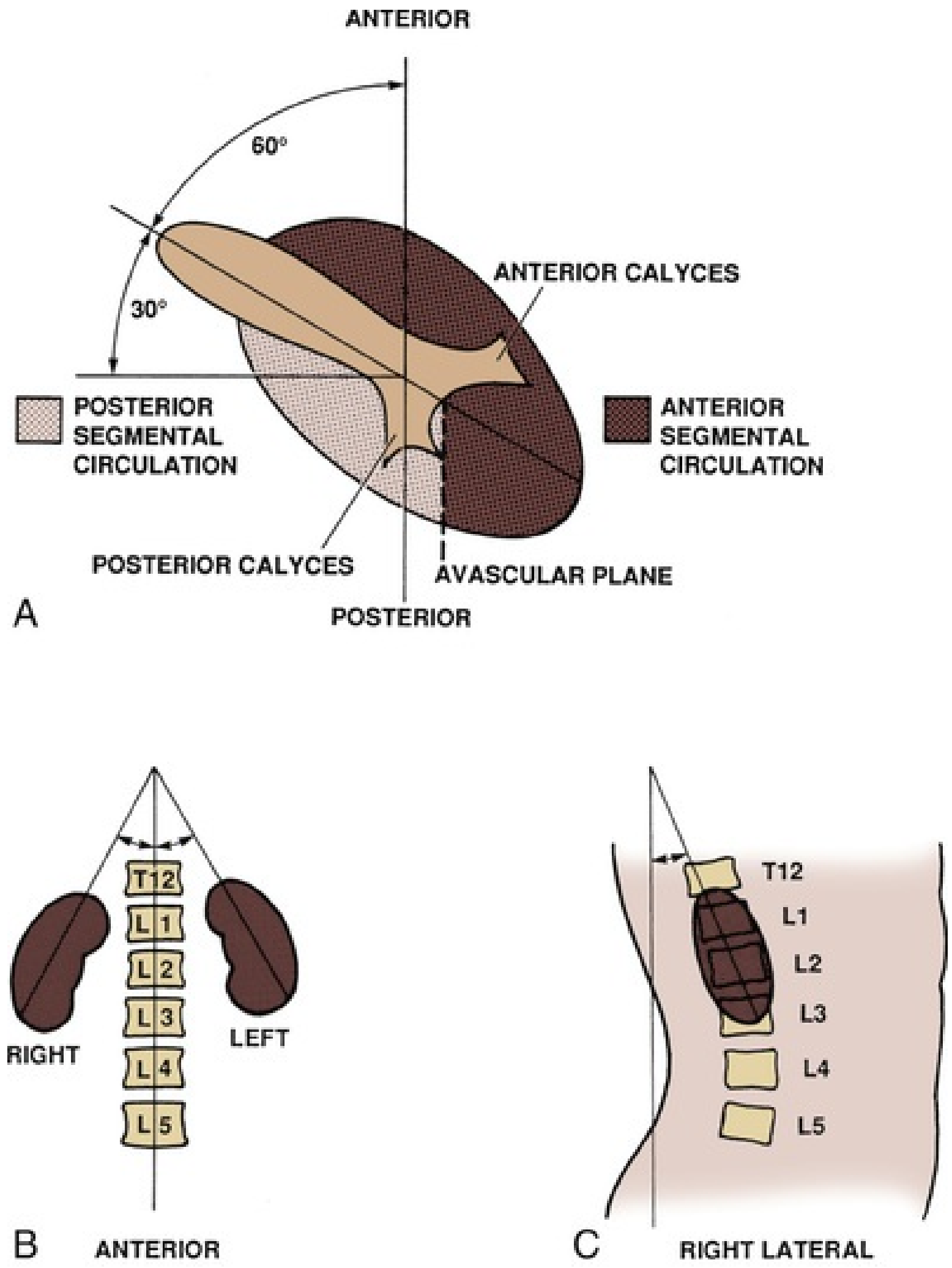
ANTERIOR
60°
30°
ANTERIOR CALYCES
POSTERIOR SEGMENTAL CIRCULATION
ANTERIOR SEGMENTAL CIRCULATION
POSTERIOR CALYCES
AVASCULAR PLANE
A
POSTERIOR
T12
L1
L2
L3
L4
L5
RIGHT
LEFT
B
ANTERIOR
C
RIGHT LATERAL

EFIG. 84.1 Normal rotational axes of the kidneys. (A) Transverse view showing approximate 30-degree anterior rotation of the left kidney from the coronal plane, relative positions of the anterior and posterior rows of calyces, and location of the relatively avascular plane separating the anterior and posterior renal circulations. (B) Coronal section demonstrating slight inward tilt of the upper poles of the kidneys. (C) Sagittal view showing anterior displacement of the lower pole of the right kidney.

Each kidney measures 10 to 12 cm in length, 5.0 to 7.5 cm in width, and 2.5 to 3.0 cm in thickness. Each adult male kidney weighs approximately 125 to 170 g; the kidney is 10 to 15 g smaller in females. The right kidney is slightly shorter and wider because of downward compression by the liver. The kidneys are relatively larger in children and have more prominent fetal lobulations, which generally disappear by the first year of life. In addition, the adult kidney's lateral contour may have a focal renal parenchymal bulge known as a **dromedary hump,** which is more common on the left side and has no pathologic significance. These dromedary humps are thought to be caused by the downward pressure from the liver or the spleen.

The **posterior relationships** of the kidneys are detailed in eFig. 84.2. Superiorly, the kidneys are related to the inferior edge of the diaphragm and the ribs. The right kidney is related to the 12th rib, and the left kidney is related to the 11th and 12th ribs. When the lower ribs are fractured during trauma, associated renal lacerations could occur. The upper poles of the kidneys come close to the diaphragm and underlying pleural cavity containing the lungs; thus any violations of the diaphragm during excision of large renal masses could lead to pleural tears and pneumothorax. Furthermore, **percutaneous access** to the upper pole of the kidneys above the 11th rib (10th intercostal space) is associated with increased risk for injuring pleura and even lungs. Therefore, when possible, subcostal (below the 12th rib) or 11th intercostal space (between the 11th and 12th ribs) access should be achieved (eFig. 84.3). More inferiorly, the kidneys are related to the psoas major muscle medially and the quadratus lumborum and aponeurosis of the transversus abdominis muscles laterally. The subcostal nerve and vessels and the iliohypogastric and ilioinguinal nerves descend obliquely across the posterior surfaces of the kidneys (Fig. 84.4).

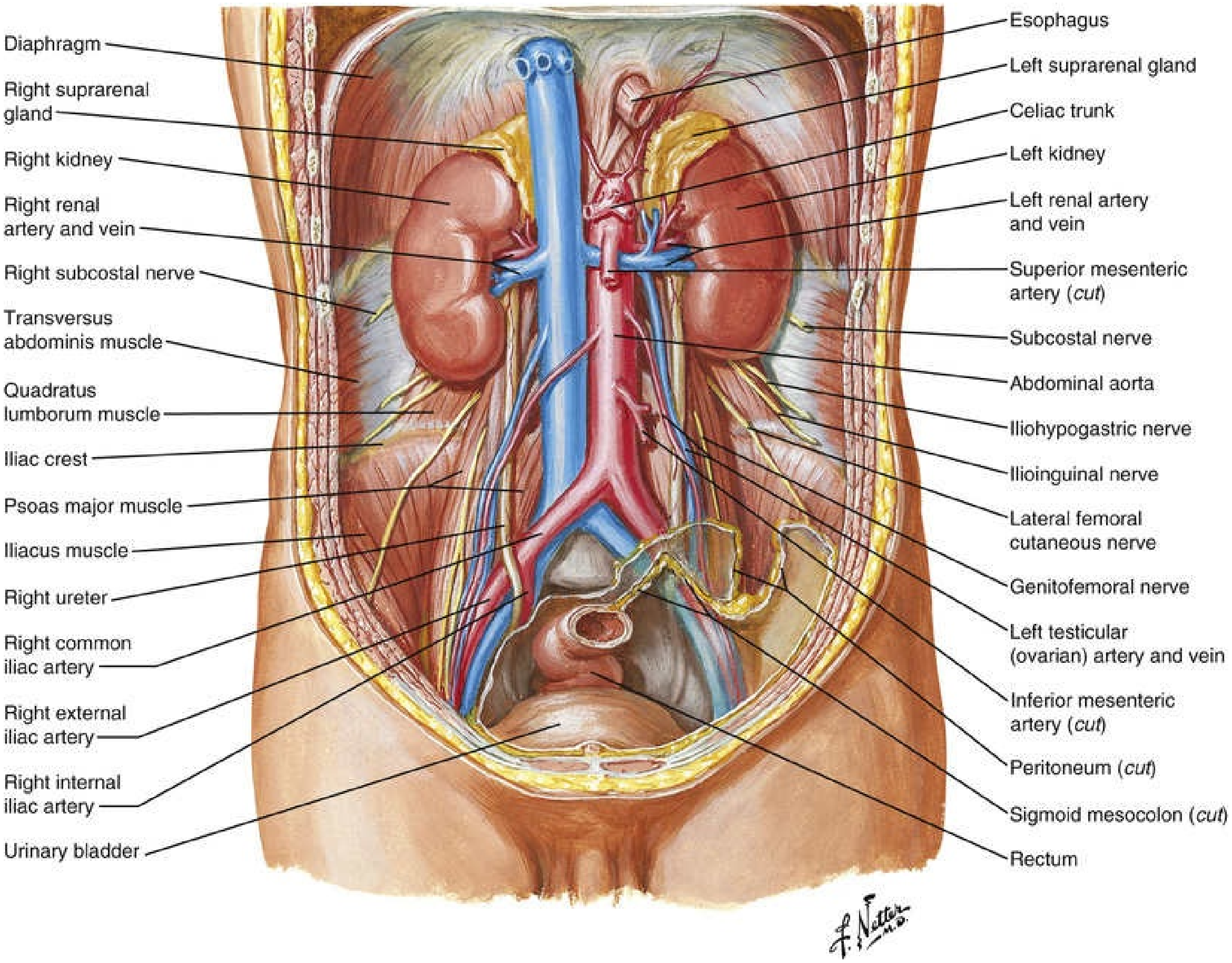
Diaphragm
Right suprarenal gland
Right kidney
Right renal artery and vein
Right subcostal nerve
Transversus abdominis muscle
Quadratus lumborum muscle
Iliac crest
Psoas major muscle
Iliacus muscle
Right ureter
Right common iliac artery
Right external iliac artery
Right internal iliac artery
Urinary bladder
Esophagus
Left suprarenal gland
Celiac trunk
Left kidney
Left renal artery and vein
Superior mesenteric artery (*cut*)
Subcostal nerve
Abdominal aorta
Iliohypogastric nerve
Ilioinguinal nerve
Lateral femoral cutaneous nerve
Genitofemoral nerve
Left testicular (ovarian) artery and vein
Inferior mesenteric artery (*cut*)
Peritoneum (*cut*)
Sigmoid mesocolon (*cut*)
Rectum
F. Netter M.D.

FIG. 84.4 Posterior abdominal wall showing great vessels, kidneys, and adrenal glands. (Copyright 2016 Elsevier Inc. All rights reserved. www.netterimages.com.)

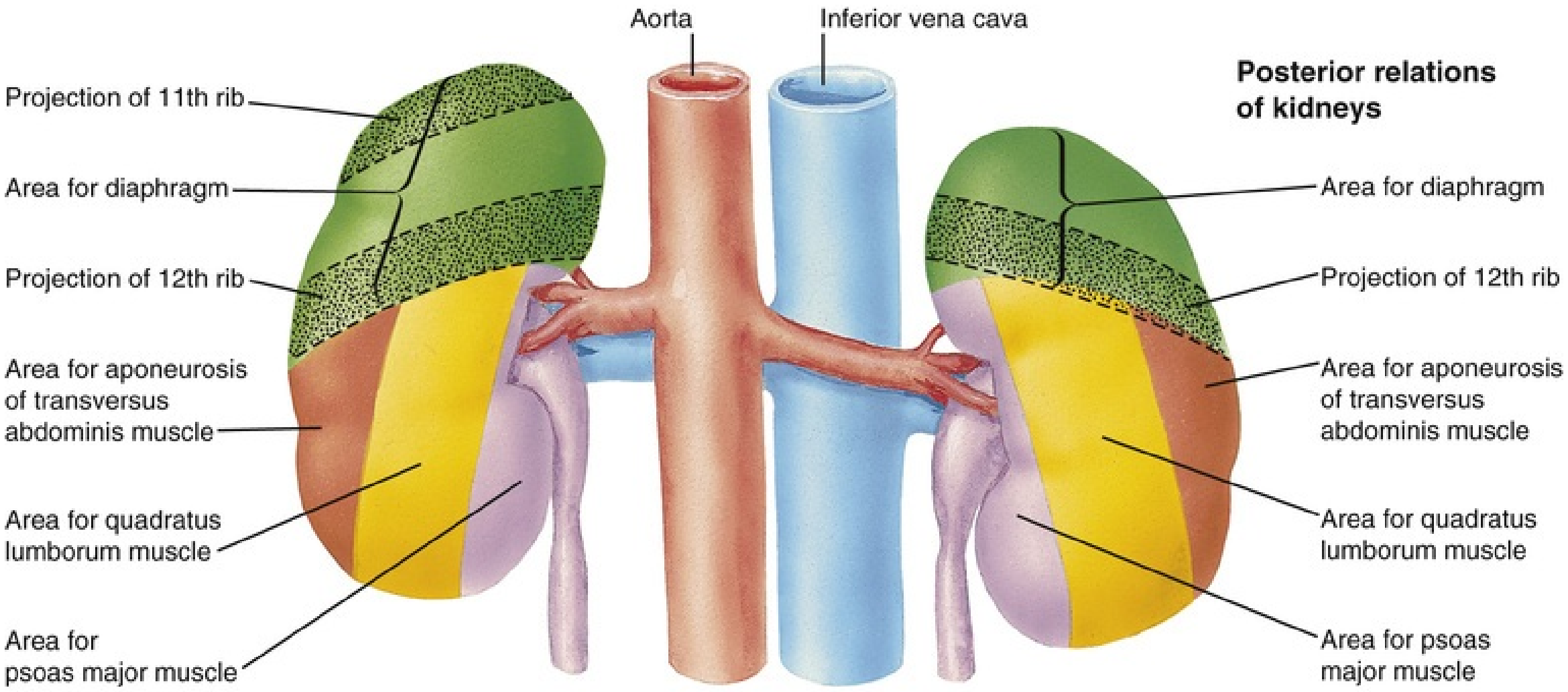
Aorta
Inferior vena cava
Posterior relations of kidneys
Projection of 11th rib
Area for diaphragm
Projection of 12th rib
Area for aponeurosis of transversus abdominis muscle
Area for quadratus lumborum muscle
Area for psoas major muscle
Area for diaphragm
Projection of 12th rib
Area for aponeurosis of transversus abdominis muscle
Area for quadratus lumborum muscle
Area for psoas major muscle

EFIG. 84.2 Posterior relationships of the kidneys. (Copyright 2016

Elsevier Inc. All rights reserved. www.netterimages.com.)

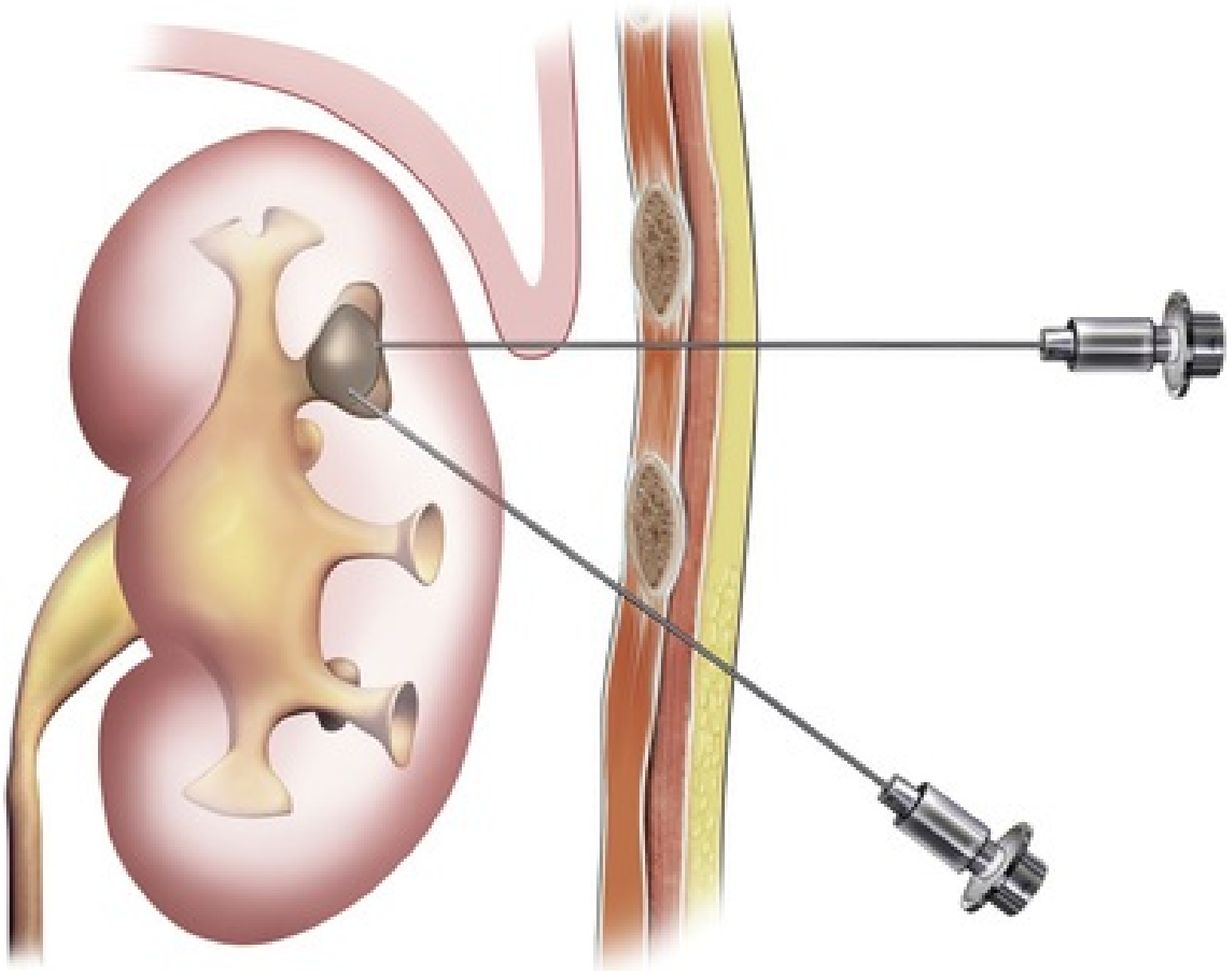

EFIG. 84.3 Subcostal and supracostal percutaneous access to an upper pole calyx. The supracostal approach provides more direct access and provides a better angle for endoscopy of the rest of the kidney. However, there is increased risk for pleural injury.

Because the kidneys are retroperitoneal organs, they are related **anteriorly** to other retroperitoneal and intraperitoneal organs (eFig. 84.5). The right kidney is related superiorly to the liver (intraperitoneal and retroperitoneal bare portions) and superomedially to the adrenal gland. Inferiorly, the right kidney is related to the small intestine and hepatic flexure of the colon, and medially it is related to the second stage of the duodenum and head of the pancreas. The parietal peritoneum bridging the upper pole of the right kidney to the liver forms the **hepatorenal ligament.** Therefore excessive downward traction of the right kidney may cause capsular tear of the liver and may lead to excessive intraoperative bleeding. The left kidney is related to the stomach and spleen superiorly, adrenal gland superomedially, jejunum and splenic flexure of the colon inferiorly, and tail of the pancreas with splenic vessels medially. The parietal peritoneum bridging the upper pole of the left kidney to the spleen forms the **splenorenal ligament.** If excessive downward pressure is applied to the left kidney, splenic capsular tears may occur, leading to hemorrhage from the spleen.

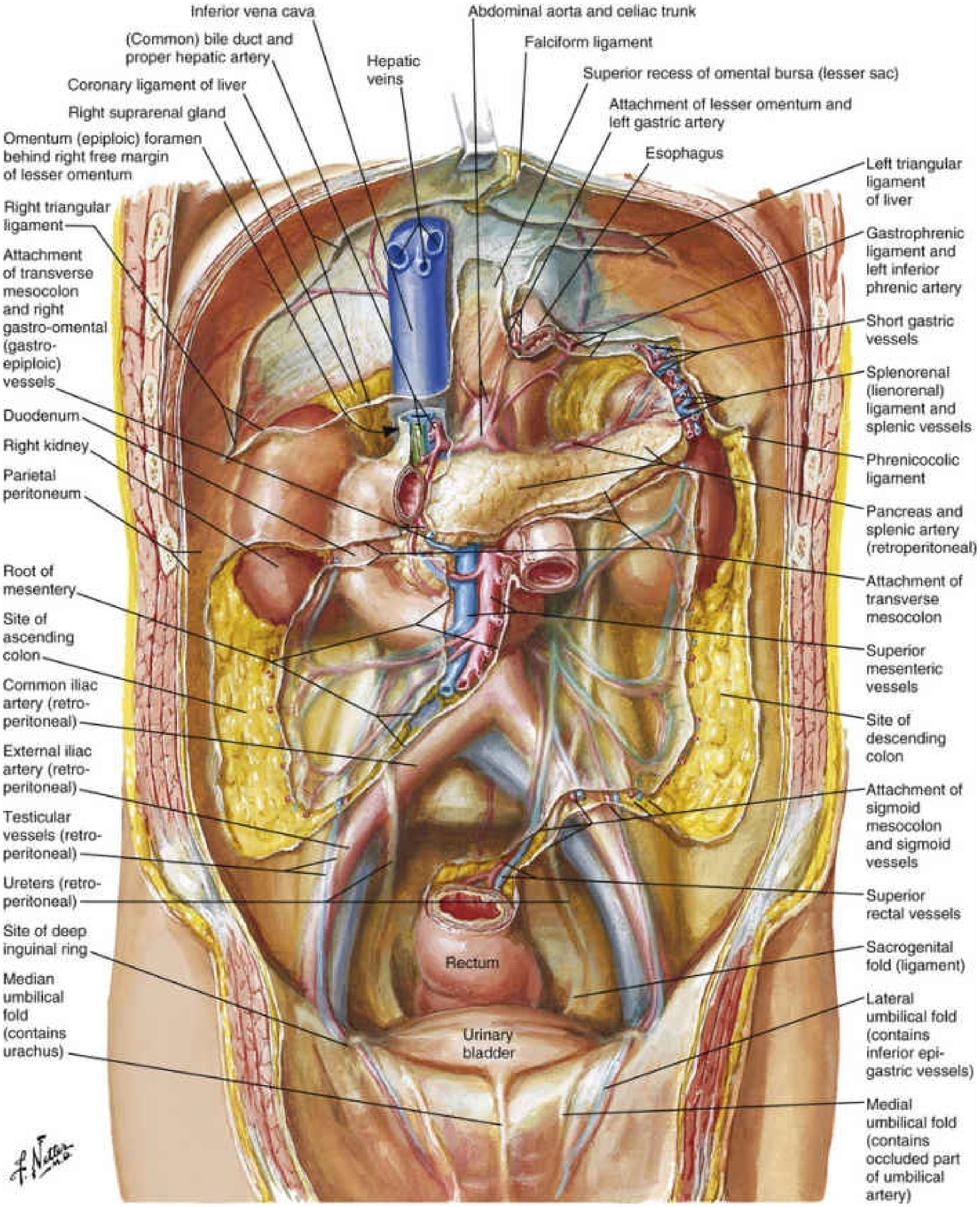
Inferior vena cava
(Common) bile duct and proper hepatic artery
Coronary ligament of liver
Right suprarenal gland
Omentum (epiploic) foramen behind right free margin of lesser omentum
Right triangular ligament
Attachment of transverse mesocolon and right gastro-omental (gastro-epiploic) vessels
Duodenum
Right kidney
Parietal peritoneum
Root of mesentery
Site of ascending colon
Common iliac artery (retro-peritoneal)
External iliac artery (retro-peritoneal)
Testicular vessels (retro-peritoneal)
Ureters (retro-peritoneal)
Site of deep inguinal ring
Median umbilical fold (contains urachus)
Hepatic veins
Abdominal aorta and celiac trunk
Falciform ligament
Superior recess of omental bursa (lesser sac)
Attachment of lesser omentum and left gastric artery
Esophagus
Left triangular ligament of liver
Gastrophrenic ligament and left inferior phrenic artery
Short gastric vessels
Splenorenal (lienorenal) ligament and splenic vessels
Phrenicocolic ligament
Pancreas and splenic artery (retroperitoneal)
Attachment of transverse mesocolon
Superior mesenteric vessels
Site of descending colon
Attachment of sigmoid mesocolon and sigmoid vessels
Superior rectal vessels
Sacrogenital fold (ligament)
Lateral umbilical fold (contains inferior epi-gastric vessels)
Medial umbilical fold (contains occluded part of umbilical artery)
Rectum
Urinary bladder

EFIG. 84.5 Anterior relationships of the kidneys and ureters. (Copyright 2016 Elsevier Inc. All rights reserved. www.netterimages.com.)

The kidneys are surrounded by a smooth, tough fibrous capsule, which is easily removed under normal conditions. Each kidney and its vessels are surrounded by a **perinephric fat** that extends into its hollow vertical cleft, the

renal hilum, which is the entrance to a space within the kidney called the **renal sinus.** The kidneys and adrenal glands, including the perirenal fat surrounding them, are enclosed by a condensed, membranous layer of **renal (Gerota) fascia,** which continues medially to fuse with the contralateral side (eFig. 84.6). This fascia extends inferomedially along the abdominal ureter as a **periureteral fascia.** The Gerota fascia encasing the kidneys, adrenal glands, and abdominal ureters is closed superiorly and laterally and serves as an anatomic barrier to the spread of malignancy and a means of containing perinephric fluid collections. Because it is open inferiorly, perinephric fluid collections can track inferiorly into the pelvis without violating the Gerota fascia.

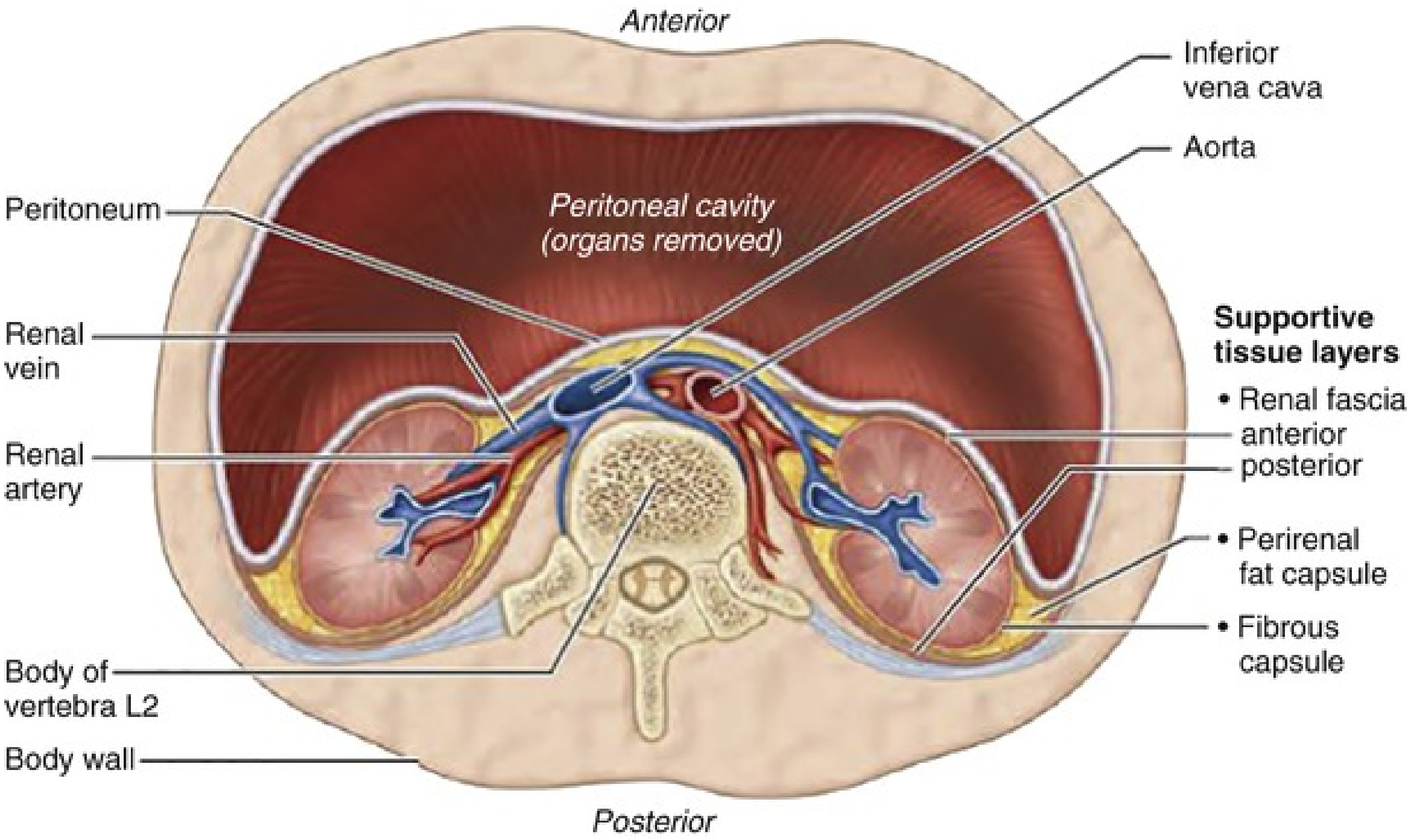
Anterior
Inferior vena cava
Aorta
Peritoneum
Peritoneal cavity (organs removed)
Renal vein
Renal artery
Supportive tissue layers
• Renal fascia
anterior
posterior
• Perirenal fat capsule
• Fibrous capsule
Body of vertebra L2
Body wall
Posterior

EFIG. 84.6 Schematic cross-sectional diagram demonstrating renal (Gerota) fascia. It shows the retroperitoneal position of the kidneys and their supportive tissues. (From Hutchinson M: *A brief atlas of the human body,* ed 2, Old Tappan, NJ, 2006, Pearson Academic.)

The Gerota fascia is further surrounded by a layer of condensed fat called the **paranephric fat,** which is most obvious posteriorly and represents the extraperitoneal fat of the lumbar region. Superiorly, the Gerota fascia is continuous with the diaphragmatic fascia on the inferior surface of the diaphragm, and inferiorly, the anterior and posterior layers of the Gerota fascia are loosely attached. The Gerota fascia is attached with the paranephric fat by collagen bundles. Therefore the kidneys are relatively kept fixed in position by these collagen bundles, the Gerota fascia, and paranephric fat.

The relationships of the kidneys have important **surgical implications.** To access the kidneys, adrenals, or abdominal ureters, the Gerota fascia must be opened. To access the kidneys transperitoneally, the colon must be mobilized from the **white line of Toldt,** which is the lateral reflection of posterior parietal peritoneum over the ascending and descending colon. To access the right renal hilum, the second stage of the duodenum and head of pancreas must be carefully mobilized using the Kocher maneuver. To access the left renal hilum, the tail of the pancreas together with the spleen and splenic vessels must be mobilized medially.

Gross and Microscopic Anatomy

Two distinct regions can be identified on the cut surface of a bisected kidney: the cortex, which is a pale outer region, and the medulla, which is a darker inner region (eFig. 84.7). The renal medulla is divided into 8 to 18 striated, distinct, conically shaped areas that are frequently called renal pyramids. The apex of the pyramids forms the renal papilla, and each papilla is cupped by an individual minor calyx. The base of the pyramids is positioned at the corticomedullary boundary. The cortex and the medulla containing the renal pyramids could be differentiated on renal imaging studies (eFig. 84.8). Furthermore, these renal papillae could be inspected endoscopically (eFig. 84.9).

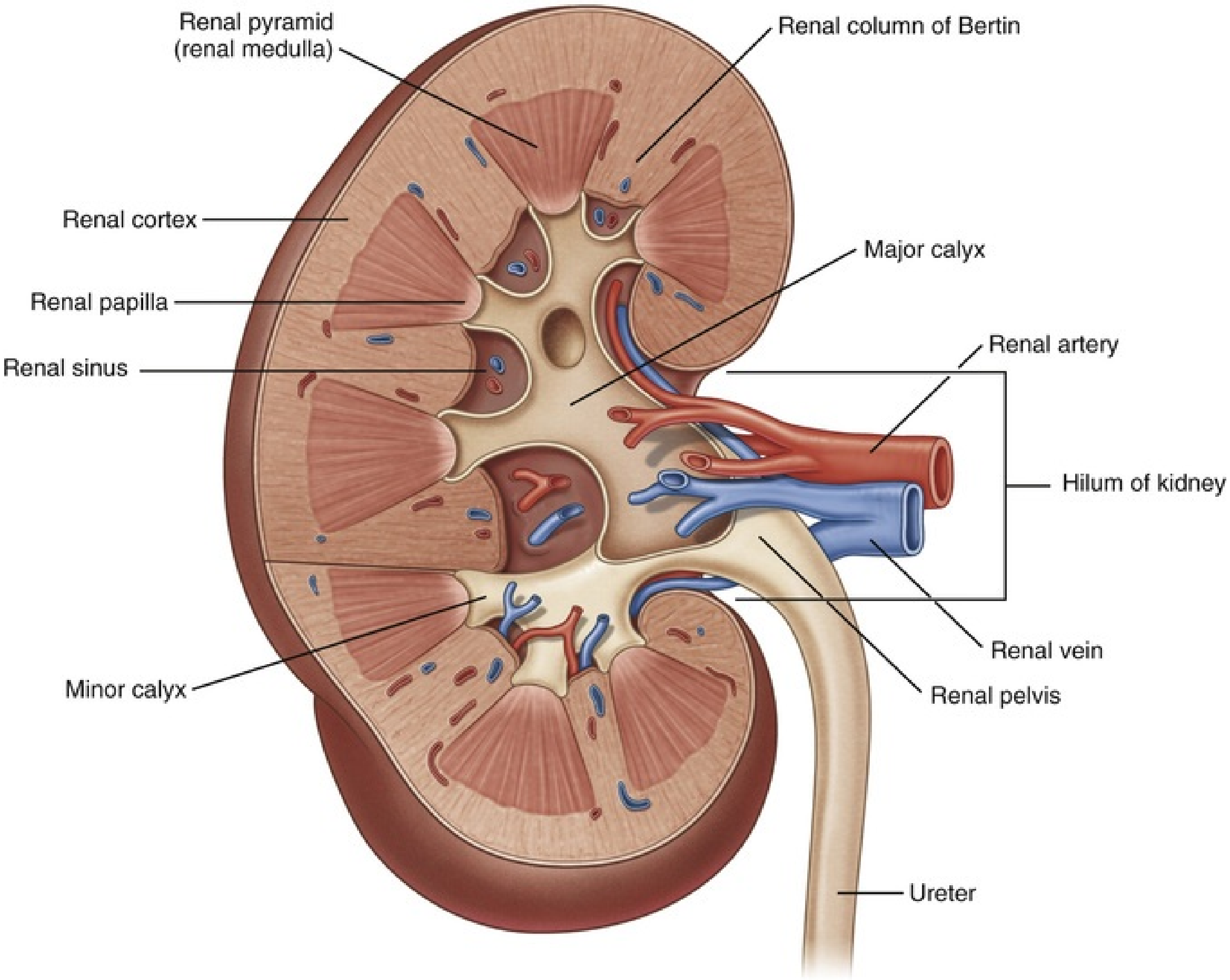
Renal pyramid
(renal medulla)
Renal column of Bertin
Renal cortex
Major calyx
Renal papilla
Renal sinus
Renal artery
Hilum of kidney
Renal vein
Minor calyx
Renal pelvis
Ureter

EFIG. 84.7 Internal structure of the right kidney. (From Drake RL, Vogl W, Mitchell AWM: *Gray's anatomy for students,* Philadelphia, 2005, Churchill Livingstone.)

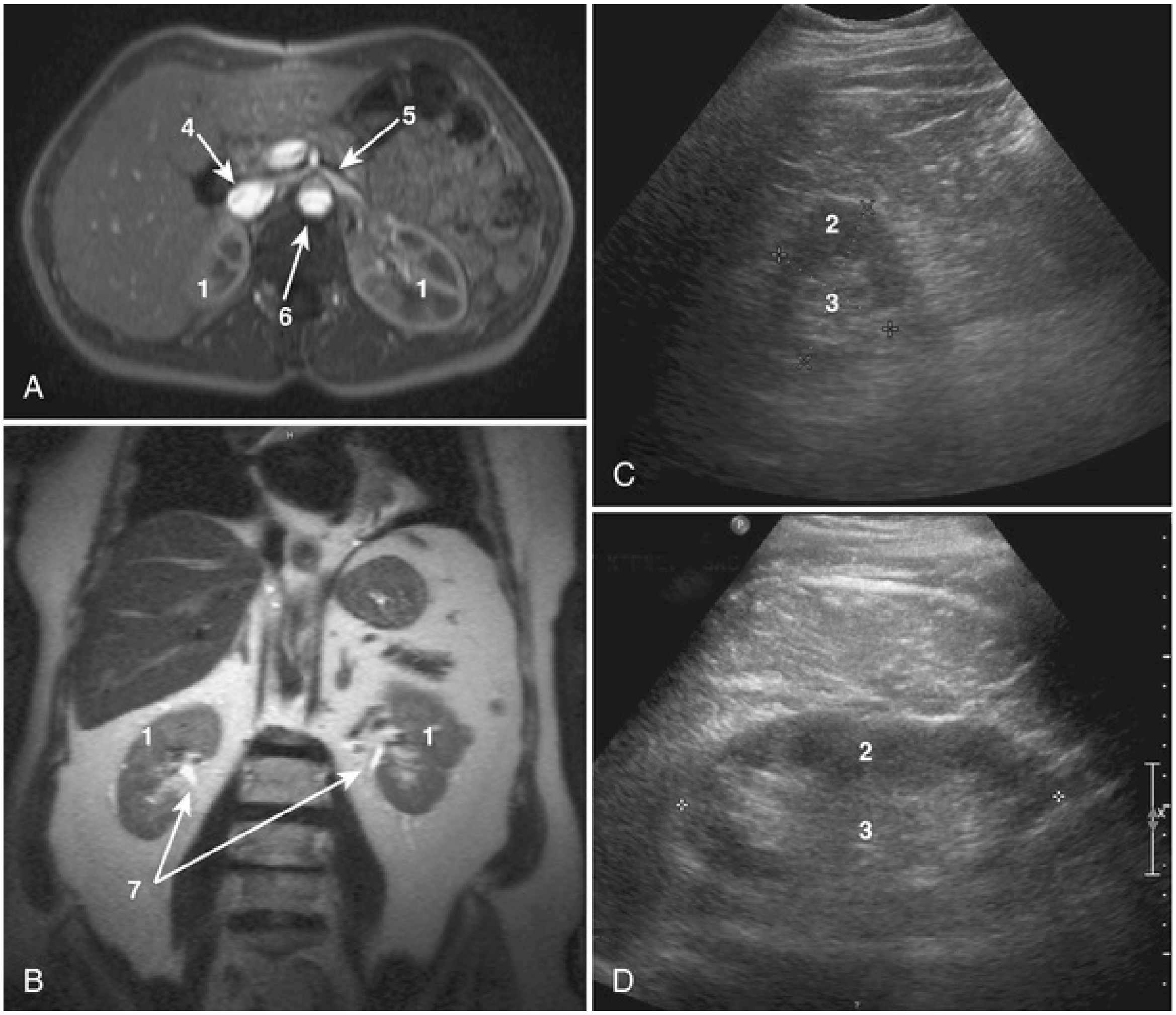

EFIG. 84.8 Cross-sectional imaging of the normal kidney. (A) T1-weighted gadolinium-enhanced axial magnetic resonance imaging (MRI) of kidneys, including the inferior vena cava, aorta, left renal vein, and superior mesenteric artery. (B) Coronal T2 MRI of the kidneys. (C) Transverse ultrasound imaging of the kidney. (D) Sagittal ultrasound imaging of the kidney. *1,* Kidney; *2,* renal cortex; *3,* renal medulla; *4,* inferior vena cava; *5,* left renal vein; *6,* aorta; *7,* renal collecting system.

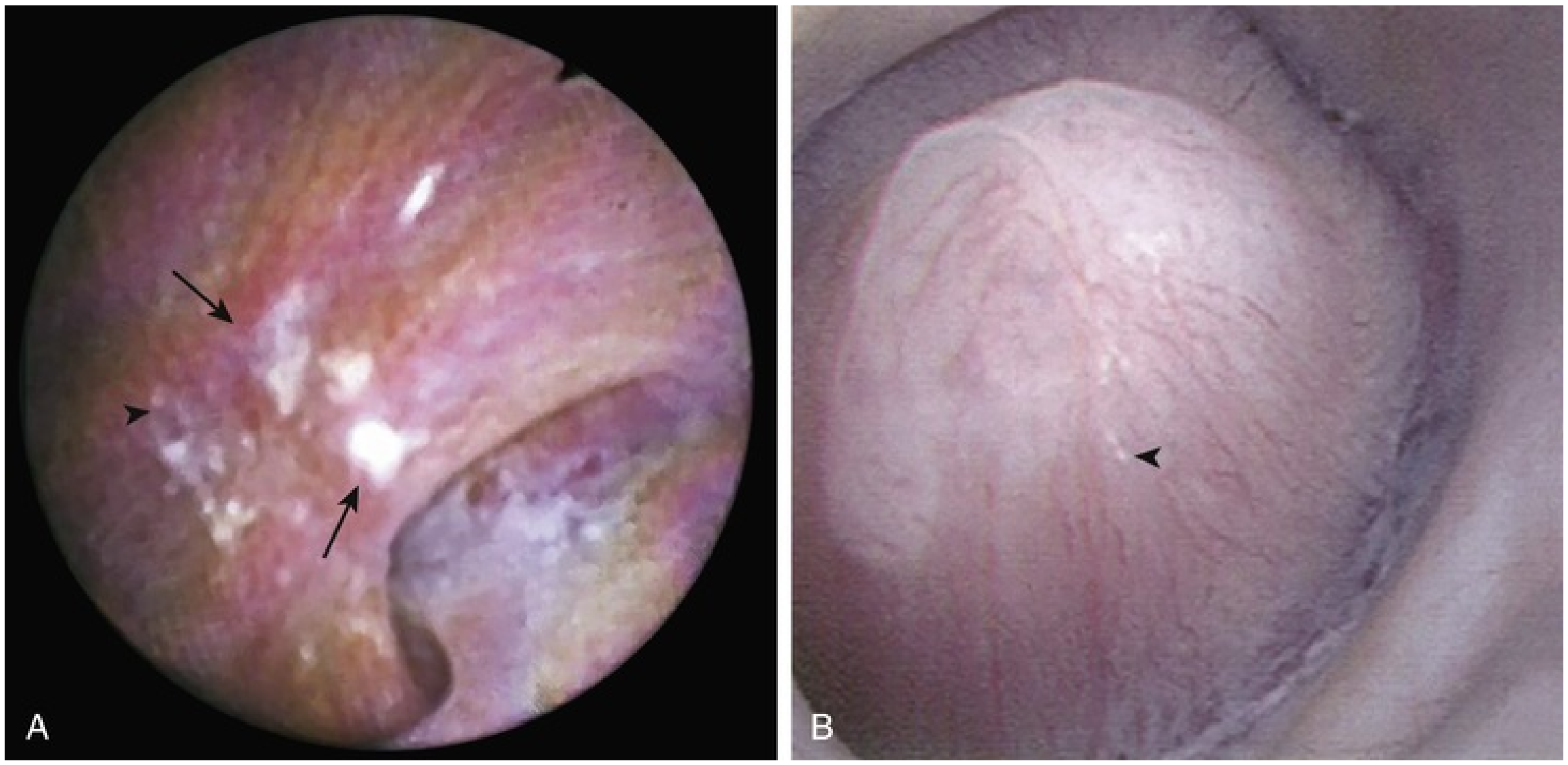

EFIG. 84.9 Renal papilla in a calcium oxalate stoneformer (A) where several Randall plaques *(arrows)* appeared as irregular white areas beneath the urothelium; the plaque site lacking a urothelial layer *(arrowhead)* may be the site where the stone was attached to papilla. Renal papilla in a non–stone former (B) where no distinct sites of Randall plaques were noted on papilla but a nodular-appearing structure *(arrowhead)* was noted alongside the papilla. (From Matlaga BR, Coe FL, Evan AP, et al.: The role of Randall's plaques in the pathogenesis of calcium stones. *J Urol* 177:31–8, 2007.)

The renal cortex is approximately 1 cm in thickness and covers the base of each renal pyramid peripherally and extends downward between the individual pyramids to form the **columns of Bertin** (see eFig. 84.7). Interlobar arteries traverse these columns of Bertin from the renal sinus to the peripheral cortex and decrease in diameter as they move peripherally. Therefore percutaneous access to the collecting system is usually performed through a renal pyramid into a calyx to avoid these columns of Bertin containing larger blood vessels. The pyramids and their associated cortex form the lobes of the kidney. The lobes are visible on the external surfaces of the kidneys in fetuses, and evidence of the lobes may persist for some time after birth.

The functional unit of the kidney is the nephron (Fig. 84.10). Approximately 0.4 to 1.2 million nephrons are found in each adult kidney. The nephron consists of a glomerulus, which is composed of a capillary tuft surrounded by epithelial cells and the thin, fibrous Bowman capsule. The glomerulus filters the blood at a rate of 125 mL/min, the glomerular filtration rate, which is considered an index of renal function. The filtrate passes into the Bowman space and then into the proximal convoluted tubule, through the thin and thick limbs of the loop of

Henle, to the macula densa adjacent to the glomerulus, and into the distal convoluted tubule. It then enters the collecting tubules and the ducts of Bellini. After absorption of approximately 90% of this filtrate, the remaining part constitutes the urine, which drips from the collecting ducts into the calyces, then to the renal pelvis, ureter, and bladder. Three layers separate the filtered blood from the Bowman space: a single layer of endothelial cells, a thin glomerular basement membrane, and a layer of podocytes on the other side of that basement membrane. The proximal and distal convoluted tubules and the loop of Henle are lined by a single layer of cubical epithelial cells. The cells lining the collecting ducts are cubical to columnar and are more resistant to damage than those of the renal tubules. The calyces, pelvis, ureters, bladder, and urethra are lined by transitional epithelium, the urothelium, which may change and give rise to a transitional cell carcinoma of the urinary tract or urothelial carcinoma.

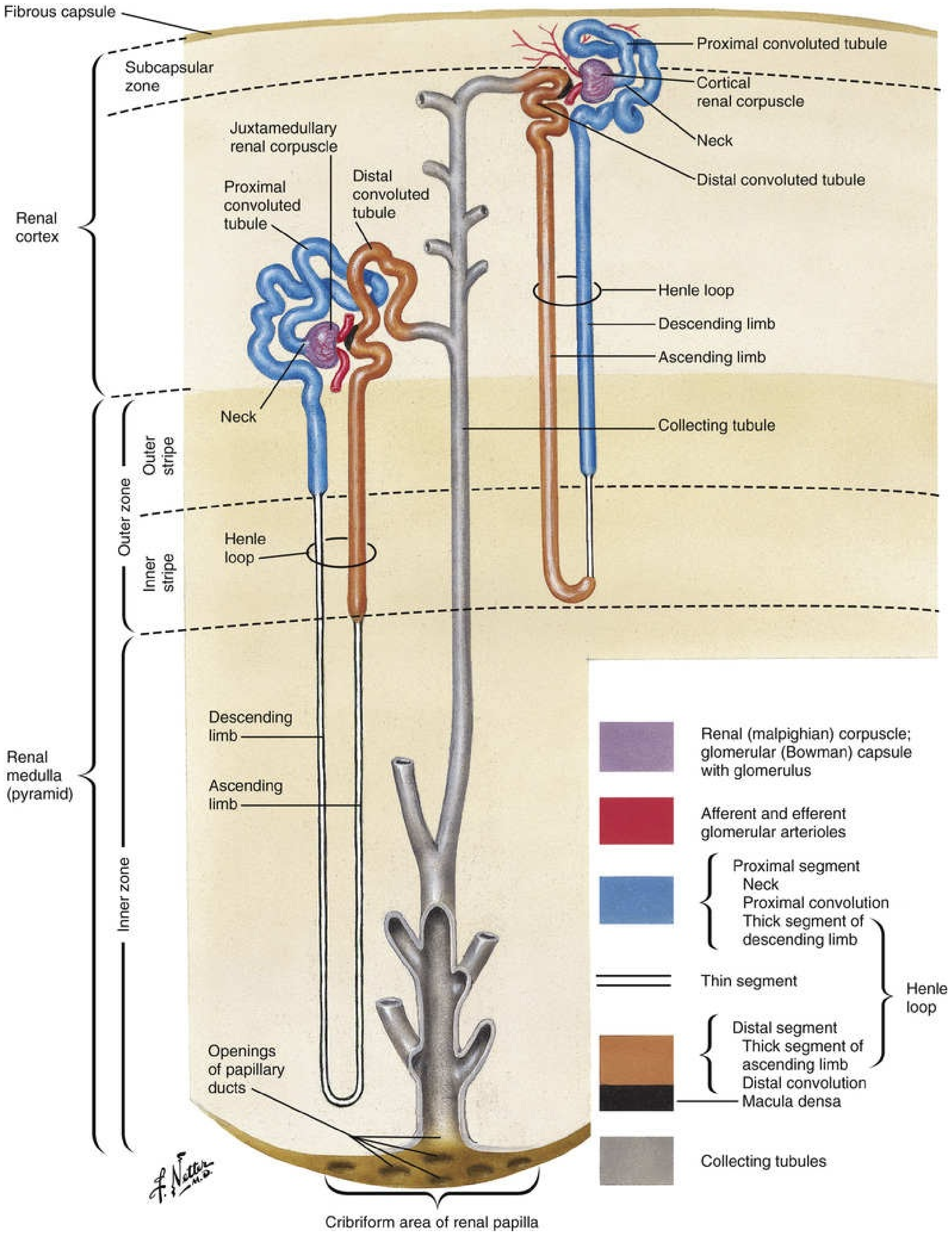
Fibrous capsule
Subcapsular zone
Renal cortex
Juxtamedullary renal corpuscle
Proximal convoluted tubule
Distal convoluted tubule
Neck
Outer zone
Outer stripe
Inner stripe
Henle loop
Proximal convoluted tubule
Cortical renal corpuscle
Neck
Distal convoluted tubule
Henle loop
Descending limb
Ascending limb
Collecting tubule
Renal medulla (pyramid)
Inner zone
Descending limb
Ascending limb
Openings of papillary ducts
Cribriform area of renal papilla
Renal (malpighian) corpuscle; glomerular (Bowman) capsule with glomerulus
Afferent and efferent glomerular arterioles
Proximal segment
Neck
Proximal convolution
Thick segment of descending limb
Thin segment
Henle loop
Distal segment
Thick segment of ascending limb
Distal convolution
Macula densa
Collecting tubules

FIG. 84.10 Schematic diagram of the microanatomy of the kidneys. (Copyright 2016 Elsevier Inc. All rights reserved. www.netterimages.com.)

Key Points: the Kidney

- Because the kidneys lie on the psoas muscles, the longitudinal axes of the kidneys are oblique, with the upper poles more medial and posterior than the inferior poles.
- The Gerota fascia envelops the kidney and the adrenal gland on all aspects except inferiorly, where it remains open.
- From anterior to posterior, the renal hilar structures are the renal vein **(V),** renal artery **(A),** renal pelvis (**U** for ureter), and posterior segmental artery **(A)—**making the mnemonic **VAUA.**
- The kidney is divided into cortex and medulla. The medullary areas are pyramidal, more centrally located, and separated by segments of cortex, the columns of Bertin.
- Each renal pyramid terminates centrally in a papilla. Each papilla is cupped by a minor calyx. A group of minor calyces join to form a major calyx. The major calyces combine to form the renal pelvis.

Radiologic Anatomy of the Renal Parenchyma

In a well-prepared plain kidney-ureter-bladder (KUB) radiograph, the renal shape, margins, dimensions, and location can be identified. Both kidney shadows are clearly visible and can be assessed with regard to their position and morphology. The psoas muscle line could also be appreciated; it disappears with retroperitoneal effusions. Radiopacities, calcifications, and radiolucencies could be identified (eFig. 84.11). In gray-scale ultrasonography, the renal cortices of newborn kidneys are isoechoic or hyperechoic to the liver and splenic parenchyma, because of the presence of loops of Henle and proportionately greater volume of glomeruli in the cortex than in adults (Hricak et al., 1983; Kasap et al., 2006). In adults, the normal kidneys have smooth margins and are isoechoic to the liver. However, renal cortices and pyramids are usually hypoechoic to the liver, spleen, and renal sinus.

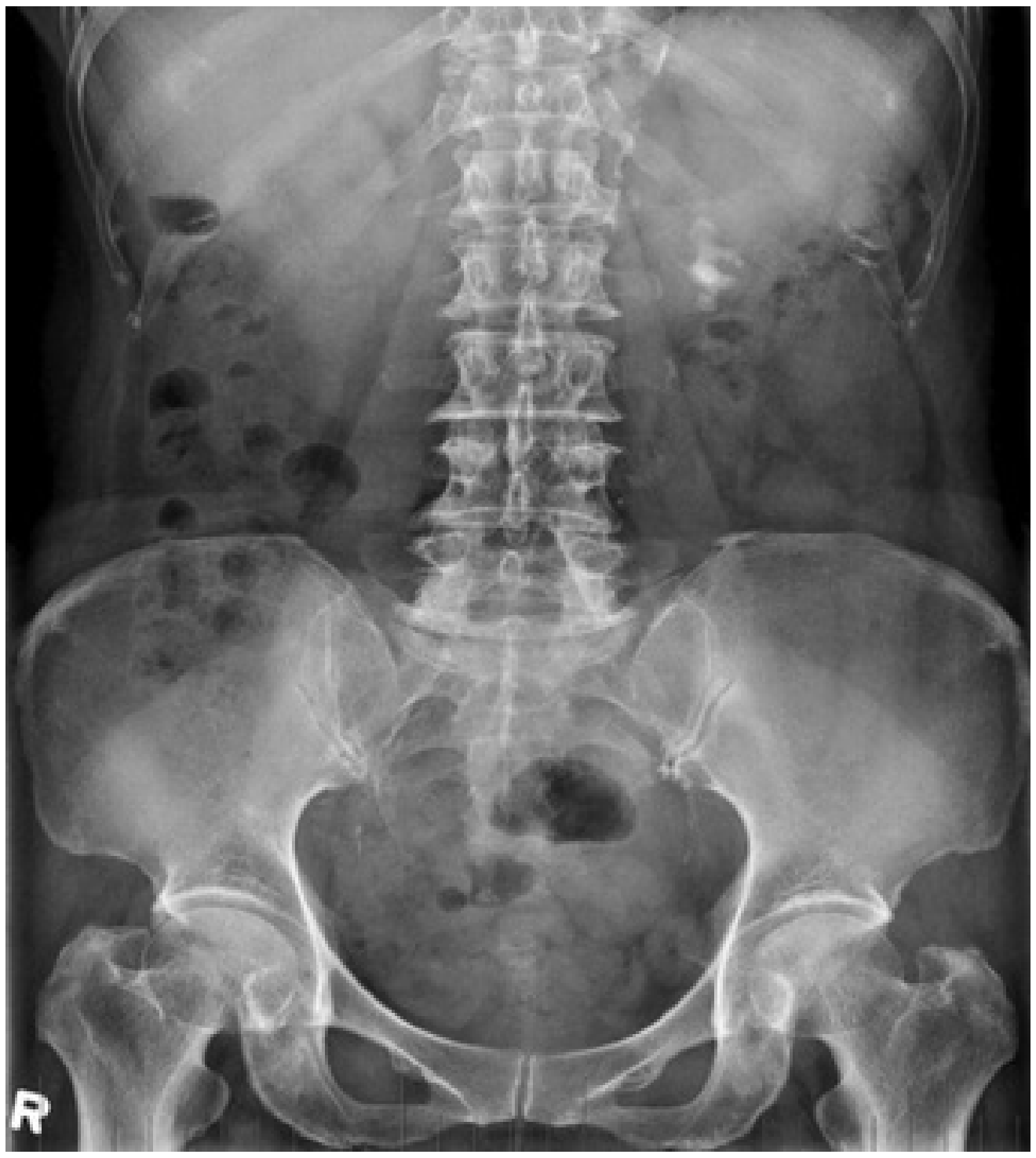

EFIG. 84.11 Plain radiograph (kidney-ureter-bladder [KUB]). This 63-year-old woman presented with recurrent urinary tract infections and was found to have a smaller left kidney with staghorn calculus on KUB.

Compared with renal size, cortical thickness, or parenchymal thickness, cortical echogenicity correlates strongly with severity of pathologic changes in renal parenchyma, such as glomerular sclerosis, tubular atrophy, interstitial fibrosis, and inflammation ($r = 0.28–0.35$) (Moghazi et al., 2005). However, this correlation coefficient is still low with subsequent poor predictive value of renal echogenicity.

Compared with renal parenchyma, the renal sinus appears hyperechoic because of the presence of hilar adipose tissue, blood vessels, and lymphatics (eFig. 84.12). On unenhanced computed tomography (CT), the renal parenchyma is homogeneous, with a density ranging from 30 to 60 Hounsfield units (HU) that increases up to 80 to 120 HU after intravenous contrast injection. After 20 to 30 seconds of contrast injection, the arterial CT phase is reached, and the corticomedullary CT phase appears after 30 to 70 seconds, when contrast accumulates in the renal cortex. The nephrographic CT phase, after 80 to 120 seconds, equally enhances renal cortex and medulla and is considered to be the optimal phase for detection of renal neoplasms. Finally, the excretory CT phase, more than 3 minutes after contrast injection, shows the opacified pelvicalyceal system, ureter, and bladder (Fig. 84.13). Magnetic resonance imaging with T1 and T2 relaxation sequences provides information regarding lipid or fat content and enhancement characteristics of tissues. T1-weighted sequences show the renal cortex much brighter than the renal medulla, whereas the cortex is slightly less intense than the medulla on T2-weighted sequences. The renal pelvis containing fat appears hyperintense on T1- and T2-weighted sequences. After injection of contrast, the nephrographic and excretory phases start after 60 to 90 and 120 seconds of contrast injection, respectively (see eFig. 84.8).

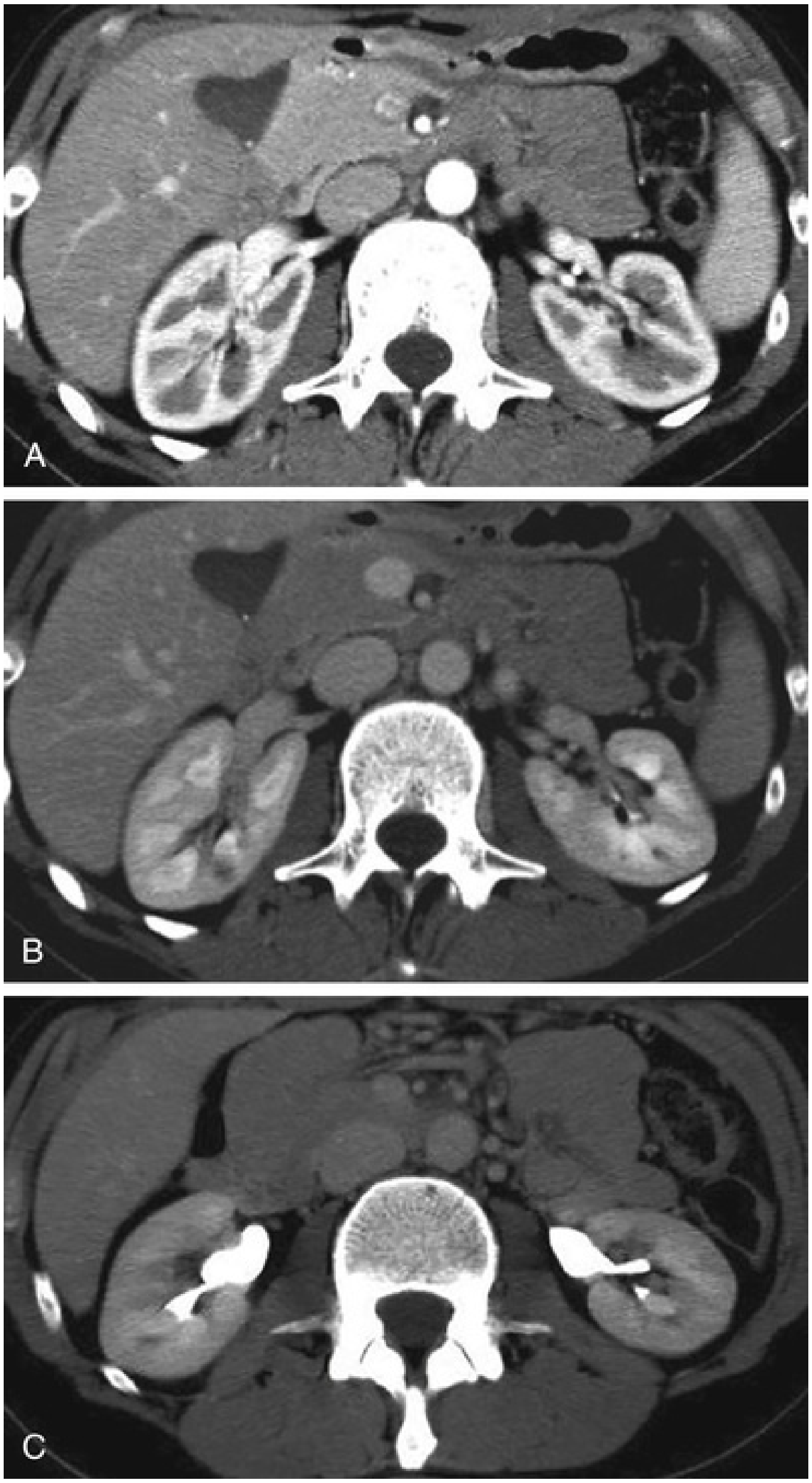

FIG. 84.13 Computed tomography of normal renal parenchyma. (A) The corticomedullary phase shows high contrast in the renal cortex after 30 to 70 seconds of contrast injection. (B) The nephrographic phase shows renal cortex and medulla with equal enhancement after 80 to 120 seconds of contrast injection. (C) The excretory phase shows the opacified urinary tract after more than 180 seconds. (From Quaia E, Martingano P, Cavallaro M, et al.: Normal radiological anatomy and anatomical variants of the kidney. In Quaia E, editor: *Radiological imaging of the kidney (medical radiology/diagnostic imaging),* New York, 2011, Springer, pp 17–78.)

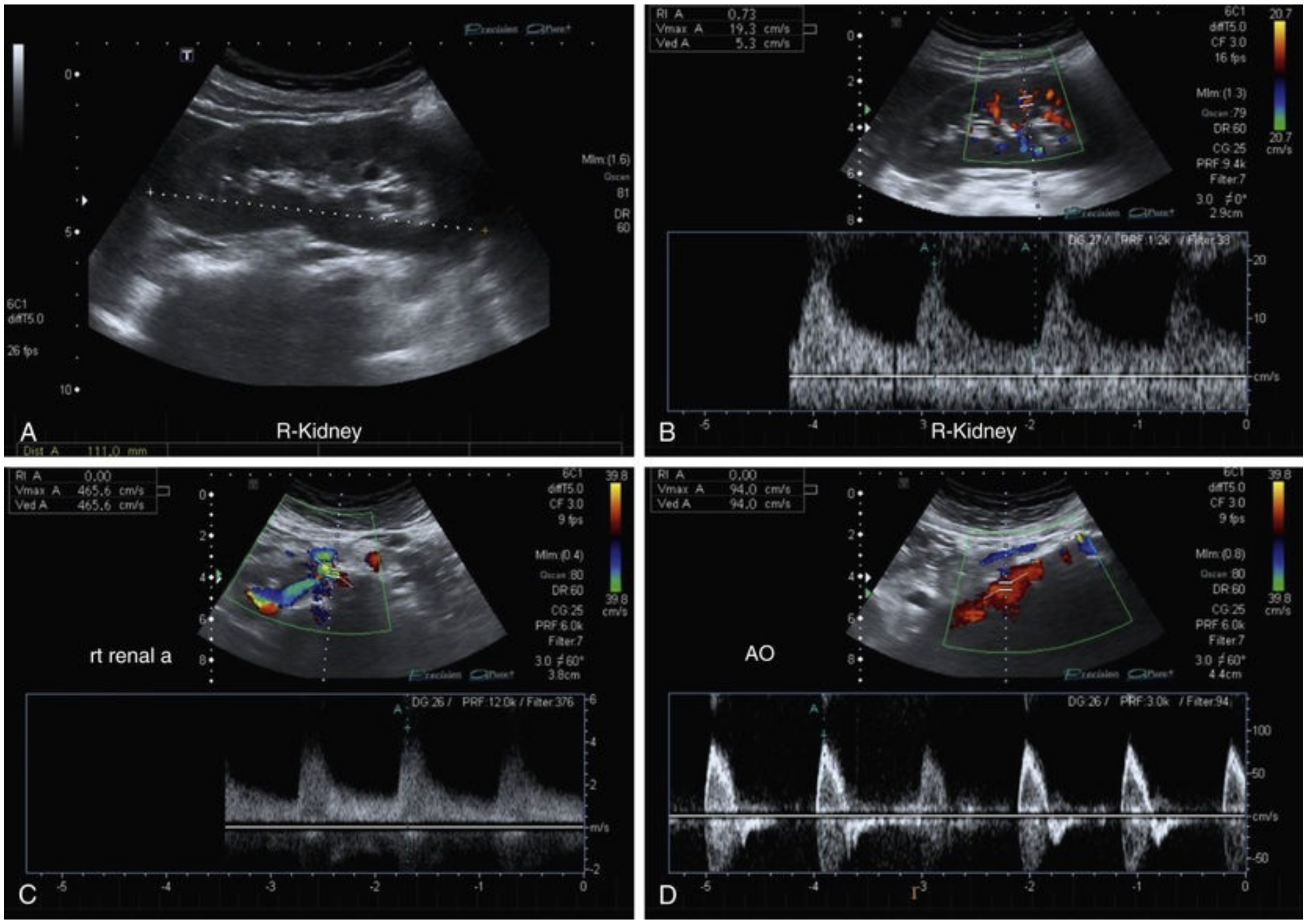
A
R-Kidney
Dist A 111.0 mm
RI A 0.73
Vmax A 19.3 cm/s
Ved A 5.3 cm/s
B
R-Kidney
RI A 0.00
Vmax A 465.6 cm/s
Ved A 465.6 cm/s
rt renal a
C
RI A 0.00
Vmax A 94.0 cm/s
Ved A 94.0 cm/s
AO
D

EFIG. 84.12 Renal ultrasonography and Doppler interrogation in a 65-year-old patient with poorly controlled hypertension. The resistive index within the renal parenchyma was 0.73. The right renal arterial peak systolic velocity reached up to 465.6 cm/sec at the ostium compared with peak systolic velocity of 94 cm/sec in the aorta (*AO*), suggesting severe (>50%) right renal arterial stenosis. (A) Renal ultrasonography in B mode. (B) Color Doppler of the renal parenchyma. (C) Measurement of peak systolic velocity in right renal artery (rt renal a). (D) Measurement of peak systolic velocity in the aorta. *R,* Right; *rt renal a,* right renal artery.

Renal cortex and medulla perform different physiologic functions and are affected by different pathophysiologic processes. Therefore assessment of the degree of separation between these two compartments by imaging studies is important. Normal corticomedullary differentiation (CMD) is visible by ultrasound or T1-weighted and T2-weighted MRI. However, assessment of CMD by CT requires injection of a contrast agent because both compartments have the same density (~30 HU). CMD decreases or disappears in patients with chronic kidney disease and acute kidney injury, without clear correlation with the level of serum creatinine (Semelka et al., 1994). However, upon restoration of renal function, CMD has been shown to reappear by MRI (Chung et al., 2001). Recently, imaging studies such as 3D CT and MRI have been used to calculate renal parenchymal volumes to assess functional parenchymal volume. Studies using customized imaging software have demonstrated a high correlation between measurements of renal and cortical volumes and renal function (Coulam et al., 2002; Vivier et al., 2008). Renal glomerular filtration correlate better with MR measurements of renal volume ($r = 0.86$) than renal bipolar length ($r = 0.78$) (Cheung et al., 2006).

Of all congenital anomalies encountered in newborns, 20% to 30% affect the kidneys and ureters (Schedl, 2007). Anomalies of number, rotation, ascent, and/or fusion may be encountered. Radiologically, renal malrotation is identified because the renal pelvis appears to arise centrally instead of its medial origin from the kidney. Some calyces are located medial to the renal pelvis, a hallmark of rotational anomalies. These renal calyces appear distorted with or without obstruction (eFig. 84.14). Arrest or exaggeration of normal ascent of the kidneys gives rise to renal ectopia and is usually associated with malrotation. Despite the ureteral length being appropriate for the kidney position, the impaired drainage results in urinary stasis and increased chances of infection and stone formation. Moreover, blood supply to the ectopic kidney is also aberrant, originating from adjacent vessels (see eFig. 84.14). A kidney may cross the midline and fuse with the opposite kidney (crossed-fused ectopia). The ureter from the ectopic lower kidney crosses the midline and usually inserts into the bladder in its normal position. The two kidneys may fuse by an isthmus at their lower pole, giving rise to the horseshoe kidney (eFig. 84.15). It is usually positioned low in the abdomen because of its arrest by the origin of the inferior mesenteric artery. The isthmus may contain a fibrotic band or functional renal parenchyma. This kidney is usually subjected to other anomalies, especially ureteropelvic junction obstruction (UPJO), vascular anomalies, duplication anomalies, stone formation, and urinary tract infections.

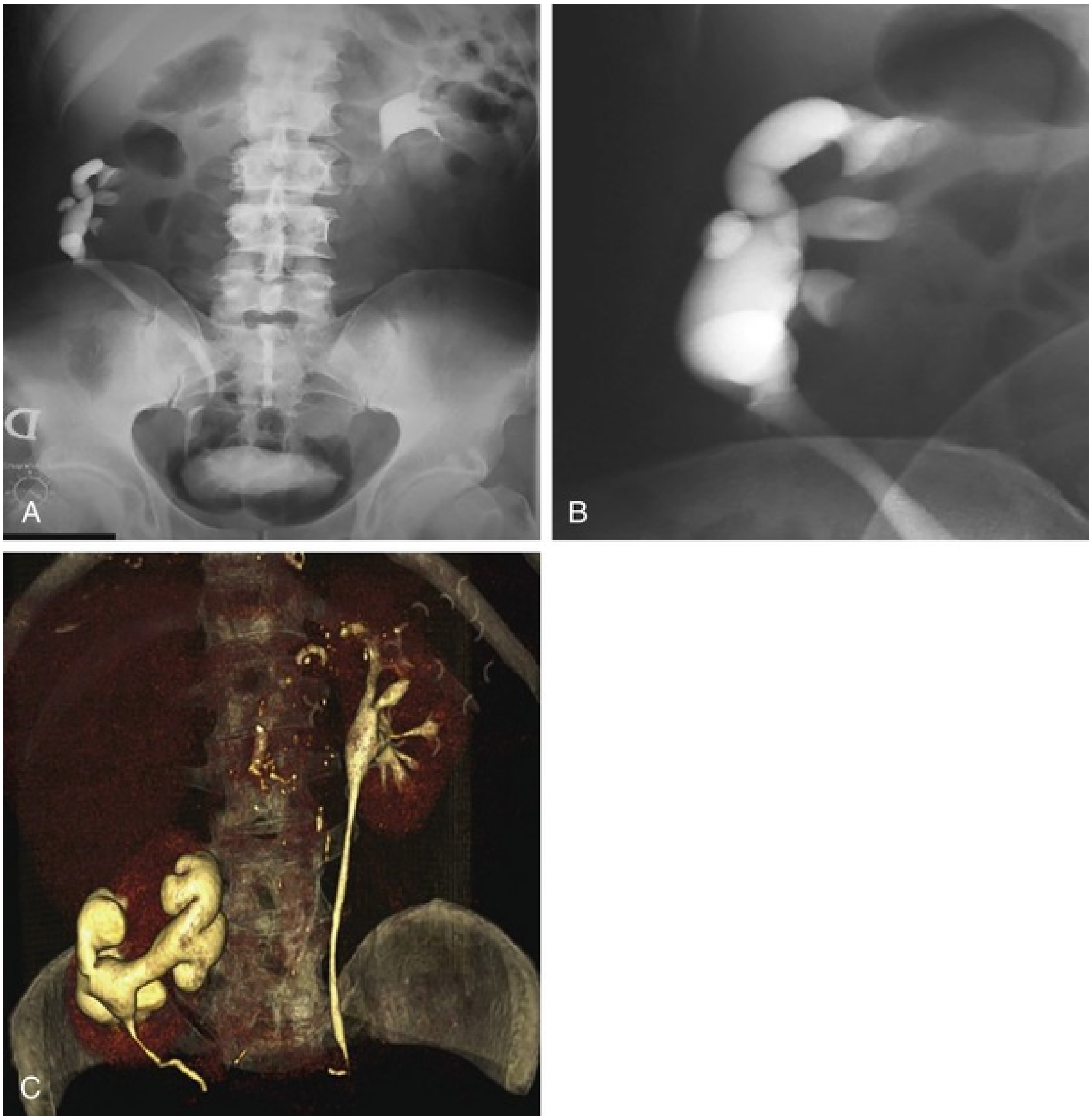

EFIG. 84.14 Intravenous excretory urography (A and B) showing malrotation of the right kidney. The right renal pelvis arises centrally instead of arising medially from the kidney. Calyces arise on either side of the pelvis, with some of them arising medial to the renal pelvis. Computed tomography urography (C) shows malrotation and ectopia of the right kidney. Color-coded three-dimensional volume-rendered images have been produced. The right kidney appears in the right pelvic region and its pelvis appears malrotated with the renal pelvis facing anteriorly with a short ureter. (From Quaia E, Martingano P, Cavallaro M, et al.: Normal radiological anatomy and anatomical variants of the kidney. In Quaia E, editor: *Radiological imaging of the kidney (medical radiology/diagnostic imaging),* New York, 2011, Springer, pp 17–78.)

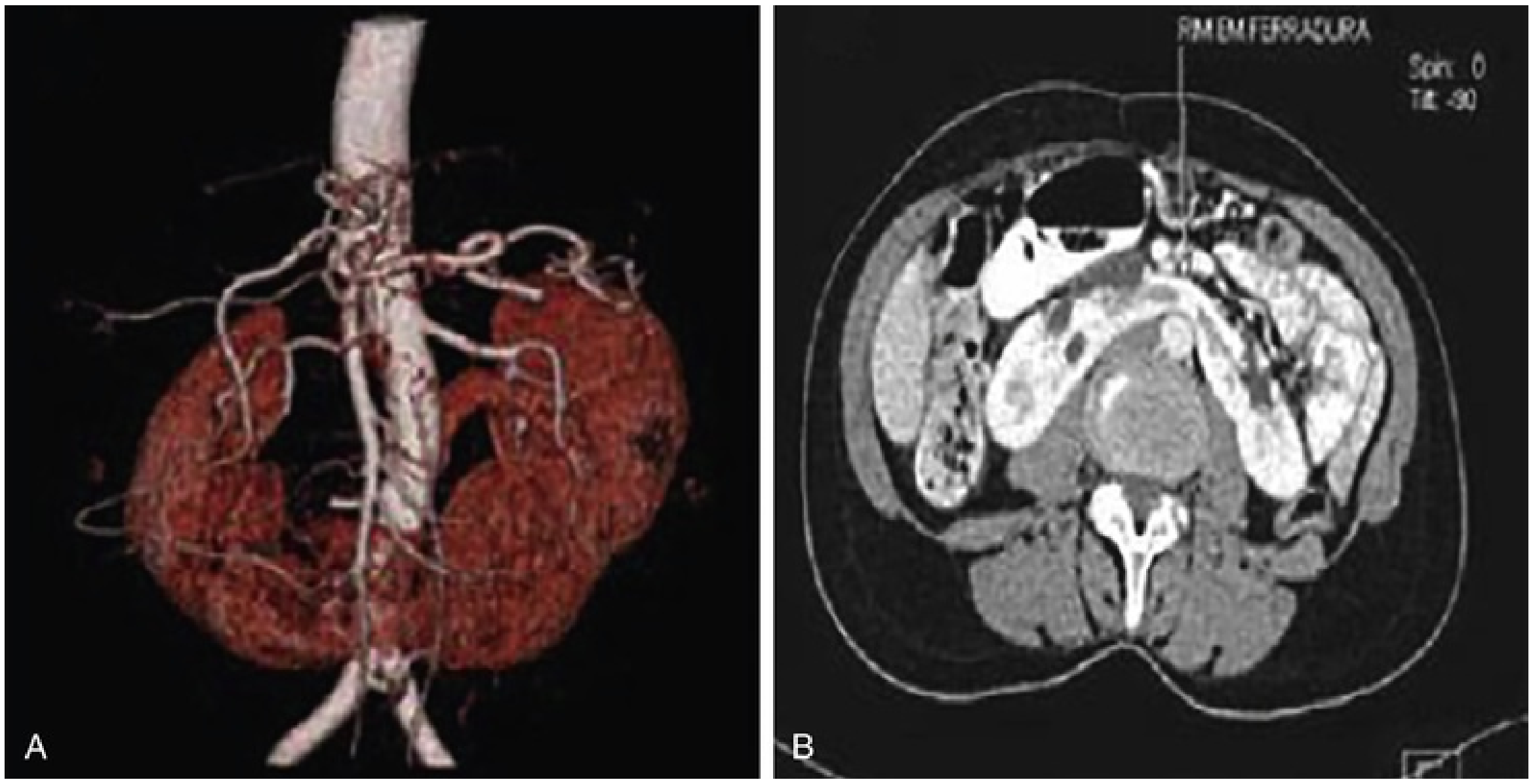

EFIG. 84.15 Computed tomography angiography with volume-rendered three-dimensional image (A) and axial view (B) of a horseshoe kidney showing the aberrant vasculature. (From Maranhao CP, de Miranda CM, dos Santos CJ, et al.: Congenital upper urinary tract abnormalities: new images of the same diseases. *Radiol Bras* 46:43–50, 2013.)

Key Points: Radiologic Anatomy of Renal Parenchyma

- Although normal kidneys are isoechoic to the liver, renal cortices and pyramids are hypoechoic to the liver, spleen, and renal sinus.
- Echogenicity correlates to the severity of pathologic changes in renal parenchyma.
- The renal parenchyma is homogeneous on unenhanced CT.
- T1-weighted sequences show the renal cortex much brighter than the renal medulla, whereas the cortex is slightly less intense than the medulla on T2-weighted sequences.
- Blood supply to an ectopic kidney originates from adjacent vessels.

Renal Vasculature

The renal pedicle classically consists of a single artery and a single vein that enter the kidney via the renal hilum (Fig. 84.16). The renal arteries arise from the aorta at the level of the intervertebral disk between the L1 and L2 vertebrae, where the longer right renal artery passes posterior to the inferior vena cava (IVC). Renal arteries give branches to the adrenal glands, renal pelves, and proximal ureters. **After entering the hilum, each artery divides into five segmental end arteries that do not anastomose significantly with other segmental arteries. Therefore occlusion or injury to a segmental branch causes segmental renal infarction. Nevertheless, the area supplied by each segmental artery could be independently surgically resected.** The renal artery usually divides to form anterior and posterior divisions. The anterior division supplies roughly the anterior two-thirds of the kidney, and the posterior division supplies the posterior one-third of the kidney. Typically, the anterior division divides into four anterior segmental branches: apical, upper, middle, and lower. The posterior segmental artery represents the first and most constant branch, which separates from the renal artery before it enters the renal hilum. A small apical segmental branch may originate from this posterior branch, but it arises most commonly from the anterior division. The posterior segmental artery from the posterior division passes posterior to the renal pelvis while the others pass anterior to the renal pelvis. **If the posterior segmental branch passes anterior to the ureter, UPJO may occur.** In 25% to 40% of kidneys, anatomic variations in the renal vasculature have been reported. **Supernumerary renal arteries** are the most common variation, with reports of up to five arteries, especially on the left side. The main renal artery may manifest early branching after originating from the abdominal aorta and before entering the renal hilum. These prehilar arterial branches should be detected in patients undergoing evaluation for donor nephrectomy. An accessory renal artery may arise from the aorta, between T11 and L4, and terminate in the kidney. Rarely, it may also originate from the iliac arteries or superior mesenteric artery. Accessory renal arteries are seen in 25% to 28% of patients and are considered the sole arterial supply to a specific portion of the renal parenchyma, commonly the lower and occasionally the upper pole of the kidney. These accessory renal arteries may contraindicate laparoscopic donor nephrectomy and result in severe bleeding if they are injured during endopyelotomy for UPJO. Multiple renal arteries that arise from the aorta or iliac arteries are frequently seen in horseshoe and pelvic kidneys. In approximately 5% of patients, the main and accessory right renal arteries pass anterior to the IVC.

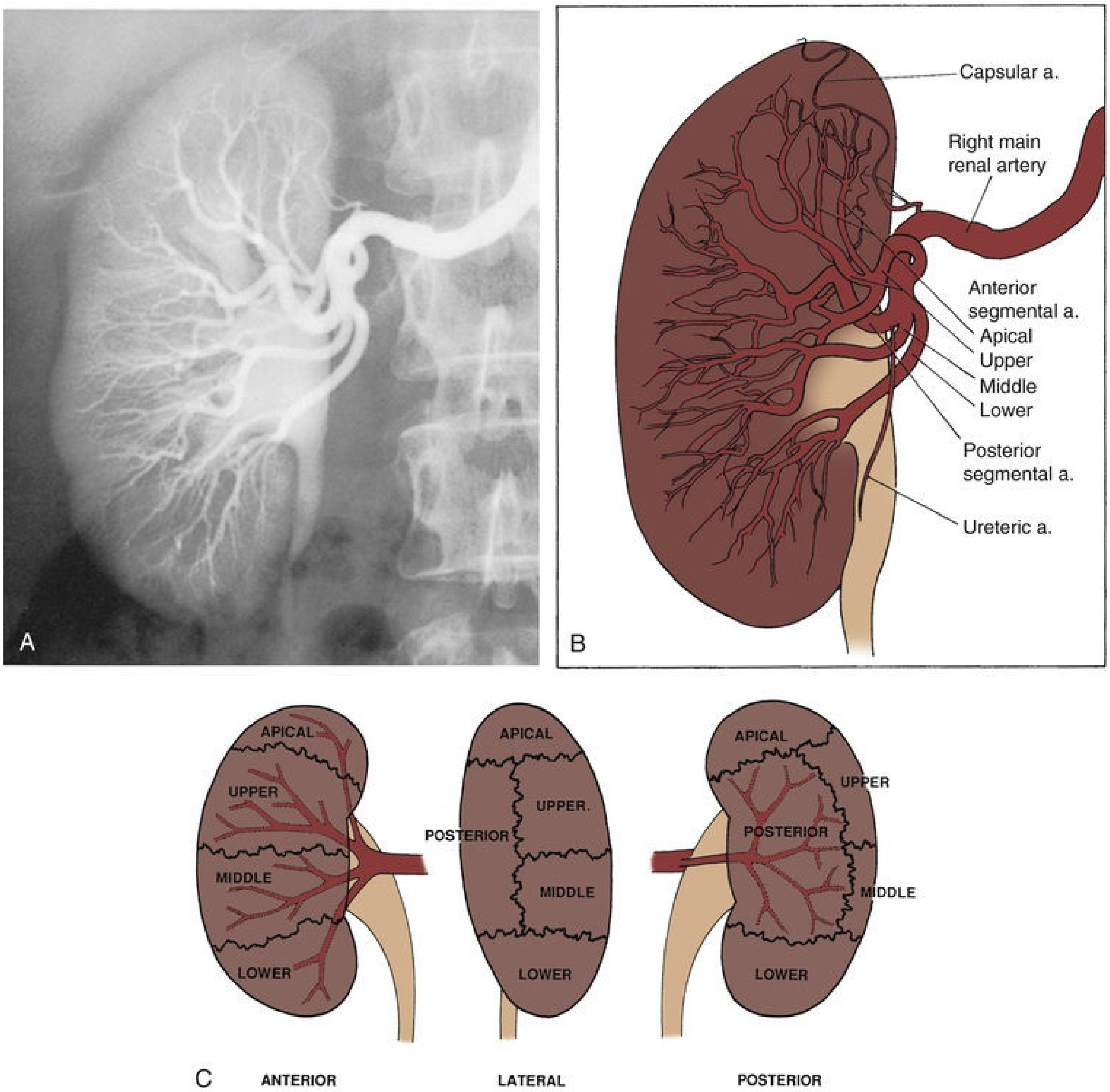
A
B
Capsular a.
Right main renal artery
Anterior segmental a.
Apical
Upper
Middle
Lower
Posterior segmental a.
Ureteric a.
APICAL
UPPER
MIDDLE
LOWER
APICAL
POSTERIOR
UPPER.
MIDDLE
LOWER
APICAL
UPPER
POSTERIOR
MIDDLE
LOWER
C
ANTERIOR
LATERAL
POSTERIOR

FIG. 84.16 Blood supply of the kidney. (A and B) Segmental branches of the right renal artery demonstrated by renal angiogram. (C) Segmental circulation of the right kidney shown diagrammatically. Note that the posterior segmental artery is usually the first branch of the main renal artery and it extends behind the renal pelvis. *a,* artery.

There is a longitudinal avascular plane (line of Brodel) between the posterior and anterior segmental arteries just posterior to the lateral aspect of the kidney through which incision results in significantly less blood loss. However, this plane may have various locations that necessitate its delineation before incision either by preoperative angiography or intraoperative segmental arterial injection of methylene blue. This has important surgical implications. For example, during percutaneous access into the kidney, posterior calyces along the line of Brodel are preferred. Furthermore, during anatrophic nephrolithotomy **(Boyce procedure),** an incision is made through this avascular plane.

At the renal sinus, each **segmental artery branches into lobar arteries,** which further subdivide in the renal parenchyma to form **interlobar arteries** (eFig. 84.17). These interlobar arteries progress peripherally within the cortical **columns of Bertin** to give the **arcuate arteries** at the base of the renal pyramids at the corticomedullary junction. Note the close relationship of the interlobar arteries to the infundibuli of minor calyces. **Interlobular arteries** branch off the arcuate arteries and move radially, where they eventually divide to form the **afferent arterioles** to the glomeruli. Each afferent arteriole supplies a glomerulus, one of approximately 2 million glomeruli, where urinary filtrate leaves the arterial system and is collected in the glomerular (Bowman) capsule. Blood returns from the glomerulus via the efferent arteriole and continues as either secondary capillary networks around the urinary tubules in the cortex or descends into the renal medulla as the vasa recta.

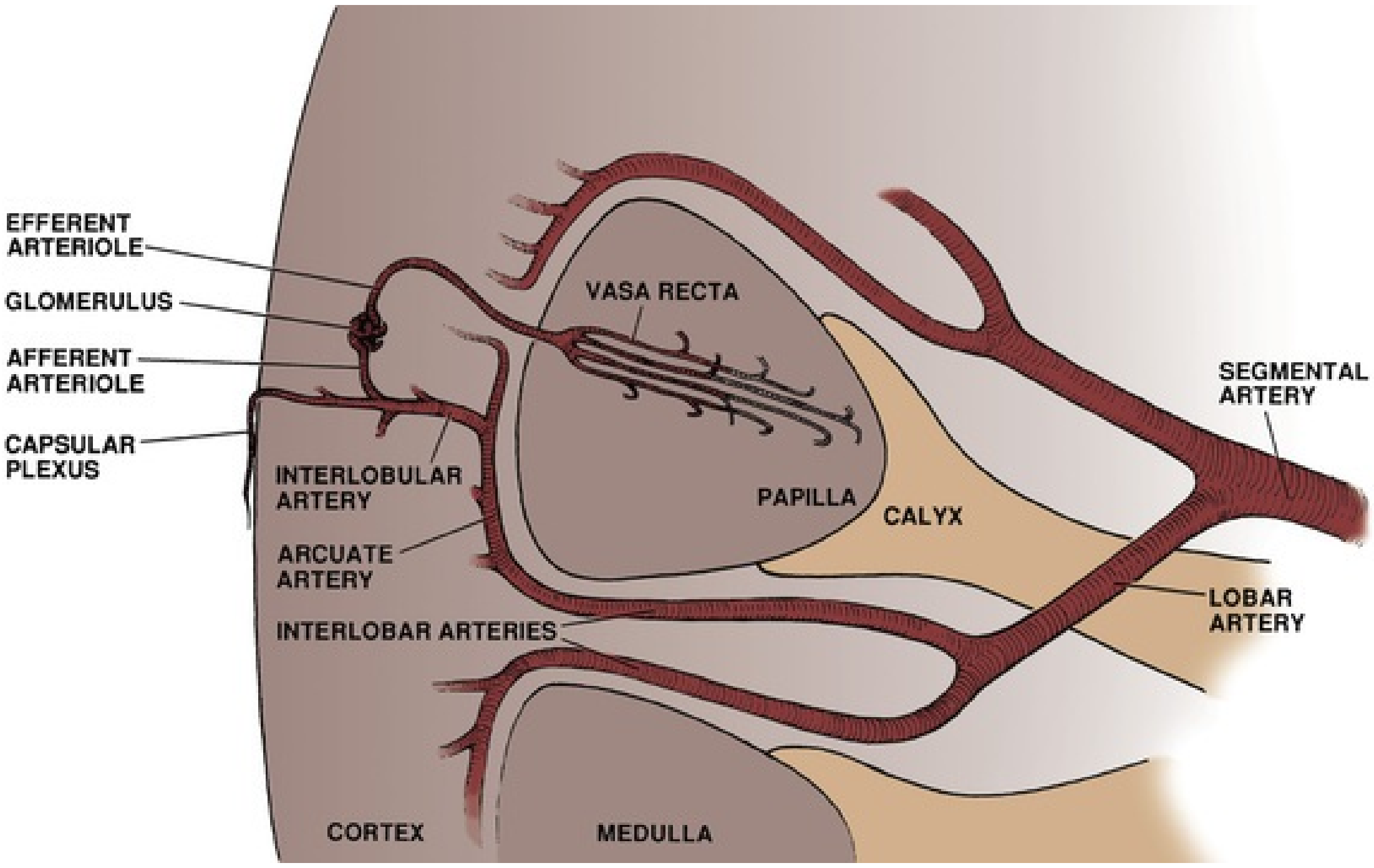
EFFERENT ARTERIOLE
GLOMERULUS
AFFERENT ARTERIOLE
CAPSULAR PLEXUS
VASA RECTA
INTERLOBULAR ARTERY
ARCUATE ARTERY
INTERLOBAR ARTERIES
PAPILLA
CALYX
SEGMENTAL ARTERY
LOBAR ARTERY
CORTEX
MEDULLA

EFIG. 84.17 Intrarenal arterial anatomy.

The **renal venous** drainage correlates closely with the arterial supply, with the exception that unlike the arterial supply, venous drainage has extensive collateral communication through the venous collars around minor calyceal infundibula (eFig. 84.18 and Figs. 84.19 and 84.20). Furthermore, the interlobular veins that drain the postglomerular capillaries also communicate freely with perinephric veins through the subcapsular venous plexus of stellate veins. The **interlobular veins** progress through the arcuate, interlobar, lobar, and segmental veins paralleling their corresponding arteries. Three to five segmental renal veins eventually unite to form the renal vein. Because the venous drainage communicates freely forming extensive collateral venous drainage of the kidney, occlusion of a segmental venous branch has little effect on venous outflow. The **right and left renal veins** lie anterior to the right and left renal arteries and drain into the IVC. Whereas the right renal vein is 2 to 4 cm long, the left renal vein is 6 to 10 cm. The longer left renal vein receives the left suprarenal (adrenal) vein and the left gonadal (testicular or ovarian) vein. The left renal vein also may receive a **lumbar vein,** which could be easily avulsed during surgical manipulation of the left renal vein (Beveridge et al., 2016). The left renal vein traverses the acute angle between the **superior mesenteric artery** anteriorly and the aorta posteriorly. In thin adolescents, the left renal vein may get compressed between the superior mesenteric artery and aorta, causing **nutcracker syndrome.** In approximately 15% of the patients, supernumerary renal veins are seen and often are retroaortic when present on the left. Accessory renal veins are more common on the right side, and the most common anomaly of the left renal venous system is the circumaortic renal vein, reported in 2% to 16% of patients. The retroaortic renal vein is less commonly seen than the circumaortic vein, in which the left renal vein bifurcates into ventral and dorsal limbs, which encircle the abdominal aorta. In the retroaortic renal vein, the single left renal vein courses posterior to the aorta and drains into the lower lumbar segment of the IVC.

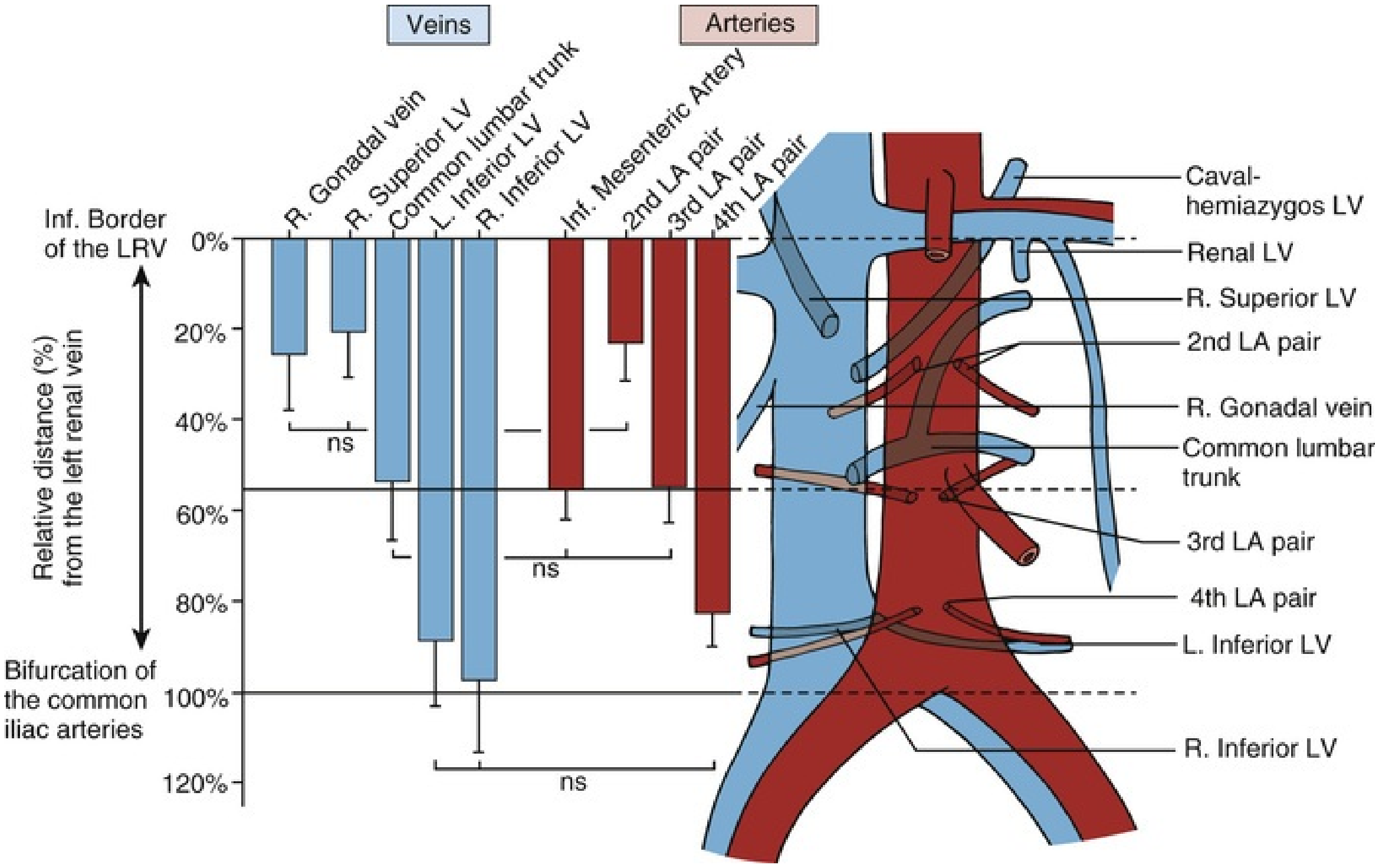

FIG. 84.19 Relative position of infrarenal lumbar arteries (*LA*) and lumbar veins (*LV*), right (*R.*) gonadal vein and inferior (*Inf.*) mesenteric artery. *Dotted lines* demarcate the inferior border of the left renal vein, origin of inferior mesenteric artery (IMA), and bifurcation of common iliac arteries. Superior vessels, including right gonadal vein, right superior lumbar vein (*LV*), the second pair of lumbar arteries, middle vessels, including common lumbar trunk, IMA, and the third pair of lumbar arteries, were significantly different in position from inferior vessels, including left (*L.*) and right inferior lumbar veins, and the fourth pair of lumbar arteries. No significant difference in position was observed in each vessel grouping (superior vessel group of right gonadal vein vs. right superior lumbar vein vs. second pair of lumbar arteries). (Modified with permission from Beveridge TS et al. Retroperitoneal lymph node dissection: anatomical and technical considerations from a cadaveric study. *J Urol* 196: 1764–1771, 2016.)

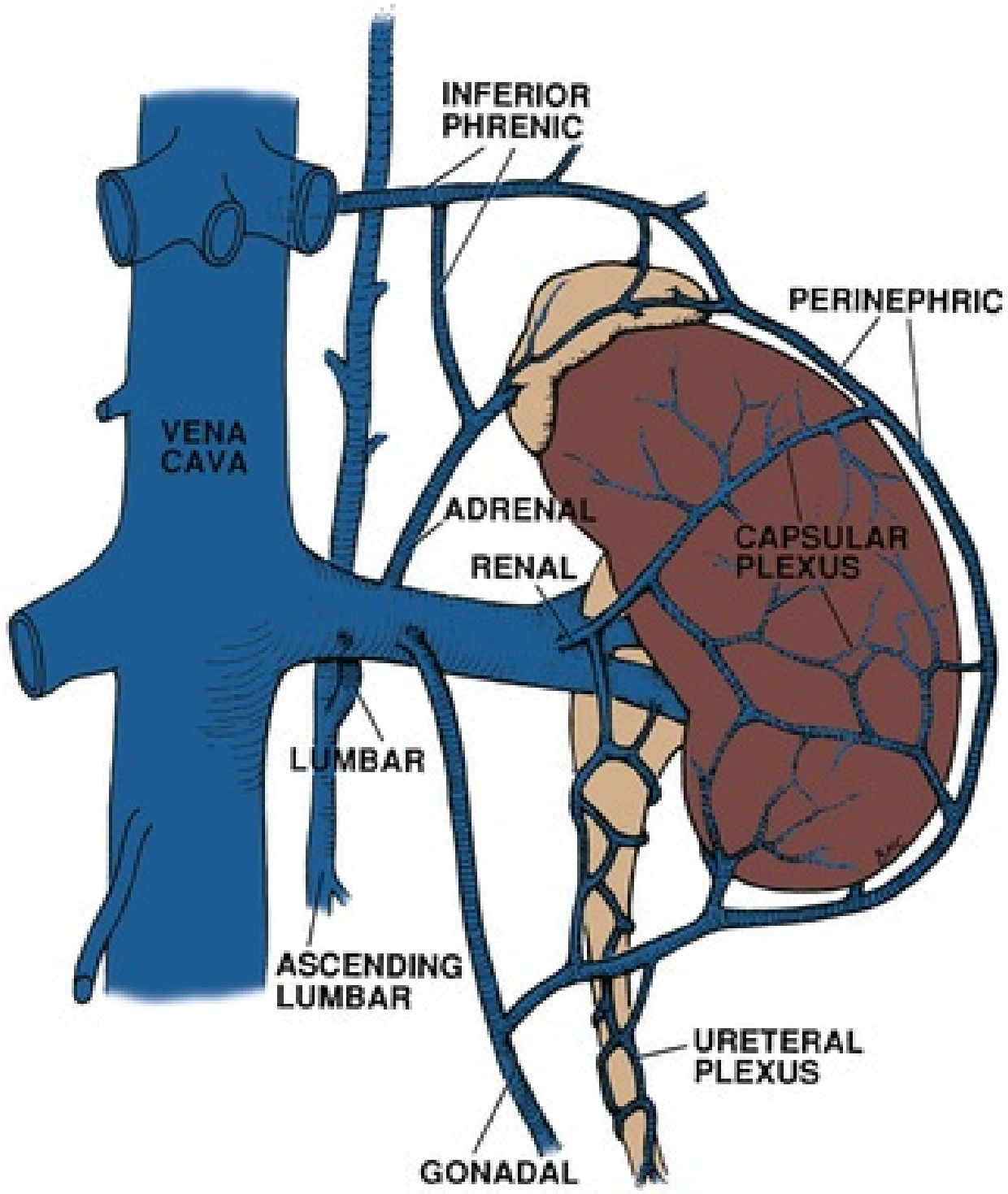
INFERIOR PHRENIC
PERINEPHRIC
VENA CAVA
ADRENAL
CAPSULAR PLEXUS
RENAL
LUMBAR
ASCENDING LUMBAR
URETERAL PLEXUS
GONADAL

FIG. 84.20 Venous drainage of the left kidney showing potentially extensive collateral circulation.

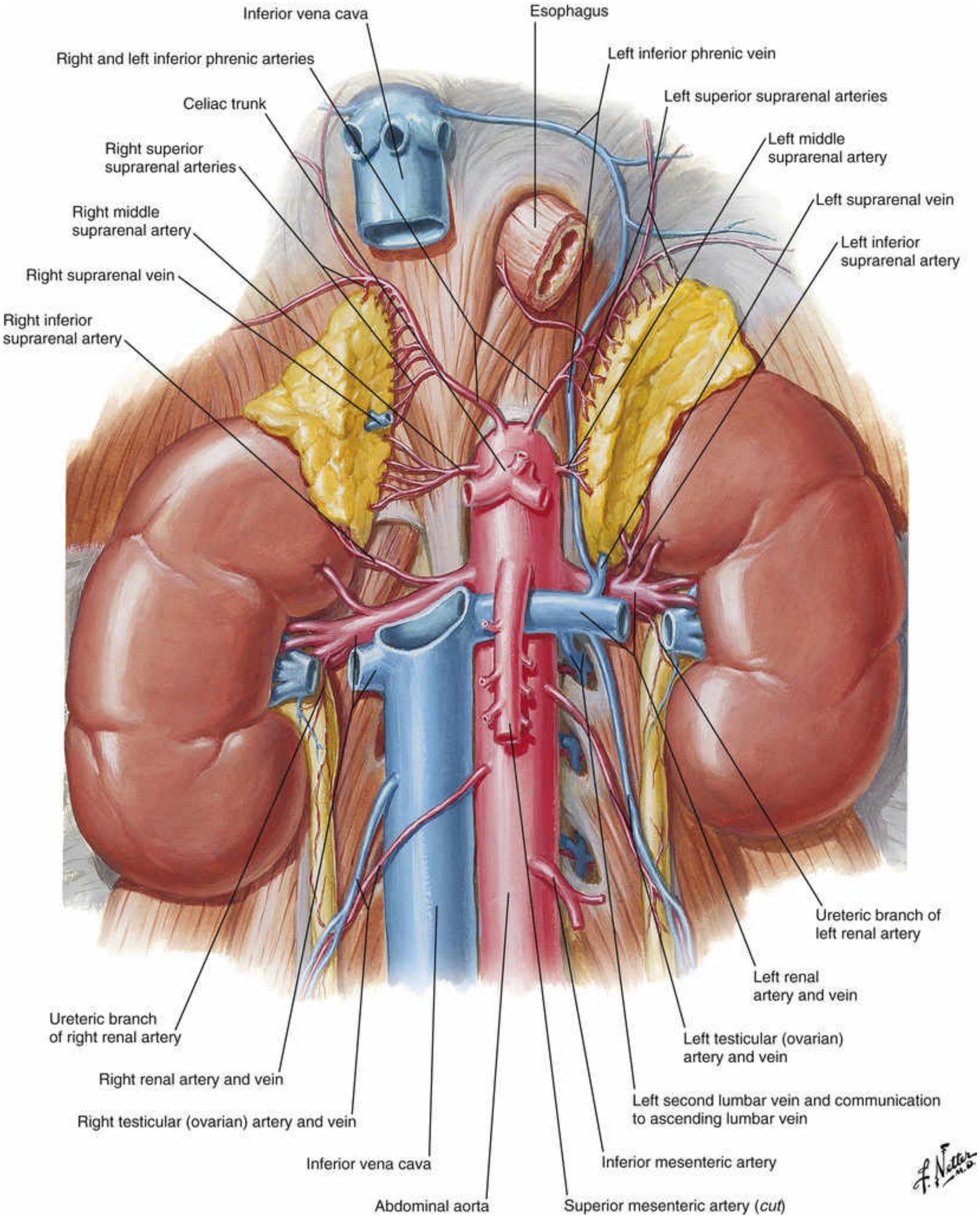
Inferior vena cava
Esophagus
Right and left inferior phrenic arteries
Left inferior phrenic vein
Celiac trunk
Left superior suprarenal arteries
Right superior suprarenal arteries
Left middle suprarenal artery
Right middle suprarenal artery
Left suprarenal vein
Left inferior suprarenal artery
Right suprarenal vein
Right inferior suprarenal artery
Ureteric branch of left renal artery
Left renal artery and vein
Ureteric branch of right renal artery
Left testicular (ovarian) artery and vein
Right renal artery and vein
Left second lumbar vein and communication to ascending lumbar vein
Right testicular (ovarian) artery and vein
Inferior vena cava
Inferior mesenteric artery
Abdominal aorta
Superior mesenteric artery (*cut*)
F. Netter M.D.

EFIG. 84.18 Venous drainage. (Copyright 2016 Elsevier Inc. All rights reserved. www.netterimages.com.)

In terms of imaging studies, Doppler ultrasonography clearly identifies renal arteries at their origin from the abdominal aorta (see eFig. 84.12). However, the main renal artery is often difficult to identify at baseline ultrasonography. Therefore computed tomography angiography (CTA) is currently considered the gold standard to assess renal arteries, with 100% sensitivity for identification of renal arteries and veins. The 3D volume-rendered CTA has emerged as a fast, reliable, and noninvasive modality that can reliably and accurately depict the number, size, course, and relationship of the renal vasculature. Arterial branches down to the segmental branches could be identified, but vessels smaller than 2 mm could be missed (see eFig. 84.15). Magnetic resonance arteriography uses no ionizing radiation, does not require arterial access, and includes different imaging techniques to visualize renal vasculature. Contrast material can give faster, better resolution and more accurate images without artifacts.

Key Points: Renal Vasculature

- Each kidney is commonly supplied by a single renal artery, which arises directly from the abdominal aorta, and a single renal vein usually drains directly to the IVC.
- Each renal artery divides into five segmental branches: posterior, apical, upper, middle, and lower segmental arteries.
- The progression of arterial supply to the kidney is as follows: renal artery → segmental artery → interlobar artery → arcuate artery → interlobular artery → afferent arteriole → glomerulus → efferent arteriole.
- The veins anastomose freely throughout the kidney, whereas the arterial supply does not.
- Anatomic variations in the renal vasculature are common in 25% to 40% of kidneys.
- CTA is currently the gold standard to assess renal arteries. Accessory renal arteries are seen in 25% to 28% of patients and are considered the sole arterial supply to a specific portion of the renal parenchyma.
- Anomalies of renal veins are less common than those of the renal arteries.

Lymphatic Drainage of the Kidney

Interstitial fluid leaves the kidney by either a superficial capsular or a deeper hilar network (eFig. 84.21). Renal lymphatics are embedded in the periarterial loose connective tissue around the renal arteries and are distributed primarily along the interlobular and arcuate arteries in the cortex. The arcuate lymphatic vessels drain into hilar lymphatic vessels through interlobar lymphatics. As these lymphatics exit the renal hilum, they join branches from the renal capsule, perinephric tissues, renal pelvis, and upper ureter, where they empty into lymph nodes associated with the renal vein. Afterward, the lymphatic drainage varies considerably between the two kidneys. Left lymphatic drainage primarily goes into the left lateral para-aortic lymph nodes (between the inferior mesenteric artery and diaphragm), with occasional additional drainage into the retrocrural nodes or directly into the thoracic duct above the diaphragm. Right renal lymphatic drainage primarily goes into the right interaortocaval and right paracaval lymph nodes (between the common iliac vessels and diaphragm), with occasional additional drainage from the right kidney into the retrocrural nodes or the left lateral para-aortic lymph nodes.

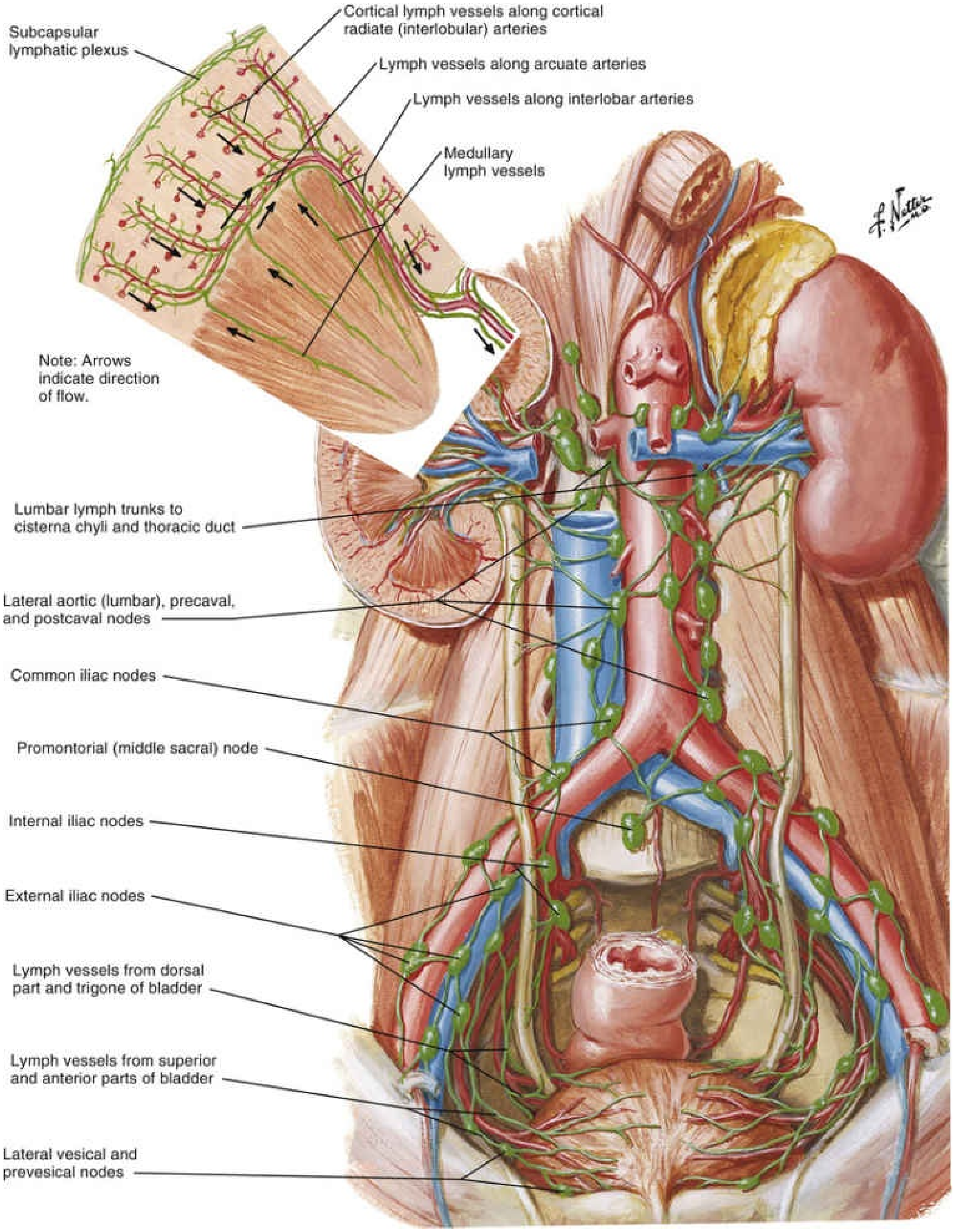
Subcapsular lymphatic plexus
Cortical lymph vessels along cortical radiate (interlobular) arteries
Lymph vessels along arcuate arteries
Lymph vessels along interlobar arteries
Medullary lymph vessels
Note: Arrows indicate direction of flow.
F. Netter M.D.
Lumbar lymph trunks to cisterna chyli and thoracic duct
Lateral aortic (lumbar), precaval, and postcaval nodes
Common iliac nodes
Promontorial (middle sacral) node
Internal iliac nodes
External iliac nodes
Lymph vessels from dorsal part and trigone of bladder
Lymph vessels from superior and anterior parts of bladder
Lateral vesical and prevesical nodes

EFIG. 84.21 Lymphatic drainage of the kidneys and ureters. (Copyright 2016 Elsevier Inc. All rights reserved. www.netterimages.com.)

Innervation of the Kidney

The kidney can function well without neurologic control, as evidenced by the successful function of transplanted kidneys (eFig. 84.22). Sympathetic preganglionic nerves originate from the eighth thoracic through first lumbar spinal segments, with contributions mainly from the celiac plexus and a lesser contribution from the greater splanchnic, intermesenteric, and superior hypogastric plexuses. Postganglionic sympathetic nerve fiber distribution generally follows the arterial vessels throughout the cortex and the outer medulla. These postganglionic fibers travel to the kidney via the autonomic plexus surrounding the renal artery. In addition, parasympathetic fibers from the vagus nerve travel with the sympathetic fibers to the autonomic plexus along the renal artery. The renal sympathetics cause vasoconstriction, and the parasympathetics cause vasodilation.

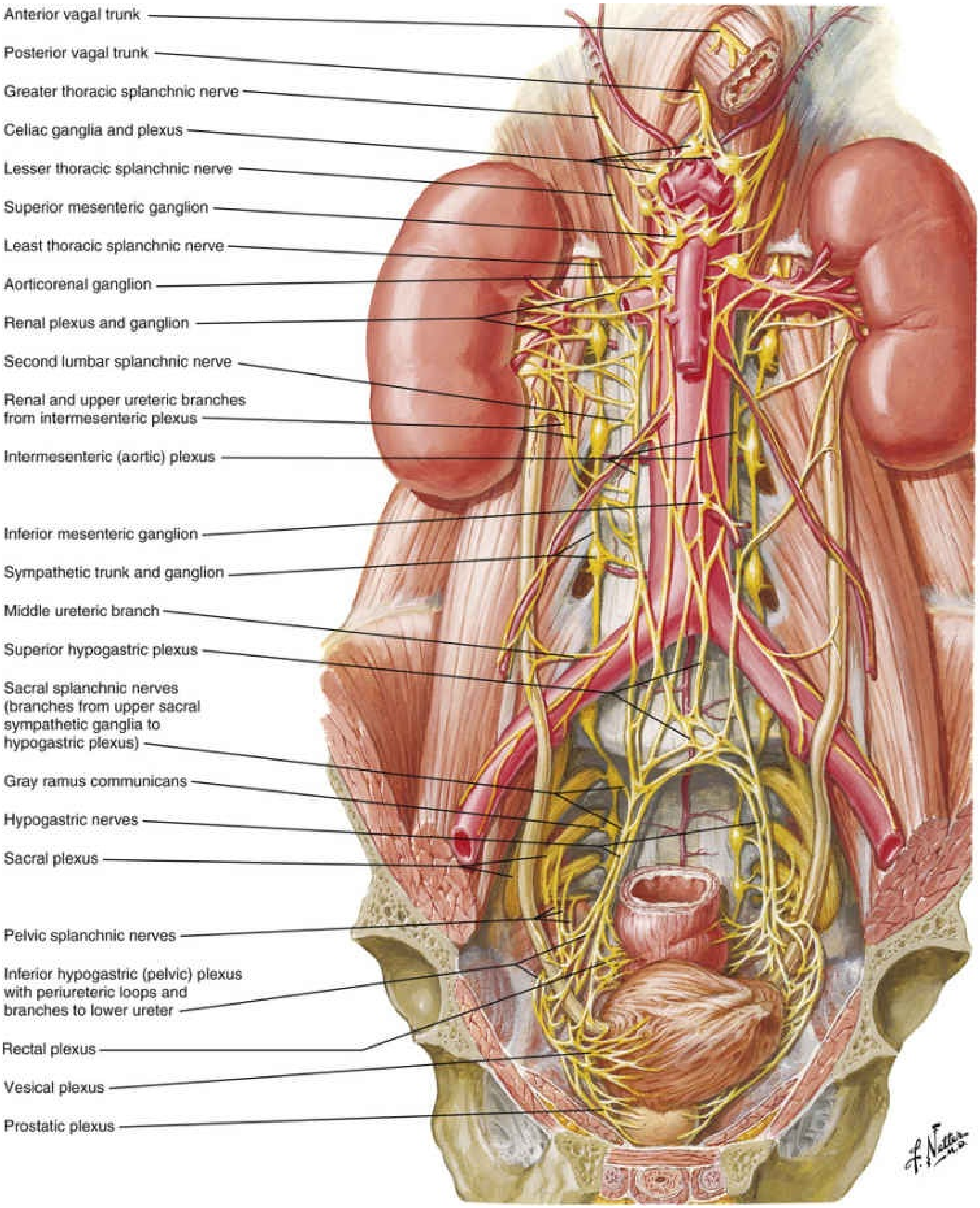
Anterior vagal trunk
Posterior vagal trunk
Greater thoracic splanchnic nerve
Celiac ganglia and plexus
Lesser thoracic splanchnic nerve
Superior mesenteric ganglion
Least thoracic splanchnic nerve
Aorticorenal ganglion
Renal plexus and ganglion
Second lumbar splanchnic nerve
Renal and upper ureteric branches from intermesenteric plexus
Intermesenteric (aortic) plexus
Inferior mesenteric ganglion
Sympathetic trunk and ganglion
Middle ureteric branch
Superior hypogastric plexus
Sacral splanchnic nerves (branches from upper sacral sympathetic ganglia to hypogastric plexus)
Gray ramus communicans
Hypogastric nerves
Sacral plexus
Pelvic splanchnic nerves
Inferior hypogastric (pelvic) plexus with periureteric loops and branches to lower ureter
Rectal plexus
Vesical plexus
Prostatic plexus
F. Netter M.D.

EFIG. 84.22 Autonomic innervations of the kidneys and ureters.
(Copyright 2016 Elsevier Inc. All rights reserved. www.netterimages.com.)

Pelvicalyceal System

Understanding the collecting system anatomy is of utmost importance for appropriate radiologic interpretation and performance of different endourologic procedures. The upper pole of the kidney usually contains three calyces and less commonly two, whereas three or four calyces could be identified at the interpolar region and two or three calyces at the lower pole (Fig. 84.23). These calyces vary considerably not only in numbers but also in size and shape because of the different numbers of papillae they receive. A calyx may receive a single papilla, two, or even three. Compound papillae are often found in the polar regions of the kidney. The upper pole is usually drained by a single midline calyceal infundibulum, and the lower pole is drained by either a single midline calyceal infundibulum or by paired calyces. The hilar region is drained by anterior and posterior rows of paired calyces. The pelvicalyceal system may have the configuration of either a true pelvis or divided double calyceal pelvis. The true pelvis is the classic type in which the calyces drain directly through elongated necks into an elongated pelvis. This pelvis may be completely imbedded within the renal sinus (intrarenal pelvis) or mostly outside it (extrarenal pelvis). The renal pelvis is roughly pyramidal, with the base facing the parenchyma and the apex funneling down into the ureter. It usually has a capacity of 3 to 10 mL of urine.

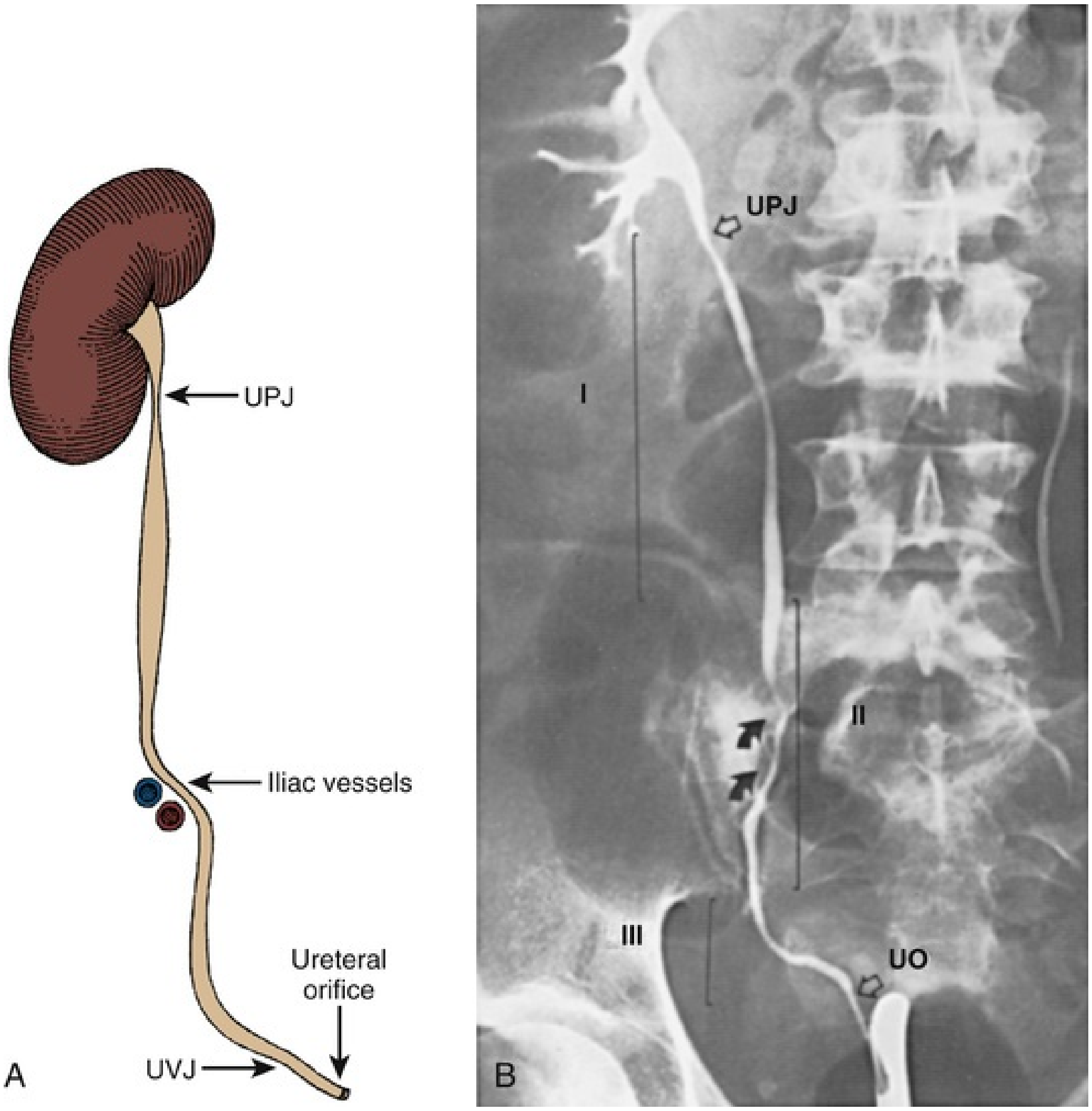

FIG. 84.23 (A) The ureter demonstrating sites of normal functional or anatomic narrowing at the ureteropelvic junction (*UPJ*), the iliac vessels, and the ureterovesical junction (*UVJ*). (B) The right ureter, illustrated by retrograde injection of contrast material. *I,* Upper or proximal ureter, extending to the upper border of the sacrum; *II,* middle ureter, extending to the lower border of the sacrum; *III,* distal or lower ureter, traversing the pelvis to end in the bladder; *UO,* ureteric orifice in the bladder; *UPJ,* ureteropelvic junction. *Arrows* indicate the course of the common iliac artery and vein.

In a divided (duplex) pelvis, it is divided at the hilum into upper and lower portions and drains a higher number of calyces than a normal pelvis. Its lower part is usually shorter but larger and often drains the hilar and the lower pole calyces. Therefore there is no direct connection between the upper and lower calyces. This usually becomes apparent during the excretory phase of a CT urogram or on retrograde pyelography. During percutaneous endoscopic evaluation of the kidney, the existence of a duplex pelvis should be considered if upper or lower pole calyces cannot be accessed through a particular calyceal access. Duplex systems are easier to recognize on retrograde nephroureteroscopy. When a duplex system is suspected during ureteroscopy, retrograde pyelography could be performed to illustrate the anomalous pelvicalyceal system.

Radiologic Anatomy of the Collecting System

After an iodinated contrast agent is injected for intravenous urography, nephrotomograms appear after 60 to 90 seconds that represent contrast material within the renal tubules. Fifteen minutes after contrast injection, a panoramic radiograph of the whole urinary tract can be obtained; the bladder finally appears 20 to 30 minutes after contrast injection. Absence of contrast excretion 24 hours after intravenous contrast injection indicates a nonfunctioning kidney. **The pelvicaliceal anatomy is variable, and no simple rule defines calyceal organization.** Currently, CT urography has replaced intravenous urography, and multidetector CT provides the ability to obtain thin (<1 mm) collimated data of the entire urinary tract during a short single breath-hold (Van Der Molen et al., 2008). Magnetic resonance urography (MRU) has two consecutive phases: a static-fluid phase and an excretory phase. The static-fluid MRU is ideally indicated for evaluation of the obstructed or dilated collecting system. The practicability of excretory MRU depends on renal function, and its quality could be improved by a low-dose furosemide diuretic. Congenital variants of the pelvicalyceal system are common, representing approximately 4% of the population. The renal pelvis may be completely intrarenal, completely extrarenal, or a combination of both (Friedenberg and Dunbar, 1990). The infundibula insert directly into the extrarenal pelvis, giving the impression of a dilated pelvis. Receiving the tip of renal papilla, the renal calyx is a concave structure with two side projections, the fornices, which surround the papilla of the renal medulla. Multiple single calyces fail to divide completely, forming a larger compound calyx that normally can be observed in the upper and lower poles of the kidneys. Each kidney contains an average of 7 to 9 calyces, although this number may vary considerably from 4 to 19 or even more. Megacalycosis represents a nonobstructive asymptomatic congenital dilation of some or all renal calyces, while the renal pelvis and ureter are normal. It involves all calyces uniformly and usually is associated with a greater number of calyces than normal. Calyceal diverticula represent a focal extrinsic dilation of a renal calyx that is connected to the calyceal fornix and projects into the renal cortex, not into the medulla. The renoureteral unit may show duplication anomalies, including a bifid renal pelvis and complete or incomplete ureteral duplication. Two separate pyelocalyceal collecting systems may be present in one kidney, ranging from a bifid pelvis to a bifid ureter (ureteropelvic duplication).

Ureters

The ureters are bilateral muscular retroperitoneal ducts with narrow lumens that carry urine from the kidneys to the urinary bladder (see Fig. 84.23). Each ureter runs inferiorly as a narrow continuation of its renal pelvis at the UPJ, passing over the pelvic brim at the bifurcation of the common iliac artery. They then run along the lateral wall of the pelvis to enter the urinary bladder. In adults, the ureter is 22 to 30 cm in length with a diameter of 1.5 to 6 mm; in neonates it measures 6.5 to 7.0 cm long. In the retroperitoneum, the ureter is situated just lateral to the tips of the transverse processes of the lumbar vertebrae. The ureters occupy a sagittal plane that intersects the tips of the transverse processes of these lumbar vertebrae. The ureter is arbitrarily divided into proximal (upper), middle (over the sacrum), and distal (lower) segments. However, according to international anatomic terminology the ureter consists of abdominal (from renal pelvis to iliac vessels), pelvic (from iliac vessels to the bladder), and intramural segments.

The abdominal parts of the ureters are adherent to the retroperitoneum throughout their entire course and extend from the renal pelvis to the pelvic brim. From the back, the surface anatomy of the ureter corresponds to a line joining a point 5 cm lateral to the L1 spinous process and the posterior superior iliac spine. Normally, three constrictions could be identified radiologically in each ureter: at its junction with the renal pelvis (UPJ), where it crosses the iliac vessels, and during its passage through the wall of the urinary bladder (intramural ureter) or ureterovesical junction (see Fig. 84.23). These constricted areas are potential sites of obstruction by ureteral calculi.

Posteriorly, both ureters descend anterior to the psoas major muscle and then cross the ventral surface of the transverse processes of the third to fifth lumbar vertebrae and enter the pelvis at the bifurcation of the common iliac vessels (see eFigs. 84.4 and 84.5). The bifurcation of the common iliac vessels is used intraoperatively as a landmark to look for the ureter. The genitofemoral nerve runs on top of the psoas major muscle behind the ureter. The right ureter begins behind the descending part of the duodenum, where it is crossed by the gonadal vessels (testicular or ovarian), which is called “water under the bridge.” The left ureter is covered at its origin by the initial part of the jejunum. The gonadal vessels cross the left ureter after running parallel to it for a small distance. The inferior mesenteric artery and its terminal branch, the superior rectal artery, follow a curved course close to the left ureter. Therefore, as the left ureter approaches the pelvis, it is crossed by the left colic vessels, the sigmoid colon, and its mesocolon. Just above the entry to the pelvis, the ureter is still covered by peritoneum by virtue of the ureteral fold. This location at the pelvic brim represents one of the most common areas of ureteral injury. Furthermore, the close relationship of the ureter with the terminal ileum, appendix, right and left colons, and sigmoid colon makes it susceptible for encroachment of inflammatory and malignant processes, resulting in clinical presentations ranging from microhematuria to ureteral obstruction or even fistulae.

The pelvic segment of the ureter is approximately 15 cm long—half of its total length. At the pelvic inlet, it crosses the common iliac vessels near their bifurcation. This crossover point is usually at the bifurcation of the common iliac artery into the internal and external iliac arteries, making this a useful landmark for pelvic procedures. The ureter then runs downward and laterally toward the ischial spine on the lateral pelvic wall along the anterior border of the greater sciatic notch, dorsally accompanied by the internal iliac artery and its visceral branches and the venous plexuses as well. It is still closely related to the posterior parietal peritoneum. At the ischial spine, the ureter turns medially to descend in the endopelvic fascia with branches of the hypogastric nerves. At the lateral wall of the pelvis, this part of the ureter crosses the obturator artery, vein, and nerve. In males, the vas deferens loops medially over this part while the ureter passes the ampulla of the vas deferens and the seminal vesicles just before it enters the bladder. In females, the descending part of the pelvic segment of the ureter courses posterior to the ovary to form the posterior boundary of the ovarian fossa. The ureter then passes through the base of the broad ligament and swings in a convex curve to cross under the uterine vessels (“water under the bridge”) in a sagittal direction approximately 1.5 to 2 cm adjacent to the supravaginal part of the uterine cervix. The terminal ureter runs forward, accompanied by the neurovascular bundle of the bladder and passes the anterior vaginal fornix just before entering the bladder. This close proximity of the ureter to the uterine vessels is the cause of ureteral injuries during gynecologic procedures. In the case of vaginal surgery, there is a high risk for injury, especially for the left ureter that crosses the anterior vaginal fornix closer than the right ureter.

Near the bladder, the terminal ureter is enveloped by a muscular layer, the Waldeyer sheath, and then pierces the bladder wall obliquely as the intramural segment (eFig. 84.24). The length of this intramural part of the ureter in adults is

1.2 to 2.5 cm, and in neonates it is approximately 0.5 to 0.8 cm long. The Waldeyer muscle bundles of the ureter coalesce with those of the detrusor muscle of the bladder wall. Therefore reflux of urine from the bladder to the ureter is prevented during increased intravesical pressure, such as during micturition. Another important feature of the 3D course of the ureter that is critical to appreciate and follow during rigid ureteroscopy is the angulation of the ureter as it courses through the retroperitoneum. When approached from the retrograde direction, the ureter courses anterolaterally as it goes along the lateral pelvic wall. Then, as it crosses the pelvic brim, it angulates posteriorly to continue as the proximal ureter. Following the 3D course of the ureter along a safety guidewire reduces the risk for perforation, especially in patients with large impacted stones.

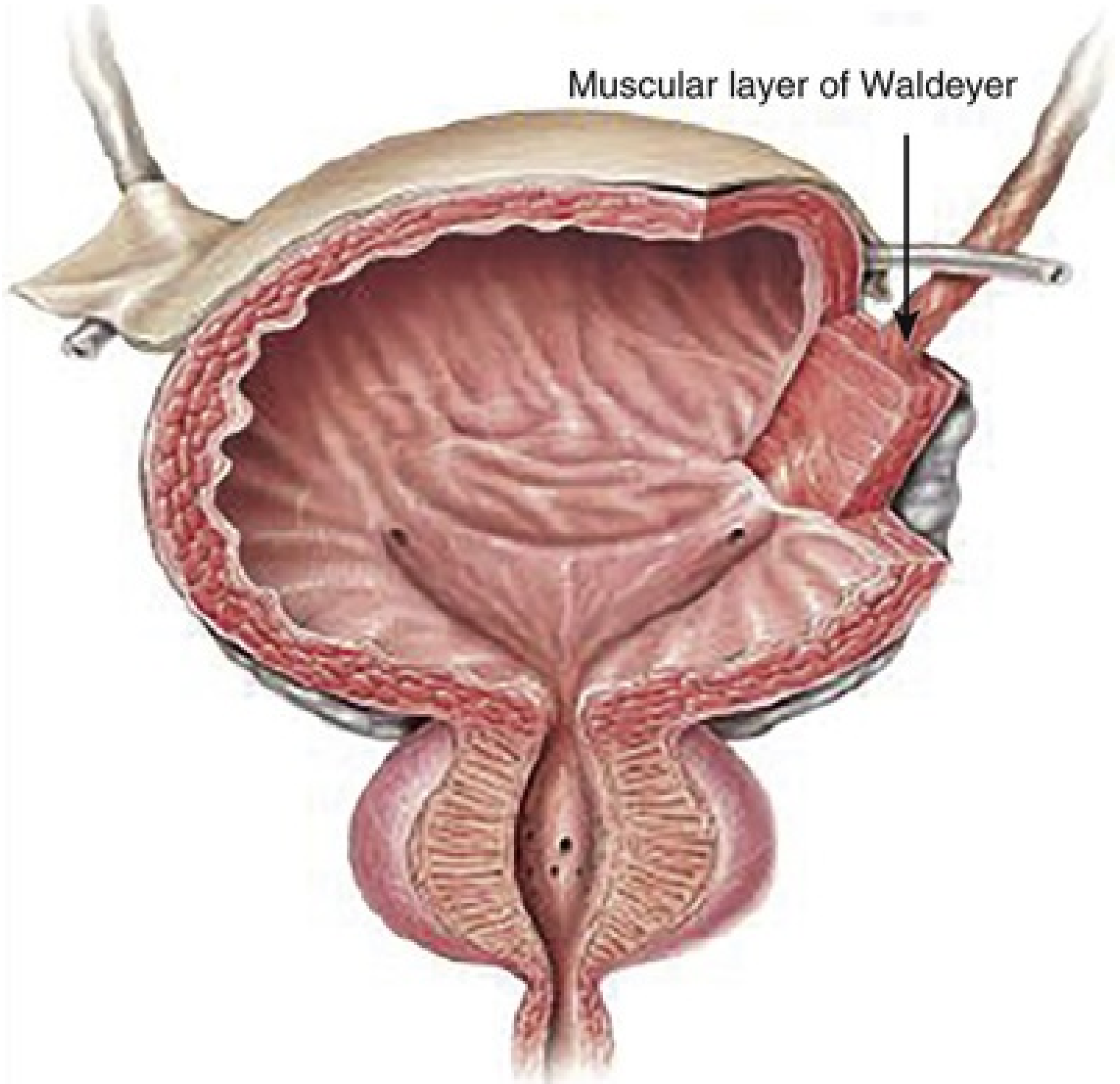

EFIG. 84.24 Intramural portion of the distal ureter. (From Frober R: Surgery illustrated: surgical atlas, surgical anatomy of the ureter. *BJU Int* 100:949–965, 2007.)

Radiologic Anatomy of the Ureter

The ureter could be delineated by excretory urography during expiration, because it may be kinked during inspiration as a result of downward movement of the kidney (Friedenberg and Dunbar, 1990). For radiologic purposes, radiologists describe three segments of the ureter: a proximal portion extending from its origin down to the upper border of the sacroiliac joint, a middle portion lying over the sacroiliac joint, and the remaining segment from the lower border of that joint to its entrance into the bladder, which represents the distal portion of the ureter.

The course of the ureter and its bilateral symmetry are subject to great variability. It may descend laterally away from the margin of the transverse processes or be displaced medial to the renal pedicle. A medially displaced right ureter might normally be seen in young black males (Adam et al., 1985). The right ureter may run medially behind the vein at the level of third lumbar vertebra before it returns to its lateral position**. The entire length of the ureter is rarely seen in a single film of the excretory urography because of its peristaltic activity.** Otherwise, ureteral atony or obstruction should be suspected (Mellins, 1986). Similarly, crossing vessels may compress the ureter and simulate areas of stricture. **Therefore the diagnosis of a ureteral stricture should not be based on a single film of excretory urography with the presence of ureteral dilatation proximal to the site of narrowing.** Ureteral duplication may be complete or incomplete (partial). Complete duplication results from the development of a second ureteric bud, and the two ureters are inserted into the bladder separately. The partial type results from redundant duplication of the single ureteric bud in which the two ureters join together above the bladder to from a single stump draining into the bladder. Complete ureteral duplication with a common or ectopic entry of the upper pole moiety is less common than incomplete duplication. The ureter draining the upper segment of the kidney prevalently inserts in the bladder inferior and medial to the ureter draining the lower segment of the kidney (Weigert-Meyer rule). These ectopic orifices are prone to ureteroceles and/or vesicoureteral reflux. The lower moiety of the completely duplicated system is generally normal. Ureteral duplication also may be bilateral. Triple moiety may be observed. In diagnosis of renal or ureteral displacement, CT scans have replaced lateral views of conventional radiography. In a standard lateral view, the normal renal collecting system should not project anterior to the spine and the ureter stays behind the anterior margin of the vertebral bodies until the level of L4. After this, the ureter lies anterior to the vertebral body by approximately one-fourth the width of the vertebral body (Friedland et al., 1983). In elderly patients with atherosclerotic vessels, ureteral narrowing at the pelvic brim at its crossing to the common iliac vessels may produce a posterior indentation that may appear as an extrinsic filling defect. Dilation proximal to that point may be differentiated from obstruction by the absence of pelvicalyceal dilation without delay in emptying on prone or erect films (Friedenberg and Dunbar, 1990). Medial displacement of both pelvic ureteral segments may result from retroperitoneal fibrosis or pelvic lipomatosis, or it may appear after abdominoperineal surgery. However, medial displacement and concavity of a single pelvic ureter may result from enlarged hypogastric nodes, a bladder diverticulum, or aneurysmal dilation of the hypogastric artery. Nevertheless, this may be a normal finding in adult women if only the right ureter is affected because of the uterine tilt to the left. In older men, benign prostatic hyperplasia may result in elevation of the bladder floor enough to cause the intramural segment of the ureter to curve superiorly, giving a characteristic “fish hook” or “hockey stick” appearance on excretory urography (Olsson, 1986).

Key Points: Radiologic Anatomy of the Ureter

- It is important to have the patient empty the bladder to evaluate the distal ureter appropriately.
- Radiologically, the ureter is divided into three segments: a proximal portion from UPJ to the sacroiliac joint, a middle portion lying over the sacroiliac joint, and a distal portion from the lower border of that joint to its entrance into the bladder.
- The entire length of the ureter is rarely seen on a single film of the excretory urography because of its peristaltic activity.

Arteries, Veins, and Lymphatic Drainage of the Ureters

The abdominal portion of the ureter is supplied mainly by arterial branches medially from the main renal arteries (eFig. 84.25). However, this segment may be uncommonly supplied by branches arising from the abdominal aorta or gonadal arteries. These branches approach the ureters medially and divide into ascending and descending branches, forming a longitudinal anastomosis on the ureteral wall. However, despite this anastomotic plexus, ureteral ischemia is not uncommon if these small and delicate ureteral branches are disrupted. Surgeons are trained to handle ureters gently to avoid unnecessary lateral retraction and removing periureteral adventitial tissues containing the blood supply to minimize ureteral ischemia and subsequent stricture. The mid-ureter is supplied by branches arising posteriorly from the common iliac arteries. The blood supply to the distal ureter comes laterally from the superior vesical artery, a branch of the internal iliac artery. Therefore the blood supply of the ureter is medially in the proximal part, posteriorly in the midportion, and laterally in the distal portion. Therefore endoureterotomy should be performed laterally in the proximal ureter, anteriorly in the midportion, and medially in the distal ureter. Another important surgical caveat is to control the obliterated umbilical artery before mobilizing the most distal aspect of the ureter as it enters the bladder.

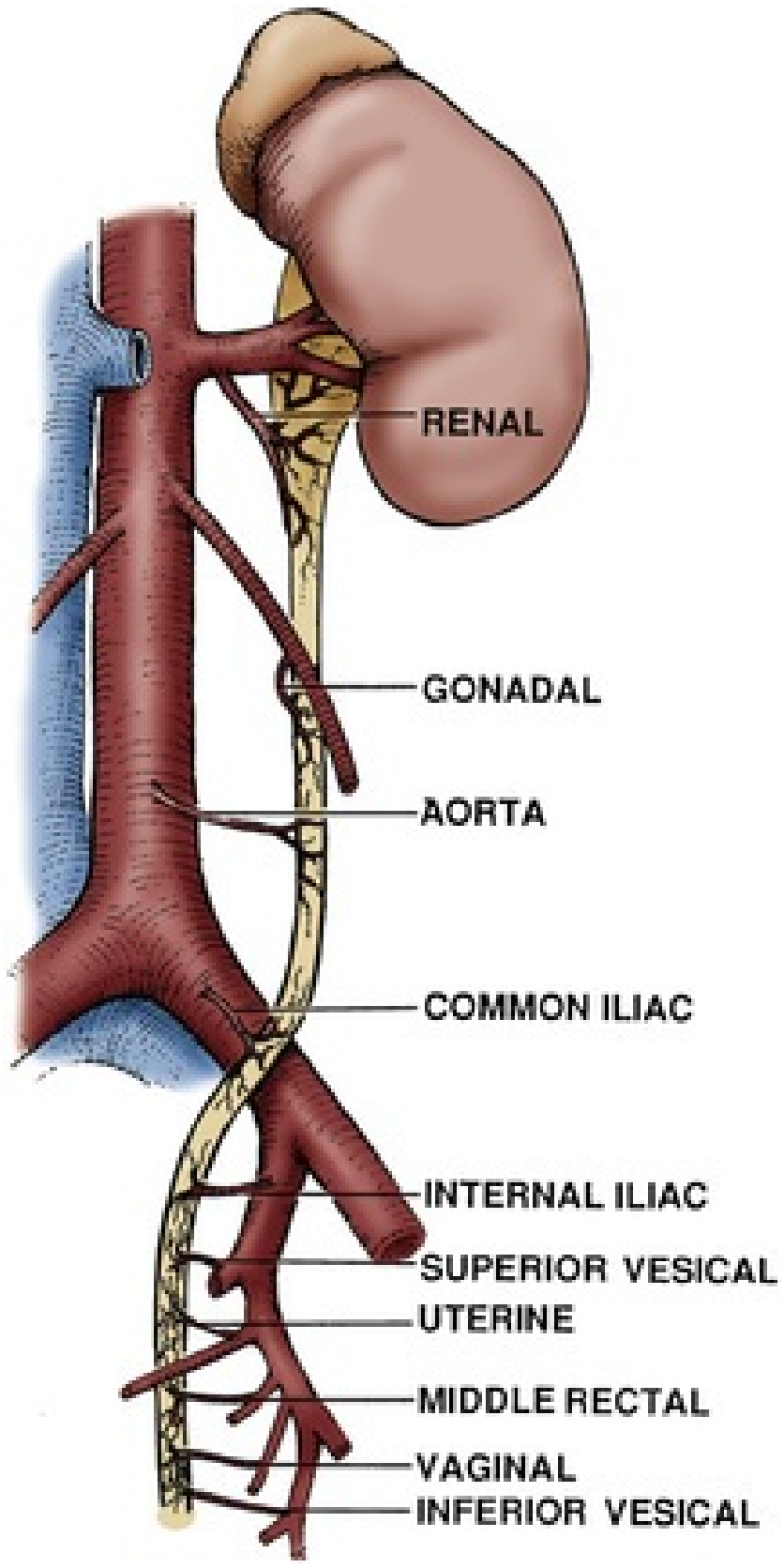

EFIG. 84.25 Arterial supply of the left ureter.

Veins draining the abdominal part of the ureters drain into the renal and gonadal veins. **Venous drainage of the mid- and distal ureters is into the**

common and internal iliac veins. The lymphatics of the ureter form plexuses within its muscular and adventitial layers. The lymphatics from the left abdominal ureter drain into the left para-aortic lymph nodes, and the lymphatics from the right abdominal ureter drain into the right paracaval and interaortocaval lymph nodes. Lymphatic vessels from the middle part usually drain into the common iliac lymph nodes, whereas lymphatics from its intrapelvic part drain into the common, external, and internal iliac lymph nodes.

Key Points: Ureters

- The course of the ureter begins posterior to the renal artery and continues along the anterior edge of the psoas muscle.
- The gonadal vessels cross anterior to the ureter in this region *(water under bridge).* The ureter next passes over the bifurcation of the common iliacs into the internal and external iliacs.
- The blood supply of the proximal ureter is medially, mid-ureter is posteriorly, and distal ureter is laterally.

Nerve Supply of the Ureter

The ureter receives a rich autonomic nerve supply that originates from the celiac, aortorenal, and mesenteric ganglia, together with the superior and inferior hypogastric (pelvic) plexuses. The sympathetic supply to the ureter arises from the preganglionic fibers of the 11th and 12th thoracic and 1st lumbar segments. Parasympathetic vagal fibers supply the upper part of the ureter via the celiac plexus, and the lower portion is supplied by the sacral segments S2 to S4. Therefore afferent nerves from the upper portion of the ureter reach the spinal cord with the sympathetic fibers between T11 and L1 and those from the lower ureter travel via the pelvic plexus between S2 and S4. These fibers conduct afferent sensory stimuli from the ureters and have a minor, if any, role in the control of ureteral motility. This is because excised portions of the ureter continue to contract without nervous control and denervation of the lower portion of the ureter does not result in reflux. As mentioned earlier, the peristalsis of the ureter originates from pacemakers in the minor calyces. Thus the exact role of autonomic input of the ureters is unclear. Distention of the renal capsule and the collecting system causes stimulation of renal pain fibers that carry signals through the sympathetic nerves, thus resulting in visceral-type referred pain in the flank, groin, or scrotal (labial) regions.

Microscopic Anatomy of the Ureter

The ureter consists of three distinct layers. The innermost is the mucosa, the middle muscular layer is the muscularis, and the outer layer is the adventitia. The mucosa consists of transitional epithelium, which has four to six layers of cells when the ureter is contracted. These cells encircle a large number of junctional complexes containing a consistent level of keratin precursors that is responsible for the waterproof property of this layer. The mucosa also contains many longitudinal folds that give the empty ureter a characteristic stellar outline. The epithelium rests on a layer of connective tissue, the lamina propria, which contains the blood vessels and nerve fibers to the ureter (eFig. 84.26).

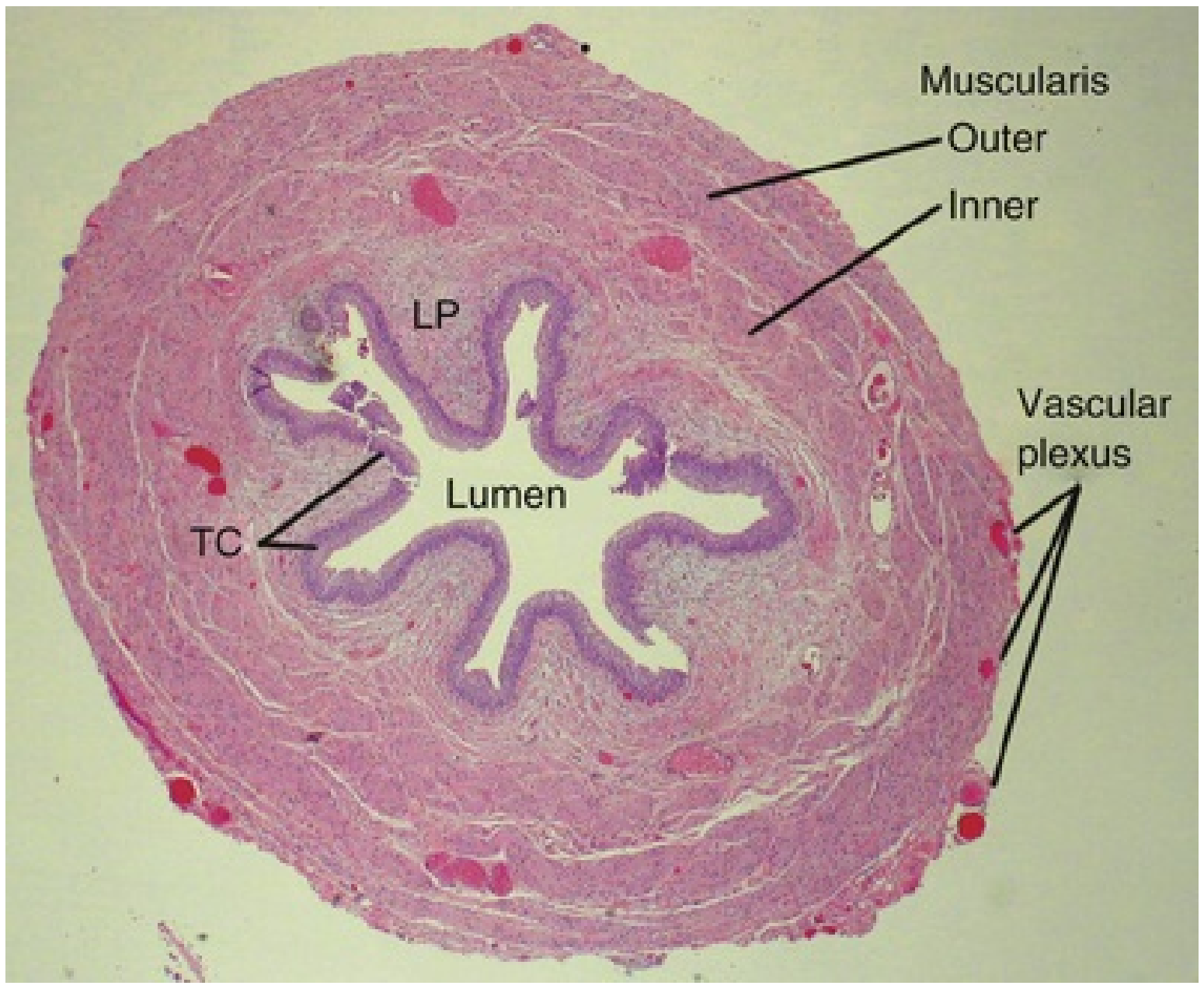

EFIG. 84.26 Transverse section through the ureter. The inner longitudinal layer is distinguished from the outer circular and oblique muscle fibers. The rich vascular supply of the ureter is also demonstrated. *LP,* Lamina propria; *TC,* transitional epithelium. (Courtesy Dr. Hossein Saboorian.)

The muscular wall of the ureter consists of two longitudinal layers separated by a middle circular layer that may not be distinct from each other, especially in the abdominal segment of the ureter. Mostly, these muscle fibers appear to be spirally arranged by the light microscopy. However, in the distal ureter, the inner spirals are steep and the outer spirals are horizontal, thus appearing as inner longitudinal and outer circular layers in cross section. These smooth muscle layers are contiguous with the smooth muscle covering the minor renal calyces, where the pacemaker is located to initiate the rhythmic peristalsis to deliver urine.

The outermost layer, the adventitia, consists of a dense network of collagen and elastic fibers, including many blood vessels and unmyelinated nerve fibers among them. This layer is continuous proximally with the capsule at the renal pelvis while it is thickened distally by a specialized muscle fibers and fibrous tissue to form the Waldeyer sheath.

In a normal kidney, the UPJ does not differ histologically from the renal pelvis. However, in an obstructed kidney, the longitudinal muscle fibers are significantly increased with more collagen deposits around the muscle fibers in addition to attenuation of muscle bundles, leading to the physiologic obstruction known clinically as UPJO.

Endoscopic Anatomy of the Ureter and Pelvicalyceal System

Once the cystoscope is inside the bladder neck, the trigone can be seen as a raised, smooth triangle. The apex of that triangle is situated at the bladder neck, and its base is formed by the interureteral ridge or Mercier bar, extending between the two ureteric orifices. The interureteral ridge is more prominent in males than females, and the ureteric orifices are symmetrically located along it, approximately 1 to 2 cm from the midline. The trigone is the most vascular part of the bladder and is formed by an extension of the longitudinal muscle fibers of the ureters over the detrusor muscle. Therefore it appears cystoscopically to be more deeply colored than the rest of the bladder.

The normal ureteric orifice may appear as a volcano or a horseshoe that is prominent and obvious on endoscopy. However, it may look like a slit that can be identified with only meticulous examination. It is pushed out laterally during bladder filling and may vary in position and appearance. In a normal bladder, the ureteric orifices are usually surrounded by prominent mucosal vessels (Bagley et al., 1985).

The ureteric orifices are classified according to their position or configuration. They are normally located at the medial aspect of the trigone (position A). However, they may be located at the lateral wall of the bladder or at its junction with the trigone (position C) or in between positions A and C (position B) (Lyon et al., 1969). In terms of configuration, grade 0 indicates a normal ureteric orifice that looks like a cone or a volcano. Grades 1, 2, and 3 describe stadium, horseshoe, and golf-hole orifices, respectively. **The higher the grade of the orifice, the higher the tendency to be laterally located and to reflux** (eFig. 84.27).

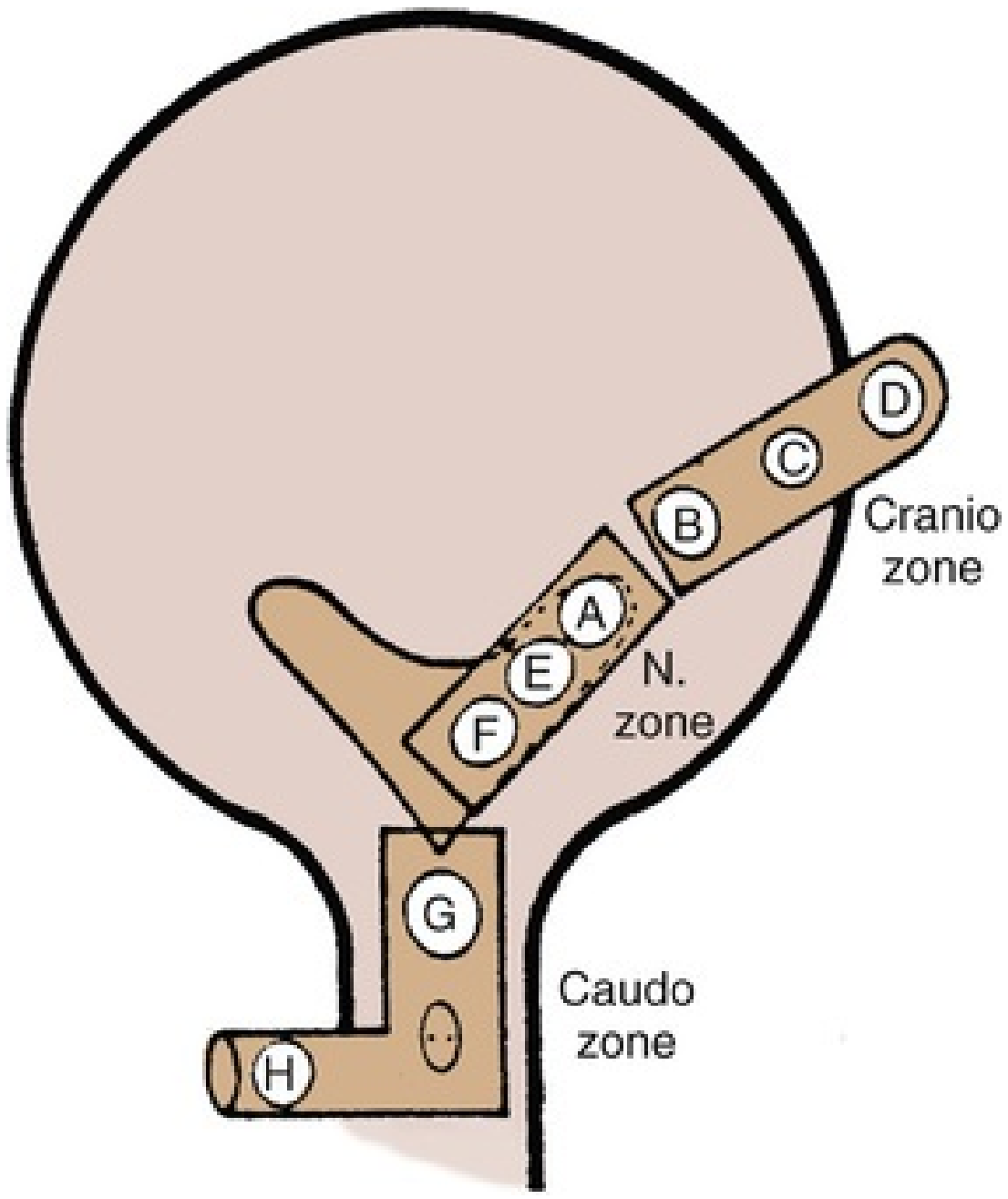

EFIG. 84.27 Classification of ureteric orifice position. Obstruction usually occurs in the caudo zone, and ureters positioned in the cranio zone are likely to result in reflux. Ureters positioned in the normal (*N*) zone are associated with normal kidneys. Because of ureteric bud abnormality, renal dysplasia occurs with ureters projecting from both abnormal positions. (From Mackie GC, Stephens FD: Duplex kidneys: a correlation of renal dysplasia with position of the ureteric orifice. *J Urol* 114:274, 1975.)

The intramural ureter represents the narrowest part of the ureter, with an average diameter of 3 to 4 mm. It extends from the ureteric orifice for approximately 1.5 cm, posterolaterally for 0.5 cm, and then obliquely through the detrusor hiatus for approximately 1 cm (Politano, 1972). Being the narrowest ureteral segment, the intramural ureter may have to be dilated before ureteroscopy. The other ureteral narrowing areas at the pelvic brim and UPJ are identified endoscopically by being stenotic and relatively nondistensible. However, they are relatively wider than the intramural segment. They can be easily instrumented with enough pressure from the irrigation fluid. The pulsating iliac vessels could be seen endoscopically as the ureters cross the pelvic brim and angulate posteriorly in the proximal portion.

The proximal ureter goes straight up to the UPJ; the ureter lies on the psoas major muscle, with the appearance of a typical stellate nondistended ureter. The UPJ could be identified easily endoscopically during its frequent opening and closing. The UPJ merges into the wider and more dependent part of the renal pelvis. The respiratory movement of the kidney could be seen by endoscopy after passing the relatively fixed UPJ. The kidneys lie on the diaphragm, and thus they are affected by the respiratory movements. **Therefore, during ureteroscopy, the tidal volume could be decreased to minimize renal excursions during respiration.** Moreover, the physiologic ureteral contractions or peristalsis can be observed endoscopically. It is important to wait for the ureter to relax before pushing the ureteroscope to avoid mucosal trauma (Andonian et al., 2008b, 2010b).

The UPJ represents the apex of the funnel-shaped or conical normal renal pelvis. An extrarenal pelvis is usually larger and has longer major calyceal infundibula than an intrarenal pelvis. In the renal pelvis, the flexible ureteroscope first faces the ostia of the major calyces, which look like circular openings separated by carinae. Then the flexible ureteroscope enters a long tubular infundibulum that branches into the minor calyces. These infundibula usually connect the ostia of major calyces with their apex. For a flexible ureteroscope to pass from the axis of the upper ureteral segment to the axis of the lower infundibulum, it should deflected 140 (104 to 175) degrees at the ureteroinfundibular angle (Bagley and Rittenberg, 1987).

A circular muscle layer extends around the base of the papilla to help expel urine jets from papillary ducts. The renal papillae appear endoscopically as protruding discs surrounded by calyceal fornices, paler in color than the pink friable epithelium covering the papillae. Each papilla represents the apex of a renal pyramid, receiving the papillary ducts of Bellini that drain the pyramids. These ducts are minute openings that become more dilated and obvious with distal obstruction (Andonian et al., 2008a, 2010a).

Segmental and interlobar branches of the renal artery, together with major intrarenal tributaries of the renal vein, run in close relation with the anterior and posterior surfaces of the major caliceal infundibula as well as the necks of minor calices (Sampaio, 2009). Therefore, if infundibulotomy must be performed, it should be performed in either the superior or inferior quadrants, which are free of major vessels. Anatomically, the following sequence is recommended if more than one infundibular incision is necessary: the first two incisions should be done, respectively, in the superior and inferior quadrants, the third incision between the superior and posterior quadrants, and the fourth between the inferior and posterior quadrants. Further incision would be performed in the posterior quadrant, avoiding anterior incisions as much as possible (Sampaio, 2009).

See Videos 84.1, 84.2, 84.3, 84.4, 84.5, and 84.6 for procedures related to this chapter.

Key Points: Endoscopic Anatomy

- The trigone is the most vascular part of the bladder and is formed by an extension of the longitudinal muscle fibers of the ureters over the detrusor muscle.
- Both ureteric orifices are rarely seen in a single endoscopic view.
- The interureteral ridge is more prominent in males than females, and the ureteric orifices are symmetrically located along it, approximately 1 to 2 cm from the midline.
- The intramural ureter represents the narrowest part of the ureter, with an average diameter of 3 to 4 mm.
- The extrarenal pelvis is usually larger and has longer major calyceal infundibula than the intrarenal pelvis.
- The renal papillae appear endoscopically as protruding discs surrounded by calyceal fornices, paler in color than the pink friable epithelium covering the papillae.
- If infundibulotomy needs be performed, it should be performed in either the superior or inferior quadrants, which are free of major vessels. Anterior infundibular incision should be avoided to avoid injuring of large intrarenal blood vessels leading to severe bleeding.

Suggested Readings

Drake RL, Vogl W, Mitchell AWM. *Gray's anatomy for students*. Churchill Livingstone: Philadelphia; 2005.

Frober R. Surgery illustrated: surgical anatomy of the ureter. *BJU Int*. 2007;100:949–965.

Hinman F, Stempen PH. *Atlas of urosurgical anatomy*. WB Saunders: Philadelphia; 1993.

Moore KL, Dalley AF, Agur AM. *Clinically oriented anatomy*. 6th ed. Lippincott Williams & Wilkins: Philadelphia; 2010:292–365.

Netter FH. *Atlas of human anatomy*. 5th ed. Saunders: Philadelphia; 2010.

Quaia E, Martingano P, Cavallaro M, et al. Normal radiological anatomy and anatomical variants of the kidney. Quaia E. *Radiological imaging of the kidney*. Springer: New York; 2011:17–78.

Sampaio FJB. Renal anatomy: endourologic considerations. *Urol Clin North Am*. 2000;27:585–607.

Silverman SG, Leyendecker JR, Amis SE. What is the current role of CT urography and MR urography in the evaluation of the urinary tract? *Radiology*. 2009;250:309–323.

References

Adam EJ, Desai SC, Lawton G. Racial variations in normal ureteric course. *Clin Radiol*. 1985;36:373–375.

Andonian S, Okeke Z, Anidjar M, et al. Digital nephroscopy: the next step. *J Endourol*. 2008;22:601–602.

Andonian S, Okeke Z, Anidjar M, et al. Digital nephroscopy: the next step. *J Endourol Part B Videourology*. 2010;24.

Andonian S, Okeke Z, Smith AD. Digital ureteroscopy: the next step. *J Endourol*. 2008;22:603–606.

Andonian S, Okeke Z, Smith AD. Digital ureteroscopy: the next step. *J Endourol Part B Videourology*. 2010;24.

Bagley DH, Huffman JL, Lyon ES. Normal anatomy of the urethra, prostate, and bladder. Bagley DH, Huffman JL, Lyon ES. *Urologic endoscopy*. Little Brown: Boston; 1985:3–12.

Bagley DH, Rittenberg MH. Intrarenal dimension: guidelines for flexible ureteropyeloscopes. *Surg Endosc*. 1987;1:119–121.

Beveridge TS, Allman BL, Johnson M, et al. Retroperitoneal lymph node dissection: anatomical and technical considerations from a cadaveric study. *J Urol*. 2016;196:1764–1771.

Cheung CM, Shurrab AE, Buckley DL, et al. MR-derived renal morphology and renal function in patients with atherosclerotic renovascular disease. *Kidney Int*. 2006;69:715–722.

Chung JJ, Semelka RC, Martin DR. Acute renal failure: common occurrence of preservation of corticomedullary differentiation on MR images. *Magn Reson Imaging*. 2001;19:789–793.

Coulam CH, Bouley DM, Sommer FG. Measurement of renal volumes with contrast- enhanced MRI. *J Magn Reson*

Imaging. 2002;15(2):174–179.

Friedenberg RM, Dunbar JS. Excretory urography. Pollack HM. *Clinical urography*. Saunders: Philadelphia; 1990:101–207.

Friedland GW, Filly R, Goris ML, et al. Anatomy. Friedland GW, Filly R, Goris ML. *Uroradiology: an integrated approach*. Churchill Livingstone: New York; 1983:11–153.

Hricak H, Slovis TL, Callen CW, et al. Neonatal kidneys: sonographic anatomic correlation. *Radiology*. 1983;147:699.

Kasap B, Soylu A, Türkmen M, et al. Relationship of increased renal cortical echogenicity with clinical and laboratory findings in pediatric renal disease. *J Clin Ultrasound*. 2006;34:339–342.

Lyon RP, Marshall S, Tanagho EA. The ureteric orifice: its configuration and competency. *J Urol*. 1969;102:504–509.

Mellins HZ. Urography and cystourethrography. Walsh PC, Gittes RF, Perlmutter AD, et al. *Campbell's urology*. 5th ed. Saunders: Philadelphia; 1986:312–358.

Moghazi S, Jones E, Schroepple J, et al. Correlation of renal histopathology with sonographic findings. *Kidney Int*. 2005;67:1515–1520.

Olsson CA. Anatomy of the upper urinary tract. Walsh PC, Gittes RF, Perlmutter AD, et al. *Campbell's urology*. 5th ed. WB Saunders: Philadelphia; 1986:12–46.

Politano VA. Ureterovesical junction. *J Urol*. 1972;107:239–242.

Sampaio FJB. Review: anatomic background for intrarenal endourologic surgery. *J Endourol*. 2009;6(5):301–304.

Schedl A. Renal abnormalities and their developmental origin. *Nat Rev Genet*. 2007;8:791–802.

Semelka RC, Corrigan K, Ascher SM, et al. Renal corticomedullary differentiation: observation in patients with differing serum creatinine levels. *Radiology*. 1994;190:149–152.

Van Der Molen AJ, Cowan NJ, Mueller-Lisse UG, et al. CT urography: definition, indications and techniques: a guideline for clinical practice. *Eur Radiol*. 2008;18:4–11.

Vivier PH, Dolores M, Gardin I, et al. In vitro assessment of a 3D segmentation algorithm based onthe belief functions theory in calculating renal volumes by MRI. *Am J Roentgenol*. 2008;191(3):W127–W134.

85

Physiology and Pharmacology of the Renal Pelvis and Ureter

Dana A. Weiss MD, Robert M. Weiss MD

The function of the ureter is to transport urine from the kidney to the bladder. Under normal conditions, ureteral peristalsis originates with electric activity at pacemaker sites located in the proximal portion of the urinary collecting system (Bozler, 1942; Constantinou, 1974; Gosling and Dixon, 1974; Hurtado et al., 2010; Lammers et al., 1996; Tsuchida and Yamaguchi, 1977; Weiss et al., 1967, 2006; Zhang and Lang, 1994). The electric activity is then propagated distally and gives rise to the mechanical event of peristalsis, ureteral contraction, which propels the bolus of urine distally. Efficient propulsion of the urinary bolus depends on the ureter's ability to completely coapt its walls (Woodburne and Lapides, 1972). Urine passes into the bladder by way of the ureterovesical junction (UVJ), which, under normal conditions, permits urine to pass from the ureter into the bladder, but not from the bladder into the ureter.

Cellular Anatomy

The primary functional anatomic unit of the ureter is the ureteral smooth muscle cell. The cell is extremely small, approximately 250 to 400 µm in length and 5 to 7 µm in diameter. The **nucleus** is ellipsoid and **contains a darkly staining body, the nucleolus, and the genetic material of the cell. Surrounding the nucleus is the sarcoplasm, which contains the structures involved in cell function.** Frequently in close relation to the nucleus, **mitochondria** in the cytoplasm **perform many of the nutritive functions of the cell. Endoplasmic or sarcoplasmic reticulum dispersed in the cytoplasm serves as Ca^{++} storage sites.**

Dispersed in the sarcoplasm are the **contractile proteins, actin and myosin**. Depending on the local calcium ion (Ca^{2+}) concentration, they interact to produce contraction or relaxation. **Any process that leads to a significant increase in the Ca^{2+} concentration in the region of the contractile proteins results in contraction; conversely, any process that leads to a significant decrease in the Ca^{2+} concentration in the region of the contractile proteins results in relaxation.** Actin is dispersed throughout the sarcoplasm in hexagonal clumps and is interspersed with the less numerous clumps of more deeply staining myosin. Dark bands along the cell surface are referred to as *attachment plaques* that, along with dense bodies dispersed in the cytoplasm, serve as attachment devices for the actin.

Around the periphery of the cell are numerous cavitary structures, some of which open to the outside of the cell and are referred to as ***caveolae***. These **caveolae contain a cytoskeletal protein, caveolin, and a variety of signal transduction molecules and receptors for growth factors and cytokines** (William and Lisanti, 2004). **A double-layer cell membrane surrounds the cell. The inner plasma membrane surrounds the entire cell, but the outer basement membrane is absent at areas of close cell-to-cell contact, referred to as intermediate junctions.**

Development of the Ureter

The ureter, a 25- to 30-cm tube extending from the renal pelvis to the bladder, **arises as an outpouching from the mesonephric duct.** This begins on embryonic day 10.5 (E10.5) in mice and E28 in humans. Signals from the metanephric mesenchyme, stroma, and angioblasts induce the ureteral bud to arise from the mesonephric duct, invade the metanephric mesenchyme, and undergo branching. The nephric (mesonephric or Wolffian) duct cells express a number of surface receptors, including RET, FGFR, AT_2R, and ALK (Fig. 85.1). RET signaling is induced by glial cell line–derived neurotrophic factor (GDNF), **derived from adjacent metanephrogenic mesenchyme** (Pepicelli et al., 1997; Sainio et al., 1997; Shakya et al., 2005), and leads to a rearrangement of the nephric duct cells (Woolf and Davies, 2013). This movement of cells is regulated by the transcription factors ETV4 and ETV5 (Kuure et al., 2010; Yosypiv, 2013; see Fig. 85.1). GDNF-RET signaling is a major pathway in the development of the ureter (Woolf and Davies, 2013) and may be potentiated by neuropeptide Y (NPY) (Choi et al., 2009; Constantini, 2012; Shakya et al., 2005). GDNF signals through the *c-Ret* receptor tyrosine kinase (Vega et al., 1996) and leads to activation of the RAS/ERK MAP kinase, P13K-Akt, and PLC Y-Ca^{++} pathways, which results in increased phosphatidylinositol 3-kinase (P13-kinase) activity and Akt/PKB phosphorylation (Tang et al., 2002). The upregulation of Spry1 by Ret acts as a negative feedback loop (Basson et al., 2006). The expression of GDNF and *c-Ret* is activated by a transcription factor present in the metanephric mesenchyme, paired box 2 *(Pax-2)* (Brophy et al., 2001; Clarke et al., 2006), which is increased by angiotensin II (AT2) (Zhang et al., 2004). A number of other growth factors, including transforming growth factor-β (TGF-β), hepatocyte growth factor (HGF), and fibroblast growth factors (FGF-1, -2, -7, and -10), transcription factors including *Foxd1* and *Wnt11*, and matrix molecules such as heparin sulphate proteoglycans, laminins, integrins, and matrix metalloproteinases (MMP-9) are involved in stimulation or inhibition of growth and branching of the ureteral bud (Basson et al., 2006; Bush et al., 2004; Chen et al., 2004; Davies et al., 1995, 2001; Majumdar et al., 2003; Mendelsohn et al., 1999; Pohl et al., 2000; Qiao et al., 1999, 2001; Sakurai et el., 2003; Takemura et al., 2002).

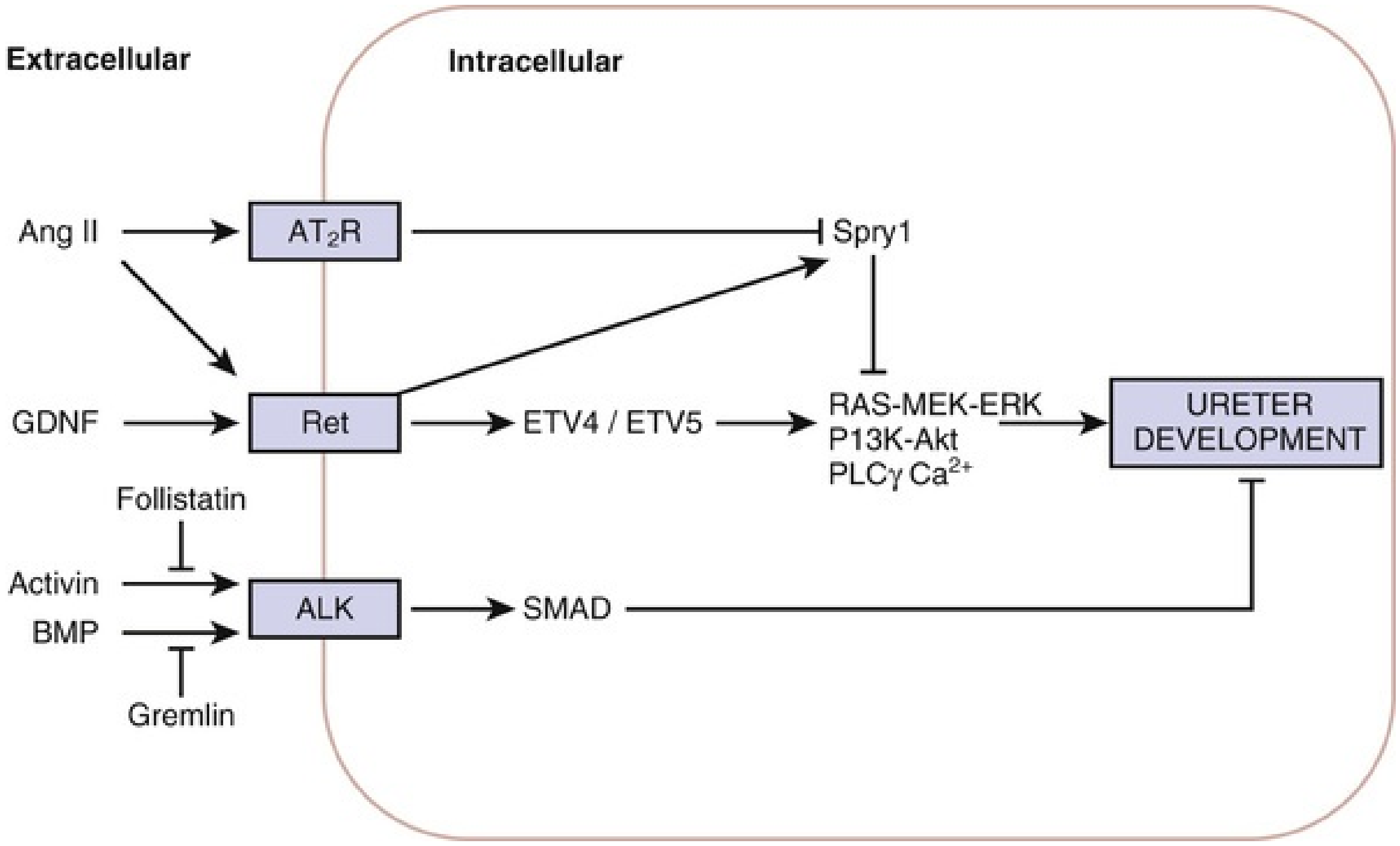

FIG. 85.1 Schematic representation of selected pathways involved in ureter development.

The nephric ducts also express ALK receptors, which are activated by activins and BMPs (TGF-β family members), leading to activation of SMADs, which inhibit ureteric bud outgrowth and ureteral development (Maeshima et al., 2006). Activin A inhibits GDNF-induced ureteral bud formation, and this is accompanied by inhibition of cell proliferation, reduced expression of pax-2, and decreased phosphorylation of PI3-kinase and MAP kinase in the Wolffian duct. The tip of each ureteral bud is capable of inducing adjacent metanephric mesenchyme to undergo mesenchymal-to-epithelial transition (MET) with the formation of the nephron (Ekblom, 1989). Antagonists of the anti-branching factors activin and BMP4 are Gremlin-1 and follistatin, respectively (Woolf and Davies, 2013).

Programmed cell death, or apoptosis, is involved in branching of the ureteric bud and subsequent nephrogenesis. Inhibitors of caspases, which are involved in the apoptotic signaling pathway, inhibit ureteral bud branching (Araki et al., 1999)**. During development, the ureteral lumen is obliterated, and then it recanalizes** (Alcaraz et al., 1991; Russo-Gil et al., 1975)**. It appears that angiotensin (Ang) acting through the AT2 receptor is involved in the recanalization process** (Yerkes et al., 1998) and in the inhibition of aberrant ureteral budding (Oshima et al., 2001). Knockout mice for the *ATR2* gene have congenital anomalies of the kidney and urinary tract, including duplicated collecting systems with a hydronephrotic upper pole moiety, multicystic dysplastic kidneys, megaureters, and ureteropelvic junction (UPJ) obstructions. Mutant mice lacking AT2 type I receptors fail to develop a renal pelvis and lack ureteral peristaltic activity (Miyazaki et al., 1998). Angiotensin II acting via AT2 type I receptors also is involved in ureteric bud cell branching, a process that depends on phosphorylation of the EGF receptor (Iosipiv and Schroeder, 2003; Yosypiv et al., 2006) and can stimulate in vitro branching morphogenesis by directly acting on the ureteric bud (Song et al., 2011). In addition, AT2 induces the expression of the GDNF/c-Ret/Wnt11 pathway and represses SpryI during ureteric bud branching (Song et al., 2010; Yosypiv et al., 2008). Ureteric branching also is promoted by AT2-induced signaling through PI3K/Akt and ERK (Song et al., 2011; Yosypiv, 2013). Some GDNF targets upregulated by AT2 include transcription factors (Etv4, Etv5), signaling molecules (Vsnl1), and receptors (Crlf1) (Song et al., 2011).

Another player in regulating normal ureter development is Brg1 (or SMARCA4). Brg1 is an epigenetic regulator and is part of the switch/sucrose nonfermentable (Swi/Snf) chromatin-remodeling complex. Global loss of Brg1 results in embryonic lethality (Bultman et al., 2000). Brg1 has been shown to be upstream of p63, Pparγ, and sonic hedgehog. Ablation of Brg1 leads to ureter malformation (Weiss et al., 2013).

Calcineurin, a Ca^{++}-dependent serine/threonine phosphatase, also appears to be an essential signaling molecule in urinary tract development. Mutant mice in which calcineurin function is removed are noted to have reduced proliferation of smooth muscle and mesenchymal cells in the developing urinary tract with abnormal development of the renal pelvis and ureter with resultant defective pyeloureteral peristalsis (Chang et al., 2004).

Electric Activity

The electric properties of all excitable tissues depend on the distribution of ions on the inside and the outside of the cell membrane and on the relative permeability of the cell membrane to these ions (Hodgkin, 1958). The ionic basis for electric activity in ureteral smooth muscle has not been fully described; however, many of its properties resemble those in other excitable tissues.

Resting Potential

When a ureteral muscle cell is in a nonexcited or resting state, the electric potential difference across the cell membrane, transmembrane potential, is referred to as the resting membrane potential (RMP). The RMP is determined primarily by the distribution of potassium ions (K^+) across the cell membrane and by the permeability of the membrane to K^+ (Hendrickx et al., 1975). In the resting state, the K^+ concentration on the inside of the cell is greater than that on the outside of the cell, that is,

$$[K^+]_i > [K^+]o,$$

and the membrane is preferentially permeable to K^+. Because of the tendency for the positively charged K^+ ions to diffuse from the inside of the cell, where they are more concentrated, to the outside of the cell, where they are less concentrated, an electric gradient is created, with the inside of the cell membrane more negative than the outside (Fig. 85.2A). The electric gradient that is formed tends to oppose the further movement of K^+ outward across the cell membrane along its concentration gradient, and an equilibrium is reached.

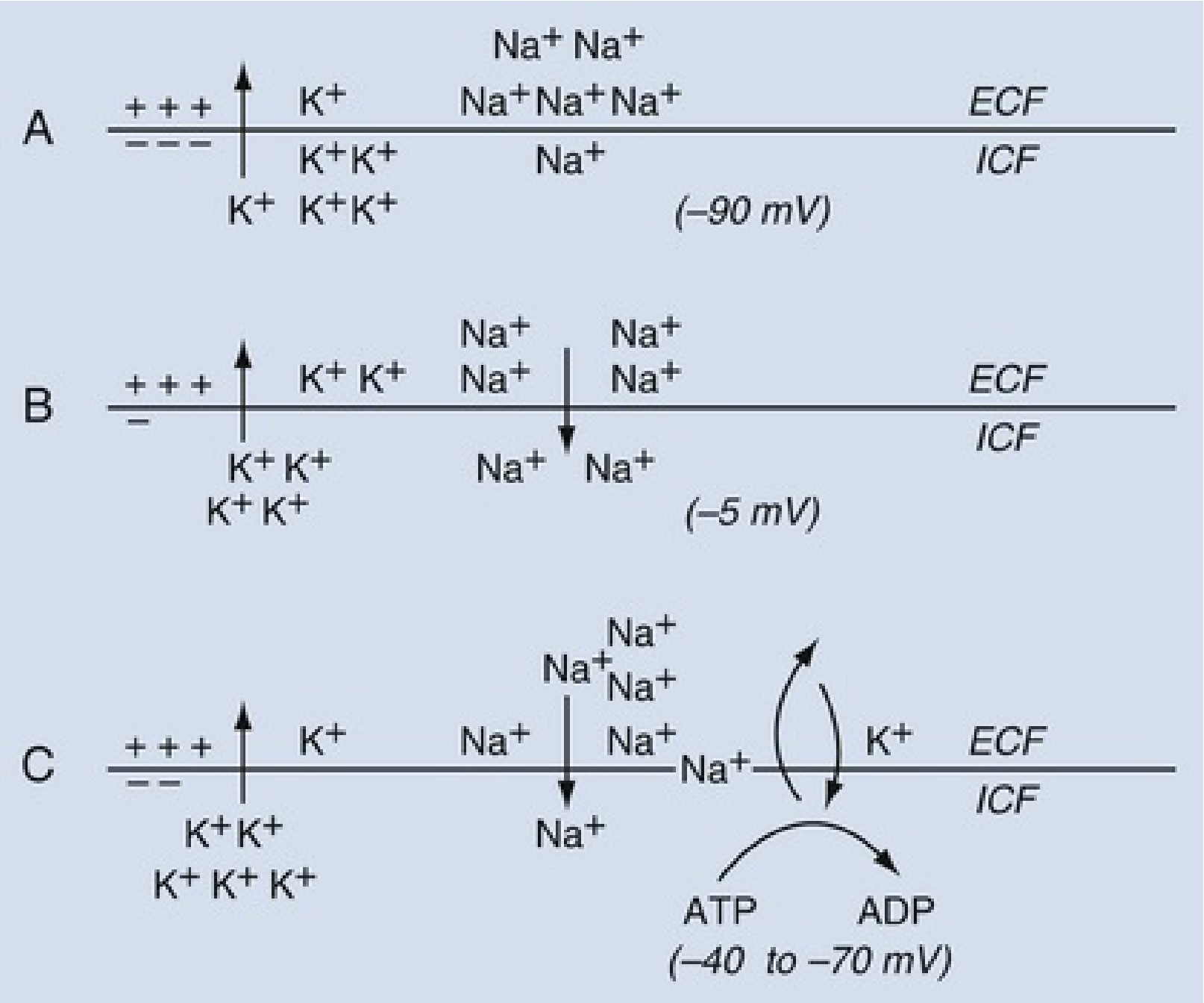

FIG. 85.2 Ionic basis for the resting membrane potential (RMP) in smooth muscle. In the resting state, the K^+ concentration inside the cell is greater than the K^+ concentration outside the cell, and the Na^+ concentration outside the cell is greater than the Na^+ concentration inside the cell. (A) Electrochemical changes that would occur if the membrane were solely permeable to potassium. Potassium would diffuse from the inside of the cell, where it is more concentrated, to the outside of the cell, where it is less concentrated. The outward movement of the positively charged K^+ ions would make the inside of the cell membrane negative with respect to the outside of the cell membrane. (B) Electrochemical changes that would occur if the resting membrane were also permeable to sodium. An inward movement of Na^+ along its concentration gradient would make the inside of the cell membrane less negative with respect to the outside of the cell membrane than is depicted in A. (C) Pump mechanism for extruding Na^+ from within the cell against concentration and electrochemical gradients. Inward movement of K^+ is coupled with outward movement of Na^+. This mechanism helps to maintain a steady state of ion distribution across the cell membrane and a stable RMP. *ADP,* Adenoside disphosphate; *ATP,* adenosine triphosphate; *ECF,* extracellular fluid; *ICF,* intracellular fluid. (A to C, From Weiss RM: Ureteral function. *Urology* 12:114, 1978.)

If the membrane in the resting state were exclusively permeable to K^+, the measured RMP of the ureteral smooth muscle cell would approximate –90 mV, the K^+ equilibrium potential, as predicted by the Nernst equation:

$$E_k = -RT/nF \ln [K^+]_i / [K^+]_o$$

where E_k is the potential difference attributable to the concentration difference of K^+ across the cell membrane, R is the molar gas constant, T is the absolute temperature, n is the number of mols of K^+, and F is the faraday (Nernst, 1908). However, **in the ureter and in other smooth muscles, the RMP is considerably less than the K^+ equilibrium potential, with values of –33 to –70 mV, the inside of the cell being negative with respect to the outside** (Kuriyama et al., 1967). Studies from single isolated ureteral cells show spontaneous transient hyperpolarizations with the RMP transiently becoming more negative (Imaizumi et al., 1989). This phenomenon appears to be due to spontaneous release of Ca^{2+} from the sarcoplasmic reticulum with activation of tetraethylammonium (TEA) and charbydotoxin sensitive Ca^{2+}-dependent K^+ channels ($I_{K[Ca]}$). Although the low resting potential of ureteral cells may be explained in part by a relatively small resting K^+ conductance (Imaizumi et al., 1989), it also may be due to the contribution of other ions.

One such ion that could account for the relatively low RMP of the ureter and other smooth muscles is the sodium ion (Na^+) (Kuriyama, 1963). In the resting state, the Na^+ concentration on the outside of the cell membrane is greater than that on the inside, that is, $[Na^+]_o > [Na^+]_i$. If the resting membrane were somewhat permeable to Na^+, the concentration and the electric gradient would support an inward movement of Na^+ across the cell membrane, with a resultant decrease in the electronegativity of the inner surface of the cell membrane (see Fig. 85.2B).

If such an inward movement of Na^+ went unchecked, the RMP would be expected to decrease to a level lower than that actually observed, and the concentration gradient for Na^+ may become reversed. To maintain a steady-state ion distribution across the cell membrane with $[K^+]_o < [K^+]_i$ and $[Na^+]_o > [Na^+]_i$ and to prevent the transmembrane potential from becoming lower than the measured ureteral RMP, an active mechanism capable of extruding Na^+ from within the cell against a concentration and electrochemical gradient is required (see Fig. 85.2C). Such an outward Na^+ pump that is coupled with an inward movement of K^+ derives its energy requirements from the dephosphorylation of adenosine triphosphate (ATP) (Casteels, 1970). Na^+-Ca^{2+} exchange also may play a role in Na^+ extrusion, especially when the Na^+ pump is inhibited (Aickin, 1987; Aickin et al., 1987; Lamont et al., 1998).

The dynamic processes illustrated in Fig. 85.2 enable the ureter in its resting state to maintain a relatively low RMP. In addition to the mechanisms described, the distribution of chloride ions (Cl^-) across the cell membrane and the relative permeability of the membrane to Cl^- may affect the maintenance of the RMP in the ureter and other smooth muscles (Kuriyama, 1963; Washizu, 1966). Activation of Ca^{2+}-activated Cl^- channels (ClCa) also can decrease the membrane potential and therefore depolarizes the membrane (Verkman and Galietta, 2009).

Action Potential

The transmembrane potential of an inactive or resting ureteral cell remains stable until it is excited by an external stimulus (electric, mechanical, or chemical) or by conduction of electric activity (action potential) from an already excited adjacent cell. **When a ureteral cell is stimulated, depolarization occurs, with the inside of the cell membrane becoming less negative than it was before stimulation. If a sufficient area of the cell membrane is depolarized rapidly enough to reach a critical level of transmembrane potential, referred to as the threshold potential, a regenerative depolarization, or action potential, is initiated.**

The changes that occur are diagrammatically depicted in Fig. 85.3. If a stimulus is very weak, as shown by *arrow a,* the transmembrane potential may remain unchanged. A slightly stronger, yet subthreshold, stimulus may result in an abortive displacement of the transmembrane potential, but not to such a degree that an action potential is generated *(arrow b).* If the stimulus is strong enough to decrease the transmembrane potential to the threshold potential, the cell becomes excited and produces an action potential *(arrow c).* The **action potential**, which **is the primary event in the conduction of the peristaltic impulse**, has the capability to act as the stimulus for excitation of adjacent quiescent cells and, through a complicated chain of events, **gives rise to the ureteral contraction.**

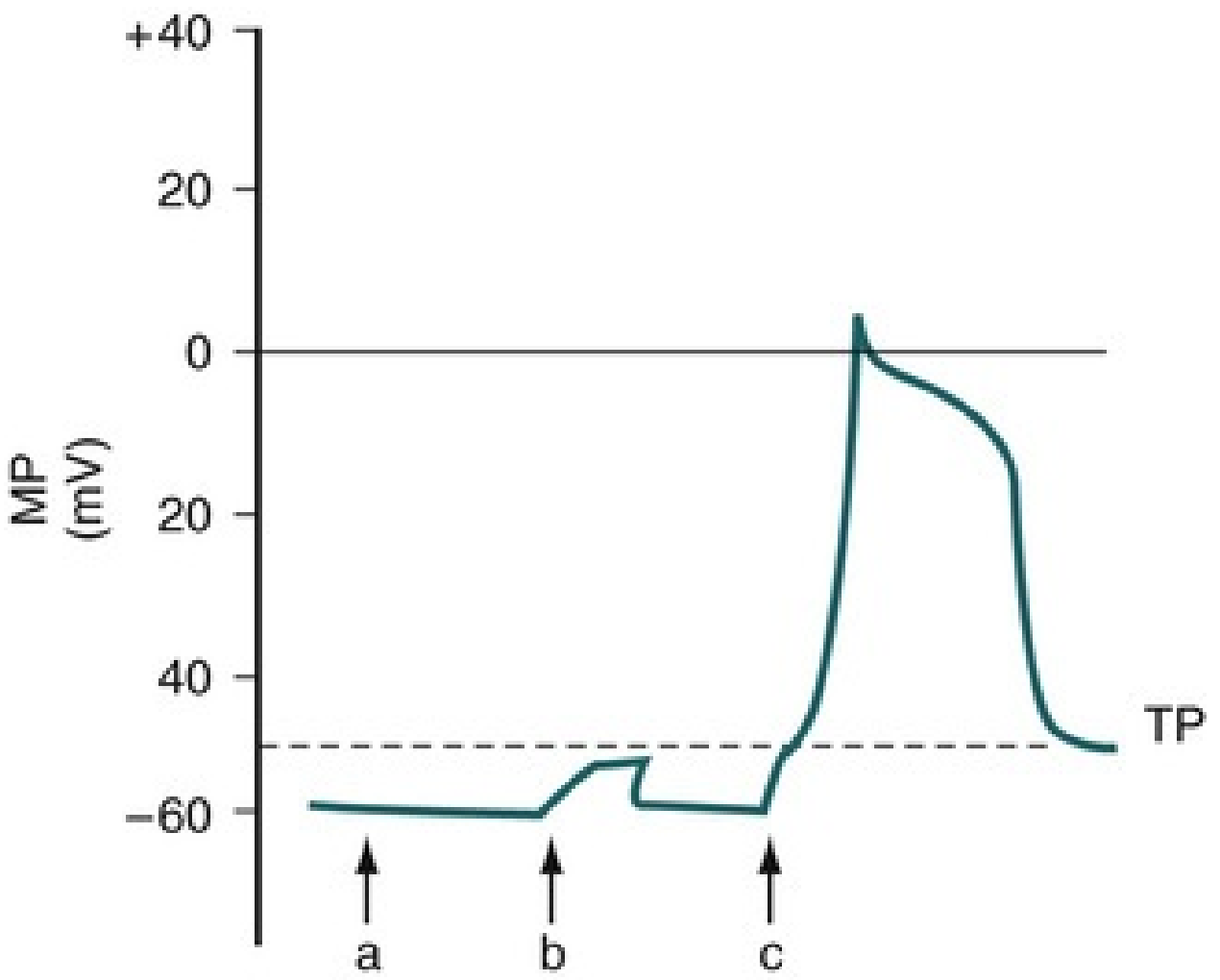

FIG. 85.3 Response of ureteral transmembrane potential to stimuli. At *arrow a,* a weak stimulus is applied that does not alter the resting membrane potential (*MP*). At *arrow b,* a stimulus is applied that decreases the transmembrane potential but not to the level of the threshold potential (*TP*) (subthreshold stimulus). At *arrow c,* a stimulus is applied that decreases the transmembrane potential to TP, and an action potential is initiated (suprathreshold stimulus). (From Weiss RM: Ureteral function. *Urology* 12:114, 1978.)

When the ureteral cell is excited, its membrane loses its preferential permeability to K^+ and becomes more permeable to Ca^{2+} ions that move inward across the cell membrane primarily through fast L-type Ca^{2+} channels and gives rise to the upstroke of the action potential (Fig. 85.4A) (Imaizumi et al., 1989; Kobayashi, 1965; Kuriyama and Tomita, 1970; Lang, 1989, 1990; Smith et al., 2002; Sui and Kao, 1997a, 1997b). L-type Ca^{2+} channels are inhibited by the calcium channel blocker nifedipine, and by cadmium (Cd^{2+}), and are potentiated by barium (Ba^{2+}). As the positively charged Ca^{2+} ions move inward across the cell membrane, the inside of the membrane becomes less negative with respect to the outside and may even become positive at the peak of the action potential, a state referred to as overshoot. Na^+ ions also may play a role in the upstroke of the ureteral action potential (Kobayashi, 1964, 1965; Muraki et al., 1991). The rate of rise of the upstroke of the ureteral action potential is relatively slow, 1.2 ± 0.06 V/sec in the cat (Kobayashi, 1969). This compares with a 610-V/sec rate of rise in dog cardiac Purkinje fibers (Draper and Weidmann, 1951) and a 740-V/sec rate of rise in skeletal muscle (Ferroni and Blanchi, 1965). The slow rate of upstroke rise of the ureteral action potential accounts for the slow conduction velocity in the ureter.

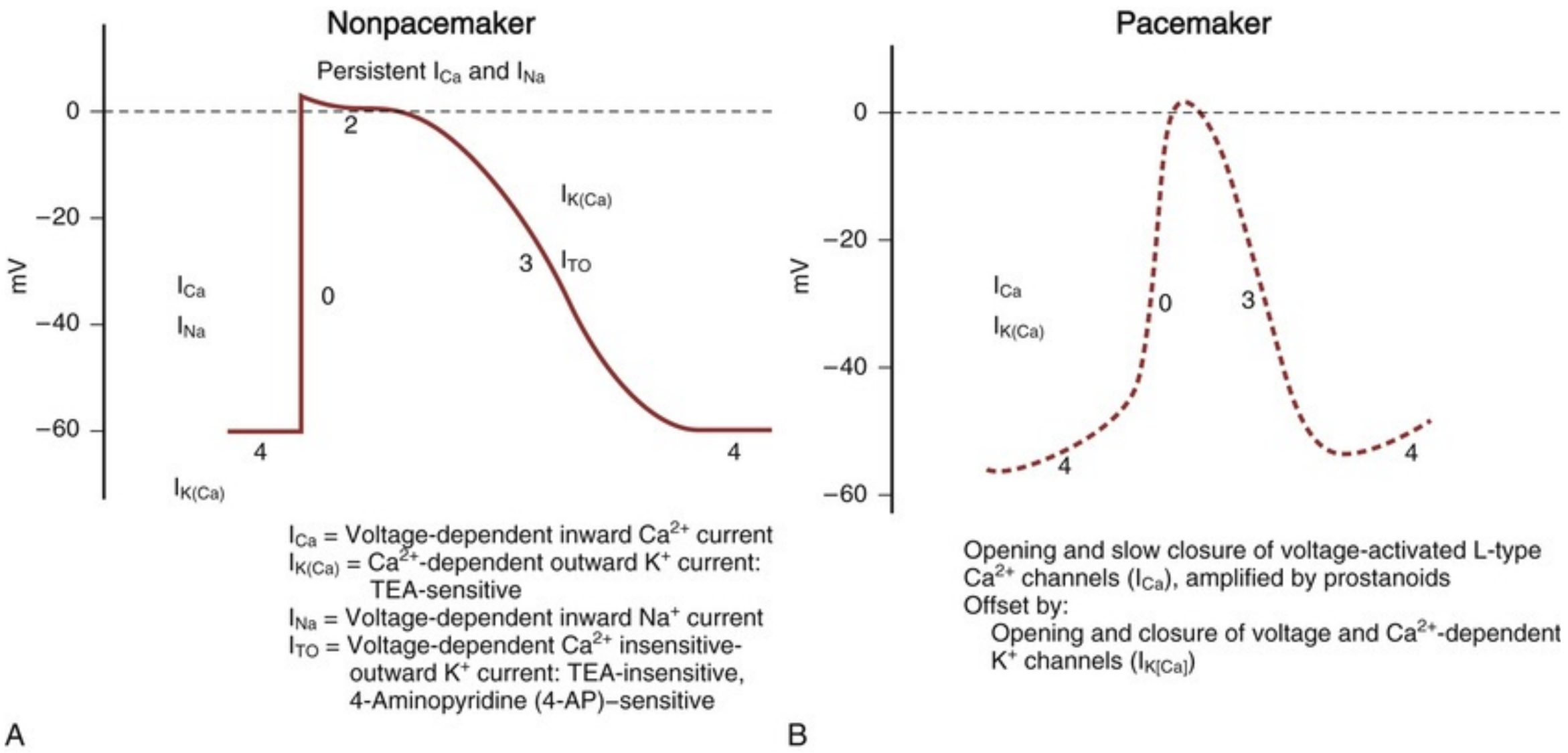

FIG. 85.4 Schematic representation of ionic currents in (A) nonpacemaker *(solid line)* and (B) pacemaker *(dashed line)* action potentials: (0) upstroke or depolarization phase; (2) plateau phase; (3) repolarization phase; and (4) resting potential of the nonpacemaker cell and spontaneous depolarization phase of the pacemaker cell. A spontaneous decrease in the transmembrane potential of pacemaker cells accounts for their spontaneous activity. (*TEA,* Tetraethyl ammonium.)

After reaching the peak of its action potential, the ureter maintains its potential for a period of time (plateau of the action potential) before the transmembrane potential returns to its resting level (repolarization) (Kuriyama et al., 1967). The plateau phase of the guinea pig action potential is superimposed with multiple oscillations, a phenomenon not observed in the rat, rabbit, or cat (Figs. 85.5A and B; Bozler, 1938). The plateau phase appears to depend on the persistence of an inward Ca^{2+} current and on Na^+ influx through a voltage-dependent Na^+ channel (see Fig. 85.4A; Imaizumi et al., 1989; Kuriyama and Tomita, 1970; Sui and Kao, 1997b). Also involved in the plateau formation is the maintenance of depolarization by an inward calcium-dependent chloride current ($I_{Cl[Ca]}$), which is countered by outward voltage-gated and Ca^{2+}-activated K^+ currents (K_{Ca}) (Smith et al., 2002). There are species differences in the ionic currents involved in the formation of the action potential with the Ca^{2+} activated chloride current present in the rat but not in the guinea pig ureter. The inward Cl^- current can be inhibited by niflumic acid and by Ba^{2+} (Smith et al., 2002). The oscillations on the plateau of the guinea pig action potential appear to depend on the repetitive activation of an inward Ca^{2+} current (Kuriyama and Tomita, 1970) and of a Ca^{2+}-dependent outward K^+ current (Imaizumi et al., 1989). Prolongation of the inward calcium current and the duration of the action potential correlate with an increase force of contraction (Burdyga and Wray, 1999b).

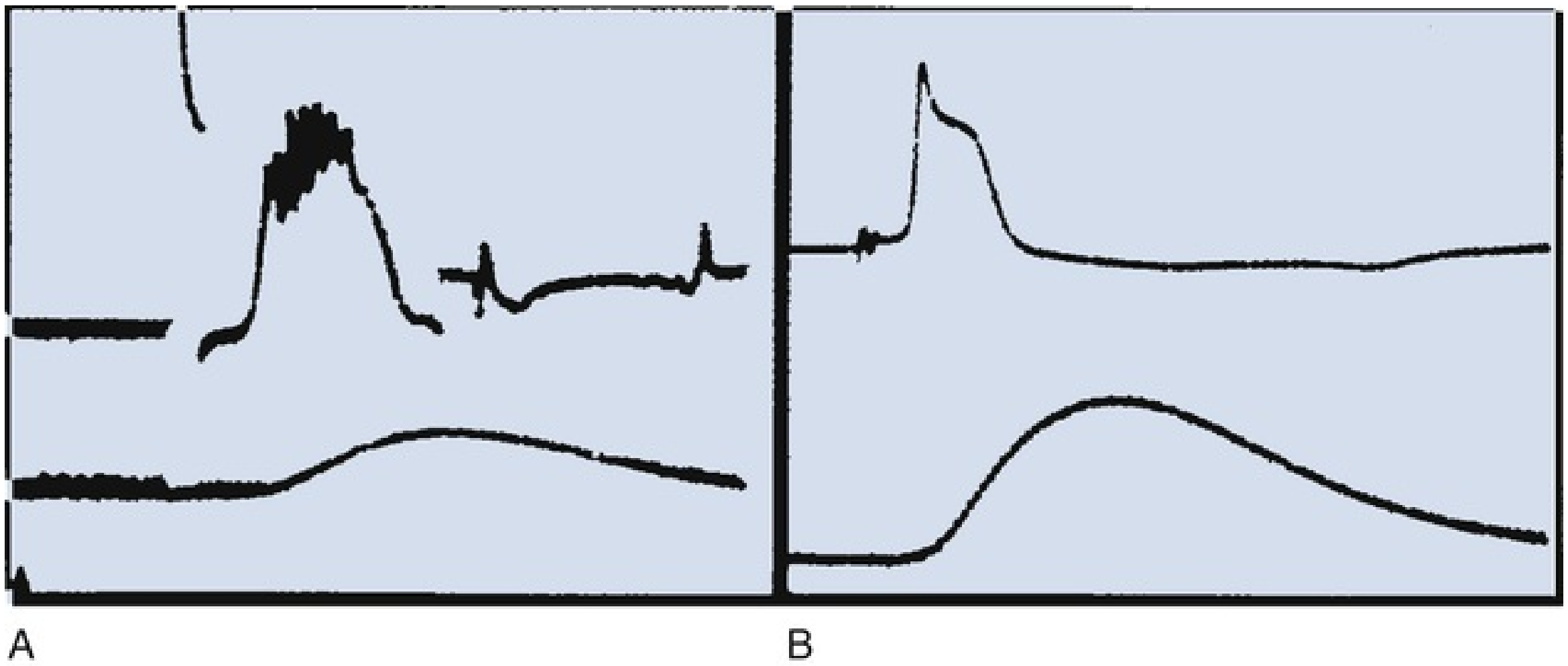

FIG. 85.5 Intracellular recordings of ureteral action potentials (upper tracings) and isometric recordings of contractions (lower tracings) in response to electrical stimuli. Action potentials precede contractions. (A) Guinea pig ureter; oscillations on the plateau of the action potential. (B) Cat ureter; no oscillations on the plateau of the action potential. (A and B, From Weiss RM: Ureteral function. *Urology* 12:114, 1978.)

The activation of a Ca^{2+}-dependent K^+ current that is involved in repolarization is mainly due to Ca^{2+} release from the endoplasmic reticulum that is triggered by the influx of extracellular Ca^{2+} through voltage-dependent Ca^{2+} channels. The increase in intracellular Ca^{2+} concentration during the upstroke and plateau of the action potential finally may activate the outward Ca^{2+}-dependent K^+ current ($I_{K[Ca]}$) to such a degree that repolarization occurs with return of the transmembrane potential to its resting level (see Fig. 85.4A; Imaizumi et al., 1989; Sui and Kao, 1997c). The $I_{K(Ca)}$ is sensitive to inhibition by TEA. TEA increases the amplitude and duration of in vitro ureteral contractions (Floyd et al., 2008). A voltage-dependent, Ca^{2+}-insensitive outward K^+ current (I_{TO}) also appears to be involved in the repolarization (Imaizumi et al., 1990; Lang, 1989). These currents are TEA insensitive and 4-aminopyridine (4-AP) sensitive. In the rat but not the guinea pig ureter there is a late TEA, Cd^{2+}, and Ca^{2+}-insensitive outward K^+ current, which also is involved in the repolarization process. The duration of the action potential in the cat ranges from 259 to 405 msec (Kobayashi and Irisawa, 1964).

Key Points

- The RMP of the ureteral cell is approximately –33 to –70 mV and is determined primarily by the distribution of K^+ ions across the cell membrane and the relatively selective permeability of the resting cell membrane to K^+.
- When excited by a suprathreshold stimulus, the membrane becomes less permeable to K^+ and more permeable to Ca^{2+}, which moves inward across the cell membrane and provides the ionic mechanism for the development of the upstroke of the action potential.
- After reaching the peak of its action potential, the membrane maintains a depolarized state—plateau of the action potential—for a period of time before the membrane potential of the activated cell returns to its resting level (repolarization).
- The plateau appears to be related to a persisting inward Ca^{2+} current and to an influx of Na^+. Repolarization of the membrane is related to a renewed increase in permeability to K^+.

Pacemaker Potentials and Pacemaker Activity

Electric activity arises in a cell either spontaneously or in response to an external stimulus. If the activity arises spontaneously, the cell is referred to as a pacemaker cell. Pacemaker cells differ from nonpacemaker cells in that their transmembrane resting potential is lower (less negative) than that of nonpacemaker cells (Lang and Zhang, 1996) and does not remain constant but rather undergoes a slow spontaneous depolarization (see Fig. 85.4B). If the spontaneously changing membrane potential reaches the threshold potential, the upstroke of an action potential occurs. The **ionic conduction underlying pacemaker activity in the upper urinary tract is due to the opening and slow**

closure of voltage-activated L-type Ca^{2+} channels (Santicioli et al., 1995a). This is opposed by the opening and closure of voltage and Ca^{2+}-dependent K^+ channels. It has been suggested that prostaglandins and excitatory tachykinins, released from sensory nerves, help maintain autorhythmicity in the upper urinary tract through maintenance of Ca^{++} mobilization (Lang et al., 2002a; Nguyen et al., 2016). **Tetrodotoxin and blockers of the autonomic nervous system, parasympathetic and sympathetic, have little effect on peristalsis, suggesting that autonomic neurotransmitters have little role in maintaining pyeloureteral motility** (Lang et al., 2001; 2002b). Changes in the frequency of action potential development may result from a change in the level of the threshold potential, a change in the rate of slow spontaneous depolarization of the resting potential, or a change in the level of the resting potential.

Bozler (1942), using small extracellular surface electrodes, demonstrated the characteristic slow spontaneous depolarization of pacemaker-type fibers in the proximal portion of the isolated ureter of a unicalyceal upper collecting system. In a multicalyceal kidney, Morita et al. (1981), using extracellular electrodes, recorded low-voltage potentials that appeared to be pacemaker potentials from the border of the pig minor calyces and the major calyx with the contraction rhythm varying between each calyx. Multiple pacemakers fire simultaneously as coupled oscillators or individually as pacemaker activity shifts from one site to another along the renal pelvis of the unicalyceal kidney or the pelvicalyceal border of the multicalyceal pig and sheep kidney (Constantinou and Yamaguchi, 1981; Constantinou et al., 1977; Golenhofen and Hannappel, 1973; Lammers et al., 1996).

Gosling and Dixon (1971, 1974) provided morphologic evidence of specialized pacemaker tissue in the proximal portion of the urinary collecting system and described species differences. **In species with a multicalyceal system, such as the pig, sheep, and human, the "pacemaker cells" are located near the pelvicalyceal border** (Dixon and Gosling, 1973). In species with an unicalyceal system, such as the dog, cat, rat, rabbit, and guinea pig, the "pacemaker cells" extend from the pelvicalyceal border to the UPJ. These **atypical smooth muscle cells that give rise to pacemaker activity**, in contrast to typical smooth muscle cells, have less than 40% of their cellular area occupied by contractile elements and demonstrate sparse immunoreactivity for smooth muscle and actin (Klemm et al., 1999; Lang et al., 2001). These atypical smooth muscle spindle-shaped cells are 90 to 230 µm in length, and their electrical activity consists of simple waveforms of alternating depolarizing and repolarizing phases that occur at a relatively rapid frequency of 8 to 15/min (Fig. 85.6A; Klemm et al., 1999; Tsuchida and Suzuki, 1992). Pacemaker potentials have a lower resting membrane potential (RMP), a slower rate of rise, and a lower amplitude than action potentials recorded from nonpacemaker cells. In the guinea pig these atypical, presumably pacemaker cells make up more than 80% of the cells at the pelvicalyceal junction, about 15% of the cells in the proximal renal pelvis, but are not present in the distal renal pelvis or ureter (Klemm et al., 1999). Electrical recordings correlate with histologic findings in that pacemaker potentials were not observed in the distal renal pelvis or ureter (Klemm et al., 1999).

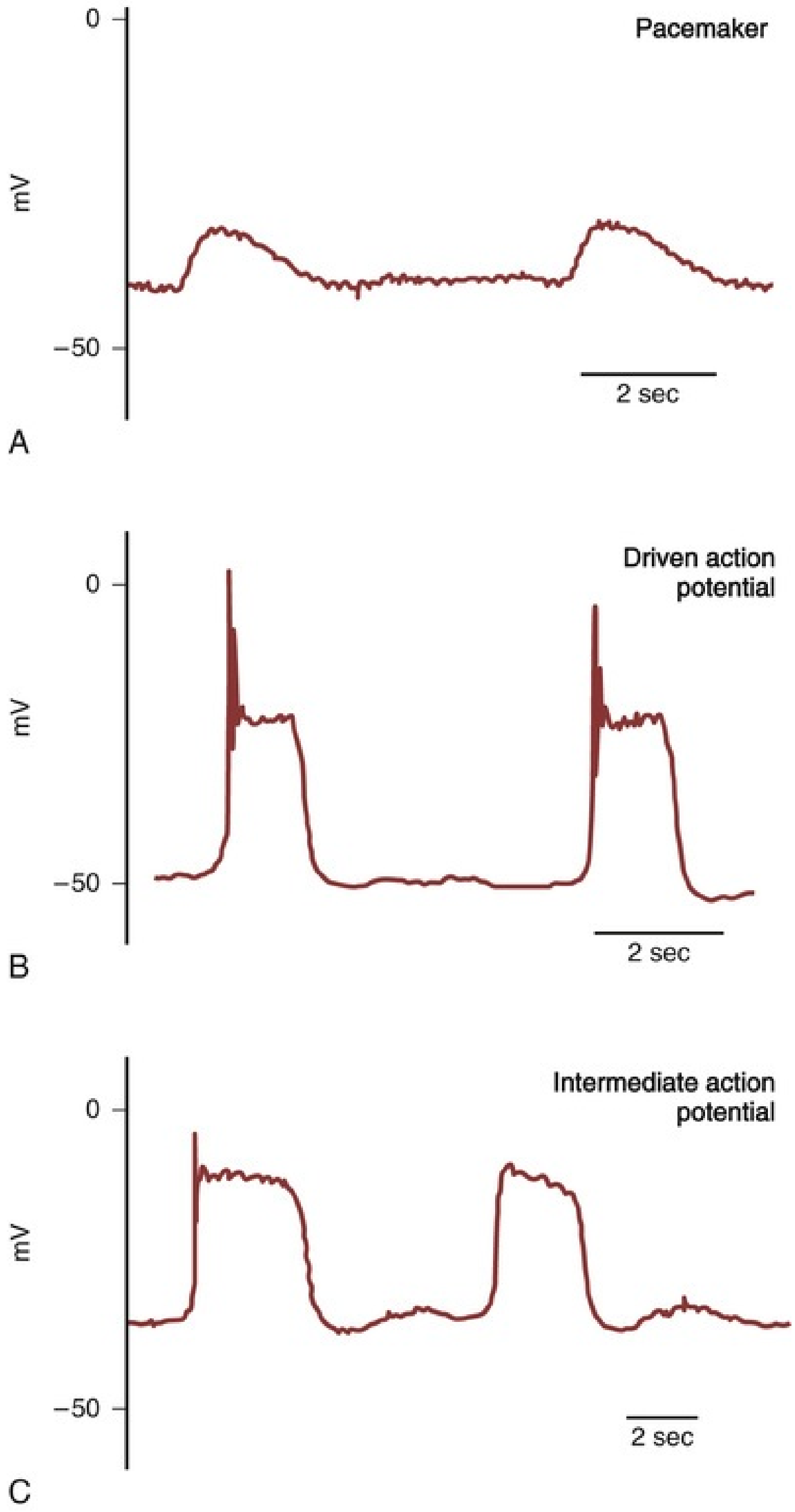

FIG. 85.6 Action potentials in the upper urinary tract of the guinea pig. (A) Pacemaker potentials. (B) Driven action potentials, which fire at a lower frequency than pacemaker potentials, recorded from longer spindle-shaped typical smooth muscle cells. (C) Intermediate action potentials, from "ICC-like cells," have a single spike, a plateau, and a rapid depolarization phase.

(Modified with permission from Klemm MF, Exintaris B, Lang RJ: Identification of the cells underlying pacemaker activity in the guinea pig upper urinary tract. *J Physiol (Lond)* 519:867, 1999.)

Driven action potentials that fire at lower frequency (3–5/min) than pacemaker potentials are recorded from longer (150–400 µm) spindle-shaped typical smooth muscle cells (Fig. 85.6B; Klemm et al., 1999). Most muscle cells of the ureter (100%), distal renal pelvis (97.5%), and proximal renal pelvis (83%) are typical nonpacemaker smooth muscle cells with typical action potentials. Lang et al. (1998) described fibroblast-like cells resembling the interstitial cells of Cajal (ICCs), which serve as pacemaker cells in the intestine, in the proximal portion of the guinea pig renal pelvis. These “ICC-like” cells are irregular shaped with oval nuclei and many branching interconnecting processes and contain numerous mitochondria, caveolae, and prominent endoplastic reticulum. The “ICC-like” cells in the guinea pig are not immunoreactive for α-smooth muscle actin, which is present in typical smooth muscle cells, or for C-kit, a tyrosine kinase receptor that is expressed in intestinal ICC pacemaker cells (Klemm et al., 1999). The immunoreactivity to C-kit appears to be species specific as “ICC-like” cells that are immunoreactive to antibodies raised against the C-kit proto-oncogene are present in the upper urinary tract of a number of mammals (Lang and Klemm, 2005; Metzger et al., 2005). Electrical recordings from these cells demonstrate action potentials with properties intermediate to pacemaker and driven action potentials. Intermediate action potentials in the guinea pig have a single spike, a plateau without the superimposed spikes seen in driven action potentials, and a rapid repolarization phase (Fig. 85.6C). Intermediate action potentials are noted in 11% to 17% of cells at the pelvicalyceal junction and the proximal and distal renal pelvis (Lang et al., 2001). These **“ICC-like” cells (telocytes) in the upper urinary tract do not appear to be primary pacemaker cells but rather may provide for preferential conduction of electrical signals from pacemaker cells to typical smooth muscle cells** of the renal pelvis and ureter (Klemm et al., 1999). In the mouse ureteropelvic junction c-KIT–positive “ICC-like” cells have been identified that show high-frequency spontaneous transient inward currents that often occur in bursts and sum to produce long-lasting large inward currents (Lang et al., 2007b). **It is postulated that in the absence of a proximal pacemaker that these “ICC-like” cells could act as pacemaker cells and trigger contractions in adjacent smooth muscle cells in the ureteropelvic junction. Thus atypical smooth muscle cells and “ICC-like” cells may play a**

pacemaker role in the initiation and propagation of pyeloureteric peristalsis (Lang et al., 2006, 2007a).

c-KIT is a tyrosine kinase receptor that promotes cell migration and proliferation of melanoblasts, hematopoietic progenitors, and primordial germ cells. Mice expressing mutant inactivating c-KIT alleles lack intestinal ICCs and have abnormal intestinal peristalsis and develop bowel obstruction, showing that **c-KIT is important in the development of pacemaker activity and peristalsis of the gut** (Der-Silaphet et al., 1998). Pezzone et al. (2003) identified c-KIT–positive cells in the mouse ureter. They suggested that the difference from previous studies in the guinea pig upper urinary tract in which c-KIT positivity was not identified in ICC-like cells (Klemm et al., 1999) may be due to species differences, the c-KIT antibody used, and/or the fixation methods. **c-KIT expression** was noted to be **upregulated in the embryonic murine ureter before its development of unidirectional peristaltic contractions** (David et al., 2005). Incubation of isolated cultured embryonic murine ureters with antibodies that neutralize c-KIT activity altered ureteral morphology and inhibited unidirectional peristalsis. These data suggest that c-KIT–containing cells, which are most probably "ICC-like" cells, have an important role in pyeloureteric peristalsis. c-KIT–positive cells have been identified in the human ureter (Metzger et al., 2004; van der Aa et al., 2004) and in the human UPJ (Solari et al., 2003). In the presence of obstruction, c-KIT–positive ICC-like cells at the UPJ have been reported decreased (Solari et al., 2003; Yang et al., 2009) or increased (Koleda et al., 2012).

More recently, **hyperpolarization-activated cation-3 channels (HCN3) were shown to be expressed at the pelvis-kidney junction and to play a role in the development of pacemaker activity. Uncoordinated peristalsis was demonstrated in renal pelvis-ureter explants that were treated with an HCN3 channel blocker** (Hurtado et al., 2010). Furthermore, it has been shown that hedgehog signaling controls KIT and HCN3 expression and that the hedgehog signaling pathway is required for the development of pacemaker function and coordinated peristalsis in the mouse ureter (Cain et al., 2011). Inhibition of either c-KIT or HCN3 results in impaired ureteral peristaltic activity, suggesting that both are required for normal ureteral function.

Although the primary pacemaker for ureteral peristalsis is located in the proximal portion of the collecting system, other areas of the ureter may act as **latent pacemakers.** Under normal conditions, the latent pacemaker regions are dominated by activity arising at the primary pacemaker sites. When the latent pacemaker site is freed of its domination by the primary pacemaker, it, in turn, may act as a pacemaker. To demonstrate latent pacemaker sites, Shiratori and Kinoshita (1961) transected the in vivo dog ureter at various levels. Before transection, peristaltic activity arose proximally from the primary pacemaker. When the ureter was transected at the UPJ, antiperistaltic waves of lower frequency than the previous normoperistaltic waves originated from the UVJ. Division of the ureter at the UVJ did not affect the normoperistaltic waves. After division of the midureter, the normoperistaltic waves in the upper segment remained unchanged, and the lower segment demonstrated antiperistaltic waves, which originated at the UVJ at a frequency less than that of the normoperistaltic waves in the upper segment. Thus cells at the UVJ of the dog may act as pacemaker cells when freed of control from the primary proximally located pacemaker. Latent pacemaker cells are present throughout the ureter (Imaizumi et al., 1989; Meini et al., 1995).

Propagation of Electric Activity

Excitable cells possess resistive and capacitative membrane properties similar to those of a cable or core conductor. The transverse resistance of the membrane is higher than the longitudinal resistance of the extracellular or intracellular fluid; this allows current resulting from a stimulus to propagate along the length of the fibers. The spread of current is referred to as *electrotonic spread* (Hoffman and Cranefield, 1960). The space constant (λ) determines the degree to which the electrotonic potential dissipates with increasing distance from an applied voltage. In a cable, this relation is expressed by

$$P = P_o\, e^{-X/\lambda}$$

where X is the distance from the applied voltage, P is the displacement of the membrane potential at X, P_o is the displacement of the membrane potential at the site of the applied voltage, e is the base of the natural logarithm, and λ is the space constant. Thus the electrotonic potential decreases by 1/e in 1 space constant. The space constant of the guinea pig ureter measured by extracellular stimulation is 2.5 to 3 mm (Kuriyama et al., 1967).

The time constant τ_m is expressed by

$$\tau_m = RC$$

where R is the membrane resistance and C is the membrane capacity. The time constant τ_m signifies that a small displacement of potential is decreased by 1/*e* of its value in 1 τ_m. The time constant of the guinea pig ureter measured by extracellular stimulation is 200 to 300 msec (Kuriyama et al., 1967).

The ureter acts as a **functional syncytium.** Engelmann (1869, 1870) showed that stimulation of the ureter produces a contraction wave that propagates proximally and distally from the site of stimulation. Under normal conditions, **electric activity** arises proximally and is **conducted distally from one muscle cell to another across areas of close cellular apposition referred to as intermediate junctions** (Libertino and Weiss, 1972; Uehara and Burnstock, 1970). The similarity of these close cellular contacts to nexuses, which have been shown to be low-resistance pathways for cell-to-cell conduction in other smooth muscles (Barr et al., 1968), suggests that a similar mechanism for conduction may be present in the ureter. **Gap junctions consisting of groups of channels in the plasma membrane of adjacent smooth muscle cells enable exchange of ions and small molecules and play a role in electrical coupling between adjacent cells and in electromechanical coupling** (Gabella, 1994; Santicioli and Maggi, 2000). 18β-Glycyrrhetinic acid, a gap junction inhibitor, inhibits cell-to-cell electrical coupling in guinea pig renal pelvis and ureter and dissociates electrical and mechanical events (Santicioli and Maggi, 2000). **Conduction velocity in the ureter is 2 to 6 cm/sec** (Kobayashi, 1964; Kuriyama et al., 1967); it has been shown to vary with temperature, the time interval between stimuli (van Mastrigt et al., 1986), and with the pressure within the ureter (Tsuchiya and Takei, 1990). This is in comparison with conduction velocities ranging from 1.5 to 2 m/sec in cardiac Purkinje fibers (Rosen et al., 1981), and myelinated nerves can conduct at speeds up to 150 m/sec. Conduction in the ureter is similar to that in cardiac tissue, even to the extent that the Wenckebach phenomenon (a partial conduction block) has been demonstrated in the ureter as it has been in specialized cardiac fibers (Weiss et al., 1968).

Contractile Activity

The contractile event depends on the concentration of free sarcoplasmic Ca^{2+} in the region of the contractile proteins, actin and myosin. Any process that results in a significant increase in Ca^{2+} in the region of the contractile proteins favors the development of a contraction; any process that results in a significant decrease in Ca^{2+} in the region of the contractile proteins favors relaxation (Fig. 85.7).

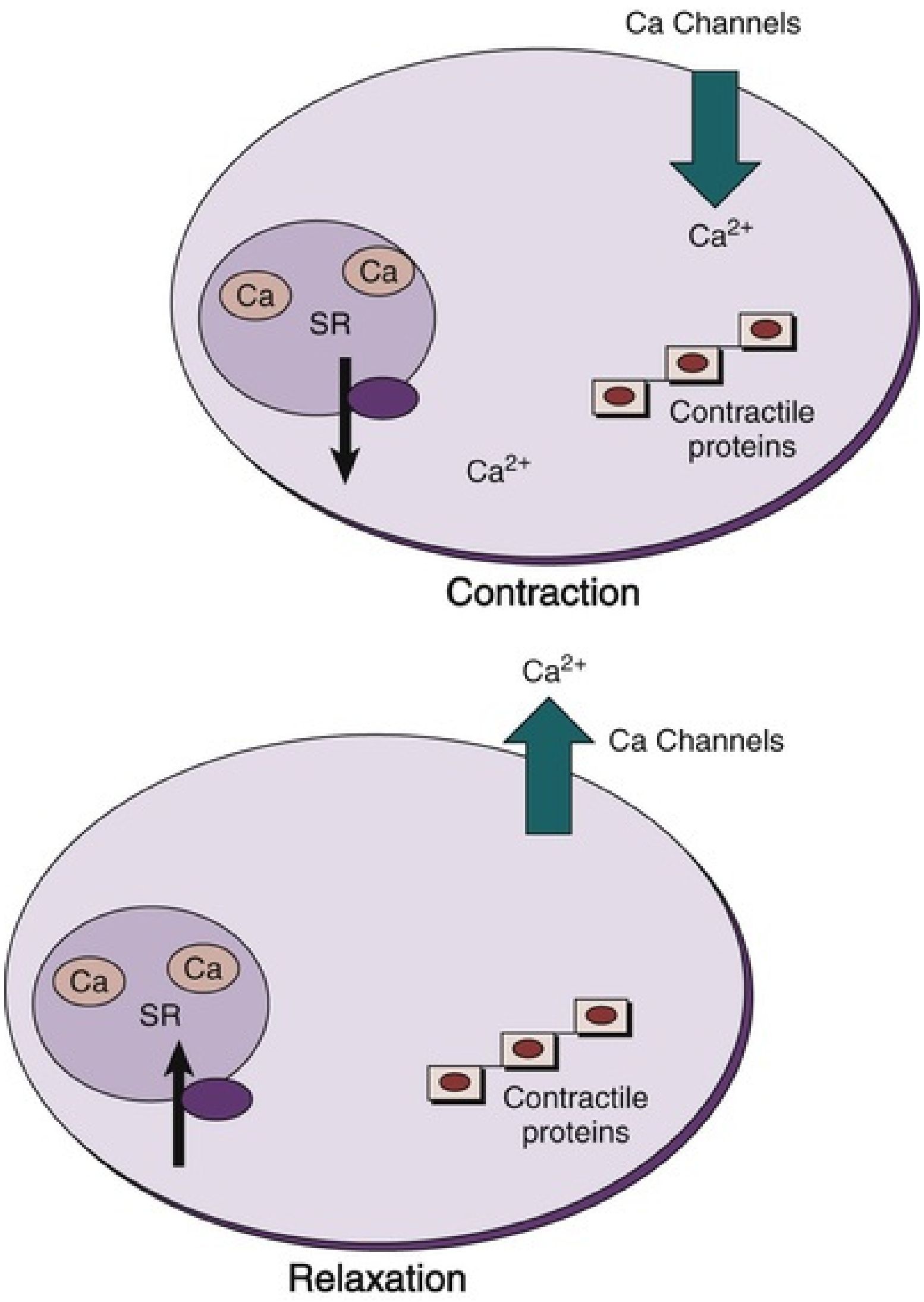
Ca Channels
Ca^{2+}
Ca
Ca
SR
Contractile proteins
Ca^{2+}
Contraction
Ca^{2+}
Ca Channels
Ca
Ca
SR
Contractile proteins
Relaxation

FIG. 85.7 Schematic representation of calcium ion movements during contraction and relaxation. *SR,* Sarcoplasmic reticulum.

Contractile Proteins

In skeletal muscle, Ca^{2+} appears to act as a derepressor. It is thought that in the relaxed state, a regulator system, consisting of the proteins troponin and tropomyosin, prevents the interaction of actin and myosin. In the relaxed state, the troponin that is attached to the tropomyosin is inactive, and the tropomyosin prevents the interaction between actin and myosin. With activation, there is an increase in the sarcoplasmic Ca^{2+} concentration. The Ca^{2+} binds to the troponin, producing a conformational change that results in the displacement of tropomyosin, thus allowing interaction of actin and myosin and the development of a contraction.

In smooth muscle, on the other hand, Ca^{2+} appears to act as an activator. The most widely accepted theory suggests that **phosphorylation of myosin is involved in the contractile process** and that a troponin-like system does not constitute the primary regulatory mechanism, as it does in skeletal and cardiac muscle. **With excitation, there is a transient increase in the sarcoplasmic Ca^{2+} concentration** from its steady-state concentration of 10^{-8} to 10^{-7} M to a concentration of 10^{-6} M or higher. At this higher concentration, **Ca^{2+} forms an active complex with the Ca^{2+}-binding protein calmodulin** (Cho et al., 1988; Watterson et al., 1976). Calmodulin without Ca^{2+} is inactive (Fig. 85.8). **The Ca^{2+}-calmodulin complex activates a calmodulin-dependent enzyme, myosin light-chain kinase (see Fig. 85.8). The activated myosin light-chain kinase, in turn, catalyzes the phosphorylation of the 20,000-dalton light chain of myosin** (Fig. 85.9). **Phosphorylation of the myosin light chain allows actin to activate myosin Mg^{2+}-ATPase activity, leading to hydrolysis of ATP and the development of smooth muscle tension or shortening** (Fig. 85.10). Actin cannot activate the ATPase activity of the dephosphorylated myosin light chain.

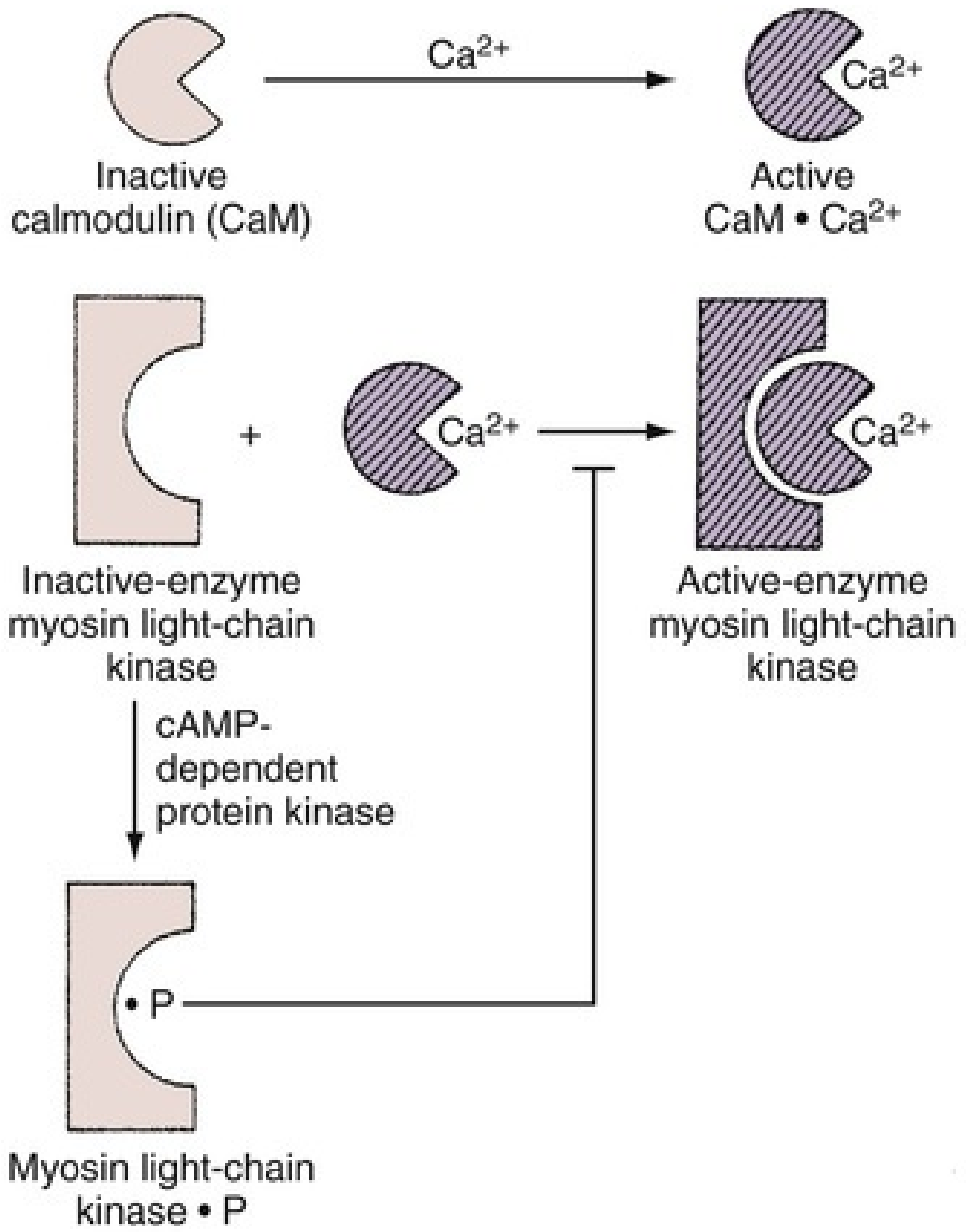
Ca2+
Ca2+
Inactive calmodulin (CaM)
Active CaM • Ca2+
+
Ca2+
Ca2+
Inactive-enzyme myosin light-chain kinase
Active-enzyme myosin light-chain kinase
cAMP-dependent protein kinase
• P
Myosin light-chain kinase • P

FIG. 85.8 Schematic representation of the contractile process in smooth muscle. Calmodulin is activated by Ca^{2+}. The activated calcium-calmodulin complex activates the enzyme myosin light-chain kinase, which phosphorylates the light chain of myosin. Phosphorylation of myosin light-chain kinase decreases the rate of activation of the enzyme by the Ca^{2+}-calmodulin complex.

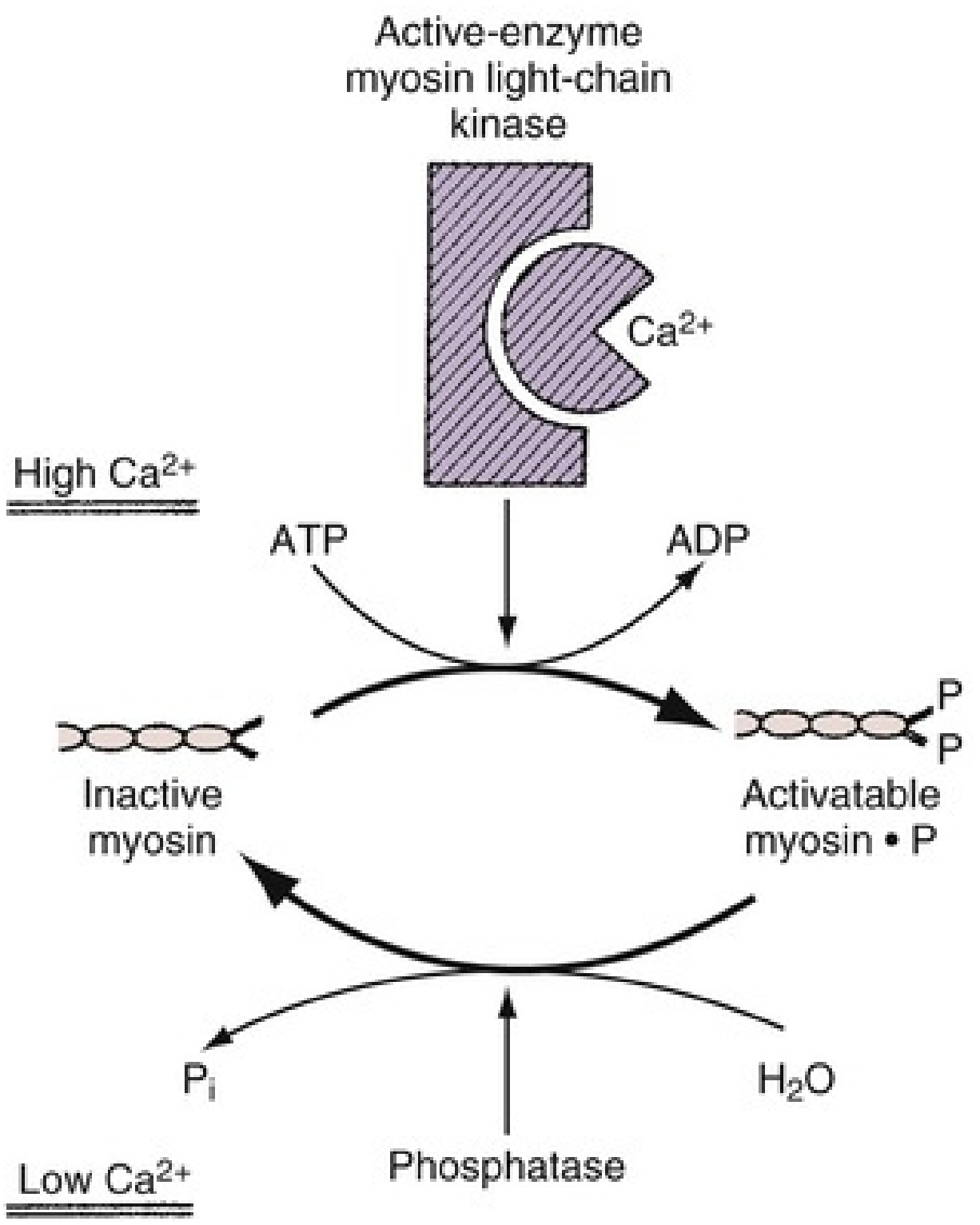
Active-enzyme
myosin light-chain
kinase
Ca2+
High Ca2+
ATP
ADP
P
P
Inactive
myosin
Activatable
myosin • P
Pi
H2O
Low Ca2+
Phosphatase

FIG. 85.9 Schematic representation of the contractile process in smooth muscle. The activated enzyme myosin light-chain kinase catalyzes the phosphorylation of myosin. Myosin must be phosphorylated for actin to activate myosin ATPase.

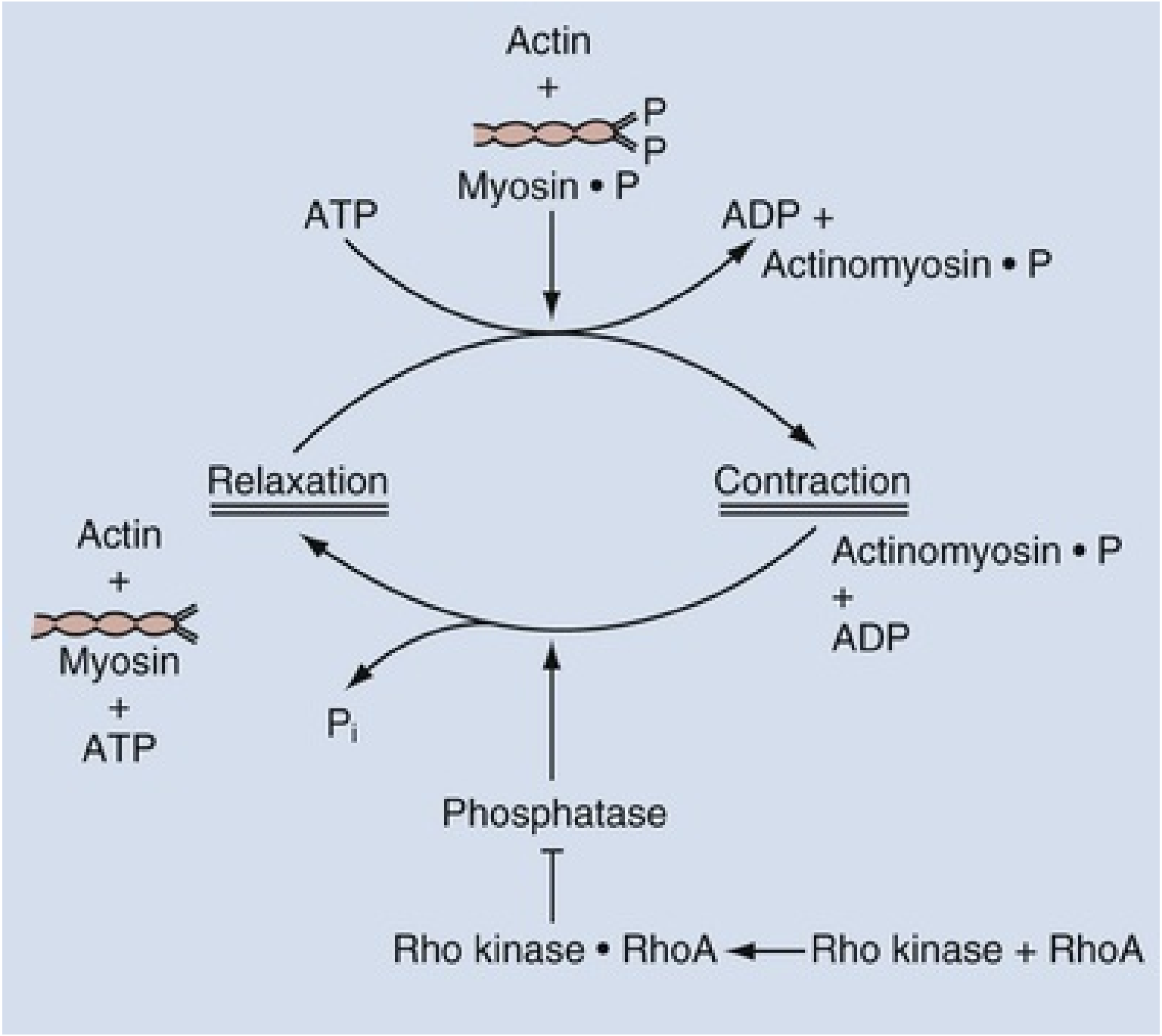
Actin
+
P
P
Myosin • P
ATP
ADP +
Actinomyosin • P
Relaxation
Contraction
Actin
+
Myosin
+
ATP
Actinomyosin • P
+
ADP
Pi
Phosphatase
Rho kinase • RhoA
Rho kinase + RhoA

FIG. 85.10 Schematic representation of the contractile process in smooth muscle. Actin activates ATPase activity of phosphorylated myosin. This allows interaction of actin and myosin with the development of a contraction. A phosphatase dephosphorylates phosphorylated myosin to lead to relaxation. Rho kinase combines with RhoA to inhibit the phosphatase, leading to sustained contraction.

When the Ca^{2+} concentration in the region of the contractile proteins is low, the myosin light-chain kinase is not active, because calmodulin requires Ca^{2+} to activate the enzyme. This prevents activation of the contractile apparatus, because the myosin light chain cannot be phosphorylated, a process that must precede tension development. Furthermore, a phosphatase dephosphorylates the myosin light chain, thus preventing actin activation of myosin ATPase activity, and relaxation results.

A Rho/Rho kinase signaling pathway affects contractility by altering the Ca^{2+}-sensitivity of the contractile system (Somlyo and Somlyo, 2003). The Rho-kinase pathway is involved in ureteral contractions in a number of species (Hong et al., 2005; Levent and Buyukafsar, 2004; Shabir et al., 2004). RhoA, a small GTP-binding protein, binds to Rho-kinase and causes its migration to the cell membrane, where it becomes maximally active (Ishizaki et al., 1996; Leung et al., 1995). Rho-kinase inhibits myosin phosphatase by phosphorylation of its regulatory subunit, MYPT1 (myosin targeting subunit of myosin light chain phosphatase), which prevents dephosphorylation of myosin light chain, which in turn leads to Ca^{2+} sensitization of the smooth muscle with subsequent increase in contractility (Borysova et al., 2011) (see Fig. 85.10). Y-27632, an inhibitor of Rho-kinase, decreases spontaneous and EFS-induced contractile responses of in vitro rat and human ureteral segments without causing changes in calcium (Hong et al., 2005; Shabir et al., 2004).

Evidence indicates that phosphorylation of the enzyme myosin light-chain kinase by a cyclic adenosine monophosphate (cAMP)–dependent protein kinase (see Fig. 85.8) decreases myosin light-chain kinase activity by decreasing the affinity of this enzyme for calmodulin (Adelstein et al., 1981).

Although Ca^{2+} is required for most smooth muscle contractile events, there is evidence that Ca^{2+}-independent contractions can occur (Yoshimura and Yamaguchi, 1997). Carbachol, a muscarinic cholinergic agonist, and phorbol ester, which activates protein kinase C (PKC), can induce contraction in Ca^{2+}-depleted bladder strips that can be inhibited by a PKC inhibitor, H7. It is suggested that activation of PKC coupled with agonist stimulation of the muscarinic receptor can induce a Ca^{2+}-independent contraction. Furthermore, activation of Rho-kinase affects smooth muscle contractility without causing changes in calcium.

Calcium and Excitation-Contraction Coupling

The mechanical event of ureteral peristalsis follows an electric event to which it is related. The Ca^{2+} involved in the ureteral contraction is derived from two main sources. Because smooth muscle cells have a very small diameter, the **inward movement of extracellular Ca^{2+} into the cell through L-type voltage-dependent Ca^{2+} channels during the upstroke of the action potential provides a significant source of sarcoplasmic Ca^{2+}** (Brading et al., 1983; Floyd et al., 2008; Hertle and Nawrath, 1989; Maggi and Giuliani, 1995; Maggi et al., 1994a; Yoshida et al., 1992; see Fig. 85.7). This inward movement of Ca^{2+} across the cell membrane is the major source of calcium used for contraction in most smooth muscles. Na^{+}-Ca^{2+} exchange, with an outward movement of Na^{+} and an inward movement of Ca^{2+}, also plays a role in the ureteral contraction (Lamont et al., 1998). Furthermore, in response to an excitatory impulse, Ca^{2+} release from tightly bound storage sites (i.e., the endoplasmic or sarcoplasmic reticulum) also increases the Ca^{2+} concentration in the sarcoplasm (Burdyga and Wray, 1999a; Burdyga et al., 1998; Lang et al., 2002b). Calcium may be released from the sarcoplasmic reticulum (SR) of smooth muscle by an inositol trisphosphate (IP_3)–induced release mechanism or by Ca^{2+}-induced Ca^{2+} release (CICR) (Somlyo and Somlyo, 1994). These processes appear to be species dependent. CICR, which involves ryanodine receptors, appears to be the sole mechanism for calcium release from the SR in the guinea pig ureter, whereas the SR store in the rat ureter appears to be exclusively under the control of IP_3 receptors (Burdyga et al., 1995). IP_3 and ryanodine receptors are expressed in the human ureter (Floyd et al., 2008). The opening of caffeine-sensitive ryanodine receptors produces small local elevations of Ca^{2+} that are termed Ca^{2+} sparks (Nelson et al., 1995). In addition to providing a source of calcium for contraction, Ca^{2+} released from the SR activates Ca^{2+}-sensitive surface membrane channels and modulates membrane excitability (Carl et al., 1996; Imaizumi et al., 1989). Calcium-activated outward potassium currents (K_{Ca}) or STOCs (spontaneous transient outward currents) and calcium-activated inward chloride currents (Cl_{Ca}) or STICs (spontaneous transient inward currents) have been identified in smooth muscles. These currents affect membrane potential and thus affect calcium entry through L-type Ca^{2+} channels in the membrane. The Ca^{2+}-activated chloride currents are present in rat but not guinea pig ureteral smooth muscle (Burdyga and Wray, 2002). Thus some Ca^{2+} released from SR results in contraction, but caffeine-induced release of SR Ca^{2+} in the form of Ca^{2+} sparks increases outward potassium currents (K_{Ca}) or STOCS with an inhibitory effect on action potentials and contractility (Borysova et al., 2007). At least in the guinea pig ureter this increase in the outward potassium current hyperpolarizes the membrane and determines the refractory period, which is important in determining the frequency of ureteral peristalsis (Burdyga and Wray, 2005).

Support for use of a dual source of Ca^{2+} in the ureter has been provided by Vereecken et al. (1975), who noted that it took approximately 45 minutes for spontaneous contractions of isolated guinea pig ureters to cease when the tissue was placed in a Ca^{2+}-free medium. They interpreted this to indicate that some of the Ca^{2+} involved in the contractile process is derived from tightly bound intracellular stores. They also noted that recovery of the contractile response to electric stimuli was almost immediate when the tissue was returned to a physiologic solution containing a normal concentration of Ca^{2+}. This suggests that free extracellular Ca^{2+} entering the cell during excitation also provides a source of Ca^{2+} for the contractile machinery. A similar conclusion was reached by Hong et al. (1985). There is, however, some evidence that Ca^{2+} release from the sarcoplasmic reticulum may not play a significant role in ureteral contractions, at least in the guinea pig (Maggi et al., 1994a, 1995, 1996), and some perturbations of contractility may be related to movements of ions other than Ca^{2+}. The increase in developed force in the guinea pig ureter with intracellular acidification and decrease with intracellular alkalinization appear to result from modulation of outward K^+ currents rather than effects on inward Ca^{2+} currents (Smith et al., 1998). That is, alkalinization (increasing intracellular pH) enhances outward K^+ currents, and this reduces excitability; acidification has the opposite effect. Relaxation results from a decrease in the concentration of free sarcoplasmic Ca^{2+} in the region of the contractile proteins. The decrease in sarcoplasmic Ca^{2+} can result from the uptake of Ca^{2+} into intracellular storage sites (Maggi et al., 1994a, 1995) or from extrusion of Ca^{2+} from the cell

(Burdyga and Magura, 1988).

Urothelial Effects on Contractile Activity

Furchgott (1999) showed in blood vessels that the endothelium produced a factor that had a relaxing action on the smooth muscle layer of the blood vessel. This factor was originally termed endothelium-derived relaxing factor (EDRF) and was subsequently shown to be nitric oxide (NO). Mastrangelo et al. (2003) showed that the urothelium of rat ureter produced NO, which inhibited contractile responses of the rat ureter. It was shown that the urothelium inhibited spontaneous contractions of isolated rat ureteral segments and that removal of the urothelium potentiated the stimulatory effects of neurokinin A, vasopressin, carbachol, bradykinin and angiotensin II (Mastrangelo and Iselin, 2007). In intact ureteral segments cyclooxygenase inhibitors potentiated the stimulatory effects of neurokinin A, vasopressin, carbachol, bradykinin, and angiotensin II. Cyclooxygenase inhibitors had no effect on the responses to these agents in urothelium-free ureters. These data suggest that the inhibitory effects of the urothelium on ureteral contractile events may involve the participation of a urothelial cyclooxygenase product such as prostacyclin.

Second Messengers

The functional response to a number of hormones, neurotransmitters, and other agents is mediated by *second messengers*. The agonist, or first messenger, interacts with a specific membrane-bound receptor (Alquist, 1948; Furchgott, 1964); the agonist-receptor complex then activates or inactivates an enzyme that leads to alteration of an amount of a second messenger within the cell. These **second messengers include cAMP, cyclic guanosine monophosphate (GMP), Ca^{2+}, inositol 1,4,5-trisphosphate (IP_3), and diacylglycerol (DG).** They mediate the functional response to the agonist (first messenger) through a process that frequently involves protein phosphorylation.

cAMP mediates the relaxing effects of β-adrenergic agonists in a variety of smooth muscles (Andersson, 1972; Triner et al., 1971; Vesin and Harbon, 1974). According to this concept, a β-adrenergic agonist, such as isoproterenol, serves as the first messenger and combines with a receptor on the outer surface of the cell membrane (Fig. 85.11). Isoproterenol itself does not enter the cell. The **β-adrenergic agonist-receptor** complex activates the enzyme adenylyl cyclase on the inner surface of the cell membrane in close morphologic relation to the receptor. **In the presence of magnesium (Mg^{2+}) and a guanine nucleotide (GTP), adenylyl cyclase catalyzes the conversion of ATP to cAMP within the cell.**

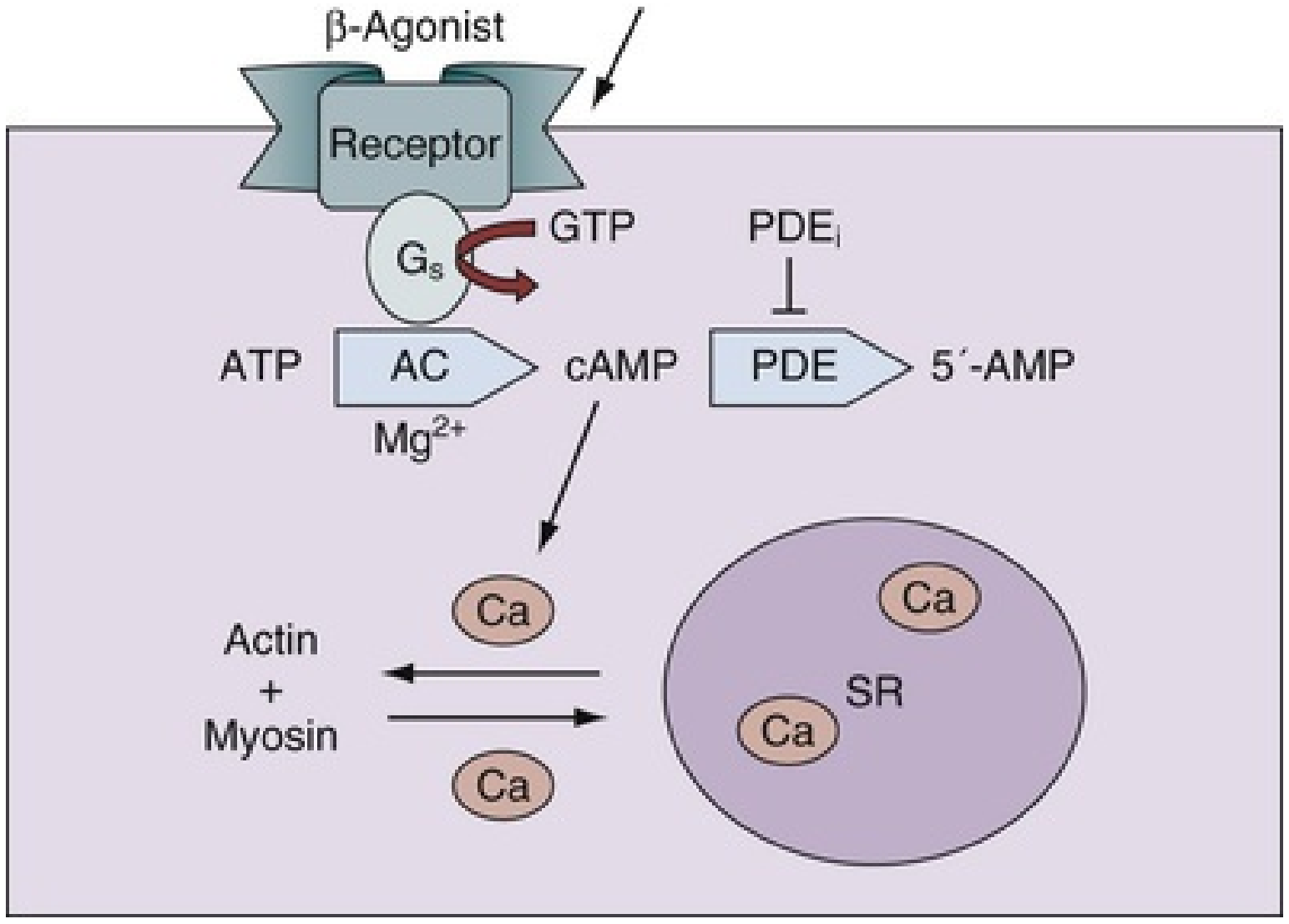

FIG. 85.11 Schematic representation of the role of cAMP in β-adrenergic agonist–induced relaxation of smooth muscle. Agonist combines with receptor on the outer side of the cell membrane. The receptor-agonist complex, in turn, via a stimulatory G-protein, G_S, activates the enzyme adenylyl cyclase (*AC*) on the inner surface of the cell membrane, which in the presence of Mg^{2+} GTP results in the conversion of ATP to cAMP. cAMP is postulated to cause an increased uptake of Ca^{2+} into intracellular storage sites with a resultant decrease in Ca^{2+} in the region of the contractile proteins that results in relaxation. cAMP may also have other actions (not shown) that inhibit the contractile process. The enzyme phosphodiesterase (*PDE*) degrades cAMP to 5′AMP and is inhibited by PDE inhibitors such as theophylline and papaverine. *SR,* Sarcoplasmic reticulum.

A stimulatory guanine nucleotide–regulatory protein, or G protein (G_S), acts as a functional communication between the agonist-receptor complex and the catalytic or active unit of the enzyme adenylyl cyclase. cAMP acts as a second, or “internal,” messenger of the response elicited by the β-adrenergic agonist. It has been suggested that the increase in cAMP through activation of an enzyme, that is, a protein kinase, and phosphorylation of proteins leads to the uptake of Ca^{2+} into intracellular storage sites (i.e., the endoplasmic or sarcoplasmic reticulum) with the resultant decrease of free sarcoplasmic Ca^{2+} in the region of the contractile proteins (Andersson and Nilsson, 1972). The decrease in sarcoplasmic Ca^{2+} in the region of the contractile proteins leads to relaxation of the smooth muscle. β-adrenoceptor induced relaxation of smooth muscle also may be due to the opening of Ca^{2+}-activated K^+ channels (Ferro, 2006; Uchida et al., 2005).

cAMP levels may be increased within the cell in two ways. One is by increasing synthesis, which involves activation of the enzyme adenylyl cyclase; the other is by decreasing degradation. **The degradation of cAMP involves activation of an enzyme, phosphodiesterase, thus agents that either increase adenylyl cyclase activity, such as the β-adrenergic agonist isoproterenol, or decrease phosphodiesterase activity, that is, phosphodiesterase inhibitors such as theophylline and papaverine, increase intracellular cAMP levels and cause smooth muscle relaxation** (see Fig. 85.11).

Weiss et al. (1977) demonstrated the presence of adenylyl cyclase and phosphodiesterase activities in the ureter. They showed in the ureter that isoproterenol stimulates adenylyl cyclase activity and theophylline inhibits phosphodiesterase activity. These two agents that relax ureteral smooth muscle would be expected to increase cAMP levels: isoproterenol by increasing synthesis and theophylline by decreasing degradation. Further support of **a role for cAMP in smooth muscle relaxation** can be derived from the finding that dibutyryl cAMP, which more readily diffuses into the intact cell and is less likely to be broken down by phosphodiesterase than is cAMP, has been shown to relax a variety of smooth muscles, including the ureter (Takago et al., 1971; Wheeler et al., 1990), and forskolin, which activates the catalytic subunit of adenylyl cyclase, which relaxes the ureter (Hernández et al., 2004; Wheeler et al., 1986).

In addition to receptors and G proteins that are involved in stimulation of adenylyl cyclase and the formation of cAMP, as in the actions of β-adrenergic agonists, other receptors and G proteins inhibit adenylyl cyclase activity (Londos et al., 1981). Some actions of α_2-adrenergic and muscarinic cholinergic agonists involve stimulation of these inhibitory G proteins (Gi) with subsequent inhibition of adenylyl cyclase activity.

Another cyclic nucleotide, **cGMP, also causes smooth muscle relaxation. cGMP is synthesized from GTP by the enzyme guanylyl cyclase and is degraded to 5′-GMP by a phosphodiesterase.** Phosphodiesterase activity that can degrade cAMP and cGMP has been demonstrated in the canine ureter, and various inhibitors can preferentially inhibit the breakdown of one or the other cyclic nucleotide (Stief et al., 1995; Weiss et al., 1981). Insulin has been shown to activate cAMP phosphodiesterase activity in the ureter (Weiss and Wheeler, 1988), and 8-bromo-cGMP has been shown to cause relaxation of a number of smooth muscles (Schultz et al., 1979), including the ureter (Cho et al., 1984). BAY 41-2272, a soluble guanylyl cyclase stimulator, has been shown to relax isolated human ureteral segments (Miyaoka et al., 2014).

NO stimulates soluble guanylyl cyclase activity and causes smooth muscle relaxation (Dokita et al., 1991, 1994). **Nitric oxide synthase (NOS) converts L-arginine to NO and L-citrulline in a reaction that requires nicotinamide adenosine dinucleotide phosphate (NADPH). There are three NOS isoforms. Neuronal NOS (nNOS) is present in neuronal tissues and is Ca^{2+} and NADPH dependent** (Bredt and Snyder, 1990). It is thought that with neuronal excitation, there is an increase in Ca^{2+} concentration within nerves that leads to the synthesis of NO from L-arginine. NO released from the nerve **activates** the enzyme **guanylyl cyclase in the smooth muscle cell with the resultant conversion of GTP to cGMP and thus smooth muscle relaxation** (Fig. 85.12). **Endothelial NOS (eNOS), is Ca^{2+} and NADPH dependent** (Sessa, 1994). Similar to neuronal NOS, eNOS produces small amounts of NO for prolonged periods of time. An **inducible NOS isoform (iNOS), is NADPH dependent but Ca^{2+} independent** and has been identified in ureteral smooth muscle (Smith et al., 1993). iNOS produces large amounts of NO for short periods of time.

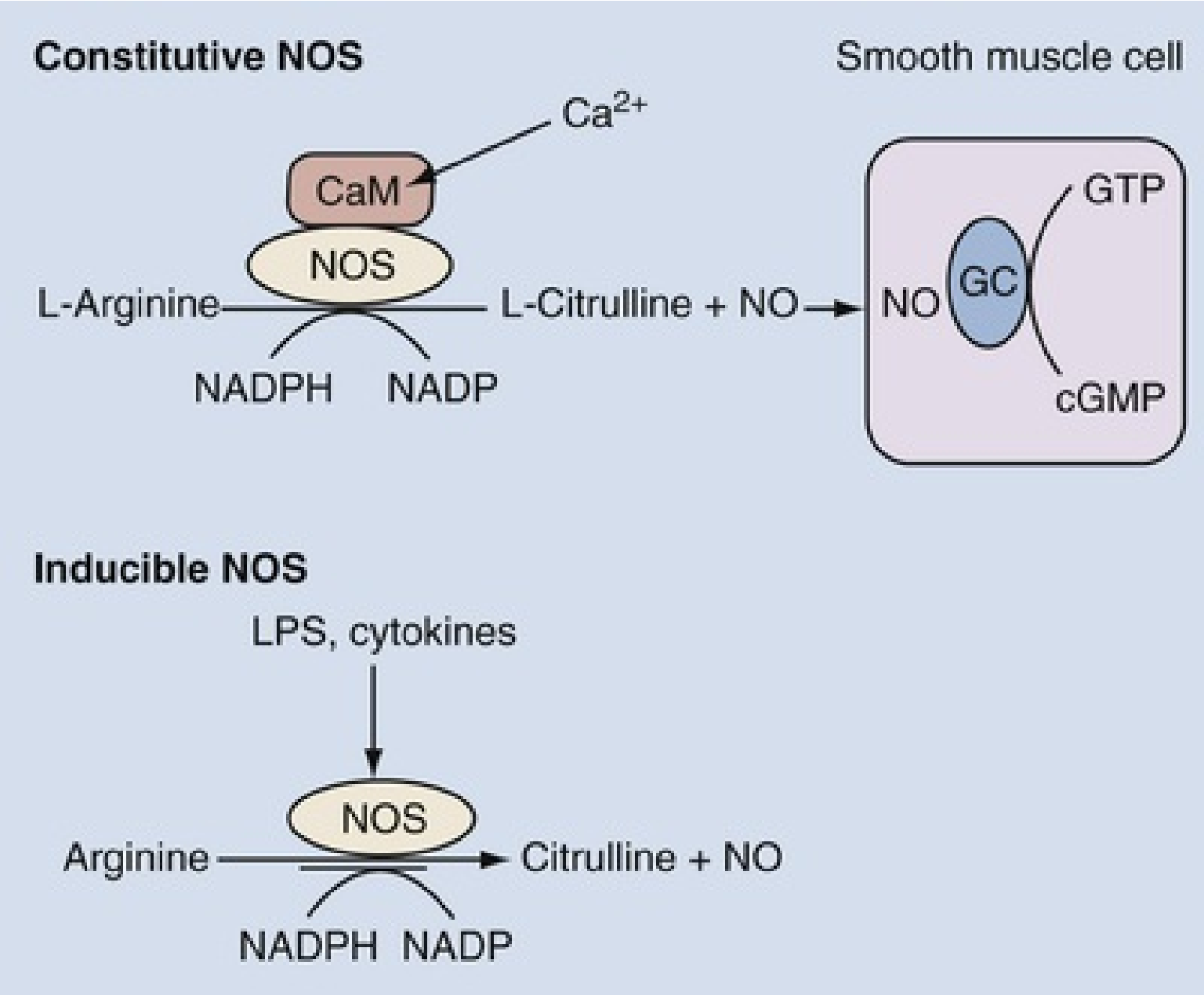
Constitutive NOS
Smooth muscle cell
Ca2+
CaM
NOS
L-Arginine
L-Citrulline + NO
NADPH
NADP
NO
GC
GTP
cGMP
Inducible NOS
LPS, cytokines
NOS
Arginine
Citrulline + NO
NADPH
NADP

FIG. 85.12 Schematic representation of inducible and constitutive nitric oxide synthase (*NOS*). *CaM,* Calmodulin; *GC;* guanylyl cyclase; *LPS,* lipopolysaccharide.

NOS-containing nerves have been demonstrated in the human ureter (Goessl et al., 1995; Iselin et al., 1998; Stief et al., 1996), and NOS has been demonstrated in the pig UVJ (Hernández et al., 1995; Phillips et al., 1995) and in the upper ureter and calyces of pigs and humans (Iselin et al., 1998; 1999). NOS colocalizes with vasoactive polypeptide and NPY in nerves supplying the human ureter (Iselin et al., 1997; Smet et al., 1994). NOS localizes to parasympathetic and sensory nerves but not to adrenergic neurons. In primary cultures of rat ureteral cells NO production was detected in urothelial but not in smooth muscle cells (Mastrangelo et al., 2003). These cells contain eNOS and iNOS.

There is evidence that the NO pathway is involved in human ureteral relaxation (Iselin et al., 1997; Stief et al., 1996). The NO donor, SIN-1, relaxes human ureteral segments, an action that is inhibited by the **guanylyl cyclase inhibitor methylene blue.** NO donors also inhibit agonist-induced contractions of isolated pig calyceal and rat, pig, and human intravesical ureteral segments, actions that are associated with an increase in cGMP. Furthermore, NO has been shown to be involved in nonadrenergic, noncholinergic-induced relaxation of the pig UVJ (Hernández et al., 1995).

Some actions of **α_1-adrenergic and muscarinic cholinergic agonists** and a number of other hormones, neurotransmitters, and biologic substances are associated with an increase in intracellular Ca^{2+} and are related to changes in inositol lipid metabolism. These agonists **combine with a receptor on the cell membrane, and the agonist-receptor complex, via a process that involves a G protein, activates an enzyme, phospholipase C, that leads to the hydrolysis of polyphosphatidylinositol 4,5-bisphosphate (PIP_2) with the formation of two second messengers, IP_3 and DG** (Berridge, 1984; Fig. 85.13). **IP_3 mobilizes Ca^{2+} from intracellular stores (i.e., endoplasmic or sarcoplasmic reticulum)** with an initiation of a cascade of events through the calmodulin branch of the Ca^{2+} messenger system. In smooth muscles, **IP_3 is thought to be involved in brief contractile responses or in the initial phase of sustained responses** (Park and Rasmussen, 1985).

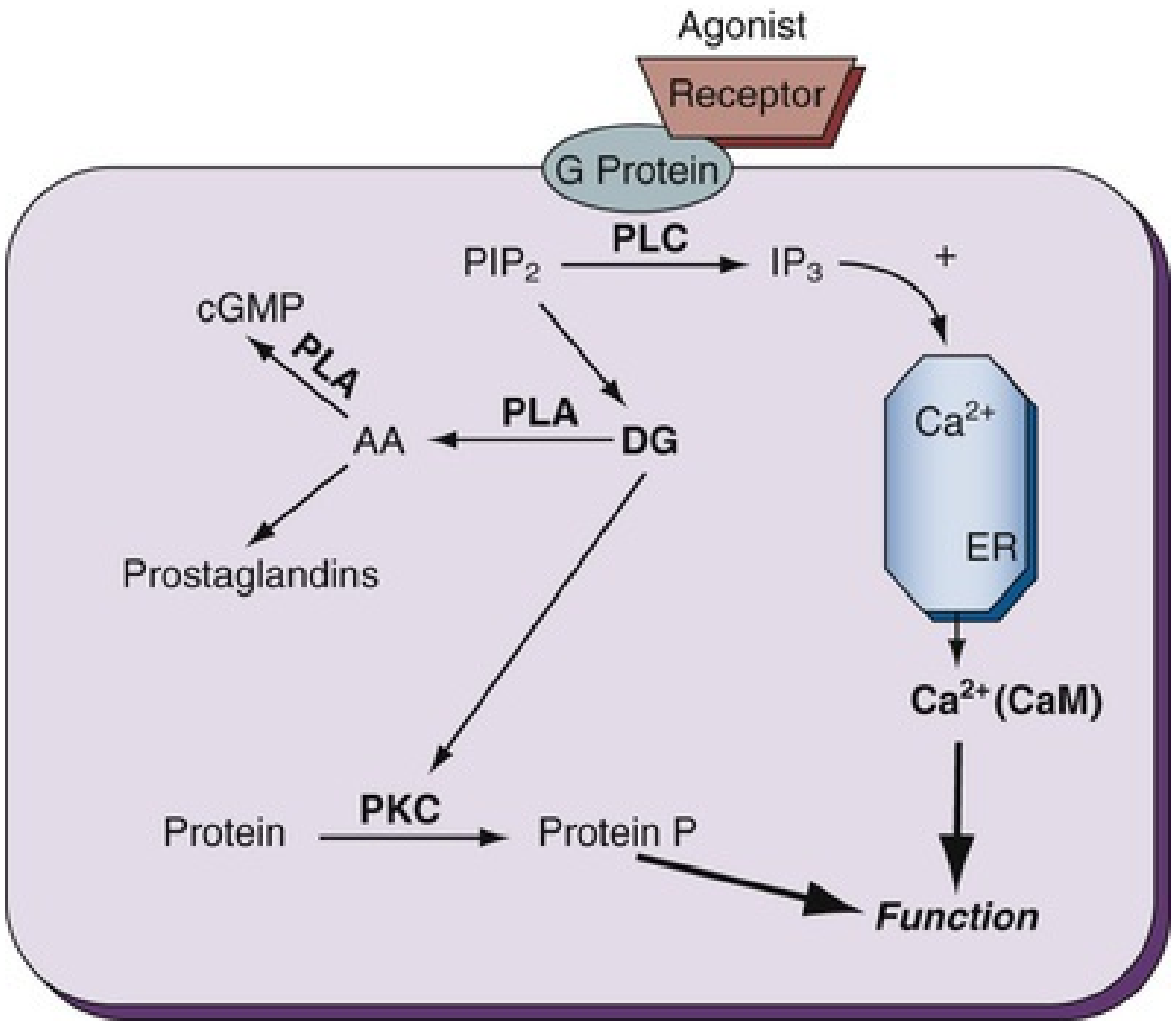

FIG. 85.13 Schematic representation of the role of inositol lipid metabolism in smooth muscle function. The agonist combines with the receptor on the outer side of the cell membrane. The receptor-agonist complex in turn activates the enzyme phospholipase C (*PLC*), which leads to the hydrolysis of polyphosphatidylinositol 4,5-bisphosphate (*PIP_2*), with the formation of two second messengers, inositol 1,4,5-trisphosphate (*IP_3*) and diacylglycerol (*DG*). The activation of PLC involves a G protein. IP_3 mobilizes calcium from intracellular stores (i.e., endoplasmic reticulum), and this leads to a functional response. DG binds to an enzyme, protein kinase C (*PKC*), which results in phosphorylation of proteins and a subsequent functional response. DG also activates PLA, and is a source of AA, the substrate for prostaglandin synthesis. AA then stimulates guanylyl cyclase (*GC*) activity to form cGMP. *AA,* Arachidonic acid; *ER,* endoplasmic reticulum; *PLA,* phospholipase A.

The other second messenger, **DG, binds to an enzyme, PKC,** translocates to the cell membrane, and, by reducing the concentration of Ca^{2+} required for PKC activation, results in an increase in this enzyme's activity. The **actions of PKC involve the phosphorylation of proteins** (Nishizuka, 1984; see Fig. 85.13). The **PKC branch of the Ca^{2+} messenger system is thought to be responsible for the sustained phase of the contractile response in smooth muscle** (Park and Rasmussen, 1985) and is responsive to hormonally induced changes in intracellular Ca^{2+}. PKC has been implicated in Ca^{2+}-independent smooth muscle contractions (Yoshimura and Yamaguchi, 1997). Numerous PKC isoforms have been identified. The functional activity and specificity of function of these isoforms appear to be determined primarily by the state of phosphorylation of the isoenzyme and its subcellular localization (Dempsey et al., 2000).

DG also activates the enzyme phospholipase A, which serves as a source of arachidonic acid, the substrate for prostaglandin synthesis (Mahadevappa and Holub, 1983). Arachidonic acid, in turn, may stimulate guanylyl cyclase activity with the subsequent formation of cGMP (Berridge, 1984) (see Fig. 85.13), and this would explain the Ca^{2+}-dependent increase in cGMP levels associated with muscarinic cholinergic and α_1-adrenergic agonist–induced contractions in smooth muscle. The observed increases in cGMP levels follow, rather than precede, the onset of contractions induced by these agonists.

Thus a group of second messengers are involved in the transduction of the signal that is initiated when an agonist combines with a specific receptor on the cell membrane of the smooth muscle. This process of **signal transduction** ultimately results in the functional response to the agonist.

Role of the Nervous System in Ureteral Function

Some smooth muscles have a specific innervation of each smooth muscle fiber, whereas other, syncytial-type smooth muscles lack discrete neuromuscular junctions and depend on a diffuse release of transmitter from a bundle of nerves with a subsequent spread of excitation from one muscle cell to another. **The ureter is a syncytial type of smooth muscle without discrete neuromuscular junctions** (Burnstock, 1970).

Because peristalsis may persist after transplantation (O'Conor and Dawson-Edwards, 1959) or denervation (Wharton, 1932), because spontaneous activity may occur in isolated in vitro ureteral segments (Finberg and Peart, 1970), and because normal antegrade peristalsis continues after reversal of a segment of ureter in situ (Melick et al., 1961), it is apparent that **ureteral peristalsis can occur without innervation.** However, analysis of the data in the literature clearly indicates that the **nervous system plays at least a modulating role in ureteral peristalsis, and nerves are present in the muscular layer and adventitia of the ureter, especially the distal ureter** (Vernez et al., 2017). Autonomic innervation does not appear to have a direct effect on peristalsis but may indirectly modulate peristalsis via activation of sensory nerve nicotinic receptors and the release of calcitonin gene-related peptide (CGRP) or via closure of K_v7 channels located on interstitial cells within the renal pelvis (Nguyen et al, 2013). Morita et al. (1987) have provided evidence that the autonomic nervous system may affect urine transport through the ureter by affecting peristaltic frequency and bolus volume. Catecholamine fluorescence and acetylcholine (ACh) release studies indicate that the human ureter is supplied by sympathetic (noradrenaline-containing) and parasympathetic (ACh-containing) neurons (Del Tacca, 1978; Duarte-Escalante et al., 1969).

Parasympathetic Nervous System

Although the role of the parasympathetic nervous system in the control of ureteral peristalsis has not been well defined, muscarinic cholinergic receptors have been demonstrated in the ureter of a number of species including the human (Hernández et al., 1993; Latifpour et al., 1989, 1990; Sakamoto et al., 2006). There are five cloned muscarinic subtypes: M_1 to M_5. The excitatory muscarinic receptors, M_1, M_3, and M_5, work through an excitatory G protein, Gq, and increase intracellular calcium by generating 1-, 4-, 5-trisphosphate (IP_3) and 1-, 2-DG. The inhibitory muscarinic receptors, M_2 and M_4, work through an inhibitory G protein, Gi, with inhibition of adenylyl cyclase (van Koppen and Kaiser, 2003; Wu et al., 2000). Carbachol induced contractile responses are primarily mediated via the M_3 receptor subtype (Tomiyama et al., 2003b). It has been suggested that M_2 receptor activation may inhibit smooth muscle relaxation that results from activation of adenylyl cyclase (Hegde et al., 1997). There is a higher density of M_2 than M_3 muscarinic receptors in the human ureter (Sakamoto et al., 2006).

Acetylcholinesterase-positive nerve fibers have been demonstrated in the equine ureter (Prieto et al., 1994). The cholinergic innervation is especially rich in the distal and intravesical ureter (Hernández et al., 1993). Furthermore, ACh has been shown to be released from isolated guinea pig, rabbit, and human ureters in response to electric field stimulation (Del Tacca, 1978), and this release is inhibited by the neural poison tetrodotoxin. These data suggest, but do not prove, that the parasympathetic nervous system has at least a modulatory role in the control of ureteral activity.

The prototypic cholinergic agonist is ACh, which serves as the neurotransmitter at (1) neuromuscular junctions of somatic motor nerves (nicotinic sites); (2) preganglionic parasympathetic and sympathetic neuroeffector junctions (nicotinic sites); and (3) postganglionic parasympathetic neuroeffector sites (muscarinic sites). ACh synthesis involves

$$\text{Acetyl CoA} + \text{Choline} \xrightarrow[\text{acetyltransferase}]{\text{choline}} \text{ACh}$$

where CoA is coenzyme A. The ACh is stored in vesicles within the synaptic terminal; its release depends on the influx of Ca^{2+} into the terminal, which presumably causes vesicle fusion with the presynaptic terminal membrane, thereby expelling ACh into the synaptic cleft. ACh subsequently is hydrolyzed by acetylcholinesterase. The muscarinic effects of cholinergic agonists can be blocked by atropine. The effects of nicotinic agonists can be blocked by nondepolarizing ganglionic blocking agents or by high concentrations of the nicotinic agonist, which may cause ganglionic blockade by desensitization of receptor sites after an initial period of ganglionic stimulation.

Cholinergic agonists, including ACh, methacholine (Provocholine), carbamylcholine (carbachol), and bethanechol (Urecholine), in general have been observed to have an excitatory effect on ureteral and renal pelvic function; that is, they increase the frequency and force of contractions (Hernández et al., 1993; Longrigg, 1974; Maggi and Giuliani, 1992; Morita et al., 1986, 1987b; Prieto et al., 1994; Rose and Gillenwater, 1974; Vereecken, 1973). The excitatory effect of carbachol on isolated canine ureter is mediated by the excitatory M_3-receptor subtype and carbachol-induced inhibition of potassium chloride (KCl)–induced contractions of longitudinal canine ureteral preparations is mediated primarily via the inhibitory M_4-receptor subtype (Tomiyama et al., 2003b). ACh also has been shown to increase the duration of the guinea pig and rat ureteral action potential (Ichikawa and Ikeda, 1960; Prosser et al., 1955) and the number of oscillations on the plateau of the guinea pig ureteral action potential (Ichikawa and Ikeda, 1960).

Nicotinic agonists, such as nicotine, tetramethylammonium, and dimethylphenylpiperazinium, cause an initial stimulation of nicotinic receptors followed by desensitization of the receptor sites; the receptors then become unresponsive to nicotinic agonists and also to endogenous ACh, with a resultant transmission blockade. Nicotine, as would be expected, has been shown to have excitatory (Boyarsky et al., 1968), biphasic (Labay and Boyarsky, 1967; Satani, 1919), or inhibitory (Prosser et al., 1955; Vereecken, 1973) actions on the ureter.

Anticholinesterases prevent the hydrolysis of ACh by cholinesterases and thus increase the duration and intensity of ACh action at muscarinic and nicotinic receptor sites. With prolonged administration in high doses, they can result in desensitization blockade at nicotinic sites. The effects of **anticholinesterases**, such as **physostigmine and neostigmine**, parallel the excitatory effects of ACh and other parasympathomimetics on the ureter (Satani, 1919; Vereecken, 1973).

Atropine is a competitive antagonist of the muscarinic effects of ACh. The inhibitory effects of atropine may be preceded by a transitory stimulatory effect on muscarinic receptors. Although atropine has been shown to inhibit the excitatory effects of parasympathomimetic agents (Longrigg, 1974; Vereecken, 1973) and physostigmine (Macht, 1916a) on a variety of ureteral and calyceal preparations, the majority of studies have shown that atropine has little direct effect on ureteral activity in a number of species (Butcher et al., 1957; Gibbs, 1929; Gould et al., 1955; Reid et al., 1976; Vereecken, 1973; Washizu, 1967), including humans (Kiil, 1957). Even when atropine has been observed to inhibit ureteral activity, its effects are frequently minimal and inconsistent (Ross et al., 1967), thus providing little rationale for its use in the treatment of ureteral colic. Reports of the direct effects on ureteral activity of two other parasympathetic blocking agents, methantheline and propantheline, also have been inconsistent (Draper and Zorgniotti, 1954; Kiil, 1957; Reid et al., 1976).

Sympathetic Nervous System

The sympathetic nervous system appears to modulate ureteral activity as evidenced by the demonstration of adrenergic receptors in the ureter (Latifpour et al., 1989, 1990; Morita et al., 1994), the identification of catecholaminergic neurons in the ureter as determined by labeling tyrosine hydroxylase as a marker (Edyvane et al., 1994), and the demonstration that catecholamines are released from the ureter (Weiss et al., 1978) and renal calyx (Longrigg, 1975) in response to electric field stimulation.

According to the general consensus, **agents that primarily activate α-adrenergic receptors, such as norepinephrine and phenylephrine, tend to stimulate ureteral and renal pelvic activity** (Danuser et al., 2001; Hannappel and Golenhofen, 1974; Hernández et al., 1992; McLeod et al., 1973; Morita et al., 1987a; Nguyen et al., 2013; Rivera et al., 1992; Rose and Gillenwater, 1974; Santicioli and Maggi, 1998; Vereecken, 1973), and **agents that primarily activate β-adrenergic receptors, such as isoproterenol and orciprenaline, tend to inhibit ureteral and renal pelvic activity** (Ancill et al., 1972; Danuser et al., 2001; Finberg and Peart, 1970; Hannappel and Golenhofen, 1974; Hernández et al., 1992; McLeod et al., 1973; Rivera et al., 1992; Rose and Gillenwater, 1974; Vereecken, 1973; Weiss et al., 1978).

The ureter contains excitatory α-adrenergic and inhibitory β-adrenergic receptors that have been demonstrated with receptor-binding techniques (Latifpour et al., 1989, 1990). In the human ureter, renal pelvis and calyces α_{1D}- and α_{1A}-adrenoceptor subtypes are more prevalent than the α_{1B}-adrenoceptor subtype (Itoh et al., 2007; Karabacak et al., 2013; Sigala et al., 2005). The highest density of α_1-adrenoceptors is found in the distal ureter with the relative density being $\alpha_{1D} > \alpha_{1A} > \alpha_{1B}$. This is in accord with the finding that phenylephrine, an α-adrenergic agonist, induces a greater contractile force in isolated human ureteral segments obtained from the distal than the proximal ureter (Sasaki et al., 2011). The expression of α_1-adrenoceptors is species dependent with a higher density of α_{1A}-adrenoceptors in the mouse ureter and a higher density of α_{1D}-adrenoceptors in the dog and hamster ureter (Kobayashi et al., 2009a, b; Tomiyama et al., 2007). The α_{1A}-adrenoceptor subtype is the primary receptor subtype that participates in the contraction of the mouse, hamster, and human ureter (Kobayashi et al., 2009c; Sasaki et al., 2008, 2011; Tomiyama et al., 2007). α_{1A}-Adrenoceptors appear to be more involved in the maintenance of baseline ureteral tonus than in the potentiation of ureteral peristaltic activity (Morita et al., 1987a; Tomiyama et al., 2002).

Norepinephrine, **primarily an α-adrenergic agonist (although it also can stimulate β-adrenergic receptors),** increases the force of electrically induced ureteral contractions (Weiss et al., 1978). When administered in the presence of **phentolamine** (Regitine), **an α-adrenergic blocking agent,** norepinephrine, decreases the force of ureteral contractions (Weiss et al., 1978). A similar reversal of action occurs in the in vivo ureter (McLeod et al., 1973) and can be explained by norepinephrine's primary action on inhibitory β-adrenergic receptors when the excitatory α-adrenergic receptors are blocked. Propranolol (Inderal), a β-adrenergic antagonist, potentiates the increase in contractile force induced by norepinephrine (Weiss et al., 1978). This can be explained by norepinephrine's acting more exclusively on excitatory α-adrenergic receptors when the inhibitory β-adrenergic receptors are blocked. Furthermore, **isoproterenol, a β-adrenergic agonist,** depresses contractility (Weiss et al., 1978). These data provide evidence for excitatory α-adrenergic and inhibitory β-adrenergic receptors in the ureter and are in accord with the observations of McLeod et al. (1973) and Rose and Gillenwater (1974) on in vivo ureters.

Further support for the presence of excitatory α-adrenergic and inhibitory β-adrenergic receptors in the ureter includes the demonstration of adenylyl cyclase activity in the ureter (Weiss et al., 1977; Wheeler et al., 1986) and the finding that the ureters of rabbits depleted of catecholamines by the administration of reserpine undergo greater degrees of deformation when a given intraluminal pressure is applied than would result from the application of the same pressure load to the ureters of normal, non–reserpine-treated animals (Weiss et al., 1974). Finally, electric stimulation with high-intensity, high-frequency, short-duration stimuli has been shown to release neurotransmitter, presumably from intrinsic neural tissue within the wall of the ureter (Weiss et al., 1978) and renal calyx (Longrigg, 1975).

Norepinephrine, the chemical mediator responsible for adrenergic transmission, is synthesized in the neuron from tyrosine. After its release from the nerve terminal, some of the norepinephrine combines with receptors in the effector organ, leading to a physiologic response. The greatest percentage of the norepinephrine is actively taken up (reuptake or neuronal uptake) into the neuron. Neuronal reuptake regulates the duration that norepinephrine is in contact with the innervated tissue and thus regulates the magnitude and duration of the catecholamine-induced response. Agents such as cocaine and imipramine (Tofranil), that inhibit neuronal uptake, potentiate the physiologic response to norepinephrine (Boyarsky and Labay, 1969). Tyramine, whose adrenergic agonist effects are due primarily to the release of norepinephrine from adrenergic terminals, also has a stimulatory effect on the upper urinary tract (Boyarsky and Labay, 1969; Finberg and Peart, 1970; Longrigg, 1974). The enzymes monoamine oxidase and catechol-O-methyltransferase provide degradative pathways for norepinephrine.

The α-adrenergic antagonists phentolamine and phenoxybenzamine (Dibenzyline) have been shown to inhibit the stimulatory effects of norepinephrine and other α-adrenergic agonists in a variety of preparations (Finberg and Peart, 1970; Gosling and Waas, 1971; Hannappel and Golenhofen, 1974; Hernández et al., 1992; Longrigg, 1974; McLeod et al., 1973; Rose and Gillenwater, 1974; Vereecken, 1973; Weiss et al., 1978). The α-adrenergic antagonist, doxazosin, has been shown to slightly reduce spontaneous contractility of in vitro pig ureter and to inhibit the contractile effects of epinephrine and phenylephrine (Nakada et al., 2007). Tamsulosin inhibited the contractility of human ureters in vitro (Rajpathy et al., 2008) and in vivo (Davenport et al., 2007). Silodosin, a selective α_{1A}-receptor antagonist, was more effective in inhibiting electrical field stimulation (EFS)–induced contractions of human and rat isolated ureters than tamsulosin, a selective $\alpha_{1A/D}$receptor antagonist, or prazosin, a non-selective α-adrenergic receptor antagonist (Villa et al., 2013).

The β-adrenergic subtypes involved in ureteral relaxation are species specific; β_1-adrenoceptors in rats, β_2-adrenoceptors in rabbits, mainly β_3-adrenoceptors in dogs, and β_2- and β_3-adrenoceptors in pigs and humans (Park et al., 2000; Tomiyama et al., 1998, 2003a; Wanajo et al, 2004). All three β-adrenergic receptor subtypes are expressed in the human ureter (Matsumoto et al., 2013; Park et al., 2000). Immunohistochemical studies show that the β-adrenergic receptors are expressed in the smooth muscle and the urothelium of the human ureter (Matsumoto et al., 2013) and the expression of β_1, β_2, and β_3 are decreased in the dilated ureter (Shen et al., 2017). A relatively specific β_3-adrenoceptor agonist, TRK-380, relaxes in vitro human ureteral segments, and it has been suggested that the β_3-agonist mirabegron may do the same (Matsumoto et al., 2013). A synthesized β_2-/β_3-adrenoceptor agonist, KUL-7211, was a more potent relaxant of isolated dog ureteral segments than the α-adrenergic antagonists, tamsulosin and prazosin; the calcium channel blocker, verapamil; and the phosphodiesterase inhibitor, papaverine (Wanajo et al., 2005). KUL-7211 also is a potent relaxant of the pig ureter (Wanajo et al., 2011). Intraluminal isoproterenol has been shown to lower renal pelvic pressures during ureteroscopy, with the presumption that this would decrease intrarenal backflow that has potential harmful effects (Jakobsen, 2013; Jung et al., 2008). In the rabbit renal pelvis β_2-adreneric agonists inhibit contractile activity of the distal renal pelvis and β_1-adrenergic agonists potentiate contractile activity of the proximal renal pelvis (Kondo et al., 1989).The β-adrenergic antagonist propranolol has been shown to block or attenuate the inhibitory effects of β-adrenergic agonists, such as isoproterenol, in a variety of preparations (Longrigg, 1974; McLeod et al., 1973; Rose and Gillenwater, 1974; Vereecken, 1973; Weiss et al., 1978).

Sensory Innervation and Peptidergic Agents in the Control of Ureteral Function

Sensory nerves can play a sensory afferent and motor efferent role in a given tissue. Tachykinins and CGRP are neurotransmitters released from peripheral endings of sensory nerves (Maggi, 1995)**. Tachykinins stimulate and CGRP inhibit electrical and contractile activity. Capsaicin-sensitive sensory nerves are located in the ureter** (Ammons, 1992; Dray et al., 1989; Maggi and Meli, 1988; Maggi et al., 1986) and contain the tachykinins, substance P, neurokinin A, and neuropeptide K (Hua et al., 1985; Sann et al., 1992), as well as CGRP (Gibbins et al., 1985; Sann et al., 1992; Tamaki et al., 1992). Release of prostaglandins and neuropeptides from sensory nerves plays a role in the maintenance of peristalsis (Nguyen et al., 2016). Immunoreactivity for tachykinins and CGRP is less in the human than in the guinea pig ureter (Edyvane et al., 1992; 1994; Hua et al., 1987; Su et al., 1986). Capsaicin in low doses inhibits ureteral activity, presumably because of the release of CGRP, but in high doses it increases ureteral activity, presumably because of release of the tachykinins neurokinin A, neuropeptide K, and substance P (Hua and Lundberg, 1986). Capsaicin administration to neonatal rats causes degeneration of CGRP-containing sensory nerves in the ureter that is accompanied by an increase in sympathetic innervation (Sann et al., 1995). Because nerve growth factor (NGF) is responsible for increased sensory and noradrenergic innervation, capsaicin-induced degeneration of sensory nerves decreases NGF uptake into sensory neurons with a resultant increase in the amount of NGF available for stimulating sympathetic innervation (Schicho et al., 1998). The excitatory effects of the tachykinins are more prominent in the renal pelvis than in the ureter, and the inhibitory effects of CGRP are more prominent in the ureter than in the renal pelvis (Maggi et al., 1992b). The excitatory effects of tachykinins involve excitation of NK-2 receptors in the human, pig, and guinea pig ureter, pig intravesical ureter, and guinea pig renal pelvis (Bustamante et al., 2001; Jerde et al., 1999; Nakada et al., 2001; Patacchini et al., 1998). The inhibitory actions of the neurotransmitter CGRP appear to involve multiple mechanisms (Maggi and Giuliani, 1991; Maggi et al., 1994b). By opening ATP-sensitive K^+ channels, CGRP causes membrane hyperpolarization with a resultant blocking of voltage-sensitive Ca^{2+} channels that are involved in generation of the ureteral action potential and ureteral contraction (Maggi et al., 1994c; Meini et al., 1995; Santicioli and Maggi, 1994). CGRP-induced ureteral relaxation also may result from stimulation of adenylyl cyclase activity with a resultant increase in cAMP (Santicioli et al., 1995b). The action of CGRP on the ureter may be regulated by an endopeptidase that degrades the CGRP released from the sensory nerves (Maggi and Giuliani, 1994). Histochemical studies show that the tachykinins and CGRP colocalize in the same nerves in the ureter (Hua et al., 1987).

Renal pelvic sensory nerves contain substance P (SP) and CGRP. Increases in renal pelvic pressure result in the release of SP and a subsequent increase in afferent renal nerve activity. CGRP potentiates the afferent renal nerve activity responses to SP by retarding the metabolism of SP, thus resulting in increased amounts of SP available for potentiating afferent renal nerve activity (Gontijo et al., 1999). Prostaglandins also contribute to sensory receptor activation (Kopp et al., 2000).

Nonadreneric, noncholinergic (NANC) excitatory neurotransmission is functional in the pig intravesical ureter (Bustamante et al., 2000; 2001). In the presence of agents that block adrenergic neurotransmission, muscarinic cholinergic receptors, NO synthase activity, prostaglandin synthesis, and A_1/A_2 adenosine receptors, EFS induced (5 H_z) contractions that were potentiated by the tachykinins SP and neurokinin A and that were inhibited by a sensory neurotoxin, capsaicin, and by a NK_2 receptor antagonist, GR94800. The EFS-induced contractions were abolished by tetrodotoxin, providing evidence that the contractions were neurogenic in origin. It has been suggested that tachykinins, especially neurokinin A, released from capsaicin-sensitive afferent nerves and activating NK_2-receptors are involved in NANC excitatory neurotransmission.

Peptidergic neurons containing NPY and vasoactive intestinal polypeptide (VIP) also are present in the ureter (Allen et al., 1990; Edyvane et al., 1992; Prieto et al., 1997). VIP and pituitary adenylate cyclase–activating polypeptide (PACAP) have been shown to relax pig intravesical ureteral segments through a cAMP-dependent mechanism (Hernández et al., 2004). Edyvane et al. (1994) have provided evidence for at least four, and possibly six, different immunohistochemical populations of nerve fibers in the human ureter. The predominant types include noradrenergic nerves containing NPY, neurons containing NPY and vasoactive polypeptide, neurons containing substance P and CGRP, and neurons containing CGRP. NPY potentiates the excitatory effects of norepinephrine on the ureter (Prieto et al., 1997). Rare coexistences also were observed between CGRP and vasoactive polypeptide, CGRP and NPY, and CGRP and tyrosine hydroxylase, a marker of noradrenergic neurons. These investigators demonstrated regional differences in the innervation of the ureter, with a more extensive innervation noted in the lower than in the upper ureter. There also is evidence that adenosine relaxes the pig intravesical ureter through a process independent of NO (Hernández et al., 1999).

Hydrogen sulfide (H_2S), which is synthesized from cystathione by the enzyme cystathione γ-lyase (CSE), has been shown to relax the pig intravesical ureter via K_{ATP} channel activation (Fernandes and Hernández, 2016; Fernandes et al., 2014). H_2S is an activator of transient receptor potential A1 (TRPA1) expressed in CGRP-positive sensory nerves and interstitial cells in human ureter (Weinhold et al., 2017). TRPA1 agonists and H_2S inhibit EFS-induced contractions in the ureter.

Purinergic Nervous System

Burnstock et al. (1972) postulated that ATP could act as an excitatory transmitter in the bladder. It was subsequently shown that ATP is released along with acetylcholine in response to nerve stimulation (Kasakov and Burnstock, 1982) and that the excitatory response in the bladder is mediated through P2X receptors (Theobald, 1995). ATP activation of P2X purinoceptors promotes influx of extracellular Ca^{2+} into the muscle cells with resultant contraction. **Although there is no evidence for ATP mediating contractions in the ureter, there is evidence to suggest that ATP is involved in nociceptive processes.** P2X receptors are present in the ureter (Lee et al., 2000), and $P2Y_4$ receptors are present in ureteral urothelium (Shabir et al., 2013). ATP is released from the urothelium of human and guinea pig ureter in response to ureteral distention (Calvert et al., 2008; Knight et al., 2002) and stimulates sensory nerves that contain purinergic receptors (Calvert et al., 2008; Rong and Burnstock, 2004). Two classes of mechanosensitive afferent fibers have been identified in the guinea pig ureter (Cervero and Sann, 1989). It would appear that one group of fibers are tension receptors that respond to normal ureteral peristalsis, whereas the other is involved in the signaling of noxious events such as kidney stones and increased intraluminal pressures. Both groups are chemosensitive, excited by K^+, bradykinin, and capsaicin (Sann, 1998). Because ureteral distention and exogenous ATP increase afferent nerve discharge (Rong and Burnstock, 2004), ATP may be involved in signaling visceral pain with ureteral dilatation, that is, renal colic (Burnstock, 2006, 2009). It has been proposed that ureteral distention causes release of ATP from the urothelium, which in turn activates purinoceptors on suburothelial nociceptive sensory nerves. Consistent with this postulation ATP has been shown to be released with distention of isolated human ureteral segments, and this was accompanied by staining of P2X(3) and capsaicin receptors (Calvert et al., 2008).

Mechanical Properties

Mechanical characteristics of muscle are commonly assessed by defining force-length and force-velocity relations. Isometric force-length measurements depend on the number of linkages between the contractile proteins, actin and myosin, that are brought into action during contraction. Force-velocity relations depend on the rate of formation and breakdown of linkages between the contractile proteins. Interventions may affect force-velocity relations, with or without affecting force-length relations. In addition to these methods of assessing mechanical properties of the ureter, the bidimensional nature of the ureter has lent itself to studies of pressure-length-diameter relations.

Force-Length Relations

Force-length relations express the relation between the force developed by muscle when it is stimulated under isometric conditions and the resting length of the muscle at the time of stimulation. With stretching of the ureter (muscle lengthening), the resting force (i.e., the tension present when the muscle is not excited) increases at a progressive rate (Weiss et al., 1972). The force developed during isometric contraction also increases with elongation until a length is reached at which the maximal contractile force is achieved. With further lengthening, the developed force decreases (Thulesius et al., 1989; Weiss et al., 1972). The ureter at this length is overstretched, or beyond the peak of its force-length curve. Ureteral resting tension is high at the length at which maximal contractile force is developed.

Because the ureter is a viscoelastic structure (Weiss et al., 1972)**, the resting or contractile force developed at any given length depends on the direction in which the change in length is occurring and on the rate of length change** (Vereecken et al., 1973; Weiss et al., 1972). **This is referred to as hysteresis;** for the ureter, at any given length, the resting force is less and the contractile force is greater when the ureter is allowed to shorten than when the ureter is being stretched (Fig. 85.14).

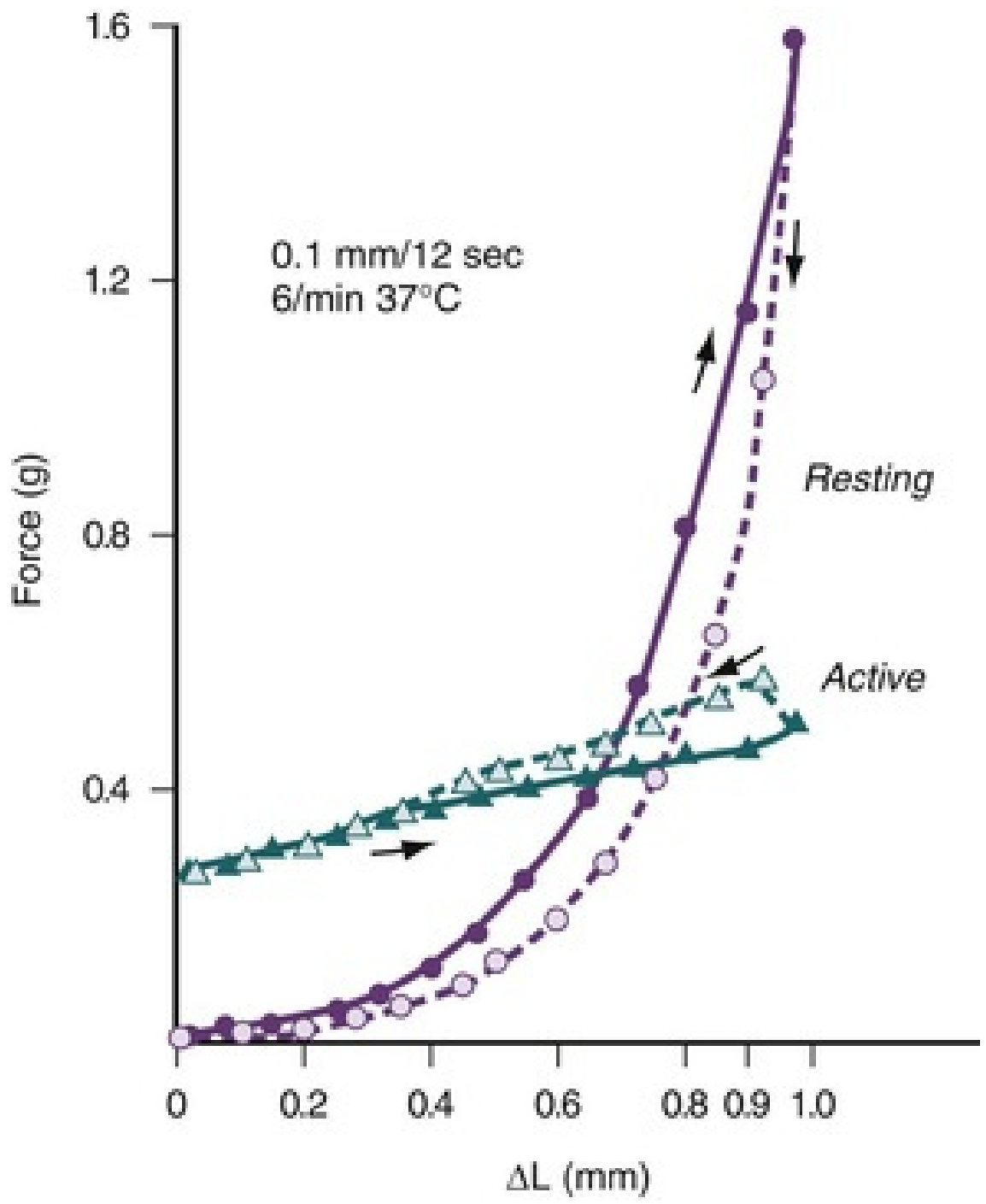

FIG. 85.14 Hysteresis. Resting and contractile (active) force of cat ureter during muscle lengthening and shortening. Force is on the ordinate; change in length (ΔL) is on the abscissa. *Solid symbols* and *solid lines* show data obtained during muscle lengthening. *Open symbols* and *dashed lines* show data obtained during muscle shortening. *Circles* show resting force, and *triangles* show active or contractile force. The length and the direction of length change influence resting and contractile force. (From Weiss RM, Bassett AL, Hoffman BF: Dynamic length-tension curves of cat ureter. *Am J Physiol* 222:388, 1972.)

When the ureter is stretched, the resting force increases. If the length is kept constant at its new longer length after a stretch, changes occur that result in a decrease in the resting force, or stress relaxation (Fig. 85.15; Weiss et al., 1972). Within certain limits, when the ureter is stretched to a length beyond the peak of the force-length curve—that is, when the ureter is stretched to a length at which the contractile force declines in the face of increasing muscle length—the degree of stress relaxation may be such that, within a period of time, the developed force no longer declines, even though the increased length is kept constant (Weiss et al., 1972). Stress relaxation can thus be considered a compensatory mechanism of a viscoelastic structure to stretch.

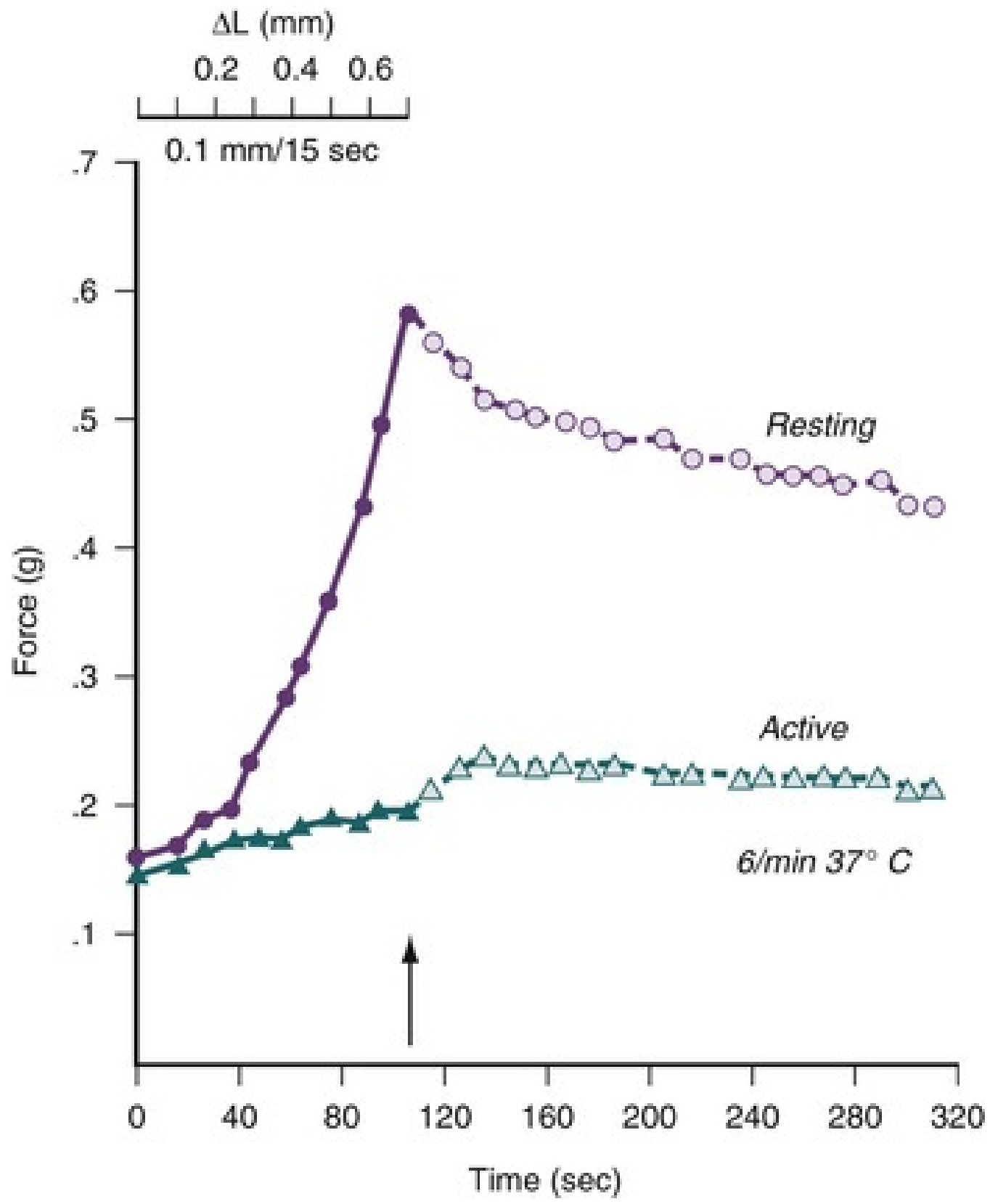

FIG. 85.15 Stress relaxation. The resting and contractile (active) force of cat ureter is on the ordinate, the time from the onset of stretching is on the lower abscissa, and the change in length (ΔL) is on the left upper corner abscissa. Muscle is stretched by a given amount and then held at a fixed length. *Solid symbols* and *solid lines* show data obtained during muscle lengthening; *open symbols* and *dashed lines* show data obtained after stretching has ceased *(arrow)* and muscle is maintained at a constant length. Resting force decreases when muscle is held at a constant length after a stretch (stress relaxation). Contractile (active) force increases during this period of time. (From Weiss RM, Bassett AL, Hoffman BF: Dynamic length-tension curves of cat ureter. *Am J Physiol* 222:388, 1972.)

Force-Velocity Relations

Force-velocity curves depict the relation between the load and the velocity of shortening. A typical force-velocity curve, as predicted by Hill's equation (Hill, 1938) for muscle shortening, has a hyperbolic configuration (Fig. 85.16; Biancani et al., 1984). From the force-velocity curve, one can extrapolate the **maximal velocity of shortening (V_{max}),** which **represents the velocity of shortening at zero load (i.e., at isotonic conditions).** V_{max} is determined by the level at which the force-velocity curve crosses the ordinate. V_{max} values in the ureter are in the range of 0.5 to 0.7 lengths per second (Biancani et al., 1984). The force-velocity curve intersects the abscissa at zero shortening, that is, at isometric conditions at which the load is great. Shortening depends on the total load lifted, with the ureter shortening to a lesser extent with heavier loads. At conditions near those of zero load, that is, conditions of free shortening (isotonic conditions), the in vitro guinea pig ureter shortens by 25% to 30% of its initial length (Biancani et al., 1984).

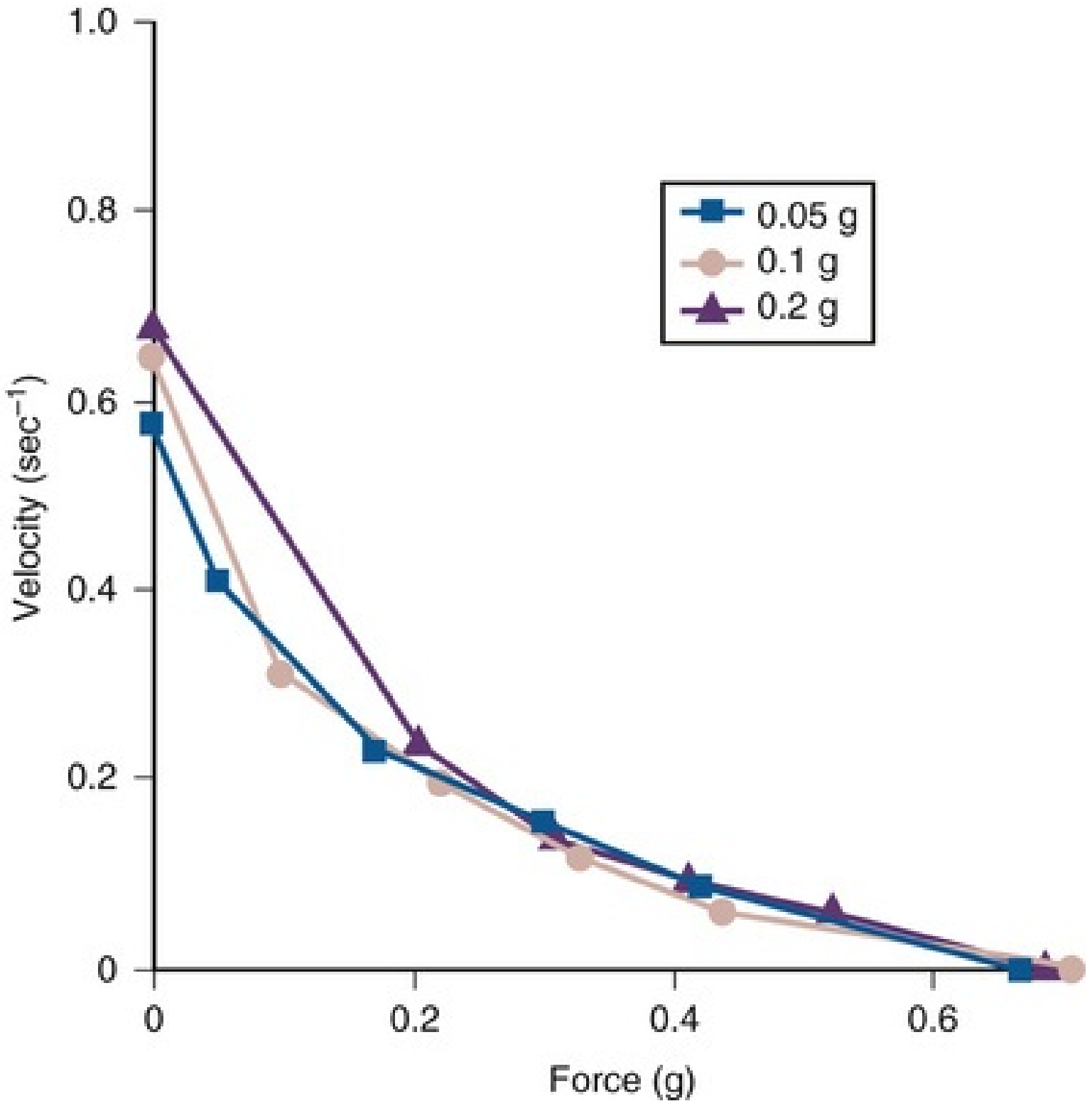

FIG. 85.16 Force-velocity relation of guinea pig ureter. Specimens were stretched by three different preloads (0.05, 0.1, and 0.2 g). The velocity of shortening on the ordinate is plotted as a function of the total load lifted on the abscissa. V_{max} is obtained by extrapolating the experimental curves to intersect the ordinate. Isometric force is given by data points where velocity equals zero. (From Biancani P, Onyski JH, Zabinski MP, et al.: Force-velocity relationships of the pig ureter. *J Urol* 131:988, 1984.)

Pressure-Length-Diameter Relations

Ureteral muscle fibers are arranged in a longitudinal, circumferential, and spiral configuration (Tanagho, 1971), although there is evidence that it is primarily longitudinal in the rat (Spronk et al., 2014). Because longitudinal and diametral deformation of the ureter are interrelated, simultaneous studies of length and diameter changes in response to an intraluminal pressure load are another means of assessing the mechanical properties of a tubular structure. After application of an intraluminal pressure, the ureter increases in length and diameter, a process known as *creep* (Biancani et al., 1973). Deformation in response to a given intraluminal pressure load is greater in vitro than in vivo; this difference is partially negated if the in vivo preparation is pretreated with reserpine to suppress adrenergic influences (Weiss et al., 1974). Such data provide support for a role of the adrenergic nervous system in the control of ureteral function.

Urine Transport

Physiology of the Ureteropelvic Junction

At normal urine flows, the frequency of calyceal and renal pelvic contractions is greater than that in the upper ureter, and there is a relative block of electric activity at the UPJ (Morita et al., 1981)**. At these flows, the renal pelvis fills; as renal pelvic pressure rises, urine is extruded into the upper ureter, which is initially in a collapsed state** (Griffiths and Notschaele, 1983)**. Ureteral contractile pressures that move the bolus of urine are higher than renal pelvic pressures, and a closed UPJ may be protective of the kidney in dissipating backpressure from the ureter. As the flow rate increases, the block at the UPJ ceases and a 1:1 correspondence between pacemaker and ureteral contractions develops** (Constantinou and Hrynczuk, 1976; Constantinou and Yamaguchi, 1981).

UPJ obstruction can be due to multiple causes. There may be areas of narrowing or valvelike processes (Maizels and Stephens, 1980) or mucosal folds (Takeyama and Sakai, 2007). Alternatively, there may be no gross narrowing at the UPJ, and abnormal propagation of the peristaltic impulse creates the obstruction. In these instances, there appears to be a functional obstruction at the UPJ, because a large-caliber catheter can be passed readily through the UPJ, even though urine transport is inadequate. Murnaghan (1958) related the functional abnormality to an alteration in the configuration of the muscle bundles at the UPJ, and Foote et al. (1970) observed a decrease in musculature at the UPJ. Hanna (1978), in an electron microscopic study of severe UPJ obstructions, noted abnormalities in the musculature of the renal pelvis and disruption of intercellular relations at the UPJ. Increased accumulation of collagen has been described in the region of the UPJ with obstruction (Murakumo et al., 1997), and it has been suggested that differences in types I and III collagen in the region of the obstructed UPJ may be age dependent (Yoon et al., 1998). Increases in smooth muscle myosin heavy-chain isoforms also have been described in congenital UPJ obstruction (Hosgor et al., 2005). Studies also have shown a decrease in nerves and in nerve growth factor mRNA expression in UPJ obstruction specimens compared with controls (Murakumo et al., 1997; Wang et al., 1995). An increase in apoptosis of smooth muscle cells in the region of congenital UPJ obstruction has been reported to accompany a decrease in smooth muscle and nerve terminals and an increase in collagen and elastin (Cutroneo et al., 2011; Kajbafzadeh et al., 2006). In addition, changes in the differentiation of the urothelial cells at the level of the UPJ have been suspected as a contributor to pathogenic obstruction. Overexpression of annexin A7 and A11, EGFR, and keratin 5 and a decrease in uroplakin III have been described with UPJ obstruction (Hou et al., 2014). A murine knockout of Cld-4, a claudin involved in tight junctions of the urothelium, was found to develop hydronephrosis in utero as a result of hyperplasia and thickening of the urothelium (Fujita et al., 2012), whereas deficiency in the miR-143/145 cluster of miRNA led to hydronephrosis resulting from abnormal ureteral peristalsis (Medrano et al., 2014). Furthermore, persistent TGF-β in the UVJ region may be associated with primary megaureter (Ozturk et al., 2016). c-KIT–positive ICC-like cells, which appear to aid in the propagation of electrical impulses from pacemaker cells to typical ureteral smooth muscle cells, have been reported to be decreased (Senol et al., 2016; Solari et al., 2003; Yang et al., 2009), increased (Koleda et al., 2012), or unchanged (Apoznanski et al., 2013) at the obstructed UPJ. Defective contractility of UPJ segments obtained at the time of pyeloplasty has been described (Pontincasa et al., 2006). As a corollary to the finding that the signaling pathway is involved in the development of the ureteropelvic junction, it was found that two downstream transcription factors of Shh, Gli3 and Teashirt3, are significantly decreased in the setting of UPJ obstruction (UPJO) (Chen et al., 2016) and that deletion of the Shh receptor *Patched 1* (*Ptch1*) causes obstructive hydronephrosis in mice (Sheybani-Deloui et al., 2017). A vessel or adhesive band crossing the UPJ may potentiate the degree of dilatation in any of the forms of UPJO.

The differences in the reported findings suggest a histopathologic spectrum in the group of cases referred to as UPJOs. **It appears possible that, at least in some instances, disruption of cell-to-cell propagation of peristaltic activity results in impairment of urine transport across the UPJ.**

The effects of diuresis and obstruction appear to be complementary and additive with respect to the development of renal pelvic and calyceal dilatation, and input and output must be considered when predicting whether or not dilatation will occur. Some UPJs can handle urine flow regardless of the magnitude of diuresis, others cause dilatation at even the lowest flows, and still others can handle low flows but cause massive dilatation at high flows, thus leading to the clinical presentation known as Dietl's crisis (Fig. 85.17).

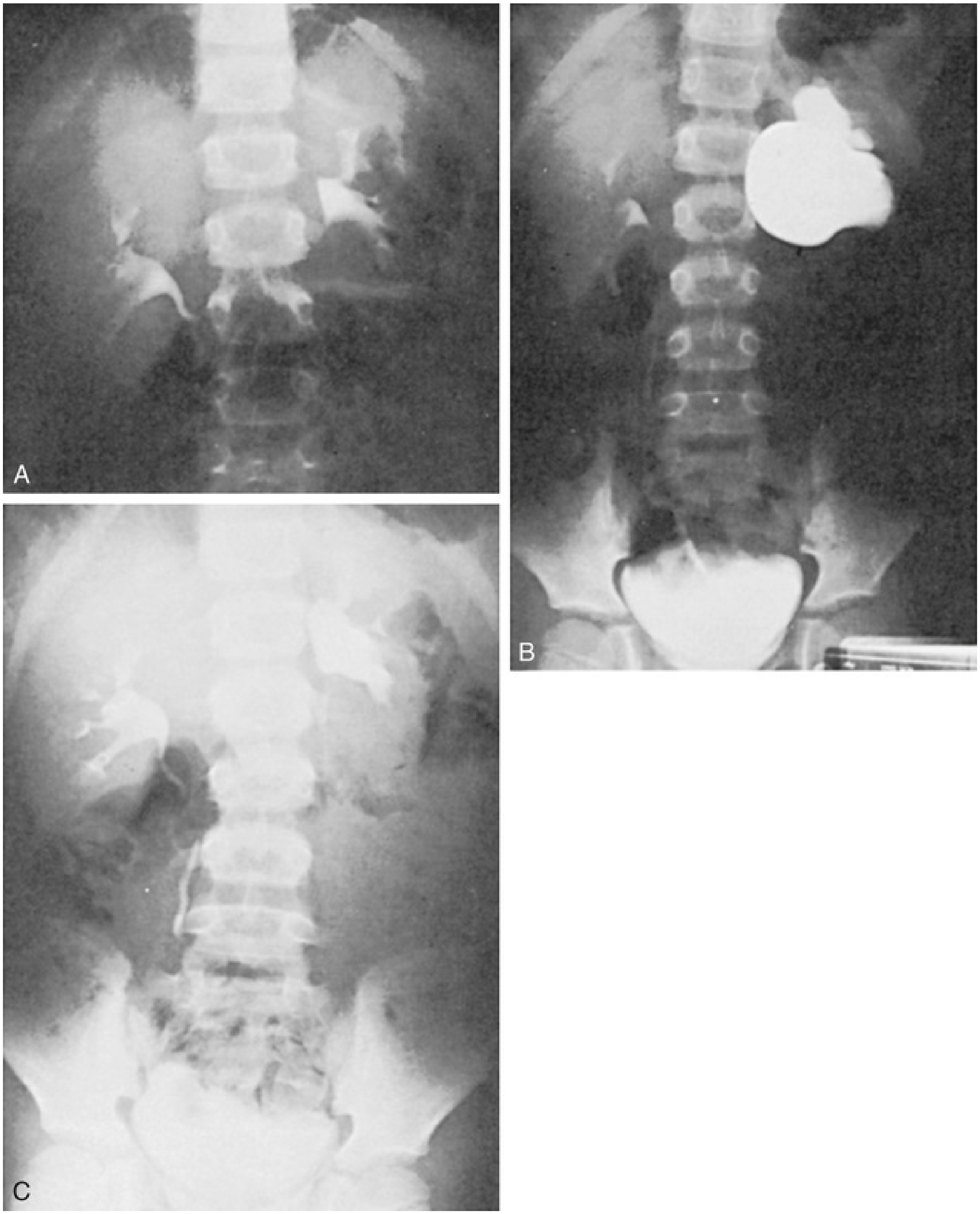

FIG. 85.17 Although no longer commonly used, intravenous pyelograms (IVPs) could demonstrate obstruction induced by a large diuresis. (A) IVP shows essentially normal upper urinary tracts. (B) Film from the same child taken immediately after a cardiac angiogram, which produces a massive diuresis. (C) IVP 6 weeks after the angiogram. (A to C, From Weiss RM: Clinical implications of ureter physiology. *J Urol* 121:401, 1979.)

Propulsion of Urinary Bolus

The theoretical aspects of the mechanics of urine transport within the ureter have been described in detail by Griffiths and Notschaele (1983); these are depicted in Fig. 85.18.

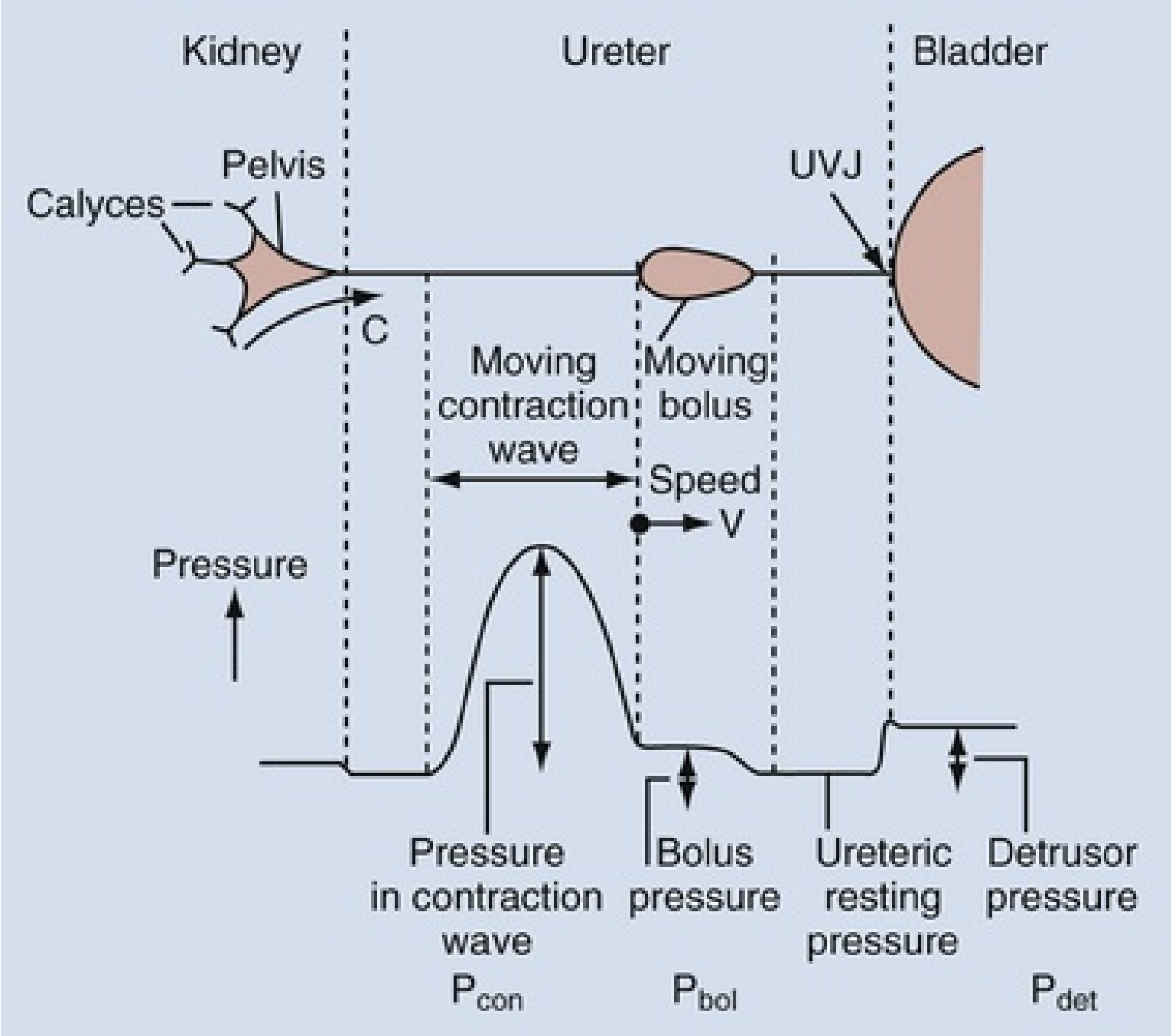
Kidney
Ureter
Bladder
Pelvis
Calyces
UVJ
C
Moving contraction wave
Moving bolus
Speed
V
Pressure
Pressure in contraction wave
P_{con}
Bolus pressure
P_{bol}
Ureteric resting pressure
Detrusor pressure
P_{det}

FIG. 85.18 Schematic representation of a single bolus in the ureter moving away from the renal pelvis and toward the bladder. *Arrow C* indicates the direction of bolus transport. The corresponding distribution of pressure within the urinary tract is shown in the lower tracing. *UVJ,* Ureterovesical junction. (From Griffiths DJ, Notschaele C: The mechanics of urine transport in the upper urinary tract. *Neurourol Urodyn* 2:155, 1983.)

At normal flow rates, as the renal pelvis fills, a rise in renal pelvic pressure occurs, and urine is extruded into the upper ureter, which initially is in a collapsed state. The contraction wave originates in the most proximal portion of the ureter and moves the urine in front of it in a distal direction. The urine that had previously entered the ureter is formed into a bolus. To propel the bolus of urine efficiently, the contraction wave must completely coapt the ureteral walls (Griffiths and Notschaele, 1983; Woodburne and Lapides, 1972), and the pressure generated by this contraction wave provides the primary component of what is recorded by intraluminal pressure measurements. **The bolus that is pushed in front of the contraction wave lies almost entirely**

in a passive, noncontracting part of the ureter (Fung, 1971; Weinberg, 1974).

Baseline, or resting, ureteral pressure is approximately 0 to 5 cm H_2O, and superimposed ureteral contractions ranging from 20 to 80 cm H_2O occur two to six times per minute (Kiil, 1957; Ross et al., 1972). The urine traverses the UVJ to enter the bladder; when functioning properly, the UVJ ensures one-way transport of urine. The bolus is forced into the bladder by the advancing contraction wave that then dissipates at the UVJ.

As with any tubular structure, the ureter can transport a set maximal amount of fluid per unit time. Under normal flows, in which bolus formation occurs, the amount of urine transported per unit time is significantly less than the maximal transport capacity of the ureter. At extremely high flows, as are employed in perfusion studies (Whitaker, 1973)**, the ureteral walls do not coapt, and a continuous column of fluid, rather than a series of boluses, is transported.**

When transport becomes inadequate, stasis of urine occurs with resultant ureteral dilatation. **Inadequate transport can result either from too much fluid entering the ureter per unit time or from too little fluid exiting the ureter per unit time.** Input and output must be considered in predicting whether ureteral dilation will occur. For example, a minor degree of obstruction to outflow causes more dilation at high flow rates than at low flow rates. Even a normal, nonobstructed ureter impedes urine transport if the rate of flow is great enough.

Changes in ureteral dimensions that occur in pathologic states may result in inefficient urine transport, even if the contractile force of the individual fibers is unchanged. The Laplace equation expresses the relation between the variables that affect intraluminal pressure:

$$T = PR$$

and

$$P = T/R$$

where T = wall tension, P = internal pressure, R = radius of a cylinder.

An increase in ureteral diameter can decrease intraluminal pressure and result in inefficient urine transport. Such dimensional changes may, at least theoretically, be deleterious (Griffiths, 1983). Another factor may be the histologic composition of the dilated ureter, as evidenced by the description of different amounts of type I and type III collagen in primary obstructed and refluxing megaureters (Lee et al., 1998).

Effect of Diuresis on Ureteral Function

With increasing urine flow rates, the initial response of the ureter is to increase peristaltic frequency. After the maximal frequency is achieved, further increases in urine transport occur by means of increases in bolus volume (Constantinou et al., 1974; Morales et al., 1952). **At relatively low flow rates, small increases in flow result in large increases in peristaltic frequency. At higher flow rates, relatively large increases in flow result in only small increases in peristaltic frequency. As the flow rate continues to increase, several of the boluses coalesce, and finally the ureter becomes filled with a column of fluid and dilates. At these high flow rates, urine transport is through an open tube.**

Effects of Bladder Filling and Neurogenic Vesical Dysfunction on Ureteral Function

Ureteral dilatation can result either from an increase in fluid input or from a decrease in fluid output from the ureter. The relation between ureteral intraluminal pressure and intravesical pressure is important in determining the efficacy of urine passage across the UVJ into the bladder. In the case of the normal ureter under normal physiologic rates of flow, ureteral contractile pressure exceeds intravesical pressure, resulting in passage of urine into the bladder. In the dilated, poorly contracting ureter or in the normal ureter at extreme flow rates, the ureter does not coapt its walls to form boluses, and the baseline pressure in the column of urine within the ureter must exceed intravesical pressure for urine to pass into the bladder.

The pressure within the bladder during the storage phase is paramount in determining the efficacy of urine transport across the UVJ. This is the pressure that the ureter must work against for the longest period of time. During filling of the normal bladder, sympathetic impulses and the viscoelastic properties of the bladder wall inhibit the magnitude of the intravesical pressure rise, that is, the tonus limb. With filling, the normal bladder maintains a relatively low intravesical pressure (McGuire, 1983) that facilitates the transport of urine across the UVJ and prevents ureteral dilatation. In the noncompliant fibrotic bladder and in some forms of neurogenic vesical dysfunction, the bladder is autonomous, and relatively small increases in bladder volume result in large increases in intravesical pressure with resultant impairment of ureteral emptying. The ureter initially responds to its decreased ability to empty by increasing its peristaltic frequency (Fredericks et al., 1972; Rosen et al., 1971; Zimskind et al., 1969). Ultimately, stasis occurs with the development of ureteral dilatation. **The ureter has been shown to decompensate when sustained intravesical pressure approaches 40 cm H_2O** (McGuire et al., 1981).

Physiology of the Ureterovesical Junction

Griffiths (1983) has analyzed the factors involved in urine transport across the UVJ. Under normal conditions and at normal flow rates, the contraction wave, which occludes the ureteral lumen, propagates distally with the urine bolus in front of it. When the bolus reaches the UVJ, the pressure within the bolus must exceed intravesical pressure for the bolus of urine to pass across the UVJ into the bladder. Under these conditions, in which the contraction wave is able to coapt the ureteral wall and move the urinary bolus distally, the pressure generated by the contraction wave exceeds the pressure within the urinary bolus. The contracted ureteral ring just proximal to the ureteral orifice at the UVJ is relevant in the antireflux mechanism (Roshani et al., 1996). As the bolus is ejected into the bladder, the distal ureter retracts within its sheaths; this telescoping of the ureter within its sheaths aids in decreasing UVJ resistance to flow and thus facilitates urine passage into the bladder (Blok et al., 1985). The UVJ does not relax (Weiss and Biancani, 1983). **Impediment of efficient bolus transfer across the UVJ into the bladder can occur when there is an obstruction at the UVJ, when intravesical pressure is excessive, or when flow rates are so high as to exceed the transport capacity of the normal UVJ. Under such conditions, in which the bolus of urine cannot pass freely into the bladder, the pressure within the bolus increases and may exceed the pressure in the contraction wave proximal to it. This results in an inability of the contraction wave to completely occlude the ureter; there is retrograde flow of urine from the bolus, and only a fraction of the urinary bolus passes across the UVJ into the bladder.** Griffiths (1983) has presented theoretical evidence to show that a similar situation of impaired bolus transport across the UVJ would be expected if the ureter were wide or weakly contracting, even if the UVJ were perfectly normal. The wider and more weakly contracting the ureter, the lower the UVJ resistance must be not to interfere with bolus transport. The resistance to flow at the UVJ has been variously attributed to forces in the trigone (Tanagho et al., 1968) and to detrusor pressure (Coolsaet et al., 1982).

The theoretical considerations outlined by Griffiths (1983) have direct clinical implications. **If the UVJ is obstructed (i.e., has an abnormally high resistance to flow) or if the detrusor pressure is excessive, large boluses occurring at high-flow conditions would not be completely discharged into the bladder, because the contraction wave pushing the bolus would be forced open and intraureteral reflux would occur.** Such obstruction at the UVJ would be detected by perfusion studies as popularized by Whitaker (1973) (i.e., the Whitaker test). On the other hand, Griffiths' (1983) theory suggests that a similar breakdown of bolus discharge into the bladder can occur in the wide or weakly contracting ureter at high flow rates even if the UVJ is normal, and that such a condition would go undetected by a Whitaker perfusion test.

There is evidence that gravity may assist urine transport and that the erect position may aid urine transport across the UVJ, especially in individuals with dilated upper tracts (Schick and Tanagho, 1973). From a practical standpoint, George et al. (1984) suggested that bed rest may be deleterious to renal function in individuals with urinary retention and wide upper urinary tracts.

Pathologic Processes Affecting Ureteral Function

Effect of Obstruction on Ureteral Function

General

The effect of obstruction on ureteral function depends on the degree and duration of the obstruction, on the rate of urine flow, and on the presence or absence of infection. After the onset of obstruction, a backup of urine occurs within the urinary collecting system, along with an associated increase in baseline (resting) ureteral intraluminal pressure and an increase in ureteral dimensions, that is, an increase in both length and diameter (Fig. 85.19; Biancani et al., 1976; Rose and Gillenwater, 1973). **The increase in intraluminal pressure depends on the kidney's continued production of urine that cannot pass beyond the site of obstruction; the increase in ureteral dimensions results from the increased ureteral intraluminal pressure and the increased volume of urine retained within the ureter. A transient increase in the amplitude and frequency of the peristaltic contraction waves accompanies these initial dimensional and ureteral baseline (resting) pressure changes** (Hammad et al., 2011; Rose and Gillenwater, 1978). There also is a decrease in the velocity of electrical impulses that correlates with decreased peristaltic activity (Hammad et al., 2011). **With time, as the ureter fills with urine, the peristaltic contraction waves become smaller and are unable to coapt the ureteral wall. Urine transport then becomes dependent on hydrostatic forces generated by the kidney** (Rose and Gillenwater, 1973)**. Superimposed infection may result in a complete absence of contractions in the obstructed ureter and contributes to impairment of urine transport** (Rose and Gillenwater, 1973).

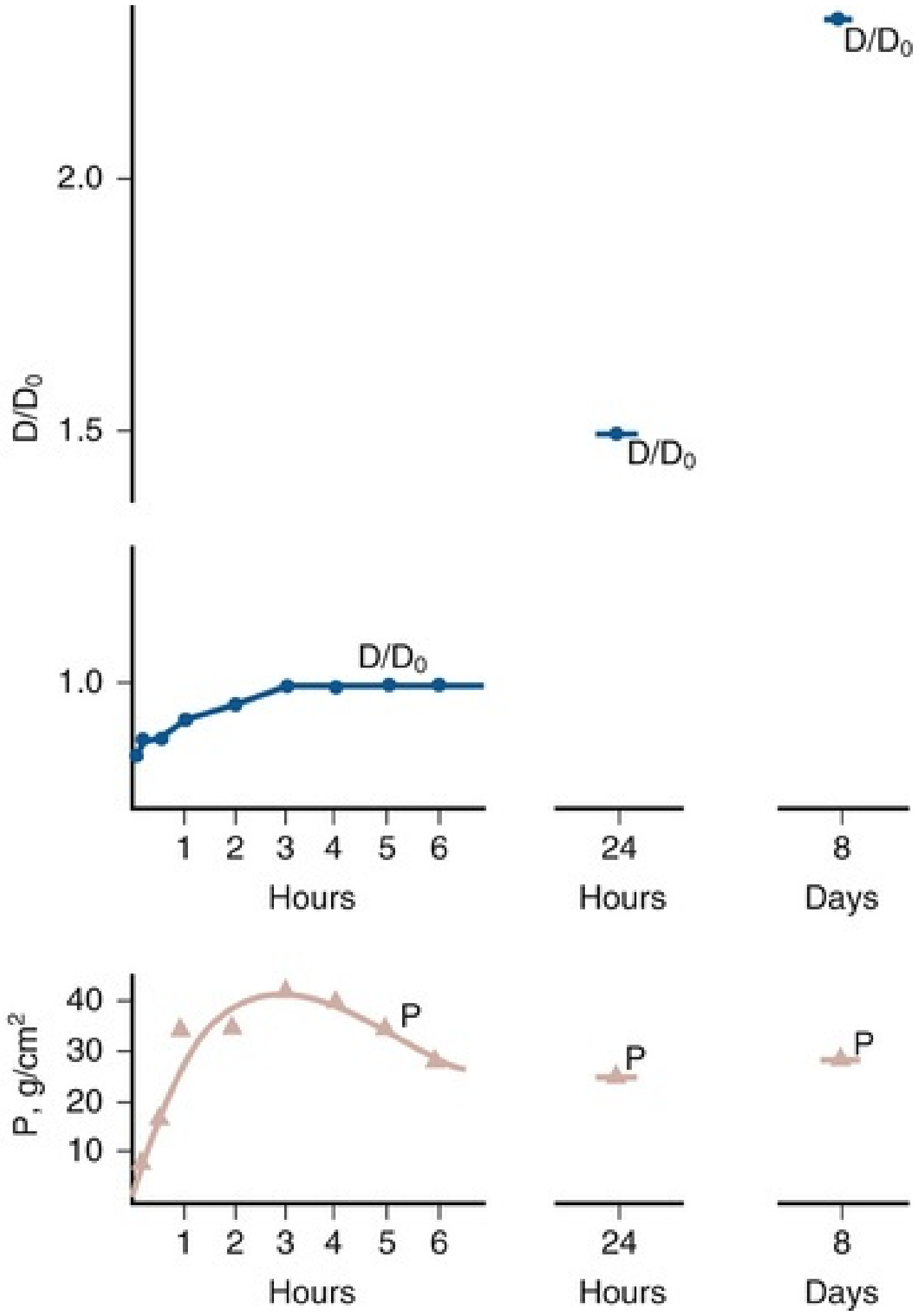

FIG. 85.19 Intraluminal pressure and diameter changes after obstruction of rabbit ureter. The time from the onset of obstruction is on the abscissa. The change in diameter (D/D_0) is on the upper ordinate, and the intraluminal pressure is on the lower ordinate. During the initial 3 hours of obstruction, intraluminal pressure increased to reach a maximum and was associated with an increase in diameter. Between 3 and 6 hours after the onset of obstruction, pressure declined, although diametral deformation persisted. After 6 hours, pressure remained essentially unchanged, although the diameter continued to increase. Each data point represents the mean ± standard error of mean (SEM). *D,* Diameter during deformation; D_0, initial diameter; *P,* intraluminal pressure. (Modified from Biancani P, Zabinski MP, Weiss RM: Time course of ureteral changes with acute and chronic obstruction. *Am J Physiol* 231:393, 1976.)

Within a few hours after the onset of obstruction, the intraluminal baseline ureteral pressure reaches a peak and then declines to a level only slightly higher than the normal baseline pressure. This occurs at a time in which dimensional changes remain stable (Biancani et al., 1976). The decrease in ureteral pressure can be attributed to changes in intrarenal hemodynamics, such as a reduction in renal blood flow (Vaughan et al., 1971), with resultant decreases in the glomerular filtration rate and intratubular hydrostatic pressure (Gottschalk and Mylle, 1956). Fluid reabsorption into the venous and lymphatic systems and a decrease in wall tension also may play a role in the reduction in baseline ureteral pressure (Rose and Gillenwater, 1978). The persistence of dimensional changes in the face of a decrease in intraluminal pressure depends on the hysteretic properties of the viscoelastic ureteral structure (Fig. 85.20; Biancani et al., 1973, 1976; Vereecken et al., 1973; Weiss et al., 1972).

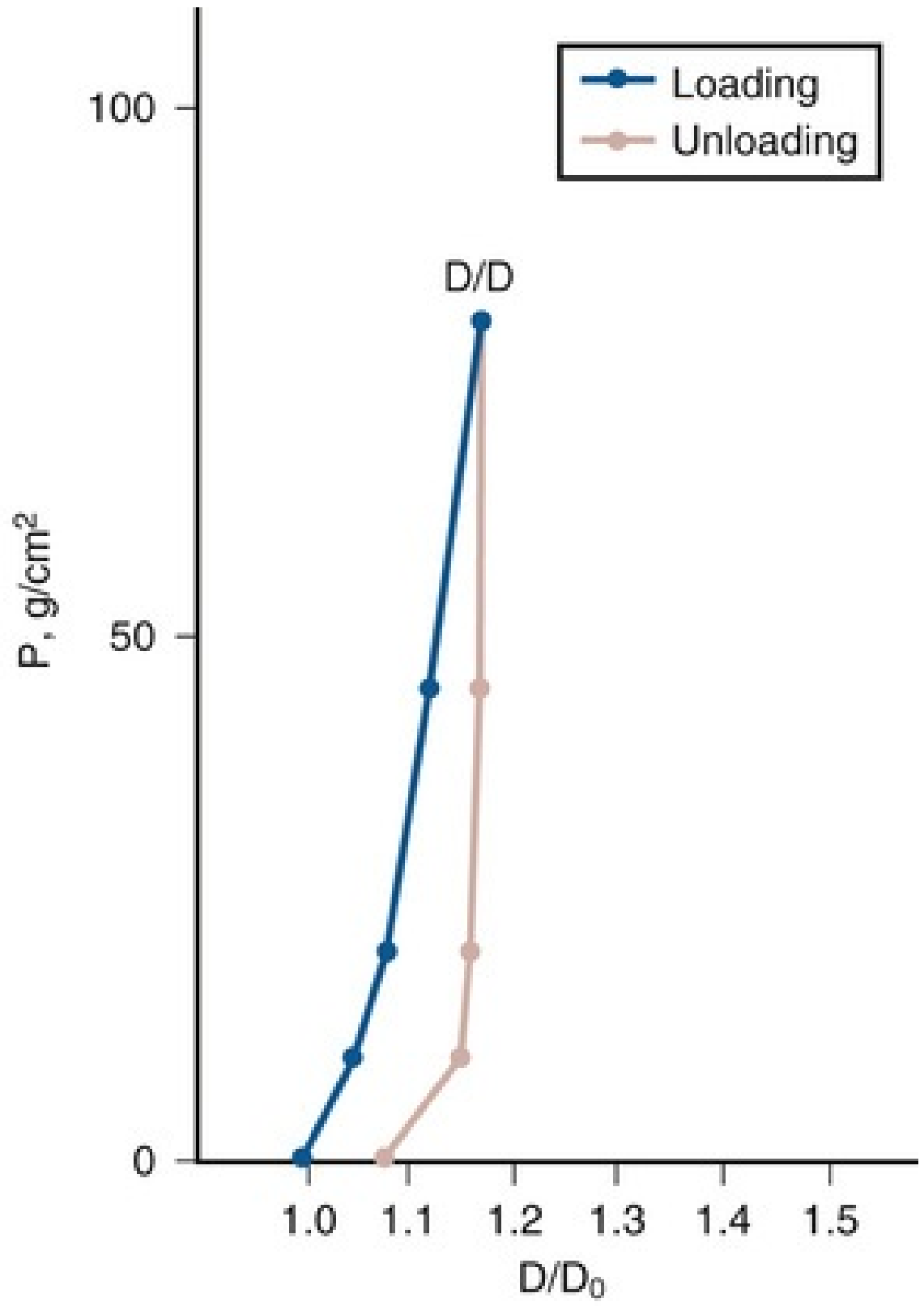

FIG. 85.20 Demonstration of hysteretic properties of ureter show that dimensional changes depend on intraluminal pressure and on the direction of change of that pressure. At comparable pressures, deformations are greater during ureteral emptying than during ureteral filling. The *blue line* shows data obtained during loading; the *pink line,* data obtained during unloading. *D,* Diameter during deformation; D_0, initial diameter; *P,* intraluminal pressure in grams per square centimeter. (Modified from Biancani P, Zabinski MP, Weiss RM: Time course of ureteral changes with acute and chronic obstruction. *Am J Physiol* 231:393, 1976.)

As the obstruction persists, there is a gradual increase in ureteral length

and diameter, which reaches considerable dimensions. This occurs even though ureteral pressure remains at a relatively low and constant level. This process, observed in viscoelastic structures, is referred to as creep (Biancani et al., 1973). A continued, albeit small, urine production is required for the continuing increase in intraureteral volume. Such changes account for the relatively low intrapelvic pressures clinically observed in the massively dilated, chronically obstructed upper urinary tract (Backlund et al., 1965; Djurhuus and Stage, 1976; Struthers, 1969; Vela-Navarrete, 1971); and in experimentally produced obstruction (Koff and Thrall, 1981a; Schweitzer, 1973). One could postulate that with prolonged complete obstruction, the total cessation of urine output ultimately occurs. A subsequent decrease in ureteral dimensions would depend on whether urine is reabsorbed and on the mechanical properties of the ureter at that time.

To determine the effect of obstruction on the contractile properties of the ureter, a rabbit model in which the ureter is totally obstructed for 2 weeks has been employed (Biancani et al., 1982; Hausman et al., 1979). After 2 weeks of obstruction, the cross-sectional muscle area increases by 250%, ureteral length by 24%, and ureteral outer diameter by 100%. In addition to undergoing **muscle hypertrophy**, in vitro segments from obstructed ureters develop greater contractile forces, in longitudinal and circumferential directions, than segments from control ureters (Fig. 85.21). With experimental obstruction at the UPJ there also is an increase in the frequency and amplitude of spontaneous mechanical contractions of the renal pelvis and an increase in the amplitude of phenylephrine and 5-HT–induced contractions (Ekinci et al., 2004). Determination of stress (force per unit area of muscle) provides a means of determining whether the observed increases in developed force result from an increase in contractility or from an increase in muscle mass alone. The increases in force were associated with an increase in maximal active circumferential stress but no change in maximal active longitudinal stress (Fig. 85.22). Because there is an increase in circumferential stress and no change in longitudinal stress, the sum of the stresses (total stress) or overall contractility increases after 2 weeks of obstruction. For these differences in longitudinal and circumferential stresses to occur after obstruction, rotation of muscle bundles must occur; otherwise, longitudinal and circumferential stresses would increase equally. The rotation could result from the greater increase in diameter than in length after obstruction, from remodeling of the muscle fibers, or from both. In addition to an increase in EFS-induced ureteral contractions with obstruction, carbachol, phenylephrine, and KCl also caused a greater increase in contractions in obstructed ureters, and the Rho-kinase inhibitor, Y-27632, has a more pronounced effect in inhibiting these contractile events in the obstructed ureter (Turna et al., 2007; Yalcin et al., 2013). The expression of the two Rho kinase isoforms, ROCK-1 and ROCK-2, is increased in the obstructed ureter (Turna et al., 2007).

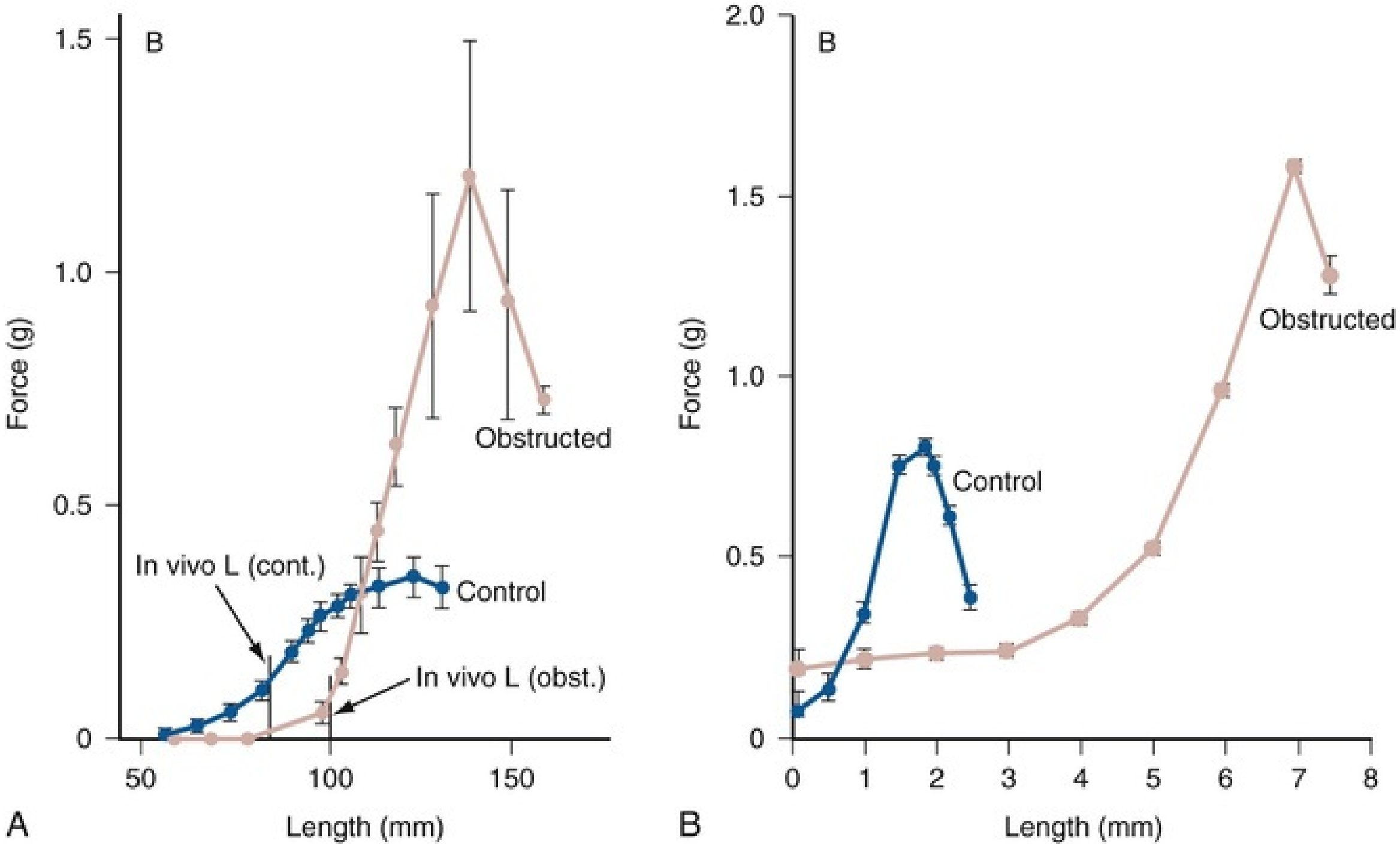

FIG. 85.21 (A) Active (contractile) longitudinal force-length relations of control *(blue circles)* and obstructed *(pink circles)* rabbit ureters. Each data point represents mean ± SEM. (B) Active (contractile) circumferential force-length relations of obstructed *(pink circles)* and control *(blue circles)* ureteral rings. Vertical bars correspond to in vivo lengths of control and obstructed segments. (A, From Hausman M, Biancani P, Weiss RM: Obstruction induced changes in longitudinal force-length relations of rabbit ureter. *Invest Urol* 17:223, 1979. Copyright by Williams & Wilkins, 1979. B, From Biancani P, Hausman, M, Weiss RM: Effect of obstruction on ureteral circumferential force-length relation. *Am J Physiol* 243:F204, 1982.)

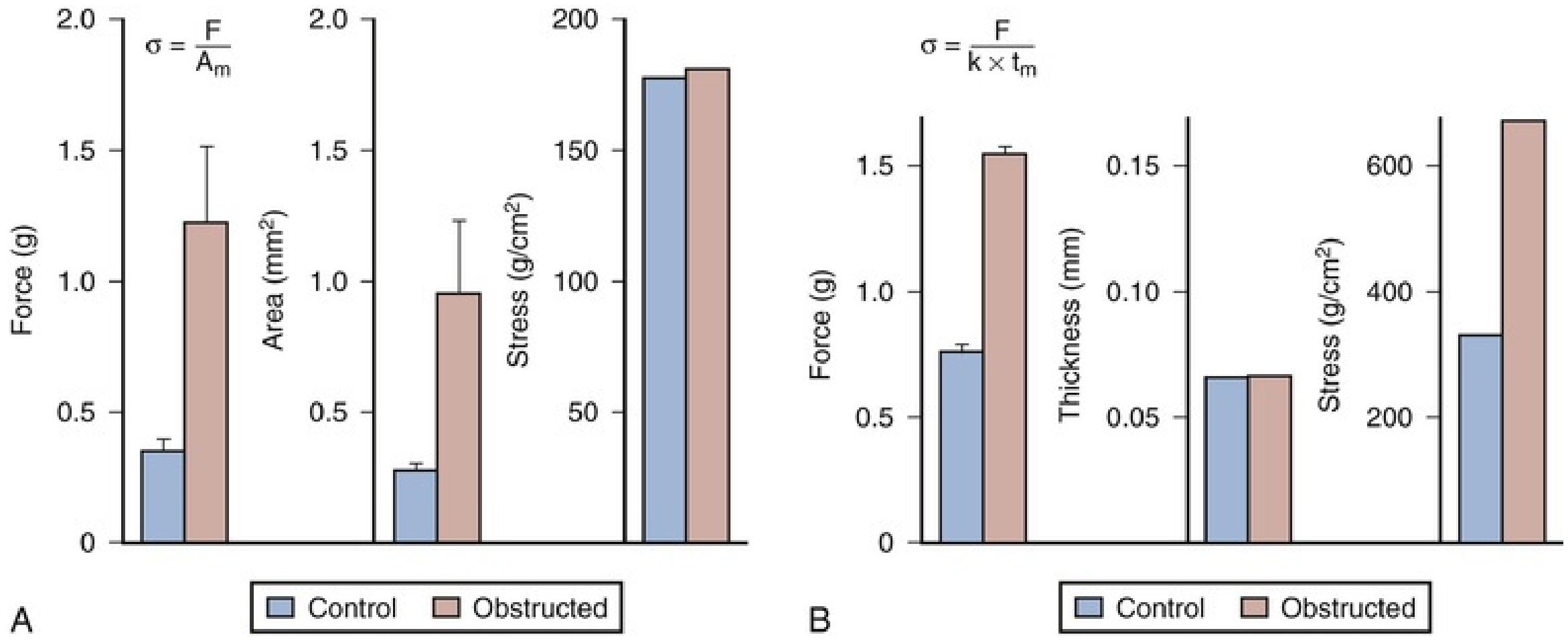

FIG. 85.22 (A) Longitudinal force, cross-sectional muscle area, and longitudinal stress at the length of maximal active force development. (B) Circumferential force, average muscle thickness, and circumferential stress at the length of maximal active force development. A_m, Cross-sectional muscle area; σ, stress; F, force; t_m, average thickness of muscle layer, a constant. (From Weiss RM, Biancani P: A rationale for ureteral tapering. *Urology* 20:482, 1982.)

Thus the ureter dilated after 2 weeks of obstruction is not mechanically decompensated but rather undergoes changes that result in an increase in contractility. **Despite the muscle hypertrophy and the increase in contractility, it is clinically and experimentally evident that the obstructed, dilated ureter is less able than the normal ureter to generate the contractile pressures required for urine transport** (Rose and Gillenwater, 1973). The decrease in the ability to generate an intraluminal pressure despite an increase in contractility results from the increase in ureteral diameter that occurs after obstruction and can be explained by the **Laplace relation**:

$$\text{Pressure} = \frac{\text{stress} \times \text{wall thickness}}{\text{radius}}$$

Although contractility (stress) increases after 2 weeks of obstruction, the decrease in the wall's thickness-to-radius ratio, resulting from the marked increase in intraluminal diameter and thinning of the muscle layer, accounts for the decrease in pressure. A longer duration of obstruction or the presence of infection may alter these relations.

Estimates of intraluminal pressures as a function of diameter (pressure-diameter curves) can be calculated from in vitro circumferential force-length data (Fig. 85.23; Biancani et al., 1982; Weiss and Biancani, 1982) and provide insight as to how obstruction interferes with urine transport. The validity of such calculations is supported by their correspondence to actual in vivo measurements (Biancani et al., 1976; Rose and Gillenwater, 1973). The obstructed ureter at in vivo dimensions has a higher resting (baseline) pressure and a lower contractile (active) pressure than does a control ureter. In the control ureter, the total (active plus passive or resting) pressure developed at all diameters exceeds the passive pressure marked by the horizontal dotted line, and thus the generated active or contractile pressures are able to fully coapt the ureteral lumen and propel the urine bolus. In the obstructed ureter at diameters less than 3.3 mm, the passive pressure, as marked by the horizontal dotted line, exceeds the total pressure. The contraction ring therefore is incapable of contracting below this diameter, and the pressure in the whole ureter remains approximately uniform and equal to the passive pressure. The principal effect of the contraction wave in the obstructed dilated ureter is to slightly reduce the ureteral volume and thereby slightly raise the overall resting pressure. Thus, although the obstructed ureter is able to develop greater circumferential contractile forces than the control ureter, the expected intraluminal pressure generated by the obstructed ureter would differ little from baseline (resting) pressure, and the contraction wave occurring during propagation of peristalsis would be incapable of coapting the ureteral lumen and propelling the urine bolus in an effective manner.

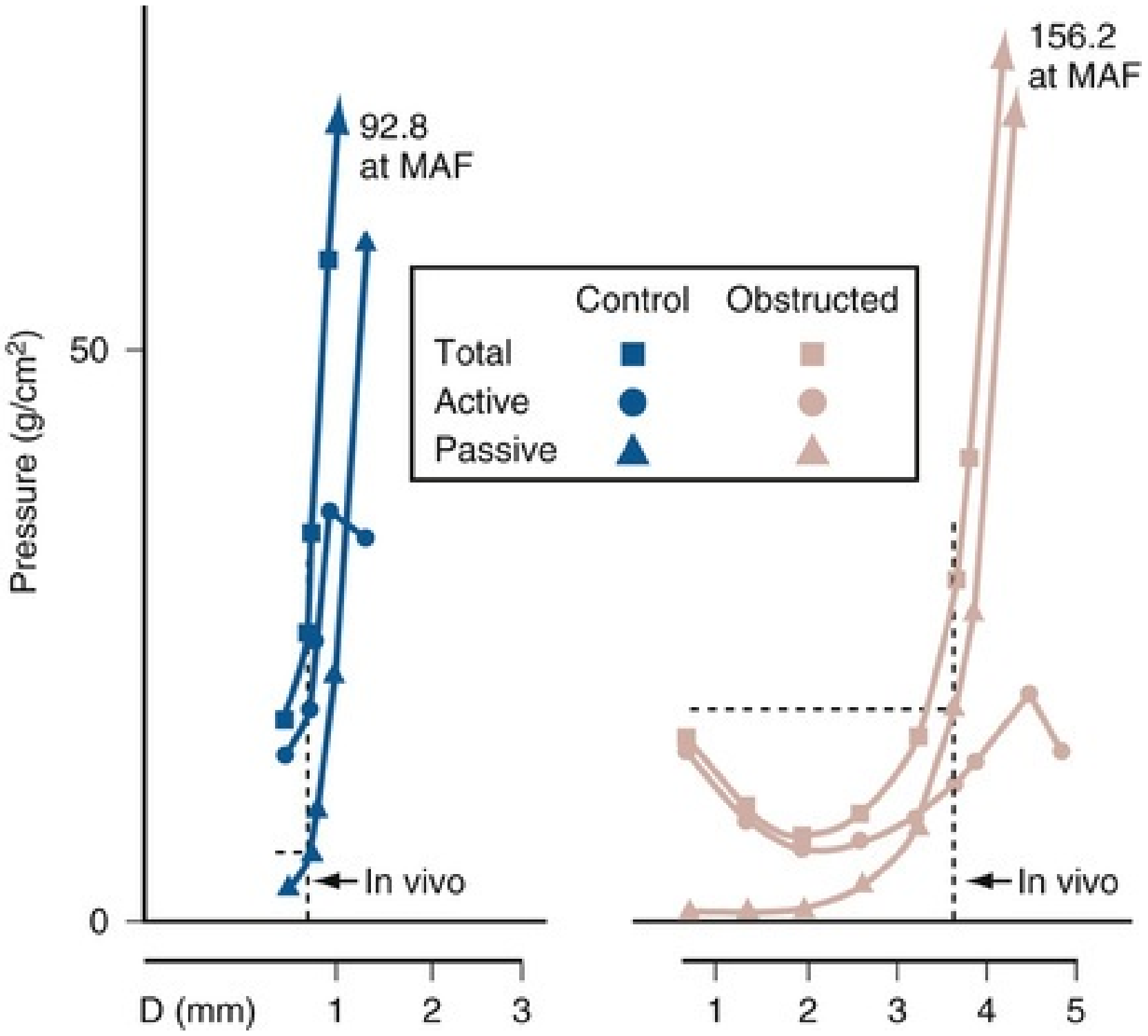

FIG. 85.23 Pressure-diameter relationships of control and obstructed ureters. Calculated total, active, and passive pressures are shown as a function of intraluminal diameter (*D*). In vivo passive pressures are indicated by *horizontal dashed lines* and in vivo dimensions by *vertical dashed lines.* (Modified from Biancani P, Hausman M, Weiss RM: Effect of obstruction on ureteral force-length relations. *Am J Physiol* 243:F204, 1982.)

The calculated active pressure in the obstructed ureter estimates the pressure that would develop if the whole ureter contracted simultaneously and uniformly throughout its whole length, rather than the pressure measured in a peristaltic contraction wave, which involves contraction of only a small segment of ureter at a given time. The fact that the calculated pressures in the obstructed ureter are, if anything, a slight overestimate of expected pressures only further supports the conclusion that **the obstructed ureter is incapable of coapting its lumen and efficiently propelling the urine bolus. If, however, the urine were removed from the lumen of the ureter (e.g., by relieving the obstruction), the ureter obstructed for 2 weeks would be able to immediately coapt its lumen and produce pressures comparable with those of control ureters.** This can be appreciated from Fig. 85.24, in which the total pressure in the obstructed ureter near zero diameter can be seen to be comparable with the total pressure in the control ureter at a similar diameter. Thus **2 weeks of obstruction results in an increase in ureteral contractility but a decrease in contractile intraluminal**

pressures. This decrease in the ability to generate an active intraluminal pressure and to coapt the ureteral lumen impairs urine transport in the obstructed ureter. In a mouse model it has been shown that erythropoietin accelerates return of ureteral peristaltic activity after release of obstruction. In addition, erythropoietin levels increased in the obstructed ureter, suggesting a compensatory mechanism (Jansson et al., 2015).

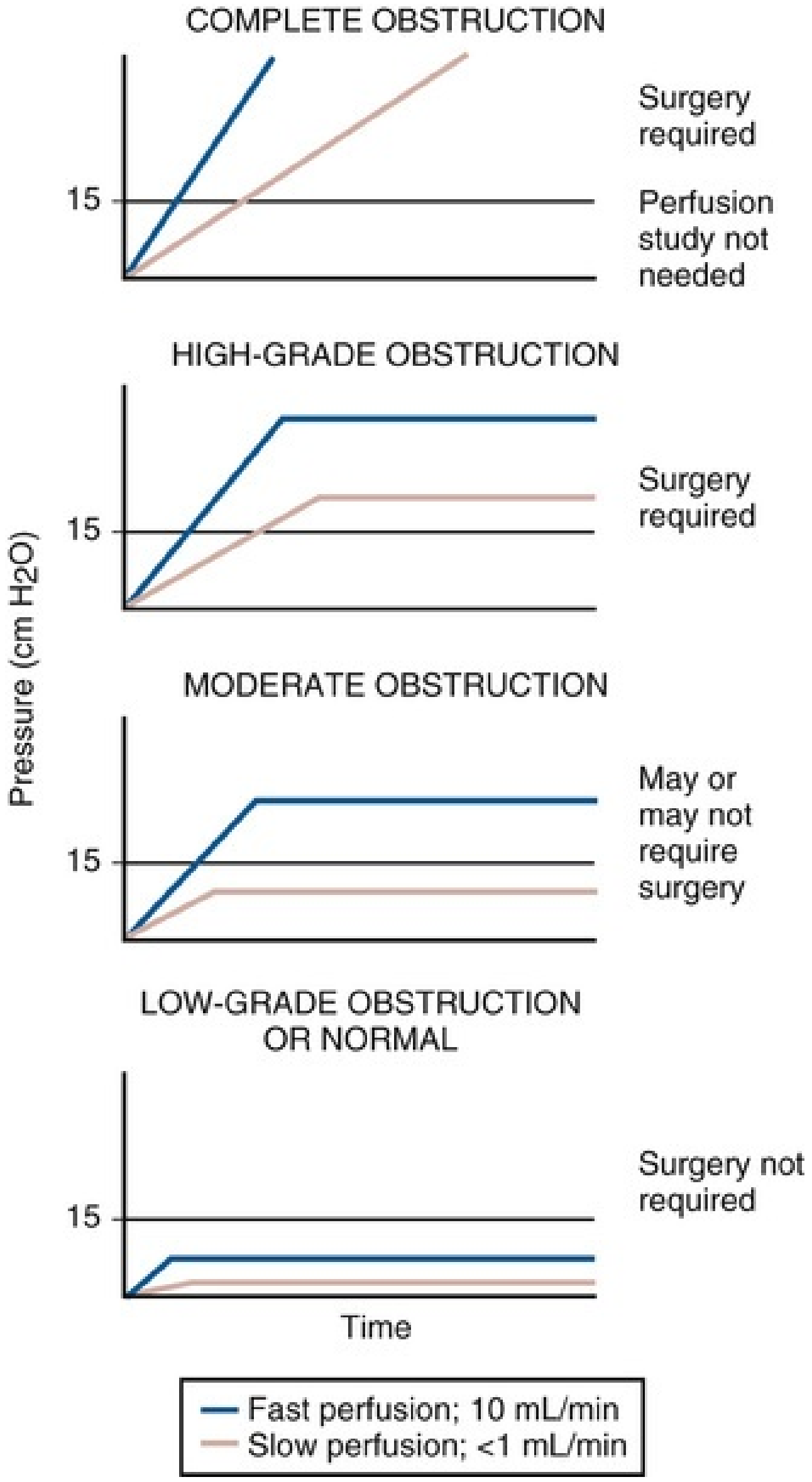

FIG. 85.24 Schematic representation of data that can be obtained with perfusion studies. A fast perfusion rate, 10 mL/min, would be used in a standard Whitaker test. A slow perfusion rate, less than 1 mL/min, would be closer to more physiologic rates of flow. (From Weiss RM: Clinical implications of ureteral physiology. *J Urol* 1979;121:401.)

Obstruction of the fetal ureter also is accompanied by an increase in ureteral weight, smooth muscle mass, extracellular matrix, and the frequency and amplitude of spontaneous ureteral contractile activity (Santis et al., 2000). Obstructed and refluxing dilated ureters have an increase in type I and type III collagen and an increased ratio of collagen to smooth muscle (Gearhart et al., 1995; Lee et al., 1998). Obstruction also has been shown to alter the hierarchic organization of the multiple coupled pacemakers that normally coordinate peristaltic activity (Constantinou and Djurhuus, 1981; Djurhuus and Constantinou, 1982). Such disruption causes discoordination of pelvic contractility with resultant incomplete emptying of the renal pelvis that contributes to upper urinary tract dilatation. Retrograde propagation of electrical activity or absence of electrical activity has been observed distal to an experimental obstruction (Hammad et al., 2011).

Physiologic Methodologies for Assessing Clinical Obstruction

A variety of radiographic methodologies, the rationale for whose use is based on physiologic principles, are employed in the evaluation of upper urinary tract dilatation and obstruction. Description of these examinations, which include diuretic urograms, diuretic MR urography, diuretic ultrasonography, diuretic radionuclide renograms, pulsed Doppler sonographic assessment of renal vascular resistance, and ultrasonographic evaluation of ureteral peristalsis, is beyond the scope of this chapter. The best methods now available for differentiating obstructive from nonobstructive dilatation depend on assessing the efficacy of urine transport. When transport becomes inadequate, urine stagnates and dilatation occurs. **Dilation depends on the compliance of the system and can result either from too much fluid entering the system per unit time or from too little fluid exiting the system per unit time.** The properly functioning upper urinary tract should transport urine over the entire range of physiologically possible flow rates without undergoing marked deformational changes or increases in intraluminal pressure of a magnitude that would be deleterious to the function of the ureter, renal pelvis, or kidney.

Measurement of basal or resting intraluminal pressures does not help in differentiating obstructive from nonobstructive dilation because the pressures may be low even when obstruction is present (Backlund et al., 1965; Struthers, 1969; Vela-Navarrete, 1971). The values obtained vary with the state of hydration, the degree of renal function, the severity and duration of obstruction, and the compliance of the system. **Perfusion studies are used in an attempt to differentiate dilated systems that are obstructed from dilated systems that are not obstructed** (Backlund and Reuterskiöld, 1969a, 1969b; Reuterskiöld, 1969, 1970; Whitaker, 1973, 1978). The technique involves cannulating the dilated upper urinary tract and perfusing the system at a rate of 10 mL/min. Pressures are measured after the achievement of steady-state conditions, which occur when an equilibrium is reached between the flow into and out of the system. Fluoroscopic monitoring aids in the interpretation of the data. **The basic hypothesis in perfusion studies is that if the dilated upper urinary tract can transport 10 mL/min (a fluid load greater than it would ever be expected to handle during usual physiologic states) without an inordinate increase in pressure, any degree of obstruction that is present is not clinically significant.** Whitaker concluded from a large clinical experience that under these flow conditions, a pressure less than 15 cm H_2O correlates with a nonobstructive state, whereas pressures greater than 22 cm H_2O invariably correlate with clinically significant obstruction (Whitaker, 1978; Witherow and Whitaker, 1981). With this definition, minor degrees of obstruction could go undetected; however, **the presumption is that if at high flows the hydrostatic pressure in the system is not at a level that would produce renal deterioration, then lower, more physiologic flows surely will be tolerated.** The high flows are used to stress the system and thus to detect the slightest propensity to obstruction. The interpretation of data obtained by perfusion studies is schematically shown in Fig. 85.25.

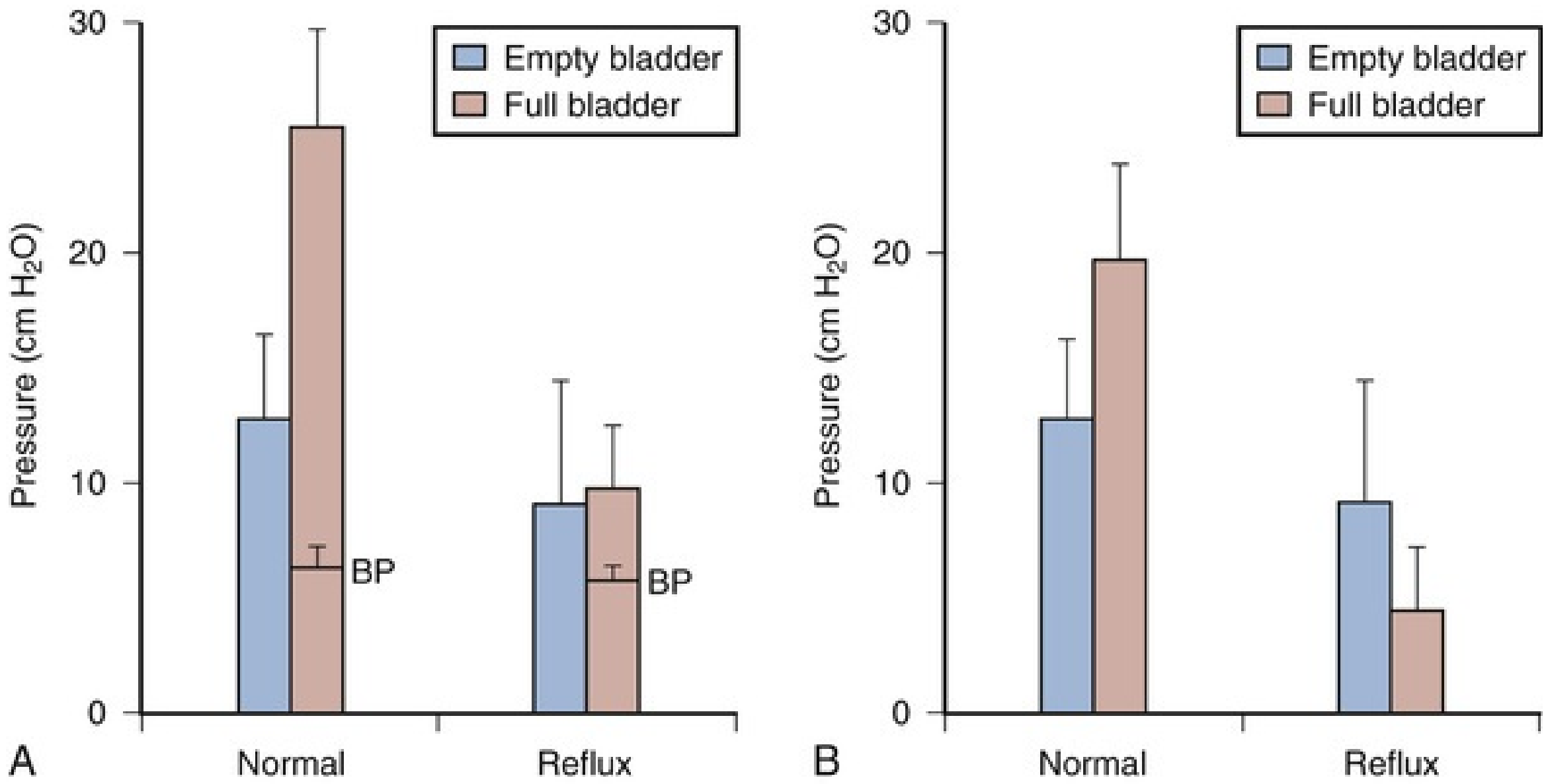

FIG. 85.25 (A) Ureterovesical junction pressures. Bladder pressure is approximately 0 cm H_2O with the bladder empty and is labeled BP with the bladder full. (B) Pressure gradient across the ureterovesical junction, obtained by subtracting the bladder pressure from the ureterovesical junction pressure. (From Weiss RM, Biancani P: Characteristics of normal and refluxing ureterovesical junctions. *J Urol* 129:858, 1983.)

To obtain relevant information, strict adherence to detail is required in the performance of perfusion studies. Care must be taken to ensure that an equilibrium state has been reached before making pressure measurements. Extrinsic factors that affect the resistance to flow, such as the needle size, length and compliance of extrinsic tubing, viscosity of the perfusion fluid, temperature, and flow rate, must be considered when quantitative data are obtained (Toguri and Fournier, 1982). Furthermore, the bladder should be continuously drained to eliminate the bladder's effect on urine transport.

When performed and interpreted properly, perfusion studies may provide clinically relevant information in select cases. The basic problem in the interpretation of data with this and other diagnostic methods is the definition of “clinically relevant obstruction”—that is, just how much resistance to flow or increase in pressure is required to produce renal functional or anatomic deterioration as a function of time, taking into account the compliance of the system (Koff and Thrall, 1981b). Also, it is theoretically possible that the wide or weakly contracting ureter at high flow rates may interfere with bolus transport even if the UVJ is normal (Griffiths, 1983). Such an obstructive process would not be detected by perfusion studies.

These theoretical considerations provide a rationale for **ureteral tapering** (Hendren, 1970). The Laplace relation provides a possible explanation for anticipated improvement in function resulting from tapering. With ureteral tapering, muscle thickness and the ability of the ureteral fibers to contract (stress) are unchanged. The decrease in radius resulting from tapering itself, according to the Laplace relation, could account for higher intraluminal pressures, which could improve urine transport. Thus the tapered ureter may coapt its walls more readily and generate higher intraluminal pressures, even though the material has not changed (Weiss and Biancani, 1982). Although the possibility of deleterious effects of the wide “nonobstructed” ureter remains controversial, urologists should consider such effects when interpreting data obtained with the present modalities for diagnosing obstruction and when determining management.

Relation Between Vesicoureteral Reflux and Ureteral Function

Factors that have been implicated in the development of vesicoureteral reflux (VUR) include (1) anatomic and functional abnormalities at the UVJ, (2) inordinately high intravesical pressures, and (3) impaired ureteral function. The normal intravesical ureter is approximately 1.5 cm in length and takes an oblique course through the bladder wall. It is composed of an intramural segment surrounded by detrusor muscle and a submucosal segment that lies directly under the bladder urothelium (Tanagho et al., 1968). The relation between the length and the diameter of this intravesical segment of ureter appears to be a factor in the prevention of VUR. Paquin (1959) noted that the normal ratio of intravesical tunnel length to ureteral diameter was 5:1, and Tanagho et al. (1969) noted that the ratio was 1.4:1 in children with VUR. The 5:1 ratio may be an overestimation, and a more recent study reported the proportion of intravesical ureteral length to intravesical ureteral diameter to be 2.23:1 (Oswald et al., 2003b). The ratio of intravesical ureteral length to ureteral diameter is smaller in the fetus: 0.69:1 and 1.23:1 in 11- and 20-week old fetuses, respectively (Oswald et al., 2003a). Reflux may occur when the intravesical tunnel is destroyed. Trigonal function also may be a factor in the prevention of VUR. Tanagho et al. (1965) created VUR in the cat by disruption of the trigone and by sympathectomy. The development of VUR in individuals with bladder outlet obstruction and neurogenic vesical dysfunction provides evidence that increased intravesical pressures also may be a factor in certain instances of reflux.

A significant percentage of units with VUR improve spontaneously with age. In a study by Jorgensen et al. (1984), 35% of young pigs had VUR that disappeared with age. In the pig, significant growth and organization of smooth muscle and increase in innervation occurs during the postnatal period, and this may be the anatomic correlate of maturation of the UVJ during infancy and the spontaneous functional disappearance of reflux (Pirker et al., 2007).

Although an abnormality of the UVJ is the primary etiologic factor in most cases of reflux, evidence suggests that decreased ureteral peristaltic activity can be a contributory factor. This may explain why a normal ureter may not reflux even when reimplanted into a bladder without a submucosal tunnel (Debruyne et al., 1978) or why a defunctionalized refluxing ureter may cease to reflux when a proximal diversion is taken down (Teele et al., 1976; Weiss, 1979). The observation that VUR may temporarily cease after ureteral electric stimulation (Melick et al., 1966) further supports this possibility.

Even the mildest forms of VUR are associated with a decreased frequency of ureteral peristalsis (Kirkland et al., 1971; Weiss and Biancani, 1983). Although this may offer further evidence that decreased peristaltic activity is a possible etiologic factor in the development of reflux, an alternative interpretation is that the decreased peristaltic activity reflects changes in ureteral or renal function resulting from the reflux. Finally, **the success rate of antireflux procedures is lower with poorly functioning dilated ureters, and, although this may be related to technical factors, decreased peristaltic activity may be another reason for failure**.

Studies in normal and mildly refluxing systems have shown that there is a high-pressure zone in the distal ureter, with a resultant pressure gradient across the UVJ (Weiss and Biancani, 1983). Although the cause of the UVJ gradient is not known, the weight of the fluid within the bladder compressing the intravesical ureter may be a factor. Another causative factor may be bladder or trigonal tension involving myogenic or neurohumoral mechanisms. With bladder filling, there is an increase in the amplitude of the high-pressure zone that is greater in nonrefluxing than in refluxing systems. With bladder filling, the resultant UVJ-bladder pressure gradient increases in nonrefluxing systems, whereas it decreases and may disappear in refluxing systems (Fig. 85.26; Weiss and Biancani, 1983). This decrease in pressure gradient may correspond to the time when reflux occurs and may be related to lateralization of the ureteral orifice and shortening of the intravesical tunnel. More recent studies have shown a decrease in basal and maximum pressures at the UVJ of refluxing ureters that correlated with histologic changes (Arena et al., 2007). The histologic changes included a degree of smooth muscle deterioration and atrophy, an increase in collagen deposition, and fewer c-KIT–positive ICC-like cells at the UVJ in patients with VUR (Arena et al., 2007; Oswald et al., 2004; Schwentner et al., 2005). Matrix metalloproteinase-1 (MMP-1) production and the number of CD68$^+$ macrophages are increased, whereas S-100–positive myelinated nerves are decreased in the distal portion of refluxing ureters (Oswald et al., 2004; Radmayr et al., 2010). MMP-1 cleaves collagen and is frequently seen in collagen-rich regions. Some MMPs can damage nerves. CD68+ macrophages presumably phagocytize cells undergoing apoptosis. TGF-β1 levels were found to be higher and VEGF levels lower in refluxing ureters (Izol et al., 2014). Furthermore, deletion of fibroblast growth factor receptor 2 was associated with a high incidence of VUR in newborn mice (Narla et al., 2017). A heterozygous null mutation in odd-skipped related 1 (*Osr1*), a transcriptional repressor involved in maintaining the mesenchymal stem cell population, is associated with a 21% incidence of VUR and a shortened intravesical tunnel in newborn mice and has been considered a candidate gene in the development of VUR in humans (Fillion et al., 2017). *Pax2*, a nuclear transcription factor involved in the development of the urinary tract, was increased in refluxing human ureters (Zheng et al., 2015). Contraction of the longitudinal muscles at the UVJ also may function as an active antireflux mechanism (Schwentner et al., 2005).

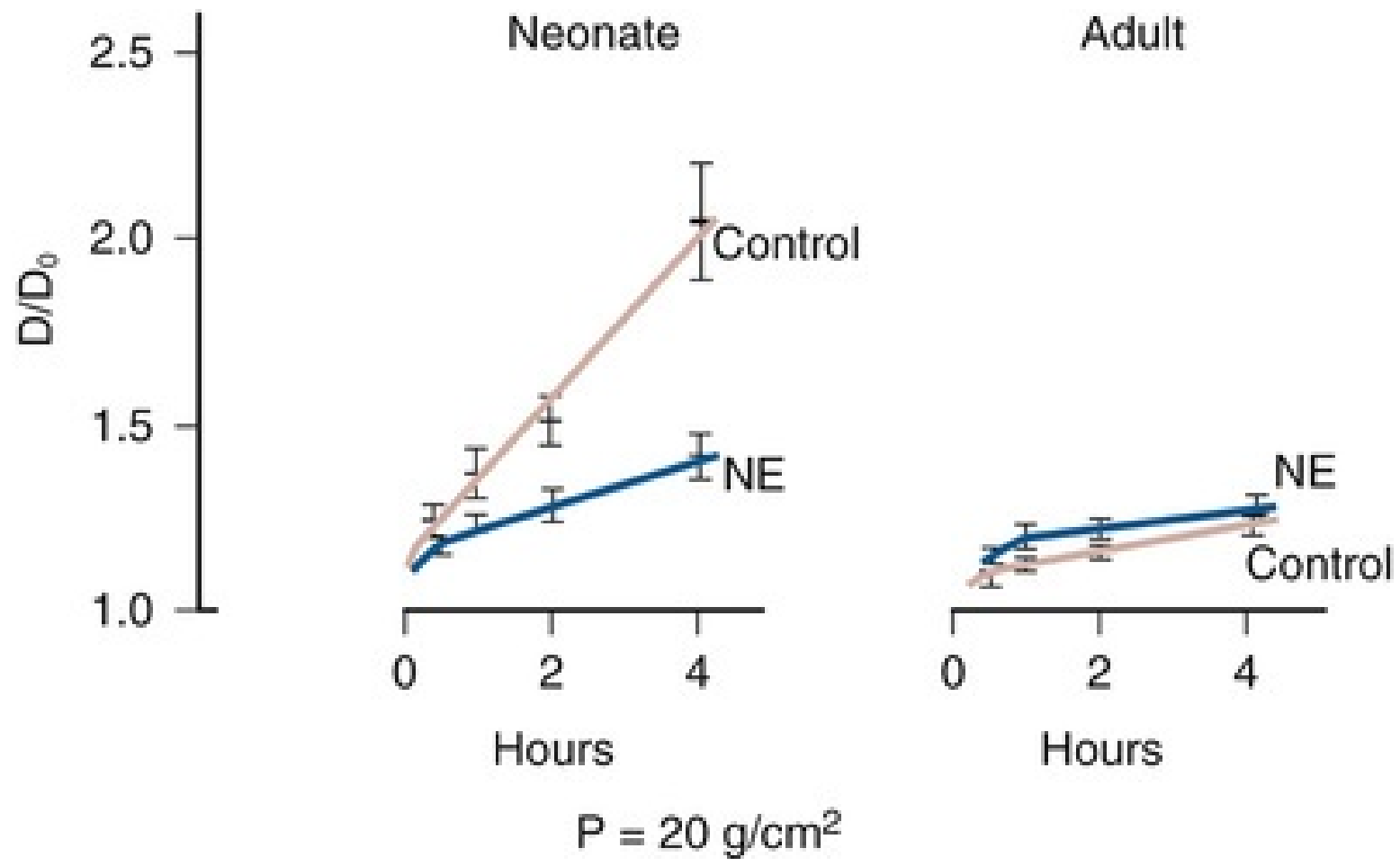

FIG. 85.26 Changes in diameter of neonatal and adult rabbit ureteral segments as a function of time after the application of a constant intraluminal pressure (P) of 20 g/cm^2. Diametral deformation (D/D_0) of

control neonatal ureters was significantly greater than that of control adult ureters. Norepinephrine (10^{-5} M) decreased the diametral deformation of the neonatal ureters but had no significant effect on the deformation of the adult ureteral segments. D, Diameter during deformation; D_0, initial diameter. (From Akimoto M, Biancani P, Weiss RM: Comparative pressure = length – diameter relationships of neonatal and adult rabbit ureters. *Invest Urol* 14:297, 1977.)

Effect of Infection on Ureteral Function

Infection within the upper urinary tract may impair urine transport. Pyelonephritis in the monkey has been associated with decreased peristaltic activity (Roberts, 1975). Furthermore, Rose and Gillenwater (1973) have shown that infection can potentiate the deleterious effects of obstruction on ureteral function. In 1913 Primbs showed that *Escherichia coli* and staphylococcal toxins inhibited contractions of in vitro guinea pig ureteral segments. **A number of studies have confirmed that bacteria and *E. coli* endotoxin can inhibit ureteral activity** (Grana et al., 1965; King and Cox, 1972), although these findings have not been universal (Struthers, 1976; Thulesius and Araj, 1987). Uropathogenic *E. coli* (UPEC) decreased phasic and potassium induced contractions of isolated human and rat ureteral segments (Floyd et al., 2010). These inhibitory changes were due to activation of K^+ channels with resultant inhibition of calcium entry through voltage dependent L-type calcium channels. UPEC also caused impairment of urothelial barrier function. Urothelial cells show an increased expression of iNOS in response to bacterial invasion. Activation of iNOS leads to the formation of NO a known smooth muscle relaxant, and this may contribute to inhibitory effects of infection on ureteral contractility (Poljakovic and Persson, 2003).

In humans, irregular peristaltic contractions with an often-decreased amplitude have been recorded with infection, and an absence of activity has been noted in the more severe cases (Ross et al., 1972). Furthermore, ureteral dilation has been reported to result from retroperitoneal inflammatory processes secondary to appendicitis, regional enteritis, ulcerative colitis, or peritonitis (Makker et al., 1972). Infection also may reduce the compliance of the intravesical ureter and permit reflux to occur in situations in which the UVJ is intrinsically of marginal competence (Cook and King, 1979).

Effect of Calculi and Stents on Ureteral Function

Factors that affect the spontaneous passage of calculi are (1) the size and shape of the stone (Ueno et al., 1977); **(2) intrinsic areas of narrowing within the ureter; (3) ureteral peristalsis; (4) hydrostatic pressure of the column of urine proximal to the calculus** (Sivula and Lehtonen, 1967); **and (5) edema, inflammation, and spasm of the ureter at the site at which the stone is lodged** (Holmlund and Hassler, 1965).

In an attempt to understand the physiologic processes that contribute to or hinder the passage of stones through the ureter, Crowley et al. (1990) created acute ureteral obstruction in the dog with an intraluminal balloon catheter and measured intraluminal ureteral pressures and peristaltic activity above and below the acutely obstructed site. The peristaltic rate and baseline, peak, and delta (peak minus baseline) pressures increased proximal to the site of obstruction. In contrast, the peristaltic rate remained unchanged distal to the obstruction, despite decreases in the baseline, peak, and delta pressures. It has been suggested that failure of transmission of effective peristalsis across the site of obstruction may hinder stone passage. Implantation of an artificial calculus in a rat ureter resulted in an increase in the amplitude of contractions, a decrease in the rate of contractions, and a decrease in baseline pressure (Laird et al., 1997). These changes persisted for a period after spontaneous passage of the calculus. It was suggested that the increased motility caused by a stone contributes to the visceral pain associated with ureteral stone passage.

Two factors that appear to be most useful in facilitating stone passage are an increase in hydrostatic pressure proximal to a calculus and relaxation of the ureter in the region of the stone. In support of the theory that hydrostatic pressure facilitates stone passage, artificial concretions with holes were shown to move more slowly in the rabbit and dog ureter than those without holes (Sivula and Lehtonen, 1967). Furthermore, ureteral ligation proximal to a concretion, which decreases hydrostatic pressure by decreasing urine output and decreases peristaltic activity proximal to a stone, hampers stone passage (Sivula and Lehtonen, 1967).

With respect to the potential facilitative effect of ureteral relaxation on stone passage, spasmolytic agents phentolamine, an α-adrenergic antagonist, and orciprenaline and isoproterenol β-adrenergic agonists have been shown to dilate the ureteral lumen or decrease ureteral wall tension at the level of an artificial concretion and thus permit increased fluid flow beyond the concretion (Miyatake et al., 2001; Peters and Eckstein, 1975). **Pharmacologic data can be interpreted to imply that ureteral relaxation in the region of a concretion could aid in stone passage.** Agents such as theophylline (Green et al., 1987; Weiss et al., 1977), with strong relaxant effects on the ureter, have potential value in facilitating stone passage. It also has been reported that local aminophylline facilitates ureteroscopy and transureteral lithotripsy (Barzegarnezhad et al., 2012) and that endoluminal administration of isoproterenol reduces renal pelvic pressures during flexible ureterorenoscopy (Jakobsen, 2013) and facilitates passage of ureteral access sheaths during ureterorenoscopy in a pig model (Lildal et al., 2016). In a rabbit in vivo model rolipram, a cAMP-specific PDE inhibitor (PDE4 inhibitor), caused a more marked ureteral relaxation than did the nonspecific PDE inhibitors, papaverine and theophylline, and without the circulatory side effects seen with the nonspecific PDE inhibitors (Becker et al., 1998). Because the relaxant effect of rolipram was similar in human and rabbit in vitro ureteral segments, it was suggested that rolipram could potentially be beneficial in the treatment of renal colic and in the facilitation of stone passage (Becker et al., 1998). Rolipram also has been shown to relax pig intravesical ureteral segments (Hernández et al., 2004). In addition to the PDE4 inhibitor rolipram, PDE5 inhibitors (cGMP-specific PDE inhibitors) relax in vitro pig, sheep, and human ureteral segments (Al-Aown et al., 2011; Kuhn et al., 2000; Kyriazis et al., 2015; Liatsikos et al., 2013). The relaxant effects of PDE4 and PDE5 inhibitors were paralleled by an increase in cAMP and cGMP, respectively. Gratzke et al. (2007) showed that PDE5 inhibitors reversed KCl-induced increases in tension of isolated human ureteral segments, with a rank order of efficacy (most efficient to least) of vardenafil (Levitra), sildenafil (Viagra), then tadalafil (Cialis). Species differences in PDE subtypes may exist. Although the nonspecific PDE inhibitor papaverine decreased the frequency of ureteral peristalsis in the pig, the PDE4 inhibitor, rolipram, had no effect (Danuser et al., 2001).

A combination of the calcium channel blocker nifedipine, which causes ureteral relaxation and the corticosteroid deflazacort, which reduces edema, was shown to facilitate spontaneous passage of 1-cm or smaller distal ureteral stones (Borghi et al., 1994; Porpiglia et al., 2000). Spontaneous expulsion of 79% of stones (average size 5.8±1.8 mm) occurred in an average of 7 days in patients treated with nifedipine and deflazacort compared with spontaneous passage of 35% of stones (average size 5.5±1.4 mm) within an average of 20 days in untreated patients (Porpiglia et al., 2000). In a subsequent study, this same group showed that nifedipine and the α-adrenegic antagonist tamsulosin, when combined with deflazacort, increased the rate of spontaneous passage of lower ureteral calculi, and that, in addition, tamsulosin, a selective $\alpha_{1A/1D}$-adrenergic receptor antagonist, reduced the time to spontaneous expulsion (Porpiglia et al., 2004, 2006). They showed that tamsulosin alone was effective in facilitating expulsion of distal ureteral stones, and that this effect was potentiated by steroids. Steroids alone were ineffective. α_1-Adrenergic receptors are present throughout the human ureter with the greatest quantity of α_1-adrenergic receptors being in the distal ureter (Sigala et al., 2004, 2005). α_{1D} mRNA was expressed throughout the human ureter, with significantly greater amounts than the α_{1A}- and α_{1B}-receptor subtypes in the proximal and distal ureter. $\alpha 1_{A/1D}$-Adrenergic receptors are present in the distal ureter. **A number of other studies have noted an increased spontaneous stone expulsion rate and expulsion rate after ESWL, a decrease in renal colic, and an improved tolerance of ureteral stents with the administration of tamsulosin and other α-adrenergic antagonists** (Al-Ansari et al., 2010; Autorino et al., 2005; Cervenakov et al., 2002; Dellabella et al., 2003; De Sio et al., 2006; El Said et al., 2015; Gravas et al., 2007; Gravina et al., 2005; Kupeli et al., 2004; Liatsikos et al., 2007; Liu et al., 2015; Losek and Mauro, 2008; Lu et al., 2012a; Resim et al., 2005; Sur et al., 2015; Yencilek et al., 2010; Yilmaz et al., 2005). Yilmaz et al. (2005) reported that doxazosin and terazosin were equally effective in facilitating stone passage, and Dellabella et al. (2005) reported that tamsulosin was more effective than the calcium channel blocker nifedipine in facilitating stone expulsion. Naftopidil, an α_{1D}-adrenergic receptor antagonist, also has been reported to be effective in facilitating the expulsion of intramural ureteral stones (Lu et al., 2012b), although others have failed to show effectiveness of naftopidil in medical expulsive therapy (MET) (Cho et al., 2017). Furthermore, a large multicenter analysis failed to show effectiveness of either nifedipine or tamsulosin in aiding stone passage (Pickard et al., 2015).

Indwelling ureteral stents are frequently used to bypass an obstructing ureteral calculus and/or to dilate the ureter to facilitate subsequent ureterorenoscopy. A variety of α-adrenergic antagonists have been used to ameliorate stent-induced discomfort (Beddingfield et al., 2009; Damiano et al., 2008; Dellis et al., 2014). In addition to ureteral dilation, stents decrease ureteral activity, increase tissue inflammation and decrease expression of GLi1, a downstream target of Shh signaling (Janssen et al., 2017).

Effect of Diabetes on Ureteral Function

In cases of diabetes, changes in bladder function affect the ureter. In addition, there is some evidence of a direct effect of diabetes on the ureter. The length and velocity of movement of the urinary bolus is decreased in the streptozotocin (STZ) diabetic rat (Watanabe and Miyagawa, 2002). Although the frequency of contractions of in vitro segments of the renal pelvis and ureter of STZ-induced diabetic rats are unchanged, the amplitude of contractions is increased in comparison with renal pelvic and ureteral segments from control sucrose-induced diuretic rats (Davidson and Lang, 2007). Capsaicin is known to release tachykinins from sensory nerves and it is postulated that a supersensitivity of the upper urinary tract of STZ-induced diabetic rats to the sensory neurotoxin capsaicin, and to the sensory excitatory neuropeptides substance P and neurokinin A, results from a sensory neuropathy (Davidson and Lang, 2007).

Effect of Age on Ureteral Function

Clinically, the response of the ureter to pathologic conditions varies with age. **More marked degrees of ureteral dilatation are observed in the neonate and young child than in the adult.** Experimental data corroborating this clinical impression can be derived from observed age-dependent differences in the response of in vitro ureteral segments to an intraluminal pressure load. The neonatal rabbit ureter undergoes a greater degree of deformation in response to an applied intraluminal pressure than does the adult rabbit ureter (Akimoto et al., 1977). Furthermore, norepinephrine decreases the diametral deformation of the neonatal rabbit ureter in response to an applied intraluminal pressure but has little effect on the deformation of the adult rabbit ureter (Fig. 85.27). Thus the in vitro neonatal rabbit ureter appears to be more compliant and more sensitive to norepinephrine than the adult rabbit ureter.

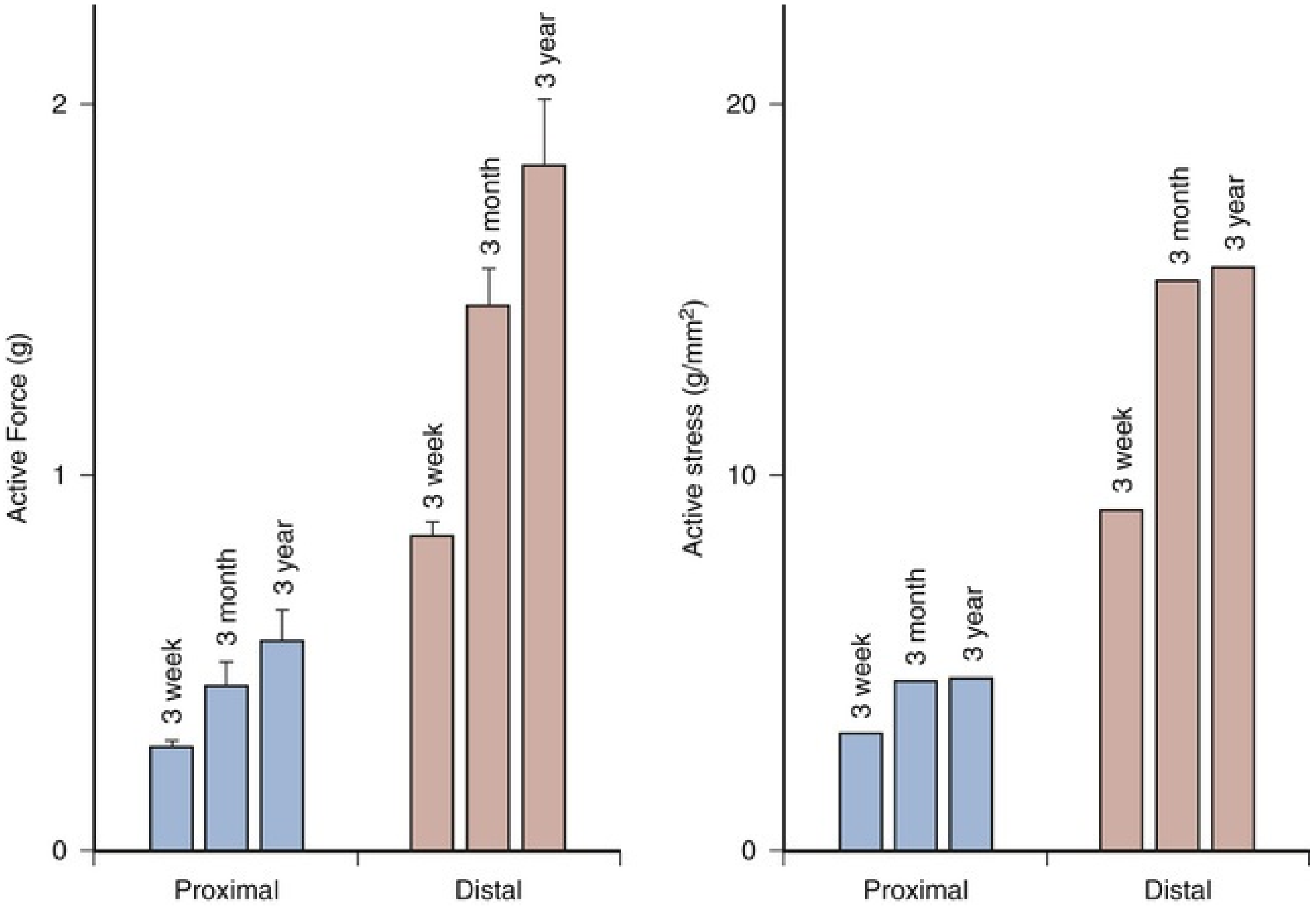

FIG. 85.27 Maximal active (contractile) force and maximal active stress of proximal and distal guinea pig ureteral segments as a function of age.

Age also affects the response of the ureter to β-adrenergic agonists; with aging there is a decrease in the relaxant response to the β-adrenergic agonist isoproterenol (Wheeler et al., 1990). The relaxant response to β-adrenergic agonists is related, in part, to cAMP levels. It has been shown that with aging there is a decrease in the enzymatic activities involved in the synthesis of cAMP (Wheeler et al., 1986) but no change in the enzymatic activities involved in cAMP degradation (Cho et al., 1988). These data suggest that the decrease in the ability of isoproterenol to relax the ureter with aging is due to a decrease in the ability of isoproterenol to activate adenylyl cyclase, the enzyme involved in cAMP synthesis. Developmental differences in the response of the ureter to metabolic inhibitors are evident, with cyanide causing a larger decrease in force in the adult than in the neonatal guinea pig ureter (Bullock and Wray, 1998a, 1998b). Furthermore, the response to 5-HT_2 is greater in a young than an old pig ureter (Lim et al., 2018).

A progressive increase in ureteral cross-sectional muscle area is observed in the guinea pig between 3 weeks and 3 years of age. This is in accord with the findings of Cussen (1967), who noted in a human autopsy study of subjects ranging in age from 12 weeks’ gestation to 12 years, a progressive increase in the population and a small increase in the overall size of the individual smooth muscle cells with age. In addition, an irregular increase in the number of elastic fibers was observed with increasing age.

The contractility of the ureter also is affected by age. The maximal active force of isolated guinea pig ureteral segments increases between 3 weeks and 3 years of age (see Fig. 85.27) (Hong et al., 1980). The increase in force developed between 3 weeks and 3 months of age seems to be attributable to an increase in contractility, because there is an associated increase in active stress (force per unit area of muscle). The increase in force developed between 3 months and 3 years of age can be explained by an increase in muscle mass alone because there is no change in active stress between these two age groups (see Fig. 85.27).

Although changes in the force-length relations of guinea pig ureter occur with age, the force-velocity relations do not change with age (Biancani et al., 1984). Thus, although ureteral contractility increases during early development, as shown by an increase in force per unit area of muscle, or stress, no significant change is apparent in the rate of the driving reactions that control the contractile process, that is, no change in shortening, velocity, work, or power.

Effect of Pregnancy on Ureteral Function

Hydroureteronephrosis of pregnancy begins in the second trimester of gestation and subsides within the first month after parturition. It is more severe on the right side, and the ureteral dilatation does not occur below the pelvic brim. Roberts (1976) has presented a strong case in favor of obstruction as the etiologic factor in the development of hydroureteronephrosis of pregnancy, whereas other investigators have suggested a hormonal mechanism for the ureteral dilatation of pregnancy (van Wagenen and Jenkins, 1939).

Roberts (1976) emphasized the following: (1) Elevated baseline (resting) ureteral pressures consistent with obstructive changes have been recorded above the pelvic brim in pregnant women, and these pressures decrease when positional changes permit the uterus to fall away from the ureters (Sala and Rubi, 1967). (2) Normal ureteral contractile pressures recorded during pregnancy suggest that hormonally induced ureteral atony is not the prime factor in ureteral dilatation of pregnancy. (3) Women whose ureters do not cross the pelvic brim (i.e., those with pelvic kidneys or ileal conduits) do not develop hydronephrosis of pregnancy. (4) Hydronephrosis of pregnancy usually does not occur in quadrupeds, whose uterus hangs away from the ureters (Traut and Kuder, 1938). (5) Elevated ureteral pressures in the pregnant monkey return to normal when the uterus is elevated from the ureters at laparotomy or when the fetus and placenta are removed from the uterus.

Observed hormonal effects on ureteral function have been used to implicate a hormonal mechanism in the ureteral dilatation of pregnancy, although difficulties in interpretation arise from inconsistencies in the data. Several studies have shown an inhibitory effect of **progesterone** on ureteral function (Kumar, 1962). Progesterone has been noted to increase the degree of ureteral dilatation during pregnancy and to retard the rate of disappearance of hydroureter in postpartum women (Lubin et al., 1941). Other studies, however, have failed to demonstrate an effect of progesterone on ureteral activity in animals (McNellis and Sherline, 1967) or in humans (Lapides, 1948), and still others have failed to induce changes in ureteral activity in women through the administration of estrogens, progesterone, or a mixture of these drugs (Clayton and Roberts, 1973; Marchant, 1972). Although some have noted that estrogens increase ureteral activity (Hundley et al., 1942), the majority of investigators have failed to observe an effect of estrogens in animal models (Abramson et al., 1953) or in humans (Kumar, 1962). Thus **obstruction appears to be the primary factor in the development of hydronephrosis of pregnancy,** although some evidence suggests that a combination of hormonal and obstructive factors is involved (Fainstat, 1963).

Effect of Drugs on the Ureter

This section provides an assessment of the effects of the major classes of drugs on ureteral function. Many of the studies referred to were performed in animal models, and extrapolation of the data to the intact human ureter is often difficult. In the clinical situation, the relatively sparse blood supply to the ureter limits the distribution of drugs to the ureter, and the pharmacokinetics are different in the laboratory than in the clinic. In addition, many drugs with potential usefulness in the management of ureteral abnormalities have potential untoward side effects when used in concentrations required to affect the ureter.

To assess the effect of drugs on the ureter, it is necessary to understand the anatomic, physiologic, and biochemical properties of the ureter, in addition to understanding the principles of drug action. For a drug to elicit a given response, it is necessary to achieve and maintain an appropriate concentration of that drug at its site of action. Factors that can influence the achievement of an effective concentration of drug at a site of action are (1) the route of administration and cellular distribution of the drug; (2) the dosage of the drug administered; (3) the biotransformation, including metabolism and excretion, of the drug; (4) the binding of the drug to plasma and tissue proteins; and (5) the effects of age and disease on the absorption, distribution, metabolism, and elimination of the drug.

The literature contains considerable confusing and conflicting information concerning the effects of drugs on the ureter. To some extent, the discrepancies in the available data are due to poorly controlled experimental procedures or to attempts to compare dissimilar functional responses of the ureter with a given drug. To simplify the present section, no attempt is made to analyze the validity of each pharmacologic study or to rationalize discrepancies in the literature; rather, an overview is presented with an attempt to provide a consensus that, at times, may be prejudiced by personal bias. Furthermore, discussion of drugs related to the nervous system, pregnancy, and a variety of pathologic states is included in earlier sections of this chapter, and will not be duplicated in this section.

Histamine and Its Antagonists

Histamine has a dual action on smooth muscle; it may (1) release catecholamines from sympathetic nerve endings or (2) act directly on receptors within the smooth muscle. In addition, **histamine may have excitatory or inhibitory effects on ureteral function.** The majority of studies have shown an excitatory effect of histamine on ureteral function (Benedito et al., 1991; Borgstedt et al., 1962; Sharkey et al., 1965; Smita et al., 2006; Vereecken, 1973), a finding that may be species dependent (Tindall, 1972). **Histamine's excitatory effect on the ureter and UVJ appears to be mediated by H_1 receptors** as they are inhibited by the H_1-receptor antagonists mepyramine, pheniramine, and dimethindene but not by the H_2-receptor antagonists cimetidine and ranitidine (Benedito et al., 1991; Dodel et al., 1996; Smita et al., 2006). An H_1 agonist, 2-(2-pyridyl)ethylamine, increases ureteral contractility (Dodel et al., 1996). The H_1 inhibitor, pheniramine, has no effect on spontaneous activity of isolated goat ureter (Smita et al., 2006). The excitatory effect of histamine on the sheep UVJ is partially blocked by scopolamine, suggesting an indirect stimulatory action of histamine on intramural parasympathetic nerves. H_1 histamine receptors are expressed in the smooth muscle and urothelium of the human ureter (Floyd et al., 2008). The antihistamines diphenhydramine (Benadryl) and tripelennamine have been shown to inhibit the effects of histamine on the ureter (Borgstedt et al., 1962; Sharkey et al., 1965). **The H_2 receptor mediates inhibitory effects of histamine**. Histamine and the H_2-receptor agonist impromidine relax precontracted ureteral segments, actions that are inhibited by the H_2-receptor antagonist cimetidine (Dodel et al., 1996).

Serotonin

Serotonin (5-hydroxytryptamine, 5-HT) usually has been reported to stimulate the ureter (Dodel et al., 1996; Hauser et al., 2002; Hernández et al., 2003; Lim et al., 2018; Vereecken, 1973), although serotonin has been reported to inhibit ureteral contractility (Mazzella and Schroeder, 1960), or to have no effect (Finberg and Peart, 1970) on a variety of ureteral preparations. In the pig ureter the contractile effects appear to be mediated by 5-HT_2 receptors (Hauser et al., 2002; Hernández et al., 2003), specifically the 5-HT_{2A} subtype (Lim et al., 2018). Gidener et al. (1999) showed that 5-hydroxytryptamine induces concentration-dependent contractions of isolated human ureteral segments. Tetrodotoxin, guanethidine, and phentolamine had an inhibitory effect on 5-HT–induced contractions of pig isolated intravesical ureteral segments, suggesting that part of the contractile effects of 5-HT are indirectly mediated through release of norepinephrine from sympathetic nerves (Hernández et al., 2003).

Kinins

The kinins—kallidin, eledoisin, and bradykinin—increase the frequency of contraction and baseline intraluminal pressure of the dog ureter (Boyarsky et al., 1966a, b; Labay and Boyarsky, 1966). Although bradykinin has been reported to increase the contractility of pig intravesical ureter via excitation of bradykinin B2 receptors (Ribeiro et al., 2016), it has been reported to decrease the contractile force of the sheep ureter (Kaygisiz et al., 1995).

Angiotensin

Angiotensin has a stimulatory effect on the ureter. Angiotensin II (AT2) and mRNA for angiotensinogen, a principal precursor of AT2, renin, angiotensin-converting enzyme (ACE), and the type I angiotensin receptor are expressed in the human ureter (Santis et al., 2003). The AT2 type I receptor also is expressed in the rat ureter (Paxton et al., 1993). Losartin, an AT2-receptor antagonist, decreases the amplitude and frequency of spontaneous contractions of human ureteral segments (Jankovik et al., 2016). AT2 induces phasic contractions of rat ureteral segments, an effect that is inhibited by losartan (Fujinaka et al., 2000).

Narcotic Analgesics

Morphine has been reported to increase ureteral tone or the frequency and amplitude of ureteral contractions or both in a variety of experimental preparations and in humans (Macht, 1916b; Gruber, 1928; Ockerblad et al., 1935; Vereecken, 1973). Others, however, have failed to observe an effect of morphine on ureteral function (Gould et al., 1955; Kiil, 1957; Ross et al., 1967; Weinberg and Maletta, 1961).

Meperidine (Demerol) appears to have a similar excitatory effect on the activity of the intact dog ureter (Sharkey et al., 1968). Kiil (1957), however, failed to observe an effect of meperidine on ureteral peristalsis in humans. **If one considers only the effects on ureteral activity, there is no basis to preferentially favor morphine or meperidine in the treatment of renal colic. Both agents may have ureteral spasmogenic effects that theoretically would**

detract from their value in the management of ureteral colic. They certainly do not have potentially valuable spasmolytic actions. Their efficacy in treating colic depends on their central nervous system (CNS) actions, which decrease the perception of pain.

Prostaglandins

Prostaglandins are derived from fatty acids and have a variety of biologic actions in various systems of the body. Their effects vary with the species, type of prostaglandin, endocrine status of the tissue, experimental conditions, and origin of the smooth muscle. **The "primary" prostaglandins (PGs), PGE_1, PGE_2, and $PGF_{2\alpha}$, are synthesized from the fatty acid arachidonic acid by enzymatic reactions involving two cyclooxygenase (COX) isoforms, COX-1 and COX-2** (Vane, 1998). In most tissues COX-1 is constitutively expressed and is involved in the regulation of normal physiologic processes, whereas COX-2 is induced in response to processes such as inflammation and mitogenesis (Mitchell and Warner, 1999). **These enzymatic reactions can be inhibited by indomethacin and aspirin, and by a number of COX-1 and COX-2 inhibitors.** COX-1 and COX-2 receptors have been identified in the human ureter (Chaignat et al., 2008).

Prostaglandin $\mathbf{E_2}$ acts via four G-protein–coupled receptors, $PTGER_{1\text{-}4}$, and prostaglandin $\mathbf{F_{2\alpha}}$ acts via PTGFR. $PTGER_1$ and $PTGER_3$ induce smooth muscle contractions, $PTGER_1$ via activation of phosphatidylinositol hydrolysis and $PTGER_3$ via cAMP inhibition. Prostaglandin receptors $PTGER_1$ and $PTGFR_3$ are highly expressed in human ureter urothelium and muscle (Oll et al., 2012). PTGER2 and PTGER4 induce smooth muscle relaxation via cAMP stimulation.

PGE_1 inhibits the activity of the dog (Abrams and Feneley, 1976; Boyarsky et al., 1966b; Wooster, 1971) and guinea pig ureter (Vermue and Den Hertog, 1987). PGE_1 inhibition of ureteral activity in the guinea pig is associated with an increase in cAMP levels (Vermue and Den Hertog, 1987). In the ureter, PGE_1 activates adenylyl cyclase, and this may account for the increase in cAMP (Wheeler et al., 1986). Johns and Wooster (1975) suggested that the inhibitory effects of PGE_1 on ureteral activity depended on the sequestration of Ca^{2+} at the inner surface of the cell membrane, with a resultant increase in outward K^+ conductance and hyperpolarization of the membrane.

Although reports have indicated that PGE_2 relaxes the ureter (Vermue and Den Hertog, 1987), other reports describe an excitatory action of PGE_2 on sheep (Thulesius and Angelo-Khattar, 1985), dog (Boyarsky and Labay, 1969), and human (Angelo-Khattar et al., 1985; Cole et al., 1988) ureters and on renal pelvic smooth muscle (Lundstam et al., 1985). Although PGE_2 relaxes normal porcine ureter, it increases the contractility of acutely obstructed porcine ureters (Ankem et al., 2005; Lowry et al., 2005) and chronically obstructed human ureters. In human ureteral preparations PGE_1 and PGE_2 have been shown to decrease spontaneous contractions, whereas $\mathbf{PGF_{2\alpha}}$ increased ureteral contractility (Abrams and Feneley, 1976). In human renal pelvis and ureter there is a higher concentration of $PGF_{2\alpha}$ than PGE_2 (Zwergel et al., 1991). $\mathbf{PGF_{2\alpha}}$ increased contractility of porcine ureteral segments (Ankem et al., 2005). The prostanoid PGI_2 is synthesized in the urothelium of the ureter (Ali et al., 1998). COX inhibitors such as indomethacin have been shown to inhibit the activity of rat (Davidson and Lang, 2000), guinea pig (Davidson and Lang, 2000), sheep (Thulesius and Angelo-Khattar, 1985), and human ureters (Angelo-Khattar et al., 1985; Cole et al., 1988) and renal pelvic smooth muscle (Davidson and Lang, 2000; Lundstam et al., 1985; Santicioli et al., 1995a; Zhang and Lang, 1994).

Indomethacin has been employed in the management of ureteral colic (Flannigan et al., 1983; Holmlund and Sjöden, 1978; Jönsson et al., 1987). The beneficial effects probably are due to indomethacin's inhibition of the prostaglandin-mediated vasodilatation that occurs subsequent to obstruction (Allen et al., 1978; Sjöden et al., 1982). The vasodilatation theoretically would result in an increase in glomerular capillary pressure and a subsequent increase in pelviureteral pressure. Indomethacin, by reducing pelviureteral pressure and thus pelviureteral wall tension, may eliminate some of the pain of renal colic that is dependent on distention of the upper urinary tract. An upregulation of COX-2 mRNA and protein with obstruction supports the potential use of selective COX-2 inhibitors in the treatment of obstructive ureteral disease (Nakada et al., 2002). **A potential problem with the use of indomethacin for the treatment of renal colic is that prostaglandin-mediated vasodilatation aids in preserving renal function; thus indomethacin may provide pain relief, but it may be potentially deleterious to renal function** (Kristova et al., 2000; Perlmutter et al., 1993).

The nonspecific COX inhibitor, diclofenac, and the selective COX-2 inhibitors, NS-398 and celecoxib, have been shown to be equipotent in inhibiting agonist-induced contractions of isolated pig and human ureter (Mastrangelo et al., 2000; Nakada et al., 2000). Diclofenac also has been shown to relax human ureteral segments that were precontracted with KCl (Sivrikava et al., 2003). NS-398 inhibition of ureteral contractility also may involve blockade of voltage-dependent calcium channels (Lee et al., 2010). The COX-2 selective inhibitor celecoxib, and indomethacin-inhibited porcine ureteral contractility and TNF-α induced prostanoid release (Jerde et al., 2005). Diclofenac, but not the COX-2 selective inhibitor valdecoxib, decreased the contractile amplitude of electrically stimulated in vitro human ureteral segments and valdecoxib decreased the contractility of normal, but not obstructed, ureters of the pig in vivo (Chaignat et al., 2008). Species differences may exist with COX-2 as the primary enzyme involved in synthesizing PGs in the guinea pig upper urinary tract, and COX-1 the primary enzyme involved in PG synthesis in the rat upper urinary tract (Davidson and Lang, 2000).

Chronic obstruction upregulates COX-2 activity in the human ureter (Nakada et al., 2002). With stretch of the porcine ureter there is COX-2 induction in the urothelial and smooth muscle layers, with a more significant induction in the urothelium (Jerde et al., 2006). The stretch-induced upregulation on COX-2 expression in the urothelium of the obstructed mouse ureter is mediated via phosphatidylinositol 3-kinase (PI3K) (Owusu-Ofori et al., 2013). PI3K also mediates stretch-induced activation of protein kinase C (Owusu-Ofori et al., 2013). In the normal rat ureter COX-1, but not COX-2, mRNA was detected, and after obstruction there was an increase in COX-2 mRNA and protein expression, but no change in COX-1 expression (Norregaard et al., 2006). In addition to an increased synthesis of prostanoids with obstruction, there is a decrease in prostanoid degradation contributing to the increase in prostanoids with obstruction. 15-Hydroxyprostaglandin dehydrogenase (PGDH), the enzyme responsible for prostaglandin degradation, is suppressed in the human ureter with obstruction (Jerde et al., 2004). The dilated ureter after obstruction has an increase expression of COX-2, PGE_2, TGF-β_1, α-smooth muscle actin (α-SMA), fibrosis, apoptotic cells, and proliferation cell nuclear antigen (PCNA) (Chuang et al., 2007). The administration of the COX-2 selective inhibitor celecoxib abolished the expression of COX-2 and PGE_2, decreased the expression of TGF-β_1 and α-SMA, decreased apoptotic cells and fibrosis, but increased the expression of PCNA in the smooth muscle of the dilated obstructed ureter (Chuang et al., 2007). These investigators concluded that the COX-2 inhibitor may ameliorate, in part by inhibition of COX-2 and TGF-β_1 expression, ureteral damage resulting from obstruction.

Cardiac Glycosides

Ouabain, a cardiac glycoside, has an effect on ureteral activity that appears to be species dependent. In the isolated cat ureter, ouabain produces a marked increase in contractility, which usually is followed by a late decrease in excitability (Weiss et al., 1970). In the guinea pig ureter, ouabain inhibits activity without a preliminary potentiation of contractility (Hendrickx et al., 1975; Washizu, 1968). The inhibitory effects of ouabain are accompanied by a shortening of the action potential duration, a decrease of the number of oscillations on the plateau of the guinea pig action potential, and a decrease in the RMP.

Calcium Antagonists

Because Ca^{2+} is necessary for the development of the action potential and contraction of the ureter, agents that block the movement of Ca^{2+} into the cell would be expected to depress ureteral function. Voltage-dependent Ca^{2+} channel antagonist–binding sites (receptors) have been demonstrated in the ureter, and their density decreases with age (Yoshida et al., 1992). These dihydropyridine-sensitive, **L-type, voltage-dependent Ca^{2+} channels appear to provide the main inward current for generation of the ureteral action potential and the phasic contractile response** (Aickin et al., 1984; Brading et al., 1983; Imaizumi et al., 1989; Lang, 1989; Shuba, 1977). Potassium-induced ureteral contractions depend on the inward movement of Ca^{2+} through L-type voltage-dependent Ca^{2+} channels (Maggi and Giuliani, 1995). The dihydropyridine Ca^{2+} channel agonist Bay K 8644 has an excitatory effect on ureteral activity (Floyd et al., 2008; Maggi et al., 1994a) and potentiates K^+-induced contractions. The Ca^{2+} channel blockers (CCB) verapamil, D-600 (a methoxy derivative of verapamil), diltiazem, and nifedipine have been shown to inhibit ureteral activity (Davenport et al., 2006; Golenhofen and Lammel, 1972; Hertle and Nawrath, 1984; Hong et al., 1985; Maggi et al., 1994a; Sakanashi et al., 1985, 1986; Vereecken et al., 1975). More recently, the new CCB benidipine was shown to inhibit the contractility of the distal ureter (at lower concentration than in the proximal ureter) in goats, and inhibited the amplitude rather than the frequency of contractions (Mathew et al., 2017). These inhibitory effects are accompanied by decreases in the duration of the action potential, the number of oscillations on the plateau of the guinea pig action potential, excitability, and the rate of rise and amplitude of the action potential. High concentrations of verapamil and D-600 cause a complete cessation of electric and mechanical activity.

Potassium Channel Openers

Potassium channel openers such as cromakalim, nicorandil, BRL 38227, and PFK217-744b hyperpolarize smooth muscle membranes and **inhibit renal pelvic and ureteral activity** (Floyd et al., 2008; Kontani et al., 1993; Maggi et al., 1994c; Smita et al., 2006; Weiss et al., 2002). Glibenclamide, a blocker of K^+/ATP channels, on its own, had no effect on contractility (De Moura and De Lemos Neto, 1996). The inhibitory effects of cromakalim and nicorandil are prevented by glibenclamide, providing evidence that ATP-sensitive K^+ channels are involved in these processes (Maggi et al., 1994c; Smita et al., 2006). Activation of these K+ channels may reduce the probability of the opening of voltage-sensitive Ca^{2+} channels, inhibit agonist induced increases in inositol-1, 4,5-trisphosphate, or reduce Ca^{2+} sensitivity of contractile elements processes that are important in the generation of the ureteral action potential and the contractile response (Cook and Quast, 1990; Quayle et al., 1997).

The tricyclic antidepressant amitriptyline (Elavil) has been shown to relax isolated pig and human ureteral strips by opening potassium channels (Achar et al., 2003). This relaxation response is inhibited by 4-aminopyridine (4-AP), a voltage-dependent K^+ channel blocker. Nicorandil, a K^+ channel opener and NO donor, stimulates guanylyl cyclase activity with formation of cGMP and hyperpolarizes the smooth muscle with resultant relaxation of rabbit, guinea pig, and human ureter (Klaus et al., 1989; 1990; Weiss et al., 2002). The relaxant effects of nicorandil can be inhibited by the K_{ATP} antagonist glibenclamide and the guanylyl cyclase inhibitor methylene blue (Weiss et al., 2002).

Endothelins

Endothelins are potent vasoconstrictor peptides that exist in three isoforms: ET-1, ET-2, and ET-3. These peptides interact with their specific receptors: ET_A, ET_B, and ET_C. Endothelin binding sites (receptors) have been identified in the ureter and renal pelvis (Eguchi et al., 1991; Latifpour et al., 1995; Wada et al., 2001), where they are primarily of the ET_A subtype (Latifpour et al., 1995; Wada et al., 2001). Endothelins have been shown to initiate contractions in isolated guinea pig and porcine ureters (Eguchi et al., 1991; Maggi et al., 1992a) and increase the contractile force of renal pelvis smooth muscle (Wada et al., 2001). ET-1 acting on the ETA receptor increased contractile force of rat, mouse, and human renal pelvis smooth muscle (Grisk et al., 2010; Steinbach et al., 2016). COX-1 and rho kinase (ROCK) activity are required for ET-1 effects on renal pelvic contractility. ET-1, ET-2, and ET-3 increased tonic contractions and intraluminal pressures in isolated human ureteral segments. These actions were inhibited by BQ123, an ET_A-receptor antagonist, and BQ788, an ET_B-receptor antagonist. ET-1 and ET-3 inhibited spontaneous phasic activity of the isolated human ureteral segments, an action that was not blocked by either ET_A- or ET_B-receptor antagonists (Jankovic et al., 2011). Diabetes upregulates the expression of ureteral endothelin receptors (Nakamura et al., 1997).

Antibiotics

Ampicillin causes relaxation of the ureter and antagonizes the stimulatory effects of barium chloride ($BaCl_2$), histamine, serotonin, and carbachol on the ureter, thus suggesting that its action is directly on the smooth muscle (Benzi et al., 1970b). Chloramphenicol, the isoxazolyl penicillins, and gentamicin also have spasmolytic effects on the ureter (Benzi et al., 1970a, 1971, 1973). The tetracyclines, on the other hand, potentiate the contractile effects of $BaCl_2$ on the ureter (Benzi et al., 1973).

Suggested Readings

Biancani P, Hausman M, Weiss RM. Effect of obstruction on ureteral circumferential force-length relations. *Am J Physiol*. 1982;243:F204.

Biancani P, Zabinski MP, Weiss RM. Time course of ureteral changes with acute and chronic obstruction. *Am J Physiol*. 1976;231:393.

David SG, Cebrian C, Vaughan ED Jr, et al. C-kit and ureteral peristalsis. *J Urol*. 2005;173:292.

Floyd RV, Borisova L, Bakran A, et al. Morphology, calcium signaling and mechanical activity in human ureter. *J Urol*. 2008;180:398.

Griffiths DJ, Notschaele C. The mechanics of urine transport in the upper urinary tract. I. The dynamics of the isolated bolus. *Neurourol Urodyn*. 1983;2:155.

Griffiths DJ. The mechanics of urine transport in the upper urinary tract. 2. The discharge of the bolus into the bladder and dynamics at high rates of flow. *Neurourol Urodyn*. 1983;2:167.

Klemm MF, Exintaris B, Lang RJ. Identification of the cells underlying pacemaker activity in the guinea pig upper urinary tract. *J Physiol*. 1999;519:867.

Koff SA, Thrall JH. The diagnosis of obstruction in experimental hydroureteronephrosis: mechanism for progressive urinary tract dilation. *Invest Urol*. 1981;19:85.

Lang RJ, Davidson ME, Exintaris B. Pyeloureteral motility and ureteral peristalsis: essential role of sensory nerves and endogenous prostaglandins. *Exp Physiol*. 2002;87:129.

Lang RJ, Hashitani H, Tonta MA, et al. Spontaneous electrical and Ca2+ signals in typical and atypical smooth muscle cells and interstitial cell of Cajal-like cells of mouse renal pelvis. *J*

Physiol. 2007;583:1049.

Lang RJ, Tonta MA, Zoltkowski BZ, et al. Pyeloureteric peristalsis: role of atypical smooth muscle cells and interstitial cells of Cajal-like cells as pacemakers. *J Physiol*. 2006;576:695.

McGuire EJ, Woodside JR, Borden TA, et al. Prognostic value of urodynamic testing in myelodysplastic patients. *J Urol*. 1981;126:205.

Weiss RM, Tamarkin FJ, Wheeler MA. Pacemaker activity in the upper urinary tract. *J Smooth Muscle Res*. 2006;42:103.

Weiss RM. Clinical implications of ureteral physiology. *J Urol*. 1979;121:401.

Weiss RM. Ureteral function. *Urology*. 1978;12:114.

Woolf AS, Davies JA. Cell biology of ureter development. *J Am Soc Nephrol*. 2013;24:19.

References

Abrams PH, Feneley RCL. The actions of prostaglandins on the smooth muscle of the human urinary tract in vitro. *Br J Urol*. 1976;47:909.

Abramson D, Caton WL Jr, Roly CC. The effect of relaxin on the excretion of diodrast in the castrate hysterectomized rabbit. *Am J Obstet Gynecol*. 1953;65:644.

Achar E, Achar R, Paiva TB, et al. Amitriptyline eliminates caculi through urinary tract smooth muscle relaxation. *Kidney Int*. 2003;64:1356.

Adelstein RS, Pato MD, Conti MA. The role of phosphorylation in regulating contractile proteins. *Adv Cyclic Nucleotide Res*. 1981;14:361.

Aickin CC, Brading AF, Burdyga TV. Evidence for sodium-calcium exchange in the guinea-pig ureter. *J Physiol*. 1984;347:411.

Aickin CC, Brading AF, Walmsley D. An investigation of sodium-calcium exchange in the smooth muscle of guinea-pig ureter. *J Physiol*. 1987;391:325.

Aickin CC. Investigation of factors affecting the intracellular sodium activity in the smooth muscle of guinea-pig ureter. *J Physiol*. 1987;385:483.

Akimoto M, Biancani P, Weiss RM. Comparative pressure-length-diameter relationships of neonatal and adult rabbit ureters. *Invest Urol*. 1977;14:297.

Al-Ansari A, Al-Naimi A, Alobaidy A, et al. Efficacy of tamsulosin in the management of lower ureteral stones: a randomized double-blind placebo-controlled study of 100 patients. *Urology*. 2010;75:4.

Al-Aown A, Kyriazis I, Kallidonis P, et al. Vardenafil effect on ureteric smooth muscle: in vitro study in porcine model. *J*

Endourol. 2011;25:505.

Alcaraz A, Vinaixa F, Tejedo-Mateu A, et al. Obstruction and recanalization of the ureter during embryonic development. *J Urol*. 1991;145:410.

Ali M, Angelo-Khattar M, Thulesius L, et al. Urothelial synthesis of prostanoids in the ovine ureter. *Urol Res*. 1998;26:171.

Allen JM, Rodrig J, Kerlie DJ, et al. Neuropeptide Y (NPY)-containing nerves in mammalian ureter. *Urology*. 1990;35:81.

Allen JT, Vaughan ED Jr, Gillenwater JY. The effect of indomethacin on renal blood flow and ureteral pressure in unilateral ureteral obstruction in awake dogs. *Invest Urol*. 1978;15:324.

Alquist RP. Study of adrenotropic receptors. *Am J Physiol*. 1948;153:586.

Ammons WS. Bowditch Lecture. Renal afferent inputs to ascending spinal pathways. *Am J Physiol*. 1992;262:R165.

Ancill RJ, Jackson DM, Redfern PH. The pharmacology of the rat ureter *in vivo*. *Br J Pharmacol*. 1972;44:628.

Andersson R, Nilsson K. Cyclic AMP and calcium in relaxation in intestinal smooth muscle. *Nat New Biol*. 1972;238:119.

Andersson RGG. Cyclic AMP and calcium ions in mechanical and metabolic responses of smooth muscle: influence of some hormones and drugs. *Acta Physiol Scand Suppl*. 1972;382:1.

Angelo-Khattar M, Thulesius O, Nilsson T, et al. Motility of the human ureter, with special reference to the effect of indomethacin. *Scand J Urol Nephrol*. 1985;19:261.

Ankem MK, Jerde TJ, Wilkinson ER, et al. PGE_2-3 receptor is involved in ureteral contractility in obstruction. *J Endourol*. 2005;19:1088.

Apoznanski W, Koleda P, Wozniak Z, et al. The distribution of intersititial cells of Cajal in congenital ureteropelvic junction obstruction. *Int Urol Nephrol*. 2013;43:607.

Araki T, Saruta T, Okano H, et al. Caspase activity is required for nephrogenesis in the developing mouse metanephros. *Exp Cell Res*. 1999;248:423.

Arena S, Fazzari C, Arena F, et al. Altered “active” antireflux mechanism in primary vesico-ureteric reflux: a morphological and manometric study. *BJU Int*. 2007;100:407.

Autorino R, De Sio M, Damiano R, et al. The use of tamsulosin in the medical treatment of ureteral calculi: where do we stand? *Urol Res*. 2005;33:460.

Backlund L, Grotte G, Reuterskiöld A. Functional stenosis as a cause of pelvi-ureteric obstruction and hydronephrosis. *Arch Dis Child*. 1965;40:203.

Backlund L, Reuterskiöld AG. Activity in the dilated dog ureter. *Scand J Urol Nephrol*. 1969;3:99.

Backlund L, Reuterskiöld AG. The abnormal ureter in children. *Scand J Urol Nephrol*. 1969;3:219.

Barr L, Berger W, Dewey MM. Electrical transmission at the nexus between smooth muscle cells. *J Gen Physiol*. 1968;51:347.

Barzegarnezhad A, Firouzian A, Emadi SA, et al. The effects of local administration of aminophylline on transureteral lithotripsy. *Adv Urol*. 2012;2012:4.

Basson MA, Watson-Johnson J, Shakya R, et al. Branching morphogenesis of the ureteric epithelium during kidney development is coordinated by the opposing functions of GDNF and Sprouty1. *Dev Biol*. 2006;299:466.

Becker AJ, Stief CG, Meyer M, et al. The effect of the specific phosphodiesterase–IV-inhibitor rolipram of the ureteral peristalsis of the rabbit in vitro and in vivo. *J Urol*. 1998;160:920.

Beddingfield R, Pedro RN, Hinck B, et al. Alfuzosin to relieve ureteral stent discomfort: a prospective, randomized, placebo controlled study. *J Urol*. 2009;181:170.

Benedito S, Prieto D, Rivera L, et al. Mechanisms implicated in the histamine response of the sheep ureterovesical junction. *J Urol*. 1991;146:184.

Benzi G, Arrigoni E, Sanguinetti L. Antibiotics and ureter. III: chloramphenicol. *Arch Int Pharmacodyn Ther*. 1970;185:329.

Benzi G, Arrigoni E, Sanguinetti L. Antibiotics and ureter. V: gentamicin. *Arch Int Pharmacodyn Ther*. 1971;189:303.

Benzi G, Arrigoni E, Sanguinetti L. Effect of antibiotics on the ureter motor activity. *Jpn J Pharmacol*. 1973;23:559.

Benzi G, Bermudez E, Arrigoni E, et al. Antibiotics and the ureter. I: ampicillin. *Arch Int Pharmacodyn Ther*. 1970;183:159.

Berridge MJ. Inositol trisphosphate and diacylglycerol as second messengers. *Biochem J*. 1984;220:345.

Biancani P, Hausman M, Weiss RM. Effect of obstruction on ureteral circumferential force-length relations. *Am J Physiol*. 1982;243:F204.

Biancani P, Onyski JH, Zabinski MP, et al. Force-velocity relationships of the guinea pig ureter. *J Urol*. 1984;131:988.

Biancani P, Zabinski MP, Weiss RM. Bidimensional deformation of acutely obstructed in vitro rabbit ureter. *Am J Physiol*. 1973;225:671.

Biancani P, Zabinski MP, Weiss RM. Time course of ureteral changes with acute and chronic obstruction. *Am J Physiol*. 1976;231:393.

Blok C, van Venrooij GEPM, Coolsaet BLRA. Dynamics of the ureterovesical junction: a qualitative analysis of the ureterovesical pressure profile in the pig. *J Urol*. 1985;134:818.

Borghi L, Meschi T, Amato F, et al. Nifredipine and methylprednisolone in facilitating ureteral stone passage: a randomized, double-blind, placebo-controlled study. *J Urol*. 1994;152:1099.

Borgstedt HH, Benjamin JA, Emmel VM. The role of histamine in ureteral function. *J Pharmacol Exp Ther*. 1962;136:386.

Borysova L, Shabir S, Walsh MP, et al. The importance of Rho-associated kinase-induced Ca^{2+} sensitization as a component of electromechanical and pharmacomachanical coupling in rat ureteric smooth muscle. *Cell Calcium*. 2011;250:393.

Borysova L, Shmygol A, Wray S, et al. Evidence that a Ca^{2+} sparks/STOCs coupling mechanism is responsible for the inhibitory effect of caffeine on electro-mechanical coupling in guinea pig ureteric smooth muscle. *Cell Calcium*. 2007;42:303.

Boyarsky S, Catacutan-Labay P, Pircher F. Effect of eledoisin, a polypeptide kinin, on ureteral peristalsis. *Invest Urol*. 1966;4:220.

Boyarsky S, Labay P, Gerber C. Prostaglandin inhibition of ureteral peristalsis. *Invest Urol*. 1966;4:9.

Boyarsky S, Labay P, Pfautz CJ. The effect of nicotine upon ureteral peristalsis. *South Med J*. 1968;61:573.

Boyarsky S, Labay P. Ureteral motility. *Annu Rev Med*. 1969;20:383.

Bozler E. The action potentials of visceral smooth muscle. *Am J Physiol*. 1938;124:502.

Bozler E. The activity of the pacemaker previous to the discharge of a muscular impulse. *Am J Physiol*. 1942;136:543.

Brading AF, Burdyga THV, Scripnyuk ZD. The effects of papaverine on the electrical and mechanical activity of the guinea pig ureter. *J Physiol*. 1983;334:79.

Bredt DS, Snyder SH. Isolation of nitric oxide synthase, a calmodulin requiring enzyme. *Proc Natl Acad Sci USA*. 1990;87:682.

Brophy PD, Ostrom L, Lang KM, et al. Regulation of ureteric bud outgrowth by Pax2-dependent activation of the glial derived neurotrophic factor gene. *Development*. 2001;128:4747.

Bullock AJ, Wray S. Developmental and species differences in the response of the ureter to metabolic inhibition. *Pflugers Arch*. 1998;436:443.

Bullock AJ, Wray S. The effects of metabolic inhibition on force, Ca^{2+} and pH_i in guinea-pig ureteric smooth muscle. *Pflugers Arch*. 1998;435:240.

Bultman S, Gebuhr T, Yee D, et al. A Brg1 null mutation in the mouse reveals functional differences among mammalian SWI/SNF complexes. *Mol Cell*. 2000;6:1287.

Burdyga T, Wray S. Action potential refractory period in ureteer smooth muscle is set by Cs sparks and BK channels. *Nature*. 2005;436:559.

Burdyga ThV, Magura IS. Effects of temperature and Na^+ on the relaxation of phasic and tonic tension of guinea-pig ureter muscle. *Gen Physiol Biophys*. 1988;7:3.

Burdyga ThV, Taggart MJ, Crichton C, et al. The mechanism of Ca^{2+} release from the SR of permeabilised guinea-pig and rat ureteric smooth muscle. *Biochim Biophys Acta*. 1998;1402:109.

Burdyga ThV, Taggart MJ, Wray S. Major difference between rat and guinea pig ureter in the ability of agonists and caffeine to release Ca^{2+} and influence force. *J Physiol*. 1995;489:327.

Burdyga ThV, Wray S. On the mechanism whereby temperature affects excitation-contraction coupling in smooth muscle. *J Gen Physiol*. 2002;119:93.

Burdyga ThV, Wray S. The effect of cyclopiazonic acid on excitation-contraction coupling in guinea-pig ureteric smooth muscle: role of the sarcoplasmic reticulum. *J Physiol*. 1999;517:855.

Burdyga ThV, Wray S. The relationship between the action potential, intracellular calcium and force in intact phasic,

guinea pig ureteric smooth muscle. *J Physiol*. 1999;520:867.
Burnstock G, Satchell DG, Smythe A. A comparison of the excitatory and inhibitory effects of non-adrenergic, non-cholinergic nerve stimulation and exogenously applied ATP on a variety of smooth muscle preparations from different vertebrate species. *Br J Pharmacol*. 1972;46:234.
Burnstock G. Purinergic mechanosensory transduction and visceral pain. *Mol Pain*. 2009;5:69.
Burnstock G. Purinergic P2 receptors as targets for novel analgesics. *Pharmacol Ther*. 2006;110:433.
Burnstock G. Structure of smooth muscle and its innervation. Bülbring E, Brading AF, Jones AW, et al. *Smooth muscle*. Williams & Wilkins: Baltimore; 1970:1–69.
Bush KT, Sakurai H, Steer DL, et al. TGF-β superfamily members modulate growth, branching, shaping, and patterning of the ureteric bud. *Dev Biol*. 2004;266:285.
Bustamante S, Orensanz LM, Barahona MV, et al. Tachykininergic excitatory neurotransmission in the pig intravesical ureter. *J Urol*. 2000;164:1371.
Bustamante S, Orensanz LM, Barahona MV, et al. NK2 tachykinin receptors mediate contraction of the pig intravesical ureter: tachykinin-induced enhancement of non-adrenergic non-cholinergic excitatory neurotransmission. *Neurourol Urodyn*. 2001;20:297.
Butcher HR Jr, Sleator W Jr, Schmandt WL. A study of the peristaltic conduction mechanism in the canine ureter. *J Urol*. 1957;78:221.
Cain JE, Islam E, Haxho F, et al. GLI3 repressor controls functional development of the mouse ureter. *J Clin Invest*. 2011;121:1199.
Calvert RC, Thompson CS, Burnstock G. ATP release from the human ureter on distension and P2X(3) receptor expression on suburothelial sensory nerves. *Purinergic Signal*.

2008;4:377.

Carl C, Lee HK, Sanders KM. Regulation of ion channels in smooth muscles by calcium. *Am J Physiol*. 1996;271:C9.

Casteels R. The relation between the membrane potential and the ion distribution in smooth muscle cells. Bülbring E, Brading AF, Jones AW, et al. *Smooth muscle*. Williams & Wilkins: Baltimore; 1970:70–79.

Cervenakov I, Fillo J, Mardiak J, et al. Speedy elimination of ureterolithiasis in lower part of ureters with the α1-blocker tamsulosin. *Int Urol Nephrol*. 2002;34:25.

Cervero F, Sann H. Mechanically evoked responses of afferent fibres innervating the guinea-pig's ureter: an in vitro study. *J Physiol*. 1989;412:245.

Chaignat V, Danuser H, Stoffel MH, et al. Effects of a non-selective COX inhibitor and selective COX-2 inhibitors on contractility of human and porcine ureters in vitro and in vivo. *Br J Pharmacol*. 2008;154:1297.

Chang C-P, McDill BW, Neilson JR, et al. Calcineurin is required in urinary tract mesenchyme for the development of the pyeloureteral peristaltic machinery. *J Clin Invest*. 2004;113:1051.

Chen D, Roberts R, Pohl M, et al. Differential expression of collagen-and laminin-binding integrins mediates ureteric bud and inner medullary collecting duct cell tubulogenesis. *Am J Physiol*. 2004;287:F602.

Chen H, Ji H-Y, Yang Y. The expression of Gli3 and Teashirt3 in the stenotic tissue of congenital pelvi-ureteric junction obstruction in children. *Int J Med Sci*. 2016;13:412.

Cho SY, Na W, Lee SW, et al. Medical expulsive therapy for ureter stone using naftopidil: a multicenter, randomized, double-blinded, and placebo controlled trial. *PLoS ONE*. 2017;10:1371.

Cho YH, Biancani P, Weiss RM. Adenylyl and guanylyl nucleotide induced relaxation of ureteral smooth muscle. *Fed Proc*. 1984;43:353.

Cho YH, Wheeler MA, Weiss RM. Ontogeny of phosphodiesterase and of calmodulin levels in guinea pig ureter. *J Urol*. 1988;139:1095.

Choi Y, Tee JB, Gallegos TF, et al. Neuropeptide Y functions as a facilitator of GDNF-induced budding of the Wolffian duct. *Development*. 2009;136:4123.

Chuang Y-H, Chuang W-L, Huang S-P, et al. Cyclooxygenase-2 inhibitor ameliorates ureteric damage in rats with obstructed uropathy. *Eur J Pharmacol*. 2007;569:126.

Clarke JC, Patel SR, Raymond RM Jr, et al. Regulation of c-Ret in the developing kidney is responsive to *Pax2* gene dosage. *Hum Mol Genet*. 2006;15:3420.

Clayton JD, Roberts JA. Radionuclide postpartum evaluation of the urinary tract during anovular therapy. *Surg Gynecol Obstet*. 1973;137:215.

Cole RS, Fry CH, Shuttleworth KED. The action of the prostaglandins on isolated human ureteric smooth muscle. *Br J Urol*. 1988;61:19.

Constantini F. Genetic controls and cellular behaviors in branching morphogenesis of the renal collecting system. *Wiley Interdiscip Rev Dev Biol*. 2012;1:693.

Constantinou CE, Djurhuus JC. Pyeloureteral dynamics in the intact and chronically obstructed multicalyceal kidney. *Am J Physiol*. 1981;241:R398.

Constantinou CE, Grenato JJ Jr, Govan DE. Dynamics of the upper urinary tract: accommodation in the rate and stroke volume of ureteral peristalsis as a response to transient alteration in urine flow rate. *Urol Int*. 1974;29:249.

Constantinou CE, Hrynczuk JR. Urodynamics of the upper urinary tract. *Invest Urol*. 1976;14:233.

Constantinou CE, Silvert MA, Gosling J. Pacemaker system in the control of ureteral peristaltic rate in the multicalyceal kidney of the pig. *Invest Urol*. 1977;14:440.

Constantinou CE, Yamaguchi O. Multiple-coupled pacemaker system in renal pelvis of the unicalyceal kidney. *Am J Physiol*. 1981;241:R412.

Constantinou CE. Renal pelvic pacemaker control of ureteral peristaltic rate. *Am J Physiol*. 1974;226:1413.

Cook NS, Quast U. Potassium channel pharmacology. Cook NS. *Potassium channels*. Ellis Horwood: Chichester, UK; 1990:181–258.

Cook WA, King LR. Vesicoureteral reflux. Harrison J, Gittes RF, Perlmutter AD, et al. *Campbell's urology*. ed 4. WB Saunders: Philadelphia; 1979:1596–1634.

Coolsaet BLRA, van Venrooij GEPM, Blok C. Detrusor pressure versus wall stress in relation to ureterovesical resistance. *Neurourol Urodyn*. 1982;1:105.

Crowley AR, Byrne JC, Vaughan ED Jr, et al. The effect of acute obstruction on ureteral function. *J Urol*. 1990;143:596.

Cussen LJ. The structure of the normal human ureter in infancy and childhood. A quantitative study of the muscular and elastic tissue. *Invest Urol*. 1967;5:179.

Cutroneo G, Arena S, Anastasi G, et al. Altered cytoskeleton structure of smooth muscle cells in ureteropelvic junction obstruction. *J Urol*. 2011;185:2314.

Damiano R, Autorino R, De Sio M, et al. Effect of tamsulosin in preventing ureteral stent-related morbidity: a prospective study. *J Endourol*. 2008;22:651.

Danuser HRG, Weiss R, Abel D, et al. Systemic and topical drug administration in the pig ureter: effect of phosphodiesterase inhibitors, alpha1, beta, and beta2-adrenergic receptor agonists and antagonists on the frequently and amplitude of ureteral contractions. *J Urol*. 2001;166:714.

Davenport K, Timoney AG, Keeley FX Jr. A comparative in vitro study to determine the beneficial effect of calcium-channel and α1-adrenoceptor antagonism on human ureteric activity. *BJU Int*. 2006;98:651.

Davenport K, Timoney AG, Keeley FX Jr. Effect of smooth muscle relaxant drugs on proximal human ureteric activity in vivo: a pilot study. *Urol Res*. 2007;35:207.

David SG, Cebrian C, Vaughan ED Jr, et al. C-kit and ureteral peristalsis. *J Urol*. 2005;173:292.

Davidson ME, Lang RJ. Effects of selective inhibitors of cyclo-oxygenase (COX-1) and cyclo-oxygenase-2 (COX-2) on the spontaneous myogenic contractions in upper urinary tract of the guinea pig and rat. *Br J Pharmacol*. 2000;129:661.

Davidson ME, Lang RJ. Pelviureteric peristaltic contractions in diabetic rats. *J Smooth Muscle Res*. 2007;43:145.

Davies J, Lyon M, Garrod D. Sulphated proteoglycan is required for collecting duct growth and branching but not nephron formation during kidney development. *Development*. 1995;121:1507.

Davies J. Intracellular and extracellular regulation of ureteric bud morphogenesis. *J Anat*. 2001;198:257.

De Moura RS, De Lemos Neto M. Effects of potassium channel modulators cromakalim, ddtetraethylammonium and glibenclamide on contractility of the isolated human ureter. *J Urol*. 1996;156:276.

De Sio M, Autorino R, DiLorenzo G, et al. Medical expulsive ttreatment of distal-ureteral stones using tamsulosin: a single center experience. *J Endourol*. 2006;20:12.

Debruyne FMJ, Wijdeveld PGAB, Koene RAP, et al. Uretero-neo-cystostomy in renal transplantation. Is an antireflux mechanism mandatory? *Br J Urol*. 1978;50:378.

Dellabella M, Milanese G, Muzzonigro G. Efficacy of tamsulosin in the medical management of juxtavesical ureteral stones. *J Urol*. 2003;170:2202.

Dellabella M, Milanese G, Muzzonigro G. Randomized trial of the efficacy of tamsulosin, nifedipine and phloroglucinol in medical expulsive therapy for distal ureteral calculi. *J Urol*. 2005;174:167.

Dellis AE, Keeley FX Jr, Manolas V, et al. Role of alpha-blockers in the treatment of stent related-symptoms: a prospective randomized control study. *Urology*. 2014;83:56.

Del Tacca M. Acetylcholine content of and release from isolated pelviureteral tract. *Naunyn Schmiedebergs Arch Pharmacol*. 1978;302:293.

Dempsey EC, Newton AC, Mochly-Rosen D, et al. Protein kinase C isozymes and the regulation of diverse cell responses. *Am J Physiol*. 2000;279:L429.

Der-Silaphet T, Malysz J, Hagel S, et al. Interstitial cells of Cajal direct normal propulsive contractile activity in the mouse small intestine. *Gastroenterology*. 1998;114:724.

Dixon JS, Gosling JA. The fine structure of pacemaker cells in the pig renal calices. *Anat Rec*. 1973;175:139.

Djurhuus JC, Constantinou CE. Chronic ureteric obstruction and its impact on the coordinating mechanisms of peristalsis (pyeloureteric pacemaker system). *Urol Res*. 1982;10:267.

Djurhuus JC, Stage P. Percutaneous intrapelvic pressure registration in hydronephrosis during diuresis. *Acta Chir Scand*. 1976;473:43.

Dodel RC, Hafner D, Borchard U. Characterization of histamine in the ureter of the dog. *Eur J Pharmacol*. 1996;318:395.

Dokita S, Morgan WR, Wheeler MA, et al. N^G-nitro-L-arginine inhibits non-adrenergic, non-cholinergic relaxation in rabbit urethral smooth muscle. *Life Sci*. 1991;48:2429.

Dokita S, Smith SD, Nishimoto T, et al. Involvement of nitric oxide and cyclic GMP in rabbit urethral relaxation. *Eur J Pharmacol*. 1994;269:269.

Draper JW, Zorgniotti AW. The effect of banthine and similar

agents on the urinary tract. *N Y State J Med*. 1954;54:77.
Draper MH, Weidmann S. Cardiac resting and action potentials recorded with an intracellular electrode. *J Physiol*. 1951;115:74.
Dray A, Hankins MW, Yeats JC. Desensitization and capsaicin-induced release of substance P–like immunoreactivity from guinea-pig ureter in vitro. *Neuroscience*. 1989;31:479.
Duarte-Escalante O, Labay P, Boyarsky S. The neurohistochemistry of mammalian ureter: a new combination of histochemical procedures to demonstrate adrenergic, cholinergic and chromaffin structures in ureter. *J Urol*. 1969;101:803.
Edyvane KA, Smet PJ, Trussell DC, et al. Patterns of neuronal colocalisation of tyrosine hydroxylase, neuropeptide Y, vasoactive intestinal polypeptide, calcitonin gene–related peptide and substance P in human ureter. *J Auton Nerv Syst*. 1994;48:241.
Edyvane KA, Trussell DC, Jonavicius J, et al. Presence and regional variation in peptide-containing nerves in the human ureter. *J Auton Nerv Syst*. 1992;39:127.
Eguchi S, Kozuka M, Hirose S, et al. Unique contractile action of endothelins on porcine isolated ureter and characterization of the endothelin-binding sites. *Biomed Res*. 1991;12:35.
Ekblom P. Developmentally regulated conversion of mesenchyme to epithelium. *FASEB J*. 1989;3:2141.
Ekinci S, Ertunc M, Ciftci AO, et al. Evaluation of pelvic contractility in ureteropelvic junction obstruction: an experimental study. *J Pediatr Surg*. 2004;14:93.
El Said NO, El Wakeel L, Kamal KM, et al. Alfuzosin treatment improves the rate and time for stone expulsion in patients with distal ureteral stones: a prospective randomized controlled study. *Pharmacotherapy*. 2015;35:470.
Engelmann TW. Uber die electrische Erregung des Ureter, mit

Bemerkungen uber die electrische Erregung im Allgemeinen. *Pflugers Arch*. 1870;3:247.

Engelmann TW. Zur Physiologie des Ureters. *Pflugers Arch*. 1869;2:243.

Fainstat T. Ureteral dilatation in pregnancy: a review. *Obstet Gynecol Surv*. 1963;18:845.

Fernandes VS, Hernández M. The role of nitric oxide and hydrogen sulfide in urinary tract function. *Basic Clin Pharmacol Toxicol*. 2016;119:34.

Fernandes VS, Ribeiro ASF, Martinez P, et al. Hydrogen sulfide plays a role in the neurotransmission to the pig intravesical ureter. *PLoS ONE*. 2014;10:1371.

Ferro A. β-Adrenoceptors and potassium channels. *Naunyn Schmiedebergs Arch Pharmacol*. 2006;373:183.

Ferroni A, Blanchi D. Maximum rate of depolarization of single muscle fiber in normal and low sodium solutions. *J Gen Physiol*. 1965;49:17.

Fillion M-L, Andalousi J, Tokhmafshan F, et al. Heterozygous loss-of-function mutation in Odd-skipped related 1 (*Osr1*) is associated with vesicoureteric reflux, duplex systems, and hydronephrosis. *Am J Physiol*. 2017;313:1106.

Finberg JPM, Peart WS. Function of smooth muscle of the rat renal pelvis—response of the isolated pelvis muscle to angiotensin and some other substances. *Br J Pharmacol*. 1970;39:373.

Flannigan GM, Clifford RPC, Carver RA, et al. Indomethacin—an alternative to pethidine in ureteric colic. *Br J Urol*. 1983;55:6.

Floyd RV, Borisova L, Bakran A, et al. Morphology, calcium signaling and mechanical activity in human ureter. *J Urol*. 2008;180:398.

Floyd RV, Winstanley C, Bakran A, et al. Modulation of ureteric Ca signaling and contractility in humans and rats by uropathogenic *E. coli*. *Am J Physiol*. 2010;298:F900.

Foote JW, Blennerhassett JB, Wigglesworth FW, et al. Observations on the ureteropelvic junction. *J Urol*. 1970;104:252.

Fredericks CM, Anderson GF, Pierce JM. Electrical and mechanical responses of intact canine ureter to elevated intravesical pressure. *Invest Urol*. 1972;9:496.

Fujinaka H, Miyazaki Y, Matsusaka T, et al. Salutary role for angiotensin in partial urinary tract obstruction. *Kidney Int*. 2000;58:2018.

Fujita H, Hamazaki Y, Noda Y, et al. Claudin-4 deficiency results in urothelial hyperplasia and lethal hydronephrosis. *PLoS ONE*. 2012;7(12):1.

Fung YC. Peristaltic pumping: a bioengineering model. Boyarsky S, Gottschalk CW, Tanagho EA, et al. *Urodynamics*. Academic: New York; 1971:177–198.

Furchgott RF. Endothelium-derived relaxing factor: discovery, early studies, and identification as nitric oxide. *Biosci Rep*. 1999;19:235.

Furchgott RF. Receptor mechanisms. *Annu Rev Pharmacol Toxicol*. 1964;4:21.

Gabella G. Structure of smooth muscles. Springer Verlag: Berlin Heidelberg; 1994:3–34. Szekeres L, Gy J. *Handbook of experimental pharmacology*. vol 111.

Gearhart JP, Lee RL, Partin AW, et al. A quantitative histological evaluation of the dilated ureter of childhood. II. Ectopia, posterior urethral valves and prune belly syndrome. *J Urol*. 1995;153:172.

George NJR, O'Reilly PH Jr, Barnard RJ, et al. Practical management of patients with dilated upper tracts and chronic retention of urine. *Br J Urol*. 1984;56:9.

Gibbins IL, Furness JB, Costa M, et al. Co-localization of calcitonin gene–related peptide-like immunoreactivity with substance P in cutaneous vascular and visceral sensory neurons of guinea-pig. *Neurosci Lett*. 1985;57:125.

Gibbs OS. The function of the fowl's ureter. *Am J Physiol*. 1929;87:594.

Gidener S, Gumustekin M, Kirkali Z. Pharmacological analysis of 5-hydroxytryptamine effects on human isolated ureter. *Pharmacol Res*. 1999;39:487.

Goessl C, Grozdanovic Z, Knispel HH, et al. Nitroxergic innervation of the human ureterovesical junction. *Urol Res*. 1995;23:189.

Golenhofen K, Lammel E. Selective suppression of some components of spontaneous activity in various types of smooth muscle by iproveratril (verapamil). *Pflugers Arch*. 1972;331:233.

Golenhofen K, Hannappel J. Normal spontaneous activity of the pyeloureteral system in the guinea pig. *Pflugers Arch*. 1973;341:257.

Gontijo JR, Smith LA, Kopp UC. CGRP activates renal pelvic substance P receptors by retarding substance P metabolism. *Hypertension*. 1999;33:493.

Gosling JA, Dixon JS. Morphologic evidence that the renal calyx and pelvis control ureteric activity in the rabbit. *Am J Anat*. 1971;130:393.

Gosling JA, Dixon JS. Species variation in the location of upper urinary tract pacemaker cells. *Invest Urol*. 1974;11:418.

Gosling JA, Waas ANC. The behavior of the isolated rabbit renal calix and pelvis compared with that of the ureter. *Eur J Pharmacol*. 1971;16:100.

Gottschalk CW, Mylle M. Micropuncture study of pressures in proximal tubules and peritubular capillaries of the rat kidney and their relation to ureteral and renal venous pressures. *Am J Physiol*. 1956;185:430.

Gould DW, Hsieh ACL, Tinckler LF. Behavior of isolated water-buffalo ureter. *J Physiol*. 1955;129:425.

Grana L, Kidd J, Idriss F, et al. Effects of chronic urinary tract infection on ureteral peristalsis. *J Urol*. 1965;94:652.

Gratzke C, Uckert S, Kedia G, et al. In vitro effects of PDE5 inibitors sildenafil, vardenafil and tadalafil on isolated human ureteral smooth muscle: a basic research approach. *Urol Res*. 2007;35:49.

Gravas S, Tzortzis V, Karatzas A, et al. The use of tamsulozin as adjunctive treatment after ESWL in patients with distal ureteral stone: do we really need it? Results from a randomized study. *Urol Res*. 2007;35:231.

Gravina GL, Costa AM, Ronchi P, et al. Tamsulosin treatment increases clinical success rate of single extracorporeal shock wave lithotripsy. *Urology*. 2005;66:24.

Green DF, Glickman MG, Weiss RM. Preliminary results with aminophylline as smooth muscle relaxant in percutaneous renal surgery. *J Endourol*. 1987;1:243.

Griffiths DJ, Notschaele C. The mechanics of urine transport in the upper urinary tract. I. The dynamics of the isolated bolus. *Neurourol Urodyn*. 1983;2:155.

Griffiths DJ. The mechanics of urine transport in the upper urinary tract: 2. The discharge of the bolus into the bladder and dynamics at high rates of flow. *Neurourol Urodyn*. 1983;2:167.

Grisk O, Packebusch M, Steinbach AC, et al. Endothelin-1 induced activation of rat renal pelvic contractions depends on cyclooxygenase-1 and rho kinase. *Am J Physiol*. 2010;299:R1602.

Gruber CM. The effect of morphine and papaverine upon the peristaltic and antiperistaltic contractions of the ureter. *J Pharmacol Exp Ther*. 1928;33:191.

Hammad FT, Lammers WJ, Stephen B, et al. Propagation of the electrical impulse in reversible unilateral ureteral obstruction as determined at high electrophysiological resolution. *J Urol*. 2011;185:744.

Hanna MK. Some observations on congenital ureteropelvic junction obstruction. *Urology*. 1978;12:151.

Hannappel J, Golenhofen K. The effect of catecholamines on ureteral peristalsis in different species (dog, guinea pig and rat). *Pflugers Arch*. 1974;55:350.

Hauser DS, Mevissen M, Weiss R, et al. Effects of ketanserin and DOI on spontaneous and 5-HT-evoked peristalsis of the pig ureter in vivo. *Br J Pharmacol*. 2002;135:1026.

Hausman M, Biancani P, Weiss RM. Obstruction induced changes in longitudinal force-length relations of rabbit ureter. *Invest Urol*. 1979;17:223.

Hegde SS, Choppin A, Bonhaus D, et al. Functional role of M2 and M3 muscarininc receptors in the urinary bladder of rats in vitro and in vivo. *Br J Pharmacol*. 1997;120(8):1409.

Hendren WH. A new approach to infants with severe obstructive uropathy; early complete reconstruction. *J Pediatr Surg*. 1970;5:184.

Hendrickx H, Vereecken RL, Casteels R. The influence of potassium on the electrical and mechanical activity of the guinea pig ureter. *Urol Res*. 1975;3:155.

Hernández M, Barahona MV, Bustamante S, et al. A2B adenosine receptors mediate relaxation of the pig intravesical ureter: adenosine modulation of non-adrenergic non-cholinergic excitatory neurotransmission. *Br J Pharmacol*. 1999;126:969.

Hernández M, Barahona MV, Recio P, et al. Heterogeniety of neuronal and smooth muscle receptors involved in the VIP- and PACAP-induced relaxations of the pig intravesical ureter. *Br J Pharmacol*. 2004;141:123.

Hernández M, Barahona MV, Simonsen V, et al. Characterization of the 5-hydroxytryptamine receptors mediating contraction in the pig isolated intravesical ureter. *Br J Pharmacol*. 2003;138:137.

Hernández M, Prieto D, Orensanz LM, et al. Nitric oxide is involved in the non-adrenergic, non-cholinergic inhibitory neurotransmission of the pig intravesical ureter. *Neurosci Lett*. 1995;186:33.

Hernández M, Prieto D, Simonsen U, et al. Noradrenaline modulates smooth muscle activity of the isolated intravesical ureter of the pig through different types of adrenoceptors. *Br J Pharmacol*. 1992;107:924.

Hernández M, Simonsen U, Prieto D, et al. Different muscarinic receptor subtypes mediating the phasic activity and basal tone of pig isolated intravesical ureter. *Br J Pharmacol*. 1993;110:1413.

Hertle L, Nawrath H. Calcium channel blockade in smooth muscle of the upper urinary tract. I. Effects on depolarization-induced activation. *J Urol*. 1984;132:1265.

Hertle L, Nawrath H. Stimulation of voltage-dependent contractions by calcium channel activator Bay K 8644 in the human urinary tract in vitro. *J Urol*. 1989;141:1014.

Hill AV. The heat of shortening and the dynamic constants of 1 muscle. *Proc R Soc Lond B Biol Sci*. 1938;126:136.

Hodgkin AL. Ionic movements and electrical activity in giant nerve fibres. *Proc R Soc Lond B Biol Sci*. 1958;148:1.

Hoffman BF, Cranefield PF. *Electrophysiology of the heart*. McGraw-Hill: New York; 1960.

Holmlund D, Hassler O. A method of studying the ureteral reaction to artificial concrements. *Acta Chir Scand*. 1965;130:335.

Holmlund D, Sjöden JG. Treatment of ureteral colic with intravenous indomethacin. *J Urol*. 1978;120:676.

Hong KW, Biancani P, Weiss RM. “On” and “off” responses of guinea pig ureter. *Am J Physiol*. 1985;248:C165.

Hong KW, Biancani P, Weiss RM. Effect of age on contractility of guinea pig ureter. *Invest Urol*. 1980;17:459.

Hong SK, Kwak C, Jeong BC, et al. Involvement of Rho-kinase in the contractile mechanism of human ureteral smooth muscle. *Neurourol Urodyn*. 2005;24:136.

Hosgor M, Karaca I, Ulukus C, et al. Structural changes of smooth muscle in congenital ureteropelvic junction obstruction. *J Pediatr Surg*. 2005;40:1632.

Hou T, Yang X, Hai B, et al. Aberrant differentiation of urothelial cells in patients with ureteropelvic junction obstruction. *Int J Clin Exp Pathol*. 2014;9:5837.

Hua X-Y, Lundberg JM. Dual capsaicin effects on ureteric motility: low dose inhibition mediated by calcitonin gene-related peptide and high dose stimulation by tachykinins? *Acta Physiol Scand*. 1986;128:453.

Hua X-Y, Theodorsson-Norheim E, Brodin E, et al. Multiple tachykinins (neurokinin A, neuropeptide K and substance P) in capsaicin-sensitive sensory neurons in the guinea pig. *Regul Pept*. 1985;13:1.

Hua X-Y, Theodorsson-Norheim E, Lundberg JM, et al. Co-localization of tachykinins and calcitonin gene–related peptide in capsaicin-sensitive afferents in relation to motility effects on human ureter in vitro. *Neuroscience*. 1987;23:693.

Hundley JM Jr, Diehl WK, Diggs ES. Hormonal influences upon the ureter. *Am J Obstet Gynecol*. 1942;44:858.

Hurtado R, Bub G, Hertzlinger D. The pelvis-kidney junction contains HCN3, a hyperpolarization-activated cation channel that triggers ureter peristalsis. *Kidney Int*. 2010;77:500.

Ichikawa S, Ikeda O. Recovery curve and conduction of action potentials in the ureter of the guinea pig. *Jpn J Physiol*. 1960;10:1.

Imaizumi Y, Muraki K, Takeda M, et al. Characteristics of transient outward currents in single smooth muscle cells from the ureter of the guinea pig. *J Physiol*. 1990;427:301.

Imaizumi Y, Muraki K, Watanabe M. Ionic currents in single smooth muscle cells from the ureter of the guinea pig. *J Physiol*. 1989;411:131.

Iosipiv IV, Schroeder M. A role for angiotensin II AT_1 receptors in ureteric bud cell branching. *Am J Physiol*. 2003;285:F199.

Iselin CE, Alm P, Schaad NC, et al. Localization of nitric oxide synthase and hemoxygenase and functional effects of nitric oxide and carbon monoxide in the pig and human intravesical ureter. *Neurourol Urodyn*. 1997;16:209.

Iselin CE, Ny L, Larsson B, et al. The nitric oxide synthase/nitric oxide and heme oxygenase/carbon monoxide pathways in the human ureter. *Eur Urol*. 1998;33:214.

Iselin CE, Ny L, Mastrangelo D, et al. The nitric oxide pathway in pig isolated calyceal smooth muscle. *Neurourol Urodyn*. 1999;18:673.

Ishizaki T, Maekawa M, Fujisawa K, et al. The small GTP-binding protein Rho binds to and activates a 160KDa ser/thr protein kinase homologous to myotonic dystrophy kinase. *EMBO J*. 1996;15:1885.

Itoh Y, Kojima Y, Yasui T, et al. Examination of alpha 1 adrenoceptor subtypes in the human ureter. *Int J Urol*. 2007;14:749.

Izol V, Acikalin AA, Kuyucu Y, et al. Ultrastructural and immunohistopathological evaluation of intravesical ureters via electron and light microscopy in children with vesicoureteral reflux. *J Urol*. 2014;191:1110.

Jakobsen JS. Endoluminal pharmacologic stimulation of the upper urinary tract. *Dan Med J*. 2013;60:B4642.

Jankovic SM, Jankovic SV, Stojanovic V, et al. Contractile effects of endothelins on isolated human ureter. *Physiol Rev*. 2011;60:933.

Janssen C, Buttyan R, Seow CY, et al. A role of the Hedgehog effector GLi1 in mediating stent-induced ureteral smooth muscle dysfunction and aperistalsis. *Urology*. 2017;104:242.

Jansson C, Jager W, Moskalev I, et al. Erythropoietin accelerates the regeneration of ureteral function in a murine model of obstructive uropathy. *J Urol*. 2015;193:714.

Jerde TJ, Calamon-Dixon JL, Bjorling DE, et al. Celecoxib inhibits ureteral contractility and prostanoid release. *Urology*. 2005;65:185.

Jerde TJ, Mellon WS, Bjorling DE, et al. Evaluation of urothelial stretch-induced cyclooxygenase-2 expression in novel human cell culture and procine in vivo ureteral obstruction models. *J Pharmacol Exp Ther*. 2006;317:965.

Jerde TJ, Mellon WS, Fischer SM, et al. Supprssion of 15-hydroxyprostaglandin dehydrogenase messenger RNA concentration, protein expression, and enzymatic activity during human ureteral obstruction. *J Pharmacol Exp Ther*. 2004;309:398.

Jerde TJ, Saban R, Bjorling DE, et al. NK-2 is the predominant tachykinin receptor subtype in the swine ureter. *BJU Int*. 1999;83:312.

Johns A, Wooster MJ. The inhibitory effects of prostaglandin E_1 on guinea pig ureter. *Can J Physiol Pharmacol*. 1975;53:239.

Jönsson P-E, Olsson AM, Petersson B-A, et al. Intravenous indomethacin and oxycone-papaverine in the treatment of acute renal colic. A double-blind study. *Br J Urol*. 1987;59:396.

Jorgensen TM, Mortensen J, Nielsen K, et al. Pathogenic factors in vesico-ureteral reflux. A longitudinal cystometrographic study in pigs. *Scand J Urol Nephrol*. 1984;18:43.

Jung J, Norby B, Frimodt-Moller CF, et al. Endoluminal isoproterenol irrigation decreases renal pelvic pressure during flexible ureterorenoscopy: a clinical randomized, controlled study. *Eur Urol*. 2008;54:1404.

Kajbafzadeh A-M, Payabvash S, Salmasi AH, et al. Smooth muscle cell apoptosis and defective neural development in congenital ureteropelvic junction obstruction. *J Urol*. 2006;176:718.

Karabacak OR, Yilmazer D, Ozturk U, et al. The prescence and distribution of alpha adrenergic receptors in human renal pelvis and calyces. *Urolithiasis*. 2013;41:385.

Kasakov L, Burnstock G. The use of the slowly degradable analog, alpha, beta-methylene ATP, to produce desentitisation of the P_2-purinoceptor: effect on non-adrenergic, non-cholinergic responses of the guinea-pig urinary bladder. *Eur J Pharmacol*. 1982;86:291.

Kaygisiz Z, Donmez T, Uyar R, et al. Prostaglandin-independent decrease of sheep ureter contractility induced by bradykinin. *Ren Physiol Biochem*. 1995;18:49.

Kiil F. *The function of the ureter and renal pelvis*. WB Saunders: Philadelphia; 1957.

King WW, Cox CE. Bacterial inhibition of ureteral smooth muscle contractility. I. The effect of common urinary pathogens and endotoxin in an in vitro system. *J Urol*. 1972;108:700.

Kirkland IS, Ross JA, Edmond P, et al. Ureteral function in vesicoureteral reflux. *Br J Urol*. 1971;43:289.

Klaus E, Englert H, Hropot M, et al. Inhibition of the rhythmic contractions of ureters by K^+ channel openers. *Naunyn Schmiedebergs Arch Pharmacol*. 1989;340:R59.

Klaus E, Englert H, Hropot M, et al. K^+-channel openers inhibit the KCl-induced phasic-rhythmic contractions in the upper urinary tract. *Eur J Pharmacol*. 1990;183:673.

Klemm MF, Exintaris B, Lang RJ. Identification of the cells underlying pacemaker activity in the guinea pig upper urinary tract. *J Physiol*. 1999;519:867.

Knight GE, Bodin P, DeGroat WC, et al. ATP is released from guinea pig ureter epithelium on distention. *Am J Physiol*. 2002;282:F281.

Kobayashi M, Irisawa H. Effect of sodium deficiency on the action potential of the smooth muscle of ureter. *Am J Physiol*. 1964;206:205.

Kobayashi M. Conduction velocity in various regions of the ureter. *Tohoku J Exp Med*. 1964;83:220.

Kobayashi M. Effect of calcium on electrical activity in smooth muscle cells of cat ureter. *Am J Physiol*. 1969;216:1279.

Kobayashi M. Effects of Na and Ca on the generation and conduction of excitation in the ureter. *Am J Physiol*. 1965;208:715.

Kobayashi S, Tomiyama Y, Hoyano Y, et al. Gene expressions and mechanical functions of α_1 adrenoceptor subtypes in mouse ureter. *World J Urol*. 2009;27:775.

Kobayashi S, Tomiyama Y, Hoyano Y, et al. Mechanical function and gene expression of α_1 adrenoceptor subtypes in dog intravesical ureter. *Urology*. 2009;74:458.

Kobayashi S, Tomiyama Y, Maruyama K, et al. Effect of four different alpha (1)-adrenoeptor antagonists on alpha-adrenoceptor agonist-induced contractions in isolated mouse and hamster ureters. *J Smooth Muscle Res*. 2009;45:187.

Koff SA, Thrall JH. Diagnosis of obstruction in experimental hydroureteronephrosis. *Urology*. 1981;17:570.

Koff SA, Thrall JH. The diagnosis of obstruction in experimental hydroureteronephrosis: mechanism for progressive urinary tract dilation. *Invest Urol*. 1981;19:85.

Koleda P, Apoznanski W, Wozniak Z, et al. Changes in interstitial cell of Cajal-like cells density in congenital ureteropelvic junction obstruction. *Int Urol Nephrol*. 2012;44:7.

Kondo S, Latifpour J, Morita T, et al. Characterization of beta-adrenergic receptor subtypes of the upper and lower renal pelvis in rabbits. *J Urol*. 1989;142:1099.

Kontani H, Ginkawa M, Sakai T. A simple method for measurement of ureteric peristaltic function in vivo and the effects of drugs acting on ion channels applied from the ureter lumen in anesthetized rats. *Jpn J Pharmacol*. 1993;62:331.

Kopp UC, Cicha MZ, Smith LA, et al. Cyclooxygenase-2 involved in stimulation of renal mechanosensitive neurons. *Hypertension*. 2000;35:373.

Kristova V, Kriska M, Vujtko R, et al. Effect of indomethacin and deendothelisation on vascular responses in the renal artery. *Physiol Rev*. 2000;49:129.

Kuhn R, Uckert S, Stief CG, et al. Relaxation of human ureteral smooth muscle in vitro by modulation of cyclic nucleotide-dependent pathways. *Urol Res*. 2000;28:110.

Kumar D. In vitro inhibitory effect of progesterone on extrauterine smooth muscle. *Am J Obstet Gynecol*. 1962;84:1300.

Kupeli B, Irkilata L, Gurocak S, et al. Does tamsulosin enhance lower ureteral stone clearance with or without shock wave lithotripsy? *Urology*. 2004;64:1111.

Kuriyama H, Osa T, Toida N. Membrane properties of the smooth muscle of guinea-pig ureter. *J Physiol*. 1967;191:225.

Kuriyama H, Tomita T. The action potential in the smooth muscle of the guinea pig taenia coli and ureter studied by the double sucrose-gap method. *J Gen Physiol*. 1970;55:147.

Kuriyama H. The influence of potassium, sodium, and chloride on the membrane potential of the smooth muscle of taenia coli. *J Physiol*. 1963;166:15.

Kuure S, Chi X, Lu B, et al. The transcription factors Etv4 and Etv5 mediate formation of the ureteric bud tip domain during kidney development. *Development*. 2010;137:1975.

Kyriazis I, Kallidonis P, Georgiopoulos I, et al. In vitro evaluation of ureteral contractility: a comparative assessment of human, porcine and sheep ureteral responses to vardenafil. *Urol Int*. 2015;94:234.

Labay P, Boyarsky S. Bradykinin: effect on ureteral peristalsis. *Science*. 1966;151:78.

Labay P, Boyarsky S. The effect of topical nicotine on ureteral peristalsis. *J Am Med Assoc*. 1967;200:209.

Laird JM, Roza C, Cervero F. Effects of artificial calculosis on rat ureter motility: peripheral contribution to the pain of ureteric colic. *Am J Physiol*. 1997;272:R1409.

Lammers WJEP, Ahmad HR, Arafat K. Spatial and temporal variations in pacemaking and conduction in the isolated renal pelvis. *Am J Physiol*. 1996;270:F567.

Lamont C, Burdyga ThV, Wray S. Intracellular Na^+ measurements in smooth muscle using SBF1-changes in [Na+], Ca2+ and force in normal and Na+-loaded ureter. *Pflugers Arch*. 1998;435:523.

Lang RJ, Davidson ME, Exintaris B. Pyeloureteral motility and ureteral peristalsis: essential role of sensory nerves and endogenous prostaglandins. *Exp Physiol*. 2002;87:129.

Lang RJ, Exintaris B, Teele ME, et al. Electrical basis of peristalsis in the mammalian upper urinary tract. *Clin Exp Pharmacol Physiol*. 1998;25:310.

Lang RJ, Hashitani H, Keller S, et al. Modulators of internal Ca^{2+} stores and the spontaneous electrical and contractile activity of the guinea pig renal pelvis. *Br J Pharmacol*. 2002;135:1363.

Lang RJ, Hashitani H, Tonta MA, et al. Spontaneous electrical and Ca2+ signals in typical and atypical smooth muscle cells and interstitial cell of Cajal-like cells of mouse renal pelvis. *J Physiol*. 2007;583:1049.

Lang RJ, Klemm MF. Intersitial cell of Cajal-like cells in the upper urinary tract. *J Cell Mol Med*. 2005;9:543.

Lang RJ, Takano H, Davidson ME, et al. Characterization of the spontaneous electrical and cotractile activity of smooth muscle cells in the rat upper urinary tract. *J Urol*. 2001;166:329.

Lang RJ, Tonta MA, Zoltkowski BZ, et al. Pyeloureteric peristalsis: role of atypical smooth muscle cells and interstitial cells of Cajal-like cells as pacemakers. *J Physiol*. 2006;576:695.

Lang RJ, Zhang Y. The effect of K channel blockers on the spontaneous electrical and contractile activity in the proximal renal pelvis of the guinea pig. *J Urol*. 1996;155:332.

Lang RJ, Zoltkowski BZ, Hammer JM, et al. Electrical characteriztion of interstitial cells of Cajal-like cells and smooth muscle cells isolated from the mouse ureteropelvic junction. *J Urol*. 2007;177:1573.

Lang RJ. Identification of the major membrane currents in freshly dispersed single smooth muscle cells of guinea-pig ureter. *J Physiol*. 1989;412:375.

Lang RJ. The whole cell Ca^{2+} channel current in single smooth muscle cells of the guinea-pig ureter. *J Physiol*. 1990;423:453.

Lapides J. The physiology of the intact human ureter. *J Urol*. 1948;59:501.

Latifpour J, Fukumoto Y, Weiss RM. Regional differences in the density and subtype specificity of endothelin receptors in rabbit urinary tract. *Naunyn Schmiedebergs Arch Pharmacol*. 1995;352:459.

Latifpour J, Kondo S, O'Hollaren B, et al. Autonomic receptors in urinary tract: sex and age differences. *J Pharmacol Exp Ther*. 1990;253:661.

Latifpour J, Morita T, O'Hollaren B, et al. Characterization of autonomic receptors in neonatal urinary tract smooth muscle. *Dev Pharmacol Ther*. 1989;13:1.

Lee BR, Silver RJ, Partin AW, et al. A quantitative histologic analysis of collagen subtypes: the primary obstructed and refluxing megaureter of childhood. *Urology*. 1998;51:820.

Lee HY, Bardini M, Burnstock G. Distribution of P2X receptors in the urinary bladder and the ureter of the rat. *J Urol*. 2000;163:2002.

Lee SY, Lee MY, Park SH, et al. N-398 (a selective cyclooxygenase-2 inhibitor) decreases agonist-induced contraction of the human ureter via calcium channel inhibition. *J Endourol*. 2010;24:1863.

Leung T, Manser E, Tan L, et al. A novel serine/threonine kinase binding the Ras-related RhoA GTPase which translocates the kinase to peripheral membranes. *J Biol Chem*. 1995;270:29051.

Levent A, Buyukafsar K. Expression of Rho-kinase (ROCK-1 and ROCK-2) and its substantial role in the contractile activity of the sheep ureter. *Br J Pharmacol*. 2004;143:431.

Liatsikos EN, Katsakiori PF, Assimakopoulos K, et al. Doxazosin for the management of distal-ureteral stones. *J Endourol*. 2007;21:538.

Liatsikos EN, Kyriazis I, Neuhaus J, et al. Direct effects of vardenafil on the ureter: in vitro investigation and potential clinical applications of intralumenal administration. *J Endourol*. 2013;27:1400.

Libertino JA, Weiss RM. Ultrastructure of human ureter. *J Urol*. 1972;108:71.

Lildal SK, Andreassen KH, Christiansen FE, et al. Pharmacological relaxation of the ureter when using ureteral access sheaths during ureterorenoscopy: a randomized feasibility study in a porcine model. *Adv Urol*. 2016;10:1155.

Lim I, Chess-Williams R, Sellers D. 5-HT2A receptor is the predominant receptor mediating contraction of the isolated porcine distal ureter to 5-HT in young and old animals. *Eur J*

Pharmacol. 2018;818:328.

Liu C, Zeng G, Kang R, et al. Efficacy and safety of alfuzosin as medical expulsive therapy for ureteral stones: a systematic review and meta-analysis. *PLoS ONE*. 2015;10:1371.

Londos C, Cooper DMF, Rodbell M. Receptor-mediated stimulation and inhibition of adenylate cyclases: the fat cell as a model system. *Adv Cyclic Nucleotide Res*. 1981;14:163.

Longrigg N. Autonomic innervation of the renal calyx. *Br J Urol*. 1974;46:357.

Longrigg N. Minor calyces as primary pacemaker sites for ureteral activity in man. *Lancet*. 1975;1:253.

Losek RL, Mauro LS. Efficacy of tamsulosin with extracorporeal shock wave lithotripsy for passage of renal and ureteral calculi. *Ann Pharmacother*. 2008;42:692.

Lowry PS, Jerde TJ, Bjorling DE, et al. Obstruction alters the effect of prostaglandin E_2 on uretreral contractility. *J Endourol*. 2005;19:183.

Lu JL, Tang QL, Liu FD, et al. Naftopidil and tolterodine in the medical expulsive therapy for intralmural ureteral stones: a prospective randomized study. *Urol Res*. 2012;40:757.

Lu Z, Dong Z, Ding H, et al. Tamsulosin for ureteral stones: a systematic review and meta-analysis of a randomized controlled trial. *Urol Int*. 2012;89:107.

Lubin S, Drexler LS, Bilotta WA. Post-partum pyeloureteral changes following hormone administration. *Surg Gynecol Obstet*. 1941;73:391.

Lundstam S, Jönsson O, Kihl B, et al. Prostaglandin synthetase inhibition of renal pelvic smooth muscle in the rabbit. *Br J Urol*. 1985;57:390.

Macht DI. On the pharmacology of the ureter. II. Actions of drugs affecting the sacral autonomics. *J Pharmacol Exp Ther*. 1916;8:261.

Macht DI. On the pharmacology of the ureter. III. Action of the opium alkaloids. *J Pharmacol Exp Ther*. 1916;9:197.

Maeshima A, Vaughn DA, Choi Y, et al. Activin A is an endogenous inhibitor of ureterric bud outgrowth from the Wolffian duct. *Dev Biol*. 2006;295:473.

Maggi CA, Giuliani S, Santicioli P, et al. Role of intracellular calcium in K channel opener action of CGRP in the guinea-pig ureter. *Br J Pharmacol*. 1996;118:1493.

Maggi CA, Giuliani S, Santicioli P. Effect of Bay K8644 and ryanodine on the refractory period, action potential and mechanical response of the guinea-pig ureter to electrical stimulation. *Naunyn Schmiedebergs Arch Pharmacol*. 1994;349:510.

Maggi CA, Giuliani S, Santicioli P. Effect of cromakalim and glibenclamide on spontaneous and evoked motility of the guinea-pig isolated renal pelvis and ureter. *Br J Pharmacol*. 1994;111:687.

Maggi CA, Giuliani S, Santicioli P. Effect of the Ca^{2+}-ATPase inhibitor, cyclopiazonic acid, on electromechanical coupling in the guinea-pig ureter. *Br J Pharmacol*. 1995;114:127.

Maggi CA, Giuliani S, Santicioli P. Multiple mechanisms in the smooth muscle relaxant action of calcitonin gene–related peptide (CGRP) in the guinea-pig ureter. *Naunyn Schmiedebergs Arch Pharmacol*. 1994;350:537.

Maggi CA, Giuliani S. A pharmacological analysis of calcium channels involved in phasic and tonic responses of the guinea-pig ureter to high potassium. *J Auton Pharmacol*. 1995;15:55.

Maggi CA, Giuliani S. A thiorphan-sensitive mechanism regulates the action of both exogenous and endogenous calcitonin gene-related peptide (CGRP) in the guinea-pig ureter. *Regul Pept*. 1994;51:263.

Maggi CA, Giuliani S. Nonadrenergic noncholinergic excitatory innervation of the guinea-pig renal pelvis. Involvement of capsaicin-sensitive primary afferent neurons. *J Urol*. 1992;141:1394.

Maggi CA, Giuliani S. The neurotransmitter role of CGRP in the rat and guinea-pig ureter: effect of a CGRP antagonist and species related differences in the action of omega conotoxin on CGRP release from primary afferents. *Neuroscience*. 1991;43:261.

Maggi CA, Meli A. The sensory-efferent function of capsaicin-sensitive sensory neurons. *Gen Pharmacol*. 1988;19:1.

Maggi CA, Santicioli P, delBianco E, et al. Local motor responses to bradykinin and bacterial chemotactic peptide formyl-methionyl-leucyl-phenylalanine (FMLP) in the guinea-pig isolated renal pelvis and ureter. *J Urol*. 1992;148:1944.

Maggi CA, Santicioli P, Giuliani S, et al. The motor effect of the capsaicin-sensitive inhibitory innervation of the rat ureter. *Eur J Pharmacol*. 1986;126:333.

Maggi CA, Theodorsson E, Santicioli P, et al. Tachykinins and calcitonin gene–related peptides as co-transmitters in local motor responses produced by sensory activation in the guinea pig isolated renal pelvis. *Neuroscience*. 1992;46:549.

Maggi CA. Tachykinins and calcitonin gene–related peptide (CGRP) as co-transmitters released from peripheral endings of sensory nerves. *Prog Neurobiol*. 1995;45:1.

Mahadevappa VG, Holub BJ. Degradation of different molecular species of phosphatidylinositol in thrombin-stimulated human platelets. *J Biol Chem*. 1983;258:5337.

Maizels M, Stephens FD. Valves of the ureter as a cause of primary obstruction of the ureter: anatomic, embryologic, and clinical aspects. *J Urol*. 1980;123:742.

Majumdar A, Vainio S, Kispert A, et al. Wnt11 and Ret/Gdnf pathways cooperate in regulating ureteric branching during metanephric kidney development. *Development*.

2003;130:3175.

Makker SP, Tucker AS, Izant RJ Jr, et al. Nonobstructive hydronephrosis and hydroureter associated with peritonitis. *N Engl J Med*. 1972;287:535.

Marchant DJ. Effects of pregnancy and progestational agents on the urinary tract. *Am J Obstet Gynecol*. 1972;112:487.

Mastrangelo D, Baertschi AJ, Roatti A, et al. Nitric oxide production within rat urothelial cells. *J Urol*. 2003;170:1409.

Mastrangelo D, Iselin CE. Urothelium dependent inhibition of rat ureter contractile activity. *J Urol*. 2007;178:702.

Mastrangelo D, Wisard M, Rohner S, et al. Diclofenac and NS-398, a selective cyclooxygenase-2 inhibitor, decrease agonist-induced contractions of the pig isolated ureter. *Urol Res*. 2000;28:376.

Mathew S, Naik G, Peedicayil J. Inhibition by benidipine of contractility of isolated proximal and distal caprine ureter. *Int J Appl Basic Med Res*. 2017;7(3):155.

Matsumoto R, Otsuka A, Suzuki T, et al. Expression of functional role of β3-adrenoceptors in the human ureter. *Int J Urol*. 2013;20:1007.

Mazzella H, Schroeder G. Ureteral contractility in the dog and the influence of drugs. *Arch Int Pharmacodyn Ther*. 1960;128:291.

McGuire EJ, Woodside JR, Borden TA, et al. Prognostic value of urodynamic testing in myelodysplastic patients. *J Urol*. 1981;126:205.

McGuire EJ. Physiology of the lower urinary tract. *Am J Kidney Dis*. 1983;2:402.

McLeod DG, Reynolds DG, Swan RG. Adrenergic mechanisms in the canine ureter. *Am J Physiol*. 1973;224:1054.

McNellis D, Sherline DM. The rabbit ureter in pregnancy and after norethynodrel-mestranol administration. A radiographic and histologic study. *Obstet Gynecol*. 1967;30:336.

Medrano S, Sequeira-Lopez LS, Gomez RA. Deletion of the miR-143/145 cluster leads to hydronephrosis in mice. *Am J Pathol*. 2014;184:3226.

Meini S, Santicioli P, Maggi CA. Propagation of impulses in the guinea-pig ureter and its blockade by calcitonin gene-related peptide (CGRP). *Naunyn Schmiedebergs Arch Pharmacol*. 1995;351:79.

Melick WF, Brodeur AE, Herbig F, et al. Use of a ureteral pacemaker in the treatment of ureteral reflux. *J Urol*. 1966;95:184.

Melick WF, Naryka JJ, Schmidt JH. Experimental studies of ureteral peristaltic patterns in the pig. II. Myogenic activity of the pig ureter. *J Urol*. 1961;86:46.

Mendelsohn C, Batourina E, Fung S, et al. Stromal cells mediate retinoid-dependent functions essential for renal development. *Development*. 1999;126:1139.

Metzger R, Schuster T, Till H, et al. Cajal-like cells in the human upper urinary tract. *J Urol*. 2004;172:769.

Metzger R, Schuster T, Till H, et al. Cajal-like cells in the upper urinary tract: comparative study in various species. *Pediatr Surg Int*. 2005;21:169.

Mitchell JA, Warner TD. Cyclo-oxygenase-2: pharmacology, physiology biochemistry and relevance to NSAID therapy. *Br J Pharmacol*. 1999;128:1121.

Miyaoka R, Mende S, Schenka A, et al. BAY 41-2272 a soluble guanylate cyclase stimulator, relaxes isolated human ureter in a standardized in vitro model. *Urology*. 2014;83:256.

Miyatake R, Tomiyama Y, Murakami M, et al. Effects of isoproterenol and butylscopolamine on the friction between an artificial stone and the intra ureteral wall in anesthetized rabbits. *J Urol*. 2001;166:1083.

Miyazaki Y, Tsuchida S, Nishimura H, et al. Angiotensin induces the urinary peristaltic machinery during the perinatal period. *J Clin Invest*. 1998;102:1489.

Morales PA, Crowder CH, Fishman AP, et al. The response of the ureter and pelvis to changing urine flows. *J Urol*. 1952;67:484.

Morita T, Ando M, Kihara K, et al. Function and distribution of autonomic receptors in canine ureteral smooth muscle. *Neurourol Urodyn*. 1994;13:315.

Morita T, Ishizuka G, Tsuchida S. Initiation and propagation of stimulus from the renal pelvic pacemaker in pig kidney. *Invest Urol*. 1981;19:157.

Morita T, Wada I, Saeki H, et al. Ureteral urine transport: changes in bolus volume, peristaltic frequency, intraluminal pressure and volume of flow resulting from autonomic drugs. *J Urol*. 1987;137:132.

Morita T, Wada I, Saeki H, et al. Characterization of α adrenoceptor subtypes involved in regulation of ureteral fluid transport. *Tohoku J Exp Med*. 1987;152:111.

Morita T, Wheeler MA, Weiss RM. Effects of noradrenaline, isoproterenol, and acetylcholine on ureteral resistance. *J Urol*. 1986;135:1296.

Muraki K, Imaizumi Y, Watanabe M. Sodium currents in smooth muscle cells freshly isolated from stomach fundus of the rat and ureter of the guinea pig. *J Physiol*. 1991;442:351.

Murakumo M, Nonomura K, Yamashita T, et al. Structural changes of collagen components and diminution of nerves in congenital ureteropelvic junction obstruction. *J Urol*. 1997;157:1963.

Murnaghan GF. The dynamics of the renal pelvis and ureter with reference to congenital hydronephrosis. *Br J Urol*. 1958;30:321.

Nakada SY, Coyle TLC, Ankem MK, et al. Doxazosin relaxes ureteral smooth muscle and inhibits epinephrine-induced ureteral contractility in vitro. *Urology*. 2007;70:817.

Nakada SY, Jerde TJ, Bjorling DE, et al. In vitro contractile effects of neurokinin receptor blockade in human ureter. *J Urol*. 2001;166:1534.

Nakada SY, Jerde TJ, Bjorling DE, et al. Selective cyclooxygenase-2 inhibitors reduce ureteral contraction in vivo: a better alternative for renal colic? *J Urol*. 2000;163:607.

Nakada SY, Jerde TJ, Jacobson LM, et al. Cyclooxygenase-2 expression is up-regulated in obstructed human ureter. *J Urol*. 2002;168:1226.

Nakamura I, Saito M, Fukumoto Y, et al. Experimental diabetes upregulates the expression of ureteral endothelin receptors. *Peptides*. 1997;18:1091.

Narla D, Slagle SB, Schaefer CM, et al. Loss of peri-Wolffian duct stromal FRS2a expression in mice leads to abnormal ureteric bud induction and vesicoureteral reflux. *Pediatr Res*. 2017;82:1022.

Nelson MT, Cheng H, Rubart M, et al. Relaxation of arterial smooth muscle by calcium sparks. *Science*. 1995;270:633.

Nernst W. Zur Theorie des elektrischen Reizes. *Arch Ges Physiol*. 1908;122:275.

Nguyen MG, Higashi R, Ohta K, et al. Autonomic and sensory nerve modulation of peristalsis in the upper urinary tract. *Auton Neurosci*. 2016;200:1.

Nguyen MJ, Angkawaijawa S, Hashitani H, et al. Nicotinic receptor activation on primary sensory afferents modulates autorhythmicity in the mouse renal pelvis. *Br J Pharmacol*. 2013;170:1221.

Nishizuka Y. The role of protein kinase C in cell surface signal transduction and tumor production. *Nature*. 1984;308:693.

Norregaard R, Jensen BL, Topcu SO, et al. Cyclooxygenase type 2 is increased in obstructed rat and human ureter and contributes to pelvic pressure increase after obstruction.

Kidney Int. 2006;70:872.

O'Conor VJ Jr, Dawson-Edwards P. Role of the ureter in renal transplantation. I: studies of denervated ureter with particular reference to ureteroureteral anastomosis. *J Urol*. 1959;82:566.

Ockerblad NF, Carlson HE, Simon JF. The effect of morphine upon the human ureter. *J Urol*. 1935;33:356.

Oll M, Baumann C, Behbahani TE, et al. Identification of prostaglandin receptors in human ureter. *BMC Urol*. 2012;12:35.

Oshima K, Miyazaki Y, Brock JW III, et al. Angiotensin type II receptor expression and ureteral budding. *J Urol*. 2001;166:1848.

Oswald J, Brenner E, Deibl M, et al. Longitudinal and thickness measurement of the normal distal and intravesical ureter in human fetuses. *J Urol*. 2003;169:1501.

Oswald J, Brenner E, Schwentner C, et al. The intravesical ureter in children with vesicoureteral reflux- a morphological and immunohistochemical characterization. *J Urol*. 2003;170:2423.

Oswald J, Schwenter C, Brenner E, et al. Extracellular matrix degradation and reduced nerve supply in refluxing ureteral endings. *J Urol*. 2004;172:1099.

Owusu-Ofori K, Learned MK, Mellon WS, et al. PI3K mediates stretch-induced COX2 expression during urinary tract obstruction. *J Endourol*. 2013;27:220.

Ozturk E, Telli O, Golce MI, et al. Effects of transforming growth factor on the developing embryonic ureter: an in-vitro megaureter model in mice. *J Pediatr Urol*. 2016;12:310.

Paquin AJ Jr. Ureterovesical anastomosis: the description and evaluation of a technique. *J Urol*. 1959;82:573.

Park S, Rasmussen H. Activation of tracheal smooth muscle contraction: synergism between Ca^{2+} and activators of protein kinase C. *Proc Natl Acad Sci USA*. 1985;82:8835.

Park Y-C, Tomiyama Y, Hayakawa K, et al. Existence of a β3-adrenoceptor and its functional role in the human ureter. *J Urol*. 2000;164:1364.

Patacchini R, Santicioli P, Zagorodynuk V, et al. Excitatory motor and electrical effects produced by tachykinins in the human and guinea-pig isolated ureter and guinea-pig renal pelvis. *Br J Pharmacol*. 1998;125:987.

Paxton WG, Runge M, Horaist C, et al. Immunohistochemical localization of rat angiotensin II ATI receptor. *Am J Physiol*. 1993;264:F989.

Pepicelli CV, Kispert A, Rowitch DH, et al. GDNF induces branching and increased cell proliferation in the ureter of the mouse. *Dev Biol*. 1997;192:193.

Perlmutter A, Miller L, Trimble LA, et al. Toradol and NSAID used for renal colic, decreases renal perfusion and ureteral pressure in a canine model of unilateral ureteral obstruction. *J Urol*. 1993;149:926.

Peters HJ, Eckstein W. Possible pharmacological means of treating renal colic. *Urol Res*. 1975;3:55.

Pezzone MA, Watkins SC, Alber SM, et al. Identification of c-kit positive cells in the mouse ureter: the interstitial cells of Cajal of the urinary tract. *Am J Physiol*. 2003;284:F925.

Phillips JL, Wheeler MA, Weiss RM. Differential nitric oxide synthase (NOS) activity in developing fetal pig ureterovesical junction. *FASEB J*. 1995;9:A679.

Pickard R, Starr K, MacLennan G, et al. Medical expulsive therapy in adults with ureteric colic: a multicenter, randomized, placebo-controlled trial. *Lancet*. 2015;386:341.

Pirker ME, Rolle U, Shinkai T, et al. Prenatal and postnatal neuromuscular development of the ureterovesical junction. *J Urol*. 2007;177:1546.

Pohl M, Sakurai H, Bush KT, et al. Matrix metalloproteinases and their inhibitors regulate in vitro ureteric bud branching morphogenesis. *Am J Physiol*. 2000;279:F891.

Poljakovic M, Persson K. Urinary tract infection in iNOS-deficient mice with focus on bacterial sensitivity to nitric oxide. *Am J Physiol*. 2003;284:F22.

Pontincasa P, Bartoli F, Di Ciaula A, et al. Defective in vitro contractility of ureteropelvic junction in children with functional and obstructive urine flow impairment. *J Pediatr Surg*. 2006;41:1594.

Porpiglia F, Destefanis P, Fiori C, et al. Effectiveness of nifedipine and deflazacort in the management of distal ureter stones. *Urology*. 2000;56:579.

Porpiglia F, Ghignone G, Fiori C, et al. Nifedipine versus tamsulosin for management of lower ureteral stones. *J Urol*. 2004;172:568.

Porpiglia F, Vaccino D, Billia M, et al. Corticosteroids and tamsulosin in the medical expulsive therapy of symptomatic distal ureter stones: single Drug or Association? *Eur Urol*. 2006;50:339.

Prieto D, Hernández M, Rivera L, et al. Distribution and functional effects of neuropeptide Y on equine ureteral smooth muscle and resistance arteries. *Regul Pept*. 1997;69:155.

Prieto D, Simonsen U, Martín J, et al. Histochemical and functional evidence for a cholinergic innervation of the equine ureter. *J Auton Nerv Syst*. 1994;47:159.

Prosser CL, Smith CE, Melton CE. Conduction of action potentials in the ureter of the rat. *Am J Physiol*. 1955;181:651.

Qiao J, Bush KT, Steer DL, et al. Multiple fibroblast growth factors support growth of the ureteric bud but have different effects on branching morphogenesis. *Mech Dev*. 2001;109:123.

Qiao J, Uzzo R, Obara-Ishihara T, et al. FGF-7 modulates ureteric bud growth and nephron number in the developing kidney. *Development*. 1999;126:547.

Quayle JM, Nelson MT, Standen NB. ATP-sensitive and inwardly rectifying potassium channels in smooth muscle. *Physiol Rev*. 1997;77:1165.

Radmayr C, Schwentner C, Lunacek A, et al. Embryology and anatomy of the vesicoureteric junction with special reference to the etiology of vesicoureteral reflux. *Ther Adv Urol*. 2010;1:243.

Rajpathy J, Aswathaman K, Sinha M, et al. An in vitro study of human ureteric smooth muscle with the alpha1-adrenoceptor subtype blocker. *BJU Int*. 2008;102:1743.

Reid RE, Herman R, Teng C. Attempts at altering ureteral activity in the unanesthetized, conditioned dog with commonly employed drugs. *Invest Urol*. 1976;12:74.

Resim S, Ekerbicer HC, Ciftci A. Role of tamsulosin in treatment of patients with steinstrasse developing after extracorporeal shock wave lithotripsy. *Urology*. 2005;66:945.

Reuterskiöld AG. The abnormal ureter in children. II. Perfusion studies on the refluxing ureter. *Scand J Urol Nephrol*. 1970;4:99.

Reuterskiöld AG. Ureteric pressure variations at different flow rates and varying bladder pressures in normal dogs. *Acta Soc Med Ups*. 1969;74:94.

Ribeiro ASF, Fernandes VS, Matrinez MP, et al. Pre- and post-junctional bradykinin B_2 receptors regulate smooth muscle tension to the pig intravesical ureter. *Neurol Urodyn*. 2016;35:115.

Rivera L, Hernández M, Benedito S, et al. Mediation of contraction and relaxation by alpha- and beta-adrenoceptors in the ureterovesical junction of the sheep. *Res Vet Sci*. 1992;52:57.

Roberts JA. Experimental pyelonephritis in the monkey. III. Pathophysiology of ureteral malfunction induced by bacteria. *Invest Urol*. 1975;13:117.

Roberts JA. Hydronephrosis of pregnancy. *Urology*. 1976;8:1.

Rong W, Burnstock G. Activation of ureter nociceptors by exogenous and endogenous ATP in guinea pig. *Neuropharmacology*. 2004;47:1093.

Rose JG, Gillenwater JY. Effects of obstruction upon ureteral function. *Urology*. 1978;12:139.

Rose JG, Gillenwater JY. Pathophysiology of ureteral obstruction. *Am J Physiol*. 1973;225:830.

Rose JG, Gillenwater JY. The effect of adrenergic and cholinergic agents and their blockers upon ureteral activity. *Invest Urol*. 1974;11:439.

Rosen DE, Constantinou CE, Sands JP, et al. Dynamics of the upper urinary tract: effects of changes in bladder pressure on ureteral peristalsis. *J Urol*. 1971;106:209.

Rosen MR, Legato MJ, Weiss RM. Developmental changes in impulse conduction in canine heart. *Am J Physiol*. 1981;240:H546.

Roshani H, Dubhoiwala NF, Verbeek FJ, et al. Functional anatomy of the human ureterovesical junction. *Anat Rec*. 1996;245:645.

Ross JA, Edmond P, Griffiths JM. The action of drugs on the intact human ureter. *Br J Urol*. 1967;39:26.

Ross JA, Edmond P, Kirkland IS. *Behavior of the human ureter in health and disease*. Churchill Livingstone: Edinburgh; 1972.

Russo-Gil D, Coca-Payeras A, Tejedo-Maten A. Obstruction and normal re-canalization of the ureter in the human embryo, its relation to congenital ureteric obstruction. *Eur Urol*. 1975;1:287.

Sainio K, Suvanto P, Davies JA, et al. Glial cell-line derived neurotrophic factor is required for bud initiation from ureteric epithelium. *Development*. 1997;124:4077.

Sakamoto K, Suri D, Rajasekaran M. Characterization of muscarinic receptor subtypes in human ureter. *J Endourol*. 2006;20:939.

Sakanashi M, Kato T, Miyamoto Y, et al. Comparative effects of diltiazem and glycerol trinitrate on isolated ureter and coronary artery of the dog. *Pharmacology*. 1986;32:11.

Sakanashi M, Kato T, Miyamoto Y, et al. Comparison of the effects of nifedipine on ureter and coronary artery isolated from the dog. *Drug Res*. 1985;35:584.

Sakurai H. Molecular mechanism of ureteric bud development. *Semin Cell Dev Biol*. 2003;14:217.

Sala NL, Rubi RA. Ureteral function in pregnant women. II. Ureteral contractility during normal pregnancy. *Am J Obstet Gynecol*. 1967;99:228.

Sann H, Jancso G, Ambrus A, et al. Capasaicin treatment induces selective sensory degeneration and increased sympathetic innervation in the rat ureter. *Neuroscience*. 1995;67:953.

Sann H, Rössler W, Hammer K, et al. Substance P and calcitonin gene-related peptide in the ureter of chicken and guinea-pig: distribution, binding sites and possible functions. *Neuroscience*. 1992;49:699.

Sann H. Chemosensitivity of nociceptive, mechanosensitive afferent nerve fibres in the guinea-pig ureter. *Eur J Neurosci*. 1998;10:1300.

Santicioli P, Carganico G, Meini S, et al. Modulation by stereoselective inhibition of cyclooxygenase of electromechanical coupling in the guinea-pig isolated renal pelvis. *Br J Pharmacol*. 1995;114:1149.

Santicioli P, Maggi CA. Inhibitory transmitter action of CGRP in guinea-pig ureter via activation of glibenclamide-sensitive

K^+ channels. *Br J Pharmacol*. 1994;113:588.

Santicioli P, Morbidelli L, Parenti A, et al. Calcitonin gene-related peptide selectively increases cAMP levels in the guinea-pig ureter. *Eur J Pharmacol*. 1995;289:17.

Santicioli P, Maggi CA. Effect of 18β-glycyrrhetinic acid on electromechanical coupling in the guinea pig renal pelvis and ureter. *Br J Pharmacol*. 2000;129:163.

Santicioli P, Maggi CA. Myogenic and neurogenic factors in the control o fpyeloureteral motility and ureteral peristalsis. *Pharmacol Rev*. 1998;50:683.

Santis WF, Peters CA, Yalla SV, et al. Ureteral function is modulated by a local renin-angiotensin system. *J Urol*. 2003;170:259.

Santis WF, Sullivan MP, Gobet R, et al. Characterization of ureteral dysfunction in an experimental model of congenital bladder outlet obstruction. *J Urol*. 2000;163:980.

Sasaki S, Itoh Y, Kojima Y, et al. Expression level and role in ureteral contraction of alpha 1-adrenoceptor subtypes in human ureter. *Neurourol Urodyn*. 2008;179(Suppl):244.

Sasaki S, Tomiyama Y, Kobayashi S, et al. Characterization of α_1 adrenoceptor subtypes mediating contraction in human isolated ureters. *Urology*. 2011;77:e13.

Satani Y. Experimental studies of the ureter. *Am J Physiol*. 1919;49:474.

Schicho R, Kanai Y, Ishikawa T, et al. Involvement of NGF in the induction of increased noradrenergic innervation of the ureter in neonatally capsaicin-treated rats. *J Auton Nerv Syst*. 1998;73:46.

Schick E, Tanagho EA. The effect of gravity on ureteral peristalsis. *J Urol*. 1973;109:187.

Schultz K, Bohme E, Volker AWK, et al. Relaxation of hormonally stimulated smooth muscular tissues by the 8-bromo derivative of cyclic GMP. *Naunyn Schmiedebergs*

Arch Pharmacol. 1979;306:1.

Schweitzer FAW. Intrapelvic pressure and renal function studies in experimental chronic partial ureteric obstruction. *Br J Urol*. 1973;45:2.

Schwentner C, Oswald J, Lunacek A, et al. Loss of interstitial cells of Cajal and gap junction protein connexin 43 at the vesicoureteral junction in children with vesicoureteral reflux. *J Urol*. 2005;174:1981.

Senol C, Onaran M, Guor CAK, et al. Changes in Cajal cell density in ureteropelvic junction obstruction in children. *J Pediatr Urol*. 2016;12:89.

Sessa W. The nitric oxide family of proteins. *J Vasc Res*. 1994;31:131.

Shabir S, Borisova L, Wray S, et al. Rho-kinase inhibition and electromechanical coupling in rat and guinea-pig ureter smooth muscle: Ca^{2+}-dependent and –independent mechanisms. *J Physiol*. 2004;560:839.

Shabir S, Cross W, Kirkwood LA, et al. Functional expression of purinergic P_2 receptors and transient receptor potential channels by the human urothelium. *Am J Physiol*. 2013;305:F396.

Shakya R, Watanabe T, Costantini F. The role of GDNF/Ret signaling in ureteric bud cell fate and branching morphogenesis. *Dev Cell*. 2005;8:65.

Sharkey J, Boyarsky S, Catacutan-Labay P, et al. The *in vivo* effects of histamine and Benadryl on the peristalsis of the canine ureter and plasma potassium levels. *Invest Urol*. 1965;2:417.

Sharkey J, Kaplan N, Newman HR, et al. The role of potassium in ureteral physiology and pharmacology. *Invest Urol*. 1968;6:119.

Shen H, Chen Z, Mokhatar A, et al. Expression of β-adrenergic receptor subtypes in human normal and dilated ureter. *Int*

Urol Nephrol. 2017;49:1771.

Sheybani-Deloui S, Chi L, Staite MV, et al. Activated hedgehog-GL1 signaling causes congenital ureteropelvic junction obstruction. *J Am Soc Nephrol*. 2017;29:1.

Shiratori T, Kinoshita H. Electromyographic studies on urinary tract. III. Influence of pinching and cutting the ureters of dogs on their EMGs. *Tohoku J Exp Med*. 1961;73:159.

Shuba MF. The effect of sodium-free and potassium-free solutions, ionic current inhibitors and ouabain on electrophysiological properties of smooth muscle of guinea-pig ureter. *J Physiol*. 1977;264:837.

Sigala S, Dellabella M, Milanese G, et al. Alpha-1 adrenoceptor subtypes in men juxtavesical ureters: molecular and pharmacological characterization. *Eur Urol*. 2004;3:119.

Sigala S, Dellabella M, Milanese G, et al. Evidence for the presence of α_1 adrenoceptor subtypes in the human ureter. *Neurourol Urodyn*. 2005;24:142.

Sivrikava A, Celik OF, Sivrikaya N, et al. The effect of diclofenac sodium and papaverine on isolated human ureteric smooth muscle. *Int Urol Nephrol*. 2003;35:479.

Sivula A, Lehtonen T. Spontaneous passage of artificial concretions applied in the rabbit ureter. *Scand J Urol Nephrol*. 1967;1:259.

Sjöden JG, Wahlberg J, Persson AEG. The effect of indomethacin on glomerular capillary pressure and pelvic pressure during ureteral obstruction. *J Urol*. 1982;127:1017.

Smet PJ, Edyvane KA, Jonavicius J, et al. Colocalization of nitric oxide synthase with vasoactive intestinal peptide, neuropeptide Y, and tyrosine hydroxylase in nerves supplying the human ureter. *J Urol*. 1994;152:1292.

Smita K, Kumar VS, Premendran J, et al. Goat ureter—an alternative model for measuring ureteral peristalsis. *J Smooth Muscle Res*. 2006;42:117.

Smith RD, Borisova L, Wray S, et al. Characterization of the ionic currents in freshly isolated rat ureter smooth muscle cells: evidence for species-dependent currents. *Pflugers Arch*. 2002;445:444.

Smith RD, Eisner DA, Wray S. The effect of changing intracellular pH on calcium and potassium currents in smooth muscle cells from the guinea-pig ureter. *Pflugers Arch*. 1998;435:518.

Smith SD, Wheeler MA, Nishimoto T, et al. The differential expression of nitric oxide synthase in guinea-pig urinary tract. *J Urol*. 1993;149:248A.

Solari V, Piotrowska AP, Puri P. Altered expression of interstitial cells of Cajal in congenital ureteropelvic junction obstruction. *J Urol*. 2003;170:2420.

Somlyo AP, Somlyo AV. Ca^{2+} sensitivity of smooth muscle and nonmuscle myosin II: modulated by G proteins, kinases, and myosin phosphatase. *Physiol Rev*. 2003;83:325.

Somlyo AP, Somlyo AV. Signal transduction and regulation in smooth muscle. *Nature*. 1994;372:321.

Song R, Preston G, Yosypiv IV. Angiotensin II stimulates in vitro branching morphogenesis of the isolated ureteric bud. *Mech Dev*. 2011;128:359.

Song R, Spera M, Garrett C, et al. Angiotensin II induced activation of c-Ret signaling is critical in ureteric bud branching morphogenesis. *Mech Dev*. 2010;127:21.

Steinbach A, Schaper K, Koenen A, et al. Role of endothelin-1 for the regulation of renal pelvic function. *Pflugers Arch*. 2016;468:1467.

Stief CG, Taher A, Truss M, et al. Phosphodiesterase isoenzymes in human ureteral smooth muscle: identification, characterization, and functional effects of various phosphodiesterase inhibitors in vitro. *Urol Int*. 1995;55:183.

Stief CG, Uckert S, Truss MC, et al. A possible role for nitric oxide in the regulation of human ureteral smooth muscle tone in vitro. *Urol Res*. 1996;24:333.

Struthers NW. The effect of *E. coli* and *E. coli* endotoxin on peristalsis in the canine ureter. *Urol Res*. 1976;4:107.

Struthers NW. The role of manometry in the investigation of pelviureteral function. *Br J Urol*. 1969;41:129.

Su HC, Wharton J, Polak JM, et al. Calcitonin gene-related peptide immunoreactivity in afferent neurons supplying the urinary tract: combined retrograde tracing and immunohistochemistry. *Neuroscience*. 1986;18:727.

Sui JL, Kao CY. Properties of inward calcium current in guinea pig ureteral myocytes. *Am J Physiol*. 1997;272:C543.

Sui JL, Kao CY. Roles of Ca^{2+} and Na+ in the inward current and action potentials of guinea pig ureteral myocytes. *Am J Physiol*. 1997;272:C535.

Sui JL, Kao CY. Roles of outward potassium currents in the action potentials of guinea pig ureteral myocytes. *Am J Physiol*. 1997;273:C962.

Sur RL, Shore N, L'Esperance JL, et al. Sildosin to facilitate passage of ureteral stones: a multi-institutional, randomized, double-blinded, placebo-controlled trial. *Eur Urol*. 2015;67:959.

Takago K, Takayanagi I, Tomiyama A. Actions of dibutyryl cyclic adenosine monophosphate, papaverine, and isoprenaline on intestinal smooth muscle. *Jpn J Pharmacol*. 1971;21:477.

Takemura T, Hino S, Okada M, et al. Role of membrane-bound heparin-binding epidermal growth factor-like growth factor (HB-EGF) in renal epithelial cell branching. *Kidney Int*. 2002;61:1968.

Takeyama J, Sakai K. Mucosal abnormalities in congenital ureteropelvic junction obstruction. *Histopathology*. 2007;51:709.

Tamaki M, Iwanaga T, Sato S, et al. Calcitonin gene-related peptide (CGRP)—immunoreactive nerve plexuses in the renal pelvis and ureter of rats. *Cell Tissue Res*. 1992;267:29.

Tanagho EA, Guthrie TH, Lyon RP. The intravesical ureter in primary reflux. *J Urol*. 1969;101:824.

Tanagho EA, Hutch JA, Meyers FH, et al. Primary vesicoureteral reflux: experimental studies of its etiology. *J Urol*. 1965;93:165.

Tanagho EA, Meyers FH, Smith DE. The trigone: anatomical and physiological considerations. 1. In relation to the ureterovesical junction. *J Urol*. 1968;100:623.

Tanagho EA. Ureteral embryology, developmental anatomy and myology. Boyarsky S, Gottschalk CW, Tanagho EA, et al. *Urodynamics*. Academic: New York; 1971:3–27.

Tang M-J, Cai Y, Tsai S-J, et al. Ureteric bud outgrowth in response to ret activation is mediated by phosphatidylinositol 3-kinase. *Dev Biol*. 2002;243:128.

Teele RL, Lebowitz RL, Colodny AH. Reflux into the unused ureter. *J Urol*. 1976;115:310.

Theobald RJ Jr. Purineric and cholinergic components of bladder contractility and flow. *Life Sci*. 1995;56:445.

Thulesius O, Angelo-Khattar M, Sabha M. The effect of ureteral distension on peristalsis: studies on human and sheep ureters. *Urol Res*. 1989;17:385.

Thulesius O, Angelo-Khattar M. The effect of indomethacin on the motility of isolated sheep ureters. *Acta Pharmacol Toxicol*. 1985;56:298.

Thulesius O, Araj G. The effect of uropathogenic bacteria on ureteral motility. *Urol Res*. 1987;15:273.

Tindall AR. Preliminary observations on the mechanical and electrical activity of the rat ureter. *J Physiol*. 1972;223:633.

Toguri AG, Fournier G. Factors influencing the pressure-flow perfusion system. *J Urol*. 1982;127:1021.

Tomiyama Y, Hayakawa K, Shinagawa K, et al. Beta-adrenoceptor subtypes in the ureteral smooth muscle of rats, rabbits and dogs. *Eur J Pharmacol*. 1998;352:269.

Tomiyama Y, Kobayashi K, Tadachi M, et al. Expressions and mechanical functions of α_1 adrenoceptor subtypes in hamster ureter. *Eur J Pharmacol*. 2007;573:201.

Tomiyama Y, Murakami M, Akiyama K, et al. Modification of ureteral motility and promotion of urine flow around an intraureteral obstruction by CL-316243, phenylephrine, and furosemide in dogs. *Neurourol Urodyn*. 2002;21:251.

Tomiyama Y, Murakami M, Hayakawa K, et al. Pharmacological profile of Kul-7211, a selective beta-adrenoceptor agonist, in isolated ureteral smooth muscle. *J Pharmacol Sci*. 2003;92:411.

Tomiyama Y, Wanajo I, Yamazaki Y, et al. Functional muscarinic cholinoceptors in the isolated canine ureter. *Naunyn Schmiedebergs Arch Pharmacol*. 2003;367:348.

Traut HF, Kuder A. Inflammation of the upper urinary tract complicating the reproductive period of woman. Collective review. *Int Abst Surg*. 1938;67:568.

Triner L, Nahas GG, Vulliemoz Y, et al. Cyclic AMP and smooth muscle function. *Ann N Y Acad Sci*. 1971;185:458.

Tsuchida S, Suzuki T. Pacemaker activity of the pelvicalyceal border recorded by an intracellular glass microelectrode. *Urol Int*. 1992;48:121.

Tsuchida S, Yamaguchi O. A constant electrical activity of the renal pelvis correlated to ureteral peristalsis. *Tohoku J Exp Med*. 1977;121:133.

Tsuchiya T, Takei N. Pressure responses and conduction of peristaltic wave in guinea-pig ureter. *Jpn J Physiol*. 1990;40:139.

Turna B, Cinar MG, Canda AE, et al. Role of Rho-kinase in contractions of ureters from rabbits with unilateral ureteric obstruction. *BJU Int*. 2007;100:1166.

Uchida H, Shishido K, Nomiya M, et al. Involvement of cyclic AMP-dependent and -independent mechanisms in the relaxation of rat detrusor muscle via β-adrenoceptors. *Eur J Pharmacol*. 2005;518:195.

Uehara Y, Burnstock G. Demonstration of "gap junctions" between smooth muscle cells. *J Cell Biol*. 1970;44:215.

Ueno A, Kawamura T, Ogawa A, et al. Relation of spontaneous passage of ureteral calculi to size. *Urology*. 1977;10:544.

van der Aa F, Roskams T, Blyweert W, et al. Indentification of kit positive cells in the human urinary tract. *J Urol*. 2004;171:2492.

Van Koppen CJ, Kaiser B. Regulation of muscarinic acetylcholine receptor signaling. *Pharmacol Ther*. 2003;98:197.

van Mastrigt R, van de Wetering J, Glerum JJ. Influence of temperature and stimulus interval variations on the propagation of contractions in the pig ureter. *Urol Int*. 1986;41:266.

Van Wagenen G, Jenkins RH. An experimental examination of factors causing ureteral dilatation of pregnancy. *J Urol*. 1939;42:1010.

Vane JR. Cyclooxygenase 1 and 2. *Annu Rev Pharmacol Toxicol*. 1998;38:97.

Vaughan ED Jr, Shenasky JH II, Gillenwater JY. Mechanism of acute hemodynamic response to ureteral occlusion. *Invest Urol*. 1971;9:109.

Vega QC, Worby CA, Lechner JE, et al. Glial cell line-derived neurotrophic factor activates the receptor tyrosine kinase ret and promotes kidney morphogenesis. *Proc Natl Acad Sci USA*. 1996;93:10657.

Vela-Navarrete R. Percutaneous intrapelvic pressure determinations in the study of hydronephrosis. *Invest Urol*.

1971;8:526.

Vereecken RL, Derluyn J, Verduyn H. The viscoelastic behavior of the ureter during elongation. *Urol Res*. 1973;1:15.

Vereecken RL, Hendrickx H, Casteels R. The influence of calcium on the electrical and mechanical activity of the guinea pig ureter. *Urol Res*. 1975;3:149.

Vereecken RL. *Dynamical aspects of urine transport in the ureter*. Acco: Louvain, Belgium; 1973.

Verkman AS, Galietta LJ. Chloride channels as drug targets. *Nat Rev Drug Discov*. 2009;8:153.

Vermue NA, Den Hertog A. The action of prostaglandins on ureter smooth muscle of guinea pig. *Eur J Pharmacol*. 1987;142:163.

Vernez SL, Okhunov Z, Wikenheiser J, et al. Precise characterization and 3-dimensional reconstruction of the autonomic nerve distribution of the human ureter. *J Urol*. 2017;197:723.

Vesin MF, Harbon S. The effects of epinephrine, prostaglandins and their antagonists on adenosine cyclic 3’,5’-monophosphate concentrations on motility on the rat uterus. *Mol Pharmacol*. 1974;10:457.

Villa L, Buono R, Fossati N, et al. Effects by silodosin on the partially obstructed rat ureter *in vivo* and on human and rat isolated ureters. *Br J Pharmacol*. 2013;169:230.

Wada Y, Latifpour J, Saito M, et al. Developmental changes in the biochemical and functional properties of endothelium receptors in rabbit renal pelvis. *BJU Int*. 2001;88:950.

Wanajo I, Tomiyama Y, Tadachi M, et al. The potency of KUL-7211, a selective ureteral relaxant, in isolated canine ureter: comparison with various spasmolytics. *Urol Res*. 2005;33:409.

Wanajo I, Tomiyama Y, Yamazaki Y, et al. Pharmacological characterization of β adrenoceptor subtypes mediating relaxation in porcine isolated ureteral smooth muscle. *J Urol*. 2004;172:1155.

Wanajo I, Tomiyama Y, Yamazaki Y, et al. Ureteral selectivity of intravenous β-adrenoceptor agonists in pig model of acute ureteral obstruction: comparison of KUL-7211, a selective β2/β3 agonist, with isoproterenol, terbutaline, and CL-316243. *Urology*. 2011;77:1266 [e1–6].

Wang Y, Puri P, Hassan J, et al. Abnormal innervation and altered nerve growth factor messenger ribonucleic acid expression in ureteropelvic junction obstruction. *J Urol*. 1995;154:679.

Washizu Y. Grouped discharges in ureter muscle. *Comp Biochem Physiol*. 1966;19:713.

Washizu Y. Membrane potential and tension in guinea-pig ureter. *J Pharmacol Exp Ther*. 1967;158:445.

Washizu Y. Ouabain on excitation contraction in guinea pig ureter. *Fed Proc*. 1968;27:662.

Watanabe T, Miyagawa I. Characteristics of ureteral bolus in diabetic rats. *Urol Res*. 2002;30:185.

Watterson DM, Harrelson WG Jr, Keller PM, et al. Structural similarities between the Ca^{2+}-dependent regulatory proteins of 3’:5’-cyclic nucleotide phosphodiesterase and actomyosin ATPase. *J Biol Chem*. 1976;251:4501.

Weinberg SR, Maletta JJ. Measurement of peristalsis of the ureter and its relation to drugs. *JAMA*. 1961;175:109.

Weinberg SR. Ureteral function. I. Simultaneous monitoring of ureteral peristalsis. *Invest Urol*. 1974;12:103.

Weinhold P, Hennenberg M, Strittmatter F, et al. Transient receptor potential a1 (TRA1) inhibits contractions of the isolated human ureter. *Neurourol Urodyn*. 2017;1.

Weiss R, Mevissen M, Hauser DS, et al. Inhibition of human and pig ureter motility in vitro and in vivo by the K(+) channel openers PKF 217- 744b and nicorandil. *J Pharmacol*

Exp Ther. 2002;302:651.

Weiss RM, Bassett AL, Hoffman BF. Adrenergic innervation of the ureter. *Invest Urol*. 1978;16:123.

Weiss RM, Bassett AL, Hoffman BF. Dynamic length-tension curves of cat ureter. *Am J Physiol*. 1972;222:388.

Weiss RM, Bassett AL, Hoffman BF. Effect of ouabain on contractility of the isolated ureter. *Invest Urol*. 1970;8:161.

Weiss RM, Biancani P, Zabinski MP. Adrenergic control of ureteral tonus. *Invest Urol*. 1974;12:30.

Weiss RM, Biancani P. A rationale for ureteral tapering. *Urology*. 1982;20:482.

Weiss RM, Biancani P. Characteristics of normal and refluxing ureterovesical junctions. *J Urol*. 1983;129:858.

Weiss RM, Guo S, Shan A, et al. Brg1 determines urothelial cell fate during ureter development. *J Am Soc Nephrol*. 2013;24:618.

Weiss RM, Hardman JG, Wells JN. Resistance of a separated form of canine ureteral phosphodiesterase activity to inhibition by xanthines and papaverine. *Biochem Pharmacol*. 1981;30:2371.

Weiss RM, Tamarkin FJ, Wheeler MA. Pacemaker activity in the upper urinary tract. *J Smooth Muscle Res*. 2006;42:103.

Weiss RM, Vulliemoz Y, Verosky M, et al. Adenylate cyclase and phosphodiesterase activity in rabbit ureter. *Invest Urol*. 1977;15:15.

Weiss RM, Wagner ML, Hoffman BF. Localization of pacemaker for peristalsis in the intact canine ureter. *Invest Urol*. 1967;5:42.

Weiss RM, Wagner ML, Hoffman BF. Wenckebach periods of the ureter. A further note on the ubiquity of the Wenckebach phenomenon. *Invest Urol*. 1968;5:463.

Weiss RM, Wheeler MA. Insulin activation of cyclic AMP phosphodiesterase in intact ureteral segments. *J Pharmacol*

Exp Ther. 1988;247:630.

Weiss RM. Clinical implications of ureteral physiology. *J Urol*. 1979;121:401.

Wharton LR. The innervation of the ureter, with respect to denervation. *J Urol*. 1932;28:639.

Wheeler MA, Cho YH, Hong KW, et al. Age-dependent alterations in beta-adrenergic receptor function in guinea-pig ureter. *Prog Clin Biol Res*. 1990;327:711.

Wheeler MA, Housman A, Cho YH, et al. Age dependence of adenylate cyclase activity in guinea pig ureter homogenate. *J Pharmacol Exp Ther*. 1986;239:99.

Whitaker RH. Clinical assessment of pelvic and ureteral function. *Urology*. 1978;12:146.

Whitaker RH. Methods of assessing obstruction in dilated ureters. *Br J Urol*. 1973;45:15.

William T, Lisanti M. The caveolin genes: from cell biology to medicine. *Ann Med*. 2004;584-95.

Witherow RO, Whitaker RH. The predictive accuracy of antegrade pressure flow studies in equivocal upper tract obstruction. *Br J Urol*. 1981;53:496.

Woodburne RT, Lapides J. The ureteral lumen during peristalsis. *Am J Anat*. 1972;133:255.

Woolf AS, Davies JA. Cell biology of ureter development. *J Am Soc Nephrol*. 2013;24:19.

Wooster MJ. Effects of prostaglandin E_1 on the dog ureter in vitro. *J Physiol*. 1971;213:51P.

Wu G, Bogatkevich GS, Mukhin YV, et al. Identification of Gβγ binding sites in the third intracellular loop of the M3-muscarinic receptor and their role in receptor regulation. *J Biol Chem*. 2000;275:9026.

Yalcin S, Ertunc M, Ardicli B, et al. Ureterovesical junction obstruction causes increment in smooth muscle contractility, and cholinergic and adrenergic activity in distal ureter of rabbits. *J Pediatr Surg*. 2013;48:1954.

Yang X, Zhang Y, Hu J. The expression of Cajal cells at the obstruction site of congenital pelviureteric junction obstruction and quantitative image analysis. *J Pediatr Surg*. 2009;44:2339.

Yencilek F, Erturhan S, Canguven O, et al. Does tamsulosin change the management of proximally located ureteral stones? *Urol Res*. 2010;38:195.

Yerkes E, Nishimura H, Miyazaki Y, et al. Role of angiotensin in the congenital anomalies of the kidney and urinary tract in the moose and the human. *Kidney Int Suppl*. 1998;67:575.

Yilmaz E, Batislam E, Basar MM, et al. The comparison and efficacy of 3 different α1-adrenergic blockers for distal ureteral stones. *J Urol*. 2005;173:2010.

Yoon JY, Kim JC, Hwang TK, et al. Collagen studies for pediatric ureteropelvic junction obstruction. *Urology*. 1998;52:494.

Yoshida M, Latifpour J, Weiss RM. Age-related changes in calcium antagonist receptors in rabbit ureter. *Dev Pharmacol Ther*. 1992;18:100.

Yoshimura Y, Yamaguchi O. Calcium independent contraction of bladder smooth muscle. *Int J Urol*. 1997;4:62.

Yosypiv IV, Boh MK, Spera MA, et al. Downregulation of Spry-1, an inhibitor of GDNF/Ret, causes angiotensin II-induced ureteric branching. *Kidney Int*. 2008;74:1287.

Yosypiv IV, Schroeder M, El-Dahr SS. Angiotensin II type I receptor-EGF receptor cross-talk regulates ureteric bud branching morphogenesis. *J Am Soc Nephrol*. 2006;17:1005.

Yosypiv IV. Renin-angiotensin system in ureteric bud branching morphogenesis: implications for kidney disease. *Pediatr Nephrol*. 2013;1–12.

Zhang SL, Moini B, Ingelfinger JR. Angiotensin II increases Pax-2 expression in fetal kidney cells via the AT2 receptor. *J*

Am Soc Nephrol. 2004;15:1452.

Zhang Y, Lang RJ. Effects of intrinsic prostaglandins on the spontaneous contractile and electrical activity of the proximal renal pelvis of the guinea pig. *Br J Pharmacol*. 1994;113:431.

Zheng Y, Xu J, Guo W, et al. The significance of Pax2 expression in the ureter epithelium of children with vesicoureteric reflux. *Hum Pathol*. 2015;46:963.

Zimskind PD, Davis DM, Decaestecker JE. Effects of bladder filling on ureteral dynamics. *J Urol*. 1969;102:693.

Zwergel U, Zwergel T, Leis HJ, et al. Eicosanoid synthesis in the isolated human renal pelvis, ureter and bladder. *Br J Urol*. 1991;67:246.

Renal Physiology and Pathophysiology Including Renovascular Hypertension

---

Thomas Chi MD, Meyeon Park MD, MAS

Urologic disease states often result in intrinsic renal dysfunction. To provide comprehensive care to the patient, urologists must have a thorough understanding of renal physiology and pathophysiology. The aim of this chapter is to highlight the most clinically relevant aspects of these topics as they relate to urologic practice. We organize this broad topic in a clinically relevant fashion by separating renal function into three main categories: filtration and filtrate transport, hormonal regulation, and blood flow. Physiology and pathophysiology are presented together to encourage their understanding as multiple facets of one system, rather than as separate knowledge silos. Principles of physiology and pathophysiology in the kidney can direct therapeutic intervention on many levels for the practicing urologist.

Glomerular Filtration

The fundamental function of the kidney is to filter blood. **Renal blood flow (RBF) makes up 20% of cardiac output with the body at rest, and the average adult circulates nearly 5 L of blood per minute for cardiac output.** From that perspective, the kidney's capacity for continuous filtration is remarkable. In addition, the complex handling of solutes by the kidney is a critical component of maintaining homeostasis.

After blood passes from the main renal artery, it travels through smaller and smaller branching interlobar, arcuate, and interlobular arteries until it reaches the afferent arteriole. At that point, blood enters the glomerular capillary at the glomerular apparatus. Here, passive filtration occurs across the glomerular membrane, after which blood exits the glomerular apparatus via the efferent arteriole. **The glomerular filtration rate (GFR) is a reflection of the movement of the filtrate across the membrane and an estimate of hydraulic and oncotic pressure differences between the glomerular capillary and the Bowman space.** It can also be affected by membrane permeability and is represented as

$$\text{GFR} = \text{LpS} \times (\Delta\text{Hydraulic pressure} - \Delta\text{Oncotic pressure})$$

where Lp = glomerular permeability and S = glomerular surface area. Although renal plasma flow, glomerular permeability, and oncotic pressure influence GFR, the greatest determinant is the hydraulic pressure. Thus, in the setting of acute urinary obstruction, GFR can quickly deteriorate.

Because GFR cannot be directly measured, it is estimated based on renal clearance. The ideal substrate to accurately reflect GFR would be one that has a stable plasma concentration, is freely filtered across the glomerulus, and is not secreted, reabsorbed, metabolized, and synthesized once in the renal tubule. Under these circumstances, the amount of this substrate excreted would be a direct reflection of its filtration and thus a measurement of the GFR. Although inulin and radiolabeled dyes have been used to measure GFR based on these characteristics, their required intravenous administration makes them impractical for use (Perrone et al., 1990). Plasma cystatin C is an endogenous protein that has also been shown to measure renal function (Filler et al., 2005). Clearance of cystatin C is not affected by tubular secretion or excretion and is less affected by muscle mass than serum creatinine, but this test is not yet universally available for clinical use. Endogenous creatinine measurement therefore remains the most clinically relevant marker used as an estimate of GFR. Compared with inulin, some creatinine is secreted from the proximal tubule. Therefore creatinine may overestimate true GFR, and this inaccuracy is magnified as GFR declines, given that tubular secretion will increase under these circumstances (Shemesh et al., 1985; Fig. 86.1). Under some circumstances, a 24-hour collection of urine for creatinine clearance can be a useful measure of kidney function, but this relies on a patient being in steady state. Pragmatically speaking, however, measurement of serum creatinine is the most common approach to estimating GFR.

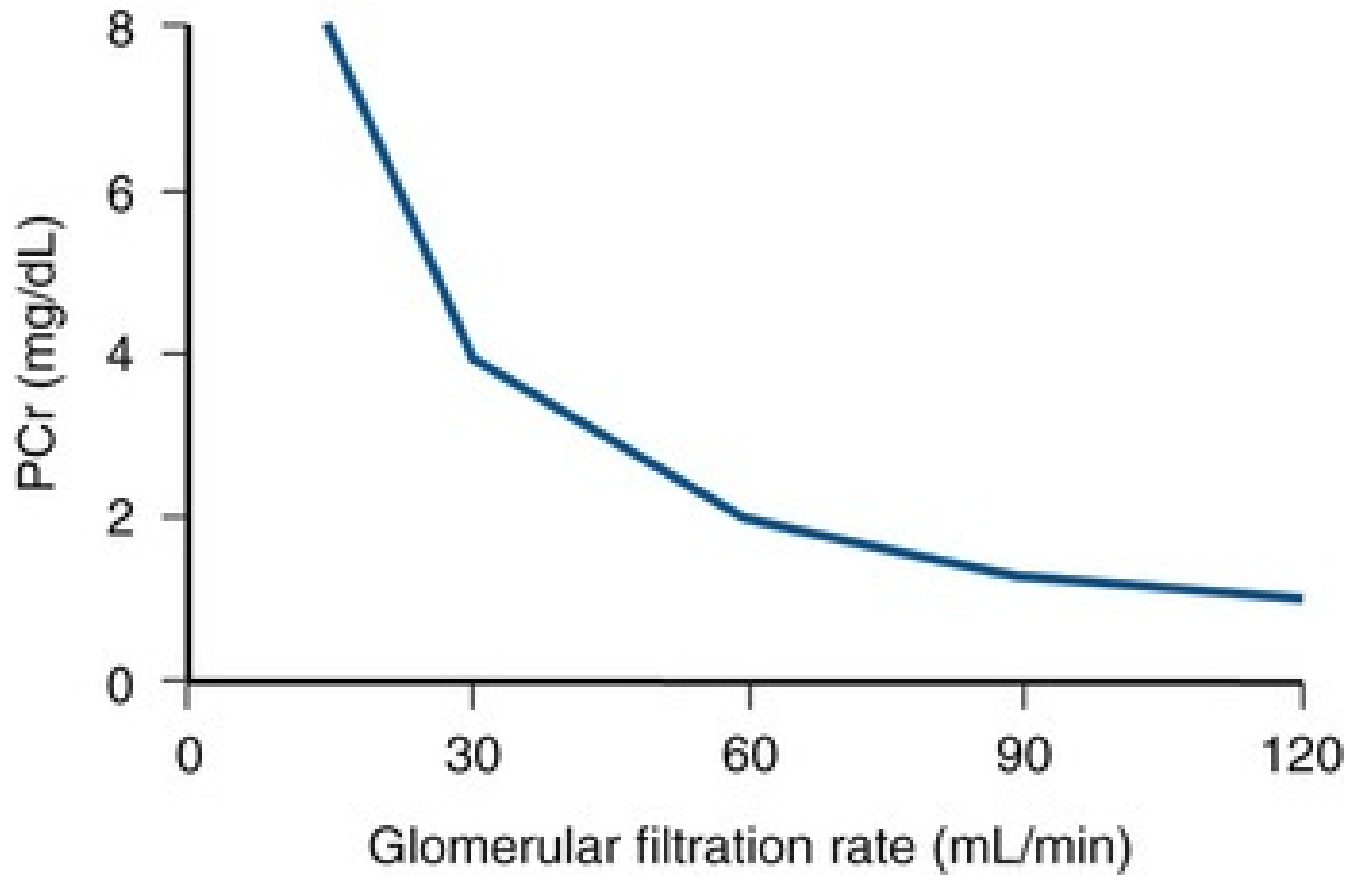

FIG. 86.1 Relationship between serum creatinine and glomerular filtration rate. *PCr,* Plasma creatinine.

With use of plasma creatinine to estimate GFR, two mathematical formulas have been widely accepted: the Cockcroft-Gault and the Modification of Diet in Renal Disease (MDRD) formulas (Cockcroft and Gault, 1976). The Cockcroft-Gault formula is as follows:

$$\mathrm{CrCl} = \frac{(140 - \mathrm{age}) \times (\mathrm{IBW\ in\ kg})}{[\mathrm{PCr\ (mg/dL)} \times 72]} \times 0.85\ (\mathrm{women})$$

The Cockcroft-Gault equation generally overestimates creatinine clearance and is no longer widely used clinically for purposes other than drug dosing estimates. The MDRD formula seen below is more accurate comparatively and accounts for severe renal impairment:

$$\begin{aligned}\mathrm{GFR}(\mathrm{mL/min/1.73\ m^2}) = 186 \times (\mathrm{PCr}\ [\mathrm{mg/dL}])^{-1.154} \times (\mathrm{age})^{-0.203} \times \\ (0.742\ \text{if female}) \times \\ (1.210\ \text{if African-American})\end{aligned}$$

Cockgroft-Gault and MDRD equations are less accurate in individuals with normal or only mildly reduced GFR (Levey, 1990). A more recent equation called CKD-EPI may be preferable for use in the general population and in older individuals and may improve risk prediction for chronic kidney disease (CKD) and adverse events associated with CKD (Rose, 1987). Many laboratories that automatically report eGFR have converted to use of CKD-EPI equation to do so (Manjunath et al., 2001).

$$\begin{aligned}\mathrm{GFR} = 141 \times \min(\mathrm{SCr}/\kappa, 1)^{\alpha} \times \max(\mathrm{SCr}/\kappa, 1)^{-1.209} \times 0.993^{\mathrm{Age}} \\ \times 1.018[\text{if female}] \times 1.159\ [\text{if black}]\end{aligned}$$

$$\kappa = 0.7\ \text{if female}$$
$$\kappa = 0.9\ \text{if male}$$

$$\alpha = -0.329\ \text{if female}$$
$$\alpha = -0.411\ \text{if male}$$

$$\min = \text{The mininum of } \mathrm{SCr}/\kappa \text{ or } 1$$
$$\max = \text{The maximum of } \mathrm{SCr}/\kappa \text{ or } 1$$

$$\mathrm{SCr} = \text{serum creatinine (mg/dL)}$$

Key Points

- GFR reflects total renal function.
- GFR can be approximated by creatinine clearance.
- Formulas based on patient's age, weight, and serum creatinine can best estimate GFR.

Nephron Anatomy

After the filtrate passes the glomerular apparatus into the renal tubule, solutes pass in and out of the tubule. Reabsorption describes movement from tubular lumen back to the blood, and secretion indicates movement from the blood into the tubular lumen. Transport mechanisms occur in a transcellular and paracellular fashion. The renal tubule is divided into anatomic segments, in which different overall functions take place (Fig. 86.2). **Starting at the proximal convoluted tubule (PCT), approximately 60% of the glomerular filtrate is reabsorbed. Under normal circumstances the PCT reabsorbs 65% of the filtered sodium, potassium, and calcium; 80% of filtered phosphate, water, and bicarbonate; and 100% of the filtered glucose and amino acids.** The PCT is also responsible for the generation of ammonia from glutamine, which is necessary for urinary acidification (Michoudet et al., 1994; Nagami, 2004).

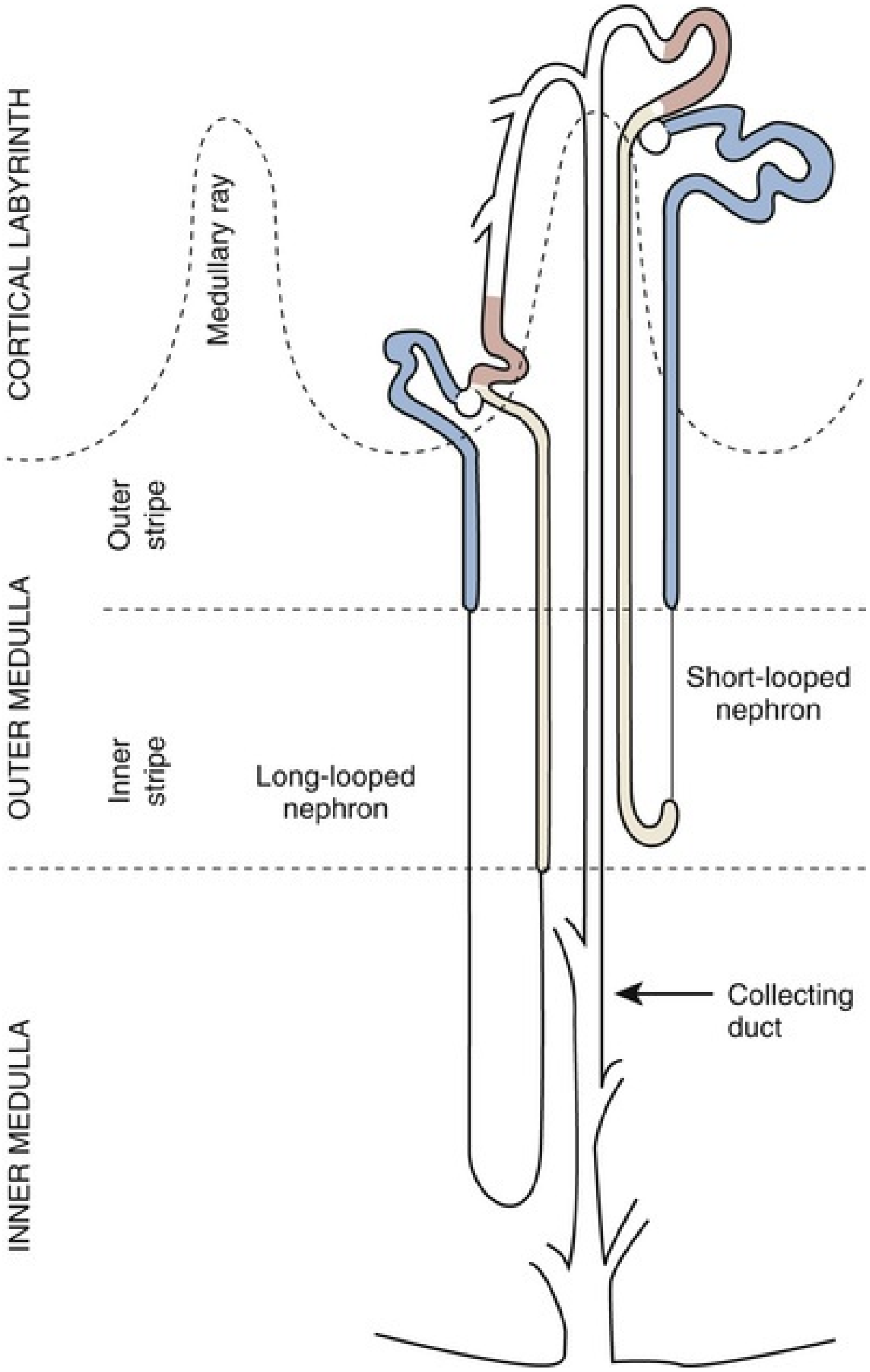
CORTICAL LABYRINTH
Medullary ray
Outer stripe
OUTER MEDULLA
Inner stripe
INNER MEDULLA
Long-looped nephron
Short-looped nephron
Collecting duct

FIG. 86.2 Organization of the renal tubule. (From Knepper MA, Gamba F: Urine concentration and dilution. In Brenner BM, editor: *Brenner and Rector's the kidney,* ed 7, Philadelphia, 2004, WB Saunders, p 601.)

After the proximal convoluted tubule comes the loop of Henle (Fig. 86.3), which comprises the thin descending limb, the thin ascending limb, the medullary thick ascending limb, and the cortical thick ascending limb. Although each segment differs in specific activity, the overall function of the loop of Henle is reabsorption of 25% to 30% of the filtered sodium (Na^+) and creation of a highly concentrated medullary interstitium, the basis of counter-current exchange (Figs. 86.4 and 86.5). The thin descending limb is highly water permeable, whereas the thin and thick ascending limbs are water impermeable.

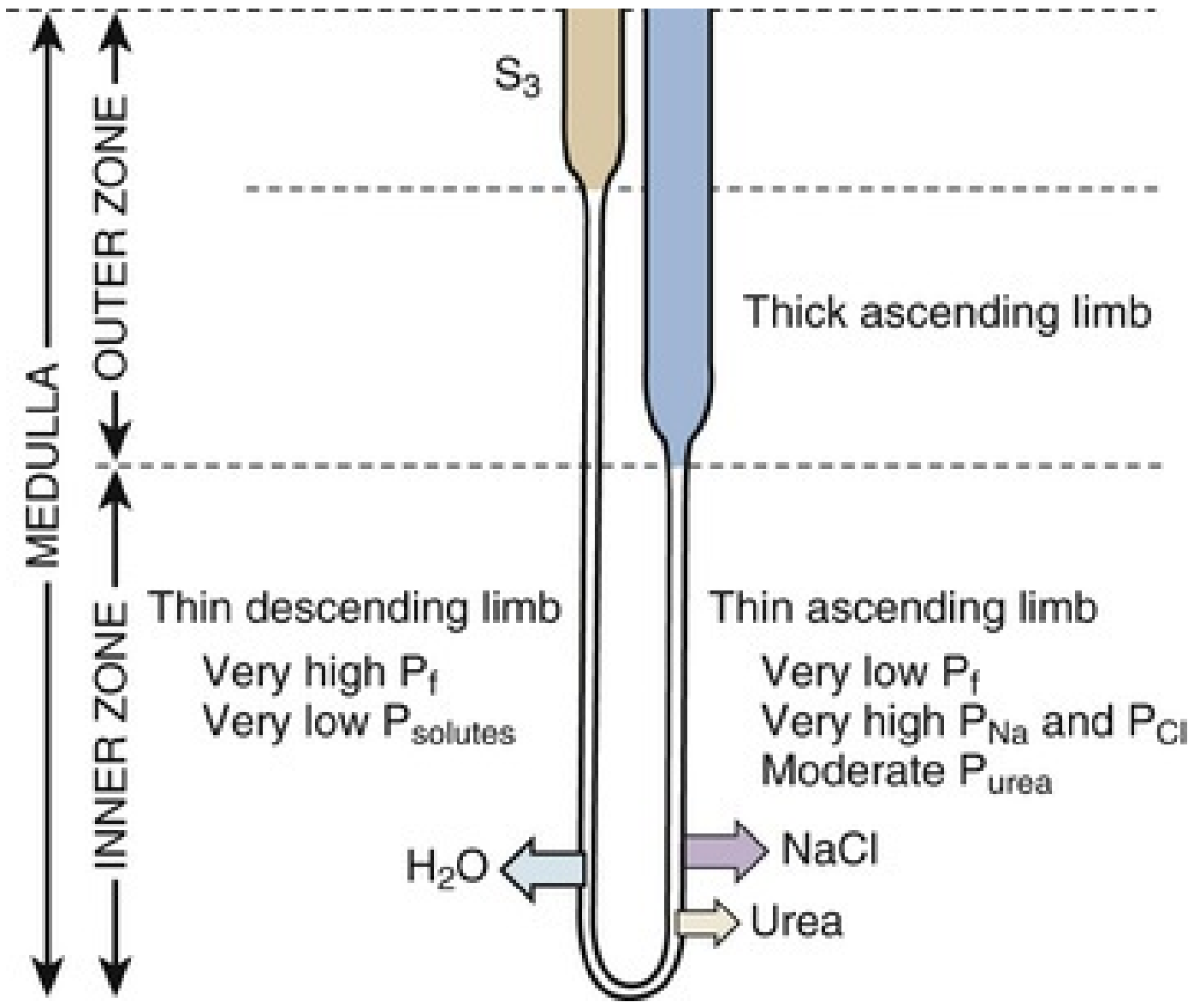
MEDULLA
OUTER ZONE
INNER ZONE
S_3
Thick ascending limb
Thin descending limb
Very high P_f
Very low $P_{solutes}$
Thin ascending limb
Very low P_f
Very high P_{Na} and P_{Cl}
Moderate P_{urea}
H_2O
NaCl
Urea

FIG. 86.3 Anatomy of the loop of Henle. (From Moe OW, Baum M, Berry CA, Rector FC Jr.: Renal transport of glucose, amino acids, sodium, chloride, and water. In Brenner BM, editor: *Brenner and Rector's the kidney*, ed 7, Philadelphia, 2004, WB Saunders, p 431.)

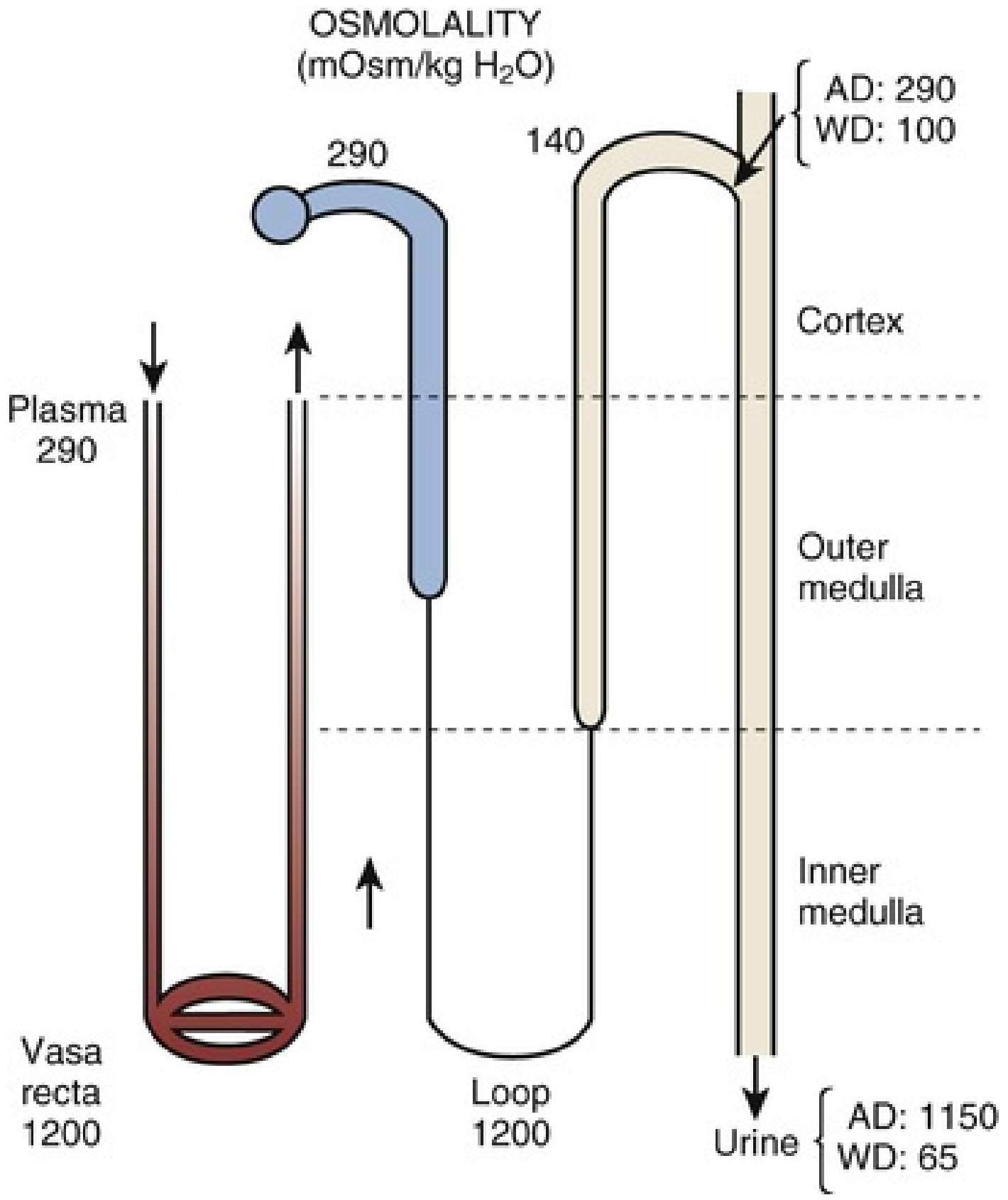
OSMOLALITY
(mOsm/kg H2O)
290
140
AD: 290
WD: 100
Cortex
Plasma
290
Outer
medulla
Inner
medulla
Vasa
recta
1200
Loop
1200
Urine
AD: 1150
WD: 65

FIG. 86.4 Countercurrent mechanism in the renal tubule. *AD,* Antidiuresis; *WD,* water diuresis. (From Knepper MA, Gamba F: Urine concentration and dilution. In Brenner BM, editor: *Brenner and Rector's the kidney,* ed 7, Philadelphia, 2004, WB Saunders, p 604.)

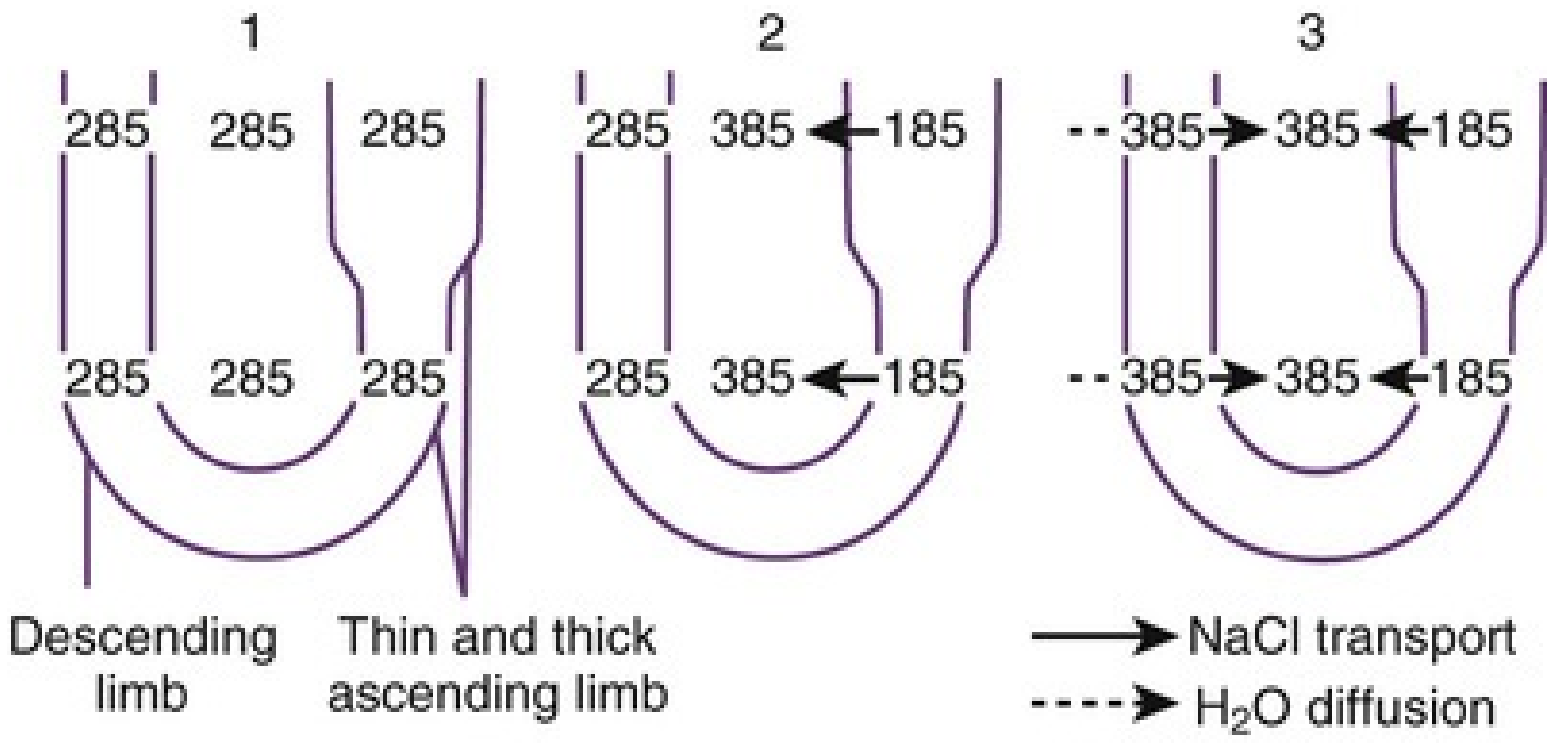
1
2
3
285
285
285
285
385
185
385
385
185
285
285
285
285
385
185
385
385
185
Descending
limb
Thin and thick
ascending limb
NaCl transport
H2O diffusion

FIG. 86.5 Role of active NaCl transport in initiating countercurrent multiplication. In step 1, at time zero, the fluid in the descending and ascending limbs and the interstitium is isosmotic to plasma. In step 2, NaCl is transported out of the ascending limb into the interstitium to a gradient of 200 mOsm/kg. In step 3, the fluid in the descending limb equilibrates osmotically with the hyperosmotic interstitium, primarily by water movement

out of the tubule. Dilution of the interstitium by this water movement is prevented by continued NaCl transport out of the ascending limb. The result is the creation of an osmotic gradient between the ascending limb and the relatively hyperosmotic descending limb and interstitium.

The distal tubule comprises first the distal convoluted tubule and the connecting tubule. In these segments significant sodium and calcium reabsorption occur. After this, the collecting tubule is encountered, in which the cortical and medullary collecting tubules demonstrate slightly different functions. Both handle transport of Na^+ via principal cells and acid loads via intercalated cells as well as potassium (K^+) via both cell types. In the medullary collecting tubule, however, tight regulated control of water and urea permeability exists, allowing for this area of the collecting tubule to concentrate urine to a much greater level than plasma.

Key Points

- The nephron has different functional segments that control homeostasis.
- Most resorption of bicarbonate and ions occurs in the proximal tubule.
- The architecture of the loop of Henle allows a highly hypertonic interstitium to develop, which is crucial to maximal urinary concentration.

Filtrate Transport

Sodium

Most of the kidney's total Na^+ reabsorption occurs in the proximal convoluted tubule (Fig. 86.6). Secondary active and passive mechanisms account for this movement (Adrogue and Madias, 2000). In secondary active reabsorption, an Na-K ATPase at the basolateral cell membrane exchanges three intracellular Na^+ for two extracellular K^+ ions, lowering the intracellular sodium levels. Na^+ then enters the tubule cell via coupled transport or an Na^+/H^+ antiporter. In passive reabsorption, Na^+ moves paracellularly into the intercellular space mediated through active chloride (Cl^-) transport that creates an electrochemical gradient, driving Na^+ out of the tubular lumen into the intercellular space.

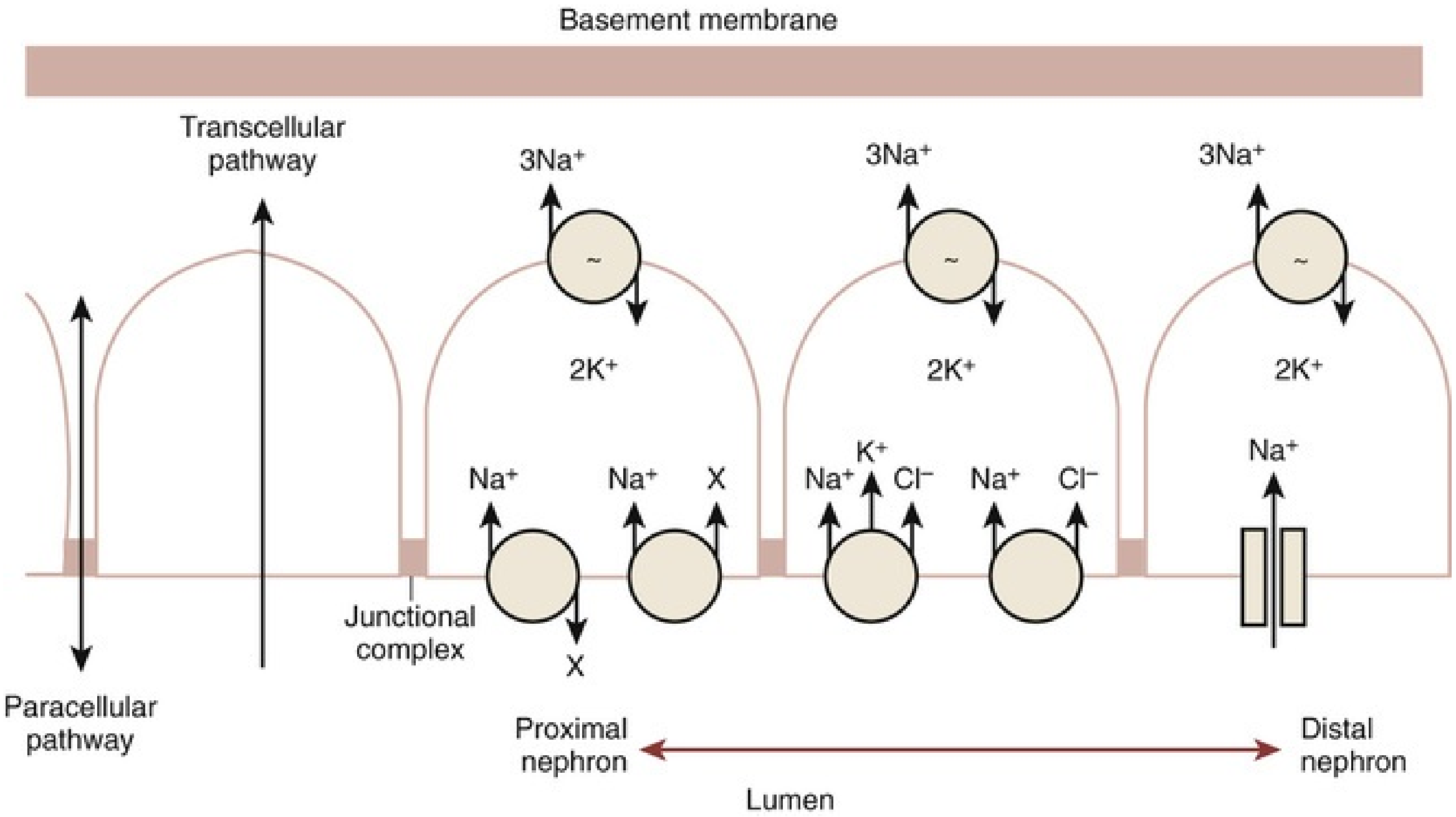
Basement membrane
Transcellular pathway
3Na+
3Na+
3Na+
2K+
2K+
2K+
Na+
Na+
X
K+
Na+
Cl−
Na+
Cl−
Na+
Junctional complex
X
Paracellular pathway
Proximal nephron
Distal nephron
Lumen

FIG. 86.6 Mechanisms of sodium reabsorption in the proximal tubule. (From Moe OW, Baum M, Berry CA, Rector FC Jr.: Renal transport of glucose, amino acids, sodium, chloride, and water. In: Brenner BM, editor: *Brenner and Rector's the kidney,* ed 7, Philadelphia, 2004, WB Saunders, p 414.)

An additional 25% to 35% of Na^+ reabsorption occurs in the thick ascending limb of the loop of Henle. Similar to the proximal convoluted tubule, a basolateral Na-K ATPase pump keeps intracellular Na^+ levels low. Na^+ is also transported by the NKCC2 transporter on the apical membrane. This functions by Cl^- being pumped across the basolateral membrane via a Cl^-/K^+ cotransporter. K^+ is then recycled back into the tubular lumen through an apical membrane K^+ channel (ROMK), where it can then be used by the NKCC2 transporter. Thus Na^+ reabsorption is linked to K^+ transport. In the thick ascending limb, this Na^+ reabsorption facilitates creation of a high interstitial concentration gradient that allows for urinary concentration in the collecting duct. Therapeutically, NKCC2 transporters are the active target of loop diuretics that bind the Cl^- receptor, thereby decreasing NaCl reabsorption, leading to diuresis.

The distal convoluted tubule then reabsorbs an additional 5% to 10% of sodium filtered through the glomerulus (Loffing and Kaissling, 2003). A basolateral Na-K ATPase pump and Na^+/Cl^- (NCC) cotransporter in addition to an Na^+/H^+ exchange transporter in the membrane of the lumen are found here.

The NCC transporter is directly inhibited by thiazide diuretics. One consideration is that this therapeutic mechanism of action works in a complementary fashion to loop diuretics. Loop diuretics increase Na^+ delivery to the distal convoluted tubule by inhibiting NKCC2 activity in the thick ascending limb. This leads to increased Na^+ reabsorption and thus a blunted response over time to loop diuretics. This can be mitigated with simultaneous administration of thiazide diuretics.

Sodium transport also occurs in the principal cells of the collecting tubule. Passive reabsorption takes place through ENaC1, a luminal sodium channel. Active Na^+ transport via basolateral Na-K ATPase pumps (as described earlier) also exists in these cells. In the principal cells, aldosterone can increase the number of open ENaC1 channels, and amiloride can block its activity. Prostaglandin E_2 (PGE_2) inhibits Na reabsorption, and thus agents that decrease PGE_2 production, including nonsteroidal antiinflammatory drugs, can cause clinical signs of sodium retention.

The pathological state of sodium imbalances in the body are driven by free water excess relative to sodium content. Sodium largely resides in the extracellular space, and therefore water balance across the intra- and extracellular space of the body (regulated by antidiuretic hormone, or ADH) is a major determinant of hyponatremia and hypernatremia as opposed to total body sodium content. Hyponatremia can lead to seizures, altered mental status, coma, and even death but is rarely symptomatic until serum sodium is below 120 mEq/L. Hyponatremia occurs when the kidney fails to excrete appropriate solute-free urine. This can occur because of states of reduced GFR, diuretic use that impairs NaCl reabsorption, or in syndrome of inappropriate ADH. Excessive free water intake above the level of the kidney's ability to clear free water can sometimes cause hyponatremia, although this is relatively uncommon except in states of reduced eGFR or psychiatric conditions (Goh, 2004).

Hypernatremia can often seem similar to hyponatremia, with tremors, lethargy, coma, and death being late symptoms after restlessness, nausea, and vomiting. Most patients with an intact thirst mechanism and access to water will consume adequate free water to prevent hypernatremia. Therefore it often is seen in the very young and old or in hospitalized patients. Other causes of hypernatremia include excess extrarenal water loss or sodium intake, Cushing syndrome, primary hyperaldosteronism, and diabetes insipidus.

Evaluation of the patient with sodium imbalances should always start

with a determination of fluid status. Clinical assessment should include evaluation of skin turgor, blood pressure including orthostatics, jugular venous distention, and looking for an abdominal fluid wave or respiratory crackles. Urinary sodium greater or less than 20 can be used as a measure of urinary osmolality in the evaluation. For example, in hyponatremia, with hypovolemic patients a low urinary sodium would be expected. If high, then a renal source including diuretic overdose, renal tubular acidosis, or mineralocorticoid deficiency may be suspected (Figs. 86.7 and 86.8).

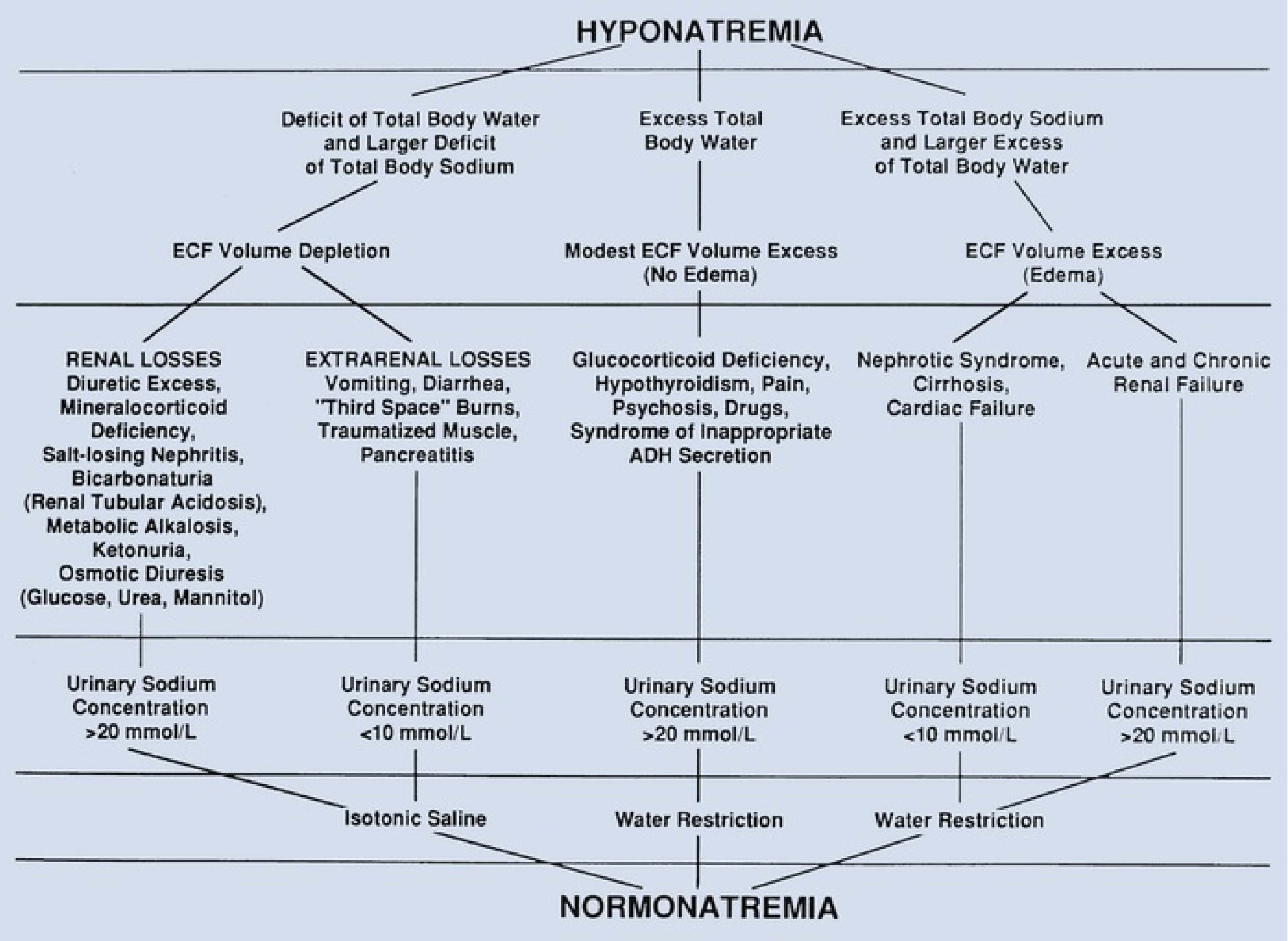
HYPONATREMIA
Deficit of Total Body Water and Larger Deficit of Total Body Sodium
Excess Total Body Water
Excess Total Body Sodium and Larger Excess of Total Body Water
ECF Volume Depletion
Modest ECF Volume Excess (No Edema)
ECF Volume Excess (Edema)
RENAL LOSSES Diuretic Excess, Mineralocorticoid Deficiency, Salt-losing Nephritis, Bicarbonaturia (Renal Tubular Acidosis), Metabolic Alkalosis, Ketonuria, Osmotic Diuresis (Glucose, Urea, Mannitol)
EXTRARENAL LOSSES Vomiting, Diarrhea, "Third Space" Burns, Traumatized Muscle, Pancreatitis
Glucocorticoid Deficiency, Hypothyroidism, Pain, Psychosis, Drugs, Syndrome of Inappropriate ADH Secretion
Nephrotic Syndrome, Cirrhosis, Cardiac Failure
Acute and Chronic Renal Failure
Urinary Sodium Concentration >20 mmol/L
Urinary Sodium Concentration <10 mmol/L
Urinary Sodium Concentration >20 mmol/L
Urinary Sodium Concentration <10 mmol/L
Urinary Sodium Concentration >20 mmol/L
Isotonic Saline
Water Restriction
Water Restriction
NORMONATREMIA

FIG. 86.7 Clinical approach to patient with hyponatremia. *ADH,* Antidiuretic hormone; *ECF,* extracellular fluid. (From Berl T, Anderson RJ, McDonald KM, Schrier RW: Clinical disorders of water metabolism. *Kidney Int* 10:117–132, 1976.)

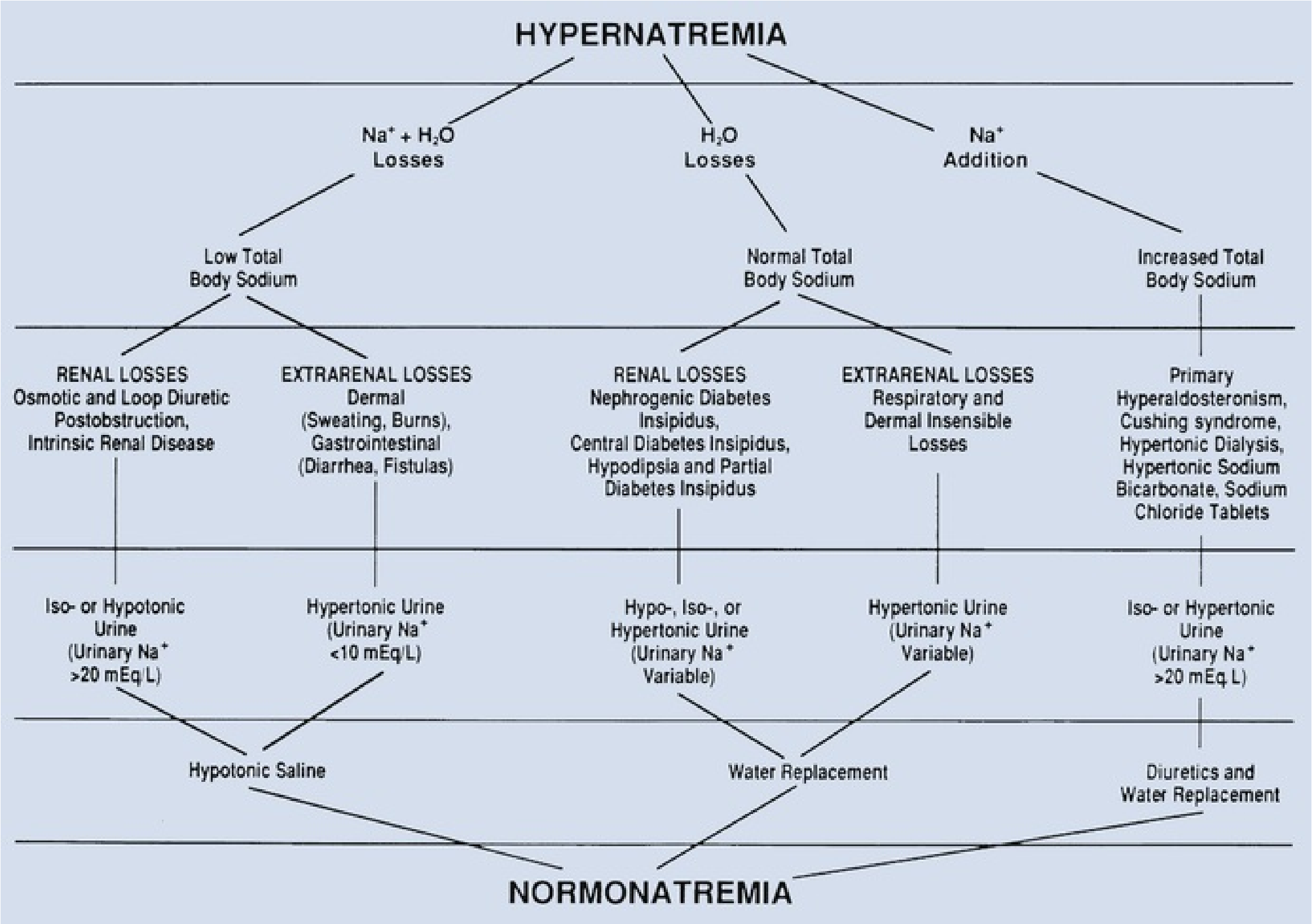
HYPERNATREMIA
Na⁺ + H₂O Losses
H₂O Losses
Na⁺ Addition
Low Total Body Sodium
Normal Total Body Sodium
Increased Total Body Sodium
RENAL LOSSES Osmotic and Loop Diuretic Postobstruction, Intrinsic Renal Disease
EXTRARENAL LOSSES Dermal (Sweating, Burns), Gastrointestinal (Diarrhea, Fistulas)
RENAL LOSSES Nephrogenic Diabetes Insipidus, Central Diabetes Insipidus, Hypodipsia and Partial Diabetes Insipidus
EXTRARENAL LOSSES Respiratory and Dermal Insensible Losses
Primary Hyperaldosteronism, Cushing syndrome, Hypertonic Dialysis, Hypertonic Sodium Bicarbonate, Sodium Chloride Tablets
Iso- or Hypotonic Urine (Urinary Na⁺ >20 mEq/L)
Hypertonic Urine (Urinary Na⁺ <10 mEq/L)
Hypo-, Iso-, or Hypertonic Urine (Urinary Na⁺ Variable)
Hypertonic Urine (Urinary Na⁺ Variable)
Iso- or Hypertonic Urine (Urinary Na⁺ >20 mEq L)
Hypotonic Saline
Water Replacement
Diuretics and Water Replacement
NORMONATREMIA

FIG. 86.8 Clinical approach to patient with hypernatremia. (From Berl T, Anderson RJ, McDonald KM, Schrier RW: Clinical disorders of water metabolism. *Kidney Int* 10:117–132, 1976.)

Treatment of hyponatremia and hypernatremia should be aimed at identifying and correcting the underlying cause, with correction by appropriate fluids as needed. Patients with acute severe hyponatremia symptomatic with confusion, convulsions, or coma, may require an initial bolus of hypertonic (3%) saline (about 1 cc/kg/h). Use of fluid restriction with or without administration of fluids (hypertonic versus isotonic) should be determined by the electrolyte-free water clearance, measured by the rate of urine sodium and potassium excretion (Fig. 86.9).

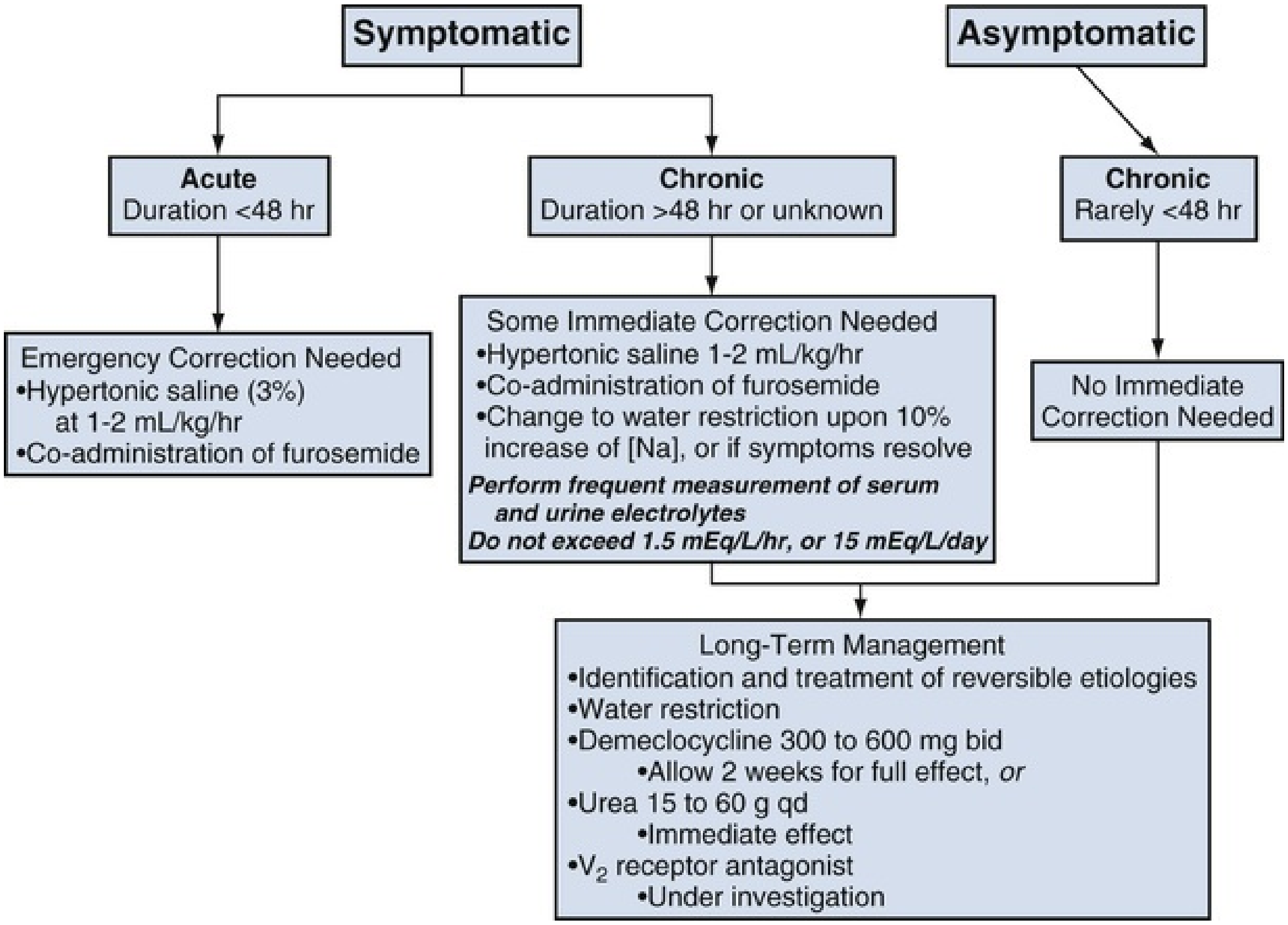
Symptomatic
Asymptomatic
Acute
Duration <48 hr
Chronic
Duration >48 hr or unknown
Chronic
Rarely <48 hr
Emergency Correction Needed
•Hypertonic saline (3%) at 1-2 mL/kg/hr
•Co-administration of furosemide
Some Immediate Correction Needed
•Hypertonic saline 1-2 mL/kg/hr
•Co-administration of furosemide
•Change to water restriction upon 10% increase of [Na], or if symptoms resolve
Perform frequent measurement of serum and urine electrolytes
Do not exceed 1.5 mEq/L/hr, or 15 mEq/L/day
No Immediate Correction Needed
Long-Term Management
•Identification and treatment of reversible etiologies
•Water restriction
•Demeclocycline 300 to 600 mg bid
•Allow 2 weeks for full effect, or
•Urea 15 to 60 g qd
•Immediate effect
•V2 receptor antagonist
•Under investigation

FIG. 86.9 Therapy of hyponatremia. (From Halterman R, Berl T: Therapy of dysnatremic disorders. In Brady H, Wilcox C, editors: *Therapy in nephrology and hypertension,* Philadelphia, 1999, WB Saunders, p 261.)

$$\mathrm{EFWC} = \mathrm{Vol}_{\mathrm{urine}} \times (1 - (\mathrm{Na}^{+} + \mathrm{K}^{+})_{\mathrm{urine}} / \mathrm{Na}^{+}{}_{\mathrm{serum}})$$

where $\mathrm{Vol}_{\mathrm{urine}}$ stands for the urine volume, $(\mathrm{Na}^{+} + \mathrm{K}^{+})_{\mathrm{urine}}$ for sodium and potassium in urine, and $\mathrm{Na}^{+}{}_{\mathrm{serum}}$ for serum sodium concentration.

Fluid overload in correction of hyponatremia is unlikely to occur in the absence of heart failure or cirrhosis but may be further reduced by simultaneous administration of a loop diuretic such as furosemide, which causes excretion of hypotonic fluid. The serum sodium concentration should be raised to no more than 6 to 8 mEq/L in the first 24 hours, at a rate of no more than 0.5 to 1 mEq/L per hour, and the target goal should be 120 to 125 mEq/L. To avoid overcorrection, subcutaneous or intranasal administration of DDAVP may be required to mitigate the brisk excretion of free water that can occur in some causes of hyponatremia as soon as fluid replacement begins. Total sodium deficit to reach this point can be calculated as

$$(\text{Volume of distribution}) \times \text{Body weight (kg)} \times (125 - \text{Plasma [Na]})$$

where volume of distribution is 0.5 for men and 0.6 for women. If the hyponatremia is severe but chronic, the rate of correction should not exceed 8 to 12 mmol/L/day; otherwise a cerebral demyelination syndrome may occur (Martin, 2004). During acute intervention for severe hyponatremia, frequent electrolyte measurements and patient reassessment are required, usually in an intensive care unit setting. Aggressive therapy should be discontinued when the serum sodium concentration is raised 10% or symptoms subside. At that point, water restriction and reversal of underlying causes should suffice. This is also the best approach for therapy of asymptomatic hyponatremia. Patients with associated hypovolemia should have this corrected with the appropriate volume of normal saline. In hypernatremia, hypovolemia should be initially corrected with half-normal saline. If the patient is awake and not symptomatic, oral hydration with water is sufficient. Otherwise, intravenous (IV) therapy should be started with the goal of slowly lowering plasma osmolality to no more than 2 mOsm/L/h to avoid cerebral edema. The water deficit can be calculated as

$$\begin{gathered}(\text{Volume of distribution}) \times \text{Body weight (kg)} \\ \times (\text{Plasma [Na]}/140 - 1)\end{gathered}$$

where, again, volume of distribution is 0.5 for men and 0.6 for women. For patients with central diabetes insipidus, desmopressin (a synthetic exogenous vasopressin) can be given intranasally. For nephrogenic diabetes insipidus, the underlying cause (lithium, hypercalcemia) should be treated. If polyuria persists while the kidney recovers, therapy includes modest sodium restriction, thiazide diuretics, and nonsteroidal anti-inflammatory drugs (Pattaragarn and Alon, 2003; Sasaki, 2004).

Key Points

- Sodium imbalances should be evaluated in the context of fluid status.
- The best tools to determine the cause of a sodium disorder are the history, volume status, and urinary sodium.
- Severe sodium deficit or excess must be corrected slowly.

Potassium

Potassium transport intersects closely with sodium. In the proximal convoluted tubule, its reabsorption is passive, occurring by the paracellular route in a parallel direction as sodium and water movement. At the level of the collecting tubule, potassium transport is handled by the same basolateral Na-K ATPase pump that manages sodium transport (Wang, 1995). Changes in sodium availability and movement thus alter potassium secretion, such as can be induced with aldosterone. In addition, K^+ channels exist whose density in the luminal membrane is altered by antidiuretic hormone (ADH). In the cortical collecting tubule, a net secretion of K^+ is the usual state, although H-K ATPase pumps become activated during periods of potassium depletion resulting in reabsorption of potassium in the tubule along with H^+ secretion and an accompanying metabolic alkalosis (Khanna and Kurtzman, 2001).

Hypo- and hyperkalemia can cause neuromuscular dysfunction leading to cardiac arrhythmias and death. The majority of potassium resides intracellularly, and regulating urinary K^+ excretion and moving K^+ between the intra- and extracellular space are primary strategies for treating potassium imbalances. **Urinary excretion can be increased in the kidney through increased aldosterone, a high sodium load in the distal tubule, and by acidosis.**

Hypokalemia is most commonly caused by gastrointestinal and renal loss as well as system alkalosis leading to intracellular shift of K^+. Other causes include medications (e.g., diuretics, laxatives, amphotericin, theophylline), postobstructive diuresis, and states associated with elevated aldosterone levels (e.g., adrenal adenoma, Cushing syndrome, adrenal cancer). Potassium supplementation in an oral or parenteral form of up to 40 mEq/h is the most common treatment while any underlying cause is addressed.

Hyperkalemia is most commonly caused by impaired potassium renal excretion and systemic acidosis driving extracellular movement of potassium. Evaluation includes a careful history as well as assessment for cardiac symptoms and electrocardiogram (ECG). Hemolysis should be ruled out as a spurious cause of hyperkalemia. Once confirmed, treatment should be dictated by severity and acuity of elevation as well as clinical signs and symptoms. Mildly elevated K^+ levels with no accompanying ECG changes can be managed with dietary restriction of potassium and reversal of underlying causes. The presence of ECG changes (classically short QT interval, peaked T waves, and ventricular arrhythmias) warrants urgent intervention. This includes sodium bicarbonate, insulin with glucose, and nebulized albuterol to drive potassium into the intracellular space. Kayexalate as a potassium-binding exchange resin can be used to reduce potassium stores and hemodialysis can be used for emergent and complete potassium removal. Calcium gluconate can be given to stabilize cardiac myocytes while hyperkalemia-induced ECG changes are addressed.

Key Points

- Potassium is primarily intracellular.
- Serum potassium levels reflect total body potassium, as well as the equilibrium between intra- and extracellular potassium.
- Symptomatic hyperkalemia requires urgent intervention to prevent cardiac dysfunction.

Water

Water reabsorption in the PCT is a passive process, driven by the reabsorption of other solutes and the subsequent osmotic gradient that develops between the lumen and intercellular space (Fig. 86.10). Water transport is not a direct source of pathology, but its movement dictates solute concentrations (sodium in particular) and gradients. Therefore water movement can indirectly cause pathological solute imbalances, whereas insufficient solute intake can be a cause of hyponatremia if relatively excess water is consumed (Mallie et al., 1997). The majority of water reabsorption occurs in the late PCT. As with Na^+ movement, water can also move either transcellularly or paracellularly. Transcellular movement accounts for 80% of water reabsorption and occurs through the specialized water channel aquaporin-1 (AQP-1) (Kwon et al., 2001). Paracellular movement accounts for only 20% of water reabsorption and occurs across the tight junctions between cells.

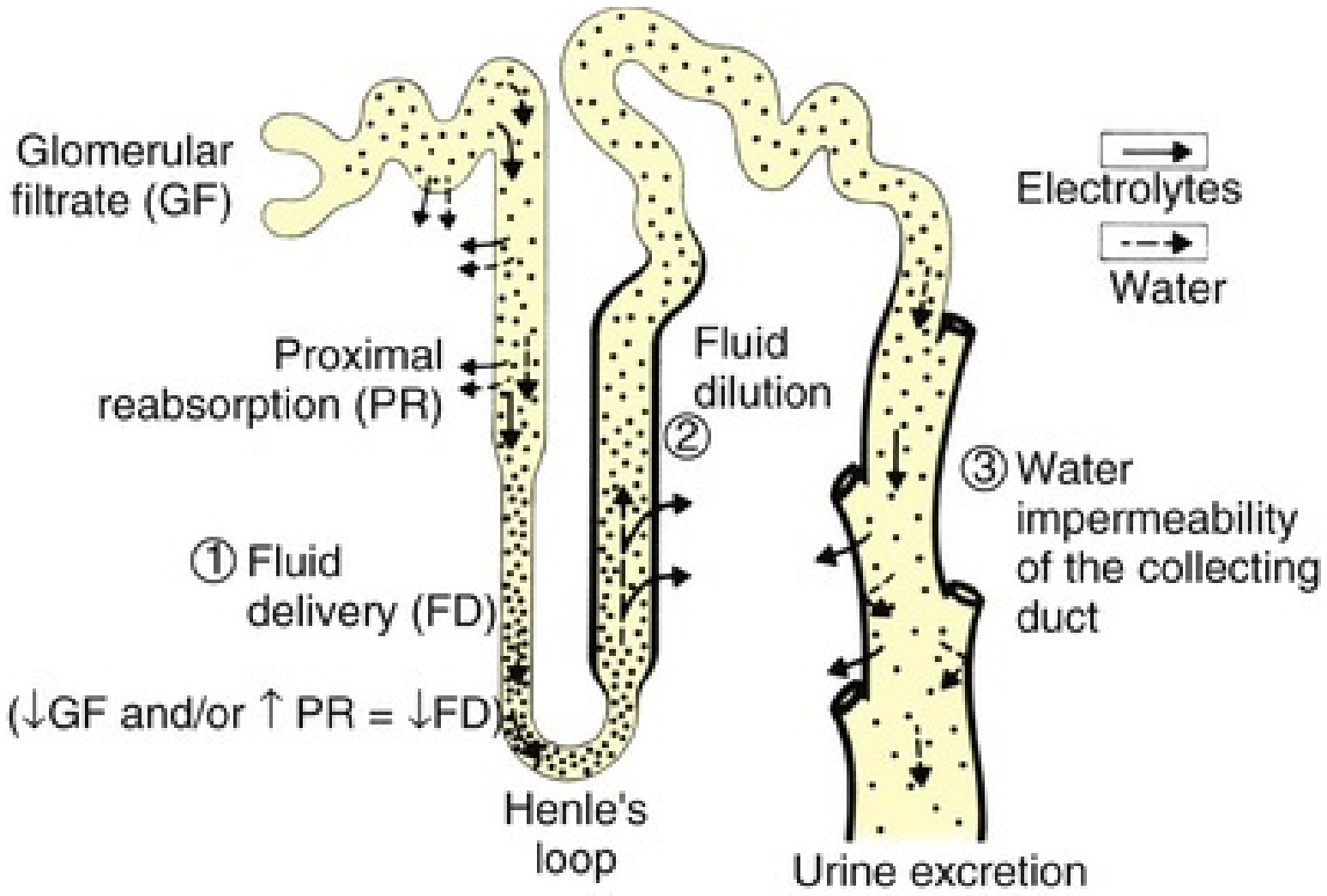

FIG. 86.10 The components of the normal urine dilution mechanisms. (Redrawn from Berl T, Schrier RW: Water metabolism and the hypo-osmolar syndrome. In Brenner BM, Stein JH, editors: *Sodium and water homeostasis,* New York, 1978, Churchill Livingstone, pp 1–23.)

The water permeability of the cortical collecting tubule is low in the basal state. However, it can be greatly increased in the presence of ADH. This is due to the insertion of preformed AQP-2 water channels into the luminal membrane, which allows water to be passively reabsorbed and equilibrate with the cortical interstitium through basolateral AQP-3 and AQP-4 channels (Agre et al., 2002). This is important for the development of highly concentrated final urine, because it decreases the volume of ultrafiltrate delivered to the medullary collecting tubule (MCT), where most of the final concentration of urine occurs.

The MCT is relatively impermeable to water in the basal state, but under the influence of ADH, permeability increases in the inner MCT and outer MCT by the insertion of AQP-2 water channels. This allows water to move out of the tubule into the hyperosmolar interstitium, and urine concentration occurs. Thirst is the primary mechanism that regulates body water intake. ADH, or vasopressin, can dysregulate this water sensitivity (Fig. 86.11). Produced in the posterior pituitary gland, it regulates free water excretion by increasing passive water reabsorption in the collecting duct. It does so by interacting with the V2 receptor, which then leads to insertion of aquaporin-2 (AQP-2) into the principal cell luminal membrane. AQP-2 allows entry of water back into the cell and from there passively into whole body circulation (Leung et al., 2005). ADH also increases urea reabsorption, sodium reabsorption, potassium excretion, prostaglandin synthesis, ACTH secretion, systemic vascular resistance, and release of factor VIII and von Willebrand factor from vascular endothelium (which has the net effect of increasing sodium). ADH release is caused by hyperosmolality (mostly a reflection of increased serum sodium concentration) and decreased effective circulating volume (as in heart failure or cirrhosis) (Miller, 1994; Robertson, 1987). Desmopressin is an analogue of vasopressin used to treat adult nocturia by taking advantage of water reabsorption to reduce urine production at night. Serum sodium must be closely monitored during its use.

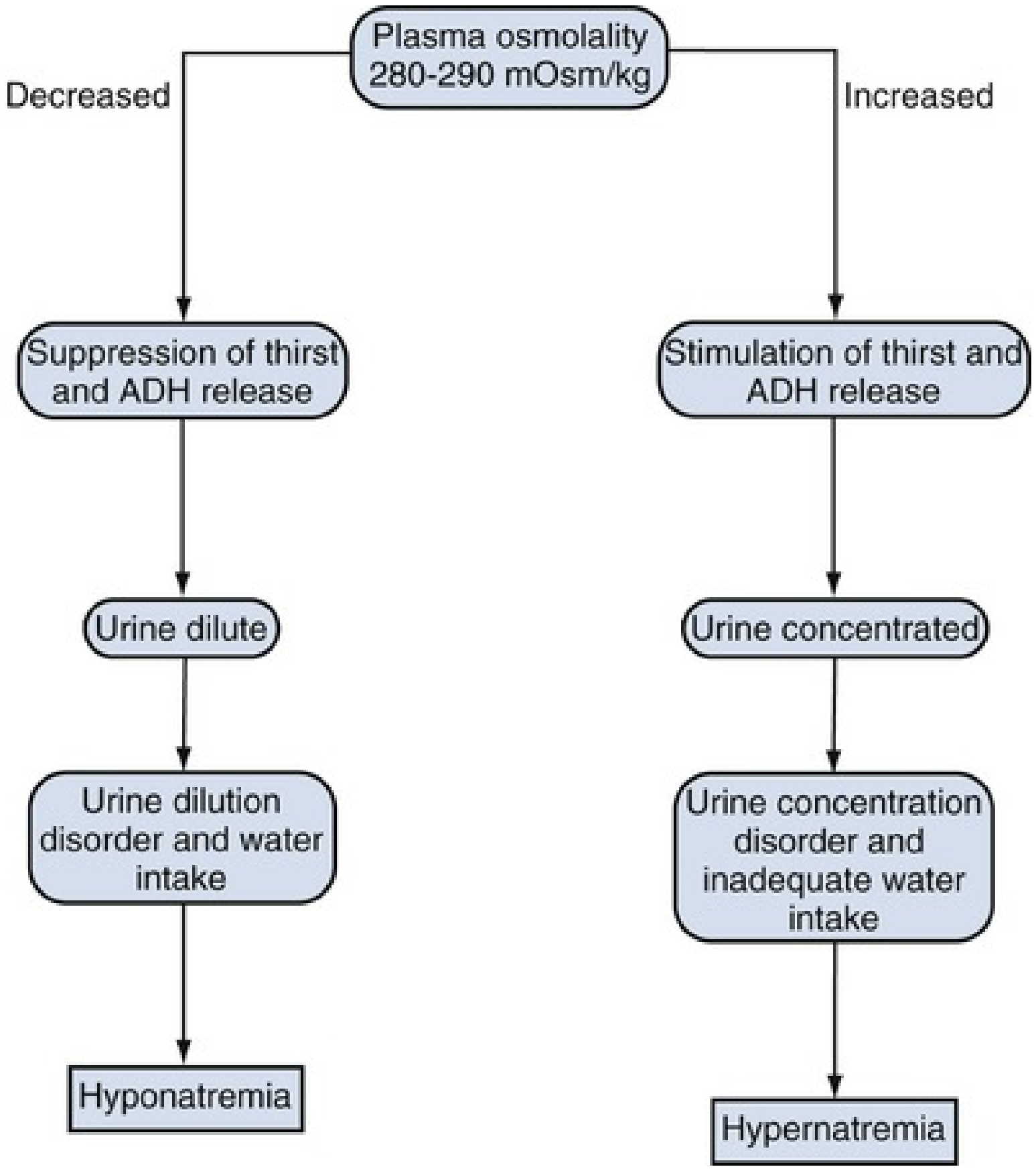
Plasma osmolality 280-290 mOsm/kg
Decreased
Increased
Suppression of thirst and ADH release
Stimulation of thirst and ADH release
Urine dilute
Urine concentrated
Urine dilution disorder and water intake
Urine concentration disorder and inadequate water intake
Hyponatremia
Hypernatremia

FIG. 86.11 Flowchart illustrating the development of disorders of water metabolism. *ADH,* Antidiuretic hormone.

Key Points

- Water movement dictates solute concentrations, **especially** important for sodium balance.

- Regulation of water movement is highly dependent on antidiuretic hormone.
- Insertion of aquaporin channels facilitates water reabsorption.

Calcium

Calcium reabsorption occurs mostly in the proximal convoluted tubule (approximately 75%) followed by the thick ascending loop of Henle (15%) and the distal convoluted tubule (10%–15%) (Fig. 86.12) (Friedman and Gesek, 1993). In the proximal convoluted tubule and the loop of Henle, transport is primarily passive across the paracellular route via the claudin-2 calcium tight junction channel and the claudin-16 channel, respectively (Amasheh et al., 2002). This movement is driven by the voltage difference between the luminal and extraluminal spaces and tied tightly to sodium concentrations. In contrast, in the distal convoluted tubule calbindin D_{28} is an intracellular binding protein that binds calcium after it is transported into the cell via the $ECaC_1$ channel. This binding process keeps intracellular levels of calcium low and allows for continued inward calcium movement. On the basolateral side, calcium leaves the cell via either a Ca^{2+}/H^+ (PMCA) or Na^+/Ca^{2+} (NCX) exchanger. Parathyroid hormone and calcitriol/vitamin D act in the distal tubule to increase calcium reabsorption. **Hypercalciuria in the context of renal stones most often represents a renal leak of calcium, although it can also be associated with a renal phosphate leak, a sign of hyperparathyroidism, or a dietary-dependent absorptive issue.** For stone prevention, hypercalciuria is treated with thiazide diuretics to decrease urinary calcium excretion.

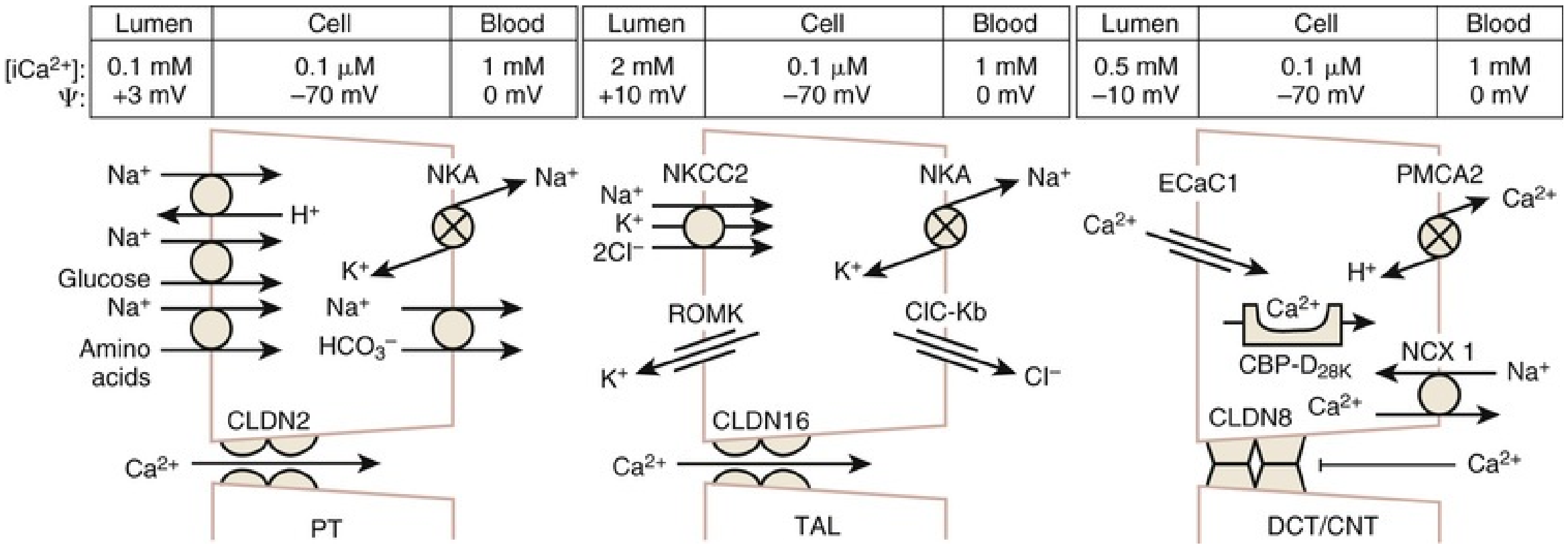
Lumen
Cell
Blood
Lumen
Cell
Blood
Lumen
Cell
Blood
[iCa2+]:
Ψ:
0.1 mM
+3 mV
0.1 µM
–70 mV
1 mM
0 mV
2 mM
+10 mV
0.1 µM
–70 mV
1 mM
0 mV
0.5 mM
–10 mV
0.1 µM
–70 mV
1 mM
0 mV
Na+
H+
Na+
Glucose
Na+
Amino acids
NKA
Na+
K+
Na+
HCO3–
CLDN2
Ca2+
PT
Na+
K+
2Cl–
NKCC2
NKA
Na+
K+
ROMK
K+
ClC-Kb
Cl–
CLDN16
Ca2+
TAL
ECaC1
Ca2+
PMCA2
Ca2+
H+
Ca2+
CBP-D28K
NCX 1
Na+
CLDN8
Ca2+
Ca2+
DCT/CNT

FIG. 86.12 Absorption of calcium by the renal tubule. *CNT,* Connecting tubule; *DCT,* distal convoluted tubule; *PT,* proximal tubule; *TAL,* thick ascending limb. (From Yu SLY: Renal transport of calcium, magnesium,

and phosphate. In Brenner BM, editor: *Brenner and Rector's the kidney,* ed 7, Philadelphia, 2004, WB Saunders, p 538.)

Acid-Base Balance

Renal physiology is critical to maintaining homeostatic acid-base balance (Corey, 2005). **Although the body's primary three mechanisms to maintain acid load balance are buffers in the blood, CO_2 excretion by the lungs, and H^+ excretion by HCO_3^-, the kidney acts mostly by regulating transport of H^+ and HCO_3^-. Bicarbonate is the main buffer regulated by the kidney, and approximately 80% of filtered bicarbonate is resorbed in the proximal convoluted tubule** (Fig. 86.13; Kildeberg, 1983). Of the remaining 20%, approximately half is resorbed in the thick ascending loop of Henle and half in the collecting duct. In all locations, its movement is closely tied to H^+ movement. In the proximal convoluted tubule and loop of Henle, as H^+ is secreted via the Na^+/H^+ antiporter, carbonic anhydrase catalyzes the combining of HCO_3^- with H^+ within the lumen, forming H_2O and CO_2. Water and carbon dioxide then diffuse into the intracellular space, where carbonic anhydrase again catalyzes the conversion back to H^+ and HCO_3^-. Bicarbonate is then secreted back into vascular circulation across the basolateral membrane through a Na^+-coupled transporter. Thus carbonic anhydrase inhibitors such as acetazolamide can be used to reduce HCO_3^- reabsorption and increase Na^+ and water excretion (Kaunisto et al., 2002; Puscas et al., 1999).

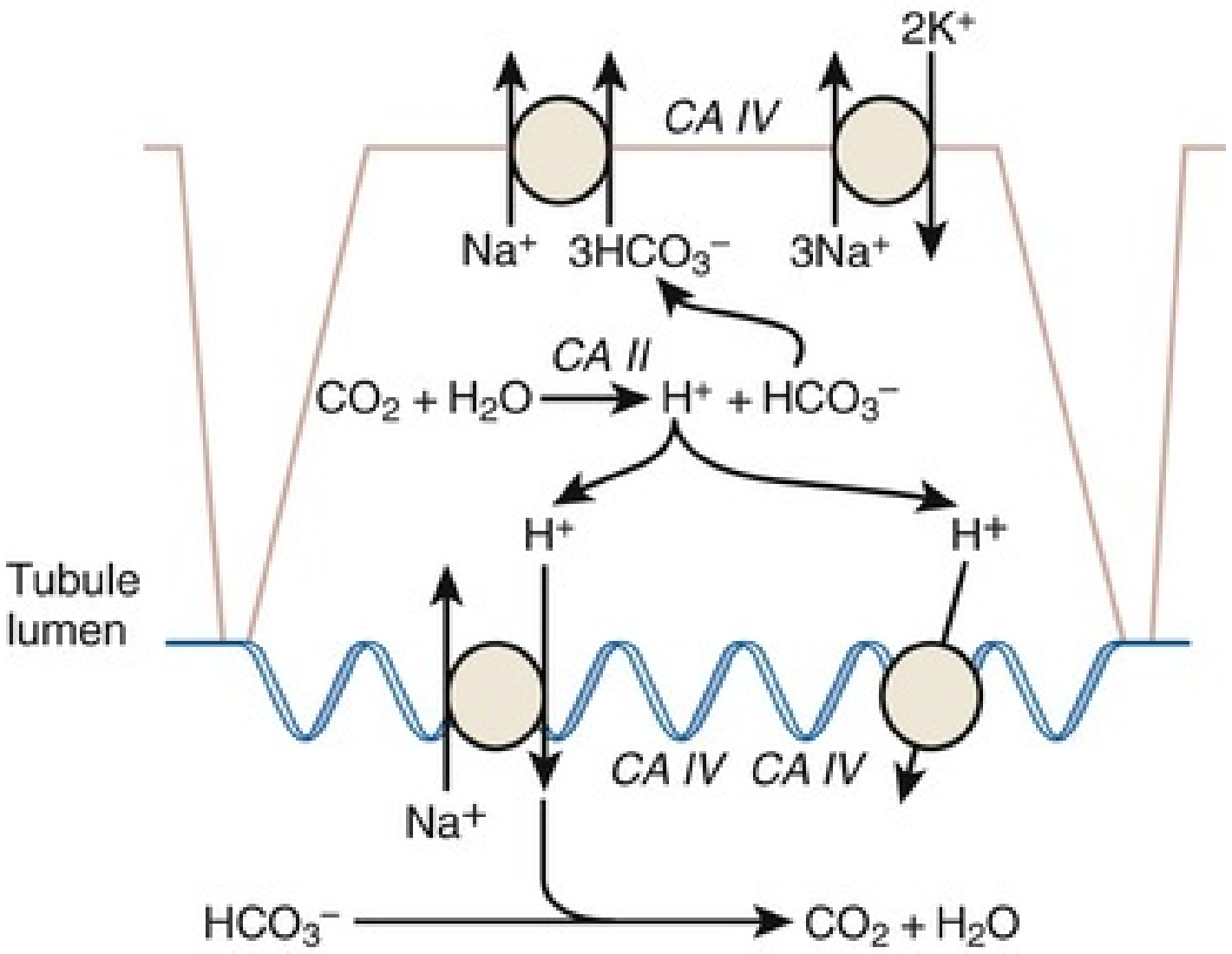

FIG. 86.13 Reabsorption of bicarbonate in the renal tubule. *CA,* Carbonic anhydrase. (From Hamm LL. Renal acidification mechanisms. In Brenner BM, editor: *Brenner and Rector's the kidney,* ed 7, Philadelphia, 2004, WB Saunders, p 500.)

Acid-base movement also occurs in the collecting duct in types A and B intercalated cells. In these areas, H^+ ATPase and H^+-K^+ ATPase pumps as well as HCO_3^-/Cl^- move hydrogen and bicarbonate in and out of the intracellular space. In type A cells, the proton pumps exist on the luminal membrane and the bicarbonate transports on the basolateral membrane. This results in a net movement of protons into the lumen, causing acidification of the urine. In type B cells, the pumps and transports exist in opposite locations (i.e., proton pumps are basolateral and bicarbonate transporters are luminal), driving net loss of bicarbonate and systemic acidification. Predominance of type A versus type B activity depends on systemic states of metabolic acidosis and alkalosis, where their activity occurs in response to balance these potentially pathological states.

Regulation of H^+ secretion occurs through multiple biochemical and hormonal actions upon the earlier-mentioned system. **Volume depletion** leads to Na retention and enhanced HCO_3^- absorption, with a net loss of H^+. **Elevated P_{CO_2},** as seen in chronic respiratory acidosis (see later), will lead to a renal response of increased H^+ secretion (Epstein and Singh, 2001). **Reduced GFR** will reduce the amount of filtered HCO_3^-, leading to increased H^+ excretion. **High aldosterone levels** indirectly increase H^+ excretion by increasing Na^+ absorption. **Low potassium and low chloride** increase HCO_3^- reabsorption and can maintain chronic metabolic alkalosis.

The kidney as a source of acid-base imbalances is usually derived from excess bicarbonate loss (metabolic acidosis) or impaired bicarbonate excretion (metabolic alkalosis). Renally derived metabolic acidosis caused by excess bicarbonate loss results in systemic acidemia, marked by an acidic arterial pH, low serum HCO_3^-, and low P_{CO_2}. The low CO_2 is caused by compensatory respiratory alkalosis (Foster et al., 2001; Levraut and Grimaud, 2003; Madias and Adrogue, 2003). Renal defects in tubular H^+ secretion can also cause a family of acid-base imbalance disorders collectively called renal tubular acidosis (RTA) (Roth and Chan, 2001). These are associated with urinary acidification and classified as types I, II, and IV based on causative mechanism. In type II RTA, bicarbonate is unable to be resorbed in the proximal tubule leading to HCO_3 loss into the urine in the distal tubule and therefore a systemic acidosis (de Mello-Aires and Malnic, 2002; Igarashi et al., 2002). Type IV RTA is caused by dysfunctional cation exchange in the distal tubule that leads to decreased H^+ and K^+ secretion (Uribarri et al., 1994). **The RTA most relevant to urologic practice is type I RTA, or distal RTA. In type I RTA, H^+ is unable to be secreted in the distal nephron, resulting in a hyperchloremic metabolic acidosis marked by a high urinary pH of more than 5.5 and low serum HCO_3 and low urinary citrate.** Type I RTA is associated with recurrent calcium phosphate stone formation, likely driven by the low urinary citrate, high urinary pH, and hypercalciuria. Potassium citrate supplementation and urinary alkalinization are the primary forms of treatment to prevent urinary stone formation (Domrongkitchaiporn et al., 2002).

Key Points

- Physiologic chemical reactions require a narrow range of serum pH.
- Acid is excreted through the lungs and the kidney.
- Type I RTA (distal) is the only type associated with renal stones.
- In acid-base disorders, first determine whether the kidney (HCO_3) or lungs (P_{CO_2}) are responsible for the primary disorder; then determine whether the compensatory response is appropriate.

Additional Solutes

Several additional solutes are handled in the kidney but are less clinically relevant to urologic practice than sodium, potassium, calcium, water, and bicarbonate (Moe et al., 2004). **Glucose** in the filtrate is normally completely reabsorbed. This occurs via a combination of passive Na^+ reabsorption and a low-capacity, high-affinity $2Na^+$/glucose transporter called SGLT-1. When plasma levels of glucose are excessive, however, the reabsorptive capacity of the kidney for glucose is overloaded, and it will be found in the urine. Filtered **phosphate** is mostly reabsorbed in the proximal convoluted tubule through an Na^+-phosphate cotransporter. When a renal phosphate leak exists, a secondary increase in renal calcitriol synthesis occurs, leading to increased intestinal calcium absorption and hypercalciuria. This phosphate leak is treated with phosphate supplementation to prevent a relatively uncommon but clinically significant source of recurrent calcium-based urinary stones. **Magnesium** is also filtered in the kidney, where it is reabsorbed partially in the proximal and distal tubule and mostly (60%–70%) in the thick ascending loop of Henle (Konrad et al., 2004; Voets et al., 2004). **Urea** exists in a high concentration in the interstitium. This facilitates an osmotic gradient that is responsible for water reabsorption and urinary concentration. The outer medullary collecting tubule is relatively impermeable to urea, in the basal state and under ADH stimulation. In contrast, the inner medullary collecting tubule has a high basal permeability for urea, largely because of the urea transporters UT-A1 and UT-A3 located mostly on the basolateral cell membrane. Short-term regulation is under the influence of ADH, which can increase urea permeability as much as fourfold through an increased number of urea transporters. Longer-term regulation can be affected by protein intake (Yang and Bankir, 2005).

Renal Hormone Effects

The kidney is involved in regulating systemic vascular tone, red blood cell production, and bone mineralization through its interaction with various hormones.

Vasoconstriction

Multiple hormones are involved in regulating vasoconstriction. **One important factor is the renin-angiotensin system where, in response to decreased renal blood flow, the kidney converts prorenin into renin and releases renin into circulation** (Dworkin and Brenner, 2004; Vaughan and Laragh, 1975). Renin in turn converts angiotensin I to angiotensin II via angiotensin-converting enzyme (ACE) **primarily** in the lungs (Romero et al., 1973). **Angiotensin II** interacts with the AT1 and AT2 receptors in the kidney, leading to vasoconstriction of the efferent arteriole, aldosterone release, and retention of sodium (Carey, 2005; Kaschina and Unger, 2003; Pimentel et al., 1995). The net effect of angiotensin II is to increase systemic vascular resistance and maintain GFR when renal blood flow is reduced (Arima, 2003; Bumpus et al., 1976; Romero et al., 1974).

Outside of the renin-angiotensin system other agents play important roles as well. **Norepinephrine** acts through the α_1 receptor to vasoconstrict all major renal blood vessels (Albanese et al., 2004). Its use as a blood pressure support agent is thus associated with preservation of renal function. **Endothelin** release, stimulated by angiotensin II, antidiuretic hormone, thrombin, cytokines, reactive oxygen species, and shearing forces acting on the vascular endothelium, causes vascular smooth muscle cell vasoconstriction (Bhangdia et al., 2003; Perez del Villar et al., 2005). In addition, it increases aldosterone secretion, stimulates atrial natriuretic peptide, decreases renal blood flow and GFR, and increases sodium excretion (Evans et al., 2004; Fellner and Arendshorst, 2004). It is the most potent vasoconstrictor currently known. **Vasopressin** directly stimulates vasoconstriction via the V1 receptor on blood vessel walls (Knepper et al., 1994; Segarra et al., 2002). At low doses, it preserves renal blood flow, whereas at high doses, it can lead to renal ischemia. It is therefore used as a blood pressure support medication at low doses in the setting of septic shock to increase systemic vascular resistance while preserving renal function (Baylis, 1987; Holmes et al., 2001; Malay et al., 2004). **Atrial natriuretic peptide** is released by the atria in response to stretching of the atrial wall in states of volume expansion (Fig. 86.14). It increases GFR and natriuresis by afferent arteriolar vasodilation and efferent arteriolar vasoconstriction as well as sodium reabsorption inhibition in the medullary collecting duct, respectively (Kim et al., 2002; Koda et al., 2005; Laragh, 1985; Sward et al., 2004, 2005; Zeidel et al., 1988).

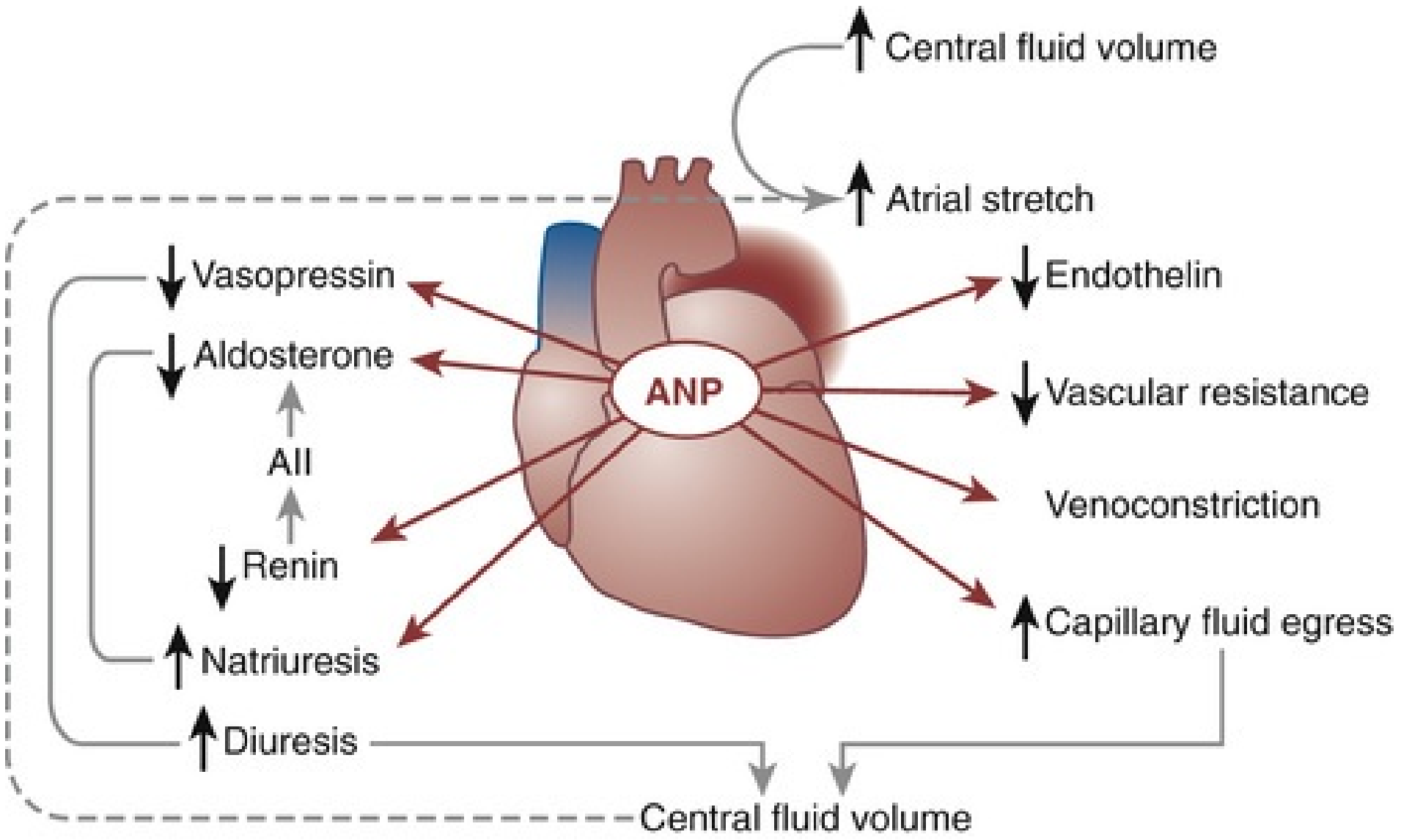
↑ Central fluid volume
↑ Atrial stretch
↓ Vasopressin
↓ Aldosterone
AII
↓ Renin
↑ Natriuresis
↑ Diuresis
ANP
↓ Endothelin
↓ Vascular resistance
Venoconstriction
↑ Capillary fluid egress
Central fluid volume

FIG. 86.14 Schematic representation of the fundamental biologic processes of atrial natriuretic peptide (ANP). *AII,* Angiotensin II.

Vasodilation

Two gases act as hormones at the level of the kidney to stimulate vasodilation. **Nitric oxide (NO)** is synthesized by the actions of the enzyme nitric oxide synthase (NOS) (Albrecht et al., 2002; Arnal et al., 1999; Cai et al., 2001; Chander et al., 2005; Harris et al., 2003). Vascular shear stress leads to NOS expression, which in turn upregulates NO production (Davis et al., 2004). NO diffuses to vascular smooth muscle cells, where it activates soluble guanylyl cyclase (sGC), producing 3′,5′-cyclic guanosine monophosphate (cGMP). Subsequently, cGMP activates cGMP- and 3′,5′-cyclic adenosine monophosphate (cAMP)-dependent protein kinases (PKG and PKA, respectively), leading to smooth muscle relaxation (Kawashima et al., 2001; Rudic et al., 1998; Schnermann and Levine, 2003). NOS inhibition increases renal vascular resistance and decreases the glomerular filtration rate (Schnermann et al., 1998; Takeda et al., 2004; Wang et al., 2003). **Carbon monoxide (CO)** is produced by heme oxygenase, an essential enzyme that catalyzes heme degradation, resulting in the formation of CO as well as iron and biliverdin (Gabbai, 2001; Hill-Kapturczak et al., 2002; Miyazono et al., 2002; Mustafa and Johns, 2001; Nakao et al., 2005; Ohta et al., 2000; Rodriguez et al., 2003; Sikorski et al., 2004; Wang et al., 2003; Zou et al., 2000). Increased CO production produces vasodilation in the kidney and can counteract catecholamine-induced vasoconstriction. In addition, CO has documented antiinflammatory, antioxidant, and cytoprotective actions.

Key Points

- The renin-angiotensin system is one of multiple chemical mediators that act on renal vascular tone to control renal blood flow.
- Endothelin is the most potent vasoconstrictor.
- NO and CO are potent vasodilators.

Red Blood Cell Production

The kidney is the major organ involved in monitoring and regulating red blood cell (RBC) levels. It does so via erythropoietin (EPO). **Basal RBC production is roughly 10 RBCs/h, but this rate can be greatly increased during times of anemia or hypoxia** (Arany et al., 1996)**. The kidney is responsible for the majority of EPO production (90%), whereas the liver may contribute a smaller amount (10%).** Kidney-derived EPO is produced by a subpopulation of interstitial fibroblasts, and possibly proximal tubular cells, in response to decreased O_2 tension (Suda et al., 1984). Under hypoxic conditions, the alpha subunit of the regulatory protein hypoxia-inducible factor-1 (HIF-1) is exposed. Binding of HIF-1α with HIF-1β, hepatic nuclear factor-4 (HNF-4), and p300 turns on erythropoietin transcription (Juul et al., 1998; Mikami et al., 2005; Munugalavadla and Kapur, 2005; Wang et al., 1995). In certain malignancies, such as renal cell carcinoma, erythropoiesis is enhanced because of a mutation in the von Hippel-Lindau (VHL) gene (Wiesener et al., 2002). As a result, there are constitutively increased levels of HIF-1 and polycythemia. In states of chronic inflammation and renal insufficiency, erythropoiesis is decreased (Suehiro et al., 2005). Thus anemia is common in the later stages of renal failure. This is due to decreased EPO levels as a result of a reduction in the number of functional EPO-producing cells within the kidney (Muta and Krantz, 1993). Recombinant human erythropoietin (rHuEPO) has been shown to be an effective treatment for this type of anemia (Bennett et al., 2008; Patel et al., 2004).

Bone Mineralization

The kidney plays an important role in the regulation of **vitamin D** activity. The major source of vitamin D is through dermal synthesis of the precursor compound cholecalciferol (vitamin D_3), or through dietary intake of vitamin D_3–fortified foods. Vitamin D_3 has minimal biologic activity. In the liver it is hydroxylated through the action of 25-hydroxylase to form 25-hydroxycholecalciferol (calcidiol). The calcidiol molecule is bound to vitamin D binding protein and transported to the kidney, where it is filtered and reabsorbed by renal tubular cells. In the tubular cell, vitamin D_3 is also hydroxylated by 1α-hydroxylase and 24α-hydroxylase to produce either inactive 24,25-dihydroxycholecalciferol or 1,25-dihydroxycholecalciferol (calcitriol), the biologically active form that is 100 times more potent than calcidiol (Portale et al., 1989; Young et al., 2004). Calcitriol production is regulated by calcidiol levels as well as the 1α-hydroxylase levels (Tuohimaa et al., 2005). These are, in turn, determined by parathyroid hormone (PTH) and plasma phosphate levels (increased enzyme activity) and serum calcitriol levels (decreased enzyme activity). However, unregulated calcitriol synthesis can occur in macrophages in granulomatous conditions such as sarcoidosis and tuberculosis, and in prostate epithelial and cancer cells. **Calcitriol functions through a single intracellular vitamin D receptor (VDR) to regulate gene transcription. Its primary function is the maintenance of serum calcium and phosphorus levels.** The four main target organs are the intestine (increases intestinal absorption of calcium, and to a lesser extent, phosphorus), the bones (regulates osteoblast activity, and in combination with PTH, allows for osteoclast activation and bone resorption), the kidney (increases reabsorption of calcium), and the parathyroid gland (suppresses PTH release) (Lowe et al., 1992). In total, vitamin D contributes to normal bone mineralization by maintaining normal serum calcium and phosphorus levels through increased intestinal absorption of calcium and phosphorus and increased renal reabsorption of calcium.

PTH production is directly influenced by serum calcium levels (Fig. 86.15). Its synthesis, secretion, and degradation is regulated through calcium-sensing receptors located on parathyroid cells. During periods of hypocalcemia, PTH synthesis and secretion are increased while degradation is decreased. The opposite occurs during hypercalcemia. In addition, calcitriol has a suppressive effect on PTH synthesis and parathyroid cell proliferation, mediated through vitamin D receptors located on the surface of parathyroid cells (Broadus et al., 1980). Hyperphosphatemia also directly stimulates PTH release, primarily in advanced renal insufficiency. PTH exerts its activity through PTH/PTHrP receptors, which are localized primarily in the kidneys and bone (Pfister et al., 1997). In the bone it stimulates bone resorption and increases serum calcium and phosphorus levels when administered continuously, whereas it leads to increased bone formation and mineral density when given intermittently.

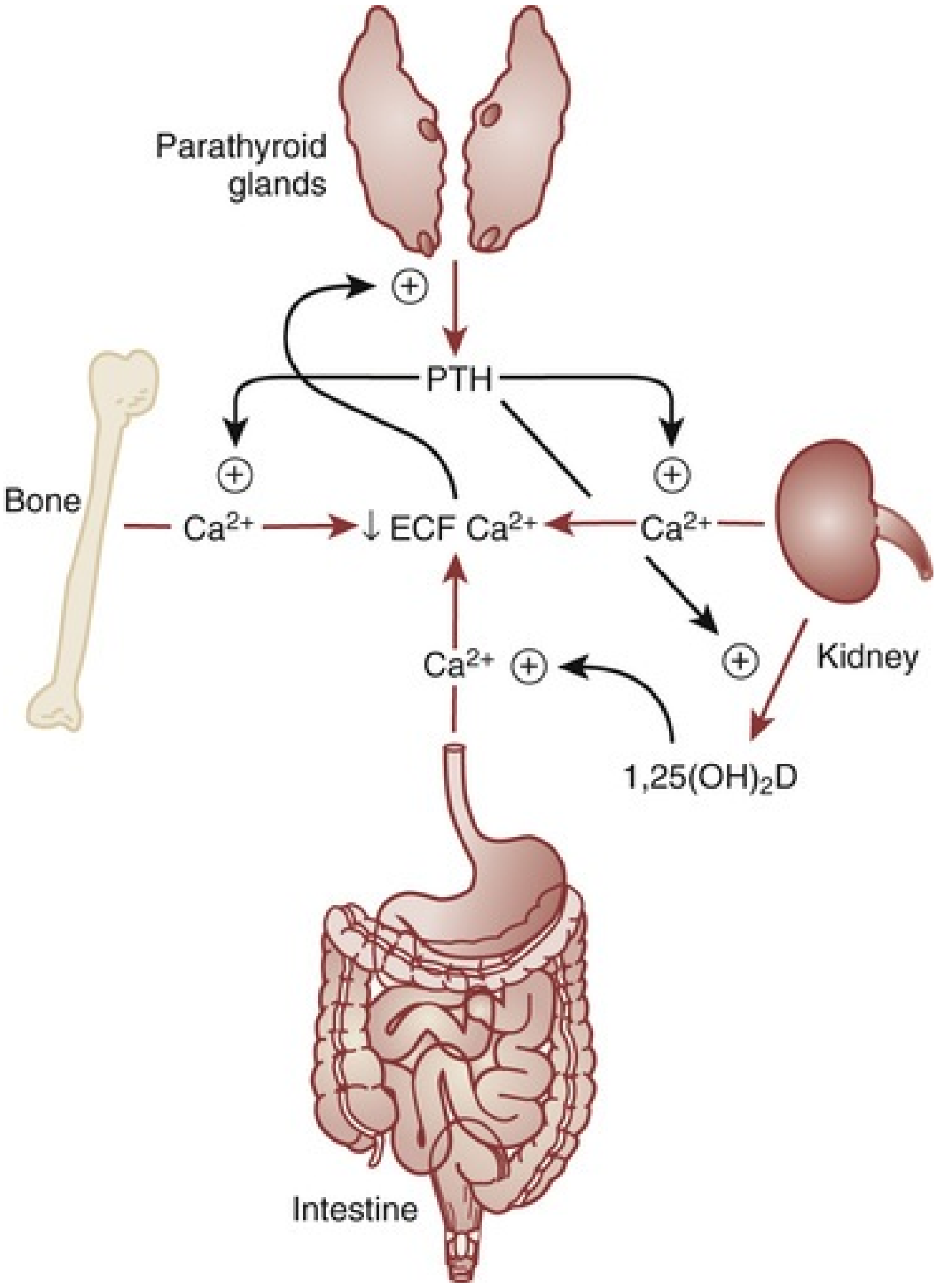

FIG. 86.15 Effects of vitamin D and parathyroid hormone (PTH) on calcium homeostasis. *ECF,* Extracellular fluid. (From Yu SLY: Renal transport of calcium, magnesium, and phosphate. In Brenner BM, editor: *Brenner and Rector's the kidney,* ed 7, Philadelphia, 2004, WB Saunders, p 536.)

In the kidney, the effects of PTH are threefold. First, it increases active calcium reabsorption at the level of the distal tubule. Second, it decreases phosphate reabsorption in the proximal convoluted tubule (and the distal tubule, to a lesser degree) through its action on the sodium phosphorus cotransporter. Third, it stimulates calcitriol production by increasing 1α-hydroxylase levels while decreasing 24α-hydroxylase levels. **Overall, PTH maintains normal serum calcium and phosphorus levels by increasing bone resorption,**

increasing renal reabsorption of calcium and excretion of phosphorus, and stimulating production of calcitriol.

Key Points

- Renal physiology influences bone metabolism through several hormonal actions.
- In the kidney, vitamin D is hydroxylated into calcitriol, which helps maintain systemic calcium and phosphate levels.
- PTH influences the kidney to increase calcium reabsorption.

Pathophysiology and Management of Renovascular Hypertension

Pathophysiology

Renovascular disease refers to states in which reduced perfusion of the kidney exist. This may occur in the absence of hypertension. For example, in ischemic nephropathy, reduced GFR is associated with reduced renal blood flow beyond levels of renal autoregulatory compensation (Chonchol and Linas, 2006; Garcia-Donaire and Alcazar, 2005; Jacobson, 1988; Meyrier et al., 1998; Novick and Fergany, 2002; Novick et al., 1996). In contrast, renovascular hypertension is a clinical syndrome marked by a rise in arterial pressure with or without associated ischemic and hypertensive renal injury (Ploth, 1995; Pohl, 1993, 1999). Its most common cause is renal artery stenosis (RAS), defined as narrowing of the renal artery by more than 50% of its natural luminal diameter (Derkx and Schalekamp, 1994; Dworkin and Cooper, 2009). RAS can be unilateral or bilateral and is separated into two major subtypes. Atherosclerotic RAS accounts for 60% to 80% of cases and fibromuscular dysplasia the remainder. Other rare causes of renovascular hypertension include arterial aneurysm, arteriovenous malformation, extrinsic renal artery compression, neurofibromatosis type 1, and Williams syndrome. **Although affecting only 5% of hypertensives, renovascular disease has been estimated to be the cause of renal failure in 5% to 15% of those older than 50 years of age and may account for as much as 10% to 20% of the end-stage renal disease population** (Mailloux et al., 1994; Svetkey et al., 1991; van Ampting et al., 2003)**.**

Atherosclerotic renal artery disease predominantly affects men and women aged 40 to 70 years (Caps et al., 1998a; Greco and Breyer, 1997; Pohl and Novick, 1985). The proximal third of the renal artery is usually involved, and in 70% to 80% of the patients there is an aortic plaque impinging on the renal ostium, whereas the remaining 30% exhibit non-ostial narrowing usually 1 to 3 cm distal to the renal artery ostium (Caps et al., 1998b; Crutchley et al., 2009).

In contrast to atherosclerotic renal artery disease, **there are four types of fibromuscular dysplasia: medial fibroplasia, perimedial fibroplasia, intimal fibroplasia, and medial hyperplasia** (Table 86.1). Medial, perimedial, and intimal fibroplastic lesions may affect the renal artery with an incidence of 30%, 5%, and 5%, respectively, and they represent 70% to 85%, 10% to 25%, and 10%, respectively, of all fibrous renal artery diseases. Medial hyperplasia, the fourth type of fibrous dysplasia, constitutes only 2% to 3% of all fibrous dysplastic lesions (Eddy, 2000; Olin, 2007; Olin and Sealove, 2011; Olin et al., 2012; Slovut and Olin, 2004).

TABLE 86.1

Frequency and Natural History of Fibrous Renal Artery Diseases

LESION	FREQUENCY, %[a]	RISK OF PROGRESSION	THREAT TO RENAL FUNCTION
Intimal fibroplasia and medial hyperplasia	10	++++	++++
Perimedial fibroplasia	10–25	++++	++++
Medial fibroplasia	70–85	++	—

[a] Frequency relates to frequency of only the fibrous renal artery diseases.

From Pohl M. Renovascular hypertension and ischemic nephropathy. In Schrier RW, editor: *Atlas of diseases of the kidney: hypertension and the kidney,* vol 3, Hoboken, NJ, 1999, Wiley-Blackwell (chapter 3, figure 3-4).

Medial fibroplasia occurs almost exclusively in women between 25 and 50 years of age. This lesion has the characteristic **“string of beads”** appearance on angiography and usually involves both renal arteries (Fig. 86.16). **The lesions involve the distal half of the main renal artery and may extend into the branches.** Histologically, the lesions are characterized by the growth of fibroblasts in the media covered by fibrous connective tissue in the stenotic areas and thinned-out medial tissue in the aneurysmal areas, thus creating the string-of-beads appearance on angiography. **These patients are not likely to progress to complete occlusion, nor are they likely to experience a decrease in their overall renal function.**

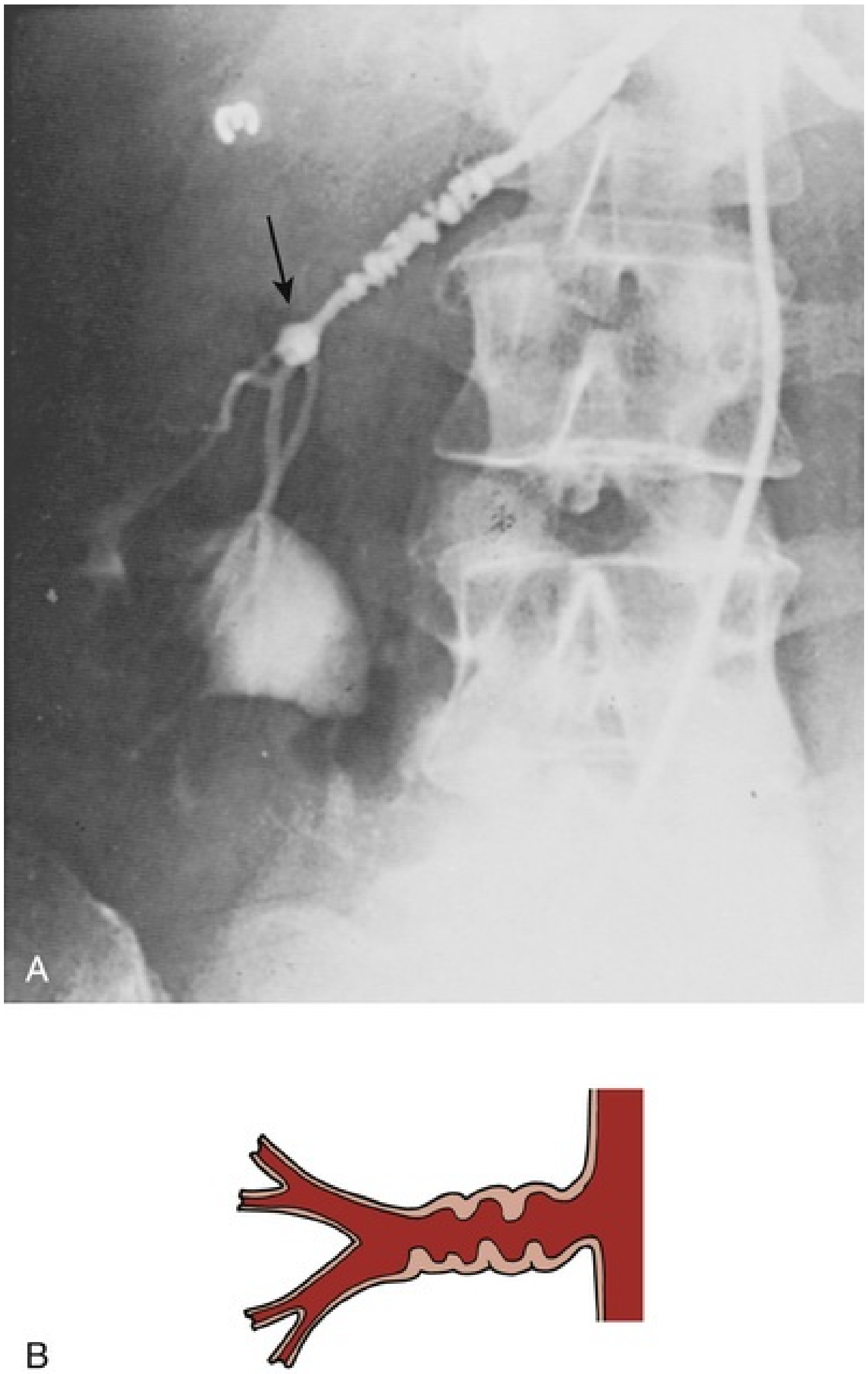

FIG. 86.16 Arteriogram and schematic diagrams of medial fibroplasia. (A) Right renal arteriogram demonstrating weblike stenosis with interposed segments of dilatation (large beads) typical of medial fibroplasia ("string-of-beads" lesion) *(arrow).* (B) Schematic diagram of perimedial fibroplasia. (A, From Novick AC: Renal vascular hypertension in children. In Kelalis PP, King LR, Belman AB, editors: *Clinical pediatric urology,* Philadelphia, 1984, Saunders. B, From Pohl M: Renovascular hypertension and ischemic nephropathy. In Schrier RW, editor: *Atlas of diseases of the kidney: hypertension and the kidney,* vol 3, Hoboken, NJ, 1999, Wiley-Blackwell [chapter 3, figure 3-5].)

Perimedial fibroplasia also occurs almost exclusively in women, but they are younger (between 5 and 15 years of age). The stenosis **occurs classically in the**

midrenal artery, although it may extend into the distal renal artery and its branches. Similar to medial fibroplasia, angiography may demonstrate a string of beads. However, unlike medial fibroplasia, the aneurysmal “beads” in perimedial fibroplasia that never exceed the diameter of the main renal artery (Fig. 86.17). Histologically, there is widespread collagen deposition in the outer half of the media. **If left untreated, perimedial fibroplasia often progresses to renal occlusion and loss of renal function.**

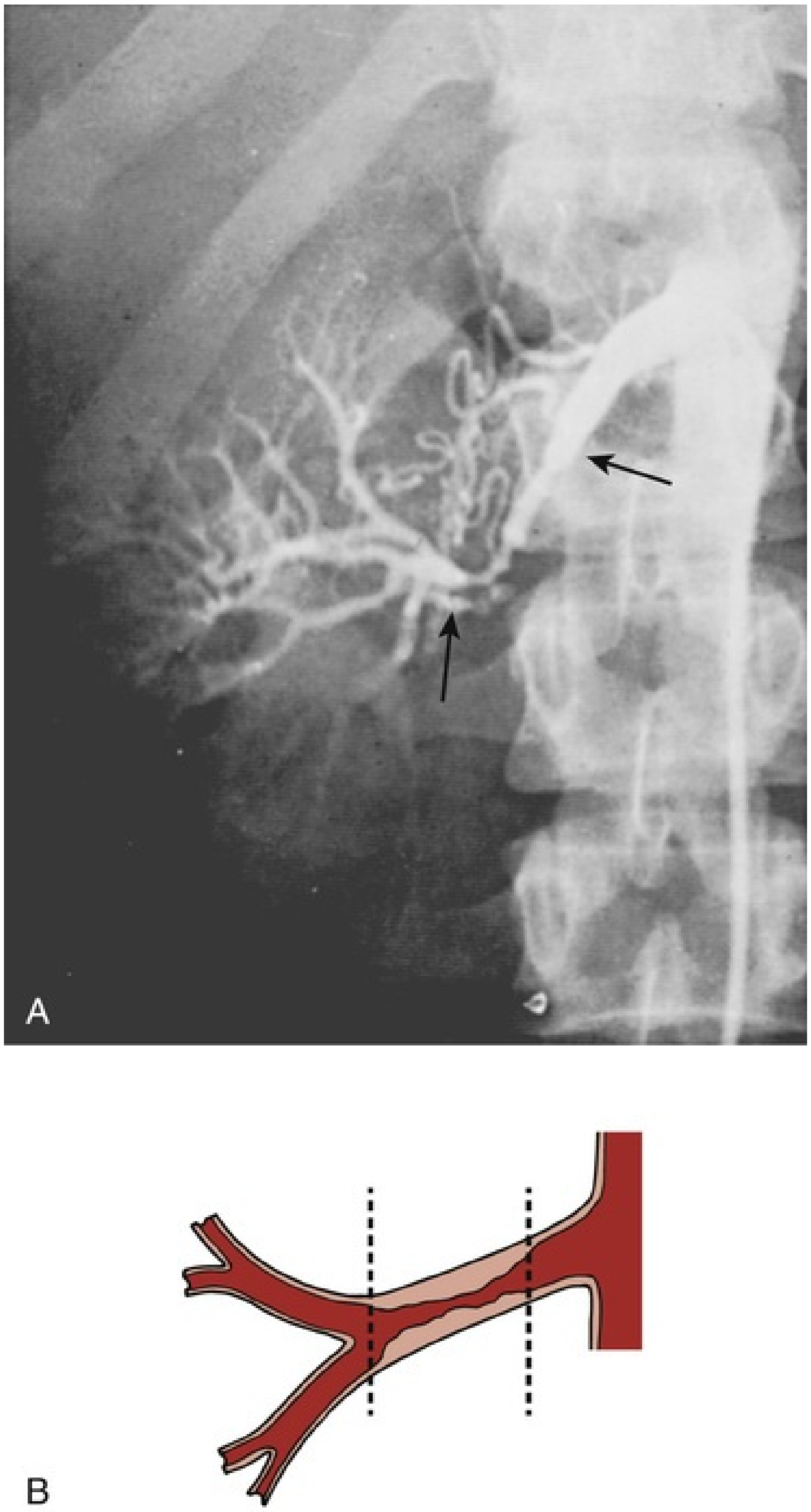

FIG. 86.17 Arteriogram and schematic diagram of perimedial fibroplasia. (A) Selective right renal arteriogram shows a tight stenosis in the midportion of the renal artery *(arrows)* with a small string-of-beads appearance, typical of perimedial fibroplasia. (B) Schematic diagram of perimedial fibroplasia. (A, From Novick AC: Renal vascular hypertension in children. In Kelalis PP, King LR, Belman AB, editors: Clinical pediatric urology, Philadelphia, 1984, Saunders. B, From Pohl M: Renovascular hypertension and ischemic nephropathy. In Schrier RW, editor: *Atlas of diseases of the kidney: hypertension and the kidney,* vol 3, Hoboken, NJ, 1999, Wiley-Blackwell [chapter 3, figure 3-6].)

Intimal fibroplasia accounts for 10% of the cases of fibromuscular dysplasia and occurs predominantly in children and younger adults. Histologically, there is collagen deposition within the intimal arterial layer. This form of fibroplasia may be complicated by disruptions of the internal elastic lamina and hence **may result in dissection, arterial wall hematoma, and renal infarction** (Fig. 86.18). The lesions are usually in the proximal renal artery; however, they may also occur in the mid- or distal renal artery and **without intervention are likely to progress and result in loss of renal function**.

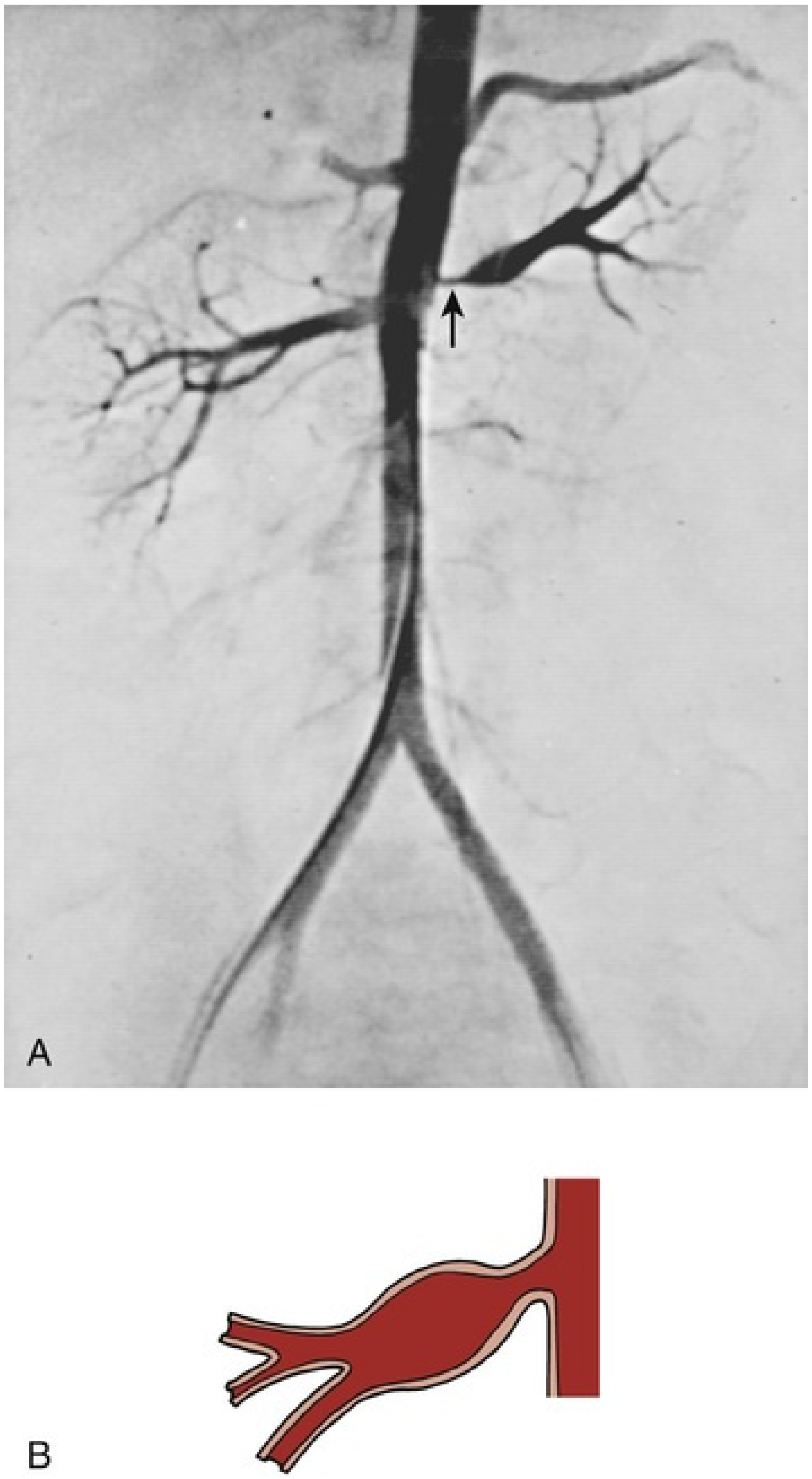

FIG. 86.18 Arteriogram and schematic diagram of intimal fibroplasia. (A) Selective right renal arteriogram demonstrates a localized, highly stenotic, smooth lesion involving the distal renal artery, from intimal fibroplasia. (B) Schematic diagram of intimal fibroplasia. Aortogram of a 6-year-old boy in (A) demonstrates proximal left renal artery stenosis *(arrow)* from intimal fibroplasia. (A, From Novick AC: Renal vascular hypertension in children. In Kelalis PP, King LR, Belman AB, editors: *Clinical pediatric urology,* Philadelphia, 1984, Saunders. B, From Pohl M: Renovascular hypertension and ischemic nephropathy. In Schrier RW, editor: *Atlas of diseases of the kidney: hypertension and the kidney,* vol 3, Hoboken, NJ, 1999, Wiley-Blackwell [chapter 3, figure 3-7].)

Medial hyperplasia is a rare disease, often angiographically indistinguishable from intimal fibroplasia. Histologically, there is smooth muscle cell hyperplasia with no associated fibrosis.

Key Points

- RAS is the most common cause of renovascular hypertension.
- Atherosclerotic vascular disease accounts for two-thirds of cases of RAS.
- Four types of fibromuscular dysplasia can also cause RAS. Of these types, medial fibroplasia is the most common and least likely to progress over time.

Diagnosis

Renovascular hypertension should be suspected in the presence of the following signs and symptoms (Working Group on Renovascular Hypertension, 1987):

1. Severe or refractory hypertension with evidence of grade III or IV hypertensive retinopathy (Davis et al., 1979)
2. Abrupt onset of moderate to severe hypertension, particularly in a normotensive or previously well-controlled hypertensive (Ram et al., 1995)
3. Onset of hypertension before age 20 (early onset) or after age 50 (late onset), particularly in those without a family history of hypertension (Spitalewitz and Reiser, 2000)
4. Unexplained worsening of renal function with or without hypertension or

in association with the use of ACE inhibitors or angiotensin II receptor blockers (ARBs) or with a reduction of blood pressure (BP) to the current accepted norm with the use of other antihypertensive agents (Hricik and Dunn, 1990)
5. Paradoxic worsening of hypertension with the use of diuretics
6. Unexplained recurrent episodes of heart failure—“flash” pulmonary edema
7. The presence of a systolic-diastolic abdominal bruit that radiates to both flanks
8. The presence of diffuse vascular disease and/or evidence of cholesterol embolization

Because effective BP control may be achieved in most patients with renovascular hypertension, and **it remains uncertain whether the correction of an underlying vascular lesion results in long-term BP control or preservation of renal function,** testing for renovascular hypertension should be pursued only if revascularization is being seriously considered. Some screening techniques pose risks to those with compromised renal function and may be associated with significant morbidity.

The now-classic dog experiments performed by Goldblatt et al. in 1934 led to our current understanding of the pathogenesis of renovascular hypertension. Use of a clamp allowed control of the degree of RAS in each kidney separately in the dog model. Blood pressure was monitored in the dogs after clamping the renal artery to one or both kidneys and to one kidney after the removal of the contralateral kidney. Subsequently, **two animal models of renal hypertension have become the hallmark for all studies on experimental renovascular hypertension.** They are the two-kidney, one-clip hypertension model (Fig. 86.19), in which one renal artery is clipped and the other renal artery is left unaltered (2K1C), and the one-kidney, one-clip hypertension model (Fig. 86.20), in which one renal artery is clipped and the contralateral kidney is removed. In the two-kidney model, hypertension is mediated by angiotensin II driving aldosterone secretion and in turn sodium retention (Caravaggi et al., 1976; Imamura et al., 1995). Renin secretion in the normal contralateral kidney is suppressed and under a higher perfusion pressure is able to excrete most of the excess salt and water. Because there is limited sodium retention, there is no significant feedback inhibition of renin secretion in the stenotic kidney. Thus it continues to secrete AII and the vasoconstriction and hypertension is maintained.

This form of hypertension may be managed with reversal of the RAS, with ACE inhibition, or with angiotensin receptor blockade (Michel et al., 1986). In contrast to the two-kidney model, the absence of a normal contralateral kidney prevents natriuresis and diuresis in response to RAS. Thus there is volume expansion, and renin secretion is suppressed in the clipped kidney because of feedback inhibition. Volume expansion remains, and there is sustained hypertension in spite of the decreased vasoconstriction associated with the now-suppressed RAS (Vasuvattakul et al., 1992). The one-kidney model is driven by volume expansion and sodium retention with normal circulating levels of AII.

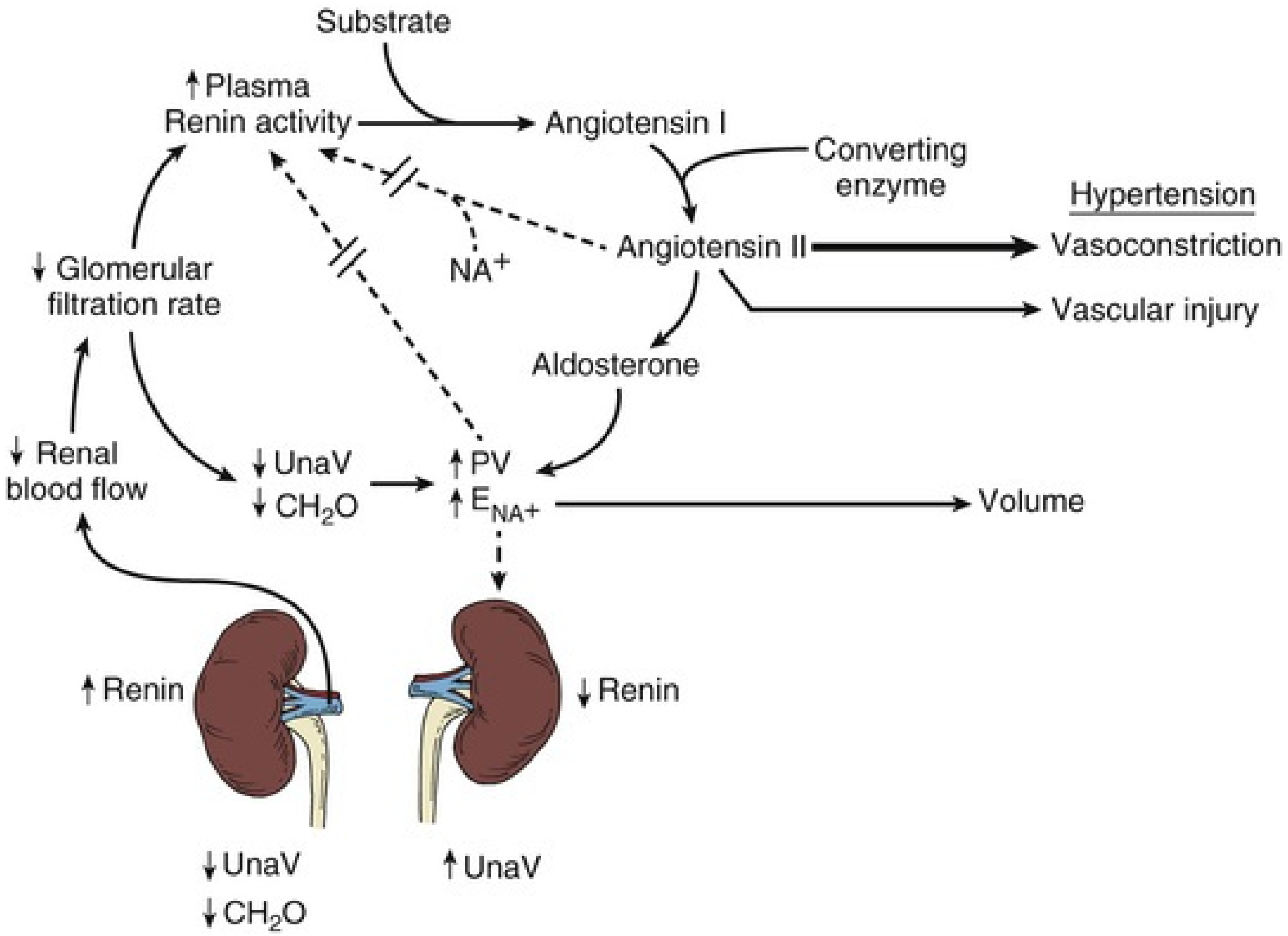
Substrate
↑Plasma Renin activity
Angiotensin I
Converting enzyme
Hypertension
NA+
Angiotensin II
Vasoconstriction
Vascular injury
↓Glomerular filtration rate
Aldosterone
↓Renal blood flow
↓UnaV
↓CH2O
↑PV
↑ENA+
Volume
↑Renin
↓Renin
↓UnaV
↓CH2O
↑UnaV

FIG. 86.19 The renin system in the setting of unilateral renal artery stenosis with a normal contralateral kidney characterized by (1) high peripheral plasma renin activity, (2) contralateral suppression of renin release, and (3) a decrease in ipsilateral renal blood flow (RBF). The resultant hypertension is mediated by angiotensin II-induced vasoconstriction. (From Vaughan E, Laragh J: New concepts of the renin system and vasoconstriction-volume mechanisms: diagnosis and treatment of renovascular and renal hypertensions. *Urol Clin North Am* 2:240–241, 1975, figure 2.)

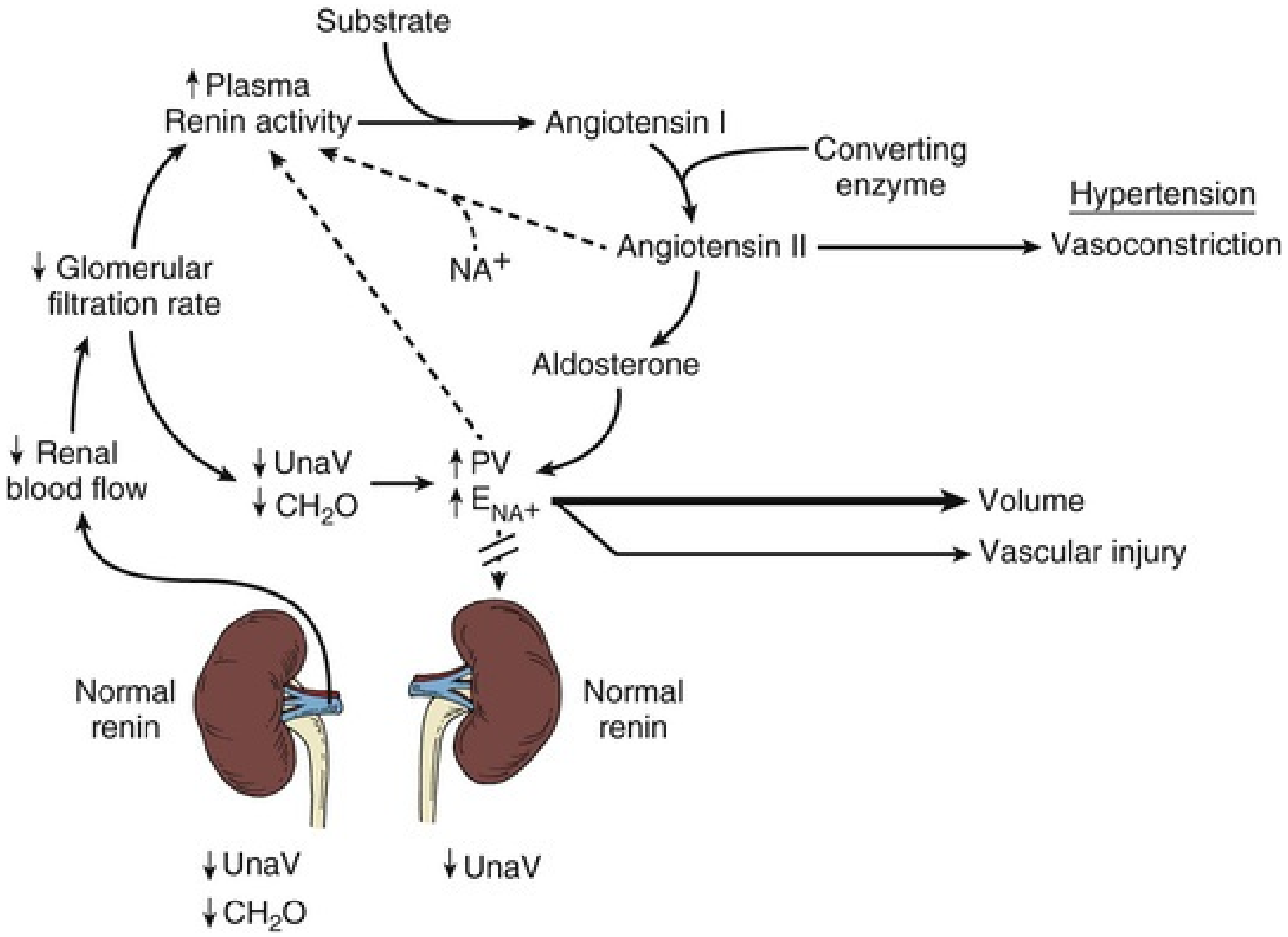
Substrate
↑Plasma
Renin activity
Angiotensin I
Converting
enzyme
Hypertension
Vasoconstriction
Angiotensin II
NA+
↓Glomerular
filtration rate
Aldosterone
↓Renal
blood flow
↓UnaV
↓CH2O
↑PV
↑ENA+
Volume
Vascular injury
Normal
renin
Normal
renin
↓UnaV
↓CH2O
↓UnaV

FIG. 86.20 The renin system in the setting of unilateral renal artery stenosis (or parenchymal disease) with an abnormal contralateral kidney. Disease in the opposite kidney limits sodium excretion, thereby allowing volume (sodium) retention, which feeds back to lower the peripheral renin to normal or subnormal values. In addition, contralateral renin secretion continues so that contralateral renin suppression does not occur. The hypertension is maintained by an inappropriate interaction of vasoconstriction and volume with the volume factor predominating. (From Vaughan E, Laragh J: New concepts of the renin system and vasoconstriction-volume mechanisms: diagnosis and treatment of renovascular and renal hypertensions. *Urol Clin North Am* 2:240–1, 1975, figure 2.)

Multiple screening tests for renovascular hypertension exist (Canzanello and Textor, 1994; Mann and Pickering, 1992; White et al., 2006). Intravenous pyelography (IVP), measurement of plasma renin activity, and renal scintigraphy were used in the past (Pedersen, 1994; Rene et al., 1995; Setaro et al., 1991; van Jaarsveld et al., 1997), but they have been replaced by more sensitive and specific techniques. Currently, the noninvasive screening tests that provide the highest sensitivity and specificity are magnetic resonance angiography (MRA) (de Haan et al., 1996; Klatzburg et al., 1994; Postma et al., 1997; Sommer et al., 1992), spiral (helical) computed tomography (CT) (Kim et al., 1998; Olbricht et al., 1995), and duplex Doppler ultrasonography (Hoffman et al., 1991; Kaplan-

Pavlovcic and Nadja, 1998; Kliewer et al., 1994; Stavros and Harshfield, 1994). Concerns regarding the possibility of gadolinium-induced nephrogenic systemic fibrosis raise the need for caution for MRA use in patients with unstable or reduced renal function (GFR <30 mL/min), although it has the greatest sensitivity and specificity (100% and 71%–96%, respectively) of the three tests (Rieumont et al., 1997; Schoenberg et al., 1998; Tan et al., 2002). CT angiography has a sensitivity of 98% and a specificity of 94% for detecting renovascular lesions, but the sensitivity and specificity of CT angiography decline (93% and 81%, respectively) in the presence of renal insufficiency (serum creatinine >1.7 mg/dL), and the risk of dye-induced nephrotoxicity increases. Comparatively, duplex Doppler ultrasonography provides many advantages. It can demonstrate bilateral disease, does not require the discontinuation of antihypertensive therapy or the exposure to potentially nephrotoxic contrast, and is accurate for those with renal failure (Radermacher et al., 2001; Williams et al., 2007). Despite these advantages, the use of duplex Doppler ultrasonography is limited by the fact that it is time consuming, is highly operator dependent, and is a technically difficult test to perform (Olin et al., 1995). If suspicion for a renovascular lesion remains high despite a negative noninvasive screening test, conventional renal angiography and intraarterial digital subtraction angiography (DSA) remain the gold standard for diagnosing renovascular disease and are indicated particularly if intervention is contemplated (Dunnick et al., 1989; Hawkins et al., 1994).

Key Points

- Suspect renovascular hypertension in patients with severe or abrupt-onset hypertension who otherwise have no risk factors for high blood pressure.
- Two models of renovascular hypertension were established with classic dog model experiments: the two-kidney, one-clip and one-kidney, one-clip models.
- Noninvasive diagnostic imaging, including MR angiography, CT angiography, and duplex ultrasonography, should be first-line screening to diagnosis RAS.

Management

Medical Therapy

Control of BP in those with renovascular hypertension may be achieved in more than 90% of patients with medical therapy alone (Aurell and Jensen, 1997; Hirsch et al., 2006). Because of the severity of the hypertension, however, therapy generally requires multiple antihypertensive medications. Although all classes of antihypertensives may be used (Franklin and Smith, 1985), drugs that inhibit AII production **(ACE inhibitors)** or block its receptor site **(ARBs) have been shown to be particularly efficacious** because the hypertension is often the result of activation of the renin-angiotensin system (Hollenberg, 1987; Ishidoya et al., 1995; van de Ven et al., 1999). When used as monotherapy, ACE inhibitors may control BP in 80% of patients, and when combined with a diuretic, control may be increased to almost 90%. **Medical therapy may reduce BP below a critical level and induce ongoing renal ischemia** distal to the arterial lesion, resulting in tubular atrophy, interstitial fibrosis, glomerulosclerosis, and progressive loss of function in the affected kidney(s). **Although these changes are more likely to be observed with antihypertensives that inhibit angiotensin or block its receptors than with others**, this is not uniformly seen in clinical practice (Tullis et al., 1999). In addition, with the exception of medial fibromuscular dysplasia, all forms of RAS can progress in severity despite medical therapy (Safian and Textor, 2001; Schreiber et al., 1984; Strandness, 1994; Wollenweber et al., 1968). Therefore **renal function should be closely monitored whenever antihypertensive agents are used in patients with renovascular hypertension** (Baboolal et al., 1998), particularly when they are combined with a diuretic. In addition to monitoring the serum creatinine concentration and estimated GFR or creatinine clearance, renal sizes and cortical blood flow velocity by duplex scanning should be assessed, because they may more quickly provide evidence of irreversible nephron loss (Rimmer and Gennari, 1993). ACE inhibitors and ARBs, particularly in the setting of volume contraction, may also result in acute (usually reversible) renal failure in 10% to 20% of those with either bilateral RAS or RAS affecting a solitary kidney.

Percutaneous Intervention

Percutaneous transluminal renal artery angioplasty (PTRA) is an angiographic technique by which stenotic renal arteries are dilated with a balloon-tipped catheter (Kidney and Deutsch, 1996; Libertino and Beckmann, 1994; Sos, 1991).

Lesions that are most amenable to PTRA include those that are less than 10 mm in length, are partially occluded, and do not involve the ostium (Fig. 86.21; Geyskes, 1988; Tuttle et al., 1998; van de Ven et al., 1995). After successful PTRA, an improvement in BP may be seen as quickly as 4 to 6 hours after the procedure but is more commonly seen after 48 hours, although the maximal antihypertensive effect may not be observed for several weeks (Bonelli et al., 1995; Canzanello et al., 1989; O'Donovan et al., 1992; Ramsay and Waller, 1990; van Jaarsveld et al., 2000). In general, the absence of an early antihypertensive response suggests that a long-term improvement of hypertension is unlikely (Webster et al., 1998). PTRA without stenting has proved successful for patients with underlying fibromuscular dysplasia (Fig. 86.22; Dorros et al., 1995,1998a,b; Mousa et al., 2012; Plouin et al., 1998). In contrast, successful PTRA in patients with unilateral atherosclerotic RAS is technically more difficult to achieve (technical success rates may be as low as 70%), and rates of cure or long-term improvement of hypertension have not been consistent. Although the placement of an intraluminal stent may increase success rates (Harden et al., 1997; Iannone et al., 1996; Marana et al., 1998; Marshall et al., 1990; Rees, 1999; Rees et al., 1991; Rundback et al., 1998), **the restenosis rate remains at about 15% to 25%** (Blum et al., 1997; Boisclair et al., 1997; Isles et al., 1999; Rocha-Singh et al., 2005). **The effects on BP after PTRA in patients with bilateral RAS have been disappointing as well**, in part, because of the frequent presence of ostial or completely occluded lesions. **Even when technically successful, the restenosis rate after PTRA is significant** (30% for nonostial and 50% for ostial lesions) and may occur shortly after the procedure (15% to 30% within 2 years) with recurrence of uncontrolled or accelerated hypertension.

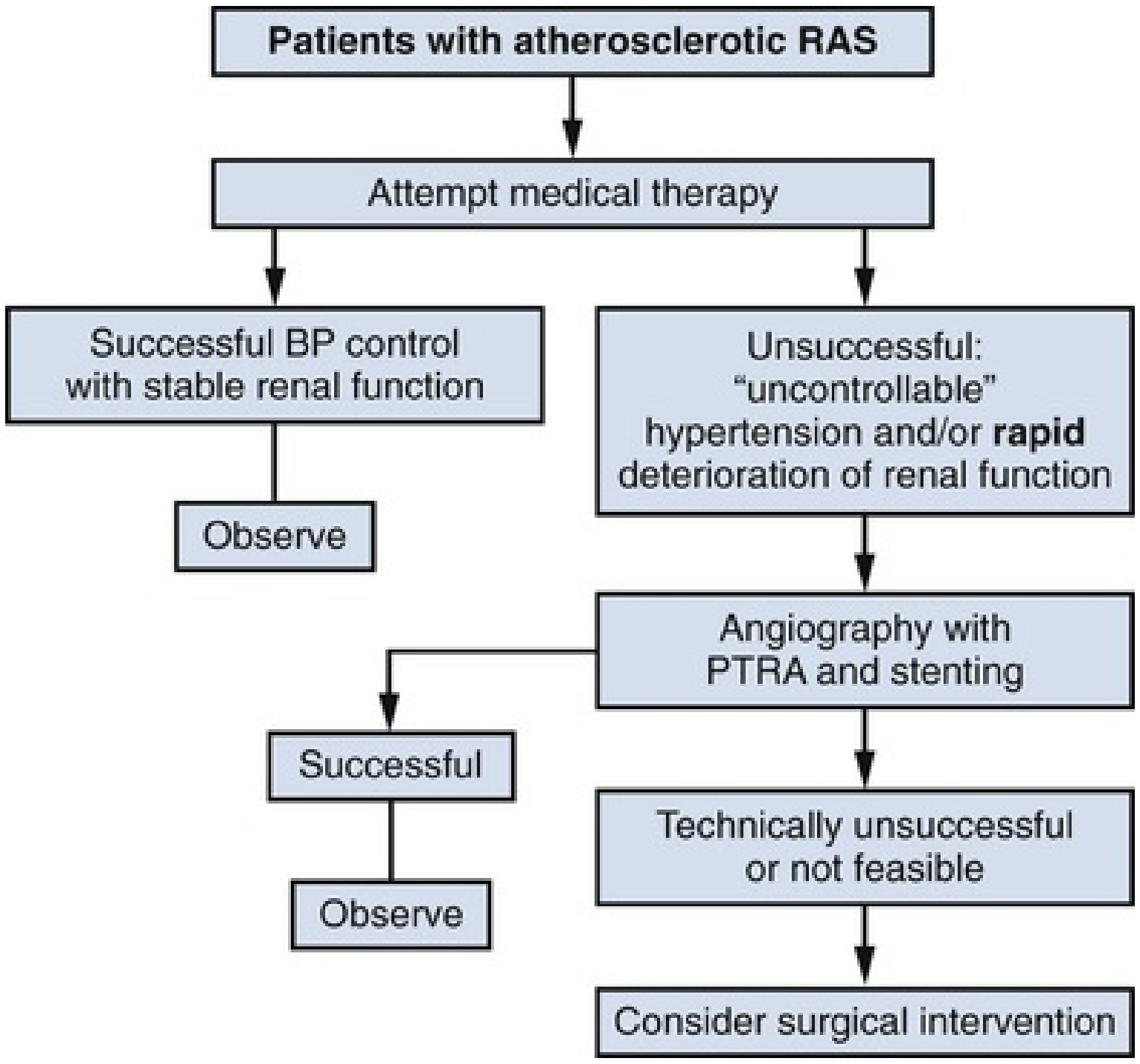
Patients with atherosclerotic RAS
Attempt medical therapy
Successful BP control with stable renal function
Observe
Unsuccessful: "uncontrollable" hypertension and/or rapid deterioration of renal function
Angiography with PTRA and stenting
Successful
Observe
Technically unsuccessful or not feasible
Consider surgical intervention

FIG. 86.21 Algorithm for the management of patients with arteriosclerotic renal artery stenosis (RAS). *BP,* Blood pressure; *PTRA,* percutaneous transluminal renal angioplasty.

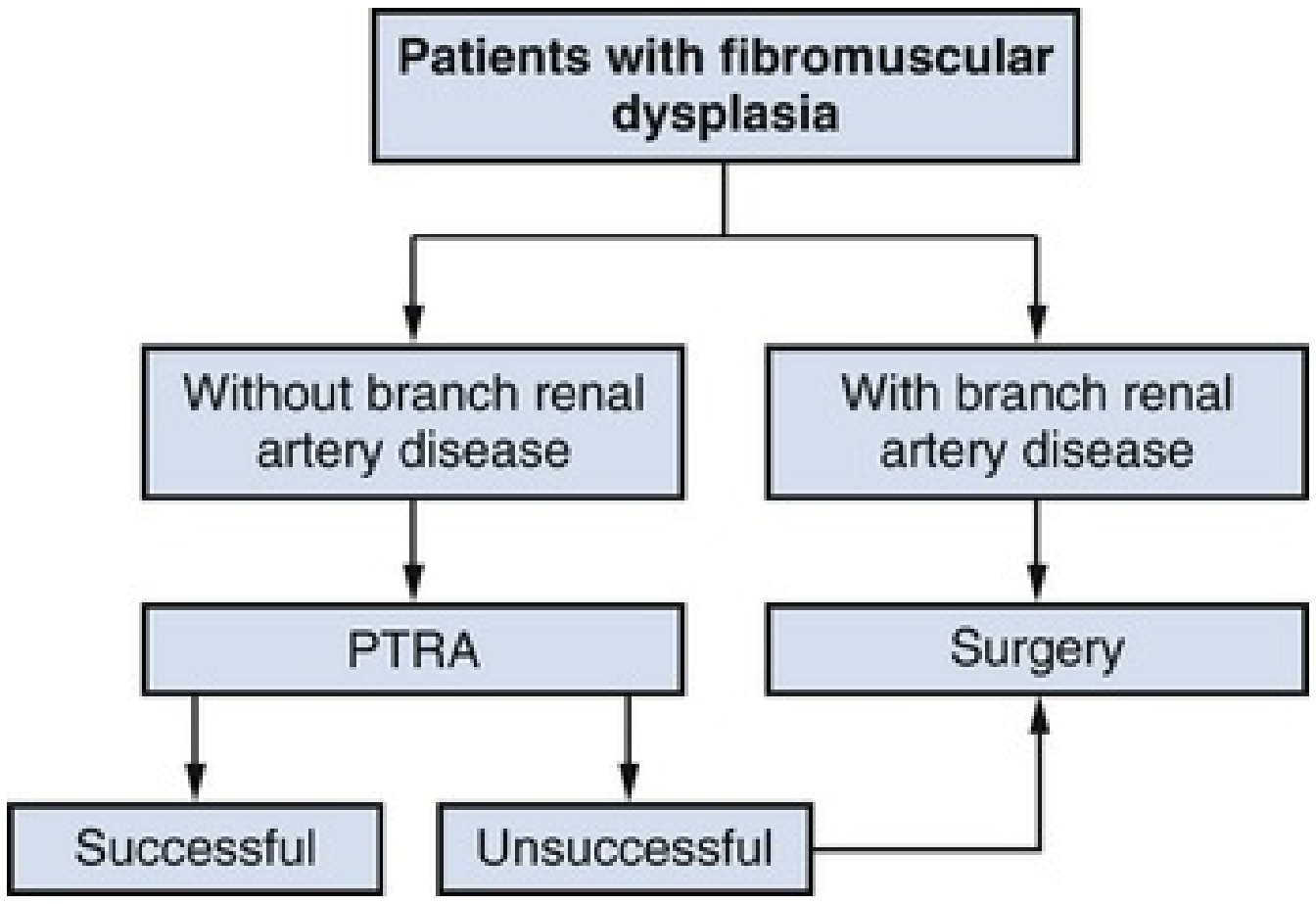
Patients with fibromuscular dysplasia
Without branch renal artery disease
With branch renal artery disease
PTRA
Surgery
Successful
Unsuccessful

FIG. 86.22 Algorithm for the management of patients with fibromuscular dysplasia. *PTRA,* Percutaneous transluminal renal angioplasty.

Although the results of many earlier studies suggest that PTRA with stenting may cure or improve control of hypertension, three more recent randomized studies raise questions about the effectiveness of revascularization with stenting for BP control. The Stent Placement and

Blood Pressure and Lipid-lowering for Prevention of Progression of Renal Dysfunction Caused by Atherosclerotic Ostial Stenosis of the Renal Artery **(STAR)** trial enrolled 140 patients with BP controlled to less than 140/90 mm Hg, and with a renal ostial lesion greater than 50%, and prospectively randomized the patients to either renal artery stenting and medical therapy or medical therapy alone. At the end of follow-up, **there was no difference in the degree of BP control** (Bax et al., 2009; Corriere et al., 2008). In the Angioplasty and Stenting for Renal Artery Lesions **(ASTRAL)** trial, 806 patients with atherosclerotic RAS were randomized to undergo revascularization and medical therapy or to undergo medical therapy alone. After a median follow-up of **34 months, there was no difference in BP control between the two groups,** although the number of antihypertensive medications required was slightly higher in the medically managed group (ASTRAL Investigators et al., 2009). The Cardiovascular Outcomes and Renal Atherosclerotic Lesions (CORAL) study was a multicentered, open-label, randomized controlled trial that compared medical therapy alone with medical therapy plus renal artery stenting in patients with atherosclerotic RAS and elevated BP, chronic kidney disease, or both. **Medical therapy consisted of an ARB, a calcium channel blocker, a statin, a diuretic, and other medications as necessary.** Overall, a reduction of systolic BP of a mean of 15 to 16 mm Hg was achieved in both groups with **an average of 3.4 medications, not different in either group.** In addition, for all three studies, no long-term preservation of renal function was shown with vascular stenting. These studies raise the question of whether the risk of stenting for RAS is worth the potential benefit regarding BP control or prevention of renal failure, although many believe that a subset of patients may benefit from endovascular intervention (Cooper et al., 2014; Ives et al., 2003; Korsakas et al., 2004; Krijnen et al., 2004; Nordmann et al., 2003).

Surgical Treatment

With the advent of ACE inhibitors, angiotensin receptor blockade, statins, and PTRA, **the need for surgical revascularization and reconstruction of the renal artery has diminished.** However, an indication for surgical intervention in a select group of patients remains (Bhatt et al., 2014). Patients with RAS with concomitant aneurysmal or occlusive aortic disease in which surgery is indicated may benefit from surgical intervention to correct both lesions if the aortic disease cannot be repaired without correcting the renal occlusive disease as well. Surgery is also indicated in patients with macroaneurysms of the renal artery associated with the stenosis because rupture of these lesions may occur if they are larger than 4 cm. Patients who exhibit malignant/accelerated or uncontrollable hypertension, who do not tolerate medical therapy, or who show rapid deterioration of renal function (1 to 6 months before presentation) with serum creatinine remaining between 1.5 and 3.0 mg/dL may also benefit from surgical intervention (Textor, 1998). Although PTRA can still be performed under most circumstances in these latter groups, for an ostial lesion greater than 10 mm in length, there may still be a role for surgical revascularization. Therefore there remains a group of patients who will require surgical intervention (Middleton, 1998; Novick et al., 1987).

Key Points

- Medical management for renovascular hypertension is the mainstay of therapy.
- Percutaneous intervention to treat RAS may be effective, but growing evidence calls into question its efficacy to control blood pressure or prevent renal failure long term.
- Although surgical treatment is no longer first-line therapy for RAS, its role still exists for the appropriately selected patient.

Suggested Readings

Hormonal

Delles C, Klingbeil AU, Schneider MP, et al. The role of nitric oxide in the regulation of glomerular haemodynamics in humans. *Nephrol Dial Transplant*. 2004;19:1392–1397.

Lariviere R, Lebel M. Endothelin-1 in chronic renal failure and hypertension. *Can J Physiol Pharmacol*. 2003;81:607–621.

Robertson GL. Physiology of ADH secretion. *Kidney Int Suppl*. 1987;21:S20–S26.

Renal Tubular Function

Cockcroft DW, Gault MH. Prediction of creatinine clearance from serum creatinine. *Nephron*. 1976;16:31–41.

Shemesh O, Golbetz H, Kriss JP, et al. Limitations of creatinine as a filtration marker in glomerulopathic patients. *Kidney Int*. 1985;28:830–838.

Wang T. Role of iNOS and eNOS in modulating proximal tubule transport and acid-base balance. *Am J Physiol Renal Physiol*. 2002;283:F658–F662.

Sodium, Water, and Potassium Imbalances

Kaschina E, Unger T. Angiotensin AT1/AT2 receptors: regulation, signaling and function. *Blood Press*. 2003;12:70–88.

Miller M. Inappropriate antidiuretic hormone secretion. *Curr Ther Endocrinol Metab*. 1994;5:186–189.

Yeates KE, Singer M, Morton AR. Salt and water: a simple approach to hyponatremia. *CMAJ*. 2004;170:365–369.

Acid-Base

Corey HE. Bench-to-bedside review: fundamental principles of acid-base physiology. *Crit Care*. 2005;9:184–192.

Levraut J, Grimaud D. Treatment of metabolic acidosis. *Curr Opin Crit Care*. 2003;9:260–265.

Roth KS, Chan JC. Renal tubular acidosis: a new look at an old problem. *Clin Pediatr (Phila)*. 2001;40:533–543.

Renovascular Hypertension

ASTRAL Investigators, Wheatley K, Ives N, et al. Revascularization versus medical therapy for renal-artery stenosis. *N Engl J Med*. 2009;361:1953–1962.

Bax L, Woittiez AJ, Kouwenberg HJ, et al. Stent placement in patients with atherosclerotic renal artery stenosis and impaired renal function: a randomized trial. *Ann Intern Med*. 2009;150:840–848.

Cooper CJ, Murphy TP, Cutlip DE, et al. Stenting and medical therapy for atherosclerosis renal-artery stenosis. *N Engl J Med*. 2014;370:13–22.

Dworkin LD, Cooper CJ. Renal-artery stenosis. *N Engl J Med*. 2009;361:1972–1978.

Slovut DP, Olin JW. Fibromuscular dysplasia. *N Engl J Med*. 2004;350:1862–1871.

References

Adrogue HJ, Madias NE. Hypernatremia. *N Engl J Med*. 2000;342:1493–1499.

Agre P, King LS, Yasui M, et al. Aquaporin water channels—from atomic structure to clinical medicine. *J Physiol*. 2002;542:3–16.

Albanese J, Leone M, Garnier F, et al. Renal effects of norepinephrine in septic and nonseptic patients. *Chest*. 2004;126:534–539.

Albrecht EW, Stegeman CA, Tiebosch AT, et al. Expression of inducible and endothelial nitric oxide synthases, formation of peroxynitrite and reactive oxygen species in human chronic renal transplant failure. *Am J Transplant*. 2002;2:448–453.

Amasheh S, Meiri N, Gitter AH, et al. Claudin-2 expression induces cation-selective channels in tight junctions of epithelial cells. *J Cell Sci*. 2002;115:4969–4976.

Arany Z, Huang LE, Eckner R, et al. An essential role for p300/CBP in the cellular response to hypoxia. *Proc Natl Acad Sci USA*. 1996;93:12969–12973.

Arima S. Role of angiotensin II and endogenous vasodilators in the control of glomerular hemodynamics. *Clin Exp Nephrol*. 2003;7:172–178.

Arnal JF, Dinh-Xuan AT, Pueyo M, et al. Endothelium-derived nitric oxide and vascular physiology and pathology. *Cell Mol Life Sci*. 1999;55:1078–1087.

ASTRAL Investigators, Wheatley K, Ives N, et al. Revascularization versus medical therapy for renal-artery stenosis. *N Engl J Med*. 2009;361:1953–1962.

Aurell M, Jensen G. Treatment of renovascular hypertension. *Nephron*. 1997;75:373–383.

Baboolal K, Evans C, Moore RH. Incidence of end-stage renal disease in medically treated patients with severe bilateral atherosclerotic renovascular disease. *Am J Kidney Dis*. 1998;31:971–977.

Bax L, Woittiez AJ, Kouwenberg HJ, et al. Stent placement in patients with atherosclerotic renal artery stenosis and impaired renal function: a randomized trial. *Ann Intern Med*. 2009;150:840–848.

Baylis PH. Osmoregulation and control of vasopressin secretion in healthy humans. *Am J Physiol*. 1987;253:R671–R678.

Bennett CL, Silver SM, Djulbegovic B, et al. Venous thromboembolism and mortality associated with recombinant erythropoietin and darbepoetin administration for the treatment of cancer-associated anemia. *JAMA*. 2008;299(8):914–924.

Bhangdia DK, Gulmi FA, Chou SY, et al. Alterations of renal hemodynamics in unilateral ureteral obstruction mediated by activation of endothelin receptor subtypes. *J Urol*. 2003;170:2057–2062.

Bhatt DL, Kandzari DE, O'Neill WW, et al. A controlled trial of renal denervation for resistant hypertension. *N Engl J Med*. 2014;370:1393–1401.

Blum U, Krumme B, Flugel P. Treatment of ostial renal-artery stenoses with vascular endoprostheses after unsuccessful balloon angioplasty. *N Engl J Med*. 1997;336:459–465.

Boisclair C, Therasse E, Oliva VL, et al. Treatment of renal angioplasty failure by percutaneous renal artery stenting with Palmaz stents: midterm technical and clinical results. *AJR Am J Roentgenol*. 1997;168:245–251.

Bonelli FS, McKusick MA, Textor SC. Renal artery angioplasty: technical results and clinical outcome in 320 patients. *Mayo Clin Proc*. 1995;70:1041–1052.

Broadus AE, Horst RL, Lang R, et al. The importance of circulating 1,25-dihydroxyvitamin D in the pathogenesis of hypercalciuria and renal-stone formation in primary hyperparathyroidism. *N Engl J Med*. 1980;302:421–426.

Bumpus F, Sen S, Smeby R, et al. Use of angiotensin II antagonists in experimental hypertension. *Circ Res*. 1976;38:315–321.

Cai H, Davis ME, Drummond GR, et al. Induction of endothelial NO synthase by hydrogen peroxide via a Ca (2+)/calmodulin-dependent protein kinase II/janus kinase 2-dependent pathway. *Arterioscler Thromb Vasc Biol*. 2001;21:1571–1576.

Canzanello VJ, Millan VG, Spiegel JE. Percutaneous transluminal angioplasty in management of atherosclerotic renovascular hypertension: results in 100 patients. *Hypertension*. 1989;13:163–172.

Canzanello VJ, Textor SC. Noninvasive diagnosis of renovascular disease. *Mayo Clin Proc*. 1994;69:1172–1181.

Caps MT, Perissinotto C, Zierler RE, et al. Prospective study of atherosclerotic disease progression in the renal artery. *Circulation*. 1998;98:2866–2872.

Caps MT, Zierler ER, Polissar NL, et al. Risk of atrophy in kidneys with atherosclerotic renal artery stenosis. *Kidney Int*. 1998;53:735–742.

Caravaggi A, Bianchi G, Brown J, et al. Blood pressure and plasma angiotensin II concentration and angiotensin infusion in the dog. *Circ Res*. 1976;38:315–321.

Carey RM. Update on the role of the AT2 receptor. *Curr Opin Nephrol Hypertens*. 2005;14:67–71.

Chander V, Tirkey N, Chopra K. Resveratrol, a polyphenolic phytoalexin protects against cyclosporine-induced nephrotoxicity through nitric oxide dependent mechanism. *Toxicology*. 2005;210:55–64.

Chonchol M, Linas S. Diagnosis and management of ischemic nephropathy. *Clin J Am Soc Nephrol*. 2006;1:172–181.

Cockcroft DW, Gault MH. Prediction of creatinine clearance from serum creatinine. *Nephron*. 1976;16:31–41.

Cooper CJ, Murphy TP, Cutlip DE, et al. Stenting and medical therapy for atherosclerosis renal-artery stenosis. *N Engl J Med*. 2014;370:13–22.

Corey HE. Bench-to-bedside review: fundamental principles of acid-base physiology. *Crit Care*. 2005;9:184–192.

Corriere MA, Pearce JD, Edwards MS, et al. Endovascular management of atherosclerotic renovascular disease: early results following primary intervention. *J Vasc Surg*. 2008;48:580–587.

Crutchley TA, Pearce JD, Craven TE, et al. Clinical utility of the resistive index in atherosclerotic renovascular disease. *J Vasc Surg*. 2009;49:148–155.

Davis BA, Crook JE, Vestal RE, et al. Prevalence of renovascular hypertension in patients with grade III or IV retinopathy. *N Engl J Med*. 1979;301:1273–1276.

Davis ME, Grumbach IM, Fukai T, et al. Shear stress regulates endothelial nitric-oxide synthase promoter activity through nuclear factor kappaB binding. *J Biol Chem*. 2004;279:163–168.

de Haan MW, Kouwenhoven M, Thelissen GRP, et al. Renovascular disease in patients with hypertension: detection with systolic and diastolic gating in three-dimensional phase contrast MR angiography. *Radiology*. 1996;198:449–456.

de Mello-Aires M, Malnic G. Distal tubule bicarbonate transport. *J Nephrol*. 2002;15(Suppl 5):S97–S111.

Derkx FH, Schalekamp MA. Renal artery stenosis and hypertension. *Lancet*. 1994;344:237–239.

Domrongkitchaiporn S, Khositseth S, Stitchantrakul W, et al. Dosage of potassium citrate in the correction of urinary abnormalities in pediatric distal renal tubular acidosis patients. *Am J Kidney Dis*. 2002;39:383–391.

Dorros G, Jaff M, Jain A, et al. Follow-up of primary Palmaz-Schatz stent placement for atherosclerotic renal artery stenosis. *Am J Cardiol*. 1995;75:1051–1055.

Dorros G, Jaff MR, Mathiak L, et al. Four-year follow-up of Palmaz-Schatz stent revascularization as treatment for atherosclerotic renal artery stenosis. *Circulation*. 1998;98:642–647.

Dorros G, Jaff MR, Mathiak L, et al. Stent revascularization for atherosclerotic renal artery stenosis: one year clinical follow-up. *Tex Heart Inst J*. 1998;25:40–43.

Dunnick NR, Svetkey LP, Cohan RH, et al. Intravenous digital subtraction renal angiography: use in screening for renovascular hypertension. *Radiology*. 1989;171:219–222.

Dworkin DL, Brenner BM. The renal circulation. Brenner BM. *Brenner and Rector's the kidney*. ed 7. WB Saunders: Philadelphia; 2004:309–352.

Dworkin LD, Cooper CJ. Renal-artery stenosis. *N Engl J Med*. 2009;361:1972–1978.

Eddy A. Molecular basis of renal fibrosis. *Pediatr Nephrol*. 2000;15:290–301.

Epstein SK, Singh N. Respiratory acidosis. *Respir Care*. 2001;46:366–383.

Evans RG, Eppel GA, Anderson WP, et al. Mechanisms underlying the differential control of blood flow in the renal medulla and cortex. *J Hypertens*. 2004;22:1439–1451.

Fellner SK, Arendshorst WJ. Endothelin A and B receptors of preglomerular vascular smooth muscle cells. *Kidney Int*. 2004;65:1810–1817.

Filler G, Bokenkamp A, Hofmann W, et al. Cystatin C as a marker of GFR—history, indications, and future research. *Clin Biochem*. 2005;38:1–8.

Foster GT, Vaziri ND, Sassoon CS. Respiratory alkalosis. *Respir Care*. 2001;46:384–391.

Franklin SS, Smith RD. Comparison of the effects of enalapril plus hydrochlorothiazide versus standard triple therapy on renal function in renovascular hypertension. *Am J Med*. 1985;79(3C):14–23.

Friedman PA, Gesek FA. Calcium transport in renal epithelial cells. *Am J Physiol*. 1993;264:F181–F198.

Gabbai FB. Effects of nitric oxide synthase blockers on renal function. *Nephrol Dial Transplant*. 2001;16(Suppl 1):10–13.

Garcia-Donaire J, Alcazar J. Ischemic nephropathy: detection and therapeutic intervention. *Kidney Int*. 2005;68(Suppl 99):S131–S136.

Geyskes GG. Treatment of renovascular hypertension with percutaneous transluminal renal angioplasty. *Am J Kidney Dis*. 1988;12:253–265.

Goh KP. Management of hyponatremia. *Am Fam Physician*. 2004;69:2387–2394.

Goldblatt H, Lynch J, Hanzal RF, et al. Studies on experimental hypertension: I. The production of persistent elevation of systolic blood pressure by means of renal ischemia. *J Exp Med*. 1934;59:347–379.

Greco BA, Breyer JA. Atherosclerotic ischemic renal disease. *Am J Kidney Dis*. 1997;29:167–187.

Harden PN, MacLeod MJ, Rodger RS, et al. Effect of renal-artery stenting on progression of renovascular renal failure. *Lancet*. 1997;349:1133–1136.

Harris MB, Blackstone MA, Ju H, et al. Heat-induced increases in endothelial NO synthase expression and activity and endothelial NO release. *Am J Physiol Heart Circ Physiol*. 2003;285:H333–H340.

Hawkins IF, Wilcox CS, Kerns SR, et al. CO_2 digital angiography: a safer contrast agent for renal vascular imaging. *Am J Kidney Dis*. 1994;24:685–694.

Hill-Kapturczak N, Chang SH, Agarwal A. Heme oxygenase and the kidney. *DNA Cell Biol*. 2002;21:307–321.

Hirsch AT, Haskal ZJ, Hertzer NR, et al. ACC/AHA Guidelines for the management of patients with peripheral arterial disease (lower extremity, renal, mesenteric, and abdominal aortic): a collaborative report from the American Association of Vascular Surgery/Society for Vascular Surgery, Society for Cardiovascular Angiography and Interventions, Society for Interventional Radiology, Society for Vascular Medicine and Biology and the American College of Cardiology/American Heart Association Task Force on Practice Guidelines. *Circulation*. 2006;113:e463–e654.

Hoffman U, Edwards JM, Carter S, et al. Role of duplex scanning for the detection of atherosclerotic renal artery disease. *Kidney Int*. 1991;39:1232–1239.

Hollenberg NK. The treatment of renovascular hypertension: surgery, angioplasty and medical therapy with converting enzyme inhibitors. *Am J Kidney Dis*. 1987;10(Suppl 1):52–60.

Holmes CL, Patel BM, Russell JA, et al. Physiology of vasopressin relevant to management of septic shock. *Chest*. 2001;120:989–1002.

Hricik DE, Dunn MJ. Angiotensin-converting enzyme inhibitor-induced renal failure: causes, consequences and diagnostic uses. *J Am Soc Nephrol*. 1990;1:845–858.

Iannone LA, Underwood PL, Nath A, et al. Effect of primary balloon expandable renal artery stents on long-term patency, renal function, and blood pressure in hypertensive and renal insufficient patients with renal artery stenosis. *Cathet Cardiovasc Diagn*. 1996;37:243–250.

Igarashi T, Sekine T, Watanabe H. Molecular basis of proximal renal tubular acidosis. *J Nephrol*. 2002;15(Suppl 5):S135–S141.

Imamura A, Mackenzie HS, Lacy ER. Effects of chronic treatment with an angiotensin converting enzyme inhibitor or an angiotensin receptor antagonist in two-kidney, one-clip hypertensive rats. *Kidney Int*. 1995;47:1394–1402.

Ishidoya S, Morrissey J, McCracken R, et al. Angiotensin II receptor antagonist ameliorates renal tubulointerstitial fibrosis caused by unilateral ureteral obstruction. *Kidney Int*. 1995;47:1285–1294.

Isles CG, Robertson S, Hill D. Management of renovascular disease: a review of renal artery stenting in ten studies. *QJM*. 1999;92:159–167.

Ives NJ, Wheatley K, Stowe RL, et al. Continuing uncertainty about the value of percutaneous revascularization in atherosclerotic renovascular disease: a meta-analysis of randomized trials. *Nephrol Dial Transplant*. 2003;18:298–304.

Jacobson HR. Ischemic renal disease: an overlooked clinical entity? *Kidney Int*. 1988;134:729–743.

Juul SE, Yachnis AT, Christensen RD. Tissue distribution of erythropoietin and erythropoietin receptor in the developing human fetus. *Early Hum Dev*. 1998;52:235–249.

Kaplan-Pavlovcic S, Nadja C. Captopril renography and duplex Doppler sonography in the diagnosis of renovascular hypertension. *Nephrol Dial Transplant*. 1998;13:313–317.

Kaschina E, Unger T. Angiotensin AT1/AT2 receptors: regulation, signaling and function. *Blood Press*. 2003;12:70–88.

Kaunisto K, Parkkila S, Rajaniemi H, et al. Carbonic anhydrase XIV: luminal expression suggests key role in renal acidification. *Kidney Int*. 2002;61:2111–2118.

Kawashima S, Yamashita T, Ozaki M, et al. Endothelial NO synthase overexpression inhibits lesion formation in mouse model of vascular remodeling. *Arterioscler Thromb Vasc Biol*. 2001;21:201–207.

Khanna A, Kurtzman NA. Metabolic alkalosis. *Respir Care*. 2001;46:354–365.

Kidney DD, Deutsch LS. The indications and results of percutaneous transluminal angioplasty and stenting in renal artery stenosis. *Semin Vasc Surg*. 1996;9:188–197.

Kildeberg P. Acid-base status of biological fluids: amount of acid, kind of acid, anion-cation difference, and buffer value. *Scand J Clin Lab Invest*. 1983;43:103–109.

Kim SW, Li Y, Kim S, et al. Local renal and vascular natriuretic peptide system in obstructive uropathic rats. *Urol Res*. 2002;30:97–101.

Kim TS, Chung JW, Park JH, et al. Renal artery evaluation: comparison of spiral CT angiography to intra-arterial DSA. *J Vasc Interv Radiol*. 1998;9:553–559.

Klatzburg RW, Dumoulin CL, Buonocore MA, et al. Noninvasive measurement of renal hemodynamic functions using gadolinium-enhanced magnetic resonance imaging. *Invest Radiol*. 1994;29:5123–5126.

Kliewer MA, Tupler RH, Hertzberg BS, et al. Doppler evaluation of renal artery stenosis: interobserver agreement in the interpretation of wave form morphology. *AJR Am J Roentgenol*. 1994;162:1371–1376.

Knepper MA, Nielsen S, Chou CL, et al. Mechanism of vasopressin action in the renal collecting duct. *Semin Nephrol*. 1994;14:302–321.

Koda M, Sakamoto A, Ogawa R. Effects of atrial natriuretic peptide at a low dose on water and electrolyte metabolism during general anesthesia. *J Clin Anesth*. 2005;17:3–7.

Konrad M, Schlingmann KP, Gudermann T. Insights into the molecular nature of magnesium homeostasis. *Am J Physiol Renal Physiol*. 2004;286:F599–F605.

Korsakas S, Mohaupt MG, Dinkel HP, et al. Delay of dialysis in end-stage renal failure: prospective study on percutaneous renal artery interventions. *Kidney Int*. 2004;65:251–258.

Krijnen P, van Jaarsveld BC, Deinum J, et al. Which patients with hypertension and atherosclerotic renal artery stenosis benefit from immediate intervention? *J Hum Hypertens*. 2004;18:91–96.

Kwon TH, Hager H, Nejsum LN, et al. Physiology and pathophysiology of renal aquaporins. *Semin Nephrol*. 2001;21:231–238.

Laragh JH. Atrial natriuretic hormone, the renin-aldosterone axis, and blood pressure-electrolyte homeostasis. *N Engl J Med*. 1985;313:1330–1340.

Leung JC, Chan LY, Tsang AW, et al. Differential expression of aquaporins in the kidneys of streptozotocin-induced diabetic mice. *Nephrology (Carlton)*. 2005;10:63–72.

Levey AS. Measurement of renal function in chronic renal disease. *Kidney Int*. 1990;38:167–184.

Levraut J, Grimaud D. Treatment of metabolic acidosis. *Curr Opin Crit Care*. 2003;9:260–265.

Libertino JA, Beckmann CF. Surgery and percutaneous angioplasty in the management of renovascular hypertension. *Urol Clin North Am*. 1994;21:235–243.

Loffing J, Kaissling B. Sodium and calcium transport pathways along the mammalian distal nephron: from rabbit to human. *Am J Physiol Renal Physiol*. 2003;284:F628–F643.

Lowe KE, Maiyar AC, Norman AW. Vitamin D-mediated gene expression. *Crit Rev Eukaryot Gene Expr*. 1992;2:65–109.

Madias NE, Adrogue HJ. Cross-talk between two organs: how the kidney responds to disruption of acid-base balance by the lung. *Nephron Physiol*. 2003;93:P61–P66.

Mailloux LU, Napolitano B, Bellucci AG. Renal vascular disease causing end-stage renal disease, incidence, clinical correlates, and outcomes: a 20-year clinical experience. *Am J Kidney Dis*. 1994;24:622–629.

Malay MB, Ashton JL, Dahl K, et al. Heterogeneity of the vasoconstrictor effect of vasopressin in septic shock. *Crit Care Med*. 2004;32:1327–1331.

Mallie JP, Bichet DG, Halperin ML. Effective water clearance and tonicity balance: the excretion of water revisited. *Clin Invest Med*. 1997;20:16–24.

Manjunath G, Sarnak MJ, Levey AS. Prediction equations to estimate glomerular filtration rate: an update. *Curr Opin Nephrol Hypertens*. 2001;10:785–792.

Mann SJ, Pickering TG. Detection of renovascular hypertension: state of the art. *Ann Intern Med*. 1992;117:845–853.

Marana I, Airoldi F, Burdick L, et al. Effects of balloon angioplasty and stent implantation on intrarenal echo-Doppler velocimetric indices. *Kidney Int*. 1998;53:1795–1800.

Marshall FI, Hagen S, Mahaffy RG, et al. Percutaneous transluminal angioplasty for atheromatosis renal artery stenosis—blood pressure response and discriminant analysis of outcome predictors. *Q J Med*. 1990;75:483–489.

Martin RJ. Central pontine and extrapontine myelinolysis: the osmotic demyelination syndromes. *J Neurol Neurosurg Psychiatry*. 2004;75(Suppl. 3):iii22–28.

Meyrier A, Hill GS, Simon P. Ischemic renal diseases: new insights into old entities. *Kidney Int*. 1998;54:2–13.

Michel JB, Dussaule JC, Choudat L. Effects of antihypertensive treatment in one-clip, two kidney hypertension in rats. *Kidney Int*. 1986;29:1011–1020.

Michoudet C, Chauvin MF, Baverel G. Glutamine synthesis from glucose and ammonium chloride by guinea-pig kidney tubules. *Biochem J*. 1994;297:69–74.

Middleton JP. Ischemic disease of the kidney: how and why to consider revascularization. *J Nephrol*. 1998;3:123–136.

Mikami M, Sadahira Y, Haga A, et al. Hypoxia-inducible factor-

1 drives the motility of the erythroid progenitor cell line, UT-7/Epo, via autocrine motility factor. *Exp Hematol*. 2005;33:531–541.

Miller M. Inappropriate antidiuretic hormone secretion. *Curr Ther Endocrinol Metab*. 1994;5:186–189.

Miyazono M, Garat C, Morris KGJ, et al. Decreased renal heme oxygenase-1 expression contributes to decreased renal function during cirrhosis. *Am J Physiol Renal Physiol*. 2002;283:F1123–F1131.

Moe O, Baum M, Berry C, et al. Renal transport of glucose, amino acids, sodium, chloride and water. Brenner BM. *Brenner and Rector's the kidney*. ed 7. WB Saunders: Philadelphia; 2004:413–452.

Mousa AY, Campbell JE, Stone PA, et al. Short- and long-term outcomes of percutaneous transluminal angioplasty/stenting of renal fibromuscular dysplasia over a ten-year period. *J Vasc Surg*. 2012;55:421–427.

Munugalavadla V, Kapur R. Role of c-Kit and erythropoietin receptor in erythropoiesis. *Crit Rev Oncol Hematol*. 2005;54:63–75.

Mustafa MR, Johns EJ. The role of haem oxygenase in renal vascular reactivity in normotensive and hypertensive rats. *J Hypertens*. 2001;19:1105–1111.

Muta K, Krantz SB. Apoptosis of human erythroid colony-forming cells is decreased by stem cell factor and insulin-like growth factor I as well as erythropoietin. *J Cell Physiol*. 1993;156:264–271.

Nagami GT. Ammonia production and secretion by S3 proximal tubule segments from acidotic mice: role of ANG II. *Am J Physiol Renal Physiol*. 2004;287:F707–F712.

Nakao A, Neto JS, Kanno S, et al. Protection against ischemia/reperfusion injury in cardiac and renal transplantation with carbon monoxide, biliverdin and both.

Am J Transplant. 2005;5:282–291.

Nordmann AJ, Woo K, Parkes R, et al. Balloon angioplasty or medical therapy for hypertensive patients with atherosclerotic renal artery stenosis? A meta-analysis of randomized controlled trials. *Am J Med*. 2003;114:44–50.

Novick AC, Fergany A. Renovascular hypertension and ischemic nephropathy. [chapter 7] ed 8. Saunders: Philadelphia; 2002. Walsh PC, Retik AB, Vaughan ED Jr, et al. *Campbell's urology*. vol 1.

Novick AC, Scoble J, Hamilton G. *Renal vascular disease*. Saunders: London; 1996.

Novick AC, Ziegelbaum M, Vidt DG. Trends in surgical revascularization for the renal artery disease—ten years' experience. *JAMA*. 1987;257:498–501.

O'Donovan RM, Gutierrez OH, Izzo JL Jr. Preservation of renal function by percutaneous renal angioplasty in high-risk elderly patients: short-term outcome. *Nephron*. 1992;60:187–192.

Ohta K, Yachie A, Fujimoto K, et al. Tubular injury as a cardinal pathologic feature in human heme oxygenase-1 deficiency. *Am J Kidney Dis*. 2000;35:863–870.

Olbricht CJ, Paul K, Prokop M, et al. Minimally invasive diagnosis of renal artery stenosis by spiral computed tomography angiography. *Kidney Int*. 1995;48:1332–1337.

Olin JW, Froehlich J, Gu X, et al. The United States Registry for Fibromuscular Dysplasia: results in the first 447 patients. *Circulation*. 2012;125:3182–3190.

Olin JW, Piedmonte MR, Young JR, et al. The utility of duplex ultrasound scanning of the renal arteries for diagnosing renal artery stenosis. *Ann Intern Med*. 1995;122:833–838.

Olin JW, Sealove B. Diagnosis, management, and future developments of fibromuscular dysplasia. *J Vasc Surg*. 2011;53(3):826–836.e1.

Olin JW. Recognizing and managing fibromuscular dysplasia. *Cleve Clin J Med*. 2007;74:273–274 [277–282].

Patel NS, Sharples EJ, Cuzzocrea S, et al. Pretreatment with EPO reduces the injury and dysfunction caused by ischemia/reperfusion in the mouse kidney in vivo. *Kidney Int*. 2004;66:983–989.

Pattaragarn A, Alon US. Treatment of congenital nephrogenic diabetes insipidus by hydrochlorothiazide and cyclooxygenase-2 inhibitor. *Pediatr Nephrol*. 2003;18:1073–1076.

Pedersen EB. Angiotensin-converting enzyme inhibitor renography: pathophysiological, diagnostic and therapeutic aspects in renal artery stenosis. *Nephrol Dial Transplant*. 1994;9:482–492.

Perez del Villar C, Garcia Alonso CJ, Feldstein CA, et al. Role of endothelin in the pathogenesis of hypertension. *Mayo Clin Proc*. 2005;80:84–96.

Perrone RD, Steinman TI, Beck GJ, et al. Utility of radioisotopic filtration markers in chronic renal insufficiency: simultaneous comparison of 125I-iothalamate, 169Yb-DTPA, 99mTc-DTPA, and inulin. The Modification of Diet in Renal Disease Study. *Am J Kidney Dis*. 1990;16:224–235.

Pfister MF, Lederer E, Forgo J, et al. Parathyroid hormone-dependent degradation of type II Na+/Pi cotransporters. *J Biol Chem*. 1997;272:20125–20130.

Pimentel JL Jr, Sundell CL, Wang S, et al. Role of angiotensin II in the expression and regulation of transforming growth factor-β in obstructive nephropathy. *Kidney Int*. 1995;48:1233–1246.

Ploth DW. Renovascular hypertension. Jacobson HR, Striker GE, Klahr S. *The principles and practice of nephrology*. ed 2. Mosby: St. Louis; 1995:379–386.

Plouin PF, Chatellier BD, Raynaud A. Blood pressure outcome of angioplasty in atherosclerotic renal artery stenosis: a randomized trial. [for the; ESSAI multicentrique medicaments vs. angioplastie (EMMA) study group] *Hypertension*. 1998;31:823–829.

Pohl MA, Novick AC. Natural history of atherosclerotic and fibrous renal artery disease: clinical implications. *Am J Kidney Dis*. 1985;5:120–130.

Pohl MA. Renovascular hypertension and ischemic nephropathy. [chapter 3] Wiley-Blackwell: Hoboken (NJ); 1999. Schrier RW. *Atlas of diseases of the kidney: hypertension and the kidney*. vol 3.

Pohl MA. The ischemic kidney and hypertension. *Am J Kidney Dis*. 1993;21(Suppl 2):22–28.

Portale AA, Halloran BP, Morris RCJ. Physiologic regulation of the serum concentration of 1,25-dihydroxyvitamin D by phosphorus in normal men. *J Clin Invest*. 1989;83:1494–1499.

Postma CT, Joosten FB, Rosenbusch G, et al. Magnetic resonance angiography has a high reliability in the detection of renal artery stenosis. *Am J Hypertens*. 1997;10:957–963.

Puscas I, Coltau M, Baican M, et al. The inhibitory effect of diuretics on carbonic anhydrases. *Res Commun Mol Pathol Pharmacol*. 1999;105:213–236.

Radermacher J, Chavan A, Bleck J, et al. Use of Doppler ultrasonography to predict the outcome of therapy for renal artery stenosis. *N Engl J Med*. 2001;344:410–417.

Ram CVS, Clagett GP, Radford LR. Renovascular hypertension. *Semin Nephrol*. 1995;15:152–174.

Ramsay LE, Waller PC. Blood pressure response to percutaneous angioplasty: an overview of published series. *BMJ*. 1990;300:569–572.

Rees CR, Palmaz JC, Becker GJ. Palmaz stent in atherosclerotic renal arteries involving the ostia of the renal arteries:

preliminary report of a multicenter study. *Radiology*. 1991;181:507–514.

Rees CR. Stents for atherosclerotic renovascular disease. *J Vasc Interv Radiol*. 1999;10:689–705.

Rene PC, Oliva VL, Bui BT, et al. Renal artery stenosis: evaluation of Doppler US after inhibition of angiotensin-converting enzyme with captopril. *Radiology*. 1995;196:675–679.

Rieumont MJ, Kaufman JA, Geller SC, et al. Evaluation of renal artery stenosis with dynamic gadolinium-enhanced MR angiography. *AJR Am J Roentgenol*. 1997;169:39–44.

Rimmer JM, Gennari FJ. Atherosclerotic renovascular disease and progressive renal failure. *Ann Intern Med*. 1993;118:712–719.

Robertson GL. Physiology of ADH secretion. *Kidney Int Suppl*. 1987;21:S20–S26.

Rocha-Singh K, Jaff MR, Rosenfield K, ASPIRE-2 Trial Investigators. Evaluation of the safety and effectiveness of renal artery stenting after unsuccessful balloon angioplasty: the ASPIRE-2 study. *J Am Coll Cardiol*. 2005;46:776–783.

Rodriguez F, Kemp R, Balazy M, et al. Effects of exogenous heme on renal function: role of heme oxygenase and cyclooxygenase. *Hypertension*. 2003;42:680–684.

Romero J, Hoobler S, Hozak T, et al. Effects of antirenin on blood pressure of rabbits with experimental renal hypertension. *Am J Physiol*. 1973;225:810–817.

Romero J, Mak S, Hoobler S. Effect of blockade of angiotensin I converting enzyme on the blood pressure of renal hypertensive rabbits. *Cardiovasc Res*. 1974;8:681–687.

Rose BD. *Pathophysiology of renal disease*. ed 2. McGraw-Hill: New York; 1987:512–515.

Roth KS, Chan JC. Renal tubular acidosis: a new look at an old problem. *Clin Pediatr (Phila)*. 2001;40:533–543.

Rudic RD, Shesely EG, Maeda N, et al. Direct evidence for the importance of endothelium-derived nitric oxide in vascular remodeling. *J Clin Invest*. 1998;101:731–736.

Rundback JH, Gray RJ, Rozenblit G, et al. Renal artery stent placement for the management of ischemic nephropathy. *J Vasc Interv Radiol*. 1998;9:413–420.

Safian RD, Textor SC. Medical progress: renal-artery stenosis. *N Engl J Med*. 2001;344:431–442.

Sasaki S. Nephrogenic diabetes insipidus: update of genetic and clinical aspects. *Nephrol Dial Transplant*. 2004;19:1351–1353.

Schnermann J, Levine DZ. Paracrine factors in tubuloglomerular feedback: adenosine, ATP, and nitric oxide. *Annu Rev Physiol*. 2003;65:501–529.

Schnermann J, Traynor T, Yang T, et al. Tubuloglomerular feedback: new concepts and developments. *Kidney Int Suppl*. 1998;67:S40–S45.

Schoenberg SO, Prince MR, Knopp MV, et al. Renal MR angiography. *Magn Reson Imaging Clin N Am*. 1998;6:351–370.

Schreiber MJ, Pohl MA, Novick AC. The natural history of atherosclerotic and fibrous renal artery disease. *Urol Clin North Am*. 1984;11:383–392.

Segarra G, Medina P, Vila JM, et al. Increased contraction to noradrenaline by vasopressin in human renal arteries. *J Hypertens*. 2002;20:1373–1379.

Setaro JF, Saddler MC, Chen CC, et al. Simplified captopril renography in diagnosis and treatment of renal artery stenosis. *Hypertension*. 1991;18:289–298.

Shemesh O, Golbetz H, Kriss JP, et al. Limitations of creatinine as a filtration marker in glomerulopathic patients. *Kidney Int*. 1985;28:830–838.

Sikorski EM, Hock T, Hill-Kapturczak N, et al. The story so far:

molecular regulation of the heme oxygenase-1 gene in renal injury. *Am J Physiol Renal Physiol*. 2004;286:F425–F441.

Slovut DP, Olin JW. Fibromuscular dysplasia. *N Engl J Med*. 2004;350:1862–1871.

Sommer G, Noorbehesht B, Pelc N, et al. Normal renal blood flow measurement using phase-contrast cine magnetic resonance imaging. *Invest Radiol*. 1992;27:465–470.

Sos TA. Angioplasty for the treatment of azotemia and renal vascular hypertension in atherosclerotic renal artery disease. *Circulation*. 1991;83(SupplI):162–166.

Spitalewitz S, Reiser IW. Renovascular hypertension: diagnosis and treatment. Oparil S, Weber MA. *Hypertension: a companion to Brenner and Rector's the kidney*. Saunders: Philadelphia; 2000:662–674.

Stavros T, Harshfield D. Renal Doppler, renal artery stenosis and renovascular hypertension: direct and indirect duplex sonographic abnormalities in patients with renal artery stenosis. *Ultrasound Q*. 1994;12:217–263.

Strandness DE Jr. Natural history of renal artery stenosis. *Am J Kidney Dis*. 1994;24:630–635.

Suda T, Suda J, Ogawa M. Disparate differentiation in mouse hemopoietic colonies derived from paired progenitors. *Proc Natl Acad Sci USA*. 1984;81:2520–2524.

Suehiro Y, Muta K, Nakashima M, et al. A novel mechanism in suppression of erythropoiesis during inflammation: a crucial role of RCAS1. *Eur J Haematol*. 2005;74:365–373.

Svetkey LP, Kadir S, Dunnick NR, et al. Similar prevalence of renovascular hypertension in selected blacks and whites. *Hypertension*. 1991;17:678–683.

Sward K, Valsson F, Odencrants P, et al. Recombinant human atrial natriuretic peptide in ischemic acute renal failure: a randomized placebo-controlled trial. *Crit Care Med*. 2004;32:1310–1315.

Sward K, Valsson F, Sellgren J, et al. Differential effects of human atrial natriuretic peptide and furosemide on glomerular filtration rate and renal oxygen consumption in humans. *Intensive Care Med*. 2005;31:79–85.

Takeda Y, Takeno M, Iwasaki M, et al. Chemical induction of HO-1 suppresses lupus nephritis by reducing local iNOS expression and synthesis of anti-dsDNA antibody. *Clin Exp Immunol*. 2004;138:237–244.

Tan KT, van Beek EJ, Brown PW, et al. Magnetic resonance angiography for the diagnosis of renal artery stenosis: a meta-analysis. *Clin Radiol*. 2002;57:617–624.

Textor SC. Revascularization in atherosclerotic renal artery disease. *Kidney Int*. 1998;53:799–811.

Tullis MJ, Caps MT, Zierler RE, et al. Blood pressure, antihypertensive medication, and atherosclerotic renal artery stenosis. *Am J Kidney Dis*. 1999;33:675–681.

Tuohimaa P, Golovko O, Kalueff A, et al. Calcidiol and prostate cancer. *J Steroid Biochem Mol Biol*. 2005;93:183–190.

Tuttle KR, Chouinard RF, Webber JT, et al. Treatment of atherosclerotic ostial renal artery stenosis with the intravascular stent. *Am J Kidney Dis*. 1998;32:611–622.

Uribarri J, Oh MS, Pak CY. Renal stone risk factors in patients with type IV renal tubular acidosis. *Am J Kidney Dis*. 1994;23:784–787.

van Ampting JM, Penne EL, Beek FJ, et al. Prevalence of atherosclerotic renal artery stenosis in patients starting dialysis. *Nephrol Dial Transplant*. 2003;18:1147–1151.

van de Ven PJ, Beutler JJ, Kaatee R. Transluminal vascular stent for ostial atherosclerotic renal artery stenosis. *Lancet*. 1995;346:672–674.

van de Ven PJ, Kaatee R, Beutler JJ, et al. Arterial stenting and balloon angioplasty in ostial atherosclerotic renovascular disease: a randomised trial. *Lancet*. 1999;353:282–286.

van Jaarsveld BC, Krijnen P, Derx FH, et al. The place of renal scintigraphy in the diagnosis of renal artery stenosis: fifteen years of clinical experience. *Arch Intern Med*. 1997;157:1226–1234.

van Jaarsveld BC, Krijnen P, Pieterman H, et al. The effect of balloon angioplasty on hypertension in atherosclerotic renal artery stenosis. *N Engl J Med*. 2000;342:1007–1014.

Vasuvattakul S, Warner LC, Halperin ML. Quantitative role of the intracellular bicarbonate buffer system in response to an acute acid load. *Am J Physiol*. 1992;262:R305–R309.

Vaughan EF Jr, Laragh JH. New concepts of the renin system and vasoconstriction-volume mechanisms. Diagnosis and treatment of renovascular and renal hypertensions. *Urol Clin North Am*. 1975;2:240–241.

Voets T, Nilius B, Hoefs S, et al. TRPM6 forms the Mg2+ influx channel involved in intestinal and renal Mg2+ absorption. *J Biol Chem*. 2004;279:19–25.

Wang GL, Jiang BH, Rue EA, et al. Hypoxia-inducible factor 1 is a basic-helix-loop-helix-PAS heterodimer regulated by cellular O2 tension. *Proc Natl Acad Sci USA*. 1995;92:5510–5514.

Wang T, Sterling H, Shao WA, et al. Inhibition of heme oxygenase decreases sodium and fluid absorption in the loop of Henle. *Am J Physiol Renal Physiol*. 2003;285:F484–F490.

Wang WH. View of K+ secretion through the apical K channel of cortical collecting duct. *Kidney Int*. 1995;48:1024–1030.

Webster J, Marshall F, Abalalla M, et al. Randomized comparison of percutaneous angioplasty vs. continued medical therapy for hypertensive patients with atheromatous renal artery stenosis. Scottish and Newcastle Renal Artery Stenosis Collaborative Group. *J Hum Hypertens*. 1998;12:329–335.

White CJ, Jaff MR, Haskal ZJ, et al. Indications for renal arteriography at the time of coronary arteriography: a science advisory from the American Heart Association Committee on Diagnostic and Interventional Cardiac Catheterization, Council on Clinical Cardiology, and the Councils on Cardiovascular Radiology and Intervention and on Kidney in Cardiovascular Disease. *Circulation*. 2006;114:1892–1895.

Wiesener MS, Seyfarth M, Warnecke C, et al. Paraneoplastic erythrocytosis associated with an inactivating point mutation of the von Hippel-Lindau gene in a renal cell carcinoma. *Blood*. 2002;99(10):3562–3565.

Williams GJ, Macaskill P, Chan SF, et al. Comparative accuracy of renal duplex sonographic parameters in the diagnosis of renal artery stenosis: paired and unpaired analysis. *AJR Am J Roentgenol*. 2007;188:798–811.

Wollenweber J, Sheps SG, Davis GD. Clinical course of atherosclerotic renovascular disease. *Am J Cardiol*. 1968;21:60–71.

Working Group on Renovascular Hypertension. Detection, evaluation and treatment of renovascular hypertension: final report. *Arch Intern Med*. 1987;147:820–829.

Yang B, Bankir L. Urea and urine concentrating ability: new insights from studies in mice. *Am J Physiol Renal Physiol*. 2005;288:F881–F896.

Young MV, Schwartz GG, Wang L, et al. The prostate 25-hydroxyvitamin D-1 alpha-hydroxylase is not influenced by parathyroid hormone and calcium: implications for prostate cancer chemoprevention by vitamin D. *Carcinogenesis*. 2004;25:967–971.

Zeidel ML, Kikeri D, Silva P, et al. Atrial natriuretic peptides inhibit conductive sodium uptake by rabbit inner medullary collecting duct cells. *J Clin Invest*. 1988;82(3):1067–1074.

Zou AP, Billington H, Su N, et al. Expression and actions of heme oxygenase in the renal medulla of rats. *Hypertension*.

2000;35:342–347.

87

Renal Insufficiency and Ischemic Nephropathy

Joshua Augustine MD, Alvin C. Wee MD, Venkatesh Krishnamurthi MD, David A. Goldfarb MD

Acute Kidney Injury

Acute kidney injury (AKI) in is defined by an acute rise in serum creatinine (SCr) and/or an acute decline in urine output. This abrupt decline in kidney function occurs over hours to days and results in the accumulation of byproducts of metabolism and the dysregulation of electrolyte homeostasis, acid/base, and volume status. Changes in blood urea nitrogen (BUN) and SCr have been used as surrogate markers for changes in kidney function. BUN can be altered by other factors and may be disproportionately elevated in states of volume depletion, in hypercatabolic states, or in marked increased in protein loads seen with gastrointestinal bleeding or total parenteral nutrition. Creatinine is a metabolite of muscle and is used to calculate the estimated glomerular filtration rate (GFR), using GFR equations that also account for age, gender, and black race. The two equations most commonly used and often reported with routine lab values include the Modification of Diet in Renal Disease (MDRD) and the Chronic Kidney Disease Epidemiology Collaboration (CKD-EPI) equations (Levey et al., 1999, 2009). The CKD-EPI equation is a modification of the MDRD formula and is less likely to underestimate true GFR in patients with early stages of chronic kidney disease (CKD) (Levey et al., 2009). It is more predictive of mortality associated with CKD than the MDRD equation (Matsushita et al., 2012).

Because of its dependence on muscle mass, SCr may overestimate kidney function in cases of muscle wasting, such as in patients with cirrhosis or prolonged intensive care unit (ICU) stays (Schetz et al., 2014; Skluzacek et al., 2003). Alternatively, at extremes of high muscle mass, SCr may underestimate kidney function. Another marker of kidney function that has been compared with SCr is the measurement of cystatin C, a low-molecular-weight protein that is a member of the cystatin superfamily of cysteine protease inhibitors (Newman et al., 1995). Unlike creatinine, cystatin is not secreted by renal tubules, although it does undergo renal tubular metabolism. Cystatin C does not appear to be as strongly correlated with muscle mass and thus may improve the accuracy of estimating kidney function in patients with extremes of muscle mass and nutrition, such as patients with cirrhosis (Pöge et al., 2006). However, cystatin C levels appear to be altered in states of inflammation, thyroid disease, and smoking, making it an imperfect replacement for SCr (Knight et al., 2004; Manetti et al., 2005). Combining formulas that estimate GFR using both SCr and cystatin C leads to improved precision and accuracy compared with using either variable alone (Inker et al., 2012). Online calculators that allow for combining of such formulas are available. See The National Kidney Foundation website at https://www.kidney.org/professionals/KDOQI/gfr_calculator.

It is also important to recognize that changes in SCr may lag in appearance after an episode of AKI. For example, contrast nephropathy, which may induce kidney injury immediately after contrast exposure, is often associated in a change in SCr evident only after 24 to 48 hours (Rich et al., 1990). **For this reason, it is inappropriate to estimate GFR using a single SCr value in a hospitalized patient whose SCr is fluctuating.** For example, a patient whose SCr doubles from 1 to 2 mg/dL in 24 hours may have advanced kidney failure with lower clearance than a patient with a stable SCr of 2 mg/dL. Conversely, a patient recovering from AKI or after kidney transplantation with an SCr falling from 6 mg/dL to 3 mg/dL in 24 hours has a better GFR than would be reflected by a stable SCr of 3 mg/dL. Such fluctuation in kidney function can create challenges in drug dosing in the hospital setting (Lewis et al., 2016). In addition, drug dosing has historically relied on outdated methods of measurement of kidney function, such as SCr alone or the calculation of creatinine clearance using formulas such as Cockcroft-Gault. The Cockcroft-Gault formula uses patient weight but does not account for morbid obesity, which may positively skew the estimation of creatinine clearance well above the true GFR (Bouquegneau et al., 2016).

Another method occasionally used to estimate kidney function in the hospital setting is a 24-hour urine collection for creatinine clearance. Twenty-four–hour urine is often imprecise and may result in errors related to over- or undercollection. It may be used to assess kidney function in a patient who is suspected of having impaired kidney function beyond that reflected by the SCr alone, or to screen for renal recovery in a patient with nonoliguric AKI. However, in addition to errors in collection, the percentage of creatinine excreted in the tubules can vary and tends to be a higher percentage of total creatinine excretion at lower levels of GFR. Tubular secretion of creatinine may account for more than a third of creatinine measured in the urine and thus may artificially inflate creatinine clearance relative to true GFR (Doolan et al., 1962).

The gold standard for evaluating kidney function is a measurement of GFR using a marker of pure glomerular filtration (Stevens et al., 2009). Inulin has been used historically but is no longer available in the United States. GFR is more often measured by nuclear medicine testing using iothalamate or other isotopes. Few hospitals routinely use nuclear measurement of GFR, but it has been a valuable tool particularly in research designed to derive estimation formulas. It has also been used in some kidney transplant centers to evaluate kidney function in living kidney donor candidates.

One set of criteria used to define AKI is known as the Risk, Injury Failure, Loss of kidney function, and End-stage kidney disease (RIFLE) criteria (Bellomo et al., 2004; Table 87.1), which divides AKI and chronic kidney failure into stages based on severity and duration. The Kidney Disease: Improving Global Outcomes (KDIGO) definition of AKI is also widely used and is described in Table 87.2. Contrasting from the RIFLE criteria, KDIGO includes an acute rise in SCr more than 0.3 mg/dL within 48 hours as a definition of AKI, along with a rise in SCr of at least 1.5 times baseline within 7 days, or urine volume below 0.5 mL/kg/h for 6 consecutive hours (KDIGO, 2012). Unlike RIFLE, the KDIGO criteria do not include scoring related to prolonged kidney failure or end-stage renal disease (ESRD).

TABLE 87.1

The Risk, Injury Failure, Loss of Kidney Function, and End-Stage Kidney Disease (RIFLE) Criteria for Acute Kidney Injury

RIFLE CRITERIA: STAGES	
Stage I	Increase in serum creatinine 50%–99% OR
	Urine output < 0.5 mL/kg/h for 6–12 h
Stage 2	Increase in serum creatinine of 100%–200% OR
	Urine output < 0.5 mL/kg/h for 12–24 h
Failure	Increase in serum creatinine ≥ 200% OR
	Increase in serum creatinine > 0.5 mg/dL to > 4 mg/dL OR
	Urine output < 0.3 mL/kg/h for >24 h or anuria for >12 h OR
	Initiation of renal replacement therapy
Loss	Need for renal replacement therapy for >4 weeks
End stage	Need for renal replacement therapy for >3 months

TABLE 87.2

The Kidney Disease: Improving Global Outcomes (KDIGO) Definition of Acute Kidney Injury

KDIGO CRITERIA: STAGES	
Stage	Increase in serum creatinine ≥ 0.3 mg/dL or 50%–99% OR

1	Urine output < 0.5 mL/kg/h for 6–12 h
Stage 2	Increase in serum creatinine of 100%–200% OR
	Urine output < 0.5 mL/kg/h for 12–24 h
Stage 3	Increase in serum creatinine ≥ 200% OR
	Increase in serum creatinine ≥ 0.3 mg/dL to ≥ 4 mg/dL OR
	Urine output < 0.3 mL/kg/h for > 24 h or anuria for ≥ 12 h OR
	Initiation of renal replacement therapy
	In patients < 18 y/o: a decline in estimated glomerular filtration rate < 35 mL/min/1.73 m^2

Use of these AKI definitions does not account for the cause of AKI, which may be rapidly correctable in cases of volume depletion, or more severe and sustained in cases of intrinsic ischemic kidney injury. Therefore staging alone has some prognostic capability but should optimally be subdivided into cause of AKI. In addition, it is not always clear whether a patient had a normal baseline SCr before AKI, or developed “acute on chronic” kidney injury with underlying CKD. Patients with CKD have a greater risk for AKI (Chawla et al., 2012). AKI may develop before a hospital admission, with an elevation in SCr on presentation, thus affecting definitions that use the change in SCr from admission to a later hospital date. Regardless, it is recommended that the practitioner identify AKI early in its course because even small changes in SCr may indicate a significant change in kidney function. Early consultation with nephrology may also improve outcomes in hospitalized patients with AKI (Balasubramanian et al., 2011).

A classic way to divide AKI is by “prerenal,” “intrinsic,” and “postrenal” or obstructive causes. However, prolonged prerenal physiology may lead to intrinsic kidney ischemia and injury, such as is seen with prolonged hepatorenal syndrome (HRS). Prolonged obstruction can also lead to intrinsic kidney damage. **The greatest proportion of hospital acquired AKI is secondary to acute tubular necrosis (ATN).** A Spanish analysis of 748 cases of AKI in 13 tertiary care hospital centers revealed that ATN accounted for 45% of all AKI (Liaño et al., 1996). Alternatively, immune-mediated AKI from glomerulonephritis or acute interstitial nephritis accounted for less than 10% of cases (Table 87.3).

TABLE 87.3

Cause of Hospital-Acquired Acute Kidney Injury in 748 Patients in Thirteen Tertiary Care Centers in Madrid, Spain

CAUSE	**PERCENTAGE**
Acute tubular necrosis	45
Prerenal disease	21
Acute on chronic kidney disease (primarily resulting from acute tubular necrosis or prerenal)	13
Obstructive disease	10
Glomerulonephritis or vasculitis	4
Acute interstitial nephritis	2
Atheroembolic disease	1

Prerenal Kidney Injury

Prerenal AKI is caused by new renal hypoperfusion that leads to a fall in GFR typically with urinary sodium avidity, as noted by a reduction in urinary sodium or the fractional excretion of sodium (FeNa) in the urine. **The hallmark of prerenal disease is its reversibility after treatment of the underlying cause, with absence of structural damage to the kidney if treatment promptly.** Recovery of renal function within 24 to 72 hours of volume resuscitation or correction of renal hemodynamics helps to define prerenal AKI in isolation.

The kidney can maintain normal renal blood flow and GFR with systemic perfusion pressures as low as 55 to 60 mm Hg under normal conditions (Walsh et al., 2013), although such autoregulation of kidney blood flow may be compromised in CKD, making patients with chronic disease more susceptible to AKI. In the setting of low systemic blood pressure, renal angiotensin II, which has selective vasoconstriction on the efferent (postglomerular) arteriole, and vasodilatory prostaglandins, which dilate the afferent (preglomerular) arteriole, play an important role in maintaining glomerular hydrostatic pressure and GFR. **Drugs that inhibit angiotensin, such as angiotensin-converting enzyme (ACE) inhibitors and angiotensin receptor blockers (ARBs), exert a vasodilatory effect on the efferent arteriole and thus reduce glomerular pressure and filtration fraction. Such agents are of great value in treatment of diabetic nephropathy and congestive heart failure and help to reduce proteinuria and convey renal protection in proteinuric kidney disease. However, they may increase the risk of prerenal AKI as well as hyperkalemia during periods of hypotension and hypoperfusion and are thus often held in the hospital setting after identification of AKI.** In addition, drugs that inhibit prostaglandins such as nonsteroidal anti-inflammatory drugs

(NSAIDs) can contribute to the risk of prerenal and intrinsic AKI (Whelton, 1999).

Although prerenal AKI may often occur as a result of volume depletion such as after hemorrhage or GI losses, it can also occur in instances of total body overload. For example, **congestive heart failure and cirrhosis often occur with total body overload, edema and/or ascites and yet are defined by prerenal AKI typically with a low urine sodium concentration and low FeNa.** Other causes of prerenal AKI related to volume overload include third spacing related to low albumin states, sepsis, and burn injury. These conditions can create a reduction in “effective” circulating volume. Such prerenal states are difficult to manage because administration of crystalloid only worsens total body volume overload and third spacing. **Treatment is directed toward treating the underlying disease states in an effort to optimize systemic hemodynamics and renal perfusion.** In heart failure, paradoxically, prerenal AKI may improve with diuresis using agents such as loop diuretics. Improvement in right heart function (Testani et al., 2010) and reduction in venous back pressure on the kidneys (Bock and Gottlieb, 2010) may explain improved kidney function with diuresis in heart failure.

The sympathetic nervous system and the renin-angiotensin cascade are activated in prerenal AKI in the face of reduced blood flow. In addition, hypotension is a powerful stimulus for the release of antidiuretic hormone (ADH) from the posterior pituitary gland. ADH release is triggered by baroceptor activation in response to low systemic blood pressure, and it causes free water retention even in the face of normal or low serum sodium concentrations (Bankir et al., 2017). ADH binds to V2 receptors in the distal collecting tubule of the kidney, leading to increased transcription and insertion of aquaporin-2 water channels and free water absorption, often leading to hyponatremia. **The most common cause of hyponatremia in the hospital setting is related to such “hypovolemic” hyponatremia, as opposed to other conditions such as the syndrome of inappropriate ADH secretion (SIADH).** It is important to assess volume status through measurements of urine sodium, FeNa in the urine, and other measures such as orthostatic blood pressure monitoring. **In hyponatremia related to volume depletion, urinary sodium, and FeNa tend to be low (UNa < 20 mEq/L, FeNa < 1%).** Serum sodium levels correct quickly with volume repletion, typically with the use of normal saline or other isotonic crystalloid therapy. Hyponatremia in patients with volume overload but ineffective circulating volume is also typically associated with low urine sodium. It is more difficult to manage and often requires diuresis and free water restriction. Tolvaptan, an arginine vasopressin receptor antagonist, blocks the V2 receptor and leads to a rapid water diuresis in patients with a high ADH response. It has been used in patients with SIADH and in patients with congestive heart failure (Konstam et al., 2007). The use of tolvaptan has been curtailed somewhat by the rapid correction of serum sodium that can be seen, high cost of the agent, and a “black box” warning against its use in patients with liver impairment, leading to avoidance in cirrhotic patients.

HRS represents a unique and severe form of prerenal AKI in patients with cirrhosis, acute hepatitis, or any acute form of hepatic decompensation. HRS can be seen in the hospital setting, and the risk increases with additional known risk factors, including bacterial peritonitis and gastrointestinal bleeding (Wu et al., 2006). Dilation of the splanchnic vasculature mediated by nitric oxide appears to drive HRS pathophysiology (Iwakiri, 2007). Temporary improvement in AKI associated with HRS has been associated with the use of albumin, along with midodrine, an α_1 agonist, which mediates vasoconstriction, and octreotide, a somatostatin analogue that decreases splanchnic blood flow (Angeli et al., 1999). Terlipressin, a vasopressin analogue, has been shown to improve renal function in HRS relative to midodrine and octreotide (Cavallin et al., 2015), but it can cause intestinal ischemia and is currently not available in the United States. The gold standard therapy for HRS is liver transplantation, which can result in reversal of HRS pathophysiology and recovery of kidney function (Gonwa et al., 1991). Prolonged HRS, however, may result in permanent kidney injury, and the decision to allocate a kidney allograft with a liver (simultaneous liver kidney transplantation) is in part related to the duration of AKI related to HRS. Recent guidelines for combined liver kidney allocation define advanced AKI with an eGFR of 25 mL/min or less and/or dialysis dependence for 6 consecutive weeks as an appropriate duration of AKI to warrant a combined liver and kidney transplant rather than liver transplant alone (Formica et al., 2016).

Postrenal Kidney Injury

Obstruction of the urinary tract can be a cause of AKI and can be acute or chronic, complete or partial, and involve any area of the lower urinary tract. Obstructive uropathy often occurs in the outpatient setting, and patients often are seen in the clinic or hospital with functional impairment (Gottlieb et al., 1997).

Unilateral obstruction may initially go unnoticed in terms of kidney function and changes in SCr, although patients may gradually lose function in a single kidney, rendering them with reduced kidney mass and GFR. Chronic obstruction, whether partial or complete, may lead to tubule-interstitial atrophy and fibrosis, with irreversible loss of kidney function (Klahr, 1991). Patients may develop a distal renal tubular acidosis, with hyperkalemia, mild sodium wasting, and reduced serum bicarbonate levels (Batlle and Arruda, 2018). The duration of obstruction predicts recovery of kidney function, and ideally obstruction should be relieved as soon as possible and within a week of onset at most (Better et al., 1973).

Bilateral obstruction presents dramatically, often with oligoanuria, advanced kidney failure, and electrolyte perturbations. **Common causes of bilateral obstruction include congenital posterior urethral valves in a younger population, bladder dysfunction including neurogenic bladder, and prostatic disease in men. Oligoanuria is a diagnostic sign that suggests complete obstruction and is an uncommon feature of AKI overall.** Other causes of anuric AKI include shock, which is readily apparent upon presentation, severe ATN, bilateral vascular occlusion, hemolytic-uremic syndrome, or severe cases of crescentic glomerulonephritis such as anti-glomerular basement membrane (GBM) disease.

A kidney ultrasound is a sensitive test for identifying hydronephrosis related to obstruction. However, there is a high false-positive rate, which can vary depending upon the index of suspicion (Kamholtz et al., 1989). The negative predictive value is high, although false-negative tests may also be seen with early obstruction. In addition, **metastatic malignancies involving the ureters or retroperitoneal fibrosis may mask hydronephrosis by restricting the ability of the ureters to expand** (Somerville et al., 1992). Further imaging may be indicated, such as computed tomography (CT) scanning, with noncontrast imaging if there is suspicion or concern for kidney stones. A simple bladder scan may reveal a distended bladder resulting from bladder outlet obstruction. Foley catheter placement relieves obstruction related to bladder outlet obstruction and allows for sampling of the urine for urinalysis (UA) and culture. Dilation at the level of the ureteropelvic junction with minimal bladder filling is more typically a result of a kidney stone or ureteropelvic malignancy.

One challenge that urologists commonly face after the relief of obstructive uropathy is “postobstructive diuresis.” This usually represents an appropriate response to prolonged obstruction with elimination of excess fluid and sodium.

However, there may be dysregulation with inappropriate water loss resulting from tubular injury or an osmotic effect created by excretion of elevated blood urea nitrogen (Schlossberg and Vaughan, 1984). This is a condition that typically lasts 24 to 72 hours and can result in dehydration and hypernatremia, as well as electrolyte wasting. Generally it is recommended to replace one-half of the urine output using hypotonic solutions, such as one-half normal saline and to monitor electrolytes closely during this interval. Intravenous (IV) replacement with free water in dextrose may be appropriate in hypernatremic patients.

Intrinsic Kidney Injury

Acute Tubular Necrosis Resulting From Ischemic Injury

Overall, AKI may occur in 2% to 7% of hospitalized patients in tertiary care centers, and the incidence in surgical or medical ICUs may exceed 25% to 35%. **The type of AKI in hospitalized patients is ATN in the majority of cases** (Myers and Moran, 1986; Uchino et al., 2005). Hypoperfusion and ischemic injury most commonly cause ATN in the hospitalized setting related to operative bleeding and intraoperative hypotension, sepsis, and shock.

Contrast Nephropathy

Contrast-induced tubular injury (contrast nephropathy) is common in the hospital setting. It is a type of ATN that is generally reversible but can contribute to patient morbidity, mortality, and long-term kidney impairment. Patients who develop contrast nephropathy are more likely to be older with more comorbidities, including diabetes. Despite general reversibility of AKI, one analysis found a higher 30-day mortality rate in patients with contrast nephropathy than those without after controlling for other factors (Giacoppo et al., 2015). Iodinated contrast, particularly with higher osmolarity, has been shown to induce renal vasoconstriction and medullary ischemia and also cause direct toxic effects at the proximal renal tubules (Persson et al., 2005). Contrast nephropathy may occur with a low FeNa (<1%) because of constrictive or renal tubular obstructive effects (Schwab et al., 1989). An increase in SCr is generally observed at 24 to 48 hours after contrast exposure, and the AKI is typically nonoliguric. Muddy brown casts may be seen on urinary sediment.

Risk factors for contrast nephropathy include older age, preexisting CKD, diabetic nephropathy, congestive heart failure, hemodynamic

instability, high osmolar contrast (Lautin et al., 1991)**, NSAID usage, higher volume of contrast, and volume depletion before contrast exposure.** Preventive measures should be used in patients with CKD. NSAIDs, which can induce vasoconstriction, should be avoided for 24 hours before contrast exposure. Generally, diuretics are held before the procedure as well to avoid volume depletion. **The use of isotonic IV fluids before and after contrast is a staple in the prevention of contrast nephropathy despite only limited data on protection** (Jurado-Román et al., 2015; Luo et al., 2014). There are various strategies related to IV hydration, but in general normal saline is given either in bolus form at 3 mL/kg for an hour or 1 mL/kg for 6 to 12 hours before contrast exposure, followed by 1 to 1.5 mL/kg for 4 to 12 hours after contrast exposure. Sodium bicarbonate solutions may be used, although studies have been mixed in terms of any additional benefit over normal saline. Outcomes with the use of N-acetylcysteine have also been mixed. One large randomized trial with a 2×2 design was unable to demonstrate benefit with either sodium bicarbonate or N-acetylcysteine compared to standard normal saline administration (Weisbord et al., 2018). Iso-osmolar contrast agents (e.g., iodixanol) are preferred in patients with preexisting kidney disease, with slight benefit seen in one recent meta-analysis (Eng et al., 2016). Limiting contrast volume to the lowest amount possible is recommended in high risk patients, and diagnostic angiography may often be performed with minimal contrast (10–20 mL).

One important differential diagnosis in patients with AKI after arterial instrumentation is atheroembolic kidney injury. Atheroembolic disease should be suspected in patients who have other evidence of embolic injury such as lesions in fingers or toes (e.g., “blue toe syndrome”) or symptoms of gut ischemia such as pain, nausea, and vomiting. Patients may develop transient eosinophilia (Scolari et al., 2007) and hypocomplementemia (Lye et al., 1993). The natural history is different from contrast nephropathy, in that kidney injury may be gradual and unremitting, exhibiting a stuttering pattern and progressing to advanced kidney failure. On biopsy, needle-shaped clefts from cholesterol emboli that dissolve during fixation may be seen. These clefts are often surrounded by inflammatory cells, including eosinophils.

Pigment-Related Kidney Injury

Pigment injury related to hemoglobin or myoglobin may be suspected in the appropriate clinical situation, such as severe hemolysis or muscle

breakdown related to trauma, toxicity, or surgical injury, causing rhabdomyolysis. Muscle breakdown is associated with elevation in creatine phosphokinase (CPK) in the bloodstream along with high levels of phosphorus, potassium, and uric acid related to cellular breakdown. Metabolic acidosis is common and hypocalcemia can be severe related to cellular entry, and phosphorus binding is often seen. Myoglobin may cause positive testing for blood by urine dipstick testing in the absence of true hematuria. Myoglobinuria may also be seen early in the course and can contribute to the production of red-brown–tinged urine. The risk of AKI is related to the severity of muscle injury as well as volume status. Early aggressive fluid resuscitation may prevent or limit the extent of kidney injury after muscle injury. Forced alkaline diuresis with bicarbonate based therapy is controversial and requires close monitoring of arterial pH and serum calcium levels every 2 hours ideally in an ICU setting. Bicarbonate therapy may worsen hypocalcemia and promote calcium-phosphorus precipitation.

In urology, two specific clinical circumstances have been identified in association with rhabdomyolysis. The first relates to protracted exaggerated lithotomy positioning, as used in urethral stricture surgery (Anema et al., 2000; Vijay et al., 2011) and robotic-assisted radical prostatectomy (Keene et al., 2010). Gluteal muscles are often affected, and long exposure to lithotomy positioning greater than 5 hours appears to convey greater risk for muscle injury. Attention to padding, positioning, and any maneuver that can reduce the duration of exaggerated positioning help prevent this complication. A second type of surgery that has been associated with rhabdomyolysis is laparoscopic nephrectomy, including after living kidney donor surgery (Deane et al., 2008; Glassman et al., 2007; Kuang et al., 2002). Prolonged lateral decubitus positioning appears to be a risk factor for downside iliopsoas muscle injury, and risk factors also include high body mass index. Unusually severe muscle pain early after surgery along with darkened red-brown urine should prompt an early evaluation with blood CPK levels and measurement of kidney function. As stated earlier, aggressive volume resuscitation may prevent or curtail kidney injury.

Tumor Lysis Syndrome

Tumor lysis syndrome (TLS) is a condition seen in the presence of high tumor burden that may cause AKI in part because of precipitation of uric acid crystals in renal tubules causing urate nephropathy. TLS is most commonly seen after treatment for high-grade lymphomas and leukemias but has also been reported in cases of solid tumors, including renal cell and transitional cell carcinomas (Lin et al., 2007; Norberg et al., 2014). Prophylactic use of agents such as rasburicase, a urate-oxidase enzyme that converts uric acid to allantoin, has greatly reduced the incidence of urate nephropathy associated with TLS. Hyperphosphatemia with subsequent hypocalcemia and calcium-phosphate deposition remain features of TLS and may contribute to AKI by causing nephrocalcinosis. Renal replacement therapy may be required if the calcium-phosphorus product (Ca × Phos) exceeds 70 mg^2/dL^2 (Coiffier et al., 2008; Howard et al., 2011). Potassium levels may also become critically high. Cardiac monitoring and frequent assessment of electrolytes are essential in the management of TLS.

Drug Toxicity as a Cause of Acute Kidney Injury

Nephrotoxic pharmacologic agents are a common source of kidney injury through direct toxic effects or by causing inflammation (interstitial nephritis). Drugs and agents known to cause direct tubular toxicity are shown in Table 87.4. Some, like aminoglycosides, amphotericin B, cisplatin, and ifosfamide, cause renal proximal tubular toxicity, which is cumulative with repeated dosing. Patients with proximal tubular toxicity may initially have a “Fanconi syndrome,” with evidence of proximal tubular wasting, including acidosis with an alkaline urine (proximal renal tubular acidosis), phosphorus wasting, and renal glycosuria.

TABLE 87.4

Drugs/Agents Known to Cause Direct Renal Tubular and Interstitial Toxicity

Antibacterial/antifungal/antiviral
Aminoglycosides
Amphotericin B
Polymyxin, colistin
Vancomycin
Acyclovir
Foscarnet
Cidofovir
Indinavir

- Ritonavir
  - Tenofovir
  - Pentamidine

Iodinated contrast

Nonsteroidal anti-inflammatory drugs

Chemotherapeutic agents

- Cisplatin
- Carboplatin
- Ifosfamide
- Gemcitabine
- Methotrexate

Immunosuppressive/immunomodulating therapy

- Cyclosporine
- Tacrolimus
- Intravenous immunoglobulin

Psychotropics

- Lithium

Mannitol

Zoledronic acid

Some examples of agents recently identified as causing nephrotoxicity include a number of chemotherapeutic agents that have shown great promise in treating and stabilizing various metastatic malignancies. For example, tyrosine kinase inhibitors, including sorafenib and sunitinib, inhibit vascular endothelial growth factor (VEGF), and are known to cause hypertension, proteinuria (typically subnephrotic), and AKI in certain patients. Inhibition of VEGF has been shown to predispose animal models to thrombotic microangiopathy (TMA) (Eremina et al., 2008), and TMA has been a finding on kidney biopsy in patients with tyrosine kinase inhibitor–related kidney injury (Bollée et al., 2009). **Tyrosine kinase inhibitors are approved for the treatment of metastatic renal cell carcinoma, and urologists involved with treatment should be aware of the potential nephrotoxicity associated with such agents.**

Another newer group of chemotherapeutic agents that may induce AKI are the so-called checkpoint inhibitors, which are immunomodulatory agents designed to enhance the immune response against various malignancies. One class, known as programmed cell death receptor-1 (PD-1) inhibitors, includes medications such as nivolumab and pembrolizumab. These agents are used in metastatic renal cell and urothelial carcinomas, along with other malignancies. PD-1 inhibitors may cause immune mediated side effects including skin rash, colitis, hepatotoxicity, and pneumonitis. They are also known to cause AKI with acute interstitial nephritis (AIN) and occasionally immune complex glomerular disease manifesting with heavy proteinuria (Cortazar et al., 2016; Izzedine et al., 2017). **AKI associated with these agents may require cessation of drug therapy and/or corticosteroid treatment.**

Recent epidemiologic data have also linked proton pump inhibitors (PPIs) to acute and chronic kidney disease. PPIs have long been known to cause AIN in a small percentage of patients (Geevasinga et al., 2006). More recently, studies of large patient populations have linked PPIs to CKD and ESRD (Lazarus et al., 2016; Xie et al., 2016). Duration of PPI usage appeared to correlate with risk. It is not entirely clear whether such studies are flawed by residual confounding, but there may be incidences of subacute AIN that go undetected in some patients. It appears prudent to limit PPI usage in patients who can otherwise be managed with dietary changes and/or the use of histamine-2 receptor antagonists. Alternatively, patients with a history of peptic ulcer or esophageal ulceration would likely retain benefit that exceeds risk with maintenance PPI therapy.

In general, interstitial nephritis is common in the hospital setting and can occur acutely (AIN), often related to antibiotic therapy, or chronically, often related to the long-term use of NSAIDs. Table 87.5 lists common drugs associated with AIN. The acute presentation is classically described as including a rash, fever, and eosinophilia. However, a report on AIN in 128 patients described a rash in only 15%, fever in 27%, and eosinophilia in only 23%, and these findings were less common in AIN related to NSAIDs or PPIs (Baker and Pusey, 2004). Urinary eosinophils are commonly measured but are neither sensitive nor specific for AIN (Muriithi et al., 2013). The most common urinary findings are pyuria and hematuria, although a bland urine sediment does not exclude AIN. Thus the diagnosis of AIN requires a high index of suspicion. Sterile pyuria and white cell casts on urine sediment support the diagnosis, and confirmation is made by kidney biopsy. A Spanish registry analysis found AIN in 12.9% of those biopsied for AKI, and the prevalence of AIN appeared to be increasing in the more recent era, particularly in elderly patients (Goicoechea et al., 2013).

TABLE 87.5

Drugs Known to Cause Acute Interstitial Nephritis

Antibiotics
Penicillins

  - Cephalosporins
  - Sulfonamides
  - Ciprofloxacin
  - Rifampin
- **Nonsteroidal anti-inflammatory drugs**
  - Including cyclooxygenase-2 inhibitors
- **Proton pump inhibitors**
- **Checkpoint inhibitor chemotherapeutic agents**
- **Allopurinol**
- **Loop and thiazide diuretics**
- **Anticonvulsants**
  - Phenytoin
  - Carbamazepine
  - Phenobarbital
- **Indinavir**
- **Cimetidine**
- **Mesalamine**

Non–drug-related AIN may be seen in various infections and rheumatologic diseases, including systemic lupus, sarcoidosis, and Sjögren syndrome. **Another emerging disease entity that may cause AIN is so-called IgG-4 related disease, characterized by an inflammatory infiltration predominantly containing IgG-4–positive plasma cells.** Manifestations may include pancreatitis, lymphadenopathy, salivary or orbital involvement, cholangitis, and involvement of other organ systems. **Patients may have AKI related to retroperitoneal fibrosis, which can mimic the appearance of a tumor and cause obstructive uropathy.** IgG-4–related disease may also cause intrinsic kidney injury with a dense AIN displaying a nodular pattern of inflammation on biopsy that can mimic tumor infiltration (Saeki et al., 2010). Patients with kidney involvement often have extrarenal manifestations. Serum IgG-4 levels are elevated in the majority of patients, and serum complement levels are often low, suggesting complement activation. Treatment with corticosteroid therapy and other immunosuppressive agents has been proven effective (Khosroshahi et al., 2015).

Renal Vein Thrombosis

Renal vein thrombosis is a condition occasionally seen in nephrotic patients and patients with malignancy. Renal vein thrombosis is most commonly associated with membranous glomerulonephritis and is more common with glomerular disease associated with malignancy. Loss of anticoagulation factors such as anti-thrombin III and an increase in procoagulant factors predispose nephrotic patients to venous clotting (Loscalzo, 2013). **The classic clinical findings include flank pain (usually unilateral), microscopic or gross hematuria, elevated lactate dehydrogenase (LDH), and an enlarged, swollen kidney on imaging.** Severe AKI is seen in cases of bilateral acute renal vein thrombosis.

Urologists may see renal vein thrombosis associated with renal cell carcinoma with renal vein involvement or external compression or postoperative thrombosis related to manipulation of the renal circulation (partial nephrectomy or renal transplantation). Catheter-directed local thrombolytic therapy has been used with success in cases of AKI (Kim et al., 2006) and in renal transplantation (Fulton et al., 2011). In cases of renal malignancy, nephrectomy with removal of the tumor thrombus is usually the therapy of choice.

Clinical Approach to the Differential Diagnosis of Acute Kidney Injury

Distinguishing among prerenal, intrinsic, and postrenal causes of AKI should be feasible with appropriate attention to the history, physical, laboratory, and imaging results. A thorough history and physical examination to assess volume status, cardiovascular hemodynamics, potential nephrotoxic insults, and evidence of systemic disease should be undertaken in patients with AKI. All interventions and drug therapies surrounding an AKI event should be outlined against the timeline of changes in kidney function. Risk factors associated with AKI such as advanced age, heart failure, liver failure, baseline CKD, diabetes, and recent surgery should be identified. Exposures including radiocontrast and potential inciting pharmacologic agents may offer clues as to the cause. In perioperative AKI, the duration of the procedure, blood loss, hemodynamic instability, integrity of the urinary tract, and intraoperative drug treatment are critical to review.

Vital signs and hemodynamic parameters should be assessed, including the measurement of orthostatic hypotension, correctly performed, which may identify volume depletion and prerenal AKI. Hypertension and third spacing of volume identify patients who would benefit from diuresis or possible renal replacement therapy. Daily weights and accurate intake and output are essential in the management of AKI in hospitalized patients. Central venous pressure monitoring may also be beneficial, particularly after major surgery and in an ICU setting.

Examination of the UA and urinary studies is fundamental to the evaluation of the patient with AKI (Perazella and Parikh, 2009). A basic UA may distinguish between various causes of AKI. A urine sediment should also be examined. The nephrologist may assist in identifying cells and casts after urine cytospin because relying on automated laboratory reporting of urinary casts from UA samples is unreliable (Cavanaugh and Perazella, 2018). Heavy proteinuria, hematuria, and red cell casts on urinary sediment are classic findings of acute glomerulonephritis, which may require a prompt biopsy and institution of immunosuppressive therapy. Proteinuria can further be quantified by a spot urinary protein to creatinine or albumin to creatinine ratio or by 24-hour urine collection. Nephrotic range proteinuria (>3.5 g protein/24 h) is highly suggestive of glomerular disease and typically prompts a biopsy, unless there is a high suspicion for diabetic nephropathy or a contraindication to biopsy. Alternatively and more commonly in the hospital setting, a bland urine is noted on UA, and “muddy brown” casts may be seen on urine microscopy, helping to confirm the diagnosis of ATN. Sterile pyuria and hematuria in association with white blood cell casts on urine microscopy is suggestive of AIN and should prompt a careful review of medication exposure and consideration for kidney biopsy and/or treatment. Tuberculosis, chlamydia, ureaplasma, and mycoplasma are infectious agents that may also cause sterile pyuria.

The urine sodium and FeNa are helpful in delineating prerenal physiology in AKI. Typically, a urine sodium under 20 mEq/L and a FeNa under 1% are markers of a prerenal state and are usually associated with a bland UA (Table 87.6). The FeNa is superior to measurement of urinary sodium alone because it does not vary by urinary volume. Low sodium and FeNa may also be seen in shock, heart failure, HRS, contrast nephropathy, rhabdomyolysis, or acute GN. One caveat to urinary sodium analysis is that patients on diuretic therapy may have higher values despite volume depletion. An alternative measurement that may be undertaken is the fractional excretion of urea (FeUrea) (see Table 87.6). FeUrea is typically less than 35% in prerenal disease and 50% to 65% in ATN (Carvounis et al., 2002; Pépin et al., 2007). Renal reabsorption of urea relies on intact proximal tubular function and may not be accurate in the face of hyperglycemia or other causes of osmotic diuresis.

TABLE 87.6

Formulas for the Fractional Excretion of Sodium and Urea

FeNa, % = UNa × SCr / SNa × UCr × 100

FeUrea, % = Urea × SCr / SBUN × UCr × 100

B, Blood; *BUN*, blood urea nitrogen; *Cr*, creatinine; *Fe*, fractional excretion; *Na*, sodium; *U*, urine.

Imaging is typically incorporated in the evaluation of AKI. As mentioned earlier, renal ultrasound is instrumental in identifying most cases of obstructive uropathy and can also identify chronic changes that may be seen after prolonged kidney injury and CKD. Total kidney size reduction and loss of cortical echogenicity correlate with tubular atrophy and interstitial fibrosis and may guide intervention. For example, a chronically obstructed kidney that is small and atrophied may not recover significant function after ureteral stenting or surgical intervention. CT imaging with low radiation dose is a highly sensitive test to identify or confirm stone disease and can be used in the absence of IV contrast in patients with AKI. **CT has improved sensitivity in identifying kidney stones relative to plain abdominal radiography and avoids the contrast required for IV urography** (Pfister et al., 2003).

Management of Acute Kidney Injury

The management of AKI focuses on reversing any prerenal condition, restoring and maintaining euvolemia, and eliminating nephrotoxic drugs when clinically appropriate. Early consultation with a nephrologist improves the outcome of AKI in some studies of critically ill patients (Mehta et al., 2002; Ponce et al., 2011). During the initial evaluation, it is imperative to search for reversible causes such as volume depletion, obstruction, and vascular occlusion. A trial of parenteral hydration with isotonic fluids may correct AKI secondary to prerenal causes (Prowle et al., 2014). Thereafter fluid status should be monitored vigilantly to maintain euvolemia. In patients with oliguria, special attention must be provided to avoid excessive hydration and volume overload, which could precipitate the need for renal replacement therapy.

Diuretic therapy is commonly used in patients with AKI and volume overload. **Response to diuretic therapy may depend on the severity of kidney injury, but diuretic therapy used appropriately neither hinders nor hastens recovery from AKI.** Response to diuretic therapy is a favorable prognostic sign in AKI (Cosentino, 1995). When dosing loop diuretics such as furosemide, a response to an IV bolus can be assessed within 60 minutes of administration. If there is no significant augmentation in urine output, the dose should be increased to find the threshold dose for a given patient. If a dose response is established, IV furosemide may be dosed every 6 to 8 hours at the amount required to elicit a diuretic response. Alternatively, a continuous infusion may be administered. For example, if a patient responds to 60 mg of IV furosemide bolus, he or she may be converted to a 10 mg/h continuous infusion. Continuous infusions increase the area under the curve of therapeutic efficacy, allowing for more consistent dosing. In one comparison study of heart failure patients there was a trend for increased dosage requirement with bolus dosing compared with continuous therapy, and there was a trend for fewer complications with continuous infusion as well (Felker et al., 2011).

Bumetanide and torsemide are alternative loop diuretic agents and have the advantage of increased potency and improved oral bioavailability compared with furosemide. Torsemide also exhibits a longer duration of action compared with furosemide. Comparison of dosing of loop diuretics is shown in Table 87.7. Ethacrynic acid is occasionally used when patients have exhibited drug allergies to the sulfonamide component of loop diuretics. However, ethacrynic acid may be more ototoxic than the sulfonamide diuretics at high doses, and it is difficult to administer intravenously because of the relative insolubility. **Patients who fail to respond to high doses of loop diuretics may respond to the addition of a low dose of thiazide diuretic, such as metolazone 2.5 to 5 mg/d.** Distal sodium absorption may be augmented, particularly in patients on chronic loop diuretic therapy, and an impressive increase in diuresis may be observed by combining loop and thiazide diuretic therapy. Close monitoring of electrolytes is essential with such dual diuretic therapy because hypokalemia and metabolic alkalosis are common side effects. If there is minimal response to high-dose loop diuretic therapy combined with a thiazide in an oliguric patient, then dialysis or ultrafiltration therapy should be considered.

TABLE 87.7

Comparison of Dosing, Bioavailability, and Half-Life of Various Loop Diuretics

DRUG	BIOAVAILABILITY	EQUIVALENT DOSING	DURATION OF ACTIVITY	DOSING INTERVAL
Furosemide	50% with variability	40 mg	6 h	Daily to q6h

oral				
Furosemide IV	100%	20 mg	6 h	Daily to q6h
Bumetanide oral	80%–90%	1 mg	6 h	Daily to q12h
Bumetanide IV	100%	1 mg	6 h	Daily to q12h
Torsemide oral	80%–90%	20 mg	8–12 h	Daily to q12h
Torsemide IV	100%	20 mg	8–12 h	Daily to q12h
Ethacrynic acid oral	100%	50 mg	6 h	Daily to q8h
Ethacrynic acid IV	100%	50 mg	6 h	Daily to q8h

IV, Intravenous.

Other agents such as low-dose dopamine and fenoldopam have not been shown to improve outcomes in AKI. One randomized trial assigned 328 critically ill patients to low-dose dopamine (2 μg/kg/min) versus placebo. There were no differences in renal recovery, need for dialysis, hospital stay, or mortality between groups (Bellomo et al., 2000). Even “renal” dose dopamine may precipitate cardiac arrhythmias and should be used with caution. A large randomized trial using fenoldopam, a selective dopamine receptor-1 agonist, similarly did not show any improvement in AKI compared with placebo (Bove et al., 2014). The study included 667 cardiac surgical patients with early AKI who were randomized to fenoldopam versus placebo. There were no differences in rates of dialysis or mortality, and patients on fenoldopam had a higher rate of hypotension.

Electrolyte abnormalities are common after AKI, and hyperkalemia is the most common and dangerous electrolyte abnormality in the AKI setting (Fordjour et al., 2014; Hoorn et al., 2013). If serum potassium levels exceed 6 mEq/L, an electrocardiogram (ECG) should be obtained and evaluated. Peaked T waves may be observed with broadening of the PR interval, which may lead to QRS broadening and the potential for maturation into a sine waveform. The goals for treatment of hyperkalemia in the face of ECG changes include stabilization of the cardiac conduction system, shifting potassium intracellularly, and eventual elimination of excess potassium from the body. Stabilizing the cardiac membrane may be achieved by immediate administration of calcium salts. Shifting potassium into cells may be accomplished by insulin therapy (usually with glucose to prevent hypoglycemia), sodium bicarbonate, or β_2-adrenergic agonist therapy. A cationic binding resin such as sodium polystyrene sulfonate (SPS) may be used to augment potassium excretion in the gut. SPS appears to have modest efficacy (Hagan et al., 2016). There are reported cases of intestinal necrosis with SPS, with or without the concomitant use of sorbitol (Goutorbe et al., 2011). Its use should be avoided in patients with postoperative ileus, intestinal obstruction, or active colitis.

Two newer agents have been approved that augment the excretion of potassium and are the first agents available since SPS was approved for use in 1958. Patiromer is a nonabsorbed polymer that exchanges potassium for calcium in the gastrointestinal tract. It has efficacy in dropping potassium levels over days by approximately 0.75 mEq/L in patients with CKD, with minimal adverse effects including constipation and hypomagnesemia (Bushinsky et al., 2015; Weir et al., 2015). It is taken in powder form mixed with water and must be separated from other oral medications. However, because of its delayed onset of action, patiromer is not indicated for the treatment of severe acute hyperkalemia. **A second agent, sodium zirconium cyclosilicate (ZSC), was approved for use in the United States in 2018. It is also a nonabsorbed inorganic cation exchange agent that works in the gastrointestinal tract by exchanging potassium for hydrogen and sodium.** It also can lower potassium over 48 hours and is not approved for emergent treatment of severe hyperkalemia but holds promise as an agent with minimal adverse effects (Hoy, 2018).

Despite medical intervention, dialysis therapy may be required for patients with severe, persistent AKI. The indications for initiation of dialysis therapy include volume overload, severe hyperkalemia, severe metabolic acidosis, pericarditis, selected poisonings and drug overdoses, and uremic symptomatology. There are disparate outcomes from studies examining the utility of starting dialysis earlier in the course of AKI in the ICU setting. One study in patients with septic shock and advanced failure by RIFLE criteria (see Table 87.1) were randomized to early renal replacement therapy within 12 hours versus delaying more than 48 hours if there was no urgent indication for dialysis. Mortality rates were similar at 90 days between groups, and dialysis was avoided altogether in 38% of the delayed group (Barbar et al., 2018). A theoretical concern exists that the dialysis treatment may have a detrimental impact on recovery of AKI. A drop in urine output is often seen during and after intermittent dialysis therapy, and hypotension often occurs during therapy. There may be a greater risk for ischemic injury during dialysis treatment, and efforts should be made to avoid exacerbating hypotension and hemodynamic instability. Slower, continuous dialysis modalities are often used in the ICU setting, particularly in hypotensive patients or in patients dependent on pharmacologic vasopressor support.

Key Points: Acute Kidney Injury

- AKI is defined by an acute rise in SCr and/or an acute decline in urine output. This abrupt decline in kidney function occurs over hours to days and results in the accumulation of byproducts of metabolism and the dysregulation of electrolyte homeostasis, acid/base, and volume status.
- A classic way to divide AKI is by “prerenal,” “intrinsic,” and “postrenal” or obstructive causes. The hallmark of prerenal disease is its reversibility after treatment of the underlying cause, with absence of structural damage to the kidney if treatment promptly.
- Prolonged prerenal physiology may lead to intrinsic kidney ischemia and injury. The greatest proportion of hospital-acquired AKI is secondary to ATN.
- Nephrotoxic pharmacologic agents are a common source of kidney injury through direct toxic effects or by causing inflammation (interstitial nephritis).
- Examination of the UA and urinary studies, including measurement of electrolytes and protein concentration, are fundamental to the evaluation of the patient with AKI.

Chronic Kidney Disease

CKD is defined as kidney impairment sustained beyond 3 months with a reduction in GFR, structural abnormalities in the kidneys, and/or proteinuria (often defined specifically by albuminuria). As described earlier, estimations in GFR may be derived from the MDRD and CKD-EPI equations and should be used when kidney function and SCr are at steady state. The 2012 KDIGO guidelines included albuminuria in the definition of CKD to emphasize the prognostic implications related to abnormal urinary protein excretion. For example, a patient with diabetic nephropathy who has a GFR of 60 mL/min/1.73 m^2 and is excreting 3 g/day of albuminuria is more likely to progress to ESRD than a patient with a GFR of 45 mL/min/1.73 m^2 related to prior kidney injury and no albuminuria. The interplay between albuminuria and GFR as outlined by the 2012 KDIGO guidelines is shown in Fig. 87.1.

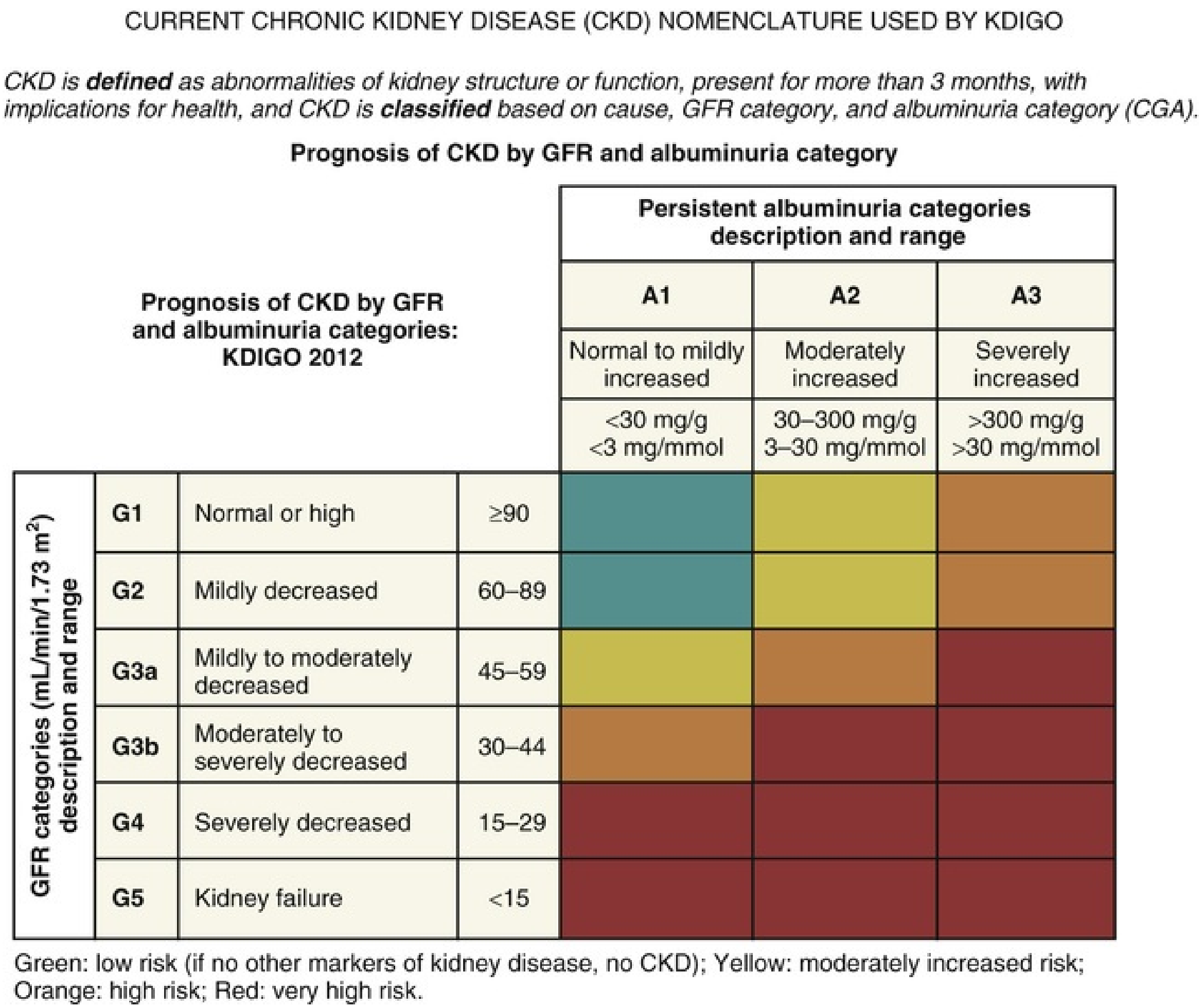

CURRENT CHRONIC KIDNEY DISEASE (CKD) NOMENCLATURE USED BY KDIGO

*CKD is **defined** as abnormalities of kidney structure or function, present for more than 3 months, with implications for health, and CKD is **classified** based on cause, GFR category, and albuminuria category (CGA).*

Prognosis of CKD by GFR and albuminuria category

Prognosis of CKD by GFR and albuminuria categories: KDIGO 2012				**Persistent albuminuria categories description and range**		
				A1	**A2**	**A3**
				Normal to mildly increased	Moderately increased	Severely increased
				<30 mg/g <3 mg/mmol	30–300 mg/g 3–30 mg/mmol	>300 mg/g >30 mg/mmol
GFR categories (mL/min/1.73 m^2) description and range	**G1**	Normal or high	≥90	🟩	🟨	🟧
	G2	Mildly decreased	60–89	🟩	🟨	🟧
	G3a	Mildly to moderately decreased	45–59	🟨	🟧	🟥
	G3b	Moderately to severely decreased	30–44	🟧	🟥	🟥
	G4	Severely decreased	15–29	🟥	🟥	🟥
	G5	Kidney failure	<15	🟥	🟥	🟥

Green: low risk (if no other markers of kidney disease, no CKD); Yellow: moderately increased risk; Orange: high risk; Red: very high risk.

FIG. 87.1 Chronic kidney disease (CKD) risk for progression based on Kidney Disease: Improving Global Outcomes (KDIGO) 2013 classification of glomerular filtration rate (GFR) and albuminuria. (From KDIGO Committee: KDIGO 2012 Clinical Practice Guideline for the Evaluation and Management of Chronic Kidney Disease. *Kidney Int Suppl* 3[1]:2012.)

The presence of CKD has implications in terms of greater risk for AKI, and recognizing that CKD is a risk factor for AKI should lead to measures taken to prevent AKI in the hospital or office setting. Precautions should be taken in CKD patients to avoid nephrotoxic drugs, avoid or limit iodinated contrast exposure, and to dose medications appropriately with adjustment for level of kidney function. Conversely, it is important to recognize that AKI often leads to CKD that will require monitoring after renal recovery (Lewington et al., 2013; Pannu, 2013).

Deficits in nephron number may predispose to progressive kidney disease and hypertension. Nephron number averages approximately 600,000 ± 200,000 per normal kidney. Loss of kidney mass through ablation or partial nephrectomy may trigger progressive glomerular injury in the remnant kidney. The injury is associated with hyperfiltration, glomerular hypertrophy, and systemic hypertension (Brenner and Mackenzie, 1997). Proteinuria appears to correlate with degree of nephron loss and time from the loss (Novick et al., 1991). Reduced birth weight or solitary kidney from birth may similarly lead to kidney injury over time because of low nephron number (Bhathena et al., 1985; Hughson et al., 2003; Lopes and Port, 1995). In general, monitoring of kidney function, albuminuria, and blood pressure should be undertaken after loss of kidney mass. This includes living kidney donors, although the typical natural history in kidney donors is an improvement in GFR and lack of proteinuria in the years after donation (Fehrman-Ekholm et al., 2011). The development of albuminuria should lead to targeted therapy in patients with reduced renal mass. The use of ACE inhibitors or ARBs appears to be protective and can reduce proteinuria in a “remnant kidney” model (NDT 9: 131, 1994), (Novick and Schreiber, 1995).

The causes of progressive CKD parallel the most common causes of ESRD. Table 87.8 lists the incident causes of ESRD from the US Renal Data System (USRDS, 2013). Diabetes mellitus and hypertension account for the largest percentage of cases (63%) followed by glomerular diseases (14%). A caveat to such reporting is that many patients go without kidney biopsy and lack a definitive cause of ESRD. **Genetic disease or other occult kidney diseases may commonly go undiagnosed or unrecognized, resulting in the labeling of “hypertensive” kidney disease in the absence of a definitive diagnosis.** This is particularly common in the black community, in which the diagnosis of hypertensive kidney failure is increasingly being recognized to correlate with genetic risk of CKD.

TABLE 87.8

Incidence of Reported Causes of End-Stage Renal Disease

DIAGNOSIS	PERCENTAGE
Diabetes mellitus	38
Hypertension	25
Glomerulonephritis	14
Cystic kidney disease	5
Urologic disease	2
Other/missing/unknown	15

Accordingly, special mention should be made to the identification of genetic risk for CKD in a subset of black patients, which relates to variants in apolipoprotein genetics. Polymorphisms in the genes that encode apolipoprotein L1 (APOL1) are found in patients of sub-Saharan African ancestry, and two separate variants have been identified: G1 and G2. These gene variants appear to convey protection against African sleeping sickness caused by *Trypanosoma* parasitic infection, whether inherited as a single or dual variant (Vanhamme et al., 2003). Inheritance of two *APOL1* gene variants of any combination (G1/G1, G1/G2, or G2/G2) appears to greatly increase the risk of CKD related to hypertensive kidney disease, focal sclerosis, diabetic nephropathy, lupus nephritis, and human immunodeficiency virus associated nephropathy (HIVAN) in patients of African descent (Cohen et al., 2017; Larsen et al., 2013; Parsa et al., 2013). Two gene variants are found in approximately 13% of the black population (Friedman et al., 2011) and explain to a large extent the increased risk of CKD and ESRD seen in blacks in the United States (Freedman et al., 2018). Although APOL1 is a circulating protein, it has also been localized to the podocyte, proximal tubule, and vasculature of the kidney (Madhavan et al., 2011). The idea that the integrity of the kidney may be affected by APOL1 gene variation is suggested by studies in kidney transplantation, which demonstrate reduced allograft survival when kidneys came from deceased donors with high-risk gene variants (Freedman et al., 2016). The long-recognized risk of inferior transplant outcomes with kidneys from black deceased donors also appears to be entirely explained by the disproportionate risk related to the smaller percentage of donors with two APOL1 gene variants (Julian et al., 2017).

Glomerulonephritis

Glomerulonephritis is evolving in terms of accuracy of diagnosis and identification of cause. The diagnosis of focal segmental glomerulosclerosis (FSGS) may represent a primary immune process or a secondary pattern of injury. Secondary forms of FSGS may develop for many reasons, including loss of renal mass such as after partial or total nephrectomy, genetic risk such as *APOL1* gene variants in blacks, a consequence of morbid obesity (Goumenos et al., 2009), or as a consequence of other prior drug or immune-mediated injury. In addition, primary FSGS may be familial rather than immune mediated. Familial FSGS is suggested by a positive family history of disease and an onset of nephrotic syndrome at a very young age (Sadowski et al., 2015). Identifying such secondary or genetic forms of FSGS is critical because these patients would not be expected to benefit from immunotherapy with medications such as corticosteroids or calcineurin inhibitors. Diffuse podocyte effacement on electron microscopic biopsy in the absence of genetic association may alternatively point to a primary FSGS for which immunotherapy would potentially convey benefit (De Vriese et al., 2018). Such primary FSGS patients are more likely to be young adults, Caucasian, and have heavy proteinuria in the nephrotic range.

Nephrotic syndrome is a clinical presentation that may be caused by FSGS or other primary or secondary glomerular diseases. It is characterized clinically by a urinary protein excretion of greater than 3.5 g/day, hypoalbuminemia, and peripheral edema. Primary diseases that may cause nephrotic syndrome include FSGS; minimal change disease, which is especially common in children; membranous nephropathy; and certain types of membranoproliferative diseases. Secondary nephrotic syndrome may be seen in secondary FSGS related to infection such as HIV infection, lupus-associated membranous nephropathy, hereditary diseases, and amyloid or light chain deposition caused by monoclonal proteins.

Abnormal monoclonal proteins in the absence of defined myeloma or amyloidosis may be seen with variable nephrotic and nephritic presentations in the kidneys and has been termed *monoclonal gammopathy of renal significance (MGRS)* (Leung et al., 2012). Accordingly, testing for monoclonal proteins as a potential cause of glomerular disease is essential, with risk for MGRS increasing with age. Serum and urine electrophoresis along with measurements of free light chains kappa and lambda may detect low level monoclonal proteins that may be involved in renal glomerular or tubular pathology. Treatment with agents used to treat myeloma may be indicated even in the absence of other organ disease if renal pathology is present (Sethi and Rajkumar, 2013).

Membranous nephropathy is one of the most common causes of nephrotic syndrome in adults. The diagnosis and treatment of membranous nephropathy have improved because of the discovery of a target antibody against a podocyte protein that is positive in 70% to 80% of idiopathic membranous disease cases. The antibody targets the M-type phospholipase A2 receptor (PLA2R), a transmembrane receptor that is highly expressed in glomerular podocytes (Beck et al., 2009). This antibody may be identified in the glomerulus on kidney biopsy by immunofluorescence or immunohistochemistry staining and may be detected in the circulation by ELISA or other methods. Monitoring of PLA2R Ab titers is useful to guide treatment of membranous nephropathy because clearance of the antibody often precedes a reduction in proteinuria and is predictive of remission (Beck et al., 2011). Reemergence of antibodies may also predict disease recurrence (Ruggenenti et al., 2015). Other antibodies have been identified that are present in a minority of membranous cases, including one targeting thrombospondin type-1 domain-containing 7A (THSD7A), another podocyte transmembrane protein. THSD7A antibodies have been detected in 10% of patients with membranous who lack antibodies to PLA2R (Ren et al., 2018). Some cases of membranous nephropathy with antibodies against THSD7A have been associated with malignancy, and clearance of the antibody leading to remission of glomerular disease has been described with the use of chemotherapy targeting the malignancy directly (Hoxha et al., 2016).

End-Stage Renal Disease Demographics and Treatment Options

There continues to be a steady growth of ESRD patients on renal replacement therapies (RRTs) throughout the world. In the United States the incidence rate for ESRD in 2016 was 373 new cases per million people (US Renal Data System, 2018). The prevalence of ESRD patients has continued to increase since 2006, and the number of patients with ESRD in the United States in 2016 was approximately 726,000. The number of kidney transplants performed annually in the United States has increased slightly and in 2016 was just more than 20,000, with approximately one-third of transplants coming from living kidney donors. Rates of living donation have declined slightly since 2004 and remained relatively level in more recent years. In 2016, 87% of patients with incident ESRD in the United States started hemodialysis, 10% started on peritoneal dialysis, and 3% received a preemptive kidney transplant (before any dialysis therapy). By the end of 2016, 63% of prevalent ESRD patients were on hemodialysis, 7% were on peritoneal dialysis, and 30% had a functioning kidney transplant. **Although home hemodialysis is a modality that has demonstrated improved survival** (Mailloux et al., 1996) **and cost effectiveness** (McGregor et al., 2000)**, only 2% of hemodialysis patients received home treatments in 2016.**

Poor long-term survival of ESRD patients is illustrated by comparing the expected remaining lifetime on dialysis or transplant with the general US population. The expected survival for dialysis patients was less than one-third of those age-matched in the general population, whereas the expected survival in transplant patients was 69% to 85% of that in the general population. The adjusted mortality rate in patients on dialysis was 164 per 1000 patient-years, whereas the rate in transplant recipients was 29 per 1000 patient-years. Importantly, however, survival is improving for patients on dialysis and with transplantation. Between 2001 and 2016, adjusted mortality rates decreased in dialysis patients by 29%. Such improved survival is contributing to the growing prevalence of ESRD patients. This improvement in survival was similar to that seen in non-dialysis patients on Medicare with diabetes and cancer. In transplant patients, the adjusted mortality rates between 2001 and 2016 decreased by 40%. The transplant population is aging. In 2001, 8% of transplant recipients were over the age of 65, and in 2016 the rate increased to 24% (USRDS, 2018).

Outcome comparisons suggest that kidney transplantation is still the best overall treatment for ESRD patients, despite advances in dialysis care and modalities. The time on dialysis (vintage) has an impact on transplant outcomes, with inferior outcomes seen with longer dialysis vintage (Meier-Kriesche et al., 2000). This finding likely relates in part to progressive vascular disease on dialysis therapy but also reflects socioeconomic status and timeliness of listing (Schold et al., 2010). Patients who progress to stage IV CKD with an estimated or measured GFR of 20 mL/min/1.73 m^2 or less are eligible for active transplant listing in the United States and should be counseled and referred for transplant evaluation. Patients at advanced age or with severe medical comorbidities or problems with medical adherence may be excluded from transplant listing. **For those approved, preemptive transplantation, before initiation of dialysis therapy, should be the goal. Because of long waiting times for deceased donor transplantation, preemptive transplant is most likely to be achieved with kidney donation from a living donor.**

Atherosclerotic Renal Artery Stenosis

Atherosclerotic renal artery stenosis, a recognized cause of severe, secondary hypertension and impaired renal function, is present in approximately 7% of individuals older than 65 years (Hansen et al., 2002) and in 40% to 50% of patients with atherosclerotic disease in other vascular beds (Miralles et al., 1998). Clinically relevant complications, specifically resistant hypertension and/or renal atrophy with progressive decline in renal function, develop in 15% to 20% of cases of atherosclerotic renal artery stenosis (Caps et al., 1998; Chabova et al., 2000). In addition, atherosclerotic renal artery stenosis appears to be an independent risk factor for adverse cardiovascular events and increased cardiovascular mortality. In 3 recent studies, patients with atherosclerotic renal artery stenosis had between a two- and fivefold increases in mortality compared with healthy age-matched normotensive control patients (Conlon et al., 2001; Edwards et al., 2005; Johansson et al., 1999). Moreover, the increased risk profile appears to remain despite anatomic correction of atherosclerotic renal artery stenosis.

Atherosclerotic renal artery stenosis accounts for 90% of the lesions that impede blood flow within the renal artery. Fibromuscular dysplasias, vasculitides, congenital bands, and intrinsic and extrinsic causes make up the remaining 10% of causes. Atherosclerosis typically involves the ostium and proximal one-third of the renal artery and can also involve the adjacent aorta. Involvement of segmental renal arteries and higher-order branches is uncommon. Because atherosclerosis is a systemic condition, atherosclerotic renal artery stenosis most often occurs in patients with risk factors for atherosclerosis, such as hypertension, hyperlipidemia, diabetes mellitus, and tobacco use.

Early studies determined the prevalence of renal artery disease in autopsy series. In patients older than 60 years and with a history of hypertension, moderate to severe renal artery stenosis was found in approximately 50% of patients (Holley et al., 1964; Schwartz et al., 1964). Because atherosclerosis-related complications are a leading cause of death, autopsy studies may overestimate the prevalence of atherosclerotic renal artery disease but nonetheless suggest a direct relationship to increasing patient age and severity of hypertension.

The clinical prevalence of atherosclerotic renal artery stenosis, which is frequently identified in patients with cerebrovascular, coronary, and peripheral arterial disease depends on the radiographic definition (percent of renal artery luminal narrowing), imaging technique, and the patient population being studied. In a general population of patients older than 65 years of age the prevalence was noted to be 6.8%, when assessed with duplex Doppler ultrasonography (Hansen et al., 2002). In a systematic review of studies using more sensitive imaging techniques and defining atherosclerotic renal artery stenosis as at least 50%

luminal narrowing, the prevalence ranged between 10.5% in consecutive patients undergoing coronary angiography to 54.1% in patients with congestive heart failure (de Mast et al., 2009). In patients with underlying atherosclerotic conditions, atherosclerotic renal artery stenosis can be anticipated in approximately 10% to 20% of cases. With these sensitive imaging techniques the prevalence of bilateral atherosclerotic renal artery stenosis is 4.2%, in contrast to 0.8% when identified by duplex ultrasonography (de Mast et al., 2009; Hansen et al., 2002).

Pathophysiology of Hypertension in Atherosclerotic Renal Artery Stenosis

Basic Concepts in Arterial Physiology.

Blood flows throughout the circulatory system primarily because of differences in total fluid energy but from a functional standpoint, blood flow can be attributed to differences in pressure gradients. A pressure gradient is maintained by cardiac contractions and elasticity of the arterial system. The basic concept that describes the relationship between blood pressure (and/or flow) and blood vessel diameter follows Pouiseuille's law, which states that the **pressure difference** between two points along a tube is directly proportional to the flow velocity (Q), length of tube (L), and fluid viscosity (η) and is inversely proportional to the second power of the radius of the tube.

$$\text{Pouiseuille's law} = \Delta P = Q8L\eta / r^2$$

Viewed simplistically, this relationship shows that as the radius (or diameter) of a tube decreases, the difference in pressure increases exponentially. Therefore, as the diameter of a blood vessel decreases, the decline in pressure, **ΔP**, increases.

The second important concept relates to the relationship between luminal diameter and cross-sectional area. The cross-sectional area of a tube, which is equal to that of a circle, is expressed as $A=\pi r^2$. This can be further expanded to consider diameter or $A=\pi (d/2)^2$ or $\pi d^2/4$. Again showing that as the diameter of a vessel decreases, the luminal area decreases by the square of the diameter reduction. Early experiments have conclusively shown that clinically significant vascular stenosis, specifically those that cause a pressure drop, occur when the luminal area is reduced by more than 70%, also expressed as “70% stenosis” (May et al., 1963; Fig. 87.2). This corresponds to a diameter reduction of approximately 50% because such a diameter reduction will result in a reduction in cross-sectional area to 25% of the original area.

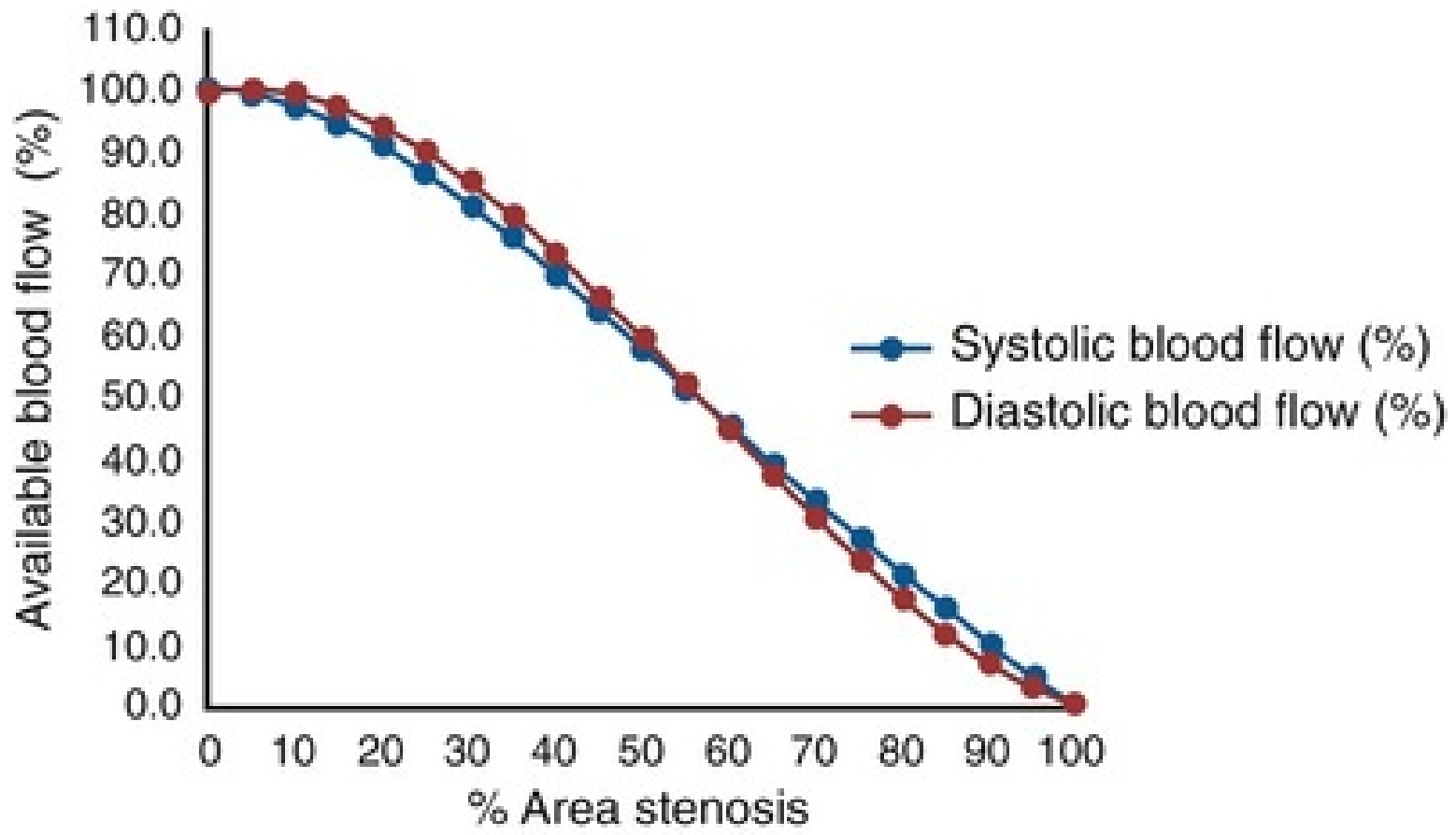

FIG. 87.2 Relationship of blood flow to increasing arterial stenosis.

Given that a constant amount of fluid (blood) circulates through the vascular system, another basic assumption is that blood flow (volume of blood per time) is maintained in all parts of the circulatory system. Extending from the Bernoulli equation, as the diameter of tube decreases, the velocity of the moving fluid increases to maintain the conservation of energy principle of flowing fluids. Importantly, these concepts are based on laminar flow of frictionless fluids through rigid tubes, markedly different from the human circulatory system. Flow is maintained in human arteries by increasing velocity until a critical level of stenosis or approximately a 70% decrease in area. Beyond 70%, flow begins to decrease rapidly, and beyond a 90% stenosis flow and velocity are reduced, compatible with “trickle-flow” (Fig. 87.3).

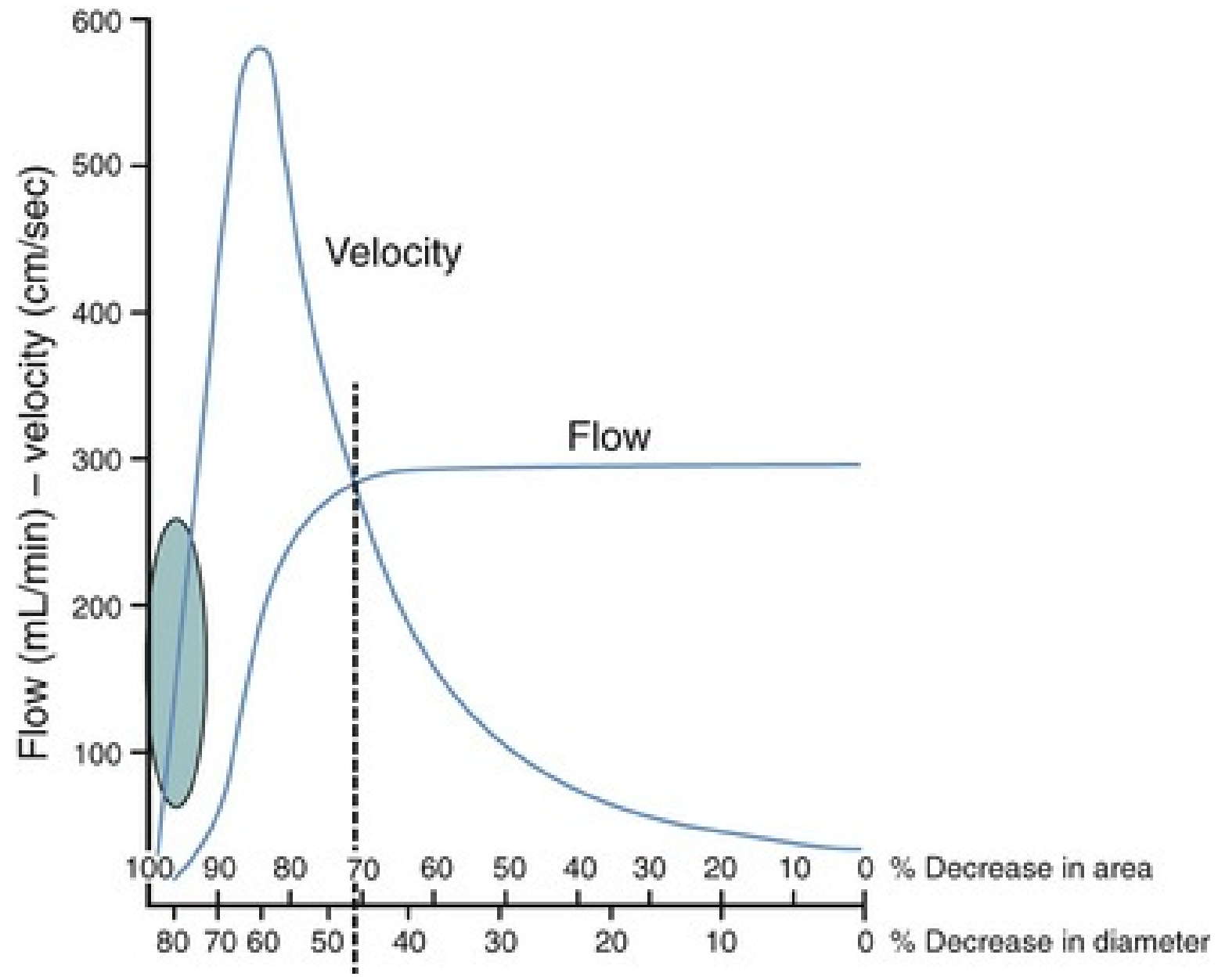

FIG. 87.3 Correlation of percent diameter reduction with increases in blood flow velocity (cm/sec) and reduction in volume flow (mL/min) in arteries. Note that a high-grade (>95%) diameter-reducing stenosis causes volume flow to decrease toward zero, whereas the velocity within the stenosis may be minimally elevated.

Based upon this relationship, flow decreases markedly at critical levels of stenosis (>70%). Under normal systolic blood pressures (120 mm Hg) there is an approximately 40- to 60-mm Hg pressure drop to the level of the afferent arterioles within the kidney (Fig. 87.4).

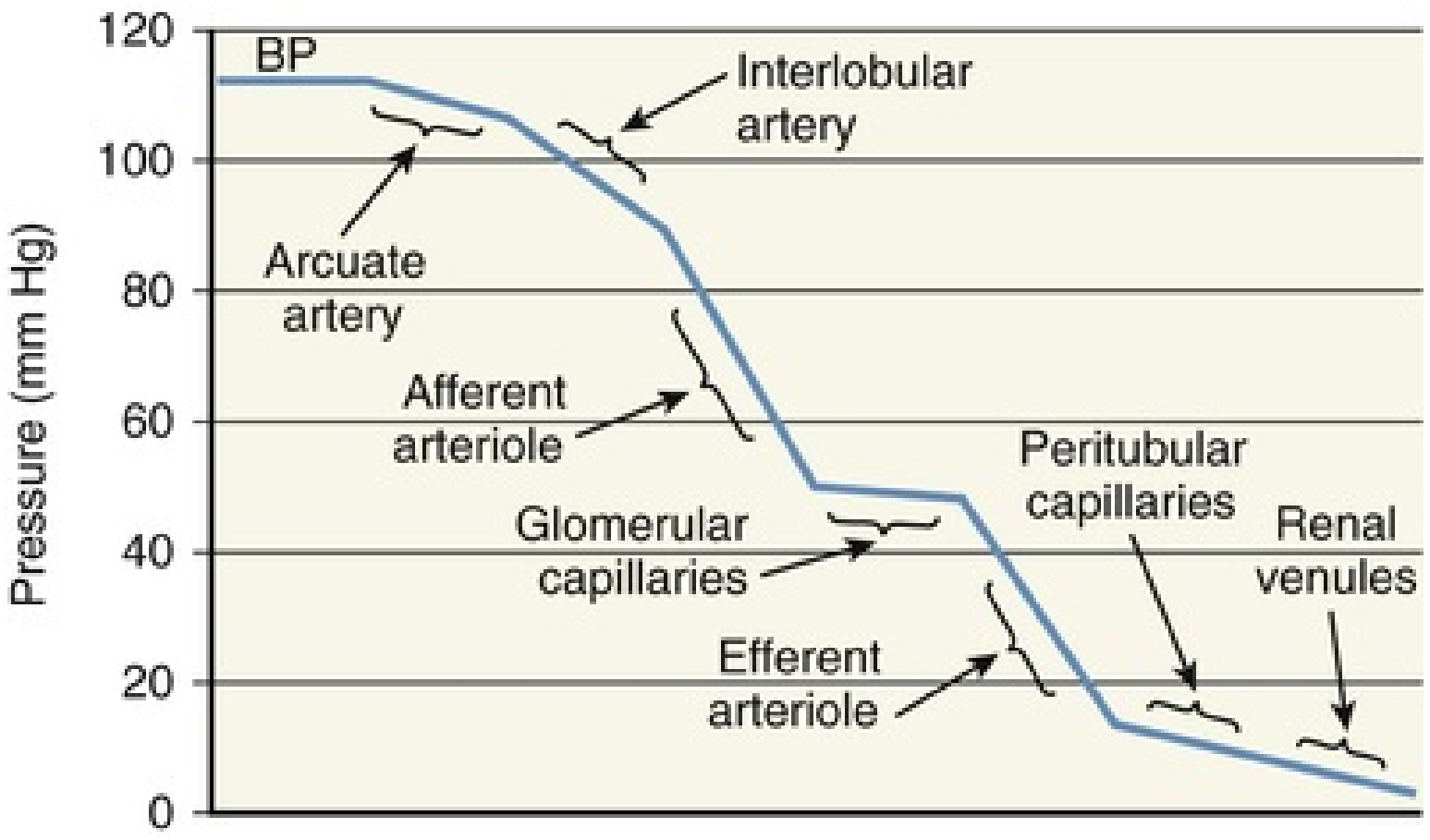

FIG. 87.4 Hydraulic pressure profile in the renal vasculature based on a variety of micropuncture studies in superficial nephrons of the rat and squirrel monkey as well as values obtained by micropuncture of juxtamedullary nephrons in the rat. For these latter studies, the arcuate

artery was perfused with whole blood at normal arterial pressures, and hydraulic pressures were measured at downstream sites, including the interlobular artery, the proximal and distal portions of the afferent arteriole, the glomerular capillaries, the proximal and late segments of the efferent arteriole, the peritubular capillaries, and the renal vein.

De Bruyne et al. (2006) have shown that as the degree of stenosis increases to approximately 50%, the pressure in the renal artery distal to stenosis is 60 to 70 mm Hg. It is likely therefore that at this lower perfusion pressure, the pressure and flow, at the afferent arteriole reaches precipitously low levels, thus initiating the pathophysiologic processes.

The pathophysiologic basis for hypertension resulting from impaired renal blood flow was first elegantly described more than 75 years ago (Goldblatt et al., 1941). These initial studies stimulated numerous experiments that outlined the hormonal basis for the kidney's role in blood pressure control. Adding to these initial studies, it is now well outlined that a reduction in renal perfusion leads to a decrease in glomerular filtration. Consequently, the reduction in distal tubular sodium chloride (NaCl) delivery to the macula densa cells of the juxtaglomerular apparatus initiates an epithelial response that consists of activation of multiple mitogen-activated protein kinases and stimulation of cyclooxygenase-2 activity and induction of cyclooxygenase-2 expression. This is subsequently followed by the appearance in the juxtaglomerular interstitium of prostaglandin E2 and the suppression of adenosine. Prostaglandin E2 activates receptors on granular cells which then results in adenylate cyclase activation and phosphokinase A-mediated renin secretory and transcriptional activation (Schnermann et al., 2003).

Renin, in turn, cleaves hepatically-produced angiotensinogen to produce angiotensin I, which is then converted by the angiotensin converting enzyme in the pulmonary vasculature to angiotensin II. In addition to causing hypertension via its potent vasoconstrictive effects, angiotensin II stimulates adrenal synthesis of aldosterone, which further results in sodium and fluid retention.

In the classic 2-kidney, 1-clip model, increased renin release from the affected kidney leads to hypertension and sodium retention. However, the contralateral (unaffected) kidney senses increased perfusion pressure, which, in turn, promotes a natriuresis and volume loss. **Therefore maintenance of hypertension in unilateral renal artery stenosis and normal contralateral kidney is driven primarily by renin and angiotensin. In contrast, in the setting of bilateral renal artery stenosis or renal artery stenosis affecting a**

solitary kidney, sodium and volume retention are not modified to the extent of having a normal contralateral kidney. Renin and angiotensin levels do not remain elevated, and hypertension remains sodium and volume dependent.

Given the transient elevation in renin and angiotensin, several other pressor pathways participate in the development of hypertension. These pathways include sympatho-adrenergic activation, oxidative stress pathways, and impaired vasodilatory responses within the kidney and systemic microcirculation (Lerman et al., 2001).

Pathophysiology of Ischemic Nephropathy in Atherosclerotic Renal Artery Stenosis

A reduction in renal perfusion resulting from atherosclerotic renal artery disease, which in turn leads to renal parenchymal loss and declining renal function, describes a condition known as ischemic nephropathy. Several interrelated pathophysiologic mechanisms are likely responsible for the renal structural and functional changes that occur in atherosclerotic renal artery disease. The impairment in microvascular blood flow, in combination with conditions that contribute to the atherosclerotic milieu, such as hypercholesterolemia, diabetes mellitus, and hypertension, lead to vascular dysfunction, which is mediated by endothelial injury, reduced bioavailability of nitric oxide, and increased vascular tone resulting from the predominance of vasoconstrictors, primarily angiotensin II. Concomitant cellular activation leads to migration of mononuclear cells and release inflammatory mediators including nuclear factor kappa-B (NF-κB). Upregulated tubular and glomerular expression of profibrotic factors, including transforming growth factor β (TGF-β), tissue inhibitor of metalloproteinase-1, and plasminogen activator inhibitor-1 leads to structural changes of tubulointerstitial fibrosis, vascular changes and/or glomerulosclerosis (Chade et al., 2003; Lerman et al., 2009).

Changes in intrarenal blood flow have been identified using blood oxygen level–dependent (BOLD) magnetic resonance imaging (MRI) analysis. Gloviczki et al. (2013) found that in cases of severe renal artery stenosis in which tissue hypoxia may occur, there is preferential redistribution of blood flow away from the renal cortex and toward the medulla. At the same time, there are changes in metabolic processes to preserve oxygen (Eirin et al., 2013).

Studies sampling renal vein blood from patients with atherosclerotic renal artery stenosis compared with those with essential hypertension found multiple markers reflecting active inflammation, suggesting kidney injury and reduced function. Endothelial progenitor cells expressing the markers CD34 and KDR were sequestered in kidneys with atherosclerotic renal artery stenosis, whereas levels of E-selectin, vascular cell adhesion molecule-1, and several inflammatory molecules were increased (Eirin et al., 2013).

In summary, atherosclerotic renal artery stenosis, in combination with other atherosclerotic risk factors, results in progressive loss of renal function through a complex interplay between inflammatory and immune responses, angiotensin II, oxidative stress, vascular rarefaction, and fibrosis. These molecular and cellular level processes ultimately lead to renal atrophy and diminished renal function.

Diagnostic Evaluation of Atherosclerotic Renal Artery Stenosis

Clinical Features.

The primary goal when undertaking diagnostic evaluation for suspected atherosclerotic renal artery stenosis is to identify patients who, if found to have a lesion, are most likely to benefit from treatment. Given that most patients with atherosclerotic renal artery stenosis are asymptomatic, the decision to pursue diagnostic assessment, particularly with invasive studies, should be driven by the probability that renovascular disease is a significant contributor to the patient's condition and will result in potential clinical consequences. If blood pressure and renal function are satisfactorily controlled with medical therapy, further diagnostic evaluation may not lead to treatment gains.

In general, the clinical criteria that should prompt evaluation are (1) early onset of hypertension (age < 30 years), (2) accelerated hypertension, (3) severe hypertension, or (4) hypertension resistant to optimal medical therapy, (5) asymmetric kidney size with more than 1.5 cm difference in craniocaudal length, (6) unexplained loss of kidney function, (7) rapid or recurrent decline in GFR in association with systemic blood pressure reduction, and (8) decline in GFR (SCr at least 30% from pretreatment level) after initiation of ACE inhibitors or ARBs. In addition, although most likely unrelated to atherosclerosis, all children with unexplained hypertension should be screened for renal artery stenosis.

Other clinical features that are often present in patients with atherosclerotic renal artery stenosis are typical for patients with systemic atherosclerotic disease. These include advanced age; atherosclerotic risk factors, including hypertension, CKD, hyperlipidemia, diabetes mellitus, tobacco exposure; and history of atherosclerotic disease in the coronary, cerebral, and/or the peripheral arterial circulation. On physical examination these patients often have severe hypertension and may also have fewer common signs, such as diminished lower extremity pulses, peripheral edema, and abdominal bruits.

To generate uniformity, the American Heart Association proposed the following classification scheme in patients with renal artery disease (Rocha-Singh et al., 2008):

Grade I: Renal artery stenosis present, but no clinical manifestations (normotensive and normal renal function)
Grade II: Renal artery stenosis present, but patients have medically controlled hypertension and normal renal function
Grade III: Renal artery stenosis present and patients have evidence of abnormal renal function, medically refractory hypertension, or evidence of volume overload

Laboratory Features

Apart from decreased GFR, patients with atherosclerotic renal artery stenosis typically do not have notable laboratory abnormalities. The urine analysis is likely to be unremarkable. On routine chemistry panels, patients may have low or low normal serum potassium because of aldosterone secretion.

Ritchie et al. (2014) retrospectively reviewed 467 patients with at least 50% atherosclerotic renal artery stenosis and noted that nearly half of their patient group was asymptomatic. One or more "high-risk presentations," defined as flash pulmonary edema, refractory hypertension (>140 mm Hg systolic and/or >90 mm Hg diastolic) despite use of 3 or more different classes of antihypertensive agents, or rapidly declining kidney function (SCr level more than 1.2-fold or 1.14 mg/dL greater than baseline within the previous 6 months) was present in 51% of the patients, and 30% to 40% had a history of angina, previous myocardial infarction, cerebrovascular accident/transient ischemic attack, peripheral arterial disease, or diabetes (Ritchie et al., 2014)

These data underscore a guiding principle for diagnostic evaluation in atherosclerotic renal artery stenosis. Patients who are asymptomatic, have normal renal function, and have satisfactory blood pressure control likely do not need evaluation. Alternatively, patients who fail to improve or who decline while on medical therapy may benefit from additional diagnostic testing.

Radiographic Assessment of Atherosclerotic Renal Artery Stenosis

Radiographic evaluation of suspected atherosclerotic renal artery stenosis should begin with noninvasive imaging studies. Given the wide availability, low cost, ease to the patient, and diagnostic accuracy, **duplex ultrasonography should be considered the screening test of choice.** Duplex ultrasonography combines anatomic information (B- or brightness-mode and color Doppler imaging) with acquisition of blood flow.

The primary diagnostic advantage of duplex ultrasonography is the ability to accurately determine blood flow velocity. A duplex ultrasonographic examination for renal artery stenosis should be done by an experienced technologist, and patients should undergo an overnight fast to minimize bowel gas. Imaging is performed from anterior and flank (lateral decubitus) approaches, with attention directed to the perirenal aorta, looking for aneurysmal change, stenosis, or occlusion. The lateral decubitus position may aid in the obese patients and/or in the setting of excessive bowel gas. Peak systolic velocity in the aorta is recorded. Subsequently each renal artery is imaged, and velocities and waveforms are recorded from the proximal, mid, and distal segments of the renal arteries. Duplex ultrasonography with color-flow and Doppler imaging is used to determine the patency and phasicity of the renal veins. Velocity measurements within the superior, mid, and lower poles of the kidneys are used to calculate resistive indices and acceleration times. Last, the duplex ultrasonographic study determines renal parenchymal anatomic details including kidney size, parenchymal thickness and echogenicity, and potentially unanticipated findings such as masses, calculi, and/or hydronephrosis.

The most commonly measured duplex ultrasonographic parameters include peak systolic velocity (PSV), end diastolic velocity (EDV), and adjacent aortic peak systolic velocity. The ratio of velocity in the main renal artery to the aorta (renal aortic ratio, RAR) and resistive index within the renal parenchyma ($RI = [(PSV-EDV)/PSV]$) can be derived from these measurements. In addition, arterial blood flow characteristics such as tardus/parvus, acceleration time, and acceleration index can be determined within the main, accessory, and intraparenchymal renal arteries.

The accuracy of duplex ultrasonography for the diagnosis of renal artery stenosis varies according to predetermined velocity thresholds, which in turn, depend on individual vascular laboratory experience. AbuRahma et al. (2012) reviewed their institution's large experience and found that a PSV of 285 cm/s or a RAR of 3.7 alone had the best overall accuracy in diagnosing at least 60% stenosis when compared with angiography. Using these thresholds, these investigators were able to achieve more than 80% accuracy. Lower velocity thresholds, although more sensitive, were less accurate. These findings reinforce the notion that clinicians should recognize the expertise in their individual vascular laboratories and use the data to screen patients who require more invasive examination.

Computed tomography (CT) and magnetic resonance imaging (MRI) have sensitivity of more than 90% in detecting atherosclerotic renal artery stenosis, and MRI has a specificity of 91% (Eklof et al., 2006). CT and MRI provide excellent anatomic detail; however, the blood flow changes that result from the stenosis cannot be determined. The functional consequences of these lesions may be indirectly determined by the findings of parenchymal atrophy. Another drawback of CT is the cost and need for intravenously administered radiographic contrast agents. Because many patients with suspected atherosclerotic renal artery disease may have co-existent renal insufficiency, administration of iodinated contrast agents raises concerns of contrast nephropathy. Patients with estimated glomerular filtration rate (GFR) below 50 mL/min should receive IV hydration before contrast administration and those with GFR below 30 mL/min should not receive iodinated contrast as part of a diagnostic procedure (contrast should be reserved for use during a therapeutic procedure). Administration of IV gadolinium for magnetic resonance angiography (MRA) in patients with GFR below 30 mL/min should be avoided because it is associated with the development of nephrogenic systemic fibrosis.

Renal arteriography, the “gold standard” for the diagnosis of atherosclerotic renal artery stenosis, can also provide detailed imaging of the aorta, segmental renal arteries, and intrarenal vasculature. Digital subtraction improves resolution and allows a reduction in the amount of contrast material. Angiography is an invasive study with risks of bleeding from arterial puncture, arterial dissection, arterial spasm, and thromboembolism. Additionally iodinated contrast material cannot be administered in patients with contrast allergy or significant renal dysfunction, and use of carbon dioxide may reduce the amount of contrast.

Two additional diagnostic studies that warrant discussion are radionuclide renography and plasma renin determination. With radionuclide or nuclear renography, a radiopharmaceutical agent, either diethylenetriaminepentaacetic acid (DTPA) or mercaptoacetyltriglycine (MAG 3), is administered intravenously, and images are reviewed to determine a renal functional difference, delay in time to peak uptake of the radioisotope, or delayed excretion of the isotope. Additional imaging after administration of captopril, an ACE inhibitor, may show decreased function (GFR), suggesting the influence of angiotensin II maintaining glomerular filtration. Radionuclide renography has largely fallen out of favor because of its unreliability. In addition to diagnostic limitations in patients with diminished renal function (SCr > 2.0 mg/dL) or bilateral arterial disease, these imaging studies have poor sensitivity and specificity (Vasbinder et al., 2001). Currently the primary role of renography in evaluating patients with hypertension may be to determine differential function before recommending nephrectomy.

Plasma renin activity or determination of renin level from the renal vein has been suggested to be highly diagnostic for the presence of renal artery stenosis, but these studies are limited by their invasiveness and stringent testing conditions. The patient's volume status must be optimized, concurrent medications must be addressed, and blood pressure must be tightly controlled. Last, and as mentioned previously, renin may be elevated early in the course of atherosclerotic renal artery stenosis and likely declines over time as other pathophysiologic processes maintain the hypertensive state.

Therapeutic Options for Atherosclerotic Renal Artery Stenosis

Medical Management.

Medical management makes up the foundation of atherosclerotic renal artery stenosis treatment. The general objectives of therapy are control of blood pressure, preservation of renal function, and prevention of atherosclerosis-related complications. Antihypertensive treatment with ACE inhibitors or ARBs are the first-line approach for blood pressure control and for their beneficial effect on cardiovascular risk reduction (Heart Outcomes Prevention Evaluation Study Investigators, 2000). Use of these agents may initiate concerns of renal insufficiency from loss of glomerular filtration as a result of blockade of the AII-induced efferent arteriolar constriction. However, significant renal function decline is uncommon in most series and, when it occurs, is almost diagnostic of renal artery stenosis. If additional antihypertensive agents are needed, beta-blockers, diuretics, and calcium-channel blockers can be added.

Given the presence of systemic atherosclerosis, many patients with atherosclerotic renal artery stenosis also have pre-existing cardiovascular risk factors, including essential hypertension, diabetes mellitus, dyslipidemia, and smoking. Established additional related therapies include glycemic control, statins, antiplatelet agents, and lifestyle modifications, including tobacco cessation.

Procedural Management.

Whether all patients with atherosclerotic renal artery stenosis should undergo renal revascularization in addition to medical therapy remains a controversial practice, although recent trials do not support this procedure. Renal revascularization, with open surgical renal artery bypass and percutaneous transluminal angioplasty with or without stent placement, has been the subject of several randomized prospective trials. Numerous single-center retrospective studies have reported on various techniques of open surgical revascularization and have shown durable long-term patency rates (Cambria et al., 1996; Cherr et al., 2002; Darling et al., 1999; Fergany et al., 1995; Hansen et al., 2000; Marone et al., 2004; Paty et al., 2001). Notwithstanding these results, open surgical renal artery repair is associated with considerable perioperative mortality (5%) and morbidity (20%) rates and therefore is generally reserved for young patients and those with hemodynamically significant atherosclerotic renal artery stenosis and significant juxtarenal or suprarenal aortic disease (Edwards et al., 2009).

Renal revascularization with percutaneous transluminal renal artery angioplasty (PTRA) has been compared with medical therapy in three randomized controlled trials, none of which showed improved renal function, hypertension management, or survival with PTRA (Plouin et al., 1998; van Jaarsveld et al., 2000; Webster et al., 1998). These trials enrolled small numbers of patients, excluded patients with severe renal functional impairment, had extensive crossover between treatment groups, and did not use current medical therapy, thus making the results difficult to apply to current practice.

When compared with PTRA alone, percutaneous transluminal renal artery angioplasty with stenting (PTRS) was found to have superior technical success rates, increased patency rates, and decreased restenosis rates, leading to widespread adoption of PTRS as the standard endovascular management for atherosclerotic renal artery stenosis during the 1990s and early 2000s (Liang et al., 2013; van de Ven et al., 1999). A comparison of PTRS and medical management for atherosclerotic renal artery stenosis has been the subject of several randomized controlled trials. In three of these trials, which were presented or published in 2009, nearly 1000 patients with atherosclerotic renal artery stenosis were enrolled and followed for 2 to 4 years (Bax et al., 2009; Kumbhani et al., 2011; Wheatley et al., 2009). Aside from a slight reduction in number of antihypertensive medications, no significant improvement in systolic or diastolic blood pressure, renal function decline, or adverse cardiovascular events was seen with PTRS and medical management in comparison with medical management alone. Despite the randomized prospective design, these trials have faced several criticisms, including discrepancies in atherosclerotic renal artery stenosis diagnosis, flaws in the intention-to-treat analysis, and inclusion of patients with wide-ranging degrees of stenosis.

The NIH sponsored Cardiovascular Outcomes in Renal Atherosclerotic Lesions, or CORAL, trial attempted to correct these limitations and definitively answer whether revascularization of hemodynamically significant atherosclerotic renal artery stenosis in hypertensive patients prevents adverse cardiovascular and renal events when added to optimal medical therapy (Cooper et al., 2014). **The CORAL study enrolled 947 patients with atherosclerotic renal artery stenosis and hypertension between 2005 and 2010 and randomly assigned these patients to medical therapy plus renal artery stenting or medical therapy alone. After a median follow-up period of 43 months, the rate of the primary composite end point, made up of cardiovascular and renal sequelae, was not significantly different between participants who underwent stent placement in addition to medical therapy versus those who received medical therapy alone** (Cooper et al., 2014)**. Although the limitations of these studies continue to be debated, the conclusions reached by the CORAL study reliably show the lack of benefit of renal artery stenting in most patients with atherosclerotic renal artery stenosis.**

Complications of PTRS, although generally less frequent than those seen with open surgical revascularization, can still account for significant morbidity. Periprocedural mortality rate is approximately 0.7%, and renal artery complications range from 1% to 10% (Kumbhani et al., 2011).

In contrast to asymptomatic patients who are found to have high-grade atherosclerotic renal artery stenosis, a subgroup of patients who appear to benefit from renal artery revascularization are those with flash pulmonary edema. As stated earlier, randomized prospective trials included mostly asymptomatic patients. Ritchie et al. (2014) evaluated outcomes between medical management alone compared with medical management plus percutaneous renal artery revascularization with stent placement in patients with high-risk clinical presentation, defined as flash pulmonary edema, rapidly declining renal function, or refractory hypertension. In this large analysis, flash pulmonary edema appeared to be an adverse prognostic marker with increased risk of death and cardiovascular events in medically treated patients, whereas the combination with renal artery revascularization reduced the risk of death (Ritchie et al., 2014).

Nonatherosclerotic Renal Artery Diseases

Fibromuscular Dysplasia

Fibromuscular dysplasia (FMD) is a nonatherosclerotic, noninflammatory vascular disease that most often affects small to medium arteries. Unlike atherosclerosis, FMD mostly involves the **mid- to distal renal artery** and can affect segmental renal artery branches. FMD has a female predominance and typically occurs in patients between 20 and 60 years of age but can occur in older and pediatric patient populations. Asymptomatic patients are most often diagnosed on imaging studies. Symptomatic patients can experience sequelae of arterial disease such as stenosis, occlusion, arterial dissection, or aneurysm. Although FMD can occur in any arterial bed in the body, involvement of the renal artery is most common.

Epidemiology of Renal Artery Fibromuscular Dysplasia.

Because many patients with FMD remain asymptomatic, the true prevalence of FMD is difficult to assess. The overall prevalence can be estimated from the evaluation of renal donors, a suitable representation of healthy adult population. The prevalence of FMD in renal donors ranges between 2.6% to 6.6% with the variance most likely resulting from differences in imaging technique and patient populations (Cragg et al., 1989; McKenzie et al., 2013; Neymark et al., 2000). Bilateral renal artery involvement is seen in approximately one-third of FMD cases (McKenzie et al., 2013; Olin et al., 2011). FMD has a marked female preponderance: nearly **90% of cases occur in women.** Several causative factors, including hormonal and environmental causes, have been proposed for the development of FMD; however, the prevailing thought is that FMD is idiopathic.

Histopathology of Fibromuscular Dysplasia.

FMD is classified according to the affected layer of arterial wall; specifically, the intima, media, and adventitia. FMD involving the media occurs most commonly and can be further subdivided into medial fibroplasia, perimedial fibroplasia, and medial hyperplasia. The latter two conditions are very uncommon, whereas **medial fibroplasia accounts for 90% of all types of FMD.** Medial fibroplasia is characterized by multiple diaphragm-like thickened areas of media that result in segments of arterial stenosis and poststenotic dilatation, typically seen as a “string of beads” appearance on CT angiography (Fig. 87.5).

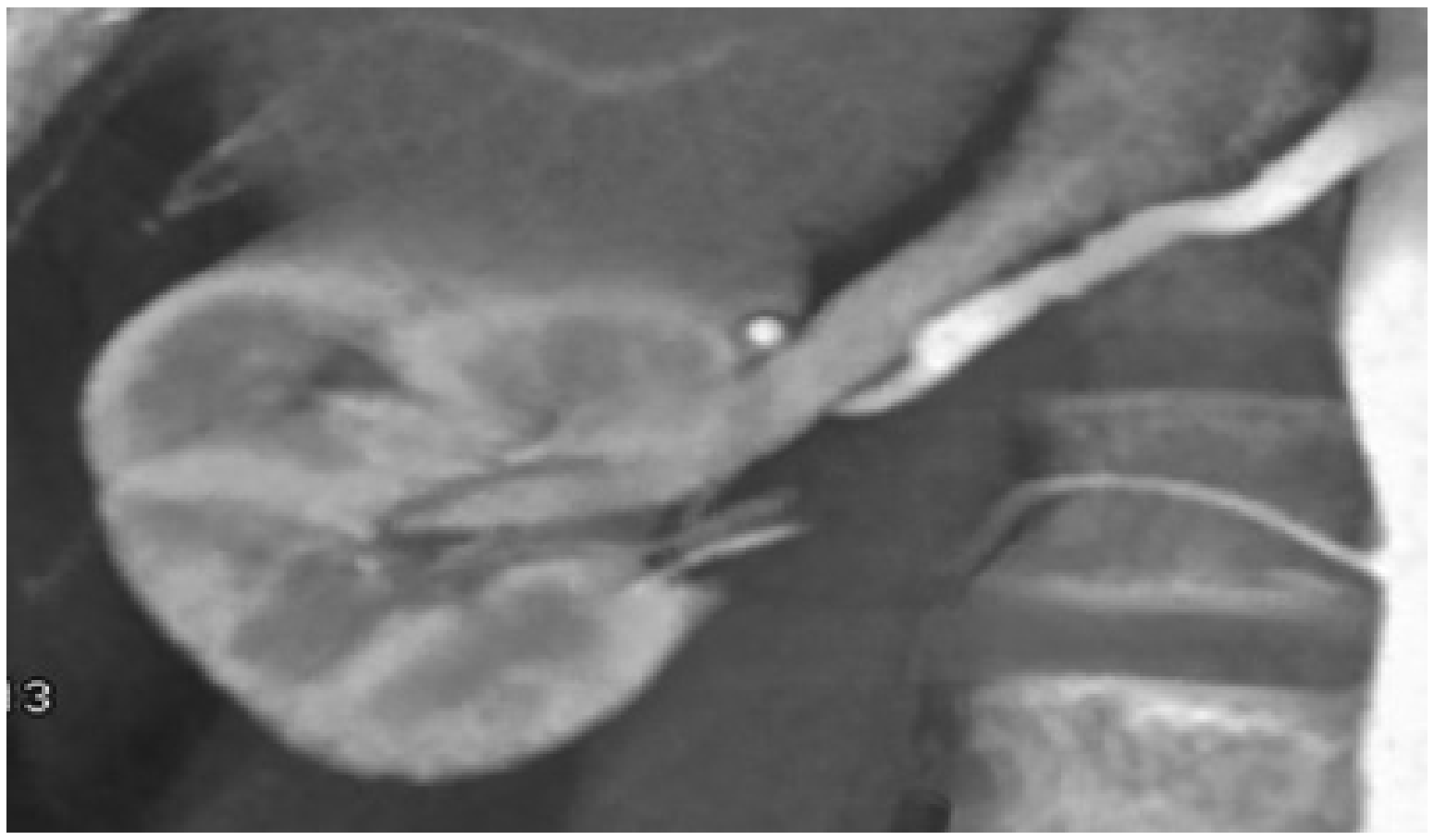

FIG. 87.5 “String of beads” appearance of the right renal artery typical of fibromuscular dysplasias.

Accounting for the remaining 10% of cases of FMD, intimal fibroplasia is due to collagen deposition within the intima with resultant fragmentation of the intimal layer. On angiography, intimal fibroplasia often appears as a concentric stenosis and, occasionally, as a long, diffuse narrowing.

Clinical Presentation.

As mentioned previously, the diagnosis of renal artery FMD is often made in asymptomatic patients undergoing abdominal imaging for other reasons. The most common symptomatic presentation is **a middle-age woman with new-onset or difficult-to-control hypertension.** Other clinical presentations of renal artery FMD include flank pain and/or hematuria, both of which can result from dissection or occlusion of the renal artery and aneurysmal changes involving the artery. Interestingly, unless dissection occurs, medial fibroplasia rarely results in renal dysfunction. Intimal and perimedial fibroplasia may be associated with renal dysfunction, arterial dissection, and progression to occlusion (Stokes et al., 1996).

Diagnostic Evaluation.

As with atherosclerotic renal artery stenosis, angiography remains the gold standard to diagnose and evaluate renal artery FMD. Catheter-based angiography provides excellent resolution of the main and segmental renal arteries and can identify luminal changes such as aneurysm formation and dissection that may affect the smaller vessels. More recently intravascular ultrasound has been used as an adjunct to angiography and can depict pressure gradients and even provide virtual histology of the arterial lumen (Prasad et al., 2009). CT and MRA are able to suggest the diagnosis of FMD in main renal vessels but are limited by poor visualization along branch renal vessels.

Management of Fibromuscular Dysplasia.

The primary treatment goals in patients with renal artery FMD are control of hypertension and prevention of secondary complications of hypertension. Because ischemic nephropathy is not a sequela of FMD, preservation of renal function is not a consideration in the treatment of FMD. The primary factors in considering which patients with FMD merit treatment are patient age, temporal relationship between onset of hypertension and diagnosis of FMD, adequacy of blood pressure control with anti-hypertensive agents, and duration of hypertension.

Asymptomatic, normotensive patients with renal artery FMD should be followed for the development of hypertension. Young, otherwise healthy patients in whom FMD is diagnosed proximate to the onset of hypertension should be referred for PTRA, which provides immediate and long-term blood pressure control in nearly 75% of patients (Davies et al., 2008; Trinquart et al., 2010). Patients in whom hypertension has been present for many years should be continued on antihypertensive medications as long as blood pressure control is satisfactory. Dopper ultrasound–based surveillance of kidney length and cortical thickness should be done once or twice per year.

If blood pressure control becomes difficult, medication side effects become intolerable, or renal size or function decrease, PTRA should be performed (Olin, 2011). Balloon angioplasty alone is a very effective treatment for renal artery FMD, thereby making stent placement unnecessary. Surgical revascularization is reserved for cases not amenable to percutaneous approaches such as those with aneurysms or FMD involving distal extrarenal branches. Indications for stent placement in FMD are inability to eliminate a pressure gradient with angioplasty alone and intimal dissection.

Treatment success is fairly similar between PTRA and surgery. Approximately

50% of patients have cure of hypertension, but the complications are markedly fewer after PTRA. Major complication rates after PTRA are approximately 12%, in contrast to 17% after surgery (Trinquart, 2010).

Restenosis can occur after PTRA, particularly if the angioplasty was inadequate. Most instances of restenosis can be successfully treated with repeat angioplasty. Use of intravascular ultrasound (IVUS) in this setting can document resolution of a pressure gradient. Similar to patients on antihypertensive medications, patients are advised to continue with routine surveillance for recurrence of hypertension and for Doppler ultrasound of renal length and cortical thickness. Routine use of aspirin (81 mg) is advised for all patients with renal artery FMD (Olin, 2011).

Key Points: Chronic Kidney Diease

- CKD is defined as kidney impairment sustained beyond 3 months with a reduction in GFR, structural abnormalities in the kidneys, and/or proteinuria.
- There continues to be a steady increase in the number of patients with ESRD on RRTs throughout the world. Outcome comparisons suggest that kidney transplantation is still the best overall treatment for ESRD patients, despite advances in dialysis care and modalities.
- Hemodynamically significant narrowing in the renal artery, or renal artery stenosis, can result in secondary hypertension and/or diminishing renal function.
- Atherosclerotic vascular disease accounts for 90% of causes of renal artery stenosis, and fibromuscular dysplasias account for the remaining 10%.
- Renal artery stenosis can lead to renal parenchymal loss and diminished renal function, a condition known as *ischemic nephropathy.*
- Although the limitations of these studies continue to be debated, the conclusions reached by the CORAL study reliably show the lack of benefit of renal artery stenting in most patients with atherosclerotic renal artery stenosis.

Suggested Readings

Bax L, Woittiez AJ, Kouwenberg HJ, et al. Stent placement in patients with atherosclerotic renal artery stenosis and impaired renal function: a randomized trial. *Ann Intern Med*. 2009;150(12):840–848 [W150–841].

Beck LH, Bonegio RG, Lambeau G, et al. M-type phospholipase A2 receptor as target antigen in idiopathic membranous nephropathy. *N Engl J Med*. 2009;361(1):11–21.

Cavanaugh C, Perazella MA. Urine sediment examination in the diagnosis and management of kidney disease: core curriculum 2019. *Am J Kidney Dis*. 2018.

Chawla LS, Kimmel PL. Acute kidney injury and chronic kidney disease: an integrated clinical syndrome. *Kidney Int*. 2012;82(5):516–524.

Cooper CJ, Murphy TP, Cutlip DE, et al. Stenting and medical therapy for atherosclerotic renal-artery stenosis. *N Engl J Med*. 2014;370(1):13–22.

Freedman BI, Limou S, Ma L, et al. APOL1-Associated Nephropathy: a key contributor to racial disparities in CKD. *Am J Kidney Dis*. 2018;72(5S1):S8–S16.

Goicoechea M, Rivera F, López-Gómez JM. Increased prevalence of acute tubulointerstitial nephritis. *Nephrol Dial Transplant*. 2013;28(1):112–115.

Khosroshahi A, Wallace ZS, Crowe JL, et al. International consensus guidance statement on the management and treatment of IgG4-related disease. *Arthritis Rheumatol*. 2015;67(7):1688–1699.

Liaño F, Pascual J. Epidemiology of acute renal failure: a prospective, multicenter, community-based study. Madrid Acute Renal Failure Study Group. *Kidney Int*. 1996;50(3):811–818.

May AG, De Weese JA, Rob CG. Hemodynamic effects of arterial stenosis. *Surgery*. 1963;53:513–524.

References

AbuRahma AF, Srivastava M, Mousa AY, et al. Critical analysis of renal duplex ultrasound parameters in detecting significant renal artery stenosis. *J Vasc Surg*. 2012;56(4):1052–1059 [1060 e1051; discussion 1059–1060].

Anema JG, Morey AF, McAninch JW, et al. Complications related to the high lithotomy position during urethral reconstruction. *J Urol*. 2000;164(2):360–363.

Angeli P, Volpin R, Gerunda G, et al. Reversal of type 1 hepatorenal syndrome with the administration of midodrine and octreotide. *Hepatology*. 1999;29(6):1690–1697.

Baker RJ, Pusey CD. The changing profile of acute tubulointerstitial nephritis. *Nephrol Dial Transplant*. 2004;19(1):8–11.

Balasubramanian G, Al-Aly Z, Moiz A, et al. Early nephrologist involvement in hospital-acquired acute kidney injury: a pilot study. *Am J Kidney Dis*. 2011;57(2):228–234.

Bankir L, Bichet DG, Morgenthaler NG. Vasopressin: physiology, assessment and osmosensation. *J Intern Med*. 2017;282(4):284–297.

Barbar SD, Clere-Jehl R, Bourredjem A, et al. Timing of renal-replacement therapy in patients with acute kidney injury and sepsis. *N Engl J Med*. 2018;379(15):1431–1442.

Batlle D, Arruda J. Hyperkalemic forms of renal tubular acidosis: clinical and pathophysiological aspects. *Adv Chronic Kidney Dis*. 2018;25(4):321–333.

Bax L, Woittiez AJ, Kouwenberg HJ, et al. Stent placement in patients with atherosclerotic renal artery stenosis and impaired renal function: a randomized trial. *Ann Intern Med*. 2009;150(12):840–848 [W150–841].

Beck LH, Bonegio RG, Lambeau G, et al. M-type phospholipase A2 receptor as target antigen in idiopathic membranous nephropathy. *N Engl J Med*. 2009;361(1):11–21.

Beck LH, Fervenza FC, Beck DM, et al. Rituximab-induced depletion of anti-PLA2R autoantibodies predicts response in membranous nephropathy. *J Am Soc Nephrol*. 2011;22(8):1543–1550.

Bellomo R, Chapman M, Finfer S, et al. Low-dose dopamine in patients with early renal dysfunction: a placebo-controlled randomised trial. Australian and New Zealand Intensive Care Society (ANZICS) Clinical Trials Group. *Lancet*. 2000;356(9248):2139–2143.

Bellomo R, Ronco C, Kellum JA, workgroup ADQI, et al. Acute renal failure - definition, outcome measures, animal models, fluid therapy and information technology needs: the Second International Consensus Conference of the Acute Dialysis Quality Initiative (ADQI) Group. *Crit Care*. 2004;8(4):R204–R212.

Better OS, Arieff AI, Massry SG, et al. Studies on renal function after relief of complete unilateral ureteral obstruction of three months' duration in man. *Am J Med*. 1973;54(2):234–240.

Bhathena DB, Julian BA, McMorrow RG, et al. Focal sclerosis of hypertrophied glomeruli in solitary functioning kidneys of humans. *Am J Kidney Dis*. 1985;5(5):226–232.

Bock JS, Gottlieb SS. Cardiorenal syndrome: new perspectives. *Circulation*. 2010;121(23):2592–2600.

Bollée G, Patey N, Cazajous G, et al. Thrombotic microangiopathy secondary to VEGF pathway inhibition by sunitinib. *Nephrol Dial Transplant*. 2009;24(2):682–685.

Bouquegneau A, Vidal-Petiot E, Moranne O, et al. Creatinine-based equations for the adjustment of drug dosage in an obese population. *Br J Clin Pharmacol*. 2016;81(2):349–361.

Bove T, Zangrillo A, Guarracino F, et al. Effect of fenoldopam on use of renal replacement therapy among patients with acute kidney injury after cardiac surgery: a randomized clinical trial. *J Am Med Assoc*. 2014;312(21):2244–2253.

Brenner BM, Mackenzie HS. Nephron mass as a risk factor for progression of renal disease. *Kidney Int Suppl*. 1997;63:S124–S127.

Bushinsky DA, Williams GH, Pitt B, et al. Patiromer induces rapid and sustained potassium lowering in patients with chronic kidney disease and hyperkalemia. *Kidney Int*. 2015;88(6):1427–1433.

Cambria RP, Brewster DC, L'Italien GJ, et al. Renal artery reconstruction for the preservation of renal function. *J Vasc Surg*. 1996;24(3):371–380 [discussion 380–372].

Caps MT, Zierler RE, Polissar NL, et al. Risk of atrophy in kidneys with atherosclerotic renal artery stenosis. *Kidney Int*. 1998;53(3):735–742.

Carvounis CP, Nisar S, Guro-Razuman S. Significance of the fractional excretion of urea in the differential diagnosis of acute renal failure. *Kidney Int*. 2002;62(6):2223–2229.

Cavallin M, Kamath PS, Merli M, et al. Terlipressin plus albumin versus midodrine and octreotide plus albumin in the treatment of hepatorenal syndrome: a randomized trial. *Hepatology*. 2015;62(2):567–574.

Cavanaugh C, Perazella MA. Urine sediment examination in the diagnosis and management of kidney disease: core curriculum 2019. *Am J Kidney Dis*. 2018.

Chabova V, Schirger A, Stanson AW, et al. Outcomes of atherosclerotic renal artery stenosis managed without revascularization. *Mayo Clin Proc*. 2000;75(5):437–444.

Chade AR, Rodriguez-Porcel M, Grande JP, et al. Mechanisms of renal structural alterations in combined hypercholesterolemia and renal artery stenosis. *Arterioscler Thromb Vasc Biol*. 2003;23(7):1295–1301.

Chawla LS, Kimmel PL. Acute kidney injury and chronic kidney disease: an integrated clinical syndrome. *Kidney Int*. 2012;82(5):516–524.

Cherr GS, Hansen KJ, Craven TE, et al. Surgical management of atherosclerotic renovascular disease. *J Vasc Surg*. 2002;35(2):236–245.

Cohen SD, Kopp JB, Kimmel PL. Kidney diseases associated with human immunodeficiency virus infection. *N Engl J Med*. 2017;377(24):2363–2374.

Coiffier B, Altman A, Pui CH, et al. Guidelines for the management of pediatric and adult tumor lysis syndrome: an evidence-based review. *J Clin Oncol*. 2008;26(16):2767–2778.

Conlon PJ, Little MA, Pieper K, et al. Severity of renal vascular disease predicts mortality in patients undergoing coronary angiography. *Kidney Int*. 2001;60(4):1490–1497.

Cooper CJ, Murphy TP, Cutlip DE, et al. Stenting and medical therapy for atherosclerotic renal-artery stenosis. *N Engl J Med*. 2014;370(1):13–22.

Cortazar FB, Marrone KA, Troxell ML, et al. Clinicopathological features of acute kidney injury associated with immune checkpoint inhibitors. *Kidney Int*. 2016;90(3):638–647.

Cosentino F. Drugs for the prevention and treatment of acute renal failure. *Cleve Clin J Med*. 1995;62(4):248–253.

Cragg AH, Smith TP, Thompson BH, et al. Incidental fibromuscular dysplasia in potential renal donors: long-term clinical follow-up. *Radiology*. 1989;172(1):145–147.

Darling RC 3rd, Kreienberg PB, Chang BB, et al. Outcome of renal artery reconstruction: analysis of 687 procedures. *Ann Surg*. 1999;230(4):524–530 [discussion 530–522].

Davies MG, Saad WE, Peden EK, et al. The long-term outcomes of percutaneous therapy for renal artery fibromuscular dysplasia. *J Vasc Surg*. 2008;48(4):865–871.

De Bruyne B, Manoharan G, Pijls NH, et al. Assessment of renal artery stenosis severity by pressure gradient measurements. *J Am Coll Cardiol*. 2006;48(9):1851–1855.

de Mast Q, Beutler JJ. The prevalence of atherosclerotic renal artery stenosis in risk groups: a systematic literature review. *J Hypertens*. 2009;27(7):1333–1340.

De Vriese AS, Sethi S, Nath KA, et al. Differentiating primary, genetic, and secondary FSGS in adults: a clinicopathologic approach. *J Am Soc Nephrol*. 2018;29(3):759–774.

Deane LA, Lee HJ, Box GN, et al. Third place: flank position is associated with higher skin-to-surface interface pressures in men versus women: implications for laparoscopic renal surgery and the risk of rhabdomyolysis. *J Endourol*. 2008;22(6):1147–1151.

Doolan PD, Alpen EL, Theil GB. A clinical appraisal of the plasma concentration and endogenous clearance of creatinine. *Am J Med*. 1962;32:65–79.

Edwards MS, Corriere MA. Contemporary management of atherosclerotic renovascular disease. *J Vasc Surg*. 2009;50(5):1197–1210.

Edwards MS, Craven TE, Burke GL, et al. Renovascular disease and the risk of adverse coronary events in the elderly: a prospective, population-based study. *Arch Intern Med*. 2005;165(2):207–213.

Eirin A, Gloviczki ML, Tang H, et al. Inflammatory and injury signals released from the post-stenotic human kidney. *Eur Heart J*. 2013;34(7):540–548a.

Eklof H, Ahlstrom H, Magnusson A, et al. A prospective comparison of duplex ultrasonography, captopril renography, MRA, and CTA in assessing renal artery stenosis. *Acta Radiol*. 2006;47(8):764–774.

Eng J, Wilson RF, Subramaniam RM, et al. Comparative effect of contrast media type on the incidence of contrast-induced nephropathy: a systematic review and meta-analysis. *Ann Intern Med*. 2016;164(6):417–424.

Eremina V, Jefferson JA, Kowalewska J, et al. VEGF inhibition and renal thrombotic microangiopathy. *N Engl J Med*. 2008;358(11):1129–1136.

Fehrman-Ekholm I, Kvarnström N, Söfteland JM, et al. Post-nephrectomy development of renal function in living kidney donors: a cross-sectional retrospective study. *Nephrol Dial Transplant*. 2011;26(7):2377–2381.

Felker GM, Lee KL, Bull DA, et al. Diuretic strategies in patients with acute decompensated heart failure. *N Engl J Med*. 2011;364(9):797–805.

Fergany A, Kolettis P, Novick AC. The contemporary role of extra-anatomical surgical renal revascularization in patients with atherosclerotic renal artery disease. *J Urol*. 1995;153(6):1798–1801 [discussion 1801–1792].

Fordjour KN, Walton T, Doran JJ. Management of hyperkalemia in hospitalized patients. *Am J Med Sci*. 2014;347(2):93–100.

Formica RN, Aeder M, Boyle G, et al. Simultaneous liver-kidney allocation policy: a proposal to optimize appropriate utilization of scarce resources. *Am J Transplant*. 2016;16(3):758–766.

Freedman BI, Limou S, Ma L, et al. APOL1-associated nephropathy: a key contributor to racial disparities in CKD. *Am J Kidney Dis*. 2018;72(5S1):S8–S16.

Freedman BI, Pastan SO, Israni AK, et al. APOL1 genotype and kidney transplantation outcomes from deceased African American donors. *Transplantation*. 2016;100(1):194–202.

Friedman DJ, Kozlitina J, Genovese G, et al. Population-based risk assessment of APOL1 on renal disease. *J Am Soc Nephrol*. 2011;22(11):2098–2105.

Fulton C, McGregor T, Forbes TL, et al. Catheter-directed thrombolysis with tPA to restore renal function after iliac venous thrombosis post-renal transplantation. *Ann Transplant*. 2011;16(1):61–65.

Geevasinga N, Coleman PL, Webster AC, et al. Proton pump inhibitors and acute interstitial nephritis. *Clin Gastroenterol Hepatol*. 2006;4(5):597–604.

Giacoppo D, Madhavan MV, Baber U, et al. Impact of contrast-induced acute kidney injury after percutaneous coronary intervention on short- and long-term outcomes: pooled analysis from the HORIZONS-AMI and ACUITY Trials. *Circ Cardiovasc Interv*. 2015;8(8):e002475.

Glassman DT, Merriam WG, Trabulsi EJ, et al. Rhabdomyolysis after laparoscopic nephrectomy. *JSLS*. 2007;11(4):432–437.

Gloviczki ML, Saad A, Textor SC. Blood oxygen level-dependent (BOLD) MRI analysis in atherosclerotic renal artery stenosis. *Curr Opin Nephrol Hypertens*. 2013;22(5):519–524.

Goicoechea M, Rivera F, López-Gómez JM. Increased prevalence of acute tubulointerstitial nephritis. *Nephrol Dial Transplant*. 2013;28(1):112–115.

Goldblatt H, Weinstein H, Kahn JR. Studies on experimental hypertension : xiv. The effect of intermittent renal arterial occlusion on the blood pressure of the dog. *J Exper Med*. 1941;73(3):439–451.

Gonwa TA, Morris CA, Goldstein RM, et al. Long-term survival and renal function following liver transplantation in patients with and without hepatorenal syndrome–experience in 300 patients. *Transplantation*. 1991;51(2):428–430.

Gottlieb RH, Weinberg EP, Rubens DJ, et al. Renal sonography: can it be used more selectively in the setting of an elevated serum creatinine level? *Am J Kidney Dis*. 1997;29(3):362–

367.

Goumenos DS, Kawar B, El Nahas M, et al. Early histological changes in the kidney of people with morbid obesity. *Nephrol Dial Transplant*. 2009;24(12):3732–3738.

Goutorbe P, Montcriol A, Lacroix G, et al. Intestinal necrosis associated with orally administered calcium polystyrene sulfonate without sorbitol. *Ann Pharmacother*. 2011;45(2):e13.

Hagan AE, Farrington CA, Wall GC, et al. Sodium polystyrene sulfonate for the treatment of acute hyperkalemia: a retrospective study. *Clin Nephrol*. 2016;85(1):38–43.

Hansen KJ, Cherr GS, Craven TE, et al. Management of ischemic nephropathy: dialysis-free survival after surgical repair. *J Vasc Surg*. 2000;32(3):472–481 [discussion 481–472].

Hansen KJ, Edwards MS, Craven TE, et al. Prevalence of renovascular disease in the elderly: a population-based study. *J Vasc Surg*. 2002;36(3):443–451.

Heart Outcomes Prevention Evaluation Study Investigators. Effects of Ramipril on cardiovascular and microvascular outcomes in people with diabetes mellitus: results of the HOPE study and MICRO-HOPE substudy. *Lancet*. 2000;355(9200):253–259.

Holley KE, Hunt JC, Brown AL Jr, et al. Renal artery stenosis. A clinical-pathologic study in normotensive and hypertensive patients. *Am J Med*. 1964;37:14–22.

Hoorn EJ, Tuut MK, Hoorntje SJ, et al. Dutch guideline for the management of electrolyte disorders–2012 revision. *Neth J Med*. 2013;71(3):153–165.

Howard SC, Jones DP, Pui CH. The tumor lysis syndrome. *N Engl J Med*. 2011;364(19):1844–1854.

Hoxha E, Wiech T, Stahl PR, et al. A mechanism for cancer-associated membranous nephropathy. *N Engl J Med*.

2016;374(20):1995–1996.

Hoy SM. Sodium zirconium cyclosilicate: a review in hyperkalaemia. *Drugs*. 2018;78(15):1605–1613.

Hughson M, Farris AB, Douglas-Denton R, et al. Glomerular number and size in autopsy kidneys: the relationship to birth weight. *Kidney Int*. 2003;63(6):2113–2122.

Inker LA, Schmid CH, Tighiouart H, et al. Estimating glomerular filtration rate from serum creatinine and cystatin C. *N Engl J Med*. 2012;367(1):20–29.

Iwakiri Y. The molecules: mechanisms of arterial vasodilatation observed in the splanchnic and systemic circulation in portal hypertension. *J Clin Gastroenterol*. 2007;41(Suppl 3):S288–S294.

Izzedine H, Mateus C, Boutros C, et al. Renal effects of immune checkpoint inhibitors. *Nephrol Dial Transplant*. 2017;32(6):936–942.

Johansson M, Herlitz H, Jensen G, et al. Increased cardiovascular mortality in hypertensive patients with renal artery stenosis. Relation to sympathetic activation, renal function and treatment regimens. *J Hypertens*. 1999;17(12 Pt 1):1743–1750.

Julian BA, Gaston RS, Brown WM, et al. Effect of replacing race with apolipoprotein L1 genotype in calculation of kidney donor risk index. *Am J Transplant*. 2017;17(6):1540–1548.

Jurado-Román A, Hernández-Hernández F, García-Tejada J, et al. Role of hydration in contrast-induced nephropathy in patients who underwent primary percutaneous coronary intervention. *Am J Cardiol*. 2015;115(9):1174–1178.

Kamholtz RG, Cronan JJ, Dorfman GS. Obstruction and the minimally dilated renal collecting system: US evaluation. *Radiology*. 1989;170(1 Pt 1):51–53.

Keene R, Froelich JM, Milbrandt JC, et al. Bilateral gluteal compartment syndrome following robotic-assisted prostatectomy. *Orthopedics*. 2010;33(11):852.

Khosroshahi A, Wallace ZS, Crowe JL, et al. International consensus guidance statement on the management and treatment of IgG4-related disease. *Arthritis Rheumatol*. 2015;67(7):1688–1699.

Kidney Disease: Improving Global outcomes section 2: AKI definition. *Kidney Int Suppl (2011)*. 2012;2(1):19–36.

Kim HS, Fine DM, Atta MG. Catheter-directed thrombectomy and thrombolysis for acute renal vein thrombosis. *J Vasc Interv Radiol*. 2006;17(5):815–822.

Klahr S. New insights into the consequences and mechanisms of renal impairment in obstructive nephropathy. *Am J Kidney Dis*. 1991;18(6):689–699.

Knight EL, Verhave JC, Spiegelman D, et al. Factors influencing serum cystatin C levels other than renal function and the impact on renal function measurement. *Kidney Int*. 2004;65(4):1416–1421.

Konstam MA, Gheorghiade M, Burnett JC, et al. Effects of oral tolvaptan in patients hospitalized for worsening heart failure: the EVEREST Outcome Trial. *J Am Med Assoc*. 2007;297(12):1319–1331.

Kuang W, Ng CS, Matin S, et al. Rhabdomyolysis after laparoscopic donor nephrectomy. *Urology*. 2002;60(5):911.

Kumbhani DJ, Bavry AA, Harvey JE, et al. Clinical outcomes after percutaneous revascularization versus medical management in patients with significant renal artery stenosis: a meta-analysis of randomized controlled trials. *Am Heart J*. 2011;161(3):622–630 [e621].

Larsen CP, Beggs ML, Saeed M, et al. Apolipoprotein L1 risk variants associate with systemic lupus erythematosus-associated collapsing glomerulopathy. *J Am Soc Nephrol*. 2013;24(5):722–725.

Lautin EM, Freeman NJ, Schoenfeld AH, et al. Radiocontrast-associated renal dysfunction: a comparison of lower-osmolality and conventional high-osmolality contrast media. *Am J Roentgenol*. 1991;157(1):59–65.

Lazarus B, Chen Y, Wilson FP, et al. Proton pump inhibitor use and the risk of chronic kidney disease. *J Am Med Assoc Intern Med*. 2016;176(2):238–246.

Lerman LO, Nath KA, Rodriguez-Porcel M, et al. Increased oxidative stress in experimental renovascular hypertension. *Hypertension*. 2001;37(2 Pt 2):541–546.

Lerman LO, Textor SC, Grande JP. Mechanisms of tissue injury in renal artery stenosis: ischemia and beyond. *Prog Cardiovasc Dis*. 2009;52(3):196–203.

Leung N, Bridoux F, Hutchison CA, et al. Monoclonal gammopathy of renal significance: when MGUS is no longer undetermined or insignificant. *Blood*. 2012;120(22):4292–4295.

Levey AS, Bosch JP, Lewis JB, et al. A more accurate method to estimate glomerular filtration rate from serum creatinine: a new prediction equation. Modification of Diet in Renal Disease Study Group. *Ann Intern Med*. 1999;130(6):461–470.

Levey AS, Stevens LA, Schmid CH, et al. A new equation to estimate glomerular filtration rate. *Ann Intern Med*. 2009;150(9):604–612.

Lewington AJ, Cerdá J, Mehta RL. Raising awareness of acute kidney injury: a global perspective of a silent killer. *Kidney Int*. 2013;84(3):457–467.

Lewis SJ, Mueller BA. Antibiotic dosing in patients with acute kidney injury: “enough but not too much”. *J Intens Care Med*. 2016;31(3):164–176.

Liang P, Hurks R, Bensley RP, et al. The rise and fall of renal artery angioplasty and stenting in the United States, 1988-2009. *J Vasc Surg*. 2013;58(5):1331–1338 [e1331].

Liaño F, Pascual J. Epidemiology of acute renal failure: a prospective, multicenter, community-based study. Madrid Acute Renal Failure Study Group. *Kidney Int*. 1996;50(3):811–818.

Lin CJ, Lim KH, Cheng YC, et al. Tumor lysis syndrome after treatment with gemcitabine for metastatic transitional cell carcinoma. *Med Oncol*. 2007;24(4):455–457.

Lopes AA, Port FK. The low birth weight hypothesis as a plausible explanation for the black/white differences in hypertension, non-insulin-dependent diabetes, and end-stage renal disease. *Am J Kidney Dis*. 1995;25(2):350–356.

Loscalzo J. Venous thrombosis in the nephrotic syndrome. *N Engl J Med*. 2013;368(10):956–958.

Luo Y, Wang X, Ye Z, et al. Remedial hydration reduces the incidence of contrast-induced nephropathy and short-term adverse events in patients with ST-segment elevation myocardial infarction: a single-center, randomized trial. *Intern Med*. 2014;53(20):2265–2272.

Lye WC, Cheah JS, Sinniah R. Renal cholesterol embolic disease. Case report and review of the literature. *Am J Nephrol*. 1993;13(6):489–493.

Madhavan SM, O'Toole JF, Konieczkowski M, et al. APOL1 localization in normal kidney and nondiabetic kidney disease. *J Am Soc Nephrol*. 2011;22(11):2119–2128.

Mailloux LU, Kapikian N, Napolitano B, et al. Home hemodialysis: patient outcomes during a 24-year period of time from 1970 through 1993. *Adv Ren Replace Ther*. 1996;3(2):112–119.

Manetti L, Pardini E, Genovesi M, et al. Thyroid function differently affects serum cystatin C and creatinine concentrations. *J Endocrinol Invest*. 2005;28(4):346–349.

Marone LK, Clouse WD, Dorer DJ, et al. Preservation of renal function with surgical revascularization in patients with atherosclerotic renovascular disease. *J Vasc Surg*.

2004;39(2):322–329.

Matsushita K, Mahmoodi BK, Woodward M, et al. Comparison of risk prediction using the CKD-EPI equation and the MDRD study equation for estimated glomerular filtration rate. *J Am Med Assoc*. 2012;307(18):1941–1951.

May AG, De Weese JA, Rob CG. Hemodynamic effects of arterial stenosis. *Surgery*. 1963;53:513–524.

McGregor DO, Buttimore AL, Lynn KL. Home hemodialysis: excellent survival at less cost, but still underutilized. *Kidney Int*. 2000;57(6):2654–2655.

McKenzie GA, Oderich GS, Kawashima A, et al. Renal artery fibromuscular dysplasia in 2,640 renal donor subjects: a CT angiography analysis. *J Vasc Interv Radiol*. 2013;24(10):1477–1480.

Mehta RL, McDonald B, Gabbai F, et al. Nephrology consultation in acute renal failure: does timing matter? *Am J Med*. 2002;113(6):456–461.

Meier-Kriesche HU, Port FK, Ojo AO, et al. Effect of waiting time on renal transplant outcome. *Kidney Int*. 2000;58(3):1311–1317.

Miralles M, Corominas A, Cotillas J, et al. Screening for carotid and renal artery stenoses in patients with aortoiliac disease. *Ann Vasc Surg*. 1998;12(1):17–22.

Muriithi AK, Nasr SH, Leung N. Utility of urine eosinophils in the diagnosis of acute interstitial nephritis. *Clin J Am Soc Nephrol*. 2013;8(11):1857–1862.

Myers BD, Moran SM. Hemodynamically mediated acute renal failure. *N Engl J Med*. 1986;314(2):97–105.

Newman DJ, Thakkar H, Edwards RG, et al. Serum cystatin C measured by automated immunoassay: a more sensitive marker of changes in GFR than serum creatinine. *Kidney Int*. 1995;47(1):312–318.

Neymark E, LaBerge JM, Hirose R, et al. Arteriographic detection of renovascular disease in potential renal donors: incidence and effect on donor surgery. *Radiology*. 2000;214(3):755–760.

Norberg SM, Oros M, Birkenbach M, et al. Spontaneous tumor lysis syndrome in renal cell carcinoma: a case report. *Clin Genitourin Cancer*. 2014;12(5):e225–e227.

Novick AC, Gephardt G, Guz B, et al. Long-term follow-up after partial removal of a solitary kidney. *N Engl J Med*. 1991;325(15):1058–1062.

Novick AC, Schreiber MJ. Effect of angiotensin-converting enzyme inhibition on nephropathy in patients with a remnant kidney. *Urology*. 1995;46(6):785–789.

Olin JW, Sealove BA. Diagnosis, management, and future developments of fibromuscular dysplasia. *J Vasc Surg*. 2011;53(3):826–836 [e821].

Pannu N. Bidirectional relationships between acute kidney injury and chronic kidney disease. *Curr Opin Nephrol Hypertens*. 2013;22(3):351–356.

Parsa A, Kao WH, Xie D, et al. APOL1 risk variants, race, and progression of chronic kidney disease. *N Engl J Med*. 2013;369(23):2183–2196.

Paty PS, Darling RC 3rd, Lee D, et al. Is prosthetic renal artery reconstruction a durable procedure? An analysis of 489 bypass grafts. *J Vasc Surg*. 2001;34(1):127–132.

Pépin MN, Bouchard J, Legault L, et al. Diagnostic performance of fractional excretion of urea and fractional excretion of sodium in the evaluations of patients with acute kidney injury with or without diuretic treatment. *Am J Kidney Dis*. 2007;50(4):566–573.

Perazella MA, Parikh CR. How can urine microscopy influence the differential diagnosis of AKI? *Clin J Am Soc Nephrol*. 2009;4(4):691–693.

Persson PB, Hansell P, Liss P. Pathophysiology of contrast medium-induced nephropathy. *Kidney Int*. 2005;68(1):14–22.

Pfister SA, Deckart A, Laschke S, et al. Unenhanced helical computed tomography vs intravenous urography in patients with acute flank pain: accuracy and economic impact in a randomized prospective trial. *Eur Radiol*. 2003;13(11):2513–2520.

Plouin PF, Chatellier G, Darne B, et al. Blood pressure outcome of angioplasty in atherosclerotic renal artery stenosis: a randomized trial. Essai Multicentrique Medicaments vs Angioplastie (EMMA) Study Group. *Hypertension*. 1998;31(3):823–829.

Pöge U, Gerhardt T, Stoffel-Wagner B, et al. Calculation of glomerular filtration rate based on cystatin C in cirrhotic patients. *Nephrol Dial Transplant*. 2006;21(3):660–664.

Ponce D, Zorzenon Cde P, dos Santos NY, et al. Early nephrology consultation can have an impact on outcome of acute kidney injury patients. *Nephrol Dial Transplant*. 2011;26(10):3202–3206.

Prasad A, Zafar N, Mahmud E. Assessment of renal artery fibromuscular dysplasia: angiography, intravascular ultrasound (with virtual histology), and pressure wire measurements. *Catheter Cardiovasc Interv*. 2009;74(2):260–264.

Prowle JR, Kirwan CJ, Bellomo R. Fluid management for the prevention and attenuation of acute kidney injury. *Nat Rev Nephrol*. 2014;10(1):37–47.

Ren S, Wu C, Zhang Y, et al. An update on clinical significance of use of THSD7A in diagnosing idiopathic membranous nephropathy: a systematic review and meta-analysis of THSD7A in IMN. *Ren Fail*. 2018;40(1):306–313.

Rich MW, Crecelius CA. Incidence, risk factors, and clinical course of acute renal insufficiency after cardiac catheterization in patients 70 years of age or older. A prospective study. *Arch Intern Med*. 1990;150(6):1237–1242.

Ritchie J, Green D, Chrysochou C, et al. High-risk clinical presentations in atherosclerotic renovascular disease: prognosis and response to renal artery revascularization. *Am J Kidney Dis*. 2014;63(2):186–197.

Rocha-Singh KJ, Eisenhauer AC, Textor SC, et al. Atherosclerotic Peripheral Vascular Disease Symposium II: intervention for renal artery disease. *Circulation*. 2008;118(25):2873–2878.

Ruggenenti P, Debiec H, Ruggiero B, et al. Anti-phospholipase a2 receptor antibody titer predicts post-rituximab outcome of membranous nephropathy. *J Am Soc Nephrol*. 2015;26(10):2545–2558.

Sadowski CE, Lovric S, Ashraf S, et al. A single-gene cause in 29.5% of cases of steroid-resistant nephrotic syndrome. *J Am Soc Nephrol*. 2015;26(6):1279–1289.

Saeki T, Nishi S, Imai N, et al. Clinicopathological characteristics of patients with IgG4-related tubulointerstitial nephritis. *Kidney Int*. 2010;78(10):1016–1023.

Schetz M, Gunst J, Van den Berghe G. The impact of using estimated GFR versus creatinine clearance on the evaluation of recovery from acute kidney injury in the ICU. *Intensive Care Med*. 2014;40(11):1709–1717.

Schlossberg SM, Vaughan ED. The mechanism of unilateral post-obstructive diuresis. *J Urol*. 1984;131(3):534–536.

Schnermann J, Homer W. Smith Award lecture. The juxtaglomerular apparatus: from anatomical peculiarity to physiological relevance. *J Am Soc Nephrol*. 2003;14(6):1681–1694.

Schold JD, Sehgal AR, Srinivas TR, et al. Marked variation of the association of ESRD duration before and after wait listing on kidney transplant outcomes. *Am J Transplant*. 2010;10(9):2008–2016.

Schwab SJ, Hlatky MA, Pieper KS, et al. Contrast nephrotoxicity: a randomized controlled trial of a nonionic and an ionic radiographic contrast agent. *N Engl J Med*. 1989;320(3):149–153.

Schwartz CJ, White TA. Stenosis of renal artery: an unselected necropsy study. *Br Med J*. 1964;2(5422):1415–1421.

Scolari F, Ravani P, Gaggi R, et al. The challenge of diagnosing atheroembolic renal disease: clinical features and prognostic factors. *Circulation*. 2007;116(3):298–304.

Sethi S, Rajkumar SV. Monoclonal gammopathy-associated proliferative glomerulonephritis. *Mayo Clin Proc*. 2013;88(11):1284–1293.

Skluzacek PA, Szewc RG, Nolan CR 3rd, et al. Prediction of GFR in liver transplant candidates. *Am J Kidney Dis*. 2003;42(6):1169–1176.

Somerville CA, Chmiel R, Niall JF, et al. Non-dilated urinary tract obstruction. *Med J Aust*. 1992;156(10):721–723.

Stevens LA, Levey AS. Measured GFR as a confirmatory test for estimated GFR. *J Am Soc Nephrol*. 2009;20(11):2305–2313.

Stokes JB, Bonsib SM, McBride JW. Diffuse intimal fibromuscular dysplasia with multiorgan failure. *Arch Intern Med*. 1996;156(22):2611–2614.

Testani JM, Khera AV, St John Sutton MG, et al. Effect of right ventricular function and venous congestion on cardiorenal interactions during the treatment of decompensated heart failure. *Am J Cardiol*. 2010;105(4):511–516.

Trinquart L, Mounier-Vehier C, Sapoval M, et al. Efficacy of revascularization for renal artery stenosis caused by fibromuscular dysplasia: a systematic review and meta-analysis. *Hypertension*. 2010;56(3):525–532.

U.S. Renal Data System. USRDS 2013 Annual Data Report. *Atlas of Chronic Kidney Disease and End Stage Renal*

Disease in the United States. [Bethesda, MD: National Institutes of Health, National Institute of Diabetes and Digestive and Kidney Diseases] 2013.

US Renal Data System. USRDS 2013 Annual Data Report. *Epidemiology of Kidney Disease in the United States*. [Bethesda, MD: National Institutes of Health, National Institute of Diabetes and Digestive and Kidney Diseases] 2013.

Uchino S, Kellum JA, Bellomo R, et al. Acute renal failure in critically ill patients: a multinational, multicenter study. *J Am Med Assoc*. 2005;294(7):813–818.

van de Ven PJ, Kaatee R, Beutler JJ, et al. Arterial stenting and balloon angioplasty in ostial atherosclerotic renovascular disease: a randomised trial. *Lancet*. 1999;353(9149):282–286.

van Jaarsveld BC, Krijnen P, Pieterman H, et al. The effect of balloon angioplasty on hypertension in atherosclerotic renal-artery stenosis. Dutch Renal Artery Stenosis Intervention Cooperative Study Group. *N Engl J Med*. 2000;342(14):1007–1014.

Vanhamme L, Paturiaux-Hanocq F, Poelvoorde P, et al. Apolipoprotein L-I is the trypanosome lytic factor of human serum. *Nature*. 2003;422(6927):83–87.

Vasbinder GB, Nelemans PJ, Kessels AG, et al. Diagnostic tests for renal artery stenosis in patients suspected of having renovascular hypertension: a meta-analysis. *Ann Intern Med*. 2001;135(6):401–411.

Vijay MK, Vijay P, Kundu AK. Rhabdomyolysis and myogloginuric acute renal failure in the lithotomy/exaggerated lithotomy position of urogenital surgeries. *Urol Ann*. 2011;3(3):147–150.

Walsh M, Devereaux PJ, Garg AX, et al. Relationship between intraoperative mean arterial pressure and clinical outcomes after noncardiac surgery: toward an empirical definition of hypotension. *Anesthesiology*. 2013;119(3):507–515.

Webster J, Marshall F, Abdalla M, et al. Randomised comparison of percutaneous angioplasty vs continued medical therapy for hypertensive patients with atheromatous renal artery stenosis. Scottish and Newcastle Renal Artery Stenosis Collaborative Group. *J Hum Hypertens*. 1998;12(5):329–335.

Weir MR, Bakris GL, Bushinsky DA, et al. Patiromer in patients with kidney disease and hyperkalemia receiving RAAS inhibitors. *N Engl J Med*. 2015;372(3):211–221.

Weisbord SD, Gallagher M, Jneid H, et al. Outcomes after angiography with sodium bicarbonate and acetylcysteine. *N Engl J Med*. 2018;378(7):603–614.

Wheatley K, Ives N, et al. Revascularization versus medical therapy for renal-artery stenosis. *N Engl J Med*. 2009;361(20):1953–1962.

Whelton A. Nephrotoxicity of nonsteroidal anti-inflammatory drugs: physiologic foundations and clinical implications. *Am J Med*. 1999;106(5B):13S–24S.

Wu CC, Yeung LK, Tsai WS, et al. Incidence and factors predictive of acute renal failure in patients with advanced liver cirrhosis. *Clin Nephrol*. 2006;65(1):28–33.

Xie Y, Bowe B, Li T, et al. Proton Pump Inhibitors and Risk of Incident CKD and Progression to ESRD. *J Am Soc Nephrol*. 2016;27(10):3153–3163.

Urologic Complications of Renal Transplantation

Mohammed Shahait MBBS, Stephen V. Jackman MD, Timothy D. Averch MD

Renal transplantation is the most cost-effective treatment for patients with end-stage renal disease and improves their chances of survival and their quality of life. Nevertheless, kidney transplantation is associated with a distinct array of urologic complications that must be managed promptly to prevent deterioration of graft function and improve graft survival. Urologic complications after renal transplantation are the most common surgical adverse event; overall rates range between 8% and 9.5%. These complications have been associated with high morbidity and increased care cost. The majority of the urologic complications are related to the transplanted ureter and ureterovesical anastomosis. The goal of this chapter is to review the major urologic complications encountered after kidney transplant and help the urologist to manage these complications.

Hematuria

Hematuria during the immediate postoperative period is typically related to the ureterovesical anastomosis. **In the majority of the cases, hematuria resolves over several days and rarely requires bladder irrigation.** Hematuria is observed more commonly after Leadbetter anastomosis compared with other types of anastomosis (Alberts et al., 2014).

Conversely, persistent hematuria after allograft biopsy is caused by an arteriovenous collecting system fistula. Duplex ultrasound (US) establishes the diagnosis and can be confirmed by magnetic resonance angiography. **Fortunately, in 70% of the cases, fistulas tend to resolve spontaneously; when they do not, highly selective embolization is indicated** (Branchereau et al., 2016).

The evaluation of asymptomatic microscopic hematuria (AMH) in transplant recipients follows the American Urology Association guidelines for AMH; the biggest difference is adding BK virus as part of the differential diagnosis. This may be suspected by viral cytopathic changes seen on cytology and confirmed by urine BK virus titers (Davis et al., 2012).

Ureteral Stent Management

Timing of Stent Removal

Several randomized clinical trials confirmed the utility of the routine use of a ureteral stent across the ureteovesical anastomosis during renal transplantation to decrease the incidence of urine leak and stricture of the ureter (Bassiri et al., 1995; Benoit et al., 1996; Dominguez et al., 2000; Kumar et al., 1998; Osman et al., 2005; Pleass et al., 1995). On the other hand, ureteral stent insertion is associated with an intrinsic risk of bacterial colonization. This risk can be substantial because 27% of the ureteral stents are colonized regardless of the indwelling time, and subsequent urinary tract infection (UTI) may pose a significant risk for graft infection and graft failure (Bonkat et al., 2012).

Several measures can be taken to improve outcome and decrease transplant stent-related complications such as infection and idiosyncratic stent-related complications. In a recent meta-analysis, early stent removal, defined by removal of the stent before the third postoperative week (before day 15), has been shown to reduce the incidence of UTI (RR 0.45, 95% CI 0.29–0.70; $I^2 = 13\%$) without discernible effect on the incidence of urine leak and stenosis (Thompson et al., 2018).

Nevertheless, a case-by-case approach to the timing of stent removal for every patient must take into consideration surgeon satisfaction with the anastomosis and the patient's related risk factors such as diabetes, transplant revision, and presence of UTI.

Retained Stent

A retained stent can be due to a technical error during the ureteroneocystostomy closure in which the anastomosis suture inadvertently has caught the stent or because of stent encrustation. If the suture holds the stent, then leaving the stent until the suture dissolves is an option versus endoscopic stitch transection.

Stent encrustation is a significant problem for stents left for extended periods, with an incidence ranging from 0 to 5.7% (Guleria et al.,1998; Lynch et al., 2007). **Because of renal allograft denervation, kidney transplant recipients rarely manifest the classical symptoms of ureteral obstruction.** A transplant recipient with an encrusted stent usually presents with a progressive decline in renal function, a decrease in urine output and recurrent UTIs. In a rare instance, patients may experience a poorly characterized ache over the allograft because of irritation of peritoneum.

Prevention

Stent encrustation is a prime example of Reasons' Swiss Cheese Model of system failure and can be attributed to a chain of errors such as lack of documentation regarding stent insertion and poor team communication, as well as inadequate patient counseling about the temporary function of the stent, expected complications, and the importance of timely follow-up for stent removal. Different methods have been proposed to ensure timely removal; log books, stent cards, computerized tracking registry, web-based stent registry, and Smartphone application have been proposed and studied, yet none have yet been shown to be completely reliable (Ather et al., 2000; Lynch et al., 2007; McCahy et al., 1996; Molina et al., 2017; Sabharwal et al., 2014; Tang et al., 2008).

Diagnosis and Treatment

Computed tomography (CT) scan should be obtained in all patients with stent encrustation to assess encrustation burden and distribution, which will help guide the surgical approach (Fig. 88.1). **The first step of management is typically a urinary diversion by a nephrostomy tube, which will allow for decompression of the renal collecting system, improvement in renal function as well as antegrade access.** Different combinations of percutaneous nephrolithotomy, retrograde intrarenal renal surgery, and extracorporeal wave shock lithotripsy have been described to treat the encrusted transplant stent (Veltman et al., 2010; Wu et al., 2014).

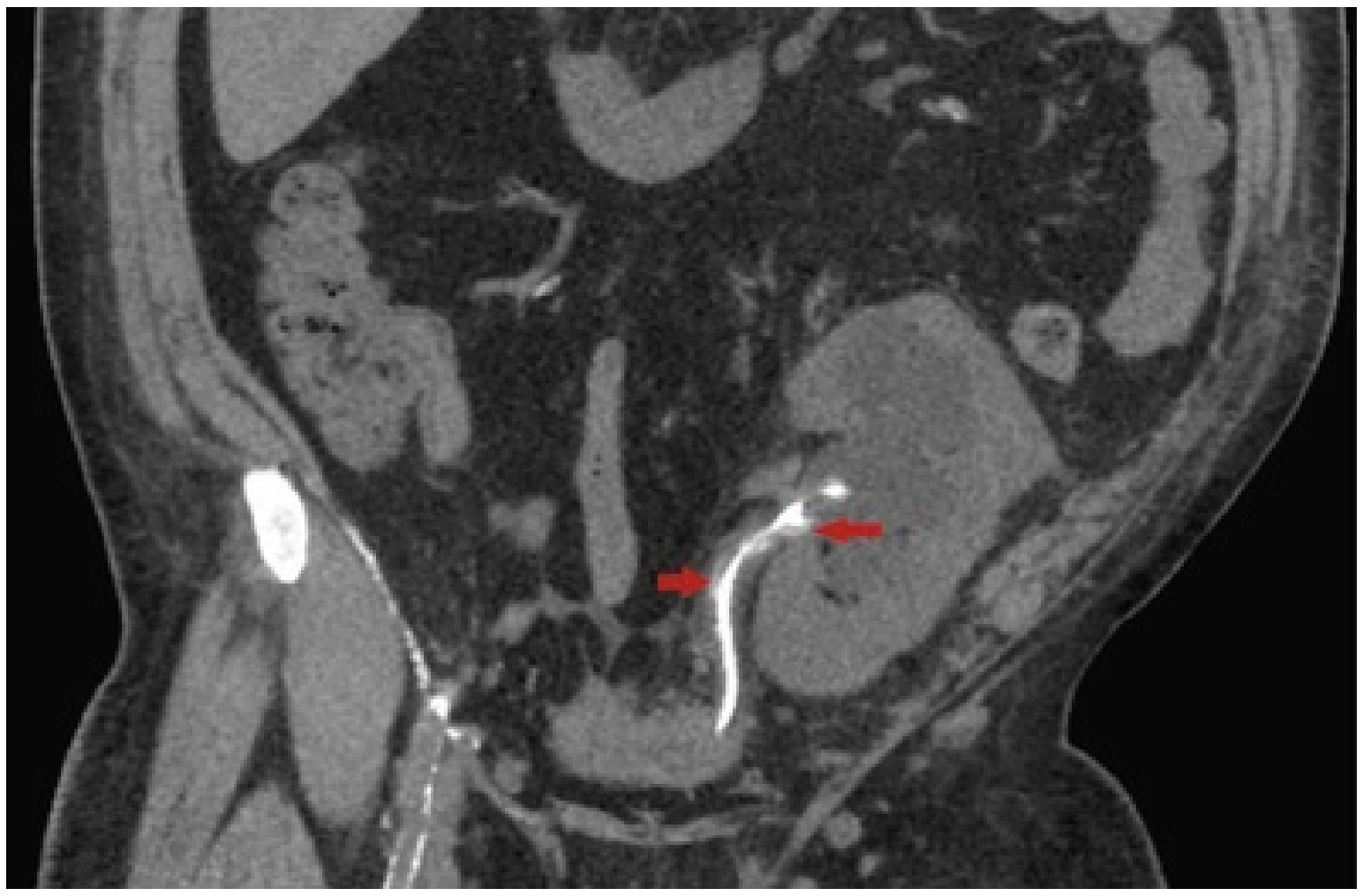

FIG. 88.1 Encrusted ureteral stent. Computed tomography scan demonstrates deposition of stone-like material *(arrows)* in the upper ureter. It is no longer functional (i.e., side holes and lumen are occluded).

Key Points: Hematuria and Ureteral Stent Management

- Majority of post-op hematuria is self-limiting.
- Consider duplex US for severe or persistent hematuria after renal biopsy to rule out AV fistula.
- Ureteral stent decreases ureteral stricture and urinary leak.
- Individualized stent removal after 3 weeks post-transplantation.

Urinary Leak

Urine leak is the most common early urologic complication after renal transplantation, with an incidence ranging from 1.2% to 8.9% (Dinckan et al., 2007; Lempinen et al., 2015; Streeter et al., 2002). **Compromising the blood supply to the distal ureter during organ procurement is the main risk factor for ureteral necrosis and urine leak.** This has been observed more frequently in advanced donor age, extended criteria donors, allograft with multiple arteries, and failure to re-implant the lower polar artery (Branchereau et al., 2016; Rahnemai-Azar et al., 2015).

Additional causes for urine leak can be related to bladder dysfunction and other technical issues, which are outlined in Box 88.1.

Box 88.1

Additional Causes of Urinary Leak

- An excessively long ureter
- Premature removal of bladder and/or ureteric drainage
- Technical problem such as suture dehiscence, ureteric twisting, or kinking
- Acute urine retention/bladder catheter obstruction
- Necrosis of renal parenchyma
- Parenchymal perforation during double-J stent placement

Diagnosis

Early urine leak can be manifested as high fluid output from the drain with a concomitant decrease in urine output and an elevated serum creatinine. Alternatively, if the drain has been removed or omitted by the surgeon at the time of surgery, urine leak can be evident as a fluid leak from the wound, wound dehiscence, scrotal swelling, and/or pelvic or abdominal pain. US or non-enhanced CT scan can establish the diagnosis of fluid collection. The diagnosis can be confirmed by analysis of the content of collection sampled by CT/US-guided aspiration or fluid from the drain or the wound discharge. If the fluid is urine, the creatinine in the fluid will be significantly higher than the serum creatinine.

Treatment

The initial goal of treatment of a urine leak after transplantation is to divert urine away from the region of extravasation, improve graft function, and ameliorate the patient's general status. This can be achieved by a Foley catheter and a percutaneous nephrostomy tube. A nephrostomy tube can be used to perform an antegrade nephrostogram and characterize the leak further. In addition, it provides access for antegrade stent placement. Retrograde stent placement has also been proposed when a double-J stent was not placed at the time of surgery. However, retrograde insertion can be challenging because of the angulation required to access the neoureteral orifice, edema of the orifice, and the potential to further disrupt the anastomosis. If a substantial urinoma forms or causes ureteral obstruction or there is evidence of infection, then percutaneous drainage is recommended. In the instance of a small anastomotic leak, periodic contrast studies are performed to asses for healing every 1 to 2 weeks. A Foley catheter can be used to help facilitate healing in instances of a urine leak. The Foley catheter and nephrostomy tube can be removed when the leak is resolved. Patients should follow up diligently because they have the potential to develop ureteral stenosis in the future. The success rate of the endourologic management of the urine leak after kidney transplant ranges between 36% and 87% at a mean follow-up of 35 months (Alcaraz et al., 2005; Berli et al., 2015; Bhagat et al., 1998; Campbell et al., 1993; Matalon et al., 1990; Nie et al., 2009; Swierzewski et al., 1993; Tillou et al., 2009).

Early exploration and reconstructive surgery should be offered to patients with a proximal large leak, or persistent leak despite maximal drainage. The rationale for early surgical intervention is the low success rate of conservative management, the lack of intraabdominal adhesion, the minimal degree of postoperative fibrosis, and the decreased risk of subsequent ureteric stenosis. If the ureter remnant has an adequate blood supply, a tension-free ureteroneocystostomy should be attempted. Otherwise, other options should be entertained such as ureterureteral anastomosis using the patient's native ipsilateral ureter, a bladder flap, or a pyelovesicostomy (Branchereau et al., 2016).

Ureteral Stricture

Strictures are the predominant cause of ureteral obstruction in patients greater than 3 months poststransplantation. They affect 1% to 9% of patients; early ureteral obstruction can be due to technical faults during the construction of the ureteroneocystostomy, such as not using a ureteral stent, anastomotic edema, redundant ureter length or extrinsic compression by lymphocele, hematoma, or abscess (Table 88.1; Faenza et al., 1999; Pereira et al., 2011).

TABLE 88.1

Common Causes of Ureteral Obstruction

EARLY URETERAL OBSTRUCTION (<3 MONTHS)
Technical error during ureteroneocystostomy anastomosis
Forgoing ureteral stent
Anastomosis edema
Redundant ureter
Extrinsic compression (lymphocele, hematoma, abscess)
LATE URETERAL OBSTRUCTION (>3 MONTHS)
Stones
Ureteral strictures
Lymphocele
Fibrosis related to immunosuppressant medications

The primary cause of ureteral stricture development is ischemia. Other causes for stricture development are related to urine leak, a component of graft rejection phenomena, or chronic infection. Also, BK and cytomegalovirus have been linked to ureteral stricture formation. Ureteral stricture development rates do not show a difference across the variety of types of the urinary anastomosis (Karam et al., 2004).

Diagnosis

The diagnosis of ureteral stricture should be considered when any deterioration of renal function is observed, especially when it is associated with hydronephrosis of the renal transplant. Hydronephrosis may be less than expected because of the inability of the system to expand secondary to surrounding fibrosis. Antegrade nephrostogram or a Whitaker test may be needed to establish the diagnosis.

Treatment

The priority in the management of ureteral obstruction is to decompress the collecting system and allow the allograft to recover. Nephrostomy, nephroureteral stent, antegrade stent, or retrograde stent placement can be used. Retrograde stent insertion can be cumbersome because of the location of the neoureteral orifice, location of stricture, and ureteral tortuosity. Antegrade nephrostomy helps to obtain a detailed antegrade nephrostogram of the pathology and provides versatile access for various endoscopic tools (Fig. 88.2; Duty et al., 2015; Orvieto et al., 2006). Once a stent is in place, retrograde exchange is usually straightforward, making long-term nephrostomy unnecessary in conservatively managed strictures.

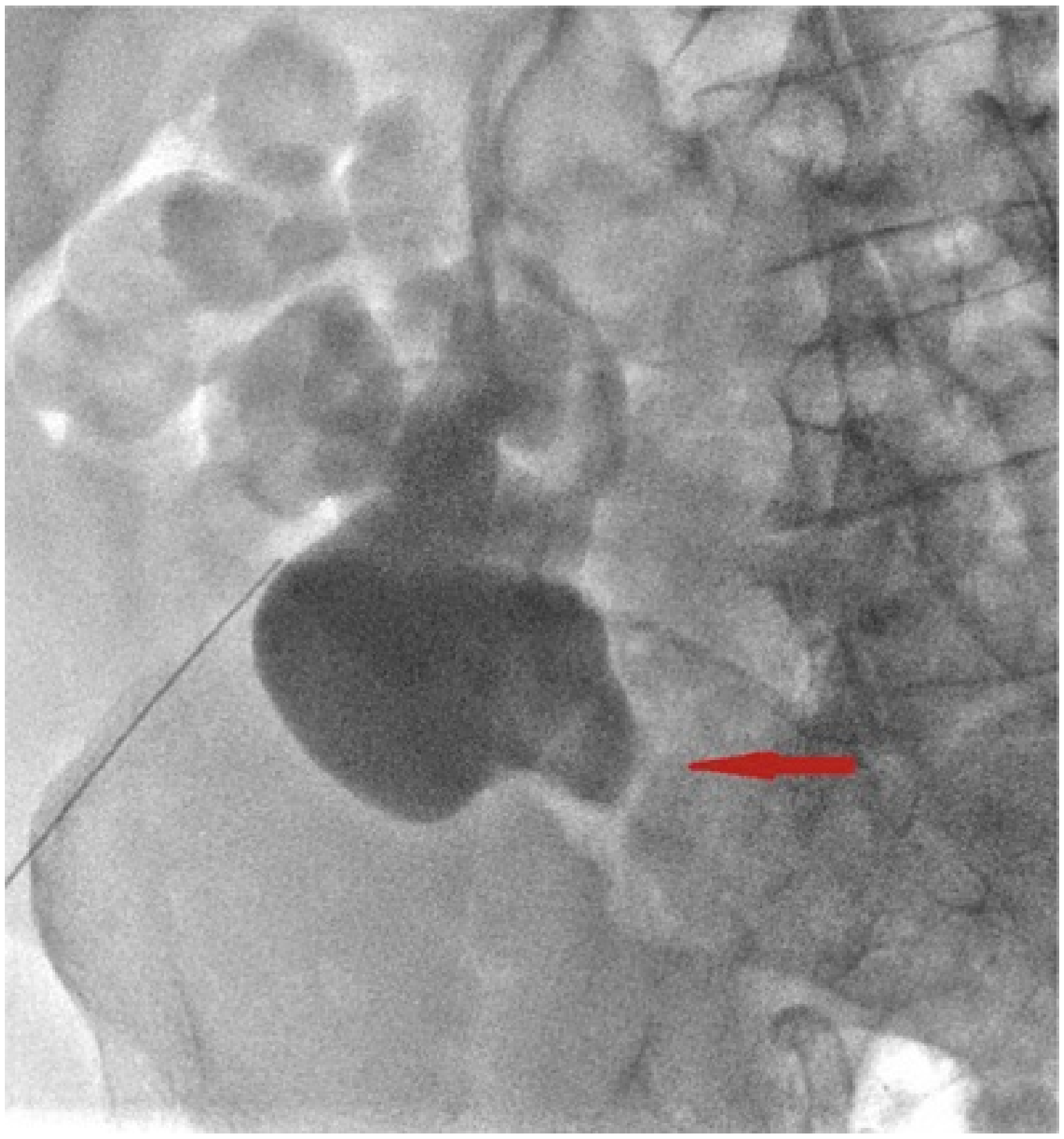

FIG. 88.2 Proximal ureteral stricture. Antegrade nephrostogram reveals hydronephrosis in the allograft without visulization of the ureter.

The decision to proceed with endoscopic or surgical management depends on several factors: patient performance status, the presence of comorbidities, and length and location of the stricture.

Endoscopic options include double-J stent insertion, ureteral balloon dilation, and different variations of endoureterotomy (i.e., cold knife, holmium laser). In a small case series, the intermediate-term success rate of antegrade double-J stent insertion was 33% (Bhagat et al., 1998). Balloon dilation is associated with a 3-year success rate of 51% (range 44% to 62%) (Bachar et al., 2004; Bromwich et al., 2006; Juaneda et al., 2005).

Several series have reported on the efficacy of different techniques of endoureterotomy in treating allograft ureteral stricture, with success rate of 79%, 78%, and 55% for holmium laser endoureterotomy, Acucise balloon cutting device, and electrocautery with the T loop of a resectoscope, respectively (Duty et al., 2015).

With respect to these results, definitive open surgical repair remains the most effective treatment modality with superior long-term results when compared with endoscopic management. Open surgical reconstructive options vary, depending on the size and location of the stricture and consist of allograft ureter reimplantation, ureter-ureteral anastomosis using ipsilateral native ureter, Boari flap, appendix or ilium interposition or pyelovesicostomy (Adani et al., 2015). Recently, different series reported on the translation of different open ureteral reconstructive options to robotic-assisted laparoscopic surgery with a comparable short-term outcome (Benamran et al., 2017; Hauser et al., 2011).

Key Points: Ureteral Stricture

- Strictures are the predominant cause of ureteral obstruction in patients greater than 3 months posttransplantion.
- The primary cause of ureteral stricture development is ischemia.
- Stricture should be suspected in patients with hydronephrosis and decreased graft function.
- A variety of endourologic treatment options have been described to treat ureteral strictures; however, open reconstructive surgery offers superior long-term results.

Vesicoureteral Reflux

Several modifications of the ureterovesical anastomosis have been described to replicate an antireflux mechanism. Nevertheless, on voiding cystography, the incidence of vesicoureteral reflux (VUR) can be evident in 50% to 86% of the cases, whereas the incidence of symptomatic or clinically significant VUR is less than 1% and independent of the ureterovesical anastomosis technique (Masahiko et al., 2000; Ostrowski et al.,1999). The clinical sequelae of VUR are unclear; in one study it was found that, at 5 years, patients with VUR had a higher incidence of hypertension and trended toward an increased susceptibility for urosepsis (Mastrosimone et al., 1993).

VUR can be related to a technical error during the ureteroneocystostomy anastomosis, bladder outlet obstruction, or high-pressure urine storage secondary to either detrusor overactivity or reduced bladder compliance.

Diagnosis

Patients with recurrent urinary tract infections should be evaluated for VUR by voiding cystography. Once the diagnosis of VUR is established, a comprehensive workup to rule out bladder outlet obstruction and high-pressure urine storage is recommended.

Treatment

Therapy should be focused on the underlying cause for the symptomatic reflux. Patients with high-pressure urine storage or bladder outlet obstruction can be treated in the usual fashion. In rare cases, the reflux itself can be addressed.

Traditionally, the standard treatment for VUR involved revision of the anastomosis or ureter-reimplantation to the ipsilateral native ureter. However, endoscopic submucosal injection of various composites, either Teflon or Macroplastique, is a less invasive alternative. The success rate of submucosal injection depends on the grade of reflux; it reaches 90% in grades I and II disease, whereas it is only 30% in high-grade disease. Thus an endoscopic submucosal injection should be attempted only in patients with clinically significant low-grade VUR. **On the other hand, patients with high-grade reflux or failed previous endoscopic treatment with persistent symptoms are**

best managed by reconstructive surgery (Elder et al., 2006; Pichler et al., 2011; Seifert et al., 2007; Stenberg et al., 1995; Yucel et al., 2010).

Lymphocele

A lymphocele is a pseudocyst with lymph content covered by a hard fibrous capsule around the graft. Lymphocele is radiographically evident in 0.6% to 33.9% of recipients. However, the incidence of symptomatic lymphocele ranges from 0.03% to 26%. A lymphocele most frequently develops within the first 6 months after transplantation with a peak incidence at 6 weeks (Dubeaux et al., 2004; Ebadzadeh et al., 2008).

Lymphoceles occur mainly because of extensive dissection of the lymphatics around the iliac vessels of the recipient or renal vessels of the donor occuring during the time of organ procurement surgery or back table preparation. Other factors found to be associated with lymphocele formation include obesity, recipient age, duration of dialysis treatment, warm ischemia time, use of prophylaxis low-molecular-weight heparin, delayed graft function, acute rejection, redo-transplant, and the use of mTOR inhibitors (Cash et al., 2012; Dean et al., 2004; Goel et al., 2004; Huber et al., 2007; Khauli et al., 1993; Martinez-Ocana et al., 1995; Mokos et al., 2010; Pengel et al., 2011; Stephanian et al., 1992; Tiong et al., 2009).

The majority of patients with lymphocele are asymptomatic. However, large lymphoceles may present as unilateral lower limb edema, deterioration of graft function, symptoms related to bladder compression, fever, and deep vein thrombosis as a consequence of compression of the external iliac vein.

Diagnosis

Confirmation of the presence of a fluid collection around the graft can be determined on US examination or CT scan. Biochemical and microbiological analysis of the fluid from the lymphocele can be obtained directly from the drain or the aspirate using a US-guided/CT-guided fine-needle percutaneous aspiration. This should be performed to differentiate lymphocele from urinoma, seroma, or abscess.

Treatment

As mentioned earlier, the majority of lymphoceles are asymptomatic, and no treatment is required because they tend to resolve spontaneously. Treatment for lymphoceles is necessary in less than 15% of the cases. Primary treatment modalities include aspiration with or without sclerotherapy, drain placement, and laparoscopic or open decortication surgery with possible peritoneal window. The success rate for aspiration alone, sclerotherapy using different composite, drain placement, laparoscopic, and open surgery is 41%, 69%, 50%, 92%, and 84%, respectively. **Open drainage should be considered in patients with wound complications and those with a small lymphocele adjacent to vital renal structures** (Lucewicz et al., 2011; Ulrich et al., 2010; Zagdoun et al., 2010; Zietek et al., 2007).

Nephrolithiasis

The estimated incidence of kidney stones in kidney transplant recipients is 1.0%. The mean time to stone onset is 28 ± 22 months. The most common stone composition is calcium-based stones (67%), followed by struvite stones (20%) and uric acid stones (13%) (Branchereau et al., 2018; Cheungpasitporn et al., 2016).

Several factors favor stone formation in kidney transplant patients, such as secondary hyperparathyroidism, recurrent urinary tract infections, and metabolic abnormalities such as hypercalciuria, hyperuricosuria, hypocitraturia, or hyperoxaluria. In addition, the deleterious effect of certain immunosuppressive medications on the urine environment has been noted; for example, cyclosporine induces chronic hyperuricemia, and calcineurin inhibitors cause hyperoxaluria and hypocitraturia (Stapenhorst et al., 2005).

Treatment

The treatment of kidney stones in transplant patients follows the algorithm of stone management in native kidneys. In asymptomatic patients with a nonobstructing stone less than 4 mm, observation with serial US and creatinine level has been shown to be a feasible option. When growing or symptomatic, extracorporeal wave shock lithotripsy, retrograde intrarenal renal surgery, percutaneous nephrolithotomy and various combinations of these approaches have been described in treating urolithiasis in transplant allograft (Challacombe et al., 2005; Gupta et al., 2007; Klingler et al., 2002).

After management of the stone, patients should be followed for development of silent hydronephrosis after ureteral instrumentation. Patients should undergo comprehensive metabolic screening to identify and treat underlying metabolic abnormalities.

Lower Urinary Tract Complications

Voiding Dysfunction

Voiding dysfunction is common after renal transplantation. Because the majority of patients are oliguric before transplant, low urine volume may conceal bladder outlet obstruction or incontinence symptoms pretransplant. An intricate interaction between a small bladder capacity (<300 mL), preexisting anatomic abnormalities, and the direct effect of the immunosuppression on bladder function by decreasing bladder mass play a significant role in voiding dysfunction in kidney transplant recipients (Karam et al., 2011; Shenasky, 1976).

Evaluation of patients with voiding dysfunction should include a detailed history of urologic and neurologic disorders and previous urologic surgeries and be supported by a complete urologic and gynecologic physical exam. Assessing the symptoms using standardized questionnaires from the International Continence Society and the International Prostate Symptom score, and using a voiding diary is desirable. The indication for further testing such as uroflowmetry, urodynamic testing, and cystoscopy depends on individual risk factors and symptoms.

Small Bladder After Transplant

The bladder capacity in anuric recipients tends to grow gradually to reach normal capacity after kidney transplantation. **As a result, efforts to increase the bladder capacity before transplantation by bladder rehabilitation or surgical augmentation are unnecessary.**

If the bladder symptoms affecting the quality of life of the recipients, patients may benefit from the standard spectrum of treatments from anticholinergics and botox to bladder capacity is insufficient, or there is evidence of high storage pressure, or lower urinary tract augmentation or urinary diversion using an ileal conduit.

Benign Prostatic Hyperplasia

Benign prostatic hypertrophy (BPH) is a disease of aging men and as such is more common in the renal transplant population compared with the general population. It can be challenging to detect in anuric patients. The estimated 3-year incidence of BPH among renal transplant patients is 9.7% and has been shown to be associated with an increased risk of urinary tract infection and graft loss (Hurst et al., 2009; Tsaur et al., 2009).

If the preoperative evaluation or intraoperative findings are suggestive of the presence of significant BPH, precautionary measures should be considered, such as starting patients on an alpha-blocker and aggressive treatment of constipation before removing the Foley catheter. In selected cases, insertion of a suprapubic tube at the time of transplant can be performed.

Surgical resection of the prostate before transplantation while the patient is still anuric or oliguric may increase the risk of developing a bladder neck contracture or a urethral stricture secondary to the lack of urine during healing. Transurethral resection of prostate (TURP) or holmium enucleation of the prostate has been reported to be safe and effective in this subset of patients if performed at least 3 weeks posttransplant. **It is crucial to avoid TURP in the first 2 weeks and in the presence of a ureteral stent after the transplant because it has been associated with devastating complications such as sepsis and death** (Pedraza et al., 2004; Reinberg et al., 1992; Volpe et al., 2013).

Urine Incontinence

The estimated prevalence of urinary incontinence among female recipients is 28% (Heit et al., 2004). The diagnosis and treatment of stress incontinence in transplant patients are similar to nontransplant patients. Several reports have described the feasibility and safety of tension-free vaginal tape (TVT), transobturator tape (TOT), sacral neuromodulation, and laparoscopic sacrocolpopexy in female recipients (Rouffilange et al., 2017).

Limited reporting in the literature supports the feasibility of insertion of an artificial urinary sphincter prosthesis in kidney transplant patients after radical prostatectomy (O'Malley et al., 1999).

Genitourinary Malignancies

Renal Cell Carcinoma

The incidence of renal cell carcinoma (RCC) is higher in transplant recipients than in the general population. RCC represents 4.6% of posttransplant cancers compared with 3% of tumors in the general population. However, only 10% occurred in kidney grafts (Fig. 88.3). The mean time to develop a de novo tumor in the graft is 131 months (Chapman et al., 2013; Hickman et al., 2018; Penn, 1995).

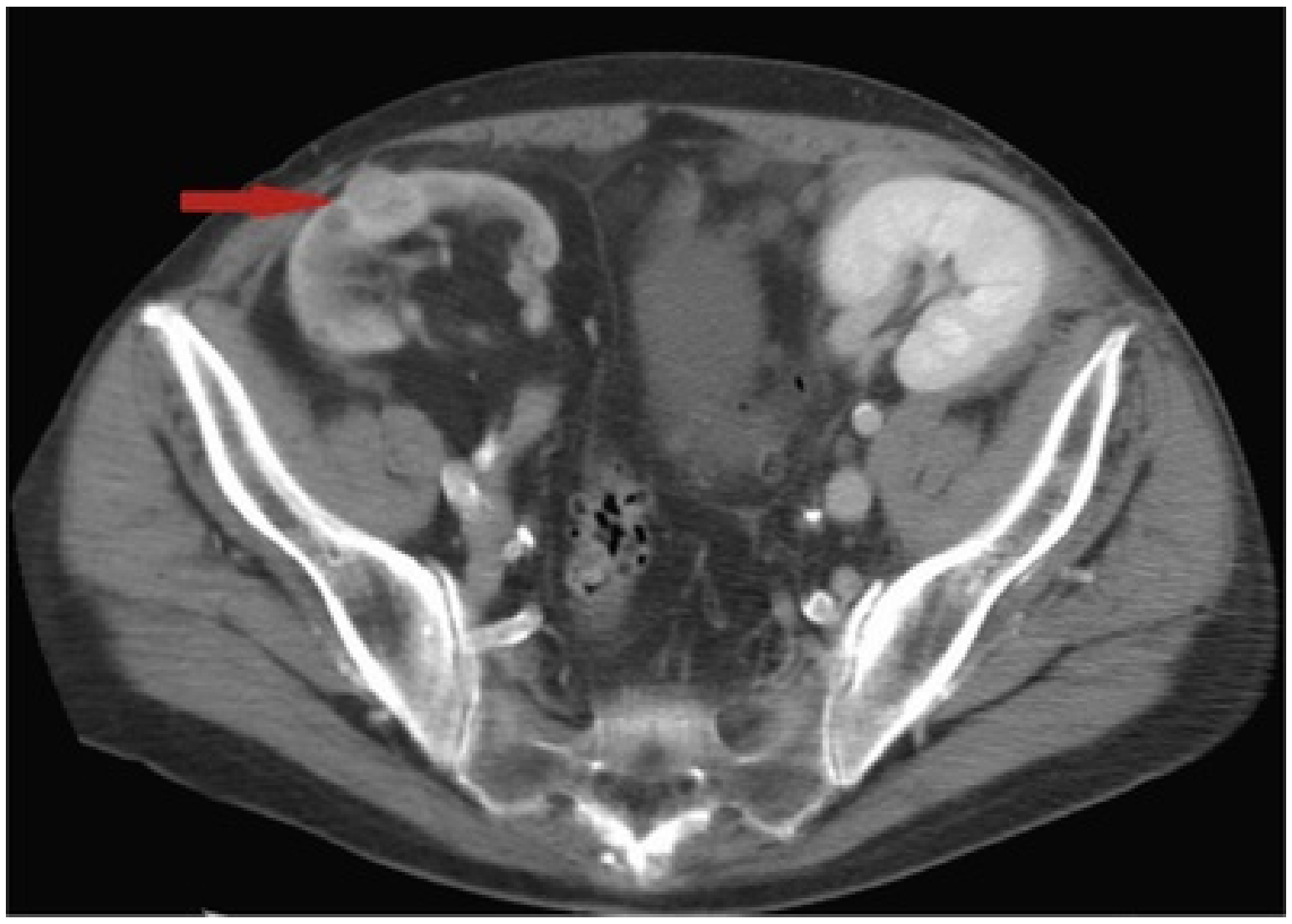

FIG. 88.3 Renal mass in transplanted kidney. Computed tomography scan reveals exophytic renal mass in nonfunctioning allograft in an 80-year-old patient. Biopsy was performed and low-grade papillary renal cell carcinoma, type 1 was found. Cryotherapy was used to ablate this mass.

Tillou et al. (2012) analyzed the histology subtype of de novo RCC in kidney grafts and found that papillary carcinomas are reported in 56% of kidney graft tumors, and low-grade tumors (Fuhrman grades 1 and 2) accounted for 65% of nonpapillary kidney graft tumors.

The treatment of RCC in kidney transplant patients is similar to RCC in the general population (Fig. 88.4).

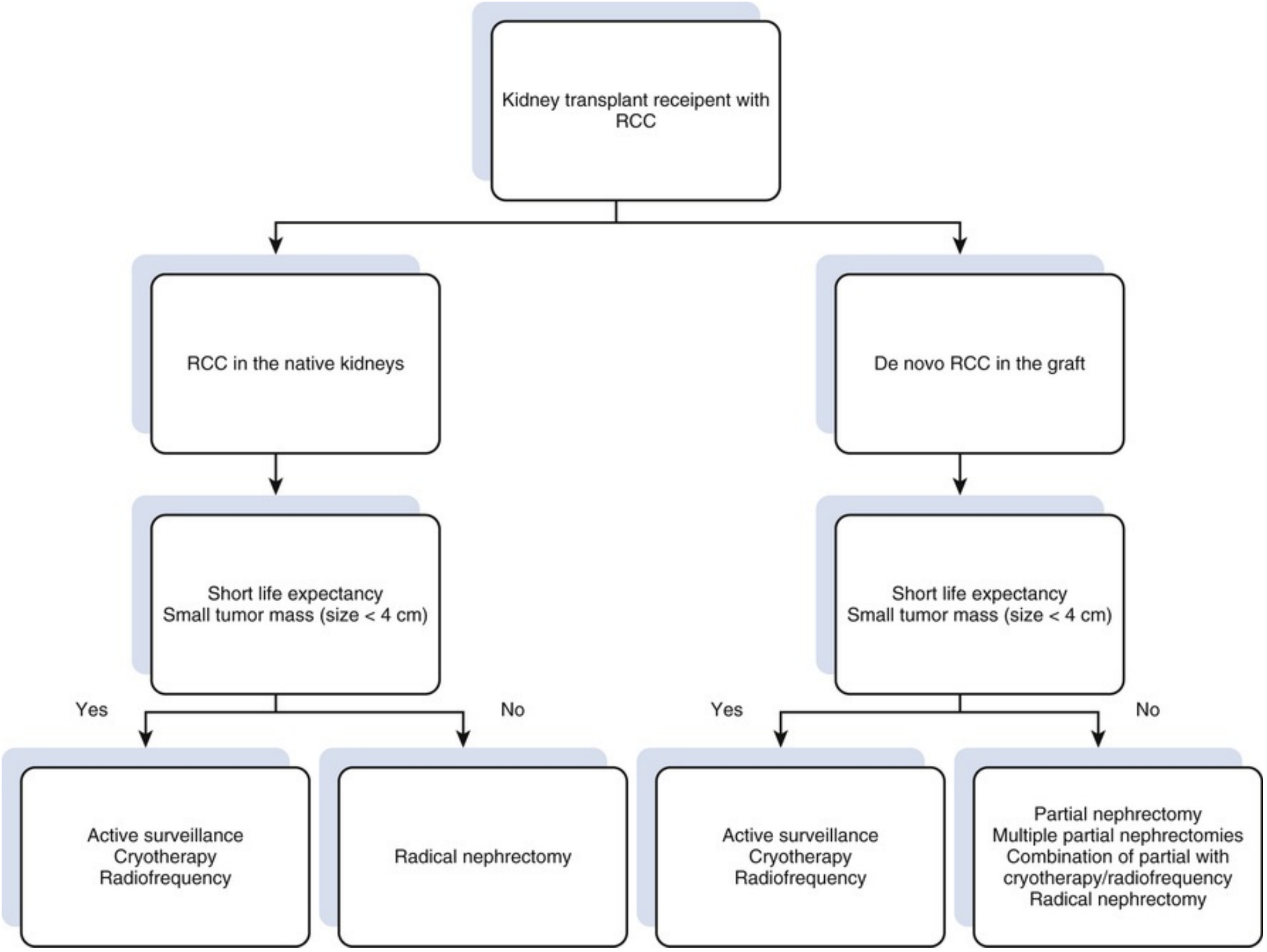
Kidney transplant receipent with RCC
RCC in the native kidneys
De novo RCC in the graft
Short life expectancy
Small tumor mass (size < 4 cm)
Short life expectancy
Small tumor mass (size < 4 cm)
Yes
No
Yes
No
Active surveillance
Cryotherapy
Radiofrequency
Radical nephrectomy
Active surveillance
Cryotherapy
Radiofrequency
Partial nephrectomy
Multiple partial nephrectomies
Combination of partial with cryotherapy/radiofrequency
Radical nephrectomy

FIG. 88.4 Renal cell carcinoma management in kidney transplant patients.

No specific recommendations exist regarding modifications to the immunosuppressive regimen after diagnosing malignancy in recipients. However, in the case of metastatic RCC originating from the graft, some authors have proposed stopping immunosuppression medications after the allograft nephrectomy to help the recipient immune system recover and reject the donor-associated cancer cells.

Despite the high incidence of RCC, the Kidney Disease: Improving Global Outcomes (KDIGO) guidelines do not endorse screening of the native kidneys posttransplantation because no evidence exists that the benefits of screening outweigh any potential harm. **However, consider screening high-risk recipients with a previous history of RCC, analgesic nephropathy, tuberous sclerosis, or known acquired cystic disease** (Kasiske et al., 2010).

Prostate Cancer

The incidence of prostate cancer in kidney transplant recipients is similar to that in the general population. However, the performance of PSA testing in transplant patients is not similar to the general population. The preoperative workup for the older male recipient generally includes a PSA. Nevertheless, no definite national recommendation exists for or against prostate cancer screening in recipients, except following the current guidelines for prostate cancer screening in the general populace (Hickman et al., 2018; Kasiske et al., 2010).

Management of prostate cancer in kidney transplant recipients poses a challenge for the treating physician because of the risk of direct or indirect injury to the transplanted kidney that may occur as a result of its anatomic proximity to the surgical or radiation field. In addition, recipients are maintained on immunosuppressive medications that put them at increased risk of infection, lymphocele, impaired wound healing, and wound complications.

In a recent meta-analysis, the majority of kidney transplant patients with prostate cancer who underwent treatment had organ-confined disease, and Gleason score of 6 or less. **The most common modality of treatment is surgical extirpation by any approach, followed by radiation therapy and then active surveillance, which was underused** (Marra et al., 2018). The variety of prostate cancer treatment modalities in kidney transplant recipients provide comparable oncologic outcomes to those observed in the nontransplant patients (Sierra et al., 2016).

Bladder Cancer

Kidney transplant patients are at a significantly increased risk of developing bladder cancer compared with the general population (SIR = 3.18; 95% CI: 1.34–7.53; *P* = 0.008). Bladder cancer in kidney transplant patients is aggressive and tends to be associated with higher recurrence rates, progression, and metastasis. Therefore an aggressive surveillance regimen is necessary. The mean time between transplantation and bladder cancer diagnosis ranges between 2.8 and 4 years (Buzzeo et al., 1997; Wallerand et al., 2010; Yan et al., 2011).

Bladder cancer management in kidney transplant recipients is challenging because of immunosuppression and high overall comorbidity. **Intravesical bacillus Calmette-Guerin can be used in selected patients with high-risk non-muscle-invasive bladder cancer.** Muscle invasive bladder cancer can be treated with chemoradiotherapy or radical cystoprostatectomy and urinary diversion. During cystectomy with lymph node dissection, care must be taken to avoid injury to the graft vessels or blood supply to the ureter or the ureter itself (Demirdag et al., 2017; Hickman et al., 2018; Moses et al., 2013; Prabharasuth et al., 2013; Tomaszewski et al., 2011).

Key Points: Genitourinary Malignancies

- Most of the kidney tumors develop in the native kidneys and are low-grade tumors.
- Active surveillance, radiation, and surgery (open and minimally invasive) are reasonable options to treat prostate cancer in kidney transplant patients.
- Kidney transplant recipients have a three-fold risk of urothelial carcinoma (UC) compared with the general population, and it is biologically more aggressive.

Conclusion

In conclusion, renal transplant patients are at risk for multiple urologic complications as described. The management, in most instances, mirrors the management of these issues in the general population with some special considerations as discussed. Diligence in recognition and treatment of these issues by the urologist is important to ensure the optimal survival of graft and host.

See Videos 88.1▶ and 88.2▶ for procedures related to this chapter.

Suggested Readings

Arpali E, Al-Qaoud T, Martinez E, et al. Impact of ureteral stricture and treatment choice on long-term graft survival in kidney transplantation. *Am J Transplant*. 2018;18(8):1977–1985.

Boissier R, Hevia V, Bruins HM, et al. The risk of tumour recurrence in patients undergoing renal transplantation for end-stage renal disease after previous treatment for a urological cancer: a systematic review. *Eur Urol*. 2018;73(1):94–108.

Branchereau J, Timsit MO, Neuzillet Y, et al. Management of renal transplant urolithiasis: a multicentre study by the French Urology Association Transplantation Committee. *World J Urol*. 2018;36(1):105–109.

EAU guidelines on renal transplantation. [(website):] http://www.uroweb.org/guideline/renal-transplantation/; 2017.

Hevia V, Zakri RH, Taylor CF, et al. Effectiveness and harms of using kidneys with small renal tumors from deceased or living donors as a source of renal transplantation: a systematic review. *Eur Urol Focus*. 2019;5(3):508–517.

Thompson ER, Hosgood SA, Nicholson ML, et al. *Early versus late ureteric stent removal after kidney transplantation*. Cochrane Libr. 2018 [Jan 1].

References

Adani GL, Pravisani R, Baccarani U, et al. Extended ureteral stricture corrected with appendiceal replacement in a kidney transplant recipient. *Urology*. 2015;86(4):840–843.

Alberts VP, Idu MM, Legemate DA, et al. Ureterovesical anastomotic techniques for kidney transplantation: a systematic review and meta-analysis. *Transplant Int*. 2014;27(6):593–605.

Alcaraz A, Bujons A, Pascual X, et al. Percutaneous management of transplant ureteral fistulae is feasible in selected cases. *Transplant Proc*. 2005;37(5):2111–2114.

Ather MH, Talati J, Biyabani R. Physician responsibility for removal of implants: the case for a computerized program for tracking overdue double-J stents. *Tech Urol*. 2000;6(3):189–192.

Bachar GN, Mor E, Bartal G, et al. Percutaneous balloon dilatation for the treatment of early and late ureteral strictures after renal transplantation: long-term follow-up. *Cardiovasc Intervent Radiol*. 2004;27(4):335–338.

Bassiri A, Amiransari B, Yazdani M, et al. Renal transplantation using ureteral stents. *Transplant Proc*. 1995;27(5):2593–2594.

Benamran DA, Klein J, Hadaya K, et al. Post-kidney transplant robot-assisted laparoscopic ureteral (donor-receiver) anastomosis for kidney graft reflux or stricture disease. *Urology*. 2017;108:96–101.

Benoit G, Blanchet P, Alexandre L, et al. Insertion of a double pigtail ureteral stent for the prevention of urological complications in renal transplantation: a prospective randomized study. *J Urol*. 1996;156(3):881–884.

Berli JU, Montgomery JR, Segev DL, et al. Surgical management of early and late ureteral complications after renal transplantation: techniques and outcomes. *Clin Transplant*. 2015;29(1):26–33.

Bhagat VJ, Gordon RL, Osorio RW, et al. Ureteral obstructions and leaks after renal transplantation: outcome of percutaneous antegrade ureteral stent placement in 44 patients. *Radiology*. 1998;209:15967.

Bonkat G, Rieken M, Siegel FP, et al. Microbial ureteral stent colonization in renal transplant recipients: frequency and influence on the short-time functional outcome. *Transpl Infect Dis*. 2012;14(1):57–63.

Branchereau J, Karam G. Management of urologic complications of renal transplantation. *Eur Urol Suppl*. 2016;15(9):408–414.

Branchereau J, Timsit MO, Neuzillet Y, et al. Management of renal transplant urolithiasis: a multicentre study by the French Urology Association Transplantation Committee. *World J Urol*. 2018;36(1):105–109.

Bromwich E, Coles S, Atchley J, et al. A 4-year review of balloon dilation of ureteral strictures in renal allografts. *J Endourol*. 2006;20(12):1060–1061.

Buzzeo BD, Heisey DM, Messing EM. Bladder cancer in renal transplant recipients. *Urology*. 1997;50(4):525–528.

Campbell SC, Streem SB, Zelch M, et al. Percutaneous management of transplant ureteral fistulas: patient selection and long-term results. *J Urol*. 1993;150(4):1115–1117.

Cash H, Slowinski T, Buechler A, et al. Impact of surgeon experience on complication rates and functional outcomes of 484 deceased donor renal transplants: a single-centre retrospective study. *BJU Int*. 2012;110(8 Pt B):E368–E373.

Challacombe B, Dasgupta P, Tiptaft R, et al. Multimodal management of urolithiasis in renal transplantation. *BJU Int*. 2005;96(3):385–389.

Chapman JR, Webster AC, Wong G. Cancer in the transplant recipient. *Cold Spring Harb Perspect Med*. 2013;3(7):a015677.

Cheungpasitporn W, Thongprayoon C, Mao MA, et al. Incidence of kidney stones in kidney transplant recipients: a systematic review and meta-analysis. *World J Transplant*. 2016;6(4):790.

Davis R, Jones JS, Barocas DA, et al. *Diagnosis, evaluation and follow-up of asymptomatic microhematuria (AMH) in adults, American Urological Association*. [(website):] http://www.auanet.org/guidelines/asymptomatic-microhematuria; 2012.

Dean PG, Lund WJ, Larson TS, et al. Wound-healing complications after kidney transplantation: a prospective, randomized comparison of sirolimus and tacrolimus. *Transplantation*. 2004;77(10):1555–1561.

Demirdag C, Citgez S, Talat Z, et al. Management of bladder cancer after renal transplantation. *Transplant Proc*. 2017;49(2):293–296.

Dinckan A, Tekin A, Turkyilmaz S, et al. Early and late urological complications corrected surgically following renal transplantation. *Transpl Int*. 2007;20(8):702–707.

Dominguez J, Clase CM, Mahalati K, et al. Is routine ureteric stenting needed in kidney transplantation? A randomized trial. *Transplantation*. 2000;70(4):597–601.

Dubeaux VT, Oliveira RM, Moura VJ, et al. Assessment of lymphocele incidence following 450 renal transplantations. *Int Braz J Urol*. 2004;30(1):18–21.

Duty BD, Barry JM. Diagnosis and management of ureteral complications following renal transplantation. *Asian J Urol*. 2015;2(4):202–207.

Ebadzadeh MR, Tavakkoli M. Lymphocele after kidney transplantation: where are we standing now? *Urol J*.

2008;5(3):144–148.
Elder JS, Diaz M, Caldamone AA, et al. Endoscopic therapy for vesicoureteral reflux: a meta-analysis. I. Reflux resolution and urinary tract infection. *J Urol*. 2006;175(2):716–722.
Faenza AL, Nardo B, Catena F, et al. Ureteral stenosis after kidney transplantation. *Transpl Int*. 1999;12(5):334–340.
Goel M, Flechner SM, Zhou L, et al. The influence of various maintenance immunosuppressive drugs on lymphocele formation and treatment after kidney transplantation. *J Urol*. 2004;171(5):1788–1792.
Guleria S, Agarwal S, Kumar R, et al. The double J stent: its impact on the urological complications in live - related transplantation. *Indian J Urol*. 1998;14(2):101–104.
Gupta M, Lee MW. Treatment of stones associated with complex or anomalous renal anatomy. *Urol Clin North Am*. 2007;34(3):431–441.
Hauser J, Tran S, Schwartz J. Robotic assisted uretero-ureteral (receiver-donor) anastomosis. *Eur Urol Suppl*. 2011;10(8):564.
Heit M, Blackwell L, Thomas S, et al. Prevalence and severity of urinary incontinence in kidney transplant recipients. *Obstet Gynecol*. 2004;103(2):352–358.
Hickman LA, Sawinski D, Guzzo T, et al. Urologic malignancies in kidney transplantation. *Am J Transplant*. 2018;18(1):13–22.
Huber S, Bruns CJ, Schmid G, et al. Inhibition of the mammalian target of rapamycin impedes lymphangiogenesis. *Kidney Int*. 2007;71(8):771–777.
Hurst FP, Neff RT, Falta EM, et al. Incidence, predictors, and associated outcomes of prostatism after kidney transplantation. *Clin J Am Soc Nephrol*. 2009;4(2):329–336.
Juaneda B, Alcaraz A, Bujons A, et al. Endourological management is better in early-onset ureteral stenosis in

kidney transplantation. *Transplant Proc*. 2005;37(9):3825–3827.

Karam G, Giessing M. Bladder dysfunction following renal transplantation is it predictable? *Transplant Proc*. 2011;43(1):387–390.

Karam G, Maillet F, Parant S, et al. Ureteral necrosis after kidney transplantation: risk factors and impact on graft and patient survival. *Transplantation*. 2004;78:725–729.

Kasiske BL, Zeier MG, Chapman JR, et al. KDIGO clinical practice guideline for the care of kidney transplant recipients: a summary. *Kidney Int*. 2010;77(4):299–311.

Khauli RB, Stoff JS, Lovewell T, et al. Post-transplant lymphoceles: a critical look into the risk factors, pathophysiology and management. *J Urol*. 1993;150(1):22–26.

Klingler HC, Kramer G, Lodde M, et al. Urolithiasis in allograft kidneys. *Urology*. 2002;59(3):344–348.

Kumar A, Kumar R, Bhandari M. Significance of routine JJ stenting in living related renal transp lantation: a prospective randomised study. *Transplant Proc*. 1998;30(7):2995–2997.

Lempinen M, Stenman J, Kyllönen L, et al. Surgical complications following 1670 consecutive adult renal transplantations: a single center study. *Scand J Surg*. 2015;104(4):254–259.

Lucewicz A, Wong G, Lam VW, et al. Management of primary symptomatic lymphocele after kidney transplantation: a systematic review. *Transplantation*. 2011;92(6):663–673.

Lynch MF, Ghani KR, Frost I, et al. Preventing the forgotten ureteral stent: implementation of a web-based stent registry with automatic recall application. *Urology*. 2007;70(3):423–426.

Marra G, Dalmasso E, Agnello M, et al. Prostate cancer treatment in renal transplant recipients: a systematic review.

BJU Int. 2018;121(3):327–344.

Martinez-Ocana JC, Lauzurica R, Castellote E, et al. Adult polycystic kidney disease: a risk factor for lymphocele formation after renal transplantation? *Transplant Proc*. 1995;27(4):2246.

Masahiko H, Kazunari T, Tokumoto T, et al. Comparative study of urosurgical complications in renal transplantation: intravesical versus extravesical ureterocystoneostomy. *Transplant Proc*. 2000;32(7):1844–1846.

Mastrosimone S, Pignata G, Maresca MC, et al. Clinical significance of vesicoureteral reflux after kidney transplantation. *Clin Nephrol*. 1993;40(1):38–45.

Matalon TA, Thompson MJ, Patel SK, et al. Percutaneous treatment of urine leaks in renal transplantation patients. *Radiology*. 1990;174(3):1049–1051.

McCahy PJ, Ramsden PD. A computerized ureteric stent retrieval system. *BJU Int*. 1996;77(1):147–148.

Mokos I, Basic-Jukic N, Kastelan Z, et al. Influence of long-term dialysis treatment on operative complications after renal transplantation. *Transplant Proc*. 2010;42(7):2531–2533.

Molina WR, Pessoa R, da Silva RD, et al. A new patient safety smartphone application for prevention of “forgotten” ureteral stents: results from a clinical pilot study in 194 patients. *Patient Saf Surg*. 2017;11(1):10.

Moses KA, Bochner BH, Prabharasuth D, et al. Radical cystectomy and orthotopic urinary reconstruction in patients with bladder cancer after renal transplantation: clinical outcomes and description of technique. *Transplant Proc*. 2013;45(4):1661–1666.

Nie ZL, Zhang KQ, Li QS, et al. Treatment of urinary fistula after kidney transplantation. *Transplant Proc*. 2009;41(5):1624–1626.

O'Malley KJ, Hickey DP, Kapoor A, et al. Artificial urinary sphincter insertion in renal transplant recipients. *Urology*. 1999;54(5):923.

Orvieto MA, Chien GW, Shalhav AL, et al. Case report: robot-assisted laparoscopic pyeloureterostomy in a transplanted kidney with ureteral stricture. *J Endourol*. 2006;20(1):31–32.

Osman Y, Ali-el-Dein B, Shokeir AA, et al. Routine insertion of ureteral stent in live-donor renal transplantation: is it worthwhile? *Urology*. 2005;65(5):867–871.

Ostrowski M, Włodarczyk Z, Wesołowski T, et al. Influence of ureterovesical anastomosis technique on the incidence of vesicoureteral reflux in renal transplant recipients. *Ann Transplant*. 1999;4(1):54–58.

Pedraza R, Samadi A, Eshghi M. Holmium laser enucleation of the prostate in critically ill patients with technique modification. *J Endourol*. 2004;18(8):795–798.

Pengel LH, Liu LQ, Morris PJ. Do wound complications or lymphoceles occur more often in solid organ transplant recipients on mTOR inhibitors? A systematic review of randomized controlled trials. *Transpl Int*. 2011;24(12):1216–1230.

Penn I. Primary kidney tumors before and after renal transplantation. *Transplantation*. 1995;59(4):480–485.

Pereira H, Buchler M, Brichart N, et al. Ureteral stenosis after renal transplantation: risk factors and impact on survival. *Prog Urol*. 2011;21(6):389–396.

Pichler R, Buttazzoni A, Rehder P, et al. Endoscopic application of dextranomer/hyaluronic acid copolymer in the treatment of vesico-ureteric reflux after renal transplantation. *BJU Int*. 2011;107(12):1967–1972.

Pleass HC, Clark KR, Rigg KM, et al. Urologic complications after renal transplantation: a prospective randomized trial comparing different techniques of ureteric anastomosis and the use of prophylactic ureteric stents. *Transplant Proc*.

1995;27(1):1091–1092.

Prabharasuth D, Moses KA, Bernstein M, et al. Management of bladder cancer after renal transplantation. *Urology*. 2013;81(4):813–819.

Rahnemai-Azar AA, Gilchrist BF, Kayler LK. Independent risk factors for early urologic complications after kidney transplantation. *Clin Transplant*. 2015;29(5):403–408.

Reinberg Y, Manivel JC, Sidi AA, et al. Transurethral resection of prostate immediately after renal transplantation. *Urology*. 1992;39:319.

Rouffilange J, Deslandes M, Lopez L. Laparoscopic management of pelvic organ prolapse in a kidney transplant recipient. *Urol Case Rep*. 2017;13:145–146.

Sabharwal S, Macaden AR, Abrol N, et al. A novel computer based stent registry to prevent retained stents: will patient directed automated short message service and letter generator help? *Indian J Urol*. 2014;30(2):150.

Seifert HH, Mazzola B, Ruszat R, et al. Transurethral injection therapy with dextranomer/hyaluronic acid copolymer (Deflux®) for treatment of secondary vesicoureteral reflux after renal transplantation. *J Endourol*. 2007;21(11):1357–1360.

Shenasky JH. Renal transplantation in patients with urologic abnormalities. *J Urol*. 1976;115(5):490–493.

Sierra JM, Paniagua MC, Romo MG, et al. Robot assisted radical prostatectomy in kidney transplant recipients. Our clinical experience and a systematic review. *Urol Int*. 2016;97(4):440–444.

Stapenhorst L, Sassen R, Beck B, et al. Hypocitraturia as a risk factor for nephrocalcinosis after kidney transplantation. *Pediatr Nephrol*. 2005;20(5):652–656.

Stenberg A, Lackgren G. A new bioimplant for the endoscopic treatment of vesicoureteral reflux: experimental and short-term clinical results. *J Urol*. 1995;154(2):800–803.

Stephanian E, Mat AJ, Gores P, et al. Retransplantation as a risk factor for lymphocele formation. *Transplantation*. 1992;53(3):676–677.

Streeter EH, Little DM, Cranston DW, et al. The urological complications of renal transplantation: a series of 1535 patients. *BJU Int*. 2002;90(7):627–634.

Swierzewski SJ, Konnak JW, Ellis JH. Treatment of renal transplant ureteral complications by percutaneous techniques. *J Urol*. 1993;149(5):986–987.

Tang VC, Gillooly J, Lee EW, et al. Ureteric stent card register–a 5-year retrospective analysis. *Ann R Coll Surg Engl*. 2008;90(2):156–159.

Thompson ER, Hosgood SA, Nicholson ML, et al. *Early versus late ureteric stent removal after kidney transplantation*. Cochrane Libr. 2018.

Tillou X, Doerfler A, Collon S, et al. De novo kidney graft tumors: results from a multicentric retrospective national study. *Am J Transplant*. 2012;12(12):3308–3315.

Tillou X, Raynal G, Demailly M, et al. Endoscopic management of urologic complications following renal transplantation: impact of ureteral anastomosis. *Transplant Proc*. 2009;41(8):3317–3319.

Tiong HY, Flechner SM, Zhou L, et al. A systematic approach to minimizing wound problems for de novo sirolimus-treated kidney transplant recipients. *Transplantation*. 2009;87(2):296–302.

Tomaszewski JJ, Larson JA, Smaldone MC, et al. Management of bladder cancer following solid organ transplantation. *Adv Urol*. 2011;2011:256985.

Tsaur I, Jones J, Melamed RJ, et al. Postoperative voiding dysfunction in older male renal transplant recipients. *Transplant Proc*. 2009;41(5):1615–1618.

Ulrich F, Niedzwiecki S, Fikatas P, et al. Symptomatic lymphoceles after kidney transplantation–multivariate analysis of risk factors and outcome after laparoscopic fenestration. *Clin Transplant*. 2010;24(2):273–280.

Veltman Y, Shields JM, Ciancio G, et al. Percutaneous nephrolithotomy and cystolithalapaxy for a “forgotten” stent in a transplant kidney: case report and literature review. *Clin Transplant*. 2010;24(1):112–117.

Volpe A, Billia M, Quaglia M, et al. Transurethral resection of the prostate in kidney transplant recipients: urological and renal functional outcomes at long-term follow-up. *BJU Int*. 2013;112(3):386–393.

Wallerand H, Ravaud A, Ferrière JM. Bladder cancer in patients after organ transplantation. *Curr Opin Urol*. 2010;20(5):432–436.

Wu FM, Lim M, Deng Z, et al. Successful Endourological Management of the ‘Forgotten'Stent in a Transplanted Kidney. *Urol Int*. 2014;92(3):373–376.

Yan L, Chen P, Chen EZ, et al. Risk of bladder cancer in renal transplant recipients: a meta-analysis. *Br J Cancer*. 2011;110(7):1871.

Yucel S, Akin Y, Celik O, et al. Endoscopic vesicoureteral reflux correction in transplanted kidneys: does injection technique matter? *J Endourol*. 2010;24(10):1661–1664.

Zagdoun E, Ficheux M, Lobbedez T, et al. Complicated lymphoceles after kidney transplantation. *Transplant Proc*. 2010;42(10):4322–4325.

Zietek Z, Sulikowski T, Tejchman K, et al. Lymphocele after kidney transplantation. *Transplant Proc*. 2007;39(9):2744–2747.

PART IX

Upper Urinary Tract Obstruction and Trauma

OUTLINE

89 Management of Upper Urinary Tract Obstruction
90 Upper Urinary Tract Trauma

89

Management of Upper Urinary Tract Obstruction

Stephen Y. Nakada MD, FACS, FRCS(Glasg.), Sara L. Best MD

Technologic advances evolve the diagnostic and therapeutic alternatives available in the contemporary management of upper urinary tract obstruction. The obstructive processes may be intrinsic, extrinsic, congenital, or iatrogenic, and in many patients the cause of obstruction may not be immediately evident. Making an accurate diagnosis of obstruction is paramount for therapeutic treatment.

The treatments for upper tract obstruction range from ureteral stent placement to ileal interposition. Myriad skills are required for total surgical management of upper urinary tract obstruction. Not surprisingly, endourology, laparoscopy, and robotics continue to be more prominent in the surgical management of upper urinary tract obstruction. As a result of the wide array of available treatments, the urologist must have an understanding of the indications and risks of all the alternatives.

This chapter provides a state-of-the-art presentation of the diagnostic and therapeutic management strategies for patients with upper urinary tract obstruction. The chapter is organized by the anatomic location of obstruction. The cause, diagnosis, indications for intervention, risks, and therapeutic options (including endoscopic, laparoscopic, robotic, and open approaches) are thoroughly reviewed.

Evaluation of Upper Tract Obstruction

The use of computed tomography (CT) scanning and renal ultrasound in emergency departments and for various screening purposes has led to frequent suspicion of upper tract obstruction (Davis et al., 2012; Smith-Bindman et al., 2014). **Moreover, the widespread use of noncontrast, low-dose CT scans may necessitate follow-up imaging** (Zagoria and Dixon, 2009). After low-dose CT, the urologist can use ultrasound, diuretic renography, CT urography, retrograde pyelography, Whitaker tests, and ureteroscopy to delineate the precise cause and subsequent treatment strategy of upper tract obstruction. For each disorder we will discuss the recommended approach to the upper tract evaluation.

Ureteropelvic Junction Obstruction

The diagnosis of ureteropelvic junction (UPJ) obstruction (UPJO) describes a functionally significant impairment of urinary transport from the renal pelvis to the ureter. Although most cases are congenital, the problem may not become clinically apparent until much later in life (Jacobs et al., 1979). Acquired conditions such as stone disease, postoperative or inflammatory stricture, or urothelial neoplasm may also manifest clinically with symptoms and signs of obstruction at the level of the UPJ. Similarly, extrinsic obstruction can occur at this level. This section focuses primarily on the diagnosis and treatment of "congenital" UPJO, although these techniques may be applied to the management of certain acquired conditions, such as urinary stones.

Pathogenesis

Congenital UPJO usually results from intrinsic disease. A frequently found defect is the presence of an aperistaltic segment of the ureter, perhaps similar to that found in primary obstructive megaureter. In these cases, histopathologic studies reveal that the spiral musculature normally present has been replaced by abnormal longitudinal muscle bundles or fibrous tissue (Allen, 1970; Foote et al., 1970; Gosling and Dixon, 1978; Hanna et al., 1976; Fig. 89.1). This results in failure to develop a normal peristaltic wave for propagation of urine from the renal pelvis to the ureter. Recognition that this type of segmental defect is often responsible for UPJO is of utmost importance clinically because such ureters may appear grossly normal at the time of surgery and, in fact, may often be calibrated to 14 Fr or greater. Further studies in the cause of UPJO have shown decreased density of interstitial cells of Cajal at the UPJ in children, but less so in cases involving solely intrinsic UPJO (Koleda et al., 2012; Solari et al., 2003). In addition, cytokine production in the urothelium has also been proposed to exacerbate UPJO (Chiou et al., 2005). Other experimental studies have implicated transforming growth factor-β, epidermal growth factor expression, nitric oxide, and neuropeptide Y in UPJ stenosis (Knerr et al., 2001; Yang et al., 2003). A less frequent intrinsic cause of congenital UPJO is true ureteral stricture. Such congenital ureteral strictures are most frequently found at the UPJ, although they may be located at sites anywhere along the lumbar ureter. Abnormalities of ureteral musculature have been implicated as electron microscopy has demonstrated excessive collagen deposition at the site of the stricture (Hanna et al., 1976).

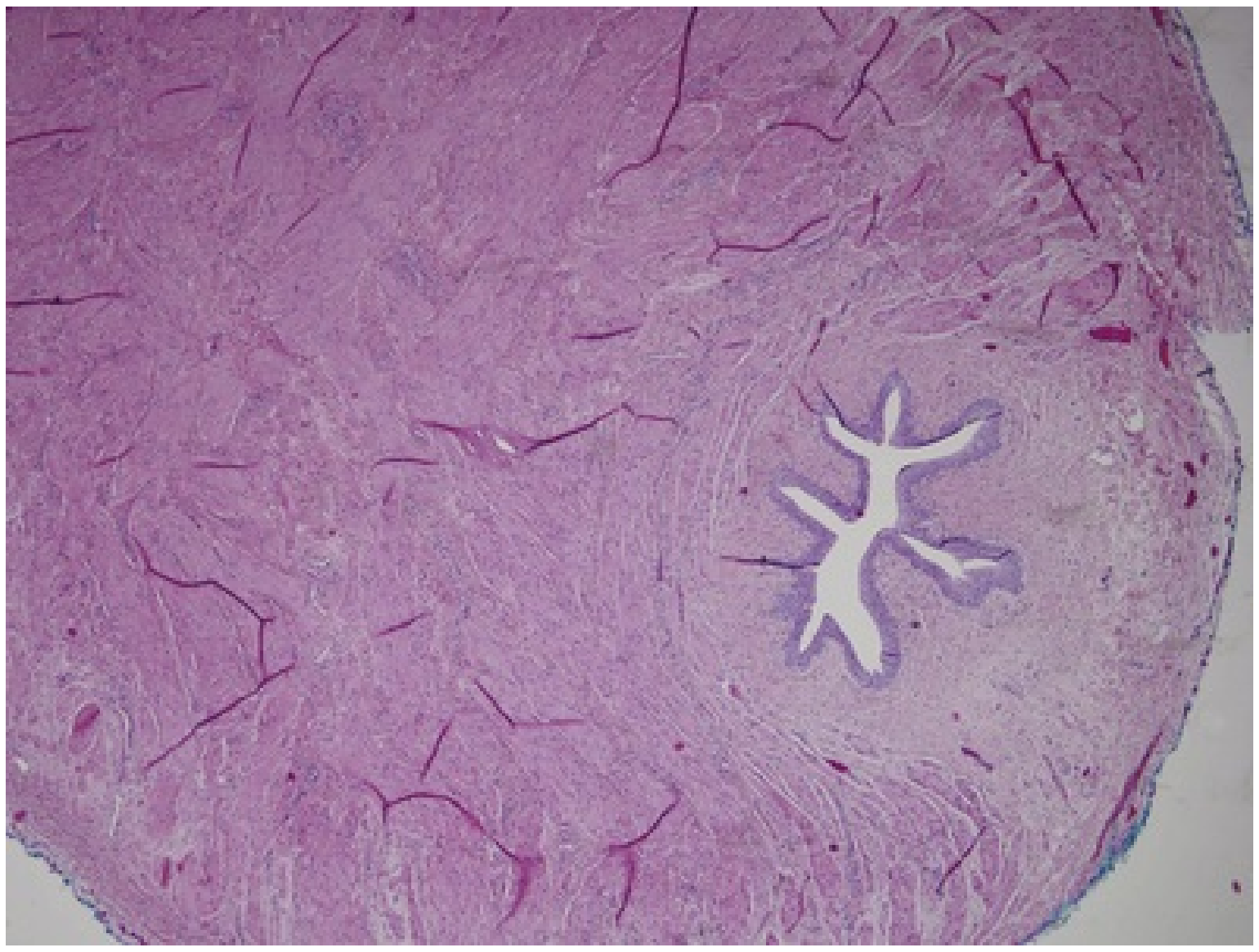

FIG. 89.1 The microphotograph is taken through the ureteropelvic junction. There is marked attenuation of smooth muscles and smooth muscle in disarray and hypertrophy surrounding the urothelial lining.

Intrinsic obstruction at the UPJ may also result from kinks or valves produced by infoldings of the ureteral mucosa and musculature (Maizels and Stephens, 1980). In these patients the obstruction may actually be at the level of the proximal ureter. This phenomenon appears to result from retention or exaggeration of congenital folds normally found in the ureter of developing fetuses. In some of these patients the defects are bridged by ureteral adventitia. Grossly, this can manifest as external bands or adhesions that appear to be causing the obstruction. In fact, Johnston et al. (1977) reported that lysis of external adhesions can at times reestablish flow without pyeloplasty. In the majority of patients, these bands or adhesions are likely to be a secondary phenomenon associated with intrinsic obstruction, thus operative pyeloplasty would usually be most effective. The presence of these kinks, valves, bands, or adhesions may also produce angulation of the ureter at the lower margin of the renal pelvis in such a manner that as the pelvis dilates anteriorly and inferiorly, the ureteral insertion is carried further proximally. In these patients the most dependent portion of the pelvis is inadequately drained, and the apparent high insertion of the ureteral ostium is actually a secondary phenomenon (Kelalis, 1976). In at least some patients, however, the high insertion is likely the primary obstructing lesion because this phenomenon is found more frequently in the presence of renal ectopia or fusion anomalies (Das and Amar, 1984; Zincke et al., 1974). Thus a high insertion can have implications in the subsequent surgical management, particularly endourologic approaches.

Controversy persists regarding the potential role of “aberrant” vessels in the cause of UPJO. Significant crossing vessels have been noted in up to 63% of patients with UPJO but in as little as 20% of individuals with normal kidneys (Quillin et al., 1996; Richstone et al., 2009; Zeltser et al., 2004). Although these lower pole vessels have often been referred to as aberrant, these segmental vessels, which may be branches from the main renal artery or arise directly from the aorta, are usually normal variants (Stephens, 1982). In some patients, these lower pole vessels cross the ureter posteriorly and truly have an aberrant course. Historically, it has been believed that the associated vessel alone does not cause the primary obstruction (Hanna, 1978). In fact, the true cause is an intrinsic lesion at the UPJ or proximal ureter that causes dilation and ballooning of the renal pelvis over the polar or aberrant vessel. Recent studies using three-dimensional (3D) multidetector row CT demonstrated that the precise location of crossing vessels did not correspond to the obstructive transition point in patients with UPJO (Lawler et al., 2005). In contrast, one group found improvement in patients undergoing only ligation of crossing vessels (Keeley et al., 1996). Richstone et al. (2009) reviewed histopathology from 95 patients with UPJO and found that 43% of 65 patients with a crossing vessel had no intrinsic abnormality. Another histopathologic study identified only increased inflammation at the point of crossing vessels (Cancian et al., 2017). Regardless, the presence of crossing vessels most certainly has been shown to have a detrimental effect on the success rates of endopyelotomy (Nakada et al., 1998; Van Cangh et al., 1994). UPJO with concomitant anatomic anomalies such as horseshoe kidney and pelvic kidney also present surgical challenges. **Notably, the increased use of laparoscopic and robotic pyeloplasty has decreased the need for preoperative assessment of crossing vessels; this can be addressed at the time of pyeloplasty.**

UPJO may also result from acquired lesions. In children, vesicoureteral reflux can lead to upper tract dilation with subsequent elongation, tortuosity, and kinking of the ureter. In some patients these changes may only mimic the radiographic findings of true UPJO. However, true UPJO can definitely coexist with vesicoureteral reflux, although it may be difficult to determine whether the anomalies are merely coincident or whether the upper tract ureteral obstruction has resulted from the reflux (Lebowitz and Johan, 1982). Diuretic renography remains the first-line modality for differentiating between UPJO and reflux. Other acquired causes of obstruction at the UPJ include benign lesions such as fibroepithelial polyps (Berger et al., 1982; Macksood et al., 1985), urothelial malignancy, stone disease, and postinflammatory or postoperative scarring or ischemia. For these acquired diseases, the surgical techniques discussed in this section may be useful adjuncts for management of the obstruction as long as the primary problem is also addressed where appropriate. For instance, fibroepithelial polyps can be managed using retrograde ureteroscopy and holmium laser excision (Lam et al., 2003a).

Patient Presentation and Diagnostic Studies

UPJO, although most often a congenital problem, can manifest clinically at any time of life. Historically, the most common presentation in neonates and infants was the finding of a palpable flank mass. However, **the use of maternal prenatal ultrasonography has led to a dramatic increase in the number of asymptomatic newborns being diagnosed with hydronephrosis, many of whom are subsequently found to have UPJO** (Bernstein et al., 1988; Wolpert et al., 1989). A fraction of cases may also be found during evaluation of azotemia, which may result from bilateral obstruction in a functionally or anatomically solitary kidney. UPJO may also be incidentally found during studies performed to evaluate unrelated anomalies such as congenital heart disease (Roth and Gonzales, 1983). In older children or adults, intermittent abdominal or flank pain, at times associated with nausea or vomiting, is a frequent presenting symptom. Hematuria, either spontaneous or associated with otherwise relatively minor trauma, may also be an initial symptom. Laboratory findings of microhematuria, pyuria, or frank urinary tract infection may also bring an otherwise asymptomatic patient to the urologist. Rarely, hypertension may be a presenting finding (Riehle and Vaughan, 1981).

Radiographic studies should be performed with a goal of determining the anatomic location and the functional significance of an apparent obstruction. Historically, excretory urographic findings include delay in function associated with a dilated pelvicalyceal system. If the ureter is visualized, it should be of normal caliber. In some patients, symptoms may be intermittent, and urography findings between painful episodes may be normal. In such cases, the study should be repeated during an acute episode when the patient is symptomatic (Nesbit, 1956). Today, provocative testing with diuretic renography may allow accurate diagnosis in most patients. The patient should be well hydrated and the study then performed after injection of furosemide, 0.3 to 0.5 mg/kg (Malek, 1983; Fig. 89.2). Studies have recently shown using P40, or the percentage of maximal tracer at 40 minutes, that the sensitivity of renal scan can be increased from 49% to 73% (Liu et al., 2017).

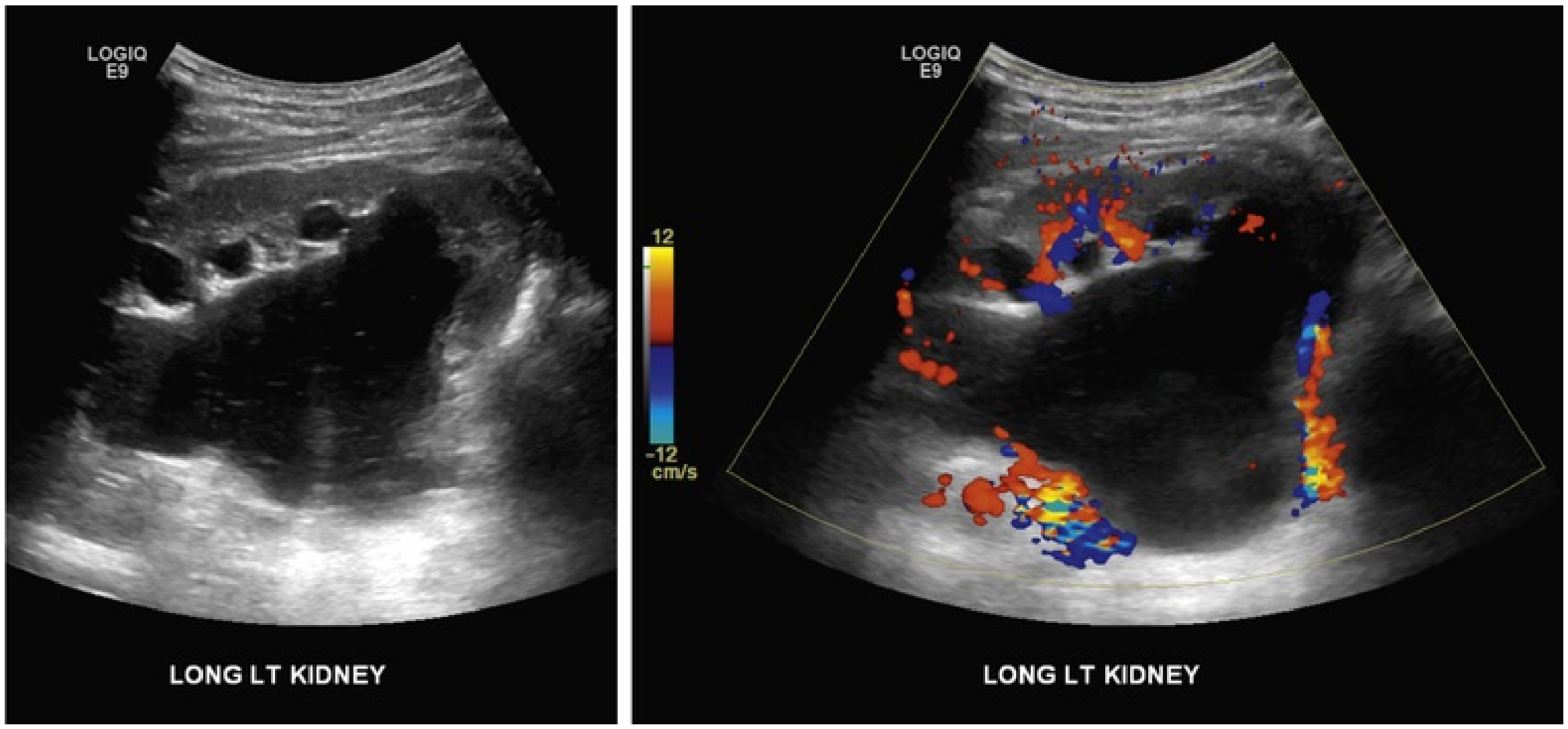

FIG. 89.2 Typical ultrasound image of ureteropelvic junction obstruction, with dilated renal pelvis and infundibula and calyces, including color Doppler images. Note, the ureter is not visualized in this image.

Noncontrast CT scan is commonly obtained for patients with acute flank pain (Dalrymple et al., 1998; Fielding et al., 1997; Vieweg et al., 1998; Fig. 89.3). **Moreover, contrast-enhanced CT scans provide detailed anatomic and functional information to aid in diagnosis of UPJO** (Fig. 89.4). In fact one study showed contrast-enhanced CT can be a surrogate test for renography when assessing patients for UPJO repair (Ark et al., 2016). Ultrasonography and CT scanning also have a role in differentiating acquired causes of obstruction such as radiolucent calculi or urothelial tumors. **In neonates and infants, the diagnosis of UPJO has usually been suggested either by routine performance of maternal ultrasonography or by the finding of a flank mass. In either setting, renal ultrasonography is usually the first radiographic study performed. Ideally, ultrasonography should be able to visualize dilation of the collecting system to help differentiate UPJO from multicystic**

kidney and determine the level of obstruction. UPJO and multicystic kidneys are distinguishable in the majority of patients by ultrasound alone. With UPJO, the pelvis is visualized as a large, medial sonolucent area surrounded by smaller, rounded sonolucent structures representing dilated calyces. At times, dilated calyces will be seen connecting to the pelvis via dilated infundibula (Fig. 89.5). More recently, Dias et al. (2013) have shown that prenatal renal pelvis dilation can predict the need for surgical repair of the UPJ.

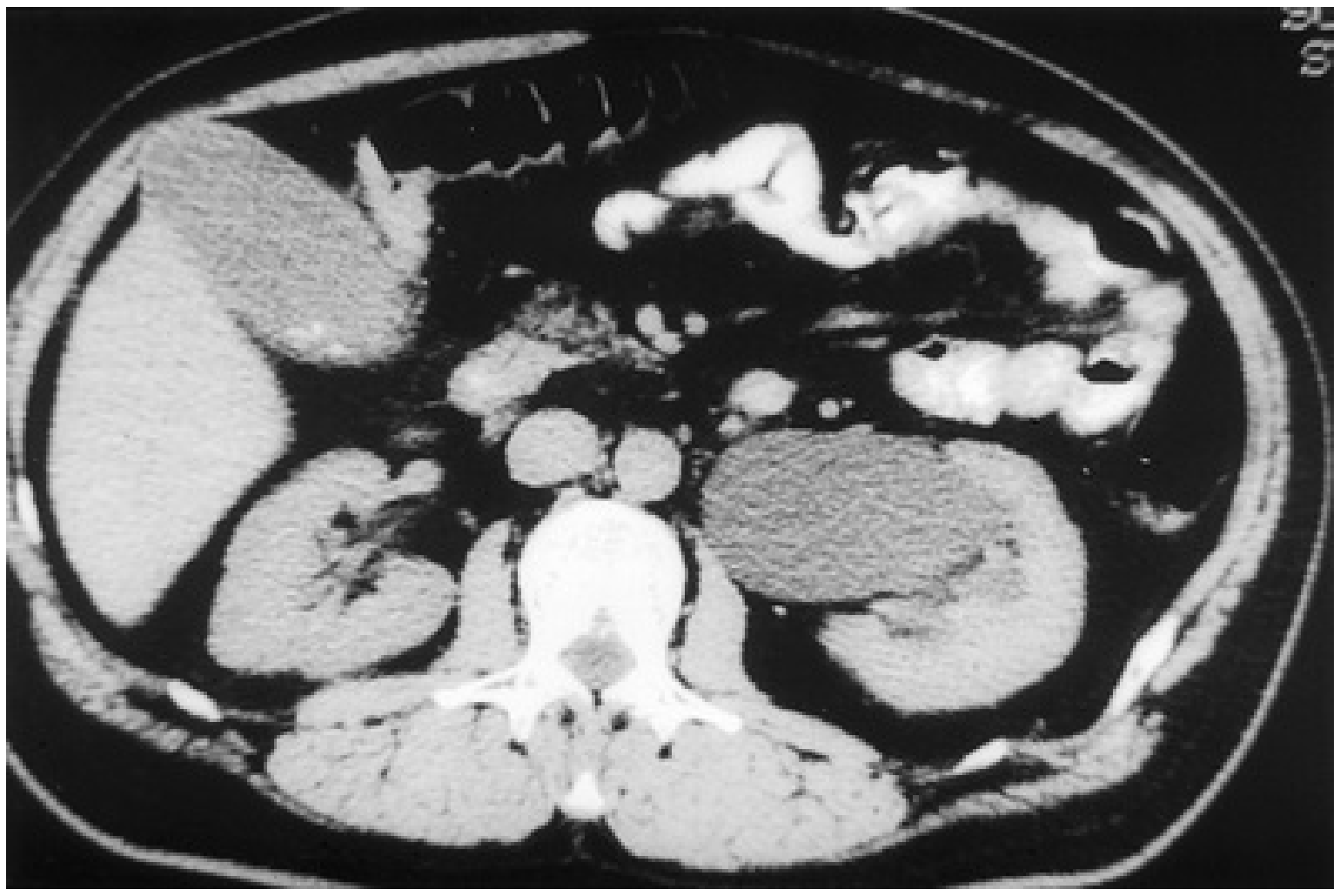

FIG. 89.3 Noncontrast computed tomography scan performed as the initial radiographic study in a patient with left flank pain revealed hydronephrosis to the level of the ureteropelvic junction (UPJ). No calculus was visualized, and a presumed diagnosis of UPJ obstruction was considered. This proved correct on subsequent radiographic studies.

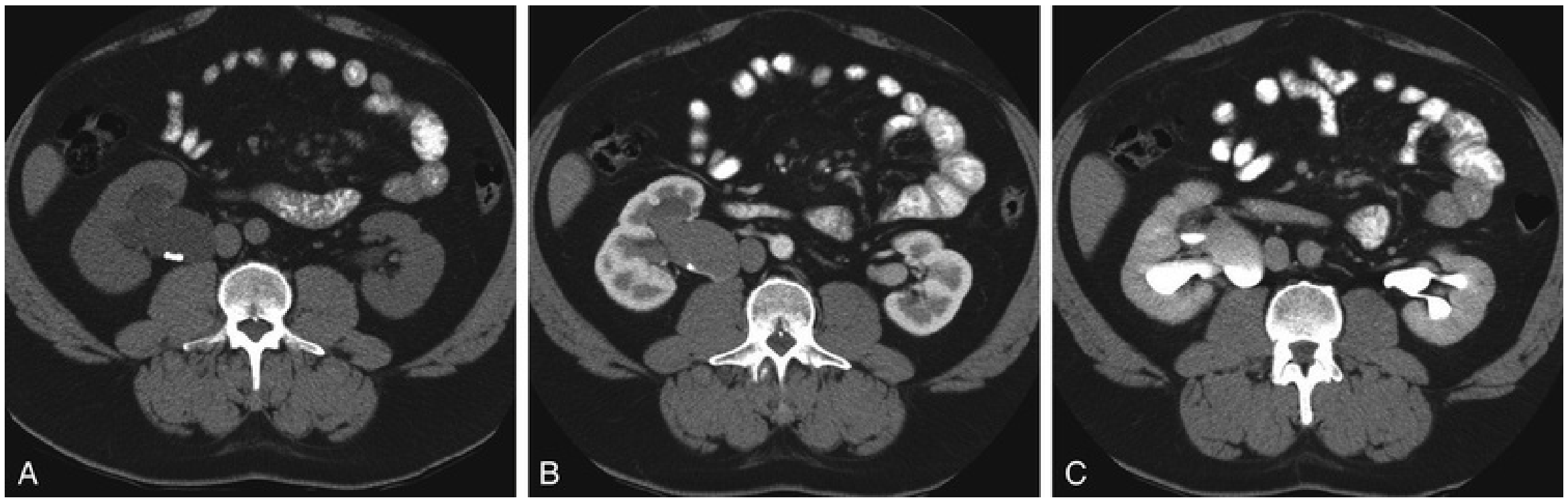

FIG. 89.4 (A) Contrast-enhanced computed tomography scan identifies a classic ureteropelvic junction (UPJ) appearance in early phase imaging. (B) Early images reveal normal nephrogram and delayed filling of the

obstructed, dilated UPJ. (C) Delayed images demonstrate holdup of contrast drainage on the right compared with the normal left side.

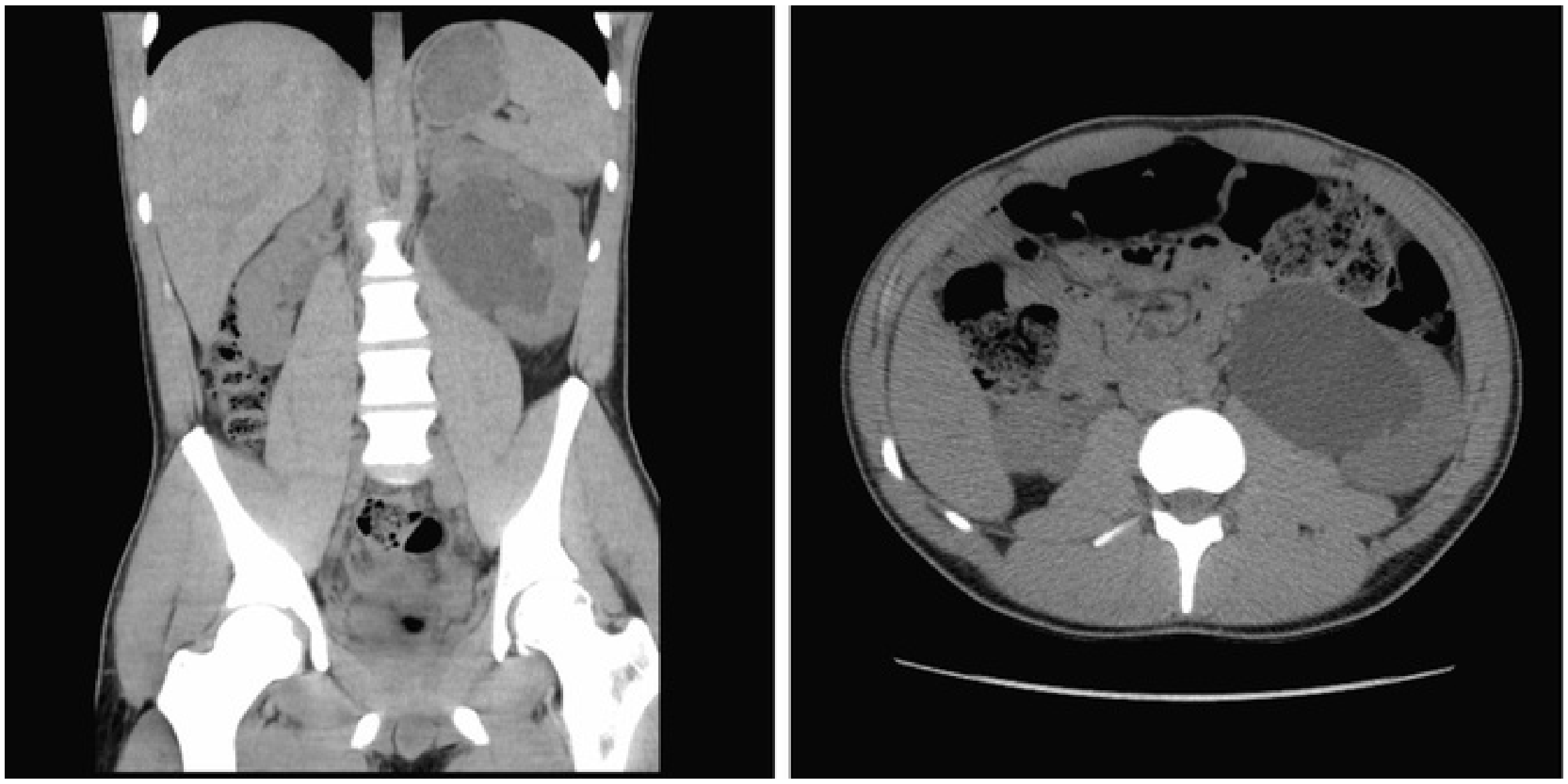

FIG. 89.5 Noncontrast computed tomography of left ureteropelvic junction obstruction, typical coronal and axial image.

Occasionally, a solid-appearing renal cortex can be seen surrounding the sonolucent areas or separating the dilated calyces. In contrast, the cysts of multicystic kidneys are visualized as various-sized sonolucent areas in random distribution. Although the cysts may be connected, this is rarely visualized sonographically. Furthermore, little solid tissue is seen, and what is present has a random distribution among the cysts. Rarely a large, centrally located cyst may cause confusion in the diagnosis (King et al., 1984a). In this setting, a renal scan should be performed. Specifically, a technetium^{99m}-diethylenetriamenepentaacetic acid (^{99m}Tc-DTPA) scan allows differentiation of these two entities. Multicystic kidneys rarely reveal concentration of this isotope. When uptake is seen, the areas of functioning tissue are initially discrete and are usually medial to the bulk of the mass, which remains a “cold” area. In contrast, neonatal kidneys with UPJO usually exhibit good concentration of the isotope. Furthermore, even with severe obstruction in which only a cortical rim remains, uptake of the isotope will be seen peripherally in the cortex, again helping to differentiate this from multicystic kidney (King et al., 1984a).

Diuretic renography is effective in predicting recovery of function in cases in which intravenous urography has revealed nonvisualization. Diuretic renography allows quantification of the degree of obstruction and can help differentiate the level of obstruction. Today, ^{99m}Tc-mercaptoacetyltriglycine (^{99m}Tc-MAG3, or MAG3) is the preferred isotope over ^{99m}Tc-DTPA or radioiodinated Hippuran because of favorable imaging and dosimetry considerations (Roarke and Sandler, 1998). **Diuretic renography remains a reliable study for diagnosing UPJ and ureteral obstruction because it provides quantitative data regarding differential renal function and obstruction, even in hydronephrotic renal units.** Diuretic renography is noninvasive and readily available in most medical centers. Ideally, diuretic renography can be used to follow patients for functional loss, most effectively when a standard protocol is used. The diuretic is given 20 minutes into the study to allow time for filling of the collecting system. One study found diuretic renography to be useful in children to rule out concomitant UPJO with associated high-grade reflux (Stauss et al., 2003). There is evidence that diuretic renography using MAG3 is a most accurate study for patients with UPJO after therapeutic intervention (Niemczyk et al., 1999; Fig. 89.6).

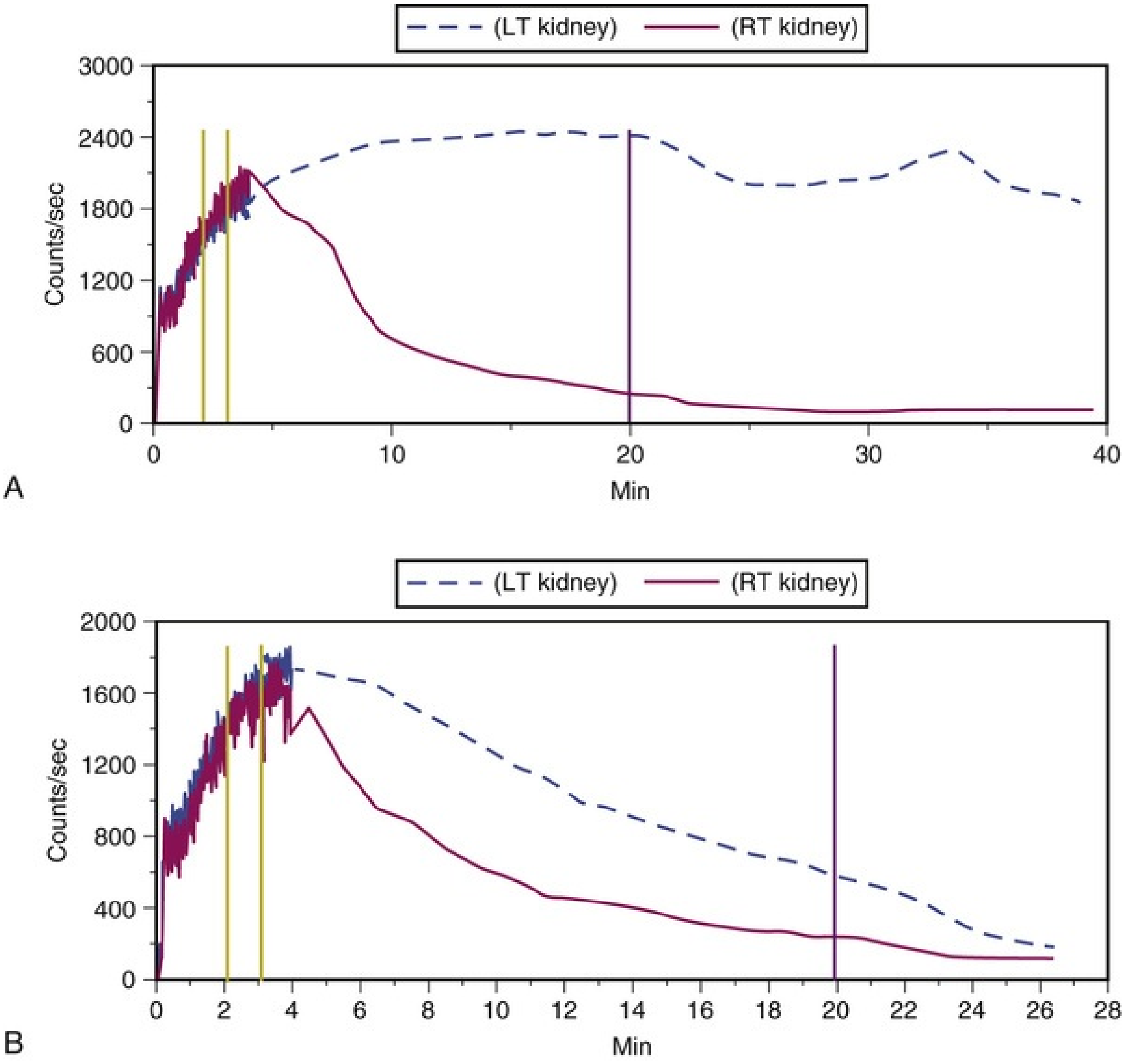

FIG. 89.6 (A) ^{99m}Tc-mercaptoacetyltriglycine (MAG3) diuretic renography revealing functional ureteropelvic junction obstruction of the left kidney, with a $T_{1/2}$ greater than 40 minutes. Furosemide was administered 20 minutes into the study *(vertical purple line).* (B) Follow-up study reveals normal renal drainage after robotic pyeloplasty with spontaneous drainage before furosemide administration.

The diagnosis of UPJO can generally be made with a high degree of certainty on the basis of the clinical presentation and the results of any one or more of the imaging studies already cited. It is preferable to have a combination of anatomic and functional studies, such as retrograde pyelogram and diuretic renography, to best plan therapy. Retrograde pyelography thus retains a role for confirmation of the diagnosis and for demonstration of the exact site and nature of obstruction before repair. In most cases, this study is performed at the time of the planned operative intervention to avoid the risk of introducing infection in the face of obstruction. However, retrograde pyelography is used emergently whenever the UPJO requires acute decompression, such as in the setting of infection or compromised renal function. **If cystoscopic retrograde manipulation has been unsuccessful or may be hazardous, particularly in neonates or infants, placement of a percutaneous nephrostomy is an alternative. This also facilitates antegrade studies that will help define the nature and exact anatomic site of obstruction.** It also allows decompression of the system in patients with associated infection or compromised renal function and allows assessment of recoverability of renal function after decompression. **When there remains some doubt as to the clinical significance of a dilated collecting system, placement of a percutaneous nephrostomy tube also facilitates dynamic pressure perfusion studies.** First described by Whitaker in 1973, the renal pelvis is continuously perfused at 10 mL/min with normal saline solution or dilute radiographic contrast solution under fluoroscopic control through a nephrostomy tube. Renal pelvic pressure is monitored during the infusion, and the pressure gradient across the UPJ is determined. The bladder is continuously drained with an indwelling catheter to prevent transmission of intravesical pressures. Renal pelvic pressure ranging up to 12 to 15 cm H_2O during this infusion suggests a nonobstructed system. In contrast, pressures in excess of 15 to 20 cm H_2O are suggestive of a functional obstruction. Although equivocal studies were a concern, a recent study identified equivocal pressures in less than 5% of cases (Lupton and George, 2010; O'Reilly, 1986).

Although pressure perfusion studies can often provide valuable information regarding the functional significance of an apparent obstruction, these studies can at times be inaccurate. This inaccuracy may be a result of variations in renal pelvic anatomy and compliance (Koff et al., 1986) or positional variations (Ellis et al., 1995). Moreover, the procedure is invasive and should be reserved for cases that are nondiagnostic using less invasive methods (Lupton BJUI 2014). The urologist must collate the clinical presentation and results of all diagnostic studies performed to identify the best clinical intervention.

Indications and Options for Intervention

Contemporary indications for intervention for UPJO include the presence of symptoms associated with the obstruction, impairment of overall renal function or progressive impairment of ipsilateral function, development of

stones or infection, or, rarely, causal hypertension. The primary goals of intervention are relief of symptoms and preservation of renal function. Traditionally, such intervention should be a reconstructive procedure aimed at restoring nonobstructed urinary flow. This is especially true for neonates, infants, or children in whom early repair is desirable because these patients will have the best chance for improvement in renal function after relief of obstruction (Bejjani and Belman, 1982; Roth and Gonzales, 1983; Wolpert et al., 1989). However, timing of the repair in neonates remains controversial (DiSandro and Kogan, 1998; Hanna, 2000; Koff, 1998, 2000; Shokeir and Nijman, 2000), mostly because of difficulty in defining those kidneys truly at risk for functional obstruction. In a prospective study of 104 neonates with primary unilateral hydronephrosis suspected of being caused by UPJO, after a mean follow-up of 21 months, only 7 (7%) required pyeloplasty for functional obstruction, defined as a progression of hydronephrosis or a 10% reduction in differential glomerular filtration rate on serial ultrasonography and diuretic renography (Koff and Campbell, 1994). All treated patients had a return of renal function to predetermination levels, supporting selective nonoperative management of neonatal hydronephrosis.

UPJO may not become apparent until middle age or later (Jacobs et al., 1979). **Occasionally, if the patient is asymptomatic and the physiologic significance of the obstruction seems indeterminate, careful observation with serial follow-up renal scans is appropriate.** Gurbuz et al. (2011) observed minimally symptomatic UPJO and found 29% required surgery over a 4-year period. Gulur et al. (2009) noted that 3 of 14 patients with UPJO lost less than 10% renal function over a mean of 44 months of observation. However, the majority of affected patients ultimately benefit from reconstructive intervention (Clark and Malek, 1987; Jacobs et al., 1979; O'Reilly, 1989). **When intervention is indicated, the procedure of choice has historically been open dismembered pyeloplasty; however, less invasive endourologic incisional procedures have emerged as an alternative, particularly in secondary UPJO** (Brannen et al., 1988; Cohen et al., 1996; Conlin, 2002; Gerber and Kim, 2000; Kletscher et al., 1995; Lechevallier et al., 1999; Motola et al., 1993a; Nadler et al., 1996; Nakada, 2000; Tawfiek et al., 1998; Thomas et al., 1996). **More recently, laparoscopic and robotic pyeloplasty has gained acceptance as primary therapy in most major centers** (DiMarco et al., 2006; Jacobs et al., 2013; Rassweiler et al., 2007).

Although success rates with most endourologic techniques have not proven comparable with those of pyeloplasty, it has been suggested that the success rates may be improved with careful patient selection. In an important prospective study, Van Cangh et al. (1994) achieved an overall success rate for endopyelotomy of 73%. However, these investigators found the presence of crossing vessels to be a major determinant of outcome (42% success rate in the setting of a crossing vessel vs. 86% success without a crossing vessel). Furthermore, when endopyelotomy was applied to patients with “a high degree of obstruction,” the success rate was only 60% compared with an 81% success rate for those patients with “low-grade” obstruction. When patients with a crossing vessel and a high degree of obstruction were excluded from analysis, the success rate improved to 95%, which is comparable with that of open pyeloplasty. However, other studies have suggested a less important role for these factors with regard to their impact on a successful outcome (Danuser et al., 1998; Gupta et al., 1997; Nakada et al., 1998). Also, the incisional approach may be favored in patients who are poor surgical candidates or in patients poorly suited to an abdominal approach (ElAbd et al., 2009). In most primary UPJO, minimally invasive pyeloplasty has become a common procedure in adults and in many centers for children as well (Jacobs et al., 2013). A more recent study showed a 10-fold increase in the rate of minimally invasive pyeloplasties, whereas open pyeloplasties decreased 40% and endopyelotomies remained stable over a 9-year period (Jacobs et al., 2017a). A recent comparative effectiveness study showed a higher treatment failure rate for endopyelotomy compared with open or minimally invasive pyeloplasty, which were equivalent (Jacobs et al., 2018).

Although the indications for intervention for UPJO are similar regardless of technique, it is critical to discuss the risks and benefits of each available option with patients. As a result of studies linking crossing vessels to hindered endourologic successes, there is increased interest in intraoperative management of primary UPJO by either an open, laparoscopic, or robotic approach (Conlin, 2002). **Notably, for secondary UPJO, it remains reasonable to recommend an open or laparoscopic approach to any patient in whom primary endourologic management has failed and an endourologic approach to those in whom open or laparoscopic repair has failed.** The results of endourologic management after failed pyeloplasty remain excellent (Canes et al., 2008; Jabbour et al., 1998; Patel et al., 2011).

Rarely, nephrectomy may be the procedure of choice. Indications for nephrectomy as primary therapy include diminished function or nonfunction of the involved renal moiety and a normal contralateral kidney on the basis of radiographic and nuclear studies. These patients may be symptomatic with urinary tract infections or pain. In such cases, ultrasonography or CT scanning is typically performed and will reveal only a thin shell of parenchyma remaining. **Renography can provide quantitative measures of renal function, and, in general, kidneys with less than 15% to 20% differential function are considered nonsalvageable in adults. If the potential for salvageability of function is still unclear, an internal stent or percutaneous nephrostomy may be placed for temporary relief of obstruction and renal function studies subsequently repeated.** Nephrectomy may also be considered for patients in whom the obstruction has led to extensive stone disease with chronic infection and significant loss of function in the face of a normal contralateral kidney. Removal of the kidney may also be chosen over reconstruction for patients in whom repeated attempts at repair have already failed and in whom further intervention would therefore be extremely complicated. This option should be considered only when the contralateral kidney is essentially normal.

Options for Intervention

Endourologic Management.

Endourologic management of UPJO was introduced by Ramsay et al. in 1984 as a “percutaneous pyelolysis” and then popularized in the United States by Badlani et al. (1986), who coined the term *endopyelotomy.* **Although various nuances in the technique have been described** (Korth et al., 1988; Ono et al., 1992; Van Cangh et al., 1989), **the basic concept of the endopyelotomy is a full-thickness lateral incision through the obstructing proximal ureter, from the ureteral lumen out to the peripelvic and periureteral fat.** A stent is placed across the incision and is left to heal, in keeping with the original work of Davis in 1943, who performed an “intubated ureterotomy” to repair UPJO. Subsequently, alternative techniques using a retrograde approach to the UPJ were developed. The retrograde approach most used today is the ureteroscopic approach, typically using the holmium laser to incise the UPJ under direct visual control. Alternatively, a cautery wire balloon endopyelotomy, which incises the UPJ under fluoroscopic control, or percutaneous endopyeloplasty may be used (ElAbd et al., 2009; Gill et al., 2002). Recently, Vaarala et al. (2008) reported a small series of 64 patients who underwent either antegrade or retrograde cold knife or cautery wire balloon endopyelotomy. In this study, success rates ranged from 79% to 83%, without statistically significant differences among the three treatments. Transplantation complications are particularly suited to endoscopic management, either antegrade or retrograde (Gdor et al., 2008b; Schumacher et al., 2006). **As far as efficacy is concerned, there continues to be little evidence for significant differences among endopyelotomy techniques. The differences lie in technical considerations and complications.**

Operative intervention for UPJO has historically provided a widely patent, dependently positioned, well-funneled UPJ. In addition, the option to reduce the size of the renal pelvis is readily available with this approach. Although formal pyeloplasty has stood the test of time with a published success rate of nearly 95%, endourologic alternatives to standard operative reconstruction are still used (Clark et al., 1987; ElAbd et al., 2009). **The advantages of endourologic approaches include reduced hospital stays and postoperative recovery. However, the success rate does not approach that of open, laparoscopic, or robotic pyeloplasty. Furthermore, whereas open, laparoscopic, or robotic pyeloplasty can be applied to almost any anatomic variation of UPJO, consideration of any of the less invasive alternatives requires that the surgeon take into account the degree of hydronephrosis, ipsilateral renal function, concomitant calculi, and possibly the presence of crossing vessels.**

Percutaneous Antegrade Endopyelotomy

Indications and Contraindications.

The indications to intervene for any patient with UPJO include the presence of symptoms, progressive or overall impairment of renal function, development of upper tract stones or infection, or, rarely, causal hypertension. Historically, a percutaneous approach for definitive management of UPJO was offered only to those patients undergoing percutaneous removal of associated stones or to those in whom open pyeloplasty had previously failed. However, encouraging results ultimately led many centers to offer percutaneous endopyelotomy as primary therapy for almost any patient with UPJO. **Even with the acceptance of laparoscopic and robotic pyeloplasty, percutaneous endopyelotomy remains appropriate for patients with UPJO and concomitant pyelocalyceal stones requiring percutaneous access, which can then be managed simultaneously. Contraindications to a percutaneous endopyelotomy are similar to the contraindications to any endourologic approach and include a long segment (>2 cm) of obstruction, active infection, and untreated coagulopathy.** Often these cases can also be managed robotically (Pedro and Buchholz, 2018). Whereas the impact of crossing vessels is controversial, the mere presence of crossing vessels is not a contraindication to an endopyelotomy (Lam et al., 2003b; Motola et al., 1993b; Nakada et al., 1998). However, significant entanglement of the UPJ by crossing vessels can occasionally be identified, and this may render any endourologic approach unsuccessful. Vessel entanglement can be reliably identified with 3D helical CT (Kumon et al., 1997; Fig. 89.7).

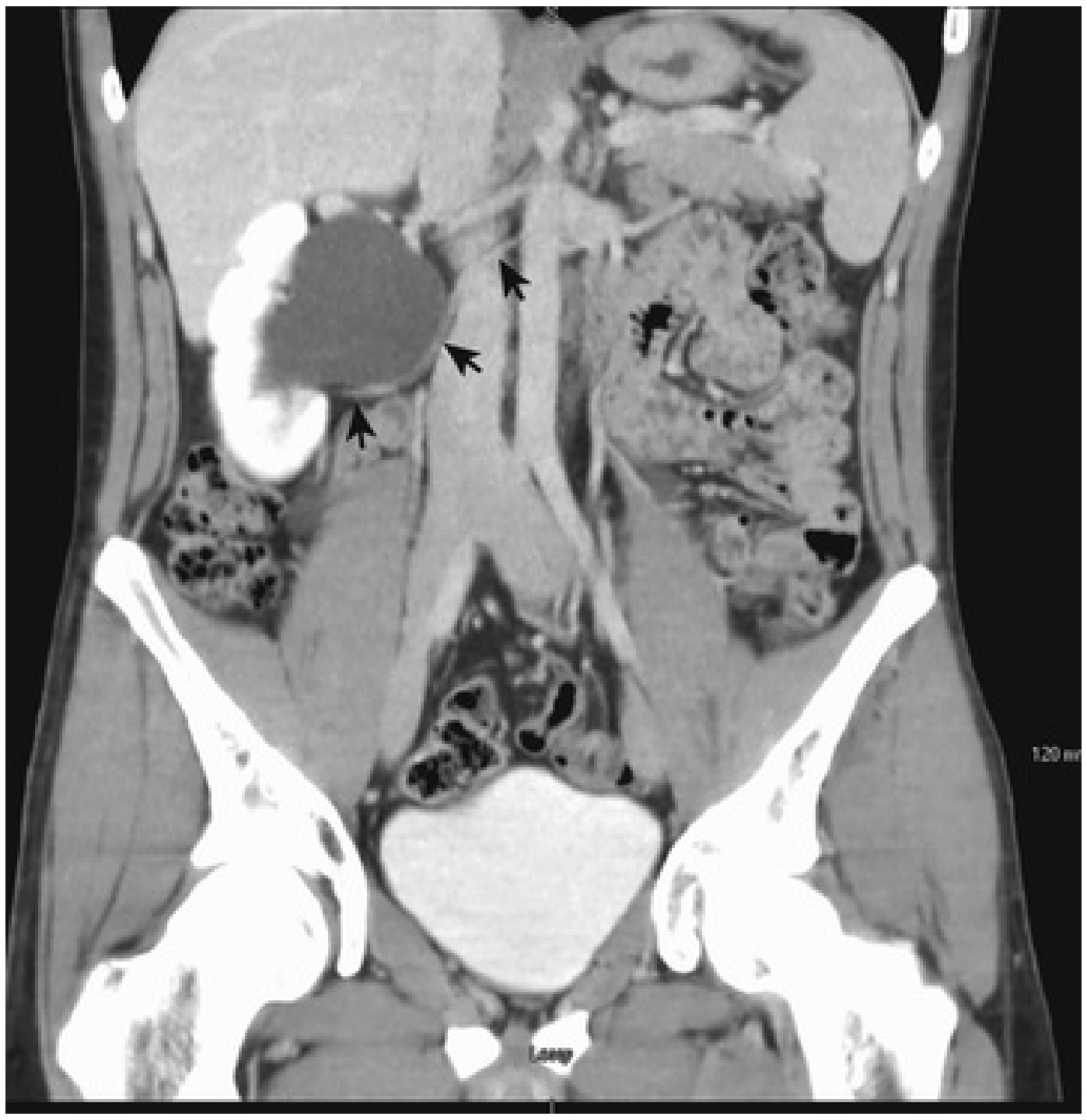

FIG. 89.7 Contrast-enhanced computed tomography scan reveals apparent right ureteropelvic junction obstruction in this patient with right flank pain. A crossing lower pole artery is visible on this coronal section.

Patient Preparation.

Patients undergoing a percutaneous endopyelotomy undergo preoperative evaluation and preparation as if they were undergoing any percutaneous, laparoscopic, or open renal intervention. The evaluation includes an assessment for any comorbidity that may increase the risk of anesthesia. Sterile urine should be ensured at the time of definitive intervention. If upper tract infection cannot be cleared because of obstruction, temporization should be accomplished through use of internal stenting or percutaneous nephrostomy drainage alone.

The patient should be counseled as to the risks and benefits of the procedure, and in particular the fact that the success rate of any endourologic approach, including percutaneous endopyelotomy, may be less than that of formal reconstruction. Patients should also be counseled of the risk of bleeding requiring transfusion, urinary leak, drainage-related complications, and hydropneumothorax, particularly if upper pole access is used.

Technique.

An endopyelotomy cannot be performed safely by any route until access across the UPJ is established. This can be accomplished in a retrograde fashion cystoscopically or in an antegrade manner percutaneously. For retrograde access, the UPJ can almost always be traversed using a hydrophilic wire passed through an open-end catheter. Once the hydrophilic wire is successfully positioned in the pyelocalyceal system, the open-end catheter is advanced over it into the renal pelvis. The wire can then be withdrawn so that contrast material can be injected through the open-end catheter to guide subsequent percutaneous access.

With the patient in the prone position, the site for percutaneous access is chosen to allow straightforward access to the UPJ. In general, a midposterior or superolateral calyx is chosen. Typically, the UPJ can be intubated in an antegrade fashion when the tract is initially established with fluoroscopic control. Alternatively, once the tract has been dilated and nephroscopy has been performed, a wire can again be passed in a retrograde fashion through the open-end catheter and grasped from above so that through-and-through access is reestablished. In either case, as soon as access is obtained with one wire, an introducing catheter is used to pass a second wire as a safety wire, so a working and a safety wire are now both in place. At this point, percutaneous access is complete and the endopyelotomy may be performed.

In the original descriptions of the technique from the Institute of Urology in London (Ramsay et al., 1984) and from Long Island Jewish Hospital in New York (Badlani et al., 1986), the endopyelotomy was performed using a cold knife technique under direct vision. With one or two wires in place across the UPJ, a direct vision “endopyelotome” is used. This hook-shaped cold knife may be used to completely incise the UPJ in a full-thickness manner, from the ureteral lumen to periureteral and peripelvic fat. **Rigorous anatomic studies have shown the incision should usually be made laterally because this is the location devoid of crossing vessels** (Sampaio, 1998; Sampaio and Favorito, 1993). However, in cases of high insertion, the incision should instead “marsupialize” the proximal ureter into the renal pelvis, such that an anterior or posterior incision may be required. When such incisions are done under direct vision, any crossing vessel can be directly visualized and avoided. In addition to the endopyelotome, the holmium laser at tissue settings may be used to perform an antegrade endopyelotomy.

Once the incision is complete, stenting is accomplished. There remains no consensus as to the optimal stent size or duration for endopyelotomy. A No. 14/7-Fr endopyelotomy stent may be used, passed in an antegrade fashion with the larger-diameter end of the stent positioned across the UPJ. In some cases, especially when the patient has not been prestented, passage of this large-caliber stent may be difficult. In those instances, a No. 10/7-Fr endopyelotomy stent or even a standard No. 8-Fr internal stent may be used without compromising the ultimate outcome. Once proper positioning of the stent has been determined fluoroscopically, any remaining safety wires are withdrawn. One group showed no difference between larger and standard stents in a porcine study of endopyelotomies (Moon et al., 1995). Alternatively, Danuser et al. (2001) demonstrated improved success rates using a modified 27-Fr stent after percutaneous endopyelotomy at nearly 2 years of follow-up.

In the setting of a high insertion, the incision can often be extended to the dependent portion of the renal pelvis under direct vision, bridging the gap between the lateral wall of the ureter and the medial wall of the pelvis, across the periureteral and peripelvic fat (Fig. 89.8).Once the incision is complete, the stent is already in place and nephrostomy drainage is instituted for 24 to 48 hours.

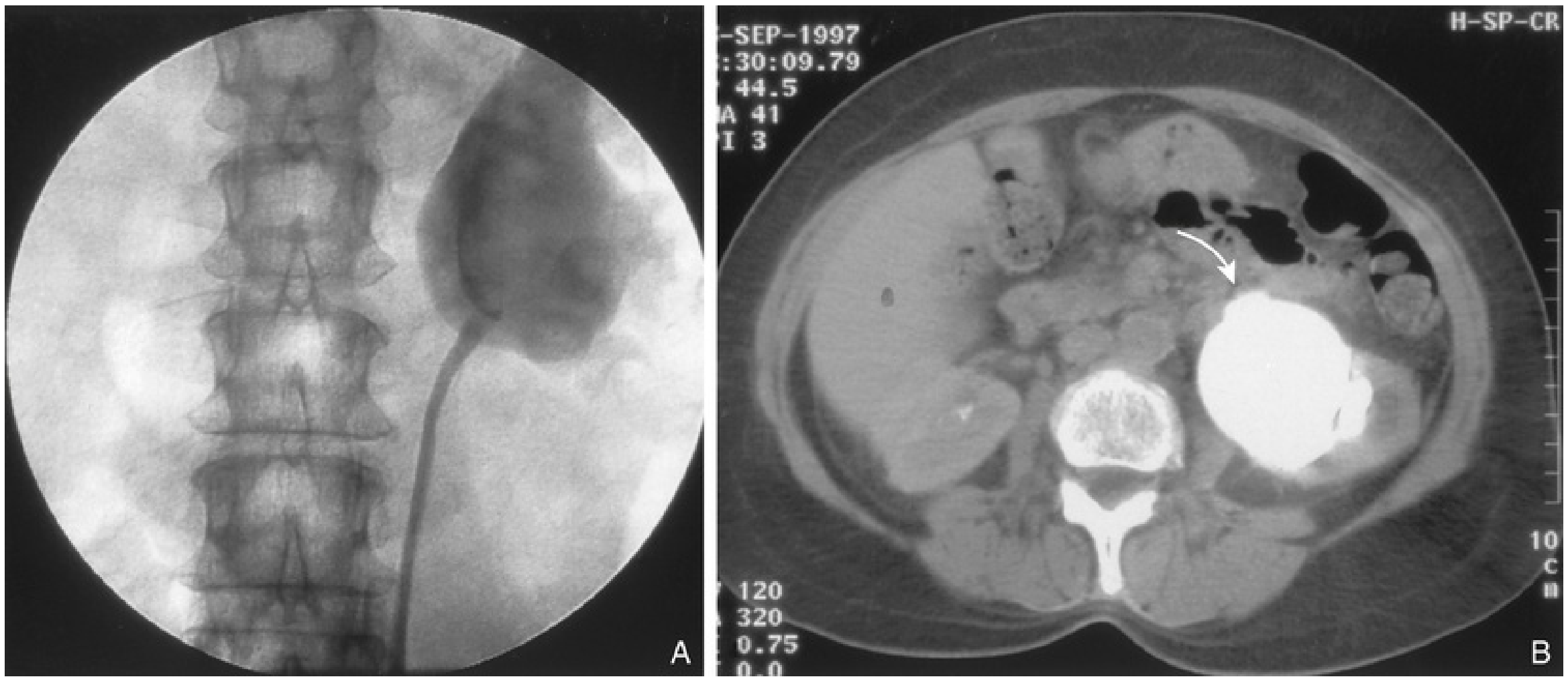

FIG. 89.8 (A) Retrograde study in this patient with left ureteropelvic junction obstruction reveals a “high insertion” of the left ureter. (B)

Computed tomography scan in the same patient reveals the ureter inserting on the anatomically anterior aspect of the renal pelvis. A marsupializing incision must be made in a true posterior direction from the ureter into the renal pelvis.

Postoperative Care.

Avoidance of strenuous activity for 8 to 10 days after the procedure is recommended. The ideal stent size, duration of stent placement, and radiographic follow-up after endopyelotomy remain unclear (Canes et al., 2008). One study did report a benefit to larger stents in patients undergoing antegrade endopyelotomy (71% vs. 93%); however, a large-bore (27-Fr) catheter was used for the initial 3 weeks postoperatively (Danuser et al., 2001). On the other hand, Kletscher et al. (1995) reported no benefit to larger stents, as did Hwang et al. (1996). Wolf et al. (1997) reported improved success using larger stents (12 Fr) in endoureterotomy patients in a retrospective review. Regarding stent duration, less is known. The original report and recommendation of 6 weeks by Davis (1943) is still often used, although Mandhani et al. (2003) identified no difference in results when comparing 57 patients stented for 2 weeks versus 4 weeks. Although the need for prophylactic antibiotics while the stent is indwelling is not literature based, many use a daily suppressive dose.

Once the stent is removed, the patient returns 1 month later for clinical follow-up and radiographic evaluation. In general, this includes a history, physical examination, urinalysis, and diuretic renography. If the patient remains asymptomatic and the diuretic renography reveals normal drainage (normal $T_{1/2}$), reevaluation is performed at 6 months and then at 12-month intervals. Most literature indicates that the majority of endopyelotomy failures occur within the first year of the procedure; however, longer-term studies demonstrate failures well beyond that timeframe (Albani et al., 2004; DiMarco et al., 2006; Doo et al., 2007; Nadler et al., 1996). For most adults, 2- to 3-year follow-up is justified because studies indicate that even at 36 months some late failures are identified, but relatively few are identified at 60 months (Doo et al., 2007).

Results.

The immediate and long-term results of percutaneous endopyelotomy are well established. Although percutaneous endopyelotomy compares favorably with open operative pyeloplasty in terms of postoperative pain, length of hospital stay, and return to prehospitalization activities (Brooks et al., 1995; Karlin et al., 1988), retrograde endopyelotomy and laparoscopic and robotic pyeloplasty also offer favorable convalescence.

Gerber and Lyon in 1994 reviewed the outcome of percutaneous endopyelotomy in 672 patients reported from 12 centers and found a success rate ranging from 57% to 100% (mean, 73.5%) at follow-up ranging from 2 to 96 months. Currently, success rates approaching 85% to 90% are being reported at experienced centers, with little difference in outcome noted in those patients undergoing the procedure for primary versus secondary UPJO (Kletscher et al., 1995; Motola et al., 1993a; Shalhav et al., 1998). Knudsen et al. (2004) reported long-term results in 80 patients after use of the cold knife and holmium laser for antegrade endopyelotomy, with 55-month follow-up. This series had a success rate of 67%, slightly lower than otherwise reported. DiMarco et al. (2006) reported on 182 antegrade endopyelotomies with a recurrence-free survival over 10 years at a single center as low as 41%. Schumacher et al. (2006) reported on three successful antegrade endopyelotomies in transplanted kidneys in 2006.

When percutaneous endopyelotomy does fail, several options exist, including a retrograde endopyelotomy; repeat percutaneous endopyelotomy; and laparoscopic, robotic, or open operative intervention. There remains a role for CT angiography in failed endopyelotomy, to rule out a crossing vessel. If a significant vessel is found, repeat endopyelotomy is usually not recommended (Nakada, 2000; Nakada et al., 1998; Sampaio, 1998). **Alternatively, operative intervention is typically offered to any patient in whom an endourologic approach has failed.** Studies suggest that the results of laparoscopic pyeloplasty will not be compromised, although Sundaram et al. (2003) reported longer operative times in these circumstances (Conlin, 2002; Gupta et al., 1997; Motola et al., 1993b). Albani et al. (2004) reported contemporary long-term results with various endopyelotomy approaches to have a success rate of 67%, with the majority of failures in the first 32 months. DiMarco et al. (2006) reported long-term follow-up of more than 400 patients undergoing either percutaneous antegrade endopyelotomy or pyeloplasty. The 3-, 5-, and 10-year success rates were superior for pyeloplasty, 85% versus 63%, 80% versus 55%, and 75% versus 41%. Moreover, Rassweiler et al. (2007) compared retrograde laser endopyelotomy with laparoscopic retroperitoneal pyeloplasty in 256 patients in a 10-year single-surgeon experience and found success rates were 73% for laser endopyelotomy compared with 94% for pyeloplasty. One recent literature review for laser endopyelotomy found success rates ranging from 44% to 89% with follow-up ranging from 10 to 63 months (Elmussareh et al., 2017). Kim et al.

(2012) reported a 65% success rate in 37 pediatric patients after primary endopyelotomy at 34 months, but a 94% success rate in children at 61 months using secondary endopyelotomy.

Complications.

The complications associated with percutaneous endopyelotomy are analogous to those associated with percutaneous nephrolithotomy (Badlani et al., 1988; Bellman, 1996; Cassis et al., 1991; Malden et al., 1992; Weiss et al., 1988), **and hemorrhage is a risk of any percutaneous upper tract procedure, including endopyelotomy.** However, because in patients with UPJO the renal parenchyma is often atrophied and usually thinner than that of a normal kidney, the risk of bleeding may be higher than that of stone patients undergoing percutaneous manipulation. Acute management in this setting is usually conservative to start: bed rest, hydration, and transfusion if necessary. The nephrostomy tube should not be irrigated acutely. Rather, it is preferable to allow the pyelocalyceal system to tamponade the bleeding. When continued bleeding does not respond to these conservative measures, the next step is selective angiographic embolization. **In general, the urologist should have a low threshold to proceeding to angiography, to minimize the need for transfusion and potential exploration. Successful angiographic embolization usually obviates the need for operative intervention.**

Infection is a risk of any urinary tract manipulation including percutaneous endopyelotomy, and all attempts should be made to sterilize the urinary tract before the procedure. Whereas the role of prophylactic antibiotics at the outset of the procedure in the setting of a sterile urine is unproven, most urologists give a second-generation cephalosporin “on call” to the procedure. Consideration should be given to the use of prophylactic antibiotics while the endopyelotomy stent is indwelling for the month after the procedure, especially in women who are more prone to bacteriuria.

Persistent obstruction is rare in the early postoperative period because of the internal stent. Occasionally the stent can be obstructed from blood clots, and continued nephrostomy drainage for a few days typically allows the problem to resolve spontaneously.

Special Considerations.

Percutaneous endopyelotomy and nephrolithotomy remain appropriate when the UPJO is associated with upper tract stone disease because the

stones can be managed concomitantly. In such cases, percutaneous access is established with a wire across the UPJ. The stone should be removed before the endopyelotomy so that stone fragments do not migrate into the peripyeloureteral tissue, as can happen if the endopyelotomy is performed first. Otherwise, localized obstruction may result from fibrosis or granuloma formation (Giddens et al., 2000; Streem, 2000). The urologist must ensure that the UPJO is not a result of edema from the concomitant stone disease, in particular with stone disease in the renal pelvis. In this circumstance, initial management of the stone percutaneously and subsequent radiographic assessment of the UPJ once the stone has been removed are most prudent. In addition, if a nephrostomy tube is retained, a Whitaker test is straightforward and definitive to assess for persistent obstruction. Conversely, UPJO and solitary lower pole calculi do not represent a dilemma regarding UPJ edema, and combined percutaneous management remains most efficient. Alternatively, laparoscopic or robotic pyeloplasty with concomitant stone removal is also effective for these patients. Often the deciding factor between percutaneous and laparoscopic approaches relates to the stone burden present and the experience of the surgeon (Sutherland and Jarrett, 2009). Percutaneous endopyeloplasty is an uncommon hybrid technique described as an endoscopic Heineke-Mikulicz repair performed through a percutaneous tract. Stein et al. (2007) reported 55 patients with short-term follow-up with more than 90% success. Endopyeloplasty may not be effective for secondary UPJO because tissue scarring may inhibit the endoscopic reconstruction. More recently a technique modification was reported requiring no specialized equipment (laparoscopic needle holders and a nephroscope) in 10 patients (Lezrek et al., 2012).

Retrograde Ureteroscopic Endopyelotomy.

A ureteroscopic approach to endopyelotomy was first reported in 1985 when Bagley et al. reported a combined percutaneous and flexible ureteroscopic procedure approach for management of an “obliterated” UPJ. Subsequently, Inglis and Tolley (1986) reported a ureteroscopic “pyelolysis” for UPJO. Shortly thereafter, Clayman et al. (1990) reported an initial experience in a small number of patients with ureteroscopic endopyelotomy with a 3-Fr or 5-Fr cutting electrode passed under direct vision using large, rigid or flexible ureteroscopes. In that series, however, an 8-Fr nephrostomy tube was placed at the outset of the procedure and left indwelling for at least 48 hours. Therefore that series still represented a “combined” endourologic approach to endopyelotomy. Stents were routinely left in place for 6 to 8 weeks, after which diagnostic studies were performed. With a mean follow-up approaching 1 year, a success rate of 81% was achieved in 16 patients. However, two patients developed distal ureteral strictures, probably resulting from the larger-diameter rigid instrumentation. Cold-knife ureteroscopic endopyelotomies are still reported. Butani and Eshghi (2008) identified 96% success rates in primary procedures with an average 5-year follow-up, although rigid ureteroscopy and preprocedure stents were necessary.

Advances in instrumentation and technique now allow a ureteroscopic approach to be performed reliably at a single setting (Conlin and Bagley, 1998), and this is now considered the standard. **The main advantage of a ureteroscopic approach is that it allows direct visualization of the UPJ and assurance of a properly situated, full-thickness endopyelotomy incision without the need for percutaneous access.** Another advantage of the ureteroscopic approach is a decrease in cost compared with the use of the cautery wire balloon, assuming ureteroscopic equipment and electroincision or holmium laser are already available. Moreover, the risks and morbidity of percutaneous access are avoided with the ureteroscopic procedure. Gettman et al. (2003) found that the retrograde ureteroscopic endopyelotomy was more cost effective than hot-wire cutting balloon endopyelotomy, antegrade endopyelotomy, and pyeloplasty for treating UPJO when taking into account treatment failures. Another study showed endopyeltomies to be less expensive than minimally invase or open pyeloplasty. Open and minimally invasive pyeloplasty approaches were cost neutral, making minimally invasive pyeloplasty the best option when available (Jacobs et al., 2017b).

Indications and Contraindications.

The indications for a ureteroscopic endopyelotomy include functionally significant obstruction, as defined earlier. Contraindications include long areas of obstruction and upper tract stones, which are best managed simultaneously with alternative approaches, usually percutaneously or laparoscopically. Another consideration is that in patients with significant hydronephrosis, the evidence indicates an antegrade endopyelotomy may be more efficacious (Lam et al., 2003b).

Technique.

In women, the UPJ can be reached with a 6.9-Fr semirigid ureteroscope, although typically a flexible ureteroscope is used. In men, flexible ureteroscopes are used with ureteral access sheaths and flexible ureteroscopes for most retrograde endopyelotomies.

General anesthesia is used to minimize patient movement during ureteroscopy and the subsequent incision of the UPJ. In preparation for the endopyelotomy, a retrograde pyelogram is performed under fluoroscopic control at the outset of the procedure. A hydrophilic guidewire is passed cystoscopically under fluoroscopic control and coiled in the pyelocalyceal system. The cystoscope is then withdrawn and an access sheath is placed. A flexible ureteroscope is passed alongside the guidewire to the level of the UPJ. If the distal ureter is too narrow to allow easy passage of the ureteroscope, the intramural ureter can be dilated using a 5-mm balloon or a 9- or 10-Fr “introducing” catheter. If the ureter is still too narrow at any point to easily accommodate the ureteroscope, then an internal stent is placed and the procedure postponed for 5 to 10 days to allow passive ureteral dilation. Alternatively, an actively deflecting flexible ureteroscope may be used, and in most cases a ureteral access sheath is useful. The sheath allows for rapid transfer of the ureteroscope for assessment of the UPJ. Once the flexible ureteroscope is passed to the UPJ, a 200-μm holmium fiber is placed through the working channel and the UPJ is incised in the appropriate location, as suggested by the radiographic studies (Figs. 89.9 and 89.10).

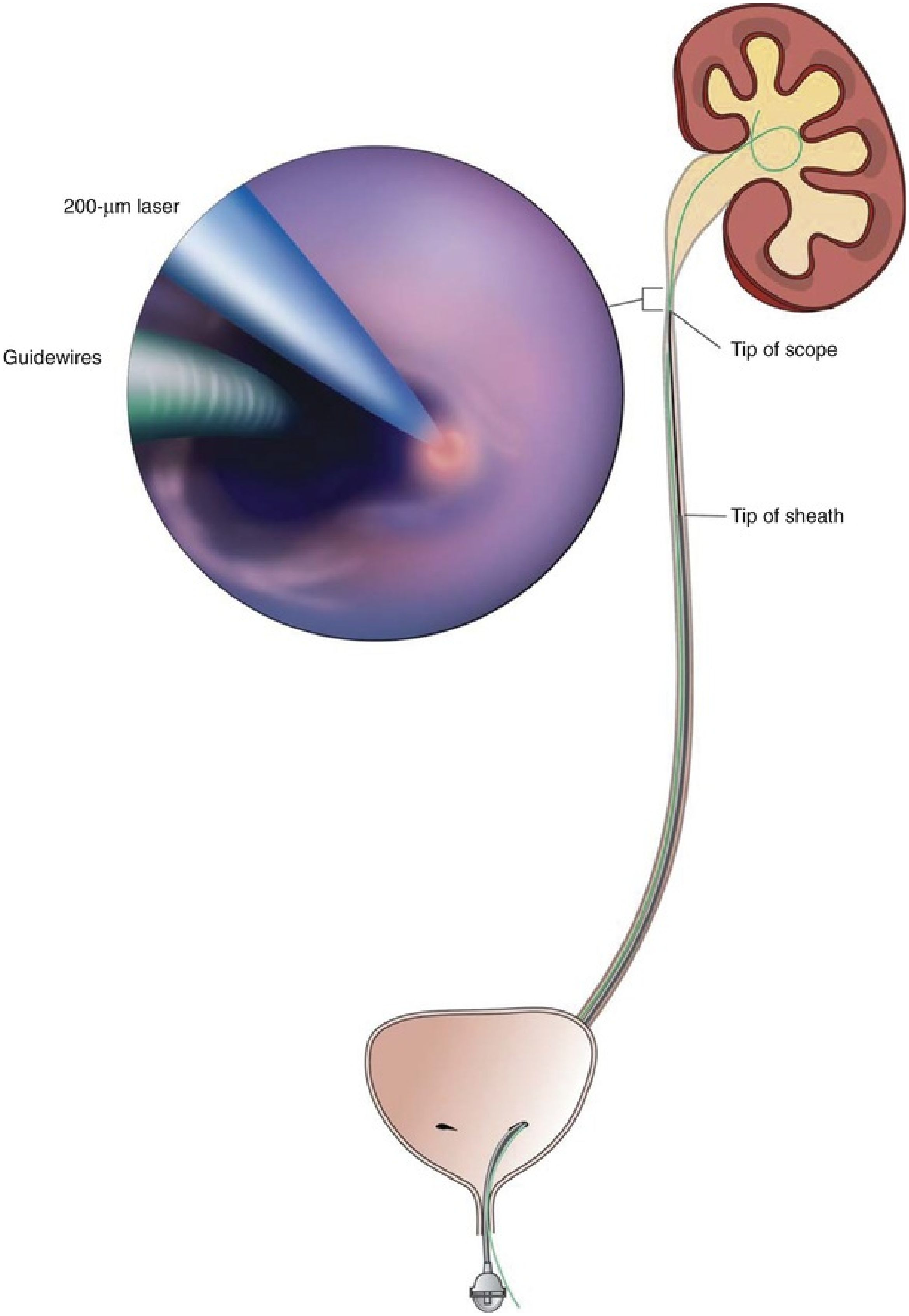
200-µm laser
Guidewires
Tip of scope
Tip of sheath

FIG. 89.9 Flexible ureteroscopic endopyelotomy using holmium laser,

demonstrating endoscopic view of the ureteropelvic junction *(inset).* A safety wire is in place, and the ureteroscope is passed through a ureteral access sheath as a lateral incision is being made under endoscopic view, using holmium laser fiber. A properly sited, complete incision is straightforward with this direct visualization technique.

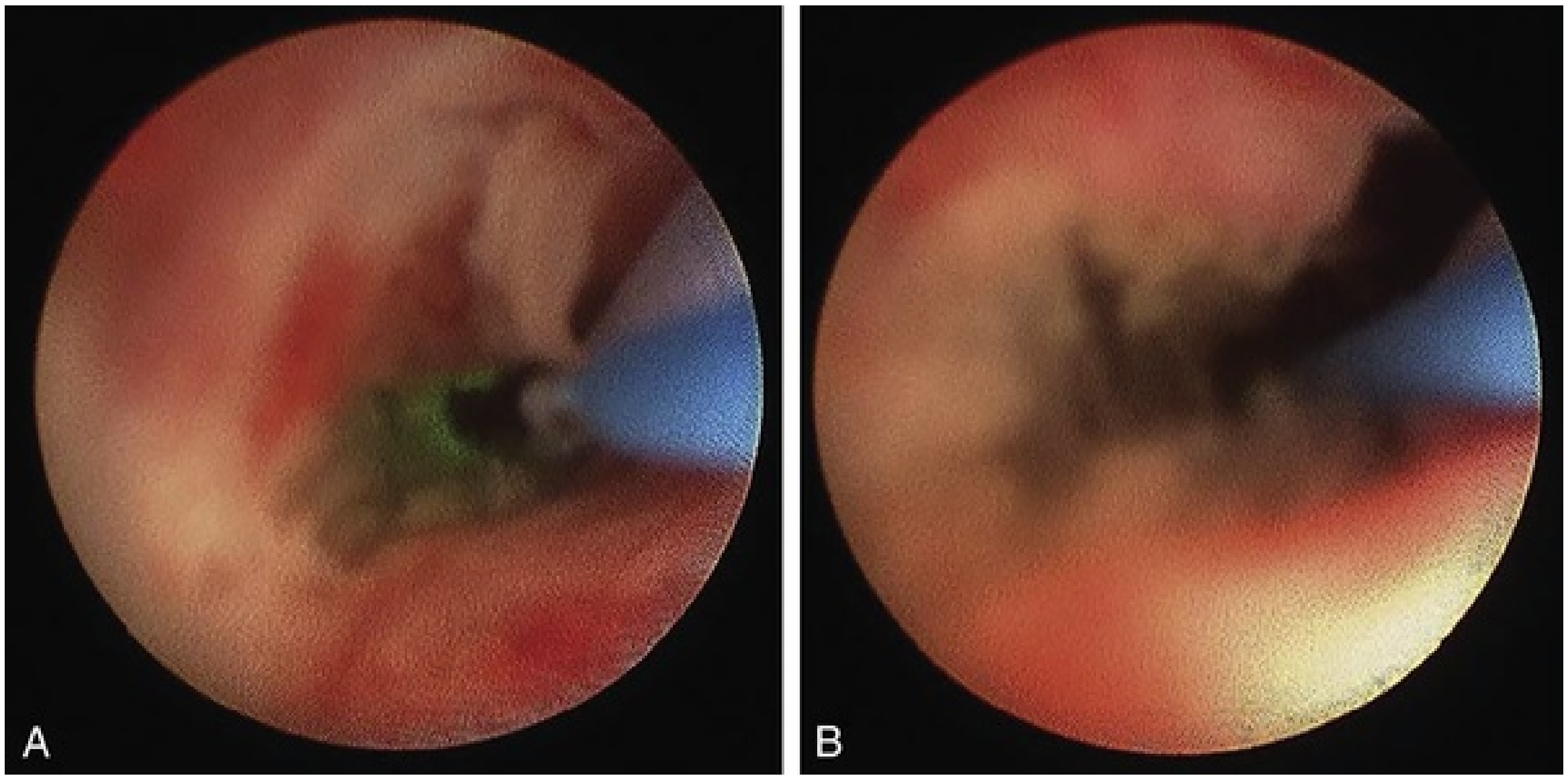

FIG. 89.10 (A) Endoscopic view of ureteropelvic junction (UPJ) stenosis with safety wire and laser fiber during incision. (B) After incision, note full-thickness incision and minimal bleeding with capacious UPJ.

Once the UPJ is reached with the ureteroscope, the renal pelvis is drained to assist movement across the UPJ during the incision. When a semirigid ureteroscope is used, the 200- or 365-μm holmium laser fiber is inserted through the working channel as the ureteroscope is positioned at the proximal extent of the UPJ or in the renal pelvis. At a setting of 0.8 to 1.2 J and a frequency of 10 to 15 Hz, the UPJ is incised, usually in a lateral direction, while the ureteroscope is withdrawn back down across the UPJ. This procedure is repeated, and the incision gradually deepened to extend into the peripelvic and periureteral retroperitoneal space. Because this is done gradually and under direct vision, any visualized vessels, and thus potentially significant bleeding, is usually avoided.

The incision is carried caudally into normal ureteral tissue, until the UPJ is widely patent. Injection of contrast material through the ureteroscope can demonstrate extravasation and confirm an adequate depth of incision, although this is usually not necessary because the entire procedure has been performed under direct vision. Balloon dilation up to 24 Fr can also be performed to complete the incision. If any small bleeding points are visualized ureteroscopically, they can be treated by defocusing the holmium laser. Similarly, the balloon can be reinflated to allow tamponade for 10 minutes to see if the bleeding will subside. The ureteroscope is then withdrawn from the ureter while the safety wire is left in place in the renal pelvis for subsequent passage of a stent. Experimental studies have shown that 36-Fr balloon dilation alone can create linear incisions in the UPJ (Pearle et al., 1994). **Although retrograde balloon dilation alone has been reported for treatment of UPJO, long-term follow-up studies have shown a diminishing success rate over time, as low as 42%** (McClinton et al., 1993; Webber et al., 1997).

Once the ureteroscope has been removed, a stent is advanced over the remaining wire using fluoroscopic guidance. A Foley catheter is left indwelling, again to obviate the risk of reflux and extravasation at the site of the endopyelotomy incision and to rapidly identify any significant bleeding. Diuretic renography is performed 4 weeks after stent removal to assess results. Clinical and radiographic follow-up is then continued at 6- to 12-month intervals for 24 to 32 months.

Results.

Biyani et al. (1997) described their initial experience with a ureteroscopic approach using holmium laser energy. With a mean follow-up of slightly more than 12 months, they achieved a success rate of 87.5% in a small group of patients. One patient developed a urinoma, which was managed conservatively. In 1998 Renner et al. reported a larger series of patients undergoing ureteroscopic laser endopyelotomy. With a semirigid ureteroscope, the UPJ was incised at a posterolateral location unless vessels were visualized in that area, in which case a contralateral incision was made. Tawfiek et al. (1998) reported the Jefferson Medical College experience with ureteroscopic endopyelotomy. These investigators combined endoluminal ultrasound with their ureteroscopic approach to definitively identify crossing vessels or a ureteropelvic septum, which is present in patients with high-inserting ureters. The authors believed this helped them definitively site their endopyelotomy incision. Different modalities were used for the endopyelotomy, including electrocautery and holmium laser. An 87.5% success rate was achieved in 32 patients. There were no significant bleeding complications, and all patients were discharged within 24 hours of the procedure.

Several investigators have reported success rates of 70% to 80% with follow-up out to 5 years using ureteroscopic holmium laser endopyelotomy (ElAbd et al., 2009; Gerber and Kim, 2000; Matin et al., 2003). Yanke et al. (2008) reported on 128 retrograde ureteroscopic endopyelotomies with a 60% success rate at 20 months; Rassweiler et al. (2007) reported 73% success in 113 patients at 63 months. Improved results (91% success rates) were reported by Conlin (2002) with retrograde endopyelotomy in patients when culling patients with crossing vessels greater than 4 mm using preoperative ultrasonography. Giddens et al. (2000) also published excellent results after culling patients with anterior and posterior crossing vessels from retrograde endopyelotomy using endoluminal ultrasound. However, endoluminal ultrasound is rarely used to identify crossing vessels because similar data can be obtained using less invasive studies (Mitterberger et al., 2008). **Regardless, the best retrograde endopyelotomy success rates still lag behind those of open or laparoscopic pyeloplasty.**

Complications.

Complications of this approach have diminished in frequency and severity with the refinement of ureteroscopic instrumentation and the introduction of small-caliber holmium laser fibers. Postprocedural ureteral strictures are rare in contemporary series, and angiographic embolization and nephrectomy are rare when the retrograde approach is used. Most complications are minor and relate primarily to urinary leak, stent migration, and infection (Gerber and Kim, 2000; Tawfiek et al., 1998). Castle et al. (2009) reported on ureteroarterial fistula 2 weeks after retrograde laser endopyelotomy, which could be fulgurated ureteroscopically.

Other Retrograde Techniques.

Use of fluoroscopically guided cautery wire balloon for management of UPJO was first reported in a clinical series by Chandhoke et al. in 1993. Ponsky and Streem (2006) reported on 64 patients undergoing either ureteroscopic endopyelotomy or fluoroscopically guided cautery balloon endopyelotomy and found equivalent success rates with both procedures yet higher major complication rates in the cautery wire balloon endopyelotomy, specifically transfusion and selective embolization. ElAbd et al. (2009) reported a higher rate of hemorrhage using this technique compared with direct vision laser incisional approach. **Improved ureteroscopic instrumentation, laser technology, and better outcomes make ureteroscopic endopyelotomy the current retrograde**

approach of choice.

Key Points: Endourologic Management of Ureteropelvic Junction Obstruction

- Contemporary indications for intervention for UPJO include the presence of symptoms associated with the obstruction, impairment of overall renal function or progressive impairment of ipsilateral function, development of stones or infection, or, rarely, causal hypertension.
- The advantage of endoscopic management is the avoidance of the intra-abdominal approach; however, the success rates do not approach that of laparoscopic or robotic pyeloplasty.
- Endourologic approaches to UPJO should be carried out under direct visualization.
- In general, the urologist should have a low threshold to proceeding to angiography in patients with bleeding after endopyelotomy to minimize the need for transfusion and potential exploration. Successful angiographic embolization can obviate the need for operative exploration, which can lead to nephrectomy.

Operative Interventions

Historical Notes.

The historical aspects of UPJ repair were previously examined by Kay in 1989 and by Schaeffer and Grayhack in 1986. The first reconstructive procedure was performed by Trendelenburg in 1886; however, the patient died of postoperative complications. In 1891 Kuster divided the ureter and reanastomosed it to the renal pelvis, thus apparently performing the first successful dismembered pyeloplasty. Kuster's technique, however, was prone to recurrent stricture. In 1892 Fenzer applied the Heineke-Mikulicz principle to UPJ repair. This surgical technique involves transverse closure of a longitudinal incision. However, this technique can cause shortening of the suture line on one side, thus resulting in buckling or kinking of the UPJ with recurrent obstruction. In 1916 Schwyzer introduced the Y-V-pyeloplasty, which was subsequently modified by Foley in 1937. However, this technique was best applied to high ureteral insertions and was essentially unsuitable when the UPJ was already in a dependent position. Later on, flap techniques were developed that were more universally applicable including the spiral flap of Culp and DeWeerd (1951) and the vertical flap of Scardino and Prince (1953). Thompson et al. (1969) reported the use of a renal capsular flap for complex cases in which an adequate amount of renal pelvis is not available for repair.

In 1949 Nesbit followed the principle of Kuster's dismembered procedure and further modified it by creating an elliptical anastomosis to decrease the likelihood of stricture formation at the site of repair. Also in 1949, Anderson and Hynes described their modifications of this dismembered technique that involved anastomosis of the spatulated ureter to a projection of the lower aspect of the pelvis after a redundant portion was excised. Use of healing by secondary intention was also investigated in the similar time period. The techniques of intubated ureterotomy were popularized by Davis in 1943, but they had been previously described by Fiori in 1905, Albarran in 1909, and Keyes in 1915.

Developments in minimally invasive surgery have led to a dramatic rise in the use of laparoscopic and robotic techniques in the reconstruction of the UPJ (Jacobs et al., 2013). Despite the increased used of minimally invasive techniques, open approaches remain common in many centers, even in adults, with open surgery representing 41% of pyeloplasties performed between 2002 and 2010 in a review of MarketScan surgeries by Jacobs et al. (2017a). Irrespective of surgical approach, several basic principles must always be applied to maximize the success of surgical repair. **For any procedure, the resultant anastomosis should be widely patent and completed in a watertight fashion without tension. In addition, the reconstructed UPJ should allow a funnel-shaped transition between the pelvis and the ureter that is in a position of dependent drainage.** Because the goal of minimally invasive surgery is to mimic open surgery, the operative principles will be reviewed together with specific technical nuances for each approach.

Before the definitive surgical management, drainage of a kidney with UPJ obstruction is recommended only in select circumstances, including infection associated with the obstruction or azotemia resulting from obstruction in a solitary kidney or bilateral disease. Procedural drainage may be of value in the uncommon scenario of severe, unrelenting pain requiring emergent relief of obstruction. For any of these situations, such drainage can be achieved by placement of an internal ureteral stent or a percutaneous nephrostomy tube. Although most patients do not require preoperative drainage, most urologists place an indwelling ureteral stent at the time of pyeloplasty in adults. Our preference is for routine placement of a soft, inert, self-retaining internal ureteral stent, which is removed 4 to 6 weeks postoperatively. Stents in adults can be easily removed in an outpatient office setting under local anesthesia. Routine use of internal ureteral stents offers several advantages, especially in the early postoperative period. Such practice appears to decrease the amount and length of time of urinary extravasation at the surgical repair site, thereby decreasing the risk of secondary fibrosis. Decreased urinary extravasation also allows earlier removal of external drains. For the uncomplicated pyeloplasty in adult patients, there appears to be no advantage to using a nephrostomy tube and a stent because this may result in a prolonged hospital stay and an increased incidence of infection (Wollin et al., 1989). Instead, nephrostomy tubes may be reserved for complicated procedures such as those required for secondary UPJ obstruction or those associated with active inflammation. However, if a percutaneous nephrostomy tube had been placed preoperatively, it is generally left in place to allow proximal diversion and access for antegrade radiographic studies during the postoperative period.

At the completion of the pyeloplasty procedure, surgeons typically provide external drainage of the surgical bed. Such external drainage may be achieved with a closed suction drain placed near, but not on, the suture line and brought out through a separate stab incision. This practice helps to minimize the risk of urinoma formation leading to possible disruption of the suture line, scarring, or sepsis.

Dismembered Pyeloplasty

Indications.

At present, a dismembered pyeloplasty is preferred by most urologists in the surgical repair of UPJ obstruction because this procedure is almost universally applicable to the different clinical scenarios. This approach can be used regardless of whether the ureteral insertion is high on the pelvis or already dependent. It also permits reduction of a redundant pelvis or straightening of a tortuous proximal ureter. Furthermore, **anterior or posterior transposition of the UPJ can be achieved when the obstruction is due to accessory or aberrant lower pole vessels.** In addition, unlike the flap techniques, **only a dismembered pyeloplasty allows complete excision of the anatomically or functionally abnormal UPJ. A dismembered pyeloplasty is not well suited to**

UPJ obstruction associated with lengthy or multiple proximal ureteral strictures or to patients in whom the UPJ obstruction is associated with a small, relatively inaccessible intrarenal pelvis. This surgical repair can be accomplished by either open or minimally invasive techniques; the reconstruction of the UPJ is essentially the same.

Technique.

Surgical exposure to the UPJ is achieved by first identifying the proximal ureter in the retroperitoneum. The proximal ureter is then dissected cephalad to the renal pelvis, leaving a large amount of periureteral tissue to preserve the ureteral blood supply. A marking stitch of fine suture can be placed on the lateral aspect of the proximal ureter, below the level of the obstruction, to assist proper orientation for the subsequent repair (Fig. 89.11A). The UPJ tissue is typically excised, and the proximal ureter is then spatulated on its lateral aspect. The apex of this lateral, spatulated aspect of the proximal ureter is brought to the inferior border of the renal pelvis, while the medial side of the ureter is brought to the superior aspect (Fig. 89.11B). The anastomosis is then performed with fine interrupted or running absorbable sutures, placed full thickness through the ureteral and renal pelvic walls, in a watertight manner (Fig. 89.11C). As discussed earlier, our preference for adult patients is to routinely perform the anastomosis over an internal ureteral stent, which is left indwelling.

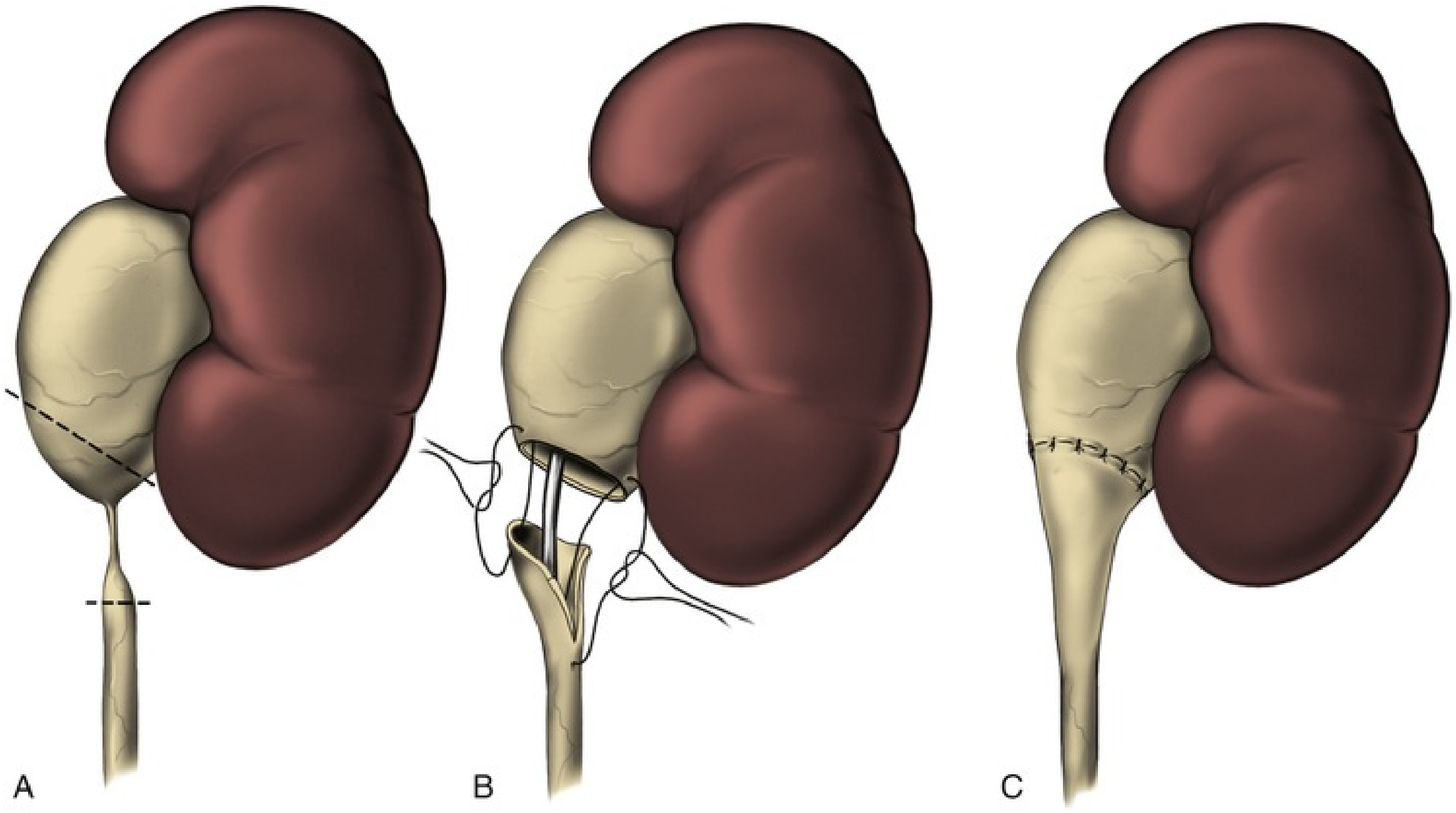

FIG. 89.11 (A) Traction sutures are placed on the medial and lateral aspects of the dependent portion of the renal pelvis in preparation for dismembered pyeloplasty. A traction suture is also placed on the lateral aspect of the proximal ureter, below the level of obstruction. This will help maintain proper orientation for the subsequent repair. (B) Ureteropelvic junction is excised. The proximal ureter is spatulated on its lateral aspect. The apex of this lateral, spatulated aspect of the ureter is then brought to the inferior border of the pelvis while the medial side of the ureter is brought to the superior edge of the pelvis. (C) Anastomosis is then performed with fine interrupted or running absorbable sutures placed full thickness through the ureteral and renal pelvis walls in a watertight fashion. In general, we prefer to leave an indwelling internal stent for adult patients. The stent is removed 4 to 6 weeks later.

If the renal pelvis is exceptionally redundant, a "reduction" pyeloplasty can be performed by excising the redundant portion of the pelvis, but this is often unnecessary (Morsi et al., 2013; Stein et al., 1996; Fig. 89.12A). The cephalad aspect of the pelvis is then closed with running absorbable sutures down to the dependent portion, which will subsequently be anastomosed to the ureter. In the event that aberrant or accessory lower pole vessels are found in association with the UPJ obstruction, a dismembered pyeloplasty allows transposition of the UPJ in relation to these vessels (Fig. 89.13).

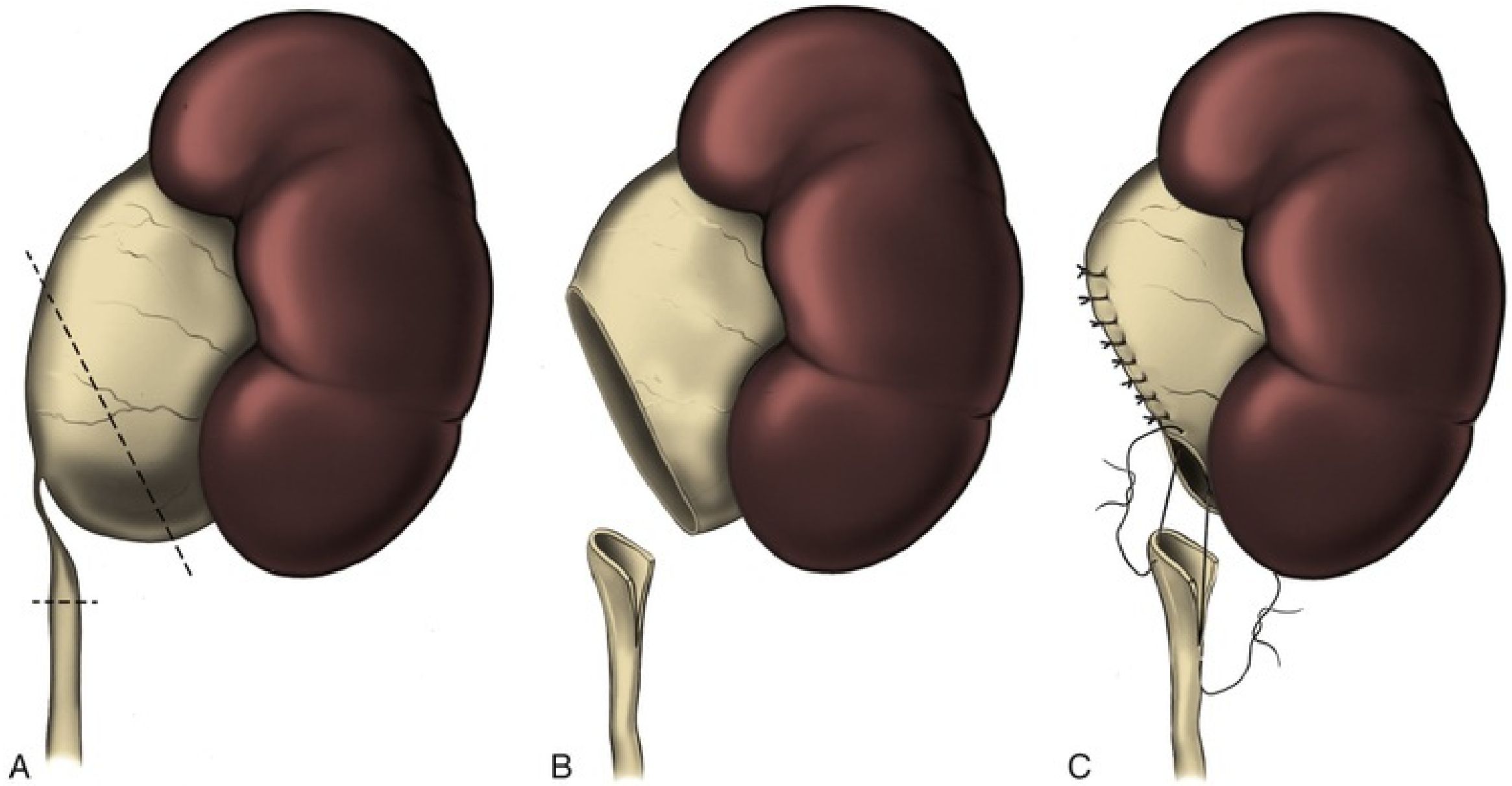

FIG. 89.12 (A) For large or redundant renal pelves, a reduction pyeloplasty is performed by excising the redundant portion between traction sutures. (B) The cephalad aspect of the pelvis is then closed with running absorbable suture down to the dependent portion. (C) The

dependent aspect of the pelvis is then anastomosed to the proximal ureter.

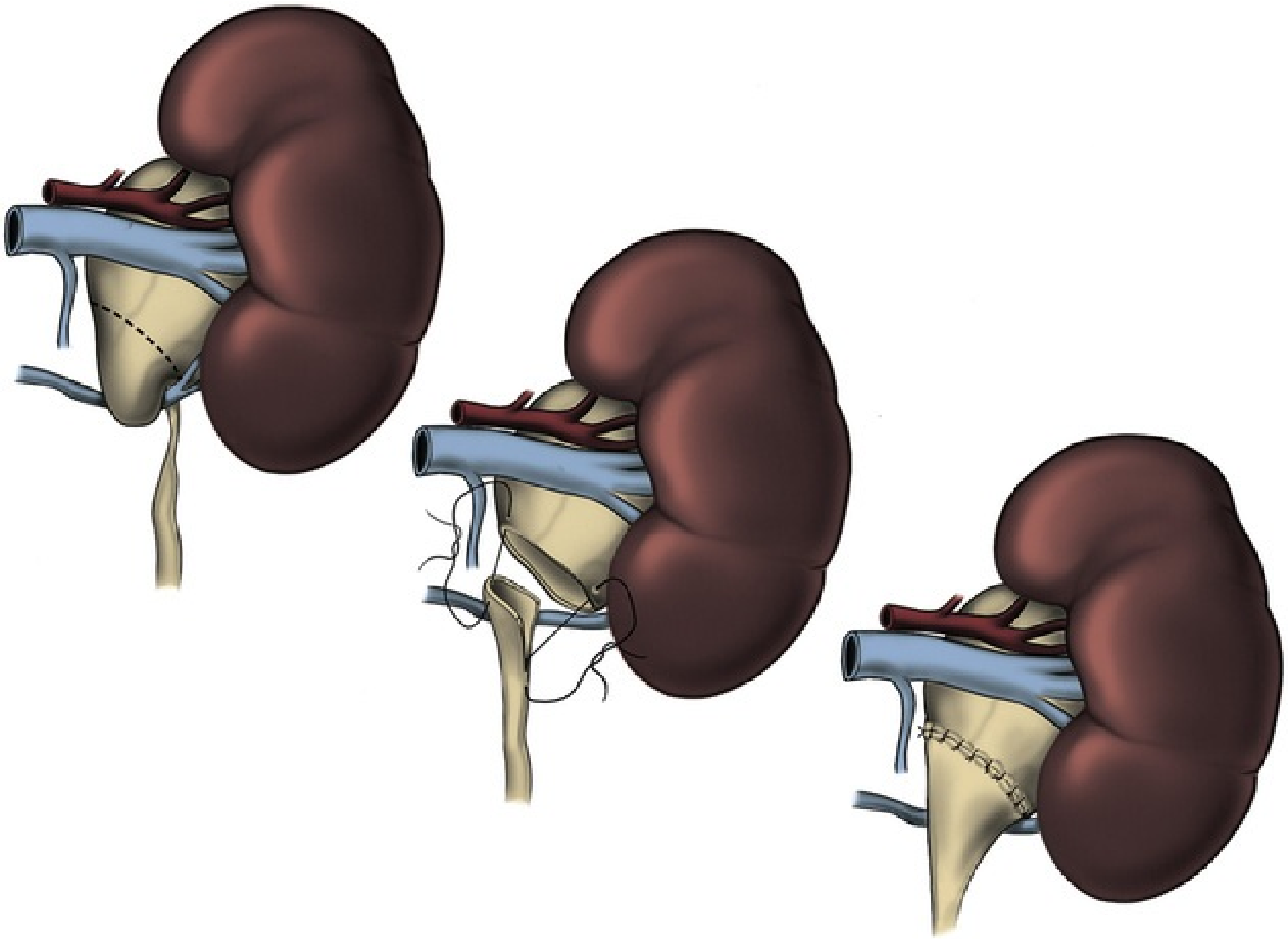

FIG. 89.13 When aberrant or accessory lower pole vessels are found in association with the ureteropelvic junction (UPJ) obstruction, a dismembered pyeloplasty allows transposition of the UPJ in relation to the vessels.

Surgical Approaches for Pyeloplasty

Open Surgery.

Several types of open surgical incisions have been used for a pyeloplasty in the management of UPJO. The preference of many surgeons for the open surgical repair of UPJO is an extraperitoneal flank approach, similar to that used for other open renal operations such as partial nephrectomy. This incision may be subcostal but is usually performed through the bed of the 12th rib or carried anteriorly off its tip. The extraperitoneal flank approach is advantageous in that it is familiar to all urologists and provides excellent exposure without regard to body habitus. An anterior extraperitoneal approach is chosen by some because it allows surgical repair with minimal mobilization of the pelvis and proximal ureter. Alternatively, a posterior lumbotomy provides direct exposure to the UPJ and again allows repair with minimal mobilization of the surrounding structures. Like the anterior extraperitoneal approach, posterior lumbotomy is best suited to relatively thin patients without previous ipsilateral surgery. In the presence of other renal anomalies associated with the UPJ, such as horseshoe or pelvic kidney, anterior extraperitoneal approaches are often preferable, although laparoscopic management may be considered in this setting.

Laparoscopic and Robotic Intervention.

Laparoscopic approach to pyeloplasty (▶Video 90.1) was first introduced in 1993 by Schuessler et al. (1993) and has been developed worldwide as a viable minimally invasive alternative to open pyeloplasty and endopyelotomy. Relative to open pyeloplasty and endopyelotomy, laparoscopic pyeloplasty is associated with greater technical complexity and a steeper learning curve. **In the hands of the experienced laparoscopic surgeons, it has been shown to provide lower patient morbidity, shorter hospitalization, and faster convalescence, with the reported success rates matching those of open pyeloplasty (≥90%).** Autorino et al. (2014) conducted a meta-analysis of studies comparing open and minimally invasive pyeloplasty techniques and found they have similar success and complication rates with a weighted mean difference in hospital stay of 2.68 days favoring minimally invasive surgery. Following the similar surgical principles of anatomic dissection and repair used in open pyeloplasty, laparoscopic pyeloplasty has been shown to provide success rates surpassing those of endopyelotomy by approximately 10% to 30%. In the same meta-analysis the authors found that in case series containing more than 100 patients, laparoscopic pyeloplasty was associated with success rates ranging from 94% to 100%, although follow-up intervals tended to be short (Autorino et al., 2014).

The introduction of the surgical robotic platform (▶Video 90.2), with its shorter learning curve and wristed instrumentation that facilitates the ergonomics of intracorporeal suturing, has led to widespread use of minimally invasive pyeloplasty. Gettman et al. (2002) reported the first patient experience with robotic-assisted laparoscopic pyeloplasty in 2002. Jacobs et al. (2013) reported a 360% increase in the use of minimally invasive pyeloplasty between 2001 and 2009; this is thought to be related, at least in part, to adoption of robotic pyeloplasty at many centers. Similarly, Sukumar et al. (2012) found that the use of minimally invasive pyeloplasty in the United States increased from 2.4% to 55.3% from 1998 to 2009, driven by robotics, which accounted for 45.1% of pyeloplasties performed in 2009. Preoperative, intraoperative, and postoperative techniques are analagous in these approaches; thus the next section refers to laparoscopic and robotic pyeloplasty.

Indications and Contraindications.

The indications and contraindications for a laparoscopic repair are similar to those for either an endourologic or an open operative procedure. Indications to intervene include the presence of clinical symptoms of UPJO, the progressive impairment of renal function, and the development of ipsilateral upper tract calculi or infection. Cases requiring the transposition of crossing vessels obstructing the ureteropelvic junction or the size reduction for massively dilated renal pelvis are suitable for the laparoscopic approach. **Absolute contraindications to intervene include the presence of uncorrected coagulopathy, the absence of adequate treatment of active urinary tract infection, and the presence of cardiopulmonary compromise unsuitable for surgery. The objective of the laparoscopic surgery is to provide a tension-free, water-tight repair with a funnel-shaped drainage product to relieve clinical symptoms and to preserve renal function.**

Techniques.

Several laparoscopic techniques for pyeloplasty have been described in the literature including the standard transperitoneal approach (including transmesenteric), retroperitoneal approach, anterior extraperitoneal approach, laparoendoscopic single-site (LESS) approach, and robotic-assisted approach. For each approach, a dismembered Andersen-Hynes pyeloplasty, which is preferred by most surgeons, or one of the nondismembered methods such as Y-V plasty and flap pyeloplasty (Culp) analogous to those described for the open pyeloplasty can be used.

Transperitoneal Laparoscopic Approach.

The initial transperitoneal approach to laparoscopic pyeloplasty was first described by Schuessler et al. (1993) and Kavoussi et al. (1993). **This approach has been the most widely used laparoscopic method because of its associated large working space and familiar anatomy.** Before the laparoscopic portion of the procedure, cystoscopy with retrograde pyelography may be first performed to define the anatomy and confirm the diagnosis, followed by placement of a ureteral stent and a urethral Foley catheter. Alternatively, the surgeon may place a stent laparoscopically in an antegrade fashion after incising the UPJ. The patient is placed in a 45-degree lateral decubitus position, and access to the peritoneal cavity is obtained via either the Veress needle or the Hassan access technique. Three to five laparoscopic ports are placed after the creation of CO_2 pneumoperitoneum. Typically the umbilical port is for the laparoscope use. Colonic mobilization to expose the retroperitioneal structures is the initial step of the laparoscopic procedure, although transmesenteric approach without bowel mobilization has been reported if renal pelvis or ureter can be readily recognized through the descending colonic mesentery (Romero et al., 2006). In a nontransmesenteric approach, after medial mobilization of the colon, the ureter is identified and dissected in the cephalad direction to achieve mobilization of the ipsilateral proximal ureter, ureteropelvic junction, and renal pelvis (Fig. 89.14A). Extensive dissection of the ureter and excessive electrocautery use in close proximity to the ureter should be avoided to minimize injury to its vascular supply. At this time, the anatomy of the proximal ureter, renal pelvis, and nearby vasculature are carefully examined to determine the cause of the UPJO and the appropriate type of surgical repair. The general methods and principles of various types of surgical repair for laparoscopic pyeloplasty are identical to those described for open pyeloplasty.

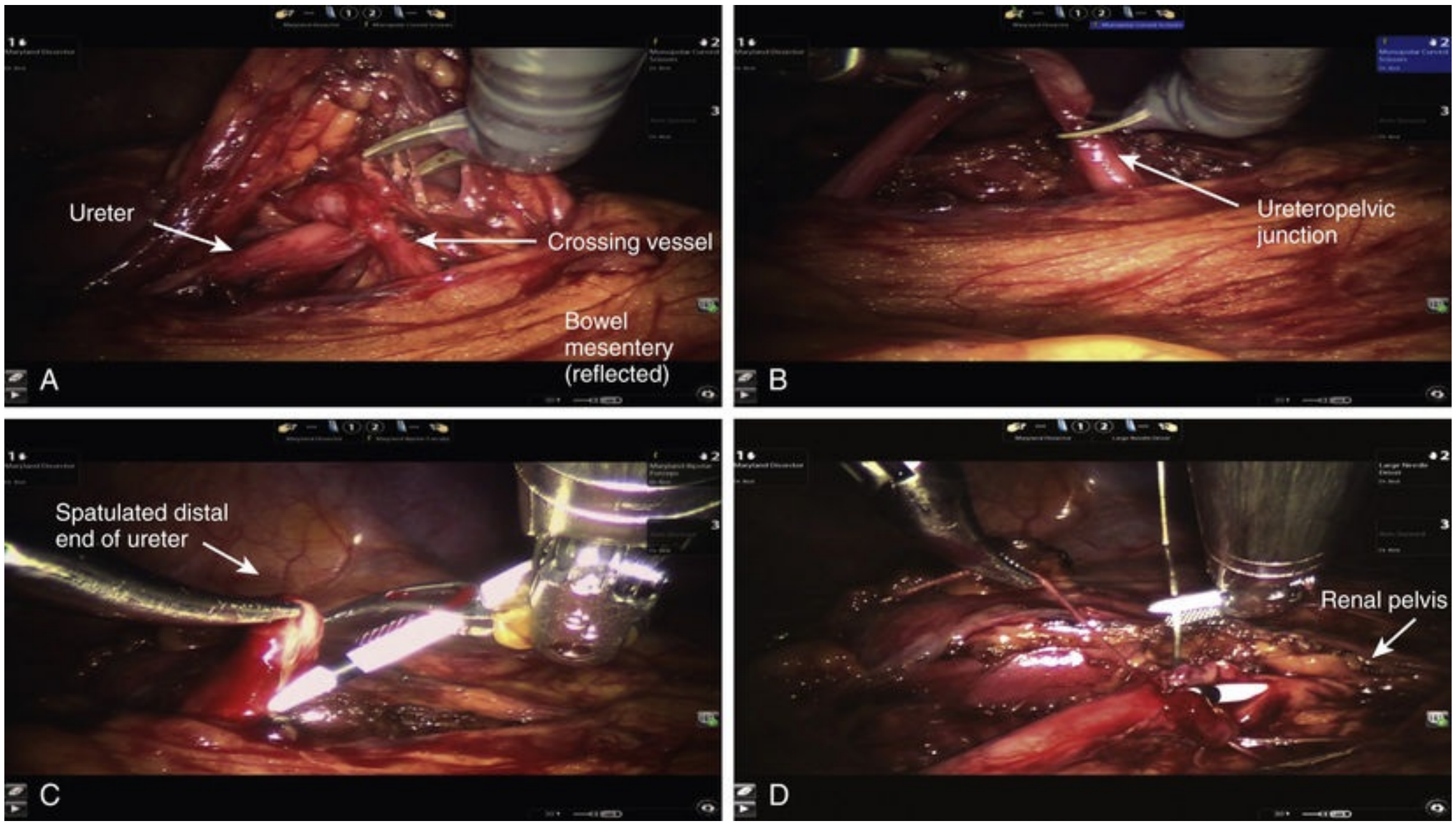

FIG. 89.14 Transperitoneoscopic view of a patient undergoing a right robotic laparoendoscopic single-site pyeloplasty. Patient's head is to the right of the images. (A) A lower pole crossing vessel is being mobilized off the anterior surface of the ureteropelvic junction (UPJ). (B) The right proximal ureter being transected sharply after complete mobilization of the proximal ureter and UPJ. (C) Percutaneous antegrade placement of a double-J ureteral stent through a small puncture in the subcostal region (not shown). (D) Completion of the anterior portion of the ureteropelvic anastomosis.

If dismembered pyeloplasty is to be performed, the renal pelvis is first transected circumferentially above the ureteropelvic junction and the lateral aspect of the proximal ureter is spatulated (Fig. 89.14B). The renal pelvis and proximal ureter are then transposed to the opposite side of the crossing vessel, if such vessel is present, and the ureteropelvic anastomosis is then completed with intracorporeal suturing techniques (Figs. 89.14C and D). If the surgeon opted for antegrade laparoscopic stent placement, this can be accomplished by passing a wire down the ureter though either the upper quadrant port or alternatively, percutaneously after advancing a wire with the help of a 14-gauge angiocatheter passed through the subcostal region. Clamping the Foley catheter and allowing the bladder to fill before wire passage can facilitate this process. After the wire has been placed, a stent can be inserted over the wire using the pusher. Watching for drainage of urine through the stent perforations can be a helpful sign that the distal end of the stent is well positioned in the bladder and is another reason to consider clamping the catheter until the stent is in place. In the presence of redundant renal pelvis, reduction pelvioplasty may be performed by excising redundant renal pelvic tissue and closing the pyelotomy. The actual laparoscopic suturing maneuver can be accomplished either freehand or with a semiautomated device (EndoStitch, US Surgical, Newark, CT). Either continuous running or simple interrupted suturing method may be used in the dismembered laparoscopic pyeloplasty, typically with a 4-0 absorbable suture. A surgical drain is placed after the completion of the anastomosis, and one of the trocar sites is typically used as the drain exit site.

Transmesenteric Modification of the Transperitoneal Approach.

In select cases, it may be possible to forgo the initial step of colonic mobilization to reveal the UPJ by instead carefully opening the mesocolonic mesentery directly over the UPJ, being careful to not damage any mesenteric or crossing vessels. After incision of the mesentery, the UPJ is mobilized and reconstructed in the same fashion as the standard retrocolic approach described above. To use the transmesenteric approach approach, the dilated renal pelvis must be well visualized, and this is more often possible in thinner, younger patients with less adipose in their mesenteries. Also, preoperative stent placement typically deflates the renal pelvis and may obscure its visualization in this approach. Because the colon is not reflected, operative times using the transmesenteric approach may be shorter (Castillo et al., 2007; Romero et al., 2006; Shadpour et al., 2012). Some authors have reported a shorter hospital stay in transmesenteric approach patients, theorizing an earlier return of bowel function as a result of minimal bowel manipulation during surgery (Porpiglia et al., 2008; Romero et al., 2006; Shadpour et al., 2012).

Vascular Transposition.

An alternative approach has been described to treat an obstruction related to lower pole crossing vessels, also known as the “vascular hitch,” in which the lower pole vessels are mobilized and moved to a more cranial position overlying the renal pelvis rather than the UPJ without dismembering the UPJ itself (Sakoda et al., 2011). The majority of the reports on this approach describe its use in the pediatric population, although a series of 42 patients ranging in age from 7 to 69 years reported a 90% success rate (Nouralizadeh et al., 2010). Gundeti et al. (2008) performed vascular transposition procedures in 20 children with a 95% success rate at a mean of 22 months’ follow-up. However, Nerli et al. (2009) noted the uncertainty regarding whether the crossing vessels are the sole cause of obstruction as a possible reason for the failure they noted in a 9-year-old on whom they performed a vascular hitch.

Retroperitoneal Laparoscopic Approach.

The initial retroperitoneoscopic approach to pyeloplasty was first reported by Janetschek et al. (1996). Cystoscopy with retrograde pyelography and ureteral stent placement are first performed as described earlier. For the retroperitoneal approach, the patient is usually positioned in the flank position with the use of flexion and elevation of the kidney rest. Following Hassan access technique to enter the retroperitoneum, a retroperitoneal working space can be created with balloon dilation. Following CO_2 pneumoretroperitoneum, three to four laparoscopic ports are used to perform the laparoscopic pyeloplasty. The ureter is usually identified early in the procedure, and the dissection, mobilization, and UPJ repair steps are identical to those described for the transperitoneal approach.

Anterior Extraperitoneal Laparoscopic Approach.

The anterior extraperitoneal laparoscopic approach to pyeloplasty was first described by Hsu et al. (2003). Cystoscopy with retrograde pyelography and ureteral stent placement are first performed as described earlier. For the anterior extraperitoneal approach, the medial mobilization of the peritoneal sac containing the bowel contents en bloc. Subsequently, full exposure of the anterior aspects of the retroperitoneal structures including the ipsilateral ureter and kidney comes into view. The proximal ureter, UPJ, and renal pelvis are identified, dissected, mobilized, and repaired as in the transperitoneal laparoscopic pyeloplasty. The entire procedure is completed in an extraperitoneal manner. A surgical drain is similarly placed at the end of the procedure.

Robotic-Assisted Laparoscopic Approach.

The robotic-assisted laparoscopic pyeloplasty in the experimental setting was first reported by Sung et al. (1999). Its feasibility was subsequently confirmed with worldwide clinical application in recent years (Gettman et al., 2002; Mufarrij et al., 2007; Palese et al., 2005; Schwentner et al., 2007; Yanke et al., 2008). The most widely used robotic system in the clinical setting today is the da Vinci Robot (Intuitive Surgical, Sunnyvale, CA), and the reported benefits of the robot include enhanced 3D vision, motion scaling, tremor reduction, improved dexterity, and increased range of motion. Typically the procedure is performed in a transperitoneal manner providing a larger working space for the robotic arms, although the feasibility of retroperitoneal approach has been demonstrated (Cestari et al., 2010; Kaouk et al., 2008). A ureteral stent may be placed via a cystoscopic retrograde or laparoscopic antegrade manner. In transperitoneal and retroperitoneal approaches, four trocars are typically used in a robotic-assisted procedure including three for the robotic arms (including one for the camera) and one for the surgical assistant to perform suction, irrigation, retraction, and suture introduction. After the initial laparoscopic access and trocar placement, the robotic system is placed in close proximity to the operating table, and the robotic arms are attached to the laparoscope and specifically designed laparoscopic instruments. The surgeon at the console operates via the control of the robotic arms, while the assistant remains at the bedside and performs suction, retraction, exchange of laparoscopic instruments, suture needle introduction, and removal. The general surgical steps are identical to those described for non–robotic-assisted laparoscopic pyeloplasty.

Laparoendoscopic Single-Site Surgery Approach.

Since the adoption of laparoscopic and robotic techniques, LESS has been developed in an effort to further decrease surgical invasiveness and improve morbidity (Kaouk et al., 2011). Proponents of the LESS approach suggest it may offer patients improved cosmetic outcomes by decreasing the number of ports from 3 to 5 to a single intra- or periumbilical incision that is often inconspicuous (Fig. 89.15). In LESS, all of the instruments are inserted through a single location. This approach abandons the common laparoscopic principle of triangulation of the ports and results in ergonomic challenges and the clashing of instruments as they compete for space in a limited working envelope. Although this approach increases the level of complexity in performing the procedure, in experienced hands, complication rates of LESS pyeloplasty are similar to those with other minimally invasive approaches (Rais-Bahrami et al., 2013; Tugcu et al., 2013). Pyeloplasty is particularly appealing for LESS, because there is no sizable specimen to be extracted and the incisions can be kept small. However, laparoscopic suturing can be challenging in LESS. Some authors report using an accessory subcostal needlescopic instrument/port to facilitate anastomotic suturing.

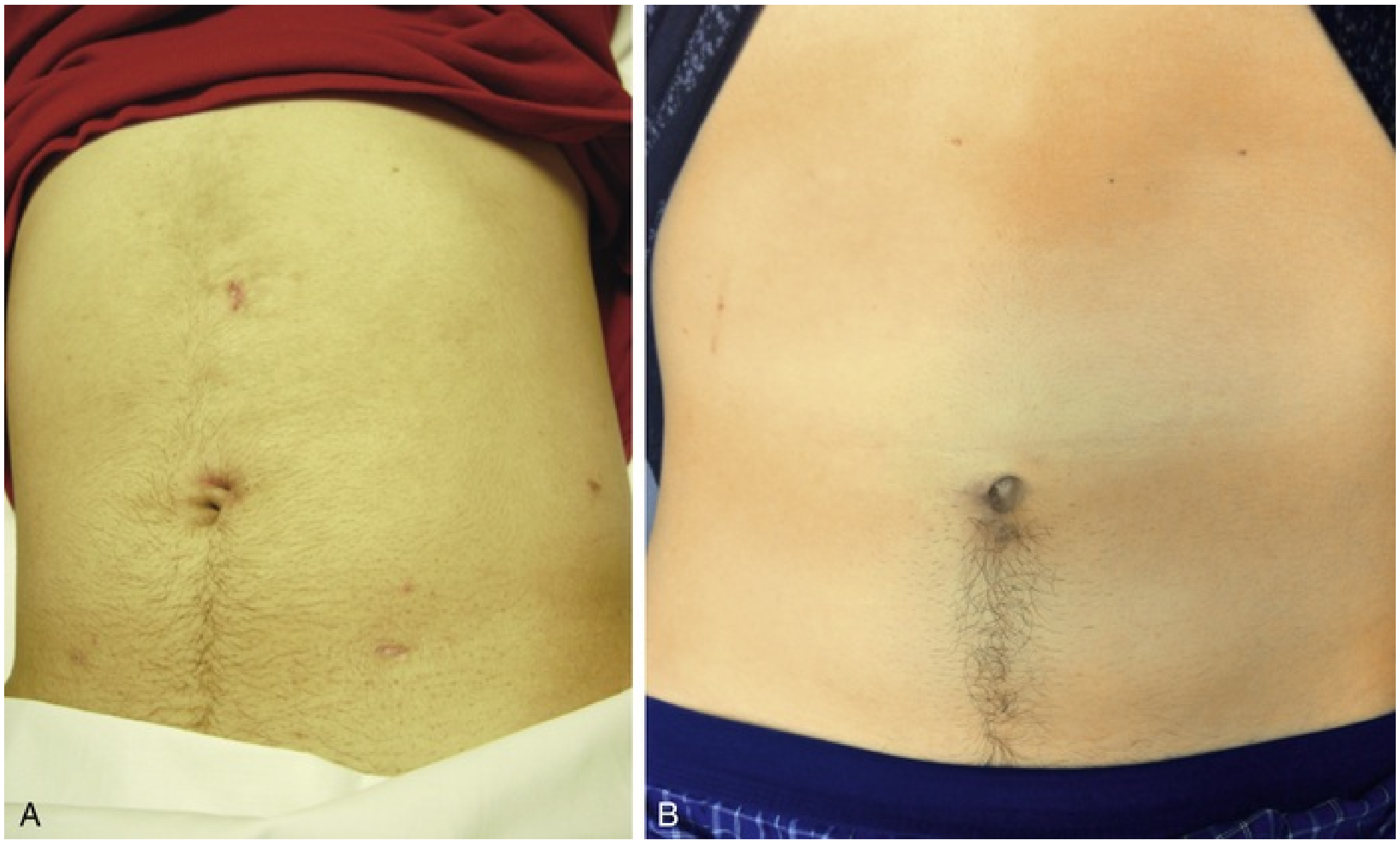

FIG. 89.15 (A) Postoperative photograph of the abdomen of a patient with left-sided laparoscopic dismembered pyeloplasty. Note the four small scars

from the laparoscopic procedure. (B) Postoperative appearance of the scar from a right-sided robotic laparoendoscopic single-site pyeloplasty, performed through a single incision at the umbilicus.

Typically, a 2.5- to 3-cm intra- or periumbilical incision is made using the Hassan technique. A variety of purpose-built LESS port devices are commercially available. Alternatively, 3 separate 5-mm ports can be placed in individual incisions inside the umbilicus. A 5-mm laparoscope is commonly used in LESS to reduce instrument conflict and a right-angle adapter for the light cord can also be helpful to reduce external conflicts with other operating instruments. A variety of bent and articulating instruments are available to help reduce instrument conflicts (“swordfighting”) inside the abdomen. Some surgeons have found a deflecting laparoscope to be helpful as well.

The technical challenges of LESS suturing have led some urologists to apply the robotic platform to LESS pyeloplasty. Just as the articulating instrumentation can shorten the learning curve and facilitate anastomotic reconstruction in standard robotic pyeloplasties, robotic LESS has been reported by several authors as having ergonomic advantages over standard LESS (Cestari et al., 2012; Desai et al., 2009; Olweny et al., 2012; Stein et al., 2010; Tobis et al., 2013). Purpose-designed equipment for robotic LESS remains limited at this time, but future technologic advances may further adoption of these advanced techniques. Renal functional outcomes of LESS and robotic LESS pyeloplasty have been reportedly excellent, with symptomatic and radiographic success seen in 93% of patients in a recent study by Harrow et al. (2013).

Postoperative Care and Complications.

Typically, a clear liquid diet is initiated on postoperative day 1 and advanced rapidly after minimally invasive pyeloplasty. Perioperative prophylactic antibiotic coverage is maintained. The Foley catheter is usually removed 24 to 36 hours postoperatively, and the surgical drain is removed before hospital discharge if the drain output remains negligible. If the drain output increases after the Foley catheter removal, the Foley catheter should be replaced for 7 days to eliminate urinary reflux along the stent in the treated ureter and decrease urinary extravasation at the ureteropelvic anastomosis. The ureteral stent is typically removed 4 to 6 weeks later in an outpatient setting, and follow-up, including the use of imaging studies such as diuretic renography, is performed as for an open pyeloplasty. Most of the complications of laparoscopic pyeloplasty are similar to those of general laparoscopic procedures, including colonic injury, hemorrhage, ileus, pneumonia, congestive heart failure, thrombophlebitis, and urinoma formation. In the first 100 cases of laparoscopic pyeloplasty performed at Johns Hopkins (Jarrett et al., 2002), such complications occurred in 12% of the patients. Another large-scale review involving 189 cases of laparoscopic pyeloplasty identified approximately 2% to 2.3% intraoperative complication rate and 12.9% to 15.8% postoperative complication rate (Rassweiler et al., 2008).

Results

Open Approach.

The overall success of open dismembered pyeloplasty has been favorable in the literature. In a retrospective review, Persky et al. (1977) noted that none of their 109 dismembered pyeloplasties for UPJO required subsequent nephrectomy. In another retrospective review involving 111 patients with UPJO undergoing open surgical repair over a 15-year period, Clark and Malek (1987) found 95% success in resolution of clinical symptoms and 91% success in decompression of pelviocalyceal system on urography after one surgical repair. Of the 111 patients with open pyeloplasty, 95 (86%) patients underwent dismembered pyeloplasty. Examining the functional outcomes on the basis of split-function analysis from preoperative and postoperative renal scans, O'Reilly (1989) found that open Anderson-Hynes dismembered pyeloplasty arrests functional deterioration in almost every case and improves function significantly in the majority in 26 consecutive patients with UPJO.

Minimally Invasive Approaches.

Most of the published laparoscopic pyeloplasty reports have used the classic Andersen-Hynes dismembered technique because most laparoscopic surgeons attempt to duplicate the well-established principles of open surgery (Bachmann et al., 2006; Eden et al., 2001; Inagaki et al., 2005; Janetschek et al., 2000; Jarrett et al., 2002; Rassweiler et al., 2008; Soulie et al., 2001; Turk et al., 2002). The overwhelming majority of patients in these recent series had primary laparoscopic pyeloplasties, and the mean operative times are in the range of 119 to 252 minutes. In experienced hands, the entire procedure can be consistently performed in less than 3.5 hours (Jarrett et al., 2002), reflecting greater confidence in intracorporeal suturing and knot tying. Perioperative complication rates are low, ranging from 2% to 15.8%, demonstrating the safety of the laparoscopic procedure. Open conversion rates are also low, in the range of 0% to 5.5%. Furthermore, blood transfusion risks are low, limited to anecdotal reports. Postoperative analgesic use is generally minimal. Mean length of hospital stay is about 2.7 days with minimally invasive pyeloplasty, compared with 4.2 days for open (Jacobs et al., 2018). With mean follow-up times of 14 to 26 months, the rates of surgical success (defined as durable clinical and/or radiographic success) reach the range of 87% to 99%; the majority of contemporary series report success rates of greater than 95%. The safety and efficacy of laparoscopic pyeloplasty have also been demonstrated in the pediatric population including patients younger than 1 year (Metzelder et al., 2006).

Most failures from laparoscopic pyeloplasty occur in the first 2 years, although up to 30% of failed cases may occur after 2 years postoperatively (Madi et al., 2008). **For the patients who fail laparoscopic pyeloplasty, open surgery has been used as a salvage procedure, with success rates of approximately 86%** (Thomas et al., 2005). **However, most cases can be well managed with endoscopic intervention such as endopyelotomy, with success rates of approximately 70%** (Varkarakis et al., 2004). Although success rates of pediatric pyeloplasty are typically high in the literature, a recent review of the MarketScan database found that 1 in 9 pediatric patients underwent a secondary procedure, suggesting failure is not rare (Dy et al., 2016).

More data on robotic-assisted laparoscopic pyeloplasty have emerged recently (Table 89.1; Mufarrij et al., 2007; Palese et al., 2005; Schwentner et al., 2007; Yanke et al., 2008). Like the conventional laparoscopic studies, the overwhelming majority of the patients in these recent series had primary robotic-assisted laparoscopic pyeloplasties. The mean operative times are in the range of 100 to 299 minutes. Perioperative complication rates are low (3% to 24%). Open conversion rates are also relatively low (0% to 6.8%). Postoperative analgesic use is generally minimal. Mean length of hospital stay is in the range of 2.2 to 2.8 days. With mean follow-up times of 11 to 39 months, the rates of surgical success (defined as durable clinical and/or radiographic success) are 94.7% to 100%. These results were similar to those from the historic laparoscopic series in the literature. The feasibility of the robotic approach has also been demonstrated in the pediatric patients (Atug et al., 2005b; Lee et al., 2006). The additional reported benefits provided by the robot include better 3D magnification, increased range of motion, and ease of dissection and suturing. However, the value of the robot in the setting of clinical pyeloplasty remains controversial and has been addressed by one recent study (Link et al., 2006). In this study comparing robotic and laparoscopic pyeloplasty in a prospective manner, the mean operative time and total room time for robotic cases were found to be significantly longer than laparoscopic cases by 19.5 and 39 minutes, respectively. Robotic cases were also found to be more costly than laparoscopic cases (2.7 times) because of longer operative time, increased cosumables costs, and depreciation of the robot system. In the hands of experienced laparoscopic surgeons, the use of the robot does not seem to confer significant clinical or cost advantage compared with conventional laparoscopic approach. Beyond cost, additional concerns for the robotic-assisted laparoscopic pyeloplasty include limited instrumentation and need for experienced bedside laparoscopic assistance (Peschel et al., 2004).

TABLE 89.1

Comparative Series of Robotic Versus Laparoscopic Pyeloplasty

---

AUTHOR, YEAR		n	MEAN AGE (yr)	EBL (mL)	OR TIME (min)	DURATION OF FOLLOW-UP (months)	HOSPITAL STAY (days)	COMPLIC
Link et al., 2006	LP	10	38.0	NSD	80.7 ± 21.9[a]	5.6		None
	RAP	10	46.5	NSD	100.2 ± 9.1[a]	5.6		10% (1 dela leak)
Weise and Winfield, 2006	LP	14	24.5		271	10	2	0
	RAP	31	26		299	6	2	0

Kim et al., 2008	LP	58	Peds		196 ± 38		0.9 ± 0.23	3.4%
	RAP	84	Peds		188 ± 45.8		1.5 ± 0.55	0
Hemal et al., 2010	LP	30	28.1	100	145 ± 44	18	5.5 ± 3.8	10%
	RAP	30	24.9	40	99 ± 29	18	2.5 ± 0.8	3.3%
García-Galisteo et al., 2011	LP	33	NR	NR	152.1 ± 23.3	42.5	4.5 ± 1.5	51.5%
	RAP	17	NR	NR	121.6 ± 13.3	20.6	2.4 ± 0.5	23.5%
Olweny et al., 2012[b]	LP (LESS)	10	35.8	42	188	10	2.6	20
	RAP (LESS)	10	40.3	56	226	3	2.6	10
Kumar and Nayak, 2013	LP	11	25	46	150 (11–200)	NR	2.9	None
	RAP	19	21	54	129 (70–180)	NR	2.8	None

[a] Significant difference, $P = 0.018$.

[b] LESS LP versus LESS RAP.

EBL, Estimated blood loss; *LESS,* laparoendoscopic single-site surgery; *LP,* laparoscopic pyeloplasty; *NR,* not reported; *NSD,* no significant difference; *OR,* operating room; *Peds,* pediatric cases only; *RAP*, robotic-assisted pyeloplasty.

Although success rates of pyeloplasty are generally high, late failures can occur and long-term follow-up may be helpful in identifying these patients. DiMarco et al. (2006) reported that success rates of pyeloplasty in their series of 175 patients, defined as absence of radiographic obstruction and flank pain, dropped from 85% at 3 years to 75% at 10 years, lower than they anticipated. A more recent series of robotic pyeloplasties had limited radiographic follow-up (mean 12.2 months) but found an 8-year pyeloplasty failure-free survival of 91.55% at a mean telephone follow-up of 64.8 months (Hopf et al., 2016).

Primary UPJO associated with renal anomalies such as horseshoe kidneys and pelvic kidneys have also been managed with laparoscopic pyeloplasty safely and successfully (Bovie et al., 2004; Hsu et al., 2003; Janetschek et al., 1996). Furthermore, secondary UPJO has similarly been managed with success. In a retrospective review, Sundaram et al. (2003) identified 36 cases of laparoscopic transperitoneal pyeloplasty for secondary UPJO, mostly after failed retrograde or antegrade endopyelotomies. Mean operative time was 6.2 hours, longer than the reported times associated with primary UPJO. Open conversion was necessary in 1 patient, and postoperative complication occurred in 8 patients. With a mean follow-up of 21.8 months, the overall success rate of a greater than 50% decrease in pain, a patent UPJ, and stable or improved function of the affected renal unit was 83% (30 of 36 patients). Shapiro et al. (2009) identified 9 cases of laparoscopic transperitoneal pyeloplasty for secondary UPJO after a failed open procedure. Mean operative time was 204 minutes. At a median follow-up of 66 months, 89% (eight of nine) patients had clinical and radiologic resolution of UPJO, with stable renal function, pain-free status, and patent UPJ.

Special Situations of Laparoscopic and Robotic-Assisted Laparoscopic Management of Ureteropelvic Junction Obstruction

Laparoscopic and Robotic-Assisted Laparoscopic Ureterocalicostomy.

Ureterocalicostomy has been completed successfully via laparoscopic and robotic-assisted laparoscopic approaches. Gill et al. (2004) performed laparoscopic ureterocalicostomy in two patients with UPJO associated with small renal pelvis and dilated lower pole calix. In both patients a double-J ureteral stent was first placed into the ipsilateral ureter cystoscopically. With the patient in a 45- to 60-degree flank position, a transperitoneal approach using three or four ports was used to gain access to the ipsilateral renal unit laparoscopically. A circular rim of the tip of the thin lower pole renal parenchyma was identified and excised. The UPJ was transected, followed by ligation of the renal pelvic opening. The ureter was spatulated laterally, and end-to-end ureterocaliceal anastomosis with mucosa-to-mucosa apposition over the preplaced double-J stent was performed with free-hand intracorporeal suturing and knot-tying techniques. The general reconstructive principles are identical to those of open ureterocalicostomy described previously, including the need to achieve tension-free, water-tight, dependent drainage.

The largest series of ureterocalicostomies reports outcomes in 72 procedures, 38 of which were laparoscopic, while the rest were open procedures (Srivastava, 2017). Mean follow-up was 60 months, and 82% of patients had had previous ipsilateral renal surgery. The authors reported a 69.5% success rate, **identifying poor ipsilateral renal function and thin renal parenchyma as risk factors for failure.** This success rate is fairly similar to other “redo” pyeloplasty series, although it contrasts with some smaller ureterocalicostomy series, suggesting the importance of technical and patient factors in the decision to perform this operation. In a series of laparoscopic ureterocalicostomies by Arap et al. (2014), all six procedures remained successful radiographically at a mean of 30 months' follow-up, and there were no major complications.

Casale et al. (2008) reported successful robotic-assisted laparoscopic ureterocalicostomy in 9 pediatric patients, following the identical reconstructive principles described earlier. Mean operative time was 168 minutes, and feasibility of the use of a robot was well demonstrated. All patients were found to have no evidence of obstruction on diuretic radionuclide imaging at 12 months postoperatively.

Laparoscopic and Robotic-Assisted Pyeloplasty With Concomitant Pyelolithotomy.

Presence of calculi in the setting of UPJO can be managed laparoscopically with success. In a retrospective review, Ramakumar et al. (2002) reported 20 cases of laparoscopic pyeloplasty with concomitant extraction of renal stones through the pyelotomy site under laparoscopic guidance. In the series, extraction of the caliceal stones was assisted by the use of a flexible cystoscope introduced through a 10- to 12-mm port site. At a mean follow-up of 3 months, 90% of patients were stone free, and 90% patients had patent UPJ radiographically. In another retrospective review, Stein et al. (2008) reported 15 cases of laparoscopic pyeloplasty with concomitant pyelolithotomy, involving the use of laparoscopic graspers, flexible cystoscopes, and/or laparoscopic irrigation. The overall stone-free rate was 80%. Robotic-assisted laparoscopic pyeloplasty with concomitant pyelolithotomy has also been demonstrated in eight patients, using the similar instruments including laparoscopic graspers (Atug et al., 2005a). To complete the pyelolithotomy, one of the robotic arms was temporarily undocked to allow passage of a flexible nephroscope into the renal pelvis to gain visualization of the stones in the collecting system. In this small series, all patients were rendered stone free.

Laparoscopic Dismembered Tubularized Flap Pyeloplasty.

Presence of a significant upper ureteral defect after the excision of ureteropelvic junction stricture may also be managed laparoscopically with success. Kaouk et al. (2002) described a case of laparoscopic pyeloplasty for secondary ureteropelvic junction obstruction, in which a 3-cm upper ureteral defect was found following excision of the long stricture. Using a four-port transperitoneal approach, a wide-base renal pelvic flap was created and tubularized to bridge the defect, using intracorporeal freehand suturing techniques. At a 2-month follow-up, excretory urography and diuretic renal scan confirmed a widely patent upper ureter.

Laparoscopic Calicovesicostomy.

Presence of a large-capacity bladder in the setting of UPJO associated with a low-lying obstructed renal unit can be managed successfully using an unconventional laparoscopic reconstructive strategy. Hsu et al. (2006) described a case of laparoscopic management of UPJO involving a horseshoe kidney with a unilateral hydronephrotic yet functioning lower pole moiety, ipsilateral ureteral duplication with high bifurcation, and complex anomalous renal vasculature. Rather than performing tedious anatomic dissection and complex ureteral reconstruction in such a scenario as required in conventional laparoscopic pyeloplasty, a nephrotomy was created at the most dependent portion of the hydronephrotic lower pole moiety and then laparoscopically anastomosed to the bladder dome vesicostomy using intracorporeal freehand suturing and knot-tying techniques. At the 4-month follow-up, patent calicovesicostomy was confirmed endoscopically and clinically.

Key Points: Laparoscopic and Robotic Intervention

- Transperitoneal laparoscopic approach is the most widely used method because of its associated large working space and familiar anatomy. Retroperitoneal laparoscopic approach and anterior extraperitoneal approach rely on creation of a working space using manual or balloon dilation.
- Laparoscopic management of UPJO has been shown to provide low perioperative complication rate, short hospital stay, and success rates

greater than 95% in the experienced hands.

Other Reconstructive Procedures Involving the Ureteropelvic Junction (Non–Anderson-Hynes)

Although the Anderson-Hynes dismembered pyeloplasty is the most commonly performed technique for reconstruction of the UPJ, other techniques or modifications may be useful in particular situations as dictated by patient anatomy. These variations in many cases may be performed through either open or minimally invasive approaches, depending on the skill level of the surgeon.

Flap Procedures

Foley Y-V-Plasty

Indications.

The Foley Y-V-plasty was originally designed for repair of a UPJO secondary to a high ureteral insertion. Like other flap techniques, however, its use has generally been replaced by the more versatile dismembered pyeloplasty. As in other flap techniques, the Foley Y-V-plasty is specifically contraindicated when transposition of lower pole vessels is necessary. In situations requiring concomitant reduction of redundant renal pelvis, this technique is also of little value.

Technique.

In Foley Y-V-plasty, the renal pelvis and proximal ureter are first exposed, and a widely based triangular or V-shaped flap is outlined with methylene blue or fine stay sutures. The base of the V is positioned on the dependent, medial aspect of the ipsilateral renal pelvis and the apex at the UPJ. The incision from the apex of the flap (the stem of the Y) is then performed along the lateral aspect of the proximal ureter. The surgical incision in the ureter should be long enough to completely traverse the area of stenosis and extend for several millimeters into the normal-caliber ureter (Fig. 89.16A). The renal pelvic flap and ureterotomy are then created. A fine scalpel blade is used for the initial pelvic incision, after which a Potts or a fine Metzenbaum scissors is used to complete the flap and ureterotomy (Fig. 89.16B). An internal ureteral stent is placed and the repair performed over it. First, the apex of the pelvic flap is approximated to the apex (inferior aspect) of the ureterotomy incision using fine, absorbable suture. The posterior walls are then approximated using fine interrupted or running suture (Fig. 89.16C). Interrupted technique is likely to minimize pursing or buckling of the suture line, as well as local tissue ischemia. Anastomosis of the anterior walls is then performed, thereby completing the surgical repair (Fig. 89.16D).

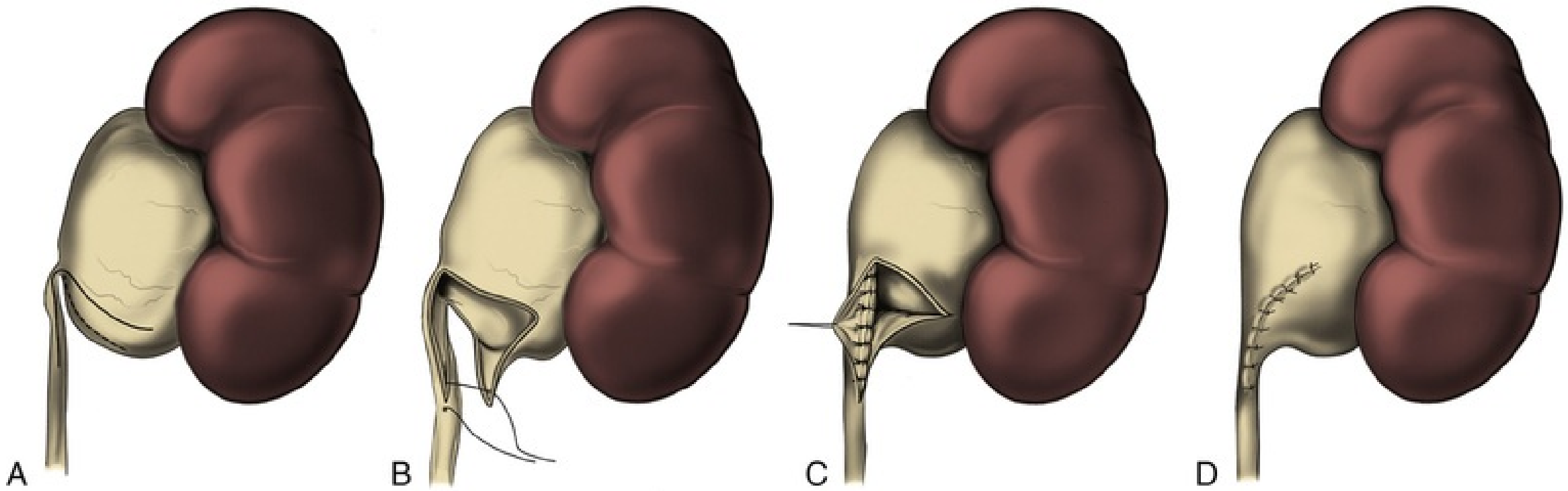

FIG. 89.16 (A) Foley Y-V plasty is best applied to a ureteropelvic junction (UPJ) obstruction associated with a high insertion of the ureter. The flap is outlined with tissue marker or stay sutures. The base of the V is positioned on the dependent, medial aspect of the renal pelvis and the apex at the UPJ. The incision from the apex of the flap, which represents the stem of the Y, is then carried along the lateral aspect of the proximal ureter well into an area of normal caliber. (B) The flap is developed with fine scissors. The apex of the pelvic flap is then brought to the most inferior aspect of the ureterotomy incision. (C) The posterior walls are then approximated using interrupted or running fine absorbable suture. (D) The anastomosis is completed with approximation of the anterior walls of the pelvic flap and ureterotomy.

Culp-DeWeerd Spiral Flap

Indications.

The Culp-DeWeerd spiral flap is generally best suited for large, readily accessible extrarenal pelves, in which the ureteral insertion is already in a dependent, oblique position. Although most of these patients are also good candidates for a standard or reduction dismembered pyeloplasty, the spiral flap may be of significant value when UPJO and a relatively long segment of proximal ureteral narrowing or stricture occur in the same setting.

Technique.

The spiral flap is first outlined with a broad base positioned obliquely on the dependent aspect of the renal pelvis. To maximize preservation of the flap's blood supply, the base is placed in a position anatomically lateral to the UPJ, that is, between the ureteral insertion and the renal parenchyma. The pelvic flap may be spiraled posteriorly to anteriorly or vice versa. In either case, the anatomically medial line of incision (farthest from the parenchyma) is carried down the proximal ureter, completely traversing through the obstructed segment (Fig. 89.17A). Appropriate placement of the apex of the flap is determined by the length of flap needed. This, in turn, depends on the length of proximal ureter to be bridged. The longer the flap required, the farther away the apex will be from the base. However, to preserve vascular integrity of the flap, the ratio of flap length to width should not be greater than 3 : 1. In general, the outline of the flap should be made longer than what may initially be perceived as necessary because the flap will shrink once the pelvis is incised. If the flap is found to be too long, excess length can be reduced by trimming back the apex, thereby preserving its blood supply. Once the flap is created, the apex is rotated down to the most inferior aspect of the ureterotomy (Fig. 89.17B). The anastomosis with fine absorbable sutures is subsequently performed over an internal stent (Fig. 89.17C).

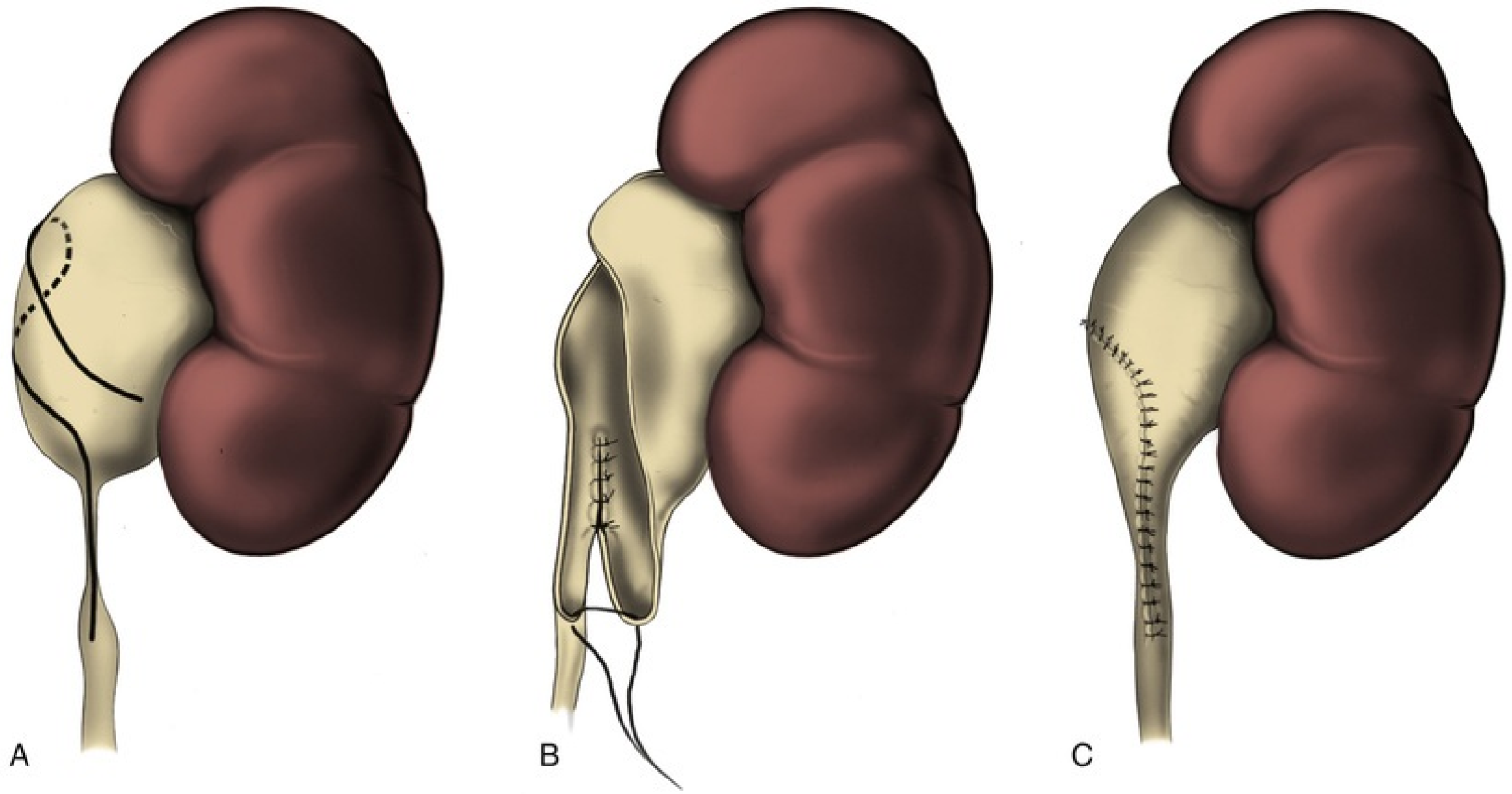

FIG. 89.17 (A) A spiral flap may be indicated for relatively long areas of proximal ureteral obstruction when the ureteropelvic junction (UPJ) is already in a dependent position. The spiral flap is outlined with the base situated obliquely on the dependent aspect of the renal pelvis. The base of the flap is positioned anatomically lateral to the UPJ, between the ureteral

insertion and the renal parenchyma. The flap is spiraled posteriorly to anteriorly or vice versa. The anatomically medial line of incision is carried down completely through the obstructed proximal ureteral segment into normal-caliber ureter. The site of the apex for the flap is determined by the length of flap required to bridge the obstruction. The longer the segment of proximal ureteral obstruction, the farther away is the apex because this will make the flap longer. However, to preserve vascular integrity of the flap, the ratio of flap length to width should not exceed 3 : 1. (B) Once the flap is developed, the apex is rotated down to the most inferior aspect of the ureterotomy. (C) The anastomosis is then completed, usually over an internal stent, again using fine absorbable sutures.

Scardino-Prince Vertical Flap

Indications.

The Scardino-Prince vertical flap technique generally has limited clinical application. It may be appropriately used only when a dependent UPJ is situated at the medial margin of a large, square (“box-shaped”) extrarenal pelvis (Fig. 89.18A). Its use in most instances has been replaced by a standard dismembered pyeloplasty, although the vertical flap may be preferable for relatively long areas of proximal ureteral narrowing. The vertical flap technique generally cannot produce as long a flap as the spiral flap.

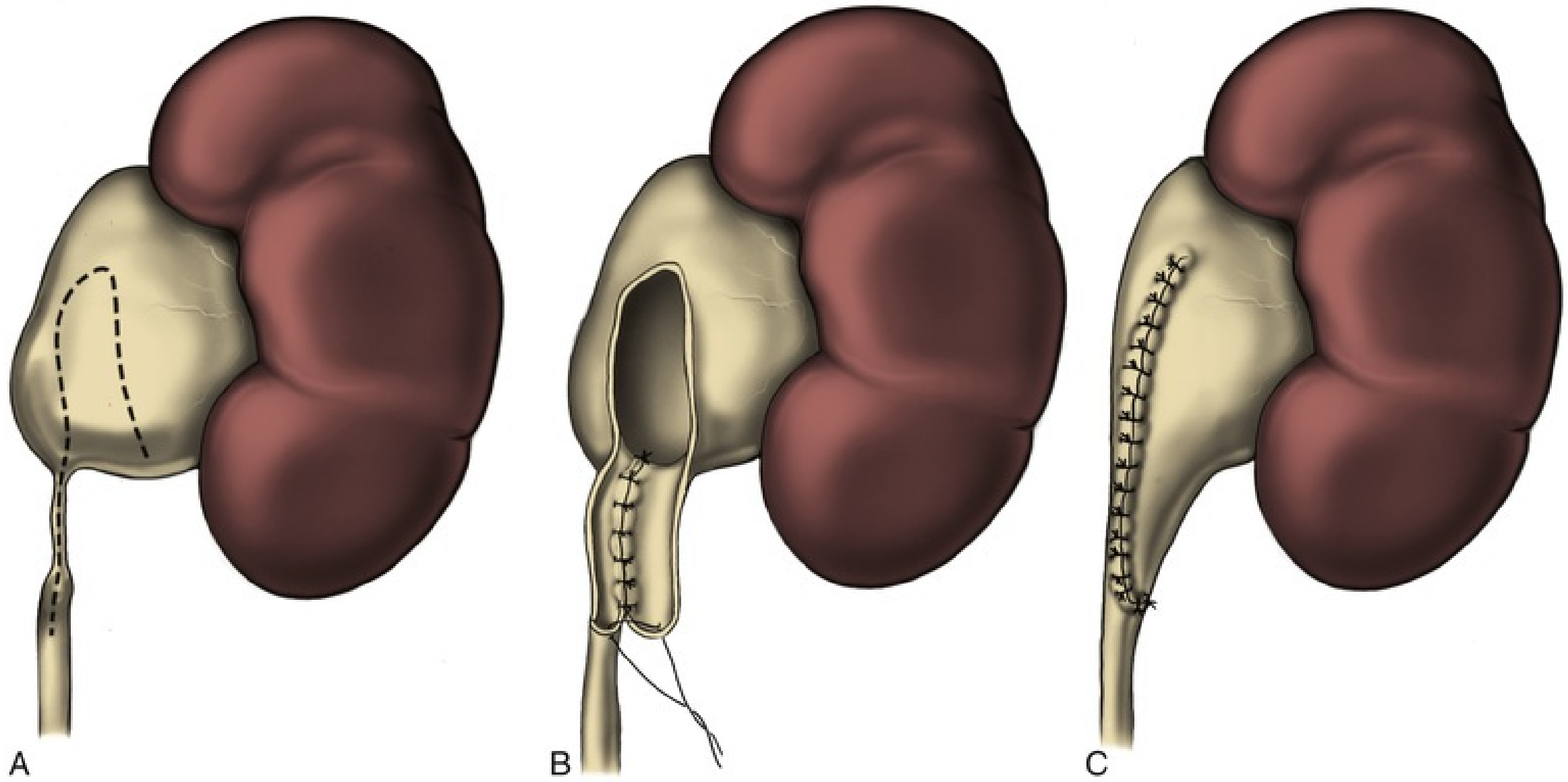

FIG. 89.18 (A) A vertical flap technique may be used when a dependent ureteropelvic junction (UPJ) is situated at the medial margin of a large, box-shaped extrarenal pelvis. In contrast to the spiral flap, the base of the

vertical flap is situated more horizontally on the dependent aspect of the renal pelvis, between the UPJ and the renal parenchyma. The flap itself is formed by two straight incisions converging from the base vertically up to the apex on either the anterior or the posterior aspect of the renal pelvis. As for the spiral flap, the position of the apex determines the length of the flap, which should be a function of the length of proximal ureter to be bridged. The medial incision of the flap is carried down the proximal ureter completely through the strictured area into normal-caliber ureter. (B) The apex of the flap is rotated down to the most inferior aspect of the ureterotomy. (C) The flap is then closed by approximating the edges with interrupted or running fine absorbable sutures.

Technique.

The Scardino-Prince vertical flap is similar to the spiral flap technique except that the base of the flap is positioned more horizontally on the dependent aspect of the renal pelvis, between the UPJ and the renal parenchyma. The flap is created by straight incisions converging from the base vertically to the apex on either the anterior or the posterior aspects of the renal pelvis. The site of the apex and the length of the flap are determined by the length of proximal ureter to be bridged. The medial incision is carried down the proximal ureter, completely traversing through the stenotic area and into normal-caliber ureter, using fine scissors (Fig. 89.18B). The apex of the flap is then rotated down and approximated to the most inferior aspect of the ureterotomy. Finally, the flap is closed with interrupted or running fine absorbable sutures (Fig. 89.18C).

Intubated Ureterotomy

Indications.

The Davis intubated ureterotomy, which is rarely used today, was developed for surgical repair of lengthy or multiple ureteral strictures. If these strictures are found in association with UPJO, the intubated ureterotomy may be combined with any of the standard pyeloplasty procedures. However, in such a situation, the intubated ureterotomy would be best combined with a spiral flap procedure. Compared with the vertical flap, the spiral flap can be made longer, which allows more of the strictured area to be bridged by a pelvic flap, thereby leaving a shorter area to rely on healing by “secondary intention.” In fact, in this specific clinical setting, any flap technique would be preferable to a dismembered repair, at least in regard to blood supply preservation of and subsequent healing.

Technique.

A flap is outlined as described previously, with the ureterotomy to be made completely through the long, strictured area (Fig. 89.19A). The flap is then created, with minimal dissection of the ureter to preserve its blood supply. Unlike the uncomplicated pyeloplasties, these cases require routine nephrostomy tube drainage to prevent postoperative urinoma formation. Nephrostomy drainage in these cases also allows access for subsequent antegrade radiographic studies during the postoperative period.

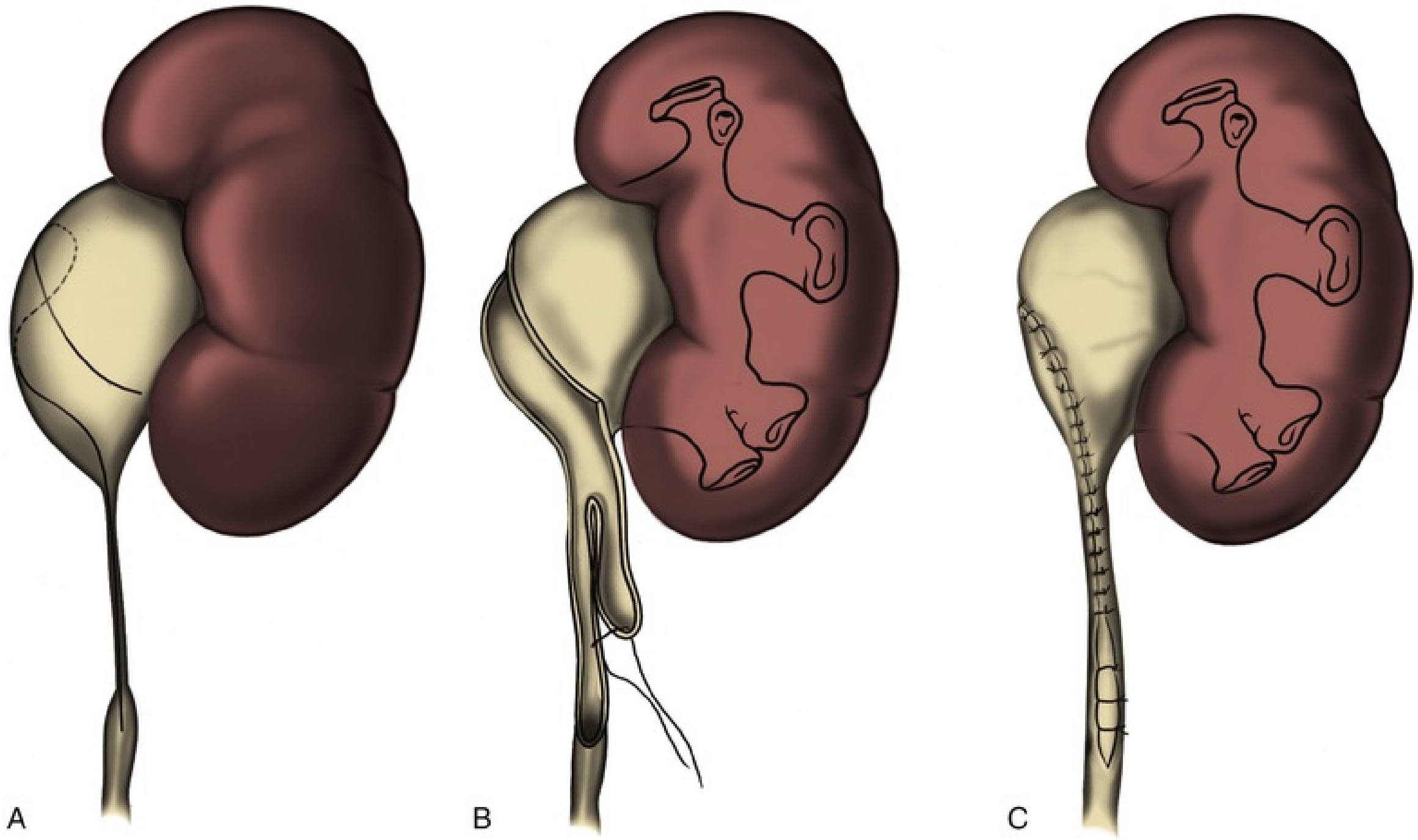

FIG. 89.19 (A) Intubated ureterotomy may be of value when a ureteropelvic junction obstruction is associated with extremely long or multiple ureteral strictures. A spiral flap is outlined and developed as described in Fig. 89.20. The ureterotomy incision will be carried completely through the long strictured areas or through each of the multiple areas of stricture. (B) The flap is developed, taking care to use minimal dissection of the ureter to preserve its blood supply. In contrast to uncomplicated repairs, nephrostomy tube drainage is used routinely. A self-retaining, soft, inert internal ureteral stent is then placed and positioned proximally in the renal pelvis or lower infundibulum and distally in the bladder. The apex of the flap is then brought as far down as possible over the stent on the ureterotomy, and the flap is closed with interrupted or running absorbable suture. (C) The distal aspect of the ureterotomy is left open to heal secondarily by ureteral regeneration. A few fine absorbable sutures may be loosely placed to keep the sides of the ureter in apposition to the stent.

On the basis of the original description, the ureteral intubation is achieved with a stenting catheter that is placed across the stenotic area to the distal ureter or bladder. Proximally, it is brought out through the renal cortex alongside a nephrostomy tube. Currently, most urologists use a self-retaining, soft, inert, internal ureteral stent instead. The apex of the flap is brought over the stent as far down as possible on the ureterotomy, and the flap is closed with either interrupted or running absorbable suture (Fig. 89.19B). The distal aspect of the ureterotomy is then left open for secondary healing via ureteral regeneration (Fig. 89.19C).

An antegrade nephrostogram is usually obtained 6 weeks after the surgery. If there is no extravasation, the ureteral stent is removed cystoscopically and an antegrade radiographic study is repeated. When ureteral patency without extravasation is ensured with such study, the nephrostomy tube is clamped and subsequently removed.

Ureterocalicostomy

Indications.

Ureterocalycostomy may be used as a primary reconstructive procedure whenever a UPJO or proximal ureteral stricture is associated with a relatively small intrarenal pelvis (Fig. 89.20A).

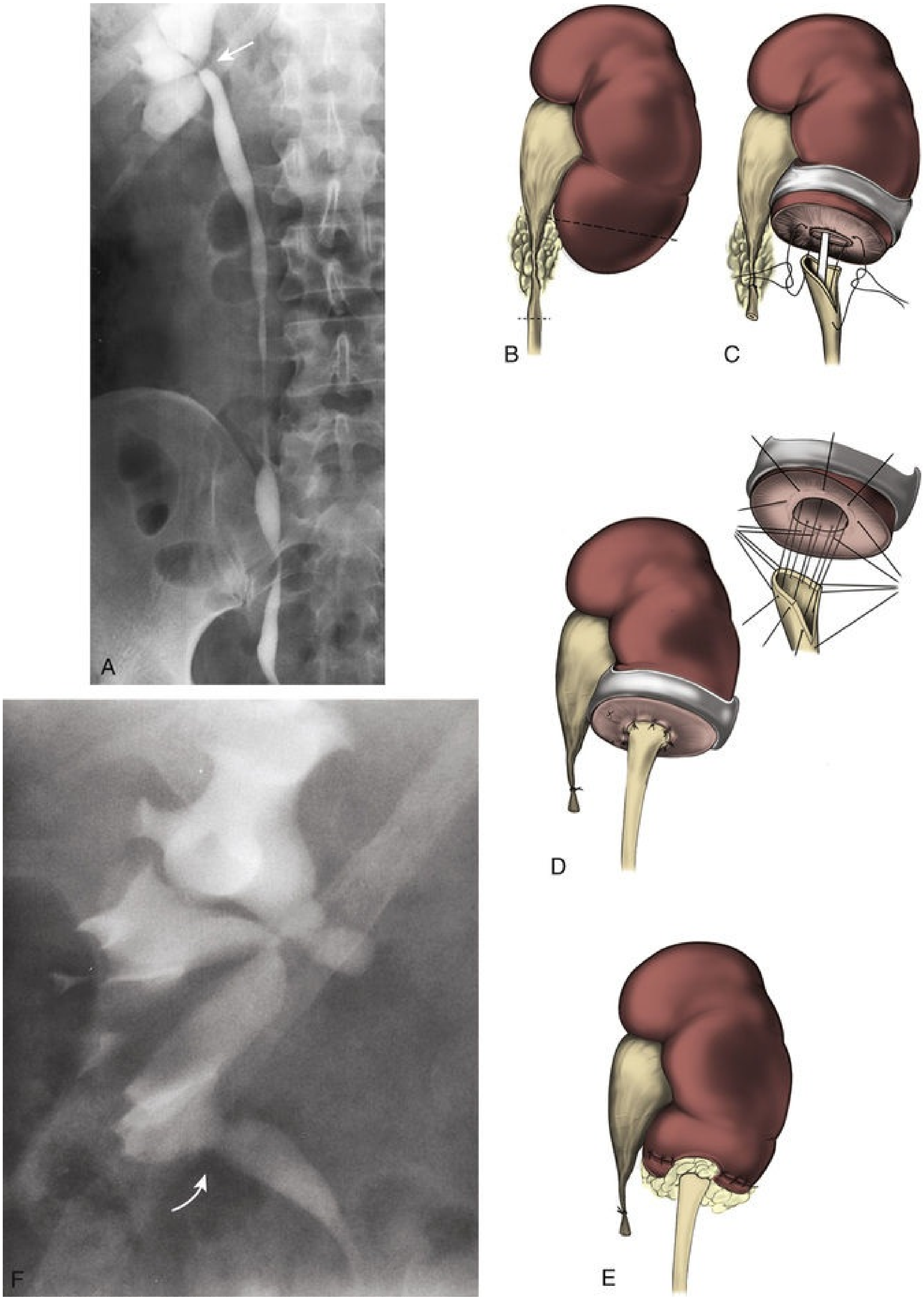

FIG. 89.20 (A) This patient reported progressive right flank pain and was

found on this retrograde study to have a ureteropelvic junction obstruction *(arrow)* associated with a small intrarenal pelvis. This situation may be best managed with a ureterocalicostomy. (B) The ureter is identified in the retroperitoneum and dissected proximally as far as possible. The kidney is mobilized as much as necessary to gain access to the lower pole and to subsequently perform the anastomosis without tension. A lower pole nephrectomy is performed, removing as much parenchyma as necessary to widely expose a dilated lower pole calyx. (C) The proximal ureter is spatulated laterally. The anastomosis should subsequently be performed over an internal stent, and consideration should also be given to leaving a nephrostomy tube. The initial sutures are placed at the apex of the ureteral spatulation, and the lateral wall of the calyx with a second suture is placed 180 degrees from that. (D) Anastomosis is then completed in an open fashion, placing each suture circumferentially *(inset)* but not securing them until the anastomosis has been completed. (E) Renal capsule is closed over the cut surface of the parenchyma whenever possible. However, the capsule should not be closed near the anastomosis because that may compromise the lumen by extrinsic compression. Instead, the anastomosis should be protected with a graft of perinephric fat or a peritoneal or omental flap. (F) Intravenous urogram 2 months after right ureterocalicostomy reveals a widely patent ureterocalyceal anastomosis at the lower pole *(arrow).*

When the UPJ is associated with rotational anomalies such as horseshoe kidney (Levitt et al., 1981), ureterocalycostomy may be useful to provide completely dependent drainage. Furthermore, ureterocalycostomy is a well-accepted salvage technique for the failed pyeloplasty (Ross et al., 1990).

Technique.

The ureter is first identified in the retroperitoneum and dissected proximally with a generous amount of periureteral tissue. For secondary procedures, however, extensive scarring may preclude adequate identification and dissection of the renal pelvis (Fig. 89.20B). The kidney is then mobilized to gain access to the lower pole. An important technical point in ureterocalycostomy is that the parenchyma overlying the lower pole calyx must be resected rather than simply incised because a simple nephrotomy may lead to a secondary stricture (Couvelaire et al., 1964).

The proximal ureter is first spatulated laterally, and the ureterocalyceal anastomosis is completed over an internal stent. Leaving an indwelling nephrostomy tube should also be considered in these cases. The first suture is placed at the apex of the ureteral spatulation and lateral wall of the calyx, and the second suture is placed 180 degrees apart. The remainder of the anastomosis is then performed using an interrupted “open” suture technique. That is, each suture placed is left untied until the final one is in place (Fig. 89.20C). This method seems to provide a more accurate anastomosis under direct vision. When the full set of circumferential sutures has been placed, the sutures are secured down together (Fig. 89.20D). The renal capsule is closed over the cut surface of the parenchyma if possible. However, such closure should not be close enough to the anastomosis to cause extrinsic compression on the anastomosis. Instead, the anastomosis should be covered with perinephric fat or a peritoneal or omental flap (Fig. 89.20E). A follow-up urogram is generally obtained at 1 month after the ureteral stent extraction (Fig. 89.20F).

Reports exist of laparoscopic and robotic ureterocalycostomy (Casale et al., 2008; Gill et al., 2004; Korets et al., 2007). Arap et al. (2014) report 100% success at a mean of 30 months after laparoscopic ureterocalycostomy in 6 patients.

Salvage Procedures.

Failed open pyeloplasty is a challenging problem that is usually best managed initially using an endourologic approach. In some cases, such approach may not be applicable. In these cases, successful reconstruction can at times be achieved using one of the flap or dismembered techniques already described. The secondary open operative reconstruction may be significantly aided by the placement of a ureteral catheter to aid intraoperative identification and dissection of the ureter and renal pelvis. In these situations, there is often a relatively long length of proximal ureteral stenosis to repair, and wide mobilization of the kidney and ureter is generally a necessity. This helps to bridge the area of stenosis and allows a tension-free secondary pyeloplasty.

Several other options are available for these secondary and often complex repairs. These surgical alternatives include those generally available for any extensive ureteral problem such as ileoureteral replacement and autotransplantation with a Boari flap pyelovesicostomy. For cases in which function of the involved kidney is already significantly compromised and the contralateral kidney is normal, nephrectomy is considered.

Postoperative Care and Management of Complications.

In general, external drains are removed 24 to 48 hours after cessation of urinary drainage, and internal ureteral stents, if placed, are removed on an outpatient basis approximately 4 to 6 weeks after the surgery. If a nephrostomy tube is used, a nephrostogram is obtained no sooner than 7 to 10 days postoperatively, or even later for particularly complicated repairs. If nephrostogram demonstrates a patent anastomosis without obstruction or extravasation, the tube is clamped for 12 to 24 hours and removed if there is no flank pain, fever, or leakage around the tube.

Retrocaval Ureter

Etiology and Diagnosis

Retrocaval ureter is a rare congenital urologic anomaly. It occurs as a consequence of the persistence of the posterior cardinal veins during embryologic development (Considine, 1966). Its presence should be suspected with the finding of a characteristic S-shaped deformity on intravenous or retrograde pyelography (Fig. 89.21A). Today, a definitive diagnosis can be made noninvasively using 3D CT imaging (Fig. 89.21B; Pienkny et al., 1999). Procedural intervention is indicated in the presence of functionally significant obstruction leading to pain or renal function deterioration.

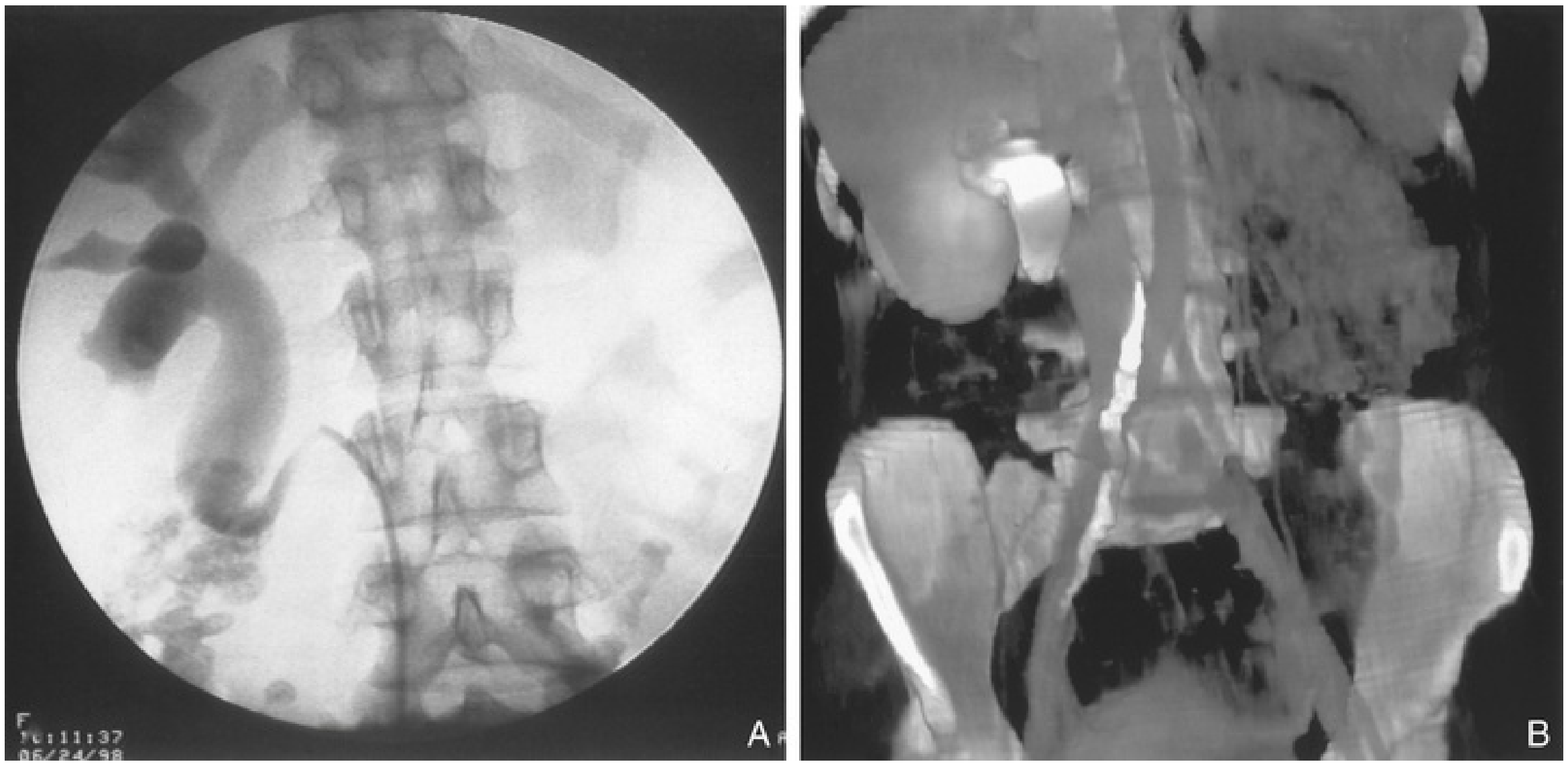

FIG. 89.21 (A) Retrograde pyelography in a patient with right-sided hydronephrosis. This study reveals a typical S-shaped deformity secondary to the ureter coursing laterally to medially posterior to the inferior vena cava. (B) Three-dimensional spiral computed tomography demonstrates the presence of a retrocaval ureter.

Operative Intervention

The standard repair of retrocaval ureter is surgical pyelopyelostomy. **In this procedure, the ureter, dilated renal pelvis, and inferior vena cava are**

identified and dissected using the standard open surgical techniques. The dilated renal pelvis is then transected, after which the ureter is transposed to its normal anatomic position anterior to the vena cava (Fig. 89.22). Pyelopyelostomy is then performed circumferentially with absorbable sutures in a tension-free, water-tight manner. Surgical drain and internal ureteral stent are typically used.

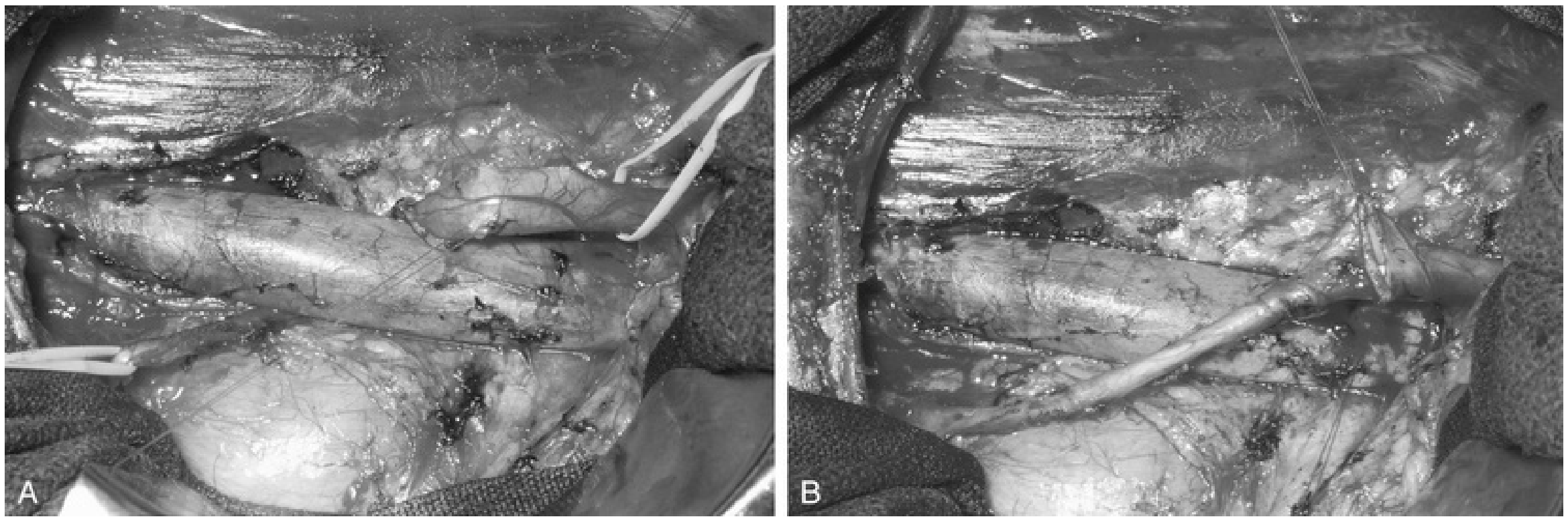

FIG. 89.22 (A) Intraoperative photograph of a patient with retrocaval ureter undergoing surgical repair via a retroperitoneal flank approach. Right side of the photo represents the cephalad direction. Note the dilated proximal right ureter passing behind the inferior vena cava. (B) Right ureteropelvic anastomosis has been completed after transection of the right renal pelvis and transposition of the ureter anterior to the inferior vena cava.

Laparoscopic Surgical Management

Retrocaval ureter has been managed successfully with the laparoscopic approach in the clinical setting as shown by a series of sporadic case reports (Baba et al., 1994; Gupta et al., 2001; Matsuda et al., 1996; Polascik et al., 1998; Ramalingam et al., 2003; Salomon et al., 1999). Either a transperitoneal or a retroperitoneal approach may be used laparoscopically. A double-J ureteral stent is first placed into the ipsilateral ureter cystoscopically. After transperitoneal or retroperitoneal laparoscopic access, the ipsilateral ureter is identified and mobilized off the inferior vena cava. The ureter is then divided at the most distal segment of the dilated ureter. Redundant segment of dilated proximal ureter and stenotic segment of ureter are excised if present. The ureteral ends are positioned anterolateral to the vena cava, spatulated for 1.5 to 2 cm on opposite ends, and then anastomosed with absorbable sutures using intracorporeal suturing techniques over the stent. Tension-free, water-tight anastomosis is the objective. A surgical drain is then left in place and typically removed within a few days postoperatively, and the ureteral stent is typically removed 4 to 6 weeks postoperatively.

Today retrocaval ureter has been managed successfully with the robotic-assisted laparoscopic approach (Hemal et al., 2008; Mufarrij et al., 2007; Smith et al., 2009). A transperitoneal approach providing a large working space is typically used. The general principles of laparscopic ureteral dissection, division, transposition, and anastomosis are identical to those described in conventional laparoscopic approach. At least four different ports are involved, including three for the robot and one for the surgical assistant providing suction, irrigation, suture introduction, and retraction.

Clinical results with laparoscopic/robotic repair have been favorable, indicating minimal postoperative patient morbidity, short convalescence, and anastomotic patency on short-term radiographic follow-up.

Key Points: Retrocaval Ureter

- Retrocaval ureter results from the persistence of the posterior cardinal veins.
- Retrocaval ureter can be diagnosed using retrograde pyelography or CT.
- Procedural intervention is indicated in the presence of functionally significant obstruction, and open and laparoscopic approaches can be successfully applied.

Ureteral Stricture Disease

Etiology

Common causes of ureteral stricture formation include ischemia, surgical and nonsurgical trauma, periureteral fibrosis, malignancy, and congenital factors (Box 89.1). **Proper evaluation and treatment of a ureteral stricture are essential to preserve renal function and rule out the presence of malignancy.** Although the classic radiographic presentation of a transitional cell carcinoma of the ureter is a radiolucent filling defect within the lumen with the characteristic goblet sign, it may have the same appearance as a benign stricture. In addition, metastatic tumors such as cervical, prostate, ovarian, breast, and colon cancer may appear as a ureteral stricture (Lau et al., 1998). Although the incidence of ureteral strictures in the general population is unknown, it is clear that the **presence of ureteral calculi and associated treatment of stones are risk factors.** Roberts et al. (1998) evaluated 21 patients with impacted ureteral stones and found that impaction for more than 2 months' duration was associated with a 24% incidence of stricture formation. Any ureteral instrumentation can lead to the development of a ureteral stricture. As advances in ureteroscopic technology have provided smaller, more actively deflecting instruments with digital optics, ureteroscopic procedures have become less traumatic and are now associated with a long-term complication rate of less than 5% (Ambani et al., 2013; Delvecchio et al., 2003; Harmon et al., 1997). Alternately, the more prevalent use of access sheaths for upper tract ureteroscopy led to one study documenting ureteral injury in up to 13% of cases involving the smooth muscle layers (Traxer and Thomas, 2013). No other clinical studies have been reported to verify this report. Other causes of benign ureteral strictures include radiation; abdominal aortic aneurysm; infections such as tuberculosis and schistosomiasis; endometriosis; and trauma including iatrogenic injury from previous abdominal or pelvic surgery or post–renal ablation injury (ElAbd et al., 1996; Johnson et al., 2004; Lacquet et al., 1997; Oh et al., 2000; Ramanathan et al., 1998). Patients with presumed idiopathic ureteral strictures should be evaluated with CT scan to rule out the presence of an intrinsic ureteral malignancy or a lesion causing extrinsic compression.

Box 89.1

Cause of Ureteral Stricture

Malignancy (e.g., transitional cell carcinoma, cervical cancer)
Ureteral calculus
Radiation
Ischemia or trauma caused by surgical dissection
Periureteral fibrosis caused by abdominal aortic aneurysm or endometriosis
Endoscopic instrumentation
Renal ablation injury
Infection (tuberculosis)
Idiopathic condition

Diagnostic Studies and Indications for Intervention

The presence of obstruction on standard CT can identify ureteral stricture disease, but antegrade or retrograde pyelogram, CT urography, or diagnostic ureteroscopy is typically necessary to define the location and length of the ureteral stricture. Subsequent ureteroscopy with biopsy or barbotage should be performed in any patient in whom the cause of the stricture is not certain. Diuretic renography will provide differential renal function and evaluate the renal unit for functional obstruction. **It is important to assess the renal unit for function before starting treatment because endourologic therapies, in general, require 25% function of the ipsilateral moiety to have reasonable success rates** (Wolf et al., 1997). Once a ureteral stricture is diagnosed, indications for intervention include the need to rule out malignancy, ongoing renal obstruction, recurrent pyelonephritis, and pain associated with functional obstruction.

Endourologic Options for Intervention

Ureteral Stent Placement

Ureteral stent placement is effective acutely in treating most ureteral strictures, in particular intrinsic ureteral strictures. Wenzler et al. (2008) reported good success rates in treating intrinsic ureteral obstruction, with 88% success rates at 26 months. Although intrinsic ureteral strictures can be managed or temporized with ureteral stents, patients with extrinsic ureteral compression eventually require percutaneous drainage or surgical management (Chung et al., 2004; Docimo and Dewolf, 1989).

If the patient is not a candidate for definitive repair or has a poor prognosis, chronic stent placement with periodic stent changes can be considered. In addition, patients undergoing systemic treatments for malignancies can be managed with periodic stent changes. **The use of chronic stent placement must be guarded, particularly when treating ureteral obstruction from extrinsic compression because adequate drainage may be short-lived** (Chung et al., 2004; Docimo and Dewolf, 1989). Careful monitoring of the upper tracts and patient symptoms is warranted in this subgroup of patients. Rosevear et al. (2007) reported an 84% success rate at 16 months in their series using ureteral stents, with 68% of the patients having malignancy. The remainder included patients with retroperitoneal fibrosis (RPF) and other benign extrinsic diseases. **The use of tandem ureteral stent placement (two parallel stents) has been shown to be effective in benign and malignant extrinsic ureteral obstruction** (Elsamra et al., 2013; Yohannes and Smith, 2001). Elsamra et al. (2013) reported on 66 patients managed with tandem ureteral stent placement, with stent failure in 12% of patients with malignant obstruction and none with benign ureteral obstruction. Alternatively, tandem ureteral stent placement may be an excellent option in patients in whom single-stent drainage fails.

After initial reports in 2006, the use of metallic stents in patients with malignant ureteral obstruction has gained popularity (Borin et al., 2006). Liatsikos et al. (2010) reported on 50 patients treated with the full metallic stent, and although concerns arose regarding stent exchange and encrustation, overall the study supported use of the stent at 12-month intervals. Kadlec et al. (2013) reported 5-year data showing good results for use of full-length metal stents with up to a 3-year duration of stent drainage of long-term benign and malignant obstruction in select patients. Expandable metallic mesh stents that allow tissue ingrowth have proven to have problems with encrustation, hyperplastic reactions, and tumor ingrowth (Liatsikos et al., 2009).

Alternatively, Papatsoris et al. (2010) reported using nonmesh thermoexpandable metallic stents with both drainage and therapeutic benefits, although urinary tract infections, stent migration, encrustation, and obstruction were similarly identified. Goldsmith et al. (2012) found a 35% failure rate of metallic stents in 25 patients undergoing stent placement for malignant obstruction. Persistent obstruction, distal stent migration, and subcapsular hematoma were noted, and at the present time there is no clear consensus regarding the benefits of metallic stents. More recently, a systematic review of the literature confers that metallic stents are a viable alternative because of a low migration rate (1%); however, high-quality studies are needed in this area (Khoo et al., 2018).

Balloon Dilation

Retrograde Balloon Dilation.

Retrograde dilation of ureteral strictures has historically been part of the urologic armamentarium. The technique was rarely definitive and usually required repeated dilations on a regular basis. In the early 1980s angiographic and vascular balloons were introduced into urologic practice, and the technique of balloon dilation with temporary internal stenting became an accepted mode of treatment (Banner et al., 1983; Finnerty et al., 1984).

As for any patient with a ureteral stricture, the indications to intervene include functionally significant obstruction. Contraindications to this approach include active infection or a stricture longer than 2 cm because dilation alone will rarely be successful in this setting. Moreover, any endoscopic technique is likely to fail with strictures greater than 2 cm (Fig. 89.23).

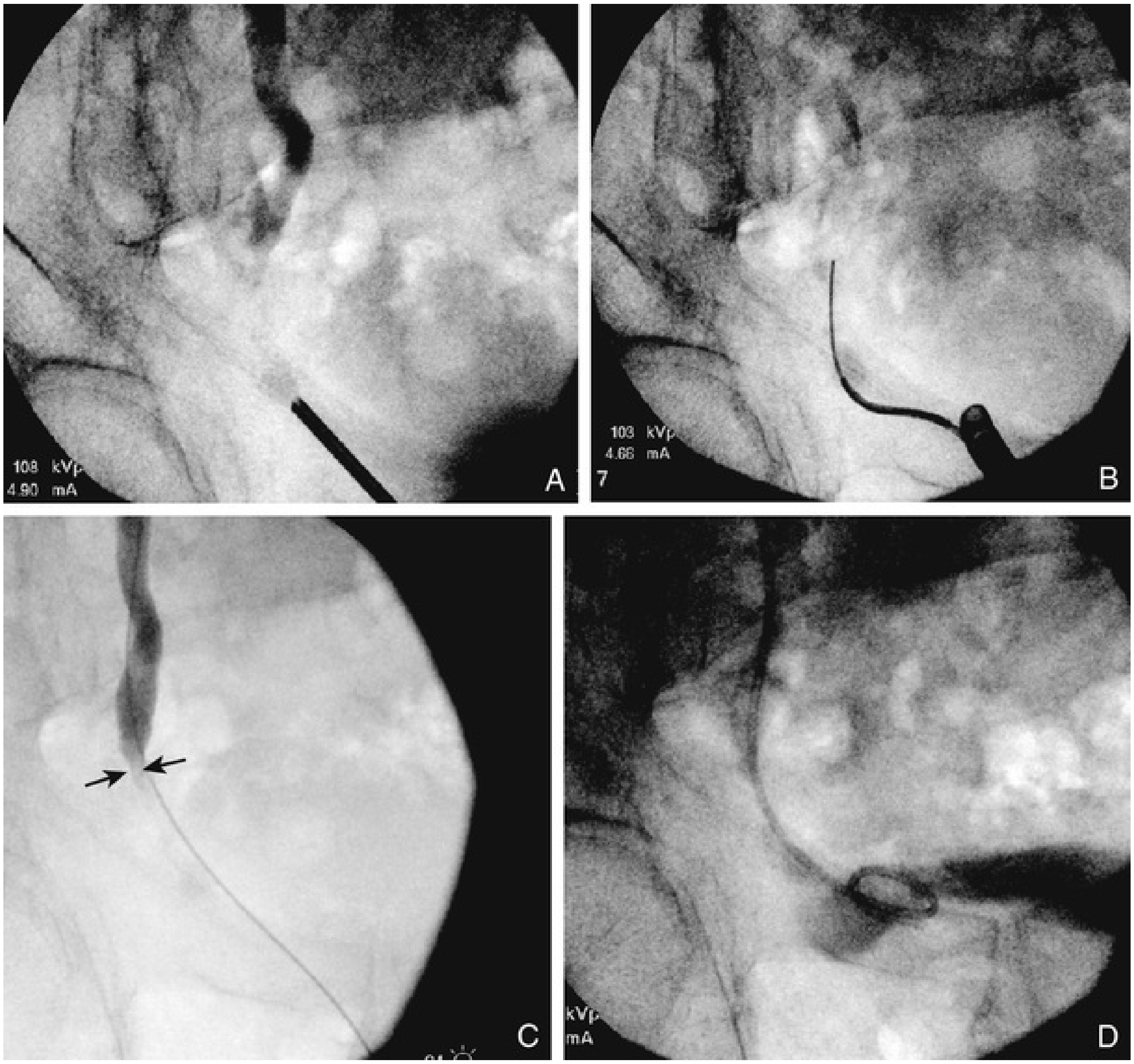

FIG. 89.23 (A) Antegrade and retrograde contrast demonstrating a distal ureteral stricture after prior traumatic ureteroscopic stone procedure. (B) Image demonstrating complex guidewire access across this long and narrow stricture with retained proximal stones. (C) The stricture is greater than 2 cm, and minimal contrast would pass through antegrade. (D) Image after ureteral stent placement. This patient required ureteral reimplantation and stone removal.

A retrograde approach is indicated whenever access across the strictured area is easily accomplished using transurethral techniques. In general, the procedure begins with a retrograde pyelogram performed under fluoroscopic control to precisely delineate the site and length of stricture. A floppy-tipped guidewire is passed in a retrograde fashion across the strictured area and coiled proximally in the pyelocalyceal system. This is most easily accomplished by passing an open-ended catheter up to the level of the stricture to use as a guide for the hydrophilic or floppy-tipped wire. Passage of the open-ended catheter through the strictured area over the wire will then aid subsequent passage of a balloon catheter. Techniques for bypassing difficult areas of obstruction have been described in detail (Mata et al., 1994).

At this point, the open-ended catheter is withdrawn and replaced with a high-pressure, 4-cm–long, 5- to 8-mm balloon. Under fluoroscopic control, the balloon catheter is positioned across the strictured area, with proper position ensured by visualization of radiopaque markers at the tips of the balloon. Balloon inflation is then begun, and a waist will be visualized at the strictured area, which will disappear with progressive balloon inflation (Fig. 89.24). After 10 minutes of tamponade, the balloon is deflated and withdrawn. A guidewire is still in place, and this is used to pass an internal stent, which is left indwelling for 2 to 4 weeks. Follow-up diuretic renography is usually performed approximately 1 month after stent extraction and at 6- to 12-month intervals thereafter.

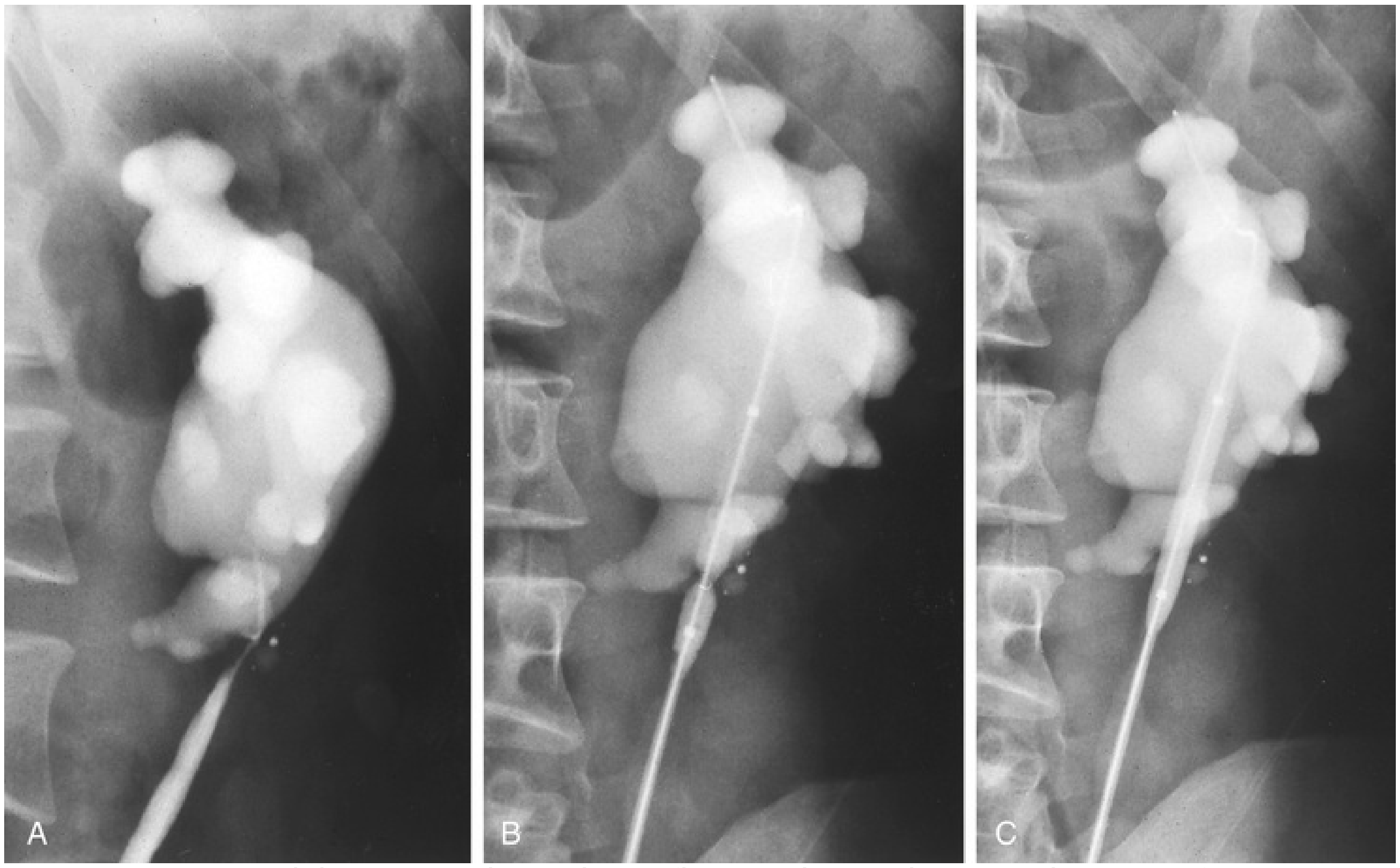

FIG. 89.24 (A) Retrograde study confirms a short stricture at the level of the ureteropelvic junction in this patient with a horseshoe kidney referred after failed ureteroscopic management of a ureteral calculus impacted at that level. (B) The stricture has been traversed with a guidewire, over which a high-pressure balloon has been passed. A waist is evident at the level of the stricture during initial balloon inflation. (C) Balloon inflation and stricture

dilation are complete with disappearance of the waist.

Occasionally, access across the involved area cannot be obtained using fluoroscopic control alone. In such cases direct ureteroscopic visualization can aid initial passage of the guidewire, and the procedure can be continued as described. Alternatively, a low-profile balloon can be passed through the ureteroscope and the stricture dilated under direct vision.

Antegrade Balloon Dilation.

At times, retrograde access across a strictured area is impossible. In such cases, access can be obtained using an antegrade approach and fluoroscopic control (Banner and Pollack, 1984; Mitty et al., 1983), with or without direct antegrade ureteroscopic visualization (de Jonge et al., 1986). **Percutaneous nephrostomy drainage is established; in cases associated with infection or compromised renal function, percutaneous drainage alone is instituted to allow resolution of infection and return to baseline renal function.** Once that is accomplished, the percutaneous tract is used for access for a fluoroscopically or ureteroscopically guided approach. The procedure is then analogous to a retrograde approach. Under fluoroscopic guidance, an antegrade contrast agent study is used to definitively define the site and length of the stricture. A floppy-tipped guidewire or glidewire is passed antegrade across the level of obstruction; then a balloon catheter is passed, and the balloon is progressively inflated until the waist disappears. The balloon catheter is withdrawn over a wire and replaced with an internal stent, and a nephrostomy tube is also left indwelling. A follow-up nephrostogram is obtained within 24 to 48 hours to ensure proper positioning of a functional internal stent, and at that time the nephrostomy tube can be removed. Alternatively, access can be maintained by the use of an internal-external stent, which can be capped to allow internal drainage.

Results.

Initial reports of retrograde and antegrade balloon dilation of ureteral strictures suggested that results were better when the stricture was anastomotic and of relatively short duration and length (Chang et al., 1987; King et al., 1984b; Netto et al., 1990). Goldfischer and Gerber (1997) **reviewed the literature regarding results of balloon dilation of ureteral strictures and found reported success rates ranging from 50% to 76%. In that review, the best results were obtained in patients with iatrogenic, nonanastomotic strictures such as those**

who had undergone ureteroscopic instrumentation. In that setting, a success rate of 85% was achieved compared with a rate of 50% for anastomotic strictures. Alternatively, Ravery et al. (1998) found a 40% success rate using retrograde balloon dilation in treating inflammatory ureteral strictures at 16 months' follow-up. Richter et al. (2000) reviewed their results with balloon dilation in 114 patients with a minimum 2-year follow-up. As in other series, balloon dilation was more successful for patients with relatively short strictures. In addition, these authors noted the significance of an intact vascular supply on the success of this procedure. Koukouras et al. (2010) reported antegrade percutaneous balloon treatment of iatrogenic ureteral strictures with 72% success at 1-year follow-up. One series of transplant ureteral strictures in which percutaneous balloon dilation was used in 14 transplant patients demonstrated 79% success at 29 months. Notably, these were short, anastomotic strictures in patients on immunosuppression (Voegeli et al., 1988). Others report endoureterotomy as the primary treatment option in such cases (Duty et al., 2013). In experimental models, balloon dilation created longitudinal incisions similar to endoureterotomy, explaining some of the success seen with use of balloon dilation in ureteral strictures (Nakada et al., 1996).

Endoureterotomy

Endoluminal ureteral incision is a logical extension of balloon dilation for "minimally invasive" management of ureteral strictures. As for balloon dilation, access to and across the strictured area can be obtained in a retrograde or antegrade fashion, although a retrograde approach is preferred because it is less invasive. The antegrade approach is indicated when percutaneous access is already present. The procedure is performed under direct vision using ureteroscopic control or it can be guided fluoroscopically using the hot-wire cutting balloon catheter. In general, radiographic follow-up using diuretic renography is recommended for up to 2 years to detect most late failures (Wolf et al., 1997).

Retrograde Ureteroscopic Approach.

A retrograde study is performed under fluoroscopic control at the outset of the procedure. Whenever possible, a floppy-tipped guidewire or hydrophilic glidewire is passed across the level of obstruction as outlined earlier. If a wire cannot be passed across the strictured area using fluoroscopic control alone, the flexible ureteroscope is passed to the level of obstruction, and the guidewire is advanced through the ureteroscope across the involved area under direct vision. The ureteroscope is then withdrawn, but a safety wire is always left in place across the stricture. The ureteroscope is then reintroduced and passed alongside the guidewire to the level of obstruction.

The position for the endoureterotomy incision is chosen as a function of the level of the ureter involved. In general, lower ureteral strictures are incised in an anteromedial direction, taking care to stay away from the iliac vessels. In contrast, upper ureteral strictures are incised laterally or posterolaterally, again away from the great vessels (Meretyk et al., 1992; Fig. 89.25).

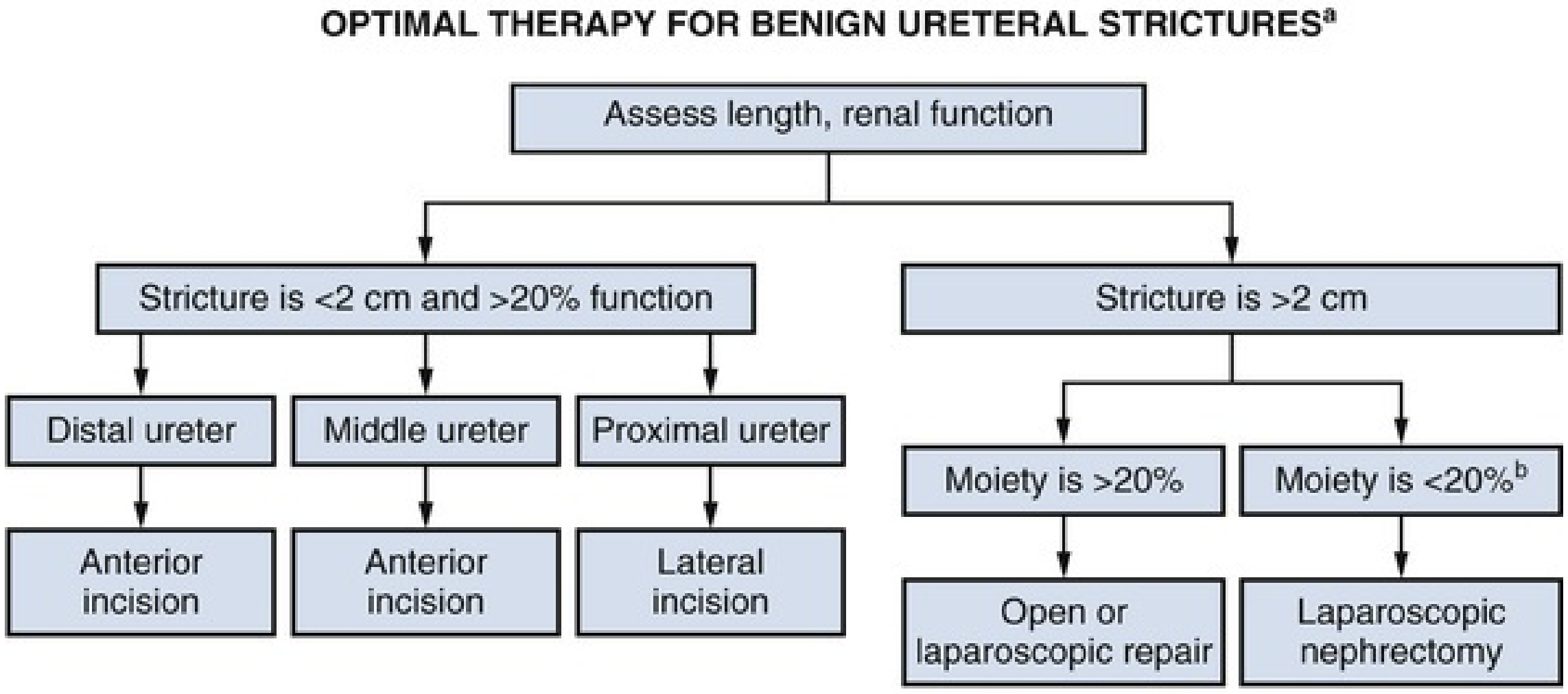
OPTIMAL THERAPY FOR BENIGN URETERAL STRICTURES[a]
Assess length, renal function
Stricture is <2 cm and >20% function
Stricture is >2 cm
Distal ureter
Middle ureter
Proximal ureter
Moiety is >20%
Moiety is <20%[b]
Anterior incision
Anterior incision
Lateral incision
Open or laparoscopic repair
Laparoscopic nephrectomy

[a]Consider balloon if transplant on immunosuppression.
[b]Pediatric patients and select patients with renal insufficiency may warrant repair.

FIG. 89.25 Algorithm for management of benign ureteral stricture disease.

The ureterotomy incision can be performed using a cold knife (Schneider et al., 1991; Yamada et al., 1995), a cutting electrode (Conlin et al., 1996), or a holmium laser. Today, the holmium laser represents the dominant approach to endoscopic incisions. In all cases the incision is made from the ureteral lumen out to periureteral fat in a full-thickness fashion. Proximally and distally, the endoureterotomy should encompass 2 to 3 mm of normal ureteral tissue. In certain instances the stricture must be balloon dilated to gain access across the stricture (Fig. 89.26). Similarly, the strictures may be balloon dilated after endoincision, to enlarge the incision. Once the endoureterotomy incision is complete, the remaining guidewire is used to pass an internal stent. In general, the larger-diameter stents should be considered because larger stents (8 to 12 Fr) have been associated with improved results (Hwang et al., 1996; Wolf et al., 1997). Similarly, Wolf et al. (1997) found benefit in the injection of triamcinolone ureteroscopically after endoureterotomy. Steroids and other biologic response modifiers may eventually have a role in the future in managing select strictures.

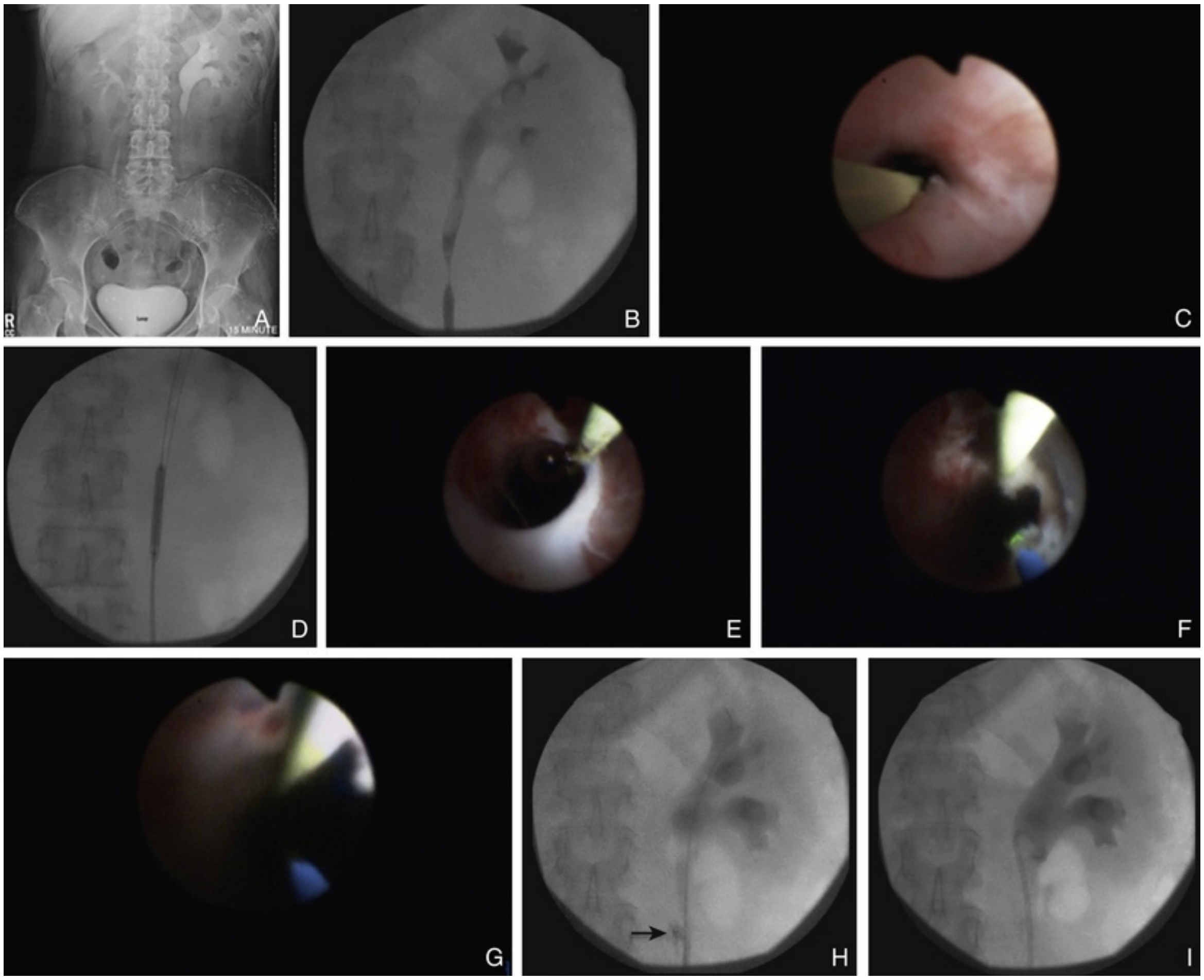

FIG. 89.26 (A) Preoperative excretory urogram showing proximal ureteral stricture after ureteral injury. (B) Fluoroscopic image of flexible ureteroscope at stricture. (C) Corresponding endoscopic image of stricture. (D) Fluoroscopic image of balloon dilation to enable incision of ureteral stricture. (E) Endoscopic image of strictured area after balloon dilation (note resultant full-thickness, lateral incision). (F) Endoscopic view completing laser incision of stricture. (G) Endoscopic view of full-thickness incision. (H) Fluoroscopic image demonstrating extravasation *(arrow).* (I) Fluoroscopic image after stent placement.

Results.

The success of holmium laser endoureterotomy ranges from 66% to 83% in series of more than 10 patients with longer than 12 months' follow-up (Gdor et al., 2008b; Hibi et al., 2007; Lane et al., 2006). There is early evidence that strictures related to stone impaction and prior stone treatment may have lower success rates (56% in one series) than typical benign strictures (Gdor et al., 2008a). As ureteroscopy and laser lithotripsy continue to grow, more strictures involving impacted stones may be encountered, and this may become a growing clinical problem. Gdor et al. (2008b) reported 67% success in treating transplant ureteral strictures using the holmium laser at 58 months' follow-up, and more recently Mano et al. (2012) reported an 83% success rate in 26 transplant patients at 44 months' follow-up, with 67% of the patients having undergone initial percutaneous balloon dilation. **The familiarity of ureteroscopy, coupled with relative availability of the holmium laser, makes retrograde laser endoureterotomy an attractive initial management strategy for ureteral strictures less than 2 cm in length.** Meretyk et al. (1992) and Razdan et al. (2005) reported poor results using the retrograde approach in patients with strictures longer than 2 cm.

Antegrade Approach.

When direct visual ureteroscopic access to the strictured area cannot be accomplished in a retrograde fashion, an antegrade approach may be used. Nephrostomy tube drainage is instituted, and any associated infection or compromised renal function is allowed to resolve before definitive incision. The percutaneous tract is dilated to a size large enough to allow a working sheath through which a flexible ureteroscope is passed. The procedure is then performed in a fashion analogous to a retrograde approach. A safety wire should be in place at all times alongside the ureteroscope, across the obstructed area and coiled distally in the bladder.

Combined Retrograde and Antegrade Approach.

Rarely, a ureteral stricture is associated with an area of complete ureteral obliteration across which a wire cannot be passed to allow subsequent balloon dilation or ureteroscopic endoureterotomy. Typically open or robotic reconstruction is best when possible. In cases where surgery is high risk, a combined retrograde and antegrade approach has been described (Beaghler et al., 1997; Cardella et al., 1985; Conlin et al., 1996; Knowles et al., 2001). This approach should be taken on with caution. The obstructed area is defined radiographically with a simultaneous antegrade and retrograde pyelogram. Endoscopes are passed simultaneously in a retrograde and an antegrade manner, and the two opposing ureteral ends are localized under fluoroscopic guidance. A working guidewire is then passed from one end of the ureter, through and through to the other lumen, using a combination of fluoroscopic and direct visual control. For completely obliterated ureteral segments, this is most easily accomplished using the stiff end of a guidewire passed through a semirigid ureteroscope via the retrograde approach, although when a semirigid ureteroscope cannot be placed, a flexible ureteroscope or even an open-ended ureteral catheter can be used to stabilize the wire from above or below. The ureteral segments are aligned as closely as possible under endoscopic and fluoroscopic guidance, and the light source to one of the ureteroscopes is turned off. The light from the opposite ureteroscope is then used to aid incisional restoration of urinary continuity. The strictured area is then recannulated using the stiff end of a guidewire, a small electrocautery electrode, or holmium laser. Once through-and-through control is obtained with a guidewire, a stent is passed and left in place for 8 to 10 weeks. As with other endourologic approaches to ureteral strictures, success rates are inversely related to the length of the strictured area. **Although success rates may be uncertain, internalization of urinary flow, even when dependent on long-term stent placement, can be a quality-of-life advantage for certain high-risk patients.** Knowles et al. (2001) reported a 90% patency rate at 36 months' follow-up for use of cautery wire balloon incision to treat 10 patients with obliterated distal ureteral segments, 3 of whom required the combined. Bach et al. (2008) reported a retrograde blind (fluoroscopically guided) endoureterotomy with a 61% success rate in patients with subtotal ureteral strictures.

Key Points: Endourologic Management of Ureteral Strictures

- Proper evaluation and treatment of a ureteral stricture are essential to preserve renal function and rule out the presence of malignancy. It is critical to assess the renal unit for function before starting treatment because endourologic therapies typically require 25% function of the ipsilateral moiety.
- The use of chronic stent placement for extrinsic ureteral obstruction must be

guarded because the drainage is often limited. Innovations in stents and stent techniques have led to long-term success in select patients with malignant ureteral obstruction.

- The indications to intervene for ureteral stricture disease include clinical symptoms and functionally significant obstruction. Contraindications to this approach include active infection or a stricture longer than 2 cm.
- Current available reports and the familiarity of ureteroscopy, coupled with relative availability of the holmium laser, make retrograde laser endoureterotomy an attractive initial management strategy for short ureteral strictures.
- The position for the endoureterotomy incision is chosen as a function of the level of the ureter involved. In general, lower ureteral strictures are incised in an anteromedial direction, taking care to stay away from the iliac vessels. In contrast, upper ureteral strictures are incised laterally or posterolaterally, away from the great vessels.

Surgical Repair

Before any surgical repair, it is essential to conduct careful evaluation of the nature, location, and length of the ureteral stricture. Preoperative assessment typically includes an intravenous pyelogram (or antegrade nephrostogram) and a retrograde pyelogram if indicated as the location and length of the stricture heavily influence the options for repair. Other studies such as a nuclear medicine diuretic renogram to assess renal function and ureteroscopy, ureteral barbotage, and/or brushing to rule out carcinoma should be individualized. On the basis of such information, the appropriate surgical procedure can then be planned for the patient (Table 89.2).

TABLE 89.2

Bridging Various Ureteral Defect Lengths With Different Reconstructive Surgical Techniques

TECHNIQUE	URETERAL DEFECT LENGTH (cm)
Ureteroureterostomy	2–3
Ureteroneocystostomy	4–5
Psoas hitch	6–10
Boari flap	12–15

Renal descensus	5–8

Ureteroureterostomy

A short defect involving the upper ureter or midureter, either in the form of stricture or as a consequence of recent injury, is most appropriate for ureteroureterostomy. On the other hand, a lower ureteral stricture is usually best managed by ureteroneocystostomy with or without a psoas hitch or Boari flap. In the transplant setting, a donor ureteral stricture may be managed by a ureteroureterostomy to a healthy, native ureter. Because tension on the anastomosis almost always leads to stricture formation, only short defects should be managed by end-to-end ureteroureterostomy. Determination of whether enough ureteral mobility can be achieved to allow tension-free ureteroureterostomy usually cannot be made until the time of surgery, and thus the urologist must be prepared to pursue other options.

Open Approach.

The choice of surgical incision depends on the level of the ureteral stricture. A flank incision is appropriate for the upper ureter. A Gibson or a lower midline incision is suitable for the middle and lower ureter. If the patient has sustained an iatrogenic ureteral injury from a previous surgery performed through a Pfannenstiel incision, the same incision may be used for the ureteral reconstruction. In such situations, proximal ureteral dissection may be difficult through the Pfannenstiel incision, requiring cephalad extension of the lateral portion of the incision in a “hockey-stick” fashion. Extraperitoneal dissection is usually performed except in cases of transperitoneal surgical ureteral injury.

After surgical incision, the retroperitoneal space is developed as the peritoneum is mobilized and retracted medially. Frequently, the ureter can be easily identified as it crosses the iliac vessels. A Penrose drain or vessel loop may be placed around the ureter to assist its atraumatic handling. Direct handling of the ureter with forceps should be minimized. Care should be taken to preserve its adventitia, which loosely attaches the blood supply to the ureter.

During ureteral dissection and mobilization, enough mobility must be achieved to avoid tension after the excision of the diseased ureter. With a gunshot injury, devitalized tissue and an adjacent segment of normal-appearing ureter should be excised to eliminate late ischemia and stricture formation from the blast effect. Once both ends of the ureter have been adequately trimmed to healthy areas, mobilized, and correctly oriented, they are spatulated for approximately 5 to 6 mm. Spatulation is performed for both ureteral segments at 180 degrees apart. If a grossly dilated ureter is involved, it may be transected obliquely and not spatulated to match the circumference of the nondilated segment. A fine, absorbable suture is placed in the corner of one ureteral segment and the apex of the other, and the two ends of the suture are tied outside the ureteral lumen. The opposite corner and apex are similarly sutured and approximated. The anastomosis may then be completed by running these two sutures continuously and tying them to each other or in an interrupted fashion (Fig. 89.27). A double-J ureteral stent should be placed before completion of the anastomotic closure. Stent placement can be facilitated by passing the wire through one of the side holes in the middle of the stent to straighten and stiffen the stent enough to permit it to pass. Observation of reflux of methylene blue irrigant from the bladder to the ureterotomy can be used to verify the appropriate placement of the distal stent in the bladder. Retroperitoneal fat or omentum may be used to cover the anastomosis.

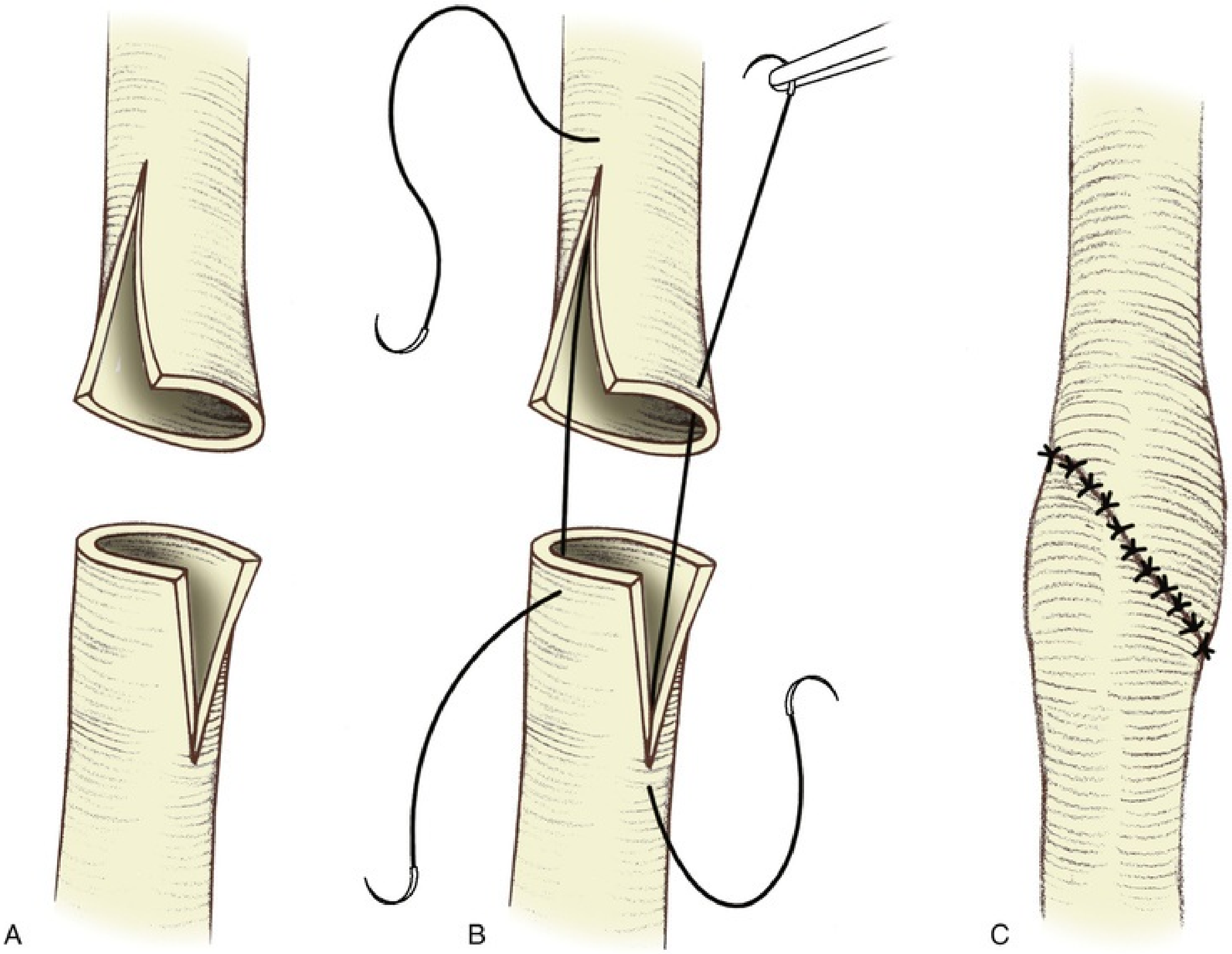

FIG. 89.27 (A) Spatulated ureteral ends. (B) Placement of sutures. (C) End-to-end ureteroureterostomy.

Laparoscopic or Robotic Approach.

A laparoscopic or robotic approach may be offered to patients with ureteral stricture disease. Nezhat et al. (1992) first reported laparoscopic management of an obstructed ureter resulting from endometriosis. In this case, ureteroureterostomy was performed laparoscopically over a ureteral stent after resection of the obstructed ureteral site. Most of the studies since that time consist of single case reports or small series. Several reports of laparoscopic ureteroureterostomy to unobstruct a duplicated system in the pediatric population have appeared (Piaggio et al., 2007; Smith et al., 2009). More recently, the robotic-assisted approach has been applied to laparoscopic ureteroureterostomy in a small number of patients (Lee et al., 2010; Mufarrij et al., 2007; Passerotti et al., 2008). Lee et al. (2010) reported a series of three robotic ureteroureterostomies, all successful by symptom and nuclear renal scan criteria at an average of 24 months. The overall clinical experience in minimally invasive ureteroureterostomy is limited worldwide. However, in the hands of the experienced surgeons, it appears to be a viable minimally invasive approach applicable to almost any patient with a relatively short area of obstruction.

Postoperative Care.

The postoperative care of ureteroureterostomy patients is similar, regardless of surgical approach. A surgical drain is placed, and a Foley catheter is generally left indwelling for 1 to 2 days. The surgical drain may be removed if there is minimal output for 24 to 48 hours. If the surgical procedure is not performed entirely in a retroperitoneal manner, it is important to determine the nature of the fluid from the surgical drain, which can be achieved by checking the creatinine level of the fluid. If there is no urinary extravasation, the drain can then be removed. The double-J ureteral stent is removed endoscopically, usually 4 to 6 weeks postoperatively.

The success rate for a tension-free, watertight ureteroureterostomy is high—more than 90% (Carlton et al., 1969; Guiter et al., 1985). If a urinary fistula is suspected, a plain abdominal radiograph should first be obtained to verify the position of the double-J stent. The proximity of a drain to the anastomosis should also be checked because it may exacerbate a leak. If this occurs, suction should be stopped if a suction drain device is used because straight drainage may assist closure of the ureteral leakage site. Reflux from voiding or bladder spasms may also contribute to prolonged urinary extravasation, a problem that can be managed by Foley catheter drainage and anticholinergics. Prolonged urinary leakage from the anastomosis may require the placement of a nephrostomy tube for proximal urinary diversion.

Ureteroneocystostomy

Ureteroneocystostomy in an adult is appropriate for injury or obstruction affecting the distal 3 to 4 cm of the ureter. As is the case in all ureteral repairs, a tension-free anastomosis is critical and thus modifications such as a psoas hitch or Boari flap may be necessary. Repair of the distal ureter can be accomplished by either open or minimally invasive techniques. Successful laparoscopic application to ureteroneocystostomy has been reported by a variety of investigators (Ehrlich et al., 1993; Gözen et al., 2010; Reddy et al., 1994; Yohannes and Smith, 2001). In the management of distal ureteral stricture, laparoscopic ureteroneocystostomy is usually performed transperitoneally incorporating intracorporeal suturing techniques because it provides a large working space. Ureteral stenting is typically used postoperatively as in open surgery. Although this procedure requires intracorporeal laparoscopic suturing, the overall clinical experience for laparoscopic management of distal ureteral strictures has been increasing over time. Abraham et al. (2011) reported their experience performing laparoscopic ureteral reimplantation in 36 patients and reported success in all patients at a mean of 16 months' follow-up. Overall, the clinical outcomes have been reported favorable to and comparable with those of open surgical data while providing minimal postoperative morbidity, as in many other laparoscopic urologic procedures. LESS neocystostomy has been reported as well (Khanna et al., 2012).

As is the case for many reconstructive urologic procedures, urologists have reported finding the robotic platform useful in neocystostomy (Fig. 89.28; Laungani et al., 2008; Mufarrij et al., 2007; Williams et al., 2009). This procedure can typically be performed using a 4-arm robotic approach with port placement similar to that of a robotic prostatectomy or with ports shifted slightly cephalad. Isac et al. (2013) reported similar success rates for robotic and open neocystostomy with the robotic approach being associated with a significantly shorter hospital stay (3 vs. 5 days, $P = 0.0004$) and less narcotic use (morphine equivalent, mg 104.6 vs. 290, $P = 0.0001$). Musch et al. (2013) reported a robotic approach to be effective even in cases requiring a psoas hitch or Boari flap.

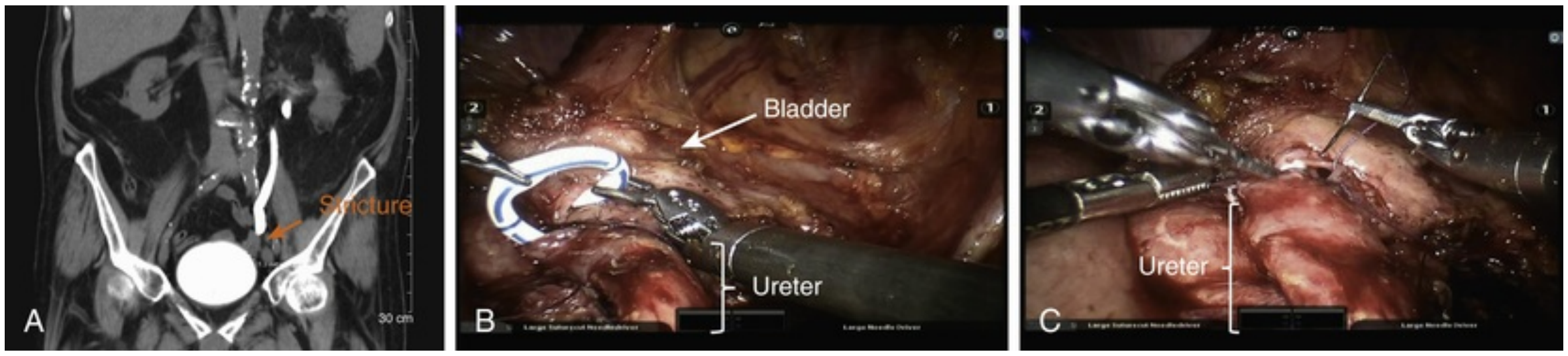

FIG. 89.28 Intraoperative photograph of a patient undergoing a robotic right ureteral neocystostomy for distal ureteral stricture seen in computed tomography urography (A). (B) The distal coil of the ureteral stent being placed through the opening in the bladder after completion of half the ureteral anastomosis. (C) Completing the ureteral anastomosis.

Psoas Hitch

The psoas hitch is an effective method to bridge a defect of the lower third of the ureter, providing an additional up to 5 cm of length compared with simple ureteroneocystostomy. However, a ureteral defect extending proximal to the pelvic brim usually requires more than a psoas hitch alone. Indications include distal ureteral stricture, injury, and failed ureteroneocystostomy (Ehrlich et al., 1978; Prout and Koontz, 1970; Rodo Salas et al., 1991). A psoas hitch may also be used in conjunction with other maneuvers such as a transureteroureterostomy (TUU) in more complicated urinary tract reconstruction. **Generally, a small, contracted bladder with limited mobility is considered a contraindication.** In addition to the preoperative radiographic and endoscopic evaluation described previously, urodynamic studies may provide information regarding bladder capacity and compliance before the surgery. Bladder outlet obstruction or neurogenic dysfunction, if present, must be treated preoperatively.

Relative to Boari flap, the advantages of psoas hitch include increased technical simplicity and decreased risk for vascular compromise and voiding difficulties. The success rate of ureteroneocystostomy with a psoas hitch is greater than 85% in adults and children (Ahn and Loughlin, 2001; Mathews and Marshall, 1997). Complications occur uncommonly but have included urinary fistula, ureteral obstruction, nerve injury, bowel injury, iliac vein injury, and urosepsis.

Boari Flap

When the diseased ureteral segment is too long or when ureteral mobility is too limited to perform a tension-free ureteroureterostomy, a Boari flap may be a useful alternative. Boari first described the use of this technique in the canine model in 1894. **A Boari flap can be constructed to bridge a 10- to 15-cm ureteral defect, and a spiraled bladder flap can reach the renal pelvis in some circumstances, especially on the right side.** As in a psoas hitch, evaluation of bladder function and capacity should be performed preoperatively in addition to the ureteral evaluation. Bladder outlet obstruction and neurogenic dysfunction, if present, should be addressed preoperatively. **A small bladder capacity is likely to be associated with difficult or inadequate Boari flap creation, warranting consideration of alternative methods in the preoperative surgical planning.**

The number of reported patients treated with a Boari flap is small, yet the results are good if a well-vascularized flap is used (Middleton, 1980; Motiwala et al., 1990; Ockerblad, 1947; Scott and Greenberg, 1972; Thompson and Ross, 1974). The most common complication is clearly recurrent stricture formation, resulting from either ischemia or excessive tension on the anastomosis. Rare pseudodiverticulum has also been reported (Berzeg et al., 2003). Mauck et al. (2011) reported success in 9 out of 10 patients with proximal ureteral strictures treated with a Boari flap (+/- simultaneous downward nephropexy) at 12.8 months' mean follow-up.

A series of 98 patients undergoing ureteral reimplantation by Wenske et al. (2013), 76 of whom had a psoas hitch with or without Boari flap, particularly studied postoperative changes in renal function. They found that in 44% of the cases, postoperative eGFR declined in the first 2 years after surgery, despite hydronephrosis resolving in most patients. Interestingly, men and those patients with abnormal preoperative renal function were more likely to experience a loss of function during follow-up. These findings may help counsel patients about their chances of experiencing a renal functional improvement with surgical repair.

Fugita, Dinlenc, and Kavoussi reported three successful cases of laparoscopic Boari flap for distal ureteral obstruction, in which a transperitoneal approach was used (Fugita et al., 2001). Following the same principles in open surgery, the bladder flap was created and anastomosed to the ureteral end over a stent in a tension-free, water-tight manner. Operative time ranged from 120 to 330 minutes, and blood loss ranged from 400 to 600 mL. Two patients were discharged home within 3 days postoperatively, whereas 1 patient was hospitalized for 13 days for *Clostridium difficile* colitis. With a follow-up of more than 6 months, there was radiographically demonstrated patency of the anastomosis. In this report, the information of the length of distal ureteral stricture was not available. More recently, laparoscopic Boari flap assisted by the robot has been successfully performed (Allaparthi et al., 2010; Kozinn et al., 2012; Musch et al., 2013; Schimpf and Wagner, 2009; Yang et al., 2011). Transperitoneal approach was used in all cases reported thus far.

The issue of refluxing versus antirefluxing anastomosis in ureteroneocystostomy in adults has been examined previously. In a retrospective review of adult patients with ureteroneocystostomy, no significant difference in the preservation of renal function or risk of stenosis was identified in the refluxing versus antirefluxing procedures (Stefanovic et al., 1991). However, it is unclear if a nonrefluxing anastomosis decreases the risk of pyelonephritis in an adult patient.

Renal Descensus

Renal mobilization, which was originally described by Popescu in 1964, can provide additional length to bridge a defect in the upper ureter or decrease tension on a ureteral repair (Harada et al., 1964; Passerini-Glazel et al., 1994). A transperitoneal, subcostal, midline, or paramedian incision may be used to gain access to the kidney and the appropriate level of the ureter. Following entry to the Gerota fascia, the kidney is completely mobilized and rotated inferiorly and medially on its vascular pedicle. The lower pole of the kidney is then secured to the retroperitoneal muscle using several absorbable sutures. Up to 8 cm of additional length may be gained using this technique. In such cases the renal vessels—especially the renal vein—limit the extent to which the kidney can be mobilized. As a solution, the technique for division of the renal vein with reanastomosis more inferiorly to the inferior vena cava may be performed but rarely applied clinically. Renal decensus may also be combined with other reconstructive techniques such as a Boari flap to repair panureteral strictures. In addition, laparoscopic techniques have been reported (Sutherland et al., 2011).

Transureteroureterostomy

The initial clinical application of TUU was described by Higgins in 1934. In the management of ureteral stricture, a TUU may be used when ureteral length is insufficient for anastomosis to the bladder (Brannan, 1975). **The only absolute contraindication is insufficient length of the donor ureter to reach the contralateral recipient ureter in a tension-free manner. However, any disease process that may affect both ureters represents a relative contraindication. Absolute contraindications include the presence of a diseased recipient ureter or a donor ureter of inadequate length. Relative contraindications include history of nephrolithiasis, retroperitoneal fibrosis, urothelial malignancy, chronic pyelonephritis, and abdominopelvic radiation. Reflux to the recipient ureter, if present, must be identified and corrected simultaneously.** Therefore a voiding cystogram should be performed preoperatively, in addition to the other imaging and endoscopic studies previously described for thorough evaluation of both ureters.

In performing a TUU, a midline, transperitoneal approach is used to gain access to both ureters. After medial colonic mobilization, the affected ureter is mobilized, preserving the adventitia with the ureteral blood supply, and divided just proximal to the level of obstruction. The contralateral colon is medially mobilized. Only the portion of recipient ureter needed for the anastomosis is exposed, which is generally 5 cm proximal to the level of division of the affected ureter. A tunnel under the sigmoid colon mesentery is created proximal to the inferior mesenteric artery to avoid ureteral tethering by this vessel, after which the donor ureter is then brought through the tunnel to the recipient side. Mobilization of the recipient ureter should be minimized to help preserve the integrity of its vascular supply. An anteromedial ureterotomy is made in the recipient ureter, which is then anastomosed to the spatulated donor ureteral end in a tension-free, watertight manner using either interrupted or running absorbable sutures. A double-J ureteral stent is usually passed from the donor renal pelvis, through the anastomosis and into the bladder. A second ureteral stent may also be placed throughout the length of the recipient ureter if the ureter is found to be adequately large in diameter.

The clinical success of TUU has been demonstrated by multiple investigators. Hendren and Hensle (1980) reported 75 cases of pediatric TUU without compromising a single recipient kidney. Hodges et al. (1980) reported a similar success in a large group of children and adults. However, two patients required revision because of ureteral kinking by the inferior mesenteric artery. The successful application of TUU was further confirmed more recently by Pesce et al. (2001). In two other recent studies, nephrectomy for ureteral stenosis was found to be rarely necessary (Mure et al., 2000; Sugarbaker et al., 2003).

A few reports of successful laparoscopic TUU exist. This may be a viable option in skilled hands, although long-term clinical data to support this technique do not yet exist (Kaiho et al., 2011; Piaggio et al., 2007).

Ileal Ureteral Substitution

Surgical management of long length of ureteral defect or loss, especially the proximal ureter, is particularly challenging (Benson et al., 1990). Reconstruction of the ureter with tissue lined with urothelium is most preferable because urothelium is not absorptive and is resistant to the inflammatory and potentially carcinogenic effects of urine (Harzmann et al., 1986). Incorporation of other tissue in ureteral repair is therefore reserved for situations in which a defect cannot be bridged by other methods or the bladder is unsuitable for reconstruction. In this scenario, ileal interposition has been demonstrated to be a satisfactory option for complicated ureteral reconstruction. On the other hand, the appendix and fallopian tube have been found to be unreliable ureteral substitutes.

Shoemaker reported the first ileal ureter in a woman with tuberculous involvement of the urinary tract in 1909. Later, the metabolic and physiologic effects of the ileal ureter have been investigated in the canine model (Hinman and Oppenheimer, 1958; Martinez et al., 1965). When an isoperistaltic segment of ileum is directly anastomosed to the bladder, reflux and renal pelvic pressure increase are generally seen only during voiding. The retrograde transmission of intravesical pressure is dependent on the length of ileum segment used in interposition and the voiding pressure. In patients with ileal segments longer than 15 cm, Waldner et al. (1999) found no reflux into the renal pelvis in a report involving 19 cases of ileal ureter with refluxing ileovesical anastomosis. Comparing dogs with tapered versus nontapered ileal segments, Waters et al. (1981) found no difference in renal perfusion pressure or metabolic derangements. A large clinical experience in ileal ureter involving 89 patients was reported by Boxer et al. (1979). Only 12% of patients with normal preoperative renal function developed significant metabolic problems postoperatively, and preoperative renal function was identified to be an important prognostic factor.

In a separate study, nearly half of those with a serum creatinine of greater than 2 mg/dL developed hyperchloremic metabolic acidosis, requiring conversion to a conduit (Koch and McDougal, 1985). Patients with bladder dysfunction also experienced more complications. No sufficient clinical data exist to establish the superiority of a tapered segment, a nonrefluxing anastomosis, or a shorter, segmental replacement over a standard ileal substitution (Waters et al., 1981). **Therefore the contraindications to an ileal ureteral substitution are baseline renal insufficiency with a serum creatinine of greater than 2 mg/dL, bladder dysfunction or outlet obstruction, inflammatory bowel disease, or radiation enteritis.**

Before the surgical procedure, a full mechanical and antibiotic bowel preparation is often used. A long midline incision is made. The ipsilateral colon is mobilized medially, and the affected ureter is dissected proximally to the level of healthy tissue. The proximal anastomosis may be performed at the level of the renal pelvis if the entire upper ureter is unhealthy. The length of the ureteral defect is measured, and an appropriate segment of distal ileum is chosen. The segment should be at least 15 cm away from the ileocecal valve, and adequate blood supply should be confirmed before harvesting. The mesentery is usually divided more extensively than with a standard ileal conduit to provide greater mobility. Occasionally, a segment of colon may be more accessible than ileum and is harvested using the similar surgical principles. **In the presence of a scarred or intrarenal pelvis, ileocalycostomy may be performed** (McQuitty et al., 1995). In this circumstance, excision of a piece of lower pole renal parenchymal tissue is helpful in preventing stenosis at the anastomosis, as in a typical ureterocalicostomy. After bowel division, the distal end of the ileal segment is marked for orientation and bowel-to-bowel continuity is reestablished. A small window is made in the colonic mesentery, through which the segment of ileum is delivered laterally. Alternatively, the cecum and ascending colon can be reflected superiorly to avoid mesenteric window creation in performing right ureteral reconstruction. The orientation of the ileal segment is checked to ensure isoperistalsis, and the anastomoses are performed at the level of the renal pelvis or lower pole calyx and at the bladder (Fig. 89.29). Bilateral ileal ureteral substitution may be achieved by using a longer segment that travels intraperitoneally from one kidney to the other and then to the bladder. An alternative to such is to use two separate bowel segments.

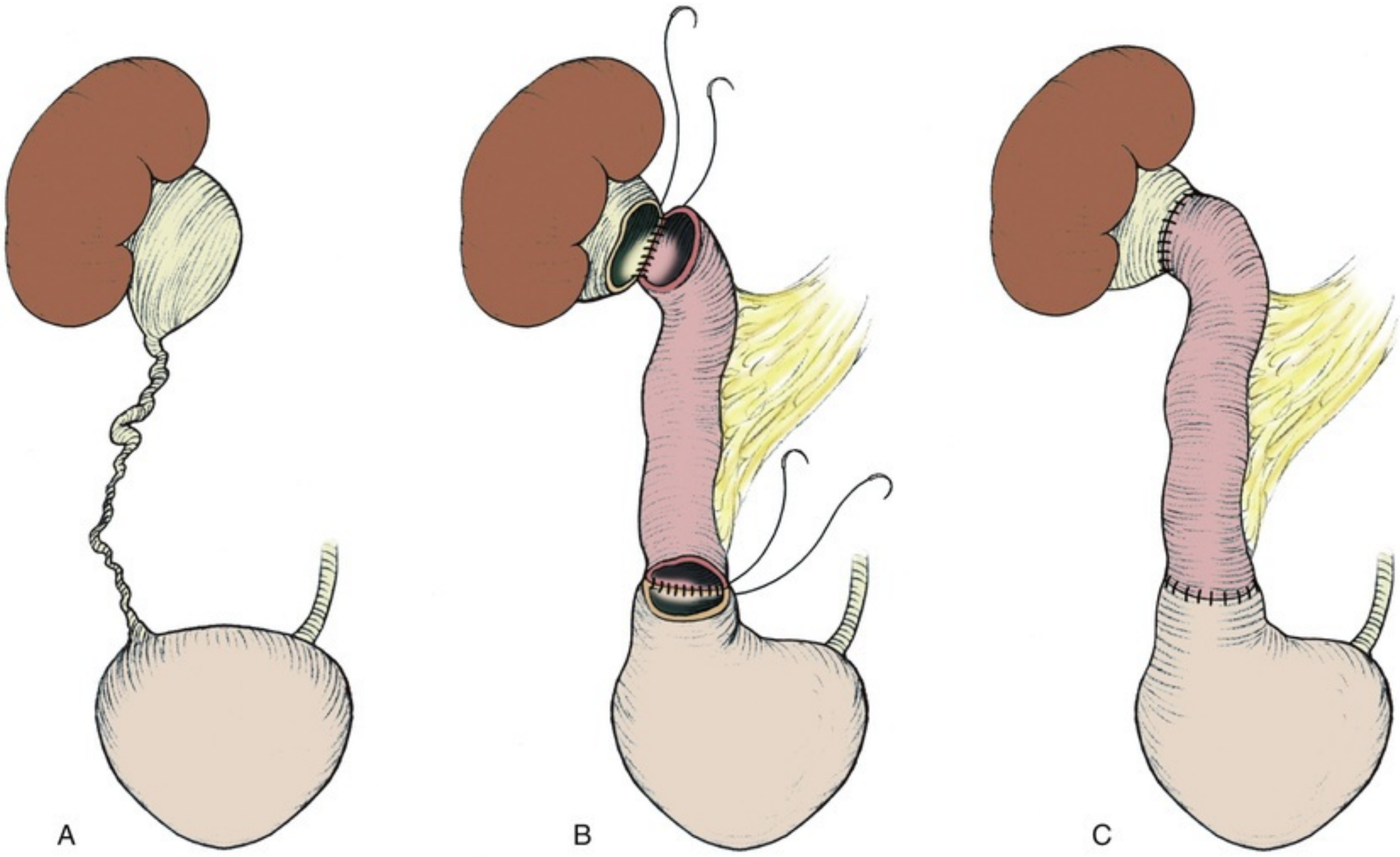

FIG. 89.29 (A) In ileal ureteral substitution, the affected ureter is first identified and dissected; this is followed by removal of the diseased portion. (B) A piece of ileum is brought through the colonic mesentery to bridge the renal pelvis and the bladder. (C) Proximal and distal anastomoses are completed in a full-thickness, watertight, tension-free manner.

Perioperative complications associated with ileal ureter include early urinary extravasation or urinoma formation and obstruction from edema, a mucous plug, or a kink in the segment. Ischemic necrosis of the ileal segment may occur and should be considered if signs of an acute abdomen are present. Significant electrolyte abnormalities and renal insufficiency are unusual if preoperative renal function is normal. **Patients with worsening metabolic abnormalities associated with a progressively dilating ileal ureter should be evaluated for bladder outlet obstruction. Furthermore, malignancy arising from ileal ureter segment has been reported in four cases in the literature** (Austen et al., 2004), **and it is recommended that regular endoscopic examination should be performed starting at postoperative year 3 for early detection of such malignancy.** However, Bonfig et al. (2004) confirmed the safety and reliability of ileal ureter creation for complex ureteral stricture/loss in 43 patients with a mean follow-up of 40.8 months. A more recent study from Wolff et al. (2011) reported long-term follow-up on 17 patients undergoing ileal ureteral substitution (median 174 months) and found that 15 patients still had ileal ureters at the end of the study interval, although 3 patients were later on dialysis. The mean creatinine value at last follow-up was 1.8±0.6 mg/dL.

Larger series with longer follow-up are now appearing in the literature. Kocot et al. (2017) reported outcomes over a mean 54 months in their series of 157 patients. Although functional drainage was not reported, 85% of kidneys displayed a decrease in hydronephrosis, and serum creatinine remained stable or improved in 94%. Hyperchloremic metabolic acidosis requiring pharmacologic treatment was noted in 19.5% of patients. Their conclusion from their 25-year experience with ileal ureteral substitution was that a refluxing anastomosis was typically safe when the ileal segment was anastomosed to a functional bladder but that nonrefluxing reconstruction may be useful in cases in which the urine reservoir is expected to be colonized with bacteria, such as continent cutaneous diversions, to reduce the risk of pyelonephritis. No cases of malignancy in the reconstructed system have been identified.

Minimally Invasive Ileal Ureteral Substitution

The clinical experience in laparoscopic ileal ureteral substitution is limited worldwide, yet this procedure appears to hold significant promise. Gill et al. (2000a) reported successful laparoscopic ileal ureter replacement using a transperitoneal, three-port approach. The feasibility of the laparoscopic approach is affirmed in a more recent publication from Stein et al. (2009), which compared 7 laparoscopic ileal ureters created during the same time period as 7 open procedures. This retrospective comparison found analgesic use and time to convalescence to favor the laparoscopic approach (median morphine equivalents 38.9 vs. 322.2 mg, $P = 0.035$, and 4 vs. 5.5 weeks, $P = 0.03$, respectively). Although median follow-up was short, particularly in the laparoscopic cohort (13 months, range 2–79), the authors report that all procedures were successful by imaging and symptomatic measurements. Since then, several other small case series have been reported favoring the approach.

In addition, several series of robotic-assisted laparoscopic ileal ureter have been published (Brandao et al., 2014; Chopra et al., 2016; Ubrig et al., 2018; Wagner et al., 2008). Of three patients undergoing completely intracorporeal robotic ileal substitution, Chopra et al. (2016) reported one patient had recurrence of urothelial cancer affecting the ipsilateral kidney necessitating later nephroureterectomy; another patient experienced volvulus causing ischemia of the ileal segment postoperative day 4, and this required emergent resection. Although other authors with similarly small series had favorable outcomes, longer follow-up will be needed to assess the outcomes of this approach.

Buccal Mucosa Grafting

The repair of complex, long, or reoperative stricture disease at any position in the ureter remains a challenging prospect, as evidenced by the variety of approaches described to tackle them. The success experienced by surgeons repairing complex urethral strictures using buccal mucosa harvested from the patient's oral cavity has led some surgeons to investigate this tissue as a tool for repairing complex ureteral strictures. This was first reported in humans by Naude in 1999 after working in an animal model, since that time a number of small case series have appeared using this technique in open and minimally invasive approaches, most commonly as an “onlay” similar to urethral repair. A recent multi-institutional series of 19 patients who underwent robotic buccal grafting illustrates the early findings of this technique. Median stricture length was 4 cm, and half of patients had had a prior repair. An omental flap was sewn to the graft to provide blood supply. At a median follow-up of 26 months, 17 of 19 patients remained stricture free (Zhao et al., 2017).

Autotransplantation

In 1963 Hardy performed the first autotransplantation for a patient with proximal ureteral injury. Since then, clinical autotransplantation has been performed for a variety of problems including extensive ureteral loss or stricture (Chuang et al., 1999; Hardy, 1963; Novick and Stewart, 1981; Wotkowicz et al., 2004). Generally, autotransplant is considered when the contralateral kidney is absent or poorly functioning or when other methods for ureteral substitution or repair are not feasible. The kidney is harvested with maximal vessel length as in a typical live donor nephrectomy for allotransplantation, and the renal vessels are anastomosed to the iliac vessels to reestablish renal perfusion. A healthy segment of the proximal ureter is anastomosed to the bladder (Bodie et al., 1986). Alternatively, the ipsilateral renal pelvis may be anastomosed directly to the bladder (Kennelly et al., 1993). Not surprisingly, laparoscopy has been successfully incorporated in autotransplantation for severe ureteral loss. Nephrectomy can be performed laparoscopically as in any typical laparoscopic donor nephrectomy, followed by renal graft retrieval, bench preparation, and autotransplantation in the ipsilateral iliac fossa via a Gibson incision using the standard open surgical techniques (Blueblond-Langner et al., 2004; Fabrizio et al., 2000; Meng et al., 2003). The use of laparoscopy in autotransplantation has been shown to provide reduced postoperative analgesic need and faster recovery because a large open upper abdominal or flank incision for renal harvest is avoided. Laparoscopic nephrectomy in autotransplantation is most commonly performed transperitoneally. However, retroperitoneal approach for such purpose has been applied successfully by Gill et al. (2000b).

Key Points: Surgical Repair of Ureteral Stricture

- Only short ureteral defects may be managed by end-to-end ureteroureterostomy.
- Distal ureteral stricture may be managed with ureteroneocystostomy with a psoas hitch or Boari flap.
- Boari flap may be used to bridge a 10- to 15-cm ureteral defect. Small bladder capacity is a contraindication to such flap creation. Care should be taken to ensure adequate vascular supply to the flap.
- Transureteroureterostomy is contraindicated in the presence of any disease process that may affect both ureters. It is also contraindicated if there is insufficient length of the donor ureter to reach the contralateral recipient ureter in a tension-free manner.
- Ileal ureter is useful in the presence of extensive ureteral loss. It is

contraindicated in cases of baseline renal insufficiency with a serum creatinine of greater than 2 mg/dL, bladder dysfunction or outlet obstruction, inflammatory bowel disease, or radiation cystitis.

- Autotransplantation is considered when the contralateral kidney is absent or poorly functioning or when other methods for ureteral substitution or repair are not feasible.
- Laparoscopic or robotic reconstructive techniques in the hands of urologists skilled in these approaches may provide quicker recovery for patients.

Ureteroenteric Anastomotic Stricture

Incidence and Etiology

Several factors determine the incidence of stricture formation at the anastomosis of the ureter and intestine at the time of urinary diversion. The longest follow-up data available are for urinary conduits, in which the stricture rate is 4% to 9%, and strictures are more common on the left (Anderson et al., 2013; Mattei et al., 2008; Schmidt et al., 1973; Skinner et al., 1980; Westerman et al., 2016). Factors potentially influencing outcome in this population include the technique used for ureteral dissection, the segment of bowel used for the diversion, and the type of anastomosis performed. Because ureteral ischemia is central to the cause of ureteroenteric strictures, careful attention to dissection is necessary to prevent complications. Anderson et al. (2013) found no difference in risk of ureteroenteric anastomotic stricture comparing open versus robotic/lap-assisted radical cystectomy. Another study found most of these strictures were benign (85%) and risk factors included CIS in the ureteral margin (Westerman et al., 2016).

The ureteral blood supply runs parallel to the ureter in the adventitia, and although ureteral mobilization is necessary to approximate the ureter and bowel and prevent tension on the anastomosis, stripping the ureter of its surrounding adventitia can lead to ureteral ischemia and stricture formation. The ileotomy technique is also a consideration. Cheng et al. (2011) reported using a shield-shaped ileotomy rather than a slit-shaped incision and found a 4.3% stricture rate compared with 8.3% in a retrospective assessment. Barbieri et al. (2010) reported ureteroileal anastomosis with intraluminal visualization in 118 patients with a 4.2% stricture rate at 15 months, all on the left side. With this approach the conduit is opened on the antimesenteric border to allow for direct visualization of the anastomosis. Moreover, Mattei et al. (2008) reported numerous advantages to routine stenting of ureteroileal anastomosis. **When an ileal conduit is performed, the left ureter is brought underneath the sigmoid mesentery just overlying the aorta. The additional length and dissection needed on the left and the possibility of angulation around the inferior mesenteric artery may lead to a higher incidence of stricture formation on the left** (Barbieri et al., 2010; Mansson et al., 1989).

Controversy exists over the choice of bowel segment used for conduit diversion. One theoretic advantage to the use of colon is the feasibility of performing a nonrefluxing anastomosis. However, the reported incidence of renal deterioration with a nonrefluxing versus a refluxing ureterocolonic anastomosis has been mixed, and there does not appear to be a clear advantage with respect to renal function and colonization with a nonrefluxing anastomosis. The issues influencing stricture formation in continent urinary diversions become even more complex because of the variety of bowel segments, reservoir configurations, and types of anastomoses available for reconstruction. **The reported rate of ureteroenteric anastomotic stricture after continent diversion is 3% to 25%, with the majority occurring within the first 2 years** (Kouba et al., 2007; Lugagne et al., 1997; Weijerman et al., 1998). Despite the paucity of randomized studies, there remains evidence in the literature that the risk of obstruction with a nonrefluxing anastomosis is significantly higher than that of a refluxing anastomosis. Pantuck et al. (2000) compared 60 nonrefluxing ureteroenteric anastomoses with 56 direct, refluxing anastomoses and found the long-term stricture rates to be 13% and 1.7%, respectively. With a mean follow-up of 41 months, there was no significant difference in the two groups with respect to hydronephrosis, pyelonephritis, nephrolithiasis, or renal insufficiency. Similarly, Roth et al. (1996) found a greater than fivefold increase in ureteral strictures in the group undergoing a nonrefluxing anastomosis. Their data also indicated that the risk of obstruction was unrelated to surgical expertise.

Studer et al. (1995) have reported a randomized study evaluating a nonrefluxing versus a refluxing anastomosis into an isoperistaltic afferent ileal limb. Thirteen percent of nonrefluxing anastomoses resulted in stricture formation, as compared with 3% of refluxing anastomoses. Although there is no clear evidence that reflux into an adult kidney is detrimental, it is clear that obstruction is harmful to renal function. These studies and others support the use of a refluxing anastomosis in low-pressure continent reservoirs.

Kouba et al. (2007) compared the Wallace and Bricker techniques of ureteroileal anastomosis for continent and incontinent diversions and found low rates of stricture (0% to 3%) using both techniques in 186 patients with 34-month follow-up. Notably, with use of the Wallace technique (joined ureters) no strictures were identified, compared with 3.7% in patients undergoing the Bricker technique (separate ureters). The group undergoing the Bricker anastomosis had a higher body mass index than the Wallace group.

Evaluation

Screening of the upper tracts in patients who have undergone any type of urinary diversion may include renal ultrasound, CT, or magnetic resonance imaging (MRI). If a stone or recurrent tumor is suggested, a CT scan or MRI is necessary for a more detailed assessment. In addition, patients with renal colic, recurrent urinary tract infection, or loss of renal function will require evaluation. In patients with hydronephrosis, CT urography, excretory urography, loopogram, or antegrade nephrostogram can provide information on the length and location of a stricture. Diuretic renography is indicated in patients with hydronephrosis to assess differential renal function and confirm the presence of functional obstruction. If hydronephrosis is present but renal function is insufficient for intravenous urogram or renography, placement of a nephrostomy tube and performance of an antegrade nephrostogram are diagnostic and therapeutic. This approach is also useful before endoscopic intervention because it clarifies stricture length, which aids in surgical planning.

Initial Management and Intervention

Not all patients with urinary diversion and hydronephrosis require intervention. **Most patients with a long-term urinary conduit will have an element of chronic hydronephrosis that is not secondary to obstruction. In this population, a decrease in renal function or loss of reflux on a routine loopogram should prompt diuretic renography to quantitatively assess for functional obstruction.** Indications for intervention in patients with diversions and hydronephrosis include pain, infection, and renal insufficiency associated with functional obstruction. Although recurrence of transitional cell carcinoma at the level of the anastomosis is uncommon, the radiographic picture of an irregular mass at the level of the stricture and the rapid progression of obstruction and loss of renal function should prompt further evaluation and intervention (Tsuji et al., 1996).

A particularly challenging subset of patients is those undergoing urinary diversion as part of a pelvic exenteration for gynecologic malignancy. Penalver et al. (1998) reported on 66 patients, 95% of whom had undergone previous pelvic irradiation. Early and late complications at the ureteroenteric anastomosis were 22% and 10%, respectively. Eighty-five percent of the postoperative complications were managed successfully by conservative measures such as percutaneous nephrostomy.

Open or robotic repair has been reported to be highly successful in 1 series of 50 patients (Gin et al., 2017). Open repair was associated with a 33% complication rate and 6-day hospitalization compared with 3-day hospitalization with robotic repair (Gin et al., 2017).

Endourologic Management

Endourologic management of ureteroenteric strictures has evolved in a manner analogous to that for ureteral stricture disease. Although the initial procedures involved simple balloon dilation and stent placement, unsatisfactory results led to incisional techniques using electrocautery; more recently, the laser was applied using fluoroscopic and direct endoscopic control. The current state-of-the-art incisional technique for endoureterotomy includes small-caliber flexible ureteroscopic instrumentation along with holmium laser incision (Cornud et al., 1992; Delvecchio et al., 2000; Laven et al., 2001, 2003; Muench et al., 1987; Schöndorf et al., 2013; Siegel et al., 1982).

Endourologic management of ureteroenteric or ureterocolic strictures, unlike the management of ureteral strictures, still favors antegrade management (Gomez et al., 2017). Accordingly, endourologic procedures typically begin with antegrade percutaneous access. Simple percutaneous drainage is continued to allow relief of any associated infection or obstruction-related renal dysfunction. Once the patient's condition is clinically stable, fluoroscopic control is used to pass a guidewire in an antegrade fashion across the anastomotic stricture, over which a balloon catheter can be positioned and inflated until the waist disappears. Stents are a routine part of endourologic management, and these are typically inserted in this same antegrade fashion. However, because of difficulty with mucous plugging of stents in this setting, many centers routinely use an internal-external stent, which can be easily flushed or changed over a wire. In addition, retrograde looposcopic access can be combined with percutaneous access and antegrade passage of a wire. With through-and-through control, the anastomosis can be visualized fluoroscopically or, preferably, with direct ureteroscopic, looposcopic, or trans-stomascopic visualization. Any number of procedures can then be used for the dilation, including balloon dilation alone, electroincision with an electrode or hot-wire cutting balloon, or holmium laser incision. In all cases, a stent is placed, usually for 4 to 8 weeks.

Balloon dilation of ureteroenteric strictures was one of the first endourologic forms of management used, and fortunately long-term results are available. Notably, short-term reports of use of high-pressure balloon dilation have demonstrated success rates as high as 61% (Ravery et al., 1998). Alternatively, Shapiro et al. (1988) reported balloon dilation for 37 benign ureteroenteric strictures in 29 patients. Only 6 dilations (16%) were considered to have a successful result at least 1 year after interventional treatment, and repeat dilations were often required to maintain ureteral patency. Similarly, Kwak et al. (1995) achieved an overall success rate of less than 30% at 9 months for patients undergoing antegrade balloon dilation of ureteroenteric strictures. More recently, DiMarco et al. (2001) reported a 5% 3-year success rate in 52 balloon dilations of ureteroenteric anastomotic strictures. Recently Schöndorf et al. (2013) reported on 74 patients with ureteroenteric anastomotic strictures with a 26% success rate with endourologic intervention compared with a 91% success rate with open intervention at 29 months. For strictures greater than 1 cm, the endourologic success rate was 6%, compared with a 50% success rate in strictures less than 1 cm. **Endourologic intervention was successful 19% on the left compared with 41% on the right, whereas no difference was noted in sidedness with open repair** (Schöndorf et al., 2013)**. More recently, one series reported 100% success rate in 7 patients with strictures smaller than 1 cm and overall 71% success rate using antegrade or retrograde balloon or sheath dilation with or without laser incision with 25-month median follow-up** (Gomez et al., 2017). These authors eventually advocated for antegrade approach based on their experience.

Metallic stents have also been used for ureteroenteric anastomotic strictures, with acceptable short-term results. Overall, of 30 patients in the published literature, the reported patency rate is greater than 80% with 6- to 22-month follow-up (Kurzer and Leveillee, 2005). **There is a higher incidence of encrustation and stone formation with use of metallic stents for ureteroenteric anastomotic strictures, in addition to the risks of tissue ingrowth, recurrent obstruction,** and stent migration (Gorin et al., 2011; Kurzer and Leveillee, 2005; Ng et al., 2013). This may explain the limited published data regarding use of this approach.

Cautery wire balloon incision has also been reported in patients treated for ureteroenteric strictures (Lin et al., 1999; Schöndorf et al., 2013). For benign strictures, stent-free long-term patency was achieved in only 30% of patients. Meretyk et al. (1991) reviewed the long-term results of endourologic management of ureteroenteric anastomotic strictures at Washington University.

In that study, 15 patients with 19 ureteroenteric strictures were followed for an average of 2½ years. An antegrade approach was used most frequently and was usually combined with electroincision. A 57% long-term stent-free patency rate was achieved, even with follow-up longer than 2 years. **Historically long-term patency of most endoscopic procedures approaches has been lower than operative revision, thus these approaches may be used preferentially as the initial intervention in select patients. Definitive operative management is reserved for patients in whom endourologic intervention fails and for patients with strictures longer than 1 cm** (Gin et al., 2017; Kramolowsky et al., 1987, 1988; Schöndorf et al., 2013).

Cornud et al. (1996) reported their long-term results with percutaneous electroincision of ureterointestinal anastomotic strictures and specifically compared the results of fluoroscopic and endoscopic guidance. Twenty-seven patients were followed for longer than 1 year after stent removal, and an overall patency rate of 71% was reported. These investigators found better results when direct endoscopic control was combined with fluoroscopic guidance, compared with fluoroscopic guidance alone. In that report, right common iliac artery damage was reported during electroincision in 1 patient who had the procedure performed under fluoroscopic guidance alone. As a result, direct visual approaches have been favored for the management of ureteroenteric or ureterocolic anastomotic strictures, and the holmium laser has proven to be an excellent incisional tool. Endoureterotomy is typically performed in an antegrade manner, and success rates ranging from 50% to 80% have been reported (Laven et al., 2001; Singal et al., 1997; Watterson et al., 2002). These reports suggest the left side is more resistant to management because the majority of the failures occurred on the left side (Laven et al., 2003; Schöndorf et al., 2013). **When endoscopic incision of a left ureteroenteric stricture is considered, the risk of hemorrhage is a concern because the sigmoid mesentery can be in close proximity. This, taken with the lower success rates of all endoscopic approaches on the left side, supports serious consideration for primary repair when treating left ureteroenteric anastomotic strictures** (Fig. 89.30). In spite of this, Lovaco et al. (2005) reported success treating 25 ureteroenteric strictures with endoureterotomy by an intraluminal invagination technique, with 80% success at more than 50 months’ follow-up. This approach increases the distance between the incision site and surrounding vessels and viscera and does not favor left or right strictures.

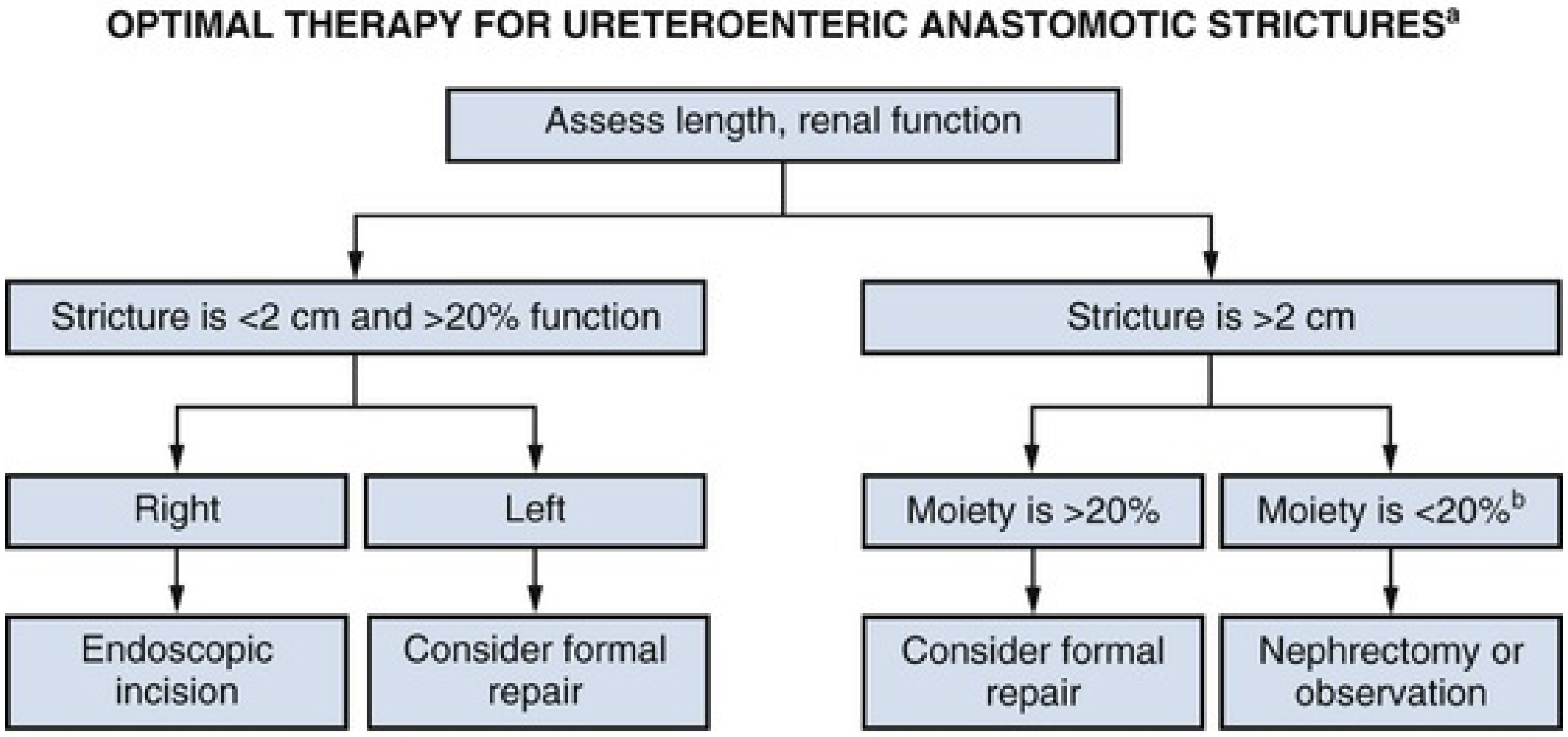
OPTIMAL THERAPY FOR URETEROENTERIC ANASTOMOTIC STRICTURES[a]
Assess length, renal function
Stricture is <2 cm and >20% function
Stricture is >2 cm
Right
Left
Moiety is >20%
Moiety is <20%[b]
Endoscopic incision
Consider formal repair
Consider formal repair
Nephrectomy or observation

[a] Consider balloon if transplant on immunosuppression.
[b] Pediatric patients and select patients with renal insufficiency may warrant repair.

FIG. 89.30 Algorithm for management of ureteroenteric anastomotic stricture disease.

Key Points: Ureteroenteric Strictures

- Although long-term patency of minimally invasive procedures for ureteroenteric strictures is in the range of 50%, such approaches are still used as the initial intervention, reserving operative management for those patients in whom endourologic intervention fails.
- When considering endoscopic incision of a left ureteroenteric anastomotic stricture in an ileal conduit, hemorrhage is a concern because the sigmoid mesentery can be in close proximity. With the low success rates of endoscopic approaches in this scenario, these patients may be best treated with definitive repair.
- Acceptable long-term success rates have been reported with open or robotic repair of ureteroenteric anastomotic strictures. As expected, strictures longer than 1 cm were more likely to recur, and procedures on the left side had lower success rates.

Retroperitoneal Fibrosis

Presentation and Etiology

RPF is typically characterized by the presence of an inflammatory, fibrotic process in the retroperitoneum causing compression of the retroperitoneal structures including the ureters. RPF most commonly affects patients who are 40 to 60 years of age. However, more than 30 cases of RPF have been reported in patients younger than 18 years of age (van Bommel, 2002). RPF cases are rare, have a male predominance, with a male-to-female ratio of 2 : 1 to 3 : 1, although one recent outcomes series showed no gender predominance (Jadhav et al., 2017). The true incidence is unknown but has been estimated to be 1 per 200,000 to 500,000 per year.

In general, the retroperitoneal fibrotic mass centers around the distal aorta at L4 to L5 and wraps around the ureters, leading to hydronephrosis via extrinsic compression on the ureters or interference with ureteral peristalsis (Koep and Zuidema, 1987; Lepor and Walsh, 1979). In most patients, the presenting symptom is pain in the lower back and/or flank. The pain, which is typically dull, noncolicky, and unchanged with posture, may radiate to the lower abdomen or groin. Furthermore, the pain is often relieved by aspirin rather than narcotics. Other symptoms include weight loss, anorexia, nausea, generalized malaise, fever, hypertension, and oliguria or anuria. The mass may compress the inferior vena cava, resulting in deep venous thrombosis and lower extremity edema (Rhee et al., 1994). The mass may extend proximally to the renal hilum and encase the renal vein, resulting in renal vein hypertension and subsequent gross hematuria (Powell et al., 2000). Aortic obstruction and involvement of the mediastinum, the biliary system, the mesentery, and the kidney are rare (Azuma et al., 1999; Dejaco et al., 1999; Klisnick et al., 1999; Tripodi et al., 1998). Distal extension to the bifurcation of the iliac vessels may occur, and extension to the spermatic cord with scrotal involvement has been reported (Palmer and Rosenthal, 1999; Schulte-Baukloh et al., 1999). Duration of symptoms before diagnosis is usually 4 to 6 months, and approximately half of the patients have fibrosis that has caused significant ureteral obstruction and symptoms secondary to uremia.

In approximately 70% of patients, the disease is idiopathic. Currently, idiopathic RPF is considered part of the spectrum of chronic periaortitis, a

large vessel vasculitis (Pipitone et al., 2012). Ceroid, a complex polymer of oxidized lipids and protein found in atherosclerotic plaques, has been suggested as the antigen initiating the inflammatory response (Parums et al., 1991). Indeed, a higher incidence of aortic aneurysms has been identified in patients with RPF (Breems et al., 2000). RPF usually occurs as an isolated disease entity, but it may occur as part of multifocal fibrosclerosis, a rare syndrome characterized by fibrosis involving multiple organ systems. In such a scenario, the clinical presentation may include RPF, sclerosing mediastinitis, sclerosing cholangitis, orbital pseudotumor, and Riedel thyroiditis (Dehner and Coffin, 1998; Özgen and Cila, 2000). The pathogenesis of these disorders is unknown but appears to be autoimmune.

Among the 30% of RPF patients who have an identifiable cause, drugs such as methysergide (Sansert) and other ergot alkyloids are most commonly associated with RPF. Beta-blockers and phenacetin have also been implicated. The exact pathophysiology of drug-induced RPF remains unknown. Other causes of RPF include malignancies such as lymphoma, the most common malignancy in RPF cases, and multiple myeloma, carcinoid, pancreatic cancer, prostate cancer, and sarcoma (Usher et al., 1977; Webb and Dawson-Edwards, 1967). Radiotherapy for retroperitoneal malignancy is also known to produce a residual fibrotic mass leading to secondary ureteral obstruction. Asbestos exposure has also been associated with RPF in exposed workers in Finland, via gastrointestinal and pulmonary lymphatic drainage (Scheel and Feeley, 2013). In addition, infectious causes such as tuberculosis, *Actinomyces*, gonorrhea, and schistosomiasis have been suggested in the pathogenesis of RPF.

Association of RPF with membranous glomerulonephritis has also been documented in the literature (Mercadal et al., 2000; Shirota et al., 2002). The exact cause remains unclear, although the association has been speculated to be secondary to an unknown antigen triggering systemic immune response that leads to RPF. Association of RPF with ankylosing spondylitis and Wegener granulomatosis has also been reported, further suggesting an underlying immune cause in some patients (Izzedine et al., 2002; LeBlanc et al., 2002).

Pathologically, the typical gross appearance of RPF is that of a smooth, flat, tan, dense mass enveloping the surrounding retroperitoneal structures. It is also known to invade the ureter or psoas muscle. Histologically, the appearance of RPF is that of a nonspecific inflammatory process that varies with the stage of the disease. Early in the disease, affected tissue consists mainly of collagen bundles with capillary proliferation and inflammatory cells including lymphocytes, plasma cells, and fibroblasts. In the later stage, the mass becomes relatively acellular and avascular, consisting of sheets of hypocellular collagen. RPF secondary to malignancy is often histologically indistinguishable from idiopathic RPF, and it can be identified only on the basis of the demonstration of small islands of tumor cells within the fibrotic mass.

Evaluation

In most RPF patients, the clinical symptoms are generally nonspecific, and physical examination is usually unrevealing. Laboratory evaluation may reveal an elevated erythrocyte sedimentation rate (ESR), elevated C-reactive protein (CRP), moderate leukocytosis, anemia, and variable renal insufficiency with associated electrolyte abnormalities. The ESR and CRP are elevated in one-half to two-thirds of patients with idiopathic RPF (Pipitone et al., 2012). If the overall renal function is normal CT urography may be performed. Typical findings include hydronephrosis with medial deviation of the proximal ureter and midureter and a smoothly tapered ureter at the level of obstruction. Urinary obstruction is usually bilateral, but unilateral cases have been described. Uncommonly, there are patients with symptoms of urinary obstruction but little hydronephrosis on imaging.

CT scan typically reveals hydronephrosis associated with a well-delineated retroperitoneal soft tissue mass enveloping the great vessels and the ureters (Fig. 89.31). If the patient has significant renal impairment, a retrograde pyelogram may be performed**. In the radiographic evaluation of RPF, MRI is useful as the fibrotic mass has characteristic T1- and T2-weighted characteristics. RPF is characterized as a diffusely low signal intensity on T1-weighted imaging, although the T2 signal may vary considerably, with high signal intensity consistent with active disease** (Fig. 89.32). With treatment, T2 signal often diminishes and thus provides a measure of therapeutic efficacy. Moreover, gadolinium enhancement may also prove valuable in assessing the response to treatment because associated decreases in gadolinium contrast enhancement should also be expected after appropriate therapy (Cronin et al., 2008). Similarly, contrast enhancement on CT can also be used to monitor therapy, as can positron emission tomography (PET). In fact, PET appears to be the most sensitive imaging study for disease activity and may obviate the need for biopsy (Fernando et al., 2017; Pipitone et al., 2012). In addition, single-stop PET and contrast-enhanced CT has been used for ongoing assessment of patients with RPF (Guignard et al., 2012).

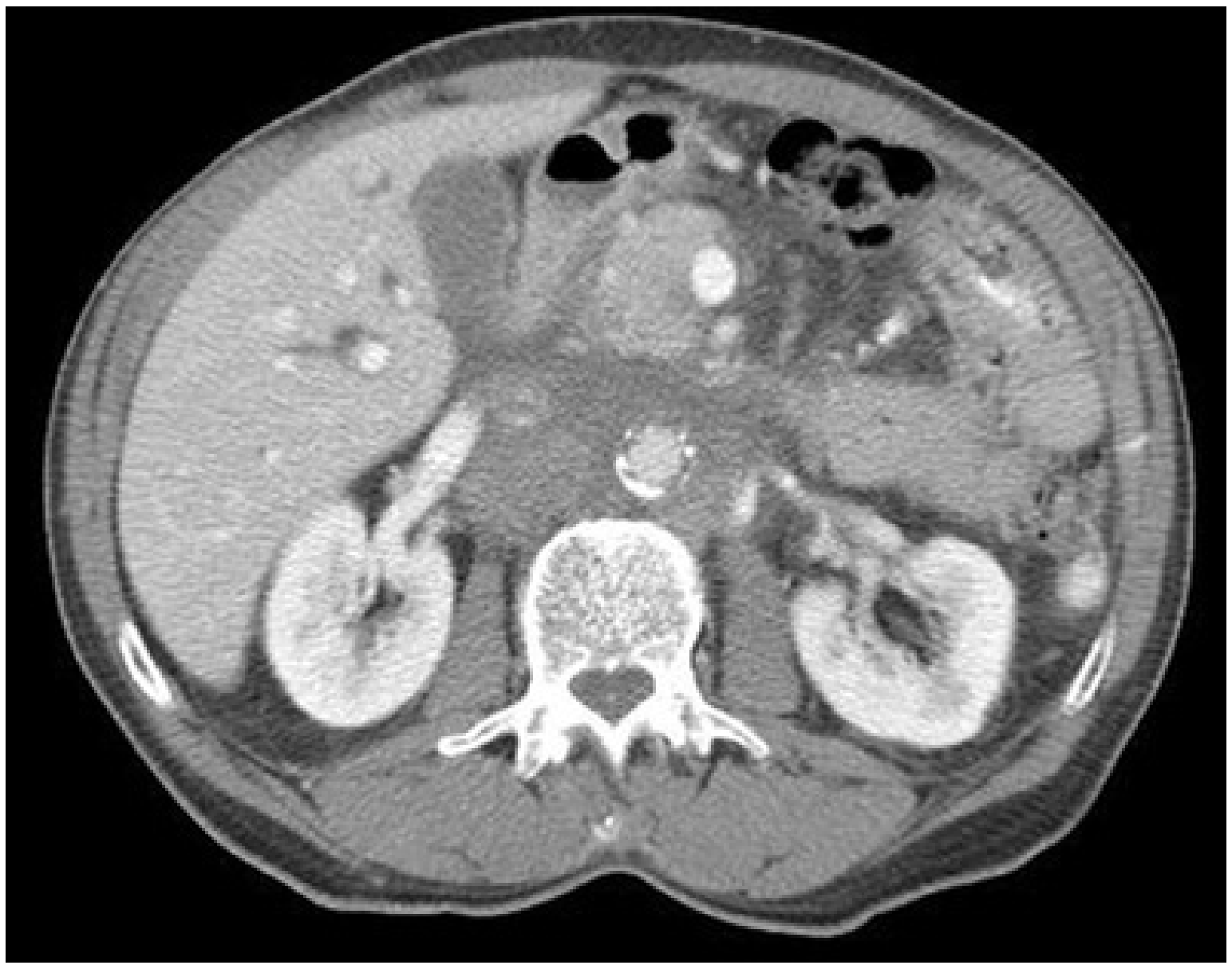

FIG. 89.31 Typical computed tomographic findings of retroperitoneal fibrosis. The study demonstrates the presence of a homogeneous mass obliterating the outline of the great vessels at the lumbar area.

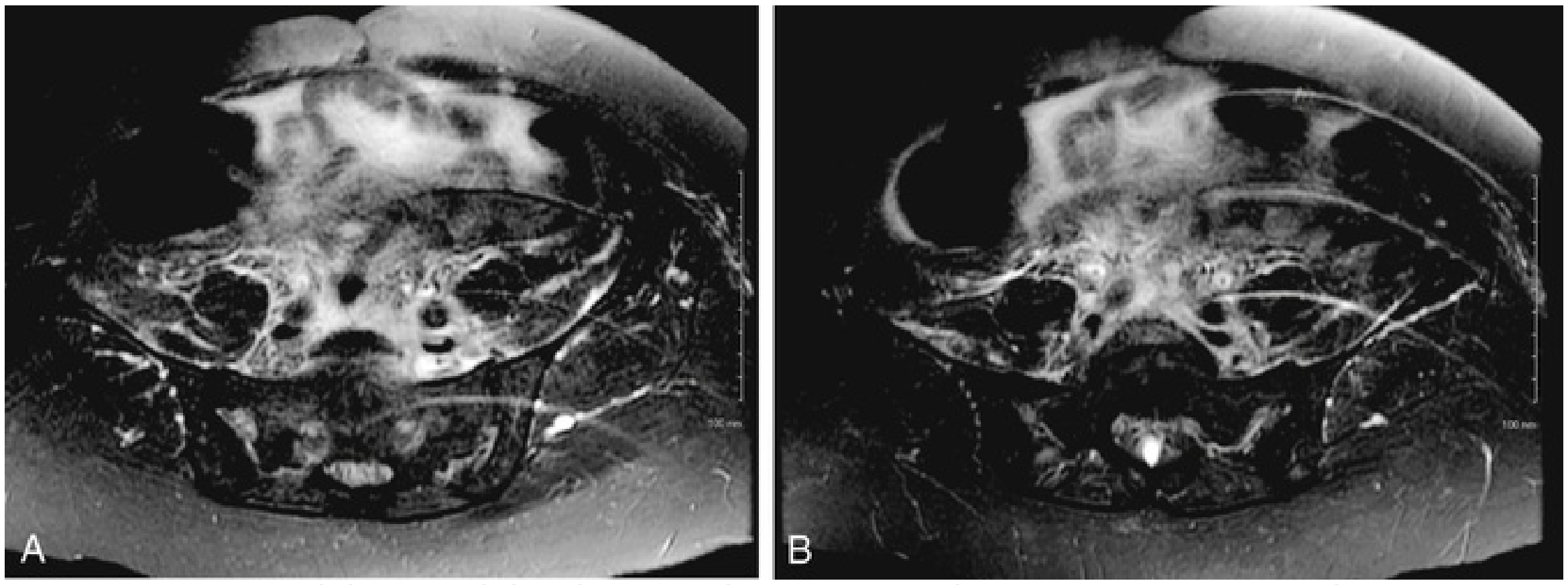

FIG. 89.32 (A) T2-weighted magnetic resonance image of a symptomatic patient demonstrating retroperitoneal fibrosis with enhancement and thus active disease. (B) Same patient after 1 month of medical therapy; note the decrease in enhancement on this corroborative T2-weighted image.

If a kidney is suspected to be nonfunctioning, differential renography should be considered to determine renal function because it may affect surgical planning. Representative biopsy samples of the mass may be obtained percutaneously or at the time of surgery to rule out malignancy if the diagnosis remains uncertain after imaging.

Management

Initial Management

The initial management of RPF depends on the patient's clinical status. Patients with hydronephrosis and uremia should be emergently decompressed by either percutaneous nephrostomy or indwelling ureteral stents. The advantages to placing ureteral stents include the opportunity to perform retrograde pyelograms to evaluate the anatomy as well as the convenience of internal drainage. Ureteral stent placement is usually not difficult to perform in the setting of ureteral obstruction caused by RPF. In a critically ill patient with electrolyte abnormalities and little or no urine output, nephrostomy tube placement is favored. **After renal decompression, the patient should be monitored closely for postobstructive diuresis, renal function status, and appropriate replacement of fluids and electrolytes.**

After the initial management, an attempt to identify the cause of RPF should be made. Methysergide or any other potentially inciting drug, if identified, should be discontinued. Although most patients with malignant RPF have a prior history of malignancy, a thorough evaluation for occult malignancy with careful application of imaging studies is necessary. Biopsy to rule out malignancy, performed percutaneously or at the time of ureterolysis to provide long-term relief of obstruction, should be considered. **However, some believe that in patients with no history of prior malignancy, no classic radiographic features on MRI or CT, and no lymphadenopathy, a biopsy is not essential before medical therapy. This concept has been further strengthened with the use of PET scans** (Fernando et al., 2017).

Medical Management

Once the diagnosis of idiopathic RPF is made, the common primary medical management has been steroid therapy. In the medical literature there are approximately 170 cases of idiopathic RPF treated with steroids that resulted in about an 80% clinical response, including a decrease in size of the mass and improvement in ureteral obstruction or inferior vena cava compression (Adam et al., 1998; Baker et al., 1987; Fry et al., 2008; Higgins et al., 1998; Kearney et al., 1976; van Bommel, 2002). The characteristic clinical response to steroid therapy includes resolution of pain and constitutional symptoms within days after treatment, a rapid fall of ESR, and diuresis. Dose and duration of steroid therapy vary considerably in the literature, but most regimens start with initial doses of 60 mg daily tapered to 5 mg daily. Chronic steroid therapy up to 2 years has been shown to provide significant improvement in clinical symptoms and regression of retroperitoneal mass (Kardar et al., 2002), although relapse during tapering occurs in 25% to 50% of patients (Pipitone et al., 2012). Patients who have evidence of active inflammation—manifested by increased ESR, CRP, leukocytosis, or active inflammation on a biopsy—are more likely to respond to steroid therapy.

In addition to steroids, immunosuppressive agents including azathioprine, cyclophosphamide, cyclosporine, colchicine, and mycophenolate mofetil have been described to provide benefit in idiopathic RPF in isolated reports (Grotz et al., 1998; Marzano et al., 2001; McDougal et al., 1991; Vega et al., 2009; Wagenknecht et al., 1981). Medroxyprogesterone acetate, progesterone, and particularly tamoxifen have also been found to be beneficial in idiopathic RPF (Al-Musawi et al., 1998; Benson and Baum, 1993; Clark et al., 1991; Dedeoglu et al., 2000; Pipitone et al., 2012; Puce et al., 2000). The exact mechanisms of action of these medications are unclear, but they are believed to inhibit fibroblastic proliferation leading to clinical response. **Use of immunosuppressive agents is reserved for patients in whom steroid therapy fails, because relapses are as high as 50% during steroid tapering** (Pipitone et al., 2012).

Surgical Management

Ureterolysis may be performed open surgically or laparoscopically, although open surgery has been considered the standard (Elashry et al., 1996; Lindell and Lehtonen, 1988). **When an open surgery is performed, a midline, transperitoneal abdominal incision is made to allow access to both ureters. For laparoscopic or robotic bilateral ureterolysis, the patient is typically placed in the modified flank position and repositioned to the other flank after the first side is complete.** The surgical principles are the same regardless of approach. Placement of ureteral catheters or stents at the beginning of the procedure is advisable to assist identification and dissection of the ureters. **Although hydronephrosis may be unilateral on preoperative assessment, the**

process is generally bilateral requiring bilateral ureterolysis. After medial mobilization of the ascending and descending colon, deep biopsies of the mass should be obtained for frozen and permanent section to rule out malignancy and confirm the diagnosis. Dissection should begin at the distal, nondilated ureteral segment to avoid injury to the thin, dilated proximal segment. A right-angle clamp can be placed between the ureter and the retroperitoneal mass along the course of the ureter, and the fibrotic tissue is then incised above the clamp, the so-called "split and roll technique." This is repeated throughout the length of the entrapped ureter, using blunt and sharp dissection techniques to free the affected ureter from its fibrous bed. The ureteral wall may become thin at times after the dissection. An inadvertent ureterotomy should be closed with absorbable suture. Ureteral excision with ureteroureterostomy is usually unnecessary.

After bilateral ureterolysis, the surgeon must physically separate the newly freed ureters from the fibrotic tissue that encased them, lest the obstructive process recur. Several surgical options may be considered to accomplish this goal, but the key principles favor an approach that provides a new healthy tissue layer that is not affected by the fibrotic process, ideally one with good blood supply such as the omentum, as well as a reconstruction that does not kink the ureters. One option is to retract the ureters laterally after they have been released and then close the parietal peritoneum over the fibrotic "bed" that contained them, creating a physical separation that should prevent the ureters from re-entering the retroperitoneum and becoming entrapped again. Some surgeons will accomplish a similar intraperitonealization of the ureter by moving the previously reflected colon behind the mobilized ureter and securing the peritoneal edge of the bowel to the abdominal side wall. It is important not to obstruct or kink the ureter in the closure of the peritoneum at the ureteral hiatus. In a report on a group of patients with idiopathic RPF undergoing intraperitoneal placement of the ureters or lateral retroperitoneal placement of the ureters, no difference in the radiologic or clinical outcome was found (Barbalias and Liatsikos, 1999). In the setting of extensive RPF, a more definitive approach is to surround the ureters with omentum after repositioning them within the peritoneal cavity (Carini et al., 1982; Tresidder et al., 1972). To perform the omental wrap, the omentum is first mobilized from its attachment to the transverse colon, followed by its division along its midline with ligation of the small omental vessels up to the gastric attachment. The short gastric vessels are then divided and ligated at the level of the stomach wall, after which the two halves of the omentum can be retracted laterally on the basis of the right and left gastroepiploic arteries. The entire length of the ureter can be surrounded by omental tissue, which is tacked in place with absorbable sutures (Fig. 89.33A and B). The omentum provides protection of the ureter against recurrent extrinsic compression and vascularity to a potentially ischemic ureter. Steroid therapy may be used postoperatively in an attempt to prevent recurrent upper tract compression. If no ureterotomy occurs during ureterolysis, the previously placed stents may be removed shortly after surgery.

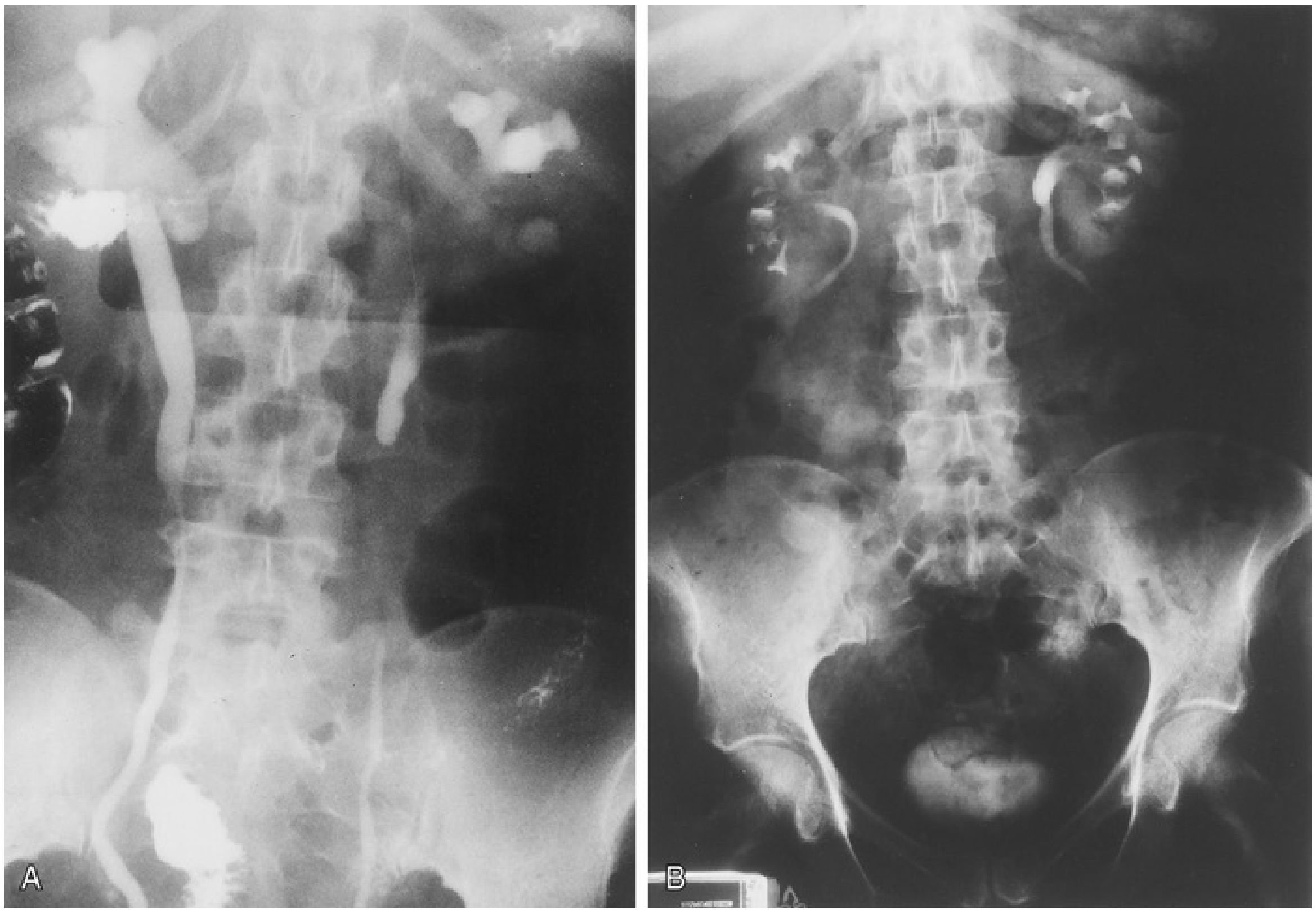

FIG. 89.33 (A) Preoperative intravenous contrast-enhanced radiograph of a patient with idiopathic retroperitoneal fibrosis, showing bilateral hydronephrosis with medial deviation of the ureters. (B) Postoperative radiograph of the same patient after surgical ureterolysis with intraperitoneal omental wrapping.

If ureterolysis is impossible to perform because of extensive periureteral fibrosis, renal autotransplantation may be performed if the ipsilateral renal unit demonstrates satisfactory function (Penalver et al., 2001). If no significant renal function can be recovered after an adequate time period of decompression in the presence of the satisfactory contralateral renal function, nephrectomy may be considered.

Outcomes of Ureterolysis

A recent report demonstrated 94% of patients were stent free at 12 months after open ureterolysis (O'Brien and Fernando, 2017). Another report showed good results employing ureterolysis, ureteral reconstruction, or ileal ureter (Jadhav et al., 2017). The first laparoscopic ureterolysis was reported by Kavoussi and Clayman in 1992. Subsequent success with this technique was confirmed by others (Puppo et al., 1994). Another report described an experience with laparoscopic ureterolysis in 13 patients, including bilateral procedure in 7 and unilateral procedure in 6 (Fugita et al., 2001). Preoperative stent placement was performed in all cases before laparoscopy. For each ureter, the laparoscopic procedure was performed using a transperitoneal four-port approach. After incision of the posterior peritoneum and mobilization of the colon, the affected ureter was dissected free from the retroperitoneal fibrotic tissue. Multiple frozen-section biopsies of the periureteral tissue were obtained to rule out malignancy. The edge of the posterior peritoneum was reapproximated to the sidewall underneath the ureter to intraperitonealize the ureter. Laparoscopic ureterolysis was completed successfully in 85% (11) of the cases, with 2 (15%) open conversions resulting from iliac vein injury (in 1 patient) and marked fibrosis (in 1 patient). Mean operative time was 381 minutes for bilateral procedures and 192 minutes for unilateral procedures. Mean use of parenteral analgesics was 59 mg of morphine sulfate equivalent. Mean hospital stay was 4 days. Postoperative complications occurred in 30% (4) of the patients, including epididymitis, umbilical port erythema, prolonged ileus, and urinary retention. Pathology showed fibrous tissue with lymphocytes, plasma cells, macrophages, and fibroblast proliferation in all cases. At a mean follow-up of 30 months, upper tract imaging such as intravenous urography or renal scan showed lack of obstruction in 92% (12) of the patients. A multi-institutional survey that included 17 academic centers identified that centers with a fellowship-trained laparoscopist performed laparoscopic ureterolysis, and in 59% of centers urologists performed the medical management. Notably in this survey the reported laparoscopic success rates were 83% (Duchene et al., 2007).

A more recent retrospective comparison of laparoscopic and open ureterolysis (16 ureters in each group) concluded that the minimally invasive approach was associated with a shorter hospital stay (mean 2.1 vs. 5.9 days, $P = 0.004$) but that success and complication rates were similar with both approaches (Styn et al., 2011).

Robotic ureterolysis for retroperitoneal fibrosis has also been reported. Keehn et al. (2011) treated a total of 21 renal units in 17 patients with robotic ureterolysis and omental wrapping. Fourteen percent recurred and required a secondary surgical intervention, whereas 86% remained patent at a mean follow-up of 20.5 months. They reported one perioperative complication, an enterocutaneous fistula from an unrecognized thermal bowel injury that required bowel resection.

Key Points: Retroperitoneal Fibrosis

- The retroperitoneal fibrotic mass generally centers around the distal aorta at L4-L5 and wraps around the ureters, leading to hydronephrosis via extrinsic compression on the ureters or interference with ureteral peristalsis. In most cases the disease is idiopathic, associated with chronic aortitis.
- RPF symptoms and signs are usually nonspecific. Laboratory evaluation may show an elevated erythrocyte sedimentation rate, C-reactive protein, moderate leukocytosis, anemia, and variable renal insufficiency associated with electrolyte abnormalities.
- Initial management of RPF in the presence of hydronephrosis and uremia includes emergent decompression by percutaneous nephrostomy or indwelling ureteral stents. After decompression, the patient should be monitored closely for postobstructive diuresis.
- The most common primary medical management of idiopathic RPF has been steroid therapy, with immunosuppressive agents as second line.
- In surgical bilateral ureterolysis, the ureters need to be protected by intraperitonealization or omental wrapping. Both open and laparoscopic techniques may be applied successfully. If ureterolysis is impossible to perform, renal autotransplantation may be performed.

Suggested Readings

Jarrett TW, Chan DY, Charambura TC, et al. Laparoscopic pyeloplasty: the first 100 cases. *J Urol*. 2002;167:1253.

Khanna R, Isac W, Laydner H, et al. Laparoendoscopic single site reconstructive procedures in urology: medium term results. *J Urol*. 2012;187:1702.

Link RE, Bhayani SB, Kavoussi LR. A prospective comparison of robotic and laparoscopic pyeloplasty. *Ann Surg*. 2006;243:486.

Mufarrij PW, Woods M, Shah OD, et al. Robotic dismembered pyeloplasty: a 6-year, multi-institutional experience. *J Urol*. 2008;180:1391.

Ockerblad NF. Reimplantation of the ureter into the bladder by a flap method. *J Urol*. 1947;57:845.

Pipitone N, Vaglio A, Salvarani C. Retroperitoneal fibrosis. *Best Pract Res Clin Rheumatol*. 2012;26:439.

Razdan S, Silberstein IK, Bagley DH. Ureteroscopic endoureterotomy. *BJU Int*. 2005;95(Suppl 2):94.

Richstone L, Seideman CA, Reggio E, et al. Pathologic findings in patients with ureteropelvic junction obstruction and crossing vessels. *Urology*. 2009;73:716.

Schöndorf D, Meierhans-Ruf S, Kiss B, et al. Ureteroileal strictures after urinary diversion with an ileal segment—is there a place for endourological treatment at all? *J Urol*. 2013;190:585.

Turner-Warwick RT, Worth PH. The psoas bladder-hitch procedure for the replacement of the lower third of the ureter. *Br J Urol*. 1969;41:701.

References

Abraham GP, Das K, Ramaswami K, et al. Laparoscopic reconstruction of iatrogenic-induced lower ureteric strictures: does timing of repair influence the outcome? *Indian J Urol*. 2011;27:465.

Adam U, Mack D, Forstner R, et al. Conservative treatment of acute Ormond's disease. *Tech Urol*. 1998;5:54.

Ahn M, Loughlin KR. Psoas hitch ureteral reimplantation in adults—analysis of modified technique and timing of repair. *Urology*. 2001;58:184.

Albani JM, Yost AJ, Streem SB. Ureteropelvic junction obstruction: determining durability of endourological intervention. *J Urol*. 2004;171:579.

Allaparthi S, Ramanathan R, Balaji KC. Robotic distal ureterectomy with Boari flap reconstruction for distal ureteral urothelial cancers: a single institutional pilot experience. *J Laparoendosc Adv Surg Tech A*. 2010;20:165.

Allen TD. Congenital ureteral stricture. *J Urol*. 1970;104:196.

Al-Musawi P, Mitchenere P, Al-Akraa M. Idiopathic retroperitoneal fibrosis treated with tamoxifen only. *Br J Urol*. 1998;82:442.

Ambani SN, Faerber GJ, Roberts WW, et al. Ureteral stents for impassable ureteroscopy. *J Endourol*. 2013;27:549.

Anderson CB, Morgan TM, Kappa S, et al. Ureteroenteric anastomotic strictures after radical cystectomy—does operative approach matter? *J Urol*. 2013;189:541.

Anderson JC, Hynes W. Retrocaval ureter: a case diagnosed preoperatively and treated successfully by a plastic operation. *Br J Urol*. 1949;21:209.

Arap MA, Andrade H, Torricelli FC, et al. Laparoscopic ureterocalicostomy for complicated upper tract obstruction:

mid-term follow-up. *Int Urol Nephrol*. 2014;46:865.

Ark JT, Mitchell CR, Marien TP, et al. Use of contrasted computerized tomography as a surrogate for nuclear medicine renogram to categorize renal function in the setting of ureteropelvic junction obstruction. *Urology*. 2016;97:238.

Atug F, Castle EP, Burgess SV, et al. Concomitant management of renal calculi and pelvi-ureteric junction obstruction with robotic laparoscopic surgery. *BJU Int*. 2005;96:1365.

Atug F, Woods M, Burgess SV, et al. Robotic assisted laparoscopic pyeloplasty in children. *J Urol*. 2005;174:1440.

Austen M, Kalble T. Secondary malignancies in different forms of urinary diversion using isolated gut. *J Urol*. 2004;172:831.

Autorino R, Eden C, El-Ghoneimi A, et al. Robot-assisted and laparoscopic repair of ureteropelvic junction obstruction: a systemic review and meta-analysis. *Eur Urol*. 2014;65:430.

Azuma T, Kato Y, Suetomi T, et al. Idiopathic retroperitoneal fibrosis presenting as duodenal obstruction. *J Urol*. 1999;162:1680.

Baba S, Oya M, Miyahara M, et al. Laparoscopic surgical correction of circumcaval ureter. *Urology*. 1994;44:122.

Bach T, Geavlete B, Herrmann TW, et al. Retrograde blind endoureterotomy for subtotal ureteral strictures: a new technique. *J Endourol*. 2008;22:2565.

Bachmann A, Ruszat R, Forster T, et al. Retroperitoneoscopic pyeloplasty for ureteropelvic junction obstruction (UPJO): solving the technical difficulties. *Eur Urol*. 2006;49:264.

Badlani G, Eshghi M, Smith AD. Percutaneous surgery for ureteropelvic junction obstruction (endopyelotomy): technique and early results. *J Urol*. 1986;135:26.

Badlani G, Karlin G, Smith AD. Complications of endopyelotomy: analysis in series of 64 patients. *J Urol*. 1988;140:473.

Bagley DH, Huffman J, Lyon E, et al. Endoscopic ureteropyelostomy: opening the obliterated ureteropelvic junction with nephroscopy and flexible ureteropyeloscopy. *J Urol*. 1985;133:462.

Baker LR, Mallinson WJ, Gregory MC, et al. Idiopathic retroperitoneal fibrosis. A retrospective analysis of 60 cases. *Br J Urol*. 1987;60:497.

Banner MP, Pollack HM, Ring EJ, et al. Catheter dilatation of benign ureteral strictures. *Radiology*. 1983;147:427.

Banner MP, Pollack HW. Dilatation of ureteral stenosis: techniques and experience in 44 patients. *AJR Am J Roentgenol*. 1984;143:789.

Barbalias GA, Liatsikos EN. Idiopathic retroperitoneal fibrosis revisited. *Int Urol Nephrol*. 1999;31:423.

Barbieri CE, Schwartz MJ, Boorjian SA, et al. Ureteroileal anastomosis with intraluminal visualization: technique and outcomes. *Urology*. 2010;76:1496.

Beaghler MA, Taylor FC, McLaughlin KP. A combined antegrade and retrograde technique for reestablishing ureteral continuity. *Tech Urol*. 1997;3:44.

Bejjani B, Belman AB. Ureteropelvic junction obstruction in newborns and infants. *J Urol*. 1982;128:770.

Bellman GC. Complications of endopyelotomy. *J Endourol*. 1996;10:177.

Benson JR, Baum M. Tamoxifen for retroperitoneal fibrosis. *Lancet*. 1993;341:836.

Benson MC, Ring KS, Olsson CA. Ureteral reconstruction and bypass: experience with ileal interposition, the Boari flap–psoas hitch and renal autotransplantation. *J Urol*. 1990;143:20.

Berger RM, Lebowitz JM, Carroll PA. Ureteral polyps presenting as ureteropelvic junction obstruction in children. *J Urol*. 1982;128:805.

Bernstein GT, Mandell J, Lebowits RL, et al. Ureteropelvic junction obstruction in the neonate. *J Urol*. 1988;140:1216.

Berzeg S, Baumgart E, Beyersdorff D, et al. Late complication of Boari bladder flap. *Eur Radiol*. 2003;13:1604.

Biyani CS, Cornford PA, Powell CS. Retrograde endoureteropyelotomy with the holmium:YAG laser. Initial experience. *Eur Urol*. 1997;32:471.

Blueblond-Langner R, Rha KH, Pinto PA, et al. Laparoscopic-assisted renal autotransplantation. *Urology*. 2004;63:853.

Bodie B, Novick AC, Rose M, et al. Long-term results with renal autotransplantation for ureteral replacement. *J Urol*. 1986;136:1187.

Bonfig R, Gerharz EW, Riedmiller H. Ileal ureteric replacement in complex reconstruction of the urinary tract. *BJU Int*. 2004;93:575.

Borin JF, Melamud O, Clayman RV. Initial experience with full length metal stent to relieve malignant ureteral obstruction. *J Endourol*. 2006;20:300.

Bovie P, Ong AM, Rha K, et al. Laparoscopic management of ureteropelvic junction obstruction in patients with upper urinary tract anomalies. *J Urol*. 2004;171:77.

Boxer RJ, Fritzsche P, Skinner DG, et al. Replacement of the ureter by small intestine: clinical application and results of the ileal ureter in 89 patients. *J Urol*. 1979;121:728.

Brandao LF, Autorino R, Zargar H, et al. Robotic ileal ureter: a completely intracorporeal technique. *Urology*. 2014;83:951.

Brannan W. Useful applications of transureteroureterostomy in adults and children. *J Urol*. 1975;113:460.

Brannen GE, Bush WH, Lewis GP. Endopyelotomy for primary repair of ureteropelvic junction obstruction. *J Urol*. 1988;139:29.

Breems DA, Haye H, van der Meulen J. The role of advanced atherosclerosis in idiopathic retroperitoneal fibrosis. *Neth J Med*. 2000;56:38.

Brooks JD, Kavoussi LR, Preminger GM, et al. Comparison of open and endourologic approaches to the obstructed ureteropelvic junction. *Urology*. 1995;46:791.

Butani RP, Eshghi M. Cold knife retrograde endopyelotomy: a long term follow-up. *J Endourol*. 2008;22:657.

Cancian M, Pareek G, Caldamone A, et al. Histopathology in ureteropelvic junction obstruction with and without crossing vessels. *Urology*. 2017;107:209.

Canes D, Berger A, Gettman MT, et al. Minimally invasive approaches to ureteropelvic junction obstruction. *Urol Clin North Am*. 2008;35:25.

Cardella JF, Hunter DW, Castaneda-Zuniga WR, et al.

Electrolysis for recanalization of urinary collecting system obstructions: a percutaneous approach. *Radiology*. 1985;155:87.

Carini M, Selli C, Rizzo M, et al. Surgical treatment of retroperitoneal fibrosis with omentoplasty. *Surgery*. 1982;91:137.

Carlton CE Jr, Guthrie AG, Scott R Jr. Surgical correction of ureteral injury. *J Trauma*. 1969;9:457.

Casale P, Mucksavage P, Resnick M, et al. Robotic ureterocalicostomy in the pediatric population. *J Urol*. 2008;180:2643.

Cassis AN, Brannen GE, Bush WH, et al. Endopyelotomy: review of results and complications. *J Urol*. 1991;146:1492.

Castillo OA, Vitagliano G, Alvarez JM, et al. Transmesocolic pyeloplasty: experience of a single center. *J Endourol*. 2007;21:415.

Castle EP, Nunez R, Desai PJ, et al. Ureteroarterial fistula following laser endopyelotomy. *J Urol*. 2009;181:1343.

Cestari A, Buffi NM, Lista G, et al. Feasibility and preliminary clinical outcomes of robotic laparoendoscopic single-site (R-LESS) pyeloplasty using a new single-port platform. *Eur Urol*. 2012;62:175.

Cestari A, Buffi NM, Lista G, et al. Retroperitoneal and transperitoneal robot-assisted pyeloplasty in adults: techniques and results. *Eur Urol*. 2010;58:711.

Chandhoke PS, Clayman RV, Stone AM, et al. Endopyelotomy and endoureterotomy with the Acucise ureteral cutting balloon device: preliminary experience. *J Endourol*. 1993;7:45.

Chang R, Marshall FF, Mitchell S. Percutaneous management of benign ureteral strictures and fistulas. *J Urol*. 1987;137:1126.

Cheng M, Looney SW, Brown JA. Ureteroileal anastomotic strictures after a Bricker ileal conduit: 50 case assessment of the impact of conversion from a slit incision to a “shield shaped” ileotomy. *Can J Urol*. 2011;18:5644.

Chiou YY, Shieh CC, Cheng HL, et al. Intrinsic expression of Th2 cytokines in urothelium of congenital ureteropelvic junction obstruction. *Kidney Int*. 2005;67:638.

Chopra S, Metcalfe C, Satkunasivam R, et al. Initial series of four-arm robotic completely intracorporeal ileal ureter. *J Endourol*. 2016;30:395.

Chuang CK, Chu SH, Liao SK. Renal autotransplantation for ureter stricture and renovascular disorders. *Chang Keng I Hsueh Tsa Chih*. 1999;22:621.

Chung SY, Stein RJ, Landsittel D, et al. 15-year experience with the management of extrinsic ureteral obstruction with indwelling ureteral stents. *J Urol*. 2004;172:592.

Clark CP, Vanderpool D, Preskitt JT. The response of retroperitoneal fibrosis to tamoxifen. *Surgery*. 1991;109:502.

Clark WR, Malek RS. Ureteropelvic junction obstruction: observations on the classic type I adults. *J Urol*. 1987;138:276.

Clayman RV, Basler JW, Kavoussi L, et al. Ureteronephroscopic endopyelotomy. *J Urol*. 1990;144:246.

Cohen TD, Gross MB, Preminger GM. Long-term follow-up of Acucise incision of ureteropelvic junction obstruction and ureteral strictures. *Urology*. 1996;47:317.

Conlin MJ, Bagley DH. Ureteroscopic endopyelotomy at a single setting. *J Urol*. 1998;159:727.

Conlin MJ, Gomella LG, Bagley DH. Endoscopic ureteroureterostomy for obliterated ureteral segments. *J Urol*. 1996;156:1394.

Conlin MJ. Results of selective management of ureteropelvic junction obstruction. *J Endourol*. 2002;16:233.

Considine J. Retrocaval ureter. *Br J Urol*. 1966;38:412.

Cornud F, Lefebvre JF, Chretien Y, et al. Percutaneous transrenal electro-incisions of ureterointestinal anastomotic strictures: long-term results and comparison of fluoroscopic and endoscopic guidance. *J Urol*. 1996;155:1575.

Cornud F, Mendelsberg M, Chretien Y, et al. Fluoroscopically guided percutaneous transrenal electro-incision of ureterointestinal anastomotic strictures. *J Urol*. 1992;147:578.

Couvelaire R, Auvert J, Moulonguet A. Implantations et anastomoses ureterocalicielles: techniques et indications. *J Urol Nephrol*. 1964;70:437.

Cronin CG, Lohan DG, Blake MA, et al. Retroperitoneal fibrosis: a review of clinical features and imaging findings. *Am J Roentgenol*. 2008;191:423.

Culp OS, DeWeerd JH. A pelvic flap operation for certain types of ureteropelvic obstruction: preliminary report. *Mayo Clin Proc*. 1951;26:483.

Dalrymple NC, Verga M, Anderson KR, et al. The value of unenhanced helical computerized tomography in the management of acute flank pain. *J Urol*. 1998;159:735.

Danuser H, Ackermann DK, Bohlen D, et al. Endopyelotomy for primary ureteropelvic junction obstruction: risk factors determine the success rate. *J Urol*. 1998;159:56.

Danuser H, Hochreiter WW, Ackermann DK, et al. Influence of stent size on the success of antegrade endopyelotomy for primary ureteropelvic junction obstruction: results of 2 consecutive series. *J Urol*. 2001;166:902.

Das S, Amar AD. Ureteropelvic junction obstruction with associated renal anomalies. *J Urol*. 1984;131:872.

Davis DM. Intubated ureterostomy: a new operation for ureteral and ureteropelvic strictures. *Surg Gynecol Obstet*. 1943;76:513.

Davis R, Jones JS, Barocas DA, et al. *Diagnosis, evaluation and follow-up of asymptomatic microhematuria (AMH) in adults*

(2016). [website] https://www.auanet.org/guidelines/asymptomatic-microhematuria-(amh)-guideline; 2012.
de Jonge MK, van der Beek C, Weil EH, et al. Antegrade ureteroscopy: a new tool in management of severe ureteral strictures. *Urology*. 1986;27:49.
Dedeoglu F, Rose CD, Athreya BH. Successful treatment of retroperitoneal fibrosis with tamoxifen in a child. *J Rheum*. 2000;28:1693.
Dehner LP, Coffin CM. Idiopathic fibrosclerotic disorders and other inflammatory pseudotumors. *Semin Diagn Pathol*. 1998;15:161.
Dejaco C, Ferenci P, Schober E, et al. Stenosis of the common bile duct due to Ormond's disease: case report and review of literature. *J Hepatol*. 1999;31:156.
Delvecchio FC, Auge BK, Brizuela RM, et al. Assessment of stricture formation with the ureteral access sheath. *Urology*. 2003;61:518.
Delvecchio FC, Kuo RL, Iselin CE, et al. Combined antegrade and retrograde endoscopic approach for the management of urinary diversion–associated pathology. *J Endourol*. 2000;14:251.
Desai MM, Berger AK, Brandina R, et al. Laparoendoscopic single-site surgery: initial hundred patients. *Urology*. 2009;74:805.
Dias CS, Silva JM, Pereira AK, et al. Diagnostic accuracy of renal pelvic dilatation for detecting surgically managed ureteropelvic junction obstruction. *J Urol*. 2013;190:661.
DiMarco DS, Gettman MT, McGee SM, et al. Long-term success of antegrade endopyelotomy compared with pyeloplasty at a single institution. *J Endourol*. 2006;20:707.
DiMarco DS, LeRoy AJ, Thieling S, et al. Long-term results of treatment for ureteroenteric strictures. *Urology*. 2001;58:909.

DiSandro MJ, Kogan BA. Neonatal management: role for early intervention. *Urol Clin North Am*. 1998;25:187.

Docimo SG, Dewolf WC. High failure rate of indwelling ureteral stents in patients with extrinsic obstruction: experience at 2 institutions. *J Urol*. 1989;142:277.

Doo CK, Hong B, Park T, et al. Long-term outcome of endopyelotomy for the treatment of ureteropelvic junction obstruction: how long should patients be followed up? *J Endourol*. 2007;21:158.

Duchene DA, Winfield HN, Cadeddu JA, et al. Multi-institutional survey of laparoscopic ureterolysis for retroperitoneal fibrosis. *Urology*. 2007;69:1017.

Duty BD, Conlin MJ, Fuchs EF, et al. The current role of endourologic management of renal transplantation complications. *Adv Urol*. 2013;2013:246520.

Dy GW, His RS, Holt SK, et al. National trends in secondary procedures following pediatric pyeloplasty. *J Urol*. 2016;195:1209.

Eden CG, Cahill D, Allen JD. Laparoscopic dismembered pyeloplasty: 50 consecutive cases. *BJU Int*. 2001;88:526.

Ehrlich RM, Gershman A, Fuchs G. Laparoscopic vesicoureteroplasty in children: initial case reports. *Urology*. 1993;43:255.

Ehrlich RM, Melman A, Skinner DG. The use of vesicopsoas hitch in urologic surgery. *J Urol*. 1978;119:322.

ElAbd SA, El Shaer AF, El Mahrouky AS, et al. Long-term results of endourologic and percutaneous management of ureteral strictures in bilharzial patients. *J Endourol*. 1996;10:35.

ElAbd SA, Elbahnasy AM, Farahat YA, et al. Minimally invasive correction of ureteropelvic junction obstruction: do retrograde endo-incision techniques still have a role in the era of laparoscopic pyeloplasty? *Ther Adv Urol*. 2009;1:227.

Elashry OM, Nakada SY, Wolf SK Jr, et al. Ureterolysis for extrinsic ureteral obstruction: a comparison of laparoscopic and open surgical techniques. *J Urol*. 1996;156:1403.

Ellis JH, Campo RP, Mars MV, et al. Genitourinary radiology: positional variation in the Whitaker test. *Radiology*. 1995;197:253.

Elmussareh M, Traxer O, Somani BK, et al. Laser endopyelotomy in the management of pelviureteric junction obstruction in adults: a systematic review of the literature. *Urology*. 2017;107:11.

Elsamra SE, Motato H, Moreira DM, et al. Tandem ureteral stents for the decompression of malignant and benign obstructive uropathy. *J Endourol*. 2013;17:1297.

Fabrizio MD, Kavoussi LR, Jackman S, et al. Laparoscopic nephrectomy for autotransplantation. *Urology*. 2000;55:145iii.

Fernando A, Pattison J, Horsfield C, et al. [18F]-Fluorodeoxyglucose positron emission tomography in the diagnosis, treatment stratification, and monitoring of patients with retroperitoneal fibrosis: a prospective clinical study. *Eur Urol*. 2017;71:926.

Fielding JR, Steele G, Fox LA, et al. Spiral computerized tomography in the evaluation of acute flank pain: a replacement for excretory urography. *J Urol*. 1997;157:2071.

Finnerty DP, Trulock TS, Berman W, et al. Transluminal balloon dilations of ureteral strictures. *J Urol*. 1984;131:1056.

Foley FE. New plastic operation for stricture at the ureteropelvic junction. *J Urol*. 1937;38:643.

Foote JW, Blennerhassett JB, Wigglesworth FW, et al. Observations on the ureteropelvic junction. *J Urol*. 1970;104:252.

Fry AC, Singh S, Gunda SS, et al. Successful use of steroids and ureteric stents in 24 patients with idiopathic retroperitoneal fibrosis: a retrospective study. *Nephron Clin Pract*. 2008;108:c213.

Fugita OE, Dinlenc C, Kavousi L. The laparoscopic Boari flap. *J Urol*. 2001;166:51.

García-Galisteo E, Emmanuel-Tejero E, Navarro Vílchez P, et al. Comparison of the operation time and complications between conventional and robotic-assisted laparoscopic pyeloplasty. *Actas Urol Esp*. 2011;35:523.

Gdor Y, Gabr AH, Faerber GJ, et al. Ho:YAG laser endoureterotomy for the treatment of transplant ureteral strictures. *Transplantation*. 2008;85:1318.

Gdor Y, Gabr AH, Faerber GJ, et al. Success of laser endoureterotomy of ureteral strictures associated with ureteral stones is related to stone impaction. *J Endourol*. 2008;22:2507.

Gerber GS, Kim JC. Ureteroscopic endopyelotomy in the treatment of patients with ureteropelvic junction obstruction. *Urology*. 2000;55:198.

Gerber GS, Lyon ES. Endopyelotomy: patient selection, results, and complications. *Urology*. 1994;43:1.

Gettman MT, Lotan Y, Roerhborn CG, et al. Cost-effective treatment for ureteropelvic junction obstruction: a decision tree analysis. *J Urol*. 2003;169:228.

Gettman MT, Neururer R, Bartsch G, et al. Anderson-Hynes dismembered pyeloplasty performed using the da Vinci robotic system. *Urology*. 2002;60:509.

Giddens JL, Grotas AB, Grasso M. Stone granuloma causes ureteropelvic junction obstruction after percutaneous nephrolithotomy and antegrade endopyelotomy. *J Urol*. 2000;164:118.

Gill IS, Cherullo EE, Steinberg AP, et al. Laparoscopic ureterocalicostomy: initial experience. *J Urol*. 2004;171:1227.

Gill IS, Desai MM, Kaouk JH, et al. Percutaneous endopyeloplasty: description of new technique. *J Urol*. 2002;168:2097.

Gill IS, Savage SJ, Senagore AJ, et al. Laparoscopic ileal ureter. *J Urol*. 2000;163:1199.

Gill IS, Uzzo R, Hobart MG, et al. Laparoscopic retroperitoneal live donor right nephrectomy for purposes of allotransplantation and autotransplantation. *J Urol*. 2000;164:1500.

Gin GE, Ruel NH, Parihar JS, et al. Ureteroenteric anastomotic revision as initial management of stricture after urinary diversion. *Int J Urol*. 2017;25:390.

Goldfischer ER, Gerber GS. Endoscopic management of ureteral strictures. *J Urol*. 1997;157:770.

Goldsmith ZG, Wang AJ, Bañez LL, et al. Outcomes of metallic stents for malignant ureteral obstruction. *J Urol*. 2012;188:851.

Gomez FD, Thomas A, Sempels M, et al. Outcomes following first-line endourologic management of ureteroenteric anastomotic strictures after urinary diversion: a single-center study. *Urology*. 2017;102:38.

Gorin MA, Antebi E, Manoharan M, et al. Endoscopic retrieval of a retained self-expanding metal stent placed for a ureteroileal anastomotic stricture. *J Endourol*. 2011;25:911.

Gosling JA, Dixon JS. Functional obstruction of the ureter and renal pelvis: a histological and electron microscopic study. *Br J Urol*. 1978;50:145.

Gözen AS, Cresswell J, Canda AE, et al. Laparoscopic ureteral reimplantation: prospective evaluation of medium-term results and current developments. *World J Urol*. 2010;28:221.

Grotz W, Zedtwitz I, Andre M, et al. Treatment of retroperitoneal fibrosis by mycophenolate mofetil and corticosteroids. *Lancet*. 1998;352:1195.

Guignard R, Simukoniene M, Garibotto V, et al. 18F-FDG PET/CT and contrast-enhanced CT in a one-stop diagnostic procedure: a better strategy for management of patients suffering from retroperitoneal fibrosis. *Clin Nucl Med*. 2012;37:453.

Guiter J, Cuenant E, Mourad G, et al. Re-establishment of urinary continuity by uretero-ureterostomy in renal transplantation. Apropos of 135 cases. *J Urol (Paris)*. 1985;91:27.

Gulur DM, Young JG, Painter DJ, et al. How successful is the conservative management of pelvi-uretereic junction obstruction in adults? *BJU Int*. 2009;103:1414.

Gundeti MS, Reynolds WS, Duffy PG, et al. Further experience with the vascular hitch (laparoscopic transposition of lower pole crossing vessels): an alternate treatment for pediatric ureterovascular ureteropelvic junction obstruction. *J Urol*. 2008;180:1832.

Gupta M, Tuncay OL, Smith AD. Open surgical exploration after failed endopyelotomy: a 12-year perspective. *J Urol*. 1997;157:1613.

Gupta NP, Hemal AK, Singh I, et al. Retroperitoneoscopic ureterolysis and reconstruction of retrocaval ureter. *J Endourol*. 2001;15:291.

Gurbuz C, Best SL, Donnally C, et al. Intermediate term outcomes associated with the surveillance of ureteropelvic junction obstruction in adults. *J Urol*. 2011;185:926.

Hanna MK, Jeffs RD, Sturgess JM, et al. Ureteral structure and ultrastructure: part II. Congenital ureteropelvic junction obstruction and primary obstructive megaureter. *J Urol*. 1976;116:725.

Hanna MK. Antenatal hydronephrosis and ureteropelvic junction obstruction: the case for early intervention. *Urology*. 2000;55:612.

Hanna MK. Some observations on congenital ureteropelvic junction obstruction. *Urology*. 1978;12:151.

Harada N, Tanimura M, Fukuyama K, et al. Surgical management of a long ureteral defect: advancement of the ureter by descent of the kidney. *J Urol*. 1964;92:192.

Hardy JD. High ureteral injuries: management by autotransplantation of the kidney. *J Am Med Assoc*. 1963;184:111.

Harmon WJ, Sershon PD, Blute ML, et al. Ureteroscopy: current practice and long-term complications. *J Urol*. 1997;157:28.

Harrow BR, Bagrodia A, Olweny EO, et al. Renal function after laparoendoscopic single site pyeloplasty. *J Urol*. 2013;190:565.

Harzmann R, Kopper B, Carl P. Cancer induction by urinary drainage or diversion through intestinal segments? *Urologe A*. 1986;25:198.

Hemal AK, Mukherjee S, Singh K. Laparoscopic pyeloplasty versus robotic pyeloplasty for ureteropelvic junction obstruction: a series of 60 cases performed by a single surgeon. *Can J Urol*. 2010;17(1):5012–5016.

Hemal AK, Rao R, Sharma S, et al. Pure robotic retrocaval ureter repair. *Int Braz J Urol*. 2008;34:734.

Hendren WH, Hensle TW. Transureteroureterostomy: experience with 75 cases. *J Urol*. 1980;123:826.

Hibi H, Ohori T, Taki T, et al. Long-term results of endoureterotomy using a holmium laser. *Int J Urol*. 2007;14:872.

Higgins CC. Transuretero-ureteral anastomosis: report of clinical case. *Trans Am Assoc Genitourin Surg*. 1934;27:279.

Higgins PM, Bennett-Jones DN, Naish PF, et al. Non-operative management of retroperitoneal fibrosis. *Br J Surg*. 1998;75:573.

Hinman F, Oppenheimer R. Functional characteristics of the ileal segment as a valve. *J Urol*. 1958;80:448.

Hodges CV, Barry JM, Fuchs EF, et al. Transureteroureterostomy: 25-year experience with 100 patients. *J Urol*. 1980;123:834.

Hopf HL, Bahler CD, Sundaram CP. Long-term outcomes of robot-assisted laparoscopic pyeloplasty for ureteropelvic junction obstruction. *Urology*. 2016;90:106.

Hsu TH, Chang S, Hsu S. Laparoscopic calicovesicostomy: a novel surgical procedure. *Urology*. 2006;68:413.

Hsu TH, Presti JC. Anterior extraperitoneal approach to laparoscopic pyeloplasty in horseshoe kidney: a novel technique. *Urology*. 2003;62:1114.

Hwang TK, Yoon JY, Ahn JH, et al. Percutaneous endoscopic management of upper ureteral stricture: size of stent. *J Urol*. 1996;155:882.

Inagaki T, Rha KH, Ong AM. Laparoscopic pyeloplasty: current status. *BJU Int*. 2005;95:102.

Inglis JA, Tolley DA. Ureteroscopic pyelolysis for pelviureteric junction obstruction. *Br J Urol*. 1986;58:250.

Isac W, Kaouk J, Altunrende F, et al. Robot-assisted ureteroneocystostomy: technique and comparative outcomes. *J Endourol*. 2013;27:318.

Izzedine H, Servais A, Launay-Vacher V, et al. Retroperitoneal fibrosis due to Wegener's granulomatosis: a misdiagnosis as tuberculosis. *Am J Med*. 2002;113:164.

Jabbour ME, Goldfischer ER, Klima WJ, et al. Endopyelotomy after failed pyeloplasty: the long-term results. *J Urol*. 1998;160:690.

Jacobs BL, Kaufman SR, Morgenstern H, et al. Trends in the treatment of adults with ureteropelvic junction obstruction. *J Endourol*. 2013;27(3):355.

Jacobs BL, Lai JC, Seelam R, et al. The comparative effectiveness of treatments for ureteropelvic junction obstruction. *Urology*. 2018;111:72.

Jacobs BL, Lai JC, Seelam R, et al. Variation in the use of open pyeloplasty, minimally invasive pyeloplasty, and endopyelotomy for the treatment of ureteropelvic junction obstruction in adults. *J Endourol*. 2017;31(2):210.

Jacobs BL, Seelam R, Lai JC, et al. Cost analysis of treatments for ureteropelvic junction obstruction. *J Endourol*. 2017;31(2):201.

Jacobs JA, Berger BW, Goldman SM, et al. Ureteropelvic obstruction in adults with previously normal pyelograms: a report of five cases. *J Urol*. 1979;121:242.

Jadhav KK, Kumar V, Punatar CB, et al. Retroperitoneal fibrosis-clinical presentation and outcome analysis from urological perspective. *Investig Clin Urol*. 2017;58:371.

Janetschek G, Peschel R, Altarac S. Laparoscopic and retroperitoneoscopic repair of ureteropelvic junction obstruction. *Urology*. 1996;47:311.

Janetschek G, Peschel R, Frauscher F. Laparoscopic pyeloplasty. *Urol Clin North Am*. 2000;7:695.

Jarrett TW, Chan DY, Charambura TC, et al. Laparoscopic pyeloplasty: the first 100 cases. *J Urol*. 2002;167:1253.

Johnson DB, Solomon SB, Su LM, et al. Defining the complications of cryoablation and radiofrequency ablation of small renal tumors: a multi-institutional review. *J Urol*. 2004;172:874.

Johnston JH, Evans JP, Glassberg KI, et al. Pelvic hydronephrosis in children: a review of 219 personal cases. *J Urol*. 1977;117:97.

Kadlec AO, Ellimoottil CS, Greco KA, et al. Five-year experience with metallic stents for chronic ureteral obstruction. *J Urol*. 2013;190:937.

Kaiho Y, Ito A, Numahata K, et al. Retroperitoneoscopic transureteroureterostomy with cutaneous ureterostomy to salvage failed ileal conduit urinary diversion. *Eur Urol*. 2011;59:875.

Kaouk JH, Autorino R, Kim FJ, et al. Laparoendoscopic single-site surgery in urology: worldwide multi-institutional analysis of 1076 cases. *Eur Urol*. 2011;60:998.

Kaouk JH, Hafron J, Parekattil S, et al. Is retroperitoneal approach feasible for robotic dismembered pyeloplasty: initial experience and long-term results. *J Endourol*. 2008;22:2153.

Kaouk JH, Kuang W, Gill IS. Laparoscopic dismembered tubularized flap pyeloplasty: a novel technique. *J Urol*. 2002;167:229.

Kardar AH, Kattan S, Lindstedt E, et al. Steroid therapy for idiopathic retroperitoneal fibrosis: dose and duration. *J Urol*. 2002;168:550.

Karlin GS, Badlani GH, Smith AD. Endopyelotomy versus open pyeloplasty: comparison in 88 patients. *J Urol*. 1988;140:476.

Kavoussi LR, Clayman RV, Brunt LM, et al. Laparoscopic ureterolysis. *J Urol*. 1992;147:426.

Kavoussi LR, Peters CA. Laparoscopic pyeloplasty. *J Urol*. 1993;150:1891.

Kay R. Procedures for ureteropelvic junction obstruction. Novick AC, Streem SB, Pontes JE. *Stewart's operative urology*. 2nd ed. Williams & Wilkins: Baltimore; 1989:220–233.

Kearney GP, Mahoney EM, Sciammas FD, et al. Venacavography, corticosteroids and surgery in the management of idiopathic retroperitoneal fibrosis. *J Urol*. 1976;115:32.

Keehn AY, Mufarrij PW, Stifelman MD. Robotic ureterolysis for relief of ureteral obstruction from retroperitoneal fibrosis.

Urology. 2011;77:1370.

Keeley FX Jr, Bagley DH, Kulp-Hugues D, et al. Laparoscopic division of crossing vessels at the ureteropelvic junction. *J Endourol*. 1996;10:163.

Kelalis PP. Ureteropelvic junction. Kelalis PP, King LR. *Clinical pediatric urology*. Saunders: Philadelphia; 1976:239–257.

Kennelly MJ, Konnak JW, Herwig KR. Vesicopyeloplasty in renal transplant: a 20 year follow-up. *J Urol*. 1993;150:1118.

Khanna R, Isac W, Laydner H, et al. Laparoendoscopic single site reconstructive procedures in urology: medium term results. *J Urol*. 2012;187:1702.

Khoo CC, Abboudi H, Cartwright R, et al. Metallic ureteric stents in malignant ureteric obstruction: a systematic review. *Urology*. 2018;118:12.

Kim EH, Tanagho YS, Traxel EJ, et al. Endopyelotomy for pediatric ureteropelvic junction obstruction: a review of our 25-year experience. *J Urol*. 2012;188(4 Suppl):1628.

Kim S, Canter D, Leone N, et al. A comparative study between laparoscopic and robotically assisted pyeloplasty in the pediatric population. *J Urol*. 2008;179:357.

King LR, Coughlin PW, Bloch EC, et al. The case for immediate pyeloplasty in the neonate with ureteropelvic junction obstruction. *J Urol*. 1984;132:725.

King LR, Coughlin PW, Ford KK, et al. Initial experiences with percutaneous and transurethral ablation of postoperative ureteral strictures in children. *J Urol*. 1984;131:1167.

Kletscher BA, Segura JW, LeRoy AJ, et al. Percutaneous antegrade endoscopic pyelotomy: review of 50 consecutive cases. *J Urol*. 1995;153:701.

Klisnick A, Fourcade J, Rulvard M, et al. Combined idiopathic retroperitoneal and mediastinal fibrosis with pericardial involvement. *Clin Nephrol*. 1999;52:51.

Knerr I, Dittrich K, Miller J, et al. Alteration of neuronal and endothelial nitric oxide synthase and neuropeptide Y in congenital ureteropelvic junction obstruction. *Urol Res*. 2001;29:134.

Knowles DR, Staiman VR, Gupta M. Long-term results of the treatment of complete distal ureteral stenosis using a cutting balloon catheter device. *J Urol*. 2001;166:2087.

Knudsen BE, Cook AJ, Watterson JD, et al. Percutaneous antegrade endopyelotomy: long-term results from one institution. *Urology*. 2004;63:230.

Koch MO, McDougal WS. The pathophysiology of hyperchloremic metabolic acidosis after urinary diversion through intestinal segments. *Surgery*. 1985;98:561.

Kocot A, Kalogirou C, Vergho D, et al. Long-term results of ileal ureteric replacement: a 25-year single-centre experience. *BJU Int*. 2017;120:273.

Koep L, Zuidema GD. The clinical significance of retroperitoneal fibrosis. *Surgery*. 1987;81:250.

Koff SA, Campbell KD. The nonoperative management of unilateral neonatal hydronephrosis: natural history of poorly functioning kidneys. *J Urol*. 1994;152:593.

Koff SA, Hayden LJ, Cirulli C, et al. Pathophysiology of ureteropelvic junction obstruction: experimental and clinical observations. *J Urol*. 1986;136:336.

Koff SA. Neonatal management of unilateral hydronephrosis: role for delayed intervention. *Urol Clin North Am*. 1998;25:181.

Koff SA. Postnatal management of antenatal hydronephrosis using an observational approach. *Urology*. 2000;55:609.

Koleda P, Apoznanski W, Wozniak Z, et al. Changes in interstitial cell of Cajal-like cells density in congenital ureteropelvic junction obstruction. *Int Urol Nephrol*. 2012;44:7.

Korets R, Hyams ES, Shah OD, et al. Robotic-assisted laparoscopic ureterocalicostomy. *Urology*. 2007;70:366.

Korth K, Kuenkel M, Erschig M. Percutaneous pyeloplasty. *Urology*. 1988;31:503.

Kouba E, Wallen EM, Pruthi RS. Management of ureteral obstruction due to advanced malignancy: optimizing therapeutic and palliative outcomes. *J Urol*. 2007;180:444.

Koukouras D, Petsas T, Liatsikos E, et al. Percutaneous minimally invasive management of iatrogenic ureteral injuries. *J Endourol*. 2010;24:1921.

Kozinn SI, Canes D, Sorcini A, et al. Robotic versus open distal ureteral reconstruction and reimplantation for benign stricture disease. *J Endourol*. 2012;26:147.

Kramolowsky EV, Clayman RV, Weyman PJ. Endourological management of ureteroileal anastomotic strictures: is it effective? *J Urol*. 1987;137:390.

Kramolowsky EV, Clayman RV, Weyman PJ. Management of ureterointestinal anastomotic strictures: comparison of open surgical and endourological repair. *J Urol*. 1988;139:1195.

Kumar R, Nayak B. Robotic versus conventional laparoscopic pyeloplasty: a single surgeon concurrent cohort review. *Indian J Urol*. 2013;29:19.

Kumon H, Tsugawa M, Hashimoto H, et al. Impact of 3-dimensional helical computerized tomography on selection of operative methods for ureteropelvic junction obstruction. *J Urol*. 1997;158:1696.

Kurzer E, Leveillee RJ. Endoscopic management of ureterointestinal strictures after radical cystectomy. *J Endourol*. 2005;19:677.

Kuster E. Ein fall von resection des ureter. *Arch Klin Chir*. 1892;44:850.

Kwak S, Leef JA, Rosenblum JD. Percutaneous balloon catheter dilatation of benign ureteral strictures: effect of multiple dilatation procedures on long-term patency. *Am J Roentgenol*. 1995;165:97.

Lacquet JP, Cacroix H, Nevelsteen A, et al. Inflammatory abdominal aortic aneurysms. A retrospective study of 110 cases. *Acta Chir Belg*. 1997;97:286.

Lam JS, Bingham JB, Gupta M. Endoscopic treatment of fibroepithelial polyps of the renal pelvis and ureter. *Urology*. 2003;62:810.

Lam JS, Cooper KL, Greene TD, et al. Impact of hydronephrosis and renal function on treatment outcome: antegrade versus retrograde endopyelotomy. *Urology*. 2003;61:1107.

Lane BR, Desai MM, Hegarty NJ, et al. Long-term efficacy of holmium laser endoureterotomy for benign ureteral strictures. *Urology*. 2006;67:894.

Lau KO, Hia TN, Cheng C, et al. Outcome of obstructive uropathy after pelvic irradiation in patients with carcinoma of the uterine cervix. *Ann Acad Med Singapore*. 1998;27:631.

Laungani R, Patil N, Krane LS. Robotic-assisted ureterovaginal fistula repair: report of efficacy and feasibility. *J Laparoendosc Adv Surg Tech A*. 2008;18:731.

Laven B, O'Connor RC, Steinberg GD, et al. Long-term results of antegrade endoureterotomy using the holmium laser in patients with ureterointestinal strictures. *Urology*. 2001;58:924.

Laven BA, O'Connor RC, Gerber GS, et al. Long-term results of endoureterotomy and open surgical revision for the management of ureteroenteric strictures after urinary diversion. *J Urol*. 2003;170:1226.

Lawler LP, Jarret TW, Corl FM, et al. Adult ureteropelvic junction obstruction: insights with three-dimensional multi-detector row CT. *Radiographics*. 2005;25:121.

LeBlanc CM, Inman RD, Dent P, et al. Retroperitoneal fibrosis:

an extraarticular manifestation of ankylosing spondylitis. *Arthritis Rheum*. 2002;47:210.

Lebowitz RL, Johan BG. The coexistence of ureteropelvic junction obstruction and reflux. *Am J Roentgenol*. 1982;140:231.

Lechevallier E, Eghazarian C, Ortega JC, et al. Retrograde Acucise endopyelotomy: long-term results. *J Endourol*. 1999;13:575.

Lee DI, Schwab CW, Harris A. Robot-assisted ureteroureterostomy in the adult: initial clinical series. *Urology*. 2010;75:570.

Lee RS, Retik AB, Borer JG, et al. Pediatric robot assisted laparoscopic dismembered pyeloplasty: comparison with a cohort of open surgery. *J Urol*. 2006;175:683.

Lepor H, Walsh PC. Idiopathic retroperitoneal fibrosis. *J Urol*. 1979;122:1.

Levitt SB, Nabizadeh I, Javaid M, et al. Primary calicoureterostomy for pelvioureteral junction obstruction: indications and results. *J Urol*. 1981;126:382.

Lezrek M, Bazine K, Moufid K, et al. A more “conventional” way to perform percutaneous endopyeloplasty: a feasibility study. *Urology*. 2012;79:227.

Liatsikos E, Kallidonis P, Kyriazis I, et al. Ureteral obstruction: is the full metallic double-pigtail stent the way to go? *Eur Urol*. 2010;57:480.

Liatsikos EN, Karnabatidis D, Katsanos K, et al. Ureteral metal stents: 10-year experience with malignant ureteral obstruction treatment. *J Urol*. 2009;182:2613.

Lin DW, Bush WH, Mayo ME. Endourological treatment of ureteroenteric strictures: efficacy of Acucise endoureterotomy. *J Urol*. 1999;162:696.

Lindell OI, Lehtonen TA. Surgical treatment of ureteric obstruction in idiopathic retroperitoneal fibrosis. *Scand J*

Urol Nephrol Suppl. 1988;110:299.

Link RE, Bhayani SB, Kavoussi LR. A prospective comparison of robotic and laparoscopic pyeloplasty. *Ann Surg*. 2006;243:486.

Liu D, Zhou H, Chao M, et al. Transumbilical single-site multiport laparoscopic pyeloplasty for children with ureteropelvic junction obstruction in China: a multicenter study. *J Laparoendosc Adv Surg Tech A*. 2017;27:655.

Lovaco F, Serrano A, Fernández I, et al. Endoureterotomy by intraluminal invagination for non-malignant ureterointestinal anastomotic strictures: description of a new surgical technique and long-term follow up. *J Urol*. 2005;174:1851.

Lugagne PM, Herve JM, Lebret T, et al. Ureteroileal implantation in orthotopic neobladder with Le Duc-Camey mucosal-through technique: risk of stenosis and long-term follow-up. *J Urol*. 1997;158:765.

Lupton EW, George NJ. The Whitaker test: 35 years on. *BJU Int*. 2010;105:94.

Macksood MJ, Roth DR, Chang CH, et al. Benign fibroepithelial polyps as a cause of intermittent ureteropelvic junction obstruction in a child: a case report and review of the literature. *J Urol*. 1985;134:951.

Madi R, Roberts WW, Wolf JS Jr. Late failures after laparoscopic pyeloplasty. *Urology*. 2008;71:677.

Maizels M, Stephens FD. Valves of the ureter as a cause of primary obstruction of the ureter: anatomic, embryologic and clinical aspects. *J Urol*. 1980;123:742.

Malden ES, Picus D, Clayman RV. Arteriovenous fistula complicating endopyelotomy. *J Urol*. 1992;148:1520.

Malek RS. Intermittent hydronephrosis: the occult ureteropelvic obstruction. *J Urol*. 1983;130:863.

Mandhani A, Kapoor R, Zaman W, et al. Is a 2-week duration sufficient for stenting in endopyelotomy? *J Urol*.

2003;169:886.

Mano R, Golan S, Holland R, et al. Retrograde endoureterotomy for persistent ureterovesical anastomotic strictures in renal transplant kidneys after failed antegrade balloon dilation. *Urology*. 2012;80:255.

Mansson W, Ahlgren G, White T. Glomerular filtration rate up to 10 years after urinary diversion of different types. A comparative study of ileal and colonic conduit, refluxing and antirefluxing ureteral anastomosis and continent caecal reservoir. *Scand J Urol Nephrol*. 1989;23:195.

Martinez J, Kaplan N, Boyarsky S. Laboratory and clinical studies of ureteral replacement by ileum. *J Urol*. 1965;93:185.

Marzano A, Trapani A, Leone N, et al. Treatment of idiopathic retroperitoneal fibrosis using cyclosporin. *Ann Rheum Dis*. 2001;60:427.

Mata JA, Culkin DJ, Venable DD. Techniques for bypassing and stenting ureteral obstructions. *J Urol*. 1994;152:917.

Mathews R, Marshall FF. Versatility of the adult psoas hitch ureteral reimplantation. *J Urol*. 1997;158:2078.

Matin SF, Yost A, Streem SB. Ureteroscopic laser endopyelotomy: a single-center experience. *J Endourol*. 2003;17:401.

Matsuda T, Yasumoto R, Tsujino T. Laparoscopic treatment of a retrocaval ureter. *Eur Urol*. 1996;29:115.

Mattei A, Birkhaeuser RD, Baermann C, et al. To stent or not to stent perioperatively the ureteroileal anastomosis of ileal orthotopic bladder substitutes and ileal conduits? Results of a prospective randomized trial. *J Urol*. 2008;179:582.

Mauck RJ, Hudak SJ, Terlecki RP, et al. Central role of Boari bladder flap and downward nephropexy in upper ureteral reconstruction. *J Urol*. 2011;186:1345.

McClinton S, Steyn JH, Hussey JK. Retrograde balloon dilatation for pelviureteric junction obstruction. *Br J Urol*. 1993;71:152.

McDougal WS, MacDonell RC Jr. Treatment of idiopathic retroperitoneal fibrosis by immunosuppression. *J Urol*. 1991;145:112.

McQuitty DA, Boone TB, Preminger GM. Lower pole calicostomy for the management of iatrogenic ureteropelvic junction obstruction. *J Urol*. 1995;153:142.

Meng MV, Freise CE, Stoller ML. Expanded experience with laparoscopic nephrectomy and autotransplantation for severe ureteral injury. *J Urol*. 2003;169:1363.

Meng MV, Stoller ML. Hellstrom technique revisited: laparoscopic management of ureteropelvic junction obstruction. *Urology*. 2003;62:404.

Mercadal L, Martinez F, Barrou B, et al. Retroperitoneal fibrosis and membranous nephropathy. *Clin Nephrol*. 2000;53:71.

Meretyk S, Albala DM, Clayman RV, et al. Endoureterotomy for treatment of ureteral strictures. *J Urol*. 1992;147:1502.

Meretyk S, Clayman RV, Kavoussi LR, et al. Endourological treatment of ureteroenteric anastomotic strictures: long-term follow-up. *J Urol*. 1991;145:723.

Metzelder ML, Schier F, Petersen C, et al. Laparoscopic transabdominal pyeloplasty in children is feasible irrespective of age. *J Urol*. 2006;175:688.

Middleton RG. Routine use of the psoas hitch in ureteral reimplantation. *J Urol*. 1980;123:352.

Mitterberger M, Pinggera GM, Neururer R, et al. Compariosn of contrast-enhanced color Doppler imaging (CDI), computed tomography (CT), and magnetic resonance imaging (MRI) for the detection of crossing vessels in patients with ureteropelvic junction obstruction (UPJO). *Eur Urol*. 2008;53:1254.

Mitty HA, Train JS, Dan SJ. Antegrade ureteral stenting in the management of fistulas, strictures, and calculi. *Radiology*. 1983;149:433.

Moon YT, Kerbl K, Pearle MS, et al. Evaluation of optimal stent size after endourologic incision of ureteral strictures. *J Endourol*. 1995;9:15.

Morsi HA, Mursi K, Abdelaziz AY, et al. Renal pelvis reduction during dismembered pyeloplasty: is it necessary? *J Pediatr Urol*. 2013;9:303.

Motiwala HG, Shah SA, Patel SM. Ureteric substitution with Boari bladder flap. *Br J Urol*. 1990;66:369.

Motola JA, Badlani GH, Smith AD. Results of 212 consecutive endopyelotomies: an 8-year follow-up. *J Urol*. 1993;149:453.

Motola JA, Fried R, Badlani GH, et al. Failed endopyelotomy: implications for future surgery on the ureteropelvic junction. *J Urol*. 1993;150:821.

Muench PJ, Cates HR, Raney AM, et al. Endoscopic management of the obliterated ureteroileal anastomosis. *J Urol*. 1987;137:277.

Mufarrij PW, Shah OD, Berger AD, et al. Robotic reconstruction of the upper urinary tract. *J Urol*. 2007;278:2007.

Mure PY, Mollard P, Mouriquand P. Transureteroureterostomy in childhood and adolescence: long-term results in 69 cases. *J Urol*. 2000;163:946.

Musch M, Hohenhorst L, Pailliart A, et al. Robot-assisted reconstructive surgery of the distal ureter: single institution experience in 16 patients. *BJU Int*. 2013;111:773.

Nadler RB, Rao GS, Pearle MS, et al. Acucise endopyelotomy: assessment of long-term durability. *J Urol*. 1996;156:1094.

Nakada SY, Soble JJ, Gardner SM, et al. Comparison of Acucise endopyelotomy and endoballoon rupture for management of secondary proximal ureteral stricture in the porcine model. *J Endourol*. 1996;10:311.

Nakada SY, Wolf JS Jr, Brink JA. Retrospective analysis of the effect of crossing vessels on successful retrograde endopyelotomy outcomes using spiral computerized tomography angiography. *J Urol*. 1998;159:62.

Nakada SY. Surgical techniques in urology: acucise endopyelotomy. *Urology*. 2000;55:277.

Naude JH. Buccal mucosal grafts in the treatment of ureteric lesions. *Br J Urol*. 1999;83:751.

Nerli RB, Jayanthi VR, Reddy M, et al. Pelvi-ureteric junction obstruction with crossing renal vessels: a case report of failed laparoscopic vascular hitch. *J Pediatr Urol*. 2009;5:147.

Nesbit RM. Diagnosis of intermittent hydronephrosis: importance of pyelography during episodes of pain. *J Urol*. 1956;75:767.

Netto NR Jr, Ferreira U, Lemos GC, et al. Endourological management of ureteral strictures. *J Urol*. 1990;144:631.

Nezhat C, Nezhat F, Green B. Laparoscopic treatment of obstructed ureter due to endometriosis by resection and ureteroureterostomy: a case report. *J Urol*. 1992;148:865.

Ng KL, Nawawi O, Lim BK, et al. Antegrade repositioning of Memokath stent in malignant ureteroileal anastomotic stricture. *Asian J Urol*. 2013 [pii: S1015-9584(13)00102-4].

Niemczyk P, Krisch EB, Zeiger L, et al. Use of diuretic renogram in evaluation of patients before and after endopyelotomy. *Urology*. 1999;53:271.

Nouralizadeh A, Simforoosh N, Basiri A, et al. Laparoscopic management of ureteropelvic junction obstruction by division of the aberrant vein and cephalad relocation of the crossing artery: a long-term follow-up of 42 cases. *J Endourol*. 2010;24:987.

Novick AC, Stewart BH. Experience with extracorporeal renal operations and autotransplantation in the management of complicated urologic disorders. *Surg Gynecol Obstet*.

1981;153:10.

O'Brien T, Fernando A. Contemporary role of ureterolysis in retroperitoneal fibrosis: treatment of last resort for first intent? An analysis of 50 cases. *BJU Int*. 2017;120:556.

O'Reilly PH. Diuresis renography eight years later: an update. *J Urol*. 1986;136:993.

O'Reilly PH. Functional outcome of pyeloplasty for ureteropelvic junction obstruction: prospective study in 30 consecutive cases. *J Urol*. 1989;142:273.

Ockerblad NF. Reimplantation of the ureter into the bladder by a flap method. *J Urol*. 1947;57:845.

Oh BR, Kwon DD, Park KS, et al. Late presentation of ureteral injury after laparoscopic surgery. *Obstet Gynecol*. 2000;95:337.

Olweny EO, Park SK, Tan YK, et al. Perioperative comparison of robotic assisted laparoendoscopic single-site (LESS) pyeloplasty versus conventional LESS pyeloplasty. *Eur Urol*. 2012;61:410.

Ono Y, Ohshima S, Kinukawa T, et al. Endopyeloureterotomy via a transpelvic extraureteral approach. *J Urol*. 1992;147:352.

Özgen A, Cila A. Riedel's thyroiditis in multifocal fibrosclerosis: CT and MR imaging findings. *AJNR Am J Neuroradiol*. 2000;21:320.

Palese MA, Munver R, Phillips CK, et al. Robot-assisted laparoscopic dismembered pyeloplasty. *JSLS*. 2005;9:252.

Palmer LS, Rosenthal SA. Testicular encasement by retroperitoneal fibrosis: a rare testicular mass. *Urology*. 1999;53:619.

Pantuck AJ, Han KR, Perrotti M, et al. Ureteroenteric anastomosis in continent urinary diversion: long-term results and complications of direct versus nonrefluxing techniques. *J Urol*. 2000;163:450.

Papatsoris AG, Buchholz N. A novel thermo-expandable ureteral metal stent for the minimally invasive management of ureteral strictures. *J Endourol*. 2010;24:487.

Parums DV, Choudhury RP, Shields SA, et al. Characterisation of inflammatory cells associated with idiopathic retroperitoneal fibrosis. *Br J Urol*. 1991;67:564.

Passerini-Glazel G, Meneghini A, Aragona F, et al. Technical options in complex ureteral lesions: “ureter-sparing” surgery. *Eur Urol*. 1994;25:273.

Passerotti CC, Diamond DA, Borer JG, et al. Robot-assisted laparoscopic ureteroureterostomy: description of technique. *J Endourol*. 2008;22:581.

Patel T, Kellner CP, Katsumi H, et al. Efficacy of endopyelotomy in patients with secondary ureteropelvic junction obstruction. *J Endourol*. 2011;25:587.

Pearle MS, Moon YT, Endicott RC, et al. Comparison of retrograde endo-pyelotomy and endo-balloon rupture of the ureteropelvic junction in a porcine model. *J Urol*. 1994;152:2232.

Pedro RN, Buchholz N. Laparoscopic and robotic surgery for stone disease. *Urolithiais*. 2018;46:125.

Penalver GC, Sanchez TA, Gonzalez DR, et al. Follow-up of a case of retroperitoneal fibroses treated sequentially via right side autotransplant and left ureterolysis with wrapper of posterior preperitoneal fat. *Int Urol Nephrol*. 2001;32:629.

Penalver MA, Angioli R, Mirhashemi R, et al. Management of early and late complications of ileocolonic continent reservoir (Miami pouch). *Gynecol Oncol*. 1998;69:185.

Persky L, Krause JR, Boltuch RL. Initial complications and late results in dismembered pyeloplasty. *J Urol*. 1977;118:162.

Pesce C, Costa L, Campobasso P, et al. Successful use of transureteroureterostomy in children: a clinical study. *Eur J Pediatr Surg*. 2001;11:395.

Peschel R, Neururer R, Bartsch G, et al. Robotic pyeloplasty: technique and results. *Urol Clin North Am*. 2004;31:737.

Piaggio LA, Gonzalez R. Laparoscopic transureteroureterostomy: a novel approach. *J Urol*. 2007;177:2311.

Pienkny AJ, Herts B, Streem SB. Contemporary diagnosis of retrocaval ureter. *J Endourol*. 1999;13:721.

Pipitone N, Vaglio A, Salvarani C. Retroperitoneal fibrosis. *Best Pract Res Clin Rheumatol*. 2012;26:439.

Polascik JT, Chen NR. Laparoscopic ureteroureterostomy for retrocaval ureter. *J Urol*. 1998;160:121.

Ponsky LE, Streem SB. Retrograde endopyelotomy: a comparative study of hot-wire balloon and ureteroscopic laser. *J Endourol*. 2006;20:823.

Popescu C. The surgical management of postoperative ureteral fistulas. *Surg Gynecol Obstet*. 1964;119:1079.

Porpiglia F, Billia M, Volpe A, et al. Transperitoneal left laparoscopic pyeloplasty with transmesocolic access to the pelvi-ureteric junction: technique description and results with a minimum follow-up of 1 year. *BJU Int*. 2008;101:1024.

Powell CR, Schwartz BF, Stoney RJ, et al. Gross hematuria secondary to renal vein hypertension from unilateral retroperitoneal fibrosis. *Urology*. 2000;55:436.

Prout GR Jr, Koontz WW Jr. Partial vesical immobilization: an important adjunct to ureteroneocystostomy. *J Urol*. 1970;103:147.

Puce R, Porcaro AB, Curti P, et al. Treatment of retroperitoneal fibrosis with tamoxifen: case report and review of literature. *Arch Esp Urol*. 2000;53:184.

Puppo P, Carmignani G, Galluci M, et al. Bilateral laparoscopic ureterolysis. *Eur Urol*. 1994;25:82.

Quillin SP, Brink JA, Heiken JP, et al. Helical (spiral) CT angiography for identification of crossing vessels at the ureteroscopic junction. *Am J Roentgenol*. 1996;166:1125.

Rais-Bahrami S, Rizkala ER, Cadeddu JA, et al. Laparoendoscopic single-site pyeloplasty: outcomes of an international multi-institutional study of 140 patients. *Urology*. 2013;82:366.

Ramakumar S, Lancini V, Chan DY, et al. Laparoscopic pyeloplasty with concomitant pyelolithotomy. *J Urol*. 2002;167:1378.

Ramalingam M, Selvarajan K. Laparoscopic transperitoneal repair of retrocaval ureter: report of two cases. *J Endourol*. 2003;17:85.

Ramanathan R, Kumar A, Kapoor R, et al. Relief of urinary tract obstruction in tuberculosis to improve renal function. Analysis of predictive factors. *Br J Urol*. 1998;81:199.

Ramsay JW, Miller RA, Kellett MJ, et al. Percutaneous pyelolysis: indications, complications and results. *Br J Urol*. 1984;56:586.

Rassweiler JJ, Subotic S, Feist-Schwenk M, et al. Minimally invasive treatment of ureteropelvic junction obstruction: long-term experience with an algorithm for laser endopyelotomy and laparoscopic retroperitoneal pyeloplasty. *J Urol*. 2007;177:1000.

Rassweiler JJ, Teber D, Frede T. Complications of laparoscopic pyeloplasty. *World J Urol*. 2008;26:539.

Ravery V, de la Taille A, Hoffmann P, et al. Balloon catheter dilatation in the treatment of ureteral and ureteroenteric stricture. *J Endourol*. 1998;12:335.

Razdan S, Silberstein IK, Bagley DH. Ureteroscopic endoureterotomy. *BJU Int*. 2005;95(Suppl 2):94.

Reddy PK, Evans RM. Laparoscopic ureteroneocystostomy. *J Urol*. 1994;152:2057.

Renner C, Frede T, Seemann O, et al. Laser endopyelotomy: minimally invasive therapy of ureteropelvic junction stenosis.

J Endourol. 1998;12:537.

Rhee RY, Gloviczki P, Luthra HS, et al. Iliocaval complications of retroperitoneal fibrosis. *Am J Surg*. 1994;168:179.

Richstone L, Seideman CA, Reggio E, et al. Pathologic findings in patients with ureteropelvic junction obstruction and crossing vessels. *Urology*. 2009;73:716.

Richter F, Irwin RJ, Watson RA, et al. Endourologic management of benign ureteral strictures with and without compromised vascular supply. *Urology*. 2000;55:652.

Riehle RA Jr, Vaughan ED Jr. Renin participation in hypertension associated with unilateral hydronephrosis. *J Urol*. 1981;126:243.

Roarke MC, Sandler CM. Provocative imaging: diuretic renography. *Urol Clin North Am*. 1998;25:227.

Roberts WW, Cadeddu JA, Micali S, et al. Ureteral stricture formation after removal of impacted calculi. *J Urol*. 1998;159:723.

Rodo Salas J, Martin Hortiguela E, Salarich de Arbell J. Psoas fixation of the bladder. An efficient aid in cases of repeat surgery of the uretero-vesical junction. *Arch Esp Urol*. 1991;44:125.

Romero FR, Wagner AA, Trapp C, et al. Transmesenteric laparoscopic pyeloplasty. *J Urol*. 2006;176:2526.

Rosevear HM, Kim SP, Wenzler DL. Retrograde ureteral stents for extrinsic ureteral obstruction: nine years' experience at University of Michigan. *Urology*. 2007;70:846.

Ross JH, Streem SB, Novick AC, et al. Ureterocalicostomy for reconstruction of complicated pelviureteric junction obstruction. *Br J Urol*. 1990;65:322.

Roth DR, Gonzales ET Jr. Management of ureteropelvic junction obstruction in infants. *J Urol*. 1983;129:108.

Roth S, Weining C, Hertle L. Simplified uretero-intestinal implantation in continent cutaneous urinary diversion using ileovalvular segment as afferent loop and appendix as continent outlet. *J Urol*. 1996;155:1200.

Sakoda A, Cherian A, Mushtaq I. Laparoscopic transposition of lower pole crossing vessels (‘vascular hitch’) in pure extrinsic pelvi-ureteric junction (PUJ) obstruction in children. *BJU Int*. 2011;108:1364.

Salomon L, Hoznek A, Balian C, et al. Retroperitoneal laparoscopy of a retrocaval ureter. *BJU Int*. 1999;84:181.

Sampaio FJ, Favorito LA. Ureteropelvic junction stenosis: vascular anatomical background for endopyelotomy. *J Urol*. 1993;150:1787.

Sampaio FJ. Vascular anatomy at the ureteropelvic junction. *Urol Clin North Am*. 1998;25:251.

Scardino PL, Prince CL. Vertical flap ureteropelvioplasty: preliminary report. *South Med J*. 1953;46:325.

Schaeffer AJ, Grayhack JT. Surgical management of ureteropelvic junction obstruction. Walsh PC, Gittes RF, Perlmutter AD, et al. *Campbell's urology*. 5th ed. Saunders: Philadelphia; 1986:2505–2533.

Scheel PJ Jr, Feeley N. Retroperitoneal fibrosis. *Rheum Dis Clin North Am*. 2013;39:365.

Schimpf MO, Wagner JR. Robot-assisted laparoscopic distal ureteral surgery. *JSLS*. 2009;13:44.

Schmidt JD, Hawtrey CE, Flocks RH, et al. Complications, results and problems of ileal conduit diversions. *J Urol*. 1973;109:210.

Schneider AW, Conrad S, Busch R, et al. The cold-knife technique for endourological management of stenosis in the upper urinary tract. *J Urol*. 1991;146:961.

Schöndorf D, Meierhans-Ruf S, Kiss B, et al. Ureteroileal strictures after urinary diversion with an ileal segment—is there a place for endourological treatment at all? *J Urol*. 2013;190:585.

Schuessler WW, Grune MT, Tecuanhuey LV, et al. Laparoscopic dismembered pyeloplasty. *J Urol*. 1993;150:1795.

Schulte-Baukloh H, Knispel HH, Dallenbach F, et al. Scrotal involvement with idiopathic retroperitoneal fibrosis. *J Urol*. 1999;162:1692.

Schumacher M, Studer UE, Danuser H. Antegrade endopyelotomy for the treatment of ureteropelvic junction obstruction in transplanted kidneys. *J Endourol*. 2006;20:305.

Schwentner C, Pelzer A, Neururer R. Robotic Anderson-Hynes pyeloplasty: 5-year experience of one center. *BJU Int*. 2007;100:880.

Scott FB, Greenberg M. Submucosal bladder flap ureteroplasty: clinical experience. *South Med J*. 1972;65:1308.

Shadpour P, Nayyeri RK, Daneshvar R, et al. Prospective clinical trial to compare standard colon-reflecting with transmesocolic laparoscopic pyeloplasty. *BJU Int*. 2012;110:1814.

Shalhav AL, Giusti G, Elbahnasy AM, et al. Adult endopyelotomy: impact of etiology and antegrade versus retrograde approach on outcome. *J Urol*. 1998;160:685.

Shapiro EY, Cho JS, Srinivasan A, et al. Long-term follow-up for salvage laparoscopic pyeloplasty after failed open pyeloplasty. *Urology*. 2009;73:115.

Shapiro MJ, Banner MP, Amendola MA, et al. Balloon catheter dilation of ureteroenteric strictures: long-term results. *Radiology*. 1988;168:385.

Shirota S, Tsuchiya K, Takada M, et al. Retroperitoneal fibrosis associated with membranous nephropathy effectively treated with steroids. *Intern Med*. 2002;41:20.

Shokeir AA, Nijman RJ. Antenatal hydronephrosis: changing concepts in diagnosis and subsequent management. *BJU Int*. 2000;85:987.

Siegel JH, Padula G, Yatto RP, et al. Combined endoscopic and percutaneous approach for the treatment of ureterocolic strictures. *Radiology*. 1982;145:841.

Singal RK, Denstedt JD, Razvi HA, et al. Holmium-YAG laser endoureterotomy for treatment of ureteral stricture. *Urology*. 1997;50:875.

Skinner DG, Crawford ED, Kaufman JJ. Complications of radical cystectomy for carcinoma of the bladder. *J Urol*. 1980;123:640.

Smith KM, Shrivastava D, Ravish IR, et al. Robot-assisted laparoscopic ureteroureterostomy for proximal ureteral obstruction in children. *J Pediatr Urol*. 2009;5:475.

Smith-Bindman R, Aubin C, Bailitz J, et al. Ultrasonography versus computed tomography for suspected nephrolithiasis. *N Engl J Med*. 2014;371:1100.

Solari V, Piotrowska AP, Puri P. Altered expression of interstitial cells of Cajal in congenital ureteropelvic junction obstruction. *J Urol*. 2003;170:2420.

Soulie M, Salomon L, Patard JJ, et al. Extraperitoneal laparoscopic pyeloplasty: a multicenter study of 55 procedures. *J Urol*. 2001;166:48.

Srivastava D, Sureka SK, Yadav P, et al. Ureterocalicostomy for reconstruction of complicated ureteropelvic junction obstruction in adults: long-term outcome and factors predicting failure in a contemporary cohort. *J Urol*. 2017;198:1374.

Stauss J, Connolly LP, Connolly SA, et al. Dynamic renal scintigraphy in children with vesicoureteral reflux and suspected coexisting ureteropelvic junction obstruction. *J Urol*. 2003;170:1966.

Stefanovic KB, Bukurov NS, Marinkovic JM. Non-antireflux versus antireflux ureteroneocystostomy in adults. *Br J Urol*. 1991;67:263.

Stein R, Ikoma F, Salge S, et al. Pyeloplasty in hydronephrosis:

examination of surgical results from a morphologic point of view. *Int J Urol*. 1996;3:348.

Stein RJ, Gill IS, Desai MM. Comparison of surgical approaches to ureteropelvic junction obstruction: endopyeloplasty versus endopyelotomy versus laparoscopic pyelooplasty. *Curr Urol Rep*. 2007;8:140.

Stein RJ, Turna B, Nguyen MM, et al. Laparoscopic pyeloplasty with concomitant pyelolithotomy: technique and outcomes. *J Endourol*. 2008;22:1251.

Stein RJ, Turna B, Patel NS, et al. Laparoscopic assisted ileal ureter: technique, outcomes and comparison to the open procedure. *J Urol*. 2009;182:1032–1039.

Stein RJ, White WM, Goel RK, et al. Robotic laparoendoscopic single-site surgery using GelPort as the access platform. *Eur Urol*. 2010;57:132.

Stephens FD. Ureterovascular hydronephrosis and the “aberrant” renal vessels. *J Urol*. 1982;128:984.

Streem SB. Percutaneous endopyelotomy. *Urol Clin North Am*. 2000;27:685.

Studer UE, Danuser H, Merz VW, et al. Experience in 100 patients with an ileal low pressure bladder substitute combined with an afferent tubular isoperistaltic segment. *J Urol*. 1995;154:49.

Styn NR, Frauman S, Faerber GJ, et al. University of Michigan surgical experience with ureterolysis for retroperitoneal fibrosis: a comparison of laparoscopic and open surgical approaches. *Urology*. 2011;77:339.

Sugarbaker PH, Gutman M, Verghese M. Transureteroureterostomy: an adjunct to the management of advanced primary and recurrent pelvic malignancy. *Int J Colorectal Dis*. 2003;18:40.

Sukumar S, Sun M, Karakiewicz PI, et al. National trends and disparities in the use of minimally invasive adult pyeloplasty.

J Urol. 2012;188:913.

Sundaram CP, Grubb RL, Rehman J, et al. Laparoscopic pyeloplasty for secondary ureteropelvic junction obstruction. *J Urol*. 2003;169:2037.

Sung GT, Gill IS, Hsu TH. Robotic-assisted laparoscopic pyeloplasty: a pilot study. *Urology*. 1999;53:1099.

Sutherland DE, Jarrett TW. Surgical options in the management of ureteropelvic junction obstruction. *Curr Urol Rep*. 2009;10:23.

Sutherland DE, Williams SB, Jarrett TW. Laparoscopic renal descensus for upper tract reconstruction. *J Endourol*. 2011;25:271.

Tawfiek ER, Liu J, Bagley DH. Ureteroscopic treatment of ureteropelvic junction obstruction. *J Urol*. 1998;160:1643.

Thomas JC, DeMarco RT, Donohoe JM, et al. Management of the failed pyeloplasty: a contemporary review. *J Urol*. 2005;174:2363.

Thomas R, Monga M, Klein E. Ureteroscopic retrograde endopyelotomy for management of ureteropelvic junction obstruction. *J Endourol*. 1996;10:141.

Thompson IM, Baker J, Robards VL, et al. Clinical experience with renal capsule flap pyeloplasty. *J Urol*. 1969;101:487.

Thompson IM, Ross G Jr. Long-term results of bladder flap repair of ureteral injuries. *J Urol*. 1974;111:483.

Tobis S, Houman J, Thomer M, et al. Robot-assisted transumbilical laparoendoscopic single-site pyeloplasty: technique and perioperative outcomes from a single institution. *J Laparoendosc Adv Surg Tech A*. 2013;23:702.

Traxer O, Thomas A. Prospective evaluation and classification of ureteral wall injuries resulting from insertion of a ureteral access sheath during retrograde intrarenal surgery. *J Urol*. 2013;189:580.

Tresidder GC, Blandy JP, Singh M. Omental sleeve to prevent recurrent retroperitoneal fibrosis under the ureter. *Urol Int*. 1972;27:144.

Tripodi SA, Mattei FM, Giovannelli V, et al. Idiopathic retroperitoneal fibrosis simulating renal malignancy. *J Urol*. 1998;160:2145.

Tsuji Y, Nakamura H, Ariyoshi A. Upper urinary tract involvement after cystectomy and ileal conduit diversion for primary bladder carcinoma. *Eur Urol*. 1996;29:216.

Tugcu V, Ilbey YO, Sonmezay E, et al. Laparoendoscopic single-site versus conventional transperitoneal laparoscopic pyeloplasty: a prospective randomized study. *Int J Urol*. 2013;20:1112.

Turk IA, Davis JW, Winkelmann B, et al. Laparoscopic dismembered pyeloplasty—the method of choice in the presence of an enlarged renal pelvis and crossing vessels. *Eur Urol*. 2002;42:268.

Ubrig B, Janusonis J, Paulics L, et al. Functional outcome of completely intracorporeal robotic ileal ureteric replacement. *Urology*. 2018;114:193–197.

Usher SM, Brendler H, Ciavarra V. Retroperitoneal fibrosis secondary to metastatic neoplasm. *Urology*. 1977;9:191.

Vaarala MH, Marttila T, Paananen I, et al. Retrospective analysis of long-term outcomes of 64 patients treated by endopyelotomy in two low volume hospitals: good and durable results. *J Endourol*. 2008;22:1659.

van Bommel EF. Retroperitoneal fibrosis. *Neth J Med*. 2002;60:231.

Van Cangh PJ, Jorion JL, Wese FX, et al. Endoureteropyelotomy: percutaneous treatment of ureteropelvic junction obstruction. *J Urol*. 1989;141:1317.

Van Cangh PJ, Wilmart JF, Opsomer RJ, et al. Long-term results and late recurrence after endoureteropyelotomy: a critical analysis of prognostic factors. *J Urol*. 1994;151:934.

Varkarakis IM, Bhayani SB, Allaf ME, et al. Management of secondary ureteropelvic junction obstruction after failed primary laparoscopic pyeloplasty. *J Urol*. 2004;172:180.

Vega J, Goecke H, Tapia H, et al. Treatment of idiopathic retroperitoneal fibrosis with colchicine and steroids: a case series. *Am J Kidney Dis*. 2009;53:628.

Vieweg J, Teh C, Freed K, et al. Unenhanced helical computerized tomography for the evaluation of patients with acute flank pain. *J Urol*. 1998;160:679.

Voegeli DR, Crummy AB, McDermott JC, et al. Percutaneous dilation of ureteral strictures in renal transplant patients. *Radiology*. 1988;169:185.

Wagenknecht LV, Hardy JC. Value of various treatments for retroperitoneal fibrosis. *Eur Urol*. 1981;7:193.

Wagner JR, Schimpf MO, Cohen JL. Robot-assisted laparoscopic ileal ureter. *JSLS*. 2008;12:306.

Waldner M, Hertle L, Roth S. Ileal ureteral substitution in reconstructive urological surgery: is an antireflux procedure necessary? *J Urol*. 1999;162:323.

Waters WB, Whitmore WF, Lage AL, et al. Segmental replacement of the ureter using tapered and non-tapered ileum. *Invest Urol*. 1981;18:258.

Watterson JD, Sofer M, Wollin TA, et al. Holmium: YAG laser endoureterotomy for ureterointestinal strictures. *J Urol*. 2002;167:1692.

Webb AJ, Dawson-Edwards P. Malignant retroperitoneal fibrosis. *Br J Surg*. 1967;54:505.

Webber RJ, Pandian SS, McClinton S, et al. Retrograde balloon dilatation for pelviureteric junction obstruction: long-term follow-up. *J Endourol*. 1997;11:239.

Weijerman PC, Schurmans JR, Hop WC, et al. Morbidity and quality of life in patients with orthotopic and heterotopic continent urinary diversion. *Urology*. 1998;51:51.

Weise ES, Winfield HN. Robotic computer-assisted pyeloplasty versus conventional laparoscopic pyeloplasty. *J Endourol*. 2006;20:813.

Weiss JN, Badlani GH, Smith AD. Complications of endopyelotomy. *Urol Clin North Am*. 1988;15:449.

Wenske S, Olsson CA, Benson MC. Outcomes of distal ureteral reconstruction through reimplantation with psoas hitch, Boari flap, or ureteroneocystostomy for benign or malignant ureteral obstruction or injury. *Urology*. 2013;82:231.

Wenzler DL, Kim SP, Rosevear HM, et al. Success of ureteral stents for intrinsic ureteral obstruction. *J Endourol*. 2008;22:295.

Westerman ME, Parker WP, Viers BR, et al. Malignant ureteroenteric anastomotic stricture following radical cystectomy with urinary diversion: patterns, risk factors, and outcomes. *Urol Oncol*. 2016;34:485.

Williams SK. Levillee RJ. Expanding the horizons: robot-assisted reconstructive surgery of the distal ureter. *J Endourol*. 2009;23:457.

Wolf JS Jr, Elashry OM, Clayman RV. Long-term results of endoureterotomy for benign ureteral and ureteroenteric strictures. *J Urol*. 1997;158:759.

Wolff B, Chartier-Kastler E, Mozer P, et al. Long-term functional outcomes after ileal ureter substitution: a single-center experience. *Urology*. 2011;78:692.

Wollin M, Duffy PG, Diamond DA, et al. Priorities in urinary diversion following pyeloplasty. *J Urol*. 1989;142:576.

Wolpert JJ, Woodard JR, Parrott TS. Pyeloplasty in the young infant. *J Urol*. 1989;142:573.

Wotkowicz C, Libertino JA. Renal autotransplantation. *BJU Int*. 2004;93:253.

Yamada S, Ono Y, Ohshima A, et al. Transurethral ureteroscopic ureterotomy assisted by a prior balloon dilation for relieving ureteral strictures. *J Urol*. 1995;153:1418.

Yang C, Jones L, Rivera ME, et al. Robotic-assisted ureteral reimplantation with Boari flap and psoas hitch: a single-institution experience. *J Laparoendosc Adv Surg Tech A*. 2011;21:829.

Yang Y, Zhou X, Gao H, et al. The expression of epidermal growth factor and transforming growth factor-beta 1 in the stenotic tissue of congenital pelvi-ureteric junction obstruction in children. *J Pediatr Surg*. 2003;38:1656.

Yanke BV, Lallas CD, Pagnani C, et al. The minimally invasive treatment of ureteropelvic junction obstruction: a review of our experience during the last decade. *J Urol*. 2008;180:1397.

Yohannes P, Smith AD. Dual stent placement for the treatment of a persistent urine leak after partial nephrectomy—comment. *Urology*. 2001;57:356.

Zagoria RJ, Dixon RL. Radiology of urolithiasis: implications of radiation exposure and new aging modalities. *Adv Chronic Kidney Dis*. 2009;16:48.

Zeltser IS, Liu JB, Bagley DH. The incidence of crossing vessels in patients with normal ureteropelvic junction examined with endoluminal ultrasound. *J Urol*. 2004;172:2304.

Zhao LC, Weinberg AC, Lee Z, et al. Robotic ureteral reconstruction using buccal mucosa grafts: a multi-institutional experience. *Eur Urol*. 2017 [Epub ahead of print].

Zincke H, Kelasis PP, Culp OS. Ureteropelvic obstruction in children. *Surg Gynecol Obstet*. 1974;139:873.

Upper Urinary Tract Trauma

Steven B. Brandes MD, Jairam R. Eswara MD

Renal Injuries

The kidney is the most commonly injured urologic organ from external trauma. Advances in radiographic staging, improvements in hemodynamic monitoring, and wider use of angioembolization have improved the rates of renal preservation and decreased unnecessary surgery. **The majority of blunt and select penetrating injuries to the kidneys can be safely managed non-operatively. Complications that arise from expectant management can often be successfully managed percutaneously, endoscopically or by selective angioembolization. Absolute indications for immediate renal intervention is hemodynamic instability with no or transient response to resuscitation or a pulsatile or expanding retroperitoneal hematoma.**

Presentation and History

Motor vehicle accidents, falls from heights, and assaults cause the majority of blunt renal trauma. Direct transmission of kinetic energy and rapid deceleration forces place the kidneys at risk. In the United States, blunt trauma accounts for 80% to 90% of all renal injuries, whereas penetrating trauma accounts for 10% to 20%. The kidney is injured in 1% to 5% of all trauma and accounts for 24% of all solid organ injury (Hardee et al., 2013; Hotaling et al., 2012; Meng et al., 1999; Smith et al., 2005). The majority of renal injuries are minor and heal spontaneously. Most renal injuries, 78% to 82%, are low grade (AAST grades I–II) and are managed conservatively with little or no long-term consequence (Keihani et al., 2018; Zinman and Vanni, 2016).

Perhaps the most important information to obtain in the history of blunt renal injury is the mechanism of injury. This should include the speed of the car or the height of the fall, to better determine if significant deceleration injury was a component of the injury pattern. The kidney is particularly vulnerable to deceleration injury. Significant deceleration can cause the kidney to tear at retroperitoneal points of fixation, such as the renal hilum or ureteropelvic junction, resulting in renal artery thrombosis, renal vein disruption, renal pedicle avulsion, or ureteropelvic junction disruption. A more specific history of injury mechanism can be helpful. For example, the majority of the renal injuries after automobile accidents occur in unrestrained drivers upon direct impact on the steering wheel or side impact with the lateral door, often with 30 cm or more of door incursion (Kuan et al., 2007). Eliciting details of the accident from first responders at the scene can increase the level of suspicion for renal injury.

Penetrating renal injuries most often come from gunshot and stab wounds, and the kidneys are injured in approximately 10% of all abdominal penetrating injuries. More than 77% of patients with penetrating renal injuries have associated abdominal injuries. Gunshot wounds make up the majority of the penetrating trauma, with stab wounds a distant second (86% vs. 14%). Penetrating renal injuries have higher rates of significant and persistent renal bleeding, need for renorrhaphy/nephrectomy, and complications when managed nonoperatively. Of all patients sustaining renal trauma, civilian renal gunshot wounds are typically low velocity and occurr in approximately 4% (McAninch et al., 1993). Low velocity gunshot wounds cause less damage and are not as devastating as high velocity, unless they penetrate the renal hilum or collecting system. High velocity bullet wounds cause blast effect and often cause delayed tissue necrosis.

Stab wound entry sites that include the upper abdomen, flank, and lower chest, should raise suspicion for possible renal involvement. **Trauma to the anterior axillary line is more prone to damage important renal structures such as the renal hilum and pedicle compared with the posterior axillary line, which more commonly results in parenchymal injury.** Should the weapon be recovered, the size of the blade should be noted, to better understand the depth of the injury and the chance for organ damage.

Physical examination of all body systems must be detailed and complete. In a conscious patient, a thorough history can be taken during the examination. Rapid resuscitation according to American Association for the Surgery of Trauma (AAST) guidelines should be followed for polytrauma. With a blunt mechanism, cervical spine immobilization is mandated until confirmed intact by radiography. Examination of the abdomen, chest, and back must be performed. Indicators of possible renal injury on physical exam include flank ecchymoses, abdominal or flank tenderness, rib fractures, a significant blow to the flank, and penetrating injuries to the low thorax or flank. **It is important to consider concurrent intraabdominal injuries especially to the liver, intestine, and spleen in such trauma. Ipsilateral rib fracture can increase the incidence of significant renal trauma threefold.**

Gunshot injuries can be misleading in that small entrance wounds may underestimate larger tissue destruction within the body. Exit wounds are frequently, but not necessarily, much larger. Soft tissue and bone can alter the bullet's trajectory; thus the projectile may not take a direct path from entrance to exit. Bullet fragments can create secondary missiles, resulting in multiple injury tracts. When radiographs of the chest and abdomen are taken, a small metallic object should be placed at each entrance and exit site, to help define these locations on the films, and thus the path of the bullet.

Hematuria

The best indicators of significant urinary system injury include gross and microscopic hematuria (>5 red blood cells/high-power field [RBCs/HPF] or positive dipstick finding), especially when associated with acceleration/deceleration injury, penetrating trauma, or hypotension in the field or emergency room (systolic blood pressure <90 mm Hg).

The degree of hematuria and the severity of the renal injury do not consistently correlate. Gross hematuria has been observed in minor renal contusions, and microscopic hematuria has been seen in some with severe renal injuries. Hematuria was absent in 7% of 420 grade IV renal injuries in a recent analysis (Shariat et al., 2008a), 11% of patients with renal gunshot wounds (Voelzke and McAninch, 2009), and 36% of renal vascular injuries from blunt trauma (Cass, 1983). Also, approximately 50% of injuries to the ureteropelvic junction have no microscopic or gross hematuria. In patients with blunt trauma, microscopic hematuria associated with shock significantly increases the incidence of severe renal injuries (Mee and McAninch, 1989; Mee et al., 1989; Miller and McAninch, 1995; Nicolaisen et al., 1985). In addition, recreational injuries (primarily blunt) have a far lower rate of gross hematuria or microscopic hematuria with hypotension than urban renal trauma, and using hematuria as a criterion for imaging would have missed 23% of grades II to IV injuries (Lloyd et al., 2012).

The first aliquot of urine obtained by catheterization or voiding is used to determine the presence of hematuria. Later urine samples may be diluted by diuresis from resuscitation fluids, resulting in an underestimation or absence of hematuria. Any degree of visible blood in the urine is regarded as gross hematuria. Microscopic hematuria can be detected by dipstick analysis or microanalysis. The dipstick method is rapid and has a sensitivity and specificity for detection of microhematuria of more than 97%, even though a poor correlation with actual urinalysis was noted in a single study (Chandhoke and McAninch, 1988). **Although critical to the initial evaluation of traumatic**

urinary tract injury, the presence or absence of hematuria should not be the sole determinant in the assessment of a patient with suspected renal trauma. Mechanism of injury and concurrent injuries should also play a role. Because the significance of hematuria varies with blunt and penetrating mechanisms, the importance of proper detection and staging of renal injuries, usually by computed tomography (CT), must be emphasized.

Classification

The AAST Organ Injury Scaling Committee (Moore et al., 1989) is the most widely used and accepted classification of renal injury (Table 90.1, Fig. 90.1). Based on accurate grading by contrast-enhanced CT, the kidney AAST injury severity scale has been validated in multiple series, as a predictive tool for clinical outcomes, such as the need for surgical or angiographic intervention or the rate of nephrectomy (Phan et al., 2018; Shariat et al., 2007). The organ injury scale for renal trauma was recently updated (Kozar et al., 2018). The grading scale remains largely unchanged. However, Grade IV now includes vascular injuries such as arterio-venous malformation or pseudo-aneurysm, and Grade V now includes a devascularized kidney with active bleeding and a shattered kidney with loss of identifiable parenchymal renal anatomy.

TABLE 90.1

American Association for the Surgery of Trauma Organ Injury Severity Scale for the Kidney

GRADE[a]	TYPE	DESCRIPTION
I	Contusion	Microscopic or gross hematuria, urologic studies normal
	Hematoma	Subcapsular, nonexpanding without parenchymal laceration
II	Hematoma	Nonexpanding perirenal hematoma confined to renal retroperitoneum
	Laceration	<1 cm parenchymal depth of renal cortex without urinary extravasation
III	Laceration	>1 cm parenchymal depth of renal cortex without collecting system rupture or urinary extravasation
IV	Laceration	Parenchymal laceration extending through renal cortex, medulla, and collecting system
	Vascular	Main renal artery or vein injury with contained hemorrhage
V	Laceration	Completely shattered kidney
	Vascular	Avulsion of renal hilum, devascularizing the kidney

[a] Advance one grade for bilateral injuries up to grade III.

Data from Moore EE, Shackford SR, Pachter HL, et al.: Organ injury scaling: spleen, liver, and kidney. *J Trauma* 29:1664–1666, 1989.

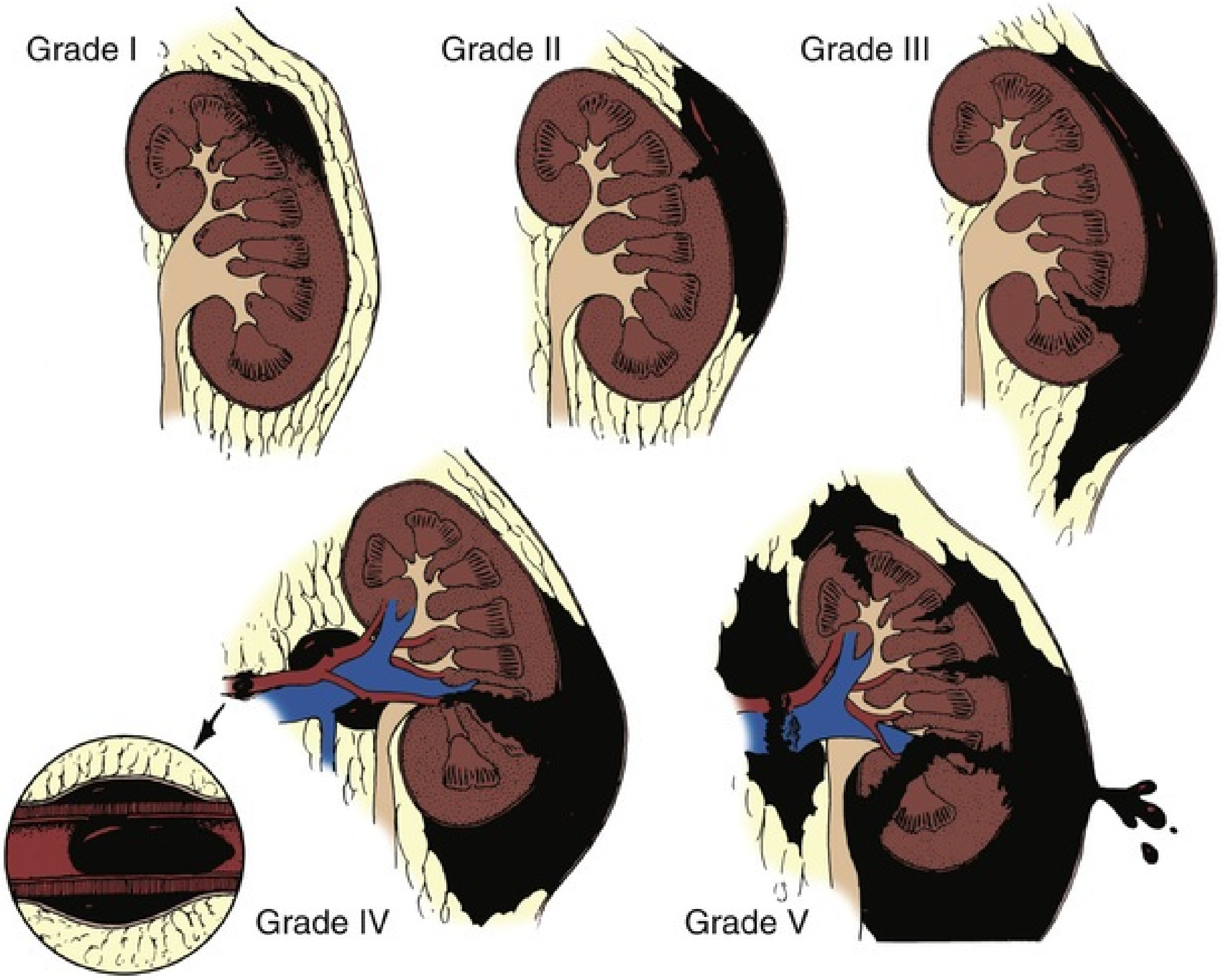

FIG. 90.1 Classification of renal injuries by grade. (Modified from the organ injury scale of the American Association for the Surgery of Trauma. Based on Moore EE, Shackford SR, Pachter HL, et al.: Organ injury scaling: spleen, liver, and kidney. *J Trauma* 29:1661–1664, 1989.)

Indications for Renal Imaging

Based on the AUA Urotrauma guidelines and EAU Upper Urinary Tract Trauma guidelines published in 2014, the criteria for radiographic imaging include the following (Morey et al., 2014; Serafetinides et al., 2015)**:**

1. **All patients with a penetrating trauma with a likelihood of renal injury (abdomen, flank, ipsilateral rib fracture, significant flank**

ecchymosis, or low chest entry/exit wound) who are hemodynamically stable enough to have a CT (instead of going directly to the operating room or angiography suite)

2. **All patients with blunt trauma with significant acceleration/deceleration mechanism of injury, specifically rapid deceleration as would occur in a high-speed motor vehicle accident or a fall from heights**
3. **All patients with blunt trauma and gross hematuria**
4. **All patients with blunt trauma with microhematuria and hypotension (defined as a systolic pressure of less than 90 mm Hg at any time during evaluation and resuscitation)**
5. **All pediatric patients with greater than 5 RBCs/HPF**

The preferred imaging test is an abdominal/pelvic CT using IV contrast with immediate and delayed images.

An extensive prospective study based at San Francisco General Hospital evaluating indications for radiographic imaging continued for more than 25 years. The findings have been updated in three reports (Mee and McAninch, 1989; Miller and McAninch, 1995; Nicolaisen et al., 1985; Fig. 90.2). Based on information from this study, all patients with blunt trauma with gross hematuria and patients with microscopic hematuria and shock (systolic blood pressure <90 mm Hg any time during evaluation and resuscitation) should undergo renal imaging, usually with CT using intravenous (IV) contrast and with delayed films to evaluate urinary extravasation.

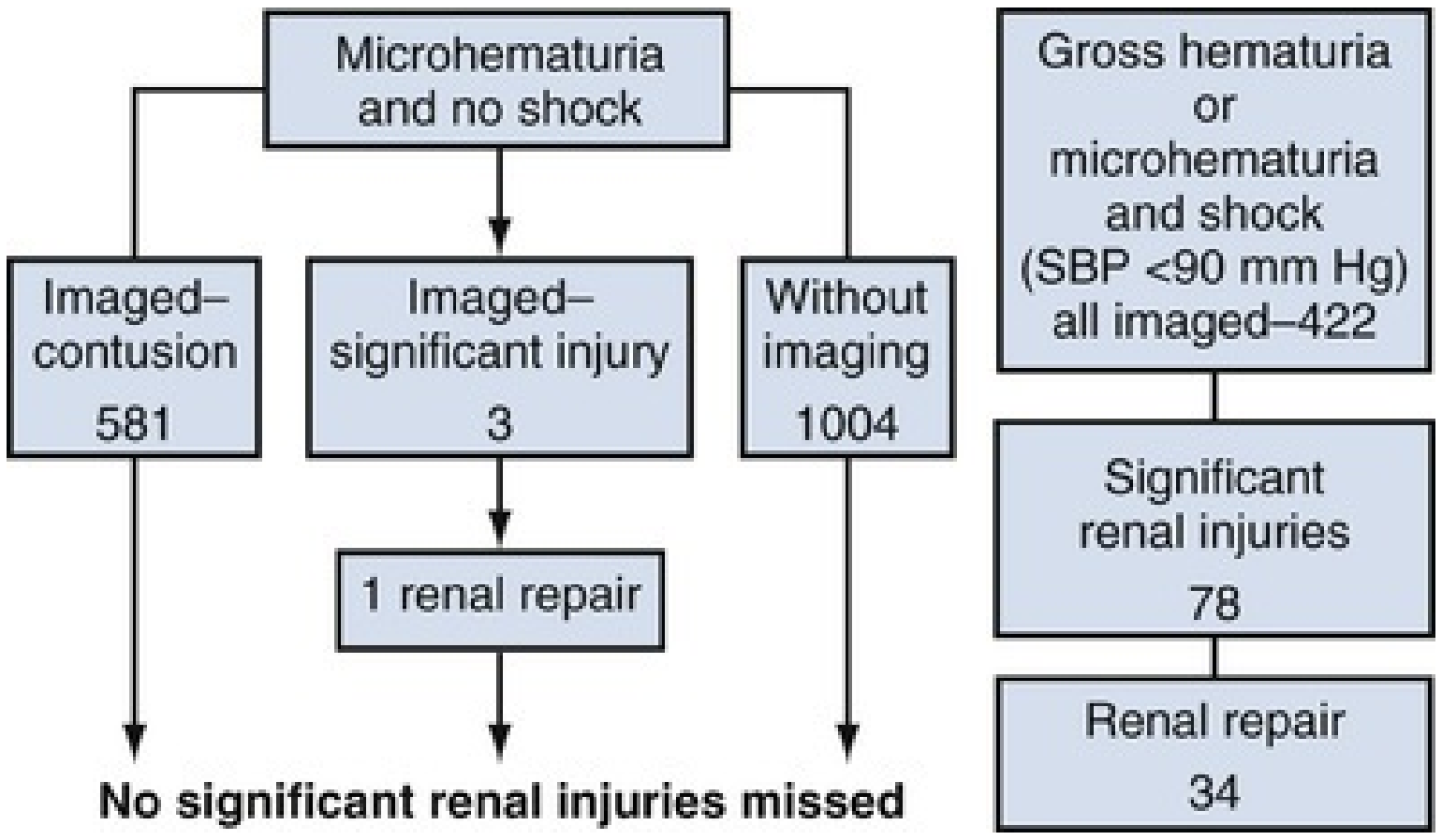
Microhematuria and no shock
Imaged–contusion 581
Imaged–significant injury 3
Without imaging 1004
1 renal repair
No significant renal injuries missed
Gross hematuria or microhematuria and shock (SBP <90 mm Hg) all imaged–422
Significant renal injuries 78
Renal repair 34

FIG. 90.2 Algorithm demonstrating the results of the authors' study on radiographic assessment of renal injuries. In adults with blunt trauma,

imaging studies may be performed selectively. *SBP,* Systolic blood pressure. (From Miller KS, McAninch JW: Radiographic assessment of renal trauma: our 15-year experience. *J Urol* 154:352–355, 1995.)

Patients with microscopic hematuria without hypotension or acceleration/deceleration injury can be observed clinically without imaging. First noted by Miller and McAninch (1995) but confirmed by several subsequent findings, these patients rarely have a significant injury (<0.0016%) (Cimbanassi et al., 2018). **However, if renal injury is suspected on the basis of history, mechanism of injury, examination, or the patient's subsequent clinical course, imaging should be performed.** It is important to remember that blunt rapid deceleration injuries, such as high-speed motor vehicle accidents or falls from great heights, pose a higher risk for vascular pedicle or ureteral pelvic junction injury.

Penetrating injuries with any degree of hematuria should be imaged. In a report by Carroll and McAninch (1985), 27 of 50 patients with penetrating renal trauma had only microscopic hematuria. Three of these had practically undetectable amounts of microhematuria—0 to 3 RBCs/HPF. Despite this, one of the three had a renal pedicle injury. A more recent study from South Africa showed a stronger correlation between degree of hematuria and severity of injury (Moolman et al., 2012). Microscopic hematuria was associated with grade III or lesser injury in 85% of patients while gross hematuria was noted in 94% of patients with grade III injury or worse.

Pediatric patients (younger than 18 years) sustaining blunt renal trauma generally can be evaluated like adults (Santucci et al., 2004), with a few caveats:

1. Children have an up to 50% higher risk for renal trauma than adults after blunt abdominal injury, such as motor vehicle accidents (Kurtz et al., 2017) and 33% higher risk for high grade injury. Possible explanations are the larger comparative kidney size, less perirenal fat, non-ossified bones, and less relative rib coverage over the kidneys in children (Buckley and McAninch, 2004).
2. Importantly, children often do not become hypotensive with major blood loss, and in the absence of this sign can still have an exsanguinating renal injury. Liberal use of renal imaging is probably warranted. Children have a high catecholamine output after trauma, which maintains blood pressure until approximately 50% of blood volume has been lost.

3. Children have a higher proportion of congenital renal abnormalities such as severe hydronephrosis or uretero-pelvic junction obstruction, which may result in significant renal injury from seemingly minor trauma.

Imaging Studies

Contrast-enhanced CT with immediate and delayed images, is the best method for genitourinary imaging in renal trauma (Bretan et al., 1986; Morey et al., 2014). Quick, highly sensitive, and specific, CT provides the most definitive staging information—parenchymal lacerations are clearly defined; extravasation of contrast-enhanced urine can easily be detected (Fig. 90.3); associated injuries to the bowel, pancreas, liver, spleen, and other organs can be identified; and the degree of retroperitoneal bleeding can be assessed by the size of the retroperitoneal hematoma. Lack of uptake of contrast material in the parenchyma suggests arterial thrombosis (Fig. 90.4) or transection. Detection of fine anatomic detail of the most serious injuries (urinary extravasation, active arterial bleeding, and severe parenchymal/vascular injuries) has improved confidence in our ability to understand which injuries can be managed nonoperatively.

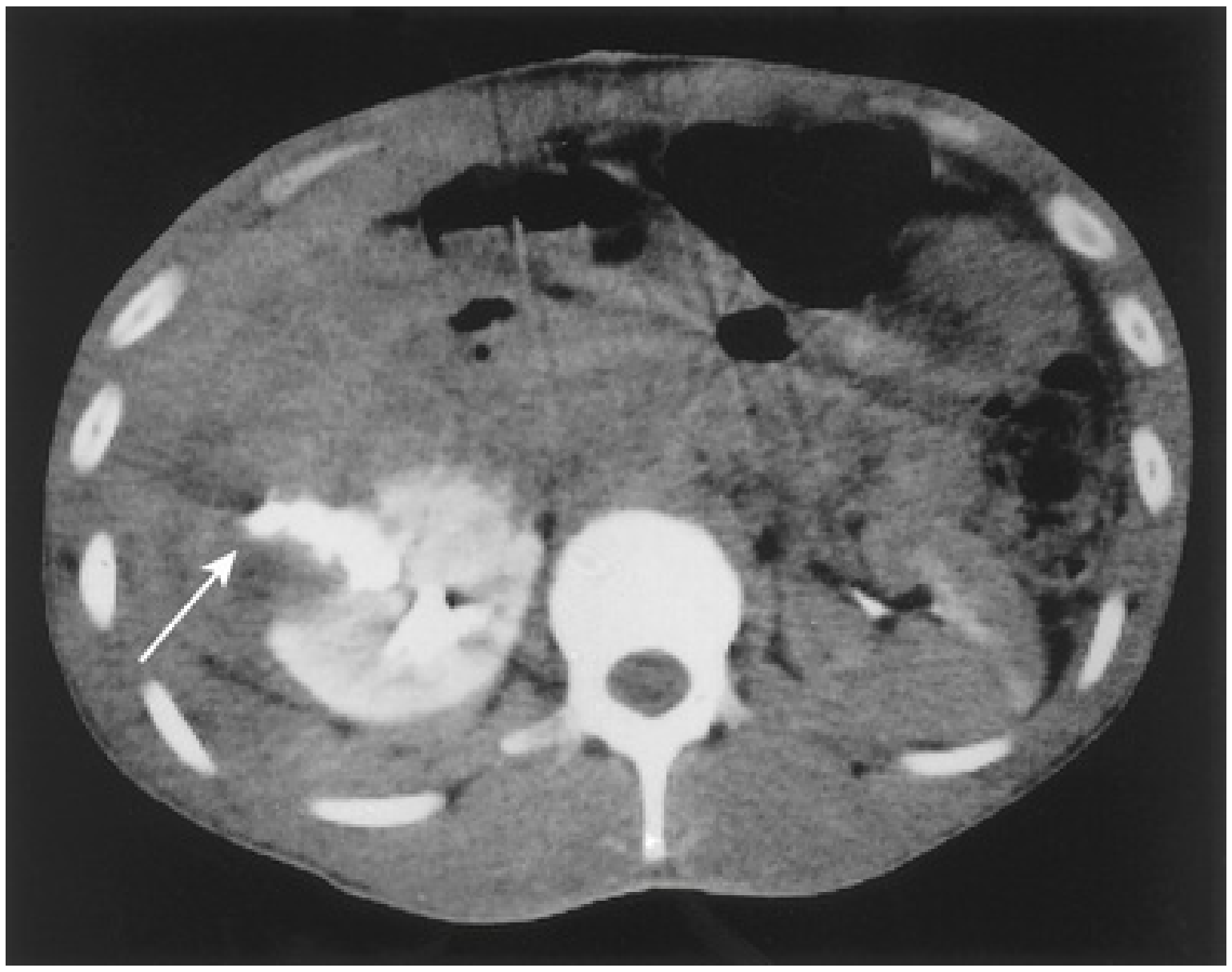

FIG. 90.3 Computed tomography scan of a right renal stab wound (grade IV) *(arrow)*, demonstrating extensive urinary extravasation and large retroperitoneal hematoma.

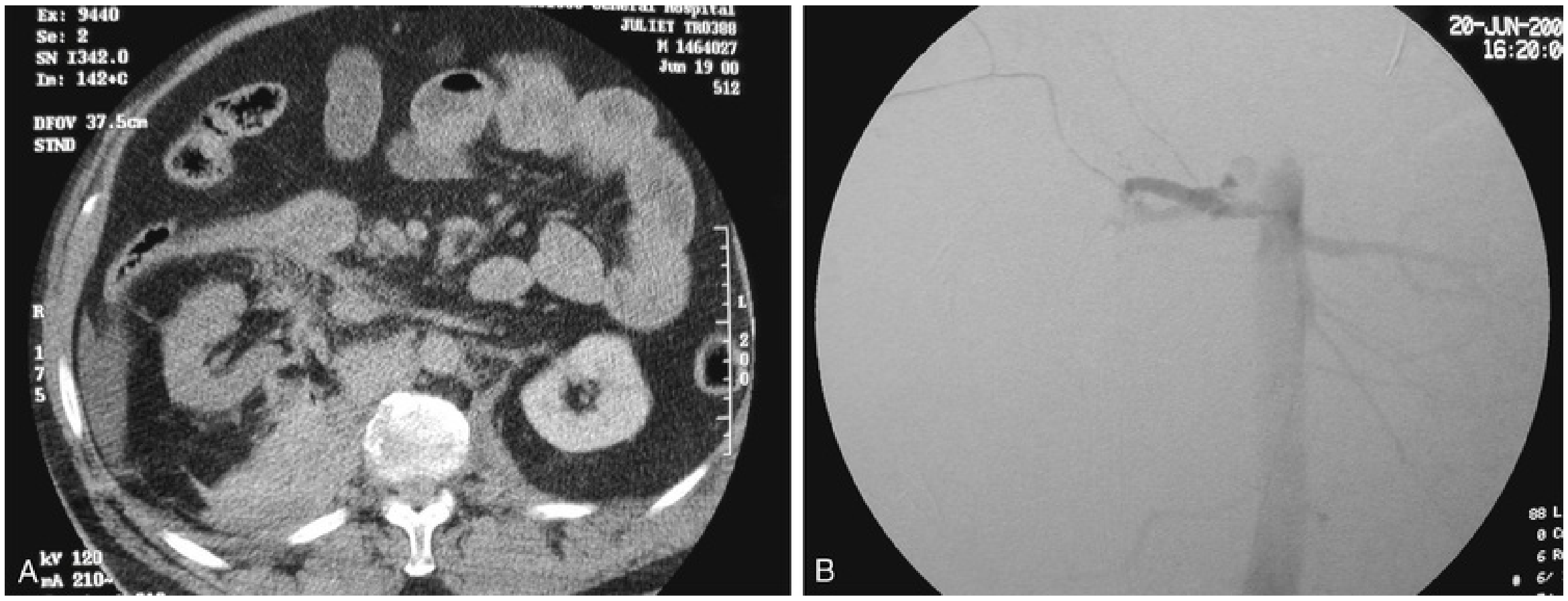

FIG. 90.4 (A) Computed tomography showing right renal artery thrombosis after crush injury. Note poor contrast uptake in right kidney compared with left and diffuse soft tissue injury medial to right kidney in the area of the renal artery. (B) Angiogram showing right renal artery thrombosis after crush injury.

Arteriovenous CT scanning (typically 80 seconds after contrast administration) provides visualization of the kidneys in the nephrogenic phase of contrast excretion and is necessary to detect arterial extravasation. Injury to the renal collecting system may be missed if contrast material has not had time to be excreted into the parenchyma and collecting system adequately. Delayed scanning of the kidneys 10 to 15 minutes after injection of contrast identifies parenchymal lacerations and urinary extravasation accurately and reliably**.** Expert opinion holds that delayed films may be omitted when the kidneys are deemed normal, and no perinephric, retroperitoneal, pelvic, or perivesical fluid is present (Morey et al., 2014). **Findings on CT that raise suspicion for major injury are (1) medial hematoma, suggesting vascular injury; (2) medial urinary extravasation, suggesting renal pelvis or ureteropelvic junction avulsion injury; (3) global lack of contrast enhancement of the parenchyma, suggesting renal artery occlusion; and (4) the combination of two or more of the following: large hematoma greater than 3.5 cm, medial renal laceration, and vascular contrast extravasation (suggesting brisk active bleeding), which constitute an AAST grade IVb injury** (Dugi et al., 2010).

Patients with grade IVb injuries require open surgery or angioembolization nine times more frequently than those with none or one of these features (Dugi et al., 2010). Also, active extravasation of intravascular contrast seen on CT (i.e., the patients are bleeding so briskly as to be detectible on the vascular phase CT scan) is highly associated with the need for subsequent angioembolization (Nuss et al., 2009; Fig. 90.5). The widespread use and anatomic detail provided by CT imaging has now supplanted the much less sensitive, less specific, and rarely used excretory urography (IV pyelography [IVP]) for grading purposes. The need for delayed-phase contrast-enhanced CT for pediatric trauma patients has been questioned, however (Fuchs et al., 2018).

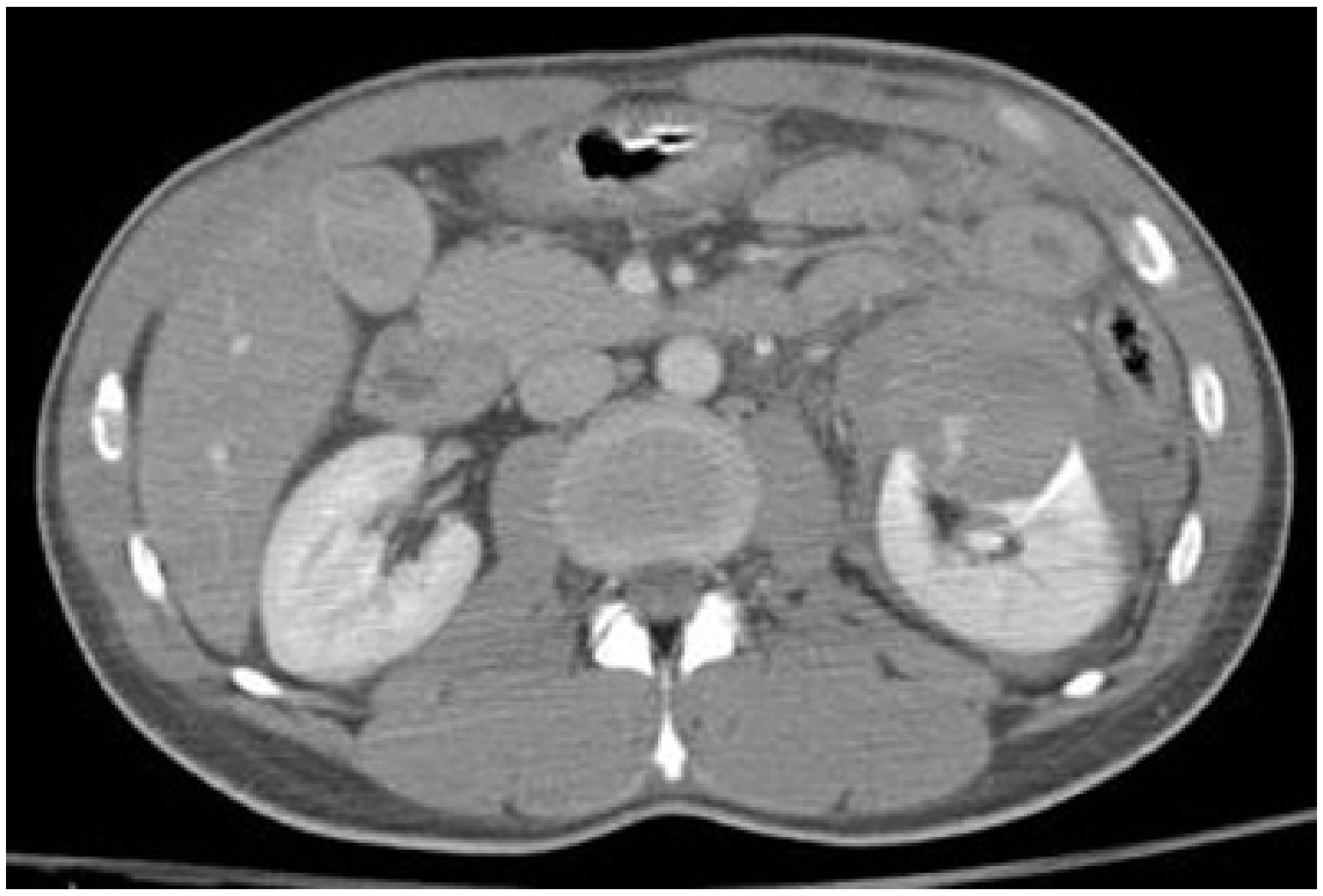

FIG. 90.5 Computed tomography showing left renal fossa hematoma after blunt renal trauma, with bright jet of active extravasation of intravascular contrast indicating brisk active bleeding.

One major limitation of CT is the inability to define a renal venous injury adequately. With normal arterial perfusion, the parenchyma appears normal and the collecting system may contain contrast material. A medial hematoma accompanying the preceding findings suggests a venous injury. Most venous injuries result in either hemorrhage requiring surgery or angioembolization or tamponade and stop bleeding and thus require no further treatment. The true clinical significance of the insensitivity of CT to renal vein injury is currently unknown.

In contemporary practice, there is a limited role for intraoperative "one-shot" IVP. The indications are uncommon, such as when the surgeon encounters an unexpected retroperitoneal hematoma surrounding a kidney during abdominal exploration in an unstable trauma patient without a previous CT scan, and are contemplating renal exploration or nephrectomy. **The main purpose of the one-shot IVP is to assess the presence of a functioning contralateral kidney.** It is vital to know if a patient has only one kidney, because urgent surgical exploration of renal injuries often leads to nephrectomy for the injured kidney. **The IVP technique is key to gaining important information and minimizing**

the time involved. Only a single film is taken 10 minutes after IV injection (IV push) of 2 mL/kg of contrast material. The study can also be helpful in assessing for urinary contrast extravasation. If the study is normal, exploration of the injured side may be avoided. If findings are not near normal, further imaging is recommended or the kidney explored to complete the staging of the injury.

Morey et al. (1999) reported their experience with one-shot intraoperative IVP for the immediate management of renal injuries. In 50 patients, the film quality was adequate and properly done to avoid renal exploration in 32%. However, it is often difficult to obtain a well performed or timed one-shot IVP because unstable trauma patients are typically hypoperfused. Moreover, most trauma surgeons today use retroperitoneal palpation to assess for the presence of a normal caliber contralateral kidney, and rarely utilize one-shot IVP (Yeung and Brandes, 2012).

Sonography is typically used in the immediate evaluation of abdominal injuries (focused assessment with sonography for trauma [FAST] examination), but has poor specificity in the adult renal patient for renal injuries. FAST is limited by obesity, subcutaneous air and prior abdominal operations. If necessary, sonography can confirm the presence of two kidneys and can detect a retroperitoneal collection. It cannot differentiate between a hematoma and a urine leak.

Angioembolization

Renal arteriography and embolization is a commonly used modality in renal trauma and is increasingly being used for higher-grade injuries (Otsuka et al., 2018). In the correct setting, it can be used to stop significant renal bleeding without the need for laparotomy, and its indications are increasing. It is vital that if angioembolization is used and the local angiography team is experienced, the procedure can be done without delay, and the patient can be monitored and even resuscitated during transport to and in the angiography suite. Superselective embolization therapy for renal trauma may provide an effective and less invasive technique to avoid unnecessary exploration that could otherwise result in nephrectomy. Initial failure is common, between 13% and 88% (Breyer et al., 2008; Sugihara et al., 2012), but subsequent embolization is highly successful in at least one series (Hotaling et al., 2011). A recent survey of urologists and interventional radiologists showed that urologists are more willing to use angioembolization for grade IV and V injuries (Glass et al., 2014). Another study found increasing use of angioembolization for grade IV and highly select

V injuries, with hemodynamic instability and grade being independent predictors of surgical treatment (Lanchon et al., 2016).

Traumatic pseudoaneurysms and arteriovenous fistulas are often treated by angiographic embolization with a high expected success rate (Fig. 90.6). A recent study found a pseudoaneurysm rate of 2.5% among all grades of renal trauma with successful angioembolization in 84.6% of patients (Guyot et al., 2017). Endovascular stents have been used with success during angiography in patients with acute renal artery thrombosis occurring from intimal flaps (Goodman et al., 1998). Longer term follow-up and more cases are needed to determine whether this will be a successful management approach, especially considering kidney warm ischemia time, and that most stents require anticoagulation after placement, which may not be possible in a trauma patient.

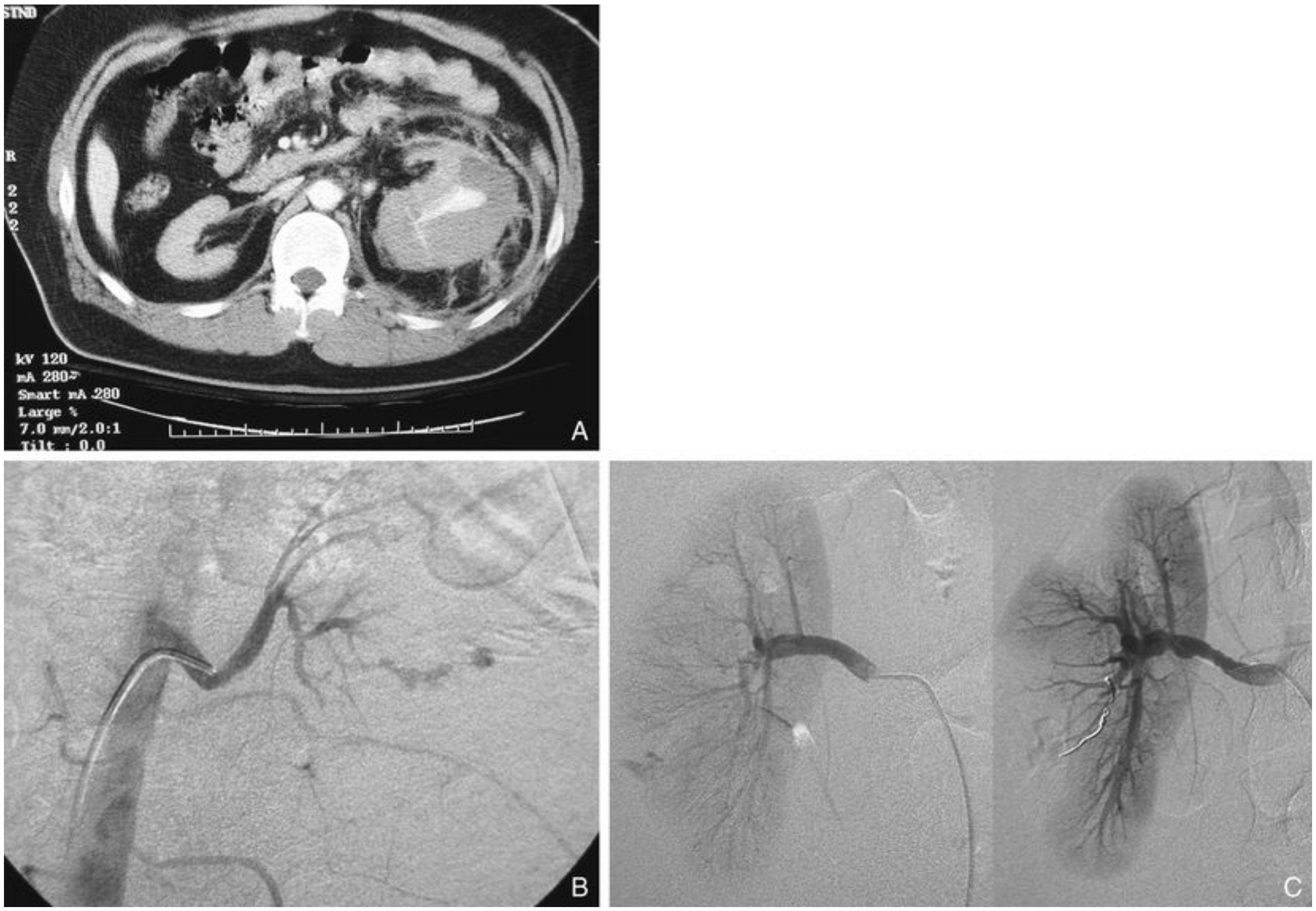

FIG. 90.6 (A) Computed tomography showing left post-traumatic arteriovenous fistula. (B) Angiogram showing left post-traumatic arteriovenous fistula. (C) Angioembolization of right renal laceration: arteriography demonstrating active arterial bleeding. Coil embolization was used to control bleeding. Note the presence of the coil and large, triangular area of infarct.

Nonoperative Management

Significant renal injuries (grades II to V) are found in only 5% of renal trauma cases (Keihani et al., 2018). **Nonoperative management is the standard of care in hemodynamically stable, well-staged patients with AAST grades I to IVa renal injuries, regardless of mechanism** (Dugi et al., 2010; Morey et al., 2014). **Most experts agree that patients with grades IV and V injuries more often require surgical exploration, but even these high-grade injuries can be managed without renal operation if carefully staged and selected** (Fig. 90.7) (Buckley and McAninch, 2006; Santucci and McAninch, 2000; Umbreit et al., 2009; van der Wilden et al., 2013). Interestingly, conservative management of high-grade renal injuries has not been associated with increased length of stay (Hampson et al., 2018) and may even be associated with a shorter length of stay and likely higher renal preservation rate (Sujenthiran et al., 2019).

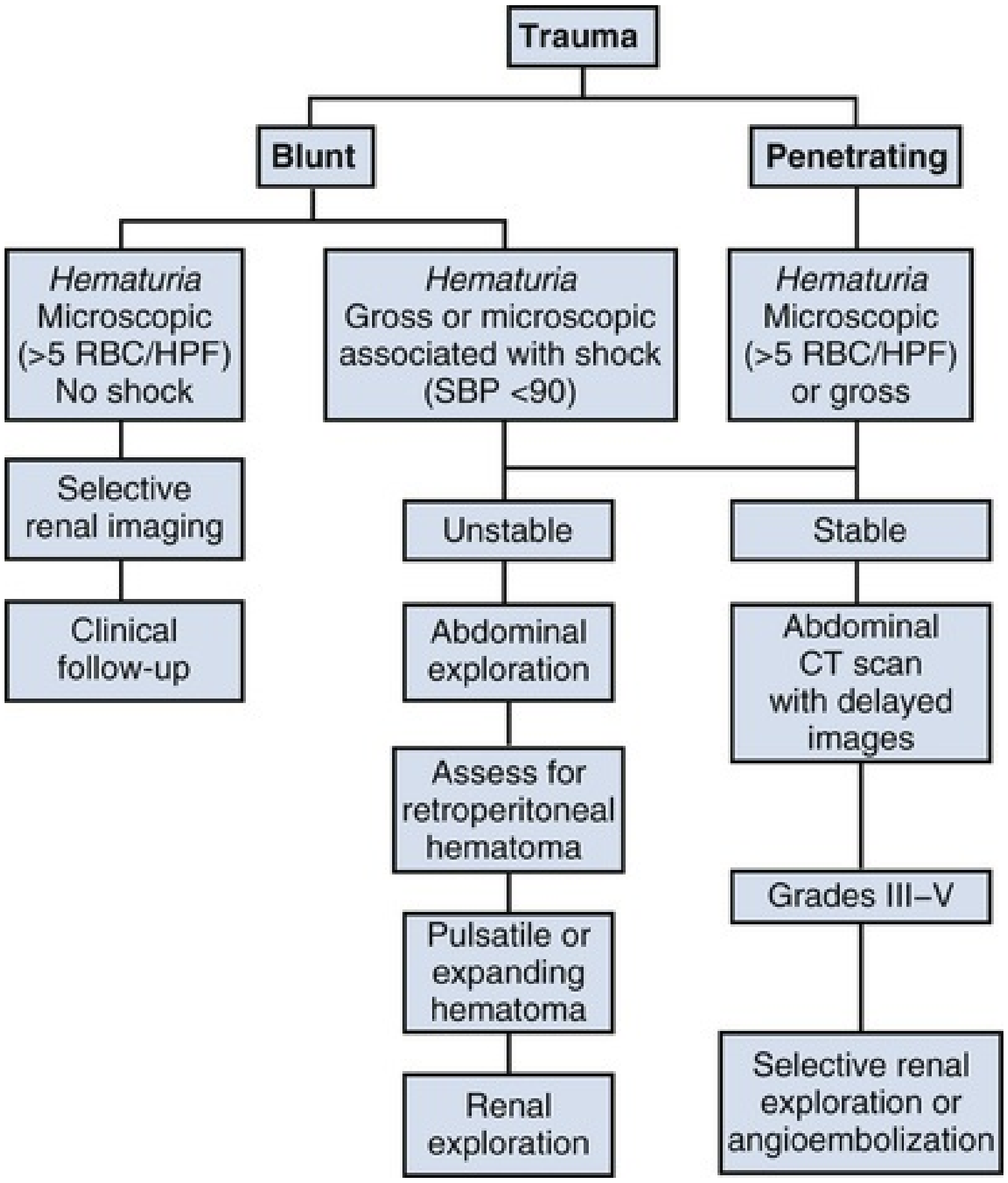
Trauma
Blunt
Penetrating
Hematuria Microscopic (>5 RBC/HPF) No shock
Hematuria Gross or microscopic associated with shock (SBP <90)
Hematuria Microscopic (>5 RBC/HPF) or gross
Selective renal imaging
Clinical follow-up
Unstable
Stable
Abdominal exploration
Abdominal CT scan with delayed images
Assess for retroperitoneal hematoma
Grades III–V
Pulsatile or expanding hematoma
Renal exploration
Selective renal exploration or angioembolization

FIG. 90.7 Flow chart for adult renal injuries to serve as a guide for decision making. *CT,* Computed tomography; *IVP,* intravenous

pyelography; *RBC/HPF,* red blood cells per high-power field; *SBP,* systolic blood pressure.

A trial of expectant management has been advocated for most adult blunt renal parenchymal injuries, many isolated (kidney only) renal stab wounds, and select and isolated renal gunshot wounds. Bluntly injured kidneys often heal well when managed conservatively, even in the setting of urinary extravasation and nonviable tissue. Overall, over 90% can be successfully managed without exploration. Even select high-grade injuries can successfully be treated nonoperatively. In a series of six hemodynamically stable, grade V blunt “shattered” kidney injuries, all were treated successfully without surgery (Altman et al., 2000). Patients who are exsanguinating (hemodynamically unstable) from the kidney, however demand exploration and subsequent nephrectomy/renorrhaphy. Those who are hemodynamically stable can in select circumstances be successfully treated without surgery (Moolman et al., 2012). Significant delayed renal bleeding is usually amenable to angioembolization, occurs in 9%. Another series showed a 93% renal salvage rate among patients with grades IV and V injury (May et al., 2016).

Select gunshot or stab wounds isolated to the kidney can be managed nonoperatively in stable patients. In one large series, 55% of renal stab wounds and 24% of gunshot wounds were successfully managed nonoperatively in carefully selected patients with well-staged injuries (McAninch et al., 1991). The AAST GU Trauma Study recently reported managing 57 patients (13%) with isolated, low-velocity gunshot wounds conservatively with few complications (Keihani et al., 2018). High grade penetrating injuries (AAST grade III or IV) are typically managed surgically because of the high rate of delayed bleed (24%) and the necessity to explore for associated intra-abdominal injuries. Stab wounds posterior to the posterior axillary line are less likely to have visceral injuries, and thus more likely to be successfully managed conservatively. The penetrating wound can often disrupt Gerota’s fascia significantly, and thus can uncontain the perirenal hematoma. If the injury is isolated to the kidney, however, and no major intra-abdominal structure has been injured, it is safe to manage expectantly. Such patients must undergo frequent serial abdominal exams, particularly in the first 24 hours. Any new tenderness or abdominal guarding warrant abdominal exploration.

Stab injuries have even more evidence to support conservative management. Nonoperative management was successful and resulted in no delayed nephrectomies in a cohort of 108 hemodynamically stable patients with stab wounds (Armenakas et al., 1999). Some blunt and penetrating abdominal trauma may require laparotomy because of associated nonurologic injury, but even in these cases it is not necessary to explore the kidney additionally, especially if Grade 1–3 (Shariat et al., 2008b). The only absolute intraoperative indication for kidney exploration is a pulsatile and expanding retroperitoneal hematoma, that suggests a life-threatening renal artery laceration.

All patients with high-grade injuries selected for nonoperative management should be closely observed with serial hematocrit readings and vital signs. Classic teaching is to prescribe bed rest until gross hematuria resolves. However, this practice is empiric and there is little to no support in the literature for such.

Routine follow up CT imaging for Grade IV–V renal injuries is prudent at 48 to 72 hours post injury, to evaluate for a troublesome urinoma, collection or hematoma. **Recently, there is mounting evidence that significant complications almost always present with symptoms (fever, flank pain, dropping hematocrit, increasing hematuria, etc.)** (Davis et al., 2010). Thus, routine follow-up CT may be unnecessary in the asymptomatic patient. Routine follow-up CT imaging is not needed for uncomplicated Grade I–III injuries because it is unlikely to change management and not cost effective. Although most grade II to IV injuries resolve uneventfully, delayed renal bleeding sometimes can occur (Wessells et al., 1997). Should bleeding persist or delayed bleeding occur, angiography with selective embolization of bleeding vessels can obviate surgical intervention. The patient should be periodically undergo blood pressure monitoring for up to a year post injury, for the rare instance of acute or delayed renovascular hypertension. Delayed bleeding after discharge to home is rare and usually occurs within 2 weeks post injury.

Conservative management rarely fails within the first 24 hours (2.7% of patients). Risk factors for failure include renal injury grade, nonrenal abdominal injuries, and penetrating injuries (Bjurlin et al., 2017). Most patients for whom conservative management fails require only a ureteral stent or angioembolization. The complication rate of nonoperative treatment is much lower than that of aggressive surgical exploration and results in shorter intensive care unit (ICU) stays, shorter hospital stays, lower mortality, and fewer transfusions (Bjurlin et al., 2011). **However, patients who are hemodynamically unstable with no or transient response to resuscitation from the kidney injury require rapid open surgical exploration or in some cases quick expert angioembolization to avoid death.** Although nonoperative management for renal trauma has been increasing, recent study shows that the rate of surgical intervention for renal trauma varies significantly among high-, medium-, and low-volume trauma centers, with high-volume centers intervening in only 12.6% of patients (Dagenais et al., 2016).

Initial observation is warranted for patients with renal injury and urinary extravasation (Morey et al., 2014). **Such injuries often resolve spontaneously in over 90%, unless a renal pelvis avulsion or proximal ureteral avulsion injury is present. Medial extravasation of contrast from the kidney, with lack of contrast in the distal ureteral on delayed CT imaging, suggests UPJ avulsion.** For such patients, prompt intervention is required, either endoscopically or open, depending on the clinical situation. When continued urinary drainage leads to enlarging urinoma, fistula, infection, or signs of chemical peritonitis such as pain, fever, ileus, urinary drainage via ureteral stent and/or urinoma drain are required. In severe renal injuries with continued urinary extravasation, placement of an internal ureteral stent alone for drainage usually prevents prolonged urinary extravasation and decreases the chance of perirenal urinoma formation. On occasion, retrograde placement of ureteral stents is not possible. Examples include concomitant pelvic fracture urethral distraction defects, severe genital trauma prohibiting urethral access, complete ureteral transection, and fractures prohibiting the dorsal lithotomy position. Percutaneous nephrostomy drainage with consideration for antegrade ureteral stent placement is a viable option in these situations.

Fluid collections seen on serial imaging for renal trauma are either hematomas, urinomas, or abscesses. Urinomas can be distinguished from hematomas by their radiographic characteristics: urinomas range from 0 to 20 Hounsfield units (HU), whereas hematomas typically are greater than 30 HU (Federle and Jeffrey, 1983). Also, urinomas enhance with contrast pooling dependently during delayed phase imaging (5 to 20 minutes after IV injection of contrast). Abscesses have rim enhancement and high attenuation fluid (HU >20) on contrasted films (Allen et al., 2012). When the perinephric fluid collection persists despite ureteral stenting or percutaneous nephrostomy drainage, placement of a percutaneous drain can facilitate healing and prevent or treat abscesses.

Operative Management

Indications for renal exploration or speedy angioembolization after trauma can be separated into absolute and relative (Morey et al., 2014). **Absolute**

indications include (1) hemodynamic instability with no or transient response to resuscitation, (2) expanding/pulsatile renal hematoma (usually indicating renal artery laceration), (3) suspected renal vascular pedicle avulsion, and (4) ureteropelvic junction avulsion. Relative indications are (1) urinary extravasation with significant renal parenchymal devascularization (older data suggested a higher complication rate than average if watched, but these also can be closely observed), (2) renal injury together with colon/pancreatic injury (these patients have a higher complication rate if their renal injury is not repaired at the time of colon/pancreatic injury, but the renal injury may be closely observed after repair of the enteric injury), (3) arterial thrombosis, and (4) urinary extravasation from parenchymal injury. More recent data suggest that patients with renal devascularization and urine leak actually have excellent outcomes, with only 1 of 18 (6%) patients requiring subsequent intervention during conservative management of segmental renal artery injuries (Elliott et al., 2007). Also, more recent data suggest that concurrent renal and colonic injuries do not have to be managed operatively (Oosthuizen et al., 2018).

Urinary extravasation alone from a grade IV parenchymal laceration can be safely managed nonoperatively with an expectation of spontaneous resolution of more than 90%. Should nonviable tissue constitute more than 25% in association with a parenchymal laceration, urinary extravasation, or both, the potential for complications (i.e., abscess) increases, and thus a threshold for renal exploration should be lower (Alsikafi et al., 2006).

Renal Exploration

Surgical exploration of the acutely injured kidney is best by a transabdominal approach, which allows complete inspection of intra-abdominal organs and bowel. In some reported series of penetrating injuries, nonrenal organ injury has been noted to be as high as 94% (McAninch et al., 1993). Injuries to the great vessels, liver, spleen, pancreas, and bowel can be identified and stabilized, if necessary, before renal exploration.

The surgical approach to renal exploration is shown in Fig. 90.8 (McAninch and Carroll, 1989). The renal vessels are isolated before exploration to provide the immediate capability to occlude them if massive bleeding should ensue when Gerota fascia is opened (Scott and Selzman, 1966). The small bowel is eviscerated and lifted out of the surgical field. This exposes the mid-retroperitoneum. An incision is made over the aorta in the retroperitoneum just superior to the inferior mesenteric artery. The incision is extended superiorly to the ligament of Treitz. Exposure of the anterior surface of the aorta is accomplished and followed superiorly to the left renal vein, which crosses the aorta anteriorly. A vessel loop is placed on the right or left renal vein as necessary. The vein usually must be retracted cephalad, with a vein or-Gil Vernet retractor, to expose the left and right renal arteries beneath. The artery is secured with vessel loops. The right renal vein also can be secured through this incision; but if this proves difficult, reflecting the second portion of the duodenum provides excellent exposure to the vein.

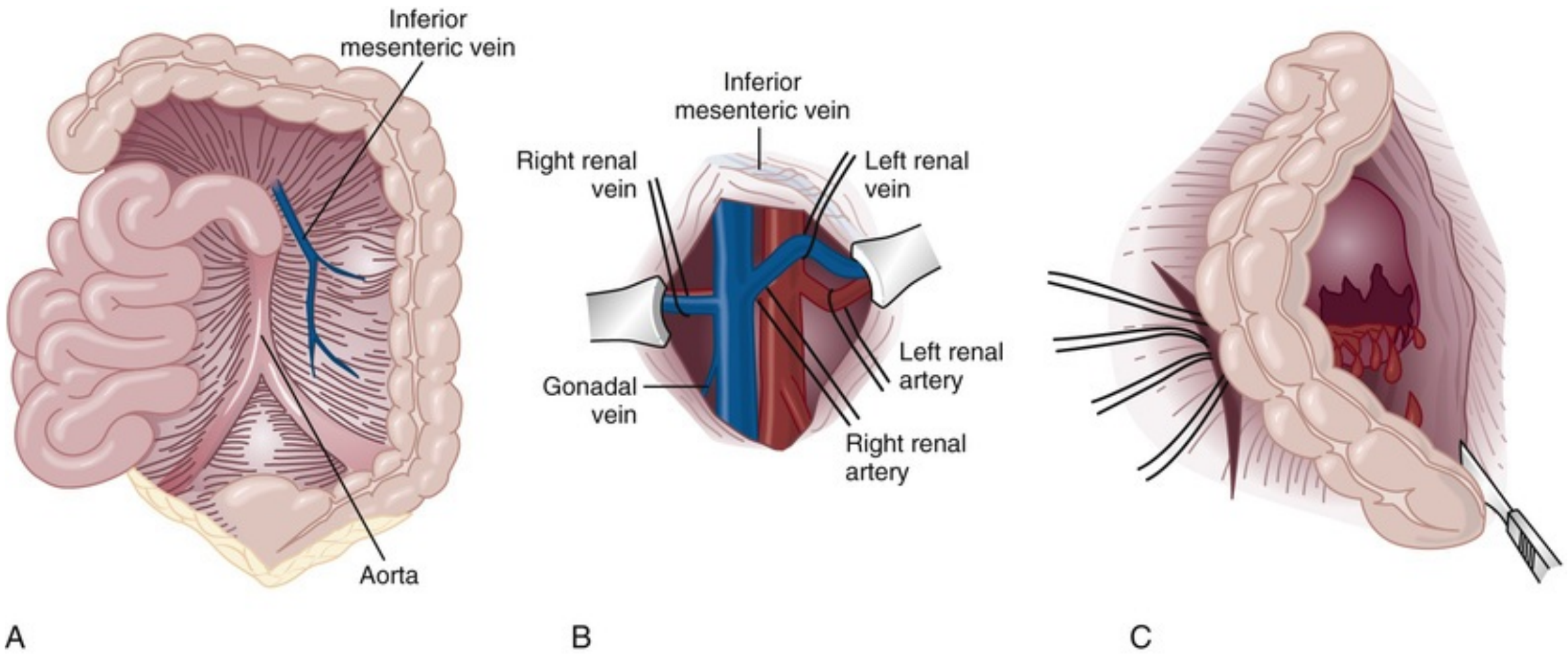

FIG. 90.8 The surgical approach to the renal vessels and kidney. (A) Retroperitoneal incision over the aorta medial to the inferior mesenteric vein. (B) Anatomic relationships of the renal vessels. (C) Retroperitoneal incision lateral to the colon, exposing the kidney.

Large hematomas may extend over the aorta and obscure the landmarks for the planned initial retroperitoneal incision. In such instances, the inferior mesenteric vein can be used as an anatomic guide for an appropriate incision. By making the retroperitoneal incision just medial to the inferior mesenteric vein and dissecting through the hematoma, the anterior surface of the aorta can be identified and followed superiorly to the crossing left renal vein.

The kidney is then exposed by incising the peritoneum lateral to the colon, followed by mobilization off Gerota fascia. This maneuver often requires release of the splenic (left) or hepatic (right) attachments of the colon. Gerota fascia is then opened, and the kidney with injury is completely dissected from the surrounding hematoma. Should troublesome bleeding develop, the previously isolated vessels can be temporarily occluded with a vascular clamp or a vessel loop tourniquet.

Is Early Vessel Isolation Necessary?

Debate surrounds the method of renal vascular control. Some manadate that control of the renal artery and vein need to be done proximal to the injury site, prior to opening Gerota's fascia. The argument being, that proximal vascular control avoids a potential massive bleed, from release of the tamponade effect. Thus, obtaining early vascular control before opening Gerota fascia can decrease renal loss, depending on the injury site. In a comparative series, the total nephrectomy rate was reduced from 56% to 18% when vascular control was obtained (McAninch and Carroll, 1982). Carroll et al. (1989) reported that the looped vessels only had to be temporarily clamped in approximately 2% of renal explorations. In a series of 133 renal units in which early vessel isolation and control were achieved before opening Gerota fascia, McAninch et al. (1991) found that a renal salvage rate of 89% was possible.

Corriere et al. (1991) reported a series of renal units in which vascular control was obtained only if needed after opening Gerota fascia. In this group, the total nephrectomy rate was 37%. Atala et al. (1991) reported a similar group of patients with a total nephrectomy rate of 36%. Others argue that mobilizing the kidney from Gerota's fascia laterally before proximal control yields equivalent blood loss and renal salvage (Gonzalez, 1999), and that most parenchymal kidney bleeding can be controlled by manual compression and, if need be, a Satinsky clamp across the hilum.

Overall, the goal of kidney exploration is to control the bleeding first, repair the kidney (when possible) and retroperitoneal drainage. The AUA urotrauma guideline states that the benefit of "primary vascular control in modern series are inconclusive, although older studies suggest that it is beneficial" (Morey et al., 2014). **Regardless of the method of vascular control, when unstable, high grade kidney trauma patients undergo open retroperitoneal exploration, nephrectomy is often the result.**

Renal Reconstruction

The principles of renal reconstruction after trauma include complete renal exposure, measures for temporary vascular control, limited debridement of nonviable tissue, hemostasis by individual suture ligation of bleeding vessels, watertight closure of the collecting system if necessary/possible, re-approximation of the parenchymal defect, coverage with nearby fascio-

adipose flaps (Gerota fascia or omentum) if feasible, and liberal use of drains (Fig. 90.9).

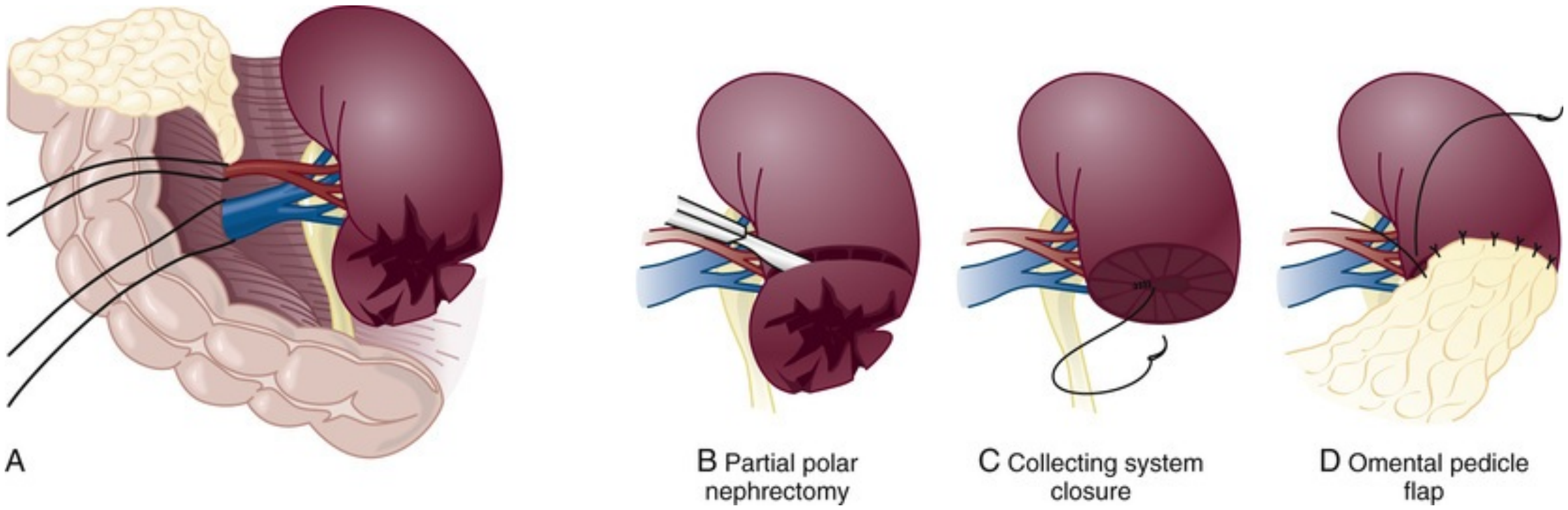
A
B Partial polar nephrectomy
C Collecting system closure
D Omental pedicle flap

FIG. 90.9 Technique for partial nephrectomy. (A) Total renal exposure. (B) Sharp removal of nonviable tissue. (C) Hemostasis obtained and collecting system closed. (D) Defect covered.

Renorrhaphy is illustrated in Fig. 90.10. Note the approximation of the margins of the laceration (3-0 Vicryl or similar suture) with the use of renal capsule over an absorbable hemostatic agent bolster such as Surgicel or Nu-Knit (oxidized rgenerated cellulose; Ethicon, NJ), or Gelfoam (Pfizer, New York, NY).

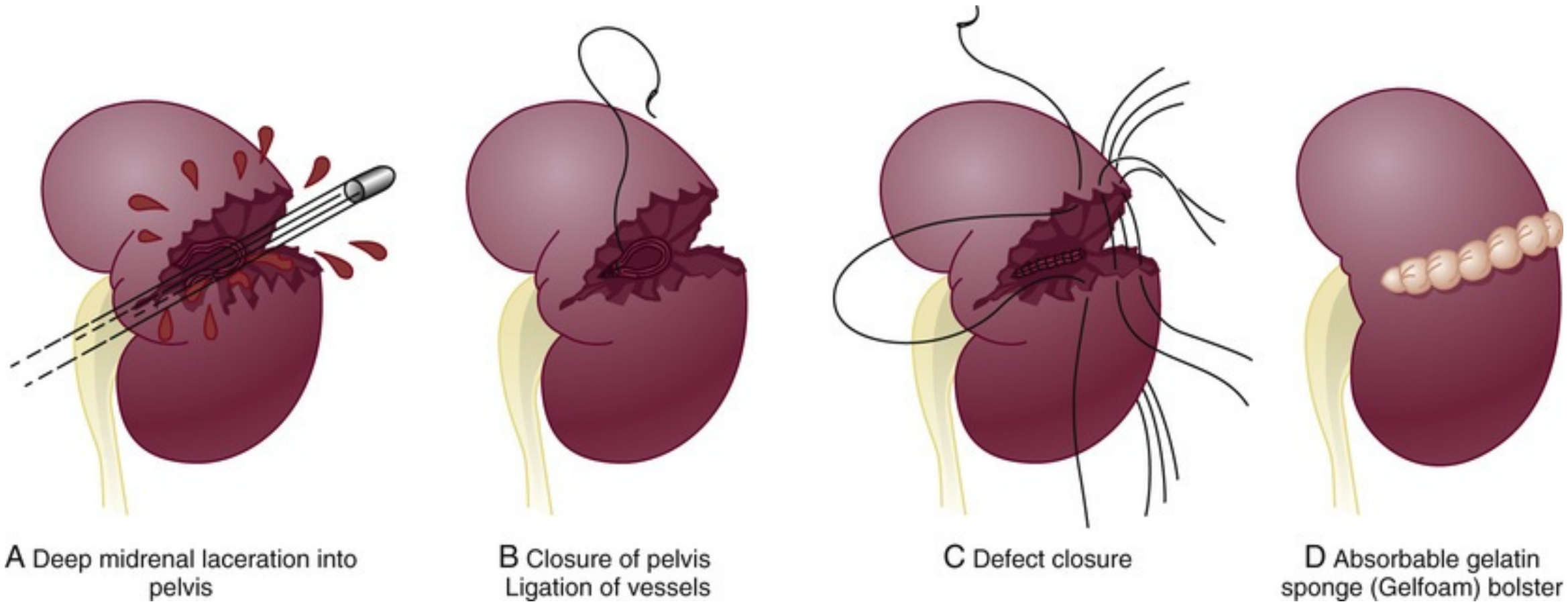
A Deep midrenal laceration into pelvis
B Closure of pelvis
Ligation of vessels
C Defect closure
D Absorbable gelatin sponge (Gelfoam) bolster

FIG. 90.10 Technique for renorrhaphy. (A) Typical injury in midportion of kidney. (B) Debridement, hemostasis, and collecting system closure. (C) Approximation of parenchymal margins. (D) Sutures tied over gelatin sponge bolster.

When polar injuries cannot be reconstructed, a partial nephrectomy can be performed. The open parenchyma should be covered when possible by a pedicle flap of omentum (see Fig. 90.9). With its rich vascular and lymphatic supply, omentum promotes wound healing and decreases the risk for delayed bleeding and urinary extravasation. Should it not be available, the use of absorbable mesh, peritoneal graft, or retroperitoneal fat also has been successful.

Hemostatic agents such as Floseal, thrombin plus gelatin (Baxter, Deerfield, IL) are potent and have an increasing role in the management of genitourinary trauma (Fig. 90.11). Based on experience from nephron-sparing surgery, gelatin matrix was applied to a porcine model of complex renal trauma and demonstrated less mean blood loss than conventional suture treatment (Hick et al., 2005).

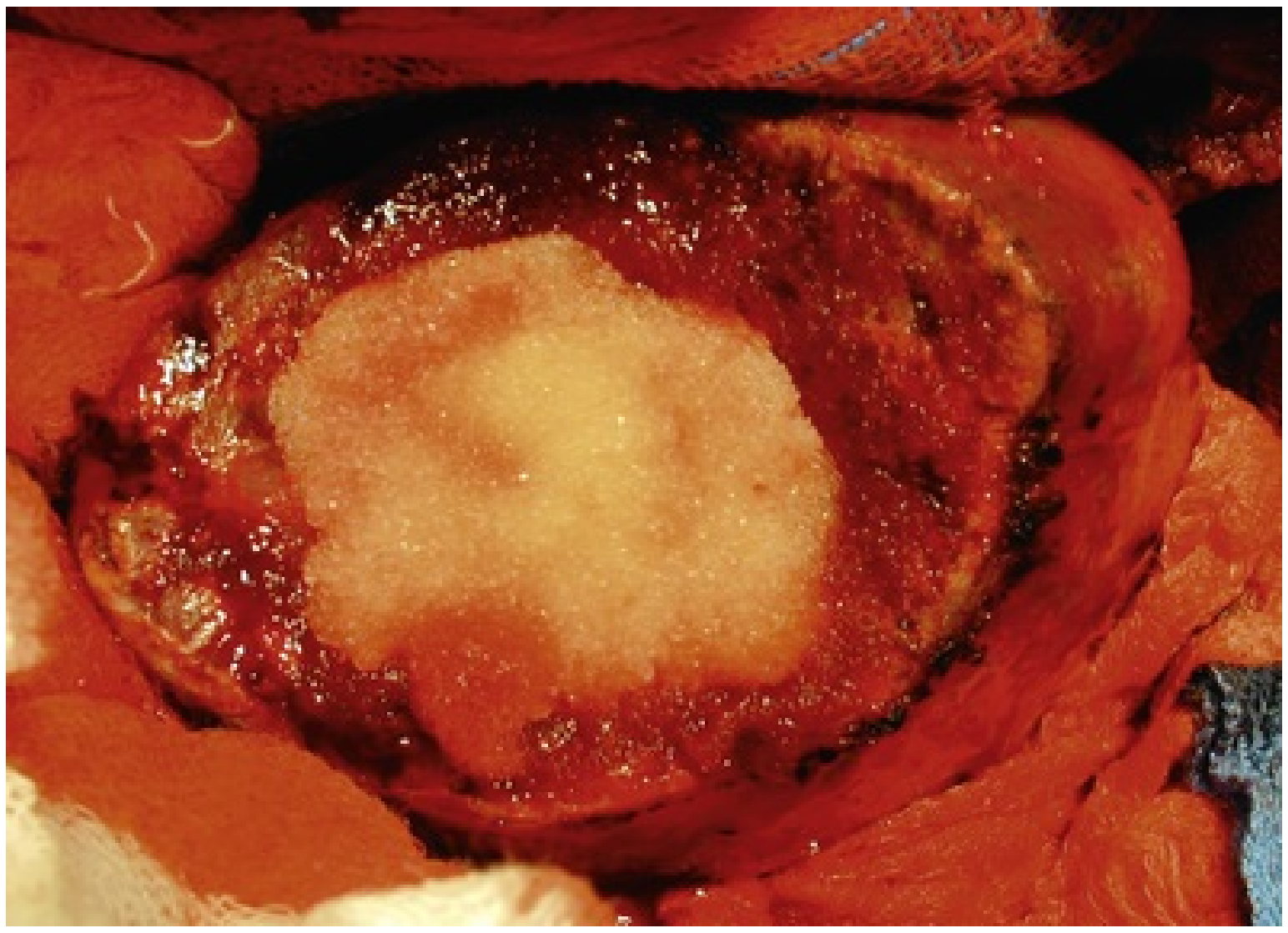

FIG. 90.11 Partial nephrectomy showing excellent hemostasis with use of Floseal (hemostatic agent).

In a high percentage of major renal injuries, intra-abdominal structures are also injured, with the liver and spleen being the most common. Injuries to the colon, pancreas, and stomach also occur frequently. In previous years total nephrectomy was suggested because of the high complication rate with attempted renal salvage. However, renal repair concomitantly with these associated injuries can be successful with few complications (Master and McAninch, 2006; Oosthuizen et al., 2018; Rosen and McAninch, 1994; Wessells and McAninch, 1996). Drains should be used liberally after these repairs.

Renovascular Injuries.

Renovascular penetrating or avulsion injuries after trauma are uncommon and often have associated injuries requiring operative intervention. For major renovascular injuries in patients with two kidneys, prompt nephrectomy is advocated. In rare instances in which vascular repair is technically feasible, renal salvage rates are disappointingly low, exemplified by a 33% renal salvage rate for main renal artery reconstruction even in the most expert of hands (Elliott et al., 2007). Vascular repair requires occlusion of the involved vessel with vascular clamps. The lacerated main renal vessels can be repaired with 5-0 nonabsorbable vascular suture (Fig. 90.12).

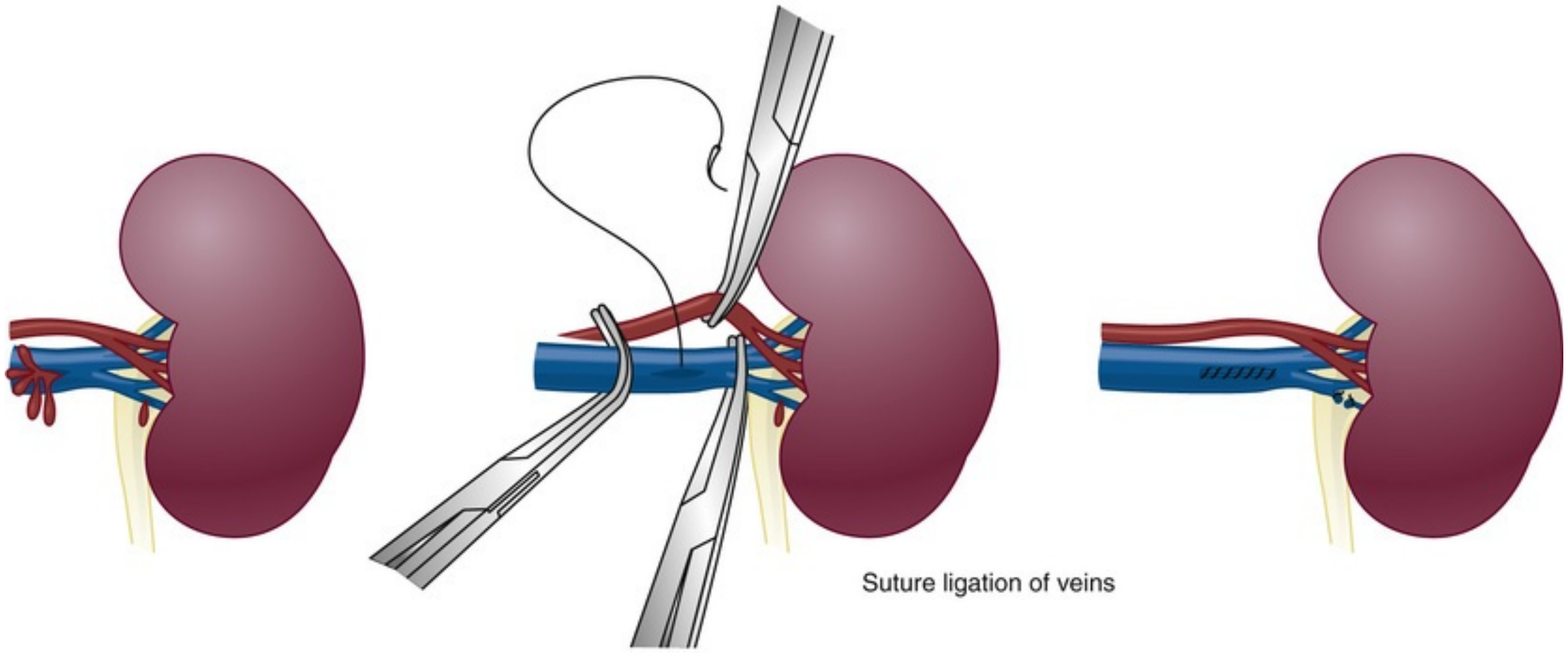

FIG. 90.12 Vascular injuries. *Left,* Venous injuries may occur in the main renal vein or the segmental branches. *Middle,* Repair of main renal vein. *Right,* Ligation of segmental branch can be done safely.

Main renal artery thrombosis from blunt trauma occurs most often secondary to deceleration injuries. The mobility of the kidney results in stretch on the renal artery, which in turn causes the arterial intima, low in elastic fibers, to disrupt. The consequent thrombus occludes the vessel, rendering the kidney ischemic (Fig. 90.13). **For unilateral arterial thrombosis, revascularization rarely results in a successful salvage or a viable kidney.** As long as the contra-lateral kidney is normal, observation is often the best management. In contrast, for bilateral renal hilar injuries, revascularization should be attempted, as up to 56% of patients can potentially avoid dialysis by prompt intervention (Knudson et al., 2000; Haas and Sprinak, 1998).

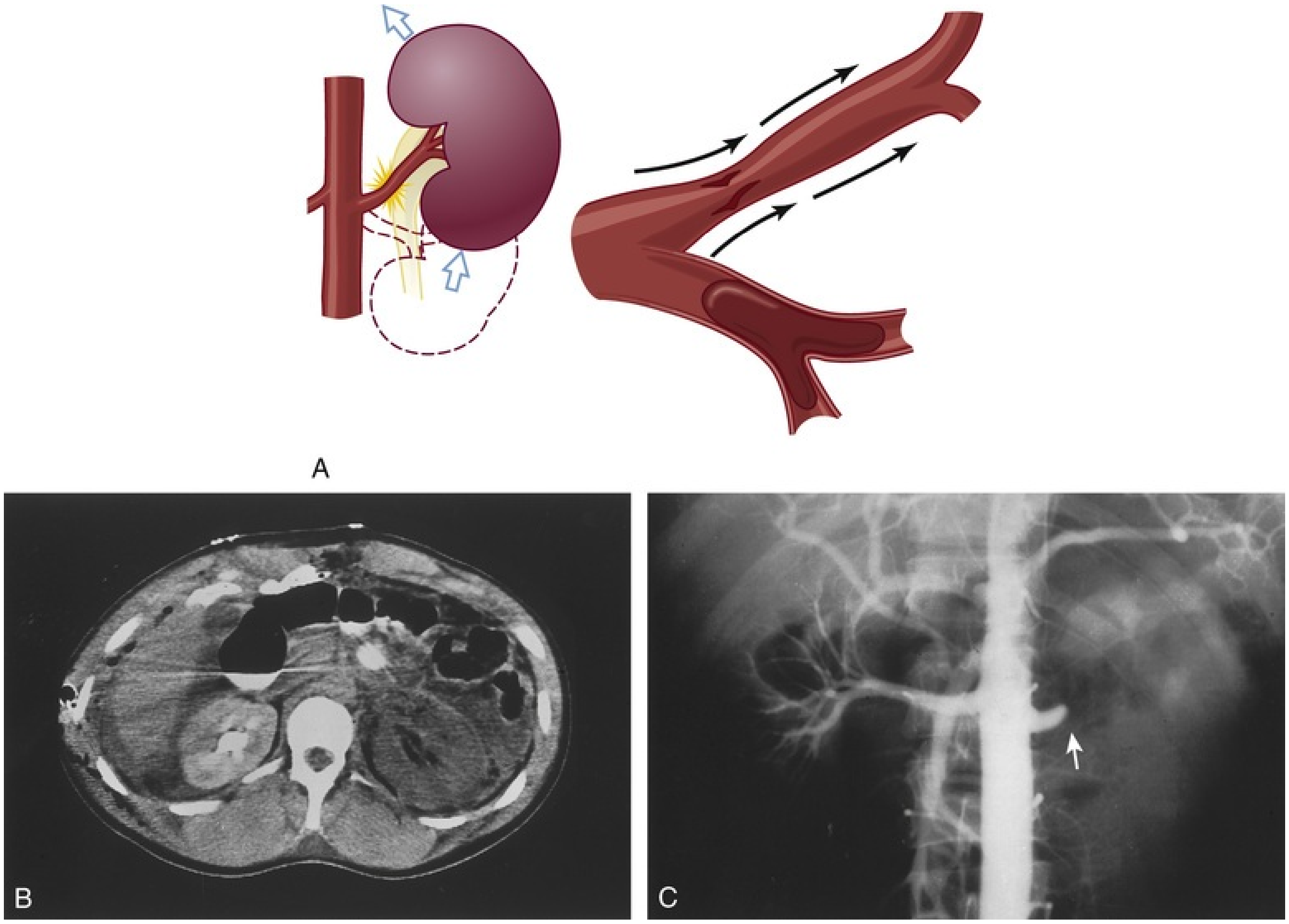

FIG. 90.13 (A) Movement of the kidney from blunt trauma (deceleration injury) causes stretch on the renal artery, resulting in rupture of the arterial intima and formation of a thrombus. (B) Computed tomography of a left kidney with renal artery thrombosis, demonstrating lack of contrast material perfusion to the kidney. (C) Arteriography demonstrating complete occlusion of the left renal artery *(arrow)* secondary to thrombus formation.

Case reports of successful renal revascularization through the use of endovascular stents during angiography offers a promising approach to the problem of blunt trauma renal artery thrombosis caused by the intimal flap (Inoue et al., 2004; Memon and Cheung, 2005). The great disadvantage of this approach has been the inability to safely institute post-stent anticoagulation in the patient with polytrauma.

Surgical revascularization is seldom successful in renal artery thrombosis, and at least 43% of patients with repairs develop hypertension (Haas et al., 1998). Periodic blood pressure monitoring for hypertension for up to a year after injury is thus warranted. Many patients with renal vascular injury are critically injured, with numerous associated organ injuries; time constraints thus limit any attempt at vascular repair.

Penetrating injuries to the renal hilar vessels are uncommon and very challenging. A penetrating injury to the right renal hilum often has associated injuries to the pancreatoduodenal complex, the right renal artery artery, the right renal vein and/or the IVC. Thus, such hilar injuries typically result in nephrectomy. If the patient is stable, surgical repair with fine vascular suture (5-0) can be attempted (see Fig. 90.12). Partial occlusion of the vein is ideal during repair, but in some instances total temporary occlusion with vascular clamps is necessary. On the left, if the injury is proximal to the gonadal and adrenal branches, the renal vein can be ligated, unlike the right renal vein, which is uncolateralized. For the injured renal artery, the simpliest repair possible is warranted, in order to limit ischemic time.

Damage Control

Once exanguinating hemorrhage is controlled and bowel contamination limited, Coburn (1997) and Pursifull et al. (2006) noted the benefit of damage control to improve renal salvage after polytrauma and further benefit was noted by Yeung and Brandes (2011). If there is active oozing from Gerota’s fascia, the area around the injured kidney can be packed with laparotomy pads to control bleeding, with a planned return in 24 to 48 hours to explore and evaluate the extent of injury. Furthermore, managing a nonpulsatile, contained, and nonexpanding retroperitoneal hematoma by observation is another method of damage control of the injured kidney. This allows the cold, acidotic, and coagulopathic patient to be stabilized in the ICU before any attempt at potentially lengthy renal reconstruction is attempted. At times, the bleeding kidney can be controlled by angioembolization, after the patient has been being resuscitated. Damage control may allow patients with complex renal injuries to avoid unneeded nephrectomy. However, if the kidney is massively injured, and the patient persistently unstable, a quick damage control nephrectomy can be life saving. Survival predictors in patients undergoing damage control surgery include Glasgow Coma Scale below 8, base excess below −13.9, and low preoperative diastolic pressure (Wang et al., 2014).

Indications for Nephrectomy

The ability to reconstruct an injured kidney depends on numerous factors. In an unstable patient, if damage control is not an option, total nephrectomy would be indicated immediately when the patient's life would be threatened by attempting a renal repair. When Nash et al. (1995) examined the reasons for nephrectomy in patients with renal injuries, 77% required removal because of the extent of parenchymal, vascular, or combined injury. The remaining 23% required nephrectomy in otherwise reconstructable kidneys because of hemodynamic instability. Factors predictive for nephrectomy are high injury severity score, high grade of renal injury, and hemodynamic instability (Davis et al., 2006).

Complications

Persistent urinary extravasation can result in urinoma, perinephric infection, and, rarely, renal loss. These patients are initially administered systemic antibiotics, although data supporting their use do not exist. In a high percentage, the extravasation resolves spontaneously (Matthews et al., 1997). Should it persist, placement of an internal ureteral stent often corrects the problem. The addition of a percutaneous nephrostomy or transcutaneously placed urinoma drain may be required in patients not cured by ureteral stent placement.

Delayed renal bleeding can occur up to several weeks after injury but usually occurs within 21 days. The initial management is bed rest and hydration. Should the bleeding persist, angiography frequently can localize and control the bleeding vessel by embolization.

Perinephric abscess rarely occurs after renal injury; persistent urinary extravasation and urinoma are the typical precursors. Urinary drainage with a ureteral stent with or without percutaneous nephrostomy followed by percutaneous abscess drainage offers a good initial method of management, followed by surgical drainage (rarely) if necessary.

Hypertension is seldom noted in the early postinjury period but can occur later (Monstrey et al., 1989). The basic mechanisms for arterial hypertension as a complication of trauma are (1) renal vascular injury, leading to stenosis or occlusion of the main renal artery or one of its branches (Goldblatt kidney); (2) compression of the renal parenchyma with extravasated blood or urine (Page kidney); and (3) post-trauma arteriovenous fistula. In these instances, the renin-angiotensin axis is stimulated by partial renal ischemia, resulting in hypertension (Cosgrove et al., 1973; Goldblatt et al., 1934).

In addition, patients should be followed for decline in renal function. A retrospective study of renal trauma patients managed nonoperatively showed a postinjury decline in renal function that correlated with severity of injury (Tasian et al., 2010).

Key Points: Renal Trauma

- Expectant management strategies of renal trauma allow for maximal renal preservation.
- The degree of hematuria and the severity of renal injury do not consistently correlate.
- Contrast-enhanced CT is the best imaging method to assess and grade for renal trauma.
- Patients with microscopic hematuria without shock can be observed clinically without imaging studies.
- Hemodynamically stable, well-staged renal injuries can be conservatively managed (even with high-grade injuries).
- Selective embolization provides an effective and minimally invasive means to stop active bleeding from parenchymal lacerations and segmental arterial injury.
- CT findings suspicious for significant renal injury include (1) medial hematoma (vascular pedicle injury), (2) medial urinary extravasation (renal pelvis or ureteropelvic junction injury), (3) lack of contrast enhancement of the parenchyma (main renal arterial injury), and (4) active intravascular contrast extravasation (arterial injury with brisk bleeding).
- Kidney injuries with hemodynamic instability, despite resuscitation, suggests uncontrolled and ongoing bleeding and warrants immediate intervention (surgery or in selected situations, angioembolization).
- Kidney injuries with urinary extravasation can often be managed conservatively and resolve spontaneously. Renal pelvis or proximal ureteral avulsion demand prompt intervention.

Ureteral Injuries

Cause

Acute ureteral injury results from external trauma, open surgery, laparoscopy, and endoscopic procedures. Intraoperative suture ligation, sharp incision and transection, avulsion, devascularization, and heat (e.g., microwave, electrocautery, or vibratory energy) or freezing (e.g., cryoablation) energies can produce ureteral damage. In addition, penetrating stab and gunshot wounds and external injury from high-speed blunt mechanisms contribute to the overall incidence; 95% are penetrating and 5% are blunt injuries. Of all urologic trauma, roughly 1% to 2.5% are ureteral (Presti et al., 1989; Siram et al., 2010). An unrecognized or mismanaged ureteral injury can lead to significant complications, including urinoma, abscess, ureteral stricture, urinary fistula, and potential loss of an ipsilateral renal unit. Increased nephrectomy rates and a prolonged hospital stay are associated with a delayed or missed diagnosis from penetrating ureteral trauma (Kunkle et al., 2006). **Ureteral injuries are often subtle, and clinicians must maintain a high index of suspicion to prevent a delay in diagnosis and comorbidity.**

External Trauma

Damage to the ureter after external violence is rare, occurring in less than 4% of all penetrating and less than 1% of all cases of blunt trauma (Table 90.2). During wartime in the past century, 3% to 15% of urologic injuries involved the ureter, with an average of 5% from World War II up to modern conflicts (Busch et al., 1967; Elliott and McAninch, 2006; Marekovic et al., 1997; Selikowitz, 1977; Serkin et al., 2010). In the nonmilitary setting, a similar 2% to 3% of ureteral injuries are caused by civilian gunshot wounds. **These patients often have significant concurrent injuries and a high degree of mortality that approaches one-third** (Medina et al., 1998). **More than 90% of patients with ureteral injuries have a concurrent abdominal or retroperitoneal organ injury** (Pereira et al., 2010). Associated visceral injury is common—predominantly small (39% to 65%) and large (28% to 33%) bowel perforation (Cinman et al., 2013; Presti et al., 1989). A significant percentage (10% to 28%) of patients with ureteral injuries also have associated renal injuries (Medina et al., 1998; Presti et al., 1989). A smaller percentage (5%) have associated bladder injuries (Medina et al., 1998).

TABLE 90.2

American Association for the Surgery of Trauma Organ Injury Severity Scale for the Ureter

GRADE[a]	TYPE	DESCRIPTION
I	Hematoma	Contusion or hematoma without devascularization
II	Laceration	<50% transection
III	Laceration	≥50% transection
IV	Laceration	Complete transection with <2 cm devascularization
V	Laceration	Avulsion with >2 cm devascularization

[a] Advance one grade for bilateral up to grade III.

Data from Moore EE, Cogbill TH, Jurkovich GJ, et al.: Organ injury scaling. III. Chest wall, abdominal vascular, ureter, bladder, and urethra. *J Trauma* 33:337–339, 1992.

The mechanism by which bullets injure the ureter is thought to be similar to the mechanism by which they injure analogous structures such as blood vessels—that is, not only by direct transection but by disruption of the delicate intramural blood supply. In experimental models, such microvascular damage has been found as far away as 2 cm from the point of transection, although ureters seldom need extensive debridement and can generally be minimally debrided back to a bleeding edge (Amato et al., 1970).

Whereas penetrating trauma imparts a large degree of energy over a small area (as in the course of a bullet), patients with blunt trauma with ureteral injuries are subject to extreme force applied over the entire body, such as during a fall from heights, pedestrian vs. motor vehicle, or high-speed motor vehicle accident. The great degree of energy imparted to the victim is associated with such uncommon injuries as fractured lumbar processes (Evans and Smith, 1976) and thoracolumbar spinal dislocation (Campbell et al., 1992). The presence of massive force injuries in the patient with blunt trauma should always increase the level of suspicion for ureteral injury.

Patients with penetrating trauma with any degree of hematuria or a wound pattern that suggests the possibility of genitourinary injury should be imaged. Patients with blunt trauma with gross hematuria or microhematuria plus hypotension, a history of significant deceleration, or significant associated injuries also should be imaged (Morey et al., 2014; Serafetinides et al., 2015). **Absence of hematuria, however, cannot be relied**

upon to exclude ureteral injury. Mechanism of injury and physical examination findings must be taken into account. For example, a history of rapid deceleration was found in 100% of patients with ureteropelvic junction (UPJ) injury in one small series (Boone et al., 1993).

Surgical Injury

Any abdominopelvic surgical procedure, whether gynecologic, obstetric, general surgical, or urologic, can potentially injure the ureter. The overall incidence of ureteral injury varies between 0.5% and 10% (Al-Awadi et al., 2005), although more recent studies suggest a lower rate closer to 0.3% for gynecologic surgeries (Wong et al., 2018). A similar study of colorectal surgeries found an overall rate of 0.18% (Eswara et al., 2015b), whereas another found the rate to be 0.6% for open surgeries and 1.0% for laparoscopic surgeries (Marcelissen et al., 2016). Ureteral injury is more commonly associated with thermal injury, whereas bladder injuries are associated with lysis of adhesions. Analysis of 13 published studies concluded that the following procedures contribute to iatrogenic ureteral injuries: hysterectomy (54%), colorectal surgery (14%), pelvic procedures such as ovarian tumor removal (8%), transabdominal urethropexy (8%), and abdominal vascular surgery (6%) (St Lezin and Stoller, 1991). One series reported that repeat cesarean section also can result in a large proportion of ureteral injuries, in this case up to 23% of the reported ureteral injuries at one hospital (Ghali et al., 1999). Historically, open urologic procedures, because they often occur in proximity to the ureters, were also responsible for a significant number (21%) of reported ureteral injuries (Selzman and Spirnak, 1996). However, they are now extremely rare because of improved ureteroscopic techniques and equipment, although a study from Wake Forest questioned whether familiarity with ureteroscopy is leading to increasingly aggressive technique and a rise in ureteral injuries (Romero et al., 2011).

Vascular Surgery.

Intraoperative ureteral manipulation resulting in subsequent hydronephrosis is common after aortoiliac and aortofemoral bypass surgery (12% to 20%), but the course is benign in most (St Lezin and Stoller, 1991). Surgical devascularization or inflammation can result in symptomatic ureteral stenosis, often delayed in manifestation by months, occurring in only 1% to 2% of these patients (Adams et al., 1992; Brandes and McAninch, 1999; St Lezin and Stoller, 1991).

In patients undergoing intra-abdominal vascular surgery, risk factors for surgical injury of the ureter include reoperation; placement of a vascular graft anterior to the ureter (Adams et al., 1992); and large, dilated arterial aneurysms that cause retroperitoneal inflammation that can involve the ureter. The majority (up to 85%) of surgical injuries to the ureter after vascular procedures are not recognized immediately (Adams et al., 1992). Postoperative symptoms of missed ureteral injury include flank pain (36% to 90%), fever, ileus, abdominal distention, and urinary fistula (Adams et al., 1992; St Lezin and Stoller, 1991).

Arterioureteral fistulas are a rare and potentially catastrophic condition that should be diagnosed and treated immediately because it can cause life-threatening hematuria. The initial presentation usually consists of either microscopic or gross hematuria. The fistula is typically located between the ureter and ipsilateral iliac artery, although the aorta can be involved. This process is associated with previous pelvic surgery, radiation therapy, long-term indwelling ureteral stents, infection, primary vascular disease, and pregnancy. Placement of an endovascular stent graft bridging the fistula site has been shown to be a safe and effective treatment in multiple series (Araki et al., 2008; Kerns et al., 1996; van den Bergh et al., 2009). Many will have to be repaired primarily, but up to 13% of patients will die of an arterioureteral fistula-related cause.

Robotic and Laparoscopic Surgery.

Since the inception of laparoscopic surgery in the 1960s and robotic surgery in the 1990s, ureteral injuries have occurred (Grainger et al., 1990). The explosion of laparoscopic and robotic surgery into other surgical specialties has meant that the incidence of ureteral injury during and after minimally invasive surgery has increased. At one center, the incidence of ureteral injuries from laparoscopy went from 0% of all reported ureteral injuries in the early 1980s to 25% of all the reported ureteral injuries only 5 years later (Assimos et al., 1994). As laparoscopic experience has grown, however, the initially high incidence of injury fell to a baseline of 0.8% on a subsequent review of 1300 laparoscopic urologic procedures (Vallancien et al., 2002). Currently, the reported rate of ureteral injury varies between 0.5% (experienced surgeons) and 14% (inexperienced surgeons) after laparoscopic hysterectomy (Härkki-Siren et al., 1999; Léonard et al., 2007). In a modern series, the rate of ureteral injury after robot-assisted hysterectomy is reported to be the same as it was for laparoscopic and open hysterectomies (0.92% vs. 0.90% vs. 0.96%, respectively) (Petersen et al., 2018). Similarly, no difference was noted between robotic and open sacrocolpopexies (Anand et al., 2014). Interestingly, a recent series comparing laparoscopic and open colectomy found a *lower* rate of ureteral injury with the minimally invasive technique (Zafar et al., 2014).

A large percentage of ureteral injuries after gynecologic laparoscopy occur during electrosurgical or laser-assisted lysis of endometriosis (Grainger et al., 1990). There are three reasons for this: (1) endometrioma can involve the ureter either extrinsically or intrinsically; (2) long-standing endometriosis can cause intraperitoneal adhesion, making ureteral visualization difficult (Ribeiro et al., 1999); and (3) the disease can deviate the ureters medially away from their normal anatomic position (Nackley and Yeko, 2000). A significant number of ureteral injuries also occur during tubal ligation, even when bipolar cautery is used (Grainger et al., 1990).

Technologic advances have allowed for thermoablative treatment of renal tumors that can result in ureteral damage. With experience, the real clinical risks have decreased. A multi-institutional review of 271 thermoablative procedures for small renal tumors reported only one ureteral injury (Johnson and Pearle, 2004). There may be a potentially higher risk for ureteral stricturing associated with ablation of medial or lower pole masses. A study from Massachusetts General Hospital showed a stricture rate of 4% when retrograde irrigation for ureteral cooling was used to protect the ureter during high-risk cases adjacent to the ureter (Eswara et al., 2015a).

In distinction to open surgery, in which at least one-third of ureteral injuries are recognized immediately, fewer injuries to the ureter are immediately identified after laparoscopy (Grainger et al., 1990; Parpala-Spårman et al., 2008). **Therefore, during laparoscopy and robotic surgery, a high index of suspicion for ureteral injury is required.** The symptoms may develop acutely or insidiously, depending on the mechanism. Postoperatively, patients must be monitored for fever, abdominal pain, port site pain, and leukocytosis, which herald the potential for missed ureteral injury (Grainger et al., 1990; Parpala-Spårman et al., 2008). A smaller number of patients with missed ureteral injury present with hematuria or a pelvic mass representing urinoma (Grainger et al., 1990). A low threshold for postoperative imaging is required, especially in those with these symptoms.

Avoiding and Detecting Ureteral Injury.

Avoidance of ureteral injury is predicated on intimate knowledge of its location, especially its relation to the uterine and ovarian arteries, if those structures are going to be ligated, as in a hysterectomy (Fig. 90.14).

Visualization of the ureter in the area of the ureterosacral ligaments can be especially difficult, and special care must be taken in this area. It is an axiom that ureteral injury is more likely in cases of uncontrolled bleeding, and adequate intraoperative hemostasis and surgical exposure should further decrease these injuries, even in high-risk cases (Liapis et al., 2001). Intraoperative hydration or diuretic administration has been suggested to enhance ureteral visualization and potentially decrease the risk for injury, although data to support this claim do not exist. Preoperative ureteral stenting can be used to ease identification of the ureter in high-risk cases; however, published data in the gynecologic and colectomy literature are unclear about whether they actually decrease ureteral injuries (Bothwell et al., 1994; Chou et al., 2009; Leff et al., 1982). Although older studies showed no benefit, a more recent review of the National Surgical Quality Improvement Program (NSQIP) showed that stents were associated with a lower rate of ureteral injury after colectomy (Coakley et al., 2018). Ureteral stents are not without complications; the rate of anuria after bilateral prophylactic ureteral stent placement has been reported between 1% and 5% (Kyzer and Gordon, 1994; Leff et al., 1982; Sheikh and Khubchandani, 1990), and the rate of iatrogenic ureteral injury during stent placement is 1% (Bothwell et al., 1994). Ureteral stent placement is not always successful; stents cannot be placed on one side in 13% of cases, and total failure to place either catheter can occur in 2% (Bothwell et al., 1994). Lighted fiberoptic ureteral catheters have been used with good effect (Ben-Hur and Phipps, 2000), and smaller 5-Fr models may avoid the complications of ureteral edema and obstruction, which have been reported after the use of larger, older-model lighted stents (Chahin et al., 2002). A 5-year review of the use of lighted stents for laparoscopic colorectal surgery showed no ureteral injuries and no infections (Boyan et al., 2017).

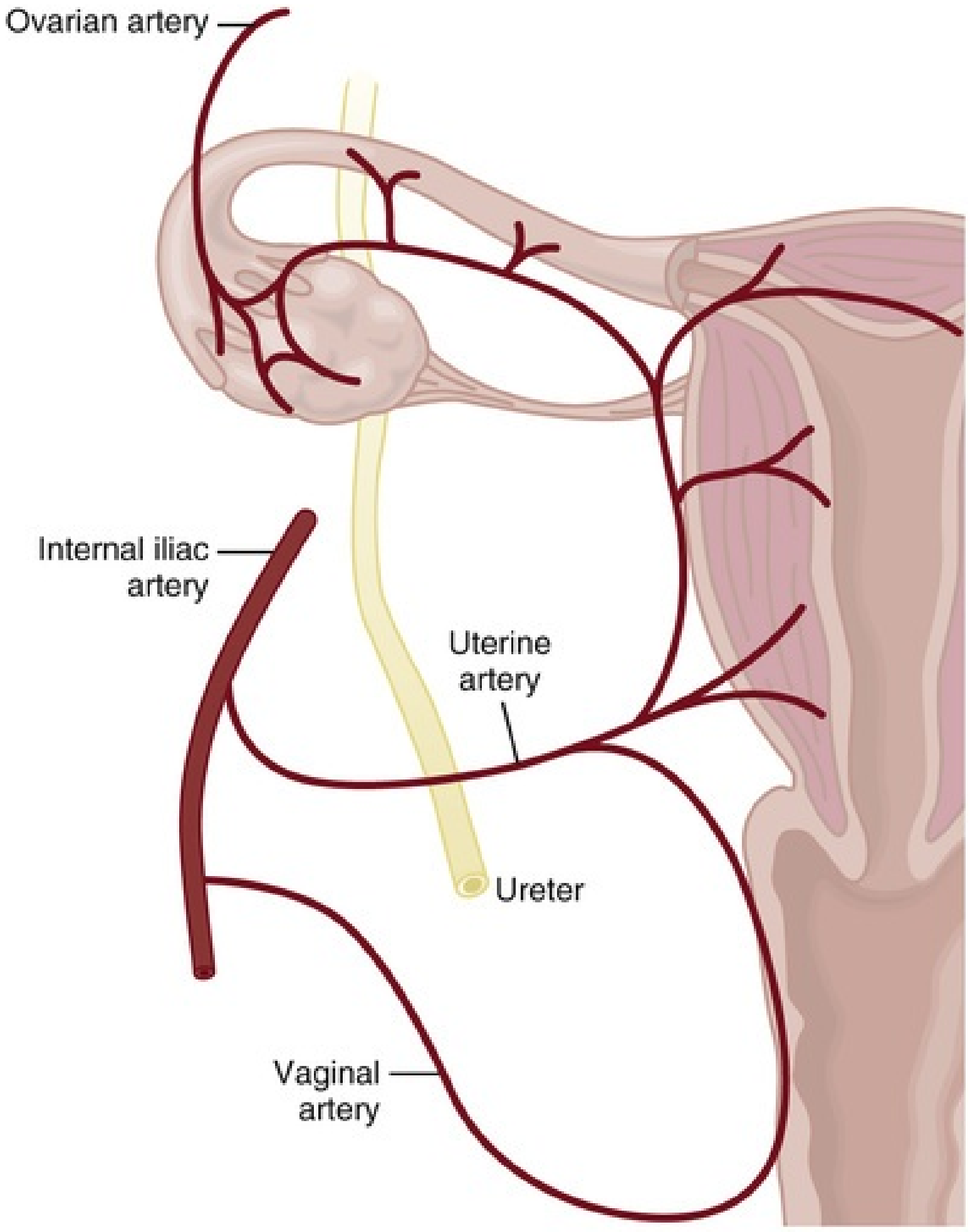

FIG. 90.14 Ureteral anatomy showing relationship to fallopian tube and uterine artery.

Some authors have advocated maneuvers to check the patency of the ureter after all surgeries in which ureter injury is commonly reported (e.g., hysterectomy). Cystoscopy alone, used to look for the absence of hematuria and the presence of bilateral ureteral jets, is typically a poor predictor of injury. In one decade-long study, cystoscopy missed more injuries than it detected (Dandolu et al., 2003). In another, it increased the detection rate from 30% to 96% (Vakili et al., 2005). Purposefully opening the retroperitoneum before or after hysterectomy has been advocated to avoid ureteral injury or at least allow intraoperative detection. A majority of authors advocate this approach (Cruikshank, 1986; Liapis et al., 2001), yet this may contribute to ureteral devascularization by inadvertent disruption of the delicate distal ureteral blood supply (Nezhat et al., 1995). Digital palpation of the ureter, through the unopened retroperitoneum, is also ineffective (Symmonds, 1976). Some have advocated that grasping the ureter with forceps to evoke ureteral peristalsis can be a measure of an uninjured ureter, but this is highly ineffective and unreliable. Finally, some authors recommend routine injection of 5 to 10 mL of IV indigo carmine methylene blue, or fluorescein dye, or oral phenazopyridine (started pre-surgery) followed by cystoscopy to ensure patency of the ureters after hysterectomy. In 118 patients undergoing laparoscopic hysterectomy, 4 of 4 cases of ureteral occlusion were identified immediately by the lack dye from the ureteral orifice (mostly caused by suture ligation) and repaired immediately without complications (Ribeiro et al., 1999).

IV methylene blue should be avoided in pregnant women and in patients who are taking selective serotonin reuptake inhibitors (SSRIs; e.g., paroxetine, sertraline, fluoxetine, fluvoxamine, citalopram) or serotonin and norepinepherine reuptake inhibitors (SNRIs; e.g., duloxetine, venlafaxine) or monoamine oxidase inhibitors (MAOIs; e.g., isocarboxid, phenelzine). Methylene blue is a potent monoamine oxidase inhibitor and can cause serious serotonin toxicity (and in rare circumstances, serotonin syndrome and death) in patients taking medications that increase serotonin levels. IV methylene blue also should be avoided in patients with glucose-6-phosphate dehydrogenase deficiency because it can cause methemoglobinemia and hemolysis. IV methylene blue can also result in underestimation of blood oxygen saturation by pulse oximetry. IV indigo carmine is safe but has been implicated in case reports of bronchospasm, bradycardia, hypertension, hypotension (most common), and anaphylactoid reactions (Jeon et al., 2012). Indigo carmine is rapidly renal excreted, has a half life of 4 to 5 minutes and appears blue in the urine within 5 to 10 minutes (depending on patient hydration).

Tenuous Ureteral Blood Supply.

The distal ureteral blood supply is variable (Daniel and Shackman, 1952). It is estimated by cadaver studies that 10% of females carry a disproportionate amount of their distal ureteral blood supply via uterine artery branches. These branches are necessarily severed when the uterine artery is ligated during the course of a normal hysterectomy. In cadaveric experiments, it was noted that 40% of females have decreased ureteral perfusion after ligating the uterine artery. The resultant hypothesis is that distal ureteral devascularization may be an unavoidable consequence in a small percentage of women after hysterectomy (Michaels, 1948). Ureteral devascularization tends to manifest differently from other ureteral injuries. Patients tend to present late (more than a week after surgery, but as late as 1 to 2 months), usually with ureteral stenosis, urinoma, or even ureterovaginal fistula that was not seemingly present at the time of surgery or the early days after surgery.

Ureteroscopic Injury

Since the first reported ureteral injury after rigid ureteroscopy in 1984, countless ureteral misadventures have resulted (Kaufman, 1984). In fact, ureteroscopic injury was the most common cause of iatrogenic ureteral trauma in some modern series (Johnson and Pearle, 2004). In the late 1980s, an explosion of ureteral injuries coincided with the widespread use of ureteroscopy (Huffman, 1989). Improvements in equipment and operator experience subsequently decreased the rate of ureteral perforation, to a stable average of 7% in the 1990s (range 0% to 28%) (Huffman, 1989), whereas contemporary series report the stricture rate after ureteroscopy as 0.6% (El-Abd et al., 2014).

One factor associated with ureteral injury during ureteroscopy was continued stone basket attempts after recognition of a ureteral tear. Current recommendations are to stop the procedure and place a ureteral stent when ureteral perforations are identified (Chang and Marshall, 1987). The wide use of the holmium:yttrium-aluminum-garnet (Ho:YAG) laser to fragment larger stones before basket manipulation is attempted should further decrease the potential for this complication (Bagley et al., 2004). Extraureteric extrusion of calculi during laser fragmentation or basket retrieval has shown to be a minor complication and only rarely leads to stricture formation (Kriegmair and Schmeller, 1995).

It is also recommended to perform ureteroscopy alongside or over a wire placed up into the renal pelvis (Chang and Marshall, 1987; Flam et al., 1988), although some experts no longer use a safety wire during routine flexible ureteroscopy (Bratslavsky and Moran, 2004). This wire facilitates not only safe ureteroscopy but also placement of a ureteral stent later in the case if necessary. **Factors associated with higher complication rates during ureteroscopy are longer surgery times, treatment of renal calculi, surgeon inexperience, and previous irradiation** (Huffman, 1989)**, whereas other series have identified stone size, number, and the presence of congenital renal abnormalities** (Baş et al., 2017). During stone fragmentation attempts, electrohydraulic lithotripsy (now hardly used) is associated with the highest risk for ureteral injury, followed by the neodymium:yttrium-aluminum-garnet (Nd:YAG) laser and finally by the Ho:YAG laser (Johnson and Pearle, 2004). Factors that are thought to protect against ureteral injury are smaller and flexible ureteroscopes (Flam et al., 1988;

Huffman, 1989). Ureteral access sheaths also protect the ureter, but the sheaths can cause ureteral wall injury, especially if the patient did not receive a ureteral stent preoperatively (Traxer and Thomas, 2013). Smaller diameter (≤14-Fr) sheaths are preferred for nonstented ureters.

Diagnosis

Gunshot and Stab Wounds

Hematuria.

Hematuria is a nonspecific indicator of urologic injury. Significant ureteral injury can occur in the absence of hematuria (Brandes et al., 2004; Elliott and McAninch, 2006). **Because many (25% to 45%) cases of ureteral injury do not demonstrate even microscopic hematuria, a high index of suspicion is required in cases of potential ureteral injury after penetrating trauma** (Brandes et al., 1994; Campbell et al., 1992; Palmer et al., 1999; Presti et al., 1989).

Intraoperative Recognition.

In an analysis of previously published reports of ureteral injury secondary to violent injury, Armenakas et al. (1999) noted that 93% of injuries were recognized promptly, including 57% that were identified intraoperatively. Every attempt should be made to diagnose these injuries during surgical exploration (Armenakas et al., 1999; Brandes et al., 1994; Medina et al., 1998). Intraoperative detection requires a high degree of suspicion, and there is evidence that vigilance for ureteral injuries may decrease the incidence of missed injuries (McGinty and Mendez, 1977). The trajectory of the knife or missile must be carefully examined during laparotomy and ureteral exploration undertaken in all cases of potential injury. Direct ureteral inspection is necessary in patients suspected to have ureteral injury who undergo laparotomy without adequate pre-surgical imaging. **Direct exploration is typically the most accurate method for diagnosis, but can be difficult because of overlying hematoma.** Care must be taken not to devascularize the ureter during exploration. Intravenous indigo carmine is helpful in identifying ureteral injury by searching for extravasation of blue dye from the injury site. Ureteral integrity can also be tested by retrograde injection of indigo and/or saline though a ureteral stent or pediatric feeding tube, placed by cystoscopy or cystotomy (depending on the clinical situation) (Elliott and McAninch, 2003).

Inadequate exploration or a low index of suspicion in the presence of multiple injuries is often responsible for missed ureteral injury. In a large meta-analysis, analyzing 16 busy trauma centers with 429 ureteral injuries with laparotomy, a collective 11% miss rate of ureteral injury was noted (Kunkle et al., 2006). Another study found that 62% of ureteral injuries were missed after hysterectomy (Blackwell et al., 2018). Delayed diagnosis in these series was associated with a prolonged hospital stay, increased rates of nephrectomy, and death. An unrecognized or undertreated ureteral injury can lead to other significant complications, including urinoma, abscess, ureteral stricture, and urinary fistula.

Vigilance for delayed presentation of ureteral injuries allows detection of initially missed injuries. Fever, leukocytosis, and local peritoneal irritation are the most common signs and symptoms of missed ureteral injury and always should prompt CT examination. Retrograde ureterography is most often used for diagnosing such “missed” ureteral injury, in a stable patient, and has the added benefit of allowing immediate attempt at ureteral stent passage to aid urinary drainage, and avoid or treat urinoma.

Imaging Studies

Computed Tomography.

CT urography with delayed images is the best study for detecting ureteral injuries (Kawashima et al., 2001). Ureteral injuries often manifest with absence of contrast in the ureter on delayed images. This underscores the necessity of tracing both ureters throughout their entire course on CT scans obtained to evaluate urogenital injuries (Townsend and DeFalco, 1995). **Because modern CT scanners can obtain images rapidly, before IV contrast dye is excreted in the urine, delayed images must be obtained (10 minutes after contrast injection) to allow contrast material to extravasate from the injured collecting system, renal pelvis, or ureter** (Brown et al., 1998; Kawashima et al., 2001; Mulligan et al., 1998). CT findings suggestive of ureteral injury are contrast extravasation, delayed ipsilateral nephrogram, ipsilateral hydronephrosis, and lack of contrast in the distal ureter, and a periureteral urinoma (Gayer et al., 2002; Siegel, 2002).

In reported series, all patients with significant ureteropelvic laceration, for instance, had either medial extravasation of contrast material or nonopacification of the ipsilateral ureter on CT (Kawashima et al., 2001; Fig. 90.15) or a "circumrenal" contrast extravasation. Delayed images that demonstrate medial or circumrenal extravasation but do not opacify the distal ureter suggest an avulsion injury (Kawashima et al., 1997).

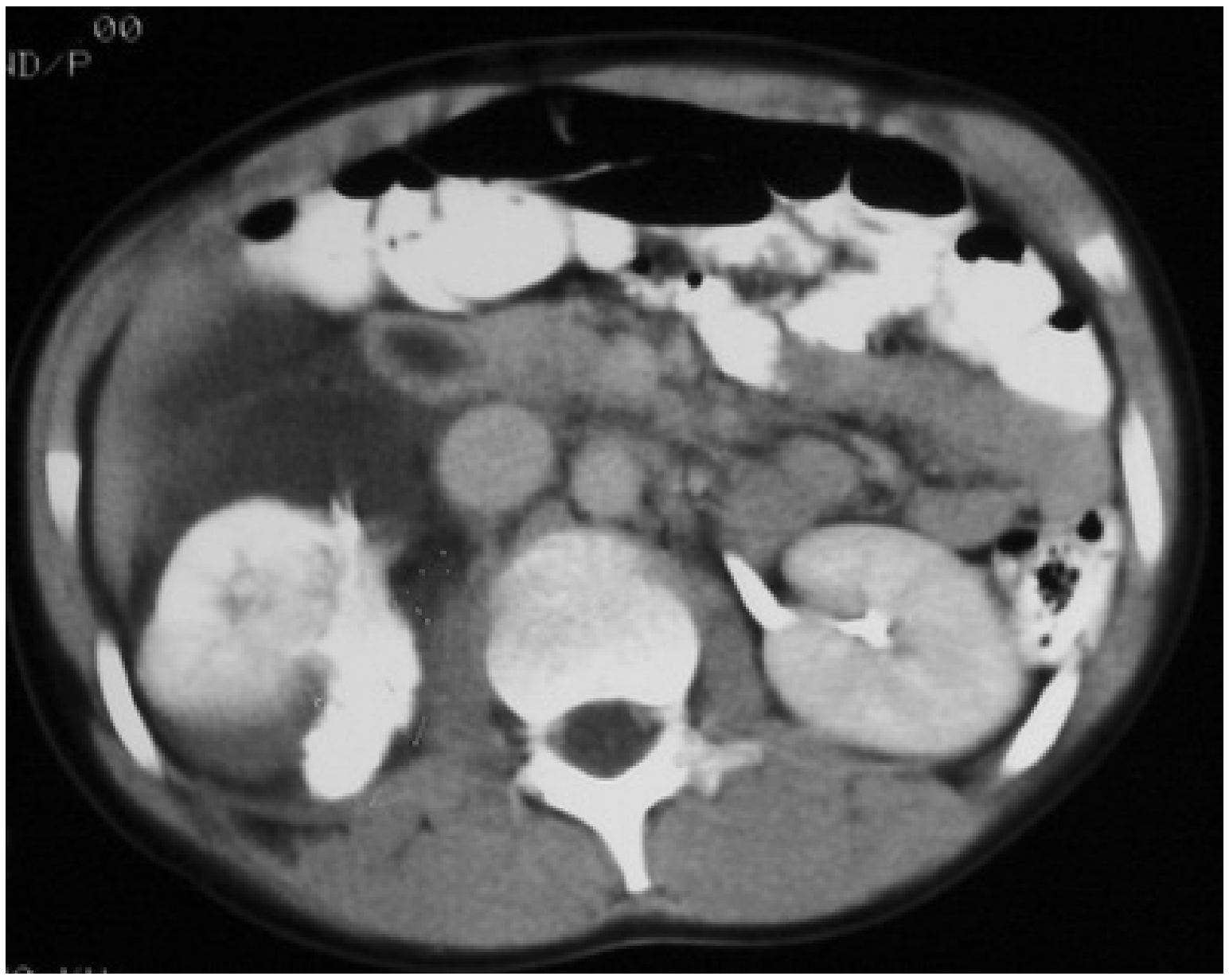

FIG. 90.15 Computed tomography showing right medial extravasation of contrast material in a patient with a renal pelvis laceration.

Retrograde Ureterography.

Retrograde ureterogram is the most sensitive radiographic test for ureteral injury (Campbell et al., 1992). Although accurate in demonstrating site, presence, and location of extravasation, retrograde ureterography is often time consuming and cumbersome. Thus, it often has a limited role in the acute trauma setting, especially if the patient is unstable. Retrograde ureterography is most commonly used to diagnose initially missed ureteral injuries, because it allows the simultaneous placement of a ureteral stent if possible.

Antegrade Ureterography.

In cases in which ureteral injury is discovered, and retrograde stent placement is not possible (usually secondary to a large gap in the two ends of the transected ureter), anterograde ureterography and stent placement at the time of percutaneous nephrostomy placement, should be performed, when possible

(Toporoff et al., 1992).

Intravenous Pyelography.

Although rarely used today, IVPs still play a role in resource poor countries where CT scans are not readily available (Fig. 90.16). One-shot IVP is often unhelpful, proving nondiagnostic 33% to 100% of the time for ureteral injury, and thus should not be solely used for this purpose (Azimuddin et al., 1998; Brandes et al., 1994; Campbell et al., 1992; Elliott and McAninch, 2003; Palmer et al., 1983; Presti et al., 1989). Findings on IVP that are suggestive of ureteral injury are incomplete visualization of the entire ureter, ureteral deviation or dilation, urinary extravasation, and hydronephrosis. Insensitivity of these usual diagnostic tools and high false-negative rates are some of the reasons why delay of detection occurs in 8% to 20% of cases (Brandes et al., 1994; Palmer et al., 1999; Presti et al., 1989).

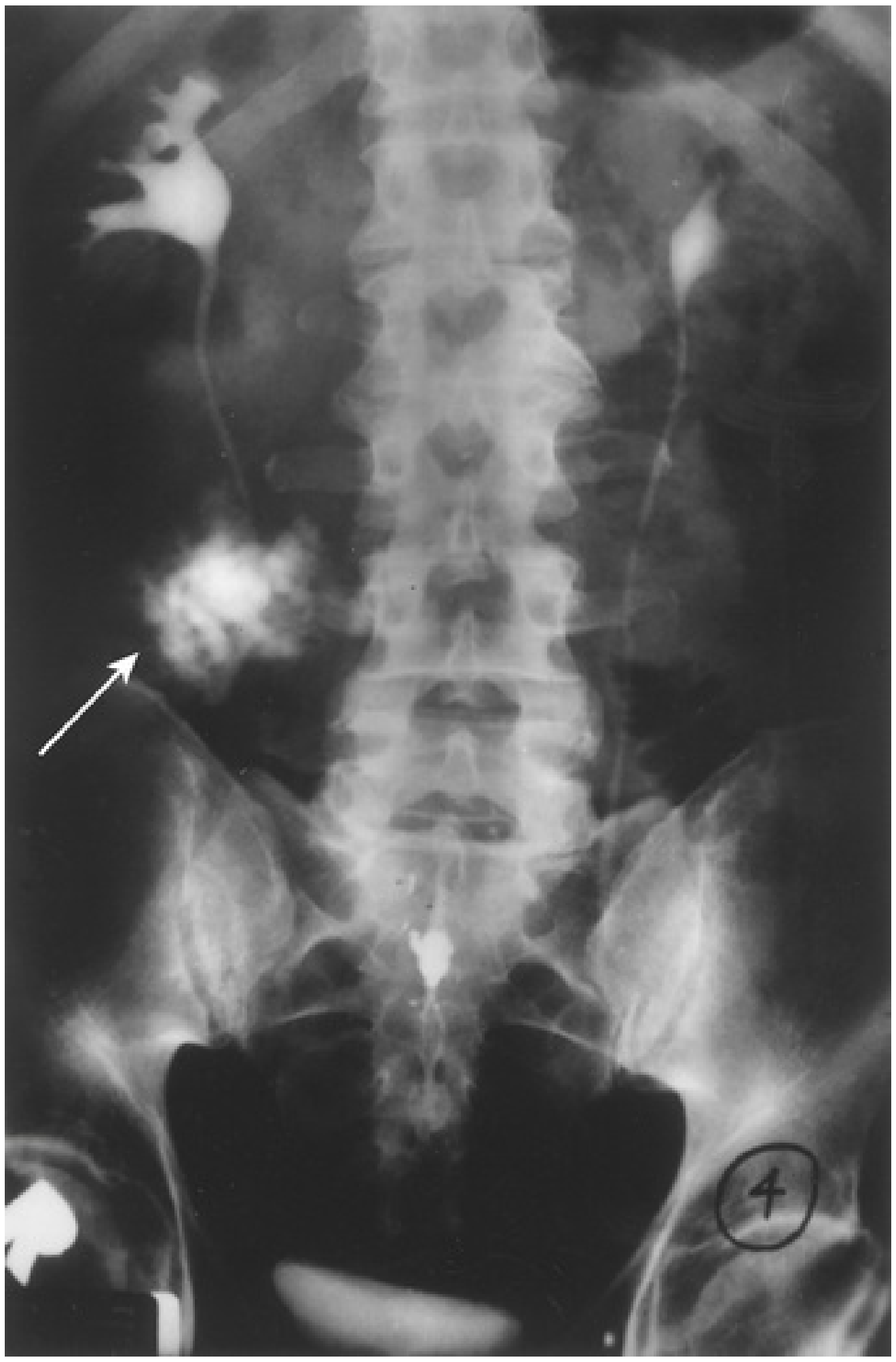

FIG. 90.16 Excretory urography demonstrating extravasation in the upper right ureter consequent to stab wound. Note lack of contrast *(arrow)* in the ureter below the site of injury, indicating complete ureteral transection.

Management

See Fig. 90.17.

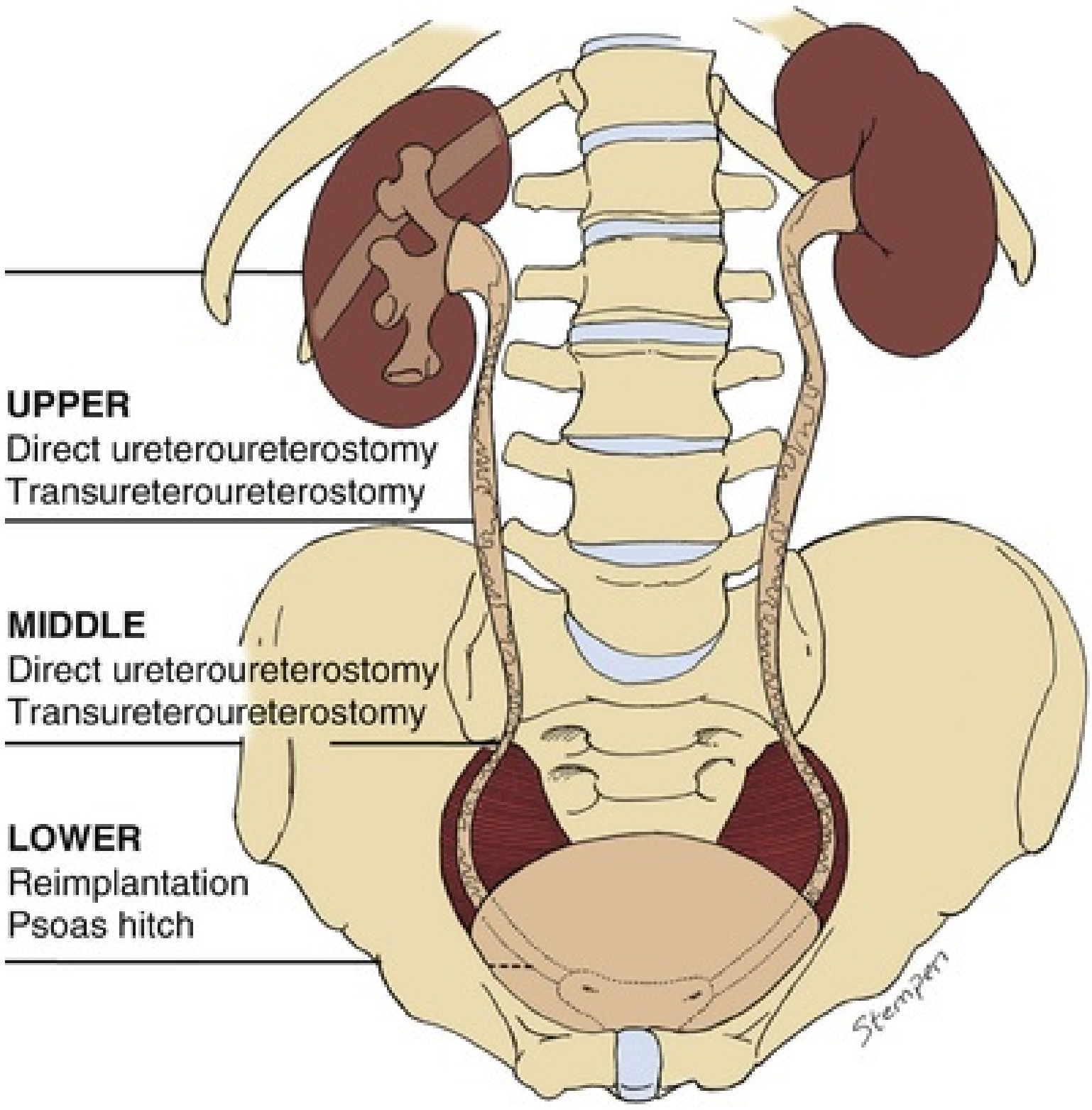
UPPER
Direct ureteroureterostomy
Transureteroureterostomy
MIDDLE
Direct ureteroureterostomy
Transureteroureterostomy
LOWER
Reimplantation
Psoas hitch
Stemper

FIG. 90.17 Suggested management options for ureteral injuries at different levels.

General Principles

When possible, repair of the injured ureter should be performed at the same time as the initial laparotomy, in a stable patient. Immediate repair of the ureter is often not appropriate in the unstable, complex polytrauma patient. Ureteral blood supply is tenuous, and a sequela of imperfect repair can be urine leakage that can result in patient debility, nephrectomy, and, in rare cases, even death. Principles of management of the injured ureter are as follows (Fig. 90.18):

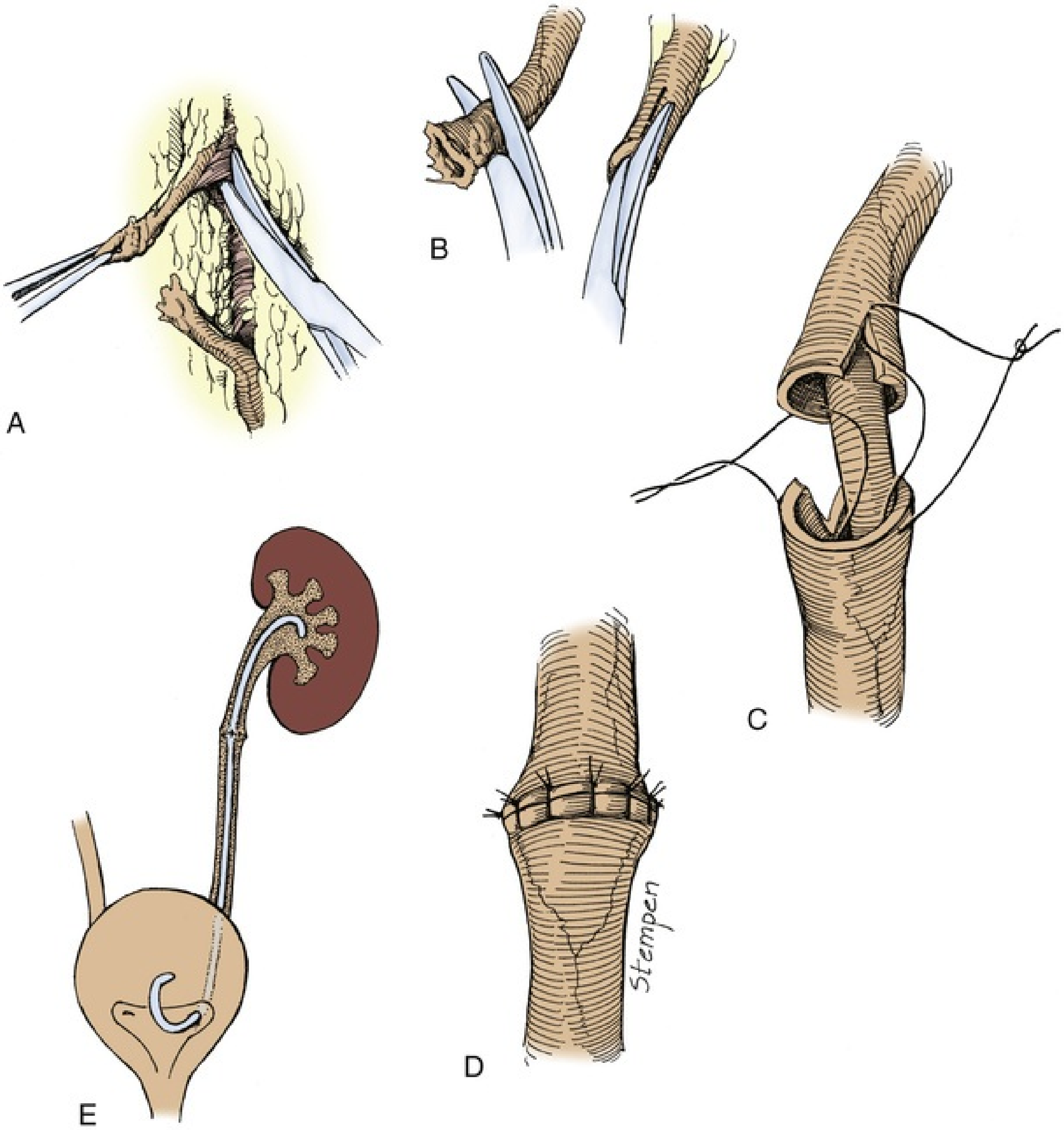

FIG. 90.18 Technique of ureteroureterostomy after traumatic disruption. (A) Injury site definition by ureteral mobilization. (B) Debridement of margins and spatulation. (C) Stent placement. (D) Approximation with 5-0 absorbable suture. (E) Final result.

1. Mobilize the injured ureter carefully, sparing the adventitia widely, so as not to devascularize the ureter further.
2. Debride the ureter minimally but judiciously until edges bleed, especially in high-velocity gunshot wounds.
3. Repair ureters with spatulated, tension-free, stented (Palmer et al., 1983)

watertight anastomosis, using fine absorbable sutures and retroperitoneal drainage afterward.

4. Retroperitonealize the ureteral repair by closing peritoneum over it if possible.
5. Do not tunnel ureteroneocystostomies but rather create a widely spatulated nontunneled anastomosis.
6. With severely injured ureters, blast effect, concomitant vascular surgery, and other complex cases, consider omental interposition to isolate the repair when possible.
7. If immediate repair is not possible, or the patient hemodynamically unstable, one management option is to ligate the ureter with long silk or polypropylene suture, and plan to repair it later, or place a nephrostomy tube after ICU resuscitation (damage control). The other option is a temporary cutaneous ureterostomy over a single-J stent or pediatric feeding tube with a suture tied around the ureter proximal to the injury site, in order to secure the stent in place, and to prevent urinary leakage.

External Trauma

Contusion.

Ureteral contusions, although the most minor of ureteral injuries, can heal with stricture or breakdown later if microvascular injury results in ureteral necrosis. Contusion is not uncommon with proximity gunshot wounds with blast injury. **Severe or large areas of contusion that appear to lack viability should be treated with excision of the damaged area and ureteroureterostomy/ureteroneocystostomy. In general, intact contused ureters, when identified at laparotomy, are primarily managed by ureteral stenting (placed by cystoscopy or cystotomy, depending on the clinical setting).**

When a missed ureteral contusion later presents as a leak, retrograde imaging with ureteral stent placement should be initially performed. When antegrade stenting is not possible a percutaneous nephrosotmy tube and subsequent antegrade ureteral stent should be placed for 6 weeks, which provides surprisingly good success rates (83% [Toporoff et al., 1992] to 88% [Lang, 1984]).

Upper Ureteral Injuries

Ureteroureterostomy.

Ureteral avulsion from the renal pelvis, or even very proximal ureter, can be managed by reimplantation of the ureter directly into the renal pelvis (Fig. 90.19). These can be done open, or in a delayed fashion, laparoscopically, or robotically (Marien et al., 2015; Mufarrij et al., 2007). Ureteroureterostomy, or so-called end-to-end repair, is used in acute injuries to the upper two-thirds of the ureter. It is required commonly—up to 32% of the time in large series (Elliott and McAninch, 2003; Presti et al., 1989) and has a reported success rate as high as 90% (Carlton et al., 1971). For long ureteral strictures that develop in a delayed fashion, some authors now advocate for the use of buccal graft ureteroplasty with 90% success (Zhao et al., 2017). Complications after ureteroureterostomy, usually urine leakage, occur 10% to 24% of the time (Bright and Peters, 1977; Campbell et al., 1992; Medina et al., 1998; Pitts and Peterson, 1981; Presti et al., 1989; Velmahos et al., 1996). Other acute complications include abscess and fistula, which can occur in up to 12% of patients (Lee et al., 2012). Chronic complications, usually ureteral stenosis, are less common, involving approximately 5% (Palmer et al., 1999) to 12% (Velmahos et al., 1996) of patients. Interestingly, some authors report prolonged leakage of urine from the drain after UPJ avulsion repair but otherwise did well. Steers et al. (1985) reported that most of their patients had persistent drainage (averaging 12 days) from the retroperitoneal Penrose drain after repair. Routine retroperitonealization of the repair may decrease the time or severity of postoperative urine leakage.

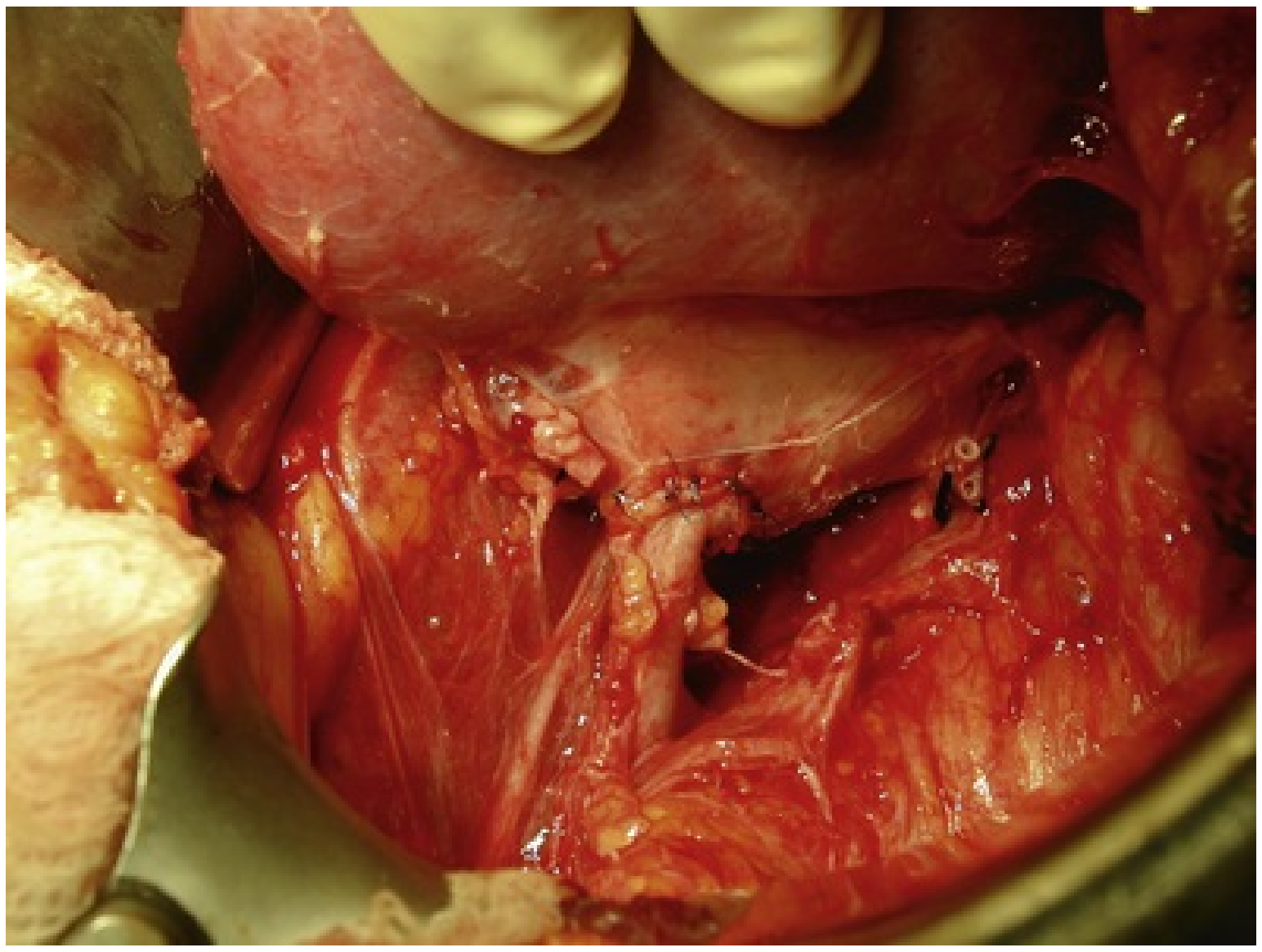

FIG. 90.19 Proximal ureter is spatulated and sutured to the renal pelvis.

Rarely, ureterocalycostomy, in which the ureteral stump is sewn end-to-side into an exposed renal calyx, also can be used where there is profound damage to the renal pelvis and UPJ (Matlaga et al., 2005). This is a technically challenging case. It can be difficult to find an inferior calyx. Moreover, this technique requires renal surgery equivalent to a partial nephrectomy. Often, the technical complexity of sewing the small, medially located ureter to a large laterally located renal calyx can be difficult or even impossible. Recently, robotics for the non-acute and stable trauma patient can be successfully and safely used for a wide variety of delayed upper urinary tract reconstructions, including dismembered pyeloplasty, ureteroureterostomy, and ureterocalicostomy.

Autotransplantation.

Autotransplantation of the kidney has been used after profound ureteral loss or after multiple attempts at ureteral repair have failed. Such surgery is reserved only for a delayed repair in select patients and has no role in the acute trauma patient (Cowan et al., 2015). This maneuver remains the final option before nephrectomy. Despite great efforts, renal units are sometimes lost after autotransplantation, occurring between 5% and 10% (Bodie et al., 1986; Cowan et al., 2015; Eisenberg et al., 2008), although centers with significant transplant experience have reported good results. Early high-grade complications (Clavien III or higher) including bleeding and infection occurred in 15% of patients.

Bowel Interposition.

Delayed ureteral repairs, especially when a very long segment of ureter is destroyed, also can be performed by creation of an ileal “chimney” in much the same way that an ileal conduit is constructed to drain the urine after cystectomy. Success rates for ileal replacement of the ureter have been reported to be 81% (Boxer et al., 1979; Verduyckt et al., 2002) to 100% (Bonfig et al., 2004; Kocot et al., 2017; Matlaga et al., 2003). A review of long-term complications of 99 renal units reported a 3% anastomotic stricture and 6% fistula rate (Armatys et al., 2009). A recent series, and the largest to date, involving 157 patients found that complications were not uncommon (Kocot et al., 2017). Hyperchloremic metabolic acidosis occurred in 20% of patients, pyelonephritis in 9%, and surgical intervention in 4%. Some have successfully used the Monti procedure, in which short segments of small or large bowel are sewn together to make a long, thin tube in ureteral reconstruction (Ali-el-Dein and Ghoneim, 2003; Bao et al., 2017; Ubrig et al., 2001). Laparoscopic and robotic ileal interposition have been described (Brandao et al., 2014; Castillo et al., 2008; Chopra et al., 2016; Gill et al., 2000). The use of appendix in open (Jang et al., 2002) and laparoscopic (Reggio et al., 2009) ureteral substitution has also been reported. Most practitioners create a wide-open, refluxing, ileal replacement of the ureter (Fig. 90.20), because significant clinical reflux is not a problem (Waldner et al., 1999). We often prefer to combine the ileal chimney with an ipsilateral Psoas bladder hitch, in order to shorten the length of the conduit and hypothetically decrease the risk of metabolic and mucus complications. Ileal interposition has *no* role in the acute repair of ureteral injury and should be reserved only for delayed or staged repairs.

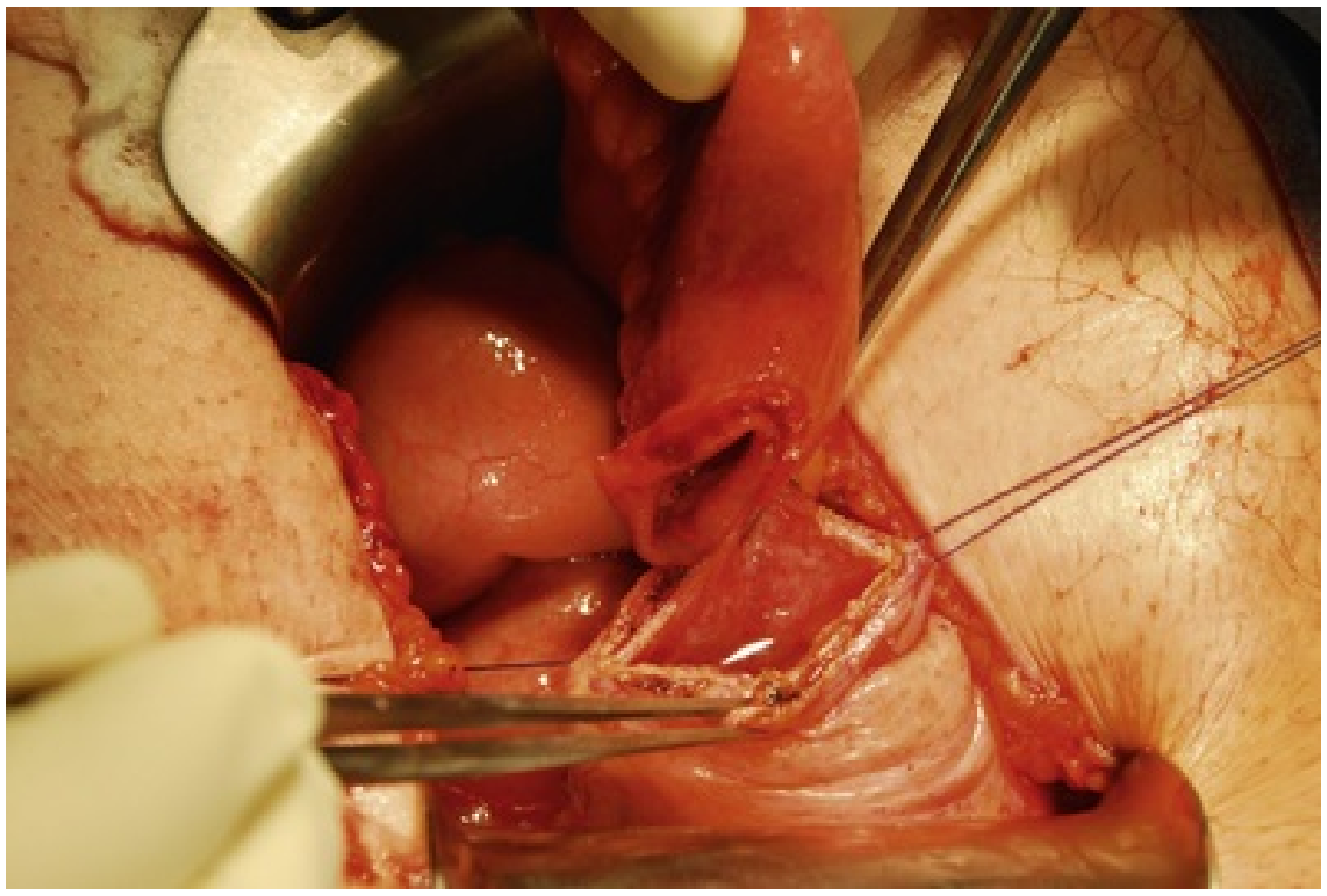

FIG. 90.20 Nontapered distal ileal segment is anastomosed to the bladder in a wide-open, and refluxing fashion.

Monitoring After Ureteral Repair.

There is little consensus in the literature when and how to image for silent hydronephrosis/ureteral obstruction after traumatic ureteral reconstruction. Typically a diuretic renogram or renal ultrasound with doppler imaging for ureteral jets is performed at 4 to 12 weeks and at 1 year post injury. If the patient had severe polytrauma and requires CT imaging for the associated non-renal injuries, then a CT with IV contrast with delayed cuts should be done. Because ureteral injury repairs often happen in the setting of ureteral devascularization, late stenosis can occur and is often clinically silent.

Nephrectomy.

Rarely, acute nephrectomy is required to treat ureteral injury after external trauma. Reasons for nephrectomy include hemodynamic instability and associated severe visceral injuries (although damage control without nephrectomy is nearly always preferable) or severe associated injury to the ipsilateral kidney when renal repair is not possible (McGinty and Mendez, 1977). Delayed nephrectomy may be required because of poor renal function (which can sometimes be seen after delayed recognition of an obstructing ureteral injury), severe panureteral injury when ileal ureter or other reconstruction is impossible, or persistent ureteral fistula (especially vascular fistula) despite previous intervention (Ghali et al., 1999). In general, nephrectomy must be avoided if at all possible no matter the severity of the ureteral injury, and instead a damage control and delayed reconstruction approach be followed.

Midureteral Injuries.

The majority of midureteral complete transections (above the iliac vessels), regardless of the mechanism, can be repaired by primary ureteroureterostomy over a stent. When the midureteral injury/defect is very long, however, and the ends of the ureters cannot be brought together without tension, then a transureteroureterostomy (TUU) can be considered.

Transureteroureterostomy.

TUU is a rarely used (Presti et al., 1989) but often (90% to 97%) successful (Kawamura et al., 2017; Rainwater et al., 1991; Sugarbaker et al., 2003) technique in adults is transureteroureterostomy (TUU). Pediatric series show a lower success rate of 70% (Mure et al., 2000). This form of repair involves bringing the injured ureter across the midline and anastomosing it end-to-side into the contra-lateral, uninjured ureter (a 2 cm or more ureterotomy in the recipient ureter is advised). TUU has little role in the acute trauma setting and is typically performed as a secondary or delayed procedure. As an alternative, in the acute setting, the injured ureter can be treated in a damage control approach by ligation or diversion to the skin over a stent. It also may be mandated in some cases of middle or distal ureteral injury in which ureteroureterostomy or bladder flap/hitch repair is impossible (usually because of severe bladder scarring, a congenitally small bladder, or very long segment of missing ureter, or pelvic phlegmon) or when there are associated rectal, major pelvic vascular or extensive bladder injuries. Laparoscopic transureteroureterostomy has been performed successfully in the pediatric population (Piaggio and González, 2007).

Relative contraindications to performing a TUU is in patients with a history of urothelial cancer or calculi, genitourinary tuberculosis, pelvic radiation, retroperitoneal fibrosis, or chronic pyleonephritis. At the time of ureteral injury, however, this information is seldom available to the operating trauma surgeon. Caution is required while performing this procedure because it involves surgery on the uninjured, contralateral ureter with the theoretical risk for converting unilateral ureteral injury into (iatrogenic) bilateral ureteral injury.

Lower Ureteral Injuries

Ureteroneocystostomy.

Ureteroneocystostomy is used to repair distal ureteral injuries that occur so close to the bladder that the bladder does not need to be brought up to the ureteral stump with a psoas hitch or Boari procedure. For the non-acute trauma patient, and in an elective fashion, robotic ureteroneocystostomy is increasingly common with a success rate of around 95% (Fifer et al., 2014; Gellhaus et al., 2015). Standard principles of ureteroneocystostomy include a long, nontunneled, spatulated, stented anastomosis. Refluxing ureteroneobladder (Minervini et al., 2005) and ureteroileal loop (Wiesner and Thüroff, 2004) anastomoses show no increase in complications related to urine reflux, although these populations of patients are different from the average trauma population and reports do not address whether ureteral implantation into the native bladder is equally safe. A comparison of nonrefluxing and refluxing anastomoses in neobladders found a higher rate of stricture leading to renal deterioration in the nonrefluxing group (Shaaban et al., 2006). As such, we favor nontunneled anastomoses for the trauma patient, because we prefer the very low risk of clinically significant reflux to the higher risk of ureteral obstruction using a tunneled approach.

Psoas Bladder Hitch.

The psoas hitch procedure (Fig. 90.21) is a mainstay in the treatment of injuries to the lower third of the ureter and has a high success rate, from 95% to 100% (Ahn and Loughlin, 2001; Middleton, 1980; Riedmiller et al., 1984). We prefer it over ureteroureterostomy in lower ureteral injuries because the tenuous ureteral blood supply may not survive transection. Some authors prefer end-to-end repair in lower ureteral injuries when the distal stump is preserved (Paick et al., 2006). For lower ureteral injuries, the ureteral gap can be bridged by “hitching” (suturing) the apex of the bladder to the ipsilateral psoas muscle and psoas minor tendon. The contralateral superior vesical pedicle is often divided to improve mobilzation. When hitching the bladder, it is important not to injure or entrap the genitofemoral nerve in the sutures. The psoas hitch is relatively quick to perform, but is only appropriate in the stable trauma patient. If the patient is unstable, the procedure should be delayed until a planned and staged repair.

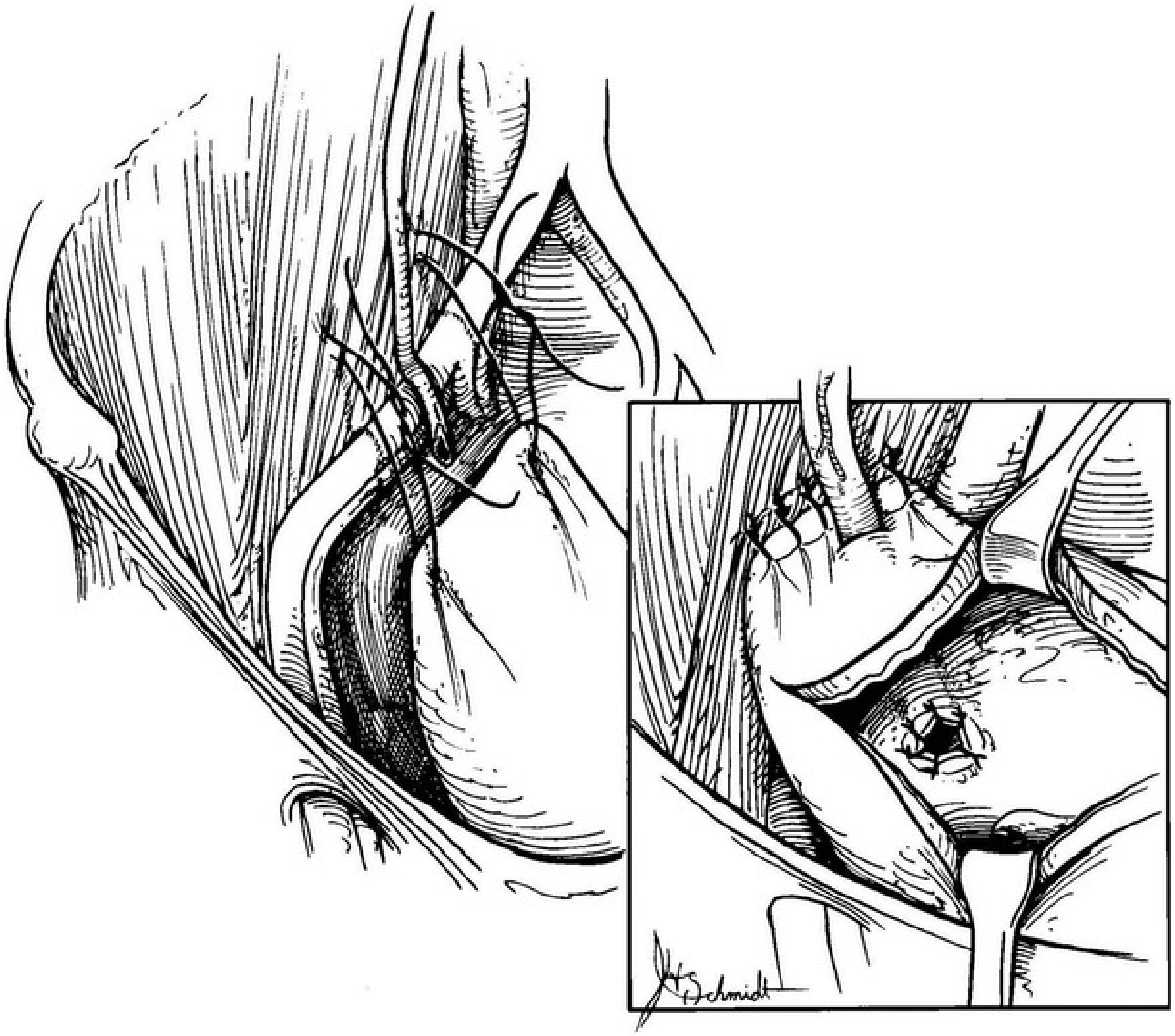

FIG. 90.21 Psoas hitch. Bladder is opened and secured to the psoas muscle to facilitate ureteral anastomosis. (From Hohenfellner M, Santucci RA: *Emergencies in urology,* Heidelberg, Germany, 2007, Springer. Copyright 2007, Dr. Markus Hohenfellner, with permission.)

Boari Flap.

Injuries to the lower two-thirds of the ureter with long ureteral defects (too long to be bridged by bringing the bladder up in the psoas hitch procedure) can be managed with a Boari flap or a transureteroureterostomy (Fig. 90.22). If the bladder is normal in size and thickness, a long pedicle of bladder can be incised and rotated cephalad and tubularized to bridge the gap to the injured ureter. The procedure is time-consuming, however, and is not appropriate for most acute injuries. It is not commonly performed, but authors report a high success rate with the open or robotic technique (Benson et al., 1990; Stolzenburg et al., 2016).

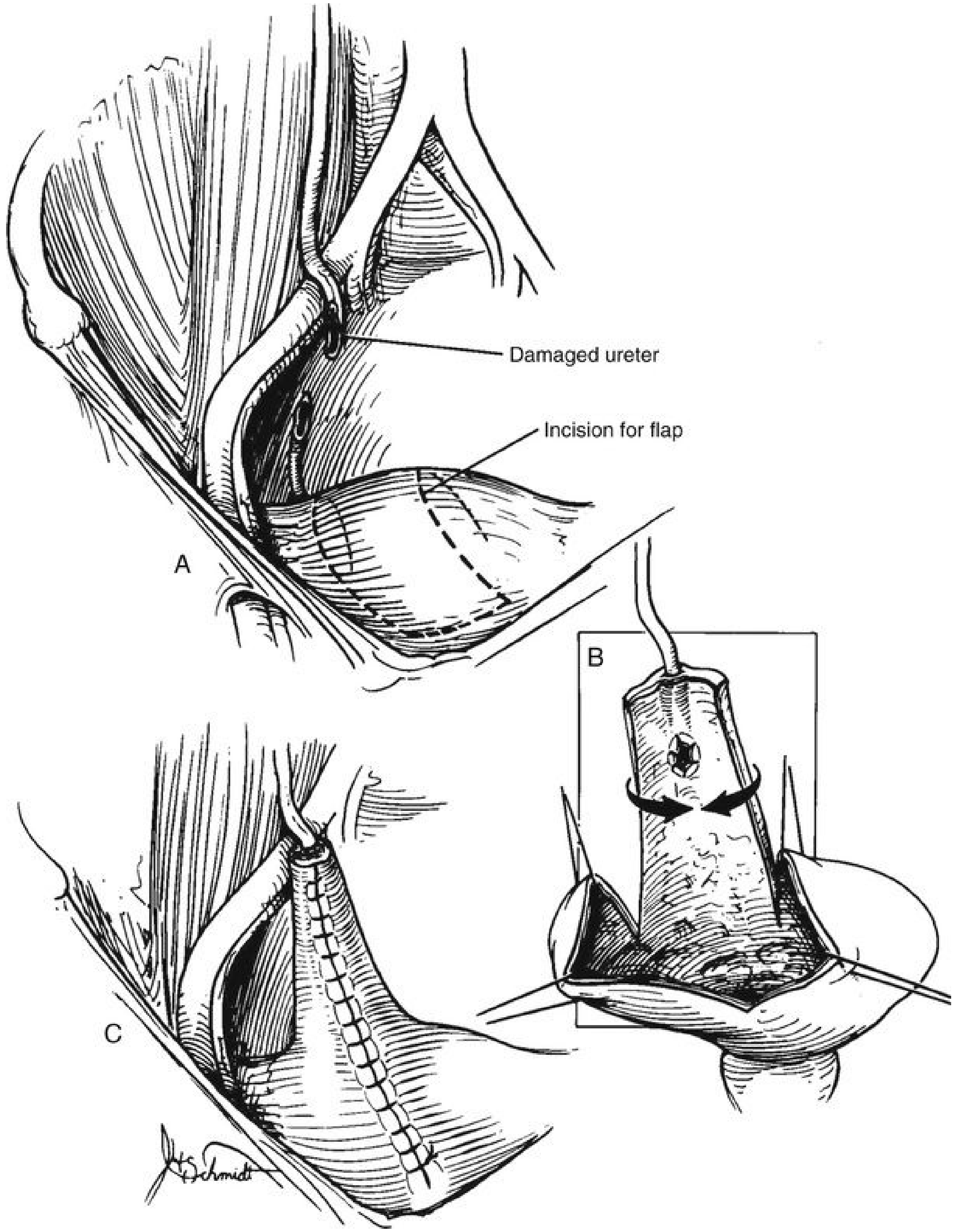
Damaged ureter
Incision for flap
A
B
C

FIG. 90.22 Boari flap. Bladder flap is marked (A), mobilized free (B), tubularized (C). (From Hohenfellner M, Santucci RA: *Emergencies in urology,* Heidelberg, Germany, 2007, Springer. Copyright 2007, Dr. Markus Hohenfellner, with permission.)

Partial Transection.

Primary repair of a partial transection is used in the majority of ureteral injuries, up to 58% of the time in one large series (Presti et al., 1989). Principles of primary repair involve spatulated, watertight closure, with interrupted or running absorbable suture such as Maxon (polyglyconate), Vicryl (polyglactin 910), or Dexon (polyglycolic acid). The ureteral injury is closed by converting a longitudinal laceration into a transverse one so as not to narrow the ureteral lumen (Heineke-Mikulicz procedure) and retroperitonealize if possible. A ureteral stent and retroperitoneal drain are always placed.

Damage Control.

In cases of ureteral injury after trauma, it is sometimes necessary to treat the injured ureter by deferring definitive treatment until later. This is usually because the patient is too unstable to tolerate the operative time required to complete the repair (Cass, 1983). Some have suggested that in cases of severe hemorrhagic shock, uncontrollable intraoperative bleeding, or severe colon injury (especially those requiring colectomy), ureteral reconstruction should be delayed until the patient is fully resuscitated and performed as a staged repair (Velmahos et al., 1996).

The four options for damage control in ureteral injuries are (1) do nothing, but plan a reoperation when the patient is more stable, usually within 24 hours; (2) place a ureteral stent into the proximal end of the transected ureter and exteriorize the stent to the skin; (3) mobilize and exteriorize the ureter, as in a cutaneous ureterostomy; or (4) ligate the ureter and plan a staged percutaneous nephrostomy (Hirshberg et al., 1994). In most cases of planned staged repair, we prefer to ligate the proximal end of the damaged ureter, using long silk or polypropylene ties to aid the dissection of the ureteral stump during the second-stage repair. The kidney is then drained percutaneously. We advocate percutaneous (not intraoperative or intra-abdominal) placement of a nephrostomy tube, only once the patient has been fully stabilized and in a delayed fashion. Open nephrostomy placement is too time-consuming and has no role in these unstable patients. Alternatively, a single-J stent or 5-Fr pediatric feeding tube can be placed into the proximal end of the injured ureter, with minimal to no mobilization of the proximal ureter, a nonabsorbale tie placed around the proximal ureter to secure the stent in place, the stent, and the stent end externalized through the abdominal wall into a urostomy pouch (Ball et al., 2005). If possible, appropriate planned ureteric reconstruction should be performed after functional and anatomic imaging.

Surgical Injury

Timing of Repair.

Ureteral repair of traumatic injuries should be performed at the time of initial laparotomy, when possible. Immediate repair, however, may not be appropriate in unstable, complex polytrauma patients. Even with immediate recognition, success is not ensured. In small series, patients with immediately repaired ureteral injuries still suffered urine leak, fistula, and even nephrectomy (Grainger et al., 1990; Mandal et al., 1990). The AUA urotrauma guidelines state that injuries diagnosed postoperatively or in a delayed fashion can be considered for immediate repair if the injury is recognized with 1 week (Morey, 2014). Injuries discovered after this 1-week period, should be managed by retrograde ureteral imaging with ureteral stent placement, percutaneous nephrostomy, or both, and definitive repair delayed until a minimum of 6 weeks after injury. This putatively avoids an inflammatory phase, when ureteral repairs are thought to be less reliable. Others recommend immediate repair even when discovered weeks to months, and cite low complication rates, similar to injuries that are recognized immediately (Ghali et al., 1999; Witters et al., 1986). However, delayed diagnosis of ureteral injury increase the complication rate of the repair significantly (Selzman and Spirnak, 1996), from 10% to 40% in one series (Campbell et al., 1992). Some have suggested that delaying the repair (6 or more weeks) avoids this risk by allowing for maximal resolution of perioperative inflammation. A recent report suggests that even delayed repairs have a slightly higher rate of failure than immediate repair (Eswara et al., 2015b).

Most delayed diagnosed ureteral injuries, are discovered within 6 weeks of surgery (Hatch et al., 1984; Oh et al., 2000), and in one series almost half were discovered more than 6 weeks after the initial surgery (Badenoch et al., 1987). Cure rates appear equal in the early (within 1 week) and late discovery groups (Brandt et al., 2001; Liapis et al., 2001). Another study found no difference between repairs performed immediately, within 1 month, or at 3 months (Li et al., 2012). Overall, it is most prudent to repair the ureteral injury immediately if identified within 1 week or wait at least 6 weeks for inflammation to subside.

Ligation.

Ligation of the ureter discovered intraoperatively should be treated by

removal of the ligature and observation of the ureter for viability. If viability is in question, ureteroureterostomy or ureteral reimplantation should be performed (Assimos et al., 1994; Brandes et al., 2004; Fig. 90.23). Even if the ureter looks healthy, a ureteral stent should be placed at minimum, either by opening the bladder or by immediate cystoscopic placement.

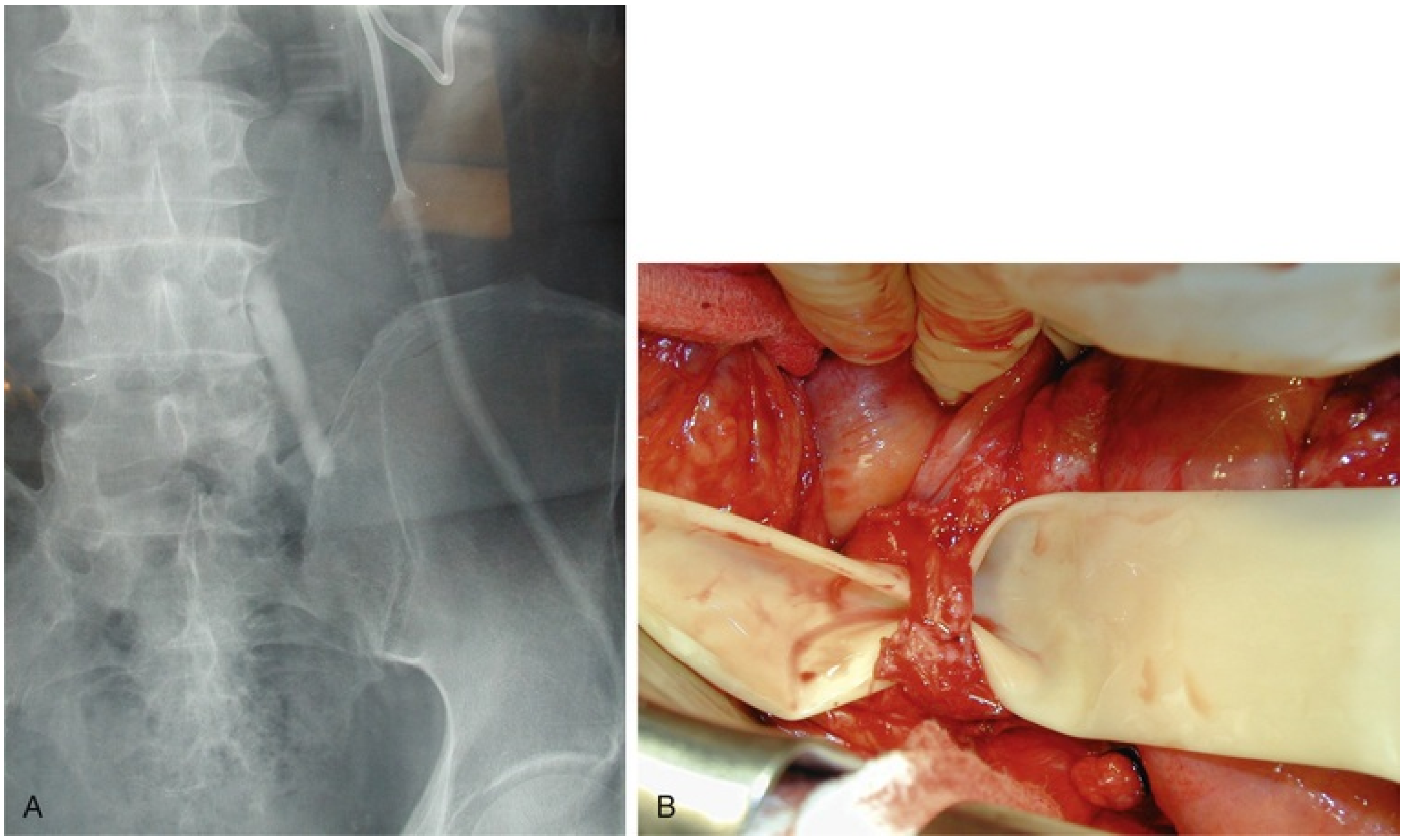

FIG. 90.23 (A) Left nephrostogram showing abrupt midureteral cutoff consistent with (inadvertent) suture ligation of the ureter. (B) Intraoperative view of left midureteral suture ligation.

Transection

Immediate Recognition.

Injuries discovered immediately after nonaortic surgery are largely treated in the same way as ureteral injury after external trauma. Most lacerations can be treated with ureteroureterostomy, although additional maneuvers such as omental wrapping of the repair or placement of an ipsilateral nephrostomy tube have been advocated to decrease the potential for urine leakage or breakdown of the repair (Adams et al., 1992). With increasing laparoscopic and robotic popularity, many iatrogenic injuries are now being treated without the need for open conversion (Andrade et al., 2016; Dinlenc et al., 2004; Menderes et al., 2015; Ou et al., 2005). Ureteroscopic ureteroureterostomies for operative ureteral injuries have even been described (Tsai et al., 2000).

Ureteral injuries that occur during vascular graft surgery are a special case. Intraoperative management of these should be primary ureteroureterostomy with isolation of the repair with omentum (Adams et al., 1992). Nephrectomy in cases of ureteral injury should be avoided. Although nephrectomy avoids the potential for postoperative urine leakage around an aortic or iliac vascular graft (Schapira et al., 1981), it is associated with increased mortality. In patients with a ruptured aneurysm, it can increase the mortality rate fourfold, from 3% to 12% (Schapira et al., 1981). We recommend careful repair of the ureteral injury, reserving nephrectomy for patients who develop urine leakage postoperatively.

Delayed Recognition.

Intraoperative recognition of ureteral injuries occurs in as few as 34% of patients undergoing open operation (Ghali et al., 1999) and even more rarely during laparoscopic surgery (Grainger et al., 1990). Delayed diagnosis of ureteral injury is most often (66% to 76%) determined by CT urography, or retrograde ureterography (Ghali et al., 1999; Grainger et al., 1990). In a series of 35 ureteral injuries, patients had a variety of signs and symptoms: anuria (14%, most with bilateral injury), urogenital fistula (11%), persistent pain or fever (9%), urinary leakage from the wound (9%), hydronephrosis (3%), and hematuria (3%) (Ghali et al., 1999). Some authors cite a triad of fever, leukocytosis, and generalized peritoneal signs as being most diagnostic for missed ureteral injury (Medina et al., 1998). Repair of these delayed-recognition injuries is controversial. When an incomplete ureteral injury presents in a delayed fashion, the AUA urotrauma guideline recommends retrograde ureteral imaging with ureteral stent placement (Morey, 2014). Reported success of retrograde stent placement varies widely: 5% to 10% (Dowling et al., 1986; Hoch et al., 1975), 20% (Ghali et al., 1999; Oh et al., 2000), and 50% (Cormio et al., 1993). When stent placement is possible, ultimate success rate without the need for eventual open surgery is variable, from as low as 0% to as high as 73% (Dowling et al., 1986; Oh et al., 2000). Usually, failure to place a stent is due to complete obstruction of the ureter or complete ureteral transection with a long defect/gap (Cormio et al., 1993). Some authors have suggested that stenting alone has the highest failure rate in those with multiple previous pelvic operations, radiation therapy, or significant previous ureteral surgery (Chang and Marshall, 1987). The ideal length of time to leave the stent has never been studied in a randomized, prospective, double-blind fashion, but most authors recommend at least 6 weeks (Selzman and Spirnak, 1996). The literature and our experience seem to indicate that a majority of patients will eventually require definitive repair of significant ureteral injuries, whether or not stent placement is possible. If stents cannot be placed, or the patient is so unstable as to preclude a retrograde stent attempt, then a percutaneous nephrostomy should be placed (Morey et. al., 2014). If the nephrostomy alone does not adequately control the urine leak, then further treatment is usually percutaneous urinoma drain placement or open ureteral repair.

Percutaneous nephrostomy tube placement is the single procedure most likely to be successful at draining the collecting system and diverting urine away from the ureteral injury site. In addition, when compared with ureteral stenting, a percutaneous nephrostomy tube allows for decreased periureteral inflammation at the time of the repair and thus more favorable anatomy. Ureteral balloon catheters, which are designed to stop urine from traveling down the ureter, have been advocated if simple stenting does not eliminate associated urine leakage or urinoma, although we often have found them to be ineffective. We think the safest approach is to wait at least 6 weeks for complete healing of the wounds, then attempt open or robotic repair. Some have recommended even longer ureteral drainage and delay until definitive repair, in certain special cases, such as in the presence of ureteroenteric fistula (Bright and Peters, 1977).

Some authors have advocated treating postinjury ureteral stenosis endoscopically with either balloon dilation (Richter et al., 2000) or laser incision (Patel and Newman, 2004; Singal et al., 1997). Others have used endoluminal stents for ureteral obstruction after injury with good results in limited numbers of patients (Wenzler et al., 2008). In general, endoscopic dilation and incision techniques in the long, devascularized, postinjury or postoperative ureteral strictures typically have poor results.

Ureteroscopy Injury

Avulsion.

Ureteral avulsion during ureteroscopy is treated in the same manner as ureteral injuries after open or laparoscopic surgery, as detailed in the section on ureteral transection.

Perforation.

Ureteral perforation during ureteroscopy can be treated by ureteral stenting, usually with no subsequent complications (Flam et al., 1988; Huffman, 1989). The safest approach is to avoid injury by always performing ureteroscopy over a ureteral guidewire and by placing a second ureteral safety wire that is always in place during ureteroscopy and facilitates ureteral stent placement in the presence of problems. We recognize that some expert centers do not use a ureteral guidewire during ureteroscopy and that some no longer use a safety wire, but we believe that at least a safety wire is most prudent for the majority of practitioners.

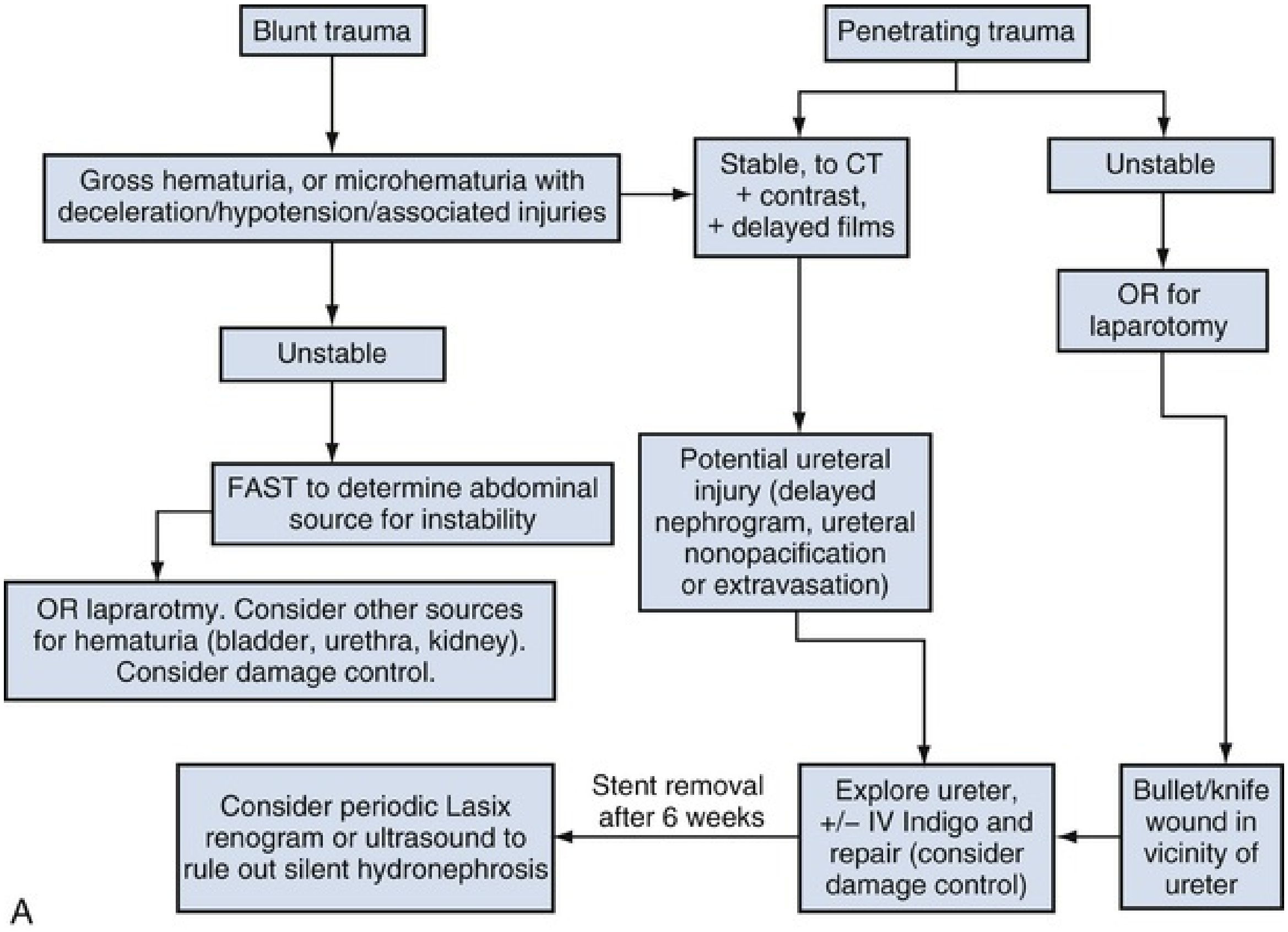
Blunt trauma
Penetrating trauma
Gross hematuria, or microhematuria with deceleration/hypotension/associated injuries
Stable, to CT + contrast, + delayed films
Unstable
Unstable
OR for laparotomy
FAST to determine abdominal source for instability
Potential ureteral injury (delayed nephrogram, ureteral nonopacification or extravasation)
OR laprarotmy. Consider other sources for hematuria (bladder, urethra, kidney). Consider damage control.
Consider periodic Lasix renogram or ultrasound to rule out silent hydronephrosis
Stent removal after 6 weeks
Explore ureter, +/– IV Indigo and repair (consider damage control)
Bullet/knife wound in vicinity of ureter
A

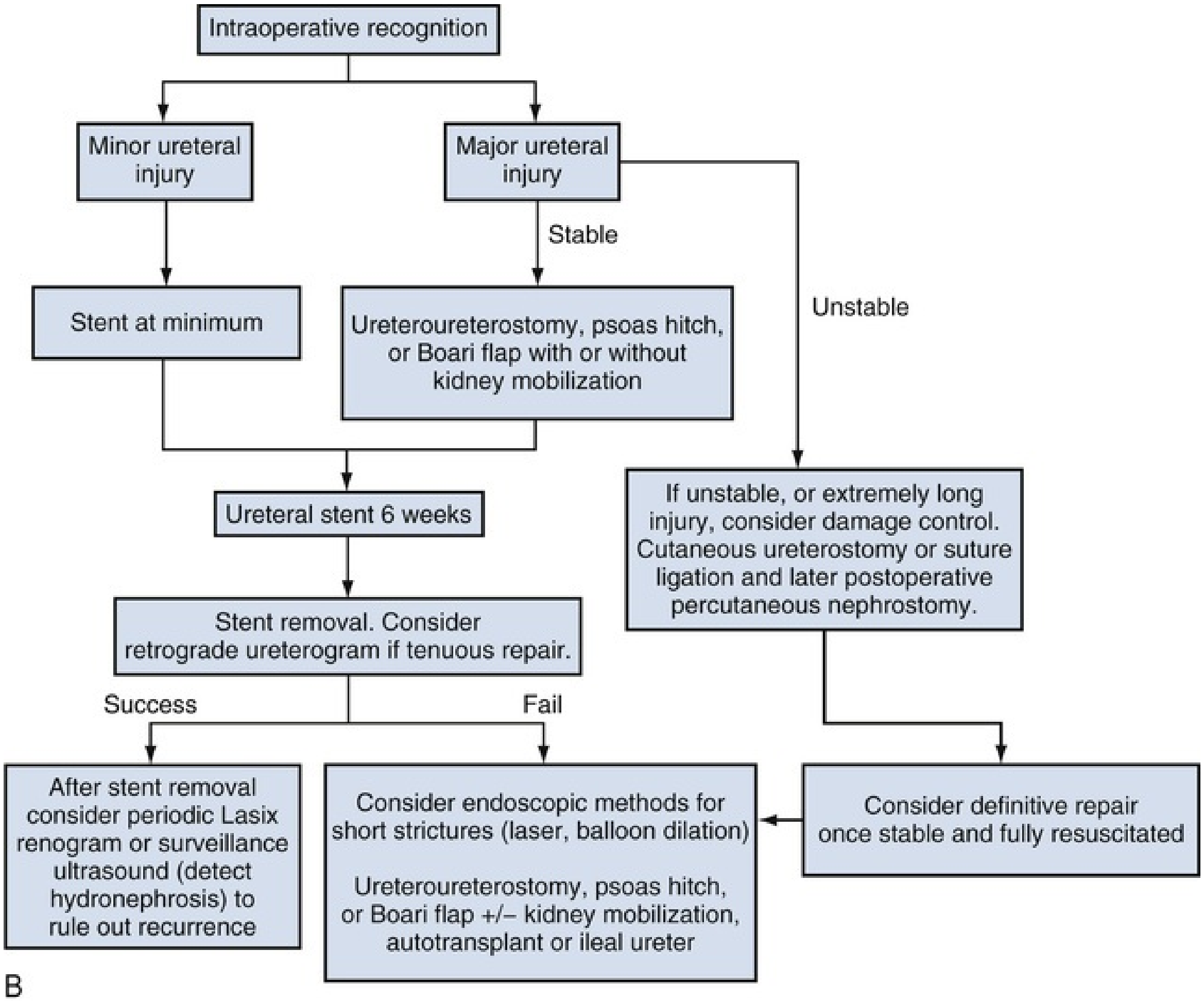
Intraoperative recognition
Minor ureteral injury
Major ureteral injury
Stable
Unstable
Stent at minimum
Ureteroureterostomy, psoas hitch, or Boari flap with or without kidney mobilization
Ureteral stent 6 weeks
If unstable, or extremely long injury, consider damage control. Cutaneous ureterostomy or suture ligation and later postoperative percutaneous nephrostomy.
Stent removal. Consider retrograde ureterogram if tenuous repair.
Success
Fail
After stent removal consider periodic Lasix renogram or surveillance ultrasound (detect hydronephrosis) to rule out recurrence
Consider endoscopic methods for short strictures (laser, balloon dilation)
Ureteroureterostomy, psoas hitch, or Boari flap +/− kidney mobilization, autotransplant or ileal ureter
Consider definitive repair once stable and fully resuscitated

B

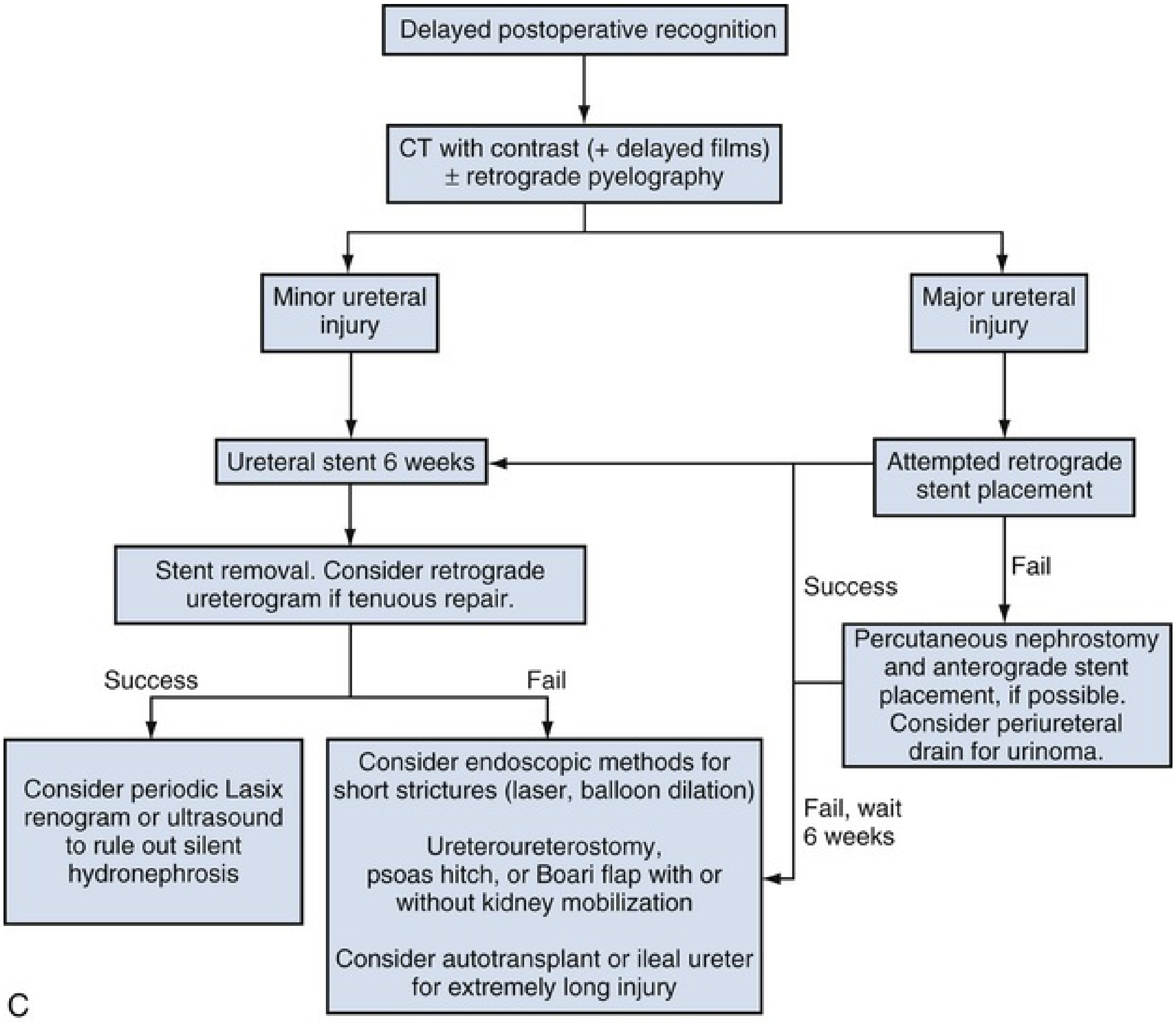
Delayed postoperative recognition
CT with contrast (+ delayed films) ± retrograde pyelography
Minor ureteral injury
Major ureteral injury
Ureteral stent 6 weeks
Attempted retrograde stent placement
Success
Fail
Stent removal. Consider retrograde ureterogram if tenuous repair.
Percutaneous nephrostomy and anterograde stent placement, if possible. Consider periureteral drain for urinoma.
Success
Fail
Consider periodic Lasix renogram or ultrasound to rule out silent hydronephrosis
Consider endoscopic methods for short strictures (laser, balloon dilation)
Ureteroureterostomy, psoas hitch, or Boari flap with or without kidney mobilization
Consider autotransplant or ileal ureter for extremely long injury
Fail, wait 6 weeks
C

FIG. 90.24 Algorithms for the diagnosis and treatment of ureteral injuries. (A) From external violence. (B) Discovered intraoperatively. (C) Discovered postoperatively. *CT,* Computed tomography; *IVP,* intravenous pyelography; *OR,* operating room.

Key Points: Ureteral Trauma

- Ureteral injury diagnosis requires a low index of suspicion. Absence of hematuria does not reliably rule out ureteral injury.
- Stable patients with suspected ureteral injury should undergo CT urogram with delayed images.
- After penetrating injury, determine the course of the knife or bullet tract to ensure that the ureter is not at risk.

- If delayed recognition is suspected, image with CT urogram or retrograde ureterogram.
- Ureteral repair should be performed in stable patients at the time of laparotomy, when possible.
- Consider damage control, followed by delayed definite repair for unstable patients with ureteral injuries.
- Manage ureteral contusions with stenting or, if severe, resection and primary repair.
- Place a nephrostomy tube for delayed diagnosed injuries that cannot be stented retrograde.
- Retroperitoneal surgery should be undertaken only with constant attention to the location of the ureter. Intraoperatively, the ureter should be exposed and inspected when ureteral injury is suspected.
- See Fig. 90.24.

Suggested Readings

Brandes S, Coburn M, Armenakas N, et al. Diagnosis and management of ureteric injury: an evidence-based analysis. *BJU Int*. 2004;94:277–289.

Bretan PN Jr, McAninch JW, Federle MP, et al. Computerized tomographic staging of renal trauma: 85 consecutive cases. *J Urol*. 1986;136:561–565.

Broghammer JA, Fisher MB, Santucci RA. Conservative management of renal trauma: a review. *Urology*. 2007;70:623–629.

Buckley JC, McAninch JW. Pediatric renal injuries: management guidelines from a 25-year experience. *J Urol*. 2004;172:687–690 [discussion 690].

Carroll PR, Klosterman P, McAninch JW. Early vascular control for renal trauma: a critical review. *J Urol*. 1989;141:826–829.

Chandhoke PS, McAninch JW. Detection and significance of microscopic hematuria in patients with blunt renal trauma. *J Urol*. 1988;140:16–18.

Miller KS, McAninch JW. Radiographic assessment of renal trauma: our 15-year experience. *J Urol*. 1995;154:352–355.

Moore EE, Shackford SR, Pachter HL, et al. Organ injury scaling: spleen, liver, and kidney. *J Trauma*. 1989;29:1664–1666.

Morey AF, Brandes SB, Dugi DD, et al. Urotrauma: AUA guideline. *J Urol*. 2014;192:327–335.

Presti JC Jr, Carroll PR, McAninch JW. Ureteral and renal pelvic injuries from external trauma: diagnosis and management. *J Trauma*. 1989;29:370–374.

Santucci RA, Wessells H, Bartsch G, et al. Evaluation and management of renal injuries: consensus statement of the renal trauma subcommittee. *BJU Int*. 2004;93:937–954.

Selzman AA, Spirnak JP. Iatrogenic ureteral injuries: a 20-year experience in treating 165 injuries. *J Urol*. 1996;155:878–881.

Voelzke BB, McAninch JW. The current management of renal injuries. *Am Surg*. 2008;74:667–678.

References

Adams JR, Mata JA, Culkin DJ, et al. Ureteral injury in abdominal vascular reconstructive surgery. *Urology*. 1992;39(1):77–81.

Ahn M, Loughlin KR. Psoas hitch ureteral reimplantation in adults–analysis of a modified technique and timing of repair. *Urology*. 2001;58(2):184–187.

Al-Awadi K, Kehinde EO, Al-Hunayan A, et al. Iatrogenic ureteric injuries: incidence, aetiological factors and the effect of early management on subsequent outcome. *Int Urol Nephrol*. 2005;37(2):235–241.

Ali-el-Dein B, Ghoneim MA. Bridging long ureteral defects using the Yang-Monti principle. *J Urol*. 2003;169(3):1074–1077.

Allen BC, Barnhart H, Bashir M, et al. Diagnostic accuracy of intra-abdominal fluid collection characterization in the era of multidetector computed tomography. *Am Surg*. 2012;78(2):185–189.

Alsikafi NF, McAninch JW, Elliott SP, et al. Nonoperative management outcomes of isolated urinary extravasation following renal lacerations due to external trauma. *J Urol*. 2006;176(6 Pt 1):2494–2497.

Altman AL, Haas C, Dinchman KH, et al. Selective nonoperative management of blunt grade 5 renal injury. *J Urol*. 2000;164(1):27–30.

Amato JJ, Billy LJ, Gruber RP, et al. Vascular injuries. An experimental study of high and low velocity missile wounds. *Arch Surg*. 1970;101(2):167–174.

Anand M, Woelk JL, Weaver AL, et al. Perioperative complications of robotic sacrocolpopexy for post-hysterectomy vaginal vault prolapse. *Int Urogynecol J*.

2014;25(9):1193–1200.

Andrade HS, Kaouk JH, Zargar H, et al. Robotic ureteroureterostomy for treatment of a proximal ureteric stricture. *Int Braz J Urol*. 2016;42(5):1041–1042.

Araki T, Nagata M, Takihana Y, et al. Endovascular treatment of ureteroarterial fistulas with stent-grafts. *Radiat Med*. 2008;26(6):372–375.

Armatys SA, Mellon MJ, Beck SD, et al. Use of ileum as ureteral replacement in urological reconstruction. *J Urol*. 2009;181(1):177–181.

Armenakas NA, Duckett CP, McAninch JW. Indications for nonoperative management of renal stab wounds. *J Urol*. 1999;161(3):768–771.

Assimos DG, Patterson LC, Taylor CL. Changing incidence and etiology of iatrogenic ureteral injuries. *J Urol*. 1994;152(6 Pt 2):2240–2246.

Atala A, Miller FB, Richardson JD, et al. Preliminary vascular control for renal trauma. *Surg Gynecol Obstet*. 1991;172(5):386–390.

Azimuddin K, Milanesa D, Ivatury R, et al. Penetrating ureteric injuries. *Injury*. 1998;29(5):363–367.

Badenoch DF, Tiptaft RC, Thakar DR, et al. Early repair of accidental injury to the ureter or bladder following gynaecological surgery. *Br J Urol*. 1987;59(6):516–518.

Bagley DH, Kuo RL, Zeltser IS. An update on ureteroscopic instrumentation for the treatment of urolithiasis. *Curr Opin Urol*. 2004;14(2):99–106.

Ball CG, Kirkpatrick AW, Laupland KB, et al. Incidence, risk factors, and outcomes for occult pneumothoraces in victims of major trauma. *J Trauma*. 2005;59(4):917–924 [discussion 24–25].

Bao JS, He Q, Li Y, et al. Yang-Monti principle in bridging long ureteral defects: cases report and a systemic review. *Urol J*.

2017;14(4):4055–4061.

Baş O, Tuygun C, Dede O, et al. Factors affecting complication rates of retrograde flexible ureterorenoscopy: analysis of 1571 procedures—a single-center experience. *World J Urol*. 2017;35(5):819–826.

Ben-Hur H, Phipps JH. Laparoscopic hysterectomy. *J Am Assoc Gynecol Laparosc*. 2000;7(1):103–106.

Benson MC, Ring KS, Olsson CA. Ureteral reconstruction and bypass: experience with ileal interposition, the Boari flap-psoas hitch and renal autotransplantation. *J Urol*. 1990;143(1):20–23.

Bjurlin MA, Fantus RJ, Villines D. Comparison of nonoperative and surgical management of renal trauma: can we predict when nonoperative management fails? *J Trauma Acute Care Surg*. 2017;82(2):356–361.

Bjurlin MA, Jeng EI, Goble SM, et al. Comparison of nonoperative management with renorrhaphy and nephrectomy in penetrating renal injuries. *J Trauma*. 2011;71(3):554–558.

Blackwell RH, Kirshenbaum EJ, Shah AS, et al. Complications of recognized and unrecognized iatrogenic ureteral injury at time of hysterectomy: a population-based analysis. *J Urol*. 2018;199(6):1540–1545.

Bodie B, Novick AC, Rose M, et al. Long-term results with renal autotransplantation for ureteral replacement. *J Urol*. 1986;136(6):1187–1189.

Bonfig R, Gerharz EW, Riedmiller H. Ileal ureteric replacement in complex reconstruction of the urinary tract. *BJU Int*. 2004;93(4):575–580.

Boone TB, Gilling PJ, Husmann DA. Ureteropelvic junction disruption following blunt abdominal trauma. *J Urol*. 1993;150(1):33–36.

Bothwell WN, Bleicher RJ, Dent TL. Prophylactic ureteral catheterization in colon surgery. A five-year review. *Dis Colon Rectum*. 1994;37(4):330–334.

Boxer RJ, Fritzsche P, Skinner DG, et al. Replacement of the ureter by small intestine: clinical application and results of the ileal ureter in 89 patients. *J Urol*. 1979;121(6):728–731.

Boyan WP, Lavy D, Dinallo A, et al. Lighted ureteral stents in laparoscopic colorectal surgery; a five-year experience. *Ann Transl Med*. 2017;5(3):44.

Brandao LF, Autorino R, Zargar H, et al. Robotic ileal ureter: a completely intracorporeal technique. *Urology*. 2014;83(4):951–954.

Brandes S, Coburn M, Armenakas N, et al. Diagnosis and management of ureteric injury: an evidence-based analysis. *BJU Int*. 2004;94(3):277–289.

Brandes SB, Chelsky MJ, Buckman RF, et al. Ureteral injuries from penetrating trauma. *J Trauma*. 1994;36(6):766–769.

Brandes SB, McAninch JW. Reconstructive surgery for trauma of the upper urinary tract. *Urol Clin North Am*. 1999;26(1):183–199 [x].

Brandt FT, Albuquerque CD, Lorenzato FR. Transperitoneal unstented ureteral reimplantation for injuries postgynecological surgery. *World J Urol*. 2001;19(3):216–219.

Bratslavsky G, Moran ME. Current trends in ureteroscopy. *Urol Clin North Am*. 2004;31(1):181–187 [xi].

Bretan PN, McAninch JW, Federle MP, et al. Computerized tomographic staging of renal trauma: 85 consecutive cases. *J Urol*. 1986;136(3):561–565.

Breyer BN, McAninch JW, Elliott SP, et al. Minimally invasive endovascular techniques to treat acute renal hemorrhage. *J Urol*. 2008;179(6):2248–2253.

Bright TC, Peters PC. Ureteral injuries due to external violence: 10 years' experience with 59 cases. *J Trauma*.

1977;17(8):616–620.

Brown SL, Hoffman DM, Spirnak JP. Limitations of routine spiral computerized tomography in the evaluation of blunt renal trauma. *J Urol*. 1998;160(6 Pt 1):1979–1981.

Buckley JC, McAninch JW. Pediatric renal injuries: management guidelines from a 25-year experience. *J Urol*. 2004;172(2):687–690.

Buckley JC, McAninch JW. Selective management of isolated and nonisolated grade IV renal injuries. *J Urol*. 2006;176(6 Pt 1):2498–2502.

Busch FM, Chenault OW, Zinner NR, et al. Urological aspects of Vietnam War injuries. *J Urol*. 1967;97(4):763–765.

Campbell EW, Filderman PS, Jacobs SC. Ureteral injury due to blunt and penetrating trauma. *Urology*. 1992;40(3):216–220.

Carlton CE, Scott R, Guthrie AG. The initial management of ureteral injuries: a report of 78 cases. *J Urol*. 1971;105(3):335–340.

Carroll PR, Klosterman P, McAninch JW. Early vascular control for renal trauma: a critical review. *J Urol*. 1989;141(4):826–829.

Carroll PR, McAninch JW. Operative indications in penetrating renal trauma. *J Trauma*. 1985;25(7):587–593.

Cass AS. Blunt renal pelvic and ureteral injury in multiple-injured patients. *Urology*. 1983;22(3):268–270.

Castillo OA, Sanchez-Salas R, Vitagliano G, et al. Laparoscopy-assisted ureter interposition by ileum. *J Endourol*. 2008;22(4):687–692.

Chahin F, Dwivedi AJ, Paramesh A, et al. The implications of lighted ureteral stenting in laparoscopic colectomy. *JSLS*. 2002;6(1):49–52.

Chandhoke PS, McAninch JW. Detection and significance of microscopic hematuria in patients with blunt renal trauma. *J Urol*. 1988;140(1):16–18.

Chang R, Marshall FF. Management of ureteroscopic injuries. *J Urol*. 1987;137(6):1132–1135.

Chopra S, Metcalfe C, Satkunasivam R, et al. Initial series of four-arm robotic completely intracorporeal ileal ureter. *J Endourol*. 2016;30(4):395–399.

Chou MT, Wang CJ, Lien RC. Prophylactic ureteral catheterization in gynecologic surgery: a 12-year randomized trial in a community hospital. *Int Urogynecol J Pelvic Floor Dysfunct*. 2009;20(6):689–693.

Cimbanassi S, Chiara O, Leppaniemi A, et al. Nonoperative management of abdominal solid organ injuries following blunt trauma in adults: results from an international consensus conference. *J Trauma Acute Care Surg*. 2018;84(3):517–531.

Cinman NM, McAninch JW, Porten SP, et al. Gunshot wounds to the lower urinary tract: a single-institution experience. *J Trauma Acute Care Surg*. 2013;74(3):725–730 [discussion 30–31].

Coakley KM, Kasten KR, Sims SM, et al. Prophylactic ureteral catheters for colectomy: a national surgical quality improvement program-based analysis. *Dis Colon Rectum*. 2018;61(1):84–88.

Coburn M. Damage control for urologic injuries. *Surg Clin North Am*. 1997;77(4):821–834.

Cormio L, Battaglia M, Traficante A, et al. Endourological treatment of ureteric injuries. *Br J Urol*. 1993;72(2):165–168.

Corriere JN, McAndrew JD, Benson GS. Intraoperative decision-making in renal trauma surgery. *J Trauma*. 1991;31(10):1390–1392.

Cosgrove MD, Mendez R, Morrow JW. Traumatic renal arteriovenous fistula: report of 12 cases. *J Urol*. 1973;110(6):627–631.

Cowan NG, Banerji JS, Johnston RB, et al. Renal autotransplantation: 27-year experience at 2 institutions. *J Urol*. 2015;194(5):1357–1361.

Cruikshank SH. Surgical method of identifying the ureters during total vaginal hysterectomy. *Obstet Gynecol*. 1986;67(2):277–280.

Dagenais J, Leow JJ, Haider AH, et al. Contemporary trends in the management of renal trauma in the United States: a national community hospital population-based analysis. *Urology*. 2016;97:98–104.

Dandolu V, Mathai E, Chatwani A, et al. Accuracy of cystoscopy in the diagnosis of ureteral injury in benign gynecologic surgery. *Int Urogynecol J Pelvic Floor Dysfunct*. 2003;14(6):427–431.

Daniel O, Shackman R. The blood supply of the human ureter in relation to ureterocolic anastomosis. *Br J Urol*. 1952;24(4):334–343.

Davis P, Bultitude MF, Koukounaras J, et al. Assessing the usefulness of delayed imaging in routine followup for renal trauma. *J Urol*. 2010;184(3):973–977.

Dinlenc CZ, Gerber E, Wagner JR. Ureteral reimplantation during robot assisted laparoscopic radical prostatectomy. *J Urol*. 2004;172(3):905.

Dowling RA, Corriere JN, Sandler CM. Iatrogenic ureteral injury. *J Urol*. 1986;135(5):912–915.

Dugi DD, Morey AF, Gupta A, et al. American Association for the Surgery of Trauma grade 4 renal injury substratification into grades 4a (low risk) and 4b (high risk). *J Urol*. 2010;183(2):592–597.

Eisenberg ML, Lee KL, Zumrutbas AE, et al. Long-term outcomes and late complications of laparoscopic nephrectomy with renal autotransplantation. *J Urol*. 2008;179(1):240–243.

El-Abd AS, Suliman MG, Abo Farha MO, et al. The development of ureteric strictures after ureteroscopic treatment for ureteric calculi: a long-term study at two academic centres. *Arab J Urol*. 2014;12(2):168–172.

Elliott SP, McAninch JW. Ureteral injuries from external violence: the 25-year experience at San Francisco General Hospital. *J Urol*. 2003;170(4 Pt 1):1213–1216.

Elliott SP, McAninch JW. Ureteral injuries: external and iatrogenic. *Urol Clin North Am*. 2006;33(1):55–66 [vi].

Elliott SP, Olweny EO, McAninch JW. Renal arterial injuries: a single center analysis of management strategies and outcomes. *J Urol*. 2007;178(6):2451–2455.

Eswara JR, Gervais DA, Mueller PR, et al. Renal radiofrequency ablation with pyeloperfusion. *Int J Urol*. 2015;22(1):131–132.

Eswara JR, Raup VT, Potretzke AM, et al. Outcomes of iatrogenic genitourinary injuries during colorectal surgery. *Urology*. 2015;86(6):1228–1233.

Evans RA, Smith MJ. Violent injuries to the upper ureter. *J Trauma*. 1976;16(7):558–561.

Federle MP, Jeffrey RB. Hemoperitoneum studied by computed tomography. *Radiology*. 1983;148(1):187–192.

Fifer GL, Raynor MC, Selph P, et al. Robotic ureteral reconstruction distal to the ureteropelvic junction: a large single institution clinical series with short-term follow up. *J Endourol*. 2014;28(12):1424–1428.

Flam TA, Malone MJ, Roth RA. Complications of ureteroscopy. *Urol Clin North Am*. 1988;15(2):167–181.

Fuchs ME, Beecroft N, Dajusta DG, et al. Is delayed phase computed tomography imaging necessary after blunt renal trauma in children? *Urology*. 2018;113:187–191.

Gayer G, Zissin R, Apter S, et al. Urinomas caused by ureteral injuries: CT appearance. *Abdom Imaging*. 2002;27(1):88–92.

Gellhaus PT, Bhandari A, Monn MF, et al. Robotic management of genitourinary injuries from obstetric and gynaecological operations: a multi-institutional report of outcomes. *BJU Int*. 2015;115(3):430–436.

Ghali AM, El Malik EM, Ibrahim AI, et al. Ureteric injuries: diagnosis, management, and outcome. *J Trauma*. 1999;46(1):150–158.

Gill IS, Savage SJ, Senagore AJ, et al. Laparoscopic ileal ureter. *J Urol*. 2000;163(4):1199–1202.

Glass AS, Appa AA, Kenfield SA, et al. Selective angioembolization for traumatic renal injuries: a survey on clinician practice. *World J Urol*. 2014;32(3):821–827.

Goldblatt H, Lynch J, Hanzal RF, et al. Studies on experimental hypertension: I. The production of persistent elevation of systolic blood pressure by means of renal ischemia. *J Exp Med*. 1934;59(3):347–379.

Gonzalez RP, Falimirski M, Holevar MR, et al. Surgical management of renal trauma: is vascular control necessary. *J Trauma*. 1999;47(6):1039–1042.

Goodman DN, Saibil EA, Kodama RT. Traumatic intimal tear of the renal artery treated by insertion of a Palmaz stent. *Cardiovasc Intervent Radiol*. 1998;21(1):69–72.

Grainger DA, Soderstrom RM, Schiff SF, et al. Ureteral injuries at laparoscopy: insights into diagnosis, management, and prevention. *Obstet Gynecol*. 1990;75(5):839–843.

Guyot R, Arnoux V, Descotes JL, et al. [Management of intraparenchymal pseudoaneurysm after blunt renal trauma: results from a series of 325 patients]. *Prog Urol*. 2017;27(3):190–199.

Haas CA, Dinchman KH, Nasrallah PF, et al. Traumatic renal artery occlusion: a 15-year review. *J Trauma*. 1998;45(3):557–561.

Hampson LA, Radadia KD, Odisho AY, et al. Conservative management of high-grade renal trauma does not lead to prolonged hospital stay. *Urology*. 2018;115:92–95.

Hardee MJ, Lowrance W, Stevens MH, et al. Process improvement in trauma: compliance with recommended imaging evaluation in the diagnosis of high-grade renal injuries. *J Trauma Acute Care Surg*. 2013;74(2):558–562.

Härkki-Siren P, Sjöberg J, Kurki T. Major complications of laparoscopy: a follow-up Finnish study. *Obstet Gynecol*. 1999;94(1):94–98.

Hatch KD, Parham G, Shingleton HM, et al. Ureteral strictures and fistulae following radical hysterectomy. *Gynecol Oncol*. 1984;19(1):17–23.

Hick EJ, Morey AF, Harris RA, et al. Gelatin matrix treatment of complex renal injuries in a porcine model. *J Urol*. 2005;173(5):1801–1804.

Hirshberg A, Wall MJ, Mattox KL. Planned reoperation for trauma: a two year experience with 124 consecutive patients. *J Trauma*. 1994;37(3):365–369.

Hoch WH, Kursh ED, Persky L. Early, aggressive management of intraoperative ureteral injuries. *J Urol*. 1975;114(4):530–532.

Hotaling JM, Sorensen MD, Smith TG, et al. Analysis of diagnostic angiography and angioembolization in the acute management of renal trauma using a national data set. *J Urol*. 2011;185(4):1316–1320.

Hotaling JM, Wang J, Sorensen MD, et al. A national study of trauma level designation and renal trauma outcomes. *J Urol*. 2012;187(2):536–541.

Huffman JL. Ureteroscopic injuries to the upper urinary tract. *Urol Clin North Am*. 1989;16(2):249–254.

Inoue S, Koizumi J, Iino M, et al. Self-expanding metallic stent placement for renal artery dissection due to blunt trauma. *J Urol*. 2004;171(1):347–348.

Jang TL, Matschke HM, Rubenstein JN, et al.

Pyeloureterostomy with interposition of the appendix. *J Urol*. 2002;168(5):2106–2107.

Jeon HJ, Yoon JS, Cho SS, et al. Indigo carmine-induced hypotension in patients undergoing general anaesthesia. *Singapore Med J*. 2012;53(3):e57–e59.

Johnson DB, Pearle MS. Complications of ureteroscopy. *Urol Clin North Am*. 2004;31(1):157–171.

Kaufman JJ. Ureteral injury from ureteroscopic stone manipulation. *Urology*. 1984;23(3):267–269.

Kawamura J, Tani M, Sumida K, et al. The use of transureteroureterostomy during ureteral reconstruction for advanced primary or recurrent pelvic malignancy in the era of multimodal therapy. *Int J Colorectal Dis*. 2017;32(1):135–138.

Kawashima A, Sandler CM, Corl FM, et al. Imaging of renal trauma: a comprehensive review. *Radiographics*. 2001;21(3):557–574.

Kawashima A, Sandler CM, Corriere JN, et al. Ureteropelvic junction injuries secondary to blunt abdominal trauma. *Radiology*. 1997;205(2):487–492.

Keihani S, Xu Y, Presson AP, et al. Contemporary management of high-grade renal trauma: results from the American Association for the Surgery of Trauma Genitourinary Trauma Study. *J Trauma Acute Care Surg*. 2018;84(3):418–425.

Kerns DB, Darcy MD, Baumann DS, et al. Autologous vein-covered stent for the endovascular management of an iliac artery-ureteral fistula: case report and review of the literature. *J Vasc Surg*. 1996;24(4):680–686.

Knudson MM, Harrison PB, Hoyt DB, et al. Outcome after major renovascular injuries: a Western trauma association multicenter report. *J Trauma*. 2000;49(6):1116–1122.

Kocot A, Kalogirou C, Vergho D, et al. Long-term results of ileal ureteric replacement: a 25-year single-centre experience.

BJU Int. 2017;120(2):273–279.

Kozar RA, Crandell M, Shanmuganathan K, et al. Organ injury scaling 2018 update: spleen, liver and kidney. *J Trauma*. 2018;85(6):1119–1122.

Kriegmair M, Schmeller N. Paraureteral calculi caused by ureteroscopic perforation. *Urology*. 1995;45(4):578–580.

Kuan JK, Kaufman R, Wright JL, et al. Renal injury mechanisms of motor vehicle collisions: analysis of the crash injury research and engineering network data set. *J Urol*. 2007;178(3 Pt 1):935–940.

Kunkle DA, Kansas BT, Pathak A, et al. Delayed diagnosis of traumatic ureteral injuries. *J Urol*. 2006;176(6 Pt 1):2503–2507.

Kurtz MP, Eswara JR, Vetter JM, et al. Blunt abdominal trauma from motor vehicle collisions from 2007 to 2011: renal injury probability and severity in children versus adults. *J Urol*. 2017;197(3 Pt 2):906–910.

Kyzer S, Gordon PH. The prophylactic use of ureteral catheters during colorectal operations. *Am Surg*. 1994;60(3):212–216.

Lanchon C, Fiard G, Arnoux V, et al. High grade blunt renal trauma: predictors of surgery and long-term outcomes of conservative management. A Prospective Single Center Study. *J Urol*. 2016;195(1):106–111.

Lang EK. Antegrade ureteral stenting for dehiscence, strictures, and fistulae. *Am J Roentgenol*. 1984;143(4):795–801.

Lee YS, Hah YS, Kim MJ, et al. Factors associated with complications of the ureteral stump after proximal ureteroureterostomy. *J Urol*. 2012;188(5):1890–1894.

Leff EI, Groff W, Rubin RJ, et al. Use of ureteral catheters in colonic and rectal surgery. *Dis Colon Rectum*. 1982;25(5):457–460.

Léonard F, Fotso A, Borghese B, et al. Ureteral complications from laparoscopic hysterectomy indicated for benign uterine pathologies: a 13-year experience in a continuous series of 1300 patients. *Hum Reprod*. 2007;22(7):2006–2011.

Li J, Chen Z, Zhu Q, et al. Early repair of pelvic and abdominal nonurological surgery-induced iatrogenic ureteral injuries in three distinct waiting-for-repair time periods. *Am Surg*. 2012;78(11):1270–1275.

Liapis A, Bakas P, Giannopoulos V, et al. Ureteral injuries during gynecological surgery. *Int Urogynecol J Pelvic Floor Dysfunct*. 2001;12(6):391–393.

Lloyd GL, Slack S, McWilliams KL, et al. Renal trauma from recreational accidents manifests different injury patterns than urban renal trauma. *J Urol*. 2012;188(1):163–168.

Mandal AK, Sharma SK, Vaidyanathan S, et al. Ureterovaginal fistula: summary of 18 years' experience. *Br J Urol*. 1990;65(5):453–456.

Marcelissen TA, Den Hollander PP, Tuytten TR, et al. Incidence of iatrogenic ureteral injury during open and laparoscopic colorectal surgery: a single center experience and review of the literature. *Surg Laparosc Endosc Percutan Tech*. 2016;26(6):513–515.

Marekovic Z, Derezic D, Krhen I, et al. Urogenital war injuries. *Mil Med*. 1997;162(5):346–348.

Marien T, Bjurlin MA, Wynia B, et al. Outcomes of robotic-assisted laparoscopic upper urinary tract reconstruction: 250 consecutive patients. *BJU Int*. 2015;116(4):604–611.

Master VA, McAninch JW. Operative management of renal injuries: parenchymal and vascular. *Urol Clin North Am*. 2006;33(1):21–31 [v–vi].

Matlaga BR, Shah OD, Hart LJ, et al. Ileal ureter substitution: a contemporary series. *Urology*. 2003;62(6):998–1001.

Matlaga BR, Shah OD, Singh D, et al. Ureterocalicostomy: a contemporary experience. *Urology*. 2005;65(1):42–44.

Matthews LA, Smith EM, Spirnak JP. Nonoperative treatment of major blunt renal lacerations with urinary extravasation. *J Urol*. 1997;157(6):2056–2058.

May AM, Darwish O, Dang B, et al. Successful nonoperative management of high-grade blunt renal injuries. *Adv Urol*. 2016;2016:3568076.

McAninch JW, Carroll PR, Armenakas NA, et al. Renal gunshot wounds: methods of salvage and reconstruction. *J Trauma*. 1993;35(2):279–283.

McAninch JW, Carroll PR, Klosterman PW, et al. Renal reconstruction after injury. *J Urol*. 1991;145(5):932–937.

McAninch JW, Carroll PR. Renal exploration after trauma. Indications and reconstructive techniques. *Urol Clin North Am*. 1989;16(2):203–212.

McAninch JW, Carroll PR. Renal trauma: kidney preservation through improved vascular control—a refined approach. *J Trauma*. 1982;22(4):285–290.

McGinty DM, Mendez R. Traumatic ureteral injuries with delayed recognition. *Urology*. 1977;10(2):115–117.

Medina D, Lavery R, Ross SE, et al. Ureteral trauma: preoperative studies neither predict injury nor prevent missed injuries. *J Am Coll Surg*. 1998;186(6):641–644.

Mee SL, McAninch JW, Robinson AL, et al. Radiographic assessment of renal trauma: a 10-year prospective study of patient selection. *J Urol*. 1989;141(5):1095–1098.

Mee SL, McAninch JW. Indications for radiographic assessment in suspected renal trauma. *Urol Clin North Am*. 1989;16(2):187–192.

Memon S, Cheung BY. Long-term results of blunt traumatic renal artery dissection treated by endovascular stenting. *Cardiovasc Intervent Radiol*. 2005;28(5):668–669.

Menderes G, Clark LE, Azodi M. Incidental ureteral injury and repair during robotic-assisted total laparoscopic hysterectomy. *J Minim Invasive Gynecol*. 2015;22(3):320.

Meng MV, Brandes SB, McAninch JW. Renal trauma: indications and techniques for surgical exploration. *World J Urol*. 1999;17(2):71–77.

Michaels JP. Study of ureteral blood supply and its bearing on necrosis of the ureter following the Wertheim operation. *Surg Gynecol Obstet*. 1948;86(1):36–44.

Middleton RG. Routine use of the psoas hitch in ureteral reimplantation. *J Urol*. 1980;123(3):352–354.

Miller KS, McAninch JW. Radiographic assessment of renal trauma: our 15-year experience. *J Urol*. 1995;154(2 Pt 1):352–355.

Minervini A, Boni G, Salinitri G, et al. Evaluation of renal function and upper urinary tract morphology in the ileal orthotopic neobladder with no antireflux mechanism. *J Urol*. 2005;173(1):144–147.

Monstrey SJ, Beerthuizen GI, vander Werken C, et al. Renal trauma and hypertension. *J Trauma*. 1989;29(1):65–70.

Moolman C, Navsaria PH, Lazarus J, et al. Nonoperative management of penetrating kidney injuries: a prospective audit. *J Urol*. 2012;188(1):169–173.

Moore EE, Shackford SR, Pachter HL, et al. Organ injury scaling: spleen, liver, and kidney. *J Trauma*. 1989;29(12):1664–1666.

Morey AF, Brandes S, Dugi DD, et al. Urotrauma: AUA guideline. *J Urol*. 2014;192(2):327–335.

Morey AF, McAninch JW, Tiller BK, et al. Single shot intraoperative excretory urography for the immediate evaluation of renal trauma. *J Urol*. 1999;161(4):1088–1092.

Mufarrij PW, Shah OD, Berger AD, et al. Robotic reconstruction of the upper urinary tract. *J Urol*. 2007;178(5):2002–2005.

Mulligan JM, Cagiannos I, Collins JP, et al. Ureteropelvic junction disruption secondary to blunt trauma: excretory phase imaging (delayed films) should help prevent a missed diagnosis. *J Urol*. 1998;159(1):67–70.

Mure PY, Mollard P, Mouriquand P. Transureteroureterostomy in childhood and adolescence: long-term results in 69 cases. *J Urol*. 2000;163(3):946–948.

Nackley AC, Yeko TR. Ureteral displacement associated with pelvic peritoneal defects and endometriosis. *J Am Assoc Gynecol Laparosc*. 2000;7(1):131–133.

Nash PA, Bruce JE, McAninch JW. Nephrectomy for traumatic renal injuries. *J Urol*. 1995;153(3 Pt 1):609–611.

Nezhat F, Nezhat CH, Admon D, et al. Complications and results of 361 hysterectomies performed at laparoscopy. *J Am Coll Surg*. 1995;180(3):307–316.

Nicolaisen GS, McAninch JW, Marshall GA, et al. Renal trauma: re-evaluation of the indications for radiographic assessment. *J Urol*. 1985;133(2):183–187.

Nuss GR, Morey AF, Jenkins AC, et al. Radiographic predictors of need for angiographic embolization after traumatic renal injury. *J Trauma*. 2009;67(3):578–582.

Oh BR, Kwon DD, Park KS, et al. Late presentation of ureteral injury after laparoscopic surgery. *Obstet Gynecol*. 2000;95(3):337–339.

Oosthuizen GV, Weale R, Kong VY, et al. The effect of a concomitant renal injury on the outcome of colonic trauma. *Am J Surg*. 2018;216(2):230–234.

Otsuka H, Sato T, Sakurai K, et al. Use of interventional radiology as initial hemorrhage control to improve outcomes for potentially lethal multiple blunt injuries. *Injury*. 2018;49(2):226–229.

Ou CS, Huang IA, Rowbotham R. Laparoscopic ureteroureteral anastomosis for repair of ureteral injury involving stricture. *Int Urogynecol J Pelvic Floor Dysfunct*. 2005;16(2):155–157.

Paick JS, Hong SK, Park MS, et al. Management of postoperatively detected iatrogenic lower ureteral injury: should ureteroureterostomy really be abandoned? *Urology*. 2006;67(2):237–241.

Palmer JK, Benson GS, Corriere JN. Diagnosis and initial management of urological injuries associated with 200 consecutive pelvic fractures. *J Urol*. 1983;130(4):712–714.

Palmer LS, Rosenbaum RR, Gershbaum MD, et al. Penetrating ureteral trauma at an urban trauma center: 10-year experience. *Urology*. 1999;54(1):34–36.

Parpala-Spårman T, Paananen I, Santala M, et al. Increasing numbers of ureteric injuries after the introduction of laparoscopic surgery. *Scand J Urol Nephrol*. 2008;42(5):422–427.

Patel RC, Newman RC. Ureteroscopic management of ureteral and ureteroenteral strictures. *Urol Clin North Am*. 2004;31(1):107–113.

Pereira BM, Ogilvie MP, Gomez-Rodriguez JC, et al. A review of ureteral injuries after external trauma. *Scand J Trauma Resusc Emerg Med*. 2010;18:6.

Petersen SS, Doe S, Rubinfeld I, et al. Rate of urologic injury with robotic hysterectomy. *J Minim Invasive Gynecol*. 2018;25(5):867–871.

Phan QB, Mourey E, Estivalet L, et al. Reliability and reproducibility of the American Association for the Surgery of Trauma scaling for renal injury and impact on radiologic follow-up. *Prog Urol*. 2018;28(1):12–17.

Piaggio LA, González R. Laparoscopic transureteroureterostomy: a novel approach. *J Urol*. 2007;177(6):2311–2314.

Pitts JC, Peterson NE. Penetrating injuries of the ureter. *J Trauma*. 1981;21(11):978–982.

Presti JC, Carroll PR, McAninch JW. Ureteral and renal pelvic injuries from external trauma: diagnosis and management. *J*

Trauma. 1989;29(3):370–374.

Pursifull NF, Morris MS, Harris RA, et al. Damage control management of experimental grade 5 renal injuries: further evaluation of FloSeal gelatin matrix. *J Trauma*. 2006;60(2):346–350.

Rainwater LM, Leary FJ, Rife CC. Transureteroureterostomy with cutaneous ureterostomy: a 25-year experience. *J Urol*. 1991;146(1):13–15.

Reggio E, Richstone L, Okeke Z, et al. Laparoscopic ureteroplasty using on-lay appendix graft. *Urology*. 2009;73(4):928 [e7–10].

Ribeiro S, Reich H, Rosenberg J, et al. The value of intra-operative cystoscopy at the time of laparoscopic hysterectomy. *Hum Reprod*. 1999;14(7):1727–1729.

Richter F, Irwin RJ, Watson RA, et al. Endourologic management of benign ureteral strictures with and without compromised vascular supply. *Urology*. 2000;55(5):652–657.

Riedmiller H, Becht E, Hertle L, et al. Psoas-hitch ureteroneocystostomy: experience with 181 cases. *Eur Urol*. 1984;10(3):145–150.

Romero V, Akpinar H, Smith JJ, et al. Changing patterns in iatrogenic ureteral injuries. *Rev Urol*. 2011;13(4):e179–e183.

Rosen MA, McAninch JW. Management of combined renal and pancreatic trauma. *J Urol*. 1994;152(1):22–25.

Santucci RA, Langenburg SE, Zachareas MJ. Traumatic hematuria in children can be evaluated as in adults. *J Urol*. 2004;171(2 Pt 1):822–825.

Santucci RA, McAninch JW. Diagnosis and management of renal trauma: past, present, and future. *J Am Coll Surg*. 2000;191(4):443–451.

Schapira HE, Li R, Gribetz M, et al. Ureteral injuries during vascular surgery. *J Urol*. 1981;125(3):293–297.

Scott RF, Selzman HM. Complications of nephrectomy: review of 450 patients and a description of a modification of the transperitoneal approach. *J Urol*. 1966;95(3):307–312.

Selikowitz SM. Penetrating high-velocity genitourinary injuries. Part I. Statistics mechanisms, and renal wounds. *Urology*. 1977;9(4):371–376.

Selzman AA, Spirnak JP. Iatrogenic ureteral injuries: a 20-year experience in treating 165 injuries. *J Urol*. 1996;155(3):878–881.

Serafetinides E, Kitrey ND, Djakovic N, et al. Review of the current management of upper urinary tract injuries by the EAU Trauma Guidelines Panel. *Eur Urol*. 2015;67(5):930–936.

Serkin FB, Soderdahl DW, Hernandez J, et al. Combat urologic trauma in US military overseas contingency operations. *J Trauma*. 2010;69(Suppl 1):S175–S178.

Shaaban AA, Abdel-Latif M, Mosbah A, et al. A randomized study comparing an antireflux system with a direct ureteric anastomosis in patients with orthotopic ileal neobladders. *BJU Int*. 2006;97(5):1057–1062.

Shariat SF, Jenkins A, Roehrborn CG, et al. Features and outcomes of patients with grade IV renal injury. *BJU Int*. 2008;102(6):728–733 [discussion 33].

Shariat SF, Roehrborn CG, Karakiewicz PI, et al. Evidence-based validation of the predictive value of the American Association for the Surgery of Trauma kidney injury scale. *J Trauma*. 2007;62(4):933–939.

Shariat SF, Trinh QD, Morey AF, et al. Development of a highly accurate nomogram for prediction of the need for exploration in patients with renal trauma. *J Trauma*. 2008;64(6):1451–1458.

Sheikh FA, Khubchandani IT. Prophylactic ureteric catheters in colon surgery–how safe are they? Report of three cases. *Dis Colon Rectum*. 1990;33(6):508–510.

Siegel C. Urinomas caused by ureteral injuries: CT appearance. *J Urol*. 2002;168(4 Pt 1):1644.

Singal RK, Denstedt JD, Razvi HA, et al. Holmium:YAG laser endoureterotomy for treatment of ureteral stricture. *Urology*. 1997;50(6):875–880.

Siram SM, Gerald SZ, Greene WR, et al. Ureteral trauma: patterns and mechanisms of injury of an uncommon condition. *Am J Surg*. 2010;199(4):566–570.

Smith J, Caldwell E, D’Amours S, et al. Abdominal trauma: a disease in evolution. *ANZ J Surg*. 2005;75(9):790–794.

St Lezin MA, Stoller ML. Surgical ureteral injuries. *Urology*. 1991;38(6):497–506.

Steers WD, Corriere JN, Benson GS, et al. The use of indwelling ureteral stents in managing ureteral injuries due to external violence. *J Trauma*. 1985;25(10):1001–1003.

Stolzenburg JU, Rai BP, Do M, et al. Robot-assisted technique for Boari flap ureteric reimplantation: replicating the techniques of open surgery in robotics. *BJU Int*. 2016;118(3):482–484.

Sugarbaker PH, Gutman M, Verghese M. Transureteroureterostomy: an adjunct to the management of advanced primary and recurrent pelvic malignancy. *Int J Colorectal Dis*. 2003;18(1):40–44.

Sugihara T, Yasunaga H, Horiguchi H, et al. Management trends, angioembolization performance and multiorgan injury indicators of renal trauma from Japanese administrative claims database. *Int J Urol*. 2012;19(6):559–563.

Sujenthiran A, Elshout PJ, Veskimae E, et al. Is nonoperative management the best first-line option for high-grade renal trauma? A systematic review. *Eur Urol Focus*. 2019;5(2):290–300.

Symmonds RE. Ureteral injuries associated with gynecologic surgery: prevention and management. *Clin Obstet Gynecol*.

1976;19(3):623–644.

Tasian GE, Aaronson DS, McAninch JW. Evaluation of renal function after major renal injury: correlation with the American Association for the Surgery of Trauma Injury Scale. *J Urol*. 2010;183(1):196–200.

Toporoff B, Sclafani S, Scalea T, et al. Percutaneous antegrade ureteral stenting as an adjunct for treatment of complicated ureteral injuries. *J Trauma*. 1992;32(4):534–538.

Townsend M, DeFalco AJ. Absence of ureteral opacification below ureteral disruption: a sentinel CT finding. *Am J Roentgenol*. 1995;164(1):253–254.

Traxer O, Thomas A. Prospective evaluation and classification of ureteral wall injuries resulting from insertion of a ureteral access sheath during retrograde intrarenal surgery. *J Urol*. 2013;189(2):580–584.

Tsai CK, Taylor FC, Beaghler MA. Endoscopic ureteroureterostomy: long-term followup using a new technique. *J Urol*. 2000;164(2):332–335.

Ubrig B, Waldner M, Roth S. Reconstruction of ureter with transverse retubularized colon segments. *J Urol*. 2001;166(3):973–976.

Umbreit EC, Routh JC, Husmann DA. Nonoperative management of nonvascular grade IV blunt renal trauma in children: meta-analysis and systematic review. *Urology*. 2009;74(3):579–582.

Vakili B, Chesson RR, Kyle BL, et al. The incidence of urinary tract injury during hysterectomy: a prospective analysis based on universal cystoscopy. *Am J Obstet Gynecol*. 2005;192(5):1599–1604.

Vallancien G, Cathelineau X, Baumert H, et al. Complications of transperitoneal laparoscopic surgery in urology: review of 1,311 procedures at a single center. *J Urol*. 2002;168(1):23–26.

van den Bergh RC, Moll FL, de Vries JP, et al. Arterioureteral fistulas: unusual suspects-systematic review of 139 cases. *Urology*. 2009;74(2):251–255.

van der Wilden GM, Velmahos GC, Joseph DK, et al. Successful nonoperative management of the most severe blunt renal injuries: a multicenter study of the research consortium of New England Centers for Trauma. *J Am Med Assoc Surg*. 2013;148(10):924–931.

Velmahos GC, Degiannis E, Wells M, et al. Penetrating ureteral injuries: the impact of associated injuries on management. *Am Surg*. 1996;62(6):461–468.

Verduyckt FJ, Heesakkers JP, Debruyne FM. Long-term results of ileum interposition for ureteral obstruction. *Eur Urol*. 2002;42(2):181–187.

Voelzke BB, McAninch JW. Renal gunshot wounds: clinical management and outcome. *J Trauma*. 2009;66(3):593–600.

Waldner M, Hertle L, Roth S. Ileal ureteral substitution in reconstructive urological surgery: is an antireflux procedure necessary? *J Urol*. 1999;162(2):323–326.

Wang SY, Liao CH, Fu CY, et al. An outcome prediction model for exsanguinating patients with blunt abdominal trauma after damage control laparotomy: a retrospective study. *BMC Surg*. 2014;14:24.

Wenzler DL, Kim SP, Rosevear HM, et al. Success of ureteral stents for intrinsic ureteral obstruction. *J Endourol*. 2008;22(2):295–299.

Wessells H, McAninch JW, Meyer A, et al. Criteria for nonoperative treatment of significant penetrating renal lacerations. *J Urol*. 1997;157(1):24–27.

Wessells H, McAninch JW. Effect of colon injury on the management of simultaneous renal trauma. *J Urol*. 1996;155(6):1852–1856.

Wiesner C, Thüroff JW. Techniques for uretero-intestinal

reimplantation. *Curr Opin Urol*. 2004;14(6):351–355.
Witters S, Cornelissen M, Vereecken R. Iatrogenic ureteral injury: aggressive or conservative treatment. *Am J Obstet Gynecol*. 1986;155(3):582–584.
Wong JMK, Bortoletto P, Tolentino J, et al. Urinary tract injury in gynecologic laparoscopy for benign indication: a systematic review. *Obstet Gynecol*. 2018;131(1):100–108.
Yeung LL, Brandes SB. Contemporary management of renal trauma: differences between urologists and trauma surgeons. *J Trauma Acute Care Surg*. 2012;72(1):68–75.
Yeung L, Brandes S. The ultimate in genitourinary damage control: minimally invasive management of synchronous grade 4 and 5 bilateral penetrating renal injuries. *J Trauma*. 2011;70(5):1299.
Zafar SN, Ahaghotu CA, Libuit L, et al. Ureteral injury after laparoscopic versus open colectomy. *JSLS*. 2014;18(3).
Zhao LC, Weinberg AC, Lee Z, et al. Robotic ureteral reconstruction using buccal mucosa grafts: a multi-institutional experience. *Eur Urol*. 2017 [Epub ahead of print].
Zinman LN, Vanni AJ. Surgical management of urologic trauma and iatrogenic injuries. *Surg Clin North Am*. 2016;96(3):425–439.

PART X

Urinary Lithiasis and Endourology

OUTLINE

91 Urinary Lithiasis Etiology, Epidemiology, and Pathogenesis
92 Evaluation and Medical Management of Urinary Lithiasis
93 Strategies for Nonmedical Management of Upper Urinary Tract Calculi
94 Surgical Management for Upper Urinary Tract Calculi
95 Lower Urinary Tract Calculi

91

Urinary Lithiasis

Etiology, Epidemiology, and Pathogenesis

Margaret S. Pearle MD, PhD, Jodi A. Antonelli MD, Yair Lotan MD

Although stone disease is one of the most common afflictions of modern society, it has been described since antiquity. With Westernization of global culture, however, the site of stone formation has migrated from the lower to the upper urinary tract, and the disease once limited to men is increasingly gender blind. Revolutionary advances in the minimally invasive and noninvasive management of stone disease over the past few decades have greatly facilitated stone removal. However, surgical treatments, although they remove the offending stone, do little to alter the course of the disease. Indeed, the overall estimated annual expenditure for individuals with insurance claims corresponding to a diagnosis of nephrolithiasis exceeded $10 billion in 2012, reflecting a nearly fivefold increase since 2000 (Litwin et al., 2005). Given the frequency with which stones recur, the development of a medical prophylactic program to prevent stone recurrences is desirable. To this end, a thorough understanding of the cause, epidemiology, and pathogenesis of urinary tract stone disease is necessary.

Epidemiology of Renal Calculi

The lifetime prevalence of kidney stone disease is estimated at 1% to 15%, varying according to age, gender, race, and geographic location. Around the world prevalence rates vary ranging from 7% to 13% in North America, 5% to 9% in Europe, and 1% to 5% in Asia (Sorokin et al., 2017). **Data from the National Health and Nutrition Examination Survey (NHANES) data sets have demonstrated a linear increase in the prevalence of kidney stones for US adults over the last several decades** (Stamatelou et al., 2003)**, with the most recent prevalence estimate of 8.8% for the period 2007 to 2010** (Scales et al., 2012). Tasian et al. (2016) examined temporal trends in nephrolithiasis incidence among a subset of the US population and found a 16% rise in annual stone incidence (from 206 to 239 per 100,000 persons) between 1997 and 2012.

The rise in kidney stone prevalence is a global phenomenon. Data from five European countries, Japan, and the United States showed that the incidence and prevalence of stone disease has been increasing over time around the world (Romero et al., 2010). In a unique data set derived from a series of nationwide surveys conducted by the Japanese Society on Urolithiasis Research, Yasui et al. (2008) found an increase in the age-adjusted annual incidence of first-time stone events from 54.2 per 100,000 in 1965 to 114.3 per 100,000 in 2005. Although the incidence increased in all age groups and in men and women, the age of peak incidence shifted in men from 20 to 49 years in 1965 to 30 to 69 years in 2005 and in women from 20 to 29 years in 1965 to 50 to 79 years in 2005. A population-based analysis from Taiwan using the Longitudinal Health Insurance Database 2005 contains data on all medical benefit claims from 1997 to 2010 for 1 million beneficiaries randomly chosen from the 2005 enrollment file. This analysis showed that the prevalence of stone disease overall was 7.4% (5.8% in women and 9.0% in men), with an overall peak prevalence of 19.4% in 60- to 69-year-old adults (Huang et al., 2013). A similar population-based study in Korea showed that the lifetime prevalence of kidney stones was 3.5% (1.8% in women and 6% in men) (Bae et al., 2014).

It has been suggested that the rise in stone incidence and prevalence seen in the United States and worldwide can be attributed in part to a rise in the detection of asymptomatic calculi through increased use of radiographic imaging, particularly computed tomography (CT) (Boyce et al., 2010; Edvardsson et al., 2013). Edvardsson et al. (2013) identified 5945 incident stone formers in the Icelandic population from 1985 to 2008 and found that the annual incidence of stones increased significantly from 108 per 100,000 in the first 5 years of the study to 138 per 100,000 through the remainder of the study interval ($P < 0.001$). However, they found that the annual incidence of symptomatic stones did not increase significantly, despite significant increases in the incidence of asymptomatic stones in both genders (from 7 to 24 per 100,000 in men, $P < 0.001$, and from 7 to 21 per 100,000 in women, $P < 0.001$).

Gender

Historically, stone disease affected adult men more commonly than adult women. By a variety of indicators, including inpatient admissions, outpatient office visits, and emergency department visits, men were affected two to three times more often than women (Pearle et al., 2005; Soucie et al., 1994). However, recent evidence suggests that the difference in incidence between men and women is narrowing. Using the National Inpatient Sample data set representing hospital discharges, Scales et al. (2007) found that, although overall population-adjusted discharges for a diagnosis of renal or ureteral calculus increased by only 1.6% from 1997 to 2002, discharges for women increased by 17%, while discharges for men decreased by 8.1%. This trend reflects a change in the ratio of male-to-female discharges from 1.7 in 1997 to 1.3 in 2002. Lieske et al. (2006) used the Rochester Epidemiology Project data (including office, emergency department, and nursing home visits and inpatient and outpatient admissions) to compare the age-adjusted incidence of new symptomatic stone disease from 1970 to 2000 and found similar trends with regard to gender. Although the total rate of symptomatic stone disease for each decade in this time period remained relatively flat ($P = 0.33$), the rate of symptomatic stones in men declined by 1.7% per year (age-adjusted $P = 0.019$) but increased in women by 1.9% per year (age-adjusted $P = 0.064$), resulting in an overall decrease in the male-to-female ratio of symptomatic stones from 3.2 to 1.3 ($P = 0.006$) during this time period. Another, more contemporary geographic epidemiologic database, the Marshfield Epidemiologic Study Area Database, showed a decline in the male-to-female ratio for urolithiasis from 1.4 in 1992 to 1.0 in 2008 (Penniston et al., 2011).

Using NHANES data, Stamatelou et al. (2003) reported a slight decrease in the male-to-female ratio of stone disease, from 1.75 (between 1976 and 1980) to 1.54 (between 1988 and 1994), with the most recent NHANES data (2007–2010) revealing a stone prevalence of 10.6% in men and 7.1% in women for a ratio of 1.49, which is only slightly lower than that reported for 1988 to 1994 (Scales et al., 2012). Tasian et al. (2016) used US census and South Carolina Medical Encounter data from 1997 to 2012 to capture temporal trends in nephrolithiasis incidence among South Carolina residents. After adjusting for age and race, they found that the incidence of nephrolithiasis in women increased by an estimated 15% per 5 years (incidence rate ratio [IRR] 1.15, 95% CI 1.14–1.16) but was stable in men (IRR 0.99, 95% CI 0.98–1.00) during this time period. Furthermore, they found a gender differential in age-specific incidence rates: women showed a 10% to 28% increase per 5 years with the highest increase in 10- to 19-year-olds, while men older than 25 years demonstrated less than 5% change in incidence per 5 years.

Walker et al. (2013) retrospectively analyzed their database of 2799 eligible patients (1983 men and 816 women) at a tertiary care stone clinic in the UK and found a male:female ratio of 2.43 : 1. Furthermore, they noted that the prevalence of risk factors for stone formation differed between men and women in this cohort, with family history, recurrent urinary tract infections, and anatomic abnormalities occurring more commonly in women and gout and bladder outlet obstruction occurring more commonly in men. Likewise, 24-hour urine parameters showed gender disparity, with men excreting greater amounts and having higher urinary concentrations of calcium, oxalate, and uric acid, whereas women had higher citrate levels.

Race and Ethnicity

Racial and ethnic differences in the incidence of stone disease have been observed. **Among US men, Soucie et al.** (1994) **found the highest prevalence of stone disease in whites, followed by Hispanics, Asians, and African-Americans, who had prevalences of 70%, 63%, and 44% of whites, respectively.** Among US women, the prevalence was highest among whites but lowest among Asian women (about half that of whites). According to the most recent NHANES data set, Hispanics (odds ratio [OR] 0.60, 95% CI 0.49–0.73, $P < 0.001$) and black non-Hispanics (OR 0.37, 95% CI 0.28–0.49, $P < 0.001$) were significantly less likely to report a history of stone disease compared with white non-Hispanics (Scales et al., 2012). However, a population-based study of adults and children in South Carolina demonstrated that independent of age and gender the incidence of kidney stones increased an estimated 3% per 5 years in whites

(IRR 1.03, 95% CI, 1.02–1.03) compared with 15% for African-Americans (IRR 1.15, 95% CI 1.14–1.17) (Tasian et al., 2016).

Mente et al. (2007) attempted to identify genetic influences on stone disease by comparing stone prevalence among different ethnic groups residing in the same geographic region. Using Europeans (Caucasians) as the reference group, the relative risk of calcium stones was higher in individuals of Arabic (OR 3.8, 95% CI 2.7–5.2), West Indian (OR 2.5, 95% CI 1.8–3.4), West Asian (OR 2.4, 95% CI 1.7–3.4), and Latin American (OR 1.7, 95% CI 1.2–2.4) origin and significantly lower in those of East Asian (OR 0.4, 95% CI 0.3–0.5) and African (OR 0.7, 95% CI 0.5–0.9) descent. Interestingly, despite differences in prevalence of stone disease according to ethnicity, Maloney et al. (2005) observed a remarkably similar incidence of metabolic abnormalities between white and nonwhite stone formers from the same geographic region, although the distribution of abnormalities differed, suggesting that dietary and other environmental factors may outweigh the contribution of ethnicity in determining stone risk.

The gender distribution of stone disease varies according to race. Sarmina et al. (1987) **noted a male-to-female ratio among whites of 2.3 and among African-Americans of 0.65.** Michaels et al. (1994) also noted a reversal of the male predisposition of stone disease in Hispanics and African-Americans, reporting a male-to-female ratio of 1.8 among Asians, 1.6 among whites, 0.7 among Hispanics, and 0.5 among African-Americans, among a group of patients undergoing shockwave lithotripsy. Tasian et al. (2016) corroborated these findings by observing that the estimated changes in incidence of kidney stone disease over time were greater in African-American women than in African-American men. Dall'era et al. (2005) reviewed emergency department records to identify patients with symptomatic renal or ureteral calculi and found a male-to-female ratio of 1.17 among Hispanic patients compared with 2.05 for white patients.

Age

Historically it was relatively uncommon for stones to occur in individuals under age 20. However, over the last few decades stone disease has been increasing at a rate of 5% to 10% annually in the pediatric population (Bonzo and Tasian, 2017). Routh et al. (2010) queried the Pediatric Health Information System Database, which includes inpatient admissions and emergency and outpatient surgery visits for 42 freestanding US pediatric hospitals, for patients treated for stones between 1999 and 2008. After adjusting for increases in total patient volume over this time period, they found that the portion of pediatric patients with urolithiasis increased from 18.4 per 100,000 in 1999 to 57.0 per 100,000 in 2008, representing a mean annual increase of 10.6% ($P < 0.0001$). Dwyer et al. (2012) analyzed data from the Rochester Epidemiologic Project and identified 207 patients under 18 years of age diagnosed with a symptomatic stone in Olmsted County, Minnesota, between 1984 and 2008. During this 25-year time period the overall incidence of stone disease increased by 4% per year. However, among adolescents 12 to 17 years of age the annual increase was 6%. Although an increase in stone disease among children has been consistently observed, the factors accounting for this trend have not been completely elucidated. It has been suggested that epidemiologic changes, by which risk factors such as obesity and metabolic syndrome that predispose to kidney stones are more often affecting younger generations, may play a role (Alfandary et al., 2018; Kuroczycka-Saniutzcz et al., 2015; Tiwari et al., 2012).

In adults, the incidence of kidney stones peaks in the fourth to sixth decades of life (Johnson et al., 1979; Marshall et al., 1975). Lieske et al. (2006) found a peak incidence in the age group 60 to 69 years in men but observed relatively little change in incidence between 20 and 70 years of age in women, with just a slightly higher incidence in women in the age groups 30 to 39 and 60 to 69.

It has been observed that women show a bimodal distribution of stone disease, demonstrating a second peak in incidence in the sixth decade of life corresponding to the onset of menopause and a fall in estrogen levels (Johnson et al., 1979; Marshall et al., 1975). This finding and the lower incidence of stone disease in women compared with men have been attributed to the protective effect of estrogen against stone formation in premenopausal women because of enhanced renal calcium absorption and reduced bone resorption (McKane et al., 1995; Nordin et al., 1999). Indeed, Heller et al. (2002) identified lower urinary saturation of calcium oxalate and brushite in women compared with men. Moreover, urinary calcium was lower in women than in men until beyond age 50, when it reached equivalence in the two groups. Estrogen-treated postmenopausal women had lower urinary calcium and saturation of calcium oxalate than untreated women.

Fan et al. (1999) found that androgens increased and estrogens decreased urinary and serum oxalate in an experimental rat model, perhaps accounting for the reduced risk of stone formation in women. However, van Aswegen et al. (1989) found lower levels of urinary testosterone in stone formers compared with non–stone-forming control subjects, further confounding the issue.

Geography

The geographic distribution of stone disease tends to roughly follow environmental risk factors; **a higher prevalence of stone disease is found in hot, arid, or dry climates such as the mountains, desert, or tropical areas.** However, genetic factors and dietary influences may outweigh the effects of geography. Finlayson (1974) reviewed several worldwide geographic surveys and found that areas of high stone prevalence included the United States, the British Isles, Scandinavian and Mediterranean countries, northern India and Pakistan, northern Australia, central Europe, portions of the Malay peninsula, and China. Within the United States, Mandel and Mandel (1989a, 1989b) **identified the highest rates of hospital discharges for patients with calcium oxalate stones in the Southeast and for uric acid stones in the East, among the veteran patient population** (Fig. 91.1)**. Soucie et al.** (1994) **found increasing age-adjusted prevalence rates in men and women going from north to south and west to east, with the highest prevalence observed in the Southeast.** After controlling for other risk factors, the authors determined that ambient temperature and sunlight were independently associated with stone prevalence (Soucie et al., 1996). Unfortunately, the multitude of factors that affect stone formation and the considerable variability in documentation and availability of data in some parts of the world limit our ability to accurately capture true variation in incidence and prevalence of stone disease worldwide (Sorokin et al., 2017).

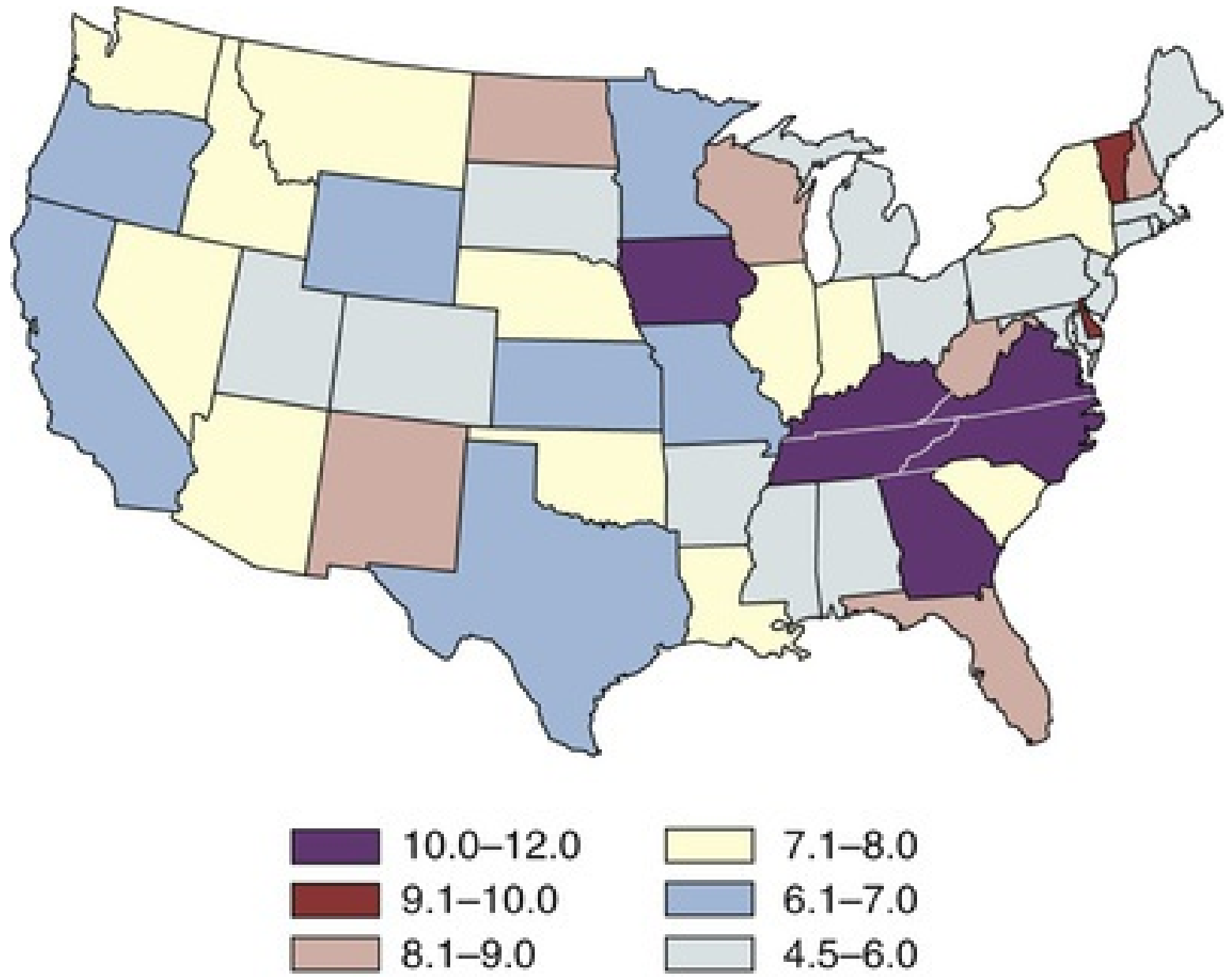

FIG. 91.1 Geographic distribution of urinary tract stone disease in the US veteran population from 1983 to 1986. Data are expressed as urinary tract stone patients per 1000 hospital discharges. (From Mandel NS, Mandel GS: Urinary tract stone disease in the United States veteran population: II. Geographical analysis of variations in composition. *J Urol* 142:1516, 1989.)

Climate

Seasonal variation in stone disease is likely related to temperature by way of fluid losses from perspiration and perhaps by sunlight-induced increases in vitamin D. Prince and Scardino (1960) noted the highest incidence of stone disease in the summer months, July through September, with the peak occurring within 1 to 2 months of maximal mean temperatures (Prince et al., 1956). Using data obtained from the Taiwan National Health Insurance Research Database (1999–2003), Chen et al. (2008) analyzed monthly inpatient and outpatient medical benefit claims for a primary diagnosis of renal or ureteral calculi or renal colic and found that the peak incidence of stone-related claims occurred in July through September, with a sharp decline in claims in October. Ambient temperature, atmospheric pressure, and hours of sunshine correlated with monthly stone-related claims, but after adjusting for seasonality, month, and trend, ambient temperature was found to be the most important determinant of stone-related events. The link between seasonal high ambient temperatures and increased risk of kidney stones worldwide has been validated in a systematic review of the literature over a 26-year period (Geraghty et al., 2017).

Tasian et al. (2014) used the MarketScan Commercial Claims data set to perform time-series, nonlinear modeling to estimate the relative risk of kidney stone presentation associated with mean daily temperature in five large metropolitan areas geographically distributed throughout the United States. They noted that as mean daily temperature increased to greater than 10°C, kidney stone presentation in most cities correspondingly increased in the ensuing 10 days. Furthermore, the association between kidney stone presentation and mean daily temperature was greatest at 30°C compared with 10°C and occurred within 3 days of that temperature, with a second peak at 4 to 6 days, indicating that the time interval between hot days and kidney stone presentation is actually short.

The study of military personnel translocated to desert locations has provided a unique opportunity to study the effect of climate on a defined population. Pierce and Bloom (1945) reported that American soldiers in an undisclosed desert location had an increase in symptomatic episodes of renal colic during the summer season. Another study of military personnel who developed symptomatic stones after arrival in Kuwait and Iraq revealed a mean time interval to stone formation of 93 days (Evans and Costabile, 2005). Finally, Parry and Lister (1975) measured urinary calcium and magnesium levels in soldiers before and 10 days after transfer to the Persian Gulf. They noted increased urinary calcium levels from baseline in those soldiers transferred during the summer months but not among those transferred during the "cold season," which was attributed to sunlight-induced increased production of 1,25-dihydroxyvitamin D_3 (1,25$[OH]_2D_3$). Thus it is likely that climate and geography influence the prevalence of stone disease indirectly, through effects on temperature and possibly sunlight.

Ordon et al. (2016), using a population-based, time-series analysis of linked health care databases in Ontario, Canada, showed that the increase in presentation to the emergency department during times of warmer ambient temperature was more pronounced in men than women (RR = 1.64 vs. 1.22, respectively, $P = 0.006$) and in those patients aged 40 to 69 compared with other adult age groups. The pathophysiology responsible for these gender and age differences in response to temperature has not been elucidated but is likely affected by confounders such as differential sunlight exposure, occupation, and hydration status.

Brikowski et al. (2008) constructed two alternate models describing the temperature dependence of stone disease on the basis of reported regional stone prevalence rates and corresponding mean annual temperatures to predict the anticipated change in stone prevalence resulting from global warming. Prevalence rates obtained from the Second Cancer Prevention Survey of 1982 (Soucie et al., 1996) were consistent with a nonlinear, or peaked, relationship between temperature and stone prevalence, whereas a data set from the Veterans Administration that was analyzed by the Urologic Diseases in America project (Pearle et al., 2005) more closely approximated a linear fit. Using a moderate-severity warming model to predict temperature change resulting from global warming in the United States, the authors estimated an increase of 1 to 1.5 million lifetime cases of climate-related nephrolithiasis by 2050. According to the linear model of temperature dependence, the net effect of warming will be a northward expansion of the current-day "stone belt" (which occupies primarily the Southeast region of the United States) into the Midwest, such that by 2050 it will occupy the entire Southeast portion of the country and all of California. The nonlinear model predicts that the zone of elevated stone risk currently located in the Southeast will expand northward to include a band of states from Kansas to Virginia and Northern California, but with the increase in prevalence primarily concentrated south of the temperature threshold.

Fakheri and Goldfarb (2009) later revisited the analysis correlating mean annual temperature and stone prevalence and confirmed that temperature positively correlated with rate of stone prevalence. However, they further established that the temperature dependence of stone disease could be attributed primarily to an effect on men. For every unit degree Fahrenheit increase in temperature, the percentage prevalence rate increased by 0.15 ($R^2 = 0.37$) in men and 0.04 ($R^2 = 0.51$) in women. A hypothesis for the increased incidence of stones related to temperature is that more people are exposed to urban heat islands as a result of progressive urbanization. The effects of urban architecture and infrastructure coupled with reduced vegetation result in cities that are warmer than more rural areas (Goldfarb et al., 2015). A study examining this association that takes into account relevant variables such as fluid intake, diet, and socioeconomic status is lacking.

Occupation

Heat exposure and dehydration constitute occupational risk factors for stone disease as well. Cooks and engineering room personnel, who are exposed to high temperatures, were found to have the highest rates of stone formation among personnel of the Royal Navy (Blacklock, 1969). Likewise, Atan et al. (2005)

found a significantly higher incidence of stones among steelworkers exposed to high temperatures (8%) compared with those working in normal temperatures (0.9%). Metabolic evaluation of these two groups of workers showed a higher incidence of low urine volume and hypocitraturia among the workers in the hot area. Borghi et al. (1993) also noted differences in the incidence of stone disease and urinary stone risk factors between workers at a glass plant who were or were not chronically exposed to high temperatures causing massive perspiration. Those exposed to high temperatures exhibited lower urine volumes and pH, higher uric acid levels, and higher urine specific gravity, leading to higher urinary saturation of uric acid. Accordingly, those workers who formed stones had a remarkably high incidence of uric acid stones (38%).

Individuals with sedentary occupations such as those in managerial or professional positions have been found to carry an increased risk of stone formation for unclear reasons (Blacklock, 1969). This finding is consistent with the work of Robertson et al. (1980), who reported an increased risk of stone disease in affluent individuals, countries, and societies, which may be reflective of a more indulgent diet and lifestyle. In addition, those with occupations that limit bathroom access, such as taxi drivers and operating room personnel, have been shown to have an increased risk of stones (Linder et al., 2013; Mass et al., 2014).

Obesity, Diabetes, and Metabolic Syndrome

The association of body size and incidence of stone disease has been extensively investigated. In two large prospective cohort studies of men and women, **the prevalence and incident risk of stone disease directly correlated with weight and body mass index (BMI) in both sexes, although the magnitude of the association was greater in women than in men** (Curhan et al., 1998; Taylor et al., 2005b). Furthermore, they found that obesity and weight gain were independent risk factors for incident stone formation that could not be accounted for by diet alone (Taylor et al., 2005b). Nowfar et al. (2011) used a large all-payer inpatient care data set and found an increased risk of stones with obesity that was more pronounced in women than men. Yoshimura et al. (2016) followed more than 4000 Japanese male gas company workers without stones at baseline for a period of 19 years and found that BMI was independently associated with risk of incident kidney stones. Finally, Semins et al. (2010) using claims data found an increasing risk of kidney stones with increasing BMI, up to a BMI of

30 kg/m^2, at which point the risk stabilized.

Sorensen et al. (2013) investigated the independent effects of caloric intake, physical activity, and BMI on stone risk in 84,225 postmenopausal women with no prior stone history in the Women's Health Initiative Observational Study. They found that in addition to BMI, less physical activity and increased dietary energy intake (more than 2200 kcal/day) were each associated with an increased incident risk of kidney stones, which supports dietary and physical activity components of weight loss counseling as part of an overall kidney stone prevention program.

The constellation of visceral obesity along with hyperlipidemia, hypertriglyceridemia, hyperglycemia, and/or hypertension, known as metabolic syndrome, has been linked to an increased risk for kidney stones. Using the NHANES III (1988–1994) data set, West et al. (2008) found that those with a diagnosis of metabolic syndrome were significantly more likely to report a history of kidney stones compared with healthy subjects (8.8% vs. 4.3%, respectively, $P < 0.001$). Furthermore, they found that the prevalence of a self-reported history of kidney stones increased with the number of metabolic syndrome traits, with the prevalence of kidney stones estimated at 3% for no traits, 7.5% for three traits, and 9.8% for five traits. Multivariate analysis revealed that the presence of four or five metabolic syndrome traits was associated with a more than twofold increase in the odds of a self-reported stone history (OR 2.42, 95% CI 1.57–3.73). Wong et al. (2016) corroborated these findings in a systematic review of six studies comprising 219,255 patients.

Metabolic syndrome has been implicated as a potential precursor of type 2 diabetes mellitus. Taylor et al. (2005a) prospectively studied the association between diabetes and incident kidney stones in three large cohorts (Nurses' Health Study I [NHS I] composed of older women; Nurses' Health Study II [NHS II] composed of younger women; and the Health Professionals Follow-Up Study [HPFS] composed of men) and found that, after adjusting for BMI, diet, and thiazide use, a history of diabetes was associated with an increase in incident kidney stones in women but not men. Conversely, a history of kidney stones was associated with an increase in the incidence of self-reported diabetes for women and men (OR 1.33, 95% CI 1.18–1.50 for older women; OR 1.48, 95% CI 1.14–1.91 for younger women; and OR 1.49, 95% CI 1.29–1.72 for men). In addition, Chung et al. (2011) observed a 1.3-fold higher likelihood of being diagnosed with diabetes among individuals within 5 years of a diagnosis of kidney stones than in a comparison cohort of individuals who did not form stones (95% CI

1.26–1.39, $P < 0.001$). Stone formers with type 2 diabetes have been shown to have higher urinary oxalate and lower urine pH than nondiabetic stone formers (Eisner et al., 2010a).

Although the association between obesity, diabetes, and metabolic syndrome has been explored in the epidemiologic literature, the exact pathophysiologic mechanism responsible for this association has yet to be completely defined; however, a central theme of these comorbidities is a metabolic state of insulin resistance. Evidence linking obesity and insulin resistance with low urine pH and uric acid stones (Maalouf et al., 2004a, 2004b), as well as an association between hyperinsulinemia and hypercalciuria (Kerstetter et al., 1991; Nowicki et al., 1998; Shimamoto et al., 1995), could account for an increased risk of uric acid and/or calcium stones in obese patients. Overweight (BMI 25–30 kg/m^2) has also been shown to be associated with lower urine pH and higher urinary sodium, uric acid, and calcium compared with normal weight (Shavit et al., 2015). Furthermore, evidence suggests that urinary abnormalities may be harder to correct in overweight and obese compared with normal individuals. Astrova et al. (2016) found a significant inverse relationship between BMI and response to potassium citrate in patients with low urine pH and hypocitraturia, with more frequent dose adjustments required to correct these abnormalities in patients with higher BMI.

A study of stone-forming and non–stone-forming participants in the HPFS (599 stone-forming and 404 non–stone-forming men), NHS I (888 stone-forming and 398 non–stone-forming older women), and NHS II (689 stone-forming and 295 non–stone-forming younger women) for whom 24-hour urine studies were collected correlated urinary stone risk profiles with BMI (Taylor and Curhan, 2006). **Subjects with higher BMI excreted more urinary oxalate, uric acid, sodium, and phosphorus than those with lower BMI. Furthermore, similar to other studies, urinary supersaturation of uric acid increased with BMI.**

It has been suggested that the association of obesity with calcium oxalate stone formation is primarily due to increased excretion of promoters of stone formation (Negri et al., 2007; Siener et al., 2004)**. In contrast, the association of obesity and uric acid stone formation is primarily influenced by urinary pH.**

Cardiovascular Disease

A number of investigators have explored the association between hypertension and kidney stones. In a recent meta-analysis, Shang et al. (2017) found that patients with nephrolithiasis had a significantly increased risk of hypertension (OR 1.43; 95% CI 1.30–1.56) compared with those without a history of stones, an association that was more pronounced in women (OR 1.43; 95% CI 1.21–1.69) than men (OR 1.31; 95% CI 1.25–1.37). Increased dietary intake of substances associated with hypertension and stone disease, including calcium, sodium, and potassium, has been proposed as a possible explanation for this finding. Indeed, Borghi et al. (1999) observed higher urinary calcium, uric acid, oxalate and supersaturation of calcium oxalate in men and women with hypertension compared with normotensive individuals, and Eisner et al. (2010b) found that hypertensive stone formers excrete about 25 mg/day more calcium than normotensive stone formers.

Stone disease has also been linked to heart disease. One longitudinal study found a 31% higher incidence of myocardial infarction (MI) among those with a history of kidney stones compared with those without stones, even after adjusting for comorbidities, including chronic kidney disease (Rule et al., 2010). In addition, Reiner et al. (2011) documented an association between history of kidney stones and subclinical carotid atherosclerosis in young men and women. Ferraro et al. (2013b) explored the association between kidney stones and risk of heart disease in three large cohort studies, NHS I, NHS II, and HPFS, and found that a history of kidney stones was associated with a modest but significant increase in heart disease in both female cohorts but not in the male cohort. Alexander et al. (2013), in a cohort study of more than 3 million people in Alberta, Canada, found that after adjusting for cardiovascular and other potential confounding variables, those with a history of at least one kidney stone had a higher risk of subsequent cardiovascular events such as acute MI (HR 1.4, 95% CI 1.30–1.51) and stroke (HR 1.26, 95% CI 1.12–1.42) than those without stones, a risk that was greater in younger individuals (age <50 versus ≥50 years, $P < 0.001$) and women ($P < 0.01$). Although the factors responsible for the association between nephrolithiasis and cardiovascular disease have yet to be elucidated, dyslipidemia (high total cholesterol, high triglycerides, and low high-density lipoprotein [HDL]) has been associated with alterations in urine chemistry that can predispose to kidney stone formation (Torricelli et al., 2014).

Chronic Kidney Disease

Epidemiologic studies have demonstrated a link between nephrolithiasis and development of chronic kidney disease (CKD). In a case control study, Vupputuri et al. (2004) demonstrated that patients with a history of kidney stones had a higher risk of CKD (OR 1.9; 95% CI 1.1–3.3) even after controlling for confounding factors. Furthermore, Gillen et al. (2005) demonstrated that stone formers, particularly those with a BMI of at least 27 kg/m^2, had a mean estimated glomerular filtration rate (eGFR) 3.4 mL/min/1.73 m^2 lower (95% CI −5.8–1.1, $P = 0.005$) and were nearly twice as likely to have stage 3 CKD (RR 1.87, 95% CI 1.06–3.30) compared with a group of non–stone-forming controls.

Two prospective cohort studies involving insured, predominantly white individuals demonstrated a higher risk of incident CKD in patients with a history of kidney stones (Alexander et al., 2012; Rule et al., 2009). Likewise, in a multivariate analysis adjusting for other comorbid conditions, Shoag et al. (2014) found that a history of kidney stones was associated with CKD (OR 1.50, 95% CI 1.10–2.04, $P = 0.013$) and end-stage renal disease (ESRD) requiring dialysis (OR 2.37, 95% CI 1.13–4.96, $P = 0.025$), a finding largely accounted for by women as there was no association between kidney stones and CKD or ESRD in men. In a population-based cohort study, El-Zoghby et al. (2012) also found that symptomatic stone formers were at an increased risk of developing ESRD (HR 2.09, 95% CI 1.45–3.01). Further studies are needed to elucidate the relationship between CKD and nephrolithiasis.

Water

The beneficial effect of a high fluid intake on stone prevention has long been recognized. In two large observational studies, fluid intake was found to be inversely related to the risk of incident kidney stone formation (Curhan et al., 1993, 1997). Furthermore, in a prospective, randomized trial assessing the effect of fluid intake on stone recurrence among first-time idiopathic calcium stone formers, urine volume was significantly higher in the group assigned to a high fluid intake compared with the control group receiving no recommendations, and, accordingly, stone recurrence rates were significantly lower (12% vs. 27%, respectively) (Borghi et al., 1996).

Geographic differences in the incidence of stone disease have been ascribed in some cases to differences in the mineral and electrolyte content of water in different areas. Although several investigators reported a lower incidence of stone disease in geographic regions with a “hard” water supply compared with a “soft” water supply, where water “hardness” is determined by content of calcium carbonate (Churchill et al., 1978; Sierakowski et al., 1979), others found no difference. Schwartz et al. (2002) found no association between water hardness and incidence of stone episodes, although they did observe a correlation between water hardness and urinary magnesium, calcium, and citrate levels.

Key Points: Epidemiology

- Upper urinary tract stones occur more commonly in men than women, but there is evidence that the gender gap is narrowing.
- Whites have the highest incidence of upper tract stones compared with Asians, Hispanics, and African-Americans.
- Prevalence of stone disease shows geographic variability, with the highest prevalence of stone disease in the Southeast.
- The risk of stone disease correlates with weight and BMI.
- Stone disease has been correlated with a number of systemic disorders, including diabetes, metabolic syndrome, cardiovascular disease, and CKD.

Physicochemistry and Pathogenesis

The physical process of stone formation comprises a complex cascade of events that occurs as the glomerular filtrate traverses the nephron. It begins with urine that becomes supersaturated with respect to stone-forming salts, such that dissolved ions or molecules precipitate out of solution and form crystals or nuclei. Once formed, crystals may flow out with the urine or become retained in the kidney at anchoring sites that promote growth and aggregation, ultimately leading to stone formation. The discussion that follows describes the process of stone formation from a physicochemical standpoint.

State of Saturation

A solution containing ions or molecules of a sparingly soluble salt is described by the *concentration product,* which is a mathematical expression of the product of the concentrations of the pure chemical components (ions or molecules) of the salt. For example, the concentration product (CP) expression for sodium chloride is

$$CP = [Na^+][Cl^-].$$

A pure aqueous solution of a salt is considered *saturated* when it reaches the point at which no further added salt crystals will dissolve. The concentration product at the point of saturation is called the *thermodynamic solubility product* (K_{sp}), which is the point at which the dissolved and crystalline components are in equilibrium for a specific set of conditions. At this point, addition of further crystals to the saturated solution will cause the crystals to precipitate unless the conditions of the solution, such as pH or temperature, are changed.

In urine, despite concentration products of stone-forming salt components such as calcium oxalate that exceed the solubility product, crystallization does not necessarily occur because of the presence of inhibitors and other molecules that allow higher concentrations of calcium oxalate to be held in solution before precipitation or crystallization occurs. In this state of saturation, urine is considered to be *metastable* with respect to the salt. As concentrations of the salt increase further, the point at which it can no longer be held in solution is reached and crystals form. The concentration product at this point is called the *formation product* (K_f).

The solubility product and the formation product differentiate the three major states of saturation in urine: undersaturated, metastable, and unstable (Fig. 91.2). Below the solubility product, crystals will not form under any circumstances, and dissolution of crystals is theoretically possible. At concentrations above the formation product, the solution is unstable and crystals will form. In the metastable range between the solubility product and the formation product, in which the concentration products of most common stone components reside, spontaneous nucleation or precipitation does not occur despite urine that is supersaturated. In this area modulation of factors controlling stone formation can take place and therapeutic intervention is directed.

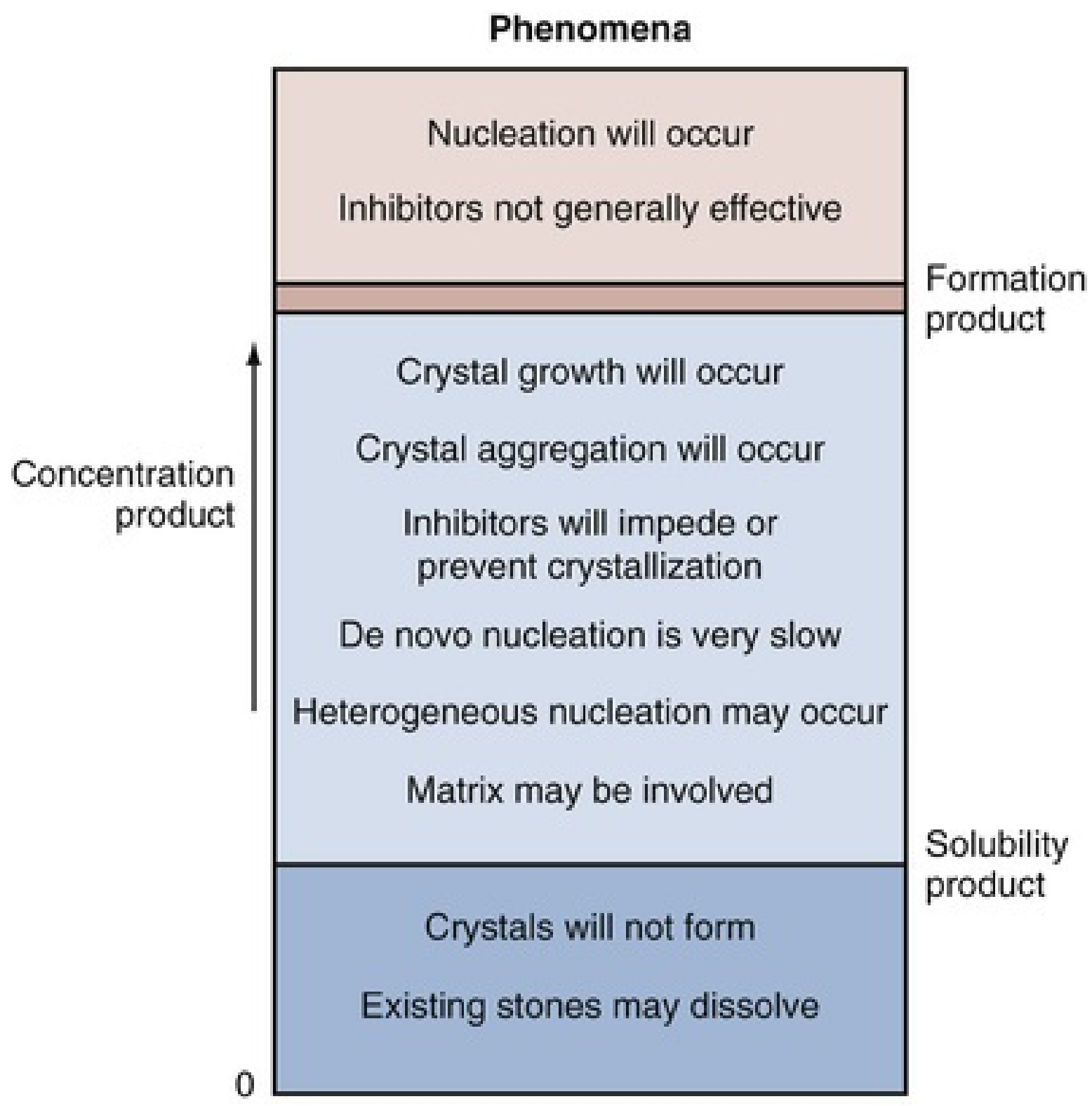
Phenomena
Nucleation will occur
Inhibitors not generally effective
Formation product
Crystal growth will occur
Crystal aggregation will occur
Inhibitors will impede or prevent crystallization
De novo nucleation is very slow
Heterogeneous nucleation may occur
Matrix may be involved
Concentration product
Solubility product
Crystals will not form
Existing stones may dissolve
0

FIG. 91.2 States of saturation. Listed are solid-solution phenomena that are likely to occur at a given range of concentration products. Three general situations are considered: (1) concentrations less than the solubility product (undersaturation), (2) concentrations that are metastable with respect to de novo precipitation (between the solubility product and the formation product), and (3) concentrations that are greater than the formation product (unstable). (From Meyer JL: Physicochemistry of stone formation. In Resnick MI, Pak CYC, editors: *Urolithiasis: a medical and*

surgical reference, Philadelphia, 1990, Saunders, pp 11–34.)

In the metastable range of concentration products, although crystal growth can occur on existing crystals, de novo formation of crystals cannot occur in the length of time it normally takes for the filtered urine to reach the bladder. However, crystal formation can occur in this range under certain circumstances. First, in parts of the nephron local concentration products may exceed the formation product for long enough time periods to allow nucleation to occur. Second, local areas of obstruction or stasis in the upper urinary tract may prolong urinary transit time and allow crystal formation to occur in metastable urine. Finally, microscopic impurities or other constituents in the urine can facilitate the nucleation process by adsorption of the crystal components in a geometric way that resembles the native crystal. The energy required for this “heterogeneous nucleation” process is much less than that required for “homogeneous nucleation.”

To estimate the state of saturation for any given crystal system such as calcium oxalate or calcium phosphate, Pak and Chu (1973) developed a mathematical formula, the *activity product ratio*, that takes into account urine pH and the ionic activities of all major ion species directly involved in the stone-forming process or those that affect the overall ionic strength of the urine. Finlayson subsequently developed a computer program, EQUIL 2, to measure the state of saturation, which is commonly used today (Werness et al., 1985). The *relative saturation ratio* (RSR) or *concentration product ratio* (CPR) is defined as the ratio of the concentration product of the urine to the solubility product of the specified stone-forming salt. A reduction in the numerator will lead to undersaturation of the urine with respect to the stone-forming salt and consequently reduce the likelihood of precipitation. Thus at RSR values less than 1, crystals will dissolve; at RSR values greater than 1, crystals will form and grow. Reducing the RSR can be accomplished by reducing the urinary concentrations of the stone components (e.g., calcium or oxalate), by reducing the filtered load, or by increasing urinary reabsorption. In addition, complexation with substances such as citrate reduce available free ionic calcium and decrease the RSR. On the other hand, manipulation of factors such as pH can significantly affect the concentration of ions such as phosphate, the generation of which is highly pH dependent. Manipulation of pH has little effect on oxalate concentration, however, because oxalic acid is a strong acid (pK = 4), and pH changes within the physiologic range will have little effect on oxalate concentration.

Rodgers et al. (2006) introduced another computer program, JESS (Joint Expert Speciation System), to calculate urinary saturation of stone-forming salts as an estimate of the propensity for stone formation, thereby challenging the accuracy of the widely accepted EQUIL 2 computer program. The JESS program recognizes several soluble complexes not taken into account by EQUIL 2, including dicalcium-dihydrogen phosphate and calcium phosphocitrate, whose formation depends on pH and citrate. Consequently, the fraction of ionized calcium, phosphate, and oxalate estimated by JESS will be lower than that estimated by EQUIL 2. To resolve the discrepancy between the two programs, the supersaturation index (SI) according to JESS and the RSR according to EQUIL 2 were compared with experimentally determined urinary saturation of brushite (Pak et al., 2009b) and calcium oxalate (Pak et al., 2009a). The experimentally determined method measures the CPR without using computer-derived ionic activities. By determining the concentration product before and after incubation with a synthetic stone-forming salt, this method directly estimates saturation by measuring the extent of stone growth (in a supersaturated solution) or dissolution (in an undersaturated solution). No significant difference was found between experimentally determined CPR and JESS-derived SI, for either brushite or calcium oxalate. However, EQUIL 2–derived RSR was consistently and significantly higher than CPR and SI, overestimating CPR by about 80% for brushite and 50% for calcium oxalate. **Because CPR is too labor intensive for routine use, SI according to JESS probably provides a more reliable estimation of urinary saturation than RSR derived from EQUIL 2.**

Historically, urinary oxalate has been considered a more important contributor to calcium oxalate stone formation than urinary calcium, because a rise in urinary calcium concentration affected urinary saturation of calcium oxalate less than a rise in oxalate concentration (Nordin et al., 1972; Robertson and Peacock, 1980). Furthermore, at high urinary calcium concentrations the saturation of calcium oxalate reached a plateau that did not exceed the theoretic formation product of calcium oxalate, whereas high oxalate concentrations did, thereby increasing the risk of calcium oxalate crystal formation. Pak et al. (2004), however, challenged the notion that urinary oxalate exerts a greater pathogenetic effect than calcium in calcium oxalate stone formation. They demonstrated that the choice of stability constant used for calculating the RSR determines the relative effects of urinary calcium and oxalate concentration. Using the commonly accepted stability constant of 2.746×10^3 (used in the EQUIL 2 program), the effect of urinary calcium and oxalate proved to be equivalent. Thus they concluded that **urinary calcium and oxalate are important and equal contributors to calcium oxalate stone formation** (Fig. 91.3). As such, reduction in calcium and oxalate will be effective in reducing the RSR, and intervention to prevent stone formation can be directed at either. When these studies were repeated using JESS, the same finding of an equivalent effect of calcium and oxalate on urinary SI of calcium oxalate was found, although the dependence of SI on calcium and oxalate was less marked than was demonstrated for RSR (Pak et al., 2009a).

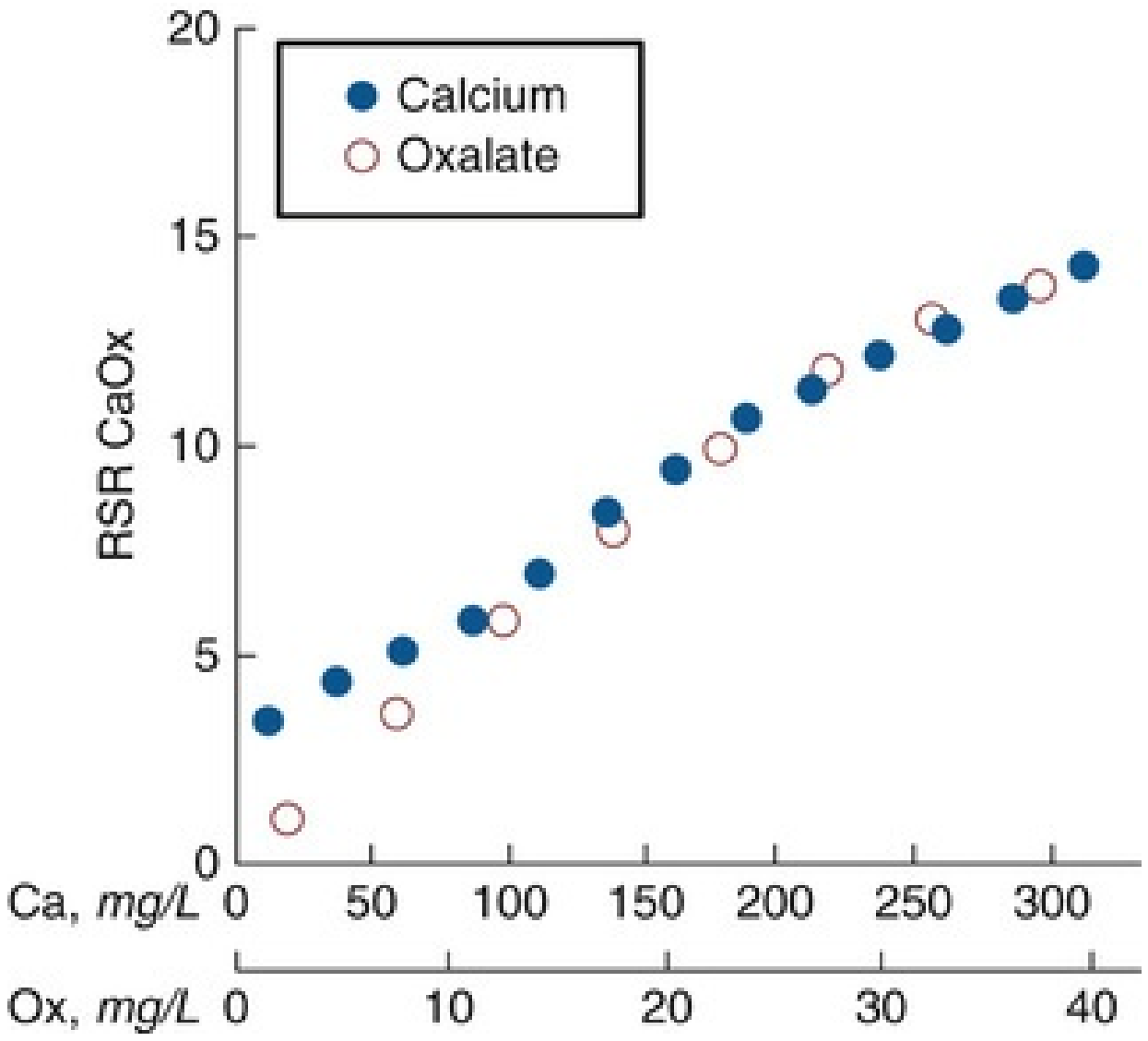

FIG. 91.3 Approximation of the actual relationship between relative saturation ratio (RSR) of calcium oxalate and calcium concentration by the actual relationship between RSR and oxalate concentration. Group mean RSRs of calcium oxalate for each 25 mg/L interval of calcium concentration from 667 patients are shown (•), and group mean RSRs for each 5 mg/L interval of oxalate are depicted (○). (From Pak CY, Adams-Huet B, Poindexter JR, et al.: Rapid communication: relative effect of urinary calcium and oxalate on saturation of calcium oxalate. *Kidney Int* 66:2032–2037, 2004.)

Nucleation and Crystal Growth, Aggregation, and Retention

In normal human urine, the concentration of calcium oxalate is four times higher than its solubility in water. Urinary factors favoring stone formation include low volume and citrate, whereas increased calcium, oxalate, phosphate, and uric acid increase calcium oxalate supersaturation. Once the concentration product of calcium oxalate exceeds the solubility product, crystallization can potentially occur. However, in the presence of urinary inhibitors and other substances, calcium oxalate precipitation occurs only when supersaturation exceeds solubility by 7 to 11 times.

Homogeneous nucleation is the process by which nuclei form in pure solution. Nuclei are the earliest crystal structures that will not dissolve. Small nuclei are unstable; below a critical size threshold, dissolution of the crystal is favored over crystal growth. If the driving force (supersaturation level) and the stability of the nuclei are favorable and the lag time to nucleation is sufficiently short compared with the transit time of urine through the nephron, the nuclei will persist. Inhibitors, such as citrate, destabilize nuclei, whereas promoters stabilize nuclei by providing a surface with a binding site that accommodates the crystal structure of the nucleus. In urine, crystal nuclei usually form through heterogeneous nucleation by adsorption onto existing surfaces of epithelial cells (Umekawa et al., 2001), cell debris (Fasano and Khan, 2001), or other crystals (Kok, 1997).

Within the timeframe of transit of urine through the nephron, estimated at 5 to 7 minutes, crystals cannot grow to reach a size sufficient to occlude the tubular lumen. However, if enough nuclei form and grow, aggregation of the crystals will form larger particles within minutes that can occlude the tubular lumen. Inhibitors can prevent the process of crystal growth or aggregation. Magnesium and citrate inhibit crystal aggregation. Nephrocalcin, an acidic glycoprotein made in the kidney, inhibits calcium oxalate nucleation, growth, and aggregation (Asplin et al., 1991; Nakagawa et al., 1987). Tamm-Horsfall mucoprotein, the most abundant protein in urine, inhibits aggregation (Hess et al., 1991), and uropontin inhibits crystal growth (Shiraga et al., 1992). Bikunin, the light chain of inter-α-trypsin, has been shown to be an efficient inhibitor of crystal nucleation and aggregation.

Opposing views regarding the formation and growth of crystal particles have led to controversy over the concept of free crystal particle growth versus fixed particle growth. Although it was initially concluded that free particle stone formation, based solely on growth and aggregation of crystals and subsequent retention in the tubules, was impossible within the normal transit time through the nephron (Finlayson and Reid, 1978), later recalculation using current nephron dimensions, supersaturation, and crystal growth rates determined that crystalline particles can be formed that are large enough to be retained during normal transit time through the kidney (Kok and Khan, 1994). This theory is supported by histologic evidence of crystals occluding the intermedullary collecting ducts in select patients (Evan et al., 2003, 2005, 2006b, 2007, 2008).

Fixed particle growth theory presupposes an anchoring site to which crystals bind, thereby prolonging the time the crystals are exposed to supersaturated urine and facilitating crystal growth and aggregation. Randall (1937) first suspected the renal papilla was the anchoring site for stone formation after he observed subepithelial plaque on the renal papillae of 17% of 429 pairs of kidneys examined at autopsy. He implicated the basement membrane as the site of origin of the plaque and postulated subsequent erosion into the papillary luminal surface, thereby providing a nidus for stone formation. Low and Stoller (1997) found that papillary plaques occurred in 74% of stone formers compared with only 43% of control subjects undergoing endoscopy for conditions unrelated to stone disease.

Evan et al. (2003) validated and refined this theory for the pathogenesis of stone formation based on extensive analysis of papillary plaques derived from biopsies obtained during percutaneous nephrolithotomy in idiopathic calcium oxalate stone formers. **They localized the origin of the plaque to the basement membrane of the thin limbs of the loops of Henle and demonstrated that the plaque subsequently extends through the medullary interstitium to a subepithelial location** (Fig. 91.4)**. Once the plaque erodes through the urothelium, it is thought to constitute a stable, anchored surface on which calcium oxalate crystals can nucleate and grow as attached stones.**

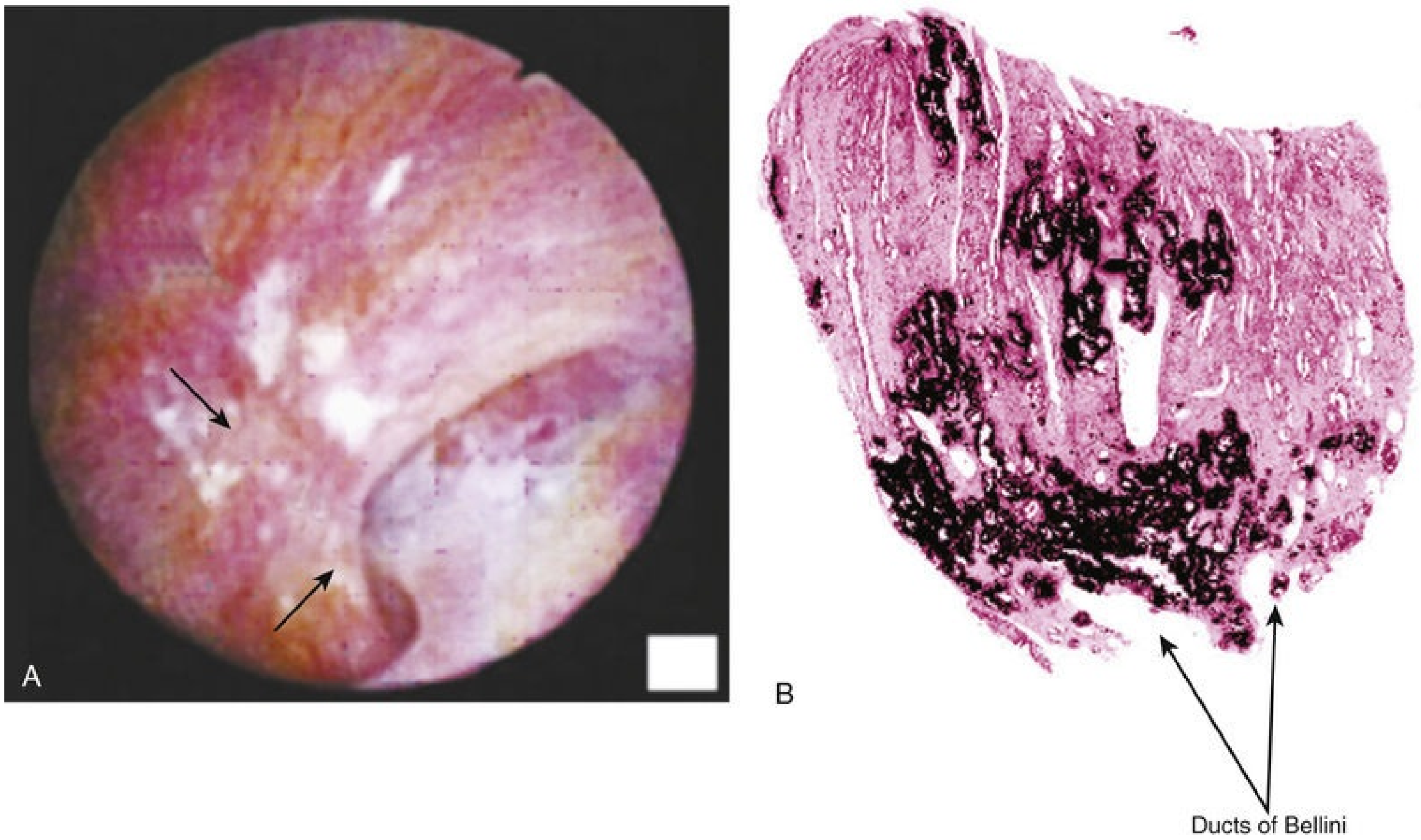

FIG. 91.4 Endoscopic (A) and histologic (B) images of Randall plaques in calcium oxalate patients. (A) Sites of Randall plaques *(arrows)* appear as irregular white areas beneath the urothelium. (B) A low-magnification light-microscopic image of a papillary biopsy specimen. Sites of calcium deposits were stained black by the Yasue metal substitution method for calcium histochemistry. (From Evan AP, Lingeman JE, Coe FL, et al.: Randall's plaque of patients with nephrolithiasis begins in basement membranes of thin loops of Henle. *J Clin Invest* 111:607–616, 2003.)

Using high-resolution Fourier transform infrared microspectroscopy and electron diffraction, the crystal component of plaque was determined to be calcium apatite (Evan et al., 2003). Daudon et al. (2007) analyzed more than 5000 stones associated with plaque and also found that carbapatite constituted the main component of the plaque in nearly all cases. Further analysis by Evan et al. (2005) revealed that the deposits consisted of individual laminated particles with mineral and organic layers. All crystals were coated with organic material, and osteopontin was identified on the outer surface of the crystal at the junction of the overlying organic molecular layer, potentially implicating osteopontin in plaque biology (Evan et al., 2005). The apatite crystals appear as spherical units, spherulites, that grow, aggregate, and fuse into larger particles. In the basement membrane, they are embedded in amorphous matrix and may be associated with membrane-bound vesicles. As they migrate into the interstitium, they propagate the mineralization front as they come in contact with collagen and cellular degradation products until they reach the subepithium of the renal papilla, comprising Randall plaque (Khan et al., 2012).

Another intriguing but unproven hypothesis for the origin of the calcium phosphate crystal involves calcifying nanoparticles (CNPs), also known as nanobacteria, which have been implicated in other types of pathologic calcifications such as atherosclerotic plaques (Shiekh et al., 2009). Ciftçioğlu et al. (2008) found an association between presence of CNPs and Randall plaques in kidneys removed for neoplasia. Although not necessarily causative, these findings suggest at least a loose association between CNPs and Randall plaque.

Because this process of calcium phosphate deposition in association with collagen has been observed in atherosclerotic lesions, some investigators have proposed a vascular origin for Randall plaque formation. Stoller et al. (2004) hypothesized that the inciting event in the pathogenesis of stone formation may be vascular injury to the vasa recta near the renal papilla. Repair of damaged vessel walls could involve an atherosclerotic-like reaction that results in calcification of the endothelial wall, followed by erosion into the papillary interstitium and then into the collecting ducts, where it could serve as a nidus for stone formation. Analogous to vascular smooth muscle, which has been shown to undergo transformation to an osteogenic phenotype in the presence of high concentrations of calcium and phosphate, renal tubular epithelial cells in rats have demonstrated a similar potential for osteogenic activity when exposed to high levels of oxalate or calcium oxalate and calcium phosphate crystals (Joshi et al., 2015). This process is thought to be mediated by nicotinamide adenine dinucleotide phosphate (NADPH) oxidase activation and the production of reactive oxygen species.

The pathogenesis of stone formation in other calcium stone formers and in noncalcium stone formers may differ from that of typical idiopathic calcium oxalate stone formers. Indeed, Randall plaques are not a universal finding in all types of stone formers. **Patients with enteric hyperoxaluria resulting from intestinal bypass for obesity demonstrate no plaque but instead show apatite crystal deposits plugging the inner medullary collecting duct lumens, along with associated epithelial cell damage with interstitial inflammation and fibrosis** (Fig. 91.5; Evan et al., 2003)**. Brushite stone formers have been found to have pathology intermediate between idiopathic calcium oxalate stone formers and intestinal bypass patients, demonstrating interstitial apatite plaque *and* apatite plugging of the inner medullary and terminal collecting ducts, along with associated collecting duct injury and interstitial fibrosis** (Fig. 91.6; Evan et al., 2005). The pathogenesis of brushite stones has been postulated by Evan et al. (2005) to occur by way of crystallization of apatite in the collecting ducts, leading to collecting duct injury, cell death, and enlargement of collecting ducts. Interstitial inflammation in response to the injured cells may finally lead to progressive involvement of adjacent renal tissue. Krambeck et al. (2010) hypothesized that some brushite stones may start as calcium oxalate stones until an inciting insult such as infection or shockwave lithotripsy leads to tubular dysfunction, resulting in an alkaline environment, inflammation, and intraductal hyaluronic acid deposition, thereby prompting a transition from calcium oxalate to brushite stones. Ductal plugs have been observed in a number of other metabolic conditions that predispose to renal stone disease, including distal renal tubular acidosis (RTA) (Evan et al., 2007), primary and secondary hyperparathyroidism (Evan et al., 2008), and cystinuria (Evan et al., 2006b).

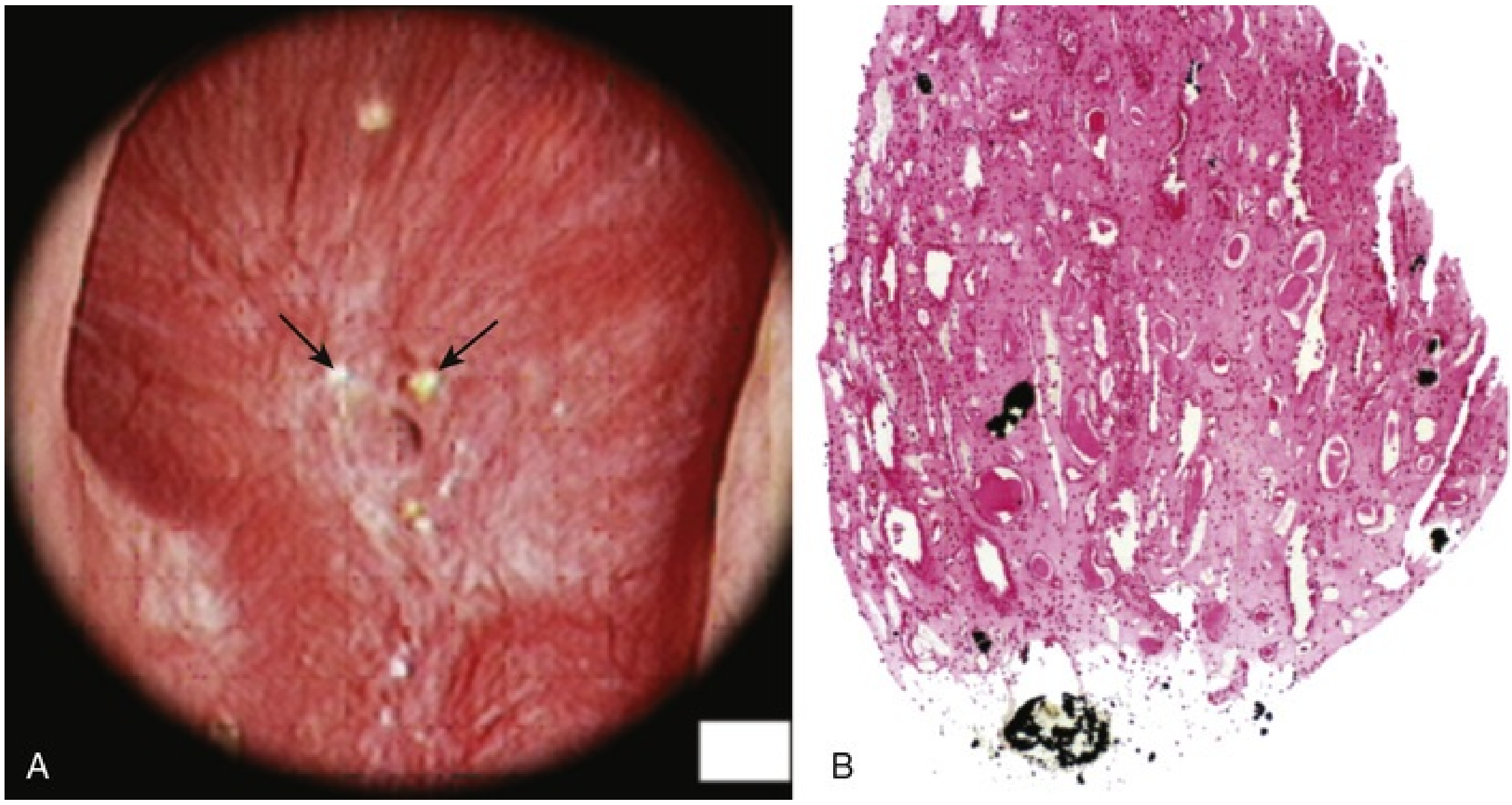

FIG. 91.5 Endoscopic (A) and histologic (B) images of Randall plaques in intestinal bypass patients. (A) Sites of Randall plaques *(arrows)* appear as irregular white areas beneath the urothelium. (B) A low-magnification light-microscopic image of a papillary biopsy specimen. Sites of calcium deposits were stained black by the Yasue metal substitution method for calcium histochemistry. (From Evan AP, Lingeman JE, Coe FL, et al.: Randall's plaque of patients with nephrolithiasis begins in basement membranes of thin loops of Henle. *J Clin Invest* 111:607–616, 2003.)

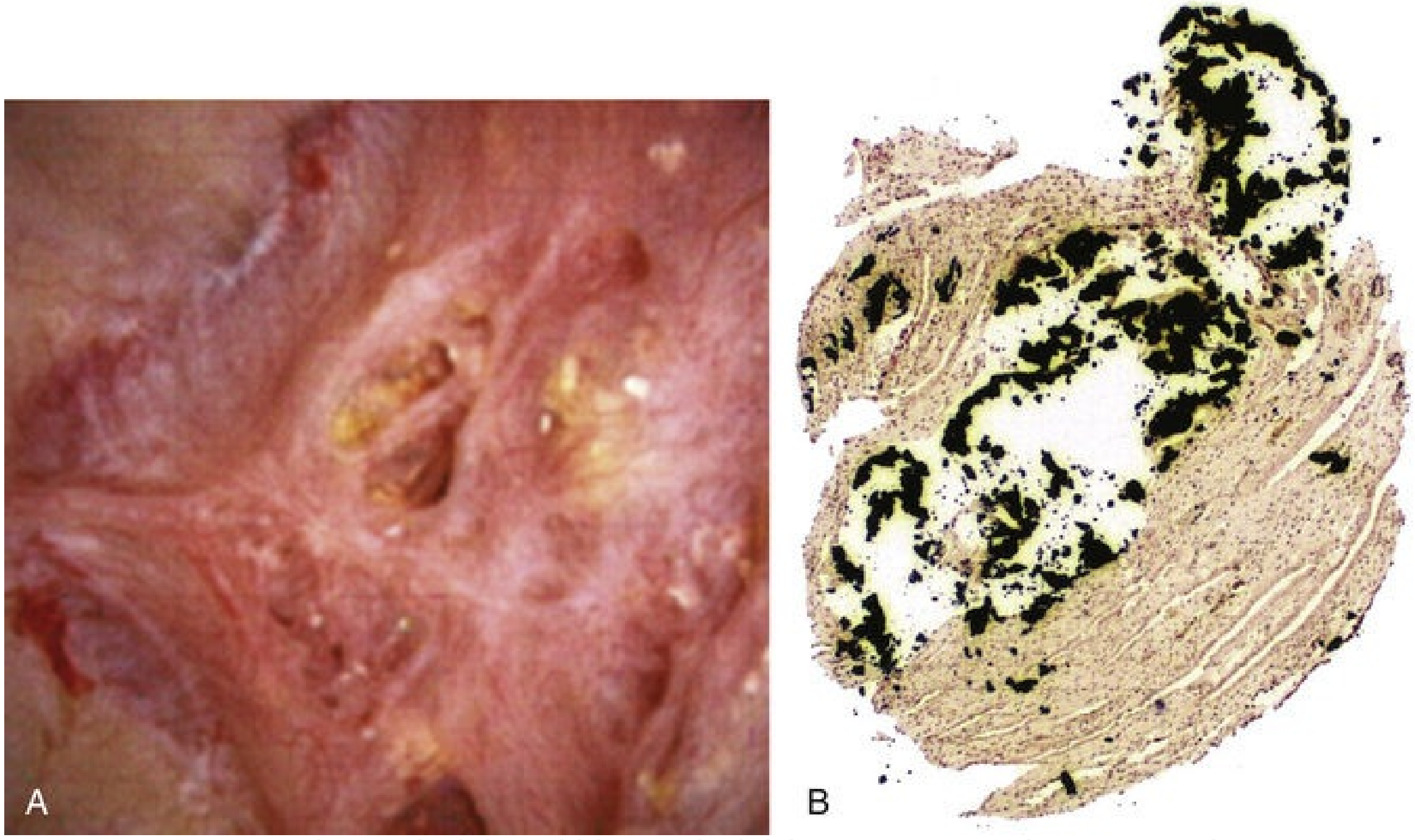

FIG. 91.6 Endoscopic (A) and histologic (B) images of Randall plaques in brushite patients. (A) Sites of Randall plaque appear as irregular white areas of crystalline deposit beneath the urothelium. In addition, a yellowish crystalline deposit is apparent at the opening of the ducts of Bellini. (B) A low-magnification light-microscopic image of a papillary biopsy specimen. Sites of calcium deposits were stained black by the Yasue metal substitution method for calcium histochemistry. A large amount of Yasue-positive material is seen in the ducts of Bellini. (From Evan AP, Lingeman JE, Coe FL, et al.: Crystal-associated nephropathy in patients with brushite nephrolithiasis. *Kidney Int* 67:576–591, 2005.)

Historically, the pathogenesis of idiopathic calcium stone formation was thought to originate exclusively in papillary plaques. Evidence in support of this assumption came from the positive correlation between plaque surface area and the number of stones formed (Kim et al., 2005) as well as plaque surface area and 24-hour urine parameters (Kuo et al., 2003a, 2003b). In addition, mapping studies detailing sites of stone attachment on the renal papillae of calcium oxalate stone formers along with micro–computed tomographic analysis of the removed stones suggested that the stones originated on interstitial plaque (Matlaga et al., 2006; Miller et al., 2009, 2010). Thus the prevailing presumption was that the finding of plaques implied an idiopathic cause of calcium stone formation.

More recently, however, the distinction between stone formers with plaques versus those with ductal plugs has been less clear cut. Linnes et al. (2013)

demonstrated that 99% of patients from a cohort of 78 patients undergoing consecutive endoscopic stone procedures had Randall plaques, including uric acid stone formers. Furthermore, they observed ductal plugging in 50% of uric acid stone formers. Conversely, ductal plugs were seen in up to 32% (severe in 11%) of the idiopathic calcium oxalate stone formers in the group (Linnes et al., 2013). Not only was tubular plugging more common than previously reported but also it too predictably correlated with urinary stone risk parameters. Furthermore, only 3.6% ± 4.2% of the papillary surface in idiopathic calcium oxalate stone formers, versus 7.4% as previously reported, comprised plaque (Kuo et al., 2003b), and no distinct correlation was found between urinary parameters and plaque coverage (Linnes et al., 2013). The discrepancy between the observations of Linnes et al. (2013) and those of the Indianapolis group may reflect the greater metabolic diversity of the idiopathic calcium oxalate group in Linnes' study, which was not restricted solely to hypercalciuria. In light of these important differences, the role of plaque versus plug in calcium oxalate stone formation may differ according to the underlying metabolic background, such as severe hypercalciuria. Nonetheless, available evidence suggests that the presence of ductal plugs should raise suspicion for a secondary cause of stone disease. Larger studies of demographically and metabolically heterogenous patients are needed to clarify roles of plaques and plugs in idiopathic and other causes of calcium stone formation.

Incorporating available clinical and experimental data, Khan et al. (2015) proposed a "unified" theory for the formation of plaques and plugs. They postulated that renal epithelial cells when subjected to oxidative stress induced by excessive urinary excretion of calcium, oxalate, and phosphate and/or decreased production of crystallization inhibitors, de-differentiate into osteoblast-like cells. As a result, calcium phosphate crystals, forming within membrane-bound vesicles, grow and propagate beyond the basement membrane. When the crystals make contact with collagen and membranous degradation products, they form a plaque that extends through the interstitium causing local inflammation and fibrosis further propagating the plaque. Finally, with the assistance of matrix metalloproteinases to breach the papillary surface epithelium, the plaque is exposed to urine in the renal pelvis, which facilitates stone growth. With regard to the formation of plugs in the collecting ducts, Khan et al. (2015) theorized that the plugs formed by supersaturated tubular fluid and pelvic urine slow movement of urine from the ducts to the renal pelvis, thereby promoting crystal formation and aggregation through retention.

Although tissue culture, experimental animal models, and clinical data have provided much insight into the pathophysiology of stone formation, it is likely that our knowledge of these processes will remain incomplete until we have a reliable animal model for stone formation.

Inhibitors and Promoters of Crystal Formation

At the concentrations at which most stone-forming salt components (including calcium, oxalate, and phosphate) are present in urine, urine is supersaturated, thereby favoring crystal formation. However, **the presence of molecules that raise the level of supersaturation needed to initiate crystal nucleation or reduce the rate of crystal growth or aggregation prevents stone formation from occurring on a routine basis.** Although inhibitors have been identified that prevent calcium oxalate and calcium phosphate crystallization, no specific inhibitors are known that affect uric acid crystallization. In addition, interference with the site of adhesion of crystals to the renal epithelium can prevent calculus retention and growth (Kumar et al., 2005).

Whole urine, when added to a solution of calcium phosphate, raises the supersaturation level required to initiate calcium phosphate crystallization (formation product) (Fleisch and Bisaz, 1962). Inorganic pyrophosphate was found to be responsible for 25% to 50% of the inhibitory activity of whole urine against calcium phosphate crystallization. Using different methodology, citrate, magnesium, and pyrophosphate together were noted to account for approximately 20% of the inhibitory activity of whole urine, with citrate as the most important factor (Bisaz et al., 1978).

Citrate acts as an inhibitor of calcium oxalate and calcium phosphate stone formation by a variety of actions. First, it complexes with calcium, thereby reducing the availability of ionic calcium to interact with oxalate or phosphate (Meyer and Smith, 1975; Pak et al., 1982). Second, it directly inhibits the spontaneous precipitation of calcium oxalate (Nicar et al., 1987) and prevents the agglomeration of calcium oxalate crystals (Kok et al., 1986). Although it has limited inhibitory effect on calcium oxalate crystal growth, it has potent activity in reducing calcium phosphate crystal growth (Meyer and Smith, 1975). Third, citrate prevents heterogeneous nucleation of calcium oxalate by monosodium urate (Pak and Peterson, 1986).

The inhibitory activity of magnesium is derived from its complexation with oxalate, which reduces ionic oxalate concentration and calcium oxalate supersaturation (Meyer and Smith, 1975). A recent study showed that magnesium reduced the contact time between calcium and oxalate molecules in vitro, an effect that showed synergism with citrate and was negated by the presence of uric acid (Riley et al., 2013). Grases et al. (2015) performed a turbidimetric assay in synthetic urine to determine the induction time and morphology of calcium oxalate crystal formation in the presence or absence of magnesium, citrate, and phytate. Their results confirmed the inhibitory effects of magnesium, citrate, and phytate and demonstrated the synergistic effects of magnesium and phytate. Pyrophosphate, phosphate, and magnesium have been shown to inhibit crystal growth, but only high concentrations of magnesium and pyrophosphate have been shown to inhibit aggregation (Kok et al., 1988).

Polyanion macromolecules, including glycosaminoglycans, acid mucopolysaccharides, and RNA, have been shown to inhibit crystal nucleation and growth by bonding with surface calcium ions. The most prominent glycosaminoglycan in human urine is chondroitin sulfate (Angell and Resnick, 1989). However, among the glycosaminoglycans, heparin sulfate interacts most strongly with calcium oxalate monohydrate crystals (Yamaguchi et al., 1993). Erturk et al. (2002) used a dye-binding assay to measure urinary glycosaminoglycan concentration and found a significantly lower concentration in stone formers than in controls. Furthermore, recurrent stone formers demonstrated lower levels of glycosaminoglycans than those who had experienced a single stone episode. Although these macromolecular proteins have been shown to inhibit stone aggregation, Reid et al. (2011) demonstrated through nuclear magnetic resonance spectroscopy that glycosaminoglycans and proteins are strongly integrated into the mineral lattice of apatite-predominant phosphate stones. Furthermore, they found that nonphosphate crystals such as calcium oxalate and uric acid did not exhibit composite lattices containing these proteins. These findings are consistent with plaque formation as apatitic foci that develop in a basement membrane environment rich in extracellular matrix proteins and glycosaminoglycans.

Two urinary glycoproteins, nephrocalcin and Tamm-Horsfall, are potent inhibitors of calcium oxalate monohydrate crystal aggregation (Nakagawa et al., 1987). Nephrocalcin is an acidic glycoprotein containing predominantly acidic amino acids that is synthesized in the proximal renal tubules and the thick ascending limb. In simple solution, nephrocalcin strongly inhibits the growth of calcium oxalate monohydrate crystals (Nakagawa et al., 1987), and it has been shown to inhibit nucleation and aggregation of calcium oxalate crystals (Coe et al., 1994). Nephrocalcin has been identified in four isoforms: non–stone formers excrete greater quantities of two isoforms associated with the most inhibitory activity, whereas stone formers excrete urine enriched for the two isoforms lacking inhibitory activity (Nakagawa, 1997). The isoforms with inhibitory activity were found to contain γ-carboxyglutamic acid residues that were lacking in the isoforms isolated from stone formers.

Tamm-Horsfall protein, also known as uromodulin, is expressed by renal epithelial cells in the thick ascending limb and the distal convoluted tubule as a membrane-anchored protein that is released into the urine after cleavage of the anchoring site by phospholipases or proteases. **Tamm-Horsfall is the most abundant protein found in the urine and a potent inhibitor of calcium oxalate monohydrate crystal aggregation, but not growth.** The role of Tamm-Horsfall protein in stone formation is controversial and may depend on the state of the molecule, which determines whether it functions as an inhibitor or a promoter of crystal formation. In alkaline urine it is a strong inhibitor of calcium oxalate monohydrate crystal aggregation, whereas in acidic urine it polymerizes into a configuration that promotes crystal aggregation (Hess, 1992). There are several studies that support the involvement of uromodulin in the regulation of renal tubular calcium reabsorption, including a genome-wide association study (GWAS) that found that a specific uromodulin allele was protective against calcium-containing kidney stones (Gudbjartsson et al., 2010).

A study using a Tamm-Horsfall knockout *(Thp−/−)* mouse model demonstrated spontaneous formation of calcium oxalate crystals in the kidneys of mice fed ethylene glycol and vitamin D, suggesting a protective role of Tamm-Horsfall protein against crystallization of calcium salts (Mo et al., 2004). A subsequent study on more than 250 Tamm-Horsfall protein–null mice demonstrated a consistent phenotype of progressive renal calcification that consisted of hydroxyapatite in the interstitial space of renal papillae resembling the plaques seen in idiopathic calcium oxalate stone formers (Liu et al., 2010). More recent studies have suggested that uromodulin may also regulate TRPV5 and TRPV6, which are channels critical for renal transcellular Ca^{2+} reabsorption (Wolf et al., 2013). Osteopontin, or uropontin, is an acidic phosphorylated glycoprotein expressed in bone matrix and renal epithelial cells of the ascending limb of the loop of Henle and the distal tubule. **Osteopontin has been shown to inhibit nucleation, growth, and aggregation of calcium oxalate crystals, as well as to reduce binding of crystals to renal epithelial cells in vitro** (Asplin et al., 1998; Wesson et al., 1998). In an osteopontin knockout mouse model, intratubular calcium oxalate crystals could be induced in mice exposed to high levels of oxalate by ethylene glycol feeding (Wesson et al., 2003). Interestingly, in a *Thp*−/− mouse model, mice fed ethylene glycol and vitamin D exhibited a dramatic increase in osteopontin levels over baseline but still formed calcium oxalate crystals (Mo et al., 2004). The authors concluded that osteopontin may constitute an inducible inhibitor of calcium oxalate crystallization that works in conjunction with constitutively expressed Tamm-Horsfall protein to prevent crystallization.

Urinary prothrombin fragment 1 (F1) is a crystal matrix protein named for its resemblance to the F1 degradation product of prothrombin. Ryall et al. (1995) purified urinary prothrombin F1 from human urine and used an artificial crystallization system to determine that it was associated with a reduction in crystal aggregation and deposition.

Matrix GLA protein (MGP) is a vitamin K–dependent protein that functions primarily as an inhibitor of vascular calcifications (Khan et al., 2013). MGP gene polymorphism is associated with vascular calcification and myocardial infarction (Herrmann et al., 2000). A single nucleotide polymorphism (SNP) has been shown to be associated with calcium oxalate kidney stone disease in Japanese and Chinese patients (Lu et al., 2012).

Lastly, inter-α-trypsin is a glycoprotein synthesized in the liver that is composed of three polypeptides (two heavy chains and one light chain), of which bikunin makes up the light chain. Bikunin is a strong inhibitor of calcium oxalate crystallization, aggregation, and growth in vitro (Atmani and Khan, 1999; Hochstrasser et al., 1984), and its expression has been shown to be upregulated in a rat model when exposed to oxalate.

Matrix

Renal calculi consist of crystalline and noncrystalline components. The noncrystalline component is termed *matrix*, which typically accounts for about 2.5% of the weight of the stone (Boyce and Garvey, 1956). In some cases, matrix comprises the majority of the stone (up to 65%), usually in association with chronic urinary tract infection (Allen and Spence, 1966; Boyce and Garvey, 1956). The exact composition of matrix is difficult to ascertain because only 25% of it is soluble (Ryall, 1993); however, chemical analysis reveals a heterogeneous mixture consisting of approximately 65% protein, 9% nonamino sugars, 5% glucosamine, 10% bound water, and 12% organic ash (Boyce, 1968).

Among the proteins incorporated into the matrix substance are Tamm-Horsfall protein, nephrocalcin, a γ-carboxyglutamic acid–rich protein, renal lithostathine, albumin, glycosaminoglycans, free carbohydrates, and a mucoprotein called matrix substance A (Hess and Kok, 1996). Boyce et al. (1962) found that substance A is immunologically unique and present in the matrix component of all stone formers. Moore and Gowland (1975) determined that substance A is composed of three or four distinct antigens unique to stones that were detected in the urine of 85% of stone formers but in no normal individuals. A study using reverse-phase, high-performance liquid chromatography and tandem mass spectrometry to evaluate calcium oxalate stones identified 68 distinct proteins with 95% confidence, including a significant number of inflammatory proteins (immunoglobulins, defensin-3, clusterin, complement C3a, kininogen, and fibrinogen) (Canales et al., 2008). Comparing the matrix component of 13 calcium oxalate and 12 calcium phosphate stones, these investigators found that inflammatory proteins were the predominant proteins in both stone types, with many proteins in common, suggesting a shared pathogenesis for the two stone types that involves inflammation (Canales et al., 2010).

Okumura et al. (2013) analyzed calcium oxalate stones from 9 patients and found highly heterogeneous electrophoretic mobilities of certain matrix proteins for which they subsequently performed solution protease digestion and proteomic analysis that identified 92 proteins. All stones had some osteopontin, prothrombin F1 fragments, and THP among other proteins, but their amounts were highly variable among individual stones. Furthermore, some stones had leukocyte-derived proteins such as myeloperoxidase and lactotransferrin. Although the exact role of matrix in stone formation, whether as promoter, inhibitor, or passive bystander, has yet to be elucidated, the variability in type and proportion of protein species in this study supports a diverse etiology, likely influenced by heredity, and provides a target for future research.

Key Points: Physicochemistry and Pathogenesis

- Urine must be supersaturated for stones to form.
- Supersaturation alone is not sufficient for crystallization to occur in urine because of the presence of urinary inhibitors.
- Nephrocalcin, uropontin, and Tamm-Horsfall protein are important

inhibitors of crystal nucleation, growth, or aggregation.

- Urinary calcium and oxalate contribute equally to urinary saturation of calcium oxalate.
- Common calcium stones may originate from subepithelial plaques composed of calcium apatite that serve as an anchor on which calcium oxalate stones can grow.
- The noncrystalline component of stones is matrix, which is composed of a combination of mucoproteins, proteins, carbohydrates, and urinary inhibitors.

Mineral Metabolism

Calcium

Between 30% and 40% of dietary calcium is absorbed from the intestine, with most being absorbed in the small intestine and only approximately 10% absorbed in the colon (Bronner and Pansu, 1999). By a process of intestinal adaptation, absorption of calcium varies with calcium intake. At times of low calcium intake, fractional calcium absorption is enhanced; during high calcium intake, fractional calcium absorption is reduced. With a calcium-rich diet, a nonsaturable, paracellular pathway for calcium absorption predominates. A saturable, vitamin D–dependent transcellular pathway constitutes the major pathway for intestinal calcium absorption when calcium intake is limited; this pathway is downregulated by a diet replete in calcium (Bronner et al., 1986; Buckley and Bronner, 1980). Because of the saturable component of calcium transport, a larger portion of calcium is absorbed when it is divided into several doses taken hours apart than with a large single dose (Phang et al., 1968). A small amount of calcium is secreted into the lumen of the intestine, thereby reducing net calcium absorption such that, overall, 100 to 300 mg of a total average calcium intake of 600 to 1200 mg daily will be absorbed.

Calcium is absorbed in the ionic state, and incomplete calcium absorption is due in part to formation of soluble calcium complexes in the intestinal lumen. **Therefore substances that complex with calcium, such as phosphate, citrate, oxalate, sulfate, and fatty acids, reduce the availability of ionic calcium for absorption** (Allen, 1982). Calcium readily complexes with phosphate in the intestinal lumen, but because calcium phosphate formation is dependent on pH (pK = 6.1), high luminal pH favors calcium phosphate complexation, thereby reducing calcium availability. On the other hand, calcium oxalate complex formation displays less pH dependence and complex formation is less reversible. Consequently, an oxalate-rich diet reduces calcium absorption. Transcellular calcium absorption is mediated by $1,25(OH)_2D_3$ (calcitriol), which is reported to enhance calcium permeability at the brush border of the intestinal epithelial cells (Fontaine et al., 1981).

The active form of vitamin D, $1,25(OH)_2D_3$, is the most potent stimulator of intestinal calcium absorption. After conversion of 7-dehydrocholesterol in the skin to previtamin D_3 promoted by sunlight, previtamin D_3 is hydroxylated in the liver to 25-hydroxyvitamin D_3, which is further hydroxylated in the proximal renal tubule to $1{,}25(OH)_2D_3$. The conversion of 25-hydroxyvitamin D_3 to $1{,}25(OH)_2D_3$ is stimulated by parathyroid hormone (PTH) and by hypophosphatemia. **A decrease in serum calcium increases secretion of PTH, which in turn directly stimulates the enzyme 1α-hydroxylase, which is located in the mitochondria of the proximal renal tubule.** After transport via the bloodstream to the intestine, $1{,}25(OH)_2D_3$ binds to the vitamin D receptor in the brush border membrane epithelial cells to enhance calcium absorption.

Calcitriol acts on the bone and kidney in addition to its action in increasing intestinal calcium absorption. In the bone, $1{,}25(OH)_2D_3$, along with PTH, promotes the recruitment and differentiation of osteoclasts that subsequently mobilize calcium from the bone. Consequently, the filtered load of calcium and phosphate increases. However, PTH increases renal calcium reabsorption and enhances phosphate excretion, leading to a further net increase in serum calcium, which suppresses further PTH secretion and synthesis of $1{,}25(OH)_2D_3$. Calcitriol modulates parathyroid function by inhibiting synthesis of PTH through enhanced vitamin D receptor and calcium-sensing receptor (CaSR) expression in the parathyroid glands (Dusso et al., 2005).

PTH is critical in maintaining normal calcium concentration in the extracellular fluid. PTH is an 84–amino acid protein that is the cleavage product of the precursor protein prepro-PTH. **Only mature PTH is secreted from the parathyroid gland, and the most potent stimulus for its secretion is a decrease in serum calcium** (Sherwood et al., 1968). In response to serum calcium levels, the G-protein–coupled extracellular CaSR regulates PTH secretion and renal tubular calcium reabsorption (Devuyst and Pirson, 2007). PTH stimulates mobilization of calcium from bone through the action of osteoclasts, further raising serum calcium and phosphorus. The action of PTH is mediated through changes in cyclic adenosine monophosphate and phospholipase C (Dunlay and Hruska, 1990; Muff et al., 1992). **At the kidney, PTH enhances renal calcium reabsorption and reduces renal tubular reabsorption of phosphate.** It also stimulates synthesis of $1{,}25(OH)_2D_3$, which leads to enhanced intestinal calcium and phosphate absorption. PTH has no direct effect on intestinal calcium absorption.

Calcium absorption in the kidney is complex, but recent work has begun to elucidate the proteins and mechanisms involved. On average, only 1% to 3% of filtered calcium is excreted in the urine, with most being reabsorbed paracellularly in the renal proximal tubule (60% to 65%) and thick ascending limb of the loop of Henle (25% to 30%). The remaining 8% to 10% of filtered calcium is reabsorbed transcellularly in the distal convoluted tubule (Friedman, 2007).

The paracellular absorption of calcium in the proximal tubule and thick ascending limb of the loop of Henle occurs by several mechanisms. First, calcium travels through paracellular channels found at the tight junctions of epithelial cells in the proximal tubule. The integral membrane proteins of the tight junction include occludin, junctional adhesion molecules, and claudins (Ebnet et al., 2004; Furuse et al., 1993; Hou, 2013). Claudins are a family of proteins with four transmembrane domains (Hou, 2013; Lal-Nag and Morin, 2009), including claudin-2, which has been implicated in paracellular reabsorption of calcium and other cations in the proximal tubule (Muto et al., 2010), and claudin-16 and claudin-19, which form a paracellular channel complex that allows selective cation permeation in the thick ascending limb (Hou et al., 2008, 2009).

Calcium is passively reabsorbed from the lumen of the thick ascending limb of the loop of Henle into the interstitial space through a paracellular pathway driven by a lumen-positive transepithelial voltage gradient (Hou, 2013). The positive luminal voltage occurs as a result of apical potassium secretion and basolateral chloride secretion, as well as by way of a transepithelial NaCl concentration gradient over the cation-selective paracellular channel in the thick ascending limb.

The CaSR plays a role in renal handling of calcium, and its expression predominates in the thick ascending limb. Serum calcium stimulates the CaSR to increase expression of claudin-14, which blocks the calcium channels formed by the claudin-16/19 complex, thereby reducing paracellular calcium reabsorption (Gong et al., 2012; Toka et al., 2012).

Transcellular calcium absorption in the distal convoluted tubule occurs via several mechanisms (Mensenkamp et al., 2006, 2007). Calcium enters the epithelial cells of the distal tubule through a transcellular channel (transient receptor potential vanilloid 5, or TRPV5), which is unique among other channels in the TRP family because of its high calcium selectivity. Calcium flux through TRPV5 into the distal tubule cells is controlled at several levels, including *TRPV5* gene expression, feedback inhibition, and trafficking across the plasma membrane. Inactivation of TRPV5 in mice leads to severe hypercalciuria, which is compensated for by increased intestinal calcium absorption resulting from enhanced calcitriol synthesis. Calcium is bound in the cell to a chaperone protein (calbindin-D28k), which facilitates diffusion across the cell from the apical to the basolateral space where calcium can then exit.

Phosphorus

Like calcium, inorganic phosphate absorption is dependent on saturable transcellular and nonsaturable paracellular transport. At low phosphorus concentrations (1 to 3 mmol/L), saturable absorptive transport occurs. At higher phosphorus levels, absorption increases without saturation (Walton and Gray, 1979). Approximately 60% of dietary phosphate is absorbed in the intestine. Active absorption of phosphate from the intestine involves a $1,25(OH)_2D_3$-regulated, sodium-dependent transport process (Danisi and Straub, 1980; Lee et al., 1986). Phosphate absorption is highly pH dependent; low luminal pH reduces while high pH enhances phosphate transport.

Approximately 65% of absorbed phosphate is excreted by the kidney and the remainder by the intestine. In normal healthy adults, 80% to 90% of the filtered load of phosphate is reabsorbed in the renal tubule and 10% to 20% is excreted in the urine. **Regulation of renal phosphate handling is primarily by way of PTH, which inhibits renal tubular reabsorption of filtered phosphate.**

Magnesium

Magnesium is absorbed from the intestine by passive diffusion or active transport, although passive diffusion accounts for most of the net magnesium absorption. Magnesium is absorbed in the large and small intestine, with the majority absorbed from the distal small intestine. Hormonal regulation of magnesium is primarily through vitamin D.

Oxalate

Oxalate metabolism differs markedly from calcium metabolism. Although 30% to 40% of ingested calcium is absorbed from the intestine, only 6% to 14% of ingested oxalate is absorbed (Hesse et al., 1999; Holmes et al., 1995). Oxalate absorption occurs throughout the intestinal tract, with about half or more occurring in the small intestine and half in the colon (Holmes et al., 1995).

Although oxalate absorption is difficult to measure directly, it has historically been estimated by urinary oxalate excretion, a relationship that is valid only if there is a linear relationship between ingested and excreted oxalate and if absorbed oxalate is not significantly taken up in the tissues, metabolized, or secreted back into the intestine. Holmes et al. (2001) in fact demonstrated that the relationship between ingested oxalate and absorbed oxalate is curvilinear because of higher absorption of oxalate at low intake than at high intake. Moreover, they showed that oxalate absorption varies widely among individuals, ranging from 10% to 72% of ingested oxalate. A recent study suggested that hyperoxaluric stone formers absorb more oxalate in response to an oral oxalate load than stone formers with normal oxalate excretion (Krishnamurthy et al., 2003). Knight et al. (2007), however, found no difference between normal subjects and stone formers in intestinal absorption or renal handling of oxalate. In patients with small bowel disease or history of intestinal resection and an intact colon, oxalate absorption is markedly increased (Barilla et al., 1978).

Oxalate transport occurs via transcellular and paracellular pathways. Although transport by way of paracellular pathways and some nonmediated transcellular pathways is primarily passive, driven by electrochemical or concentration gradients, transcellular transport is largely actively mediated by membrane carriers. The transport protein responsible for oxalate secretion has been suspected to belong to the SLC26 family of solute-linked carrier (SLC) anion exchangers. A putative anion exchange transporter, SLC26A6, which is expressed in the apical membrane of small intestinal and perhaps colonic epithelial cells, has been implicated in intestinal oxalate transport (Hatch and Freel, 2005). Evidence suggests that oxalate may be secreted, as well as absorbed, in the intestine (Jiang et al., 2006). In vitro flux studies using intestinal segments of mutant mice lacking SLC26A6 showed enhanced net absorption of oxalate as a result of defective oxalate secretion. Furthermore, in vivo *Slc26a6*-null mice were found to have elevated plasma and urinary oxalate levels, reduced fecal oxalate excretion, and a high incidence of calcium oxalate bladder stones compared with wild-type mice. These findings provide compelling evidence for a possible role of SLC26A6 in oxalate secretion and suggest a potential target for therapeutic agents that modify urinary oxalate absorption.

A number of other factors can influence oxalate absorption, including the presence of oxalate-binding cations such as calcium or magnesium and oxalate-degrading bacteria. Coingestion of calcium- and oxalate-containing foods leads to formation of calcium oxalate complexes, which limits the

availability of free oxalate ion for absorption (Hess et al., 1998; Liebman and Chai, 1997; Penniston and Nakada, 2009). Oxalate-degrading bacteria, notably *Oxalobacter formigenes*, use oxalate as an energy source and consequently reduce intestinal oxalate absorption. The mechanism of action of *O. formigenes* in reducing urinary oxalate excretion may not be entirely accounted for by degradation of intestinal oxalate. In vivo and ex vivo studies in *O. formigenes*–colonized rats demonstrated reduced urinary oxalate excretion and net colonic oxalate secretion, suggesting that *O. formigenes* may interact directly with intestinal mucosal cells to stimulate secretion of endogenously derived oxalate (Hatch et al., 2006).

The potential for therapeutic use of probiotics or oxalate-degrading enzyme preparations has been explored in mice models and in several short-term clinical trials. In two knockout mice models, one of which resembles primary hyperoxaluria, administration of an oxalate-degrading enzyme reduced urinary oxalate and prevented nephrocalcinosis (Grujic et al., 2009). Likewise, in a small study of patients with primary hyperoxaluria and normal renal function or varying degrees of renal failure, administration of *O. formigenes* was associated with a reduction in serum and/or urinary oxalate (Hoppe et al., 2006). However, a subsequent randomized trial in 43 patients with primary hyperoxaluria administered oral *O. formigenes* versus placebo failed to show a treatment effect in reducing urinary oxalate (Hoppe et al., 2011). Similarly, although one uncontrolled study (Campieri et al., 2001) of calcium oxalate stone formers with mild hyperoxaluria showed a 24% to 40% reduction in urinary oxalate with the administration of a preparation of mixed lactic acid bacterium species, a randomized, controlled trial (Goldfarb et al., 2007) failed to demonstrate an effect of the same probiotic. At this time, the contribution of *O. formigenes* to the overall risk of stone formation is not fully understood, and although *O. formigenes* is the most potent oxalate-degrading bacterium, other bacterial species have demonstrated oxalate-degrading activity in vitro (Klimesova et al., 2014; Magwira et al., 2012).

Absorbed oxalate is nearly completely excreted in the urine (Hodgkinson and Wilkinson, 1974; Prenan et al., 1982). Urinary oxalate is derived from endogenous production in the liver (from ascorbic acid and glycine) and dietary sources. **Evidence suggests that, on average, half of urinary oxalate is derived from the diet, with the precise amount depending on the relative amount of ingested calcium and oxalate** (Holmes et al., 2001).

It is estimated that between 86% and 98% of oxalate is ultrafilterable.

However, renal tubular handling of oxalate has not been clearly defined, although secretion and reabsorption have been suspected. There is evidence from a number of animal models of a secretory pathway for oxalate that likely resides in the renal proximal tubule (Holmes and Assimos, 2004). The SLC26 transport proteins responsible for oxalate secretion include one implicated in intestinal oxalate secretion, SLC26A6. However, no specific transporter has been definitively linked to renal oxalate secretion, and a recent study in a rat model investigating the role of a likely candidate, the basolateral anion exchanger sulfate anion transporter-1 (SAT1, or SLC26A1), found no correlation between changes in renal expression of SAT1 messenger RNA or protein and hyperoxaluria (Freel and Hatch, 2012).

Clinical evidence also supports renal oxalate secretion, although it is not clear if renal handling of oxalate differs between stone formers and non–stone formers (Holmes et al., 2005; Knight et al., 2007; Schwille et al., 1989). Holmes et al. (2005) studied six normal subjects administered increasing oral oxalate loads and found oxalate clearance ratios consistent with renal oxalate secretion, with up to 50% of urinary oxalate accounted for by oxalate secretion at the highest oxalate load. These investigators subsequently compared plasma and urine oxalate levels in idiopathic hypercalciuric stone formers versus normal subjects while fasting and after consuming three low-oxalate meals (Bergsland et al,. 2011). Despite no difference in plasma oxalate between the two groups in either the fasting or fed states, urinary oxalate and fractional excretion was higher in patients than normal subjects. Fractional excretion of oxalate exceeded 1, indicating oxalate secretion, in almost a third of patients and no controls, suggesting that renal oxalate secretion may play a role in regulating plasma oxalate levels.

Key Points: Mineral Metabolism

- Calcium absorption occurs primarily in the small intestine at a rate that is dependent on calcium intake.
- 1,25-Dihydroxyvitamin D_3 is the most potent stimulator of intestinal calcium absorption.
- PTH stimulates 1α-hydroxylase in the proximal tubule of the kidney to convert 25-hydroxyvitamin D_3 to $1,25(OH)_2D_3$.

- PTH enhances proximal tubular reabsorption of calcium and renal phosphate excretion.
- Intestinal oxalate absorption is influenced by luminal calcium, magnesium, and oxalate-degrading bacteria.

Pathophysiology of Upper Urinary Tract Calculi

Classification of Nephrolithiasis

The most common component of urinary calculi is calcium, which is a major constituent of nearly 80% of stones. Calcium oxalate makes up about 60% of all stones, mixed calcium oxalate and hydroxyapatite 20%, and brushite stones 2%. Uric acid and struvite (magnesium ammonium phosphate) each account for approximately 7% of stones, and cystine stones represent only about 1% (Table 91.1; Wilson, 1989). Stones associated with medications and their byproducts, such as triamterene, silica, indinavir, and ephedrine, are uncommon and usually preventable.

TABLE 91.1

Stone Composition and Relative Occurrence

STONE COMPOSITION	OCCURRENCE (%)
CALCIUM-CONTAINING STONES	
Calcium oxalate	60
Hydroxyapatite	20
Brushite	2
NON–CALCIUM-CONTAINING STONES	
Uric acid	7
Struvite	7
Cystine	1–3
Triamterene	<1
Silica	<1
2,8-Dihydroxyadenine	<1

From Pearle MS, Pak YC: Renal calculi: a practical approach to medical evaluation and management. In Andreucci VE, Fine LG, editors: *International yearbook of nephrology,* New York, 1996, Oxford University Press, pp 69–80.

Most classification systems for nephrolithiasis differentiate stones on the basis of the underlying metabolic or environmental abnormalities with which they are associated (Table 91.2). A number of pathophysiologic derangements contribute to calcium stone formation, either alone or in combination, including hypercalciuria, hypocitraturia, hyperuricosuria, and hyperoxaluria (Coe et al., 2005). Uric acid, cystine, and struvite stones form in relatively unique settings; uric acid stones form only in an acid urine, cystine stones are the result of impaired renal reabsorption of cystine, and infection stones occur in alkaline urine produced by urease-producing bacteria. For some stones such as cystine, knowledge of the chemical composition of the stone may provide sufficient information to initiate appropriate therapy. However, because of the multiple causes associated with calcium-based stones, an understanding of the underlying metabolic disorders and environmental factors that predispose to stone formation is required to implement a rational treatment plan. Recent investigation into the molecular and genetic causes of stone formation may ultimately translate into newer treatment strategies (Devuyst and Pirson, 2007; Frick and Bushinsky, 2003; Langman, 2004).

TABLE 91.2

Diagnostic Classification of Nephrolithiasis

CONDITION	METABOLIC/ENVIRONMENTAL DEFECT	PREVALENCE (%)
Absorptive hypercalciuria	Increased gastrointestinal calcium absorption	20–40
Renal phosphate leak	Impaired renal phosphorus absorption	
Renal hypercalciuria	Impaired renal calcium reabsorption	5–8
Resorptive hypercalciuria	Primary hyperparathyroidism	3–5
Hyperuricosuric calcium nephrolithiasis	Dietary purine excess, uric acid overproduction	10–40
Hypocitraturic calcium nephrolithiasis		10–50
Isolated	Idiopathic	
Chronic diarrheal syndrome	Gastrointestinal alkali loss	
Distal renal tubular acidosis	Impaired renal acid excretion	
Thiazide-induced	Hypokalemia	
Hyperoxaluric calcium nephrolithiasis		2–15
Primary hyperoxaluria	Oxalate overproduction	
Dietary hyperoxaluria	Increased dietary oxalate	
Enteric hyperoxaluria	Increased intestinal oxalate absorption	
Hypomagnesiuric calcium nephrolithiasis	Decreased intestinal magnesium absorption	5–10

Idiopathic low urine pH	Low urinary pH	15–30
Cystinuria	Impaired renal cystine reabsorption	<1
Infection stones	Infection with urease-producing bacteria	1–5
Low urine volume	Inadequate fluid intake	10–50
Miscellaneous or no abnormality	NA	<3

Modified from Pearle MS, Pak CY: Renal calculi: a practical approach to medical evaluation and management. In Andreucci VE, Fine LG, editors: *International yearbook of nephrology,* New York, 1996, Oxford University Press, pp 69–80.

Calcium Stones

Hypercalciuria

Hypercalciuria is the most common abnormality identified in calcium stone formers (Bushinsky, 1998; Coe et al., 1992; Pak et al., 1982). However, the role of hypercalciuria in stone formation is controversial because of the overlap in urine calcium levels between stone formers and non–stone formers (Coe et al., 1992; Robertson and Morgan, 1972). Several lines of evidence support a pathogenetic role for hypercalciuria in stone formation. First, hypercalciuria is common in stone-forming patients, occurring in 35% to 65% of patients (Levy et al., 1995). Indeed, treatment strategies aimed at reducing urinary calcium levels are associated with a reduction in stone recurrence rates (Pearle et al., 1999), and medical therapy often fails in patients with persistent hypercalciuria (Strauss et al., 1982). In addition, multivariate analysis of a subset of men and women from three large epidemiologic studies in whom 24-hour urine studies were available revealed that, after adjusting for other factors, the risk of incident stone formation increased with increasing urinary calcium (Curhan et al., 2001). Lastly, recent investigations of Randall plaques as potential precursors to calcium stone formation have shown that plaques occur more commonly in stone formers and their number directly correlates with urine calcium levels and number of stone episodes (Kim et al., 2005; Kuo et al., 2003b).

High urinary calcium concentrations lead to increased urinary saturation of calcium salts (Pak and Holt, 1976) and reduced urinary inhibitory activity by way of complexation with negatively charged inhibitors such as citrate and chondroitin sulfate (Zerwekh et al., 1988). The normal kidney filters approximately 270 mmol of calcium daily and reabsorbs all but 4 mmol

(Bushinsky, 1998). However, a variety of conditions lead to elevated urinary calcium levels and increased urinary saturation of calcium salts. Criteria defining hypercalciuria are variable, but **the strictest definition classifies hypercalciuria as greater than 200 mg of urinary calcium/day after adherence to a 400-mg calcium, 100-mg sodium diet for 1 week** (Menon, 1986). **Parks and Coe** (1986) **defined hypercalciuria as excretion of greater than 4 mg/kg/day or greater than 7 mmol/day in men and 6 mmol/day in women. However, arguably a threshold level of calcium that separates hypercalciuria from normocalciuria is artificial, as urinary calcium demonstrates a spectrum of effects over its range by which higher or lower calcium levels are associated with a greater or lesser effect.**

Historically, the term *idiopathic hypercalciuria* was applied to stone formers for whom classification of their metabolic abnormality was difficult. Calcium transport is regulated at three sites: intestine, bone, and kidney. Dysregulation at any of these sites can lead to hypercalciuria. In 1974 Pak et al. divided hypercalciuria into three distinct subtypes on the basis of unique pathophysiologic abnormalities: absorptive hypercalciuria resulting from increased intestinal absorption of calcium, renal hypercalciuria resulting from primary renal leak of calcium, and resorptive hypercalciuria resulting from increased bone demineralization.

Although historically this classification system was used because of its utility in simplifying the understanding and treatment of specific metabolic derangements, many have argued that hypercalciuria is associated with multiple, interrelated disturbances that cannot be readily separated into a specific organ system (Coe et al., 1992). Furthermore, studies into the molecular mechanisms of stone formation have identified gene mutations that can affect several organ systems, culminating in hypercalciuria (Frick and Bushinsky, 2003; Langman, 2004). Indeed, use of a classification system for hypercalciuria has not been associated with superior therapeutic efficacy and is therefore not routinely implemented in clinical practice. Although improved understanding of the molecular and genetic causes of stone disease may change the categorization and management of stones in the future, for the purposes of this chapter, the standard classification system is used.

Absorptive Hypercalciuria.

Absorptive hypercalciuria (AH) is defined as increased urinary calcium excretion (>0.2 mg/mg creatinine) after an oral calcium load. Although fasting urinary calcium is usually normal in AH (<0.11 mg/dL glomerular filtration), severe forms of AH may occasionally be associated with fasting hypercalciuria as well. The underlying pathophysiologic abnormality in AH is increased intestinal absorption of calcium, which occurs in approximately 30% of stone formers. Dietary calcium restriction may normalize urinary calcium in some patients with AH (type II) but not in others (type I). **The added systemic load of calcium caused by intestinal calcium hyperabsorption results in a transient increase in serum calcium, which suppresses serum PTH and results in increased renal filtration of calcium, ultimately leading to hypercalciuria. Because the increase in intestinal absorption of calcium is matched by enhanced renal calcium excretion, serum calcium level remains normal.**

The cause of increased intestinal absorption of calcium has been variously ascribed to vitamin D–independent and dependent processes, as well as to upregulation of the vitamin D receptor (Breslau et al., 1992). However, no proposed mechanism completely accounts for all the findings associated with absorptive hypercalciuria, and there is no clear evidence that upregulation of intestinal calcium absorption is the primary cause. There are several genetic abnormalities that can potentially affect vitamin D activity. The active form of vitamin D, 1,25$(OH)_2D_3$, is generated by way of 1-hydroxylation of 25$(OH)D_3$ by the gene product of cytochrome P450 (CYP) 27B1 *(CYP27B1)*, which is present in a variety of tissues. The mitochondrial enzyme 1,25$(OH)_2$D-24-hydroxylase (CYP24A1), which is present in the intestine and kidney, inactivates both major vitamin D metabolites, 25$(OH)D_3$ and 1,25$(OH)_2D_3$. Bi-allelic mutations in *CYP24A1* have been shown to reduce activity of the enzyme, resulting in elevated levels of 1,25$(OH)_2D_3$, particularly in individuals taking large amounts of vitamin D (Schlingmann et al., 2011). Mutations in this gene are responsible for increased sensitivity to vitamin D supplementation in the autosomal recessive disorder idiopathic infantile hyperkalemia. In adults, recessive mutations in *CYP24A1* have been associated with a syndrome characterized by hypercalcemia, hypercalciuria, nephrocalcinosis, and nephrolithiasis (Dinour et al., 2013; Nesterova et al., 2013). Genome-wide association studies revealed an association between *CYP24A1* variants and serum vitamin D concentrations (Wang et al., 2010). The frequency of 1,25$(OH)_2$D-24-hydroxylase deficiency is estimated at 4% to 20% in the general population (Nesterova et al., 2013). However, although these mutations may be common, not all affected individuals demonstrate clinically significant abnormalities.

Hypersensitivity to vitamin D has also been shown to increase intestinal calcium absorption and cause hypercalciuria (Bushinsky and Monk, 1998). Moreover, several studies have linked hypercalciuria and the vitamin D receptor *(VDR)* gene. Jackman et al. (1999) identified a polymorphism in *VDR* in 19 patients with a family history of nephrolithiasis and hypercalciuria, thereby establishing a potential link. Likewise, Scott et al. (1999) identified linkage between a microsatellite marker and the *VDR* locus on chromosome 12q12-q14 in a cohort of 47 French-Canadian pedigrees with idiopathic hypercalciuria and calcium nephrolithiasis.

Other studies, however, failed to confirm the association of *VDR* abnormalities with hypercalciuria (Zerwekh et al., 1995, 1998). Indeed, other genetic loci have been identified in association with AH. Reed et al. (1999, 2002) mapped the locus for an inherited form of AH to chromosome 1q23.3-q24 and found a putative gene (subsequently shown by others to be homologous with the rat soluble adenylate cyclase gene) in this region in 12 unrelated white AH patients.

Another proposed cause of AH is renal phosphate wasting leading to a subsequent increase in active vitamin D. Patients with hereditary hypophosphatemic rickets with hypercalciuria (HHRH) manifest this abnormality, which is characterized by decreased renal reabsorption of phosphate, hypophosphatemia, and a subsequent compensatory increase in vitamin D levels, leading to enhanced absorption of calcium and phosphate from the intestine and hypercalciuria (Tieder et al., 1987). The mutations associated with HHRH are thought to be inherited in an autosomal recessive pattern. Candidate genes for HHRH include *SLC34A1* and *SLC34A3*, which encode sodium-coupled phosphate transporters located in the apical membrane of the renal proximal tubule (NaPi-IIa and NaPi-IIc, respectively) (Devuyst and Pirson, 2007). Renal phosphate leak, however, is a rare cause of nephrolithiasis, affecting at most 2% to 4% of patients (Levy et al., 1995).

Renal Hypercalciuria.

The kidney filters approximately 270 mmol of calcium and must reabsorb more than 98% of it to maintain calcium homeostasis (Bushinsky, 1998). Approximately 70% of calcium reabsorption occurs in the proximal tubule, with paracellular pathways predominating (Frick and Bushinsky, 2003; Moor and Bonny, 2016). In renal hypercalciuria, impaired renal tubular reabsorption of calcium results in elevated urinary calcium levels leading to secondary hyperparathyroidism (Coe et al., 1973). Serum calcium levels remain normal because the renal loss of calcium is compensated by enhanced intestinal absorption of calcium and bone resorption as a result of increased secretion of PTH and enhanced synthesis of 1,25$(OH)_2D_3$. **High fasting urinary calcium levels (>0.11 mg/dL glomerular filtration) with normal serum calcium values are characteristic of renal hypercalciuria.** The elevated fasting urinary calcium and serum PTH levels can differentiate a primary renal cause from a primary intestinal cause of hypercalciuria.

The actual cause of renal calcium leak is not known. However, alterations in transcellular and paracellular pathways for calcium reabsorption are likely implicated. Studies of several monogenetic disorders associated with hypercalciuria and nephrolithiasis provide insight into the mechanisms involved (Devuyst and Pirson, 2007; Ferraro et al., 2013a; Gambaro et al., 2004; Langman, 2004). In Dent disease (X-linked recessive nephrolithiasis), defects in chloride channel-5 (ClC-5), which is located in the proximal tubule, thick ascending limb, and α-type intercalated cells of the collecting ducts lead to hypercalciuria, proteinuria, nephrolithiasis, nephrocalcinosis, and progressive renal failure. Familial hypomagnesemia with hypercalciuria and nephrocalcinosis (FHHNC) is caused by mutations in claudin-16 (also known as paracellin-1) and claudin-19, members of the claudin gene family of tight junction proteins that are involved in the voltage-driven paracellular reabsorption of magnesium and calcium in the thick ascending limb and distal convoluted tubule (Konrad et al., 2006; Simon et al., 1999). Other claudin abnormalities, including defects in claudin-14, have been associated with nephrolithiasis (Thorleifsson et al., 2009). Finally, Bartter syndrome encompasses a group of autosomal recessive disorders involving dysfunction in the thick ascending limb that is characterized by salt wasting and hypokalemic metabolic acidosis, with variable occurrence of hypercalciuria and nephrolithiasis (Devuyst and Pirson, 2007). This disorder arises from a mutation in any of the genes encoding membrane proteins involved in transepithelial sodium chloride transport across the thick limb of the loop of Henle: *SLC12A1*, which encodes the Na^+,K^+,$2Cl^-$ cotransporter, NKCC2; *KCNJ*, which encodes the apical renal outer medullary potassium channel, ROMK; *CLCNKB*, which encodes the basolateral chloride channel, ClC-Kb; and *BSND*, which encodes a subunit (Barttin) for the chloride channel proteins ClC-Ka and ClC-Kb.

The CaSR is the main calcium sensor involved in the maintenance of calcium metabolism. Mutations of the genes encoding CaSR *(CASR)*, G protein alpha 11 *(GNA11)*, and adaptor-related protein complex 2 sigma 1 subunit *(AP2S1)* can shift the set point for calcium sensing, leading to hyper- or hypocalcemic disorders (Mayr et al., 2016). Activating mutations in the gene encoding the CaSR have been associated with an autosomal dominant form of hypocalcemia by which a lower set-point for extracellular calcium sensing leads to decreased serum PTH levels, reduced renal calcium reabsorption, and subsequent hypocalcemia and hypercalciuria (Devuyst and Pirson, 2007). A potent activating mutation in the CaSR has been associated with salt-losing nephropathy and secondary hyperaldosteronism (Bartter syndrome type V), which is likely related to dysfunction of ROMK as a result of constitutive activation of the abnormal CaSR (Vargas-Poussou et al., 2002). CaSR regulates calcium reabsorption in the thick ascending limb through changes in paracellular permeability (Loupy et al., 2012).

Loss-of-function polymorphisms in the *CaSR* gene have also been associated with idiopathic nephrolithiasis. Two synonymous single nucleotide polymorphisms (rs6776158 and rs1501899) that significantly reduce renal CaSR messenger RNA levels have been shown to be highly associated with normocitraturic nephrolithiasis (Vezzoli et al., 2010, 2011). Reduced CaSR expression can increase paracellular calcium reabsorption in the thick ascending limb of the loop of Henle, leading to interstitial calcium precipitation and hypocalciuria. Diminished calcium delivery to the collecting duct may affect the cellular mechanism for urinary acidification and concentration, leading to calcium oxalate stone formation. Other mutations in the genes for the Na^+-K^+-$2Cl^-$ cotransporter NKCC2 and the potassium channel ROMK have been associated with autosomal recessive disorders characterized by fasting hypercalciuria and nephrocalcinosis.

Understanding these genetic disorders has the potential to further elucidate the tubular handling of calcium and the pathophysiology of renal hypercalciuria.

Resorptive Hypercalciuria.

Resorptive hypercalciuria is an infrequent abnormality most commonly associated with primary hyperparathyroidism. Primary hyperparathyroidism is the cause of nephrolithiasis in about 5% of cases (Broadus, 1989). **Excessive parathyroid hormone (PTH) secretion from a parathyroid adenoma leads to excessive bone resorption and increased renal synthesis of $1,25(OH)_2D_3$, which in turn enhances intestinal absorption of calcium. The net effect is**

elevated serum and urine calcium levels and reduced serum phosphorus levels. Although most patients with primary hyperparathyroidism demonstrate hypercalcemia and hypercalciuria, a normal serum calcium level in the presence of an inappropriately high serum PTH value may be seen in some cases, making the diagnosis more difficult. Administration of a thiazide diuretic will enhance renal calcium reabsorption and exacerbate the hypercalcemia, without suppression of PTH production, thereby facilitating the diagnosis ("thiazide challenge") (Eisner et al., 2009).

Primary hyperparathyroidism is associated with nephrolithiasis in less than 5% of affected individuals (Heath et al., 1980; Parks et al., 1980). However, the diagnosis should be suspected in patients with nephrolithiasis and serum calcium levels greater than 10.1 mg/dL (Broadus et al., 1980; Menon, 1986). Serum calcium levels can vary by up to 5%, and patients with mild hyperparathyroidism may exhibit relatively small increases of serum calcium (Yendt and Gagne, 1968). Therefore repeated measurements of serum calcium, along with serum intact PTH, may be necessary to make the diagnosis. Measurement of serum ionized calcium may help in equivocal cases because ionized calcium may be elevated in the setting of normal serum calcium (Yendt and Gagne, 1968). PTH also increases excretion of bicarbonate and phosphorus from the proximal renal tubule, resulting in phosphaturia and mild hyperchloremic acidosis.

Hypercalcemic-Induced Hypercalciuria

Sarcoid and Granulomatous Disease.

Additional, rare causes of hypercalciuria include hypercalcemia of malignancy, sarcoidosis, thyrotoxicosis, and vitamin D toxicity. Many granulomatous diseases, including tuberculosis, sarcoidosis, histoplasmosis, leprosy, and silicosis, have been reported to produce hypercalcemia. Among these, sarcoidosis is most commonly associated with urolithiasis. **Macrophages in the sarcoid granuloma, through synthesis of 1α-hydroxylase, increase production of 1,25$(OH)_2D_3$, which enhances intestinal absorption of calcium and promotes bone resorption, ultimately leading to hypercalciuria** (Adams et al., 1983, 1985). As such granulomatous diseases manifest absorptive and resorptive hypercalciuria. Pulmonary alveolar cells and lymph node homogenates in patients with sarcoidosis are capable of synthesizing vitamin D, a function usually limited to the kidney. Most patients with sarcoidosis have a suppressed level of PTH secondary to hypercalcemia (Cushard et al., 1972). Sarcoidosis can also be differentiated from other diagnoses by the rapid resolution of hypercalcemia with initiation of corticosteroid therapy (Breslau et al., 1982).

Malignancy-Associated Hypercalcemia.

Although primary hyperparathyroidism is the most common cause of hypercalcemia in an outpatient setting, malignancy is the main cause of hypercalcemia in hospitalized patients (Rizzoli and Bonjour, 1992). Measuring intact PTH can help distinguish patients with hyperparathyroidism from those with other causes of hypercalcemia (Burtis et al., 1990). Tumors in patients with humoral hypercalcemia produce a PTH-related protein (PTHrP) whose production is regulated by CaSRs on the cell surface (Chattopadhyay, 2006). Lung and breast cancers account for about 60% of malignancy-associated hypercalcemia, whereas renal cell (10% to 15%), head and neck (10%), and hematologic cancers such as lymphoma and myeloma (10%) account for the rest. Although direct mechanical destruction of bone constitutes one cause of hypercalcemia, many tumors secrete humoral factors, including PTHrP, transforming growth factor-α, and cytokines such as interleukin-1 and tumor necrosis factor, which activate osteoclasts and result in bone lysis and hypercalcemia (Burtis et al., 1990; Edelson and Kleerekoper, 1995; Mundy, 1990). Like PTH, PTHrP increases renal calcium absorption and stimulates osteoblasts to secrete receptor activator of nuclear factor-κB ligand (RANKL), which binds to the RANK receptor on osteoclasts, leading to differentiation of osteoclast precursors into mature osteoclasts and subsequently to enhanced bone resorption and hypercalcemia (Mirrakhimov, 2015). Furthermore, PTHrP stimulates 1-α hydroxylation of $25(OH)_2D_3$, leading to increased production of calcitriol and enhanced intestinal calcium absorption and bone turnover.

Glucocorticoid-Induced Hypercalcemia.

Glucocorticoids can significantly alter calcium metabolism through their actions on bone, intestine, and parathyroid glands. Their most potent effect is related to calcium metabolism in bones, where glucocorticoids promote bone resorption and reduce bone formation, ultimately leading to osteopenia with chronic use (Manelli and Giustina, 2000). In addition, they stimulate release of PTH (Fucik et al., 1975). On the other hand, glucocorticoids inhibit intestinal absorption of calcium, which accounts for their effectiveness in preventing hypercalciuria induced by sarcoidosis (Manelli and Giustina, 2000). The net effect probably favors promotion of stone formation because nephrolithiasis is common in patients with Cushing syndrome (Faggiano et al., 2003). In one study, stones were found in 50% of patients with active Cushing syndrome, 27% of cured patients, and 6.5% of controls. Compared with controls, patients with active disease had a significantly higher prevalence of hypercalciuria, hypocitraturia, and hyperuricosuria, but these patients were also at greater risk of obesity and diabetes, which have been linked to stone formation (Faggiano et al., 2003).

Hyperoxaluria

Hyperoxaluria, defined as urinary oxalate greater than 40 mg/day, leads to increased urinary saturation of calcium oxalate and subsequent promotion of calcium oxalate stones. In addition, oxalate has been implicated in crystal growth and retention by means of renal tubular cell injury mediated by lipid peroxidation and the generation of oxygen free radicals (Ravichandran and Selvam, 1990). Membrane injury facilitates the fixation of calcium oxalate crystals and subsequent crystal growth. Antioxidant therapy has been shown to prevent calcium oxalate precipitation in the rat kidney and to reduce oxalate excretion in stone patients (Selvam, 2002). Similarly, calcium oxalate crystal deposition on urothelium in vitro was prevented by free radical scavengers such as phytic acid and mannitol, purportedly by protecting the membrane from free radical–mediated damage (Selvam, 2002; Thamilselvan and Selvam, 1997). Human studies, however, failed to demonstrate increases in markers of oxidative stress or renal injury in normal subjects and stone formers ingesting large doses of oxalate (up to 8 mmol), thus calling into question the importance of oxalate-induced cell membrane damage in calcium oxalate stone formation (Knight et al., 2007).

Causes of hyperoxaluria include disorders in biosynthetic pathways (primary hyperoxaluria); intestinal malabsorptive states associated with inflammatory bowel disease, celiac sprue, or intestinal resection (enteric hyperoxaluria); and excessive dietary intake or high substrate levels (vitamin C) (dietary hyperoxaluria).

Primary Hyperoxaluria.

The primary hyperoxalurias (PHs) are the result of rare autosomal recessive inherited disorders in glyoxylate metabolism by which the normal conversion of glyoxylate to glycine is prevented, leading to preferential

oxidative conversion of glyoxylate to oxalate, an end product of metabolism (Fig. 91.7). The markedly high levels of urinary oxalate that ensue (>100 mg/day) lead to increased saturation of calcium oxalate and formation of calcium oxalate complexes and crystals in the renal tubular lumen. Some crystals attach to the surface of renal tubular epithelial cells and further aggregate into stones, whereas others are internalized into tubular cells and then extruded into the renal interstitium, leading to marked nephrocalcinosis (Hoppe et al., 2009). Renal injury may be a consequence of direct cell toxicity from either high oxalate concentration or calcium oxalate crystals, mediated through reactive oxygen species. Renal impairment occurs from recurrent obstructing calcium oxalate stones and as a result of renal parenchymal inflammation and interstitial fibrosis from severe nephrocalcinosis (Mulay et al., 2013). With progressive renal damage, renal elimination of oxalate is impaired, leading to systemic deposition of calcium oxalate crystals, or systemic oxalosis.

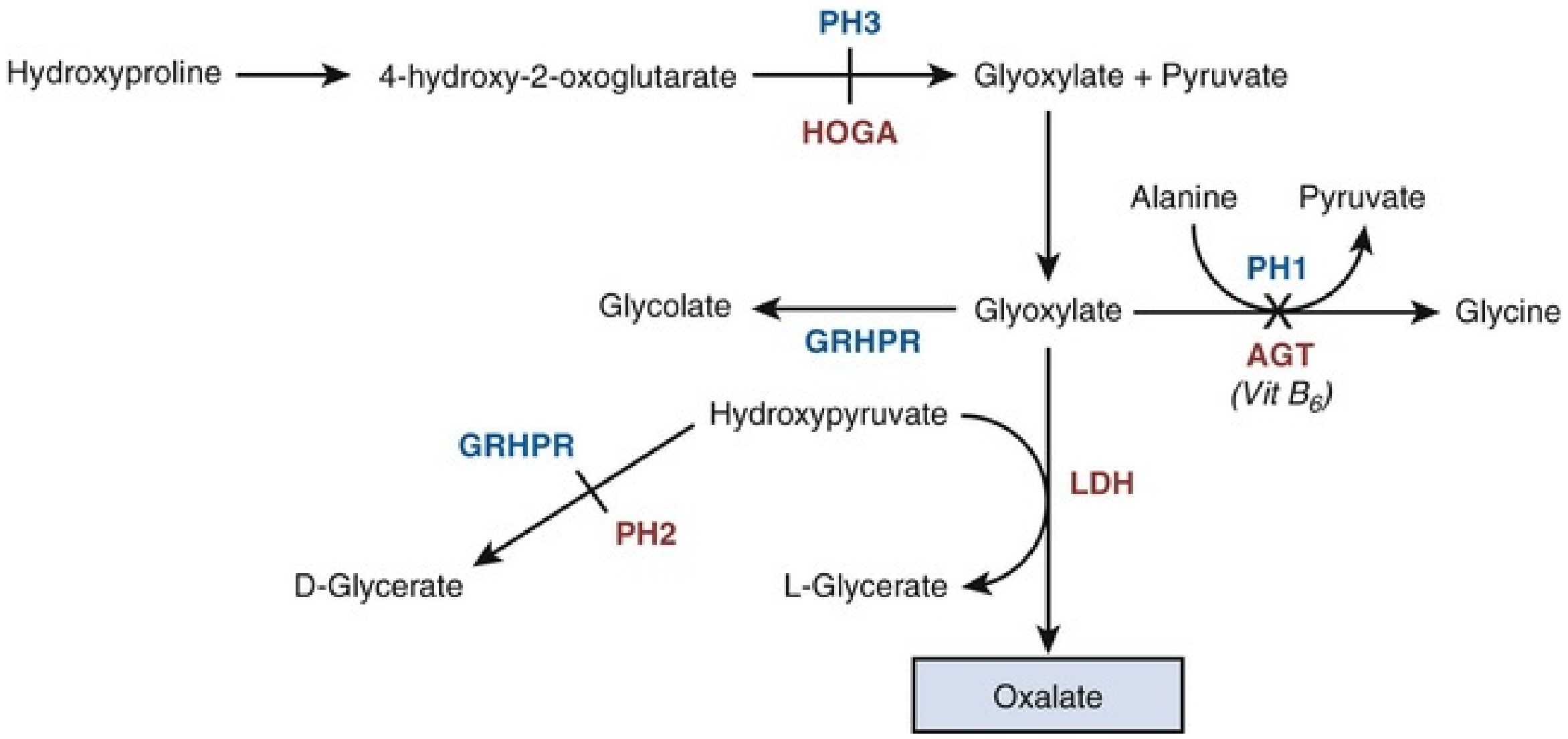
Hydroxyproline
4-hydroxy-2-oxoglutarate
PH3
HOGA
Glyoxylate + Pyruvate
Alanine
Pyruvate
PH1
Glycolate
GRHPR
Glyoxylate
Glycine
AGT
(Vit B6)
Hydroxypyruvate
GRHPR
PH2
LDH
D-Glycerate
L-Glycerate
Oxalate

FIG. 91.7 Pathway of oxalate metabolism in the liver. Defects in alanine glyoxylate aminotransferase (AGT) are associated with primary hyperoxaluria type 1 (PH1), defects in glyoxylate reductase/hydroxypyruvate reductase (GRHPR) are associated with primary hyperoxaluria type 2 (PH2), and defects in 4-hydroxy-2-oxoglutarate aldolase (HOGA) are associated with primary hyperoxaluria type 3 (PH3). *LDH,* Lactate dehydrogenase.

Three forms of PH have been identified (types 1, 2, and 3) that differ in the enzyme and intracellular organelle affected. The primary enzyme catalyzing glyoxylate conversion to glycine is the pyridoxal phosphate–dependent alanine-glyoxylate aminotransferase (AGT), which is synthesized in the liver peroxisome. Mutations in this gene *(AGXT)* result in primary hyperoxaluria type 1 (PH1), and patients with this disorder have elevated levels of oxalate and frequently glycolate. ESRD occurs during the second to third decades of life in most patients with PH1, making it the most aggressive form of the disease (Hoppe et al., 2009). Elucidation of the crystal structure of AGT to 2.5 Å has improved the understanding of mutations in the gene for this protein (Zhang et al., 2003). The most common mutation of *AGXT* results in a substitution of glycine by arginine at position 170; in the setting of a proline-to-leucine substitution at position 11 present in a polymorphic minor allele, the enzyme inappropriately targets the liver mitochondria, where it is metabolically inactive, rather than the liver peroxisomes (Fargue et al., 2013a). Patients with this mutation are responsive to pyridoxine therapy because pyridoxine is metabolized to pyridoxal phosphate, an essential cofactor for AGT, which results in an increased enzyme catalytic activity and enhanced peroxisome targeting (Fargue et al., 2013b). At least 178 mutations have been identified in the *AGXT* gene.

Primary hyperoxaluria type 2 (PH2) is associated with a defect in glyoxylate reductase/hydroxypyruvate reductase (GRHPR) in the liver, resulting in hyperoxaluric nephrolithiasis, but with a less aggressive course with regard to renal failure than PH1 (Johnson et al., 2002). Patients with PH2 have elevated urinary levels of L-glyceric acid and oxalate because reduced GRHPR enzyme activity leads to increased hydroxypyruvate and glyoxylate, which are converted by lactate dehydrogenase to L-glyceric acid and oxalate, respectively. A total of 30 mutations have been identified in the *GRHPR* gene (Cochat and Rumsby, 2013).

A third type of primary hyperoxaluria is caused by a defective mitochondrial enzyme, 4-hydroxy-2-oxoglutarate aldolase (HOGA), which is thought to play a role in hydroxyproline metabolism (Belostotsky et al., 2010). Hydroxy-2-oxoglutarate derived from hydroxyproline is converted to pyruvate and glyoxylate in a reaction catalyzed by HOGA. However, the mechanism by which this defect leads to hyperoxaluria has not been established. There are two common pathologic variants, including a 3 bp deletion (c.944_946delAGG, p.Glu315del), which is prevalent in the Ashkenazi Jewish population, and another mutation, c.700+5G > T, which causes missplicing in hepatic RNA (Belostotsky et al., 2010; Williams et al., 2012). Although PH3 is associated with hyperoxaluria and severe hypercalciuria, the recurrent calcium oxalate stone formation seen in early childhood may become clinically silent later in life, and there are no reports of progression to ESRD in these patients (Hoppe, 2012).

If untreated, PH1 inevitably leads to end-stage renal failure, which occurs by age 15 in 50% of affected patients and is associated with an overall death rate of approximately 30% (Cochat et al., 1999). Because the liver is the only organ responsible for detoxification of glyoxylate, combined liver-kidney transplantation is the accepted treatment for most patients with severe PH. Reported 5-year patient survival and liver allograft survival after combined liver-kidney transplantation are 80% and 72%, respectively (Jamieson, 2005). Furthermore, the renal function of survivors reportedly remains stable over time (Cochat et al., 1999; Hoppe and Langman, 2003). Isolated kidney transplantation is the treatment of choice for patients with PH2 and ESRD, because hypoxanthine-guanine phosphoribosyl transferase (HGPRT) is not liver specific. PH3 has not been associated with ESRD, and transplantation in this setting has not been reported.

Genetic testing is available for all three forms of PH, which can provide confirmation of biochemical testing and allows prenatal diagnosis and the confirmation or exclusion of disease in other family members. Because all three forms of PH may remain clinically asymptomatic until adulthood, it is imperative to screen family members. Furthermore, because renal transplantation may constitute a part of the treatment plan for patients with PH1 and PH2, it is imperative to exclude PH in family members before consideration of living-related kidney donation from within the family. One caveat for genetic testing is that not all carriers develop primary hyperoxaluria.

Another inherited cause of calcium oxalate stones associated with hyperoxaluria is mutations in the SAT1 sulphate-oxalate transporter, encoded by *SLC26A1* (Gee et al., 2016). Mutations in this gene may account for suspected inherited hyperoxaluria in patients in whom the three known forms of PH have been excluded.

Enteric Hyperoxaluria.

The most common cause of acquired hyperoxaluria is enteric hyperoxaluria. This abnormality is associated with chronic diarrheal states, by which **fat malabsorption results in saponification of fatty acids with divalent cations such as calcium and magnesium, thereby reducing calcium oxalate complexation and increasing the pool of available oxalate for reabsorption** (Earnest et al., 1975; Fig. 91.8). The poorly absorbed fatty acids and bile salts may increase colonic permeability to oxalate, further enhancing intestinal oxalate absorption (Dobbins and Binder, 1976; Hatch and Freel, 2008). A strong relationship between fecal fat and urinary oxalate excretion has been demonstrated in patients with steatorrhea (Fig. 91.9; Worcester, 1996). Dehydration, hypokalemia, hypomagnesiuria, hypocitraturia, and low urine pH also increase the risk of calcium oxalate stone formation in patients with chronic diarrheal syndrome. Malabsorption from any cause can lead to increased intestinal absorption of oxalate. As such, small bowel resection, intrinsic disease, and jejunoileal bypass (Cryer et al., 1975) have been associated with hyperoxaluria.

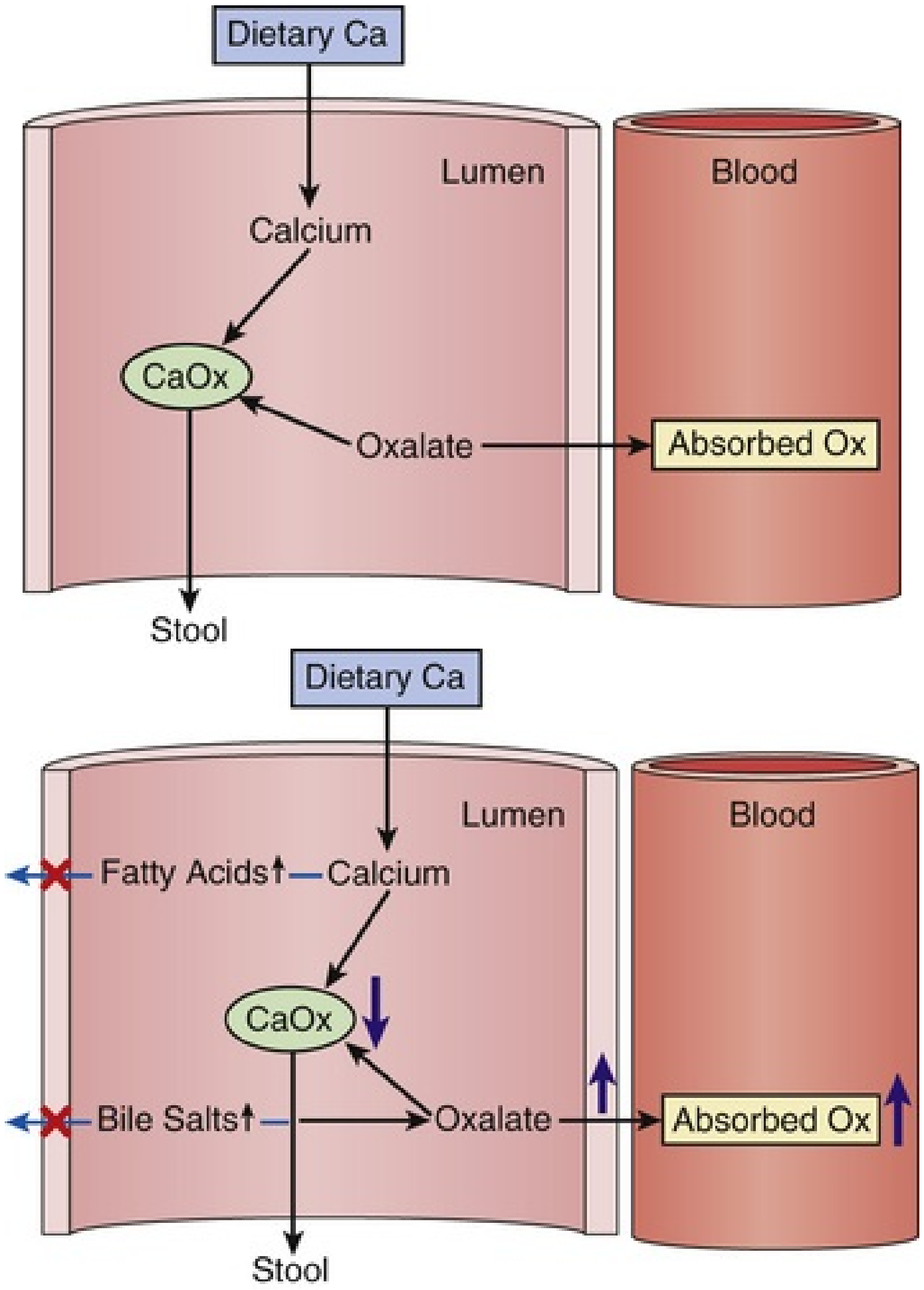
Dietary Ca
Lumen
Blood
Calcium
CaOx
Oxalate
Absorbed Ox
Stool
Dietary Ca
Lumen
Blood
Fatty Acids↑
Calcium
CaOx
Bile Salts↑
Oxalate
Absorbed Ox
Stool

FIG. 91.8 Mechanism of enteric hyperoxaluria. (A) Under normal intestinal and dietary conditions, dietary calcium combines in the intestinal lumen with oxalate, forming a calcium oxalate complex that is excreted in the stool. (B) In malabsorptive conditions, poorly absorbed fatty acids bind cations such as calcium and magnesium in the process of saponification, thereby decreasing calcium-oxalate complex formation and increasing luminal oxalate, which is overabsorbed and excreted in the urine. Poorly

absorbed bile salts increase colonic permeability of oxalate, furthering increasing absorbed oxalate.

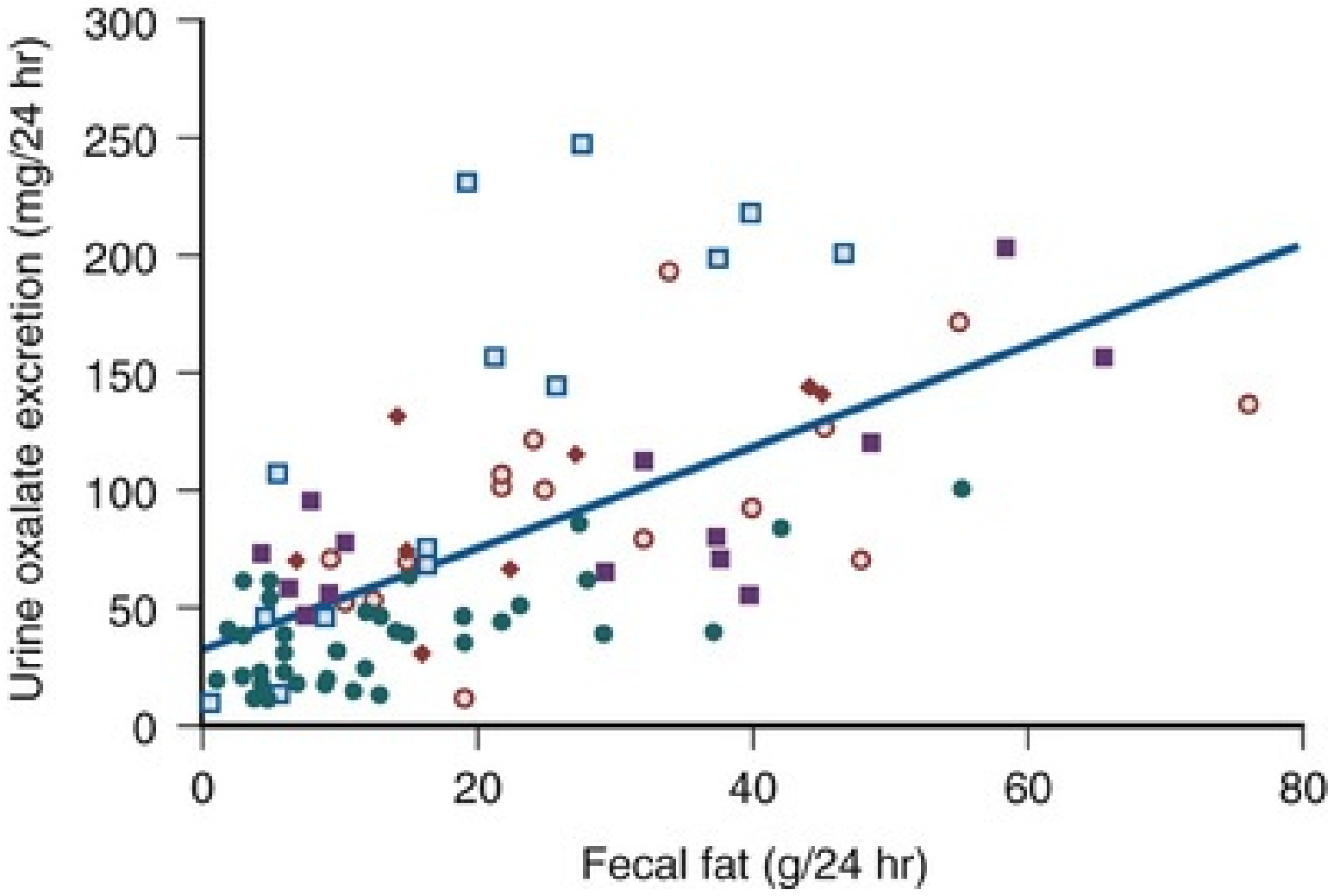

FIG. 91.9 The relationship between fecal fat and urinary oxalate excretion in patients with steatorrhea. Diet oxalate was 300 to 500 mg/day in all but one study, in which it was 55 to 90 mg/day. Diet calcium was 500 to 900 mg/day in all studies when reported. Normal urine citrate was less than 50 mg/day in all studies, except one in which it was less than 34 mg/day. Oxalate = 2.1 × fecal fat + 30.7 ($r^2 = 0.4$, $n = 96$, $P < 0.001$). (From Worcester EM: Stones due to bowel disease. In Coe F, Favus M, Pak C, et al, editors: *Kidney stones: medical and surgical management*, New York, 1996, Lippincott-Raven, pp 883–903.)

As the prevalence of obesity in the population has increased, bariatric surgery has become more popular and pervasive. Although jejunoileal bypass for obesity was discontinued in the past in part because of renal failure and nephrolithiasis induced by severe hyperoxaluria, modern bariatric surgery was thought to provide a safer alternative for weight loss. However, a 2005 report from the Mayo Clinic revealed two patients with oxalate nephropathy and renal failure who required dialysis and/or renal transplantation among 23 patients with enteric hyperoxaluria and calcium oxalate stones after Roux-en-Y gastric bypass surgery (Nelson et al., 2005). Since then, a number of retrospective (Asplin and Coe, 2007; Patel et al., 2009), cross-sectional (Maalouf et al., 2010), and prospective (Duffey et al., 2010; Park et al., 2009) studies have shown increased urinary oxalate excretion in non–stone-forming individuals after Roux-en-Y gastric bypass and other malabsorptive bariatric procedures. The rise in urinary oxalate was shown to develop at least 6 months after bypass surgery (Sinha et al., 2007).

To varying degrees, the increase in urinary oxalate was offset by a decline in urinary calcium and uric acid, leading to conflicting effects on urinary saturation of calcium oxalate.

Despite some variation in the observed effect on urinary analytes, an increased rate of stone formation has been reported after gastric bypass surgery. Using a claims database, Matlaga et al. (2009) found that 7.65% of 4639 patients after Roux-en-Y gastric bypass surgery versus 4.63% of 4639 obese controls were diagnosed with kidney stones ($P < 0.0001$) after a median observation period of 4.6 years and 4.1 years, respectively. In a telephone survey of patients who underwent Roux-en-Y gastric bypass surgery, Haddad et al. (2014) also found a postsurgical rate of symptomatic urolithiasis of 7.3% at a mean follow-up of 7 years, with a 5% rate of de novo symptomatic stones. The median time to presentation of the first symptomatic stone was 3.1 years. The risk appears to be limited to patients undergoing gastric bypass surgery, as another claims study demonstrated a *higher rate* of stone formation in a control group compared with a group of patients undergoing gastric banding (5.97% vs. 1.49%, respectively) (Semins et al., 2009). Indeed, a comparison of 27 patients after Roux-en-Y gastric bypass surgery with 12 patients after gastric banding revealed higher urinary oxalate, lower urinary calcium, and marginally lower urinary citrate in the bypass group compared with the banding group, suggesting that gastric banding is not associated with malabsorption and enteric hyperoxaluria (Penniston et al., 2009).

The cause of the hyperoxaluria observed after gastric bypass surgery has not been fully elucidated. Although loss of *O. formigenes*, an oxalate-degrading bacterium that resides in the intestinal tract, has been suggested as a possible source, the presence of low *O. formigenes* colonization levels in morbidly obese patients before Roux-en-Y gastric bypass surgery argues against this hypothesis (Duffey et al., 2011). Moreover, no significant difference in *O. formigenes* colonization was found between 10 post–bariatric surgery patients and 13 morbidly obese controls (40% vs. 15%, respectively) (Froeder et al., 2012). However, the urinary oxalate response to an oral oxalate load was more pronounced in patients after bariatric surgery than before and greater than the response in morbidly obese controls, suggesting that hyperoxaluria observed after bariatric surgery is due to increased intestinal absorption of dietary oxalate. Indeed, Kumar et al. (2011) prospectively studied 11 morbidly obese subjects before and 6 and 12 months after bariatric surgery (Roux-en-Y gastric bypass or biliopancreatic diversion–duodenal switch) and found significant increases in plasma oxalate, urine calcium oxalate supersaturation, and fecal fat excretion at both time points after surgery. Unlike previous studies, no significant increase in urinary oxalate or decline in urinary calcium was observed, likely as a result of aggressive calcium supplementation postsurgery. However, urinary oxalate was elevated in a 24-hour urine collection obtained after an oral oxalate load at both 6 and 12 months. These findings suggest that the cause of the hyperoxaluria and increased stone risk associated with bariatric surgery is at least in part the result of malabsorption and enteric hyperoxaluria.

Dietary Hyperoxaluria.

Overindulgence in oxalate-rich foods such as nuts, chocolate, brewed tea, spinach, potatoes, beets, and rhubarb can result in hyperoxaluria in otherwise normal individuals. The contribution of dietary oxalate to urinary oxalate excretion can range from 24% to 42% (Holmes et al., 2001). In addition, severe calcium restriction may result in reduced intestinal binding of oxalate and increased intestinal oxalate absorption. Ascorbic acid supplementation has been shown to increase urinary oxalate levels by in vivo conversion to oxalate (Traxer et al., 2003), although increased clinical rates of stone formation have not been unequivocally linked to ascorbic acid use (Curhan et al., 1996, 1999).

Recent studies have also implicated *O. formigenes*, an oxalate-degrading intestinal bacterium, as a potential modulator of intestinal oxalate levels (Duncan et al., 2002). Stone formers were found to have reduced levels or absent colonization of *O. formigenes* compared with non–stone-forming control subjects, and individuals lacking the bacteria have been shown to have higher urinary oxalate levels (Mikami et al., 2003; Sidhu et al., 1999; Troxel et al., 2003). In a large case-control study of age- and gender-matched recurrent calcium oxalate stone formers (*n* = 274) and normal subjects (*n* = 259), 17% of stone formers and 38% of normal subjects tested positive for *O. formigenes* (Kaufman et al., 2008). Controlling for confounding factors, the OR for colonization (case vs. control) was 0.3 (95% CI 0.2–0.5). Interestingly, median urinary oxalate levels did not differ between those with or without *O. formigenes* colonization. **Cystic fibrosis patients, many of whom are exposed to prolonged antibiotic use, have also been shown to have absence of *O. formigenes* from the intestinal tract and corresponding elevated urinary oxalate levels** (Sidhu et al., 1998). Likewise, *O. formigenes* colonization was compared between a group of patients with *Helicobacter pylori* treated with antibiotics and a group of patients without *H. pylori*. Among 12 patients positive for *O. formigenes* not treated with antibiotics, 92% of patients remained *O. formigenes*–positive at 1 and 6 months. In contrast, among 19 subjects with *H. pylori* who received antibiotics, only 36.8% remained colonized with *O. formigenes* 1 and 6 months after treatment (Kharlamb et al., 2011). These findings highlight the potential prolonged effect of antibiotic therapy on intestinal colonization of *O. formigenes* and a potential role in modulating stone risk.

Interestingly, a recent case-control study among more than 13 million children and adults using electronic medical record data from the United Kingdom demonstrated that after adjusting for confounding factors, exposure to any of 5 different antibiotic classes 3 to 12 months before the index encounter was associated with an increased likelihood of developing kidney stones (Tasian et al., 2018). Although antibiotic exposure has been postulated by some investigators to account for the decreased *O. formigenes* colonization in some stone formers, the bacterium has been shown to be resistant to some of the antibiotics evaluated in the previous study (Lange et al., 2011), suggesting that the increased stone risk associated with antibiotic exposure may not be mediated solely by *O. formigenes* but may instead be the result of lower diversity of the intestinal microbiome resulting from antibiotic use. Indeed, multivariate logistic regression analysis comparing fecal samples from 52 stone formers and 48 controls subjects revealed that fecal microbial diversity was lower in stone formers than in controls (Chao 1 biodiversity index 1460 vs. 1658 operational taxonomic units, $P = 0.02$) (Ticinesi et al., 2018). Moreover, although 3 taxa were significantly underrepresented in the stone-forming group, *Oxalobacter* abundance did not differ significantly between the two groups. On the other hand, genes involved in oxalate degradation *were* significantly underrepresented among stone formers and correlated inversely with 24-hour urinary oxalate levels ($r = -0.87$, $P = 0.002$). These finding may account for the lack of benefit of probiotic products containing *O. formigenes* and lactobacilli in reducing urinary oxalate excretion and suggest that gut microbiota, specifically other bacterial species with oxalate-degrading properties, may contribute to risk of stone formation.

Idiopathic Hyperoxaluria.

Several studies have suggested that mild hyperoxaluria is as important a factor as hypercalciuria in the pathogenesis of idiopathic calcium oxalate stones (Menon, 1986; Robertson and Hughes, 1993). In some populations, such as those inhabiting the Arabian Peninsula, the prevalence of calcium-containing stones is considerably higher than in the West despite the almost complete absence of hypercalciuria (Robertson and Hughes, 1993). Hyperoxaluria is implicated as the predominant risk factor in this population.

Abnormalities in the metabolism and transport of oxalate may contribute to calcium oxalate nephrolithiasis. Baggio et al. (1986) detected a higher rate of oxalate flux across the red blood cell membrane at steady state in 114 patients with a history of calcium oxalate kidney stones compared with control subjects. Treatment with oral hydrochlorothiazide (50 mg/day), amiloride (5 mg/day), or both restored normal or nearly normal red blood cell oxalate exchange in all of the patients who initially demonstrated increased rates. Up to 50% of the time, however, the abnormality in red blood cell oxalate transport is not associated with hyperoxaluria. Furthermore, Motola et al. (1992) found high rates of oxalate flux in non–calcium oxalate stone formers as well, thus leading some to question the importance of this mechanism in calcium oxalate stone formation.

Hyperuricosuria

Hyperuricosuria is defined as urinary uric acid exceeding 600 mg/day. Up to 10% of calcium stone formers have high urinary uric acid levels as an isolated abnormality, but it is found in combination with other metabolic abnormalities in up to 40% of calcium stone formers (Preminger, 1992). The mechanism by which hyperuricosuria induces calcium oxalate stones is not completely elucidated. Hyperuricosuria has been postulated to increase urinary levels of monosodium urate, which in turn promotes calcium oxalate crystallization through **heterogeneous nucleation, or epitaxial crystal growth** (Coe et al., 1975; Pak and Arnold, 1975). In addition, **the colloidal form of sodium urate has been shown to adsorb naturally occurring macromolecular inhibitors of crystallization, thereby reducing their effectiveness and promoting nucleation of calcium oxalate** (Pak et al., 1977; Robertson et al., 1976). However, some investigators dispute the effect of monosodium urate and attribute **the effect of uric acid on calcium oxalate stone formation to the simple process of “salting out,” whereby the solubility of calcium oxalate in solution is decreased by the addition of another salt** (Grover and Ryall, 1994; Ryall et al., 1991). Whether any or all of these three pathogenetic mechanisms contributes to uric acid-induced calcium oxalate nephrolithiasis is not clear, but there is compelling evidence in support of each one individually (Fig. 91.10; Moe and Xu, 2018).

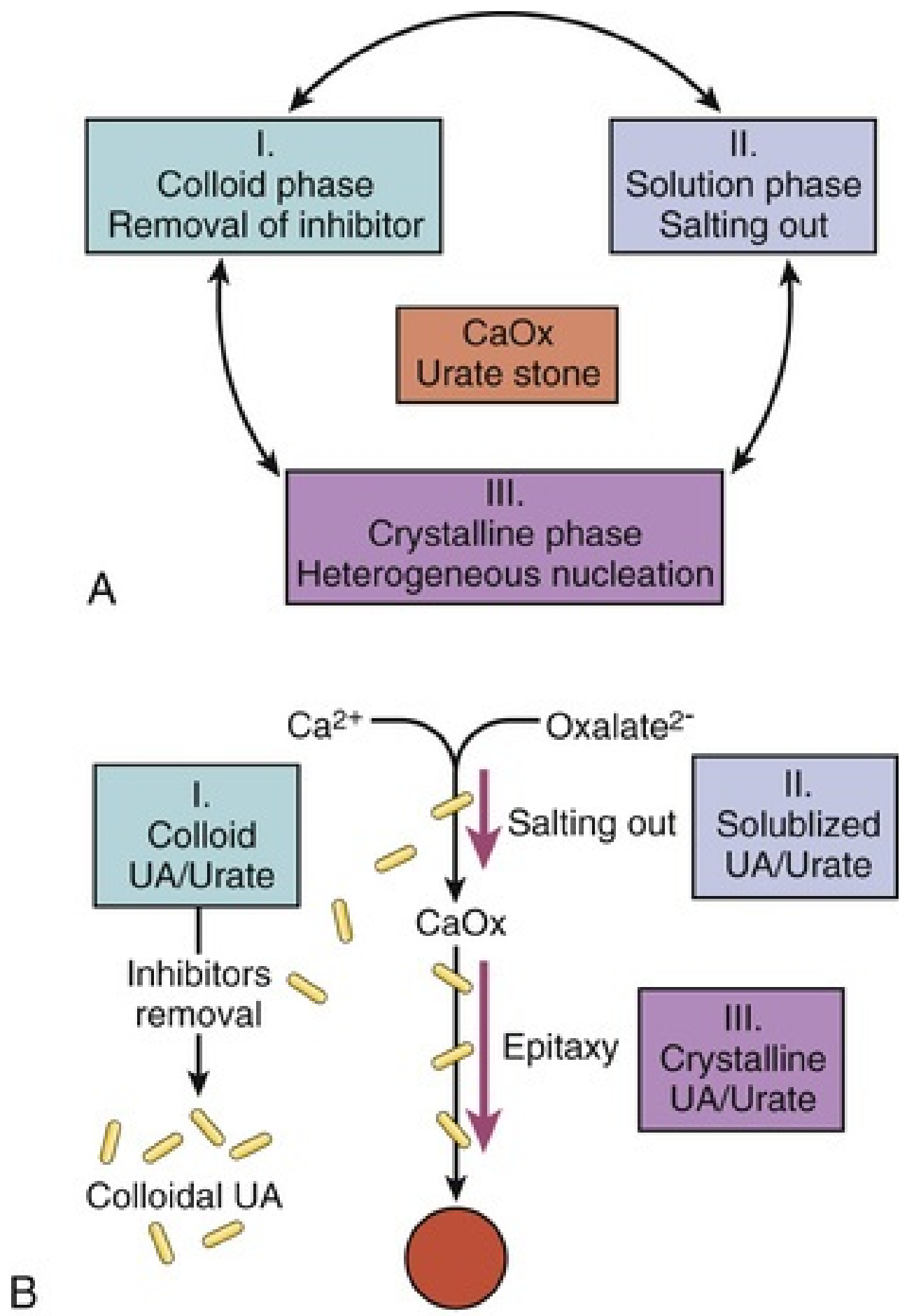
I.
Colloid phase
Removal of inhibitor
II.
Solution phase
Salting out
CaOx
Urate stone
III.
Crystalline phase
Heterogeneous nucleation
A
Ca2+
Oxalate2-
I.
Colloid
UA/Urate
Salting out
II.
Solublized
UA/Urate
CaOx
Inhibitors
removal
Epitaxy
III.
Crystalline
UA/Urate
Colloidal UA
B

FIG. 91.10 Pathophysiologic mechanisms of hyperuricosuric calcium nephrolithiasis. (A) Mechanisms of sodium urate–induced calcium oxalate crystallization and growth (I) colloidal phase (II) solution phase (III) crystalline phase. (B) (I) Adsorption of inhibitors by colloidal uric acid (II); “Salting-out” of calcium oxalate by soluble urate salts; (III) Heterogenous nucleation (epitaxy) of calcium oxalate crystals by sodium urate nidi. (Data from Moe OW, Xu LHR: Hyperuricosuric calcium urolithiasis. *J Nephrol* 31:189–196, 2018.)

The most common cause of hyperuricosuria is increased dietary purine intake. However, acquired and hereditary diseases may also be accompanied by hyperuricosuria, including gout, myeloproliferative and lymphoproliferative disorders, multiple myeloma, secondary polycythemia, pernicious anemia, hemolytic disorders, hemoglobinopathies and thalassemia, complete or partial HGPRT deficiency, overactivity of phosphoribosylpyrophosphate synthetase, and hereditary renal hypouricemia (Halabe and Sperling, 1994). The identification of a urate transporter, the anion exchanger URAT1, in the proximal renal tubule may provide new insight into the causes of hyperuricosuria (Enomoto et al., 2002; Ichida et al., 2004). Mutations in *SLC22A12*, the gene encoding URAT1, have been shown to cause hyperuricosuric hypouricemia (renal uric acid leak) along with exercise-induced acute renal failure and a high risk of kidney stones (Enomoto et al., 2002; Ichida et al., 2004; Iwai et al., 2004; Tanaka et al., 2003).

Not all evidence supports a role for uric acid in calcium oxalate stone formation. Among 3350 male and female participants (2237 stone formers and 1113 non–stone formers) from three large cohort studies who collected 24-hour urine specimens for stone risk analysis, after adjusting for other urinary parameters, urinary uric acid excretion was significantly inversely associated with incident kidney stone formation in men, marginally inversely associated in younger women, and not associated in older women (Curhan and Taylor, 2008). On the other hand, a randomized trial among hyperuricosuric, normocalciuric calcium oxalate stone formers demonstrated a greater than twofold reduction in stone recurrence rates among patients randomized to allopurinol versus those taking placebo (Ettinger et al., 1986). However, the mechanism of action of allopurinol in reducing stone recurrence rates cannot be definitively attributed to its effect in reducing urinary uric acid.

Hypocitraturia

Hypocitraturia is an important and correctable abnormality associated with nephrolithiasis that exists as an isolated abnormality in up to 10% of calcium stone formers and is associated with other abnormalities in 20% to 60% of stone formers (Levy et al., 1995; Pak, 1994). Citrate is an important inhibitor that can reduce calcium stone formation by several mechanisms. First, citrate reduces urinary saturation of calcium salts by complexing with calcium (Pak et al., 1982). Second, citrate directly prevents spontaneous nucleation of calcium oxalate (Sakhaee et al., 1987). Third, citrate inhibits agglomeration and sedimentation of calcium oxalate crystals (Kok et al., 1986; Tiselius et al., 1993a, 1993b), as well as the growth of calcium oxalate and calcium phosphate crystals (Meyer and Smith, 1975). Finally, normal urinary citrate levels can enhance the inhibitory effect of Tamm-Horsfall glycoprotein (Hess et al., 1993).

Hypocitraturia is defined as a urinary citrate level less than 320 mg/day. **Acid-base state is the primary determinant of urinary citrate excretion. Metabolic acidosis reduces urinary citrate levels secondary to enhanced renal tubular reabsorption and decreased synthesis of citrate in peritubular cells** (Hamm, 1990). A study comparing normal subjects and stone formers noted comparable mean serum citrate levels and filtered citrate loads in the two groups; however, 24-hour urinary citrate and the fasting citrate-to-creatinine ratio were significantly reduced and mean tubular reabsorption of citrate was significantly increased in the stone formers compared with control subjects (Minisola et al., 1989).

Indirect evidence for a primarily renal cause of hypocitraturia comes from a study comparing intestinal absorption of citrate in idiopathic hypocitraturic stone formers and normal subjects (Fegan et al., 1992). Oral ingestion of citrate was followed by rapid and efficient absorption in both groups, with 96% to 98% absorbed within 3 hours. As such, hypocitraturia is unlikely to arise from impaired gastrointestinal absorption of citrate in stone formers without overt bowel disease.

Low urinary citrate results from a variety of pathologic states associated with acidosis. Distal RTA is characterized by high urine pH (>6.8), high serum chloride, and low serum bicarbonate and potassium (Preminger et al., 1985). The inability to acidify urine in response to an oral acid (ammonium chloride) load confirms the diagnosis of RTA. Chronic diarrheal states cause intestinal alkali loss in the stool with subsequent systemic acidosis and hypocitraturia (Rudman et al., 1980). Excessive animal protein intake can provide an acid load, reducing citrate levels (Breslau et al., 1988). Indeed, a metabolic study evaluating the effect of a high-protein, low-carbohydrate diet demonstrated a significant reduction in urinary citrate and pH, likely as a result of low citrus and high animal protein intake (Reddy et al., 2002). Diuretics such as thiazides induce hypokalemia and intracellular acidosis (Nicar et al., 1984). Angiotensin-converting enzymes can cause hypocitraturia independently of systemic acidosis or hypokalemia, perhaps as a result of intracellular acidosis (Melnick et al., 1998). Finally, strenuous exercise may induce lactic acidosis (Sakhaee et al., 1987). However, hypocitraturia may also represent an isolated abnormality unrelated to an acidotic state.

Citrate levels in the urine increase in alkalotic states, as well as with elevated levels of PTH, estrogen, magnesium, calcitonin, and vitamin D (Hamm and Hering-Smith, 2002).

Low Urine pH

At low urine pH (<5.5), the undissociated form of uric acid predominates, leading to uric acid and/or calcium stone formation. Calcium oxalate stones form as a result of heterogeneous nucleation with uric acid crystals (Coe and Kavalach, 1974; Pak et al., 1974). Any disorder leading to low urine pH may predispose to stone formation. Chronic metabolic acidosis can lead to low urine pH, hypercalciuria, and hypocitraturia. Acidosis increases bone resorption and produces renal calcium leak (Lemann, 1999; Lemann et al., 2003). Idiopathic low urine pH, previously referred to as “gouty diathesis,” refers to stone-forming propensity characterized by low urine pH of unknown cause with or without associated gouty arthritis (Levy et al., 1995).

Renal Tubular Acidosis

RTA is a clinical syndrome characterized by metabolic acidosis resulting from defects in renal tubular hydrogen ion secretion or bicarbonate reabsorption. There are three types of RTA: 1, 2, and 4. Type 1 (distal) RTA is of particular significance to urologists not only because it is the most common form of RTA but also because it is the form of RTA most frequently associated with stone formation, which occurs in up to 70% of affected individuals (Van den Berg et al., 1983). Indeed, symptoms associated with nephrolithiasis led to the initial diagnosis of RTA in upward of 50% of cases (Van den Berg et al., 1983).

Acid-base balance is maintained by the kidney through several mechanisms involving the proximal and distal nephron. Because bicarbonate is freely filtered at the glomerulus, the **kidney must reabsorb or regenerate nearly all of the filtered bicarbonate each day** (≈4500 mmol) to maintain its buffering capacity, a process that takes place primarily in the proximal renal tubule (Pohlman et al., 1984). **Furthermore, the kidney must excrete excess acid,** which accumulates from the breakdown of carbohydrates, fats, and proteins and as a result of bicarbonate loss in the stool. Net acid excretion occurs in the distal renal tubule. A defect in either bicarbonate reabsorption or acid excretion will lead to metabolic acidosis.

Filtered bicarbonate (HCO_3^-) is almost completely reabsorbed in the proximal renal tubule through an indirect mechanism involving hydrogen (H^+) secretion (Laing et al., 2005). Carbonic anhydrase in the tubular cells generates H^+ and HCO_3^-, thereby providing H^+ ions that are secreted into the tubular lumen by way of a Na^+,H^+ exchanger in the apical membrane. Sodium (Na^+) pumped out of the proximal tubule cell by the sodium-potassium adenosine triphosphatase (Na^+,K^+-ATPase) exchanger located in the basolateral membrane drives the Na^+,H^+ exchanger in the apical membrane by reducing intracellular sodium. At the same time, HCO_3^- is transferred via a basolateral Na^+,HCO_3^- cotransporter into the plasma. Additional active H^+ secretion into the tubular lumen is accomplished by an apical H^+-ATPase. Luminal H^+ ion combines with filtered HCO_3^- to form H_2CO_3, which is rapidly converted by another form of carbonic anhydrase to H_2O and CO_2, which diffuses back in to the cell. **The net effect is transepithelial HCO_3^- absorption without causing net H^+ secretion or a significant change in urinary pH.**

The distal nephron is the site of net elimination of H^+, although 5% to 10% of filtered bicarbonate is also reabsorbed there in a manner similar to the proximal nephron. **Hydrogen binds with urinary buffers such as titratable acid (mainly phosphate) and ammonia, allowing net elimination of hydrogen in the form of NH_4^+. H^+ excretion occurs through active secretion from α-intercalated cells.** These cells secrete H^+ into the distal tubule using H^+-ATPase and a H^+,K^+-ATPase exchanger (Laing et al., 2005). The intercalated cells also have a Cl^-,HCO_3^- anion exchanger that transports HCO_3^- into the blood. **These active pumps generate a 1000 : 1 hydrogen ion gradient between the cell and the tubular lumen, allowing reduction of urine pH to as low as 4.5** (Kinkead and Menon, 1995). Another contributing factor is the lack of luminal carbonic anhydrase that prevents the rapid dissociation of carbonic acid catalyzed by the enzyme.

Distal and proximal RTA occurs as a result of impairment of net excretion of acid into the urine (distal or type 1) or of reabsorption of bicarbonate (proximal or type 2). Distinction between these abnormalities provides the basis for classification of RTA into proximal or distal, although both share the characteristic findings of hyperchloremic metabolic acidosis associated with inappropriately high urinary pH.

Type 1 (Distal) Renal Tubular Acidosis.

Type 1 RTA comprises a syndrome of abnormal collecting duct function characterized by inability to acidify the urine in the presence of systemic acidosis. The classic findings include hypokalemic, hyperchloremic, non–anion gap metabolic acidosis along with nephrolithiasis, nephrocalcinosis, and elevated urine pH (>6.0). Patients with incomplete RTA also demonstrate defective renal acid excretion manifested as failure to lower urine pH below 5.5 after an acid load, but they do not manifest metabolic acidosis and consequently have normal serum electrolytes (Osther et al., 1989).

The most common stone composition associated with distal RTA is calcium phosphate as a result of **hypercalciuria, hypocitraturia, and increased urinary pH** (Pohlman et al., 1984; Van den Berg et al., 1983). The metabolic acidosis promotes bone demineralization, which leads to secondary hyperparathyroidism and hypercalciuria. **Profound hypocitraturia, perhaps the most important factor in stone formation in this setting, is due to impaired citrate excretion as a result of metabolic acidosis** but may also be related to abnormal renal tubular citrate transport or migration of citrate into the mitochondria as a result of intracellular acidosis (Kinkead and Menon, 1995; Osther et al., 1989).

Distal RTA is a heterogeneous disorder that may be hereditary, idiopathic, or acquired, and although most cases are sporadic, autosomal dominant and autosomal recessive patterns of inheritance have been identified (Laing et al., 2005). The inherited forms of distal RTA are associated with growth retardation, nephrocalcinosis, renal calculi, and hypokalemic metabolic acidosis. The autosomal recessive form of the disease is more severe, tends to occur earlier in life, and is associated with mental retardation and sensorineural hearing loss. Children make up one-third of affected individuals and often experience vomiting or diarrhea, failure to thrive, or growth retardation. Secondary distal RTA occurs in association with autoimmune diseases such as Sjögren syndrome and systemic lupus erythematosus, or it may occur with obstructive uropathy, pyelonephritis, acute tubular necrosis, hyperparathyroidism, and idiopathic hypercalciuria.

Distal RTA occurs as a consequence of dysfunction of the α-type intercalated cells, which secrete protons into the urine via an apical H^+-ATPase that is coupled to an anion exchanger (AE1) located at the basolateral membrane (Fig. 91.11; Karet, 2002). Mutations in three genes in the α-type intercalated cells have been implicated in hereditary distal RTA; *SLC4A1* encodes the AE1 Cl^-,HCO_3^- anion exchanger, and *ATP6V1B1* and *ATP6V0A4* encode the B1 and A4 subunits, respectively, of H^+-ATPase. A fourth gene, *CA2,* encodes carbonic anhydrase II, which is found in the proximal tubule, the loop of Henle, and the α-intercalated cells of the collecting duct. Because carbonic anhydrase II affects bicarbonate reabsorption as well as H^+ secretion, mutations in *CA2* present a mixed pattern of proximal and distal RTA (Batlle and Haque, 2012).

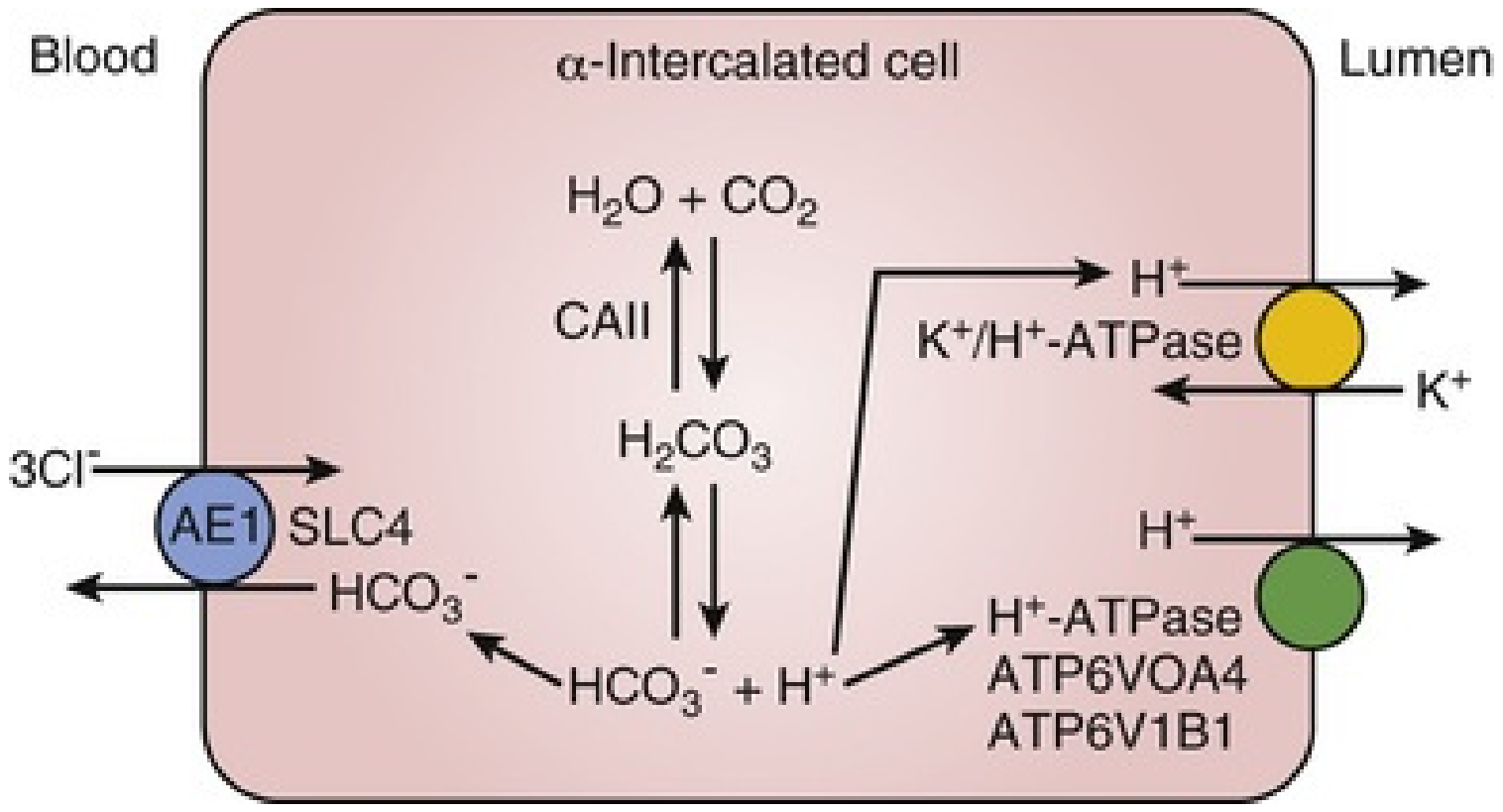

FIG. 91.11 Mechanism of acidification in the collecting duct α-intercalated cell. The α-intercalated cells secrete H^+ into the lumen of the distal tubule and collecting duct by way of an apical H^+-ATPase and possibly an H^+,K^+-ATPase exchanger. Bicarbonate is transported into the blood via a Cl^-,HCO_3^- anion exchanger (AE1) on the basolateral membrane. Defects in the AE1 Cl^-,HCO_3^- anion exchanger or in H^+-ATPase result in failure to acidify the urine in distal RTA. *CAII,* Carbonic anhydrase II.

Mutations in the *SLC4A1* gene are most commonly associated with the autosomal dominant form of distal RTA, which can present in the complete or incomplete form. Hearing loss is not usually a feature of mutations in the *SLC4A1* gene (Battle and Haque, 2012). Mutations in the *ATP6V1B1* and *ATP6V0A4* genes encoding H^+-ATPase have been primarily associated with autosomal recessive distal RTA (Battle et al., 2006). Recent findings suggest that incomplete distal RTA may be the result of a hypofunctional vacuolar-type H^+-ATPAase in heterozygous carriers of a mutation in the B1 subunit (Dhayat et al., 2016; Zhang et al., 2014) of the transporter. Finally, *CA2* mutations are recessive and lead to a mixed proximal-distal RTA picture characterized by bicarbonate wasting, inability to acidify the urine below pH 5.5, and reduced NH_4^+ excretion (Battle and Haque, 2012).

Type 2 (Proximal) Renal Tubular Acidosis.

Proximal RTA is characterized by a defect in HCO_3^- reabsorption associated with initial high urine pH that normalizes as plasma HCO_3^- decreases and the amount of filtered HCO_3^- falls (Laing et al., 2005). With reduced capacity of the proximal tubule to reclaim filtered HCO_3^-, more HCO_3^- is delivered to the distal tubule, which has a limited capacity for bicarbonate reabsorption. Consequently, bicarbonaturia ensues, resulting in reduced net acid excretion and metabolic acidosis. As the filtered HCO_3^- load declines with progressive metabolic acidosis, less bicarbonate reaches the distal tubule until eventually the capacity of the distal tubule is sufficient to handle the load and no further bicarbonate is lost. At steady state, serum HCO_3^- is low (15 to 18 mEq/L) and urine pH is acidic (<5.5).

This syndrome is usually associated with generalized defects in proximal tubule function similar to Fanconi syndrome, with loss of glycogen, protein, uric acid, and phosphate (Rocher and Tannen, 1986). The clinical manifestations of proximal RTA include growth retardation and hypokalemia in children resulting from metabolic acidosis. **Nephrolithiasis is uncommon in this disorder because of relatively normal urinary citrate excretion** (Laing et al., 2005).

Type 4 (Distal) Renal Tubular Acidosis.

Type 4 RTA is associated with chronic renal damage, usually seen in patients with interstitial renal disease and diabetic nephropathy. Reduction in glomerular filtration results in hyperkalemic, hyperchloremic metabolic acidosis caused by loss of HCO_3^- in the urine and decreased excretion of ammonium (Pohlman et al., 1984). Aldosterone resistance is commonly associated with type 4 RTA (Davidman and Schmitz, 1988). Because aldosterone contributes to stimulation of distal acidification and H^+,K^+ exchange, aldosterone resistance results in decreased ammonia generation and further exacerbates hyperkalemia (Davidman and Schmitz, 1988). Patients with type 4 RTA can still generate acidic urine in response to an acid challenge.

Renal stone formation is uncommon in patients with type 4 RTA. **The protection against renal stone formation in these patients may be attributed to reduced renal excretion of stone-forming substances such as calcium and uric acid because of impaired renal function** (Uribarri et al., 1994).

Hypomagnesiuria

Hypomagnesiuria is a rare cause of nephrolithiasis, affecting less than 1% of stone formers as an isolated abnormality, although it can be found in conjunction with other abnormalities in 6% to 11% of cases (Levy et al., 1995; Schwartz et al., 2001). **Magnesium complexes with oxalate and calcium salts, and therefore low magnesium levels result in reduced inhibitory activity. Low urinary magnesium is also associated with decreased urinary citrate levels, which may further contribute to stone formation** (Preminger et al., 1989;

Schwartz et al., 2001). Whether low magnesium is the cause or effect of low citrate is not clear. Low magnesium levels occur with poor dietary intake or as a result of reduced intestinal absorption associated with intestinal abnormalities producing chronic diarrheal syndrome.

Although a number of studies in rats have implicated hypomagnesiuria as a factor in stone formation (Rushton and Spector, 1982), others (Borden and Lyon, 1969; Faragalla and Gershoff, 1963; Rattan et al., 1993) have questioned the impact of magnesium (Su et al., 1991). Clinical studies regarding the role of magnesium are contradictory. Schwartz et al. (2001) found that hypomagnesiuric patients had higher stone recurrence rates than patients with normal urinary magnesium. However, other studies found no difference in magnesium excretion between stone patients and controls (Esen et al., 1991; Johansson et al., 1980). The lack of difference in mean magnesium levels may be a result of the small fraction of stone formers with low urinary magnesium levels.

Although magnesium has been shown to increase urinary pH, citrate, and magnesium levels and therefore to decrease urinary saturation of calcium oxalate in vitro (Khan et al., 1993) and in vivo (Curhan et al., 2001), two randomized trials comparing magnesium oxide with placebo or no treatment in stone formers failed to demonstrate clinical benefit (Ettinger et al., 1988; Wilson et al., 1984).

Uric Acid Stones

Most mammals, except humans and Dalmatians, synthesize the hepatic enzyme uricase, which catalyzes the conversion of uric acid to allantoin, the end product of purine metabolism (Bannasch et al., 2004; Yu, 1981). Consequently, humans accumulate significantly higher levels of uric acid in their blood and urine (Watts, 1976; Yu, 1981). Because allantoin is 10 to 100 times more soluble in urine than uric acid, humans are prone to uric acid stone formation. Uric acid makes up 8% to 10% of all kidney stones in the United States and up to 25% in certain regions in Germany (Maalouf et al., 2004a).

Uric acid is a weak acid with a pK_a of 5.35 at 37°C. At that pH, half the uric acid is present as the urate salt and half as free uric acid. Because sodium urate is approximately 20 times more soluble than the free acid, the relative proportion present as free uric acid strongly determines the risk of stone formation. **Urine pH is a critical factor in determining uric acid solubility;** at pH 5, even modest amounts of uric acid exceed uric acid solubility, whereas at pH 6.5, concentrations of uric acid exceeding 1200 mg/L remain soluble (Fig. 91.12;

Asplin, 1996). Under normal conditions, the limit of uric acid solubility is approximately 96 mg/L, a level readily exceeded by normal daily uric acid excretion, which averages 500 to 600 mg/L. Consequently, urine may reach supersaturation, particularly at pH less than 6. Low urine pH increases concentrations of sparingly soluble undissociated uric acid, which leads to direct precipitation of uric acid. Uric acid and sodium urate have been implicated as nidi for calcium oxalate stones through heterogeneous nucleation and epitaxial crystal growth, and thus low urine pH is thought to be a risk factor for uric acid, calcium oxalate, and mixed calcium and uric acid stones (Maalouf, 2011).

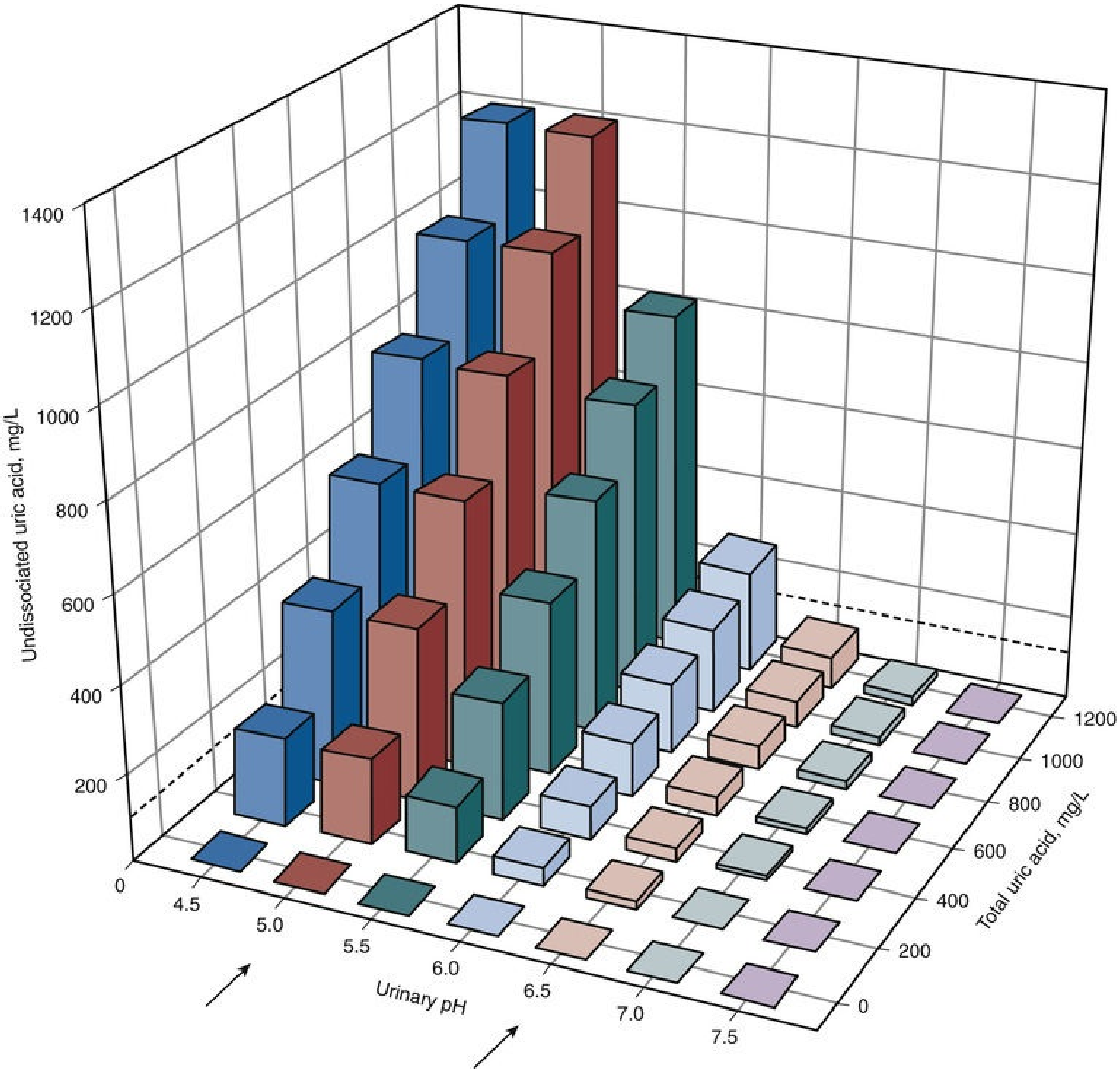

FIG. 91.12 Relationship among undissociated uric acid, total uric acid, and urinary pH. The limit of solubility of undissociated uric acid is depicted by the *dotted line* (≈100 mg/L). Two hypothetical urine pH values are

considered *(arrows)*. At low pH (e.g., 5.0), even a modest amount of total urinary uric acid will exceed its solubility. At high pH (e.g., 6.5), even massive hyperuricosuria is well tolerated. (From Maalouf NM, Cameron MA, Moe OW, et al.: Novel insights into the pathogenesis of uric acid nephrolithiasis. *Curr Opin Nephrol Hypertens* 13:181–189, 2004.)

The process of uric acid stone formation once uric acid crystals precipitate has not been fully elucidated. Although some investigators have suggested that uric acid crystal adhesion to kidney epithelial cells (Koka et al., 2000) and inhibitors such as glycosaminoglycans (Ombra et al., 2003) may play a role in uric acid stone formation, the involvement or importance of these factors in uric acid stone formation is unclear. No urinary inhibitors of uric acid stones formation have been identified (Doizi et al., 2016).

The three main determinants of uric acid stone formation are low pH, low urine volume, and hyperuricosuria (Fig. 91.13)**. The most important pathogenetic factor is low urine pH because most patients with uric acid stones have normal uric acid excretion but invariably demonstrate persistent low urine pH** (Pak et al., 2001; Sakhaee et al., 2002). Uric acid stones can develop as a result of congenital, acquired, or idiopathic causes. Congenital disorders associated with uric acid stones involve renal tubular urate transport or uric acid metabolism, leading to hyperuricosuria. Acquired causes of uric acid stones such as chronic diarrhea, volume depletion, myeloproliferative disorders, high animal protein intake, and uricosuric drugs may affect any of the three factors determining uric acid stone formation. Patients with “gouty diathesis” or idiopathic uric acid nephrolithiasis typically demonstrate decreased fractional excretion of urate and do not have gout (Maalouf et al., 2004a). Patients with idiopathic uric acid nephrolithiasis differ from those with hyperuricosuric calcium nephrolithiasis in that the former generally have normal urinary uric acid levels and acidic urine, whereas the latter have hyperuricosuria and normal urine pH (Pak et al., 2002). Patients with hyperuricosuria frequently have high urinary sodium and calcium levels leading to increased urinary saturation of sodium urate and calcium oxalate, placing them at risk for calcium oxalate stones (Sorensen and Chandhoke, 2002).

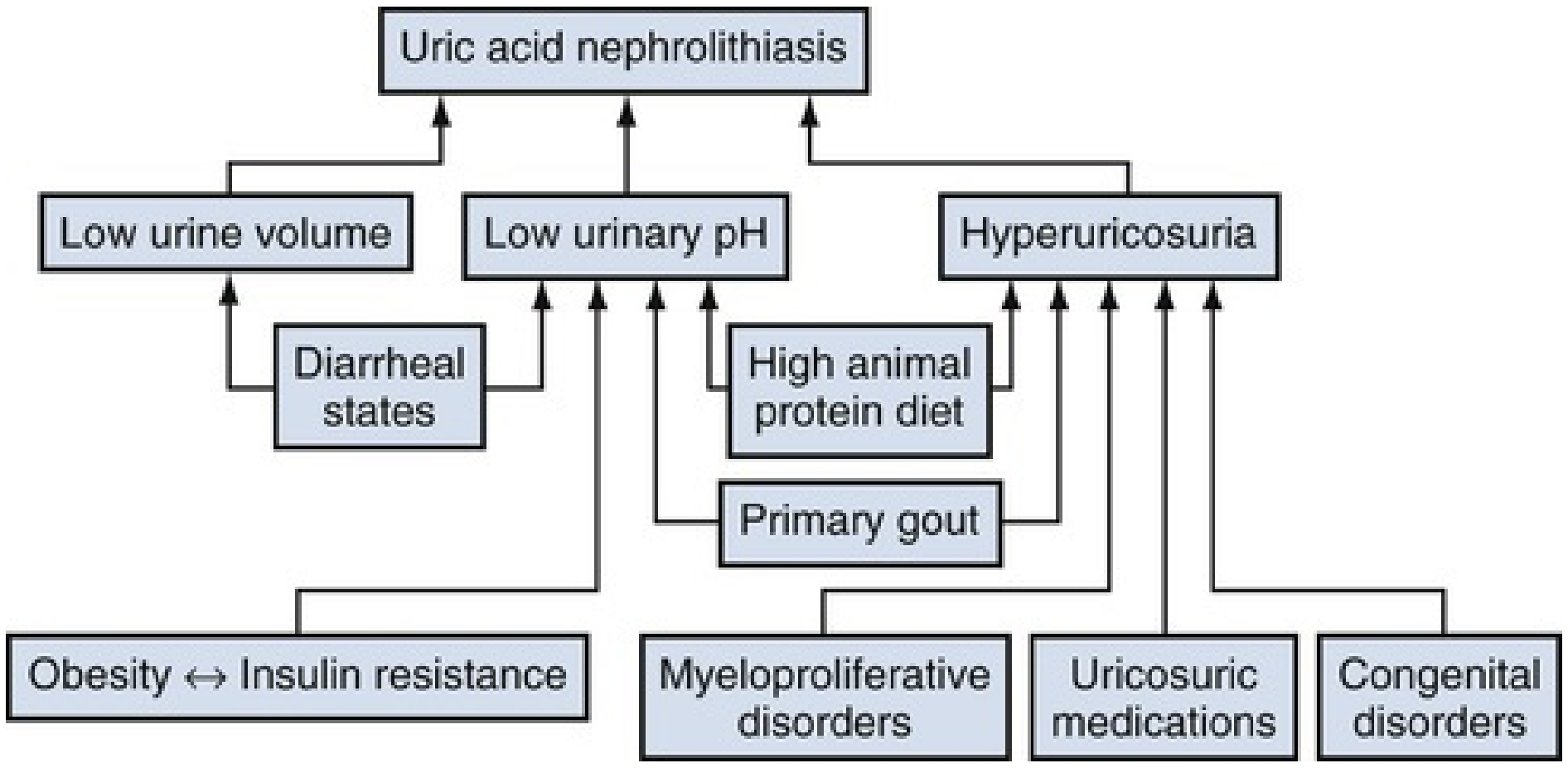

Uric acid nephrolithiasis
Low urine volume
Low urinary pH
Hyperuricosuria
Diarrheal states
High animal protein diet
Primary gout
Obesity ↔ Insulin resistance
Myeloproliferative disorders
Uricosuric medications
Congenital disorders

FIG. 91.13 Pathophysiology and etiology of uric acid nephrolithiasis. The three major pathophysiologic mechanisms that contribute to uric acid nephrolithiasis are low urine volume, low urinary pH, and hyperuricosuria. Each of these mechanisms can result from diverse causes. The most important pathogenetic factor is low urinary pH. (From Maalouf NM, Cameron MA, Moe OW, et al.: Novel insights into the pathogenesis of uric acid nephrolithiasis. *Curr Opin Nephrol Hypertens* 13:181–189, 2004.)

Pathogenesis of Low Urine pH

Although the pathogenesis of low urine pH in idiopathic uric acid stone formers is not known with certainty and may be multifactorial, several potential mechanisms have been proposed. Sakhaee et al. (2002) first observed that normouricosuric individuals with pure uric acid stones were more likely to have diabetes mellitus or to demonstrate glucose intolerance than normal individuals or those with mixed uric acid–calcium oxalate or pure calcium oxalate stones. Furthermore, when a group of normouricosuric uric acid stone formers was placed on a controlled metabolic diet, the urinary pH was lower than that of either normal volunteers or other stone formers (mixed uric acid–calcium oxalate or calcium oxalate). Further investigation revealed that the uric acid stone formers excreted less acid into the urine as ammonium and proportionately more titratable acid and less citrate to maintain normal overall acid-base balance. **This apparent impairment in ammonium excretion in uric acid stone formers has been putatively linked to an insulin-resistant state.**

Supporting this hypothesis, Pak et al. (2003) noted a higher prevalence of uric acid stones and low urinary pH among patients with non–insulin-dependent diabetes mellitus (34%) than among nondiabetic stone formers. Daudon et al. (2006) analyzed 2464 calculi and also found that uric acid stones made up 36%

of stones among 272 patients with type 2 diabetes mellitus but only 11% among 2192 patients without type 2 diabetes. Furthermore, uric acid stone formers have been found to share many of the characteristic features of the metabolic syndrome (a condition defined by insulin resistance and high-risk atherosclerotic cardiovascular disease), including hypertriglyceridemia, hyperglycemia, obesity, and hypertension (Pak et al., 2003; Sakhaee et al., 2002). In an elegant series of experiments, Abate et al. (2004) performed hyperinsulinemic euglycemic clamps to measure insulin sensitivity in a diverse group of non–stone-forming normal volunteers and a group of uric acid stone formers and determined that among normal subjects, low urine pH correlated with low rates of glucose disposal (indicating insulin resistance) in both groups, but uric acid stone formers displayed the most severe levels of insulin resistance. This association of insulin resistance with low urinary pH was further corroborated by the finding of a strong inverse association of body weight (known to be associated with peripheral insulin resistance) and urinary pH, even after adjusting for urinary sulfate (a marker of animal protein intake) (Maalouf et al., 2004b).

The mechanism by which insulin resistance leads to low urine pH has not been completely elucidated. However, insulin has been shown in vitro to promote renal ammoniagenesis from the substrate glutamine (Chobanian and Hammerman, 1987; Nissim et al., 1995) and also to stimulate the Na^+,H^+ exchanger (NHE3) in the proximal tubule, which is responsible for either the direct transport or trapping of ammonium in the urine (Klisic et al., 2002). **Impaired ammonium production or excretion as a result of insulin resistance could leave hydrogen ions unbuffered in the urine, thereby leading to reduction in urine pH** (Fig. 91.14).

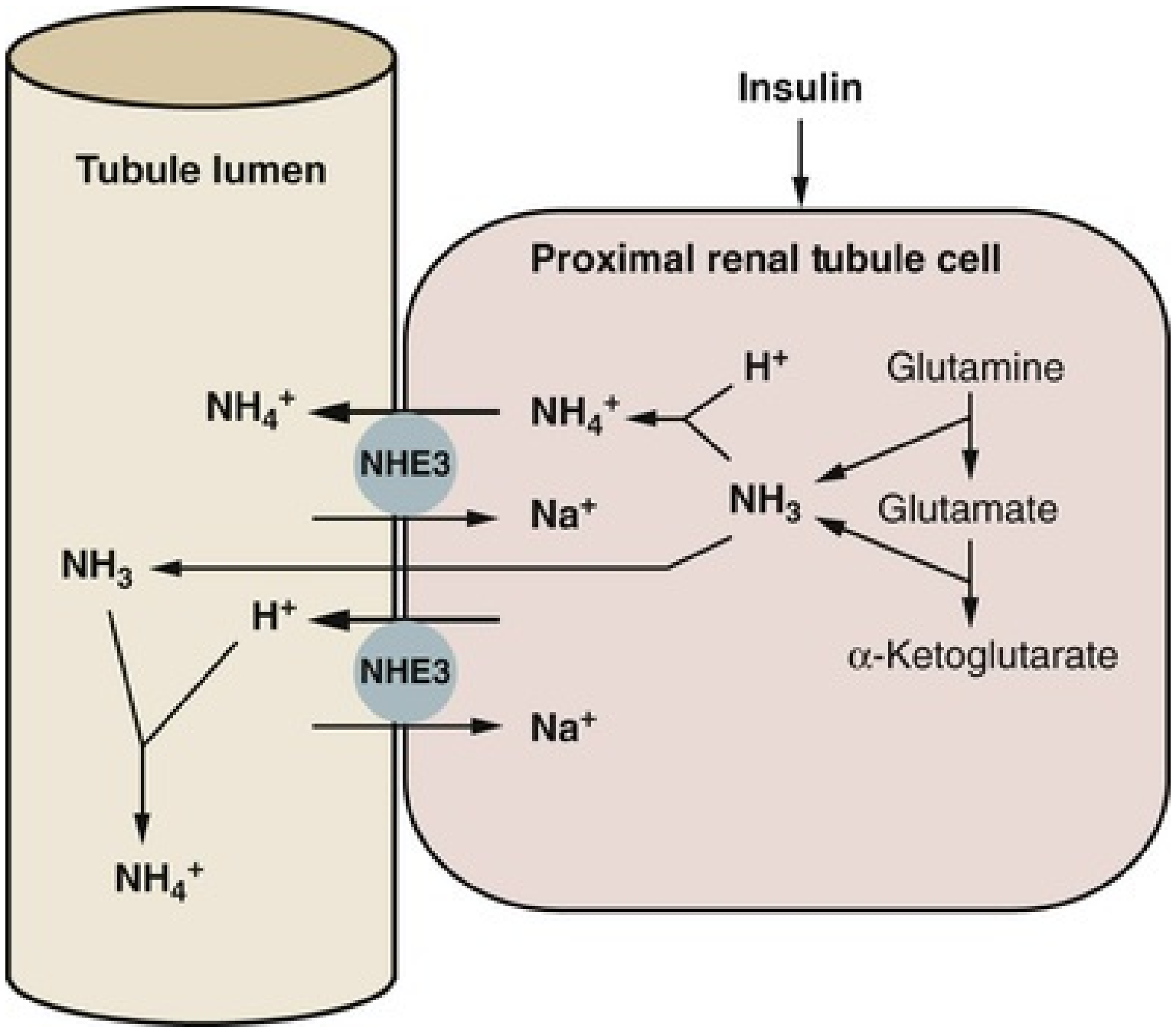

FIG. 91.14 Potential effects of the insulin-resistant state on the generation and secretion of ammonium in the proximal tubule. The deamination of glutamine and glutamate provides ammonia. Insulin stimulates glutamine metabolism, as well as the sodium-hydrogen exchanger NHE3. NHE3 mediates ammonium transport by either directly carrying the ammonium ion or providing the luminal hydrogen ion to trap ammonia. The end product of glutamine metabolism is α-ketoglutarate. (Modified from Maalouf NM, Cameron MA, Moe OW, et al.: Novel insights into the pathogenesis of uric acid nephrolithiasis. *Curr Opin Nephrol Hypertens* 13:181–189, 2004.)

Acidic urine pH may also be promoted by increased endogenous acid production or by dietary influences. When idiopathic uric acid stone formers and normal subjects were maintained on a fixed, low acid-ash diet, net acid excretion was higher in the former group compared with the latter, implicating higher endogenous acid production (Sakhaee et al., 2002). Furthermore, when controlled for urinary sulfate (a marker of acid intake), net acid excretion was higher in uric acid stone formers and in non–stone formers with type 2 diabetes compared with normal controls (Cameron et al., 2006). These studies suggest that, in the setting of impaired ammonium excretion and increased endogenous acid production resulting from obesity and/or insulin resistance, titratable acids make up the primary urinary buffer, and although acid-base equilibrium can be maintained, it occurs at a lower urine pH than is typically maintained by ammonium, which has a higher pK_a.

Lipotoxicity, a process whereby fat is redistributed into nonadipocyte tissues such as the heart, liver, skeletal muscle, and pancreatic beta cells, resulting in cellular injury, has been implicated in impaired insulin sensitivity, cardiac dysfunction, and hepatic steatohepatitis and has been postulated to play a role in the pathogenesis of chronic renal disease (Bagby, 2004; Wahba and Mak, 2007; Weinberg, 2006). Whether lipotoxicity plays a role in impaired ammonium excretion or increased endogenous acid production leading to low urine pH in uric acid stone formers is unknown (Sakhaee, 2009). However, studies in a rodent model of metabolic syndrome (Zucker diabetic fatty rat) and a proximal tubular cell line demonstrated that renal steatosis may be responsible for the reduced expression and activity of NHE3, the primary mediator of ammonium excretion (Bobulescu et al., 2008, 2009). Interestingly, recent proteomic analysis of the matrix component of uric acid stones identified 242 unique proteins among five stones, with the largest proportion of proteins involved in the inflammation and complement pathways; the most commonly involved metabolic pathways associated with these proteins were the phospholipid and fatty acid pathways (Jou et al., 2012). Finally, in a recent study of 98 stone formers using axial CT imaging to measure visceral fat, multivariable logistic regression analysis revealed that low urine pH (<6) was associated with higher visceral fat area (OR 11.1, 95% CI 2.18–56.3, $P < 0.004$) (Patel et al., 2017). Furthermore, low urine pH (OR 5.87, 95% CI 1.59–58.3, $P = 0.26$) and visceral fat area greater than 48% (OR 5.33, 95% CI 1.05–27.2, $P = 0.047$) were independently associated with uric acid stone composition.

Dietary content also plays a role in determining urine acidity. Breslau et al. (1988) evaluated 15 normal subjects in a three-way randomized, crossover study involving three 12-day phases of study in which subjects were maintained on a controlled metabolic diet containing vegetable protein, vegetable and egg protein, or animal protein, with increasing sulfate content, respectively, in the three diets. As the fixed acid content of the diets increased, urinary calcium excretion increased from 103 mg/day on the vegetarian diet to 150 mg/day on the animal protein diet ($P < 0.02$). Moreover, the animal protein–rich diet was associated with the highest excretion of undissociated uric acid and lowest excretion of citrate because of the reduction in urinary pH. Urinary crystallization studies revealed that the animal protein diet, when matched for electrolyte composition and quantity of protein with the vegetarian diet, conferred an increased risk of uric acid stones, but because of opposing factors, not of calcium oxalate or calcium phosphate stones.

Hyperuricosuria

Hyperuricosuria is defined as urinary uric acid exceeding 600 mg/day. Hyperuricosuria predisposes to uric acid stone formation by causing supersaturation of the urine with respect to sparingly soluble undissociated uric acid. Patients with gout and urinary uric acid levels less than 600 mg/day had significantly fewer stones than those with uric acid levels greater than 1000 mg/day (Hall et al., 1967; Yu and Gutman, 1967). The causes of hyperuricosuria have been discussed previously but include dietary factors as well as acquired and hereditary diseases and defects in the urate transporter.

Low Urinary Volume

All conditions that contribute to low urinary volume increase the risk of uric acid supersaturation. Borghi et al. (1993) noted high uric acid relative supersaturation in workers exposed to hot temperatures compared with those working in normal temperatures. Likewise, high rates of uric acid stone formation have been found in populations living in warmer climates such as Israel (Shekarriz and Stoller, 2002).

Cystine Stones

Under normal conditions amino acids are freely filtered by the glomerulus and almost completely reabsorbed in the renal proximal tubule. Cystine and the other dibasic amino acids are transported across the apical membrane of the renal proximal tubule and in the jejunum by a sodium-independent heteromeric amino acid transporter (HAT) in exchange for neutral amino acids. The cystine transporter is composed of the rBAT heavy subunit, encoded by *SLC3A1* (Calonge et al., 1994; Pras et al., 1994), which resides on the short arm of chromosome 2, and the bo,+AT light subunit encoded by *SLC7A9* (Feliubadaló et al., 1999) located on the long arm of chromosome 19. The two subunits form a heterodimer that resides in the apical membrane of the proximal tubule cells, and mutations in the genes of either subunit lead to cystinuria. As of 2010, 133 and 95 mutations had been reported in the *SLC3A1*and the *SLC7A9* genes, respectively (Chillaron et al., 2010). Cystinuria is inherited as an autosomal recessive disorder (or rarely autosomal dominant with incomplete penetrance).

Under normal conditions, the fractional excretion of cystine is approximately 0.4% but rises to 100% in cystinuria. Although there is significant loss of other dibasic amino acids, the poor solubility of cystine leads to stone formation. Cystine is a dimer composed of two cysteine molecules linked via a disulfide bond. Cystine is much less soluble than cysteine and is responsible for cystine stone formation. Cystine is reduced intracellularly to cysteine, thereby providing a favorable gradient for continued cystine reabsorption (Broer, 2008). Cystine stones are rare, occurring in the United States and Europe with an incidence of only 1 in 1000 to 1 in 17,000 (Cabello-Tomas et al., 1999; Knoll et al., 2005). In children, cystinuria is the cause of up to 10% of all stones (Erbağci et al., 2003; Faerber, 2001; Knoll et al., 2005).

Several factors determine the solubility of cystine, including cystine concentration, pH, ionic strength, and urinary macromolecules. The main contributor to cystine crystallization is supersaturation because there is no specific inhibitor of cystine crystallization in the urine (Pak and Fuller, 1983). Because of the poor solubility of cystine in urine, precipitation of cystine and subsequent stone formation occur at physiologic urine conditions (Joly et al., 1999). The solubility of cystine is highly pH dependent, with solubilities of 300 mg/L, 400 mg/L, and 1000 mg/L at pH levels of 5, 7, and 9, respectively (Dent and Senior, 1955). Ionic strength also influences solubility, and as much as 70 mg of additional cystine can be dissolved in each liter of solution as ionic strength increases from 0.005 to 0.3 (Pak and Fuller, 1983). Macromolecules such as colloid also increase cystine solubility, although the mechanism is unclear (Pak and Fuller, 1983). Therefore cystine is more soluble in urine than in synthetic solution (Fig. 91.15).

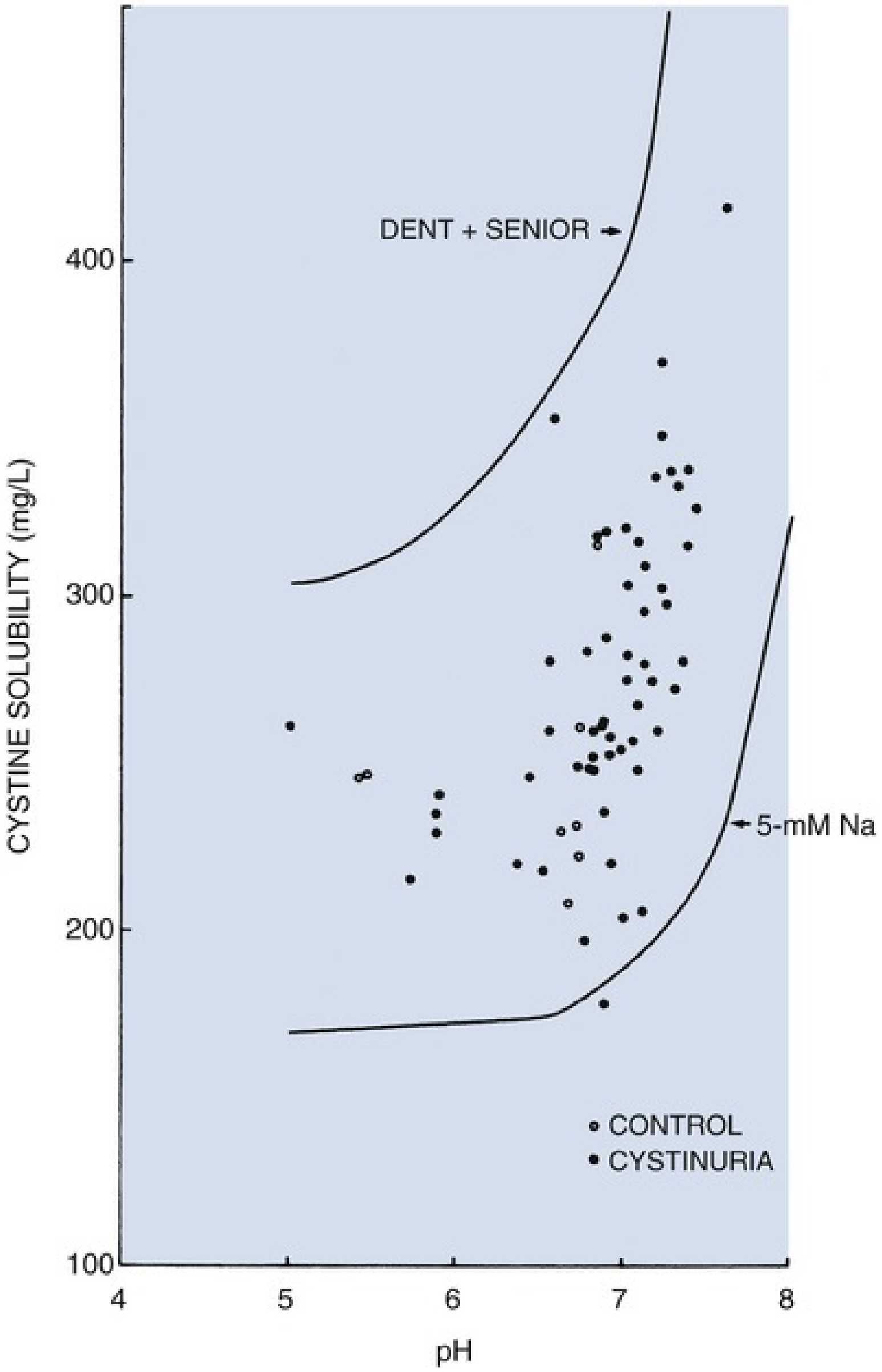

FIG. 91.15 Cystine solubility in urine. Each point represents solubility of cystine determined in a separate urine sample by incubation with an excess of solid cystine. The solubility curve of Dent and Senior (1955) and that obtained in a 5-mM sodium cacodylate solution are plotted for comparison. (From Pak CY, Fuller CJ: Assessment of cystine solubility in urine and of heterogeneous nucleation. *J Urol* 129:1066–1070, 1983.)

Other factors may contribute to stone formation in cystinuric patients as well. Sakhaee et al. (1989) evaluated 27 patients with documented cystine nephrolithiasis and identified hypercalciuria in 19%, hyperuricosuria in 22%, and hypocitraturia in 44%, which could contribute to formation of not only cystine stones but also calcium or mixed calcium-cystine stones.

Although historically cystinuria was classified on the basis of levels of urinary cystine in obligate heterozygote parents of the proband (Rosenberg et al., 1966), this classification correlated poorly with molecular findings and was subsequently revised by the International Cystinuria Consortium (ICC) to take into account the chromosomal localization of the mutation: type A (chromosome 2), type B (chromosome 19), and type AB (both chromosomes) (Dello Strologo et al., 2002). Homozygotes with the condition exhibit urinary cystine levels as high as 2000 µmol/g of creatinine. Review by the ICC revealed that the average age at first stone diagnosis was 12.2 years, with a mean number of stone episodes of 0.42 and 0.21 per year occurring in men and women, respectively (Dello Strologo et al., 2002). Although mean urinary cystine levels are significantly higher in heterozygotes with type B abnormalities (475 µmol/g creatinine) compared with those with type A abnormalities (70 µmol/g creatinine), there is no difference in stone formation between the two groups, and, in fact, stone formation is uncommon (Dello Strologo et al., 2002).

Although stone formers in general have been found to have a higher likelihood of developing chronic kidney disease (Worcester et al., 2006b), cystine stone formers have been shown to have lower creatinine clearances than other stone formers (Worcester et al., 2006a). A potential explanation for this finding is the observation that cystinuric patients undergo more open surgical procedures, including nephrectomy, than their calcium oxalate stone-forming counterparts (Assimos et al., 2002). Histologically, these patients have been observed to have dilated ducts of Bellini plugged by cystine crystals as well as evidence of cortical glomerulosclerosis and interstitial fibrosis (Evan et al., 2006b).

Infection Stones

Infection stones are composed primarily of magnesium ammonium phosphate hexahydrate ($MgNH_4PO_4 \cdot 6H_2O$) but may in addition contain calcium phosphate in the form of carbonate apatite ($Ca_{10}[PO_4]_6 \cdot CO_3$). A Swedish geologist discovered magnesium ammonium phosphate in guano and named it “struvite” after his mentor, naturalist H.C.G. von Struve (Griffith and Osborne, 1987). Brown (1901) first theorized that bacteria split urea, thereby setting up the condition for stone formation, and he later isolated *Proteus vulgaris* from a stone. Hager and Magath (1925) postulated that a bacterial enzyme hydrolyzed urea, and Sumner (1926) isolated urease from *Canavalia ensiformis*. It is now well established that struvite stones (magnesium ammonium phosphate) occur only in association with urinary infection by urea-splitting bacteria (Griffith and Musher, 1973).

Pathogenesis

The process of urealysis provides an alkaline urinary environment and sufficient concentrations of carbonate and ammonia to induce the formation of infection stones. Because urease is not present in sterile human urine, infection with urease-producing bacteria is a prerequisite for the formation of infection stones. A cascade of chemical reactions generates the conditions conducive to the formation of infection stones. Urinary urea, a constituent of normal urine, is first hydrolyzed to ammonia and carbon dioxide in the presence of bacterial urease:

$$(NH_2)_2CO + H_2O \rightarrow 2NH_3 + CO_2$$

The alkaline urine that results from this reaction (pH 7.2 to 8.0) favors the formation of ammonium:

$$NH_3 + H_2O \rightarrow NH_4 + OH^- \ (pK = 9.0)$$

Under physiologic conditions, the alkaline urine would prevent further generation of ammonium. However, in the presence of urease, ammonia continues to be produced, further increasing urinary pH. The alkaline environment also promotes the hydration of carbon dioxide to carbonic acid, which then dissociates into HCO_3^- and H^+. Further dissociation of HCO_3^- yields carbonate and another hydrogen ion:

$$CO_2 + H_2O \rightarrow H_2CO_3 \ (pK = 4.5)$$

$$H_2CO_3 \rightarrow H^+ + HCO_3^- \ (pK = 6.3)$$

$$HCO_3^- \rightarrow H^+ + CO_3^{2-} \ (pK = 10.2)$$

The dissociation of hydrogen phosphate under alkaline conditions provides phosphate, thereby completing the generation of constituent ions for infection stone formation:

$$H_2PO_4^- \rightarrow H^+ + HPO_4^{2-} \ (pK = 7.2)$$

$$HPO_4^{2-} \rightarrow H^+ + PO_4^{3-} \ (pK = 12.4)$$

This chemical cascade, along with physiologic concentrations of magnesium, provides the constituents necessary for precipitation of struvite. In addition, the concentrations of calcium, phosphate, and carbonate allow precipitation of carbonate apatite and hydroxyapatite, thereby composing the components of infection stones (Fig. 91.16).

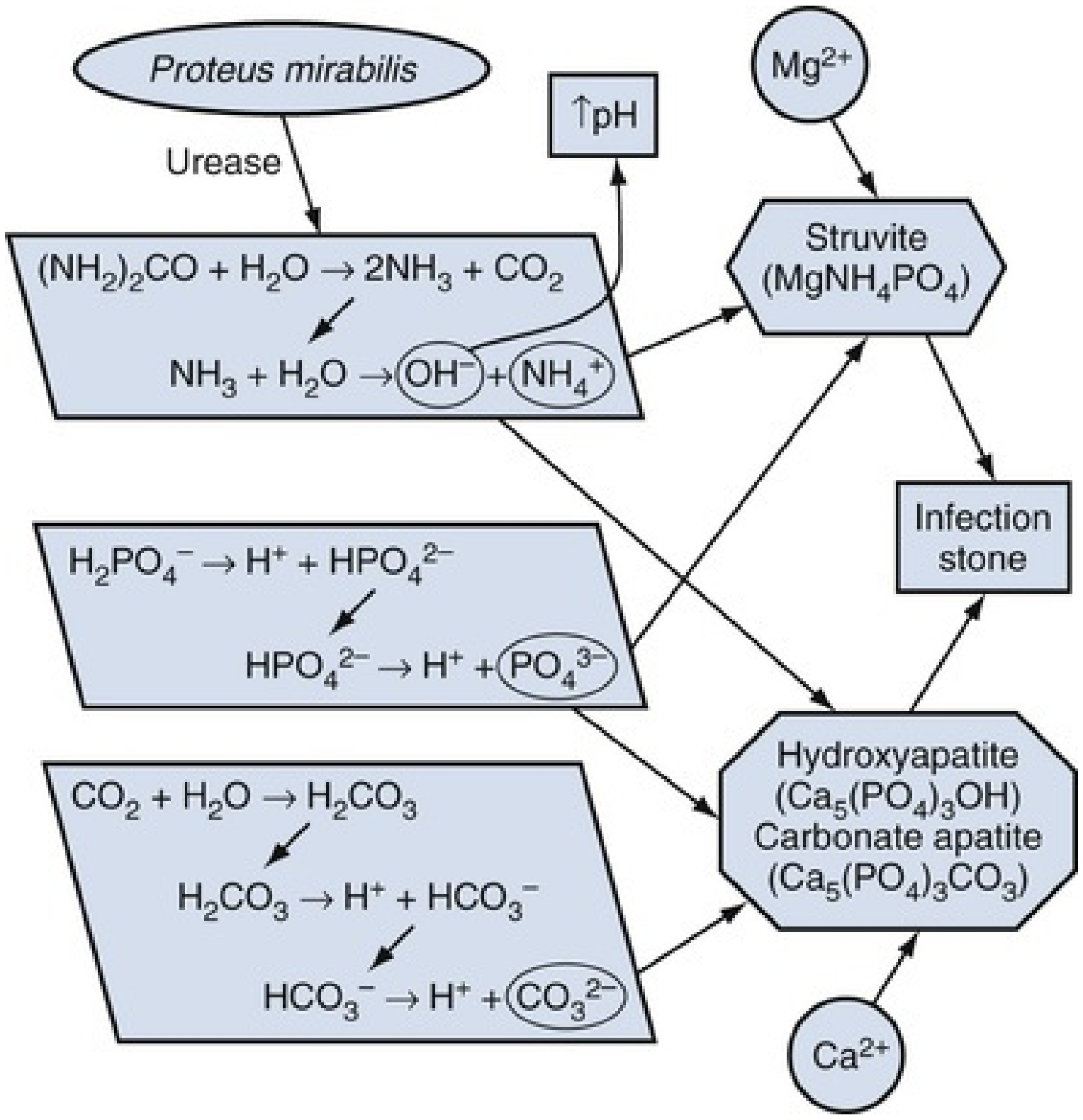
Proteus mirabilis
Urease
↑pH
Mg2+
(NH2)2CO + H2O → 2NH3 + CO2
NH3 + H2O → OH− + NH4+
Struvite (MgNH4PO4)
Infection stone
H2PO4− → H+ + HPO42−
HPO42− → H+ + PO43−
Hydroxyapatite (Ca5(PO4)3OH)
Carbonate apatite (Ca5(PO4)3CO3)
CO2 + H2O → H2CO3
H2CO3 → H+ + HCO3−
HCO3− → H+ + CO32−
Ca2+

FIG. 91.16 Schematic depicting concurrent events leading to struvite stone formation. (From Johnson DB, Pearle MS: Struvite stones. In Stoller ML, Meng MV, editors: *Urinary stone disease: the practical guide to medical and surgical management,* Totowa, NJ, 2007, Humana Press.)

Although infection stones are a direct result of persistent or recurrent infection with urease-producing bacteria, they may also be associated with or exacerbated by urinary obstruction or stasis (Bichler et al., 2002). Therefore growth of infection stones can progress at a rapid rate.

Bacteriology

Although the family Enterobacteriaceae makes up the majority of urease-producing pathogens, a variety of gram-positive and gram-negative bacteria and some yeasts and *Mycoplasma* species have the capacity to synthesize urease (Table 91.3). **The most common urease-producing pathogens are *Proteus, Klebsiella, Pseudomonas,* and *Staphylococcus* species**, **with *Proteus mirabilis* the most common organism associated with infection stones.** Although *Escherichia coli* is a common cause of urinary tract infections, only rare species of *E. coli* produce urease (Bichler et al., 2002). A recent multicenter review of 121 struvite and/or carbonate apatite stones obtained from patients undergoing surgical intervention for stones at four participating centers revealed preoperative urine cultures that grew *Proteus* species in 11.3% and *E. coli* in 15.2% of cases (Flannigan et al., 2018)

TABLE 91.3

Organisms That May Produce Urease

ORGANISMS	USUALLY (>90% OF ISOLATES)	OCCASIONALLY (5%–30% OF ISOLATES)
Gram-negative	*Proteus rettgeri* *Proteus vulgaris* *Proteus mirabilis* *Proteus morganii* *Providencia stuartii* *Haemophilus influenzae* *Bordetella pertussis* *Bacteroides corrodens* *Yersinia enterocolitica* *Brucella* species	*Klebsiella pneumoniae* *Klebsiella oxytoca* *Serratia marcescens* *Haemophilus parainfluenzae* *Bordetella bronchiseptica* *Aeromonas hydrophila* *Pseudomonas aeruginosa* *Pasteurella* species
Gram-positive	*Flavobacterium species* *Staphylococcus aureus* *Micrococcus* *Corynebacterium ulcerans* *Corynebacterium renale*	*Staphylococcus epidermidis* *Bacillus* species *Corynebacterium murium* *Corynebacterium equi* *Peptococcus asaccharolyticus*

	Corynebacterium ovis *Corynebacterium hofmannii*	*Clostridium tetani* *Mycobacterium rhodochrous* group
Mycoplasma	T-strain *Mycoplasma* *Ureaplasma urealyticum*	
Yeasts	*Cryptococcus* *Rhodotorula* *Sporobolomyces* *Candida humicola* *Trichosporon cutaneum*	

From Gleeson MJ, Griffith DP: Infection stones. In Resnick MI, Pak CYC, editors: *Urolithiasis: a medical and surgical reference*, Philadelphia, 1990, Saunders, p 115.

Bacteria may be involved in stone formation by damaging the mucosal layer of the urinary tract, resulting in increased bacterial colonization and crystal adherence (Djojodimedjo et al., 2013; Grenabo et al., 1988; Parsons et al., 1984). It has been proposed that ammonium, generated as a result of urealysis, may alter the glycosaminoglycan layer present on the surface of the transitional cell layer and significantly increase bacterial adherence to normal bladder mucosa, further exacerbating infection risk (Parsons et al., 1984). In addition, a study in rats found that injury to the bladder mucosa increased crystal adherence to the bladder wall, a process that was potentiated by the presence of common bacteria such as *Proteus*, *E. coli*, *Enterococcus*, and *Ureaplasma urealyticum* (Grenabo et al., 1988). Another potential mechanism for increased stone formation in the presence of bacteria is the finding that particular bacteria, such as *E. coli* and *Proteus*, may alter the activity of urokinase and sialidase, whereas organisms not typically associated with infection stones do not (du Toit et al., 1992). This altered enzymatic activity may explain the frequent association of *E. coli* with stone formation despite lacking urease activity (Holmgren et al., 1989).

Epidemiology

Although infection stones account for only 5% to 15% of all stones (Levy et al., 1995), they have been thought to be the most common component of staghorn calculi. However, a recent analysis of the composition of 52 staghorn calculi demonstrated that only 44% of stones were infection stones, whereas 56% of stones were metabolic, with calcium phosphate the most common (Viprakasit et al., 2011). Moreover, struvite–carbonate apatite was the most common stone composition among a population of African-American stone formers in Ohio, accounting for one-third of stones in males and nearly half of stones in females in this population (Sarmina et al., 1987). **Because infection stones occur most commonly in those prone to frequent urinary tract infections, struvite stones occur more often in women than men by a ratio of 2 : 1** (Resnick, 1981). Other populations at risk of recurrent infection include the elderly (Kohri et al., 1991), premature infants or infants born with congenital urinary tract malformation, patients with diabetes, and those with urinary stasis as a result of urinary tract obstruction, urinary diversion, or neurologic disorders. Spinal cord–injured patients are at particular risk for infection and metabolic stones because of neurogenic urinary tract dysfunction and hypercalciuria related to immobility. Patients with a functionally complete cord transection are at highest risk of developing a staghorn calculus (DeVivo et al., 1984).

Miscellaneous Stones

Xanthine and Dihydroxyadenine Stones

Autosomal recessive disorders of purine metabolism have been implicated in stone disease. Deficiencies of the enzymes adenine phosphoribosyltransferase (APRT) and xanthine dehydrogenase (XDH) lead to an accumulation of precursors immediately proximal to the site of enzyme action (Rumsby, 2016). XDH deficiency results in accumulation of xanthine and APRT deficiency leads to accumulation of adenine which is metabolized to 2,8-dihydroxyadenine (DHA) by XDH. Xanthine and DHA stones are highly insoluble and completely radiolucent, often resulting in them being mistaken for uric acid stones. Accumulation of DHA leads to stone formation and obstructive nephropathy or crystalline nephritis.

Allopurinol, which inhibits XDH and is consequently used to treat hyperuricemia and hyperuricosuria, can, at high levels, predispose to xanthine stones. This side effect is distinctly uncommon because the drug causes only partial inhibition of the enzyme and rarely reduces serum uric acid to levels lower than 3 mg/dL. Patients with Lesch-Nyhan syndrome who suffer from an inherited deficiency of the purine salvage enzyme HGPRT are occasionally treated with high enough doses of allopurinol to place them at risk for xanthine stones (Cameron et al., 1993).

Children with inherited deficiencies of APRT in infancy can have renal complications and stones (Cameron et al., 1993). The APRT enzyme is encoded by *APRT*, a gene on the long arm of chromosome 16 (16q24) (Fratini et al., 1986). More than 40 mutations have been described, including Met136Thr, which is common in Japanese individuals (Kamatani et al., 1992), whereas a single T insertion in a splice donor site in intron 4 was the most common mutation (40%) in a French cohort (Bollée et al., 2010). Children with APRT deficiency may be difficult to distinguish from those with HGPRT deficiency because the insoluble product excreted, 2,8-dihydroxyadenine, is chemically similar to uric acid. Like xanthine stones, 2,8-dihydroxyadenine stones are extremely insoluble at any pH, but stone formation can be averted by the administration of allopurinol.

Ammonium Acid Urate Stones

Ammonium acid urate stones represent about 1% of all stones (Pichette et al., 1997; Soble et al., 1999). In developing countries, however, endemic ammonium acid urate urolithiasis is still observed because it makes up bladder calculi in children (Vanwaeyenbergh et al., 1995).

Ammonium urate stones are radiolucent and occur in patients with chronic diarrhea, inflammatory bowel disease, ileostomy bowel diversions, laxative abuse, recurrent urinary tract infection, and recurrent uric acid stone formation (Dick et al., 1990; Pichette et al., 1997; Soble et al., 1999). Soble et al. (1999) reviewed their experience with 44 patients identified as having stones composed of ammonium acid urate, although the ammonium acid urate contribution varied from 2% to 60%. Among these patients, 25% had a history of inflammatory bowel disease, 14% had a history of significant laxative abuse, 41% were morbidly obese, 36% had a history of recurrent urinary tract infections, and 21% had a history of recurrent uric acid stones. The subgroup of patients with inflammatory bowel disease and ileostomy as the sole clinical risk factor had the highest mean ammonium acid urate content (39%), and ammonium acid urate constituted the predominant stone type in seven of eight such patients. In a more contemporary series Lomas et al. (2017) identified 111 ammonium acid urate stones in 89 patients and found 22% had a history of prostate surgery with bladder neck contracture. They found no association with laxative use.

Patients with ileostomy after colectomy have markedly reduced urinary volume, pH, and sodium and are not prone to hyperoxaluria as are other individuals with bowel disease because the colon is the main site of dietary oxalate absorption (Kennedy et al., 1982). Therefore these patients are prone to ammonium acid urate and uric acid stones rather than calcium oxalate stones. **The underlying pathophysiologic mechanism of ammonium acid urate stone**

formation attributable to laxative abuse has been postulated to be dehydration resulting from gastrointestinal fluid loss, causing intracellular acidosis and enhanced ammonia excretion. Because urinary sodium is low in the setting of laxative use, urate complexes with abundant ammonia, thereby leading to urinary supersaturation of ammonium acid urate.

Bowyer et al. (1979) demonstrated that ammonium acid urate precipitation is favored at pH 6.2 to 6.3. The association of recurrent uric acid stones with ammonium acid urate stones is likely related to the shared risk factors of low urine volume and pH. Soble et al. (1999) identified nine patients with stones of mixed composition, containing uric acid and ammonium acid urate (mean ammonium acid urate content 27%), although 8 of the 9 patients had uric acid as the predominant constituent (range 40% to 95%). They theorized that transient fluctuations in urinary acidity and ammonium and sodium levels may shift the balance between uric acid and sodium- or ammonium-bound urate excretion.

Among the ammonium acid urate stone producers in the study by Soble et al. (1999), obesity (BMI >30) was the most prevalent characteristic in 41% of patients, after excluding patients with inflammatory bowel disease and ileostomy (none of whom was obese). Indeed, a statistically significant correlation was found between BMI and ammonium acid urate content. This is consistent with recent evidence suggesting a correlation between stone risk and obesity (Powell et al., 2000) and between obesity and low urine pH (Maalouf et al., 2004b).

Matrix Stones

The association between urinary proteins and stone formation has long been recognized. Early experiments demonstrated that protein suspensions could promote calcium stone formation (Kimura et al., 1976). Osteopontin and calprotectin have been shown to play a role in forming the matrix structure of urinary calcium stones (Kleinman et al., 2004; Tawada et al., 1999). However, stones composed predominantly of matrix are rare; these “stones” are typically radiolucent and may be mistaken for tumor or uric acid stones depending on the imaging study obtained (Bani-Hani et al., 2005).

The literature regarding matrix stones is sparse, consisting mostly of anecdotal case reports (Allen and Spence, 1966; Bani-Hani et al., 2005; Boyce and King, 1963). The matrix component of calcium-based stones makes up only 2.5% of the dry weight of the stone, whereas pure matrix stones may contain more than 65% protein (Allen and Spence, 1966). Boyce and Garvey (1956) determined that the composition of matrix stones was approximately two-thirds mucoprotein and one-third mucopolysaccharide by weight. Furthermore, they found that the matrix substance in crystalline calculi is closely related to the matrix substance found in matrix calculi. However, it is unclear why some matrix calculi fail to fully calcify. Although some have theorized that reduced urinary calcium levels may account for the preferential formation of matrix stones (Allen and Spence, 1966; Boyce and King, 1959), a recent metabolic evaluation of five patients with matrix stones revealed normal urinary calcium excretion (Bani-Hani et al., 2005). In renal failure patients undergoing dialysis, proteinuria may contribute to an increased risk of matrix stone formation. In these patients, matrix stones have been shown to include microfibrillar protein (Bommer et al., 1979) and β_2-microglobulin (Linke et al., 1986). Recent analysis of the matrix stone from a single patient with *Proteus* urinary tract infection by scanning electron microscopy revealed fibrous netlike laminations containing bacterial, cellular, and crystalline material (Canales et al., 2009). Proteomic analysis identified 33 unique proteins, of which 90% had not been previously reported as components of matrix stones and 70% are considered inflammatory or defensive.

Medication-Related Stones

Drug-induced stones form either directly as a result of precipitation and crystallization of a drug or its metabolite or indirectly by altering the urinary environment, making it favorable for metabolic stone formation (Daudon, 1999). Drugs such as loop diuretics (furosemide, bumetanide) and carbonic anhydrase inhibitors (acetazolamide, topiramate, and zonisamide) contribute to calcium stone formation (Matlaga et al., 2003). Ephedrine (Assimos et al., 1999; Powell et al., 1998), triamterene (Carr et al., 1990; Ettinger et al., 1980), guaifenesin (Assimos et al., 1999), silicate (Farrer and Rajfer, 1984), indinavir (Bruce et al., 1997; Gentle et al., 1997), and ciprofloxacin (Matlaga et al., 2003) have been associated with stones composed of the drug in patients who consumed excessive amounts.

Medications That Directly Promote Stone Formation

Antiretroviral Agents.

Indinavir sulfate is a protease inhibitor that has been shown to be effective in increasing CD4+ cell counts and decreasing HIV-RNA titers in patients infected with human immunodeficiency virus (HIV) or who have acquired immunodeficiency syndrome (Wu and Stoller, 2000). However, indinavir poses a risk for indinavir stone formation in treated patients, leading to an estimated incidence of 4% to 13% (Wu and Stoller, 2000). Indinavir is rapidly absorbed from the intestine, achieving peak plasma concentrations in less than 1 hour. The drug is metabolized in the liver and eliminated primarily in the stool, but about half of the ingested dose of indinavir is excreted essentially unchanged in the urine (Sutherland et al., 1997). In pure form, indinavir is relatively insoluble in aqueous solution, although the solubility is pH dependent. With a pK_a of 5.5, indinavir has a solubility of 0.300 mg/mL at pH 5, 0.035 mg/mL at pH 6.0, and 0.020 mg/mL at pH 7.0 (Daudon et al., 1997; Hermieu et al., 1999). Although indinavir solubility increases significantly at pH levels below 5.5, the standard dose of indinavir in an individual with an average urine volume and pH would produce a urinary concentration of indinavir near the limit of solubility 3 hours after ingestion (Daudon et al., 1997). As such, **individuals taking indinavir on a regular basis are at high risk of producing indinavir stones because of the high urinary excretion and poor solubility of the drug at physiologic urinary pH.** Initiation of indinavir in 54 asymptomatic, indinavir-naive, HIV-positive individuals led to indinavir crystalluria in 67% of subjects (Gagnon et al., 2000). After the first 2 weeks, indinavir crystalluria remained constant at a frequency of approximately 25% of urine sediments examined at each test point.

Indinavir is now an infrequently used antiretroviral agent, replaced with newer generation agents. Kidney stone formation has been associated with a number of newer antiretroviral agents, including lopinavir-ritonavir (Doco-Lecompte et al., 2004), ritonavir-boosted atazanavir (Hamada et al., 2012; Rockwood et al., 2011), nelfinavir (Engeler et al., 2002), and amprenavir (Feicke et al., 2008). Ritonavir-boosted atazanavir, currently one of the more widely used agents, has been shown to have a nearly 7% incidence of stone formation, higher than most of the other new agents (Hamada et al., 2012; Rockwood et al., 2011). Because stone formation associated with these agents is thought to be the result of high urinary excretion and low solubility of the drug in urine, agents with higher excretion rates are associated with higher rates of stone formation; 7% of ritonavir-boosted atazanavir is excreted in the urine unmetabolized versus less than 3% for nelfinavir and amprenavir, which have lower rates of stone formation.

Triamterene.

Triamterene is a potassium-sparing diuretic commonly used for the treatment of hypertension. It is an uncommon stone composition, accounting for only 0.4% of

50,000 calculi in one report, with only one-third of the stones composed largely or entirely of triamterene (Ettinger et al., 1980). An evaluation of triamterene stone formers revealed no significant differences between patients and matched control subjects with respect to total recovery of the drug, hourly excretion patterns, and urinary concentrations of triamterene and its sulfate metabolite (Ettinger, 1985). Approximately half of all subjects tested demonstrated urine concentrations of the sulfate metabolite that exceeded the observed solubility limit. One investigation determined that triamterene is more likely to become incorporated into existing stones or stone nidi than to promote stone formation independently (Werness et al., 1982). This may account for the rarity of this stone in nonrecurrent stone formers, as well as the finding that hospitalization rates for urinary stones did not differ between patients prescribed triamterene and hydrochlorothiazide (Jick et al., 1982).

Guaifenesin and Ephedrine.

Consumption of large quantities of guaifenesin and ephedrine can lead to stones composed of their metabolites (Assimos et al., 1999; Powell et al., 1998). Most of the patients reported to have these stones are found to have consumed large quantities of over-the-counter preparations of cold medicine for the stimulatory properties of the ephedrine component, and a history of drug abuse is not uncommon (Assimos et al., 1999). Herbal ecstasy and ma huang are also popular ephedrine-containing preparations that are abused for stimulatory properties (Mack, 1997). Unfortunately, chronic ephedrine use leads to tachyphylaxis and prompts the use of increasing doses to achieve a comparable effect. Serious toxicity may result from ephedrine abuse, including death, cardiomyopathy, stroke, hypertension, and seizures.

Silicate Stones.

Silica is a common element seen in vegetables, whole grains, seafood, and even drinking water that is easily excreted in the urine (Matlaga et al., 2003). Silicate stones are extremely rare and have been associated with consumption of large amounts of silicate-containing antacids such as magnesium trisilicate (Daudon, 1999; Haddad and Kouyoumdjian, 1986).

Medications That Indirectly Promote Stone Formation.

Other medications indirectly promote stone formation by increasing urinary stone risk factors. Corticosteroids, vitamin D, and phosphate-binding antacids can induce hypercalciuria. **Thiazides cause intracellular acidosis and subsequent hypocitraturia** (Nicar et al., 1984). Loop diuretics such as furosemide and bumetanide inhibit sodium and calcium resorption in the thick ascending loop of Henle, which in addition to a diuretic effect results in hypercalciuria (Matlaga et al., 2003). Renal calculi have been identified in up to 64% of low-birth-weight infants receiving furosemide therapy, and stones are consistently composed of calcium oxalate (Hufnagle et al., 1982; Shukla et al., 2001).

Carbonic anhydrase inhibitors such as acetazolamide block resorption of sodium bicarbonate at multiple segments in the nephron, thereby inducing a metabolic acidosis and leading to urinary alkalinization (Parfitt, 1969). **Chronic use results in hypocitraturia, hypercalciuria, and increased risk for calcium phosphate stones** (Matlaga et al., 2003). Topiramate is a widely used drug approved for the treatment of seizures and prophylaxis of migraine headaches but is additionally increasingly used for the treatment of a variety of other disorders, such as obesity, neuropathic pain, alcoholism, type 2 diabetes, cigarette smoking, and cocaine dependence. Topiramate inhibits several isoenzymes of carbonic anhydrase with subsequent stone-potentiating effects (Vega et al., 2007). Although the incidence of calcium stones with topiramate use in adults based on short-term clinical trials was reported as 1.2% to 1.5% in the package insert, this number is thought to be an underestimate. Indeed, a recent retrospective study identified 150 individuals who were treated with topiramate out of 1500 adults in an electronic database from an epilepsy monitoring unit, among whom 75 were successfully contacted and queried regarding their kidney stone history (Maalouf et al., 2011). A total of eight subjects reported a diagnosis of kidney stones since the start of topiramate use, resulting in 10.7% prevalence. Furthermore, 15 patients among the 67 patients without a history of stones from the same study group were evaluated with computed tomographic imaging at an average of 43 months of topiramate use, revealing a 20% prevalence of asymptomatic stones, suggesting the problem is much more prevalent than previously suspected.

The risk of stone formation with topiramate use is related to its action as a carbonic anhydrase inhibitor. A recent cross-sectional study comparing 32 topiramate-treated patients with 50 normal controls revealed systemic metabolic acidosis, increased fractional excretion of bicarbonate, higher urine pH, and lower urinary citrate excretion in the topiramate-treated group (Welch et al., 2006). Likewise, in a short-term longitudinal study of seven patients before and

3 months after initiation of topiramate, significant metabolic acidosis and increased urine pH, bicarbonate excretion, and saturation of calcium phosphate were seen with initiation of the drug (Welch et al., 2006). Furthermore, topiramate-induced hypocitraturia demonstrates a dose-dependent response that additionally correlates inversely with duration of treatment (Kaplon et al., 2011). Zonisamide, a sulfonamide agent that also exerts an antiepileptic effect and has a weak carbonic anhydrase activity, has also been associated with increased risk of kidney stone formation (Zaccara et al., 2011).

Laxative abuse has also been associated with stone formation because persistent diarrhea increases the risk of ammonium acid urate stones. Patients abusing laxatives excrete large amounts of ammonia in the urine to eliminate excess acid, resulting in low urine pH. In the setting of low urine volume resulting from dehydration and low urinary sodium from laxative use, the urine of these patients can be highly supersaturated with respect to ammonium urate (Matlaga et al., 2003; Soble et al., 1999). Last, cytotoxic agents promote a high cell turnover, resulting in urinary excretion of large amounts of uric acid.

Anatomic Predisposition to Stones

Patients with anatomic anomalies associated with urinary obstruction and/or stasis have been noted to have a high incidence of associated stones. It has long been debated whether the predisposition to stone disease is a result of urinary stasis and delayed transit time through the nephron, leading to higher likelihood of crystal formation and retention, or if these patients form stones as a result of the same or unique metabolic abnormalities associated with stone formation.

Ureteropelvic Junction Obstruction

The incidence of renal calculi in patients with ureteropelvic junction obstruction (UPJO) is nearly 20% (Clark and Malek, 1987; David and Lavengood, 1975; Lowe and Marshall, 1984). However, Husmann et al. (1995) **provided several lines of evidence to suggest that patients with UPJO and concurrent renal calculi carry the same metabolic risks as other stone formers in the general population.** First, among 111 adult patients with UPJO and stones for whom long-term follow-up was available, 62% developed recurrent stones after treatment of the UPJO and 43% of the recurrences occurred in the contralateral kidney. These findings suggest that a metabolic predisposition persisted despite correction of the obstruction. Second, 76% of 42 patients with noninfectious stones who underwent a metabolic evaluation demonstrated an underlying metabolic abnormality that could account for the stones, a rate comparable to that of other stone formers (Pak, 1982; Yagisawa et al., 1999). Finally, the type and distribution of metabolic abnormalities identified in these patients were similar to those of the general stone-forming population: hypercalciuria in 46% of patients, hyperuricosuria in 11%, hypocitraturia in 13%, primary hyperparathyroidism in 13%, and RTA in 3% (Pak et al., 1980). Treatment of patients with identifiable abnormalities significantly reduced their rate of recurrence, from 55% in patients managed conservatively to 17% in treated patients.

Matin and Streem (2000) also performed metabolic evaluations before definitive repair in 47 patients with UPJO with or without associated stones. An identifiable abnormality was found in 67% of the stone patients compared with only 33% of the control group; urinary calcium and the incidence of hypercalciuria and hyperuricosuria were significantly higher in the patients with stones compared with the controls, further underscoring the contribution of pathophysiologic background to stone-forming risk in patients with anatomic abnormalities.

Similar findings in two series of children with UPJO and concurrent renal calculi further support a metabolic contribution to stone formation in the presence of renal obstruction. Tekin et al. (2001) prospectively compared children with UPJO with and without stones to a control group of calcium stone formers without UPJO. Both groups of stone formers, those with and without UPJO, exhibited significantly higher urinary levels of citrate and lower levels of oxalate compared with the non–stone-forming children with UPJO. Husmann et al. (1996) reported a 70-fold increased risk of stone formation in the pediatric population with UPJO compared with normal children. Among 22 children who underwent treatment of their stones and UPJO, 68% of patients with nonstruvite stones developed a recurrence after surgical treatment, and a metabolic abnormality was identified in 68%. Among the seven patients with nonstruvite renal calculi who did not experience a recurrence, only 29% had an identifiable metabolic abnormality. Thus correction of the UPJO did not prevent recurrent stones in most patients, further emphasizing the role of underlying metabolic abnormalities in the cause of renal calculi in patients with UPJO.

Horseshoe Kidneys

Horseshoe kidneys occur with a prevalence of 0.25% but have an associated rate of renal calculi of 20% (Cussenot et al., 1992; Janetschek and Kunzel, 1988). Because of the high insertion of the ureter into the renal pelvis, there is a relative impairment of renal drainage, predisposing to UPJO. Therefore the risk of stone formation has been attributed to urinary stasis rather than to metabolic derangements. Raj et al. (2004) reviewed 37 patients with horseshoe kidneys and stones and identified at least one metabolic abnormality in all 11 patients in whom 24-hour urine collections were available. Compared with a group of stone formers with normal renal anatomy, the patients with horseshoe kidneys exhibited a similar distribution of metabolic derangements, with the exception that hypocitraturia was over-represented (55% in the patients with horseshoe kidneys vs. 31% in controls). It seems clear that **although urinary stasis likely contributes to a propensity toward stone formation in patients with horseshoe kidneys, an underlying metabolic abnormality is required for stone formation to occur.**

Caliceal Diverticula

Caliceal diverticula are associated with stones in up to 40% of patients (Middleton and Pfister, 1974). Like stones in horseshoe kidneys, it is unclear whether the stones are caused by local anatomic obstruction and urinary stasis or are due to underlying metabolic factors. Two groups of investigators have addressed this issue. Hsu and Streem (1998) identified metabolic abnormalities, including hypercalciuria, hyperoxaluria, and hyperuricosuria, in 50% of 14 patients with stone-bearing caliceal diverticula. Notably, 64% of patients reported a history of synchronous or metachronous stones at a site distinct from the diverticulum, supporting the idea of underlying metabolic risk as a contributing cause of the stones. In contrast, Liatsikos et al. (2000) compared 49 patients with caliceal diverticula and stones with 44 stone formers without diverticula and found a low rate of metabolic abnormalities in both groups (25% in patients with diverticula and 23% in the control patients). However, the metabolic evaluation in this study involved measurement of only urinary volume, creatinine, calcium, phosphorus, oxalate, and uric acid. Because low urinary pH and hypocitraturia are identified in approximately 10% and 28% of recurrent stone formers, respectively (Levy et al., 1995), the number of metabolic abnormalities reported in this series is likely under-represented. Finally, a study by Matlaga et al. (2007) evaluated 29 patients who underwent percutaneous treatment of stone-bearing calyceal diverticuli and compared their 24-hour urine collections with those of 245 calcium oxalate stone formers and

162 normal controls. The urinary stone risk parameters of the patients with calyceal diverticular stones were similar to those of calcium oxalate stone formers, who demonstrated significantly greater hypercalciuria and higher calcium oxalate supersaturation compared with normal controls. Interestingly, urine aspirated directly from the diverticulum had lower calcium oxalate supersaturation than that of urine obtained from the ipsilateral and contralateral renal pelves. These findings imply that calyceal diverticular calculi arise from a combination of metabolic abnormalities and urinary stasis.

Stones formed in caliceal diverticula are mainly composed of calcium oxalate monohydrate, but they can also contain struvite–carbonate apatite because of an infectious component. Concomitant urinary tract infection is found in up to 40% of cases, with *E. coli*, *Proteus*, and *Pseudomonas* the most frequent pathogens (Daudon et al., 2003; Monreal et al., 1998).

Medullary Sponge Kidney

Medullary sponge kidney (MSK) is a disorder characterized by ectasia of the renal collecting ducts. Nephrocalcinosis and renal calculi are frequent complications of MSK (Ginalski et al., 1990; Lavan et al., 1971; Parks et al., 1982; Sage et al., 1982), but the exact risk factors for stone formation are not clearly understood. Although recurrent infection and urinary stasis within the ectatic tubules pose a risk for stone formation (Ginalski et al., 1990), renal tubular defects, including hypercalciuria, impaired renal concentrating ability, and defective urinary acidification after an ammonium chloride load, have been detected in some MSK patients (Granberg et al., 1971), further potentiating the risk of stone formation. Osther et al. (1988) performed ammonium chloride load tests in 13 patients with MSK and found renal acidification defects in 9 patients: 8 with distal RTA and 1 with proximal RTA. Likewise, Higashihara et al. (1984) reported renal acidification defects in 80% of 11 MSK patients (36% with distal RTA) and impaired concentrating ability in 90% of these 11 patients. The identification of mutations in the hydrogen proton pump genes *ATP6V1B1* and *ATP6V0A4* in two patients with MSK lends further support to an association between MSK and distal RTA (Carboni et al., 2009).

Despite these findings, three studies performed specifically on MSK patients with nephrolithiasis revealed no case of associated RTA (O'Neill et al., 1981; Parks et al., 1982; Yagisawa et al., 2001). O'Neill et al. (1981) identified hypercalciuria as the most common metabolic abnormality in 17 patients with MSK and nephrolithiasis, occurring in 88% of patients and attributed to absorptive hypercalciuria in most cases (59%). The spectrum of abnormalities in these patients was judged to be comparable with that of the general stone-forming population. Other investigators identified hypercalciuria less frequently, in only 9% to 44% of MSK patients with nephrolithiasis. In some cases, the cause of the hypercalciuria was attributed to renal calcium leak by which renal calcium reabsorption was presumed to be impaired by damaged renal tubules (Parks et al., 1982; Yagisawa et al., 2001; Yendt, 1981). Yagisawa et al. (2001) identified hypocitraturia as the most common metabolic abnormality, occurring in 77% of 22 MSK patients. Kinoshita (1990) likewise reported hypocitraturia in 58% of MSK patients. **Thus it appears that although renal acidification defects may be associated with MSK, hypercalciuria and hypocitraturia are likely contributing factors even in the absence of RTA.**

Stones in Pregnancy

Symptomatic stones during pregnancy occur at a rate of 1 in 250 (Lewis et al., 2003) to 1 in 3000 (Butler et al., 2000) pregnant women. Unlike the rest of the population, the incidence of nephrolithiasis in pregnant women did not increase when comparing 1991 to 2000 and 2001 to 2011 (Riley et al., 2014). Similar to stones in nonpregnant women, they occur more commonly in white than African-American women (Lewis et al., 2003). The majority of symptomatic stones occur in the second and third trimesters of pregnancy, heralded by symptoms of flank pain or hematuria (Biyani and Joyce, 2002; Butler et al., 2000; Lewis et al., 2003; Stothers and Lee, 1992). The diagnosis can be difficult in this patient population; up to 28% of women are misdiagnosed with appendicitis, diverticulitis, or placental abruption (Stothers and Lee, 1992).

A number of physiologic changes occur during pregnancy. Physiologic hydronephrosis occurs in up to 90% of pregnant women and persists up to 4 to 6 weeks postpartum (Swanson et al., 1995). Although hydronephrosis may be in part due to the effects of progesterone, compression of the ureters by the gravid uterus is at least a contributory, if not the primary, factor (Gorton and Whitfield, 1997; McAleer and Loughlin, 2004). Dilation is typically greater in the right ureter as a result of the engorged uterine vein and derotation of the enlarged uterus (Biyani and Joyce, 2002). The physiologic dilation may promote crystallization as a result of urinary stasis (Swanson et al., 1995), and the increased renal pelvic pressure has been suggested to increase the likelihood of stone movement and symptoms.

Important physiologic changes in the kidney occur during pregnancy and modulate urinary stone risk factors. Renal blood flow increases, leading to a 30% to 50% rise in glomerular filtration rate, which subsequently increases the filtered loads of calcium, sodium, and uric acid (McAleer and Loughlin, 2004). Hypercalciuria is further enhanced by placental production of 1,25$(OH)_2D_3$, which increases intestinal calcium absorption and secondarily suppresses PTH (Biyani and Joyce, 2002; Gertner et al., 1986). Resim et al. (2006) demonstrated that hypercalciuria of pregnancy is a reversible physiologic condition by performing 24-hour urine collections on 25 pregnant women during each trimester and postpartum. Hyperuricosuria has also been reported as a result of increased filtered load of uric acid (Swanson et al., 1995).

Despite increases in a number of stone-inducing analytes, pregnant women have been shown to excrete increased amounts of inhibitors such as citrate, magnesium, and glycoproteins (Maikranz et al., 1987; Smith et al., 2001). Therefore the overall risk of stone formation has been reported to be similar in gravid and nongravid women (Coe et al., 1978; Drago et al., 1982). Although some studies found that the stone composition is similar between gravid and nongravid women, one multi-institutional study found that 74% of stones from pregnant women were composed predominantly of calcium phosphate and 26% were predominantly calcium oxalate (Ross et al., 2008). Meria et al. (2010) compared stone composition in 244 pregnant patients to 5712 age-matched nonpregnant female patients in France and found a significantly higher percentage of calcium phosphate carbapatite stones in pregnant compared with nonpregnant patients (65.6% and 31.4%, respectively, $P < 0.0001$). The higher prevalence of calcium phosphate stones observed in some studies of pregnant women may suggest that changes in pH during pregnancy could contribute to a higher likelihood of calcium phosphate stone formation, although this remains speculative.

Key Points: Pathogenesis

- Absorptive hypercalciuria is characterized by normal serum calcium, normal or suppressed PTH, normal fasting urinary calcium, and elevated urinary calcium.
- Renal hypercalciuria is due to impaired renal calcium reabsorption, which

stimulates PTH secretion and leads to fasting hypercalciuria.

- Resorptive hypercalciuria is primarily due to primary hyperparathyroidism but may be seen with granulomatous diseases that elaborate $1,25(OH)_2D_3$.
- The most important determinant of uric acid stone formation is low urinary pH.
- Low urine pH seen in uric acid stone formers is likely due to impaired ammoniagenesis as a result of insulin resistance and excess acid production.
- In distal RTA, a defective H^+-ATPase accounts for excretion of excess acid into the distal tubule.
- Formation of infection stones requires alkaline urine that can be achieved only with infection with urease-producing bacteria.

Suggested Readings

Devuyst O, Pirson Y. Genetics of hypercalciuric stone forming diseases. *Kidney Int*. 2007;72:1065–1072.

Evan A, Lingeman J, Coe FL, et al. Randall's plaque: pathogenesis and role in calcium oxalate nephrolithiasis. *Kidney Int*. 2006;69:1313–1318.

Holmes RP, Assimos DG. The impact of dietary oxalate on kidney stone formation. *Urol Res*. 2004;32:311–316.

Hoppe B. An update on primary hyperoxaluria. *Nat Rev Nephrol*. 2012;8:467–475.

Khan SR. Is oxidative stress, a link between nephrolithiasis and obesity, hypertension, diabetes, chronic kidney disease, metabolic syndrome? *Urol Res*. 2012;40:95–112.

Maalouf NM, Cameron MA, Moe OW, et al. Novel insights into the pathogenesis of uric acid nephrolithiasis. *Curr Opin Nephrol Hypertens*. 2004;13:181–189.

Matlaga BR, Shah OD, Assimos DG. Drug-induced urinary calculi. *Rev Urol*. 2003;5:227–231.

Miller NL, Evan AP, Lingeman JE. Pathogenesis of renal calculi. *Urol Clin North Am*. 2007;34:295–313.

Pearle MS, Calhoun EA, Curhan GC. Urologic Diseases in America project: urolithiasis. *J Urol*. 2005;173:848–857.

Sakhaee K, Maalouf NM, Sinnott B. Kidney stones 2012: pathogenesis, diagnosis and management. *J Clin Endocrinol Metab*. 2012;97:1847–1860.

Scales CD, Smith AC, Hanley JM, et al. Prevalence of kidney stones in the United States. *Eur Urol*. 2012;62:160–165.

Siva S, Barrack ER, Reddy GP, et al. A critical analysis of the role of gut Oxalobacter formigenes in oxalate stone disease. *BJU Int*. 2009;103:18–21.

References

Abate N, Chandalia M, Cabo-Chan AV Jr, et al. The metabolic syndrome and uric acid nephrolithiasis: novel features of renal manifestation of insulin resistance. *Kidney Int*. 2004;65:386–392.

Adams JS, Sharma OP, Gacad MA, et al. Metabolism of 25-hydroxyvitamin D3 by cultured pulmonary alveolar macrophages in sarcoidosis. *J Clin Invest*. 1983;72(5):1856–1860.

Adams JS, Singer FR, Gacad MA, et al. Isolation and structural identification of 1,25-dihydroxyvitamin D3 produced by cultured alveolar macrophages in sarcoidosis. *J Clin Endocrinol Metab*. 1985;60(5):960–966.

Alexander RT, Hemmelgarn BR, Wiebe N, et al. Kidney stones and cardiovascular events: a cohort study. *Clin J Am Soc Nephrol*. 2013;9(3):506–512.

Alexander RT, Hemmelgarn BR, Wiebe N, et al. Kidney stones and kidney function loss: a cohort study. *BMJ*. 2012;345:e5287.

Alfandary H, Haskin O, Davidovits M, et al. Increasing prevalence of nephrolithiasis in association with increased body mass index in children: a population based study. *J Urol*. 2018;199(4):1044–1049.

Allen LH. Calcium bioavailability and absorption: a review. *Am J Clin Nutr*. 1982;35:783–808.

Allen TD, Spence HM. Matrix stones. *J Urol*. 1966;95:284–290.

Angell AH, Resnick MI. Surface interaction between glycosaminoglycans and calcium oxalate. *J Urol*. 1989;141:1255–1258.

Asplin JR, Arsenault D, Parks JH, et al. Contribution of human uropontin to inhibition of calcium oxalate crystallization. *Kidney Int*. 1998;53:194–199.

Asplin JR, Coe FL. Hyperoxaluria in kidney stone formers treated with modern bariatric surgery. *J Urol*. 2007;177:565–569.

Asplin JR, DeGanello S, Nakagawa YN, et al. Evidence that nephrocalcin and urine inhibit nucleation of calcium oxalate monohydrate crystals. *Am J Physiol*. 1991;261:F824–F830.

Asplin JR. Uric acid stones. *Semin Nephrol*. 1996;16:412–424.

Assimos DG, Langenstroer P, Leinbach RF, et al. Guaifenesin- and ephedrine-induced stones. *J Endourol*. 1999;13:665–667.

Assimos DG, Leslie SW, Ng C, et al. The impact of cystinuria on renal function. *J Urol*. 2002;168:27–30.

Astrova GM, Neisius A, Tsivian M, et al. Treatment response in patients with stones, and low urinary pH and hypocitraturia stratified by body mass index. *J Urol*. 2016;195(3):653–657.

Atan L, Andreoni C, Ortiz V, et al. High kidney stone risk in men working in steel industry at hot temperatures. *Urology*. 2005;65:858–861.

Atmani F, Khan SR. Role of urinary bikunin in the inhibition of calcium oxalate crystallization. *J Am Soc Nephrol*. 1999;10(Suppl 14):S385–S388.

Bae SR, Seong JM, Kim LY, et al. The epidemiology of reno-ureteral stone disease in Koreans: a nationwide population-based study. *Urolithiasis*. 2014;42(2):109–114.

Bagby SP. Obesity-initiated metabolic syndrome and the kidney: a recipe for chronic kidney disease? *J Am Soc Nephrol*. 2004;15:2775–2791.

Baggio B, Gambaro G, Marchini F, et al. An inheritable anomaly of red-cell oxalate transport in “primary” calcium nephrolithiasis correctable with diuretics. *N Engl J Med*. 1986;314:599–604.

Bani-Hani AH, Segura JW, Leroy AJ. Urinary matrix calculi:

our experience at a single institution. *J Urol*. 2005;173:120–123.

Bannasch DL, Ling GV, Bea J, et al. Inheritance of urinary calculi in the Dalmatian. *J Vet Intern Med*. 2004;18:483–487.

Barilla DE, Notz C, Kennedy D, et al. Renal oxalate excretion following oral oxalate loads in patients with ileal disease and with renal and absorptive hypercalciurias: effect of calcium and magnesium. *Am J Med*. 1978;64:579–585.

Batlle D, Haque SK. Genetic causes and mechanisms of distal renal tubular acidosis. *Nephrol Dial Transplant*. 2012;27:3691–3704.

Batlle D, Moorthi KM, Schleuter W, et al. Distal renal tubular acidosis and the potassium enigma. *Semin Nephrol*. 2006;26:471–478.

Belostotsky R, Seboun E, Idelson GH, et al. Mutations in *DHDPSL* are responsible for primary hyperoxaluria type III. *Am J Hum Genet*. 2010;87:392–399.

Bergsland KJ, Zisman AL, Asplin JR, et al. Evidence for net renal tubule oxalate secretion in patients with calcium kidney stones. *Am J Physiol Renal Physiol*. 2011;300:F311–F318.

Bichler KH, Eipper E, Naber K, et al. Urinary infection stones. *Int J Antimicrob Agents*. 2002;19:488–498.

Bisaz S, Felix R, Neuman WF, et al. Quantitative determination of inhibitors of calcium phosphate precipitation in whole urine. *Miner Electrolyte Metab*. 1978;1:74–83.

Biyani CS, Joyce AD. Urolithiasis in pregnancy: I. Pathophysiology, fetal considerations and diagnosis. *BJU Int*. 2002;89:811–818.

Blacklock NJ. The pattern of urolithiasis in the Royal Navy. Hodgkinson A, Nordin BEC. *Renal stone research symposium*. J & A Churchill: London; 1969:33–47.

Bobulescu IA, Dubree M, Zhang J, et al. Effect of renal lipid accumulation on proximal tubule Na^+/H^+ exchange and ammonium secretion. *Am J Physiol Renal Physiol*. 2008;294:F1315–F1322.

Bobulescu IA, Dubree M, Zhang J, et al. Reduction of renal triglyceride accumulation: effects on proximal tubule Na^+/H^+ exchange and urinary acidification. *Am J Physiol Renal Physiol*. 2009;297:F1419–F1426.

Bollée G, Dollinger C, Boutaud L, et al. Phenotype and genotype characterization of adenine phosphoribosyltransferase deficiency. *J Am Soc Nephrol*. 2010;21(4):679–688.

Bommer J, Ritz E, Tschope W, et al. Urinary matrix calculi consisting of microfibrillar protein in patients on maintenance hemodialysis. *Kidney Int*. 1979;16:722–728.

Bonzo JR, Tasian GE. The emergence of kidney stone disease during childhood—impact on adults. *Curr Urol Rep*. 2017;18(6):44.

Borden TA, Lyon ES. The effects of magnesium and pH on experimental calcium oxalate stone disease. *Invest Urol*. 1969;6:412–422.

Borghi L, Meschi T, Amato F, et al. Hot occupation and nephrolithiasis. *J Urol*. 1993;150:1757–1760.

Borghi L, Meschi T, Amato F, et al. Urinary volume, water and recurrences in idiopathic calcium nephrolithiasis: a 5-year randomized prospective study. *J Urol*. 1996;155:839–843.

Borghi L, Meschi T, Guerra A, et al. Essential arterial hypertension and stone disease. *Kidney Int*. 1999;55:2397–2406.

Bowyer RC, McCulloch RK, Brockis JG, et al. Factors affecting the solubility of ammonium acid urate. *Clin Chim Acta*. 1979;95:17–22.

Boyce CJ, Pickhardt PJ, Lawrence EM, et al. Prevalence of urolithiasis in asymptomatic adults: objective determination using low dose noncontrast computerized tomography. *J*

Urol. 2010;183:1017–1021.

Boyce WH, Garvey FK. The amount and nature of the organic matrix in urinary calculi: a review. *J Urol*. 1956;76:213–227.

Boyce WH, King JS Jr. Crystal-matrix interrelations in calculi. *J Urol*. 1959;81:351–365.

Boyce WH, King JS Jr. Present concepts concerning the origin of matrix and stones. *Ann N Y Acad Sci*. 1963;104:563–578.

Boyce WH, King JS, Fielden ML. Total non-dialyzable solids (TNDS) of human urine: XII. Immunological detection of a component peculiar to renal calculous matrix and to urine of calculous patients. *J Clin Invest*. 1962;41:1180.

Boyce WH. Organic matrix of human urinary concretions. *Am J Med*. 1968;45:673–683.

Breslau NA, Brinkley L, Hill KD, et al. Relationship of animal protein-rich diet to kidney stone formation and calcium metabolism. *J Clin Endocrinol Metab*. 1988;66:140–146.

Breslau NA, McGuire JL, Zerwekh JE, et al. The role of dietary sodium on renal excretion and intestinal absorption of calcium and on vitamin D metabolism. *J Clin Endocrinol Metab*. 1982;55:369–373.

Breslau NA, Preminger GM, Adams BV, et al. Use of ketoconazole to probe the pathogenetic importance of 1,25-dihydroxyvitamin D in absorptive hypercalciuria. *J Clin Endocrinol Metab*. 1992;75:1446–1452.

Brikowski TH, Lotan Y, Pearle MS. Climate-related increase in the prevalence of urolithiasis in the United States. *Proc Natl Acad Sci USA*. 2008;105:9841–9846.

Broadus AE, Horst RL, Littledike ET, et al. Primary hyperparathyroidism with intermittent hypercalcaemia: serial observations and simple diagnosis by means of an oral calcium tolerance test. *Clin Endocrinol (Oxf)*. 1980;12:225–235.

Broadus AE. Primary hyperparathyroidism. *J Urol*.

1989;141:723–730.

Broer S. Amino acid transport across mammalian intestinal and renal epithelia. *Physiol Rev*. 2008;88:249–286.

Bronner F, Pansu D, Stein WD. An analysis of intestinal calcium transport across the rat intestine. *Am J Physiol*. 1986;250:G561–G569.

Bronner F, Pansu D. Nutritional aspects of calcium absorption. *J Nutr*. 1999;129:9–12.

Brown TR. On the relation between the variety of microorganisms and the composition of stone in calculous pyelonephritis. *J Am Med Assoc*. 1901;36:1395–1397.

Bruce RG, Munch LC, Hoven AD, et al. Urolithiasis associated with the protease inhibitor indinavir. *Urology*. 1997;50:513–518.

Buckley M, Bronner F. Calcium-binding protein biosynthesis in the rat: regulation by calcium and 1,25-dihydroxyvitamin D_3. *Arch Biochem Biophys*. 1980;202:235–241.

Burtis WJ, Brady TG, Orloff JJ, et al. Immunochemical characterization of circulating parathyroid hormone-related protein in patients with humoral hypercalcemia of cancer. *N Engl J Med*. 1990;322:1106–1112.

Bushinsky DA, Monk RD. Electrolyte quintet: calcium. *Lancet*. 1998;352:306–311.

Bushinsky DA. Nephrolithiasis. *J Am Soc Nephrol*. 1998;9:917–924.

Butler EL, Cox SM, Eberts EG, et al. Symptomatic nephrolithiasis complicating pregnancy. *Obstet Gynecol*. 2000;96:753–756.

Cabello-Tomas ML, Garcia-Gomez AM, Guillen-Dominguez ML. Pilot screening programme for cystinuria in the Valencian community. *Eur J Epidemiol*. 1999;15:681–684.

Calonge MJ, Gasparini P, Chillarón J, et al. Cystinuria caused by mutations in rBAT, a gene involved in the transport of cystine. *Nat Genet*. 1994;6(4):420–425.

Cameron JS, Moro F, Simmonds HA. Gout, uric acid and purine metabolism in paediatric nephrology. *Pediatr Nephrol*. 1993;7:105–118.

Cameron MA, Maalouf NM, Adams-Huet B, et al. Urine composition in type 2 diabetes: predisposition to uric acid nephrolithiasis. *J Am Soc Nephrol*. 2006;17:1422–1428.

Campieri C, Campieri M, Bertuzzi V, et al. Reduction of oxaluria after an oral course of lactic acid bacteria at high concentration. *Kidney Int*. 2001;60:1097–1105.

Canales BK, Anderson L, Higgins L, et al. Comprehensive proteomic analysis of human calcium oxalate monohydrate kidney stone matrix. *J Endourol*. 2008;22:1161–1167.

Canales BK, Anderson L, Higgins L, et al. Proteome of human calcium kidney stones. *Urology*. 2010;76(1017):e13–e20.

Canales BK, Anderson L, Higgins L, et al. Proteomic analysis of a matrix stone: a case report. *Urol Res*. 2009;37:323–329.

Carboni I, Andreucci E, Caruso MR, et al. Medullary sponge kidney associated with primary distal renal tubular acidosis and mutations of the H^+-ATPase genes. *Nephrol Dial Transplant*. 2009;24:2734–2738.

Carr MC, Prien EL Jr, Babayan RK. Triamterene nephrolithiasis: renewed attention is warranted. *J Urol*. 1990;144:1339–1340.

Chattopadhyay N. Effects of calcium-sensing receptor on the secretion of parathyroid hormone-related peptide and its impact on humoral hypercalcemia of malignancy. *Am J Physiol Endocrinol Metab*. 2006;290:E761–E770.

Chen YK, Lin HC, Chen CS, et al. Seasonal variations in urinary calculi attacks and their association with climate: a population based study. *J Urol*. 2008;179:564–569.

Chillaron J, Font-Llitjos M, Fort J, et al. Pathophysiology and treatment of cystinuria. *Nat Rev Nephrol*. 2010;6:424–434.

Chobanian MC, Hammerman MR. Insulin stimulates ammoniagenesis in canine renal proximal tubular segments. *Am J Physiol*. 1987;253:F1171–F1177.

Chung SD, Chen YK, Lin HC. Increased risk of diabetes in patients with urinary calculi: a 5-year followup study. *J Urol*. 2011;186:1888–1893.

Churchill D, Bryant D, Fodor G, et al. Drinking water hardness and urolithiasis. *Ann Intern Med*. 1978;88:513–514.

Ciftçioğlu N, Vejdani K, Lee O, et al. Association between Randall's plaque and calcifying nanoparticles. *Int J Nanomedicine*. 2008;3:105–115.

Clark WR, Malek RS. Ureteropelvic junction obstruction: I. Observations on the classic type in adults. *J Urol*. 1987;138:276–279.

Cochat P, Gaulier JM, Koch Nogueira PC, et al. Combined liver-kidney transplantation in primary hyperoxaluria type 1. *Eur J Pediatr*. 1999;158(Suppl 2):S75–S80.

Cochat P, Rumsby G. Primary hyperoxaluria. *N Engl J Med*. 2013;369:649–658.

Coe FL, Canterbury JM, Firpo JJ, et al. Evidence for secondary hyperparathyroidism in idiopathic hypercalciuria. *J Clin Invest*. 1973;52:134–142.

Coe FL, Evan A, Worcester E. Kidney stone disease. *J Clin Invest*. 2005;115:2598–2608.

Coe FL, Kavalach AG. Hypercalciuria and hyperuricosuria in patients with calcium nephrolithiasis. *N Engl J Med*. 1974;291:1344–1350.

Coe FL, Lawton RL, Goldstein RB, et al. Sodium urate accelerates precipitation of calcium oxalate in vitro. *Proc Soc Exp Biol Med*. 1975;149:926–929.

Coe FL, Nakagawa Y, Asplin J, et al. Role of nephrocalcin in inhibition of calcium oxalate crystallization and nephrolithiasis. *Miner Electrolyte Metab*. 1994;20:378–384.

Coe FL, Parks JH, Asplin JR. The pathogenesis and treatment of kidney stones. *N Engl J Med*. 1992;327:1141–1152.

Coe FL, Parks JH, Lindheimer MD. Nephrolithiasis during pregnancy. *N Engl J Med*. 1978;298:324–326.

Cryer PE, Garber AJ, Hoffsten P, et al. Renal failure after small intestinal bypass for obesity. *Arch Intern Med*.

1975;135:1610–1612.

Curhan GC, Taylor EN. 24-h uric acid excretion and the risk of kidney stones. *Kidney Int*. 2008;73:489–496.

Curhan GC, Willett WC, Rimm EB, et al. A prospective study of dietary calcium and other nutrients and the risk of symptomatic kidney stones. *N Engl J Med*. 1993;328:833–838.

Curhan GC, Willett WC, Rimm EB, et al. A prospective study of the intake of vitamins C and B_6, and the risk of kidney stones in men. *J Urol*. 1996;155:1847–1851.

Curhan GC, Willett WC, Rimm EB, et al. Body size and risk of kidney stones. *J Am Soc Nephrol*. 1998;9:1645–1652.

Curhan GC, Willett WC, Speizer FE, et al. Comparison of dietary calcium with supplemental calcium and other nutrients as factors affecting the risk for kidney stones in women. *Ann Intern Med*. 1997;126:497–504.

Curhan GC, Willett WC, Speizer FE, et al. Intake of vitamins B_6 and C and the risk of kidney stones in women. *J Am Soc Nephrol*. 1999;10:840–845.

Curhan GC, Willett WC, Speizer FE, et al. Twenty-four-hour urine chemistries and the risk of kidney stones among women and men. *Kidney Int*. 2001;59:2290–2298.

Cushard WG Jr, Simon AB, Canterbury JM, et al. Parathyroid function in sarcoidosis. *N Engl J Med*. 1972;286:395–398.

Cussenot O, Desgrandchamps F, Ollier P, et al. Anatomical bases of percutaneous surgery for calculi in horseshoe kidney. *Surg Radiol Anat*. 1992;14:209–213.

Dall'era JE, Kim F, Chandhoke PS. Gender differences among Hispanics and Caucasians in symptomatic presentation of kidney and ureteral stones. *J Endourol*. 2005;19:283–286.

Danisi G, Straub RW. Unidirectional influx of phosphate across the mucosal membrane of rabbit small intestine. *Pflugers Arch*. 1980;385:117–122.

Daudon J, Traxer O, Junders P, et al. Stone morphology suggestive of Randall's plaque. Evan AP, Lingeman JE, Williams JC Jr. *Renal stone disease*. American Institute of Physics: Melville NY; 2007:24–26.

Daudon M, Cohen-Solal F, Lacour B, et al. Urinary stones and urinary tract abnormalities. Is the stone composition independent of the anatomical abnormality? *Prog Urol*. 2003;13:1320–1329.

Daudon M, Estepa L, Viard JP, et al. Urinary stones in HIV-1-positive patients treated with indinavir. *Lancet*. 1997;349:1294–1295.

Daudon M, Traxer O, Conort P, et al. Type 2 diabetes increases the risk for uric acid stones. *J Am Soc Nephrol*. 2006;17:2026–2033.

Daudon M. Drug-induced urinary calculi in 1999. *Prog Urol*. 1999;9:1023–1033.

David HS, Lavengood RW Jr. Ureteropelvic junction obstruction in nephrolithiasis: an etiologic factor. *Urology*. 1975;5:188–190.

Davidman M, Schmitz P. Renal tubular acidosis: a pathophysiologic approach. *Hosp Pract (Off Ed)*. 1988;23(1A):77–81 [84–88, 93–96].

Dello Strologo L, Pras E, Pontesilli C, et al. Comparison between *SLC3A1* and *SLC7A9* cystinuria patients and carriers: a need for a new classification. *J Am Soc Nephrol*. 2002;13:2547–2553.

Dent CE, Senior B. Studies on the treatment of cystinuria. *Br J Urol*. 1955;27:317–332.

DeVivo MJ, Fine PR, Cutter GR, et al. The risk of renal calculi in spinal cord injury patients. *J Urol*. 1984;131:857–860.

Devuyst O, Pirson Y. Genetics of hypercalciuric stone forming diseases. *Kidney Int*. 2007;72:1065–1072.

Dhayat NA, Schaller A, Albano G, et al. The vacuolar H+-

ATPase B1 subunit polymorphism p.E161K associates with impaired urinary acidification in recurrent stone formers. *J Am Soc Nephrol*. 2016;27(5):1544–1554.

Dick WH, Lingeman JE, Preminger GM, et al. Laxative abuse as a cause for ammonium urate renal calculi. *J Urol*. 1990;143:244–247.

Dinour D, Beckerman P, Ganon L, et al. Loss-of-function mutations of CYP24A1, the vitamin D 24-hydroxylase gene, cause long-standing hypercalciuric nephrolithiasis and nephrocalcinosis. *J Urol*. 2013;190:552–557.

Djojodimedjo T, Soebadi DM, Soetjipto. *Escherichia coli* infection induces mucosal damage and expression of proteins promoting urinary stone formation. *Urolithiasis*. 2013;41:295–301.

Dobbins JW, Binder HJ. Effect of bile salts and fatty acids on the colonic absorption of oxalate. *Gastroenterology*. 1976;70:1096–1100.

Doco-Lecompte T, Garrec A, Thomas L, et al. Lopinavir-ritonavir (Kaletra) and lithiasis: seven cases. *AIDS*. 2004;18:705–706.

Doizi S, Rodgers K, Poindexter J, et al. Assessment of urinary inhibitor or promoter activity in uric acid nephrolithiasis. *J Urol*. 2016;195(6):1799–1804.

Drago JR, Rohner TJ Jr, Chez RA. Management of urinary calculi in pregnancy. *Urology*. 1982;20:578–581.

du Toit PJ, van Aswegen CH, Steyn PL, et al. Effects of bacteria involved with the pathogenesis of infection-induced urolithiasis on the urokinase and sialidase (neuraminidase) activity. *Urol Res*. 1992;20:393–397.

Duffey BG, Alanee S, Pedro RN, et al. Hyperoxaluria is a long-term consequence of Roux-en-Y gastric bypass: a 2-year prospective longitudinal study. *J Am Coll Surg*. 2010;211:8–15.

Duffey BG, Miyaoka R, Holmes R, et al. *Oxalobacter* colonization in the morbidly obese and correlation with urinary stone risk. *Urology*. 2011;78:531–534.

Duncan SH, Richardson AJ, Kaul P, et al. *Oxalobacter formigenes* and its potential role in human health. *Appl Environ Microbiol*. 2002;68:3841–3847.

Dunlay R, Hruska K. PTH receptor coupling to phospholipase C is an alternate pathway of signal transduction in bone and kidney. *Am J Physiol*. 1990;258:F223–F231.

Dusso AS, Brown AJ, Slatopolsky E, et al. Vitamin D. *Am J Physiol Renal Physiol*. 2005;289:F8–F28.

Dwyer ME, Krambeck AE, Bergstralh EJ, et al. Temporal trends in incidence of kidney stones among children: a 25-year population based study. *J Urol*. 2012;188(1):247–252.

Earnest DL, Williams HE, Admirand WH. A physicochemical basis for treatment of enteric hyperoxaluria. *Trans Assoc Am Physicians*. 1975;88:224–234.

Ebnet K, Suzuki A, Ohno S, et al. Junctional adhesion molecules (JAMs): more molecules with dual functions? *J Cell Sci*. 2004;117:19–29.

Edelson GW, Kleerekoper M. Hypercalcemic crisis. *Med Clin North Am*. 1995;79:79–92.

Edvardsson VO, Indridason OS, Haraldsson G, et al. Temporal trends in the incidence of kidney stone disease. *Kidney Int* 83:146–152, 2013. *Erratum in Kidney Int*. 2013;83:972.

Eisner BH, Ahn J, Stoller ML. Differentiating primary from secondary hyperparathyroidism in stone patients: the “thiazide challenge”. *J Endourol*. 2009;23:191–192.

Eisner BH, Porten SP, Bechis SK, et al. Diabetic kidney stone formers excrete more oxalate and have lower urine pH than nondiabetic stone formers. *J Urol*. 2010;183:2244–2248.

Eisner BH, Porten SP, Bechis SK, et al. Hypertension is associated with increased urinary calcium excretion in patients with nephrolithiasis. *J Urol*. 2010;183:576–579.

El-Zoghby ZM, Lieske JC, Foley RN, et al. Urolithiasis and the risk of ESRD. *Clin J Am Soc Nephrol*. 2012;7(9):1409–1415.

Engeler DS, John H, Rentsch KM, et al. Nelfinavir urinary stones. *J Urol*. 2002;167:1384–1385.

Enomoto A, Kimura H, Chairoungdua A, et al. Molecular identification of a renal urate anion exchanger that regulates blood urate levels. *Nature*. 2002;417:447–452.

Erbağci A, Erbağci AB, Yilmaz M, et al. Pediatric urolithiasis—evaluation of risk factors in 95 children. *Scand J Urol Nephrol*. 2003;37:129–133.

Erturk E, Kiernan M, Schoen SR. Clinical association with urinary glycosaminoglycans and urolithiasis. *Urology*. 2002;59:495–499.

Esen T, Akinci M, Tellaloğlu S, et al. Role of inhibitor deficiency in urolithiasis: II. Deficiency grade-adjusted and intermittent augmentation therapy for magnesium and citrate deficiency. *Eur Urol*. 1991;19:244–248.

Ettinger B, Citron JT, Livermore B, et al. Chlorthalidone reduces calcium oxalate calculous recurrence but magnesium hydroxide does not. *J Urol*. 1988;139:679–684.

Ettinger B, Oldroyd NO, Sorgel F. Triamterene nephrolithiasis. *J Am Med Assoc*. 1980;244:2443–2445.

Ettinger B, Tang A, Citron JT, et al. Randomized trial of allopurinol in the prevention of calcium oxalate calculi. *N Engl J Med*. 1986;315:1386–1389.

Ettinger B. Excretion of triamterene and its metabolite in triamterene stone patients. *J Clin Pharmacol*. 1985;25:365–368.

Evan A, Lingeman J, Coe FL, et al. Randall's plaque: pathogenesis and role in calcium oxalate nephrolithiasis. *Kidney Int*. 2006;69:1313–1318.

Evan AE, Lingeman JE, Coe FL, et al. Histopathology and surgical anatomy of patients with primary hyperparathyroidism and calcium phosphate stones. *Kidney Int*. 2008;74:223–229.

Evan AP, Coe FL, Lingeman JE, et al. Renal crystal deposits and histopathology in patients with cystine stones. *Kidney Int*. 2006;69:2227–2235.

Evan AP, Coe FL, Rittling SR, et al. Apatite plaque particles in inner medulla of kidneys of calcium oxalate stone formers: osteopontin localization. *Kidney Int*. 2005;68:145–154.

Evan AP, Lingeman J, Coe F, et al. Renal histopathology of stone-forming patients with distal renal tubular acidosis. *Kidney Int*. 2007;71:795–801.

Evan AP, Lingeman JE, Coe FL, et al. Randall's plaque of patients with nephrolithiasis begins in basement membranes of thin loops of Henle. *J Clin Invest*. 2003;111:607–616.

Evans K, Costabile RA. Time to development of symptomatic urinary calculi in a high risk environment. *J Urol*. 2005;173:858–861.

Faerber GJ. Pediatric urolithiasis. *Curr Opin Urol*. 2001;11:385–389.

Faggiano A, Pivonello R, Melis D, et al. Nephrolithiasis in Cushing's disease: prevalence, etiopathogenesis, and modification after disease cure. *J Clin Endocrinol Metab*. 2003;88:2076–2080.

Fakheri RJ, Goldfarb DS. Association of nephrolithiasis prevalence rates with ambient temperature in the United States: a re-analysis. *Kidney Int*. 2009;76:798.

Fan J, Chandhoke PS, Grampsas SA. Role of sex hormones in experimental calcium oxalate nephrolithiasis. *J Am Soc Nephrol*. 1999;10(Suppl 14):S376–S380.

Faragalla FF, Gershoff SN. Interrelations among magnesium, vitamin B_6, sulfur and phosphorus in the formation of kidney stones in the rat. *J Nutr*. 1963;81:60–66.

Fargue S, Lewin J, Rumsby G, et al. Four of the most common mutations in primary hyperoxaluria type 1 unmask the cryptic mitochondrial targeting sequence of alanine:glyoxylate aminotransferase encoded by the polymorphic minor allele. *J Biol Chem*. 2013;288:2475–2484.

Fargue S, Rumsby G, Danpure CJ. Multiple mechanisms of action of pyridoxine in primary hyperoxaluria type 1. *Biochim Biophys Acta*. 2013;1832:1776–1783.

Farrer JH, Rajfer J. Silicate urolithiasis. *J Urol*. 1984;132:739–740.

Fasano JM, Khan SR. Intratubular crystallization of calcium oxalate in the presence of membrane vesicles: an in vitro study. *Kidney Int*. 2001;59:169–178.

Fegan J, Khan R, Poindexter J, et al. Gastrointestinal citrate absorption in nephrolithiasis. *J Urol*. 1992;147:1212–1214.

Feicke A, Rentsch KM, Oertle D, et al. Same patient, new stone composition: amprenavir urinary stone. *Antivir Ther*. 2008;13:733–734.

Feliubadaló L, Font M, Purroy J, et al. International Cystinuria Consortium. Non-type I cystinuria caused by mutations in *SLC7A9,* encoding a subunit ($b^{o,+}$AT) of rBAT. *Nat Genet*. 1999;23:52–57.

Ferraro PM, D'Addessi A, Gambaro G. When to suspect a genetic disorder in a patient with renal stones, and why. *Nephrol Dial Transplant*. 2013;28:811–820.

Ferraro PM, Taylor EN, Eisner BH, et al. History of kidney stones and the risk of coronary heart disease. *JAMA*. 2013;310:408–415.

Finlayson B, Reid F. The expectation of free and fixed particles in urinary stone disease. *Invest Urol*. 1978;15:442–448.

Finlayson B. Symposium on renal lithiasis: renal lithiasis in review. *Urol Clin North Am*. 1974;1:181–212.

Flannigan RK, Battison A, De S, et al. Evaluating factors that dictate struvite stone composition: a multi-institutional clinical experience from the EDGE Research Consortium. *Can Urol Assoc J*. 2018;12:131–136.

Fleisch H, Bisaz S. Isolation from urine of pyrophosphate, a calcification inhibitor. *Am J Physiol*. 1962;203:671–675.

Fontaine O, Matsumoto T, Goodman DB, et al. Liponomic control of Ca^{2+} transport: relationship to mechanism of action of 1,25-dihydroxyvitamin D_3. *Proc Natl Acad Sci USA.* 1981;78:1751–1754.

Fratini A, Simmers RN, Callen DF, et al. A new location for the human adenine phosphoribosyltransferase gene *(APRT)* distal to the haptoglobin *(HP)* and fra(16)(q23) (*FRA16D*) loci. *Cytogenet Cell Genet*. 1986;43(1–2):10–13.

Freel RW, Hatch M. Hyperoxaluric rats do not exhibit alterations in renal expression patterns of Slc26a1 (SAT1) mRNA or protein. *Urol Res*. 2012;40:647–654.

Frick KK, Bushinsky DA. Molecular mechanisms of primary hypercalciuria. *J Am Soc Nephrol*. 2003;14:1082–1095.

Friedman PA. Renal calcium metabolism. ed 4. Elsevier Academic Press: Boston; 2007:1851–1890. Alpern RJ, Herbert SC. *Seldin and Giebisch's The kidney—physiology & pathophysiology*. vol 2.

Froeder L, Arasaki CH, Malheiros CA, et al. Response to dietary oxalate after bariatric surgery. *Clin J Am Soc Nephrol*. 2012;7:2033–2040.

Fucik RF, Kukreja SC, Hargis GK, et al. Effect of glucocorticoids on function of the parathyroid glands in man. *J Clin Endocrinol Metab*. 1975;40:152–155.

Furuse M, Hirase T, Itoh M, et al. Occludin—a novel integral membrane protein localizing at tight junctions. *J Cell Biol*. 1993;123:1777–1788.

Gagnon RF, Tecimer SN, Watters AK, et al. Prospective study of urinalysis abnormalities in HIV-positive individuals treated with indinavir. *Am J Kidney Dis*. 2000;36:507–515.

Gambaro G, Vezzoli G, Casari G, et al. Genetics of hypercalciuria and calcium nephrolithiasis: from the rare monogenic to the common polygenic forms. *Am J Kidney Dis*. 2004;44:963–986.

Gee HY, Jun I, Braun DA, et al. Mutations in SLC26A1 cause nephrolithiasis. *Am J Hum Genet*. 2016;98(6):1228–1234.

Gentle DL, Stoller ML, Jarrett TW, et al. Protease inhibitor-induced urolithiasis. *Urology*. 1997;50:508–511.

Geraghty RM, Proietti S, Traxer O, et al. Worldwide impact of warmer seasons on the incidence of renal colic and kidney stone disease: evidence from a systematic review of literature. *J Endourol*. 2017;31(8):729–735.

Gertner JM, Coustan DR, Kliger AS, et al. Pregnancy as state of physiologic absorptive hypercalciuria. *Am J Med*. 1986;81:451–456.

Gillen DL, Worcester EM, Coe FL. Decreased renal function among adults with a history of nephrolithiasis: a study of NHANES III. *Kidney Int*. 2005;67(2):685–690.

Ginalski JM, Portmann L, Jaeger P. Does medullary sponge kidney cause nephrolithiasis? *Am J Roentgenol*. 1990;155:299–302.

Goldfarb DS, Hirsch J. Hypothesis: urbanization and exposure to urban heat islands contribute to increasing prevalence of kidney stones. *Med Hypotheses*. 2015;85(6):953–957.

Goldfarb DS, Modersitzki F, Asplin JR. A randomized, controlled trial of lactic acid bacteria for idiopathic hyperoxaluria. *Clin J Am Soc Nephrol*. 2007;2:745–749.

Gong Y, Renigunta V, Himmerkus N, et al. Claudin-14 regulates renal Ca^{++} transport in response to CaSR signalling via a novel microRNA pathway. *EMBO J*. 2012;31:1999–2012.

Gorton E, Whitfield HN. Renal calculi in pregnancy. *Br J Urol*. 1997;80(Suppl 1):4–9.

Granberg PO, Lagergren C, Theve NO. Renal function studies in medullary sponge kidney. *Scand J Urol Nephrol*. 1971;5:177–180.

Grases F, Rodriguez A, Costa-Bauza A. Efficacy of mixtures of magnesium, citrate and phytate as calcium oxalate crystallization inhibitors in urine. *J Urol*. 2015;194(3):812–819.

Grenabo L, Hedelin H, Hugosson J, et al. Adherence of urease-induced crystals to rat bladder epithelium following acute infection with different uropathogenic microorganisms. *J Urol*. 1988;140:428–430.

Griffith DP, Musher DM. Prevention of infected urinary stones by urease inhibition. *Invest Urol*. 1973;11:228–233.

Griffith DP, Osborne CA. Infection (urease) stones. *Miner Electrolyte Metab*. 1987;13:278–285.

Grover PK, Ryall RL. Urate and calcium oxalate stones: from repute to rhetoric to reality. *Miner Electrolyte Metab*. 1994;20:361–370.

Grujic D, Salido EC, Shenoy BC, et al. Hyperoxaluria is reduced and nephrocalcinosis prevented with an oxalate-degrading enzyme in mice with hyperoxaluria. *Am J Nephrol*. 2009;29:86–93.

Gudbjartsson DF, Holm H, Indridason OS, et al. Association of variants at UMOD with chronic kidney disease and kidney stones-role of age and comorbid diseases. *PLoS Genet*. 2010;6(7):e1001039.

Haddad FS, Kouyoumdjian A. Silica stones in humans. *Urol Int*. 1986;41:70–76.

Haddad N, Scheffler P, Elkoushy MA, et al. Long-term incidence of symptomatic urolithiasis post-bariatric surgery. *Can Urol Assoc J*. 2014;8(9–10):E688–E694.

Hager BH, Magath TB. The etiology of encrusted cystitis with alkaline urine. *J Am Med Assoc*. 1925;85:1352–1355.

Halabe A, Sperling O. Uric acid nephrolithiasis. *Miner Electrolyte Metab*. 1994;20:424–431.

Hall AP, Barry PE, Dawber TR, et al. Epidemiology of gout and hyperuricemia: a long-term population study. *Am J Med*. 1967;42:27–37.

Hamada Y, Nishijima T, Watanabe K, et al. High incidence of renal stones among HIV-infected patients on ritonavir-boosted atazanavir than in those receiving other protease inhibitor-containing antiretroviral therapy. *Clin Infect Dis*. 2012;55:1262–1269.

Hamm LL, Hering-Smith KS. Pathophysiology of hypocitraturic nephrolithiasis. *Endocrinol Metab Clin North Am*. 2002;31:885–893 [viii].

Hamm LL. Renal handling of citrate. *Kidney Int*. 1990;38:728–735.

Hatch M, Cornelius J, Allison M, et al. *Oxalobacter* sp. reduces urinary oxalate excretion by promoting enteric oxalate secretion. *Kidney Int*. 2006;69:691–698.

Hatch M, Freel RW. Intestinal transport of an obdurate anion: oxalate. *Urol Res*. 2005;33:1–16.

Hatch M, Freel RW. The roles and mechanisms of intestinal oxalate transport in oxalate homeostasis. *Semin Nephrol*. 2008;28:143–151.

Heath H 3rd, Hodgson SF, Kennedy MA. Primary hyperparathyroidism. Incidence, morbidity, and potential economic impact in a community. *N Engl J Med*. 1980;302:189–193.

Heller HJ, Sakhaee K, Moe OW, et al. Etiological role of estrogen status in renal stone formation. *J Urol*. 2002;168:1923–1927.

Hermieu J, Prevot M, Ravery V, et al. Urolithiasis and the protease inhibitor indinavir. *Eur Urol*. 1999;35:239–241.

Herrmann SM, Whatling C, Brand E, et al. Polymorphisms of the human matrix gla protein (MGP) gene, vascular calcification, and myocardial infarction. *Arterioscler Thromb Vasc Biol*. 2000;20(11):2386–2393.

Hess B, Jost C, Zipperle L, et al. High-calcium intake abolishes hyperoxaluria and reduces urinary crystallization during a 20-fold normal oxalate load in humans. *Nephrol Dial Transplant*. 1998;13:2241–2247.

Hess B, Kok DJ. Nucleation, growth, and aggregation of stone-forming crystals. Coe FL, Favus MJ, Pak CYC, et al. *Kidney stones: medical and surgical management*. Lippincott-Raven: Philadelphia; 1996:3–32.

Hess B, Nakagawa Y, Parks JH, et al. Molecular abnormality of Tamm-Horsfall glycoprotein in calcium oxalate nephrolithiasis. *Am J Physiol*. 1991;260:F569–F578.

Hess B, Zipperle L, Jaeger P. Citrate and calcium effects on Tamm-Horsfall glycoprotein as a modifier of calcium oxalate crystal aggregation. *Am J Physiol*. 1993;265:F784–F791.

Hess B. Tamm-Horsfall glycoprotein—inhibitor or promoter of calcium oxalate monohydrate crystallization processes? *Urol Res*. 1992;20:83–86.

Hesse A, Schneeberger W, Engfeld S, et al. Intestinal hyperabsorption of oxalate in calcium oxalate stone formers: application of a new test with [13C2]oxalate. *J Am Soc Nephrol*. 1999;10(Suppl 14):S329–S333.

Higashihara E, Nutahara K, Tago K, et al. Medullary sponge kidney and renal acidification defect. *Kidney Int*. 1984;25:453–459.

Hochstrasser K, Reisinger P, Albrecht GJ, et al. Isolation of acid-resistant urinary trypsin inhibitors by high performance liquid chromatography and their characterization by N-terminal amino-acid sequence determination. *Hoppe Seylers Z Physiol Chem*. 1984;365:1123–1130.

Hodgkinson A, Wilkinson R. Plasma oxalate concentration and renal excretion of oxalate in man. *Clin Sci Mol Med*. 1974;46:61–73.

Holmes RP, Ambrosius WT, Assimos DG. Dietary oxalate loads and renal oxalate handling. *J Urol*. 2005;174:943–947.

Holmes RP, Assimos DG. The impact of dietary oxalate on kidney stone formation. *Urol Res*. 2004;32:311–316.

Holmes RP, Goodman HO, Assimos D. Contribution of dietary oxalate to urinary oxalate excretion. *Kidney Int*. 2001;59:270–276.

Holmes RP, Goodman HO, Assimos DG. Dietary oxalate and its intestinal absorption. *Scanning Microsc*. 1995;9:1109–1118 [discussion 1118–1120].

Holmgren K, Danielson BG, Fellstrom B, et al. The relation between urinary tract infections and stone composition in renal stone formers. *Scand J Urol Nephrol*. 1989;23:131–136.

Hoppe B, Beck BB, Gatter N, et al. Oxalobacter formigenes: a potential tool for the treatment of primary hyperoxaluria type 1. *Kidney Int*. 2006;70:1305–1311.

Hoppe B, Beck BB, Milliner DS. The primary hyperoxalurias. *Kidney Int*. 2009;75:1264–1271.

Hoppe B, Groothoff JW, Hulton SA, et al. Efficacy and safety of *Oxalobacter formigenes* to reduce urinary oxalate in primary hyperoxaluria. *Nephrol Dial Transplant*. 2011;26:3609–3615.

Hoppe B, Langman CB. A United States survey on diagnosis, treatment, and outcome of primary hyperoxaluria. *Pediatr Nephrol*. 2003;18:986–991.

Hoppe B. An update on primary hyperoxaluria. *Nat Rev Nephrol*. 2012;8:467–475.

Hou J, Renigunta A, Gomes AS, et al. Claudin-16 and claudin-19 interaction is required for their assembly into tight junctions and for renal reabsorption of magnesium. *Proc Natl Acad Sci USA*. 2009;106:15350–15355.

Hou J, Renigunta A, Konrad M, et al. Claudin-16 and claudin-19 interact and form a cation-selective tight junction complex. *J Clin Invest*. 2008;118:619–628.

Hou J. The role of claudin in hypercalciuric nephrolithiasis. *Curr Urol Rep*. 2013;14:5–12.

Hsu TH, Streem SB. Metabolic abnormalities in patients with caliceal diverticular calculi. *J Urol*. 1998;160:1640–1642.

Huang WY, Chen YF, Carter S, et al. Epidemiology of upper urinary tract stone disease in a Taiwanese population: a nationwide, population based study. *J Urol*. 2013;189(6):2158–2163.

Hufnagle KG, Khan SN, Penn D, et al. Renal calcifications: a complication of long-term furosemide therapy in preterm infants. *Pediatrics*. 1982;70:360–363.

Husmann DA, Milliner DS, Segura JW. Ureteropelvic junction obstruction with a simultaneous renal calculus: long-term followup. *J Urol*. 1995;153:1399–1402.

Husmann DA, Milliner DS, Segura JW. Ureteropelvic junction obstruction with concurrent renal pelvic calculi in the pediatric patient: a long-term followup. *J Urol*. 1996;156:741–743.

Ichida K, Hosoyamada M, Hisatome I, et al. Clinical and molecular analysis of patients with renal hypouricemia in Japan—influence of URAT1 gene on urinary urate excretion. *J Am Soc Nephrol*. 2004;15:164–173.

Iwai N, Mino Y, Hosoyamada M, et al. A high prevalence of renal hypouricemia caused by inactive *SLC22A12* in Japanese. *Kidney Int*. 2004;66:935–944.

Jackman SV, Kibel AS, Ovuworie CA, et al. Familial calcium stone disease: TaqI polymorphism and the vitamin D receptor. *J Endourol*. 1999;13:313–316.

Jamieson NV, European PH1 Transplantation Study Group. A 20-year experience of combined liver/kidney transplantation for primary hyperoxaluria (PH1): the European PH1 Transplant Registry experience 1984-2004. *Am J Nephrol*. 2005;25:282–289.

Janetschek G, Kunzel KH. Percutaneous nephrolithotomy in horseshoe kidneys: applied anatomy and clinical experience. *Br J Urol*. 1988;62:117–122.

Jiang Z, Asplin JR, Evan AP, et al. Calcium oxalate urolithiasis in mice lacking anion transporter Slc26a6. *Nat Genet*. 2006;38:474–478.

Jick H, Dinan BJ, Hunter JR. Triamterene and renal stones. *J Urol*. 1982;127:224–225.

Johansson G, Backman U, Danielson BG, et al. Biochemical and clinical effects of the prophylactic treatment of renal calcium stones with magnesium hydroxide. *J Urol*. 1980;124:770–774.

Johnson CM, Wilson DM, O'Fallon WM, et al. Renal stone epidemiology: a 25-year study in Rochester, Minnesota. *Kidney Int*. 1979;16:624–631.

Johnson SA, Rumsby G, Cregeen D, et al. Primary hyperoxaluria type 2 in children. *Pediatr Nephrol*. 2002;17:597–601.

Joly D, Rieu P, Mejean A, et al. Treatment of cystinuria. *Pediatr Nephrol*. 1999;13:945–950.

Joshi S, Clapp WL, Wang W, et al. Osteogenic changes in kidneys of hyperoxaluric rats. *Biochim Biophys Acta*. 2015;1852(9):2000–2012.

Jou YC, Fang CY, Chen SY, et al. Proteomic study of renal uric acid stone. *Urology*. 2012;80:260–266.

Kamatani N, Hakodo M, Otsuka S, et al. Only three mutations account for almost all defective alleles causing adenine phosphoribosyltransferase deficiency in Japanese patients. *J Clin Invest*. 1992;90(1):130–135.

Kaplon DM, Penniston KL, Nakada SY. Patients with and without prior urolithiasis have hypocitraturia and incident kidney stones while on topiramate. *Urology*. 2011;77:295–298.

Karet FE. Inherited distal renal tubular acidosis. *J Am Soc Nephrol*. 2002;13:2178–2184.

Kaufman DW, Kelly JP, Curhan GC, et al. *Oxalobacter formigenes* may reduce the risk of calcium oxalate kidney stones. *J Am Soc Nephrol*. 2008;19:1197–1203.

Kennedy HJ, Fletcher EW, Truelove SC. Urinary stones in subjects with a permanent ileostomy. *Br J Surg*. 1982;69:661–664.

Kerstetter J, Caballero B, O'Brien K, et al. Mineral homeostasis in obesity: effects of euglycemic hyperinsulinemia. *Metabolism*. 1991;40:707–713.

Khan A, Wang W, Khan SR. Calcium oxalate nephrolithiasis and expression of matrix GLA protein in the kidneys. *World J Urol*. 2013;32(1):123–130.

Khan SR, Canales BK. Unified theory on the pathogenesis of Randall's plaques and plugs. *Urolithiasis*. 2015;43(Suppl 1):109–123.

Khan SR, Shevock PN, Hackett RL. Magnesium oxide administration and prevention of calcium oxalate nephrolithiasis. *J Urol*. 1993;149:412–416.

Khan SR. Is oxidative stress, a link between nephrolithiasis and obesity, hypertension, diabetes, chronic kidney disease, metabolic syndrome? *Urol Res*. 2012;40:95–112.

Kharlamb V, Schelker J, Francois F, et al. Oral antibiotic treatment of *Helicobacter pylori* leads to persistently reduced intestinal colonization rates with *Oxalobacter formigenes*. *J Endourol*. 2011;25:1781–1785.

Kim SC, Coe FL, Tinmouth WW, et al. Stone formation is proportional to papillary surface coverage by Randall's plaque. *J Urol*. 2005;173:117–119 [discussion 119].

Kimura Y, Kisaki N, Ise K. The role of the matrix substance in formation of urinary stones. *Urol Int*. 1976;31:355–367.

Kinkead TM, Menon M. Renal tubular acidosis [lesson 7]. *AUA Update Series*. 1995;14:54–59.

Kinoshita H. [Clinical studies on medullary sponge kidney evaluated from urolithiasis]. *Nihon Hinyokika Gakkai Zasshi*. 1990;81:372–379 [in Japanese].

Kleinman JG, Wesson JA, Hughes J. Osteopontin and calcium stone formation. *Nephron Physiol*. 2004;98:43–47.

Klimesova K, Whittamore JM, Hatch M. Bifidobacterium animalis subsp. lactis decreases urinary oxalate excretion in a mouse model of primary hyperoxaluria. *Urolithiasis*. 2014;43(2):107–117.

Klisic J, Hu MC, Nief V, et al. Insulin activates Na^+/H^+ exchanger 3: biphasic response and glucocorticoid dependence. *Am J Physiol Renal Physiol*. 2002;283:F532–F539.

Knight J, Holmes RP, Assimos DG. Intestinal and renal handling of oxalate loads in normal individuals and stone formers. *Urol Res*. 2007;35:111–117.

Knoll T, Zollner A, Wendt-Nordahl G, et al. Cystinuria in childhood and adolescence: recommendations for diagnosis, treatment, and follow-up. *Pediatr Nephrol*. 2005;20:19–24.

Kohri K, Ishikawa Y, Katoh Y, et al. Epidemiology of urolithiasis in the elderly. *Int Urol Nephrol*. 1991;23:413–421.

Kok DJ, Khan SR. Calcium oxalate nephrolithiasis, a free or fixed particle disease. *Kidney Int*. 1994;46:847–854.

Kok DJ, Papapoulos SE, Bijvoet OL. Excessive crystal agglomeration with low citrate excretion in recurrent stone-formers. *Lancet*. 1986;1:1056–1058.

Kok DJ, Papapoulos SE, Blomen LJ, et al. Modulation of calcium oxalate monohydrate crystallization kinetics in vitro.

Kidney Int. 1988;34:346–350.

Kok DJ. Intratubular crystallization events. *World J Urol*. 1997;15:219–228.

Koka RM, Huang E, Lieske JC. Adhesion of uric acid crystals to the surface of renal epithelial cells. *Am J Physiol Renal Physiol*. 2000;278:F989–F998.

Konrad M, Schaller A, Seelow D, et al. Mutations in the tight-junction gene claudin 19 *(CLDN19)* are associated with renal magnesium wasting, renal failure, and severe ocular involvement. *Am J Hum Genet*. 2006;79:949–957.

Krambeck AE, Handa SE, Evan AP, et al. Brushite stone disease as a consequence of lithotripsy? *Urol Res*. 2010;38:293–299.

Krishnamurthy MS, Hruska KA, Chandhoke PS. The urinary response to an oral oxalate load in recurrent calcium stone formers. *J Urol*. 2003;169:2030–2033.

Kumar R, Lieske JC, Collazo-Clavell ML, et al. Fat malabsorption and increased intestinal oxalate absorption are common after Roux-en-Y gastric bypass surgery. *Surgery*. 2011;149:654–661.

Kumar V, Pena de la Vega L, Farell G, et al. Urinary macromolecular inhibition of crystal adhesion to renal epithelial cells is impaired in male stone formers. *Kidney Int*. 2005;68:1784–1792.

Kuo RL, Lingeman JE, Evan AP, et al. Endoscopic renal papillary biopsies: a tissue retrieval technique for histological studies in patients with nephrolithiasis. *J Urol*. 2003;170:2186–2189.

Kuo RL, Lingeman JE, Evan AP, et al. Urine calcium and volume predict coverage of renal papilla by Randall's plaque. *Kidney Int*. 2003;64:2150–2154.

Kuroczycka-Saniutycz E, Porowski T, Protas PT, et al. Does obesity or hyperuricemia influence lithogenic risk profile in children with urolithiasis? *Pediatr Nephrol*. 2015;30(5):797–

803.

Laing CM, Toye AM, Capasso G, et al. Renal tubular acidosis: developments in our understanding of the molecular basis. *Int J Biochem Cell Biol*. 2005;37:1151–1161.

Lal-Nag M, Morin PJ. The claudins. *Genome Biol*. 2009;10:235.

Lange JN, Wood KD, Wong H, et al. Sensitivity of human strains of *Oxalobacter formigenes* to commonly prescribed antibiotics. *Urology*. 2011;79(6):1286–1289.

Langman CB. The molecular basis of kidney stones. *Curr Opin Pediatr*. 2004;16:188–193.

Lavan JN, Neale FC, Posen S. Urinary calculi: clinical, biochemical and radiological studies in 619 patients. *Med J Aust*. 1971;2:1049–1061.

Lee DB, Walling MW, Corry DB. Phosphate transport across rat jejunum: influence of sodium, pH, and 1,25-dihydroxyvitamin D_3. *Am J Physiol*. 1986;251:G90–G95.

Lemann J Jr, Bushinsky DA, Hamm LL. Bone buffering of acid and base in humans. *Am J Physiol Renal Physiol*. 2003;285:F811–F832.

Lemann J Jr. Relationship between urinary calcium and net acid excretion as determined by dietary protein and potassium: a review. *Nephron*. 1999;81(Suppl 1):18–25.

Levy FL, Adams-Huet B, Pak CY. Ambulatory evaluation of nephrolithiasis: an update of a 1980 protocol. *Am J Med*. 1995;98:50–59.

Lewis DF, Robichaux AG 3rd, Jaekle RK, et al. Urolithiasis in pregnancy: diagnosis, management and pregnancy outcome. *J Reprod Med*. 2003;48:28–32.

Liatsikos EN, Bernardo NO, Dinlenc CZ, et al. Caliceal diverticular calculi: is there a role for metabolic evaluation? *J Urol*. 2000;164:18–20.

Liebman M, Chai W. Effect of dietary calcium on urinary oxalate excretion after oxalate loads. *Am J Clin Nutr*. 1997;65:1453–1459.

Lieske JC, Pena de la Vega LS, Slezak JM, et al. Renal stone epidemiology in Rochester, Minnesota: an update. *Kidney Int*. 2006;69:760–764.

Linder BJ, Rangel LJ, Krambeck AE. The effect of work location on urolithiasis in health care professionals. *Urolithiasis*. 2013;41(4):327–331.

Linke RP, Bommer J, Ritz E, et al. Amyloid kidney stones of uremic patients consist of beta 2-microglobulin fragments. *Biochem Biophys Res Commun*. 1986;136:665–671.

Linnes MP, Krambeck AE, Cornell L, et al. Phenotypic characterization of kidney stone formers by endoscopic and histological quantification of intrarenal calcification. *Kidney Int*. 2013;84(4):818–825.

Litwin MS, Saigal CS, Yano EM, et al. Urologic Diseases in America Project: analytical Methods and principal findings. *J Urol*. 2005;173(3):933–937.

Liu Y, Mo L, Goldfarb DS, et al. Progressive renal papillary calcification and ureteral stone formation in mice deficient for Tamm-Horsfall protein. *Am J Physiol Renal Physiol*. 2010;299:F469–F478.

Lomas DJ, Jaeger CD, Krambeck AE. Profile of the ammonium acid urate stone former based on a large contemporary cohort. *Urology*. 2017;102:43–47.

Loupy A, Ramakrishnan SK, Wootla B, et al. PTH-independent regulation of blood calcium concentration by the calcium-sensing receptor. *J Clin Invest*. 2012;122:3355–3367.

Low RK, Stoller ML. Endoscopic mapping of renal papillae for Randall's plaques in patients with urinary stone disease. *J Urol*. 1997;158:2062–2064.

Lowe FC, Marshall FF. Ureteropelvic junction obstruction in adults. *Urology*. 1984;23:331–335.

Lu X, Gao B, Liu Z, et al. A polymorphism of matrix Gla protein gene is associated with kidney stone in the Chinese Han population. *Gene*. 2012;511(2):127–130.

Maalouf NM, Cameron MA, Moe OW, et al. Novel insights into the pathogenesis of uric acid nephrolithiasis. *Curr Opin Nephrol Hypertens*. 2004;13:181–189.

Maalouf NM, Langston JP, Van Ness PC, et al. Nephrolithiasis in topiramate users. *Urol Res*. 2011;39:303–307.

Maalouf NM, Sakhaee K, Parks JH, et al. Association of urinary pH with body weight in nephrolithiasis. *Kidney Int*. 2004;65:1422–1425.

Maalouf NM, Tondapu P, Guth ES, et al. Hypocitraturia and hyperoxaluria after Roux-en-Y gastric bypass surgery. *J Urol*. 2010;183:1026–1030.

Maalouf NM. Metabolic syndrome and the genesis of uric acid stones. *J Ren Nutr*. 2011;21:128–131.

Mack RB. “All but death, can be adjusted.” Ma huang (ephedrine) adversities. *N C Med J*. 1997;58:68–70.

Magwira CA, Kullin B, Lewandowski S, et al. Diversity of faecal oxalate-degrading bacteria in black and white South African study groups: insights into understanding the rarity of urolithiasis in the black group. *J Appl Microbiol*. 2012;113(2):418–428.

Maikranz P, Coe FL, Parks J, et al. Nephrolithiasis in pregnancy. *Am J Kidney Dis*. 1987;9:354–358.

Maloney ME, Springhart WP, Ekeruo WO, et al. Ethnic background has minimal impact on the etiology of nephrolithiasis. *J Urol*. 2005;173:2001–2004.

Mandel NS, Mandel GS. Urinary tract stone disease in the United States veteran population: I. Geographical frequency of occurrence. *J Urol*. 1989;142:1513–1515.

Mandel NS, Mandel GS. Urinary tract stone disease in the United States veteran population: II. Geographical analysis of variations in composition. *J Urol*. 1989;142:1516–1521.

Manelli F, Giustina A. Glucocorticoid-induced osteoporosis. *Trends Endocrinol Metab*. 2000;11:79–85.

Marshall V, White RH, Chaput de Saintonge M, et al. The natural history of renal and ureteric calculi. *Br J Urol*. 1975;47:117–124.

Mass AY, Goldfarb DS, Shah O, et al. Taxi cab syndrome: a review of the extensive genitourinary pathology experienced by taxi cab drivers and what we can do to help. *Rev Urol*. 2014;16(3):99–104.

Matin SF, Streem SB. Metabolic risk factors in patients with ureteropelvic junction obstruction and renal calculi. *J Urol*. 2000;163:1676–1678.

Matlaga BR, Miller NL, Terry C, et al. The pathogenesis of calyceal diverticular calculi. *Urol Res*. 2007;35:35–40.

Matlaga BR, Shah OD, Assimos DG. Drug-induced urinary calculi. *Rev Urol*. 2003;5:227–231.

Matlaga BR, Shore AD, Magnuson T, et al. Effect of gastric bypass surgery on kidney stone disease. *J Urol*. 2009;181:2573–2577.

Matlaga BR, Williams JC Jr, Kim SC, et al. Endoscopic evidence of calculus attachment to Randall's plaque. *J Urol*. 2006;175:1720–1724.

Mayr B, Schnabel D, Dorr HG, et al. Genetics in endocrinology: gain and loss of function mutations of the calcium-sensing receptor and associated proteins: current treatment concepts. *Eur J Endocrinol*. 2016;174(5):R189–R208.

McAleer SJ, Loughlin KR. Nephrolithiasis and pregnancy. *Curr Opin Urol*. 2004;14:123–127.

McKane WR, Khosla S, Burritt MF, et al. Mechanism of renal calcium conservation with estrogen replacement therapy in women in early postmenopause—a clinical research center study. *J Clin Endocrinol Metab*. 1995;80:3458–3464.

Melnick JZ, Preisig PA, Haynes S, et al. Converting enzyme inhibition causes hypocitraturia independent of acidosis or hypokalemia. *Kidney Int*. 1998;54:1670–1674.

Menon M. Calcium oxalate renal lithiasis: endocrinology and metabolism. Rajfer J. *Urologic endocrinology*. Saunders: Philadelphia; 1986:386–407.

Mensenkamp AR, Hoenderop JG, Bindels RJ. Recent advances in renal tubular calcium reabsorption. *Curr Opin Nephrol Hypertens*. 2006;15:524–529.

Mensenkamp AR, Hoenderop JG, Bindels RJ. TRPV5, the gateway to Ca^{2+} homeostasis. *Handb Exp Pharmacol*. 2007;179:207–220.

Mente A, Honey RJ, McLaughlin JR, et al. Ethnic differences in relative risk of idiopathic calcium nephrolithiasis in North America. *J Urol*. 2007;178:1992–1997.

Meria P, Hadjadj H, Jungers P, et al. Stone formation and pregnancy: pathophysiological insights gained from morphoconstitutional stone analysis. *J Urol*. 2010;183(4):1412–1416.

Meyer JL, Smith LH. Growth of calcium oxalate crystals: II. Inhibition by natural urinary crystal growth inhibitors. *Invest Urol*. 1975;13:36–39.

Michaels EK, Nakagawa Y, Miura N, et al. Racial variation in gender frequency of calcium urolithiasis. *J Urol*. 1994;152:2228–2231.

Middleton AW Jr, Pfister RC. Stone-containing pyelocaliceal diverticulum: embryogenic, anatomic, radiologic and clinical characteristics. *J Urol*. 1974;111:2–6.

Mikami K, Akakura K, Takei K, et al. Association of absence of intestinal oxalate degrading bacteria with urinary calcium oxalate stone formation. *Int J Urol*. 2003;10:293–296.

Miller NL, Gillen DL, Williams JC Jr, et al. A formal test of the hypothesis that idiopathic calcium oxalate stones grow on Randall's plaque. *BJU Int*. 2009;103:966–971.

Miller NL, Williams JC Jr, Evan AP, et al. In idiopathic calcium oxalate stone-formers, unattached stones show evidence of having originated as attached stones on Randall's plaque. *BJU Int*. 2010;105:242–245.

Minisola S, Rossi W, Pacitti MT, et al. Studies on citrate metabolism in normal subjects and kidney stone patients. *Miner Electrolyte Metab*. 1989;15:303–308.

Mirrakhimov AE. Hypercalcemia of malignancy: an update on pathogenesis and management. *North Am J Med Sci*. 2015;7(11):483–493.

Mo L, Huang HY, Zhu XH, et al. Tamm-Horsfall protein is a critical renal defense factor protecting against calcium oxalate crystal formation. *Kidney Int*. 2004;66:1159–1166.

Moe OW, Xu LHR. Hyperuricosuric calcium urolithiasis. *J Nephrol*. 2018;31(2):189–196.

Monreal García De Vicuña F, García Penit J, Miniño Pimentel L, et al. [Lithiasis in megacalycosis.]. *Arch Esp Urol*. 1998;51:160–162 [in Spanish].

Moor MB, Bonny O. Ways of calcium reabsorption in the kidney. *Am J Physiol Renal Physiol*. 2016;310(11):F1337–F1350.

Moore S, Gowland G. The immunological integrity of matrix substance A and its possible detection and quantitation in urine. *Br J Urol*. 1975;47:489–494.

Motola JA, Urivetsky M, Molia L, et al. Transmembrane oxalate exchange: its relationship to idiopathic calcium oxalate nephrolithiasis. *J Urol*. 1992;147:549–552.

Muff R, Fischer JA, Biber J, et al. Parathyroid hormone receptors and intracellular mediators in control of proximal tubular function. *J Endocrinol Invest*. 1992;15:143.

Mulay SR, Kulkarni OP, Rupanagudi KV, et al. Calcium oxalate crystals induce renal inflammation by NLRP3-mediated IL-1beta secretion. *J Clin Invest*. 2013;123:236–246.

Mundy GR. Pathophysiology of cancer-associated hypercalcemia. *Semin Oncol*. 1990;17:10–15.

Muto S, Hata M, Taniguchi J, et al. Claudin-2-deficient mice are defective in the leaky and cation-selective paracellular permeability properties of renal proximal tubules. *Proc Natl Acad Sci USA*. 2010;107:8011–8016.

Nakagawa Y, Ahmed M, Hall SL, et al. Isolation from human calcium oxalate renal stones of nephrocalcin, a glycoprotein inhibitor of calcium oxalate crystal growth: evidence that nephrocalcin from patients with calcium oxalate nephrolithiasis is deficient in gamma-carboxyglutamic acid. *J Clin Invest*. 1987;79:1782–1787.

Nakagawa Y. Properties and function of nephrocalcin: mechanism of kidney stone inhibition or promotion. *Keio J Med*. 1997;46:1–9.

Negri AL, Spivacow R, Del Valle E, et al. Clinical and biochemical profile of patients with “pure” uric acid nephrolithiasis compared with “pure” calcium oxalate stone formers. *Urol Res*. 2007;35:247–251.

Nelson WK, Houghton SG, Milliner DS, et al. Enteric hyperoxaluria, nephrolithiasis, and oxalate nephropathy: potentially serious and unappreciated complications of Roux-en-Y gastric bypass. *Surg Obes Relat Dis*. 2005;1:481–485.

Nesterova G, Malicdan MC, Yasuda K, et al. 1,25-$(OH)_2$D-24 hydroxylase (CYP24A1) deficiency as a cause of nephrolithiasis. *Clin J Am Soc Nephrol*. 2013;8:649–657.

Nicar MJ, Hill K, Pak CY. Inhibition by citrate of spontaneous precipitation of calcium oxalate in vitro. *J Bone Miner Res*. 1987;2:215–220.

Nicar MJ, Peterson R, Pak CY. Use of potassium citrate as potassium supplement during thiazide therapy of calcium nephrolithiasis. *J Urol*. 1984;131:430–433.

Nissim I, States B, Nissim I, et al. Hormonal regulation of glutamine metabolism by OK cells. *Kidney Int*. 1995;47:96–105.

Nordin BE, Need AG, Morris HA, et al. Biochemical variables in pre- and postmenopausal women: reconciling the calcium and estrogen hypotheses. *Osteoporos Int*. 1999;9:351–357.

Nordin BEC, Peacock M, Wilkinson R. Hypercalciuria and calcium stone disease. *Clin Endocrinol Metab*. 1972;1:169–183.

Nowfar S, Palazzi-Churas K, Chang DC, et al. The relationship of obesity and gender prevalence changes in United States inpatient nephrolithiasis. *Urology*. 2011;78:1029–1033.

Nowicki M, Kokot F, Surdacki A. The influence of hyperinsulinaemia on calcium-phosphate metabolism in renal failure. *Nephrol Dial Transplant*. 1998;13:2566–2571.

Okumura N, Tsujihata M, Momohara C, et al. Diversity in protein profiles of individual calcium oxalate kidney stones. *PLoS ONE*. 2013;8(7):e68624.

Ombra MN, Casula S, Biino G, et al. Urinary glycosaminoglycans as risk factors for uric acid nephrolithiasis: case control study in a Sardinian genetic isolate. *Urology*. 2003;62:416–420.

O'Neill M, Breslau NA, Pak CY. Metabolic evaluation of nephrolithiasis in patients with medullary sponge kidney. *J Am Med Assoc*. 1981;245:1233–1236.

Ordon M, Welk B, Li Q, et al. Ambient temperature and the risk of renal colic: a population-based study of the impact of demographics and comorbidity. *J Endourol*. 2016;30(10):1138–1143.

Osther PJ, Hansen AB, Rohl HF. Renal acidification defects in medullary sponge kidney. *Br J Urol*. 1988;61:392–394.

Osther PJ, Hansen AB, Rohl HF. Screening renal stone formers for distal renal tubular acidosis. *Br J Urol*. 1989;63:581–583.

Pak CY, Adams-Huet B, Poindexter JR, et al. Rapid communication: relative effect of urinary calcium and oxalate on saturation of calcium oxalate. *Kidney Int*. 2004;66:2032–2037.

Pak CY, Arnold LH. Heterogeneous nucleation of calcium oxalate by seeds of monosodium urate. *Proc Soc Exp Biol Med*. 1975;149:930–932.

Pak CY, Britton F, Peterson R, et al. Ambulatory evaluation of nephrolithiasis: classification, clinical presentation and diagnostic criteria. *Am J Med*. 1980;69:19–30.

Pak CY, Chu S. A simple technique for the determination of urinary state of saturation with respect to brushite. *Invest Urol*. 1973;11:211–215.

Pak CY, Fuller C. Assessment of cystine solubility in urine and of heterogeneous nucleation. *J Urol*. 1983;129:1066–1070.

Pak CY, Holt K. Nucleation and growth of brushite and calcium oxalate in urine of stone-formers. *Metabolism*. 1976;25:665–673.

Pak CY, Maalouf NM, Rodgers K, et al. Comparison of semi-empirical with computer-derived methods for estimating urinary saturation of calcium oxalate. *J Urol*. 2009;182:2951–2956.

Pak CY, Moe OW, Maalouf NM, et al. Comparison of semi-empirical and computer derived methods for estimating urinary saturation of brushite. *J Urol*. 2009;181:1423–1428.

Pak CY, Nicar M, Northcutt C. The definition of the mechanism of hypercalciuria is necessary for the treatment of recurrent stone formers. *Contrib Nephrol*. 1982;33:136–151.

Pak CY, Oata M, Lawrence EC, et al. The hypercalciurias: causes, parathyroid functions, and diagnostic criteria. *J Clin Invest*. 1974;54:387–400.

Pak CY, Poindexter JR, Peterson RD, et al. Biochemical distinction between hyperuricosuric calcium urolithiasis and gouty diathesis. *Urology*. 2002;60:789–794.

Pak CY, Sakhaee K, Moe O, et al. Biochemical profile of stone-forming patients with diabetes mellitus. *Urology*. 2003;61:523–527.

Pak CY, Sakhaee K, Peterson RD, et al. Biochemical profile of idiopathic uric acid nephrolithiasis. *Kidney Int*. 2001;60:757–761.

Pak CY, Waters O, Arnold L, et al. Mechanism for calcium urolithiasis among patients with hyperuricosuria supersaturation of urine with respect to monosodium urate. *J Clin Investig*. 1977;59(3):426–431.

Pak CY. Citrate and renal calculi: an update. *Miner Electrolyte Metab*. 1994;20:371–377.

Pak CY. Should patients with single renal stone occurrence undergo diagnostic evaluation? *J Urol*. 1982;127:855–858.

Pak CYC, Peterson R. Successful treatment of hyperuricosuric calcium oxalate nephrolithiasis with potassium citrate. *Arch Intern Med*. 1986;146:863–868.

Parfitt AM. Acetazolamide and sodium bicarbonate induced nephrocalcinosis and nephrolithiasis; relationship to citrate and calcium excretion. *Arch Intern Med*. 1969;124:736–740.

Park AM, Storm DW, Fulmer BR, et al. A prospective study of risk factors for nephrolithiasis after Roux-en-Y gastric bypass surgery. *J Urol*. 2009;182:2334–2339.

Parks JH, Coe FL, Favus M. Hyperparathyroidism in nephrolithiasis. *Arch Intern Med*. 1980;140:1479–1481.

Parks JH, Coe FL, Strauss AL. Calcium nephrolithiasis and medullary sponge kidney in women. *N Engl J Med*. 1982;306:1088–1091.

Parks JH, Coe FL. A urinary calcium-citrate index for the evaluation of nephrolithiasis. *Kidney Int*. 1986;30:85–90.

Parry ES, Lister IS. Sunlight and hypercalciuria. *Lancet*.

1975;1:1063–1065.

Parsons CL, Stauffer C, Mulholland SG, et al. Effect of ammonium on bacterial adherence to bladder transitional epithelium. *J Urol*. 1984;132:365–366.

Patel BN, Passman CM, Fernandez A, et al. Prevalence of hyperoxaluria after bariatric surgery. *J Urol*. 2009;181:161–166.

Patel ND, Ward RD, Calle J, et al. Computerized tomography based diagnosis of visceral obesity and hepatic steatosis is associated with low urine pH. *J Urol*. 2017;198(5):1085–1090.

Pearle MS, Calhoun EA, Curhan GC. Urologic Diseases in America project: urolithiasis. *J Urol*. 2005;173:848–857.

Pearle MS, Roehrborn CG, Pak CY. Meta-analysis of randomized trials for medical prevention of calcium oxalate nephrolithiasis. *J Endourol*. 1999;13:679–685.

Penniston KL, Kaplon DM, Gould JC, et al. Gastric band placement for obesity is not associated with increased urinary risk of urolithiasis compared to bypass. *J Urol*. 2009;182:2340–2346.

Penniston KL, McLaren ID, Greenlee RT, et al. Urolithiasis in a rural Wisconsin population from 1992 to 2008: narrowing of the male-to-female ratio. *J Urol*. 2011;185:1731–1736.

Penniston KL, Nakada SY. Effect of dietary changes on urinary oxalate excretion and calcium oxalate supersaturation in patients with hyperoxaluric stone formation. *Urology*. 2009;73:484–489.

Phang JM, Kales AN, Hahn TJ. Effect of divided calcium intake on urinary calcium excretion. *Lancet*. 1968;2(7559):84–85.

Pichette V, Bonnardeaux A, Cardinal J, et al. Ammonium acid urate crystal formation in adult North American stone-formers. *Am J Kidney Dis*. 1997;30:237–242.

Pierce LW, Bloom B. Observations on urolithiasis among

American troops in a desert area. *J Urol*. 1945;54:466–470.

Pohlman T, Hruska KA, Menon M. Renal tubular acidosis. *J Urol*. 1984;132:431–436.

Powell CR, Stoller ML, Schwartz BF, et al. Impact of body weight on urinary electrolytes in urinary stone formers. *Urology*. 2000;55:825–830.

Powell T, Hsu FF, Turk J, et al. Ma-huang strikes again: ephedrine nephrolithiasis. *Am J Kidney Dis*. 1998;32:153–159.

Pras E, Arber N, Aksentijevich I, et al. Localization of a gene causing cystinuria to chromosome 2p. *Nat Genet*. 1994;6:415–419.

Preminger GM, Baker S, Peterson R, et al. Hypomagnesuric hypocitraturia: an apparent new entity for calcium nephrolithiasis. *J Lith Stone Dis*. 1989;1:22–25.

Preminger GM, Sakhaee K, Skurla C, et al. Prevention of recurrent calcium stone formation with potassium citrate therapy in patients with distal renal tubular acidosis. *J Urol*. 1985;134:20–32.

Preminger GM. Renal calculi: pathogenesis, diagnosis, and medical therapy. *Semin Nephrol*. 1992;12:200–216.

Prenan JA, Boer P, Mees EJ, et al. Renal clearance of [14C]oxalate: comparison of constant-infusion with single-injection techniques. *Clin Sci*. 1982;63:47–51.

Prince CL, Scardino PL, Wolan CT. The effect of temperature, humidity and dehydration on the formation of renal calculi. *J Urol*. 1956;75:209–215.

Prince CL, Scardino PL. A statistical analysis of ureteral calculi. *J Urol*. 1960;83:561–565.

Raj GV, Auge BK, Assimos D, et al. Metabolic abnormalities associated with renal calculi in patients with horseshoe kidneys. *J Endourol*. 2004;18:157–161.

Randall A. The origin and growth of renal calculi. *Ann Surg*.

1937;105:1009–1020.

Rattan V, Thind SK, Jethi RK, et al. Oxalate metabolism in magnesium-deficient rats. *Magnes Res*. 1993;6:127–133.

Ravichandran V, Selvam R. Increased lipid peroxidation in kidney of vitamin B-6 deficient rats. *Biochem Int*. 1990;21:599–605.

Reddy ST, Wang CY, Sakhaee K, et al. Effect of low-carbohydrate high-protein diets on acid-base balance, stone-forming propensity, and calcium metabolism. *Am J Kidney Dis*. 2002;40:265–274.

Reed BY, Gitomer WL, Heller HJ, et al. Identification and characterization of a gene with base substitutions associated with the absorptive hypercalciuria phenotype and low spinal bone density. *J Clin Endocrinol Metab*. 2002;87:1476–1485.

Reed BY, Heller HJ, Gitomer WL, et al. Mapping a gene defect in absorptive hypercalciuria to chromosome 1q23.3-q24. *J Clin Endocrinol Metab*. 1999;84:3907–3913.

Reid DG, Jackson GJ, Duer MJ, et al. Apatite in kidney stones is a molecular composite with glycosaminoglycans and proteins: evidence from nuclear magnetic resonance spectroscopy, and relevance to Randall's plaque, pathogenesis and prophylaxis. *J Urol*. 2011;185:725–730.

Reiner AP, Kahn A, Eisner BH, et al. Kidney stones and subclinical atherosclerosis in young adults: the CARDIA study. *J Urol*. 2011;185:920–925.

Resim S, Ekerbicer HC, Kiran G, et al. Are changes in urinary parameters during pregnancy clinically significant? *Urol Res*. 2006;34(4):244–248.

Resnick MI. Evaluation and management of infection stones. *Urol Clin North Am*. 1981;8:265–276.

Riley JM, Dudley AG, Semins MJ. Nephrolithiasis and pregnancy: has the incidence been rising? *J Endourol*. 2014;28(3):383–386.

Riley JM, Kim H, Averch TD, et al. Effect of magnesium on calcium and oxalate ion binding. *J Endourol*. 2013;27:1487–1492.

Rizzoli R, Bonjour JP. Management of disorders of calcium homeostasis. *Baillieres Clin Endocrinol Metab*. 1992;6:129–142.

Robertson WG, Hughes H. Importance of mild hyperoxaluria in the pathogenesis of urolithiasis—new evidence from studies in the Arabian peninsula. *Scanning Microsc*. 1993;7:391–401 [discussion 401–402].

Robertson WG, Morgan DB. The distribution of urinary calcium excretions in normal persons and stone-formers. *Clin Chim Acta*. 1972;37:503–508.

Robertson WG, Peacock M, Heyburn PJ, et al. Epidemiological risk factors in calcium stone disease. *Scand J Urol Nephrol Suppl*. 1980;53:15–30.

Robertson WG, Peacock M, Marshall RW, et al. Saturation-inhibition index as a measure of the risk of calcium oxalate stone formation in the urinary tract. *N Engl J Med*. 1976;294:249–252.

Robertson WG, Peacock M. The cause of idiopathic calcium stone disease: hypercalciuria or hyperoxaluria? *Nephron*. 1980;26:105–110.

Rocher LL, Tannen RL. The clinical spectrum of renal tubular acidosis. *Annu Rev Med*. 1986;37:319–331.

Rockwood N, Mandalia S, Bower M, et al. Ritonavir-boosted atazanavir exposure is associated with an increased rate of renal stones compared with efavirenz, ritonavir-boosted lopinavir and ritonavir-boosted darunavir. *AIDS*. 2011;25:1671–1673.

Rodgers A, Allie-Hamdulay S, Jackson G. Therapeutic action of citrate in urolithiasis explained by chemical speciation: increase in pH is the determinant factor. *Nephrol Dial*

Transplant. 2006;21:361–369.

Romero V, Akpinar H, Assimos DG. Kidney stones: a global picture of prevalence, incidence, and associated risk factors. *Rev Urol*. 2010;12:e86–e96.

Rosenberg LE, Downing S, Durant JL, et al. Cystinuria: biochemical evidence for three genetically distinct diseases. *J Clin Invest*. 1966;45:365–371.

Ross AE, Handa S, Lingeman JE, et al. Kidney stones during pregnancy: an investigation into stone composition. *Urol Res*. 2008;36:99–102.

Routh JC, Graham DA, Nelson CP. Epidemiological trends in pediatric urolithiasis at United States freestanding pediatric hospitals. *J Urol*. 2010;184(3):1100–1104.

Rudman D, Dedonis JL, Fountain MT, et al. Hypocitraturia in patients with gastrointestinal malabsorption. *N Engl J Med*. 1980;303:657–661.

Rule AD, Bergstralh EJ, Melton LJ 3rd, et al. Kidney stones and the risk for chronic kidney disease. *Clin J Am Soc Nephrol*. 2009;4(4):804–811.

Rule AD, Roger VL, Melton LJ 3rd, et al. Kidney stones associate with increased risk for myocardial infarction. *J Am Soc Nephrol*. 2010;21:1641–1644.

Rumsby G. Genetic defects underlying renal stone disease. *Int J Surg*. 2016;36(Pt D):590–595.

Rushton HG, Spector M. Effects of magnesium deficiency on intratubular calcium oxalate formation and crystalluria in hyperoxaluric rats. *J Urol*. 1982;127:598–604.

Ryall RL, Grover PK, Marshall VR. Urate and calcium stones—picking up a drop of mercury with one's fingers? *Am J Kidney Dis*. 1991;17:426–430.

Ryall RL, Grover PK, Stapleton AM, et al. The urinary F1 activation peptide of human prothrombin is a potent inhibitor of calcium oxalate crystallization in undiluted human urine in vitro. *Clin Sci*. 1995;89:533–541.

Ryall RL. The scientific basis of calcium oxalate urolithiasis: predilection and precipitation, promotion and proscription. *World J Urol*. 1993;11:59–65.

Sage MR, Lawson AD, Marshall VR, et al. Medullary sponge kidney and urolithiasis. *Clin Radiol*. 1982;33:435–438.

Sakhaee K, Adams-Huet B, Moe OW, et al. Pathophysiologic basis for normouricosuric uric acid nephrolithiasis. *Kidney Int*. 2002;62:971–979.

Sakhaee K, Nigam S, Snell P, et al. Assessment of the pathogenetic role of physical exercise in renal stone formation. *J Clin Endocrinol Metab*. 1987;65:974–979.

Sakhaee K, Poindexter JR, Pak CY. The spectrum of metabolic abnormalities in patients with cystine nephrolithiasis. *J Urol*. 1989;141:819–821.

Sakhaee K. Recent advances in the pathophysiology of nephrolithiasis. *Kidney Int*. 2009;75:585–595.

Sarmina I, Spirnak JP, Resnick MI. Urinary lithiasis in the black population: an epidemiological study and review of the literature. *J Urol*. 1987;138:14–17.

Scales CD Jr, Curtis LH, Norris RD, et al. Changing gender prevalence of stone disease. *J Urol*. 2007;177:979–982.

Scales CD Jr, Smith AC, Hanley JM, et al. Prevalence of kidney stones in the United States. *Eur Urol*. 2012;62:160–165.

Schlingmann KP, Kaufmann M, Weber S, et al. Mutations in *CYP24A1* and idiopathic infantile hypercalcemia. *N Engl J Med*. 2011;365:410–421.

Schwartz BF, Bruce J, Leslie S, et al. Rethinking the role of urinary magnesium in calcium urolithiasis. *J Endourol*. 2001;15:233–235.

Schwartz BF, Schenkman NS, Bruce JE, et al. Calcium nephrolithiasis: effect of water hardness on urinary electrolytes. *Urology*. 2002;60:23–27.

Schwille PO, Manoharan M, Rumenapf G, et al. Oxalate measurement in the picomol range by ion chromatography: values in fasting plasma and urine of controls and patients with idiopathic calcium urolithiasis. *J Clin Chem Clin Biochem*. 1989;27:87–96.

Scott P, Ouimet D, Valiquette L, et al. Suggestive evidence for a susceptibility gene near the vitamin D receptor locus in idiopathic calcium stone formation. *J Am Soc Nephrol*. 1999;10:1007–1113.

Selvam R. Calcium oxalate stone disease: role of lipid peroxidation and antioxidants. *Urol Res*. 2002;30:35–47.

Semins MJ, Matlaga BR, Shore AD, et al. The effect of gastric banding on kidney stone disease. *Urology*. 2009;74:746–749.

Semins MJ, Shore AD, Makary MA, et al. The association of increasing body mass index and kidney stone disease. *J Urol*. 2010;183:571–575.

Shang W, Li Y, Ren Y, et al. Nephrolithiasis and risk of hypertension: a meta-analysis of observational studies. *BMC Nephrol*. 2017;18(1):344.

Shavit L, Ferraro PM, Johri N, et al. Effect of being overweight on urinary metabolic risk factors for kidney stone formation. *Nephrol Dial Transplant*. 2015;30(4):607–613.

Shekarriz B, Stoller ML. Uric acid nephrolithiasis: current concepts and controversies. *J Urol*. 2002;168:1307–1314.

Sherwood LM, Ayer GP, Ramberg CF, et al. Regulation of parathyroid hormone secretion: proportional control by calcium, lack of effect of phosphate. *Endocrinology*. 1968;83:1043–1051.

Shiekh FA, Miller VM, Lieske JC. Do calcifying nanoparticles promote nephrolithiasis? A review of the evidence. *Clin Nephrol*. 2009;71:1–8.

Shimamoto K, Higashiura K, Nakagawa M, et al. Effects of hyperinsulinemia under the euglycemic condition on calcium and phosphate metabolism in non-obese normotensive subjects. *Tohoku J Exp Med*. 1995;177:271–278.

Shiraga H, Min W, VanDusen WJ, et al. Inhibition of calcium oxalate crystal growth *in vitro* by uropontin: another member of the aspartic acid-rich protein superfamily. *Proc Natl Acad Sci USA*. 1992;89:426–430.

Shoag J, Halpern J, Goldfarb DS, et al. Risk of chronic and end stage kidney disease in patients with nephrolithiasis. *J Urol*. 2014;192(5):1440–1445.

Shukla AR, Hoover DL, Homsy YL, et al. Urolithiasis in the low birth weight infant: the role and efficacy of extracorporeal shock wave lithotripsy. *J Urol*. 2001;165:2320–2323.

Sidhu H, Hoppe G, Hesse A, et al. Absence of *Oxalobacter formigenes* in cystic fibrosis patients: a risk factor for hyperoxaluria. *Lancet*. 1998;352:1026–1029.

Sidhu H, Schmidt ME, Cornelius JG, et al. Direct correlation between hyperoxaluria/oxalate stone disease and the absence of the gastrointestinal tract-dwelling bacterium *Oxalobacter formigenes:* possible prevention by gut recolonization or enzyme replacement therapy. *J Am Soc Nephrol*. 1999;10(Suppl 14):S334–S340.

Siener R, Glatz S, Nicolay C, et al. The role of overweight and obesity in calcium oxalate stone formation. *Obes Res*. 2004;12:106–113.

Sierakowski R, Finlayson B, Landes R. Stone incidence as related to water hardness in different geographical regions of the United States. *Urol Res*. 1979;7:157–160.

Simon DB, Lu Y, Choate KA, et al. Paracellin-1, a renal tight junction protein required for paracellular Mg^{2+} resorption. *Science*. 1999;285:103–106.

Sinha MK, Collazo-Clavell ML, Rule A, et al. Hyperoxaluric nephrolithiasis is a complication of Roux-en-Y gastric bypass surgery. *Kidney Int*. 2007;72:100–107.

Smith CL, Kristensen C, Davis M, et al. An evaluation of the physicochemical risk for renal stone disease during pregnancy. *Clin Nephrol*. 2001;55:205–211.

Soble JJ, Hamilton BD, Streem SB. Ammonium acid urate calculi: a reevaluation of risk factors. *J Urol*. 1999;161:869–873.

Sorensen CM, Chandhoke PS. Hyperuricosuric calcium nephrolithiasis. *Endocrinol Metab Clin North Am*. 2002;31:915–925.

Sorensen MD, Chi T, Shara NM, et al. Activity, energy intake, obesity, and the risk of incident kidney stones in postmenopausal women: a report from the Women's Health Initiative. *J Am Soc Nephrol*. 2013;25(2):362–369.

Sorokin I, Mamoulakis C, Miyazawa K, et al. Epidemiology of stone disease across the world. *World J Urol*. 2017;35(9):1301–1320.

Soucie JM, Coates RJ, McClellan W, et al. Relation between geographic variability in kidney stones prevalence and risk factors for stones. *Am J Epidemiol*. 1996;143:487–495.

Soucie JM, Thun MJ, Coates RJ, et al. Demographic and geographic variability of kidney stones in the United States. *Kidney Int*. 1994;46:893–899.

Stamatelou KK, Francis ME, Jones CA, et al. Time trends in reported prevalence of kidney stones in the United States: 1976–1994. *Kidney Int*. 2003;63:1817–1823.

Stoller ML, Meng MV, Abrahams HM, et al. The primary stone event: a new hypothesis involving a vascular etiology. *J Urol*. 2004;171:1920–1924.

Stothers L, Lee LM. Renal colic in pregnancy. *J Urol*. 1992;148:1383–1387.

Strauss AL, Coe FL, Deutsch L, et al. Factors that predict relapse of calcium nephrolithiasis during treatment: a prospective study. *Am J Med*. 1982;72:17–24.

Su CJ, Shevock PN, Khan SR, et al. Effect of magnesium on calcium oxalate urolithiasis. *J Urol*. 1991;145:1092–1095.

Sumner JB. The isolation and crystallization of the enzyme urease. *J Biol Chem*. 1926;69:435–441.

Sutherland SE, Reigle MD, Seftel AD, et al. Protease inhibitors and urolithiasis. *J Urol*. 1997;158:31–33.

Swanson SK, Heilman RL, Eversman WG. Urinary tract stones in pregnancy. *Surg Clin North Am*. 1995;75:123–142.

Tanaka M, Itoh K, Matsushita K, et al. Two male siblings with hereditary renal hypouricemia and exercise-induced ARF. *Am J Kidney Dis*. 2003;42:1422–1493.

Tasian GE, Jemielita T, Goldfarb DS, et al. Oral antibiotic exposure and kidney stone disease. *J Am Soc Nephrol*. 2018;29(6):1731–1740.

Tasian GE, Pulido JE, Gasparrini A, et al. Daily mean temperature and clinical kidney stone presentation in five U.S. metropolitan areas: a time-series analysis. *Environ Health Perspect*. 2014;122(10):1081–1087.

Tasian GE, Ross ME, Song L, et al. Annual incidence of nephrolithiasis among children and adults in South Carolina from 1997 to 2012. *Clin J Am Soc Nephrol*. 2016;11(3):488–496.

Tawada T, Fujita K, Sakakura T, et al. Distribution of osteopontin and calprotectin as matrix protein in calcium-containing stone. *Urol Res*. 1999;27:238–242.

Taylor EN, Curhan GC. Body size and 24-hour urine composition. *Am J Kidney Dis*. 2006;48:905–915.

Taylor EN, Stampfer MJ, Curhan GC. Diabetes mellitus and the risk of nephrolithiasis. *Kidney Int*. 2005;68:1230–1235.

Taylor EN, Stampfer MJ, Curhan GC. Obesity, weight gain, and the risk of kidney stones. *JAMA*. 2005;293:455–462.

Tekin A, Tekgul S, Atsu N, et al. Ureteropelvic junction obstruction and coexisting renal calculi in children: role of metabolic abnormalities. *Urology*. 2001;57:542–545 [discussion 545–546].

Thamilselvan S, Selvam R. Effect of vitamin E and mannitol on renal calcium oxalate retention in experimental nephrolithiasis. *Indian J Biochem Biophys*. 1997;34:319–323.

Thorleifsson G, Holm H, Edvardsson V, et al. Sequence variants in the *CLDN14* gene associate with kidney stones and bone mineral density. *Nat Genet*. 2009;41:926–930.

Ticinesi A, Milani C, Guerra A, et al. Understanding the gut-kidney axis in nephrolithiasis: an analysis of the gut microbiota composition and functionality of stone formers. *Gut*. 2018;67(12):2097–2106.

Tieder M, Modai D, Shaked U, et al. Idiopathic hypercalciuria and hereditary hypophosphatemic rickets: two phenotypical expressions of a common genetic defect. *N Engl J Med*. 1987;316:125–129.

Tiselius HG, Berg C, Fornander AM, et al. Effects of citrate on the different phases of calcium oxalate crystallization. *Scanning Microsc*. 1993;7:381–389 [discussion 389–390].

Tiselius HG, Fornander AM, Nilsson MA. The effects of citrate and urine on calcium oxalate crystal aggregation. *Urol Res*. 1993;21:363–366.

Tiwari R, Campfield T, Wittcopp C, et al. Metabolic syndrome in obese adolescents is associated with risk for nephrolithiasis. *J Pediatr*. 2012;160(4):615–620.

Toka HR, Al-Romaih K, Koshy JM, et al. Deficiency of the calcium-sensing receptor in the kidney causes parathyroid hormone–independent hypocalciuria. *J Am Soc Nephrol*. 2012;23:1879–1890.

Torricelli FC, De SK, Gebreselassie S, et al. Dyslipidemia and kidney stone risk. *J Urol*. 2014;191(3):667–672.

Traxer O, Huet B, Poindexter J, et al. Effect of ascorbic acid consumption on urinary stone risk factors. *J Urol*. 2003;170:397–401.

Troxel SA, Sidhu H, Kaul P, et al. Intestinal *Oxalobacter formigenes* colonization in calcium oxalate stone formers and its relation to urinary oxalate. *J Endourol*. 2003;17:173–176.

Umekawa T, Iguchi M, Kurita T. The effect of osteopontin immobilized collagen granules in the seed crystal method. *Urol Res*. 2001;29:282–286.

Uribarri J, Oh MS, Pak CY. Renal stone risk factors in patients with type IV renal tubular acidosis. *Am J Kidney Dis*. 1994;23:784–787.

van Aswegen CH, Hurter P, van der Merwe CA, et al. The relationship between total urinary testosterone and renal calculi. *Urol Res*. 1989;17:181–183.

Van den Berg CJ, Harrington TM, Bunch TW, et al. Treatment of renal lithiasis associated with renal tubular acidosis. *Proc Eur Dial Transplant Assoc*. 1983;20:473–476.

Vanwaeyenbergh J, Vergauwe D, Verbeeck RM. Infrared spectrometric analysis of endemic bladder stones in Niger. *Eur Urol*. 1995;27:154–159.

Vargas-Poussou R, Huang C, Hulin P, et al. Functional characterization of a calcium-sensing receptor mutation in severe autosomal dominant hypocalcemia with a Bartter-like syndrome. *J Am Soc Nephrol*. 2002;13:2259–2266.

Vega D, Maalouf NM, Sakhaee K. Increased propensity for calcium phosphate kidney stones with topiramate use. *Expert Opin Drug Saf*. 2007;6:547–557.

Vezzoli G, Terranegra A, Arcidiacono T, et al. Calcium kidney stones are associated with a haplotype of the calcium-sensing receptor gene regulatory region. *Nephrol Dial Transplant*. 2010;25:2245–2252.

Vezzoli G, Terranegra A, Rainone F, et al. Calcium-sensing receptor and kidney stones. *J Transl Med*. 2011;9:201.

Viprakasit DP, Sawyer MD, Herrell SD, et al. Changing composition of staghorn calculi. *J Urol*. 2011;186:2285–2290.

Vupputuri S, Soucie JM, McClellan W, et al. History of kidney stones as a possible risk factor for chronic kidney disease. *Ann Epidemiol*. 2004;14(3):222–228.

Wahba IM, Mak RH. Obesity and obesity-initiated metabolic syndrome: mechanistic links to chronic kidney disease. *Clin J Am Soc Nephrol*. 2007;2:550–562.

Walker V, Stansbridge EM, Griffin DG. Demography and biochemistry of 2800 patients from a renal stones clinic. *Ann Clin Biochem*. 2013;50(Pt 2):127–139.

Walton J, Gray TK. Absorption of inorganic phosphate in the human small intestine. *Clin Sci*. 1979;56:407–412.

Wang TJ, Zhang F, Richards JB, et al. Common genetic determinants of vitamin D insufficiency: a genome-wide association study. *Lancet*. 2010;376:180–188.

Watts RW. Uric acid biosynthesis and its disorders. *J R Coll Physicians Lond*. 1976;11:91–106.

Weinberg JM. Lipotoxicity. *Kidney Int*. 2006;70:1560–1566.

Welch BJ, Graybeal D, Moe OW, et al. Biochemical and stone-risk profiles with topiramate treatment. *Am J Kidney Dis*. 2006;48:555–563.

Werness PG, Bergert JH, Smith LH. Triamterene urolithiasis: solubility, pK, effect on crystal formation, and matrix binding of triamterene and its metabolites. *J Lab Clin Med*. 1982;99:254–262.

Werness PG, Brown CM, Smith LH, et al. EQUIL2: a BASIC computer program for the calculation of urinary saturation. *J Urol*. 1985;134:1242–1244.

Wesson JA, Johnson RJ, Mazzali M, et al. Osteopontin is a critical inhibitor of calcium oxalate crystal formation and retention in renal tubules. *J Am Soc Nephrol*. 2003;14:139–

147.

Wesson JA, Worcester EM, Wiessner JH, et al. Control of calcium oxalate crystal structure and cell adherence by urinary macromolecules. *Kidney Int*. 1998;53:952–957.

West B, Luke A, Durazo-Arvizu RA, et al. Metabolic syndrome and self-reported history of kidney stones: the National Health and Nutrition Examination Survey (NHANES III) 1988-1994. *Am J Kidney Dis*. 2008;51:741–747.

Williams EL, Bockenhauer D, van't Hoff WG, et al. The enzyme 4-hydroxy-2-oxoglutarate aldolase is deficient in primary hyperoxaluria type 3. *Nephrol Dial Transplant*. 2012;27(8):3191–3195.

Wilson DM. Clinical and laboratory approaches for evaluation of nephrolithiasis. *J Urol*. 1989;141:770–774.

Wilson DR, Strauss AL, Manuel MA. Comparison of medical treatments for the prevention of recurrent calcium nephrolithiasis. *Urol Res*. 1984;12:39.

Wolf MT, Wu XR, Huang CL. Uromodulin upregulates TRPV5 by impairing caveolin-mediated endocytosis. *Kidney Int*. 2013;84(1):130–137.

Wong Y, Cook P, Roderick P, et al. Metabolic syndrome and kidney stone disease: a systematic review of literature. *J Endourol*. 2016;30(3):246–253.

Worcester EM, Coe FL, Evan AP, et al. Reduced renal function and benefits of treatment in cystinuria vs other forms of nephrolithiasis. *BJU Int*. 2006;97:1285–1290.

Worcester EM, Parks JH, Evan AP, et al. Renal function in patients with nephrolithiasis. *J Urol*. 2006;176:600–603.

Worcester EM. Stones due to bowel disease. Coe F, Favus M, Pak C, et al. *Kidney stones: medical and surgical management*. Lippincott-Raven: New York; 1996:883–903.

Wu DS, Stoller ML. Indinavir urolithiasis. *Curr Opin Urol*. 2000;10:557–561.

Yagisawa T, Chandhoke PS, Fan J. Comparison of comprehensive and limited metabolic evaluations in the treatment of patients with recurrent calcium urolithiasis. *J Urol*. 1999;161:1449–1452.

Yagisawa T, Kobayashi C, Hayashi T, et al. Contributory metabolic factors in the development of nephrolithiasis in patients with medullary sponge kidney. *Am J Kidney Dis*. 2001;37:1140–1143.

Yamaguchi S, Yoshioka T, Utsunomiya M, et al. Heparin sulfate in the stone matrix and its inhibitory effect on calcium oxalate crystallization. *Urol Res*. 1993;21:187–192.

Yasui T, Iguchi M, Suzuki S, et al. Prevalence and epidemiologic characteristics of urolithiasis in Japan: national trends between 1965 and 2005. *Urol*. 2008;71:209–213.

Yendt E. Medullary sponge kidney and nephrolithiasis. *N Engl J Med*. 1981;306:1106–1107.

Yendt ER, Gagne RJ. Detection of primary hyperparathyroidism, with special reference to its occurrence in hypercalciuric females with “normal” or borderline serum calcium. *Can Med Assoc J*. 1968;98:331–336.

Yoshimura E, Sawada SS, Lee IM, et al. Body mass index and kidney stones: a cohort study of Japanese men. *J Epidemiol*. 2016;26(3):131–136.

Yu T, Gutman AB. Uric acid nephrolithiasis in gout: predisposing factors. *Ann Intern Med*. 1967;67:1133–1148.

Yu TF. Urolithiasis in hyperuricemia and gout. *J Urol*. 1981;126:424–430.

Zaccara G, Tramacere L, Cincotta M. Drug safety evaluation of zonisamide for the treatment of epilepsy. *Expert Opin Drug Saf*. 2011;10:623–631.

Zerwekh JE, Hughes MR, Reed BY, et al. Evidence for normal vitamin D receptor messenger ribonucleic acid and genotype in absorptive hypercalciuria. *J Clin Endocrinol Metab*.

1995;80:2960–2965.

Zerwekh JE, Hwang TI, Poindexter J, et al. Modulation by calcium of the inhibitor activity of naturally occurring urinary inhibitors. *Kidney Int*. 1988;33:1005–1008.

Zerwekh JE, Reed BY, Heller HJ, et al. Normal vitamin D receptor concentration and responsiveness to 1, 25-dihydroxyvitamin D_3 in skin fibroblasts from patients with absorptive hypercalciuria. *Miner Electrolyte Metab*. 1998;24:307–313.

Zhang J, Fuster DG, Cameron MA, et al. Incomplete distal renal tubular acidosis from a heterozygous mutation of the V-ATPase B1 subunit. *Am J Physiol Renal Physiol*. 2014;307(9):F1063–F1071.

Zhang X, Roe SM, Hou Y, et al. Crystal structure of alanine:glyoxylate aminotransferase and the relationship between genotype and enzymatic phenotype in primary hyperoxaluria type 1. *J Mol Biol*. 2003;331:643–652.

Evaluation and Medical Management of Urinary Lithiasis

Nicole L. Miller MD, Michael S. Borofsky MD

Evaluation of Urinary Lithiasis

Urinary stone disease is one of mankind's oldest and longest recognized urologic afflictions. Historic records describing symptoms related to stones and efforts to dissolve them date back to ancient Mesopotamia between 3200 and 1200 BCE (Tefekli and Cezayirli 2013). Some of history's most famous physicians proposed hypotheses for how stones form and diagnostic and treatment recommendations including Hippocrates (460 BCE), Aristotle (384 BCE), and Galen (131 to 200 AD) (Shah, 2002). The understanding of how stones form and the therapies used to treat and prevent them have evolved dramatically in the hundreds of years since these initial descriptions. Nonetheless, despite such efforts, urinary stone disease remains one of the most common urologic conditions. A proper conceptual understanding of the mechanisms by which stones form and the methods by which stone growth may be reduced are necessary for the practicing urologist. Not only are stones likely to recur without identification and modifications of the factors that enabled them to form in the first place, but they may also be indicative of a larger systemic disease. Herein, the basis for a proper stone evaluation and an overview of the available conservative and medical treatments to prevent them are provided.

Epidemiology and Morbidity From Urinary Lithiasis

The prevalence of urinary stone disease is rising at a rapid rate. Recent national estimates from the United States suggest that stones affect 1 in 11 at some point in their lifetime, nearly double the rate it was 15 years earlier (Scales et al., 2012). Historically stone disease tended to affect more men than it did women, but a disproportional increase in stones particularly among younger females has leveled the gender disparity and made it close to equal (Lieske et al. 2006). Several recent estimates of gender distribution of stones between men and women have reported ratios between 1.2 and 1.45 : 1 (Nowfar, 2011; Pearle, 2005; Scales et al., 2007). Although the precise reason for this demographic change is unclear, it does not appear to be a result of a decrease in male stone formation but rather as a significant increase in female stone formation (Pearle, 2005).

The morbidity attributed to stone disease is classically considered in the acute sense where severe colic, emergency medical care, life interruption, missed work, and often surgical treatment are undesired aspects of a single stone episode. However, it is important to consider the long-term impact of stone disease on quality of life, particularly as stone recurrence is quite common. **First-time stone formers often have been estimated to have a 50% risk for recurrence within the subsequent 10 years** (Uribarri, 1989). In two separate studies, Ljunghall and Danielson attempted to measure the incidence of stone recurrence in a Northern European population (Ljunghall, 1984, 1987). A retrospective review estimated the chance of recurrence at nearly 50% at 5 years, whereas a prospective evaluation noted a lower overall rate of 53% within 8 years. Males had both a higher incidence of calculi overall and a higher recurrence rate. Patients had a higher risk for repeat stones in the years immediately after their first episode. It is not completely apparent whether these were preexisting stones that passed later or whether they represent the formation of new calculi.

Recognizing that the risk for stone recurrence can vary greatly from one patient to another, Rule et al. developed the recurrence of kidney stone (ROKS) nomogram to help better predict the risk for a second kidney stone. They found that by taking various demographic and clinical considerations into account, 10-

year recurrence risk could be better predicted and ranged from 12% among patients with the lowest risk scores to 56% to those with the highest risk stratification. Significant predictors of stone recurrence included younger age, male sex, family history, prior stone event, nonobstructing renal stones, symptomatic renal pelvis/lower pole stones and uric acid composition. Notably, urinary chemistries were unable to be taken into consideration of the nomogram (Rule et al., 2014).

The effect of stone disease on overall quality of life (QOL) is gaining greater appreciation as patient-reported outcomes measures are increasingly utilized in modern health care systems. This is particularly true among patients with recurrent urinary stones whose health-related QOL has the potential to suffer for a variety of reasons including chronic/episodic pain, frequent clinic visits, recurrent interventions, or side effects from medications or dietary measures being used for prophylaxis. **Application of generic health and well-being questionnaires such as the SF-36 has demonstrated that the health-related QOL for stone formers is lower than the population mean,** with women reporting greater impairment than men (Penniston, 2007a). The National Institutes of Health (NIH)-supported Patient-Reported Outcome Measurement Information System (PROMIS) has also been applied to patients with stone disease. Studies using this tool have shown that stone patients have subjectively worse pain intensity, pain interference, and physical function relative to the general population at various phases of a stone episode (Borofsky et al., 2017; Patel, 2017). A disease-specific health-related QOL measurement system has also been validated for the purpose of studying the effect of stone disease on QOL (Penniston, 2017). To date, this system has proven useful and has led to a number of notable findings including a poorer QOL in cystine versus noncystine stone formers (Streeper et al., 2017) and decreased QOL in patients with asymptomatic stones compared with those with no stones (Penniston, 2016).

Key Points

- The incidence of nephrolithiasis is increasing.
- The historic male predominance of stone formers is disappearing.
- Risk for stone recurrence is variable but has been estimated at 50% between 5 and 10 years.

- Quality of life for stone formers is poorer than for non–stone formers.

Imaging for Urinary Lithiasis

Diagnostic imaging is a cornerstone in the evaluation of stone disease. American Urological Association (AUA) guidelines recommend obtaining and/or reviewing imaging studies to quantify stone burden as part of a routine medical evaluation for stone disease (Pearle et al., 2014). An overview of the different imaging modalities used in urology can be found in Chapters 2 to 4, but there are several unique considerations that should be made when looking for stones in particular. Utilization of the most appropriate diagnostic test will depend on the clinical scenario and the resources that are available. Consideration should be made regarding whether or not the patient is symptomatic, if surgery is being planned, and how much detail is needed regarding the potential stones themselves versus the collecting system of the kidneys.

Computed Tomography

Noncontrast computed tomography (CT) imaging is the gold standard in terms of diagnostic accuracy for stones, with a reported sensitivity of 98% and a specificity of 97% (Fulgham et al., 2013). Advantages of CT include the diagnostic certainty, ability to obtain rapid results, and relative ubiquity of CT scanners in medical settings. As a result, CT is the most commonly utilized test for evaluation of flank pain in emergency room settings, with the number of CT scans ordered for kidney stone evaluation having tripled between 1992 and 2009 (Fwu et al., 2013). An additional advantage of CT scanning for stones is the ability to obtain detailed anatomic information about the kidney itself including the presence or absence of hydronephrosis, perinephric stranding, and parenchymal abnormalities.

CT also has the potential to provide insight into stone composition. The classic example of this is for uric acid stones, which are radiolucent on conventional radiography but well visualized on CT. Furthermore, uric acid stones have lower Hounsfield units (HU) relative to other stones, a feature that has been shown to have clinical utility regarding the likelihood of that stone to respond to shock wave lithotripsy (Pareek et al., 2003; Saw et al., 2000). Recently, there is evidence that dual-energy CT may be able to further distinguish stone composition including uric acid, calcium phosphate, cystine, struvite, and calcium oxalate (Ascenti et al., 2010; Boll et al., 2009; Hidas et al.,

2010).

CT scans are not without their limitations. They are more expensive than alternative studies and have been estimated to be ten times as expensive as radiographs of the kidneys, ureter, and bladder (KUB) and five times as expensive as a renal ultrasonography (RUS) (Brisbane et al., 2016). They are also not able to visualize 100% of stones with several rare types of calculi that are radiolucent on CT including those made of drugs or bacteria (protease inhibitors and pure matrix). Another significant limitation of CT scans is the associated exposure to ionizing radiation with a mean effective dose of around 10 mSv per scan (Fulgham et al., 2013) (Table 92.1). **Patients with kidney stones are at particular risk for high levels of radiation exposure given the nature of stone recurrence and the potential for additional radiation exposure during surgical treatments and in surveillance.** Ferrandino et al. found that within the first year of an acute stone event, patients underwent an average of four radiographic examinations (mean of 1.2 KUBs, 1.7 CTs, 1 intravenous pyelogram (IVP). Median effective radiation dose per patient was 29.7 mSv with 20% receiving greater than 50 mSv, the recommended yearly dose limit for occupational exposure by the International Commission on Radiological Protection (Valentin and ICRP, 2005).

TABLE 92.1

Estimated Effective Radiation Dose (mSv) by Type of Examination

IMAGING MODAILTY	**EXAMINATION TYPE**	**EFFECTIVE DOSE (mSv)**
Ultrasonography	Abdomen and pelvis	0
MRI	Abdomen and pelvis	0
Conventional radiography		
	KUB	0.7
	KUB with tomograms	3.9
	IVU	3.0
CT		
	Noncontrast abdomen and pelvis	10.0
	Without and with contrast, abdomen and pelvis (2-phase)	15.0
	Without and with contrast, abdomen and pelvis (3-phase)	20.0

	Noncontrast CT, abdomen and pelvis (low-dose protocol)	3.0
	Noncontrast CT, abdomen and pelvis (ultra-low-dose protocol)	<1.0

CT, Computed tomography; *IVU,* intravenous urogram; *KUB,* kidney, ureter, bladder; *MRI,* magnetic resonance imaging.

Modified from Fulgham PF, Assimos DG, Pearle MS, Preminger GM. Clinical effectiveness protocols for imaging in the management of ureteral calculous disease: AUA technology assessment. *J Urol* 189(4):1203-1213, 2013.

Low-dose CT scans have been introduced with the intention of preserving the diagnostic accuracy of a regular CT scan with a lower dose of radiation exposure (Fig. 92.1). There is no standard terminology for what a low-dose CT means, but radiation exposure <3 to 4 mSv has been proposed (Fulgham et al., 2013; Gervaise et al., 2016). Several studies have demonstrated the ability to maintain a greater than 90% sensitivity and specificity for upper-tract stones using this approach (Liu et al., 2000; Tack et al., 2003). To date, this technique has shown promise but is underutilized for stones. A 2018 report looking specifically at the utilization of CT scans for stones found that despite a near threefold increase in utilization over a four-year period, overall low-dose CT scans only accounted for 7.6% of the CT scans ordered for stone evaluations across the United States (Weisenthal et al., 2018). Body mass index (BMI) is an important factor when considering low-dose CT as accuracy suffers when the BMI is greater than 30 (Fulgham et al., 2013). Ultra-low– dose CT scans (mSV <1) have also been proposed, though to date, studies have found a suboptimal sensitivity and specificity in the 70% range frequently caused by missing small stones 3 mm or less (Glazer et al., 2014; McLaughlin et al., 2014).

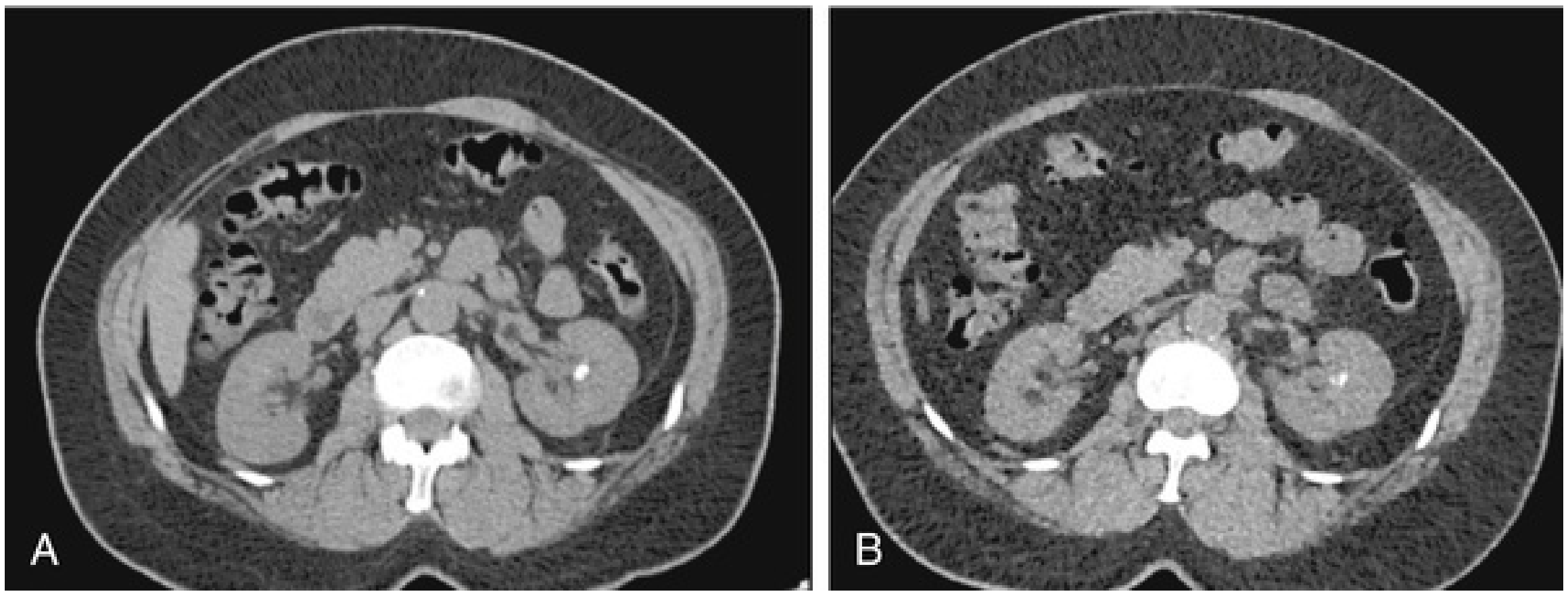

FIG. 92.1 Comparison of standard-dose (A) and low-dose CT (B) for the evaluation of renal stones.

Radiography (KUB and IVP)

Plain radiographs of the KUB are the oldest method of identifying stones in the body. Used alone, without contrast, KUB has an estimated sensitivity of 57% and a specificity of 76% (Fulgham et al., 2013). Limitations of this technique include an inability to visualize all stone types, particularly uric acid, and the potential for overlying structures such as bones or bowel gas to interfere with stone identification. IVPs can improve the ability to detect stones through better delineation of the pelvicalyceal and ureteral anatomy, but even so, they have an estimated sensitivity of only 70% despite a better specificity (95%) (Fulgham et al., 2013). Limitations of this approach include the required use of intravenous contrast and a limited degree to obtain information that might offer insight into other causes of symptoms (Dale et al., 2017).

Ultrasound

RUS is one of the most active areas of research in terms of stone imaging. Use of ultrasonography is very appealing as it is widely available, cost effective, and does not expose patients to ionizing radiation. The biggest disadvantage of RUS for stones though remains a poor sensitivity (61%) despite adequate specificity (97%) (Fulgham et al., 2013). RUS may still provide clinical utility, particularly of the kidney itself, where it is an excellent test for hydronephrosis. Application of Doppler ultrasonography can help find ureteral jets that may not be present in the setting of obstruction. Doppler ultrasonography can also be used to find a twinkling artifact (Fig. 92.2). This finding describes a mosaic of colors that appears over the stone and can help distinguish a stone from other echogenic structures, in turn improving the specificity of stone detection (Cunitz et al., 2014; Simon et al., 2018).

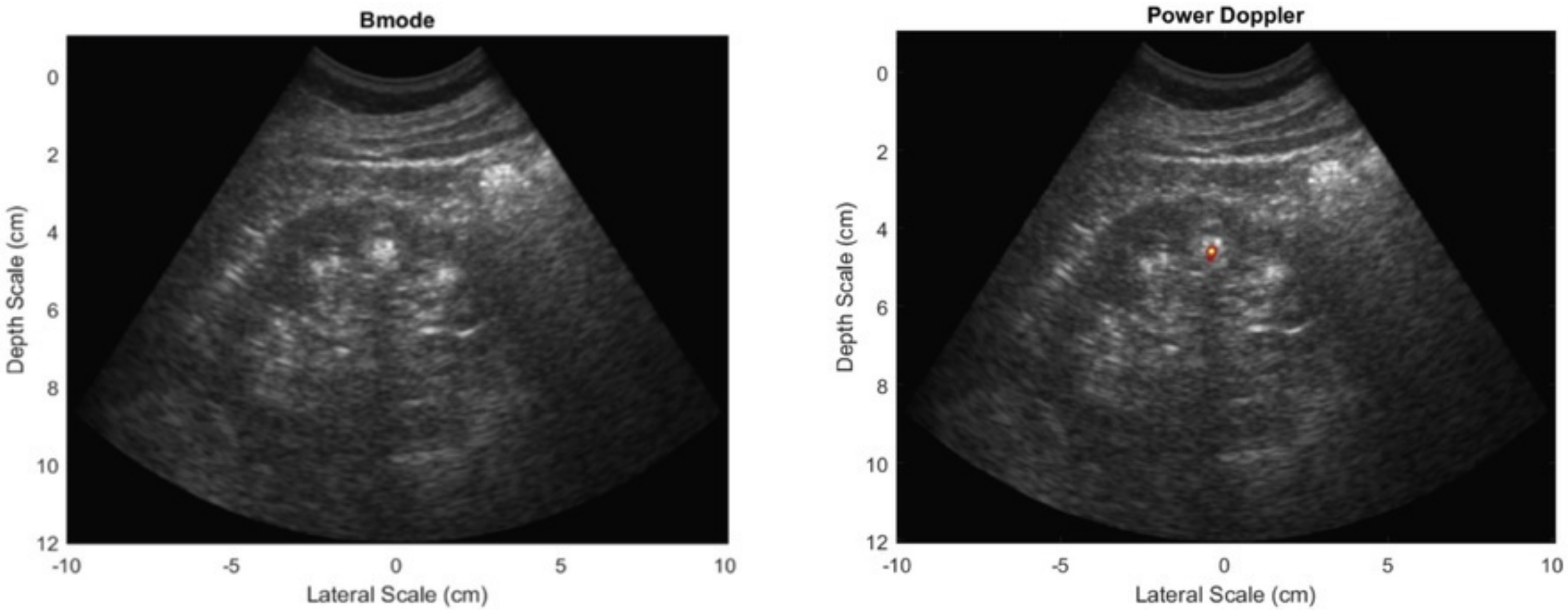

FIG. 92.2 Standard brightness mode *(B-mode)* ultrasound image of a stone in a kidney *(left)* and the same image with the stone identified with the twinkling artifact on power Doppler ultrasound. Twinkling adds color and contrast to the background to make the stone more easily identified in the image. The white brightness of the stone itself is seen in both images, although it is hard to distinguish form other bright objects. With the eye directed to the color on the stone, the shadow behind the stone may also be more obvious. (Courtesy of Bryan Cunitz and Michael Bailey, PhD, University of Washington.)

Even when stones are properly identified via ultrasonography, there is potential for misinterpretation of their size (Fowler et al., 2002). Small stones seen on ultrasound were previously found to be misclassified as over 5 mm in nearly one-half of cases because of issues related to interpretation, image acquisition, body habitus, and other patient-specific factors (Ray et al., 2010). One method that may improve the accuracy of stone sizing is measuring the acoustic shadow produced by an echogenic stone rather than the stone itself (Fig. 92.3). Dunmire et al. tested this hypothesis and found that this technique significantly improved the accuracy of measurements, with 78% of measured shadow sizes being accurate within 1 mm of the true stone size when measured in vitro (Dunmire et al., 2016). Several additional methods of RUS optimization have been explored as well including smoothing algorithms, compression of high–signal-intensity regions, and sharpening of contrast at the stone edge to better detect the posterior acoustic shadow. When used together, this has been referred to as S-mode (stone-specific mode) and has been shown to have improved ability to detect stones (78% vs. 61%) and properly size them compared to traditional ultrasonography (Dai et al., 2018).

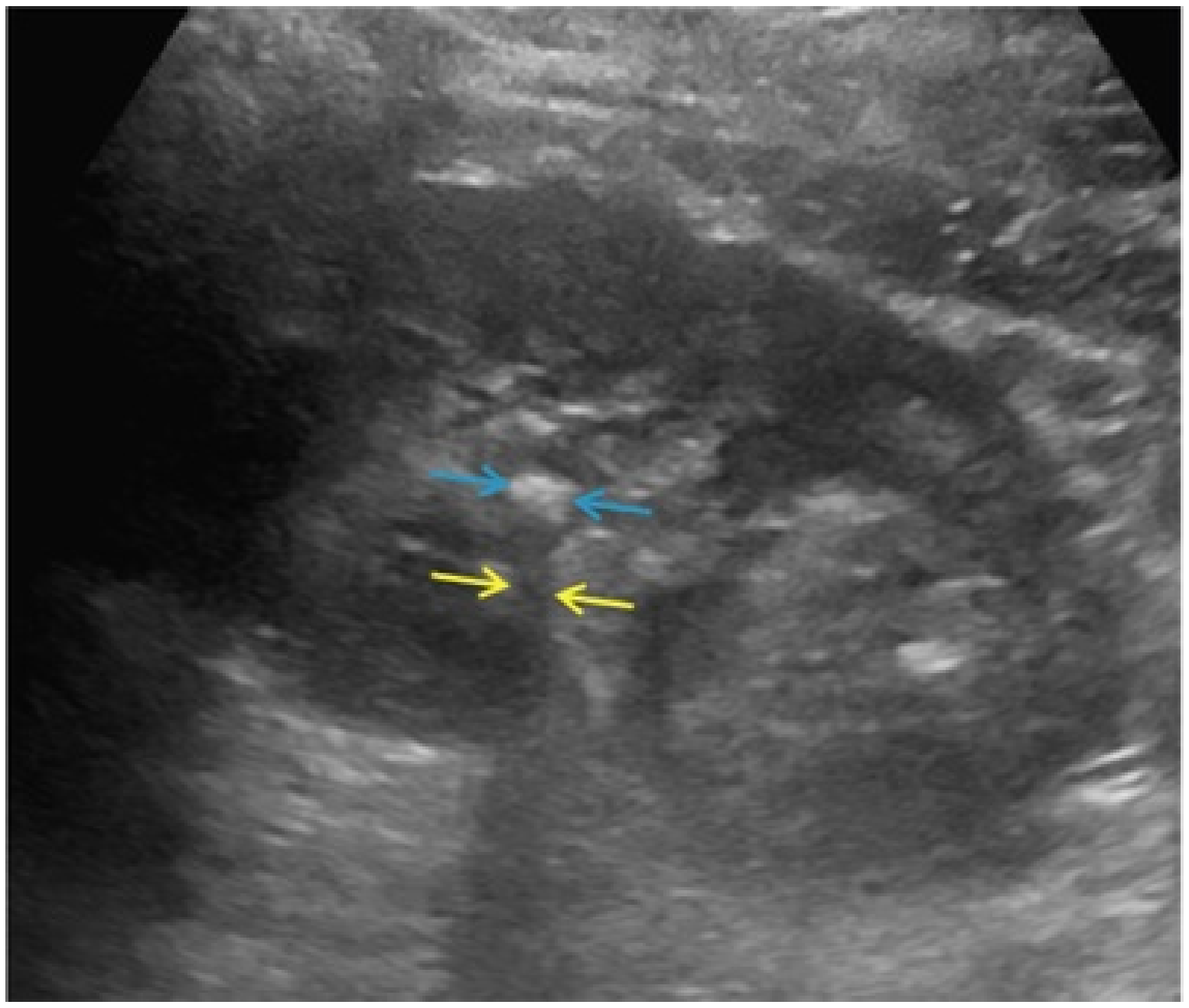

FIG. 92.3 Demonstration of stone shadow seen on ultrasound. Presence of a shadow can not only be used to improve confirmation of stone visualization, it can also improve accuracy of stone measurement. In this example, the hyperechoic area of the stone *(blue arrows)* measures 4.9 mm compared with the shadow, which measures 3.5 mm. Stone size on CT is 3.8 m. (Image courtesy of Barbrina Dunmire and Michael Bailey, PhD. University of Washington.)

Other Imaging Modalities

One lesser used but promising technique to find stones is digital tomosynthesis (DT). DT is akin to a conventional abdominal radiograph (KUB) but obtains several low-dose images via a tomographic sweep of the x-ray emitter. Multiple coronal slice images are then reconstructed by digital software. DT has been shown to have improved sensitivity over that of plain KUB for the detection of renal stones and significantly less radiation than a standard noncontrast CT (Mermuys, 2010; Neisius et al., 2014).

The ability of magnetic resonance imaging (MRI) to detect upper urinary tract stones is variable and most commonly is used to infer stones based on a signal void rather than true identification of the stone itself (Robson et al., 2003). Nonetheless, sensitivity and specificity of this technique are 82% and 98.3%, respectively (Fulgham et al., 2013). An advantage of MRI is the lack of ionizing radiation, yet the high cost and lengthy time for image acquisition are barriers to widespread adoption of this technique. A common clinical scenario in which

MRI may be useful is for evaluation of flank pain during pregnancy, and it is recommended as a second-line imaging test when ultrasonography is nondiagnostic (Coursey et al., 2012, Fulgham et al., 2013).

Key Points

- CT is the gold standard imaging modality for the detection of urolithiasis.
- Low-dose CT is an attractive option for stone evaluation that can maintain high diagnostic accuracy with less exposure to ionizing radiation.
- Ultrasound technology continues to evolve with several new modes being developed to improve identification and sizing of stones.

Metabolic Evaluation

Through even a rudimentary understanding of the physiologic causes of urinary calculus formation, physicians may offer a straightforward approach to elucidating the metabolic basis of nephrolithiasis for any given patient. This evaluation should be simple to perform, it must be economically viable, and it should provide information that can be applied toward a selective, rational therapy of stone disease (Pak et al., 1980).

Any evaluation should be able to identify associated metabolic disorders responsible for recurrent stone disease. These metabolic problems include distal renal tubular acidosis (RTA), primary hyperparathyroidism, enteric hyperoxaluria, cystinuria, and gouty diathesis. In many of these relatively uncommon conditions, it is generally agreed that selective medical therapy is indicated not only to prevent further stone formation but also to correct underlying physiologic disturbances that may lead to nonrenal complications (Pak et al., 2002, 2003b).

First-Time Stone Formers

Considering that dietary and fluid manipulation alone can reduce rates of stone recurrence, some suggest that first-time stone formers should be provided empirical fluid and dietary recommendations until they suffer a recurrence (Borghi et al., 1996). Indeed, studies of single stone formers placed on a conservative program of high fluid intake alone or combined with avoidance of dietary excess, revealed a low incidence of recurrent stone disease (Hosking et al., 1983). Calling this finding the *stone clinic effect,* Hosking et al. noted metabolic inactivity in nearly 60% of all patients followed for over 5 years.

In comparison, Pak found that single stone formers have an equally high incidence of metabolic abnormalities as recurrent stone formers (Pak, 1982). Furthermore, these derangements are just as severe, leading the authors to conclude that single stone formers should undergo the same evaluation as recurrent stone formers. Similar findings were reported in a series of 182 patients in which one-half of the patients had hypercalciuria or hyperuricosuria and roughly 20% had a systemic disorder that predisposed them to the formation of calculi (Strauss et al., 1982b). The remainder, 29.1%, had no metabolic disorder. Patients with single stones tended to be older when they passed their stones and required a greater rate of intervention to treat the calculus. The recurrence for both groups of patients was very similar (~10% at 3 years). Because the authors did not note substantial differences between solitary and recurrent stone disease, they recommended that first-time stone formers be evaluated similarly to patients with recurrent stone disease. A more recent study comparing the frequencies of metabolic abnormalities between first-time stone formers and recurrent stone formers found no difference between the two groups (Eisner et al., 2012). Approximately 40% of both first-time and recurrent stone formers had hypercalciuria, 45% of both groups had hypocitraturia, and approximately 30% had hyperoxaluria. The authors suggest it is reasonable to perform a full metabolic evaluation in first-time stone formers.

The AUA guideline for the medical management of kidney stones states "clinicians should perform additional metabolic testing in high-risk or interested first-time stone formers" (evidence strength: grade B) (Pearle et al., 2014). **Importantly, the formation of a first stone may be the harbinger of a more severe underlying systemic disorder such as RTA, bone disease, or hypercalcemia resulting from hyperparathyroidism. In such patients, metabolic evaluation is justified solely to make the correct diagnosis to prevent extrarenal complications.** The decision to thoroughly investigate a first-time stone former should ideally be shared by the physician and the patient. Whereas some first-time stone formers will readily accept and follow conservative therapy, others may elect to undergo a thorough evaluation. A "know your numbers approach" has been shown to be quite effective in other chronic diseases such as diabetes mellitus. It is quite reasonable to determine the extent of evaluation according to the estimation of potential/risk for recurrent stone formation (Smith, 1984).

Defining the High-Risk Stone Former

All patients with newly diagnosed kidney or ureteral stones should undergo a screening evaluation that includes a detailed medical and dietary history (Pearle et al., 2014). The purpose of this evaluation is to identify patients at highest risk for stone formation and evaluate for systemic etiologies for kidney stone disease. **Patients identified as high-risk stone formers include those with a family history of stone disease, those with obesity and/or metabolic syndrome, and patients with medical conditions that predispose to stone formation such as gastrointestinal (GI) disease or prior surgical resection resulting in**

malabsorption, primary hyperparathyroidism, renal tubular acidosis, sarcoidosis, gout, type 2 diabetes mellitus, and urinary tract infection (UTI). Stone composition when known can also help identify high-risk patients who would benefit from a metabolic evaluation, such as those with cystine or uric acid stones in whom the likelihood of finding a metabolic abnormality requiring medical therapy is high (Box 92.1).

Box 92.1

Indications for a Metabolic Stone Evaluation

- Recurrent stone formers
- Strong family history of stones
- Intestinal disease (particularly chronic diarrhea)
- Pathologic skeletal fractures
- Osteoporosis
- History of urinary tract infection with calculi
- Personal history of gout
- Infirm health (unable to tolerate repeat stone episodes)
- Solitary kidney
- Anatomic abnormalities
- Renal insufficiency
- Stones composed of cystine, uric acid, struvite

In addition, the overwhelming consensus is that all children should undergo a full metabolic evaluation because they have been found to have a significant risk for underlying metabolic disturbances (Bartosh, 2004; Coward et al., 2003; Pietrow et al., 2002; Polito et al., 2000; Tekin et al., 2001). Moreover, pediatric patients with metabolic abnormalities have been shown to have recurrence at a higher rate than those without metabolic risk factors (Abhishek et al., 2013). Additionally, these young patients have more at stake, because early, repeated episodes of urinary obstruction, UTI, and repeated radiographic imaging all have associated morbidities.

Race and ethnicity may also play a role in identifying the high-risk stone former. Mente et al. found that compared with Europeans, East Asian and African patients had a decreased relative risk for calcium nephrolithiasis, and Arabic, West Indian, West Asian, and Latin American patients had an increased relative risk (Mente et al., 2007). The authors found differing urinary profiles for a variety of the ethnicities reported when compared with those of Europeans. However, despite the decreased risk for calcium stone formation, patients of African ancestry demonstrated no significant differences in urinary metabolic derangements. A more recent study investigating the prevalence of stones in the United States between 2007 and 2010 found a significantly lower rate of stones in African-Americans, Hispanics, and multiracial persons compared with that in whites (Scales et al., 2012). Although the prevalence of stones in African-Americans remained lower than in whites, the increase in stone prevalence from the previous report (1988 to 1994) to the current report (2007 to 2010) was over 150%. Hsi et al. (2018)investigated race-sex associations with risk among whites and blacks in the southeastern US Southern Community Cohort Study (SCCS) and found that among black men and women, incidence rates were 2.19 and 2.47 per 1000 person-years, respectively. Among white SCCS participants, the corresponding rates were 5.98 and 4.50 per 1000 person-years for men and women, respectively, which are higher than what was previously reported.

Following the assumption that a lower incidence of calculi might imply a significant risk for a metabolic or anatomic abnormality in patients who still manage to make calculi, it seems reasonable to advocate for the performance of a metabolic evaluation for all patients of African-American descent. This suggestion is supported by recent studies that assessed the underlying metabolic abnormalities of nonwhite stone formers. **African-Americans, Asians, and Hispanics appear to have a surprisingly similar incidence of underlying metabolic disturbances when compared with white stone formers. These results suggest that dietary and environmental factors may be as important as ethnicity in the cause of stone disease** (Beukes et al., 1987, Maloney et al., 2005).

Finally, patients with anatomic abnormalities that may increase the risk for stone formation or complicate the treatment of it should be considered for metabolic evaluation. These would include patients with horseshoe kidney, calyceal diverticulum, ureteropelvic junction obstruction, medullary sponge kidney disease, urinary diversion, and solitary kidney.

Key Points: Selection of Patients for Metabolic Evaluation

- All first-time stone formers should undergo a detailed medical and dietary history.
- High-risk stone formers include those with GI disease, obesity, metabolic syndrome, diabetes mellitus, primary hyperparathyroidism, renal tubular acidosis, sarcoidosis, gout, and family history of nephrolithiasis.
- Children should generally be evaluated because of concerns about renal damage and long-term sequelae of stone recurrence.

Screening Evaluation for Newly Diagnosed Stone Formers

In newly diagnosed stone formers, the following screening evaluation should be applied (Box 92.2). A thorough medical history should be obtained for any underlying conditions that may have contributed to the stone disease. Because of the association between bowel disease and calcium oxalate nephrolithiasis (enteric hyperoxaluria), a careful history of bowel habits and bowel disease should be sought (Bohles et al., 1988; Lindsjo et al., 1989; McConnell et al., 2002; Parks, 2003b; Smith et al., 1972; Worcester, 2002)**. This includes questions regarding chronic diarrhea that could be caused by inflammatory bowel disease (Crohn disease, ulcerative colitis) or irritable bowel syndrome. A history of gout should be elicited because this finding may predispose the patient to hyperuricosuria or gouty diathesis with either uric acid calculi or calcium oxalate stone formation** (Grover and Ryall, 1994; Khatchadourian et al., 1995; Kramer and Curhan, 2002)**. As described by Pak et al.** (2003b)**, patients with a history of diabetes mellitus may be at an increased risk for developing calcium oxalate and/or uric acid stones, with altered ammonium excretion and acidic urine.**

Box 92.2

Abbreviated Evaluation of Single Stone Formers

History

- Underlying predisposing conditions (see Box 92.1)
- Medications (calcium, vitamin C, vitamin D, acetazolamide, steroids)
- Dietary excesses, inadequate fluid intake, excessive fluid loss

Multichannel Blood Screen

- Basic metabolic panel (sodium, potassium, chloride, carbon dioxide, blood urea nitrogen, creatinine)
- Calcium
- Intact parathyroid hormone
- Uric acid

Urine

- Urinalysis
    - pH >7.5: infection lithiasis
    - pH <5.5: uric acid lithiasis
    - Sediment for crystalluria
- Urine culture
    - Urea-splitting organisms: suggestive of infection lithiasis
- Qualitative cystine

Radiography

- Radiopaque stones: calcium oxalate, calcium phosphate, magnesium ammonium phosphate (struvite), cystine.
- Radiolucent stones: uric acid, xanthine, triamterene
- Intravenous pyelogram: radiolucent stones, anatomic abnormalities

Stone Analysis

A thorough surgical history should be obtained focusing particularly on bariatric surgery and surgeries on the intestinal tract. Roux-en-Y gastric bypass surgery has been shown to significantly increase the risk for kidney stones (Matlaga et al., 2009). This study demonstrated a significantly higher rate of stones in obese patients who underwent gastric bypass surgery compared with obese patients who had not (7.65% vs. 4.63%). In contrast with gastric bypass surgery, restrictive bariatric surgeries such as gastric sleeve or gastric band do not seem to increase the risk for kidney stone formation (Chen et al., 2013). Bowel resection, particularly of the small intestines, can lead to malabsorption with an increased risk for kidney stone formation, and patients with prior bowel surgery should be considered for a metabolic evaluation.

In addition, information should be obtained concerning the patient's dietary habits, including fluid consumption and excessive intake of certain foods, and a list of all medications taken. A social history may provide obvious clues regarding a patient's hydration status. Does the patient have access to fluids on a regular basis? Does the patient perform daily tasks that would increase the insensible losses of fluids? Patients on prolonged bed rest demonstrate alterations in urinary chemistry such that urinary calcium and phosphorus excretion increase significantly, leading to significant increases in urinary saturation of calcium phosphate, calcium oxalate, and monosodium urate, particularly during bed rest (Hwang et al., 1988). A family history may reveal a genetic predisposition to urinary calculi if there is a history of close relatives affected by nephrolithiasis. Age of onset of the patient or of affected relatives may give clues regarding genetic disorders such as autosomal recessive cystinuria.

The screening evaluation of newly diagnosed patients with kidney or ureteral stones should also include serum chemistries including electrolytes (sodium, potassium, chloride, bicarbonate), calcium, creatinine, and uric acid (Pearle et al., 2014)**. These serum studies are helpful in identifying certain systemic problems** such as primary hyperparathyroidism (high serum calcium and low serum phosphorus), renal phosphate leak (hypophosphatemia), uric acid lithiasis (hyperuricemia), and distal RTA (hypokalemia, decreased serum carbon dioxide). For patients in whom primary hyperparathyroidism is suspected (hypercalcemia), a serum intact parathyroid hormone (PTH) level is also recommended (Pearle et al., 2014). Even mid-range or high-normal PTH in the face of higher serum calcium should lead to the suspicion of primary hyperparathyroidism because under normal circumstances, PTH should be suppressed when serum calcium is elevated.

A voided urine specimen should be obtained for comprehensive urinalysis including dipstick and microscopic analysis to assess urine pH, find indicators of infection, and identify crystals pathognomonic of stone type (Pearle et al., 2014) (Table 92.2). Urinary pH greater than 7.0 is suggestive of infection lithiasis or RTA, whereas a pH less than 5.5 suggests a risk for uric acid stone formation. **The urine sediment should be examined for crystalluria, because particular crystal types may give a clue as to the composition of stones the patient is forming.** Tetrahedral “envelopes” are seen in calcium oxalate lithiasis, and rectangular, “coffin-lid” crystals are often seen in patients with struvite calculi. Hexagonal crystals confirm cystinuria; uric acid crystals may be seen as amorphous fibers or as irregular plates. The microscopic appearances of common calculi are summarized in Fig. 92.4.

TABLE 92.2

Microscopic Appearance of Common Urinary Calculi

CHEMICAL TYPE	APPEARANCE
Calcium oxalate monohydrate	Hourglass
Calcium oxalate dihydrate	Envelope, tetrahedral
Calcium phosphate-apatite	Amorphous
Brushite	Needle shaped
Magnesium ammonium phosphate (struvite)	Rectangular, coffin-lid
Cystine	Hexagonal
Uric acid	Amorphous shards, plates



FIG. 92.4 Scanning electron micrographs of various urinary crystals. (A) Apatite. (B) Struvite. (C) Calcium oxalate dehydrate. (D) Calcium oxalate monohydrate. (E) Cystine. (F) Ammonium acid urate. (G) Brushite. (Courtesy of Dr. SR Khan, University of Florida, Gainesville, FL.)

When the urinalysis is suggestive of urinary tract infection or the patient is known to have an infection-related stone, a urine culture is useful not only to determine the source of infection but also to identify the presence of urea-

splitting bacteria *(Proteus, Pseudomonas, Klebsiella, Staphylococcus aureus,* and *Staphylococcus epidermidis)* **that may predispose to struvite stone formation.** A positive culture also will warrant therapy with appropriate antibiotics before initiation of any surgical procedure to remove the stone. Surgical treatment of a calculus during an active infection will place the patient at great risk for bacteremia or sepsis. **Unfortunately, many infected calculi will harbor bacteria even after treatment with broad-spectrum antibiotics.** Korets et al. evaluated the concordance between preoperative bladder urine cultures with renal pelvic urine cultures and stone cultures in patients undergoing percutaneous nephrolithotomy. They found that despite treatment with culture-specific antibiotics, stone culture was positive in 17 patients (8.6%) who had a positive preoperative bladder urine culture. Another 16 patients had a positive stone culture associated with a negative preoperative bladder culture (Korets et al., 2011). Furthermore, McAleer et al. demonstrated that infection calculi contain large quantities of endotoxin after disintegration (McAleer et al., 2002). In a comparison of infected versus noninfected calculi, infected stones contained 36 times more endotoxin. One-half of the infected calculi grew bacterial cultures that were different from the preoperative urine specimens. The same investigators described how endotoxin can cause a vascular collapse because it induces physiologic changes consistent with those of septic shock.

Finally, the screening evaluation should include review of stone analysis and imaging studies when available (Pearle et al., 2014). As mentioned earlier, stone composition can help identify high-risk patients who would benefit from a metabolic evaluation such as those with cystine or uric acid stones in whom the likelihood of finding a metabolic abnormality requiring medical therapy is high. In addition, calcium phosphate stone composition, particularly brushite, may indicate systemic etiologies of stone formation such as RTA, primary hyperparathyroidism, medullary sponge kidney disease, and the use of carbonic anhydrase inhibitors (Kourambas et al., 2001; Pak and Adams-Huet, 2004). Imaging studies are not only helpful to quantify the existing stone burden, but they also identify patients at greater risk for recurrence or who may have underlying metabolic or anatomic conditions predisposing to stone formation. For example, patients with multiple or bilateral renal calculi at initial presentation may be a greater risk for recurrence. Furthermore, the presence of nephrocalcinosis may be an indicator of RTA, primary hyperparathyroidism, or medullary sponge kidney disease.

Key Points: Screening Evaluation for Newly Diagnosed Stone Formers

- A complete medical and dietary history should be obtained.
- Patients should be screened for medical diseases that predispose to calculi.
- Serum metabolic panel and urinalysis tests should be performed.
- Urine microscopy for crystals may provide clues to diagnosis.
- Stone analysis may improve the accuracy of further evaluation.
- Basic radiography (plain films) should screen for existing calculi.

Metabolic Evaluation for High-Risk and Recurrent Stone Formers

The AUA guidelines on the medical management of kidney stones recommends that clinicians perform additional metabolic testing in high-risk or interested first-time stone formers and recurrent stone formers (evidence strength: Grade B) (Pearle et al., 2014). High-risk stone formers were defined in the previous section. The AUA guidelines define recurrent stone formers as patients with recurrent stone episodes and multiple stones at initial presentation. These individuals are thought to benefit from a more extensive diagnostic evaluation as it may provide targeted recommendations for diet and/or medical therapy. Regardless of whether a particular patient requires a full metabolic evaluation, it is prudent to perform at least a screening evaluation combined with a thorough history and physical examination to assess for underlying systemic syndromes that may cause recurrent calculi and extrarenal complications. This assessment also should screen for patients at an increased risk for stone recurrence, as outlined in the previous paragraphs.

In these patients, a more extensive evaluation is recommended. In addition, obese patients with stones, particularly obese women, have a significantly elevated risk for recurrence and should be given consideration for metabolic evaluation (Taylor et al., 2005). Diabetes has been correlated with an increased risk for stone disease, and patients with diabetes and stones, particularly those with poorly controlled diabetes, should be considered for a full metabolic evaluation (Weinberg et al., 2014). Any patients with stones composed of cystine, uric acid, or struvite should undergo a complete metabolic workup.

Pak et al. previously recommended an extensive outpatient ambulatory protocol that included multiple office visits with 24-hour urine collections, laboratory studies, and a fast and calcium load study (Levy et al., 1995; Pak et al., 1980). The purpose of this testing was to delineate between various forms of hypercalciuria such as absorptive versus renal leak hypercalciuria. However, despite its high diagnostic yield and reliability, this testing is no longer recommended as it is cumbersome and has not been shown to change clinical practice (Lein and Keane, 1983; Pak, 1997; Pak et al., 2011; Pearle et al., 2014). Lifshitz et al. advocated for a less complex approach (Lifshitz et al., 1999). All patients undergo a basic metabolic screening, searching for systemic disorders that could pose a long-term health risk. They suggest that all patients should be advised about conservative nonspecific preventive measures. Patients at high risk for forming stones should have a more extensive metabolic evaluation based on two 24-hour urine samples.

Based on expert opinion of the guidelines panel, metabolic testing should consist of one or two 24-hour urine collections obtained on a random diet and analyzed at minimum for total volume, pH, calcium, oxalate, uric acid, citrate, sodium, potassium, and creatinine (Pearle et al., 2014). As indicated by the panel recommendation, there is no clear consensus based on the available literature regarding whether one or two 24-hour urine samples are necessary. A retrospective study by Pak et al. (2001) supports collection of a single 24-hour urine sample. They compared the results of two 24-hour urine samples collected on a random diet and found no significant difference in the excretion of urinary calcium, oxalate, uric acid, citrate, pH, total volume, sodium, potassium, sulfate, or phosphorus. The researchers concluded that the reproducibility of urinary stone risk factors was adequate in repeat samples, and therefore a single 24-hour urine collection was sufficient.

However, other studies have demonstrated a benefit to two separate 24-hour collections citing significant disparities in the results of the two studies. Parks et al. examined more than 1000 patients from both private practice and academic settings noting that within nearly 70% of the comparisons, there were large enough differences that the standard deviation would contain clinically relevant disparities (Parks et al., 2002). The authors therefore conclude that relying on one specimen alone could easily lead to misdiagnosis and, consequently, mismanagement. Healy et al. similarly advocate for two collections based on their study of 813 stone formers who submitted two 24-hour urine collections ≤10 days apart and found that a single 24-hour urine collection may have changed clinical decision making in up to 45% of patients (Healy et al., 2013). Finally, Rivers et al. (2000) recommended collection of two samples while the patient is on differing diets (random and restricted) to discern between absorptive hypercalciuria II and renal leak (hypercalciuria disappears while the patient is on the restricted diet in absorptive hypercalciuria II) (Box 92.3).

Box 92.3

Potential Causes of Erroneous 24-Hour Urine Collection Results

Error in collection technique (e.g., improper use of preservatives, ice)
Failure to collect a full 24 hours' worth of urine
Changes in the patient's diet for the sake of the study
Intermittent indiscretions in diet
Failure of specimen to accurately represent typical day
Bacterial contamination

Despite the guidelines panel recommendations, a recent population-based study found that the prevalence of metabolic testing in high-risk kidney stone formers was only 7.4% (Milose et al., 2014). The benefit of 24-hour urine testing in all recurrent stone formers has also recently been questioned. Hsi et al. cite several limitations of 24-hour urine testing such as complexity of interpretation, need for repeat collections, inability to predict stone recurrence with individual parameters and supersaturation values, unclear rationale of laboratory cutoff values, and difficulty of determining collection adequacy (Hsi et al., 2017). However, there is support for the effectiveness of a targeted approach given that urinary supersaturation values correlate closely with stone type, and a prospective trial has demonstrated that selective dietary recommendations based on 24-hour urine data was more effective than general dietary measures in preventing stone recurrence (Kocvara et al., 1999; Parks et al., 1997).

In an effort to develop alternate strategies to metabolic testing for stone formers, Otto et al. (2017) performed a retrospective study of 392 recurrent calcium oxalate stone formers with 24-hour urine testing and used logistic regression and receiver operating characteristic curve analysis to assess their predictive ability of age, gender, BMI, and comorbidities to detect abnormal 24-

hour urine parameters. Essentially they were attempting to define surrogates for metabolic testing that might obviate the cost and burden of 24-hour urine testing while still providing appropriate stone-prevention treatment. They found that age significantly affected urinary calcium, oxalate, citrate, and pH, with older age associated with greater urinary oxalate, lower urinary uric acid, and lower urinary pH. Urinary calcium levels peaked at 40 to 49 years of age, and citrate nadired at 18 to 29 years of age. The study concluded that age, gender, and BMI can be used to predict 24-hour urine abnormalities and may be able to serve as a surrogate for 24-hour urine results.

Key Points: Metabolic Evaluation for High-Risk and Recurrent Stone Formers

- High-risk and recurrent stone formers should undergo the screening evaluation.
- In addition, metabolic testing should consist of one or two 24-hour urine collections obtained on a random diet and analyzed at minimum for total volume, pH, calcium, oxalate, uric acid, citrate, sodium, potassium, and creatinine.
- Despite guideline recommendations, prevalence of metabolic testing in high-risk stone formers remains low.

24-Hour Urine Collection

The cornerstone of reliable 24-hour urine analysis has been the development of a urine preservation method that allows collection of urine without refrigeration. The patient is then able to submit an aliquot to a central laboratory for an analysis of various stone-forming substances (Nicar et al., 1987). The urinary constituents most commonly assayed include calcium, oxalate, citrate, total volume, sodium, magnesium, potassium, pH, uric acid, and sulfate. Although most of these parameters are self-evident, sulfate is added to the list to assess the volume of protein loading from animal meat. From such determinations, the urinary saturation with respect to stone-forming salts can be calculated.

At present, multiple laboratories offer services focused on simplified, accurate

24-hour urine assessment for stone-forming risk factors. These laboratories provide collection containers with chemical preservatives (obviating iced storage and transport) and extrapolate 24-hour cumulative data from the submission of a small aliquot of the entire collection. After the values of all urinary constituents and saturations have been determined, the physician receives a computer printout that provides a numeric display of the test results (Fig. 92.5). These results should aid the physician in formulating a metabolic/physiologic diagnosis. It may be difficult to make a definitive diagnosis on a single 24-hour urinalysis; therefore repeated evaluation is often warranted. For example, it is desirable to confirm the presence of hypocitraturia or hyperuricosuria by repeat measurements.

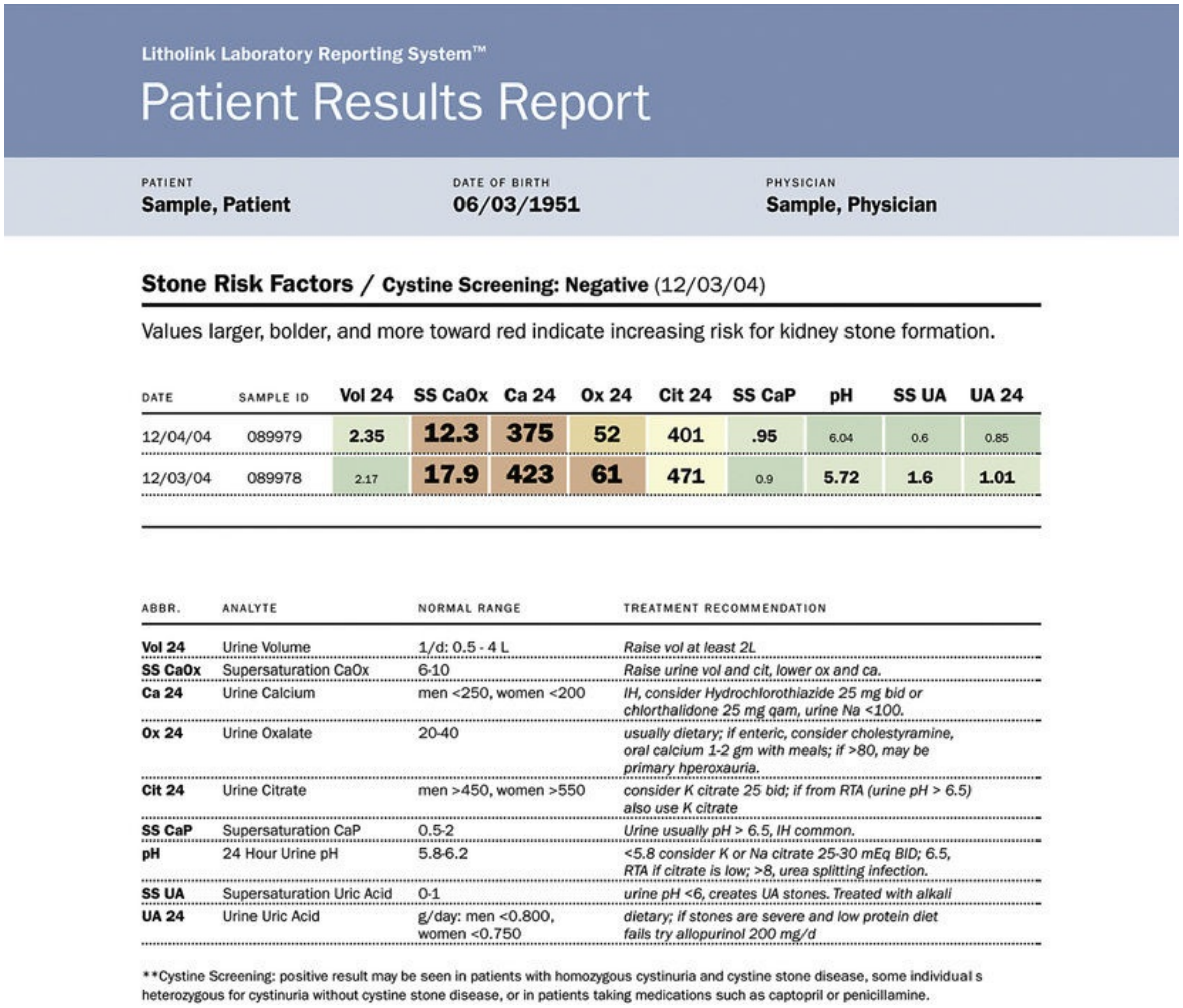

Litholink Laboratory Reporting System™

Patient Results Report

PATIENT	DATE OF BIRTH	PHYSICIAN
Sample, Patient	**06/03/1951**	**Sample, Physician**

Stone Risk Factors / Cystine Screening: Negative (12/03/04)

Values larger, bolder, and more toward red indicate increasing risk for kidney stone formation.

DATE	SAMPLE ID	Vol 24	SS CaOx	Ca 24	Ox 24	Cit 24	SS CaP	pH	SS UA	UA 24
12/04/04	089979	2.35	**12.3**	**375**	52	401	.95	6.04	0.6	0.85
12/03/04	089978	2.17	**17.9**	**423**	**61**	471	0.9	5.72	1.6	1.01

ABBR.	ANALYTE	NORMAL RANGE	TREATMENT RECOMMENDATION
Vol 24	Urine Volume	1/d: 0.5 - 4 L	*Raise vol at least 2L*
SS CaOx	Supersaturation CaOx	6-10	*Raise urine vol and cit, lower ox and ca.*
Ca 24	Urine Calcium	men <250, women <200	*IH, consider Hydrochlorothiazide 25 mg bid or chlorthalidone 25 mg qam, urine Na <100.*
Ox 24	Urine Oxalate	20-40	*usually dietary; if enteric, consider cholestyramine, oral calcium 1-2 gm with meals; if >80, may be primary hperoxauria.*
Cit 24	Urine Citrate	men >450, women >550	*consider K citrate 25 bid; if from RTA (urine pH > 6.5) also use K citrate*
SS CaP	Supersaturation CaP	0.5-2	*Urine usually pH > 6.5, IH common.*
pH	24 Hour Urine pH	5.8-6.2	*<5.8 consider K or Na citrate 25-30 mEq BID; 6.5, RTA if citrate is low; >8, urea splitting infection.*
SS UA	Supersaturation Uric Acid	0-1	*urine pH <6, creates UA stones. Treated with alkali*
UA 24	Urine Uric Acid	g/day: men <0.800, women <0.750	*dietary; if stones are severe and low protein diet fails try allopurinol 200 mg/d*

**Cystine Screening: positive result may be seen in patients with homozygous cystinuria and cystine stone disease, some individual s heterozygous for cystinuria without cystine stone disease, or in patients taking medications such as captopril or penicillamine.

FIG. 92.5 Commercial 24-hour urine results are available and simplify the collection and reporting process. (Courtesy of Litholink, Chicago, IL.)

Most patients will require detailed instructions on the proper collection of a complete 24-hour urine specimen. The patient should choose a day when all voids can be completely captured and when the specimen will represent a typical day. The first morning void is discarded, because this represents urine from the previous night and may not have had a predictable starting point. From that point on, all urine must be collected in the appropriate, laboratory-provided container. The canister may need to be kept on ice, and/or preservatives should have been added according to the requirements of the specific laboratory. When the patient awakens the next morning, the first morning void is collected with the rest of the specimen, thereby completing a full 24 hours. Total urinary creatinine should be measured to provide an internal check. Males will be expected to have produced roughly 20 to 25 mg of creatinine for every kilogram of body weight during the 24-hour period. Females generally have less muscle mass and therefore will typically produce 15 to 20 mg of creatinine for every kilogram of body weight in 24 hours. Significant aberrations in total creatinine excretion from these estimated values imply incomplete collection, overcollection, greater-than-expected muscle mass, or less-than-expected muscle mass.

Before and throughout the period of evaluation, the patient is instructed to discontinue any medication known to interfere with the metabolism of calcium, uric acid, or oxalate. These medications include vitamin D, calcium supplements, antacids, diuretics, acetazolamide, and vitamin C. Any current medication for stone treatment (thiazides, phosphate, allopurinol, or magnesium) should be discontinued as well, to better determine the patient's baseline physiology (and pathophysiology). Two random 24-hour urine samples are collected. These 24-hour specimens are obtained with the patient on a random diet, which is reflective of his or her usual dietary intake. It is important to stress to the patient to maintain his or her normal diet and fluid intake during urine collections. An attempt on the patient's part to suddenly eat well or to increase fluid consumption for the sake of the test will only mask the underlying causes of the stone disease.

Economics of Metabolic Evaluation

There is no doubt that the costs associated with the treatment of nephrolithiasis are substantial. Estimations of the annual medical expenditures for stone disease in the United States for 2000 were $2.1 billion, inclusive of $971 million for inpatient services, $607 million for physician office and hospital-based outpatient services, and $490 million for emergency room charges (Pearle, 2005). These calculations are based on a range of nationally available datasets and do not necessarily reflect the additional societal costs of lost productivity and social service support. These costs are clearly not negligible because the peak incidence of urolithiasis occurs in patients between 20 and 60 years of age (the years of highest worker productivity), and an analysis of more than 300,000 beneficiaries from 25 large US employers identified that 30% of patients with urolithiasis missed an average of 19 hours of work and had an additional $3500 in annual medical costs (Saigal et al., 2005).

With the increasing incidence of stone disease, it only can be concluded that the national health care expenditure for urolithiasis will continue to rise. Particularly worrisome is the increasing evidence that obesity confers an increased risk for nephrolithiasis, which is quite sobering considering the epidemic of obesity that is enveloping the United States (Curhan et al., 1998; Ekeruo et al., 2004; Morrill and Chinn, 2004; Rigby et al., 2004; Scales et al., 2012; Strumpf, 2004; Taylor et al., 2005).

With these figures in mind, prudence would dictate that medical prevention could help curb runaway costs and prevent long-term sequelae of recurrent nephrolithiasis. **However, office visits, serum studies, and 24-hour urine studies have their own costs. Is there a break-even point at which the costs of a metabolic evaluation, pharmacologic prophylaxis, and continued office visits are less than the expense of surgical management?**

Chandhoke (2002) compared the cost of medical prophylaxis with the cost of clinically managing recurrent stone episodes. Additionally, he determined the stone recurrence rate without prophylaxis (stone frequency) at which these two treatment approaches became cost-equivalent. This review conducted a cost survey in 10 countries to compare costs of medical prophylaxis and managing recurrent acute stone episodes. Costs of an acute stone episode included an emergency department visit, associated radiographic imaging to confirm diagnosis of a symptomatic stone, and outpatient treatment of upper urinary tract stones that did not pass spontaneously. Costs of medical management included an initial limited metabolic evaluation, drug therapy, a follow-up office visit every 6 months that included a 24-hour urinalysis, and yearly radiographic KUB imaging. Not surprisingly, the costs of medical prophylaxis and managing an acute stone episode varied significantly from country to country. The stone frequency at which costs of these management options became equivalent ranged from 0.3 to 4 stone episodes per year. This study concluded that medical management of a first stone episode is not cost-effective and that individual decisions should be determined by local costs.

Researchers at the University of Texas, Southwestern Medical Center have created a decision tree model to evaluate the cost-effectiveness and stone recurrence rates of common management strategies in stone formers (Lotan et al., 2004). They evaluated four common medical strategies: dietary measures alone (conservative), empirical drug treatment, or directed drug therapy based on simple or comprehensive metabolic evaluation. The model made reasonable assumptions regarding costs for evaluation, medications, emergency treatment, and surgery for stone recurrence. A review of the literature guided estimations of stone recurrence and risk reduction from various medical therapies. They found that first-time stone formers were best treated with a conservative approach because it was the least costly and it yielded a stone formation rate of 0.07 stone per patient yearly. For recurrent stone formers, conservative treatment was less costly than drug treatments but it was associated with a higher stone recurrence rate (0.3 stone per patient yearly). Directed medical therapies were more costly than conservative treatment ($885 to $1187 vs. $258 yearly), but they provided the obvious advantage of decreasing recurrence rates by 60% to 86%.

The authors went on to compare the expense of the simple medical evaluation and associated management as described earlier in this chapter and noted it to be more costly than empirical treatment but also more effective. Importantly, a complete evaluation with attendant treatment offered no advantage in cost or efficacy over empirical treatment or modified simple metabolic evaluation and management. The authors also recommended that first-time stone formers be treated with conservative therapy because it is both cost-effective and efficacious. In contrast, however, **recurrent stone formers should be treated medically after a simplified evaluation, because of the high recurrence rate of stone formation.**

Key Points: Economics of Metabolic Evaluation

- Routine performance of a comprehensive metabolic evaluation may not be economically sound if applied to all stone patients.
- Many first-time stone formers may not benefit economically from a metabolic evaluation unless initial screening puts them in a high-risk category.

- Recurrent stone formers are best treated with a metabolic evaluation and directed medical therapy.

Stone Analysis

Stone analysis can provide valuable insight into how and why a patient may have formed a stone. In some instances, a stone analysis may be more practical to obtain than a 24-hour urine collection, and in other cases it can serve as a useful adjunct to serum and urine metabolic evaluation. **The AUA guidelines on medical management of kidney stones recommend obtaining a stone analysis at least once when one is available to help classify patients and guide preventive measures.** They also recommend repeating stone analysis in the event further stones are available, particularly if not responding to treatment as stones are known to vary in composition from event to event.

Because most stones are a mixture of more than one component, the relative ratios or predominance of any particular molecule may have predictive value (Table 92.3). In an analysis of almost 1400 patients who had both stone analysis and a complete metabolic evaluation, Pak et al. noted that calcium phosphate and mixed calcium oxalate–calcium phosphate stones were associated with the diagnoses of RTA and primary hyperparathyroidism (odds ratio [OR], ≥ 2), but not with chronic diarrheal syndromes (Pak et al., 2003b). As the phosphate content of the stone increased from calcium oxalate to mixed calcium oxalate–calcium phosphate, and finally to calcium phosphate, the percentage of patients with RTA increased from 5% to 39%, and those with primary hyperparathyroidism increased from 2% to 10%. Not surprisingly, pure and mixed uric acid stones were strongly associated with a gouty diathesis, and brushite stones were associated with RTA. As expected, a very strong association was found between infection stones and infection and between cystine stones and cystinuria.

TABLE 92.3

Mineralogic Names of Renal Calculi

RENAL CALCULI	MINERAL NAME
Calcium oxalate monohydrate	Whewellite
Calcium oxalate dihydrate	Weddellite
Calcium hydrogen phosphate dihydrate	Brushite
Tricalcium phosphate	Whitlockite
Carbonite-apatite	Carbonite-apatite

Magnesium ammonium phosphate	Struvite
Cystine	None
Uric acid	None

Parks et al. also evaluated the clinical significance of calcium phosphate percentage in mixed stones and identified greater numbers of shock wave lithotripsy procedures in patients with high percentages of calcium phosphate. They also identified the potential for calcium oxalate stone formers to convert to calcium phosphate stone formers (Parks et al., 2004). Although the precise mechanism for this change remains unclear, acidification defects from prior shock wave lithotripsy and citrate supplementation have been postulated to be contributing factors (Parks et al., 2004, 2009; Evan et al., 2015a).

There are several different methods of performing a stone analysis. The two most widely recommended and utilized methods are x-ray diffraction or Fourier-transform infrared spectroscopy (Gilad et al., 2017; Mandel et al., 2017; Tiselius et al., 2017). Although highly reliable in optimized settings, real-world data to date has shown heterogeneity in reported findings ranging from 30% to 50% depending on the mineral being evaluated (Krambeck 2010a, 2010b; Siener et al., 2016). Inaccuracies in struvite and calcium phosphate have been identified as particularly challenging (Krambeck, 2010b). One potential reason is the heterogeneity and lack of quality-control standards and best-practice policies for testing. An assessment of stone analysis laboratories across Europe identified only 56% as meeting quality requirements (Siener et al., 2016).

An inherent limitation of these techniques is that they are destructive methods that rely on turning the stone into a powder before analysis. Once the stone is destroyed, the opportunity to evaluate the microstructure and different compositions relative to one another is lost. There is increasing recognition that such information may provide more useful information than previously recognized.

Gross morphologic analysis of stones has been suggested to help elucidate the etiology of stone formation, and a morphologic classification system has been previously described by Daudon et al. (Cloutier et al., 2015; Daudon et al., 1993). This system, which features 6 main types of stones and 22 subtypes, has proved superior to stone composition alone in predicting the likelihood of stone recurrence. Daudon et al. (2018b) also linked stone morphology to metabolic disorders in a published analysis of over 30,000 intact stones. In the study, over one-third harbored Randall's plaque residues. Notably, the rate of such stones increased significantly over three decades and was associated with younger age of onset, higher serum ionized calcium levels, and increased serum osteoclasts providing potential insight into the rising prevalence of stone disease (Letavernier et al., 2015).

Another emerging technique to better appreciate the structure and composition of stones is microCT. MicroCT is a nondestructive imaging technique whereby small structures such as stones can be visualized at 1000 times the resolution of clinical CT scanners (Borofsky et al., 2016a). MicroCT images allow for identification of mineral subtypes with roughly the same accuracy as infrared spectroscopy but preserves the microstructure such that the relationships of the crystals to one another can be analyzed (Fig. 92.6) (Borofsky et al., 2016b). One example of how microCT may improve stone classification is via identification of stones that form on Randall's plaque compared with those that form on ductal plugs (Fig. 92.7) (Williams et al., 2015, 2018).

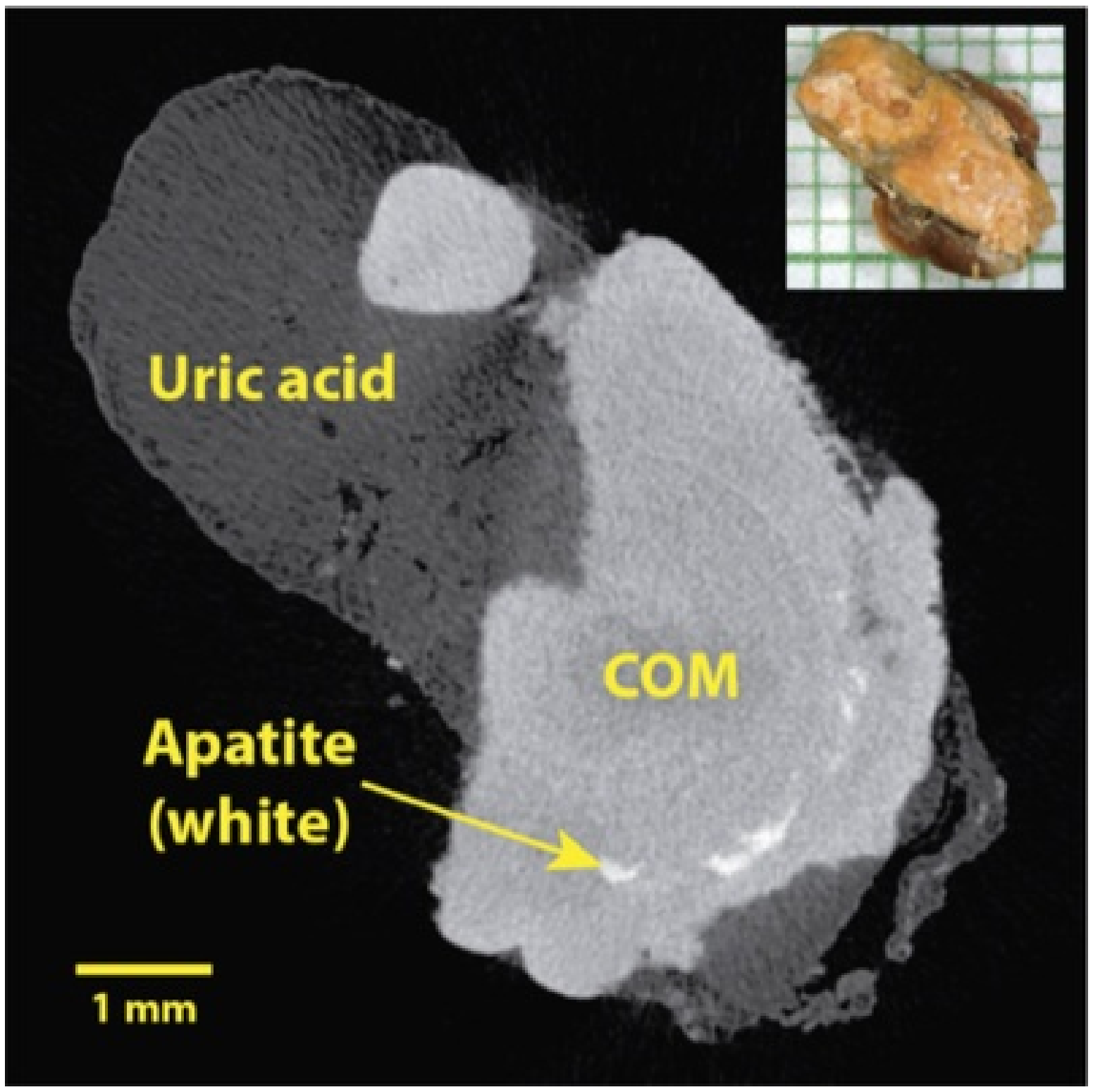

FIG. 92.6 MicroCT appearance of a 7-mm stone removed from the kidney. Note is made of the mixed composition of mineral components with uric acid appearing dark, calcium oxalate monohydrate (COM) slightly brighter, and calcium phosphate (Apatite) white. (Courtesy of Drs. James Williams and James Lingeman, Indiana University School of Medicine.)



FIG. 92.7 MicroCT appearance of stone forming over Randall's plaque *(top)* and ductal plug *(bottom).* The brighter-appearing regions on the microCT images are calcium phosphate. On the *top right* image, the plaque demonstrates several small cylindrical empty spaces indicative of peritubular calcification within the papillary interstitium over which stones can form. On the *bottom right* figure, a more dense mineral accumulation has formed via accretion and layering forming a ductal plug of calcium phosphate over which a stone may grow. (Courtesy of Drs. James Williams and James Lingeman, Indiana University School of Medicine.)

Key Points: Stone Analysis

- Stones should be sent for analysis when available.
- Repeat stone analysis should be performed if stone formation continues, particularly if they are not responding to treatment.
- Stones commonly have mixed mineral composition.
- The most common method of stone analysis is x-ray diffraction or Fourier-transform infrared spectroscopy.
- MicroCT is an emerging method of stone analysis that is nondestructive.

Classification of Nephrolithiasis

Classification of stone formers is a challenging concept that is under constant evolution as more is learned about the mechanisms by which stones form. Different information can be obtained from the results of stone analysis, evaluation of serum chemistries, and results of 24-hour urine testing. There is also increasing interest and investigation in using endoscopic appearances of the renal papillae as a method to classify patients (Almeras et al., 2016; Borofsky et al., 2016b; Marien and Miller, 2016). Under ideal circumstances, all of these factors are taken into consideration; however, as previously discussed, this can be a taxing process and is not always feasible. Identification of a single metabolic process is not always possible, and at times more than one metabolic abnormality may be identified. The scientific rationale and physiologic processes by which these abnormalities lead to stone formation can be found in Chapter 91.

General Recommendations for Stone Formers

Certain conservative recommendations should be made for all patients regardless of the underlying cause of their stone disease. In a recent study, Ferraro et al. examined dietary and lifestyle risk factors associated with incident kidney stones in men and women (Ferraro et al., 2016b). Using data from the Health Professionals Follow-up Study (HPFS) and the Nurses' Health Study (NHS) I and II, they demonstrated that five modifiable risk factors (fluid intake, BMI, DASH diet, dietary calcium intake, and intake of sugar-sweetened beverages) accounted for greater than 50% of incident kidney stones. The results suggest that preventive measures centered on these factors could substantially decrease the burden of kidney stone disease.

Fluid Recommendations

Low urine volume is perhaps the most important risk factor for kidney stone formation. Increased fluid intake is a powerful tool in preventing stone recurrence for all stone types and likely does so via a decrease in urinary supersaturation of stone components (Pak et al., 1980). In a randomized controlled trial of idiopathic calcium oxalate stone formers, Borghi et al. (1996)

demonstrated that increased fluid intake sufficient to maintain a urine volume greater than 2L/day significantly lowered the stone recurrence rate over a 5-year follow-up period compared with a control group (12.1% vs. 27%, $P = 0.008$). High fluid intake has also been found to be protective in relation to stone formation in several large prospective observational studies. In the HPFS, stone incidence was 192 per 100,000 person-years for fluid intake greater than 2.5 L/day compared with 372 per 100,000 person-years for fluid intake less than 1.2 L/day ($P < 0.01$). The NHS I demonstrated similar findings, with stone incidence lower for fluid intake greater than 2.5 L/day (Curhan et al., 1993). Furthermore, researchers at the University of Chicago demonstrated that failure to increase urine output was one of three very strong predictors of relapse for patients followed in a dedicated stone clinic (Strauss et al., 1982a). **Therefore, a mainstay of conservative management for kidney stone prevention is increased fluid intake to achieve a urine output of at least 2.5 L/day.** This recommendation is supported by the American Urological Association and the European Association of Urology (EAU) guidelines for medical management of nephrolithiasis (Pearle et al., 2014; Skolarikos et al., 2015). The economic impact of increasing fluid intake to decrease stones has also been considered. Models based on the French health care system estimated that increased fluid intake could prevent over 11,000 stone events per year and save the health care system almost 50 million euros (Lotan et al., 2012).

Although the concept of increased fluid intake is quite simple, patient compliance with this therapy can be difficult particularly in the long term. Parks et al. (2003) demonstrated in a large series of 2877 university and private practice patients that the average increase in urinary volume was only 0.3 L/day. Khambati et al. (2017) retrospectively investigated factors associated with compliance to increased fluid intake and urine volume following dietary counseling in first-time kidney stone patients. They found the compliance rate of obtaining a urine volume greater than 2.5 L/day was 50.1% at 6 months. Logistic regression found male sex, stone-related surgical procedures, and baseline 24-hour urine volume greater than 1 L/day were associated with greater odds of compliance, and age older than 58 years and presence of lower urinary tract symptoms were associated with lower odds of compliance. There are practical recommendations to help patients achieve increased fluid intake including measuring out the desired fluid intake for the day ahead of time, keeping fluid (preferably water) in one's line of sight while at work or home (at desk, refrigerator, even bathroom while brushing teeth), and keeping a log of fluid intake (Clayman et al., 2018).

Furthermore, smart phone applications and devices have also been developed to improve patient compliance. Mobile health technology including utilization of smart phone applications, fitness trackers, social media engagement, and improved communication methods has been demonstrated to be effective in facilitating health behavior changes across a wide spectrum of diseases (Zhao et al., 2016). This technology has been applied to stone prevention in several ways. The most common stone-related applications are those directed at increasing fluid intake, with over 50 such applications available at the time of this publication. These applications use a variety of behavior change techniques, most commonly control-based theory techniques featuring goal setting, self-monitoring, and behavioral feedback (Conroy et al., 2017). Smart water bottles are another novel technology that has been applied toward promoting fluid intake by tracking the amount of fluid consumed through the bottle over designated periods and communicating data to smart phone–based applications (Borofsky et al., 2018). Other applications related to stone prevention include information-based services, health professional resources, and dietary recording tools. One potential concern related to mobile health applications is accuracy. A review of 42 unique applications directed at kidney stones found that only 36% had clear input from health professionals, and many offered guideline-inconsistent recommendations (Stevens et al., 2015).

The impact of beverages on stone risk has also been studied. A full discussion of citrus and citrate-containing beverages can be found in the hypocitraturia section to follow. However, the effect of beverages other than water can have a considerable influence on overall stone risk. **Epidemiologic data has demonstrated that consumption of sugar-sweetened soda and punch is associated with a higher risk for stone formation, and coffee, tea, beer, and wine are associated with a lower risk for stone formation** (Curhan et al., 1996a, 1998b; Ferraro et al., 2013). The diuretic properties of coffee, tea, and alcohol have been cited as the factor potentially reducing kidney stone risk (Ferraro et al., 2013). Sugar-sweetened beverages contain fructose, and this simple sugar has been shown to increase urinary calcium excretion in both rats and humans and the production and excretion of uric acid in humans (Koh et al., 1989; Milne and Nielsen, 2000; Taylor and Curhan, 2008). Taylor and Curhan's analysis of the HPFS and NHS (I and II) documented that increasing fructose intake correlated with an increasing relative risk for incident stone formation, regardless of BMI, caloric intake, or other risk factors (Taylor and Curhan, 2008). In a randomized controlled trial, Shuster et al. studied 1009 male subjects, who reported consuming at least 160 mL/day of soft drinks (Shuster et al., 1992). One-half of the subjects were randomized to refrain from consuming soft drinks, and the remaining subjects served as controls. The intervention group had an observed 6.4% advantage in actuarial 3-year freedom from recurrence over the control group. One important secondary finding was that those who reported that their most consumed drink was acidified by phosphoric acid but not citric acid had a 15% higher 3-year recurrence-free rate than controls**.** Meanwhile, those who consumed drinks acidified by citric acid had no increase in stone episodes when compared with controls.

Animal Protein

Nondairy animal protein (meat, fish, poultry, eggs) intake can affect several urinary parameters that may increase kidney stone risk including calcium, uric acid, oxalate, and citrate. Urinary calcium excretion has been shown to increase secondary to animal protein consumption through a mechanism of bone reabsorption and lower tubular calcium reabsorption (Reddy et al., 2002; Frank et al., 2009; Bonny and Edwards, 2013). In addition, high animal protein as a source of purines can deliver an acid load that reduces tubular reabsorption of citrate and hypocitraturia and increases urinary uric acid levels resulting in hyperuricosuria (Breslau et al., 1988; Choi et al., 2004; Kok et al., 1990; Tracy et al., 2014). The effect of high animal protein intake appears to be most harmful when coupled with a diet that is low in calcium (Martini and Heilberg, 2002). The effect of nondairy animal protein on urinary oxalate has yielded conflicting results, with some studies demonstrating no change and others suggesting increased oxalate (Giannini et al., 1999; Holmes et al., 1993; Marangella et al., 1989; Nguyen et al., 2001). In a study evaluating short-term dietary protein restriction in hypercalciuric stone formers, Gianni et al. demonstrated a beneficial effect on urinary parameters including reduced urinary excretion of calcium, phosphate, hydroxyproline, uric acid, and oxalate and increased urinary citrate excretion (Giannini et al., 1999).

Epidemiologic studies have suggested that the incidence of nephrolithiasis is higher in populations in which there is increased animal protein intake. For example, in the northern and western regions of India, animal protein intake is approximately 100% greater than in the southern and eastern regions, and the rate of kidney stones is four times greater. When populations are matched for economic status, the intake of protein and other dietary constituents does not differ in patients with recurrent stones and controls; however, patients with stones secrete greater quantities of calcium in the urine than do controls for a given intake of protein (Wasserstein et al., 1987). The explanation for this finding may be that patients with recurrent nephrolithiasis are more sensitive to the calciuric action of protein than normal subjects (Goldfarb, 1990).

More recent observational studies have reported conflicting results regarding the effect of animal protein intake on kidney stone risk. In the NHS I and II cohorts, no association was demonstrated, and in the HPFS the positive association between animal protein consumption and risk for kidney stone formation was only in men with a BMI less than 25 (Curhan et al., 1997, 2004; Taylor et al., 2004). Ferraro et al. reported that kidney stone risk may vary by protein type (Ferraro et al., 2016). Again using the NHS I and II and the HPFS, they found that subjects in the highest quintile of nondairy animal protein intake had 54 mg/dL lower urinary citrate, 24 mg/dL higher urinary uric acid, lower urinary pH, and higher relative supersaturation for uric acid. Vegetable protein was not associated with risk for stones, and dairy protein was associated with decreased risk in younger women. In addition, a major finding of the study was a strong inverse association between higher dietary potassium intake and risk for stones with a 33% to 56% lower risk for stones for subjects in the highest quintile of potassium intake. **The results of this study suggest that diets high in potassium and lower in animal protein may be effective in preventing kidney stone formation.**

Unfortunately, despite the known alteration in urinary parameters related to the intake of animal protein, few clinical trials have evaluated the effect of animal protein restriction on kidney stone formation. Hiatt et al. conducted a randomized controlled trial of a low–animal protein, high-fiber diet in calcium oxalate stone formers who were followed for over 4 years with food questionnaires and serum and urine chemistry measurements (Hiatt et al., 1996). The control group was instructed only on fluid intake and adequate calcium. They found that the intervention group actually had an increased relative risk for recurrent stone formation compared with the control group and concluded that a low–animal protein, high-fiber diet had no advantage over high fluid intake alone. However, one problem limiting the conclusions of this study is that several participants in the intervention group appeared to have poor compliance with the prescribed diet. Another 4-year randomized trial compared the effect of two diets, a low animal protein–diet and high-fiber diet, to a normal diet in 175 idiopathic calcium stone formers for secondary prevention of calcium nephrolithiasis (Dussol et al., 2008). There was no change in urinary calcium levels or stone recurrence rates for either group compared with the control group. In comparison, Borghi et al. (2002) prospectively randomized hypercalciuric stone formers to either a low-protein, low-salt, moderate-calcium diet or to a low-calcium diet. Although acknowledging that it is difficult to separate the potential effects of the three facets of the first diet, there was a convincing 50% reduction in stone events compared with those patients on the low-calcium diet.

Although increased animal protein induces effects on urinary parameters that should increase kidney stone risk, to date there are no studies demonstrating that restriction of animal protein in isolation reduces stone recurrence. Furthermore, long-term compliance with animal protein restriction may be challenging, particularly in Western populations. **However, more recently the Dietary Approaches to Stop Hypertension (DASH) diet has been evaluated for its effect on kidney stone formation. The DASH diet is rich in fruits and vegetables, moderate in low-fat dairy products, and low in animal protein. In a prospective population-based study, higher DASH scores were associated with a lower risk for kidney stone formation** (Taylor and Curhan, 2009). The inhibitory effect of the DASH diet is likely related to increases in urinary citrate and urine volume (Taylor et al., 2010). Meschi et al. (2004) also showed the benefits of a diet high in fruits and vegetables on urinary parameters. Twelve normal subjects had fruits and vegetables eliminated from their diet, and 26 hypocitraturic calcium-stone formers had their diet supplemented with low-oxalate–containing fruits and vegetables. Compared with normal subjects, the hypocitraturic calcium-stone formers with increased fruit and vegetable intake significantly increased their urinary volume, pH, potassium, magnesium, and citrate. In addition, the supersaturation of calcium oxalate and uric acid fell in the stone formers with increased fruit and vegetable intake. **In summary, patients with calcium oxalate or uric acid stones are most likely to benefit from a diet limiting nondairy animal protein and increasing fruit and vegetable intake** (Pearle et al., 2014, Skolarikos et al., 2015).

Key Points: Fluids and Animal Protein

- Fluid intake over 2.5 L/day is recommended for prevention of recurrent stones.

- Compliance with high fluid recommendations is challenging and can be potentially aided by behavioral changes and mobile health applications.
- Randomized studies have confirmed the advantage of a diet with reduced nondairy animal protein intake.
- A diet high in fruits and vegetables imparts a reduced risk for stone formation over diets high in animal protein.

Calcium-Based Calculi

Calcium-based calculi are the most common type of stone. A review of nearly 90,000 stone analyses over a 35-year period from Mandel et al. identified primary calcium-based composition in 78% of stones (42% calcium oxalate, monohydrate, 18% calcium oxalate dihydrate, 15% calcium phosphate, 3% brushite) (Mandel et al., 2017). Not surprisingly, this stone type also has the greatest number of potential contributing metabolic factors and therapies.

Not all calcium stones are the same, and the metabolic considerations related to stone composition are considerable. One of the most important distinctions is calcium oxalate versus calcium phosphate (hydroxyapatite) versus brushite stone disease. This is not always a clear distinction as **stones are often composed of more than one mineral subtype.** Traditionally, the stone is classified as a calcium oxalate or calcium phosphate stone based on the dominant mineral subtype in the analysis (Parks et al., 2004). From a clinical and metabolic perspective, this distinction may have relevance. **Calcium phosphate stone disease appears to differ from calcium oxalate stone disease in that it tends to affect women more than men, present at a younger age, and is associated with alkaline urinary pH** (Asplin et al., 1998; Parks et al., 1997, 2004). Furthermore, a high percentage of calcium phosphate in stones has been linked to metabolic abnormalities and nephrocalcinosis (Bhojani et al., 2015; Kacker et al., 2008). Recent epidemiologic studies have demonstrated that young women are the demographic group with the most rapidly rising incidence of stone disease. Calcium phosphate stones are more common in young women, and it has been hypothesized that this is part of the reason stone rates based on gender are becoming more even (Scales et al., 2007; Singh et al., 2015; Kittanamongkolchai et al., 2018).

Brushite is another subtype of calcium stone worth consideration. Brushite is a precursor to hydroxyapatite and is a subtype of calcium phosphate stones only identified in 2% to 3% of stone analyses (Mandel et al., 2017). Unlike calcium oxalate and calcium phosphate (hydroxyapatite) stones, which are classified using a dominant percentage of mineral, **the unique clinical and metabolic associations with brushite calculi have led some experts to classify a stone former as a brushite stone former if any brushite mineral is identified on stone composition** (Evan et al., 2005). Brushite stones present several unique clinical challenges in that they are among the hardest stones to break and are refractory to shock wave lithotripsy (Klee et al., 1991; Williams et al., 2012b). They are also strongly associated with metabolic abnormalities. A relatively large-scale analysis of 82 brushite stone formers identified metabolic abnormalities in 100% of cases including hypercalciuria in 81% and elevated urinary pH (>6.2) in 62%. Recurrence rates were very high as well, with recurrence demonstrated in 38% of patients at a mean of only 33 months (Krambeck et al., 2010a). The distinct profile of the brushite stone former relative to calcium phosphate (apatite) has been demonstrated both in terms of endoscopy/tissue biopsy and urinary profiles, where brushite stone formers may have higher degrees of hypercalciuria (Evan et al., 2014; Moreira et al., 2013).

In 2016, a consensus statement from 44 international experts in calcium stone disease was published regarding the metabolic diagnosis and prevention of calcium stone disease. Among the numerous issues addressed, one was on proper classification of calcium stone formers. It was recommended that twenty different medical conditions be ruled out before assigning a designation for someone as being an “idiopathic” calcium stone former, a diagnosis of exclusion (Box 92.4) (Gambaro et al., 2016).

Box 92.4

Medical Conditions Associated With Calcium Nephrolithaisis

Hyperparathyroidism
Hyperthyroidism
Sarcoidosis
Vitamin D excess
Calcium supplementation
Prolonged immobilization
Clinical evidence of bone disease
Malignant neoplasms
Distal renal tubular acidosis
Medullary sponge kidney
Primary hyperoxaluria
Enteric hyperoxaluria

Bowel disease
Chronic pancreatitis
Vitamin C supplements
Chronic diarrhea
Lithogenic drugs
Urinary infection
Gouty diathesis
Cystinuria

Modified from Gambaro G, Croppi E, Coe F, et al. Consensus Conference. Metabolic diagnosis and medical prevention of calcium nephrolithiasis and its systemic manifestations: a consensus statement. *J Nephrol* 29(6):715–734, 2016.

Role of Dietary Calcium

The preponderance of evidence now supports the maintenance of moderate calcium intake in the face of calcareous nephrolithiasis (Borghi et al., 2002; Curhan et al., 1993, 1997; Heller et al., 2003; Lewandowski et al., 2001; Martini et al., 2000; Takei et al., 1998; Taylor et al., 2004; Trinchieri et al., 1998)**. Older recommendations to significantly restrict calcium intake likely led to an increase in available intestinal oxalate.** As a result, this limitation in dietary calcium may subsequently increase oxalate absorption, thereby raising the supersaturation of calcium oxalate. As noted earlier, a prospective, randomized study has shown that patients on a moderate-calcium diet, combined with salt restriction and moderation of animal protein had one-half as many stone episodes as those who attempted to follow a calcium-restricted diet (Borghi et al., 2002). Review of a large cohort of middle-aged nurses revealed that there was a decreased incidence of nephrolithiasis in subjects who had increased levels of dietary calcium (Curhan et al., 1997). Interestingly, this protection did not remain for those who received increased calcium intake from supplements instead of from dietary sources (i.e., dairy products).

There is further evidence to suggest that calcium supplementation can be safe if attention is paid to preparation and especially to timing. In a review of postmenopausal women, authors demonstrated that initiation of calcium supplementation does not have deleterious effects on urinary calcium, oxalate, or citrate levels. Furthermore, calcium supplement with a meal or combined calcium supplement and estrogen therapy was not associated with a significant increased risk for calcium oxalate stone formation in the majority of postmenopausal osteoporotic patients (Domrongkitchaiporn et al., 2002). Additional work from the same group determined that the timing of calcium supplementation may have positive or negative effects (Domrongkitchaiporn et al., 2004). In a study of healthy male recruits, the authors compared the urinary effects of calcium carbonate supplementation taken with meals versus at bedtime. In both instances, urinary calcium excretion increased equal amounts. However, for those taking the calcium supplement with meals, this increase was offset by an equally significant decrease in urinary oxalate. As a result, there was no increase in urinary supersaturation of calcium oxalate when calcium supplementation was taken with meals, a protection that did not remain for the nighttime bolus ingestion.

Evidence also suggests that the type of calcium supplementation may have an impact on the potential of stone formation. Two long-term studies from researchers in Dallas document that supplementation with calcium citrate does not have a significant impact on stone formation. Calcium citrate is an over-the-counter calcium preparation that provides 950 mg of calcium citrate and 200 mg of elemental calcium in each tablet. As with other available calcium supplements, calcium citrate will significantly increase urinary calcium excretion. Yet, this preparation offers the benefit of also increasing urinary citrate excretion. The concomitant increase in citraturia potentially offsets the lithogenic potential of calcium supplement–induced hypercalciuria and therefore provides a more stone-friendly calcium supplement (Sakhaee et al., 2004).

One clinical trial further studied the effects of long-term calcium citrate supplementation in premenopausal women. This investigation demonstrated that the urinary saturation of calcium oxalate and calcium phosphate (brushite) did not significantly change during calcium citrate therapy. It appears that the lack of calcium supplement–induced hypercalciuria was secondary to the downregulation of intestinal calcium absorption, because of prolonged calcium supplementation and the inhibitory effects of citrate included in the calcium citrate preparation. The results of this long-term calcium citrate trial suggest that calcium supplementation using calcium citrate does not increase the propensity for crystallization of calcium salts within the urine. This protective effect is most likely caused by an attenuated increase in urinary calcium excretion (from a decrease in fractional intestinal calcium absorption), a decrease in urinary phosphorus, and an increased citraturic response (Sakhaee et al., 1994).

Key Points: Calcium Based Calculi

- Calcium-based calculi are the most common type of urinary stones.
- Calcium oxalate is the most common subtype.
- Calcium phosphate stones are more common in young women and associated with alkaline urinary pH.
- Brushite is a type of calcium phosphate strongly associated with rapid stone growth and recurrence.
- Dietary calcium restriction actually increases stone recurrence risk.
- Calcium supplementation is likely safest when taken with meals.
- Calcium citrate appears to be a more stone-friendly calcium supplement because of the additional inhibitory action of citrate.

Hypercalciuria (>200 mg/day)

Clinical Considerations

Hypercalciuria is the most common metabolic contributor to kidney stone disease (Pearle et al., 2014). The term itself is used to describe an excess of urinary calcium. **There is no exact level at which the amount of calcium in the urine become pathologic; rather, the higher the degree of hypercalciuria, the higher the associated risk for calcium stone formation** (Curhan et al., 2001). A level of >200 mg/day has been recommended based on epidemiologic studies suggesting that over this level, the relative risk for stone formation among both men and women becomes greater than 1 (Curhan et al., 2001). Nonetheless, lowering the levels of urinary calcium even below this may be warranted if stone activity persists at these levels (Coe et al., 2016). The goal of a metabolic evaluation in these cases should be to identify modifiable factors contributing to high urinary calcium.

Resorptive Hypercalciuria (Primary Hyperparathyroidism)

Primary hyperparathyroidism (PHPT) is one of the most common modifiable causes of hypercalciuria in stone formers, with an estimated incidence between 2% and 8% (Rodman and Mahler, 2000). **Patients with PHPT suffer from an overproduction of PTH from either one dominant adenoma or diffuse hyperplasia of all four glands.** Elevated levels of PTH in turn lead to an excess of calcium in the blood and urine from increased bone turnover and intestinal reabsorption (Silverberg et al., 1990). An elevated serum calcium level should trigger suspicion for PHPT as should other factors including a high percentage of calcium phosphate in stone composition, and high urinary calcium level (Pearle et al., 2014). Rarely, patients may develop PHPT as a result of multiple endocrine neoplasia or parathyroid carcinoma (Craven et al., 2008).

Patients with PHPT frequently demonstrate hypercalcemia and elevations of parathyroid hormone (PTH). Several considerations should be made before proceeding with an evaluation for PHPT. First, care should be taken to identify any medications that the patient may be taking that can interfere with calcium and PTH levels. Thiazide diuretics can artificially elevate serum PTH levels and should be held for 2 weeks before measurement (Porpiglia et al., 2015). Lithium is another medication that can raise serum calcium and PTH levels (Albert et al., 2013). Consideration should also be made regarding the timing of the lab draw as recent ingestion of calcium either through supplements or diet has been shown to cause transient elevations in serum calcium levels. For this reason, a fasting serum calcium level is preferred (Siyam and Klachko, 2013).

Unfortunately, some patients may have normocalcemic PHPT. These patients may be hard to distinguish from those with renal leak hypercalciuria, during which serum calcium will be normal but a mild elevation of PTH can occur, creating a secondary hyperparathyroidism. In these instances, the patient can be treated with a 2-week course of a thiazide diuretic, such as chlorthalidone 25 mg daily. If the patient actually has renal leak, the calcium loss should be suppressed and the PTH should return to normal (Aroldi et al., 1979; Barilla and Pak, 1979; Zechner et al., 1981). Those with true primary hyperparathyroidism will continue to circulate elevated levels of PTH and may become mildly hypercalcemic, although this latter feature has been debated in the literature (Farquhar et al., 1990; Klimiuk et al., 1981; Strong et al., 1991).

Parathyroidectomy is the optimum treatment for nephrolithiasis in patients with primary hyperparathyroidism (Fraker 2000). This therapy may include resection of a dominant adenoma or removal of all four hyperplastic glands. After removal of abnormal parathyroid tissue, urinary calcium is expected to return to normal, commensurate with a decline in serum calcium and intestinal calcium absorption. However, these findings are not always dependable, because some patients may suffer from changes in tubular and glomerular functions as a result of long-standing hypercalcemia/hypercalciuria (Farias et al., 1996). Moreover, it is imperative to repeat a 24-hour urinary calcium determination to make sure the hypercalciuria has resolved.

There is no established medical treatment for the nephrolithiasis of primary hyperparathyroidism. Although orthophosphates have been recommended for the disease of mild-to-moderate severity, their safety or efficacy has not yet been proved. These medications should be used only when parathyroid surgery cannot be undertaken. Estrogen has been reported to be useful in reducing serum and urinary calcium in postmenopausal women with primary hyperparathyroidism (Boucher et al., 1989; Coe et al., 1986; Diamond et al., 1996; Herbai and Ljunghall, 1983; Marcus et al., 1984; Orr-Walker et al., 2000; Selby and Peacock, 1986).

Key Points: Resorptive Hypercalciuria

- An elevated serum calcium level should trigger suspicion for hyperparathyroidism.
- A high calcium phosphate percentage in stone and elevated urinary calcium may also be indicative of hyperparathyroidism.

Sarcoidosis and Granulomatous Disease

Patients with sarcoidosis and other granulomatous disease are predisposed to hypercalcemia and hypercalciuria. The mechanism by which this occurs is via extrarenal production of calcitriol by 1-alpha hydroxylase, which is produced by macrophages within the granulomas. Low serum PTH despite high serum and urinary calcium may provide clinical suspicion for such a disorder. The mechanism behind this process is further described in Chapter 91. Treatment is typically accomplished using glucocorticoids, which decrease the granulomatous activity and ultimately the hypercalciuria that results from it (Iannuzzi and Fontana, 2011).

Idiopathic Causes of Hypercalciuria

Hypercalciuria used to be distinguished into three broad categories; absorptive, renal, and idiopathic. In absorptive hypercalciuria, urinary calcium levels are elevated as a result of increased calcium absorption by the GI tract. Renal hypercalcuria refers to calcium wasting through the nephron. **Fasting and dietary calcium loading tests used to be recommended as a way to distinguish the various types of absorptive and renal pathophysiologies but have fallen out of favor and are no longer recommended by the AUA guidelines as they are not believed to change clinical practice** (Lein and Keane, 1983; Pak et al., 2011; Pearle et al., 2014). As a result, such patients who have high urinary calcium levels and no identifiable diseases that may be contributing are referred to as having idiopathic hypercalciuria (Coe et al., 2016). Of note, idiopathic hypercalciuria alone is not a disease and can be found in both normal subjects and stone formers (Coe and Favus, 1980; Coe and Bushinsky, 1984).

Calcium Supplementation

The influence of dietary and supplemental calcium and vitamin D remains an incompletely understood process. Administration of exogenous calcium and vitamin D supplements has been found to correlate with higher urinary calcium levels, but the overall effect this may have on stone formation remains unclear (Gallagher et al., 2014; Riggs et al., 1998). In one large randomized controlled trial, 36,000 postmenopausal women were randomized to receive either placebo or 500 mg of calcium carbonate plus 200 units of vitamin D_3 two times a day. At 7 years, the cohort that was prescribed supplementation had a 17% increased rate of stone formation (Wallace et al., 2011). A similar (20%) increased risk was observed as part of the NHS I observational study among women taking supplemental calcium (Curhan et al., 1997). On the contrary, several other large-scale observational studies among younger women and men that have examined the potential association between calcium supplements and stones failed to identify a correlation (Curhan et al., 2004; Taylor et al., 2004). It is suspected that some of the aforementioned discrepancies may have to do with oversupplementation and timing of calcium supplement ingestion at separate times than meals (Pearle et al., 2014). The most recent AUA guidelines on medical management of stones recommends that if a patient with known history of calcium stones is on or is interested in taking calcium supplements, he or she should limit total calcium intake to 1000 to 1200 mg/day and should be advised to perform 24-hour urine testing on and off the supplements. If indeed the urinary supersaturation of the calcium salt in question rises while the patient is taking it, calcium supplementation should be stopped (Pearle et al., 2014).

There is similar controversy over the stone-specific effects of vitamin D supplementation. 1,25 Dihydroxyvitamin D, or calcitriol, is the active form of vitamin D that exerts biologic effects. Correlations between serum calcitriol levels and intestinal calcium absorption have been proven (Wilz et al., 1979) as have correlations between calcitriol and urinary calcium (Halalsheh et al., 2017). One of the reasons it has been difficult to determine the influence of vitamin D administration on stone risk is the fact that most randomized and placebo-controlled studies administer vitamin D with calcium, making the independent risk assessment of the vitamin difficult to quantify. **There are conflicting sentiments about the influence of vitamin D repletion in patients with low vitamin D levels and histories of kidney stones.** Cochrane review meta-analyses have found a 17% increased risk for stone formation among patients taking vitamin D and analogues (Avenell et al., 2014; Bjelakovic et al., 2014). However, few studies have prospectively evaluated the effect of vitamin D supplementation among stone formers with low serum vitamin D levels. Among 29 vitamin D–depleted patients, Leaf et al. (2012) found that supplementation led to an overall increase in serum vitamin D levels without significant change in urinary calcium levels. A subset of patients did have an appreciable rise in urinary calcium, but urinary sodium levels were higher as well, likely reflecting dietary variability over direct effects of vitamin D supplementation (Abt et al., 2017). Johri et al. (2017) found that among 37 vitamin D–deficient stone formers, supplementation resulted in a significant rise in vitamin D levels without a significant rise in urinary calcium levels, though hypercalciuria did occur is several instances. Ferroni et al. randomized patients with a history of calcium stones and low vitamin D to low dose (1000 IU daily) versus high dose (50,000 IU weekly) and found that only the high-dose regimen significantly improved vitamin D levels. Notably, neither regimen led to hypercalciuria. The results of these studies support the notion that vitamin D supplementation can likely be safely administered, though the potential for hypercalcuria to occur in a subset of patients is real, and patients who start therapy should have urine calcium levels monitored after initiation.

Conservative Strategies for Hypercalciuria

Sodium and Hypercalciuria

Dietary sodium increases urinary calcium levels because sodium and calcium share a common transport mechanism in the renal tubule. High sodium intake will result in decreased proximal sodium reabsorption and reduced distal renal tubular calcium reabsorption. The end result is hypernatriuria and hypercalciuria, which are risk factors that contribute to calcium nephrolithiasis. The degree of hypercalciuria has been shown to increase proportionally with the amount of sodium excreted in the urine (Sakhaee et al., 1993). Earlier studies reported that for every 100 mEq increase in dietary sodium, there was a 25- to 40-mg increase in urinary calcium excretion in normal subjects and an 80- to 120-mg increase in hypercalciuric stone formers (Bleich et al., 1979; Burtis et al., 1994; Martini et al., 1998; Muldowney et al., 1982; Phillips and Cooke, 1967; Silver et al., 1983). A more recent study suggests that the effect of sodium on urinary calcium excretion may be slightly overestimated as the investigators found in a short-term randomized controlled trial of hypercalciuric calcium oxalate stone formers a reduction of urinary calcium of approximately 64 mg/day for every 100-mmol reduction in urinary sodium (Nouvenne et al., 2010).

Epidemiologic studies have shown an independent association of dietary sodium consumption with kidney stone formation, particularly in women (Curhan et al., 1993, 1997). A more recent cross-sectional study by Taylor et al. (2009) found that subjects in the highest quartiles of urinary sodium excreted 37 mg/day more urinary calcium than participants in the lowest quartile. **Beyond the risk for stone formation, the adverse effects of high sodium intake and hypercalciuria include decreased bone mineral density and bone loss.** Martini et al. demonstrated that calcium stone formers who ingest large quantities of daily salt are more likely to suffer from decreased bone mineral density (Martini et al., 2000). In this study of 85 patients, all females were premenopausal, underscoring the risks for further osteopenia that they might develop later in life. After adjustment for calcium and protein intakes, age, weight, BMI, urinary calcium, citrate and uric acid excretion, and duration of stone disease, multiple-regression analysis showed that a high sodium chloride intake (≥16 g/day) was the single variable that was predictive of risk for low bone density in calcium stone formers (OR = 3.8).

A 3-month randomized controlled trial by Nouvenne et al. (2010) investigated the effects of a low-sodium diet on idiopathic hypercalciuria in calcium oxalate stone formers. There were 210 patients randomly assigned to a control diet that consisted of recommendations for water intake only or a low-sodium diet that included elimination of kitchen salt and strict limitation of foods containing high quantities of salt in addition to water therapy. They found that the stone formers consuming the low-sodium diet had a reduction in urinary calcium (271 vs. 361 mg/day) and oxalate (28 vs. 32 mg/day) compared with the control group. In addition, a low-sodium diet corrected the idiopathic hypercalciuria in approximately 30% of patients. These findings are supported by an earlier randomized controlled trial performed by Borghi et al. (2002), which found a low-sodium diet, limited to 50 mmol/day of sodium chloride, in conjunction with normal calcium intake and low animal protein reduced urinary calcium excretion in hypercalciuric stone formers. **In addition, when combined with animal protein restriction and moderate calcium ingestion, a reduced-sodium diet decreased stone episodes by roughly 50%. A recommended target for patients with calcium stones is sodium consumption of less than**

or equal to 100 mEq (2300 mg) per day (Pearle et al., 2014).

Key Points: Idiopathic Hypercalciuria

- Fasting and calcium-loading tests are no longer routinely recommended to distinguish types of hypercalciuria.
- Calcium and vitamin D supplementation may increase urinary calcium levels, but overall effect on risk for stone-formation risk remains unclear.
- Randomized controlled trials have demonstrated a benefit of dietary sodium restriction in both normal subjects and stone formers.
- The recommended sodium intake for patients with calcium stones is less than or equal to 100 mEq (2300 mg) per day.

Medical Therapy for Hypercalciuria

Thiazides and Thiazide-Like Diuretics

Thiazide diuretics are the preferred medical agent for hypercalciuria. They are among the best- studied medications for stone prevention, with evidence supporting their use both in disease-specific and nonspecific subgroups of stone formers (Borghi et al., 1993; Brocks et al., 1981; Ettinger et al., 1988; Laerum and Larsen, 1984; Mortensen et al., 1986; Ohkawa et al., 1992). As such, they are currently favored by the AUA guidelines and recommended for patients with hypercalciuria and recurrent calcium stones and those suffering from recurrent calcium stones in spite of normal metabolic evaluations (Pearle et al., 2014).

The use of thiazides was first described by Yendt et al. (1966) for the treatment of undifferentiated hypercalciuria. **Thiazides directly stimulate calcium resorption in the distal nephron while promoting excretion of sodium.** A list of available thiazides and other medications used in stone prevention can be found in Table 92.4. This table includes indapamide, which is a thiazide-like diuretic that is effective against hypercalciuria (Ceylan et al., 2005). Two double-blind randomized controlled trials have tested the treatment effect of hypercalciuria. Ettinger et al. identified a 90% decrease in predicted rates of stone formation for patients on chlorthalidone (25 or 50 mg daily) relative to placebo or magnesium hydroxide (Ettinger et al., 1988). Laerum and Larsen (1984) found that patients administered hydrochlorathiazide 25 mg two times a day had a 75% likelihood of not forming a stone at a median of 3 years follow-up compared with 45% among patients administered a placebo. A Cochrane review on the topic also identified a protective effect of thiazides. Among 316 patients included from five separate studies, patients on thiazide therapy had a 60% reduction in new stone recurrences relative to those on placebo (Escribano et al., 2009).

TABLE 92.4

Dosages of Common Medications Used to Prevent Urinary Calculi

MEDICATION	DOSAGE
Thiazide diuretics	
Hydrochlorothiazide	25 mg PO bid
Chlorthalidone	25–50 mg PO daily
Indapamide	2.5 mg PO daily
Sodium cellulose phosphate	10–15 g/day divided with meals
Orthophosphate	0.5 g PO tid
Potassium citrate	20 mEq PO bid-tid
Allopurinol	300 mg PO daily
Magnesium gluconate	0.5–1 g tid
Pyridoxine (B6)	100 mg PO daily
d-Penicillamine	250 mg PO daily (titrated to effect)
α-Mercaptopropionyl glycine	100 mg PO bid (titrated to effect)
Captopril	25 mg PO tid
Acetohydroxamic acid	250 mg PO bid-tid

Long-term thiazide therapy results in volume depletion, extracellular volume contraction, and proximal tubular resorption of sodium and calcium. Thiazides may increase urinary excretion of magnesium and zinc, but these responses are not consistent. **Potassium losses from thiazide therapy can cause hypocitraturia, as a result of hypokalemia with intracellular acidosis. As a result, potassium supplementation should be considered either in the form of potassium citrate or potassium chloride.** Serum potassium levels should be monitored within 1 to 2 weeks after initiating therapy or adjusting the dose, and particular caution should be exercised for patients who have known potassium deficiencies, are on digitalis therapy, or develop hypocitraturia. Addition of potassium citrate has been documented to prevent occurrence of hypokalemia and hypochloremic metabolic acidosis in patients undergoing long-term thiazide therapy (Odvina et al., 2003).

Amiloride in combination with thiazide (Moduretic) may be more effective than thiazide alone in reducing calcium excretion (Leppla et al., 1983; Maschio et al., 1981). However, this medication does not augment citrate excretion. Because amiloride is a potassium-sparing agent, potassium replacement is not necessary and could, in fact, be problematic**. It is not advisable to provide potassium supplementation to patients receiving a potassium-sparing diuretic.** Although the potassium-sparing effects of amiloride may be beneficial, the use of triamterene, another potassium-sparing agent, should be undertaken with caution because of reports of triamterene stone formation (Watson et al., 1981).

Thiazide therapy has the potential to affect bone mineral density and has been shown to be protective against osteopenia. Pak et al. studied a subset of patients with absorptive hypercalciuria who were treated with a thiazide and potassium citrate and a low-calcium, low-oxalate diet and followed them for a mean of 3.7 years. During the period of treatment, stone formation decreased from 2.94 to 0.05 per year, and bone mineral density increased by 5.7% to 7.1% (Pak et al., 2003b). There is also data showing that patients on thiazide diuretics have a decreased risk for bony fractures. A Cochrane review on this topic identified a 24% reduction in hip fractures among patients taking thiazides (Aung and Htay, 2011)

Side effects of thiazides are typically mild at low doses and often improve with time (Table 92.5). Nonetheless, they can be bothersome and have been estimated to lead to quitting therapy in as many as 1 in 6 patients (ALLHAT, 2002). Side effects that may be experienced include increased thirst, polyuria, cramps, and GI upset. Initiation of a thiazide also has the potential to precipitate gout or diabetes owing to disturbances in serum uric acid and glucose levels (York et al., 2015). Finally, decreased libido or sexual dysfunction can be seen in a small percentage of patients (Derby et al., 2001).

TABLE 92.5

Potential Side Effects of Medications Used to Prevent Urinary Lithiasis

MEDICATION	SIDE EFFECT
Thiazide diuretics Hydrochlorothiazide Chlorthalidone Indapamide	Potassium wasting, muscle cramps, hyperuricosuria, intracellular acidosis, hypocitraturia

Sodium cellulose phosphate (SCP)	GI distress, hypomagnesemia, hyperoxaluria, PTH stimulation
Orthophosphate	Similar to SCP, soft tissue calcification
Potassium citrate	GI upset, hyperkalemia
Allopurinol	Rash, myalgia
Magnesium gluconate pyridoxine (B_6)	Diarrhea
d-Penicillamine	Nephrotic syndrome, dermatitis pancytopenia
α-Mercaptopropionyl glycine	Rash, asthenia, rheumatologic complaints, GI distress, mental status changes
Captopril	Rash, cough, hypotension
Acetohydroxamic acid	Thromboembolic phenomena, tremor, headache, palpitations, edema, GI distress, loss of taste, rash, alopecia, anemia, abdominal pain

GI, Gastrointestinal; *PTH,* parathyroid hormone.

Occasionally, thiazides unmask primary hyperparathyroidism (i.e., “thiazide challenge”). Patients with normal serum calcium may develop elevated serum calcium. Wermers et al. (2007) reported that this occurs an average of 6 years after initiation of thiazide. In this heterogeneous population (3% of whom were known stone formers), hyperparathyroidism was diagnosed in 64% of patients who had persistently elevated serum calcium after the thiazide was stopped (Wermers et al., 2007). Another way a thiazide challenge can be used is to differentiate primary and secondary hyperparathyroidism (Eisner et al., 2009). In patients with nephrolithiasis, hypercalciuria, and elevated serum parathyroid hormone, hydrochlorothiazide 25 mg orally twice daily is administered for 2 weeks. If the parathyroid hormone remains elevated, the diagnosis of primary hyperparathyroidism is confirmed. If it returns to normal, the diagnosis is secondary hyperparathyroidism from renal leak hypercalciuria.

Orthophosphate

Orthophosphate (neutral or alkaline salt of sodium and/or potassium, 0.5 g phosphorus three or four times per day) has been shown to inhibit 1,25-(OH)$_2$D synthesis (Insogna et al., 1989; Van Den Berg et al., 1980)**. However, there is as yet no convincing evidence from randomized controlled trials that this treatment restores normal intestinal calcium absorption.** Orthophosphate reduces urinary calcium probably by directly impairing the renal tubular reabsorption of calcium and by binding calcium in the intestinal tract. Urinary phosphorus is markedly increased during therapy, a finding reflecting the absorbability of soluble phosphate. Physicochemically, orthophosphate reduces the urinary saturation of calcium oxalate but increases that of brushite. Moreover, the urinary inhibitor activity is increased, probably owing to the stimulated renal excretion of pyrophosphate and citrate. Although contrary reports have appeared, this treatment program has been reported to cause soft tissue calcification and parathyroid stimulation (Dudley and Blackburn, 1970). Orthophosphate is contraindicated in nephrolithiasis complicated by UTI because of the increased phosphorus load.

Sodium Cellulose Phosphate

Sodium cellulose phosphate, given orally, is a nonabsorbable ion exchange resin that binds calcium and inhibits calcium absorption (Pak, 1973). **Unfortunately, despite early enthusiasm, the use of sodium cellulose phosphate has largely fallen out of favor, and this medication is no longer available in the United States.**

Key Points: Medications for Hypercalciuria

- Thiazides and thiazide-like medications are the preferred pharmacotherapy for medical management of hypercalciuria.
- Potassium levels should be monitored, and potassium supplementation should be coadministered with thiazides.
- Thiazide therapy may be protective against osteopenia.

Hypocitraturia (<550 mg/day Female, <450 mg/day Male)

Clinical Considerations

Hypocitraturia is considered one of the more common metabolic diagnoses, probably second only to hypercalciuria. Citrate is an inhibitor of crystal aggregation and can reduce calcium stone risk, particularly of calcium oxalate. The physiology of this process is better elucidated in Chapter 91. When citrate levels are low, stone risks rise. Citrate repletion may reduce stone risk by forming soluble complexes with calcium and reducing supersaturation (Pak et al., 1986b). Defining a normal level of urinary citrate excretion is somewhat controversial, particularly as citrate levels can vary by gender and age. Early studies from Dr. Pak's research group identified hypocitraturia in up to 50% of patients being evaluated for stone disease, and it was often associated with other metabolic abnormalities (Nicar et al., 1983). Despite noting gender differences, Resnick Martin and Pak (1990) define normal urine citrate as greater than 320 mg for both genders. Parks and Coe also noted the importance of urinary citrate for the prevention of calcareous stones and set the limits of normal at higher values, with men greater than 450 mg and women greater than 550 mg daily (Parks, 1986a, 1986b). Hypocitraturia may be a reflection of a systemic disease (distal renal tubular acidosis, chronic diarrhea). It may also occur as a result of medical therapy (thiazides) or urinary tract infection. In many instances, however, hypocitraturia is an idiopathic process.

Conservative Strategies for Hypocitraturia

Citrus Juices

Citrus juices, predominantly lemonade and orange juice, have long been used as an adjunct to water to provide increased urinary volume and increased urinary citrate excretion. Citrate is a weak organic acid, but it can act as a conjugate base when paired with a cation such as sodium or potassium (Kurtz and Eisner, 2011). Oral citrate is absorbed by the intestine and nearly completely metabolized to bicarbonate providing an alkali load that increases urinary pH and citrate excretion. Citrate is an effective inhibitor of calcium oxalate stone formation as it forms soluble complexes with calcium and affects crystal nucleation and growth (Siener, 2016). Using nuclear magnetic resonance spectroscopy, the citrate concentrations of a number of commercially available citrus and citrus-based beverages was assessed (Haleblian et al., 2008). This finding confirmed that natural juices are highest in citrate and potassium content, with grapefruit juice containing the greatest amount of citrate (197.5 mEq/L), followed closely by lemon and orange juice (145.48 and 144.57 mEq/L, respectively). Of the commercially available citrus-based beverages, Crystal Light (Kraft Foods, Northfield, IL) exhibited the highest concentration of citrate (117.2 mEq/L). Citrate in orange and grapefruit juices is complexed mainly by potassium, which results in increased urinary pH, and citrate in lemon juice is in the form of citric acid and therefore does not result in as significant of an alkali load. More recently, malate, another organic anion found in some beverages, has been shown to increase urinary citrate as well (Eisner et al., 2010). Therefore, the amount of alkaline citrate may be more important than the total citrate content of a beverage in terms of raising urinary citrate (Kurtz and Eisner, 2011).

Several studies have investigated the effects of citrus juices on urinary parameters. In a study of 12 hypocitraturic patients, lemonade made from reconstituted lemon juice resulted in a more than twofold rise in urinary citrate levels and corrected the hypocitraturia in seven subjects (Seltzer et al., 1996). Urinary calcium excretion decreased an average of 39 mg daily, whereas oxalate excretion did not change. The lemonade mixture was well tolerated and inexpensive (estimated $2 per week), with only two patients reporting mild indigestion that did not require cessation of therapy. Similar benefits of homemade lemonade therapy were demonstrated in two other studies, with urinary citrate levels increasing at least twofold, and in the study by Kang et al., mean stone burden also decreased by 18% in patients on lemonade therapy (Kang et al., 2007; Aras et al., 2008). Despite these studies suggesting benefit to lemonade therapy, at least three other studies have questioned the benefit (Koff et al., 2007, Odvina, 2006, Penniston, 2007b). Koff et al. (2007) compared reconstituted lemonade (1 oz ReaLemon in ¾ cup of water) to 60 mEq of potassium citrate and found that potassium citrate increased urinary citrate but the lemonade solution did not. Penniston et al. (2007) also examined lemonade therapy alone versus lemonade therapy combined with potassium citrate and found that the combination therapy resulted in increased urinary citrate levels but lemonade therapy alone did not.

Orange juice has been shown to have less citrate content than lemon juice;

however, citrate in oranges is complexed with potassium and therefore may have a greater impact on raising urinary citrate. Data from three large cohort studies found that orange juice consumption was associated with a lower risk for stone formation (Ferraro et al., 2013). Wabner and Pak evaluated the effects of orange juice on the urinary parameters of normal subjects and found that compared with potassium citrate, orange juice delivered an equivalent alkali load and caused a similar increase in urinary pH (6.48 vs. 6.75 from 5.71 mg/day) and urinary citrate (952 vs. 944 from 571 mg/day) (Wabner and Pak, 1993). However, orange juice increased urinary oxalate and did not alter calcium excretion, whereas potassium citrate decreased urinary calcium without altering urinary oxalate. Odvina performed a crossover study of 14 patients examining the effects of distilled water, orange juice, and lemonade on urinary citrate levels (Odvina et al., 2006). They found that urinary citrate and pH were significantly increased in response to orange juice (mean increase of 500 mg citrate per day), and no difference was observed for lemonade or water. However, urinary oxalate levels increased in the orange juice arm, which would not be ideal for calcium oxalate stone formers. Although less vigorously studied, other fruit juices (lime, cranberry, black currant, grapefruit, and tomato) have been shown to result in variable increases in urinary citrate (Gettman et al., 2005; Goldfarb and Asplin, 2001; Kessler et al., 2002; McHarg et al., 2003; Tosukhowong et al., 2008; Yilmaz et al., 2010). Perhaps the greatest concern with using fruit juices as a dietary fluid prevention for stone formation is the caloric content. Given that many stone formers are already overweight, obese, or have diabetes mellitus, consumption of large quantities of sweetened fruit juice may actually be detrimental. In this aspect, lemonade is preferable as the sweetener added and caloric content of the beverage can be better controlled.

A number of citrus-flavored low-calorie sodas (orange flavored, lemon/lime flavored) have been shown to have high citrate content, which may aid in stone prevention (Haleblian et al., 2008, Eisner et al., 2010). In addition, the effects on urinary citrate levels of two citrus-based sports drinks, Performance and Gatorade, were compared in 19 non–stone formers. Performance increased mean citrate excretion by 170 mg/day and increased urine pH by 0.31, and Gatorade had no effect on either parameter (Goodman et al., 2009). However, like the fruit juices, the fructose and calorie content of these sports drinks may be too considerable for them to be preferred beverages for stone prevention.

In summary, although several beverages have been shown to increase urinary citrate levels, none has demonstrated superiority. The greatest amount of clinical evidence exists for lemonade therapy, and this is most widely prescribed. **For kidney stone prevention, the absolute amount of fluid consumed per day is more important than the type of fluid. Stone formers should be encouraged to drink at least 3000 mL/day to maintain a urine output greater than 2500 mL/day.**

Medical Therapy for Hypocitraturia

Idiopathic Hypocitraturic Calcium Nephrolithiasis

This entity includes hypocitraturia occurring alone, and in conjunction with other abnormalities (e.g., hypercalciuria or hyperuricosuria). Stones formed in this condition may be composed of calcium oxalate, calcium phosphate, or a combination of the two (Gambaro et al., 2016). Treatment of hypocitraturia is typically accomplished with citrate repletion (Pak et al., 1986b). **Orally ingested citrate salts are metabolized to bicarbonate in the liver. The resulting alkali load in turn inhibits proximal tubular citrate reabsorption, which leads to increased levels of citrate in the urine.** Several commercially available forms of citrate are available. In the United States, potassium citrate is the predominant form that is used. It is available in a wax tablet, as a liquid, and in a crystal/powder form meant to be dissolved (York et al., 2015). The usual therapeutic dose is 30 to 60 mEq/day given in divided doses or as a single evening dose (Berg et al., 1992). Another dosing strategy is ½ mEq/kg/day given in divided doses until the urinary pH is sufficiently alkaline (i.e., pH is 6 to 6.5) (York et al., 2015). Sodium citrate is another formulation that is more commonly used in Europe or reserved for patients with concerns about causing hyperkalemia. Sodium citrate does not lower urinary calcium excretion, perhaps as a result of the increased sodium load associated with this therapy (Preminger et al., 1988; Sakhaee et al., 1983). **Current AUA guidelines recommend that clinicians offer potassium citrate to patients with recurrent calcium stones and low urinary citrate** (Pearle et al., 2014). Additionally, similar to thiazides, potassium citrate is recommended, even in the absence of hypocitraturia or other metabolic abnormalities in recurrent calcium stone formers (Pearle et al., 2014).

Long-term therapy with citrates has been shown to provide a favorable and durable response in alteration of urinary parameters and stone formation rate (Robinson et al., 2009) In a retrospective study published by Robinson et al. of 503 patients on potassium citrate therapy for a mean of 41 months (range 6 to 168), urinary pH and citrate demonstrated significant increases (pH, 5.9 to 6.46;

citrate, 470 to 700 mg/day), with substantial improvement in urinary parameters in as short as 6 months of therapy. In addition, potassium citrate decreased the stone formation rate from 1.89 stones per patient per year to 0.46 (Robinson et al., 2009).

Several randomized control trials have evaluated the effect of citrate on new stone formation. Ettinger et al. randomized 64 recurrent calcium oxalate stone formers to either potassium magnesium citrate or placebo and found that the citrate cohort had a 0.16 relative risk for new stone formation relative to the placebo cohort at 3 years (Ettinger et al., 1997). Another randomized control placebo trial from Barcelo et al. found similar results with patients on potassium citrate therapy exhibiting significant reductions in stone formation rate at 3 years (0.1 vs. 1.1 new stones per patient year). **A Cochrane review among predominantly calcium oxalate stone formers found that patients on citrate had a relative risk of 0.26 (95% CI 0.10 to 0.68) for new stone formation compared with patients who were not on citrate** (Phillips et al., 2015).

Citrates are generally well tolerated, though several common side effects exist. The most common side effect is GI upset. The wax matrix tablet has been suggested to reduce this complication, though data supporting this is limited. Taking the medication with water and after meals may reduce GI irritation as well (York et al., 2015). Patients should also be informed that it is common to see the wax component of the potassium citrate tablet in their stool and should be reassured that this does not mean the medication is not being absorbed (Fegan et al., 1992). The aforementioned Cochrane review on citrate therapy did not show a significant difference in GI side effects in patients on citrate, though citrate was associated with an increased number of study dropouts from medication-related adverse events (Phillips et al., 2015). Another potential concern specific to potassium citrate supplementation is hyperkalemia. **Potassium levels should be regularly monitored for patients with renal insufficiency and should be avoided for those on potassium-sparing diuretics.**

One unique side effect that relates directly to stone formation is the effect of citrate therapy on urinary pH. As discussed earlier, citrate therapy raises urinary pH. In some cases, this is a desired effect, particularly among calcium oxalate stone formers, where inhibitors of stone formation may be more effective in alkaline urine. **However, exceedingly alkaline urine also raises the risk for calcium phosphate stone formation, particularly at a pH of 7 or greater** (Coe 2010; Evan et al., 2005, 2015b; Pearle et al., 2014)**. Higher utilization of**

citrate therapy has been postulated as a contributing factor in the rise of calcium phosphate stone disease. Parks et al. identified a threefold increase in calcium phosphate content of stones over the past three decades and identified an association of this trend with rising urinary pH (Parks 2004) Furthermore, the same group found that patients who transformed their stone content to increased calcium phosphate received more potassium citrate compared with those who did not transform (Parks et al., 2009).

The role of citrate supplementation in patients who form calcium phosphate stones is subsequently controversial. **No randomized controlled trials to date have evaluated the effect of citrate on stone recurrence among patients with calcium phosphate stones, though nonrandomized studies among diseases commonly associated have suggested a benefit** (Gambaro et al., 2016; Preminger et al., 1985). Subsequently, investigation into alternative therapies for such patients has been identified as an opportunity for future research (Gambaro et al., 2016). In the interim, **if citrates are started on a patient with prior calcium phosphate stones, a follow-up 24-hour urine collection is advised, with specific attention directed toward the corresponding urinary citrate levels, pH, and supersaturation. Those whose pH rises in the absence of a significant rise in urinary citrate may not benefit to the same degree as those whose citrate levels rise without production of an exceedingly alkaline urine.**

Key Points: Hypocitraturia

- Citrus juices (particularly lemon and orange) and low-calorie citrus soda with citric acid may decrease stone risk and be an alternative to water.
- Citrate supplementation is a primary treatment for patients with hypocitraturia and recurrent calcium stones.
- Common side effects from citrate therapy include GI upset and hyperkalemia.
- Serum potassium levels should be monitored in patients on citrates.
- There is controversy as to whether citrates are beneficial in calcium phosphate stone disease as higher urinary pH could increase calcium phosphate stone risk

Distal Renal Tubular Acidosis (Type 1)

Patients may have either an acquired or an inheritable version of RTA, with the incomplete version representing a less serious clinical pattern (Box 92.5). Regardless of the actual cause, the laboratory hallmark of this disease is a low urine citrate (hypocitraturia) with an inappropriately high urine pH (Evan et al., 2007). Often, the measured 24-hour urine citrate will be quite diminished, with values less than 100 mg/day. The urine pH will be elevated to 6.5 or above. Hypokalemia is often evident on the serum studies, as is hyperchloremia. A non–anion gap acidosis may be present as well with carbon dioxide values in the mid-teens (Preminger et al., 1985). First-void urine samples can be evaluated to assess urine pH and screen for RTA. Patients with RTA will be unable to acidify urine overnight and should have a urine pH no lower than 5.5.

Box 92.5

Causes of Acquired Renal Tubular Acidosis

Obstructive uropathy
Recurrent pyelonephritis
Acute tubular necrosis
Renal transplantation
Analgesic nephropathy
Sarcoidosis
Idiopathic hypercalciuria
Primary hyperparathyroidism

Distal RTA may manifest as an isolated entity, or it may be the secondary manifestation of a variety of systemic and renal disorders. More than two-thirds of patients with distal RTA are adults, but occasionally children are identified with this disorder. Infants generally present with vomiting or diarrhea, failure to thrive, and growth restriction; children often present with metabolic bone disease and renal stones; and adults frequently present with symptoms attributable to nephrolithiasis and nephrocalcinosis (Fig. 92.8).

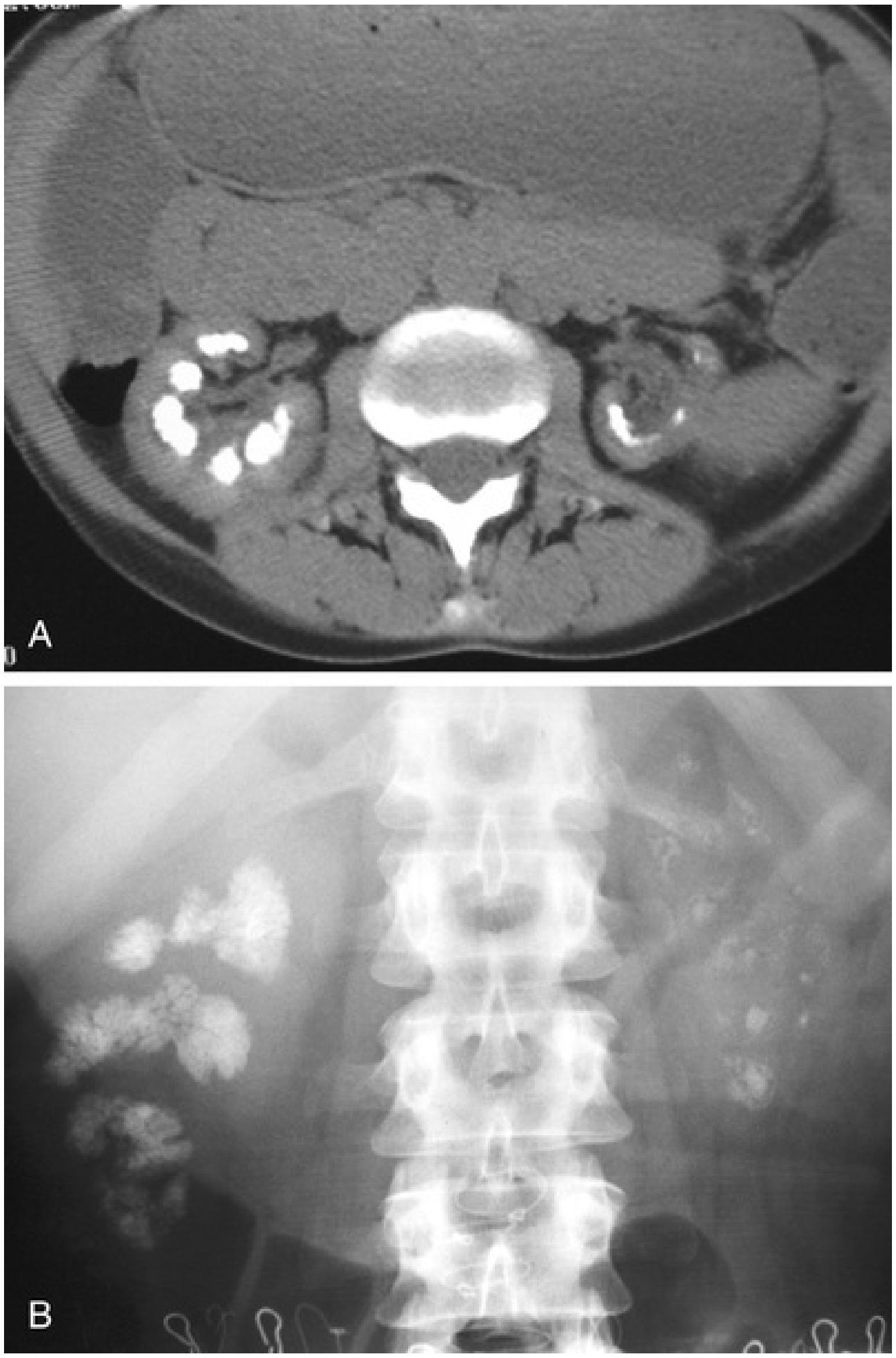

FIG. 92.8 Computed tomography (CT) (A) and plain film (B) of a patient with renal tubular acidosis and renal failure. Both kidneys demonstrate severe calcification of the medullary pyramids consistent with nephrocalcinosis. Note the atrophic left kidney on the CT image (A).

Up to 70% of adults with distal RTA have kidney stones (Caruana and Buckalew, 1988). Those patients with onset at an early age or with severe forms of the disorder may develop nephrocalcinosis and eventual renal insufficiency. RTA is more common in women, accounting for nearly 80% of all cases. It is very important to note that secondary RTA can be induced by many common urologic disorders that also may be sought after a diagnosis of acquired RTA. These include obstructive uropathy, pyelonephritis, acute tubular necrosis, renal transplantation, analgesic nephropathy, sarcoidosis, idiopathic hypercalciuria, and primary hyperparathyroidism and can lead to secondary RTA (Buckalew, 1989).

Some patients will have an incomplete variant of the disease with less marked hypocitraturia and a more normal urine pH level. Incomplete variants of distal RTA can be diagnosed with the use of an ammonium chloride loading challenge. In this evaluation, the fasting patient is given ammonium chloride 0.1 g/kg of body weight in crushed granules mixed with a soft drink. Subsequently, hourly measurements of urinary pH and bi-hourly measurements of serum pH or bicarbonate are taken over 4 to 6 hours (Pohlman et al., 1984). If the serum pH falls below 7.32, or the bicarbonate falls below 16 mmol/L but urinary pH remains at or above 5.5, the diagnosis of incomplete distal RTA is confirmed. If at any time the urinary pH falls below 5.5, the diagnosis of incomplete distal RTA is excluded (Preminger et al., 1985, 1987). More recently, a furosemide/fludrocortisone test whereby these two agents are administered simultaneously and urine acidity measured has been tested as an alternative diagnostic test with the potential to be easier to perform and better tolerated by patients (Walsh et al., 2007). Initial experiences have shown promise with excellent sensitivity and negative predictive value relative to the ammonium chloride loading challenge. However, a low specificity means that ammonium chloride testing is still recommended as the gold standard if the diagnosis remains in question (Dhayat et al., 2017; Shavit et al., 2016).

Alkali supplementation (such as potassium citrate), typically in the form of potassium citrate, is a cornerstone of therapy for RTA as it is able to correct the metabolic acidosis and hypokalemia found in the disease (Preminger et al., 1985). In addition, this medication is capable of restoring normal urinary citrate, although large doses (up to 120 mEq/day) may be required in severe acidotic states. With correction of the acidosis, urinary calcium should decline into the normal range. Because urinary pH is generally high to begin with in patients with RTA, the overall rise in urinary pH is small.

Potassium citrate therapy typically produces a sustained decline in the urinary saturation of calcium oxalate (from reduction in urinary calcium and in citrate complexation of calcium). The urinary saturation of calcium phosphate should not increase because the rise in phosphate dissociation is relatively small and is adequately compensated by a decline in ionic calcium concentration. In addition, the inhibitory activity against the crystallization of calcium oxalate and calcium phosphate is augmented because of the direct action of citrate.

Clinical data evaluating the efficacy of potassium citrate in stone management related to RTA is limited. In 1985, Preminger et al. administered 60 to 80 mEq/day of potassium citrate to nine patients with confirmed RTA. At a mean treatment interval of 34 months, none of the patients reported new stones since starting therapy despite reporting a mean of 39.3 stones per patient formed during the 3 years before starting treatment (Preminger et al., 1985).

Chronic Diarrheal States

The full management of enteric stone disease is discussed later in this chapter. Part of the management should involve the use of citrate to correct the acidosis that accompanies the chronic bicarbonate losses with diarrhea. The amount of potassium citrate will depend on the severity of hypocitraturia in these patients, with dosages ranging from 60 to 120 mEq in three or four divided doses.

It is recommended that a liquid preparation of potassium citrate be used rather than the slow-release tablet preparation; the slow-release medication may be poorly absorbed because of rapid intestinal transit time. In addition, frequent dose schedules (3 or 4 times per day) for the liquid preparation is necessary because this form of the medication has a relatively short duration of biologic action.

Thiazide-Induced Hypocitraturia

One of the side effects of thiazide therapy is the development of hypocitraturia. This defect is presumably secondary to the hypokalemia and resultant intracellular acidosis that may develop after prolonged therapy with thiazides (Pak et al., 1985). Therefore **it should be a common practice to administer potassium supplementation, preferably in the form of potassium citrate, to patients receiving thiazides for treatment of hypercalciuria.** Potassium citrate has been shown to be equally effective as potassium chloride in correcting thiazide-induced hypokalemia. Moreover, the addition of potassium citrate not only prevents a decrease in urinary citrate during thiazide therapy, but may increase citrate excretion (Pak et al., 1985). Because thiazides are still widely used as a diuretic and for the management of hypertension, some patients may present with a stone episode after prolonged therapy with this medication. Stone patients who are treated with thiazides for the control of hypercalciuria should be screened for hypocitraturia (Pak et al., 1985).

Hyperoxaluria (>40 mg/day)

Clinical Considerations

Hyperoxaluria is one of the more common metabolic abnormalities identified during metabolic evaluations. Like urinary calcium levels, there is no set level above which stone risk suddenly occurs; rather, stone risk rises in line with increases in urinary oxalate levels, even when urinary oxalate levels are in the “normal” range (Curhan et al., 2001). Oxalate is a ubiquitous molecule that originates from both diet and a byproduct of metabolism (Holmes et al., 2001). To date, there is no recognized functional role of oxalate in human metabolism. Elevated urinary oxalate may occur via a variety of mechanisms.

Certain people may be more susceptible to dietary oxalate absorption than others. The importance of dietary oxalate and the possibility of an inheritable sensitivity to oral oxalate loads are debated and are discussed in Chapter 91. It appears increasingly evident that a deficiency of a bacterium found within intestinal flora *(Oxalobacter formigenes)* is a factor in the formation of calcium oxalate calculi (Allison et al., 1986; Barnett et al., 2016; Sidhu et al., 1999; Siener et al., 2013; Troxel et al., 2003). In some patients, the cause of *Oxalobacter* deficiency may be iatrogenic because it is sensitive to a number of commonly prescribed antibiotics (Lange et al., 2012; Tasian et al., 2018). There are ongoing efforts investigating a potential therapeutic role in recolonization of the GI tract with *Oxalobacter*.

Enteric Hyperoxaluria

The term *enteric hyperoxaluria* is used to describe elevations in urinary oxalate levels (>40 mg/day) that occur in the context of and as a result of GI malabsorption and diarrhea. Malabsorption mainly leads to increased oxalate reabsorption as a result of saponification of oral calcium with poorly absorbed fats in the GI tract, although it can also increase stone risk via dehydration, hypokalemia, bicarbonate loss, and hypocitraturia. Further details regarding this pathophysiology can be found in the preceding chapter. Urine oxalate levels can be quite high in this condition well over 60 to 70 mg/day. Furthermore, urinary calcium levels may be quite low (well under 100 mg/day).

Another increasingly common etiology of enteric hyperoxaluria is gastric bypass surgery performed for obesity**. Malabsorptive procedures, such as Roux-en-Y gastric bypass (RYGB) has been shown to increase the risk for stone formation**. Restrictive bariatric surgeries such as lap banding or sleeve gastrectomy may also infer additional stone risk, mainly via dehydration, and the direct risk for stone formation as a result of the procedure is less. Among 277 non–stone formers who underwent pre- and post-RYGB 24-hour urine testing, urinary oxalate levels increased from 28 to 44 mg/day, an increase of 34% (Espino-Grosso and Canales, 2017). As anticipated, urinary citrate levels and volume have also been demonstrated to decrease after RYGB (Park et al., 2009; Valezi et al., 2013). Using claims data, Matlaga et al. identified a 7.65% risk for stone formation within 2 years after RYGB compared with a 4.6% rate in a matched control group of patients with obesity (Matlaga et al., 2009).

Primary Hyperoxaluria

Primary hyperoxaluria (PH) is an extremely rare disorder caused by an inborn error of glyoxalate metabolism. Three genetic types of PH have been described to date. The more common variant, type 1, is caused by a defect of the enzyme alanine glyoxylate aminotransferase (AGXT) via an autosomal recessive inheritance. Type 2 is a less common variant thought secondary to a defect in D-glycerate dehydrogenase (GRHPR). More recently, primary hyperoxaluria type 3 has been described, which occurs as a result of a mutation in the hydroxy-2-oxoglutarate aldolase gene *(HOGA1)* and is inherited in an autosomal recessive manner. Estimates suggest that 70% of patients with PH have PH1, 10% have PH2, 10% have PH3, and 10% have PH from an unidentified genetic cause (Hopp et al., 2015).

The clinical manifestations of the different subtypes of PH have considerable overlap. The disease usually manifests during childhood with early stone formation, tissue deposition of oxalate (oxalosis), and commonly renal failure resulting from nephrocalcinosis. Death can occur before 20 years of age in untreated patients (Williams and Smith, 1968; Leumann and Hoppe, 1999). Metabolic evaluation will reveal high urine oxalate excretion (often over 100 mg/day) and high serum levels of this molecule. PH3 has been suggested to have a milder course and tends to have lower levels of urinary oxalate with decreased risk for developing renal failure and systemic oxalosis. Patients with PH3 are also more likely to have concomitant hypercalciuria (Monico et al., 2011; Williams, 2012a, Hopp et al., 2015).

Conservative Strategies for Hyperoxaluria

A review of a patient's dietary habits may reveal a predisposition for foods that are particularly high in oxalate. Although oxalate cannot be entirely avoided even with the best efforts, recognition and avoidance of high-oxalate foods is a cornerstone in management of urinary hyperoxaluria (Holmes and Assimos, 2004; Holmes et al., 2001, 2016). The contribution of dietary oxalate consumption to urinary oxalate can vary. Some have estimated that only 10% to 20% of urinary oxalate is usually derived from dietary sources (Williams and Wandzilak, 1989). More recently, Holmes et al. found that the contribution of dietary oxalate to urinary oxalate ranged from 24.4% ± 1.5% on a diet of 10 mg/day of oxalate to 41.5% ± 9.1% on a diet of 250 mg/day of oxalate. They also demonstrated that the mean contribution of dietary oxalate increased when calcium consumption decreased (Holmes et al., 2001).

Although dietary oxalate clearly plays a role in increased urinary oxalate, it is difficult to restrict its intake because oxalate is ubiquitous and found in most vegetable matter. However, it is important to avoid large portions of foodstuffs that are rich in oxalate, such as spinach, beets, chocolate, nuts, and tea. **Whereas general advice on a restricted-oxalate intake might be given to patients with recurrent nephrolithiasis, a low-oxalate diet would be most useful in patients with enteric hyperoxaluria, those with underlying bowel abnormalities, or patients who have undergone gastric bypass surgery** (Holmes and Assimos, 2004).

Box 92.6 presents an extensive list of foods containing a high level of oxalate. It is notable that recent work has illustrated similar relationships of dietary intake and urinary excretion of oxalate in a cross-sectional analysis of HPFS and NHS (I and II) for both stone formers and non–stone formers, thereby further adding to the question of the impact that dietary oxalate has on urinary oxalate excretion (Taylor and Curhan, 2004).

Box 92.6

Foods Containing High Levels of Oxalate

Black tea
Cocoa
Spinach

Mustard greens
Pokeweed
Swiss chard
Beets
Rhubarb
Okra
Berries (some)
Chocolate
Nuts
Wheat germ
Soy crackers
Pepper

Repeated concerns have been raised regarding the risk associated with vitamin C (ascorbic acid) ingestion and the possibility of its conversion to oxalate with subsequent urinary excretion. Unfortunately, conflicting evidence has been presented by multiple authors (Curhan 1996b; Curhan et al., 1999; Traxer et al., 2003). In fact, conflicting conclusions have been reported even from the same group of authors, underscoring the need for close scrutiny of presented data. Some of the confusion stems from differences in study end points. Although ingestion of large amounts of vitamin C may demonstrate increases in 24-hour oxalate excretion and therefore calcium oxalate supersaturation, this does not guarantee an eventual increase in the formation of symptomatic calculi. A recent large, prospective cohort of men found that increased ascorbic acid intake was associated with a twofold increased risk for kidney stone formation (Thomas et al., 2013).

In the end, it seems reasonable to avoid heavy dosing of vitamin C. Limiting one's intake to a maximum daily dose of less than 2 g is an easy recommendation to follow (Traxer et al., 2003).

Medical Therapy for Hyperoxaluria

Oxalate avoidance and treatment of any underlying pathophysiologies are the cornerstones for management of idiopathic hyperoxaluria; however, medications may occasionally be useful.

Enteric Hyperoxaluria: Medical Therapy

No randomized controlled trials have been performed regarding treatment of enteric hyperoxaluria to date. Calcium supplementation is one of the primary treatment methods of lowering urinary oxalate levels with several prior studies having shown benefit when supplemental calcium supplements are administered (Hylander et al., 1980; Pang et al., 2012). Typically, over-the-counter calcium supplements have been recommended to provide the patient with up to 1 g/day of calcium in divided doses. Calcium citrate is one formulation commonly used for this purpose that has been shown to not only lower urinary oxalate levels but also raise urinary citrate and pH by providing an alkali load (Harvey et al., 1985). It is important that supplements are administered with meals to maximize oxalate binding potential. It is also important that patients maintain very high fluid intake during calcium treatment to avoid the potential of the calcium supplementation actually increasing overall stone risk.

Another mechanism by which oxalate reabsorption may be reduced in this disease state is via binding of bile salts, which can in turn decrease colonic mucosal irritability and resulting oxalate hyperabsorption. This has been previously attempted with the administration of cholestyramine, a bile acid sequestrant. Although this should be effective in principle and has been demonstrated to be efficacious in animal models of hyperoxaluria, studies testing the efficacy of cholestyramine in human subjects have been less favorable (Nordenvall et al., 1983).

Hypomagnesiuria may also play a role in the elevated levels of urinary oxalate seen in enteric hyperoxaluria. Normally, magnesium has the potential to act as an oxalate binder and can destabilize calcium oxalate crystal formation (Li et al., 1985; Riley et al., 2013). However, the underlying GI issues that can lead to enteric hyperoxaluria may lead to impaired intestinal magnesium absorption as well, leading to hypomagnesiuria and elevated levels of unbound urinary oxalate. Oral magnesium supplements may be administered to correct low urinary magnesium levels; however, caution must be exercised to ensure the supplementation does not provoke further diarrhea. Magnesium supplementation can be administered as magnesium gluconate, oxide, and hydroxide. Optimal dosing has yet to be established. It has also been suggested to have a complementary role when added to potassium citrate therapy for stone prevention (Massey, 2005).

Patients with enteric hyperoxaluria are at risk for stone formation for reasons beyond solely high levels of urinary oxalate as well. It is critical for patients to maintain a high fluid diet at minimum over 2 L/day to combat the additional fluid losses resulting from GI malabsorption. Additionally, potassium citrate supplementation can help correct resulting hypokalemia and metabolic acidosis. As mentioned earlier, preference should be given toward the liquid form of potassium citrate in patients with rapid GI transit times, because the liquid form of this medication may be better absorbed than the slow-release, wax matrix pills.

Medical Therapy for Primary Hyperoxaluria

There are limited treatment options for PH. Pyridoxine (vitamin B_6) is one therapeutic agent that has been studied. It has been shown to be capable of increasing the expression, catalytic activity, and peroxisomal import of AGT (the missing enzyme responsible for PH1) by acting as a cofactor (Fargue et al., 2013). It has also shown some potential benefit in patients with idiopathic hyperoxaluria. In a retrospective study, Ortiz-Alvarado et al. (2011) found that a combination of dietary counseling (low-oxalate diet) and pyridoxine significantly reduced urinary oxalate in patients with idiopathic hyperoxaluria without note of any significant side effects.

Another potential therapy for patients with PH is oral *Oxalobacter forminges* administration. Conceptually, increased levels of *Oxalobacter* in the gut could help improve intestinal oxalate elimination. A previous study showed promising results after patients with PH were administered enteric-coated capsules containing lyophilized *Oxalobacter* for 4 weeks (Hoppe et al., 2006). However, follow-up studies using modified formulations for longer duration failed to replicate these findings (Hoppe et al., 2017; Milliner et al., 2018).

Key Points: Hyperoxaluria

- Urine oxalate reduction may be accomplished by following a low-oxalate diet.
- GI malabsorption can lead to hyperoxaluria via increased amounts of unbound oxalate and mucosal irritation from excess bile salts.
- Calcium supplementation with meals can lower urinary oxalate levels in enteric hyperoxaluria.
- Primary hyperoxaluria is a genetic disease characterized by extremely high urinary oxalate levels.

- Gut flora *(Oxalobacter forminges)* likely plays a role in dietary oxalate degradation and can be affected by exposure to antibiotics.

Other Causes of Calcium Stone Formation

Hyperuricosuric Calcium Oxalate Nephrolithiasis

Patients with hyperuricosuria may be prone to the formation of calcium oxalate calculi through the process of heterogeneous nucleation (also referred to as epitaxy) (Coe 1978; Coe and Kavalach, 1974; Pak and Arnold, 1975; Pak et al., 1976). The details of this process are outlined in Chapter 91. These patients give a history of calcium oxalate nephrolithiasis and may have a history of hyperuricemia with symptomatic gout. During metabolic evaluation, these patients will demonstrate hyperuricosuria (>800 mg/day).

There are two pharmacologic approaches to the management of hyperuricosuric calcium nephrolithiasis. The first involves decreasing the production of uric acid. Physicochemical changes ensuing from restoration of normal urinary uric acid include an increase in the urinary limit of metastability of calcium oxalate (Pak et al., 1978). Thus the spontaneous nucleation of calcium oxalate is slowed by allopurinol treatment, probably via inhibition of monosodium urate–induced stimulation of calcium oxalate crystallization (Coe, 1980).

Allopurinol is the most well-studied medication for this purpose and may be used to block the ability of xanthine oxidase to convert xanthine to uric acid (Coe and Raisen, 1973). There are few convincing randomized trials demonstrating the efficacy of allopurinol for the treatment of hyperuricosuria. However, one study by Ettinger et al. does stand out (Ettinger et al., 1986). In this double-blind, prospective, randomized trial, allopurinol was given to 60 patients with hyperuricosuria, normocalciuria, and recurrent calcium oxalate stones. A 6-month grace period was established, during which any new calculus that was passed was not considered to represent failure of therapy. With a follow-up of up to 39 months, new stone events (stone growth or recurrence) occurred in 58% of the patients on placebo and 31% of the patients on allopurinol. The placebo group had 63.4% fewer calculi, whereas the allopurinol group had 81.2% fewer calculi. The mean rate of calculus events was 0.26 per patient per year in the placebo group and 0.12 in the allopurinol group. The allopurinol group had a significantly longer time before the recurrence of stones (Ettinger et al., 1986). This study is the basis for AUA guideline recommendations that clinicians offer allopurinol to patients with recurrent calcium oxalate stones who have hyperuricosuria and normal urinary calcium (Pearle et al., 2014).

Recently, a newer-generation xanthine oxidase inhibitory, febuxostat (80 mg/day), has also been suggested to have similar efficacy in this regard with potentially fewer side effects. In one randomized controlled trial, patients on febuxostat had greater decreases in urinary uric acid from baseline than those on allopurinol or placebo (Goldfarb et al., 2013).

Alternatively, management of hyperuricosuria may be approached by altering the urinary milieu such that uric acid remains in a dissolved state (Pak et al., 1986). Central to this approach would be the obvious advantage of copious amounts of dilute urine to maintain uric acid at a low concentration. Attempts to maintain the urine at a pH above the pKa also may be successful by promoting dissolution of this molecule (Pak et al., 1986). This effect is usually achieved by the use of an alkalinizing agent such as potassium citrate (at a dose of 30 to 60 mEq/day in divided doses). In the study by Pak et al., the treatment produced a sustained rise in urinary pH by 0.55 to 0.85 to the high-normal range. Urinary citrate levels increased by 249 to 402 mg/day. Commensurate with these changes, urinary saturation of calcium oxalate (relative saturation ratio) and the amount of undissociated uric acid decreased significantly. Stone formation decreased from 1.55 per patient-year to 0.38 per patient-year during the mean treatment period of 2.35 years. Stones ceased to form in 16 of 19 patients during treatment.

Hypomagnesuric Calcium Nephrolithiasis (<80 mg)

Hypomagnesuric calcium nephrolithiasis is characterized by low urinary magnesium and is frequently seen in the setting of inflammatory bowel diseases accompanied by other stone-forming factors such as hypocitraturia and low urine volume. Treatment is achieved with magnesium supplementation.

The administration of magnesium salts was first advocated on the theory that it reduced urinary excretion of oxalate. Some magnesium salts increase urinary magnesium excretion and thus produce a more favorable magnesium-to-calcium ratio in the urine, a condition that offers relative protection against stone formation. Magnesium also decreases renal tubular citrate resorption through the chelation of citrate and thus increases urinary citrate excretion. Several treatment studies to date have demonstrated efficacy when using magnesium supplementation for stone prevention (Johansson et al., 1980; Melnick et al., 1971; Prien and Gershoff, 1974). Conversely, at least one randomized trial showed no difference in recurrence rates between treated and untreated patients (Ettinger et al., 1988).

Several magnesium salts have been used for the treatment of stone disease including magnesium oxide, hydroxide, gluconate, and potassium–magnesium citrate. **GI intolerance is the major side effect of magnesium therapy.** At this time, magnesium supplementation is not widely used (Table 92.6).

TABLE 92.6

Physicochemical and Physiologic Effects of Pharmacologic Therapy for Calcium Stone Disease

	SODIUM CELLULOSE PHOSPHATE	ORTHOPHOSPHATE	THIAZIDE	ALLOPURINOL
Urinary calcium	Marked decrease	Mild decrease	Moderate decrease	No change
Urinary phosphorus	Mild increase	Marked increase	Mild increase/no change	No change
Urinary uric acid	No change	No change	Mild increase/no change	Marked decrease
Urinary oxalate	Mild increase	Mild increase/no change	Mild increase/mild decrease	No change
Urinary citrate	No change	Mild increase	Mild decrease	No change
Calcium oxalate saturation	Mild decrease/no change	Mild decrease	Mild decrease	No change
Brushite saturation	Moderate decrease	Mild increase	Mild decrease	No change

Uric Acid Stones

Clinical Considerations

The proportion of uric acid stones in increasing. Xu et al. retrospectively analyzed the records of 1516 patients diagnosed with either a calcium or uric acid stone at a university kidney stone clinic from 1980 to 2015 (Xu et al., 2017). **During this time, the proportion of uric acid stones increased from 7% to 14%, and uric acid stone formers were consistently older with higher BMI and lower urinary pH than calcium stone formers.** The strongest clinical discriminant of uric acid versus calcium stones was urinary pH. Perhaps this increase in uric acid stones can be explained by the rise in metabolic syndrome and obesity as major health burdens affecting 30% of the general population in the United States (Cheal et al., 2004; Flegal et al., 2010). The pathophysiology of uric acid nephrolithiasis is explained in detail in Chapter 91 but does deserve some mention to better understand its diagnosis. **There are essentially three main determinants of uric acid stone formation: low urinary pH, hyperuricosuria, and low urine volume.** Disorders known to result in one or more of these urinary abnormalities include chronic diarrheal states, inflammatory bowel disease, ileostomy, myeloproliferative disorders, high animal protein intake, uricosuric medications, primary gout, obesity, metabolic syndrome, type 2 diabetes mellitus, and rare inherited diseases with mutations in the enzymatic pathways for uric acid production such as Lesch-Nyhan syndrome (deficiency of the enzyme hypoxanthine-guanine phosphoribosyltransferase [HGPRT]). Although these congenital and acquired disorders can result in uric acid stone formation, idiopathic uric acid nephrolithiasis is most common. **Idiopathic uric acid nephrolithiasis is characterized by decreased fractional excretion of urate, normal urinary uric acid levels, and acidic urine** (Maalouf et al., 2004).

Low Urine pH

Urine pH is the most important determinant of uric acid solubility. Because there are no known inhibitors of uric acid crystallization, undissociated uric acid will precipitate when the urine becomes supersaturated. The sigmoidal-shaped solubility curve will predict that at a pH of 6.5, more than 90% of all uric acid is ionized and therefore soluble. Fifty percent of uric acid is soluble at a pH of roughly 5.5 (pK_a) (Gutman and Yu, 1968). Urine pH <5.5 will increase the urinary content of undissociated uric acid and result in uric acid precipitation. **Low urine pH (<5.5) is the most common cause of uric acid stone formation** (Pak et al., 2002; Sakhaee et al., 2002)**. There are essentially two pathogenic mechanisms for low urine pH: increased net acid excretion and reduced renal ammonium excretion** (Cameron et al., 2006; Sakhaee et al., 2002). Patients with uric acid stones and non–stone formers with type 2 diabetes mellitus on controlled diets have been shown to have a net acid excretion 1.5 times the normal and reduced renal ammonium excretion (Cameron et al., 2006; Maalouf et al., 2010) (Fig. 92.9). It has been postulated that the increased net acid excretion may be secondary to differences in gut microflora in diabetics and uric acid stone formers (Larsen et al., 2010). Ammonium is a high-capacity buffer that works to buffer most of the hydrogen secreted by the kidney and maintain acid base hemostasis. Renal proximal tubular cells are the main renal segment for production and secretion of ammonium (Sakhaee, 2014). Animal studies have suggested that renal steatosis may be responsible for the reduced ammonium excretion (Bobulescu et al., 2008). **The impairment in ammonium excretion has been linked to insulin resistance in diabetic uric acid stone formers** (Sakhaee, 2014)**. Impaired ammonium production can leave hydrogen ions either unbuffered or buffered by titratable acid, and the result is low urinary pH.**

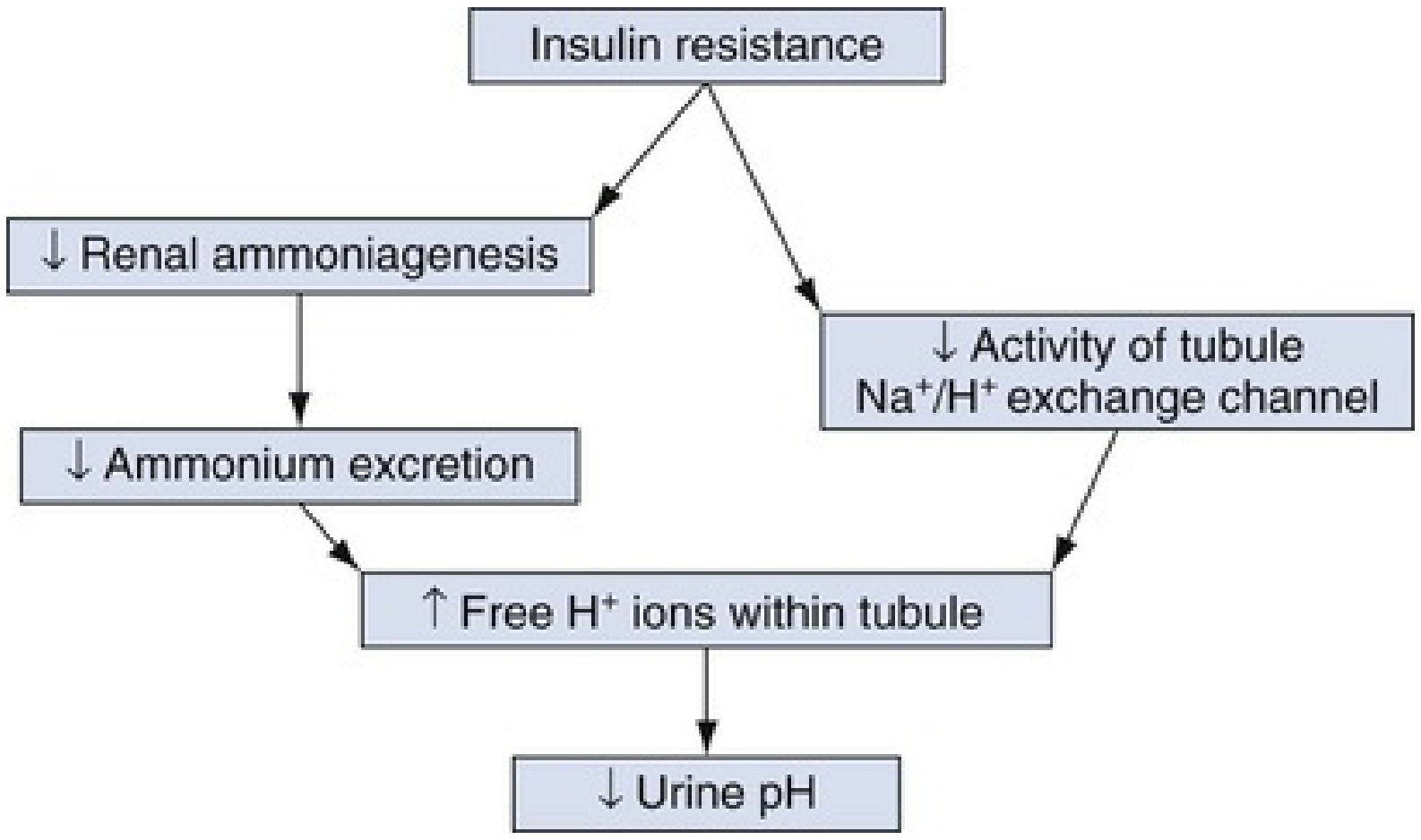
Insulin resistance
↓ Renal ammoniagenesis
↓ Activity of tubule Na⁺/H⁺ exchange channel
↓ Ammonium excretion
↑ Free H⁺ ions within tubule
↓ Urine pH

FIG. 92.9 Pathophysiology of low urine pH in patients with insulin resistance. (From Wollin DA, Skolarikos A, Preminger GM: Obesity and metabolic stone disease, *Curr Opin Urol* 27(5):422–427, 2017.)

Diabetes, Obesity, and Metabolic Syndrome

Metabolic syndrome consists of a cluster of disease states—glucose intolerance, elevated blood pressure, dyslipidemia, and central obesity—that increase the risk for developing type 2 diabetes and coronary vascular disease. All of these issues are frequently found in the obese population. Assessment of the overall rise of type 2 diabetes, obesity, metabolic syndrome, and stone disease suggests potential correlation among these states. A number of investigations have shown an increased risk for stone disease in patients with metabolic syndrome (Kadlec et al., 2012; Sakhaee et al., 2012). Cho et al. reported on the stone composition of patients with metabolic syndrome (Cho et al., 2013). Although the most common stone composition was calcium oxalate, these patients had a significantly higher risk for having a uric acid stone compared with patients without metabolic syndrome.

A number of studies have identified an increased risk for stone disease in diabetics (Lieske et al., 2006; Pak et al., 2003; Taylor et al., 2005; Weinberg et al., 2014). Lieske et al. identified an OR of 1.22 for diabetes among stone formers, whereas Taylor et al. found a relative risk of 1.31 to 1.38 of stone formation in patients with diabetes, depending on age and sex (Lieske et al., 2006; Taylor et al., 2005). These studies confirm the earlier work by Pak et al., in which uric acid stones were identified in a statistically significant predominance for patients with diabetes, indicating innate metabolic abnormalities specific to patients with diabetes.

Recent studies suggest that the increased incidence of uric acid stone formation in obese stone formers may be secondary to the production of more acidic urine than in nonobese patients. Combined data from the two largest stone centers in the United States found that urine pH appears to be directly correlated with body size (Maalouf et al., 2004). Furthermore, patients with type 2 diabetes have been found to have lower urinary pH than nondiabetics independent of the formation of uric acid stones (Cameron et al., 2006). When evaluating patients who form uric acid stones, Sakhaee et al. (2002) identified a much higher incidence of diabetes (both types 1 and 2) compared with other groups. Because individuals with diabetes have impaired ammonium excretion, they have been shown to have an increased incidence of uric acid stone formation (Abate 2004; Pak et al., 2003b). Finally, low urine pH has been shown to directly correlate with the number of metabolic syndrome features (Maalouf et al., 2007). From evaluation of 24-hour urinalyses in 148 non–stone-forming patients, a statistically significant linear relationship was identified in which each additional characteristic of metabolic syndrome portended a decrease in urine pH. Additionally, the degree of insulin resistance was also inversely related to urinary pH.

The Curhan group formally studied the association between body size and risk for stone formation (Curhan et al., 1998a). In two large cohorts, the HPFS and the NHS, the prevalence of stone disease history and the incidence of new stone formation were directly associated with weight and BMI. The magnitude of the association was greater in women than in men. Subsequently, Taylor and Curhan performed a subset analysis on the HPFS and NHS cohorts with evaluation of 24-hour urinalyses (Taylor and Curhan, 2006). Higher BMI was found to be associated with increased urinary excretion of oxalate, sodium, uric acid, calcium, and phosphorus, and lower pH. These same cohorts of patients have been continuously followed, and the group from Boston has provided a recent update on the role of obesity and nephrolithiasis. **They demonstrated that increased BMI, larger waist size, and weight gain correlated with an increased risk for stone episodes. This increased stone risk was still more pronounced for women** (Taylor et al., 2005).

In a review of a large national database, Powell et al. examined the serum and 24-hour urine parameters from nearly 6000 patients with a history of nephrolithiasis (Powell et al., 2000). Within this cohort, obese patients had increased urinary excretion of sodium, calcium, magnesium, citrate, sulfate, phosphate, oxalate, uric acid, and cystine combined with a decrease in urinary pH. One study has specifically evaluated the metabolic disturbances of obese patients, defined as a BMI greater than 30 (Ekeruo et al., 2004). It was determined that the most common manifesting metabolic abnormalities among obese patients included gouty diathesis (54%), hypocitraturia (54%), and hyperuricosuria (43%), which manifested at levels that were significantly higher than those found in nonobese stone formers. When present, chemical stone analysis showed a predominance of uric acid calculi, implicating excessively acidic urine in these subjects. Directed medical therapy and dietary recommendations were able to dramatically reduce stone episodes for these patients.

Diagnosis

The diagnosis of uric acid nephrolithiasis is best made with stone analysis; however, a detailed patient history is important to identify conditions known to increase the risk for uric acid stone formation as described previously (chronic diarrheal states, inflammatory bowel disease, ileostomy, myeloproliferative disorders, high animal protein intake, uricosuric medications, primary gout, obesity, metabolic syndrome, type 2 diabetes mellitus, rare inherited diseases). Uric acid calculi are notoriously radiolucent. Tomography may overcome this difficulty, as can the acquisition of an noncontrast CT scan. Dual-energy CT can be used to distinguish uric acid calculi from calcium stones with a high degree of accuracy (Primak et al., 2007). These stones frequently have an orange/canary yellow appearance, especially when viewed endoscopically. Uric acid stone formers can have a propensity to produce large volumes of very small calculi that may cause obstruction as they pass down the ureter.

Once the diagnosis of uric acid nephrolithiasis is made, a dietary history should be obtained to assess for purine gluttony (high intake of animal protein). 24-hour urine testing is also recommended to evaluate the three main determinants of uric acid stone formation: urine volume, urine pH, and urinary uric acid levels. Often, 24-hour urine collections can underestimate the total amount of uric acid if the specimen pH drops lower than 5.5. In this scenario, the uric acid forms precipitates and settles to the bottom of the collection container. Up to 20% of patients with gout will develop uric acid calculi, prompting examination of serum for hyperuricemia.

Conservative Treatment for Uric Acid Stone Prevention

Low urine volume is a major risk factor for stone formation, and fluid intake is the main determinant of urine volume. Similar to other stone types, uric acid stone formers should maintain fluid intake high enough to achieve a urine volume of at least 2.5 L/day (Pearle et al., 2014). **Uric acid stone formers with hyperuricosuria should be counseled to limit nondairy animal protein as diet-derived purines account for an estimated 30% of urinary uric acid (Pearle et al., 2014).** In addition, these patients should be encouraged to consume foods that confer an alkali load, such as fruits and vegetables, to raise urine pH. In addition, physical activity, weight loss, and glucose control are useful adjuncts for stone prevention in patients with obesity, metabolic syndrome, and/or diabetes mellitus (Torricelli et al., 2014).

Medical Treatment for Uric Acid Stone Prevention

The major goal in the management of uric acid stones is to increase the urinary pH above 5.5, preferably between 6.0 and 6.5 (Khatchadourian et al., 1995). In the past, urine alkalinization has been accomplished with either sodium bicarbonate or various combinations of sodium and potassium alkali therapy. Although sodium alkali may enhance dissociation of uric acid and inhibit uric stone acid formation by raising urinary pH, this medication may be complicated by the development of calcium-containing stones (calcium phosphate and/or calcium oxalate). Potassium citrate is advantageous because it is not only a good alkalinizing agent, but it appears to be devoid of the complication of calcium stones. Potassium citrate should be given at doses sufficient to maintain urinary pH at approximately 6.5 (30 to 60 mEq/day in two or three divided doses). Attempts at alkalinizing the urine to a pH of greater than 7.0 should be avoided because at a higher pH there is a danger of increasing the risk for calcium phosphate stone formation.

Allopurinol should not be routinely offered as first-line therapy in patients with uric acid stones as low urinary pH is by far the predominant risk factor (Maalouf et al., 2004; Pearle et al., 2014). Patients with hyperuricemia and hyperuricosuria, such as may be seen with primary gout, may be an exception. The AUA guidelines also suggest allopurinol may be used as adjunctive therapy in patients in whom alkalinization of the urine is not successful or who continue to form stones despite appropriate alkalinization of the urine. If allopurinol is to be used, the typical dose is 300 mg/day orally. Allopurinol is primarily eliminated by the kidney; therefore, dose reduction is required in patients with impaired renal function. Common side effects include skin rash, muscle pain, nausea, vomiting, and diarrhea. In 2% to 8% of patients, allopurinol can cause adverse reactions ranging from cutaneous hypersensitivity reactions to the potentially life-threatening allopurinol hypersensitivity syndrome (AHS), which causes death in up to 27% of cases. Allopurinol is also reported to be a common cause of Stevens-Johnson syndrome (erythema multiforme exudativum) and complicated renal failure. Adverse reactions were reported in association with higher dosage, renal insufficiency, and diuretic and statin use (Ryu et al., 2013). Finally, hypersensitivity reactions may be increased in patients with decreased renal function who receive thiazides and allopurinol concurrently.

Key Points: Uric Acid Stones

- The proportion of uric acid stones is increasing.
- The most common cause of uric acid stones is low urinary pH (<5.5).
- Low urine pH results from increased net acid excretion and reduced renal ammonium excretion.

- Obesity, metabolic syndrome, and diabetes mellitus increase the risk for uric acid stone formation.
- Prevention and treatment of uric acid stones centers on reduction of non-dairy animal protein and alkalinization of the urine.

Cystinuria

Clinical Considerations

Cystinuria occurs secondary to mutations in the *SLC3A1* gene (located on chromosome 2) and the *SLC7A9* gene (located on chromosome 19), which encode the two subunits of the amino acid transporter, resulting in failure of absorption of dibasic amino acids in the proximal tubule including cystine, ornithine, lysine, and arginine (Pak and Fuller, 1983; Thier et al., 1965). The *SLC3A1* gene encodes the heavy subunit of the renal amino acid transporter (rBAT), which is needed to localize the transporter to the plasma membrane (Eggermann et al., 2012). The *SLC7A9* gene encodes the light subunit of the renal amino acid transporter (b0, +AT), which compromises the catalytic, transporting component. The type of genetic mutation and the mode of inheritance has been used to categorize cystinuria as types A, B, and AB. Cystinuria type A is defined by mutations in the *SLC3A1* gene with autosomal recessive inheritance and high penetrance, meaning increased urinary cystine excretion and kidney stone formation. Cystinuria type B is caused by mutations in the *SLC7A9* gene, which can be inherited as autosomal recessive or autosomal dominant with incomplete penetrance. Type B homozygotes present similar to type A, and carriers (parents, siblings, and children) may have elevated cystine levels but reduced stone formation. In rare cases (1.2% to 4%), patients may have mutations in both genes and be classified as cystinuria type AB. Although no clinical differences have been found between types A and B cystinuria, one benefit of knowing genotype is to estimate recurrence risk in the family.

Cystine has limited solubility in the physiologic range of urine pH, and therefore crystallization occurs when concentrations rise above the saturation point (~250 mg cystine per liter of urine) (Pak and Fuller, 1983). Patients with cystinuria may present with stones at a young age and have affected first-degree relatives. The stones are often yellow and waxy and relatively faint on plain radiography. Staghorn calculi or multiple, filled calyces are common. Historically, a diagnosis of cystinuria was made with the use of a sodium nitroprusside spot test that displays a purple color in the presence of cystine (Smith, 1977). Microscopic analysis of the urine may also demonstrate the pathognomonic hexagonal cystine crystals (see Fig. 92.4). These tests are primarily used to screen for cystinuria as they do not provide a quantitative measurement. Once the diagnosis of cystinuria is made, cystine excretion can be measured by 24-hour urine collection. However, quantitative measurements of cystine can be difficult to perform because of interference from other sulfhydryl-containing compounds (e.g., medications used to treat this disorder) or from significant variances with minor changes in urine pH or creatinine content (Pak and Fuller, 1983). For example, most chromatographic cystine assays cannot distinguish cystine from soluble thiol-cysteine drug complexes. Coe et al. developed a more reliable method of cystine supersaturation measurement known as *cystine capacity* (Coe et al., 2001). The assay involves adding a known amount of solid cystine to the urine of a patient with cystinuria to measure the change in solid phase after incubation. In undersaturated urine, some of the solid-phase cystine will dissolve and thereby reduce the amount that was initially added (positive capacity). In supersaturated urine, the cystine already in the urine precipitates on the added cystine crystals, and the amount of solid phase cystine recovered is greater than what was initially added (negative capacity). In other words, undersaturated urine has positive cystine capacity, and supersaturated urine has negative cystine capacity. Cystine capacity has proved to be equivalent to cystine concentration and supersaturation to predict clinical stone capacity and greatly aids in the diagnosis and management of cystinuria (Nakagawa et al., 2000).

Patients with cystinuria may demonstrate additional metabolic anomalies on 24-hour urine studies (Sakhaee et al., 1989). In a controlled dietary assessment of 27 patients with cystinuria, hypercalciuria was noted in 18.5% of patients and hyperuricosuria in 22.2%. Hypocitraturia was identified in 44.4% and was associated with defective renal acidification in 80% of the patients in whom it was tested. The authors noted that hypercalciuria, hyperuricosuria, and hypocitraturia frequently accompany cystinuria and speculated that these conditions might be renal in origin, rather than a result of dietary or environmental aberrations. They further concluded that these unrelated anomalies may contribute to the formation of calcium and uric acid stones, which sometimes complicate cystine nephrolithiasis. In addition, alkalinizing agents prescribed as treatment for cystinuria may have the effect of raising urine pH and increasing the risk for calcium phosphate stone formation.

Conservative Strategies for Cystine Stone Prevention

The primary goal in the treatment of cystinuria is to decrease the risk for stone formation by lowering cystine concentration (below 250 mg/L) and increasing cystine solubility (Andreassen et al., 2016; Pak and Fuller, 1983). Measures that lower cystine concentration include hydration and dietary measures, and alkalinization of the urine and cystine-binding drugs are used to increase solubility. High fluid intake, although preventive for many different types of stones, is absolutely essential in the prevention of cystine stones. The fluid intake must be high enough for a person to produce at least 3 L/day of urine and evenly distributed throughout the 24-hour period to prevent the physiologic concentration of urine that typically occurs at night. This amount of urine output will dramatically raise the denominator of the concentration fraction and help reduce the supersaturation of urine with respect to cystine. Recommendations for fluid intake vary from 3 to 5 L/day for adults and 3 L/day for children depending on age and weight. In addition, fluid intake must be adjusted during periods of increased insensible losses such as heavy exercise, fever, and high ambient temperature.

In addition to hydration, other dietary measures known to reduce cystine excretion include sodium reduction and protein restriction (Fjellstedt et al., 2001; Lindell et al., 1995; Norman and Manette, 1990; Rodriguez et al., 1995). The AUA guideline on the Medical Management of Kidney Stones recommends that clinicians counsel patients with cystine stones to limit sodium and protein intake (Pearle et al., 2014). Restricting sodium intake to 1 mmol/kg/day has been shown to not only decrease cystine excretion but also increase proximal tubular reabsorption of cystine (Lindell et al., 1995). In fact, Fjellstedt et al. (2001) showed that when sodium citrate was used to alkalinize the urine of patients with cystinuria rather than potassium citrate, the efficacy of other medical interventions, such as the sulfhydryl-containing compound α-mercaptoprionylglycine (Thiola), was diminished. A general recommendation for sodium intake in cystinuric patients is ≤2300 mg/day. Animal protein is rich in amino acids cystine and methionine, which is ultimately metabolized to cystine. Therefore, limiting animal protein such as eggs, fish, chicken, beef, and pork has been suggested as a means of decreasing cystine excretion. Rodman et al. (1984) demonstrated this in a study in which urinary cystine excretion was significantly decreased in homozygous cystinuric patients who were maintained on a low-protein diet of less than 9% of total calories compared with those on a diet in which 27% of total calories were from protein. However, protein restriction should not be recommended in children and adolescents as methionine is an essential amino acid for growth and is limited in plant foods. Furthermore, an effect on cystine stone recurrence of a protein-restricted diet has yet to be demonstrated. Cystinuric patients should be encouraged to consume fruits and vegetables that contain malate and citrate, which may have the effect of raising urine pH.

Medical Therapy for Cystine Stone Prevention

In addition to hydration and the dietary measures discussed earlier, **first-line treatment for cystinuria includes urinary alkalinization, which is best achieved by oral administration of soluble alkali at a dose sufficient to raise the urinary pH to 7.0 to 7.5** (Chow and Streem, 1998; Joly et al., 1999). This treatment strategy attempts to increase the solubility of the filtered cystine to prevent crystal formation. Although sodium bicarbonate, sodium citrate, and potassium citrate all have the ability to alkalinize the urine, **potassium citrate is the preferred alkali in cystine stone formers** as a sodium load may actually increase cystine excretion. The usual dose of potassium citrate is 30 to 60 mEq/day but should be titrated to achieve the goal of a urinary pH of 7.0 to 7.5. Although the pKa of cystine is 8.3, which would achieve greatest solubility for cystine, it is quite difficult to achieve a urine pH this high, and raising the urine pH over 7.5 introduces the risk for calcium phosphate stone formation. Common side effects of potassium citrate include nausea, abdominal pain, vomiting, and diarrhea, which are reduced when patients take the medication with a meal. **Potassium citrate must be used with caution in patients with impaired GI motility as it may lead to gastric ulceration and in patients with impaired renal function or those taking angiotensin-converting enzyme (ACE) inhibitors as hyperkalemia may develop.**

When first-line therapy with hydration, dietary measures, and alkalinization are not enough to prevent cystine stone formation, **second-line therapy consists of agents that increase cystine solubility in urine by formation of a more soluble mixed-disulfide bond (i.e., cystine to drug, rather than cystine to cystine). These agents include α-mercaptopropionylglycine (Tiopronin [Thiola]), D-penicillamine (Cuprimine), and captopril.** Thiols are organosulfur compounds that contain a sulfhydryl group that combines with cystine to form a more soluble drug-cysteine complex.

Introduced in 1963, D-penicillamine was the first thiol drug used in the treatment of cystinuria. Interestingly, very little has been written specifically about this agent and its use in the treatment of cystinuria since the 1960s to 1970s (Combe et al., 1993; Crawhall and Thompson, 1965; Lotz et al., 1966; McDonald and Henneman, 1965). Dahlberg et al. (1977) demonstrated a reduction in stone recurrence, stone passage, and stone growth when D-penicillamine was added to conservative therapy in cystinuric stone formers. Two follow-up studies further demonstrated benefit of thiol drugs. The first study evaluated 27 adult cystine stone formers treated with D-penicillamine or α-mercaptopropionylglycine (Tiopronin) in addition to hydration and alkalinizing agents, and found a significant decrease in stone episodes and urologic procedures (Barbey et al., 2000). The second study conducted in 16 cystinuric patients with long-term follow-up (7 to 141 months) demonstrated that the stone event per patient year decreased from 1.58 to 0.52 (or 65% decrease in yearly stone event rate) when thiol drugs were added to conservative management. Although moderately effective, D-penicillamine has largely been replaced by α-mercaptopropionylglycine (Tiopronin) because of frequent adverse effects including rash, fever, arthralgia, pancytopenia, proteinuria, and nephrotic syndrome. However, there are some long-time cystinuric patients originally started on D-penicillamine who tolerate the drug without significant side effects. One recent study documented 9 in 11 patients without toxicity for an average of 109 months of follow-up after an initial dose escalation (DeBerardinis et al., 2008). Typical doses of D-penicillamine for adults start at 250 mg/day and are titrated to effect.

The second-generation medication to be introduced for the treatment of cystinuria was α-mercaptopropionylglycine (Tiopronin [Thiola]), which was approved by the Food and Drug Administration in 1988 (Hautmann et al., 1977; Johansen et al., 1980; Remien et al., 1975). This agent also contains a sulfhydryl group that forms a disulfide bond with cystine. **α-mercaptopropionylglycine (Tiopronin) is possibly more effective than D-penicillamine and is associated with fewer adverse effects, making it the thiol drug of choice in patients with cystinuria** (Pak et al., 1986a; Pearle et al., 2014). Pak et al. (1986a) showed that among the patients who took both drugs, 30.6% had to stop taking α-mercaptopropionylglycine, whereas 69.4% could not tolerate D-penicillamine. Typical dosages of α-mercaptopropionylglycine (Tiopronin) start at 300 mg, taken orally two times per day, up to as high as 1200 mg/day and titrated to achieve urinary concentrations of cystine less than 250 mg/L urine. Side effects may still occur with α-mercaptopropionylglycine (Tiopronin) including asthenia, GI distress, rash, joint aches, and mental status changes; however, serious adverse reactions requiring cessation of therapy are less common (Pak et al., 1986a).

Finally, the ACE inhibitor captopril has been used to treat cystinuria because it contains a sulfhydryl group and can form a captopril-cysteine disulphide shown to increase cystine solubility in vitro nearly 200 times (Sloand and Izzo, 1987). Although this agent enjoyed early enthusiasm (Streem and Hall, 1989; Cohen et al., 1995), its popularity seems to have waned because of predominantly case-based reports and contradictory results (Michelakakis et al., 1993). Captopril has mainly been used in patients intolerant of other thiols and the recommended dose is 25 mg orally three times daily. Side effects are less severe than the other agents and include fatigue, hypotension, and chronic cough. **Yet, there have been no long-term clinical trials demonstrating the effectiveness of captopril in preventing recurrent cystine stone formation perhaps because its excretion in the urine at maximal doses may not be sufficient to have an effect in binding cystine** (Michelakakis et al., 1993; Pearle et al., 2014).

A novel treatment for the prevention of cystine nephrolithiasis has been studied using the *Slc3a1*−/− mouse model of cystinuria. Zee et al. compared *Slc3a1*−/− mice treated with the nutritional supplement alpha lipoic acid with untreated mice and found alpha lipoic acid was effective in inhibiting cystine stone formation by increasing the solubility of urinary cystine (Zee et al., 2017). The authors postulate that alpha lipoic acid undergoes extensive metabolism resulting in urine metabolites that are ultimately responsible for preventing cystine stone formation. The effect on cystine solubility was also achieved without inducing any change in urinary pH. If the results can be confirmed in human subjects, this could be a promising new therapy for cystinuric patients as the supplement is widely available and has few adverse side effects (Ziegler et al., 2006).

Follow-Up

The goals of care for cystinuric patients include preventing stone formation, preserving renal function, limiting adverse effects of medical therapy, and ensuring patient compliance. The AUA guidelines for the medical management of kidney stones recommends for stone formers an initial 24-hour urine study, a repeat study within 6 months of initiating dietary and/or medical therapy, followed by repeat testing annually or with greater frequency depending on stone activity (Pearle et al., 2014). As mentioned previously, 24-hour measurement of urinary cystine concentration may not be adequate to determine treatment efficacy because most cysteine assays do not distinguish cysteine from soluble thiol-cysteine drug complexes. Therefore, cysteine capacity may be a more effective tool for guiding patient response to therapy. A recent study by Friedlander et al. evaluated urinary cystine parameters including cystine capacity to determine if any could reliably predict clinical stone recurrence (Friedlander et al., 2018). They prospectively followed 48 cystinuric patients using 24-hour urine collections and serial imaging while recording stone activity. Urinary cystine parameters at times of stone activity were compared with those obtained during periods of stone inactivity. Cystine concentration and supersaturation were significantly lower and cystine capacity was significantly higher during stone inactivity than during periods of active stone formation. Cystine capacity proved to be equivalent to cystine concentration and supersaturation to predict clinical stone activity but seemed to be the parameter most reflective of stone-forming potential in any individual urine sample. The authors also suggested that the target value for cystine capacity to prevent stone recurrence should be lowered to 90 mg/L rather than the current recommendation of 150 mg/dL. In addition to maintaining cystine capacity (>90 to 150 mg/dL), treatment goals include 24-hour urine volume (>3 L/day), pH (7.0 to 7.5), and sodium (<100 mmol/day).

Chronic kidney disease has been reported in 5% to 17% of cystinuric patients, with end-stage renal failure occurring in less than 5% (Lindell et al., 1997). Assimos et al. (2002) examined the clinical status of 40 cystinuric patients followed at two medical centers and compared their kidney health to that of 3964 calcium oxalate stone formers enrolled in a database. The mean serum creatinine for stone-forming cystinuric patients was significantly higher than that of the calcium oxalate cohort. Male gender, increasing number of open surgical stone removal procedures, and nephrectomy were significant variables associated with an increased serum creatinine. An alarming number of cystinuric patients had undergone nephrectomy for any reason (14%) versus the patients in the calcium oxalate cohort (3%). These statistics underscore the necessity to regularly monitor renal function in cystine stone formers and actively manage comorbid conditions that may affect renal function such as hypertension and diabetes mellitus.

In addition to preserving renal function, cystinuric patients on thiol drugs must be monitored for adverse effects including neutropenia, thrombocytopenia, anemia, proteinuria, rash, and copper/zinc deficiency. Complete blood count, liver enzymes, and 24-hour urinary protein or urine protein-to-creatinine ratio should be evaluated at least annually in these patients.

Compliance and Quality of Life

The medical management of cystinuria can be quite challenging. Although the array of medication choices is not particularly complicated, it is often difficult to achieve patient compliance (Barbey et al., 2000). Perhaps this is not surprising given the rare hereditary nature of the disease, which results in recurrent stone formation and the risk for chronic stone passage and/or stone treatment (Lindell et al., 1997). A recent study suggests that few patients are able to achieve and maintain targeted goals of medical intervention (Pietrow et al., 2003). Of the 26 patients followed at a dedicated stone center, only 15% achieved and maintained therapeutic success, as defined by urine cystine concentration less than 300 mg/L. An additional 42% achieved therapeutic success but subsequently had failure at an average of 16 months (range 6 to 27). Of these patients, two-thirds were able to regain therapeutic success at an average of 9.4 months (range 4 to 20). However, 19% never achieved therapeutic success, and an additional 23% failed to present to follow-up appointments or provide subsequent 24-hour urine studies, despite having been referred to a tertiary care center. It is very important to note that patient self-assessment of medical compliance was uniformly high regardless of physician perceptions or treatment results.

Given the known challenges of compliance and adherence to prescribed dietary and medical therapy, cystinuric patients may also suffer from decreased health-related quality of life (HRQOL). Streeper et al. used a stone-specific Wisconsin Stone Quality of Life (WISQOL) questionnaire to compare HRQOL in cystine stone formers compared with noncystine stone formers (Streeper et al., 2017). They found that compared with noncystine stone formers, cystine stone formers had significantly lower total WISQOL scores, lower HRQOL scores for subscales (domains) related to social impact, emotional impact, disease impact, and vitality and reported significantly more sleep problems, nocturia, and fatigue.

Efforts to improve compliance and disease management in cystinuric patients include patient education, support groups, and an interdisciplinary approach (urology, nephrology, dietician, pediatrics). The Rare Kidney Stone Consortium (http://www.rarekidneystones.org) facilitates cooperative exchange of information and resources among investigators, clinicians, patients, and researchers to improve care and outcomes for patients with rare stone diseases such as cystinuria. Other patient resources include the International Cystinuria Foundation (http://www.cystinuria.org) and the Cystinuria Support Network (http://cystinuria.net).

Key Points: Cystinuria

- Cystinuria is an inherited disease that occurs secondary to mutations in the *SLC3A1* and *SLC7A9* genes resulting in failure of absorption of dibasic amino acids in the proximal tubule including cystine, ornithine, lysine, and arginine.
- Cystinuria manifests when urinary concentrations exceed 250 mg/L.
- Cystinuria may be accompanied by other metabolic abnormalities.
- First-line treatment for cystinuria includes hydration, limitation of dietary sodium/protein, and alkalinization of the urine (potassium citrate).
- Thiol drugs are recommended for cystine stone formers who are unresponsive to dietary modifications and alkalinization.
- α-Mercaptopropionylglycine (Tiopronin) is the thiol drug of choice because it has fewer adverse effects.
- The medical compliance of patients with cystinuria remains a challenge but can be improved with a patient-centered multidisciplinary approach and patient education.

Infection Calculi

The term *infection stone* typically refers to stones that form secondary to infection of the urine with urease-producing bacteria. This can result in stones composed of magnesium ammonium phosphate (struvite) or calcium carbonate apatite. **Infection calculi form in the presence of alkaline urine (pH >7.2) and in an environment rich in ammonia** (Nemoy and Staney, 1971)**. Urease splits urea into ammonia and carbon dioxide. Ammonia reacts with water to become ammonium and hydroxide ions, which creates an alkaline urine. The ammonium combines with magnesium, phosphate, and water to create magnesium ammonium phosphate (struvite) stones. The carbon dioxide**

eventually breaks down to carbonate, which combines with calcium and phosphate to form calcium carbonate apatite stones (Fig. 92.10) (Marien and Miller, 2015). Many bacterial organisms are able to produce the urease enzyme (Table 92.7), the most notorious of which is *Proteus mirabilis*. Although most *Escherichia coli* species are not able to split urea, 1.4% of *E. coli* species have been reported as producing urease, and *E. coli* may be associated with struvite calculi, perhaps through a metachronous infection. A recent study by Flannigan et al. retrospectively analyzed data from patients with infection stones over a 4-year period from four different institutions and found that struvite stones were most often heterogeneous in composition (only 13.2% were pure struvite), and urease-producing bacteria were only present in 30% of cases (Flannigan et al., 2018). *Proteus, E. coli*, and *Enterococcus* were the most common bacterial isolates from perioperative urine, and only 40% of patients had a urinalysis that was nitrite-positive, indicating that urinalysis alone is not reliable for diagnosing infection stones, and patients with struvite stones can have urinary tract pathogens other than urease-producing bacteria.

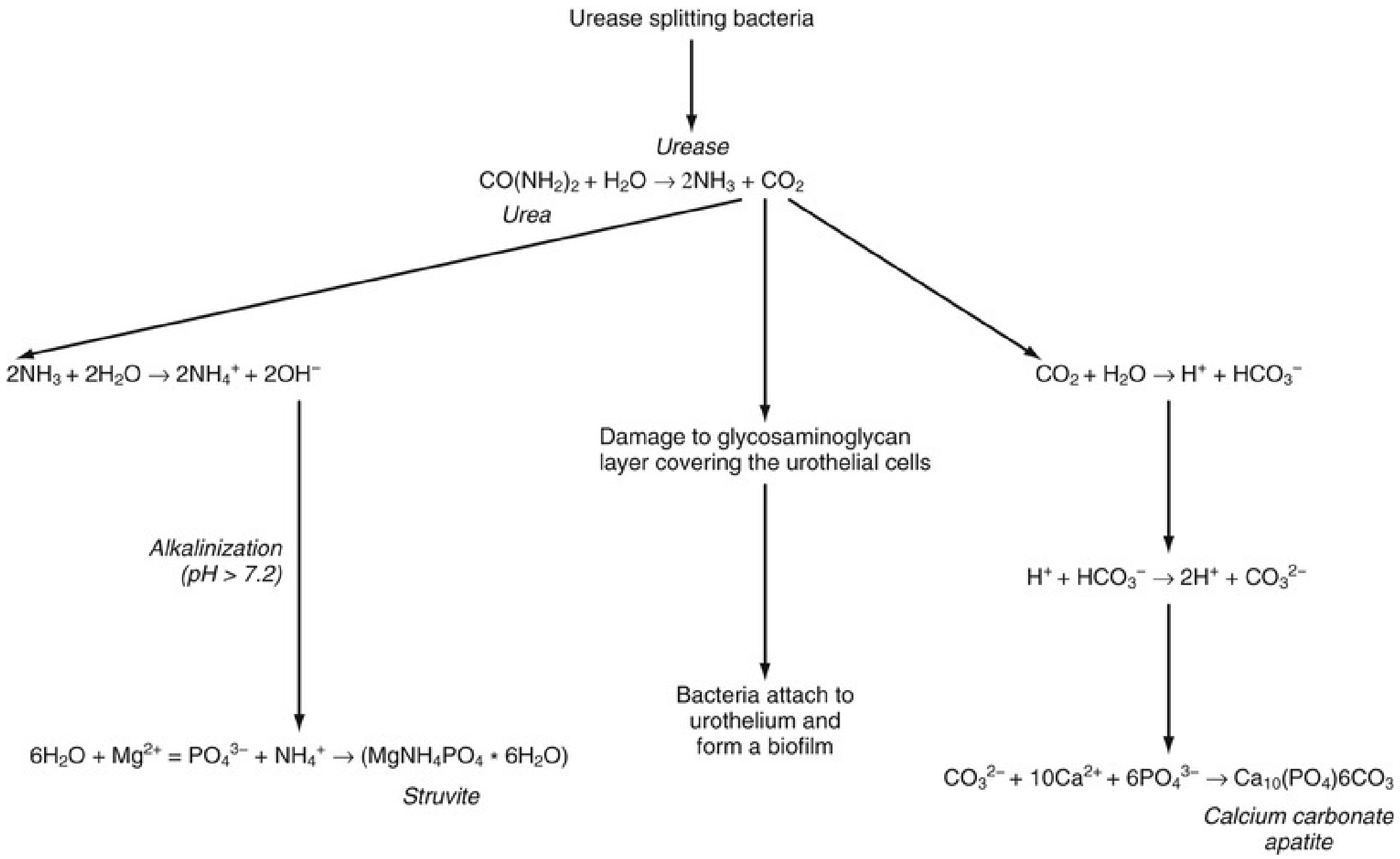
Urease splitting bacteria
Urease
$CO(NH_2)_2 + H_2O \rightarrow 2NH_3 + CO_2$
Urea
$2NH_3 + 2H_2O \rightarrow 2NH_4^+ + 2OH^-$
Damage to glycosaminoglycan layer covering the urothelial cells
$CO_2 + H_2O \rightarrow H^+ + HCO_3^-$
Alkalinization (pH > 7.2)
$H^+ + HCO_3^- \rightarrow 2H^+ + CO_3^{2-}$
Bacteria attach to urothelium and form a biofilm
$6H_2O + Mg^{2+} = PO_4^{3-} + NH_4^+ \rightarrow (MgNH_4PO_4 \cdot 6H_2O)$
Struvite
$CO_3^{2-} + 10Ca^{2+} + 6PO_4^{3-} \rightarrow Ca_{10}(PO_4)6CO_3$
Calcium carbonate apatite

FIG. 92.10 Pathophysiology of infection stone. (Marien T, Miller NL. Treatment of the infected stone. *Urol Clin North Am* 42(4):459–472, 2015.)

TABLE 92.7

Urea-Splitting Organisms

ORGANISMS	**USUALLY (>90% OF ISOLATES)**	**OCCASIONALLY (5%–30% OF ISOLATES)**
Gram negative	*Proteus rettgeri*	*Klebsiella pneumoniae*
	Proteus vulgaris	*Klebsiella oxytoca*
	Proteus mirabilis	*Serratia marcescens*
	Proteus morganii	*Haemophilus parainfluenzae* *Bordetella bronchiseptica* *Aeromonas hydrophila* *Pseudomonas aeruginosa* *Pasteurella* spp.
	Providencia stuartii	
	Haemophilus influenzae	
	Bordetella pertussis	
	Bacteroides corrodens	
	Yersinia enterocolitica	
	Brucella spp.	
Gram positive	*Flavobacterium* spp. *Staphylococcus aureus* *Micrococcus* *Corynebacterium ulcerans* *Corynebacterium renale* *Corynebacterium ovis* *Corynebacterium hofmannii*	*Staphylococcus epidermidis*
		Bacillus spp.
		Corynebacterium murium
		Corynebacterium equi
		Peptococcus asaccharolyticus
		Clostridium tetani
		Mycobacterium rhodochrous group
Mycoplasma	T-strain *Mycoplasma*	
	Ureaplasma urealyticum	
Yeasts	*Cryptococcus*	
	Rhodotorula	
	Sporobolomyces	
	Candida humicola	
	Trichosporon cutaneum	

From Gleeson MJ, Griffith DP. Infection stones. In: Resnick MI, Pak CYC, eds. *Urolithiasis: a medical and surgical reference.* Philadelphia, PA: Saunders; 1990:115.

Patients with infection calculi may present with symptoms of acute pyelonephritis, including fevers, chills, flank pain, dysuria, frequency, urgency, and malodorous, cloudy urine. Some patients may exhibit more chronic symptoms of malaise, fatigue, loss of appetite, and generalized weakness. Rarely, infections and obstruction have been long-standing enough to produce xanthogranulomatous pyelonephritis, which may cause the failure of an entire kidney or may just affect a portion. Jaeger et al. examined the endoscopic characteristics of renal papillae in struvite stone formers undergoing percutaneous nephrolithotomy and found less Randall's plaque formation than calcium oxalate stone formers and evidence of severe parenchymal and interstitial inflammation compared with other stone formers (Jaeger et al., 2016). The natural history of these stones is associated with progressive morbidity and mortality, with the 10-year mortality rate reported at 28% with nonsurgical management versus 7% with surgical treatment (Koga et al., 1991). Spontaneous fistulae may develop to external surfaces or to peritoneal contents.

The incidence of infection stones has decreased over the past 30 years, likely a result of improved medical care. However, women are more often affected than men (10% to 11% versus 4% in men) as are the elderly, and this is likely a result of increased susceptibility to urinary tract colonization (Daudon et al., 2004; Knoll et al., 2011). Patients with neurogenic bladder, urinary diversion, or history of a foreign body (e.g., forgotten stent, suture material, staple, indwelling stent) are at highest risk for developing infection stones. Struvite calculi can be quite large and take on a typical partial or full staghorn configuration. Urine cultures often will reveal a bacterial pathogen, although, as noted previously, the presence of a sterile urine culture does not preclude the sequestration of bacteria within the calculus itself.

The preferred management of infection (struvite) calculi involves aggressive surgical management with the goal of complete stone clearance. The American Urological Association Nephrolithiasis Guidelines Committee has strongly recommended endoscopic-based procedures (i.e., percutaneous nephrolithotomy) as the first-line therapy for managing complex renal staghorn calculi (Assimos et al., 2016a, 2016b; Preminger, 2005). This report noted that complete elimination of all infected stone material is essential for the prevention of recurrent struvite stone formation.

The medical management of infection calculi centers on the prevention of recurrence, rather than medical dissolution. Thus long-standing effective control of infection with urea-splitting organisms should be achieved if at all possible with improved bladder health, adequate urinary drainage, and monitoring of patients for reinfection with urease-producing organisms (Bichler et al., 2002; Hess, 1990; Pearle et al., 2014). Unfortunately, such control is difficult to obtain in the face of residual calculi because stones often harbor organisms and endotoxin within their interstices (McAleer et al., 2002, 2003; Rocha and Santos, 1969). Antibiotics should be tailored to the predominant organism found on culture and sensitivity screening (Hugosson et al., 1990). Notably, cultures do not always correlate well between a patient's urine and a resuspension of stone material (Fowler, 1984). Therefore strong clinical suspicion is always indicated, and all patients undergoing removal of presumed infection calculi should be covered with broad-spectrum antibiotics that account for local resistance patterns. Although cultures may become negative during treatment, it is important to remember that recurrence of colonization is likely if residual fragments remain within the collecting system.

Acetohydroxamic acid (AHA) is an oral urease inhibitor. It may reduce the urinary saturation of struvite and therefore retard stone formation (Griffith et al., 1978)**. When given at a dose of 250 mg three times per day, AHA has been shown to prevent recurrence of new stones and inhibit the growth of stones in patients with chronic urea-splitting infections.** AHA achieves high levels in the urine and can penetrate bacterial cell walls. Randomized and placebo-controlled studies have proven AHA's ability to significantly reduce stone growth (Griffith et al., 1991; Williams 1984). In a randomized, double-blind, placebo-controlled trial of AHA in 210 spinal cord injury patients, Griffith et al. (1988) reported a significant decrease in stone growth for those receiving AHA versus placebo (33% and 60%, respectively). In addition, in a limited number of patients, this agent has caused dissolution of existing struvite calculi (Rodman et al., 1983). According to the AUA guidelines for the medical management of stones, clinicians may offer AHA to patients with residual or recurrent struvite stones only after surgical options have been exhausted (evidence strength Grade B) (Pearle et al., 2014).

The problem with AHA is that a significant percentage of patients, up to 30%, experience side effects including tremor, headache, palpitations, edema, GI distress, loss of taste, rash, alopecia, anemia, and abdominal pain (York et al., 2015). In addition, hemolytic anemia occurs in 3% to 15% of patients, which requires cessation of the medication. **The most severe complication of treatment with AHA is deep venous thrombosis.** Rodman et al. (1987) demonstrated that patients receiving AHA enter into a state of low-grade intravascular coagulation requiring careful follow-up for signs of thrombosis. Furthermore, renal insufficiency increases the risk for toxicity. AHA is contraindicated in patients with creatinine >2.5 and pregnant women and those of childbearing age who are not using birth control (Daudon et al., 2004). In the previously noted randomized studies, 22% to 68% of treated patients had to stop therapy and withdraw from the investigation (Griffith et al., 1988, 1991;

Williams et al., 1984). Because of these concerns, AHA is frequently reserved for patients deemed unfit for surgical management.

Controversy exists as to whether patients with infection stones warrant metabolic evaluation with 24-hour urine collections**.** Resnick (1981) advocated for the performance of a metabolic evaluation for all patients with infection calculi given a high incidence of positive findings. Conversely, Lingeman et al. (1995) studied 22 patients with infection calculi and noted that patients with pure struvite calculi were significantly less likely to have metabolic anomalies on 24-hour urine evaluation than those with mixed compositions of struvite and calcium oxalate. More recently, Iqbal et al. (2016) reviewed their experience with struvite stones. They reported that 60% of pure struvite stone formers and 77% of mixed struvite stone formers had metabolic abnormalities on 24-hour urine collections. The most common abnormalities were hypercalciuria and hypocitraturia. The authors found that with appropriate medical management of both the metabolic abnormalities and the UTI with either AHA and/or suppressive antibiotics, 60% of patients with residual stone demonstrated no stone growth at a median follow-up of 22 months. Therefore, there may be some value for preventing recurrence in performing 24-hour urine collections in patients with struvite stones and appropriately managing their metabolic abnormalities.

Key Points: Infection Calculi

- Women and the elderly are at higher risk for infection calculi.
- Infection calculi (struvite and calcium carbonate apatite) form as a result of urinary tract infection with urea-splitting microorganisms.
- Infection calculi form in alkaline urine.
- Infection calculi commonly produce staghorn stones.
- Infection calculi are best managed with complete surgical removal.
- Acetohydroxamic acid (AHA, Lithostat) can effectively inhibit urease, but its widespread use is precluded by significant side effects.
- Metabolic evaluation should be considered in patients with infection calculi for prevention of recurrence.

Miscellaneous and Drug-Induced Stones

Drug-induced stones represent 1% to 2% of all renal calculi. Several medications have been associated with stone disease and are listed in Box 92.7. There are essentially two mechanisms by which drugs can contribute to stone formation. **The first mechanism involves crystallization of the drug itself in the urine typically secondary to poor solubility and high dosage of the drug. The second mechanism includes drugs that induce stone formation by producing metabolic abnormalities in the urine such as effects on urine pH, citrate, and calcium** (Daudon et al., 2018a).

Box 92.7

Medications Associated With Renal Calculus Formation

Calculi Formed From Drug

Indinavir
Ephedrine
Triamterene
Magnesium trisilicate antacids (silicates)
Trimethoprim-sulfamethoxazole

Calculi Provoked by Drug

Carbonic anhydrase inhibitors
Topiramate
Furosemide
Vitamin C (excess)
Vitamin D (excess)
Laxatives

Drug-Containing Calculi

Although many drugs have been reported to crystalize in the urine, the most common are the protease inhibitors used to treat human immunodeficiency virus

(HIV), namely indinavir and atazanavir, the antimicrobials sulfadiazine and ceftriaxone, the potassium-sparing diuretic triamterene, and the cough suppressant/stimulant guaifenesin and ephedrine. Bennett et al. reported abuse of ephedrine and guaifenesin taken individually or in combination accounted for nearly 35% of drug-induced stones in the United States (Bennett et al., 2004). Because not all patients who take these drugs develop stones, the formation of drug-induced stones involves not only characteristics specific to the drug but also patient factors. Common patient risk factors include dehydration/low urine volume, acidic urine (low pH), urinary stasis, and altered hepatic function, and drug-specific risk factors include high drug dosage or prolonged drug treatment and poor solubility (Table 92.8).

TABLE 92.8

Patient-Dependent and Drug-Specific Risk Factors of Drug-Induced Calculi

Patient-dependent risk factors
Personal or family history of nephrolithiasis
Pre-existing stones
Urinary stasis (malformative uropathy, prostatic hypertrophy)
Underlying lithogenic metabolic abnormalities (e.g., hypercalciuria, hyperoxaluria, hypocitraturia)
Detoxification enzyme pattern
Abnormally low or high urine pH
Urinary tract infection
Environmental factors (e.g., hot temperature)
Low urine output
Drug-specific risk factors of drug-induced calculi or crystal formation and retention
High daily dose of drug
Long-standing treatment
High urinary excretion of the drug and/or its metabolites
Low aqueous solubility of the drug and/or its metabolites
Short half-life of the drug, inducing concentration peaks in urine

Concomitant therapy that causes changes in the pharmacokinetics or metabolism of the drug

Size of drug crystals

Morphology of drug crystals

Interaction between drug crystals and tissue (tubular obstruction, inflammation)

Daudon M, Frochot V, Bazin D, Jungers P. Drug-induced kidney stones and crystalline nephropathy: pathophysiology, prevention and treatment. *Drugs*78(2):163–201, 2018a.

The classic example of drugs that crystallize in the urine and form calculi include the antiretroviral medications for HIV, namely indinavir and atazanavir (Bach and Godofsky, 1997; Hug et al., 1999; Saltel et al., 2000; Sundaram and Saltzman, 1999). Indinavir is used much less commonly now than atazanavir perhaps largely because of the high incidence of nephrolithiasis seen with indinavir treatment ranging from 7% to 15% of patients in the majority of publications (Daudon et al., 1997; Kopp et al., 1997). One of the greatest difficulties in diagnosing indinavir stones is their radiolucency and inability to visualize on plain film radiography or even stone protocol CT imaging (Gentle et al., 1997; Sundaram and Saltzman, 1999). Lafaurie et al. (2014) examined risk factors for atazanavir-associated stones in a retrospective case-control study comparing 30 HIV-positive patients who formed atazanavir calculi with 90 HIV-positive controls with no history of stone formation but also receiving atazanavir therapy. They identified a previous history of urolithiasis of any type, long duration of atazanavir exposure, and high serum free bilirubin as independent risk factors for atazanavir stone formation. Treatment of these stones centers on aggressive hydration and endoscopic surgical intervention for obstructing stones. Prevention is best accomplished by discontinuing the medication in patients who develop stones, initiating a different antiretroviral agent, and avoiding atazanavir treatment in patients with a history of urolithiasis or with hepatic dysfunction.

As described earlier, triamterene, a potassium-sparing antihypertensive agent, may crystallize in the urinary tract, requiring cessation of this medication (Sorgel et al., 1985; Werness et al., 1982). Two risk factors for triamterene-associated stone formation include high daily drug dosage (150 to 200 mg daily) and low urine pH (<6.0). For this reason, triamterene should be avoided in patients with a history of uric acid nephrolithiasis or those known to have low urine pH such as diabetics. In addition, renal failure has been reported in patients taking a combination of triamterene and thiazide diuretics; therefore, triamterene is not recommended as an adjunct to thiazides for treatment of hypercalciuria.

Antibacterial drugs that can crystallize in the urine include the sulfonamides, aminopenicillins, cephalosprins (ceftriaxone), quinolones, and furanes (nitrofurantoin). Sulfadiazine, a first-generation sulfonamide, has largely been used to treat cerebral toxoplasmosis in patients with HIV and chronically immunosuppressed transplant patients (Guitard et al., 2005; Izzedine et al., 2005). Sulfadiazine undergoes fast liver *N*-acetylation with high urinary excretion of both the drug and its metabolites, both of which are poorly soluble. In addition, the *N*-acetylsulfadiazine crystals rapidly aggregate and can form calculi and obstruction of renal tubules (Daudon et al., 2018a). The patient risk factors for sulfadiazine stone formation include low urine volume, low urinary pH, high daily dosing, and urinary stasis. Ceftriaxone stone formation is much more common in children, with incidence varying worldwide from 1% to 8% (Avci et al., 2004; Mohkam et al., 2007; Youssef et al., 2016). Approximately 33% to 67% of ceftriaxone is excreted in the urine as unchanged drug, and it may complex with calcium in the urine to form calcium ceftriaxonate (Chutipongtanate and Thongboonkerd, 2011; Patel, 1984). The best treatment for these types of stones is discontinuation of the medication. If this is not possible, then one should consider aggressive hydration and alkalinization of the urine.

The high incidence of guaifenesin and ephedrine stones in the United States is likely secondary to the abuse of these medications as over-the-counter combination preparations. Ephedrine in particular has been widely abused for its stimulant properties including weight loss, enhanced energy, sexual performance, and euphoria (Daudon et al., 2018a). The dispensing of these over-the-counter medications is not strictly regulated.

Drugs That Induce Metabolic Stone Formation

Carbonic anhydrase inhibitors may be associated with the formation of calcium-based calculi, particularly calcium phosphate (Kondo et al., 1968; Parfitt, 1969). In this scenario, use of the medication creates a chronic intracellular acidosis. This effect, in turn, creates a urinary milieu reminiscent of a distal tubular acidosis with hyperchloremic acidosis, high urine pH, extremely low urinary citrate, and hypercalciuria. Treatment may be accomplished with potassium citrate replacement or, more logically, cessation of the medication.

Topiramate is prescribed for the treatment of refractory epilepsy and recurrent migraine headaches and was recently approved for weight loss. Unfortunately, it may mimic the effect of a carbonic anhydrase inhibitor with resultant metabolic acidosis, hypocitraturia, hypercalciuria, and elevated urine pH (Kossoff et al., 2002; Kuo et al., 2002; Lamb et al., 2004). Potassium citrate has been shown to restore urinary citrate and prevent recurrent stone disease (Kaplon et al., 2011; McNally et al., 2009; Vega et al., 2007; Warner et al., 2008).

Finally, **multiple authors have described calculi that have formed in patients taking over-the-counter supplements containing ephedrine** (Assimos et al., 1999; Bennett et al., 2004; Blau, 1998; Hoffman et al., 2003; Powell et al., 1998; Smith et al., 2004; Whelan and Schwartz, 2004). These calculi are likely radiolucent but have been reported to be "visible" on noncontrast CT. Ephedrine stones have been treated with a variety of methods, including shock wave lithotripsy, endoscopy, and even alkalinization therapy. Because this supplement has a risk for abuse, it may be difficult to effectively interfere with the formation of future stone events.

Ammonium Acid Urate Stones

Ammonium acid urate calculi are infrequently seen in industrialized nations and are often associated with laxative abuse (Dick et al., 1990; Kato et al., 2004). In an earlier series reported in 1999 (Soble et al., 1999), 23 women and 21 men ranging from 20 to 81 years of age (mean 48.7 years) were treated for stones partly composed of ammonium acid urate. Stone composition ranged from 2% to 60% ammonium acid urate (mean 24.1%) of the total stone mass. No patient had a pure ammonium acid urate stone, although 11 (25%) had stones with ammonium acid urate as the predominant crystal. The authors identified one or more potential risk factors for ammonium acid urate for most patients. Of the patients, 25% had a history of inflammatory bowel disease, with 22.7% having undergone ileostomy diversion, 13.6% admitted to a history of significant laxative use or abuse, 40.9% were morbidly obese, 36.4% had a history of recurrent UTIs, and 20.5% had a history of recurrent uric acid stones. Based on these findings, the authors suggested that laxative abuse should not be assumed for all patients with ammonia acid urate calculi, but rather conditions resulting in metabolic acidosis, the prime risk factor for urate stones. A more recent study by Lomas et al. (2017) retrospectively identified 111 stones in 89 patients with at least 10% of the total composition being ammonium acid urate. In addition to the previously described risk factors, they identified patients with prior prostate surgery and bladder neck contracture or a surgically altered bladder to be at increased risk for ammonium acid urate stone formation. Therefore, a full history and metabolic evaluation should be sought for each patient.

Medical treatment for these calculi is determined by the underlying cause of the stone. Those with laxative abuse are strongly encouraged to develop a healthier bowel regimen. Those with chronic infections are treated much like those with struvite calculi. Bowel disease is treated, if possible, while standard recommendations of fluid intake, oral calcium, alkalinization, and oxalate reduction are made. Those with a history of uric acid calculi are also treated in a similar manner with increased fluid intake, protein and salt restriction, alkalinization with potassium citrate, and the possible use of allopurinol.

Medical Management of Bladder Calculi

The pathogenesis of bladder stones has been historically believed to be mainly attributable to urinary stasis, but it is likely that metabolic factors play an underappreciated role in this process as well. Bladder calculi occur in 3% to 8% of men with bladder outlet obstruction secondary to benign prostatic hypertrophy (BPH) (Childs et al., 2013; Douenias et al., 1991) yet are known to occur in the absence of pathologic BPH. Bladder stones can occasionally occur in women with normal functioning urinary tracts (Rabani, 2016) and young male patients with metabolic stone diseases such as cystinuria and primary hyperparathyroidism (Gurdal et al., 2003; Halalsheh et al., 2017).

In general, the most common mineral composition of a bladder stone is calcium oxalate, calcium phosphate, and uric acid (Childs et al., 2013). Among a series of matched patients undergoing BPH surgery with and without bladder stones, men with stones were more likely to have prior nephrolithiasis and gout. There were also different 24-hour urine profiles between the cohorts, with bladder stone patients having lower urinary pH levels, lower magnesium, and higher uric acid supersaturation. The presence of bladder stones in the setting of urinary obstruction (i.e., bladder outlet obstruction from BPH) is typically an indication for surgical correction of the underlying problem. Nonetheless, it is reasonable to believe that the same preventive therapies that are applied toward renal stone prevention apply to bladder stone prevention in the absence of an identifiable source of mechanical or functional obstruction or stasis.

One particularly challenging etiology that can lead to bladder stone formation is in the case of augmentation cystoplastly and urinary reconstruction using intestine. Patients with intestinally reconstructed bladders have a high potential for stone formation, with estimates ranging from 3% to 52% (Kisku et al., 2015). They are predisposed to bladder stones for a variety of reasons. In addition to urinary stasis, there is potential for stone overgrowth from either built-up mucous or foreign bodies related to catheterization or the surgical procedure itself. Struvite stones may occur in this population as a result of predisposition to urinary tract infection. In such instances, presence of a urea-splitting organism may raise urinary pH and favor stone formation. Urinary pH may also be elevated as a result of the metabolic consequences of incorporating intestinal segments into the urinary tract. In such instances, patients are prone to a hyperchloremic metabolic acidosis with intestinal absorption of ammonium and exchange of bicarbonate into the urine. Finally, urinary oxalates should be measured and can be elevated as a result of intestinal surgery, particularly if the distal ileum has been used, which could lead to enteric hyperoxaluria. Among 83 patients with stones in such instances, a majority (45%) were infectious with 33% mixed and 23% metabolic. Additionally, metabolic abnormalities on 24-hour urine were common, with all patients having alkaline urine and hypocitraturia (Marien et al., 2017). Prevention of stones in these circumstances is challenging. Routine catheterization, irrigation, and monitoring for stone development are critical. High urine outputs are undoubtedly beneficial, whereas other medical treatments remain somewhat controversial, particularly in the case of potassium citrate, when the beneficial effects of citrate must be weighed against the potential for exacerbation of stone formation secondary to exceedingly alkaline urinary pH.

Follow-Up Considerations in the Medical Management of Urinary Lithiasis

An integral part of the medical management of urinary lithiasis is ensuring appropriate follow-up to determine if the goals of therapy have been achieved and maintained (Fig. 92.11). Previously in this chapter, 24-hour urine testing was discussed as part of the metabolic evaluation for high-risk and recurrent stone formers. There is inadequate evidence to define how often these studies should be repeated, however, it is the expert opinion of the AUA Guidelines Panel that a single 24-hour urine sample should be obtained within 6 months of initiation of treatment to assess response to dietary and/or medical therapy. Furthermore, after the initial follow-up, a 24-hour urine collection is recommended annually or with greater frequency, depending on stone activity (Pearle et al., 2014). However, there is significant geographic variation in the quality of secondary prevention. Alruwaily et al. (2015) used Litholink corporation data to identify patients with abnormal urine biochemistries on the initial 24-hour urine collection and then determined if follow-up testing was performed on-treatment. The mean rate on-treatment testing was low at 11.9%, and there was a fourfold variation in the rate across hospital referral regions from 6.6% to 23.4%, with the highest follow-up testing seen in regions with a wealthier, more educated population and those with more primary care physicians.

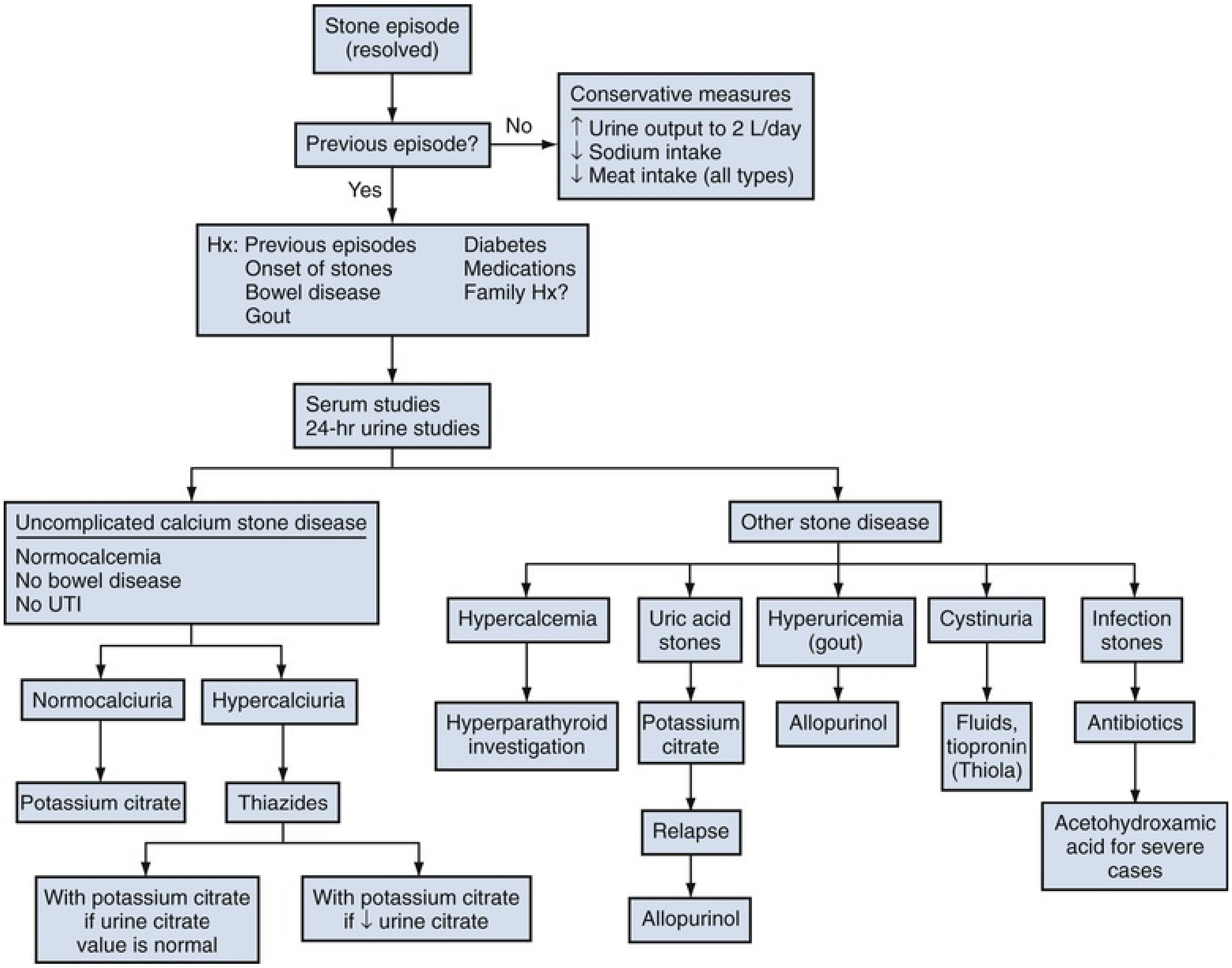
Stone episode (resolved)
Previous episode?
No
Conservative measures
↑ Urine output to 2 L/day
↓ Sodium intake
↓ Meat intake (all types)
Yes
Hx: Previous episodes
Onset of stones
Bowel disease
Gout
Diabetes
Medications
Family Hx?
Serum studies
24-hr urine studies
Uncomplicated calcium stone disease
Normocalcemia
No bowel disease
No UTI
Other stone disease
Normocalciuria
Hypercalciuria
Potassium citrate
Thiazides
With potassium citrate if urine citrate value is normal
With potassium citrate if ↓ urine citrate
Hypercalcemia
Hyperparathyroid investigation
Uric acid stones
Potassium citrate
Relapse
Allopurinol
Hyperuricemia (gout)
Allopurinol
Cystinuria
Fluids, tiopronin (Thiola)
Infection stones
Antibiotics
Acetohydroxamic acid for severe cases

FIG. 92.11 Simplified treatment algorithm for the evaluation and medical management of urinary lithiasis. *Hx,* History; *UTI*, urinary tract infection. (Modified from Pak CY, Britton F, Peterson R, et al: Ambulatory evaluation of nephrolithiasis. Classification, clinical presentation and diagnostic criteria, *Am J Med* 69(1):19–30, 1980.)

In addition to ensuring adherence to therapy, it is also critical for the clinician to assess for any adverse effects, particularly as may be seen with pharmacologic therapy. Periodic blood testing is indicated in patients on thiazide therapy, allopurinol tiopronin, and potassium citrate (Pearle et al., 2014). For patients with struvite stones, follow-up should include monitoring for reinfection with urease-producing organisms by obtaining periodic surveillance urine cultures (Pearle et al., 2014). Patients with the highest risk are typically those with urinary diversion or altered lower urinary tract anatomy.

In patients with rapid stone growth or those who are not responding to treatment despite compliance, clinicians should obtain a repeat stone analysis (Pearle et al., 2014). Some patients based on medical history and/or diet may be at risk for more than one stone type, for example, the obese patient who could make both calcium oxalate and uric acid stones. In addition, patients may convert from one stone composition to another as has been reported for calcium oxalate to calcium phosphate stone formation (Mandel et al., 2003).

Recognizing that kidney stones have high potential for recurrence, the AUA and EAU both recommend periodic imaging to assess for new stones. The timing and type of imaging depend both on the presence or absence of existing stones and the stone activity. The AUA recommends annual surveillance for stable patients with plain abdominal radiographs, RUS, or low-dose CT (Pearle et al., 2014). The EAU offers recommendation options for patients with untreated renal stones with initial surveillance imaging at 6 months and then annually, also with plain abdominal radiographs, RUS, or low-dose CT (Turk et al., 2016).

References

Abate N, Chandalia M, Cabo-Chan AV Jr, et al. The metabolic syndrome and uric acid nephrolithiasis: novel features of renal manifestation of insulin resistance. *Kidney Int*. 2004;65(2):386–392.

Abt D, Dötzer K, Honek P, et al. The German linguistic validation of the Ureteral Stent Symptoms Questionnaire (USSQ). *World J Urol*. 2017;35(3):443–447.

Albert U, De Cori D, Aguglia A, et al. Lithium-associated hyperparathyroidism and hypercalcaemia: a case-control cross-sectional study. *J Affect Disord*. 2013;151(2):786–790.

ALLHAT Officers and Coordinators for the ALLHAT Collaborative Research Group. Major outcomes in moderately hypercholesterolemic, hypertensive patients randomized to pravastatin vs usual care: the Antihypertensive and Lipid-Lowering Treatment to Prevent Heart Attack Trial (ALLHAT-LLT). *JAMA*. 2002;288(23):2998–3007.

Allison MJ, Cook HM, Milne DB, et al. Oxalate degradation by gastrointestinal bacteria from humans. *J Nutr*. 1986;116(3):455–460.

Almeras C, Daudon M, Ploussard G, et al. Endoscopic description of renal papillary abnormalities in stone disease by flexible ureteroscopy: a proposed classification of severity and type. *World J Urol*. 2016;34(11):1575–1582.

Alruwaily AF, Dauw CA, Bierlein MJ, et al. Geographic variation in the quality of secondary prevention for nephrolithiasis. *Urology*. 2015;86(3):454–458.

Andreassen KH, Pedersen KV, Osther SS, et al. How should patients with cystine stone disease be evaluated and treated in the twenty-first century? *Urolithiasis*. 2016;44(1):65–76.

Aras B, Kalfazade N, Tugcu V, et al. Can lemon juice be an alternative to potassium citrate in the treatment of urinary calcium stones in patients with hypocitraturia? A prospective randomized study. *Urol Res*. 2008;36(6):313–317.

Aroldi A, Graziani G, Mioni G, et al. Thiazide diuretics in renal hypercalciuria. *Proc Eur Dial Transplant Assoc*. 1979;16:571–576.

Ascenti G, Siragusa C, Racchiusa S, et al. Stone-targeted dual-energy CT: a new diagnostic approach to urinary calculosis. *AJR Am J Roentgenol*. 2010;195(4):953–958.

Asplin J, Parks J, Lingeman J, et al. Supersaturation and stone composition in a network of dispersed treatment sites. *J Urol*. 1998;159(6):1821–1825.

Assimos DG, Langenstroer P, Leinbach RF, et al. Guaifenesin- and ephedrine-induced stones. *J Endourol*. 1999;13(9):665–667.

Assimos DG, Leslie SW, Ng C, et al. The impact of cystinuria on renal function. *J Urol*. 2002;168(1):27–30.

Assimos D, Krambeck A, Miller NL, et al. Surgical management of stones: American Urological Association/Endourological Society Guideline, PART I. *J Urol*. 2016;196(4):1153–1160.

Assimos D, Krambeck A, Miller NL, et al. Surgical management of stones: American Urological Association/Endourological Society Guideline, PART II. *J Urol*. 2016;196(4):1161–1169.

Aung K, Htay T. Thiazide diuretics and the risk of hip fracture. *Cochrane Database Syst Rev*. 2011;(10) [CD005185].

Avci Z, Koktener A, Uras N, et al. Nephrolithiasis associated with ceftriaxone therapy: a prospective study in 51 children. *Arch Dis Child*. 2004;89(11):1069–1072.

Avenell A, Mak JC, O'Connell D. Vitamin D and vitamin D analogues for preventing fractures in post-menopausal women and older men. *Cochrane Database Syst Rev*. 2014;

(4) [CD000227].

Bach MC, Godofsky EW. Indinavir nephrolithiasis in warm climates. *J Acquir Immune Defic Syndr Hum Retrovirol*. 1997;14(3):296–297.

Barbey F, Joly D, Rieu P, et al. Medical treatment of cystinuria: critical reappraisal of long-term results. *J Urol*. 2000;163(5):1419–1423.

Barilla DE, Pak CY. Pitfalls in parathyroid evaluation in patients with calcium urolithiasis. *Urol Res*. 1979;7(3):177–182.

Barnett C, Nazzal L, Goldfarb DS, et al. The presence of Oxalobacter formigenes in the microbiome of healthy young adults. *J Urol*. 2016;195(2):499–506.

Bartosh SM. Medical management of pediatric stone disease. *Urol Clin North Am*. 2004;31(3):575–587 [x–xi].

Bennett S, Hoffman N, Monga M. Ephedrine- and guaifenesin-induced nephrolithiasis. *J Altern Complement Med*. 2004;10(6):967–969.

Berg C, Larsson L, Tiselius HG. The effects of a single evening dose of alkaline citrate on urine composition and calcium stone formation. *J Urol*. 1992;148(3 Pt 2):979–985.

Beukes GJ, de Bruiyn H, Vermaak WJ. Effect of changes in epidemiological factors on the composition and racial distribution of renal calculi. *Br J Urol*. 1987;60(5):387–392.

Bhojani N, Paonessa JE, Hameed TA, et al. Nephrocalcinosis in calcium stone formers who do not have systemic disease. *J Urol*. 2015;194(5):1308–1312.

Bichler KH, Eipper E, Naber K, et al. Urinary infection stones. *Int J Antimicrob Agents*. 2002;19(6):488–498.

Bjelakovic G, Gluud LL, Nikolova D, et al. Vitamin D supplementation for prevention of mortality in adults. *Cochrane Database Syst Rev*. 2014;(1) [CD007470].

Blau JJ. Ephedrine nephrolithiasis associated with chronic ephedrine abuse. *J Urol*. 1998;160(3 Pt 1):825.

Bleich HL, Moore MJ, Lemann J Jr, et al. Urinary calcium excretion in human beings. *N Engl J Med*. 1979;301(10):535–541.

Bobulescu IA, Dubree M, Zhang J, et al. Effect of renal lipid accumulation on proximal tubule Na+/H+ exchange and ammonium secretion. *Am J Physiol Renal Physiol*. 2008;294(6):F1315–F1322.

Bohles H, Beifuss OJ, Brandl U, et al. Urinary factors of kidney stone formation in patients with Crohn's disease. *Klin Wochenschr*. 1988;66(3):87–91.

Boll DT, Patil NA, Paulson EK, et al. Renal stone assessment with dual-energy multidetector CT and advanced postprocessing techniques: improved characterization of renal stone composition—pilot study. *Radiology*. 2009;250(3):813–820.

Bonny O, Edwards A. Calcium reabsorption in the distal tubule: regulation by sodium, pH, and flow. *Am J Physiol Renal Physiol*. 2013;304(5):F585–F600.

Borghi L, Meschi T, Amato F, et al. Urinary volume, water and recurrences in idiopathic calcium nephrolithiasis: a 5-year randomized prospective study. *J Urol*. 1996;155(3):839–843.

Borghi L, Meschi T, Guerra A, et al. Randomized prospective study of a nonthiazide diuretic, indapamide, in preventing calcium stone recurrences. *J Cardiovasc Pharmacol*. 1993;22(Suppl 6):S78–S86.

Borghi L, Schianchi T, Meschi T, et al. Comparison of two diets for the prevention of recurrent stones in idiopathic hypercalciuria. *N Engl J Med*. 2002;346(2):77–84.

Borofsky MS, Dauw CA, Cohen A, et al. Integration and utilization of modern technologies in nephrolithiasis research. *Nat Rev Urol*. 2016;13(9):549–557.

Borofsky MS, Paonessa JE, Evan AP, et al. A proposed grading system to standardize the description of renal papillary appearance at the time of endoscopy in patients with nephrolithiasis. *J Endourol*. 2016;30(1):122–127.

Borofsky MS, Lane GI, Neises SM, et al. Patient-reported outcomes measurement system (PROMIS®) for patients with urolithiasis: initial report. *J Urol*. 2017;198(5):1091–1097.

Borofsky MS, Dauw CA, York N, et al. Accuracy of daily fluid intake measurements using a smart water bottle. *Urolithiasis*. 2018;46(4):343–348.

Boucher A, D'Amour P, Hamel L, et al. Estrogen replacement decreases the set point of parathyroid hormone stimulation by calcium in normal postmenopausal women. *J Clin Endocrinol Metab*. 1989;68(4):831–836.

Breslau NA, Brinkley L, Hill KD, et al. Relationship of animal protein-rich diet to kidney stone formation and calcium metabolism. *J Clin Endocrinol Metab*. 1988;66(1):140–146.

Brisbane W, Bailey MR, Sorensen MD. An overview of kidney stone imaging techniques. *Nat Rev Urol*. 2016;13(11):654–662.

Brocks P, Dahl C, Wolf H, et al. Do thiazides prevent recurrent idiopathic renal calcium stones? *Lancet*. 1981;2(8238):124–125.

Buckalew VM Jr. Nephrolithiasis in renal tubular acidosis. *J Urol*. 1989;141(3 Pt 2):731–737.

Burtis WJ, Gay L, Insogna KL, et al. Dietary hypercalciuria in patients with calcium oxalate kidney stones. *Am J Clin Nutr*. 1994;60(3):424–429.

Cameron MA, Maalouf NM, Adams-Huet B, et al. Urine composition in type 2 diabetes: predisposition to uric acid nephrolithiasis. *J Am Soc Nephrol*. 2006;17(5):1422–1428.

Caruana RJ, Buckalew VM Jr. The syndrome of distal (type 1) renal tubular acidosis. Clinical and laboratory findings in 58 cases. *Medicine (Baltimore)*. 1988;67(2):84–99.

Ceylan K, Topal C, Erkoc R, et al. Effect of indapamide on urinary calcium excretion in patients with and without urinary stone disease. *Ann Pharmacother*. 2005;39(6):1034–1038.

Chandhoke PS. When is medical prophylaxis cost-effective for recurrent calcium stones? *J Urol*. 2002;168(3):937–940.

Cheal KL, Abbasi F, Lamendola C, et al. Relationship to insulin resistance of the adult treatment panel III diagnostic criteria for identification of the metabolic syndrome. *Diabetes*. 2004;53(5):1195–1200.

Chen T, Godebu E, Horgan S, et al. The effect of restrictive bariatric surgery on urolithiasis. *J Endourol*. 2013;27(2):242–244.

Childs MA, Mynderse LA, Rangel LJ, et al. Pathogenesis of bladder calculi in the presence of urinary stasis. *J Urol*. 2013;189(4):1347–1351.

Cho ST, Jung SI, Myung SC, et al. Correlation of metabolic syndrome with urinary stone composition. *Int J Urol*. 2013;20(2):208–213.

Choi HK, Atkinson K, Karlson EW, et al. Purine-rich foods, dairy and protein intake, and the risk of gout in men. *N Engl J Med*. 2004;350(11):1093–1103.

Chow GK, Streem SB. Contemporary urological intervention for cystinuric patients: immediate and long-term impact and implications. *J Urol*. 1998;160(2):341–344 [discussion 344–345].

Chutipongtanate S, Thongboonkerd V. Ceftriaxone crystallization and its potential role in kidney stone formation. *Biochem Biophys Res Commun*. 2011;406(3):396–402.

Clayman RV, Patel RM, Pearle M. STONE TREES: metabolic evaluation and medical treatment of the urolithiasis patient made easy. *J Endourol*. 2018;32(5):387–392.

Cloutier J, Villa L, Traxer O, et al. Kidney stone analysis: give me your stone, I will tell you who you are!. *World J Urol*. 2015;33(2):157–169.

Coe FL. Hyperuricosuric calcium oxalate nephrolithiasis. *Kidney Int*. 1978;13(5):418–426.

Coe FL. Hyperuricosuric calcium oxalate nephrolithiasis. *Adv Exp Med Biol*. 1980;128:439–450.

Coe FL, Bushinsky DA. Pathophysiology of hypercalciuria. *Am J Physiol*. 1984;247(1 Pt 2):F1–F13.

Coe FL, Clark C, Parks JH, et al. Solid phase assay of urine cystine supersaturation in the presence of cystine binding drugs. *J Urol*. 2001;166(2):688–693.

Coe FL, Evan AP, Lingeman JE, et al. Plaque and deposits in nine human stone diseases. *Urol Res*. 2010;38(4):239–247.

Coe FL, Favus MJ. Idiopathic hypercalciuria in calcium nephrolithiasis. *Dis Mon*. 1980;26(12):1–36.

Coe FL, Favus MJ, Parks JH. Is estrogen preferable to surgery for postmenopausal women with primary hyperparathyroidism? *N Engl J Med*. 1986;314(23):1508–1509.

Coe FL, Kavalach AG. Hypercalciuria and hyperuricosuria in patients with calcium nephrolithiasis. *N Engl J Med*. 1974;291(25):1344–1350.

Coe FL, Raisen L. Allopurinol treatment of uric-acid disorders in calcium-stone formers. *Lancet*. 1973;1(7795):129–131.

Coe FL, Worcester EM, Evan AP. Idiopathic hypercalciuria and formation of calcium renal stones. *Nat Rev Nephrol*. 2016;12(9):519–533.

Cohen TD, Streem SB, Hall P. Clinical effect of captopril on the formation and growth of cystine calculi. *J Urol*. 1995;154(1):164–166.

Combe C, Deforges-Lasseur C, Chehab Z, et al. Cystine lithiasis and its treatment with d-penicillamine. The experience in a nephrology service in a 23-year period.

Apropos of 26 patients]. *Ann Urol (Paris)*. 1993;27(2):79–83.

Conroy DE, Dubansky A, Remillard J, et al. Using behavior change techniques to guide selections of mobile applications to promote fluid consumption. *Urology*. 2017;99:33–37.

Coursey CA, Casalino DD, Remer EM, et al. ACR Appropriateness Criteria® acute onset flank pain—suspicion of stone disease. *Ultrasound Q*. 2012;28(3):227–233.

Coward RJ, Peters CJ, Duffy PG, et al. Epidemiology of paediatric renal stone disease in the UK. *Arch Dis Child*. 2003;88(11):962–965.

Craven BL, Passman C, Assimos DG. Hypercalcemic states associated with nephrolithiasis. *Rev Urol*. 2008;10(3):218–226.

Crawhall JC, Thompson CJ. Cystinuria: effect of d-penicillamine on plasma and urinary cystine concentrations. *Science*. 1965;147:1459–1460.

Cunitz B, Dunmire B, Paun M, et al. Improved detection of kidney stones using an optimized Doppler imaging sequence. *IEEE Int Ultrason Symp*. 2014;2014:452–455.

Curhan GC, Willett WC, Rimm EB, et al. A prospective study of dietary calcium and other nutrients and the risk of symptomatic kidney stones. *N Engl J Med*. 1993;328(12):833–838.

Curhan GC, Willett WC, Rimm EB, et al. Prospective study of beverage use and the risk of kidney stones. *Am J Epidemiol*. 1996;143(3):240–247.

Curhan GC, Willett WC, Rimm EB, et al. A prospective study of the intake of vitamins C and B6, and the risk of kidney stones in men. *J Urol*. 1996;155(6):1847–1851.

Curhan GC, Willett WC, Speizer FE, et al. Comparison of dietary calcium with supplemental calcium and other nutrients as factors affecting the risk for kidney stones in women. *Ann Intern Med*. 1997;126(7):497–504.

Curhan GC, Willett WC, Rimm EB, et al. Body size and risk of kidney stones. *J Am Soc Nephrol*. 1998;9(9):1645–1652.

Curhan GC, Willett WC, Speizer FE, et al. Beverage use and risk for kidney stones in women. *Ann Intern Med*. 1998;128(7):534–540.

Curhan GC, Willett WC, Speizer FE, et al. Intake of vitamins B6 and C and the risk of kidney stones in women. *J Am Soc Nephrol*. 1999;10(4):840–845.

Curhan GC, Willett WC, Speizer FE, et al. Twenty-four-hour urine chemistries and the risk of kidney stones among women and men. *Kidney Int*. 2001;59(6):2290–2298.

Curhan GC, Willett WC, Knight EL, et al. Dietary factors and the risk of incident kidney stones in younger women: Nurses' Health Study II. *Arch Intern Med*. 2004;164(8):885–891.

Dahlberg PJ, Kurtz SB, et al. Clinical features and management of cystinuria. *Mayo Clin Proc*. 1977;52(9):533–542.

Dai JC, Dunmire B, Sternberg KM, et al. Retrospective comparison of measured stone size and posterior acoustic shadow width in clinical ultrasound images. *World J Urol*. 2018;36(5):727–732.

Dale J, Gupta RT, Marin D, et al. Imaging advances in urolithiasis. *J Endourol*. 2017;31(7):623–629.

Daudon M, Bader CA, Jungers P. Urinary calculi: review of classification methods and correlations with etiology. *Scanning Microsc*. 1993;7(3):1081–1104 [discussion 1104–1086].

Daudon M, Dore JC, Jungers P, et al. Changes in stone composition according to age and gender of patients: a multivariate epidemiological approach. *Urol Res*. 2004;32(3):241–247.

Daudon M, Estepa L, Viard JP, et al. Urinary stones in HIV-1-positive patients treated with indinavir. *Lancet*. 1997;349(9061):1294–1295.

Daudon M, Frochot V, Bazin D, et al. Drug-induced kidney stones and crystalline nephropathy: pathophysiology, prevention and treatment. *Drugs*. 2018;78(2):163–201.

Daudon M, Jungers P, Bazin D, et al. Recurrence rates of urinary calculi according to stone composition and morphology. *Urolithiasis*. 2018;46(5):459–470.

DeBerardinis RJ, Coughlin CR 2nd, Kaplan P. Penicillamine therapy for pediatric cystinuria: experience from a cohort of American children. *J Urol*. 2008;180(6):2620–2623.

Derby CA, Barbour MM, Hume AL, et al. Drug therapy and prevalence of erectile dysfunction in the Massachusetts Male Aging Study cohort. *Pharmacotherapy*. 2001;21(6):676–683.

Dhayat NA, Gradwell MW, Pathare G, et al. Furosemide/fludrocortisone test and clinical parameters to diagnose incomplete distal renal tubular acidosis in kidney stone formers. *Clin J Am Soc Nephrol*. 2017;12(9):1507–1517.

Diamond T, Ng AT, Levy S, et al. Estrogen replacement may be an alternative to parathyroid surgery for the treatment of osteoporosis in elderly postmenopausal women presenting with primary hyperparathyroidism: a preliminary report. *Osteoporos Int*. 1996;6(4):329–333.

Dick WH, Lingeman JE, Preminger GM, et al. Laxative abuse as a cause for ammonium urate renal calculi. *J Urol*. 1990;143(2):244–247.

Domrongkitchaiporn S, Ongphiphadhanakul B, Stitchantrakul W, et al. Risk of calcium oxalate nephrolithiasis in postmenopausal women supplemented with calcium or combined calcium and estrogen. *Maturitas*. 2002;41(2):149–156.

Domrongkitchaiporn S, Sopassathit W, Stitchantrakul W, et al. Schedule of taking calcium supplement and the risk of nephrolithiasis. *Kidney Int*. 2004;65(5):1835–1841.

Douenias R, Rich M, Badlani G, et al. Predisposing factors in bladder calculi. Review of 100 cases. *Urology*. 1991;37(3):240–243.

Dudley FJ, Blackburn CR. Extraskeletal calcification complicating oral neutral-phosphate therapy. *Lancet*. 1970;2(7674):628–630.

Dunmire B, Harper JD, Cunitz BW, et al. Use of the acoustic shadow width to determine kidney stone size with ultrasound. *J Urol*. 2016;195(1):171–177.

Dussol B, Iovanna C, Rotily M, et al. A randomized trial of low-animal-protein or high-fiber diets for secondary prevention of calcium nephrolithiasis. *Nephron Clin Pract*. 2008;110(3):c185–c194.

Eggermann T, Venghaus A, Zerres K. Cystinuria: an inborn cause of urolithiasis. *Orphanet J Rare Dis*. 2012;7:19.

Eisner BH, Ahn J, Stoller ML. Differentiating primary from secondary hyperparathyroidism in stone patients: the thiazide challenge. *J Endourol*. 2009;23(2):191–192.

Eisner BH, Asplin JR, Goldfarb DS, et al. Citrate, malate and alkali content in commonly consumed diet sodas: implications for nephrolithiasis treatment. *J Urol*. 2010;183(6):2419–2423.

Eisner BH, Sheth S, Dretler SP, et al. Abnormalities of 24-hour urine composition in first-time and recurrent stone-formers. *Urology*. 2012;80(4):776–779.

Ekeruo WO, Tan YH, Young MD, et al. Metabolic risk factors and the impact of medical therapy on the management of nephrolithiasis in obese patients. *J Urol*. 2004;172(1):159–163.

Escribano J, Balaguer A, Pagone F, et al. Pharmacological interventions for preventing complications in idiopathic hypercalciuria. *Cochrane Database Syst Rev*. 2009;(1) [CD004754].

Espino-Grosso PM, Canales BK. Kidney stones after bariatric surgery: risk assessment and mitigation. *Bariatr Surg Pract Patient Care*. 2017;12(1):3–9.

Ettinger B, Citron JT, Livermore B, et al. Chlorthalidone reduces calcium oxalate calculous recurrence but magnesium hydroxide does not. *J Urol*. 1988;139(4):679–684.

Ettinger B, Pak CY, Citron JT, et al. Potassium-magnesium citrate is an effective prophylaxis against recurrent calcium oxalate nephrolithiasis. *J Urol*. 1997;158(6):2069–2073.

Ettinger B, Tang A, Citron JT, et al. Randomized trial of allopurinol in the prevention of calcium oxalate calculi. *N Engl J Med*. 1986;315(22):1386–1389.

Evan AP, Lingeman JE, Coe FL, et al. Crystal-associated nephropathy in patients with brushite nephrolithiasis. *Kidney Int*. 2005;67(2):576–591.

Evan AP, Lingeman J, Coe F, et al. Renal histopathology of stone-forming patients with distal renal tubular acidosis. *Kidney Int*. 2007;71(8):795–801.

Evan AP, Lingeman JE, Worcester EM, et al. Contrasting histopathology and crystal deposits in kidneys of idiopathic stone formers who produce hydroxy apatite, brushite, or calcium oxalate stones. *Anat Rec (Hoboken)*. 2014;297(4):731–748.

Evan AP, Coe FL, Connors BA, et al. Mechanism by which shock wave lithotripsy can promote formation of human calcium phosphate stones. *Am J Physiol Renal Physiol*. 2015;308(8):F938–F949.

Evan AP, Worcester EM, Coe FL, et al. Mechanisms of human kidney stone formation. *Urolithiasis*. 2015;43(Suppl 1):19–32.

Fargue S, Rumsby G, Danpure CJ. Multiple mechanisms of action of pyridoxine in primary hyperoxaluria type 1. *Biochim Biophys Acta*. 2013;1832(10):1776–1783.

Farias ML, Delgado AG, Rosenthal D, et al. The cause of maintained hypercalciuria after the surgical cure of primary hyperparathyroidism is a defect in renal calcium reabsorption. *J Endocrinol Invest*. 1996;19(1):12–20.

Farquhar CW, Spathis GS, Barron JL, et al. Failure of thiazide diuretics to increase plasma calcium in mild primary hyperparathyroidism. *Postgrad Med J*. 1990;66(779):714–716.

Fegan J, Khan R, Poindexter J, et al. Gastrointestinal citrate absorption in nephrolithiasis. *J Urol*. 1992;147(5):1212–1214.

Ferraro PM, Mandel EI, Curhan GC, et al. Dietary protein and potassium, diet-dependent net acid load, and risk of incident kidney stones. *Clin J Am Soc Nephrol*. 2016;11(10):1834–1844.

Ferraro PM, Taylor EN, Gambaro G, et al. Soda and other beverages and the risk of kidney stones. *Clin J Am Soc Nephrol*. 2013;8(8):1389–1395.

Fjellstedt E, Denneberg T, Jeppsson JO, et al. A comparison of the effects of potassium citrate and sodium bicarbonate in the alkalinization of urine in homozygous cystinuria. *Urol Res*. 2001;29(5):295–302.

Flannigan RK, Battison A, De S, et al. Evaluating factors that dictate struvite stone composition: a multi-institutional clinical experience from the EDGE Research Consortium. *Can Urol Assoc J*. 2018;12(4):131–136.

Flegal KM, Carroll MD, Ogden CL, et al. Prevalence and trends in obesity among US adults, 1999-2008. *JAMA*. 2010;303(3):235–241.

Fowler JE Jr. Bacteriology of branched renal calculi and accompanying urinary tract infection. *J Urol*. 1984;131(2):213–215.

Fowler KA, Locken JA, Duchesne JH, et al. US for detecting renal calculi with nonenhanced CT as a reference standard. *Radiology*. 2002;222(1):109–113.

Fraker DL. Update on the management of parathyroid tumors. *Curr Opin Oncol*. 2000;12(1):41–48.

Frank H, Graf J, Amann-Gassner U, et al. Effect of short-term high-protein compared with normal-protein diets on renal hemodynamics and associated variables in healthy young men. *Am J Clin Nutr*. 2009;90(6):1509–1516.

Friedlander JI, Antonelli JA, Canvasser NE, et al. Do urinary cystine parameters predict clinical stone activity? *J Urol*. 2018;199(2):495–499.

Fulgham PF, Assimos DG, Pearle MS, et al. Clinical effectiveness protocols for imaging in the management of ureteral calculous disease: AUA technology assessment. *J Urol*. 2013;189(4):1203–1213.

Fwu CW, Eggers PW, Kimmel PL, et al. Emergency department visits, use of imaging, and drugs for urolithiasis have increased in the United States. *Kidney Int*. 2013;83(3):479–486.

Gallagher JC, Smith LM, Yalamanchili V. Incidence of hypercalciuria and hypercalcemia during vitamin D and calcium supplementation in older women. *Menopause*. 2014;21(11):1173–1180.

Gambaro G, Croppi E, Coe F, et al. Metabolic diagnosis and medical prevention of calcium nephrolithiasis and its systemic manifestations: a consensus statement. *J Nephrol*. 2016;29(6):715–734.

Gentle DL, Stoller ML, Jarrett TW, et al. Protease inhibitor-induced urolithiasis. *Urology*. 1997;50(4):508–511.

Gervaise A, Gervaise-Henry C, Pernin M, et al. How to perform low-dose computed tomography for renal colic in clinical practice. *Diagn Interv Imaging*. 2016;97(4):393–400.

Gettman MT, Ogan K, Brinkley LJ, et al. Effect of cranberry juice consumption on urinary stone risk factors. *J Urol*. 2005;174(2):590–594 [quiz 801].

Giannini S, Nobile M, Sartori L, et al. Acute effects of moderate dietary protein restriction in patients with idiopathic hypercalciuria and calcium nephrolithiasis. *Am J Clin Nutr*. 1999;69(2):267–271.

Gilad R, Williams JC Jr, Usman KD, et al. Interpreting the results of chemical stone analysis in the era of modern stone analysis techniques. *J Nephrol*. 2017;30(1):135–140.

Glazer DI, Maturen KE, Cohan RH, et al. Assessment of 1 mSv urinary tract stone CT with model-based iterative reconstruction. *AJR Am J Roentgenol*. 2014;203(6):1230–1235.

Goldfarb DS, Asplin JR. Effect of grapefruit juice on urinary lithogenicity. *J Urol*. 2001;166(1):263–267.

Goldfarb DS, MacDonald PA, Gunawardhana L, et al. Randomized controlled trial of febuxostat versus allopurinol or placebo in individuals with higher urinary uric acid excretion and calcium stones. *Clin J Am Soc Nephrol*. 2013;8(11):1960–1967.

Goldfarb S. The role of diet in the pathogenesis and therapy of nephrolithiasis. *Endocrinol Metab Clin North Am*. 1990;19(4):805–820.

Goodman JW, Asplin JR, Goldfarb DS. Effect of two sports drinks on urinary lithogenicity. *Urol Res*. 2009;37(1):41–46.

Griffith DP, Gibson JR, Clinton CW, et al. Acetohydroxamic acid: clinical studies of a urease inhibitor in patients with staghorn renal calculi. *J Urol*. 1978;119(1):9–15.

Griffith DP, Khonsari F, Skurnick JH, et al. A randomized trial of acetohydroxamic acid for the treatment and prevention of infection-induced urinary stones in spinal cord injury patients. *J Urol*. 1988;140(2):318–324.

Griffith DP, Gleeson MJ, Lee H, et al. Randomized, double-blind trial of Lithostat (acetohydroxamic acid) in the palliative treatment of infection-induced urinary calculi. *Eur Urol*. 1991;20(3):243–247.

Grover PK, Ryall RL. Urate and calcium oxalate stones: from repute to rhetoric to reality. *Miner Electrolyte Metab*. 1994;20(6):361–370.

Guitard J, Kamar N, Mouzin M, et al. Sulfadiazine-related obstructive urinary tract lithiasis: an unusual cause of acute renal failure after kidney transplantation. *Clin Nephrol*. 2005;63(5):405–407.

Gurdal M, Ayyildiz A, Huri E, et al. A huge bladder cystine stone. *Int Urol Nephrol*. 2003;35(4):497–499.

Gutman AB, Yu TF. Uric acid nephrolithiasis. *Am J Med*. 1968;45(5):756–779.

Halalsheh O, Sahawneh F, Altopajee K, et al. Single large bladder stone in a young male adult with primary hyperparathyroidism. *Urol Case Rep*. 2017;13:162–164.

Haleblian GE, Leitao VA, Pierre SA, et al. Assessment of citrate concentrations in citrus fruit-based juices and beverages: implications for management of hypocitraturic nephrolithiasis. *J Endourol*. 2008;22(6):1359–1366.

Harvey JA, Zobitz MM, Pak CY. Calcium citrate: reduced propensity for the crystallization of calcium oxalate in urine resulting from induced hypercalciuria of calcium supplementation. *J Clin Endocrinol Metab*. 1985;61(6):1223–1225.

Hautmann R, Terhorst B, Stuhlsatz HW, et al. Mercaptopropionylglycine: a progress in cystine stone therapy. *J Urol*. 1977;117(5):628–630.

Healy KA, Hubosky SG, Bagley DH. 24-hour urine collection in the metabolic evaluation of stone formers: is one study adequate? *J Endourol*. 2013;27(3):374–378.

Heller HJ, Doerner MF, Brinkley LJ, et al. Effect of dietary calcium on stone forming propensity. *J Urol*. 2003;169(2):470–474.

Herbai G, Ljunghall S. Normalization of hypercalcaemia of primary hyperparathyroidism by treatment with methallenestril, a synthetic oestrogen with low oestrogenicity. *Urol Int*. 1983;38(6):371–373.

Hess B. Prophylaxis of infection-induced kidney stone formation. *Urol Res*. 1990;18(Suppl 1):S45–S48.

Hiatt RA, Ettinger B, Caan B, et al. Randomized controlled trial of a low animal protein, high fiber diet in the prevention of recurrent calcium oxalate kidney stones. *Am J Epidemiol*. 1996;144(1):25–33.

Hidas G, Eliahou R, Duvdevani M, et al. Determination of renal stone composition with dual-energy CT: in vivo analysis and comparison with x-ray diffraction. *Radiology*. 2010;257(2):394–401.

Hoffman N, McGee SM, Hulbert JC. Resolution of ephedrine stones with dissolution therapy. *Urology*. 2003;61(5):1035.

Holmes RP, Assimos DG. The impact of dietary oxalate on kidney stone formation. *Urol Res*. 2004;32(5):311–316.

Holmes RP, Goodman HO, Assimos DG. Contribution of dietary oxalate to urinary oxalate excretion. *Kidney Int*. 2001;59(1):270–276.

Holmes RP, Goodman HO, Hart LJ, et al. Relationship of protein intake to urinary oxalate and glycolate excretion. *Kidney Int*. 1993;44(2):366–372.

Holmes RP, Knight J, Assimos DG. Lowering urinary oxalate excretion to decrease calcium oxalate stone disease. *Urolithiasis*. 2016;44(1):27–32.

Hopp K, Cogal AG, Bergstralh EJ, Rare Kidney Stone Consortium, et al. Phenotype-genotype correlations and estimated carrier frequencies of primary hyperoxaluria. *J Am Soc Nephrol*. 2015;26(10):2559–2570.

Hoppe B, Beck B, Gatter N, et al. Oxalobacter formigenes: a potential tool for the treatment of primary hyperoxaluria type 1. *Kidney Int*. 2006;70(7):1305–1311.

Hoppe B, Niaudet P, Salomon R, et al. A randomised Phase I/II trial to evaluate the efficacy and safety of orally administered Oxalobacter formigenes to treat primary hyperoxaluria. *Pediatr Nephrol*. 2017;32(5):781–790.

Hosking DH, Erickson SB, Van den Berg CJ, et al. The stone clinic effect in patients with idiopathic calcium urolithiasis. *J Urol*. 1983;130(6):1115–1118.

Hsi RS, Kabagambe EK, Shu X, et al. Race- and sex-related differences in nephrolithiasis risk among blacks and whites in the Southern Community Cohort Study. *Urology*. 2018;118:36–42.

Hsi RS, Sanford T, Goldfarb DS, et al. The role of the 24-hour urine collection in the prevention of kidney stone recurrence. *J Urol*. 2017;197(4):1084–1089.

Hug B, Naef M, Bucher HC, et al. Treatment for human immunodeficiency virus with indinavir may cause relevant urological side-effects, effectively treatable by rehydration. *BJU Int*. 1999;84(6):610–614.

Hugosson J, Grenabo L, Hedelin H, et al. Bacteriology of upper urinary tract stones. *J Urol*. 1990;143(5):965–968.

Hwang TI, Hill K, Schneider V, et al. Effect of prolonged bedrest on the propensity for renal stone formation. *J Clin Endocrinol Metab*. 1988;66(1):109–112.

Hylander E, Jarnum S, Nielsen K. Calcium treatment of enteric hyperoxaluria after jejunoileal bypass for morbid obesity. *Scand J Gastroenterol*. 1980;15(3):349–352.

Iannuzzi MC, Fontana JR. Sarcoidosis: clinical presentation, immunopathogenesis, and therapeutics. *JAMA*. 2011;305(4):391–399.

Insogna KL, Ellison AS, Burtis WJ, et al. Trichlormethiazide and oral phosphate therapy in patients with absorptive hypercalciuria. *J Urol*. 1989;141(2):269–274.

Iqbal MW, Youssef RF, Neisius A, et al. Contemporary management of struvite stones using combined endourologic and medical treatment: predictors of unfavorable clinical outcome. *J Endourol*. 2016;30(7):771–777; 10.1089/end.2013.0257 [Epub 2013 Nov 19].

Izzedine H, Launay-Vacher V, Deray G. Antiviral drug-induced nephrotoxicity. *Am J Kidney Dis*. 2005;45(5):804–817.

Jaeger CD, Rule AD, Mehta RA, et al. Endoscopic and pathologic characterization of papillary architecture in struvite stone formers. *Urology*. 2016;90:39–44.

Johansen K, Gammelgard PA, Jorgensen FS. Treatment of cystinuria with alpha-mercaptopropionylglycine. *Scand J Urol Nephrol*. 1980;14(2):189–192.

Johansson G, Backman U, Danielson BG, et al. Biochemical and clinical effects of the prophylactic treatment of renal calcium stones with magnesium hydroxide. *J Urol*. 1980;124(6):770–774.

Johri N, Jaeger P, Ferraro PM, et al. Vitamin D deficiency is prevalent among idiopathic stone formers, but does correction pose any risk? *Urolithiasis*. 2017;45(6):535–543.

Joly D, Rieu P, Mejean A, et al. Treatment of cystinuria. *Pediatr Nephrol*. 1999;13(9):945–950.

Kacker R, Meeks JJ, Zhao L, et al. Decreased stone-free rates after percutaneous nephrolithotomy for high calcium phosphate composition kidney stones. *J Urol*. 2008;180(3):958–960 [discussion 960].

Kadlec AO, Greco K, Fridirici ZC, et al. Metabolic syndrome and urinary stone composition: what factors matter most? *Urology*. 2012;80(4):805–810.

Kang DE, Sur RL, Haleblian GE, et al. Long-term lemonade based dietary manipulation in patients with hypocitraturic nephrolithiasis. *J Urol*. 2007;177(4):1358–1362 [discussion 1362; quiz 1591].

Kaplon DM, Penniston KL, Nakada SY. Patients with and without prior urolithiasis have hypocitraturia and incident kidney stones while on topiramate. *Urology*. 2011;77(2):295–298.

Kato Y, Hou K, Saga Y, et al. Ammonium acid urate stone due to laxative abuse: a case report]. *Hinyokika Kiyo*. 2004;50(11):799–803.

Kessler T, Jansen B, Hesse A. Effect of blackcurrant-, cranberry- and plum juice consumption on risk factors associated with kidney stone formation. *Eur J Clin Nutr*. 2002;56(10):1020–1023.

Khambati A, Matulewicz RS, Perry KT, et al. Factors associated with compliance to increased fluid intake and urine volume following dietary counseling in first-time kidney stone patients. *J Endourol*. 2017;31(6):605–610.

Khatchadourian J, Preminger GM, Whitson PA, et al. Clinical and biochemical presentation of gouty diathesis: comparison of uric acid versus pure calcium stone formation. *J Urol*. 1995;154(5):1665–1669.

Kisku S, Sen S, Karl S, et al. Bladder calculi in the augmented bladder: a follow-up study of 160 children and adolescents. *J Pediatr Urol*. 2015;11(2):66 [e1–e6].

Kittanamongkolchai W, Vaughan LE, Enders FT, et al. The changing incidence and presentation of urinary stones over 3 decades. *Mayo Clin Proc*. 2018;93(3):291–299.

Klee LW, Brito CG, Lingeman JE. The clinical implications of brushite calculi. *J Urol*. 1991;145(4):715–718.

Klimiuk PS, Davies M, Adams PH. Primary hyperparathyroidism and thiazide diuretics. *Postgrad Med J*. 1981;57(664):80–83.

Knoll T, Schubert AB, Fahlenkamp D, et al. Urolithiasis through the ages: data on more than 200,000 urinary stone analyses. *J Urol*. 2011;185(4):1304–1311.

Kocvara R, Plasgura P, Petrik A, et al. A prospective study of nonmedical prophylaxis after a first kidney stone. *BJU Int*. 1999;84(4):393–398.

Koff SG, Paquette EL, Cullen J, et al. Comparison between lemonade and potassium citrate and impact on urine pH and 24-hour urine parameters in patients with kidney stone formation. *Urology*. 2007;69(6):1013–1016.

Koga S, Arakaki Y, Matsuoka M, et al. Staghorn calculi—long-term results of management. *Br J Urol*. 1991;68(2):122–124.

Koh ET, Reiser S, Fields M. Dietary fructose as compared to glucose and starch increases the calcium content of kidney of magnesium-deficient rats. *J Nutr*. 1989;119(8):1173–1178.

Kok DJ, Iestra JA, Doorenbos CJ, et al. The effects of dietary excesses in animal protein and in sodium on the composition and the crystallization kinetics of calcium oxalate monohydrate in urines of healthy men. *J Clin Endocrinol Metab*. 1990;71(4):861–867.

Kondo T, Sakaue E, Koyama S, et al. Urolithiasis during treatment of carbonic anhydrase inhibitors]. *Nippon Ganka Kiyo*. 1968;19(4):576–584.

Kopp JB, Miller KD, Mican JA, et al. Crystalluria and urinary tract abnormalities associated with indinavir. *Ann Intern Med*. 1997;127(2):119–125.

Korets R, Graversen JA, Kates M, et al. Post-percutaneous nephrolithotomy systemic inflammatory response: a prospective analysis of preoperative urine, renal pelvic urine and stone cultures. *J Urol*. 2011;186(5):1899–1903.

Kossoff EH, Pyzik PL, Furth SL, et al. Kidney stones, carbonic anhydrase inhibitors, and the ketogenic diet. *Epilepsia*. 2002;43(10):1168–1171.

Kourambas J, Aslan P, Teh CL, et al. Role of stone analysis in metabolic evaluation and medical treatment of nephrolithiasis. *J Endourol*. 2001;15(2):181–186.

Krambeck AE, Handa SE, Evan AP, et al. Profile of the brushite stone former. *J Urol*. 2010;184(4):1367–1371.

Krambeck AE, Khan NF, Jackson ME, et al. Inaccurate reporting of mineral composition by commercial stone analysis laboratories: implications for infection and metabolic stones. *J Urol*. 2010;184(4):1543–1549.

Kramer HM, Curhan G. The association between gout and nephrolithiasis: the National Health and Nutrition Examination Survey III, 1988-1994. *Am J Kidney Dis*. 2002;40(1):37–42.

Kumar J, Mandhani A, et al. Pediatric urolithiasis: experience from a tertiary referral center. *J Pediatr Urol*. 2013;9(6 Pt A):825–830.

Kuo RL, Moran ME, Kim DH, et al. Topiramate-induced nephrolithiasis. *J Endourol*. 2002;16(4):229–231.

Kurtz MP, Eisner BH. Dietary therapy for patients with hypocitraturic nephrolithiasis. *Nat Rev Urol*. 2011;8(3):146–152.

Laerum E, Larsen S. Thiazide prophylaxis of urolithiasis. A double-blind study in general practice. *Acta Med Scand*. 1984;215(4):383–389.

Lafaurie M, De Sousa B, Ponscarme D, et al. Clinical features and risk factors for atazanavir (ATV)-associated urolithiasis: a case-control study. *PLoS ONE*. 2014;9(11):e112836.

Lamb EJ, Stevens PE, Nashef L. Topiramate increases biochemical risk of nephrolithiasis. *Ann Clin Biochem*. 2004;41(Pt 2):166–169.

Lange JN, Wood KD, Wong H, et al. Sensitivity of human strains of Oxalobacter formigenes to commonly prescribed antibiotics. *Urology*. 2012;79(6):1286–1289.

Larsen N, Vogensen FK, van den Berg FW, et al. Gut microbiota in human adults with type 2 diabetes differs from non-diabetic adults. *PLoS ONE*. 2010;5(2):e9085.

Leaf DE, Korets R, Taylor EN, et al. Effect of vitamin D repletion on urinary calcium excretion among kidney stone formers. *Clin J Am Soc Nephrol*. 2012;7(5):829–834.

Lein JW, Keane PM. Limitations of the oral calcium loading test in the management of the recurrent calcareous renal stone former. *Am J Kidney Dis*. 1983;3(1):76–79.

Leppla D, Browne R, Hill K, et al. Effect of amiloride with or without hydrochlorothiazide on urinary calcium and saturation of calcium salts. *J Clin Endocrinol Metab*. 1983;57(5):920–924.

Letavernier E, Vandermeersch S, Traxer O, et al. Demographics and characterization of 10,282 Randall plaque-related kidney stones: a new epidemic? *Medicine (Baltimore)*. 2015;94(10):e566.

Leumann E, Hoppe B. What is new in primary hyperoxaluria? *Nephrol Dial Transplant*. 1999;14(11):2556–2558.

Levy FL, Adams-Huet B, Pak CY. Ambulatory evaluation of nephrolithiasis: an update of a 1980 protocol. *Am J Med*. 1995;98(1):50–59.

Lewandowski S, Rodgers A, Schloss I. The influence of a high-oxalate/low-calcium diet on calcium oxalate renal stone risk factors in non-stone-forming black and white South African subjects. *BJU Int*. 2001;87(4):307–311.

Li MK, Blacklock NJ, Garside J. Effects of magnesium on calcium oxalate crystallization. *J Urol*. 1985;133(1):123–125.

Lieske JC, Peña de la Vega LS, Slezak JM, et al. Renal stone epidemiology in Rochester, Minnesota: an update. *Kidney Int*. 2006;69(4):760–764.

Lifshitz DA, Shalhav AL, Lingeman JE, et al. Metabolic evaluation of stone disease patients: a practical approach. *J Endourol*. 1999;13(9):669–678.

Lindell A, Denneberg T, Edholm E, et al. The effect of sodium intake on cystinuria with and without tiopronin treatment. *Nephron*. 1995;71(4):407–415.

Lindell A, Denneberg T, Granerus G. Studies on renal function in patients with cystinuria. *Nephron*. 1997;77(1):76–85.

Lindsjo M, Fellstrom B, Ljunghall S, et al. Treatment of enteric hyperoxaluria with calcium-containing organic marine hydrocolloid. *Lancet*. 1989;2(8665):701–704.

Lingeman JE, Siegel YI, Steele B. Metabolic evaluation of infected renal lithiasis: clinical relevance. *J Endourol*. 1995;9(1):51–54.

Liu W, Esler SJ, Kenny BJ, et al. Low-dose nonenhanced helical CT of renal colic: assessment of ureteric stone detection and measurement of effective dose equivalent. *Radiology*. 2000;215(1):51–54.

Ljunghall S. Incidence of upper urinary tract stones. *Miner Electrolyte Metab*. 1987;13(4):220–227.

Ljunghall S, Danielson BG. A prospective study of renal stone recurrences. *Br J Urol*. 1984;56(2):122–124.

Lomas DJ, Jaeger CD, Krambeck AE. Profile of the ammonium acid urate stone former based on a large contemporary cohort. *Urology*. 2017;102:43–47.

Lotan Y, Buendia Jimenez I, Lenoir-Wijnkoop I, et al. Primary prevention of nephrolithiasis is cost-effective for a national healthcare system. *BJU Int*. 2012;110(11 Pt C):E1060–E1067.

Lotan Y, Cadeddu JA, Roerhborn CG, et al. Cost-effectiveness of medical management strategies for nephrolithiasis. *J Urol*. 2004;172(6 Pt 1):2275–2281.

Lotz M, Potts JT Jr, Holland JM, et al. D-penicillamine therapy in cystinuria. *J Urol*. 1966;95(2):257–263.

Maalouf NM, Cameron MA, Moe OW, et al. Low urine pH: a novel feature of the metabolic syndrome. *Clin J Am Soc*

Nephrol. 2007;2(5):883–888.

Maalouf NM, Cameron MA, Moe OW, et al. Metabolic basis for low urine pH in type 2 diabetes. *Clin J Am Soc Nephrol*. 2010;5(7):1277–1281.

Maalouf NM, Sakhaee K, Parks JH, et al. Association of urinary pH with body weight in nephrolithiasis. *Kidney Int*. 2004;65(4):1422–1425.

Maloney ME, Springhart WP, Ekeruo WO, et al. Ethnic background has minimal impact on the etiology of nephrolithiasis. *J Urol*. 2005;173(6):2001–2004.

Mandel N, Mandel I, Fryjoff K, et al. Conversion of calcium oxalate to calcium phosphate with recurrent stone episodes. *J Urol*. 2003;169(6):2026–2029.

Mandel NS, Mandel IC, Kolbach-Mandel AM. Accurate stone analysis: the impact on disease diagnosis and treatment. *Urolithiasis*. 2017;45(1):3–9.

Marangella M, Bianco O, Martini C, et al. Effect of animal and vegetable protein intake on oxalate excretion in idiopathic calcium stone disease. *Br J Urol*. 1989;63(4):348–351.

Marcus R, Madvig P, Crim M, et al. Conjugated estrogens in the treatment of postmenopausal women with hyperparathyroidism. *Ann Intern Med*. 1984;100(5):633–640.

Marien T, Miller NL. Treatment of the infected stone. *Urol Clin North Am*. 2015;42(4):459–472.

Marien TP, Miller NL. Characteristics of renal papillae in kidney stone formers. *Minerva Urol Nefrol*. 2016;68(6):496–515.

Marien T, Robles J, Kammann TM, et al. Characterization of urolithiasis in patients following lower urinary tract reconstruction with intestinal segments. *J Endourol*. 2017;31(3):217–222.

Martini LA, Cuppari L, Cunha MA, et al. Potassium and sodium intake and excretion in calcium stone forming patients. *J Ren Nutr*. 1998;8(3):127–131.

Martini LA, Cuppari L, Colugnati FA, et al. High sodium chloride intake is associated with low bone density in calcium stone-forming patients. *Clin Nephrol*. 2000;54(2):85–93.

Martini LA, Heilberg IP. Stop dietary calcium restriction in kidney stone-forming patients. *Nutr Rev*. 2002;60(7 Pt 1):212–214.

Maschio G, Tessitore N, D'Angelo A, et al. Prevention of calcium nephrolithiasis with low-dose thiazide, amiloride and allopurinol. *Am J Med*. 1981;71(4):623–626.

Massey L. Magnesium therapy for nephrolithiasis. *Magnes Res*. 2005;18(2):123–126.

Matlaga BR, Shore AD, Magnuson T, et al. Effect of gastric bypass surgery on kidney stone disease. *J Urol*. 2009;181(6):2573–2577.

McAleer IM, Kaplan GW, Bradley JS, et al. Staghorn calculus endotoxin expression in sepsis. *Urology*. 2002;59(4):601.

McAleer IM, Kaplan GW, Bradley JS, et al. Endotoxin content in renal calculi. *J Urol*. 2003;169(5):1813–1814.

McConnell N, Campbell S, Gillanders I, et al. Risk factors for developing renal stones in inflammatory bowel disease. *BJU Int*. 2002;89(9):835–841.

McDonald JE, Henneman PH. Stone dissolution in vivo and control of cystinuria with d-penicillamine. *N Engl J Med*. 1965;273:578–583.

McHarg T, Rodgers A, Charlton K. Influence of cranberry juice on the urinary risk factors for calcium oxalate kidney stone formation. *BJU Int*. 2003;92(7):765–768.

McLaughlin PD, Murphy KP, Hayes SA, et al. Non-contrast CT at comparable dose to an abdominal radiograph in patients with acute renal colic; impact of iterative reconstruction on image quality and diagnostic performance. *Insights Imaging*. 2014;5(2):217–230.

McNally MA, Pyzik PL, Rubenstein JE, et al. Empiric use of potassium citrate reduces kidney-stone incidence with the ketogenic diet. *Pediatrics*. 2009;124(2):e300–e304.

Melnick I, Landes RR, Hoffman AA, et al. Magnesium therapy for recurring calcium oxalate urinary calculi. *J Urol*. 1971;105(1):119–122.

Mente A, Honey RJ, McLaughlin JR, et al. Ethnic differences in relative risk of idiopathic calcium nephrolithiasis in North America. *J Urol*. 2007;178(5):1992–1997 [discussion 1997].

Mermuys K, De Geeter F, Bacher K, et al. Digital tomosynthesis in the detection of urolithiasis: diagnostic performance and dosimetry compared with digital radiography with MDCT as the reference standard. *AJR Am J Roentgenol*. 2010;195(1):161–167.

Meschi T, Maggiore U, Fiaccadori E, et al. The effect of fruits and vegetables on urinary stone risk factors. *Kidney Int*. 2004;66(6):2402–2410.

Michelakakis H, Delis D, Anastasiadou V, et al. Ineffectiveness of captopril in reducing cystine excretion in cystinuric children. *J Inherit Metab Dis*. 1993;16(6):1042–1043.

Milliner D, Hoppe B, Groothoff J. A randomised Phase II/III study to evaluate the efficacy and safety of orally administered Oxalobacter formigenes to treat primary hyperoxaluria. *Urolithiasis*. 2018;46(4):313–323.

Milne DB, Nielsen FH. The interaction between dietary fructose and magnesium adversely affects macromineral homeostasis in men. *J Am Coll Nutr*. 2000;19(1):31–37.

Milose JC, Kaufman SR, Hollenbeck BK, et al. Prevalence of 24-hour urine collection in high risk stone formers. *J Urol*. 2014;191(2):376–380.

Mohkam M, Karimi A, Gharib A, et al. Ceftriaxone associated nephrolithiasis: a prospective study in 284 children. *Pediatr Nephrol*. 2007;22(5):690–694.

Monico CG, Rossetti S, Belostotsky R, et al. Primary hyperoxaluria type III gene HOGA1 (formerly DHDPSL) as a possible risk factor for idiopathic calcium oxalate urolithiasis. *Clin J Am Soc Nephrol*. 2011;6(9):2289–2295.

Moreira DM, Friedlander JI, Hartman C, et al. Differences in 24-hour urine composition between apatite and brushite stone formers. *Urology*. 2013;82(4):768–772.

Morrill AC, Chinn CD. The obesity epidemic in the United States. *J Public Health Policy*. 2004;25(3–4):353–366.

Mortensen JT, Schultz A, Ostergaard AH. Thiazides in the prophylactic treatment of recurrent idiopathic kidney stones. *Int Urol Nephrol*. 1986;18(3):265–269.

Muldowney FP, Freaney R, Moloney MF. Importance of dietary sodium in the hypercalciuria syndrome. *Kidney Int*. 1982;22(3):292–296.

Nakagawa Y, Asplin JR, Goldfarb DS, et al. Clinical use of cystine supersaturation measurements. *J Urol*. 2000;164(5):1481–1485.

Neisius A, Astroza GM, Wang C, et al. Digital tomosynthesis: a new technique for imaging nephrolithiasis. Specific organ doses and effective doses compared with renal stone protocol noncontrast computed tomography. *Urology*. 2014;83(2):282–287.

Nemoy NJ, Staney TA. Surgical, bacteriological, and biochemical management of infection stones. *JAMA*. 1971;215(9):1470–1476.

Nguyen QV, Kalin A, Drouve U, et al. Sensitivity to meat protein intake and hyperoxaluria in idiopathic calcium stone formers. *Kidney Int*. 2001;59(6):2273–2281.

Nicar MJ, Hsu MC, Johnson T, et al. The preservation of urine samples for determination of renal stone risk factors. *Lab Med*. 1987;18(6):382–384.

Nicar MJ, Skurla C, Sakhaee K, et al. Low urinary citrate excretion in nephrolithiasis. *Urology*. 1983;21(1):8–14.

Nordenvall B, Backman L, Larsson L, et al. Effects of calcium, aluminium, magnesium and cholestyramine on hyperoxaluria in patients with jejunoileal bypass. *Acta Chir Scand*. 1983;149(1):93–98.

Norman RW, Manette WA. Dietary restriction of sodium as a means of reducing urinary cystine. *J Urol*. 1990;143(6):1193–1195.

Nouvenne A, Meschi T, Prati B, et al. Effects of a low-salt diet on idiopathic hypercalciuria in calcium-oxalate stone formers: a 3-mo randomized controlled trial. *Am J Clin Nutr*. 2010;91(3):565–570.

Nowfar S, Palazzi-Churas K, Chang DC, et al. The relationship of obesity and gender prevalence changes in United States inpatient nephrolithiasis. *Urology*. 2011;78(5):1029–1033.

Odvina CV. Comparative value of orange juice versus lemonade in reducing stone-forming risk. *Clin J Am Soc Nephrol*. 2006;1(6):1269–1274.

Odvina CV, Preminger GM, Lindberg JS, et al. Long-term combined treatment with thiazide and potassium citrate in nephrolithiasis does not lead to hypokalemia or hypochloremic metabolic alkalosis. *Kidney Int*. 2003;63(1):240–247.

Ohkawa M, Tokunaga S, Nakashima T, et al. Thiazide treatment for calcium urolithiasis in patients with idiopathic hypercalciuria. *Br J Urol*. 1992;69(6):571–576.

Orr-Walker BJ, Evans MC, Clearwater JM, et al. Effects of hormone replacement therapy on bone mineral density in postmenopausal women with primary hyperparathyroidism: four-year follow-up and comparison with healthy postmenopausal women. *Arch Intern Med*. 2000;160(14):2161–2166.

Ortiz-Alvarado O, Miyaoka R, Kriedberg C, et al. Pyridoxine and dietary counseling for the management of idiopathic hyperoxaluria in stone-forming patients. *Urology*. 2011;77(5):1054–1058.

Otto BJ, Bozorgmehri S, Kuo J, et al. Age, body mass index, and gender predict 24-hour urine parameters in recurrent idiopathic calcium oxalate stone formers. *J Endourol*. 2017;31(12):1335–1341.

Pak CY. Sodium cellulose phosphate: mechanism of action and effect on mineral metabolism. *J Clin Pharmacol New Drugs*. 1973;13(1):15–27.

Pak CY, Arnold LH. Heterogeneous nucleation of calcium oxalate by seeds of monosodium urate. *Proc Soc Exp Biol Med*. 1975;149(4):930–932.

Pak CY, Hayashi Y, Arnold LH. Heterogeneous nucleation with urate, calcium phosphate and calcium oxalate. *Proc Soc Exp Biol Med*. 1976;153(1):83–87.

Pak CY, Barilla DE, Holt K, et al. Effect of oral purine load and allopurinol on the crystallization of calcium salts in urine of patients with hyperuricosuric calcium urolithiasis. *Am J Med*. 1978;65(4):593–599.

Pak CY, Britton F, Peterson R, et al. Ambulatory evaluation of nephrolithiasis. Classification, clinical presentation and diagnostic criteria. *Am J Med*. 1980;69(1):19–30.

Pak CY, Sakhaee K, Crowther C, et al. Evidence justifying a high fluid intake in treatment of nephrolithiasis. *Ann Intern Med*. 1980;93(1):36–39.

Pak CY. Should patients with single renal stone occurrence undergo diagnostic evaluation? *J Urol*. 1982;127(5):855–858.

Pak CY, Fuller CJ. Assessment of cystine solubility in urine and of heterogeneous nucleation. *J Urol*. 1983;129(5):1066–1070.

Pak CY, Peterson R, Sakhaee K, et al. Correction of hypocitraturia and prevention of stone formation by combined thiazide and potassium citrate therapy in thiazide-unresponsive hypercalciuric nephrolithiasis. *Am J Med*. 1985;79(3):284–288.

Pak CY, Fuller C. Idiopathic hypocitraturic calcium-oxalate nephrolithiasis successfully treated with potassium citrate. *Ann Intern Med*. 1986;104(1):33–37.

Pak CY, Peterson R. Successful treatment of hyperuricosuric calcium oxalate nephrolithiasis with potassium citrate. *Arch Intern Med*. 1986;146(5):863–867.

Pak CY, Fuller C, Sakhaee K, et al. Management of cystine nephrolithiasis with alpha-mercaptopropionylglycine. *J Urol*. 1986;136(5):1003–1008.

Pak CY, Sakhaee K, Fuller C. Successful management of uric acid nephrolithiasis with potassium citrate. *Kidney Int*. 1986;30(3):422–428.

Pak CY. Southwestern Internal Medicine Conference: medical management of nephrolithiasis—a new, simplified approach for general practice. *Am J Med Sci*. 1997;313(4):215–219.

Pak CY, Peterson R, Poindexter JR. Adequacy of a single stone risk analysis in the medical evaluation of urolithiasis. *J Urol*. 2001;165(2):378–381.

Pak CY, Peterson RD, Poindexter J. Prevention of spinal bone loss by potassium citrate in cases of calcium urolithiasis. *J Urol*. 2002;168(1):31–34.

Pak CY, Poindexter JR, Peterson RD, et al. Biochemical distinction between hyperuricosuric calcium urolithiasis and gouty diathesis. *Urology*. 2002;60(5):789–794.

Pak CY, Heller HJ, Pearle MS, et al. Prevention of stone formation and bone loss in absorptive hypercalciuria by combined dietary and pharmacological interventions. *J Urol*. 2003;169(2):465–469.

Pak CY, Poindexter JR, Adams-Huet B, et al. Predictive value of kidney stone composition in the detection of metabolic abnormalities. *Am J Med*. 2003;115(1):26–32.

Pak CY, Sakhaee K, Moe O, et al. Biochemical profile of stone-forming patients with diabetes mellitus. *Urology*. 2003;61(3):523–527.

Pak CY, Adams-Huet B. Elucidation of factors determining formation of calcium phosphate stones. *J Urol*. 2004;172(6 Pt 1):2267–2270.

Pak CY, Sakhaee K, Pearle MS. Detection of absorptive hypercalciuria type I without the oral calcium load test. *J Urol*. 2011;185(3):915–919.

Pang R, Linnes MP, O'Connor HM, et al. Controlled metabolic diet reduces calcium oxalate supersaturation but not oxalate excretion after bariatric surgery. *Urology*. 2012;80(2):250–254.

Pareek G, Armenakas NA, Fracchia JA. Hounsfield units on computerized tomography predict stone-free rates after extracorporeal shock wave lithotripsy. *J Urol*. 2003;169(5):1679–1681.

Parfitt AM. Acetazolamide and sodium bicarbonate induced nephrocalcinosis and nephrolithiasis; relationship to citrate and calcium excretion. *Arch Intern Med*. 1969;124(6):736–740.

Park AM, Storm DW, Fulmer BR, et al. A prospective study of risk factors for nephrolithiasis after Roux-en-Y gastric bypass surgery. *J Urol*. 2009;182(5):2334–2339.

Parks JH, Coe FL. A urinary calcium-citrate index for the evaluation of nephrolithiasis. *Kidney Int*. 1986;30(1):85–90.

Parks JH, Coe FL. Urine citrate and calcium in calcium nephrolithiasis. *Adv Exp Med Biol*. 1986;208:445–449.

Parks JH, Coward M, Coe FL. Correspondence between stone composition and urine supersaturation in nephrolithiasis. *Kidney Int*. 1997;51(3):894–900.

Parks JH, Goldfisher E, Asplin JR, et al. A single 24-hour urine collection is inadequate for the medical evaluation of nephrolithiasis. *J Urol*. 2002;167(4):1607–1612.

Parks JH, Goldfischer ER, Coe FL. Changes in urine volume accomplished by physicians treating nephrolithiasis. *J Urol*. 2003;169(3):863–866.

Parks JH, Worcester EM, O'Connor RC, et al. Urine stone risk factors in nephrolithiasis patients with and without bowel disease. *Kidney Int*. 2003;63(1):255–265.

Parks JH, Worcester EM, Coe FL, et al. Clinical implications of abundant calcium phosphate in routinely analyzed kidney stones. *Kidney Int*. 2004;66(2):777–785.

Parks JH, Coe FL, Evan AP, et al. Urine pH in renal calcium stone formers who do and do not increase stone phosphate content with time. *Nephrol Dial Transplant*. 2009;24(1):130–136.

Patel IH, Kaplan SA. Pharmacokinetic profile of ceftriaxone in man. *Am J Med*. 1984;77(4C):17–25.

Patel N, Brown RD, Sarkissian C, et al. Quality of life and urolithiasis: the patient-reported outcomes measurement information system (PROMIS). *Int Braz J Urol*. 2017;43(5):880–886.

Pearle MS, Calhoun EA, Curhan GC. Urologic diseases in America project: urolithiasis. *J Urol*. 2005;173(3):848–857.

Pearle MS, Goldfarb DS, Assimos DG, American Urological Association, et al. Medical management of kidney stones: AUA guideline. *J Urol*. 2014;192(2):316–324.

Penniston KL, Nakada SY. Health related quality of life differs between male and female stone formers. *J Urol*. 2007;178(6):2435–2440 [discussion 2440].

Penniston KL, Steele TH, Nakada SY. Lemonade therapy increases urinary citrate and urine volumes in patients with recurrent calcium oxalate stone formation. *Urology*. 2007;70(5):856–860.

Penniston KL, Sninsky BC, Nakada SY. Preliminary evidence of decreased disease-specific health-related quality of life in asymptomatic stone patients. *J Endourol*. 2016;30(Suppl 1):S42–S45.

Penniston KL, Antonelli JA, Viprakasit DP, et al. Validation and reliability of the Wisconsin Stone Quality of Life Questionnaire. *J Urol*. 2017;197(5):1280–1288.

Phillips MJ, Cooke JN. Relation between urinary calcium and sodium in patients with idiopathic hypercalciuria. *Lancet*. 1967;1(7504):1354–1357.

Phillips R, Hanchanale VS, Myatt A, et al. Citrate salts for preventing and treating calcium containing kidney stones in adults. *Cochrane Database Syst Rev*. 2015;(10) [CD010057].

Pietrow PK, Auge BK, Weizer AZ, et al. Durability of the medical management of cystinuria. *J Urol*. 2003;169(1):68–70.

Pietrow PK, Pope JC 4th, Adams MC, et al. Clinical outcome of pediatric stone disease. *J Urol*. 2002;167(2 Pt 1):670–673.

Pohlman T, Hruska KA, Menon M. Renal tubular acidosis. *J Urol*. 1984;132(3):431–436.

Polito C, La Manna A, Cioce F, et al. Clinical presentation and natural course of idiopathic hypercalciuria in children. *Pediatr Nephrol*. 2000;15(3–4):211–214.

Porpiglia F, Fiori C, Bertolo R, et al. Temporary implantable nitinol device (TIND): a novel, minimally invasive treatment for relief of lower urinary tract symptoms (LUTS) related to benign prostatic hyperplasia (BPH): feasibility, safety and functional results at 1 year of follow-up. *BJU Int*. 2015;116(2):278–287.

Powell CR, Stoller ML, Schwartz BF, et al. Impact of body weight on urinary electrolytes in urinary stone formers. *Urology*. 2000;55(6):825–830.

Powell T, Hsu FF, Turk J, et al. Ma-huang strikes again: ephedrine nephrolithiasis. *Am J Kidney Dis*. 1998;32(1):153–

159.

Preminger GM, Assimos DG, Lingeman J, et al. *Report on the management of staghorn calculi*. American Urological Association: Baltimore, MD; 2005.

Preminger GM, Sakhaee K, Pak CY. Hypercalciuria and altered intestinal calcium absorption occurring independently of vitamin D in incomplete distal renal tubular acidosis. *Metabolism*. 1987;36(2):176–179.

Preminger GM, Sakhaee K, Pak CY. Alkali action on the urinary crystallization of calcium salts: contrasting responses to sodium citrate and potassium citrate. *J Urol*. 1988;139(2):240–242.

Preminger GM, Sakhaee K, Skurla C, et al. Prevention of recurrent calcium stone formation with potassium citrate therapy in patients with distal renal tubular acidosis. *J Urol*. 1985;134(1):20–23.

Prien EL Sr, Gershoff SF. Magnesium oxide-pyridoxine therapy for recurrent calcium oxalate calculi. *J Urol*. 1974;112(4):509–512.

Primak AN, Fletcher JG, Vrtiska TJ, et al. Noninvasive differentiation of uric acid versus non-uric acid kidney stones using dual-energy CT. *Acad Radiol*. 2007;14(12):1441–1447.

Rabani SM. Giant bladder stone in a healthy young female: a case report. *Acta Med Iran*. 2016;54(11):754–755.

Ray AA, Ghiculete D, Pace KT, et al. Limitations to ultrasound in the detection and measurement of urinary tract calculi. *Urology*. 2010;76(2):295–300.

Reddy ST, Wang CY, Sakhaee K, et al. Effect of low-carbohydrate high-protein diets on acid-base balance, stone-forming propensity, and calcium metabolism. *Am J Kidney Dis*. 2002;40(2):265–274.

Remien A, Kallistratos G, Burchardt P. Treatment of cystinuria with Thiola (alpha-mercaptopropionyl glycine). *Eur Urol*.

1975;1(5):227–228.

Resnick MI. Evaluation and management of infection stones. *Urol Clin North Am*. 1981;8(2):265–276.

Resnick MI, Pak CYC. *Urolithiasis: a medical and surgical reference*. Saunders: Philadelphia, PA; 1990.

Rigby NJ, Kumanyika S, James WP. Confronting the epidemic: the need for global solutions. *J Public Health Policy*. 2004;25(3–4):418–434.

Riggs BL, O'Fallon WM, et al. Long-term effects of calcium supplementation on serum parathyroid hormone level, bone turnover, and bone loss in elderly women. *J Bone Miner Res*. 1998;13(2):168–174.

Riley JM, Kim H, Averch TD, et al. Effect of magnesium on calcium and oxalate ion binding. *J Endourol*. 2013;27(12):1487–1492.

Rivers K, Shetty S, Menon M. When and how to evaluate a patient with nephrolithiasis. *Urol Clin North Am*. 2000;27(2):203–213.

Robinson MR, Leitao VA, Haleblian GE, et al. Impact of long-term potassium citrate therapy on urinary profiles and recurrent stone formation. *J Urol*. 2009;181(3):1145–1150.

Robson MD, Gatehouse PD, Bydder M, et al. Magnetic resonance: an introduction to ultrashort TE (UTE) imaging. *J Comput Assist Tomogr*. 2003;27(6):825–846.

Rocha H, Santos LC. Relapse of urinary tract infection in the presence of urinary tract calculi: the role of bacteria within the calculi. *J Med Microbiol*. 1969;2(3):372–376.

Rodman JS, Williams JJ, Peterson CM. Partial dissolution of struvite calculus with oral acetohydroxamic acid. *Urology*. 1983;22(4):410–412.

Rodman JS, Blackburn P, Williams JJ, et al. The effect of dietary protein on cystine excretion in patients with cystinuria. *Clin Nephrol*. 1984;22(6):273–278.

Rodman JS, Williams JJ, Jones RL. Hypercoagulability produced by treatment with acetohydroxamic acid. *Clin Pharmacol Ther*. 1987;42(3):346–350.

Rodman JS, Mahler RJ. Kidney stones as a manifestation of hypercalcemic disorders. Hyperparathyroidism and sarcoidosis. *Urol Clin North Am*. 2000;27(2):275–285 [viii].

Rodriguez LM, Santos F, Malaga S, et al. Effect of a low sodium diet on urinary elimination of cystine in cystinuric children. *Nephron*. 1995;71(4):416–418.

Rule AD, Lieske JC, Li X, et al. The ROKS nomogram for predicting a second symptomatic stone episode. *J Am Soc Nephrol*. 2014;25(12):2878–2886.

Ryu HJ, Song R, Kim HW, et al. Clinical risk factors for adverse events in allopurinol users. *J Clin Pharmacol*. 2013;53(2):211–216.

Saigal CS, Joyce G, Timilsina AR. Direct and indirect costs of nephrolithiasis in an employed population: opportunity for disease management? *Kidney Int*. 2005;68(4):1808–1814.

Sakhaee K, Nicar M, Hill K, et al. Contrasting effects of potassium citrate and sodium citrate therapies on urinary chemistries and crystallization of stone-forming salts. *Kidney Int*. 1983;24(3):348–352.

Sakhaee K, Poindexter JR, Pak CY. The spectrum of metabolic abnormalities in patients with cystine nephrolithiasis. *J Urol*. 1989;141(4):819–821.

Sakhaee K, Harvey JA, Padalino PK, et al. The potential role of salt abuse on the risk for kidney stone formation. *J Urol*. 1993;150(2 Pt 1):310–312.

Sakhaee K, Baker S, Zerwekh J, et al. Limited risk of kidney stone formation during long-term calcium citrate supplementation in nonstone forming subjects. *J Urol*. 1994;152(2 Pt 1):324–327.

Sakhaee K, Adams-Huet B, Moe OW, et al. Pathophysiologic basis for normouricosuric uric acid nephrolithiasis. *Kidney Int*. 2002;62(3):971–979.

Sakhaee K, Poindexter JR, Griffith CS, et al. Stone forming risk of calcium citrate supplementation in healthy postmenopausal women. *J Urol*. 2004;172(3):958–961.

Sakhaee K, Capolongo G, Maalouf NM, et al. Metabolic syndrome and the risk of calcium stones. *Nephrol Dial Transplant*. 2012;27(8):3201–3209.

Sakhaee K. Epidemiology and clinical pathophysiology of uric acid kidney stones. *J Nephrol*. 2014;27(3):241–245.

Saltel E, Angel JB, Futter NG, et al. Increased prevalence and analysis of risk factors for indinavir nephrolithiasis. *J Urol*. 2000;164(6):1895–1897.

Saw KC, McAteer JA, Fineberg NS, et al. Calcium stone fragility is predicted by helical CT attenuation values. *J Endourol*. 2000;14(6):471–474.

Scales CD Jr, Curtis LH, Norris RD, et al. Changing gender prevalence of stone disease. *J Urol*. 2007;177(3):979–982.

Scales CD Jr, Smith AC, Hanley JM, Urologic Diseases in America Project, et al. Prevalence of kidney stones in the United States. *Eur Urol*. 2012;62(1):160–165.

Selby PL, Peacock M. Ethinyl estradiol and norethindrone in the treatment of primary hyperparathyroidism in postmenopausal women. *N Engl J Med*. 1986;314(23):1481–1485.

Seltzer MA, Low RK, McDonald M, et al. Dietary manipulation with lemonade to treat hypocitraturic calcium nephrolithiasis. *J Urol*. 1996;156(3):907–909.

Shah J, Whitfield HN. Urolithiasis through the ages. *BJU Int*. 2002;89(8):801–810.

Shavit L, Chen L, Ahmed F, et al. Selective screening for distal renal tubular acidosis in recurrent kidney stone formers: initial experience and comparison of the simultaneous furosemide and fludrocortisone test with the short ammonium chloride test. *Nephrol Dial Transplant*. 2016;31(11):1870–1876.

Shuster J, Jenkins A, Logan C, et al. Soft drink consumption and urinary stone recurrence: a randomized prevention trial. *J Clin Epidemiol*. 1992;45(8):911–916.

Sidhu H, Schmidt ME, Cornelius JG, et al. Direct correlation between hyperoxaluria/oxalate stone disease and the absence of the gastrointestinal tract-dwelling bacterium Oxalobacter formigenes: possible prevention by gut recolonization or enzyme replacement therapy. *J Am Soc Nephrol*. 1999;10(Suppl 14):S334–S340.

Siener R. Can the manipulation of urinary pH by beverages assist with the prevention of stone recurrence? *Urolithiasis*. 2016;44(1):51–56.

Siener R, Bangen U, Sidhu H, et al. The role of Oxalobacter formigenes colonization in calcium oxalate stone disease. *Kidney Int*. 2013;83(6):1144–1149.

Siener R, Buchholz N, Daudon M, EAU Section of Urolithiasis (EULIS), et al. Quality assessment of urinary stone analysis: results of a multicenter study of laboratories in Europe. *PLoS ONE*. 2016;11(6):e0156606.

Silver J, Rubinger D, Friedlaender MM, et al. Sodium-dependent idiopathic hypercalciuria in renal-stone formers. *Lancet*. 1983;2(8348):484–486.

Silverberg SJ, Shane E, Jacobs TP, et al. Nephrolithiasis and bone involvement in primary hyperparathyroidism. *Am J Med*. 1990;89(3):327–334.

Simon JC, Sapozhnikov OA, Kreider W, et al. The role of trapped bubbles in kidney stone detection with the color Doppler ultrasound twinkling artifact. *Phys Med Biol*. 2018;63(2):025011.

Singh P, Enders FT, Vaughan LE, et al. Stone composition among first-time symptomatic kidney stone formers in the community. *Mayo Clin Proc*. 2015;90(10):1356–1365.

Siyam FF, Klachko DM. What is hypercalcemia? The importance of fasting samples. *Cardiorenal Med*. 2013;3(4):232–238.

Skolarikos A, Straub M, Knoll T, et al. Metabolic evaluation and recurrence prevention for urinary stone patients: EAU guidelines. *Eur Urol*. 2015;67(4):750–763.

Sloand JA, Izzo JL Jr. Captopril reduces urinary cystine excretion in cystinuria. *Arch Intern Med*. 1987;147(8):1409–1412.

Smith A. Evaluation of the nitroprusside test for the diagnosis of cystinuria. *Med J Aust*. 1977;2(5):153–155.

Smith CL. When should the stone patient be evaluated? Early evaluation of single stone formers. *Med Clin North Am*. 1984;68(2):455–459.

Smith CL, Gemar SK, Lewis MJ. Pseudoephedrine urolithiasis associated with acute renal failure. *Nephrol Dial Transplant*. 2004;19(1):263–264.

Smith LH, Fromm H, Hofmann AF. Acquired hyperoxaluria, nephrolithiasis, and intestinal disease. Description of a syndrome. *N Engl J Med*. 1972;286(26):1371–1375.

Soble JJ, Hamilton BD, Streem SB. Ammonium acid urate calculi: a reevaluation of risk factors. *J Urol*. 1999;161(3):869–873.

Sorgel F, Ettinger B, Benet LZ. The true composition of kidney stones passed during triamterene therapy. *J Urol*. 1985;134(5):871–873.

Stevens DJ, McKenzie K, Cui HW, et al. Smartphone apps for urolithiasis. *Urolithiasis*. 2015;43(1):13–19.

Strauss AL, Coe FL, Deutsch L, et al. Factors that predict relapse of calcium nephrolithiasis during treatment: a prospective study. *Am J Med*. 1982;72(1):17–24.

Strauss AL, Coe FL, Parks JH. Formation of a single calcium stone of renal origin. Clinical and laboratory characteristics of patients. *Arch Intern Med*. 1982;142(3):504–507.

Streem SB, Hall P. Effect of captopril on urinary cystine excretion in homozygous cystinuria. *J Urol*. 1989;142(6):1522–1524.

Streeper NM, Wertheim ML, Nakada SY, et al. Cystine stone formers have impaired health-related quality of life compared with noncystine stone formers: a case-referent study piloting the Wisconsin Stone Quality of Life Questionnaire Among Patients with Cystine Stones. *J Endourol*. 2017;31(S1):S48–S53.

Strong P, Jewell S, Rinker J, et al. Thiazide therapy and severe hypercalcemia in a patient with hyperparathyroidism. *West J Med*. 1991;154(3):338–340.

Strumpf E. The obesity epidemic in the United States: causes and extent, risks and solutions. *Issue Brief (Commonw Fund)*. 2004;713:1–6.

Sundaram CP, Saltzman B. Urolithiasis associated with protease inhibitors. *J Endourol*. 1999;13(4):309–312.

Tack D, Sourtzis S, Delpierre I, et al. Low-dose unenhanced multidetector CT of patients with suspected renal colic. *AJR Am J Roentgenol*. 2003;180(2):305–311.

Takei K, Ito H, Masai M, et al. Oral calcium supplement decreases urinary oxalate excretion in patients with enteric hyperoxaluria. *Urol Int*. 1998;61(3):192–195.

Tasian GE, Jemielita T, Goldfarb DS, et al. Oral antibiotic exposure and kidney stone disease. *J Am Soc Nephrol*. 2018;29(6):1731–1740.

Taylor EN, Curhan GC. Role of nutrition in the formation of calcium-containing kidney stones. *Nephron Physiol*. 2004;98(2):p55–p63.

Taylor EN, Curhan GC. Body size and 24-hour urine composition. *Am J Kidney Dis*. 2006;48(6):905–915.

Taylor EN, Curhan GC. Fructose consumption and the risk of kidney stones. *Kidney Int*. 2008;73(2):207–212.

Taylor EN, Curhan GC. Demographic, dietary, and urinary factors and 24-h urinary calcium excretion. *Clin J Am Soc Nephrol*. 2009;4(12):1980–1987.

Taylor EN, Fung TT, Curhan GC. DASH-style diet associates with reduced risk for kidney stones. *J Am Soc Nephrol*. 2009;20(10):2253–2259.

Taylor EN, Stampfer MJ, Curhan GC. Dietary factors and the risk of incident kidney stones in men: new insights after 14 years of follow-up. *J Am Soc Nephrol*. 2004;15(12):3225–3232.

Taylor EN, Stampfer MJ, Curhan GC. Obesity, weight gain, and the risk of kidney stones. *JAMA*. 2005;293(4):455–462.

Taylor EN, Stampfer MJ, Mount DB, et al. DASH-style diet and 24-hour urine composition. *Clin J Am Soc Nephrol*. 2010;5(12):2315–2322.

Tefekli A, Cezayirli F. The history of urinary stones: in parallel with civilization. *ScientificWorldJournal*. 2013;2013:423964.

Tekin A, Tekgul S, Atsu N, et al. Ureteropelvic junction obstruction and coexisting renal calculi in children: role of metabolic abnormalities. *Urology*. 2001;57(3):542–545 [discussion 545–546].

Thier SO, Segal S, Fox M, et al. Cystinuria: defective intestinal transport of dibasic amino acids and cystine. *J Clin Invest*. 1965;44:442–448.

Thomas LD, Elinder CG, Tiselius HG, et al. Ascorbic acid supplements and kidney stone incidence among men: a prospective study. *JAMA Intern Med*. 2013;173(5):386–388.

Tiselius HG, Daudon M, Thomas K, et al. Metabolic work-up of patients with urolithiasis: indications and diagnostic algorithm. *Eur Urol Focus*. 2017;3(1):62–71.

Torricelli FC, De S, Li I, et al. Can obese stone formers follow dietary recommendations? *J Endourol*. 2014;28(2):248–251.

Tosukhowong P, Yachantha C, Sasivongsbhakdi T, et al. Citraturic, alkalinizing and antioxidative effects of limeade-based regimen in nephrolithiasis patients. *Urol Res*. 2008;36(3–4):149–155.

Tracy CR, Best S, Bagrodia A, et al. Animal protein and the risk of kidney stones: a comparative metabolic study of animal protein sources. *J Urol*. 2014;192(1):137–141.

Traxer O, Pearle MS, Gattegno B, et al. Vitamin C and stone risk. Review of the literature]. *Prog Urol*. 2003;13(6):1290–1294.

Trinchieri A, Nespoli R, Ostini F, et al. A study of dietary calcium and other nutrients in idiopathic renal calcium stone formers with low bone mineral content. *J Urol*. 1998;159(3):654–657.

Troxel SA, Sidhu H, Kaul P, et al. Intestinal Oxalobacter formigenes colonization in calcium oxalate stone formers and its relation to urinary oxalate. *J Endourol*. 2003;17(3):173–176.

Turk C, Petrik A, Sarica K, et al. EAU Guidelines on Diagnosis and Conservative Management of Urolithiasis. *Eur Urol*. 2016;69(3):468–474.

Uribarri J, Oh MS, Carroll HJ. The first kidney stone. *Ann Intern Med*. 1989;111(12):1006–1009.

Valentin J, International Commission on Radiological Protection (ICRP). Protecting people against radiation exposure in the event of a radiological attack. A report of The International Commission on Radiological Protection. *Ann ICRP*. 2005;35(1):1–110 [iii–iv].

Valezi AC, Fuganti PE, Junior JM, et al. Urinary evaluation after RYGBP: a lithogenic profile with early postoperative increase in the incidence of urolithiasis. *Obes Surg*.

2013;23(10):1575–1580.

Van Den Berg CJ, Kumar R, Wilson DM, et al. Orthophosphate therapy decreases urinary calcium excretion and serum 1,25-dihydroxyvitamin D concentrations in idiopathic hypercalciuria. *J Clin Endocrinol Metab*. 1980;51(5):998–1001.

Vega D, Maalouf NM, Sakhaee K. Increased propensity for calcium phosphate kidney stones with topiramate use. *Expert Opin Drug Saf*. 2007;6(5):547–557.

Wabner CL, Pak CY. Effect of orange juice consumption on urinary stone risk factors. *J Urol*. 1993;149(6):1405–1408.

Wallace RB, Wactawski-Wende J, O'Sullivan MJ, et al. Urinary tract stone occurrence in the Women's Health Initiative (WHI) randomized clinical trial of calcium and vitamin D supplements. *Am J Clin Nutr*. 2011;94(1):270–277.

Walsh SB, Shirley DG, Wrong OM, et al. Urinary acidification assessed by simultaneous furosemide and fludrocortisone treatment: an alternative to ammonium chloride. *Kidney Int*. 2007;71(12):1310–1316.

Warner BW, LaGrange CA, Tucker T, et al. Induction of progressive profound hypocitraturia with increasing doses of topiramate. *Urology*. 2008;72(1):29–32 [discussion 32–23].

Wasserstein AG, Stolley PD, Soper KA, et al. Case-control study of risk factors for idiopathic calcium nephrolithiasis. *Miner Electrolyte Metab*. 1987;13(2):85–95.

Watson RA, Ettinger B, Deshon GE Jr, et al. Triamterene stone: advantage of crystallographic analysis. *Urology*. 1981;18(3):238–240.

Weinberg AE, Patel CJ, Chertow GM, et al. Diabetic severity and risk of kidney stone disease. *Eur Urol*. 2014;65(1):242–247.

Weisenthal K, Karthik P, Shaw M, et al. Evaluation of kidney stones with reduced-radiation dose CT: progress from 2011-

2012 to 2015-2016—Not There Yet. *Radiology*. 2018;286(2):581–589.

Wermers RA, Kearns AE, Jenkins GD, et al. Incidence and clinical spectrum of thiazide-associated hypercalcemia. *Am J Med*. 2007;120(10):911 [e9–15].

Werness PG, Bergert JH, Smith LH. Triamterene urolithiasis: solubility, pk, effect on crystal formation, and matrix binding of triamterene and its metabolites. *J Lab Clin Med*. 1982;99(2):254–262.

Whelan C, Schwartz BF. Bilateral guaifenesin ureteral calculi. *Urology*. 2004;63(1):175–176.

Williams HE, Smith LH Jr. L-glyceric aciduria. A new genetic variant of primary hyperoxaluria. *N Engl J Med*. 1968;278(5):233–238.

Williams JJ, Rodman JS, Peterson CM. A randomized double-blind study of acetohydroxamic acid in struvite nephrolithiasis. *N Engl J Med*. 1984;311(12):760–764.

Williams HE, Wandzilak TR. Oxalate synthesis, transport and the hyperoxaluric syndromes. *J Urol*. 1989;141(3 Pt 2):742–749.

Williams EL, Bockenhauer D, van't Hoff WG, et al. The enzyme 4-hydroxy-2-oxoglutarate aldolase is deficient in primary hyperoxaluria type 3. *Nephrol Dial Transplant*. 2012;27(8):3191–3195.

Williams JC Jr, Hameed T, Jackson ME, et al. Fragility of brushite stones in shock wave lithotripsy: absence of correlation with computerized tomography visible structure. *J Urol*. 2012;188(3):996–1001.

Williams JC Jr, Lingeman JE, Coe FL, et al. Micro-CT imaging of Randall's plaques. *Urolithiasis*. 2015;43(Suppl 1):13–17.

Williams JC Jr, Borofsky MS, Bledsoe SB, et al. Papillary ductal plugging is a mechanism for early stone retention in brushite stone disease. *J Urol*. 2018;199(1):186–192.

Wilz DR, Gray RW, Dominguez JH, et al. Plasma 1,25-(OH)2-vitamin D concentrations and net intestinal calcium, phosphate, and magnesium absorption in humans. *Am J Clin Nutr*. 1979;32(10):2052–2060.

Worcester EM. Stones from bowel disease. *Endocrinol Metab Clin North Am*. 2002;31(4):979–999.

Xu LHR, Adams-Huet B, Poindexter JR, et al. Temporal changes in kidney stone composition and in risk factors predisposing to stone formation. *J Urol*. 2017;197(6):1465–1471.

Yendt ER, Gagne RJ, Cohanim M. The effects of thiazides in idiopathic hypercalciuria. *Am J Med Sci*. 1966;251(4):449–460.

Yilmaz E, Batislam E, Kacmaz M, et al. Citrate, oxalate, sodium, and magnesium levels in fresh juices of three different types of tomatoes: evaluation in the light of the results of studies on orange and lemon juices. *Int J Food Sci Nutr*. 2010;61(4):339–345.

York NE, Borofsky MS, Lingeman JE. Risks associated with drug treatments for kidney stones. *Expert Opin Drug Saf*. 2015;14(12):1865–1877.

Youssef DM, Sherief LM, Sherbiny HS, et al. Prospective study of nephrolithiasis occurrence in children receiving cefotriaxone. *Nephrology (Carlton)*. 2016;21(5):432–437.

Zechner O, Kovarik J, Willvonseder R. Normocalcemic hyperparathyroidism. *Eur Urol*. 1981;7(6):327–330.

Zee T, Bose N, Zee J, et al. alpha-Lipoic acid treatment prevents cystine urolithiasis in a mouse model of cystinuria. *Nat Med*. 2017;23(3):288–290.

Zhao J, Freeman B, Li M. Can mobile phone apps influence people's health behavior change? An evidence review. *J Med Internet Res*. 2016;18(11):e287.

Ziegler D, Ametov A, Barinov A, et al. Oral treatment with alpha-lipoic acid improves symptomatic diabetic polyneuropathy: the SYDNEY 2 trial. *Diabetes Care*. 2006;29(11):2365–2370.

93

Strategies for Nonmedical Management of Upper Urinary Tract Calculi

---

David A. Leavitt MD, Jean J.M.C.H. de la Rosette MD, PhD, David M. Hoenig MD

Kidney Calculi

Although calculi in the kidney were rare before the Industrial Revolution (Shah and Whitfield, 2002), the existence of nephrolithiasis was known to Hippocrates, who described the symptoms of renal colic: “An acute pain is felt in the kidney, the loins, the flank and the testis of the affected side; the patient passes urine frequently; gradually the urine is suppressed. With the urine, sand is passed.” It is not certain whether Hippocrates actually performed surgery on patients with renal calculi, but he did describe the following operations: the drainage of tuberculous and nontuberculous pyelonephritic abscesses, the incision of swelling in the loin caused by renal tumefaction resulting from stone, and the drainage of kidneys with acute congestion caused by pyelonephritis (Wershub, 1970). In the centuries that followed Hippocrates, there was little scientific progress in the surgical therapy for patients with renal calculi. The alleged first account of a surgical attempt to remove a stone from a patient's kidney is the case of the French archer of Bagnolet. Little is known of the authenticity of this tale of a condemned man with a renal calculus who agreed to allow surgery on the affected kidney with the condition that if he survived he would be freed. According to the anecdote, the man survived the open surgical stone removal and was freed in 1474 (Herman, 1973). Unfortunately, there are no first-hand records of this event. The first verifiable account of renal stone surgery was in 1550, when Cardan of Milan opened a lumbar abscess on a young girl and removed 18 calculi (Desnos, 1972). For the next two centuries, most surgeons were in agreement that the only indication for open renal surgery was the infected calculus kidney, distended by the accumulation of purulent matter, or those kidneys in which the calculus could be palpated in the organ.

In 1734 Lafite incised a swelling in a patient's loin and drained considerable purulence. Twenty-two days later the pus reaccumulated; he probed the incision and found a stone in the region of the kidney. Lafite widened the prior incision and removed two calculi; the patient recovered well. Four years later Lafite again removed stones from a man who had undergone drainage of a lumbar swelling 11 years before and who had a persistent urinary fistula. Lafite concluded that it was possible to remove the stones at the time of the first surgical intervention rather than subject the patient to multiple procedures (Ballenger et al., 1933). In 1872 William Ingalls of Boston City Hospital removed a large calculus from the right kidney of a 31-year-old woman with a persistent pyelocutaneous fistula (Spirnak and Resnick, 1983). Ingalls incised the sinus tract of the fistula and extracted the stone with forceps, thus performing the first recorded nephrolithotomy in America. In 1880 Henry Morris of England was the first to remove a stone from an otherwise healthy kidney by nephrolithotomy, extracting a 31-g mulberry calculus from the kidney of a young woman (Dudley, 1973).

As the surgical techniques of nephrolithotomy evolved, renal parenchymal incisions were made in a variety of different ways in an effort to reduce hemorrhagic morbidity. Heineke in 1879 first described a pyelotomy incision for the extraction of calculi. The operation rapidly found favor and was used by many surgeons, although it was not possible to extend the incision to permit extraction of large renal calculi without damaging the retropelvic renal artery (Wershub, 1970). Josef Hyrtl in 1882 and Max Brödel in 1902 described a relatively avascular plane near the midline (5 mm posterior) of the convex border of the kidney through which the collecting system of the kidney could be entered. In continental Europe, credit for the plane was given to Hyrtl; but in England and the United States it was called the *Brödel bloodless line* or the *Brödel white line* (Schultheiss et al., 2000). Although the existence of this avascular plane was an important discovery, surgeons continued to find that bleeding during nephrolithotomy was a considerable problem. Zuckerkandl described an inferior pyelonephrolithotomy in which a pyelotomy incision was extended into the lower pole of the kidney. Partner recommended a V-shaped incision with two limbs radiating toward the poles of the kidney. Other attempts were made to control the persistent problem of bleeding, including compression of the hilar vessels and various methods of suturing. In 1887 Czerny was the first to approximate the cut edges of the incised kidney with suture to control hemorrhage and to prevent fistula formation. In the same year, Guyon reported that nephrectomy, although efficacious in curing patients with calculus pyonephrosis, was more dangerous than nephrolithotomy because lithiasis was often bilateral (Wershub, 1970). In 1889 Kümmell was the first surgeon to perform a partial nephrectomy for calculus pyonephrosis (Redman, 1983). Lower, in 1913, revived interest in pyelolithotomy when he suggested that this technique may be a safer and easier method of removing renal calculi than nephrolithotomy. Although several small series of cases indicated that there may be a higher incidence of stone recurrence after pyelolithotomy, other studies showed that recurrence was no more common than it was after nephrolithotomy (Murphy, 1972). These findings, in conjunction with rapid advancements in the field of radiography, brought about a decided preference for pyelolithotomy (Gil-Vernet and Culla, 1981). In 1943 Dees and Fox reported the first use of coagulum to remove small stones and stone fragments from the renal pelvis and calyces (Marshall, 1983). Fibrinogen and thrombin were used to make a coagulum that was injected into the renal pelvis and produced a flexible cast of the pelvis and calyces. The use of this technique was limited initially because of the scarcity of materials and the risk of blood-borne disease transmission. However, interest in coagulum pyelolithotomy was renewed when cryoprecipitate was found to be a safe and readily available source of concentrated fibrinogen (Fischer et al., 1980).

An important advance in the open surgical approach to the kidney was the intrasinusally extended pyelolithotomy, pioneered by Gil-Vernet in 1965. Because of its wide applicability and minimal morbidity, this approach to the renal collecting system became the procedure of choice for treatment of the majority of renal pelvic calculi. Patients harboring large or complex calculi could be effectively treated with extended pyelolithotomy combined with multiple radial nephrotomies (Wickham et al., 1974). In 1968 Smith and Boyce **described anatrophic nephrolithotomy, a procedure that derived its name from the technique of incising the renal parenchyma along the avascular plane between the anterior and posterior vascular distributions. Because an incision in this plane does not interrupt the blood supply to the renal parenchyma, it does not result in atrophy, hence the term *anatrophic*.** This procedure permits a relatively bloodless operation that encompasses stone removal, reconstruction of the calyceal system, and closure of the renal capsule with preservation of renal function. **Although stone-free rates of these modern surgical techniques were excellent, morbidity was significant, and the search for new techniques and technologies continued.**

Ureteral Calculi

Ambroise Paré is credited with the first account of a ureteral calculus, when, in 1564, he described “the cruel pain [that] tormented the patient in that place where the stone lodged.” Paré also stated that death was the consequence of having calculi impacted in both ureters (Murphy, 1972). Morris recounted that surgical intervention was an option in the treatment of ureteral stones when he reported in 1898 that “operations on the ureter are an advance of the last few years, but not many have been recorded up to the present time” (Ballenger et al., 1933). Thomas Emmet of New York published an account in 1879 of three female patients with stones impacted at the distal aspect of the ureter. In one patient Emmet opened the bladder and removed the stone with forceps; in a second patient he removed a stone by cutting down on it through the vaginal wall. These procedures were the first records of a surgeon making a definite diagnosis of ureteral calculus and deliberately and successfully performing a ureterolithotomy. In the years that followed, intraperitoneal, perineal, sacral, transrectal, and transvaginal approaches were used. In 1910 **Gibson of New York described an incision parallel to and just above the Poupart ligament, wholly extraperitoneal, by which the lower ureter, even down to its entrance into the bladder, could be readily exposed.** This safe and comparatively easy approach to the ureter gave open ureterolithotomy a solid basis for success.

Rise of Endourology

Before the development of endoscopy, attempts to blindly extract calculi were not uncommon. In 1889 Gustav Kolisher performed the first successful stone manipulation, reporting that he “located the stone with a metal-tipped catheter several inches above the ureteric orifice and through it injected 30 cc of sterile oil,” displacing the stone (Murphy, 1972).

The development of minimally invasive surgical techniques for the treatment of patients with urinary lithiasis has been greatly dependent on technologic advances in the fields of **fiber optics, radiographic imaging, and lithotripsy (shock wave, ultrasonic, electrohydraulic, and laser).** These advancements have accelerated the evolution of modern techniques of calculus removal, including **ureterorenoscopy (URS), percutaneous nephrolithotomy (PCNL), and extracorporeal shock wave lithotripsy (SWL). In 1979 Arthur Smith defined the term *endourology* as closed controlled manipulation within the genitourinary tract** (Smith et al., 1979).

Ureterorenoscopy

The practice of URS began by happenstance when in 1912 Hugh Hampton Young introduced a pediatric cystoscope into the massively dilated ureter of a child with posterior urethral valves (Young and McKay, 1929). Aided by the child's secondary ureteral dilation, Young was able to advance the cystoscope to the level of the renal pelvis, thus becoming the first urologist to view the intrarenal collecting system endoscopically. Unfortunately, the following three decades held few significant advances in ureteroscopic technology until knowledge of fiber optics could be put to clinical use. By 1957 Curtiss and Hirschowitz combined a large number of glass fibers into a coherent bundle and fused the fibers at their ends to allow them to move individually along their length, thus creating the first flexible endoscope (Hirschowitz et al., 1957). In 1964 Marshall reported the first urologic use of this new type of flexible endoscope when he passed the scope through an open ureterotomy to the level of the renal pelvis, thereby performing the first flexible URS. Subsequently, two of his associates, McGovern and Walzak, performed the first transurethral flexible URS when they passed the same 9-Fr flexible endoscope to inspect a ureteral calculus. Since then, developments in optics and mechanics have greatly improved the design of flexible ureteroscopes.

Currently available ureteroscopes range from 54 to 70 cm in length and have a tapered shaft diameter that increases proximally. As the tip of the ureteroscope is inserted into the ureter and passed retrograde, the ureter is slowly dilated. Initial ureteroscopes had neither a working nor an irrigating channel. Most modern ureteroscopes have a single working channel, and some have a second irrigation channel, that distend the ureter and maintain visualization.

Early flexible ureteroscopes were passive, and the subsequent incorporation of active tip deflection has greatly increased their usefulness. *Active deflection* refers to deflection of the tip of the endoscope, which is controlled by the surgeon through a lever mechanism on the handle of the endoscope. Flexible ureteroscopes have been introduced with two segments of active deflection, with the active primary site of deflection providing 170 to 180 degrees of up-and-down movement; the secondary active deflection, located several centimeters proximal to the primary deflection, is a 130-degree one-way downward deflection. This design greatly facilitates entry into the lower pole infundibulum. Other manufacturers have designed flexible ureteroscopes with 270 degrees of deflection, which also facilitates entry into the lower pole infundibulum.

More recently, efforts have been devoted to advancing the imaging capability of the flexible ureteroscope. Digital endoscopes, which incorporate an optical chip (complementary metal-oxide semiconductor [CMOS] or charge-coupled device [CCD]) at the tip have been introduced. Although the initial generation of these chips were large, further refinements have reduced their size so that they can be applied to flexible ureteroscopes. Advantages associated with this technology include improved optical characteristics, obviating focus and white-balancing issues, and decreased surgeon fatigue, because cumbersome proximal camera and light cord attachments are not required. Image-processing software permits digital zoom capability as well. In comparing digital flexible URS with conventional fiberoptic flexible URS, investigators have noted that the digital devices are associated with superior imaging characteristics (Humphreys et al., 2008). Disadvantages of the digital device must be recognized, however. Digital ureteroscopes are larger in diameter than their fiberoptic counterparts, and the technology also is more costly.

The first reports of rigid URS trailed those of flexible URS by almost 10 years. In 1977 Goodman reported on three cases in which a pediatric cystoscope was used to treat patients with ureteral maladies. These initial rigid ureteroscopes used a rod-lens system that was large (10 to 13 Fr) and inflexible.

Most rigid ureteroscope designs have replaced this rod-lens system of image transmission with fiber optics, which allows significant reduction in the size of the endoscope. In addition, the flexibility of the fiberoptic bundles allows the shaft of the endoscope to become somewhat bendable along its vertical axis, hence the term *semirigid ureteroscope*.

Parallel to improvements in rigid and flexible ureteroscopes were advances in intracorporeal lithotripters, including ultrasonic, electrohydraulic, pneumatic, and laser probes, allowing efficient stone fragmentation through the miniaturized modern ureteroscopic equipment. Many new stone-retrieval devices, designed to pass through the working channel of a ureteroscope, have been introduced with the capability for manipulation and deflection.

Percutaneous Stone Removal

The first description of percutaneous stone removal was that of Rupel and Brown (1941) of Indianapolis, who removed a stone through a previously established surgical nephrostomy. It was not until 1955, however, that Goodwin et al. described the first placement of a percutaneous nephrostomy tube to drain a grossly hydronephrotic kidney. These researchers did not have the benefit of radiographic guidance, and so the drainage tube was placed without imaging. In 1976 Fernstrom and Johannson first reported the establishment of percutaneous access with the specific intention of removing a renal stone. Subsequent advances in endoscopes, imaging equipment, and intracorporeal lithotripters allowed urologists and radiologists to refine these percutaneous techniques through the late 1970s and early 1980s into well-established methods for removal of upper urinary tract calculi.

Extracorporeal Shock Wave Lithotripsy

The phenomenon that sound waves can be focused has been known since antiquity. The ancient Greeks, as taught by Dionysius, used this knowledge to construct vaults that allowed them to overhear the conversations of their imprisoned enemies. In the 18th and 19th centuries, cabinets constructed with echo or sound mirrors were capable of transmitting the ticking of a pocket watch over a distance exceeding 60 feet.

High-energy shock waves, too, have been recognized for many years. Examples of high-energy shock waves include the blast effect associated with explosions, as well as the potentially window-shattering sonic boom created when aircraft pass beyond the speed of sound. Engineers at Dornier Medical Systems in what was then West Germany, during research on the effects of shock waves on military hardware, demonstrated that these shock waves are reflectable and therefore focusable. The possibility of applying shock wave energy to human tissue was discovered when, by chance, a test engineer touched a target body at the very moment of impact of a high-velocity projectile. The engineer felt a sensation similar to an electric shock, although the contact point at the skin showed no damage at all (Hepp, 1984). This observation and its potential military applications led Dornier to pursue a method of generating a reproducible shock wave.

Beginning in 1969 and funded by the German Ministry of Defense, Dornier began a study of the effects of shock waves on tissue. Specifically, the study was to determine if the shock waves generated by a projectile striking the wall of a military tank would damage the lungs of a crew member leaning against the same wall. During the study, Dornier engineers developed techniques to reproducibly generate shock waves. In the course of this effort the engineers discovered that shock waves generated in water could pass through living tissue (except for the lung) without discernible damage to the tissue but that brittle materials in the path of the shock waves would be fragmented.

At some point a possible medical application of shock waves became apparent: If shock waves could safely pass through tissue but fragment brittle materials, perhaps they could be used to break up kidney stones. Dornier engineers found that lower-energy shock waves, which would be appropriate for medical applications, could be generated in a predictable and reproducible manner by an underwater electrical spark discharge.

In 1972, on the basis of preliminary studies performed by Dornier Medical Systems, an agreement was reached with Egbert Schmiedt, director of the urologic clinic at the University of Munich, to proceed with further investigation of the therapeutic potential of this technology (Chaussy and Fuchs, 1986, 1989). This research was supported by the West German Federal Ministry of Research and Technology, and the development of the Dornier lithotripter progressed through several prototypes, ultimately culminating in February 1980 with the first treatment of a human by SWL. The production and distribution of the Dornier HM3 lithotripter began in late 1983, and SWL was approved by the US Food and Drug Administration in 1984. Since Dornier's pioneering work, numerous other companies have demonstrated that shock waves capable of stone fragmentation may be generated by electromagnetic induction, microexplosions, focused lasers, and piezoelectric crystals. More than 3000 lithotripters of all types have been placed worldwide, and more than 1 million patients are treated annually with SWL.

Renal Calculi

One of the core tenets of renal stone surgery is to maximize stone removal while minimizing attendant morbidity to the patient. Before the era of endourology, stones were removed via open stone surgery, which provided high stone-free rates but was associated with a high rate of complications. In the early 1980s SWL was developed and proved to have an excellent safety profile while achieving acceptable stone-free rates. During the same time period, PCNL was developed and refined such that it is now considered the gold standard for large and complex kidney stone disease for most patients. Over the last three decades as the technology has improved and the surgical technique diffused, URS has been used with increasing frequency in the treatment of renal stones. More recently, in experienced hands, it has been demonstrated that laparoscopic and robotic-assisted renal stone surgery can be safely used in selected patients with good outcomes. In areas where endourologic technology is widely available, open stone surgery is pursued only 1% of the time or less, and even in developing countries open stone surgery rates have dropped dramatically from 26% to 3.5% (Honeck et al., 2009; Paik and Resnick, 2000).

Thus for most urologists the armamentarium to surgically treat kidney stones consists of four minimally invasive modalities including SWL, URS, PCNL, and laparoscopic or robotic-assisted stone surgery. Staged procedures of a given modality and combinations of different modalities (i.e., “sandwich technique” using SWL and PCNL, and SWL and URS) have been described as well. There appears to be an evolving paradigm shift in the surgical treatment of upper tract stones, with an increasing use of URS, a reciprocal decreasing use of SWL, and a miniaturization in the tract size and instrumentation for PCNL (Lee and Bariol, 2011; Ordon et al., 2014).

Deciding on the optimal treatment for a given patient is not always clear and depends on many variables, which can be broadly lumped into stone-related factors, renal anatomic factors, and clinical factors (Box 93.1). The combination of these factors, availability of technology and equipment, and familiarity of the urologist with the different surgical techniques ultimately determines which treatment is preferred for a given patient. The purpose of this section is to provide a framework to help guide the urologist in matching a given patient's unique clinical situation and renal stone disease characteristics to the most effective and least morbid surgical therapy (Fig. 93.1).

Box 93.1

Factors Affecting Management of Renal Stones

Stone-Related Factors

Size
Number
Location
Composition

Renal Anatomic Factors

Obstruction or stasis
Hydronephrosis
Ureteropelvic junction obstruction
Calyceal diverticulum
Horseshoe kidney
Renal ectopia or fusion
Lower pole

Clinical (Patient) Factors

Infection
Obesity
Body habitus deformity
Coagulopathy
Juvenile
Elderly
Hypertension
Renal failure or transplant
Solitary kidney
Urinary diversion
Pregnancy
Patient symptoms

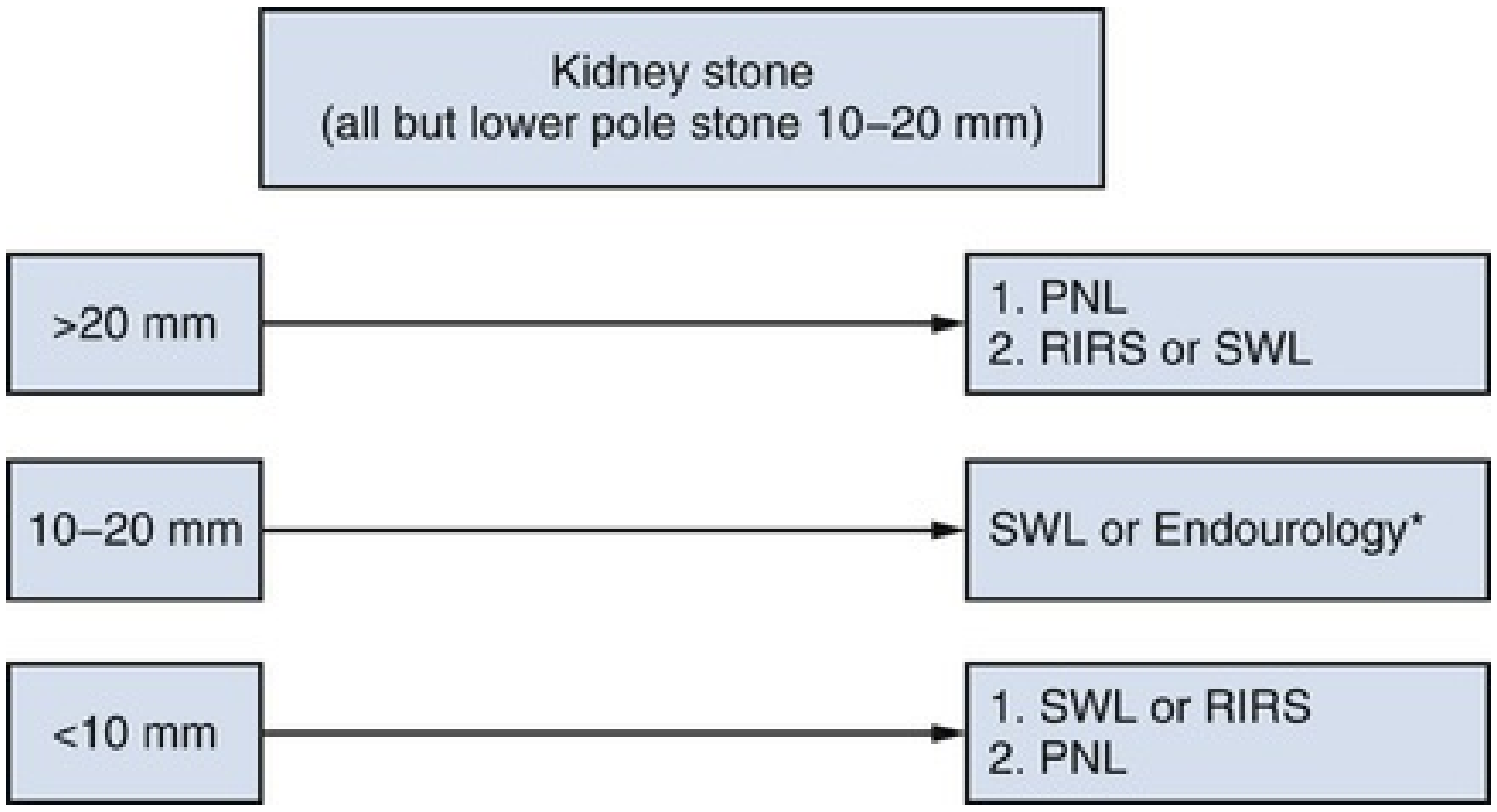

FIG. 93.1 Treatment algorithm: renal stones. *PNL,* Percutaneous nephrolithotomy; *RIRS,* retrograde intrarenal surgery; *SWL,* shock wave lithotripsy; *URS,* ureterorenoscopy. Endourology includes all PNL and URS. RIRS includes retrograde URS. (Modified from Turk et al.: *EAU Guidelines on urolithiasis,* 2017.)

Natural History

The incidence of asymptomatic renal stones has been reported in approximately 10% of screened populations. In one evaluation of just more than 5000 patients undergoing screening computed tomography (CT) colonography, asymptomatic urinary stones were found in 7.8% of patients, with a mean size of 3 mm and an average of two stones per patient (Boyce et al., 2010). In another study evaluating almost 2000 potential kidney donors, asymptomatic renal stones were found in 9.7% of patients (Lorenz et al., 2011). The true natural history of renal calculi, in particular asymptomatic renal calculi, has not been well characterized. Treatment is generally recommended for symptomatic stones, including those associated with pain, infection, obstruction, active stone growth, and significant hematuria. However, the available evidence is less clear on how to approach minimally symptomatic or asymptomatic renal calculi.

Before the era of minimally invasive stone treatments, asymptomatic and minimally symptomatic stones were not actively removed, given the high morbidity associated with treatment. Currently, with the expanding availability of SWL and URS, treatment of small stones can be offered with low surgical morbidity. Although some small, asymptomatic renal stones may never require treatment, a review of the known behavior of such stones suggests that many will grow over time, become symptomatic, and ultimately require treatment.

Nonstaghorn Renal Calculi

A number of studies have reviewed the fate of asymptomatic renal stones while under observation; however, the longest follow-up for any of these series is approximately 10 years, with the majority of them following patients for less than 5 years. Thus the true natural history of asymptomatic renal stones over an extended time period is unknown. Most studies evaluating this type of stone presentation report the rate of spontaneous passage, the rate of intervention, and the rate of stone progression, often defined as stone growth, development of symptoms, or need for intervention.

Hubner and Porpaczy (1990) reviewed the natural history of renal stones in 62 patients managed before the advent of SWL or widespread URS. Of this cohort, spontaneous passage was seen in 16%, whereas 40% required surgical intervention. Stone growth was noted in 45% of patients, urinary tract infection (UTI) occurred in 68%, and pain developed in 51%. Similar results were found by Glowacki et al. (1992), with 32% of initially asymptomatic renal stones becoming symptomatic. Of these patients, half (15%) spontaneously passed their stones, and the calculated 5-year probability of developing symptoms from initially asymptomatic renal stones was 48.5%. Keeley et al. (2001) randomized 228 patients with asymptomatic renal stones to SWL or observation. Spontaneous passage was noted in 17% of the observation group and 28% of the SWL group ($P = 0.06$). There was no difference in the need for additional interventions (analgesics, antibiotics, SWL, stent insertion, URS) between the observation and SWL groups (15% vs. 21%, $P = 0.27$); however, invasive interventions were required only in the observation group. Despite this, there was no appreciable difference in renal function, quality of life, or stone-related symptoms between the two groups, leading the authors to conclude that SWL was not advantageous for small, asymptomatic renal stones.

Burgher et al. (2004) retrospectively reviewed 300 male patients with asymptomatic renal stones with a mean follow-up of 3.26 years. Disease progression, defined as the need for intervention, stone growth, or the development of stone-related pain, was seen in 77% of patients, with 26% of patients requiring surgery. Larger stone size and renal pelvis location were associated with disease progression. All renal pelvis stones and those larger than 15 mm experienced disease progression. The extrapolated risk of intervention at 7 years was 50%. In a similar study by Boyce et al. (2010), 20.5% of initially asymptomatic patients with renal stones became symptomatic over a 10-year period. Koh et al. (2012) found a 20% rate of spontaneous passage, 46% rate of stone progression, and 7.1% rate of intervention.

Inci et al. (2007) showed that approximately one-third of lower pole calculi enlarge, 21% pass spontaneously, and 11% eventually require intervention. Mean stone size was 8.8 mm, and average follow-up was 52 months. No intervention was required in any patient during the first 2 years of observation. In a similar prospective, randomized study, Yuruk et al. (2010) demonstrated an 18.7% intervention rate for asymptomatic lower pole renal stones, with a median time to intervention of 22.5 months. Kang et al. (2013) reported a 29% spontaneous passage rate, 24.5% intervention rate, and 53.6% stone-related-events rate in 347 patients with mean follow-up of 31 months.

Taken together, these studies imply a number of findings about asymptomatic renal stones that can be used to advise patients regarding their ideal care. **First, overall stone disease progression, as defined by the development of stone-related symptoms or stone growth, occurs in as many as 50% to 80% of cases, with a calculated risk of approximately 50% at 5 years. Second, spontaneous stone passage occurs about 15% of the time and is more likely in stones 5 mm in size or smaller. Third, larger stones and those located in the renal pelvis are more likely to become symptomatic. Finally, the risk of eventual surgical intervention for initially asymptomatic renal stones is approximately 10% to 20% at 3 to 4 years after the stones are initially discovered**.

Staghorn Calculi

Staghorn calculi are large renal stones that occupy most or all of the renal collecting system. The name arises from the fact that these branched stones look like the antlers of a deer or stag on imaging (Fig. 93.2). The stones frequently involve the renal pelvis and branch into the surrounding infundibula and calyces. No standardized definitions exist for complete and partial staghorn stones, although most consider complete staghorn stones to occupy the entire renal collecting system, whereas partial staghorn stones occupy less. Struvite composes the majority of staghorn stones, although this configuration of collecting system involvement can include any type of stone (Segura et al., 1994). Before the era of endourology, staghorn stones were not always treated, because the surgical morbidity was high and achieving stone-free status was challenging (Segura, 1997). More recent data have improved our understanding of the natural history of staghorn stones, and the contemporary consensus is that staghorn stones should be treated. **Untreated, staghorn stones are associated**

with recurrent UTIs, urosepsis events, renal functional deterioration, renal loss, end-stage renal disease, and a higher likelihood of death (Blandy and Singh, 1976; Koga et al., 1991; Segura et al., 1994; Teichman et al., 1995). **Complete renal function loss in 50% of affected kidneys can occur after 2 years without treatment. Indeed, the American Urological Association (AUA) guideline on the surgical management of stones** (2016) **and an older guideline specifically developed for the management of staghorn calculi (2005) advocate for the surgical treatment of staghorn stones in patients healthy enough for treatment, with complete stone removal as the therapeutic goal** (Assimos et al., 2016; Preminger et al., 2005).

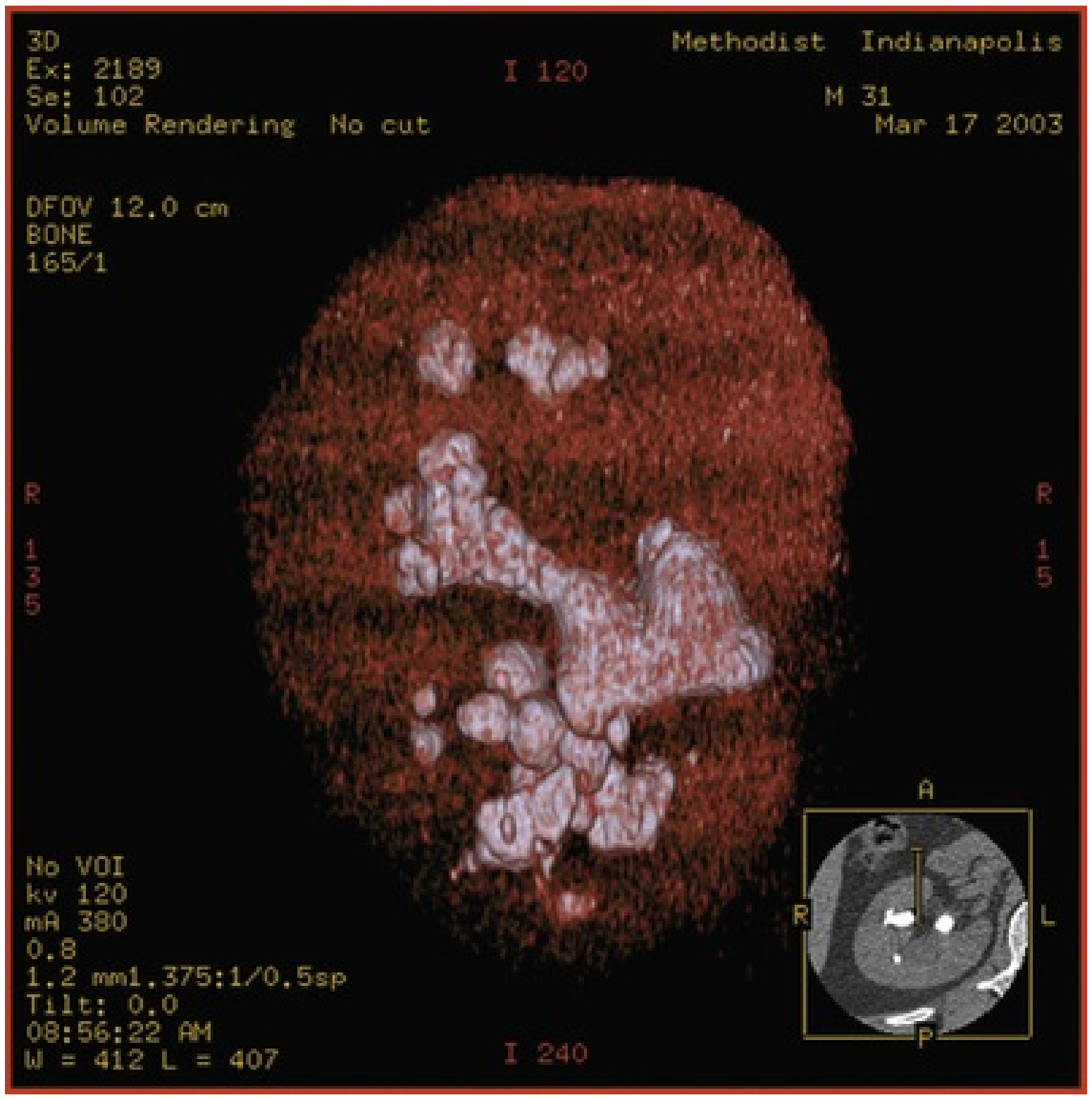
3D
Ex: 2189
Se: 102
Volume Rendering No cut
I 120
Methodist Indianapolis
M 31
Mar 17 2003
DFOV 12.0 cm
BONE
165/1
R
1
3
5
R
1
5
A
R
L
P
No VOI
kv 120
mA 380
0.8
1.2 mm1.375:1/0.5sp
Tilt: 0.0
08:56:22 AM
W = 412 L = 407
I 240

FIG. 93.2 Three-dimensional computed tomography reconstructed image of a staghorn calculus.

Pretreatment Assessment

Before the surgical treatment of renal and ureteral stones, a thorough medical history and physical examination, proper imaging studies, and appropriate laboratory tests are necessary in all patients. In some instances, more elaborate laboratory analysis and upper urinary tract anatomic and functional studies may provide important additional information that is useful in surgical decision making.

Medical History

A number of medical and surgical conditions affect urinary calculi formation and have an impact on treatment planning. Medical conditions that predispose to nephrolithiasis formation should be considered in all stone formers (Strauss et al., 1982). Hyperparathyroidism, renal tubular acidosis (type 1), inflammatory bowel disease and chronic diarrhea, prior intestinal resection and gastric bypass surgery, sarcoidosis, cystinuria, metabolic syndrome and diabetes, gout, recurrent UTIs, spinal cord injury, prior urinary tract surgery, anatomic abnormalities, and medullary sponge kidney, among others, are associated with urinary stone formation. In addition to treating symptomatic stones in these patients, medical treatment is often required for the underlying disorder and usually assists in preventing further stone formation.

An understanding of a patient's prior stone surgeries and stone composition is also important. Patients with particularly dense stones (i.e., cystine, calcium oxalate monohydrate, brushite) and obese patients are less well suited for SWL, and complete stone clearance is essential with infectious stones. Failed prior approaches may certainly suggest the need for a more invasive or comprehensive approach for the new presentation, as well as a correction of any anatomic factors that may be associated.

Certainly, all patients, and in particular those with a history of cardiovascular and cerebrovascular disease, need to be risk stratified and medically optimized before any stone therapy. Patients on anticoagulation, those with high cardiovascular risk, and those with recent coronary artery stents may need to remain on anticoagulation or antiplatelet agents perioperatively, which must be considered when selecting the best surgical approach. Consultation with the patient's cardiologist, hematologist, or internist is recommended.

Imaging

Preoperative urinary tract imaging is required in all patients before surgical intervention, to assess stone burden, location, density, obstruction, and anatomic considerations. In the past, plain abdominal radiography and intravenous urography and tomography were routinely used; however, plain abdominal radiography (kidney-ureter-bladder [KUB] study) has limited sensitivity and specificity, and its ability to easily demonstrate a stone is subject to multiple stone and patient anatomic factors. Approximately 10% to 20% of stones are uric acid and hence radiolucent, and roughly a third of ureteral stones occur in the mid-ureter and therefore are screened by the sacroiliac bone structure. In addition, body habitus can influence film quality, as will the presence of bowel contents, which can screen a stone from view (Jackman et al., 2000; Levine et al., 1997).

More recently, noncontrast helical CT has gained widespread acceptance as the imaging modality of choice for urinary stones (Heidenreich et al., 2002). CT visualizes almost all renal stone types and has sensitivities and specificities of greater than 95%, which is considerably better than any other imaging modality, even at low dose protocols and across all body habitus (Chen et al., 1999; Hamm et al., 2001; Pfister et al., 2003; White, 2012; White et al., 2007). In addition, CT has the advantage of providing three-dimensional anatomic information about the kidney and adjacent organs, relevant treatment strategy considerations such as skin-to-stone distance, and stone density characteristics to help guide therapeutic choices (White, 2012).

Routine CT scanning may expose patients to cumulative radiation risks; accordingly, modern low-dose imaging protocols are widely used to adhere to the ALARA (“as low as reasonably achievable”) principle and thus reduce the radiation exposure while retaining sufficient anatomic and stone details (Lipkin and Preminger, 2013). Only on occasion are more detailed anatomic and functional studies necessary, such as contrast-enhanced studies or renal scintigraphy.

Renal ultrasound has become a more widely used modality for initial evaluation. Greater experience in its use among urologists and emergency medicine physicians has led to its greater availability as a screening tool to determine whether a CT scan is necessary (Dalziel and Noble, 2013). Ultrasound has a sensitivity of 45% to detect kidney and ureteral stones; furthermore, its use as the primary imaging modality for adults arriving at the emergency department with acute flank pain appears to be safe and may significantly reduce cumulative radiation exposure (Smith-Bindman et al., 2014; Turk et al., 2017). Kocher et al. (2011) reported that use of CT for suspected renal colic had increased from 4% to 42% between 1996 and 2007, although there was no overall increase in stone diagnosis or hospital admissions during the same period of time. Recognition of this overuse of CT scanning has led to the implementation of urinalysis- and renal ultrasound–based algorithms to try to decrease it (Edmonds et al., 2010; Riddell et al., 2014).

Chronic kidney stone formers can also be monitored over time with serial ultrasound examinations as a means to reduce radiation exposure to these patients. The limitations of renal ultrasound include the inability to visualize most ureteral stones and a well-recognized poor correlation between measured and actual stone size and location.

More recently, high-Tesla magnetic resonance imaging (MRI) and magnetic resonance urography are being explored as possible alternatives to CT. Preliminary studies have reported sensitivities, specificities, and diagnostic accuracies of 80% or higher for renal and ureteral stones (Semins et al., 2013).

Laboratory Tests

Preoperative urinalysis and culture are mandatory before any stone surgery, and positive cultures should prompt appropriate treatment before the day of surgery. Administration of preoperative antibiotics for 1 week preceding surgery may reduce associated complications (Bag et al., 2011; Mariappan et al., 2006). Despite appropriate antibiotic therapy, sepsis is still a risk; stone culture and renal pelvis culture are better predictors of postoperative sepsis and infectious complications than bladder urine culture results (Mariappan et al., 2005). Therefore patients with radiographic or clinical histories suspicious for infectious or struvite stones should receive culture-directed or broad-spectrum antibiotics before surgery.

Urinalysis may reveal clues to underlying stone composition based on the presence of crystals, and urinary pH may add useful information about uric acid stones or the presence of urease-producing bacteria.

Assessment of underlying renal function is necessary, and serum creatinine often serves as an adequate evaluation, although it reflects total function only. As stated earlier, prolonged presence of untreated staghorn stones, or a long-term, chronically obstructed kidney can significantly affect function of the affected kidney, and in patients with severe, unrecoverable compromise, nephrectomy rather than stone removal may be the most prudent treatment.

Preoperative serum chemistries are important because they may provide clues to underlying systemic diseases such as renal tubular acidosis or hyperparathyroidism or other metabolic derangements. When PCNL or laparoscopic or open stone removal is contemplated, preoperative complete blood counts should be obtained. Routine assessment of coagulation status using prothrombin time (PT) and activated partial thromboplastin time (APTT) is imperative in patients on anticoagulation therapy, but recent reviews have suggested that routine testing may not be necessary. This has been slow to be adopted in clinical practice because of a lack of prospective, randomized controlled trials (Dzik, 2004).

Stone Factors

When treatment for any patient with a renal stone is being contemplated, the main stone-related factors include stone burden (total number and size of stones), stone location, and stone composition. Unless prior stone composition is known, absolute stone type is difficult to determine preoperatively. Certain predictions regarding stone composition can be made based on CT scan data, with increasing resistance to fragmentation associated with higher Hounsfield unit (HU) measurements. In addition to stone density, patient body habitus, stone burden, and location play important roles in the selection of the optimal surgical approach.

Treatment Decision by Stone Burden

The total kidney stone burden, or total volume of stone(s) requiring treatment, is arguably the most important factor influencing treatment decisions. Problematically, however, there is no standard for reporting kidney stone burden. Accordingly, the following decision analysis is based on the largest single-dimensional stone diameter measured on plain radiography or CT. Based on the available evidence, it is convenient to stratify stone burdens as those up to 1 cm, those between 1 cm and 2 cm, and those greater than 2 cm.

Because staghorn stones reflect additional complexity with respect to treatment because of the volume and the branched nature of the stone, and because there is ample literature specifically regarding staghorn stones, these are discussed separately.

Kidney Stone Burden Up to 1 cm.

The majority (50% to 60%) of solitary kidney stones are 1 cm or less in diameter, and many of them are asymptomatic (Cass, 1995; Logarakis et al., 2000; Renner and Rassweiler, 1999). Given enough time, however, many will enlarge or become associated with clinical factors that warrant treatment. Almost all renal stones 1 cm or smaller may be treated with SWL, URS, or PCNL.

Laparoscopic or open stone removal is necessary in exceedingly rare cases, most often when there is underlying aberrant anatomy.

SWL has been considered first-line treatment for these smaller kidney stones without complicating clinical or renal anatomic considerations because it is the least invasive modality, achieves reasonably high stone-free rates, and requires the least technical skill. **More recently, flexible URS use, instrumentation, and familiarity are growing within the urologic community. As reflected in the most recent European Association of Urology (EAU) and AUA urolithiasis guidelines, flexible URS is now considered an alternative first-line therapy for kidney stone burden 1 cm or less in size** (Assimos et al., 2016; Turk et al., 2017). Stones with high attenuation on CT (≥900 HU) and those located in lower pole calyces represent special situations for which SWL clearance rates are poor. In these instances, URS or PCNL may be the preferred first-line treatment options or become necessary if SWL fails.

For kidney stones 1 cm or less in diameter, SWL achieves stone-free rates of approximately 50% to 90% and effectiveness quotients of approximately 50% to 70% (Abdel-Khalek et al., 2004; Ackermann et al., 1994; Albala et al., 2005; Galvin and Pearle, 2006; Micali et al., 2009; Tailly et al., 2008). Most of these studies have assessed stone-free outcomes using renal ultrasound or plain radiography. Successful clearance is highest for stones in the renal pelvis and ureteropelvic junction (UPJ; 80% to 88%), favorable for stones in the upper and middle calyces (approximately 70%), and consistently less for lower pole stones (35% to 69%) (Albala et al., 2001; Danuser et al., 2007; Fialkov et al., 2000; Pearle et al., 2005). Stone-free rates with the newer second- and third-generation SWL machines have been somewhat disappointing and have yet to match those seen with Dornier HM3, which is considered the gold standard treatment in SWL. This has been the consequence of downsizing the newer generation lithotripters in an attempt to make them more portable and decrease anesthetic requirements.

Even for kidney stones smaller than 1 cm, myriad circumstances exist for which SWL is contraindicated or is significantly less effective than other modalities. Box 93.2 lists the contraindications for SWL; Box 93.3 describes clinical and renal anatomic factors that make SWL less favorable than URS or PCNL for treating kidney stones.

Box 93.2

Contraindications to Shock Wave Lithotripsy

Pregnancy
Uncorrected coagulopathy or bleeding diathesis
Untreated urinary tract infection
Arterial aneurysm near stone (renal or abdominal aortic aneurysms)
Obstruction of urinary tract distal to stone
Inability to target stone (skeletal malformation)

Box 93.3

Factors Negatively Affecting Shock Wave Lithotripsy Success

Stone composition (cystine, brushite, calcium oxalate monohydrate, matrix)
Stone attenuation ≥1000 HU
Skin-to-stone distance >10 cm (morbid obesity)
Renal anatomic anomalies (horseshoe kidney, calyceal diverticulum)
Unfavorable lower pole anatomy (narrow infundibulopelvic angle, narrow infundibulum, long lower pole calyx)
Relative or complete patient immobility

Over the last decade, technologic advances in flexible endoscope design and instrumentation have facilitated the use of URS, also referred to as *retrograde intrarenal surgery*, for the treatment of kidney stones. Multiple reports have now clearly established URS as a reasonable alternative for the treatment of most kidney stones, especially those smaller than 1 cm. Flexible, rather than semirigid, URS is usually necessary to access most middle and lower calyces. Compared with SWL, URS has the advantage of actively removing stones and thereby expediting stone clearance.

Contemporary URS for renal stones 1 cm or smaller offers stone-free rates of approximately 80% to 90%, with recent series reporting even better outcomes. Note that many of these reports are from high-volume stone centers. Thus URS for small renal stones in experienced hands consistently provides stone-free rates superior to those of SWL and requires fewer ancillary procedures to do so.

Sabnis et al. (2013) randomized 70 patients with renal stones smaller than 1.5 cm to either micro-PCNL or URS and found a 94% clearance rate for URS and 97% clearance rate for micro-PCNL. Sener et al. (2014) prospectively randomized patients with lower pole calculi to SWL or flexible URS and found a significantly better stone-free rate with URS (100% vs. 91.5%), whereas the SWL cohort required an average of 2.7 treatment sessions. The Global Ureteroscopy Study, which included an international, multi-institutional cohort of 11,885 patients, reported an 85.6% stone-free rate, although this study included ureteral and renal stones (de la Rosette et al., 2014).

These excellent results contrast sharply to those from the well designed, multicenter, prospective, randomized Lower Pole II study, which reported only a 50% stone-free rate for URS of lower pole stones 1 cm or smaller (Pearle et al., 2005). This difference is believed to be secondary to the use of CT to evaluate stone-free status and the fact that this study accrued patients more than a decade ago, closing in 2003. Since that time, URS has experienced marked technologic advances, which are believed to have made URS safer and better. However, more recent URS series evaluating stone-free status by CT similarly show stone free rates between 50% and 60% (Macejko et al., 2009; Portis et al., 2006; Rippel et al., 2012).

The increased stone clearance of URS compared with SWL comes at the cost of a traditionally higher, albeit low, complication rate. Contemporary ureteroscopic series have shown a noticeably lower rate of complications than in prior years. In the Global Ureteroscopy Study, the overall complication rate was 3.5%, with sepsis (0.3%), ureteral stricture (0.3%), and death (0.02%) occurring rarely (de la Rosette et al., 2014). Similarly low complication rates have been reported by others, with rates of ureteral perforation, avulsion, and stricture rates all below 1%, and often below 0.5% (Butler et al., 2004; Geavlete et al., 2006). **Taken together, the recent literature suggests that URS in experienced hands has an excellent safety profile, with stone-free rates and treatment efficiency superior to SWL for small renal stones.**

PCNL is generally reserved for failures of SWL and URS, or for patients with anatomic considerations that make PCNL vastly superior, such as lower pole stones with acute infundibulopelvic angles or calyceal diverticula. So-called “mini” and “micro” PCNL procedures appear to offer similar stone-free rates as traditional PCNL, but with an overall lower complication rate thought to be secondary to the smaller tract dilation. Such techniques may be ideally suited for stones smaller than 1 cm that require PCNL.

Kidney Stone Burden Between 1 and 2 cm.

For renal stones between 1 cm and 2 cm, SWL, URS, and PCNL are the most frequently used treatments, with laparoscopic and open stone removal seldom necessary. Stone location, composition, and density and patient anatomic factors become increasingly relevant as stone burden enlarges and have an important impact on treatment outcomes. Larger stone burdens located in lower pole calyces, increasing skin-to-stone distance, and unfavorable lower renal pole anatomy decrease the success rates of SWL and URS but have limited influence on PCNL outcomes. Thus, for renal calculi between 1 cm and 2 cm, stone-specific and anatomic factors must be carefully considered when weighing the relative outcomes and invasiveness of each procedure (see Fig. 93.1).

As a general principle, the efficacy of SWL decreases while the need for ancillary procedures and re-treatment increases as stone burden enlarges (Drach et al., 1986; El-Assmy et al., 2006; Lingeman et al., 1986; Wiesenthal et al., 2011). The same holds true for URS, although to a lesser degree. Although clearance of residual fragments has been observed up to 2 years after SWL, larger initial stone burdens are associated with larger postoperative residual fragments and higher re-treatment rates (Fig. 93.3).

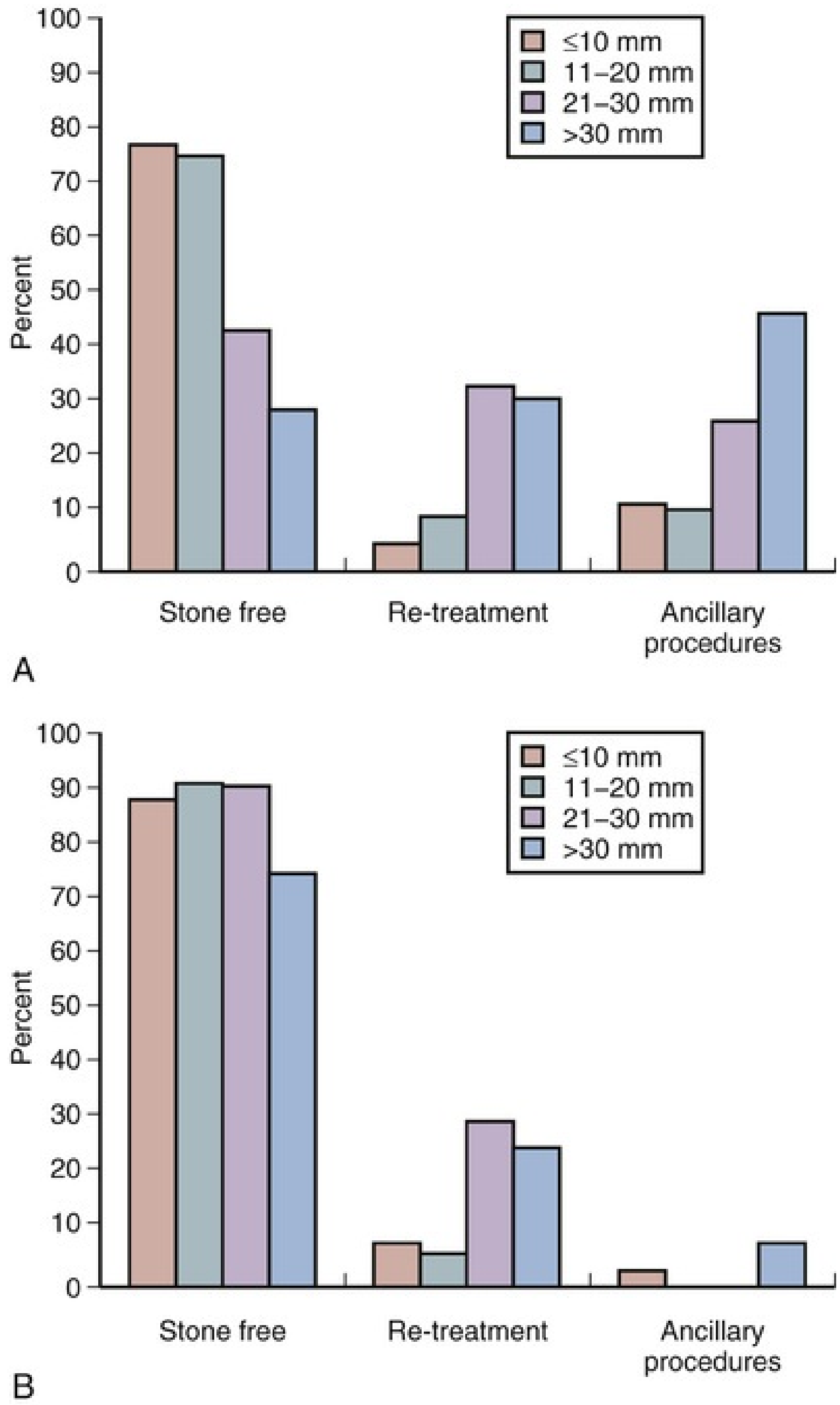

FIG. 93.3 (A) Solitary nonstaghorn calculi treated by shock wave lithotripsy, stratified by size. (B) Solitary nonstaghorn calculi treated by percutaneous nephrolithotomy, stratified by size.

For stones between 1 cm and 2 cm that are *not* located in the lower pole, SWL had traditionally been recommended as first-line therapy. However, for the reasons discussed in the prior section about expanded use and improved outcomes with URS, the most current AUA and EAU stone guidelines recommend URS and SWL as alternative first-line therapeutic

options (Assimos et al., 2016; Turk et al., 2017)**. In general, SWL outcomes are improved when stones are not located in the lower pole, stone attenuation is less than approximately 900 HU, skin-to-stone distance is less than 10 cm, and the patient has no history of SWL-resistant minerals (cysteine, calcium oxalate monohydrate, brushite).** When these factors are present, URS or PCNL should be considered a more desirable initial treatment because SWL is more likely to fail.

SWL treatment success rates exceeding 70% have been reported for stones in the upper (71.8%) and middle (76.5%) calyces (Saw and Lingeman, 1999). Lower pole stone clearance rates range significantly lower, between 37% and 61% (Albala et al., 2001; Riedler et al., 2003; Saw and Lingeman, 1999). Nomograms have been developed to predict SWL treatment success and reflect worse outcomes with increasing stone burden and skin-to-stone distance (Kanao et al., 2006; Tran et al., 2015; Wiesenthal et al., 2011). The nomogram by Kanao et al. (2006) predicts stone-free rates after a single SWL session of 56.8% (11 to 15 mm) and 35.1% (16 to 20 mm) for solitary calyceal stones and 64.4% (11 to 15 mm) and 42.7% (16 to 20 mm) for renal pelvis stones.

URS is a reasonable treatment approach for many kidney stones between 1 cm and 2 cm. In general, URS provides stone-free outcomes that are at least comparable, and often superior, to SWL for such renal stones. Moreover, fewer treatment sessions are usually necessary. The tradeoff, again, is a historically higher rate of complications for URS inherent in its more invasive nature. Grasso (2000) reviewed the outcomes of URS at a single, high-volume stone center and found an overall success rate of 81% after one procedure and 90% after two procedures. Single-procedure treatment success was highest for stones in upper and middle calyces (90%) and lower for stones in the renal pelvis and lower pole calyces (approximately 80%).

URS is also useful as a salvage therapy for failed SWL, rendering 58% of these patients stone free after a single treatment session and up to 76% of patients stone free after two URS sessions (Jung et al., 2006). Unlike SWL, which becomes less effective with increasing skin-to-stone distance, similar URS results have been found in patients with normal, overweight, and obese body mass indexes (BMIs) (Caskurlu et al., 2013).

PCNL accomplishes higher stone-free rates and requires fewer auxiliary procedures than SWL or URS for renal stones between 1 cm and 2 cm. The greater invasiveness and higher rate of significant complications of PCNL limit its widespread adoption to the treatment of all renal stones larger than 1 cm.

Several series have emerged comparing outcomes among SWL, URS, and PCNL for kidney stones 1 to 2 cm in size (Bas et al., 2014; Resorlu et al., 2013). Success rates were highest for PCNL (91% to 98%), respectable for URS (87% to 91%), and significantly lower for SWL (66% to 86%). As expected, the PCNL groups experienced more overall and serious complications, but they also had the lowest need for additional procedures. The difference in treatment success is even more apparent when comparing SWL (37%) with PCNL (95%) for lower pole stones as demonstrated in the prospective, randomized Lower Pole I study (Albala et al., 2001).

In the last few years, smaller PCNL access sheaths have been used in an attempt to reduce PCNL-related morbidity, and out of this experience have come the terms “mini-perc” and “micro-perc.” No precise definitions have been coined, but mini-perc in general refers to PCNL performed through sheaths from 12 Fr to 20 Fr, whereas micro-perc is performed through a 16-gauge needle (Helal et al., 1997; Sabnis et al., 2012).

A few prospective reports with small samples sizes have surfaced evaluating mini-perc and micro-perc (Mishra et al., 2011; Sabnis et al., 2012, 2013). In general, mini-perc has demonstrated equivalent stone clearance to standard PCNL (96% vs. 100%) with a smaller hemoglobin drop, shorter hospital stay, and decreased analgesic requirement. Mini-perc and URS were also found to be essentially the same in terms of stone clearance (100% vs. 97%), whereas URS was associated with a lower hemoglobin drop and less analgesic medication. Similarly, micro-perc and URS showed similar stone clearance (97% vs. 94%) and essentially equivalent blood loss, postoperative pain, and length of stay. Notably, mini-perc and micro-perc techniques are mainly performed in highly specialized, high-volume stone centers. These procedures are of significant interest, although the techniques have not yet been widely adopted by the urologic community at large. Certainly, additional studies with larger sample sizes are necessary to better evaluate these techniques and their learning curves.

Kidney Stone Burden Greater Than 2 cm.

PCNL should be considered first-line therapy for kidney stone burdens 2 cm and greater (Assimos et al., 2016; Turk et al., 2017). Unlike URS and SWL, **the success of PCNL is relatively independent of stone location and stone composition.** Stone clearance was once considered independent of stone burden as well, although more recent studies suggest that stone-free rates decrease as stone burdens increase (Desai et al., 2011; Lingeman et al., 1987). Nonetheless, modern-day PCNL is the most efficient means to remove stone burdens 2 cm and greater in a single surgical setting. It is also routinely associated with shorter operative times and a lower likelihood of requiring a staged procedure, which is usually the norm when URS, SWL, or both are used to tackle larger stones. Meanwhile, the complication and re-treatment rates rise noticeably when SWL monotherapy is used to approach these larger stones.

As the most efficient means to remove large stones from the kidney, PCNL has consistently achieved stone clearance rates of at least 75%, and often much higher, when used by many different groups across the world (Albala et al., 2001; de la Rosette et al., 2011; Osman et al., 2005a; Segura et al., 1985). Clearance of lower pole stones is also excellent with PCNL, with a rate that has been reported as high as 95% in the Lower Pole I study (Albala et al., 2001). The superior stone-free rates come as a tradeoff for more frequent and more serious complications after PCNL compared with either URS or SWL. **Overall complication rates between 20% and 30% have been reported, with most contemporary series showing rates of transfusion of 5% to 10%, severe sepsis of 1% or less, delayed bleeding requiring angioembolization of 1% or less, thoracic complications of about 3% or less, organ injury of less than 1% and death of less than 0.3%** (de la Rosette et al., 2011; Michel et al., 2007; Turk et al., 2017). Stone-free rates can be improved and blood loss decreased when flexible nephroscopy is used to augment standard PCNL (Gucuk et al., 2013).

Early after its introduction, SWL was recognized as a suboptimal modality to efficiently clear renal stones 2 cm or greater, as was reported at a National Institutes of Health (NIH) consensus conference (Consensus conference, 1988). Subsequent studies confirmed overall success rates below 30% for stones 3 cm and greater treated with SWL monotherapy (Murray et al., 1995). More recently, stone-free rates of 59% were demonstrated after SWL monotherapy for larger renal stones; however, steinstrasse (23%) and the need for secondary procedures (20%) occurred frequently (El-Assmy et al., 2006). The previously described SWL nomograms predict a stone clearance of 30% or less for renal stones 2 cm or greater (Kanao et al., 2006). When SWL is combined with URS under a single anesthesia, stone clearance rates of nearly 77% can be achieved but require multiple stages (Hafron et al., 2005).

In the late 1990s URS surfaced as a viable, low-morbidity alternative to SWL for large renal stones. One of the first series was reported by Grasso et al. (1998), with a stone-free rate of 76% after a single URS procedure and improving to 91% after a second stage. Unfortunately, at 6 months of follow-up only 60% of patients were completely clear of stones. **Since this report, however, many others have followed, which describe similarly encouraging outcomes, including a mean stone-free rate of 93.7% (77% to 96.7%), an average minor complication rate of 5%, an average major complication rate of 5%, and an average of 1.6 procedures to accomplish such success** (Aboumarzouk et al., 2012a; Bader et al., 2010; Breda et al., 2008, 2009; Mariani, 2008). In many of these studies, stone-free rates were typically evaluated with KUB and/or renal ultrasound. There was no standardization in terms of what size residual fragments were considered insignificant, and patients were therefore categorized as "stone free."

More recently, a few studies have directly compared PCNL with URS for stones 2 cm and larger (Akman et al., 2012a, 2012c; Bryniarski et al., 2012). Overall, stone clearance rates remain consistently higher for PCNL (91% to 96%) than for URS (71% to 93%), and URS cohorts required staged procedures 20% to 30% of the time. **Thus PCNL remains the first-line treatment for kidney stone burdens 2 cm and greater, unless significant comorbidities or contraindications to PCNL are present (frailty, coagulopathy, refusal of transfusion). In such patients, although less efficient and potentially requiring multiple stages, less invasive alternatives such as URS should be considered.**

Staghorn Stones

PCNL is the method of choice for treating partial and complete staghorn kidney stones, with the caveat that poorly functioning or nonfunctioning kidneys and those associated with xanthogranulomatous pyelonephritis may be best managed with nephrectomy. The AUA Nephrolithiasis Guideline Panel and the EAU urolithiasis guidelines recommend PCNL as the first-line therapy for staghorn stones in most patients (Assimos et al., 2016; Preminger et al., 2005; Turk et al., 2017). Stone-free rates are higher with PCNL (78%) than with SWL (22% to 54%) or open surgery (71%). When staghorn stones are discovered, active stone removal should be pursued unless the patient cannot safely tolerate the surgery. **Observation and nonoperative management should be generally discouraged, because the natural history of untreated staghorn stones has shown that they may eventually cause complete loss of function in the affected kidney, can be the cause of recurrent UTIs and sepsis episodes, and are associated with an increased overall mortality** (Blandy and Singh, 1976;

Koga et al., 1991; Preminger et al., 2005; Rous and Turner, 1977; Segura et al., 1994; Teichman et al., 1995). However, nonoperative management may not be as harmful as previously suggested, especially for unilateral staghorn stones; and it is a prudent consideration in those of highest surgical and anesthetic risk (Deutsch and Subramonian, 2016). PCNL has proven safe and effective in the adult and pediatric populations (Kumar et al., 2011).

No standardized classification system exists for staghorn kidney stones; however, in general they are defined as branched stones that occupy much of the intrarenal collecting system. Most staghorn stones occupy the renal pelvis and extend into one or more of the surrounding calyces. Historically, staghorn stones have been described as either partial or complete, depending on how fully they occupy the intrarenal collecting system. Multiple other staghorn classification schemes have been developed but have not been widely adopted because they are cumbersome to use and have not yet made a meaningful impact on clinical decision making (Ackermann et al., 1989; Di Silverio et al., 1990; Griffith and Valiquette, 1987; Mishra et al., 2012; Rocco et al., 1984). CT with sagittal and coronal reformatting can provide excellent anatomic and stone dimension details and is valuable in preoperative treatment planning (Nadler et al., 2004; Thiruchelvam et al., 2005).

Infectious stones, those composed of magnesium-ammonium-phosphate (or “struvite”), alone or in combination with calcium carbonate apatite, have long been considered the most frequently occurring composition of staghorn calculi; cystine, uric acid, and calcium oxalate also are able to form staghorn configurations. A more recent report challenged this concept, describing a single-center experience with 52 complete staghorn stones of which 56% were metabolic in nature and 44% were infectious (Gettman and Segura, 1999; Viprakasit et al., 2011). Complete stone clearance is paramount in patients with infectious stones. Incomplete stone removal in these patients can predispose to further UTIs and rapid stone recurrence, because the urease-producing bacteria can persist within the residual stone fragments (Nemoy and Staney, 1971).

Staghorn stones are challenging to treat, frequently require multiple percutaneous access tracts and/or multiple stages, and have high treatment-related morbidity. Surgical strategy should focus on selecting the procedure, or combination of procedures, most likely to render the patient stone free while minimizing morbidity. For most patients, SWL monotherapy should be avoided because it is highly unlikely to be successful and frequently is complicated by steinstrasse. In the only prospective, randomized trial comparing SWL with

PCNL for staghorn stones, PCNL provided superior stone-free rates (74% vs. 22%), shorter overall treatment duration, and fewer septic complications (Meretyk et al., 1997).

Combination therapy with multiple endourologic modalities has been used as an alternative to PCNL monotherapy. In one such approach, referred to as sandwich therapy and popularized in the 1990s, staghorn stones were treated first with PCNL, then with SWL for residual or inaccessible stones, and finally with another percutaneous procedure to clear any remaining fragments (Streem et al., 1997). However, outcomes for combination therapy were comparable with those attained with PCNL monotherapy or open nephrolithotomy (Lam et al., 1992b). **Because PCNL allows rapid and effective treatment of large stone burdens, as well as efficient stone clearance rather than requiring spontaneous passage, combined approaches should be based around PCNL as the principal procedure.** The use of flexible nephroscopy during PCNL can improve stone clearance and reduce the number of access tracts necessary by allowing access to calyces unreachable with rigid instruments (Wong and Leveillee, 2002). Flexible nephroscopy is considered a guideline recommendation by the AUA (Assimos et al., 2016). Retrograde flexible URS can be of similar benefit (Marguet et al., 2005).

URS as the sole modality to treat complete staghorn stones is highly unlikely to be successful and has not been reported. URS may be considered an alternative to PCNL for simple partial staghorn stones in patients with favorable anatomy or with contraindications to PCNL, although it often requires multiple stages (Cohen et al., 2013).

Laparoscopic and robotic-assisted techniques have been described in small series for the treatment of complete, or nearly complete, staghorn stones (Giedelman et al., 2012; King et al., 2014). Although these techniques have been shown to be feasible, actual stone-free rates were relatively low (29% to 67%), and the techniques provide no obvious advantage over PCNL for routine staghorn stones in anatomically straightforward situations. In extenuating circumstances, such as ectopic kidneys, laparoscopic or robotic assistance may prove helpful in allowing safe access into the collecting system.

Open nephrolithotomy, once the preferred approach to staghorn stones, is now reserved for rare instances in which complicating factors make PCNL impossible or unlikely to achieve reasonable stone clearance within an acceptable number or combination of procedures. Stone-free rates for open surgery have been reported to be as high as 85%; however, since the rise of endourology and PCNL, superior stone-free rates are routinely achievable with PCNL (Al-Kohlany et al., 2005; Lingeman et al., 1987). In addition, length of hospital stay, the risks for blood transfusions and of renal function loss, and postoperative pain and convalescence favor PCNL over open nephrolithotomy.

Treatment Decision by Stone Localization

Although total stone burden is arguably the most important consideration when deciding how to approach a given patient's stone disease, the location and distribution of stones within the kidney are often the next most important considerations; this is particularly true for stones between 1 cm and 2 cm. The location of stones within the kidney can be simplified to two groups: lower pole stones and non–lower pole stones. Lower pole stones tend to prove the most difficult to treat, especially when the lower pole anatomy is unfavorable (acute infundibulopelvic angle, long infundibular length, narrow infundibular width), because it becomes challenging to reach this location ureteroscopically or to ensure stone clearance with SWL. Because stones within the lower pole are dependently positioned, they are less likely to pass spontaneously after fragmentation by SWL or URS without adjunctive positioning or the use of percussion techniques to assist passage. In addition, the unfavorable anatomic factors may limit passage of fragments even with those adjunctive treatments.

Many studies have evaluated the impact of lower pole stone location on treatment success and complications for a variety of stone treatment modalities. Further discussion of lower pole stones and the influence of lower pole anatomy on treatment outcomes is covered in the section on lower pole calculi. **Stones situated in the lower pole prove more difficult to clear with URS or SWL, and therefore stones 1 cm or larger within the lower pole may be most efficiently treated with PCNL. Stones in a non–lower pole location tend to respond more readily to SWL and URS, making those techniques more competitive with PCNL.**

For non–lower pole renal stones treated with SWL, firm conclusions about treatment outcomes based on differences in non–lower pole renal stone location are difficult to make because the available studies use a variety of different lithotripters and include non-uniform stone burdens and wide variation in the assessment and definition of successful stone clearance. Nevertheless, some patterns emerge when the available data are pooled (Coz et al., 2000; Egilmez et al., 2007; Graff et al., 1988; Khalil, 2012; Kosar et al., 1998; Neisius et al., 2013; Obek et al., 2001; Seitz et al., 2008; Turna et al., 2007). **In general, non–lower**

pole kidney stone treatment success by SWL tends to be similar for any given stone size regardless of the precise intrarenal location. That is, stone clearance rates and effectiveness quotients are reported as statistically similar for stones in the renal pelvis, upper pole calyces, and middle calyces within a given study, despite differences in absolute numbers among studies. Thus stone size and composition, rather than stone location, should dictate SWL treatment decisions.

Few recent studies have evaluated URS outcomes based on stone location. With the vast advancements in endourology over the past decade, flexible ureteroscopes can often access all locations within the intrarenal collecting system.

Before the newer-generation flexible ureteroscopes with improved deflection capabilities, lower pole calculi often proved more challenging to access and completely clear. With modern flexible ureteroscopes, however, lower pole stones can be reached in most instances, and small or partially fragmented stones can often be repositioned into more favorable intrarenal locations (e.g., renal pelvis or upper pole). **Excellent stone clearance with URS has been reported for all renal stone locations (>80% to 90%), suggesting that stone size and density, along with patient anatomy, are more important factors than intrarenal stone location when considering URS treatment decisions** (Hussain et al., 2011; Perlmutter et al., 2008; Portis et al., 2006).

Similar to URS, data are sparse with regard to PCNL outcomes based on specific stone location. With the addition of flexible nephroscopy at the time of initial PCNL, much of the kidney and hence stones in many intrarenal locations are accessible through the initial percutaneous tract. However, **some evidence suggests that upper pole calyceal stone location in patients undergoing PCNL is an independent predictor of incomplete stone clearance,** although this study concentrated on single-tract PCNL only (Shahrour et al., 2012). In developing a nomogram to predict stone-free status after PCNL, Smith et al. found that stones within the middle calyx and renal pelvis were more likely to be cleared than stones in an upper or lower calyceal location (Smith et al., 2013). Other than for staghorn stones, upper calyx location was associated with the lowest stone clearance, inferior even to stones within the lower pole.

Results from the PCNL global study demonstrated a higher rate of postoperative complications for large calyceal stones compared with large renal pelvis stones. However, those in the large calyceal stone group had more overall comorbidities and higher American Society of Anesthesiologist scores, which may be significant confounding variables (Xue et al., 2012).

Anterior versus posterior calyceal stone location may also affect PCNL outcomes. When targeting directly into the stone-bearing calyx, anteriorly located calyces require longer tract lengths and traverse more renal parenchyma than posteriorly located calyces. Tepeler et al. (2013) explored this hypothesis in a series in which patients were divided into anterior or posterior calyceal stone location, and found no difference in overall success and complication rates but did note a trend toward increased severe hemorrhagic events in the cohort with anterior calyceal stones.

Treatment by Stone Composition

Stone composition has significant implications with respect to treatment outcomes primarily with SWL, whereas URS, PCNL, and laparoscopic and open stone surgery appear to be only minimally affected. When composition is known, a prior stone analysis can be used to better decide on therapy.

In general, cystine, calcium phosphate (specifically “brushite”), and calcium oxalate monohydrate stones are the most resistant to SWL. The remainder of the common stone types by order of increasing fragility are struvite, calcium oxalate dihydrate, and finally uric acid stones (Pittomvils et al., 1994; Saw and Lingeman, 1999; Zhong and Preminger, 1994).

Zhong and Preminger (1994) showed that brushite and calcium oxalate monohydrate stones’ resistance to SWL can be explained by their inherent mechanical properties (higher Young's modulus, greater hardness, and fracture toughness). The resistance of cystine stones to SWL lies in their ductile structure, which conveys a higher resilience to internal crack propagation and a higher deformation capability. **In addition, SWL fragmentation of cystine, brushite, and calcium oxalate monohydrate results in relatively larger stone fragments than other stone compositions, which may negatively affect subsequent stone clearance** (Dretler, 1988; Pittomvils et al., 1994; Rutchik and Resnick, 1998).

In vitro studies have shown that holmium laser lithotripsy fragmentation efficiency is also dependent on stone composition, with the poorest fragmentation seen for calcium oxalate monohydrate stones and moderate fragmentation seen for uric acid and cystine stones (Teichman et al., 1998a). However, this may have little clinical practicality, as a separate study by Teichman et al. (1998b) demonstrated that holmium laser lithotripsy was able to successfully fragment all stone types tested and resulted in no fragments larger than 4 mm. Moreover, when stone basket extraction was added to holmium laser lithotripsy, Wiener et al. (2012) showed that operative time was independent of stone composition.

Stone attenuation values (in Hounsfield units) on CT have been correlated to stone composition, although overlap exists across many stone types. Numerous investigators have shown that **uric acid stones consistently have lower Hounsfield unit values than calcium oxalate monohydrate stones and can be readily discerned from them on helical CT** (Kulkarni et al., 2013; Marchini et al., 2013; Mitcheson et al., 1983; Mostafavi et al., 1998; Nakada et al., 2000). Moreover, uric acid stones tend to display more homogeneous attenuation throughout a given stone than calcium oxalate stones (Marchini et al., 2013). Discriminating between struvite- and calcium-containing stones is usually not possible based on stone attenuation alone, because considerable overlap exists between them.

Even though stone attenuation values are far from perfect in accurately determining stone composition, stone attenuation can be helpful in predicting treatment success with SWL. **Multiple studies now show that attenuation values higher than 900 to 1000 HU are associated with poorer outcomes with SWL** (El-Nahas et al., 2007; Gupta et al., 2005; Joseph et al., 2002; Tran et al., 2015; Wang et al., 2005). Indeed, Gupta et al. (2005) have shown a linear relationship between SWL fragmentation success and stone attenuation, with decreasing fragmentation as stone attenuation increases. Joseph et al. (2002) reported that stone clearance with SWL occurred in just 54.5% of patients with stone attenuation levels above 1000 HU, whereas success was seen in 85.7% of patients when stone attenuation was between 500 and 1000 HU and in all patients with stone attenuation below 500 HU. Ouzaid et al. (2012) showed that a threshold of 970 HU was the most sensitive and specific cutoff value to predict treatment success with SWL. Stones below 970 HU were associated with an SWL treatment success rate of 96%, whereas stones above 970 HU were successfully treated only 38% of the time. Similar to the study by Gupta et al. (2005), this study found a linear association between SWL success and stone attenuation.

Matrix

Matrix renal stones are rare, and unlike most other renal stones in that they are predominantly (approximately 65%, range 42% to 84%) composed of organic proteins, sugars, and glucosamines, whereas other crystalline calculi have only minimal organic material (2.5%) (Boyce and King, 1959). In addition, these stones are soft, gelatinous, and relatively amorphous (Fig. 93.4). Matrix stones can be challenging to diagnose preoperatively because they can mimic upper tract collecting system soft-tissue masses and require a high index of suspicion. Traditionally described as radiolucent, these stones often exhibit either a radiodense calcific center or faint peripheral rim of radiodensity, and both of these signs are frequently visible on preoperative imaging (Fig. 93.5; Bani-Hani et al., 2005; Shah et al., 2009). These stones tend to be large and can assume partial staghorn configurations, and therefore **PCNL is the preferred treatment approach for most matrix renal stones because of its high success rates and low recurrence rates.** Descriptions of successful treatment with URS have been reported (Chan et al., 2010; Rowley et al., 2008; Shah et al., 2009; Stoller et al., 1994b), but SWL is ineffective in these stones, given their soft composition and relative paucity of brittle mineral content.

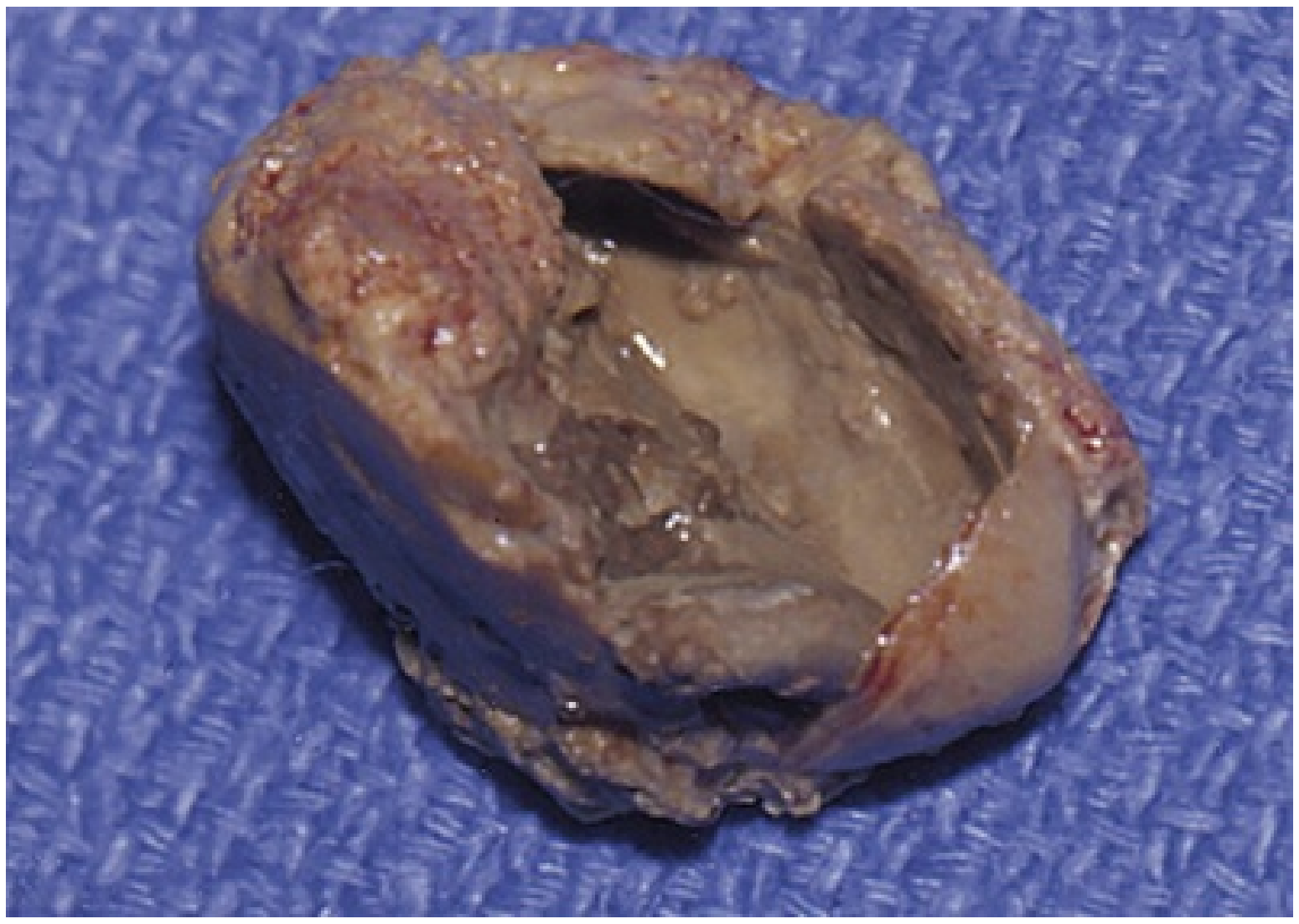

FIG. 93.4 Matrix stone with soft, gelatinous, amorphous consistency and air pocket. (From Bani-Hani AH, Segura JW, Leroy AJ: Urinary matrix calculi: our experience at a single institution. *J Urol* 173:120–123, 2005.)

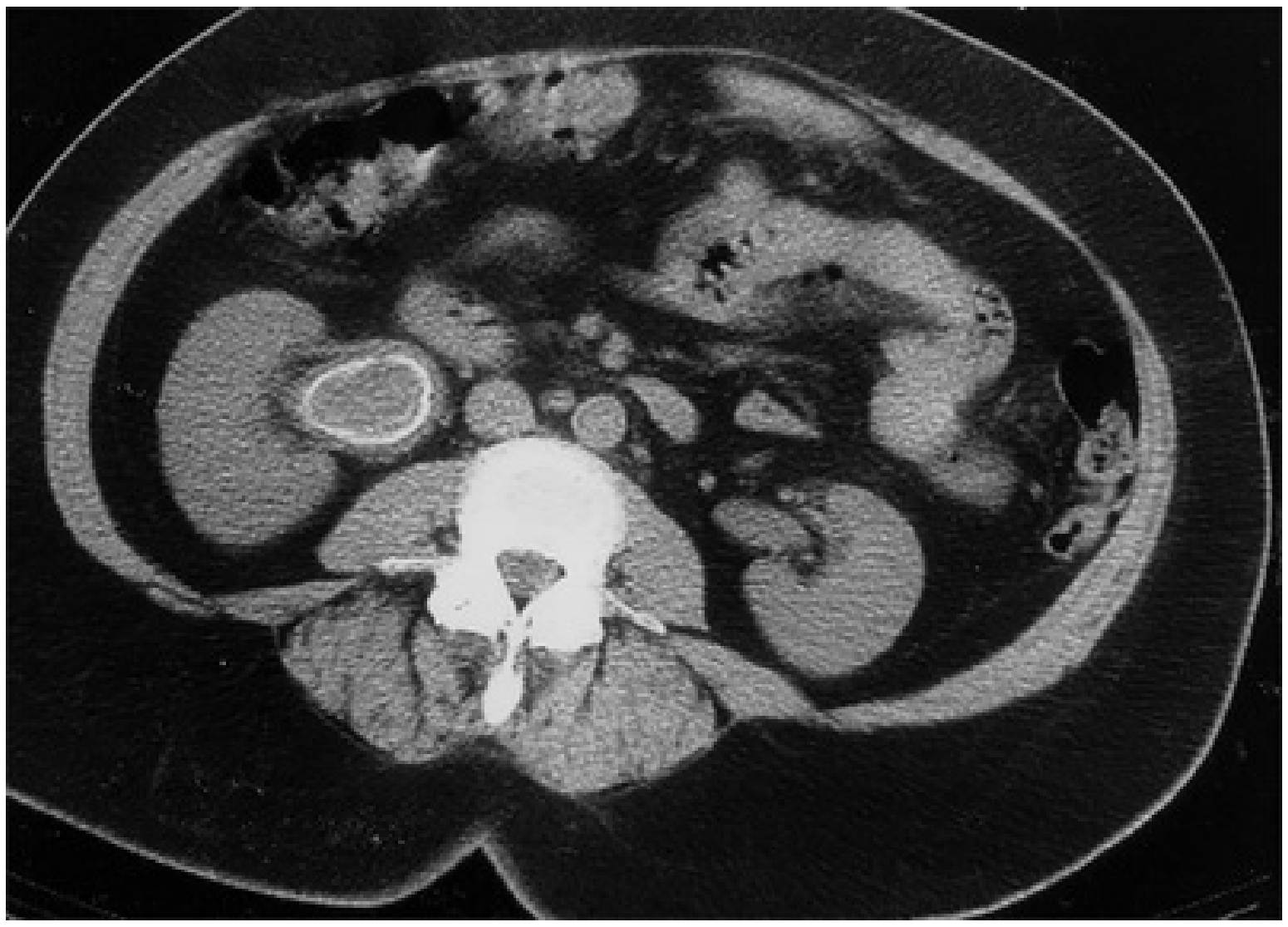

FIG. 93.5 Computed tomography imaging of matrix stone showing radiodense rim and radiolucent center. (From Bani-Hani AH, Segura JW, Leroy AJ: Urinary matrix calculi: our experience at a single institution. *J Urol* 173:120–123, 2005.)

Stone composition has the largest impact on SWL results, whereas URS, PCNL, and laparoscopic and open stone surgery are less affected by stone composition, if at all. Therefore factoring stone composition into treatment decision analysis is most relevant for stones 2 cm or less, for which SWL is often considered first-line therapy or as a first-line therapeutic option. **In general, cystine, calcium phosphate (specifically "brushite"), and calcium oxalate monohydrate stones are the most resistant to SWL. When patients are known to harbor such stones, in particular when combined with lower pole stone location, long skin-to-stone distances, or increasing stone burdens above 1 cm, SWL success rates decrease substantially. In such patients, recognition of this limitation should prompt consideration of another modality (e.g., URS or PCNL).**

In 1988 Dretler introduced the concept of stone fragility, describing it as "the ease with which a stone fragments during SWL." He demonstrated in vitro that calculi of various compositions fragment differently under a given set of SWL parameters (Dretler, 1988). Thereafter, additional investigations revealed that cystine, brushite, and calcium oxalate monohydrate stones were the most refractory to SWL fragmentation, and cystine and brushite the most resistant. The remainder of the common stone types by order of increasing fragility are struvite, calcium oxalate dihydrate, and finally uric acid stones (Pittomvils et al., 1994; Saw and Lingeman, 1999; Zhong and Preminger, 1994).

Zhong and Preminger (1994) showed that brushite and calcium oxalate monohydrate stones’ resistance to SWL can be explained by their inherent mechanical properties (higher Young's modulus, greater hardness, and fracture toughness). The resistance of cystine stones to SWL lies in their ductile structure, which conveys a higher resilience to internal crack propagation and a higher deformation capability. In addition, SWL fragmentation of cystine, brushite, and calcium oxalate monohydrate results in relatively larger stone fragments than other stone compositions, which may negatively affect subsequent stone clearance (Dretler, 1988; Pittomvils et al., 1994; Rutchik and Resnick, 1998). Williams et al. (2003) evaluated the number of shock waves necessary to completely fragment stones of different compositions and demonstrated a considerably higher mean number of shocks necessary for cystine (5937 shocks) and brushite (1681 shocks) stones compared with other stone types; uric acid stones (400 shocks) require the least.

The internal structure of a stone, not just its composition, influences stone fragility, and stones of a given mineral type can exhibit a wide range of fragility (Williams et al., 2003). This is particularly relevant for cystine stones, for which the prevailing belief is that these stones are all resistant to SWL. In actuality, early work by Bhatta et al. (1989) showed that cystine calculi come in two predominant substructures: those with a rough external surface and those that are smooth. The rough cystine stones had well-formed, repeating internal hexagonal crystals, whereas the smooth cystine stones had irregular crystals that did not interlace well. Kim et al. took this one step further, showing that cystine stones with mixed internal low- and high-attenuation regions on CT were more readily fragmented by SWL than those with a homogeneous appearance (Kim et al., 2007). In fact, the homogeneous cystine stones required approximately 60% more shocks for comminution. This same phenomenon has been seen in calcium oxalate monohydrate stones as well with more homogeneous stones relatively more resistant to SWL than those with a heterogeneous appearance on CT (eFig. 93.6) (Zarse et al., 2007). Viewing the CT scan with bone windows can facilitate the identification of the internal structure of renal stones (Williams et al., 2002).



EFIG. 93.6 Photographic and helical computed tomography images show structural variability in stones of the same type. Note that although all stones depicted are calcium oxalate in type, some have a mottled structure and others have a lamellar structure.

In vitro studies have shown that holmium laser lithotripsy fragmentation efficiency is also dependent on stone composition, with the poorest fragmentation seen for calcium oxalate monohydrate stones and moderate fragmentation seen for uric acid and cystine stones (Teichman et al., 1998a). However, this may have little clinical practicality; a separate study by Teichman et al. (1998b) demonstrated that holmium laser lithotripsy was able to successfully fragment all stone types tested and resulted in no fragments larger than 4 mm. Moreover, when stone basket extraction was added to holmium laser lithotripsy, Wiener et al. (2012) showed that operative time was independent of stone composition. This study included cystine, calcium oxalate monohydrate, brushite, and uric acid stone types, among others (Wiener et al., 2012).

Unfortunately for the vast majority of patients requiring surgical treatment for kidney stones, the stone composition is unknown before surgery, and treatment decisions must be made according to information available preoperatively. Considerable information may be gleaned from preoperative imaging that can inform treatment decisions. Details about stone size, shape, and density are readily obtainable from modern CT imaging software, and noncontrast helical CT is the most sensitive and the most widely used initial imaging study in the evaluation of suspected urolithiasis. Anatomic detail and skin-to-stone distance can also be easily determined on axial CT slices. **The combination of anatomic and stone characteristics becomes most important when deciding if a given stone is amenable to SWL or if another treatment modality should be chosen.**

Before the widespread use of CT, the imaging nuances of plain radiography were used in an attempt to predict stone fragility by SWL. Uric acid stones are radiolucent on plain radiography but readily visible on CT and respond well to SWL if they can be appropriately targeted. Stones with irregular contour and reticulated, spiculated structure tended to fragment more easily than stones with homogeneous architecture and smooth edges (Dretler, 1988; Dretler and Polykoff, 1996). Assessments of relative stone radiodensity suggested that stones more dense than nearby bony structures (transverse process or 12th rib) were more resistant to SWL than less dense stones. In addition, cystine stones have been noted to appear as ground glass on plain radiography, and when this is seen preoperatively, treatments other than SWL should be sought.

Stone attenuation values (in HU) on CT have been correlated to stone composition, although overlap exists across many stone types. Numerous investigators have shown that **uric acid stones consistently have lower HU values than calcium oxalate monohydrate stones and can be readily discerned from them on helical CT** (Kulkarni et al., 2013; Marchini et al., 2013; Mitcheson et al., 1983; Mostafavi et al., 1998; Nakada et al., 2000). Moreover, uric acid stones tend to display more homogeneous attenuation throughout a given stone than calcium oxalate stones (Marchini et al., 2013). Discriminating between struvite- and calcium-containing stones is usually not possible based on stone attenuation alone, because considerable overlap exists between them.

Differentiation among the various calcium-containing stones remains difficult, but in vitro evaluation using dual-source CT has shown promise in distinguishing between calcium oxalate and calcium phosphate stones (Boll et al., 2009; Matlaga et al., 2008). More recently, single-source dual-energy CT has been shown to accurately predict stone composition in stone formers with uric acid stones (6 patients), cystine stones (1 patient), and 79% of patients with calcium stones (15 of 19 patients) (Hidas et al., 2010). In the same study, the sole patient with a struvite stone was incorrectly predicted.

Even though stone attenuation values are far from perfect in accurately determining stone composition, stone attenuation can be helpful in predicting treatment success with SWL. **Multiple studies now show that attenuation values higher than 900 to 1000 HU are associated with poorer outcomes with SWL** (El-Nahas et al., 2007; Gupta et al., 2005; Joseph et al., 2002; Wang et al., 2005). Indeed, Gupta et al. (2005) have shown a linear relationship between SWL fragmentation success and stone attenuation, with decreasing fragmentation as stone attenuation increases. Joseph et al. (2002) reported that stone clearance with SWL occurred in just 54.5% of patients with stone attenuation levels exceeding 1000 HU, whereas success was seen in 85.7% of patients when stone attenuation was between 500 and 1000 HU and in all patients with stone attenuation below 500 HU. Ouzaid et al. (2012) showed a threshold of 970 HU to be the most sensitive and specific cutoff value to predict treatment success with SWL. Stones below 970 HU were associated with an SWL treatment success rate of 96%, whereas stones above 970 HU were successfully treated only 38% of the time. Similar to the study by Gupta et al. (2005), this study found a linear association between SWL success and stone attenuation.

Cystine.

As previously described, cystine stones prove more resistant to SWL than other stone types based on their inherent chemical structure, which gives them a ductile nature, or ability to deform instead of crack, rather than any underlying hardness or density. The natural history for most cystinuric patients is recurrent stone formation over their lifetime, and although medical management can prove useful in prevention, compliance with it is difficult and overall poor (Ahmed et al., 2008; Pietrow et al., 2003). Recurrence rates as high as 73% are seen at 5 years, and patients with residual fragments undergo more frequent re-treatments than those rendered stone free (Chow and Streem, 1998; Knoll et al., 1988). Furthermore, cystinurics have relatively worse renal function compared with calcium oxalate stone formers, and the greatest decline in renal function is found in those cystinurics who have required more stone surgeries (Assimos et al., 2002; Barbey et al., 2000). The goal, then, is to minimize surgery in these patients and, when possible, treat them in a minimally invasive manner.

Of the currently available treatment modalities, URS should assume a prominent role in the surgical management of cystinurics. Although PCNL may be necessary to treat excessively large stone burdens or complete staghorn stones, repeated PCNL, and in particular open stone removal, can contribute to renal functional decline. Therefore URS for stone burdens in excess of 2 cm may still be the preferred surgical approach if stone clearance can be reasonably expected within one or two stages. For smaller cystine stones in non–lower pole locations and in patients with favorable anatomy (i.e., skin-to-stone distance <10 cm), SWL may be considered as a treatment option if flexible URS equipment or the technical familiarity to perform flexible URS proficiently is unavailable.

However, poorer stone clearance rates than for noncystine stones should be expected, and the patient counseled appropriately.

Ureterorenoscopic management of cystine stone formers has shown favorable results with minimal morbidity (Ahmed et al., 2008; Rudnick et al., 1999; Ruggera et al., 2011; Trinchieri et al., 2007). Unfortunately, no contemporary studies using present-day flexible ureteroscopic technology have been reported, but given the limited clinical effect of stone composition on holmium laser lithotripsy, similarly excellent results should be expected for cystinurics undergoing URS. Despite this, the results of Rudnick et al. (1999) almost two decades ago demonstrating that encouraging treatment success (83%) with URS was achievable in cystinuric patients with stones up to 3 cm challenged the prevailing treatment algorithm at the time proposed by Kachel et al. (1991). Based on their work, Kachel et al. (1991) recommended that cystine stones smaller than 1.5 cm in diameter be treated with SWL and cystine stones larger than 1.5 cm in diameter be approached with PCNL. Stone-free rates with PCNL for cystine stones routinely offer stone-free rates exceeding 90%, whereas SWL outcomes are lower, with a 70.5% stone-free rate for stones smaller than 20 mm and a 41% stone-free rate for stones 20 mm or larger (Hockley et al., 1989).

Brushite.

From a treatment decision perspective, brushite stones should be approached like cystine stones, and minimally invasive therapies should assume a primary role. The main reason for this is that brushite stones are relatively refractory to SWL, surpassed only by cystine stones (Dretler, 1988; Ringden and Tiselius, 2007). With contemporary URS achieving stone-free rates in excess of 90%, even for stones larger than 2 cm, URS in skilled hands should be at the top of the minimally invasive treatment options for brushite stone formers (Aboumarzouk et al., 2012a). With an average of 1.5 treatment sessions necessary, SWL monotherapy has been shown to achieve treatment success in only 65% of patients and complete stone-free status in only a meager 11% of patients (Klee et al., 1991).

A retrospective review of 82 brushite stone formers showed that stone-free status was attainable in 92% of patients with one or two procedures, with most of these being PCNL (Krambeck et al., 2010). In this analysis, recurrent stone events were seen in 38% of patients at an average of 33 months after last treatment, and all had some underlying metabolic derangement found on 24-hour urine analysis, underscoring the importance of metabolic stone evaluation and long-term management in this population. Up until a decade ago, SWL appears to have been used more frequently in brushite stone formers than in calcium oxalate stone formers (Parks et al., 2004). It is unclear if this is a result of the lower fragility of brushite stones, thereby subjecting brushite stone formers to more SWL treatments per stone burden, on average.

Medication-Precipitated Stones.

Renal calculi composed predominantly of a medication or one of its metabolites have been described, albeit rarely. Ephedrine and guaifenesin are radiolucent but respond well to minimally invasive therapy such as SWL and URS (Assimos et al., 1999; Blau, 1998; Powell et al., 1998). Indinavir is a protease inhibitor used to treat patients with human immunodeficiency virus and has been shown to precipitate and form stones in 4% to 13% of patients who use this medication (Wu and Stoller, 2000). Average time between medication initiation and stone event has been reported as 21.5 weeks (Reiter et al., 1999). The stones are often small and are radiolucent on plain radiography and CT. Smaller stones pass spontaneously in more than 60% of reported cases, so a trial of nonoperative management with analgesics, alpha-blockers, and hydration is warranted (Daudon et al., 1997; Kohan et al., 1999; Nadler et al., 2003). It is recommended that indinavir be temporarily discontinued as well. Indications for surgical treatment or intervention, therefore, are no different than for other stones of similar size, and all minimally invasive modalities (URS, SWL, PCNL) have been successfully applied to protease inhibitor stones.

In addition, other medications have been known to form stones, including triamterene, magnesium trisilicate, ciprofloxacin, and sulfa drugs (Matlaga et al., 2003b). Finally, drug-induced calculi can occur because of loop diuretics or increased metabolites that precipitate, such as xanthine stones induced by allopurinol (Greene et al., 1969).

Renal Anatomic Factors

Ureteral Pelvic Junction Obstruction

Ureteropelvic junction obstruction (UPJO) is associated with kidney stones up to 20% to 30% of the time (Berkman et al., 2009; Rutchik and Resnick, 1998). It is vital to, b**efore undertaking any surgical correction, try to distinguish if the UPJO is the underlying disorder with subsequent renal stone formation, or if a renal pelvis or UPJ stone provoked edema at the UPJ, giving the**

misleading appearance of UPJO when none actually exists. Although this is not always straightforward, review of CT cross-sectional imaging can provide some insights. For example, when smaller stones are found in calyceal locations with a significantly hydronephrotic renal pelvis and tight UPJ or proximal ureter, UPJO is likely the primary pathology with resulting stone formation. On the contrary, a stone lodged at the UPJ or a renal pelvis stone in close proximity to the UPJ may be the primary pathology causing the obstruction, and no UPJO may actually exist.

If there is any question about primary UPJO or a mimic from a UPJ or renal pelvis stone, then the kidney stones should be treated and no specific therapy should be directed at the UPJ. Rather, 4 to 6 weeks after the stone has been treated, follow-up renal imaging (sonogram, CT, or MRI) can be performed to ascertain if hydronephrosis persists, and if so, further renal functional imaging may be indicated (diuretic renogram). Alternatively, if a nephrostomy tube is in place and the presence of UPJO remains equivocal, then a Whitaker test can be performed. If UPJO is confirmed at that time, only then is UPJ repair recommended.

Similarly, it is important to determine the overall renal function of the affected kidney if it appears atrophic or with thinned parenchyma. If a nonfunctioning or poorly functioning kidney is confirmed, then the simplest option may be nephrectomy rather than simply treating the stone. It is also important to determine if the UPJ has been operated on in the past. Reports have shown that UPJO that recurs after previous endopyelotomy responds favorably to minimally invasive or open pyeloplasty and that UPJO that recurs after previous pyeloplasty responds well to endopyelotomy (Canes et al., 2008; Patel et al., 2011).

A variety of strategies can be used to treat UPJO with concomitant kidney stones, with the ultimate goal of repairing the UPJO and restoring normal renal drainage while simultaneously rendering the patient stone free. PCNL with antegrade endopyelotomy, laparoscopic or robotic pyeloplasty with pyelolithotomy or nephrolithotomy, and retrograde endopyelotomy with URS stone removal have been described. Endopyelotomy should be discouraged when long strictures (>2 cm) are encountered, high UPJ insertions are found, or prior endopyelotomy has been performed and failed.

As a general rule, it is prudent to clear the stone burden before incising the UPJO during endopyelotomy and before completing the UPJ repair with pyeloplasty. This is particularly important for PCNL with antegrade endopyelotomy so that stone fragments do not extrude or settle near the area of the UPJ incision. Stone incorporated in or near the endopyelotomy site can lead to restricturing through granuloma and fibrosis formation (Giddens et al., 2000). Retrograde endopyelotomy with URS stone treatment is also susceptible to this problem because endopyelotomy is necessary as an initial step to allow the ureteroscope access to the kidney, and any subsequent attempts at stone fragmentation or retrieval may result in residual fragments lodging in close proximity to the UPJ.

Over the last decade an increasing number of reports have surfaced describing laparoscopic and robotic pyeloplasty with simultaneous kidney stone removal, and when combined with the available literature on minimally invasive UPJO repair, a number of patterns emerge. There appears to be no difference in operative outcomes, success, or complications of UPJO repair between laparoscopic and robotic pyeloplasty (Braga et al., 2009). Short-term success for laparoscopic and robotic pyeloplasty is excellent at more than 90% and appears superior to that of antegrade endopyelotomy, which is closer to 70% to 80% (Berkman et al., 2009; Knudsen et al., 2004; Rassweiler et al., 2007). Berkman et al. (2009) found PCNL at the time of percutaneous antegrade endopyelotomy to have no effect on success rates of relieving obstruction. Long-term outcomes with endopyelotomy or pyeloplasty are worse than short-term results, with recurrence seen in 25% of pyeloplasties and approximately 60% of endopyelotomies after 10 years (DiMarco et al., 2006).

Laparoscopic, and more recently robotic, pyeloplasty with concurrent renal calculi removal through a pyelolithotomy achieves a stone-free rate of 75% to 100%, and resolution of the UPJO exceeding 90% (Atug et al., 2005; Mufarrij et al., 2008; Ramakumar et al., 2002; Srivastava et al., 2008; Stein et al., 2008; Stravodimos et al., 2014). Laparoscopic graspers, flexible nephroscopes, and wire baskets passed through laparoscopic or robotic trocars, laparoscopic irrigation, and robotic graspers have been used to remove renal stones through the pyelotomy incision. Operative times are approximately 3.5 to 4 hours. In one small series, combined robotic nephrolithotomy and UPJO repair was undertaken and the use of intraoperative ultrasound aided in stone identification within the kidney to direct small nephrolithotomy incisions (Ghani et al., 2014).

In very select cases in which patients have larger, highly complex stone burdens and calyceal anatomy unlikely to permit adequate stone clearance through the standard pyeloplasty incisions, performing standard PCNL first and then performing laparoscopic pyeloplasty under the same anesthetic has been described with encouraging results (Agarwal et al., 2008). However, this approach is associated with longer operative time of almost 4 hours. All patients were stone free by renal sonography at 6 months and demonstrated adequate renal drainage on renogram.

Calyceal Diverticula

Calyceal diverticula are urothelium-lined, nonsecretory, cystic dilations of the intrarenal collecting system that are thought to arise embryonically. They were first described by Rayer in 1841 and were first given the name *calyceal diverticula* in 1941 by Prather. They have a narrow connection to the normal pelvicalyceal system, which is thought to allow for preferential urine filling and poor urine drainage from the diverticulum. Calyceal diverticula are rare, with a reported incidence of 0.2% to 0.6% in patients undergoing intravenous urography (IVU) (Michel et al., 1985; Middleton and Pfister, 1974; Timmons et al., 1975; Wulfsohn, 1980). They may arise from any portion of the pelvicalyceal system, with (approximately) 50% or more originating from the upper pole calyces, 30% from the middle pole calyces or renal pelvis, and 20% stemming from the lower pole calyces (Abeshouse and Abeshouse, 1963; Waingankar et al., 2014).

Stone formation within calyceal diverticula has been reported to occur between 10% and 50% of the time (Middleton and Pfister, 1974; Williams et al., 1969; Yow and Bunts, 1955). A combination of urinary stasis and metabolic derangements is believed to underlie stone development in these structures (Burns et al., 1984; Hsu and Streem, 1998; Liatsikos et al., 2000; Matlaga et al., 2007; Parkhomenko et al., 2017). Hsu and Streem (1998) reported a 50% rate of metabolic abnormalities in 14 patients with stones in calyceal diverticuli. In contrast, Liatsikos et al. (2000) reported that only 25% of patients with calyceal diverticular stones have metabolic abnormalities, compared with 77% of patients without urinary tract anatomic anomalies.

A large percentage of calyceal diverticula are asymptomatic and require no treatment; however, **diverticular stones associated with pain, recurrent infections, hematuria, or a decline in renal function warrant treatment.** Similar to other locations in the kidney, stones within calyceal diverticula have been managed through a variety of approaches, including open surgery, SWL, URS, PCNL, and laparoscopic and robotic modalities. The preferred management approach depends on stone and diverticular anatomic characteristics. Open surgery is primarily of historic interest except in extenuating circumstances, and when undertaken, the diverticulum is marsupialized and cavity lining fulgurated.

SWL has been used to treat calyceal diverticular stones, albeit with modest results, and should not be considered first-line therapy for most symptomatic diverticular stones. Although the underlying pathogenesis is not fully understood, ablation of the calyceal diverticular lining, dilation of the diverticular neck to improve drainage, or both are considered integral to achieving stone clearance and preventing stone recurrence (Cohen and Preminger, 1997). Neither of these is accomplished with SWL. Stone-free rates for SWL are typically poor, ranging from 4% to 58% (Renner and Rassweiler, 1999; Turna et al., 2007). In one of the largest reported series involving SWL of calyceal diverticular stones, Turna et al. (2007) showed a 21% stone-free rate, although 60% of patients did experience symptom relief. Symptom-free status has been achieved in 36% to 86% of patients after SWL across a number of series, with the average closer to 60%; all studies, however, involved relatively few patients. Streem and Yost (1992) reported the highest symptom relief (86%) and stone-free rates (58%) after SWL, and these results appear to be reliant on strict patient selection criteria, including stones smaller than 1.5 cm and large, patent diverticular necks on IVU. With longer follow-up averaging about 24 months (12 to 49 months), the symptom-free rate had declined to 75%, and stone recurrence was witnessed in one patient. In general, with longer follow-up, symptom-free status consistently appears to diminish (Jones et al., 1991a; Streem and Yost, 1992; Turna et al., 2007).

URS is a reasonable first-line treatment approach for patients with small (<2 cm) calyceal diverticular stones arising from an upper or middle calyx, and with a diverticular neck that is short and identifiable (Grasso et al., 1995b; Waingankar et al., 2014). Diverticular stones in these locations are usually accessible via retrograde URS, whereas lower pole diverticular stones present more of a challenge because of angulation. The holmium laser can be used to incise the narrow diverticular neck, fragment stones within, and ablate the diverticular lining. Stone-free rates of 50% to 90% are found in most series, although Auge et al. (2002) found a much lower symptom-free rate of 35% (Auge et al., 2002; Batter and Dretler, 1997; Chong et al., 2000; Fuchs and David, 1989; Grasso et al., 1995b; Legraverend et al., 2013). Adequate diverticular obliteration is lower with the ureteroscopic approach (approximately 20%) than with a percutaneous approach (>70%), hence the need to ensure a patent and well-draining diverticular neck.

In general, most URS failures have occurred in lower pole diverticula, although a small number have occurred in upper pole and interpolar diverticula with unfavorable acute-angle offshoots of the calyceal diverticular neck. Unfortunately, the ostium to calyceal diverticulum cannot be successfully located in up to 25% of cases, and when this occurs the diverticular stones cannot be treated ureteroscopically (Auge et al., 2002; Canales and Monga, 2003). Legraverend et al. reported a 62% stone-free rate, which increased to 84% when residual fragments less than 3 mm were included. Symptom-free rate was 93%. Overall, stone-free rates are superior to those achievable with SWL but inferior to those of PCNL. Furthermore, staged URS procedures are not uncommon in this setting.

PCNL should be considered first-line treatment for most calyceal diverticular stones. Stone-free rates (70% to 100%) and symptom-free rates (77% to 100%) are excellent for PCNL, and the most data supports the efficacy of the percutaneous approach (Al-Basam et al., 2000; Auge et al., 2002; Cohen and Preminger, 1997; Hulbert et al., 1986; Monga et al., 2000; Kim et al., 2005; Krambeck and Lingeman, 2009; Parkhomenko et al., 2017; Shalhav et al., 1998). Diverticular ablation rates are also excellent (>70%) with a percutaneous approach, and the overall success rates appear durable (Monga et al., 2000; Shalhav et al., 1998). Directly puncturing into the calyceal diverticulum is preferable and allows for stone fragmentation and removal, easy fulguration of the diverticular lining, and dilation of the diverticular neck if visible and desired. Ultrasound or CT guidance can be used in selected cases when retrograde contrast instillation does not fill the calyceal diverticulum and when diverticular stones are nonradiopaque (Matlaga et al., 2006a). Posteriorly located diverticuli are particularly well suited for a percutaneous approach because there is usually minimal renal parenchyma between the diverticulum and renal capsule. Anteriorly located calyceal diverticula can also be managed with a percutaneous approach; however, it is often difficult to incise and dilate the diverticular neck secondary to unfavorable angles between the entry vector and the neck.

Laparoscopic and robotic approaches for the treatment of symptomatic stones within calyceal diverticuli have been described and are usually reserved for anteriorly located, symptomatic diverticuli with thin overlying renal parenchyma, which are otherwise not amenable to less invasive endoscopic methods (Akca et al., 2014; Curran et al., 1999; Gluckman et al., 1993; Harewood et al., 1996; Hoznek et al., 1998; Miller et al., 2002; Ruckle and Segura, 1994; Terai et al., 2004; Wyler et al., 2005). Retroperitoneal and transperitoneal approaches have been used; the retroperitoneal method provides easier access to posteriorly located diverticula. Outcomes are superb, with a 100% stone-free rate in those series reporting it as an outcome, approximately a 92% cavity ablation rate, and a 75% to 87% average symptom resolution rate (Basiri et al., 2013; Waingankar et al., 2014; Waxman and Winfield, 2009). The average operative time reported in these studies is approximately 180 minutes, which is longer than for the other surgical approaches. Important common considerations for this approach include the use of intraoperative ultrasound to assist with diverticulum localization, direct cavity lining ablation using electrocautery or argon beam coagulation, and suturing of the diverticular neck when required to manage wide-mouthed diverticulum.

Horseshoe Kidneys and Renal Ectopia

Horseshoe Kidneys.

Horseshoe kidneys are the most common renal fusion anomaly, with a reported incidence of 1 in 400 live births (Evans and Resnick, 1981; Pitts and Muecke, 1975). **There is a 15% to 20% incidence of kidney stone disease in horseshoe kidneys.** Most stones are composed of calcium oxalate, and the most common locations are the renal pelvis and posterior lower pole calyces (Evans and Resnick, 1981; Tan et al., 2013). Embryonically, the abnormal medial fusion of the left and right metanephric blastemata creates an isthmus that anchors the fused kidneys at the level of the inferior mesenteric artery, leading to incomplete renal ascent and malrotation (Hohenfellner et al., 1992; Figs. 93.7 through 93.9).

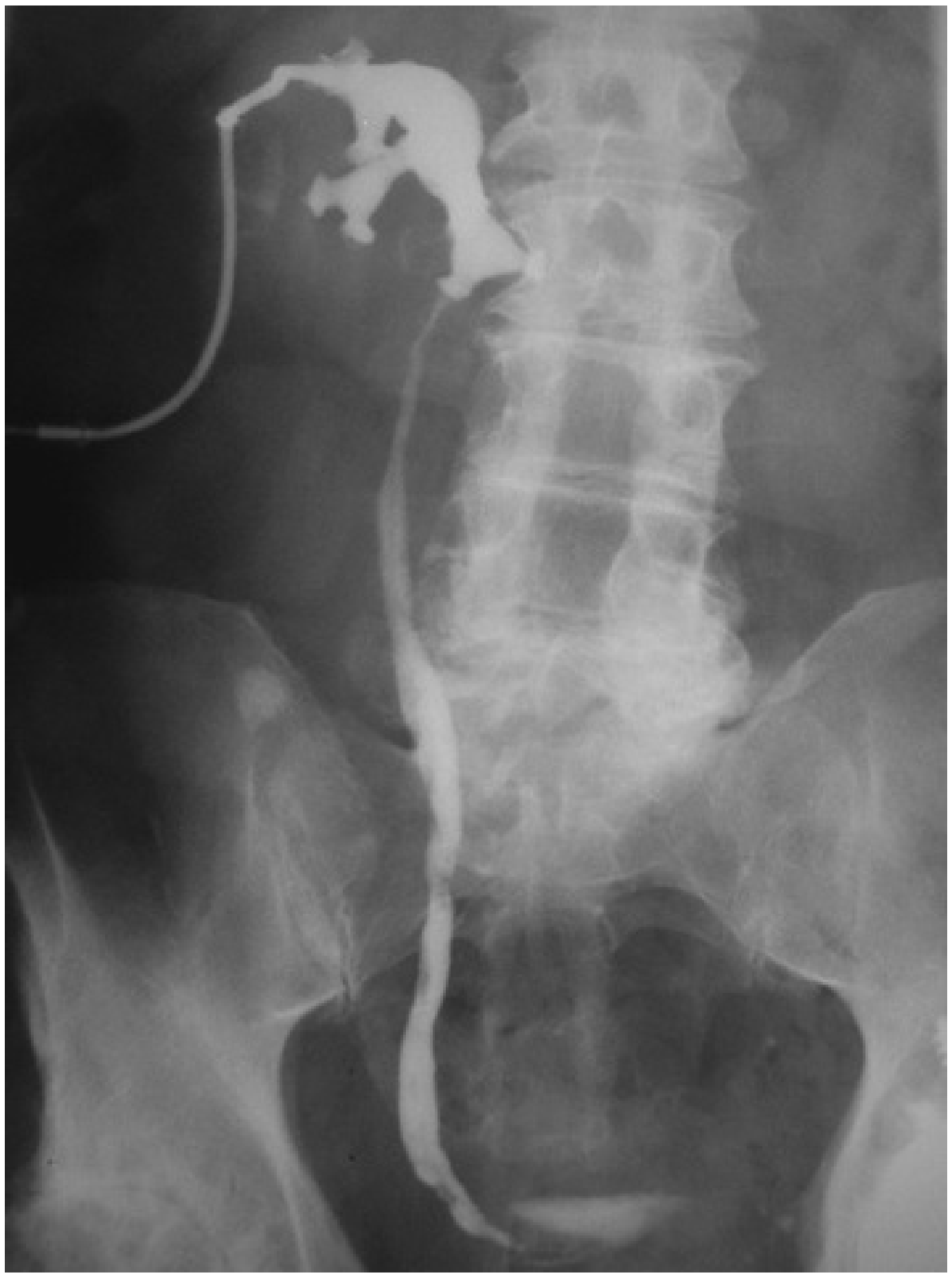

FIG. 93.7 Antegrade nephrostogram obtained after percutaneous nephrolithotomy of a horseshoe kidney via an upper pole access. Note the subcostal nature of the access and the unique calyceal orientation inherent in a horseshoe kidney.

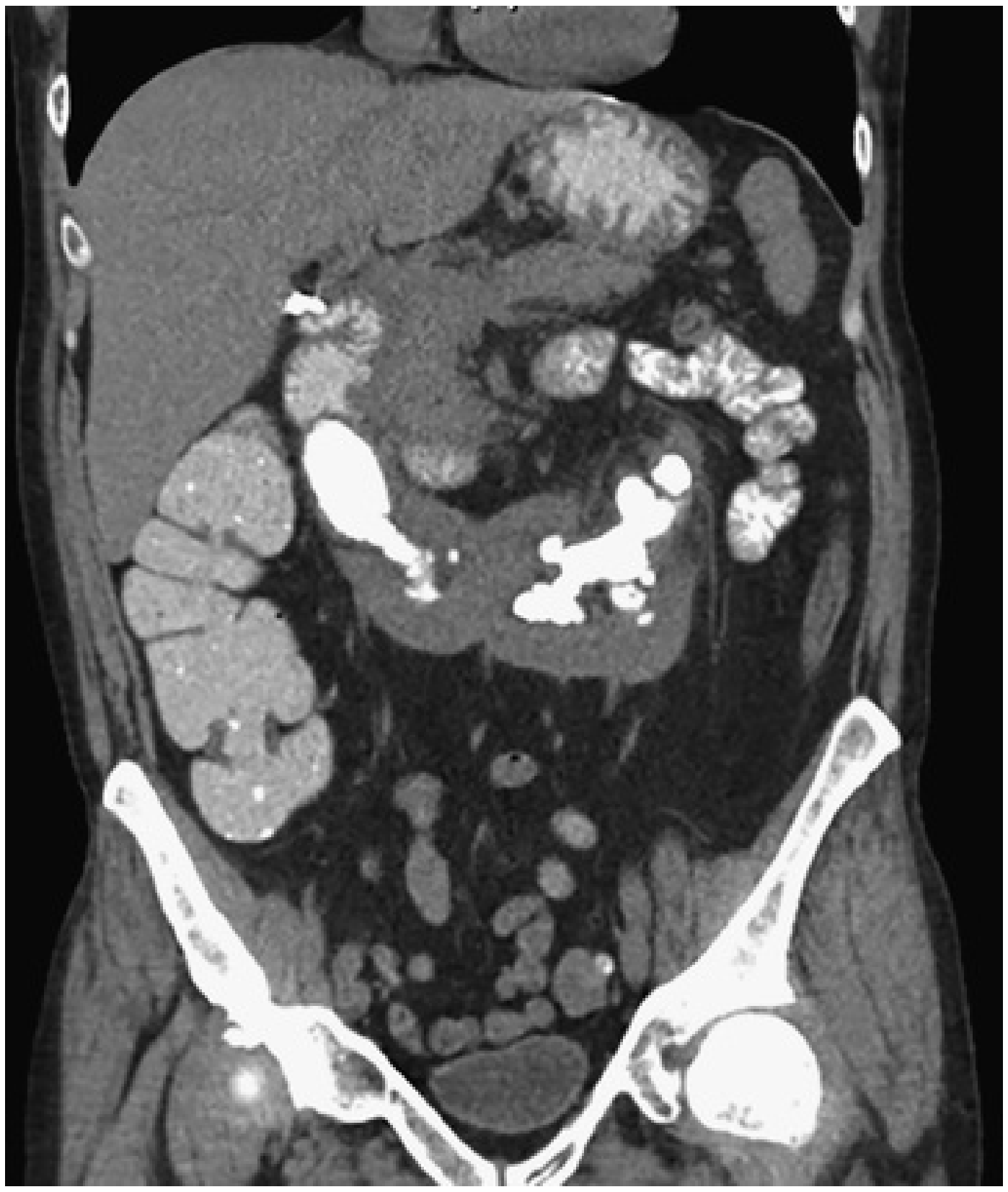

FIG. 93.8 Coronal computed tomographic reconstruction of horseshoe kidney with bilateral staghorn calculi. Note the medial and inferior position of the horseshoe kidney.

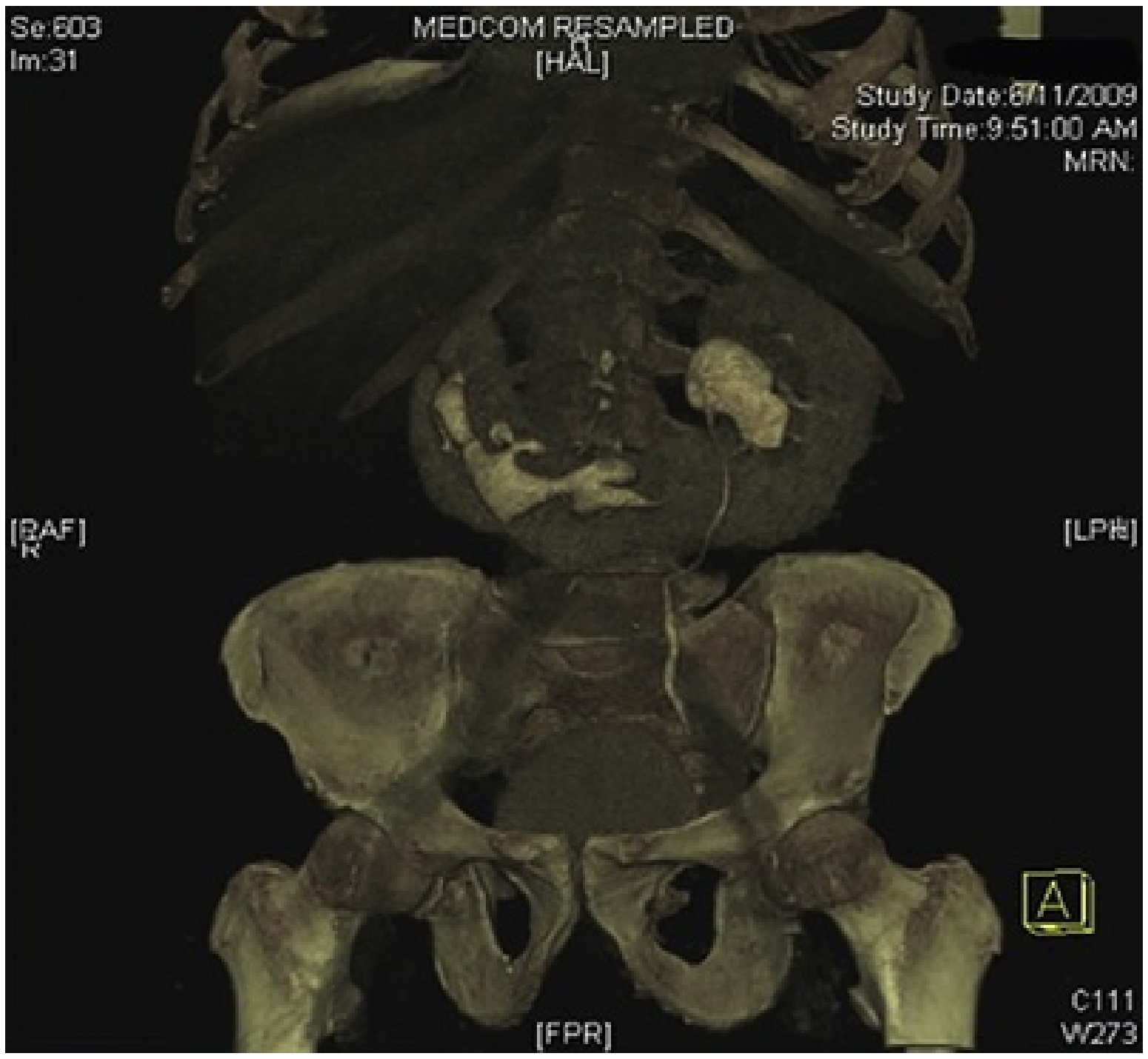

FIG. 93.9 Three-dimensional computed tomographic reconstruction of horseshoe kidney with bilateral staghorn calculi. Note the medial and inferior position of the horseshoe kidney. (From Tan YK, Cha DY, Gupta M: Management of stones in abnormal situations. *Urol Clin North Am* 40:79–97, 2013.)

As a result, a number of anatomically important changes are noted. The renal pelvis becomes elongated and anteriorly located, the UPJ has a high insertion into the renal pelvis and is anteriorly situated, and the proximal ureter courses more anteriorly than usual because it must traverse over the isthmus of the horseshoe kidney. **Collectively, these changes are thought to impede normal urinary drainage and to promote urinary stasis and renal stone formation.** These anatomic and functional changes have an impact on the various treatment options for renal stones, and specific horseshoe kidney anatomy, stone location, and stone size must also be considered when choosing the optimal stone treatment. The presence of impaired renal drainage or UPJO should preclude SWL treatment, and other modalities that can address the obstruction, such as PCNL or laparoscopic pyeloplasty, should be pursued. **In general, stones smaller than 15 mm and not situated in the lower pole can be approached with SWL or URS. Stones that fail treatment with SWL or URS and stones larger than 15 mm should be considered for PCNL. Based on numerous reports, stone clearance and complications in horseshoe kidneys appear to be no different than for PCNL on orthotopic kidneys.**

SWL can be considered for stones less than 1.5 cm in diameter located in the renal pelvis or nondependent upper pole and mid-pole calyces. Stone-free rates of 28% to 80% have been reported, with an average closer to 58%. Moreover, multiple treatment sessions are almost always necessary (Elliott et al., 2010; Lampel et al., 1996; Ray et al., 2011; Tan et al., 2013). On average, a higher number of shocks are necessary per treatment session, and a higher re-treatment rate is found versus similar stones in orthotopic, anatomically normal kidneys (Chaussy and Schmiedt, 1984; Drach et al., 1986; Lingeman et al., 1986).

In a series of 11 patients by Vandeursen and Baert (1992), an average of 3.8 treatment sessions per renal unit were required to achieve a 55% stone-free rate, whereas the series by Ray et al. (2011) showed an average of 1.7 SWL sessions for a stone-free rate of 39%. In addition, Ray et al. (2011) reported an abysmal 9.1% stone-free rate and 25% treatment success rate after single-session SWL at 3 months in 41 patients with horseshoe kidneys. In this series, 73% of patients required additional treatments in the form of repeat SWL, PCNL, or URS, and stone-free rate and overall success rate improved to 39.1% and 63.6%, respectively (Ray et al., 2011). The efficiency quotient was disappointing, at 10.5%. Just as SWL efficacy diminishes as stone burden increases in anatomically normal kidneys, so too it diminishes in horseshoe kidneys with increasing stone burden. Sheir et al. (2003) found superior stone-free rates of 79% for stones up to 15 mm, compared with 53% for stones larger than 15 mm. Kirkali et al. (1996) similarly found poor stone-free rates (28%) for stones larger than 10 mm.

Before SWL treatment, UPJO and poor pelvicalyceal drainage must be excluded, because these are not uncommon in horseshoe kidneys and severely curtail SWL success. The more medial and central location of the horseshoe kidney makes it more difficult to properly target calyceal and renal pelvis stones because of the overlying vertebrae, pelvic bones, and bowel gas. Anteromedially located calyceal stones present the greatest difficulty. Positioning patients in the prone position or in the modified supine position can optimize stone targeting and is often necessary for stones situated below the pelvic brim (Gupta and Lee, 2007; Jenkins and Gillenwater, 1988). In addition, long skin-to-stone distances are frequently encountered in horseshoe kidneys, which can also hinder SWL efficacy. When SWL is chosen and skin-to-stone distances are outside of the focal zone of the lithotripter, a “blast path” technique can be used, during which the stone is targeted along the same axis but beyond

F2, and relies on shock wave energy transmission past F2 to fragment the stone (Locke et al., 1990).

URS is challenging in horseshoe kidneys because of the high ureteral insertion and tortuous course of the anteriorly displaced ureter. The need for ureteral dilation is not uncommon, and ureteral access sheaths, if able to be placed safely, can significantly expedite repeated entry to and withdrawal from the pelvicalyceal system. Flexible ureteroscopes are almost always necessary to access renal stones in a retrograde fashion, and the use of small-caliber nitinol baskets and holmium laser fibers can minimize loss of URS tip deflection. **Given the aberrant anatomy, ureteroscopy appears to be ideally limited to stone burdens 2 cm or less.** Moreover, staged procedures are common when approaching these stones ureteroscopically, and particularly so among the largest stones. Given the often compromised drainage associated with horseshoe kidneys, fragmented stones should be basket extracted rather than left in situ and left to pass spontaneously.

A number of small retrospective series report favorable surgical outcomes and low morbidity with URS for stone burdens less than 2 cm in horseshoe kidneys (Andreoni et al., 2000; Legemate et al., 2017; Symons et al., 2008; Weizer et al., 2005). No reports focus on larger stone burdens, and none compare URS with SWL or PCNL in a direct fashion. Atis et al. (2013) reviewed outcomes in 20 patients with 25 stones in horseshoe kidneys. Mean stone size was 17.8 mm and stone-free rate after a single procedure was 70%. Weizer et al. (2005) detailed the URS outcomes in 4 patients with horseshoe kidneys and four pelvic kidneys. Mean stone size was 1.4 cm, complete stone clearance was found in 75% of patients, and 88% of patients were symptom free after the procedure. Molimard et al. (2010) reported results in 17 patients with horseshoe kidneys, 4 of whom had undergone failed previous PCNL and 8 of whom had undergone failed prior SWL. In this series, mean stone burden was 16 mm, and an average of 1.5 procedures per patient were required to achieve an 88% stone-free rate, which included residual fragments smaller than 3 mm. In subgroup analysis from the Global Ureteroscopy Study, Legemate et al. (2017) found a 77% and 85% stone-free rate for renal and ureteral stones, respectively, in 43 patients with horseshoe kidneys. Thus URS can render patients stone free more than 70% of the time when stone burdens are less than 2 cm, although a staged approach may be necessary at least half the time.

PCNL is the treatment of choice for stone burdens 2 cm and greater in horseshoe kidneys, with treatment results similar to those obtained in

normal kidneys. It is also the preferred method when less invasive methods, such as SWL and URS, fail to adequately treat lesser stone burdens, or when stone density may further decrease expected successful treatment with those methods. Stone-free rates are superior to those achieved with SWL or URS. Overall, an average stone-free rate of 82% to 84% has been reported, with contemporary series describing stone-free rates of 90% or greater with the concomitant use of flexible nephroscopy (Al-Otaibi and Hosking, 1999; Blackburne et al., 2016; Elliott et al., 2010; Esuvaranathan et al., 1991; Gupta et al., 2009b; Janetschek and Kunzel, 1988; Jones et al., 1991b; Ozden et al., 2010; Raj et al., 2003; Shokeir et al., 2004).

Familiarity with the anatomy of the horseshoe kidney is key to safely performing PCNL. Percutaneous access to the horseshoe kidney is often preferentially directed at a posterior upper pole calyx, which results in an access tract situated more medially than those created in orthotopic kidneys. This is because the malrotation of the horseshoe kidney positions the renal pelvis anteriorly and angles the posterior calyces almost directly posteriorly compared with normally positioned kidneys. Percutaneous tracts through the posterior upper pole calyx provide easy access into the renal pelvis and laterally positioned calyces (Elliott et al., 2010).

However, the high insertion of the lower pole, combined with the anteromedially situated calyces, often requires a flexible nephroscope to reach all calyces in the system. In addition, the more anteriorly and centrally positioned horseshoe kidney causes the access tract to be longer, and this may necessitate use of extra-long access sheaths, nephroscopes, and instruments, especially in obese patients. A retrorenal colon may accompany horseshoe kidneys, and given the altered anatomy, preoperative CT is recommended to fully evaluate the safest percutaneous tract. Supracostal access is rarely necessary because the entire horseshoe kidney is often situated below the 12th ribs, and consequently pleural injuries are rare (Raj et al., 2003; Shokeir et al., 2004). The Clinical Research Office of the Endourological Society (CROES) PCNL study group showed that median operative time was longer and percutaneous access more likely to be unsuccessful (5% vs. 1.7%) in horseshoe kidneys than orthotopic kidneys (Osther et al., 2011).

Laparoscopic assistance is only rarely used for stone surgery on horseshoe kidneys, and only a few case reports exist. In general, this adjunctive technique can be useful when particularly large renal pelvis stones exist or when concomitant UPJO exists and pyelolithotomy with or without pyeloplasty is contemplated (Stein and Desai, 2007; Symons et al., 2008; Tan et al., 2013).

Renal Ectopia.

Ectopic kidneys are most commonly situated in the pelvis, with the incidence of pelvic kidneys estimated at 1 in 2200 to 1 in 3000 patients. More rarely, ectopic kidneys can be located in the abdomen, in the thoracic cavity, or in a crossed, retroperitoneal location. The approach to kidney stone treatment in these instances should be highly tailored to the specific individual, stone burden, and kidney location, along with any associated kidney drainage impediments. Similarly to horseshoe kidneys, evaluation for impaired renal drainage or UPJO is prudent before embarking down a treatment path, because pelvic kidneys are routinely malrotated and often have a high ureteral insertion or UPJO, which can further hinder stone fragment passage (Gleason et al., 1994). In the appropriate setting, SWL, URS, PCNL, and laparoscopy can be selectively applied to achieve good stone clearance rates.

SWL achieves stone-free rates of 25% to 92%, although multiple treatment sessions are the norm (Gallucci et al., 2001; Semerci et al., 1997; Sheir et al., 2003; Talic, 1996; Theiss et al., 1993; Tunc et al., 2004). With the pelvic kidney shielded posteriorly by the bony pelvis, prone positioning, or rotating the treatment head of the lithotripter anterior to the supine patient, is often necessary to improve shock wave delivery to the pelvic kidney stones when this technique is selected. If treatment with SWL is entertained for stones in ectopic kidneys, renal functional studies evaluating renal drainage (e.g., renography) are recommended, because the presence of impaired kidney drainage is a relative contraindication to proceeding with SWL. Ureteroscopy has also been described for pelvic and ectopic kidneys with stone-free rates of 75% after a single setting, showing that URS and SWL can achieve similar outcomes, but URS is more efficient (Bozkurt et al., 2014; Singh et al., 2017; Weizer et al., 2005). This is likely because of the active fragment removal with URS, whereas SWL requires spontaneous drainage of fragments, which can be problematic in a poorly draining ectopic kidney. Ureteral access sheaths can greatly facilitate re-entry into the ectopic kidney; however, their placement should be undertaken with caution because the associated ureters can be tortuous and perhaps prone to injury with sheath advancement.

Stones within pelvic kidneys present unique challenges to performing PCNL because clear access to the kidney is seldom encountered. Nonetheless, stone clearance rates are better for PCNL than for SWL, at least in part because of active stone extraction and the ability to perform flexible nephroscopy. Traditional posterior access is hampered by the bony pelvis, and even when it can be safely accomplished can result in debilitating femoral neuropathy (Monga et al., 1995). Patients must usually be in the supine position, and safe access into the collecting system is rarely feasible without CT or laparoscopic assistance, although it has been described ultrasonographically. Desai and Jasani (2000) report a technique exploiting transperitoneal ultrasound guidance for supine PCNL in pelvic kidneys in which the ultrasound probe is used to target the kidney and maneuver intervening intra-abdominal contents out of the way of the proposed access tract (Desai, 2009). In this series of 16 patients, 1 experienced a bowel injury. Given its limitations, this method is unlikely to prove successful in overweight or obese patients. Rare case reports of transhepatic, transiliac, and trans-sciatic punctures have been described; however, such approaches should be considered only in the highly selected patient and done in conjunction with CT guidance and the interventional radiologist (Matlaga et al., 2006b).

Laparoscopic assistance has been used during PCNL to ensure a safe percutaneous access tract into the kidney by mobilizing and displacing any overlying intestines and directly observing the needle puncture into the kidney (Fig. 93.10). This was first described by Eshghi et al. (1985), and others have followed suit since then (Elbahnasy et al., 2011; El-Kappany et al., 2007; Gowel et al., 2006; Holman and Toth, 1998; Maheshwari et al., 2004; Matlaga et al., 2006b). Excellent stone-free rates are reported and overall morbidity is low. Most of these techniques use a Trendelenburg position to mobilize the intestines during a transperitoneal procedure. To minimize the risks of urinary leakage to the peritoneal cavity, appropriate postoperative drain placement is recommended. Zafar and Lingeman (1996) have described a simultaneous laparoscopic nephrostomy closure and ureteral catheter placement during pelvic kidney PCNL, thereby avoiding the need for an intra-abdominal drain. An entirely extraperitoneal approach to minimize the risk of intraperitoneal leakage has also been described (Holman and Toth, 1998).

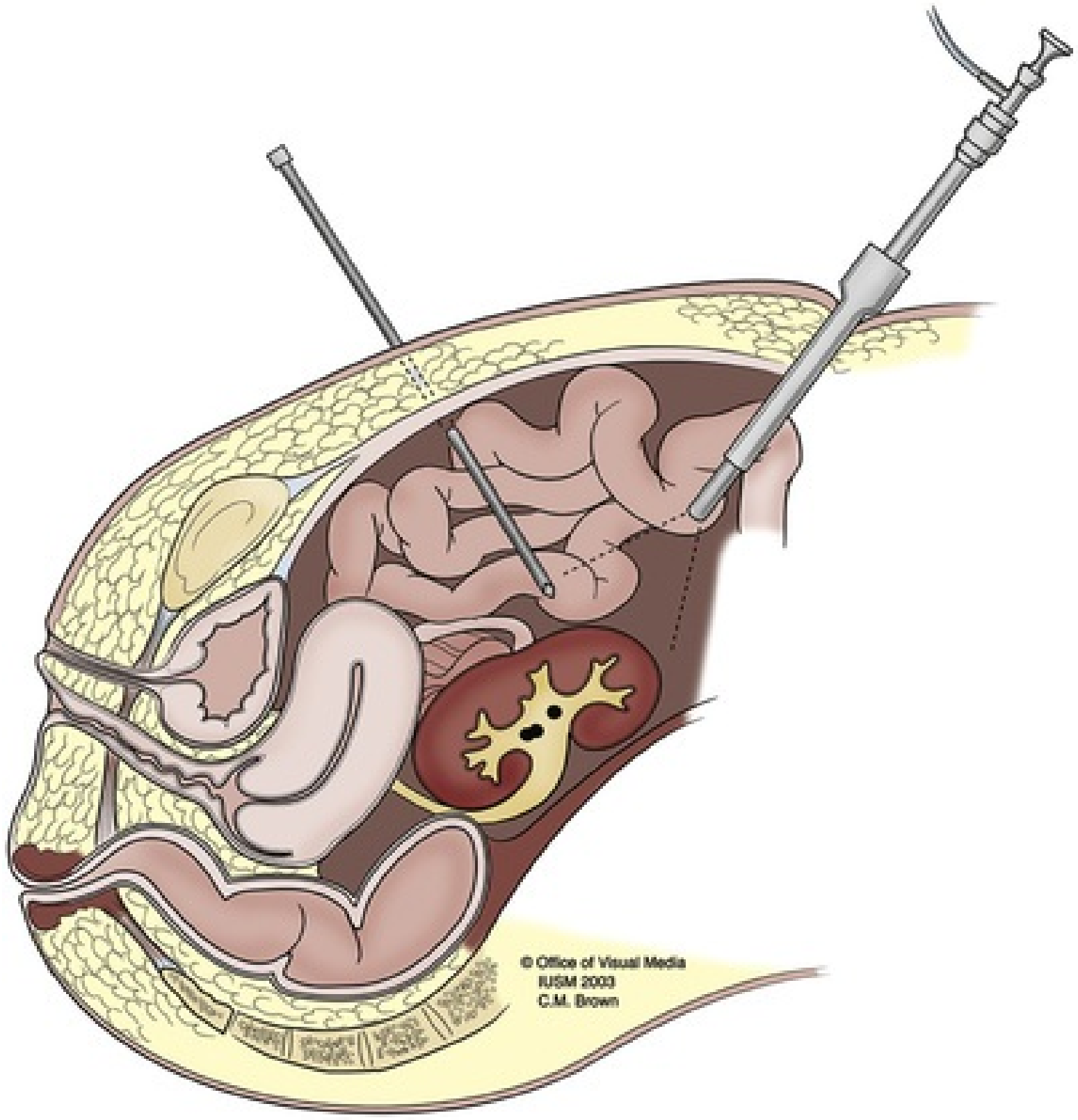

FIG. 93.10 Laparoscopy-assisted percutaneous nephrolithotomy technique in which the bowel is reflected off the ectopic kidney before radiographically and laparoscopically guided percutaneous access. (Copyright 2003, Indiana University Medical Illustration Department.)

Purely laparoscopic or robotic approaches to pelvic and ectopic kidneys provide high success with low morbidity and are particularly appealing treatment options when simultaneous repair of UPJO is planned (Chang and Dretler, 1996; El-Bahnasy et al., 2011; Hoenig et al., 1997; Kamat and Khandelwal, 2004; Nayyar et al., 2010). The concept is the same as for horseshoe kidneys: a pyelotomy is made to clear renal pelvis stones, and a flexible nephroscope and stone basket are then inserted through one of the laparoscopic trocars to access and clear calyceal stones. Stone-free rates of 80% to 100% have been reported (Atug et al., 2005, Masson and Hoenig, 2008; Ramakumar and Segura, 2000). Most authors use a transperitoneal approach, although Gaur et al. (1994) detail a retroperitoneal approach.

For kidney stones in ectopic and horseshoe kidneys, SWL is a reasonable treatment option when stones are smaller than 1.5 cm and there is no UPJO or demonstration of poor renal drainage. URS may also be reasonable for stone burdens less than 2 cm, although they may require multiple treatment

sessions. For stone burdens of 2 cm or more, PCNL or laparoscopy should be the initial treatment; a combination of the two procedures is expected for pelvic kidneys. When UPJO is confirmed, laparoscopy is the treatment of choice because it can address the stones and provides the highest success rate for UPJ repair.

Lower Pole Calculi

The preferred treatment of lower pole renal calculi has generated appreciable controversy over the last few decades (Armagan et al., 2015; Bozzini et al., 2017; Chan et al., 2017; Donaldson et al., 2015; Kandemir et al., 2017; Raman and Pearle, 2008; Sener et al., 2015; Soliman et al., 2016; Tolley and Downey, 1999; Yuruk et al., 2010). Regarding non–lower pole intrarenal calculi, stones within the lower pole tend to have worse surgical stone clearance rates compared with other locations when stratified by size and composition. The management strategy for lower pole stones continues to evolve as ureteroscopic capabilities improve, percutaneous stone removal instrumentation miniaturizes, and the limitations of the newer generations of shock wave lithotripters become more evident (Fig. 93.11; see also Fig. 93.1).

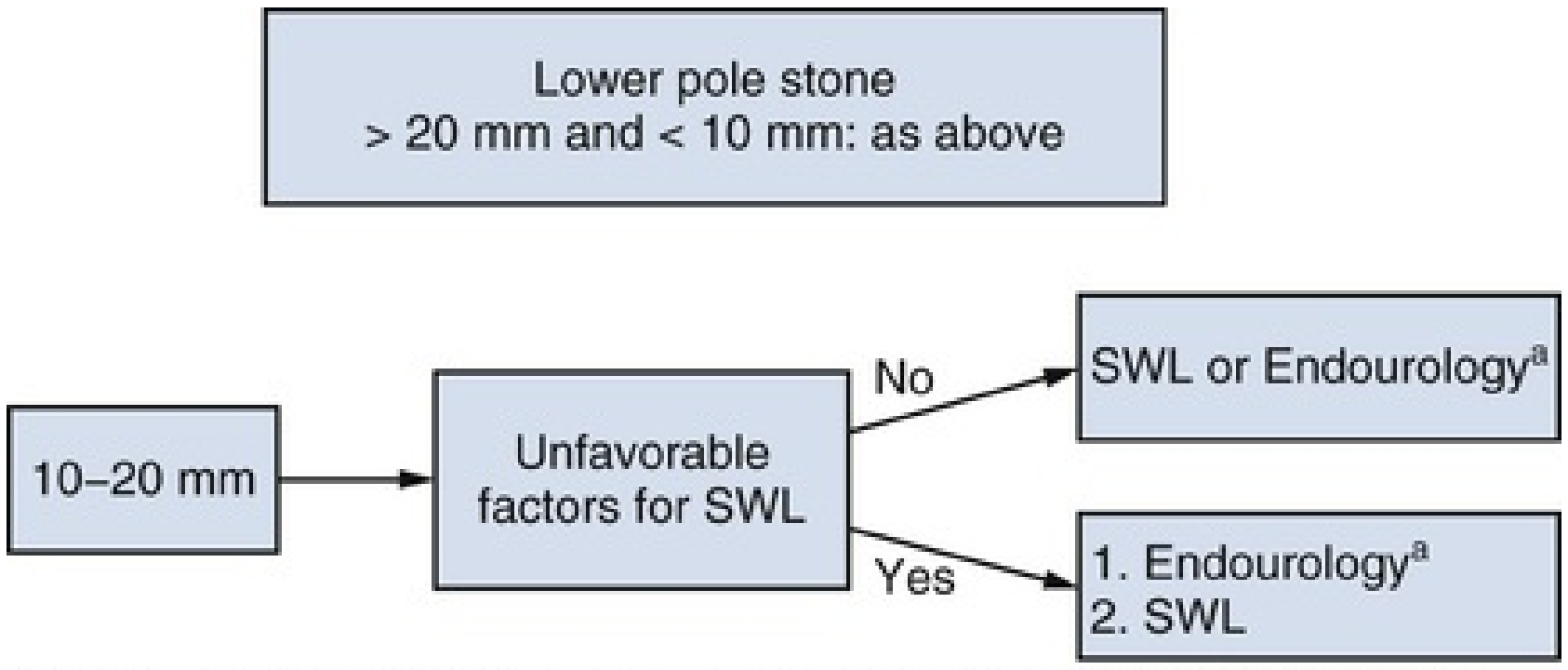

[a] *The term ‘Endourology’ encompasses all PNL and URS interventions.*

FIG. 93.11 Treatment algorithm: lower pole stones. *PNL,* Percutaneous nephrolithotomy; *RIRS,* retrograde intrarenal surgery; *SWL,* shock wave lithotripsy; Endourology includes all PNL and URS. RIRS includes retrograde URS. (Modified from Turk et al.: *EAU Guidelines on urolithiasis,* 2017.)

As discussed previously in the section on stone factors, overall stone burden is the main driver of treatment decisions for lower pole stones. Treatment decisions are most conveniently divided into stone burdens less than 1 cm, stone burdens of 1 to 2 cm, and stone burdens greater than 2 cm (see Figs. 93.1 and 93.11).

Lower pole kidney stone burdens 2 cm or larger are best approached with PCNL because the collective evidence shows that PCNL offers a considerably higher stone-free rate in a single procedure than URS or SWL. For lower pole stone burdens of 1 cm to 2 cm, PCNL remains the most efficient treatment option, although it is more invasive, and is preferred when prior URS or SWL attempts have been unsuccessful. Ureteroscopy is the treatment modality of choice when PCNL is completely or relatively contraindicated and is a reasonable first-line option in experienced hands. In general, SWL results are disappointing for lower pole stone burdens over 1 cm, and therefore SWL should not be recommended as an initial treatment modality for such stones. For lower pole stones 1 cm or less, stone characteristics and patient factors become relatively more important than for larger stone burdens and should be incorporated into treatment recommendations. Stone burdens 1 cm or less in size may be reasonably approached with any modality including observation if completely asymptomatic, although future stone disease progression is likely. Lower-density stones, in nonobese patients without acute lower pole infundibulopelvic angles are among the few in the lower pole for which SWL provides a reasonable chance of success. Meanwhile, URS, with improved ureteroscopes and accessory instrumentation, has allowed better access into the lower pole and improved outcomes. Finally, PCNL should be used for stones that have failed less invasive treatment modalities or are extremely large or dense.

Historically, shortly after its clinical dissemination, it was realized that SWL provided unsatisfactory results for larger lower pole stones (Consensus conference, 1988). In fact, multiple series over the last 20 years have shown stone-free rates of approximately 50% or less for lower pole stones 1 to 2 cm and less than approximately 30% for lower pole stones larger than 2 cm (Table 93.1). It was hypothesized that the gravity-dependent nature of the lower pole and certain lower pole anatomic characteristics may impede stone clearance (Elbahnasy et al., 1998; Sampaio and Aragao, 1992, 1994). Sampaio and Arago executed a series of elegant anatomic studies to better define the anatomy of the lower pole by creating polyester resin endocasts of the pelvicalyceal collecting system using adult cadaveric kidneys. They hypothesized that a number of different lower pole anatomic features may reduce stone passage, including a narrow lower pole infundibulum (width <4 mm), an acute lower pole infundibulopelvic angle (<90 degrees), and multiple lower pole infundibula rather than a single infundibulum (Fig. 93.12). Similar findings have been demonstrated in subsequent investigations, suggesting that lower pole infundibular length greater than 3 cm, infundibular width less than 5 mm, and infundibulopelvic angle less than 70 degrees inhibit lower pole stone clearance during SWL (Elbahnasy et al., 1998; Madbouly et al., 2001; Manikandan et al., 2007; Sabnis et al., 1997; Sumino et al., 2002). Other studies have shown no effect of lower pole anatomy on stone clearance after SWL (Albala et al., 2001; Sorensen and Chandhoke, 2002).

TABLE 93.1

Treatment Outcomes for Lower Pole Calculi

STUDY	STONE-FREE RATE (%)		
	SHOCK WAVE LITHOTRIPSY	URETEROSCOPY	PERCUTANEOUS NEPHROLITHOTOMY
LOWER POLE CALCULI <1 CM			
Lingeman et al., 1994	74		100
Elashry et al., 1996		87	
Elbahnasy et al., 1998	52	62	
Grasso and Ficazzola, 1999		82	
Gupta et al., 2000	72		
Kourambas et al., 2000		85	
Albala et al., 2001	63		100
Hollenbeck et al., 2001		82	
Schuster et al., 2002		79	
Sorensen and Chandhoke, 2002	74		
Pareek et al., 2005	47		
Pearle et al.,	35	50	

2005[a]			
Kumar et al., 2014	72	88	
Sener et al., 2014	92	100	
LOWER POLE CALCULI 1 TO 2 CM			
Lingeman et al., 1994	56		89
Grasso and Ficazzola, 1999		71	
Saw and Lingeman, 1999	55		
Gupta et al., 2000	51		
Albala et al., 2001	23		93
Hollenbeck et al., 2001		63	
Madbouly et al., 2001	57		
Schuster et al., 2002		64	
Sorensen and Chandhoke, 2002	41		
Sumino et al., 2002	54		
Kuo et al., 2003[a]		31	76
Yuruk et al., 2010	55		97
El-Nahas et al., 2012	68	87	
Singh et al., 2014	54	86	
Burr et al., 2015	25	93	
Soliman et al., 2016	76		96 (mini-PCNL)
Chan et al., 2017	36	67	67
Kandemir et al., 2017		87	83 (micro-PCNL)
Bozzini et al.,	62	82	87

2017			
LOWER POLE CALCULI >2 CM			
Lingeman et al., 1994	33		94
Grasso et al., 1998		76	
Grasso and Ficazzola, 1999		65	
Albala et al., 2001	14		86
El-Anany et al., 2001		60	

[a] Computed tomography–measured outcome.

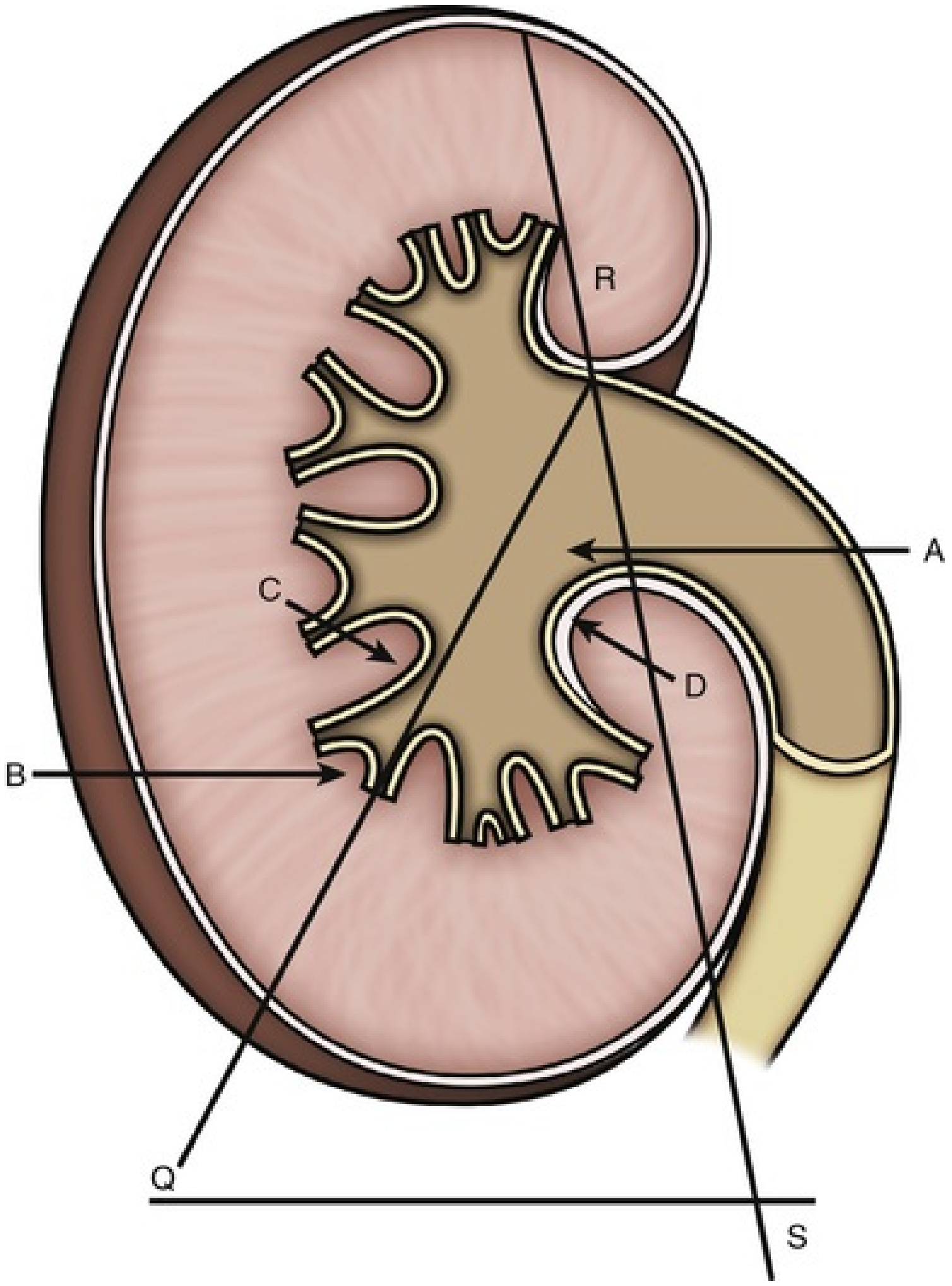

FIG. 93.12 Measurement scheme for lower pole anatomy. Lower pole

infundibular length: measure A to B. Lower pole infundibular width: measure C to D. Lower pole infundibulopelvic angle: measure QRS angle. (From Albala DM, Assimos DG, Clayman RV, et al.: Lower pole I: a prospective randomized trial of extracorporeal shock wave lithotripsy and percutaneous nephrostolithotomy for lower pole nephrolithiasis—initial results. *J Urol* 166:2072–2080, 2001.)

In an attempt to improve stone clearance rates after SWL of lower pole calculi, a number of supplemental therapies have been proposed and examined. McCullough (1989) anecdotally reported that postural drainage may assist in the elimination of retained fragments from dependent calyces. Brownlee et al. (1990) subsequently treated patients with residual lower pole fragments with controlled inversion therapy, using intravenous hydration, inversion, and percussion. D'a Honey et al. (2000) reported a pilot study to determine whether mechanical percussion with inversion therapy and furosemide-induced diuresis can move stone fragments out of the lower pole of the kidney. At a mean time of 63 days after SWL, this group reported an 83% stone passage rate. In a subsequent study, Pace et al. (2001) compared the effectiveness of mechanical percussion, inversion, and furosemide-induced diuresis with observation for elimination of lower calyceal fragments after SWL. They reported that 40% of patients with residual lower pole fragments treated with this regimen became stone free compared with 3% in the observation group; the observation group was then treated with this regimen as part of a crossover design, and 43% were rendered stone free.

Chiong et al. (2005) performed a similar study and showed that percussion, diuresis, and inversion therapy improved stone-free rates after SWL for lower pole stones. A recent Cochrane review included the studies by Pace et al. and Chiong et al. and concluded that overall evidence was limited, but that percussion, diuresis, and inversion were safe, were well tolerated, and appeared to modestly aid in stone passage after SWL (Liu et al., 2013). Other authors have reported lower pole irrigation techniques as adjuncts to SWL (Graham and Nelson, 1994; Nicely et al., 1992). More recently, pharmacotherapy with potassium citrate and thiazide diuretics has been described (Arrabal-Martin et al., 2006; Soygur et al., 2002). However, at this point in time none of these techniques has gained widespread acceptance.

The superiority of PCNL over SWL in clearing lower pole stones first became widely evident in a meta-analysis performed by Lingeman et al. in 1994. **In this report, PCNL achieved an overall 90% stone-free rate compared with 60% for SWL.** Subgroup analysis stratified by stone burden showed that stones 10 mm or smaller had a 74% clearance rate with SWL and 100% clearance rate with PCNL, whereas stones 10 to 20 mm had a 56% clearance rate with SWL and an 89% clearance rate with PCNL (see Table 93.1). An even larger difference was appreciated for lower pole stones larger than 2 cm, for which stone-free rates were 94% for PCNL and only 33% for SWL. On regression analysis, increasing stone size was associated with decreasing stone clearance for SWL but had no demonstrable effect on PCNL.

After these retrospective data, a number of prospective trials ensued confirming the dominance of PCNL over SWL for the vast majority of lower pole stones (Albala et al., 2001; Yuruk et al., 2010). In the multicenter, prospective, randomized Lower Pole I study by Albala et al. (2001), stone-free rates as evaluated by nephrotomograms at 3 months after treatment were 95% for PCNL and only 37% for SWL. Stone-free rates for SWL were particularly low for stones 10 mm and larger: 23% for stones 1 to 2 cm, and 14% for stones larger than 2 cm. Yuruk et al. (2010) randomized 90 patients with lower pole stones 2 cm or smaller to SWL, PCNL, or observation. PCNL achieved a 97% stone-free rate compared with a 55% stone-free rate with SWL when patients were assessed at 3 months after treatment. As an additional component of this study, dimercaptosuccinic acid (DMSA) renal scintigraphy was performed in all patients, and a higher percentage of SWL patients (16%) were found to have developed renal scarring compared with the PCNL cohort (3%). These SWL patients had received three treatment sessions with an average of 1863 shocks per session. Ozturk et al. retrospectively reviewed 221 SWL, 144 PCNL, and 38 URS procedures and showed a 94% success rate with PCNL, a 76% success rate with SWL, and a 73% success rate for URS (Ozturk et al., 2013). Bozzini et al. (2017) completed a prospective, randomized comparison among SWL, URS, and PCNL for lower pole stones less than 2 cm and found overall stone-free rates of 62% (SWL), 82% (URS), and 87% (PCNL) on CT at 3 months after surgery.

In an analogous fashion, SWL has been compared with URS for lower pole stone treatment, and the most contemporary results favor URS, although this was not always the case. In the seminal prospective, multicenter randomized trial by Pearle et al. (2005) comparing URS with SWL for lower pole stones 1 cm or smaller, stone-free status was accomplished in 50% of URS cases and only 35% of SWL cases, although the difference was not found to be statistically significant. Not unexpectedly, the convalescence time was less, and the health care–related quality of life measures were better for the SWL cohort (Pearle et al., 2005). More recently, Sener et al. (2014) performed a single-center randomized trial comparing SWL with URS for lower pole stones 1 cm or less in diameter. Treatment success was defined as stone-free or residual fragments less than 3 mm, and patients with acute infundibulopelvic angles (<30 degrees) were excluded. Stone-free status was achieved in 100% of URS cases and 91.5% of SWL cases, although an average of 2.7 SWL sessions per patient were necessary.

Recent series evaluating outcomes for lower pole stone burdens of 1 to 2 cm further highlight the ascendency of URS over SWL, especially with respect to treating increasing lower pole stone burden. Stone-free rates of 85% and higher have been reported for single-session URS compared with 54% to 83% for multisession SWL (Chan et al., 2017; El-Nahas et al., 2012; Resorlu et al., 2013; Singh et al., 2014). Moreover, re-treatment rates and auxiliary treatment rates are consistently higher for SWL, whereas complication rates are commensurate between the two modalities. These studies echo the results of Pearle et al. (2005), because voiding symptoms and convalescence time are more favorable for SWL than URS.

Since the early reports of URS for lower pole calculi in the mid and late 1990s, endourology has witnessed considerable progress in instrument design and surgical technique. These, in turn, have made URS more effective than SWL in treating lower pole stones (Elashry et al., 1996; Grasso and Ficazzola, 1999). Smaller ureteroscopes with improved tip deflection and better stone manipulation instruments aid in accessing and fragmenting lower pole stones. Nitinol stone baskets have been used to reposition stones from the lower pole to more optimal intrarenal positions for lithotripsy, such as the middle or upper pole calyces (Kourambas et al., 2000). Stone-free rates approaching and exceeding 90% have been reported when stones were repositioned out of the lower pole, compared with stone-free rates closer to 80% when stones were fragmented in situ within the lower pole (Kourambas et al., 2000; Schuster et al., 2002). Furthermore, contemporary URS outcomes appear to depend on lower pole infundibulopelvic angle, as was shown by Resorlu et al. (2012b), who found that URS was successful in 91% of cases when the angle was greater than 45 degrees versus only 65% of the time with more acute angles. In this same study, infundibular length and width did not affect URS outcomes.

Given the advancements in ureteroscopic design and technique, a number of investigators have sought to compare URS and PCNL for lower pole stones (Armagan et al., 2015; Bozkurt et al., 2011; Bozzini et al., 2017; Jung et al., 2015; Kandemir et al., 2017; Kirac et al., 2013, Kuo et al., 2003). The Lower Pole Study Group compared URS and PCNL for lower pole stones of 1 cm to

2.5 cm. PCNL achieved a 71% stone-free rate, whereas URS achieved a 37% stone-free rate as determined by CT. The length of hospitalization was shorter for those undergoing URS; however, overall convalescence was not statistically different and was attributed to ureteral stent–related morbidity in the URS cohort (Kuo et al., 2003). Bozkurt et al. (2011) retrospectively compared outcomes between PCNL and URS for lower pole stones of 1.5 cm to 2 cm. Single-stage stone-free rates of 93% (PCNL) and 89% (URS) were appreciated. The PCNL group required more blood transfusions, but otherwise complications were similar between groups. It is important to recognize that this was not a randomized study, and patients with unfavorable lower pole anatomy (acute infundibulopelvic angles, small infundibular width) were preferentially treated with PCNL.

The same group also retrospectively compared URS with mini-PCNL for stones smaller than 1.5 cm and found equivalent stone-free rates of 89% between the two modalities. Not surprisingly, operative time, mean fluoroscopy time, and length of hospital stay were longer for PCNL (Kirac et al., 2013). Taken collectively, these data suggest that URS performed by clinicians experienced with the technique can produce excellent stone-free rates approaching those of PCNL. **The key to excellent URS outcomes appears to be careful patient selection, which includes those patients with favorable lower pole anatomy (nonacute lower infundibulopelvic angle, wide lower pole infundibulum).**

Not enough data exist to determine the optimal place for mini- and micro-PCNL in the treatment of lower pole stones, although initial results are encouraging in terms of stone clearance and overall morbidity.

Key Points: Renal Calculi

- Stones that are symptomatic, obstructing, or associated with infections should be treated, with the goal of complete stone clearance.
- SWL success is highest in stones 1 cm or smaller, 800 to 900 HU or lower, with shorter skin-to-stone distances, and in a non–lower pole location.
- PCNL offers the highest successful stone treatment for stones larger than 2 cm (including staghorn configuration), across all density measurements, and in all intrarenal locations.
- URS offers excellent success for all stone locations, although it may have

decreased effectiveness in the lower pole.

- Staghorn stones should be treated if the patient can tolerate surgery.
- The outcomes of PCNL and URS are relatively independent of the patient's BMI, whereas SWL success falls more sharply with increasing obesity.

Ureteral Calculi

Just as for renal calculi, the **urologists's armamentarium to surgically treat ureteral stones consists of four minimally invasive modalities including SWL, URS, PCNL, and laparoscopic or robotic-assisted stone surgery.** Open ureteral stone surgery is rarely performed when access to minimally invasive modalities exists and is often reserved for instances in which less invasive options have failed. There appears to be an evolving paradigm shift in the surgical treatment of upper tract stones, with an increasing use of URS and a reciprocal decreasing use of SWL for upper urinary tract stone disease (Lee and Bariol, 2011; Ordon et al., 2014). Determining the optimal treatment for a given patient is not always straightforward and depends on stone-related factors, clinical factors, and technical factors (Box 93.4). It is the interplay of these factors and the familiarity of the urologist with each surgical technique that ultimately determine the best treatment modality for a given patient. The purpose of this section is to provide a framework to help guide the urologist in matching a given patient's unique clinical situation and ureteral stone disease characteristics to the most effective and least morbid surgical therapy (Fig. 93.13).

Box 93.4

Factors Affecting Management of Ureteral Stones

Stone-Related Factors

Location
Size
Composition
Degree of obstruction

Clinical Factors

Symptom severity
Patient's expectations
Associated infection

Solitary kidney
Abnormal ureteral anatomy
Coagulopathy
Obesity

Technical Factors

Available equipment
Cost

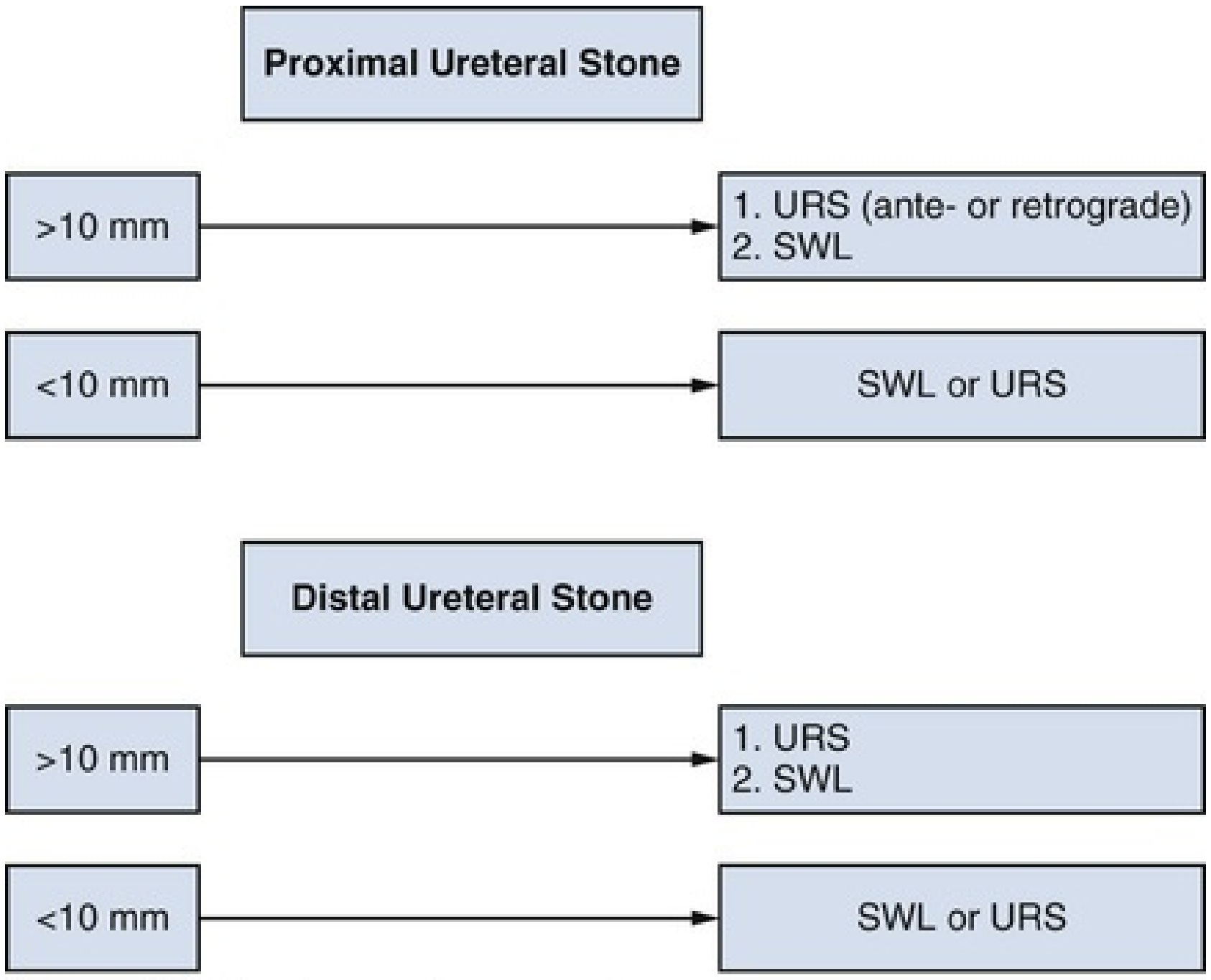
Proximal Ureteral Stone
>10 mm
1. URS (ante- or retrograde)
2. SWL
<10 mm
SWL or URS
Distal Ureteral Stone
>10 mm
1. URS
2. SWL
<10 mm
SWL or URS

**Upgraded following panel consensus.*

FIG. 93.13 Treatment algorithm: ureteral stones. *SWL,* Shock wave lithotripsy; *URS,* ureterorenoscopy. (Modified from Turk et al.: *EAU Guidelines on urolithiasis,* 2017.)

Natural History

When a renal calculus begins to pass, it moves from the kidney into the UPJ and into the ureter proper. At that point, depending on the size of the stone relative to the ureter throughout its course, the stone will begin to obstruct the kidney. The first manifestation of this is an increase in the intra–collecting system pressure, which will stretch the renal pelvis, calyces, and renal capsule. It is during this phase that the traditional colic of a stone episode begins.

This increase in intraluminal pressure will increase the hydrostatic pressure exerted on the walls of the renal pelvis and ureter, which can cause the failure of normal peristalsis. Pressure further increases at that point, with direct transmission to the nephron tubules, with a resulting drop in the glomerular filtration rate (GFR). Pressure will subsequently decrease to the levels present before obstruction developed, usually within 12 to 24 hours. Accordingly, the renal colic episode caused by a stone is often limited to severe pain from the acute renal stretch, followed by gradual resolution of the pain. Further movement of the stone down the ureter can relieve the pressure and reobstruct further distally, explaining the intermittent nature of renal colic as a stone passes.

Long-term obstruction can cause permanent damage to the kidney's function; therefore, regardless of the absence of pain or infection, a stone must either pass spontaneously or be surgically treated. Key to the passage of a stone is ureteral peristalsis, not hydrostatic pressure (Lennon et al., 1997). When the ureter is not otherwise obstructed, **the chief determinant of stone passage is the diameter of the stone in its transverse orientation** (Ueno et al., 1977). Next most important is the location of the stone within the ureter at presentation, with a review of the literature demonstrating **a 71% chance of passage of a distal ureteral stone versus 22% for proximal stones** (Morse and Resnick, 1991). Additional evidence supports the idea that the likelihood of spontaneous passage may be directly related to stone location at the time of presentation (Coll et al., 2002; Hubner et al., 1993).

With respect to size as a predictor of spontaneous passage, meta-analysis of the available literature (as described in the AUA ureteral stone guidelines) demonstrates a 68% chance of passage for stones 5 mm or smaller, and an estimated 47% chance for stones 6 to 10 mm in size (Preminger et al., 2007). More recent, albeit smaller, prospective, randomized studies suggest an approximately 80% spontaneous passage rate for stones 10 mm or less at 4 weeks after stone presentation. These rates may be enhanced with medical expulsive therapy (MET) using either calcium channel blockers (such as nifedipine) or, more commonly, α-receptor blockers (such as tamsulosin); however, the utility of MET remains controversial (Furyk et al., 2016; Hollingsworth et al., 2016; Pickard et al., 2015; Ye et al., 2017). **There appears to be limited, if any, benefit with MET for stones less than 5 mm. For distal ureteral stones 5 mm and greater, there may be up to a 57% increase in**

spontaneous stone passage with MET, as well as a shorter time to stone passage and a potential reduction in pain medication needed during stone passage (Table 93.2).

TABLE 93.2

Likelihood of Spontaneous Stone Passage

STUDY	NO. OF PATIENTS	NO. REQUIRING INTERVENTION (%)	NO. PASSING STONE (%)
STONE SIZE <5 MM			
Miller and Kane, 1999	59	4 (7)	55 (93)
Hussain et al., 2001	9	0 (0)	9 (100)
Coll et al., 2002	114	29 (25)	85 (75)
Kupeli et al., 2004	15	12 (80)	3 (20)
Furyk et al., 2016	114 (placebo) 125 (tamsulosin)	4 (2.8) 1 (0.7)	102 (81.9) 110 (87)
STONE SIZE ≥5 MM			
Miller and Kane, 1999	16	8 (50)	8 (50)
Hussain et al., 2001	15	6 (40)	9 (60)
Coll et al., 2002	73	42 (58)	31 (42)
Furyk et al., 2016	41 (placebo) 36 (tamsulosin)	4 (7.6) 4 (8)	25 (61) 30 (83)

Pretreatment Assessment

The pretreatment assessment, including medical history, imaging, and laboratory testing, for ureteral stones is similar to that for renal stones, and the reader is directed to the previous section on this topic in the renal calculi section of this chapter. Particular attention should be directed toward the duration of symptoms, given the fact that long-term obstruction can result in irreversible nephron loss.

Any suggestion of fever in the setting of a ureteral stone strongly suggests the presence of infection proximal to the point of obstruction, and, regardless of how the patient appears at presentation, there should be a low threshold to proceed with urgent or immediate urinary tract drainage.

Specific symptoms may give clues to the course of the episode: New-onset urgency and frequency may herald a stone at the ureterovesical junction (UVJ) irritating the bladder, or the sudden relief of flank pain may indicate either passage or forniceal rupture as the pressure in the collecting system dramatically decreases. Assessment of renal function is paramount because ureteral stones are often obstructing at the time of presentation, and therefore renal function may be impaired by obstruction, dehydration, or a combination of both. The associated physiologic stress of an acutely obstructing stone can lead to white blood cell (WBC) demarginalization and an elevated serum WBC count. Thus leukocytosis in these patients may or may not represent an actual infection. In addition, urinary tract stones frequently lead to pyuria and leukocyte esterase positivity on urinalysis, and these findings do not always represent an active UTI. However, if there is any concern regarding an associated UTI, then the immediate focus should be on urinary tract decompression rather than definitive stone surgery.

Stone Factors

Treatment Decision by Localization

Proximal and Mid-Ureter.

The chief determinant of the optimal treatment for calculi in these locations is size. As previously mentioned, those which are more proximal and greater in size are significantly less likely to pass spontaneously. There is a paucity of data on the effectiveness of MET use in proximal and mid-ureteral stones, although since many of these stones do migrate distally, presumptive use of MET is not contraindicated (Hollingsworth et al., 2006, 2016; Seitz et al., 2009; Ye et al., 2017).

For stones that do not move in a reasonable time frame, or in the setting of recurring severe pain, or if the patient prefers, surgical therapy is indicated. Primary options include SWL and URS, although PCNL and antegrade nephroscopy may be indicated for select cases. Pooled data, as evaluated in the 2007 AUA ureteral stone guidelines, have defined outcomes in proximal and mid-ureteral stones (of all sizes) in patients who underwent SWL, with overall 82% and 73% treatment success rates, respectively (Preminger et al., 2007). In consideration of proximal ureteral stones that are 1 cm or smaller, SWL success rises among these pooled series to 90% (85% to 93%), and 84% (65% to 95%) for mid-ureteral stones. For stones larger than 1 cm, rates of complete stone clearance drop in both groups, to 68% for proximal and 76% for mid-ureter stones. Updated systematically reviewed data from the 2016 AUA Guideline on the Surgical Management of Stones show overall ureteral stone treatment success rate with SWL to be 64% for stones smaller than 10 mm, and 62% for stones larger than 10 mm (Assimos et al., 2016).

Similarly, the guidelines pooled numerous studies to evaluate outcome success for URS for these locations and sizes, demonstrating an overall success of 81% for proximal and 86% for mid-ureteral stones (Preminger et al., 2007). Calculi 1 cm or smaller again demonstrated higher success rates in both groups than did larger stones. In the updated 2016 AUA stone guidelines, success rates of 93% for stones smaller than 10 mm and 83% for stones larger than 10 mm were reported (Assimos et al., 2016). A further breakdown of selected studies assessing stone-free rates after ureteroscopy for proximal ureteral stones is shown in Table 93.3.

TABLE 93.3

Ureteroscopic Treatment Outcomes for Proximal Ureteral Calculi

STUDY	NO. OF PATIENTS	MEAN STONE SIZE (mm)	STONE-FREE RATE (%)
Lam et al., 2002	31	8.2	97
Sofer et al., 2002	194	12.0	97
Aghamir et al., 2003	115	>10	75
Sozen et al., 2003	36	7.4	83
Fong et al., 2004	51	9.0	90
Wu et al., 2005	39	15.1	92
Lee et al., 2006	20	18.5	35
Preminger et al., 2007	2242	<10 >10	80 79
Perez Castro et al., 2014	2611	81 mm^2	85

The likelihood of postoperative results requiring additional procedures was 1.5 with SWL for these larger stones, and only 1.07 for URS. Of related interest, the cost-efficiency of management of proximal ureteral stones has been shown to be superior for URS when compared with SWL, when used as the initial treatment procedure (Lotan et al., 2002).

For very large proximal ureteral calculi not amenable to either SWL or URS (including large or dense stones, severe inflammatory response at the site of stone impaction that prevents passage of a guidewire from below, or associated ureteral pathology), **a percutaneous and antegrade approach may be ideal** (Maheshwari et al., 1999). Depending on the exact location within the ureter and calyx for percutaneous entry, such stones may be amenable to either rigid or flexible endoscopy. The opportunity to clear stone fragments using the access tract may offer optimal success for these challenging stones.

Last, laparoscopic and robotic ureterolithotomy have been described for proximal and mid-ureteral calculi, with success rates for stone clearance in selected cases of 93% to 100% (Hemal et al., 2010; Yasui et al., 2013). Significant discussion regarding such an approach, in many cases significantly more invasive than SWL, URS, or PCNL with antegrade endoscopy, should be undertaken with the patient when considering this option.

Stones in a mid-ureteral location are typically handled in much the same way as proximal calculi, although some considerations relative to the pelvic anatomy apply. With respect to SWL, the presence of the bony structures lying posterior to the ureter at this level can interfere with fluoroscopic or plain film imaging of the stone, as well as pose challenges to positioning the patient so that shock wave energy does not pass through the bone. Oblique or prone positioning may be required for SWL at this level.

Finally, URS for the mid-ureteral stone can often be accomplished with a semirigid ureteroscope; however, limitations caused by the iliac vessels, particularly in male patients, may be encountered. In addition, proximal migration of these stones can sometimes present a challenge with semirigid instrumentation. **The availability of flexible ureteroscopes and the skills to perform flexible URS will improve the overall success rates and decrease complications** (Perez Castro et al., 2014).

Distal Ureter.

As discussed earlier, distal stones are most likely to pass with observation or MET (Assimos et al., 2016; Hollingsworth et al., 2016; Preminger et al., 2007; Turk et al., 2017). The most typical site for impaction in this region of the ureter is at the UVJ; stones reaching this location often cause significant irritative symptoms because of stimulation of the bladder, a clinical sign that helps localize them. When stones fail to pass, once again surgical therapy is indicated.

SWL and URS remain the mainstays of treatment of distal ureteral stones. Once again, the AUA ureteral stone guidelines present a detailed review of pooled studies to identify success rates in both procedures. Among reviewed series using SWL for distal ureteral stones, the overall success rate was 74%. For stones 1 cm or smaller, an overall success rate of 86% was noted, whereas stones larger than 1 cm yielded a success rate of 74% (Preminger et al., 2007). In the updated AUA stone guideline from 2016, success for distal ureteral stones less than and greater than 1 cm was 74% and 71%, respectively (Assimos et al., 2016).

In the same 2007 AUA stone guidelines, URS for distal ureteral calculi was shown to yield a 94% overall success rate, with stones 1 cm or smaller at 97% and more than 1 cm at 93% success rate (Preminger et al., 2007). In the updated 2016 AUA stone guidelines, URS accomplished stone-free rates of 94% and 92%, respectively, for stones less than and greater than 1 cm (Assimos et al., 2016). A further breakdown of selected studies assessing stone-free rates after ureteroscopy for distal ureteral stones is shown in Table 93.4.

TABLE 93.4

Ureteroscopic Treatment Outcomes for Distal Ureteral Calculi

STUDY	NO. OF PATIENTS	MEAN STONE SIZE (mm)	STONE-FREE RATE (%)
Pearle et al., 2001	32	6.4	91
Sofer et al., 2002	348	10.3	99
Zeng et al., 2002	180	6–20	93
Aghamir et al., 2003	247	<10	96
Sozen et al., 2003	464	8.8	95
Preminger et al., 2007	5952	<10 >10	97 93
Perez Castro et al., 2014	4446	67 mm^2	94

When SWL is compared with URS for the distal stone, reviewing the combined data for SWL in this fashion, the variation must be considered in lithotripters used that would affect overall outcomes in the multitude of series. In one randomized controlled trial comparing SWL with URS for distal ureteral calculi up to 15 mm, SWL was equally as effective as URS (100% in both groups), although this series used only the highly effective HM3 lithotripter (Pearle et al., 2001).

All Locations.

Additional factors to consider in addition to stone-free success rates in the choice of therapy include the following:

- Complications of therapy such as sepsis, steinstrasse, ureteral stricture, and ureteral injury
- Anesthetic requirements
- Bleeding risk in patients with anticoagulation or antiplatelet therapy
- Recovery expectations
- Potential need for adjunctive procedures
- Previously placed ureteral stent

Treatment Decision by Stone Burden

As described earlier, SWL success for ureteral stones at all locations is significantly affected by the total stone burden, just as it is for renal calculi: the larger the stone(s), the less effective the treatment (Assimos et al., 2016; Preminger et al., 2007). As a specific example, the success rates for SWL at the distal ureter were 86% for stones 1 cm or smaller and 74% for those larger than 1 cm, and such differences held true for all locations. In contrast, URS had a much smaller degree of variation in terms of success based on stone burden: 97% success for stones 1 cm or smaller and 93% for those larger than 1 cm.

In a cost-comparison study of the management of ureteral calculi, Lotan et al. (2002) demonstrated that URS was associated with a lower cost than SWL for proximal stones, even before factoring in the higher adjunctive procedure rate associated with SWL. The prospective comparison of SWL to URS for distal stones by Pearle et al. (2001) showed that the overall complication rate was lower for SWL (9%) compared with URS (25%), although this was shown to mostly be related to urinary retention or significant colic requiring emergency evaluation or admission for pain control (and more likely to be clarified as a “minor” complication in the current literature).

Treatment by Stone Composition

As discussed earlier with respect to renal calculi, stone composition, if known or able to be predicted radiologically, can be useful in selecting the most appropriate therapy. Brushite (calcium phosphate) stones, calcium oxalate monohydrate, and cysteine stones are more resistant to SWL therapy and can be expected to have better rates at all sizes and locations with URS (Ahmed et al., 2008; Rudnick et al., 1999). Similarly to renal calculi, assessment of ureteral stone density based on the Hounsfield units on CT scan can offer valuable predictive ability as to the stone-free rate using SWL (El-Nahas et al., 2007; Gupta et al., 2005; Joseph et al., 2002; Wang et al., 2005). In identical fashion as well, skin-to-stone distance—reflected in body habitus—can be measured on the CT scan, again allowing more informed prediction of SWL success.

Therefore, where possible to obtain prior stone composition data or prediction of composition based on radiologic studies, this should be undertaken to best inform the patient regarding choices of therapy.

It is imperative to tailor therapy choices to the individual patient, after careful discussion of outcomes of treatment: success rates, adjunctive procedures, and treatment-related morbidity. Patient factors (body habitus, coagulation status, medical comorbidities) and stone factors (location, burden, composition) must be considered when selecting the optimal treatment for ureteral calculi.

Ureteral Anatomic Factors

Megaureter

Congenital megaureter most often is seen in children and usually represents an abnormality of the distal ureter or UVJ, in which there is either an aperistaltic segment (causing obstruction) or incompetent UVJ (causing reflux), which yields dilation of the ureter. The first description of this condition in the literature was by Caulk in 1923. Subsequently, a number of attempts to classify megaureter were undertaken, culminating in the consensus of a committee made up of members of the American Academy of Pediatrics, Society of Pediatric Urological Surgeons, and the Society for Pediatric Urology. These criteria have remained the most comprehensive system for classifying the megaureter (Stephens, 1977). Under this system, megaureters can be identified as refluxing, obstructed, and nonrefluxing and nonobstructed.

The majority of megaureters that are obstructed or refluxing are discovered when symptomatic during childhood and may require surgical repair. Reports of nonoperative, conservative management have been published, suggesting that some of these will resolve with the evolution of the UVJ as the child grows (Oliveira et al., 2000; Pitts and Muecke, 1974). The most typical operative repair has been ureteral reimplantation with, or without, tapering, but a recent report suggests that short-segment megaureters may be able to be successfully managed with endoureterotomy (Christman et al., 2012).

Megaureter has been associated with stones in the pediatric population and rarely the adult population (Rosenblatt et al., 2009). Management strategies significantly depend on the patient's surgical history, if any, and on recognition of any intrinsic ureteral obstruction that exists independent of the stone's location. Previously reimplanted ureters may be difficult to access in retrograde fashion, limiting the ability to place stents or approach stones via URS. In addition, an obstructed megaureter must be expected to lead to difficulties passing fragments after URS is performed.

Guidance as to ideal management is limited because only case reports or small series have been reported in adults. In a nonobstructed megaureter, MET, SWL, and URS are viable initial strategies. In the obstructed megaureter, strategies to manage the stone and the underlying pathology have included the following:

- Retropulsion of the stones to the kidney, treatment of the stones via PCNL, and repositioning the patient to perform ureteroneocystostomy (Kumar et al., 2014)
- Ureterolithotomy with ureteroneocystostomy, open (Demirtas et al., 2013; Solinas et al., 2010) or robotic-assisted laparoscopic (Hemal et al., 2009)
- Ureteroscopy with endoureterotomy (in short-segment cases <3 cm), which would make concomitant ureteroscopic treatment of stone possible (Christman et al., 2012)

Clearly, when considering stone treatment in patients with a megaureter, one must choose a strategy that will account for the stone and the underlying ureteral pathology.

Duplicated Collecting System

Duplication anomalies of the collecting system arise from ureteral bud abnormalities during gestation, occurring with an incidence of approximately 0.8% and following the Weigert-Meyer "rule" (Schlussel, 2007). This principle explains that in complete duplications, separate ureters enter the bladder with the more medial and inferior orifice draining the upper pole, whereas the more lateral and superior orifice drains the lower pole. In incomplete duplications, there is only one ureteral orifice on that side within the bladder, with a variable level of bifurcation of the separate ureters, which lead to the upper and lower moieties.

There are limited reports describing URS management of stones in partially or completely duplicated systems, but it is clear that ureteroscopy for these systems is little different from the more common single ureter. In the setting of a complete duplication, retrograde pyelography should be performed for each orifice to confirm which ureter contains the stone to be treated, and then treatment proceeds as usual.

In partial duplications, retrograde pyelography should be performed to locate the level of bifurcation in addition to the stone, with recognition of the fact that an intramural ureter location of the division of the two systems is most common (Rich, 1988). This can potentially inhibit visualization if the retrograde catheter is past the point of bifurcation. In this situation, ureteroscopy, after dilation of the ureteral orifice when necessary, can be used to directly inspect for the other moiety of the second ureter. In such cases, simultaneous stenting of upper and lower pole ureteral segments may be necessary.

Ureteral Stricture or Stenosis

The presence of intrinsic ureteral obstruction certainly affects the selection of ideal stone treatment in a number of ways. First, an untreated stricture or stenosis precludes fragment passage and hence creates an expectation of SWL failure. Second, the mechanism that is chosen to deal with the obstruction may facilitate and/or dictate how the stone will be managed. Finally, the physical properties of the stricture may mandate a particular course of action.

Most important, not every narrow point that is encountered in the ureter reflects a pathologic stricture, particularly when a stone may be impacted there. Inflammatory reaction and ureteral spasm may account for a significant portion of apparent obstructions encountered. In these situations, it is critical to recognize that overdilation of the ureter via endoscopic approach may cause localized ureteral injury (Eshghi, 1988). Despite this concern, balloon dilation of the ureter, when required for ureteroscopy, is safe and effective in the vast majority of patients (Huffman and Bagley, 1988). If the area of obstruction is thought to reflect spasm, placing a stent to allow passive dilation facilitates a second-stage procedure in pediatric and adult patients (Hubert and Palmer, 2005; Rubenstein et al., 2007).

When a definite stricture is present, underlying causes must be considered. Methods of dealing with ureteral strictures are covered elsewhere in this text and may provide the primary guidance for dealing with a ureteral stricture; a post-ureteroscopy stricture is obviously significantly different from a radiation-induced one.

Endoureterotomy can be performed at all levels of the ureter; however, it will have a lower rate of long-term success in longer strictures (Wolf et al., 1997). Few data have been reported on the concomitant use of ureteroscopic laser lithotripsy at the time of an endoureterotomy or endopyelotomy, although there is a recognized potential for stone fragments to come to rest in the periureteral space and cause granulomatous inflammatory reaction and recurrent stricture (Dretler and Young, 1993). It is possible that, if URS is the preferred management strategy, endoureterotomy should be undertaken as a first stage, with placement of a ureteral stent to allow healing, and subsequent URS to manage the stone at a second stage.

Alternatively, consideration may lead one to proceed with open, laparoscopic, or robotic-assisted laparoscopic treatment for the stricture and the stone in the same session. Numerous reports of laparoscopic and robotic-assisted ureterolithotomy have been reported, and the identical techniques and approaches used for management of a ureteral stricture can be used to also treat a ureteral stone in the same session (Dogra et al., 2013; Nasseh et al., 2013; Singh et al., 2013).

Technical Factors

The treatment of patients with ureteral calculi depends on multiple surgical technologies, and the availability of certain equipment will affect the possible options for treatment. Few operating environments will have all possible lithotripters, ureteroscopes, lithotrites, or stone-retrieval devices immediately available. In addition, the surgeon's preference and technical expertise will also affect the technique chosen. The majority of urologists and patients with stone disease in the United States do not have direct access to a fixed lithotripter on an unlimited basis. Therefore treatment decisions may have to be modified according to lithotripter availability. Patients with symptomatic ureteral stones and no immediate lithotripter access have several options: they may be clinically observed with pain and emetic control; they can undergo placement of an internal ureteral stent to relieve the symptoms of renal colic (but then may develop stent-related morbidities); or they may have primary ureteroscopic removal of the stone, provided the requisite endoscopic equipment is available.

Because of recent pressure to decrease resource use, there is increasing emphasis in the modern medical environment on the reduction of cost. Such economic pressures have promoted the movement toward less invasive, more cost-effective therapy for patients with ureteral stones. Most studies performed in the United States have found that ureteroscopy is a more cost-effective intervention than SWL, a differential that is likely a result of the higher re-treatment rate associated with SWL. Grasso et al. (1995a) analyzed the cost of ureteroscopy and SWL for patients with ureteral calculi. When they compared outpatient ureteroscopic lithotripsy with SWL monotherapy, treatment costs were similar. However, the addition of re-treatments and auxiliary procedures after SWL more than doubled the costs and weighed heavily against this modality's cost effectiveness. Kapoor et al. (1992) compared the treatment costs of SWL and ureteroscopy: as a consequence of the significantly higher success rates (97% vs. 75%), ureteroscopy was the more cost-effective treatment approach. Parker et al. (2004) studied the cost associated with treating proximal ureteral stones and found that ureteroscopy was less costly, again as a consequence of its superior initial treatment success. Several investigators have approached the question of cost-effective treatment for ureteral calculi by constructing decision analysis models. Wolf et al. (1995) used a literature-based probability decision tree to determine the more effective and cost-efficient therapy for patients with distal ureteral calculi and found that although initial SWL was only slightly more expensive than ureteroscopy, the cost differential increased when additional complications and re-treatments were calculated. Lotan et al. (2002) also constructed a decision analysis model to determine the most cost-effective treatment for ureteral stones. Although observation was the least costly intervention, ureteroscopy was a less costly intervention than SWL for the treatment of stones at all locations in the ureter. A recent systematic review comparing the cost of SWL versus URS evaluated 10 different studies and found overwhelmingly that URS saved costs and achieved a higher stone-free rate for ureteral stones at all locations than SWL, although few of the studies were well designed. Thus, taken all together, **ureteroscopy is the most cost-effective treatment strategy for ureteral stones at all locations, after observation fails.**

Key Points: Ureteral Calculi

- Conservative therapy has its greatest success in stones 5 mm or smaller but may still see fair success rates in stones up to 10 mm.
- Medical expulsive therapy (alpha-blockers) appear to be most effective for distal ureteral stones 5 mm or larger.
- Fever, or the presence of clinical or laboratory signs of UTI, may herald impending sepsis, a life-threatening condition; emergent drainage and decompression with either stent or nephrostomy should be undertaken.
- SWL and URS are considered first-line therapies for stones at all locations within the ureter, although a higher rate of ancillary procedures should be expected with stones larger than 10 mm.
- Positioning challenges may be present for SWL in the mid-ureteral stone, requiring prone or oblique positioning for a clear blast path to the stone.

Clinical Factors for Upper Urinary Tract Calculi

Complete treatment planning for upper tract stones must incorporate the relevant clinical factors for a given patient, in addition to the stone-specific and anatomic factors (see Boxes 93.1 and 93.4). Certain patient conditions, anatomic aberrations, and underlying comorbidities assume significant importance in counseling patients on the relative risks and benefits of the different treatment options, because each can influence surgical outcomes and complications. Therefore a tailored approach to the individual patient is best.

Urinary Tract Infection

UTIs are common in the setting of upper tract calculi and should be adequately treated before any stone treatment. Offending bacteria may reside deep within stones and prove impossible to eradicate without complete stone removal. Because of this, it may be difficult to completely sterilize the urine before stone surgery, in which case at least a short course of preoperative, culture-directed antibiotics is recommended. When infectious stones are suspected, every attempt at complete removal of stones should be undertaken because residual fragments commonly harbor bacteria that can serve as a nidus for recurrent UTIs and promote rapid stone regrowth (Bichler et al., 2002). **Therefore PCNL and URS, when active stone extraction is possible, are preferred over SWL, in which stone clearance relies on physiologic stone passage and may take months to reach completion.**

The rate of sepsis after PCNL or SWL is approximately 1% when preoperative urine cultures are negative. However, when preoperative bacteriuria exists or there is evidence of distal obstruction, the rate of sepsis associated with SWL for staghorn stones increases substantially (2% to 56%), and SWL should not be pursued (Lam et al., 1992a; Meretyk et al., 1992, 1997; Zink et al., 1988).

A UTI associated with an obstructing upper tract stone (ureteral or renal) represents a true urologic emergency and requires emergent urinary tract drainage. This is accomplished by either ureteral stenting or percutaneous nephrostomy. Attempts to definitively treat the obstructing stone should be postponed until the patient is stabilized and the infection is completely treated. Measures to treat the stone before patient stabilization and clearance of the infection risk worsening sepsis and death. In these instances, a urine culture from the obstructed segment is helpful to guide subsequent antibiotic therapy.

Renal Function

Assessment of underlying renal function becomes most important when there is suspicion that nephrectomy rather than stone removal is the treatment of choice. This scenario is encountered most frequently with staghorn stones, a history of recurrent pyelonephritis or renal abscess episodes, or xanthogranulomatous pyelonephritis and with chronic, relatively asymptomatic renal obstruction from ureteral stones. Renal imaging can provide clues to poor underlying renal function, including renal cortical atrophy or thinned renal parenchyma. In these instances, further functional renal studies, such as diuretic renography, can be used to quantify remaining renal function. In equivocal cases, temporary relief of obstruction with ureteral stenting or percutaneous nephrostomy is warranted, after which renal function can be reassessed. **The general consensus is that symptomatic upper tract stones located in renal units with approximately 15% or less split function should be considered for nephrectomy, and stone-specific, nephron-sparing treatments should not be pursued.**

A considerable body of evidence exists evaluating the effects of SWL and

PCNL on renal function, whereas there is a relative paucity of data surrounding URS effects on renal function (Kartha et al., 2013; Sninsky et al., 2014; Wood et al., 2011). It is believed that URS induces minimal renal parenchymal damage, and although few studies have evaluated this directly at a histologic or biochemical level, no change in long-term renal function has been reported even after multiple URS treatments (Lee and Bagley, 2001; Sninsky et al., 2014). More robust and in-depth data exist and have consistently shown that SWL and single–access tract PCNL do not appear detrimental to total renal function over the long term (Canes et al., 2009; Chandhoke et al., 1992; El-Tabey et al, 2014; Lee and Bagley 2001; Sninsky et al., 2014). These results have been repeatedly shown in patients with renal insufficiency and with solitary kidneys for SWL (Chandhoke et al., 1992; Cass, 1994; Eassa et al., 2008; El-Assmy et al, 2008; Krambeck et al., 2008a; Kulb et al., 1986; Zanetti et al., 1992) and PCNL (Agrawal et al., 1999; Alken, 1982; Canes et al., 2009; Kuzgunbay et al., 2010; Marberger et al., 1985; Schiff et al., 1986; Singh et al., 2001; Unsal et al., 2010). Renal scintigraphy and single-photon emission computed tomography (SPECT) evaluation of kidneys after PCNL have also confirmed no changes in total renal function, although new focal cortical defects and reduced renal functional activity were seen in a minority of patients at the site of percutaneous renal access (Akman et al., 2012a; Unsal et al., 2010). The effects of multi–access tract PCNL on renal functional outcomes are mixed; some investigators suggest no effect on renal function (Moskovitz et al., 2006), and others demonstrate renal deterioration (El-Tabey et al., 2014).

Considering the available evidence, as long as adequate renal function exists and nephrectomy is not being entertained, stone treatment decisions should not, in general, be based on renal function. Rather, they should be based on stone-specific characteristics, renal anatomic factors, and other more relevant clinical factors.

Solitary Kidney

The main considerations in treating stones in congenitally, surgically, and functionally solitary kidneys include having a lower threshold to treat asymptomatic renal stones and ensuring sufficient renal drainage after stone treatment. Because only one kidney exists or is functioning, a single, obstructing stone leads to total urinary obstruction and demands urgent attention. **It is for this reason that proactive treatment of asymptomatic stones, which may otherwise be observed when two functioning kidneys exist, is recommended**

in solitary kidneys. The perils of complete ureteral obstruction, especially with concomitant UTI, can be life-threatening for patients with solitary kidneys. In the setting of clinical instability, UTI, or electrolyte abnormalities, initial urinary decompression via ureteral stenting or percutaneous nephrostomy drainage should be undertaken. Once the patient is clinically stable, and after treatment of any associated infection, definitive stone treatment may be pursued following the strategies outlined in the ureteral calculi section. Although not mandatory based on any meaningful evidence, it is highly advocated to place a ureteral stent after ureteroscopic manipulation, because temporary ureteral edema and occlusion caused by spasm or fragments can result in acute kidney injury and anuria.

Morbid Obesity

A BMI above 40 kg/m^2 is considered morbid obesity by the World Health Organization. Obesity, and in particular morbid obesity, can pose physiologic and technical challenges that must be accounted for when recommending stone treatment to such patients (Freedman et al., 2002; Giblin et al., 1995). Proper preoperative medical optimization and risk stratification are imperative, because obesity has been linked to a number of medical conditions that increase anesthetic risk, including cardiovascular disease, diabetes mellitus type II, and obstructive sleep apnea (among others). **Ureterorenoscopy and PCNL outcomes appear to be relatively independent of obesity status, whereas those after SWL are drastically worse.**

SWL is frequently suboptimal in morbidly obese patients, and in some cases it is actually impossible because patients may exceed the weight limitations of the lithotripter table or gantry. Many studies have shown increasing BMI to be a negative prognosticator for stone-free status after SWL (Ackermann et al., 1994; Portis et al., 2003). Moreover, the significant adipose tissue found in the morbidly obese can attenuate x-ray through-transmission, making it difficult to localize stones with fluoroscopy. If the stone is visible but located beyond the F2 focus of the lithotripter, a blast path technique may be used in which the stone is targeted along the same axis as the F2 focal point and relies on high pressures, although slightly defocused, generated beyond F2 to fragment the stone (Locke et al., 1990; Whelan et al., 1988). Given this, it is often necessary to use higher energy settings in obese patients, and lithotripters offering the highest peak pressures and longest focal length are preferred.

Skin-to-stone distance, or the distance between the SWL transducer and stone, has emerged as an important factor affecting SWL outcomes and is readily measured on axial CT slices. In general, the larger the skin-to-stone distance, the worse the fragmentation during SWL. Many studies have shown that **SWL outcomes worsen when skin-to-stone distance exceeds 10 cm** (El-Nahas et al., 2007; Foda et al., 2013; Pareek et al., 2005; Wiesenthal et al., 2011). Furthermore, Pareek et al. (2005) found that skin-to-stone distance was a stronger predictor of stone-free status than BMI. Perks et al. (2008) reviewed SWL in 111 patients with solitary stones 5 to 20 mm in size and found the best treatment success (91%) for skin-to-stone distances below 9 cm and stone attenuation below 900 HU, and the least successful treatment (41%) for skin-to-stone distances greater than 9 cm and stone attenuation exceeding 900 HU.

More recently, excessive visceral fat, as measurable on noncontrast CT, has proved to be a useful prognosticator for SWL outcomes. Indeed, increasing abdominal circumference, visceral fat, subcutaneous fat, and perirenal and pararenal fat are associated with decreasing stone-free rates after SWL (Juan et al., 2012). Taking this one step further, Zhou et al. (2013) demonstrated that increasing visceral fat was an independent predictor of uric acid stones. Hence a trial of urinary alkalinization is recommended in obese patients with radiolucent stones, a low urinary pH, and no other indications for urgent decompression.

PCNL in the morbidly obese is feasible and reportedly safe but also requires some technical modifications. Extra-long instruments (fascial dilators, access sheath, nephroscope, stone graspers) may become necessary, and mobility around the collecting system from a given access tract may be hindered by the long tract length. **Most available data confirm that stone-free rates are not affected by obesity, although there is some suggestion that stone-free rates are lower, and major complication rates are higher, in the morbidly obese** (Koo et al., 2004; Pearle et al., 1998). El-Assmy et al. (2007) and Kuntz et al. (2014) found no difference in stone-free rates, complications, auxiliary procedure rates, or length of stay among patients stratified by BMI, and proved that “tubeless” PCNL could be performed safely in these individuals. The CROES PCNL global study found equivalent stone-free rates for normal, overweight, and obese cohorts (approximately 80%), but significantly lower stone-free rates for the morbidly obese group (65.6%) (Fuller et al., 2012). Overall complication rates did not differ either among groups, although a greater percentage of major complications (Clavien-Dindo III to V) were found in the morbidly obese (10.5%) relative to the other groups (3.5% to 3.9%).

Initial reports suggested URS success and safety did not appear to change in the morbidly obese (Dash et al., 2002; Natalin et al., 2009; Preminger et al., 2007). More recent data from a systematic review (Ishii et al., 2016) and from the global ureteroscopy study (Krambeck et al., 2017) point toward a small decrease in stone-free rates and an increase in re-treatment rates and postoperative complications in the morbidly obese. However, total complications remained relatively low (3%–9%), and overall treatment success with URS remained relatively high, between 73% and 83%. **Accordingly, URS may be the preferable treatment modality for obese patients without exceedingly complex or large stone burdens.** Chew et al. (2013) performed a multicenter trial comparing URS in patients with normal BMIs with those considered overweight or obese; no significant difference was found in stone-free rates. Aboumarzouk et al. (2012c) performed a systematic review of URS in obese patients (mean BMI 42.2 kg/mm^2) and found an excellent pooled stone-free rate (87.5%), mean operative time (97.1 minutes), and complication rate (11.4%).

Old Age and Frailty

Recently the concept of frailty has gained considerable attention in the surgical literature, although it has been somewhat slow to permeate into the field of urology. There is mounting evidence to suggest that the degree of frailty a patient exhibits, rather than his or her chronologic age, is a more robust predictor of postoperative complications (Makary et al., 2010; Revenig et al., 2014). At present, there are limited data on the effects of frailty on stone treatment outcomes; however, extrapolating from the available frailty literature in other fields, the frailest of patients may be better served with less invasive stone treatments (URS or SWL). Resorlu et al. (2012a) conducted a multicenter, retrospective review of PCNLs in elderly patients and found that a higher Charlson Comorbidity Index score was associated with a significantly higher rate of severe medical complications and hemorrhage. Similarly, many elderly patients have less physiologic reserve to handle an acute, obstructing stone event well, or to successfully tolerate a drawn-out trial of passage. In these instances, a more direct treatment strategy with early relief of urinary obstruction is prudent.

A number of groups have looked at PCNL outcomes in elderly populations and have found essentially unchanged surgical success, albeit with a higher rate of complications. Doré et al. (2004) reviewed PCNL outcomes in 201 patients age 70 and older and found a stone-free rate of 70.8%. Early work by Stoller et al. (1994a) showed that PCNL was safe in patients older than 65 years but was associated with more frequent blood transfusions (26% vs.

14%). Akman et al. (2012b) compared URS and PCNL outcomes in patients older than 65 years and reported excellent stone-free rates (93% for URS, 96% for PCNL), reasonable operative times (65 minutes for URS, 41 minutes for PCNL), and acceptable complication rates (10.7% for PCNL, 7.1% for URS). In the largest published series on the topic, no difference was appreciated in stone-free rates (79% vs. 82%) or length of hospitalization in elderly (median age 74 years) versus younger (median age 49 years) cohorts, but there was a higher overall complication rate (19.9% vs. 6.6%) in the elderly (Okeke et al., 2012).

SWL in the elderly is feasible as well, but it may be associated with an increased risk of perinephric hematoma. Dhar et al. (2004) found a 1.67-times increased risk of hematoma formation after SWL with every 10-year increase in patient age, although subsequent studies have not consistently borne this out. Reports on treatment success with SWL in the elderly are mixed, showing a trend toward lesser success for renal stones and no effect on ureteral stones (Abe et al., 2005; Delakas et al., 2003; Ng et al., 2007). Furthermore, URS does not appear to confer any known additional surgical risks to the elderly.

Spinal Deformity or Limb Contractures

Patients with spinal deformities and limb contractures present a number of challenges that can be anticipated preoperatively. Despite its minimally invasive nature, SWL is often unsuccessful, and with high re-treatment and auxiliary procedure rates, because it can be difficult or impossible to properly position these patients on the lithotripter table. Moreover, stone targeting may be fraught with difficulties, as scoliosis and abnormal pelvic anatomy can preclude an acceptable shock wave blast path. Fragment passage can also be hindered by aberrant renal location and associated poor upper tract drainage. Few contemporary reports exist, but older studies show only modest stone-free results in this population, along with a frequent need for multiple treatment sessions (Lazare et al., 1988; Neuwirth et al., 1986).

PCNL and URS are good alternatives to SWL, and both have been used with good success, although special considerations are necessary with each (Goumas-Kartalas et al., 2010; Resorlu et al., 2012c; Rubenstein et al., 2004). For URS, patient anatomy may preclude rigid instrument use (cystoscope and ureteroscope). The use of ureteral access sheaths is encouraged, if they can be safely placed, because they can provide rapid re-entry into the otherwise challenging-to-access upper collecting system. PCNL remains the preferred method of stone treatment in many of these patients, particularly with large and complex stone burdens. Stone clearance rates with PCNL are no different than in the general population, although there is a greater need for secondary procedures. Furthermore, PCNL in these circumstances is associated with a higher rate of infectious complications (Culkin et al., 1990; Goumas-Kartalas et al., 2010; Nabbout et al., 2012; Symons et al., 2006). Given the abnormal anatomic relationships in these patients, preoperative CT of the abdomen and pelvis is essential in planning optimal renal access and may reveal the need for ultrasound guidance, CT guidance, or potentially even laparoscopic guidance in selected situations to avoid bowel or solid organ injury (Matlaga et al., 2003a).

Uncorrected Coagulopathy

Uncorrected coagulopathy is a contraindication to SWL and PCNL; however, URS can be successfully undertaken in such circumstances with little to no increase in surgical morbidity. When coagulopathies have been corrected, patients should be considered candidates for SWL and PCNL, assuming no other contraindications exist. Many instances of life-threatening retroperitoneal hemorrhage have been reported after SWL use in patients on continuous anticoagulant and antiplatelet agents (Alsaikhan and Andonian, 2011; Katz et al., 1997; Ruiz and Saltzman, 1990; Sare et al., 2002; Streem and Yost, 1990; Zanetti et al., 2001).

For patients with imperative indications to remain on antiplatelet therapy (e.g., recent coronary artery stenting) or anticoagulant agents (e.g., high-risk atrial fibrillation, venous thromboembolic disease, or mechanical cardiac valves), URS with holmium:yttrium-aluminum-garnet (Ho:YAG) laser lithotripsy is the treatment modality of choice. Since Grasso and Chalik (1998) first reported the safe use of URS and Ho:YAG laser lithotripsy in patients with uncorrected coagulopathies, numerous other reports have followed recapitulating not only the safety but also the high efficacy of URS in these challenging scenarios (Aboumarzouk et al., 2012b; Turna et al., 2008; Watterson et al., 2002). Ho:YAG laser lithotripsy is preferred and is considered safer than other intracorporeal lithotripters (Watterson et al., 2002).

Prior Renal Surgery

Prior renal surgery or trauma can lead to fibrosis, scarring, and deformity of the intrarenal collecting system, which in turn can complicate renal stone surgery. This situation is less frequently encountered today because fewer open stone surgeries are performed worldwide. **Prior renal surgery is not a contraindication to any form of renal stone surgery and presents no new specific concerns. Thus all treatment modalities may be employed as necessary, given appropriate indications (SWL, URS, PCNL).** Certain precautions should be taken, however; the possibility of poor renal drainage should be entertained, because previous surgery can predispose to infundibular stenosis, iatrogenic UPJO, and ureteral stenosis. If obstruction is found or suspected, a treatment modality other than SWL should be chosen. URS and PCNL may be used as previously described. During URS an infundibulotomy may be necessary to adequately access a stone trapped behind an area of infundibular stenosis. Nevertheless, stone-free rates of 79% after a single URS and 92% after a secondary URS have been described (Osman et al., 2012).

PCNL after prior open kidney surgery and after prior SWL has been described by multiple investigators. For the most part, prior renal surgery (open or SWL) has no effect on PCNL complication rates (Gupta et al., 2009a; Resorlu et al., 2010; Tugcu et al., 2008; Yuruk et al., 2009; Zhong et al., 2013). A single recent retrospective study found a higher need for renal angioembolization to control postoperative bleeding in patients with previous open nephrolithotomy; however, this finding has not been corroborated by others (Yesil et al., 2013). The effect of prior open surgery on stone-free rates is less consistent; some studies show rates that are worse (Gupta et al., 2009a), and others show unchanged rates (Resorlu et al., 2010; Tugcu et al., 2008).

Prior SWL therapy can make salvage PCNL more difficult, as evidenced by longer operative times and lower stone-free rates (Yuruk et al., 2009; Zhong et al., 2013). This is the presumed result of stone fragment scattering after SWL and the tendency for some of the stones to embed suburothelially within the renal parenchyma. In fact, the more ineffective the prior SWL attempt (i.e., less fragmentation), the better the expected results from the following PCNL. Bon et al. (1993) found a 92% success rate for nonfragmented stones compared with a 64% success rate in patients with numerous fragments.

Urinary Diversion

Renal and ureteral stones in patients with urinary diversions present unique obstacles. Adequate preoperative imaging is essential to provide details on the anatomy of the urinary diversion and provide clues to possible routes to access the stone. It may also suggest the presence of urinary stasis and obstruction within the diversion, which, if present, should also be addressed to minimize the risk of stone recurrence. In general, SWL, PCNL and antegrade URS, retrograde URS, or a combination thereof can be exploited.

As in other instances, SWL should not be used in the setting of urinary obstruction. However, without urinary obstruction, a single session of SWL can achieve success rates of 60% to 65% (Deliveliotis et al., 2002; El-Assmy et al., 2005). Retrograde URS is usually confined to flexible instruments, and redundant ileal conduits and large-capacity urinary reservoirs with some form of nonrefluxing ureteral anastomosis often require flexible instruments to locate the ureteral "orifices." Successful access to the upper urinary tract has been reported up to 75% of the time in urinary diversions, with a much lower rate seen in Indiana pouches (Hyams et al., 2009). Loopograms or pouchograms can aid in locating ureteral insertions when upper tract reflux exists. Alternatively, intravenous indigo carmine or contrast can be used as well. For patent ureteroenteric anastomoses, the judicious use of ureteral access sheaths can facilitate upper tract re-entry and protect the anastomotic site.

For larger stone burdens and when retrograde access is not possible, PCNL becomes the treatment modality of choice, with a reported stone-free rate of 75% to 88% (El-Nahas et al., 2006; Hertzig et al., 2013; Wolf and Stoller, 1991). In addition, percutaneous access can allow antegrade URS to achieve access to the ureter when retrograde techniques fail. Complication rates of 8% to 30% have been reported for percutaneous approaches to stones in these patients. Percutaneous access may require ultrasound guidance if retrograde or antegrade contrast filling of the pelvicalyceal system is not possible.

Renal Transplants

The general consensus is to remove upper tract stones within renal transplants, because the consequences of an obstructing stone can be devastating. Indeed, because of the lack of innervation in renal transplants, obstructing stones do not manifest with typical renal colic. Rather, vague graft site discomfort, fevers, oliguria, hematuria, or rising creatinine may be the only presenting signs.

SWL has been described for stones in transplant kidneys and is an option for stones smaller than 1.5 cm; however, high re-treatment rates and auxiliary procedure rates should be expected (Challacombe et al., 2005; Klingler et al., 2002). Given that the renal allograft is located near the bony pelvis, prone positioning is often necessary. Antegrade and retrograde URS have been used to successfully treat transplant kidney and ureteral stones. Angled catheters and guidewires are often indispensable in achieving retrograde access, and prior placement of a percutaneous nephrostomy tube can facilitate antegrade URS and obviate the need for percutaneous tract dilation (Hyams et al., 2012). Stone-free rates of 67% to 92% have been reported, although no large series exist (Basiri et al., 2006; Del Pizzo et al., 1998).

PCNL remains the preferred treatment choice for large-burden stones (>1.5 cm) or if less invasive methods have failed. Stone-free rates ranging from 77% to 100%, similar to rates in the general population, have been reported (He et al., 2007; Krambeck et al., 2008b; Rifaioglu et al., 2008). When obtaining percutaneous access to transplant kidneys, CT or ultrasound guidance is advisable because there is a risk for intervening bowel. Furthermore, some reports describe difficulty with percutaneous access secondary to a fibrous capsule that develops around certain transplanted kidneys and may require use of metal fascial dilators to overcome. Percutaneous access with a 16-Fr peel-away sheath has been illustrated; this mini-PCNL technique is thought to carry a lower risk of surgical bleeding and still be of significant usefulness for these stones (He et al., 2007).

Duration of Ureteral Stone Presence

As discussed in the natural history section on ureteral calculi, after the initially reversible physiologic changes seen with acute ureteral obstruction, chronic ureteral obstruction can ultimately lead to permanent renal damage. Patients attempting to spontaneously pass a ureteral stone should be intermittently imaged to evaluate for persistent or worsening hydronephrosis and stone location and passage. The exact duration of renal blockage beyond which irreversible kidney damage begins is unknown in humans. Furthermore, it is possible that a ureteral stone may cause intermittent obstruction rather than permanent obstruction, and how this ultimately influences renal function is also not known. Despite this uncertainty, in general active stone treatment of any form is recommended when obstruction has persisted for approximately 4 to 6 weeks (Assimos et al., 2016; Singal and Denstedt, 1997). Continued renal blockage after this time may lead to irreversible kidney damage (Vaughan and Gillenwater, 1971). Moreover, at least one prior small prospective study showed the vast majority (95%) of stones that spontaneously pass, do so in the first 6 weeks (Miller and Kane, 1999). Holm-Nielsen et al. (1981) reported that of 134 patients with unilateral ureteral stones, one-third of the patients with obstruction lasting more than 4 weeks developed irreversible renal damage. Similarly, Kelleher et al. (1991) found that sequential renal scintigraphy performed on 76 patients with obstructive ureteral calculi demonstrated an 18% incidence of reduced renal function (defined as a decrease in relative function greater than 7%).

Key Points: Clinical Factors

- Definitive stone treatment should be undertaken only in the setting of sterile urine, although a negative urinalysis may be an applicable surrogate to negative culture.
- Morbid obesity significantly decreases SWL success rate.
- Kidneys with inherent drainage problems, such as those with UPJO, infundibular stenosis, or ectopic or horseshoe configuration, must have the underlying obstruction managed in addition to treatment of the stone.
- In kidneys with poor (<15%) function, nephrectomy may be the optimal treatment.
- Active treatment should be strongly considered for ureteral stones that have not passed after 4 to 6 weeks.

Evaluation of Outcome

Assessment and Fate of Residual Fragments

In the era of open stone surgery, residual fragments of any size suggested a failed procedure. In the modern era with the rise of endourology and the frequent use of SWL, URS, and PCNL, postoperative residual fragments are common. However, the definition and optimal management of residual fragments continue to generate controversy.

With the increasing popularity of SWL in the 1980s and the observation that many patients retained small fragments of questionable clinical relevance after such therapy, the concept of **clinically insignificant residual fragments (CIRF)** was introduced and would become incorporated into the definition of a successful treatment outcome (Newman et al., 1988). These fragments were initially, and arbitrarily, defined as residual fragments 4 mm or less in diameter that were nonobstructive, noninfectious, associated with sterile urine, and in an otherwise asymptomatic patient (Newman et al., 1988). Since then, the term has been applied to fragments of various sizes, with most studies using a cutoff between 2 mm and 4 mm.

Therefore, since the introduction of SWL, treatment outcomes for patients with renal calculi have been reported by two different terms: stone-free rate and success rate. The stone-free rate is self-explanatory, but the success rate includes patients who are stone free as well as those with CIRF. These different methods of reporting treatment results, the lack of a standard definition for CIRF, and the various modalities used for assessing postprocedural stone-free status (KUB studies, nephrotomography, ultrasonography, CT) make the comparison of endourologic stone outcomes difficult. Further complicating matters is the fact that stone fragment passage after SWL is not immediate; as many as 85% of patients have radiologic evidence of residual fragments several days after SWL (Drach et al., 1986). Although most fragments pass spontaneously during the first 3 months after SWL, continued clearance can occur for more than 24 months after treatment (Chaussy and Schmiedt, 1984; Graff et al., 1988; Kohrmann et al., 1993).

In an attempt to better characterize the clinically meaningful success of any given stone treatment, Clayman et al. (1989) introduced the effectiveness quotient:

$$\frac{\%\ \text{Stone free}}{100\% + \text{Re-treatment} + \%\ \text{Auxiliary procedures}} \times 100$$

The effectiveness quotient accounts for the re-treatment rate, stone-free rate, and number of ancillary procedures and is useful in comparing results among different treatment modalities. For example, the study by Netto et al. (1991) compared PCNL and SWL for the treatment of stones in lower pole calyces. The PCNL group had a 93.6% stone-free rate with no need for re-treatment, whereas the SWL group had a 79.2% success rate with a 41.6% re-treatment rate. The relative success rates for PCNL and SWL were not significantly different; however, a significant difference was appreciated when comparing the effectiveness quotients (93.7% for PCNL vs. 55.9% for SWL).

The term *clinically insignificant residual fragments* may be a misnomer because **many small residual fragments eventually become clinically significant and symptomatic by dislodging and causing obstruction, serving as niduses for further stone growth, or acting as a source for persistent infections** (Candau et al., 2000; Delvecchio and Preminger, 2000; Streem et al., 1996; Zanetti et al., 1997). Streem et al. (1996) reported that 43% of initially deemed CIRF became symptomatic at a mean follow-up of 23 months. Moreover, complete stone removal appears to decrease the risk of stone recurrence (Newman et al., 1988; Patterson et al., 1987; Singh et al., 1975). Stone recurrence rates of 6% to 15% have been reported for patients rendered stone free after SWL, compared with rates of 17% to 80% when residual fragments remained (Beck and Riehle, 1991; Fuchs et al., 1991; Graff et al., 1988; Nakamoto et al., 1993; Newman et al., 1988; Nijman et al., 1989; Zanetti et al., 1991). Residual fragments are most likely to pass when located within the ureter and least likely to pass when located in the lower pole.

In a large review on SWL by Rassweiler et al. (2001), CIRF were found to spontaneously pass in 25%, remain stable in 55%, and become clinically significant in 20% of patients, with anywhere from 4% to 25% of patients requiring a subsequent intervention to address the residual fragment. A similar spontaneous passage rate of 25% to 30% has been reported by others (Candau et al., 2000; Streem et al., 1997). **When the findings from the available prospective data are pooled, the probability that CIRF after SWL later become clinically significant increases with lower pole fragments, increasing fragment burden, increasing fragment number, and longer follow-up** (Khaitan et al., 2002; Osman et al., 2005b; Streem et al., 1996).

Many investigators have noted that, **after SWL, residual fragments are commonly localized to lower pole calyces no matter where the stone was treated in the kidney** (Drach et al., 1986; Graff et al., 1988; Kohrmann et al., 1993; Liedle et al., 1988; Zanetti et al., 1991). The incidence of stone recurrence is greater in the lower pole calyces after SWL than it is after PCNL (Carr et al., 1996; Kohrmann et al., 1993; Zanetti et al., 1991). Furthermore, at 1-year follow-up there is a significantly greater rate of new stone formation in those treated with SWL, and the recurrent stones are more likely to be in the lower calyces. A plausible explanation for these results is that fine debris, undetectable by imaging, persists after SWL and, because of gravity, settles in the most dependent calyces and serves as a nidus for new stone formation. Supporting this hypothesis are the results from Carr et al. (1996) showing that de novo stone formation occurs significantly more often after SWL (22%) than PCNL (4%).

Stone-free rates after PCNL vary widely from 40% to well above 90%. However, as with SWL reporting, the definition of stone free is not consistent across studies (Park et al., 2007; Skolarikos and de la Rosette, 2008). Raman et al. (2009) found an 8% rate of residual fragments by CT scan, with approximately half located in the lower pole. Of the patients with residual fragments, 43% developed a stone-related event at a median of 32 months after initial PCNL. Fragments larger than 2 mm in greatest diameter were more likely to undergo a secondary procedure and independently predicted a postoperative stone-related event. Similarly, fragments located in the renal pelvis and ureter were associated with a stone event on multivariate analysis but also were associated with the highest likelihood of spontaneously passing (Ganpule et al., 2009; Raman et al., 2009). In another retrospective study, Emmott et al. (2018) showed a 45% rate of residual fragments after PCNL, and of these patients almost one-third (31%) had a subsequent stone-related event (21% required re-intervention, 9% required no intervention) at a median time of approximately 20 months after initial PCNL.

Few investigators have evaluated the destiny of residual fragments after URS. The recent meta-analysis by the AUA and EAU revealed that residual fragments occur in 6% of cases for distal ureteral stones, 14% of cases for mid-ureteral stones, and 19% of cases for proximal ureteral stones (Preminger et al., 2007). The limited data in which CT was used to evaluate residual fragment status after URS have shown stone-free rates of only 50% to 54% (Pearle et al., 2005; Portis et al., 2006). Expanding the definition of treatment success to also include fragments 2 mm or smaller improves the success rate to 62% to 84% (Macejko et al., 2009; Portis et al., 2006; Rippel et al., 2012). Schatloff et al. (2010) found that patients with residual fragments after semirigid ureteroscopy were significantly more likely to experience unanticipated medical visits (3% vs. 30%) and exhibited a trend toward more ancillary procedures (0 vs. 7%) and more frequent rehospitalization (0 vs. 10%). Over a 19-month period after URS, Rebuck et al. (2011) reported a 20% rate of unplanned stone events, a 22% rate of spontaneous passage, and a 57% rate of persistent residual fragments (≤4 mm). A retrospective, multicenter study of 232 ureteroscopy patients with residual fragments showed almost half of these patients (44%) experienced a subsequent primary stone event (15% required no intervention, 29% required intervention) (Chew et al., 2016).

In patients with infection-related calculi, the consequence of residual fragments is particularly harmful. Residual fragments may harbor offending bacteria and thus predispose to persistent infection. Furthermore, stone regrowth has been reported in up to 75% of such patients after SWL, compared with 10% of patients who experienced complete stone removal (Beck and Riehle, 1991; Zanetti et al., 1991).

For patients with metabolic stone disease, complete stone removal does not prevent stone recurrence, but it does prolong the intervals between symptomatic events and treatment (Chow and Streem, 1998). Thus residual stones, including small stones, may not have an immediate clinical relevance but are likely to affect the patient's well-being in the long term.

The sensitivity of the method used to detect remaining fragments has important effects on the reported incidence and size of residual fragments. As stated, plain radiography, nephrotomography, ultrasonography, intravenous urography, and CT have all been used to evaluate residual fragments. Plain radiography, ultrasonography, and CT are used most frequently in contemporary practice. In the current era with the recognition that repeated radiation exposure from CT may be harmful, the routine use of CT scan for follow-up studies should be done cautiously and only when necessary. Some of this concern can be tempered with the use of low-dose and ultra-low–dose protocols for CT, although widespread availability of these modalities is limited.

In early studies investigating stone clearance after SWL, plain radiography was commonly used to determine stone-free status for radiopaque calculi and could detect opaque stone fragments as small as 2 mm (Thornbury and Parker, 1982). Plain radiography has a sensitivity of approximately 60% for detecting urinary stones (Assi et al., 2000; Ege et al., 2004; Johnston et al., 2009; Mutgi et al., 1991). However, Denstedt et al. (1991) reported that for patients with large renal calculi treated by a combination of PCNL and SWL, plain radiography overestimated stone-free rates by 35% and 17%, respectively, compared with flexible nephroscopy. Nephrotomography, although becoming obsolete in many centers, has proved superior to plain radiography in detecting residual fragments (Goldwasser et al., 1989; Hjollund Madsen, 1972; Schwartz et al., 1984).

Traditionally, ultrasonography has been inferior to plain radiography in detecting urinary calculi, with particular deficiency in detecting ureteral stones (Older and Jenkins, 2000; Yilmaz et al., 1998). The sensitivity of ultrasonography to detect urinary calculi over the last decade has ranged from 24% to 57% (Fowler et al., 2002; Ulusan et al., 2007; Viprakasit et al., 2012), although these results were potentially confounded because CT scans and ultrasounds were rarely done on the same day and infrequently performed by a dedicated uro-ultrasonographer. Kanno et al. (2014) recently reported a 70% ultrasound sensitivity in detecting renal stones when the ultrasound was done the same day as the CT, average patient BMI was 23, and all ultrasounds were performed by experienced ultrasonographers. Therefore, even under the most favorable circumstances, ultrasound may still miss up to 30% of renal stones.

Despite its shortcomings, in detecting ureteral stones, ultrasound is highly effective in diagnosing hydronephrosis. In fact, some advocate for ultrasonography after all ureteroscopic procedures because silent obstruction has been reported to occur in certain, albeit rare, instances (Weizer et al., 2002). A prospective study comparing the relative efficacy of abdominal radiography and renal ultrasonography versus excretory urography for the evaluation of asymptomatic patients 1 month after SWL treatment demonstrated that the combination of ultrasonography and abdominal radiography was as good as or better than intravenous urography in identifying residual stone fragments and hydronephrosis, suggesting that **routine radiologic evaluation of asymptomatic patients after SWL could be limited to abdominal radiography and ultrasonography** (Coughlin et al., 1989).

Although flexible nephroscopy may be considered the gold standard for assessment of residual stones after PCNL, its routine use has been challenged by studies showing the high sensitivity of CT in detecting residual stones after PCNL. Pearle et al. (1999) noted that CT had 100% sensitivity for detecting residual stones after PCNL in 36 patients evaluated with both CT and flexible nephroscopy. Selective use of flexible nephroscopy based on positive CT findings would have avoided an unnecessary procedure in 20% of patients. In a retrospective study of 121 patients who underwent CT after PCNL (including 59% stone-free patients and 16% patients with fragments of 1 to 3 mm), Waldmann et al. (1999) reported that routine nephroscopy would not have been required in 75% of cases. Given its wide availability and high sensitivity, CT is becoming more popular for the evaluation of residual stone fragments after PCNL. However, this must be balanced with the need to minimize unnecessary radiation exposure in patients, and when available, strong consideration for low- and ultra-low–dose CT is prudent.

Key Points: Residual Fragments

- Many small residual fragments eventually become clinically significant and symptomatic.
- In the setting of infectious stones, residual stones portend a future of UTIs and stone recurrence; therefore aggressive treatment with removal of fragments is usually indicated.

- Risks for stone recurrence are higher in the setting of residual stone fragments, because stone growth on an existing crystal matrix is harder to prevent than spontaneous nucleation of new stones.

Suggested Readings

Albala DM, Assimos DG, Clayman RV, et al. Lower Pole I: a prospective randomized trial of extracorporeal shock wave lithotripsy and percutaneous nephrostolithotomy for lower pole nephrolithiasis-initial results. *J Urol*. 2001;166(6):2072–2080.

Assimos D, Krambeck A, Miller NL, et al. Surgical management of stones: American Urological Association/Endourological Society guideline, PART I. *J Urol*. 2016;196:1153–1160.

Assimos D, Krambeck A, Miller NL, et al. Surgical management of stones: American Urological Association/Endourological Society guideline, PART II. *J Urol*. 2016;196:1161–1169.

de la Rosette J, Assimos D, Desai M, et al. The Clinical Research Office of the Endourological Society percutaneous nephrolithotomy global study: indications, complications, and outcomes in 5803 patients. *J Endourol*. 2011;25(1):11–17.

de la Rosette J, Denstedt J, Geavlete P, et al. The Clinical Research Office of the Endourological Society ureterorenoscopy global study: indications, complications, and outcomes in 11,885 patients. *J Endourol*. 2014;28(2):131–139.

Lingeman JE, Siegel YI, Steele B, et al. Management of lower pole nephrolithiasis: a critical analysis. *J Urol*. 1994;151(3):663–667.

Pearle MS, Lingeman JE, Leveillee R, et al. Prospective, randomized trial comparing shock wave lithotripsy and ureteroscopy for lower pole caliceal calculi 1 cm or less. *J Urol*. 2005;173:2005–2009.

Pearle MS, Nadler R, Bercowsky E, et al. Prospective randomized trial comparing shock wave lithotripsy and ureteroscopy for management of distal ureteral calculi. *J Urol*. 2001;166:1255–1260.

Preminger GM, Assimos DG, Lingeman JE, et al. AUA guideline on management of staghorn calculi: diagnosis and treatment recommendations. *J Urol*. 2005;173(6):1991–2000.

Preminger GM, Tiselius HG, Assimos DG, et al. 2007 Guideline for the management of ureteral calculi. *J Urol*. 2007;178:2418–2434.

Semins MJ, Trock BJ, Matlaga BR. The safety of ureteroscopy during pregnancy: a systematic review and meta-analysis. *J Urol*. 2009;181:139–143.

Tan YK, Cha DY, Gupta M. Management of stones in abnormal situations. *Urol Clin North Am*. 2013;40:79–97.

Turk C, Neisius A, Petrik A, European Association of Urology (EAU) Guidelines Office, et al. *European Association of Urology guidelines on urolithiasis*. 32nd ed. EAU Annual Congress: London; 2017.

References

Abdel-Khalek M, Sheir KZ, Mokhtar AA, et al. Prediction of success rate after extracorporeal shock-wave lithotripsy of renal stones—a multivariate analysis model. *Scand J Urol Nephrol*. 2004;38(2):161–167.

Abe T, Akakura K, Kawaguchi M, et al. Outcomes of shockwave lithotripsy for upper urinary-tract stones: a large-scale study at a single institution. *J Endourol*. 2005;19(7):768–773.

Abeshouse BS, Abeshouse GA. Calyceal diverticulum: a report of sixteen cases and review of the literature. *Urol Int*. 1963;15:329–357.

Aboumarzouk OM, Monga M, Kata SG, et al. Flexible ureterorenoscopy and laser lithotripsy for stones > 2 cm: a systemic review and meta-analysis. *J Endourol*. 2012;26(10):1257–1263.

Aboumarzouk OM, Somani B, Monga M. Safety and efficacy of ureteroscopic lithotripsy for stone disease in obese patients: a systematic review of the literature. *BJU Int*. 2012;110(8 Pt B):E374–E380.

Aboumarzouk OM, Somani BK, Monga M. Flexible ureterorenoscopy and holmium:YAG lithotripsy for stone disease in patients with bleeding diathesis: a systematic review of the literature. *Int Braz J Urol*. 2012;38(3):298–305 [discussion 306].

Ackermann D, Griffith DP, Dunthorn M, et al. Calculation of stone volume and urinary stone staging with computer assistance. *J Endourol*. 1989;3:355.

Ackermann DK, Fuhrimann R, Pfluger D, et al. Prognosis after extracorporeal shock wave lithotripsy of radiopaque renal calculi: a multivariate analysis. *Eur Urol*. 1994;25(2):105–

109.

Agarwal A, Varsheny A, Bansal BS. Concomitant percutaneous nephrolithotomy and transperitoneal laparoscopic pyeloplasty for ureteropelvic junction obstruction complicated by stones. *J Endourol*. 2008;22(10):2251–2255.

Aghamir SK, Mohseni MG, Ardestani A. Treatment of ureteral calculi with ballistic lithotripsy. *J Endourol*. 2003;17:887–890.

Agrawal MS, Aron M, Asopa HS. Endourological renal salvage in patients with calculus nephropathy and advanced uraemia. *BJU Int*. 1999;84:252–256.

Ahmed K, Khan MS, Thomas K, et al. Management of cystinuric patients: an observational, retrospective, single-centre analysis. *Urol Int*. 2008;80:141–144.

Akca O, Zargar H, Autorino R, et al. Robotic partial nephrectomy for caliceal diverticulum: a single-center case series. *J Endourol*. 2014;28(8):958–961.

Akman T, Binbay M, Aslan R, et al. Long-term outcomes of percutaneous nephrolithotomy in 177 patients with chronic kidney disease: a single center experience. *J Urol*. 2012;187(1):173–177.

Akman T, Binbay M, Ozgor F, et al. Comparison of percutaneous nephrolithotomy and retrograde flexible nephrolithotripsy for the management of 2–4 cm stones: a matched-pair analysis. *BJU Int*. 2012;109(9):1384–1389.

Akman T, Binbay M, Ugurlu M, et al. Outcomes of retrograde intrarenal surgery compared with percutaneous nephrolithotomy in elderly patients with moderate-size kidney stones: a matched-pair analysis. *J Endourol*. 2012;26(6):625–629.

Albala DM, Assimos DG, Clayman RV, et al. Lower pole I: a prospective randomized trial of extracorporeal shock wave lithotripsy and percutaneous nephrolithotomy for lower pole nephrolithiasis—initial results. *J Urol*. 2001;166(6):2072–2080.

Albala DM, Siddiqui KM, Fulmer B, et al. Extracorporeal shock wave lithotripsy with a transportable electrohydraulic lithotripter: experience with >300 patients. *BJU Int*. 2005;96:603–607.

Al-Basam S, Bennett JD, Layton ZA, et al. Treatment of caliceal diverticular stones: transdiverticular percutaneous nephrolithotomy with creation of a neoinfundibulum. *J Vasc Interv Radiol*. 2000;11:885–889.

Alken P. Percutaneous ultrasonic destruction of renal calculi. *Urol Clin North Am*. 1982;9:145–151.

Al-Kohlany KM, Shokeir AA, Mosbah A, et al. Treatment of complete staghorn stones: a prospective randomized comparison of open surgery versus percutaneous nephrolithotomy. *J Urol*. 2005;173:469–473.

Al-Otaibi K, Hosking DH. Percutaneous stone removal in horseshoe kidneys. *J Urol*. 1999;162(Pt 1):674–677.

Alsaikhan B, Andonian S. Shock wave lithotripsy in patients requiring anticoagulation or antiplatelet agents. *Can Urol Assoc J*. 2011;5:53–57.

Andreoni C, Portis AJ, Clayman RV. Retrograde renal pelvic access sheath to facilitate flexible ureteroscopic lithotripsy for the treatment of urolithiasis in a horseshoe kidney. *J Urol*. 2000;164(4):1290–1291.

Armagan A, Karatag T, Buldu I, et al. Comparison of flexible ureterorenoscopy and micropercutaneous nephroilthotomy in the treaetment for modereately size lower-pole stones. *World J Urol*. 2015;33:1827–1831.

Arrabal-Martin M, Fernandez-Rodriguez A, Arrabal-Polo MA, et al. Extracorporeal renal lithotripsy: evolution of residual lithiasis treated with thiazides. *Urology*. 2006;68:956–959.

Assi Z, Platt JF, Francis IR, et al. Sensitivity of CT scout radiography and abdominal radiography for revealing ureteral calculi on helical CT: implications for radiologic follow-up. *AJR Am J Roentgenol*. 2000;175:333–337.

Assimos D, Krambeck A, Miller NL, et al. Surgical management of stones: American Urological Association/Endourological Society guideline, PART I. *J Urol*. 2016;196:1153–1160.

Assimos D, Krambeck A, Miller NL, et al. Surgical management of stones: American Urological Association/Endourological Society guideline, PART II. *J Urol*. 2016;196:1161–1169.

Assimos DG, Langenstroer P, Leinbach RF, et al. Guaifenesin- and ephedrine-induced stones. *J Endourol*. 1999;13:665–667.

Assimos DG, Leslie SW, Ng C, et al. The impact of cystinuria on renal function. *J Urol*. 2002;168:27–30.

Atis G, Resorlu B, Gurbuz C, et al. Retrograde intrarenal surgery in patients with horseshoe kidneys. *Urolithiasis*. 2013;41(1):79–83.

Atug F, Castle EP, Burgess SV, et al. Concomitant management of renal calculi and pelvi-ureteric junction obstruction with robotic laparoscopic surgery. *BJU Int*. 2005;96:1365–1368.

Auge BK, Munver R, Kourambas J, et al. Endoscopic management of symptomatic caliceal diverticula: a retrospective comparison of percutaneous nephrolithotripsy and ureterorenoscopy. *J Endourol*. 2002;16:557–563.

Bader MJ, Gratzke C, Walther S, et al. Efficacy of retrograde ureteropyeloscopic holmium laser lithotripsy for intrarenal calculi > 2 cm. *Urol Res*. 2010;38(5):397–402.

Bag S, Kumar S, Taneja N, et al. One week of nitrofurantoin before percutaneous nephrolithotomy significantly reduces upper tract infection and urosepsis: a prospective controlled study. *Urology*. 2011;77(1):45–49.

Ballenger EG, Frontz WA, Hamer HG, et al. *History of urology.*

Prepared under the auspices of the American Urological Association. Williams & Wilkins: Baltimore; 1933.

Bani-Hani AH, Segura JW, Leroy AJ. Urinary matrix calculi: our experience at a single institution. *J Urol*. 2005;173:120–123.

Barbey F, Joly D, Rieu P, et al. Medical treatment of cystinuria: critical reappraisal of long-term results. *J Urol*. 2000;163:1419–1423.

Bas O, Bakirtas H, Sener NC, et al. Comparison of shock wave lithotripsy, flexible ureterorenoscopy and percutaneous nephrolithotomy on moderate size renal pelvis stones. *Urolithiasis*. 2014;42(2):115–120.

Basiri A, Nikoobakht MR, Simforoosh N, et al. Ureteroscopic management of urological complications after renal transplantation. *Scand J Urol Nephrol*. 2006;40:53–56.

Basiri A, Radfar MH, Lashav A. Laparoscopic management of caliceal diverticulum: our experience, literature review, and pooling analysis. *J Endourol*. 2013;27(5):583–586.

Batter SJ, Dretler SP. Ureterorenoscopic approach to the symptomatic caliceal diverticulum. *J Urol*. 1997;158(3 Pt 1):709–713.

Beck EM, Riehle RA Jr. The fate of residual fragments after extracorporeal shock wave lithotripsy monotherapy of infection stones. *J Urol*. 1991;145:6–9 [discussion 10].

Berkman DS, Landman J, Gupta M. Treatment outcomes after endopyelotomy performed with or without simultaneous nephrolithotomy: 10-year experience. *J Endourol*. 2009;23(9):1409–1413.

Bhatta KM, Prien EL Jr, Dretler SP. Cystine calculi—rough and smooth: a new clinical distinction. *J Urol*. 1989;142(4):937–940.

Bichler KH, Eipper E, Naber K, et al. Urinary infection stones. *Int J Antimicrob Agents*. 2002;19(6):488–498.

Blackburne AT, Rivera ME, Gettman MT, et al. Endoscopic management of urolithiasis in the horseshoe kidney. *Urology*. 2016;90:45–49.

Blandy J, Singh M. The case for a more aggressive approach to staghorn stones. *J Urol*. 1976;115:505–506.

Blau JJ. Ephedrine nephrolithiasis associated with chronic ephedrine abuse. *J Urol*. 1998;160:825.

Boll DT, Patil NA, Paulson EK, et al. Renal stone assessment with dual-energy multidetector CT and advanced postprocessing techniques: improved characterization of renal stone composition—pilot study. *Radiology*. 2009;250:813–820.

Bon D, Doré B, Fournier F, et al. Percutaneous nephrolithotomy after failure of extracorporeal shockwave lithotripsy. Indications, results, perspectives. *Prog Urol*. 1993;3:951–958.

Boyce CJ, Pickhardt PJ, Lawrence EM, et al. Prevalence of urolithiasis in asymptomatic adults: objective determination using low dose noncontrast CT. *J Urol*. 2010;183:1017–1021.

Boyce WH, King JS Jr. Crystal-matrix interrelations in calculi. *J Urol*. 1959;81:351.

Bozkurt OF, Resorlu B, Yildiz Y, et al. Retrograde intrarenal surgery versus percutaneous nephrolithotomy in the management of lower-pole renal stones with a diameter of 15 to 20 mm. *J Endourol*. 2011;25(7):1131–1135.

Bozkurt OF, Tepeler A, Sininsky B, et al. Flexible ureterorenoscopy for the treatment of kidney stones within pelvic ectopic kidney. *Urology*. 2014;84:1285–1289.

Bozzini G, Verze P, Arcaniolo D, et al. A prospective randomized comparison among swl, pcnl and rirs for lower calyceal stones less than 2 cm: a multicenter experience: a better understanding on the treatment options for lower pole stones. *World J Urol*. 2017;35:1967–1975.

Braga LH, Pace K, DeMaria J, et al. Systematic review and meta-analysis of robotic-assisted versus conventional laparoscopic pyeloplasty for patients with ureteropelvic junction obstruction: effect on operative time, length of hospital stay, postoperative complications, and success rate. *Eur Urol*. 2009;56(5):848–857.

Breda A, Ogunyemi O, Leppert JT, et al. Flexible ureterorenoscopy and laser lithotripsy for single intrarenal stones 2 cm or greater—is this the new frontier? *J Urol*. 2008;179(3):981–984.

Breda A, Ogunyemi O, Leppert JT, et al. Flexible ureterorenoscopy and laser lithotripsy for multiple unilateral intrarenal stones. *Eur Urol*. 2009;55(5):1190–1196.

Brownlee N, Foster M, Griffith DP, et al. Controlled inversion therapy: an adjunct to the elimination of gravity-dependent fragments following extracorporeal shock wave lithotripsy. *J Urol*. 1990;143:1096–1098.

Bryniarski P, Paradysz A, Zyczkowski M, et al. A randomized controlled study to analyze the safety and efficacy of percutaneous nephrolithotripsy and retrograde intrarenal surgery in the management of renal stones more than 2 cm in diameter. *J Endourol*. 2012;26(1):52–57.

Burgher A, Beman M, Holtzman JL, et al. Progression of nephrolithiasis: long-term outcomes with observation of asymptomatic calculi. *J Endourol*. 2004;18:534–539.

Burns JR, Finlayson B, Gauthier J. Calcium oxalate retention in subjects with crystalluria. *Urol Int*. 1984;39:36–39.

Burr J, Ishii H, Simmonds N, et al. Is flexible ureterorenoscopy and laser lithotripsy the new gold standard for lower pole renal stones when compared to shock wave lithotripsy: comparative outcomes from a University hospital over similar time period. *Cent European J Urol*. 2015;68(2):183–186.

Butler MR, Power RE, Thornhill JA, et al. An audit of 2273 ureteroscopies—a focus on intra-operative complications to justify proactive management of ureteric calculi. *Surgeon*. 2004;2(1):42–46.

Canales B, Monga M. Surgical management of the calyceal diverticulum. *Curr Opin Urol*. 2003;13:255–260.

Candau C, Saussine C, Lang H, et al. Natural history of residual renal stone fragments after ESWL. *Eur Urol*. 2000;37:18–22.

Canes D, Berger A, Gettman MT, et al. Minimally invasive approaches to ureteropelvic junction obstruction. *Urol Clin North Am*. 2008;35:425–439.

Canes D, Hegarty NJ, Kamoi K, et al. Functional outcomes following percutaneous surgery in the solitary kidney. *J Urol*. 2009;181(1):154–160.

Carr LK, D'A Honey J, Jewett MA, et al. New stone formation: a comparison of extracorporeal shock wave lithotripsy and percutaneous nephrolithotomy. *J Urol*. 1996;155:1565–1567.

Caskurlu T, Atis G, Arikan O, et al. The impact of body mass index on the outcomes of retrograde intrarenal stone surgery. *Urology*. 2013;81(3):517–521.

Cass A. Comparison of first generation (Dornier HM3) and second generation (Medstone STS) lithotriptors: treatment results with 13,864 renal and ureteral calculi. *J Urol*. 1995;153(Pt 1):588–592.

Cass AS. Renal function after extracorporeal shock wave lithotripsy to a solitary kidney. *J Endourol*. 1994;8:15–19.

Caulk JR. Megaloureter. *J Urol*. 1923;9:315.

Challacombe B, Dasgupta P, Tiptaft R, et al. Multimodal management of urolithiasis in renal transplantation. *BJU Int*. 2005;96:385–389.

Chan CH, El-Hakim A, Andonian S. Renal matrix stone managed by ureteroscopic holmium laser lithotripsy. *Can J Urol*. 2010;17(2):5127–5130.

Chan LH, Good DW, Laing K, et al. Primary swl is an efficient and cost-effective treatment for lower pole renal stones between 10 and 20 mm: a large single center study. *J Endourol*. 2017;31:510–516.

Chandhoke PS, Albala DM, Clayman RV. Long-term comparison of renal function in patients with solitary kidneys and/or moderate renal insufficiency undergoing extracorporeal shock wave lithotripsy or percutaneous nephrolithotomy. *J Urol*. 1992;147(5):1226–1230.

Chang TD, Dretler SP. Laparoscopic pyelolithotomy in an ectopic kidney. *J Urol*. 1996;156:1753.

Chaussy C, Fuchs G. Extracorporeal lithotripsy in the treatment of renal lithiasis. 5 years' experience. *J Urol (Paris)*. 1986;92:339–343.

Chaussy C, Fuchs G. Current state and future developments of noninvasive treatment of human urinary stones with extracorporeal shock wave lithotripsy. *J Urol*. 1989;141(Pt 2):782–789.

Chaussy C, Schmiedt E. Extracorporeal shock wave lithotripsy (ESWL) for kidney stones: an alternative to surgery? *Urol Radiol*. 1984;6:80–87.

Chen MY, Zagoria RJ, Saunders HS, et al. Trends in the use of unenhanced helical CT for the acute urinary colic. *AJR Am J Roentgenol*. 1999;173(6):1447–1450.

Chew BH, Brotherhood HL, Sur RL, et al. Natural history, complications and re-intervention rates of asymptomatic residual stone fragments after ureteroscopy: a report from the EDGE research consortium. *J Urol*. 2016;195:982–986.

Chew BH, Zavaglia B, Paterson RF, et al. A multicenter comparison of the safety and effectiveness of ureteroscopic laser lithotripsy in obese and normal weight patients. *J Endourol*. 2013;27(6):710–714.

Chiong E, Hwee ST, Kay LM, et al. Randomized controlled study of mechanical percussion, dieresis, and inversion therapy to assist passage of lower pole renal calculi after shock wave lithotripsy. *Urology*. 2005;65(6):1070–1074.

Chong TW, Bui MH, Fuchs GJ. Calyceal diverticula. Ureteroscopic management. *Urol Clin North Am*. 2000;27:647–654.

Chow GK, Streem SB. Contemporary urological intervention for cystinuric patients: immediate and long-term impact and implications. *J Urol*. 1998;160:341–344 [discussion 344–345].

Christman MS, Kasturi S, Lambert SM, et al. Endoscopic management and the role of double stenting for primary obstructive megaureters. *J Urol*. 2012;187:1018–1022.

Clayman RV, McClennan BL, Garvin TJ, et al. Lithostar: an electromagnetic acoustic shock wave unit for extracorporeal lithotripsy. *J Endourol*. 1989;3:307–313.

Cohen J, Cohen S, Grasso M. Ureteropyeloscopic treatment of large, complex intrarenal and proximal ureteral calculi. *BJU Int*. 2013;111(3 Pt B):E127–E131.

Cohen TD, Preminger GM. Management of calyceal calculi. *Urol Clin North Am*. 1997;24:81–96.

Coll DM, Varanelli MJ, Smith RC, et al. Relationship of spontaneous passage of ureteral calculi to stone size and location as revealed by unenhanced helical CT. *AJR Am J Roentgenol*. 2002;178:101–103.

Consensus conference. Prevention and treatment of kidney stones. *J Am Med Assoc*. 1988;260:977–981.

Coughlin BF, Risius B, Streem SB, et al. Abdominal radiograph and renal ultrasound versus excretory urography in the evaluation of asymptomatic patients after extracorporeal shock wave lithotripsy. *J Urol*. 1989;142:1419–1423 [discussion 1423–1424].

Coz F, Orvieto M, Bustos M, et al. Extracorporeal shockwave lithotripsy of 2000 urinary calculi with the modulith SL-20: success and failure according to size and location of stones. *J Endourol*. 2000;14(3):239–246.

Culkin DJ, Wheeler JS, Nemchausky BA, et al. Percutaneous nephrolithotomy: spinal cord injury vs. ambulatory patients. *J Am Paraplegia Soc*. 1990;13(2):4–6.

Curran MJ, Little AF, Bouyounes B, et al. Retroperitoneoscopic technique for treating symptomatic caliceal diverticula. *J Endourol*. 1999;13:723–725.

D'a Honey RJ, Luymes J, Weir MJ, et al. Mechanical percussion inversion can result in relocation of lower pole stone fragments after shock wave lithotripsy. *Urology*. 2000;55:204–206.

Dalziel PJ, Noble VE. Bedside ultrasound and the assessment of renal colic: a review. *Emerg Med J*. 2013;30(1):3–8.

Danuser H, Muller R, Descoeudres B, et al. Extracorporeal shock wave lithotripsy of lower calyx calculi: how much is treatment outcome influenced by the anatomy of the collecting system? *Eur Urol*. 2007;52(2):539–546.

Dash A, Schuster TG, Hollenbeck BK, et al. Ureteroscopic treatment of renal calculi in morbidly obese patients: a stone-matched comparison. *Urology*. 2002;60:393–397.

Daudon M, Estepa L, Viard JP, et al. Urinary stones in HIV-1-positive patients treated with indinavir. *Lancet*. 1997;349:1294–1295.

de la Rosette J, Assimos D, Desai M, et al. The Clinical Research Office of the Endourological Society percutaneous nephrolithotomy global study: indications, complications, and outcomes in 5803 patients. *J Endourol*. 2011;25(1):11–17.

de la Rosette J, Denstedt J, Geavlete P, et al. The Clinical Research Office of the Endourological Society ureterorenoscopy global study: indications, complications, and outcomes in 11,885 patients. *J Endourol*.

2014;28(2):131–139.

Del Pizzo JJ, Jacobs SC, Sklar GN. Ureteroscopic evaluation in renal transplant recipients. *J Endourol*. 1998;12:135–138.

Delakas D, Karyotis I, Daskalopoulos G, et al. Independent predictors of failure of shockwave lithotripsy for ureteral stones employing a second-generation lithotripter. *J Endourol*. 2003;17(4):201–205.

Deliveliotis C, Varkarakis J, Argiropoulos V, et al. Shockwave lithotripsy for urinary stones in patients with urinary diversion after radical cystectomy. *J Endourol*. 2002;16:717–720.

Delvecchio FC, Preminger GM. Management of residual stones. *Urol Clin North Am*. 2000;27(2):347–354.

Demirtas A, Sahin N, Akinsal EC, et al. Primary obstructive megaureter with giant ureteral stone: a case report. *Case Rep Urol*. 2013;2013:198592.

Denstedt JD, Clayman RV, Picus DD. Comparison of endoscopic and radiological residual fragment rate following percutaneous nephrolithotripsy. *J Urol*. 1991;145:703–705.

Desai M, De Lisa A, Turna B, et al. The Clinical Research Office of the Endourological Society percutaneous nephrolithotomy global study: staghorn versus nonstaghorn stones. *J Endourol*. 2011;25(8):1263–1268.

Desai M. Ultrasonography-guided punctures with and without puncture guide. *J Endourol*. 2009;23(10):1641–1643.

Desai MR, Jasani A. Percutaneous nephrolithotripsy in ectopic kidneys. *J Endourol*. 2000;14:289–292.

Desnos E. The history of urology to the nineteenth century. Murphy LJ. *The history of urology*. Charles C. Thomas: Springfield, IL; 1972.

Deutsch PG, Subramonian K. Conservative management of staghorn calculi: a single-centre experience. *BJU Int*. 2016;118:444–450.

Dhar NB, Thornton J, Karafa MT, et al. A multivariate analysis of risk factors associated with subcapsular hematoma formation following electromagnetic shock wave lithotripsy. *J Urol*. 2004;172(6 Pt 1):2271–2274.

Di Silverio F, Gallucci M, Alpi G. Staghorn calculi of the kidney: classification and therapy. *Br J Urol*. 1990;65:449–452.

DiMarco DS, Gettman MT, McGee SM, et al. Long-term success of antegrade endopyelotomy compared with pyeloplasty at a single institution. *J Endourol*. 2006;20:707–712.

Dogra PN, Regmi SK, Singh P, et al. Lower ureteral stones revisited: expanding the horizons of robotics. *Urology*. 2013;82(1):95–99.

Donaldson JF, Lardas M, Scrimgeour D, et al. Systematic review and meta-analysis of the clinical effectiveness of shock wave lithotripsy, retrograde intrarenal surgery, and percutaneous nephrolithotomy for lower-pole renal stones. *Eur Urol*. 2015;67:612–616.

Doré B, Conort P, Irani J, et al. Percutaneous nephrolithotomy (PCNL) in subjects over the age of 70: a multicentre retrospective study of 210 cases. *Prog Urol*. 2004;14(6):1140–1145.

Drach GW, Dretler S, Fair W, et al. Report of the United States cooperative study of extracorporeal shock wave lithotripsy. *J Urol*. 1986;135(3):1127–1133.

Dretler SP, Polykoff G. Calcium oxalate stone morphology: fine tuning our therapeutic distinctions. *J Urol*. 1996;155:828–833.

Dretler SP, Young RH. Stone granuloma: a cause of ureteral stricture. *J Urol*. 1993;150(6):1800–1802.

Dretler SP. Stone fragility—a new therapeutic distinction. *J Urol*. 1988;139:1124–1127.

Dudley NE. Sir Henry Morris, Bart. (1844–1926). *Invest Urol*. 1973;11:170–171.

Dzik WH. Predicting hemorrhage using preoperative coagulation screening assays. *Curr Hematol Rep*. 2004;3(5):324–330.

Eassa WA, Sheir KZ, Gad HM, et al. Prospective study of the long-term effects of shock wave lithotripsy on renal function and blood pressure. *J Urol*. 2008;179:964–969.

Edmonds ML, Yan JW, Sedran RJ, et al. The utility of renal ultrasonography in the diagnosis of renal colic in emergency department patients. *CJEM*. 2010;12:201–206.

Ege G, Akman H, Kuzucu K, et al. Can computed tomography scout radiography replace plain film in the evaluation of patients with acute urinary tract colic? *Acta Radiol*. 2004;45:469–473.

Egilmez T, Tekin MI, Gonen M, et al. Efficacy and safety of a new-generation shockwave lithotripsy machine in the treatment of single renal or ureteral stones: experience with 2670 patients. *J Endourol*. 2007;21:23–27.

El-Anany FG, Hammouda HM, Maghraby HA, et al. Retrograde ureteropyeloscopic holmium laser lithotripsy for large renal calculi. *BJU Int*. 2001;88:850–853.

Elashry OM, DiMeglio RB, Nakada SY, et al. Intracorporeal electrohydraulic lithotripsy of ureteral and renal calculi using small caliber (1.9F) electrohydraulic lithotripsy probes. *J Urol*. 1996;156(5):1581–1585.

El-Assmy A, El-Nahas AR, Hekal IA, et al. Longterm effects of extracorporeal shock wave lithotripsy on renal function: our experience with 156 patients with solitary kidney. *J Urol*. 2008;179(6):2229–2232.

El-Assmy A, El-Nahas AR, Madbouly K, et al. Extracorporeal shock-wave lithotripsy monotherapy of partial staghorn calculi: prognostic factors and long-term results. *Scand J*

Urol Nephrol. 2006;40:320–325.

El-Assmy A, El-Nahas AR, Mohsen T, et al. Extracorporeal shock wave lithotripsy of upper urinary tract calculi in patients with cystectomy and urinary diversion. *Urology*. 2005;66:510–513.

El-Assmy AM, Shokeir AA, El-Nahas AR, et al. Outcome of percutaneous nephrolithotomy: effect of body mass index. *Eur Urol*. 2007;52(1):199–204.

Elbahnasy AM, Elbendary MA, Radwan MA, et al. Laparoscopic pyelolithotomy in selected patients with ectopic pelvic kidney: a feasible minimally invasive treatment option. *J Endourol*. 2011;25(6):985–989.

Elbahnasy AM, Shalhav AL, Hoenig DM, et al. Lower caliceal stone clearance after shock wave lithotripsy or ureterorenoscopy: the impact of lower pole radiographic anatomy. *J Urol*. 1998;159:676–682.

El-Kappany HA, El-Nahas AR, Shoma AM, et al. Combination of laparoscopy and nephroscopy for treatment of stones in pelvic ectopic kidneys. *J Endourol*. 2007;21(10):1131–1136.

Elliott VL, Clements T, Gettle L, et al. Management of stones in anomalous kidneys. *AUA Update Series*. 2010;29:210–219.

El-Nahas AR, El-Assmy AM, Mansour O, et al. A prospective multivariate analysis of factors predicting stone disintegration by extracorporeal shock wave lithotripsy: the value of high-resolution noncontrast computed tomography. *Eur Urol*. 2007;51(6):1688–1694.

El-Nahas AR, Eraky I, El-Assmy AM, et al. Percutaneous treatment of large upper tract stones after urinary diversion. *Urology*. 2006;68:500–504.

El-Nahas AR, Ibrahim HM, Youssef RF, et al. Flexible ureterorenoscopy versus extracorporeal shock wave lithotripsy for treatment of lower pole stones of 10–20 mm. *BJU Int*. 2012;110(6):898–902.

El-Tabey NA, El-Nahas AR, Eraky I, et al. Long-term functional outcome of percutaneous nephrolithotomy in solitary kidneys. *Urology*. 2014;83(5):1011–1015.

Emmott AS, Brotherhood HL, Paterson RF, et al. Complications, re-intervention rates, and natural history of residual stone fragments after percutaneous nephrolithotomy. *J Endourol*. 2018;32:28–32.

Eshghi AM, Roth JS, Smith AD. Percutaneous transperitoneal approach to a pelvic kidney for endourological removal of staghorn calculus. *J Urol*. 1985;134:525–527.

Eshghi M. Pressure-controlled hydraulic dilation of the ureter: “one-step” ureteroscopy. *J Urol*. 1988;140:950–953.

Esuvaranathan K, Tan EC, Tung KH, et al. Stones in horseshoe kidneys: results of treatment by extracorporeal shock wave lithotripsy and endourology. *J Urol*. 1991;146:1213–1215.

Evans WP, Resnick MI. Horseshoe kidney and urolithiasis. *J Urol*. 1981;125:620–621.

Fernstrom I, Johansson B. Percutaneous pyelolithotomy: a new extraction technique. *Scand J Urol Nephrol*. 1976;10:257–259.

Fialkov JM, Hedican SP, Fallon B, et al. Reassessing the efficacy of the Dornier MFL-5000 lithotriptor. *J Urol*. 2000;164:640–643.

Fischer CP, Sonda LP 3rd, Diokno AC. Use of cryoprecipitate coagulum in extracting renal calculi. *Urology*. 1980;15:6–13.

Foda K, Abdeldaeim H, Youssif M, et al. Calculating the number of shock waves, expulsion time, and optimum stone parameters based on noncontrast computerized tomography characteristics. *Urology*. 2013;82(5):1026–1031.

Fong YK, Ho SH, Peh OH, et al. Extracorporeal shockwave lithotripsy and intracorporeal lithotripsy for proximal ureteric calculi—a comparative assessment of efficacy and safety. *Ann Acad Med Singapore*. 2004;33:80–83.

Fowler KA, Locken JA, Duchesne JH, et al. US for detecting renal calculi with nonenhanced CT as a reference standard. *Radiology*. 2002;222(1):109–113.

Freedman DS, Khan LK, Serdula MK, et al. Trends and correlates of class 3 obesity in the United States from 1990 through 2000. *J Am Med Assoc*. 2002;288:1758–1761.

Fuchs AM, Wolfson BA, Fuchs GJ. Staghorn stone treatment with extracorporeal shock wave lithotripsy monotherapy: long term results. *J Endourol*. 1991;5:45.

Fuchs GJ, David RD. Flexible ureterorenoscopy, dilatation of narrow caliceal neck, and ESWL: a new, minimally invasive approach to stones in caliceal diverticula. *J Endourol*. 1989;3:255–263.

Fuller A, Razvi H, Denstedt JD, et al. The CROES percutaneous nephrolithotomy global study: the influence of body mass index on outcomes. *J Urol*. 2012;188(1):138–144.

Furyk JS, Chu K, Banks C, et al. Distal ureteric stones and tamsulosin: a double-blind, placebo-controlled, randomized, multicenter trial. *Ann Emerg Med*. 2016;67:86–95.

Gallucci M, Vincenzoni A, Schettini M, et al. Extracorporeal shock wave lithotripsy in ureteral and kidney malformations. *Urol Int*. 2001;66(2):61–65.

Galvin DJ, Pearle MS. The contemporary management of renal and ureteric calculi. *BJU Int*. 2006;98(6):1283–1288.

Ganpule A, Desai M. Fate of residual stones after percutaneous nephrolithotomy: a critical analysis. *J Endourol*. 2009;23:399–403.

Gaur DD, Agarwal DK, Purohit KC, et al. Retroperitoneal laparoscopic pyelolithotomy. *J Urol*. 1994;151:927–929.

Geavlete P, Georgescu D, Nita G, et al. Complications of 2735 retrograde semirigid ureterorenoscopy procedures: a single-center experience. *J Endourol*. 2006;20(3):179–185.

Gettman MT, Segura JW. Struvite stones: diagnosis and current treatment concepts. *J Endourol*. 1999;13:653–658.

Ghani KR, Trinh QD, Jeong W, et al. Robotic nephrolithotomy and pyelolithotomy with utilization of the robotic ultrasound probe. *Int Braz J Urol*. 2014;40(1):125–126.

Giblin JG, Lossef S, Pahira JJ. A modification of standard percutaneous nephrolithotripsy technique for the morbidly obese patient. *Urology*. 1995;46:491–493.

Giddens JL, Grotas AB, Grasso M. Stone granuloma causes ureteropelvic junction obstruction after percutaneous nephrolithotomy and antegrade endopyelotomy. *J Urol*. 2000;164:118.

Giedelman C, Arriaga J, Carmona O, et al. Laparoscopic anatrophic nephrolithotomy: developments of the technique in the era of minimally invasive surgery. *J Endourol*. 2012;26(5):444–450.

Gil-Vernet J. New surgical concepts in removing renal calculi. *Urol Int*. 1965;20:255–288.

Gil-Vernet JM, Culla A. Advances in intraoperative renal radiography: 3-dimensional radiography of the kidney. *J Urol*. 1981;125:614–619.

Gleason PE, Kelalis PP, Husmann DA, et al. Hydronephrosis in renal ectopia: incidence, etiology and significance. *J Urol*. 1994;151:1660–1661.

Glowacki LS, Beecroft ML, Cook RJ, et al. The natural history of asymptomatic urolithiasis. *J Urol*. 1992;147:319–321.

Gluckman GR, Stoller M, Irby P. Laparoscopic pyelocaliceal diverticula ablation. *J Endourol*. 1993;7:315–317.

Goldwasser B, Cohan RH, Dunnick NR, et al. Role of linear tomography in evaluation of patients with nephrolithiasis. *Urology*. 1989;33:253–256.

Goodman TM. Ureterorenoscopy with pediatric cystoscope in adults. *Urology*. 1977;9:394.

Goodwin WE, Casey WC, Woolf W. Percutaneous trocar (needle) nephrostomy in hydronephrosis. *JAMA*. 1955;157:891–894.

Goumas-Kartalas I, Montanari E. Percutaneous nephrolithotomy in patients with spinal deformities. *J Endourol*. 2010;24(7):1081–1089.

Gowel R, Yadav R, Gupta NP, et al. Laparoscopic assisted percutaneous nephrolithotomy (PCNL) in ectopic kidneys: two different techniques. *Int Urol Nephrol*. 2006;38(1):75–78.

Graff J, Diederichs W, Schulze H. Long-term followup in 1,003 extracorporeal shock wave lithotripsy patients. *J Urol*. 1988;140(3):479–483.

Graham JB, Nelson JB. Percutaneous caliceal irrigation during extracorporeal shock wave lithotripsy for lower pole renal calculi. *J Urol*. 1994;152(Pt 2):2227.

Grasso M, Beaghler M, Loisides P. The case for primary endoscopic management of upper urinary tract calculi. II. Cost and outcome assessment of 112 primary ureteral calculi. *Urology*. 1995;45:372–376.

Grasso M, Chalik Y. Principles and applications of laser lithotripsy: experience with the holmium laser lithotrite. *J Clin Laser Med Surg*. 1998;16:3–7.

Grasso M, Conlin M, Bagley D. Retrograde ureteropyeloscopic treatment of 2 cm or greater upper urinary tract and minor staghorn calculi. *J Urol*. 1998;160(2):346–351.

Grasso M, Ficazzola M. Retrograde ureteropyeloscopy for lower pole caliceal calculi. *J Urol*. 1999;162:1904–1908.

Grasso M, Lang G, Loisides P, et al. Endoscopic management of the symptomatic caliceal diverticular calculus. *J Urol*. 1995;153:1878–1881.

Grasso M. Ureteropyeloscopic treatment of ureteral and intrarenal calculi. *Urol Clin North Am*. 2000;27(4):623–631.

Greene ML, Fujimoto WY, Seegmiller JE. Urinary xanthine stones—a rare complication of allopurinol therapy. *N Engl J Med*. 1969;280:426–427.

Griffith DP, Valiquette L. PICA/burden: a staging system for upper tract urinary stones. *J Urol*. 1987;138:253–257.

Gucuk A, Kemahli E, Uyeturk U, et al. Routine flexible nephroscopy for percutaneous nephrolithotomy for renal stones with low density: a prospective, randomized study. *J Urol*. 2013;190(1):144–148.

Gupta M, Lee MW. Treatment of stones associated with complex or anomalous renal anatomy. *Urol Clin North Am*. 2007;34:431–441.

Gupta NP, Ansari MS, Kesarvani P, et al. Role of computed tomography with no contrast medium enhancement in predicting the outcome of extracorporeal shock wave lithotripsy for urinary calculi. *BJU Int*. 2005;95(9):1285–1288.

Gupta NP, Mishra S, Nayyar R, et al. Comparative analysis of percutaneous nephrolithotomy in patients with and without a history of open stone surgery: single center experience. *J Endourol*. 2009;23:913–916.

Gupta NP, Mishra S, Seth A, et al. Percutaneous nephrolithotomy in abnormal kidneys: single-center experience. *Urology*. 2009;73:710–715.

Gupta NP, Singh DV, Hemal AK, et al. Infundibulopelvic anatomy and clearance of inferior caliceal calculi with shock wave lithotripsy. *J Urol*. 2000;163:24–27.

Hafron J, Fogarty JD, Boczko J, et al. Combined ureterorenoscopy and shock wave lithotripsy for large renal stone burden: an alternative to percutaneous nephrolithotomy? *J Endourol*. 2005;19(4):464–468.

Hamm M, Wawroschek F, Weckermann D, et al. Unenhanced helical computed tomography in the evaluation of acute flank pain. *Eur Urol*. 2001;39(4):460–465.

Harewood LM, Agarwal D, Lindsay S, et al. Extraperitoneal laparoscopic caliceal diverticulectomy. *J Endourol*. 1996;10:425–430.

He Z, Li X, Chen L, et al. Minimally invasive percutaneous nephrolithotomy for upper urinary tract calculi in transplanted kidneys. *BJU Int*. 2007;99:1467–1471.

Heidenreich A, Desgrandchamps F, Terrier F. Modern approach of diagnosis and management of acute flank pain: review of all imaging modalities. *Eur Urol*. 2002;41:351–362.

Helal M, Black T, Lockhart J, et al. The Hickman peel-away sheath: alternative for pediatric percutaneous nephrolithotomy. *J Endourol*. 1997;11:171–172.

Hemal AK, Nayyar R, Gupta NP, et al. Experience with robotic assisted laparoscopic surgery in upper tract urolithiasis. *Can J Urol*. 2010;17:5299–5305.

Hemal AK, Nayyar R, Rao R. Robotic repair of primary symptomatic obstructive megaureter with intracorporeal or extracorporeal ureteric tapering and ureterneocystotomy. *J Endourol*. 2009;23:2041–2046.

Hepp W. *Survey of the development of shock wave lithotripsy*. Dornier Medizintechnik GmbH: Wessling (Germany); 1984.

Herman JR. *Urology, a view through the retrospectoscope*. Harper & Row: Hagerstown, MD; 1973.

Hertzig LL, Iwaszko MR, Rangel LJ, et al. Urolithiasis after ileal conduit urinary diversion: a comparison of minimally invasive therapies. *J Urol*. 2013;189:2152–2157.

Hidas G, Eliahou R, Duvdevani M, et al. Determination of renal stone composition with dual-energy CT: in vivo analysis and comparison with x-ray diffraction. *Radiology*. 2010;257(2):394–401.

Hirschowitz BI, Peters CW, Curtiss LE. Preliminary report on a long fiberscope for examination of stomach and duodenum. *Med Bull (Ann Arbor)*. 1957;23:178–180.

Hjollund Madsen E. The value of tomography for the demonstration of small intrarenal calcifications. *Br J Radiol*. 1972;45:203–206.

Hockley NM, Lingeman JE, Hutchinson CL. Relative efficacy of extracorporeal shock wave lithotripsy and percutaneous nephrostolithotomy in the management of cystine calculi. *J Endourol*. 1989;3:273–285.

Hoenig DM, Shalhav AL, Elbahnassy AM, et al. Laparoscopic pyelolithotomy in a pelvic kidney: a case report and review of the literature. *JSLS*. 1997;1:163–165.

Hohenfellner M, Schultz-Lampel D, Lampel A, et al. Tumor in the horseshoe kidney: clinical implications and review of embryogenesis. *J Urol*. 1992;147:1098–1102.

Hollenbeck BK, Schuster TG, Faerber GJ, et al. Flexible ureteroscopy in conjunction with in situ lithotripsy for lower pole calculi. *Urology*. 2001;58:859–863.

Hollingsworth JM, Canales BK, Rogers MA, et al. Alpha blockers for treatmet of ureteric stones: systematic review and meta-analysis. *BMJ*. 2016;355.

Hollingsworth JM, Rogers MA, Kaufman SR, et al. Medical therapy to facilitate urinary stone passage: a meta-analysis. *Lancet*. 2006;368(9542):1171–1179.

Holman E, Toth C. Laparoscopically assisted percutaneous transperitoneal nephrolithotomy in pelvic dystopic kidneys: experience in 15 successful cases. *J Laparoendosc Adv Surg Tech A*. 1998;8(6):431–435.

Holm-Nielsen A, Jorgensen T, Mogensen P, et al. The prognostic value of probe renography in ureteric stone obstruction. *Br J Urol*. 1981;53:504–507.

Honeck P, Wendt-Nordahl G, Krombach P, et al. Does open stone surgery still play a role in the treatment of urolithiasis? Data of a primary urolithiasis center. *J Endourol*. 2009;23(7):1209–1212.

Hoznek A, Herard A, Ogiez N, et al. Symptomatic caliceal diverticula treated with extraperitoneal laparoscopic marsupialization fulguration and gelatin resorcinol formaldehyde glue obliteration. *J Urol*. 1998;160:352–355.

Hsu TH, Streem SB. Metabolic abnormalities in patients with caliceal diverticular calculi. *J Urol*. 1998;160:1640–1642.

Hubert KC, Palmer JS. Passive dilation by ureteral stenting before ureteroscopy: eliminating the need for active dilation. *J Urol*. 2005;174:1079–1080.

Hubner W, Porpaczy P. Treatment of caliceal calculi. *Br J Urol*. 1990;66:9–11.

Hubner WA, Irby P, Stoller ML. Natural history and current concepts for the treatment of small ureteral calculi. *Eur Urol*. 1993;24:172–176.

Huffman JL, Bagley DH. Balloon dilation of the ureter for ureteroscopy. *J Urol*. 1988;140:9540–9956.

Hulbert JC, Reddy PK, Hunter DW, et al. Percutaneous techniques for the management of caliceal diverticula containing calculi. *J Urol*. 1986;135:225–227.

Humphreys MR, Miller NL, Williams JC Jr, et al. A new world revealed: early experience with digital ureterorenoscopy. *J Urol*. 2008;179:970–975.

Hussain M, Acher P, Penev B, et al. Redefining the limits of flexible ureterorenoscopy. *J Endourol*. 2011;25(1):45–49.

Hussain Z, Inman RD, Elves AW, et al. Use of glyceryl trinitrate patches in patients with ureteral stones: a randomized, double-blind, placebo-controlled study. *Urology*. 2001;58(4):521–525.

Hyams E, Marien T, Bruhn A, et al. Ureterorenoscopy for transplant lithiasis. *J Endourol*. 2012;26(7):819–822.

Hyams ES, Winer AG, Shah O. Retrograde ureteral and renal access in patients with urinary diversion. *Urology*. 2009;74:47–50.

Inci K, Sahin A, Islamoglu E, et al. Prospective long-term followup of patients with asymptomatic lower pole caliceal stones. *J Urol*. 2007;177:2189–2192.

Ishii H, Couzins M, Aboumarzouk O, et al. Outcomes of systematic review of ureteroscopy for stone disease in the obese and morbidly obese population. *J Endourol*. 2016;30:135–145.

Jackman SV, Potter SR, Regan F, et al. Plain abdominal x-ray versus computerized tomography screening: sensitivity for stone localization after nonenhanced spiral computerized tomography. *J Urol*. 2000;164:308–310.

Janetschek G, Kunzel KH. Percutaneous nephrolithotomy in horseshoe kidneys. Applied anatomy and clinical experience. *Br J Urol*. 1988;62(2):117–122.

Jenkins AD, Gillenwater JY. Extracorporeal shock wave lithotripsy in the prone position: treatment of stones in the distal ureter or anomalous kidney. *J Urol*. 1988;139:911–915.

Johnston R, Lin A, Du J, et al. Comparison of kidney-ureter-bladder abdominal radiography and computed tomography films for identifying renal calculi. *BJU Int*. 2009;104(5):670–673.

Jones DJ, Wickham JE, Kellett MJ. Percutaneous nephrolithotomy for calculi in horseshoe kidneys. *J Urol*. 1991;145(3):481–483.

Jones JA, Lingeman JE, Steidle CP. The roles of extracorporeal shock wave lithotripsy and percutaneous nephrostolithotomy in the management of pyelocaliceal diverticula. *J Urol*. 1991;146:724–727.

Joseph P, Mandal AK, Singh SK, et al. Computerized tomography attenuation value of renal calculus: can it predict successful fragmentation of the calculus by extracorporeal shock wave lithotripsy? A preliminary study. *J Urol*. 2002;167:1968–1971.

Juan HC, Lin HY, Chou YH, et al. Abdominal fat distribution on computed tomography predicts ureteric calculus fragmentation by shock wave lithotripsy. *Eur Radiol*. 2012;22(8):1624–1630.

Jung GH, JUng JH, Ahn TS, et al. Comparison of retrograde intrarenal surgery versus a single-session percutaneous nephrolithotomy for lower-pole stones with a diameter of 15 to 30 mm: a propensity score-matching study. *Korean J Urol*. 2015;56(7):525–532.

Jung H, Norby B, Osther PJ. Retrograde intrarenal stone surgery for extracorporeal shock-wave lithotripsy-resistant kidney stones. *Scand J Urol Nephrol*. 2006;40(5):380–384.

Kachel TA, Vijan SR, Dretler SP. Endourological experience with cystine calculi and a treatment algorithm. *J Urol*. 1991;145:25–28.

Kamat N, Khandelwal P. Laparoscopic pyelolithotomy—a technique for the management of stones in the ectopic pelvic kidney. *Int J Urol*. 2004;11(7):581–584.

Kanao K, Nakashima J, Nakagawa K, et al. Preoperative nomograms for predicting stone-free rate after extracorporeal shock wave lithotripsy. *J Urol*. 2006;176(4 Pt 1):1453–1457.

Kandemir A, Guven S, Balasar M, et al. A prospective randomized comparison of micropercutaneous nephrolithotomy (microperc) and retrograde intrarenal surgery (rirs) for the management of lower pole kidney stones. *World J Urol*. 2017;35:1771–1776.

Kang HW, Lee SK, Kim WT, et al. Natural history of asymptomatic renal stones and prediction of stone related events. *J Urol*. 2013;189:1740–1746.

Kanno T, Kubota M, Sakamoto H, et al. The efficacy of ultrasonography for the detection of renal stone. *Urology*. 2014;84:285–288.

Kapoor DA, Leech JE, Yap WT, et al. Cost and efficacy of extracorporeal shock wave lithotripsy versus ureteroscopy in the treatment of lower ureteral calculi. *J Urol*. 1992;148(Pt 2):1095–1096.

Kartha G, Calle JC, Marchini GS, et al. Impact of stone disease: chronic kidney disease and quality of life. *Urol Clin North Am*. 2013;40(1):135–147.

Katz R, Admon D, Pode D. Life-threatening retroperitoneal hematoma caused by anticoagulant therapy for myocardial infarction after SWL. *J Endourol*. 1997;11:23–25.

Keeley FX Jr, Tilling K, Elves A, et al. Preliminary results of a randomized controlled trial of prophylactic shock wave lithotripsy for small asymptomatic renal calyceal stones. *BJU Int*. 2001;87:1–8.

Kelleher JP, Wakefield AJ, Gordon I, et al. Renal injury in complete ureteric obstruction: a functional and morphological study. *Urol Res*. 1991;19:245–248.

Khaitan A, Gupta NP, Hemal AK, et al. Post-ESWL, clinically insignificant residual stones: reality or myth? *Urology*. 2002;59:20–24.

Khalil MM. Which is more important in predicting the outcome of extracorporeal shockwave lithotripsy of solitary renal stones: stone location or stone burden? *J Endourol*. 2012;26(5):535–539.

Kim SC, Burns EK, Lingeman JE, et al. Cystine calculi: correlation of CT-visible structure, CT number, and stone morphology with fragmentation by shock wave lithotripsy. *Urol Res*. 2007;35(6):319–324.

Kim SC, Kuo RL, Tinmouth WW, et al. Percutaneous nephrolithotomy for caliceal diverticular calculi: a novel single stage approach. *J Urol*. 2005;173:1194–1198.

King SA, Klaassen Z, Madi R. Robot-assisted anatrophic nephrolithotomy: description of technique and early results. *J Endourol*. 2014;28(3):325–329.

Kirac M, Bozkurt OF, Tunc L, et al. Comparison of retrograde intrarenal surgery and mini-percutaneous nephrolithotomy in management of lower-pole renal stones with a diameter of smaller than 15 mm. *Urolithiasis*. 2013;41(3):241–246.

Kirkali Z, Esen AA, Mungan MU. Effectiveness of extracorporeal shockwave lithotripsy in the management of stone-bearing horseshoe kidneys. *J Endourol*. 1996;10:13–15.

Klee LW, Brito CG, Lingeman JE. The clinical implications of brushite calculi. *J Urol*. 1991;145:715–718.

Klingler HC, Kramer G, Lodde M, et al. Urolithiasis in allograft kidneys. *Urology*. 2002;59:344–348.

Knoll LD, Segura JW, Patterson DE, et al. Long-term followup in patients with cystine urinary calculi treated by percutaneous ultrasonic lithotripsy. *J Urol*. 1988;140:246–248.

Knudsen BE, Cook AJ, Watterson JD, et al. Percutaneous antegrade endopyelotomy: long-term results from one institution. *Urology*. 2004;63(2):230–234.

Kocher KE, Meurer WJ, Fazel R, et al. National treads in the use of computed tomography in the emergency department. *Ann Emerg Med*. 2011;58:452–462.

Koga S, Araki Y, Matsuoka MD, et al. Staghorn calculi: long-term results of management. *Br J Urol*. 1991;68:122–124.

Koh LT, Ng FC, Ng KK. Outcomes of long-term follow-up of patients with conservative management of asymptomatic renal calculi. *BJU Int*. 2012;109:622–625.

Kohan AD, Armenakas NA, Fracchia JA. Indinavir urolithiasis: an emerging cause of renal colic in patients with human immunodeficiency virus. *J Urol*. 1999;161(6):1765–1768.

Kohrmann KU, Rassweiler J, Alken P. The recurrence rate of stones following ESWL. *World J Urol*. 1993;11:26–30.

Koo BC, Burtt G, Burgess NA. Percutaneous stone surgery in the obese: outcome stratified according to body mass index.

BJU Int. 2004;93:1296–1299.

Kosar A, Turkolmez K, Sarica K, et al. Calyceal stones: fate of shock wave therapy with respect to stone location. *Int Urol Nephrol*. 1998;30(4):433–438.

Kourambas J, Delvecchio FC, Munver R, et al. Nitinol stone retrieval–assisted ureterorenoscopy management of lower pole calculi. *Urology*. 2000;56(6):935–939.

Krambeck AE, Handa SE, Evan AP, et al. Profile of the brushite stone former. *J Urol*. 2010;184(4):1367–1371.

Krambeck AE, LeRoy AJ, Patterson DE, et al. Longterm outcomes of percutaneous nephrolithotomy compared to shock wave lithotripsy and conservative management. *J Urol*. 2008;179:2233–2237.

Krambeck AE, LeRoy AJ, Patterson DE, et al. Percutaneous nephrolithotomy success in the transplant kidney. *J Urol*. 2008;180:2545–2549.

Krambeck AE, Lingeman JE. Percutaneous management of caliceal diverticuli. *J Endourol*. 2009;23(10):1723–1729.

Krambeck AE, Wijnstok N, Olbert P, et al. The influence of body mass index on outcomes in ureteroscopy: results from the clinical research office of endourological society URS global study. *J Endourol*. 2017;31:20–26.

Kulb TB, Lingeman JE, Coury TA, et al. Extracorporeal shock wave lithotripsy in patients with a solitary kidney. *J Urol*. 1986;136:786–788.

Kulkarni NM, Eisner BH, Pinho DF, et al. Determination of renal stone composition in phantom and patients using single-source dual-energy computed tomography. *J Comput Assist Tomogr*. 2013;37(1):37–45.

Kumar A, Goel A, Singh M, et al. Urolithiasis in primary obstructive megaureter: a management dilemma. *BMJ Case Rep*. 2014;2014.

Kumar R, Anand A, Saxena V, et al. Safety and efficacy of

PCNL for management of staghorn calculi in pediatric patients. *J Pediatr Urol*. 2011;7(3):248–251.

Kuntz NJ, Neisius A, Astroza GM, et al. Does body mass index impact the outcomes of tubeless percutaneous nephrolithotomy? *BJU Int*. 2014;114:404–411.

Kuo RL, Lingeman JE, Leveillee RJ, et al. A randomized clinical trial of ureterorenoscopy and percutaneous nephrolithotomy for lower pole stones between 11 and 25 mm. *J Endourol*. 2003;17:A31.

Kupeli B, Irkilata L, Gurocak S, et al. Does tamsulosin enhance lower ureteral stone clearance with or without shock wave lithotripsy? *Urology*. 2004;64(6):1111–1115.

Kuzgunbay B, Gul U, Turunc T, et al. Long-term renal function and stone recurrence after percutaneous nephrolithotomy in patients with renal insufficiency. *J Endourol*. 2010;24:305–308.

Lam HS, Lingeman JE, Barron M, et al. Staghorn calculi: analysis of treatment results between initial percutaneous nephrostolithotomy and extracorporeal shock wave lithotripsy monotherapy with reference to surface area. *J Urol*. 1992;147:1219–1225.

Lam HS, Lingeman JE, Mosbaugh PG, et al. Evolution of the technique of combination therapy for staghorn calculi: a decreasing role for extracorporeal shock wave lithotripsy. *J Urol*. 1992;148(Pt 2):1058–1062.

Lam JS, Greene TD, Gupta M. Treatment of proximal ureteral calculi: holmium:YAG laser ureterolithotripsy versus extracorporeal shock wave lithotripsy. *J Urol*. 2002;167:1972–1976.

Lampel A, Hohenfellner M, Schultz-Lampel D, et al. Urolithiasis in horseshoe kidneys: therapeutic management. *Urology*. 1996;47(2):182–186.

Lazare JN, Saltzman B, Sotolongo J. Extracorporeal shock wave lithotripsy treatment of spinal cord injury patients. *J Urol*. 1988;140:266–269.

Lee DI, Bagley DH. Long-term effects of ureteroscopic laser lithotripsy on glomerular filtration rate in the fact of mild to moderate renal insufficiency. *J Endourol*. 2001;15(7):715–717.

Lee MC, Bariol SV. Evolution of stone management in Australia. *BJU Int*. 2011;108(Suppl 2):29–33.

Lee YH, Tsai JY, Jiaan BP, et al. Prospective randomized trial comparing shock wave lithotripsy and ureteroscopic lithotripsy for management of large upper third ureteral stones. *Urology*. 2006;67:480–484.

Legemate JD, Baseskioglu B, Dobruch J, et al. Ureteroscopic urinary stone treatment among patients with renal anomalies: patient characteristics and treatment outcomes. *Urology*. 2017;110:52–62.

Legraverend D, Al-Qahtani SM, Doizi S, et al. Endoscopic treatment of renal diverticular stones (single centre study of 45 cases). *Prog Urol*. 2013;23(7):450–455.

Lennon GM, Thornhill JA, Grainger R, et al. Double pigtail ureteric stent versus percutaneous nephrostomy: effects on stone transit and ureteric motility. *Eur Urol*. 1997;31(1):24–29.

Levine JA, Neitlich J, Verga M, et al. Ureteral calculi in patients with flank pain: correlation of plain radiography with unenhanced helical CT. *Radiology*. 1997;204:27–31.

Liatsikos EN, Bernardo NO, Dinlenc CZ, et al. Caliceal diverticular calculi: is there a role for metabolic evaluation? *J Urol*. 2000;164:18–20.

Liedle B, Jocham D, Lunz C, et al. Five year follow-up of urinary stone treatment with extracorporeal shock wave lithotripsy. *J Endourol*. 1988;2:157–162.

Lingeman JE, Coury TA, Newman DM, et al. Comparison of results and morbidity of percutaneous nephrostolithotomy and extracorporeal shock wave lithotripsy. *J Urol*. 1987;138:485–490.

Lingeman JE, Newman D, Mertz JH, et al. Extracorporeal shock wave lithotripsy: the Methodist Hospital of Indiana experience. *J Urol*. 1986;135:1134–1137.

Lingeman JE, Siegel YI, Steele B, et al. Management of lower pole nephrolithiasis: a critical analysis. *J Urol*. 1994;151:663–667.

Lipkin ME, Preminger GM. Imaging techniques for stone disease and methods for reducing radiation exposure. *Urol Clin North Am*. 2013;40(1):47–57.

Liu LR, Li QJ, Wei Q, et al. Percussion, dieresis, and inversion therapy for the passage of lower pole kidney stones following shock wave lithotripsy. *Cochrane Database Syst Rev*. 2013;(12) [CD008569].

Locke DR, Newman RC, Steinbock GS, et al. Extracorporeal shock-wave lithotripsy in horseshoe kidneys. *Urology*. 1990;35:407–411.

Logarakis NF, Jewett MA, Luymes J, et al. Variation in clinical outcome following shock wave lithotripsy. *J Urol*. 2000;163:721–725.

Lorenz EC, Lieske JC, Vrtiska TJ, et al. Clinical characteristics of potential kidney donors with asymptomatic kidney stones. *Nephrol Dial Transplant*. 2011;26:2695–2700.

Lotan Y, Gettman MT, Roehrborn CG, et al. Management of ureteral calculi: a cost comparison and decision making analysis. *J Urol*. 2002;167:1621–1629.

Macejko A, Okotie OT, Zhao LC, et al. Computed tomography-determined stone-free rates for ureterorenoscopy of upper-tract stones. *J Endourol*. 2009;23:379–382.

Madbouly K, Sheir KZ, Elsobky E. Impact of lower pole renal anatomy on stone clearance after shock wave lithotripsy: fact or fiction? *J Urol*. 2001;165:1415–1418.

Maheshwari PN, Bhandarkar DS, Shah RS, et al. Laparoscopy-assisted transperitoneal percutaneous nephrolithotomy for recurrent calculus in isthmic calyx of horseshoe kidney. *J Endourol*. 2004;18(9):858–861.

Maheshwari PN, Oswal AT, Andankar M, et al. Is antegrade ureteroscopy better than retrograde ureteroscopy for impacted large upper ureteral calculi? *J Endourol*. 1999;13:441–444.

Makary MA, Segev DL, Pronovost PJ, et al. Frailty as a predictor of surgical outcomes in older patients. *J Am Coll Surg*. 2010;210(6):901–908.

Manikandan R, Gall Z, Gunendran T, et al. Do anatomic factors pose a significant risk in the formation of lower pole stones? *Urology*. 2007;69:620–624.

Marberger M, Stackl W, Hruby W, et al. Late sequelae of ultrasonic lithotripsy of renal calculi. *J Urol*. 1985;133:170–173.

Marchini GS, Remer EM, Gebreselassie S, et al. Stone characteristics on noncontrast computed tomography: establishing definitive patterns to discriminate calcium and uric acid compositions. *Urology*. 2013;82(3):539–546.

Marguet CG, Springhart WP, Tan YH, et al. Simultaneous combined use of flexible ureterorenoscopy and percutaneous nephrolithotomy to reduce the number of access tracts in the management of complex renal calculi. *BJU Int*. 2005;96(7):1097–1100.

Mariani AJ. Combined electrohydraulic and holmium:YAG laser ureteroscopic nephrolithotripsy of large (>2 cm) renal calculi. *Indian J Urol*. 2008;24(4):521–525.

Mariappan P, Smith G, Bariol SV, et al. Stone and pelvic urine culture and sensitivity are better than bladder urine as predictors of urosepsis following percutaneous nephrolithotomy: a prospective clinical study. *J Urol*.

2005;173:1610–1614.

Mariappan P, Smith G, Moussa SA, et al. One week of ciprofloxacin before percutaneous nephrolithotomy significantly reduces upper tract infection and urosepsis: a prospective controlled study. *BJU Int*. 2006;98(5):1075–1079.

Marshall S. Coagulum pyelolithotomy. *Urol Clin North Am*. 1983;10:659–664.

Marshall VF. Fiber optics in urology. *J Urol*. 1964;91:110–114.

Masson BM, Hoenig D. Carbon dioxide based nephroscopy: a trick for laparoscopic pyelolithotomy. *J Endourol*. 2008;22:2661–2663.

Matlaga BR, Kawamoto S, Fishman E. Dual source computed tomography: a novel technique to determine stone composition. *Urology*. 2008;72:1164–1168.

Matlaga BR, Kim SC, Watkins SL, et al. Percutaneous nephrolithotomy for ectopic kidneys: over, around, or through. *Urology*. 2006;67:513–517.

Matlaga BR, Kim SC, Watkins SL, et al. Pre-percutaneous nephrolithotomy opacification for caliceal diverticular calculi. *J Endourol*. 2006;20(3):175–178.

Matlaga BR, Miller NL, Terry C, et al. The pathogenesis of calyceal diverticular calculi. *Urol Res*. 2007;35:35–40.

Matlaga BR, Shah OD, Assimos DG. Drug-induced urinary calculi. *Rev Urol*. 2003;5:227–231.

Matlaga BR, Shah OD, Zagoria RJ, et al. Computerized tomography guided access for percutaneous nephrostolithotomy. *J Urol*. 2003;170(1):45–47.

McCullough DL. Extracorporeal shock wave lithotripsy and residual stone fragments in lower calices. *J Urol*. 1989;141:140.

Meretyk S, Bigg S, Clayman RV, et al. Caveat emptor: caliceal stones and the missing calix. *J Urol*. 1992;147:1091–1095.

Meretyk S, Gofrit ON, Gafni O, et al. Complete staghorn calculi: random prospective comparison between extracorporeal shock wave lithotripsy monotherapy and combined with percutaneous nephrostolithotomy. *J Urol*. 1997;157(3):780–786.

Micali S, Sighinolfi MC, Grande M, et al. Dornier lithotripter S 220 F EMSE: the first report of over 1000 treatments. *Urology*. 2009;74:1211–1214.

Michel MS, Trojan L, Rassweiler JJ. Complications in percutaneous nephrolithotomy. *Eur Urol*. 2007;51(4):899–906.

Michel W, Funke PJ, Tunn UW, et al. Pyelocalyceal diverticula. *Int Urol Nephrol*. 1985;17:225–230.

Middleton AW Jr, Pfister RC. Stone-containing pyelocaliceal diverticulum: embryogenic, anatomic, radiologic and clinical characteristics. *J Urol*. 1974;111:2–6.

Miller OF, Kane CJ. Time to stone passage for observed ureteral calculi: a guide for patient education. *J Urol*. 1999;162(Pt 1):688–690 [discussion 690–691].

Miller SD, Ng CS, Streem SB, et al. Laparoscopic management of caliceal diverticular calculi. *J Urol*. 2002;167:1248–1252.

Mishra S, Sabnis RB, Desai M. Staghorn morphometry: a new clinical classification and prediction model for percutaneous nephrolithotomy monotherapy. *J Endourol*. 2012;26(1):6–14.

Mishra S, Sharma R, Garg C, et al. Prospective comparative study of miniperc and standard PNL for treatment of 1 to 2 cm size renal stone. *BJU Int*. 2011;108(6):896–899.

Mitcheson HD, Zamenhof RG, Bankoff MS, et al. Determination of the chemical composition of urinary calculi by computerized tomography. *J Urol*. 1983;130(4):814–819.

Molimard B, Al-Qahtani S, Lakmichi A, et al. Flexible ureterorenoscopy with holmium laser in horseshoe kidneys. *Urology*. 2010;76(6):1334–1337.

Monga M, Castaneda-Zuniga WR, Thomas R. Femoral neuropathy following percutaneous nephrolithotomy of a pelvic kidney. *Urology*. 1995;45(6):1059–1061.
Monga M, Smith R, Ferral H, et al. Percutaneous ablation of caliceal diverticulum: long-term followup. *J Urol*. 2000;163:28–32.
Morse RM, Resnick MI. Ureteral calculi: natural history and treatment in an era of advanced technology. *J Urol*. 1991;145:263–265.
Moskovitz B, Halachmi S, Sopov V, et al. Effect of percutaneous nephrolithotripsy on renal function: assessment with quantitative SPECT of (99m) Tc-DMSA renal scintigraphy. *J Endourol*. 2006;20(2):102–106.
Mostafavi MR, Ernst RD, Saltzman B. Accurate determination of chemical composition of urinary calculi by spiral computerized tomography. *J Urol*. 1998;159:673–675.
Mufarrij PW, Woods M, Shah OD, et al. Robotic dismembered pyeloplasty: a 6-year multi-institutional experience. *J Urol*. 2008;180(4):1391–1396.
Murphy LJ. *The history of urology*. Charles C. Thomas: Springfield (IL); 1972.
Murray MJ, Chandhoke PS, Berman CJ, et al. Outcome of extracorporeal shockwave lithotripsy monotherapy for large renal calculi: effect of stone and collecting system surface areas and cost-effectiveness of treatment. *J Endourol*. 1995;9:9–13.
Mutgi A, Williams JW, Nettleman M. Renal colic. Utility of the plain abdominal roentgenogram. *Arch Intern Med*. 1991;151:1589–1592.
Nabbout P, Slobodov G, Mellis AM, et al. Percutaneous nephrolithotomy in spinal cord neuropathy patients: a single institution experience. *J Endourol*. 2012;26(12):1610–1613.
Nadler RB, Rubenstein JN, Eggener SE, et al. The etiology of

urolithiasis in HIV infected patients. *J Urol*. 2003;169(2):475–477.

Nadler RB, Stern JA, Kimm S, et al. Coronal imaging to assess urinary tract stone size. *J Urol*. 2004;172:962–964.

Nakada SY, Hoff DG, Attai S, et al. Determination of stone composition by noncontrast spiral computed tomography in clinical setting. *Urology*. 2000;55(6):816–819.

Nakamoto T, Sagami K, Yamasaki A, et al. Long-term results of endourologic treatment of urinary calculi: investigation of risk factors for recurrence or regrowth. *J Endourol*. 1993;7:297–301.

Nasseh H, Pourreza F, Kazemnejad LE, et al. Laparoscopic transperitoneal ureterolithotomy: a single-center experience. *J Laparoendosc Adv Surg Tech A*. 2013;23:495–499.

Natalin R, Xavier K, Okeke Z, et al. Impact of obesity on ureteroscopic laser lithotripsy of urinary tract calculi. *Int Braz J Urol*. 2009;35(1):36–41 [discussion 41–42].

Nayyar R, Singh P, Gupta NP. Robot-assisted laparoscopic pyeloplasty with stone removal in an ectopic pelvic kidney. *JSLS*. 2010;14(1):130–132.

Neisius A, Wollner J, Thomas C, et al. Treatment efficacy and outcomes using a third generation shockwave lithotripter. *BJU Int*. 2013;112(7):972–981.

Nemoy NJ, Staney TA. Surgical, bacteriological, and biochemical management of infection stones. *JAMA*. 1971;215:1470–1476.

Netto NR Jr, Claro JF, Lemos GC, et al. Renal calculi in lower pole calices: what is the best method of treatment? *J Urol*. 1991;146:721–723.

Neuwirth H, Royce PL, Chaussy C. Use of extracorporeal shock-wave lithotripsy in quadriplegic patients. *JAMA*. 1986;256:1295.

Newman DM, Lingeman JE, Mosbaugh PM, et al. Two year follow up of patients treated with extracorporeal shock wave lithotripsy. *J Endourol*. 1988;2:163–171.

Ng CF, Wong A, Tolley D. Is extracorporeal shock wave lithotripsy the preferred treatment option for elderly patients with urinary stone? A multivariate analysis of the effect of patient age on treatment outcome. *BJU Int*. 2007;100(2):392–395.

Nicely ER, Maggio MI, Kuhn EJ. The use of a cystoscopically placed cobra catheter for directed irrigation of lower pole caliceal stones during extracorporeal shock wave lithotripsy. *J Urol*. 1992;148(Pt 2):1036–1039.

Nijman RJ, Ackaert K, Scholtmeijer RJ, et al. Long-term results of extracorporeal shock wave lithotripsy in children. *J Urol*. 1989;142(Pt 2):609–611 [discussion 619].

Obek C, Onal B, Kantay K, et al. The efficacy of extracorporeal shock wave lithotripsy for isolated lower pole calculi compared with isolated middle and upper caliceal calculi. *J Urol*. 2001;166:2081–2084 [discussion 2085].

Okeke Z, Smith AD, Labate G, et al. Prospective comparison of outcomes of percutaneous nephrolithotomy in elderly patients versus younger patients. *J Endourol*. 2012;26(8):996–1001.

Older RA, Jenkins AD. Stone disease. *Urol Clin North Am*. 2000;27:215–229 [vii].

Oliveira EA, Diniz JS, Rabelo EA, et al. Primary megaureter detected by prenatal ultrasonography: conservative management and prolonged follow-up. *Int Urol Nephrol*. 2000;32:13–18.

Ordon M, Urbach D, Mamdani M, et al. The surgical management of kidney stone disease: a population-based time series analysis. *J Urol*. 2014;192(5):1450–1456.

Osman M, Alfano Y, Kamp S, et al. 5-year-follow-up of patients with clinically insignificant residual fragments after extracorporeal shockwave lithotripsy. *Eur Urol*.

2005;47:860–864.

Osman M, Wendt-Nordahl G, Heger K, et al. Percutaneous nephrolithotomy with ultrasonography guided renal access: experience from over 300 cases. *BJU Int*. 2005;96(6):875–878.

Osman MM, Gamal WM, Gadelmoula MM, et al. Ureteroscopic retrograde intrarenal surgery after previous open renal stone surgery: initial experience. *Urol Res*. 2012;40(4):403–408.

Osther PJ, Razvi H, Liatsikos E, et al. Percutaneous nephrolithotomy among patients with renal anomalies: patient characteristics and outcomes; a subgroup analysis of the Clinical Research Office of the Endourological Society global percutaneous nephrolithotomy study. *J Endourol*. 2011;25(10):1627–1632.

Ouzaid I, Al-gahtani S, Dominique S, et al. A 970 Hounsfield units (HU) threshold of kidney stone density on non-contrast computed tomography (NCCT) improves patients' selection for extracorporeal shockwave lithotripsy (ESWL): evidence from a prospective study. *BJU Int*. 2012;110(11 Pt B):E438–E442.

Ozden E, Bilen CY, Mercimek MN, et al. Horseshoe kidney: does it really have any negative impact on surgical outcomes of percutaneous nephrolithotomy? *Urology*. 2010;75:1049–1052.

Ozturk U, Sener NC, Goktug HN, et al. Comparison of percutaneous nephrolithotomy, shock wave lithotripsy, and retrograde intrarenal surgery for lower pole renal calculi 10–20 mm. *Urol Int*. 2013;91(3):345–349.

Pace KT, Tariq N, Dyer SJ, et al. Mechanical percussion, inversion and diuresis for residual lower pole fragments after shock wave lithotripsy: a prospective, single blind, randomized controlled trial. *J Urol*. 2001;166:2065–2071.

Paik ML, Resnick MI. Is there a role for open stone surgery?

Urol Clin North Am. 2000;27(2):323–331.

Pareek G, Hedican SP, Lee FT Jr, et al. Shock wave lithotripsy success determined by skin-to-stone distance on computed tomography. *Urology*. 2005;66(5):941–944.

Park J, Hong B, Park T, et al. Effectiveness of noncontrast computed tomography in evaluation of residual stones after percutaneous nephrolithotomy. *J Endourol*. 2007;21:684–687.

Parker BD, Frederick RW, Reilly TP, et al. Efficiency and cost of treating proximal ureteral stones: shock wave lithotripsy versus ureteroscopy plus holmium:yttrium-aluminum-garnet laser. *Urology*. 2004;64(6):1102–1106.

Parkhomenko E, Tran T, Thai J, et al. Percutaneous management of stones containing calyceal diverticula: associated factors and outcoes. *J Urol*. 2017;198:864–868.

Parks JH, Worcester EM, Coe FL, et al. Clinical implications of abundant calcium phosphate in routinely analyzed kidney stones. *Kidney Int*. 2004;66(2):777–785.

Patel T, Kellner CP, Katsumi H, et al. Efficacy of endopyelotomy in patients with secondary ureteropelvic junction obstruction. *J Endourol*. 2011;25(4):587–591.

Patterson DE, Segura JW, LeRoy AJ. Long term follow-up of patients treated by percutaneous ultrasonic lithotripsy for struvite staghorn calculi. *J Endourol*. 1987;1:177–180.

Pearle MS, Lingeman JE, Leveillee R, et al. Prospective, randomized trial comparing shock wave lithotripsy and ureterorenoscopy for lower pole renal caliceal calculi 1 cm or less. *J Urol*. 2005;173(6):2005–2009.

Pearle MS, Nadler R, Bercowsky E, et al. Prospective randomized trial comparing shock wave lithotripsy and ureteroscopy for management of distal ureteral calculi. *J Urol*. 2001;166:1255–1260.

Pearle MS, Nakada SY, Womack JS, et al. Outcomes of contemporary percutaneous nephrostolithotomy in morbidly obese patients. *J Urol*. 1998;160(Pt 1):669–763.

Pearle MS, Watamull LM, Mullican MA. Sensitivity of noncontrast helical computerized tomography and plain film radiography compared to flexible nephroscopy for detecting residual fragments after percutaneous nephrostolithotomy. *J Urol*. 1999;162:23–26.

Perez Castro E, Osther PJ, Jinga V, et al. Differences in ureteroscopic stone treatment and outcomes for distal, mid-, proximal, or multiple ureteral locations: the Clinical Research Office of the Endourological Society ureteroscopy global study. *Eur Urol*. 2014;66:102–109.

Perks AE, Schuler TD, Lee J, et al. Stone attenuation and skin-to-stone distance on computed tomography predicts for stone fragmentation by shock wave lithotripsy. *Urology*. 2008;72(4):765–769.

Perlmutter AE, Talug C, Tarry WF, et al. Impact of stone location on success rates of endoscopic lithotripsy for nephrolithiasis. *Urology*. 2008;71(2):214–217.

Pfister SA, Deckart A, Laschke S, et al. Unenhanced helical computed tomography vs. intravenous urography in patients with acute flank pain: accuracy and economic impact in a randomized prospective trial. *Eur Radiol*. 2003;13(11):2513–2520.

Pickard R, Starr K, MacLennan G, et al. Medical expulsive therapy in adults with ureteric colic: a multicenter, randomized, placebo-controlled trial. *Lancet*. 2015;386:341–349.

Pietrow PK, Auge BK, Weizer AZ, et al. Durability of the medical management of cystinuria. *J Urol*. 2003;169:68–70.

Pittomvils G, Vandeursen H, Wevers M, et al. The influence of internal stone structure upon the fracture behaviour of urinary calculi. *Ultrasound Med Biol*. 1994;20:803–810.

Pitts WR Jr, Muecke EC. Congenital megaloureter: a review of 80 patients. *J Urol*. 1974;111:468–473.

Pitts WR, Muecke EC. Horseshoe kidneys: a 40-year experience. *J Urol*. 1975;113:743–746.

Portis AJ, Rygwall R, Holtz C, et al. Ureteroscopic laser lithotripsy for upper urinary tract calculi with active fragment extraction and computerized tomography followup. *J Urol*. 2006;175:2129–2133.

Portis AJ, Yan Y, Pattaras JG, et al. Matched pair analysis of shock wave lithotripsy effectiveness for comparison of lithotriptors. *J Urol*. 2003;169:58–62.

Powell T, Hsu FF, Turk J, et al. Ma-huang strikes again: ephedrine nephrolithiasis. *Am J Kidney Dis*. 1998;32:153–159.

Prather GC. Calyceal diverticulum. *J Urol*. 1941;45:55.

Preminger GM, Assimos DG, Lingeman JE, et al. AUA guideline on management of staghorn calculi: diagnosis and treatment recommendations. *J Urol*. 2005;173:1991–2000.

Preminger GM, Tiselius HG, Assimos DG, et al. 2007 guideline for the management of ureteral calculi. *J Urol*. 2007;178:2418–2434.

Raj GV, Auge BK, Weizer AZ, et al. Percutaneous management of calculi within horseshoe kidneys. *J Urol*. 2003;170:48–51.

Ramakumar S, Lancini V, Chan DY, et al. Laparoscopic pyeloplasty with concomitant pyelolithotomy. *J Urol*. 2002;167(3):1378–1380.

Ramakumar S, Segura JW. Laparoscopic surgery for renal urolithiasis: pyelolithotomy, caliceal diverticulectomy, and treatment of stones in a pelvic kidney. *J Endourol*. 2000;14(10):829–832.

Raman JD, Bagrodia A, Gupta A, et al. Natural history of residual fragments following percutaneous nephrostolithotomy. *J Urol*. 2009;181:1163–1168.

Raman JD, Pearle MS. Management options for lower pole renal calculi. *Curr Opin Urol*. 2008;18(2):214–219.

Rassweiler JJ, Renner C, Chaussy C, et al. Treatment of renal stones by extracorporeal shock wave lithotripsy: an update. *Eur Urol*. 2001;39(2):187–199.

Rassweiler JJ, Subotic S, Feist-Schwenk M, et al. Minimally invasive treatment of ureteropelvic junction obstruction: long-term experience with an algorithm for laser endopyelotomy and laparoscopic retroperitoneal pyeloplasty. *J Urol*. 2007;177:1000–1005.

Ray AA, Ghiculete D, D'A Honey RJ, et al. Shockwave lithotripsy in patients with horseshoe kidney: determinants of success. *J Endourol*. 2011;25(3):487–493.

Rayer PP. *Traitements des maladies des reins 3*. Baillere: Paris; 1841:507.

Rebuck DA, Macejko A, Bhalani V, et al. The natural history of renal stone fragments following ureterorenoscopy. *Urology*. 2011;77(3):564–568.

Redman JF. Partial nephrectomy. *Urol Clin North Am*. 1983;10:677–684.

Reiter WJ, Schon-Pernerstorfer H, Dorfinger K, et al. Frequency of urolithiasis in individuals seropositive for human immunodeficiency virus treated with indinavir is higher than previously assumed. *J Urol*. 1999;161(4):1082–1084.

Renner C, Rassweiler J. Treatment of renal stones by extracorporeal shock wave lithotripsy. *Nephron*. 1999;81(Suppl 1):71–81.

Resorlu B, Diri A, Atmaca AF, et al. Can we avoid percutaneous nephrolithotomy in high-risk patients using Charlson comorbidity index? *Urology*. 2012;79(5):1042–1047.

Resorlu B, Kara C, Senocak C, et al. Effect of previous open renal surgery and failed extracorporeal shockwave lithotripsy on the performance and outcomes of percutaneous nephrolithotomy. *J Endourol*. 2010;24(1):13–16.

Resorlu B, Oguz U, Resorlu EB, et al. The impact of pelvicaliceal anatomy on the success of retrograde intrarenal surgery in patients with lower pole renal stones. *Urology*. 2012;79:61–66.

Resorlu B, Ozyuvali E, Oguz U, et al. Retrograde intrarenal surgery in patients with spinal deformities. *J Endourol*. 2012;26(9):1131–1135.

Resorlu B, Unsal A, Ziypak T, et al. Comparison of retrograde intrarenal surgery, shockwave lithotripsy, and percutaneous nephrolithotomy for treatment of medium-sized radiolucent renal stones. *World J Urol*. 2013;31(6):1581–1586.

Revenig LM, Canter DJ, Master VA, et al. A prospective study examining the association between preoperative frailty and postoperative complications in patients undergoing minimally invasive surgery. *J Endourol*. 2014;28(4):476–480.

Rich MA. Ureteroscopy of the abnormal ureter. *Urol Clin North Am*. 1988;15:407–412.

Riddell J, Case A, Wopat R, et al. Sensitivity of emergency bedside ultrasound to detect hydronephrosis in patients with computed tomography-proven stones. *West J Emerg Med*. 2014;15:96–100.

Riedler I, Trummer H, Hebel P, et al. Outcome and safety of extracorporeal shock wave lithotripsy as first-line therapy of lower pole nephrolithiasis. *Urol Int*. 2003;71(4):350–354.

Rifaioglu MM, Berger AD, Pengune W, et al. Percutaneous management of stones in transplanted kidneys. *Urology*. 2008;72(3):508–512.

Ringden I, Tiselius HG. Composition and clinically determined hardness of urinary tract stones. *Scand J Urol Nephrol*. 2007;41(4):316–323.

Rippel C, Nikkel L, Lin YK, et al. Residual fragments following ureteroscopic lithotripsy: incidence and predictors on postoperative computerized tomography. *J Urol*. 2012;188(6):2246–2251.

Rocco F, Mandressi A, Larcher P. Surgical classification of renal calculi. *Eur Urol*. 1984;10:121–123.

Rosenblatt GS, Takesita K, Fuchs GJ. Urolithiasis in adults with congenital megaureter. *Can Urol Assoc J*. 2009;3:E77–E80.

Rous SN, Turner WR. Retrospective study of 95 patients with staghorn calculus disease. *J Urol*. 1977;118:902–904.

Rowley MW, Faerber GJ, Wolf JS Jr. The University of Michigan experience with percutaneous nephrostolithotomy for urinary matrix calculi. *Urology*. 2008;72(1):61–64.

Rubenstein JN, Gonzalez CM, Blunt LW, et al. Safety and efficacy of percutaneous nephrolithotomy in patients with neurogenic bladder dysfunction. *Urology*. 2004;63(4):636–640.

Rubenstein RA, Zhao LC, Loeb S, et al. Prestenting improves ureteroscopic stone-free rates. *J Endourol*. 2007;21:1277–1280.

Ruckle HC, Segura JW. Laparoscopic treatment of a stone-filled, caliceal diverticulum: a definitive, minimally invasive therapeutic option. *J Urol*. 1994;151:122–124.

Rudnick DM, Bennett PM, Dretler SP. Retrograde renoscopic fragmentation of moderate-size (1.5–3.0-cm) renal cystine stones. *J Endourol*. 1999;13:483–485.

Ruggera L, Zanin M, Beltrami P, et al. Retrograde transurethral approach: a safe and efficient treatment for recurrent cystine renal stones. *Urol Res*. 2011;39(5):411–415.

Ruiz H, Saltzman B. Aspirin-induced bilateral renal hemorrhage after extracorporeal shock wave lithotripsy: implications and conclusions. *J Urol*. 1990;143:791–792.

Rupel E, Brown R. Nephroscopy with removal of stone following nephrostomy for obstructive calculus anuria. *J Urol*. 1941;46:177.

Rutchik SD, Resnick MI. Ureteropelvic junction obstruction and renal calculi: pathophysiology and implications for management. *Urol Clin North Am*. 1998;25:317–321.

Sabnis R, Naik K, Desai MR, et al. Extracorporeal shockwave lithotripsy for lower calyceal stones: can clearance be predicted? *Br J Urol*. 1997;80:853–857.

Sabnis RB, Ganesamoni R, Doshi A, et al. Micropercutaneous nephrolithotomy (microperc) vs. retrograde intrarenal surgery for the management of small renal calculi: a randomized controlled trial. *BJU Int*. 2013;112(3):355–361.

Sabnis RB, Jagtap J, Mishra S, et al. Treating renal calculi 1–2 cm in diameter with minipercutaneous or retrograde intrarenal surgery: a prospective comparative study. *BJU Int*. 2012;110(8 Pt B):E346–E349.

Sampaio FJ, Aragao AH. Inferior pole collecting system anatomy: its probable role in extracorporeal shock wave lithotripsy. *J Urol*. 1992;147:322–324.

Sampaio FJ, Aragao AH. Limitations of extracorporeal shockwave lithotripsy for lower caliceal stones: anatomic insight. *J Endourol*. 1994;8:241–247.

Sare GM, Lloyd FR, Stower MJ. Life-threatening haemorrhage after extracorporeal shockwave lithotripsy in a patient taking clopidogrel. *BJU Int*. 2002;90:469.

Saw KC, Lingeman JE. Management of calyceal stones. *AUA Update Series*. 1999;20:154–159.

Schatloff O, Linder U, Ramon J, et al. Randomized trial of stone fragment active retrieval versus spontaneous passage during holmium laser lithotripsy for ureteral stones. *J Urol*. 2010;183:1031–1036.

Schiff RG, Lee WJ, Eshghi M, et al. Morphologic and functional changes in the kidney after percutaneous nephrosto-lithotomy. *AJR Am J Roentgenol*. 1986;147:283–286.

Schlussel RN. Ectopic ureter, ureterocele, and other anomalies of the ureter. Wein AJ. *Campbell-Walsh urology*. 9th ed. Saunders: Philadelphia; 2007:3383–3422.

Schultheiss D, Engel RM, Crosby RW, et al. Max Brödel (1870–1941) and medical illustration in urology. *J Urol*. 2000;164:1137–1142.

Schuster TG, Hollenbeck BK, Faerber GJ, et al. Ureteroscopic treatment of lower pole calculi: comparison of lithotripsy in situ and after displacement. *J Urol*. 2002;168:43–45.

Schwartz G, Lipschitz S, Becker JA. Detection of renal calculi: the value of tomography. *AJR Am J Roentgenol*. 1984;143:143–145.

Segura JW, Patterson D, Leroy AJ, et al. Percutaneous removal of kidney stones: review of 1000 cases. *J Urol*. 1985;134:1077–1081.

Segura JW, Preminger GM, Assimos DG, et al. Nephrolithiasis Clinical Guidelines Panel summary report on the management of staghorn calculi. The American Urological Association Nephrolithiasis Clinical Guidelines Panel. *J Urol*. 1994;151:1648–1651.

Segura JW. Staghorn calculi. *Urol Clin North Am*. 1997;24:71–80.

Seitz C, Liatsikos E, Porpiglia F, et al. Medical therapy to facilitate the passage of stones: what is the evidence? *Eur Urol*. 2009;56(3):455–471.

Seitz C, Martini T, Berner L, et al. Efficacy and treatment outcome of a new electromagnetic lithotripter for upper urinary tract calculi. *J Endourol*. 2008;22(11):2519–2525.

Semerci B, Verit A, Nazli O, et al. The role of ESWL in the treatment of calculi with anomalous kidneys. *Eur Urol*. 1997;31(3):302–304.

Semins MJ, Feng Z, Trock B, et al. Evaluation of acute renal colic: a comparison of non-contrast CT versus 3-T non-contrast HASTE MR urography. *Urolithiasis*. 2013;41(1):43–46.

Sener NC, Bas O, Sener E, et al. Asymptomatic lower pole small renal stones: shock wave lithotripsy, flexible ureteroscopy, or observation? A prospective randomized trial. *Urology*. 2015;85:33–37.

Sener NC, Imamoglu MA, Bas O, et al. Prospective randomized trial comparing shock wave lithotripsy and flexible ureterorenoscopy for lower pole stones smaller than 1 cm. *Urolithiasis*. 2014;42(2):127–131.

Shah HN, Kharodawala S, Sodha HS, et al. The management of renal matrix calculi: a single-centre experience over 5 years. *BJU Int*. 2009;103(6):810–814.

Shah J, Whitfield HN. Urolithiasis through the ages. *BJU Int*. 2002;89:801–810.

Shahrour K, Tomaszewski J, Ortiz T, et al. Predictors of immediate postoperative outcome of single-tract percutaneous nephrolithotomy. *Urology*. 2012;80(1):19–25.

Shalhav AL, Soble JJ, Nakada SY, et al. Long-term outcome of caliceal diverticula following percutaneous endosurgical management. *J Urol*. 1998;160:1635–1639.

Sheir KZ, Madbouly K, Elsobky E. Extracorporeal shock wave lithotripsy in anomalous kidneys: 11-year experience with two second-generation lithotripters. *Urology*. 2003;62:10–15.

Shokeir AA, El-Nahas AR, Shoma AM, et al. Percutaneous nephrolithotomy in treatment of large stones within horseshoe kidneys. *Urology*. 2004;64:426–429.

Singal RK, Denstedt JD. Contemporary management of ureteral stones. *Urol Clin North Am*. 1997;24(1):59–70.

Singh AG, Chhabra JS, Sabnis R, et al. Role of flexible uretero-renoscopy in management of renal calculi in anomalous kidneys: single-center experience. *World J Urol*. 2017;35:319–324.

Singh BP, Prakash J, Sankhwar SN, et al. Retrograde intrarenal surgery vs. extracorporeal shock wave lithotripsy for intermediate size inferior pole calculi: a prospective assessment of objective and subjection outcomes. *Urology*. 2014;83(5):1016–1022.

Singh I, Gupta NP, Hemal AK, et al. Efficacy and outcome of surgical intervention in patients with nephrolithiasis and chronic renal failure. *Int Urol Nephrol*. 2001;33:293–298.

Singh M, Marshall V, Blandy J. The residual renal stone. *Br J Urol*. 1975;47:125–129.

Singh V, Sinha RJ, Gupta DK, et al. Transperitoneal versus retroperitoneal laparoscopic ureterolithotomy: a prospective randomized comparison study. *J Urol*. 2013;189:940–945.

Skolarikos A, de la Rosette J. Prevention and treatment of complications following percutaneous nephrolithotomy. *Curr Opin Urol*. 2008;18:229–234.

Smith A, Averech TD, Shahrour K, et al. A nephrolithometric nomogram to predict treatment success of percutaneous nephrolithotomy. *J Urol*. 2013;190(1):149–156.

Smith AD, Lange PH, Fraley EE. Applications of percutaneous nephrostomy: new challenges and opportunities in endo-urology. *J Urol*. 1979;121:382.

Smith MJ, Boyce WH. Anatrophic nephrotomy and plastic calyrhaphy. *J Urol*. 1968;99:521–527.

Smith-Bindman R, Aubin C, Bailitz J, et al. Ultrasonography versus computed tomography for suspected nephrolithiasis. *N Engl J Med*. 2014;371:1100–1110.

Sninsky BC, Jhagroo RA, Astor BC, et al. Do multiple ureteroscopies alter long term renal function? A study using estimated glomerular filtration rate. *J Endourol*. 2014;28(11):1295–1298.

Sofer M, Watterson JD, Wollin TA, et al. Holmium:YAG laser lithotripsy for upper urinary tract calculi in 598 patients. *J Urol*. 2002;167(1):31–34.

Soliman T, Sherif H, Sebaey A, et al. Miniperc vs shockwave lithotripsy for average-sized, radiopaque lower pole calculi: a prospective randomized study. *J Endourol*. 2016.

Solinas A, Pau A, Ayyoub M, et al. Primary obstructive megaureter in adults: management strategy in a young woman. *Arch Ital Urol Androl*. 2010;82:192–194.

Sorensen CM, Chandhoke PS. Is lower pole calicyeal anatomy predictive of extracorporeal shock wave lithotripsy success for primary lower pole kidney stones? *J Urol*. 2002;168:2377–2382.

Soygur T, Akbay A, Kupeli S. Effect of potassium citrate therapy on stone recurrence and residual fragments after shockwave lithotripsy in lower caliceal calcium oxalate urolithiasis: a randomized controlled trial. *J Endourol*. 2002;16:149–152.

Sozen S, Kupeli B, Tunc L, et al. Management of ureteral stones with pneumatic lithotripsy: report of 500 patients. *J Endourol*. 2003;17(9):721–724.

Spirnak JP, Resnick MI. Anatrophic nephrolithotomy. *Urol Clin North Am*. 1983;10:665–675.

Srivastava A, Singh P, Gupta M, et al. Laparoscopic pyeloplasty with concomitant pyelolithotomy—is it an effective mode of treatment? *Urol Int*. 2008;80(3):306–309.

Stein RJ, Desai MM. Management of urolithiasis in the congenitally abnormal kidney (horseshoe and ectopic). *Curr Opin Urol*. 2007;17(2):125–131.

Stein RJ, Turna B, Nguyen MM, et al. Laparoscopic pyeloplasty with concomitant pyelolithotomy: technique and outcomes. *J Endourol*. 2008;22(6):1251–1255.

Stephens FD. The ABC's of megaureters. Alan R. Liss: New

York; 1977:1–8. Bergsma D, Duckett JW Jr. *Birth defects, original article series*. vol 13.

Stoller ML, Bolton D, St Lezin M, et al. Percutaneous nephrolithotomy in the elderly. *Urology*. 1994;44(5):651–654.

Stoller ML, Gupta M, Bolton D, et al. Clinical correlates of the gross, radiographic, and histologic features of urinary matrix calculi. *J Endourol*. 1994;8:335–340.

Strauss AL, Coe FL, Deutsch L, et al. Factors that predict relapse of calcium nephrolithiasis during treatment: a prospective study. *Am J Med*. 1982;72(1):17–24.

Stravodimos KG, Giannakopoulos S, Tyritzis SI, et al. Simultaneous laparoscopic management of ureteropelvic junction obstruction and renal lithiasis: the combined experience of two academic centers and review of the literature. *Res Rep Urol*. 2014;20(6):43–50.

Streem SB, Yost A, Dolmatch B. Combination “sandwich” therapy for extensive renal calculi in 100 consecutive patients: immediate, long-term and stratified results from a 10-year experience. *J Urol*. 1997;158:342–345.

Streem SB, Yost A, Mascha E. Clinical implications of clinically insignificant stone fragments after extracorporeal shock wave lithotripsy. *J Urol*. 1996;155:1186–1190.

Streem SB, Yost A. Extracorporeal shock wave lithotripsy in patients with bleeding diatheses. *J Urol*. 1990;144:1347–1348.

Streem SB, Yost A. Treatment of caliceal diverticular calculi with extracorporeal shock wave lithotripsy: patient selection and extended followup. *J Urol*. 1992;148(Pt 2):1043–1046.

Sumino Y, Mimata H, Tasaki Y, et al. Predictors of lower pole renal stone clearance after extracorporeal shock wave lithotripsy. *J Urol*. 2002;168(4 Pt 1):1344–1347.

Symons S, Biyani CS, Bhargava S, et al. Challenge of percutaneous nephrolithotomy in patients with spinal neuropathy. *Int J Urol*. 2006;13(7):874–879.

Symons SJ, Ramachandran A, Kurien A, et al. Urolithiasis in the horseshoe kidney: a single-centre experience. *BJU Int*. 2008;102:1676–1680.

Tailly GG, Baert JA, Hente KR, et al. Twenty years of single center experience in ESWL 1987–2007: an evaluation of 3079 patients. *J Endourol*. 2008;22(10):2211–2222.

Talic RF. Extracorporeal shock-wave lithotripsy monotherapy in renal pelvic ectopia. *Urology*. 1996;48(6):857–861.

Tan YK, Cha DY, Gupta M. Management of stones in abnormal situations. *Urol Clin North Am*. 2013;40:79–97.

Teichman JM, Long RD, Hulbert JC. Long-term renal fate and prognosis after staghorn calculus management. *J Urol*. 1995;153:1403–1407.

Teichman JM, Vassar GJ, Bishoff JT, et al. Holmium:YAG lithotripsy yields smaller fragments than lithoclast, pulsed dye laser or electrohydraulic lithotripsy. *J Urol*. 1998;159(1):17–23.

Teichman JM, Vassar GJ, Glickman RD. Holmium:yttrium-aluminum-garnet lithotripsy efficiency varies with stone composition. *Urology*. 1998;52(3):392–397.

Tepeler A, Bozukurt OF, Resorlu B, et al. Is the percutaneous nephrolithotomy procedure complicated in patients with anterior caliceal stones? *Urol Int*. 2013;90(4):389–393.

Terai A, Habuchi T, Terachi T, et al. Retroperitoneoscopic treatment of caliceal diverticular calculi: report of two cases and review of the literature. *J Endourol*. 2004;18:672–674.

Theiss M, Wirth MP, Frohmuller HG. Extracorporeal shock wave lithotripsy in patients with renal malformations. *Br J Urol*. 1993;72(Pt 1):534–538.

Thiruchelvam N, Mostafid H, Ubhayakar G. Planning percutaneous nephrolithotomy using multidetector computed tomography urography, multiplanar reconstruction and three-dimensional reformatting. *BJU Int*. 2005;95:1280–1284.

Thornbury JR, Parker TW. Ureteral calculi. *Semin Roentgenol*. 1982;17:133–139.

Timmons JW Jr, Malek RS, Hattery RR, et al. Caliceal diverticulum. *J Urol*. 1975;114:6–9.

Tolley DA, Downey P. Current advances in shock wave lithotripsy. *Curr Opin Urol*. 1999;9:319–323.

Tran TY, McGillen K, Cone EB, et al. Triple D score is reportable predictor of shockwave lithotripsy stone-free rates. *J Endourol*. 2015;29:226–230.

Trinchieri A, Montanari E, Zanetti G, et al. The impact of new technology in the treatment of cystine stones. *Urol Res*. 2007;35:129–132.

Tugcu V, Su FE, Kalfazade N, et al. Percutaneous nephrolithotomy (PCNL) in patients with previous open stone surgery. *Int Urol Nephrol*. 2008;40:881–884.

Tunc L, Tokgoz H, Tan MO, et al. Stones in anomalous kidneys: results of treatment by shock wave lithotripsy in 150 patients. *Int J Urol*. 2004;11:831–836.

Turk C, Neisius A, Petrik A, European Association of Urology (EAU) Guidelines Office, et al. *European Association of Urology guidelines on urolithiasis*. 32nd ed. EAU Annual Congress: London; 2017.

Turna B, Raza A, Moussa S, et al. Management of calyceal diverticular stones with extracorporeal shock wave lithotripsy and percutaneous nephrolithotomy: long-term outcomes. *BJU Int*. 2007;100(1):151–156.

Turna B, Stein RJ, Smaldone MC, et al. Safety and efficacy of flexible ureterorenoscopy and holmium:YAG lithotripsy for intrarenal stones in anticoagulated cases. *J Urol*. 2008;179(4):1415–1419.

Ueno A, Kawamura T, Ogawa A, et al. Relation of spontaneous passage of ureteral calculi to size. *Urology*. 1977;10:544–546.

Ulusan S, Koc Z, Tokmak N. Accuracy of sonography for detecting renal stone: comparison with CT. *J Clin Ultrasound*. 2007;35(5):256–261.

Unsal A, Koca G, Resorlu B, et al. Effect of percutaneous nephrolithotomy and tract dilation methods on renal function: assessment by quantitative single-photon emission computed tomography of technetium-99m-dimercaptosuccinic acid uptake by the kidneys. *J Endourol*. 2010;24(9):1497–1502.

Vandeursen H, Baert L. Electromagnetic extracorporeal shock wave lithotripsy for calculi in horseshoe kidneys. *J Urol*. 1992;148(Pt 2):1120–1122.

Vaughan ED Jr, Gillenwater JY. Recovery following complete chronic unilateral ureteral occlusion: functional, radiographic and pathologic alterations. *J Urol*. 1971;106(1):27–35.

Viprakasit DP, Sawyer MD, Herrell SD, et al. Changing composition of staghorn calculi. *J Urol*. 2011;186(6):2285–2290.

Viprakasit DP, Sawyer MD, Herrell SD, et al. Limitations of ultrasonography in the evaluation of urolithiasis: a correlation with computed tomography. *J Endourol*. 2012;26:209–213.

Waingankar N, Hayek S, Smith AD, et al. Calyceal diverticula: a comprehensive review. *Rev Urol*. 2014;16(1):29–43.

Waldmann TB, Lashley DB, Fuchs EF. Unenhanced computerized axial tomography to detect retained calculi after percutaneous ultrasonic lithotripsy. *J Urol*. 1999;162:312–314.

Wang LJ, Wong YC, Chuang CK, et al. Predictions of outcomes of renal stones after extracorporeal shock wave lithotripsy from stone characteristics determined by unenhanced helical computed tomography: a multivariate analysis. *Eur Radiol*. 2005;15:2238–2243.

Watterson JD, Girvan AR, Cook AJ, et al. Safety and efficacy of holmium:YAG laser lithotripsy in patients with bleeding diatheses. *J Urol*. 2002;168(2):442–445.

Waxman SW, Winfield HN. Laparoscopic management of caliceal diverticulum. *J Endourol*. 2009;23(10):1731–1732.

Weizer AZ, Auge BK, Silverstein AD, et al. Routine postoperative imaging is important after ureteroscopic stone manipulation. *J Urol*. 2002;168:46–50.

Weizer AZ, Springhart WP, Ekeruo WO, et al. Ureteroscopic management of renal calculi in anomalous kidneys. *Urology*. 2005;65:265–269.

Wershub LP. *Urology, from antiquity to the 20th century*. WH Green: St Louis; 1970.

Whelan JP, Finlayson B, Welch J, et al. The blast path: theoretical basis, experimental data and clinical application. *J Urol*. 1988;140:401–404.

White JR. *Evidence report for imaging in the management of ureteral calculous disease*. [(website)] http://www.auanet.org/common/pdf/education/clinical-guidance/Imaging-Evidence-Report.pdf; 2012.

White WM, Zite NB, Gash J, et al. Low-dose computed tomography for the evaluation of flank pain in the pregnant population. *J Endourol*. 2007;21:1255–1260.

Wickham JE, Coe N, Ward JP. One hundred cases of nephrolithotomy under hypothermia. *J Urol*. 1974;112:702–705.

Wiener SV, Detras LA, Pais VM Jr. Effect of stone composition on operative time during ureteroscopic holmium:yttrium-aluminum-garnet laser lithotripsy with active fragment retrieval. *Urology*. 2012;80(4):790–794.

Wiesenthal JD, Ghiculete D, Ray AA, et al. A clinical nomogram to predict the successful shock wave lithotripsy of renal and ureteral calculi. *J Urol*. 2011;186(2):556–562.

Williams G, Blandy JP, Tresidder GC. Communicating cysts and diverticula of the renal pelvis. *Br J Urol*. 1969;41:163–170.

Williams JC Jr, Paterson RF, Kopecky KK, et al. High resolution detection of internal structure of renal calculi by helical computerized tomography. *J Urol*. 2002;167:322–326.

Williams JC Jr, Saw KC, Patterson RF, et al. Variability of renal stone fragility in shock wave lithotripsy. *Urology*. 2003;61(6):1092–1097.

Wolf JS Jr, Carroll PR, Stoller ML. Cost-effectiveness vs. patient preference in the choice of treatment for distal ureteral calculi: a literature-based decision analysis. *J Endourol*. 1995;9:243–248.

Wolf JS Jr, Elashry OM, Clayman RV. Long-term results of endoureterotomy for benign ureteral and ureteroenteric strictures. *J Urol*. 1997;158:759–764.

Wolf JS Jr, Stoller ML. Management of upper tract calculi in patients with tubularized urinary diversions. *J Urol*. 1991;145:266–269.

Wong C, Leveillee RJ. Single upper-pole percutaneous access for treatment of > or = 5 cm complex branched staghorn calculi: is shockwave lithotripsy necessary? *J Endourol*. 2002;16(7):477–481.

Wood K, Keys T, Mufarrij P, et al. Impact of stone removal on renal function: a review. *Rev Urol*. 2011;13(2):73–89.

Wu CF, Chen CS, Lin WY, et al. Therapeutic options for proximal ureter stone: extracorporeal shock wave lithotripsy versus semirigid ureterorenoscope with holmium:yttrium aluminum garnet laser lithotripsy. *Urology*. 2005;65:1075–1079.

Wu DS, Stoller ML. Indinavir urolithiasis. *Curr Opin Urol*. 2000;10:557–561.

Wulfsohn MA. Pyelocaliceal diverticula. *J Urol*. 1980;123:1–8.

Wyler SF, Bachmann A, Jayet C, et al. Retroperitoneoscopic management of caliceal diverticular calculi. *Urology*. 2005;65:380–383.

Xue W, Pacik D, Boellaard W, et al. Management of single large nonstaghorn renal stones in the CROES PCNL global study. *J Urol*. 2012;187(4):1293–1297.

Yasui T, Okada A, Hamamoto S, et al. Efficacy of retroperitoneal laparoscopic ureterolithotomy for the treatment of larger proximal ureteric stones and its impact on renal function. *Springerplus*. 2013;2:600 [eCollection].

Ye Z, Zeng G, Yang H, et al. Efficacy and safety of tamsulosin in medical expulsive therapy for distal ureteral stones with renal colic: a multicenter, randomized, double-blind, placebo-controlled trial. *Eur Urol*. 2017.

Yesil S, Ozturk U, Goktug HN, et al. Previous open renal surgery increased vascular complications in percutaneous nephrolithotomy (PCNL) compared with primary and secondary PCNL and extracorporeal shock wave lithotripsy patients: a retrospective study. *Urol Int*. 2013;91(3):331–334.

Yilmaz S, Sindel T, Arslan G, et al. Renal colic: comparison of spiral CT, US and IVU in the detection of ureteral calculi. *Eur Radiol*. 1998;8:212–217.

Young HH, McKay RW. Congenital valvular obstruction of the prostatic urethra. *Surg Gynecol Obstet*. 1929;48:509.

Yow RM, Bunts RC. Calyceal diverticulum. *J Urol*. 1955;73:663–670.

Yuruk E, Binbay M, Sari E, et al. A prospective, randomized trial of management for asymptomatic lower pole calculi. *J Urol*. 2010;183:1424–1428.

Yuruk E, Tefekli A, Sari E, et al. Does previous extracorporeal shock wave lithotripsy affect the performance and outcome of percutaneous nephrolithotomy? *J Urol*. 2009;181(2):663–667.

Zafar FS, Lingeman JE. Value of laparoscopy in the management of calculi complicating renal malformations. *J Endourol*. 1996;10(4):379–383.

Zanetti G, Kartalas-Goumas I, Montanari E, et al. Extracorporeal shockwave lithotripsy in patients treated with antithrombotic agents. *J Endourol*. 2001;15:237–241.

Zanetti G, Montanari E, Mandressi A, et al. Long-term results of extracorporeal shock wave lithotripsy in renal stone treatment. *J Endourol*. 1991;5:61.

Zanetti G, Seveso M, Montanari E, et al. Renal stone fragments following shock wave lithotripsy. *J Urol*. 1997;158:352–355.

Zanetti GR, Montanari E, Guarneri A, et al. Long-term followup after extracorporeal shock wave lithotripsy treatment of kidney stones in solitary kidneys. *J Urol*. 1992;148:1011–1014.

Zarse CA, Hameed TA, Jackson ME, et al. CT visible internal stone structure, but no Hounsfield unit value, of calcium oxalate monohydrate (COM) calculi predicts lithotripsy fragility in vitro. *Urol Res*. 2007;35(4):201–206.

Zeng GQ, Zhong WD, Cai YB, et al. Extracorporeal shock wave versus pneumatic ureteroscopic lithotripsy in treatment of lower ureteral calculi. *Asian J Androl*. 2002;4(4):303–305.

Zhong P, Preminger GM. Mechanisms of differing stone fragility in extracorporeal shockwave lithotripsy. *J Endourol*. 1994;8(4):263–268.

Zhong W, Gong T, Wang L, et al. Percutaneous nephrolithotomy for renal stones following failed extracorporeal shockwave lithotripsy: different performances and morbidities. *Urolithiasis*. 2013;41(2):165–168.

Zhou T, Watts K, Agalliu I, et al. Effects of visceral fat area and other metabolic parameters on stone composition in patients undergoing percutaneous nephrolithotomy. *J Urol*. 2013;190(4):1416–1420.

Zink RA, Frohmueller HG, Eberhardt JE. Urosepsis following

ESWL. *J Urol*. 1988;139(Suppl):265.

Surgical Management for Upper Urinary Tract Calculi

Brian R. Matlaga MD, MPH, Amy E. Krambeck MD

Extracorporeal Shock Wave Lithotripsy

Methods and Physical Principles

In extracorporeal shock wave lithotripsy (SWL) a source external to the patient's body generates a shock wave. Specifically, the energy source rapidly deposits pulses of energy into a fluid environment, which results in the generation of a shock wave. **Shock waves are surfaces that divide material ahead, not yet affected by the disturbance from that behind, which has been compressed as a consequence of energy input at the source** (Sturtevant, 1996). These waves move faster than the speed of sound, and the stronger the initial shock, the faster the shock wave moves. **Shock wave behavior is characteristic of the propagation of nonlinear waves**. Although the shock waves in lithotripters generate large pressures, they are relatively weak in that they induce only slight compression and deformation of a material. **The shock wave lithotripter uses weak, nonintrusive waves that are generated externally, transmitted through the body, and focused onto the stone. The shock waves build to sufficient strength only at the target, where they generate enough force to fragment a stone.**

Generator Type

The three primary types of shock wave generators are electrohydraulic (spark gap), electromagnetic, and piezoelectric.

Electrohydraulic (Spark Gap) Generator.

In the electrohydraulic shock wave lithotripter, a spherically expanding shock wave is generated by an underwater spark discharge (Cleveland et al., 2000). High voltage is applied to two opposing electrodes; the resulting spark produces a vaporization bubble. The bubble expands and collapses rapidly producing a high-energy pressure wave. **The resulting shock wave occurs at F1 (the electrode) located on an ellipsoid, which focuses the wave on the stone target (F2)**. Fig. 94.1 shows a hemiellipsoid reflector and a spark gap typical of those used in the older electrohydraulic machines.

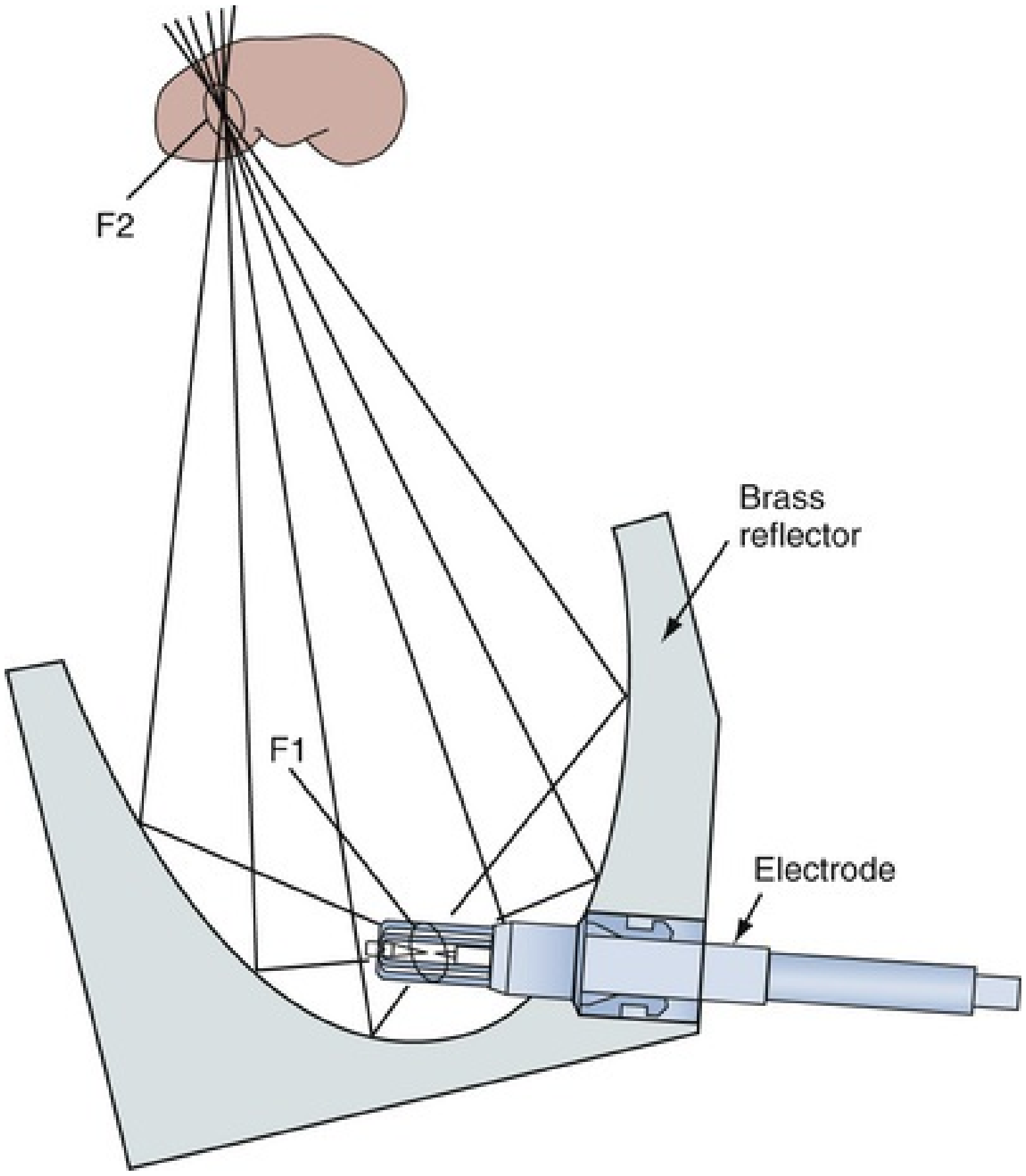

FIG. 94.1 Schematic view of an electrohydraulic shock wave generator. An electrode is used to generate a shock wave. *F1,* Focus 1; *F2,* focus 2.

The clear advantage of this generator is its effectiveness in breaking kidney stones (Lingeman, 1997)**. Disadvantages are the substantial pressure fluctuations from shock to shock.** As the electrode deteriorates, it wears down. With a 1-mm displacement of the electrode tip off F1, the F2 can shift up to 1 cm off the initial stone target.

Electromagnetic Generator.

The electromagnetic generators produce a magnetic field in either a flat plane or around a cylinder. The flat plane waves are focused by an acoustic lens (Fig. 94.2); the cylindric waves are reflected by a parabolic reflector (Fig. 94.3) and transformed into a spherical wave. Fig. 94.2 shows a system that uses a water-filled shock tube containing two conducting cylindric plates separated by a thin insulating sheet. When an electrical current is sent through one or both of the conductors, a strong magnetic field is produced between the conductors, moving the plate against the water and thereby generating a pressure wave. The *magnetic pressure* causes a corresponding pressure (shock wave) in the water. The shock front produced is a plane wave that is of the same diameter as the current-carrying plates. **The energy in the shock wave is concentrated onto the target by focusing it with an acoustic lens.** The electromagnetic system that uses a cylindric source (see Fig. 94.3) also has a cylindric coil surrounded by a cylindric membrane that is pushed away from the coil by the induction of a magnetic field between the two components. In both systems the pressure pulse has only one focal point (F2) that is positioned on the target.

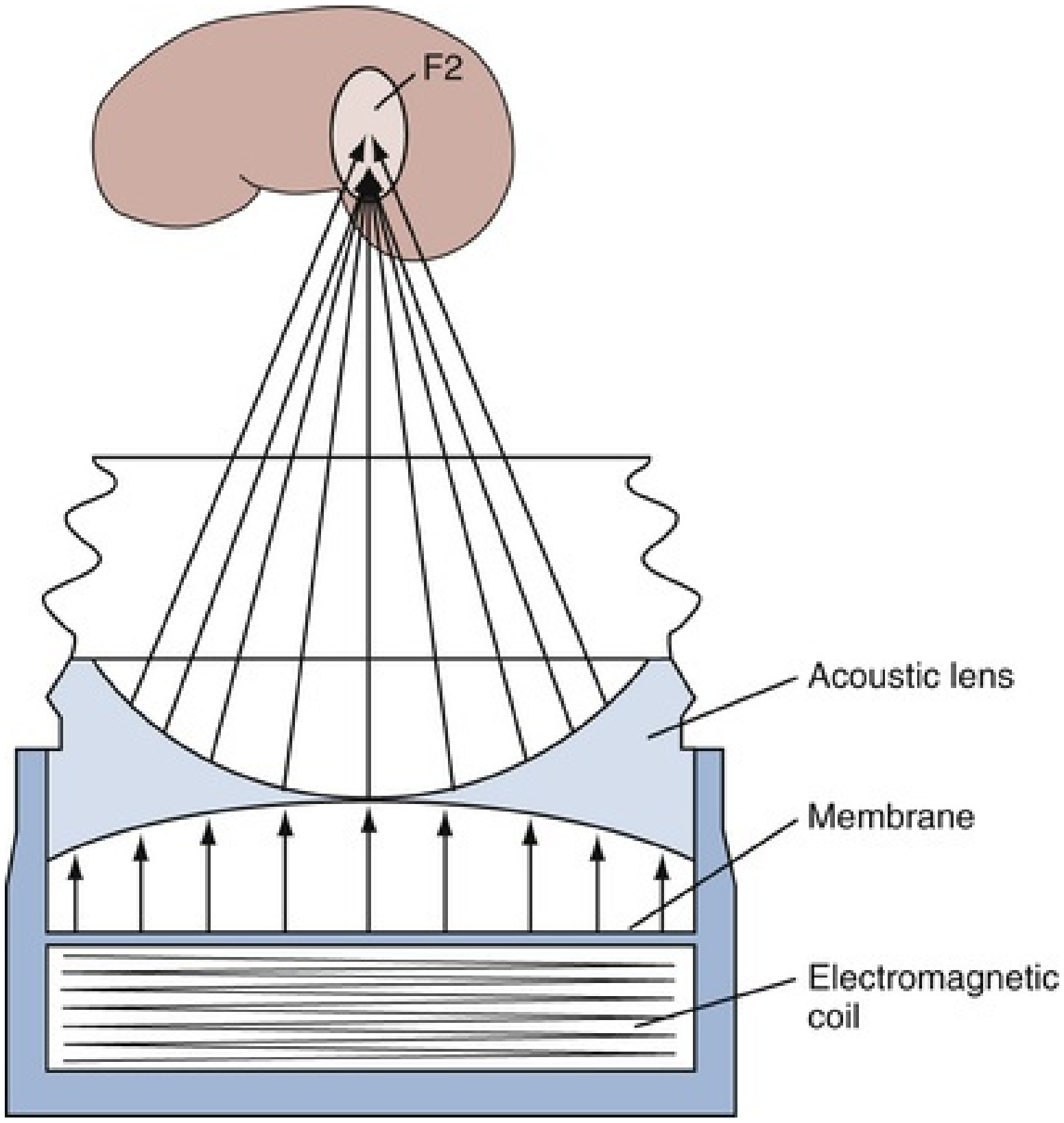

FIG. 94.2 Schematic view of an electromagnetic shock wave generator that uses an acoustic lens to focus the shock wave. An electromagnetic coil is used to generate the shock wave. *F2,* Focus 2.

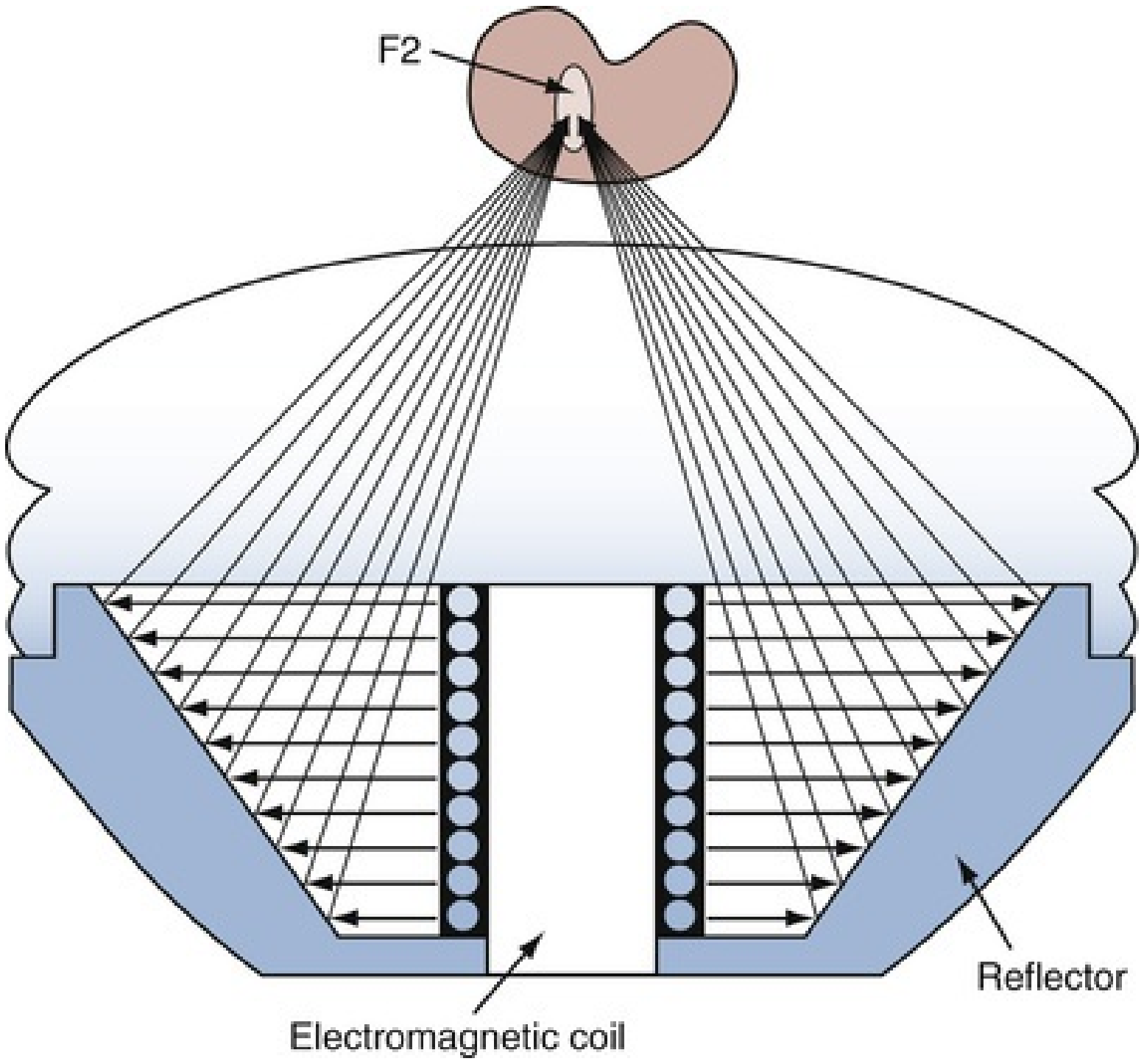

FIG. 94.3 Schematic view of an electromagnetic shock wave generator that uses a parabolic reflector to focus the shock wave. An electromagnetic coil is used to generate the shock wave. *F2,* Focus 2.

Electromagnetic generators are more controllable and reproducible than electrohydraulic generators because they do not use a spark gap generator. Another advantage of the electromagnetic generators is it will deliver several hundred thousand shock waves before requiring servicing, thereby eliminating the need for frequent electrode replacement. Electromagnetic lithotripters introduce energy into the body over a large skin area, causing less pain; however, they also generate a high-energy density at the stone (F2). This high-energy density at F2 has resulted in an increased rate of subcapsular hematoma formation over the older electrohydraulic models. The rate of subcapsular hematoma formation for the Storz Modulith (Storz Medical, Tägerwilen, Switzerland) has been suggested to be 3.1% to 3.7% (Dhar et al., 2004). Piper et al. (2001) suggested that perinephric hematomas may occur in up to 12% of patients treated with a DoLi S lithotripter (Dornier Medical Systems, Kennesaw, GA), which is higher than what has been reported for the original HM3 electrohydraulic lithotripters (Chaussy and Schmiedt, 1984; Knapp et al., 1987).

Piezoelectric Generator.

The piezoelectric lithotripter also produces plane shock waves with directly

converging shock fronts. A capacitor is fired through a collection of several hundred to several thousand piezoceramic elements positioned on a reflector, often shaped like a satellite dish (Fig. 94.4). Each element produces a limited power shock front that is focused on the same F2.

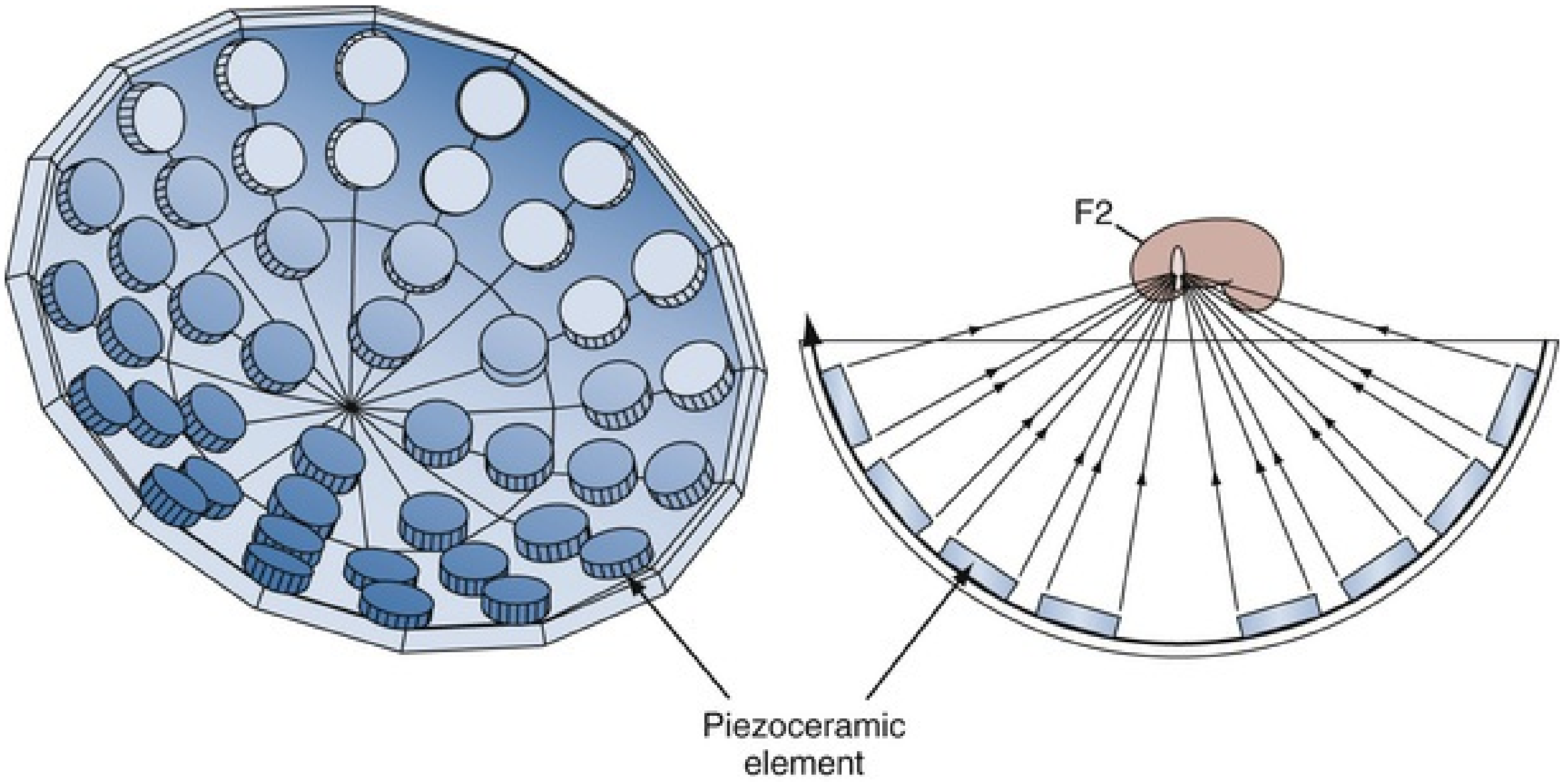

FIG. 94.4 Schematic view of a piezoelectric shock wave generator. Numerous polarized polycrystalline ceramic elements are positioned on the inside of a spherical dish. *F2,* Focus 2. The focal plane at the focus *(circles).*

The advantages of piezoelectric generators include the focusing accuracy, a long service life, and the possibility of an anesthetic-free treatment because of the relatively low-energy density at the skin entry point of the shock wave (Marberger et al., 1988). The piezoelectric energy sources produce some of the highest peak pressures of any lithotripter currently available. However, **the actual energy delivered to the stone per shock wave is several orders of magnitude lower than that delivered by an electrohydraulic machine because of the extremely tiny volume of F2, making poor stone comminution a disadvantage of this technology.**

Imaging Systems

There are three basic designs used by lithotripter manufacturers for stone localization. They are fluoroscopy alone, ultrasonography alone, and the combination of ultrasonography and fluoroscopy.

Fluoroscopy Alone.

The original Dornier HM3 lithotripter used two x-ray converters arranged at oblique angles to the patient and 90 degrees from each other to localize the stone effectively at F2. To reduce the cost of lithotripters, an adjustable C-arm has been subsequently introduced on many devices. Furthermore, in an attempt to develop multifunctional operating rooms and tables, the fluoroscopic systems used by lithotripter manufacturers have become more standardized. The fluoroscopic system typically consists of a high-quality digitized x-ray imaging system mounted on a rotatable C-arm with an isocentrically integrated shock wave source. Because the shock wave head can be rotated out of the field of the fluoroscopic system, the table can be used for other routine urologic fluoroscopic applications.

The primary advantages of fluoroscopy still include its familiarity to most urologists, the ability to visualize radiopaque calculi throughout the urinary tract, the ability to use iodinated contrast agents to aid in stone localization, and the ability to display anatomic detail. The disadvantages include the exposure of the staff and patient to ionizing radiation, the high maintenance demands of the equipment, and the inability to visualize radiolucent calculi without the use of radiographic contrast agents.

Ultrasonography Alone.

Ultrasonic localization was initially designed to aid multifunctional lithotripters for treatment of urinary and biliary stones. It is presently used in several low-cost machines because it is inexpensive to manufacture and maintain compared with fluoroscopic systems. Another major advantage of this technology is in the treatment of children and infants when concern exists about the dose of ionizing radiation. In addition, ultrasonography can localize slightly opaque or nonopaque calculi.

Despite its advantages, ultrasound imaging has a number of significant disadvantages. Sonographic localization of a kidney stone requires a highly trained operator, and many urologists are not comfortable or familiar with identifying stones ultrasonically. Complicating the issue of stone detection is the fact that it is almost impossible to view a kidney stone in areas such as the middle third of the ureter or when there is an indwelling ureteral catheter. Furthermore, once a stone is fragmented, it is difficult to identify each individual stone piece. Unfortunately, these disadvantages tend to overshadow the advantages of ultrasound imaging.

Combination of Ultrasonography and Fluoroscopy.

As the demand for interdisciplinary lithotripters has increased, the lithotripsy industry has responded, in some cases combining ultrasonography and fluoroscopy for stone localization. There are clearly advantages to these setups, but each system has a drawback that limits one of the functions of the system.

Stone Fragmentation

A typical pressure pulse generated by an electrohydraulic shock wave lithotripter is shown in Fig. 94.5. The pressure wave involves **an initial short and steep compressive front with pressures of approximately 40 megapascals (MPa) that is followed by a longer, lower amplitude negative (tensile) pressure of 10 MPa, with the entire pulse lasting for a duration of 4 microseconds.** The ratio of the positive to negative peak pressures is approximately 5 : 1. (Cleveland et al., 2000; Müller, 1990). **Stone fragmentation during SWL, also called comminution, occurs as a result of mechanical stressors created by two mechanisms that can occur simultaneously or separately: (1) directly by the incident shock wave or (2) indirectly by the collapse of bubbles.** The different mechanical stresses that result from SWL and contribute to stone fragmentation are as follows: spall fracture, squeezing, shear stress, superfocusing, acoustic cavitation, and dynamic fatigue (Fig. 94.6).

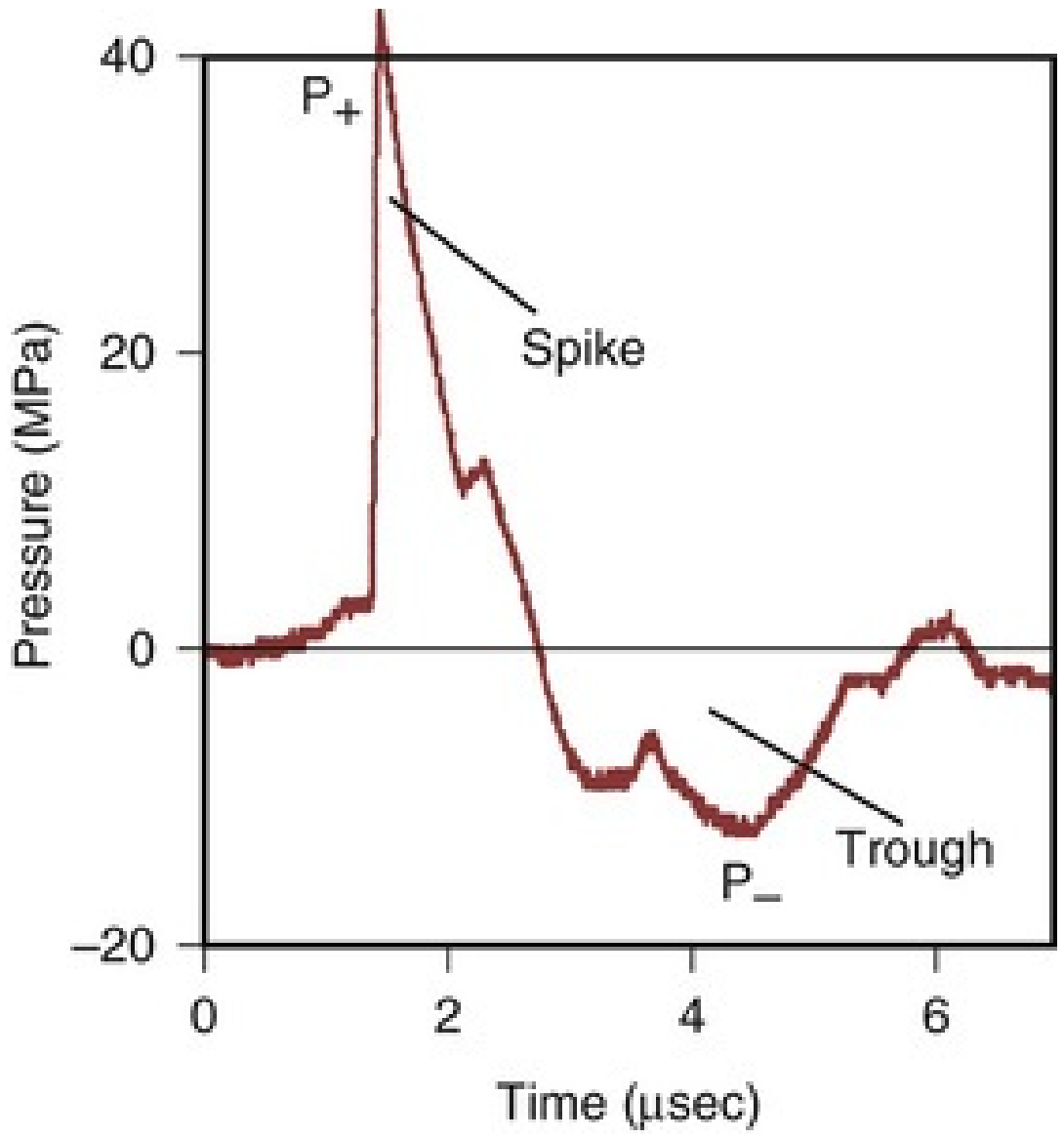

FIG. 94.5 A typical pressure pulse at the lithotripter focus (F2) as measured by a polyvinylidene difluoride membrane hydrophone. First, there is a steep positive pressure front of about 40 MPa, which is followed

by a negative pressure of 10 MPa, with the entire pulse lasting for a duration of 4 µsec. (From Coleman AJ, Saunders JE, Preston RC, et al.: Pressure waveforms generated by a Dornier extracorporeal shock wave lithotriptor. *Ultrasound Med Biol* 13:651–657, 1987.)

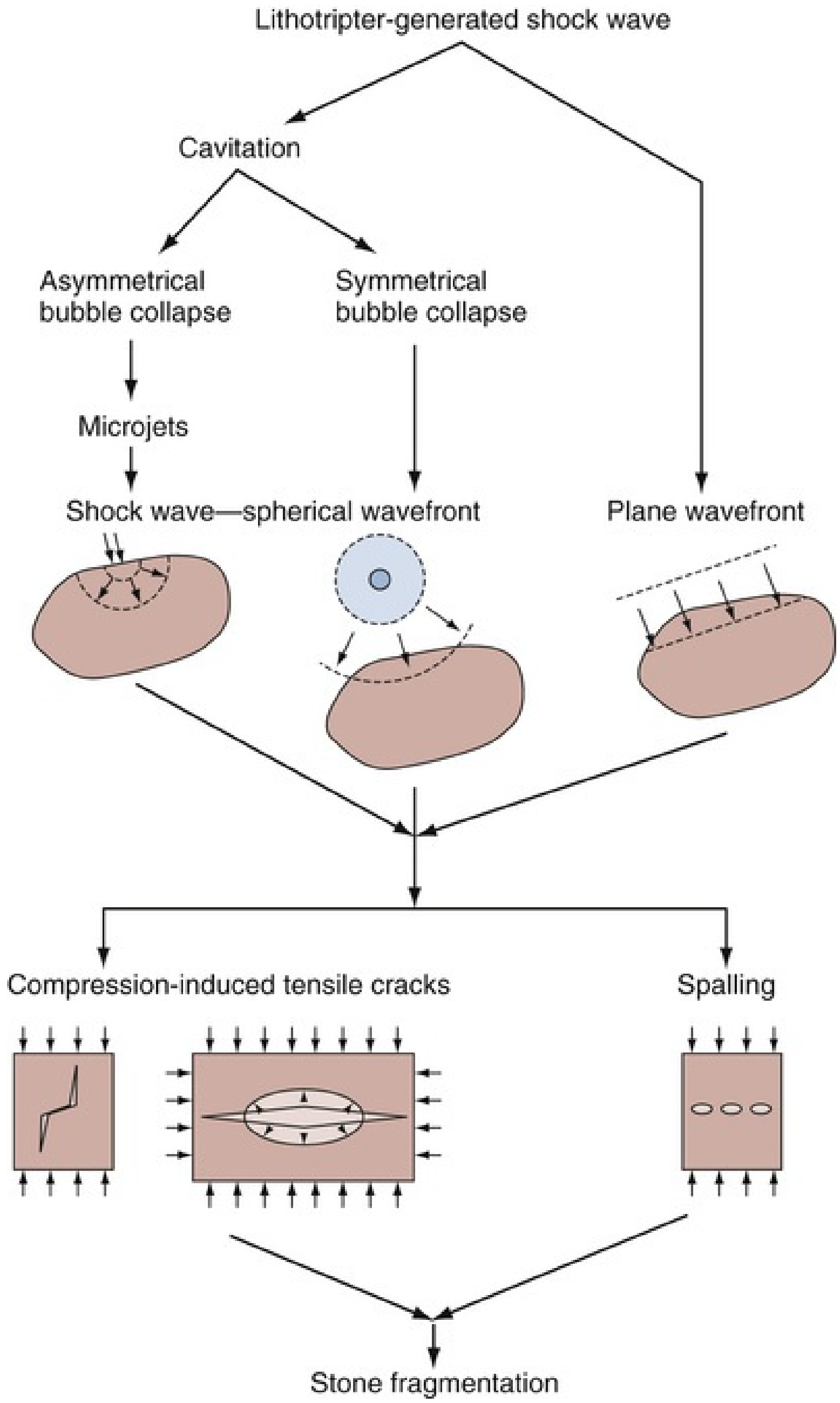
Lithotripter-generated shock wave
Cavitation
Asymmetrical bubble collapse
Symmetrical bubble collapse
Microjets
Shock wave—spherical wavefront
Plane wavefront
Compression-induced tensile cracks
Spalling
Stone fragmentation

FIG. 94.6 Summary of how the various mechanical forces generated by a lithotripsy shock wave may cause a kidney stone to fracture. (Reproduced with permission from Dr. Bradley Sturtevant.)

Spall fracture, also known as spallation, is the calescence of microcracks within a stone resulting in comminution. The fragmentation plan is perpendicular to the applied stress. Once the shock wave enters the stone, it will be reflected at sites of impedance mismatch, such as the distal stone-urine interface. As the shock wave is reflected, it is inverted in phase to a tensile (negative) wave. Fragmentation occurs when the tensile wave exceeds the tensile strength of the stone. Because they are a brittle material, kidney stones are theorized more likely to fail under tension rather than compression (Johrde and Cocks, 1985).

The second mechanism for stone breakage, *squeezing-splitting* or *circumferential compression*, occurs because of the difference in sound speed between the stone and the surrounding fluid (Eisenmenger, 1998). The shock wave inside the stone advances faster through the stone than the shock wave in the fluid outside the stone. The shock wave in the fluid outside the stone produces a circumferential force on the stone, resulting in a tensile stress at the proximal and distal ends of the stone. It has been theorized that squeezing should be enhanced when the entire stone falls within the diameter of the focal zone; thus a wider F2 or focal zone in a lithotripter may be of benefit.

The third mechanism is shear stress. Shear stress will be generated by shear waves (also termed *transverse waves*) that develop as the shock wave passes into the stone. The shear waves propagate through the stone, which results in shifting of molecules perpendicular or transverse to the wave. Mathematical modeling has demonstrated that shear waves are a more power force in stone comminution than the spall effect (Sapozhnikov et al., 2007). However, the intensity of the shear wave is dependent on the width of F2 or focal zone with larger focal zones being more beneficial.

The fourth mechanism for stone breakage, superfocusing, is the amplification of stresses inside the stone because of the geometry of that stone. The shock wave that is reflected at the distal surface of the stone can be focused by either refraction or diffraction from the corners of the stone to create areas of high stress in the interior of the stone (Gracewski et al., 1993; Xi and Zhong, 2001). The regions of high stress (tensile and shear) depend on the geometry of the stone and elastic properties.

The fifth mechanism for SWL stone breakage is cavitation (Coleman et al., 1987; Crum, 1988; Vakil and Everbach, 1993; Zhong and Chuong, 1993; Zhong et al., 1993). *Cavitation* is the formation and subsequent collapse of bubbles. The negative pressure in the trailing part of the shock pulse causes bubble formation.

As these bubbles grow, they oscillate in size for about 200 microseconds and then collapse violently, giving rise to high pressures and temperatures. This release of energy is generally in the form of a positive and negative wave that can create all the comminution mechanisms described. However, in the presence of a boundary, a liquid jet, also termed a *cavitation microjet,* forms inside the bubble during the collapse (Crum, 1979, 1988). If the cavitation microjet is near the surface of a stone, it creates a locally compressive stress field in the stone, which propagates into the stone interior.

The final mechanism of stone fragmentation to be considered is the accumulation of damage induced by SWL that eventually destroys the structure of the stone. Essential to this process are nucleation, growth, and coalescence of flaws within the stone caused by a tensile or shear stress. Because renal calculi are not homogeneous but rather have either a lamellar crystalline structure bonded by an organic matrix material or an agglomeration of crystalline and noncrystalline material there are numerous sites of preexisting flaws (microcracks). All of the fracture mechanisms described have the potential to generate progressive damage to the interior of the stone. By use of a mathematical model taking, Lokhandwalla and Sturtevant (2000) were able to calculate the number of shock waves required for comminution to occur in a typical calcium oxalate monohydrate calculus. The values they determined had a range of two orders of magnitude (30 to 3000 shocks), which is well within the clinical dose presently used to treat patients.

Bioeffects: Clinical Studies

Acute Extrarenal Damage

SWL induces acute injury in a variety of extrarenal tissues (Evan et al., 1991, 1998)**.** Although rarely clinically significant, SWL has been associated with trauma to organs such as the liver and skeletal muscle, as evidenced by elevated levels of bilirubin, lactate dehydrogenase, serum aspartate transaminase, and creatinine phosphokinase within 24 hours of treatment (Lingeman et al., 1986; Parr et al., 1988; Ruiz Marcellan and Ibarz Servio, 1986). Such laboratory parameter changes begin to normalize within 3 to 7 days of SWL treatment and are normalized by 3 months. There have also been reports of surrounding visceral injuries after SWL, such as perforation of the colon, hepatic hematoma, splenic rupture, pancreatitis, and abdominal wall abscess. Extrarenal vascular complications have been reported to occur as well, such as rupture of the hepatic artery, rupture of the abdominal aorta, and iliac vein thrombosis. Thoracic events, such as pneumothorax and urinothorax, have even been described. Fortunately, these events are exceedingly rare and have generally been presented as isolated incidents.

Early clinical studies noted that shock waves could induce a cardiac arrhythmia, an observation that led to electrocardiographic synchronization with R-wave triggering on the Dornier HM3 device (Chaussy and Schmiedt, 1984). However, later clinical studies with non–water bath lithotripters have concluded that SWL is safe to the electrophysiology of the heart and gating to the cardiac rhythm is unnecessary.

Although a shock wave lithotripter focuses its waves and peak pressure on the stone (the focal zone, or F2), it is known that high acoustic pressure does extend beyond this zone (Fig. 94.7). Therefore it is reasonable to expect that organs other than the kidney are exposed to stresses sufficient to cause injury. One such organ is the pancreas; a retrospective follow-up study from the Mayo Clinic suggests that patients who underwent SWL for the treatment of kidney stones in 1985 were at increased risk for developing diabetes mellitus compared with controls (Krambeck et al., 2005). The development of diabetes was related to the total number of shock waves and the power level of the lithotripter. Although these data are provocative, there were a number of limitations of the study, including that the stone disease of the SWL cohort was more severe than that of the control cohort; a family history of diabetes was not ascertained for either group; and the data for the SWL group were collected by self-report questionnaire, whereas the control group was examined by chart review. A follow-up study by Rashed et al. in 2017, also a retrospective review, noted an increase in blood serum glucose levels, diagnosis of diabetes, and prescription of antidiabetic therapy after SWL. However, several other groups have subsequently investigated the association of diabetes mellitus and SWL and have not noted an association (Chew et al., 2012, Fankhauser et al., 2015; Makhlouf et al., 2009; Sato et al., 2008). Notably, de Cogain et al. (2012) performed a population-based study of Olmsted County, Minnesota, and did not find any association between SWL and diabetes mellitus in the general community setting.

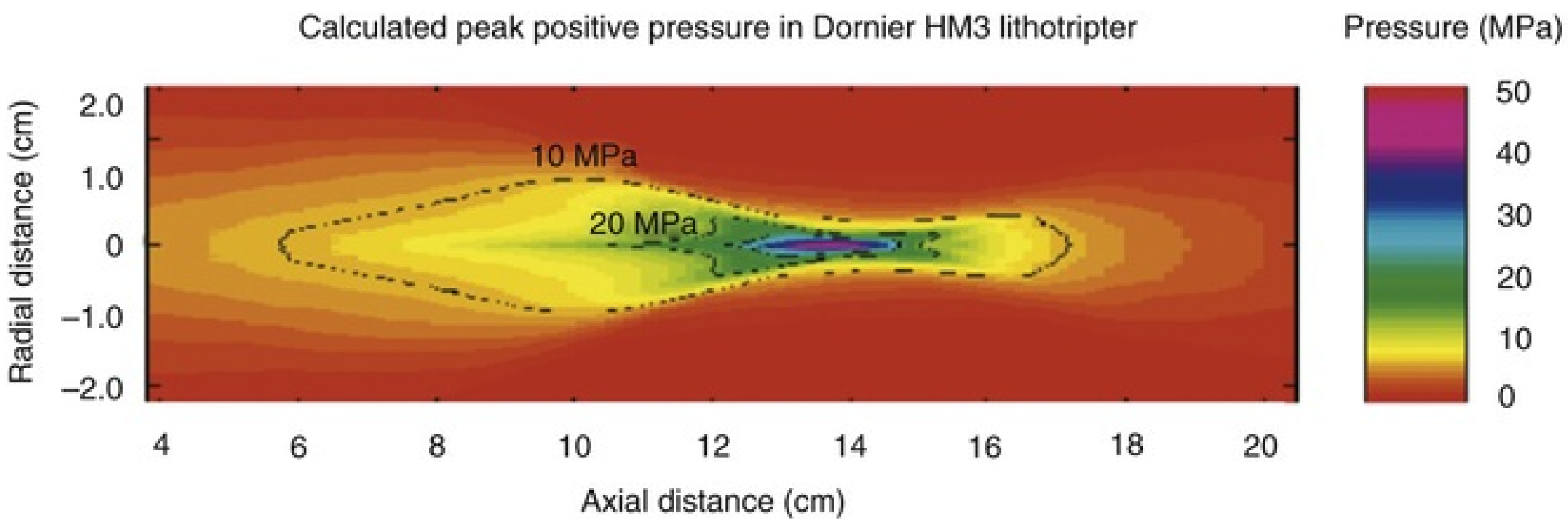

FIG. 94.7 Predicted peak positive pressure in a Dornier HM3 lithotripter. The pressure is not focused to a point but extends over a finite volume.

Acute Renal Injury: Structural and Functional Changes

Almost all patients who undergo SWL for renal stones demonstrate hematuria after approximately 200 shock waves. Hematuria is so common that it may be considered an incidental finding, and its severity is rarely of concern. Although hematuria was initially considered to be a consequence of irritation of the urothelium as stones were fragmented by shock waves, it is now known that damage to the kidney is the most likely source. Morphologic studies in the canine and porcine models have demonstrated that shock waves rupture blood vessels and can damage surrounding renal tubules (Fig. 94.8). In the porcine model SWL-injured vessels ranging in size from the glomerular and cortical capillaries and vasa recta to the larger arcuate and intralobular vessels have been identified after therapeutic levels of shock waves have been received. The resulting hemorrhagic lesion generally extends from cortex to medulla and comprises torn blood vessels with platelet aggregation and red blood cells in the interstitial space (Fig. 94.9). In the setting of a more severe injury induced in the porcine model, complete necrosis of the endothelium and vascular smooth muscle may result. In laboratory studies a typical clinical dose of 2000 shock waves with the Dornier HM3 lithotripter, operated at 24 kV with shock waves delivered at 2 Hz, produces a lesion measuring 5% to 6% of the functional renal volume (Fig. 94.10).

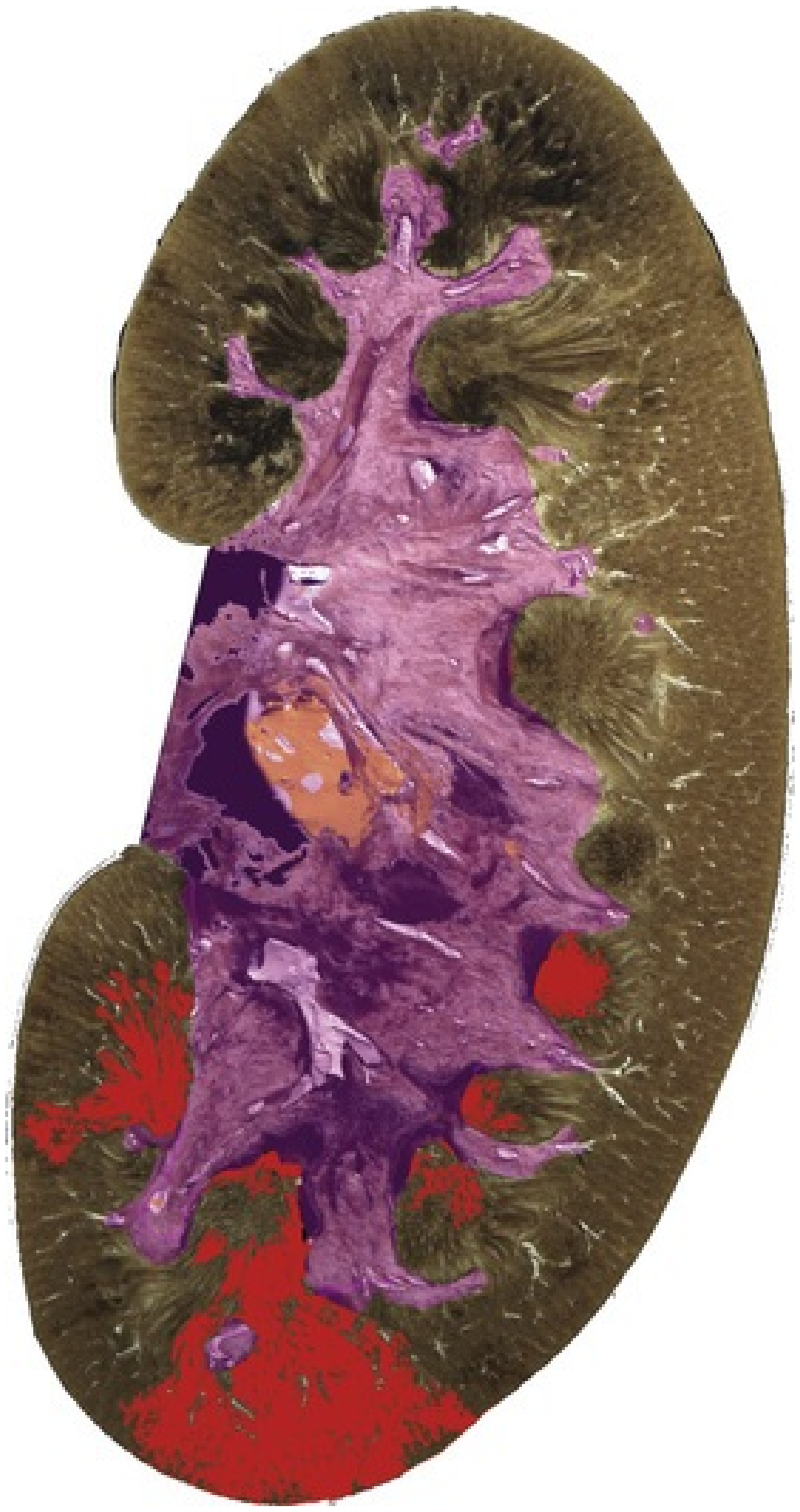

FIG. 94.8 Macroscopic photomicrograph of a coronal section through the kidney of a juvenile pig (~6 weeks old) treated with 2000 shocks at 24 kV by an unmodified Dornier HM3 lithotripter and examined 4 hours after treatment. The region of intraparenchymal hemorrhage has been colored red by an automated computer color recognition program. Note that the lesion involves multiple papillae and in some regions extends through the cortex to the renal capsule, where a subcapsular hematoma may develop.

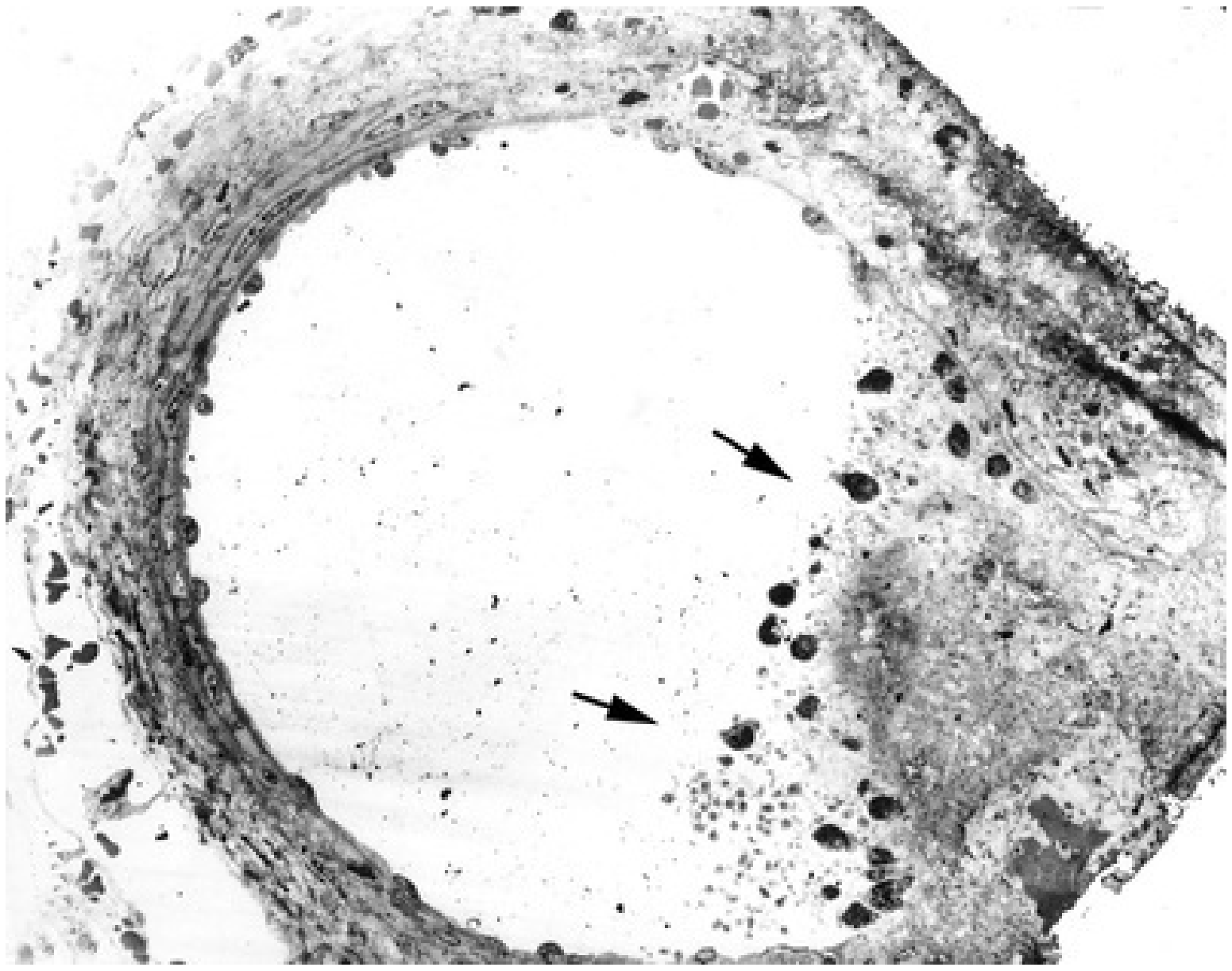

FIG. 94.9 Low-magnification transmission electron micrograph demonstrating injury to a medium-sized artery located within F2 of a pig treated with 2000 shock waves at 24 kV. The shock wave-induced injury to the right side of this vessel resulted in a rupture site that permitted extravasation of blood into the nearby interstitium. The site of injury in the vessel wall is plugged with a clot *(arrows)*.

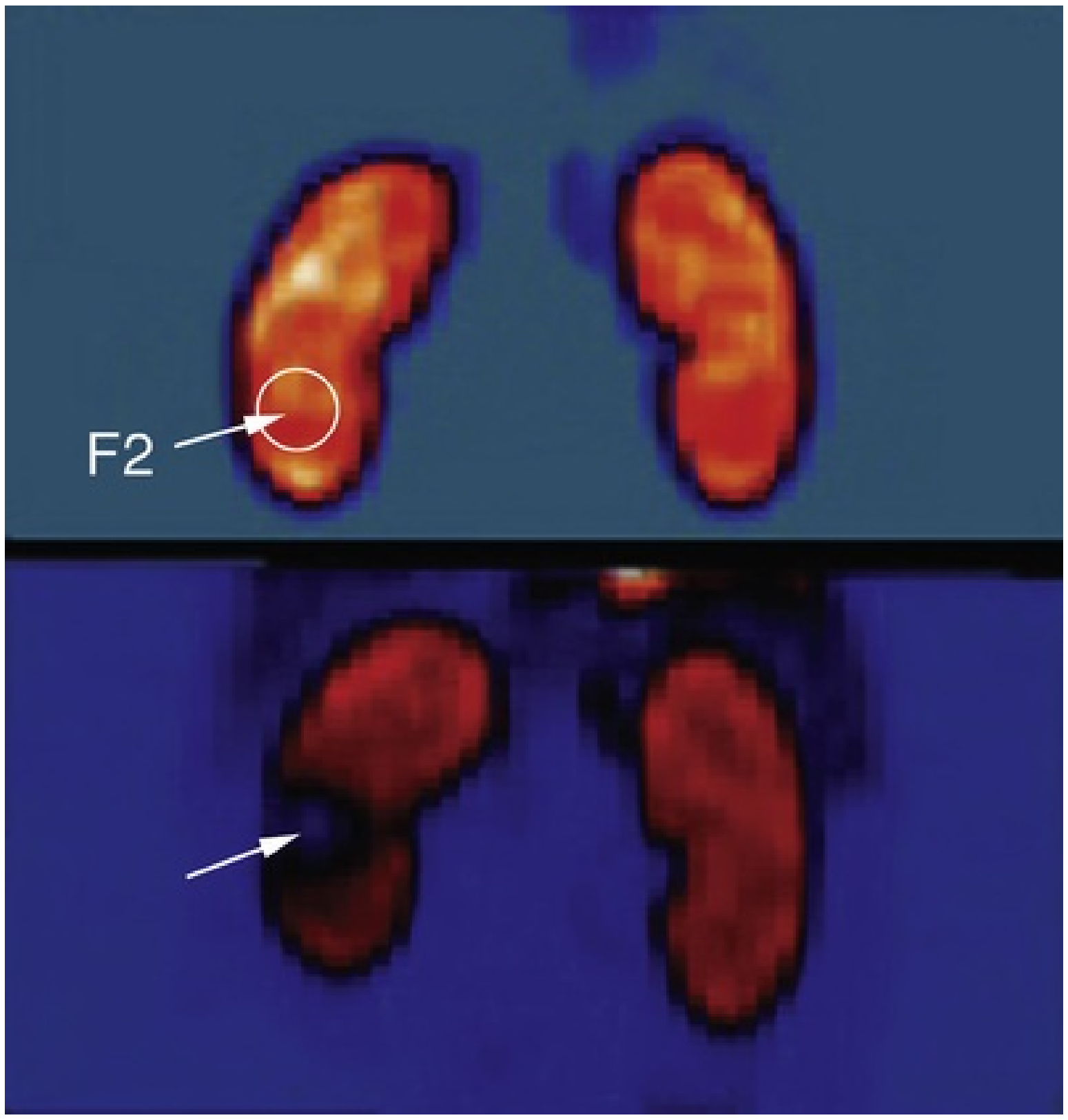

FIG. 94.10 Shock wave lithotripsy–treated and control kidneys imaged by positron emission tomographic scanning before and immediately after treatment with 3500 shock waves to the lower pole, at level six, with a DoLi 50 device. The site of focus 2 (F2) (lower pole) on the shocked kidney shows a 50% reduction of renal blood flow *(arrow)*.

In the clinical setting, there have been reports of moderate-to-severe renal injury occurring after SWL, generally manifesting as a hemorrhagic event. Hematoma rates range from less than 1% to as high as 20%, depending on the type of lithotripter used and the treatment parameters employed, as well as the radiographic modality and timing of imaging follow-up. Some of the third-generation lithotripters have very high peak positive pressures; therefore the rate of reported clinically significant renal hematomas are rising (3% to 12%) (Kohrmann et al., 1995; Piper et al., 2001; Thuroff et al., 1988; Ueda et al., 1993). The appearance of renal hematomas can range in severity from a mild contusion localized within the renal parenchyma to a large hematoma (Fig. 94.11) associated with severe bleeding, possibly necessitating blood transfusion or rarely even angiographic embolization. Although some hematomas may persist for many months to years, it has been reported that most resolve within weeks and without long-term sequelae.

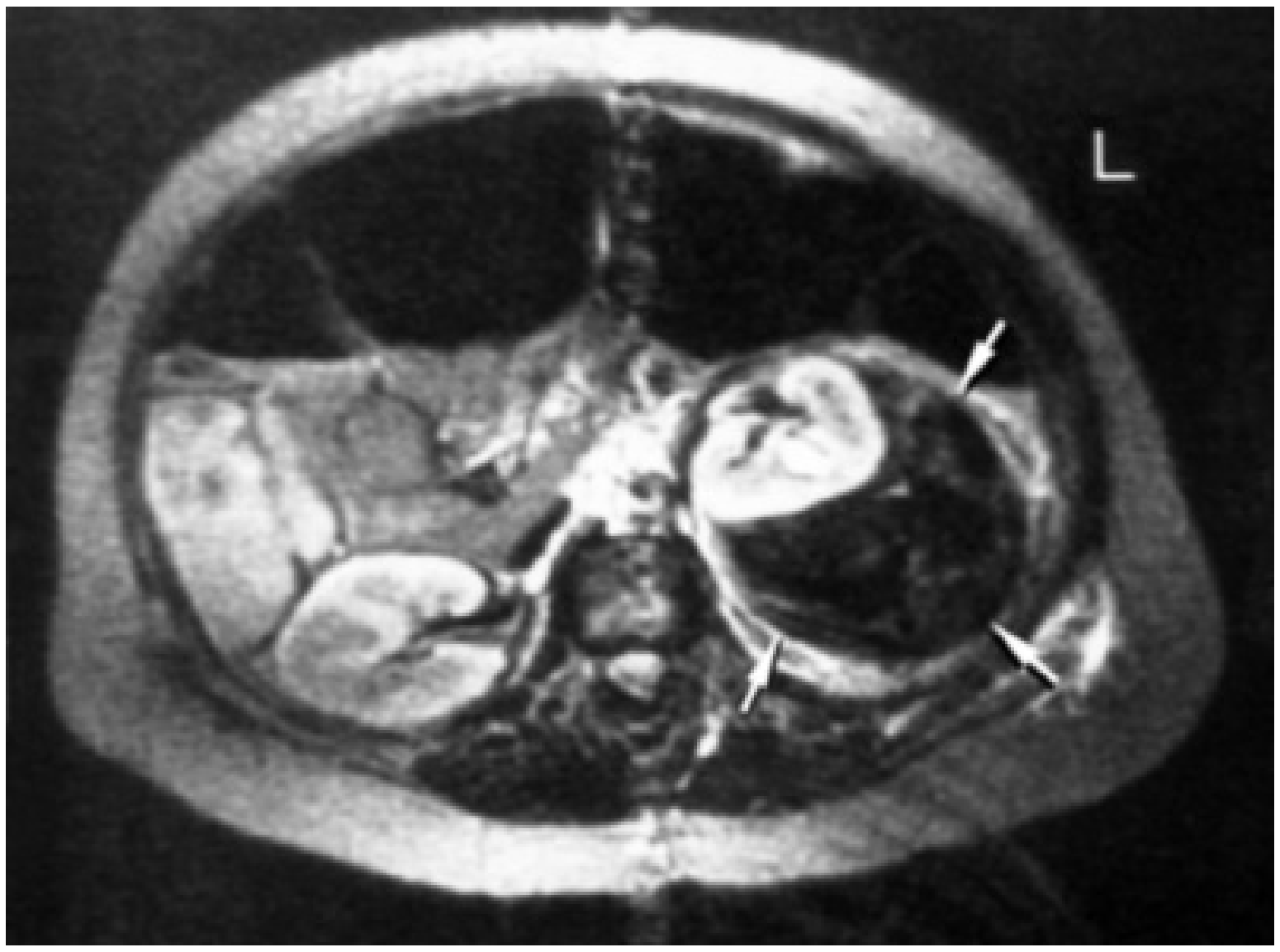

FIG. 94.11 Magnetic resonance image taken 24 hours after shock wave lithotripsy with 1200 shocks at 22 kV (by an unmodified Dornier HM3 lithotripter) shows a large subcapsular hematoma *(arrows)* in the treated (left) kidney.

Several risk factors for the development of a post-SWL hematoma have been identified (Box 94.1). Dhar et al. (2004) reported that the probability of a subcapsular hematoma increased 2.2 times for every 10-year increase in the patient's age. Knapp et al. (1988) found patients with existing hypertension to be at increased risk for the development of a perinephric hematoma as a consequence of SWL. In particular, those patients having unsatisfactory control of their hypertension at the time of SWL had the highest incidence of hematoma formation. Additional risk factors for renal hemorrhage were diabetes mellitus, coronary artery disease, and obesity, all of which suggest a link to a vascular disorder. More recently, Nussberger et al. (2017) found no difference in the presence of hypertension, diabetes mellitus, or history of anticoagulant/antiplatelet usage between patients with and without renal hematoma on routine ultrasound after SWL with a third-generation lithotripter. However, the authors found that patients with a high body mass index (BMI >30) or a low BMI (<21.5) were at a greater risk of hemorrhage compared with other patients.

Box 94.1

Acute Renal Side Effects: Risk Factors for Shock

Wave Lithotripsy

Age
Obesity
Coagulopathies
Thrombocytopenia
Diabetes mellitus
Coronary heart disease
Preexisting hypertension
Body mass index >30 or <21.5

Chronic Renal Injury: Structural and Functional Changes

It is well accepted that shock waves damage blood vessels in the human and animal model, and the resulting hemorrhage initiates an inflammatory response that ultimately leads to scar formation in the animal model. In animal studies parenchymal fibrosis, a precursor to renal scarring, is seen as early as 1 month after SWL, and scar formation also has been reported to be a dose-dependent phenomenon. In the clinical, long-term setting there are **four chronic concerns thought to potentially be associated with SWL treatment. These concerns are development of renovascular hypertension, a decrease in overall renal function, an increase in the rate of stone recurrence, and a decrease in fertility (**Table 94.1**).**

TABLE 94.1

Potential Long-Term Concerns Regarding Shock Wave Lithotripsy (SWL)

CONDITION	OVERALL FINDINGS/CONCLUSION
Hypertension	No large-scale evidence to support an association between SWL and the development of hypertension
Chronic kidney disease	No evidence to support an association between SWL and the development of chronic kidney disease
Diabetes mellitus	No large-scale evidence to support an association between SWL and the development of diabetes mellitus
Increased rate of stone recurrence	Likely an association between SWL and subsequent stone events of patient not rendered stone free
Male fertility	Sperm quality decreases immediately post-SWL for distal ureteral stones but normalizes by 3 months postoperatively
Female fertility	Data inconclusive and limited

The possibility that SWL may be associated with significant changes in systemic blood pressure was first suggested by Peterson and Finlayson (1986) and has been investigated by others. Multiple initial reports indicated a probable association between SWL and the development of hypertension (Lingeman et al., 1987; Williams et al., 1989) or even more specifically diastolic hypertension (Lingeman et al., 1990). Janetschek et al. (1997) performed a prospective study that demonstrated age was a significant risk factor for post-SWL hypertension, with an increase in intrarenal resistive index observed in patients 60 years of age and older. However, multiple subsequent studies have failed to demonstrate an association between SWL and the development of new-onset hypertension. de Cogain et al. (2012) used a population-based cohort in Olmsted County, Minnesota and found no association between SWL and the development of de novo hypertension. A more recent meta-analysis reviewed 30 studies focusing on SWL and the development of hypertension (Fankhauser et al., 2015). The follow-up period was 12 to 240 months, and the number of patients ranged from 35 to 1758. Only 6 of the 30 studies found an increase in hypertension after SWL, and the remaining 24 found no association. A subcapsular hematoma can induce hypertension; however, such changes are generally transient. **Transient changes in blood pressure control, frequent visits to the physician surrounding the stone event, pain, and broad definitions of hypertension may account for the many varied study results; however, based on the current literature, there is no strong evidence associating SWL with development of hypertension.**

Another potential concern surrounding SWL is its effect on long-term renal function. Williams et al. (1988) found a **significant decrease in the percentage of effective renal plasma flow 17 to 21 months after SWL for patients with two kidneys**. Orestano et al. (1989) noted that patients receiving more than 2500 shocks had a reduction in creatinine clearance and a prolongation of ^{131}I-Hippuran transit time 30 days after SWL in the treated kidney; in some cases, similar findings were noted in the contralateral kidney. Lingeman et al. (1990) reported that patients with a solitary kidney demonstrated elevated serum creatinine levels 5 years after SWL. These observations stand in contrast to the early reports by Chaussy and Fuchs (1986), which suggest a significant increase in renal function 3 months to 1 year after SWL. A longer follow-up study of patients treated in Munich failed to demonstrate any long-term change in renal function after SWL (Liedle et al., 1988). More recent reports have found no association between permanent decrease in renal function and SWL. A meta-analysis included 14 studies from 1992 to 2012 that focused on renal function and SWL, of which 7 were retrospective and 7 prospective (Fankhauser et al., 2015). Follow-up for the studies ranged 15 months to 17 years. None of the studies found evidence for an increase in chronic kidney disease after SWL. Thus, **based on the current literature, there is no evidence to indicate SWL is associated with long-term renal dysfunction.**

Another significant concern is that **stone recurrence rates may be higher after SWL because of residual stone debris** (Pearle et al., 2005). A study by Carr et al. (1996) documented new stone formation in 298 consecutive patients who initially were determined to be stone free after SWL and compared those recurrence rates with those of 62 patients treated by percutaneous nephrolithotomy (PCNL). The Carr study data showed a significant increase in the rate of new stone formation within 1 year of SWL treatment compared with PCNL. The authors suggested that fine sand debris generated from SWL treatment remained in the kidney and gravity acted to position it as a nidus in the calyceal system. Subsequent surgical stone research has demonstrated that residual fragments after endoscopic stone procedures result in a higher recurrence rate (Chew et al., 2016); thus the lower stone-free results after SWL compared with other treatment modalities for certain stone sizes and locations must be taken into consideration (Assimos et al., 2016a). **If SWL has a higher residual fragment rate after treatment, then it is likely to result in higher stone recurrence rates.**

Finally, the effect of SWL on the reproductive system has yet to be fully elucidated. During SWL the female reproductive organs, as well as the female and male reproductive organ vascular supplies, are directly exposed to SWL when ureteral stones are treated. Early in vitro studies have demonstrated that sperm are sensitive to the effects of SWL. Multiple investigators have demonstrated a decrease in sperm vitality and change in morphology when semen samples are exposed to SWL (Andressen et al., 1996), of which two investigators have even noted a dose-dependent change in the quality of the semen sample (Kaller et al. 1988; Ohmori et al. 1993). Clinically, the effects of SWL on sperm quality and function are not so clearly observed. The first study on male fertility and SWL was performed by Puppo et al. (1990), who analyzed 10 men before and after SWL of a distal ureteral stone and noted no change in their semen analyses. A follow-up study by Andressen et al. (1996) of 10 men undergoing SWL of a distal ureteral stone found a decrease in sperm motility and density from preoperatively to postoperatively. A more extensive study of 62 men treated with SWL for distal ureteral calculi and 62 men treated with SWL for proximal ureteral calculi compared semen analyses results from preoperatively, to 1 week postoperatively, to 3 months postoperatively (Sayed, 2006). This study found that sperm density and mobility decreased 1 week postoperative in the men treated with distal ureteral SWL from preoperatively but did not change in the men treated with SWL for a proximal ureteral stone. However, all abnormal findings normalized to baseline by 3 months postprocedure. A more recent meta-analysis of 6 studies focusing on male fertility after SWL confirms that there is a decrease in sperm concentration and motility with an increase in hematospermia after SWL; however, all findings normalized by 3 months postprocedure (Radfar et al., 2017). There are limited data focusing on female fertility after SWL. Two retrospective studies of women after SWL were of minimal benefit in determining effects of SWL on fertility. One study focusing on 67 women after SWL found that only 10 were actually trying to conceive (Vieweg et al., 1992). Another questionnaire study of 39 women found that only 10 reported pregnancy with successful delivery of 11 babies (Erturk et al., 1997). Both studies concluded that SWL did not adversely affect fertility in the female patient. However, based on the low number of women actually trying to conceive who are mentioned in the current available literature, no definitive conclusions can be made regarding the effects of SWL on female fertility.

Mechanism for Tissue Injury

The mechanism for the traumatic effects of SWL is not known, although Delius et al. (1988) have speculated that the violent collapse of cavitation bubbles generated by the shock waves is primarily responsible for the cellular changes. This cavitation concept is based on data showing that cavitation bubbles are present during shock wave application and that lithotripter shock waves can cavitate water and blood in vitro (Coleman, 1987). Zhong et al. (2001) suggested that the expansion of bubbles in a vessel leads to rupture of the wall of that blood vessel, which has been tested and proven in an in vitro setting.

Bailey et al. (2005) used a novel detection system to demonstrate cavitation of tissue in vivo. Their data found pooling of fluid in tissue at sites of cavitation, suggesting that **once blood vessels have been ruptured and blood has collected in pools, there is a greater potential for cavitation to occur. The pooling of blood provides a large fluid-filled space for cavitation bubbles to grow and collapse.**

Techniques to Optimize Shock Wave Lithotripsy Outcome

First and foremost proper patient selection is necessary for a successful SWL procedure. Selecting patients based on stone size, composition, skin-to-stone distance, stone location, Hounsfield units, and Triple D score are paramount. Proper patient selection is covered elsewhere in this volume. For device-specific variables, the urologist has the ability to control a number of lithotripter parameters that may affect the ultimate treatment outcome (Box 94.2). These parameters include the acoustic output and focal volume that are employed, optimal coupling, the number of shock waves administered, the rate at which they are dispensed, and the power or voltage that is used. In addition, other intraoperative factors that may affect stone breakage can be controlled, such as anesthetic technique.

Box 94.2

Factors That Induce the Degree of Renal Trauma Associated With Shock Wave Lithotripsy

Aggravating Factors

Number of shocks
Period of shock wave administration: Shorter period increases damage
Accelerating voltage: Higher voltage increases damage
Type of shock wave generator: First- versus second-/third-generation devices
Kidney size: Juvenile versus adult
Preexisting renal impairment

Mitigating Factors

Pretreatment with 100 to 500 shocks at low energy level to reduce lesion size
Treatment at a slow rate of shock wave delivery (≤60 shocks/min)

Although all lithotripters generate waveforms that are fundamentally similar, lithotripters may be distinguished from one another by the peak pressure and the size of their focal zone at F2. In vitro studies suggest that the focal width generated by a lithotripter affects stone breakage; a wider focal width increases the likelihood of stone breakage (Sapozhnikov et al., 2007). Because the kidney tends to move, as a consequence of respiratory motion, the stone may move in and out of a narrow focal zone. Furthermore, when the focal zone is narrower than the stone, the stress inside a stone is reduced. For the stone to be subjected to the full force of shear stress, the outer surface of the stone must be subjected to high-pressure shock wave energy, which will not occur with a small focal zone (Sapozhnikov et al., 2007). This assessment is supported by clinical studies comparing large focal zone lithotripters (Dornier HM3) with intermediate zone lithotripters (Siemens Lithostar Plus), and small zone lithotripters (Storz Modulith SLX) in which the large focal zone devices had the lowest retreatment rate, whereas the small zone devices had the highest (Dhar et al., 2004).

The present generation of lithotripters has dry treatment heads, which make them smaller and more easily transportable. However, they require a coupling medium, such as gel or oil, to join the patient to the device. Optimal coupling permits the efficient transfer of energy from the lithotripter to the patient; poor coupling will reduce stone breakage. Most commonly, energy transfer through a coupling medium is attenuated by air pockets in the coupling interface. Air pockets covering as little as 2% of the coupling area diminish stone comminution by 20% to 40% (Pishchalnikov et al., 2006). Decoupling and recoupling, which may occur during repositioning of a patient during SWL, can generate large-volume air pockets in the coupling medium (Li et al., 2012; Neucks et al., 2008; Pishchalnikov et al., 2006). With current available lithotripters, it is not possible to actively monitor coupling during treatment; however, such technology may be beneficial in future generation lithotripters. A study using video cameras placed in the head of a Dornier Doli SII lithotripter to detect air pockets in the coupling gel demonstrated that air bubbles could be actively monitored and that the presence of air bubbles affected the number of shock waves needed for stone fragmentation (Bohris et al., 2012). One measure to limit coupling defects is by altering how the agent is applied. Coupling has been found to be improved by delivering a large volume of gel as a mound dispensed from the stock jug and allowing the gel to spread on contact between the treatment head and the skin. The type of coupling media is also an important factor to consider. One study of five different coupling agents found that water-soluble lubricating jelly required the least amount of shocks for stone fragmentation, whereas local anesthetic cream (EMLA) and petroleum jelly required the greatest number of shocks (Cartledge et al., 2001).

During an SWL treatment session the urologist can directly control the rate at which shock waves are delivered and the number of shock waves dispensed. In vitro and animal studies have shown that slowing the shock wave delivery rate to less than 120 SW/min improves stone fragmentation (Greenstein and Matzkin, 1999; Paterson et al., 2002). The first clinical randomized trials also demonstrated better stone-free rates when SWL was performed at 60 SW/min as compared with 120 SW/min (Madbouly et al., 2005; Pace et al., 2005). These findings were confirmed in a literature review and meta-analysis of randomized controlled trials evaluating different shock wave delivery rates: a rate of 60 shocks per minute was found to break stones more effectively than 120 shocks per minute (Semins et al., 2008). More recently, a systematic review and network meta-analysis based on 13 randomized clinical trials found that success rates of SWL procedures at low (60–70 shocks/min) (odds ratio [OR] 2.2, 95% confidence interval [CI] 1.5–2.6) and intermediate-frequency (80–90 shocks/min) (OR 2.5, 95% CI 1.3–4.6) are significantly higher than at high (100–120 shocks/min) frequency (Kang et al., 2016). Furthermore, there was no significant difference in outcomes between low- and intermediate-frequency SWL procedures. **Cavitation is thought to play a role in improved results at lower SWL rates, because the dynamic bubbles are given a longer time interval to dissipate with a slower rate. At a higher rate the bubbles build on the surface of the stone forming a barrier to SW energy transmission and thus act as an energy draw from subsequent shocks** (Choi et al., 1993). The disadvantage of a slow rate is, of course, a longer treatment time, particularly if the number of shock waves being delivered is predetermined. Slowing the rate has also been shown to be protective of the kidney vasculature in the animal model (Evan et al., 2007). However, clinical studies in humans have found no difference in complication rates across different SWL frequency ranges (Kang et al., 2016). Despite the conflicting findings between animal studies and human outcomes it is generally recommended that **the lowest number of shock waves needed to fragment the stone be used to reduce the risk of renal injury. To minimize overtreatment physicians are encouraged to not use a preset treatment number but to instead image the stone frequently during the SWL treatment and discontinue shock wave delivery once the stone shows adequate fragmentation.**

Another parameter urologists adjust is the energy setting on the machine.

Increasing the power setting on most electromagnetic lithotripters actually narrows the focal zone, which, as discussed earlier, decreases stone breakage and may also increase the risk for renal injury and renal hematoma (Connors et al., 2000). **In vitro and in vivo studies have demonstrated a benefit of "ramping up" the energy of the lithotripter by not only improving stone fragmentation but also decreasing renal injury effects** (Fig. 94.12). In the stone phantom model (Zhou et al., 2004) and the porcine model (Connors et al., 2009; Maloney et al., 2006; Willis et al., 2006) energy-ramping protocols have demonstrated superior stone fragmentation over standard fixed treatments. Furthermore, clinical studies have demonstrated that pretreatment with a lower energy for the first 100 shocks and gradual ramping of the lithotripter energy level as the treatment progresses has resulted in higher stone-free rates (Demirci et al., 2007; Lambert et al., 2010). In the study by Lambert et al. (2010) patients were randomized to receive 500 shocks at 14 kV, 1000 at 16 kV, and 1000 at 18 kV or to a standard 18 kV for 2500 shocks. The ramping group had a significantly higher stone-free rate at 1 month compared with the standard group (81% vs. 48%). In addition, the ramping group demonstrated lower levels of beta2 microglobulin and microalbumin, markers of renal injury, 1 week postoperative compared with the standard group. Such protective effects of ramping protocols have been previously noted in the porcine model. Renal lesion size has been shown to be decreased after pretreatment with low-energy shock waves (100 to 2000 at 12 kV followed by 24 kV) (Willis et al., 2006). Interestingly, Connors et al. (2009) demonstrated in a pig model that the voltage that is initiated is less important than the actual ramping up or halt in treatment, because pretreatment groups with 100 shock waves at 18 or 24 kV had significantly smaller lesions than just treating with 2000 shock waves at 24 kV without pretreatment. The reduction in renal injury is thought to be secondary to vasoconstriction because the same beneficial effect was blocked when dopamine was administered (Willis et al., 2006). A recent study of 418 patients treated with either a fixed or ramping protocol during SWL and followed with ultrasound imaging found that significantly fewer renal hematomas occurred in the ramping group (5.6% vs. 13%) (Skuginna et al., 2016). Handa et al. (2012) reported that a pause in treatment, when switching from low-energy to high-energy settings, is not necessary provided that the delivery of low-energy shock waves lasted at least 4 minutes.

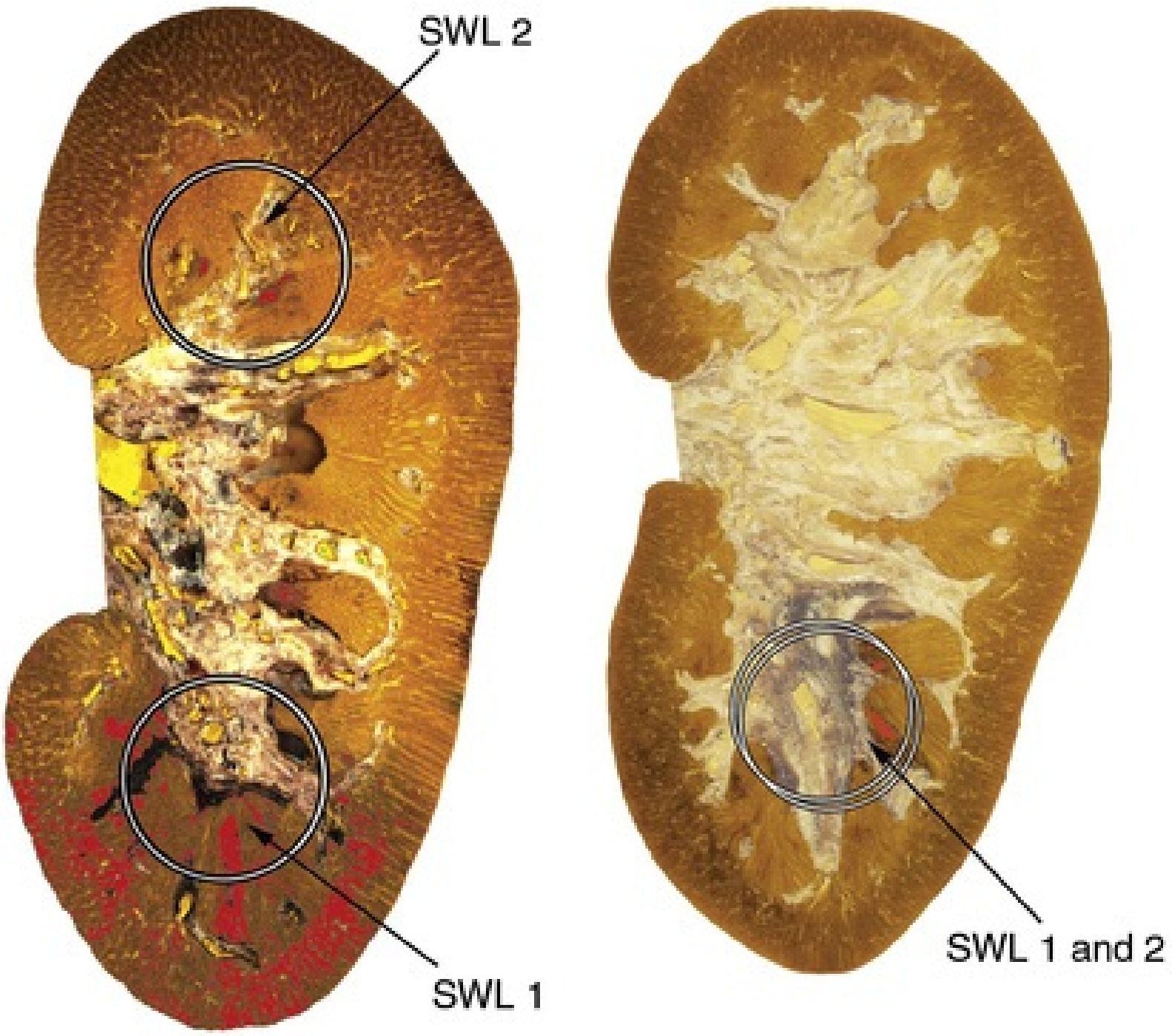

FIG. 94.12 On the left is a coronal section of a kidney from an animal treated with 2000 shocks at 24 kV first to the lower pole (shock wave lithotripsy [SWL] 1) and then an additional 2000 shocks at 24 kV to the upper pole (SWL 2) of the same kidney. The typical lesion *(in red)* is seen at the lower pole; however, a greatly reduced lesion is seen on the upper pole. These data suggest that a pretreatment protocol may reduce the lesion induced by a clinical dose of shock waves. At right, lesion size is shown in an animal first treated at the lower pole with 500 shocks at 12 kV (SWL 1) and then treated again at the lower pole with 2000 shocks at 24 kV (SWL 2). A greatly reduced lesion is also noted for this protocol.

Current generation lithotripters have been specifically developed so that treatment can be delivered without anesthesia. **The discomfort experienced during SWL is related directly to the energy density of the shock wave as it passes through the skin and the size of the focal point.** To minimize treatment discomfort the lithotripters were designed with wider aperture, which will spread the acoustic field across a broader area of the patient's skin, reducing skin surface pain. However, this wider aperture resulted in a narrow focal zone, which had a deleterious effect on stone breakage. Interestingly, the higher pressures used with these newer machines also have the potential to result in higher adverse event rates. Any movement during the SWL procedure, either by the patient because of pain or discomfort or by the kidney or stone through respiratory movement can adversely affect SWL outcomes by decreasing the number of shocks actually delivered to the stone. The kidney may move up to 50 mm during respiration, which is significant considering stone fragmentation can be reduced substantially with just 10 mm of motion in the bench top model (Cleveland et al., 2004). A study by Sorensen et al. (2012) that reviewed ultrasound videos during SWL found that only 60% of shock waves were delivered to the stone and mean stone motion was 15 mm. To reduce stone motion, urologists can perform SWL with general anesthesia, which will control the patient's respiratory rate and volume. Two clinical studies compared the outcome of SWL performed with intravenous sedation and SWL performed with general endotracheal anesthesia. General anesthesia yielded significantly better outcomes: 78% to 87% stone-free rates versus 51% to 55% with intravenous sedation (Eichel et al., 2001; Sorensen et al., 2012). Because general anesthesia is associated with superior outcomes, this may be the anesthesia of choice for SWL, unless contraindicated for medical reasons. High-frequency jet ventilation is an alternative form of ventilation during general anesthesia that may also be beneficial during SWL. One clinical study found that when high-frequency jet ventilation was used, there was minimal respiratory movement, and patients undergoing SWL required fewer shocks with lower total energy to achieve stone fragmentation (Mucksavage et al., 2010).

Adjuncts to Improve Shock Wave Lithotripsy Outcomes

Although successful SWL starts with appropriate patient selection and proper surgical technique, a few adjunctive measures may help to facilitate stone passage and limit patient morbidity in the postoperative period. Currently, the American Urological Association (AUA) guidelines do not recommend the placement of ureteral stents at the time of SWL because stent placement has not been shown to improve stone passage rates and only increases patient morbidity (Assimos et al., 2016b). However, the use of medical expulsive therapy and percussion diuresis and inversion (PDI) therapy have been found to be beneficial (Box 94.3).

Box 94.3

Ways to Improve Shock Wave Lithotripsy Outcomes

Appropriate coupling

Water-soluble lubricant applied by hand

- Decrease rate to low (60–70 shocks/min) or intermediate (80–90 shocks/min)
- Image frequently and stop shocking once fragmented
  - Do not use a preset number of shocks
- Ramping protocol
  - Treat with low power escalating to higher levels
- General anesthesia
- Do not use a ureteral stent
- Consider alpha-blockers for medical expulsive therapy
- Consider percussion, diuresis, inversion therapy

Kupeli et al. (2004) evaluated the use of alpha-blockers for 2 weeks after SWL in 48 patients. The authors found a significant improvement in stone-free rates in the patients treated with alpha-blockers compared with SWL alone (70.8% vs. 33.3%). Subsequent studies have demonstrated similar improvements in stone-free rates (Bhagat et al., 2007; Georgiev et al., 2011; Gravina et al., 2005), and recent meta-analysis of multiple different alpha-blockers shows similar benefits regardless of the type of alpha-blocker used (Skolarikos et al., 2015; Yang et al., 2017). Other investigators have found that the use of alpha-blockers in the SWL postoperative setting resulted in decreased time to fragment clearance (Kobayashi et al., 2008), and improvements in overall pain control (Georgiev et al., 2011; Gravas et al., 2007; Resim, 2005), which has been confirmed with a recent meta-analysis. Based on these studies and a limited side effect profile of alpha-blockers, they appear to be a beneficial pharmacologic tool in the immediate post-SWL period.

Another novel mean to facilitate stone fragment passage is PDI therapy. The general concept is some type of diuretic—either drinking copious amounts of fluid or taking a diuretic agent (e.g., furosemide)—is employed and the patient is placed in a prone Trendelenburg position while the flank is percussed for approximately 10 minutes. Percussion of the flank can be manual or using a mechanical device such as a chest physiotherapy vibrator. PDI is generally performed at least weekly for several weeks. Randomized prospective trials comparing PDI after SWL for fragments less than 4 mm in the lower pole versus observation alone found a higher stone-free rate (40% vs. 3%) with PDI (Pace et al., 2001). Another study randomized patients to SWL + PDI vs. SWL alone for stones smaller than 2 cm and found that stone-free rates were higher in the PDI group (62.5% vs. 35.4%) (Chiong et al., 2005).

Future Direction

Improving visual coupling of SWL may improve overall outcomes and stone-free results by increasing the percentage of shock waves impacting the stone at F2. The Visio-Track (VT) locking system has the potential to increase stone fragmentation rates and decrease fluoroscopy time. The VT is a hand-held probe with an infrared stereovision, which allows triangulation of the stone location. The VT is used with ultrasound-guided lithotripters and allows the lithotripter to “lock on” to the stones location during treatment. The preliminary data for the VT system have demonstrated a significantly higher stone-free rate when VT-SWL was used versus standard ultrasound-guided SWL (79.5% vs. 54.5%) (Abid et al., 2015).

Ultrasonic propulsion of renal and ureteral calculi is another measure thought to potentially improve outcomes with SWL. Focused ultrasound has emerged as a technology that can expel small stones or stone fragments from the urinary system (Sorensen et al., 2013). Harper et al. (2013) reported an in vitro study that effectively and rapidly migrated stone material through a urinary system using ultrasound. As a next step a handheld device has been developed that uses a higher amplitude and larger pulses of ultrasound than standard diagnostic ultrasound to physically manipulate stones in vivo (Harper et al., 2014). The stone-pushing technology has been demonstrated to be safe with minimal tissue destruction in the porcine model (Connors et al., 2014). The first human clinical trial occurred in 2016, aimed to reposition stones 10 mm or less in 15 subjects (Harper et al., 2016). Stones were successfully repositioned in 93% of subjects with a mean skin to stone depth of 11 cm. Ultrasonic propulsion also demonstrated a collection of stones rather than a solid stone in 5 subjects, which the subjects then passed after fragment relocation. Potential future uses of this technology would be to assist in expulsion of residual stone fragments after SWL or movement of a stone from an unfavorable (lower pole of the kidney) or painful location (ureter) to a more favorable location (the renal pelvis) before SWL treatment (Fig. 94.13).

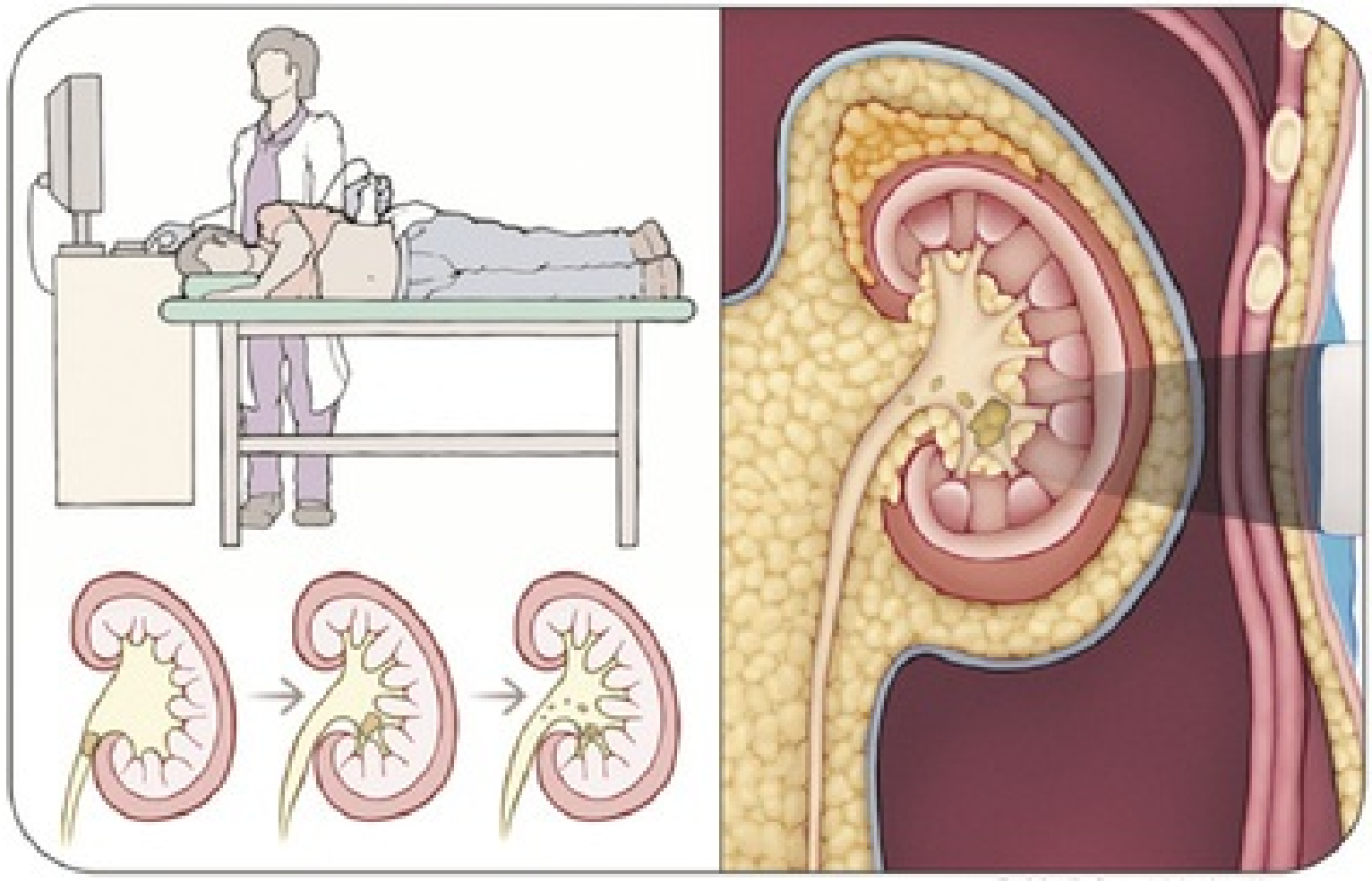
© 2017 Carol Marinelli

FIG. 94.13 Proposed use of ultrasonic propulsion to reposition a stone to a more favorable location for subsequent shock wave lithotripsy.

Poor stone-free results with later-generation lithotripters has led investigators to explore other forms of ultrasound stone fragmentation. A newly developed mode of lithotripsy has demonstrated promising initial results. Excessive bubble production through cavitation can block the surface of the stone from subsequent shock waves and protect the stone from further comminution. Burst wave lithotripsy uses sinusoidal short bursts of focused ultrasonic pulses to fragment stones. The short bursts of ultrasound eliminate the blocking effect of surface cavitation and improve stone fragmentation with lower F2 pressures. In vitro studies of burst wave lithotripsy indicate that the technology can fragment struvite and uric acid stones in seconds and calcium oxalate monohydrate stones in 10 minutes to very small fragment sizes (<2 mm) with low peak pressures of 4 mPa (Maxwell et al., 2015). In the porcine model, bust wave lithotripsy can fragment stones at less than 12 mPa and at a faster rate, less than 200 Hz (May et al., 2017). As a comparison, standard SWL uses pressures of 30 to 100 mPa and less than 2 Hz. Furthermore, because burst wave lithotripsy is ultrasound guided, it is designed to provide real-time feedback so the development of cavitation in the tissue can be identified and treatment subsequently halted, thus preventing tissue damage (Maxwell et al., 2015). Initial porcine studies in which burst wave lithotripsy was used at 21 treatment sites found that renal injury did occur in the form of focal tubular damage, as well as cellular fragmentation and necrosis similar to SWL (May et al., 2017). However, the area was minimal at less than 0.1% of the renal functional volume. When the treatment was allowed to progress at extreme doses, extended pressures, and large areas of cavitation, the damage was still confined to only 1% of the kidney (Fig. 94.14). Based on initial animal and in vitro studies, burst wave lithotripsy is an advancing technology that has the potential to revolutionize the future of SWL.

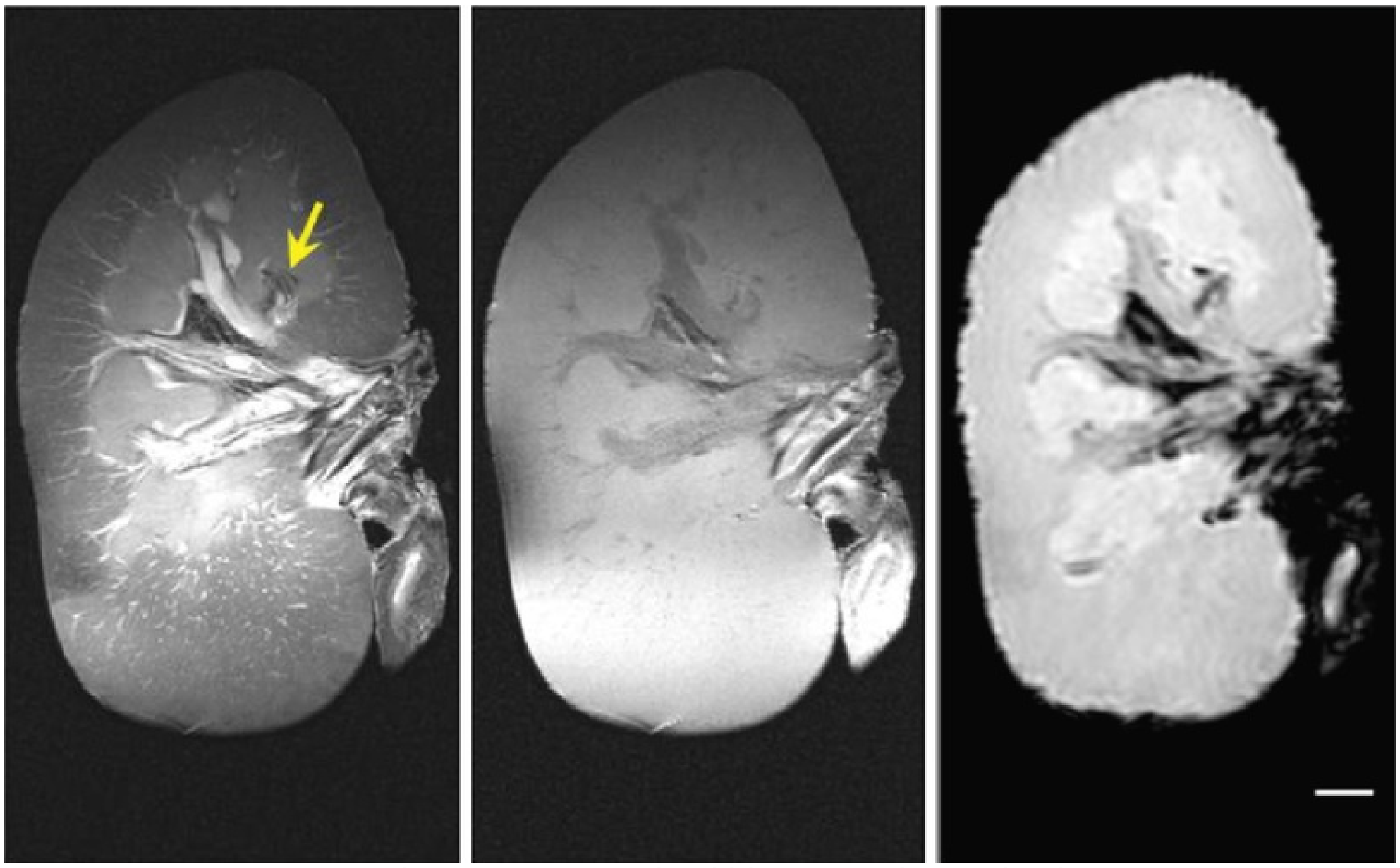

FIG. 94.14 MRI images of a porcine kidney after burst shock wave lithotripsy. *Arrow* indicates small area of renal damage and hemorrhage.

Key Points: Shock Wave Lithotripsy

- Shock waves fragment stones via multiple different mechanisms, including compressive and tensile forces.
- SWL is associated with anatomic injury to the kidney; however, extensive studies in humans have not indicated long-term adverse effects.
- Adverse outcomes with SWL are associated with high peak pressures at F2.
- The effectiveness of SWL can be enhanced by ensuring optimal coupling of the patient to the lithotripter, treating at a slow to intermediate rates (60 shocks/min), ramping the power settings, and treating with general anesthesia.

- The adverse effects of SWL may be reduced by initiating treatment at low power settings and slowly ramping up the power to standard treatment energy.

Percutaneous Nephrolithotomy

Preparation of the Patient

The initial evaluation of the patient who is being considered for PCNL should be a complete history and physical examination. A complete medical history will **identify patients with an absolute contraindication to PCNL, such as uncorrected coagulopathy, as well as those with an active, untreated urinary tract infection (UTI)**. The placement of a percutaneous nephrostomy drain, without manipulation of the calculus, may be an appropriate therapy if the stone is associated with obstruction of the renal unit and sepsis. If it is medically feasible, **aspirin and other antiplatelet or anticoagulation medications should be discontinued before surgery.** In patients with a higher risk for thrombotic complications, bridging therapy with short-acting may be necessary.

Preoperative laboratory evaluation of patients scheduled for PCNL should include a complete blood cell count as well as serum electrolyte determinations and renal function tests. A urine culture should be obtained if there is suspicion of infection; perioperative antibiotics can be appropriately tailored to culture-specific organisms. Typing and screening of the patient's blood should be considered, although preoperative crossmatching usually is not necessary.

The standard usage of helical computed tomography (CT) to evaluate the patient with urolithiasis has eliminated the need to perform preoperative intravenous urography or retrograde pyelography. **In most cases, the decision to perform PCNL may be based on the stone burden displayed on the CT images.** The main advantage of CT is the ability to assess the spatial relationship of the kidney relative to the stone and that of the kidney in relation to adjacent peritoneal and retroperitoneal structures. For example, CT permits identification of structures such as a retrorenal colon, or a liver or spleen that may be in the projected access trajectory. Patients with ectopic kidneys, congenital and iatrogenic (e.g., resulting from renal allograft, autotransplantation), as well as patients with dysmorphic body habitus because of congenital malformations such as spinal dysraphism may also benefit from cross-sectional imaging before PCNL; intra-abdominal structures, such as the bowel, may be located between the skin and the renal access point in such cases. Retrograde pyelography can be performed at the time of the surgical procedure, acquiring information about calyceal anatomy that may aid in selecting the targeted puncture site.

Radionuclide scanning may be necessary in selected patients, particularly those harboring an extensive stone burden or an atrophic kidney, to evaluate differential renal function.

Antibiotics

Although data to support the need for antibiotic prophylaxis during PCNL are limited because of the lack of randomized controlled clinical trials, it is generally accepted that antibiotic prophylaxis reduces infectious complications. Institutional antibiograms aid in the selection of a most appropriate perioperative antimicrobial regimen. Importantly, it has been reported that urinary calculi may harbor bacteria even though bacteriuria is only intermittently present. In addition, t**he fragmentation of stones, despite sterile urine, may release preformed bacterial endotoxins and viable bacteria that place the patient at risk for septic complications.** Therefore patients who have radiographic or clinical features suggestive of struvite, or in whom infection is suspected, should receive broad-spectrum antibiotics before surgery to reduce the risk for sepsis. For patients with indwelling stents, too, a course of antibiotic prophylaxis, particularly for gram-positive organisms, may be beneficial before instrumentation.

Anesthesia

PCNL can be performed after the administration of general, epidural, or local anesthesia. Typically, general anesthesia is preferred; however, local anesthesia may be an option when general anesthesia is contraindicated. A local anesthetic, such as lidocaine, can be delivered into the access tract by use of an 8.3-Fr anesthetic injection catheter with multiple side holes or with a dual-lumen ureteral access catheter or using a 23-gauge spinal needle with injection along the access tract to the renal capsule. Regional anesthesia (e.g., epidural, spinal) can be used for percutaneous procedures, but several problems may be associated with these regional anesthetic techniques. First, a relatively high block is necessary to eliminate all renal pain, and second, distention of the renal pelvis during PCNL may cause a vasovagal reaction that is not always prevented by regional anesthesia. **In cases in which upper pole puncture is contemplated, general anesthesia is preferred because it permits control of respiratory movements,** which is essential to minimize the risk for pulmonary complications. **A close relationship between the surgeon and the anesthesia**

team is essential to optimize the outcome of a PCNL procedure. The anesthesiologist should be aware that pulmonary injuries, including hydrothorax and pneumothorax, can occur during PCNL; to that end, the anesthesiologist should monitor airway pressures, end-tidal carbon dioxide levels, and oxygen saturation and should auscultate the lungs frequently. Acute anemia from blood loss or dilution also may occur, emphasizing the need for frequent hemodynamic assessments. Because of the large amounts of fluids administered to the patient during nephroscopy there is a potential risk for hypothermia. Warming of irrigation fluids as well as patient warming devices may attenuate this risk.

Stone Removal

The fundamental techniques of gaining and maintaining percutaneous access, including imaging modalities and patient positioning (prone versus supine), are reviewed in Chapter 12.

After the nephrostomy access has been appropriately dilated and the Amplatz sheath positioned, the urologist can proceed with stone removal by endoscopic techniques. **Physiologic solutions should be used for irrigation during PCNL to minimize the risk for dilutional hyponatremia in the event of large-volume extravasation.** The height of the irrigant during rigid nephroscopy should not be excessively elevated, which will minimize intrapelvic pressure and fluid absorption through pyelovenous backflow. The use of an Amplatz working sheath also prevents elevated intrapelvic pressures. Rigid nephroscopy is performed initially, and small stones may be grasped with rigid graspers or stone baskets and extracted intact through the Amplatz sheath. Larger stones, though, require fragmentation before extraction. Several intracorporeal lithotripsy techniques are available and are reviewed elsewhere in this chapter.

Rigid nephroscopy is the preferred method for stone removal; however, only the simplest intrarenal collecting systems can be completely inspected with a rigid nephroscope through a single access. Therefore **flexible nephroscopy should be used during every PCNL to survey the entire intrarenal collecting system for residual stone fragments**. With an Amplatz sheath in place, pressurization of irrigation fluid during flexible nephroscopy can be used to adequately distend the collecting system and to improve visualization. The entire collecting system should be examined systematically, including the proximal ureter. Injection of contrast material through the flexible nephroscope and occasional fluoroscopy is helpful in maintaining orientation and verifying that each calyx has been inspected. Small stone fragments can be removed with a stone basket passed through the flexible instrument, and larger stones can be fragmented with laser or electrohydraulic lithotripsy (EHL). Alternatively, fragments may be flushed or manipulated into the renal pelvis, where they may be retrieved more easily with rigid instruments. The goal of PCNL is complete or nearly complete clearance of stone material at the time of the primary procedure, which greatly simplifies secondary procedures.

Multiple different sizes and shapes of nephrostomy tubes are currently available for use at the time of PCNL. The role of nephrostomy tube drainage is to aid in healing of the nephrostomy tract, promote hemostasis, prevent urinary extravasation, drain infection, and allow re-entry if necessary. Recently, tubeless (ureteral stent is left instead of nephrostomy tube) and even totally tubeless (no drainage device used) PCNL have been introduced and popularized. Comparison of nephrostomy tube size, shape, and tubeless and totally tubeless procedures is presented in Chapter 12.

Technique Modifications

In an attempt to decrease morbidity association with PCNL, modifications have been made to the size of the renal access tract, resulting in the new designations of “mini-percutaneous nephrolithotomy,” “ultra-mini-percutaneous nephrolithotomy,” and “micro-percutaneous nephrolithotomy.” These smaller diameter access procedures have been reported to be associated with longer operative times because of the need to fragment stones into small pieces. However, blood loss and transfusion rates with mini-PCNL are lower compared with those with standard PCNL. Although all of the recent technique modifications work to decrease overall patient morbidity, because of technical limitations with the mini-, ultramini-, and micro-PCNL their exact role in the treatment of upper tract nephrolithiasis is uncertain and continues to be defined. Selection among these procedures is reviewed in Chapter 93.

Key Points: Percutaneous Nephrolithotomy

- Critical preoperative steps include correcting underlying coagulopathy and close attention to preoperative microbiologic studies and perioperative antibiotic therapy.

- Complete stone removal generally requires both rigid and flexible nephroscopy and a corresponding armamentarium of rigid and flexible lithotrites.
- There is an increasing role for smaller caliber dilation/instrumentation approaches such as mini-, micro-, and ultramini-PCNL. Their ultimate place in the spectrum of therapies is not yet well defined, but they appear to be associated with less bleeding and pain. However, the efficiency of stone clearance also may be reduced.

Special Situations

Calyceal Diverticula

Treatment of calculi within a calyceal diverticulum can be difficult, and percutaneous removal has the reported highest treatment success rate of all endourologic minimally invasive treatment modalities (Krambeck and Lingeman, 2009). Percutaneous access into stone-bearing diverticula poses several unique problems. Direct puncture is often difficult because of the small size of the cavity and the frequent occurrence of calyceal diverticula in the upper pole of the kidney. After successful puncture is achieved, negotiation of a guidewire into the renal pelvis is often not possible. A similar situation can occur when a stone fills a calyx so completely that a guidewire cannot be passed through the infundibulum into the renal pelvis or in the rare case of infundibular stenosis. To overcome these difficulties, a special access technique is required.

If the calculi are visible on fluoroscopy, it is often preferable to puncture directly onto the stone. **Direct puncture into the diverticulum allows use of rigid instruments that provide superior visualization compared with flexible instruments that are used in an indirect approach** (Fig. 94.15). Once the diverticulum is punctured with an access needle, a guidewire is coiled within the diverticulum. It is important to ensure that not only the floppy tip of the wire but also the solid core is coiled within the diverticulum so that sufficient stabilization is provided for proper placement of coaxial dilators. A safety wire is then passed through a coaxial dilator or dual-lumen catheter. With two guidewires coiled within the diverticular lumen, dilation of the tract can be performed safely. Care should be taken to avoid perforation of the back wall of the diverticulum. If a balloon dilator is used, once the balloon is inflated, the working sheath should be passed over the balloon so that it rests as closely as possible to the diverticulum. In small diverticula, this results in the placement of the sheath outside the diverticulum. An 11-Fr alligator forceps is passed through the rigid nephroscope and used to follow the wire and gently spread renal parenchyma to allow entry into the calyceal diverticulum under direct vision. Stone material is then extracted. Careful inspection of the urothelium with the rigid nephroscope, and in cases of a large diverticulum, a flexible nephroscope as well, is performed in an effort to identify a flattened renal papilla, which suggests an obstructed calyx rather than a diverticulum. The neck of the diverticulum is often difficult to identify because it can be diminutive. Methylene blue injected through the ureteral catheter can facilitate visualization of the ostium. Once a guidewire is passed into the renal pelvis, the neck of the diverticulum can be balloon dilated or incised. Alternatively, if the ostium is not identified, fulguration of the urothelium may be accomplished by a resectoscope equipped with a roller-ball electrode.

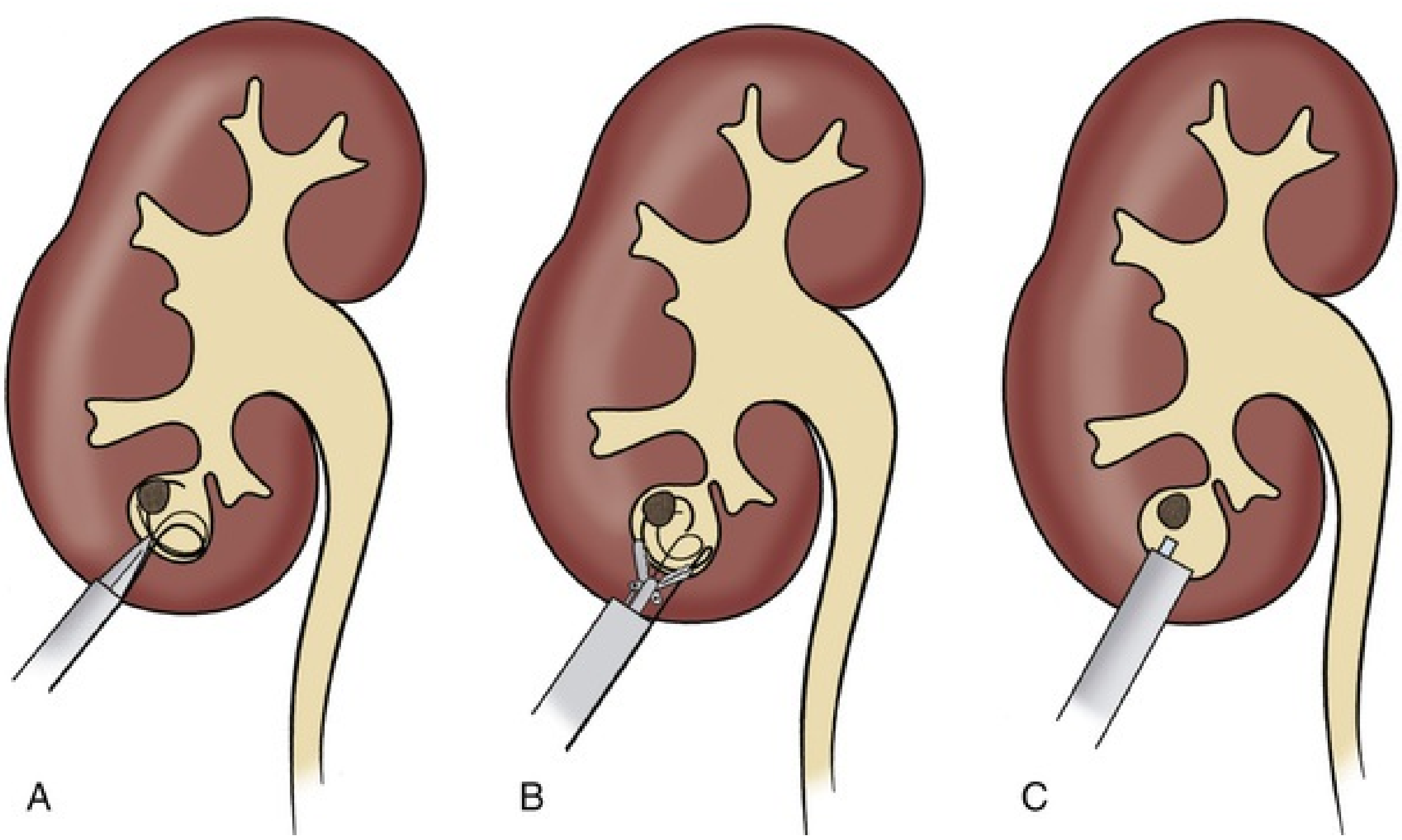

FIG. 94.15 Access into small diverticula. (A) Balloon dilator is advanced as far as possible without perforating the back wall of the diverticulum. The working sheath is placed just outside the diverticulum. (B) Alligator forceps spread the parenchyma and allow advancement of the nephroscope under vision into the diverticulum. The working sheath is then advanced over the nephroscope and into the diverticulum (C).

Horseshoe Kidney

The horseshoe kidney presents several anatomic issues that should be considered before PCNL. The unique location and orientation of the horseshoe kidney are due to the incomplete cephalad migration and malrotation of the kidney, a consequence of the entrapment of the isthmus under the inferior mesenteric artery. The ureteropelvic junction (UPJ) is commonly deformed because of the high insertion of the ureter into a typically elongated renal pelvis. The course of the proximal ureter is similarly aberrant; it drapes ventrally over the renal symphysis, where it may be compressed by the vessels that supply the lower pole and isthmus. Ureteral obstruction that may result from these anomalies can give rise to hydronephrosis, urinary stasis, sepsis, and calculi formation.

In considering PCNL in a horseshoe kidney, the characteristic lower and centrally oriented position of the kidney, the orientation of the collecting system, and the abnormal blood supply should be taken into account. Therefore **a puncture of the dorsal or dorsolateral aspect of the kidney will be well away from major renal vessels**. **The lower pole calyces lie within a coronal plane, angled medially, and are seldom suitable for direct puncture. However**, **the upper pole calyces are more posterior and lateral and are often subcostal, providing a convenient and relatively safe route for PCNL access.** The standard site for PCNL (inside the posterior axillary line just caudad to the 12th rib) is punctured, but the angle of the puncture is caudad rather than cephalad. Because most of the calyces of horseshoe kidneys point either dorsomedially or dorsolaterally, they are more favorably positioned for puncture than are normal renal units. Because of the malrotation of the kidney, the renal pelvis may be more anteriorly located, and the length of the nephrostomy tract often exceeds the length of the rigid nephroscope, necessitating the use of flexible nephroscopy or multiple accesses. Flexible nephroscopy also may be required to gain access to the lower medial calyces, where stones are often found.

Transplantation and Pelvic Kidneys

Urolithiasis is uncommon in patients who have undergone renal transplantation; factors that may predispose transplant recipients to form calculi include metabolic abnormalities, foreign bodies (nonabsorbable suture material, forgotten stents), recurrent infection, and papillary necrosis. On occasion, calculi may be present in the donor. Renal allografts present a unique anatomic situation for PCNL. The most common surgical anatomy is for the donor left kidney to be placed extraperitoneally into the recipient's right iliac fossa; alternatively, the right kidney is transplanted in the left iliac fossa. In either case, the renal pelvis is located medially, requiring that the kidney be rotated 180 degrees on its axis. Thus the posterior calyces point anteriorly and, consequently, an anterior approach to the kidney is similar to a posterior approach to native kidneys. In the usual percutaneous approach to a transplanted kidney the patient is placed in the lithotomy position, which allows simultaneous cystoscopic access to the bladder. A ureteral catheter is inserted for instillation of contrast material. Access is most safely established (i.e., avoiding intraperitoneal contents) into the lower pole with the skin puncture as caudal as possible. Percutaneous access to transplanted kidneys is actually facilitated by their superficial location. However, scar formation around the graft may make the initial needle puncture and tract dilation more difficult.

Patients with ectopic pelvic kidneys necessitate a different and more complicated approach for PCNL as a result of their unique anatomy. The pelvic kidney is retroperitoneal, posterior to the peritoneum and anterior to the sacrum. Interposing bowel loops between the kidney and the anterior abdominal wall prevent a direct puncture through the anterior abdominal wall. Laparoscopic-assisted PCNL technique for access to the kidney may be required. Alternatively, if laparoscopy will not be used to assist guidance and reflect intervening organs away from the anticipated course of percutaneous access, percutaneous access could be obtained using CT guidance (Fig. 94.16).

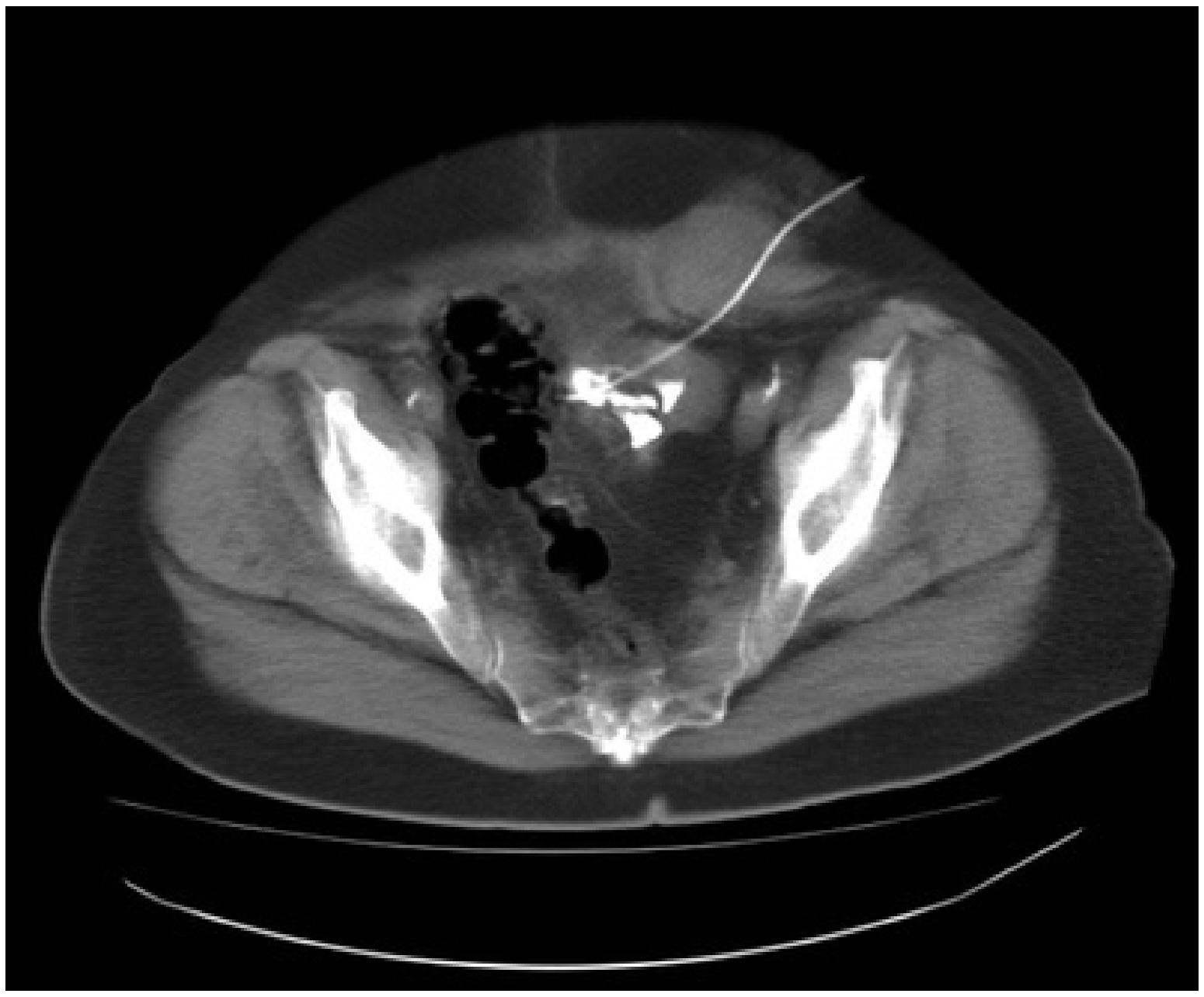

FIG. 94.16 Computed tomography–guided percutaneous access of a renal transplant for subsequent percutaneous nephrolithotomy procedure.

Staghorn Calculi or Complex Stones

Patients suffering from staghorn calculi or complex renal calculi remain a challenging problem for the practicing urologist. **Many staghorn stones are composed of struvite**. **The goal for patients with staghorn calculi should be stone free, because if all of the infected stone debris is not evacuated, urea-splitting bacteriuria may persist, which can ultimately lead to eventual stone regrowth.** PCNL techniques incorporating the use of flexible nephroscopy may provide for complete or nearly complete clearance of stone material at the time of the primary procedure.

In general, if a single access tract is to be used in treating complex branching stones, the upper pole is preferred. An upper pole access allows for treatment of the upper pole, renal pelvis, and many lower pole stones using the rigid nephroscope. Midcalyceal stones can then be treated using a flexible nephroscope and holmium laser. When pressurized irrigant is used, the debris and fragments created by the holmium laser in most cases wash out the access sheath or into the renal pelvis, where it can be retrieved with the rigid nephroscope and suction.

Morbid Obesity

Patients with morbid obesity present technical as well as anesthetic challenges during any surgical intervention. General anesthesia may be a special concern for obese patients in the prone position because of restricted respiratory capacity that may require higher ventilation pressures intraoperatively. Multiple studies have not demonstrated an increase in overall morbidity in the obese patient undergoing PCNL. Pearle et al. (1998) were the first to examine the issue of PCNL among the obese and found that performing standard prone PCNL was not associated with an increased risk for morbidity; in fact, complication and transfusion rates as well as the length of hospitalization were no different compared with those in nonobese patients. However, a multi-institutional study of 3709 PCNL procedures performed across the globe found that complication rates were not associated with BMI, but patients with a higher BMI were more likely to have comorbid conditions, including chronic anticoagulation, and a lower overall stone-free rate (Fuller et al., 2012).

Positioning the morbidly obese patient for PCNL can be difficult; and in particular for large patients, two surgical tables may have to be secured together.

Excessive body size may also be associated with rhabdomyolysis secondary to crush injuries from placement in the lateral approach; if this technique is used, care must be taken to minimize muscle crush injury. An important challenge in performing PCNL in the morbidly obese patient is the long distance from the skin to the collecting system, which may exceed the length of the working sheath or the length of the rigid nephroscope. Extralong Amplatz working sheaths (≥20 cm) and extralong rigid nephroscopes are now available that can overcome this challenge. Alternatively, the Amplatz sheath can be secured by a suture, allowing easy retrieval even when it migrates under the skin. On occasion, when the long Amplatz sheath is not sufficient to reach the kidney, an incision can be made through the subcutaneous tissue to the muscles of the flank and the PCNL tract created from the level of the muscle sheath. Another possibility is to dilate the tract and place a nephrostomy tube for 1 week to let the tract mature. In some cases, maturation of the tract allows the kidney to fall back posteriorly closer to the skin, allowing the use of standard nephroscopic instrumentation. Flexible nephroscopy also can be performed through the mature tract, reducing the necessity of rigid nephroscopy.

After stone removal, if a nephrostomy tube is placed, consideration should be given to the type of nephrostomy tube used. Tube displacement can occur in morbidly obese patients, so balloon-type catheters or re-entry Malecot catheters may be preferable. Alternatively, if a Cope loop catheter is used, placement of a ureteral catheter should be considered to ensure that access to the kidney is not lost should the nephrostomy tube become displaced.

Complications

Even for the most experienced urologist, complications can occur; up to 7% of patients undergoing PCNL suffer a major complication, and minor complications may be encountered in up to 25% of patients (Preminger et al., 2005). **Hemorrhage is a significant complication of PCNL**. Risk for hemorrhage has been associated with stone burden and operative duration. Bleeding from an arteriovenous fistula or pseudoaneurysm that requires angiographic embolization occurs in less than 1% of patients (Keoghane et al., 2013). Other potential complications include sepsis (postoperative temperature > 38.5°C [101.3°F] is found in almost one-fourth of patients undergoing PCNL), adjacent organ injury (bowel, spleen), failed access, and perforation of renal pelvis and ureter. The need for open surgery is rare and mostly reported as part of early experience in various studies. The mortality rate of PCNL is between 0.03% and 0.8% (de la Rosette et al., 2011). When supracostal puncture is performed, the risk for pneumothorax or pleural effusion requiring drainage can vary widely from 1.8% to as high as 8% in historical series (de la Rosette et al., 2011; Picus et al., 1986). Experience of the center performing the PCNL procedure also can contribute to overall complication rates and stone-free results. Opondo et al. (2012) evaluated PCNL performed at 96 centers worldwide. The results of their study found that as their institution case volume increased, so did stone-free rates. Complication rates and duration of stay diminished with increasing case volume after adjusting for stone burden and other cofactors. The highest stone-free results and lowest complication rates were observed in centers with more than 120 cases p1er year.

Because the kidney is an extremely vascular organ, some degree of bleeding occurs during every PCNL. Significant bleeding usually requires cessation of the procedure because of impaired visualization. In most cases the source of hemorrhage is venous, and placement of a nephrostomy tube is usually sufficient to control the bleeding. If bleeding persists despite the placement of a nephrostomy tube, then clamping the tube for a period of time may facilitate the tamponade of any bleeding points. If these measures do not control the hemorrhage, a Kaye nephrostomy tamponade balloon catheter should be placed. The Kaye nephrostomy tube incorporates a low-pressure 12-mm balloon that may be left inflated for prolonged periods to tamponade bleeding from the nephrostomy tract (Kaye and Clayman, 1986). If bleeding persists despite placement of a Kaye catheter, immediate angiography should be performed to identify a possible arteriovenous fistula or false aneurysm. Angiography is diagnostic and therapeutic, because arteriovenous fistulas and false aneurysms are best managed by embolization. In the rare event that bleeding cannot be controlled with angiography, partial nephrectomy may be required.

PCNL can lead to some absorption of irrigation fluid; therefore the use of physiologic irrigating solutions is mandatory. The amount of absorbed fluid depends mostly on the irrigant pressure and the length of the procedure; thus an Amplatz-type open sheath should be used. Larger amounts of fluid absorption may occur in the setting of collecting system perforation. Extravasation usually occurs into the retroperitoneal tissue and may be noted by medial displacement of the kidney during fluoroscopy. Minor perforations are common during PCNL; premature termination of the procedure usually is not necessary when a low-pressure system (e.g., Amplatz sheath) is being used. However, with more significant perforations, termination of the procedure and nephrostomy drainage are advisable. Intraperitoneal extravasation is a less common but potentially more serious complication than retroperitoneal extravasation. Because the patient is prone, abdominal distention may be difficult to recognize, although in such a situation the anesthesiologist generally notes a gradual rise in the patient's diastolic blood pressure with consequent narrowing of the pulse pressure and increase in central venous pressure. In advanced cases of a large-volume extravasation event, ventilation may become difficult because of increased abdominal pressure. Early recognition of major extravasation is crucial. Intraperitoneal extravasation may be treated by vigorous diuresis; alternatively, peritoneal drainage or even laparotomy may be required.

When a supracostal puncture is performed, extravasation of irrigant into the pleural cavity may occur. The use of an Amplatz-type access sheath tends to minimize extravasation into this space because intrarenal pressure remains low. The chest should be examined at the end of PCNL procedures in which a supracostal puncture is used. Fluoroscopy with use of the C-arm is usually sufficient to examine for pneumothorax or hydrothorax, but if the surgeon has a high index of suspicion for a thoracic complication, a chest radiograph may be obtained postoperatively. Should a pneumothorax or hydrothorax occur, aspiration may be sufficient because lung injury is extremely rare. Should the pneumothorax recur, a chest tube should be placed.

Colonic injury is an unusual complication and is often diagnosed on postoperative nephrostogram or CT imaging, although passage of gas or feculent material through the nephrostomy tract, intraoperative diarrhea, and hematochezia or peritonitis are signs of a possible colonic perforation. Typically, the injury is retroperitoneal; thus signs and symptoms of peritonitis are infrequent. If the perforation is extraperitoneal, management may be expectant, with placement of a ureteral catheter or double-J stent to decompress the collecting system and withdrawal of the nephrostomy tube from an intrarenal position to an intracolonic position to serve as a colostomy tube. The colostomy tube is left in place for a minimum of 7 days and removed after a nephrostogram or a retrograde pyelogram shows no communication between the colon and the kidney.

Ureteroscopic Stone Management

Basic ureteroscopic techniques and intracorporeal lithotripsy techniques have been reviewed elsewhere. In this section issues of anesthesia and specific points of technique and complications of ureteral stone management are reviewed.

The fundamental initiation of ureteroscopy is the advancement of the ureteroscope into the ureter. When the ureteral orifice is too narrow to accommodate the ureteroscope, dilation may be accomplished with serial dilators, balloons, or even the ureteroscope. The anatomy of male patients may not allow a rigid ureteroscope to be easily passed above the iliac vessels, but a flexible ureteroscope usually can be advanced over a guidewire. The entire ureter can be more easily accessed with a rigid ureteroscope in female patients. Once the stone is visualized, fragmentation with the lithotrite of choice is performed, as described elsewhere in this chapter.

For treatment of ureteral stones, multiple different devices are designed to prevent stone retropulsion from the ureter into the kidney during lithotripsy. These antiretropulsion devices are covered extensively elsewhere in this textbook. Their overall benefit is seen with semirigid ureteroscopy during cases when the surgeon wishes to avoid having to perform flexible nephroscopy of the kidney to retrieve a small fragment that may have traveled proximally at time of treatment of the ureteral stone.

When a retrograde ureteroscopic approach is used to treat patients with intrarenal calculi, two wires are placed initially. The flexible ureteroscope is passed over one working wire in a monorail fashion. Saline is used for irrigation. When an implement is present within the working channel, simple gravity irrigation is inadequate and pressurized irrigation is required. The holmium:YAG laser lithotripter is used in almost all cases. Stones in lower pole calyces can be treated in situ or moved, with flexible graspers or a basket, into a position that allows better visualization. A head-down patient position with the ipsilateral flank elevated may help with stone and fragment visualization because fragments tend to migrate superiorly and are thus more easily localized during treatment. If the stone is large, the collecting system often may become lined with fine dust and debris, which can obscure residual stones. Furthermore, poor visualization may lead to perforation. In such cases, either the irrigant in the intrarenal collecting system may be aspirated through the ureteroscope or a ureteral stent can be placed and the situation approached in a staged fashion.

Fragmentation of stones in situ in the lower pole can be challenging. If the lower pole infundibulum is accommodating, the most straightforward way to treat the stone is to engage it in a nitinol basket and displace it to the renal pelvis or an upper pole calyx. In this way it is generally a straight passage of the scope, with minimal deflection of the tip, which will simplify ureteroscopic laser lithotripsy. Residual fragments also should be more likely to evacuate spontaneously from the kidney.

If ureteral edema or injury is present after stone extraction, a postureteroscopy stent should be placed to prevent colic and obstruction. Multiple meta-analyses have found that for uncomplicated ureteroscopy, a ureteral stent may be safely omitted (Assimos et al., 2016a,b).

The use of a ureteral access sheath as an adjunct to ureteroscopy was initially described as a means to simplify access to the intrarenal collecting system. It was not until more than two decades later that the ureteral access sheath was rediscovered and refined, simplifying the deployment and safety of these devices. The present generation of ureteral access sheaths consists of a hydrophilic outer coating as well as a tapered transition from obturator to sheath, which facilitates their retrograde placement. The walls of the sheaths are designed not only for a slim profile but also for strength and often are reinforced so as to resist kinking. The use of an access sheath can decrease operating room time because it simplifies re-entry of the ureter during repeated ureteroscope insertions. An added benefit of ureteral access sheaths is that the use of a sheath has been reported to maintain low intrapelvic pressures during ureteroscopy (Rehman et al., 2003). In addition, as irrigating fluid drains through the access sheath external to the patient, the need for periodic emptying of the patient's bladder during a prolonged procedure is eliminated. However, potential drawbacks to the ureteral access sheath have been identified. Traxer and Thomas (2013) observed that ureteral injury can occur as a consequence of employing a ureteral access sheath.

Complications

As modern ureteroscopes have become smaller and less traumatic, as safer intracorporeal lithotripters have become widely available, and as a better understanding of the technical principles of ureteroscopy has been developed, the risk of complications arising from the management of ureteral stones has been steadily decreasing.

Fortunately, most of the complications caused by ureteral stones and their management respond favorably to simple drainage of urine with ureteral catheters or stents.

Perforation

As is true with most ureteroscopic complications, the incidence of ureteral perforation has decreased over time, as technology and technique continue to improve. In a series of ureteroscopic procedures reported in 1992, ureteral perforation was reported in approximately 15% of cases. More recent series report a perforation rate of 0 to 4% (Assimos et al., 2016a,b). **A number of actions may result in a ureteral perforation; some of the more commonly encountered scenarios include the splitting of a ureter after balloon dilation, forceful placement of ureteral access sheath, or a traumatic injury from forceful and misdirected manipulation of a stone.** In some cases an intracorporeal device such as a lithotrite or electrocautery can cause full-thickness damage to the ureter. Baskets and grasping devices also may cause injury, because in the process of grasping a stone or lesion it is possible to inadvertently snare part of the ureter, which may result in a perforation. As previously noted, placement of a ureteral access sheath may cause a ureteral perforation. In addition, pressurized irrigation can cause perforation or calyceal rupture. Finally, the risk for a ureteral perforation may be increased in the case of a prolonged ureteroscopic procedure, as visualization may decline because of bleeding and/or debris in the field and surgeon fatigue may develop. Therefore, if the procedure is difficult and not progressing, it is wise for the urologist to stop, place a stent, and plan for a staged procedure.

Adherence to the tenets of safe ureteroscopy will minimize the likelihood of a ureteral perforation. Nonetheless, such a complication may still occur, and it is important for the urologist to be familiar with the treatment of this event. **When a ureteral perforation is recognized, the ureteroscopic procedure should be terminated and a stent placed across the injury.** The risk for perforation underscores the importance of using saline as an irrigant to prevent electrolyte derangements resulting from fluid extravasation. In cases of a severe injury, with significant extravasation of fluid, a percutaneous nephrostomy drain also may be necessary. Urinoma can result from perforation as well and may have to be drained. Antibiotics should be given because of the risk for infected urine and abscess formation. In general, a stent should be left in place for approximately 4 weeks after injury. Subsequent imaging after ureteral stent removal is mandatory to evaluate for a proper healing and adequate drainage.

Stricture

The development of a postoperative ureteral stricture is one of the more serious complications that may occur after ureteroscopy. Approximately two decades ago, the reported incidence of ureteral stricture after ureteroscopy was as high as 10%. More recently, however, the incidence of a postoperative stricture is reported to be 3% to 6% (Assimos et al., 2016a,b). It is likely that the improvements in surgical technology and technique are responsible for this dramatic reduction.

Although the cause of a ureteral stricture is likely multifactorial, there are certain identifiable risk factors. Impacted stones, which are defined by the inability to pass a wire or catheter beyond the stone or stones that have been present and not moved for a prolonged period of time, can induce changes in the ureter, which increases the risk for stricture formation. Ureteral perforation also may increase the risk for stricture formation. It may be that an inflammatory response that results in devascularization and ischemia promotes this process, because such local changes can result in a cicatrization of the ureter. Patients with a history of ureteral surgery, pelvic radiation, and impacted stones are also at greater risk secondary to altered blood flow and poor healing. Devascularization injury can result in ureteral necrosis, which necessitates open or laparoscopic repair. However, some patients develop a ureteral stricture in the presence of no intraoperative misadventures, suggesting that there is much about this process that remains to be elucidated.

To reduce the risk for stricture, care should be taken during all parts of the procedure, because the traumas that may increase the risk for this event are many and varied. **Overly aggressive manipulation of a ureteroscope across a narrow segment of ureter as well as trauma or perforation from injudicious manipulation of intracorporeal devices or lithotrites may increase the risk for stricture. Because of the reported occurrence of a postoperative ureteral stricture even after an uncomplicated ureteroscopy, it is recommended that all patients undergo postoperative imaging after ureteroscopic instrumentation to ensure that such a complication is recognized.** Although most patients with a stricture are symptomatic, some may not be, so postureteroscopy imaging is recommended in all patients to exclude such cases of silent obstruction (Fulgham et al., 2013).

The management of a postureteroscopic ureteral stricture depends primarily on its length and location, although other factors such as the time elapsed since injury, nature of trauma, and patient-specific parameters merit consideration. The treatment of ureteral strictures is discussed elsewhere in this text.

Submucosal Stone and Lost Stone

The submucosal stone and the lost stone represent two points on a continuum of iatrogenic displacement of a ureteral calculus into the wall of the ureter. When the stone migrates only to the submucosa, a problematic complication can develop, because removal of such stones is difficult. If submucosal stones are encountered, laser excision followed by ureteral stent placement is recommended. Submucosal stones are of concern, because they can increase the risk for ureteral stricture formation.

Complete extrusion of a calculus, also known as a lost stone, can occur in the setting of a ureteral perforation. In most cases, if the fragment is completely outside the collecting system, it can be left in place. Attempts to retrieve the stone may exacerbate the injury and increase the risk for significant irrigant extravasation. When an extruded stone is recognized, the procedure should be terminated and a ureteral stent placed. Antibiotics should be administered to prevent the theoretical risk for abscess formation, although such a complication would be rare. One of the most serious sequelae of such an event is the later development of a ureteral stricture; for this reason patients who have calculus extrusion should undergo postoperative imaging, which will confirm the stone location. It is possible that, in the future, the lost stone could be confused for a ureteral stone, and it is important for the patient to be aware that such a situation exists.

Avulsion

Perhaps the most catastrophic complication that can occur during a ureteroscopic procedure is avulsion of the ureter. Fortunately, such a complication is a rare occurrence, reported in less than 0.06% to 0.5% of all cases (Bader et al., 2012). **Ureteral avulsion generally occurs as a consequence of overly forceful manipulation of a large or impacted calculus; however, a scabbard effect also can be created with resulting avulsion at time of scope withdrawal if too large a rigid ureteroscope is forcefully advanced up the ureter.** It has been reported that the proximal third of the ureter may be at greatest risk for avulsion, because it is the portion of the ureter that has the least muscular tissue support. A ureteral avulsion is usually diagnosed when a portion of the ureter is withdrawn from the patient, along with the stone and basket or grasper.

There are a number of maneuvers the urologist can undertake to avoid a ureteral avulsion. **Blind basketing, the removal of a ureteral calculus without the aid of endoscopy, may increase the risk for ureteral avulsion and should never be considered an appropriate method of stone extraction.** In fact, even endoscopically guided basketing should be reserved for small stones only. In general, a safe ureteroscopic procedure relies on the placement of safety and working guidewires**. Before stone in a basket or grasping device is engaged, it should be endoscopically evaluated to determine if it is of a size that would be likely to be extracted out of the ureter. When the stone is engaged in the basket or grasper, the stone and device should both be kept under direct vision as they are extracted so that the size of the stone can be continually compared with the size of the ureteral lumen.** If the stone appears to be too large to be removed intact, it should be fragmented into smaller pieces that may either pass spontaneously or be extracted. If a stone too large to pass through the ureter is inadvertently engaged with a basket or grasping device, it should be released or replaced more proximally. If it is not possible to release the stone, the basket should be disassembled and the ureteroscope passed alongside the basket and the entrapped stone fragmented in situ. The use of a grasping device, rather than a basket, may simplify the release of an entrapped stone. The great benefit of having a safety wire in place is that should a stone become entrapped in the ureter, a ureteral stent may be placed that will passively dilate the upper urinary tract and perhaps permit a more straightforward procedure at a later date.

Should a ureteral avulsion occur, a reasoned and considered approach to the management of the affected patient is advised. Although it may be tempting to perform an immediate primary repair at the time of injury, in general a delayed repair is recommended. The patient should undergo immediate diversion of the renal unit with the placement of a percutaneous nephrostomy drain. In some cases, a urinoma may develop as a consequence of urinary extravasation; these collections are generally amenable to percutaneous drainage. Subsequent ureteral reconstruction techniques depend on the location of the injury and the amount of viable ureter that remains. For extensive injuries the treatment options are generally limited to ileal interposition (ileal ureter) or renal autotransplantation. Although a transureteroureterostomy may be a replacement option for some patients who have a ureteral injury, this repair technique is contraindicated in stone formers. For a more distal ureteral injury, a ureteral reimplantation with either a psoas hitch or Boari flap also may be successful. Nephrectomy has been reported to be an option for these patients as well; however, given the recurrent nature of stone disease and the fact that stone formers may be at increased risk for hypertension and diabetes, this approach is controversial.

Intracorporeal Lithotripsy

Ureteroscopy and PCNL occupy an essential place in the treatment of urinary calculi as increasing technologic advancements allow easier access to stones in all parts of the kidney and ureter. In particular, improvements in ureteroscopic equipment emphasize the need for appropriate and effective miniaturized intracorporeal lithotripsy devices. Although smaller ureteral stones may be extracted intact, larger ureteral stones require lithotripsy to permit the safe extraction of calculus fragments. The fragmentation of renal stones during PCNL requires an approach different from that applied to during ureteroscopy. Although small and flexible endoscopic lithotrites are essential for the occasional difficult-to-approach kidney stone, renal stones can usually be visualized with a rigid nephroscope. In such situations, with a large kidney stone burden, the efficiency of the lithotrite is the most important requirement and size and flexibility are of secondary importance. The urologist who treats patients with urolithiasis thus requires an armamentarium of intracorporeal lithotripsy devices, each maximizing a different quality (e.g., size, flexibility, efficiency).

Four technologies are available for intracorporeal lithotripsy: EHL, laser lithotripsy, ultrasonic lithotripsy, and ballistic lithotripsy. These techniques can be divided into those lithotrites that are flexible (laser lithotripsy and EHL) and those that are rigid (ultrasonic and ballistic lithotripsy). In the following sections, we review the mechanisms, advantages, disadvantages, and surgical techniques of the various flexible and rigid intracorporeal lithotripters.

Flexible Lithotripters

Electrohydraulic Lithotripsy

The EHL probe is essentially an underwater spark plug composed of two concentric electrodes of different voltage polarities separated by insulation. When a current sufficient to overcome the insulative gap is applied, a spark is produced. The spark discharge causes the explosive formation of a plasma channel and vaporization of the water surrounding the electrode. The rapidly expanding plasma causes a hydraulic shock wave followed by formation of a cavitation bubble (Fig. 94.17). Depending on the proximity of the probe to the stone surface, the collapse of the cavitation bubble may be symmetrical (at a distance of ~1 mm from the stone), resulting in a strong secondary shock wave, or asymmetrical (at a distance equivalent to a maximum bubble radius of ~3 mm), leading to the formation of high-speed microjets (Vorreuther et al., 1995; Zhong et al., 1997). **Unlike in SWL the shock wave is not focused, so the stone must be placed where the shock wave is generated.** The first EHL probes developed were of larger diameters (9 Fr) and, because of their size, had a narrow margin of safety. Later improvements in technology allowed the development of smaller probes, from 1.6 to 5 Fr, that were safer and had the ability to be passed through small-diameter, flexible ureteroscopes without occluding the irrigation or working channel.

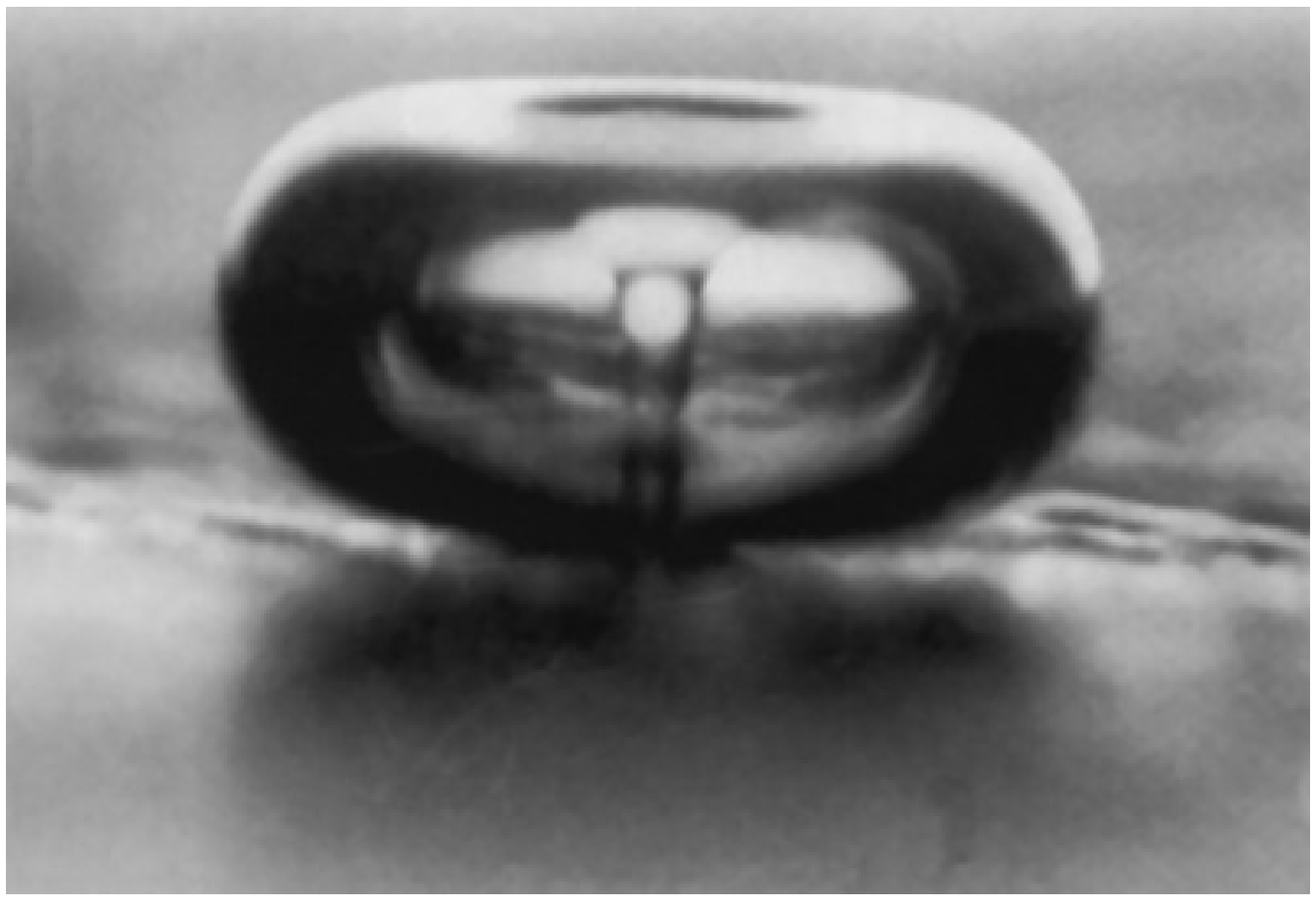

FIG. 94.17 Photograph of liquid microjet produced by an asymmetrically collapsing cavitation bubble. (Courtesy Dr. Larry Crum.)

Advantages and Disadvantages.

EHL was, at one point, a commonly used intracorporeal lithotrite because of its low cost and the flexible nature of its probes. However, the major disadvantage of EHL is its propensity to damage the ureteral mucosa and its association with ureteral perforation. The mechanism of damage caused by EHL is the expansion of the cavitation bubble, and thus injury may occur even when the probe is not in direct contact with the mucosa. The diameter of the cavitation bubble depends on the energy used and can expand to more than 1.5 cm when energies greater than 1300 mJ are employed. Therefore **the risk for perforation is greater with higher energies, such as in treatment of a hard**

stone. Primarily because of the propensity for ureteral damage, EHL has become less commonly used as an intracorporeal lithotrite.

Laser Lithotripsy

Laser is an acronym for *l*ight *a*mplification by *s*timulated *e*mission of *r*adiation, which is a concise description of how a laser works. Laser energy is produced when an atom is stimulated by an external energy source, which creates a population of electrons in an excited state. These excited or higher energy electrons can release their excess energy in the form of photons or light energy. Laser light differs from natural light in that it is coherent (all photons are in phase with one another), collimated (photons travel parallel to each other), and monochromatic (all photons have the same wavelength). These unique features of laser light allow considerable energy to be transmitted in a highly concentrated manner. Lasers are named after the medium that generates their specific wavelength of light; for example, the laser was developed in 1960 and the first medium used was the ruby. Although the ruby laser could effectively fragment urinary calculi, this continuous-wave laser simply heats the stone until vaporization occurs, which requires the laser to generate heat greater than the melting point of the stone. Consequently, it generated excessive heat and was not appropriate for clinical use. A solution for this problem came with the development of pulsed lasers: the application of pulsed energy results in high-power density at the stone's surface but little heat dissipation. The first widely available laser lithotrite was the pulsed-dye laser, which employed a coumarin green dye as the liquid laser medium. Although the coumarin pulsed-dye laser represented a major advancement in intracorporeal lithotripsy, there were a number of significant drawbacks to this technology: stones of certain composition (calcium oxalate monohydrate, cystine) would not fragment well or even at all; coumarin dye is a toxic agent and required cumbersome disposal procedures; the required eye protection made visualization of the stone and fiber difficult.

Continued technologic advancements eventually led to the development of the holmium:YAG laser. The holmium laser is a solid-state laser system that operates at a wavelength of 2140 nm in the pulsed mode. Pulse duration of the holmium laser ranges from 250 to 350 microseconds and is substantially longer than the pulse duration in pulsed-dye lasers. The holmium laser is highly absorbed by water; because tissues are composed mainly of water, the majority of the holmium laser energy is absorbed superficially, which results in superficial cutting or ablation. **The zone of thermal injury associated with laser ablation ranges from 0.5 to 1.0 mm** (Wollin and Denstedt, 1998). The mechanism of stone fragmentation of the holmium:YAG laser is different from that of the pulsed-dye lasers. **The long holmium:YAG pulse duration produces an elongated cavitation bubble that generates only a weak shock wave,** in contradistinction to the strong shock wave produced by short-pulse lasers. Therefore **holmium laser lithotripsy occurs primarily through a photothermal mechanism that causes stone vaporization** (Wollin and Denstedt, 1998).

Advantages and Disadvantages.

The holmium:YAG laser can transmit its energy through a flexible fiber, which facilitates intracorporeal lithotripsy throughout the entire collecting system. However, compared with EHL, the holmium:YAG laser is safer and more efficient. Whereas EHL may cause injury to the ureter even when the probe is activated several millimeters away from the ureteral wall, because of its low depth of penetration the holmium laser may be safely activated at a distance of 0.5 to 1 mm from the ureteral wall. **The ability of the holmium laser to fragment all stones regardless of composition is a clear advantage** over the coumarin pulsed-dye laser. Successful fragmentation of ureteral stones of all compositions has been reported, and perforation and stricture rates are generally low. During PCNL the holmium laser is most helpful in clearing smaller stones (<2 cm) when the use of flexible instruments is required for access to stones in a calyx remote from the nephrostomy site. The **holmium laser is one of the safest, most effective, and most versatile intracorporeal lithotripters.** Further advantages of the holmium laser include its production of significantly smaller fragments compared with other lithotrites. These small fragments are easily irrigated out of the collecting system, which reduces the need for extraction of the fragments with basket or grasping devices. **The holmium laser produces a weak shock wave, which reduces the likelihood of retropulsion of the stone** or stone fragments compared with EHL or pneumatic lithotrites. The degree of retropulsion can be further modulated with both laser fiber size as well as laser settings, such as the pulse duration. Additional advantages of the holmium laser include that the required eye protection for the holmium laser does not compromise the ureteroscopic view of the stone or the fiber. In fact, the holmium laser properties are such that with use of energy levels applied for stone disease (i.e., less than 15 W), the operator's cornea would be damaged only if it were positioned at a distance of 10 cm or less from the fiber (Scarpa et al., 1999).

The major disadvantage of the holmium laser is the initial high cost of the device and the cost of the laser fibers. However, **the holmium laser has multiple soft-tissue applications and can be used to treat patients with benign prostatic hyperplasia, strictures, and urothelial tumors**. In addition, certain models of laser fiber are reusable, so the effective cost of the holmium laser device and reusable fibers may be further controlled.

The thulium fiber laser has emerged as a potential therapeutic alternative to the holmium laser, because it may hold several advantages over the holmium platform. Its laser fibers are smaller, which may permit improved endoscope deflection and irrigation flow. At present, though, its use in lithotripsy remains is not well defined.

Technique.

The technique of holmium laser lithotripsy is relatively straightforward and involves placement of the fiber on the stone surface before the laser is activated. Clear vision is essential at all times to ensure the fiber maintains near contact to the stone. After initiation of holmium laser lithotripsy, a short pause is often required because of the “snowstorm effect” created by the scattering of minute stone fragments, which can be cleared by endoscopic irrigation. Caution must be exercised in operating the holmium laser near a guidewire or a basket because **the holmium laser is capable of cutting through metal.** Furthermore, the laser fiber should extend at least 2 mm beyond the tip of the endoscope to avoid destroying the lens system or the working channel of the endoscope. It is preferred that baskets used to stabilize calculi during laser lithotripsy should be composed of nitinol rather than stainless steel because should the holmium laser inadvertently transect the nitinol basket, the material will retain its basket shape and not cause a sharply barbed effect as stainless steel would. Holmium laser fibers are available in a variety of sizes, generally ranging from 200-, 365-, 550-, and 1000-μm diameters as well as end- or side-firing fibers. However, only the 200- and 365-μm fibers are used for flexible intracorporeal lithotripsy, as larger fibers cannot be accommodated in an endoscope's working channel.

Early in the introduction of Holmium laser lithotripsy, it was noted that altering the treatment parameters affected the efficiency of fragmentation and risk of retropulsion. For example, low pulse energy (0.2 J) led to smaller fragments and less retropulsion at the cost of fragmentation efficiency. Some Holmium laser devices can also provide the ability to modulate the pulse duration. A longer laser pulse duration (700 µs or 1500 µs) as compared with a traditional pulse duration (300 µs or 350 µs) has been demonstrated in in vitro studies to provide effective stone comminution while reducing laser fiber tip degradation and stone retropulsion. To maximize efficiency of Holmium laser lithotripsy, shorter pulse durations with higher pulse energy has been recommended because low frequency (5 Hz) and high pulse energy (1.2 J) leads to more efficient stone ablation as manifested by deeper and wider stone fissures.

Laser Lithotripsy Approaches

Fragmentation and Extraction.

Initially, ureteroscopic laser lithotripsy relied on an approach whereby stones were broken into fragments and then retrieved from the kidney with basket devices. Often a ureteral access sheath was used to facilitate repeated passages of the ureteroscope as the fragments were extracted. Laser setting requirements for fragmentation with extraction generally rely on combination energy settings such as 0.6 to 1.0 J along with rates of 6 to 10 Hz. In vitro studies as well as clinical practice has demonstrated that these settings create stone fragments that are larger and ideal for removing with extraction devices. A common technique is to begin with a relatively low energy and rate setting (e.g., 0.6 J, 6 Hz) and only increase if necessary. This technique not only maximizes laser tip preservation but also minimizes retropulsion or stone movement during lithotripsy.

A ureteral access sheath may expedite access, fragmentation, and subsequent clearance of the targeted stone. The midportion of the stone is typically targeted first, with the goal of breaking the stone into halves. Beginning in the midportion of the stone additionally maximizes the margin of safety between the laser fiber and the ureteral or renal wall. The generated fragments can then be sequentially further fragmented in the same fashion until they appear to be a retrievable size. A small caliber nitinol grasper or basket is used to effect stone clearance. Active extraction continues until all visible fragments have been cleared.

The process of fragmenting and retrieving kidney stones may hold several advantages. Stone composition may direct metabolic intervention to help prevent future stone episodes; absence of this information may limit the specificity of patient counseling. If residual stone material is left behind at the time of initial stone treatment, patients may also be at increased risk for future stone events. Chew et al. looked at the natural history of asymptomatic stone fragments left behind after URS and found that only 56% of patients required no intervention and remained asymptomatic (Chew et al., 2016).

Dusting.

As later-generation holmium consoles were introduced, there developed an ability to increase the pulse rate to much higher levels; pulse rates of 50 Hz became commonplace on 100-watt Holmium lasers. Investigations of the clinical effects of these higher pulse rates found that they yielded smaller stone fragments. Ultimately, an approach developed, termed “dusting,” which relied on lower pulse energy and higher pulse frequencies to fragment the stone into fine debris that could be left in situ in the kidney and then spontaneously be expelled by the patient.

A concern with a dusting approach is that there is some uncertainty as to the likelihood of passive fragment clearance. However, a prospective multicenter study of dusting versus fragmentation with stone retrieval for renal stones 15 mm or less in diameter demonstrated that in the short term, there was no difference in readmission rates, reintervention rates, or patients becoming symptomatic from residual fragments. An additional recent study, examining ureteroscopy with lithotripsy for stones 10 to 40 mm noted that active fragment retrieval using a nitinol basket was not associated with improvements in stone-free rates.

Dusting may also confer advantages in patient outcomes. For example, dusting has been associated with shorter operative times because of omission of active fragment retrieval. Another potential advantage for dusting is decrease in use of ureteral access sheaths, which may lead to decreases in ureteral trauma. However, the relationship between such ureteral trauma and subsequent ureteral stricture formation is not yet well defined. Because active retrieval is not performed during dusting, basket-associated complications can be reduced. In addition, because there is less of a need for multiple implements to be passed through the ureteroscope's working channel, there may be greater scope longevity with this approach.

The goal of dusting is to fragment the stone into tiny pieces that resemble “dust” and thus can pass spontaneously. This is accomplished by using the Holmium laser at a very high frequency with very low energy. Typical settings will depend on the laser console being used; for low-power lasers, a rate of 15 or 20 Hz may be upper limit of what can be achieved. However, for higher-power lasers, such as a 100-watt laser, a rate of 50 Hz or even higher may be achieved.

The technique of dusting involves moving the laser fiber tangentially from the very edge of the stone and taking care not to break off large fragments from the main stone. As the procedure progresses, the surgeon should continue to treat the edges of the stone circumferentially or from one leading edge to the other.

The other principle involved in dusting is to keep the laser fiber slightly off of the stone, which "defocuses" it and minimizes the mechanical acoustic effect of the laser energy. Accounting for respiratory renal movement is also important. Fine movements of the hand holding the tip of the ureteroscope as it enters into the urethra or a fine movement of the thumb-activated deflecting cables allows the surgeon to "paint" the stone from the edge toward the middle of the stone. At the beginning of the case, the laser energy is typically less than the mass of the stone and the stone does not tend to move very much and stays in place. Once the stone is ablated down to a smaller mass, the laser energy becomes greater than the stone fragment and the stone will start to bounce within the calyx, making it more difficult to shave the stone from the edges. When this happens, one can either extract the remaining pieces or place the laser fiber safely in the middle of the calyx and keep discharging the laser as fragments come into contact with the fiber—a technique known as "popcorning." Fragments may be deemed small enough to pass when they are of 1 to 2 mm. The most commonly used technique to measure stone size is to compare to a structure of known size that is in the surgical field such as a guidewire or laser fiber.

Rigid Lithotripters

Ballistic Lithotripsy

Ballistic lithotripsy relies on energy generated by the movement of a projectile (Fig. 94.18). The initial movement of the projectile can be induced by a variety of stimuli, but once the projectile is in contact with another object, the ballistic energy is transferred to the object. Flexible objects preserve the momentum of the energy, but inflexible objects, such as a stone, fragment on impact (a "jackhammer" effect).

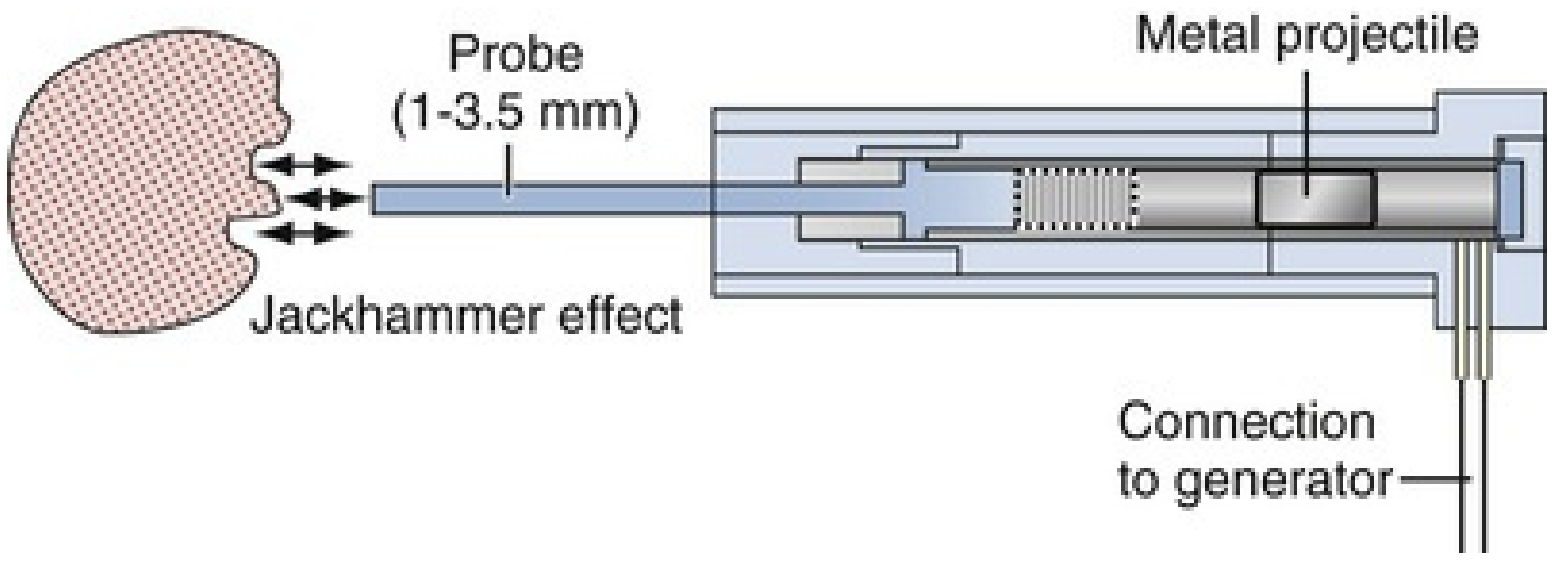

FIG. 94.18 Schematic illustration of the LithoClast (Electromedical Systems, Kaufering, Germany) hand piece mechanism. An oscillating pellet provides ballistic energy to the probe, resulting in a jackhammer-like effect on calculi. (Courtesy Dr. John Denstedt.)

Advantages and Disadvantages.

Ballistic lithotrites provide an effective means for stone fragmentation in the entire urinary tract, with a wide margin of safety. Successful fragmentation of ureteral stones of all compositions can be accomplished with a ballistic device. Ballistic devices may be especially advantageous when large or hard stones are encountered during PCNL or endoscopic lithotripsy of bladder calculi. In contrast to ureteral stones, kidney stones are easily “pinned down” against the urothelium during ballistic lithotripsy, allowing a rapid and more efficient fragmentation method than ultrasonic lithotripsy. Once the bulk of the calculus is fragmented, lithotripsy can be completed with the ultrasonic lithotripter, which can also aspirate minute stone fragments. Compared with EHL, ultrasonic lithotripsy, and laser lithotripsy, ballistic devices have a significantly lower risk for ureteral perforation. Furthermore, because no heat is produced during lithotripsy, the risk for thermal injury to the urothelium is eliminated. An additional advantage of ballistic lithotrites is their relatively low cost and low maintenance because there are may be no disposable costs and the probes have an extremely long life span.

Disadvantages of ballistic devices include the rigid nature of the technology, which requires ureteroscopes or nephroscopes with straight working channels. In addition, **ballistic lithotripsy is associated with a relatively high rate of stone retropulsion** because of their mechanism of action. In some cases, failure to fragment a stone may be related to an inability to trap a ureteral stone in a capacious ureter.

Technique.

Like other lithotrites, the ballistic lithotripter should be activated only when there is a clear view of the stone and the probe position can be identified. Fixation of the stone is rarely difficult in the kidney or the bladder but may be a problem in the ureter. Fixation of ureteral stones with a basket or proximal placement of a ureteral occlusion device is sometimes necessary. The goal of ballistic lithotripsy in the ureter is to generate fragments that are small enough to permit spontaneous passage (<2 mm). Larger fragments have to be removed with a basket or grasping device.

Ultrasonic Lithotripsy

Ultrasonic lithotripsy relies on the properties of ultrasound vibrations that fragment brittle renal calculi. The ultrasound probe works by applying electrical energy to excite a piezoceramic plate in the ultrasound transducer (Fig. 94.19). The plate resonates at a specific frequency and generates ultrasonic waves at a frequency of 23,000 to 25,000 Hz. At operating frequencies there is no audible sound, although 98 dB of ultrasonic inaudible noise levels have been measured.

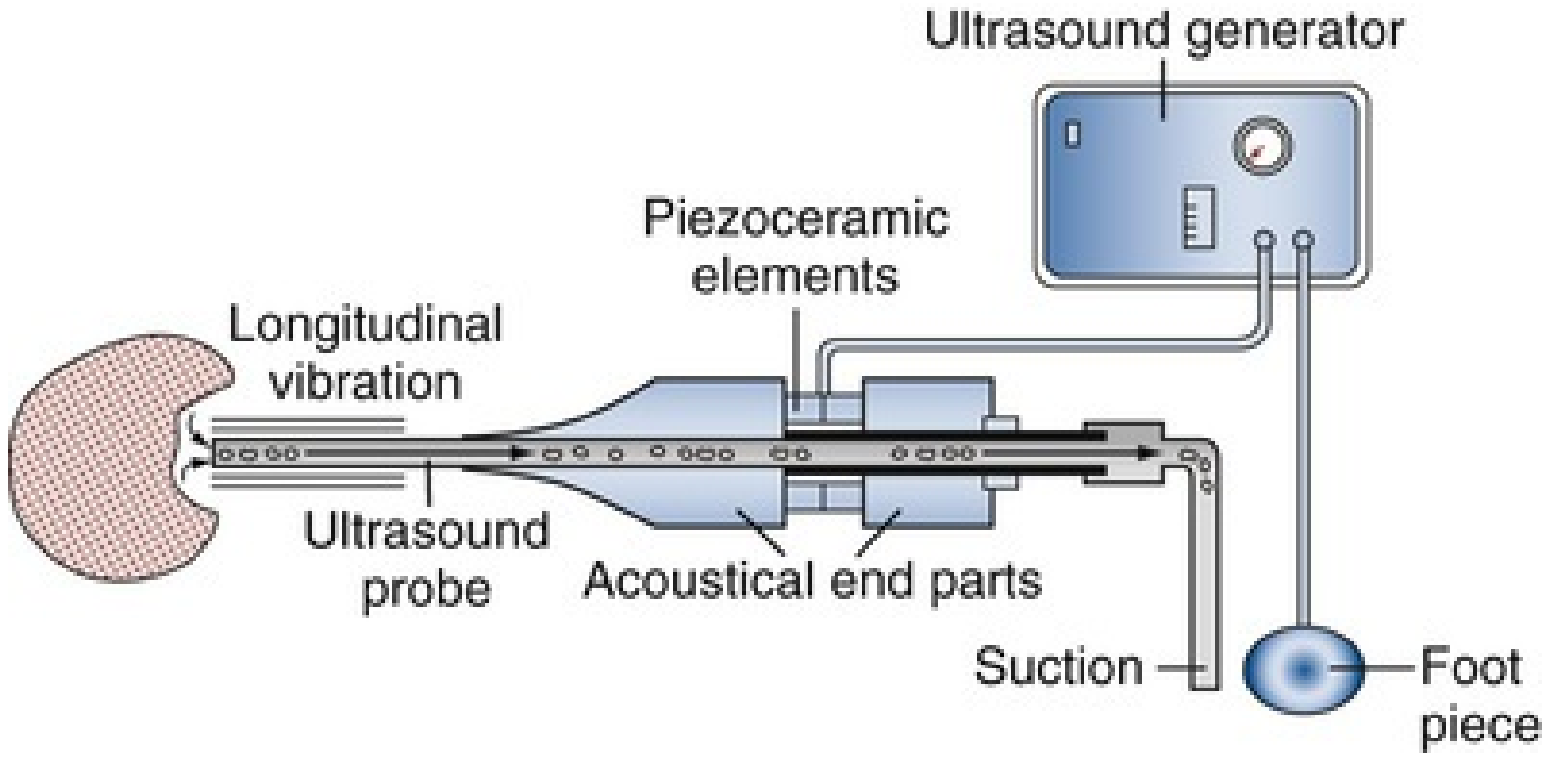

FIG. 94.19 Ultrasound lithotripsy generator and hand piece.

Ultrasound energy is transformed into longitudinal and transverse vibrations of the hollow steel probe, which then transmits the energy to the calculus. The probe tip causes the stone to resonate at high frequency and to break; but when the probe is placed on compliant tissue, such as urothelium, damage is minimal because the tissue does not resonate with the vibrational energy. Although some heat may develop at the end of the probe during lithotripsy, continuous irrigation through the endoscope minimizes any temperature increase at the tip of the probe. Because irrigation may be limited during ureteroscopy, **ultrasonic lithotripsy is more efficient during PCNL because of the greater flow of irrigant through the larger diameter ultrasonic probes that can be used**. The ultrasonic lithotripter system is connected to suction so that debris from the stone is removed continuously with the irrigating fluid during lithotripsy. In addition, the flow of fluid through the hollow probe cools the instrument. Heating of the ultrasound transducer should alert the surgeon to possible occlusion in the probe lumen, an occurrence more commonly encountered with small-diameter probes that are used in the ureter. Ultrasonic probes are available at sizes ranging from 2.5 to 12 Fr. The 2.5-Fr probe is solid and contains no hollow center for suction. Therefore, when it is used in the ureter, heat dissipation is slow.

Stones vary in their susceptibility to destruction with ultrasound. Although the chemical composition of the stone influences the time required for complete disintegration (cystine, calcium oxalate monohydrate, and uric acid being the most resistant to fragmentation), the size, density, and surface structure of the calculus appear to be more important. Smaller stones are more rapidly destroyed, as are rough stones. Smooth-surfaced large stones may be more difficult to fragment.

Advantages and Disadvantages.

The major advantage of ultrasonic lithotripsy is the efficient combination of stone fragmentation and simultaneous fragment removal. Fragments smaller than 2 mm are aspirated through the hollow lithotrite along with the irrigation fluid. Larger fragments may be removed with forceps or baskets. The efficiency of this technique coupled with the minimal risk for serious tissue damage has made this technology popular.

However, the rigid nature of ultrasonic probes and their small diameter limit the appeal of this technology in treatment of ureteral stones. A ureteroscope with a straight working channel is required. Furthermore, a relatively large 5-Fr working channel is needed to accommodate the 4.5-Fr hollow probe.

Technique.

When ultrasonic lithotripsy is applied during PCNL the stone should first be trapped between the probe and the urothelium. The application of gentle pressure to the stone enhances fragmentation, but the temptation to push too hard should be avoided because calculi can easily be pushed through the urothelium. The risk for perforation increases with smaller or more ruggedly surfaced stones because the force applied to the stone is transferred to a smaller surface area of the urothelium. The risk for perforation is particularly high in the thin-walled renal pelvis or ureter rather than in a calyx that is backed by renal parenchyma.

When ureteral stones are treated, the ureter may have to be dilated to allow passage of the offset rigid ureteroscope. The ultrasonic probe is passed through the working channel and placed directly on the stone. If necessary, the stone can be engaged in a stone basket to prevent proximal migration. As with other intracorporeal lithotripsy devices the goal of treatment is either to fragment the stone completely or to generate fragments that are small enough to be extracted or passed spontaneously.

Combination Ballistic and Ultrasonic Devices

Several manufacturers have introduced combined ultrasonic and pneumatic devices that aim to combine the superior fragmentation ability of the pneumatic component with the ability of the ultrasonic modality to simultaneously evacuate stone fragments. Broadly speaking, the combination devices are used in a similar fashion as the stand-alone units. The target stone is identified, and continuous gentle pressure is applied via the lithotrite, until fragmentation and evacuation occur. These devices have been evaluated in multiple clinical studies. Chu et al. (2013) also investigated whether pneumatic, ultrasonic, or combination devices had an effect on postoperative fever. A study of more than 5000 patients collated through the Clinical Research Office of the Endourological Society found that the lithotrite had no effect (Chu et al., 2013). York et al. performed a prospective randomized controlled trial at nine different centers between 2009 and 2016. The authors compared the Cyberwand, a dual-probe ultrasonic device, the Lithoclast Select, a combination pneumatic and ultrasonic device, and the Stone Breaker, a portable pneumatic device. Ultimately, they found no difference in stone clearance rates, and overall safety and efficacy were comparable. Perhaps the technology of the lithotrite is of secondary importance to the technique of the surgeon.

Laparoscopic and Robotic Stone Removal

The surgical technique and outcomes of laparoscopic and robotic stone surgery are discussed in subsequent chapters; the focus of the following section is a brief overview of the role of laparoscopic and robotic procedures in the modern era of stone surgery. The advent of laparoscopic and subsequently robotic renal and ureteral stone removal procedures has provided the urologist with another means to circumvent open stone surgery. However, because of higher morbidity and longer hospitalization, a laparoscopic or robotic approach to stone removal should be considered only if the results with SWL or endoscopic approaches are expected to be poor (Assimos et al., 2016a,b).

In certain cases a laparoscopic or robotic approach may be considered a preferred therapy. Situations that may benefit from a laparoscopic approach include pyeloplasty with pyelolithotomy; patients harboring stones in poorly functioning polar areas or with nonfunctioning kidneys; pelvic kidneys containing a large stone volume, in which laparoscopic techniques can be used to reflect overlying bowel, allowing pyelolithotomy or percutaneous stone removal; and ureterolithotomy for the extremely rare endoscopic failure or large/multiple impacted ureteral calculi. Such procedures can be technically demanding and require a skilled laparoscopic/robotic surgeon to be performed with minimal morbidity. In present practice, the use of laparoscopy and robotics in the treatment of renal calculi continues to be limited; Desai and Assimos (2008) reported that only 1% of patients undergo such an approach, with the most common indication being renal stones with a concomitant UPJ obstruction.

See Videos 94.1, 94.2, 94.3, and 94.4 for procedures related to this chapter.

References

Abid N, Ravier E, Promeyrat X, et al. Decreased radiation exposure and increased efficacy in extracorporeal lithotripsy using a new ultrasound stone locking system. *J Endourol*. 2015;29:1263–1269.

Andressen R, Fedel M, Sudhoff F, et al. Quality of semen after extracorporeal shock wave lithotripsy for lower urethral stones. *J Urol*. 1996;155:1281–1283.

Assimos D, Krambeck A, Miller NL, et al. Surgical management of stones: American Urological Association/Endourological Society Guideline, Part I. *J Urol*. 2016;196(4):1153–1160.

Assimos D, Krambeck A, Miller NL, et al. Surgical management of stones: American Urological Association/Endourological Society Guideline, Part II. *J Urol*. 2016;196(4):1161:9.

Bader MJ, Eisner B, Porpiglia F, et al. Contemporary management of ureteral stones. *Eur Urol*. 2012;61:764–772.

Bailey MR, Pishchalnikov YA, Sapozhnikov OA, et al. Cavitation detection during shock-wave lithotripsy. *Ultrasound Med Biol*. 2005;31:1245–1256.

Bhagat SK, Chacko NK, Kekre NS, et al. Is there a role for tamsulosin in shock wave lithotripsy for renal and ureteral calculi? *J Urol*. 2007;177:2185–2188.

Bohris C, Roosen A, Dickmann M, et al. Monitoring the coupling of the lithotripter therapy head with skin during routine shock wave lithotripsy with a surveillance camera. *J Urol*. 2012;187:157–163.

Carr LK, D'A Honey J, Jewett MA, et al. New stone formation: a comparison of extracorporeal shock wave lithotripsy and percutaneous nephrolithotomy. *J Urol*. 1996;155:1565–1567.

Cartledge JJ, Cross WR, Lloyd SN, et al. The efficacy of a range of contact media as coupling agents in extracorporeal shockwave lithotripsy. *BJU Int*. 2001;88:321–324.

Chaussy C, Fuchs G. Extracorporeal lithotripsy in the treatment of renal lithiasis. 5 years' experience. *J Urol (Paris)*. 1986;92:339–343.

Chaussy C, Schmiedt E. Extracorporeal shock wave lithotripsy (ESWL) for kidney stones: an alternative to surgery? *Urol Radiol*. 1984;6:80–87.

Chew BH, Brotherhood HL, Sur RL, et al. Natural history, complications, and re-intervention rates of asymptomatic residual stone fragments post-ureteroscopy: a report from the EDGE research consortium. *J Urol*. 2016;195(4 Pt 1):982–986.

Chew BH, Zavaglia B, Sutton C, et al. Twenty-year prevalence of diabetes mellitus and hypertension in patients receiving shock wave lithotripsy for urolithiasis. *BJU Int*. 2012;109:444–449.

Chiong E, Hwee ST, Kay LM, et al. Randomized controlled study of mechanical percussion, diuresis, and inversion therapy to assist passage of lower pole renal calculi after shock wave lithotripsy. *Urology*. 2005;75:1070–1074.

Choi MJ, Coleman AJ, Saunders JE. The influence of fluid properties and pulse amplitude on bubble dynamics in the field of a shock wave lithotripter. *Phys Med Biol*. 1993;38:1561–1573.

Chu DI, Lipkin ME, Wang AJ, et al. Lithotrites and postoperative fever: does lithotrite type matter? Results from the Clinical Research Office of the Endourological Society Percutaneous Nephrolithotomy Global Study. *Urol Int*. 2013;91:340–344.

Cleveland RO, Anglade R, Babayan RK. Effect of stone motion on in vitro comminution efficiency of Storz Modulith SLX. *J*

Endourol. 2004;18:629–633.

Cleveland RO, Bailey MR, Hartennaum B, et al. Design and characterization of a research electrohydraulic lithotriptor patterned after the Dornier HM3. *Rev Sci Instrum*. 2000;71:2514–2525.

Coleman AJ, Saunders JE, Crum LA, et al. Acoustic cavitation generated by an extracorporeal shockwave lithotripter. *Ultrasound Med Biol*. 1987;13:69–76.

Connors BA, Evan AP, Blomgren PM, et al. Comparison of tissue injury from focused ultrasonic propulsion of kidney stones versus extracorporeal shock wave lithotripsy. *J Urol*. 2014;191:235–241.

Connors BA, Evan AP, Blomgren PM, et al. Effect of initial shock wave voltage on shock wave lithotripsy–induced lesion size during step-wise voltage ramping. *BJU Int*. 2009;103:104–107.

Connors BA, Evan AP, Willis LR, et al. The effect of discharge voltage on renal injury and impairment caused by lithotripsy in the pig. *J Am Soc Nephrol*. 2000;11:310–318.

Crum L. Cavitation microjets as a contributory mechanism for renal calculi disintegration in ESWL. *J Urol*. 1988;140:1587–1590.

Crum L. Surface oscillations and jet development in pulsating bubbles. *J Phys Colloq*. 1979;40 [C8–285–8].

de Cogain M, Krambeck AE, Rule AD, et al. Shock wave lithotripsy and diabetes mellitus: a population-based cohort study. *Urology*. 2012;79:298–302.

de la Rosette J, Assimos D, Desai M, et al. The clinical research office of the endourological society percutaneous nephrolithotomy global study: indications, complications and outcomes in 5803 patients. *J Endourol*. 2011;25:11–17.

Delius M, Jordan M, Eizenhoefer H, et al. Biological effects of shock waves: kidney haemorrhage by shock waves in dogs–

administration rate dependence. *Ultrasound Med Biol*. 1988;14:689–694.

Demirci D, Sofikerim M, Yalcin E, et al. Comparison of conventional and step-wise shockwave lithotripsy in management of urinary calculi. *J Endourol*. 2007;21:1407–1410.

Desai RA, Assimos DG. Role of laparoscopic stone surgery. *Urology*. 2008;71:578–580.

Dhar NB, Thornton J, Karafa MT, et al. A multivariate analysis of risk factors associated with subcapsular hematoma formation following electromagnetic shock wave lithotripsy. *J Urol*. 2004;172(Pt 1):2271–2274.

Eichel L, Batzold P, Erturk E. Operator experience and adequate anesthesia improve treatment outcome with third-generation lithotripters. *J Endourol*. 2001;15:671–673.

Eisenmenger W. *Shock wave measuring techniques in liquids*. [Proceedings of the 16th International Congress on Acoustics and 135th Meeting of the Acoustical Society of America] 1998:2793–2794.

Erturk E, Ptak AM, Monaghan J. Fertility measures in women after extracorporeal shockwave lithotripsy of distal ureteral stones. *J Endourol*. 1997;11:315–317.

Evan AP, McAteer JA, Connors BA, et al. Renal injury during shock wave lithotripsy is significantly reduced by slowing the rate of shock wave delivery. *BJU Int*. 2007;100:624–627.

Evan AP, Willis LR, Connors B, et al. Shock wave lithotripsy–induced renal injury. *Am J Kidney Dis*. 1991;17:445–450.

Evan AP, Willis LR, Lingeman JE, et al. Renal trauma and the risk of long-term complications in shock wave lithotripsy. *Nephron*. 1998;78:1–8.

Fankhauser CD, Kranzbuhler B, Poyet C, et al. Long-term adverse effects of extracorporeal shock-wave lithotripsy for nephrolithiasis and ureterolithiasis: a systematic review.

Urology. 2015;85:991–1006.

Fulgham PF, Essimos DG, Pearle MS, et al. Clinical effectiveness protocols for imaging in the management of ureteral calculous disease: AUA technology assessment. *J Urol*. 2013;189:1203–1213.

Fuller A, Razvi H, Denstedt JD, et al. The CROES percutaneous nephrolithotomy global study: the influence of body mass index on outcome. *J Urol*. 2012;188:133–134.

Georgiev MI, Ormanov DI, Vassilev VD, et al. Efficacy of tamsulosin oral controlled absorption system after extracorporeal shock wave lithotripsy to treat urolithiasis. *Urology*. 2011;78:1023–1026.

Gracewski SM, Dahake G, Ding Z, et al. Internal stress wave measurements in solids subjected to lithotripter pulses. *J Acoust Soc Am*. 1993;94(Pt 1):652–661.

Gravas S, Tzortzis V, Karatzas A, et al. The use of tamsulosin as adjunctive treatment after ESWL in patients with distal ureteral stone: do we really need it? Results from a randomized study. *Urol Res*. 2007;35:231–235.

Gravina GL, Costa AM, Ronchi P, et al. Tamsulosin treatment increases clinical success rate of single extracorporeal shock wave lithotripsy of renal stones. *Urology*. 2005;66:24–28.

Greenstein A, Matzkin H. Does the rate of extracorporeal shock wave delivery affect stone fragmentation? *Urology*. 1999;54:430–432.

Handa RK, McAteer JA, Connors BA, et al. Optimising an escalating shockwave amplitude treatment strategy to protect the kidney from injury during shockwave lithotripsy. *BJU Int*. 2012;110(11 Pt C):E1041–E1047.

Harper JD, Cunitz BW, Dunmire B, et al. First-in-human clinical trial of ultrasonic propulsion of kidney stones. *J Urol*. 2016;195(4 Pt 1):956–964.

Harper JD, Dunmire B, Wang YN, et al. Preclinical safety and effectiveness studies of ultrasonic propulsion of kidney stones. *Urology*. 2014;84:484–489.

Harper JD, Sorensen MD, Cunitz BW, et al. Focused ultrasound to expel calculi from the kidney: safety and efficacy of a clinical prototype device. *J Urol*. 2013;190:1090–1095.

Janetschek G, Frauscher F, Knapp R, et al. New onset hypertension after extracorporeal shock wave lithotripsy: age related incidence and prediction by intrarenal resistive index. *J Urol*. 1997;158:346–351.

Johrde LG, Cocks FH. Fracture strength studies of renal calculi. *J Mater Sci Lett*. 1985;4:1264–1265.

Kaller NR, Aulitzky W, Wastiear S, et al. Effect of high energy shock wave in human spermatozoa in vitro. *Eur Urol*. 1988;14:240–242.

Kang DH, Cho KS, Ham WS, et al. Comparison of high, intermediate, and low frequency shock wave lithotripsy for urinary tract stone disease: systematic review and network meta-analysis. *PLoS ONE*. 2016;11(7):e0158661.

Kaye KW, Clayman RV. Tamponade nephrostomy catheter for percutaneous nephrostolithotomy. *Urology*. 1986;27:441–445.

Keoghane SR, Cetti RJ, Rogers AE, et al. Blood transfusion, embolization and nephrectomy after percutaneous nephrolithotomy (PCNL). *BJU Int*. 2013;111:628–632.

Knapp P, Kulb TB, Lingeman JE, et al. Extracorporeal shock wave lithotripsy–induced perirenal hematomas. *J Urol*. 1988;139:700–703.

Knapp PK, Scott J, Lingeman JE. Magnetic resonance imaging following extracorporeal shock wave lithotripsy with the Dornier HM3 lithotripter. *J Urol*. 1987;137:287.

Kobayashi M, Naya Y, Kino M, et al. Low dose tamsulosin for stone expulsion after extracorporeal shock wave lithotripsy: efficacy in Japanese male patients with ureteral stone. *Int J*

Urol. 2008;15:495–498.

Kohrmann KU, Rassweiler JJ, Manning M, et al. The clinical introduction of a third generation lithotriptor: Modulith SL 20. *J Urol*. 1995;153:1379–1383.

Krambeck AE, Lingeman JE. Percutaneous management of calyceal diverticuli. *J Endourol*. 2009;23:1723–1729.

Krambeck AE, Rohlinger AL, Lohse CM, et al. Long term effects of shock wave lithotripsy for nephrolithiasis: a nineteen year study. *J Endourol*. 2005;19(Suppl):A33.

Kupeli B, Irkilata L, Gurocak S, et al. Does tamsulosin enhance lower ureteral stone clearance with or without shock wave lithotripsy? *Urology*. 2004;64:1111–1115.

Lambert EH, Walsh R, Moreno MW, et al. Effect of escalating versus fixed voltage treatment on stone comminution and renal injury during extracorporeal shock wave lithotripsy: a prospective randomized trial. *J Urol*. 2010;183:580–584.

Li G, Williams JC Jr, Pishchalnikov YA, et al. Size and location of defects at the coupling interface affect lithotripter performance. *BJU Int*. 2012;110(11 Pt C):E871–E877.

Liedle B, Jocham D, Lunz C, et al. Five year follow-up of urinary stone treatment with extracorporeal shock wave lithotripsy. *J Endourol*. 1988;2:157–162.

Lingeman JE, Kulb TB, Newman DM, et al. Hypertension following ESWL. *J Urol*. 1987;137(Suppl):142.

Lingeman JE, Newman D, Mertz JH, et al. Extracorporeal shock wave lithotripsy: the 0 Methodist Hospital of Indiana experience. *J Urol*. 1986;135:1134–1137.

Lingeman JE, Woods JR, Toth PD. Blood pressure changes following extracorporeal shock wave lithotripsy and other forms of treatment for nephrolithiasis. *J Am Med Assoc*. 1990;263:1789–1794.

Lingeman JE. Extracorporeal shock wave lithotripsy: development, instrumentation, and current status. *Urol Clin*

North Am. 1997;24:185–211.

Lokhandwalla M, Sturtevant B. Fracture mechanics model of stone comminution in ESWL and implications for tissue damage. *Phys Med Biol*. 2000;45:1923–1940.

Madbouly K, El-Tiraifi AM, Seida M, et al. Slow versus fast shock wave lithotripsy rate for urolithiasis: a prospective randomized study. *J Urol*. 2005;173:127–130.

Makhlouf AA, Thorner D, Ugarte R, et al. Shock wave lithotripsy not associated with development of diabetes mellitus at 6 years of follow-up. *Urology*. 2009;73:4–8 [discussion 8].

Maloney ME, Marguet CG, Zhou Y, et al. Progressive increase of lithotripter output produces better in-vivo stone comminution. *J Endourol*. 2006;20:603–606.

Marberger M, Turk C, Steinkogler I. Painless piezoelectric extracorporeal lithotripsy. *J Urol*. 1988;139:695–699.

Maxwell AD, Cunitz BW, Kreider W, et al. Fragmentation of urinary calculi in vitro by burst wave lithotripsy. *J Urol*. 2015;193:338–344.

May PC, Kreider W, Maxwell AD, et al. Detection and evaluation of renal imaging in burst wave lithotripsy using ultrasound and magnetic resonance imaging. *J Endourol*. 2017;31:786–792.

Mucksavage P, Mayer WA, Mandel JE, et al. High-frequency jet ventilation is beneficial during shock wave lithotripsy utilizing a newer unit with a narrower focal zone. *Can Urol Assoc J*. 2010;4:333–335.

Müller M. Comparison of Dornier lithotripters: measurement of shock wave fields and fragmentation effectiveness. *Biomed Tech (Berl)*. 1990;35:250–262.

Neucks JS, Pishchalnikov YA, Zancanaro AJ, et al. Improved acoustic coupling for shock wave lithotripsy. *Urol Res*. 2008;36:61–66.

Nussberger F, Roth B, Metzger T, et al. A low or high BMI is a risk factor for renal hematoma after extracorporeal shock wave lithotripsy for kidney stones. *Urolithiasis*. 2017;45:317–321.

Ohmori K, Matsuda T, Horii Y, et al. Effects of shock wave lithotripsy on the male reproductive system. *Urol Int*. 1993;51:152–157.

Opondo D, Tefekli A, Esen T, et al. Impact of case volumes on the outcomes of percutaneous nephrolithotomy. *Eur Urol*. 2012;62:1181–1187.

Orestano F, Caronia N, Gallo G, et al. Functional aspects of the kidney after shock wave lithotripsy. Lingeman JE, Newman DM. *Shock wave lithotripsy 2: urinary and biliary lithotripsy*. Plenum Press: New York; 1989:15–17.

Pace KT, Ghiculete D, Harju M, et al. Shock wave lithotripsy at 60 or 120 shocks per minute: a randomized, double-blind trial. *J Urol*. 2005;174:595–599.

Pace KT, Tariq N, Dyer SJ, et al. Mechanical percussion, inversion, and diuresis for residual lower pole fragments after shock wave lithotripsy: a prospective, single blind, randomized controlled trial. *J Urol*. 2001;166:2065–2071.

Parr KL, Lingeman JE, Jordan M, et al. Creatinine kinase concentrations and electrocardiographic changes in extracorporeal shock-wave lithotripsy. *Urology*. 1988;32:21–23.

Paterson RF, Lifshitz DA, Lingeman JE, et al. Stone fragmentation during shock wave lithotripsy is improved by slowing the shock wave rate: studies with a new animal model. *J Urol*. 2002;168:2211–2215.

Pearle MS, Lingeman JE, Leveillee R, et al. Prospective, randomized trial comparing shock wave lithotripsy and ureteroscopy for lower pole caliceal calculi 1 cm or less. *J Urol*. 2005;173:2005–2009.

Pearle MS, Nakada SY, Womack JS, et al. Outcomes of contemporary percutaneous nephrostolithotomy in morbidly obese patients. *J Urol*. 1998;160(Pt 1):669–763.

Peterson JC, Finlayson B. Effects of ESWL on blood pressure. Gravenstein JS, Peter K. *Extracorporeal shock wave lithotripsy for renal stone disease: technical and clinical aspects*. Butterworths: Boston; 1986.

Picus D, Weyman PJ, Clayman RV, et al. Intercostal-space nephrostomy for percutaneous stone removal. *AJR Am J Roentgenol*. 1986;147:393–397.

Piper NY, Dalrymple N, Bishoff JT. Incidence of renal hematoma formation after ESWL using the new Dornier Doli-S lithotriptor. *J Urol*. 2001;165:377.

Pishchalnikov YA, Neucks JS, Von Der Haar RJ, et al. Air pockets trapped during routine coupling in dry head lithotripsy can significantly decrease the delivery of shock wave energy. *J Urol*. 2006;176:2706–2710.

Preminger GM, Assimos DG, Lingeman JE, et al. Chapter 1: AUA guideline on management of staghorn calculi: diagnosis and treatment recommendations. *J Urol*. 2005;173:1991–2000.

Puppo P, De Rose AF, Pittaluga P, et al. Evaluation of seminal fluid in patients treated with ESWL of pelvic ureteral calculi. *Arch Ital Urol Nefrol Androl*. 1990;62:65–68.

Radfar MH, Simforoosh N, Sotoudeh M, et al. What is the impact of extracorporeal shockwave lithotripsy on semen parameters? A systematic review and meta-analysis. *Urologia*. 2017;84:28–34.

Rashed FK, Ahmadi NR, Zolfaghari A, et al. Prevalence of diabetes mellitus after extra corporeal shock wave lithotripsy in 15 years follow-up. *Urol Ann*. 2017;9(3):268–271.

Rehman J, Monga M, Landman J, et al. Characterization of intrapelvic pressure during ureteropyeloscopy with ureteral access sheaths. *Urology*. 2003;61:713–718.

Resim S, Ekerbicer HC, Kiran G, et al. Are changes in urinary parameters during pregnancy clinically significant? *Urol Res*. 2005;34:244–248.

Ruiz Marcellan FJ, Ibarz Servio L. Evaluation of renal damage in extracorporeal lithotripsy by shock waves. *Eur Urol*. 1986;12:73–75.

Sapozhnikov OA, Maxwell AD, MacConaghy B, et al. A mechanistic analysis of stone fracture in lithotripsy. *J Acoust Soc Am*. 2007;121:1190–1202.

Sato Y, Tanda H, Kato S, et al. Shock wave lithotripsy for renal stones is not associated with hypertension and diabetes mellitus. *Urology*. 2008;71:586–591 [discussion 591–592].

Sayed MA. Semen changes after extracorporeal shock wave lithotripsy for distal ureteral stones. *J Endourol*. 2006;20:483–485.

Scarpa RM, De Lisa A, Porru D, et al. Holmium:YAG laser ureterolithotripsy. *Eur Urol*. 1999;35:233–238.

Semins MJ, Trock BJ, Matlaga BR. The effect of shock wave rate on the outcome of shock wave lithotripsy: a meta-analysis. *J Urol*. 2008;179:194–197 [discussion 197].

Skolarikos A, Grivas N, Kallidonis P, Members of RISTA Study Group, et al. The efficacy of medical expulsive therapy (MET) in improving stone-free rate and stone expulsion time, after extracorporeal shock wave lithotripsy (SWL) for upper urinary stones: a systematic review and meta-analysis. *Urology*. 2015;86:1057–1064.

Skuginna V, Nguyen DP, Seiler R, et al. Does stepwise voltage ramping protect the kidney from injury during extracorporeal shockwave lithotripsy? Results of a prospective randomized trial. *Eur Urol*. 2016;69:267–273.

Sorensen MD, Bailey MR, His RS, et al. Focused ultrasonic propulsion of kidney stones: review and update of preclinical technology. *J Endourol*. 2013;27:1183–1186.

Sorensen MD, Bailey MR, Shah AR, et al. Quantitative assessment of shock wave lithotripsy accuracy and the effect of respiratory motion. *J Endourol*. 2012;26:1070–1074.

Sturtevant B. The shock wave physics of lithotripsy. Smith AD. *Smith's textbook of endourology*. Quality Medical: St. Louis; 1996:1–29.

Thuroff S, Thorsten B, Chaussy C. Anatomy related shockwave power using Siemens Lithostar multiline. *J Urol*. 1988;159(Suppl):34.

Traxer O, Thomas A. Prospective evaluation and classification of ureteral wall injuries resulting from insertion of a ureteral access sheath during retrograde intrarenal surgery. *J Urol*. 2013;189:580–584.

Ueda S, Matsuko K, Yamashita T, et al. Perirenal hematomas caused by SWL with EDAP LT-01 lithotriptor. *J Endourol*. 1993;7:11–15.

Vakil N, Everbach EC. Transient acoustic cavitation in gallstone fragmentation: a study of gallstones fragmented in vivo. *Ultrasound Med Biol*. 1993;19:331–342.

Vieweg J, Weber HM, Miller K, et al. Female fertility following extracorporeal shock wave lithotripsy of distal ureteral calculi. *J Urol*. 1992;148:1007–1010.

Vorreuther R, Corleis R, Klotz T, et al. Impact of shock wave pattern and cavitation bubble size on tissue damage during ureteroscopic electrohydraulic lithotripsy. *J Urol*. 1995;153(Pt 1):849–853.

Williams CM, Kaude JV, Newman RC, et al. Extracorporeal shock-wave lithotripsy: long-term complications. *AJR Am J Roentgenol*. 1988;150:311–315.

Williams CM, Thomas WC Jr. Permanently decreased renal blood flow and hypertension after lithotripsy. *N Engl J Med*. 1989;321:1269–1270.

Willis LR, Evan AP, Connors BA, et al. Prevention of lithotripsy-induced renal injury by pre-treating kidneys with low energy shockwaves. *J Am Soc Nephrol*. 2006;17:663–673.

Wollin TA, Denstedt JD. The holmium laser in urology. *J Clin Laser Med Surg*. 1998;16:13–20.

Xi X, Zhong P. Dynamic photoelastic study of the transient stress field in solids during shock wave lithotripsy. *J Acoust Soc Am*. 2001;109:1226–1239.

Yang TX, Liao BH, Chen YT, et al. A network meta-analysis on the beneficial effect of medical expulsive therapy after extracorporeal shock wave lithotripsy. *Sci Rep*. 2017;7:14429.

Zhong P, Chuong CJ, Preminger GM. Propagation of shock waves in elastic solids caused by cavitation microjet impact. II. Application in extracorporeal shock wave lithotripsy. *J Acoust Soc Am*. 1993;94:29–36.

Zhong P, Chuong CJ. Propagation of shock waves in elastic solids caused by cavitation microjet impact. I. Theoretical formulation. *J Acoust Soc Am*. 1993;94:19–28.

Zhong P, Tong HL, Cocks FH, et al. Transient oscillation of cavitation bubbles near stone surface during electrohydraulic lithotripsy. *J Endourol*. 1997;11:55–61.

Zhong P, Zhou Y, Zhu S. Dynamics of bubble oscillation in constrained media and mechanisms of vessel rupture in SWL. *Ultrasound Med Biol*. 2001;27:119–134.

Zhou Y, Cocks FH, Preminger GM, et al. The effect of treatment strategy on stone comminution efficiency in shock wave lithotripsy. *J Urol*. 2004;172:349–354.

95

Lower Urinary Tract Calculi

Arvind P. Ganpule MS, DNB, Mahesh R. Desai MS, FRCS

History

The significance of subspecialization in urology was realized centuries ago when Hippocrates said, “I will not cut for stone, even for patients in whom the disease manifest, I will leave this operation to be performed by practitioners” (Herr, 2008). The history of urolithiasis dates back to the Greek, Egyptian, and the Indus Valley civilizations (Ellis, 1979). Shattock (1905) described what may be the earliest known case of lower urinary tract stone disease in a gravesite in Egypt from a 16-year-old boy. This dates back to approximately 4800 BCE (Shattock, 1905). It was well known in those days that the approach to the bladder stone involved a perineal, suprapubic, and transurethral approach (Ellis, 1979). The term *lithotomy* was coined sometime in 276 BCE by the Greek Ammonius; the writings of the same were described by Roman Cornelius Celsius 300 years later (Herr, 2008; Parladidius et al., 2007). Celsius was credited with operating on a patient with the first perineal urethrotomy. It involved restraining the patient in a lithotomy position. He described this as “methodus celsiana.” In Italy, Marianas introduced a simple operation that he termed *apparatus minor*. The term *minor* was used because no instruments were used, and the stone was retrieved by a large incision on the anus in the perineum. Subsequently, an *apparatus major* operation was described; the term *major* was used because a large number of instruments were used in the operation (Ellis, 1979).

Jean Civiale is credited for developing the art of lithotrity. He operated on Leopold I for a bladder stone. Sir Henry Thompson was credited with the development of operation of lithotrity. A British excavation revealed a bladder stone in a middle-aged man. It was concluded in the archaeological findings that the stone was most likely formed as a result of bladder outlet obstruction (BOO) (Anderson, 2001).

There has been a paradigm shift in the size and the location of stones seen in the lower urinary tract. In the past 50 years, the incidence of vesical calculus has steadily declined in the Western world. The underdeveloped nations continue to see instances of vesical calculi particularly in children (Schwartz and Stoller, 2000).

Etiopathogenesis of Bladder Calculi

Bladder stones are the most common manifestation of lower urinary tract lithiasis, **accounting for 5% of all the urinary stone diseases and approximately 1.5% of urologic hospital admissions** in the Western world (Schwartz and Stoller, 2000; Smith and O'Flynn, 1975). Bladder calculi in nonendemic areas are commonly found in adults and are secondary to some other disease process. In endemic areas, the calculi are seen frequently in children and do not exist with other anomalies (Schwartz and Stoller, 2000). The dietary intake and socioeconomic conditions are responsible for its occurrence (Andersen, 1962; Asper, 1984). **Traditionally, the bladder stones are classified as migrant, primary idiopathic, or secondary** (Phillippou et al., 2012). Primary bladder stones usually are described as those that form without any predisposing cause, whereas a secondary cause is found in most patients with certain predisposing causes.

Primary bladder stones are historically associated with nutritional deficiency. These are known to be rampant in undernourished or nutritionally compromised individuals. They are prevalent in North Africa and the Middle East (Ashworth, 1990). The cause for formation of these calculi is believed to be a combination of decreased urine output, alteration in the urine PH, and other metabolic abnormalities. Vitamin deficiency and dietary compromise in the form of deficient animal proteins is responsible for the genesis of these stones. Children in endemic areas consume a cereal-based diet that is poor in animal protein and low in phosphate (Teotia and Teotia, 1990; Thalut et al., 1976; Van Reen, 1980). Low dietary intake of phosphates leads to hypophosphaturia, promoting the precipitation of calcium oxalate and ammonium acid urate. It has been proposed in endemic areas in addition to the earlier-mentioned factors that a diet rife with oxalates leads to hyperoxaluria, leading to calcium oxalate stones (Teotia and Teotia, 1990). The primary bladder stones are known to form within the first 5 years of life and have a male preponderance (Phillippou et al., 2012). **Primary bladder calculi are most common in children younger than the age of 10 with a peak incidence at 2 to 4 years. The disease is much more common in boys than in girls with ratios ranging from 9 : 1 to as high as 33 : 1.** Primary bladder stones are most commonly solitary and rarely recur after removal (Teotia and Teotia, 1990; Van Reen, 1980). The composition of primary bladder stone is commonly ammonium acid urate, calcium oxalate, uric acid, and calcium phosphate (Valyasevi and Van Reen, 1968).

Secondary bladder stones are always associated with an underlying bladder pathology. In the Western world typically they are found in men older than 60 and usually in concert with lower urinary tract obstruction. Bladder calculi are known to occur de novo in the bladder, but sometimes they **may migrate from the upper tract and fail to expel 3% to 17% of bladder calculi** (Douenias et al., 1991; Smith and O'Flynn, 1975). The frequent absence of calcium oxalate in the nucleus of the bladder stones further argues against upper tract origin (Douenias et al., 1991). **The commonly implicated factors are foreign bodies such as migrated intrauterine devices** (Chow, 1997)**; intravaginal gynecologic accessories such as pessaries, diaphragms** (Cumming, 1997)**, and eroded clips** (Desai and Ganpule, 2017; Tugcu et al., 2009)**; and causes leading to significant postvoid residue (BOO resulting from stricture, benign prostatic hyperplasia, neurogenic bladders, urinary diversion, bladders, bladder neck contractions)** (Douenias et al., 1991). A few reported but uncommon causes of intravesical foreign bodies leading to bladder calculi formation are erosion of wire used for cerclage (Ehrenpreis et al., 1986), unrecognized anorectal impalement (Guha et al., 2012), eroded silk sutures used in dorsal vein complex (Miller et al., 1992; Scheidler et al., 1990), migration of brachytherapy seeds (Leapman et al., 2014; Miyazawa et al., 2012), and hair as a nidus after clean intermittent catheterization (Derry and Nuseibeh, 1997).

Long-term urinary catheters are one of the causative factors for bladder stone formation. The incidence is 0.7% to 2.2% in chronic indwelling catheters (Kohler-Ockmore and Feneley, 1996). Retained fragments of burst Foley balloon catheters are responsible for nidus formation (Smith and O'Flynn, 1975). Crystal formation has been implicated in formation of these stones. Homogenous nucleation rarely is to be blamed for crystallization in this entity. Heterogeneous nucleation occurs around the foreign body as a result of infection or because of obstruction with resulting supersaturation (Schwartz and Stoller, 2000).

Among the neurogenic bladder patients, those with spinal cord injury are more prone to form bladder stones (Chen et al., 2001; Ord et al., 2003). In a study by Hall 29% of patients with spinal cord injuries had bladder calculi. The factors implicated included complete neurologic lesion, urinary tract infection caused by *Klebsiella*, and Caucasian race (DeVivo, 1985; Hall, 1989). Thus continuous mucosal injury with resulting chronic inflammation secondary to indwelling Foley or chronic bladder calculi could substantiate the deficiency of glycosaminoglycan layer in these patients (Schwartz and Stoller, 2000).

In a large series, Takasaki et al. (1979) found that 52% of all stones had magnesium ammonium phosphate. In this large series no females had uric acid stones as compared with 7.7% of males.

Drugs have been implicated as a causative factor in a number of locations of urolithiasis. **Triamterene, a diuretic, is associated with urolithiasis** because it inhibits sodium reabsorption in the distal tubule. There have been reports of triamterene-associated urolithiasis in patients with BOO and those keeping high residues (Hollander, 1987). **Indinavir, a protease inhibitor, has been implicated as a causative factor for urolithiasis** (Gentle et al., 1997).

Presentation of Bladder Stones

Bladder stones are rarely asymptomatic at the time of presentation. **The most common presentation of bladder calculi is terminal hematuria** (Smith and O'Flynn, 1975). In addition, the patients have a **varied degree of lower urinary tract symptoms,** which include intermittency, frequency, urgency, decreased flow urge incontinence, and abdominal pain (Douenias et al., 1991; Ellis, 1979; Smith and O'Flynn, 1975). Children suffering from bladder stones rarely seek medical attention acutely. There are often preceding symptoms such as passage of cloudy and sandy urine. **Children often experience abdominal discomfort, dysuria, frequency, and hematuria. Pulling the penis, in children, is considered pathognomonic of bladder stone**. In adults, the presentation can be acute urinary retention; however, this is rare in children with primary bladder stone (Ali and Rifat et al., 2005; Teotia and Teotia, 1990).

Management of Bladder Stones

The options for treatment of bladder stones are medical management, extracorporeal shock wave lithotripsy, transurethral lithotripsy, suprapubic cystolithotomy, suprapubic cystolithotripsy, and open surgery.

The factors that decide the line of management are size of the stone, stone composition, age of the patient, build of the patient, coexistent location of urolithiasis elsewhere, concomitant BOO, and available expertise or equipment.

Medical Management

Chemo dissolution as a sole treatment for bladder stones is time consuming and not completely efficient. In the current era its role is limited to use in select cases as an adjunct treatment. The treatment of chemodissolution is particularly effective for encrustation over long-term catheters. This can be considered as the treatment modality as well as a prophylactic measure (Phillippou et al., 2012).

Extracorporeal Shock Wave Lithotripsy

Extracorporeal shock wave lithotripsy (ESWL) as a modality of treatment has been considered as an option in patients with bladder calculi with artificial urinary sphincters or a penile prosthesis. Any endoscopic intervention in such a situation is fraught with jeopardizing the integrity of the prosthesis or sphincter device. It has also been considered to be a treatment option in stones in neobladders and medically high-risk patients (Bhatia et al., 1994; Delakas et al., 1998; Frabboni, 1998; Hussain, 1994; Kostakopoulos et al., 1996; Millan Rodrigues et al., 2005; Razvi et al., 1996).

The protocol 22 for ESWL includes prone positioning of the patient, which avoids the artifacts from the coccyx and the rectum, and an indwelling catheter in form of a three-way Foley. The bladder is filled up to 150 mL; this enables the localization of the stone. Once the session is over, the bladder is drained. Intermittent irrigation further helps to localize the stone. **The factors that affect the outcome of ESWL in bladder stones include the amount of postvoid residue, the stone composition, and the stone size** (Frabboni, 1998).

Endourologic Approach to Bladder Stone

In the recent years the development of miniaturized endourologic equipment with efficacious energy source has ensured that majority of the bladder stones can be tackled with the endourologic approach.

A few terms that merit mention are the following:

1. Cystolithotomy: intact removal of stone
2. Cystolithotripsy: fragmenting the stone with energy source
3. Cystolitholapaxy: mechanical breakage of the stone (Fig. 95.1)

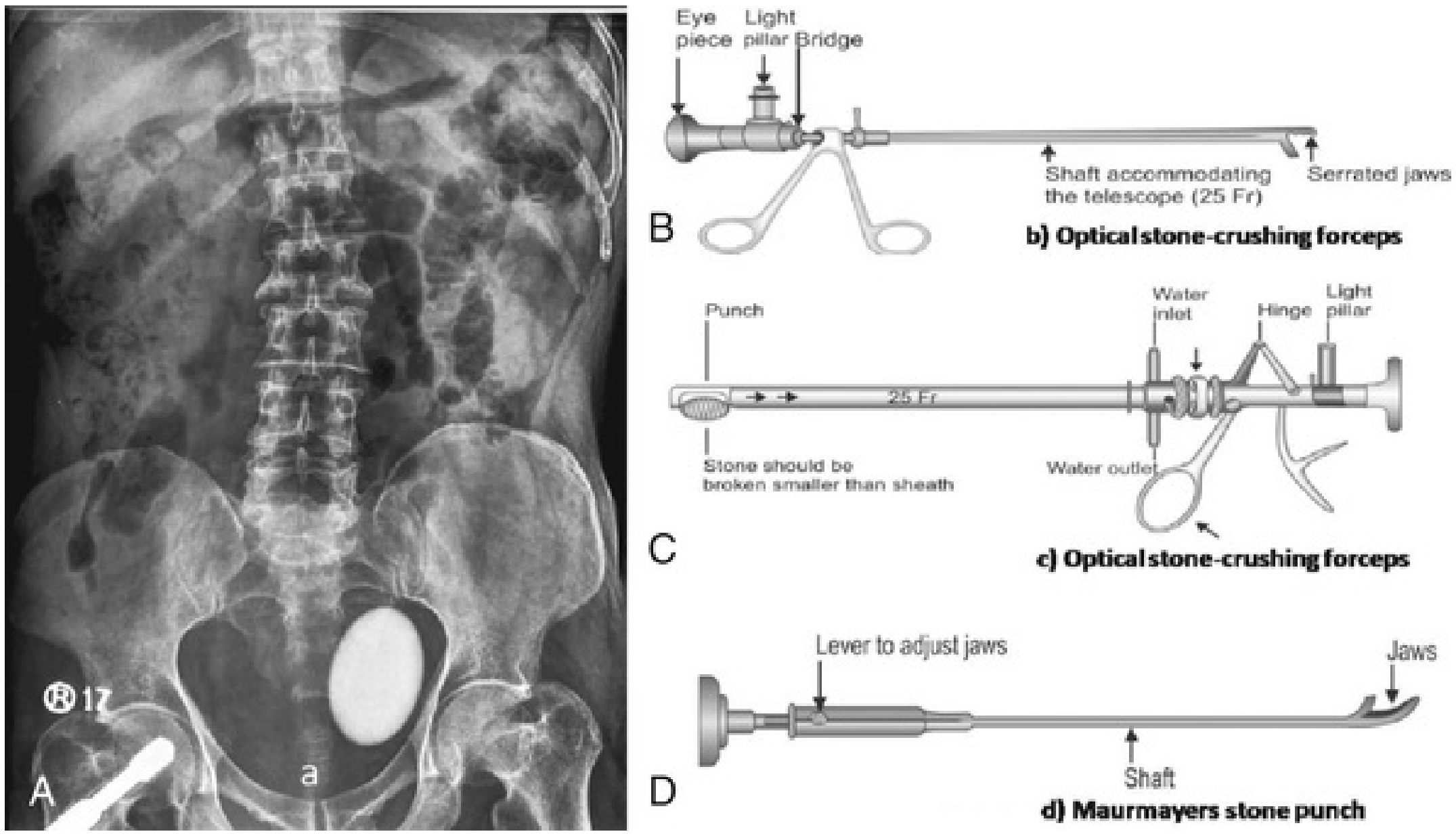
®17
A
a
Eye piece
Light pillar
Bridge
Shaft accommodating the telescope (25 Fr)
Serrated jaws
B
b) Optical stone-crushing forceps
Punch
Water inlet
Hinge
Light pillar
25 Fr
Stone should be broken smaller than sheath
Water outlet
C
c) Optical stone-crushing forceps
Lever to adjust jaws
Jaws
Shaft
D
d) Maurmayers stone punch

FIG. 95.1 Large bladder stone and cystolitholapaxy equipment used for fragmenting bladder stones. (A) Large bladder stone. (B) Stone-crushing forceps. (C) Optical stone-crushing forceps. (D) Maurmayer stone punch. (Reproduced from Sabnis RB, Patwardhan SK, Ganpule AP, editors: *Urology instrumentation: a comprehensive guide*, New Delhi, India, 2016, Jaypee Publications.)

The transurethral route has been the most popular route for managing bladder stones because of the ease of this approach and robust energy devices that can be deployed. Modern series report the use of the holmium laser, electrohydraulic lithotripter, and lithoclast technology (Isen et al., 2008; Lipke et al., 2004). The lithotrite is slowly falling out of favor because of high incidence of complications such as bladder mucosal injury and perforations (Smith and

O'Flynn, 1975).

Recently, laser lithotripsy, particularly with the use of side-firing laser, has become the modality of choice because it offers the possibility of a one-time procedure with minimal complications (Lipke et al., 2004; Teichman et al., 1997). One of the concerns with transurethral access is the possibility of urethral injury because of repeated passage of transurethral instruments. The measures described to decrease the incidence of urethral stricture are use of transurethral Amplatz sheath (Okeke et al., 2004), adequate lubrication, and preoperative meatotomy and use of a suprapubic catheter postoperatively (Sathaye, 2003).

The advantages of the percutaneous approach are safety, efficacy, and potential lesser risk to the urethra (Ikari et al., 1993)**. Percutaneous nephrolithotomy has been advocated in patients with difficult urethras, such as patients who have undergone previous bladder neck reconstruction or closures.** The percutaneous access is created with an Amplatz sheath or a Hassan cannula (Hubscher and Costa, 2011; Ikari et al., 1993). A combination of ultrasonic and pneumatic energy effectively fragments the stones. Placement of an entrapment sac for retrieval of fragments has been described (Tan et al., 2014). **The success rates for this procedure range from 89% to 100% in a single sitting.** The complications include urine leak and persistent hematuria in 1% (Ikari et al., 1993).

Open Surgery for Bladder Stones

Open cystolithotomy is associated with the need for prolonged catherization and hospital stay. Workers have also reported the feasibility of catheterless and drainless cystolithotomy in children with two-layered closure (Rattan et al., 2006). Open approach can also be considered in such situations in which there remains a contraindication for transurethral or percutaneous access to the bladder such as small-capacity bladders and stricture urethra (Miller, 2003).

Lower Tract Calculi in Special Situations

Bladder Outlet Obstruction With Bladder Lithiasis

BOO results in incomplete emptying and nonevacuation of fragments. These two factors are noted in 45% to 79% of all patients diagnosed with vesical calculi. The presence of urolithiasis secondary to BOO forms the absolute indication for treatment of BPH. The theory that secondary bladder calculi are due to outlet obstruction has been challenged. Approximately 1% to 2% of all bladder calculi are associated with BOO, which indicates that infection does play a role in the pathogenesis of bladder stones. All secondary bladder stones do not require treatment for BOO. More than 30% of all bladder stones are associated with infection. The infection is usually by a urea-splitting organism (Douenias et al., 1991).

Millan Rodrigues et al. noted a study that performed a urodynamic examination before and after treatment of bladder calculi found that only half of this subgroup of patients had urodynamic suggestion of BOO. Douenias, however, found that BOO was the cause of bladder stone in 88% of patients (Douenias et al., 1991; Millan Rodrigues et al., 2005).

Bladder Calculi in Urinary Diversions and Augmented Bladder

Calculi can occur in the upper and lower tracts after augmentation or diversion, and the incidence varies depending upon the type of surgery performed.

The cause of urolithiasis is multifactorial in patients who have urinary diversions. The reasons for stone formation can be divided into persistent bacterial colonization leading to infection, metabolic abnormalities, and anatomic and structural factors (Hensle et al., 2004; Robertson and Woodhouse, 2006). **The common metabolic abnormalities that result in usage of ileum or colon for diversions is hyperchloremic metabolic acidosis, which in turn may cause hypercalciuria because of a decrease in absorption of calcium** (Assimos, 1996). Loss of ileum can lead to enteric hyperoxaluria and diarrhea, which in turn can lead to stone formation (Terai et al., 1995).

Most of the stones in this subset of patients are mainly struvite calculi, which proves that recurrent and persistent urinary tract infections are one of the most important causative factors in these patients (Arif et al., 1999; Beiko and Razvi, 2002; Turk et al., 1999). The organisms responsible for persistence of infections in these patients are urease-producing bacteria such as *Pseudomonas, Proteus,* and *Klebsiella* (Hertzig et al., 2013). The urease leads to alkalinization of urine and promotes crystallization. The mucus in these diversions may also facilitate bacterial growth by aiding in deposition of bacterial biofilm and thereby making the penetration of antibiotics difficult (Blyth et al., 1992; Bruce et al., 1984; Khoury et al., 1997). The use of stomach for diversion helps in reducing the incidence of bladder calculi, but the complications associated with its use, such as hematuria dysuria syndrome and need for long-term proton pump inhibitors, discourages the use of stomach (Kronner et al., 1998). Urinary stasis can occur as the result of stomal stenosis in a case of conduit or poor emptying in a case of continent diversion. This urinary stasis can be a contributory factor for formation of stones. It has been proven that the incidence of calculi has significantly decreased in this subset of patients by shifting from nonabsorbable to absorbable sutures (Arif et al., 1999; Turk et al., 1999).

Surgeries for calculi in patients with urinary diversions require special considerations. Preoperative knowledge of the type of diversion used is important, and it may help in deciding the operative modality. The accurate knowledge of anatomy is important and aids in planning the puncture in percutaneous approach and avoiding bowel injury. In patients in whom the stone in the conduit is due to stomal stenosis, removal of stone alone will lead to recurrence because of persistence of anatomic obstruction. The best treatment modality is concomitant revision of the stoma. In stones in continent diversions, such as those in cutaneous continent pouches, percutaneous approaches is preferable, and any treatment option that may cause injury to the continence mechanism should be avoided. Some authors even advocate ESWL as a treatment modality in these subset of patients, even though the routine use of ESWL in lower tract calculi and in diversions is not commonly practiced (Boyd et al., 1988).

In case of small burden stones in a neobladder, transurethral procedures can be done with minimal injury to the sphincter. However, if the stone burden is large, percutaneous method or open method is preferable (L'Esperance et al., 2004). In percutaneous technique either the Amplatz sheath or laparoscopic trocars can be used (Franzoni et al., 1999; Thomas et al., 1993). Postoperative management of these patients includes adequate drainage of either the stoma or the pouches with a suprapubic catheter or stomal catheter in case of a stoma or per urethral catheter in case of neobladder. The prevention strategies include complete removal of stone, treatment of infection, correction of anatomic abnormalities, and prevention of mucus.

Bladder Calculi in Patients With Spinal Cord Injury

The risk of bladder stone formation increases in patients with neurogenic bladder resulting from spinal cord injury and meningomyelocele. The incidence depends on multiple factors such as level of lesion, the severity of the injury, previous incidence of stones, persistence of infection, and method of urinary drainage (Chen et al., 2001; Sugimura et al., 2008). **For adults with spinal cord injury, the risk of bladder stone formation peaks at 3 months after injury, and within 10 years 15% to 30% of patients have formed at least one stone** (Chen et al., 2001)**. Unfortunately this risk quadruples after first stone formation** (Ord et al., 2003). After spinal cord injury two phases are important for calculi formation: the acute phase, in which most patients are immobilized, and the second phase, which is later after recovery. The reason for calculi formation during the acute phase may be immobilization hypercalciuria, which may lead to formation of calcium stones (Naftchi et al., 1980). These stones can occur anywhere in the urinary tract, including the kidney and the bladder. In the recovery phase the main reason for calculi formation is the persistence of infection, which can be caused by either inadequate emptying or the methods deployed in emptying the urine (Burr et al., 1993).

Other causes for stone formation in spinal cord injury patients include the increase in alkalinity of urine coupled with hypocitraturia in spinal cord injury patients. Patients on clean intermittent catheterization were found to have decreased incidence of bladder stones when compared with those on indwelling catheter (Ord et al., 2003). Indwelling Foley catheters should be avoided because they are prone to encrustation and can contribute to the formation of nephrolithiasis. If an indwelling Foley catheter must be used, weekly catheter changes can dramatically reduce catheter encrustation and stone formation. In patients on indwelling catheter the incidence of stones does not vary between those on suprapubic or per urethral catheterization (Ord et al., 2003). The ways to reduce the incidence of bladder calculi in such patients include long-term antibiotic therapy, use of ascorbic acid to acidify the urine, increased fluid intake, routine bladder lavage with antibacterial irrigants, and the use of silicone catheters.

As in the general population, bladder calculi of small to intermediate size (up to 4 cm) may be treated transurethrally by electrohydraulic lithotripsy or Ho:YAG laser lithotripsy, and larger stones can be treated by percutaneous means or by open cystolithotomy (Schwartz and Stoller, 2000). ESWL for bladder stones may be an ideal treatment for spinal cord injury patients who are anesthetic risks or prone to autonomic dysreflexia (Kilciler et al., 2002).

Bladder Calculi After Renal Transplantation

Urolithiasis after renal transplantation is not uncommon and has an incidence of 1% to 1.8% (Kim et al., 2001; Schwartz and Stoller, 2000). Even though renal calculi are more common after transplantation, bladder calculi are common. There are many causative factors for bladder calculi in a post-transplant setting, especially persistent infection with *Proteus* sp. (urease-splitting organism), persistent outflow obstruction, and retained suture material. Immunosuppressive drugs such as calcineurin inhibitors and steroids can also be a contributory factor. The incidence of bladder stones has decreased after the use of absorbable suture (Klein and Goldman,1997; Lipke et al., 2004).

The first investigation in case of a bladder stone is ultrasonography to rule out the presence of concomitant renal or ureteric calculi. CT scan can be used for confirmation.

The ideal modality of treatment of bladder calculi in a post-transplantation scenario does not differ much from routine situations. The modalities that can be used are cystolitholapaxy, laser, and ESWL (Grasso, 1996; Hahnfeld et al., 1998).

Urethral Calculi

Urethral calculi amount to 0.3% to 1% of all stone disease, and obstructing urethral calculus is a very rare presentation of lower urinary tract urolithiasis (Aegukkatajit, 1999; Larkin and Weber, 1996). In the last few decades, the urethral calculi have become a rarity in the industrialized Western societies, although not so uncommon in and endemic regions of Asia and Middle East (Aegukkatajit, 1999; Amin, 1973; Menon and Martin, 2002; Seltzer et al., 1993). More recent epidemiologic studies have suggested a declining incidence of lower urinary tract bladder and urethral calculi (Trinchieri, 2008).

Urethral calculi have been exceedingly more common in males, with a bimodal age distribution. The first peak occurs in early childhood, and the second peak incidence occurs in the fourth or fifth decades of life (Kamal et al., 2004; Verit et al., 2006). Shorter length of the female urethra and higher peak flow rates in adolescence and younger age groups may have the protective effect for the younger demographic age group (Kamal et al., 2004; Verit et al., 2006).

Pathogenesis and Composition of Urethral Calculi

Urethral stones can be *primary* or *autochthonous*, those that arise de novo in the urethra, or *secondary* or *migratory*, in which the stones from the upper tracts or the bladder migrate into the urethra. The urethral stones are most commonly found proximal to the above-mentioned sites, especially prostatic urethra and less commonly in the pendulous urethra.

The majority of urethral calculi are migratory. Any pathology, either structural or functional, affecting the urethra, such as urethral stricture, meatal stenosis, or benign prostatic hyperplasia, can impede the normal stone passage and result in a migratory calculus, which otherwise would have been cleared (Hegele et al., 2002; Verit et al., 2006).

It was commonly believed that the bladder was the source of migratory calculi (Shanmugam et al., 2000), but recent evidence has suggested that the source of these migratory calculi could as well be the upper urinary tract calculi (Kaplan et al., 2006). The evidence in favor is threefold. First, the composition of these migratory calculi has been predominantly calcium oxalate (85%–90%), which is akin to those found in the upper tracts (Kamal et al., 2004; Verit et al., 2006). Second, patients with urethral calculi had concomitant bladder and upper tract calculi in 2% and 18%, respectively (Kamal et al., 2004). Third, in areas that were endemic for bladder calculi, the incidence of the bladder calculi has decreased considerably because of changes in food and lifestyle, whereas there has been no change in the incidence of urethral calculi, suggesting an origin from the upper tracts (Aegukkatajit, 1999; Kamal et al., 2004; Verit et al., 2006).

Primary Urethral Calculi

Primary urethral calculi are considered primary because they originate at the same site as they are found ultimately. **In reality, they form secondary to obstruction of urethra at any level of urinary stasis in urethral diverticula.** Presence of a foreign body and urinary infection provide a conducive milieu for stone formation (Rivilla et al., 2008; Susco et al., 2008). In the presence of infection stones, the commonly isolated organisms are *Escherichia coli, Proteus* spp., and Enterococci (Susco et al., 2008). Most of these stones are small, round, without a core or nucleus, and composed primarily of struvite (magnesium ammonium phosphate), although other types such as calcium phosphate and uric acid have been reported (Verit et al., 2006).

Urethral stricture is the leading cause for the formation of urethral stones as discussed earlier. On the other hand, placement of hair-bearing grafts for the management of urethral stricture or hypospadias has resulted in urethral stones as well. The hair acts as a nidus for precipitation and inspissation of lithogenic salts and results in primary calculi in the urethra (Singh and Hemal, 2001). These stones remain adherent to the hair ball and the urethral mucosa, causing partial obstruction and further stone formation. Attempts at epilation before engraftment have reduced but not eliminated the risk: the follicles persist and lead to hair growth in 3% to 6% of patients (Singh and Hemal, 2001).

The presence of foreign body may also serve as a nidus for stone formation. The advent of brachytherapy as a treatment modality for carcinoma prostate over the last two decades requires the placement of radioactive seeds into the prostate. These seeds can migrate or intrude into the prostatic urethra and may form a nidus for stone formation. Cryoablation causes ischemic necrosis of the gland, and necrosis with persistent inflammation may give rise to stones (Aus et al., 1997; Steinmetz and Barrett, 2006).

Clinical Presentation and Evaluation

The clinical presentation depends on the type and location of the stone. Patients with migratory calculi usually have a history of stone disease, previous surgeries for stone or instrumentation of lower tract, a vague history of flank pain in the preceding 1 or 2 weeks, suggesting origin from the upper tracts, and lower urinary tract symptoms (Verit et al., 2006). **More commonly, urethral calculi patients present with acute painful retention of urine from sudden impaction of the stone. In other patients who are able to void despite the urethral calculus, there occurs weak stream, interrupted stream, or splaying, gross hematuria, and dysuria.** Posterior urethral stones typically have perineal or rectal pain, whereas those in the pendulous urethra have pain at the penile tip. Patients with primary urethral calculi or diverticular calculi have more insidious symptoms of persistent pain during voiding, obstructive lower urinary tract symptoms, chronic pelvic pain, or recurrent urinary tract infections. Women tend to report increased urinary frequency and occasional incontinence (Susco et al., 2008).

Migratory urethral calculi are usually solitary and larger than primary calculi, although urethral steinstrasse has been reported (Atikeler et al., 2005; Verit et al., 2006). Different authors have reported differing location of the stone, with most unanimously reporting the posterior urethral stones to be more common (as high as 88%) than anterior urethral stones (4%–11%) in their series (Amin, 1973; Kamal et al., 2004; Selli et al., 1984; Shanmugam et al., 2000; Sharfi, 1991). Examination may be completely normal in a posterior urethral calculus except for a mild tender prostate, whereas those located in the bulbar or the penile urethra may be palpable as a hard mass along the course of the normal urethra. In females, it is identified as a hard mass in the anterior vaginal wall (Kaplan et al., 2006; Subbarao et al., 1998; Susco et al., 2008). Primary urethral calculi have a more protracted course and insidious symptoms. Examination reveals a urethral diverticulum, if present, and very large diverticula are readily palpable with multiple stones in the perineum (Beatrice et al., 2008; Gallo et al., 2007; Koh et al., 1999; Subbarao et al., 1998; Susco et al., 2008).

Patients with migratory calculi present immediately in view of sudden and drastic onset of the symptoms. Those who are able to void with minimal symptoms and those with urethral diverticula often seek medical attention late with a long history, often up to many years (Gallo et al., 2007; Koh et al., 1999; Susco et al., 2008). Prolonged delays have a more complicated presentation with larger calculi and urethra-cutaneous or urethra-rectal fistulas (Kaplan et al., 2006; Kumar et al., 2012). These fistulous complications are more common in those who cannot report their symptoms because of decreased sensation, especially in infants and those afflicted with spinal cord injuries (Kaplan et al., 2006; Shamsa et al., 2008).

Urine examination reveals gross or microscopic hematuria and presence of infection in cases of primary calculi. Majority of urethral stones are radiopaque and visible on plain radiographs. The density of these stones vary in individual patients, but as against the previous literature, which quotes 40% to be radiopaque, newer studies have suggested an overwhelming majority of 98% of urethral stones to be radiopaque (Kamal et al., 2004; Verit et al., 2006). A retrograde urethrogram can identify the stones as filling defect and has been the mainstay of investigation. A carefully done transrectal ultrasonography can identify the prostatic urethral calculi as a hyperechoic structure with postacoustic shadowing (Aus et al., 1997; Peabody et al., 2012). Similarly, a high-frequency (10-MHz) linear transducer, when placed on the dorsal surface of the penis along its long axis, can screen the entire urethra and identify the calculi (Peabody et al., 2012).

With the advent of ultrasonography, retrograde urethrogram is reserved for cases in which ultrasonography is inconclusive or when a stricture of the urethra is suspected as a cause for the stone. Most authors also agree with the fact that upper tract stones may coexist and therefore advocate ultrasonography of the kidney, ureter, and bladder or a cross-sectional computerized tomography, especially if a strong suspicion exists (Hayashi et al., 2007; Rivilla et al., 2008; Singh and Hemal, 2001; Susco et al., 2008).

Treatment

Treatment of urethral calculi depends on the location within the urethra and the distance from the internal or the external urethral meatus, stone characteristics, the ability of the stone to get pushed into the bladder, and associated structural abnormalities of the urethra, if any. Stones located in the posterior urethra can be pushed back into the bladder for ESWL or intracorporeal fragmentation with mechanical or electrohydraulic lithotripsy. Shockwave lithotripsy after pushback has been reported in the literature and widely followed in the past, albeit with a success rate of only 60% and residual stones (El-Sharif and Prasad, 1995). Intracorporeal laser lithotripsy is least traumatic to the mucosa and has a guaranteed success rate of 85% to 90% (Kamal et al., 2004; Verit et al., 2006). Few authors have innovated with the Microperc armamentarium for fragmenting the urethral calculi (Desai and Ganpule, 2017). It is less traumatic to the urethra, easier to handle because it is less bulky, and has its own learning curve; it still remains to be seen if it can give equivalent success rates. For stones that do not get pushed back into the bladder, in situ fragmentation using laser or pneumatic lithotripsy should be undertaken. Open cystolithotomy remains the last option in the event of failure of endourologic maneuvers (Kamal et al., 2004).

For stones in the anterior urethra, pushback into the bladder is hardly ever possible and is not to be attempted. The distance of the stone from the external meatus and the surface characteristics of the stone are the factors to be considered before contemplating treatment options. Milking the stone out from the meatus is an option, but caution regarding urethral injury should be exercised (Kamal et al., 2004). This should be attempted only for smooth-surfaced stones because the risk of urethral injury with milking is not known (Maheshwari and Shah, 2005). If the stone is large or the surface is rough and irregular, extraction by milking is to be condemned. Few authors have noted success with simple instillation of lidocaine jelly into the urethra for small distal stones (El-Sharif and El-Hafi, 1991; Kamal et al., 2004). In situ lithotripsy is feasible using either electrohydraulic or Swiss lithoclast with a success rate of up to 80% (Kamal et al., 2004). Concerns regarding urethral damage exist and have been offset with the use of Holmium laser lithotripsy (Fig. 95.2; Kamal et al., 2004; Koh et al, 1999; Maheshwari and Shah, 2005; Verit et al., 2006).

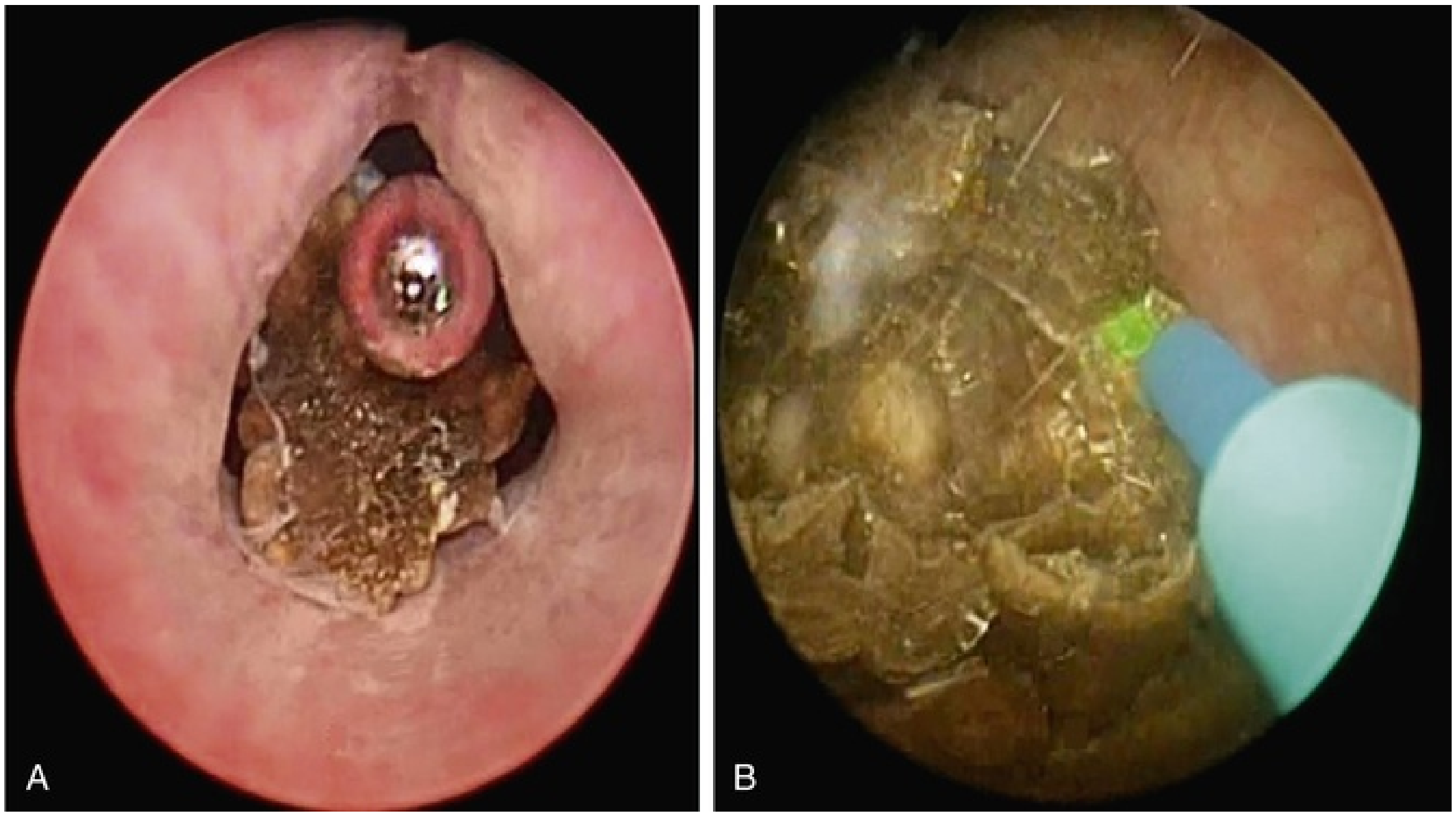

FIG. 95.2 Urethral calculi: diagnosis and management. (A) Cystourethroscopic view of a calculus impacted at the bulbomembranous junction. (B) The stone being fragmented with laser.

For stones located in the fossa navicularis and distal urethral stones, manipulation with a forceps under anesthesia is successful. A ventral meatotomy helps in controlled removal of the stone and actually reduces urethral trauma. For larger and more proximal anterior urethral stones, urethrotomy and stone extraction is advocated. When complicated by urethral stricture or urethra-cutaneous fistula, simultaneous or staged repair should be undertaken (Kamal et al., 2004; Singh and Hemal, 2001). Stones within the diverticula are usually treated with incision of the diverticulum and stone extraction. Diverticulectomy and urethral repair is usually required and can be done either in a same sitting or in a staged fashion (Maheshwari and Shah, 2005; Singh and Neogi, 2006; Subbarao et al., 1998).

Unusual Lower Tract Urolithiasis

Preputial Calculi

These commonly occur in adults (Sharma and Bapna, 1977). The common factors associated are severe phimosis along with poor hygiene and low socioeconomic status (Ellis et al., 1986). The possible causes for preputial stones are inspissation of the smegma, stasis, and resultant precipitation of salts. There can be a combination of factors (Ellis et al., 1986; Winsbury-White, 1954). The accumulated smegma initiates a vicious cycle, which in turn leads to severe phimosis as a result of scarring and inflammation (Mohapatra and Kumar, 1989). A few other unusual mechanisms for causation of preputial calculi are foreign bodies, suture material (Ellis et al., 1986), and extruded bladder calculi (Nagata et al., 1999; Williamson, 1932).

In all the cases, the presentation is lower urinary tract symptoms, most commonly difficulty in passing urine. Other symptoms include dysuria, hematuria, foul-smelling urine, and palpable swelling or calculi (Ellis et al., 1986; Mohapatra and Kumar, 1989; Sharma and Bapna, 1977; Williamson, 1932). Occasional presentation can be urinary retention (Shahi and Ram, 1962). On examination tight phimosis is encountered (Shahi and Ram, 1962; Sharma and Bapna, 1977). If any associated lymphadenopathy is detected, an imaging study may include plain radiography and, if required, CT imaging (Mohapatra and Kumar, 1989; Nagata et al., 1999).

The treatment of preputial calculi involves removal of calculi and the inciting cause. In most cases this requires circumcision and dorsal slit (Shahi and Ram, 1962; Williamson, 1932). The excised skin should be sent for histopathology (Ellis et al., 1986). The calculi are typically multiple, smooth, and rounded, and the commonest stone composition is ammonium magnesium phosphate (Shahi and Ram, 1962; Williamson, 1932).

Prostatic Calculi

In the 19th century, a correlation between the presence of prostatic calculi and pathogenesis of lower urinary tract symptoms was identified (Huggins et al., 1944; Klimas et al., 1985; Moore, 1936; Thomas et al., 1927). With a more widespread use of transrectal ultrasonography for prostatic illnesses, more and more prostatic calculi are identified, 99% of asymptomatic adult men were identified in one study with some degree of prostatic calcification in autopsy studies (Sondergaard et al., 1987).

Etiopathogenesis and Composition.

Prostatic calculi can be either prostatic urethral calculus or true prostatic calculi (within the prostate). Prostatic urethral calculus is always migratory and should be managed as any other urethral calculi. True prostatic calculi can be either primary/endogenous (occurring within the acini of the prostate) or secondary/exogenous (reflux of urine into the prostate). The majority of prostatic calculi are composed of calcium phosphate (83%), calcium carbonate phosphate (8.7%), calcium oxalate (4.5%), and mixed calcium stones (4.4%) (Dessombz et al., 2012). Exogenous calculi are caused by reflux of urine and therefore they are fewer in number and larger than primary calculi.

Clinical Presentation.

There is a increased prevalence of prostatic calculi in patients with pathologically proven benign prostatic hyperplasia. Different authors report different associations between them, ranging from 40% to 70% (Harada et al., 1979; Kim et al., 2009; Lee et al., 2003; Shoskes et al., 2007). There is no increase in incidence of prostatic carcinoma in patients with prostatic calculi. Indeed, a focused evaluation of areas of calcification/calculi has shown no correlation with the sites of adenocarcinoma (Muezzinoglu and Gurbuz, 2001).

Patients with at least one symptom of prostatitis are 3.2 times more likely to harbor a significant prostatic calculus than the age-matched asymptomatic group, and the size rather than the number of stones that correlated with the symptoms (Geramoutsos et al., 2004). Most studies suggest that prostatic calculi are common in patients with chronic pelvic pain syndrome (CPPS) and are associated with greater inflammation and symptoms (Shoskes et al., 2005, 2007). Moreover, patients with prostatic calculi are more likely to grow *E. coli, Klebsiella,* and other gram-negative pathogens on cultures and exhibit more white blood cells in expressed prostatic secretions (Shoskes et al., 2007). Other authors have found no conclusive evidence between prostatic infection, inflammation, and prostatic calculi (Sondergaard et al., 1987).

Evaluation and Management.

Prostatic calculi are identified primarily with the use of transrectal ultrasonography (TRUS) in the evaluation of lower urinary tract symptoms (LUTS) or prostatomegaly. Ultrasonography-based classification exists for prostatic calculi based on echo pattern in ultrasonography: type A, discrete and multiple small echoes evenly distributed throughout the gland, and type B, coarser and larger, but focal echoes (Harada et al., 1979). **Plain x-ray film shows calculi in 14% of patients** (Fig. 95.3). The role of CT and MRI is not clear. Apart from the use of TRUS, imaging has a limited role in the identification of calculi.

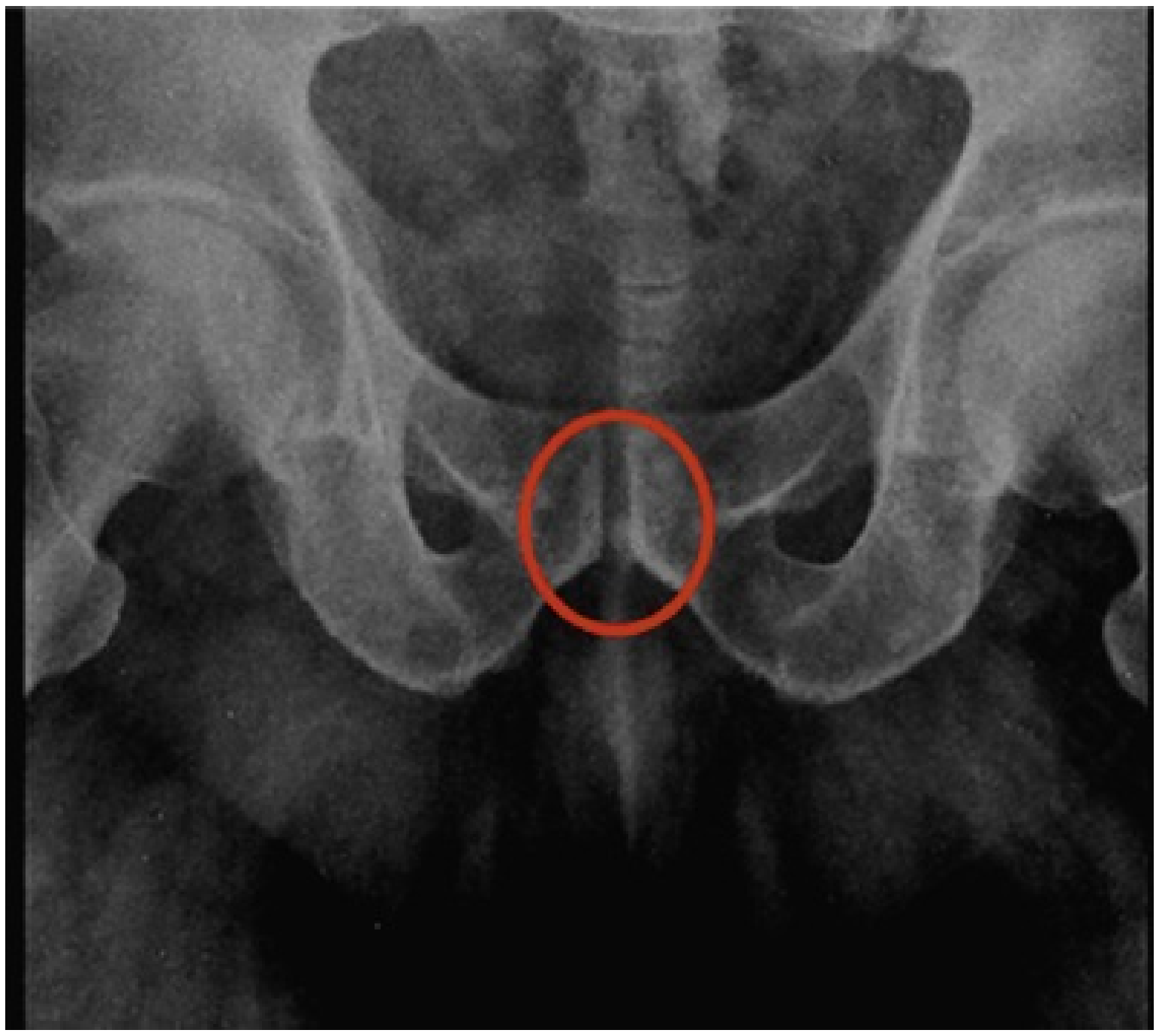

FIG. 95.3 Plain x-ray showing a prostatic urethral calculus. A plain x-ray of the pelvis in a patient with recent onset lower urinary tract symptoms depicts the urethral stone.

Prostatic calculi identified during transurethral resection of prostate require removal during the procedure using the endoloop; these patients have more symptomatic relief with removal of these calculi compared with those in whom they were not removed (Jeon et al., 2005). They also serve as a surrogate marker for the capsule during the transurethral resection.

Key Points

- Primary bladder calculi are most common in children younger than the age of 10 with a peak incidence at 2 to 4 years. The disease is much more common in boys than in girls.
- The most common presentation of bladder stones is hematuria with lower urinary tract symptoms.
- Children with bladder stones often experience abdominal discomfort, dysuria, frequency, and hematuria.
- Pulling the penis, in children, is considered pathognomonic of bladder stone.
- The options for treatment of bladder stones are medical management,

extracorporeal shock wave lithotripsy, transurethral lithotripsy, suprapubic cystolithotomy, suprapubic cystolithotripsy, and open surgery.

- The advantages of percutaneous approach in bladder stones are safety and efficacy and potential lesser risk to the urethra.
- Urethral calculi amount to 0.3% to 1% of all stone disease, and obstructing urethral calculus is a very rare presentation of lower urinary tract urolithiasis.
- More commonly urethral calculi patients present with acute painful retention of urine from sudden impaction of the stone.
- Patients with at least one symptom of prostatitis are 3.2 times more likely to harbor a significant prostatic calculus than the age-matched asymptomatic group.
- The common factors associated with preputial calculi are severe phimosis, poor hygiene, and low socioeconomic status.
- Plain x-ray film shows calculi in 14% preputial calculi in patients.

Suggested Readings

Phillippou P, Moraitis K, Massod J, et al. The management of bladder lithiasis in the modern era endourology. *Urology*. 2012;79:980–986.

Schwartz BF, Stoller ML. The vesical calculus. *Urol Clin North Am*. 2000;27:333–346.

References

Aegukkatajit S. Reduction of urinary stone in children from north-eastern Thailand. *J Med Assoc Thai*. 1999;82(12):1230–1233.

Ali SH, Rifat UN. Etiological ad clinical patterns of childhood urolithiasis in Iraq. *Pediatr Nephrol*. 2005;20:1453–1457.

Amin HA. Urethral calculi. *Br J Urol*. 1973;45:192–195.

Andersen DA. The nutritional significance of primary bladder stones. *Br J Urol*. 1962;34:160–177.

Anderson A. Recently discovered mediaeval bladder stone from Norwich, with a review of British archaeological bladder stones and documentary evidence for their treatment. *BJU Int*. 2001;88:351–354.

Arif H, Madbouly K, Mahran MR, et al. A prospective randomized study comparing absorbable and nonabsorbable staples in constructing antireflux valves of urethral hemi-Kock pouches. *BJU Int*. 1999;84:440–443.

Ashworth M. Endemic bladder stones. *BMJ*. 1990;301:826–827.

Asper R. Epidemiology and socioeconomic aspects of urolithiasis. *Urol Res*. 1984;12:1–5.

Assimos DG. Nephrolithiasis in patients with urinary diversion. *J Urol*. 1996;155:69–70.

Atikeler MK, Yüzgeç V, Geçit I, et al. Urethral stone street. *Int Urol Nephrol*. 2005;37:315.

Aus G, Bergdahl S, Hugosson J, et al. Stone formation in the prostatic urethra after cryotherapy for prostate cancer. *Urology*. 1997;50:615–617.

Beatrice J, Strebel RT. Giant calculi in urethral diverticula. *Can Med Assoc J*. 2008;178:994.

Beiko DT, Razvi H. Stones in urinary diversions: update on medical and surgical issues. *Curr Opin Urol*. 2002;12:297–303.

Bhatia V, Bhayani CS. Open surgery versus cystolithotripsy versus extracorporeal shock wave lithotripsy. *J Urol*. 1994;151:660–662.

Blyth B, Ewalt DH, Duckett JW, et al. Lithogenic properties of enterocystoplasty. *J Urol*. 1992;148:575–577.

Boyd SD, Everett RW, Schiff WM. Fugelso PD. Treatment of unusual Kock pouch urinary calculi with extracorporeal shock wave lithotripsy. *J Urol*. 1988;139:805–806.

Bruce AW, Reid G, Chan RCV, et al. Bacterial adherence in the human ileal conduit: a morphological and bacteriological study. *J Urol*. 1984;132:184–188.

Burr RG, Chem C. Nuseibeh I. Creatinine, calcium, citrate and acid-base in spinal cord injured patients. *Paraplegia*. 1993;31:742–750.

Chen Y, DeVivo MJ, Lloyd LK. Bladder stone incidence in persons with spinal cord injury: determinants and trends, 1973-1996. *Urology*. 2001;58:665–670.

Chow S. Urinary incontinence secondary to vaginal pessaries. *Urology*. 1997;49:458.

Cumming GP. An unusual case of cystolithiasis: a urological lesson for gynaecologists. *Br J Obstet Gynaecol*. 1997;104:117.

Delakas D, et al. Experience with Dornier lithotripter MPL 900-X for treatment of vesical lithiasis. *Int Urol Nephrol*. 1998;30:703–712.

Derry P, Nuseibeh I. Vesical calculi formed over a hair nidus. *Br J Urol*. 1997;80:965.

Desai MR, Ganpule AP. Miniaturized percutaneous nephrolithotomy: a decade of paradigm shift in percutaneous renal access. *Eur Urol*. 2017;72(2):236–237.

Dessombz A, Méria P, Bazin D, et al. Prostatic stones: evidence of a specific chemistry related to infection and presence of bacterial imprints. *PLoS ONE*. 2012;7:e51691.

DeVivo MJ. The risk of bladder calculi in patients with spinal cord injuries. *Arch Int Med*. 1985;145:428.

Douenias E, Rich M, Badlani G, et al. Predisposing factors in bladder calculi: review of 100 cases. *Urology*. 1991;37:240–243.

Ehrenpreis MD, Alarcon JA. Firfer R. Case profile: large bladder calculus postcervical cerclage. *Urology*. 1986;27:366–367.

Ellis DJ, Siegel AL, Elder JS, et al. Preputial calculus, a case report. *J Urol*. 1986;136:464–465.

Ellis H. A history of bladder stone. *J Royal Med*. 1979;72:248–251.

El-Sharif AE, El-Hafi R. Proposed new method for nonoperative treatment of urethral stones. *J Urol*. 1991;146:1546–1547.

El-Sharif AE, Prasad K. Treatment of urethral stones by retrograde manipulation and extracorporeal shock wave lithotripsy. *Br J Urol*. 1995;76:761–764.

Frabboni R. Echo guided SWL of vesical stones with Dornier MPL9000 lithotriptors in obstructed and unobstructed patients. *J Endourol*. 1998;12:81–86.

Franzoni DF, Decter RM. Percutaneous vesicolithotomy: an alternative to open bladder surgery in patients with an impassable or surgically ablated urethra. *J Urol*. 1999;162:777–778.

Gallo AG, Sepúlveda JPV, Montes MSM. Giant lithiasis in a female urethral diverticulum. *Eur Urol*. 2007;51:556–558.

Gentle DL, et al. Protease inhibitor induced urolithiasis. *Urology*. 1997;50:508.

Geramoutsos I, Gyftopoulos K, Perimenis P, et al. Clinical correlation of prostatic lithiasis with chronic pelvic pain syndromes in young adults. *Eur Urol*. 2004;45:333–337.

Grasso M. Experience with the holmium laser as an endoscopic lithotrite. *Urology*. 1996;48:199.

Guha P, Vaze D, Rao KLN. Rectal impalement presenting as bladder stones: delayed and unusual presentation. *J Pediatr Urol*. 2012;8:4–6.

Hahnfeld L, Nakada S, Sollinger H, et al. Endourologic therapy of bladder calculi in simultaneous kidney–pancreas transplant recipients. *Urology*. 1998;51:404.

Hall MK. Renal calculi in spinal cord injured patient: association with reflux, bladder stone and foley catheter drainage. *Urology*. 1989;34:126.

Harada K, Igari D, Tanahashi Y. Gray scale transrectal ultrasonography of the prostate. *J Clin Ultrasound*. 1979;7:45–49.

Hayashi Y, Yasui T, Kojima Y, et al. Management of urethral calculi associated with hairballs after urethroplasty for severe hypospadias. *Int J Urol*. 2007;14:161–163.

Hegele A, Olbert P, Wille S, et al. Giant calculus of the posterior urethra following recurrent penile urethral stricture. *Urol Int*. 2002;69:160–161.

Hensle TW, Bingham J, Lam J, et al. Preventing reservoir calculi after augmentation cystoplasty and continent urinary diversion: the influence of an irrigation protocol. *BJU Int*. 2004;93:585–587.

Herr HW. “Cutting for the stone”: the ancient art of lithotomy. *BJU Int*. 2008;101:1214–1216.

Hertzig LL, Iwaszko MR, Rangel LJ, et al. Urolithiasis after ileal conduit urinary diversion: a comparison of minimally invasive therapies. *J Urol*. 2013;189:2152–2157.

Hollander JB. Triamterine bladder calculus. *Urology*. 1987;30:154.

Hubscher CP, Costa J. Percutaneous intervention of large bladder calculi in neuropathic voiding dysfunction. *Int Braz J Urol*. 2011;37:636–641.

Huggins C, Bear RS. The course of the prostatic ducts and the anatomy, chemical and x-ray diffraction analysis of prostatic calculi. *J Urol*. 1944;51:37–47.

Hussain I. Primary extracorporeal shock wave lithotripsy in management of large bladder calculi. *J Endourol*. 1994;8:183–186.

Ikari O, Netto NR Jr, D'Ancona CAL, et al. Percutaneous treatment of bladder stones. *J Urol*. 1993;149:1499–1500.

Isen K, Em S, Kilic V, et al. Management of bladder stones with pneumatic lithotripsy by using a ureteroscope in children. *J Endourol*. 2008;22:1037–1040.

Jeon HJ, Chung HC, Song JM. Effects of residual prostatic calculi on lower urinary tract symptoms after transurethral resection of prostate. *Korean J Urol*. 2005;46:569–573.

Kamal BA, Anikwe RM, Darawani H, et al. Urethral calculi: presentation and management. *BJU Int*. 2004;93:549–552.

Kaplan M, Atakan IH, Kaya E, et al. Giant prostatic urethral calculus associated with urethrocutaneous fistula. *Int J Urol*. 2006;13:643–644.

Khoury AE, Salomon M, Doche R, et al. Stone formation after augmentation cystoplasty: the role of intestinal mucus. *J Urol*. 1997;158:1133–1137.

Kilciler M, Sumer F, Bedir S, et al. Extracorporeal shock wave lithotripsy treatment in paraplegic patients with bladder stones. *Int J Urol*. 2002;9:632–634.

Kim H, Cheigh J, Ham H. Urinary stones following renal transplantation. *Kor J Int Med*. 2001;16:118.

Kim SH, Jung KI, Lee BH, et al. Relations between prostatic calculi and lower urinary tract symptoms of benign prostatic hyperplasia. *J Korean Cont Soc*. 2009;13:30–36.

Klein FA, Goldman MH. Vesical calculus: an unusual complication of renal transplantation. *Clin Transplant*. 1997;11:10–12.

Klimas R, Bennett B, Gardner WA Jr. Prostatic calculi: a review. *Prostate*. 1985;7:91–96.

Koh CJ, De Filippo RE, Bochner BH, et al. Extensive bladder and urethral calculi detected with computerized tomography: diagnosis and management. *J Urol*. 1999;162:158.

Kohler-Ockmore J, Feneley RC. Long-term catheterization of the bladder: prevalence and morbidity. *Br J Urol*. 1996;77:347–351.

Kostakopoulos A, Stavropoulos NJ, Makrichoritis C, et al. Extracorporeal shock wave lithotripsy monotherapy for bladder stones. *Int Urol Nephrol*. 1996;28:157–161.

Kronner KM, Casale AJ, Cain MP, et al. Bladder calculi in the pediatric augmented bladder. *J Urol*. 1998;160:1096–1098.

Larkin GL, Weber JE. Giant urethral calculus: a rare cause of acute urinary retention. *J Emerg Med*. 1996;14:707–709.

Leapman MS, Stock RG, Stone NN, et al. Findings at cystoscopy performed for cause after prostate brachytherapy. *Urology*. 2014;83:1350–1355.

Lee SE, Ku JH, Park HK, et al. Prostatic calculi do not influence the level of serum prostate specific antigen in men without clinically detectable prostate cancer or prostatitis. *J Urol*. 2003;170:745–748.

L'Esperance JO, Sung J, Marguet C, et al. The surgical management of stones in patients with urinary diversions. *Curr Opin Urol*. 2004;14:129–134.

Lipke M, Schlusinger D, Sheynkin Y, et al. Endoscopic treatment of bladder calculi in post-renal transplant patients: a 10-year experience. *J Endourol*. 2004;18:787–790.

Maheshwari PN, Shah HN. In-situ holmium laser lithotripsy for impacted ureteral calculi. *J Endourol*. 2005;19:1009–1011.

Menon M, Martin IR. Urinary lithiasis: etiology, diagnosis, and medical management. Walsh PC, Retik AB, Vaughan ED, et al. *Campbell's urology*. 8th ed. Saunders: Philadelphia; 2002:3288–3289.

Millan Rodrigues F, et al. Treatment of bladder stones without associated prostatic surgery: results of a prospective study. *Urology*. 2005;66:505–509.

Miller DC. Percutaneous nephrolithotomy using the laparoscopic entrapment sac. *Urology*. 2003;62:333–336.

Miller JI, Clark RL, Jennings CE, et al. Anastomotic stricture with foreign body reaction and stone formation following radical retropubic prostatectomy. *Urology*. 1992;39:417–419.

Miyazawa K, Matoba M, Minato H, et al. Seed migration after transperineal prostate brachytherapy with I123 free seeds: analysis of its risk factors. *Jpn J Radiol*. 2012;30:635–641.

Mohapatra TP, Kumar S. Concurrent preputial calculi and penile carcinoma—a rare association. *Postgrad Med J*. 1989;65:256–257.

Moore RA. Morphology of prostatic corpora amylacea and calculi. *Arch Pathol*. 1936;22:22–40.

Muezzinoglu B, Gurbuz Y. Stromal microcalcification in prostate. *Malays J Pathol*. 2001;23:31–33.

Naftchi NE, Viau AT, Sell GH, et al. Mineral metabolism in spinal cord injury. *Arch Phys Med Rehabil*. 1980;61:139.

Nagata D, Sasaki S, Umemoto Y, et al. Prepucial calculi. *BJU Int*. 1999;83:1076–1077.

Okeke Z, Shabsigh A, Gupta M. Use of Amplatz sheath in male urethra during cystolitholapaxy of large bladder calculi. *Urology*. 2004;64:1026–1027.

Ord J, Lunn D, Reynard J. Bladder management and risk of bladder stone formation in spinal cord injured patients. *J Urol*. 2003;170:1734–1737.

Parladidius N, Tsiamis C, Diamantis A, et al. Methods of lithotripsy in ancient Greece and Byzantium. *J Urol*.

2007;178:1182–1183.

Peabody Christopher, Mailhot Thomas, Perera Phillips. Ultrasound diagnosis of urethral calculi. *West J Emerg Med*. 2012;13(6):515 [*PMC*. Web. 11 Feb. 2018].

Phillippou P, Moraitis K, Masood J, et al. The management of bladder lithiasis in the modern era endourology. *Urology*. 2012;79:980–986.

Rattan KN, Bhatia V, Ratan SK, et al. Catheterless and drainless open suprapubic cystolithotomy in children: a safe procedure. *Pediatr Surg Int*. 2006;22:255–258.

Razvi HA, Song TY, et al. Management of vesical calculi: comparison of lithotripsy devices. *J Endourol*. 1996;10:559–563.

Rivilla F, Luis A, Llanos D, et al. Giant urethral calculus in a 6-year-old-girl. *J Pediatr Urol*. 2008;4:469–471.

Robertson WG, Woodhouse CRJ. Metabolic factors in the causation of urinary tract stones in patients with enterocystoplasties. *Urol Res*. 2006;34:231–238.

Sathaye UV. Per-urethral endoscopic management of bladder stones: does size matter? *J Endourol*. 2003;17:511–513.

Scheidler DM, Foster RS, Bihrle R, et al. Anastomotic suture granuloma following radical retropubic prostatectomy. *J Urol*. 1990;143:133–134.

Schwartz BF, Stoller ML. The vesical calculus. *Urol Clin North Am*. 2000;27:333–346.

Selli C, Barbagli G, Carini M, et al. Treatment of male urethral calculi. *J Urol*. 1984;132:37–42.

Seltzer LG, Fischer WW, Miller SZ. Pediatric bladder outlet obstruction due to urethral calculus: case report and review of the literature. *Pediatr Radiol*. 1993;23:549–550.

Shahi UN, Ram I. Preputial calculi. *BMJ*. 1962;23:1738–1739.

Shamsa A, Kajbafzadeh AM, Parizadeh SMJ, et al. Aphallia associated with urethro-rectal fistula and stones in the bladder and urethra. *Saudi J Kidney Dis Transpl*. 2008;19:435–438.

Shanmugam TV, Dhanapal V, Rajaraman T, et al. Giant urethral calculi. *Hosp Med*. 2000;61:582.

Sharfi AR. Presentation and management of urethral calculi. *Br J Urol*. 1991;68:271–275.

Sharma SK, Bapna BC. Preputial calculi. *Int Surg*. 1977;62:553–554.

Shattock SG. A prehistoric or predynastic Egyptian calculus. *Trans Pathol Soc Lond*. 1905;56:275.

Shoskes DA, Thomas KD, Gomez E. Anti-nanobacterial therapy for men with chronic prostatitis/chronic pelvic pain syndrome and prostatic stones: preliminary experience. *J Urol*. 2005;173:474–477.

Shoskes DA, Lee CT, Murphy D, et al. Incidence and significance of prostatic stones in men with chronic prostatitis/chronic pelvic pain syndrome. *Urology*. 2007;70:235–238.

Singh I, Hemal AK. Recurrent urethral hairball and stone in a hypospadiac: management and prevention. *J Endourol*. 2001;15:645–647.

Singh I, Neogi S. Male anterior urethral diverticula with Cobb's collar and a giant stone. *J Postgrad Med*. 2006;52:73–74.

Smith JM, O'Flynn JD. Vesical stone: the clinical features of 652 cases. *Ir Med J*. 1975;22:85–89.

Sondergaard G, Vetner M, Christensen PO. Prostatic calculi. *Acta Pathol Microbiol Immunol Scand [A]*. 1987;95:141–145.

Steinmetz R, Barrett W. Urethral stone formation after permanent radioactive seed implant for prostate cancer. *Am J Clin Oncol*. 2006;29:424–425.

Subbarao P, Lal R, Bhatnagar V, et al. Multiple urethral calculi in children: report of two cases. *Jpn J Surg*. 1998;28:1210–1212.

Sugimura T, Arnold E, English S, et al. Chronic suprapubic catheterization in the management of patients with spinal cord injuries: analysis of upper and lower urinary tract complications. *BJU Int*. 2008;101:1396–1400.

Susco BM, Perlmutter AE, Zaslau S, et al. Female urethral diverticulum containing a calculus: a case report. *WV Med J*. 2008;104:15–16.

Takasaki E. A four year retrospective study of urolithiasis. *Dokkyo J Med Sci*. 1979;6:120.

Tan YK, Gupta DM, Weinberg A, et al. Minimally invasive percutaneous management of large bladder stones with laparoscopic entrapment bag. *J Endourol*. 2014;28:61–64.

Teichman JMH, Rogenes VJ, McIver BJ, et al. Holmium:yttrium-aluminum garnet laser cystolithotripsy of large bladder calculi. *Urology*. 1997;50:44–48.

Teotia M, Teotia SPS. Paediatric nephrolithiasis. Livingstone: Edinburg; 1990:44–48. Wickham JEA, Buck AC. *Renal tract stone: metabolic basis and clinical practice*. vol 50.

Terai A, Arai Y, Kawakita M, et al. Effect of urinary intestinal diversion on urinary risk factors for urolithiasis. *J Urol*. 1995;153:37–41.

Thalut K, Rizal A, Brocki JG, et al. The endemic bladder stone of Indonesia—epidemiology and clinical features. *Br J Urol*. 1976;48:617–621.

Thomas BA, Robert JT. Prostatic calculi. *J Urol*. 1927;18:470–493.

Thomas R, Lee S, Salvatore F, et al. Direct percutaneous pouch cystostomy with endoscopic lithotripsy for calculus in a continent urinary reservoir. *J Urol*. 1993;150:1235–1237.

Trinchieri A. Epidemiology of urolithiasis: an update. *Clin Cases Miner Bone Metab*. 2008;5(2):101.

Tugcu V, Polat H, Ozbay B, et al. Stone formation from intravesical hem-o-lok clip migration after laparoscopic radical prostatectomy. *J Endourol*. 2009;23(7):1111–1113.

Turk TMT, Koleski FC, Albala DM. Incidence of urolithiasis in cystectomy patients after intestinal conduit or continent urinary diversion. *World J Urol*. 1999;17:305–307.

Valyasevi A, Van Reen R. Pediatric bladder stone disease: current status of research. *J Pediatr*. 1968;72:546–553.

Van Reen R. Idiopathic urinary bladder stones of childhood. *Aust NZ J Surg*. 1980;50:18–22.

Verit A, Savas M, Ciftci H, et al. Outcomes of urethral calculi patients in an endemic region and an undiagnosed primary fossa navicularis calculus. *Urol Res*. 2006;34:37–40.

Williamson TV. Phimosed preputial sac serving as adventitious urinary reservoir. *J Am Med Assoc*. 1932;99:831.

Winsbury-White HP. Preputial calculi. Winsbury-White HP. *Stone in urinary tract*. ed 2. Mosby: St Louis; 1954:305–308.

PART XI

Neoplasms of the Upper Urinary Tract

OUTLINE

96 Benign Renal Tumors
97 Malignant Renal Tumors
98 Urothelial Tumors of the Upper Urinary Tract and Ureter
99 Surgical Management of Upper Urinary Tract Urothelial Tumors
100 Retroperitoneal Tumors
101 Open Surgery of the Kidney
102 Laparoscopic and Robotic Surgery of the Kidney
103 Nonsurgical Focal Therapy for Renal Tumors
104 Treatment of Advanced Renal Cell Carcinoma

Benign Renal Tumors

William P. Parker MD, Matthew T. Gettman MD

Benign renal tumors are an ever-increasing (because of routine axial imaging) and common entity in the urology clinic because of the widespread use of abdominal imaging (Murphy et al., 2009; Patard, 2009). Even among suspected renal cell carcinoma (RCC) cases, 20% of resected masses are benign (Kutikov et al., 2006). As such, benign masses represent a clinically significant and heterogeneous collection of pathologic conditions. These include the simple renal cyst, selected complex renal cysts, oncocytomas, angiomyolipomas (AMLs), cortical and metanephric adenomas, mixed epithelial-stromal tumors, the rarer cystic nephroma, leiomyoma, and other, rarer tumors.

Management of these lesions is based on the perceived risk of RCC, and can vary widely, from no management for the simple renal cyst to selective embolization for larger AMLs and surgical extirpation for solid renal masses. In addition, as the American Urological Association guidelines recognize, renal mass biopsy may have a role in decision making for small renal masses (Campbell et al., 2009), which has been shown to potentially reduce the need for intervention in a significant proportion of patients with benign histology (Richard et al., 2015).

Diagnosis

When symptoms are present, common symptoms are flank pain, a palpable mass, and hematuria; however, most diagnoses result from an incidental renal mass. Although the initial identification of a benign mass is through imaging, such as ultrasonography, computed tomography (CT), or magnetic resonance imaging (MRI), these modalities are imperfect in their identification of benign histology (Canvasser et al., 2017; Gordetsky and Zarzour, 2016; Monn et al., 2015; Pierorazio et al., 2013). Certainly there are clues to a benign entity, such as thin, unenhanced walls in simple cyst disease or macroscopic fat in an AML; however, these are not universal and therefore most diagnoses are made at biopsy or resection. Additional clues to the diagnosis of benign histology include smaller mass size, lack of growth in serial imaging, female sex, and older age; however, none except for lack of growth over time, can reliably rule out malignancy (Ambani et al., 2016; Lane et al., 2007; Pierorazio et al., 2016; Snyder et al., 2006).

In this chapter the most common benign entities are reviewed with specific focus on their cause, diagnosis, and management.

Renal Cysts

Epidemiology, Etiology, and Pathophysiology

Renal cysts are by far the most common benign entity encountered in the kidney. **Up to 10% of the population may harbor a renal cyst, with putative risk factors of increasing age, male gender, hypertension, and worsening renal function** (Terada et al., 2004). Renal cysts can be sporadic, acquired, or genetic in their origin. However, beyond their associations with a cause, phenotypically renal cysts are similar. Mechanistically, genetic renal cyst disease is the most well-described cause of renal cyst disease through autosomal dominant polycystic kidney disease (ADPKD) and autosomal recessive polycystic kidney disease (ARPKD).

ADPKD is an inherited renal cystic disease related to alterations in cilia function (ciliopathies); primarily through mutation of *PKD1* and *PKD2*. *PKD1* (polycystin-1) is on the short arm of chromosome 16 and is highly complicated gene that is predisposed to recombination error and thus spontaneous mutation. *PKD2* (polycystin-2) is on the long arm of chromosome 4, and by contrast, is less complicated than *PKD1*. **Together, polycstin-1 and polycystin-2 form a transmembrane complex that is hypothesized to function as a mechanosensor to the flow of urine (through the cilia), regulating intracellular calcium levels based on this flow. Reductions in intracellular calcium levels result in amplification of cyclic adenosine monophosphate levels that upregulate downstream effectors, giving rise to the typical cystic epithelial histology** (Abdul-Majeed and Nauli, 2011; Casuscelli et al., 2009; Rangan et al., 2015). The process by which cysts in ADPKD develop was initially described in microdissection studies, which demonstrated a progression from a diverticulum on the tubular epithelium that ultimately detaches from the tubule to form a true cyst in the interstitium of the kidney (Rangan et al., 2015). Growth of cysts is asynchronous but persistent and radially oriented, with gradual development of large kidneys, renal insufficiency, and mortality based on growth kinetics (Hateboer et al., 1999; Irazabal et al., 2015). **Diagnosis of ADPKD is based on presentation, with the presence of at least 2 unilateral or bilateral renal cysts before age 30, at least 2 cysts in each kidney between ages 30 and 59, or 4 cysts in each kidney in patients 60 years or older.** In addition, patients with ADPKD tend to develop hepatic and pancreatic cysts

(Grantham, 2008).

Acquired cystic kidney disease (ACKD) is a special circumstance in which renal cyst development is preceded by the development of chronic and end-stage renal disease (Rahbari-Oskoui and O'Neill, 2017). Development of cysts is largely dependent on the length of time on dialysis, with up to 80% of patients developing cysts after 10 years (Matson and Cohen, 1990). **Unlike the cysts in sporadic and genetic renal cyst disease, ACKD is associated with the development of RCC, with almost 7% developing RCC after 10 years of dialysis** (Ishikawa et al., 2003)**. Mechanistically, the cysts of ACKD arise from the proximal convoluted tubule (as in clear cell RCC), unlike the cysts of ADPKD and sporadic renal cyst disease, which arise from the distal tubule** (Liu et al., 2000).

Natural History

The natural history of renal cyst disease varies with the cause. For example, the kidneys of patients with ADPKD increase in size exponentially over time (~5% in total volume per year). This volume expansion is associated with mass effect and reduction in renal function over time (Grantham et al., 2006). Long-term follow-up of ACKD patients demonstrates that renal volumes can increase to three times their native size by 20 years of dialysis, an increase attributed to the growth of renal cysts (Ishikawa et al., 2003). Meanwhile, sporadic renal cysts increase in size and number over time, with an average growth rate of 1.6 mm/year, although notably growth rates decrease with increasing follow-up (Terada et al., 2008).

Evaluation

Most patients with renal cyst disease are diagnosed incidentally. However, patients can experience pain from local expansion, a palpable mass, hematuria, and, in the case of ADPKD, pulmonary symptoms from mass effect in the kidney. Evaluation is through imaging, which can include ultrasonography, CT, or MRI. The goal of imaging in cystic renal disease is evaluation of malignancy risk as defined by increasing complexity. For example, simple renal cysts are characterized by smooth walls, sharp outlines, and the absence of internal echoes on ultrasonography. Meanwhile, on CT and MRI the hallmark of simple cyst disease is the absence of enhancement (Eknoyan, 2009; Helenon et al., 2018).

Although CT and MRI are comparable in most aspects, MRI can help in the evaluation of hyperdense cysts but at the expense of overestimating cyst wall thickness in smaller cysts (Bosniak, 2012).

To aid in the evaluation of renal cyst disease, the Bosniak classification (Table 96.1) **is a commonly used method to characterize cysts and their risk of malignancy** (Bosniak, 1986). The Bosniak system has been reviewed and validated in multiple studies, and a recent meta-analysis confirmed the utility of this system (Schoots et al., 2017). As outlined in the table, Bosniak I and II lesions require no additional follow-up, whereas Bosniak IIF (Fig. 96.1) lesions should have interval imaging. Notably, Bosniak IIF lesions that are stable on repeat imaging have a less than 1% risk of malignancy, whereas those that increase in complexity have an approximately 85% risk of malignancy (Schoots et al., 2017). Conversely, management of Bosniak III/IV lesions is more involved given the higher risk of malignancy.

TABLE 96.1

Bosniak Classification of Renal Cysts

BOSNIAK CLASSIFICATION	IMAGING CHARACTERISTICS	INCIDENCE OF MALIGNANCY	THERAPY
I	Simple cyst with a hairline thin wall that does not contain septa, calcifications, or solid components. It measures water density in Hounsfield units and does not enhance with intravenous administration of a contrast agent.	1.7%	No therapy or follow-up required
II	Cyst may contain a few hairline thin septa and fine calcifications, or a short segment of slightly thickened calcification may be present in the wall or septa. Uniformly high-attenuation lesions <3 cm (so-called *high-density cysts*) are well marginated and do not enhance with intravenous administration of a contrast	18.5%	No therapy or follow-up required

	agent.		
IIF	Cysts may contain multiple hairline thin septa or minimal smooth thickening of their wall or septa. Their wall or septa may contain calcifications that may be thick and nodular, but no measurable contrast enhancement is present. These lesions are typically well marginated. Totally intrarenal nonenhancing high-attenuation renal lesions ≥3 cm are also included in this category.	18.5%	Repeat imaging to assess stability of size and radiographic characteristics
III	"Indeterminate" cystic masses have thickened irregular or smooth walls or septa in which measurable contrast enhancement is present.	33%	Active surveillance, excision, or ablation
IV	Clearly malignant cystic masses can have all the criteria of category III but also contain enhancing soft-tissue components.	92.5%	Excision or ablation

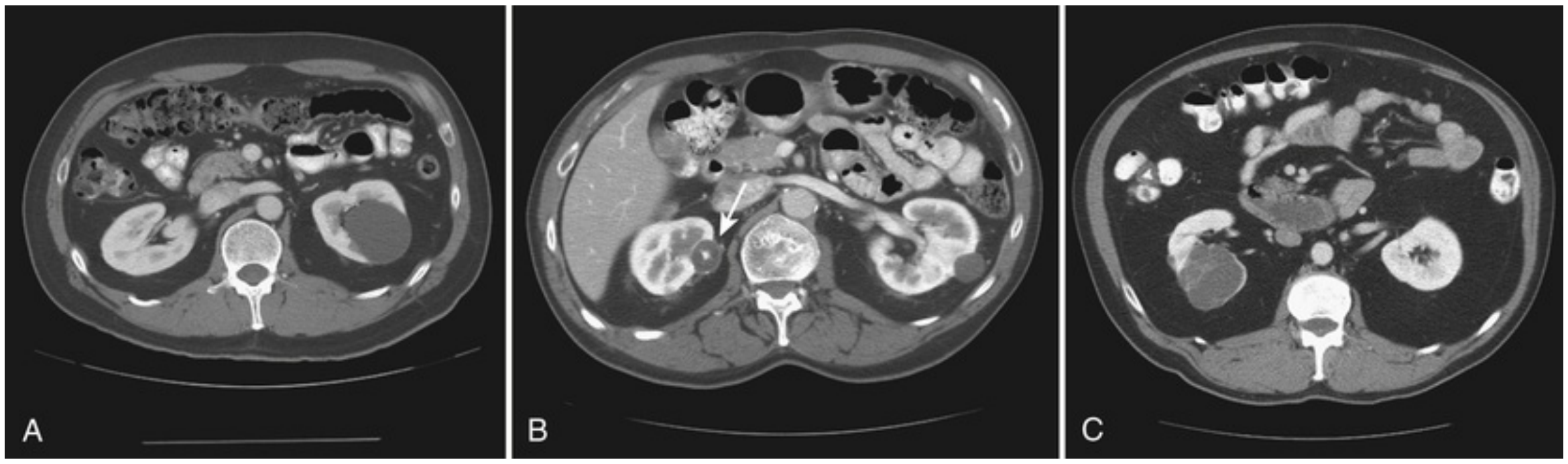

FIG. 96.1 (A) Computed tomography (CT) scan of a Bosniak I renal cyst. (B) CT scan of a Bosniak II renal cyst. Note internal calcification. (C) CT scan of a Bosniak IIF renal cyst. Several thin irregular septations are present within the cyst. (Copyright 2009, C. G. Wood.)

Management Options

The management of renal cyst disease is based on the risk of malignancy and the associated symptoms. **For most simple renal cysts, no additional follow-up is required, with the maximal intervention of serial imaging recommended for Bosniak IIF lesions.** Patients with ACKD and ADPKD should have serial imaging given the risk of malignancy in ACKD and because of the risk of mass effect, cyst infection, and chronic pain in ADPKD (Grantham, 2008; Ishikawa et al., 2003).

Conversely, surgical resection or ablation is recommended for Bosniak III/IV lesions (Fig. 96.2). Renal mass biopsy has been reported to aid in the evaluation; however, it should be limited to cases in which the risk of intervention is high, because the risk of cyst rupture could alter the radiographic anatomy during follow-up and potential seed the retroperitoneum in the case of true malignancy (Bosniak, 2003; Harisinghani et al., 2003). More recently, however, the concept of active surveillance of cystic renal masses (Bosniak III/IV) has been evaluated. Although most Bosniak III/IV lesions are malignant, they are overwhelmingly low grade and small and associated with excellent cancer-specific survival (Chandrasekar et al., 2018; Kashan et al., 2018; Mousessian et al., 2017). When intervention is selected, and given the low malignant potential of these masses, renal preservation through either partial nephrectomy or ablation should be chosen.

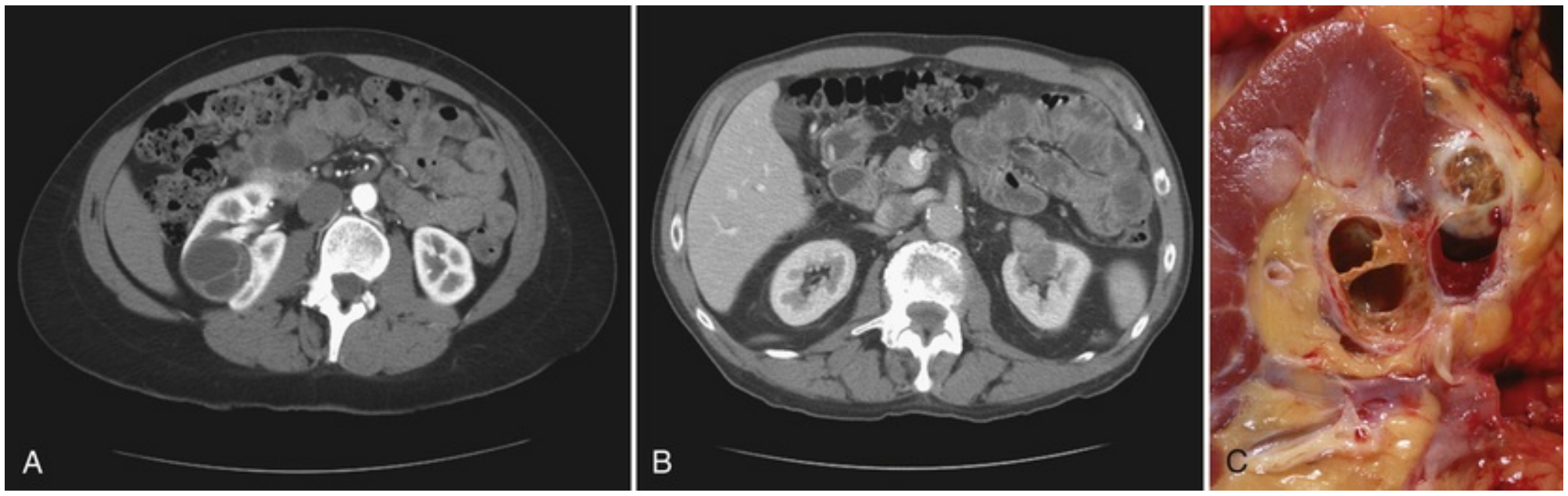

FIG. 96.2 (A) Computed tomography (CT) scan of a Bosniak III renal cyst. Thick, irregular septations are present within the cyst. (B) CT scan of a Bosniak IV renal cyst with a solid enhancing nodule. (C) Bivalved Bosniak IV renal cyst demonstrating a solid component that proved to be conventional renal cell carcinoma. (Copyright 2009, C. G. Wood.)

Outside of malignant risk, occasionally renal cysts require treatment because of local symptoms such as pain, infection, hypertension, hemorrhage, or traumatic cyst rupture (Bas et al., 2015; Lai et al., 2017; Mabillard et al., 2017; Yoder and Wolf, 2004; Zerem et al., 2009). **Management can include aspiration, cyst decortication, cyst resection, sclerotherapy, arterial embolization, and even nephrectomy depending on the cause and symptom** (Grodstein et al., 2017; Lai et al., 2017; Mabillard et al., 2017; Yoder and Wolf, 2004; Zerem et al., 2009). A host of therapies have been used in the setting of ADPKD, including nephrectomy for mass effect and renal denervation for chronic pain (Casteleijn et al., 2017; Grodstein et al., 2017). These are challenging cases, particularly in the setting of chronic pain, and recurrence of symptoms is common. Multidisciplinary care with pain management should be employed as a standard.

Key Points: Renal Cysts

- Renal cyst disease is the most common benign renal tumor.
- ACKD is associated with a significant increase in malignancy risk and should be followed closely.
- Most cysts require no additional follow-up or therapy.
- The Bosniak classification is a useful tool to estimate malignancy risk and direct therapy.

Oncocytoma

Epidemiology and Etiology

Whereas renal cyst disease is the most common benign renal tumor, oncocytoma is the most common benign enhancing renal mass (Frank et al.. 2003). **Up to 25% of renal masses smaller than 3 cm represent oncocytomas, making them a challenging diagnostic entity in clinical practice** (Shuch et al., 2015). Historically, the benignity of oncocytoma has been questioned; however, genetic studies have confirmed it as a benign renal mass, and reports of metastatic disease (extremely rare) are likely cases of eosinophilic chromophobe RCC (Kuroda et al., 2003; Oxley et al., 2007).

Pathophysiology

Pathologically, oncocytoma represents a diagnostic dilemma resulting from overlapping features with eosinophilic chromophobe RCC, succinate dehydrogenase-deficient RCC, and papillary RCC (Wobker and Williamson, 2017). Grossly, these tumors have a mahogany brown surface, similar to the appearance of normal renal parenchyma, with a variably present central scar (Fig. 96.3A). Histologically, these tumors are classically strongly eosinophilic because of the high mitochondrial density (Renshaw, 2002), with nests and tubular structures common, arising from the distal tubule (see Fig. 96.3B). Nuclei tend to be round and regular with extremely rare mitotic figures (Williamson et al., 2017)**. Interestingly, oncocytoma can be associated with perirenal fat invasion and renal vein invasion—findings that carry prognostic significance in RCC but do not in oncocytoma and should not be interpreted as an aggressive pathology** (Hes et al., 2008; Williamson, 2016; Wobker et al., 2016).

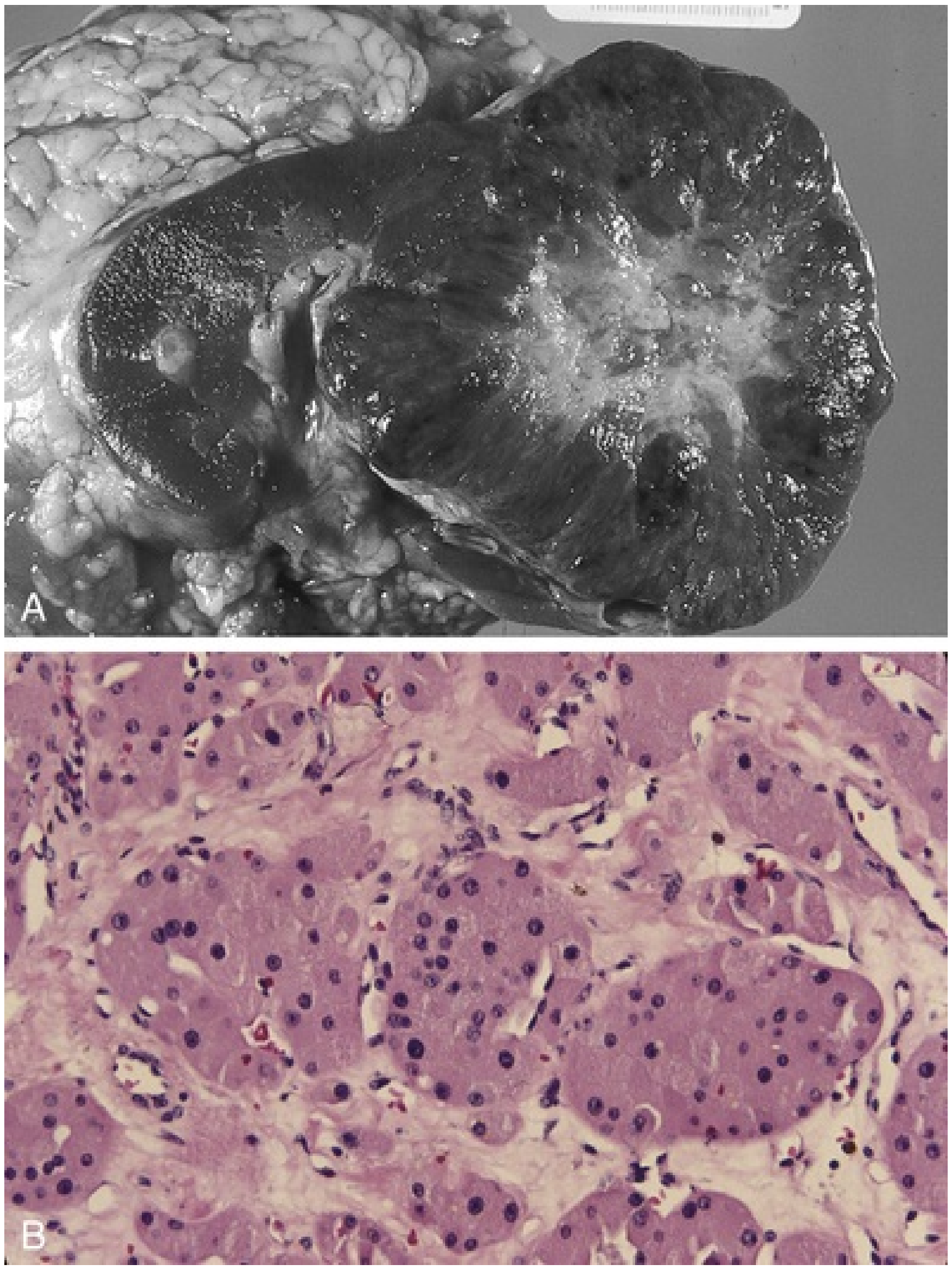

FIG. 96.3 (A) Bivalved renal oncocytoma demonstrating central scar. (B) Oncocytoma with large eosinophilic cells arranged in distinct nests.

When typical features of oncocytoma are present, histology and morphology are sufficient to establish the diagnosis pathologically; however, when morphologic variants are seen, such as the presence of papillary structures or compacted, nested architecture, the International Society of Urologic Pathology (ISUP) recommends use of immunohistochemistry to differentiate oncocytoma from non-benign tumors (such as chromophobe RCC) (Reuter et al., 2014). **In cases in which the diagnostic dilemma is between chromophobe and oncocytoma, cytokeratin-7 (CK7) can be useful. CK7 is rarely positive in oncocytoma, whereas chromophobe RCC tends to be diffusely positive and is recommended by the ISUP to distinguish these entities** (Reuter et al., 2014; Williamson et al., 2017). Other markers used to distinguish include kidney specific cadherin, S100A1, and Hale's colloidal iron (Mazal et al., 2005; Rocca et al., 2007; Tickoo et al., 1998). Colloidal iron staining can be variable, making interpretation difficult; however, the hallmark is negative staining for oncocytoma and diffuse reticular staining in chromophobe RCC (Tickoo et al., 1998). Alternatively, when the differentiation is between oncocytoma and nonchromophobe RCC histologies, CD117 and vimentin can be useful, because oncocytoma is positive for CD117 and negative for vimentin, whereas nonchromophobe RCC stains oppositely (Liu et al., 2007; Reuter et al., 2014). The central scar can stain positive for vimentin and CK7, which can cloud the picture if this is not taken into account (Hes et al., 2007). Many other markers have been assessed; however, their clinical utility is still being explored, and only CK7, CD117, and kidney-specific cadherin are supported by the ISUP for the diagnosis of oncocytoma when histology alone is insufficient (Reuter et al., 2014).

Genetically, oncocytoma is typically associated with loss of chromosome 1, X or Y, 14, and 21 along with rearrangement of 11q13 (Cyclin D-1) (Joshi et al., 2015). **In addition, genetic predisposition exists in patients with Birt-Hogg-Dube (BHD) syndrome and renal oncocytosis. BHD syndrome is an autosomal dominant disease characterized by mutations in the folliculin gene on chromosome 17 and is associated with the development of pulmonary cysts (70%–84%) that can be seen as spontaneous pneumothoraces (25%), cutaneous fibrofolliculomas (>90%), and the development of chromophobe RCC and oncocytomas (12%–34%)** (Steinlein et al., 2018). This common developmental pathway of these two tumor types in BHD underscores their histologic similarity. Indeed, there is an intermediary tumor, the “hybrid oncocytoma-chromophobe tumor,” which has been described in these and other patients, that argues toward oncocytoma and chromophobe RCC existing on a continuum (Reuter et al., 2014; Steinlein et al., 2018). Oncocytosis is a separate entity from BHD characterized by the presence of numerous, bilateral renal oncocytomas (Fig. 96.4; Giunchi et al., 2016).

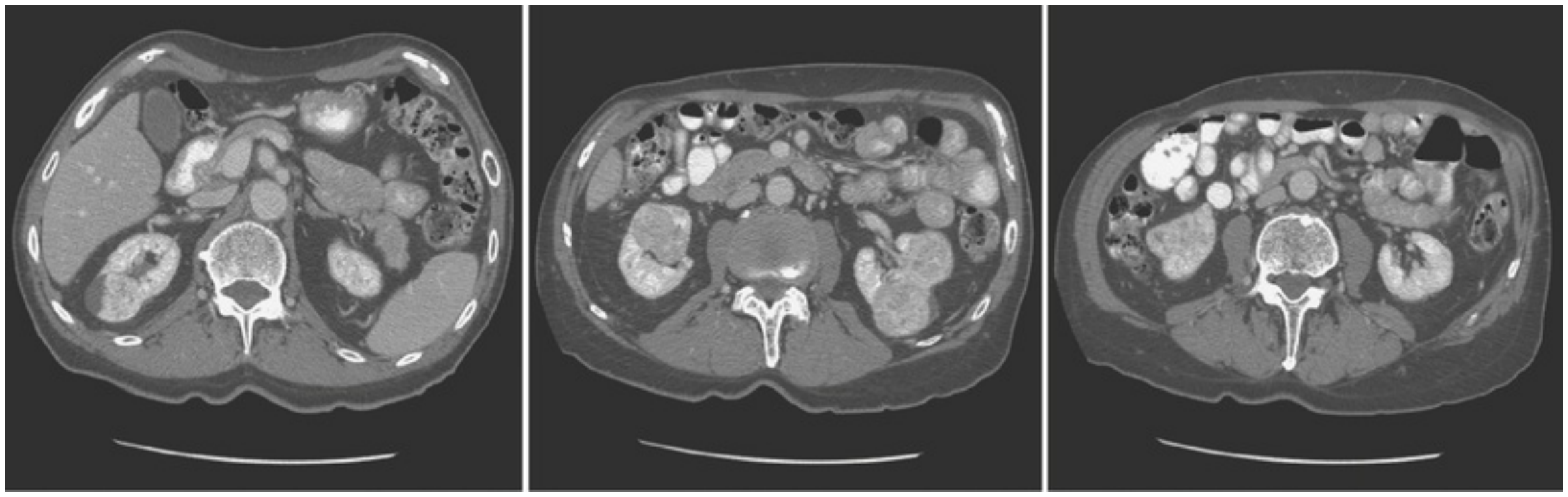

FIG. 96.4 Computed tomography scan of a patient with multiple bilateral oncocytomas. (Copyright 2009, S. F. Matin.)

Evaluation

Most cases of oncocytoma occur asymptomatically as an unilateral incidental renal mass (5% occur bilaterally) (Amin et al., 1997; Perez-Ordonez et al., 1997). Definitive diagnosis of oncocytoma is typically postoperative; however, there are certain imaging clues to the diagnosis. **Hypervascularity and a central scar on axial imaging can suggest oncocytoma as the diagnosis; however, these alone are insufficient for a definitive diagnosis** (Choudhary et al., 2009). Multiphasic MRI has been studied with some initial promising results; however, larger study is needed to confirm the clinical utility of this approach (Young et al., 2017; Zhong et al., 2017). More recently, research into technetium-99m (^{99m}Tc)-sestamibi single-photon emission computed tomography/x-ray computed tomography (SPECT/CT) has been studied with a sensitivity and specificity of 87.5% and 95.2%, respectively (Gorin et al., 2016). **When suspicion of oncocytoma is high based on imaging, renal mass biopsy has been used with some success** (Schmidbauer et al., 2008)**. However, a recent meta-analysis reported a relatively low positive predictive value of 67% for oncocytoma on renal mass biopsy, raising concern about the utility of this approach in the patient with suspected oncocytoma** (Patel et al., 2017).

Management

As most renal oncocytomas are diagnosed after surgical resection (because of perceived risk of RCC), the mainstay of management is postsurgical observation. **However, in the setting of diagnosis based on renal mass biopsy, the role of**

active surveillance has been explored with favorable results (Liu et al., 2016a and 2016b; Miller et al., 2018; Richard et al., 2016). In evaluation of 90 patients initially managed with active surveillance, only one-third received intervention (either surgery or ablation), mainly because of growth on surveillance, with 100% 5-year cancer-specific survival (Miller et al., 2018). Importantly, in patients with nononcocytic lesions, such as chromophobe RCC, the growth on interval imaging was more rapid, with an average 0.38 cm/year among chromophobe lesions compared with 0.14 mm/year for oncocytomas (Richard et al., 2016). Furthermore, because chromophobe RCC is rarely aggressive, there is little risk in observing a small chromophobe RCC while obtaining these growth kinetics (Leibovich et al., 2018). **Conversely, when oncocytoma is suspected but uncertainty exists or treatment is indicated, nephron-sparing approaches (such as ablation or partial nephrectomy) should be the standard when technically feasible given the benign nature of this disease** (Romis et al., 2004).

Key Points: Oncocytoma

- Renal oncocytoma is the most common benign enhancing renal mass.
- Oncocytomas are histologically similar to chromophobe RCC, and immunohistochemical staining may be required to distinguish the two.
- Oncocytoma is associated with Birt-Hogg-Dube syndrome: characterized by pulmonary cysts, spontaneous pneumothoraces, and fibrofolliculomas.
- When suspected, a percutaneous biopsy may provide a diagnosis when core tissue is available for additional immunohistochemical studies.
- Active surveillance represents a reasonable treatment strategy that minimizes risk and increases certainty based on growth kinetics.

Angiomyolipoma

Epidemiology

Initially described in 1900 by Grawitz, AML is a benign renal entity composed of dysmorphic blood vessels, smooth muscle, and adipose tissue (Flum et al., 2016; Grawitz, 1900; Nelson and Sanda, 2002). These tumors can occur sporadically or as part of genetic syndromes: most commonly tuberous sclerosis complex (TSC) and lymphangioleiomyomatosis (LAM). **Epidemiology studies estimate the prevalence at 0.13% in the general population, with a female predisposition and a peak in the fourth and fifth decade** (Eble, 1998; Fujii et al., 1995; Seyam et al., 2008)**. Among TSC patients, the prevalence has been reported from 55% to 90%, with an earlier presentation than sporadic cases** (Curatolo et al., 2008; Seyam et al., 2008; Steiner et al., 1993).

Pathophysiology

TSC represents the most well-described heritable cause of AML. **Genetically, TSC arises from mutations in either *TSC1* (encoding hamartin) on chromosome 9q34 or *TSC2* (encoding tuberin) on chromosome 16p13. Inheritance is autosomal dominant; however, penetrance is variable and sporadic mutations are common** (Consortium, 1993; Curatolo et al., 2008; Henske et al., 1995; van Slegtenhorst et al., 1997). Mechanistically, hamartin and tuberin dimerize to inhibit mTOR (Curatolo et al., 2008, Franz, 2011), and therefore inactivating mutations of these proteins result in unregulated mTOR activation. Downstream, this results in protein synthesis, cellular growth, and angiogenesis (Franz, 2011). Beyond the development of AML, these genetic changes result in the variable presence of epilepsy, neurocognitive impairment, autism, cortical tubers, astrocytomas, cardiac rhabdomyomas, retinal hamartomas, hypomelanotic macules, facial/ungual angiofibromas, and shagreen patches (Curatolo et al., 2008; Flum et al., 2016; Franz, 2011). Related to TSC, LAM is a disorder that predominantly affects women and genetically involves mutation of the *TSC1* or *TSC2* (Ferrans et al., 2000; Matsui et al., 2000, McCormack, 2008; Ryu et al., 2006). It can occur in isolation (rarely) or associated with TSC. Common features of LAM include (in addition to TSC features) cystic lung lesions, lymphangioleiomyomas, and chylous effusions

(Ferrans et al., 2000; Matsui et al., 2000; McCormack, 2008; Ryu et al., 2006).

Pathologically, AMLs are thought to arise from perivascular epithelioid cells and are often grouped with other perivascular epithelioid cell tumors, or PECOMAs (Bissler and Kingswood, 2004). On gross examination, tumors are well circumscribed with a tan, pink, or yellow surface, depending on the fat content (Flum et al., 2016). As previously noted, tumors are composed of blood vessels, spindle cells, and adipocytes. Vessels are thick-walled and eccentric with spindle cells around the vessels. Adipocytes are mature and without atypia (Flum et al., 2016). The proportion that each of these components contributes to the tumor can, histologically, confuse the diagnosis. **Of special circumstance is epithelioid AML, which is characterized by minimal fat content and an abundance of epithelioid cells** (Park et al., 2007; Sun and Campbell, 2018)**. Atypia within the epithelioid cells, the presence of mitotic figures, and necrosis are common and suggest a more aggressive course** (Brimo et al., 2010)**. Indeed, metastatic disease has been reported in one-third of reported cases, sporadic and TSC associated (**Bissler and Kingswood, 2004; Cibas et al., 2001; Huang et al., 2007; Kato et al., 2009; L'Hostis et al., 1999; Lee et al., 2018; Limaiem et al., 2008; Martignoni et al., 2000; Matsuyama et al., 2008; Mene et al., 2001; Moudouni et al., 2008; Nelson and Sanda, 2002; Pea et al., 1998; Saito et al., 2002; Tan et al., 2015; Zanelli et al., 2008).

Other diagnoses that can pathologically mimic AML include sarcoma (specifically, fibrosarcoma, leiomyosarcoma, and liposarcoma) and RCC (Wang et al., 2002). Indeed, leiomyosarcomas have been described as arising within an AML, raising concern for potential malignant transformation (Christiano et al., 1999; Ferry et al., 1991). **Importantly, spindle cells have melanocytic features, and therefore melanocyte markers HMB-45 and Melan-A are important immunohistochemical stains to aid in the diagnosis when in doubt** (Eble et al., 1997; Flum et al., 2016). AMLs stain strongly for estrogen receptor β, progesterone receptor, and androgen receptor, which may mechanistically explain the postpubertal female preponderance (Boorjian et al., 2008; Henske et al., 1998; L'Hostis et al., 1999).

Diagnosis

As with most renal masses, patients with AML are often diagnosed incidentally on cross-sectional imaging (Lemaitre et al., 1997; Seyam et al., 2008). However, historically up to 15% of patients have Wunderlich syndrome (spontaneous retroperitoneal hemorrhage) (Eble, 1998; Oesterling et al., 1986, Sooriakumaran et al., 2010; Steiner et al., 1993). Pregnancy has been identified as a risk factor for hemorrhage, likely because of the hormonal receptor positivity of these tumors (Boorjian et al., 2008; Eble, 1998). **Contrary to other benign renal masses, the diagnosis of AML can be made on imaging.** The presence of macroscopic fat on CT or MRI is diagnostic of AML. Ultrasonographically, masses are hyperechoic, similar to some RCCs, making ultrasound less reliable in the diagnosis (Steiner et al., 1993). **On CT the presence of intralesional fat (−15 to −20 Hounsfield units [HU]) on nonenhanced series is diagnostic** (Fig. 96.5A; Bosniak et al., 1988; Jinzaki et al., 1997; Lemaitre et al., 1997; Simpfendorfer et al., 2009). The diagnostic accuracy of CT has been evaluated in different settings. Using a cutoff of −10 HU, Davenport et al. (2011) found a c-index of 0.83 for the diagnosis of AML when the lesion was at least 19 to 24 mm in size. Meanwhile, the finding of 20 pixels with an attenuation of less than −20 HU and at least 6 pixels with an attenuation less than −30 HU was associated with a positive predictive value of 100% (Simpfendorfer et al., 2009). Similar to CT, on MRI the presence of intralesional fat is diagnostic of an AML. **Key findings on MRI include T1 and T2 hyperintensity** (Fig. 96.5B), **enhancement on gadolinium administration** (Fig. 96.5C), **hypointensity on T1 fat-suppressed sequences** (Fig. 96.5D), **and the presence of a dark boundary on in-phase/opposed-phase imaging that is also called an “India ink artifact”** (Halpenny et al., 2010; Kim et al., 2006a and 2006b; Silverman et al., 2007).

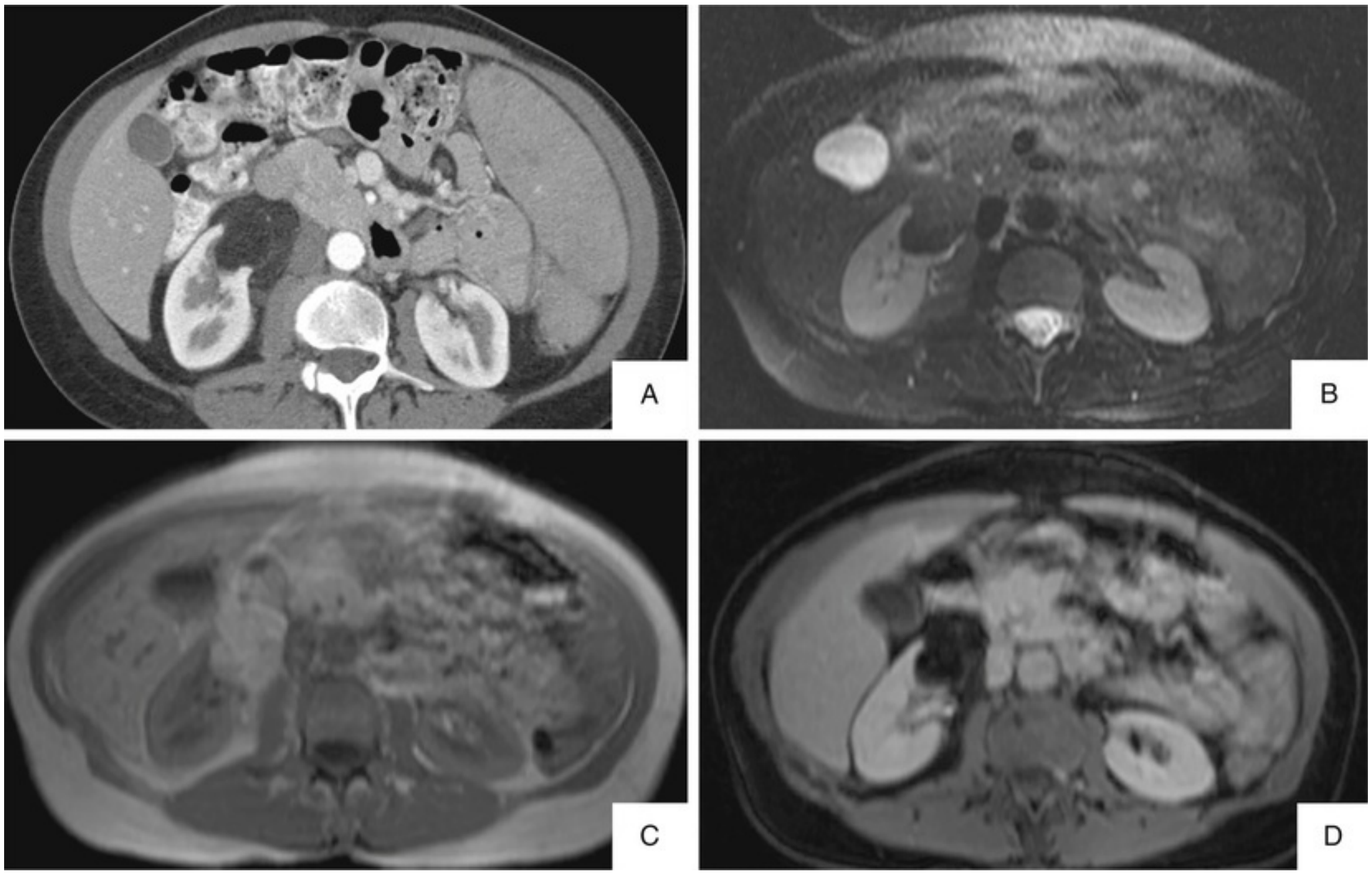

FIG. 96.5 (A) Contrast-enhanced computed tomography demonstrating macroscopic intralesional fat. (B) T2-weighted magnetic resonance imaging (MRI) with hypointensity. (C) Non–contrast-enhanced T1 MRI with hyperintensity of lesion secondary to macroscopic fat. (D) Post-contrast, fat-suppressed T1 image with signal dropout of mainly fat containing lesion, all consistent with classic angiomyolipoma. (From Flum AS, Hamoui N, Said MA, et al.: Update on the diagnosis and management of renal angiomyolipoma. *J Urol* 195[4 Pt 1]:834–846, 2016.)

Although the diagnosis can be confidently made on imaging in most circumstances, fat-poor AML (which resembles RCC), fat-containing RCC, and liposarcoma are unique situations in which the diagnosis can be problematic on imaging. Approximately 4% to 14% of AML do not contain radiographically identifiable fat and appear similar to RCC on standard imaging (hyperdense on noncontrast imaging and enhancing on contrasted series) (Hafron et al., 2005; Jinzaki et al., 1997, 2014; Kim et al., 2004; Lemaitre et al., 1997; Milner et al., 2006; Potretzke et al., 2017; Silverman et al., 2007). **In this setting MRI may be helpful, because lesions appear hyperintense on T1 sequences with subsequent hypointensity on fat-suppression and appear hypointense on T2 because of the preponderance of smooth muscle** (Halpenny et al., 2010; Jinzaki et al., 2014; Kim et al., 2006a and 2006b; Potretzke et al., 2017). When fat-poor AML is considered, percutaneous biopsy has been useful in determining the diagnosis (Lebret et al., 2007; Silverman et al., 2007). Fat-containing RCC is a rare situation; however, when described, intralesional calcification is commonly, although not universally, described, a finding not routinely seen in AML (Hayn et al., 2009; Henderson et al., 1997; Lemaitre et al., 1997; Roy et al., 1998). Finally, very large AMLs may have the appearance of retroperitoneal liposarcomas, with the key difference relating to the impact on the renal parenchyma. As AML arises from the parenchyma, an indentation in the parenchyma can be observed from this site of origination, whereas liposarcomas begin in the retroperitoneum and subsequently envelop and compress the renal parenchyma (Clark and Novick, 2001; Wang et al., 2002).

Management

Once the diagnosis is made, the management of patients with an AML should be individualized on the basis of sporadic versus syndromic AML, the presence of symptoms, and the perceived risk of hemorrhage. Flum et al. (2016) **outlined an algorithm for management of AML that summarizes the mainstays of management** (Fig. 96.6). Historically, a size of 4 cm or greater and being of child-bearing age were used as indications for intervention because of a concern for spontaneous hemorrhage and pain (Blute et al., 1988; De Luca et al., 1999; Dickinson et al., 1998; Lemaitre et al., 1995; Nelson and Sanda, 2002; Oesterling et al., 1986; Preece et al., 2015; Seyam et al., 2008, Steiner et al., 1993). **Based on these series, AML less than 4 cm in size are expected to be asymptomatic and unlikely to bleed, and therefore active surveillance is an option.** Seyam et al. (2008) monitored sporadic and TSC-associated AML and demonstrated an average growth rate of 0.19 cm and 1.25 cm per year, respectively, suggesting relative stability, particularly in the sporadic cases. Furthermore, De Luca et al. (1999) found that, for AMLs less than 5 cm in diameter, 92% remained unchanged in size during follow-up. **Although 4 cm is used as a reasonable cutoff for observation, there are reports of larger AMLs being observed without significant risk** (Bhatt et al., 2016; Danforth et al., 2007; Hadley et al., 2006; Kennelly et al., 1994)**, underscoring that 4 cm should not be used as an absolute indication for intervention.** Indeed, Ouzaid et al. (2014) described their experience with 130 AML patients on active surveillance, of whom 29% had masses larger than 4 cm. They found that among lesions larger than 4 cm, 66% remained on surveillance, suggesting overtreatment among patients with lesions larger than 4 cm managed with upfront intervention (Ouzaid et al., 2014). **As retroperitoneal hemorrhage is the overarching concern when observing an AML, Yamakado et al.** (2002) **identified that the presence of an intralesional aneurysm larger than 5 mm in diameter was predictive of subsequent hemorrhage. As such, when considering observation of a lesion more than 4 cm in size, assessment of intralesional aneurysm size with a thin-slice CT angiogram may improve the risk stratification of these patients. Finally, when considering observation, the reported association of hemorrhage during pregnancy must be considered, and prophylactic intervention in women of child-bearing age is recommended** (Preece et al., 2015). Once surveillance is selected, follow-up should be individualized but generally includes repeat imaging within the first 6 to 12 months with subsequent surveillance intervals determined by interval growth or stability (De Luca et al., 1999; Oesterling et al., 1986; Ouzaid et al., 2014).

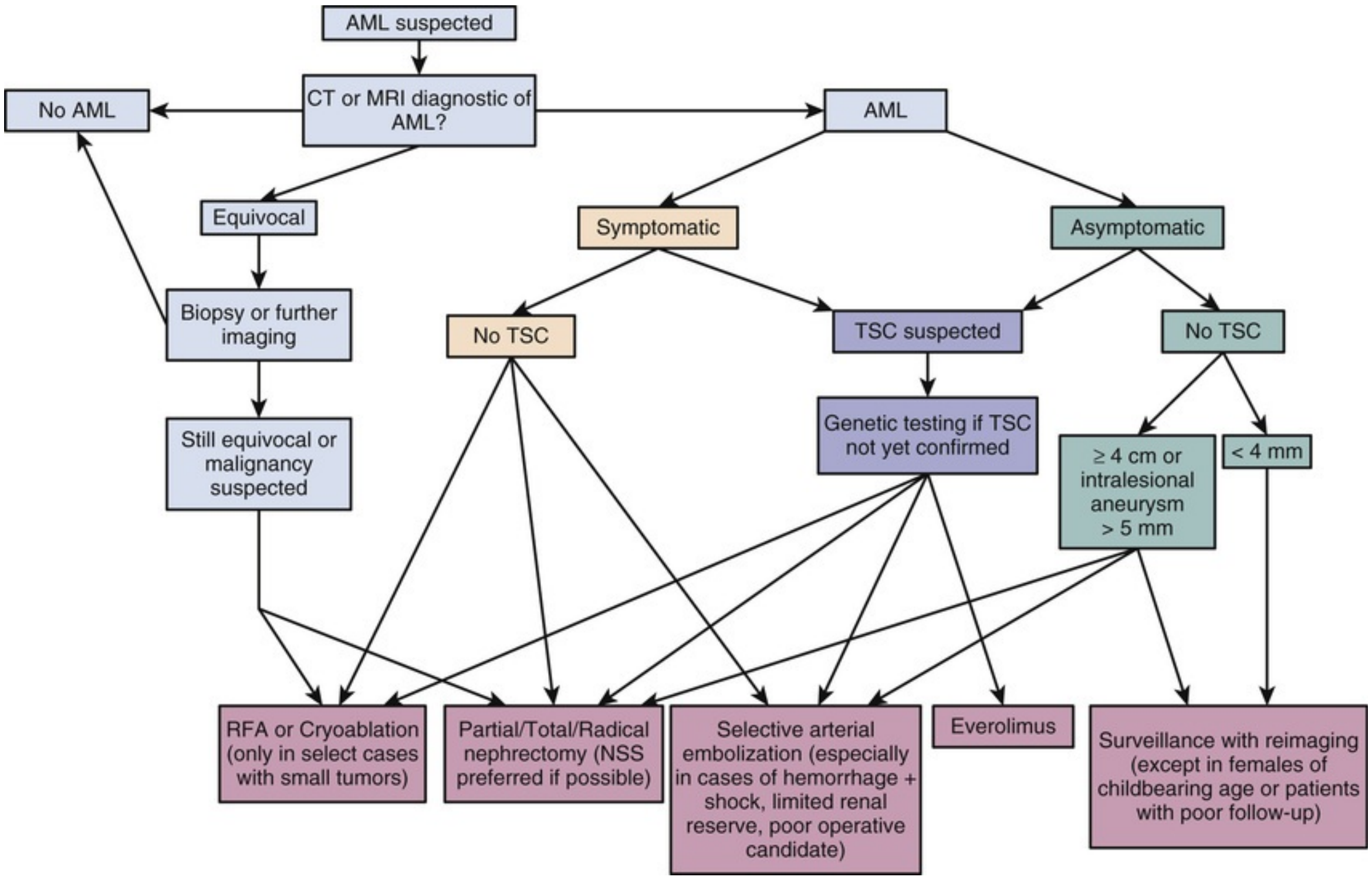
AML suspected
No AML
CT or MRI diagnostic of AML?
AML
Equivocal
Symptomatic
Asymptomatic
Biopsy or further imaging
No TSC
TSC suspected
No TSC
Genetic testing if TSC not yet confirmed
Still equivocal or malignancy suspected
≥ 4 cm or intralesional aneurysm > 5 mm
< 4 mm
RFA or Cryoablation (only in select cases with small tumors)
Partial/Total/Radical nephrectomy (NSS preferred if possible)
Selective arterial embolization (especially in cases of hemorrhage + shock, limited renal reserve, poor operative candidate)
Everolimus
Surveillance with reimaging (except in females of childbearing age or patients with poor follow-up)

FIG. 96.6 Proposed updated management algorithm for renal angiomyolipoma (AML) by Flum et al. Algorithm represents suggested options. *CT,* Computed tomography; *MRI,* magnetic resonance imaging; *NSS,* nephron sparing surgery; *RFA*, radiofrequency ablation; *TSC,* tuberous sclerosis complex. (From Flum AS, Hamoui N, Said MA, et al.: Update on the diagnosis and management of renal angiomyolipoma. *J Urol* 195[4 Pt 1]:834–846, 2016.)

When intervention is considered—because of size, concern for RCC, concern for epithelioid AML, or as prophylactic intervention—there are four mainstays of therapy: surgical resection, thermal ablation, embolization, and systemic therapy with mTOR inhibitors. When resection is chosen, nephron-sparing approaches should be performed because of improved renal function and overall mortality (Thompson et al., 2008). **Furthermore, in patients with TSC, where multifocal, bilateral, and recurring lesions are almost universal, nephron sparing is paramount.** Boorjian et al. (2007) evaluated the safety of nephron-sparing approaches in 58 patients with sporadic AML and documented a 3.4% recurrence risk and a 12% complication risk. Reported complications for open and minimally invasive partial nephrectomy in AML are no different than for traditional RCC, suggesting equivalence among well-selected patients (Boorjian et al., 2007; Heidenreich et al., 2002; Liu et al., 2016a and 2016b; Minervini et al., 2007; Msezane et al., 2010; Yip et al., 2000). Ablation is less well studied, with small case series reported using radiofrequency ablation or cryoablation, with acceptable safety (Castle et al., 2012; Makki et al., 2017; Tan et al., 2012) but require more study before routine, noninvestigational use. **Selective arterial embolization has been described as well, although it is more often reserved for the management of acute hemorrhage in AML, in which operative intervention most often results in total nephrectomy** (Chang et al., 2007; Pappas et al., 2006). When used as primary treatment of an AML, a reduction in size noted in most (Bardin et al., 2017; Hocquelet et al., 2014), but interval growth has been reported in up to 40% of patients (Bishay et al., 2010; Chan et al., 2011; Chick et al., 2010; Lee et al., 2009; Ramon et al.. 2009, Villalta et al., 2011). Indeed, repeat procedures are not infrequent, often because of pain or bleeding, and can result in total nephrectomy (Hamlin et al., 1997; Han et al., 1997; Kehagias et al., 1998; Lenton et al., 2008; Mourikis et al., 1999). Complications for embolization include potential infection/abscess, postembolization syndrome (characterized by fever, pain, and leukocytosis), and renal infarction (Andersen et al., 2015; Flum et al., 2016; Lee et al., 2009). **When therapeutic embolization to surgery is considered, it is important to note that embolization obligates the patient to continued surveillance (based on recurrence risk), whereas surgery is curative in most sporadic AML cases. Therefore the burden of post-treatment follow-up is different between the two approaches.**

As noted earlier, TSC is associated with mutations that result in activation of the mTOR pathway. Given this molecular understanding of TSC-associated AML, mTOR inhibitors have been explored as systemic therapeutic agents for managing this disease in TSC patients. The first agent explored, sirolimus, has been examined in 4 phase II trials (94 patients) (Bissler et al., 2008; Cabrera-Lopez et al., 2012; Dabora et al., 2011; Davies et al., 2011). Using Response Evaluation Criteria in Solid Tumors (RECIST) to assess response, the combined 12-month response rate (50% reduction in volume or 30% reduction in longest diameter) was 46.8%. Staehler et al. (2012) assessed the use of sirolimus in 3 patients whose tumors were too large to resect via partial nephrectomy and found that all 3 patients were ultimately able to proceed to partial nephrectomy after therapy. **More recently everolimus has been assessed in a phase III study among TSC- and LAM-associated AML** (Bissler et al., 2013)**. In this study, the authors identified a response rate of 42% (at least 50% reduction in volume), with 80% achieving at least a 30% reduction in size. Furthermore, no patient who had a tumor response suffered progression during follow-up.** The authors recently updated their findings with 4 years of follow-up (Bissler et al., 2017). They found that 92% of patients experienced a response at some point, with only 14.3% experiencing progression and no patient requiring embolization for bleeding or nephrectomy for size increase. **Given these results, everolimus is approved by the US Food and Drug Administration for the treatment of AML in the setting of TSC.** Currently it is unknown how mTOR inhibition may influence sporadic AML cases, and there are ongoing trials assessing the role of everolimus in these patients.

Key Points: Angiomyolipoma

- AML is a benign tumor of dysmorphic blood vessels, smooth muscle, and adipose tissue that can be diagnosed definitively on cross-section imaging because of the presence of macroscopic fat.
- Most patients present asymptomatically; however, AML is the most common cause of spontaneous retroperitoneal hemorrhage.
- Tuberous sclerosis is associated with the development of multifocal and bilateral renal AML and is associated with activation of the mTOR pathway.
- Treatment depends on size, presence of symptoms, and pregnancy status and

should be tailored to the patient with the goal of renal function preservation.

- The treatment of choice in patients with acute hemorrhage is selective renal angioembolization.
- Everolimus is indicated for the management of larger, multifocal AMLs in patients with TSC and LAM.

Papillary Adenoma of the Kidney

Papillary adenoma of the kidney is an entity of some controversy regarding its benignity. **In 2004 the World Health Organization defined papillary adenoma as a low-grade (grade 1–2), well-circumscribed cortical lesion measuring less than 0.5 cm** (Lopez-Beltran et al., 2006). Incidence increases with age, male sex, end-stage renal disease, acquired renal cystic disease, sporadic RCC, and hereditary papillary RCC (Denton et al., 2002; Hughson et al., 1986; Ornstein et al., 2000; Reis et al., 1988; Snyder et al., 2006; Wang et al., 2007; Xipell, 1971).

Histologically, cells are uniform with benign nuclei and are arranged as either tubular, papillary, or tubulopapillary, similar to papillary RCC (Grignon and Eble, 1998; Lopez-Beltran et al., 2006), raising concerns about the potential that papillary adenomas are a premalignant lesion. As shown by Wang et al. in 2007, papillary adenomas are associated with papillary RCC (47%) and are often multifocal when associated with papillary RCC (61%). Furthermore, in analysis of nephrectomy specimens in patients with hereditary papillary RCC, up to 3000 small papillary lesions are predicted per kidney, suggesting a common lineage from papillary adenomas to papillary RCC (Ornstein et al., 2000). **In addition, supporting this concern is the similar immunohistochemical staining (α-methylacyl CoA racemase [AMACR] positivity) and cytogenetic changes (such as trisomy 7 and 17) of papillary adenoma and papillary RCC** (Brunelli et al., 2003; Wang et al., 2007).

Because papillary adenomas are, by definition, less than 1 cm in size, they are often diagnosed pathologically as a concomitant finding with RCC (Wang et al., 2007) **and therefore require no further directed therapy.** Although the diagnosis of papillary adenoma as a benign entity remains controversial, the changing paradigm of active surveillance for small renal masses certainly supports observation of these small lesions when papillary adenoma is considered.

Key Points: Papillary Adenoma of the Kidney

- Papillary adenomas are 5 mm or smaller and are therefore not readily diagnosed on imaging.

- Papillary adenomas share common immunohistochemical staining and genetic changes and are found in association with papillary RCC, suggesting a commonality between these disease.

Metanephric Adenoma

Metanephric adenomas of the kidney is a rare benign epithelial lesion in the kidney that has been described in the literature, mainly through case reports, representing approximately 0.2% of renal masses (Amin et al., 2002; Saremian et al., 2015). **It can present at any age, although peaks in the fifth decade, and is found more often in females (2 : 1 female:male ratio)** (Bastide et al., 2009; Davis et al., 1995; Jones et al., 1995; Renshaw, 2002; Snyder et al., 2006)**. As originally described by Davis et al. in 1995, approximately one-half of patients are diagnosed incidentally; the remainder experience symptoms such as flank pain, gross hematuria, a palpable mass, and polycythemia.** The cause of polycythemia in metanephric adenoma has been investigated using in vitro cell cultures, which demonstrated the production of erythropoietin, IL-6, IL-8, G-CSF, and GM-CSF (Yoshioka et al., 2007).

Grossly, these appear as well-circumscribed, tan/brown masses that have been reported up to 15 cm (Davis et al., 1995; Jones et al., 1995). On pathologic evaluation, the differential includes Wilms tumor, papillary RCC, and papillary adenomas. Saremian et al. (2015) reviewed 14 reported cases of metanephric adenoma in which histologic findings were described from cytology (either fine-needle aspiration or core-needle biopsy). They found that all cases contained uniform cells with bland nuclei and scant cytoplasm. Where architecture was described, acinar, follicular, tubulopapillary, and glomerular structures were reported. **Importantly, necrosis, atypia, or mitotic figures, features commonly found in Wilms tumors, are not present** (Patel et al., 2009; Saremian et al., 2015)**. Although histology may differentiate Wilms tumor from metanephric adenoma, immunohistochemistry may be beneficial in distinguishing papillary RCC from this entity** (Muir et al., 2001; Olgac et al., 2006; Saremian et al. 2015)**. Specifically, metanephric adenomas stain positive for Wilms tumor protein WT1 and CD57 and negative for α-methylacyl CoA racemase (AMACR), whereas papillary RCC stains oppositely** (Muir et al., 2001; Olgac et al., 2006). Meanwhile, papillary adenomas are notable for cytokeratin-7 and epithelial membrane antigen positive, whereas metanephric adenomas are negative for these markers (Saremian et al., 2015)**.** Other markers have been explored, including S-100, cytokeratins 8, 18, and 19, and vimentin (Azabdaftari et al., 2008; Skinnider et al., 2005). Together, the description of histologic and immunohistochemical methods to differentiate metanephric adenoma from alternative diagnoses may suggest a role for renal mass biopsy when suspicion is high for such a benign entity (Bosco et al., 2007; Patel et al., 2009).

As previously noted, these tumors are histologically similar to Wilms tumor and have been hypothesized to be the most well-differentiated and mature form of Wilms tumors (Argani, 2005). Supporting this theory is the strong staining for WT1 observed in these tumors (Muir et al., 2001; Olgac et al., 2006). However, the cytogenetics of metanephric adenomas vary widely, and as descriptions are limited to case series, drawing inference from these associations is difficult. Reported mutations include 2p13 (Pesti et al., 2001), gain of chromosome 7 and 17 (Brown et al., 1997), and gain of chromosome 19 (Pan and Epstein, 2010). Because trisomy 7 and 17 are associated with papillary RCC and papillary adenoma and given the histologic similarities of metanephric adenoma to these entities, it has also been suggested that metanephric adenoma may exist on a spectrum with papillary RCC (Blanco et al., 2013; Brown et al., 1997).

On CT, these masses appear may appear hypovascular with minimal enhancement and calcifications (Bastide et al., 2009). Yan et al. (2016) performed a detailed review of radiographic features in nine histologically confirmed metanephric adenomas and found that tumors were isodense on non-contrast phase, with progressive but lower enhancement at each phase of a contrast-enhanced CT. **Notably, enhancement was uniformly less than that of the renal parenchyma; a finding in contrast to RCC, in which rapid hyperenhancement is common** (Fig. 96.7; Yan et al., 2016). Unfortunately, radiographic findings may be insufficient to establish the diagnosis, and as such, these are often diagnosed after surgical resection. When the suspicion is high, renal mass biopsy may be considered, with fine-needle aspiration to perform immunohistochemical staining. Once diagnosed, management is often nephron sparing (such as partial nephrectomy or thermal ablation), because metastatic metanephric adenoma has rarely been described (Drut et al., 2001; Paner et al., 2005; Renshaw et al.. 2000).

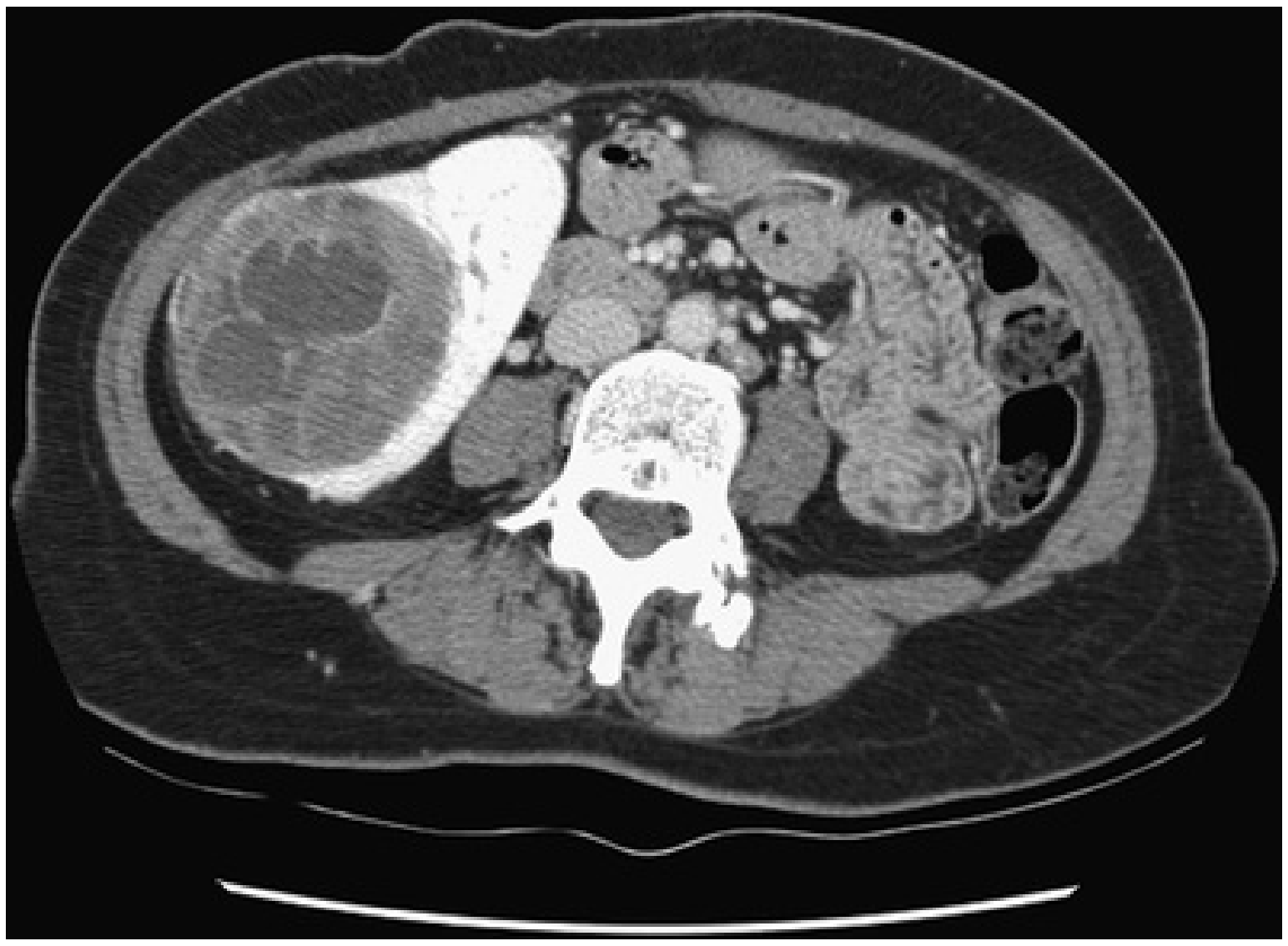

FIG. 96.7 Computed tomography scan showing a metanephric adenoma in a middle-aged woman. (Copyright 2009, S. F. Matin.)

Key Points: Metanephric Adenoma

- Metanephric adenoma is a rare, benign enhancing renal mass.
- Symptoms are present in approximately 50% of patients, with a female predisposition.
- Metanephric adenoma may exist on a continuum with Wilms tumors and papillary RCC and can be distinguished based on histology and immunohistochemical staining.

Mixed Mesenchymal and Epithelial Tumors

Cystic nephroma and mixed epithelial and stromal tumors (MESTs) are a group of tumors that are separate but genetically and morphologically related benign lesions in the kidney (Lopez-Beltran et al., 2006; Moch et al., 2016; Montironi et al., 2008; Turbiner et al., 2007, Zhou et al., 2009). Commonalities include a female predilection and frequent expression of estrogen and progesterone receptors (Montironi et al., 2008).

Cystic Nephroma

Cystic nephroma is a rare benign tumor that occurs in youth (boys predominately, 2–3 years of age) and adults (females predominately; fourth and fifth decades) (Castillo et al., 1991; Kuzgunbay et al. 2009; Madewell et al., 1983, Montironi et al., 2008, Stamatiou et al., 2008; Tamboli et al., 2000; Upadhyay and Neely, 1989).

Radiographically, tumors are often solitary, central cystic masses with calcifications, extension to the collecting system, and septal enhancement (Figs. 96.8A and B; Madewell et al., 1983; Turbiner et al., 2007). Given this appearance, in children, cystic nephroma is difficult to distinguish from Wilms tumor and is often diagnosed after surgical resection**. Because of the inability to rule out Wilms tumor radiographically, children should be managed as per the Children's Oncology Group Renal Tumor Committee guidelines, with initial radical nephrectomy** (Board, 2002). On histologic evaluation, tumors are encapsulated cystic lesions lined with cuboidal and hobnail epithelium (Fig. 96.8C) in a stroma variably composed of collagen and spindle cell fascicles (Tamboli et al., 2000). Immunohistochemical stains are notable for cytokeratin positivity in the epithelium, which stromal elements stain for CD10, calretinin, inhibin, estrogen, and progesterone (Montironi et al., 2008; Turbiner et al., 2007). **The key finding that differentiates cystic nephroma from Wilms tumor is the lack of blastemal and embryonal elements in the resected tissues** (Joshi and Beckwith, 1989). In adults, management depends on the certainty of the diagnosis; however, the radiographic appearance of an enhancing cystic mass mimics cystic clear cell RCC, and therefore resection is common. In addition, although benign, there have been reports of sarcoma, leiomyosarcoma, rhabdomyosarcoma, pleomorphic sarcoma, and clear cell RCC arising from cystic nephroma, further supporting the role of resection when feasible (Eble and Bonsib, 1998, Montironi et al., 2008; Omar et al., 2006; Sukov et al., 2007).

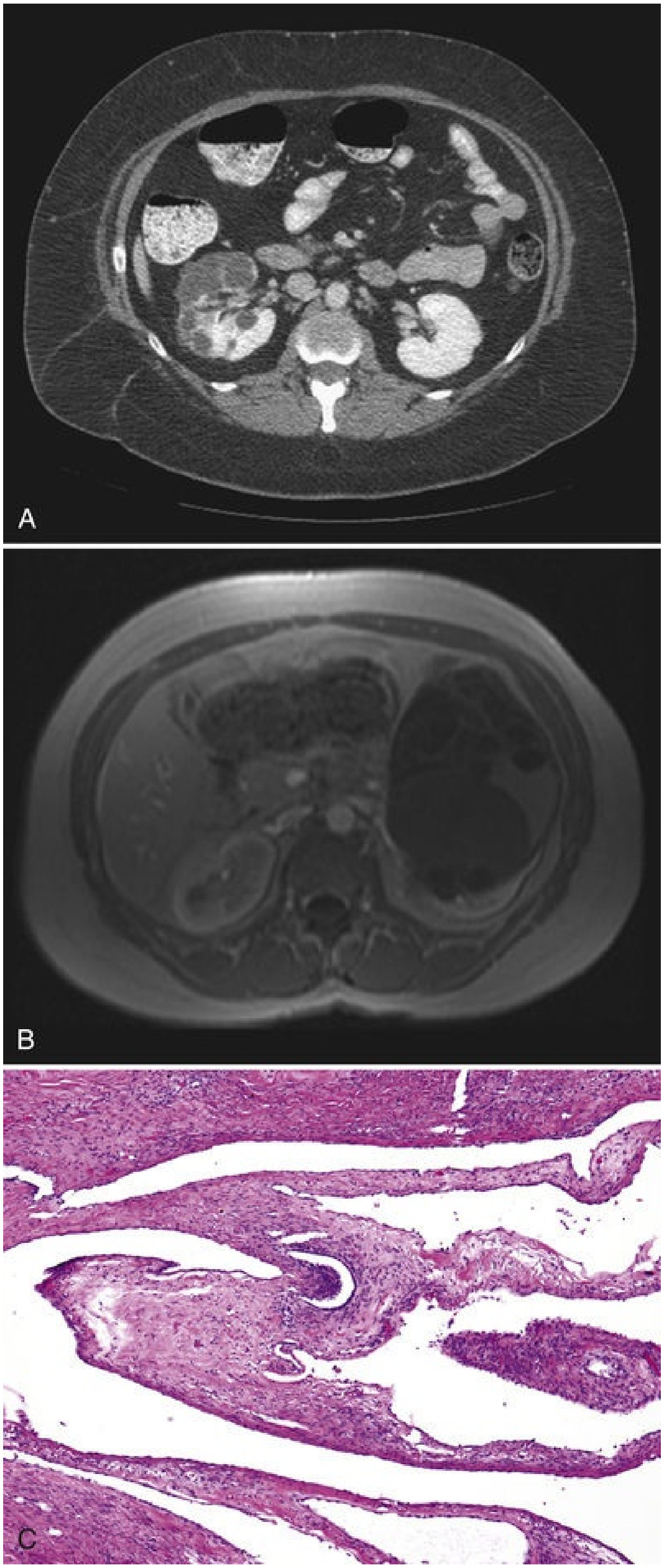
A
B
C

FIG. 96.8 Cystic nephroma. Computed tomography (A) and magnetic resonance imaging (B) scans do not allow reliable distinction from cystic renal cell carcinoma or cystic Wilms tumor. (C) The variably sized cystic spaces are lined by flattened epithelium (low magnification). (Copyright 2009, V. Margulis.)

Mixed Epithelial and Stromal Tumors

MESTs are benign tumors of the kidney that are most often identified in perimenopausal women, often with a history of estrogen replacement, with a peak incidence in the fifth decade (Adsay et al., 2000; Moslemi, 2010). In men this has been reported after long-term hormonal deprivation for prostate cancer (Adsay et al., 2000; Chuang et al., 2018).

On radiologic evaluation, MESTs often appear as a complex cystic mass, such as a Bosniak III-IV lesion, similar to RCC (Fig. 96.9A) (Adsay et al., 2000). As such, the diagnosis can be difficult and is often not made until after resection. Grossly, tumors are identified with a mean size of 6 cm and are encapsulated with solid and cystic components that often extend into the renal pelvis (Fig. 96.9B; Adsay et al., 2000; Michal, 2000; Michal et al., 2004). Because tumors are composed of mesenchymal and epithelial elements, on microscopic evaluation there are cystic components variably lined with cuboidal and columnar epithelium, although urothelium can be seen as well, interspersed in a stroma of spindle cells, smooth muscle fascicles, and collagen bands (Fig. 96.9C; Adsay et al., 2000; Antic et al., 2006; Montironi et al., 2008; Turbiner et al., 2007). Immunohistochemical staining generally reveals estrogen and progesterone positivity in the stromal elements, along with mesenchymal markers such as vimentin, CD 34, and desmin (Adsay et al., 2000). Meanwhile the epithelial components will stain positive for cytokeratin 7 (Montironi et al., 2008).

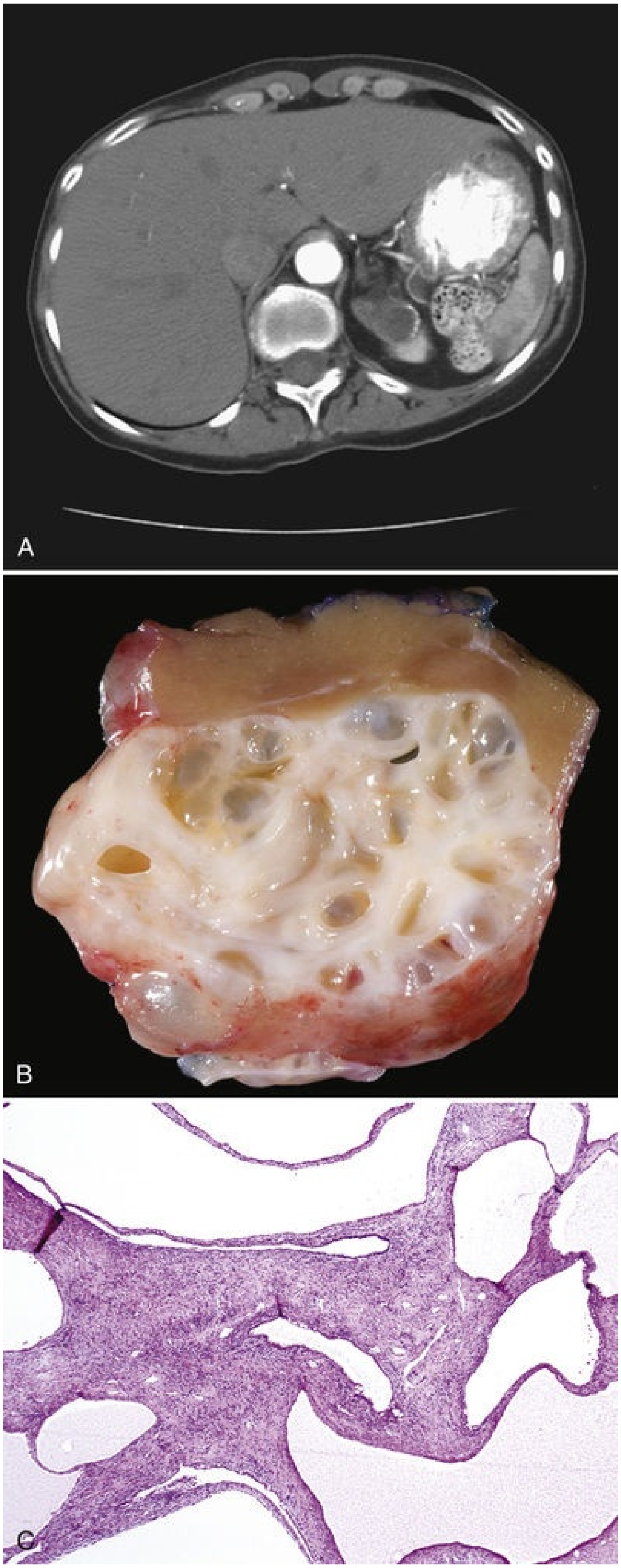
A
B
C

FIG. 96.9 Mixed epithelial and stromal tumor. (A) Computed tomography scan characteristics are not distinguishable from renal cell carcinoma. (B) Gross photograph of a partial nephrectomy specimen demonstrating a well-circumscribed mass composed of variably sized cysts separated by thick white septa. (C) Medium-power magnification shows cysts lined by hobnailed cells and spindle cell stroma. (Copyright 2009, V. Margulis.)

Importantly, malignant transformation has been observed in primary lesions and as recurrence. These transformations are observed in the stromal elements with sarcomatoid features and poor clinical outcomes are expected (Adsay et al., 2000; Nakagawa et al., 2004; Shen et al., 2007; Yap et al., 2004).

Key Points: Cystic Nephroma and Mixed Epithelial-Stromal Tumor

- Cystic nephroma and MESTs are biologically related and histologically similar.
- Frequent expression of estrogen and progesterone receptors in tumor tissue is reported with a female predisposition.
- Cystic nephroma clinically resembles Wilms tumor, particularly in children.
- If feasible, a nephron-sparing approach with partial nephrectomy is the preferred management strategy.

Leiomyoma

Leiomyoma is a rare renal tumor of smooth muscle differentiation (Moch et al., 2016). These tumors can arise anywhere in the urinary tract; the bladder is the most common site (Larbcharoensub et al., 2017; Tamboli et al., 2000). **Within the kidney, multiple sites have been described; however, the renal capsule is the most often described location** (Rao et al., 2001; Romano et al., 2017; Steiner et al. 1990; Wells et al., 1981)**. They are found more often in women (2 : 1 predominance), and account for 0.29% of primary renal mass** (Khetrapal et al., 2014).

As leiomyomas arise from the capsule, radiographically they appear as small exophytic masses that are hyperdense on noncontrast CT with hypoenhancement on intravenous contrast administration (Cong et al., 2011). **Although this enhancement is less than that observed with traditional clear cell RCC, chromophobe RCC tends to have hypoenhancement similar to leiomyoma, making the radiologic diagnosis difficult** (Fig. 96.10A; Cong et al., 2011; Steiner et al., 1990).

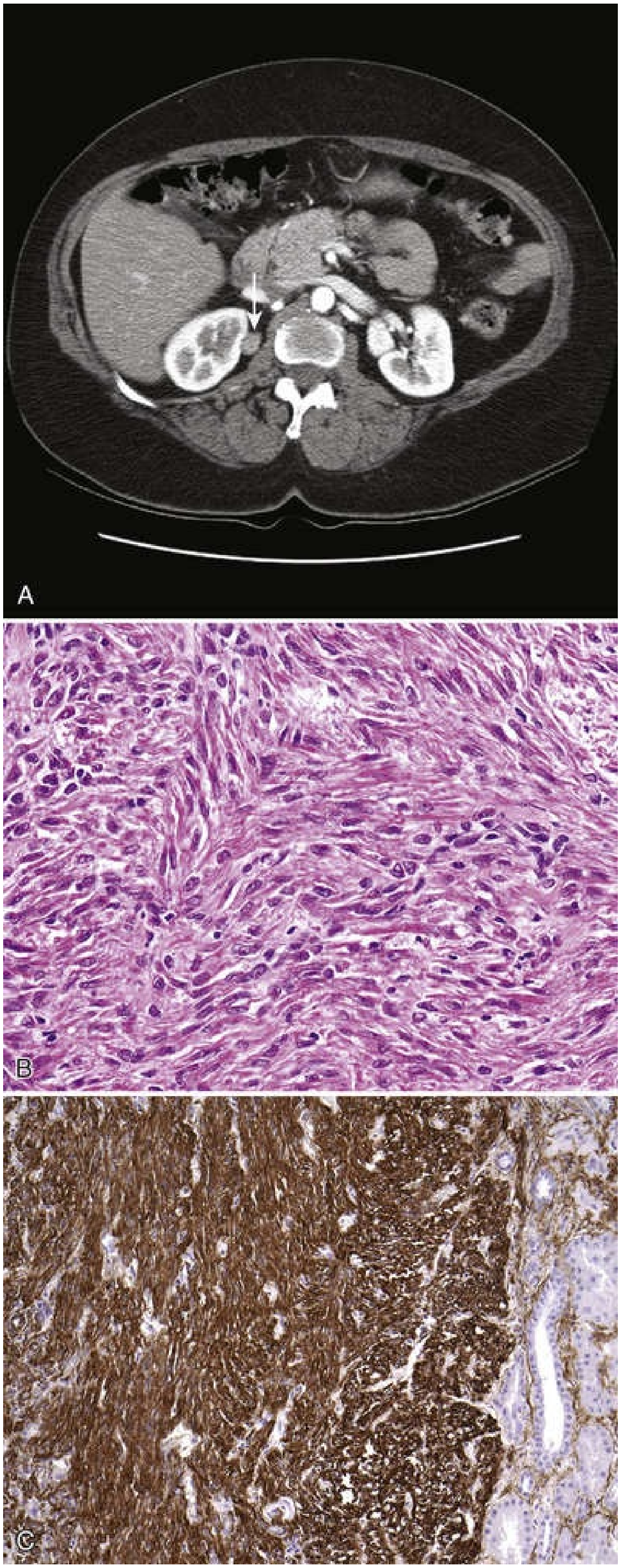
A
B
C

FIG. 96.10 Renal leiomyoma. (A) Computed tomography scan with characteristic appearance of a small renal mass arising from the renal capsule *(arrow)*. (B) Medium-power magnification shows uniform spindle cells with thin cigar-shaped nuclei, without any pleomorphism. (C) Strong positive immunohistochemical staining with smooth muscle actin in the leiomyoma. Note lack of smooth-muscle actin staining in the normal renal tubules on the right. (Copyright 2009, V. Margulis.)

On gross examination, these tumors appear well circumscribed and firm. Tumors can range in size and may have associated calcifications and focal cystic degeneration. Microscopic examination demonstrates spindle cells that form intersecting fascicles without evidence of hypercellularity, pleomorphism, mitotic figures, or necrosis (Fig. 96.10B; Larbcharoensub et al. 2017; Steiner et al., 1990; Tamboli et al., 2000). Immunohistochemical staining is notable for vimentin and smooth muscle markers desmin and caldesmon (Fig. 96.10C; Larbcharoensub et al., 2017; Romero et al. 2005). Interestingly, leiomyomas can stain for HMB-45 (Bonsib, 1996). Because AML is on the differential for a leiomyoma, the key factors differentiating these entities include the absence of melan-A staining and the absence of adiposity in leiomyomas.

Radiographically, tumors are hyperdense relative to the renal parenchyma on noncontrast imaging, with clear sharp margins (Cong et al., 2011). With contrast administration, homogeneous enhancement is observed, which increases in later phases, except in the setting of large masses, in which hemorrhage or cystic changes may result in heterogeneous patterns. As RCC typically enhances early and heterogeneously, with washout on later phases, these differences may be exploited to differentiate leiomyoma from RCC (Cong et al., 2011).

Management, as with most benign renal masses, depends on the certainty of the diagnosis before intervention, with nephron-sparing approaches preferred when treatment is considered.

Key Points: Leiomyoma

- Leiomyomas are described along the urinary tract but most often from the renal capsule.
- Radiologic examination is insufficient to confirm the diagnosis.
- Nephron-sparing approaches are preferred when technically possible.

Other Benign Renal Tumors

In addition to the commonly identified lesions outlined earlier, a host of other benign lesions have been described, including hemangiomas, lymphangiomas, juxtaglomerular cell tumors, renomedullary interstitial cell tumor, intrarenal schwannoma, and solitary fibrous tumor.

Hemangiomas are vascular lesions that are more often identified in young patients. Although most are sporadic, they can be found in association with syndromes such as Klippel-Trenaunay, Struge-Weber, and systemic angiomatosis. When identified they are often singular, associated with the renal pyramids and pelvis. There is no capsule and on histologic evaluation there are irregular vascular spaces (Tamboli et al., 2000). More recently, a potentially related lesion, renal anastomosing hemangioma (RAH), has been described (Brown et al., 2010; Kryvenko et al., 2011; Kuroda et al., 2016; Omiyale, 2015). Mean age of RAH is older, at 50 years of age with a male predisposition (Omiyale, 2015). When identified, they have a similar anatomic distribution within the kidney as other hemangiomas, although are more commonly multifocal (Kryvenko et al., 2011; Kuroda et al., 2016; Omiyale, 2015). Because most are diagnosed incidentally at nephrectomy, no specific treatment is required or suggested.

Renal lymphangiomas are rare tumors that arise from a developmental abnormality in which the perirenal lymphatics do not communicate with the rest of the lymphatic system, resulting in dilated, cystic masses around the renal capsule, renal sinus, or peripelvic fat (Mani et al., 2003). Presentation is often incidental; however, compression and involvement of the renal pelvis can cause signs and symptoms of obstructive uropathy, hypertension, hematuria, proteinuria, hemorrhage, and chyluria (Chiu et al., 2004; Kekre et al., 1998, Varela et al., 1998). Treatment depends on presence of symptoms and can include aspiration/sclerosis or surgical excision (Daali et al., 2001; Wildhaber et al., 2006).

Juxtaglomerular cell tumor (also known as *reninoma* or *JGCT*), is a tumor arising from the juxtaglomerular cells of the kidney and was originally described in 1967 by Robertson et al. It is most commonly identified in women in their second and third decades (Kim et al., 2006a and 2006b; Martin et al., 2001; McVicar et al., 1993). **The hallmark of these tumors is overproduction of renin; therefore patients often experience symptoms of hyperaldosteronism,**

such as polydipsia, polyuria, myalgias, double vision, and headaches (Haab et al., 1995; Kuroda et al., 2011; McVicar et al., 1993; Rubenstein et al., 2002; Schonfeld et al., 1991)**. On examination, hypertension, hypokalemia, and proteinuria are often identified** (Gottardo et al., 2010; Haab et al., 1995; Kuroda et al., 2011; McVicar et al., 1993). Although hypertension is a common finding, Haab et al. (1995) only identified 8 cases of JGCT among 30,000 patients in a hypertension clinic. Imaging typically reveals a small renal mass that is solid and can be hypoechoic on ultrasound and nonenhancing on CT (Gottardo et al., 2010; Mete et al., 2003; Schonfeld et al., 1991; Tanabe et al. 2001). Grossly these tumors are well circumscribed with hemorrhage commonly observed (Martin et al., 2001). On microscopic evaluation, common findings are uniform, packed, polygonal cells with indistinct borders (Kuroda et al., 2011). Staining for intracytoplasmic renin is pathognomonic (Caregaro et al., 1994; Tanaka et al., 1993). **When such small lesions are identified in a young, hypertensive patient, the diagnosis should be considered and confirmed by high plasma renin levels. Once diagnosed, surgical resection results in resolution of symptoms in the majority of patients; however, up to 10% have persistent hypertension because of the development of hypertensive angiopathy** (Kuroda et al., 2011; Squires et al., 1984). A benign post-treatment course is expected, and only one case of metastatic JGCT has been reported (Duan et al., 2004).

Renomedullary interstitial cell tumor is a tumor that arises within the renal medullary tissue. The cells of origin, renomedullary interstitial cells, synthesize prostaglandins; it was therefore thought to be the result of hypertension (Stuart et al., 1976; Zhuo, 2000). These tumors were initially described on autopsy study (Reese and Winstanley, 1958), with a recent report finding an incidence of 44% in unselected adult autopsy specimens (Calio et al., 2016). Importantly, no association between hypertension was identified in this more recent study. Tumors are small (mean 1.7 mm), often multifocal (mean 3 per patient), with spindle/stellate cells in a fibrous background with increasing collagen as age increased (Calio et al., 2016).

Intrarenal schwannomas are exceptionally rare benign renal masses arising from nerve sheath tissue in the renal parenchyma. Patients can present with nonspecific symptoms, such as malaise, weight loss, fever, and abdominal pain (Umphrey et al., 2007). They are well-circumscribed masses that can range in size. Histologically they are composed of spindle cells in a palisading pattern, which stain positive for S-100 (Alvarado-Cabrero et al., 2000; Singer and

Anders, 1996).

Solitary fibrous tumor is a rare benign tumor of mesenchymal origin that tends to occur with hematuria, flank pain, and an enlarging mass (Fursevich et al., 2016; Hirano et al., 2009; Kohl et al., 2006; Park et al., 2011). Masses are large with heterogenous enhancement, calcifications, and necrosis on CT that are hard to distinguish from RCC (Cortes et al., 2014; Katabathina et al., 2010). Histologically they are circumscribed and consist of spindle cells and collagen bands and stain positive for CD34, CD99, and BCL-2 (Magro et al., 2002; Wang et al., 2001).

Key Points: Other Benign Renal Tumors

- Multiple rare tumors of the kidney have been described.
- Radiologic differentiation from renal malignancy is not possible.
- Reninoma, a benign tumor of the renal juxtaglomerular cell apparatus, is an important but rare cause of secondary hypertension and hypokalemia.

Suggested Readings

Bissler JJ, Kingswood JC, Radzikowska E, et al. Everolimus long-term use in patients with tuberous sclerosis complex: four-year update of the EXIST-2 study. *PLoS ONE*. 2017;12(8) [e0180939].

Curatolo P, Bombardieri R, Jozwiak S. Tuberous sclerosis. *Lancet*. 2008;372(9639):657–668.

Eknoyan G. A clinical view of simple and complex renal cysts. *J Am Soc Nephrol*. 2009;20(9):1874–1876.

Flum AS, Hamoui N, Said MA, et al. Update on the diagnosis and management of renal angiomyolipoma. *J Urol*. 2016;195(4 Pt 1):834–846.

Grantham JJ. Clinical practice. Autosomal dominant polycystic kidney disease. *N Engl J Med*. 2008;359(14):1477–1485.

Halpenny D, Snow A, McNeill G, et al. The radiological diagnosis and treatment of renal angiomyolipoma-current status. *Clin Radiol*. 2010;65(2):99–108.

Helenon O, Crosnier A, Verkarre V, et al. Simple and complex renal cysts in adults: classification system for renal cystic masses. *Diagn Interv Imaging*. 2018.

Kuroda N, Gotoda H, Ohe C, et al. Review of juxtaglomerular cell tumor with focus on pathobiological aspect. *Diagn Pathol*. 2011;6:80.

Kuroda N, Ohe C, Deepika S, et al. Review of renal anastomosing hemangioma with focus on clinical and pathological aspects. *Pol J Pathol*. 2016;67(2):97–101.

Larbcharoensub N, Limprasert V, Pangpunyakulchai D, et al. Renal leiomyoma: a case report and review of the literature. *Urol Case Rep*. 2017;13:3–5.

Lopez-Beltran A, Scarpelli M, Montironi R, et al. 2004 WHO classification of the renal tumors of the adults. *Eur Urol*.

2006;49(5):798–805.

Moch H, Cubilla AL, Humphrey PA, et al. The 2016 WHO classification of tumours of the urinary system and male genital organs-part a: renal, penile, and testicular tumours. *Eur Urol*. 2016;70(1):93–105.

Montironi R, Mazzucchelli R, Lopez-Beltran A, et al. Cystic nephroma and mixed epithelial and stromal tumour of the kidney: opposite ends of the spectrum of the same entity? *Eur Urol*. 2008;54(6):1237–1246.

Pappas P, Leonardou P, Papadoukakis S, et al. Urgent superselective segmental renal artery embolization in the treatment of life-threatening renal hemorrhage. *Urol Int*. 2006;77(1):34–41.

Patel HD, Druskin SC, Rowe SP, et al. Surgical histopathology for suspected oncocytoma on renal mass biopsy: a systematic review and meta-analysis. *BJU Int*. 2017;119(5):661–666.

Rahbari-Oskoui F, O'Neill WC. Diagnosis and management of acquired cystic kidney disease and renal tumors in ESRD patients. *Semin Dial*. 2017;30(4):373–379.

Reuter VE, Argani P, Zhou M, et al. Best practices recommendations in the application of immunohistochemistry in the kidney tumors: report from the International Society of Urologic Pathology consensus conference. *Am J Surg Pathol*. 2014;38(8):e35–e49.

Saremian J, Kubik MJ, Masood S. Cytologic features of metanephric adenoma of the kidney: case report and review of the literature. *Lab Med*. 2015;46(2):153–158 [quiz e130].

Seyam RM, Bissada NK, Kattan SA, et al. Changing trends in presentation, diagnosis and management of renal angiomyolipoma: comparison of sporadic and tuberous sclerosis complex-associated forms. *Urology*. 2008;72(5):1077–1082.

Steinlein OK, Ertl-Wagner B, Ruzicka T, et al. Birt-Hogg-Dube syndrome: an underdiagnosed genetic tumor syndrome. *J Dtsch Dermatol Ges*. 2018;16(3):278–283.

Sun DZ, Campbell SC. Atypical epithelioid angiomyolipoma: a rare variant with malignant potential. *Urology*. 2018;112:20–22.

Wobker SE, Williamson SR. Modern pathologic diagnosis of renal oncocytoma. *J Kidney Cancer VHL*. 2017;4(4):1–12.

Yan J, Cheng JL, Li CF, et al. The findings of CT and MRI in patients with metanephric adenoma. *Diagn Pathol*. 2016;11(1):104.

References

Abdul-Majeed S, Nauli SM. Calcium-mediated mechanisms of cystic expansion. *Biochim Biophys Acta*. 2011;1812(10):1281–1290.

Adsay NV, Eble JN, Srigley JR, et al. Mixed epithelial and stromal tumor of the kidney. *Am J Surg Pathol*. 2000;24(7):958–970.

Alvarado-Cabrero I, Folpe AL, Srigley JR, et al. Intrarenal schwannoma: a report of four cases including three cellular variants. *Mod Pathol*. 2000;13(8):851–856.

Ambani SN, Morgan TM, Montgomery JS, et al. Predictors of delayed intervention for patients on active surveillance for small renal masses: does renal mass biopsy influence our decision? *Urology*. 2016;98:88–96.

Amin MB, Amin MB, Tamboli P, et al. Prognostic impact of histologic subtyping of adult renal epithelial neoplasms: an experience of 405 cases. *Am J Surg Pathol*. 2002;26(3):281–291.

Amin MB, Crotty TB, Tickoo SK, et al. Renal oncocytoma: a reappraisal of morphologic features with clinicopathologic findings in 80 cases. *Am J Surg Pathol*. 1997;21(1):1–12.

Andersen PE, Thorlund MG, Wennevik GE, et al. Interventional treatment of renal angiomyolipoma: immediate results and clinical and radiological follow-up of 4.5 years. *Acta Radiol Open*. 2015;4(7) [2058460115592442].

Antic T, Perry KT, Harrison K, et al. Mixed epithelial and stromal tumor of the kidney and cystic nephroma share overlapping features: reappraisal of 15 lesions. *Arch Pathol Lab Med*. 2006;130(1):80–85.

Argani P. Metanephric neoplasms: the hyperdifferentiated, benign end of the Wilms tumor spectrum? *Clin Lab Med*.

2005;25(2):379–392.

Azabdaftari G, Alroy J, Banner BF, et al. S100 protein expression distinguishes metanephric adenomas from other renal neoplasms. *Pathol Res Pract*. 2008;204(10):719–723.

Bardin F, Chevallier O, Bertaut A, et al. Selective arterial embolization of symptomatic and asymptomatic renal angiomyolipomas: a retrospective study of safety, outcomes and tumor size reduction. *Quant Imaging Med Surg*. 2017;7(1):8–23.

Bas O, Nalbant I, Can Sener N, et al. Management of renal cysts. *JSLS*. 2015;19(1) [e2014.00097].

Bastide C, Rambeaud JJ, Bach AM, et al. Metanephric adenoma of the kidney: clinical and radiological study of nine cases. *BJU Int*. 2009;103(11):1544–1548.

Bhatt JR, Richard PO, Kim NS, et al. Natural history of renal angiomyolipoma (AML): most patients with large AMLs >4 cm can be offered active surveillance as an initial management strategy. *Eur Urol*. 2016;70(1):85–90.

Bishay VL, Crino PB, Wein AJ, et al. Embolization of giant renal angiomyolipomas: technique and results. *J Vasc Interv Radiol*. 2010;21(1):67–72.

Bissler JJ, Kingswood JC. Renal angiomyolipomata. *Kidney Int*. 2004;66(3):924–934.

Bissler JJ, Kingswood JC, Radzikowska E, et al. Everolimus long-term use in patients with tuberous sclerosis complex: four-year update of the EXIST-2 study. *PLoS ONE*. 2017;12(8) [e0180939].

Bissler JJ, Kingswood JC, Radzikowska E, et al. Everolimus for angiomyolipoma associated with tuberous sclerosis complex or sporadic lymphangioleiomyomatosis (EXIST-2): a multicentre, randomised, double-blind, placebo-controlled trial. *Lancet*. 2013;381(9869):817–824.

Bissler JJ, McCormack FX, Young LR, et al. Sirolimus for angiomyolipoma in tuberous sclerosis complex or lymphangioleiomyomatosis. *N Engl J Med*. 2008;358(2):140–151.

Blanco LZ Jr, Schein CO, Patel T, et al. Fine-needle aspiration of metanephric adenoma of the kidney with clinical, radiographic and histopathologic correlation: a review. *Diagn Cytopathol*. 2013;41(8):742–751.

Blute ML, Malek RS, Segura JW. Angiomyolipoma: clinical metamorphosis and concepts for management. *J Urol*. 1988;139(1):20–24.

Board PDQPTE. *Wilms tumor and other childhood kidney tumors treatment (PDQ(R)): health professional version. PDQ Cancer Information Summaries*. [Bethesda (MD), National Cancer Institute (US)] 2002.

Bonsib SM. HMB-45 reactivity in renal leiomyomas and leiomyosarcomas. *Mod Pathol*. 1996;9(6):664–669.

Boorjian SA, Frank I, Inman B, et al. The role of partial nephrectomy for the management of sporadic renal angiomyolipoma. *Urology*. 2007;70(6):1064–1068.

Boorjian SA, Sheinin Y, Crispen PL, et al. Hormone receptor expression in renal angiomyolipoma: clinicopathologic correlation. *Urology*. 2008;72(4):927–932.

Bosco M, Galliano D, La Saponara F, et al. Cytologic features of metanephric adenoma of the kidney during pregnancy: a case report. *Acta Cytol*. 2007;51(3):468–472.

Bosniak MA. The current radiological approach to renal cysts. *Radiology*. 1986;158(1):1–10.

Bosniak MA. Should we biopsy complex cystic renal masses (Bosniak category III)? *AJR Am J Roentgenol*. 2003;181(5):1425–1426.

Bosniak MA. The Bosniak renal cyst classification: 25 years later. *Radiology*. 2012;262(3):781–785.

Bosniak MA, Megibow AJ, Hulnick DH, et al. CT diagnosis of renal angiomyolipoma: the importance of detecting small amounts of fat. *AJR Am J Roentgenol*. 1988;151(3):497–501.

Brimo F, Robinson B, Guo C, et al. Renal epithelioid angiomyolipoma with atypia: a series of 40 cases with emphasis on clinicopathologic prognostic indicators of malignancy. *Am J Surg Pathol*. 2010;34(5):715–722.

Brown JA, Anderl KL, Borell TJ, et al. Simultaneous chromosome 7 and 17 gain and sex chromosome loss provide evidence that renal metanephric adenoma is related to papillary renal cell carcinoma. *J Urol*. 1997;158(2):370–374.

Brown JG, Folpe AL, Rao P, et al. Primary vascular tumors and tumor-like lesions of the kidney: a clinicopathologic analysis of 25 cases. *Am J Surg Pathol*. 2010;34(7):942–949.

Brunelli M, Eble JN, Zhang S, et al. Gains of chromosomes 7, 17, 12, 16, and 20 and loss of Y occur early in the evolution of papillary renal cell neoplasia: a fluorescent in situ hybridization study. *Mod Pathol*. 2003;16(10):1053–1059.

Cabrera-Lopez C, Marti T, Catala V, et al. Assessing the effectiveness of rapamycin on angiomyolipoma in tuberous sclerosis: a two years trial. *Orphanet J Rare Dis*. 2012;7:87.

Calio A, Warfel KA, Eble JN. Renomedullary interstitial cell tumors: pathologic features and clinical correlations. *Am J Surg Pathol*. 2016;40(12):1693–1701.

Campbell SC, Novick AC, Belldegrun A, et al. Guideline for management of the clinical T1 renal mass. *J Urol*. 2009;182(4):1271–1279.

Canvasser NE, Kay FU, Xi Y, et al. Diagnostic accuracy of multiparametric magnetic resonance imaging to identify clear cell renal cell carcinoma in cT1a renal masses. *J Urol*. 2017;198(4):780–786.

Caregaro L, Menon F, Gatta A, et al. Juxtaglomerular cell tumor of the kidney. *Clin Exp Hypertens*. 1994;16(1):41–53.

Casteleijn NF, van Gastel MD, Blankestijn PJ, et al. Novel treatment protocol for ameliorating refractory, chronic pain in patients with autosomal dominant polycystic kidney disease. *Kidney Int*. 2017;91(4):972–981.

Castillo OA, Boyle ET Jr, Kramer SA. Multilocular cysts of kidney. A study of 29 patients and review of literature. *Urology*. 1991;37(2):156–162.

Castle SM, Gorbatiy V, Ekwenna O, et al. Radiofrequency ablation (RFA) therapy for renal angiomyolipoma (AML): an alternative to angio-embolization and nephron-sparing surgery. *BJU Int*. 2012;109(3):384–387.

Casuscelli J, Schmidt S, DeGray B, et al. Analysis of the cytoplasmic interaction between polycystin-1 and polycystin-2. *Am J Physiol Renal Physiol*. 2009;297(5):F1310–F1315.

Chan CK, Yu S, Yip S, et al. The efficacy, safety and durability of selective renal arterial embolization in treating symptomatic and asymptomatic renal angiomyolipoma. *Urology*. 2011;77(3):642–648.

Chandrasekar T, Ahmad AE, Fadaak K, et al. Natural history of complex renal cysts: clinical evidence supporting active surveillance. *J Urol*. 2018;199(3):633–640.

Chang YH, Wang LJ, Chuang CK, et al. The efficacy and outcomes of urgent superselective transcatheter arterial embolization of patients with ruptured renal angiomyolipomas. *J Trauma*. 2007;62(6):1487–1490.

Chick CM, Tan BS, Cheng C, et al. Long-term follow-up of the treatment of renal angiomyolipomas after selective arterial embolization with alcohol. *BJU Int*. 2010;105(3):390–394.

Chiu JS, Wu CJ, Sun GH, et al. Obstructive uropathy associated with bilateral renal lymphangiomatosis. *Nephrol Dial Transplant*. 2004;19(11):2923.

Choudhary S, Rajesh A, Mayer NJ, et al. Renal oncocytoma: CT features cannot reliably distinguish oncocytoma from other renal neoplasms. *Clin Radiol*. 2009;64(5):517–522.

Christiano AP, Yang X, Gerber GS. Malignant transformation of renal angiomyolipoma. *J Urol*. 1999;161(6):1900–1901.

Chuang CK, Pan PY, Kao Y, et al. Mixed epithelial stromal tumor of the kidney: the male case and literature review. *Urol Case Rep*. 2018;17:122–124.

Cibas ES, Goss GA, Kulke MH, et al. Malignant epithelioid angiomyolipoma (‘sarcoma ex angiomyolipoma’) of the kidney: a case report and review of the literature. *Am J Surg Pathol*. 2001;25(1):121–126.

Clark PE, Novick AC. Exophytic noninvasive growth pattern of renal angiomyolipomas: implications for nephron sparing surgery. *J Urol*. 2001;165(2):513–514.

Cong Z, Gong J, Wang Y. Radiological findings of renal leiomyomas: a report of five surgically confirmed cases. *Abdom Imaging*. 2011;36(5):604–608.

Consortium ECTS. Identification and characterization of the tuberous sclerosis gene on chromosome 16. *Cell*. 1993;75(7):1305–1315.

Cortes LG, Caserta NM, Billis A. Fat-forming solitary fibrous tumor of the kidney: a case report. *Anal Quant Cytopathol Histpathol*. 2014;36(5):295–298.

Curatolo P, Bombardieri R, Jozwiak S. Tuberous sclerosis. *Lancet*. 2008;372(9639):657–668.

Daali M, Touiti I, Hssaida R, et al. [Renal lymphangioma]. *Prog Urol*. 2001;11(3):520–522.

Dabora SL, Franz DN, Ashwal S, et al. Multicenter phase 2 trial of sirolimus for tuberous sclerosis: kidney angiomyolipomas and other tumors regress and VEGF- D levels decrease. *PLoS ONE*. 2011;6(9) [e23379].

Danforth TL, Lane BR, Novick AC. Conservative management of giant symptomatic angiomyolipomas in patients with the tuberous sclerosis complex. *BJU Int*. 2007;100(4):794–797.

Davenport MS, Neville AM, Ellis JH, et al. Diagnosis of renal angiomyolipoma with Hounsfield unit thresholds: effect of size of region of interest and nephrographic phase imaging. *Radiology*. 2011;260(1):158–165.

Davies DM, de Vries PJ, Johnson SR, et al. Sirolimus therapy for angiomyolipoma in tuberous sclerosis and sporadic lymphangioleiomyomatosis: a phase 2 trial. *Clin Cancer Res*. 2011;17(12):4071–4081.

Davis CJ Jr, Barton JH, Sesterhenn IA, et al. Metanephric adenoma. Clinicopathological study of fifty patients. *Am J Surg Pathol*. 1995;19(10):1101–1114.

De Luca S, Terrone C, Rossetti SR. Management of renal angiomyolipoma: a report of 53 cases. *BJU Int*. 1999;83(3):215–218.

Denton MD, Magee CC, Ovuworie C, et al. Prevalence of renal cell carcinoma in patients with ESRD pre-transplantation: a pathologic analysis. *Kidney Int*. 2002;61(6):2201–2209.

Dickinson M, Ruckle H, Beaghler M, et al. Renal angiomyolipoma: optimal treatment based on size and symptoms. *Clin Nephrol*. 1998;49(5):281–286.

Drut R, Drut RM, Ortolani C. Metastatic metanephric adenoma with foci of papillary carcinoma in a child: a combined histologic, immunohistochemical, and FISH study. *Int J Surg Pathol*. 2001;9(3):241–247.

Duan X, Bruneval P, Hammadeh R, et al. Metastatic juxtaglomerular cell tumor in a 52-year-old man. *Am J Surg Pathol*. 2004;28(8):1098–1102.

Eble JN. Angiomyolipoma of kidney. *Semin Diagn Pathol*. 1998;15(1):21–40.

Eble JN, Amin MB, Young RH. Epithelioid angiomyolipoma of the kidney: a report of five cases with a prominent and diagnostically confusing epithelioid smooth muscle component. *Am J Surg Pathol*. 1997;21(10):1123–1130.

Eble JN, Bonsib SM. Extensively cystic renal neoplasms: cystic nephroma, cystic partially differentiated nephroblastoma, multilocular cystic renal cell carcinoma, and cystic hamartoma of renal pelvis. *Semin Diagn Pathol*. 1998;15(1):2–20.

Eknoyan G. A clinical view of simple and complex renal cysts. *J Am Soc Nephrol*. 2009;20(9):1874–1876.

Ferrans VJ, Yu ZX, Nelson WK, et al. Lymphangioleiomyomatosis (LAM): a review of clinical and morphological features. *J Nippon Med Sch*. 2000;67(5):311–329.

Ferry JA, Malt RA, Young RH. Renal angiomyolipoma with sarcomatous transformation and pulmonary metastases. *Am J Surg Pathol*. 1991;15(11):1083–1088.

Flum AS, Hamoui N, Said MA, et al. Update on the diagnosis and management of renal angiomyolipoma. *J Urol*. 2016;195(4 Pt 1):834–846.

Frank I, Blute ML, Cheville JC, et al. Solid renal tumors: an analysis of pathological features related to tumor size. *J Urol*. 2003;170(6 Pt 1):2217–2220.

Franz DN. Everolimus: an mTOR inhibitor for the treatment of tuberous sclerosis. *Expert Rev Anticancer Ther*. 2011;11(8):1181–1192.

Fujii Y, Ajima J, Oka K, et al. Benign renal tumors detected among healthy adults by abdominal ultrasonography. *Eur Urol*. 1995;27(2):124–127.

Fursevich D, Derrick E, O'Dell MC, et al. Solitary fibrous tumor of the kidney: a case report and literature review. *Cureus*. 2016;8(2):e490.

Giunchi F, Fiorentino M, Vagnoni V, et al. Renal oncocytosis: a clinicopathological and cytogenetic study of 42 tumours occurring in 11 patients. *Pathology*. 2016;48(1):41–46.

Gordetsky J, Zarzour J. Correlating preoperative imaging with histologic subtypes of renal cell carcinoma and common mimickers. *Curr Urol Rep*. 2016;17(7):52.

Gorin MA, Rowe SP, Baras AS, et al. Prospective evaluation of (99m)Tc-sestamibi SPECT/CT for the diagnosis of renal oncocytomas and hybrid oncocytic/chromophobe tumors. *Eur Urol*. 2016;69(3):413–416.

Gottardo F, Cesari M, Morra A, et al. A kidney tumor in an adolescent with severe hypertension and hypokalemia: an uncommon case–case report and review of the literature on reninoma. *Urol Int*. 2010;85(1):121–124.

Grantham JJ. Clinical practice. Autosomal dominant polycystic kidney disease. *N Engl J Med*. 2008;359(14):1477–1485.

Grantham JJ, Torres VE, Chapman AB, et al. Volume progression in polycystic kidney disease. *New Engl J Med*. 2006;354(20):2122–2130.

Grawitz P. Demonstration eines grossen Angio-Myo-Lipoms der Niere. *Dtsch Med Wochenschr*. 1900;26:290.

Grignon DJ, Eble JN. Papillary and metanephric adenomas of the kidney. *Semin Diagn Pathol*. 1998;15(1):41–53.

Grodstein EI, Baggett N, Wayne S, et al. An evaluation of the safety and efficacy of simultaneous bilateral nephrectomy and renal transplantation for polycystic kidney disease: a 20-year experience. *Transplantation*. 2017;101(11):2774–2779.

Haab F, Duclos JM, Guyenne T, et al. Renin secreting tumors: diagnosis, conservative surgical approach and long-term results. *J Urol*. 1995;153(6):1781–1784.

Hadley DA, Bryant LJ, Ruckle HC. Conservative treatment of renal angiomyolipomas in patients with tuberous sclerosis. *Clin Nephrol*. 2006;65(1):22–27.

Hafron J, Fogarty JD, Hoenig DM, et al. Imaging characteristics of minimal fat renal angiomyolipoma with histologic correlations. *Urology*. 2005;66(6):1155–1159.

Halpenny D, Snow A, McNeill G, et al. The radiological diagnosis and treatment of renal angiomyolipoma-current status. *Clin Radiol*. 2010;65(2):99–108.

Hamlin JA, Smith DC, Taylor FC, et al. Renal angiomyolipomas: long-term follow-up of embolization for acute hemorrhage. *Can Assoc Radiol J*. 1997;48(3):191–198.

Han YM, Kim JK, Roh BS, et al. Renal angiomyolipoma: selective arterial embolization–effectiveness and changes in angiomyogenic components in long-term follow-up. *Radiology*. 1997;204(1):65–70.

Harisinghani MG, Maher MM, Gervais DA, et al. Incidence of malignancy in complex cystic renal masses (Bosniak category III): should imaging-guided biopsy precede surgery? *AJR Am J Roentgenol*. 2003;180(3):755–758.

Hateboer N, v Dijk MA, Bogdanova N, et al. Comparison of phenotypes of polycystic kidney disease types 1 and 2. European PKD1-PKD2 Study Group. *Lancet*. 1999;353(9147):103–107.

Hayn MH, Cannon GM Jr, Bastacky S, et al. Renal cell carcinoma containing fat without associated calcifications: two case reports and review of literature. *Urology*. 2009;73(2):443 [e445-447].

Heidenreich A, Hegele A, Varga Z, et al. Nephron-sparing surgery for renal angiomyolipoma. *Eur Urol*. 2002;41(3):267–273.

Helenon O, Crosnier A, Verkarre V, et al. Simple and complex renal cysts in adults: classification system for renal cystic masses. *Diagn Interv Imaging*. 2018;99:189–218.

Henderson RJ, Germany R, Peavy PW, et al. Fat density in renal cell carcinoma: demonstration with computerized tomography. *J Urol*. 1997;157(4):1347–1348.

Henske EP, Ao X, Short MP, et al. Frequent progesterone receptor immunoreactivity in tuberous sclerosis-associated renal angiomyolipomas. *Mod Pathol*. 1998;11(7):665–668.

Henske EP, Neumann HP, Scheithauer BW, et al. Loss of heterozygosity in the tuberous sclerosis (TSC2) region of chromosome band 16p13 occurs in sporadic as well as TSC-associated renal angiomyolipomas. *Genes Chromosomes Cancer*. 1995;13(4):295–298.

Hes O, Michal M, Kuroda N, et al. Vimentin reactivity in renal oncocytoma: immunohistochemical study of 234 cases. *Arch Pathol Lab Med*. 2007;131(12):1782–1788.

Hes O, Michal M, Sima R, et al. Renal oncocytoma with and without intravascular extension into the branches of renal vein have the same morphological, immunohistochemical, and genetic features. *Virchows Arch*. 2008;452(2):193–200.

Hirano D, Mashiko A, Murata Y, et al. A case of solitary fibrous tumor of the kidney: an immunohistochemical and ultrastructural study with a review of the literature. *Med Mol Morphol*. 2009;42(4):239–244.

Hocquelet A, Cornelis F, Le Bras Y, et al. Long-term results of preventive embolization of renal angiomyolipomas: evaluation of predictive factors of volume decrease. *Eur Radiol*. 2014;24(8):1785–1793.

Huang KH, Huang CY, Chung SD, et al. Malignant epithelioid angiomyolipoma of the kidney. *J Formos Med Assoc*. 2007;106(2 Suppl):S51–S54.

Hughson MD, Buchwald D, Fox M. Renal neoplasia and acquired cystic kidney disease in patients receiving long-term dialysis. *Arch Pathol Lab Med*. 1986;110(7):592–601.

Irazabal MV, Rangel LJ, Bergstralh EJ, et al. Imaging classification of autosomal dominant polycystic kidney disease: a simple model for selecting patients for clinical trials. *J Am Soc Nephrol*. 2015;26(1):160–172.

Ishikawa I, Saito Y, Asaka M, et al. Twenty-year follow-up of acquired renal cystic disease. *Clin Nephrol*. 2003;59(3):153–159.

Jinzaki M, Silverman SG, Akita H, et al. Renal angiomyolipoma: a radiological classification and update on recent developments in diagnosis and management. *Abdom Imaging*. 2014;39(3):588–604.

Jinzaki M, Tanimoto A, Narimatsu Y, et al. Angiomyolipoma: imaging findings in lesions with minimal fat. *Radiology*. 1997;205(2):497–502.

Jones EC, Pins M, Dickersin GR, et al. Metanephric adenoma of the kidney. A clinicopathological, immunohistochemical, flow cytometric, cytogenetic, and electron microscopic study of seven cases. *Am J Surg Pathol*. 1995;19(6):615–626.

Joshi S, Tolkunov D, Aviv H, et al. The genomic landscape of renal oncocytoma identifies a metabolic barrier to tumorigenesis. *Cell Rep*. 2015;13(9):1895–1908.

Joshi VV, Beckwith JB. Multilocular cyst of the kidney (cystic nephroma) and cystic, partially differentiated nephroblastoma. Terminology and criteria for diagnosis. *Cancer*. 1989;64(2):466–479.

Kashan M, Ghanaat M, Hotker AM, et al. Cystic renal cell carcinoma: a report on outcomes of surgery and active surveillance in patients retrospectively identified on pretreatment imaging. *J Urol*. 2018.

Katabathina VS, Vikram R, Nagar AM, et al. Mesenchymal neoplasms of the kidney in adults: imaging spectrum with radiologic-pathologic correlation. *Radiographics*. 2010;30(6):1525–1540.

Kato I, Inayama Y, Yamanaka S, et al. Epithelioid angiomyolipoma of the kidney. *Pathol Int*. 2009;59(1):38–43.

Kehagias D, Mourikis D, Kousaris M, et al. Management of renal angiomyolipoma by selective arterial embolization. *Urol Int*. 1998;60(2):113–117.

Kekre NS, Arun N, Date A. Retroperitoneal cystic lymphangioma causing intractable chyluria. *Br J Urol*. 1998;81(2):327–328.

Kennelly MJ, Grossman HB, Cho KJ. Outcome analysis of 42 cases of renal angiomyolipoma. *J Urol*. 1994;152(6 Pt 1):1988–1991.

Khetrapal S, Bhargava A, Jetley S, et al. Renal leiomyoma: an uncommon differential diagnosis of renal masses with a clinical relevance. *J Clin Diagn Res*. 2014;8(10):Fd8–Fd9.

Kim HJ, Kim CH, Choi YJ, et al. Juxtaglomerular cell tumor of kidney with CD34 and CD117 immunoreactivity: report of 5 cases. *Arch Pathol Lab Med*. 2006;130(5):707–711.

Kim JK, Kim SH, Jang YJ, et al. Renal angiomyolipoma with minimal fat: differentiation from other neoplasms at double-echo chemical shift FLASH MR imaging. *Radiology*. 2006;239(1):174–180.

Kim JK, Park SY, Shon JH, et al. Angiomyolipoma with minimal fat: differentiation from renal cell carcinoma at biphasic helical CT. *Radiology*. 2004;230(3):677–684.

Kohl SK, Mathews K, Baker J. Renal hilar mass in an 85-year-old woman. Solitary fibrous tumor. *Arch Pathol Lab Med*. 2006;130(1):117–119.

Kryvenko ON, Gupta NS, Meier FA, et al. Anastomosing hemangioma of the genitourinary system: eight cases in the kidney and ovary with immunohistochemical and ultrastructural analysis. *Am J Clin Pathol*. 2011;136(3):450–457.

Kuroda N, Gotoda H, Ohe C, et al. Review of juxtaglomerular cell tumor with focus on pathobiological aspect. *Diagn Pathol*. 2011;6:80.

Kuroda N, Ohe C, Deepika S, et al. Review of renal anastomosing hemangioma with focus on clinical and pathological aspects. *Pol J Pathol*. 2016;67(2):97–101.

Kuroda N, Toi M, Hiroi M, et al. Review of renal oncocytoma with focus on clinical and pathobiological aspects. *Histol Histopathol*. 2003;18(3):935–942.

Kutikov A, Fossett LK, Ramchandani P, et al. Incidence of benign pathologic findings at partial nephrectomy for solitary renal mass presumed to be renal cell carcinoma on preoperative imaging. *Urology*. 2006;68(4):737–740.

Kuzgunbay B, Turunc T, Bolat F, et al. Adult cystic nephroma: a case report and a review of the literature. *Urol Oncol*. 2009;27(4):407–409.

L'Hostis H, Deminiere C, Ferriere JM, et al. Renal angiomyolipoma: a clinicopathologic, immunohistochemical, and follow-up study of 46 cases. *Am J Surg Pathol*. 1999;23(9):1011–1020.

Lai S, Xu X, Diao T, et al. The efficacy of retroperitoneal laparoscopic deroofing of simple renal cyst with perirenal fat tissue wadding technique: a retrospective study. *Medicine (Baltimore)*. 2017;96(41):e8259.

Lane BR, Babineau D, Kattan MW, et al. A preoperative prognostic nomogram for solid enhancing renal tumors 7 cm or less amenable to partial nephrectomy. *J Urol*. 2007;178(2):429–434.

Larbcharoensub N, Limprasert V, Pangpunyakulchai D, et al. Renal leiomyoma: a case report and review of the literature. *Urol Case Rep*. 2017;13:3–5.

Lebret T, Poulain JE, Molinie V, et al. Percutaneous core biopsy for renal masses: indications, accuracy and results. *J Urol*. 2007;178(4 Pt 1):1184–1188 [discussion 1188].

Lee KH, Tsai HY, Kao YT, et al. Clinical behavior and management of three types of renal angiomyolipomas. *J Formos Med Assoc*. 2018.

Lee SY, Hsu HH, Chen YC, et al. Embolization of renal angiomyolipomas: short-term and long-term outcomes, complications, and tumor shrinkage. *Cardiovasc Intervent Radiol*. 2009;32(6):1171–1178.

Leibovich BC, Lohse CM, Cheville JC, et al. Predicting oncologic outcomes in renal cell carcinoma after surgery. *Eur Urol*. 2018;73(5):772–780.

Lemaitre L, Claudon M, Dubrulle F, et al. Imaging of angiomyolipomas. *Semin Ultrasound CT MR*. 1997;18(2):100–114.

Lemaitre L, Robert Y, Dubrulle F, et al. Renal angiomyolipoma: growth followed up with CT and/or US. *Radiology*. 1995;197(3):598–602.

Lenton J, Kessel D, Watkinson AF. Embolization of renal angiomyolipoma: immediate complications and long-term outcomes. *Clin Radiol*. 2008;63(8):864–870.

Limaiem F, Mekni A, Chelly I, et al. Renal epithelioid angiomyolipoma: a case report and literature review. *Pathologica*. 2008;100(1):31–35.

Liu JS, Ishikawa I, Horiguchi T. Incidence of acquired renal cysts in biopsy specimens. *Nephron*. 2000;84(2):142–147.

Liu L, Qian J, Singh H, et al. Immunohistochemical analysis of chromophobe renal cell carcinoma, renal oncocytoma, and clear cell carcinoma: an optimal and practical panel for differential diagnosis. *Arch Pathol Lab Med*. 2007;131(8):1290–1297.

Liu S, Lee S, Rashid P, et al. Active surveillance is suitable for intermediate term follow-up of renal oncocytoma diagnosed by percutaneous core biopsy. *BJU Int*. 2016;118(Suppl 3):30–34.

Liu W, Qi L, Chen M, et al. Laparoscopic retroperitoneal enucleation-separation surgery for renal angiomyolipoma: perioperative and oncologic outcomes based on a randomized controlled trial. *J Endourol*. 2016;30(8):901–905.

Lopez-Beltran A, Scarpelli M, Montironi R, et al. 2004 WHO classification of the renal tumors of the adults. *Eur Urol*. 2006;49(5):798–805.

Mabillard H, Srivastava S, Haslam P, et al. Large retroperitoneal haemorrhage following cyst rupture in a patient with autosomal dominant polycystic kidney disease. *Case Rep Nephrol*. 2017;2017.

Madewell JE, Goldman SM, Davis CJ Jr, et al. Multilocular cystic nephroma: a radiographic-pathologic correlation of 58 patients. *Radiology*. 1983;146(2):309–321.

Magro G, Cavallaro V, Torrisi A, et al. Intrarenal solitary fibrous tumor of the kidney report of a case with emphasis on the differential diagnosis in the wide spectrum of monomorphous spindle cell tumors of the kidney. *Pathol Res Pract*. 2002;198(1):37–43.

Makki A, Graumann O, Hoyer S, et al. Cryoablation of renal angiomyolipoma: an evaluation of safety and efficacy. *J Endourol*. 2017;31(11):1117–1122.

Mani NB, Sodhi KS, Singh P, et al. Renal lymphangiomatosis: a rare cause of bilateral nephromegaly. *Australas Radiol*. 2003;47(2):184–187.

Martignoni G, Pea M, Rigaud G, et al. Renal angiomyolipoma with epithelioid sarcomatous transformation and metastases: demonstration of the same genetic defects in the primary and metastatic lesions. *Am J Surg Pathol*. 2000;24(6):889–894.

Martin SA, Mynderse LA, Lager DJ, et al. Juxtaglomerular cell tumor: a clinicopathologic study of four cases and review of the literature. *Am J Clin Pathol*. 2001;116(6):854–863.

Matson MA, Cohen EP. Acquired cystic kidney disease: occurrence, prevalence, and renal cancers. *Medicine (Baltimore)*. 1990;69(4):217–226.

Matsui K, Tatsuguchi A, Valencia J, et al. Extrapulmonary lymphangioleiomyomatosis (LAM): clinicopathologic features in 22 cases. *Hum Pathol*. 2000;31(10):1242–1248.

Matsuyama A, Hisaoka M, Ichikawa K, et al. Sclerosing variant of epithelioid angiomyolipoma. *Pathol Int*. 2008;58(5):306–310.

Mazal PR, Exner M, Haitel A, et al. Expression of kidney-specific cadherin distinguishes chromophobe renal cell carcinoma from renal oncocytoma. *Hum Pathol*. 2005;36(1):22–28.

McCormack FX. Lymphangioleiomyomatosis: a clinical update. *Chest*. 2008;133(2):507–516.

McVicar M, Carman C, Chandra M, et al. Hypertension secondary to renin-secreting juxtaglomerular cell tumor: case report and review of 38 cases. *Pediatr Nephrol*. 1993;7(4):404–412.

Mene P, Festuccia F, Polci R, et al. Malignant epithelioid renal angiomyolipoma in a case of tuberous sclerosis with multiple organ involvement. *Contrib Nephrol*. 2001;136:299–305.

Mete UK, Niranjan J, Kusum J, et al. Reninoma treated with nephron-sparing surgery. *Urology*. 2003;61(6):1259.

Michal M. Benign mixed epithelial and stromal tumor of the kidney. *Pathol Res Pract*. 2000;196(4):275–276.

Michal M, Hes O, Bisceglia M, et al. Mixed epithelial and stromal tumors of the kidney. A report of 22 cases. *Virchows Arch*. 2004;445(4):359–367.

Miller BL, Mankowski Gettle L, Van Roo JR, et al. Comparative analysis of surgery, thermal ablation, and active surveillance for renal oncocytic neoplasms. *Urology*. 2018;112:92–97.

Milner J, McNeil B, Alioto J, et al. Fat poor renal angiomyolipoma: patient, computerized tomography and histological findings. *J Urol*. 2006;176(3):905–909.

Minervini A, Giubilei G, Masieri L, et al. Simple enucleation for the treatment of renal angiomyolipoma. *BJU Int*. 2007;99(4):887–891.

Moch H, Cubilla AL, Humphrey PA, et al. The 2016 WHO classification of tumours of the urinary system and male genital organs-part a: renal, penile, and testicular tumours.

Eur Urol. 2016;70(1):93–105.

Monn MF, Gellhaus PT, Patel AA, et al. Can radiologists and urologists reliably determine renal mass histology using standard preoperative computed tomography imaging? *J Endourol*. 2015;29(4):391–396.

Montironi R, Mazzucchelli R, Lopez-Beltran A, et al. Cystic Nephroma and mixed epithelial and stromal tumour of the kidney: opposite ends of the spectrum of the same entity? *Eur Urol*. 2008;54(6):1237–1246.

Moslemi MK. Mixed epithelial and stromal tumor of the kidney or adult mesoblastic nephroma: an update. *Urol J*. 2010;7(3):141–147.

Moudouni SM, Tligui M, Sibony M, et al. Malignant epithelioid renal angiomyolipoma involving the inferior vena cava in a patient with tuberous sclerosis. *Urol Int*. 2008;80(1):102–104 [discussion 104].

Mourikis D, Chatziioannou A, Antoniou A, et al. Selective arterial embolization in the management of symptomatic renal angiomyolipomas. *Eur J Radiol*. 1999;32(3):153–159.

Mousessian PN, Yamauchi FI, Mussi TC, et al. Malignancy rate, histologic grade, and progression of Bosniak Category III and IV complex renal cystic lesions. *AJR Am J Roentgenol*. 2017;209(6):1285–1290.

Msezane L, Chang A, Shikanov S, et al. Laparoscopic nephron-sparing surgery in the management of angiomyolipoma: a single center experience. *J Endourol*. 2010;24(4):583–587.

Muir TE, Cheville JC, Lager DJ. Metanephric adenoma, nephrogenic rests, and Wilms' tumor: a histologic and immunophenotypic comparison. *Am J Surg Pathol*. 2001;25(10):1290–1296.

Murphy AM, Buck AM, Benson MC, et al. Increasing detection rate of benign renal tumors: evaluation of factors predicting for benign tumor histologic features during past two decades.

Urology. 2009;73(6):1293–1297.

Nakagawa T, Kanai Y, Fujimoto H, et al. Malignant mixed epithelial and stromal tumours of the kidney: a report of the first two cases with a fatal clinical outcome. *Histopathology*. 2004;44(3):302–304.

Nelson CP, Sanda MG. Contemporary diagnosis and management of renal angiomyolipoma. *J Urol*. 2002;168(4 Pt 1):1315–1325.

Oesterling JE, Fishman EK, Goldman SM, et al. The management of renal angiomyolipoma. *J Urol*. 1986;135(6):1121–1124.

Olgac S, Hutchinson B, Tickoo SK, et al. Alpha-methylacyl-CoA racemase as a marker in the differential diagnosis of metanephric adenoma. *Mod Pathol*. 2006;19(2):218–224.

Omar AM, Khattak AQ, Lee JA. Cystic renal cell carcinoma arising from multilocular cystic nephroma of the same kidney. *Int Braz J Urol*. 2006;32(2):187–189 [discussion 189].

Omiyale AO. Anastomosing hemangioma of the kidney: a literature review of a rare morphological variant of hemangioma. *Ann Transl Med*. 2015;3(11):151.

Ornstein DK, Lubensky IA, Venzon D, et al. Prevalence of microscopic tumors in normal appearing renal parenchyma of patients with hereditary papillary renal cancer. *J Urol*. 2000;163(2):431–433.

Ouzaid I, Autorino R, Fatica R, et al. Active surveillance for renal angiomyolipoma: outcomes and factors predictive of delayed intervention. *BJU Int*. 2014;114(3):412–417.

Oxley JD, Sullivan J, Mitchelmore A, et al. Metastatic renal oncocytoma. *J Clin Pathol*. 2007;60(6):720–722.

Pan CC, Epstein JI. Detection of chromosome copy number alterations in metanephric adenomas by array comparative genomic hybridization. *Mod Pathol*. 2010;23(12):1634–1640.

Paner GP, Turk TM, Clark JI, et al. Passive seeding in metanephric adenoma: a review of pseudometastatic lesions in perinephric lymph nodes. *Arch Pathol Lab Med*. 2005;129(10):1317–1321.

Pappas P, Leonardou P, Papadoukakis S, et al. Urgent superselective segmental renal artery embolization in the treatment of life-threatening renal hemorrhage. *Urol Int*. 2006;77(1):34–41.

Park HK, Zhang S, Wong MK, et al. Clinical presentation of epithelioid angiomyolipoma. *Int J Urol*. 2007;14(1):21–25.

Park SB, Park YS, Kim JK, et al. Solitary fibrous tumor of the genitourinary tract. *AJR Am J Roentgenol*. 2011;196(2):W132–W137.

Patard JJ. Incidental renal tumours. *Curr Opin Urol*. 2009;19(5):454–458.

Patel HD, Druskin SC, Rowe SP, et al. Surgical histopathology for suspected oncocytoma on renal mass biopsy: a systematic review and meta-analysis. *BJU Int*. 2017;119(5):661–666.

Patel NP, Geisinger KR, Zagoria RJ, et al. Fine needle aspiration biopsy of metanephric adenoma: a case report. *Acta Cytol*. 2009;53(3):327–331.

Pea M, Bonetti F, Martignoni G, et al. Apparent renal cell carcinomas in tuberous sclerosis are heterogeneous: the identification of malignant epithelioid angiomyolipoma. *Am J Surg Pathol*. 1998;22(2):180–187.

Perez-Ordonez B, Hamed G, Campbell S, et al. Renal oncocytoma: a clinicopathologic study of 70 cases. *Am J Surg Pathol*. 1997;21(8):871–883.

Pesti T, Sukosd F, Jones EC, et al. Mapping a tumor suppressor gene to chromosome 2p13 in metanephric adenoma by microsatellite allelotyping. *Hum Pathol*. 2001;32(1):101–104.

Pierorazio PM, Hyams ES, Tsai S, et al. Multiphasic enhancement patterns of small renal masses (</=4 cm) on

preoperative computed tomography: utility for distinguishing subtypes of renal cell carcinoma, angiomyolipoma, and oncocytoma. *Urology*. 2013;81(6):1265–1271.

Pierorazio PM, Patel HD, Johnson MH, et al. Distinguishing malignant and benign renal masses with composite models and nomograms: a systematic review and meta-analysis of clinically localized renal masses suspicious for malignancy. *Cancer*. 2016;122(21):3267–3276.

Potretzke AM, Potretzke TA, Bauman TM, et al. Computed tomography and magnetic resonance findings of fat-poor angiomyolipomas. *J Endourol*. 2017;31(2):119–128.

Preece P, Mees B, Norris B, et al. Surgical management of haemorrhaging renal angiomyolipoma in pregnancy. *Int J Surg Case Rep*. 2015;7c:89–92.

Rahbari-Oskoui F, O'Neill WC. Diagnosis and management of acquired cystic kidney disease and renal tumors in ESRD patients. *Semin Dial*. 2017;30(4):373–379.

Ramon J, Rimon U, Garniek A, et al. Renal angiomyolipoma: long-term results following selective arterial embolization. *Eur Urol*. 2009;55(5):1155–1161.

Rangan GK, Lopez-Vargas P, Nankivell BJ, et al. Autosomal dominant polycystic kidney disease: a path forward. *Semin Nephrol*. 2015;35(6):524–537.

Rao VS, Naik R, Nayak KS. Leiomyoma of the kidney–report of two cases. *Indian J Pathol Microbiol*. 2001;44(3):343–344.

Reese AJ, Winstanley DP. The small tumour-like lesions of the kidney. *Br J Cancer*. 1958;12(4):507–516.

Reis M, Faria V, Lindoro J, et al. The small cystic and noncystic noninflammatory renal nodules: a postmortem study. *J Urol*. 1988;140(4):721–724.

Renshaw AA. Subclassification of renal cell neoplasms: an update for the practising pathologist. *Histopathology*.

2002;41(4):283–300.

Renshaw AA, Freyer DR, Hammers YA. Metastatic metanephric adenoma in a child. *Am J Surg Pathol*. 2000;24(4):570–574.

Reuter VE, Argani P, Zhou M, et al. Best practices recommendations in the application of immunohistochemistry in the kidney tumors: report from the International Society of Urologic Pathology consensus conference. *Am J Surg Pathol*. 2014;38(8):e35–e49.

Richard PO, Jewett MA, Bhatt JR, et al. Active surveillance for renal neoplasms with oncocytic features is safe. *J Urol*. 2016;195(3):581–586.

Richard PO, Jewett MA, Bhatt JR, et al. Renal tumor biopsy for small renal masses: a single-center 13-year experience. *Eur Urol*. 2015;68(6):1007–1013.

Robertson PW, Klidjian A, Harding LK, et al. Hypertension due to a renin-secreting renal tumour. *Am J Med*. 1967;43(6):963–976.

Rocca PC, Brunelli M, Gobbo S, et al. Diagnostic utility of S100A1 expression in renal cell neoplasms: an immunohistochemical and quantitative RT-PCR study. *Mod Pathol*. 2007;20(7):722–728.

Romano FU, Gonzalez-Serrano A, Moreno-Aranda J. Renal pelvis leiomyoma- an infrequent clinical case. *J Clin Diagn Res*. 2017;11(5):Pd12–pd13.

Romero FR, Kohanim S, Lima G, et al. Leiomyomas of the kidney: emphasis on conservative diagnosis and treatment. *Urology*. 2005;66(6):1319.

Romis L, Cindolo L, Patard JJ, et al. Frequency, clinical presentation and evolution of renal oncocytomas: multicentric experience from a European database. *Eur Urol*. 2004;45(1):53–57 [discussion 57].

Roy C, Tuchmann C, Lindner V, et al. Renal cell carcinoma with a fatty component mimicking angiomyolipoma on CT. *Br J Radiol*. 1998;71(849):977–979.

Rubenstein JN, Eggener SE, Pins MR, et al. Juxtaglomerular apparatus tumor: a rare, surgically correctable cause of hypertension. *Rev Urol*. 2002;4(4):192–195.

Ryu JH, Moss J, Beck GJ, et al. The NHLBI lymphangioleiomyomatosis registry: characteristics of 230 patients at enrollment. *Am J Respir Crit Care Med*. 2006;173(1):105–111.

Saito K, Fujii Y, Kasahara I, et al. Malignant clear cell “sugar” tumor of the kidney: clear cell variant of epithelioid angiomyolipoma. *J Urol*. 2002;168(6):2533–2534.

Saremian J, Kubik MJ, Masood S. Cytologic features of metanephric adenoma of the kidney: case report and review of the literature. *Lab Med*. 2015;46(2):153–158 [quiz e130].

Schmidbauer J, Remzi M, Memarsadeghi M, et al. Diagnostic accuracy of computed tomography-guided percutaneous biopsy of renal masses. *Eur Urol*. 2008;53(5):1003–1011.

Schonfeld AD, Jackson JA, Somerville SP, et al. Renin-secreting juxtaglomerular tumor causing severe hypertension: diagnosis by computerized tomography-directed needle biopsy. *J Urol*. 1991;146(6):1607–1609.

Schoots IG, Zaccai K, Hunink MG, et al. Bosniak classification for complex renal cysts reevaluated: a systematic review. *J Urol*. 2017;198(1):12–21.

Seyam RM, Bissada NK, Kattan SA, et al. Changing trends in presentation, diagnosis and management of renal angiomyolipoma: comparison of sporadic and tuberous sclerosis complex-associated forms. *Urology*. 2008;72(5):1077–1082.

Shen SS, Truong LD, Ayala AG, et al. Recently described and emphasized entities of renal neoplasms. *Arch Pathol Lab Med*. 2007;131(8):1234–1243.

Shuch B, Amin A, Armstrong AJ, et al. Understanding pathologic variants of renal cell carcinoma: distilling therapeutic opportunities from biologic complexity. *Eur Urol*. 2015;67(1):85–97.

Silverman SG, Mortele KJ, Tuncali K, et al. Hyperattenuating renal masses: etiologies, pathogenesis, and imaging evaluation. *Radiographics*. 2007;27(4):1131–1143.

Simpfendorfer C, Herts BR, Motta-Ramirez GA, et al. Angiomyolipoma with minimal fat on MDCT: can counts of negative-attenuation pixels aid diagnosis? *AJR Am J Roentgenol*. 2009;192(2):438–443.

Singer AJ, Anders KH. Neurilemoma of the kidney. *Urology*. 1996;47(4):575–581.

Skinnider BF, Folpe AL, Hennigar RA, et al. Distribution of cytokeratins and vimentin in adult renal neoplasms and normal renal tissue: potential utility of a cytokeratin antibody panel in the differential diagnosis of renal tumors. *Am J Surg Pathol*. 2005;29(6):747–754.

Snyder ME, Bach A, Kattan MW, et al. Incidence of benign lesions for clinically localized renal masses smaller than 7 cm in radiological diameter: influence of sex. *J Urol*. 2006;176(6 Pt 1):2391–2395 [discussion 2395-2396].

Sooriakumaran P, Gibbs P, Coughlin G, et al. Angiomyolipomata: challenges, solutions, and future prospects based on over 100 cases treated. *BJU Int*. 2010;105(1):101–106.

Squires JP, Ulbright TM, DeSchryver-Kecskemeti K, et al. Juxtaglomerular cell tumor of the kidney. *Cancer*. 1984;53(3):516–523.

Staehler M, Sauter M, Helck A, et al. Nephron-sparing resection of angiomyolipoma after sirolimus pretreatment in patients with tuberous sclerosis. *Int Urol Nephrol*. 2012;44(6):1657–1661.

Stamatiou K, Polizois K, Kollaitis G, et al. Cystic nephroma: a case report and review of the literature. *Cases J*. 2008;1(1):267.

Steiner M, Quinlan D, Goldman SM, et al. Leiomyoma of the kidney: presentation of 4 new cases and the role of computerized tomography. *J Urol*. 1990;143(5):994–998.

Steiner MS, Goldman SM, Fishman EK, et al. The natural history of renal angiomyolipoma. *J Urol*. 1993;150(6):1782–1786.

Steinlein OK, Ertl-Wagner B, Ruzicka T, et al. Birt-Hogg-Dube syndrome: an underdiagnosed genetic tumor syndrome. *J Dtsch Dermatol Ges*. 2018;16(3):278–283.

Stuart R, Salyer WR, Salyer DC, et al. Renomedullary interstitial cell lesions and hypertension. *Hum Pathol*. 1976;7(3):327–332.

Sukov WR, Cheville JC, Lager DJ, et al. Malignant mixed epithelial and stromal tumor of the kidney with rhabdoid features: report of a case including immunohistochemical, molecular genetic studies and comparison to morphologically similar renal tumors. *Hum Pathol*. 2007;38(9):1432–1437.

Sun DZ, Campbell SC. Atypical epithelioid angiomyolipoma: a rare variant with malignant potential. *Urology*. 2018;112:20–22.

Tamboli P, Ro JY, Amin MB, et al. Benign tumors and tumor-like lesions of the adult kidney. Part II: benign mesenchymal and mixed neoplasms, and tumor-like lesions. *Adv Anat Pathol*. 2000;7(1):47–66.

Tan G, Liu L, Qiu M, et al. Clinicopathologic features of renal epithelioid angiomyolipoma: report of one case and review of literatures. *Int J Clin Exp Pathol*. 2015;8(1):1077–1080.

Tan YK, Best SL, Olweny E, et al. Radiofrequency ablation of incidental benign small renal mass: outcomes and follow-up protocol. *Urology*. 2012;79(4):827–830.

Tanabe A, Naruse M, Ogawa T, et al. Dynamic computer tomography is useful in the differential diagnosis of juxtaglomerular cell tumor and renal cell carcinoma. *Hypertens Res*. 2001;24(4):331–336.

Tanaka T, Okumura A, Mori H. Juxtaglomerular cell tumor. *Arch Pathol Lab Med*. 1993;117(11):1161–1164.

Terada N, Arai Y, Kinukawa N, et al. The 10-year natural history of simple renal cysts. *Urology*. 2008;71(1):7–11 [discussion 11-12].

Terada N, Arai Y, Kinukawa N, et al. Risk factors for renal cysts. *BJU Int*. 2004;93(9):1300–1302.

Thompson RH, Boorjian SA, Lohse CM, et al. Radical nephrectomy for pT1a renal masses may be associated with decreased overall survival compared with partial nephrectomy. *J Urol*. 2008;179(2):468–471 [discussion 472-463].

Tickoo SK, Amin MB, Zarbo RJ. Colloidal iron staining in renal epithelial neoplasms, including chromophobe renal cell carcinoma: emphasis on technique and patterns of staining. *Am J Surg Pathol*. 1998;22(4):419–424.

Turbiner J, Amin MB, Humphrey PA, et al. Cystic nephroma and mixed epithelial and stromal tumor of kidney: a detailed clinicopathologic analysis of 34 cases and proposal for renal epithelial and stromal tumor (REST) as a unifying term. *Am J Surg Pathol*. 2007;31(4):489–500.

Umphrey HR, Lockhart ME, Kenney PJ. Benign renal schwannoma: a case report and literature review. *Radiol Case Rep*. 2007;2(2):52–55.

Upadhyay AK, Neely JA. Cystic nephroma: an emerging entity. *Ann R Coll Surg Engl*. 1989;71(6):381–383.

van Slegtenhorst M, de Hoogt R, Hermans C, et al. Identification of the tuberous sclerosis gene TSC1 on chromosome 9q34. *Science*. 1997;277(5327):805–808.

Varela JR, Bargiela A, Requejo I, et al. Bilateral renal lymphangiomatosis: US and CT findings. *Eur Radiol*. 1998;8(2):230–231.

Villalta JD, Sorensen MD, Durack JC, et al. Selective arterial embolization of angiomyolipomas: a comparison of smaller and larger embolic agents. *J Urol*. 2011;186(3):921–927.

Wang J, Arber DA, Frankel K, et al. Large solitary fibrous tumor of the kidney: report of two cases and review of the literature. *Am J Surg Pathol*. 2001;25(9):1194–1199.

Wang KL, Weinrach DM, Luan C, et al. Renal papillary adenoma–a putative precursor of papillary renal cell carcinoma. *Hum Pathol*. 2007;38(2):239–246.

Wang LJ, Wong YC, Chen CJ, et al. Computerized tomography characteristics that differentiate angiomyolipomas from liposarcomas in the perinephric space. *J Urol*. 2002;167(2 Pt 1):490–493.

Wells FC, Naylor CP, Dunn DC. Leiomyoma of the renal vein. *J R Soc Med*. 1981;74(7):542–545.

Wildhaber BE, Chardot C, Le Coultre C, et al. Total laparoscopic excision of retroperitoneal cystic lymphangioma. *J Laparoendosc Adv Surg Tech A*. 2006;16(5):530–533.

Williamson SR. Renal oncocytoma with perinephric fat invasion. *Int J Surg Pathol*. 2016;24(7):625–626.

Williamson SR, Gadde R, Trpkov K, et al. Diagnostic criteria for oncocytic renal neoplasms: a survey of urologic pathologists. *Hum Pathol*. 2017;63:149–156.

Wobker SE, Przybycin CG, Sircar K, et al. Renal oncocytoma with vascular invasion: a series of 22 cases. *Hum Pathol*. 2016;58:1–6.

Wobker SE, Williamson SR. Modern pathologic diagnosis of renal oncocytoma. *J Kidney Cancer VHL*. 2017;4(4):1–12.

Xipell JM. The incidence of benign renal nodules (a clinicopathologic study). *J Urol*. 1971;106(4):503–506.

Yamakado K, Tanaka N, Nakagawa T, et al. Renal angiomyolipoma: relationships between tumor size, aneurysm formation, and rupture. *Radiology*. 2002;225(1):78–82.

Yan J, Cheng JL, Li CF, et al. The findings of CT and MRI in patients with metanephric adenoma. *Diagn Pathol*. 2016;11(1):104.

Yap YS, Coleman M, Olver I. Aggressive mixed epithelial-stromal tumour of the kidney treated with chemotherapy and radiotherapy. *Lancet Oncol*. 2004;5(12):747–749.

Yip SK, Tan PH, Cheng WS, et al. Surgical management of angiomyolipoma: nephron-sparing surgery for symptomatic tumour. *Scand J Urol Nephrol*. 2000;34(1):32–35.

Yoder BM, Wolf JS Jr. Long-term outcome of laparoscopic decortication of peripheral and peripelvic renal and adrenal cysts. *J Urol*. 2004;171(2 Pt 1):583–587.

Yoshioka K, Miyakawa A, Ohno Y, et al. Production of erythropoietin and multiple cytokines by metanephric adenoma results in erythrocytosis. *Pathol Int*. 2007;57(8):529–536.

Young JR, Coy H, Kim HJ, et al. Performance of relative enhancement on multiphasic MRI for the differentiation of clear cell renal cell carcinoma (RCC) from papillary and chromophobe RCC subtypes and oncocytoma. *AJR Am J Roentgenol*. 2017;208(4):812–819.

Zanelli M, Cortecchia S, Righi E, et al. Epithelioid angiomyolipoma of the kidney: case report. *Pathologica*. 2008;100(3):202–205.

Zerem E, Imamovic G, Omerovic S. Simple renal cysts and arterial hypertension: does their evacuation decrease the blood pressure? *J Hypertens*. 2009;27(10):2074–2078.

Zhong Y, Wang H, Shen Y, et al. Diffusion-weighted imaging versus contrast-enhanced MR imaging for the differentiation of renal oncocytomas and chromophobe renal cell carcinomas. *Eur Radiol*. 2017;27(12):4913–4922.

Zhou M, Kort E, Hoekstra P, et al. Adult cystic nephroma and mixed epithelial and stromal tumor of the kidney are the same disease entity: molecular and histologic evidence. *Am J Surg Pathol*. 2009;33(1):72–80.

Zhuo JL. Renomedullary interstitial cells: a target for endocrine and paracrine actions of vasoactive peptides in the renal medulla. *Clin Exp Pharmacol Physiol*. 2000;27(7):465–473.

97

Malignant Renal Tumors

Steven C. Campbell MD, PhD, Brian R. Lane MD, PhD, Phillip M. Pierorazio MD

Historical Considerations

The introduction of nephrectomy for renal diseases provided the clinical information and histopathologic insight that form the basis of current concepts regarding renal tumors. Wolcott accomplished the first documented nephrectomy in 1861, mistakenly removing a tumor mass he believed was a hepatoma. **Simon performed the first planned nephrectomy in 1869** for persistent ureteral fistula, and this patient survived with cure of the fistula. One year later Gilmore in Mobile, Alabama, successfully accomplished the first planned nephrectomy in the United States for treatment of atrophic chronic pyelonephritis (Herr, 2008). Harris (1882) subsequently reported on 100 renal extirpations, a sufficient number to permit analysis of the clinical and pathologic features of renal disorders that require surgery.

With surgical intervention, tissue became available for histologic interpretation, although there were often serious professional differences of opinion. According to Carson (1928), the first accurate gross description of kidney tumors was from Konig and dates to 1826. In 1855 Robin examined solid tumors apparently arising in the kidney and concluded that renal carcinoma arose from renal tubular epithelium, and Waldeyer supported this interpretation in 1867. Unfortunately, theoretical and practical considerations of renal tumors were confused by Grawitz (1883), who contended that renal tumors arose from adrenal rests within the kidney. He introduced the terminology *struma lipomatodes aberrata renis* as descriptive nomenclature for the tumors of clear cells that he believed were derived from the adrenal glands. He based his conclusions not only on the fatty content of the tumors, analogous to that seen in the adrenal glands, but also on the location of the tumors beneath the renal capsule, approximation to the adrenal glands, and the lack of similarity of the cells to uriniferous tubules.

Subsequent investigators readily embraced the idea that renal tumors truly arose from the adrenal glands. In 1894 Lubarch endorsed the idea of a suprarenal origin of renal tumors, and the term *hypernephroid tumors,* indicating origin above the kidneys, was introduced (Birch-Hirschfeld and Doederlein, 1894). This semantic and conceptual mistake led to the term *hypernephroma,* which predominated in the literature describing parenchymal tumors of primary renal origin. Some clarification of the histopathology of renal tumors was derived from the work of Albarran and Imbert in 1903, and the four-volume contribution of Wolff, written between 1883 and 1928, improved our understanding of renal tumors (Herr, 2008).

The modern era has brought an appreciation that renal cell carcinoma (RCC) includes a number of distinct subtypes derived from the various parts of the nephron, each with a unique genetic basis and tumor biology (Linehan and Ricketts, 2013; Rini et al., 2009a). Other major advances in the past several decades have included the introduction of classic radical nephrectomy (RN) in the 1960s followed by a trend toward less radical approaches, including nephron-sparing surgery and a variety of minimally invasive approaches (Novick, 2007; Robson, 1963; Volpe et al., 2011). A common theme from early understanding to contemporary management of renal tumors **is that RCC remains primarily a surgical disease** and, although immune-based and targeted molecular approaches can occasionally provide durable clinical responses, cure is rarely seen without complete surgical excision (Petrelli et al., 2016; Pindoria et al., 2017). Unfortunately, the incidence of RCC is gradually increasing and, despite a trend toward earlier detection, mortality rates remain high.

Classification

Renal masses can be malignant, benign, or inflammatory (Table 97.1; Srigley et al., 2013), **or they can be classified based on radiographic appearance (simple cystic, complex cystic, solid)** (Table 97.2). These classification schemes have been updated based on current knowledge about the distinct subtypes of RCC and other benign and malignant tumors of the kidney (Srigley et al., 2013). Malignant renal tumors include RCC, urothelial-based malignancies, sarcomas, embryonic or pediatric tumors, lymphomas, and metastases. Benign renal tumors are diverse and present unique diagnostic challenges (see Chapter 96). Inflammatory and vascular entities must also be considered in the differential diagnosis.

TABLE 97.1

Renal Masses Classified by Pathologic Features

MALIGNANT		BENIGN

RENAL CELL CARCINOMA (RCC)
• Clear cell RCC
• Multilocular cystic clear cell renal cell neoplasm of low malignant potential
• Papillary RCC
• Chromophobe RCC
• Hybrid oncocytic chromophobe tumor
• Carcinoma of the collecting ducts of Bellini
• Renal medullary carcinoma
• MiT family translocation RCC[a]
  • Xp11 translocation RCC
  • t(6;11) RCC
• Mucinous tubular and spindle cell carcinoma
• Tubulocystic RCC
• Acquired cystic disease–
	NEPHROBLASTIC TUMORS[a]
	• Nephrogenic rests
	• Nephroblastoma (Wilms tumor)
	• Cystic partially differentiated nephroblastoma
	CARCINOMA ASSOCIATED WITH NEUROBLASTOMA
	Neuroendocrine Tumors
	• Carcinoid (low-grade neuroendocrine tumor)
	• Neuroendocrine carcinoma (high-grade neuroendocrine tumor)
	• Primitive neuroectodermal tumor
		CYSTIC LESIONS
		• Simple cyst
		• Hemorrhagic cyst
		SOLID LESIONS
		• Angiomyolipoma
		• Oncocytoma
		• Papillary adenoma (renal adenoma)
		• Metanephric tumors (adenoma, adenofibroma, stromal tumor)
		• Congenital mesoblastic nephroma[a]
		• Cystic nephroma/mixed epithelial stromal tumor
		• Reninoma (juxtaglomerular cell tumor)
		• Renomedullary interstitial tumor

associated RCC • Clear cell (tubulo) papillary RCC • Hereditary leiomyomatosis RCC syndrome–associated RCC • RCC, unclassified **UROTHELIUM-BASED CANCERS** • Urothelial carcinoma • Squamous cell carcinoma • Adenocarcinoma **SARCOMAS** • Leiomyosarcoma • Liposarcoma • Other sarcomas	• Neuroblastoma • Pheochromocytoma Hematopoietic and Lymphoid Tumors • Lymphoma • Leukemia • Plasmacytoma Germ Cell Tumors • Teratoma • Choriocarcinoma **METASTASIS** **INVASION BY ADJACENT NEOPLASM**	• Leiomyoma • Fibroma • Hemangioma • Lymphangioma • Schwannoma • Solitary fibrous tumor **VASCULAR LESIONS** • Renal artery aneurysm • Arteriovenous malformation **PSEUDOTUMOR** **INFLAMMATORY** • Abscess • Focal pyelonephritis • Xanthogranulomatous pyelonephritis • Infected renal cyst • Tuberculosis • Rheumatic granuloma

[a] More common in childhood or young adults.

Modified from Srigley JR, Delahunt B, Eble et al.: The International Society of Urological Pathology (ISUP) Vancouver Classification of Renal Neoplasia. *Am J Surg Pathol* 37(10):1469–1489, 2013.

TABLE 97.2

Radiologic and Pathologic Correlates for Renal Masses

SIMPLE CYSTIC	**STRONGLY ENHANCING MASS**	**INFILTRATIVE MASS**
Benign cyst Parapelvic cyst Hydronephrosis Caliceal diverticulum	Clear cell RCC Angiomyolipoma Oncocytoma Papillary RCC (occasionally) Chromophobe RCC (occasionally)	Lymphoma High-grade urothelial carcinoma Sarcomatoid differentiation Collecting duct carcinoma Renal medullary carcinoma Xanthogranulomatous pyelonephritis

		Metastasis (occasionally)
COMPLEX CYSTIC Cystic RCC Hemorrhagic cyst Hyperdense cyst Benign complex cyst Cystic nephroma Mixed epithelial-stromal tumor Cystic Wilms tumor Infected cyst/abscess Hydrocalix Arteriovenous malformation Renal artery aneurysm	**MODERATELY ENHANCING SOLID MASS** Papillary RCC Chromophobe RCC Clear cell RCC (occasionally) Oncocytoma Fat-poor angiomyolipoma Adenoma/metanephric adenoma Unifocal lymphoma Sarcoma Lobar nephronia Pseudotumor Infarct Metastasis	**CALCIFIED MASS** RCC Urothelial carcinoma Benign complex cyst Xanthogranulomatous pyelonephritis Renal artery aneurysm Concomitant nephrolithiasis
FAT-CONTAINING MASS Angiomyolipoma Liposarcoma Lipoma	**MULTIFOCAL/BILATERAL MASSES** Familial RCC Metastases Sporadic, multifocal RCC (particularly papillary RCC or clear cell RCC) Angiomyolipomas (tuberous sclerosis) Lymphoma Cystic tumors (autosomal dominant polycystic kidney disease)	

RCC, Renal cell carcinoma.

Modified from Simmons MN, Herts BR, Campbell SC: Image based approaches to the diagnosis of renal masses [lesson 39]. *AUA Update Series* 26:382–391, 2007.

Imaging and Clinical Risk Stratification of Renal Masses

Given the wide differential diagnosis of renal masses and current perspectives about tumor biology, clinical evaluation is extremely important in the assessment of the risk of malignancy and metastatic potential of a given renal mass in a specific patient. Clinical evaluation may include patient characteristics and mode of presentation, imaging characteristics, laboratory evaluation, and renal mass biopsy (RMB). A number of composite models and nomograms predict the likelihood of malignancy; however, these models have relatively modest concordance indices for the prediction of malignancy, generally in the range 0.55 to 0.65 (Haggstrom et al., 2013; Karakiewicz et al., 2009; Lane et al., 2007a; Yaycioglu et al., 2013). In these models and a large, systematic review of the data, **the strongest predictors of malignancy are male sex and increasing tumor size** (Pierorazio et al., 2016). In systematic meta-analysis of surgically resected tumors, men have a nearly threefold increased risk of malignancy (effect size 2.71, 95% confidence interval [CI] 2.39–3.02) compared with women. Although benign histology is more common in women, RCC still predominates in both genders.

When considering tumor size, 20% to 30% of renal masses less than 4 cm and 40% of renal masses less than 2 cm are benign (Johnson et al., 2015; Kutikov et al., 2006). The likelihood of malignancy increases per centimeter of tumor diameter (effect size 1.3 per cm increase in diameter, 95% CI 1.22–1.43) (Pierorazio et al., 2016). For example, one study reported that for tumors smaller than 1 cm 46% were benign and only 2% were high-grade RCC, whereas for tumors larger than 7 cm only 6% were benign and 58% were high-grade RCC (Frank et al., 2003). Importantly, many clinical T1a cancers (<4 cm) demonstrate indolent tumor biology. Less than 2% of patients with tumors 4 cm or smaller had or developed metastatic disease in extirpative surgical series (Thompson et al., 2009a; Umbreit et al., 2012). The emerging, prospective active surveillance (AS) literature also supports the indolent nature of small renal masses because 2% or less of patients progress to metastatic disease during short- to intermediate-term follow-up (Jewett et al., 2011; Pierorazio et al., 2015). Given the importance of tumor size in the risk-stratification of tumor biology and the fact that the majority of renal masses are discovered via incidental imaging, the initial discussion of risk stratification focuses on radiographic evaluation. Subsequent portions of the chapter cover clinical presentation, renal mass biopsy, and laboratory evaluation.

Radiographic Evaluation of Renal Masses

Radiographic evaluation of a renal mass remains the strongest predictor of malignancy and metastatic potential (Pierorazio et al., 2016). Several radiographic modalities are currently available for detection and evaluation of renal masses, each with relative strengths and limitations (Kang and Chandarana, 2012). Current guidelines recommend multiphase, cross-sectional imaging to ensure a systematic approach and diligent evaluation of suspected renal masses, given the large differential diagnosis and considerable overlap between benign and malignant renal lesions (Fig. 97.1 and see Table 97.2; Campbell et al., 2017a; Ljungberg et al., 2015; Motzer et al., 2017b).

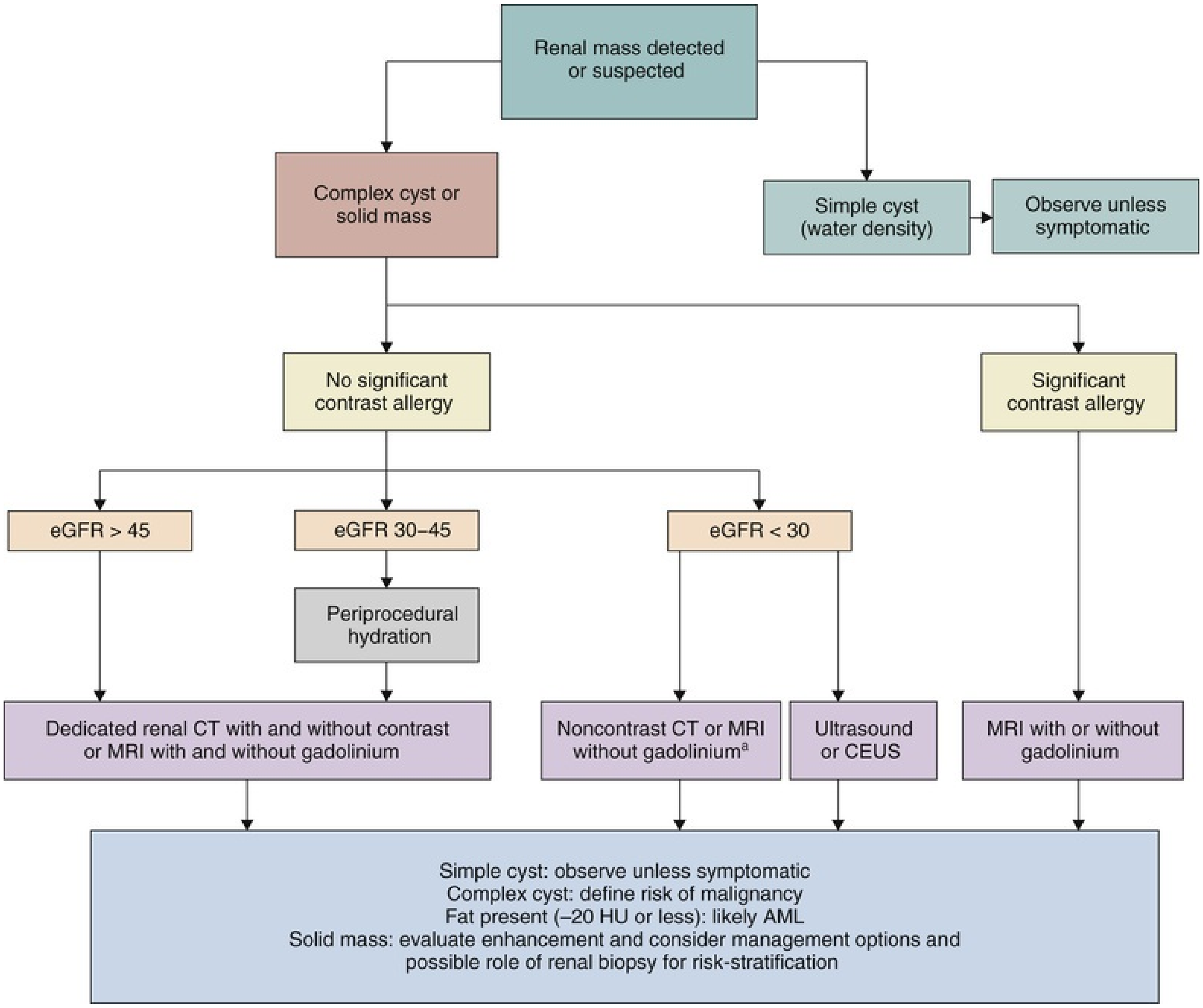
Renal mass detected or suspected
Complex cyst or solid mass
Simple cyst (water density)
Observe unless symptomatic
No significant contrast allergy
Significant contrast allergy
eGFR > 45
eGFR 30–45
eGFR < 30
Periprocedural hydration
Dedicated renal CT with and without contrast or MRI with and without gadolinium
Noncontrast CT or MRI without gadolinium[a]
Ultrasound or CEUS
MRI with or without gadolinium
Simple cyst: observe unless symptomatic
Complex cyst: define risk of malignancy
Fat present (–20 HU or less): likely AML
Solid mass: evaluate enhancement and consider management options and possible role of renal biopsy for risk-stratification

FIG. 97.1 Algorithm for radiographic evaluation of renal masses. *AML,* Angiomyolipoma; *CEUS,* contrast-enhanced ultrasound; *CT,* computed tomography; *eGFR,* estimated glomerular filtration rate in units of mL/min/1.73 m^2; *HU,* Hounsfield units; *IV,* intravenous; *MRI,* magnetic resonance imaging. [a]Based on the current literature, non-contrast CT or MRI are preferred over ultrasound or CEUS, although ultrasound-based technologies are reasonable alternatives.

Intravenous pyelography and renal arteriography are no longer recommended in the routine evaluation of renal masses. Historic features suggestive of malignancy on intravenous pyelography included calcification within the mass, increased tissue density, irregularity of the contours of the kidney, and distortion of the collecting system (Zagoria, 2000); however, the lack of sensitivity and specificity of intravenous pyelography for the detection of parenchymal tumors is well documented (Kang and Chandarana, 2012). Renal arteriography has a limited role in the diagnostic evaluation of renal masses and is primarily reserved for patients with concomitant renal artery disease. In equivocal cases, the presence or absence of neovascularity may help establish the diagnosis of RCC. However, 20% to 25% of RCCs are angiographically indistinct, even though most of these tumors are not truly avascular and demonstrate modest degrees of contrast enhancement on computed tomography (CT).

Multiphasic, cross-sectional imaging provides the most accurate characterization of renal masses while assessing for locally advanced features and intra-abdominal metastases and readily excludes angiomyolipoma by identifying intralesional fat (Davenport et al., 2017). CT and magnetic resonance imaging (MRI) are the most widely used and studied imaging modalities (Berland et al., 2010), whereas ultrasound and contrast-enhanced ultrasound (CEUS) are options for the evaluation of patients with renal masses (Gulati et al., 2015).

A dedicated renal CT remains the most important radiographic test for delineating the nature of a renal mass. CT, with and without the administration of contrast, is necessary to take full advantage of the contrast enhancement characteristics of highly vascular renal parenchymal tumors (Kang and Chandarana, 2012). **Enhancement of greater than 15 to 20 Hounsfield units (HU) is indicative of RCC, although this does not preclude benign histology** (Fig. 97.2; Berland et al., 2010). **Solid masses that also have substantial areas of negative CT attenuation numbers (**below −20 HU**) indicative of fat are diagnostic for angiomyolipoma (AML)** (Nelson and Sanda, 2002). Patients with an estimated glomerular filtration rate (eGFR) below 45 mL/min/1.73 m^2

undergoing CT with intravenous contrast should be considered for periprocedural hydration. Administration of intravenous contrast should be avoided and alternative imaging pursued if possible in patients with severe chronic kidney disease (CKD) who are nearing dialysis (see Fig. 97.1).

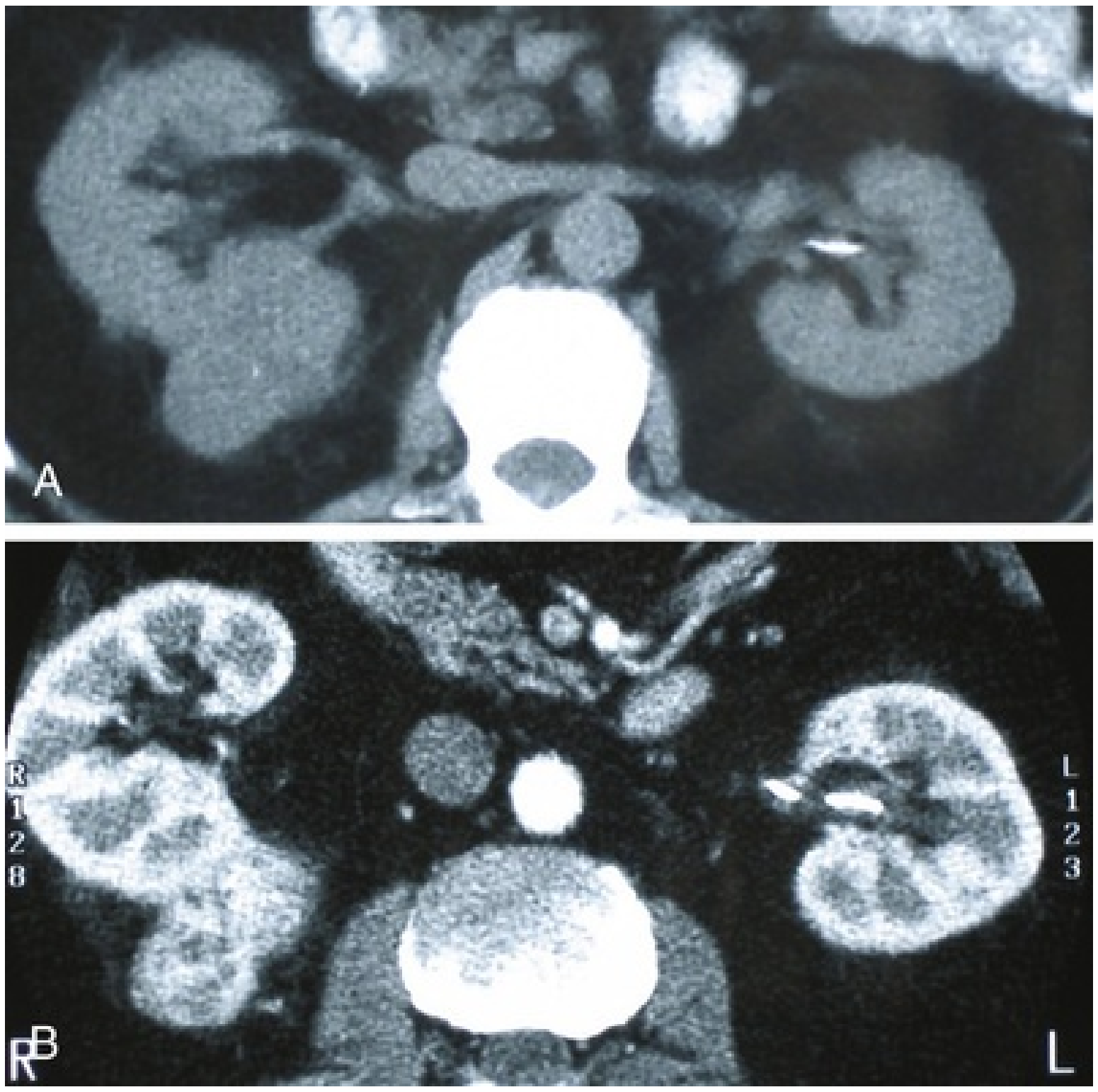

FIG. 97.2 (A) Computed tomography (CT) without administration of contrast shows solid, right posterior renal mass. (B) After administration of the contrast agent, CT shows that the mass enhances more than 20 HU and is thus highly suggestive of renal cell carcinoma (RCC). This mass was excised and confirmed to be clear cell RCC. (Courtesy Dr. Terrence Demos, Maywood, IL.)

MRI is the alternate standard imaging modality for the characterization of a renal mass (Donat et al., 2013; Kang and Chandarana, 2012). **Enhancement of greater than 20% with intravenous gadolinium-based contrast on MRI is suggestive of RCC** and may be particularly helpful in masses smaller than 2 cm (Fig. 97.3; Rofsky et al., 1991). MRI is also useful for differentiating tissue planes and for defining extent of vascular involvement in many patients with locally advanced RCC. **A significant concern with MRI with gadolinium is the uncommon but potentially serious complication of nephrogenic systemic fibrosis (NSF). NSF is most common in patients on dialysis, with CKD stage**

4 and 5, significant acute kidney injury, and/or patients receiving multiple doses of gadolinium-based contrast agents (Bach and Zhang, 2008). Therefore gadolinium-based contrast should generally be used only in patients with an eGFR greater than 30 mL/min/1.73 m^2 (Agarwal et al., 2009). Newer macrolytic gadolinium agents appear to have substantially reduced risk of NSF and will probably allow for use of MRI with contrast in patients on dialysis or those with severe CKD in the near future (ACR Committee on Drugs and Contrast Media, 2017).

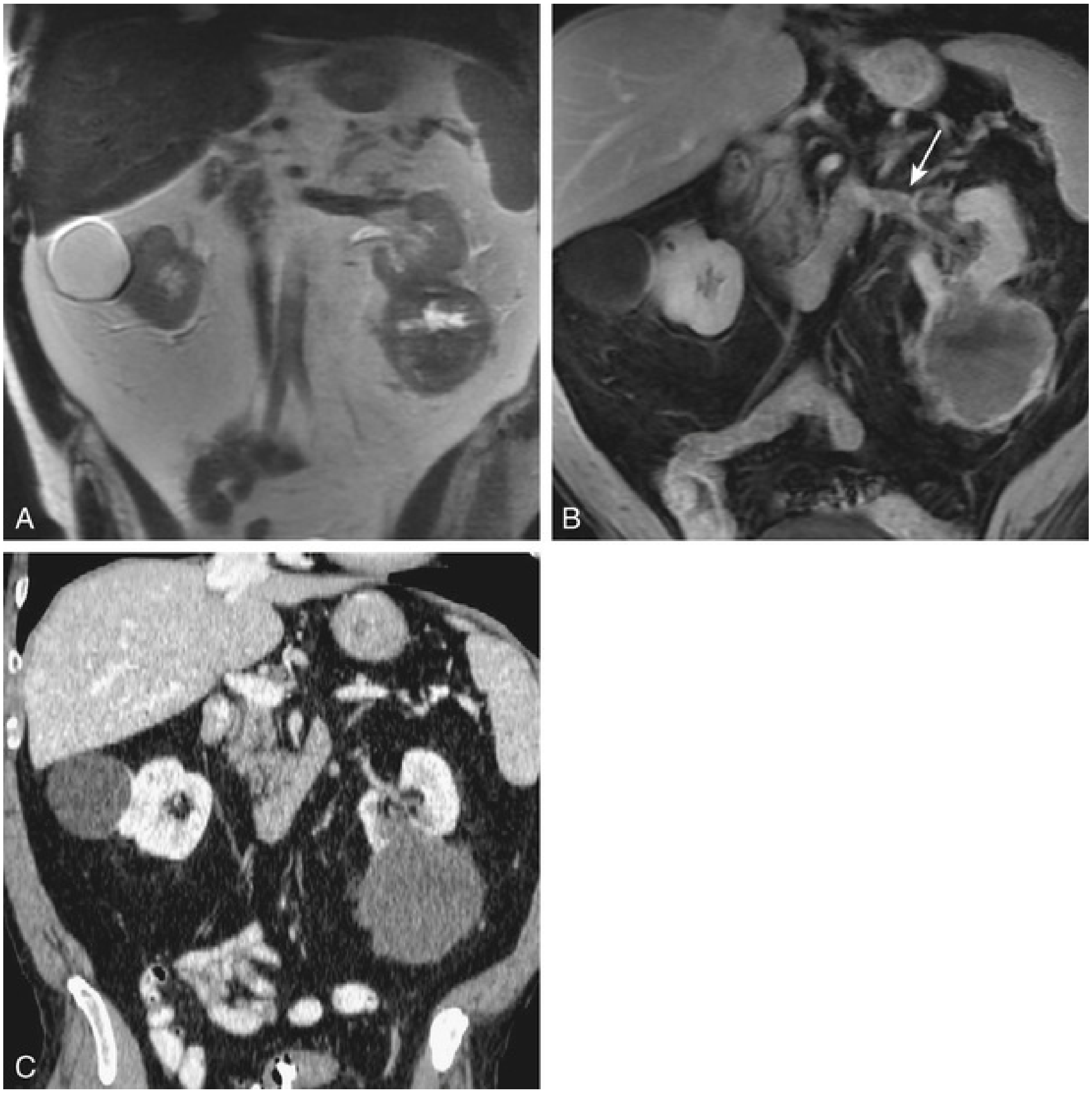

FIG. 97.3 Renal cell carcinoma on pre- and postcontrast magnetic resonance image (MRI) and contrast-enhanced computed tomography

(CT). (A) Precontrast, T2-weighted MRI showing a simple cyst in the right kidney and heterogeneous 8.5-cm, lower pole tumor in the left kidney. (B) Postcontrast, fat-saturated, T1-weighted MRI reveals further anatomic details regarding the left renal tumor, including a tumor thrombus *(arrow)* within the renal vein. (C) Contrast-enhanced CT imaging (parenchymal phase) from the same patient also shows the left renal tumor. MRI was performed in this patient because of equivocal findings on the initial CT regarding a renal vein thrombus, which was seen clearly on pre- and postcontrast MRI. (Courtesy Dr. Leena Mammen, Grand Rapids, MI.)

Ultrasonography is a noninvasive and relatively inexpensive modality that can differentiate cystic versus solid renal masses, and it continues to play an important role for such lesions. **Strict ultrasonographic criteria for simple cysts have been defined and include a smooth cyst wall, a round or oval shape without internal echoes, and through-transmission with strong acoustic shadowing posteriorly. A renal mass that is not clearly a simple cyst by strict ultrasound criteria should be evaluated further with multiphasic, cross-sectional imaging** (Campbell et al., 2017a). CEUS using microbubbles has also shown promise for the characterization and assessment of enhancement of renal masses and may play an important role in patients with CKD in the future (Gulati et al., 2015).

Regardless of imaging modality used, **imaging should comment on renal mass diameter in craniocaudal, transverse, and anterioposterior dimensions; tumor morphology, including involvement of or juxtaposition to the renal hilum, vein, or collecting system; enhancement characteristics; and associated features such as retroperitoneal lymphadenopathy and presence or absence of abdominal metastases.** As discussed earlier, increasing tumor size is the strongest predictor of malignant disease and subsequent metastatic potential (Pierorazio et al., 2016). Solid tumor architecture (versus cystic) is also predictive of malignancy, although many complex cystic masses are RCC (Israel and Bosniak, 2005). Risk-stratification of cystic renal masses is discussed below. Tumor location and complexity describe the relationship of the mass with the renal hilum, collecting system, polarity, and endophytic versus exophytic location. Composite complexity profiles include the R.E.N.A.L. (Radius, Endophytic vs. exophytic, Nearness to collecting system, Anterior/posterior, Location relative to polar lines) nephrometry score, the PADUA score, and the C-index (Ficarra et al., 2009b; Kutikov and Uzzo, 2009; Simmons et al., 2010). Tumor complexity may be useful in the selection of nephron-sparing surgery versus RN, surgical approach (open vs. minimally invasive), and assessing for risk of surgical complications (Bruner et al., 2011; Stroup et al., 2012; Tobert et al., 2012). Emerging data indicate that increasing tumor complexity may also correlate with risk of malignancy and aggressive histology (Kutikov et al., 2011; Pierorazio et al., 2016).

Infiltrative growth pattern broadens the differential diagnosis and has prognostic significance; urothelial cancer, lymphoma, infectious processes, and high-grade or sarcomatoid RCC commonly demonstrate infiltrative growth patterns and indistinct borders on imaging. Enhancement patterns can also be suggestive of tumor histology because the papillary subtype of RCC is often hypoenhancing relative to other subtypes of RCC (Pierorazio et al., 2013; Young et al., 2013). However, definitive conclusions cannot be drawn regarding biologic potential based on enhancement pattern alone because significant overlap can exist in imaging characteristics of clear cell RCC, oncocytoma, and subtypes of papillary RCC on cross-sectional imaging (Kopp et al., 2013; Young et al., 2013).

Molecular imaging exploits existing cellular processes and high-affinity radio-labeled molecules to improve diagnostic imaging. Fluorodeoxyglucose positron emission tomography (FDG-PET)-CT is used in a variety of malignancies but has a limited role in RCC because of its high levels of visual conspicuity in the kidney and at the most common sites of metastatic disease (Bagheri et al., 2017). ^{99m}Tc-sestamibi single-photon emission CT (SPECT) has demonstrated promising early results in distinguishing renal oncocytoma and hybrid oncocytic/chromophobe tumors from clear cell RCC and awaits large-scale validation (Gorin et al., 2016). Sestamibi is taken up by mitochondria, which are in abundance in oncocytomas and hybrid oncocytic/chromophobe tumors, and a strong signal is suggestive of these histologies. Additional molecular imaging agents including ^{124}I-girentuximab, which targets carbonic anhydrase IX primarily present on clear cell RCC, and prostate-specific membrane antigen (PSMA, epithelial membrane target) remain in development for RCC (Divgi et al., 2013; Rowe et al., 2015).

Evaluation of Cystic Renal Lesions

The differentiation between benign renal cysts and cystic RCC remains one of the more common and challenging problems in renal imaging (Bosniak, 2012). Simple cysts are thin-walled, fluid-filled structures with a nearly zero risk of malignancy. The risk of malignancy increases with cyst complexity as defined by evaluation of the wall of the lesion; its thickness and contour; the number, contour, and thickness of any septa; the amount, character, and location of any calcifications; the density of fluid in the lesion; the margination of the lesion; and the presence of solid components. **The Bosniak classification scheme was developed based on CT imaging criteria to define renal cystic lesions into categories that are distinct from one another in terms of the likelihood of malignancy** (Table 97.3; Israel and Bosniak, 2005). **Bosniak 1 lesions are uncomplicated, simple, benign cysts** of the kidney that are straightforward to diagnose on ultrasonography, CT, or MRI. These are by far the most common renal cystic lesions, and **in the absence of associated symptoms, no treatment or surveillance is necessary.**

TABLE 97.3

Classification of Complex Renal Cysts

BOSNIAK CLASSIFICATION	RADIOGRAPHIC FEATURES	RISK OF MALIGNANCY	MANAGEMENT
I	Water density Homogeneous, hairline thin wall No septa No calcification No enhancement	None	Surveillance not necessary
II	Few hairline septa in which “perceived” enhancement may be present Fine calcification or short segment of slightly thickened calcification in wall or septa No unequivocal enhancement	Minimal	Surveillance not necessary
	Hyperdense lesion: ≤3 cm, well marginated, with no unequivocal enhancement	Minimal	Periodic surveillance
IIF	Multiple hairline thin septa Minimal smooth wall	3%–5%	Periodic surveillance

	thickening “Perceived” enhancement of wall or septae may be present Calcification may be thick or nodular but must be without enhancement Generally well marginated No unequivocal enhancement		
	Hyperdense lesion: >3 cm or totally intrarenal with no enhancement	5%–10%	Periodic surveillance
III	“Indeterminate,” thickened irregular or smooth walls or septa in which measurable enhancement is present	50%	Surgical excision[a]
IV	Clearly malignant lesions that can have all the criteria of category III but also contain enhancing soft-tissue components	75%–90%	Surgical excision[a]

[a] Surgical excision should be considered if the patient is in good health. Active surveillance is an option for select patients. Thermal ablation is probably best avoided for cystic lesions because of concern about tumor spillage.

Bosniak 2 lesions are minimally complex cysts with a low risk of malignancy and include nonenhancing septated cysts, cysts with calcium in the wall or septum, infected cysts, and hyperdense (high-density) cysts (Fig. 97.4; Israel and Bosniak, 2005). Hyperdense cysts are benign lesions, classically less than 3 cm in diameter, with high CT attenuation before contrast administration (>20 HU) because of old, degenerated, or clotted blood. This category is now subdivided to differentiate Bosniak 2 lesions that do not require surveillance from category 2F lesions that mandate surveillance. **Bosniak 2F lesions have a 15% risk of radiographic progression to more complex cysts and a 3% to 10% risk of malignancy** (El-Mokadem et al., 2014; Graumann et al., 2013; O'Malley et al., 2009; Smith et al., 2012). Diagnostic criteria for

Bosniak 2F cysts are detailed in Table 97.3. **A major differentiating factor for complex renal cysts is the presence of unequivocal contrast enhancement, which is not seen in Bosniak 2 and 2F lesions.**

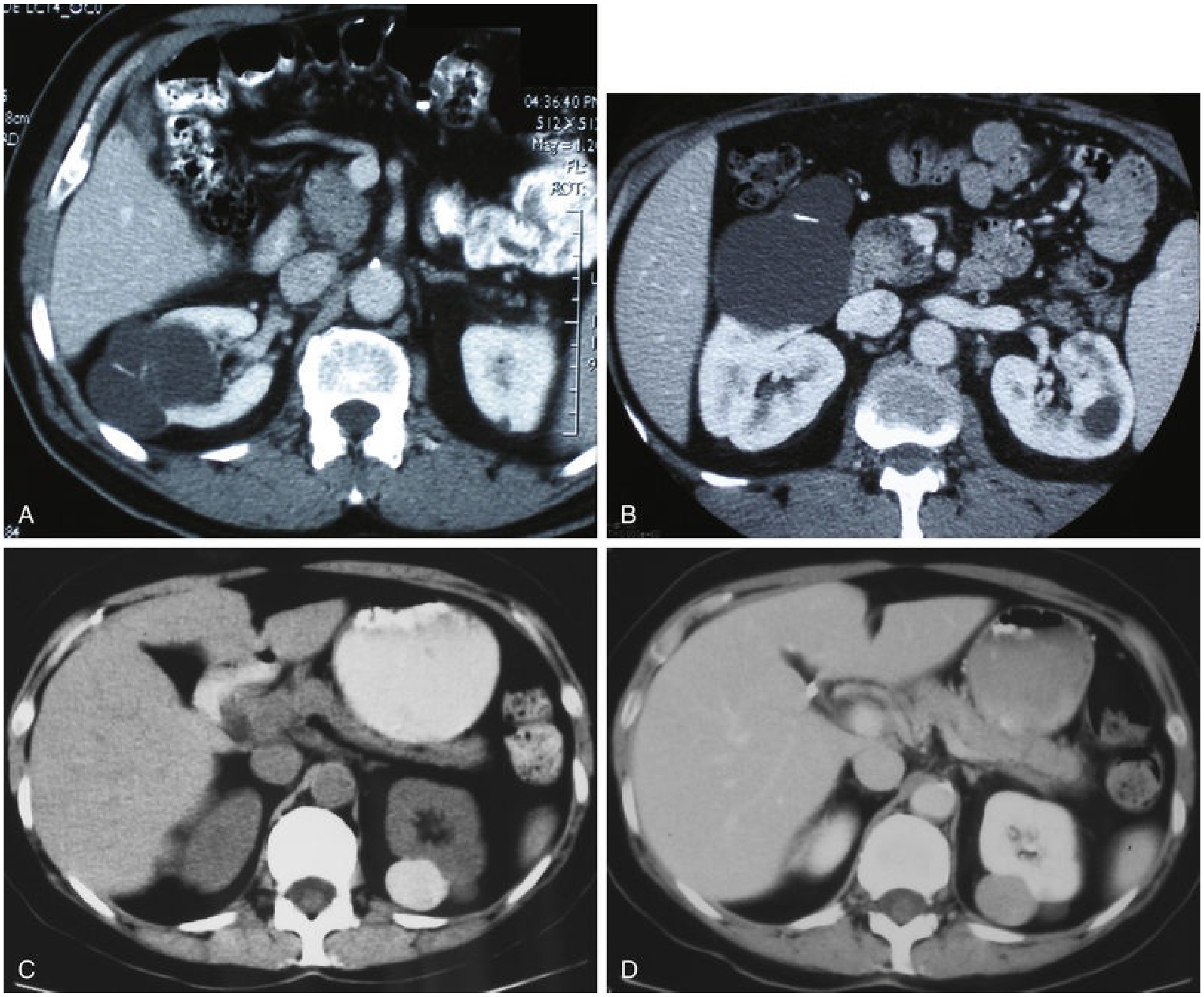

FIG. 97.4 Bosniak category 2 renal cysts. (A) Computed tomography (CT) shows right renal cyst with thin internal septation. (B) CT in another patient shows relatively thin, curvilinear calcification in the septa of the wall of right renal cyst. (C) CT without administration of contrast material shows small, smooth-walled, high-density left renal cyst. (D) CT after administration of contrast material shows no enhancement of the cyst. This is an extreme example of a hyperdense cyst. (Courtesy Dr. Terrence Demos, Maywood, IL.)

Bosniak 3 lesions are more complex renal cysts that cannot be confidently distinguished from malignant neoplasms (Goenka et al., 2013; Israel and Bosniak, 2005; Smith et al., 2012). The radiographic features include thickened irregular walls or septa, or whenever measurable enhancement can be observed in such structures (Fig. 97.5). **Bosniak 4 lesions have large cystic components; irregular, shaggy margins; and, most important, solid enhancing portions that provide a definitive diagnosis of malignancy** (Fig. 97.6; Israel and Bosniak, 2005). High-quality imaging, preferably CT, and considerable radiologic expertise are required to optimize the characterization of complex renal cystic lesions. In the absence of a mitigating factor such as renal trauma or infection, **surgical exploration is usually indicated in healthy patients with Bosniak 3 or 4 lesions** (Campbell et al., 2017a). Renal mass biopsy or aspiration is rarely performed on cystic lesions because of sampling error, poor diagnostic yield, and risk of tumor spillage (Marconi et al., 2016; Patel et al., 2016b).

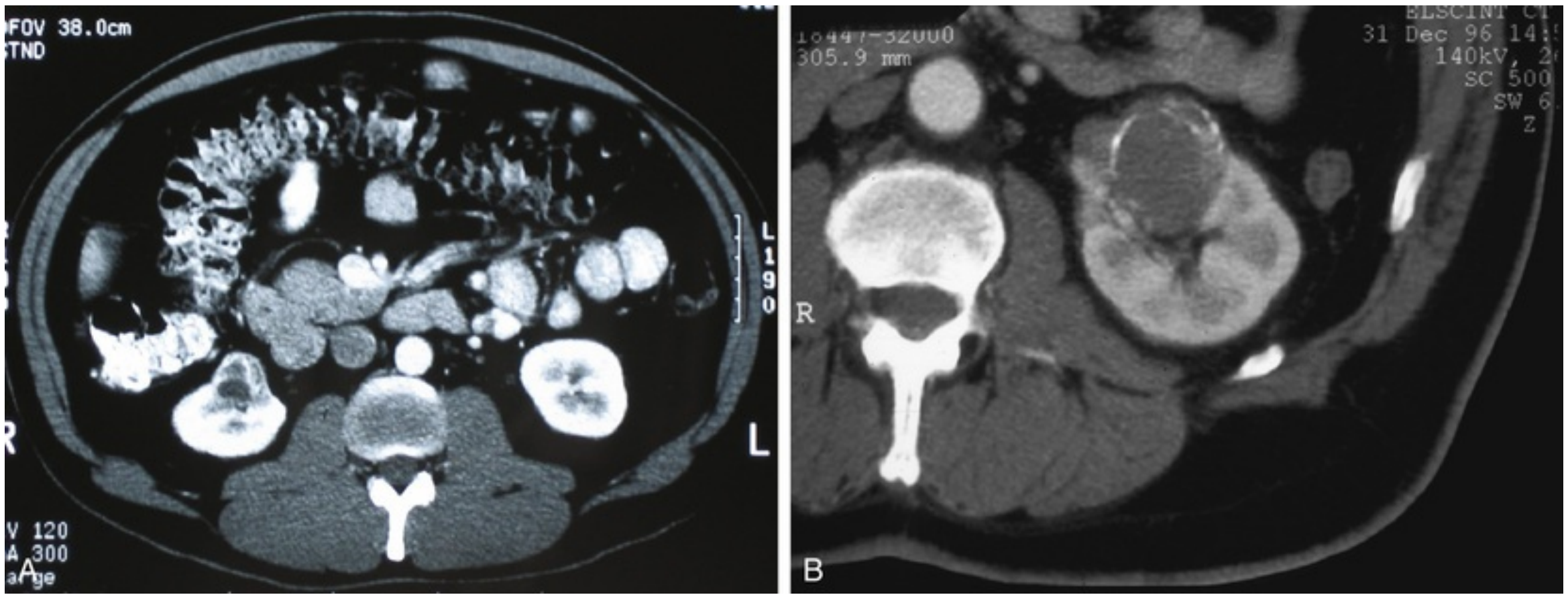

FIG. 97.5 Bosniak category 3 cysts. (A) Computed tomography (CT) shows complex right renal cyst with thick, irregular septae and inhomogeneous character. (B) CT shows thick-walled, complex left renal cyst also exhibiting irregular calcification and moderate heterogeneity. (Courtesy Dr. Terrence Demos, Maywood, IL.)

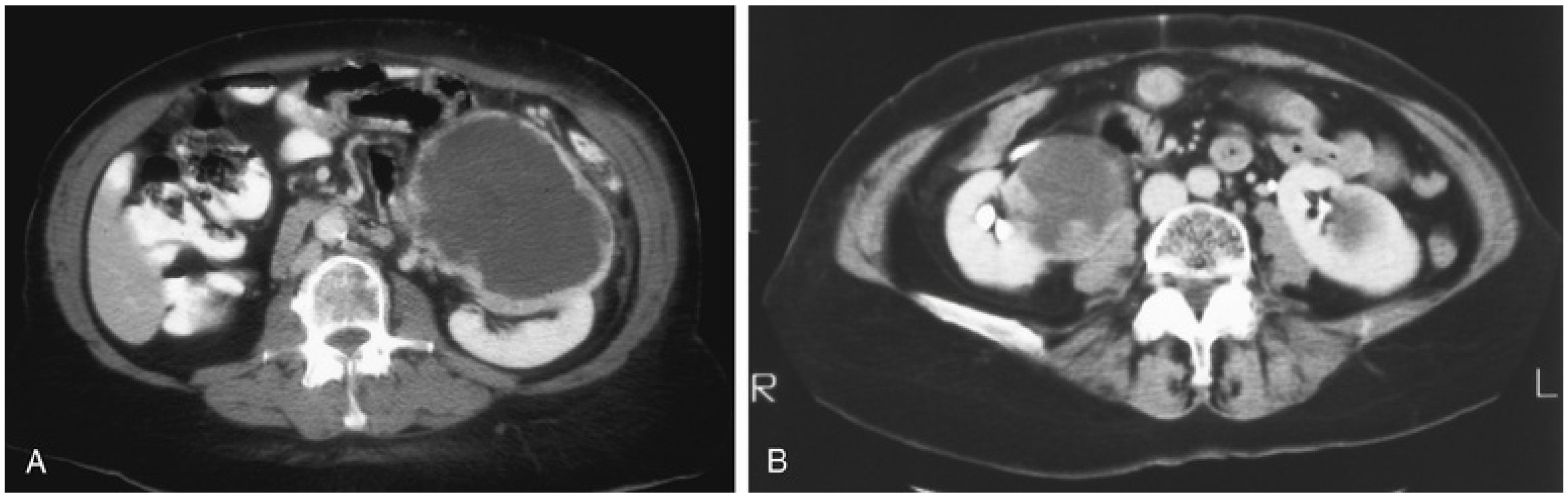

FIG. 97.6 Bosniak category 4 cysts. (A) Computed tomography (CT)

shows complex left renal cystic lesion with thick, enhancing walls. (B) CT shows complex right cystic lesion with enhancing nodular areas and inhomogeneity. Both lesions proved to be renal cell carcinoma.

Renal Cell Carcinoma

Incidence

RCC, which accounts for 2% to 3% of all adult malignant neoplasms, is the most lethal of the common urologic cancers (Siegel et al., 2017). Approximately 64,000 new diagnoses of RCC are made each year in the United States, and 14,400 patients die of disease (Siegel et al., 2017). **Overall, approximately 16 new cases are diagnosed per 100,000 population per year, with a male-to-female predominance of 1.9 to 1** (Siegel et al., 2017). **This is primarily a disease of older adults, with typical presentation between 55 and 75 years of age** (Pantuck et al., 2001b; Siegel et al., 2017; Wallen et al., 2007). However, diagnosis of renal cancer has increased more rapidly in those less than 40 years of age than any other age group (Nepple et al., 2012). Compared with Americans of other races, the incidence and death rates are about 50% lower in Asian-American/Pacific Islanders, and 5% to 10% higher in African-Americans, for unknown reasons (Chow et al., 2013; Lipworth et al., 2006; Siegel et al., 2017; Stafford et al., 2008). **The majority of cases of RCC are sporadic; only 4% to 6% are believed to be familial** (Lipworth et al., 2006; Schmidt and Linehan, 2016).

The incidence of RCC has increased since the 1970s by an average of 3% per year, largely related to more prevalent use of ultrasonography and CT for the evaluation of a variety of nonspecific abdominal complaints (Decastro and McKiernan, 2008; Kummerlin et al., 2008). This trend has correlated with an increased proportion of incidentally discovered and localized tumors and with improved 5-year survival rates for patients with this stage of disease (Kane et al., 2008; Pantuck et al., 2001b; Parsons et al., 2001). However, other factors must also be at play because a steadily increasing mortality rate from RCC per unit population has been observed in all ethnic groups and both genders since the 1980s (Chow et al., 1999; Siegel et al., 2017). This rising mortality rate is particularly troubling because the proportion of advanced tumors has actually decreased (Decastro and McKiernan, 2008; Siegel et al., 2017; Wallen et al., 2007). This suggests that a deleterious change in tumor biology may have occurred during the past several decades, perhaps related to tobacco use, dietary factors and obesity, or exposure to other carcinogens (Hock et al., 2002; Kane et al., 2008; Pantuck et al., 2001b; Parsons et al., 2001).

Although childhood renal tumors represent about 7% of all pediatric cancers, RCC is relatively uncommon in this population. About 90% of renal tumors in children are Wilms tumors or nephroblastomas, with RCC representing only 1% to 6% (Broecker, 2000; Brok et al., 2016). **Although Wilms tumor is much more common in younger children, RCC is as common as Wilms tumor during the second decade of life.** Mean age at presentation for RCC in children is 8 to 9 years, and the incidence is similar in boys and in girls. RCC in children and young adults is more likely to be symptomatic, locally advanced, high grade, and of unfavorable histologic subtypes (Argani et al., 2010; Cook et al., 2006; Estrada et al., 2005; Sanchez-Ortiz et al., 2004b). The most common RCC subtypes are characterized by translocations involving the transcription factor E3 gene *(TFE3)* on chromosome Xp11, which can fuse to other genes leading to increased *TFE3* overexpression. As many as 15% of these tumors occur in children that have received chemotherapy for other malignancies (Brok et al., 2016; Syed et al., 2017). TFE3 protein overexpression leads to a distinct pathologic subtype of RCC that exhibits clear cell and papillary features but may respond to chemotherapeutic or targeted molecular agents (Algaba et al., 2011; Brok et al., 2016). **Most studies suggest that stage for stage, children and young adults with RCC may respond better to surgical therapy,** and a number of long-term survivors have been reported after radical nephrectomy and lymphadenectomy for lymph node–positive disease (Abou El Fettouh et al., 2002; Geller et al., 2008; Sanchez-Ortiz et al., 2004b). **An aggressive surgical approach with formal lymphadenectomy has thus been recommended at the time of radical nephrectomy when RCC is suspected in children or young adults** (Bosquet et al., 2008; Selle et al., 2006).

Etiology

RCCs were traditionally thought to arise primarily from the proximal convoluted tubules, and this is probably true for the clear cell and papillary variants. However, we now know that other histologic subtypes of RCC, such as chromophobe RCC and collecting duct carcinoma, are derived from the more distal components of the nephron (Moch et al., 2016; Pantuck et al., 2001a). **The most generally accepted environmental risk factor for RCC is tobacco exposure, although the associated relative risks have been modest, ranging from 1.4 to 2.5 compared with controls.** All forms of tobacco use have been implicated, and risk increases with cumulative dose or pack-years (Cote et al., 2012; Cumberbatch et al., 2016). Relative risk is directly related to duration of smoking and begins to fall after cessation, further supporting a cause-and-effect relationship (Cumberbatch et al., 2016; Ljungberg et al., 2011). Tobacco use accounts for 20% to 30% of cases of RCC in men and 10% to 20% in women.

Obesity is now accepted as another major risk factor for RCC, with an increased relative risk of 1.07 for each additional unit of body mass index (Bagheri et al., 2016; Bhaskaran et al., 2014; Ito et al., 2017; Renehan et al., 2008). Increased prevalence of obesity has likely contributed to the increased incidence of RCC in Western countries, and it has been estimated that more than 40% of cases of RCC in the United States may be causally linked to obesity (Calle and Kaaks, 2004). Although RCC is more prevalent in patients with higher BMI, increased BMI is also associated with lower stage RCC at presentation, a so-called “obesity paradox” noted in other metabolic disorders and malignancies such as diabetes, CKD, and colon cancer (Bagheri et al., 2016; Choi et al., 2013; Hakimi et al., 2013; Ito et al., 2017). Potential mechanisms linking obesity to RCC include increased insulin-like growth factor-1 expression, increased circulating estrogen levels, and increased arteriolar nephrosclerosis and local inflammation (Calle and Kaaks, 2004; Ljungberg et al., 2011).

Hypertension appears to be the third major causative factor for RCC. Diuretics and other antihypertensive medications have also been implicated, particularly for papillary RCC (Colt et al., 2017). However, the weight of the epidemiologic evidence suggests that it is the underlying disorder, hypertension, rather than the treatment that increases the risk of RCC (Colt et al., 2017; Lipworth et al., 2006; Ljungberg et al., 2011). The proposed mechanisms are hypertension-induced renal injury and inflammation or metabolic or functional changes in the renal tubules that may increase susceptibility to carcinogens (Lipworth et al., 2006; Ljungberg et al., 2011).

Although a number of other potential causative factors have been identified in animal models, including viruses, lead compounds, and more than 100 chemicals such as aromatic hydrocarbons, no specific agent has been definitively established as causative in human RCC (Ishida et al., 2015). The potential role of trichloroethylene exposure has been actively investigated; some studies showed relative risks ranging from twofold to sixfold, but others have argued that inherent biases likely account for these results (Kelsh et al., 2010). Slightly increased relative risks for RCC have been reported for workers in the metal, chemical, rubber, and printing industries and those exposed to asbestos or cadmium, but the data are not particularly convincing (Ljungberg et al., 2011; Mariusdottir et al., 2016).

Case-control studies have shown that RCC is more common among individuals with low socioeconomic status and urban background, although the causative factors have not been defined. The typical modern Western diet, increased intake of dairy products, and increased consumption of coffee or tea have been associated with RCC, but the relative risks have been modest, and conflicting data are available in most instances (Ljungberg et al., 2011). A family history of RCC may also be a factor; one study showed a relative risk of 2.9 for individuals with a first- or second-degree relative with RCC (Gago-Dominguez et al., 2001).

Other potential iatrogenic causes include regular usage of nonsteroidal anti-inflammatory drugs, which was associated with a relative risk of 1.51, whereas aspirin and acetaminophen were not associated with increased risk (Cho et al., 2011). Retroperitoneal radiation therapy, typically administered for Wilms tumor or testicular cancer, appears to be a risk factor for RCC, although the relative risks are low (Romanenko et al., 2000). An increased incidence of RCC is also observed in patients with end-stage renal disease and certain familial syndromes such as tuberous sclerosis, as discussed later (Schmidt and Linehan, 2016).

Key Points: Incidence and Etiology of Renal Cell Carcinoma

- RCC accounts for 2% to 3% of adult malignancies, with a male-to-female predominance of 1.9 to 1.
- RCC typically is diagnosed between 55 and 75 years of age.
- The incidence of RCC has been rising, largely because of incidental detection.
- The strongest risk factor for RCC is tobacco exposure, which increases the relative risk by 1.4- to 2.5-fold compared with controls.
- Hypertension and obesity are also associated with increased prevalence of RCC.
- Approximately 4% to 6% of RCC is familial in origin.

Familial Renal Cell Carcinoma and Molecular Genetics

Since the early 1990s, several familial syndromes of RCC have been identified, and the tumor suppressor genes and oncogenes contributing to the development of sporadic and familial forms of this malignancy have been characterized (Table 97.4; Nielsen et al., 2016; Schmidt and Linehan, 2016). **The distinct nature of the various subtypes of RCC and advances in molecular genetics have contributed to a major revision in the histologic classification of this malignancy** (see Table 97.1) (Samaratunga et al., 2014; Schmidt and Linehan, 2016; Zhou, 2009). A direct and beneficial impact on patient management has also been achieved, with targeted molecular agents now extending survival for many patients with advanced RCC (Schmidt and Linehan, 2016).

TABLE 97.4

Familial Renal Cell Carcinoma Subtypes

SYNDROME	PREDISPOSING GENE (CHROMOSOME)	RENAL TUMOR HISTOLOGY AND OTHER MAJOR CLINICAL MANIFESTATIONS	RECOMMENDED MANAGEMENT FOR RENAL TUMORS
von Hippel-Lindau disease (VHL)	*VHL* (3p25)	Clear cell RCC, often multifocal Retinal angiomas Central nervous system hemangioblastomas Pheochromocytoma Other tumors	Active surveillance <3 cm Surgical excision ≥3 cm, preference for nephron-sparing approaches
Hereditary papillary renal carcinoma (HPRC)	*MET* (7q31)	Multiple, bilateral type 1 papillary RCC	Active surveillance <3 cm Surgical excision ≥3 cm, preference for nephron-sparing approaches

Hereditary leiomyomatosis and renal cell carcinoma (HLRCC)	*Fumarate hydratase (FH)* (1q42-43)	Type 2 papillary RCC most common Collecting duct carcinoma Leiomyomas of skin or uterus Uterine leiomyosarcomas Low-grade variants of RCC also seen in children	Surgical excision, preference for PN, but only when wide margins can be achieved
Succinate dehydrogenase-deficient RCC (SDH-RCC)	*SDHA* *SDHB* (1p36.13), *SDHC* (1q23.3), *SDHD* (11q23.1), *SHDAF2*	SDH-associated RCC (chromophobe, clear cell, type 2 papillary RCC; or oncocytoma), variable aggressiveness Paragangliomas (benign and malignant) Papillary thyroid carcinoma	Surgical excision, preference for PN, but only when wide margins can be achieved
Birt-Hogg-Dube syndrome (BHD)	*Folliculin* (17p11.2)	Multiple chromophobe RCC, hybrid oncocytic tumors, oncocytomas Clear cell RCC (occasionally) Papillary RCC (occasionally) Facial fibrofolliculomas Lung cysts Spontaneous pneumothorax	Active surveillance <3 cm Surgical excision ≥3 cm, preference for nephron-sparing approaches
PTEN hamartoma tumor syndrome (Cowden syndrome)	*PTEN* (10q23)	Papillary RCC or other histology Breast tumors (malignant and benign) Epithelial thyroid carcinoma	Active surveillance <3 cm Surgical excision ≥3 cm, preference for nephron-sparing approaches
Tuberous	*TSC1* (9q34) or	Multiple renal	AML:

sclerosis complex (TSC)	*TSC2* (16p13.3)	angiomyolipomas Clear cell RCC (2%-3% incidence) Renal cysts/polycystic kidney disease Cardiac rhabdomyomas Cutaneous angiofibromas Pulmonary lymphangiomyomatosis Neuropsychiatric disorders, including autism spectrum disorder and cognitive disability	surveillance for <3 cm, everolimus for 3–5 cm, consideration for embolization or excision for ≥5 cm, preference for nephron-sparing approaches RCC: surgical excision ≥3 cm, preference for nephron-sparing approaches
BAP1 tumor predisposition syndrome	*BAP1* (3p21.2)	Clear cell RCC, can be high grade	Surgical excision, preference for nephron-sparing approaches
MiTF-associated cancer syndrome	*MiTF* (3p14.1–p12.3)	Not defined	To be determined

AML, Angiomyolipoma; *CNS,* central nervous system; *MiTF,* microphthalmia-associated transcription factor; *PN,* partial nephrectomy; *PTEN,* pentaerythritol tetranitrate; *RCC,* renal cell carcinoma.

Modified from Schmidt LS, Linehan WM: Genetic predisposition to kidney cancer. *Sem Oncol* 43:566–574, 2016.

Knudson and Strong recognized that familial forms of cancer may hold the key to the identification of important regulatory elements known as tumor suppressor genes (Knudson, 1971; Knudson and Strong, 1972). **Their observations about the childhood tumor retinoblastoma, in which familial cases tend to be multifocal and early onset, led them to propose a two-hit theory of carcinogenesis. They hypothesized that a gene product that could suppress tumor development must be involved and that both alleles of this “tumor suppressor gene” must be mutated or inactivated for tumorigenesis to occur.** Furthermore, Knudson postulated that patients with familial cancers are born with one mutant allele and that all cells in that organ or tissue are at risk, accounting for the early onset and multifocal nature of the disease. In contrast, sporadic tumors develop only if a mutation occurs in both alleles within the same cell; because each event occurs with low frequency, most tumors develop late in life and in a unifocal manner (Knudson, 1971; Knudson and Strong, 1972). Knudson's hypothesis has proven true for retinoblastoma and a number of other tumor types, including RCC (Schmidt and Linehan, 2016). Identification of familial cases of RCC was particularly important because it allowed linkage analysis between affected family members.

von Hippel-Lindau Disease, *VHL* Gene, and Genetics of Clear Cell RCC

The familial form of clear cell RCC is von Hippel-Lindau (VHL) disease, an autosomal dominant disorder that occurs with a frequency of 1 per 36,000 people. **Major manifestations include the development of RCC, pheochromocytoma, retinal angiomas, and hemangioblastomas of the brainstem, cerebellum, or spinal cord** (Table 97.5; Schmidt and Linehan, 2016). All of these tumor types are highly vascular and can lead to substantial morbidity. In particular, central nervous system lesions can lead to paralysis or death and retinal lesions to blindness if they are not identified and managed in an expedient manner. Other common or important manifestations of VHL disease include renal and pancreatic cysts, inner ear tumors, neuroendocrine tumors of the pancreas, and papillary cystadenomas of the epididymis (Neumann and Zbar, 1997). Penetrance for all of these traits is far from complete, and some, such as pheochromocytomas, tend to be clustered only in certain families (Table 97.6; Neumann and Zbar, 1997). **RCC develops in about 50% of patients with VHL disease and is distinctive for early age at onset (often in the third to fifth decades of life) and bilateral and multifocal involvement** (Kim et al., 2010; Schmidt and Linehan, 2016). With improved management of the central nervous system manifestations, RCC has now become the most common cause of mortality in patients with VHL disease. Screening for VHL and important considerations for the management of RCC in this syndrome are reviewed later in this chapter.

TABLE 97.5

Manifestations of von Hippel-Lindau Disease

TUMOR	**AGE OF ONSET, MEAN (RANGE), YEARS**	**INCIDENCE, %**
CENTRAL NERVOUS SYSTEM		
Retinal hemangioblastoma	25 (1–68)	25–60
Endolymphatic sac tumor	22 (12–50)	10–15
Craniospinal hemangioblastoma (overall)	30 (9–70)	60–80
Cerebellum	33 (9–78)	44–72
Brainstem	32 (12–46)	10–25
Spinal cord	33 (11–66)	13–50
VISCERAL		
Renal cell carcinoma	39 (13–70)	25–75
Renal cysts	39 (13–70)	20–60
Pheochromocytoma	27 (5–58)	10–25
Pancreatic neuroendocrine tumors (benign and malignant)	36 (5–70)	11–17
Pancreatic cysts	36 (5–70)	45–75
Epididymal cystadenoma	Unknown	25–60
Broad ligament cystadenoma	Unknown (16–46)	Unknown

Modified from Nielsen SM, Rhodes L, Blanco I, et al.: von Hippel-Lindau disease: genetics and role of genetic counseling in a multiple neoplasia syndrome. *J Clin Oncol* 34(18): 2172–2181, 2016.

TABLE 97.6

Incidence of Major Tumor Types of von Hippel-Lindau Disease by Subtype and Type of Mutation

VHL SUBTYPE	**VHL MUTATION TYPE**	**HIGH RISK**	**LOW RISK**
Type 1	Deletions, insertions, truncations, missense	RCC, CNS/R HB	Pheo
Type 1B	Contiguous gene deletions encompassing *VHL*	CNS/R HB	Pheo, RCC
Type 2A	Missense[a] (e.g., p. Y98H, p. Y112H, p. V116F)	Pheo, CNS/R HB	RCC
Type 2B	Missense (e.g., p.R167Q, p.R167W)	RCC, Pheo, CNS/R HB	–
Type 2C	Missense (e.g., p.V84L, p.L188V)	Pheo	RCC (absent); CNS/R HB

[a] Specific missense mutations arise from a point mutation in a single nucleotide that changes one

amino acid in the encoded protein. For example, Y98H indicates that the tyrosine (Y) at position 98 in pVHL has been replaced with a histidine (H).

CNS/R HB, Central nervous system or retinal hemangioblastoma; *Pheo,* pheochromocytoma; *RCC,* renal cell carcinoma; *VHL,* von Hippel-Lindau disease.

Modified from Nielsen SM, Rhodes L, Blanco I, et al.: von Hippel-Lindau disease: genetics and role of genetic counseling in a multiple neoplasia syndrome. *J Clin Oncol* 34(18):2172–2181, 2016.

Early clues to the genetic elements involved in RCC development came from cytogenetics. These studies demonstrated a common loss of chromosome 3 in kidney cancer, particularly the clear cell variant, and led to intensive efforts to find a tumor suppressor gene in this region (Seizinger et al., 1988; Zbar et al., 1987). Reports by Kovacs et al. (1989a) and Cohen et al. (1979) of translocations involving chromosome 3 further implicated this chromosome as an important regulatory element. Sophisticated molecular genetic linkage studies in patients with VHL disease eventually led to the **identification of the *VHL* tumor suppressor gene** (Latif et al., 1993). **The role of this gene as a tumor suppressor for sporadic and familial forms of clear cell RCC has been confirmed** (Schmidt and Linehan, 2016). The *VHL* gene consists of three exons, and it encodes a protein of 213 amino acids. A large number of common mutations or “hot spots” in the gene have been identified, and a direct correlation between genotype and phenotype has been established in some cases (McNeill et al., 2009; Nielsen et al., 2016). For instance, missense mutations (type 2 mutations) that result in a full-length but nonfunctional protein are commonly found in families with VHL disease who develop pheochromocytomas, whereas deletions leading to a truncated protein (type 1 mutations) are typically found in families who do not develop pheochromocytomas (see Table 97.6; McNeill et al., 2009; Nielsen et al., 2016). The identification of this tumor suppressor gene represented a major advance in the field and required close collaboration between urologic oncologists and molecular geneticists (Schmidt and Linehan, 2016).

Subsequent work has focused on the function of the VHL protein and its likely mechanisms of action (Fig. 97.7). The VHL protein is known to bind to elongins B and C and other proteins to form an E3 ubiquitin ligase complex and thereby modulates the degradation of important regulatory proteins (Nielsen et al., 2016; Schmidt and Linehan, 2016; Shen and Kaelin, 2013). **A critically important function of the VHL protein complex is to target the hypoxia-inducible factors-1α and -2α (HIF-1α and HIF-2α) for ubiquitin-mediated degradation, keeping the levels of HIFs low under normal conditions.**

Inactivation or mutation of the *VHL* gene leads to accumulation of HIFs, most notably HIF-2α (Shen and Kaelin, 2013). **Accumulation of HIF-2α leads to a several-fold upregulation of the expression of vascular endothelial growth factor (VEGF), the primary angiogenic growth factor in RCC, contributing to the pronounced neovascularity associated with clear cell RCC.** HIF-2α also upregulates the expression of transforming growth factor-α, platelet-derived growth factor, glucose transporter 1, erythropoietin, and carbonic anhydrase IX, which also promote tumorigenesis (see Fig. 97.7). VHL also upregulates HIF-1α, which also plays a regulatory role, and this remains an important area of investigation (Shen and Kaelin, 2013).

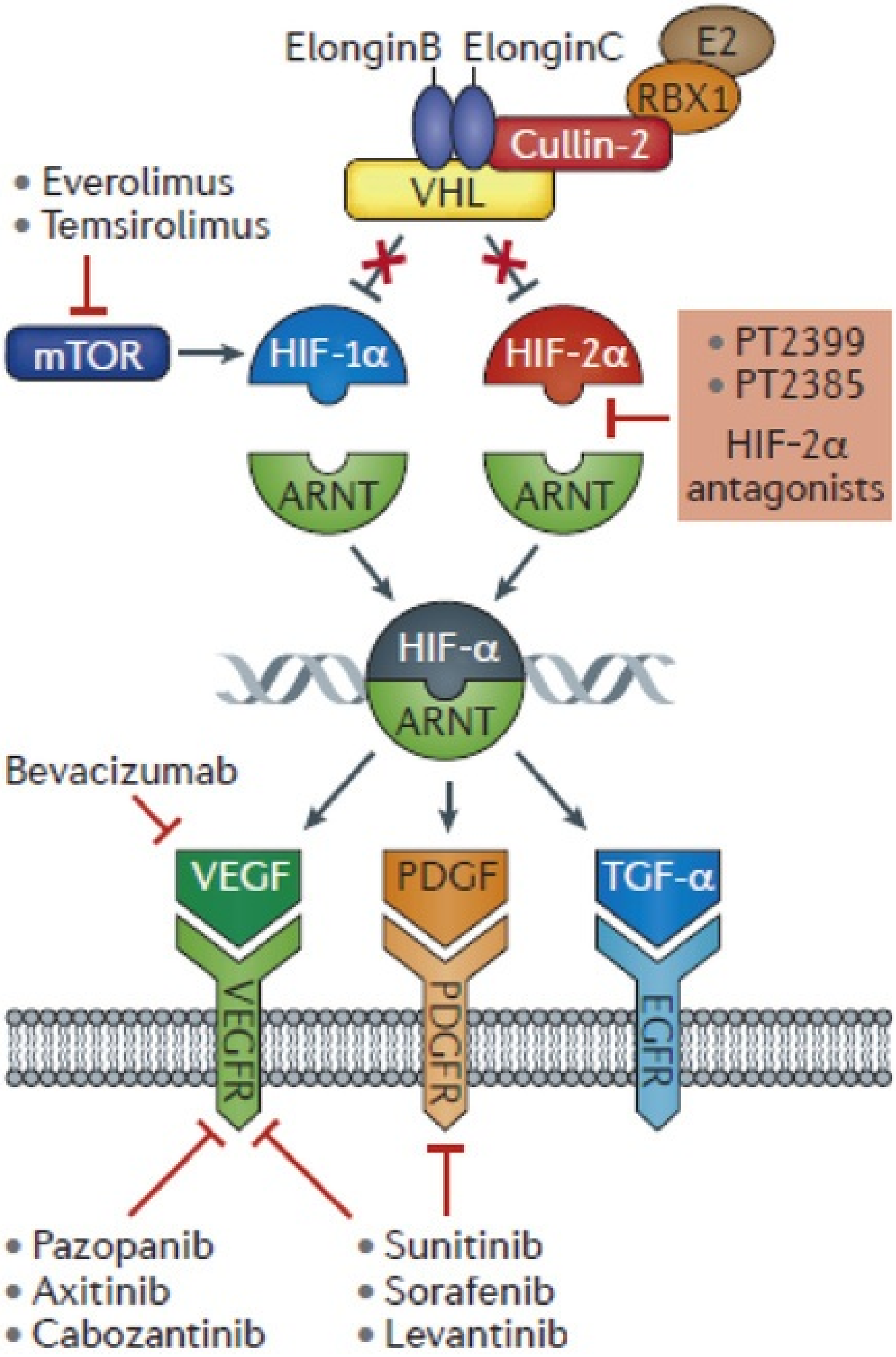
ElonginB
ElonginC
E2
RBX1
Cullin-2
VHL
• Everolimus
• Temsirolimus
mTOR
HIF-1α
HIF-2α
• PT2399
• PT2385
HIF-2α antagonists
ARNT
ARNT
HIF-α
ARNT
Bevacizumab
VEGF
PDGF
TGF-α
VEGFR
PDGFR
EGFR
• Pazopanib
• Axitinib
• Cabozantinib
• Sunitinib
• Sorafenib
• Levantinib

FIG. 97.7 The von Hippel-Lindau (VHL) pathway. The wild-type VHL protein is one component of a complex that targets the hypoxia-inducible factors HIF-1α and HIF-2α for degradation under normoxic conditions. In hypoxia, or with VHL loss (as occurs in clear cell RCC), the HIFs are stabilized, enabling dimerization with aryl hydrocarbon receptor nuclear translocator (ARNT) and increased production of vascular endothelial growth factor (VEGF), platelet-derived growth factor (PDGF), and transforming growth factor-α (TGF-α). These growth factors are involved with angiogenesis, glucose transport, and autocrine and paracrine growth stimulation, respectively. Therapeutic agents for advanced RCC can either sequester VEGF (bevaciumab), block the receptors for VEGF and PDGF (pazopanib, axitinib, cabozantinib, sunitinib, sorafenib, and levantinib), or target the mTOR pathway (temsirolimus and everolimus) to decrease

levels of HIF by inhibiting translation of de novo HIF proteins. The novel therapeutic antagonists PT2399 and PT2385 specifically inhibit the dimerization of HIF-2α and ARNT, resulting in reduced HIF-2α downstream gene expression. (Modified from Linehan WM, Ricketts CJ: Kidney cancer in 2016: RCC—advances in targeted therapeutics and genomics. *Nat Rev Urol* 14:76–78, 2017.)

The other three most commonly mutated genes involved in the development of sporadic clear cell RCC are also located on the short arm of chromosome 3, which is affected in more than 90% of clear cell RCC cases (Cancer Genome Atlas Research Network, 2013). Unlike *VHL,* these genes, which include *PBRM1, BAP1,* and *SETD2,* are involved in chromatin remodeling and histone methylation (Cancer Genome Atlas Research Network, 2013; Dalgliesh et al., 2010; Farley et al., 2013; Varela et al., 2011). BAP1 mutations occur in up to 14% of sporadic clear cell RCC and are associated with poor prognosis. Germline mutations of BAP1 have been identified in some individuals with early onset, multifocal clear cell RCC and should be considered in such patients who are wild type for VHL (Rai et al., 2016).

Hereditary Papillary Renal Carcinoma Syndrome

Several studies have documented distinct cytogenetic findings in non–clear cell histotypes of RCC; chromosome 3 and *VHL* gene abnormalities are uncommon in these variants (Schmidt and Linehan, 2016)**. These observations suggested an alternate genetic basis for non–clear cell RCC. Papillary RCC, the second most common histologic subtype of RCC, is characterized by trisomy for chromosomes 7 and 17 as well as abnormalities on chromosomes 1, 12, 16, 20, and Y** (Schmidt and Linehan, 2016). In 1995 Zbar et al. reported **a second familial syndrome of RCC—hereditary papillary renal carcinoma (HPRC)**. Median age at diagnosis in the 41 affected members from 10 families was 45 years, and most patients developed multifocal and bilateral papillary RCC. **Type 1 papillary RCC is typically found in this syndrome rather than type 2, which is commonly seen in the hereditary leiomyomatosis and RCC syndrome.** Unlike VHL disease, most patients with HPRC typically do not develop tumors in other organ systems (Schmidt and Linehan, 2016). Mean survival in affected individuals was only 52 years in Zbar's series, although the number of patients dying of RCC was not defined (Zbar et al., 1995). The development of CKD as a result of malignant replacement of the parenchyma and loss of functioning nephrons resulting from various interventions can contribute to morbidity and mortality in this syndrome (Ornstein et al., 2000).

Studies of families with HPRC demonstrate an autosomal dominant mode of transmission, similar to all of the other familial RCC syndromes (Schmidt and Linehan, 2016). Again, molecular linkage analysis in affected families played a key role in the discovery of the involved gene, which was localized to chromosome 7q31. However, in this case, the inciting event is activation of a proto-oncogene, rather than inactivation of a tumor suppressor gene. Missense mutations of the c-*MET* proto-oncogene at 7q31 were found to segregate with the disease, implicating it as the relevant genetic locus (Schmidt et al., 1997). The protein product of this gene is the receptor tyrosine kinase for hepatocyte growth factor, and its activation leads to cellular proliferation and other potential tumorigenic effects (Vira et al., 2007). **Most of the mutations in HPRC have been found in the tyrosine kinase domain of c-*MET* and apparently lead to constitutive activation** (Schmidt et al., 1997; Sudarshan and Linehan, 2006). Relatively early onset and multifocality in HPRC are due to inheritance of the mutated *c-MET* gene, which places all the cells in the kidney at risk from birth, but the incomplete penetrance and variable clinical course associated with this syndrome suggest that additional genetic loci or epigenetic phenomena may modulate the phenotype (Schmidt and Linehan, 2016). **Whereas tumors in HPRC tend to be less aggressive than their sporadic counterparts, it is clear that some can metastasize. Schmidt et al. reported *c-MET* mutations in 13% of patients with sporadic papillary RCC, suggesting that this molecular defect also contributes to a subset of this disease population** (Sudarshan and Linehan, 2006; Schmidt and Linehan, 2016). Small molecule inhibitors of the c-*MET* receptor are currently in early clinical trials for the management of HPRC and the subset of patients with sporadic RCC who harbor this mutation (Choueiri et al., 2017b).

Hereditary Leiomyomatosis and Renal Cell Carcinoma

In 2001 Launonen et al. described a familial renal cancer syndrome in which patients commonly develop cutaneous and uterine leiomyomas and type 2 papillary RCC (Launonen et al., 2001; Pithukpakorn et al., 2006; Schmidt and Linehan, 2016). Mean age at diagnosis is in the early 40s. **Renal tumors in this syndrome are unusual for familial RCC in that they are often solitary and unilateral, and they are more likely to be aggressive than other forms of familial RCC.** Collecting duct carcinoma, another highly malignant variant of RCC, has also been observed in this syndrome, which was named **hereditary leiomyomatosis and renal cell carcinoma (HLRCC) syndrome.**

The HLRCC locus was mapped to a region on 1q42-43, and this was later shown to be the site of the fumarate hydratase *(FH)* gene (Pithukpakorn et al., 2006; Schmidt and Linehan, 2016). Again, autosomal dominant inheritance was observed, and *FH* appears to be a tumor suppressor gene rather than an oncogene. *FH* is an essential enzyme in the Krebs cycle of oxidative metabolism. The exact mechanisms by which loss of *FH* expression leads to malignancy are still under investigation, although hypotheses about this date back to the 1920s and the proposed Warburg effect.

Penetrance for RCC in HLRCC is lower than for the cutaneous and uterine manifestations, with only 15% to 20% of patients developing RCC. In contrast, almost all individuals with HLRCC develop cutaneous leiomyomas and uterine fibroids (if female), usually manifesting between the ages of 20 to 35 years. A high proportion of women have had a hysterectomy for fibroids before formal diagnosis of HLRCC, and occasionally leiomyosarcoma has been reported (Pithukpakorn et al., 2006; Schmidt and Linehan, 2016). **Prompt surgical management of the renal tumors is recommended in individuals with HLRCC, given their tendency toward aggressive behavior** (Schmidt and Linehan, 2016). **This is in contrast to most of the other familial syndromes of RCC, for which management tends to be more conservative.** Recent studies have shown the utility of FDG-PET imaging for identification of small foci of metastases in patients with HLRCC, reflecting the increased metabolic activity of these tumors (Carter et al., 2017; Nakatani et al., 2011; Pithukpakorn et al., 2006; Smith et al., 2017). However, not all patients with HLRCC develop aggressive cancers; some younger patients with *FH* mutations have been described with low-grade oncocytic neoplasms that resemble succinate dehydrogenase renal cell carcinoma (SDH-RCC)–associated tumors (Carter et al., 2017; Smith et al., 2017).

Succinate Dehydrogenase Renal Cell Carcinoma

Another syndrome that shares features with HLRCC is SDH-RCC (Ricketts et al., 2012). Affected individuals present with bilateral, multifocal, early onset (<40 years) renal tumors, often along with pheochromocytomas and head and neck paragangliomas. Individuals with germline mutation of one of the multiple genes encoding subunits of the Krebs cycle enzyme succinate dehydrogenase, including *SDHA*, *SDHB*, *SDHC*, *SDHD*, and *SHDAF2*, are at increased risk for

RCC (Ricketts et al., 2008, 2012; Vanharanta et al., 2004). Another example of the Warburg effect in cancer, individuals with SDH-RCC can experience early onset and potentially aggressive disease; early studies suggested that about a third of such patients eventually developed metastatic disease (Ricketts et al., 2012). However, more recent reports have demonstrated a good prognosis for a subset of patients with SDH-RCC, particularly when low-grade features predominate. Tumors with high-grade, coagulative necrosis, or sarcomatoid features are more likely to behave aggressively (Gill et al., 2015; Kuroda et al., 2014; Williamson et al., 2015).

Birt-Hogg-Dube Syndrome

Birt-Hogg-Dube (BHD) syndrome, in which patients can develop cutaneous fibrofolliculomas, lung cysts, spontaneous pneumothoraces, and a variety of renal tumors primarily derived from the distal nephron, is named after three Canadian physicians who first described the cutaneous lesions in 1977 (Dal Sasso et al., 2015). **The renal tumors typically include chromophobe RCC, oncocytomas, and hybrid oncocytic tumors that exhibit features of both of these entities** (Boris et al., 2011). However, other forms of RCC, including a substantial proportion of clear cell RCC, have been observed (Dal Sasso et al., 2015). Overall penetrance for renal tumors is 23% to 34%, but when they occur they are often bilateral and multifocal (Dal Sasso et al., 2015; Toro et al., 2008). Average age at renal tumor diagnosis is approximately 50 years. Most renal tumors in BHD syndrome have limited biologic aggressiveness, although metastatic behavior and lethality have been reported.

The *BHD* gene responsible for this syndrome has been mapped to chromosome 17p12q11.2, and the gene product is the tumor suppressor folliculin (Khoo et al., 2001; Toro et al., 2008). Folliculin forms a complex of proteins that interfaces with the mammalian target of rapamycin (mTOR) pathway, and germline mutations in this gene have been found in 88% of kindreds (Toro et al., 2008). When folliculin is lost, mTOR signaling complexes 1 and 2 (mTORC1 and mTORC2) are activated, which leads to increased transcriptional activity and nuclear translocation of *TFE3* (Hasumi et al., 2009; Hong et al., 2010; Liu et al., 2016). An autosomal dominant pattern of inheritance is characteristic and genetic testing is now available (see Table 97.4).

Cowden Syndrome

Cowden syndrome is one of several syndromes that result from germline mutations of the phosphatase and tensin homolog *(PTEN)* tumor suppressor gene, which together are termed PTEN hamartoma tumor syndrome. Individuals with Cowden syndrome carry a 50% lifetime risk of female breast cancer, **34% lifetime risk of RCC,** and 10% lifetime risk of epithelial thyroid carcinoma (Mester et al., 2012; Starink et al., 1986). Patients with clinical features of Cowden syndrome but without *PTEN* mutations were subsequently found to have mutations in *KILLIN*, an adjacent tumor suppressor gene that was also associated with increased incidence of RCC (Bennett et al., 2010). Based on a greater than 31-fold increased risk of RCC, individuals with Cowden or Cowden-like syndrome should be screened with CT or MRI for RCC. **RCC in this syndrome is most often of papillary histology,** although chromophobe and clear cell histology have also been reported (Mester et al., 2012; Shuch et al., 2013).

Tuberous Sclerosis Complex

Tuberous sclerosis complex (TSC) is an autosomal dominant disorder that manifests with characteristic tumors in multiple organ systems (Caban et al., 2017; Schmidt and Linehan, 2016). **Major features include AML, cortical tubers, subependymal nodules or subependymal giant cell astrocytomas (SEGA), pulmonary lymphangioleiomyomatosis (LAM), cardiac rhabdomyomas, and facial angiofibromas.** Renal AML are typically multifocal, bilateral, and often large, occasionally requiring angioembolization or partial nephrectomy (PN) to treat or prevent bleeding from larger (>5 cm) tumors. Germline mutations in either the *TSC1* gene on chromosome 9q34 encoding hamartin or the *TSC2* gene on chromosome 16p13 that encodes tuberin are responsible for the manifestations of TSC (Caban et al., 2017). The TSC1/TSC2 complex normally downregulates the mTOR pathway; mTOR inhibitors (such as everolimus) have shown clinical activity against TSC-associated AMLs (see Chapter 96). RCC, typically clear cell type, can also be seen in a small proportion (2%–3%) of patients with TSC.

Microphthalmia-Associated Transcription Factor–Associated Cancer Syndrome

A germline missense variant (p.E318K) of microphthalmia-associated transcription factor (MiTF) confers a greater than fivefold increased risk

(Bertolotto et al., 2011; Yokoyama et al., 2011) of melanoma and RCC in affected individuals. MiTF regulates HIF-1α and is normally suppressed by posttranslational regulatory processes; the mutated version activates HIF-1α, potentially contributing to the development of RCC.

Tumor Biology and Clinical Implications

Resistance to Cytotoxic Therapy

RCC has demonstrated only limited responses to cytotoxic chemotherapeutic agents, contributing to the traditionally poor prognosis for patients with metastatic disease (Motzer and Russo, 2000; Rini et al., 2009b). **Study of the tumor biology of RCC has provided insight into its resistance to chemotherapy and, through elucidation of the VEGF, mTOR, and relevant immunomodulatory pathways, has yielded agents with clinical benefit for advanced disease** (Table 97.7, see Chapter 104) (Rini et al., 2009b). Expression of multidrug-resistance proteins, which act as energy-dependent efflux pumps for a wide variety of hydrophobic cytotoxic compounds, contributes to the chemorefractory nature of advanced RCC. However, the resistance of RCC to cisplatin and other agents that are not extruded by multidrug resistance proteins suggests redundancy in chemotherapy resistance mechanisms.

TABLE 97.7

Tumor Biology and Clinical Implications

BIOLOGIC CHARACTERISTIC	CLINICAL IMPLICATIONS
Expression of multidrug resistance	Contributes to chemorefractory nature of RCC
Immunogenic	10%–20% response rate with interferon or IL-2 3%–5% complete response rate with high-dose IL-2 Modulation of PD-1 and other costimulatory molecules can lead to prolonged recurrence-free survival and overall survival
Angiogenic	Vascular invasion can lead to venous tumor thrombus 20%–40% response rates with agents targeting the VEGF pathway (sunitinib, sorafenib, pazopanib, axitinib, bevacizumab, etc.) Prolonged recurrence-free survival and overall survival

	with some antiangiogenic agents
Dependence on mTOR pathway	Agents targeting mTOR prolong survival in patients with poor-risk RCC (temsirolimus) and demonstrate responses in patients failing prior targeted molecular therapies (everolimus)

IL-2, Interleukin-2; *mTOR,* mammalian target of rapamycin; *PD-1,* programmed death–1; *RCC,* renal cell carcinoma; *VEGF,* vascular endothelial growth factor.

Immunobiology and Immune Tolerance

Several lines of evidence demonstrate that RCC is immunogenic, and this has stimulated intensive efforts to harness the immune system to improve outcomes for patients with advanced disease (McDermott and Atkins, 2013; Rijnders et al., 2017; Zibelman and Plimack, 2017). Tumor-infiltrating immune cells can be readily isolated from RCC, including cytotoxic T cells, dendritic cells, and helper T cells, which express interleukin (IL)-1 and IL-2 and function as antigen-presenting cells. Study of the molecular mechanisms involved in the interactions of the host immune system with the tumor has yielded insights and effective therapies for RCC (McDermott and Atkins, 2013; Rijnders et al., 2017; Zibelman and Plimack, 2017). Immunotherapy with interferon and high-dose IL-2 was the only effective systemic therapy for RCC in the years before the discovery of the first VEGF-targeted therapies. Newer protocols that activate or maintain the viability of T cells, prime dendritic cells with tumor antigens, or block tumor-induced immunosuppression are now commonly used for metastatic RCC and hold great promise for the future (Brahmer et al., 2012; Rijnders et al., 2017; Zibelman and Plimack, 2017).

Clinical observations such as validated responses to immunotherapy, prolonged disease stabilization, and occasional spontaneous tumor regression support the immunogenicity of RCC. In the past, observed responses of RCC to immunomodulators, such as IL-2 and interferon-α, argued in favor of an important role for the immune system in the biology of RCC (Coppin, 2008; Zibelman and Plimack, 2017). **Indeed, high-dose IL-2 remains a treatment with curative potential for patients with metastatic clear cell RCC, with durable and complete regression of disease accomplished in a finite proportion (3% to 5%) of patients** (Amin and White, 2013; Coppin, 2008; Zibelman and Plimack, 2017). **The estimated incidence of spontaneous regression of RCC is between 0.3% and 1% and is believed to be due to immune surveillance** (Oliver, 1989). Most spontaneous regressions have been noted in patients with pulmonary metastases and have occurred after cytoreductive nephrectomy, but regression of primary RCC has also been reported in the absence of any form of treatment (Vogelzang et al., 1992).

Unfortunately, overall response rates with cytokine or other immune-based approaches for RCC were disappointing, typically ranging from 15% to 20%, despite a variety of creative treatment strategies, including the harvesting, ex vivo culturing, and reinfusion of tumor infiltrating lymphocytes. Suboptimal results with these ambitious protocols suggested immune tolerance, likely induced by the tumor (Amin and White, 2013; Zibelman and Plimack, 2017). A number of observations support impaired immune surveillance in RCC and a variety of mechanisms affecting virtually all levels of regulation of the immune system have been implicated, as reviewed previously (Campbell and Lane, 2016). **Factors that downregulate effector T cells are particularly important in RCC: cytotoxic T-lymphocyte antigen–4 (CTLA-4) and the programmed death–1 (PD-1) molecule, also known as B7-H1, are glycoprotein receptors expressed on T cells that are central to this process** (Fig. 97.8) (Buchbinder and Desai, 2016; Rijnders et al., 2017; Zibelman and Plimack, 2017). Under normal conditions these receptors participate in the regulation of the immune system, essentially serving an inhibitory role to prevent autoimmune diseases from developing. **Increased activation of these receptors such as by enhanced programmed death ligand–1 (PD-L1) expression by the tumor leads to downregulation of effector T cells and immune tolerance** (Rijnders et al., 2017). Thompson et al. (2006) reported that increased PD-L1 expression by clear cell RCC correlates with aggressive pathologic features and increased risk of disease progression, even after multivariate adjustment.

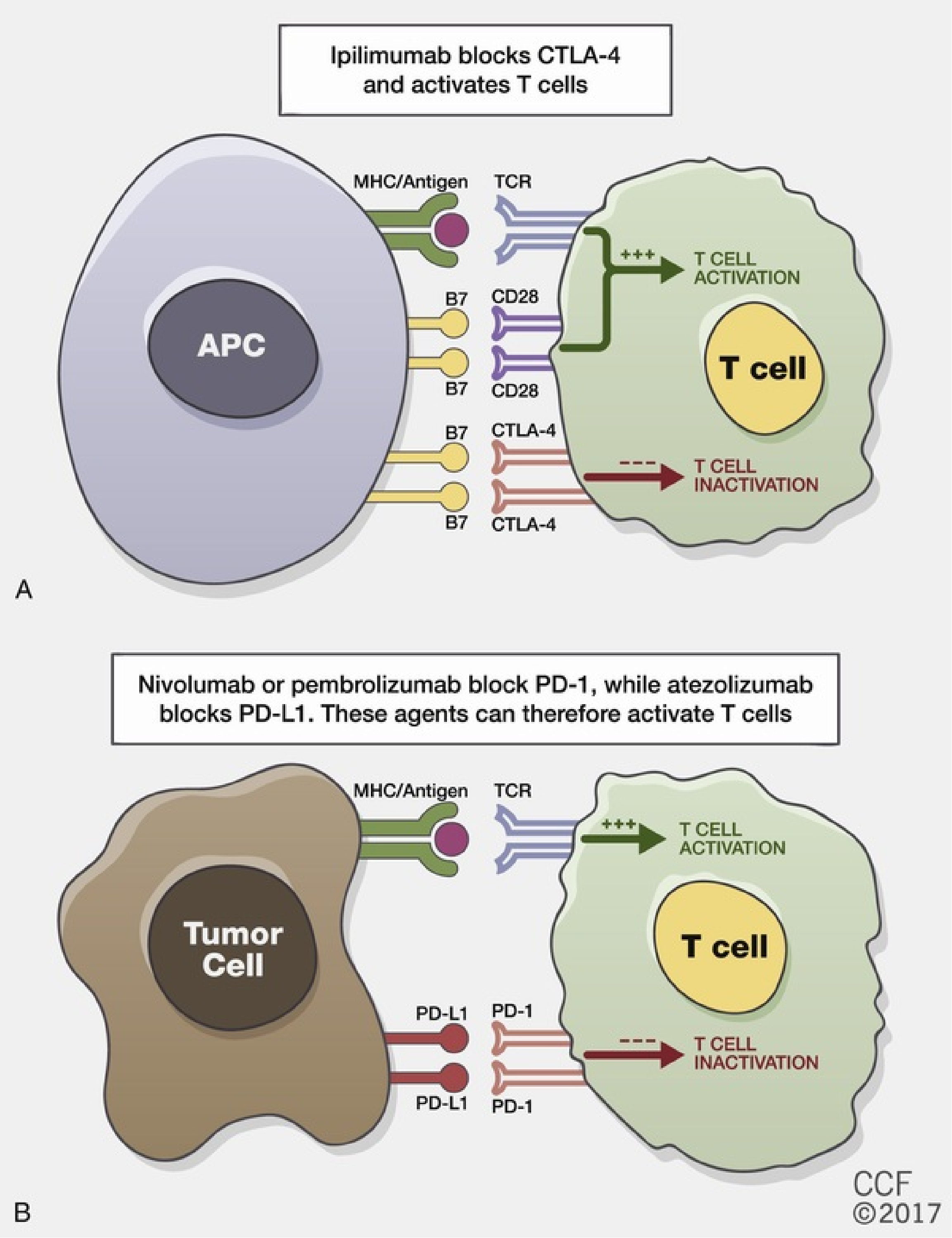
Ipilimumab blocks CTLA-4 and activates T cells
MHC/Antigen
TCR
B7
CD28
APC
B7
CD28
B7
CTLA-4
B7
CTLA-4
+++
T CELL ACTIVATION
T cell

T CELL INACTIVATION
A
Nivolumab or pembrolizumab block PD-1, while atezolizumab blocks PD-L1. These agents can therefore activate T cells
MHC/Antigen
TCR
+++
T CELL ACTIVATION
Tumor Cell
T cell
PD-L1
PD-1
PD-L1
PD-1

T CELL INACTIVATION
B
CCF ©2017

FIG. 97.8 Mechanism of action of checkpoint inhibitors. (A) Interactions between an antigen presenting cell (APC) and the T cell include activating signals and those that inhibit the T cell. Positive signals include interactions between the T cell receptor (TCR) and MHC/antigen complex and those associated with B7 and CD-28. In contrast, interactions between B7 and CTLA-4 inhibit the T cell, and the balance between these positive and

negative signals determines whether the T cell becomes activated. The checkpoint inhibitor ipilimumab blocks CTLA-4 and thus tilts the balance in favor of T cell activation. (B) Interactions between the tumor cell and the T cell are also critically important and again comprise positive and negative signals with the former primarily consisting of interactions between the TCR and MHC/antigen complex. Some tumor cells, such as kidney cancer cells, can express PD-L1, the ligand for PD-1, and the resulting interactions between these molecules can suppress the T cell. Nivolumab and pembrolizumab block PD-1, while atezolizumab blocks PD-L1. These checkpoint inhibitors thus can activate the T cells and bolster immune responses to the malignancy.

Recent trials have demonstrated that humanized antibodies that block PD-1 (e.g., nivolumab or pembrolizumab), PD-L1 (e.g., atezolizumab), or CTLA-4 (e.g., ipilimumab) can lead to complete and durable responses for patients with metastatic RCC. Improved overall survival has been documented for nivolumab when compared with everolimus for patients with metastatic RCC who have failed front-line therapy (Motzer et al., 2015). For untreated patients with metastatic RCC with intermediate or high-risk features, combination treatment with nivolumab plus ipilimumab was associated with better survival when compared with sunitinib (Escudier et al., 2017). Another combination approach, pembrolizumab plus axitinib, also appears to be active in untreated patients with metastatic kidney cancer, as it demonstrated better overall survival when compared to sunitinib monotherapy, with benefit observed in all risk groups (Rini et al., 2019). **As such, these immune modulators, also known as checkpoint inhibitors, are changing the landscape of metastatic RCC, and we have now moved into a post-TKI era** (see Chapters 61 and 104). Side effects of immune modulators can include autoimmune diseases, such as enterocolitis, hepatitis, dermatitis, or pneumonitis, as expected by their mechanism of action (Choueiri et al., 2016; Escudier et al., 2017; Hammers et al., 2017; Motzer et al., 2015; Zibelman and Plimack, 2017).

Angiogenesis and Targeted Pathways

RCC has long been recognized as one of the most vascular of cancers, as reflected by the distinctive neovascular pattern exhibited on renal angiography and robust enhancement observed on dedicated renal CT. The primary angiogenesis inducer in clear cell RCC is VEGF, which is suppressed by the wild-type VHL protein under normal conditions and is dramatically upregulated during tumor development (Gnarra et al., 1996; Iliopoulos et al., 1996). Increased levels of VEGF can be found in the serum and urine of patients with RCC, particularly in patients with hypervascular tumors when compared with hypovascular tumors, suggesting functional relevance (Takahashi et al., 1994).

VEGF is actually a family of ligands consisting of several subtypes, most of which are regulated by HIFs and VHL and bind to one or more of the corresponding VEGF receptor (VEGFR) family members (Lane et al., 2007c). VEGFR-1 (Flt-1) and VEGFR-2 (KDR/Flk-1) are receptor tyrosine kinases that are the target of several multi–tyrosine kinase inhibitors (TKIs) with activity against RCC (Carmeliet, 2005; Hicklin and Ellis, 2005). Upon binding of ligand (VEGF), key tyrosine residues along the intracellular portion of the VEGFR are phosphorylated, which leads to the binding of specific intracellular factors and activation of corresponding signal transduction pathways. Pathways known to be activated by phosphorylation of VEGFRs include the Raf-MEK-Erk and phosphatidylinositol-3-kinase/Akt/mTOR pathways that promote endothelial cell survival and proliferation (Carmeliet, 2005; Hicklin and Ellis, 2005). However, the promiscuity of the interactions between the various ligands, receptors, downstream effectors, and inhibitors can lead to a variety of effects that may be difficult to predict. This promiscuity is likely a major reason that therapeutic agents that appear to have similar modes of action (VEGFR tyrosine kinase inhibitors) are found to have somewhat disparate clinical or off-target effects. In contrast, bevacizumab is a monoclonal antibody that binds to VEGF and sequesters the ligand so that it cannot interact with VEGFR; its clinical activity is therefore almost certainly directly related to this activity.

Given the dependence of RCC on angiogenesis and the absence of generally effective forms of systemic therapies in the previous millennium, it is not surprising that RCC was one of the first malignancies targeted for anti-VEGF approaches when they became available. Promising results were initially reported for bevacizumab for patients with metastatic RCC, as it substantially reduced tumor burden and delayed time to progression when compared to placebo. A clinical niche for bevacizumab when combined with interferon-alpha was defined shortly thereafter (Escudier et al., 2007b; Rini et al., 2008; Yang et al., 2003). **A number of multiple kinase inhibitors that target the VEGF pathway were subsequently tested in clinical trials and also approved by the US Food and Drug Administration (FDA) beginning in December 2005 and extending into the current era** (see Fig. 97.7 and further details in Chapter 104) (Haddad and Rini, 2012; Motzer et al., 2006, 2013a, 2013b). More recently, cabozantinib, an inhibitor of VEGF as well as MET and

AXL, demonstrated significant activity as second-line treatment for metastatic RCC (Choueiri et al., 2015).

Cancer Genome Research

In 2013 the Cancer Genome Atlas Research Network provided a more comprehensive molecular characterization of clear cell RCC that will serve as a solid foundation for future studies in this field. Analyses performed in this landmark study included next-generation sequencing to evaluate the whole genome of 22 tumors and whole-exome sequencing of 417 additional tumors. DNA copy number and genotype, CpG DNA methylation, messenger RNA expression, microRNA expression, and protein expression were also analyzed in these same tumors, providing a wealth of information about the molecular features of clear cell RCC. The main findings included the identification of alterations in genes controlling cellular oxygen sensing, such as *VHL,* and regulation of chromatin status, such as *PBRM1, BAP1,* and *SETD2.*

In total, 19 significantly mutated genes were identified, including the previous genes as well as genes involved in the PI3K/AKT pathway (Dalgliesh et al., 2010). Mutation of the H3K36 methyltransferase *SETD2* was notable in that it is associated with widespread DNA hypomethylation, and complex integrative analyses suggested that mutations involving the switch sucrose nonfermentable (SWI/SNF) chromatin remodeling complex *(PBRM1, ARID1A, SMARCA4)* could have broad effects on other signaling pathways. **Overall, the analyses provide strong evidence for a metabolic shift in aggressive renal cancers,** with downregulation of genes involved in the tricarboxylic acid (TCA) cycle, upregulation of pentose phosphate and glutamine transporter genes, decreased AMPK and PTEN protein levels, and increased acetyl coenzyme A carboxylase protein. **The recurring theme of metabolic remodeling in clear cell RCC suggests multiple new windows into future targets for disease treatment.**

Other Signal Transduction and Cell Cycle Regulation Pathways

Aberrant activation of additional signal transduction pathways in RCC may also contribute to altered cell cycle kinetics, and these pathways represent excellent targets for therapeutic intervention. One such regulatory pathway in RCC is the mTOR pathway, which interfaces with Akt (protein kinase B) and the *PTEN* tumor suppressor gene (Barthelemy et al., 2013; Hudes, 2009).

Expression of mTOR is upregulated by various growth factors or by mutation or loss of *PTEN*. Through complex pathways involving a variety of intermediaries, the mTOR pathway leads to increased expression of HIFs and other growth-promoting and potentially tumorigenic sequelae. **Inhibition of mTOR with temsirolimus (Torisel) has yielded prolonged survival in patients with poor-risk, metastatic RCC, and everolimus (Afinitor) has shown efficacy for patients in whom tyrosine kinase inhibitors have failed, confirming the clinical relevance of the mTOR pathway** (see Fig. 97.7) (Hudes et al., 2007; Motzer et al., 2008). Both of these mTOR inhibitors are now also approved by the FDA.

Proliferative index, as defined by proliferating cell nuclear antigen or Ki-67 staining, has correlated with pathologic parameters and clinical outcomes in RCC, suggesting that regulation of the cell cycle plays an important role in the tumor biology of RCC (Bui et al., 2004; Tollefson et al., 2007). Increased expression of transforming growth factor-α and its receptor tyrosine kinase, the epidermal growth factor receptor (EGFR), have been reported in RCC and may contribute to tumorigenesis by promoting cellular proliferation or transformation through an autocrine mechanism. Unfortunately, phase II clinical trials using agents that target EGFR, including erlotinib (Tarceva), gefitinib (Iressa), panitumumab (Vectibix), and lapatinib (Tykerb), demonstrated a lack of substantial activity in patients with advanced RCC (Rini, 2010). Based on these results, agents targeting the EGFR pathway have fallen out of favor for RCC, although selective treatment of patients who overexpress EGFR may still be a consideration within precision medicine trials.

The hepatocyte growth factor and its receptor, the c-*MET* proto-oncogene, may also contribute to the pathogenesis of RCC (Gibney et al., 2013; Giubellino et al., 2009; Harshman and Choueiri, 2013). The role of activating mutations of the c-*MET* proto-oncogene in the cause of hereditary papillary RCC has already been discussed, but data suggest that upregulated expression of this ligand may also occur in most of the histologic subtypes of RCC (Giubellino et al., 2009; Harshman and Choueiri, 2013). Hepatocyte growth factor is expressed by normal proximal tubular cells, where it is involved in branching tubulogenesis of the developing kidney and regeneration after renal injury. Increased serum levels of hepatocyte growth factor have also been reported in most patients with RCC, independent of histologic subtype, and activation of the receptor by phosphorylation at two sites is associated with cancer progression, making c-*Met* a potential therapeutic target for papillary and other forms of RCC (Gibney et al., 2013). Cabozantinib, an inhibitor of VEGFR, MET, and AXL, demonstrated a significant clinical benefit versus sunitinib, which primarily targets VEGFR, as first-line treatment for intermediate- to poor-risk RCC, suggesting a potential superiority to dual pathway inhibition (Choueiri et al., 2017a).

Other potential factors involved in RCC pathogenesis include the insulin-like growth factor axis, telomerase, apoptotic factors, and extracellular matrix proteins (Campbell and Lane, 2016).

Pathology

Most RCCs are round to ovoid and circumscribed by a pseudocapsule of compressed parenchyma and fibrous tissue rather than a true histologic capsule. Unlike upper tract urothelial carcinomas, most RCCs are not grossly infiltrative, with the notable exception of collecting duct carcinoma and sarcomatoid variants. Tumor size has averaged between 4 and 8 cm in most series but can vary from a few millimeters to large enough to fill the entire abdomen. Tumors smaller than 3 cm were previously classified as benign adenomas, but small tumors have on rare occasion been associated with metastases (Daugherty et al., 2017; Nguyen and Gill, 2009). **Most pathologists agree that, with the exception of oncocytomas and some small (≤5 mm) low-grade papillary adenomas, there are no reliable histologic or ultrastructural criteria to differentiate benign from malignant renal epithelial tumors** (see Chapter 96). When they are bivalved, RCCs consist of yellow, tan, or brown tumor interspersed with fibrotic, necrotic, or hemorrhagic areas; few are uniform in gross appearance. Cystic degeneration is prominent in 10% to 25% of RCCs and appears to be associated with a better prognosis compared with purely solid RCC (Bhatt et al., 2016; Jhaveri et al., 2013; Webster et al., 2007). Calcification can be stippled or plaquelike and is found in 10% to 20% of RCCs.

Nuclear features can be highly variable and are an independent prognostic factor for RCC generally and for clear cell and papillary RCC in particular (Delahunt et al., 2014; Fuhrman et al., 1982; Klatte et al., 2010; Sukov et al., 2012). Grading has been based primarily on nuclear size and shape and the presence or absence of prominent nucleoli. Fuhrman's system (Fuhrman et al., 1982) was the most frequently used system for more than three decades but was not reliable for chromophobe RCC and has not been validated for the newer subtypes of renal carcinoma (Cheville et al., 2012; Delahunt et al., 2007;

Finley et al., 2011). **A new four-tiered grading system developed by the World Health Organization and International Society of Urological Pathology has been validated for clear cell and papillary RCC** (Delahunt et al., 2014) and is now the recommended grading system for RCC (Table 97.8).

TABLE 97.8

World Health Organization/International Society of Urological Pathology (WHO/ISUP) Grading System for Clear Cell and Papillary Renal Cell Carcinoma

GRADE	DESCRIPTION
1	Nucleoli are absent or inconspicuous and basophilic at 400× magnification
2	Nucleoli are conspicuous and eosinophilic at 400× magnification and visible but not prominent at 100× magnification
3	Nucleoli are conspicuous and eosinophilic at 100× magnification
4	There is extreme nuclear pleomorphism, multinucleated giant cells, and/or rhabdoid and/or sarcomatoid differentiation

Modified from Delahunt B, Srigley JR, Egevad L, et al.: International Society of Urological Pathology grading and other prognostic factors for renal neoplasia. *Eur Urol* 66(5):795–798, 2014.

Aggressive local behavior is not uncommon with RCC and can be expressed in a variety of ways. Invasion of the renal capsule, renal sinus, or collecting system is found in approximately 20% of cases, although displacement of these structures is a more common finding. Further spread to involve adjacent organs or the abdominal wall is often precluded by the Gerota fascia, although some high-grade RCCs are able to overcome this natural barrier. **One unique feature of RCC is its predilection for involvement of the venous system, which is found in 10% of cases,** more often than in any other tumor type (Scheff t et al., 1978; Skinner et al., 1972). Contiguous tumor thrombus can extend into the renal vein and inferior vena cava (IVC) and ascend as high as the right atrium. Many such tumor thrombi are highly vascularized by arterial blood flow (Novick et al., 1990), and some directly invade the wall of the renal vein or vena cava, which correlates with compromised prognosis (Haddad et al., 2014; Scheff t et al., 1978; Skinner et al., 1972; Zini et al., 2008).

Most sporadic RCCs are solitary. Bilateral involvement can be synchronous or asynchronous and is found in 2% to 4% of sporadic RCCs, although it is considerably more common in patients with familial forms of RCC, such as von Hippel-Lindau disease. Multicentricity, which is found in 10% to 20% of cases, is more common in association with papillary RCC

and familial RCC (Cheng et al., 1991; Krambeck et al., 2008; Mukamel et al., 1988; Nguyen et al., 2017). Satellite lesions are often small and difficult to identify by preoperative imaging, intraoperative ultrasonography, or visual inspection; they appear to be the main factor contributing to ipsilateral recurrence after partial nephrectomy (Mukamel et al., 1988). Microsatellite analysis suggests a clonal origin for most multifocal RCC within the same kidney (Junker et al., 2002), but tumor in the contralateral kidney is likely to be an independent growth if it is synchronous or a metastasis if it is asynchronous (Kito et al., 2002; Lane et al., 2009). Comprehensive sequencing of multiple biopsy specimens obtained from primary and metastatic tumors in the same patient has revealed significant intratumor heterogeneity (Gerlinger et al., 2012). These studies suggest that analysis of single biopsy samples may underestimate this inherent heterogeneity and prevent discernment of “driver” mutations from “passenger” mutations, presenting significant challenges to personalized medicine and biomarker development (Beksac et al., 2017; Gerlinger et al., 2012; Hanahan and Weinberg, 2011).

All RCCs are, by definition, adenocarcinomas, derived from renal tubular epithelial cells (Moch et al., 2016; Zhou, 2009; Table 97.9). **Most RCCs share ultrastructural features, such as surface microvilli and complex intracellular junctions, with normal proximal tubular cells and are believed to be derived from this region of the nephron** (Axelson and Johansson, 2013; Kim and Kim, 2002). Chromophobe RCC and two aggressive subtypes of RCC, renal medullary carcinoma and collecting duct carcinoma, appear to be derived from more distal elements of the nephron (Abern et al., 2012; Amin et al., 2017; Davis et al., 2014; Storkel et al., 1997; Zambrano et al., 1999).

TABLE 97.9

Pathologic Subtypes of Renal Cell Carcinoma

HISTOLOGY[a]	FAMILIAL FORM AND GENETIC FACTORS	GROSS CHARACTERISTICS	MICROSCOPIC PATHOLOGIC CHARACTERISTIC
COMMON SUBTYPES			
Clear cell RCC (70%–80%)	von Hippel-Lindau (VHL) disease *VHL* gene (3p25) mutation or	Typically well-circumscribed, lobulated, golden yellow tumor but can be infiltrative	Hypervascular tumor Nests or sheets of clear cells with delicate vascular

	hypermethylation Chromosome 3p deletions Loss of chromosome 8p, 9p, 14q; gain of chromosome 5q	Necrosis, hemorrhage, and cystic degeneration common Venous involvement also common	network IHC[b]: LMWCKs[c], vimentin, EMA, CA-IX
Papillary RCC Type 1 (5%–10%)	HPRC Altered MET proto-oncogene status present in 81% of sporadic cases Trisomy of chromosome 7 and 17	Fleshy tumor with fibrous pseudocapsule Necrosis and hemorrhage are common	Hypovascular tumor Papillary structures with single layer of cells around fibrovascular cores Basophilic cells with low-grade nuclei IHC[b]: LMWCKs[c], CK7 (type 1 > type 2), AMACR
Papillary RCC Type 2 (5%–10%)	HLRCC Fumarate hydratase *(FH)* gene (1q42-43) mutation in HLRCC	Fleshy tumor with fibrous pseudocapsule Necrosis and hemorrhage are common	Hypovascular tumor Papillary structures with single layer of cells around fibrovascular cores Eosinophilic cells with high-grade nuclei IHC[b]: LMWCKs[c], AMACR
Chromophobe RCC (3%–5%)	Birt-Hogg-Dube (BHD) syndrome Folliculin (*FLCN*) gene mutation (17p11) Loss of multiple chromosomes (1, 2, 6, 10, 13, 17, 21, Y) TPS3 and PTEN mutations	Well-circumscribed, homogeneous Tan or light brown cut surface	“Plant cells” with pale cytoplasm, perinuclear clearing or “halo,” nuclear “raisins,” and prominent cell borders (classic subtype) Positive Hale's colloidal iron staining IHC[b]: diffuse CK7

			Eosinophilic subtype has dense pink cytoplasm an mitochondrial gene mutations
Clear cell papillary RCC (~5%)	VHL disease	Well-circumscribed, well-developed capsule	Low-grade clear epithelial cells organized in linear papillae and tubules IHC[b]: diffuse CK7 cuplike CA-IX distribution
Unclassified RCC (1%–3%)	Unknown	Varied	Varied
RARE SUBTYPES (EACH REPRESENTS <1%)			
Carcinoma of the collecting ducts of Bellini (collecting duct carcinoma)	Unknown Multiple chromosomal losses	Firm, centrally located tumor with infiltrative borders Light gray to tan-white	Complex, highly infiltrative cords within inflamed (desmoplastic) stroma High-grade nuclei, mitoses
Renal medullary carcinoma	Associated with sickle cell trait	Infiltrative, gray-white Extensive hemorrhage and necrosis	Poorly differentiated cells with lacelike appearance Inflammatory infiltrate
Hereditary leiomyomatosis and renal cell carcinoma (HLRCC)-associated RCC	HLRCC Fumarate hydratase (FH) gene (1q42-43) mutation	Fleshy tumor with fibrous pseudocapsule Necrosis and hemorrhage are common	Hypovascular tumor Papillary structure with single layer o cells around fibrovascular core Eosinophilic cells with high-grade nuclei IHC[b]: LMWCKs[c], AMACR
Succinate	*SDH-RCC*	Solitary lesion	Vacuolated

dehydrogenase-deficient renal carcinoma	*SDHA*, *SDHB* (1p36.13), *SDHC* (1q23.3), *SDHD* (11q23.1), *SHDAF2*		eosinophilic or clear cells Shares features with chromophobe RCC, oncocytoma, clear cell RCC, type 2 papillary RCC IHC[b]: Loss of SDHB
MiT family translocation RCC (includes Xp11 translocation RCC and t(6;11) RCC)	Various mutations involving chromosome Xp11.2 resulting in *TFE3* gene fusion	Well-circumscribed, tan-yellow tumor	Variable; often clear cells with papillary architecture IHC[b]: nuclear *TFE3*
Acquired cystic disease-associated RCC	*VHL* gene alterations Chromosome 3p deletion	Cystic degeneration	Cribriform, microcystic or sieve-like architecture Cysts lined with single layer of clea cells IHC[b]: absent CK7
Multilocular cystic clear cell renal neoplasm of low malignant potential	Identical to clear cell RCC	Well-circumscribed mass of small and large cysts	Cysts lined by single layer of low grade clear cells No expansive nodules of tumor cells
Tubulocystic RCC	Unknown	Multiple small to medium renal cysts with spongy appearance	Enlarged nucleoli (grade 3) Eosinophilic and oncocytoma-like

			cytoplasm
Mucinous tubular and spindle cell carcinoma	Unknown	Well-circumscribed, tan-white-pink tumors centered in medulla	Mixture of tubules and spindle-shaped epithelial cells; mucin background
Hybrid oncocytic chromophobe tumor	Birt-Hogg-Dube (BHD) syndrome Folliculin (FLCN) gene mutation (17p11)	Well-circumscribed, homogeneous appearance Tan or light brown cut surface	Shares features with chromophobe RCC an oncocytoma; often coexists with these tumors in BHD patient

[a] Sarcomatoid variants of all of these subtypes have been described and are associated with compromised prognosis.

[b] Immunohistochemistry (IHC) using these markers can help to differentiate between RCC subtypes.

[c] Cytokeratin (CK): low-molecular-weight cytokeratins (LMWCKs).

AMACR, Alpha-methylacyl-coenzyme A racemase; *ARCD,* acquired renal cystic disease; *CA-IX,* carbonic anhydrase IX; *CK7,* cytokeratin 7; *EMA,* epithelial membrane antigen; *ESRD,* end-stage renal disease; *HLRCC,* hereditary leiomyomatosis and RCC; *HPRC,* hereditary papillary RCC; *IHC,* immunohistochemistry; *RCC,* renal cell carcinoma; *VHL,* von Hippel-Lindau.

Modified from Eble JN, Sauter G, Epstein JI, et al.: *WHO classification of tumours: pathology and genetics of tumours of the urinary system and male genital organs,* Lyon, France, 2004, IARC Press; Srigley JR, Delahunt B, Eble J N, et al.: The International Society of Urological Pathology (ISUP) Vancouver classification of renal neoplasia. *Am J Surg Pathol* 37(10):1469–1489, 2013; Moch H, Cubilla AL, Humphrey PA, et al.: The 2016 WHO classification of tumours of the urinary system and male genital organs–Part A: renal, penile, and testicular tumours. *Eur Urol* 70(1):93–105, 2016.

Since the early 1990s, the histologic classification of RCC has undergone several major revisions (see Table 97.9) (Algaba et al., 2011; Moch et al., 2016; Srigley et al., 2013; Zambrano et al., 1999; Zhou, 2009). Traditionally, RCC was divided into four histologic subtypes: clear cell, granular cell, tubulopapillary, and sarcomatoid. Based on advances in the molecular genetics of RCC and a more discerning interpretation of histologic and ultrastructural features, a newer classification scheme was proposed (Kovacs, 1993). In this system, granular cell tumors were reclassified into other categories based on distinct histopathologic features, chromophobe RCC was recognized as a new RCC subtype, and sarcomatoid features were categorized as variants of other histologic subtypes rather than a distinct tumor type (Storkel et al., 1997; Weiss et al., 1995; Zambrano et al., 1999). **Current practice is to identify the primary histologic subtype and comment on the presence and extent of sarcomatoid**

differentiation rather than to separate these tumors into a distinct category, although the prognostic implications have not changed (Cheville et al., 2004; Moch et al., 2016).

Depending on well-defined histologic and ultrastructural criteria, granular cell tumors were reclassified as papillary RCC, eosinophilic variants of chromophobe RCC, or clear cell RCC. Another important development was the identification of renal medullary carcinoma that is occasionally seen in young African-Americans with sickle cell trait (Abern et al., 2012; Davis et al., 1995). With additional pathologic advances, including electron microscopy, immunohistochemistry, molecular genetics, and cytogenetics, several additional unique subtypes of RCC have been identified since implementation of the 1993 classification system. Based on these findings, an updated classification of malignant epithelial tumors of the kidney was presented by the World Health Organization in 2004 and updated in 2016 (see Tables 97.1 and 97.9; Eble et al., 2004; Moch et al., 2016).

The World Health Organization classification reflects current understanding of RCC not as a single malignant neoplasm, but rather as a group comprising several different tumor subtypes, each with a distinct genetic basis and unique clinical features. Important changes include the addition of several RCC subtypes that were previously grouped within "conventional" or unclassified RCC. One example is MiT family translocation RCC, which has microscopic features of clear cell and papillary RCC and occurs primarily in children and young adults (Argani et al., 2010; Choueiri et al., 2010; Delahunt et al., 2014; Liu et al., 2016). Another is succinate dehydrogenase-deficient RCC, which also occurs in young adults and has favorable prognosis in most instances (Gill et al., 2014; Ricketts et al., 2008). Sophisticated gene expression profiling and proteomic analyses support the individuality of each of these tumor subtypes and hold great promise for differentiating additional subtypes in the future (Jonasch et al., 2012; Moch et al., 2016; Raspollini et al., 2017; Yang et al., 2006). This has clearly been a field in evolution with changes stimulated by basic science advances and astute clinical observation.

Clear Cell Renal Cell Carcinoma

Clear cell RCC accounts for 70% to 80% of all RCCs, representing the garden variety of RCC (Deng and Melamed, 2012; Moch et al., 2016; Storkel et al., 1997). **These tumors are typically yellow and highly vascular,** containing a network of delicate vascular sinusoids interspersed between sheets or acini of tumor cells (Fig. 97.9). **On microscopic examination, clear cell RCC can include clear cells, granular or eosinophilic cells, or mixed types.** Clear cells are typically round or polygonal with abundant cytoplasm containing glycogen, cholesterol, cholesterol esters, and phospholipids, all of which are readily extracted by the solvents used in routine histologic preparations, contributing to the clear appearance of the tumor cells (Farrow, 1997). Granular cells with eosinophilic cytoplasm and abundant mitochondria can predominate. Three to five percent of clear cell RCCs demonstrate sarcomatoid features, and clear cell RCC is more likely to exhibit venous tumor extension than any other subtype of RCC (Rabbani et al., 2004). **In general, patients with clear cell RCC have a worse prognosis compared with papillary type 1 or chromophobe RCC, even after stratification for stage and grade** (Cheville et al., 2003; Deng and Melamed, 2012). **Paradoxically, clear cell RCC is more likely to respond to VEGF-targeted therapy, checkpoint inhibitors, or high dose IL-2 than other subtypes of RCC, so it typically has a better prognosis when it is metastatic. Chromosome 3 alterations occur in more than 90% of clear cell RCCs, leading to mutation or inactivation of the *VHL*, *PBRM1*, *SETD2*, or *BAP1* genes, which are all present on this portion of the genome** (Cancer Genome Atlas Research Network, 2013; Schmidt and Linehan, 2016). The familial form of clear cell RCC, the VHL syndrome, in which the *VHL* tumor suppressor gene is inactivated, has already been reviewed.

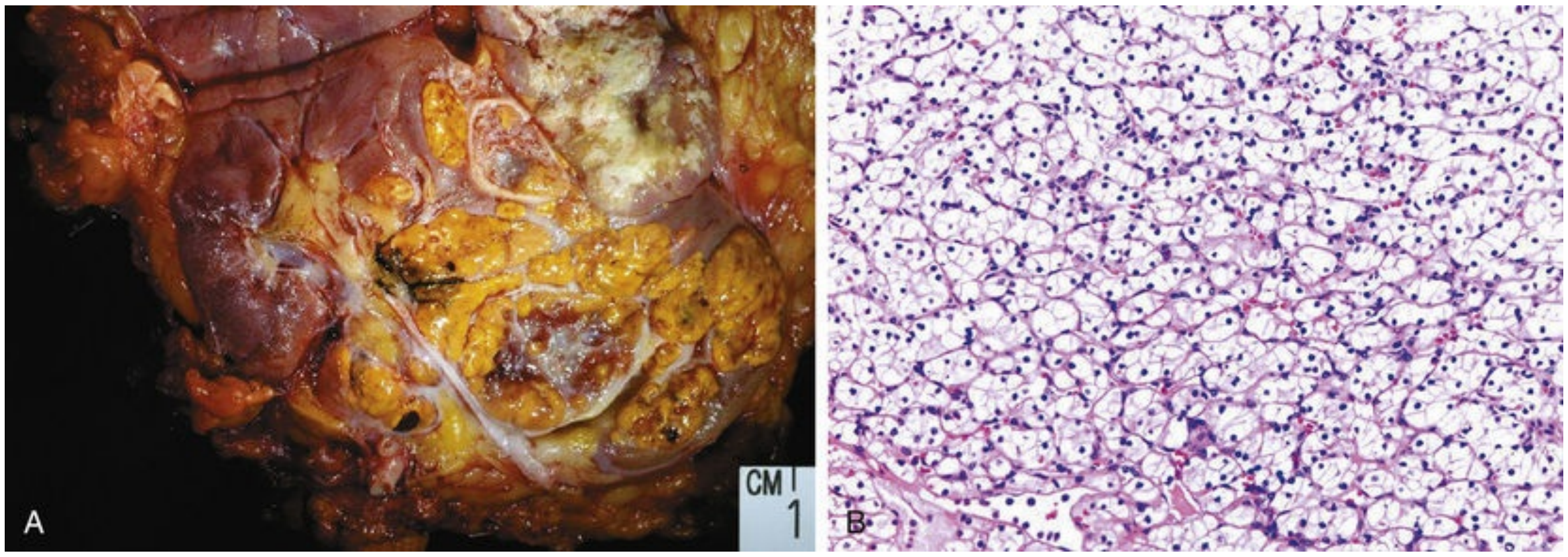

FIG. 97.9 (A) Clear cell renal cell carcinoma (RCC) with typical golden yellow color. (B) Low-power view of typical microscopic appearance of a low-grade clear cell RCC demonstrating a delicate vascular network interspersed within homogeneous nests of cells with clear cytoplasm. (Courtesy Dr. Ming Zhou, Cleveland, OH.)

Papillary Renal Cell Carcinoma

Papillary RCC, which was previously designated chromophilic RCC, is the second most common histologic subtype (10%–15%) of all RCCs (Moch et al., 2016). On microscopic examination, most tumors consist of basophilic or eosinophilic cells arranged in papillary or tubular configuration (Fig. 97.10). Gross features of papillary RCC include beige to white color, spherical boundary, and frequent hemorrhage, which may mimic cystic components radiologically. **One unique feature of papillary RCC is its tendency toward multicentricity, which approaches 40%** in many series and occurs more commonly in patients with end-stage renal disease and acquired renal cystic disease (Deng and Melamed, 2012).

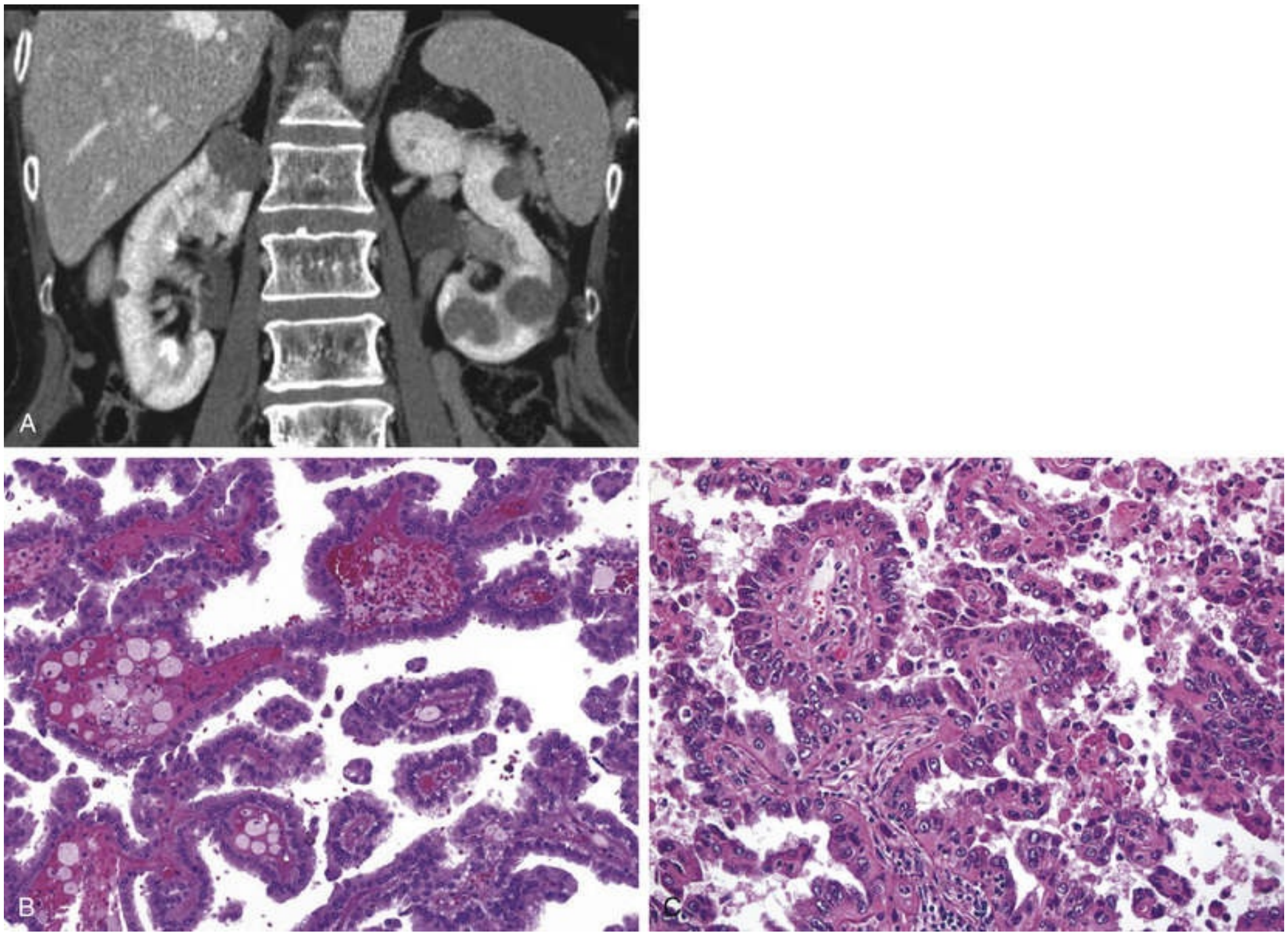

FIG. 97.10 (A) Papillary renal cell carcinoma (RCC) often presents with multiple small, modestly enhancing renal tumors as demonstrated on this computed tomography image. (B) Microscopic appearance of type 1 papillary RCC demonstrating basophilic cells with scant cytoplasm and low-grade nuclei. (C) In contrast, type 2 papillary RCC consists of eosinophilic cells with abundant granular cytoplasm and high-grade nuclei. (Courtesy Dr. Ming Zhou, Cleveland, OH.)

Two distinct variants of papillary RCC have been described by characteristic cytogenetics, immunostaining profiles, and gene expression profiling (see Fig. 97.10) (Eble et al., 2004; Pal et al., 2018; Storkel et al., 1997; Yang et al., 2005). **Type 1 papillary RCC, the more common form, consists of basophilic cells with scant cytoplasm; type 2 papillary RCC includes potentially more aggressive variants with eosinophilic cells and abundant granular cytoplasm** (Pal et al., 2018; Pignot et al., 2007).

The Cancer Genome Atlas (TCGA) analysis for papillary RCC demonstrated that many type 1 tumors have activating MET mutations, whereas three subgroups of type 2 were identified that harbor other genetic defects (Cancer Genome Atlas Research Network, 2013). **The two subtypes of papillary RCC correspond with two familial RCC syndromes: HPRC syndrome (type 1) and HLRCC syndrome (type 2)**. **The cytogenetic abnormalities associated with type 1 papillary RCC are characteristic and include trisomy of chromosomes 7 and 17 and loss of the Y chromosome** (Cancer Genome Atlas Research Network, 2013; Kovacs et al., 1989b; Pal et al., 2018). Other common findings include gain of chromosomes 12, 16, and 20 and loss of heterozygosity on chromosome 14 (Deng and Melamed, 2012; Kenck et al., 1996). Papillary RCC is more likely to be hypovascular, perhaps because of the lack of *VHL* mutations that regulate VEGF, the primary proangiogenic molecule in RCC (Blath et al., 1976). As discussed earlier, activating mutations of the c-*MET* proto-oncogene located on chromosome 7 appears to be common and pathogenic in hereditary papillary RCC (Kenck et al., 1996; Schmidt et al., 1997). Indeed, this genetic defect is now being targeted for novel treatment approaches with the use of cabozatinib (Harshman and Choueiri, 2013; Jonasch et al., 2012).

The prognosis associated with papillary RCC remains controversial. Five-year cancer-specific survival rates for patients with papillary RCC traditionally ranged from 86% to 92%, in part because papillary RCCs often presented with low stage and grade, and most studies in the past were likely enriched in type 1 tumors (Deng and Melamed, 2012; Mancilla-Jimenez et al., 1976). However, more recent studies that have used immunohistochemistry and cytogenetics to define papillary histology contain an increased proportion of high-grade and advanced tumors that, although still in the minority, can prove to be lethal. In part this is due to the ineffectiveness of systemic therapies against metastatic papillary RCC (Amin and White, 2013; Lager et al., 1995; Margulis et al., 2008; Renshaw, 2002). **Current evidence suggests that type 1 papillary RCC carries a better prognosis than clear cell RCC, whereas type 2 papillary**

RCC is similar or worse than clear cell RCC (Deng and Melamed, 2012).

Papillary adenomas are small (≤5 mm) tumors that resemble papillary RCC under the microscope, are often well encapsulated and low grade, and are commonly found at autopsy (Algaba et al., 2011). These lesions, which possess many of the same genetic alterations found in larger papillary RCCs, are generally considered benign (see Chapter 96).

Key Points: Pathology of Renal Cell Carcinoma

- Clear cell RCC is the most common subtype (70%–80%) of RCC. Origin is the proximal tubule, and hypervascularity and necrosis are frequently present. Typically, these are more aggressive than the other common subtypes of RCC but also more likely to respond to immunotherapy and other targeted molecular therapies.
- Papillary RCC (10%–15% of RCC) is divided into type 1, an indolent form associated with MET mutations and frequently multifocal, and type 2, which is associated with poorer prognosis.
- Chromophobe RCC (3%–5% of RCC) is typically an indolent type of RCC that shares some histopathologic features with benign oncocytomas.

Chromophobe Renal Cell Carcinoma

Chromophobe RCC, first described by Thoenes et al. in 1985, is a distinctive histologic subtype of RCC that represents 3% to 5% of all RCCs and appears to be derived from the distal convoluted tubules (Algaba et al., 2011; Davis et al., 2014; Haake and Rathmell, 2017; Moch et al., 2016; Thoenes et al., 1985). Chromophobe RCC is commonly seen in the BHD syndrome, but most cases are sporadic (Schmidt and Linehan, 2016). The tumor cells typically exhibit a relatively transparent cytoplasm with a fine reticular pattern that has been described as a “plant cell” appearance (Fig. 97.11). Most chromophobe RCCs are resistant to the pigment used during typical hematoxylin and eosin staining, but eosinophilic variants constitute about 30% of cases (Nagashima, 2000; Thoenes et al., 1988). In either case, **a perinuclear clearing or “halo” is typically found and electron microscopic findings consist of numerous 150- to 300-nm microvesicles, which are the single most distinctive and defining feature of chromophobe RCC. These microvesicles characteristically stain**

positive for Hale colloidal iron, indicating the presence of a mucopolysaccharide unique to chromophobe RCC (see Fig. 97.11). Immunohistochemistry typically reveals positive staining for pan-cytokeratin, epithelial membrane antigen, and parvalbumin and negative for vimentin and CD10 (Algaba et al., 2011). Multidimensional and comprehensive characterization of 66 primary chromophobe RCC by TCGA confirmed earlier discoveries of hypodiploid DNA content in most cases (Bugert et al., 1997; Davis et al., 2014). **Massive chromosomal losses, including the whole chromosomes 1, 2, 6, 10, 13, and 17 occur in 86% of cases,** and losses of chromosomes 3, 5, 8, 9, 11, 18, and 21 were noted in 12% to 58% of cancers (Davis et al., 2014). Combined mitochondrial DNA and gene expression analysis implicate changes in mitochondrial function as a common feature of chromophobe RCC (Davis et al., 2014).

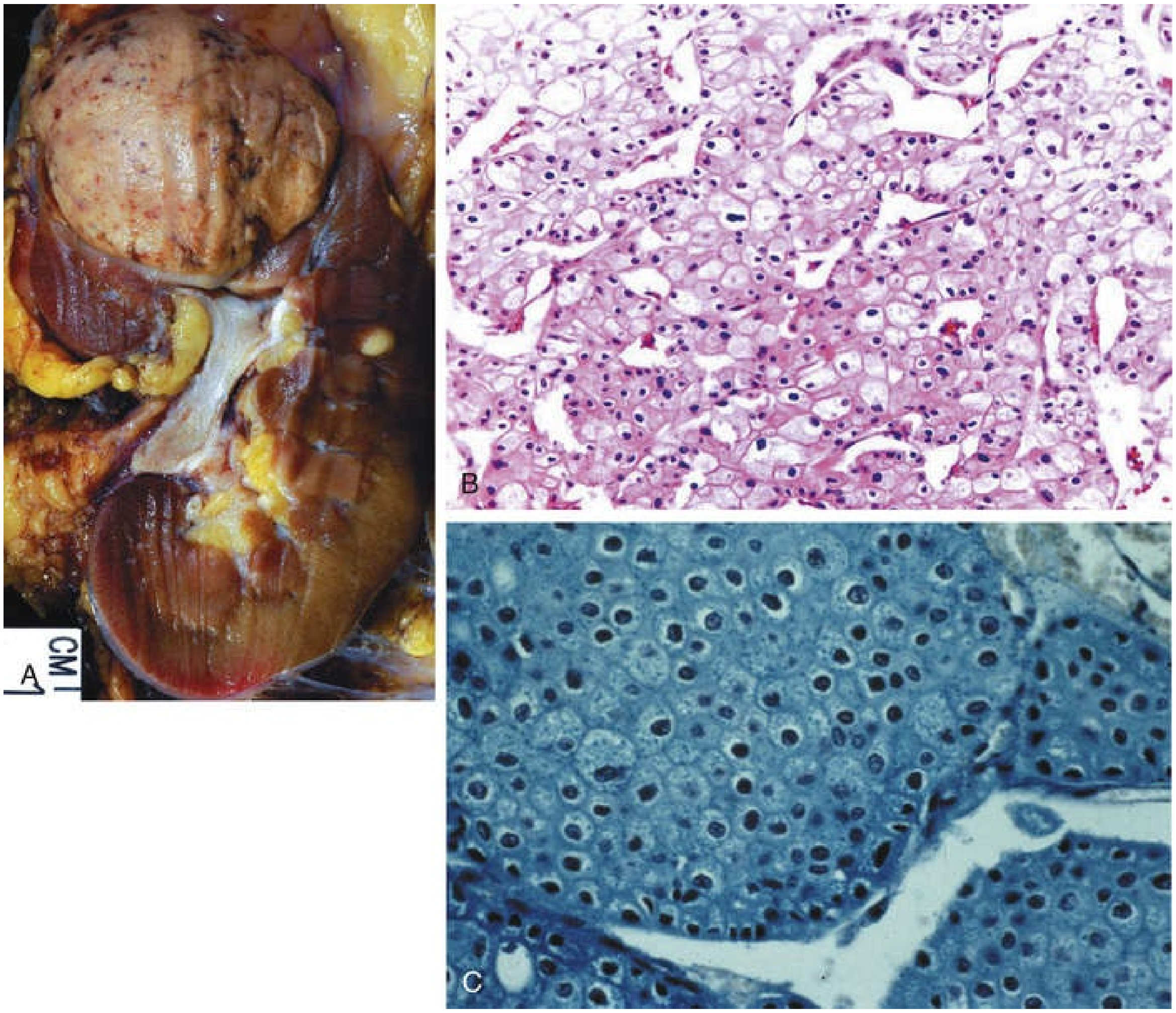

FIG. 97.11 (A) Chromophobe renal cell carcinoma (RCC) typically

appears as a well-circumscribed, homogeneous, tan tumor. (B) Chromophobe RCC with admixture of classic (chromophobic) and eosinophilic cells. Characteristic features include distinct cytoplasmic borders, perinuclear “halos,” and nuclear “raisins.” The classic variant is notable for its “plant cell” appearance. (C) Chromophobe RCC stains positive for Hale colloidal iron and demonstrates multiple microvesicles on electron microscopy. (Courtesy Dr. Ming Zhou, Cleveland, OH.)

Most studies suggest a better prognosis for localized chromophobe RCC than for clear cell RCC but a poor outcome in the small subset of patients with sarcomatoid features or metastatic disease (Klatte et al., 2008; Moch et al., 2016; Renshaw et al., 1996). Most early reports suggested a tendency to remain localized despite growth to large size, as well as a predominance of low-grade disease (Thoenes et al., 1988). Subsequent reports have verified that chromophobe RCC generally occurs at an earlier T stage, with more than 90% of patients remaining cancer free for 5 or more years after treatment (Deng and Melamed, 2012; Klatte et al., 2008). Limited data exist regarding treatment of metastatic chromophobe RCC, with most evidence suggesting limited activity of tyrosine kinase inhibitors, mTOR inhibitors, and immune modulators in this population (Kroeger et al., 2013; Tannir et al., 2012). Further clinical evaluation is required to identify effective therapeutic agents for patients with metastatic, non–clear cell RCC.

Collecting Duct Carcinoma

Carcinoma of the collecting ducts of Bellini is a relatively rare subtype of RCC, with a predictably poor prognosis (Algaba et al., 2011; Moch et al., 2016; Seo et al., 2017; Sui et al., 2017). Small collecting duct carcinomas can arise in a medullary pyramid, but most are large, infiltrative masses, and extension into the cortex is common (Deng and Melamed, 2012; Pickhardt et al., 2001). On microscopic examination, these tumors consist of an admixture of dilated tubules and papillary structures typically lined by a single layer of cuboidal cells, often creating a cobblestone appearance. The characteristic immunophenotype of these tumors is coexpression of low- and high-molecular-weight cytokeratins and *Ulex europaeus* agglutinin-1 reactivity (Rumpelt et al., 1991). Positivity for E-cadherin and c-KIT help to distinguish this entity from aggressive papillary RCC, but this staining profile can also be present in urothelial carcinoma, and differential diagnosis often requires careful examination of multiple sections (Kobayashi et al., 2008). **Most reported cases of collecting duct carcinoma have been high grade, advanced stage, and**

unresponsive to conventional therapies (Karakiewicz et al., 2007c; Tokuda et al., 2006; Wright et al., 2009). Reflecting the fact that collecting duct carcinoma may share features in common with urothelial carcinoma, some patients with advanced collecting duct carcinoma have responded to cisplatin- or gemcitabine-based chemotherapy (Dason et al., 2013; Seo et al., 2017). Multimodality therapy, including surgery, systemic therapy, and possibly radiation therapy appear to improve survival compared with nephrectomy alone for metastatic disease (Seo et al., 2017). Early reports of the use of VEGF-targeted agents and checkpoint inhibitors for this aggressive cancer indicate potential clinical benefit (Ansari et al., 2009; Mizutani et al., 2017; Tannir et al., 2012; Yin et al., 2016).

Renal Medullary Carcinoma

Renal medullary carcinoma is an uncommon subtype of RCC that occurs almost exclusively in patients with sickle cell trait. It is typically diagnosed in young African-Americans, often in the third decade of life, and many cases are locally advanced and metastatic at the time of diagnosis (Davis et al., 1995; Moch et al., 2016; Swartz et al., 2002). Most patients do not respond to therapy and succumb to their disease within months, with less than 15% surviving more than 2 years (Shah et al., 2017a). More recent treatment protocols have produced modest improvements compared with a historical report with mean survival of 15 weeks (Davis et al., 1995). Median survival in two relatively large series of patients (159 and 52) reported in 2017 were 8 and 13 months (Ezekian et al., 2017; Shah et al., 2017a). Platinum-based chemotherapy was associated with a 29% objective response rate, with no objective clinical responses seen with targeted therapy in 28 patients (Shah et al., 2017a). This tumor shares many histologic features with collecting duct carcinoma, and many consider it a subtype of collecting duct carcinoma (Algaba et al., 2011; Seo et al., 2017; Swartz et al., 2002). Renal medullary carcinoma is thought to arise from the calyceal epithelium near the renal papillae but is often highly infiltrative. The site of origin (renal papillae) and association with sickle cell trait suggest that a relatively hypoxic environment may contribute to tumorigenesis.

Sarcomatoid and Rhabdoid Differentiation

Sarcomatoid differentiation is found in 1% to 5% of RCCs, most commonly in association with clear cell RCC or chromophobe RCC, but variants of most other subtypes of RCC have been described (Moch et al., 2016; Ro et al., 1987; Shuch et al., 2012; Wei and Al-Saleem, 2017). Most authors now believe that sarcomatoid lesions represent poorly differentiated regions of RCC rather than independently derived tumors (DeLong et al., 1993; Eble et al., 2004) because it is rare to find a truly pure sarcomatoid renal mass. **For this reason, this entity is no longer recognized as a distinct histologic subtype of RCC** (Eble et al., 2004). **Sarcomatoid differentiation is characterized by spindle cell histology, positive staining for vimentin, infiltrative growth pattern, aggressive local and metastatic behavior, and poor prognosis** (Fig. 97.12). Invasion of adjacent organs is common, and median survival has been less than 1 year in most series (Kara et al., 2016; Molina et al., 2011; Ro et al., 1987; Wei and Al-Saleem, 2017). Multimodal approaches should be considered if performance status allows, based on the extremely poor prognosis with surgery alone and selected reports demonstrating modest response rates in patients receiving immunotherapy, chemotherapy, or VEGF-targeted therapy after surgery (Shuch et al., 2012).

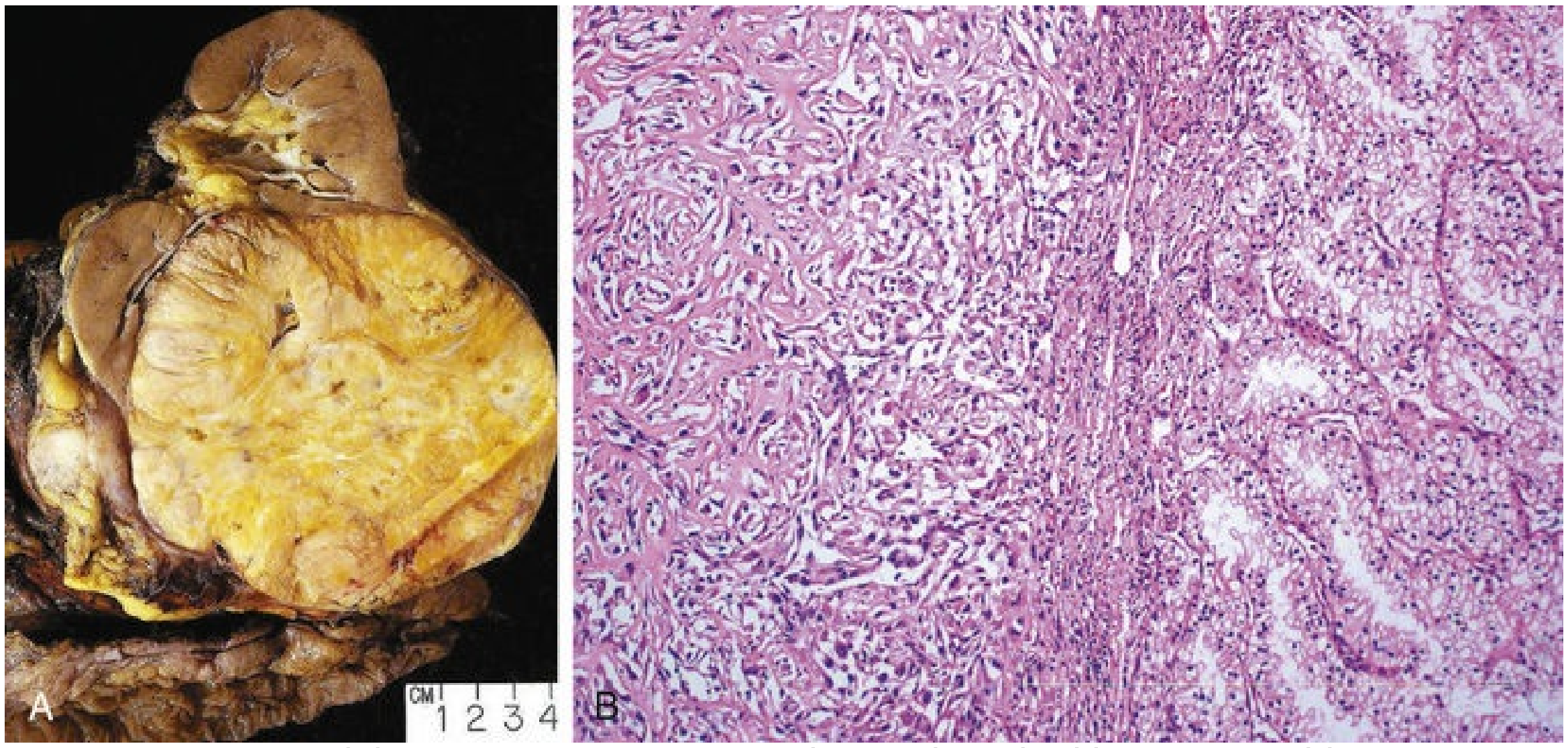

FIG. 97.12 (A) Clear cell renal cell carcinoma (RCC) with sarcomatoid differentiation demonstrating extension into the perinephric fat. (B) High-grade RCC with typical spindle cell appearance on the left indicating a component of sarcomatoid differentiation. (Courtesy Dr. Ming Zhou, Cleveland, OH.)

Similar to RCC with sarcomatoid differentiation, rhabdoid features can be seen with many of the subtypes of RCC but is not considered a separate subtype. The presence of rhabdoid cells mandates assignment of grade 4 and is generally associated with a poor prognosis (Kara et al., 2016; Przybycin et al., 2014; Zhang et al., 2015). Several studies have implicated a specific molecular mechanism affecting the switch sucrose nonfermentable (SWI/SNF) chromatin remodeling complex in rhabdoid and other de-differentiated subtypes of carcinomas from multiple organs, including the kidney, potentially identifying a target for future therapies for these aggressive cancers (Agaimy et al., 2017).

Unclassified Renal Cell Carcinoma

Unclassified RCC represents a minority of cases (1% to 5%) of presumed RCC with features that remain indeterminate even after careful analysis (Crispen et al., 2010). **Many are poorly differentiated and are associated with a highly aggressive biologic behavior and a particularly poor prognosis** (Amin et al., 2002; Karakiewicz et al., 2007b). Included within this “catch-all” category are occasional cases of RCC with extensive sarcomatoid differentiation and no discernible epithelial component. Advances in molecular diagnostics, such as gene expression profiling, may enable further classification of unusual tumors that previously would have fallen into this category and identify candidate pathways for targeted molecular therapeutics (Jonasch et al., 2012; Yang et al., 2006).

Clinical Presentation

Because of the sequestered location of the kidney within the retroperitoneum, many renal masses remain asymptomatic and nonpalpable until they are locally advanced. With the more pervasive use of noninvasive imaging for the evaluation of a variety of nonspecific symptom complexes, more than 60% of RCCs are now detected incidentally (Beisland, 2017; O'Connor et al., 2011; Silverman et al., 2008). Several studies have shown that such tumors are more likely to be confined to the kidney and a positive impact on survival has been reported, although the contributions of lead and length time biases have not been defined (Beisland, 2017; Decastro and McKiernan, 2008; Kane et al., 2008; Tsui et al., 2000).

Symptoms associated with RCC can be due to local tumor growth, hemorrhage, paraneoplastic syndromes, or metastatic disease (Table 97.10; Hu et al., 2016). Flank pain is usually due to hemorrhage and clot obstruction, although it can also occur with locally advanced or invasive disease. **The classic triad of flank pain, gross hematuria, and palpable abdominal mass is now rarely seen.** This is fortunate because this constellation of findings almost always denotes advanced disease and some refer to it as the “too late triad.” Before the advent of ultrasonography and CT, most patients with RCC presented with one or more of these signs or symptoms, and many were incurable. Other indicators of advanced disease include constitutional symptoms such as weight loss, fever, and night sweats, and physical examination findings such as palpable cervical lymphadenopathy, nonreducing varicocele, and bilateral lower extremity edema resulting from venous involvement. A minority of patients present with symptoms directly related to metastatic disease, such as bone pain or persistent cough. **A less common but important presentation of RCC is that of spontaneous perirenal hemorrhage, in which the underlying mass may be obscured. Zhang et al. have shown that more than 50% of patients with perirenal hematoma of unclear cause have an occult renal tumor, most often AML or RCC** (Xie et al., 2017; Zhang et al., 2002). Repeat CT a few months later often provides a definitive diagnosis.

TABLE 97.10

Clinical Presentation of Renal Cell Carcinoma

Incidental presentation
Symptoms of localized or locally advanced disease Hematuria Flank pain Abdominal mass Perinephric hematoma
Obstruction of the inferior vena cava Bilateral lower extremity edema Nonreducing or right-sided varicocele
Symptoms of systemic disease Persistent cough Bone pain Cervical lymphadenopathy Constitutional symptoms Weight loss/fever/malaise Paraneoplastic syndromes

Key Points: Clinical Presentation of Renal Cell Carcinoma

- Local symptoms of RCC can include flank pain, gross hematuria, and palpable abdominal mass; however, this classic triad of symptoms is now rarely seen.
- The majority of RCC are detected incidentally; early detection is more commonly associated with small primary tumors and localized disease.
- Spontaneous renal hemorrhage can occur with RCC or AML.
- Paraneoplastic syndromes are seen more commonly with metastatic disease; many resolve once the malignant lesion(s) are surgically removed. Hypercalcemia can also be managed with vigorous hydration and diuresis, or with other medical approaches.

Paraneoplastic syndromes are found in 10% to 20% of patients with RCC and few, if any, nonrenal malignancies are associated with a comparable quantity and diversity of such syndromes. In fact, **RCC was previously referred to as the internist's tumor because of the predominance of systemic rather than local manifestations.** Paraneoplastic syndromes are more common in metastatic disease and less common (almost nonexistent) in patients with small, incidental renal masses (Hu et al., 2016; Moreira et al., 2016). Now, a more appropriate name for RCC would be the radiologist's tumor, given the frequency of incidental detection (Decastro and McKiernan, 2008; Parsons et al., 2001). Nevertheless, it is still important to evaluate for paraneoplastic phenomena because they can be a source of major morbidity and can affect clinical decision making. The most common of these syndromes is elevated erythrocyte sedimentation rate, which accounts for more than 50% of identified paraneoplastic syndromes (Gold et al., 1996). Under normal circumstances, the kidney produces 1,25-dihydroxycholecalciferol, renin, erythropoietin, and various prostaglandins, all of which are tightly regulated to maintain homeostasis. RCC may produce these substances in pathologic amounts, and it may also elaborate a variety of other physiologically important factors, such as parathyroid hormone–like peptides, lupus-type anticoagulant, human chorionic gonadotropin, insulin, and various cytokines and inflammatory mediators. These substances are responsible for the development of paraneoplastic syndromes and often contribute to constitutional symptoms and decline of performance status.

Hypercalcemia has been reported in up to 13% of patients with RCC and can be due to either paraneoplastic phenomena or osteolytic metastatic involvement of the bone (Klatte et al., 2007; Schwarzberg and Michaelson, 2009). The signs and symptoms of hypercalcemia are often nonspecific and include nausea, anorexia, fatigue, and decreased deep tendon reflexes. **Medical management predominates and includes vigorous hydration followed by diuresis with furosemide and the selective use of bisphosphonates, corticosteroids, or calcitonin**. Bisphosphonate therapy is now established as a standard of care for patients with hypercalcemia of malignancy, as long as renal function is adequate (Schwarzberg and Michaelson, 2009). Zoledronic acid, 4 mg intravenously every 4 weeks, appears to be particularly effective in patients with RCC but must be withheld in the presence of renal insufficiency (Lipton et al., 2003; Schwarzberg and Michaelson, 2009). If hypercalcemia proves refractory to bisphosphonates, denosumab therapy can be considered (Hu et al., 2014). More definitive management includes nephrectomy and occasional metastasectomy, depending on the clinical circumstances. Hypercalcemia related to extensive osteolytic metastases is much more difficult to palliate because it is not amenable to surgical approaches, but many such patients may respond to bisphosphonate therapy and focused radiation therapy if limited sites of involvement can be identified (Lipton et al., 2003; Young and Coleman, 2013).

Hypertension and polycythemia are other important paraneoplastic

syndromes commonly found in patients with RCC (Moein and Dehghani, 2000; Moreira et al., 2016). Hypertension associated with RCC can be secondary to increased production of renin directly by the tumor; compression or encasement of the renal artery or its branches, effectively leading to renal artery stenosis; or arteriovenous fistula within the tumor. Less common causes include polycythemia, hypercalcemia, ureteral obstruction, and increased intracranial pressure associated with cerebral metastases. Polycythemia associated with RCC can be due to increased production of erythropoietin, either directly by the tumor or by the adjacent parenchyma in response to hypoxia induced by tumor growth (Wiesener et al., 2007).

One of the more fascinating paraneoplastic syndromes associated with RCC is nonmetastatic hepatic dysfunction, or Stauffer syndrome, which has been reported in 3% to 20% of cases (Giannakos et al., 2005; Kranidiotis et al., 2009). Almost all patients with Stauffer syndrome have an elevated serum alkaline phosphatase level, 67% have elevated prothrombin time or hypoalbuminemia, and 20% to 30% have elevated serum bilirubin or transaminase levels. Other common findings include thrombocytopenia and neutropenia, and typical symptoms include fever and weight loss. Hepatic metastases must be excluded. Biopsy, when indicated, often demonstrates nonspecific hepatitis and discrete regions of necrosis are also occasionally seen. Elevated serum levels of IL-6 have been found in patients with Stauffer syndrome, and it is believed that this and other cytokines may play a pathogenic role. Hepatic function normalizes after nephrectomy in 60% to 70% of cases. Persistence or recurrence of hepatic dysfunction is almost always indicative of viable tumor and thus represents a poor prognostic finding.

A variety of other less common, but distinct paraneoplastic syndromes associated with RCC include Cushing syndrome, hyperglycemia, galactorrhea, neuromyopathy, clotting disorders, and cerebellar ataxia (Sufrin et al., 1989). **In general, treatment of paraneoplastic syndromes associated with RCC has required surgical excision or systemic antineoplastic therapy to reduce the burden of disease and, except for hypercalcemia, medical therapies have not proved helpful.**

Screening and Clinical Associations

A number of factors make screening for RCC appealing (Carrizosa and Godley, 2009; Diaz de Leon and Pedrosa, 2017). **Most important, RCC**

remains primarily a surgical disease requiring early diagnosis to optimize the opportunity for cure. Unfortunately, our ability to salvage patients with advanced disease remains limited. Consistent with these observations, several studies have demonstrated an apparent advantage to early or incidental diagnosis of RCC (Lee et al., 2002; Leslie et al., 2003).

The primary factor that limits the widespread implementation of screening for RCC is the relatively low incidence of RCC in the general population (approximately 16 cases per 100,000 population per year) (Siegel et al., 2017). In this setting a screening test must be almost 100% specific to avoid an unacceptably high false-positive rate, which would lead to unnecessary, expensive, and potentially harmful diagnostic or therapeutic procedures. In addition, even if the test were 100% sensitive and specific, the yield from screening would be so low that it would not be considered cost effective (Carrizosa and Godley, 2009; Rini and Campbell, 2015). Even for populations with established risk factors for RCC, such as male gender, increased age, and heavy tobacco use, generalized screening would be difficult to justify because the increase in relative risk associated with each of these factors is at best twofold to threefold (Carrizosa and Godley, 2009). Another confounding factor is the prevalence of clinically insignificant tumors such as renal adenomas, which are found at autopsy in 10% to 20% of individuals, and other benign or slow-growing tumors (Pantuck et al., 2000; Parsons et al., 2001). There is clearly a risk that such clinically insignificant lesions could be detected, leading to unnecessary evaluation and treatment (Pantuck et al., 2000; Parsons et al., 2001). All these factors recommend against generalized screening efforts for the detection of RCC.

Review of the literature describing the use of dipstick analysis for hematuria and imaging for screening for RCC supports these conclusions (Carrizosa and Godley, 2009; Diaz de Leon and Pedrosa, 2017). Urinalysis is simple and inexpensive, but the yield of RCC in several screening studies has been exceedingly low. In part, this may be because small RCCs are often not associated with hematuria (gross or microscopic) because they are parenchymal rather than urothelial-based malignancies. The incidence of RCC in ultrasound or CT screening studies has ranged from 23 to 300 per 100,000 population, much higher than expected, and an increased proportion of organ-confined tumors has been found in such screened populations compared with historical controls (Carrizosa and Godley, 2009; Turney et al., 2006). However, the incidence of RCC in these studies is still relatively low, and it is unlikely that such efforts would be considered cost effective. Overall, the yield of RCC in such studies is an order of magnitude lower than the yield from prostate-specific antigen–based screening for prostate cancer, and many of the same controversies about lead and length time biases that have plagued the debate about screening for prostate cancer also apply to RCC (Carter et al., 2013). Because of these considerations, it is difficult to justify generalized screening efforts for RCC given the currently available technology.

RCC-related biomarkers in the urine or serum have the potential to distinguish patients with RCC from controls and could play a role for screening in the future (Morrissey and Kharasch, 2013; Rini and Campbell, 2015). Multiple investigations have demonstrated aquaporin-1 levels to be 10-fold higher in patients with RCC (Morrissey and Kharasch, 2013; Sreedharan et al., 2014). Subsequent phase 3 investigation confirmed that aquaporin-1 and perilipin-2 have sensitivity and specificity of at least 95% and at least 91%, respectively, for detection of RCC (Morrissey et al., 2015). Other potential biomarkers include microsatellite alterations in the DNA, *VHL* gene mutations or hypermethylation, upregulation of angiogenic factors (including VEGF), or expression of other RCC-specific proteins such as CA-IX (Jonasch et al., 2012). Further validation of these biomarkers in various clinical settings is needed, and, at least as presently constituted, such approaches would be cost prohibitive for broader populations.

For these reasons, the focus of screening for RCC must be on well-defined target populations, such as patients with end-stage renal disease and acquired renal cystic disease, tuberous sclerosis, and familial RCC (Table 97.11). Eighty percent of patients with end-stage renal disease eventually develop acquired renal cystic disease, and 1% to 2% of this cohort develops RCC (Ishikawa et al., 2010). **Overall, the relative risk of RCC in patients with end-stage renal disease has been estimated to be 5- to 20-fold higher than the general population** (Chen et al., 2015a; Farivar-Mohseni et al., 2006). Fifteen percent of patients with RCC in the setting of end-stage renal disease have metastases at the time of presentation, and many such patients die of malignant progression (Hurst et al., 2011; Ishikawa et al., 2010). Given these considerations, screening for RCC is recommended in this population, which is substantial, representing more than 660,000 patients in the United States alone (National Kidney Foundation, 2016). Concerns about screening this population include short life expectancy, increased incidence of adenomas (20% to 40% vs. 10% to 20% in the general population), complexity of imaging given the altered architecture associated with acquired renal cystic disease, and inevitable cost-related issues. **A reasonable compromise for patients with end-stage renal disease is to target those who are still relatively young and without other major comorbidities, to delay screening until the third year on dialysis, and to take into account gender and type of renal replacement therapy, although data about the last factors are admittedly controversial** (Carrizosa and Godley, 2009). Interestingly, renal transplant recipients remain at increased risk for RCC in the native kidneys, with detection in between 1.4% and 2.3% of patients within 3 years of transplantation, leading to a recommendation for continued periodic radiologic screening even after transplantation (Hurst et al., 2010; Ianhez et al., 2007).

TABLE 97.11

Screening for Renal Cell Carcinoma: Target Populations

PATIENTS WITH END-STAGE RENAL DISEASE Screen only patients with long life expectancy and minimal major comorbidities Periodic ultrasound examination or CT scan beginning during third year on dialysis
PATIENTS WITH KNOWN VON HIPPEL-LINDAU DISEASE Obtain biannual abdominal CT or ultrasound beginning at the age of 15–20 years Periodic clinical and radiographic screening for nonrenal manifestations
RELATIVES OF PATIENTS WITH VON HIPPEL-LINDAU DISEASE Obtain genetic analysis If positive, follow screening recommendations for patients with known von Hippel-Lindau disease If negative, less stringent follow-up is required
RELATIVES OF PATIENTS WITH OTHER FAMILIAL FORMS OF RENAL CELL CARCINOMA Obtain periodic ultrasound or CT and consider genetic analysis
PATIENTS WITH TUBEROUS SCLEROSIS Periodic screening with ultrasound examination or CT scan
PATIENTS WITH AUTOSOMAL DOMINANT POLYCYSTIC KIDNEY DISEASE Routine screening not justified
GENERAL POPULATION Routine screening not justified

CT, Computed tomography.

An increased incidence of RCC has also been debated in tuberous sclerosis, an autosomal dominant disorder in which patients can develop

adenoma sebaceum (a distinctive skin lesion), epilepsy, mental retardation, and renal cysts and AMLs (see Chapter 96; Henske et al., 2016; Lendvay and Marshall, 2003). Many cases of RCC in this syndrome have been characterized by early onset and multifocality, suggesting a genetic predisposition (Lendvay and Marshall, 2003). In addition, the Eker rat, which is mutant for the rodent homolog of the *TSC2* gene responsible for the development of tuberous sclerosis in humans, develops RCC at high frequency, as do *Tsc2*-deficient knockout mice (Lendvay and Marshall, 2003; McDorman and Wolf, 2002). **Such biologic and clinical observations argue in favor of an increased predisposition for RCC in this syndrome, which is consistent with most, although admittedly not all, relevant demographic data** (Schmidt and Linehan, 2016)**. A reasonable conclusion is that periodic renal imaging should be pursued in patients with tuberous sclerosis; such a policy will also facilitate follow-up for the development and progression of AML.**

Screening for RCC in autosomal dominant polycystic kidney disease (ADPKD) has been controversial. Imaging is extremely difficult in this population related to the altered intrarenal architecture, and **more recent studies have found no significantly increased risk of RCC in ADPKD** (Gregoire et al., 1987; Hajj et al., 2009; Jilg et al., 2013; Mosetti et al., 2003). The increased incidence of adenomas and other benign lesions in ADPKD also militates against a potential benefit of screening. **Taken together, these considerations suggest that routine screening for RCC in patients with ADPKD should not be pursued.**

Patients with VHL disease (and other hereditary RCC syndromes) should undergo screening for RCC and other syndrome-associated diseases. VHL should be considered in any patient with early onset or multifocal RCC or RCC in combination with any of the following: a history of visual or neurologic disorders; coexistent pancreatic cysts, epididymal lesions, or inner ear tumors; or a family history of blindness, central nervous system tumors, or renal cancer (Kim et al., 2010; Schmidt and Linehan, 2016). **Patients suspected of having VHL disease, or the appropriate relatives of those with documented disease, should strongly consider genetic evaluation. Patients with germline mutations of the *VHL* gene can be identified and offered clinical and radiographic screening that can identify the major manifestations of VHL disease at a presymptomatic phase, allowing potential amelioration of the considerable morbidity associated with this syndrome** (Nielsen et al., 2016; Schmidt and Linehan, 2016). The VHL alliance has recommended that such patients be evaluated with (1) annual physical examination and ophthalmologic evaluation beginning in infancy; (2) annual estimation of plasma or urinary metanephrines beginning at 5 years of age; (3) MRI of the central nervous system biannually beginning at the age of 16 years; (4) ultrasound examination of the abdomen annually beginning at the age of 8 years, with MRI of the abdomen or functional imaging if biochemical abnormalities are found; (5) the addition of MRI abdomen every other year beginning at age 16; and (6) biannual auditory examinations beginning at age 16 (or earlier if hearing loss, tinnitus, or vertigo) (Nielsen et al., 2016; Schmidt and Linehan, 2016; VHL Alliance, 2016). Less intensive protocols have also been advocated, although all relevant organ systems should be addressed (Fraser et al., 2007). Individuals who are found to be wild type for both alleles of *VHL* also benefit because they can be spared much of the expense and anxiety associated with such intensive surveillance protocols.

Genetic counseling and appropriate testing is also available for patients suspected of having hereditary papillary RCC and other familial forms of RCC and should be discussed with appropriate family members (Schmidt and Linehan, 2016). This should include all patients diagnosed with RCC at 46 years of age or less, based on an increased likelihood of germline mutations in this population (Campbell et al., 2017a; Nguyen et al., 2017; Shuch et al., 2014). Individuals at risk, as defined by the presence of mutations of the c-*MET* proto-oncogene or other relevant genetic alterations, and those with suggestive clinical or family histories should be screened for the development of renal lesions with abdominal ultrasonography or CT at periodic intervals. Further testing may be indicated according to the syndrome involved.

Staging

Until the 1990s, the most commonly used staging system for RCC was Robson's, and this schema is still embedded in the mindset of many older urologists (Robson, 1963; Robson et al., 1969). This classification scheme had several limitations, including the grouping of tumors with lymphatic metastases, a very poor prognostic finding, in stage III along with tumors with venous involvement, many of which can be cured with an aggressive surgical approach (Gershman et al., 2017a; Gettman and Blute, 2002; Leibovich et al., 2003; Nguyen and Campbell, 2006). Further imprecision resulted from the fact that the extent of venous involvement was not delineated in this system, and tumor size, an important prognostic parameter, was not incorporated. The tumor, node, and metastasis (TNM) system proposed by the Union International Contre le Cancer (UICC) and endorsed by the American Joint Committee on Cancer (AJCC) represents a major improvement because it defines the anatomic extent of disease more explicitly (Amin et al., 2017; Decastro and McKiernan, 2008; Leung and Ghavamian, 2002; Nguyen and Campbell, 2006).

The recommended staging system for RCC is the eighth edition of the AJCC TNM classification, which was released in 2016 (Table 97.12; Amin et al., 2017). TNM for RCC has undergone several modifications in the past three decades in an effort to more accurately reflect tumor biology and prognosis. It is important to be cognizant of these changes when comparing studies from different eras (Nguyen and Campbell, 2006). For example, in the sixth edition (2002), stage T1 was subdivided to reflect data demonstrating excellent outcomes for patients with small (≤4 cm), unilateral, confined tumors managed by either PN or RN (Igarashi et al., 2001; Nguyen and Campbell, 2006). In the seventh edition (2009), larger (>7 cm) organ-confined tumors were subdivided into stage T2a (>7 to 10 cm) and T2b (>10 cm) (Table 97.13), supported by a number of studies demonstrating prognostic relevance at the 10-cm breakpoint (Edge et al., 2010; Frank et al., 2005; Klatte et al., 2007).

TABLE 97.12

International TNM Staging System for Renal Cell Carcinoma

T: PRIMARY TUMOR	
TX	Primary tumor cannot be assessed
T0	No evidence of primary tumor
T1a	Tumor ≤ 4.0 cm and confined to the kidney
T1b	Tumor > 4.0 cm and ≤7.0 cm and confined to the kidney
T2a	Tumor > 7.0 cm and ≤10.0 cm and confined to the kidney
T2b	Tumor > 10.0 cm and confined to the kidney
T3a	Tumor extends into the renal vein or its segmental branches, or invades the pelvicalyceal system, or invades perirenal and/or renal sinus fat but not beyond Gerota fascia
T3b	Tumor grossly extends into the vena cava below the diaphragm
T3c	Tumor grossly extends into the vena cava above the diaphragm or invades the wall of the vena cava
T4	Tumor invades beyond Gerota fascia (including contiguous extension into the ipsilateral adrenal gland)
N: REGIONAL LYMPH NODES	

NX	Regional lymph nodes cannot be assessed		
N0	No regional lymph nodes metastasis		
N1	Metastasis in regional lymph node(s)		
M: DISTANT METASTASES			
MX	Distant metastasis cannot be assessed		
M0	No distant metastasis		
M1	Distant metastasis present		
STAGE GROUPING			
Stage I	T1	N0	M0
Stage II	T2	N0	M0
Stage III	T1 or T2	N1	M0
	T3	Any N	M0
Stage IV	T4	Any N	M0
	Any T	Any N	M1

Modified from Edge SB, Byrd DR, Compton CC: *AJCC cancer staging manual,* ed 8, New York, 2016, Springer-Verlag.

TABLE 97.13

Tumor, Node, Metastasis (TNM) Stage and 5-Year Cancer-Specific Survival for Renal Cell Carcinoma

FINDINGS	**ROBSON STAGE**	**TNM (6th ed. 2002)**	**TNM (7th ed. 2009)**	**TNM (8th ed. 2016)**	**5-YEAR SURVIVAL (%)**
Organ-confined (overall)	I	T1-2N0M0	T1-2N0M0	T1-2N0M0	70–90
≤4.0 cm	I	T1aN0M0	T1aN0M0	T1aN0M0	90–100
>4.0 cm to 7.0 cm	I	T1bN0M0	T1bN0M0	T1bN0M0	80–90
>7.0 to 10.0 cm	I	T2N0M0	T2aN0M0	T2aN0M0	65–80
>10.0 cm	I	T2N0M0	T2bN0M0	T2bN0M0	50–70
Invasion of pelvicalyceal system	I	T1-2N0M0	T1-2N0M0	T3aN0M0	50–70
Invasion of perinephric or renal sinus fat	II	T3aN0M0	T3aN0M0	T3aN0M0	50–70
Extension into renal vein or branches	IIIA	T3bN0M0	T3aN0M0	T3aN0M0	40–60

Extension into IVC below diaphragm	IIIA	T3cN0M0	T3bN0M0	T3bN0M0	30–50
Extension into IVC above diaphragm or invasion of IVC wall	IIIA	T3cN0M0	T3cN0M0	T3cN0M0	20–40
Direct adrenal involvement	II	T3aN0M0	T4N0M0	T4N0M0	0–30
Locally advanced (invasion beyond Gerota fascia)	IVA	T4N0M0	T4N0M0	T4N0M0	0–20
Lymph node involvement	IIIB	T(Any)N1-2M0	T(Any)N1M0	T(Any)N1M0	0–20
Systemic metastasis	IVB	T(Any)N1-2M1	T(Any)N1M1	T(Any)N1M1	0–10

IVC, Inferior vena cava.

Data from Amin MB, Edge SB, Greene FL, et al.: *AJCC cancer staging manual,* ed 8, New York, 2017, Springer; Bailey GC, Boorjian SA, Ziegelmann MJ, et al.: Urinary collecting system invasion is associated with poor survival in patients with clear-cell renal cell carcinoma. *BJU Int* 119(4):585–590, 2017; Campbell SC, Novick AC, Belldegrun A, et al.: Guideline for management of the clinical T1 renal mass. *J Urol* 182(4):1271–1279, 2009; Haddad H, Rini BI: Current treatment considerations in metastatic renal cell carcinoma. *Curr Treat Options Oncol* 13(2):212–229, 2012; Hafez KS, Fergany AF, Novick AC: Nephron sparing surgery for localized renal cell carcinoma: impact of tumor size on patient survival, tumor recurrence and TNM staging. *J Urol* 162(6):1930–1933, 1999; Kim SP, Alt AL, Weight CJ, et al.: Independent validation of the 2010 American Joint Committee on Cancer TNM classification for renal cell carcinoma: results from a large, single institution cohort. *J Urol* 185(6): 2035–2039, 2011; Lane BR, Kattan MW: Prognostic models and algorithms in renal cell carcinoma. *Urol Clin North Am* 35(4): 613–625, 2008; Leibovich BC, Cheville JC, Lohse CM, et al.: Cancer specific survival for patients with pT3 renal cell carcinoma-can the 2002 primary tumor classification be improved? *J Urol* 173(3):716-719, 2005; Martinez-Salamanca JI, Huang WC, Millan I, et al.: Prognostic impact of the 2009 UICC/AJCC TNM staging system for renal cell carcinoma with venous extension. *Eur Urol* 59(1):120-127, 2011; Thompson RH, Cheville JC, Lohse CM, et al.: Reclassification of patients with pT3 and pT4 renal cell carcinoma improves prognostic accuracy. *Cancer* 104(1):53–60, 2005a.

Other major revisions in 2009 included a reclassification of tumors with adrenal metastasis, venous thrombi, and lymphatic involvement, representing a substantial departure from previous staging paradigms for RCC (Edge et al., 2010). **Contiguous extension of tumor into the ipsilateral adrenal gland is classified as T4 and noncontiguous involvement of either adrenal as M1, reflecting likely patterns of dissemination.** The poor prognosis of adrenal involvement from RCC is well documented and supported this important change (Kirkali et al., 2007; Nguyen and Campbell, 2006;

Thompson et al., 2005b; von Knobloch et al., 2009). The favorable prognosis of isolated renal vein thrombi prompted a downgrading from stage T3b to stage T3a in the 2009 version (Leibovich et al., 2005; Margulis et al., 2007b; Moinzadeh and Libertino, 2004; Shvarts et al., 2005). Finally, lymphatic metastases, which previously were subdivided based on the number of involved nodes, were compressed to simplify this aspect of the staging process, because prognostic relevance of the previous version was not observed (Amin et al., 2017). **The only change in the eighth edition (2016) relates to stage pT3a, which now includes invasion of the pelvicalyceal system, based on multiple reports indicating this finding has independent prognostic significance in RCC** (Amin et al., 2017; Bertini et al., 2009; Moch et al., 2009). Continued re-evaluation and validation of the TNM system for RCC has optimized its value to patients and clinicians (Anderson et al., 2011; Bailey et al., 2017; Bhindi et al., 2017; Brookman-May et al., 2011; Chen et al., 2016; Jeon et al., 2009; Kim et al., 2011; May et al., 2017; Verhoest et al., 2009).

TNM staging classically is defined by the most advanced feature demonstrated by the tumor, yet important prognostic information can be lost in the process. Many renal tumors exhibit multiple adverse findings, such as high-level tumor thrombus along with ipsilateral adrenal involvement. Ideally all of the relevant anatomic staging information would be captured, at least parenthetically (e.g., “pT4 [ipsilateral adrenal involvement; also exhibiting IVC thrombus above the diaphragm]”). Future staging systems will need to capture all of this information, because several studies have confirmed a compromised prognosis for patients with multiple adverse factors (Brookman-May et al., 2015; Chen et al., 2016; Ficarra et al., 2007; Leibovich et al., 2005; Shvarts et al., 2005; Terrone et al., 2006).

The clinical staging of renal malignant disease begins with a thorough history, physical examination, and judicious use of laboratory tests (Decastro and McKiernan, 2008; Nguyen and Campbell, 2006). Systemic symptoms such as significant unintended weight loss (>10% of body weight), cachexia, or poor performance status at presentation suggest advanced disease, as do physical examination findings of a palpable mass or lymphadenopathy. A nonreducing varicocele and lower extremity edema suggest venous involvement. Significant anemia, hypercalcemia, abnormal liver function parameters or sedimentation rate, or elevated serum alkaline phosphatase or lactate dehydrogenase level point to the probability of advanced disease (Lane and Kattan, 2008; Nguyen and Campbell, 2006).

The radiographic staging of RCC can be accomplished in most cases with a high-quality abdominal CT scan and a routine chest radiograph, with selective use of MRI and other studies as indicated (Campbell et al., 2017a; Choyke et al., 2001; Diaz de Leon and Pedrosa, 2017; Herts, 2009; Ng et al., 2008). MRI can be reserved primarily for patients with locally advanced malignant disease, equivocal venous involvement, or allergy to intravenous contrast material (Choyke et al., 2001; Herts, 2009; Zhang et al., 2007). CT findings suggestive of extension into the perinephric fat include perinephric stranding (Fig. 97.13), which is a nonspecific finding, or a distinct, enhancing soft tissue density within the perinephric space, which is a more definitive but uncommon finding (Bechtold and Zagoria, 1997; Herts, 2009). Overall, the accuracy of CT or MRI for detection of involvement of the perinephric fat is low, reflecting the fact that extracapsular spread often occurs microscopically (Choyke et al., 2001; Kamel et al., 2004; Zhang et al., 2007). Ipsilateral adrenal involvement can be assessed with reasonable accuracy through a combination of preoperative CT and intraoperative inspection. **Patients with an enlarged or indistinct adrenal gland on CT, extensive malignant replacement of the kidney, or a palpably abnormal adrenal gland are at risk for malignant adrenal involvement and should be managed accordingly** (Campbell et al., 2017a; Kobayashi et al., 2008; Lane et al., 2009c; Ng et al., 2008; Paul et al., 2001; Sawai et al., 2002; Weight et al., 2011; Zhang et al., 2007).

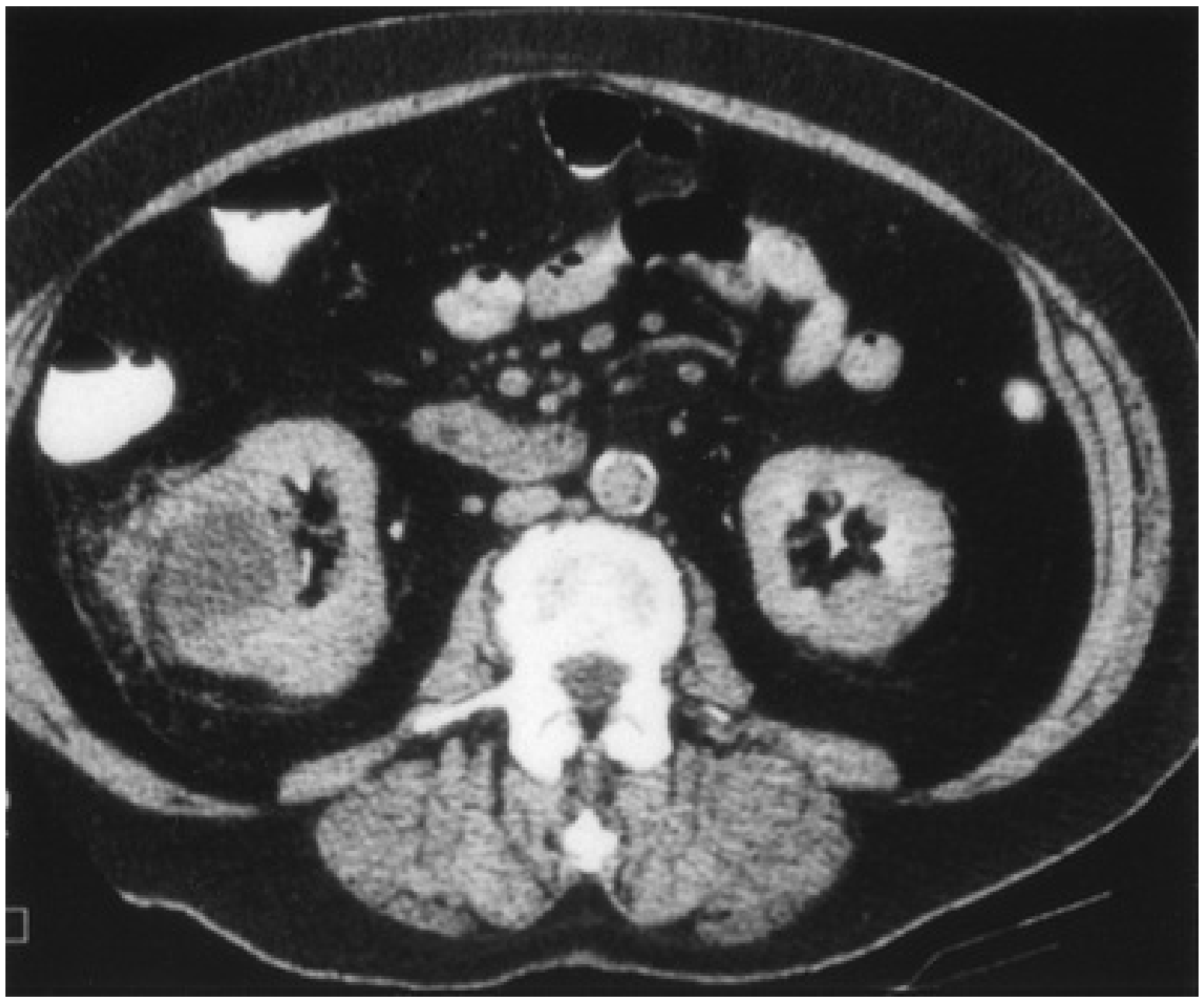

FIG. 97.13 Computed tomography scan after administration of contrast agent shows right renal tumor with perinephric stranding suggesting invasion of the perinephric fat.

Enlarged hilar or retroperitoneal lymph nodes (2 cm or more in diameter) on CT almost always harbor malignant change, but this should be confirmed by surgical exploration or percutaneous biopsy if the patient is not a surgical candidate. Many smaller lymph nodes prove to be inflammatory rather than neoplastic and should not preclude surgical therapy (Campbell et al., 2017a; Choyke et al., 2001; Gershman et al., 2017a; Herts, 2009; Israel and Bosniak, 2003; Ng et al., 2008). MRI can add specificity to the evaluation of retroperitoneal nodes by distinguishing vascular structures, such as lumbar veins, from lymphatic ones (Bassignani, 2006). **MRI is still the premier study for evaluation of invasion of tumor into adjacent structures and for surgical planning in these challenging cases** (Choyke et al., 2001; Diaz de Leon and Pedrosa, 2017; Herts, 2009; Pretorius et al., 2000). Obliteration of the fat plane between the tumor and adjacent organs (e.g., the liver) on CT can be a misleading finding for RCC and should prompt further imaging with MRI. In reality, surgical exploration is often required to make an absolute differentiation.

The sensitivities of CT for detection of renal venous tumor thrombus and IVC involvement are 78% and 96%, respectively (Herts, 2009; Ng et al., 2008). CT findings suggestive of venous involvement include venous enlargement, abrupt change in the caliber of the vein, and filling defects, and the diagnosis is strengthened by demonstration of collateral vessels. Most false-negative findings occur in patients with right-sided tumors in whom the short length of the vein and the mass effect from the tumor combine to make detection of the tumor thrombus difficult (Herts, 2009). Fortunately, most such cases are readily identified and dealt with intraoperatively. **MRI is well established as the premier study for the evaluation and staging of IVC tumor thrombus, although several studies suggest that multiplanar CT is likely equivalent in many patients** (Aslam Sohaib et al., 2002; Diaz de Leon and Pedrosa, 2017; Ng et al., 2008; Pretorius et al., 2000; Zhang et al., 2007). Venacavography is now best reserved for patients with equivocal MRI or CT findings or for patients who cannot tolerate or have other contraindications to cross-sectional imaging. Transesophageal echocardiography also appears to be accurate for establishing the cephalad extent of the tumor thrombus, but it is invasive and provides no distinct advantages over MRI or CT in the preoperative setting (Glazer and

Novick, 1997).

Metastatic evaluation in all cases should include a routine chest radiograph, systematic review of the abdominal and pelvic CT or MRI, and liver function tests (Campbell et al., 2017a; Griffin et al., 2007; Herts, 2009; Ng et al., 2008). **Bone scintiscan can be reserved for patients with elevated serum alkaline phosphatase, bone pain, or poor performance status** (Campbell et al., 2017a; Shvarts et al., 2004) **and chest CT scan for patients with pulmonary symptoms or an abnormal chest radiograph** (Campbell et al., 2017a; Choyke et al., 2001). **Patients with locally advanced disease, enlarged retroperitoneal lymph nodes, or significant comorbid disease may mandate more thorough imaging to rule out metastatic disease and to aid in treatment planning** (Campbell et al., 2017a; Choyke et al., 2001; Griffin et al., 2007). Positron emission tomography (PET) has also been investigated for patients with high risk of metastatic RCC, with most studies showing good specificity, but suboptimal sensitivity (Bagheri et al., 2017). At present, its best role is for select patients with equivocal findings on conventional imaging, as an abnormal PET scan may increase the concern about metastatic disease (Bouchelouche and Oehr, 2008; Griffin et al., 2007; Powles et al., 2007). Molecular imaging, using ^{99m}Tc-sestamibi SPECT/CT to distinguish renal oncocytoma and hybrid oncocytic/chromophobe tumors from clear cell RCC or PET imaging with either ^{124}I-girentuximab or prostate-specific membrane antigen (PSMA), is a promising technique that is still under evaluation (Divgi et al., 2013; Gorin et al., 2016; Rowe et al., 2015). **Biopsy of the primary tumor and/or potential metastatic sites is also selectively required as part of the staging process.**

Key Points: Staging and Prognosis of Renal Cell Carcinoma

- The TNM staging system has replaced the Robson system (stage I to IV).
- Tumor (T) stage is based on size and extension of the cancer into renal or extrarenal structures.
- Pathologic stage is the most important prognostic factor for RCC.
- Invasion of neighboring organs (T4), involvement of retroperitoneal lymph nodes (N1), and the presence of metastatic disease (M1) confer a poor

outcome for patients with RCC.

- Other important pathologic features include nuclear grade, tumor size, and histologic subtype.
- Important prognostic factors for cancer-specific survival in patients with RCC include specific clinical signs or symptoms, tumor-related factors, and various laboratory findings.
- Integrated systems, such as nomograms, often outperform other prediction methods.

Prognosis

Important prognostic factors for cancer-specific survival in patients with nonmetastatic RCC include specific clinical signs or symptoms, tumor-related factors, and various laboratory findings (Table 97.14) (Lane and Kattan, 2008; Meskawi et al., 2012; Sun et al., 2017). **Overall, tumor-related factors such as pathologic stage, tumor size, nuclear grade, and histologic subtype have the greatest individual predictive ability. However, an integrative approach, combining a variety of factors that have independent value on multivariate analysis, appears to be most powerful** (Campbell and Lane, 2016; Meskawi et al., 2012). Patient-related factors such as age, presence of chronic kidney disease, and comorbidities have a significant impact on overall survival and should be a primary consideration during treatment planning for patients with localized RCC (Campbell et al., 2017a; Hollingsworth et al., 2006; Kutikov et al., 2010).

TABLE 97.14

Adverse Prognostic Factors for Renal Cell Carcinoma

CLINICAL	ANATOMIC	HISTOLOGIC
Poor performance status Systemic symptoms Anemia Hypercalcemia Elevated lactate dehydrogenase Elevated erythrocyte sedimentation rate Elevated C-reactive	Larger tumor size Venous involvement Extension into contiguous organs, including adrenal gland Lymph node metastases Distant metastases and greater metastatic burden	High nuclear grade Certain histologic subtypes Sarcomatoid features Presence of histologic tumor necrosis Vascular invasion Invasion of perinephric or renal sinus fat

protein Thrombocytosis Elevated alkaline phosphatase		Collecting system invasion Positive surgical margin

Data from Lane BR, Kattan MW: Prognostic models and algorithms in renal cell carcinoma. *Urol Clin North Am* 35(4):613–625, 2008; Sun M, Vetterlein M, Harshman LC, et al.: Risk assessment in small renal masses: a review article. *Urol Clin North Am* 44(2):189–202, 2017.

Clinical findings that suggest a compromised prognosis in patients with presumed localized RCC include symptomatic presentation, unintended weight loss of more than 10% of body weight, and poor performance status (Lane and Kattan, 2008; Sun et al., 2017). Anemia, thrombocytosis, hypercalcemia, albuminuria, elevated serum alkaline phosphatase, C-reactive protein, lactate dehydrogenase, or erythrocyte sedimentation rate, as well as other paraneoplastic signs or symptoms, have also correlated with poor outcomes for patients with RCC (Lane and Kattan, 2008; Magera et al., 2008b; Sun et al., 2017). Although abnormal values are more common in patients with advanced RCC, some of these abnormalities, including hypercalcemia, anemia, and elevated erythrocyte sedimentation rate, were independent predictors of cancer-specific mortality in patients with localized clear cell RCC as well (Magera et al., 2008b).

Pathologic stage has proved to be the single most important prognostic factor for RCC (Kanao et al., 2009; Lane and Kattan, 2008; Leibovich et al., 2005; Sun et al., 2017). The RCC TNM staging system clearly distinguishes between patient groups with different predicted cancer-specific outcomes (see Table 97.13), confirming that the extent of locoregional or systemic disease at diagnosis is the primary determinant of outcomes for this disease. Several studies demonstrate 5-year survival rates of 70% to 90% for organ-confined disease and document a 10% to 15% reduction in survival associated with invasion of the perinephric fat (Lane and Kattan, 2008; Sun et al., 2017). Renal sinus involvement is classified along with perinephric fat invasion as T3a, and several studies suggest that these patients may be at even higher risk for metastasis related to increased access to the venous system (Amin et al., 2017; Bertini et al., 2009; Bonsib et al., 2000; Jeon et al., 2009; Thompson et al., 2005b). Collecting system invasion has also been shown to confer poorer prognosis in otherwise organ-confined RCC and is now incorporated into the T3a category (Amin et al., 2017; Anderson et al., 2011; Chen et al., 2016; Uzzo et al., 2002; Verhoest et al., 2009). Several reports have shown that most patients with contiguous ipsilateral adrenal involvement or noncontiguous adrenal metastasis, which are found in 1% to 2% of cases, eventually succumb to systemic disease progression, suggesting a hematogenous route of dissemination and/or highly invasive phenotype (Sagalowsky et al., 1994; von Knobloch et al., 2009).

Venous involvement was once thought to be a very poor prognostic finding for RCC, but several reports demonstrate that many patients with tumor thrombi can be salvaged with an aggressive surgical approach. These studies document 45% to 69% 5-year survival rates for patients with venous tumor thrombi as long as the cancer is otherwise confined to the kidney (Martinez-Salamanca et al., 2011). Patients with venous tumor thrombi and concomitant lymph node or systemic metastases have markedly decreased survival, and those with tumor extending into the perinephric fat have intermediate survival (Martinez-Salamanca et al., 2011). The most recent versions of the TNM system advocate capturing all such adverse features during the staging process. Some studies suggest that patients with microvascular invasion may have compromised outcomes compared with matched tumors without these features, indicating that even microscopic venous or lymphatic involvement may be a poor prognostic sign (Amin et al., 2017; Feifer et al., 2011; Kroeger et al., 2012).

The prognostic significance of the cephalad extent of tumor thrombus has been controversial, and it is difficult to compare various series because of selection biases and related covariables (Blute et al., 2007; Haddad et al., 2014; Leibovich et al., 2005; Libertino et al., 1987; Wotkowicz et al., 2008). In several series, the incidence of advanced locoregional or systemic disease increased with the cephalad extent of the tumor thrombus, likely contributing to the reduced survival associated with tumor thrombus extending into or above the level of the hepatic veins (Wotkowicz et al., 2008). **Direct invasion of the wall of the vein appears to be a more important prognostic factor than level of tumor thrombus and is now classified as pT3c independent of the level of tumor thrombus** (Hatcher et al., 1991; Zini et al., 2008).

The major drop in prognosis comes in patients whose tumor extends beyond the Gerota fascia to involve contiguous organs (stage T4) and in patients with lymph node or systemic metastases (Amin et al., 2017; Margulis et al., 2007a; Thompson et al., 2005b). **Lymph node involvement is associated with 5- and 10-year survival rates of 5% to 30% and 0 to 5%, respectively** (Crispen et al., 2011; Gershman et al., 2017a; Haddad and Rini, 2012; Lohse et al., 2015; Phillips and Taneja, 2004; Rijnders et al., 2017; Zibelman and Plimack, 2017). **Systemic metastases also portend a particularly poor prognosis for RCC, traditionally with 1-year survival of less than 50%, 5-year survival of 5% to 30%, and 10-year survival of 0% to 5%, although these numbers have improved modestly in the era of VEGF-targeted treatments and checkpoint inhibitors** (Haddad and Rini, 2012; Lohse et al., 2015; Rijnders et al., 2017; Zibelman and Plimack, 2017). Patients presenting with synchronous metastases fare worse, with many patients dying of disease progression within 1 to 2 years (Haddad and Rini, 2012; Heng et al., 2013; Leibovich et al., 2003; Mekhail et al., 2005). **For patients with asynchronous metastases, the metastasis-free interval can be a useful prognosticator because it often reflects the tempo of disease progression** (Maldazys and deKernion, 1986; Mekhail et al., 2005; Motzer et al., 2004). **Other important prognostic factors for patients with systemic metastases include performance status, number and sites of metastases, anemia, hypercalcemia, elevated alkaline phosphatase or lactate dehydrogenase levels, thrombocytosis, and sarcomatoid histology** (Heng et al., 2013; Lane and Kattan, 2008). **The presence of bone, brain, and/or liver metastases and multiple metastatic sites have been associated with further compromise in prognosis** (Escudier et al., 2007a; McKay et al., 2014; Mekhail et al., 2005). These factors have been used to effectively categorize patients with metastatic RCC as low, intermediate, and poor risk, with corresponding differences in median survival with systemic therapy (see Chapter 104; Heng et al., 2013; Motzer et al., 2004).

Another significant prognostic factor for RCC is tumor size, which has proved to be an independent prognostic factor for organ-confined and invasive RCC (Amin et al., 2017; Kattan et al., 2001; Kontak and Campbell, 2003; Lane and Kattan, 2008). To a large extent, this is due to a strong correlation between tumor size and pathologic tumor stage, but several studies have demonstrated that tumor size can function as an independent prognostic factor (Crispen et al., 2008; Kattan et al., 2001; Nguyen and Gill, 2009; Sorbellini et al., 2005). Larger tumors are more likely to exhibit clear cell histology and high nuclear grade, and both of these factors correlate with a compromised prognosis (Frank et al., 2003; Lane et al., 2007a; Thompson et al., 2009b). A review of 1771 patients with organ-confined RCC showed 10-year cancer-specific survival rates of 90% to 95%, 80% to 85%, and 75% for patients with pT1a, pT1b, and pT2 tumor, respectively (Patard et al., 2004a). Many other studies have also shown a particularly favorable prognosis for the unilateral pT1a tumors that are now being discovered with increased frequency. In series from the Cleveland Clinic and the Mayo Clinic, such tumors were associated with greater than 95% 5-year cancer-specific survival rates, whether they were managed with nephron-sparing surgery or RN (Butler et al., 1995; Cheville et al., 2001; Lane et al., 2013).

Other important prognostic factors for RCC include nuclear grade and histologic subtype. Almost all the proposed grading systems for RCC have provided prognostic information, and nuclear grade is established as an independent prognostic factor when subjected to multivariable analysis, at least for clear cell and papillary RCC (Ficarra et al., 2009a; Fuhrman et al., 1982; Lane and Kattan, 2008; 2005; Lohse and Cheville, 2005; Lohse et al., 2002; May et al., 2017; True, 2002; Zisman et al., 2001). For a variety of reasons the Fuhrman's classification system has fallen out of favor, and an alternate grading system based on nucleolar morphology is now recommended (see Pathology and Table 97.8; Delahunt et al., 2014).

Histologic subtype of RCC also carries prognostic significance. The presence of sarcomatoid or rhabdoid differentiation or collecting duct, renal medullary, or unclassified histologic subtype denotes a poor prognosis (Deng and Melamed, 2012; Kara et al., 2016; Wei and Al-Saleem, 2017; Zhou, 2009). Several studies suggest that clear cell RCC may have a worse prognosis on average compared with papillary type 1 or chromophobe RCC, although there are clearly poorly differentiated tumors in each of these subcategories that can be lethal (Deng and Melamed, 2012; Leibovich et al., 2010; Lohse et al., 2015; Teloken et al., 2009). Finally, several subtypes of RCC are predictably indolent, including multiloculated cystic clear cell RCC, mucinous tubular and spindle cell carcinoma, and clear cell/papillary RCC.

A variety of molecular factors have correlated with outcomes for RCC in observational studies and may prove to be useful in the future (Jonasch et al., 2012; Keefe et al., 2013). Increased proliferative index as assessed by Ki-67 has correlated with reduced survival in clear cell RCC (Parker et al., 2009). Other factors that may be useful include cell cycle regulators, such as the tumor suppressor gene *p53*, various growth factors and their receptors, including members of the VEGF family, adhesion molecules, and other factors, such as survivin (Campbell and Lane, 2016; Klatte et al., 2009; Parker et al., 2009). Aggressive renal cancers demonstrate downregulation of genes involved in the TCA cycle and upregulation of the pentose phosphate pathway (Cancer Genome

Atlas Research Network, 2013). In general, clinical validation has not yet been achieved with any of these factors and they remain primarily investigational (see Tumor Biology and Clinical Implications, and reviewed in Campbell and Lane, 2016).

Several investigators have developed tools that integrate clinical and pathologic factors, improving the predictive capacity for patients with RCC. Incorporation of the strongest predictors into a nomogram is one way to provide an individual assessment of risk that clinicians can use during patient counseling. Kattan et al. (2001) developed the first of these for RCC, and several nomograms have been introduced subsequent to this (Campbell and Lane, 2016; Kattan et al., 2001). One such nomogram incorporating stage, size, grade, and symptoms at presentation has been validated using multi-institutional data sets and appears to outperform several of the other existing prognostic tools for localized RCC (Karakiewicz et al., 2007a; Sun et al., 2017).

Two other integrated staging systems that have been used to risk stratify patients for clinical trials are the UCLA Integrated Staging System (UISS) and the Mayo Clinic Stage, Size, Grade, and Necrosis (SSIGN) score. The UISS was developed based on multivariate analysis revealing three independent prognostic factors for RCC, namely TNM stage, performance status, and tumor grade (Zisman et al., 2001). The UISS was subsequently modified to stratify patients with localized or metastatic disease into cohorts with low, intermediate, or high risk of disease progression and has been validated internally and externally (Cindolo et al., 2008; Parker et al., 2009; Patard et al., 2004b; Tan et al., 2010; Zisman et al., 2002). **The SSIGN score can be used to estimate cancer-specific survival based on TNM stage, tumor size, nuclear grade, and presence of histologic tumor necrosis** (Frank et al., 2002). The SSIGN score has been validated in multiple data sets, but the inclusion of histologic necrosis as a predictor limits its clinical usefulness (Ficarra et al., 2006, 2009a; Fujii et al., 2008; Parker et al., 2017; Zigeuner et al., 2010).

TNM staging systems and prognostic algorithms have different purposes. The TNM staging system is used to provide a universal language for communication between clinicians and patients and is based solely on the anatomic extent of cancer dissemination. **A wealth of literature now supports the notion that algorithms that incorporate multiple predictive elements, such as nomograms and artificial neural networks, outperform risk assessment based on expert opinion or simpler models, such as classic staging systems**

(Isbarn and Karakiewicz, 2009; Ross et al., 2002; Shariat et al., 2009; Sun et al., 2017). The development and use of these integrated staging systems can help guide counseling and follow-up of patients with RCC and identify patients more likely to benefit from specific interventions, such as adjuvant treatments.

Treatment of Localized Renal Cell Carcinoma

Localized renal masses have increased in incidence because of widespread use of cross-sectional imaging and now represent a relatively common clinical scenario (Capitanio and Montorsi, 2016; Miller et al., 2010a; Turner et al., 2017). Our perspectives about clinical T1 renal masses have changed substantially in the past two decades. Previously, all were presumed malignant and managed aggressively, mostly with RN. **We now recognize great heterogeneity in the tumor biology of these lesions, and multiple management strategies are available, including RN, PN, thermal ablation (TA), and active surveillance (AS)** (Campbell et al., 2017a; Kunkle et al., 2008; Volpe et al., 2011). Concepts that were once controversial, such as elective PN, are now accepted as standards of care. A greater understanding of the tumor biology and appreciation of the merits and limitations of the various management strategies has facilitated improved management of this patient population (Campbell et al., 2017a; Finelli et al., 2017; Ljungberg et al., 2015; Motzer et al., 2017b).

American Urological Association Guidelines for Renal Mass and Localized Renal Cancer

The 2017 American Urological Association (AUA) Guidelines for Renal Mass and Localized Renal Cancer provide an evidence-based review of this topic, along with comprehensive recommendations for evaluation, counseling, and management (Fig. 97.14; Campbell et al., 2017a). Novel elements in the guidelines include forsaking the use of index patients based on strong consensus that there are a multitude of factors to take into consideration when evaluating a patient's general health, the oncologic potential of the mass, and important functional issues. Simply put, there are just too many gray zones within each of these vitally important assessments to justify the ongoing use of index patients (Campbell et al., 2017a).

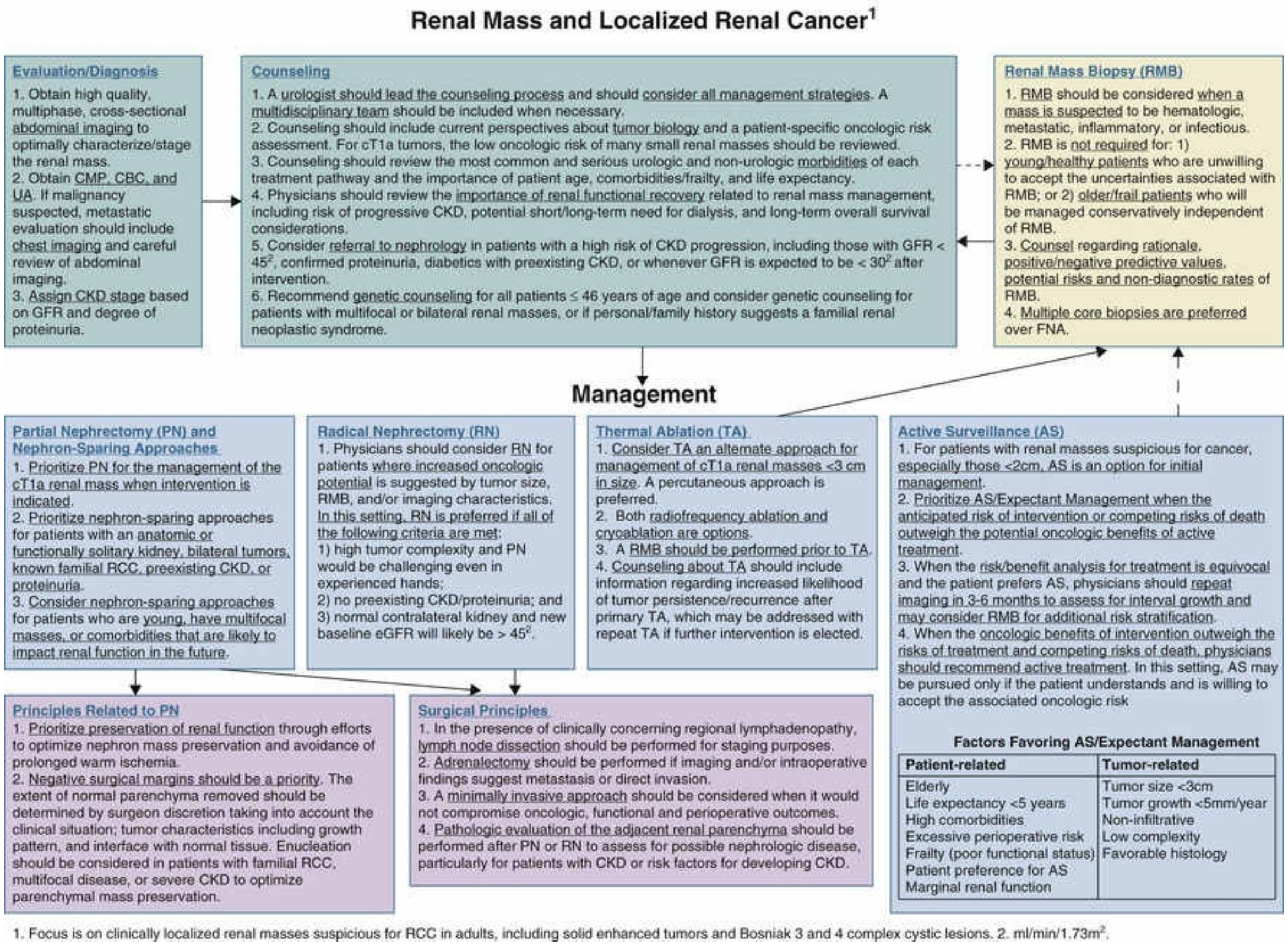

Renal Mass and Localized Renal Cancer[1]

Evaluation/Diagnosis

1. Obtain high quality, multiphase, cross-sectional abdominal imaging to optimally characterize/stage the renal mass.
2. Obtain CMP, CBC, and UA. If malignancy suspected, metastatic evaluation should include chest imaging and careful review of abdominal imaging.
3. Assign CKD stage based on GFR and degree of proteinuria.

Counseling

1. A urologist should lead the counseling process and should consider all management strategies. A multidisciplinary team should be included when necessary.
2. Counseling should include current perspectives about tumor biology and a patient-specific oncologic risk assessment. For cT1a tumors, the low oncologic risk of many small renal masses should be reviewed.
3. Counseling should review the most common and serious urologic and non-urologic morbidities of each treatment pathway and the importance of patient age, comorbidities/frailty, and life expectancy.
4. Physicians should review the importance of renal functional recovery related to renal mass management, including risk of progressive CKD, potential short/long-term need for dialysis, and long-term overall survival considerations.
5. Consider referral to nephrology in patients with a high risk of CKD progression, including those with GFR < 45[2], confirmed proteinuria, diabetics with preexisting CKD, or whenever GFR is expected to be < 30[2] after intervention.
6. Recommend genetic counseling for all patients ≤ 46 years of age and consider genetic counseling for patients with multifocal or bilateral renal masses, or if personal/family history suggests a familial renal neoplastic syndrome.

Renal Mass Biopsy (RMB)

1. RMB should be considered when a mass is suspected to be hematologic, metastatic, inflammatory, or infectious.
2. RMB is not required for: 1) young/healthy patients who are unwilling to accept the uncertainties associated with RMB; or 2) older/frail patients who will be managed conservatively independent of RMB.
3. Counsel regarding rationale, positive/negative predictive values, potential risks and non-diagnostic rates of RMB.
4. Multiple core biopsies are preferred over FNA.

Management

Partial Nephrectomy (PN) and Nephron-Sparing Approaches

1. Prioritize PN for the management of the cT1a renal mass when intervention is indicated.
2. Prioritize nephron-sparing approaches for patients with an anatomic or functionally solitary kidney, bilateral tumors, known familial RCC, preexisting CKD, or proteinuria.
3. Consider nephron-sparing approaches for patients who are young, have multifocal masses, or comorbidities that are likely to impact renal function in the future.

Radical Nephrectomy (RN)

1. Physicians should consider RN for patients where increased oncologic potential is suggested by tumor size, RMB, and/or imaging characteristics. In this setting, RN is preferred if all of the following criteria are met:
1) high tumor complexity and PN would be challenging even in experienced hands;
2) no preexisting CKD/proteinuria; and
3) normal contralateral kidney and new baseline eGFR will likely be > 45[2].

Thermal Ablation (TA)

1. Consider TA an alternate approach for management of cT1a renal masses <3 cm in size. A percutaneous approach is preferred.
2. Both radiofrequency ablation and cryoablation are options.
3. A RMB should be performed prior to TA.
4. Counseling about TA should include information regarding increased likelihood of tumor persistence/recurrence after primary TA, which may be addressed with repeat TA if further intervention is elected.

Active Surveillance (AS)

1. For patients with renal masses suspicious for cancer, especially those <2cm, AS is an option for initial management.
2. Prioritize AS/Expectant Management when the anticipated risk of intervention or competing risks of death outweigh the potential oncologic benefits of active treatment.
3. When the risk/benefit analysis for treatment is equivocal and the patient prefers AS, physicians should repeat imaging in 3-6 months to assess for interval growth and may consider RMB for additional risk stratification.
4. When the oncologic benefits of intervention outweigh the risks of treatment and competing risks of death, physicians should recommend active treatment. In this setting, AS may be pursued only if the patient understands and is willing to accept the associated oncologic risk

Factors Favoring AS/Expectant Management

Patient-related	Tumor-related
Elderly	Tumor size <3cm
Life expectancy <5 years	Tumor growth <5mm/year
High comorbidities	Non-infiltrative
Excessive perioperative risk	Low complexity
Frailty (poor functional status)	Favorable histology
Patient preference for AS	
Marginal renal function	

Principles Related to PN

1. Prioritize preservation of renal function through efforts to optimize nephron mass preservation and avoidance of prolonged warm ischemia.
2. Negative surgical margins should be a priority. The extent of normal parenchyma removed should be determined by surgeon discretion taking into account the clinical situation; tumor characteristics including growth pattern, and interface with normal tissue. Enucleation should be considered in patients with familial RCC, multifocal disease, or severe CKD to optimize parenchymal mass preservation.

Surgical Principles

1. In the presence of clinically concerning regional lymphadenopathy, lymph node dissection should be performed for staging purposes.
2. Adrenalectomy should be performed if imaging and/or intraoperative findings suggest metastasis or direct invasion.
3. A minimally invasive approach should be considered when it would not compromise oncologic, functional and perioperative outcomes.
4. Pathologic evaluation of the adjacent renal parenchyma should be performed after PN or RN to assess for possible nephrologic disease, particularly for patients with CKD or risk factors for developing CKD.

1. Focus is on clinically localized renal masses suspicious for RCC in adults, including solid enhanced tumors and Bosniak 3 and 4 complex cystic lesions. 2. ml/min/1.73m².

FIG. 97.14 Algorithm for evaluation, counseling, and management of patients presenting with a renal mass or localized renal cancer. (From Campbell SC, Uzzo RG, Allaf ME, et al.: Renal mass and localized renal cancer: AUA Guideline, 2017 [website]: https://www.auanet.org/guidelines/renal-mass-and-localized-renal-cancer-new-2017.)

Another major change relates to **increased focus on functional issues, preoperatively and postoperatively, recognizing their importance for cancer survivorship for many patients with localized RCC** (Campbell et al., 2017a; Zabell et al., 2017a). Evaluation should include a serum creatinine-based estimation of glomerular filtration rate (GFR) and assessment for proteinuria, and CKD stage at presentation should be assigned based on these parameters. Presence of proteinuria and reduced baseline GFR have both proven to be strong and independent predictors of functional stability and survival for kidney cancer patients, similar to the general population. Referral to nephrology should be considered in patients at high risk for CKD progression, including those who present with GFR of less than 45 mL/min/1.73 m^2 or confirmed proteinuria (Tourojman et al., 2016), patients with diabetes and preexisting CKD, or whenever the GFR is expected to be less than 30 mL/min/1.73 m^2 after intervention.

Other important considerations for the evaluation and counseling of this patient population are summarized in Fig. 97.14. The AUA Guidelines also provide well-defined indications for RN versus PN, updated recommendations for use of TA, and objective criteria related to intelligent use of AS, as outlined in the following sections (Campbell et al., 2017b; Pierorazio et al., 2016a). Many of these perspectives are also supported by other Guidelines from the American Society of Clinical Oncology, European Association of Urology, and National Comprehensive Cancer Network (Finelli et al., 2017; Ljungberg et al., 2015; Motzer et al., 2017b).

Risk Stratification and Renal Mass Biopsy

Overall, about 20% of solid, enhancing, clinical T1 renal masses are benign, most often oncocytomas or atypical AMLs, although the incidence of benign pathology can vary greatly in different populations (Campbell et al., 2017a; Frank et al., 2003; Gill et al., 2010). Young to middle-age women, in particular, are more likely to have benign pathology, as high as 40% in some series (Eggener et al., 2004). One potential explanation is that some benign renal masses, such as cystic nephroma and atypical AML, may be influenced by the hormonal milieu. **An even more important determinant of benign pathology is tumor size, with multiple studies confirming this** (Campbell et al., 2017b). In the series from Frank et al. (2003), 30% of tumors less than 2 cm were benign, whereas only 9.5% of clinical T1b tumors were benign (reviewed in Johnson et al., 2015). **Tumor size also correlates strongly with biologic aggressiveness for clinical T1 renal masses, as reflected by high tumor grade, locally invasive phenotype, or unfavorable histology.** In Frank's series, such adverse findings were uncommon in tumors less than 4 cm diameter: only 1.7% demonstrated invasion of the perinephric fat, 0.7% had venous involvement, 0.6% had lymph node involvement, and only 15% were high grade. Adverse features such as this were more commonly observed in clinical T1b tumors. Surveillance studies confirm a slow growth rate and low risk of metastasis for many small renal tumors (Bosniak, 1995; Campbell et al., 2017b; Kunkle et al., 2007, 2008).

A recent systematic review indicated that tumor size and male sex were the strongest predictors of malignant pathology. In contrast, the results were inconclusive or not significant for other tumor characteristics, age, body mass index, and incidental presentation (Lane et al., 2007a; Pierorazio et al., 2016). **Current algorithms incorporating clinical and radiographic factors to predict tumor aggressiveness for small renal tumors are very limited in their accuracy, with concordance indices less than 0.65, not much better than a coin flip** (Kutikov et al., 2011; Lane et al., 2007a; Patel et al., 2016a).

Renal mass biopsy (RMB) can substantially improve on this and should be considered for further risk stratification when it may influence management (see Fig. 97.14) (Ginzburg et al., 2014; Haifler and Kutikov, 2017; Jeon et al., 2016; Marconi et al., 2016; Patel et al., 2016b). Recent meta-analyses suggest that RMB is generally safe and accurate (Campbell et al., 2017b; Patel et al., 2016b).

Key Points: Renal Mass Biopsy

- RMB is safe with relatively low rates of hematoma (4.9%), clinically significant pain (1.2%), gross hematuria (1.0%), pneumothorax (0.6%), and hemorrhage requiring transfusion (0.4%).
- There have been *no* reported cases of RCC tumor seeding in the contemporary literature.
- A positive biopsy is reliable with high specificity (96%) and positive predictive value (99.8%).
- The nondiagnostic rate for RMB is approximately 14%, which can be substantially reduced with repeat biopsy.
- Histologic evaluation of RCC subtype is dependable (>90%), but accuracy for grade is variable (60%–80%).
- A nonmalignant biopsy result may *not* truly indicate that a benign entity is present.

The downsides of RMB are that it can be nondiagnostic in about 14% of cases, some series have reported occasional false-negative results, and cystic tumors may be at risk for tumor spillage. The AUA Guidelines emphasize the importance of counseling patients about the potential merits and limitations of RMB, and advocates for a utility-based approach (Campbell et al., 2017a; Patel et al., 2016b). **RMB is *not* indicated for young, healthy patients who are unwilling to accept the limitations of RMB, or for older, frail patients who**

will be managed conservatively even if RMB suggests a potentially aggressive tumor. Increased use of RMB has been documented over the past decade, and some have advocated for office-based ultrasound-guided RMB, which can be performed by the urologist (Okhunov et al., 2017). **Molecular profiling of RMB samples will also likely play an increasing role in the near future** (Fig. 97.15), analogous to the evaluation of patients with early stage prostate cancer.

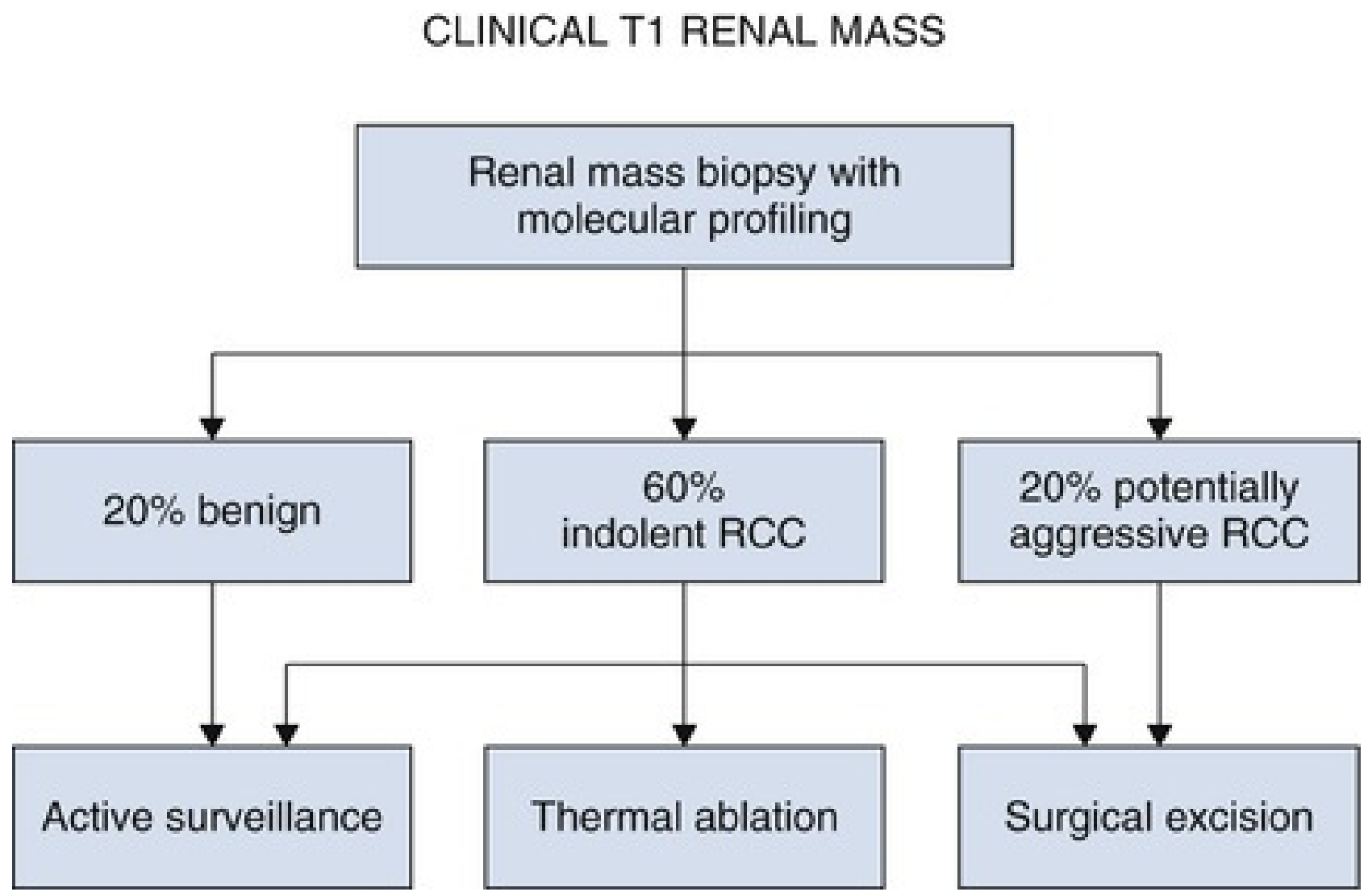
CLINICAL T1 RENAL MASS
Renal mass biopsy with molecular profiling
20% benign
60% indolent RCC
20% potentially aggressive RCC
Active surveillance
Thermal ablation
Surgical excision

FIG. 97.15 The American Urological Association guideline panel for the management of renal mass and localized renal cancer strongly advocates research priority for renal mass biopsy with molecular profiling to facilitate more rational management. The distribution of benign, indolent, and potentially aggressive RCC can vary based on tumor size, gender, and other patient and tumor characteristics. *RCC,* Renal cell carcinoma.

Molecular imaging also holds great promise as a noninvasive approach to risk stratification of renal masses (Gorin et al., 2015). PET coupled with administration of radioactively labeled anticarbonic anhydrase-IX monoclonal antibody can provide specificity for the more aggressive subtypes of renal cancer, including clear cell RCC and type 2 papillary RCC (Divgi et al., 2013; Muselaers et al., 2013). Recent studies suggest that sestamibi-based SPECT/CT imaging may allow for identification of benign or less aggressive variants or RCC, such as oncocytomas or hybrid oncocytic/chromophobe tumors (Gorin et al., 2015).

Renal Function After Partial or Radical Nephrectomy: Survival Implications

Notwithstanding advances in our understanding of the genetics and biology of RCC, surgery remains the mainstay for curative treatment of this disease. Simple nephrectomy was practiced for many decades but was supplanted by RN when Robson et al. (1969) established this procedure as the gold standard for the management of localized RCC. RN is still preferred for many patients with localized RCC, such as those with very large tumors, and it should remain a consideration whenever increased oncologic risk is suspected (see Fig. 97.14) (Robson et al., 1969; Tomaszewski et al., 2014). **RN has fallen out of favor for small renal tumors because of concerns about CKD and should only be performed when necessary in this population** (Campbell et al., 2017a; Finelli et al., 2017; Ljungberg et al., 2015; Motzer et al., 2017b).

The main downside of RN is that it predisposes to CKD, which can be associated with morbid cardiovascular events and increased mortality rates. Several studies have shown an increased risk of CKD on longitudinal follow-up after RN, including a landmark study that looked at 662 patients with a solitary tumor, a normal opposite kidney, and a “normal” serum creatinine level—essentially patients who would be considered for elective PN (Huang et al., 2006; Mashni et al., 2015). Huang et al. (2006) found that 26% of such patients had preexisting CKD (GFR <60 mL/min/1.73 m^2), demonstrating that kidney cancer patients are substantially different than the kidney transplant donor population that is often considered analogous. In reality, the donor population is not comparable because it is carefully screened to exclude CKD and related comorbidities. Huang also reported that CKD was much more common after RN than PN: 65% versus 20%, respectively ($P < 0.001$).

Several studies illustrate the potential negative implications of CKD, including a population-based analysis that reported increased rates of cardiovascular events and death as the degree of CKD worsened, even after controlling for diabetes and other potential confounding factors (Go et al., 2004). The relative death rates were 1.2, 1.8, 3.2, and 5.9 for subjects with an estimated GFR of 45 to 60, 30 to 45, 15 to 30, and less than 15 mL/min/1.73 m^2, respectively. **These data highlight the potential need to optimize renal function and underscore nephron-sparing as an important principle in the management of clinical T1 renal masses, particularly small renal masses** (Campbell et al., 2017a; Miller et al., 2008).

Multiple retrospective series in the past decade have compared PN and RN for the management of clinical T1 renal masses, almost uniformly concluding in favor of PN (Kim et al., 2012b; Tan et al., 2012; Zabell et al., 2017a). One meta-analysis looked at more than 30 such studies and reported the following statistically significant correlations in favor of PN: (1) 61% lower incidence of severe CKD; (2) 19% reduced overall mortality; and (3) 29% reduced cancer-specific mortality (Kim et al., 2012b). The retrospective nature of these studies naturally raises concern about selection bias, and the third result listed earlier substantiates this. Clearly, PN is not a stronger oncologic intervention than RN, and the only reasonable way to explain an advantage for PN with respect to oncologic outcomes is selection bias. One cannot help but wonder whether selection bias may also be contributing to the improved overall survival associated with PN in these studies (Giordano et al., 2008; Shuch et al., 2013a; Weight et al., 2013). As such, the recent AHRQ systematic review of RCC management concluded that cancer-specific survival was similar among management strategies and attributable to tumor size and stage, whereas overall survival after intervention was related to age and competing comorbidities and was reflected in the selection for specific treatment modalities (Pierorazio et al., 2016a; Zabell et al., 2017b).

A prospective trial of RN versus PN was reported in 2011 that remains controversial. EORTC 30904 randomized more than 500 patients with small (<5.0-cm), unifocal tumors and a normal contralateral kidney to RN versus elective PN. RN showed an advantage in terms of lower perioperative morbidity, whereas PN provided better functional outcomes (Scosyrev et al., 2014; Van Poppel et al., 2011b). Oncologic events were uncommon, as expected for small renal masses, and similar in both groups. Based on prevailing paradigms, we would have expected better overall survival with PN, primarily driven by reduced cardiovascular morbidity. **However, 10-year overall survival was better for RN than PN (81% vs. 76%, respectively, $P < 0.05$), and cardiovascular deaths were less common in the RN group.** This trial had substantial flaws and most thought leaders in the field have preferred to dismiss the primary findings of the study. However, EORTC 30904 has stimulated further research by suggesting that the functional advantage of PN in the setting of a healthy patient and normal contralateral kidney may not be as beneficial as previously believed (Wang et al., 2016; Zabell et al., 2017a).

Subsequent studies have suggested that there may be a difference between CKD resulting from medical causes (CKD-M) and CKD primarily related

to surgical removal of nephrons (CKD-S) (Demirjian et al., 2014; Lane et al., 2015; Parker et al., 2015). Patients with CKD caused by hypertension or diabetes will continue to suffer from these comorbidities and will likely experience progressive decline in renal function, eventually affecting survival (Go et al., 2004). However, patients with CKD-S typically do not need further surgery and can stabilize (Weight et al., 2013). This hypothesis was tested in a series of more than 4000 patients with localized RCC managed with PN or RN, including 1182 with preexisting CKD needing surgery (CKD-M/S), 927 who developed CKD only after surgery (CKD-S), and more than 2000 with no CKD even after surgery (Lane et al., 2013a). **The mean annual decline of renal function was 4.7% in patients with CKD-M/S compared with only 0.7% for the CKD-S group, and the survival of patients was CKD-S was significantly improved compared with those with CKD-M/S. Furthermore, the survival of patients with CKD-S was nearly identical to patients with no CKD, particularly if new baseline GFR was more than 45 mL/min/1.73 m^2** (Wu et al., 2018).

The functional differences between RN and PN also may not be as great as previously thought. On average, PN saves about 90% of the global renal function and RN about 65% to 70%, but there can be considerable overlap. In a study by Zabor et al. (2016), 49% of patients managed with RN experienced recovery of global renal function to within 5% of their preoperative level within 2 years after surgery (Zabor et al., 2016). Compensatory hypertrophy after RN in adults averages about 20% but may be higher in some cohorts, and RN for kidneys with reduced function will naturally have less functional impact.

Our understanding of functional outcomes after PN and RN and their potential implications on survival has advanced considerably (Kim et al., 2017). However, there is clearly a need for higher quality data in this domain.

Key Points: Partial Neprectomy Versus Radical Nephrectomy

- PN is preferred for small renal masses (stage T1a, <4.0 cm) whenever feasible. RN represents gross overtreatment for most such lesions, which often have limited biologic potential.
- PN is also strongly preferred whenever preservation of renal function is potentially important, such as patients with preexisting CKD or proteinuria,

an abnormal contralateral kidney, or multifocal or familial RCC.

- Larger tumors (clinical stages T1b/T2) have increased oncologic potential and have often already replaced a substantial portion of the parenchyma, leaving less to be saved by PN. In this setting, if a normal contralateral kidney is present, the relative merits of PN vs. RN can be debated.
- The AUA guidelines provide well-defined oncologic and functional criteria for consideration for RN (see Fig. 97.14). If these criteria are not satisfied, PN should be considered, if feasible.
- Well-designed randomized, prospective trials will be required to provide higher quality data and allow for more rational management of patients with localized renal tumors.

Radical Nephrectomy

Prototypical RN encompasses the basic principles of early ligation of the renal artery and vein, removal of the kidney with primary dissection external to Gerota fascia, excision of the ipsilateral adrenal gland, and performance of an extended lymph node dissection (LND) (O'Malley et al., 2009b). **Controversy has arisen regarding the routine need for many of these practices** (Lam et al., 2004). **Performance of a perifascial nephrectomy is of undoubted importance** during RN for preventing postoperative local tumor recurrence because approximately 25% of clinical T1b/T2 RCCs manifest perinephric fat involvement (Lam et al., 2007; Shah et al., 2017b**). Preliminary renal arterial ligation remains an accepted practice; however, in large tumors with abundant collateral vascular supply, it is not always possible to obtain complete preliminary control of the arterial circulation** (O'Malley et al., 2009b). **Removal of the ipsilateral adrenal gland is not routinely necessary** in the absence of radiographic adrenal enlargement or local invasion, unless the malignant lesion extensively involves the kidney and/or is locally advanced (Campbell et al., 2017a; Lane et al., 2009c; Weight et al., 2011).

The need for an extensive LND in all patients undergoing RN has also been challenged, and there are several factors that mitigate against a therapeutic benefit of routine LND (Blom et al., 2009; Blute et al., 2017; Crispen et al., 2011; Leibovich and Blute, 2008). RCC metastasizes through the bloodstream independent of the lymphatics in many patients, and the lymphatic drainage of the kidney is highly variable. Therefore even an extensive retroperitoneal LND may not remove all possible sites of metastasis. **Most importantly, a rigorous**

study by Gershman et al. (2016) **was not able to define a cohort of patients that experienced a therapeutic benefit from LND.** Based on these considerations, the AUA Guidelines now recommend that LND should be performed when suspicious lymphadenopathy is identified on imaging or surgical exploration. Beyond this LND can be selectively considered for locally advanced disease, although in all of these settings LND is primarily for staging and prognostic purposes. **There is strong consensus that LND need not be performed for most patients with localized kidney cancer and clinically negative nodes** (Blom et al., 2009; Campbell et al., 2017a). LND is discussed in greater detail in subsequent sections of this chapter.

Open surgical techniques for RN are described in detail in Chapter 101. **The surgical approach for RN is determined by the size and location of the tumor as well as the body habitus of the patient** (Diblasio et al., 2006). The authors prefer an extended subcostal incision for most patients undergoing open RN, although a midline incision is a reasonable alternative, and the thoracoabdominal approach can be useful for very large and potentially invasive tumors involving the upper portion of the kidney. An extraperitoneal flank incision may be appropriate in elderly patients or patients of poor surgical risk, but exposure can be limiting, particularly for large tumors or those with contentious hilar anatomy (Diblasio et al., 2006; Russo, 2006). In reality, many of these patients are now managed with a minimally invasive approach in this era.

Laparoscopic RN is now established as a less-morbid alternative to open surgery in the management of low- to moderate-volume RCCs with no local invasion, limited or no venous involvement, and manageable lymphadenopathy. Current minimally invasive techniques allow replication of the important tenets of RN, and oncologic and other outcome data reflect this (see Chapter 102) (Berger et al., 2009a; Petros et al., 2015; Wille et al., 2004). Morbidly obese patients, those with a history of previous abdominal surgery, and those with large tumor size may also be considered for minimally invasive renal surgery, although selection of patients must be judicious and surgical expertise and experience should also be taken into account (Campbell et al., 2017b; Feder et al., 2008; Gabr et al., 2008; Tan et al., 2011). **One concern is that minimally invasive RN has become particularly appealing to patients and physicians alike, and this has likely been a major driver in the overuse of RN for small renal masses over the past several years** (Fig. 97.16).

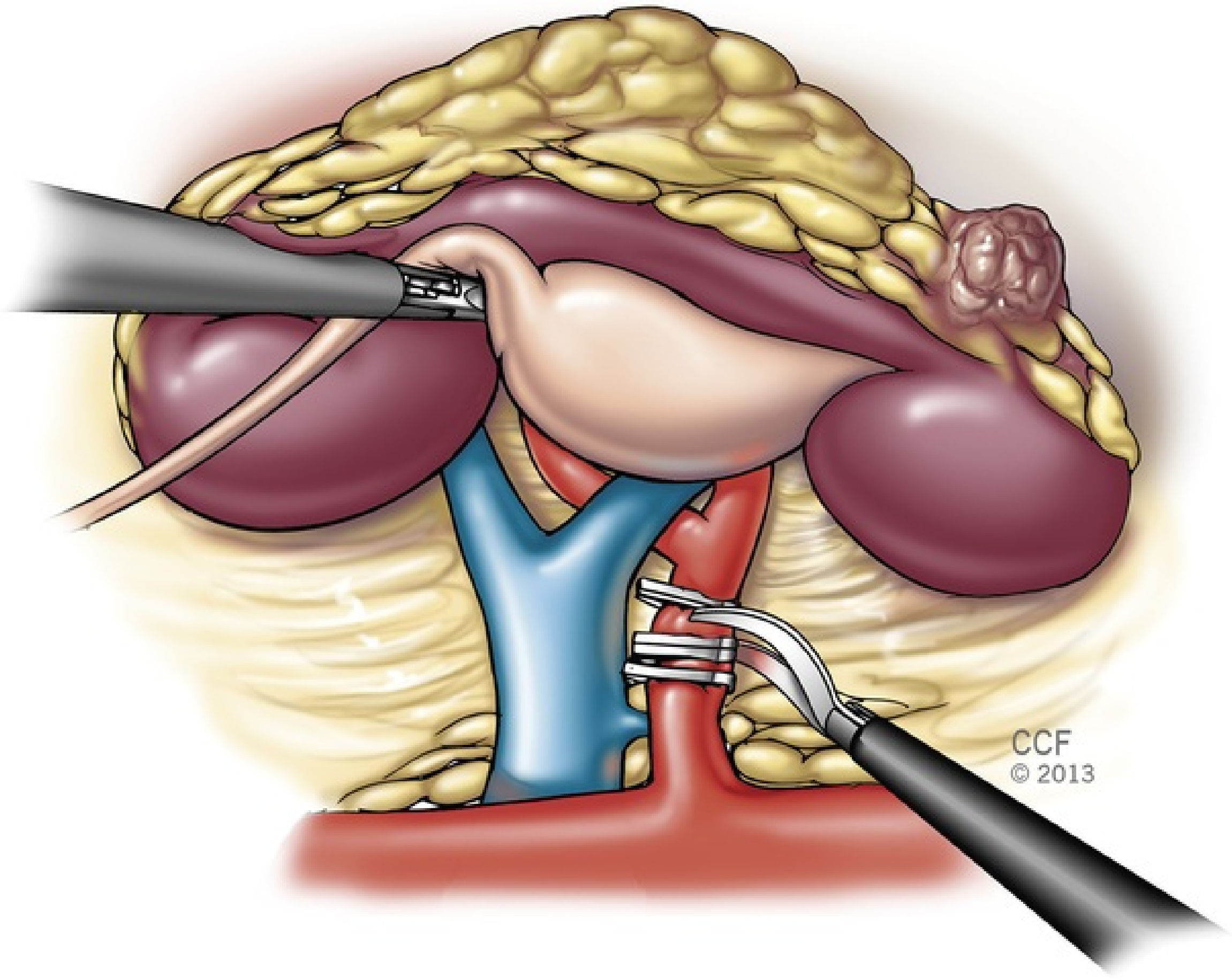

FIG. 97.16 Laparoscopic radical nephrectomy (a retroperitoneal approach is illustrated) provides excellent oncologic outcomes and rapid recovery but predisposes patients to chronic kidney disease. Partial nephrectomy should be prioritized for small renal masses. The 2017 AUA Guidelines provides well-defined criteria for consideration for radical nephrectomy. Patients not meeting these criteria should be considered for partial nephrectomy if feasible.

Several studies on outcomes after RN for localized RCC have demonstrated that the risk of postoperative recurrence is stage-dependent, and surveillance protocols should reflect this (Merrill, 2017; Stephenson et al., 2004). In 2013 an AUA Guidelines Panel provided recommendations for the surveillance of patients after renal surgery for localized renal RCC (Donat et al., 2013). Table 97.15 outlines general surveillance considerations that apply to all patients managed for a localized renal mass, including the role of laboratory testing, longitudinal assessment of renal function, and specific indications for central nervous system or bone imaging. Table 97.16 provides stage-specific information for patients managed with surgical excision, particularly the indications for abdominal and thoracic imaging.

TABLE 97.15

Surveillance for Clinically Localized Renal Neoplasms: General Considerations

FOLLOW-UP MEASURE	RECOMMENDATION
Physical examination and history	History and physical examination directed at detecting signs and symptoms of metastatic spread or local progression
Laboratory testing	Basic laboratory testing, including BUN/creatinine, urinalysis, and eGFR, for all patients Progressive renal insufficiency or proteinuria should prompt nephrology referral CBC, LDH, LFTs, alkaline phosphatase, and serum calcium per discretion of the physician
Central nervous system imaging	Acute neurologic signs should lead to prompt neurologic cross-sectional imaging of the head or spine based on localized symptoms
Bone scan	Elevated alkaline phosphatase, clinical symptoms such as bone pain, and/or radiographic findings suggestive of a bony neoplasm should prompt a bone scan Bone scan should not be performed in the absence of these signs and symptoms

BUN, Blood urea nitrogen; *CBC,* complete blood count; *eGFR,* estimated glomerular filtration rate; *LDH,* lactate dehydrogenase; *LFTs,* liver function tests.

Modified from Donat SM, Diaz M, Bishoff JT, et al.: Follow-up for clinically localized renal neoplasms: AUA guideline. *J Urol* 190:407–416, 2013.

TABLE 97.16

Surveillance After Radical or Partial Nephrectomy[a]

FOLLOW-UP MEASURE	RECOMMENDATION
LOW-RISK PATIENTS	
Abdominal imaging	**Partial Nephrectomy:** Obtain a baseline abdominal scan (CT or MRI) within 3–12 months after surgery. If the initial postoperative scan is negative, abdominal imaging (US,

	CT, or MRI) may be performed yearly for 3 years based on individual risk factors. **Radical Nephrectomy:** Patients should undergo abdominal imaging (US, CT, or MRI) within 3–12 months after surgery. If the initial postoperative imaging is negative, abdominal imaging beyond 12 months may be performed at the discretion of the clinician.
Chest imaging	**Partial and Radical Nephrectomy:** Obtain a yearly CXR for 3 years and only as clinically indicated beyond that time period.
MODERATE- TO HIGH-RISK PATIENTS (pT2-4N0Mx or pT[any]N1Mx): PARTIAL OR RADICAL NEPHRECTOMY	
Abdominal imaging	A baseline abdominal scan (CT or MRI) within 3–6 months after surgery with continued imaging (US, CT, or MRI) every 6 months for at least 3 years and annually thereafter to year 5. Imaging beyond 5 years may be performed at the discretion of the clinician. Perform site-specific imaging as symptoms warrant.
Chest imaging	Obtain a baseline chest scan (CT) within 3–6 months after surgery with continued imaging (CXR or CT) every 6 months for at least 3 years and annually thereafter to year 5. Imaging beyond 5 years is optional and should be based on individual patient characteristics and tumor risk factors.

[a] Please also refer to Table 97.15 for general considerations related to surveillance.

CT, Computed tomography; *CXR,* chest x-ray; *MRI,* magnetic resonance imaging; *US,* ultrasound.

Modified from Donat SM, Diaz M, Bishoff JT, et al.: Follow-up for clinically localized renal neoplasms: AUA guideline. *J Urol* 190:407–416, 2013.

Partial Nephrectomy

Nephron-sparing surgery for the treatment of renal tumors was first described by Czerny in 1890, but this approach was infrequently used until the 1980s (reviewed in Herr, 2005). **Interest in PN for RCC has subsequently been stimulated by advances in renal imaging, experience with renal vascular surgery for other conditions, improved methods of preventing ischemic damage, growing numbers of incidentally discovered renal tumors, greater appreciation of the potentially deleterious effects of CKD, and encouraging long-term survival in patients undergoing this form of treatment** (Uzzo and Novick, 2001). Nephron-sparing surgery entails complete local resection of the tumor while optimally preserving normal functioning parenchyma within the involved kidney (Fig. 97.17).

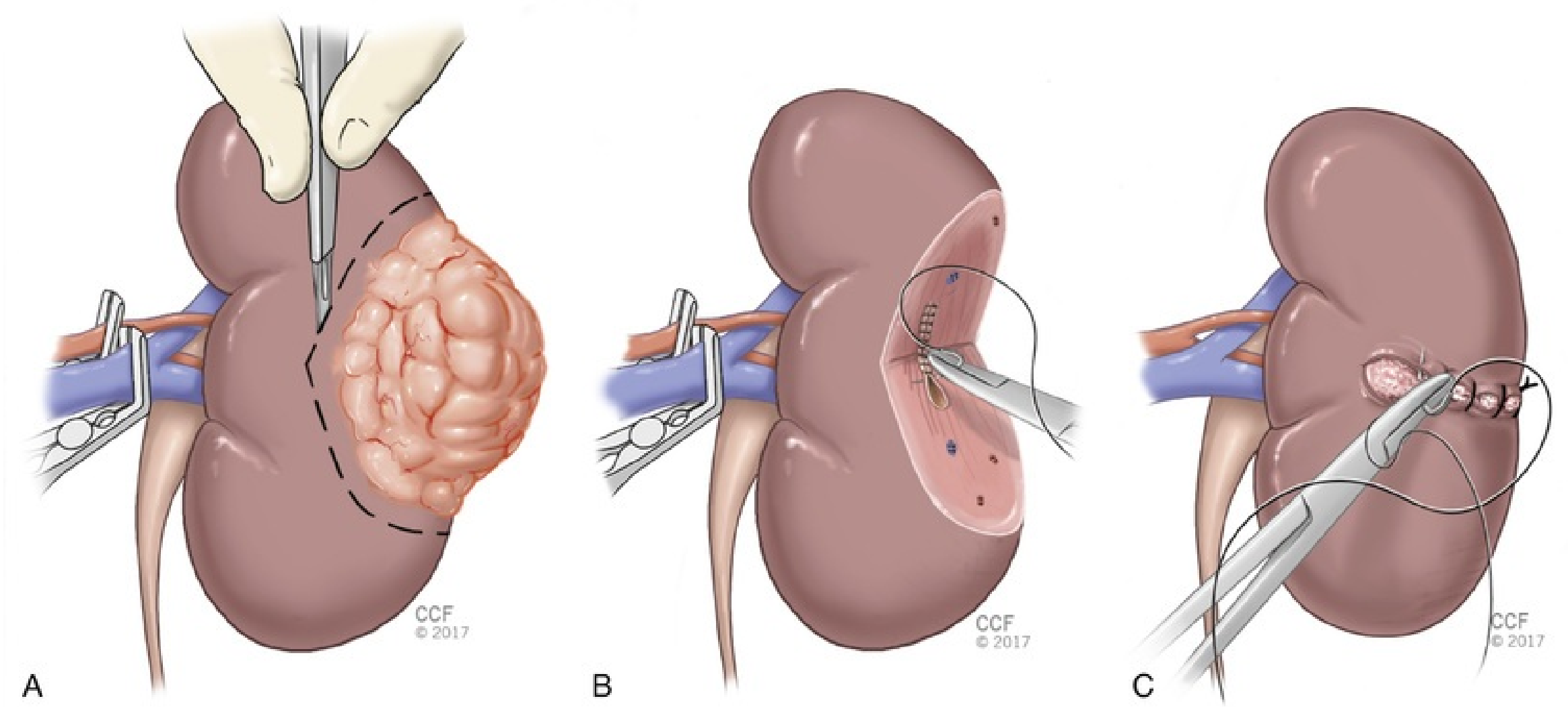

FIG. 97.17 Essential steps in traditional partial nephrectomy as illustrated with open approach. (A) Temporary occlusion of the vascular pedicle and excision of the tumor with a rim of normal parenchyma. (B) Closure of the collecting system and ligation of transected vessels. (C) Capsular reconstruction. (Reprinted with permission, Cleveland Clinic Center for Medical Art and Photography, Copyright 2017. All Rights Reserved.)

Accepted indications for PN traditionally included situations in which RN would render the patient anephric or at high risk for ultimate need of dialysis (Campbell et al., 2017a; Licht et al., 1994; Russo et al., 2008). This comprised patients with bilateral RCC or RCC involving a solitary functioning kidney. A solitary functioning kidney may be the result of unilateral renal agenesis, prior removal of the contralateral kidney, or irreversible impairment of contralateral renal function by a benign disorder. Another traditional relative indication for PN was represented by patients with unilateral RCC and a functioning opposite kidney affected by a condition that may threaten its future function, such as renal artery stenosis (Campbell et al., 1993), hydronephrosis, calculus disease, or systemic diseases such as diabetes or nephrosclerosis (Campbell et al., 2017a; Finelli et al., 2017; Uzzo and Novick, 2001).

In patients with bilateral synchronous RCC, the general approach has been to perform bilateral PNs whenever feasible, usually as staged procedures, particularly if the tumors are relatively large. When a locally extensive tumor on one side precludes nephron-sparing surgery, an RN is performed on the more involved side along with a contralateral PN (Booth et al., 2008; Nguyen et al., 2008a). **Margin width appears to be immaterial as long as the final margins are negative; this is particularly relevant when the tumor is located within the hilum and preservation of renal function is at a**

premium (Bensalah et al., 2010; Bernhard et al., 2010; Marszalek et al., 2012; Sundaram et al., 2011).

Patients with RCC involving a functionally or anatomically solitary kidney must be advised about the potential need for temporary or permanent dialysis. In the series by Fergany et al. (2006), 3.5% of patients with a solitary kidney managed with PN required temporary dialysis, and 18 of 400 patients (4.5%) eventually progressed to end-stage renal failure. Many of these patients also had preexisting CKD, and in some instances only a small remnant kidney could be preserved because of anatomic considerations. **A functioning renal remnant of at least 20% to 30% of one kidney is necessary to avoid end-stage renal failure, although this presumes good functional status of the remaining parenchyma** (Uzzo and Novick, 2001). **Overall preservation of renal function is thus achieved in the great majority of patients with PN, even in patients with traditional imperative indications** (Nguyen et al., 2008a). Local recurrence after PN for imperative indications traditionally ranged from 3% to 5%, because many of these cases were particularly challenging because of hilar tumor location, the need to minimize the amount of excised functional parenchyma, tumor multifocality, or other complexities (Nguyen et al., 2008a; Uzzo and Novick, 2001).

In some patients with absolute indications, PN may not be anatomically feasible and RN followed by dialysis may have to be considered. Renal transplantation may be an option for some of these patients after an appropriate cancer-free interval. **An alternative approach is a trial of tyrosine kinase inhibitor (TKI) therapy in an effort to downsize the tumor and enable PN,** which can be successful in appropriately selected patients, particularly those with clear cell histology (Dey et al., 2017; Gorin et al., 2012a; Kroon et al., 2013; Rini et al., 2012; Thomas et al., 2009a; Tobert et al., 2013). Meticulous surgical technique is paramount because TKIs can impair tissue healing, and these agents should be withheld for at least a few half-lives before and after PN (Chapin et al., 2011; Hellenthal et al., 2010; Thomas et al., 2009b). Complications after PN may be more common in this setting, but most are urine leaks that are readily manageable with conservative measures (Rini et al., 2015). Nevertheless, this approach should only be used when truly necessary—upfront surgery should be prioritized whenever feasible (Dey et al., 2017; Rini et al., 2015).

PN is now standard of care for the management of small renal masses (clinical T1a) in the presence of a normal contralateral kidney, presuming

that the mass is amenable to this approach (Campbell et al., 2017a; Finelli et al., 2017; Ljungberg et al., 2015; Motzer et al., 2017b). **A robust literature demonstrates equivalent oncologic outcomes for PN when compared with RN in appropriately selected patients,** and the functional outcomes tilt the balance in favor of PN whenever feasible (Pierorazio et al., 2016a; Russo and Huang, 2008; Thompson et al., 2008; Van Poppel et al., 2011a). **Prior experience with "elective" PN for T1a RCC demonstrated local recurrence rates of 1% to 2%, and overall cancer-free survival well over 90%** (Campbell et al., 2009). Most local recurrences observed after PN in this setting are a manifestation of undetected microscopic multifocal RCC—most are found distant from the previous tumor bed. Concern about local recurrence after elective PN is counterbalanced by a 1% to 2% incidence of contralateral RCC on longitudinal surveillance, in which case RN would have left the patient with tumor in a solitary kidney (Nguyen et al., 2008a; Russo et al., 2008).

The AUA Guidelines now provide evidence-based recommendations for use of PN (see Fig. 97.14) **relative to RN with emphasis on well-defined selection criteria for RN** (Campbell et al., 2017b). **Tumors that demonstrate features suggesting increased oncologic potential** (e.g., large tumor size, aggressive histology on RMB, or concerning imaging characteristics, such as infiltrative appearance) **should be considered for RN, and RN is generally preferred in this setting only if *all* of the following criteria are met: (1) high tumor complexity and PN would be challenging even in experienced hands; (2) no preexisting CKD or proteinuria; and (3) normal contralateral kidney and new baseline GFR will likely be >45 mL/min/1.73 m^2. If all of these criteria are not satisfied, PN should be considered, if feasible** (Campbell et al., 2017a; Lee et al., 2014; Tomaszewski et al., 2014; Volpe et al., 2013; Wu et al., 2018). **Adherence to these Guidelines would greatly reduce overuse of RN.**

Evaluation of patients with RCC for PN should include preoperative testing to exclude locally extensive or metastatic disease and additional specific renal imaging to delineate the relationship of the tumor to the intrarenal vascular supply and collecting system. Three-dimensional volume-rendered CT (or MRI) is now established as a noninvasive imaging modality that can accurately depict the renal parenchymal and vascular anatomy in a format familiar to urologic surgeons (Campbell et al., 2017b; Novick, 2009).

Urologic complications, such as urine leak or postoperative bleed, are more common after PN when compared with other management strategies,

because the procedure yields a reconstructed organ that is highly vascular (An et al., 2017; Becker et al., 2014; Berg et al., 2017; Jung et al., 2014; Meeks et al., 2008; Pierorazio et al., 2016a). Nevertheless, **most such complications are readily manageable with conservative measures** (Campbell et al., 2017b; Gonzalez-Aguirre and Durack, 2016). The open and minimally invasive techniques for performing nephron-sparing surgery and paradigms for managing PN-related complications are reviewed in Chapters 101 and 102. **R.E.N.A.L. and other nephrometry systems allow for assessment of tumor complexity and risk of complications and have facilitated comparison of evolving surgical techniques for PN in this era** (Joshi and Uzzo, 2017; Kutikov and Uzzo, 2009; Simhan et al., 2011; Simmons et al., 2010). In general, margin status and oncologic outcomes associated with laparoscopic or robotic PN appear to be similar to open PN in experienced hands, presuming sensible patient selection (Lane and Gill, 2007; Spana et al., 2011; Tan et al., 2014; Tanagho et al., 2013).

One ongoing controversy in the field relates to the determinants of renal function after PN, which has important implications regarding surgical technique (Mir et al., 2015; Volpe et al., 2015; Zabell et al., 2017a). One of the main objectives of PN is to preserve as much function as possible and the factors that can influence ultimate renal function include the quality of the parenchyma before surgery, the quantity of vascularized parenchyma that can be preserved, and potential deleterious effects of ischemia (Fig. 97.18). **The quality of the parenchyma is for the most part nonmodifiable, essentially setting the ceiling for functional recovery after any intervention. Most studies that have incorporated the other two factors into multivariable analysis suggest that the number of preserved nephrons is the primary factor determining functional outcomes after PN, while irreversible ischemic injury plays a secondary role** (Dong et al., 2017c; Ginzburg et al., 2015; Lane et al., 2011; Mir et al., 2015; Song et al., 2009). Stated another way, as long as prolonged warm ischemia is avoided, most nephrons will recover from the ischemic insult (Kallingal et al., 2016; Mir et al., 2013; Parekh et al., 2013; Shah et al., 2016a; Thompson et al., 2012; Zabell et al., 2017a).

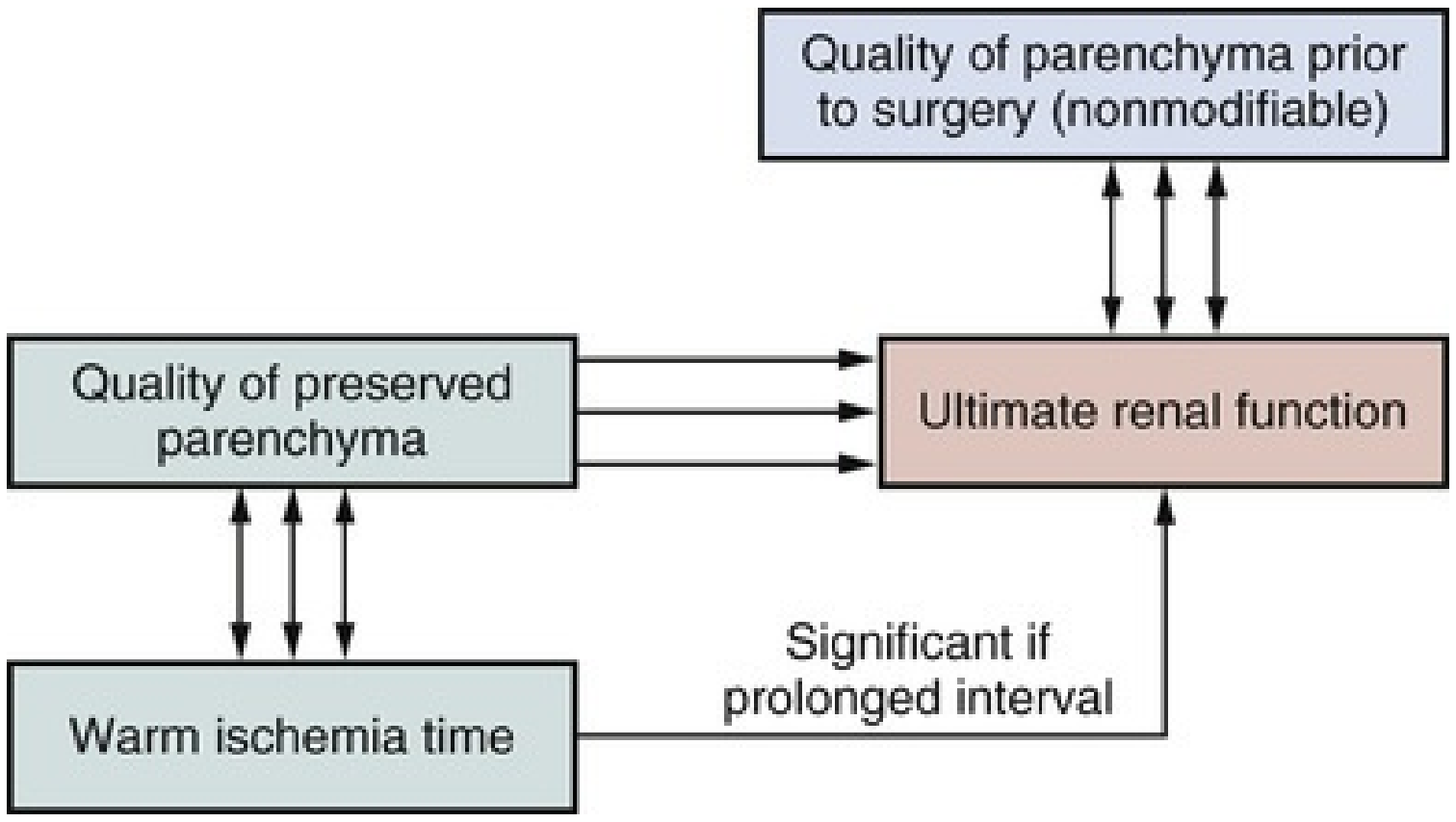
Quality of parenchyma prior to surgery (nonmodifiable)
Quality of preserved parenchyma
Ultimate renal function
Warm ischemia time
Significant if prolonged interval

FIG. 97.18 Determinants of renal function after partial nephrectomy. The quality and quantity of preserved parenchyma are the main determinants of renal function after partial nephrectomy, with ischemic injury playing a secondary role as long as limited warm ischemia or hypothermia is used. Prolonged warm ischemia, however, can lead to irreversible loss of nephron function.

Precise excision of the tumor with a small rim of normal parenchyma along with careful reconstruction of the kidney to minimize devascularization is paramount and can be facilitated by a short ischemic interval to allow for a bloodless field (Bahler et al., 2015; Dong et al., 2017b; Mir et al., 2015; Zabell et al., 2017a). **Hypothermia should be considered for more complex cases or whenever a prolonged ischemic interval (>25–30 minutes) is anticipated, particularly for patients with a solitary kidney or preexisting CKD** (Abdeldaeim et al., 2015; Kaouk et al., 2014; Mir et al., 2015; Zhang et al., 2016). However, other techniques and perspectives, such as the concept of segmental arterial clamping (Desai et al., 2014; Gill et al., 2011, 2012; Shao et al., 2011), have shown promise, and further investigation will be required to address ongoing controversies in this field (see Chapter 102; Campbell et al., 2016; Paulucci et al., 2017; Satkunasivam et al., 2015; Simone et al., 2015).

Increased contact surface area (CSA) between the tumor and normal parenchyma correlates with increased loss of vascularized parenchyma mass because of parenchyma that is excised along with the tumor and devascularization related to reconstruction, both of which are more extensive in this setting (Dong et al., 2017b; Hsieh et al., 2016; Shin et al., 2015). CSA, which can be readily estimated from cross-sectional imaging studies using a simple mathematical formula, thus correlates strongly with functional outcomes after PN (Hsieh et al., 2016).

Surveillance of patients after PN, similar to RN, can be tailored to

pathologic tumor stage; the basic recommendations are detailed in Tables 97.15 and 97.16. These protocols should help minimize costs, radiographic exposure, and patient inconvenience while still allowing for detection of most clinically relevant recurrences (Donat et al., 2013).

Patients who undergo nephron-sparing surgery for RCC may be left with a remnant kidney and are at risk for development of long-term functional impairment from hyperfiltration (Grady and Novick, 1996; Novick, 2009). In a study of 14 patients observed for up to 17 years after PN in a solitary kidney, patients with more than 50% reduction in overall renal mass were found to be at increased risk for development of proteinuria, focal segmental glomerulosclerosis (Fig. 97.19), and progressive renal failure (Novick et al., 1990). Development of proteinuria correlated directly with the length of follow-up and inversely with the amount of remaining renal tissue. **If proteinuria or progressive decline in GFR is noted in such patients, nephrology consultation should be obtained. Efforts to ameliorate the damaging effects of renal hyperfiltration have focused on dietary and pharmacologic interventions,** primarily the use of angiotensin-converting enzyme inhibitors along with a low-protein diet (Goldfarb, 1995; Novick and Schreiber, 1995).

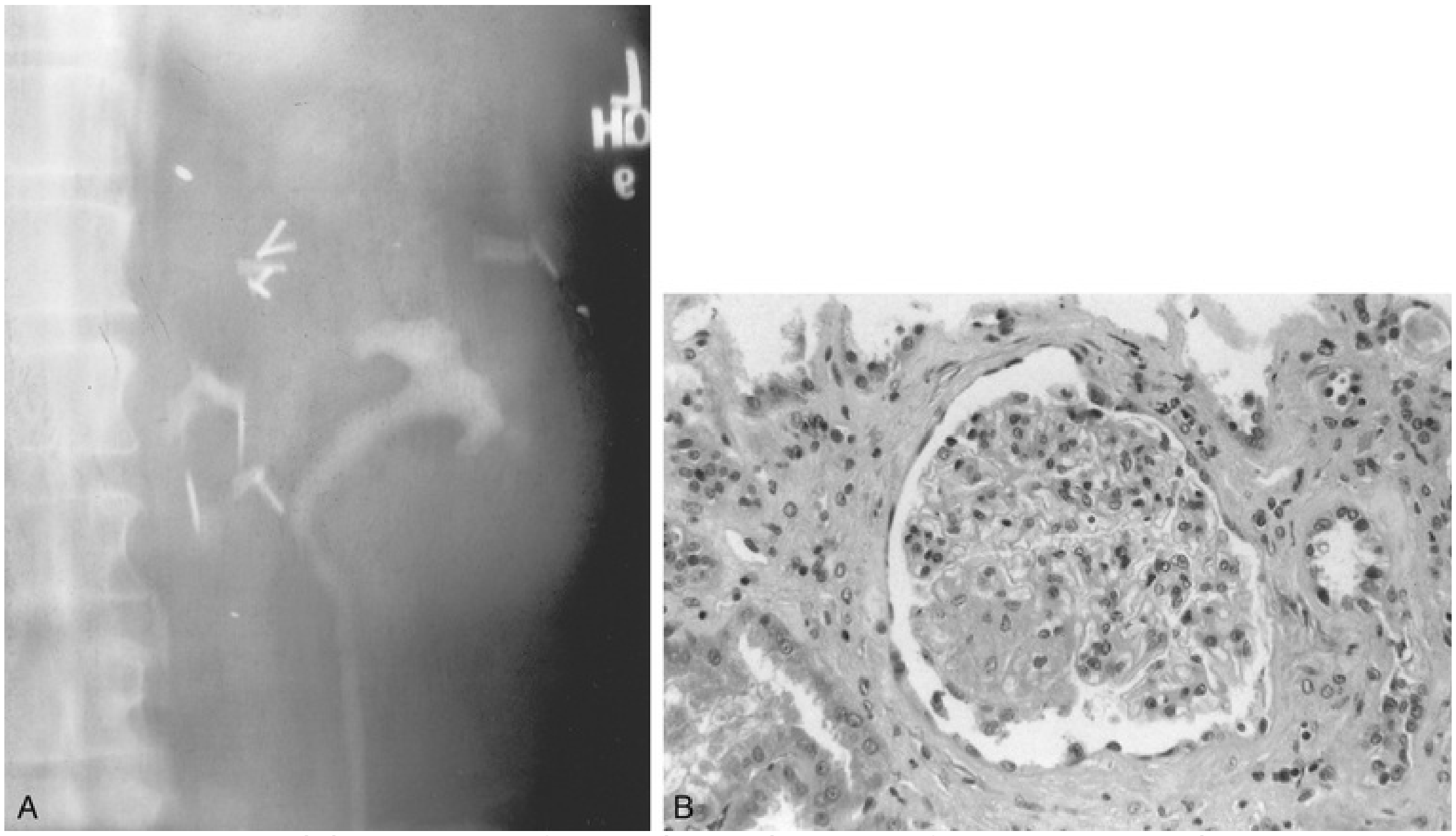

FIG. 97.19 (A) Ten years after partial nephrectomy for a large tumor in a solitary left kidney, imaging shows function of small renal remnant. The patient had developed nephrotic syndrome at this time. (B) Renal biopsy specimen demonstrates focal segmental glomerulosclerosis indicative of

hyperfiltration nephropathy.

Tumor Enucleation

Tumor enucleation (TE) is well-established for patients with familial kidney cancer, although its role for sporadic RCC remains controversial (Gupta et al., 2015). **TE entails blunt dissection along the pseudocapsule, thereby reducing the amount of normal parenchyma removed with the tumor.** In contrast, standard PN is performed by strategic sharp dissection, intentionally leaving a 2- to 3-mm rim of normal parenchymal adjacent to the tumor (Fig. 97.20). By minimizing dissection into the main substance of the kidney, TE may reduce blood loss, preclude entry into the collecting system, facilitate zero ischemia approaches to PN, and obviate the need for capsular closure. **As such, it may improve functional outcomes, although the bar is set high by standard PN, which typically saves about 90% of the global renal function.** In reality, only patients with severe preexisting CKD would be likely to benefit from the small incremental improvement in functional recovery that TE may provide (Blackwell et al., 2017; Dong et al., 2017a).

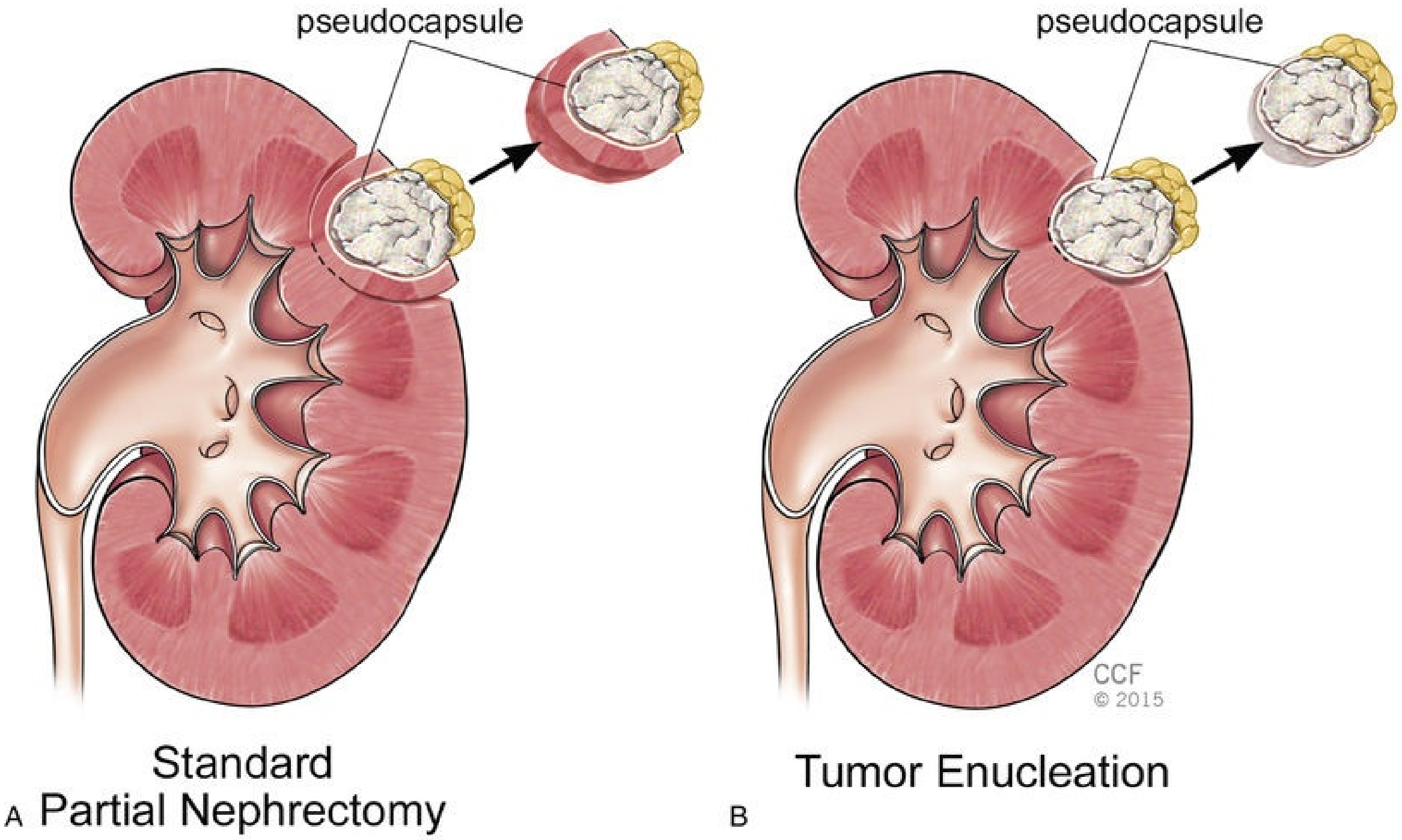

FIG. 97.20 (A) Standard partial nephrectomy is typically performed by strategic sharp dissection through the parenchyma leaving a small rim of

normal parenchyma surrounding the mass. (B) Tumor enucleation primarily consists of blunt dissection along the pseudocapsule, yielding a specimen that includes tumor surrounded by pseudocapsule with minimal or no parenchyma in most areas. (Dong W, Gupta GN, Blackwell RH, et al.: Functional comparison of renal tumor enucleation versus standard partial nephrectomy. *Eur Urol Focus* 3[4–5]:437–443, 2017.)

The main concern with TE is oncologic, as the basic tenets of surgical oncology would prioritize an approach that avoids the pseudocapsule and reduces the risk of positive surgical margins. Recent studies strongly suggest an increased risk of RCC recurrence after PN when positive margins are present, and 40% to 50% of localized RCC infiltrate into or beyond the pseudocapsule at least to some extent (Azhar et al., 2015; Gupta et al., 2015; Khalifeh et al., 2013; Minervini et al., 2009; Shah et al., 2016b). **However, most reports of TE have described relatively low rates of positive margins and encouraging longitudinal oncologic outcomes** (Carini et al., 2006; Kutikov et al., 2008; Minervini et al., 2011, 2015a; Porpiglia et al., 2016; Serni et al., 2014). Proponents of TE argue that infiltrative tumor within or beyond the pseudocapsule results in an inflammatory reaction that naturally directs dissection away from these danger zones, whereas sharp dissection as per standard PN is essentially blind and may increase the risk of an unrecognized margin in such areas. The basic concept is captured in the latter aspect of the adage, “keep your friends close, and your enemies closer.” The other way to explain such findings relates to potential methodological differences in evaluation of margins among various centers and in different settings. **Selection for TE based on favorable imaging characteristics such as homogeneity or encapsulated appearance may also be a contributing factor, and a randomized trial with uniform pathologic assessment will be required to resolve some of these controversies** (Gupta et al., 2015).

In reality, TE is likely performed more often than previously appreciated, even when standard PN is intended. A recent recommendation has been to **standardize recording of the resection technique (enucleation versus standard resection**, versus enucleoresection, which is a hybrid of the other two) **based on visual inspection of the final gross pathologic specimen**. With enucleation only the pseudocapsule is seen and for standard resection the true tumor contour cannot be appreciated. Such assessments should be taken from the Surface, Intermediate region, and Base of the tumor, and this protocol, which is termed SIB, should facilitate comparison of outcomes for the various approaches to tumor resection (Antonelli et al., 2017; Minervini et al., 2014, 2015b).

In summary, review of the TE literature suggests that this approach is reasonable for many patients, but selection criteria are not well defined. Capsular invasion appears to be less common for low-grade tumors and for chromophobe RCC and oncocytomas (Jacob et al., 2015; Volpe et al., 2016b). As expected, high-grade tumors appear to be at risk for recurrence after TE, and RMB can be considered to assess suitability for this approach (Gupta et al., 2015). **The AUA Guidelines emphasize that negative surgical margins should always be a top priority with PN** (see Fig. 97.14). **Beyond this overriding principle, the Guidelines state that "the extent of normal parenchyma removed should be determined by surgeon discretion taking into account the clinical situation; tumor characteristics including growth pattern, and interface with normal tissue"** (Campbell et al., 2017a).

Thermal Ablative Therapies

TA, including renal cryosurgery and radiofrequency ablation (RFA), are now established as alternate nephron-sparing treatments for patients with localized RCC (Bhagavatula and Shyn, 2017; Kavoussi et al., 2016; Zargar et al., 2016). **Both can be administered percutaneously and thus offer the potential for reduced morbidity** (Campbell et al., 2017a; Taylor et al., 2017). In the recent meta-analysis associated with the AUA Guidelines, the morbidity profile for TA proved to be favorable, particularly relative to PN, which can be associated with an increased incidence of urologic complications (Campbell et al., 2017b). The effect of TA on renal function is typically limited, and these modalities appear to be reasonable choices for select patients with tumor in a solitary kidney, although PN remains the preferred choice in this setting (Altunrende et al., 2011; Weisbrod et al., 2010).

In general, long-term efficacy of TA is still not as well established as surgical excision, and local recurrence rates with primary TA are somewhat higher than those reported for traditional surgical approaches (Fig. 97.21) (Campbell et al., 2017b; Klatte et al., 2014). Another concern with TA has been risk of inaccurate histologic assessment because tumor heterogeneity may not be captured by RMB (Ball et al., 2015a) and lack of pathologic staging because the tumor is left in situ. **Most local recurrences after TA can be salvaged with repeat ablation, and cancer-specific survival rates for clinical T1a tumors are generally high across all management strategies** (Campbell et al., 2017a). **Overall survival is primarily determined by age and general health status,**

not approach to management.

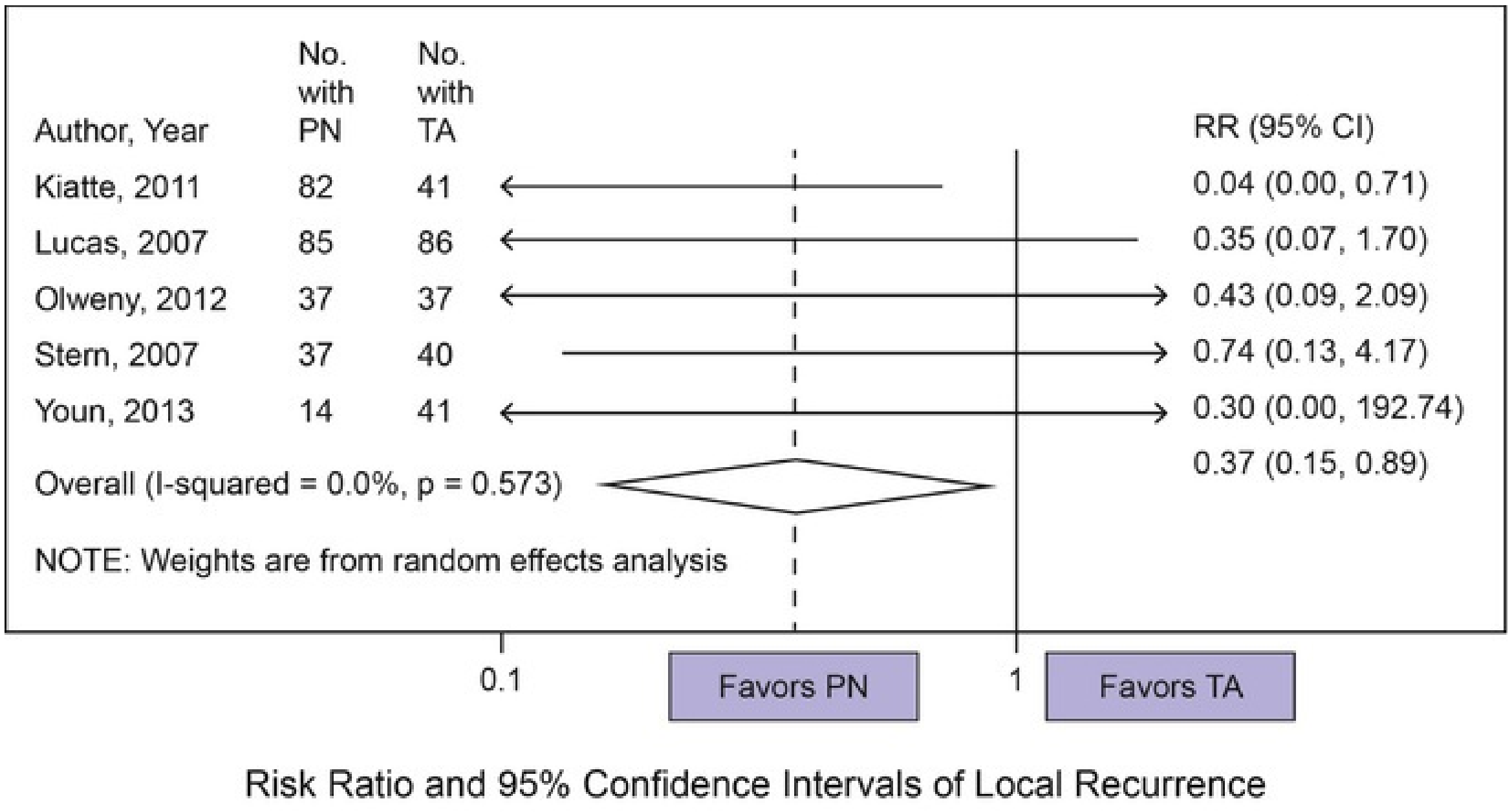

CI = confidence interval: No = numbers: PN = partial nephrectomy: RR = risk ratio for local recurrence: TA = thermal ablation

Note: The width of the horizontal lines represents the 95 percent confidence intervals for each study. The diamond at the bottom of the graph indicates the 95 percent confidence interval.

FIG. 97.21 Meta-analysis of local recurrence rates after partial nephrectomy (PN) versus primary tumor ablation (TA) incorporating studies with 48 +/− 12 months of follow-up. Risk ratios with 95% confidence intervals are shown for each study and for the overall analysis. Most such recurrences can be salvaged with repeat TA and the observed differences in local recurrence rates were no longer present when secondary ablations were taken into account. (Modified from Campbell SC, Uzzo RG, Allaf ME, et al.: Renal mass and localized renal cancer: AUA Guideline, 2017 [website]: https://www.auanet.org/guidelines/renal-mass-and-localized-renal-cancer-new-(2017).)

The traditional candidates for TA have been patients with reasonable life expectancy despite advanced age or significant comorbidities, who prefer a proactive approach but are not optimal candidates for conventional surgery. Although TA is still a reasonable choice for such patients, AS is now more commonly used in this setting. Other candidates for TA include patients with local recurrence after previous nephron-sparing surgery, and those with hereditary renal cancer who present with multifocal lesions for whom multiple PNs may be cumbersome (Johnson et al., 2008; Kavoussi et al., 2016; Liu et al., 2010; Zargar et al., 2016). Patient preference must also be considered, and some patients not fitting these profiles may also select TA, which can be supported as long as balanced counseling about the merits and limitations of these modalities has been provided (Campbell et al., 2017a; Kavoussi et al., 2016).

Tumor size is another important factor in patient selection because success rates appear to be highest for tumors smaller than 2.5 to 3.0 cm, and complication rates are also lower in this setting (Atwell et al., 2013; Campbell et al., 2017a; Tanagho et al., 2012). Some centers report local control rates of 95% to 100% with TA for such small renal masses. In general, success rates with TA appear to be lower for avidly enhancing masses and for clear cell histology, suggesting a potential role for RMB for risk stratification (Lay et al., 2015, 2016). **The 2017 AUA Guidelines advocate for TA as an alternate approach for the management of clinical T1a renal masses smaller than 3.0 cm in diameter,** which can be considered even in healthy patients (see Fig. 97.14; Campbell et al., 2017a).

Experience with renal cryosurgery predates that of RFA and has been more extensive (Nielsen et al., 2016; Zargar et al., 2016). Established prerequisites for successful cryosurgery include rapid freezing, gradual thawing, and a repetition of the freeze-thaw cycle. The mechanism of action consists of immediate membrane and cellular damage followed by microcirculatory failure and ischemia (Zondervan et al., 2016). Intracellular ice irreversibly disrupts cellular organelles and the cell membrane, and delayed microcirculatory occlusion eventually leads to cellular anoxia.

Complete and reliable tissue necrosis with cryoablation is consistently achieved only at temperatures of −19.4°C or lower, which occurs about 3 mm inside the leading edge of the iceball as visualized by real-time ultrasonography. **Thus, to ensure complete cell kill, the iceball must extend well beyond the visible margins of the targeted tumor.** In practice, we routinely extend the iceball approximately 1 cm beyond the edge of the tumor**,** as determined by real-time imaging (Gill et al., 1998). The availability of sophisticated ultrasonography and introduction of finer cryoprobes that allow for more accurate and less traumatic probe placement have contributed to improved efficacy and safety of visceral cryosurgery (Sterrett et al., 2008; Zargar et al., 2016). Further details about techniques required to achieve optimal outcomes with cryoablation are available in Chapter 103.

Clinical experience after primary renal cryoablative therapy suggests successful local control in about 80% to 90% of patients, although many studies provide only limited follow-up (Campbell et al., 2017a; Stein and

Kaouk, 2007; Zargar et al., 2016). Diagnosis of local recurrence after TA can be challenging because evolving fibrosis within the tumor bed can be difficult to differentiate from residual cancer. **In general, central or nodular enhancement within the tumor bed on extended follow-up has been considered diagnostic of local recurrence, and the clinical experience with TA has thus far supported this** (Bolte et al., 2006; Weight et al., 2008). However, only a minority of studies have incorporated routine post-therapy biopsies to provide histologic confirmation of oncologic status (Gill et al., 2000; Weight et al., 2008). Other findings that suggest local recurrence include a progressive increase in size of an ablated neoplasm, new nodularity in or around the treated zone, failure of the treated lesion to regress over time, or satellite or port site lesions (Donat et al., 2013). If these features are found, biopsy and possible retreatment should be considered. The **AUA Guidelines for surveillance after TA are outlined in Tables 97.15 and 97.17.**

TABLE 97.17

Surveillance After Renal Ablation[a]

FOLLOW-UP MEASURE	RECOMMENDATION
Diagnostic biopsy	Patients should undergo a pretreatment diagnostic biopsy.
Abdominal scan	Cross-sectional scanning (CT or MRI) with and without IV contrast unless otherwise contraindicated at 3 and 6 months after ablative therapy and with continued scanning annually thereafter for 5 years. Imaging beyond 5 years is optional based on individual risk factors.
Chest imaging	Patients who have either biopsy-proven renal cell carcinoma, oncocytoma, a tumor with oncocytic features, nondiagnostic biopsies, or no prior biopsy should undergo annual CXR for 5 years. Imaging (CXR or CT) beyond 5 years is optional based on individual patient risk factors and the determination of treatment success.
Benign biopsy	Radiographic scanning is not recommended with pathologic confirmation of benign disease at or before treatment and post-treatment radiographic confirmation of treatment success and no evidence of treatment-related complications. Oncocytoma is a possible exception for which continued surveillance should be considered.
Repeat biopsy	New enhancement, a progressive increase in size of an ablated neoplasm with or without contrast enhancement, new nodularity in or

	around the treated zone, failure of the treated lesion to regress over time, or satellite or port site lesions should prompt a repeat lesion biopsy. Observation, repeat treatment, and surgical intervention should be discussed for recurrence.

[a] Please also refer to Table 97.15 for general considerations related to surveillance.

CT, Computed tomography; *CXR,* chest x-ray; *IV,* intravenous; *MRI,* magnetic resonance imaging.

Modified from Donat SM, Diaz M, Bishoff JT, et al.: Follow-up for clinically localized renal neoplasms: AUA guideline. *J Urol* 190:407–416, 2013.

Other concerns with cryoablation and TA in general, relate to surgical salvage and potential morbidity. Most local recurrences can be salvaged with repeat ablation, although some patients with progressive disease eventually require conventional surgery. PN and minimally invasive approaches are occasionally precluded in this setting because of the extensive fibrotic reaction induced by TA (Abarzua-Cabezas et al., 2015; Cross et al., 2017; Jimenez et al., 2016; Karam et al., 2015; Kowalczyk et al., 2009). Complications associated with cryoablation can include renal fracture, hemorrhage, adjacent organ injury, ileus, and wound infection, although major morbidity is decidedly uncommon presuming good patient selection (Sidana et al., 2010; Tsivian et al., 2010; Zargar et al., 2016). As expected, the incidence of treatment failure or complications after TA correlates with tumor size and complexity (Schmit et al., 2013).

The experience with RFA was initially more variable, likely related to variance in surgeon experience, differences in platforms used to perform the procedure, and inability to monitor treatment progress as stringently as cryoablation (Chang et al., 2015; Sterrett et al., 2008). **However, as experience with RFA increased, outcomes similar to cryoablation were reported, and the AUA Guidelines Panel concluded that neither modality was notably superior,** presuming adequate experience and expertise (see Fig. 97.14; Campbell et al., 2017a).

The mechanism of action of RFA is based on high-frequency electrical currents that lead to excitation of ions, frictional forces, and heat, which in turn causes denaturation of intracellular proteins and melting of cellular membranes (Kelly and Leveillee, 2016). These effects are observed at tissue temperatures above 41°C but increase directly with increasing temperature and duration of treatment. Temperatures in excess of 100°C are typically obtained at the tips of the probes, although this rapidly dissipates further away from the tip. Multiple probes or tines are thus typically required to achieve adequate heating of the entire region of interest, and thermosensors can be used to monitor progress, at least in areas of concern (Chang et al., 2015; Kelly and Leveillee, 2016). **Nevertheless, one disadvantage of RFA is that the treatment effect is potentially more difficult to monitor in real time—there is no true "iceball equivalent"** (Chang et al., 2015)**. Rather, treatment is primarily based on empirical results from previous probe alignments, supplemented by data from strategically placed thermoprobes when necessary** (see Chapter 103).

The technology for RFA continues to improve, and most contemporary series report relatively low rates of local recurrence, particularly for small renal masses less than 3 cm in diameter. Again, most local recurrences can be salvaged with repeat ablation, and cancer-specific survival remains high (Campbell et al., 2017b). Complications from RFA are uncommon but can include acute renal failure, stricture of the ureteropelvic junction, necrotizing pancreatitis, and lumbar radiculopathy, so careful and judicious selection of patients is essential (Chang et al., 2015; Sterrett et al., 2008).

Other new technologies, including high-intensity focused ultrasound (HIFU), stereotactic body radiation therapy (SBRT), microwave ablation, and laser interstitial thermal therapy, **are also under investigation and may allow for extracorporeal treatment of small renal tumors in the future** (de Senneville et al., 2016; Lin et al., 2014; Nair et al., 2013; Siva et al., 2012; Swaminath and Chu, 2015). However, at present cell kill with these modalities is not sufficiently reliable, and they are best considered developmental (Campbell et al., 2017b).

Active Surveillance

There was once relatively little information about the growth rate of RCC because almost all renal tumors were excised shortly after detection (Jewett et al., 2011; Lane et al., 2012). **The incidental discovery of many small RCCs in asymptomatic elderly patients or those of poor surgical risk provided the opportunity to observe the growth rate of these tumors in patients who were unable or unwilling to undergo surgery** (Chen and Uzzo, 2009; Crispen et al., 2009). Bosniak (1995) reported one of the first series of AS that included 72 small (<3.5 cm) renal tumors in 68 patients who were observed with serial imaging for a mean of 3.3 years. On CT these were solid, enhancing tumors consistent with RCC. During observation these tumors exhibited a median growth rate of 0.36 cm per year. In 32 patients whose tumors grew to larger than 3 cm, surgical excision was performed; all excised tumors were organ confined and most were grade 1. No patients developed metastasis during surveillance.

Subsequent series from several institutions confirmed that many small renal masses will grow slowly (median growth rate 0.09 to 0.34 cm/year) and with a relatively low rate of metastasis (less than 2.0% during 2 to 5 years of follow-up) (Campbell et al., 2017b; Conti et al., 2015; Jewett et al., 2011; Organ et al., 2014; Pierorazio et al., 2015; Smaldone et al., 2012; Uzosike et al., 2017). However, there are potential limitations to this literature (Campbell et al., 2017b). First, most AS series are enriched with small, well-marginated, homogeneous renal masses reflecting selection bias. A substantial proportion (20% or more) of these tumors may have been benign—RMB was often not performed. Finally, in most of these series there is a subpopulation of patients with rapidly growing tumors that appear to have more aggressive characteristics (Uhlman et al., 2013). For instance, in the series from Volpe et al. (2004), 25% of the masses doubled in volume in 12 months and 22% reached a diameter of 4 cm, triggering surgical intervention (Volpe et al., 2004). Salvage of patients with metastatic RCC is unlikely, and in some patients the window of opportunity for PN or TA may be lost.

Nevertheless, these studies suggest that patients with small, solid renal lesions, who are elderly or have increased surgical risk, can safely be managed with observation and serial renal imaging at 6-month or 1-year intervals (Jewett and Zuniga, 2008; Lallas et al., 2015; Ljungberg et al., 2015; Patel et al., 2016c; Volpe, 2016a). In this population, the risk of competing non-cancer causes of death and the risk of intervention often outweigh the risk of RCC progression (Kutikov et al., 2012; Smaldone et al., 2013; Sun et al., 2014). In fact, a number of studies indicate that active treatment of small renal masses in elderly patients may not confer a measurable survival benefit (Campbell et al., 2017b; Lane et al., 2010; Mirza, 2015).

Prospective studies with more prolonged follow-up are now available and provide further support for the use of AS, even in healthy patients when the mass has low malignant potential, such as very small (<2.0 cm), incidentally discovered renal masses (Ahmad et al., 2016; Danzig et al., 2016; Jewett et al., 2011; Ristau et al., 2017). The Delayed Intervention and Surveillance for Small Renal Masses (DISSRM) Registry prospectively enrolls patients with incidentally discovered, solid, small renal masses choosing AS or primary intervention. With a median follow-up of 2 years, and many patients with greater than 5-year follow-up, no patient undergoing AS has died of RCC or developed metastatic disease, while approximately 15% have undergone delayed intervention because of tumor growth or patient preference (Pierorazio et al., 2015). For small renal masses with low oncologic potential a trial of close observation can be considered with deferred RMB or intervention if interval growth is observed (Campbell et al., 2017a). The risk of delayed intervention in this setting appears to be low: most such tumors are readily salvageable, typically with nephron-sparing approaches (Hawken et al., 2016).

The AUA Guidelines now provide specific recommendations about AS or expectant management and well-defined criteria for monitoring patients on surveillance (see Fig. 97.14 and Tables 97.15 and 97.18; Campbell et al., 2017a**). For small, solid or Bosniak 3-4 complex cystic masses, AS should be considered on option for initial management, and for tumors with reduced malignant potential, such as those smaller than 2.0 cm diameter, this applies to healthy patients too. Shared decision making about AS versus intervention can be complex, and patient and tumor-related factors that favor conservative management are detailed in Fig. 97.14.** RMB can also be considered for risk stratification before counseling.

TABLE 97.18

Active Surveillance: Imaging Recommendations[a]

FOLLOW-UP MEASURE	RECOMMENDATION
Percutaneous biopsy	Percutaneous biopsy may be considered before active surveillance.
Abdominal imaging	Cross-sectional scanning (CT or MRI) within 3–6 months of active surveillance initiation to establish a growth rate, with continued imaging (US, CT, or MRI) at least annually thereafter.
Chest imaging	Patients with biopsy-proven renal cell carcinoma or a tumor with oncocytic features on active surveillance should undergo annual CXR. Continued surveillance should also be considered by oncocytoma.

[a] Please also refer to Table 97.15 for general considerations related to surveillance.

CT, Computed tomography; *CXR,* chest x-ray; *MRI,* magnetic resonance imaging; *US,* ultrasound.

Modified from Donat SM, Diaz M, Bishoff JT, et al.: Follow-up for clinically localized renal neoplasms: AUA guideline. *J Urol* 190:407–416, 2013.

Nephron-Sparing Surgery in von Hippel-Lindau and Other Forms of Familial Renal Cell Carcinoma

RCC in VHL disease differs from its sporadic counterpart in that the diagnosis is typically made at a younger age and there are usually multiple bilateral renal tumors (Bausch et al., 2013; Byler and Bratslavsky, 2014; Linehan and Ricketts, 2013). Although these are generally low-stage tumors, they are capable of progression to metastasis and represent a frequent cause of death in patients with VHL. RCC in VHL is characterized histologically by solid tumors and renal cysts that contain either frank carcinoma or a lining of hyperplastic clear cells representing incipient carcinoma (Fig. 97.22).

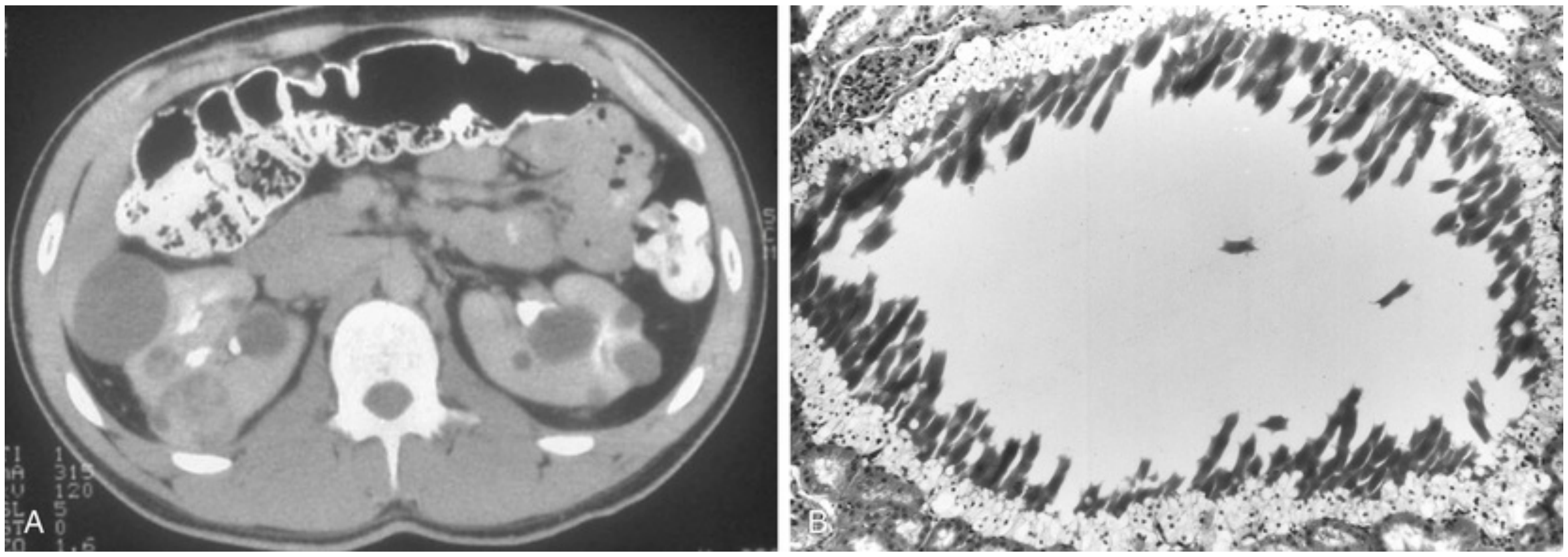

FIG. 97.22 (A) Computed tomography scan after administration of contrast agent shows bilateral solid and cystic renal masses in a patient with von Hippel-Lindau disease. (B) Histopathologic section of one of the renal cysts shows lining of clear cells representing incipient carcinoma.

The surgical options in patients with bilateral RCC and VHL disease are bilateral nephrectomy and renal replacement therapy or nephron-sparing approaches such as PN or TA to avoid end-stage renal disease. The general philosophy has been to pursue nephron-sparing strategies whenever possible, given the multifocal nature of the disease, even for centrally located tumors (Linehan and Ricketts, 2013; Metwalli and Linehan, 2014). For PN, an enucleative approach is often preferred to optimize preservation of parenchymal mass and function. Although early results of PN were promising, subsequent studies suggested a high incidence of ipsilateral postoperative tumor recurrences (Grubb et al., 2005; Novick and Streem, 1992). It is likely that most of these local recurrences were a manifestation of occult microscopic RCC that was not removed at the time of the original PN.

One multicenter study delineated the long-term outcomes after surgical treatment of localized RCC in 65 patients with VHL (Steinbach et al., 1995). RCC was present bilaterally and unilaterally in 54 and 11 patients, respectively, and RN and PN were performed in 16 and 49 patients, respectively. The 5-year and 10-year cancer-specific survival rates for all patients were 95% and 77%, respectively. The corresponding rates for patients treated with PN were 100% and 81%, respectively. Survival free of local recurrence after PN was 71% at 5 years but only 15% at 10 years, emphasizing the need for long-term surveillance.

Duffey et al. (2004) **at the National Cancer Institute have defined a 3-cm threshold for intervention in patients with VHL**. In their series, 108 patients with VHL and solid renal tumors smaller than 3 cm were observed, and none developed metastatic disease during mean follow-up of 58 months. In contrast, metastases developed in 20 of 73 patients (27%) with tumors larger than 3 cm, and the frequency of metastases increased with increasing tumor size. A 3-cm cut point has thus been proposed to reduce the number of surgical interventions, optimize renal function, and minimize the risk of metastatic disease. **This recommendation also applies to patients with HPRC and BHD syndromes** (Shuch et al., 2012b; Stamatakis et al., 2013). **However, HLRCC is an exception in that tumors in this syndrome are often more aggressive and should be managed accordingly, even when less than 3 cm** (Linehan and Rouault, 2013; Ricketts et al., 2012; Shuch et al., 2012b).

Taken together, these studies suggest that PN can provide effective initial treatment of patients with RCC and VHL but should be withheld until tumor size reaches or eclipses 3.0 cm. After initial management, patients with VHL must be observed closely because most will eventually develop locally recurrent RCC with the concomitant need for repeat renal intervention (Grubb et al., 2005; Ploussard et al., 2007). In this setting, repeat PN can be challenging because of postoperative fibrosis and TA may be considered to reclaim local control (Liu et al., 2010; Metwalli and Linehan, 2014; Shuch et al., 2012b). Targeted agents are now being investigated in an effort to slow disease progression in this syndrome (Shuch et al., 2012b). When removal of all renal tissue is necessary for oncologic reasons, subsequent renal transplantation can provide satisfactory renal replacement therapy and appears to be generally safe despite the tumor diathesis (Goldfarb et al., 1997).

Comprehensive management of patients suspected of having familial

RCC should also include genetic counseling and screening for other manifestations of the disease process (as discussed in the earlier section on familial RCC and molecular genetics) (Byler and Bratslavsky, 2014; Ho and Jonasch, 2014; Shuch et al., 2012b). For patients with VHL, identification of pheochromocytoma or central nervous system hemangioblastoma is particularly important before surgical intervention for RCC (Linehan and Ricketts, 2013).

Treatment of Locally Advanced Renal Cell Carcinoma

Inferior Vena Cava Involvement

One of the unique features of RCC is its frequent pattern of growth intraluminally into the renal venous circulation, also known as venous tumor thrombus. This growth may extend into the IVC with cephalad migration as far as the right atrium or beyond. The absence of metastases in many patients with vena cava extension is an intriguing aspect of this cancer's behavior (Gettman and Blute, 2002; Martinez-Salamanca et al., 2011; Wotkowicz et al., 2008;). **Forty-five to seventy percent of patients with RCC and IVC thrombus can be cured with an aggressive surgical approach, including RN and IVC thrombectomy** (Blute et al., 2004b; Martinez-Salamanca et al., 2011).

Key Points: Treatment of Locally Advanced Renal Cell Carcinoma

- Forty-five to seventy percent of patients with venous tumor thrombus can be cured with nephrectomy and thrombectomy, including patients with tumor thrombus extending to the cardiac atrium.
- Thrombus extending into the IVC below the main hepatic veins can be readily managed with isolation of the involved vasculature and removal of the tumor thrombus.
- Thrombus extending above the main hepatic veins requires more extensive dissection, venovenous bypass, or cardiopulmonary bypass and circulatory arrest.
- For large tumors with radiographic suspicion of invasion into adjacent structures (cT4), complete excision with en bloc resection of the involved structures provides the only chance of cure.
- Bulky lymphadenopathy carries a poor prognosis similar to metastatic disease, although surgical resection should be considered if feasible, given careful assessment of disease burden and patient age/comorbidities.

- High-quality preoperative imaging (CT or MRI) should be obtained in proximity to the anticipated surgery to plan for and achieve intraoperative success.
- Although locally advanced RCC is still primarily a surgical disease, adjuvant systemic therapy trials should be encouraged and, in select patients, neoadjuvant approaches may be considered.

Overall, involvement of the venous system with RCC occurs in 4% to 10% of patients with RCC. IVC tumor thrombus should be suspected in patients with a renal tumor who also have lower extremity edema, isolated right-sided varicocele or one that does not collapse with recumbency, dilated superficial abdominal veins, proteinuria, pulmonary embolism, right atrial mass, or nonfunction of the involved kidney. **Staging of the level of IVC thrombus is as follows: I, adjacent to the ostium of the renal vein; II, extending up to the lower aspect of the liver and below the hepatic veins; III, involving the intrahepatic portion of the IVC but below the diaphragm; and IV, extending above the diaphragm.** The IVC thrombus level is distinct from the AJCC TNM staging, which distinguishes tumors with thrombi above the diaphragm (stage T3c) from those with IVC thrombi below the diaphragm (stage T3b) and those with thrombi only within the renal vein or its major branches (stage T3a) (Amin et al., 2017). Consequently, the prognostic significance of IVC thrombus level is controversial. However, two large, multicenter retrospective cohort studies confirm tumor thrombus level as an independent predictor of survival and recurrence. The largest cohort of IVC thrombi, composed of 11 international sites and 1215 patients, demonstrates tumor thrombus level as an independent predictor of survival (Martinez-Salamanca et al., 2011). A second cohort of 636 patients from five American centers also confirms tumor thrombus level as a significant predictor of recurrence (Abel et al., 2017).

Microscopic invasion of the wall of the IVC is also a strong predictor of cancer-specific survival (Abel et al., 2017; Rodriguez Faba et al., 2017), with other studies reporting nodal or metastatic involvement, tumor grade, non–clear cell histology, preoperative anemia, and body mass index as predictors of oncologic outcomes (Abel et al., 2014; Blute et al., 2004b; Terakawa et al., 2007). **In all series, a significant proportion of patients with level IV IVC thrombi are cured with surgical resection, typically in the absence of metastases and other adverse features** (Ciancio et al., 2007; Glazer and Novick, 1996; Granberg et al., 2008; Libertino et al., 1987). Along with contemporary systemic therapies, overall survival can reach 40% at 5 years (Dashkevich et al., 2016).

The importance of high-quality preoperative imaging cannot be overemphasized, and imaging should be obtained as close as possible to the date of surgery as progression of the tumor thrombus may mandate important changes in intraoperative management (Blute et al., 2004b; Wotkowicz et al., 2008). MRI, CT, and echocardiography are useful adjuncts in the pre- and perioperative planning settings. **MRI is the preferred diagnostic study at many centers** (Goldfarb et al., 1990; Pouliot et al., 2010); **however, recent literature indicates that an appropriately performed CT can provide essentially equivalent information** (Fig. 97.23; Guzzo et al., 2009; Ng et al., 2008). Administration of contrast during the study often allows tumor thrombus to be differentiated from bland thrombus because the latter does not demonstrate enhancement.

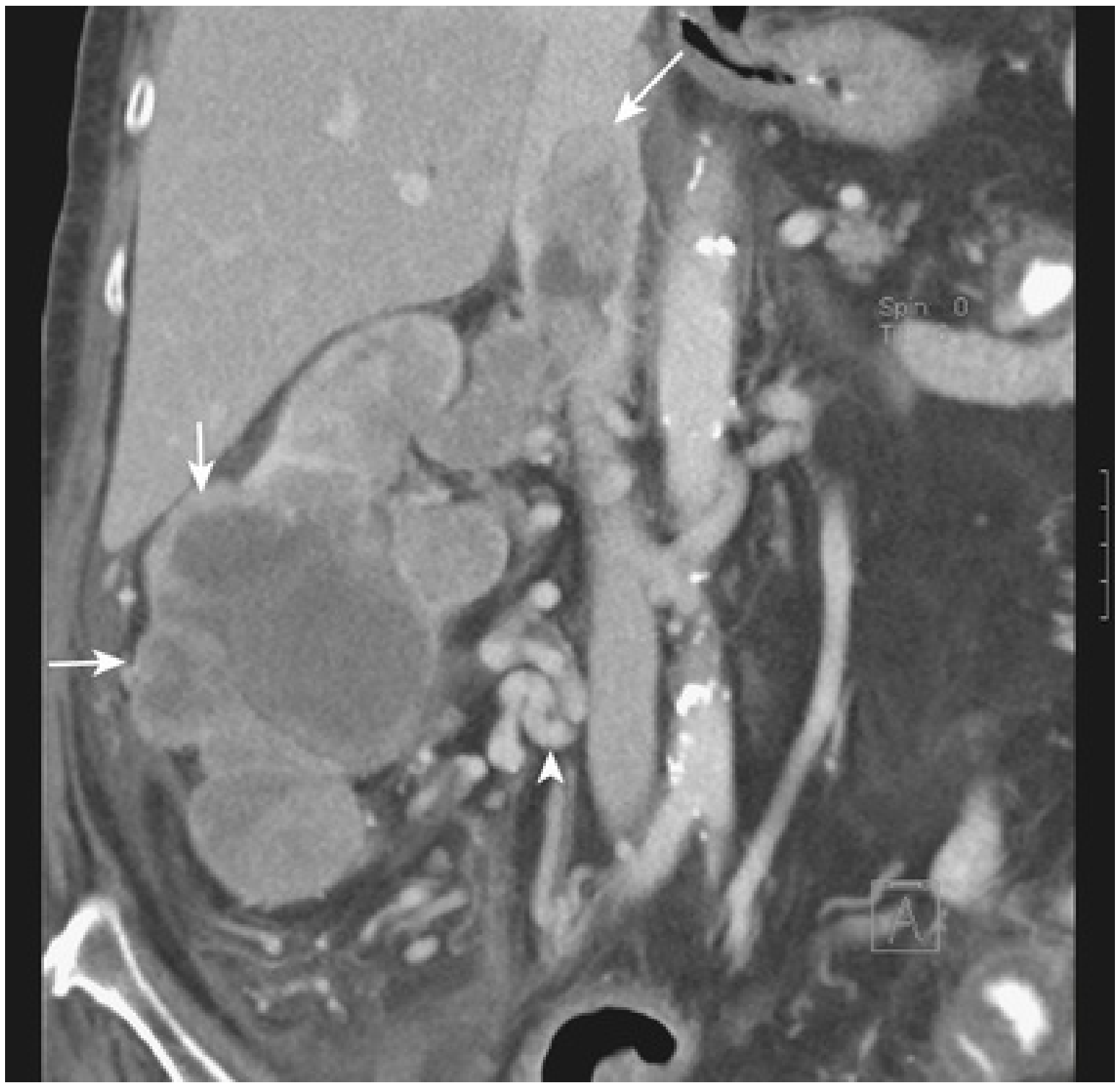

FIG. 97.23 Computed tomography demonstrating right lower pole renal cell carcinoma *(short arrows)* with level III inferior vena cava (IVC) thrombus. The *long arrow* indicates the upper extent of the tumor thrombus within the intrahepatic portion of the IVC. The *arrowhead* indicates extensive retroperitoneal venous collateral vessels associated with restricted flow within the IVC.

Invasive contrast-enhanced imaging, such as venacavography, is rarely used and reserved for patients in whom MRI and CT findings are equivocal or for whom MRI and CT are contraindicated. Interestingly, vascularization of IVC tumor thrombus is observed in 35% to 40% of cases. Preoperative **renal artery embolization** is not essential nor recommended for the routine management of IVC thrombi because there are little or no measurable objective benefits (e.g., blood loss, complications) in the literature; current data suggest an increased risk of major complications and mortality (Subramanian et al., 2009). In patients with extensive level III or IV thrombi, when adjunctive cardiopulmonary bypass with deep hypothermic circulatory arrest is considered, **preoperative coronary angiography** identifies patients who may benefit from revascularization at the time of bypass (Novick et al., 1990). **Intraoperative echocardiography** can be a valuable adjunct in the operating room to evaluate thrombus extent, monitor embolic phenomenon and cardiac function, and recognize residual tumor during and after resection (Cywinski and O'Hara, 2009; Glazer and Novick, 1997; Kostibas et al., 2017; Shuch et al., 2009; Wotkowicz et al., 2008).

The surgical approach is tailored to the level of IVC thrombus but uniformly begins with early ligation of the arterial blood supply, and in the process the kidney is gently mobilized, leaving it only attached via the renal vein (Blute et al., 2004b; Gorin et al., 2012; Shuch et al., 2009). An alternate strategy whereby the IVC thrombus is addressed before mobilization of the kidney can be considered and may reduce the risk of tumor embolism.

In general, level I thrombi are isolated by a Satinsky clamp or vascular stapler (Fig. 97.24A). Care to preserve at least 50% of the lumen of the IVC is essential to prevent downstream vascular complications related to reduced blood flow, and patch grafts should be considered when appropriate (Armstrong et al., 2014; Hyams et al., 2011). Level II thrombi require sequential clamping of the caudal IVC, contralateral renal vasculature, and cephalad IVC along with mobilization of the relevant segment of the IVC and occlusion of lumbar veins. The renal ostium is then opened and the thrombus is removed, all in a bloodless field (Fig. 97.24B). When tumor thrombus invades the wall of the vena cava, aggressive resection of the involved cava and attainment of negative surgical margins are required to minimize the risk of recurrence (Blute et al., 2007; Wotkowicz et al., 2008). IVC grafting or reconstitution is required in some instances, but patients with a completely occluded IVC may not need reconstruction because of established, collateral blood flow (Blute et al., 2007; Hyams et al., 2011; Sarkar et al., 1998). Attempts to remove distal bland thrombus within the IVC or iliac vessels are reasonable, although bland thrombus may be left in situ when resection places the patient at undue risk of complications. When left in situ, ligation of the IVC cephalad to this level or placement of a filter should be considered to prevent pulmonary embolism.

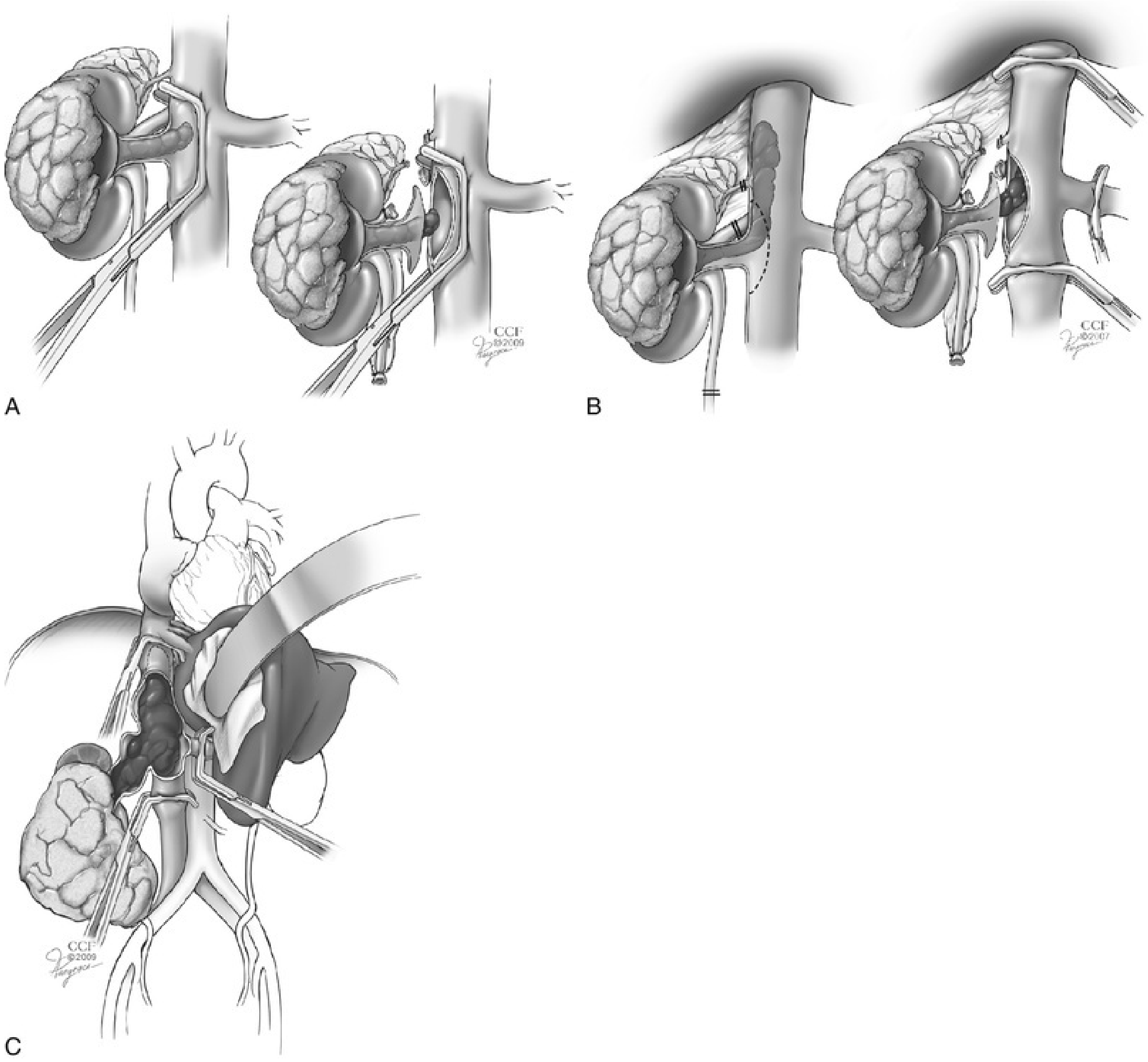

FIG. 97.24 Schematics illustrating surgical techniques for management of inferior vena cava (IVC) thrombi according to level. (A) Level I IVC thrombus managed with a Satinsky clamp to achieve vascular isolation. (B) Level II IVC thrombus managed by sequential clamping of the lower IVC, contralateral renal vein, and cephalad IVC, along with mobilization of the IVC and occlusion of lumbar veins, allowing for vascular isolation. (C) Level III IVC thrombus managed by mobilization of the liver, providing exposure of the intrahepatic IVC and retraction of the thrombus to facilitate placement of the upper IVC clamp just below the level of the hepatic veins.

Through this approach vascular isolation is achieved in a manner similar to that in B. If the cephalad clamp must be placed above the level of the hepatic veins, a Pringle maneuver should be performed to temporarily occlude the hepatic blood flow. (Reprinted with permission, Cleveland Clinic Center for Medical Art and Photography, Copyright 2007-2009. All Rights Reserved.)

Vascular control for level III and level IV IVC thrombi requires more extensive dissection, venovenous bypass, or cardiopulmonary bypass and hypothermic circulatory arrest. For level III thrombi, mobilization of the liver and exposure of the intrahepatic IVC often allows the thrombus to be mobilized caudad to the hepatic veins, and venous isolation can then proceed as for a level II thrombus (Fig. 97.24C) (Gallucci et al., 2004). Alternatively, the IVC should be clamped above the liver and a Pringle maneuver performed to temporarily occlude the portal triad (Ciancio et al., 2007, 2011). Venovenous bypass is commonly used in these cases but may not be required if adequate collateral flow is present. Level IV IVC thrombi have traditionally been managed with cardiopulmonary bypass and hypothermic circulatory arrest, and this is still the preferred approach in complex cases (Blute et al., 2007; Chen et al., 2015b; Gaudino et al., 2016; Wotkowicz et al., 2008). However, many centers are now trying to avoid hypothermic circulatory arrest because of the hypocoagulable state that ensues when coming “off pump,” and increased risk of cerebrovascular accident and myocardial infarction associated with this approach (Ciancio et al., 2011; Navia et al., 2012). If the thrombus is mobilized below the atrium, sequential vascular control can often be achieved without opening the heart (Chen et al., 2015b; Ciancio et al., 2010) or advanced veno-veno bypass techniques can be used to access the right atrium and cranial IVC (Gaudino et al., 2016). Further detail about these procedures are provided in Chapter 101.

The risk of morbidity can be substantial for thrombi extending above the diaphragm, and mortality rates associated with RN and IVC thrombectomy as high as 5% to 10% have been reported in some series, depending on patient comorbidities and tumor characteristics (Blute et al., 2004b; Ciancio et al., 2010; Navia et al., 2012). **Patient selection is critical as many patients, especially those with metastatic disease, will have a limited life expectancy** (Ciancio et al., 2010; Culp et al., 2010; Pouliot et al., 2010; Slaton et al., 1997). **However, surgery can impart a significant palliative benefit by preventing pulmonary emboli and minimizing disability from intractable edema, ascites, cardiac dysfunction, or associated local symptoms such as abdominal pain and**

hematuria.

Data regarding robot-assisted laparoscopic nephrectomy and IVC thrombectomy are emerging from a few centers around the world. Early data indicate that select patients with level I through III thrombi can undergo safe robotic surgery, although oncologic outcomes remain preliminary and more mature data is needed (Abaza, 2011; Ball et al., 2015b; Chopra et al., 2017).

Locally Invasive Renal Cell Carcinoma

Patients with locally advanced and invasive (stage T4) RCC are uncommon, accounting for less than 2% of surgical series, and usually experience pain, generally from invasion of the posterior abdominal wall, nerve roots, or paraspinous muscles (Karellas et al., 2009; Thompson et al., 2005a). Large tumors are more likely to metastasize than invade adjacent structures (Yezhelyev et al., 2009); only 40% of patients with suspected direct invasion are confirmed pathologically (Margulis et al., 2007a). A familiar scenario is the upper pole renal tumor that appears to be invading the liver, suggesting that partial hepatectomy may be required, yet on exploration the tissue planes are found to be intact. **In evaluation of patients with large, invasive retroperitoneal masses, a broad differential diagnosis should be considered, including adrenocortical carcinoma, urothelial carcinoma, sarcoma, and lymphoma, in addition to locally invasive RCC.**

Because surgical therapy is the only potentially curative management for RCC, extended operations with en bloc resection of adjacent organs are occasionally indicated. Complete excision of the tumor, including resection of the involved bowel, spleen, distal pancreas, or abdominal wall muscles, is the aim of therapy. Consequences of a complete resection of adjacent organs should be considered preoperatively, and careful perioperative management is essential including proper bowel preparation, vaccinations for splenectomized patients, and the need for endocrine replacement for patients with bilateral adrenal involvement.

However, even with an aggressive surgical approach, the prognosis remains poor. In 61 patients with pT4 RCC from MD Anderson Cancer Center, median cancer-specific survival was 37 and 8 months for patients with nonmetastatic and metastatic RCC, respectively (Borregales et al., 2016). Although negative surgical margins were achieved in 63% of patients in another series, 34 of 38 patients (90%) ultimately died of disease at a median of 12 months after surgery (Karellas et al., 2009). For these reasons, neoadjuvant systemic therapy is a valid consideration for patients with potentially unresectable RCC, because it can provide a “litmus test” to identify patients who are destined to progress rapidly (Rini et al., 2012).

Incomplete excision of a large primary tumor, or debulking, is rarely indicated because 1-year survival estimates are only 10% to 20% in this setting (Dekernion et al., 1978; Karellas et al., 2009). Given potential toxicity to adjacent bowel and limited efficacy in small case series (Cox et al., 1970; van der Werf-Messing, 1973), radiation therapy has traditionally played little role in the management of locally extensive RCC. Recent data with contemporary stereotactic radiation techniques are emerging and may alter some of these perspectives (Staehler et al., 2015).

Lymph Node Dissection for Renal Cell Carcinoma

The presence of lymph node metastasis is an important prognostic factor and defines a high-risk subset of patients with advanced RCC (Blute et al., 2004a). **Although lymphadenectomy for RCC provides accurate staging, the therapeutic benefits of routine lymphadenectomy are controversial.** Even in patients with radiographic adenopathy, only 30% to 43% of clinically enlarged lymph nodes contain metastatic disease (Capitanio et al., 2016; Ming et al., 2009; Studer et al., 1990). In a series of patients at high-risk of lymph node metastases, the rates of metastatic nodes were 20%, 29%, and 90% for nodes 7, 10 and 30 mm in size, respectively (Gershman et al., 2016). In addition to the relationship with nodal size, the prevalence of node-positive disease is also stage specific (Blute et al., 2004a; Capitanio et al., 2009; Pantuck et al., 2003; Whitson et al., 2011), and a number of well-recognized pathologic features are associated with lymph node metastases (Table 97.19). These findings were confirmed in a prospective study in which patients with two or more high-risk features were found to be at increased risk (greater than 40%) for nodal involvement (Blute et al., 2004a; Crispen et al., 2011). These features included (1) large primary tumor (>10 cm); (2) clinical stage T3/T4; (3) high tumor grade (grade 3/4); (4) sarcomatoid features; or (5) histologic tumor necrosis. Although these criteria will identify a significant proportion of patients with lymph node metastases, 45% will have positive nodes away from the renal hilum calling into question the extent and templates needed for accurate staging (Fig. 97.25; Crispen et al.,

2011).

TABLE 97.19

Risk of Regional Lymph Node Metastases in Renal Cell Carcinoma Based on Pathologic Risk Factors

NO. OF RISK FACTORS[a]	PERCENTAGE OF PATIENTS IN THIS RISK GROUP	PERCENTAGE WITH POSITIVE LYMPH NODES IN RETROSPECTIVE SERIES[b]	PERCENTAGE WITH POSITIVE LYMPH NODES IN PROSPECTIVE SERIES[c]
0	44% (729/1652)	0.4% (3/729)	—
1	18% (302/1652)	1.0% (3/302)	—
2	17% (276/1652)	4.4% (12/276)	20% (7/35)
3	13% (209/1652)	12% (26/209)	37% (26/71)
4	7.3% (121/1652)	13% (16/121)	49% (26/53)
5	0.9% (15/1652)	53% (8/15)	50% (5/10)

[a] Risk factors for regional lymph node metastases include: (1) large primary tumor (>10 cm); (2) clinical stage T3/T4; (3) high tumor grade (Fuhrman grade 3 or 4); (4) sarcomatoid features; or (5) histologic tumor necrosis.

[b] Data from (Blute et al., 2004b); lymph node dissection performed in 58% of 1652 patients overall.

[c] Data from (Crispen et al., 2011); lymph node dissection performed in 41% of 415 patients with 2+ risk factors.

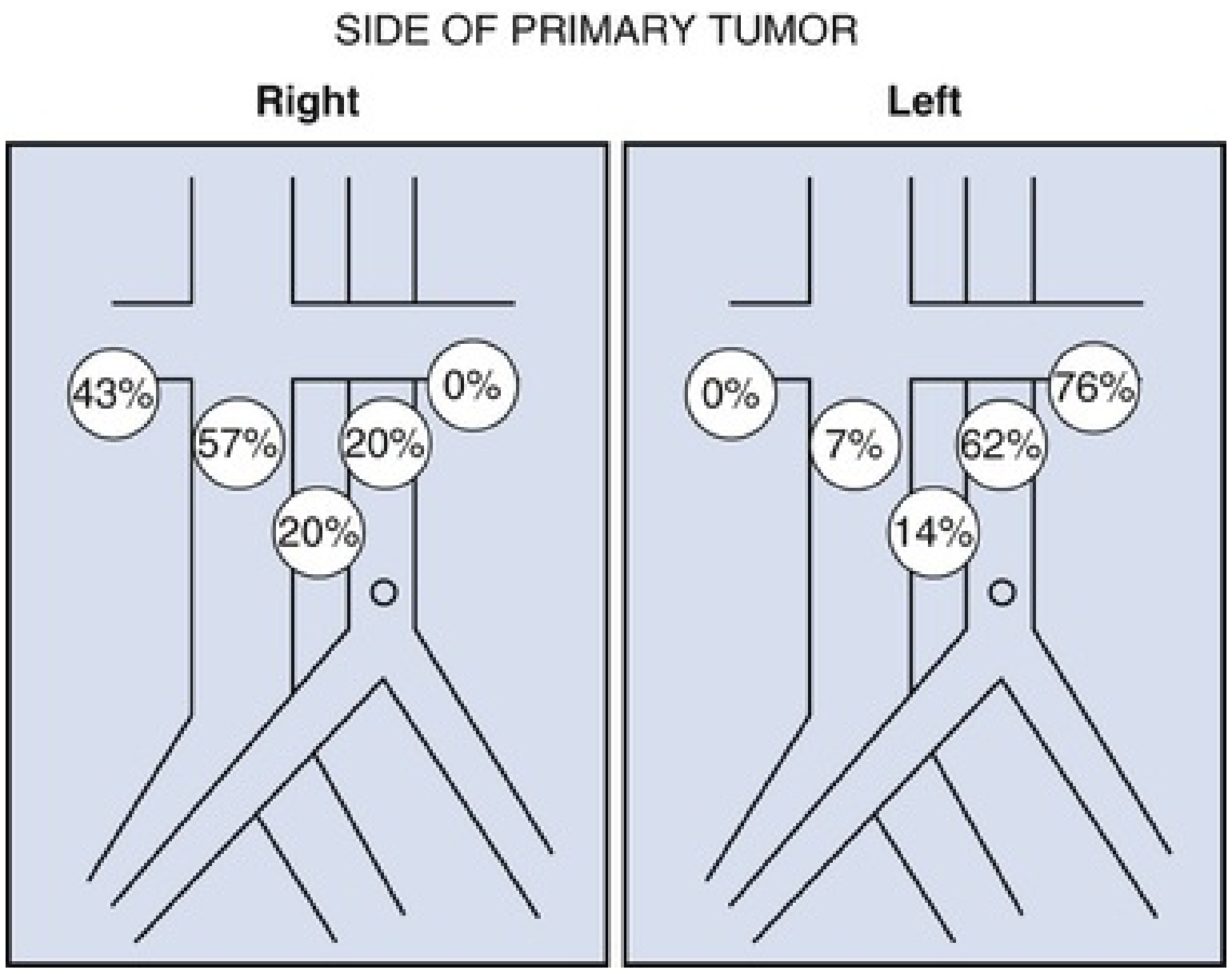

FIG. 97.25 Frequency of lymph node positivity detected at extended lymphadenectomy in patients with lymph node positive renal cancer at nephrectomy. (From Crispen PL, Breau RH, Allmer C, et al.: Lymph node dissection at the time of radical nephrectomy for high-risk clear cell renal cell carcinoma: indications and recommendations for surgical templates. *Eur Urol* 59:18–23, 2011.)

Most importantly, the EORTC 30881 randomized trial of lymphadenectomy at RN failed to show a survival advantage for most patients undergoing lymphadenectomy (Blom et al., 2009). This study has been criticized for being underpowered to detect a difference in survival because most patients were low risk for nodal metastasis (81% were grade 1 or 2 and 72% were organ confined); and lymph node metastases were present in only 4% of patients undergoing complete lymph node dissection. Contemporary, large retrospective analyses also fail to demonstrate a consistent oncologic benefit to routine lymphadenectomy. For instance, a large series from the Mayo Clinic of nearly 1800 patients failed to show a therapeutic benefit to lymphadenectomy in patients with nonmetastatic RCC, despite a comprehensive analysis that evaluated several intermediate and high-risk cohorts (Gershman et al., 2017b). However, a large, European study of 1983 patients suggested better cancer-specific survival in patients with large, bulky tumors and sarcomatoid features when a more extensive lymph node dissection was performed (Capitanio et al., 2014). In addition, rare patients with isolated lymph node metastases (analogous to isolated systemic metastases) may experience a durable survival with resection to cancer-free status (Gershman et al., 2017b). Therefore **lymphadenectomy may be performed in patients with clinically suspicious (radiographic or intraoperative) lymphadenopathy for staging purposes and, because of lack of data indicating a reliable therapeutic benefit, need not be performed routinely in patients with localized kidney cancer and clinically negative nodes.**

Local Recurrence After Radical Nephrectomy or Nephron-Sparing Surgery

Local recurrences of RCC can occur after RN and nephron-sparing surgery and present unique challenges. **Local recurrence of RCC after RN, which includes recurrence in the renal fossa, ipsilateral adrenal gland, renal vein stump or adjacent IVC, or ipsilateral retroperitoneal lymph nodes, is an uncommon**

event, occurring in 2% to 4% of cases (Margulis et al., 2009). **Risk factors include locally advanced or node-positive disease and adverse histopathologic features** (Esrig et al., 1992; Levy et al., 1998; Sandock et al., 1995). In contrast, local recurrence after RN is rare in patients with organ-confined RCC. **Only about 20% to 40% of local recurrences are isolated; the majority of patients with local recurrence also have systemic disease, and a thorough metastatic evaluation should be pursued** (Eggener et al., 2008; Schrodter et al., 2002).

Surgical resection of isolated local recurrence of RCC after RN should be considered, because it can provide long-term cancer-free status for 30% to 40% of patients (Bandi et al., 2008; Margulis et al., 2009; Master et al., 2005; Yohannan et al., 2010)**. Complete resection of abdominal recurrence is often a formidable task because the natural tissue barriers are no longer present** and invasion of contiguous organs is common. En bloc resection of adjacent organs is often required, and the risk of morbidity can be substantial (Eggener et al., 2008; Gogus et al., 2003; Margulis et al., 2009). Margulis et al. (2009) reported on 54 patients with local recurrence after nephrectomy managed by surgical resection, 69% of whom also received adjunctive systemic therapy. Risk factors associated with cancer-specific death after resection included recurrent tumor size, sarcomatoid features in the recurrence specimen, positive surgical margins, abnormal alkaline phosphatase, and increased lactate dehydrogenase. Patients with 0, 1, and greater than 1 adverse risk features demonstrated cancer-specific survival times of 111, 40, and 8 months, respectively. Intraoperative radiation has not been found to impart an oncologic benefit (Master et al., 2005), but radiation therapy may be of value for palliation of symptomatic local recurrence in patients who are not operative candidates.

Local recurrence in the remnant kidney after PN for RCC has been reported in 1.4% to 10% of patients, and the main risk factors are advanced T stage or high tumor grade (Campbell and Novick, 1994; Krambeck et al., 2008; Lane and Gill, 2007). Historically, positive surgical margins associated with PN were thought to have little impact on recurrence rates and cancer-specific survival (Bansal et al., 2017; Kutikov et al., 2008; Kwon et al., 2007; Yossepowitch et al., 2008;). However, recent data indicate that positive surgical margins, especially in patients with high-grade or high-stage disease may portend worse recurrence-free and metastases-free survival (Khalifeh et al., 2013; Shah et al., 2016b). This phenomenon may reflect expanding indications for PN or evolution of surgical technique to maximize functional renal parenchyma (Kutikov et al., 2008). Most patients with a positive surgical margin are managed with close surveillance rather than reflex completion nephrectomy, although the latter may occasionally be a valid consideration if the margins are grossly involved and the contralateral kidney is cancer-free and functioning well. **Patients with isolated local recurrence after PN can be considered for repeat PN, completion nephrectomy, TA, or AS** (Berger et al., 2009; Bratslavsky et al., 2008; Johnson et al., 2008; Magera et al., 2008a).

As a surgical management strategy, TA carries the highest risk of persistence or local recurrence following a single treatment (Pierorazio et al., 2016a). However, most local recurrences after TA can be salvaged with repeat TA, and there are no differences in metastatic recurrence rates or cancer-specific survival when compared with other treatment pathways, presuming reasonable patient selection. Reported incidences of local recurrence or persistence range between 3% and 10% for cryoablation and between 5% and 20% for RFA (Kunkle and Uzzo, 2008; Levinson et al., 2008; Weight et al., 2008). Management options are similar to those for recurrence after PN, with the caveat that salvage surgery in this setting is often challenging because of the dense inflammatory reaction induced by TA (Kowalczyk et al., 2009; Nguyen et al., 2008).

Neoadjuvant and Adjuvant Therapy for Renal Cell Carcinoma

Unfortunately, recurrence develops in a significant proportion of patients thought to be rendered disease free after surgical resection, primarily because of occult micrometastatic disease. Although postsurgical recurrence is not common in patients with low-stage, organ-confined disease, locally advanced RCC and RCC with other adverse histopathologic features carry a significant risk of recurrence. Various predictive tools can assist in the assessment of the risk in individual patients (Kim et al., 2012), although in general, **distant metastases develop in 20% to 35% and local recurrence in 2% to 5% of patients** (Lane and Kattan, 2008). In view of these findings, **a strong rationale for systemic adjuvant therapy exists in high-risk patients.**

Key Points: Treatment of Local Recurrence and Adjuvant Therapy for Renal Cell Carcinoma

- Isolated local recurrence after RN occurs in 2% to 4% of patients, and a thorough metastatic evaluation should be pursued. If this evaluation is negative, surgical excision should be considered, although en bloc resection of adjacent organs may be required because of obliteration of tissue planes.
- Local recurrence after PN is more common at sites distant from the tumor bed and can be managed by repeat PN, completion nephrectomy, TA, or AS.
- Local recurrence after TA often reflects incomplete tumor eradication; management options include repeat TA, AS, or salvage surgery.
- Despite a significant likelihood of recurrence of RCC with poor-risk features, there is no established evidence of a benefit for adjuvant therapy in patients who appear to be cancer-free after surgical resection, and observation remains the standard of care.
- Ongoing adjuvant clinical trials investigating targeted molecular agents, checkpoint inhibitors, and other novel systemic approaches should be supported in an effort to identify an efficacious adjuvant strategy.

Historically, randomized trials of adjuvant therapy failed to demonstrate any survival benefit using a variety of agents including IL-2 (Clark et al., 2003), interferon alpha (Messing et al., 2003; Pizzocaro et al., 2001), medroxyprogesterone acetate (Pizzocaro et al., 1987), and radiation therapy (van der Werf-Messing, 1973). Autologous tumor vaccine–based approaches have also been used to immunize RCC patients in the postoperative setting, again with essentially negative results (Galligioni et al., 1996; Jocham et al., 2004; Wood et al., 2008). The ARISER adjuvant trial investigated girentuximab, a chimeric monoclonal antibody directed against G250, a cell surface antigen expressed by the majority of clear cell RCC; and in 2012, the interim analysis showed no improvement in median disease-free survival and the trial was terminated (Chamie et al., 2017).

The emergence of targeted molecular agents and subsequent responses in metastatic disease led to great enthusiasm for new adjuvant trials in high-risk populations. By 2012 six ongoing adjuvant trials were enrolling worldwide, and, as of early 2019, four had been reported (Table 97.20). The double-blind, phase 3 ASSURE trial reported outcomes for 1934 patients with nonmetastatic, pT1b (high-grade), pT2-4 or N1 RCC randomized to sunitinib, sorafenib, or placebo and failed to demonstrate a recurrence-free survival benefit at 6 years (Haas et al., 2016). Importantly, 45% of patients discontinued therapy because of toxicity. The phase 3 PROTECT trial randomized 1538 patients with pT2 (high grade) or at least pT3, including N1, clear cell RCC to pazopanib versus placebo and demonstrated no benefit in disease-free survival (Motzer et al., 2017a). The phase 3 S-TRAC randomized 615 men with pT2 (high-grade), pT3-4 or N1 clear cell RCC to subitinib or placebo (Ravaud et al., 2016). S-TRAC reported a significantly longer disease-free survival in the sunitinib group (6.8 versus 5.6 years) compared with placebo. ATLAS randomized patients to 3 years of axitinib versus placebo and failed to demonstrate an advantage for disease-free survival (Gross-Goupil et al., 2018). Difference in risk profiles of the enrolled patients, average doses of TKI received in the treatment arms, and restriction to clear cell–only patients in some of the trials may account for the observed differences in outcomes. However, in all of these trials patients receiving therapy experienced significantly higher rates of adverse events and there were no differences in overall survival. **Given these results, none of the adjuvant studies in this field is convincingly positive, and the standard of care remains observation if the patient will not consider an adjuvant trial** (Haas and Uzzo, 2018; Ridyard et al., 2019; Sun et al., 2018). More recent trials are testing immunologic modulators, such as check point inhibitors, in the adjuvant setting as the search for an efficacious adjuvant strategy continues (see Table 97.20). Please refer to Chapter 104 for a more detailed discussion of these protocols and their rationale for patients with advanced RCC.

TABLE 97.20

Ongoing or Recently Completed Clinical Trials of Adjuvant Treatment for Renal Cell Carcinoma (RCC)

TRIAL	STUDY GROUPS	TREATMENT DURATION (NO. PATIENTS)	INCLUSION CRITERIA	RESULTS
TARGETED MOLECULAR AGENTS				
Adjuvant Sorafenib or Sunitinib for Unfavorable Renal Cell Carcinoma	Sunitinib vs. sorafenib vs. placebo	1 year (1943 patients)	Clear cell and non–clear cell RCC eligible Stage T2–T4 or stage T1b and G3–G4, or N1 if	No difference in disease-free or overall survival at 6 years; 45% of patients in

(ASSURE) (Haas et al., 2016)			complete dissection performed	treatment arms discontinued therapy because of toxicity leading to early discontinuation of trial
Sorafenib for Patients with Resected Primary Renal Cell Carcinoma (SORCE)	Sorafenib (for 1 or 3 years) vs. placebo	3 years (1711 patients)	Clear cell and non–clear cell RCC eligible Mayo Clinic progression score 3–11	Completed enrollment 2012; awaiting results
Sunitinib vs. Placebo for the Treatment of Patients at High Risk for Recurrent Renal Cell Cancer (S-TRAC) (Ravaud et al., 2016)	Sunitinib vs. placebo	1 year (615 patients)	Predominant clear cell histology eligible High-risk RCC according to UISS[a]	Significantly longer disease-free survival in sunitinib group (6.8 versus 5.6 years; $P = 0.03$) with higher rate of toxic events; no difference in overall survival
Everolimus for Renal Cancer Ensuing Surgical Therapy (EVEREST)	Everolimus vs. placebo	1 year (1545 patients)	Clear cell and non–clear cell RCC eligible Stage T2–T4 or stage T1b and G3–G4, or N1 if complete dissection performed	Estimated study completion, 2021
Adjuvant Axitinib Treatment of Renal Cancer (ATLAS)	Axitinib vs. placebo	3 years (700 patients)	Clear cell predominant (>50%) eligible pT2 and G3–G4, or pT3a and	No difference in disease-specific or overall survival

			> 4 cm, or pT3b/pT3c/pT4, or N1	
Pazopanib as an Adjuvant Treatment for Locally Advanced Renal Cell Carcinoma (PROTECT) (Motzer et al., 2017a)	Pazopanib vs. placebo	1 year (1538 patients)	Clear cell predominant (>50%) eligible pT2 and G3–G4, pT3, pT4, or N1	No benefit in disease-free survival or overall survival
IMMUNOMODULATORY CHECKPOINT INHIBITORS				
A Phase 3 Randomized Study Comparing Perioperative Nivolumab vs. Observation in Patients With Localized Renal Cell Carcinoma Undergoing Nephrectomy (PROSPER RCC)	Neoadjuvant nivolumab for 1 month, followed by nephrectomy, followed by adjuvant nivolumab for 9 months vs. nephrectomy alone; no placebo group	10 months (766 patients)	Up to 15% non–clear cell component; pT2–4, NX, M0; pT any, N1–N2, M0; all grades included	Estimated study completion, 2022
A Study of Atezolizumab as Adjuvant Therapy in Participants With Renal Cell Carcinoma (RCC) at High Risk of Developing Metastasis Following Nephrectomy (IMmotion010)	Adjuvant atezolizumab vs. placebo	1 year (664 patients)	Clear cell, or non–clear cell with sarcomatoid component; pT2, NX, M0, grade 4; pT3a, NX, M0, grade 3–4; pT3b/c, NX, M0, any grade; pT any, N+, M0, any grade; fully resected M1 disease; selected patients	Estimated study completion, 2024

[a]UISS: UCLA Integrated Staging System (Zisman et al., 2002).

Data from Haas NB, Manola J, Uzzo RG, et al.: Adjuvant sunitinib or sorafenib for high-risk, non-metastatic renal-cell carcinoma (ECOG-ACRIN E2805): a double-blind, placebo-controlled, randomised, phase 3 trial. *Lancet* 387(10032):2008–2016, 2016; Motzer RJ, Haas NB, Donskov F, et al.: Randomized Phase III trial of adjuvant pazopanib versus placebo after nephrectomy in patients with localized or locally advanced renal cell carcinoma. *J Clin Oncol* Jco2017735324, 2017a; Ravaud A, Motzer RJ, Pandha HS, et al.: Adjuvant sunitinib in high-risk renal-cell carcinoma after nephrectomy. *New Engl J Med* 375(23):2246–2254, 2016; Zisman A, Pantuck AJ, Wieder J, et al.: Risk group assessment and clinical outcome algorithm to predict the natural history of patients with surgically resected renal cell carcinoma. *J Clin Oncol* 20(23):4559–4566, 2002.

Neoadjuvant therapy, with either VEGF-targeted agents or checkpoint inhibitors, represents a new and promising treatment paradigm with the potential advantages of tumor cytoreduction and eradication of micrometastatic disease. Emerging data from phase 2 studies using pazopanib, sunitinib, sorafenib, or axitinib indicate consistent primary tumor size reduction with average volume reductions of 10% to 31% (Bindayi et al., 2018). In patients with imperative indications for nephron-sparing but in whom surgery is felt to be unsafe, unfeasible, or not optimized, neoadjuvant therapy may facilitate tumor resection (Rini et al., 2015). Further prospective investigation is needed before oncologic outcomes can be evaluated. Six ongoing, early phase neoadjuvant therapy trials are investigating checkpoint inhibitors or other immunomodulatory compounds (Bindayi et al., 2018).

Other Malignant Renal Tumors

Sarcomas of the Kidney

Sarcomas represent 1% to 2% of all malignant renal tumors in adults, with a peak incidence in the fifth decade of life (Miller et al., 2010a; Vogelzang et al., 1993). Renal sarcoma is less common but more lethal than sarcoma of any other genitourinary site, including the prostate, bladder, and paratesticular region (Russo et al., 1992). **Differentiation of renal sarcoma from sarcomatoid RCC is often difficult based on clinical presentation, radiographic findings, and, in some cases, pathologic analysis.** Identification of any features of the various subtypes of RCC excludes the diagnosis of primary renal sarcoma. The common signs and symptoms associated with renal sarcoma in adults include palpable mass, abdominal or flank pain, and hematuria and are similar to those seen with large, rapidly growing RCC (Economou et al., 1987). Specific findings suggestive of sarcoma rather than RCC include apparent origin from the capsule or perisinuous region, growth to large size in the absence of lymphadenopathy, presence of fat or bone suggestive of liposarcoma or osteosarcoma, and hypovascular pattern, although one notable exception is the hemangiopericytoma, which is highly vascular (Shirkhoda and Lewis, 1987). Renal sarcoma should be suspected in any of these circumstances or in any patient with a very large or rapidly growing renal mass (Table 97.21).

TABLE 97.21

Characteristics of Other Malignant Renal Tumors

TUMOR TYPE	CHARACTERISTICS	MANAGEMENT
Sarcomas	Leiomyosarcoma most common Typically hypovascular Often rapidly growing and occasionally appear to be derived from the renal capsule	Wide local excision with confirmation of negative margins
Renal lymphoma and leukemia	Multiple radiographic patterns described Typically hypovascular Suspect in patients with massive	Biopsy should be considered Extirpative surgery should be avoided

	retroperitoneal lymphadenopathy or lymphadenopathy in other regions of the body or atypical locations	Typically managed with chemotherapy and/or radiation therapy
Metastatic tumors	Most common sources include lung, breast, and gastrointestinal cancers, malignant melanoma, and hematologic malignancies Typically hypovascular and multifocal	Biopsy should be strongly considered Typically managed with systemic therapy or palliative care
Carcinoid	Typically hypovascular May present with carcinoid syndrome Derived from neuroendocrine cells	Surgical excision
Small cell carcinoma of the kidney	Neuroendocrine derivation Typically hypovascular Most locally advanced or metastatic	Multimodal therapy with surgery and platinum-based chemotherapy
Primitive neuroectodermal tumor	Derived from primitive neural crest cells Hypovascular pattern typical Poor prognosis	Multimodal therapy
Wilms tumor	Heterogeneous solid renal mass on computed tomography More common in children, but occasionally seen in adults	Multimodal therapy analogous to treatment protocols for pediatric Wilms tumor

Sarcomas of the kidney, like sarcomas of any other site, are derived from mesenchymal components and are thus free of many of the natural barriers to dissemination that confine other tumor types (Russo et al., 1992)**. These tumors are typically surrounded by a pseudocapsule that is often infiltrated with cancer cells,** which can extend for some distance into the surrounding tissues. In many cases this cannot be recognized macroscopically, although it is often manifested in the form of local recurrences, which are common after surgical extirpation, even when wide excision has been performed. **High-grade sarcomas often metastasize, with the lungs being a primary site of spread, and prognosis is poor; some patients die of disease progression in a matter of months. Low-grade sarcomas tend to pursue a more indolent course,** although local recurrences often require repeat resection to prolong survival and minimize morbidity.

In general, the most important prognostic factors for sarcomas are margin status and tumor grade. The initial resection is the key event

because this is the best chance for a long-term cure. For renal sarcomas this often mandates RN along with en bloc excision of adjacent organs (Brescia et al., 2008; Dotan et al., 2006; Wang et al., 2011). MRI can be useful for preoperative planning by defining tissue planes and proximity to vital structures. This is primarily a surgical disease, and wide excision is the goal with intraoperative monitoring of margin status. Chemotherapeutic agents traditionally used against metastatic sarcomas included doxycycline and ifosfamide, and more recently gemcitabine and docetaxel have been explored. Tyrosine kinase inhibitors and other novel approaches are also being investigated for soft tissue sarcomas, but even in the best of circumstances response rates are disappointing (Antman et al., 1993; Frezza et al., 2017; Miller et al., 2010b; Ratan and Patel, 2016; Ravi et al., 2015).

The combination of radiation therapy and chemotherapy, which has an established role in the adjuvant setting for the management of sarcomas of the extremity, has not been as effective for renal or retroperitoneal sarcomas (Russo et al., 1992; Shah et al., 2016; Wortman et al., 2016). Recent data indicate that preoperative radiation therapy may reduce the incidence of positive margins (Shah et al., 2016; Wortman et al., 2016), which is particularly important in a disease state where administration of postoperative radiation is anatomically challenging. Intraoperative radiation has demonstrated some benefit for renal and retroperitoneal sarcomas with minimal additional morbidity (Abdelfatah et al., 2017). At present, the role of such adjuvant approaches for the management of renal sarcomas is not well defined, although a multimodal approach is often pursued if performance status allows, given the poor prognosis.

The largest single-institution series of renal sarcomas include only 15 to 41 cases and represent a composite experience extending for a period of several years (Shirkhoda and Lewis, 1987; Wang et al., 2011). In all such series, leiomyosarcoma is the most common histologic subtype, and in many series, liposarcoma is the second most common entity. For retroperitoneal sarcomas, in contrast, the order is reversed with liposarcoma most common (Karakousis et al., 1995). All such series report a poor prognosis; the experience of Srinivas et al. (1984) at Memorial Sloan Kettering Cancer Center is representative. In this series of 16 patients with renal sarcomas, 15 underwent nephrectomy, often with en bloc excision of adjacent organs; 5 received adjuvant radiation therapy and chemotherapy without apparent benefit; and 13 died within 6 months after surgery.

Leiomyosarcoma accounts for 50% to 60% of renal sarcomas, and the cell of origin is the smooth muscle cell of the capsule or other perinephric structures (Fig. 97.26; Deyrup et al., 2004; Moudouni et al., 2001; Wang et al., 2011). Niceta et al. (1974) identified 66 cases of renal leiomyosarcoma in the literature and reported a female predominance with most patients diagnosed in the fourth through sixth decades of life. Renal leiomyosarcoma, like other renal sarcomas, tends to displace rather than invade the parenchyma and is characterized by rapid growth rate, frequent metastasis, and high local and systemic recurrence rates (Deyrup et al., 2004; Kendal, 2007). In the cases reviewed by Niceta et al. (1974), most patients were treated primarily with RN and died within 2 years. In the Mayo Clinic series, 14 of 15 patients with renal leiomyosarcoma died of disease progression within 4 months to 5½ years after surgery (Frank et al., 2000).

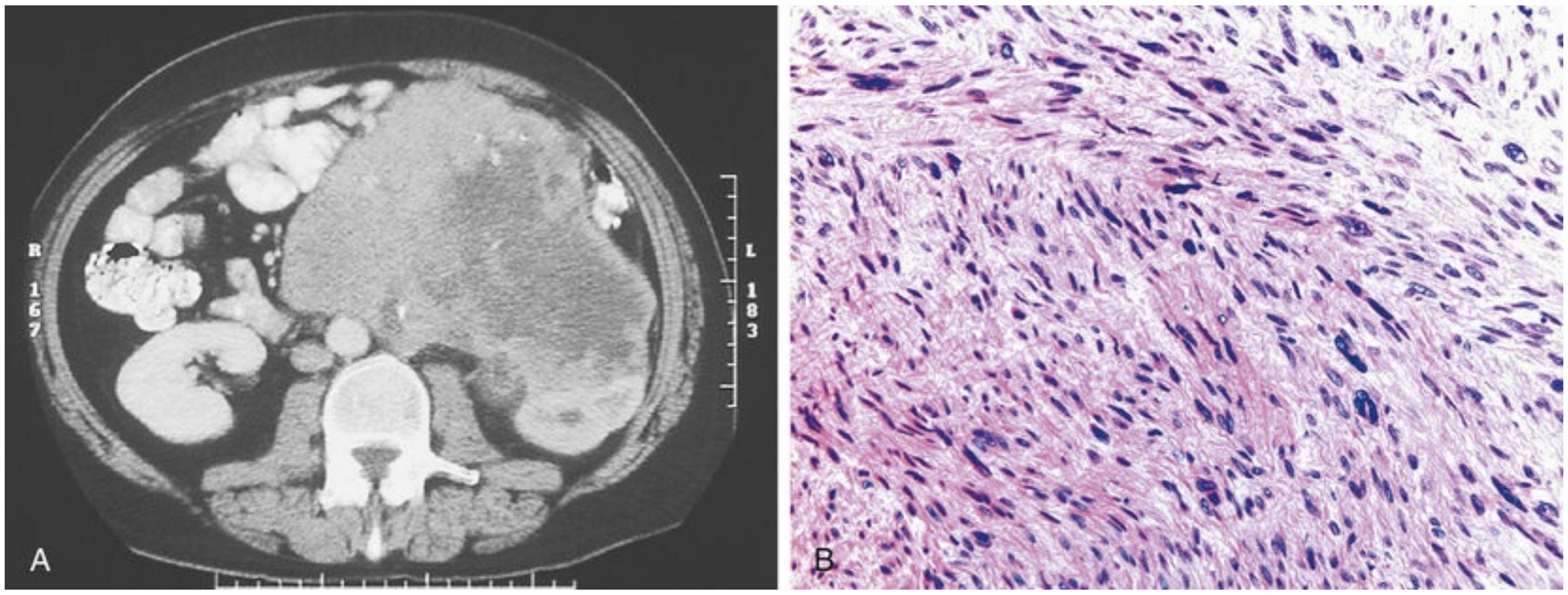

FIG. 97.26 (A) Computed tomography scan demonstrates a large leiomyosarcoma of the left kidney. (B) Microscopic features of leiomyosarcoma include spindle cells, blunt-ended nuclei, and eosinophilic cytoplasm. (Courtesy Dr. Michael McGuire, Evanston, IL and Dr. Ming Zhou, Cleveland, OH.)

Other than leiomyosarcoma, a wide variety of histologic subtypes have been described, and almost every conceivable type of sarcoma has been found in the kidney. **Liposarcoma** is readily distinguished from RCC because of the presence of adipose tissue but is often confused with AMLs or large, benign renal lipomas (Frank et al., 2000). Renal liposarcoma often grows to extremely large size. Response to radiation therapy and cisplatin-based chemotherapy in an adjuvant setting has been reported and should be considered in patients with high-grade disease or positive margins (Belldegrun and DeKernion, 1987).

Osteogenic sarcoma is a rare but distinctive form of renal sarcoma that contains calcium and is often rock hard (Leventis et al., 1997; Micolonghi et al., 1984). Extensive calcification in a large, hypovascular tumor should suggest the diagnosis. The appearance on plain films can mimic a staghorn calculus, but the readily evident mass effect should suggest xanthogranulomatous disease or, more rarely, osteogenic sarcoma. **Less common histologic subtypes include rhabdomyosarcoma, fibrosarcoma, malignant fibrous histiocytoma, and others** (see Table 97.1; Srigley et al., 2013). **Malignant hemangiopericytomas** are notable for their extensive vascularity (Brescia et al., 2008; Chaudhary et al., 2007). Preoperative angioembolization has been described and may simplify surgical excision (Smullens et al., 1982).

Renal Lymphoma and Leukemia

Renal involvement with hematologic malignancies, which include the lymphomas and leukemias, is common, found at autopsy in approximately 34% of patients dying of progressive lymphoma or leukemia. However, these processes are uncommonly seen in clinical practice because they are often silent and generally occur only as a late manifestation of systemic disease (McVary, 1991; Pollack et al., 1987). **The role of the urologist in the evaluation of renal lymphoma or leukemia is critical and can include differentiation from other renal malignant neoplasms, timely provision of a pathologic diagnosis, and preservation of renal function** (McVary, 1991).

Renal involvement is more common with non-Hodgkin lymphoma than with Hodgkin disease, and, as with most other forms of extranodal non-Hodgkin lymphoma, histologically diffuse forms predominate over nodular forms (O'Riordan et al., 2001; Pollack et al., 1987). Primary renal lymphoma is rare, with only a few well-documented case reports in the literature (Ahmad et al., 2005; Garcia et al., 2007; Pollack et al., 1987). This is not surprising given the relative paucity of lymphoid tissue in the normal renal parenchyma. Hematogenous dissemination of lymphoma to the kidney is most common and is thought to occur in 90% of cases; direct extension from retroperitoneal lymph nodes accounts for the remainder. Hartman et al. (1982) have shown that the most common pattern of renal involvement consists of multiple small malignant lymphoid nodules interlaced between the individual nephrons. Eventually, these nodules become confluent, forming radiographically detectable masses. At the extreme, they can replace the entire parenchyma, leading to renal failure.

CT scan is the radiographic modality of choice for the diagnosis of renal

lymphoma and for monitoring response to therapy, although MRI can be used in patients with renal insufficiency, contrast medium allergy, or in children and young adults in whom lifelong radiation exposure is a consideration (Pollack et al., 1987; Urban and Fishman, 2000). The common radiographic patterns associated with renal lymphoma include multiple distinct renal masses; as a solitary renal mass, which can be difficult to differentiate from RCC; as diffuse renal infiltration; or as direct invasion of the kidney from enlarged retroperitoneal nodes (Ganeshan et al., 2013; Heiken et al., 1983; Sheth et al., 2006; Table 97.22). **Renal lymphoma should be suspected in patients with massive retroperitoneal lymphadenopathy, splenomegaly, or lymphadenopathy in other regions of the body or atypical regions within the retroperitoneum.** Relative to this, the main lymphatic landing zones for RCC should be kept in mind—the interaortocaval region for right RCC and para-aortic region for left RCC—and lymphadenopathy centered outside of these areas should raise suspicion for lymphoma. Any patient with a prior history of lymphoma and a renal mass should also be evaluated for renal recurrence rather than for RCC. In general, lymphomas are more common in patients with iatrogenic immune suppression, acquired immunodeficiency syndrome, autoimmune diseases, or graft-versus-host disease, and a history of radiation therapy (McVary, 1991). These clinical associations may also increase the index of suspicion about a diagnosis of systemic lymphoma.

TABLE 97.22

Computed Tomographic Findings Associated With Renal Lymphoma

FINDING	INCIDENCE (%)
Multiple renal masses	45
Solitary renal mass	15
Renal invasion from enlarged retroperitoneal lymph nodes	25
Diffuse renal involvement	10
Predominantly perinephric involvement	5

Data from Heiken JP, Gold RP, Schnur MJ, et al.: Computed tomography of renal lymphoma with ultrasound correlation. *J Comput Assist Tomogr* 7(2):245–250, 1983; Pollack HM, Banner MP, Amendola MA: Other malignant neoplasms of the renal parenchyma. *Semin Roentgenol* 22(4):260–274, 1987.

Renal involvement related to leukemia is more common in children, paralleling the demographics of the disease, and is more commonly due to lymphocytic leukemia than the myelogenous forms (Pollack et al., 1987).

Leukemia typically involves the kidney in a diffusely infiltrative pattern and most often represents a late manifestation of systemic disease.

If lymphoma or leukemic renal involvement is suspected, consideration should be given to percutaneous biopsy or aspiration to obtain a pathologic diagnosis (Ganeshan et al., 2013; Herts, 2012); if exploratory surgery is necessary, intraoperative biopsy and frozen-section analysis should take priority. **Extirpative surgery should be avoided if renal lymphoma and leukemia are suspected because the primary treatment of these processes is systemic chemotherapy with or without radiation therapy** (McVary, 1991). The classic chemotherapy regimen for non-Hodgkin lymphoma is the CHOP protocol, which includes cyclophosphamide, doxorubicin, vincristine, and prednisolone (Colevas et al., 2000). Recent reports suggest that adding rituximab to the CHOP protocol ("R-CHOP") may improve short-term renal function and long-term survival. Nephrectomy is only indicated in patients with severe symptoms, such as uncontrollable hemorrhage. The other notable exception is the extremely rare patient with primary renal lymphoma in whom a combination of nephrectomy and systemic chemotherapy may represent optimal therapy (Garcia et al., 2007; Hart et al., 2012). Fourteen cases of marginal zone B-cell lymphoma of mucosa-associated lymphoid tissue localized to the kidney have been described, with some apparently cured by surgery alone (Garcia et al., 2007).

Renal lymphoma and leukemia are commonly silent but can be associated with hematuria, flank pain, or progressive renal failure. Fever, weight loss, and fatigue, the so-called B symptoms of lymphoma, are much more common (Zomas et al., 2004). Renal failure can be due to extensive replacement of the functioning parenchyma or bilateral ureteral obstruction associated with enlarged retroperitoneal lymph nodes (McVary, 1991). In reality, renal failure in such patients is more often related to medical causes, such as hypercalcemia or urate nephropathy, which can develop during systemic treatment of advanced disease (Luciano and Brewster, 2014).

Metastatic Tumors

Metastatic tumors are the most common malignant neoplasms in the kidney. Autopsy studies have shown that 12% of patients dying of cancer have renal metastases, making the kidney one of the most common sites for metastatic dissemination (Pollack et al., 1987). **Almost all renal metastases develop through a hematogenous route of spread because of the profuse vascularity**

of the kidney. Direct invasion of tumors derived from adjacent organs (such as the pancreas, colon, and adrenal gland) is much less common. **The most frequent sources of renal metastases include lung, breast, and gastrointestinal cancers, malignant melanoma, and the hematologic malignant neoplasms** (Aron et al., 2004; Choyke et al., 1987; Pollack et al., 1987; Tomita et al., 2015; Wu et al., 2014). Of the solid malignant neoplasms, lung cancer is most commonly associated with renal metastases. **Most renal metastases are multifocal, and almost all are associated with widespread nonrenal metastases.** However, renal metastases from lung, breast, and colon carcinomas are notable because they are occasionally large and solitary, making them difficult to differentiate from RCC (Choyke et al., 1987; Pollack et al., 1987; Wu et al., 2014).

The typical pattern of renal metastases consists of multiple small nodules that are often clinically silent, although they can lead to hematuria or flank pain in exceptional circumstances (Pollack et al., 1987). CT typically demonstrates isodense masses that enhance only moderately (5 to 30 HU) after administration of intravenous contrast material (Ahmad et al., 2005). **Renal metastases should be suspected in any patient with multiple renal lesions and widespread systemic metastases or a history of nonrenal primary cancer. If there is uncertainty about the diagnosis, percutaneous renal biopsy usually provides pathologic confirmation** (Sanchez-Ortiz et al., 2004a; Wu et al., 2014). Most patients with renal metastases are managed with systemic therapy or placed on a palliative care pathway, depending on the clinical circumstances. Nephrectomy is almost never required except in extenuating circumstances, such as renal hemorrhage that is refractory to embolization. Patients with a solitary, strongly enhancing renal lesion and a history of organ-confined, nonrenal malignant disease are more likely to have RCC, particularly if the temporal interval between the two diagnoses is substantial (Rybicki et al., 2003; Sanchez-Ortiz et al., 2004a). In one study involving 100 consecutive patients with a renal mass and a history of nonrenal malignancy, none of the 54 patients without other evidence of disease progression had a renal metastasis (Sanchez-Ortiz et al., 2004a).

Other Malignant Tumors of the Kidney

Other malignant tumors of the kidney include adult Wilms tumor and neuroendocrine tumors such as renal carcinoid, small cell carcinoma, and primitive neuroectodermal tumor (PNET). All are relatively uncommon, but each has distinct tumor biology.

Carcinoid is an uncommon renal malignant neoplasm with fewer than 60 cases reported in the English literature (Canacci and MacLennan, 2008; Hansel et al., 2007; Lane et al., 2007b; Romero et al., 2006). Median age at diagnosis is 49 years, and an association with horseshoe kidneys has been reported with increased relative risk of 82-fold compared with normal kidneys (Begin et al., 1998; Romero et al., 2006). Carcinoid tumors are derived from neuroendocrine cells and stain positive for neuron-specific enolase and chromogranin (Lane et al., 2007b). **Measurement of urinary or plasma serotonin or its metabolites can also be diagnostic** (Kulke and Mayer, 1999)**. A minority of patients will present with the carcinoid syndrome—episodic flushing, wheezing, and diarrhea** (Lane et al., 2007b; Romero et al., 2006). Unfortunately, CT findings are nonspecific. Many renal carcinoids are small and nonaggressive yet metastases were found in 46% of patients at diagnosis in one review (Romero et al., 2006). Surgical excision is the mainstay of treatment with nephron-sparing surgery preferred if the diagnosis is suspected preoperatively (Kawajiri et al., 2004). Prognosis is generally good, particularly when associated with a horseshoe kidney (Begin et al., 1998). Significant adverse prognostic factors include age older than 40 years, tumor size greater than 4 cm, high mitotic rate, purely solid morphology, metastasis at initial diagnosis, and tumor extending through the renal capsule (Niceta et al., 1974).

Other neuroendocrine tumors, including small cell carcinoma and primary large cell neuroendocrine carcinoma, can occur in the kidney but are even less common than renal carcinoids (Dundr et al., 2010; Lane et al., 2007b; Majhail et al., 2003). Approximately 30 cases of small cell carcinoma of the kidney have been reported for which another primary site could not be identified (Kilicarsalan Akkaya et al., 2003; Kuroda et al., 2014; Mirza and Shahab, 2007). **On pathologic examination, small cell carcinoma has features of neuroendocrine and epithelial neoplasms and must be differentiated from Wilms tumor, PNET, lymphoma, and metastasis from pulmonary small cell carcinoma. Positive staining for neuron-specific enolase, chromogranin, and synaptophysin is characteristic** (Kilicarsalan Akkaya et al., 2003). Preoperative differentiation from RCC is difficult, although a relatively hypovascular pattern may be an indication. Many small cell carcinomas of the kidney are locally advanced or metastatic at presentation, and flank pain or hematuria is common. Multimodal therapy with surgical tumor debulking combined with platinum-based chemotherapy regimens is advocated for extrapulmonary small cell carcinoma in general and may also be useful for the renal manifestation of this malignancy, but the prognosis remains poor (Carranza et al., 2013; Majhail et al., 2003; Mirza and Shahab, 2007).

PNET is related to the Ewing sarcoma family of tumors that are more common in the pediatric population, typically manifesting in the bone or soft tissues of the extremities, trunk, and head and neck and only rarely in the viscera or kidneys (Bartholow and Parwani, 2012; Jimenez et al., 2002; Maly et al., 2004). However, all ages may be affected, and several cases of PNET have been reported in the kidneys of adults (Ellinger et al., 2006; Narayanan et al., 2017; Thyavihally et al., 2008). These tumors are derived from primitive neural crest cells, and positive staining for CD99 in addition to vimentin, cytokeratin, and neuron-specific enolase strongly supports the diagnosis (Ellinger et al., 2006; Gonlusen et al., 2001; Maly et al., 2004). On microscopic examination, renal PNET typically shows small round cells that may form Homer-Wright rosettes (Thyavihally et al., 2008). A characteristic t(11;22)(q24;q12) translocation is highly specific for PNET and can help differentiate it from neuroblastoma or adult Wilms tumor (Jimenez et al., 2002; Parham et al., 2001). Clinical symptoms are nonspecific; CT often demonstrates a heterogeneous ill-defined mass with areas of necrosis, and equivocal enhancement with contrast medium is typical (Doerfler et al., 2001; Narayanan et al., 2017). Renal PNET appears to behave more aggressively than similar tumors at other sites, exhibiting a strong propensity for local recurrence and early metastasis to lymph nodes, lung, liver, and bone (Gonlusen et al., 2001; Parham et al., 2001; Thyavihally et al., 2008). **Multimodal treatment protocols combining tumor debulking, chemotherapy targeted to round cell or Ewing sarcoma family of tumors and radiotherapy to the renal bed are often employed, but prognosis is poor, with 5-year disease-free survival rates of 45% to 55%** (Ellinger et al., 2006; Narayanan et al., 2017; Thyavihally et al., 2008).

Wilms tumor is the most common abdominal malignant neoplasm in children, but 3% of Wilms tumors occur in adults. Of these, 20% are found between the ages of 15 and 20 years, and the remaining 80% are distributed between the third and seventh decades of life (Li et al., 2011; Winter et al., 1996). Adult and pediatric Wilms tumors are histologically similar with a distinctive triphasic pattern consisting of varying amounts of blastema, epithelium, and stroma. **Pathologic staging is the same as for pediatric Wilms tumor.** Adult Wilms tumor typically presents as a heterogeneous intrarenal mass on CT with a relatively hypovascular pattern. Differentiation from RCC can be difficult if not impossible in many cases (Modi et al., 2016; Reinhard et al., 2004; Winter et al., 1996). Clinical presentation of adult Wilms tumor is also similar to that of RCC, and this tends to be an unsuspected pathologic diagnosis in most cases. **Multimodal therapy should be considered, analogous to the treatment protocols for pediatric Wilms tumor** (Li et al., 2011; Modi et al., 2016; Reinhard et al., 2004; Terenziani et al., 2004; Varma et al., 2015). **Prognosis is worse for adults with Wilms tumor than for children** because adults are more likely to present with advanced disease and a sudden drop in performance status (Terenziani et al., 2004; Varma et al., 2015; Winter et al., 1996).

Suggested Readings

Amin MB, Edge SB, Greene FL, et al. *AJCC cancer staging manual*. ed 8. Springer: New York; 2017.

Bindayi A, Hamilton ZA, McDonald ML, et al. Neoadjuvant therapy for localized and locally advanced renal cell carcinoma. *Urol Oncol*. 2017;36(1):31–37.

Blom JH, van Poppel H, Maréchal JM, et al. Radical nephrectomy with and without lymph-node dissection: final results of European Organization for Research and Treatment of Cancer (EORTC) randomized phase 3 trial 30881. *Eur Urol*. 2009;55(1):28–34.

Blute ML, Boorjian SA, Leibovich BC, et al. Results of inferior vena caval interruption by greenfield filter, ligation or resection during radical nephrectomy and tumor thrombectomy. *J Urol*. 2007;178(2):440–445.

Borregales LD, Kim DY, Staller AL, et al. Prognosticators and outcomes of patients with renal cell carcinoma and adjacent organ invasion treated with radical nephrectomy. *Urol Oncol*. 2016;34(237):e219–e226.

Bosniak MA. The Bosniak renal cyst classification: 25 years later. *Radiology*. 2012;262:781–785.

Campbell S, Uzzo RG, Allaf ME, et al. Renal mass and localized renal cancer: AUA guideline. *J Urol*. 2017;198:520–529.

Cancer Genome Atlas Research Network. Comprehensive molecular characterization of clear cell renal cell carcinoma. *Nature*. 2013;499:43–49.

Capitanio U, Montorsi F. Renal cancer. *Lancet*. 2016;387:894–906.

Ciancio G, Gonzalez J, Shirodkar SP, et al. Liver transplantation techniques for the surgical management of renal cell carcinoma with tumor thrombus in the inferior vena cava: step-by-step description. *Eur Urol*. 2011;59:401–406.

Crispen PL, Breau RH, Allmer C, et al. Lymph node dissection at the time of radical nephrectomy for high-risk clear cell renal cell carcinoma: indications and recommendations for surgical templates. *Eur Urol*. 2011;59:18–23.

Delahunt B, Cheville JC, Martignoni G, et al. International Society of Urological Pathology (ISUP) grading system for renal cell carcinoma and other prognostic parameters. *Am J Surg Pathol*. 2013;37(10):1490–1504.

Diaz de Leon A, Pedrosa I. Imaging and screening of kidney cancer. *Radiol Clin North Am*. 2017;55(6):1235–1250.

Donat SM, Diaz M, Bishoff JT, et al. Follow-up for clinically localized renal neoplasms: AUA guideline. *J Urol*. 2013;190:407–416.

Gershman B, Thompson RH, Moreira DM, et al. Radical nephrectomy with or without lymph node dissection for nonmetastatic renal cell carcinoma: a propensity score-based analysis. *Eur Urol*. 2017;71(4):560–567.

Gupta GN, Boris RS, Campbell SC, et al. Tumor enucleation for sporadic localized kidney cancer: pro and con. *J Urol*. 2015;194:623–625.

Herr HW. Surgical management of renal tumors: a historical perspective. *Urol Clin North Am*. 2008;35(4):543–549.

Joshi SS, Uzzo RG. Renal tumor anatomic complexity: clinical implications for urologists. *Urol Clin North Am*. 2017;44:179–187.

Kang SK, Chandarana H. Contemporary imaging of the renal mass. *Urol Clin North Am*. 2012;39:161–170.

Kelly EF, Leveillee RJ. Image guided radiofrequency ablation for small renal masses. *Int J Surg*. 2016;36:525–532.

Kim SP, Campbell SC, Gill I, et al. Collaborative review of risk benefit trade-offs between partial and radical nephrectomy in the management of anatomically complex renal masses. *Eur Urol*. 2017;72:64–75.

Kutikov A, Uzzo RG. The R.E.N.A.L. nephrometry score: a comprehensive standardized system for quantitating renal tumor size, location and depth. *J Urol*. 2009;182(3):844–853.

Ljungberg B, Bensalah K, Canfield S, et al. EAU guidelines on renal cell carcinoma: 2014 update. *Eur Urol*. 2015;67:913–924.

Marconi L, Dabestani S, Lam TB, et al. Systematic review and meta-analysis of diagnostic accuracy of percutaneous renal tumour biopsy. *Eur Urol*. 2016;69:660–673.

Margulis V, McDonald M, Tamboli P, et al. Predictors of oncological outcome after resection of locally recurrent renal cell carcinoma. *J Urol*. 2009;181:2044–2051.

Massari F, Di Nunno V, Ciccarese C, et al. Adjuvant therapy in renal cell carcinoma. *Cancer Treat Rev*. 2017;60:152–157.

Moch H, Cubilla AL, Humphrey PA, et al. The 2016 WHO classification of tumours of the urinary system and male genital organs – Part A: renal, penile, and testicular tumours. *Eur Urol*. 2016;70(1):93–105.

Pierorazio PM, Patel HD, Johnson MH, et al. Distinguishing malignant and benign renal masses with composite models and nomograms: a systematic review and meta-analysis of clinically localized renal masses suspicious for malignancy. *Cancer*. 2016;122(21):3267–3276.

Pierorazio PM, Johnson MH, Patel HD, et al. Management of renal masses and localized renal cancer: systematic review and meta-analysis. *J Urol*. 2016;196:989–999.

Ravaud A, Motzer RJ, Pandha HS, et al. Adjuvant sunitinib in high-risk renal-cell carcinoma after nephrectomy. *N Engl J Med*. 2016;375(23):2246–2254.

Rijnders M, de Wit R, Boormans JL, et al. Systematic review of immune checkpoint inhibition in urological cancers. *Eur*

Urol. 2017;72:411–423.

Ristau BT, Correa AF, Uzzo RG, et al. Active surveillance for the small renal mass: growth kinetics and oncologic outcomes. *Urol Clin North Am*. 2017;44:213–222.

Scosyrev E, Messing EM, Sylvester R, et al. Renal function after nephron-sparing surgery versus radical nephrectomy: results from EORTC randomized trial 30904. *Eur Urol*. 2014;65:372–377.

Srigley JR, Delahunt B, Eble JN, et al. The International Society of Urological Pathology (ISUP) Vancouver classification of renal neoplasia. *Am J Surg Pathol*. 2013;37:1469–1489.

Sun M, Vetterlein M, Harshman LC, et al. Risk assessment in small renal masses: a review article. *Urol Clin North Am*. 2017;44:189–202.

Van Poppel H, Da Pozzo L, Albrecht W, et al. A prospective, randomised EORTC intergroup phase 3 study comparing the oncologic outcome of elective nephron-sparing surgery and radical nephrectomy for low-stage renal cell carcinoma. *Eur Urol*. 2011;59:543–552.

Volpe A, Blute ML, Ficarra V, et al. Renal ischemia and function after partial nephrectomy: a collaborative review of the literature. *Eur Urol*. 2015;68:61–74.

Zabell JR, Wu J, Suk-Ouichai C, et al. Renal ischemia and functional outcomes following kidney cancer surgery. *Urol Clin North Am*. 2017;44:243–255.

Zargar H, Atwell TD, Cadeddu JA, et al. Cryoablation for small renal masses: selection criteria, complications, and functional and oncologic results. *Eur Urol*. 2016;69:116–128.

References

Abarzua-Cabezas FG, Sverrisson E, De La Cruz R, et al. Oncological and functional outcomes of salvage renal surgery following failed primary intervention for renal cell carcinoma. *Int Braz J Urol*. 2015;41(1):147–154.

Abaza R. Initial series of robotic radical nephrectomy with vena caval tumor thrombectomy. *Eur Urol*. 2011;59(4):652–656.

Abdeldaeim HM, Abou Youssif TM, Abdel Wahab MM, et al. Prospective randomized comparison between cold and warm ischemia in patients with renal insufficiency undergoing partial nephrectomy. *Urology*. 2015;85(4):862–868.

Abdelfatah E, Page A, Sacks J, et al. Postoperative complications following intraoperative radiotherapy in abdominopelvic malignancy: a single institution analysis of 113 consecutive patients. *J Surg Oncol*. 2017;115(7):883–890.

Abel EJ, Carrasco A, Karam J, et al. Positive vascular wall margins have minimal impact on cancer outcomes in patients with non-metastatic renal cell carcinoma (RCC) with tumour thrombus. *BJU Int*. 2014;114(5):667–673.

Abel EJ, Masterson TA, Karam JA, et al. Predictive nomogram for recurrence following surgery for nonmetastatic renal cell cancer with tumor thrombus. *J Urol*. 2017;198(4):810–816.

Abern MR, Tsivian M, Polascik TJ, et al. Characteristics and outcomes of tumors arising from the distal nephron. *Urology*. 2012;80(1):140–146.

Abou El Fettouh HI, Cherullo EE, El-Jack M, et al. Sporadic renal cell carcinoma in young adults: presentation, treatment, and outcome. *Urology*. 2002;60(5):806–810.

ACR Committee on Drugs and Contrast Media. *ACR Manual on Contrast Media*. [2017 May 31; [cited; Version 10.3;

Available from] https://www.acr.org/-/media/ACR/Files/Clinical-Resources/Contrast_Media.pdf; 2017.

Agaimy A, Cheng L, Egevad L, et al. Rhabdoid and undifferentiated phenotype in renal cell carcinoma: analysis of 32 cases indicating a distinctive common pathway of dedifferentiation frequently associated with SWI/SNF complex deficiency. *Am J Surg Pathol*. 2017;41(2):253–262.

Agarwal R, Brunelli SM, Williams K, et al. Gadolinium-based contrast agents and nephrogenic systemic fibrosis: a systematic review and meta-analysis. *Nephrol Dial Transplant*. 2009;24(3):856–863.

Ahmad AE, Finelli A, Jewett MAS. Surveillance of small renal masses. *Urology*. 2016;98:8–13.

Ahmad AH, Maclennan GT, Listinsky C. Primary renal lymphoma: a rare neoplasm that may present as a primary renal mass. *J Urol*. 2005;173(1):239.

Algaba F, Akaza H, Lopez-Beltran A, et al. Current pathology keys of renal cell carcinoma. *Eur Urol*. 2011;60(4):634–643.

Altunrende F, Autorino R, Hillyer S, et al. Image guided percutaneous probe ablation for renal tumors in 65 solitary kidneys: functional and oncological outcomes. *J Urol*. 2011;186(1):35–41.

Amin A, White RL Jr. High-dose interleukin-2: is it still indicated for melanoma and RCC in an era of targeted therapies? *Oncology (Williston Park)*. 2013;27(7):680–691.

Amin MB, Amin MB, Tamboli P, et al. Prognostic impact of histologic subtyping of adult renal epithelial neoplasms: an experience of 405 cases. *Am J Surg Pathol*. 2002;26(3):281–291.

Amin MB, Edge SB, Greene FL, et al. *AJCC cancer staging manual*. ed 8. Springer: New York; 2017.

An JY, Ball MW, Gorin MA, et al. Partial vs radical nephrectomy for T1-T2 renal masses in the elderly: comparison of complications, renal function, and oncologic outcomes. *Urology*. 2017;100:151–157.

Anderson CB, Clark PE, Morgan TM, et al. Urinary collecting system invasion is a predictor for overall and disease-specific survival in locally invasive renal cell carcinoma. *Urology*. 2011;78(1):99–104.

Ansari J, Fatima A, Chaudhri S, et al. Sorafenib induces therapeutic response in a patient with metastatic collecting duct carcinoma of kidney. *Onkologie*. 2009;32(1–2):44–46.

Antman K, Crowley J, Balcerzak SP, et al. An intergroup phase III randomized study of doxorubicin and dacarbazine with or without ifosfamide and mesna in advanced soft tissue and bone sarcomas. *J Clin Oncol*. 1993;11(7):1276–1285.

Antonelli A, Furlan M, Sodano M, et al. External histopathological validation of the surface-intermediate-base margin score. *Urol Oncol*. 2017;35(5):215–220.

Argani P, Aulmann S, Illei PB, et al. A distinctive subset of PEComas harbors TFE3 gene fusions. *Am J Surg Pathol*. 2010;34(10):1395–1406.

Armstrong PA, Back MR, Shames ML, et al. Outcomes after inferior vena cava thrombectomy and reconstruction for advanced renal cell carcinoma with tumor thrombus. *J Vasc Surg Venous Lymphat Disord*. 2014;2(4):368–376.

Aron M, Nair M, Hemal AK. Renal metastasis from primary hepatocellular carcinoma. A case report and review of the literature. *Urol Int*. 2004;73(1):89–91.

Aslam Sohaib SA, Teh J, Nargund VH, et al. Assessment of tumor invasion of the vena caval wall in renal cell carcinoma cases by magnetic resonance imaging. *J Urol*. 2002;167(3):1271–1275.

Atwell TD, Schmit GD, Boorjian SA, et al. Percutaneous ablation of renal masses measuring 3.0 cm and smaller:

comparative local control and complications after radiofrequency ablation and cryoablation. *Am J Roentgenol*. 2013;200(2):461–466.

Axelson H, Johansson ME. Renal stem cells and their implications for kidney cancer. *Semin Cancer Biol*. 2013;23(1):56–61.

Azhar RA, de Castro Abreu AL, Broxham E, et al. Histological analysis of the kidney tumor-parenchyma interface. *J Urol*. 2015;193(2):415–422.

Bach AM, Zhang J. Contemporary radiologic imaging of renal cortical tumors. *Urol Clin North Am*. 2008;35(4):593–604 [vi].

Bagheri M, Speakman JR, Shemirani F, et al. Renal cell carcinoma survival and body mass index: a dose-response meta-analysis reveals another potential paradox within a paradox. *Int J Obes (Lond)*. 2016;40(12):1817–1822.

Bagheri MH, Ahlman MA, Lindenberg L, et al. Advances in medical imaging for the diagnosis and management of common genitourinary cancers. *Urol Oncol*. 2017;35(7):473–491.

Bahler CD, Dube HT, Flynn KJ, et al. Feasibility of omitting cortical renorrhaphy during robot-assisted partial nephrectomy: a matched analysis. *J Endourol*. 2015;29(5):548–555.

Bailey GC, Boorjian SA, Ziegelmann MJ, et al. Urinary collecting system invasion is associated with poor survival in patients with clear-cell renal cell carcinoma. *BJU Int*. 2017;119(4):585–590.

Ball MW, Bezerra SM, Gorin MA, et al. Grade heterogeneity in small renal masses: potential implications for renal mass biopsy. *J Urol*. 2015;193(1):36–40.

Ball MW, Gorin MA, Jayram G, et al. Robot-assisted radical nephrectomy with inferior vena cava tumor thrombectomy:

technique and initial outcomes. *Can J Urol*. 2015;22(1):7666–7670.

Bandi G, Wen CC, Moon TD, et al. Single center preliminary experience with hand-assisted laparoscopic resection of isolated renal cell carcinoma fossa recurrences. *Urology*. 2008;71(3):495–499 [discussion 9–500].

Bansal RK, Tanguay S, Finelli A, et al. Positive surgical margins during partial nephrectomy for renal cell carcinoma: results from Canadian Kidney Cancer information system (CKCis) collaborative. *Can Urol Assoc J*. 2017;11(6):182–187.

Barthelemy P, Hoch B, Chevreau C, et al. mTOR inhibitors in advanced renal cell carcinomas: from biology to clinical practice. *Crit Rev Oncol Hematol*. 2013;88(1):42–56.

Bartholow T, Parwani A. Renal primitive neuroectodermal tumors. *Arch Pathol Lab Med*. 2012;136(6):686–690.

Bassignani MJ. Understanding and interpreting MRI of the genitourinary tract. *Urol Clin North Am*. 2006;33(3):301–317.

Bausch B, Jilg C, Glasker S, et al. Renal cancer in von Hippel-Lindau disease and related syndromes. *Nat Rev Nephrol*. 2013;9(9):529–538.

Bechtold RE, Zagoria RJ. Imaging approach to staging of renal cell carcinoma. *Urol Clin North Am*. 1997;24(3):507–522.

Becker A, Ravi P, Roghmann F, et al. Laparoscopic radical nephrectomy vs laparoscopic or open partial nephrectomy for T1 renal cell carcinoma: comparison of complication rates in elderly patients during the initial phase of adoption. *Urology*. 2014;83(6):1285–1291.

Begin LR, Guy L, Jacobson SA, et al. Renal carcinoid and horseshoe kidney: a frequent association of two rare entities–a case report and review of the literature. *J Surg Oncol*. 1998;68(2):113–119.

Beisland C. Incidental detection of renal cell carcinoma. *Scand J Urol*. 2017;51(3):178–184.

Beksac AT, Paulucci DJ, Blum KA, et al. Heterogeneity in renal cell carcinoma. *Urol Oncol*. 2017;35(8):507–515.

Belldegrun A, DeKernion JB. Sarcomas of the genitourinary tract. Eilber FR. *The soft tissue sarcomas*. Grune & Stratton: Orlando, FL; 1987:219.

Bennett KL, Mester J, Eng C. Germline epigenetic regulation of KILLIN in Cowden and Cowden-like syndrome. *J Am Med Assoc*. 2010;304(24):2724–2731.

Bensalah K, Pantuck AJ, Rioux-Leclercq N, et al. Positive surgical margin appears to have negligible impact on survival of renal cell carcinomas treated by nephron-sparing surgery. *Eur Urol*. 2010;57(3):466–471.

Berg WT, Tomaszewski JJ, Yang H, et al. Complications of renal surgery. *Urol Clin North Am*. 2017;44(2):275–288.

Berger A, Brandina R, Atalla MA, et al. Laparoscopic radical nephrectomy for renal cell carcinoma: oncological outcomes at 10 years or more. *J Urol*. 2009;182(5):2172–2176.

Berger A, Kamoi K, Gill IS, et al. Cryoablation for renal tumors: current status. *Curr Opin Urol*. 2009;19(2):138–142.

Berland LL, Silverman SG, Gore RM, et al. Managing incidental findings on abdominal CT: white paper of the ACR incidental findings committee. *J Am Coll Radiol*. 2010;7(10):754–773.

Bernhard JC, Pantuck AJ, Wallerand H, et al. Predictive factors for ipsilateral recurrence after nephron-sparing surgery in renal cell carcinoma. *Eur Urol*. 2010;57(6):1080–1086.

Bertini R, Roscigno M, Freschi M, et al. Renal sinus fat invasion in pT3a clear cell renal cell carcinoma affects outcomes of patients without nodal involvement or distant metastases. *J Urol*. 2009;181(5):2027–2032.

Bertolotto C, Lesueur F, Giuliano S, et al. A SUMOylation-defective MITF germline mutation predisposes to melanoma and renal carcinoma. *Nature*. 2011;480(7375):94–98.

Bhagavatula SK, Shyn PB. Image-guided renal interventions. *Radiol Clin North Am*. 2017;55(2):359–371.

Bhaskaran K, Douglas I, Forbes H, et al. Body-mass index and risk of 22 specific cancers: a population-based cohort study of 5.24 million UK adults. *Lancet (London, England)*. 2014;384(9945):755–765.

Bhatt JR, Jewett MA, Richard PO, et al. Multilocular cystic renal cell carcinoma: pathological t staging makes no difference to favorable outcomes and should be reclassified. *J Urol*. 2016;196(5):1350–1355.

Bhindi B, Lohse CM, Mason RJ, et al. Are we using the best tumor size cut-points for renal cell carcinoma staging? *Urology*. 2017;109:121–126.

Bindayi A, Hamilton ZA, McDonald ML, et al. Neoadjuvant therapy for localized and locally advanced renal cell carcinoma. *Urol Oncol*. 2018;36(1):31–37.

Birch-Hirschfeld FV, Doederlein A. Zentralbl Krankh Horn. *Sex Org*. 1894;3.

Blackwell RH, Li B, Kozel Z, et al. Functional implications of renal tumor enucleation relative to standard partial nephrectomy. *Urology*. 2017;99:162–168.

Blath RA, Mancilla-Jimenez R, Stanley RJ. Clinical comparison between vascular and avascular renal cell carcinoma. *J Urol*. 1976;115(5):514–519.

Blom JH, van Poppel H, Marechal JM, et al. Radical nephrectomy with and without lymph-node dissection: final results of European Organization for Research and Treatment of Cancer (EORTC) randomized phase 3 trial 30881. *Eur Urol*. 2009;55(1):28–34.

Blute ML, Boorjian SA, Leibovich BC, et al. Results of inferior vena caval interruption by greenfield filter, ligation or resection during radical nephrectomy and tumor thrombectomy. *J Urol*. 2007;178(2):440–445 [discussion 4].

Blute ML Jr, Gupta M, Crispen PL. Lymph node dissection for small renal masses. *Urol Clin North Am*. 2017;44(2):269–274.

Blute ML, Leibovich BC, Cheville JC, et al. A protocol for performing extended lymph node dissection using primary tumor pathological features for patients treated with radical nephrectomy for clear cell renal cell carcinoma. *J Urol*. 2004;172(2):465–469.

Blute ML, Leibovich BC, Lohse CM, et al. The Mayo Clinic experience with surgical management, complications and outcome for patients with renal cell carcinoma and venous tumour thrombus. *BJU Int*. 2004;94(1):33–41.

Bolte SL, Ankem MK, Moon TD, et al. Magnetic resonance imaging findings after laparoscopic renal cryoablation. *Urology*. 2006;67(3):485–489.

Bonsib SM, Gibson D, Mhoon M, et al. Renal sinus involvement in renal cell carcinomas. *Am J Surg Pathol*. 2000;24(3):451–458.

Booth J, Matin SF, Ahrar K, et al. Contemporary strategies for treating nonhereditary synchronous bilateral renal tumors and the impact of minimally invasive, nephron-sparing techniques. *Urol Oncol*. 2008;26(1):37–42.

Boris RS, Benhammou J, Merino M, et al. The impact of germline BHD mutation on histological concordance and clinical treatment of patients with bilateral renal masses and known unilateral oncocytoma. *J Urol*. 2011;185(6):2050–2055.

Borregales LD, Kim DY, Staller AL, et al. Prognosticators and outcomes of patients with renal cell carcinoma and adjacent organ invasion treated with radical nephrectomy. *Urol Oncol*. 2016;34(5):237 e19–237 e26.

Bosniak MA. Observation of small incidentally detected renal masses. *Semin Urol Oncol*. 1995;13(4):267–272.

Bosniak MA. The Bosniak renal cyst classification: 25 years later. *Radiology*. 2012;262(3):781–785.

Bosquet M, Dominguez C, Balaguer J, et al. Pediatric renal adenocarcinoma: a review of our series. *Urology*. 2008;72(4):790–793.

Bouchelouche K, Oehr P. Positron emission tomography and positron emission tomography/computerized tomography of urological malignancies: an update review. *J Urol*. 2008;179(1):34–45.

Brahmer JR, Tykodi SS, Chow LQ, et al. Safety and activity of anti-PD-L1 antibody in patients with advanced cancer. *New Engl J Med*. 2012;366(26):2455–2465.

Bratslavsky G, Liu JJ, Johnson AD, et al. Salvage partial nephrectomy for hereditary renal cancer: feasibility and outcomes. *J Urol*. 2008;179(1):67–70.

Brescia A, Pinto F, Gardi M, et al. Renal hemangiopericytoma: case report and review of the literature. *Urology*. 2008;71(4):755 e9–755 e12.

Broecker B. Non-Wilms’ renal tumors in children. *Urol Clin North Am*. 2000;27(3):463–469 [ix].

Brok J, Treger TD, Gooskens SL, et al. Biology and treatment of renal tumours in childhood. *Eur J Cancer*. 2016;68:179–195.

Brookman-May S, May M, Zigeuner R, et al. Collecting system invasion and Fuhrman grade but not tumor size facilitate prognostic stratification of patients with pT2 renal cell carcinoma. *J Urol*. 2011;186(6):2175–2181.

Brookman-May SD, May M, Wolff I, et al. Evaluation of the prognostic significance of perirenal fat invasion and tumor size in patients with pT1-pT3a localized renal cell carcinoma in a comprehensive multicenter study of the CORONA project. Can we improve prognostic discrimination for patients with stage pT3a tumors? *Eur Urol*. 2015;67(5):943–951.

Bruner B, Breau RH, Lohse CM, et al. Renal nephrometry score is associated with urine leak after partial nephrectomy. *BJU Int*. 2011;108(1):67–72.

Buchbinder EI, Desai A. CTLA-4 and PD-1 Pathways: similarities, differences, and implications of their inhibition. *Am J Clin Oncol*. 2016;39(1):98–106.

Bugert P, Gaul C, Weber K, et al. Specific genetic changes of diagnostic importance in chromophobe renal cell carcinomas. *Lab Invest*. 1997;76(2):203–208.

Bui MH, Visapaa H, Seligson D, et al. Prognostic value of carbonic anhydrase IX and KI67 as predictors of survival for renal clear cell carcinoma. *J Urol*. 2004;171(6 Pt 1):2461–2466.

Butler BP, Novick AC, Miller DP, et al. Management of small unilateral renal cell carcinomas: radical versus nephron-sparing surgery. *Urology*. 1995;45(1):34–40 [discussion 1].

Byler TK, Bratslavsky G. Hereditary renal cell carcinoma: genetics, clinical features, and surgical considerations. *World J Urol*. 2014;32(3):623–630.

Caban C, Khan N, Hasbani DM, et al. Genetics of tuberous sclerosis complex: implications for clinical practice. *Appl Clin Genet*. 2017;10:1–8.

Calle EE, Kaaks R. Overweight, obesity and cancer: epidemiological evidence and proposed mechanisms. *Nat Rev Cancer*. 2004;4(8):579–591.

Campbell S, Uzzo RG, Allaf ME, et al. Renal mass and localized renal cancer: AUA Guideline. *J Urol*. 2017;198(3):520–529.

Campbell S, Uzzo RG, Allaf ME, et al. *Renal mass and localized renal cancer: AUA guideline*. [(website)] https://www.auanet.org/Documents/education/clinical-guidance/Renal-Mass-Localized-Renal-Cancer.pdf; 2017.

Campbell SC, Gupta GN, Uzzo RG, et al. Re: Raj Satkunasivam, Sheaumei Tsai, Sumeet Syan, et al. Robotic unclamped "minimal-margin" partial nephrectomy: ongoing refinement of the anatomic zero-ischemia concept. Eur Urol 2015;68:705-12. *Eur Urol*. 2016;69(5):e95–e96.

Campbell SC, Lane BR. Malignant renal tumors. Wein AJ, Kavoussi LR, Partin AW, et al. *Campbell-walsh urology*. Saunders: Philadelphia, PA; 2016:1314–1364.

Campbell SC, Novick AC. Management of local recurrence following radical nephrectomy or partial nephrectomy. *Urol Clin North Am*. 1994;21(4):593–599.

Campbell SC, Novick AC, Belldegrun A, et al. Guideline for management of the clinical T1 renal mass. *J Urol*. 2009;182(4):1271–1279.

Campbell SC, Novick AC, Streem SB, et al. Management of renal cell carcinoma with coexistent renal artery disease. *J Urol*. 1993;150(3):808–813.

Canacci AM, MacLennan GT. Carcinoid tumor of the kidney. *J Urol*. 2008;180(5):2193.

Cancer Genome Atlas Research Network. Comprehensive molecular characterization of clear cell renal cell carcinoma. *Nature*. 2013;499(7456):43–49.

Capitanio U, Deho F, Dell'Oglio P, et al. Lymphadenopathies in patients with renal cell carcinoma: clinical and pathological predictors of pathologically confirmed lymph node invasion. *World J Urol*. 2016;34(8):1139–1145.

Capitanio U, Jeldres C, Patard JJ, et al. Stage-specific effect of nodal metastases on survival in patients with non-metastatic renal cell carcinoma. *BJU Int*. 2009;103(1):33–37.

Capitanio U, Montorsi F. Renal cancer. *Lancet (London, England)*. 2016;387(10021):894–906.

Capitanio U, Suardi N, Matloob R, et al. Extent of lymph node dissection at nephrectomy affects cancer-specific survival and metastatic progression in specific sub-categories of patients with renal cell carcinoma (RCC). *BJU Int*. 2014;114(2):210–215.

Carini M, Minervini A, Masieri L, et al. Simple enucleation for the treatment of PT1a renal cell carcinoma: our 20-year experience. *Eur Urol*. 2006;50(6):1263–1268 [discussion 9–71].

Carmeliet P. VEGF as a key mediator of angiogenesis in cancer. *Oncology*. 2005;69(Suppl 3):4–10.

Carranza OE, Castanon E, Abella LE, et al. Clinical management of small-cell carcinoma of the urinary tract: a 10-year single-center's experience. *Clin Genitourin Cancer*. 2013;11(2):168–174.

Carrizosa DR, Godley PA. Epidemiology and screening of renal cell carcinoma. Campbell SC, Rini BI. *Renal cell carcinoma*. People's Medical Publishing House: Shelton, CT; 2009:15–24.

Carson WJ. *Tumors of the kidney: histologic study*. [Trans Soc Urol AMA] 1928.

Carter CS, Skala SL, Chinnaiyan AM, et al. Immunohistochemical characterization of fumarate hydratase (FH) and succinate dehydrogenase (SDH) in cutaneous leiomyomas for detection of familial cancer syndromes. *Am J Surg Pathol*. 2017;41(6):801–809.

Carter HB, Albertsen PC, Barry MJ, et al. Early detection of prostate cancer: AUA Guideline. *J Urol*. 2013;190(2):419–426.

Chamie K, Donin NM, Klopfer P, et al. Adjuvant weekly girentuximab following nephrectomy for high-risk renal cell carcinoma: the ARISER randomized clinical trial. *J Am Med Assoc Oncol*. 2017;3(7):913–920.

Chang X, Zhang F, Liu T, et al. Radio frequency ablation versus partial nephrectomy for clinical T1b renal cell carcinoma: long-term clinical and oncologic outcomes. *J Urol*. 2015;193(2):430–435.

Chapin BF, Delacroix SE Jr, Culp SH, et al. Safety of presurgical targeted therapy in the setting of metastatic renal cell carcinoma. *Eur Urol*. 2011;60(5):964–971.

Chaudhary A, Seenu V, Sedain G, et al. Hemangiopericytoma of renal pelvis–an unusual tumor in an adolescent. *Urology*. 2007;70(4):811 e13–811 e14.

Chen DY, Uzzo RG. Optimal management of localized renal cell carcinoma: surgery, ablation, or active surveillance. *J Nat Compr Cancer Netwk*. 2009;7(6):635–642 [quiz 43].

Chen K, Huang HH, Aydin H, et al. Renal cell carcinoma in patients with end-stage renal disease is associated with more favourable histological features and prognosis. *Scand J Urol*. 2015;49(3):200–204.

Chen L, Ma X, Li H, et al. Invasion of the urinary collecting system is an independent prognostic factor in pT3 renal cell carcinoma. *Urol Oncol*. 2016;34(7):293 e11–293 e16.

Chen YH, Wu XR, Hu ZL, et al. Treatment of renal cell carcinoma with a level III or level IV inferior vena cava thrombus using cardiopulmonary bypass and deep hypothermic circulatory arrest. *World J Surg Oncol*. 2015;13:159.

Cheng WS, Farrow GM, Zincke H. The incidence of multicentricity in renal cell carcinoma. *J Urol*. 1991;146(5):1221–1223.

Cheville JC, Blute ML, Zincke H, et al. Stage pT1 conventional (clear cell) renal cell carcinmoa: pathological features associated with cancer specific survival. *J Urol*. 2001;166(2):453–456.

Cheville JC, Lohse CM, Sukov WR, et al. Chromophobe renal cell carcinoma: the impact of tumor grade on outcome. *Am J Surg Pathol*. 2012;36(6):851–856.

Cheville JC, Lohse CM, Zincke H, et al. Comparisons of outcome and prognostic features among histologic subtypes of renal cell carcinoma. *Am J Surg Pathol*. 2003;27(5):612–624.

Cheville JC, Lohse CM, Zincke H, et al. Sarcomatoid renal cell carcinoma: an examination of underlying histologic subtype and an analysis of associations with patient outcome. *Am J Surg Pathol*. 2004;28(4):435–441.

Cho E, Curhan G, Hankinson SE, et al. Prospective evaluation of analgesic use and risk of renal cell cancer. *Arch Intern Med*. 2011;171(16):1487–1493.

Choi Y, Park B, Jeong BC, et al. Body mass index and survival in patients with renal cell carcinoma: a clinical-based cohort and meta-analysis. *Int J Cancer*. 2013;132(3):625–634.

Chopra S, Simone G, Metcalfe C, et al. Robot-assisted Level II-III inferior vena cava tumor thrombectomy: step-by-step technique and 1-year outcomes. *Eur Urol*. 2017;72(2):267–274.

Choueiri TK, Escudier B, Powles T, et al. Cabozantinib versus everolimus in advanced renal-cell carcinoma. *New Engl J Med*. 2015;373(19):1814–1823.

Choueiri TK, Fishman MN, Escudier B, et al. Immunomodulatory activity of nivolumab in metastatic renal cell carcinoma. *Clin Cancer Res*. 2016;22(22):5461–5471.

Choueiri TK, Halabi S, Sanford BL, et al. Cabozantinib versus sunitinib as initial targeted therapy for patients with metastatic renal cell carcinoma of poor or intermediate risk: the Alliance A031203 CABOSUN Trial. *J Clin Oncol*. 2017;35(6):591–597.

Choueiri TK, Lim ZD, Hirsch MS, et al. Vascular endothelial growth factor-targeted therapy for the treatment of adult metastatic Xp11.2 translocation renal cell carcinoma. *Cancer*. 2010;116(22):5219–5225.

Choueiri TK, Plimack E, Arkenau HT, et al. Biomarker-based Phase II trial of savolitinib in patients with advanced papillary renal cell cancer. *J Clin Oncol*. 2017;35(26):2993–3001.

Chow WH, Devesa SS, Warren JL, et al. Rising incidence of renal cell cancer in the United States. *JAMA*. 1999;281(17):1628–1631.

Chow WH, Shuch B, Linehan WM, et al. Racial disparity in renal cell carcinoma patient survival according to demographic and clinical characteristics. *Cancer*. 2013;119(2):388–394.

Choyke PL, Pavlovich CP, Daryanani KD, et al. Intraoperative ultrasound during renal parenchymal sparing surgery for hereditary renal cancers: a 10-year experience. *J Urol*. 2001;165(2):397–400.

Choyke PL, White EM, Zeman RK, et al. Renal metastases: clinicopathologic and radiologic correlation. *Radiology*. 1987;162(2):359–363.

Ciancio G, Gonzalez J, Shirodkar SP, et al. Liver transplantation techniques for the surgical management of renal cell carcinoma with tumor thrombus in the inferior vena cava: step-by-step description. *Eur Urol*. 2011;59(3):401–406.

Ciancio G, Livingstone AS, Soloway M. Surgical management of renal cell carcinoma with tumor thrombus in the renal and inferior vena cava: the University of Miami experience in using liver transplantation techniques. *Eur Urol*. 2007;51(4):988–994 [discussion 94–95].

Ciancio G, Manoharan M, Katkoori D, et al. Long-term survival in patients undergoing radical nephrectomy and inferior vena cava thrombectomy: single-center experience. *Eur Urol*. 2010;57(4):667–672.

Cindolo L, Chiodini P, Gallo C, et al. Validation by calibration of the UCLA integrated staging system prognostic model for nonmetastatic renal cell carcinoma after nephrectomy. *Cancer*. 2008;113(1):65–71.

Clark JI, Atkins MB, Urba WJ, et al. Adjuvant high-dose bolus interleukin-2 for patients with high-risk renal cell carcinoma: a cytokine working group randomized trial. *J Clin Oncol*. 2003;21(16):3133–3140.

Cohen AJ, Li FP, Berg S, et al. Hereditary renal-cell carcinoma associated with a chromosomal translocation. *New Engl J Med*. 1979;301(11):592–595.

Colevas AD, Kantoff PW, DeWolf WC, et al. Malignant lymphoma of the genitourinary tract. Volgelzang NJ. *Comprehensive textbook of genitourinary oncology*. Lippincott Williams & Wilkins: Philadelphia; 2000:1120–1132.

Colt JS, Hofmann JN, Schwartz K, et al. Antihypertensive medication use and risk of renal cell carcinoma. *Cancer Causes Control*. 2017;28(4):289–297.

Conti A, Santoni M, Sotte V, et al. Small renal masses in the era of personalized medicine: tumor heterogeneity, growth kinetics, and risk of metastasis. *Urol Oncol*. 2015;33(7):303–309.

Cook A, Lorenzo AJ, Salle JL, et al. Pediatric renal cell carcinoma: single institution 25-year case series and initial experience with partial nephrectomy. *J Urol*. 2006;175(4):1456–1460 [discussion 60].

Coppin C. Immunotherapy for renal cell cancer in the era of targeted therapy. *Expert Rev Anticancer Ther*. 2008;8(6):907–919.

Cote ML, Colt JS, Schwartz KL, et al. Cigarette smoking and renal cell carcinoma risk among black and white Americans: effect modification by hypertension and obesity. *Cancer*

Epidemiol Biomarkers Prev. 2012;21(5):770–779.

Cox CE, Lacy SS, Montgomery WG, et al. Renal adenocarcinoma: 28-year review, with emphasis on rationale and feasibility of preoperative radiotherapy. *J Urol*. 1970;104(1):53–61.

Crispen PL, Boorjian SA, Lohse CM, et al. Predicting disease progression after nephrectomy for localized renal cell carcinoma: the utility of prognostic models and molecular biomarkers. *Cancer*. 2008;113(3):450–460.

Crispen PL, Breau RH, Allmer C, et al. Lymph node dissection at the time of radical nephrectomy for high-risk clear cell renal cell carcinoma: indications and recommendations for surgical templates. *Eur Urol*. 2011;59(1):18–23.

Crispen PL, Tabidian MR, Allmer C, et al. Unclassified renal cell carcinoma: impact on survival following nephrectomy. *Urology*. 2010;76(3):580–586.

Crispen PL, Viterbo R, Boorjian SA, et al. Natural history, growth kinetics, and outcomes of untreated clinically localized renal tumors under active surveillance. *Cancer*. 2009;115(13):2844–2852.

Cross BW, Parker DC, Cookson MS. Salvage surgery after renal mass ablation. *Urol Clin North Am*. 2017;44(2):305–312.

Culp SH, Tannir NM, Abel EJ, et al. Can we better select patients with metastatic renal cell carcinoma for cytoreductive nephrectomy? *Cancer*. 2010;116(14):3378–3388.

Cumberbatch MG, Rota M, Catto JW, et al. The role of tobacco smoke in bladder and kidney carcinogenesis: a comparison of exposures and meta-analysis of incidence and mortality risks. *Eur Urol*. 2016;70(3):458–466.

Cywinski JB, O'Hara JF Jr. Transesophageal echocardiography to redirect the intraoperative surgical approach for vena cava tumor resection. *Anesth Analg*. 2009;109(5):1413–1415.

Dal Sasso AA, Belem LC, Zanetti G, et al. Birt-Hogg-Dube syndrome. State-of-the-art review with emphasis on pulmonary involvement. *Respir Med*. 2015;109(3):289–296.

Dalgliesh GL, Furge K, Greenman C, et al. Systematic sequencing of renal carcinoma reveals inactivation of histone modifying genes. *Nature*. 2010;463(7279):360–363.

Danzig MR, Chang P, Wagner AA, et al. Active surveillance for small renal masses: a review of the aims and preliminary results of the DISSRM Registry. *Curr Urol Rep*. 2016;17(1):4.

Dashkevich A, Bagaev E, Hagl C, et al. Long-term outcomes after resection of Stage IV cavoatrial tumour extension using deep hypothermic circulatory arrest. *Eur J Cardiothorac Surg*. 2016;50(5):892–897.

Dason S, Allard C, Sheridan-Jonah A, et al. Management of renal collecting duct carcinoma: a systematic review and the McMaster experience. *Curr Oncol*. 2013;20(3):e223–e232.

Daugherty M, Sedaghatpour D, Shapiro O, et al. The metastatic potential of renal tumors: influence of histologic subtypes on definition of small renal masses, risk stratification, and future active surveillance protocols. *Urol Oncol*. 2017;35(4):153 e15–e20.

Davenport MS, Hu EM, Smith AD, et al. Reporting standards for the imaging-based diagnosis of renal masses on CT and MRI: a national survey of academic abdominal radiologists and urologists. *Abdom Radiol (NY)*. 2017;42(4):1229–1240.

Davis CF, Ricketts CJ, Wang M, et al. The somatic genomic landscape of chromophobe renal cell carcinoma. *Cancer Cell*. 2014;26(3):319–330.

Davis CJ Jr, Mostofi FK, Sesterhenn IA. Renal medullary carcinoma. The seventh sickle cell nephropathy. *Am J Surg Pathol*. 1995;19(1):1–11.

de Senneville BD, Moonen C, Ries M. MRI-guided HIFU methods for the ablation of liver and renal cancers. *Adv Exp Med Biol*. 2016;880:43–63.

Decastro GJ, McKiernan JM. Epidemiology, clinical staging, and presentation of renal cell carcinoma. *Urol Clin North Am*. 2008;35(4):581–592 [vi].

Dekernion JB, Ramming KP, Smith RB. The natural history of metastatic renal cell carcinoma: a computer analysis. *J Urol*. 1978;120(2):148–152.

Delahunt B, Sika-Paotonu D, Bethwaite PB, et al. Fuhrman grading is not appropriate for chromophobe renal cell carcinoma. *Am J Surg Pathol*. 2007;31(6):957–960.

Delahunt B, Srigley JR, Egevad L, et al. International Society of Urological Pathology grading and other prognostic factors for renal neoplasia. *Eur Urol*. 2014;66(5):795–798.

DeLong W, Grignon DJ, Eberwein P, et al. Sarcomatoid renal cell carcinoma. An immunohistochemical study of 18 cases. *Arch Pathol Lab Med*. 1993;117(6):636–640.

Demirjian S, Lane BR, Derweesh IH, et al. Chronic kidney disease due to surgical removal of nephrons: relative rates of progression and survival. *J Urol*. 2014;192(4):1057–1062.

Deng FM, Melamed J. Histologic variants of renal cell carcinoma: does tumor type influence outcome? *Urol Clin North Am*. 2012;39(2):119–132 [v].

Desai MM, de Castro Abreu AL, Leslie S, et al. Robotic partial nephrectomy with superselective versus main artery clamping: a retrospective comparison. *Eur Urol*. 2014;66(4):713–719.

Dey S, Peabody HN, Noyes SL, et al. Neoadjuvant targeted molecular therapy before renal surgery. *Urol Clin North Am*. 2017;44(2):289–303.

Deyrup AT, Montgomery E, Fisher C. Leiomyosarcoma of the kidney: a clinicopathologic study. *Am J Surg Pathol*. 2004;28(2):178–182.

Diaz de Leon A, Pedrosa I. Imaging and screening of kidney cancer. *Radiol Clin North Am*. 2017;55(6):1235–1250.

Diblasio CJ, Snyder ME, Russo P. Mini-flank supra-11th rib incision for open partial or radical nephrectomy. *BJU Int*. 2006;97(1):149–156.

Divgi CR, Uzzo RG, Gatsonis C, et al. Positron emission tomography/computed tomography identification of clear cell renal cell carcinoma: results from the REDECT trial. *J Clin Oncol*. 2013;31(2):187–194.

Doerfler O, Reittner P, Groell R, et al. Peripheral primitive neuroectodermal tumour of the kidney: CT findings. *Pediatr Radiol*. 2001;31(2):117–119.

Donat SM, Diaz M, Bishoff JT, et al. Follow-up for clinically localized renal neoplasms: AUA guideline. *J Urol*. 2013;190(2):407–416.

Dong W, Gupta GN, Blackwell RH, et al. Functional comparison of renal tumor enucleation versus standard partial nephrectomy. *Eur Urol Focus*. 2017.

Dong W, Wu J, Suk-Ouichai C, et al. Devascularized parenchymal mass associated with partial nephrectomy: predictive factors and impact on functional recovery. *J Urol*. 2017;198(4):787–794.

Dong W, Wu J, Suk-Ouichai C, et al. Ischemia and functional recovery from partial nephrectomy: refined perspectives. Eur Urol. *Focus*. 2017.

Dotan ZA, Tal R, Golijanin D, et al. Adult genitourinary sarcoma: the 25-year Memorial Sloan-Kettering experience. *J Urol*. 2006;176(5):2033–2038 [discussion 8–9].

Duffey BG, Choyke PL, Glenn G, et al. The relationship between renal tumor size and metastases in patients with von Hippel-Lindau disease. *J Urol*. 2004;172(1):63–65.

Dundr P, Pesl M, Povysil C, et al. Primary large cell neuroendocrine carcinoma of the kidney. *Pathol Oncol Res*.

2010;16(1):139–142.

Eble JN, Sauter G, Epstein JI, et al. *WHO Classification of tumors: pathology and genetics of tumours of the urinary system and male genital organs*. IARC Press: Lyon, Franc; 2004.

Economou JS, Lindner A, DeKernion JB. Sarcomas of he genitourinary tract. Eilber FR. *The soft tissue sarcomas*. Grune & Stratton: Orlando; 1987:219.

Edge SB, Byrd DR, Compton CC, et al. *AJCC cancer staging manual*. ed 7. Springer: France; 2010.

Eggener SE, Rubenstein JN, Smith ND, et al. Renal tumors in young adults. *J Urol*. 2004;171(1):106–110.

Eggener SE, Yossepowitch O, Kundu S, et al. Risk score and metastasectomy independently impact prognosis of patients with recurrent renal cell carcinoma. *J Urol*. 2008;180(3):873–878 [discussion 8].

El-Mokadem I, Budak M, Pillai S, et al. Progression, interobserver agreement, and malignancy rate in complex renal cysts (>/= Bosniak category IIF). *Urol Oncol*. 2014;32(1):24 e1–24 e7.

Ellinger J, Bastian PJ, Hauser S, et al. Primitive neuroectodermal tumor: rare, highly aggressive differential diagnosis in urologic malignancies. *Urology*. 2006;68(2):257–262.

Escudier B, Choueiri TK, Oudard S, et al. Prognostic factors of metastatic renal cell carcinoma after failure of immunotherapy: new paradigm from a large phase III trial with shark cartilage extract AE 941. *J Urol*. 2007;178(5):1901–1905.

Escudier B, Pluzanska A, Koralewski P, et al. Bevacizumab plus interferon alfa-2a for treatment of metastatic renal cell carcinoma: a randomised, double-blind phase III trial. *Lancet (London, England)*. 2007;370(9605):2103–2111.

Escudier B, Tannir N, McDermott D, et al. CheckMate 214: efficacy and safety of nivolumab + ipilimumab (N+I) v sunitinib (S) for treatment-naïve advanced or metastatic renal cell carcinoma (mRCC), including IMDC risk and PD-L1 expression subgroups. *Ann Oncol*. 2017;28(Supplemental 5):621–622.

Esrig D, Ahlering TE, Lieskovsky G, et al. Experience with fossa recurrence of renal cell carcinoma. *J Urol*. 1992;147(6):1491–1494.

Estrada CR, Suthar AM, Eaton SH, et al. Renal cell carcinoma: Children's Hospital Boston experience. *Urology*. 2005;66(6):1296–1300.

Ezekian B, Englum B, Gilmore BF, et al. Renal medullary carcinoma: a national analysis of 159 patients. *Pediatr Blood Cancer*. 2017;64(11).

Farivar-Mohseni H, Perlmutter AE, Wilson S, et al. Renal cell carcinoma and end stage renal disease. *J Urol*. 2006;175(6):2018–2020 [discussion 21].

Farley MN, Schmidt LS, Mester JL, et al. A novel germline mutation in BAP1 predisposes to familial clear-cell renal cell carcinoma. *Mol Cancer Res*. 2013;11(9):1061–1071.

Farrow GM. Diseases of the kidney. Murphy WM. *Urological pathology*. WB Saunders: Philadelphia; 1997:464–470.

Feder MT, Patel MB, Melman A, et al. Comparison of open and laparoscopic nephrectomy in obese and nonobese patients: outcomes stratified by body mass index. *J Urol*. 2008;180(1):79–83.

Feifer A, Savage C, Rayala H, et al. Prognostic impact of muscular venous branch invasion in localized renal cell carcinoma cases. *J Urol*. 2011;185(1):37–42.

Fergany AF, Saad IR, Woo L, et al. Open partial nephrectomy for tumor in a solitary kidney: experience with 400 cases. *J Urol*. 2006;175(5):1630–1633 [discussion 3].

Ficarra V, Galfano A, Guille F, et al. A new staging system for locally advanced (pT3-4) renal cell carcinoma: a multicenter European study including 2,000 patients. *J Urol*. 2007;178(2):418–424 [discussion 23–24].

Ficarra V, Martignoni G, Lohse C, et al. External validation of the Mayo Clinic Stage, Size, Grade and Necrosis (SSIGN) score to predict cancer specific survival using a European series of conventional renal cell carcinoma. *J Urol*. 2006;175(4):1235–1239.

Ficarra V, Novara G, Galfano A, et al. The ‘Stage, Size, Grade and Necrosis’ score is more accurate than the University of California Los Angeles Integrated Staging System for predicting cancer-specific survival in patients with clear cell renal cell carcinoma. *BJU Int*. 2009;103(2):165–170.

Ficarra V, Novara G, Secco S, et al. Preoperative aspects and dimensions used for an anatomical (PADUA) classification of renal tumours in patients who are candidates for nephron-sparing surgery. *Eur Urol*. 2009;56(5):786–793.

Finelli A, Ismaila N, Bro B, et al. Management of small renal masses: American Society of Clinical Oncology Clinical Practice Guideline. *J Clin Oncol*. 2017;35(6):668–680.

Finley DS, Shuch B, Said JW, et al. The chromophobe tumor grading system is the preferred grading scheme for chromophobe renal cell carcinoma. *J Urol*. 2011;186(6):2168–2174.

Frank I, Blute ML, Cheville JC, et al. An outcome prediction model for patients with clear cell renal cell carcinoma treated with radical nephrectomy based on tumor stage, size, grade and necrosis: the SSIGN score. *J Urol*. 2002;168(6):2395–2400.

Frank I, Blute ML, Cheville JC, et al. Solid renal tumors: an analysis of pathological features related to tumor size. *J Urol*. 2003;170(6 Pt 1):2217–2220.

Frank I, Blute ML, Leibovich BC, et al. pT2 classification for renal cell carcinoma. Can its accuracy be improved? *J Urol*. 2005;173(2):380–384.

Frank I, Takahashi S, Tsukamoto T, et al. Genitourinary sarcomas and carcinosarcomas in adults. Vogelzang NJ. *Comprehensive textbook of genitourinary oncology*. Lippincott Williams & Wilkins: Philadelphia; 2000:1102–1119.

Fraser L, Watts S, Cargill A, et al. Study comparing two types of screening provision for people with von Hippel-Lindau disease. *Fam Cancer*. 2007;6(1):103–111.

Frezza AM, Stacchiotti S, Gronchi A. Systemic treatment in advanced soft tissue sarcoma: what is standard, what is new. *BMC Med*. 2017;15(1):109.

Fuhrman SA, Lasky LC, Limas C. Prognostic significance of morphologic parameters in renal cell carcinoma. *Am J Surg Pathol*. 1982;6(7):655–663.

Fujii Y, Saito K, Iimura Y, et al. External validation of the Mayo Clinic cancer specific survival score in a Japanese series of clear cell renal cell carcinoma. *J Urol*. 2008;180(4):1290–1295 [discussion 5–6].

Gabr AH, Elsayed ER, Gdor Y, et al. Obesity and morbid obesity are associated with a greater conversion rate to open surgery for standard but not hand assisted laparoscopic radical nephrectomy. *J Urol*. 2008;180(6):2357–2362 [discussion 62].

Gago-Dominguez M, Yuan JM, Castelao JE, et al. Family history and risk of renal cell carcinoma. *Cancer Epidemiol Biomarkers Prev*. 2001;10(9):1001–1004.

Galligioni E, Quaia M, Merlo A, et al. Adjuvant immunotherapy treatment of renal carcinoma patients with autologous tumor cells and bacillus Calmette-Guerin: five-year results of a prospective randomized study. *Cancer*.

1996;77(12):2560–2566.

Gallucci M, Borzomati D, Flammia G, et al. Liver harvesting surgical technique for the treatment of retro-hepatic caval thrombosis concomitant to renal cell carcinoma: perioperative and long-term results in 15 patients without mortality. *Eur Urol*. 2004;45(2):194–202.

Ganeshan D, Iyer R, Devine C, et al. Imaging of primary and secondary renal lymphoma. *Am J Roentgenol*. 2013;201(5):W712–W719.

Garcia M, Konoplev S, Morosan C, et al. MALT lymphoma involving the kidney: a report of 10 cases and review of the literature. *Am J Clin Pathol*. 2007;128(3):464–473.

Gaudino M, Lau C, Cammertoni F, et al. Surgical treatment of renal cell carcinoma with cavoatrial involvement: a systematic review of the literature. *Ann Thorac Surg*. 2016;101(3):1213–1221.

Geller JI, Argani P, Adeniran A, et al. Translocation renal cell carcinoma: lack of negative impact due to lymph node spread. *Cancer*. 2008;112(7):1607–1616.

Gerlinger M, Rowan AJ, Horswell S, et al. Intratumor heterogeneity and branched evolution revealed by multiregion sequencing. *New Engl J Med*. 2012;366(10):883–892.

Gershman B, Moreira DM, Thompson RH, et al. Renal cell carcinoma with isolated lymph node involvement: long-term natural history and predictors of oncologic outcomes following surgical resection. *Eur Urol*. 2017;72(2):300–306.

Gershman B, Takahashi N, Moreira DM, et al. Radiographic size of retroperitoneal lymph nodes predicts pathological nodal involvement for patients with renal cell carcinoma: development of a risk prediction model. *BJU Int*. 2016;118(5):742–749.

Gershman B, Thompson RH, Moreira DM, et al. Radical nephrectomy with or without lymph node dissection for nonmetastatic renal cell carcinoma: a propensity score-based analysis. *Eur Urol*. 2017;71(4):560–567.

Gettman MT, Blute ML. Update on pathologic staging of renal cell carcinoma. *Urology*. 2002;60(2):209–217.

Giannakos G, Papanicolaou X, Trafalis D, et al. Stauffer's syndrome variant associated with renal cell carcinoma. *Int J Urol*. 2005;12(8):757–759.

Gibney GT, Aziz SA, Camp RL, et al. c-Met is a prognostic marker and potential therapeutic target in clear cell renal cell carcinoma. *Ann Oncol*. 2013;24(2):343–349.

Gill AJ, Hes O, Papathomas T, et al. Succinate dehydrogenase (SDH)-deficient renal carcinoma: a morphologically distinct entity: a clinicopathologic series of 36 tumors from 27 patients. *Am J Surg Pathol*. 2014;38(12):1588–1602.

Gill IS, Aron M, Gervais DA, et al. Clinical practice. Small renal mass. *New Engl J Med*. 2010;362(7):624–634.

Gill IS, Eisenberg MS, Aron M, et al. Zero ischemia” partial nephrectomy: novel laparoscopic and robotic technique. *Eur Urol*. 2011;59(1):128–134.

Gill IS, Metcalfe C, Abreu A, et al. Robotic level III inferior vena cava tumor thrombectomy: initial series. *J Urol*. 2015;194(4):929–938.

Gill IS, Novick AC, Meraney AM, et al. Laparoscopic renal cryoablation in 32 patients. *Urology*. 2000;56(5):748–753.

Gill IS, Novick AC, Soble JJ, et al. Laparoscopic renal cryoablation: initial clinical series. *Urology*. 1998;52(4):543–551.

Gill IS, Patil MB, Abreu AL, et al. Zero ischemia anatomical partial nephrectomy: a novel approach. *J Urol*. 2012;187(3):807–814.

Ginzburg S, Uzzo R, Al-Saleem T, et al. Coexisting hybrid malignancy in a solitary sporadic solid benign renal mass:

implications for treating patients following renal biopsy. *J Urol*. 2014;191(2):296–300.

Ginzburg S, Uzzo R, Walton J, et al. Residual parenchymal volume, not warm ischemia time, predicts ultimate renal functional outcomes in patients undergoing partial nephrectomy. *Urology*. 2015;86(2):300–305.

Giordano SH, Kuo YF, Duan Z, et al. Limits of observational data in determining outcomes from cancer therapy. *Cancer*. 2008;112(11):2456–2466.

Giubellino A, Linehan WM, Bottaro DP. Targeting the Met signaling pathway in renal cancer. *Expert Rev Anticancer Ther*. 2009;9(6):785–793.

Glazer A, Novick AC. Preoperative transesophageal echocardiography for assessment of vena caval tumor thrombi: a comparative study with venacavography and magnetic resonance imaging. *Urology*. 1997;49(1):32–34.

Glazer AA, Novick AC. Long-term followup after surgical treatment for renal cell carcinoma extending into the right atrium. *J Urol*. 1996;155(2):448–450.

Gnarra JR, Zhou S, Merrill MJ, et al. Post-transcriptional regulation of vascular endothelial growth factor mRNA by the product of the VHL tumor suppressor gene. *Proc Natl Acad Sci USA*. 1996;93(20):10589–10594.

Go AS, Chertow GM, Fan D, et al. Chronic kidney disease and the risks of death, cardiovascular events, and hospitalization. *New Engl J Med*. 2004;351(13):1296–1305.

Goenka AH, Remer EM, Smith AD, et al. Development of a clinical prediction model for assessment of malignancy risk in Bosniak III renal lesions. *Urology*. 2013;82(3):630–635.

Gogus C, Baltaci S, Beduk Y, et al. Isolated local recurrence of renal cell carcinoma after radical nephrectomy: experience with 10 cases. *Urology*. 2003;61(5):926–929.

Gold PJ, Fefer A, Thompson JA. Paraneoplastic manifestations of renal cell carcinoma. *Semin Urol Oncol*. 1996;14(4):216–222.

Goldfarb DA. Preservation of renal function and the risk of hyperfiltration nephropathy. *Semin Urol Oncol*. 1995;13(4):292–295.

Goldfarb DA, Neumann HP, Penn I, et al. Results of renal transplantation in patients with renal cell carcinoma and von Hippel-Lindau disease. *Transplantation*. 1997;64(12):1726–1729.

Goldfarb DA, Novick AC, Lorig R, et al. Magnetic resonance imaging for assessment of vena caval tumor thrombi: a comparative study with venacavography and computerized tomography scanning. *J Urol*. 1990;144(5):1100–1103 [discussion 3–4].

Gonlusen G, Ergin M, Paydas S, et al. Primitive neuroectodermal tumor of the kidney: a rare entity. *Int Urol Nephrol*. 2001;33(3):449–451.

Gonzalez-Aguirre AJ, Durack JC. Managing complications following nephron-sparing procedures for renal masses. *Tech Vasc Interv Radiol*. 2016;19(3):194–202.

Gorin MA, Ekwenna O, Soloway MS, et al. Dramatic reduction in tumor burden with neoadjuvant sunitinib prior to bilateral nephron-sparing surgery. *Urology*. 2012;79(2):e11.

Gorin MA, Garcia-Roig M, Shirodkar SP, et al. Modified surgical technique for the management of renal cell carcinoma with level I or II tumor thrombus. *Urology*. 2012;79(2):478–481.

Gorin MA, Rowe SP, Allaf ME. Nuclear imaging of renal tumours: a step towards improved risk stratification. *Nature Rev Urol*. 2015;12(8):445–450.

Gorin MA, Rowe SP, Baras AS, et al. Prospective evaluation of (99m)Tc-sestamibi SPECT/CT for the diagnosis of renal oncocytomas and hybrid oncocytic/chromophobe tumors. *Eur*

Urol. 2016;69(3):413–416.

Grady RW, Novick AC. Hyperfiltration of renal injury: pathophysiology and clinical implications. *Urology*. 1996;47(2):273–283.

Granberg CF, Boorjian SA, Schaff HV, et al. Surgical management, complications, and outcome of radical nephrectomy with inferior vena cava tumor thrombectomy facilitated by vascular bypass. *Urology*. 2008;72(1):148–152.

Graumann O, Osther SS, Karstoft J, et al. Evaluation of Bosniak category IIF complex renal cysts. *Insights Imaging*. 2013;4(4):471–480.

Grawitz P. Die sogenannten Lipome der Niere. *Virchows Arch*. 1883;93:39.

Gregoire JR, Torres VE, Holley KE, et al. Renal epithelial hyperplastic and neoplastic proliferation in autosomal dominant polycystic kidney disease. *Am J Kidney Dis*. 1987;9(1):27–38.

Griffin N, Gore ME, Sohaib SA. Imaging in metastatic renal cell carcinoma. *Am J Roentgenol*. 2007;189(2):360–370.

Gross-Goupil M, Kwon TG, Eto M, et al. Axitinib versus placebo as an adjuvant treatment for renal cell carcinoma: results from the phase III, randomized ATLAS trial. *Ann Oncol*. 2018;29:2371–2378.

Grubb RL 3rd, Choyke PL, Pinto PA, et al. Management of von Hippel-Lindau-associated kidney cancer. *Nat Clin Pract Urol*. 2005;2(5):248–255.

Gulati M, King KG, Gill IS, et al. Contrast-enhanced ultrasound (CEUS) of cystic and solid renal lesions: a review. *Abdom Imaging*. 2015;40(6):1982–1996.

Gupta GN, Boris RS, Campbell SC, et al. Tumor enucleation for sporadic localized kidney cancer: pro and con. *J Urol*. 2015;194(3):623–625.

Guzzo TJ, Pierorazio PM, Schaeffer EM, et al. The accuracy of multidetector computerized tomography for evaluating tumor thrombus in patients with renal cell carcinoma. *JUrol*. 2009;181(2):486–490 [discussion 91].

Haake SM, Rathmell WK. Renal cancer subtypes: should we be lumping or splitting for therapeutic decision making? *Cancer*. 2017;123(2):200–209.

Haas NB, Manola J, Uzzo RG, et al. Adjuvant sunitinib or sorafenib for high-risk, non-metastatic renal-cell carcinoma (ECOG-ACRIN E2805): a double-blind, placebo-controlled, randomised, phase 3 trial. *Lancet (London, England)*. 2016;387(10032):2008–2016.

Haas NB, Uzzo RG. Perioperative therapy in renal cell carcinoma: what do we know, what have we learned, what's next? *J Clin Oncol*. 2018;36:3608–3614.

Haddad AQ, Wood CG, Abel EJ, et al. Oncologic outcomes following surgical resection of renal cell carcinoma with inferior vena caval thrombus extending above the hepatic veins: a contemporary multicenter cohort. *J Urol*. 2014;192(4):1050–1056.

Haddad H, Rini BI. Current treatment considerations in metastatic renal cell carcinoma. *Curr Treat Options Oncol*. 2012;13(2):212–229.

Haggstrom C, Rapp K, Stocks T, et al. Metabolic factors associated with risk of renal cell carcinoma. *PLoS ONE*. 2013;8(2):e57475.

Haifler M, Kutikov A. Current role of renal biopsy in urologic practice. *Urol Clin North Am*. 2017;44(2):203–211.

Hajj P, Ferlicot S, Massoud W, et al. Prevalence of renal cell carcinoma in patients with autosomal dominant polycystic kidney disease and chronic renal failure. *Urology*. 2009;74(3):631–634.

Hakimi AA, Furberg H, Zabor EC, et al. An epidemiologic and genomic investigation into the obesity paradox in renal cell carcinoma. *J Natl Cancer Inst*. 2013;105(24):1862–1870.

Hammers HJ, Plimack ER, Infante JR, et al. Safety and efficacy of nivolumab in combination with ipilimumab in metastatic renal cell carcinoma: the CheckMate 016 Study. *J Clin Oncol*. 2017 [Jco2016721985].

Hanahan D, Weinberg RA. Hallmarks of cancer: the next generation. *Cell*. 2011;144(5):646–674.

Hansel DE, Epstein JI, Berbescu E, et al. Renal carcinoid tumor: a clinicopathologic study of 21 cases. *Am J Surg Pathol*. 2007;31(10):1539–1544.

Harris RP. An analytical examination of 100 cases of extirpations of the kidney. *Am J Med Sci*. 1882;84:109.

Harshman LC, Choueiri TK. Targeting the hepatocyte growth factor/c-Met signaling pathway in renal cell carcinoma. *Cancer J*. 2013;19(4):316–323.

Hart S, Ellimoottil C, Shafer D, et al. A case of primary renal lymphoma. *Urology*. 2012;80(4):763–765.

Hartman DS, David CJ Jr, Goldman SM, et al. Renal lymphoma: radiologic-pathologic correlation of 21 cases. *Radiology*. 1982;144(4):759–766.

Hasumi Y, Baba M, Ajima R, et al. Homozygous loss of BHD causes early embryonic lethality and kidney tumor development with activation of mTORC1 and mTORC2. *Proc Natl Acad Sci USA*. 2009;106(44):18722–18727.

Hatcher PA, Anderson EE, Paulson DF, et al. Surgical management and prognosis of renal cell carcinoma invading the vena cava. *J Urol*. 1991;145(1):20–23 [discussion 3–4].

Hawken SR, Krishnan NK, Ambani SN, et al. Effect of delayed resection after initial surveillance and tumor growth rate on final surgical pathology in patients with small renal masses (SRMs). *Urol Oncol*. 2016;34(11):486 e9–e15.

Heiken JP, Gold RP, Schnur MJ, et al. Computed tomography of renal lymphoma with ultrasound correlation. *J Comput Assist*

Tomogr. 1983;7(2):245–250.

Hellenthal NJ, Underwood W, Penetrante R, et al. Prospective clinical trial of preoperative sunitinib in patients with renal cell carcinoma. *J Urol*. 2010;184(3):859–864.

Heng DY, Xie W, Regan MM, et al. External validation and comparison with other models of the International Metastatic Renal-Cell Carcinoma Database Consortium prognostic model: a population-based study. *Lancet Oncol*. 2013;14(2):141–148.

Henske EP, Jozwiak S, Kingswood JC, et al. Tuberous sclerosis complex. *Nat Rev Dis Primers*. 2016;2:16035.

Herr HW. A history of partial nephrectomy for renal tumors. *J Urol*. 2005;173(3):705–708.

Herr HW. Surgical management of renal tumors: a historical perspective. *Urol Clin North Am*. 2008;35(4):543–549 [v].

Herts BR. Imaging techniques in renal cell carcinoma. Campbell SC, Rini BI. *Renal cell carcinoma*. People's Medical Publishing House: Shelton, CT; 2009:51–69.

Herts BR. Renal lymphoma presenting as an incidental renal mass. *J Urol*. 2012;188(1):271–273.

Hicklin DJ, Ellis LM. Role of the vascular endothelial growth factor pathway in tumor growth and angiogenesis. *J Clin Oncol*. 2005;23(5):1011–1027.

Ho TH, Jonasch E. Genetic kidney cancer syndromes. *J Natl Compr Cancer Netwk*. 2014;12(9):1347–1355.

Hock LM, Lynch J, Balaji KC. Increasing incidence of all stages of kidney cancer in the last 2 decades in the United States: an analysis of surveillance, epidemiology and end results program data. *J Urol*. 2002;167(1):57–60.

Hollingsworth JM, Miller DC, Dunn RL, et al. Surgical management of low-stage renal cell carcinoma: technology does not supersede biology. *Urology*. 2006;67(6):1175–1180.

Hong SB, Oh H, Valera VA, et al. Inactivation of the FLCN tumor suppressor gene induces TFE3 transcriptional activity by increasing its nuclear localization. *PLoS ONE*. 2010;5(12):e15793.

Hsieh PF, Wang YD, Huang CP, et al. A mathematical method to calculate tumor contact surface area: an effective parameter to predict renal function after partial nephrectomy. *J Urol*. 2016;196(1):33–40.

Hu JC, Treat E, Filson CP, et al. Technique and outcomes of robot-assisted retroperitoneoscopic partial nephrectomy: a multicenter study. *Eur Urol*. 2014;66(3):542–549.

Hu SL, Chang A, Perazella MA, et al. The nephrologist's tumor: basic biology and management of renal cell carcinoma. *J Am Soc Nephrol*. 2016;27(8):2227–2237.

Huang WC, Levey AS, Serio AM, et al. Chronic kidney disease after nephrectomy in patients with renal cortical tumours: a retrospective cohort study. *Lancet Oncol*. 2006;7(9):735–740.

Hudes G, Carducci M, Tomczak P, et al. Temsirolimus, interferon alfa, or both for advanced renal-cell carcinoma. *New Engl J Med*. 2007;356(22):2271–2281.

Hudes GR. Targeting mTOR in renal cell carcinoma. *Cancer*. 2009;115(10 Suppl):2313–2320.

Hurst FP, Jindal RM, Fletcher JJ, et al. Incidence, predictors and associated outcomes of renal cell carcinoma in long-term dialysis patients. *Urology*. 2011;77(6):1271–1276.

Hurst FP, Jindal RM, Graham LJ, et al. Incidence, predictors, costs, and outcome of renal cell carcinoma after kidney transplantation: USRDS experience. *Transplantation*. 2010;90(8):898–904.

Hyams ES, Pierorazio PM, Shah A, et al. Graft reconstruction of inferior vena cava for renal cell carcinoma stage pT3b or greater. *Urology*. 2011;78(4):838–843.

Ianhez LE, Lucon M, Nahas WC, et al. Renal cell carcinoma in renal transplant patients. *Urology*. 2007;69(3):462–464.

Igarashi T, Tobe T, Nakatsu HO, et al. The impact of a 4 cm. cutoff point for stratification of T1N0M0 renal cell carcinoma after radical nephrectomy. *J Urol*. 2001;165(4):1103–1106.

Iliopoulos O, Levy AP, Jiang C, et al. Negative regulation of hypoxia-inducible genes by the von Hippel-Lindau protein. *Proc Natl Acad Sci USA*. 1996;93(20):10595–10599.

Isbarn H, Karakiewicz PI. Predicting cancer-control outcomes in patients with renal cell carcinoma. *Curr Opin Urol*. 2009;19(3):247–257.

Ishida M, Mikami S, Shinojima T, et al. Activation of aryl hydrocarbon receptor promotes invasion of clear cell renal cell carcinoma and is associated with poor prognosis and cigarette smoke. *Int J Cancer*. 2015;137(2):299–310.

Ishikawa I, Hayama S, Morita K, et al. Long-term natural history of acquired cystic disease of the kidney. *Ther Apher Dial*. 2010;14(4):409–416.

Israel GM, Bosniak MA. Renal imaging for diagnosis and staging of renal cell carcinoma. *Urol Clin North Am*. 2003;30(3):499–514.

Israel GM, Bosniak MA. An update of the Bosniak renal cyst classification system. *Urology*. 2005;66(3):484–488.

Ito R, Narita S, Huang M, et al. The impact of obesity and adiponectin signaling in patients with renal cell carcinoma: a potential mechanism for the “obesity paradox.”. *PLoS ONE*. 2017;12(2):e0171615.

Jacob JM, Williamson SR, Gondim DD, et al. Characteristics of the peritumoral pseudocapsule vary predictably with histologic subtype of T1 renal neoplasms. *Urology*. 2015;86(5):956–961.

Jeon HG, Jeong IG, Kwak C, et al. Reevaluation of renal cell carcinoma and perirenal fat invasion only. *J Urol*. 2009;182(5):2137–2143.

Jeon HG, Seo SI, Jeong BC, et al. Percutaneous kidney biopsy for a small renal mass: a critical appraisal of results. *J Urol*. 2016;195(3):568–573.

Jewett MA, Mattar K, Basiuk J, et al. Active surveillance of small renal masses: progression patterns of early stage kidney cancer. *Eur Urol*. 2011;60(1):39–44.

Jewett MA, Zuniga A. Renal tumor natural history: the rationale and role for active surveillance. *Urol Clin North Am*. 2008;35(4):627–634 [vii].

Jhaveri K, Gupta P, Elmi A, et al. Cystic renal cell carcinomas: do they grow, metastasize, or recur? *Am J Roentgenol*. 2013;201(2):W292–W296.

Jilg CA, Drendel V, Bacher J, et al. Autosomal dominant polycystic kidney disease: prevalence of renal neoplasias in surgical kidney specimens. *Nephron Clin Pract*. 2013;123(1–2):13–21.

Jimenez JA, Zhang Z, Zhao J, et al. Surgical salvage of thermal ablation failures for renal cell carcinoma. *J Urol*. 2016;195(3):594–600.

Jimenez RE, Folpe AL, Lapham RL, et al. Primary Ewing's sarcoma/primitive neuroectodermal tumor of the kidney: a clinicopathologic and immunohistochemical analysis of 11 cases. *Am J Surg Pathol*. 2002;26(3):320–327.

Jocham D, Richter A, Hoffmann L, et al. Adjuvant autologous renal tumour cell vaccine and risk of tumour progression in patients with renal-cell carcinoma after radical nephrectomy: phase III, randomised controlled trial. *Lancet (London, England)*. 2004;363(9409):594–599.

Johnson A, Sudarshan S, Liu J, et al. Feasibility and outcomes of repeat partial nephrectomy. *J Urol*. 2008;180(1):89–93 [discussion].

Johnson DC, Vukina J, Smith AB, et al. Preoperatively misclassified, surgically removed benign renal masses: a systematic review of surgical series and United States population level burden estimate. *J Urol*. 2015;193(1):30–35.

Jonasch E, Futreal PA, Davis IJ, et al. State of the science: an update on renal cell carcinoma. *Mol Cancer Res*. 2012;10(7):859–880.

Joshi SS, Uzzo RG. Renal tumor anatomic complexity: clinical implications for urologists. *Urol Clin North Am*. 2017;44(2):179–187.

Jung S, Min GE, Chung BI, et al. Risk factors for postoperative hemorrhage after partial nephrectomy. *Korean J Urol*. 2014;55(1):17–22.

Junker K, Thrum K, Schlichter A, et al. Clonal origin of multifocal renal cell carcinoma as determined by microsatellite analysis. *J Urol*. 2002;168(6):2632–2636.

Kallingal GJ, Weinberg JM, Reis IM, et al. Long-term response to renal ischaemia in the human kidney after partial nephrectomy: results from a prospective clinical trial. *BJU Int*. 2016;117(5):766–774.

Kamel IR, Hochman MG, Keogan MT, et al. Accuracy of breath-hold magnetic resonance imaging in preoperative staging of organ-confined renal cell carcinoma. *J Comput Assist Tomogr*. 2004;28(3):327–332.

Kanao K, Mizuno R, Kikuchi E, et al. Preoperative prognostic nomogram (probability table) for renal cell carcinoma based on TNM classification. *J Urol*. 2009;181(2):480–485 [discussion 5].

Kane CJ, Mallin K, Ritchey J, et al. Renal cell cancer stage migration: analysis of the National Cancer Data Base. *Cancer*. 2008;113(1):78–83.

Kang SK, Chandarana H. Contemporary imaging of the renal mass. *Urol Clin North Am*. 2012;39(2):161–170 [vi].

Kaouk JH, Samarasekera D, Krishnan J, et al. Robotic partial nephrectomy with intracorporeal renal hypothermia using ice slush. *Urology*. 2014;84(3):712–718.

Kara O, Maurice MJ, Zargar H, et al. Prognostic implications of sarcomatoid and rhabdoid differentiation in patients with grade 4 renal cell carcinoma. *Int Urol Nephrol*. 2016;48(8):1253–1260.

Karakiewicz PI, Briganti A, Chun FK, et al. Multi-institutional validation of a new renal cancer-specific survival nomogram. *J Clin Oncol*. 2007;25(11):1316–1322.

Karakiewicz PI, Hutterer GC, Trinh QD, et al. Unclassified renal cell carcinoma: an analysis of 85 cases. *BJU Int*. 2007;100(4):802–808.

Karakiewicz PI, Suardi N, Capitanio U, et al. A preoperative prognostic model for patients treated with nephrectomy for renal cell carcinoma. *Eur Urol*. 2009;55(2):287–295.

Karakiewicz PI, Trinh QD, Rioux-Leclercq N, et al. Collecting duct renal cell carcinoma: a matched analysis of 41 cases. *Eur Urol*. 2007;52(4):1140–1145.

Karakousis CP, Gerstenbluth R, Kontzoglou K, et al. Retroperitoneal sarcomas and their management. *Arch Surg*. 1995;130(10):1104–1109.

Karam JA, Wood CG, Compton ZR, et al. Salvage surgery after energy ablation for renal masses. *BJU Int*. 2015;115(1):74–80.

Karellas ME, Jang TL, Kagiwada MA, et al. Advanced-stage renal cell carcinoma treated by radical nephrectomy and adjacent organ or structure resection. *BJU Int*. 2009;103(2):160–164.

Kattan MW, Reuter V, Motzer RJ, et al. A postoperative prognostic nomogram for renal cell carcinoma. *J Urol*. 2001;166(1):63–67.

Kavoussi N, Canvasser N, Caddedu J. Ablative therapies for the treatment of small renal masses: a review of different modalities and outcomes. *Curr Urol Rep*. 2016;17(8):59.

Kawajiri H, Onoda N, Ohira M, et al. Carcinoid tumor of the kidney presenting as a large abdominal mass: report of a case. *Surg Today*. 2004;34(1):86–89.

Keefe SM, Nathanson KL, Rathmell WK. The molecular biology of renal cell carcinoma. *Semin Oncol*. 2013;40(4):421–428.

Kelly EF, Leveillee RJ. Image guided radiofrequency ablation for small renal masses. *Int J Surg*. 2016;36(Pt C):525–532.

Kelsh MA, Alexander DD, Mink PJ, et al. Occupational trichloroethylene exposure and kidney cancer: a meta-analysis. *Epidemiology*. 2010;21(1):95–102.

Kenck C, Wilhelm M, Bugert P, et al. Mutation of the VHL gene is associated exclusively with the development of non-papillary renal cell carcinomas. *J Pathol*. 1996;179(2):157–161.

Kendal WS. The comparative survival of renal leiomyosarcoma. *Can J Urol*. 2007;14(1):3435–3442.

Khalifeh A, Kaouk JH, Bhayani S, et al. Positive surgical margins in robot-assisted partial nephrectomy: a multi-institutional analysis of oncologic outcomes (leave no tumor behind). *J Urol*. 2013;190(5):1674–1679.

Khoo SK, Bradley M, Wong FK, et al. Birt-Hogg-Dube syndrome: mapping of a novel hereditary neoplasia gene to chromosome 17p12-q11.2. *Oncogene*. 2001;20(37):5239–5242.

Kilicarsalan Akkaya B, Mustafa U, Esin O, et al. Primary small cell carcinoma of the kidney. *Urol Oncol*. 2003;21(1):11–13.

Kim JJ, Rini BI, Hansel DE. Von Hippel Lindau syndrome. *Adv Exp Med Biol*. 2010;685:228–249.

Kim MK, Kim S. Immunohistochemical profile of common epithelial neoplasms arising in the kidney. *Appl Immunohistochem Mol Morphol*. 2002;10(4):332–338.

Kim SP, Alt AL, Weight CJ, et al. Independent validation of the 2010 American Joint Committee on Cancer TNM classification for renal cell carcinoma: results from a large, single institution cohort. *J Urol*. 2011;185(6):2035–2039.

Kim SP, Campbell SC, Gill I, et al. Collaborative review of risk benefit trade-offs between partial and radical nephrectomy in the management of anatomically complex renal masses. *Eur Urol*. 2017;72(1):64–75.

Kim SP, Crispen PL, Thompson RH, et al. Assessment of the pathologic inclusion criteria from contemporary adjuvant clinical trials for predicting disease progression after nephrectomy for renal cell carcinoma. *Cancer*. 2012;118(18):4412–4420.

Kim SP, Thompson RH, Boorjian SA, et al. Comparative effectiveness for survival and renal function of partial and radical nephrectomy for localized renal tumors: a systematic review and meta-analysis. *J Urol*. 2012;188(1):51–57.

Kirkali Z, Algaba F, Scarpelli M, et al. What does the urologist expect from the pathologist (and what can the pathologists give) in reporting on adult kidney tumour specimens? *Eur Urol*. 2007;51(5):1194–1201.

Kito H, Suzuki H, Igarashi T, et al. Distinct patterns of chromosomal losses in clinically synchronous and asynchronous bilateral renal cell carcinoma. *J Urol*. 2002;168(6):2637–2640.

Klatte T, Anterasian C, Said JW, et al. Fuhrman grade provides higher prognostic accuracy than nucleolar grade for papillary renal cell carcinoma. *J Urol*. 2010;183(6):2143–2147.

Klatte T, Han KR, Said JW, et al. Pathobiology and prognosis of chromophobe renal cell carcinoma. *Urol Oncol*. 2008;26(6):604–609.

Klatte T, Said JW, Belldegrun AS, et al. Differential diagnosis of hypercalcemia in renal malignancy. *Urology*. 2007;70(1):179 e7–179 e8.

Klatte T, Seligson DB, LaRochelle J, et al. Molecular signatures of localized clear cell renal cell carcinoma to predict disease-free survival after nephrectomy. *Cancer Epidemiol Biomarkers Prev*. 2009;18(3):894–900.

Klatte T, Shariat SF, Remzi M. Systematic review and meta-analysis of perioperative and oncologic outcomes of laparoscopic cryoablation versus laparoscopic partial nephrectomy for the treatment of small renal tumors. *J Urol*. 2014;191(5):1209–1217.

Knudson AG Jr. Mutation and cancer: statistical study of retinoblastoma. *Proc Natl Acad Sci USA*. 1971;68(4):820–823.

Knudson AG Jr, Strong LC. Mutation and cancer: a model for Wilms' tumor of the kidney. *J Natl Cancer Inst*. 1972;48(2):313–324.

Kobayashi N, Matsuzaki O, Shirai S, et al. Collecting duct carcinoma of the kidney: an immunohistochemical evaluation of the use of antibodies for differential diagnosis. *Hum Pathol*. 2008;39(9):1350–1359.

Kontak JA, Campbell SC. Prognostic factors in renal cell carcinoma. *Urol Clin North Am*. 2003;30(3):467–480.

Kopp RP, Aganovic L, Palazzi KL, et al. Differentiation of clear from non-clear cell renal cell carcinoma using CT washout formula. *Can J Urol*. 2013;20(3):6790–6797.

Kostibas MP, Arora V, Gorin MA, et al. Defining the role of intraoperative transesophageal echocardiography during radical nephrectomy with inferior vena cava tumor thrombectomy for renal cell carcinoma. *Urology*. 2017;107:161–165.

Kovacs G. Molecular differential pathology of renal cell tumours. *Histopathology*. 1993;22(1):1–8.

Kovacs G, Brusa P, De Riese W. Tissue-specific expression of a constitutional 3;6 translocation: development of multiple bilateral renal-cell carcinomas. *Int J Cancer*. 1989;43(3):422–

427.

Kovacs G, Wilkens L, Papp T, et al. Differentiation between papillary and nonpapillary renal cell carcinomas by DNA analysis. *J Natl Cancer Inst*. 1989;81(7):527–530.

Kowalczyk KJ, Hooper HB, Linehan WM, et al. Partial nephrectomy after previous radio frequency ablation: the National Cancer Institute experience. *J Urol*. 2009;182(5):2158–2163.

Krambeck A, Iwaszko M, Leibovich B, et al. Long-term outcome of multiple ipsilateral renal tumours found at the time of planned nephron-sparing surgery. *BJU Int*. 2008;101(11):1375–1379.

Kranidiotis GP, Voidonikola PT, Dimopoulos MK, et al. Stauffer's syndrome as a prominent manifestation of renal cancer: a case report. *Cases J*. 2009;2(1):49.

Kroeger N, Rampersaud EN, Patard JJ, et al. Prognostic value of microvascular invasion in predicting the cancer specific survival and risk of metastatic disease in renal cell carcinoma: a multicenter investigation. *J Urol*. 2012;187(2):418–423.

Kroeger N, Xie W, Lee JL, et al. Metastatic non-clear cell renal cell carcinoma treated with targeted therapy agents: characterization of survival outcome and application of the International mRCC Database Consortium criteria. *Cancer*. 2013;119(16):2999–3006.

Kroon BK, de Bruijn R, Prevoo W, et al. Probability of downsizing primary tumors of renal cell carcinoma by targeted therapies is related to size at presentation. *Urology*. 2013;81(1):111–115.

Kulke MH, Mayer RJ. Carcinoid tumors. *New Engl J Med*. 1999;340(11):858–868.

Kummerlin IP, ten Kate FJ, Wijkstra H, et al. Changes in the stage and surgical management of renal tumours during 1995-2005: an analysis of the Dutch national histopathology registry. *BJU Int*. 2008;102(8):946–951.

Kunkle DA, Crispen PL, Chen DY, et al. Enhancing renal masses with zero net growth during active surveillance. *J Urol*. 2007;177(3):849–853 [discussion 53–54].

Kunkle DA, Egleston BL, Uzzo RG. Excise, ablate or observe: the small renal mass dilemma–a meta-analysis and review. *J Urol*. 2008;179(4):1227–1233 [discussion 33–34].

Kunkle DA, Uzzo RG. Cryoablation or radiofrequency ablation of the small renal mass : a meta-analysis. *Cancer*. 2008;113(10):2671–2680.

Kuroda N, Imamura Y, Hamashima T, et al. Review of small cell carcinoma of the kidney with focus on clinical and pathobiological aspects. *Pol J Pathol*. 2014;65(1):15–19.

Kutikov A, Egleston BL, Wong YN, et al. Evaluating overall survival and competing risks of death in patients with localized renal cell carcinoma using a comprehensive nomogram. *J Clin Oncol*. 2010;28(2):311–317.

Kutikov A, Fossett LK, Ramchandani P, et al. Incidence of benign pathologic findings at partial nephrectomy for solitary renal mass presumed to be renal cell carcinoma on preoperative imaging. *Urology*. 2006;68(4):737–740.

Kutikov A, Smaldone MC, Egleston BL, et al. Anatomic features of enhancing renal masses predict malignant and high-grade pathology: a preoperative nomogram using the RENAL Nephrometry score. *Eur Urol*. 2011;60(2):241–248.

Kutikov A, Smaldone MC, Egleston BL, et al. Should partial nephrectomy be offered to all patients whenever technically feasible? *Eur Urol*. 2012;61(4):732–734 [discussion 4–5].

Kutikov A, Uzzo RG. The R.E.N.A.L. nephrometry score: a comprehensive standardized system for quantitating renal tumor size, location and depth. *J Urol*. 2009;182(3):844–853.

Kutikov A, Vanarsdalen KN, Gershman B, et al. Enucleation of renal cell carcinoma with ablation of the tumour base. *BJU*

Int. 2008;102(6):688–691.
Kwon EO, Carver BS, Snyder ME, et al. Impact of positive surgical margins in patients undergoing partial nephrectomy for renal cortical tumours. *BJU Int*. 2007;99(2):286–289.
Lager DJ, Huston BJ, Timmerman TG, et al. Papillary renal tumors. Morphologic, cytochemical, and genotypic features. *Cancer*. 1995;76(4):669–673.
Lallas CD, Trabulsi EJ, Kaffenberger SD, et al. Treatment of exophytic renal cancer smaller than 3 cm: surgery versus active surveillance. *J Urol*. 2015;193(1):16–18.
Lam JS, Klatte T, Patard JJ, et al. Prognostic relevance of tumour size in T3a renal cell carcinoma: a multicentre experience. *Eur Urol*. 2007;52(1):155–162.
Lam JS, Shvarts O, Pantuck AJ. Changing concepts in the surgical management of renal cell carcinoma. *Eur Urol*. 2004;45(6):692–705.
Lane BR, Abouassaly R, Gao T, et al. Active treatment of localized renal tumors may not impact overall survival in patients aged 75 years or older. *Cancer*. 2010;116(13):3119–3126.
Lane BR, Babineau D, Kattan MW, et al. A preoperative prognostic nomogram for solid enhancing renal tumors 7 cm or less amenable to partial nephrectomy. *J Urol*. 2007;178(2):429–434.
Lane BR, Campbell SC, Demirjian S, et al. Surgically induced chronic kidney disease may be associated with a lower risk of progression and mortality than medical chronic kidney disease. *J Urol*. 2013;189(5):1649–1655.
Lane BR, Campbell SC, Gill IS. 10-year oncologic outcomes after laparoscopic and open partial nephrectomy. *J Urol*. 2013;190(1):44–49.
Lane BR, Chery F, Jour G, et al. Renal neuroendocrine tumours: a clinicopathological study. *BJU Int*. 2007;100(5):1030–1035.

Lane BR, Demirjian S, Derweesh IH, et al. Survival and functional stability in chronic kidney disease due to surgical removal of nephrons: importance of the new baseline glomerular filtration rate. *Eur Urol*. 2015;68(6):996–1003.

Lane BR, Gill IS. 5-Year outcomes of laparoscopic partial nephrectomy. *J Urol*. 2007;177(1):70–74 [discussion 4].

Lane BR, Gill IS, Fergany AF, et al. Limited warm ischemia during elective partial nephrectomy has only a marginal impact on renal functional outcomes. *J Urol*. 2011;185(5):1598–1603.

Lane BR, Kattan MW. Prognostic models and algorithms in renal cell carcinoma. *Urol Clin North Am*. 2008;35(4):613–625 [vii].

Lane BR, Li J, Zhou M, et al. Differential expression in clear cell renal cell carcinoma identified by gene expression profiling. *J Urol*. 2009;181(2):849–860.

Lane BR, Rini BI, Novick AC, et al. Targeted molecular therapy for renal cell carcinoma. *Urology*. 2007;69(1):3–10.

Lane BR, Tiong HY, Campbell SC, et al. Management of the adrenal gland during partial nephrectomy. *J Urol*. 2009;181(6):2430–2436 [discussion 6–7].

Lane BR, Tobert CM, Riedinger CB. Growth kinetics and active surveillance for small renal masses. *Curr Opin Urol*. 2012;22(5):353–359.

Latif F, Tory K, Gnarra J, et al. Identification of the von Hippel-Lindau disease tumor suppressor gene. *Science*. 1993;260(5112):1317–1320.

Launonen V, Vierimaa O, Kiuru M, et al. Inherited susceptibility to uterine leiomyomas and renal cell cancer. *Proc Natl Acad Sci USA*. 2001;98(6):3387–3392.

Lay AH, Faddegon S, Olweny EO, et al. Oncologic efficacy of radio frequency ablation for small renal masses: clear cell vs papillary subtype. *J Urol*. 2015;194(3):653–657.

Lay AH, Stewart J, Canvasser NE, et al. Likelihood of incomplete kidney tumor ablation with radio frequency energy: degree of enhancement matters. *J Urol*. 2016;196(1):41–45.

Lee CT, Katz J, Fearn PA, et al. Mode of presentation of renal cell carcinoma provides prognostic information. *Urol Oncol*. 2002;7(4):135–140.

Lee HJ, Liss MA, Derweesh IH. Outcomes of partial nephrectomy for clinical T1b and T2 renal tumors. *Curr Opin Urol*. 2014;24(5):448–452.

Leibovich BC, Blute ML. Lymph node dissection in the management of renal cell carcinoma. *Urol Clin North Am*. 2008;35(4):673–678 [viii].

Leibovich BC, Blute ML, Cheville JC, et al. Prediction of progression after radical nephrectomy for patients with clear cell renal cell carcinoma: a stratification tool for prospective clinical trials. *Cancer*. 2003;97(7):1663–1671.

Leibovich BC, Cheville JC, Lohse CM, et al. Cancer specific survival for patients with pT3 renal cell carcinoma-can the 2002 primary tumor classification be improved? *J Urol*. 2005;173(3):716–719.

Leibovich BC, Lohse CM, Crispen PL, et al. Histological subtype is an independent predictor of outcome for patients with renal cell carcinoma. *J Urol*. 2010;183(4):1309–1315.

Lendvay TS, Marshall FF. The tuberous sclerosis complex and its highly variable manifestations. *J Urol*. 2003;169(5):1635–1642.

Leslie JA, Prihoda T, Thompson IM. Serendipitous renal cell carcinoma in the post-CT era: continued evidence in improved outcomes. *Urol Oncol*. 2003;21(1):39–44.

Leung AC, Ghavamian R. Advances in the staging of renal cell carcinoma. *Expert Rev Anticancer Ther*. 2002;2(6):673–680.

Leventis AK, Stathopoulos GP, Boussiotou AC, et al. Primary osteogenic sarcoma of the kidney–a case report and review of the literature. *Acta Oncol*. 1997;36(7):775–777.

Levinson AW, Su LM, Agarwal D, et al. Long-term oncological and overall outcomes of percutaneous radio frequency ablation in high risk surgical patients with a solitary small renal mass. *J Urol*. 2008;180(2):499–504 [discussion].

Levy DA, Slaton JW, Swanson DA, et al. Stage specific guidelines for surveillance after radical nephrectomy for local renal cell carcinoma. *J Urol*. 1998;159(4):1163–1167.

Li JJ, Huang HH, Shen J, et al. Multimodal therapy for adult Wilms' tumour: an experience from one centre. *Clin Transl Oncol*. 2011;13(9):672–676.

Libertino JA, Zinman L, Watkins E Jr. Long-term results of resection of renal cell cancer with extension into inferior vena cava. *J Urol*. 1987;137(1):21–24.

Licht MR, Novick AC, Goormastic M. Nephron sparing surgery in incidental versus suspected renal cell carcinoma. *J Urol*. 1994;152(1):39–42.

Lin Y, Liang P, Yu XL, et al. Percutaneous microwave ablation of renal cell carcinoma is safe in patients with a solitary kidney. *Urology*. 2014;83(2):357–363.

Linehan WM, Ricketts CJ. The metabolic basis of kidney cancer. *Semin Cancer Biol*. 2013;23(1):46–55.

Linehan WM, Rouault TA. Molecular pathways: fumarate hydratase-deficient kidney cancer–targeting the Warburg effect in cancer. *Clin Cancer Res*. 2013;19(13):3345–3352.

Lipton A, Zheng M, Seaman J. Zoledronic acid delays the onset of skeletal-related events and progression of skeletal disease in patients with advanced renal cell carcinoma. *Cancer*. 2003;98(5):962–969.

Lipworth L, Tarone RE, McLaughlin JK. The epidemiology of renal cell carcinoma. *J Urol*. 2006;176(6 Pt 1):2353–2358.

Liu N, Wang Z, Gan W, et al. Renal cell carcinoma associated with Xp11.2 Translocation/TFE3 gene fusions: clinical features, treatments and prognosis. *PLoS ONE*. 2016;11(11):e0166897.

Liu NW, Khurana K, Sudarshan S, et al. Repeat partial nephrectomy on the solitary kidney: surgical, functional and oncological outcomes. *J Urol*. 2010;183(5):1719–1724.

Ljungberg B, Bensalah K, Canfield S, et al. EAU guidelines on renal cell carcinoma: 2014 update. *Eur Urol*. 2015;67(5):913–924.

Ljungberg B, Campbell SC, Choi HY, et al. The epidemiology of renal cell carcinoma. *Eur Urol*. 2011;60(4):615–621.

Lohse CM, Blute ML, Zincke H, et al. Comparison of standardized and nonstandardized nuclear grade of renal cell carcinoma to predict outcome among 2,042 patients. *Am J Clin Pathol*. 2002;118(6):877–886.

Lohse CM, Cheville JC. A review of prognostic pathologic features and algorithms for patients treated surgically for renal cell carcinoma. *Clin Lab Med*. 2005;25(2):433–464.

Lohse CM, Gupta S, Cheville JC. Outcome prediction for patients with renal cell carcinoma. *Semin Diagn Pathol*. 2015;32(2):172–183.

Luciano RL, Brewster UC. Kidney involvement in leukemia and lymphoma. *Adv Chronic Kidney Dis*. 2014;21(1):27–35.

Magera JS Jr, Frank I, Lohse CM, et al. Analysis of repeat nephron sparing surgery as a treatment option in patients with a solid mass in a renal remnant. *J Urol*. 2008;179(3):853–856.

Magera JS Jr, Leibovich BC, Lohse CM, et al. Association of abnormal preoperative laboratory values with survival after radical nephrectomy for clinically confined clear cell renal cell carcinoma. *Urology*. 2008;71(2):278–282.

Majhail NS, Elson P, Bukowski RM. Therapy and outcome of small cell carcinoma of the kidney: report of two cases and a systematic review of the literature. *Cancer*. 2003;97(6):1436–1441.

Maldazys JD, deKernion JB. Prognostic factors in metastatic renal carcinoma. *J Urol*. 1986;136(2):376–379.

Maly B, Maly A, Reinhartz T, et al. Primitive neuroectodermal tumor of the kidney. Report of a case initially diagnosed by fine needle aspiration cytology. *Acta Cytol*. 2004;48(2):264–268.

Mancilla-Jimenez R, Stanley RJ, Blath RA. Papillary renal cell carcinoma: a clinical, radiologic, and pathologic study of 34 cases. *Cancer*. 1976;38(6):2469–2480.

Marconi L, Dabestani S, Lam TB, et al. Systematic review and meta-analysis of diagnostic accuracy of percutaneous renal tumour biopsy. *Eur Urol*. 2016;69(4):660–673.

Margulis V, McDonald M, Tamboli P, et al. Predictors of oncological outcome after resection of locally recurrent renal cell carcinoma. *J Urol*. 2009;181(5):2044–2051.

Margulis V, Sanchez-Ortiz RF, Tamboli P, et al. Renal cell carcinoma clinically involving adjacent organs: experience with aggressive surgical management. *Cancer*. 2007;109(10):2025–2030.

Margulis V, Tamboli P, Matin SF, et al. Redefining pT3 renal cell carcinoma in the modern era: a proposal for a revision of the current TNM primary tumor classification system. *Cancer*. 2007;109(12):2439–2444.

Margulis V, Tamboli P, Matin SF, et al. Analysis of clinicopathologic predictors of oncologic outcome provides insight into the natural history of surgically managed papillary renal cell carcinoma. *Cancer*. 2008;112(7):1480–1488.

Mariusdottir E, Ingimarsson JP, Jonsson E, et al. Occupation as a risk factor for renal cell cancer: a nationwide, prospective epidemiological study. *Scand J Urol*. 2016;50(3):181–185.

Marszalek M, Carini M, Chlosta P, et al. Positive surgical margins after nephron-sparing surgery. *Eur Urol*. 2012;61(4):757–763.

Martinez-Salamanca JI, Huang WC, Millan I, et al. Prognostic impact of the 2009 UICC/AJCC TNM staging system for renal cell carcinoma with venous extension. *Eur Urol*. 2011;59(1):120–127.

Mashni JW, Assel M, Maschino A, et al. New chronic kidney disease and overall survival after nephrectomy for small renal cortical tumors. *Urology*. 2015;86(6):1137–1143.

Master VA, Gottschalk AR, Kane C, et al. Management of isolated renal fossa recurrence following radical nephrectomy. *J Urol*. 2005;174(2):473–477 [discussion 7].

May M, Surcel C, Capitanio U, et al. Prognostic and discriminative power of the 7th TNM classification for patients with surgically treated papillary renal cell carcinoma: results of a multi-institutional validation study (CORONA subtype project). *Scand J Urol*. 2017;51(4):269–276.

McDermott DF, Atkins MB. Immune therapy for kidney cancer: a second dawn? *Semin Oncol*. 2013;40(4):492–498.

McDorman KS, Wolf DC. Use of the spontaneous Tsc2 knockout (Eker) rat model of hereditary renal cell carcinoma for the study of renal carcinogens. *Toxicol Pathol*. 2002;30(6):675–680.

McKay RR, Kroeger N, Xie W, et al. Impact of bone and liver metastases on patients with renal cell carcinoma treated with targeted therapy. *Eur Urol*. 2014;65(3):577–584.

McNeill A, Rattenberry E, Barber R, et al. Genotype-phenotype correlations in VHL exon deletions. *Am J Med Genet A*. 2009;149A(10):2147–2151.

McVary KT. Lymphoproliferative disease and the genitourinary tract. Ball TP. *AUA update series*. American Urological Association: Houston; 1991:170–176.

Meeks JJ, Zhao LC, Navai N, et al. Risk factors and management of urine leaks after partial nephrectomy. *J Urol*. 2008;180(6):2375–2378.

Mekhail TM, Abou-Jawde RM, Boumerhi G, et al. Validation and extension of the Memorial Sloan-Kettering prognostic factors model for survival in patients with previously untreated metastatic renal cell carcinoma. *J Clin Oncol*. 2005;23(4):832–841.

Merrill SB. Postoperative surveillance for renal cell carcinoma. *Urol Clin North Am*. 2017;44(2):313–323.

Meskawi M, Sun M, Trinh QD, et al. A review of integrated staging systems for renal cell carcinoma. *Eur Urol*. 2012;62(2):303–314.

Messing EM, Manola J, Wilding G, et al. Phase III study of interferon alfa-NL as adjuvant treatment for resectable renal cell carcinoma: an Eastern Cooperative Oncology Group/Intergroup trial. *J Urol*. 2003;21(7):1214–1222.

Mester JL, Zhou M, Prescott N, et al. Papillary renal cell carcinoma is associated with PTEN hamartoma tumor syndrome. *Urology*. 2012;79(5):1187 e1–1187 e7.

Metwalli AR, Linehan WM. Nephron-sparing surgery for multifocal and hereditary renal tumors. *Curr Opin Urol*. 2014;24(5):466–473.

Micolonghi TS, Liang D, Schwartz S. Primary osteogenic sarcoma of the kidney. *J Urol*. 1984;131(6):1164–1166.

Miller DC, Ruterbusch J, Colt JS, et al. Contemporary clinical epidemiology of renal cell carcinoma: insight from a population based case-control study. *J Urol*. 2010;184(6):2254–2258.

Miller DC, Schonlau M, Litwin MS, et al. Renal and cardiovascular morbidity after partial or radical nephrectomy. *Cancer*. 2008;112(3):511–520.

Miller JS, Zhou M, Brimo F, et al. Primary leiomyosarcoma of the kidney: a clinicopathologic study of 27 cases. *Am J Surg Pathol*. 2010;34(2):238–242.

Minervini A, Campi R, Kutikov A, et al. Histopathological validation of the surface-intermediate-base margin score for standardized reporting of resection technique during nephron sparing surgery. *J Urol*. 2015;194(4):916–922.

Minervini A, Carini M, Uzzo RG, et al. Standardized reporting of resection technique during nephron-sparing surgery: the surface-intermediate-base margin score. *Eur Urol*. 2014;66(5):803–805.

Minervini A, di Cristofano C, Lapini A, et al. Histopathologic analysis of peritumoral pseudocapsule and surgical margin status after tumor enucleation for renal cell carcinoma. *Eur Urol*. 2009;55(6):1410–1418.

Minervini A, Ficarra V, Rocco F, et al. Simple enucleation is equivalent to traditional partial nephrectomy for renal cell carcinoma: results of a nonrandomized, retrospective, comparative study. *J Urol*. 2011;185(5):1604–1610.

Minervini A, Tuccio A, Masieri L, et al. Endoscopic robot-assisted simple enucleation (ERASE) for clinical T1 renal masses: description of the technique and early postoperative results. *Surg Endosc*. 2015;29(5):1241–1249.

Ming X, Ningshu L, Hanzhong L, et al. Value of frozen section analysis of enlarged lymph nodes during radical nephrectomy for renal cell carcinoma. *Urology*. 2009;74(2):364–368.

Mir MC, Campbell RA, Sharma N, et al. Parenchymal volume preservation and ischemia during partial nephrectomy: functional and volumetric analysis. *Urology*. 2013;82(2):263–268.

Mir MC, Ercole C, Takagi T, et al. Decline in renal function after partial nephrectomy: etiology and prevention. *J Urol*. 2015;193(6):1889–1898.

Mirza IA, Shahab N. Small cell cancer of the pleura, kidney, and thymus. *Semin Oncol*. 2007;34(1):67–69.

Mirza M. Management of small renal masses in the older adult. *Clin Geriatr Med*. 2015;31(4):603–613.

Mizutani K, Horie K, Nagai S, et al. Response to nivolumab in metastatic collecting duct carcinoma expressing PD-L1: a case report. *Mol Clin Oncol*. 2017;7(6):988–990.

Moch H, Artibani W, Delahunt B, et al. Reassessing the current UICC/AJCC TNM staging for renal cell carcinoma. *Eur Urol*. 2009;56(4):636–643.

Moch H, Cubilla AL, Humphrey PA, et al. The 2016 WHO Classification of tumours of the urinary system and male genital organs-part a: renal, penile, and testicular tumours. *Eur Urol*. 2016;70(1):93–105.

Modi S, Tiang KW, Inglis P, et al. Adult Wilms' tumour: case report and review of literature. *J Kidney Cancer VHL*. 2016;3(2):1–7.

Moein MR, Dehghani VO. Hypertension: a rare presentation of renal cell carcinoma. *J Urol*. 2000;164(6):2019.

Moinzadeh A, Libertino JA. Prognostic significance of tumor thrombus level in patients with renal cell carcinoma and venous tumor thrombus extension. Is all T3b the same? *J Urol*. 2004;171(2 Pt 1):598–601.

Molina AM, Tickoo SK, Ishill N, et al. Sarcomatoid-variant renal cell carcinoma: treatment outcome and survival in advanced disease. *Am J Clin Oncol*. 2011;34(5):454–459.

Moreira DM, Gershman B, Lohse CM, et al. Paraneoplastic syndromes are associated with adverse prognosis among patients with renal cell carcinoma undergoing nephrectomy. *World J Urol*. 2016;34(10):1465–1472.

Morrissey JJ, Kharasch ED. The specificity of urinary aquaporin 1 and perilipin 2 to screen for renal cell carcinoma. *J Urol*. 2013;189(5):1913–1920.

Morrissey JJ, Mellnick VM, Luo J, et al. Evaluation of urine aquaporin-1 and perilipin-2 concentrations as biomarkers to screen for renal cell carcinoma: a prospective cohort study. *J Am Med Assoc Oncol*. 2015;1(2):204–212.

Mosetti MA, Leonardou P, Motohara T, et al. Autosomal dominant polycystic kidney disease: MR imaging evaluation using current techniques. *J Magn Reson Imaging*. 2003;18(2):210–215.

Motzer RJ, Bacik J, Schwartz LH, et al. Prognostic factors for survival in previously treated patients with metastatic renal cell carcinoma. *J Clin Oncol*. 2004;22(3):454–463.

Motzer RJ, Bukowski RM, Figlin RA, et al. Prognostic nomogram for sunitinib in patients with metastatic renal cell carcinoma. *Cancer*. 2008;113(7):1552–1558.

Motzer RJ, Escudier B, McDermott DF, et al. Nivolumab versus everolimus in advanced renal-cell carcinoma. *New Engl J Med*. 2015;373(19):1803–1813.

Motzer RJ, Escudier B, Tomczak P, et al. Axitinib versus sorafenib as second-line treatment for advanced renal cell carcinoma: overall survival analysis and updated results from a randomised phase 3 trial. *Lancet Oncol*. 2013;14(6):552–562.

Motzer RJ, Haas NB, Donskov F, et al. Randomized Phase III trial of adjuvant pazopanib versus placebo after nephrectomy in patients with localized or locally advanced renal cell carcinoma. *J Clin Oncol*. 2017 [Jco2017735324].

Motzer RJ, Hutson TE, Cella D, et al. Pazopanib versus sunitinib in metastatic renal-cell carcinoma. *New Engl J Med*. 2013;369(8):722–731.

Motzer RJ, Jonasch E, Agarwal N, et al. Kidney cancer, version 2.2017, NCCN clinical practice guidelines in oncology. *J Natl Compr Cancer Netwk*. 2017;15(6):804–834.

Motzer RJ, Michaelson MD, Redman BG, et al. Activity of SU11248, a multitargeted inhibitor of vascular endothelial growth factor receptor and platelet-derived growth factor receptor, in patients with metastatic renal cell carcinoma. *J Clin Oncol*. 2006;24(1):16–24.

Motzer RJ, Russo P. Systemic therapy for renal cell carcinoma. *J Urol*. 2000;163(2):408–417.

Moudouni SM, En-Nia I, Rioux-Leclerq N, et al. Leiomyosarcoma of the renal pelvis. *Scand J Urol Nephrol*. 2001;35(5):425–427.

Mukamel E, Konichezky M, Engelstein D, et al. Incidental small renal tumors accompanying clinically overt renal cell carcinoma. *J Urol*. 1988;140(1):22–24.

Muselaers S, Mulders P, Oosterwijk E, et al. Molecular imaging and carbonic anhydrase IX-targeted radioimmunotherapy in clear cell renal cell carcinoma. *Immunotherapy*. 2013;5(5):489–495.

Nagashima Y. Chromophobe renal cell carcinoma: clinical, pathological and molecular biological aspects. *Pathol Int*. 2000;50(11):872–878.

Nair VJ, Szanto J, Vandervoort E, et al. CyberKnife for inoperable renal tumors: Canadian pioneering experience. *Can J Urol*. 2013;20(5):6944–6949.

Nakatani K, Nakamoto Y, Saga T, et al. The potential clinical value of FDG-PET for recurrent renal cell carcinoma. *Eur J Radiol*. 2011;79(1):29–35.

Narayanan G, Rajan V, Preethi TR. Primitive neuroectodermal tumors of the kidney. *Proc (Bayl Univ Med Cent)*. 2017;30(2):205–208.

National Kidney Foundation. *End stage renal disease in the United States*. [(website)] https://www.kidney.org/news/newsroom/factsheets/End-Stage-Renal-Disease-in-the-US; 2016.

Navia JL, Brozzi NA, Nowicki ER, et al. Simplified perfusion strategy for removing retroperitoneal tumors with extensive cavoatrial involvement. *J Thorac Cardiovasc Surg*. 2012;143(5):1014–1021.

Nelson CP, Sanda MG. Contemporary diagnosis and management of renal angiomyolipoma. *J Urol*. 2002;168(4 Pt 1):1315–1325.

Nepple KG, Yang L, Grubb RL 3rd, et al. Population based analysis of the increasing incidence of kidney cancer in the United States: evaluation of age specific trends from 1975 to 2006. *J Urol*. 2012;187(1):32–38.

Neumann HP, Zbar B. Renal cysts, renal cancer and von Hippel-Lindau disease. *Kidney Int*. 1997;51(1):16–26.

Ng CS, Wood CG, Silverman PM, et al. Renal cell carcinoma: diagnosis, staging, and surveillance. *Am J Roentgenol*. 2008;191(4):1220–1232.

Nguyen CT, Campbell SC. Staging of renal cell carcinoma: past, present, and future. *Clin Genitourin Cancer*. 2006;5(3):190–197.

Nguyen CT, Campbell SC, Novick AC. Choice of operation for clinically localized renal tumor. *Urol Clin North Am*. 2008;35(4):645–655 [vii].

Nguyen CT, Lane BR, Kaouk JH, et al. Surgical salvage of renal cell carcinoma recurrence after thermal ablative therapy. *J Urol*. 2008;180(1):104–109 [discussion 9].

Nguyen KA, Syed JS, Shuch B. Hereditary kidney cancer syndromes and surgical management of the small renal mass. *Urol Clin North Am*. 2017;44(2):155–167.

Nguyen MM, Gill IS. Effect of renal cancer size on the prevalence of metastasis at diagnosis and mortality. *J Urol*. 2009;181(3):1020–1027 [discussion 7].

Niceta P, Lavengood RW Jr, Fernandes M, et al. Leiomyosarcoma of kidney. Review of the literature. *Urology*. 1974;3(3):270–277.

Nielsen SM, Rhodes L, Blanco I, et al. Von Hippel-Lindau disease: genetics and role of genetic counseling in a multiple neoplasia syndrome. *J Clin Oncol*. 2016;34(18):2172–2181.

Novick AC. Kidney cancer: past, present, and future. *Urol Oncol*. 2007;25(3):188–195.

Novick AC. Management of small renal masses: partial nephrectomy. Campbell SC, Rini BI. *Renal cell carcinoma*. People's Medical Publishing House: Shelton, CT; 2009:95–101.

Novick AC, Kaye MC, Cosgrove DM, et al. Experience with cardiopulmonary bypass and deep hypothermic circulatory arrest in the management of retroperitoneal tumors with large vena caval thrombi. *Ann Surg*. 1990;212(4):472–476 [discussion 6–7].

Novick AC, Schreiber MJ Jr. Effect of angiotensin-converting enzyme inhibition on nephropathy in patients with a remnant kidney. *Urology*. 1995;46(6):785–789.

Novick AC, Streem SB. Long-term followup after nephron sparing surgery for renal cell carcinoma in von Hippel-Lindau disease. *J Urol*. 1992;147(6):1488–1490.

O'Connor SD, Pickhardt PJ, Kim DH, et al. Incidental finding of renal masses at unenhanced CT: prevalence and analysis of features for guiding management. *Am J Roentgenol*. 2011;197(1):139–145.

O'Malley RL, Godoy G, Hecht EM, et al. Bosniak category IIF designation and surgery for complex renal cysts. *J Urol*. 2009;182(3):1091–1095.

O'Malley RL, Godoy G, Kanofsky JA, et al. The necessity of adrenalectomy at the time of radical nephrectomy: a systematic review. *J Urol*. 2009;181(5):2009–2017.

O'Riordan E, Reeve R, Houghton JB, et al. Primary bilateral T-cell renal lymphoma presenting with sudden loss of renal function. *Nephrol Dial Transplant*. 2001;16(7):1487–1489.

Okhunov Z, Lee T, Huynh V, et al. MP22-03 Office-based ultrasound guided percutaneous renal mass biopsy. *J Urol*. 2017;197(4):e257.

Oliver RT. Surveillance as a possible option for management of metastatic renal cell carcinoma. *Semin Urol*. 1989;7(3):149–152.

Organ M, Jewett M, Basiuk J, et al. Growth kinetics of small renal masses: a prospective analysis from the Renal Cell Carcinoma Consortium of Canada. *Can Urol Assoc J*. 2014;8(1–2):24–27.

Ornstein DK, Lubensky IA, Venzon D, et al. Prevalence of microscopic tumors in normal appearing renal parenchyma of patients with hereditary papillary renal cancer. *J Urol*. 2000;163(2):431–433.

Pal SK, Ali SM, Yakirevich E, et al. Characterization of clinical cases of advanced papillary renal cell carcinoma via comprehensive genomic profiling. *Eur Urol*. 2018;73(1):71–78.

Pantuck AJ, Zisman A, Belldegrun A. Biology of renal cell carcinoma: changing concepts in classification and staging. *Semin Urol Oncol*. 2001;19(2):72–79.

Pantuck AJ, Zisman A, Belldegrun AS. The changing natural history of renal cell carcinoma. *J Urol*. 2001;166(5):1611–1623.

Pantuck AJ, Zisman A, Dorey F, et al. Renal cell carcinoma with retroperitoneal lymph nodes: role of lymph node dissection. *J Urol*. 2003;169(6):2076–2083.

Pantuck AJ, Zisman A, Rauch MK, et al. Incidental renal tumors. *Urology*. 2000;56(2):190–196.

Parekh DJ, Weinberg JM, Ercole B, et al. Tolerance of the human kidney to isolated controlled ischemia. *J Am Soc Nephrol*. 2013;24(3):506–517.

Parham DM, Roloson GJ, Feely M, et al. Primary malignant neuroepithelial tumors of the kidney: a clinicopathologic analysis of 146 adult and pediatric cases from the National Wilms’ Tumor Study Group Pathology Center. *Am J Surg Pathol*. 2001;25(2):133–146.

Parker AS, Leibovich BC, Lohse CM, et al. Development and evaluation of BioScore: a biomarker panel to enhance prognostic algorithms for clear cell renal cell carcinoma. *Cancer*. 2009;115(10):2092–2103.

Parker D, Kutikov A, Uzzo RG, et al. Understanding chronic kidney disease of surgical versus medical origin: the missing link to the partial versus radical nephrectomy debate? *Eur Urol*. 2015;68(6):1004–1006.

Parker WP, Cheville JC, Frank I, et al. Application of the stage, size, grade, and necrosis (SSIGN) score for clear cell renal cell carcinoma in contemporary patients. *Eur Urol*. 2017;71(4):665–673.

Parsons JK, Schoenberg MS, Carter HB. Incidental renal tumors: casting doubt on the efficacy of early intervention. *Urology*. 2001;57(6):1013–1015.

Patard JJ, Dorey FJ, Cindolo L, et al. Symptoms as well as tumor size provide prognostic information on patients with localized renal tumors. *J Urol*. 2004;172(6 Pt 1):2167–2171.

Patard JJ, Kim HL, Lam JS, et al. Use of the University of California Los Angeles integrated staging system to predict survival in renal cell carcinoma: an international multicenter study. *J Clin Oncol*. 2004;22(16):3316–3322.

Patel HD, Iyoha E, Pierorazio PM, et al. A Systematic review of research gaps in the evaluation and management of localized renal masses. *Urology*. 2016;98:14–20.

Patel HD, Johnson MH, Pierorazio PM, et al. Diagnostic accuracy and risks of biopsy in the diagnosis of a renal mass suspicious for localized renal cell carcinoma: systematic review of the literature. *J Urol*. 2016;195(5):1340–1347.

Patel HD, Riffon MF, Joice GA, et al. A prospective, comparative study of quality of life among patients with small renal masses choosing active surveillance and primary intervention. *J Urol*. 2016;196(5):1356–1362.

Paul R, Mordhorst J, Busch R, et al. Adrenal sparing surgery during radical nephrectomy in patients with renal cell cancer: a new algorithm. *J Urol*. 2001;166(1):59–62.

Paulucci DJ, Rosen DC, Sfakianos JP, et al. Selective arterial clamping does not improve outcomes in robot-assisted partial nephrectomy: a propensity-score analysis of patients without impaired renal function. *BJU Int*. 2017;119(3):430–435.

Petrelli F, Coinu A, Vavassori I, et al. Cytoreductive nephrectomy in metastatic renal cell carcinoma treated with targeted therapies: a systematic review with a meta-analysis. *Clin Genitourin Cancer*. 2016;14(6):465–472.

Petros FG, Angell JE, Abaza R. Outcomes of robotic nephrectomy including highest-complexity cases: largest series to date and literature review. *Urology*. 2015;85(6):1352–1358.

Phillips CK, Taneja SS. The role of lymphadenectomy in the surgical management of renal cell carcinoma. *Urol Oncol*. 2004;22(3):214–223 [discussion 23–24].

Pickhardt PJ, Siegel CL, McLarney JK. Collecting duct carcinoma of the kidney: are imaging findings suggestive of the diagnosis? *Am J Roentgenol*. 2001;176(3):627–633.

Pierorazio PM, Hyams ES, Tsai S, et al. Multiphasic enhancement patterns of small renal masses (≤=4 cm) on preoperative computed tomography: utility for distinguishing subtypes of renal cell carcinoma, angiomyolipoma, and oncocytoma. *Urology*. 2013;81(6):1265–1271.

Pierorazio PM, Johnson MH, Ball MW, et al. Five-year analysis of a multi-institutional prospective clinical trial of delayed intervention and surveillance for small renal masses: the DISSRM registry. *Eur Urol*. 2015;68(3):408–415.

Pierorazio PM, Johnson MH, Patel HD, et al. Management of renal masses and localized renal cancer: systematic review and meta-analysis. *J Urol*. 2016;196(4):989–999.

Pierorazio PM, Patel HD, Johnson MH, et al. Distinguishing malignant and benign renal masses with composite models and nomograms: a systematic review and meta-analysis of clinically localized renal masses suspicious for malignancy. *Cancer*. 2016;122(21):3267–3276.

Pignot G, Elie C, Conquy S, et al. Survival analysis of 130 patients with papillary renal cell carcinoma: prognostic utility of type 1 and type 2 subclassification. *Urology*. 2007;69(2):230–235.

Pindoria N, Raison N, Blecher G, et al. Cytoreductive nephrectomy in the era of targeted therapies: a review. *BJU Int*. 2017;120(3):320–328.

Pithukpakorn M, Wei MH, Toure O, et al. Fumarate hydratase enzyme activity in lymphoblastoid cells and fibroblasts of individuals in families with hereditary leiomyomatosis and renal cell cancer. *J Med Genet*. 2006;43(9):755–762.

Pizzocaro G, Piva L, Colavita M, et al. Interferon adjuvant to radical nephrectomy in Robson stages II and III renal cell carcinoma: a multicentric randomized study. *J Clin Oncol*. 2001;19(2):425–431.

Pizzocaro G, Piva L, Di Fronzo G, et al. Adjuvant medroxyprogesterone acetate to radical nephrectomy in renal cancer: 5-year results of a prospective randomized study. *J Urol*. 1987;138(6):1379–1381.

Ploussard G, Droupy S, Ferlicot S, et al. Local recurrence after nephron-sparing surgery in von Hippel-Lindau disease. *Urology*. 2007;70(3):435–439.

Pollack HM, Banner MP, Amendola MA. Other malignant neoplasms of the renal parenchyma. *Semin Roentgenol*. 1987;22(4):260–274.

Porpiglia F, Mari A, Bertolo R, et al. Partial nephrectomy in clinical T1b renal tumors: multicenter comparative study of open, laparoscopic and robot-assisted approach (the RECORd Project). *Urology*. 2016;89:45–51.

Pouliot F, Shuch B, Larochelle JC, et al. Contemporary management of renal tumors with venous tumor thrombus. *J Urol*. 2010;184(3):833–841 [quiz 1235].

Powles T, Murray I, Brock C, et al. Molecular positron emission tomography and PET/CT imaging in urological malignancies. *Eur Urol*. 2007;51(6):1511–1520 [discussion 20–21].

Pretorius ES, Wickstrom ML, Siegelman ES. MR imaging of renal neoplasms. *Magn Reson Imaging Clin N Am*. 2000;8(4):813–836.

Przybycin CG, McKenney JK, Reynolds JP, et al. Rhabdoid differentiation is associated with aggressive behavior in renal cell carcinoma: a clinicopathologic analysis of 76 cases with clinical follow-up. *Am J Surg Pathol*. 2014;38(9):1260–1265.

Rabbani F, Hakimian P, Reuter VE, et al. Renal vein or inferior vena caval extension in patients with renal cortical tumors: impact of tumor histology. *J Urol*. 2004;171(3):1057–1061.

Rai K, Pilarski R, Cebulla CM, et al. Comprehensive review of BAP1 tumor predisposition syndrome with report of two new cases. *Clin Genet*. 2016;89(3):285–294.

Raspollini MR, Montagnani I, Montironi R, et al. A contemporary series of renal masses with emphasis on recently recognized entities and tumors of low malignant potential: a report based on 624 consecutive tumors from a single tertiary center. *Pathol Res Pract*. 2017;213(7):804–808.

Ratan R, Patel SR. Chemotherapy for soft tissue sarcoma. *Cancer*. 2016;122(19):2952–2960.

Ravaud A, Motzer RJ, Pandha HS, et al. Adjuvant sunitinib in high-risk renal-cell carcinoma after nephrectomy. *New Engl J*

Med. 2016;375(23):2246–2254.

Ravi V, Patel S, Benjamin RS. Chemotherapy for soft-tissue sarcomas. *Oncology (Williston Park)*. 2015;29(1):43–50.

Reinhard H, Aliani S, Ruebe C, et al. Wilms' tumor in adults: results of the Society of Pediatric Oncology (SIOP) 93-01/Society for Pediatric Oncology and Hematology (GPOH) Study. *J Clin Oncol*. 2004;22(22):4500–4506.

Renehan AG, Tyson M, Egger M, et al. Body-mass index and incidence of cancer: a systematic review and meta-analysis of prospective observational studies. *Lancet (London, England)*. 2008;371(9612):569–578.

Renshaw AA. Subclassification of renal cell neoplasms: an update for the practising pathologist. *Histopathology*. 2002;41(4):283–300.

Renshaw AA, Henske EP, Loughlin KR, et al. Aggressive variants of chromophobe renal cell carcinoma. *Cancer*. 1996;78(8):1756–1761.

Ricketts C, Woodward ER, Killick P, et al. Germline SDHB mutations and familial renal cell carcinoma. *J Natl Cancer Inst*. 2008;100(17):1260–1262.

Ricketts CJ, Shuch B, Vocke CD, et al. Succinate dehydrogenase kidney cancer: an aggressive example of the Warburg effect in cancer. *J Urol*. 2012;188(6):2063–2071.

Ridyard DG, Buller DM, Ristau BT. The current state of adjuvant therapy following surgery for high-risk renal cell carcinoma. *Eur Urol Focus*. 2019 [Epub ahead of print].

Rijnders M, de Wit R, Boormans JL, et al. Systematic review of immune checkpoint inhibition in urological cancers. *Eur Urol*. 2017;72(3):411–423.

Rini BI. New strategies in kidney cancer: therapeutic advances through understanding the molecular basis of response and resistance. *Clin Cancer Res*. 2010;16(5):1348–1354.

Rini BI, Campbell SC. Urinary biomarkers for the detection and management of localized renal cell carcinoma. *JAMA Oncol*. 2015;1(2):212–213.

Rini BI, Campbell SC, Escudier B. Renal cell carcinoma. *Lancet (London, England)*. 2009;373(9669):1119–1132.

Rini BI, Garcia J, Elson P, et al. The effect of sunitinib on primary renal cell carcinoma and facilitation of subsequent surgery. *J Urol*. 2012;187(5):1548–1554.

Rini BI, Halabi S, Rosenberg JE, et al. Bevacizumab plus interferon alfa compared with interferon alfa monotherapy in patients with metastatic renal cell carcinoma: CALGB 90206. *J Clin Oncol*. 2008;26(33):5422–5428.

Rini BI, Plimack ER, Takagi T, et al. A Phase II study of pazopanib in patients with localized renal cell carcinoma to optimize preservation of renal parenchyma. *J Urol*. 2015;194(2):297–303.

Rini BI, Plimack ER, Stus V. Pembolizumab plus axitinib versus sunitinib for advanced renal cell carcinoma. *N Engl J Med*. 2019;380:1116–1127.

Rini BI, Wilding G, Hudes G, et al. Phase II study of axitinib in sorafenib-refractory metastatic renal cell carcinoma. *J Clin Oncol*. 2009;27(27):4462–4468.

Ristau BT, Correa AF, Uzzo RG, et al. Active surveillance for the small renal mass: growth kinetics and oncologic outcomes. *Urol Clin North Am*. 2017;44(2):213–222.

Ro JY, Ayala AG, Sella A, et al. Sarcomatoid renal cell carcinoma: clinicopathologic. A study of 42 cases. *Cancer*. 1987;59(3):516–526.

Robson CJ. Radical nephrectomy for renal cell carcinoma. *J Urol*. 1963;89:37–42.

Robson CJ, Churchill BM, Anderson W. The results of radical nephrectomy for renal cell carcinoma. *J Urol*. 1969;101(3):297–301.

Rodriguez Faba O, Linares E, Tilki D, et al. Impact of microscopic wall invasion of the renal vein or inferior vena cava on cancer-specific survival in patients with renal cell carcinoma and tumor thrombus: a multi-institutional analysis from the International Renal Cell Carcinoma-Venous Thrombus Consortium. *Eur Urol Focus*. 2017.

Rofsky NM, Weinreb JC, Bosniak MA, et al. Renal lesion characterization with gadolinium-enhanced MR imaging: efficacy and safety in patients with renal insufficiency. *Radiology*. 1991;180(1):85–89.

Romanenko A, Morell-Quadreny L, Nepomnyaschy V, et al. Pathology and proliferative activity of renal-cell carcinomas (RCCS) and renal oncocytomas in patients with different radiation exposure after the Chernobyl accident in Ukraine. *Int J Cancer*. 2000;87(6):880–883.

Romero FR, Rais-Bahrami S, Permpongkosol S, et al. Primary carcinoid tumors of the kidney. *J Urol*. 2006;176(6 Pt 1):2359–2366.

Ross PL, Gerigk C, Gonen M, et al. Comparisons of nomograms and urologists' predictions in prostate cancer. *Semin Urol Oncol*. 2002;20(2):82–88.

Rowe SP, Gorin MA, Hammers HJ, et al. Imaging of metastatic clear cell renal cell carcinoma with PSMA-targeted (1)(8)F-DCFPyL PET/CT. *Ann Nucl Med*. 2015;29(10):877–882.

Rumpelt HJ, Storkel S, Moll R, et al. Bellini duct carcinoma: further evidence for this rare variant of renal cell carcinoma. *Histopathology*. 1991;18(2):115–122.

Russo P. Open radical nephrectomy for localized renal cell carcinoma. Volgelzang NJ. *Comprehensive textbook of genitourinary oncology*. Lippincott Williams & Wilkins: Philadelphia; 2006:725–731.

Russo P, Brady MS, Conlon K, et al. Adult urological sarcoma. *J Urol*. 1992;147(4):1032–1036 [discussion 6–7].

Russo P, Huang W. The medical and oncological rationale for partial nephrectomy for the treatment of T1 renal cortical tumors. *Urol Clin North Am*. 2008;35(4):635–643 [vii].

Russo P, Jang TL, Pettus JA, et al. Survival rates after resection for localized kidney cancer: 1989 to 2004. *Cancer*. 2008;113(1):84–96.

Rybicki FJ, Shu KM, Cibas ES, et al. Percutaneous biopsy of renal masses: sensitivity and negative predictive value stratified by clinical setting and size of masses. *Am J Roentgenol*. 2003;180(5):1281–1287.

Sagalowsky AI, Kadesky KT, Ewalt DM, et al. Factors influencing adrenal metastasis in renal cell carcinoma. *J Urol*. 1994;151(5):1181–1184.

Samaratunga H, Gianduzzo T, Delahunt B. The ISUP system of staging, grading and classification of renal cell neoplasia. *J Kidney Cancer VHL*. 2014;1(3):26–39.

Sanchez-Ortiz RF, Madsen LT, Bermejo CE, et al. A renal mass in the setting of a nonrenal malignancy: when is a renal tumor biopsy appropriate? *Cancer*. 2004;101(10):2195–2201.

Sanchez-Ortiz RF, Rosser CJ, Madsen LT, et al. Young age is an independent prognostic factor for survival of sporadic renal cell carcinoma. *J Urol*. 2004;171(6 Pt 1):2160–2165.

Sandock DS, Seftel AD, Resnick MI. A new protocol for the followup of renal cell carcinoma based on pathological stage. *J Urol*. 1995;154(1):28–31.

Sarkar R, Eilber FR, Gelabert HA, et al. Prosthetic replacement of the inferior vena cava for malignancy. *J Vasc Surg*. 1998;28(1):75–81 [discussion 2–3].

Satkunasivam R, Tsai S, Syan S, et al. Robotic unclamped “minimal-margin” partial nephrectomy: ongoing refinement of the anatomic zero-ischemia concept. *Eur Urol*. 2015;68(4):705–712.

Sawai Y, Kinouchi T, Mano M, et al. Ipsilateral adrenal involvement from renal cell carcinoma: retrospective study of the predictive value of computed tomography. *Urology*. 2002;59(1):28–31.

Schefft P, Novick AC, Straffon RA, et al. Surgery for renal cell carcinoma extending into the inferior vena cava. *J Urol*. 1978;120(1):28–31.

Schmidt L, Duh FM, Chen F, et al. Germline and somatic mutations in the tyrosine kinase domain of the MET proto-oncogene in papillary renal carcinomas. *Nature Genet*. 1997;16(1):68–73.

Schmidt LS, Linehan WM. Genetic predisposition to kidney cancer. *Semin Oncol*. 2016;43(5):566–574.

Schmit GD, Thompson RH, Kurup AN, et al. Usefulness of R.E.N.A.L. nephrometry scoring system for predicting outcomes and complications of percutaneous ablation of 751 renal tumors. *J Urol*. 2013;189(1):30–35.

Schrodter S, Hakenberg OW, Manseck A, et al. Outcome of surgical treatment of isolated local recurrence after radical nephrectomy for renal cell carcinoma. *J Urol*. 2002;167(4):1630–1633.

Schwarzberg AB, Michaelson MD. Supportive care in metastatic renal cell carcinoma. Campbell SC, Rini BI. *Renal cell carcinoma*. People's Medical Publishing House: Shelton, CT; 2009:273–279.

Scosyrev E, Messing EM, Sylvester R, et al. Renal function after nephron-sparing surgery versus radical nephrectomy: results from EORTC randomized trial 30904. *Eur Urol*. 2014;65(2):372–377.

Seizinger BR, Rouleau GA, Ozelius LJ, et al. Von Hippel-Lindau disease maps to the region of chromosome 3 associated with renal cell carcinoma. *Nature*. 1988;332(6161):268–269.

Selle B, Furtwangler R, Graf N, et al. Population-based study of renal cell carcinoma in children in Germany, 1980-2005:

more frequently localized tumors and underlying disorders compared with adult counterparts. *Cancer*. 2006;107(12):2906–2914.

Seo AN, Yoon G, Ro JY. Clinicopathologic and molecular pathology of collecting duct carcinoma and related renal cell carcinomas. *Adv Anat Pathol*. 2017;24(2):65–77.

Serni S, Vittori G, Masieri L, et al. Robotic vs open simple enucleation for the treatment of T1a-T1b renal cell carcinoma: a single center matched-pair comparison. *Urology*. 2014;83(2):331–337.

Shah AY, Karam JA, Malouf GG, et al. Management and outcomes of patients with renal medullary carcinoma: a multicentre collaborative study. *BJU Int*. 2017;120(6):782–792.

Shah C, Verma V, Takiar R, et al. Radiation therapy in the management of soft tissue sarcoma: a clinician's guide to timing, techniques, and targets. *Am J Clin Oncol*. 2016;39(6):630–635.

Shah PH, George AK, Moreira DM, et al. To clamp or not to clamp? Long-term functional outcomes for elective off-clamp laparoscopic partial nephrectomy. *BJU Int*. 2016;117(2):293–299.

Shah PH, Moreira DM, Okhunov Z, et al. Positive surgical margins increase risk of recurrence after partial nephrectomy for high risk renal tumors. *J Urol*. 2016;196(2):327–334.

Shah PH, Moreira DM, Patel VR, et al. Partial nephrectomy is associated with higher risk of relapse compared with radical nephrectomy for clinical stage T1 renal cell carcinoma pathologically up staged to T3a. *J Urol*. 2017.

Shao P, Qin C, Yin C, et al. Laparoscopic partial nephrectomy with segmental renal artery clamping: technique and clinical outcomes. *Eur Urol*. 2011;59(5):849–855.

Shariat SF, Capitanio U, Jeldres C, et al. Can nomograms be superior to other prediction tools? *BJU Int*. 2009;103(4):492–495 [discussion 5–7].

Shen C, Kaelin WG Jr. The VHL/HIF axis in clear cell renal carcinoma. *Semin Cancer Biol*. 2013;23(1):18–25.

Sheth S, Ali S, Fishman E. Imaging of renal lymphoma: patterns of disease with pathologic correlation. *Radiographics*. 2006;26(4):1151–1168.

Shin TY, Komninos C, Kim DW, et al. A novel mathematical model to predict the severity of postoperative functional reduction before partial nephrectomy: the importance of calculating resected and ischemic volume. *J Urol*. 2015;193(2):423–429.

Shirkhoda A, Lewis E. Renal sarcoma and sarcomatoid renal cell carcinoma: CT and angiographic features. *Radiology*. 1987;162(2):353–357.

Shuch B, Bratslavsky G, Linehan WM, et al. Sarcomatoid renal cell carcinoma: a comprehensive review of the biology and current treatment strategies. *Oncologist*. 2012;17(1):46–54.

Shuch B, Hanley J, Lai J, et al. Overall survival advantage with partial nephrectomy: a bias of observational data? *Cancer*. 2013;119(16):2981–2989.

Shuch B, Larochelle JC, Onyia T, et al. Intraoperative thrombus embolization during nephrectomy and tumor thrombectomy: critical analysis of the University of California-Los Angeles experience. *J Urol*. 2009;181(2):492–498 [discussion 8–9].

Shuch B, Ricketts CJ, Vocke CD, et al. Germline PTEN mutation Cowden syndrome: an underappreciated form of hereditary kidney cancer. *J Urol*. 2013;190(6):1990–1998.

Shuch B, Singer EA, Bratslavsky G. The surgical approach to multifocal renal cancers: hereditary syndromes, ipsilateral multifocality, and bilateral tumors. *Urol Clin North Am*. 2012;39(2):133–148 [v].

Shuch B, Vourganti S, Ricketts CJ, et al. Defining early-onset kidney cancer: implications for germline and somatic mutation testing and clinical management. *J Clin Oncol*. 2014;32(5):431–437.

Shvarts O, Lam JS, Kim HL, et al. Staging of renal cell carcinoma: current concepts. *BJU Int*. 2005;95(Suppl 2):8–13.

Shvarts O, Lam JS, Kim HL, et al. Eastern Cooperative Oncology Group performance status predicts bone metastasis in patients presenting with renal cell carcinoma: implication for preoperative bone scans. *J Urol*. 2004;172(3):867–870.

Sidana A, Aggarwal P, Feng Z, et al. Complications of renal cryoablation: a single center experience. *J Urol*. 2010;184(1):42–47.

Siegel RL, Miller KD, Jemal A. Cancer statistics, 2017. *CA Cancer J Clin*. 2017;67(1):7–30.

Silverman SG, Israel GM, Herts BR, et al. Management of the incidental renal mass. *Radiology*. 2008;249(1):16–31.

Simhan J, Smaldone MC, Tsai KJ, et al. Objective measures of renal mass anatomic complexity predict rates of major complications following partial nephrectomy. *Eur Urol*. 2011;60(4):724–730.

Simmons MN, Ching CB, Samplaski MK, et al. Kidney tumor location measurement using the C index method. *J Urol*. 2010;183(5):1708–1713.

Simone G, Gill IS, Mottrie A, et al. Indications, techniques, outcomes, and limitations for minimally ischemic and off-clamp partial nephrectomy: a systematic review of the literature. *Eur Urol*. 2015;68(4):632–640.

Siva S, Pham D, Gill S, et al. A systematic review of stereotactic radiotherapy ablation for primary renal cell carcinoma. *BJU Int*. 2012;110(11 Pt B):E737–E743.

Skinner DG, Pfister RF, Colvin R. Extension of renal cell carcinoma into the vena cava: the rationale for aggressive surgical management. *J Urol*. 1972;107(5):711–716.

Slaton JW, Balbay MD, Levy DA, et al. Nephrectomy and vena caval thrombectomy in patients with metastatic renal cell carcinoma. *Urology*. 1997;50(5):673–677.

Smaldone MC, Corcoran AT, Uzzo RG. Active surveillance of small renal masses. *Nature Rev Urol*. 2013;10(5):266–274.

Smaldone MC, Kutikov A, Egleston BL, et al. Small renal masses progressing to metastases under active surveillance: a systematic review and pooled analysis. *Cancer*. 2012;118(4):997–1006.

Smith AD, Remer EM, Cox KL, et al. Bosniak category IIF and III cystic renal lesions: outcomes and associations. *Radiology*. 2012;262(1):152–160.

Smith SC, Sirohi D, Ohe C, et al. A distinctive, low-grade oncocytic fumarate hydratase-deficient renal cell carcinoma, morphologically reminiscent of succinate dehydrogenase-deficient renal cell carcinoma. *Histopathology*. 2017;71(1):42–52.

Smullens SN, Scotti DJ, Osterholm JL, et al. Preoperative embolization of retroperitoneal hemangiopericytomas as an aid in their removal. *Cancer*. 1982;50(9):1870–1875.

Song C, Bang JK, Park HK, et al. Factors influencing renal function reduction after partial nephrectomy. *J Urol*. 2009;181(1):48–53 [discussion 4].

Sorbellini M, Kattan MW, Snyder ME, et al. A postoperative prognostic nomogram predicting recurrence for patients with conventional clear cell renal cell carcinoma. *J Urol*. 2005;173(1):48–51.

Spana G, Haber GP, Dulabon LM, et al. Complications after robotic partial nephrectomy at centers of excellence: multi-institutional analysis of 450 cases. *J Urol*. 2011;186(2):417–421.

Sreedharan S, Petros JA, Master VA, et al. Aquaporin-1 protein levels elevated in fresh urine of renal cell carcinoma patients: potential use for screening and classification of incidental renal lesions. *Dis Markers*. 2014;2014:135649.

Srigley JR, Delahunt B, Eble JN, et al. The International Society of Urological Pathology (ISUP) Vancouver classification of renal neoplasia. *Am J Surg Pathol*. 2013;37(10):1469–1489.

Srinivas V, Sogani PC, Hajdu SI, et al. Sarcomas of the kidney. *J Urol*. 1984;132(1):13–16.

Staehler M, Bader M, Schlenker B, et al. Single fraction radiosurgery for the treatment of renal tumors. *J Urol*. 2015;193(3):771–775.

Stafford HS, Saltzstein SL, Shimasaki S, et al. Racial/ethnic and gender disparities in renal cell carcinoma incidence and survival. *J Urol*. 2008;179(5):1704–1708.

Stamatakis L, Metwalli AR, Middelton LA, et al. Diagnosis and management of BHD-associated kidney cancer. *Fam Cancer*. 2013;12(3):397–402.

Starink TM, van der Veen JP, Arwert F, et al. The Cowden syndrome: a clinical and genetic study in 21 patients. *Clin Genet*. 1986;29(3):222–233.

Stein RJ, Kaouk JH. Renal cryotherapy: a detailed review including a 5-year follow-up. *BJU Int*. 2007;99(5 Pt B):1265–1270.

Steinbach F, Novick AC, Zincke H, et al. Treatment of renal cell carcinoma in von Hippel-Lindau disease: a multicenter study. *J Urol*. 1995;153(6):1812–1816.

Stephenson AJ, Chetner MP, Rourke K, et al. Guidelines for the surveillance of localized renal cell carcinoma based on the patterns of relapse after nephrectomy. *J Urol*. 2004;172(1):58–62.

Sterrett SP, Nakada SY, Wingo MS, et al. Renal thermal ablative therapy. *Urol Clin North Am*. 2008;35(3):397–414 [viii].

Storkel S, Eble JN, Adlakha K, et al. Classification of renal cell carcinoma: workgroup No. 1. Union Internationale Contre le Cancer (UICC) and the American Joint Committee on Cancer (AJCC). *Cancer*. 1997;80(5):987–989.

Stroup SP, Palazzi K, Kopp RP, et al. RENAL nephrometry score is associated with operative approach for partial nephrectomy and urine leak. *Urology*. 2012;80(1):151–156.

Studer UE, Scherz S, Scheidegger J, et al. Enlargement of regional lymph nodes in renal cell carcinoma is often not due to metastases. *J Urol*. 1990;144(2 Pt 1):243–245.

Subramanian VS, Stephenson AJ, Goldfarb DA, et al. Utility of preoperative renal artery embolization for management of renal tumors with inferior vena caval thrombi. *Urology*. 2009;74(1):154–159.

Sudarshan S, Linehan WM. Genetic basis of cancer of the kidney. *Semin Oncol*. 2006;33(5):544–551.

Sufrin G, Chasan S, Golio A, et al. Paraneoplastic and serologic syndromes of renal adenocarcinoma. *Semin Urol*. 1989;7(3):158–171.

Sui W, Matulay JT, Robins DJ, et al. Collecting duct carcinoma of the kidney: disease characteristics and treatment outcomes from the National Cancer Database. *Urol Oncol*. 2017;35(9):540 e13–e18.

Sukov WR, Lohse CM, Leibovich BC, et al. Clinical and pathological features associated with prognosis in patients with papillary renal cell carcinoma. *J Urol*. 2012;187(1):54–59.

Sun M, Becker A, Tian Z, et al. Management of localized kidney cancer: calculating cancer-specific mortality and competing risks of death for surgery and nonsurgical management. *Eur Urol*. 2014;65(1):235–241.

Sun M, Maconi L, Eisen T, et al. Adjuvant vascular endothelial growth factor-targeted therapy in renal cell carcinoma: a systematic review and pooled analysis. *Eur Urol*.

2018;74:611–620.

Sun M, Vetterlein M, Harshman LC, et al. Risk assessment in small renal masses: a review article. *Urol Clin North Am*. 2017;44(2):189–202.

Sundaram V, Figenshau RS, Roytman TM, et al. Positive margin during partial nephrectomy: does cancer remain in the renal remnant? *Urology*. 2011;77(6):1400–1403.

Swaminath A, Chu W. Stereotactic body radiotherapy for the treatment of medically inoperable primary renal cell carcinoma: current evidence and future directions. *Can Urol Assoc J*. 2015;9(7–8):275–280.

Swartz MA, Karth J, Schneider DT, et al. Renal medullary carcinoma: clinical, pathologic, immunohistochemical, and genetic analysis with pathogenetic implications. *Urology*. 2002;60(6):1083–1089.

Syed JS, Nguyen KA, Wu CQ, et al. Distinguishing pediatric and adolescent renal cell carcinoma from other renal malignancies. *Pediatr Blood Cancer*. 2017;64(5).

Takahashi A, Sasaki H, Kim SJ, et al. Markedly increased amounts of messenger RNAs for vascular endothelial growth factor and placenta growth factor in renal cell carcinoma associated with angiogenesis. *Cancer Res*. 1994;54(15):4233–4237.

Tan HJ, Norton EC, Ye Z, et al. Long-term survival following partial vs radical nephrectomy among older patients with early-stage kidney cancer. *J Am Med Assoc*. 2012;307(15):1629–1635.

Tan HJ, Wolf JS Jr, Ye Z, et al. Population level assessment of hospital based outcomes following laparoscopic versus open partial nephrectomy during the adoption of minimally invasive surgery. *J Urol*. 2014;191(5):1231–1237.

Tan HJ, Wolf JS Jr, Ye Z, et al. Population-level comparative effectiveness of laparoscopic versus open radical nephrectomy for patients with kidney cancer. *Cancer*. 2011;117(18):4184–4193.

Tan MH, Kanesvaran R, Li H, et al. Comparison of the UCLA Integrated Staging System and the Leibovich score in survival prediction for patients with nonmetastatic clear cell renal cell carcinoma. *Urology*. 2010;75(6):1365–1370 [70 e1–70 e3].

Tanagho YS, Kaouk JH, Allaf ME, et al. Perioperative complications of robot-assisted partial nephrectomy: analysis of 886 patients at 5 United States centers. *Urology*. 2013;81(3):573–579.

Tanagho YS, Roytman TM, Bhayani SB, et al. Laparoscopic cryoablation of renal masses: single-center long-term experience. *Urology*. 2012;80(2):307–314.

Tannir NM, Plimack E, Ng C, et al. A phase 2 trial of sunitinib in patients with advanced non-clear cell renal cell carcinoma. *Eur Urol*. 2012;62(6):1013–1019.

Taylor BL, Stavropoulos SW, Guzzo TJ. Ablative therapy for small renal masses. *Urol Clin North Am*. 2017;44(2):223–231.

Teloken PE, Thompson RH, Tickoo SK, et al. Prognostic impact of histological subtype on surgically treated localized renal cell carcinoma. *J Urol*. 2009;182(5):2132–2136.

Terakawa T, Miyake H, Takenaka A, et al. Clinical outcome of surgical management for patients with renal cell carcinoma involving the inferior vena cava. *Int J Urol*. 2007;14(9):781–784.

Terenziani M, Spreafico F, Collini P, et al. Adult Wilms' tumor: a monoinstitutional experience and a review of the literature. *Cancer*. 2004;101(2):289–293.

Terrone C, Cracco C, Porpiglia F, et al. Reassessing the current TNM lymph node staging for renal cell carcinoma. *Eur Urol*. 2006;49(2):324–331.

Thoenes W, Storkel S, Rumpelt HJ. Human chromophobe cell renal carcinoma. *Virchows Arch B Cell Pathol Incl Mol Pathol*. 1985;48(3):207–217.

Thoenes W, Storkel S, Rumpelt HJ, et al. Chromophobe cell renal carcinoma and its variants–a report on 32 cases. *J Pathol*. 1988;155(4):277–287.

Thomas AA, Rini BI, Lane BR, et al. Response of the primary tumor to neoadjuvant sunitinib in patients with advanced renal cell carcinoma. *J Urol*. 2009;181(2):518–523 [discussion 23].

Thomas AA, Rini BI, Stephenson AJ, et al. Surgical resection of renal cell carcinoma after targeted therapy. *J Urol*. 2009;182(3):881–886.

Thompson RH, Boorjian SA, Lohse CM, et al. Radical nephrectomy for pT1a renal masses may be associated with decreased overall survival compared with partial nephrectomy. *J Urol*. 2008;179(2):468–471 [discussion 72–73].

Thompson RH, Cheville JC, Lohse CM, et al. Reclassification of patients with pT3 and pT4 renal cell carcinoma improves prognostic accuracy. *Cancer*. 2005;104(1):53–60.

Thompson RH, Hill JR, Babayev Y, et al. Metastatic renal cell carcinoma risk according to tumor size. *J Urol*. 2009;182(1):41–45.

Thompson RH, Kuntz SM, Leibovich BC, et al. Tumor B7-H1 is associated with poor prognosis in renal cell carcinoma patients with long-term follow-up. *Cancer Res*. 2006;66(7):3381–3385.

Thompson RH, Kurta JM, Kaag M, et al. Tumor size is associated with malignant potential in renal cell carcinoma cases. *J Urol*. 2009;181(5):2033–2036.

Thompson RH, Lane BR, Lohse CM, et al. Renal function after partial nephrectomy: effect of warm ischemia relative to quantity and quality of preserved kidney. *Urology*. 2012;79(2):356–360.

Thompson RH, Leibovich BC, Cheville JC, et al. Should direct ipsilateral adrenal invasion from renal cell carcinoma be classified as pT3a? *J Urol*. 2005;173(3):918–921.

Thyavihally YB, Tongaonkar HB, Gupta S, et al. Primitive neuroectodermal tumor of the kidney: a single institute series of 16 patients. *Urology*. 2008;71(2):292–296.

Tobert CM, Kahnoski RJ, Thompson DE, et al. RENAL nephrometry score predicts surgery type independent of individual surgeon's use of nephron-sparing surgery. *Urology*. 2012;80(1):157–161.

Tobert CM, Uzzo RG, Wood CG, et al. Adjuvant and neoadjuvant therapy for renal cell carcinoma: a survey of the Society of Urologic Oncology. *Urol Oncol*. 2013;31(7):1316–1320.

Tokuda N, Naito S, Matsuzaki O, et al. Collecting duct (Bellini duct) renal cell carcinoma: a nationwide survey in Japan. *J Urol*. 2006;176(1):40–43 [discussion 3].

Tollefson MK, Thompson RH, Sheinin Y, et al. Ki-67 and coagulative tumor necrosis are independent predictors of poor outcome for patients with clear cell renal cell carcinoma and not surrogates for each other. *Cancer*. 2007;110(4):783–790.

Tomaszewski JJ, Cung B, Smaldone MC, et al. Renal pelvic anatomy is associated with incidence, grade, and need for intervention for urine leak following partial nephrectomy. *Eur Urol*. 2014;66(5):949–955.

Tomita M, Ayabe T, Chosa E, et al. Isolated renal metastasis from non-small-cell lung cancer: report of 2 cases. *Case Rep Surg*. 2015;2015:357481.

Toro JR, Wei MH, Glenn GM, et al. BHD mutations, clinical and molecular genetic investigations of Birt-Hogg-Dube syndrome: a new series of 50 families and a review of published reports. *J Med Genet*. 2008;45(6):321–331.

Tourojman M, Kirmiz S, Boelkins B, et al. Impact of reduced glomerular filtration rate and proteinuria on overall survival of patients with renal cancer. *J Urol*. 2016;195(3):588–593.

True LD. The time for accurate Fuhrman grading of renal cell carcinomas has arrived. *Am J Clin Pathol*. 2002;118(6):827–829.

Tsivian M, Chen VH, Kim CY, et al. Complications of laparoscopic and percutaneous renal cryoablation in a single tertiary referral center. *Eur Urol*. 2010;58(1):142–147.

Tsui KH, Shvarts O, Smith RB, et al. Renal cell carcinoma: prognostic significance of incidentally detected tumors. *J Urol*. 2000;163(2):426–430.

Turner RM 2nd, Morgan TM, Jacobs BL. Epidemiology of the small renal mass and the treatment disconnect phenomenon. *Urol Clin North Am*. 2017;44(2):147–154.

Turney BW, Reynard JM, Cranston DW. A case for screening for renal cancer. *BJU Int*. 2006;97(2):220–221.

Uhlman MA, Pate SC, Brown JA. Explosive growth of a renal tumor during active surveillance. *Can J Urol*. 2013;20(2):6739–6741.

Umbreit EC, Shimko MS, Childs MA, et al. Metastatic potential of a renal mass according to original tumour size at presentation. *BJU Int*. 2012;109(2):190–194 [discussion 4].

Urban BA, Fishman EK. Renal lymphoma: CT patterns with emphasis on helical CT. *Radiographics*. 2000;20(1):197–212.

Uzosike AC, Patel HD, Alam R, et al. Growth kinetics of small renal masses on active surveillance: variability and results from the DISSRM Registry. *J Urol*. 2017.

Uzzo RG, Cherullo E, Myles J, et al. Renal cell carcinoma invading the urinary collecting system: implications for staging. *J Urol*. 2002;167(6):2392–2396.

Uzzo RG, Novick AC. Nephron sparing surgery for renal tumors: indications, techniques and outcomes. *J Urol*. 2001;166(1):6–18.

van der Werf-Messing B. Proceedings: carcinoma of the kidney. *Cancer*. 1973;32(5):1056–1061.

Van Poppel H, Becker F, Cadeddu JA, et al. Treatment of localised renal cell carcinoma. *Eur Urol*. 2011;60(4):662–672.

Van Poppel H, Da Pozzo L, Albrecht W, et al. A prospective, randomised EORTC intergroup phase 3 study comparing the oncologic outcome of elective nephron-sparing surgery and radical nephrectomy for low-stage renal cell carcinoma. *Eur Urol*. 2011;59(4):543–552.

Vanharanta S, Buchta M, McWhinney SR, et al. Early-onset renal cell carcinoma as a novel extraparaganglial component of SDHB-associated heritable paraganglioma. *Am J Hum Genet*. 2004;74(1):153–159.

Varela I, Tarpey P, Raine K, et al. Exome sequencing identifies frequent mutation of the SWI/SNF complex gene PBRM1 in renal carcinoma. *Nature*. 2011;469(7331):539–542.

Varma AV, Malukani K, Rihal P, et al. Adult Wilms' tumor: a case report with review of literature. *J Cancer Res Ther*. 2015;11(4):934–936.

Verhoest G, Avakian R, Bensalah K, et al. Urinary collecting system invasion is an independent prognostic factor of organ confined renal cell carcinoma. *J Urol*. 2009;182(3):854–859.

VHL Alliance. *VHLA Suggested Active Surveillance Guidelines*. [Available from] https://www.vhl.org/wp-content/uploads/2017/07/Active-Surveillance-Guidelines.pdf; 2016.

Vira MA, Novakovic KR, Pinto PA, et al. Genetic basis of kidney cancer: a model for developing molecular-targeted therapies. *BJU Int*. 2007;99(5 Pt B):1223–1229.

Vogelzang NJ, Fremgen AM, Guinan PD, et al. Primary renal sarcoma in adults. A natural history and management study by the American Cancer Society, Illinois Division. *Cancer*. 1993;71(3):804–810.

Vogelzang NJ, Priest ER, Borden L. Spontaneous regression of histologically proved pulmonary metastases from renal cell carcinoma: a case with 5-year followup. *J Urol*. 1992;148(4):1247–1248.

Volpe A. The role of active surveillance of small renal masses. *Int J Surg*. 2016;36(Pt C):518–524.

Volpe A, Amparore D, Mottrie A. Treatment outcomes of partial nephrectomy for T1b tumours. *Curr Opin Urol*. 2013;23(5):403–410.

Volpe A, Blute ML, Ficarra V, et al. Renal ischemia and function after partial nephrectomy: a collaborative review of the literature. *Eur Urol*. 2015;68(1):61–74.

Volpe A, Bollito E, Bozzola C, et al. Classification of histologic patterns of pseudocapsular invasion in organ-confined renal cell carcinoma. *Clin Genitourin Cancer*. 2016;14(1):69–75.

Volpe A, Cadeddu JA, Cestari A, et al. Contemporary management of small renal masses. *Eur Urol*. 2011;60(3):501–515.

Volpe A, Panzarella T, Rendon RA, et al. The natural history of incidentally detected small renal masses. *Cancer*. 2004;100(4):738–745.

von Knobloch R, Schrader AJ, Walthers EM, et al. Simultaneous adrenalectomy during radical nephrectomy for renal cell carcinoma will not cure patients with adrenal metastasis. *Urology*. 2009;73(2):333–336.

Wallen EM, Pruthi RS, Joyce GF, Urologic Diseases in America P, et al. Kidney cancer. *J Urol*. 2007;177(6):2006–2018 [discussion 18–19].

Wang X, Xu R, Yan L, et al. Adult renal sarcoma: clinical features and survival in a series of patients treated at a high-volume institution. *Urology*. 2011;77(4):836–841.

Wang Z, Wang G, Xia Q, et al. Partial nephrectomy vs. radical nephrectomy for renal tumors: a meta-analysis of renal function and cardiovascular outcomes. *Urol Oncol*. 2016;34(12):533 e11–e19.

Webster WS, Thompson RH, Cheville JC, et al. Surgical resection provides excellent outcomes for patients with cystic clear cell renal cell carcinoma. *Urology*. 2007;70(5):900–904 [discussion 4].

Wei S, Al-Saleem T. The pathology and molecular genetics of sarcomatoid renal cell carcinoma: a mini-review. *J Kidney Cancer VHL*. 2017;4(2):19–23.

Weight CJ, Kaouk JH, Hegarty NJ, et al. Correlation of radiographic imaging and histopathology following cryoablation and radio frequency ablation for renal tumors. *J Urol*. 2008;179(4):1277–1281 [discussion 81–83].

Weight CJ, Kim SP, Lohse CM, et al. Routine adrenalectomy in patients with locally advanced renal cell cancer does not offer oncologic benefit and places a significant portion of patients at risk for an asynchronous metastasis in a solitary adrenal gland. *Eur Urol*. 2011;60(3):458–464.

Weight CJ, Miller DC, Campbell SC, et al. The management of a clinical t1b renal tumor in the presence of a normal contralateral kidney. *J Urol*. 2013;189(4):1198–1202.

Weisbrod AJ, Atwell TD, Frank I, et al. Percutaneous cryoablation of masses in a solitary kidney. *Am J Roentgenol*. 2010;194(6):1620–1625.

Weiss LM, Gelb AB, Medeiros LJ. Adult renal epithelial neoplasms. *Am J Clin Pathol*. 1995;103(5):624–635.

Whitson JM, Harris CR, Reese AC, et al. Lymphadenectomy improves survival of patients with renal cell carcinoma and nodal metastases. *J Urol*. 2011;185(5):1615–1620.

Wiesener MS, Munchenhagen P, Glaser M, et al. Erythropoietin gene expression in renal carcinoma is considerably more frequent than paraneoplastic polycythemia. *Int J Cancer*. 2007;121(11):2434–2442.

Wille AH, Roigas J, Deger S, et al. Laparoscopic radical nephrectomy: techniques, results and oncological outcome in 125 consecutive cases. *Eur Urol*. 2004;45(4):483–488 [discussion 8–9].

Williamson SR, Eble JN, Amin MB, et al. Succinate dehydrogenase-deficient renal cell carcinoma: detailed characterization of 11 tumors defining a unique subtype of renal cell carcinoma. *Mod Pathol*. 2015;28(1):80–94.

Winter P, Vahlensieck W Jr, Miersch WD, et al. Wilms' tumour in adults. Review of 10 cases. *Int Urol Nephrol*. 1996;28(4):469–475.

Wood C, Srivastava P, Bukowski R, et al. An adjuvant autologous therapeutic vaccine (HSPPC-96; vitespen) versus observation alone for patients at high risk of recurrence after nephrectomy for renal cell carcinoma: a multicentre, open-label, randomised phase III trial. *Lancet (London, England)*. 2008;372(9633):145–154.

Wortman JR, Tirumani SH, Jagannathan JP, et al. Radiation therapy for soft-tissue sarcomas: a primer for radiologists. *Radiographics*. 2016;36(2):554–572.

Wotkowicz C, Wszolek MF, Libertino JA. Resection of renal tumors invading the vena cava. *Urol Clin North Am*. 2008;35(4):657–671 [viii].

Wright JL, Risk MC, Hotaling J, et al. Effect of collecting duct histology on renal cell cancer outcome. *J Urol*. 2009;182(6):2595–2599.

Wu J, Suk-Ouichai C, Dong W, et al. Analysis of survival for patients with chronic kidney disease primarily related to renal cancer surgery. *BJU Int*. 2018;121(1):93–100.

Wu Z, Li M, Liu B, et al. Robotic versus open partial nephrectomy: a systematic review and meta-analysis. *PLoS ONE*. 2014;9(4):e94878.

Xie Y, Yang B, Jiang G, et al. Spontaneous perirenal hemorrhage in hemodialysis patient treated with selective embolization: a case series and review of the literature. *Hemodial Int*. 2017.

Yang JC, Sherry RM, Steinberg SM, et al. Randomized study of high-dose and low-dose interleukin-2 in patients with metastatic renal cancer. *J Clin Oncol*. 2003;21(16):3127–3132.

Yang XJ, Sugimura J, Schafernak KT, et al. Classification of renal neoplasms based on molecular signatures. *J Urol*. 2006;175(6):2302–2306.

Yang XJ, Tan MH, Kim HL, et al. A molecular classification of papillary renal cell carcinoma. *Cancer Res*. 2005;65(13):5628–5637.

Yaycioglu O, Eskicorapci S, Karabulut E, et al. A preoperative prognostic model predicting recurrence-free survival for patients with kidney cancer. *Jpn J Clin Oncol*. 2013;43(1):63–68.

Yezhelyev M, Master V, Egnatashvili V, et al. Combined nephrectomy and major hepatectomy: indications, outcomes, and recommendations. *J Am Coll Surg*. 2009;208(3):410–418.

Yin M, Wang W, Rosenberg J, et al. Targeted therapy in collecting duct carcinoma of the kidney: a case report and literature review. *Clin Genitourin Cancer*. 2016;14(2):e203–e206.

Yohannan J, Feng T, Berkowitz J, et al. Laparoscopic resection of local recurrence after previous radical nephrectomy for clinically localized renal-cell carcinoma: perioperative outcomes and initial observations. *J Endourol*. 2010;24(10):1609–1612.

Yokoyama S, Woods SL, Boyle GM, et al. A novel recurrent mutation in MITF predisposes to familial and sporadic melanoma. *Nature*. 2011;480(7375):99–103.

Yossepowitch O, Thompson RH, Leibovich BC, et al. Positive surgical margins at partial nephrectomy: predictors and oncological outcomes. *J Urol*. 2008;179(6):2158–2163.

Young JR, Margolis D, Sauk S, et al. Clear cell renal cell carcinoma: discrimination from other renal cell carcinoma subtypes and oncocytoma at multiphasic multidetector CT. *Radiology*. 2013;267(2):444–453.

Young RJ, Coleman RE. Zoledronic acid to prevent and treat cancer metastasis: new prospects for an old drug. *Future Oncol*. 2013;9(5):633–643.

Zabell J, Demirjian S, Lane BR, et al. Predictors of long-term survival after renal cancer surgery. *J Urol*. 2017;199(2):384–392.

Zabell JR, Wu J, Suk-Ouichai C, et al. Renal ischemia and functional outcomes following partial nephrectomy. *Urol Clin North Am*. 2017;44(2):243–255.

Zabor EC, Furberg H, Mashni J, et al. Factors associated with recovery of renal function following radical nephrectomy for kidney neoplasms. *Clin J Am Soc Nephrol*. 2016;11(1):101–107.

Zagoria RJ. Imaging of small renal masses: a medical success story. *Am J Roentgenol*. 2000;175(4):945–955.

Zambrano NR, Lubensky IA, Merino MJ, et al. Histopathology and molecular genetics of renal tumors toward unification of a classification system. *J Urol*. 1999;162(4):1246–1258.

Zargar H, Atwell TD, Cadeddu JA, et al. Cryoablation for small renal masses: selection criteria, complications, and functional and oncologic results. *Eur Urol*. 2016;69(1):116–128.

Zbar B, Brauch H, Talmadge C, et al. Loss of alleles of loci on the short arm of chromosome 3 in renal cell carcinoma.

Nature. 1987;327(6124):721–724.

Zbar B, Glenn G, Lubensky I, et al. Hereditary papillary renal cell carcinoma: clinical studies in 10 families. *J Urol*. 1995;153(3 Pt 2):907–912.

Zhang BY, Cheville JC, Thompson RH, et al. Impact of rhabdoid differentiation on prognosis for patients with grade 4 renal cell carcinoma. *Eur Urol*. 2015;68(1):5–7.

Zhang J, Lefkowitz RA, Bach A. Imaging of kidney cancer. *Radiol Clin North Am*. 2007;45(1):119–147.

Zhang JQ, Fielding JR, Zou KH. Etiology of spontaneous perirenal hemorrhage: a meta-analysis. *J Urol*. 2002;167(4):1593–1596.

Zhang Z, Zhao J, Velet L, et al. Functional recovery from extended warm ischemia associated with partial nephrectomy. *Urology*. 2016;87:106–113.

Zhou M. Pathology of renal cell caricnomas. Rini BI, Campbell SC. *Renal cell carcinoma*. People's Medical Publishing House: Shelton, CT; 2009:1–14.

Zibelman M, Plimack ER. Integrating immunotherapy into the management of renal cell carcinoma. *J Natl Compr Canc Netw*. 2017;15(6):841–847.

Zigeuner R, Hutterer G, Chromecki T, et al. External validation of the Mayo Clinic stage, size, grade, and necrosis (SSIGN) score for clear-cell renal cell carcinoma in a single European centre applying routine pathology. *Eur Urol*. 2010;57(1):102–109.

Zini L, Destrieux-Garnier L, Leroy X, et al. Renal vein ostium wall invasion of renal cell carcinoma with an inferior vena cava tumor thrombus: prediction by renal and vena caval vein diameters and prognostic significance. *J Urol*. 2008;179(2):450–454 [discussion 4].

Zisman A, Pantuck AJ, Dorey F, et al. Improved prognostication of renal cell carcinoma using an integrated staging system. *J Clin Oncol*. 2001;19(6):1649–1657.

Zisman A, Pantuck AJ, Wieder J, et al. Risk group assessment and clinical outcome algorithm to predict the natural history of patients with surgically resected renal cell carcinoma. *J Clin Oncol*. 2002;20(23):4559–4566.

Zomas A, Leivada A, Gortzolidis G, et al. Primary renal lymphoma presenting with chronic low-grade fever. *Int J Hematol*. 2004;79(4):361–363.

Zondervan PJ, Buijs M, de la Rosette JJ, et al. Cryoablation of small kidney tumors. *Int J Surg*. 2016;36(Pt C):533–540.

Urothelial Tumors of the Upper Urinary Tract and Ureter

Panagiotis Kallidonis MD, MSc, PhD, FEBU, Evangelos Liatsikos MD, PhD

Epidemiology

Incidence

Urothelial carcinomas are relatively common: they are the fourth most common tumor. Nevertheless, upper urinary tract carcinomas (UTUCs) make up only 5% to 10% of urothelial tumors (Munoz and Ellison, 2000; Siegel et al., 2013). The annual incidence of the UTUC in Western countries has been estimated at 2 cases per 100,000 inhabitants (Roupret et al., 2011; Soria et al., 2017). The highest incidence is observed in individuals aged 70 to 90, men, and in the Balkan countries, where UTUC represents 40% of all renal neoplasms (Grollman, 2013; Shariat et al., 2011). The incidence of UTUC has risen over the last few decades because of improved diagnostic methods employed in everyday practice (David et al., 2009; McCarron et al., 1983; Munoz and Ellison, 2000; Soria et al., 2017).

The majority of UTUCs are presented in a single renal unit, although up to 5% of patients have bilateral disease (Holmäng and Johansson, 2004). The involvement of the pelvicalyceal system is twice as common as with ureteral tumors. Multifocal presence of UTUC is diagnosed in 10% to 20% of cases. Concomitant carcinoma in situ (CIS) could be diagnosed in 11% to 36% of cases (Soria et al., 2017). Concurrent bladder cancer is diagnosed in 17% of cases (Cosentino et al., 2013). Up to 41% of American men with UTUC have a history of bladder cancer, whereas only 4% of the Chinese men with UTUC have a history of bladder cancer (Singla et al., 2017). Nonetheless, the Asian population seems to be seen initially with a higher-grade disease than other ethnic groups (Soria et al., 2017).

Disease recurrence after treatment involves the bladder in 22% to 47% of cases (Xylinas et al., 2012) and the contralateral upper tract in 2% to 6% (Li et al., 2010). Metachronous UTUC after treated bladder cancer could reach 80% of cases, and most of these occurrences take place in the renal pelvis rather than the ureter (Li et al., 2010; Novara et al., 2009). Approximately 60% of the UTUCs are invasive, and 7% have metastasized at diagnosis (Margulis et al., 2009).

The National Cancer Institute's Surveillance, Epidemiology, and End Results (SEER) database provided interesting data on the epidemiology of UTUC (Raman et al., 2010). The time ranged between 1975 to 2005. The annual incidence rates were 1.88 to 2.06 cases per 100,00 person-years. An increase in the annual incidence of ureteral neoplasms was observed during this period (0.69 to 0.91), while the pelvic lesions showed a slight decrease (1.19 to 1.15). A significantly higher proportion of earlier stage tumors has been observed over the study period. Earlier stage tumors represented only 7.2% of the UTUC cases in 1973 to 1984 and 31% in 1994 to 2005. The National Cancer Data Base (NCDB) for the United States for 1993 to 2005 confirmed the increase in early stage tumors of the ureter and pelvis and further noted an increase in the proportion of high-grade UTUCs (David et al., 2009).

Gender, Race, Age Variations, and Familial Predisposition

UTUCs are twice more frequent in men than in women (Greenlee et al., 2000; Lughezzani et al., 2010). African-Americans develop UTUC twice more often than the Caucasian population (Greenlee et al., 2000). Patients with UTUC are older than patients with urothelial bladder tumors (Melamed and Reuter, 1993) and tend to have worse prognosis (Audenet et al., 2012). Familial/hereditary upper tract tumors should be considered when the patient is younger than 60 years (Audenet et al., 2012).

Mortality Rate

Disease mortality has been related to increasing age, male gender, black non-Hispanic race, and advanced tumor stage (Raman et al., 2011). A SEER-based study evaluated data from 1973 to 1996 and showed 5-year disease-specific survival rates for overall, in situ, localized, regional, and distant disease of 75%, 95%, 88.9%, 62.5%, and 16.5%, respectively (Munoz and Ellison, 2000). Disease-specific annual mortality has been reported to be higher in black men than white men (7.4% vs. 4.9%). The same is true for women over men (6.1% vs. 4.4%) (Munoz and Ellison, 2000). Pathologic features or survival was not correlated to the gender in two multicenter studies (Fernández et al., 2009; Shariat et al., 2011). In addition, disease-specific mortality after radical nephroureterectomy was related to the gender when clinicopathologic features were controlled (hazard ratio (HR) = 1.07, $P = 0.4$). In the same study, advanced stage (pT3) disease was associated with the female gender (odds ratio [OR] = 1.15, $P = 0.03$) (Lughezzani et al., 2010).

Key Points: Epidemiology

- Upper urinary tract carcinomas make up only 5% of the urothelial cancers.
- The highest incidence is observed in individuals age 70 to 90 years in the Balkan countries, where UTUC represents the 40% of all renal neoplasms.
- Multifocal presence of UTUC is diagnosed in 10% to 20% of cases.
- Concurrent bladder cancer is diagnosed in 17% of cases.
- UTUCs are twice as frequent in men than in women.

Risk Factors

Genetic Predisposition

Familial/hereditary UTUCs are linked to hereditary nonpolyposis colorectal carcinoma (HNPCC) syndrome (or Lynch syndrome) (Lynch et al., 1990; Roupret et al., 2008). Patients with HNPCC have mutations in the DNA mismatch repair genes *MLH1* (MutL homolog 1), *MSH2* (MutS protein homolog 2), *MSH6* (MutS protein homolog 6), and *PMS2* (mismatch repair endonuclease PMS2). These patients have a higher likelihood to develop colonic, urothelial, gastric, pancreatic, uterine, sebaceous, and ovarian carcinomas. These urothelial cancers mainly involve the upper urinary tract, whereas the involvement of the bladder remains unclear (Matsuoka et al., 2003; Skeldon et al., 2013; van der Post et al., 2010). Any bladder tumor in this population of patients could have been a result of seeding of the bladder from the upper tract. Patients with HNPCC and UTUC are younger than 60 years (mean age 55 years). Moreover, there is a higher representation of female patients in UTUC patients (Lynch et al., 1990). Suspicion for genetic predisposition should be raised in young patients with UTUC, personal history, or having two first-degree relatives with a cancer related to HNPCC (especially colon or endometrial tumors). A short interview could be helpful in screening these patients according to the European Association of Urology (EAU) guidelines (Fig. 98.1; Audenet et al., 2012). DNA sequencing for the patient and family counseling should be recommended in high-risk patients for HNPCC syndrome (Acher et al., 2010; Roupret et al., 2008).

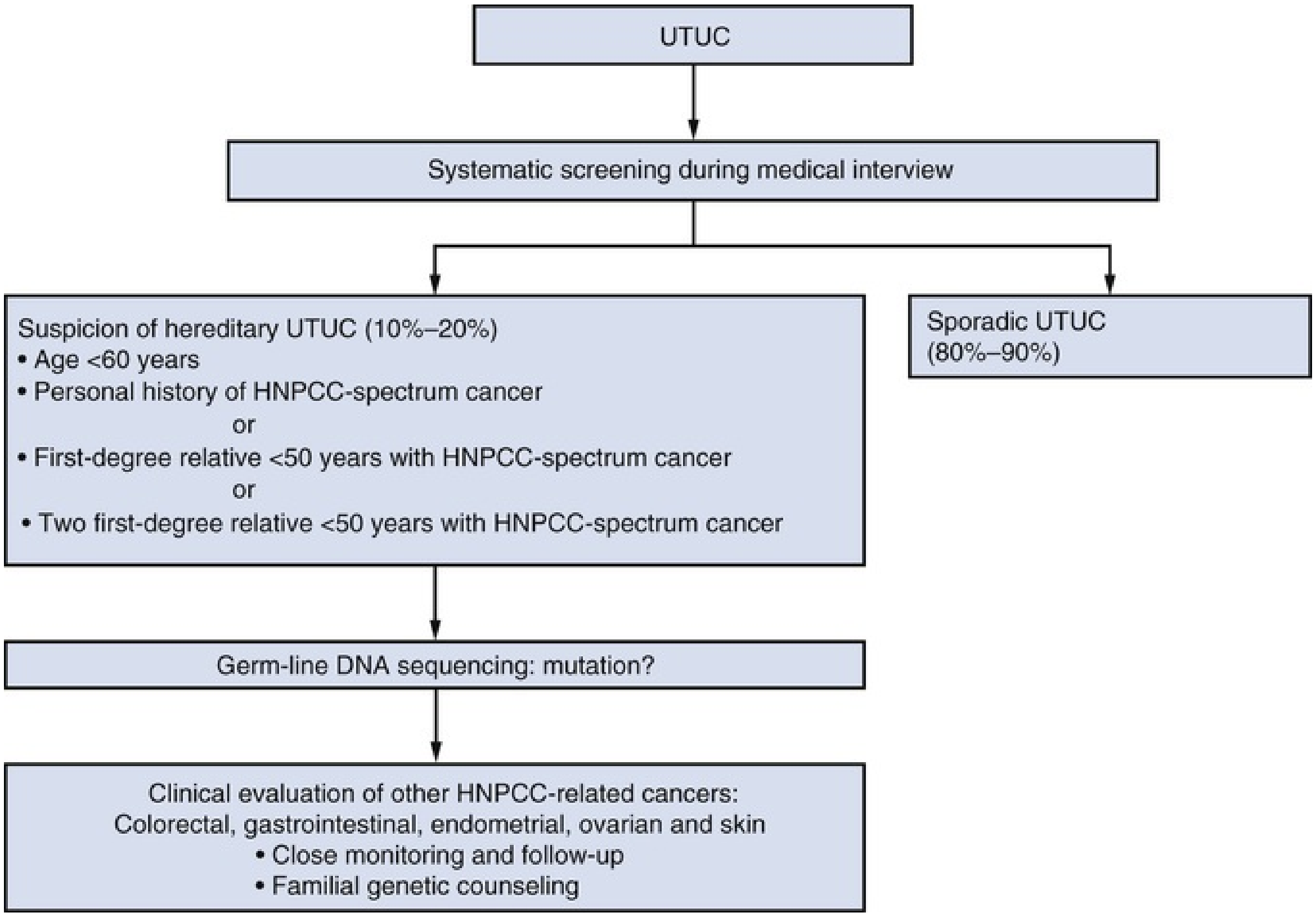
UTUC
Systematic screening during medical interview
Suspicion of hereditary UTUC (10%–20%)
• Age <60 years
• Personal history of HNPCC-spectrum cancer
or
• First-degree relative <50 years with HNPCC-spectrum cancer
or
• Two first-degree relative <50 years with HNPCC-spectrum cancer
Sporadic UTUC (80%–90%)
Germ-line DNA sequencing: mutation?
Clinical evaluation of other HNPCC-related cancers:
Colorectal, gastrointestinal, endometrial, ovarian and skin
• Close monitoring and follow-up
• Familial genetic counseling

FIG. 98.1 Selection of patients with upper tract urothelial cancer (UTUC) for hereditary screening during the first medical interview. *HNPCC,* Hereditary nonpolyposis colorectal carcinoma. (From Rouprêt M, Babjuk M, Compérat E, et al: European Association of Urology Guidelines on Upper Urinary Tract Urothelial Carcinoma: 2017 Update, *Eur Urol* 73[1]:111–122, 2018.)

Environmental Factors

There are several environmental factors that could contribute to the development of UTUC (Colin et al., 2009).

Tobacco Exposure

The routine use of tobacco increases the relative risk for UTUC from 2.5 to 7 times (Crivelli et al., 2014). Cigarette smoking is a modifiable risk factor and probably the most important one for UTUC. Smoking exposure is complex in terms of mechanism of action for carcinogenesis. A variety of toxic substances are inhaled during smoking and include aromatic amine with arylamine, benzopyrene, and dimethylbenzanthracene. These aromatic amines are metabolized by the body in the carcinogenic N-hydroxylamine. The detoxification of this derivative takes place by several enzyme systems (cytochrome P450s with CYP1A1, glutathione S-transferases, and N-acetyl transferases). Genetic polymorphisms in enzymes that neutralize N-hydroxylamine may reflect susceptibility to the carcinogenic effect of smoking (Hung et al., 2004). The risk for UTUC is modulated by the number of cigarettes consumed daily and the number of years of exposure. An odds ratio (OR) of 2.0 has been calculated for a smoking history of 20 pack-years or less. For heavy smokers such as 60 or more pack-years, the respective OR is 6.2. Smoking cessation results in decreased risk for UTUC with a risk reduction of 60% to 70% with an interruption of smoking for more than 10 years (OR 2.3 for former vs. 4.4 current smokers). The ureter is at higher risk for UTUCs in the smoking population in comparison with the pyelocaliceal system (McLaughlin et al., 1992).

Coffee, Tea, and Yerba Mate

An increased incidence of urothelial cancers has been associated with the consumption of coffee (Ross et al., 1989). Nevertheless, coffee drinkers may also be smokers, so this correlation is probably unsubstantial (Villanueva et al., 2009). A prospective European study into cancer and nutrition included 233,236 subjects with a mean follow-up period of 9.3 years. The investigation showed that the intake of water, coffee, tea, and dairy beverages was not related to urothelial cancer (Ros et al., 2011). In general, there are several studies in the literature evaluating the consumption of coffee or tea as a risk factor for UTUC, and none of them showed any significant correlation (Colin et al., 2009; De Stefani et al., 2007). A traditional beverage in South American countries is yerba mate. The consumption of yerba mate has been considered responsible for urothelial cancer. The beverage could result in providing high levels of polycyclic aromatic hydrocarbons. The risk ratio for urothelial cancer is estimated at 2.2. Nonetheless, currently no study evaluates yerba mate for its potential role in UTUC (De Stefani et al., 2007).

Occupation

UTUC “amino tumors” were related to occupational exposure to carcinogenic aromatic amines. These aromatic substances are still in use in industry in such products as dyes, textiles, rubber, chemicals, petrochemicals, and coal. The aromatic amines benzidine and beta-naphthylane are implicated in carcinogenesis (Colin et al., 2009; Matsuoka et al., 2003; Shinka et al., 1988). Both amines have been banned since the 1960s in most industrialized countries. The average duration of exposure needed to develop UTUC is 7 years, with a latency of up to 20 years after termination of exposure (Colin et al., 2009).

Persons exposed to the chemical, petroleum, and plastic industry have a risk ratio of 4. The same risk has also been identified for those exposed to coal or coke. Persons exposed to asphalt or tar have a risk ratio of 5.5 (Jensen et al., 1988). Polycyclic aromatic hydrocarbons and nitrosamines have been associated with the development of urothelial cancer. An increased risk of 1.3 times for the urothelial cancer with a significant dose effect has been reported (Clavel et al., 1994). Chlorinated solvents (trichloroethylene, tetrachloroethylene) used in metallurgy and printing have been related to urothelial carcinoma genesis with a risk of 1.8.

Aristolochic Acid Nephropathy

Dramatically higher incidence of UTUC has been reported in several studies since the 1950s. These investigations have proposed a 60 to 100 times higher incidence of UTUC in some Balkan rural areas in comparison with the rest of the world. There has been a significant reduction in these rates over the last 3 decades with a reduction in the endemic areas of the incidence of the disease from 57 times to 11 times between 1988 and 1998 (Colin et al., 2009; Stefanovic and Radovanovic, 2008). This endemic nephropathy has been also described as Balkan endemic nephropathy (BEN) and has been related to proximal tubule dysfunction. The latter is responsible for the presence of low-molecular-weight protein and a dense interstitial fibrosis within the glomeruli (Colin et al., 2009; Dragicevic et al., 2007; Grollman et al., 2007; Matsuoka et al., 2003). The special characteristics of the tumors developed in this endemic form of UTUC are the increased occurrence of bilateral disease, the lack of gender predominance, the occurrence in rural areas, and the diagnosis in an earlier age (approximately 10 years earlier) than the UTUC observed in the rest of the world (Colin et al., 2009).

The cause of BEN has been investigated over decades with several hypotheses to explain the association of environmental parameters to the UTUC. Mycotoxin ochratoxin A (OTA) has been investigated as a possible carcinogen related to the development of UTUC for more than 30 years (Colin et al., 2009; Dragicevic et al., 2007; Grollman et al., 2007; Matsuoka et al., 2003). OTA has been confirmed as a carcinogen in animals, but the histologic characteristics of the lesions developed by the toxin are not the same with the BEN UTUC (Colin et al., 2009).

Between 1992 and 1993, 43 patients were hospitalized in Belgium with end-stage renal failure, which was associated with the ingestion of Chinese herbal products (Acher et al., 2010; Audenet et al., 2012; Margulis et al., 2009). A manufacturing error led to the replacement of *Stephania tetracta* by *Aristolochia fangchi* in the mixture of these products. Almost 46% of these patients developed UTUC with similar histologic and genetic characteristics to the UTUC developed in BEN (Cosyns et al., 1999; Nortier et al., 2000). The term “Chinese herb nephropathy” was eventually proposed for this clinical entity. The high prevalence of UTUC in Taiwan and China could be connected to the use of *Aristolochia* in various herbal remedies. The highest incidence in the region is observed on the southwest coast of Taiwan, where 20% to 25% of UTUC cases are reported (Colin et al., 2009).

Specifically, aristolochic acid is found in the plants *Aristolochia fangchi* and *Aristolochia clematitis*. The plants are endemic in these countries and grow as weed in the wheat fields (Grollman et al., 2007). BEN is observed in the Balkan countries as a familial, not inherited, condition related to the dietary exposure to aristocholic acid (Radovanovic et al., 1985; Stefanovic and Radovanovic, 2008). Bladder cancer does not have a higher incidence in the affected families (Petkovic, 1975). The derivative of aristocholic acid, aristolactam, causes a mutation on codon 139 of p53 gene (A:T to T:A). This mutation is predominant in patients with BEN and Chinese herb nephropathy (Colin et al., 2009). Women (HR = 2.2), those with tumor size larger than 3 cm (HR = 2.8), and those with stage T3 or T4 disease (HR = 3.1) have a worse prognosis (Dragicevic et al., 2007).

Analgesics

Phenacetin was suspected for the first time for nephrotoxicity and development of UTUC in 1961 (Holmäng and Johansson, 2004). Phenacetin has been hypothesized to have a direct mutagenic effect and indirectly causes carcinogenesis by inducing nephrotoxicity through papillary necrosis (Colin et al., 2009). The second hypothesis has been confirmed by experimental and epidemiologic evidence (Stewart et al., 1999). The use of phenacetin was abandoned 30 years ago and paracetamol has replaced it. The average latency for the presentation of UTUC was approximately 22 years, and the prevalence of the phenacetin-related UTUC is decreasing (Stewart et al., 1999).

In general, analgesic abuse is an established risk factor for the development of UTUC (Johansson et al., 1974; McCredie et al., 1986; Morrison, 1984). Patients with pelvic and ureteral tumors have been reported to have a history of analgesic abuse in 22% and 11% of the cases, respectively. A latency period of approximately 2 years has been reported (Steffens and Nagel, 1988). Phenacetin is the best-described causative agent in analgesic nephropathy. Nonetheless, most of the patients are usually using combinations of substances, including caffeine, codeine, acetaminophen, and salicylates (De Broe and Elseviers, 1998). The pathognomonic histologic changes observed in analgesic abuse is the thickening of the basement membrane and the scarring of the papilla. When thickening of the basement membrane is observed in UTUC, the physician should be suspicious for analgesic abuse. Up to 15% of the UTUC cases may involve this histologic alteration, and the possibility for contralateral involvement should be considered (Palvio et al., 1987). Tumor grade is correlated to the degree of papillary scarring. On the contrary, the scarring is not associated with the development of squamous metaplasia or cancer (Stewart et al., 1999).

Arsenic

A disproportional incidence of UTUC has been reported in the southwest coast of Taiwan (Tan et al., 2008; Yang et al., 2002). Up to 25% of the UTUCs of the country are diagnosed in this region. The excess of inorganic arsenic in drinking water from artesian wells is a significant risk of UTUC and health problems in several regions worldwide (Tan et al., 2008; Yang et al., 2002). The chronic exposure to arsenic induces a form of peripheral vascular disease known as blackfoot disease. The latter clinical entity causes dry gangrene of the extremities and is related to the increased incidence of UTUC. The UTUC presented in the endemic areas of blackfoot disease has specific characteristics, which include the twice-more-common presentation of UTUC in the female population, the onset of the disease in a younger age (55–60 years), and the twice-more-common presentation of lesions of the ureter in comparison with the renal pelvis. The higher predominance of the disease in women may be related to the exposure of women to arsenic fumes during cooking and probably is related to the inhalation risk along with ingestion risk from the drinking water. The direct relationship of blackfoot disease and UTUC remains unclear (Lamm et al., 2006). Patients with UTUC may never be affected by blackfoot disease. Moreover, there is a high incidence of UTUC (10%–15% of the UTUC incidents) in the northeast regions of Taiwan, where blackfoot disease is not endemic. The association of arsenic and UTUC is not established in the case of UTUC but seems to play a role in bladder urothelial cancer. Nevertheless, arsenic and blackfoot disease are probably not the only relevant risk factors (Lamm et al., 2006).

Chronic Inflammation and Infection

Chronic urinary tract infections facilitate carcinogenesis by weakening the urothelium. The estimated risk for the development of UTUC is 1.5 to 2 greater in these cases (Liaw et al., 1997). The chronic irritation and/or inflammation of the urothelium induced by the stasis and the presence of urine substances may promote carcinogenesis. Thus lithiasis may be implemented in the process. The history of lithiasis is present in 5% to 8% of UTUC cases. Tumor incidence remains low in patients with urinary calculi (Colin et al., 2009). The relative risk of developing UTUC in cases with history of lithiasis ranges between 1.2 and 2.5 (Chow et al., 1997; Liaw et al., 1997). This risk is considered higher in female gender, renal pelvis calcifications, and lithiasis related to hospitalization. Chronic bacterial infection associated with urinary stones and obstruction has been associated with the development of squamous cell cancer (and less frequently adenocarcinoma) (Colin et al., 2009; Spires et al., 1993).

Iatrogenic Factors

Alkylating chemotherapy is known to induce UTUC via the associated metabolites such as acrolein. Chronic exposure to these substances leads to UTUC with epidermoid pathology. The relative risk for the development of urothelial cancer is 3.2 (Brenner and Schellhammer, 1987; McDougal et al., 1981).

Routine use of anthranoid and chemical laxatives has been implicated in the development of UTUC. When these products are used for more than 1 year, a relative risk of 9.62 has been reported. Nevertheless, the mechanism for carcinogenesis remains unclear (Pommer et al., 1999).

Radiotherapy-induced urothelial cancer could develop after the treatment of gynecologic cancers. The relative risk is 1.9, which remains lower than the respective figure for chemotherapy-treated patients. Current literature is lacking on data estimating the risk of UTUC (McDougal et al., 1981).

Key Points: Risk Factors

- Familial/hereditary UTUCs are linked to hereditary nonpolyposis colorectal carcinoma syndrome (Lynch syndrome).
- Tobacco increases the relative risk for UTUC from 2.5 to 7.
- UTUC “amino tumors” were related to occupational exposure to carcinogenic aromatic amines.
- Balkan nephropathy is observed as a familial, not inherited, condition related to the dietary exposure to aristocholic acid.
- Patients with pelvic and ureteral tumors have been reported to have a history of analgesic abuse in 22% and 11% of the cases, respectively.
- The excess of inorganic arsenic in drinking water from artesian wells is a significant risk factor for UTUC.

Histopathology

Most the upper urinary tract tumors are urothelial cancer; the pure nonurothelial cancers, such as squamous cell cancers and adenocarcinomas, represent rare conditions (Bennington and Beckwith, 1975; Ouzzane et al., 2011; Sakano et al., 2015; Vincente et al., 1995). Specifically, the urothelial origin of these cancers represents more than 90% of the cases (Roupret et al., 2018). Variants of urothelial cancer are encountered in approximately 25% of cases (Masson-Lecomte et al., 2014; Rink et al., 2012). These cases correspond to high-grade tumors, and the associated prognosis is worse in comparison with the urothelial cancer (Kim et al., 2017a,b).

Normal Upper Tract Urothelium

The renal pelvis and the ureter derive from the mesoderm and have distinct embryologic origin from the bladder (endodermal origin). The urothelial lining of the upper urinary tract is like the bladder urothelial layer. Nonetheless, the upper tract possesses a significantly thinner muscle layer in comparison with the bladder. On the contrary, the urothelium of the renal pelvis and calyces is relatively abundant. There is a continuity of the epithelial layer from the calyces to the distal ureter. Moreover, the extension of the urothelial layer to the collecting ducts has been proposed (Orsola et al., 2005). The latter possibility could lead to the use of therapeutic measures used for urothelial cancer in the carcinomas originating from the collecting ducts.

Renal Pelvis and Calyces

The pelvic and calyceal walls are lined with transitional epithelium. Two layers of muscle tissue and fibrous connective tissue represent the deeper layers (Dixon and Gosling, 1982). The muscle layers have a spiral, helical arrangement, which originates in the minor calyces.

Ureter

The ureter has two continuous spiraled thin muscle layers. The spiral configuration of the muscle fibers is tighter in the case of the external layer, whereas the internal layer has a looser structure. There is also a third outer longitudinal layer in the lower third of the ureter. These three layers merge with the three muscle layers of the bladder (inner longitudinal, middle circular, and outer longitudinal). The serosa covers the outer muscular layer and is composed of loose connective tissue, blood vessels, and lymphatics (Hanna et al., 1976; Notley, 1978).

Urothelial Neoplasms

Benign Lesions: Papillomas and von Brunn Nests

Papillomas, inverted papillomas, and von Brunn nests are benign lesions. The presentation of synchronous or metachronous UTUCs cannot be excluded. Consequently, close surveillance of these benign lesions is necessary (Chan et al., 1996; Cheville et al., 2000; Matsuoka et al., 2003; Renfer et al., 1988; Stower et al., 1990). Malignancy has been observed in 18% of the inverted papillomas of the ureter (Grainger et al., 1990). Two types of inverted papilloma have been proposed based on the malignant potential of these tumors. The type 1 lesions are benign. The type 2 lesions may be malignant. Current knowledge does not provide an efficient method to distinguish between the two types, and the surveillance of all inverted papillomas is advisable. The follow-up should be extended for at least 2 years from the diagnosis (Asano et al., 2003). Considering this, close follow-up of the inverted papilloma is necessary in all cases.

Metaplastic and Dysplastic Lesions

Current evidence suggests that UTUC develops through a gradual progression of hyperplasia to dysplasia and eventually CIS in a significant proportion of the UTUC cases (Heney et al., 1981; McCarron et al., 1983). The CIS is frequently spread in patches with extension up to the level of the collecting ducts of the kidney (Mahadevia et al., 1983). The severity of urothelial dysplasia could be associated with a worse prognosis because of a greater risk for tumor recurrence in the distal ureter and bladder.

Urothelial Malignant Lesions

Urothelial Carcinoma.

Urothelial carcinomas represent more than 90% of the upper urinary tract tumors (Fig. 98.2). Similarly, to the urothelial tumors of the bladder, the morphology of the lesions could be flat (CIS), papillary, or sessile. The distribution in the system could be unifocal or multifocal. Despite the histologic similarity of these lesions to the urothelial bladder cancer, the thinner muscle layers of the renal pelvis and ureter allow for an earlier involvement of the muscle layer in comparison with the bladder. CIS is difficult to diagnose: significant morphologic variations range from whitish plaque to epithelial hyperplasia or a smooth red patch because of increased submucosal vascularity (Fig. 98.3; Melamed and Reuter, 1993). The muscle invasion or invasion to the renal parenchyma or the surrounding adventitia is more likely to take place on the upper tract. Collecting duct carcinoma possesses similar characteristics to UTUC because of the common embryologic origin, but it is considered kidney cancer and not UTUC (Albadine et al., 2010).

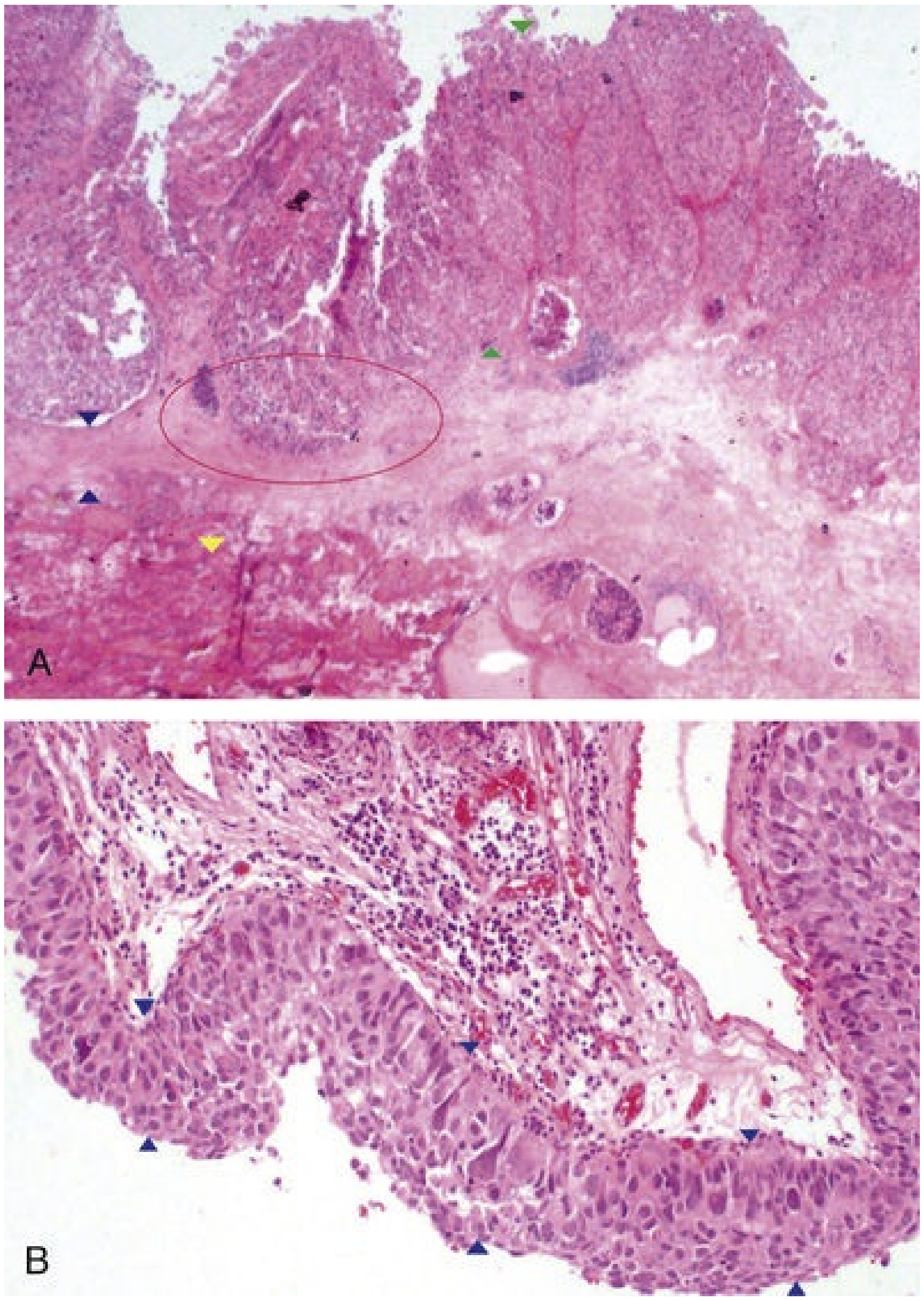

FIG. 98.2 (A) High-grade urothelial carcinoma. Between the *green arrowheads* is the urothelial layer with high-grade carcinoma. Between the *blue arrowheads* is the lamina propria. At the site of the *yellow arrowhead* lies the muscular layer. The *red circle* shows a site of invasion of the carcinoma to the lamina propria (hematoxylin-eosin staining, 2.5×). (B) Carcinoma in situ. Between the *blue arrowheads* is the urothelial layer with carcinoma. The underlying tissue is not infiltrated by carcinoma (hematoxylin-eosin staining, 20×).

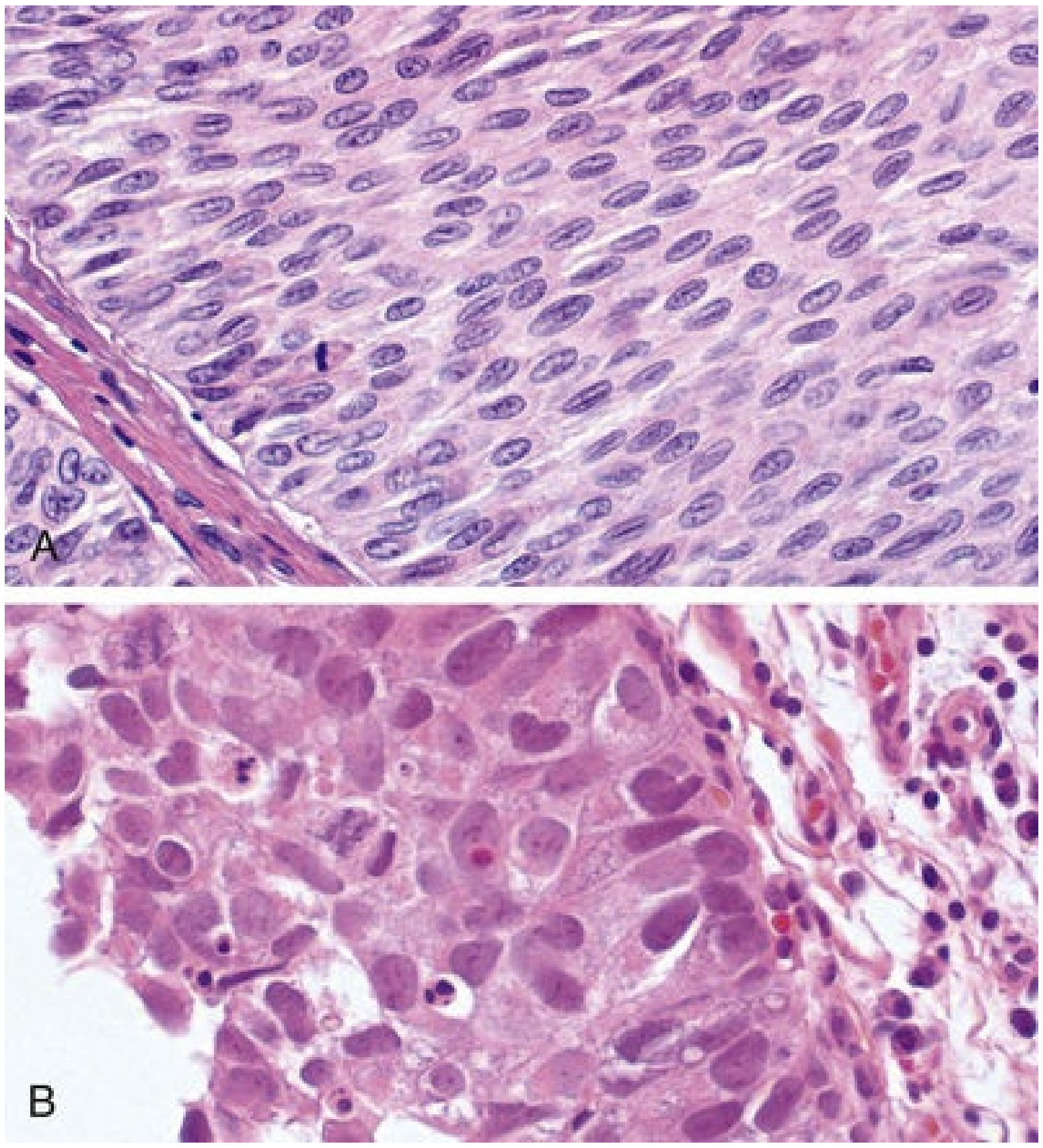

FIG. 98.3 (A) Low-grade urothelial carcinoma. The orientation of the cells is still preserved (hematoxylin-eosin staining, 20×). (B) Carcinoma in situ. The cells are dividing; there is no specific orientation of the cells. Their nuclei are in different phases of mitosis. There are sites of apoptosis (hematoxylin-eosin staining, 20×).

Micropapillary Variant of Urothelial Carcinoma.

Variants of the urothelial carcinoma could be diagnosed in up to 25% of UTUCs. These variants include squamous cell, glandular, sarcomatoid, micropapillary, neuroendocrine, and lymphoepithelial morphology. All these variants are related to aggressiveness and poor clinical outcome. Nonetheless, there is evidence that the presence of these variants does not predict poor clinical outcome if the remaining clinicopathologic features are considered (Rink et al., 2012). Two studies have proposed that the micropapillary variant is related to inferior progression- and cancer-free survival (Holmäng et al., 2006; Sung et al., 2014). The micropapillary subtype of urothelial carcinoma has a more aggressive progression in the bladder. This histologic variant is rarely diagnosed in the upper urinary tract and is associated usually with advanced disease. Holmäng et al. (2006) reported that 22 out of 26 patients with micropapillary UTUC had T3 stage at presentation. CIS and lymph node (LN) involvement was observed in 64% and 81% of the cases, respectively. Five-year survival was 26.9% and the disease-specific mortality was 77% (Holmäng et al., 2006). Sung et al. (2014) showed in a multivariate analysis that the micropapillary UTUC was an independent predictor of progression-free survival (HR 3.85, $P = 0.003$) and was related to poorer cancer-specific survival than the nonmicropapillary UTUC ($P < 0.001$).

Nonurothelial Malignant Lesions

The nonurothelial lesions of the upper urinary tract are rare and characterized by a wide variety of malignancy potential (Ouzzane et al., 2011; Sakano et al., 2015). It is a wide spectrum of lesions ranging from benign to highly malignant tumors. Squamous cell cancers and adenocarcinomas have the higher incidence among all these nonurothelial tumors.

Squamous Cell Carcinoma.

Squamous cell carcinomas (SCCs) have an incidence of 0.7% to 7.0% of upper urinary tract cancers (Babaian and Johnson, 1980; Blacker et al., 1985). The abuse of analgesics and the presence of chronic inflammation have been associated with these carcinomas (Stewart et al., 1999). The incidence of SCC is 6 times higher in the renal pelvis than in the ureter. SCCs are usually moderately to poorly differentiated and are already invasive at presentation.

Adenocarcinoma.

Adenocarcinomas are observed in less than 1% of renal pelvic tumors. There is a strong association of adenocarcinomas with urinary calculi, long-term obstruction, and inflammation (Spires et al., 1993; Stein et al., 1988). At diagnosis, adenocarcinomas are in an advanced stage and have a poor prognosis.

Other Tumors.

Fibroepithelial polyps (Blank et al., 1987; Musselman and Kay, 1986) and neurofibromas (Varela-Duran et al., 1987) are benign rare tumors. Their treatment is simple excision. There are other rare tumors of the upper tract such as neuroendocrine (Ouzzane et al., 2011) and hematopoietic (Igel et al., 1991) tumors as well as sarcomas (Coup, 1988; Madgar et al., 1988). The treatment of these very rare tumors is based on the experience with tumors of similar histology presenting in other organs. Thus these lesions are treated by excision and adjuvant therapy.

Key Points: Histopathology

- Urothelial carcinomas represent more than 90% of the upper urinary tract tumors. Pure nonurothelial upper urinary tract cancers are rare conditions.
- Variants of urothelial cancer are encountered in approximately 25% of UTUCs.
- Papillomas, inverted papillomas, and von Brunn nests are usually benign lesions.
- UTUC develops through a gradual progression of hyperplasia to dysplasia and eventually carcinoma in situ (CIS) in a significant proportion of UTUC cases.
- CIS is difficult to diagnose with significant morphologic variations.
- The muscle invasion or invasion to the renal parenchyma or the surrounding adventitia is more likely to take place on the upper tract.

Diagnosis

Upper urinary tract tumors are associated with several symptoms and signs. The common symptoms include hematuria, dysuria, and flank pain, which are usually related to localized disease. Hematuria is the most common sign of the UTUCs and could be either gross or microscopic. The incidence of hematuria is 56% to 98% of cases (Guinan et al., 1992; Matsuoka et al., 2003; Murphy et al., 1981; Raabe et al., 1992). Flank pain represents the second most frequent symptom and is observed in 20% to 30% of cases. The gradual onset of obstruction and hydronephrosis is associated with the dull nature of the flank pain. A lumbar mass could also be palpated in approximately 10% (Ito et al., 2011; Raman et al., 2011). Acute pain mimicking renal colic could also occur when clots are passing, and the collecting system is acutely obstructed. The incidence of flank pain resulting from malignant obstruction or clot is more prevalent in upper tract tumors than in bladder tumors. This incidence has been reported to be 10% to 40% of cases (Babaian and Johnson, 1980; McCarron et al., 1983; Melamed and Reuter, 1993). Asymptomatic patients represent approximately 15% of cases and are diagnosed as incidental radiologic findings. Advanced disease could be presented with flank or abdominal mass, weight loss, anorexia, and bone pain with similar frequency to the respective signs and symptoms of bladder cancer. These symptoms and signs should prompt rigorous metastatic evaluation and confer a worse prognosis (Ito et al., 2011; Raman et al., 2011). UTUC represents a rare autopsy finding, and the majority of the upper tract lesions are diagnosed before death (Resseguie et al., 1978).

The UTUC has some similarities to the respective bladder tumors. Specifically, ureteral tumors are low grade and low stage in 55% to 75% of cases (Cummings, 1980; Williams, 1991). In addition, most of the tumors are papillary (85%) and the remaining are sessile. Invasion of the lamina propria or muscle (stage T1 or T2) is observed in 50% of papillary and more than 80% of sessile tumors. Invasive tumors are more common in the ureter in comparison with the balder. Renal pelvic tumors involve the lamina propria or muscle in 50% to 60% of cases (Anderstrom et al., 1989; Williams, 1991).

Endoscopy of the Lower Tract

Cystoscopy

Cystoscopy should always be performed because the upper urinary tract tumors are often associated with bladder cancer. During the investigation of a suspicious case, the upper tract should be evaluated when the cytology is positive and the cystoscopy (including the urethra) is negative (Rosenthal et al., 2016; Witjes et al., 2010).

Endoscopy of the Upper Tract

Ureterorenoscopic Evaluation

Flexible ureteroscopy (URS) is the key approach for the visualization of the ureter, renal pelvis, and collecting system. The biopsy of suspicious lesions could also be done with URS. The diagnostic accuracy of excretory or retrograde urography alone can be increased from 75% to 85% to 90% when URS is also performed in conjunction with these studies (Fig. 98.4; Blute et al., 1989; Matsuoka et al., 2003; Streem et al., 1986). Pyelovenous and pyelolymphatic dissemination of the disease with URS has been reported without further confirmation of this phenomenon (Lim et al., 1993). Thus the URS should be performed for diagnosis whenever deemed necessary.

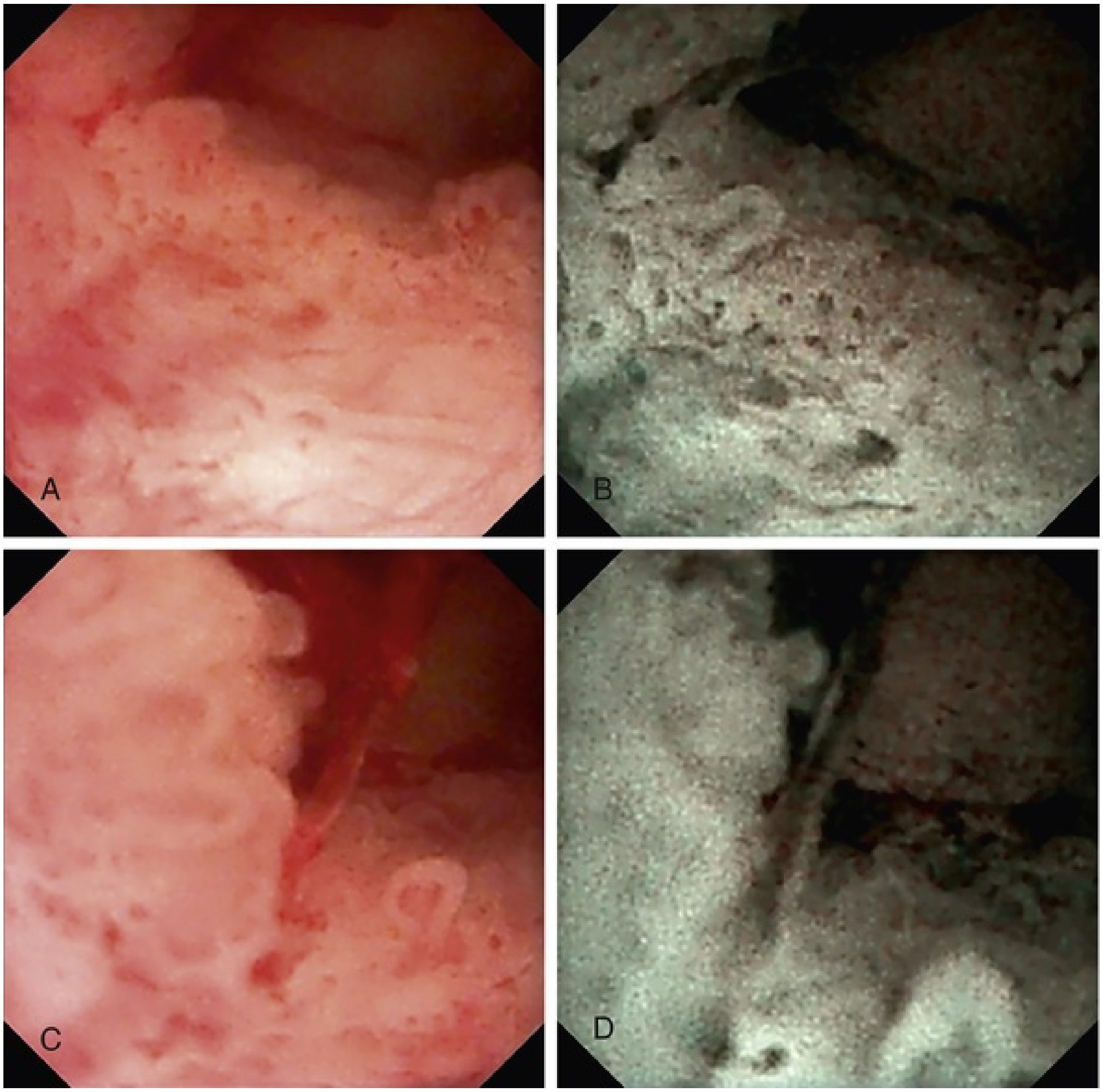

FIG. 98.4 (A) Urothelial carcinomas of the upper renal calyceal group. There are multiple carcinomas. Flexible ureteroscopes with the current digital technology provide excellent visualization of the upper urinary tract. Nevertheless, the surgeon should always scrutinize the urothelium to avoid missing sites of disease. (B) The same carcinomas as image A visualized by filters of the endoscopic system of the flexible ureteroscope. These filters could be proven useful to distinguish small tumors that could be difficult to identify in the standard image setting. (C) Sessile tumor with also some papillary morphology over its surface. (D) The same carcinoma as image C visualized by filters of the endoscopic system of the flexible ureteroscope.

Ureteroscopic biopsies can provide valuable information by determining the tumor grade in 90% of cases. Accurate biopsies by forceps or brushing are possible with URS, and these biopsies have a low false-negative rate regardless of sample size (Rojas et al., 2013).

Undergrading may occur after diagnostic biopsy, and an intensive follow-up schedule is necessary if a kidney-sparing approach is selected (Smith et al., 2011). Nevertheless, a histologic correlation of 78% to 92% between the URS biopsy specimen and the final pathologic specimen has been confirmed (Brown et al., 2007; Guarnizo et al., 2000; Keeley et al., 1997a). Histologic samples obtained by URS provide the best potential for predicting the final pathologic results. A study compared the grade and stage URS biopsy specimens of visible tumors to the surgical specimens in 42 cases (Keeley et al., 1997b). There was a 90% correlation for the low- or moderate-grade urothelial cancer specimens and 92% for the high-grade cancers. The presence of invasive cancer was successfully detected by the biopsy in 67% of cases (Keeley et al., 1997b). The visual assessment of the tumor grade during URS could be correct in 70%, and a biopsy is necessary for the staging of the upper urinary tract tumors (El-Hakim et al., 2004). URS also facilitates the selective ureteral sampling for cytology in situ (Clements et al., 2012; Ishikawa et al., 2010).

The prediction of tumor grade is accurate, but the prediction of tumor stage requires the evaluation of several parameters. According to the European guidelines, the stage assessment with the URS biopsy is notoriously difficult (Roupret et al., 2018). The URS biopsy specimens are small and usually do not include deep layers of the ureter or renal pelvis. Consequently, the precise prediction of tumor stage is difficult. Thus a more accurate prediction of the tumor stage and stratification of cases would require a combination of tumor grade, visual inspection of the tumor, radiographic studies (presence of obstruction), and urinary cytology (Clements et al., 2012; Ishikawa et al., 2010). This stratification of cases is important for decision making and the selection of radical nephroureterectomy or kidney-sparing approach for the management of UTUC (Roupret et al., 2018).

CIS of the upper urinary tract is difficult to diagnose and is hypothesized by the presence of unequivocally positive selective cytology, although the endoscopic or radiographic findings do not identify any specific lesion. The presence of ureteral CIS at the cystectomy specimen is probably the clearest diagnosis for CIS in the ureter. In a series of 40 UTUCs with localization in renal pelvis (40%), distal ureter (40%), and proximal ureter (40%), the tumor grade of the URS biopsy matched the surgical specimen in 78% of cases (Guarnizo et al., 2000). The remaining 22% the tumor grade was underestimated in URS biopsy. Lamina propria was present in the biopsy in 100% of the loop biopsies but only in 62% of the cup biopsies. In the whole population, 68% of the biopsies included the lamina propria. Ta tumors at the biopsy were upstaged to T3 stage in 45% of cases after the complete resection of the tumor (Guarnizo et al., 2000). It seems that the tumor grading may help estimating the tumor stage. Grade 3 tumor in the biopsy accurately predicts the tumor stage in more than 90% of cases (Skolarikos et al., 2003).

URS should be reserved for diagnostic uncertainty, if kidney-sparing treatment is considered, or in patients with a solitary kidney. URS could provide information regardless of obtaining biopsies or not (Roupret et al., 2018). As mentioned earlier, the tumor stage prediction requires the combination of evidence obtained by different investigations, and the decision making for a kidney-sparing approach should be based on this evidence. The surgeon should never forget that recent studies showed a higher rate of intravesical recurrence in patients (particularly in case of renal pelvic tumor) who underwent URS before RNU (Marchioni et al., 2017; Yoo et al., 2017).

Recent technologic developments in the flexible ureteroscopes and the application of novel imaging techniques have improved the visualization and diagnosis of flat tumors (Bus et al., 2015). The results of narrow band imaging are promising but require further confirmation (Abouassaly et al., 2010; Brien et al., 2010; Kata et al., 2016; Matsuoka et al., 2003). Optical coherence tomography and confocal endomicroscopy (Cellvizio) have been proposed for improved evaluation of tumor grade and/or staging. Optical coherence tomography and confocal endomicroscopy have a good correlation between the intraoperative imaging and definitive histology (Breda et al., 2018; Bus et al., 2016).

Antegrade Endoscopic Evaluation

A percutaneous approach for the diagnosis and treatment of UTUC may be necessary in some cases. Antegrade nephroscopy, ureteroscopy, and urography could be useful for visualization, biopsy, or even tumor resection. Resection of the tumor with larger caliber scopes is possible for tumor debulking in the renal pelvis (Blute et al., 1989; Matsuoka et al., 2003; Streem et al., 1986). According to EAU guidelines, the percutaneous management could be considered for low-risk UTUC in renal pelvis. Low-risk tumors inaccessible or difficult to manage with flexible ureteroscopy could be treated by percutaneous access (Roupret et al., 2018). The percutaneous approach is being abandoned because of the use of improved flexible ureteroscopes. Nevertheless, tumor cell implantation in the retroperitoneum and the nephrostomy tube tract should always be considered by the surgeon selecting this approach (Huang et al., 1995; Tomera et al., 1982).

Radiologic Imaging

Computed tomographic (CT) urography has the highest diagnostic accuracy of the available imaging techniques (Ito et al., 2013). The sensitivity of CT urography for UTUC is 0.67 to 1.0 and specificity is 0.93 to 0.99 (Cowan et al., 2007). CT is easier to perform and requires less labor than the traditional intravenous pyelography. There have been concerns regarding missing small urinary defects (<5 mm) between the slices of the traditional CT scan. The three-dimensional reconstruction of the upper tract has been shown to be equal to the intravenous pyelography in imaging the renal pelvis and ureters (McTavish et al., 2002). Rapid acquisition of thin sections allows high-resolution isotropic images that can be viewed in multiple planes to assist with diagnosis without loss of resolution (Roupret et al., 2018). Nevertheless, CT urography exposes the patient to higher doses of radiation in comparison with the intravenous pyelography.

Findings that are suggestive of upper urinary tract tumor are radiolucent filling defects, obstruction, or incomplete filling of a part of the upper tract and inability to visualize the collecting system. Filling defects could be found in 50% to 75% of cases (Fein and McClennan, 1986; Murphy et al., 1981). Differential diagnosis of filling defects includes blood clot, stones, overlying bowel gas, external compression, sloughed papilla, and fungus ball. The presence of calcification in renal ultrasonography or CT without contrast could distinguish stones. Urothelial cancers have an average density of 46 Hounsfield units (HU) and range between 10 and 70 HU (Lantz and Hattery, 1984). The average density of a radiolucent uric acid stone is 100 HU with a range of 80 to 250 HU. Measurements of the HUs in a CT could be useful in differentiating two common causes of radiolucent filling defects on excretory or retrograde urography. It is not clear if hydronephrosis or nonvisualization of the tumor could be an indicator of higher stage for renal pelvic or ureteral tumors. No visualization of the renal pelvis was observed in only 20% of the pelvic tumors (McCarron et al., 1983). No visualization was observed in 37% to 45% of the ureteral tumors; 60% of these cases were invasive (McCarron et al., 1983). The lack of visualization of the renal pelvis or ureter has not been correlated to the tumor stage by at least two studies (Anderstrom et al., 1989; Batata and Grabstald, 1976). On the contrary, hydronephrosis with or without an associated filling defect was linked to invasive ureteral tumors in up to 80% of cases (Cho et al., 2007; McCarron et al., 1983). Advanced disease and poor oncologic outcome has been associated with hydronephrosis (Hurel et al., 2015; Messer et al., 2013). Epithelial “flat lesions” without mass effect or urothelial thickening are generally not visible with CT (Roupret et al., 2018). Enlarged lymph nodes are highly predictive of metastases in upper urinary tract tumors (Verhoest et al., 2011). For staging purposes, CT provides information on the extent of invasion, mass or masses outside the collecting system, and the presence of lymph node or distant metastases (Milestone et al., 1990). CT has a poor sensitivity in assessing the invasion of the small lesions. In a study by Scolieri et al. (2000), the CT predicted accurately the TNM stage in 60% of the patients and understaged 16% and overstaged 24%. The CT could also determine poor functioning areas of a kidney such as obstructed areas based on the detection of urine (with contrast) excretion (Kenney and Stanley, 1987).

Retrograde urography could be useful for the evaluation of radiolucent, noncalcified lesions and incompletely filled or obstructed renal infundibula or calyces. These cases could be also investigated with URS with or without biopsy. Retrograde urography has an accuracy of 75% for the diagnosis of upper tract tumor and remains an option for the detection of UTUCs (Ito et al., 2011; Murphy et al., 1981; Roupret et al., 2018). Some have suggested that ultrasonography has sensitivity equal to that of urography in evaluating patients with painless gross hematuria for upper tract malignant disease (Data et al., 2002; Yip et al., 1999).

Magnetic resonance (MR) urography is indicated in patients to whom the radiation or iodinated contrast media are contraindicated and cannot undergo CT urography (Matsuoka et al., 2003; Takahashi et al., 2010). The sensitivity of MR urography is 0.75 after contrast injection for tumors smaller than 2 cm (Matsuoka et al., 2003; Takahashi et al., 2010). Gadolinium-based contrast media for MR urography should be limited in patients with severe renal impairment (<30 mL/min creatinine clearance). These contrasts have a risk of nephrogenic systemic fibrosis. CT urography is generally preferred to MR urography for diagnosing and staging UTUC (Roupret et al., 2018).

Evaluation of the contralateral kidney is important not only because of possible bilateral presence of the disease but also because it allows a determination of the functionality of the contralateral kidney. At times, a split-function renal scan may be helpful in determining the contribution of the “diseased” and the presumed “normal” kidney to the patient's overall renal function.

Cytology and Tumor Markers

Urine cytology could be used for the diagnosis of upper urinary tract tumors. Nevertheless, the sensitivity of voided urine (or bladder wash) cytology remains low and is related to the grade of the tumor. The sensitivity of cytology has been estimated at about 20% for grade 1, 45% for grade 2, and 75% for grade 3 tumors (Konety and Getzenberg, 2001; Murphy and Soloway, 1982). The interpretation of an abnormal voided cytology requires caution because the cytology does not provide any information on the site of origin of the malignant cells. Urine collection or washing of the ureter with a ureteral catheter could provide more accurate cytologic results. Cytology is less sensitive for UTUC in comparison with the bladder tumors and is advised to be performed in situ in the renal collecting system (Messer et al., 2011). Nevertheless, false-negative or false-positive results may range between 22% and 35% (Zincke et al., 1976). Saline washings increase the cell yield and improve the results of cytologic evaluation. Brush biopsy through a retrograde catheter or ureteroscope is related to better accuracy. These techniques could increase the sensitivity of urine cytology in the range of 90% (Blute et al., 1989; Streem et al., 1986). Brush biopsies have been associated with complications such as massive hemorrhage and preformation of the urinary tract (Blute et al., 1981). Cytologic specimens should be obtained before the instillation of any contrast agent. Especially, ionic, high osmolarity contrast agents may deteriorate the cytologic specimens (Messer et al., 2013; Terris, 2004).

The sensitivity of fluorescence in situ hybridization (FISH) for molecular abnormalities characteristic of UTUCs is similarly high to bladder cancer. The most appropriate population for FISH are the patients with low-grade recurrent disease under surveillance and kidney-sparing therapy for UTUCs (Chen and Grasso, 2008; Johannes et al., 2010). As a result, FISH is not routinely used for the surveillance of UTUCs (Chen and Grasso, 2008; Johannes et al., 2010).

Key Points: Diagnosis

- Localized disease is characterized by hematuria, dysuria, and flank pain.
- Advanced disease is characterized by flank or abdominal mass, weight loss, anorexia, and bone pain.
- Cystoscopy should always be performed.

- Flexible ureteroscopy with biopsy is a key approach for diagnosis.
- Computed tomography urography has the highest diagnostic accuracy.
- Urine collection or washing of the ureter with a ureteral catheter could provide the most accurate cytologic results.

Staging and Classification

Natural History

Recurrence

Poor prognosis is common in UTUCs. A study from the 1970s reported that metastatic disease is present in up to 19% of patients at diagnosis (Akaza et al., 1970). In recent years, multicenter studies showed that cancer-specific outcomes of matched cohorts have similar frequency between the upper and lower tract urothelial cancers despite the more invasive and poorly differentiated nature of UTUCs (Catto et al., 2007; Moussa et al., 2010). When patients with UTUC and bladder cancer were respectively treated with the nephroureterectomy and radical cystectomy, the prognosis for recurrence was related to the location of the tumor and stage. The UTUC had a worse prognosis in comparison with bladder cancer in pT4 disease. On the contrary, bladder cancer patients had worse prognosis in the group of non–muscle-invasive cancer, whereas the pT2 and pT3 diseases did not exhibit any statistical difference in terms of recurrence (Rink et al., 2012). The differences in the non–muscle-invasive stage may be attributed to the presence of aggressive features (high-grade disease), which are treated with transurethral resection with or without intravesical instillations for bladder cancer, whereas the UTUC cases are treated with radical nephroureterectomy because of the lack of efficient staging methods. Thus patients with bladder cancer may already harbor features of aggressive disease such as lymphovascular disease, persistent disease at transurethral invasion, and failure to respond to intravesical therapy. In the case of the pT4 cohort, patients with pT4a disease have prostatic stromal invasion, which can be still treated by radical cystoprostatectomy with curative intent (Green et al., 2013).

Involvement of the Ureter or Renal Collecting System

Ureteral tumors are in 70% of the UTUC cases in the distal ureter, 25% in the mid-ureter, and 5% in the upper ureter (Anderstrom et al., 1989). This phenomenon could be attributed to the downstream implantation of cancer cells, and this dictates the radical treatment by complete excision of the whole ureter. Synchronous or metachronous bilateral disease has an incidence of 1.6% to 6.0% of sporadic UTUC (Babaian and Johnson, 1980; Kang et al., 2003; Murphy et al., 1981). The location of the UTUC at presentation is a prognostic factor in some studies (Ouzzane et al., 2011; Yafi et al., 2012). When the effect of tumor stage is adjusted, patients with ureteral and/or multifocal tumors seem to have a worse prognosis than those with renal pelvic tumors (Chromecki et al., 2012; Ouzzane et al., 2011; Williams et al., 2013; Yafi et al., 2012).

Synchronous and Asynchronous Localizations

Upper Tract Recurrence After Bladder Cancer.

The risk for UTUC after the treatment of bladder cancer has been reported by several large series (Canales et al., 2006; Mullerad et al., 2004; Oldbring et al., 1989; Rabbani et al., 2001; Solsona et al., 1997; Sved et al., 2004; Tran et al., 2008; Wright et al., 2009). Upper tract recurrence after bladder cancer treatment has an incidence of 2% to 6% and is diagnosed later with a median time to recurrence more than 3 years (Reddy and Kader, 2018). These rates have significant fluctuation when traditional series are considered (Herr et al., 1996; Solsona et al., 1997). In most of the traditional series, the recurrence rate ranges between 2% and 4% with an interval to recurrence ranging from 17 to 170 months, but there are also series with rates up to 25%. This discrepancy in numbers could be attributed to patient selection criteria, tumor grading, and stage and dysplastic tumors included in these series. Risk factors for upper tract recurrence are the presence of distal ureteral tumor, multifocal or recurrent urothelial carcinoma, non–muscle-invasive bladder cancer, and the presence of carcinoma in situ. A recurrence rate of only 0.8% at 15 years was observed in patients without any of these factors. Patients with more than 3 of these factors had 13.5% risk of recurrence in the same period (Volkmer et al., 2009). These recurrences are diagnosed after the onset of symptoms in more than 50% of cases and at advanced stage in 70%. Primary detection is done by cytology and upper urinary tract imaging in 7% and 29.6% of cases, respectively (Picozzi et al., 2012). Symptoms include flank pain and hematuria. The prognosis is poor: 18% to 33% of the patients have metastatic lesion at diagnosis (Huguet, 2013).

Data from the SEER database from 91,245 patients with bladder cancer showed that 657 (0.7%) developed UTUC over a median follow-up period of 4.1 years. The relative risk of recurrence in the upper urinary tract was stable over long-term follow-up. Upper tract surveillance should be rigorous over extended time periods (Rabbani et al., 2001). According to several investigations, recurrences are more frequent in patients with CIS than in patients with papillary urothelial cancers and in patients treated with cystectomy for CIS rather than for invasive cancer (Canales et al., 2006; Slaton et al., 1999; Solsona et al., 1997). Upper tract recurrence was more likely to occur in patients with T1 stage than those with Ta, patients with high-grade bladder disease, and when the lesions were located at the bladder trigone or periureteral sites. The pathologic evaluation showed that the recurrence was more likely to be superficial (Ta, T1, Tis) and to involve only the distal ureter (Wright et al., 2009). On the contrary, an earlier study observed that Ta, T1, and Tis bladder cancer treated with bacille Calmette-Guérin (BCG) was associated with 21% recurrence in the upper urinary tract after a median period of 7.3 years. Most of these patients had invasive tumors at diagnosis, and 38.8% of them died from UTUC (Herr et al., 1996).

The largest meta-analysis available included more than 13,000 patients from 27 studies. All these patients underwent cystectomy for bladder cancer. The overall prevalence of UTUC after cystectomy ranged from 0.75% to 6.4%. Recurrence was observed between 2.4 to 164 months in an advanced stage or metastatic state in 64.6% and 35.6% of cases, respectively. Patients with G1 tumor had 8 times greater probability for UTUC compared with those with G2 disease. G1 cases had 10 times higher probability than G3 cases. Patients with CIS had a twice-higher probability for UTUC than those with invasive disease. Multifocality increases the risk of recurrence 3 times. Positive ureteral or urethral margin and history of UTUC increase the risk 7 times. The negative node status increases the risk eightfold. The type of urinary diversion did not influence the recurrence rate. Patients with continent diversion had more favorable disease, and consequently a selection bias was introduced to this subgroup of patients. The follow-up schedule varied among studies and there was no specific protocol for the early detection of UTUC. Symptoms usually motivated the diagnostic evaluation for UTUC. The authors proposed the elimination of cytology and excretory urography for the follow-up of these patients. Computed tomography should be used instead (Picozzi et al., 2012).

The presence of ureteral reflux and bladder cancer located close to a ureteral orifice has been shown to predispose to UTUC (Herr et al., 1992; Hudson and Herr, 1995; Zincke et al., 1984). Delayed recurrence is more frequent in the ureter in comparison with the renal pelvis and happens earlier (at 40 vs. 67 months). Patients treated by cystectomy for disease refractory to BCG and patients with CIS of the bladder treated by BCG are associated with 30% incidence of UTUC. In these cases and in all cases of high-risk bladder cancer, annual evaluation of the upper tract is advisable (Herr et al., 1996).

Bladder Recurrence After Upper Tract Tumors.

Patients with UTUC have a significant risk for recurrence of the disease in the bladder. The estimated risk is based on several reports and varies between 15% and 75% within 5 years of the development of the UTUC (Anderstrom et al., 1989; Hisataki et al., 2000; Huben et al., 1988; Kakizoe et al., 1980; Kang et al., 2003; Miyake et al., 2000). The higher incidence of metachronous bladder cancers in comparison with metachronous UTUC after bladder cancer has resulted in the proposal of several theories, which include downstream seeding, longer exposure time to carcinogens in the bladder, and greater number of urothelial cells in the bladder that are subject to random carcinogenic events. The most widely accepted theory is the downstream seeding, which is further supported by the fact that the bladder tumor recurrences after UTUC are monoclonal (Junker et al., 2005) and by the pattern of recurrence after nephroureterectomy. Bladder recurrence usually takes place within 2 years after the treatment of UTUC and is located at the site of bladder trauma after the ureterectomy (Kang et al., 2003). The high incidence of recurrences of UTUC in the bladder dictates the need for scheduled follow-up of all patients diagnosed with UTUC.

Specific gene mutations have been proposed for cases of rapidly recurrent high-grade cancers (Habuchi et al., 1993; Harris and Neal, 1992; Lunec et al., 1992). UTUC multifocality has been related to higher bladder tumor incidence (Matsui et al., 2005). Low-grade UTUCs tend to have a less rapid recurrence in the bladder, and microsatellite studies have showed that there is discordance between the upper tract tumors and the metachronous bladder tumor in 46% of cases (Takahashi et al., 2000), supporting a field effect (Takahashi et al., 2001). Increased UTUC stage at nephroureterectomy correlated to a higher risk for bladder recurrence (Hisataki et al., 2000, Matsui et al., 2005, Terakawa et al., 2008). In a multivariate analysis of a multi-institutional study, the presence of a bladder tumor before UTUC was the only independent risk factor for bladder recurrence after radical nephroureterectomy. Another study correlated only the grade of the UTUC with the pathologic findings of the metachronous bladder tumor (Novara et al., 2009).

A meta-analysis identified significant predictors for bladder recurrence after nephroureterectomy (Seisen et al., 2015). Three major categories were proposed by the authors:

1. Patient-specific factors: male gender, previous bladder cancer, smoking, and preoperative chronic kidney disease
2. Tumor-specific factors: positive preoperative urinary cytology, ureteral location, multifocality, invasive pT stage, and necrosis
3. Treatment-specific factors: laparoscopic approach, extravesical bladder cuff removal, and positive surgical margins (Roupret et al., 2018; Seisen et al., 2015)

The diagnostic ureteroscopy has been related to a higher risk of bladder recurrence after radical nephroureterectomy, especially when the UTUC is in the renal pelvis (Marchioni et al., 2017; Yoo et al., 2017).

Carcinoma in Situ.

The presence of CIS increases the incidence of bilateral and multifocal disease. Bilateral disease has an overall incidence of 3% to 5% of UTUC cases. The presence of CIS increases this incidence to 25% (Herr et al., 1996). Patients with CIS have higher risk for subsequent panurothelial disease because there is a high probability for multifocal disease. Conservative management should be considered when feasible, and follow-up investigation should include bladder, upper urinary tract, and urethra.

Metastatic Potential of Upper Urinary Tract Carcinoma

Dissemination of Disease.

UTUCs have significant spread potential. The tumors could be spread via direct invasion to the renal parenchyma or the surrounding structures. Lymphatic and hematogenous dissemination is also possible. Epithelial spread by seeding or direct extension could also take place. High-grade tumors have a propensity to invasive expansion, which could result in non–organ-confined disease (>pT2). The non–organ-confined disease is the most significant predictor of the development of metastases (95%), followed by vascular invasion (83%) and lymphatic invasion (77%) (Davis et al., 1987; Margulis et al., 2009).

Lymphatic.

The lymphatic spread of UTUC is directly associated with the depth of invasion of the tumor. The lymphatic spread is also related to the location of the tumor. Tumors in the renal pelvis and upper or lower two-thirds of the ureter may spread to the renal hilar, para-aortic, paracaval, interaortocaval, and ipsilateral common iliac and pelvic lymph nodes (Batata and Grabstald, 1976; Kondo et al., 2010).

Hematogenous.

Liver, lung, and bones are the common sites of hematogenous spread of UTUC (Batata et al., 1975; Brown et al., 2006). Direct extension of renal pelvic UTUC to the renal vein and vena cava is very rare (Geiger et al., 1986; Jitsukawa et al., 1985).

Epithelial.

The epithelial spread of urothelial carcinomas results in synchronous and metachronous tumors. The epithelial spread of the tumor with urinary seeding and/or intraepithelial migration is explained by the monoclonal theory (Harris and Neal, 1992). According to this theory, multiple tumors are originating from single genetically modified neoplastic cells, and the spread could occur in antegrade (more common) or retrograde fashion. The higher incidence of bladder recurrence could be related to the antegrade seeding. This explanation was based on the high recurrence rates in patients who underwent incomplete ureterectomy or in whom the ureteral stump was left in situ after nephrectomy (Johnson and Babaian, 1979). The “field effect” proposes that the urothelium has a propensity to diffusely form unrelated de novo tumors caused by a mutagenic environment. This theory could explain the phenomenon that some multifocal cancers have been noted to derive from different clones (Hafner et al., 2002). The idea of molecular evolution of a single clone is possible; current evidence suggests that the urothelial clones can develop monoclonally through epithelial intraluminal dissemination as well as development of cancer over a “field.”

Panurothelial Disease.

The definition of panurothelial disease is the involvement of bladder and two extravesical sites. The involvement of bladder and both ureters in a female patient represents panurothelial disease. In the case of male patients, this definition could include the bladder along with one or both upper urinary tracts and/or the prostatic urethra. The treatment of panurothelial disease and its outcomes remains unclear because the disease is uncommon and current evidence is based on retrospective studies.

In a series of 35 patients, the highest risk for panurothelial disease was observed in the patients with high-risk superficial multifocal bladder tumors and those with CIS (Solsona et al., 2002). Cystectomy was performed for high-grade or invasive disease. The noninfiltrating tumors of the upper tract were managed conservatively with local resection, whereas more aggressive tumors led to radical excision. Unfortunately, patients with panurothelial disease represent a clinical dilemma because only the removal of the whole urinary tract would allow the cure of the disease. In another study, 35 patients with bladder and bilateral upper urinary tract urothelial carcinomas were followed for an average time of 95 months (Nguyen et al., 2014). The authors divided the population into patients with primary pathology in the bladder (n = 18) and those with primary pathology in the upper urinary tract (n = 17). There was no statistically significant difference in the oncologic outcomes between the two groups. The authors observed the transition from low-grade disease to multifocal high-grade disease, tumor invasion, and progression in 8 patients. Four patients with initial presentation of low-grade multifocal disease progressed to high-grade tumors, metastases, and death. There was a similar distribution of men and women. Almost half of the patients did not have smoking history. Genetic factors may have played a role in these patients. Most of the patients with this transition of the disease aggressiveness had a history of another malignancy or a family history of cancer.

Recently, a retrospective study evaluated 64 patients who initially underwent cystectomy and radical nephroureterectomy for metachronous UTUC (Li et al., 2017). The median time from radical cystectomy to radical nephroureterectomy was 2.7 years. After the radical nephroureterectomy, the pathology showed 39% locally advanced disease (pT3/pT4) and 11% positive node status. After radical cystectomy, the respective figures were 17% and 6%. Median survival after nephroureterectomy was 3.1 years. The lymph node involvement on radical nephroureterectomy was significantly associated with worse overall mortality. The renal function is diminished after these procedures, and eventually none of the patients was eligible for cisplatin-based chemotherapy.

Patients with panurothelial disease are a complicated population with significant therapeutic dilemmas, and current literature does not provide enough evidence for establishing a management algorithm. The role of systematic disease is not established. Cystectomy is indicated for patients with multifocal high-grade disease. Close surveillance of the upper tract is also mandatory. The total removal of the genitourinary system would have been an option for younger patients with early recognition of disease progression to prevent metastases and death.

Key Points: Staging and Classification

- Ureteral tumors are in the distal ureter (70% of cases), mid-ureter (25% of cases), and upper ureter (5% of cases). Bilateral disease is found in in 3% to 5% of cases.
- Prognosis for recurrence after radical nephroureterectomy is related to the location of the tumor and stage.
- The recurrence rate is 2% to 4% with an interval of 17 to 170 months.
- Bladder recurrence is 15% to 75% within 5 years.
- CIS involves a higher incidence of bilateral and multifocal disease.
- Disease spread is typically direct expansion of the tumor to lymphatics and bloodstream.

Prognosis

TNM Classification

UTUC has a similar classification and morphology with the bladder carcinoma (Roupret et al., 2018). Noninvasive papillary tumors (papillary urothelial tumors of low malignant potential and low- and high-grade papillary UC) (Soukup et al., 2017), flat lesions (CIS), and invasive carcinoma can be distinguished. Nonurothelial differentiation (i.e., histologic variants) is associated with an adverse risk factor (Roupret et al., 2018).

The TNM classification and staging system is the most commonly used and is shown in Table 98.1 (Brierley, 2017). The regional lymph nodes (LNs) for pelvic and upper ureteral tumors are the hilar and retroperitoneal LNs. For the mid- and distal ureteral tumors the respective LNs are the intrapelvic LNs. The laterality of the LNs does not affect N classification. The renal pelvic subclassification (pT3) provides discrimination between the microscopic infiltration of the renal parenchyma, which is represented as pT3a, and the macroscopic infiltration or invasion of the peripelvic adipose tissue, which is represented as pT3b (Park et al., 2014; Rink et al., 2012; Roscigno et al., 2012). The American Joint Committee on Cancer (AJCC) staging system could also be used. The differences and similarities of these two staging systems are presented in Table 98.2.

TABLE 98.1

Tumor Node Metastasis (TNM) Classification for Upper Urinary Tract Carcinoma

T: PRIMARY TUMOR	
TX	Primary tumor cannot be assessed
T0	No evidence if primary tumor
Ta	Noninvasive papillary carcinoma
Tis	Carcinoma in situ
T1	Tumor invades subepithelial connective tissue
T2	Tumor invades muscularis
T3	Renal pelvis: tumor invades beyond muscularis into peripelvic fat or renal parenchyma
	Ureter: tumor invades beyond muscularis into perinephric fat

T4	Tumor invades adjacent organs or through the kidney into perinephric fat
N: REGIONAL LYMPH NODES	
NX	Regional lymph nodes cannot be assessed
N0	No regional lymph nodes metastasis
N1	Metastasis in a single lymph node 2 cm or less in the greatest diameter
N2	Metastasis in a single lymph node more than 2 cm in the greatest diameter
M: DISTANT METASTASIS	
M0	No distant metastasis
M1	Distant metastasis

TABLE 98.2

AJCC Staging System in Conjunction With the TNM System

AJCC STAGING SYSTEM	TNM CLASSIFICATION SYSTEM
0	T0
I	Ta, Tis, T1, N0, M0
II	T2, N0, M0
III	T3, N0, M0
IV	T4 or T, N+, M+

AJCC, American Joint Committee on Cancer; *TNM,* tumor node metastasis.

Histologic Grading

The 1973 World Health Organization (WHO) classification was used for tumor grading for several decades. The tumors were graded as G1 to G3 (Roupret et al., 2018). The 2004/2016 WHO classification distinguishes between noninvasive tumors: papillary urothelial neoplasia of low malignant potential and low- and high-grade carcinomas based on histologic characteristics (low grade vs. high grade). The current EAU guidelines are based on the 2004/2016 WHO classification (Roupret et al., 2018).

Prognostic Factors

Preoperative Factors

Age-Sex-Ethnicity.

Age is one of the most important demographic predictors of survival in UTUC

(Kim et al., 2017a and 2017b). Decreased cancer-specific survival has been reported in patients of older age at the time of radical nephroureterectomy. Older age represents an independent factor for decreased survival (Lughezzani et al., 2012; Matsuoka et al., 2003; Park et al., 2014; Shariat et al., 2010). Nevertheless, radical nephroureterectomy could be curative for elderly patients and is an inadequate indicator of outcome (Chromecki et al., 2011; Shariat et al., 2010). Thus age alone should not prevent a potentially curable approach. Gender is no longer considered an independent prognostic factor influencing UTUC mortality (Fernández et al., 2009; Lughezzani et al., 2012; Matsuoka et al., 2003).

Controversial results have been presented in the literature regarding the impact of race on the outcome of UTUC treatment. No difference in outcome among races was reported by a multicenter study (Matsumoto et al., 2011; Roupret et al., 2018). On the contrary, population-based studies showed a worse outcome for African-American patients than other ethnicities. Differences at presentation in risk factors, disease characteristics, and predictors of adverse oncologic outcomes have been noted between Chinese and American patients (risk factor, disease characteristics, and predictors of adverse oncologic outcomes) (Singla et al., 2017). The comparison of Japanese and European patients revealed no differences in survival (Matsumoto et al., 2011).

Tobacco Consumption.

There is a close association between tobacco consumption and prognosis because cessation of smoking improves cancer control (Roupret et al., 2018). Being a smoker at diagnosis increases the risk for disease recurrence and mortality after radical nephroureterectomy (Rink et al., 2012; Simsir et al., 2011) and recurrence of the urothelial cancer in the bladder (Xylinas et al., 2014).

Tumor Location.

Some studies proposed the initial location of the UTUC as a prognostic factor (Ouzzane et al., 2011; Yafi et al., 2012). Patients with ureteral and/or multifocal tumors seemed to have a worse prognosis than renal pelvic tumors when the stage was adjusted (Chromecki et al., 2012; Lughezzani et al., 2012; Ouzzane et al., 2011; Williams et al., 2013; Yafi et al., 2012).

Surgical Delay.

When an invasive UTUC is diagnosed, the delay of the treatment may increase the risk of disease progression. It is advisable to perform radical nephroureterectomy within 12 weeks, if possible, from the diagnosis and decision for the treatment (Gadzinski et al., 2012; Sundi et al., 2012; Waldert et al., 2010).

Other.

Cancer-specific survival after radical nephroureterectomy is correlated with the American Society of Anesthesiologists (ASA) score (Berod et al., 2012). ASA score is also correlated to poor performance status after radical surgery (Carrion et al., 2016). Obesity and higher body mass index has a negative impact on the cancer-specific outcomes in UTUCs (Ehdaie et al., 2011). The pretreatment-derived neutrophil-lymphocyte ratio seems to be related to higher cancer-specific mortality (Dalpiaz et al., 2014).

Postoperative Factors

Tumor Stage and Grade.

The primary recognized prognostic factors are tumor stage and grade (Clements et al., 2012; Kim et al., 2017a,b; Lughezzani et al., 2012; Mbeutcha et al., 2017; Petrelli et al., 2017). UTUCs that invade the muscle wall usually have a very poor prognosis. The 5-year specific survival is less than 50% for pT2/pT3 stage and less than 10% for pT4 stage (Abouassaly et al., 2010; Jeldres et al., 2010; Lughezzani et al., 2012). The main prognostic factors are presented in Fig. 98.5.

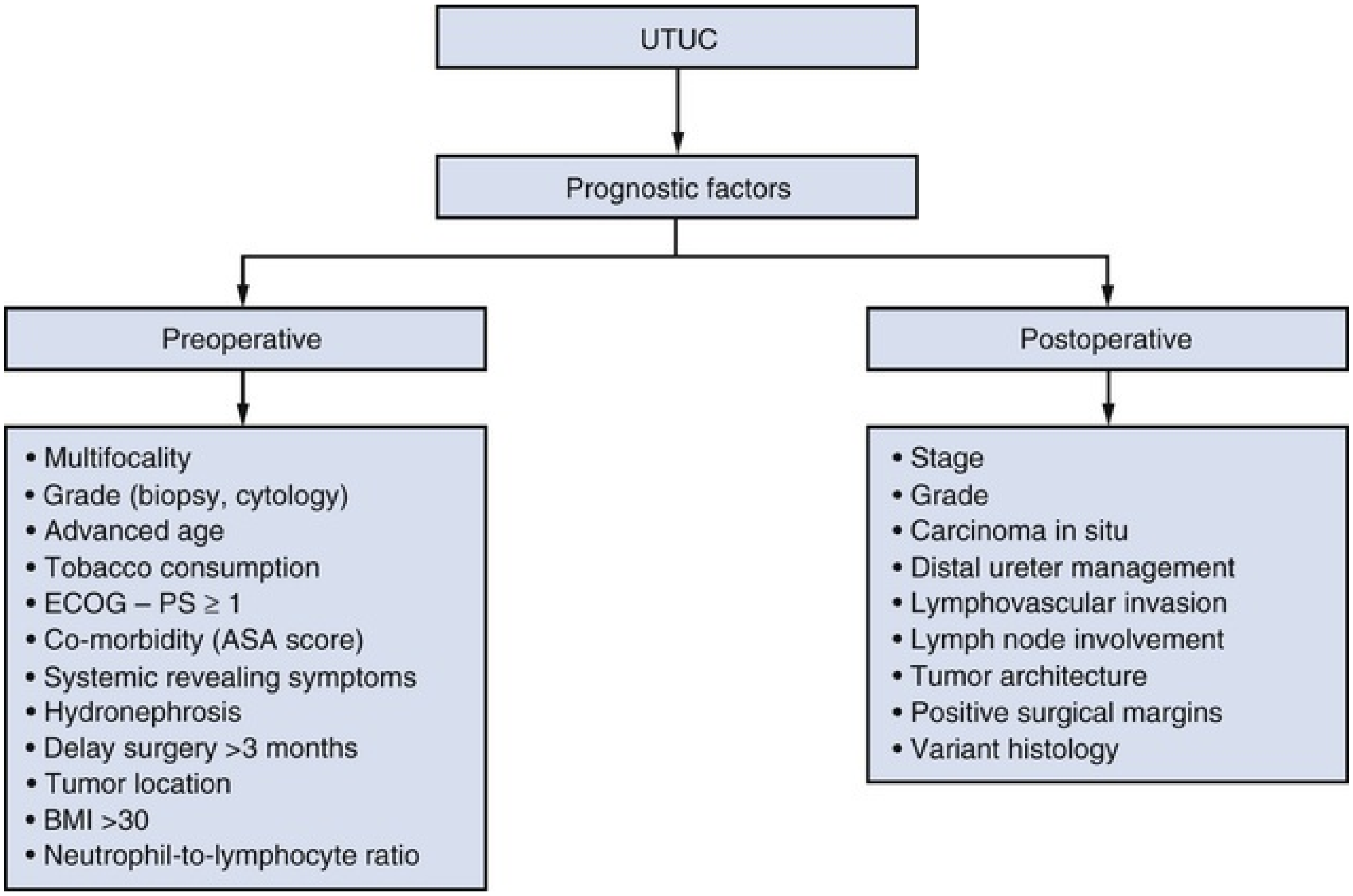
UTUC
Prognostic factors
Preoperative
Postoperative
• Multifocality
• Grade (biopsy, cytology)
• Advanced age
• Tobacco consumption
• ECOG – PS ≥ 1
• Co-morbidity (ASA score)
• Systemic revealing symptoms
• Hydronephrosis
• Delay surgery >3 months
• Tumor location
• BMI >30
• Neutrophil-to-lymphocyte ratio
• Stage
• Grade
• Carcinoma in situ
• Distal ureter management
• Lymphovascular invasion
• Lymph node involvement
• Tumor architecture
• Positive surgical margins
• Variant histology

FIG. 98.5 Upper urinary tract urothelial carcinoma (UTUC): prognostic factors. *ASA,* American Society of Anesthesiologists; *BMI,* body mass index; *ECOG – PS,* Eastern Cooperative Oncology Group Performance Status. (Modified from Rouprêt M, Babjuk M, Compérat E, et al: European Association of Urology Guidelines on Upper Urinary Tract Urothelial Carcinoma: 2017 Update, *Eur Urol* 73[1]:111–122, 2018.)

The decision making for UTUC is based on the histologic characteristics and biology of the tumor. The benign papillomas have an excellent course regardless of the extent of treatment (Batata and Grabstald, 1976; Bloom et al., 1970). The existence of low-grade papillomas of low-grade malignant potential (PUNLMP) in the bladder remains an issue of debate (Cheng et al., 1999, 2000; Oyasu, 2000). The WHO 2004/2016 classification has reassigned this histologic type from Grade 1 of the 1973 WHO classification to low-grade carcinomas (Babjuk et al., 2017). Thus PUNLMP are treated the same way as low-grade disease. Differences between upper tract papillomas and bladder papillomas are not clearly defined and require further investigation.

Papillary tumors have been suggested to have better outcomes than sessile lesions (Fritsche et al., 2012; Remzi et al., 2009). The majority of the renal pelvis tumors are papillary (85%), whereas the sessile tumors represent 15%. These figures are like those of bladder cancer. Nonetheless, 50% of tumors are papillary and 80% sessile in the T1 and T2 stages, respectively (Cummings, 1980; Williams, 1991). As a result, the invasive tumors of the renal pelvis represent 50% to 60% of cases, which contrasts the noninvasive nature of most bladder cancers. Moreover, 55% to 75% of the ureteral tumors are low grade and low stage, but invasive tumors are more commonly encountered in the ureter in comparison with the bladder (Anderstrom et al., 1989; Williams, 1991). Sessile growth pattern is a strong prognosticator for worse outcome (Fritsche et al., 2012; Remzi et al., 2009).

Renal pelvis tumors are encountered slightly more frequently than ureteral tumors (Batata and Grabstald, 1976; Maulard-Durdux et al., 1996). The incidence of ureteral tumors in the distal, middle, and proximal segments is 70%, 25%, and 5% of cases, respectively (Anderstrom et al., 1989; Babaian and Johnson, 1980; Williams, 1991). When conservative treatment has taken place, the recurrence is usually distributed in an antegrade fashion in 33% to 55% of cases, and recurrence proximal to the initial site is uncommon (Babaian and Johnson, 1980; Cummings, 1980; Johnson and Babaian, 1979; Mazeman, 1976; McCarron et al., 1983). UTUC is associated with a high rate of ipsilateral recurrence, which is probably related to the multifocal field carcinogenesis and the downstream seeding. Areas of atypia, dysplasia, and CIS are observed in 60% to 95% of the nephroureterectomy specimens for renal pelvis tumors (Harris and Neal, 1992; Heney et al., 1981; Johansson et al., 1976; Kakizoe et al., 1980; McCarron et al., 1983; Melamed and Reuter, 1993). Concomitant CIS in organ-confined UTUC and a history of bladder CIS are associated with a higher risk of recurrence and cancer-specific mortality (Redrow et al., 2017; Wheat et al., 2012).

Tumor size has not been established as a prognostic criterion. Still, tumors larger than 3 to 4 cm may be related to worse survival and a higher risk of bladder recurrence (Cho et al., 2007; Simone et al., 2009). Extensive tumor necrosis (>10% of the tumor area) is an independent prognostic predictor in patients who undergo radical nephroureterectomy (Seitz et al., 2010; Zigeuner et al., 2010). Extensive necrosis seems to correlate with aggressive clinicopathologic features such advanced stage, high grade, lymph node invasion, presence of CIS, sessile architecture, and lymph node metastases (Zigeuner et al., 2010). Controversial evidence has been reported regarding the presence of tumor necrosis and the decreased recurrence-free and cancer-specific survival (Seitz et al., 2010; Simone et al., 2009; Zigeuner et al., 2010).

Metachronous bilateral UTUCs have been reported to be a rare event and represent only 3.1% of the UTUC cases. These cases are related to increased age and short survival time after the diagnosis (Holmäng and Johansson, 2004). Recurrence in the bladder after UTUC confers a multifocal risk that should affect decision making for treatment, while it presents another expression for field carcinogenesis. CIS involves the distal ureter in 7% to 25% of the patients undergoing cystectomy (Herr et al., 1998; Melamed and Reuter, 1993; Solsona et al., 1997). History of bladder tumor is present in 15% to 50% of the UTUCs (Babaian and Johnson, 1980; Batata and Grabstald, 1976). Recurrence of the urothelial cancer in the upper urinary tract after the treatment of a bladder tumor takes place in 2% to 4% of the bladder cancer cases with a mean interval of 70 months (Herr et al., 1996; Melamed and Reuter, 1993; Oldbring et al., 1989; Shinka et al., 1988). In the patients after cystectomy, recurrence is 3% to 9% (Mufti et al., 1988; Zincke and Neves, 1984).

UTUC associated with environmental exposure (aristolochic acid nephropathy, which includes Balkan and Chinese herbal nephropathy, arsenic endemic regions), analgesic abuse, and Lynch syndrome has a higher tendency to multiple and bilateral recurrences than sporadic tumors (Hubosky et al., 2013; Johansson and Wahlqvist, 1979; Mahoney et al., 1977; Markovic, 1972; Melamed and Reuter, 1993; Petkovic, 1972; Stewart et al., 1999; Tan et al., 2008). Balkan nephropathy is commonly related to low-grade tumors. Nevertheless, these cases may also be related to renal insufficiency, which undermines the role of the conservative treatment. The degree of scarring of renal papillae seen in phenacetin abuse has been correlated in a dose-dependent manner with the risk of high tumor grade and progression. Moreover, the development of squamous carcinoma of the renal pelvis has been reported in calcified renal papillae after analgesic abuse (Stewart et al., 1999).

Tumor stage remains the single most important factor for the oncologic outcome of the UTUC patients (Anderstrom et al., 1989; Babaian and Johnson, 1980; Batata et al., 1975; Bloom et al., 1970; Cummings, 1980; Guinan et al., 1992; McCarron et al., 1983; Terrell et al., 1995). UTUCs spread through the lymphatic and hematogenous routes and by direct extension into surrounding structures. Most metastases develop in the first 2 to 3 years after surgery (Brown et al., 2006). The common metastatic sites are the lungs, liver, bones, and regional lymph nodes. The thin muscle layer of the renal pelvis and ureter could allow for an earlier involvement of surrounding tissue in comparison to the bladder cancer (Cummings, 1980; Richie, 1988). The renal parenchyma may serve as a barrier to the distant spread of renal pelvis tumors of T3 stage, whereas the periureteral spread is related to a high risk for dissemination of the disease along the periureteral vascular and lymphatic supply.

Improved survival of patients with stage T3 renal pelvis tumors versus ureteral tumors has been reported by several investigators (Batata and Grabstald, 1976; Guinan et al., 1992; Park et al., 2004). This observation was also reported from a series of 611 patients treated at 97 hospitals (Guinan et al., 1992). The 5-year survival rates for patients with stage T3 tumors of the renal pelvis and ureter were 54% and 24%, respectively. In a multivariate analysis, patients with ureteral tumors had a higher local and distant failure rate than did those with renal pelvis tumors of the same stage and grade (Park et al., 2004). Some have proposed subclassification of renal pelvis tumors into pT3a for infiltration of the renal parenchyma and pT3b for invasion of peripelvic adipose tissue, because the patients with pT3b have an increased risk of recurrence (Roscigno et al., 2012). Several studies showed that the presence of hydronephrosis is a valuable and independent predictive factor for advanced disease stage and survival in UTUC patients (Brien et al., 2010; Cho et al., 2007; Ito et al., 2011; Ng et al., 2011).

Lymph Node Involvement.

Lymph node metastases and extranodal extension are powerful predictors of survival outcomes in UTUC (Fajkovic et al., 2012). Positive regional LNs are an independent factor for poor survival prognosis (Brown et al., 2006; Hall et al., 1998; Margulis et al., 2009). Optimal tumor staging is achieved by lymph node dissection at the time of radical nephroureterectomy (Lughezzani et al., 2010). Depending on the stage and grade of the tumor, up to 40% of patients appear to harbor lymphatic metastases. In a study of patients who underwent lymphadenectomy at the time of radical nephrectomy, lymph node density of 30% or more was associated with poor clinical outcomes (Bolenz et al., 2009). Its curative role is debated.

Lymphovascular Invasion.

Lymphovascular invasion (LVI) is observed in approximately 20% of UTUCs and represents an independent predictor of survival (Kikuchi et al., 2009; Novara et al., 2010). LVI status should be identified and specifically reported in the pathologic reports of all UTUC specimens (Godfrey et al., 2012; Kikuchi et al., 2009). LVI is not identified on URS biopsy specimens and serves only as a prognostic factor after surgical resection. In a multicenter study including 1453 patients who underwent radical nephroureterectomy, the multivariate analysis showed that LVI was an independent predictor of disease recurrence and survival for patients with negative lymph nodes or unknown nodal status. LVI was not an independent predictor of outcome for lymph node–positive patients (Kikuchi et al., 2009).

Surgical Margins

The presence of positive soft tissue surgical margin after radical nephroureterectomy has been established as a significant factor for developing disease recurrence. When the stage is greater than 2, pathologists should investigate for and report positive margins at the level of ureteral transection, bladder cuff, and around the tumor (Colin et al., 2012).

Molecular Markers

The characterization of genetic pathways leading to UTUC is ongoing. Bladder cancer and UTUC share similarities but also disparities on a genetic and epigenetic level, which render these two cancers as divergent entities. There have been studies investigating the prognostic impact of molecular markers. These markers include cell adhesion (E-cadherin and CD24) (Favaretto et al., 2017), cell differentiation (Snail and human epidermal growth factor receptor [EGFR] HER-2) (Soria et al., 2017), angiogenesis (hypoxia inducible factor 1α and metalloproteinases), cell proliferation (Ki-67), epithelial-mesenchymal transition (Snail), mitosis (Aurora A), apoptosis (Bcl-2 and survivin), vascular invasion (RON), and c-met protein (MET) (Lughezzani et al., 2012; Scarpini et al., 2012). Microsatellite instability (MSI) has been proposed as an independent molecular prognostic marker (Roupret, 2005). MSI typing could facilitate the detection of germline mutations and hereditary cancers (Roupret et al., 2008). In addition, there is a prognostic value of PD-1 and PDL-1 expression in patients with high-grade UTUC (Krabbe et al., 2017). UTUC is a cancer with low incidence, and any molecular studies are retrospective, although most of them have a small sample size. Current evidence is sufficient for the introduction of any of the markers in the daily clinical practice. Nonetheless, some markers show promise for the future.

Microsatellite instability and hypermethylation are emerging as key differences between upper and lower tract urothelial tumors. Nevertheless, it has been reported that several gene foci on chromosome 9 are mutated in 50% of UTUC cases (Rigola et al., 2001). Comparative genomic hybridization showed concordance between tumors of the renal pelvis and bladder in the losses at 2q, 8p, 9q, 11p, 13q, 17p, and 18q, and gains at 1q, 6p, 8q, and 17q chromosomes (Rigola et al., 2001). Similar gene expression was observed between renal pelvic and bladder tumors. Cytogenetic alterations such as +1p36, +6p22, +7, +8q22, −9p21, +11q, −13q, +17,+19q13, and +20q were noted (Zhang et al., 2010).

Patients with HNPCC (Lynch syndrome) show genomic alterations in DNA mismatch repair genes (Amira et al., 2003). Microsatellite instability has been related to an inverted growth pattern of cancer. In the latter cases, the microsatellite instability had a sensitivity and specificity of 82% and probably could be considered a marker for inverted growth in UTUCs (Hartmann et al., 2003). A urine-based assay testing for a total panel of 77 markers for microsatellite instability was evaluated in 30 patients. The assay detected 83.3% of cases of a UTUC (Ho et al., 2008). Testing for microsatellite instability on resected tumor and normal tissues to screen for Lynch syndrome is a well-established tool for colon cancer. This approach could be considered for patients with UTUC meeting criteria suggestive of Lynch syndrome (Audenet et al., 2012).

Cell Cycle Markers.

The TP53 nuclear protein staining of cytology specimens obtained during ureteroscopy were correlated to the presence of UTUC. In a study, 28 out of 36 patients with TP53-positive specimens had evidence of urothelial carcinoma. In the serial evaluation of these patients, 80% of the remaining patients had confirmed UTUC. All 14 TP53-negative specimens were obtained from patients who did not have a sign of concurrent malignant disease on ureteroscopy (Keeley et al., 1997a). Decreased TP53 immunoreactivity and TP53 overexpression in UTUCs have been associated with advanced tumor stage and poor prognosis. When the stage and grade were considered in the multivariate analysis, no such correlation was confirmed (Zigeuner et al., 2004).

CDKN1B (formerly known as p27), a cyclin-dependent kinase inhibitor, has been proposed to predict the prognosis of UTUCs. Low levels of CDKN1B staining were indicating a worse disease-specific survival (Kamai et al., 2000).

Apoptosis.

Expression of Bcl-2 and survivin correlates with advanced cancers, and levels of survivin are associated with disease-specific survival (Jeong et al., 2009).

Cell Migration and Invasion.

Expression of E-cadherin and matrix metalloproteinases (MMPs) was related to poor prognosis (Inoue et al., 2002). There is a correlation between the immunohistochemistry of MMPs and the pT stage and disease-specific survival (Miyata et al., 2004).

Angiogenesis.

Angiogenesis is essential for tumor cell growth. Hypoxia-inducible factor-1α (HIF-1α) is a transcription factor that plays an important role in cellular hypoxia adaptation. Positive HIF-1α expression was found in two-thirds of patients with UTUC and was absent in the cases of normal urothelium. The expression of HIF-1α was significantly associated with high T stage, nodal stage, grade, and cancer-specific survival (HR = 2.23; $P = 0.004$) (Ke et al., 2008).

Cell Proliferation.

Overexpression of Ki-67 has been associated with progression, decreased disease-specific survival (Jeon et al., 2010), and development of metachronous tumors (Joung et al., 2008). Epidermal growth factor receptor (EGFR) was related to stage, grade, and squamous differentiation of UTUC. Overexpression and immunoreactivity of nuclear factor-κB (NF-κB) predicts disease-specific survival and overall survival. HER2 overexpression is rare in UTUC and was related to higher stage and grade.

Cell Differentiation.

Uroplakin III expression is associated with lower stage and grade. Cancer-specific survival is significantly better when uroplakin III is expressed. On multivariate analysis it outperformed stage and lymph node status as a predictor of survival (Ohtsuka et al., 2006). Snail contributes to the epithelial-mesenchymal transition in cell differentiation. Strong Snail staining is observed in invasive UTUC. It is associated with stage, grade, and LVI. It is a predictor of recurrence and disease-specific survival (Kosaka et al., 2010). In situ hybridization of telomerase mRNA component hTR is positive in 98.4% of UTUCs. hTR score is increased with stage and may be associated with disease-free and overall survival (Nakanishi et al., 1999).

Mitosis.

Aurora-A regulates spindle assembly during mitosis. Its overexpression was related to the presence of vascular invasion and recurrence (Scarpini et al., 2012).

The roles of members of the MET proto-oncogene family of tyrosine kinases, c-MET and RON, have been investigated in UTUC (Comperat et al., 2008). c-MET overexpression correlated with vascular invasion and a worse clinical outcome. The overexpression of RON did not correlate with the outcome of UTUC.

Abnormal expression of cyclooxygenase-2 (COX-2) has been observed in various human cancers and in bladder urothelial cancer. Abnormal expression of COX-2 in stromal cells of UTUCs was associated with high tumor stage and grade and poor prognosis (Kang et al., 2008).

Other Markers

Ploidy-flow cytometry was used for providing information on tumor ploidy. The survival of patients with UTUC was correlated with tumor aneuploidy. In a study from the 1980s, tumor aneuploidy was correlated to poor 5- and 10-year survival rates of 25% and 0, respectively (Blute et al., 1988).

Efforts have been made during recent years for the development of rapid urine tests for the detection of urothelial malignant neoplasms. These rapid urine tests have been extensively studied for bladder cancer. The knowledge of their use in UTUCs remains limited. Urinary levels of NMP22 is a nuclear matrix protein–based marker. Patients with UTUC have elevated urinary levels of NMP22 (Carpinito et al., 1996). This investigation seems to have higher sensitivity for detecting the presence of UTUC but lower specificity in comparison with cytology.

The cytogenetic detection of molecular abnormalities by fluorescent in situ hybridization (FISH) has been investigated in 16 UTUC cases. Urine FISH was reported to have a sensitivity of 87.5% and a specificity of 80% for detection of UTUCs (Akkad et al., 2007). The cytology was compared with UroVysion, which is a multitarget FISH system, in 50 patients. The overall sensitivity/specificity of cytology was 20.8%/97.4% in comparison with 100%/89.5% of FISH (Mian et al., 2010). In a study including 285 patients with hematuria and negative cytology, 11 (3.9%) patients had positive FISH, of which 9 (81.8%) had UTUC. None of the patients with negative FISH was diagnosed with UTUC. The specificity and sensitivity were 99.3% and 100%, respectively (Huang et al., 2012). One study compared the analysis of fibrinogen-fibrin degradation products (AuraTek FDP) with the bladder tumor antigen (BTA) test and urine cytology. The accuracy of the FDP test was 83% compared with 62% for BTA and 59% for cytology (Siemens et al., 2003).

Predictive Tools

Accurate predictive tools are rare for UTUC. For preoperative decision making, there are two models in the preoperative setting. The one is helpful in predicting lymph node involvement of locally advanced cancer that could guide the decision to perform an LND and to decide on the extent of LND at the time of radical nephroureterectomy (Margulis et al., 2010). The other facilitates the selection of the cases with non–organ-confined UTUC to undergo radical nephroureterectomy (Favaretto et al., 2012). Five nomograms predict the survival rates postoperatively. The prediction is based on standard pathologic features (Cha et al., 2012; Ku et al., 2013; Roupret et al., 2013; Seisen et al., 2014; Yates et al., 2012). One of these nomograms is based on only four variables and was reported to have high prognostic accuracy and risk stratification for patients with high-grade urothelial carcinoma of the upper urinary tract after extirpative surgery (Krabbe et al., 2017). Further clinical research would establish one of these nomograms in the clinical practice.

Risk Stratification

Tumor stage is difficult to assert based on the clinical criteria. The UTUC cases could be stratified between low- and high-risk tumors to distinguish the cases that are more appropriate for kidney-sparing treatment rather than radical surgery (Roupret, 2014; Seisen et al., 2015; Fig. 98.6).

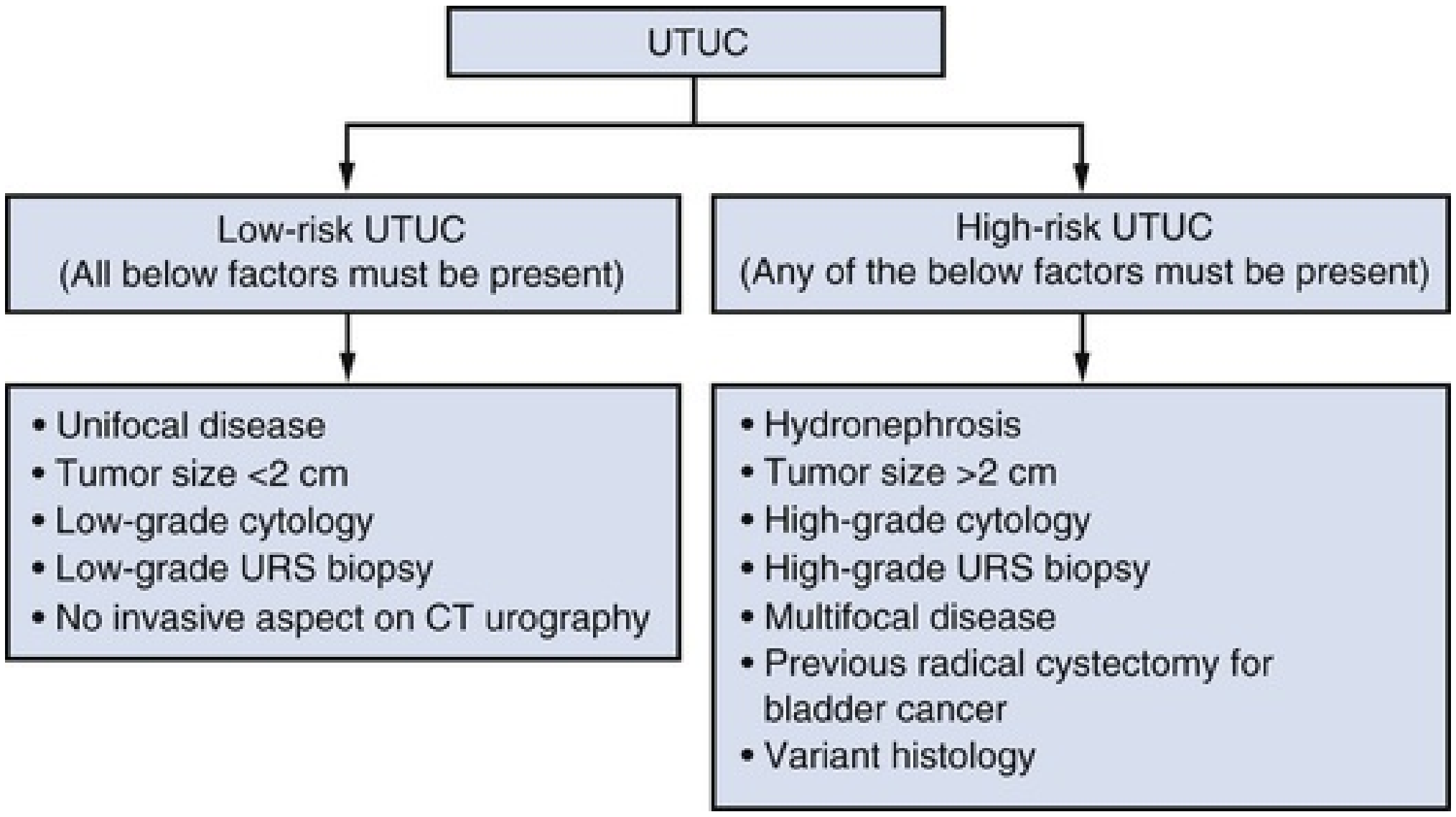
UTUC
Low-risk UTUC
(All below factors must be present)
High-risk UTUC
(Any of the below factors must be present)
• Unifocal disease
• Tumor size <2 cm
• Low-grade cytology
• Low-grade URS biopsy
• No invasive aspect on CT urography
• Hydronephrosis
• Tumor size >2 cm
• High-grade cytology
• High-grade URS biopsy
• Multifocal disease
• Previous radical cystectomy for bladder cancer
• Variant histology

FIG. 98.6 Risk stratification of upper urinary tract urothelial carcinoma (UTUC). *CT,* Computed tomography; *URS,* ureteroscopy. (Modified from Rouprêt M, Babjuk M, Compérat E, et al: European Association of Urology Guidelines on Upper Urinary Tract Urothelial Carcinoma: 2017 Update, *Eur Urol* 73[1]:111–122, 2018.)

Key Points: Prognostic Factors

- Use the TNM classification and staging system.
- Use the 2004/2016 WHO grading classification.
- Age alone should not prevent a curable approach.
- Ureteral and/or multifocal tumors have a worse prognosis than renal pelvic tumors.
- Muscle invasive tumors have a poor prognosis.
- Positive regional LNs have a poor survival prognosis.
- Lymphovascular invasion is a predictor of disease recurrence and survival.

References

Abouassaly R, Alibhai SMH, Shah N, et al. Troubling outcomes from population-level analysis of surgery for upper tract urothelial carcinoma. *Urology*. 2010;76(4):895–901.

Acher P, Kiela G, Thomas K, et al. Towards a rational strategy for the surveillance of patients with Lynch syndrome (hereditary non-polyposis colon cancer) for upper tract transitional cell carcinoma. *BJU Int*. 2010;106(3):300–302.

Akaza H, Koiso K, Niijima T. Clinical evaluation of urothelial tumors of the renal pelvis and ureter based on a new classification system. *Cancer*. 1970;26:583.

Akkad T, Brunner A, Pallwein L, et al. Fluorescence in situ hybridization for detecting upper urinary tract tumors–a preliminary report. *Urology*. 2007;70(4):753–757.

Albadine R, Schultz L, Illei P, et al. PAX8 (+)/p63 (−) immunostaining pattern in renal collecting duct carcinoma (CDC): a useful immunoprofile in the differential diagnosis of CDC versus urothelial carcinoma of upper urinary tract. *Am J Surg Pathol*. 2010;34(7):965–969.

Amira N, Rivet J, Soliman H, et al. Microsatellite instability in urothelial carcinoma of the upper urinary tract. *J Urol*. 2003;170(4 Pt 1):1151–1154.

Anderstrom C, Johansson SL, Pettersson S, et al. Carcinoma of the ureter: a clinicopathologic study of 49 cases. *J Urol*. 1989;142:280–283.

Asano K, Miki J, Maeda S, et al. Clinical studies on inverted papilloma of the urinary tract: report of 48 cases and review of the literature. *J Urol*. 2003;170(4 Pt 1):1209–1212.

Audenet F, Colin P, Yates DR, et al. A proportion of hereditary upper urinary tract urothelial carcinomas are misclassified as sporadic according to a multi-institutional database analysis:

proposal of patient-specific risk identification tool. *BJU Int*. 2012;110(11 Pt B):E583–E589.

Babaian RJ, Johnson DE. Primary carcinoma of the ureter. *J Urol*. 1980;123(3):357–359.

Babjuk M, Bohle A, Burger M, et al. EAU Guidelines on non-muscle-invasive urothelial carcinoma of the bladder: update 2016. *Eur Urol*. 2017;71(3):447–461.

Batata M, Grabstald H. Upper urinary tract urothelial tumors. *Urol Clin North Am*. 1976;3(1):79–86.

Batata MA, Whitmore WF, Hilaris BS, et al. Primary carcinoma of the ureter: a prognostic study. *Cancer*. 1975;35(6):1626–1632.

Bennington JL, Beckwith JB. Tumors of the kidney, renal pelvis, and ureter. *Atlas of tumor pathology second series fascicle 12*. Armed Forces Institute of Pathology: Washington DC; 1975.

Berod AA, Colin P, Yates DR, et al. The role of American Society of Anesthesiologists scores in predicting urothelial carcinoma of the upper urinary tract outcome after radical nephroureterectomy: results from a national multi-institutional collaborative study. *BJU Int*. 2012;110(11 Pt C):E1035–E1040.

Blacker EJ, Johnson DE, Abdul-Karim FW. Squamous cell carcinoma of renal pelvis. *Urology*. 1985;25:124.

Blank C, Lissmer L, Kaneti J, et al. Fibroepithelial polyp of the renal pelvis. *J Urol*. 1987;137(5):962–963.

Bloom NA, Vidone RA, Lytton B. Primary carcinoma of the ureter: a report of 102 new cases. *J Urol*. 1970;103(5):590–598.

Blute ML, Segura JW, Patterson DE, et al. Impact of endourology on diagnosis and management of upper urinary tract urothelial cancer. *J Urol*. 1989;141(6):1298–1301.

Blute ML, Tsushima K, Farrow GM, et al. Transitional cell carcinoma of the renal pelvis: nuclear deoxyribonucleic acid ploidy studied by flow cytometry. *J Urol*. 1988;140(5):944–949.

Blute RD Jr, Gittes RR, Gittes RF. Renal brush biopsy: survey of indications, techniques and results. *J Urol*. 1981;126(2):146–149.

Bolenz C, Shariat SF, Fernández MI, et al. Risk stratification of patients with nodal involvement in upper tract urothelial carcinoma: value of lymph-node density. *BJU Int*. 2009;103(3):302–306.

Breda GL, Tuon FF, Meis JF, et al. Breakthrough candidemia after the introduction of broad spectrum antifungal agents: a 5-year retrospective study. *Med Mycol*. 2018;56(4):406–415.

Brenner DW, Schellhammer PF. Upper tract urothelial malignancy after cyclophosphamide therapy: a case report and literature review. *J Urol*. 1987;137(6):1226–1227.

Brien JC, Shariat SF, Herman MP, et al. Preoperative hydronephrosis, ureteroscopic biopsy grade and urinary cytology can improve prediction of advanced upper tract urothelial carcinoma. *J Urol*. 2010;184(1):69–73.

Brierley JD, Gospodarowicz MK, Wittekind C. *TNM classification of malignant tumours*. ed 8. Wiley-Blackwell: Hoboken, NJ; 2017.

Brown GA, Busby JE, Wood CG, et al. Nephroureterectomy for treating upper urinary tract transitional cell carcinoma: time to change the treatment paradigm? *BJU Int*. 2006;98(6):1176–1180.

Brown GA, Matin SF, Busby JE, et al. Ability of clinical grade to predict final pathologic stage in upper urinary tract transitional cell carcinoma: implications for therapy. *Urology*. 2007;70(2):252–256.

Bus MTJ, de Bruin DM, Faber DJ, et al. Optical coherence tomography as a tool for in vivo staging and grading of upper urinary tract urothelial carcinoma: a study of diagnostic accuracy. *J Urol*. 2016;196(6):1749–1755.

Bus MTJ, de Bruin DM, Faber DJ, et al. Optical diagnostics for upper urinary tract urothelial cancer: technology, thresholds, and clinical applications. *J Endourol*. 2015;29(2):113–123.

Canales BK, Anderson JK, Premoli J, et al. Risk factors for upper tract recurrence in patients undergoing long-term surveillance for stage ta bladder cancer. *J Urol*. 2006;175(1):74–77.

Carpinito GA, Stadler WM, Briggman JV, et al. Urinary nuclear matrix protein as a marker for transitional cell carcinoma of the urinary tract. *J Urol*. 1996;156(4):1280–1285.

Carrion A, Huguet J, García-Cruz E, et al. Intraoperative prognostic factors and atypical patterns of recurrence in patients with upper urinary tract urothelial carcinoma treated with laparoscopic radical nephroureterectomy. *Scand J Urol*. 2016;50(4):305–312.

Catto JWF, Yates DR, Rehman I, et al. Behavior of urothelial carcinoma with respect to anatomical location. *J Urol*. 2007;177(5):1715–1720.

Cha EK, Shariat SF, Kormaksson M, et al. Predicting clinical outcomes after radical nephroureterectomy for upper tract urothelial carcinoma. *Eur Urol*. 2012;61(4):818–825.

Chan KW, Lam KY, Srivastava G. Accumulation of p53 protein in inverted transitional cell papilloma of the urinary bladder. *Clin Mol Pathol*. 1996;49(1):M43–M45.

Chen AA, Grasso M. Is there a role for FISH in the management and surveillance of patients with upper tract transitional-cell carcinoma? *J Endourol*. 2008;22(6):1371–1374.

Cheng L, Neumann RM, Bostwick DG. Papillary urothelial neoplasms of low malignant potential. Clinical and biologic implications. *Cancer*. 1999;86(10):2102–2108.

Cheng L, Neumann RM, Nehra A, et al. Cancer heterogeneity and its biologic implications in the grading of urothelial carcinoma. *Cancer*. 2000;88(7):1663–1670.

Cheville JC, Wu K, Sebo TJ, et al. Inverted urothelial papilloma: is ploidy, MIB-1 proliferative activity, or p53 protein accumulation predictive of urothelial carcinoma. *Cancer*. 2000;88(3):632–636.

Cho KS, Hong SJ, Cho NH, et al. Grade of hydronephrosis and tumor diameter as preoperative prognostic factors in ureteral transitional cell carcinoma. *Urology*. 2007;70(4):662–666.

Chow WH, Lindblad P, Gridley G, et al. Risk of urinary tract cancers following kidney or ureter stones. *J Natl Cancer Inst*. 1997;89(19):1453–1457.

Chromecki TF, Cha EK, Fajkovic H, et al. The impact of tumor multifocality on outcomes in patients treated with radical nephroureterectomy. *Eur Urol*. 2012;61(2):245–253.

Chromecki TF, Ehdaie B, Novara G, et al. Chronological age is not an independent predictor of clinical outcomes after radical nephroureterectomy. *World J Urol*. 2011;29(4):473–480.

Clavel J, Mandereau L, Limasset JC, et al. Occupational exposure to polycyclic aromatic hydrocarbons and the risk of bladder cancer: a French case-control study. *Int J Epidemiol*. 1994;23(6):1145–1153.

Clements T, Messer JC, Terrell JD, et al. High-grade ureteroscopic biopsy is associated with advanced pathology of upper-tract urothelial carcinoma tumors at definitive surgical resection. *J Endourol*. 2012;26(4):398–402.

Colin P, Koenig P, Ouzzane A, et al. Environmental factors involved in carcinogenesis of urothelial cell carcinomas of the upper urinary tract. *BJU Int*. 2009;104(10):1436–1440.

Colin P, Ouzzane A, Yates DR, et al. Influence of positive surgical margin status after radical nephroureterectomy on upper urinary tract urothelial carcinoma survival. *Ann Surg Oncol*. 2012;19(11):3613–3620.

Comperat E, Roupret M, Chartier-Kastler E, et al. Prognostic value of MET, RON, and histoprognostic factors for urothelial carcinoma in the upper urinary tract. *J Urol*. 2008;179:868–872.

Cosentino M, Palou J, Gaya JM, et al. Upper urinary tract urothelial cell carcinoma: location as a predictive factor for concomitant bladder carcinoma. *World J Urol*. 2013;31(1):141–145.

Cosyns JP, Jadoul M, Squifflet JP, et al. Urothelial lesions in Chinese-herb nephropathy. *Am J Kidney Dis*. 1999;33(6):1011–1017.

Coup AJ. Angiosarcoma of the ureter. *Br J Urol*. 1988;62(3):275–276.

Cowan NC, Turney BW, Taylor NJ, et al. Multidetector computed tomography urography for diagnosing upper urinary tract urothelial tumour. *BJU Int*. 2007;99(6):1363–1370.

Crivelli JJ, Xylinas E, Kluth LA, et al. Effect of smoking on outcomes of urothelial carcinoma: a systematic review of the literature. *Eur Urol*. 2014;65(4):742–754.

Cummings KB. Nephroureterectomy: rationale in the management of transitional cell carcinoma of the upper urinary tract. *Urol Clin North Am*. 1980;7(3):569–578.

Dalpiaz O, Pichler M, Mannweiler S, et al. Validation of the pretreatment derived neutrophil-lymphocyte ratio as a prognostic factor in a European cohort of patients with upper tract urothelial carcinoma. *Br J Cancer*. 2014;110(10):2531–2536.

Data SN, Allen GM, Evans R, et al. Urinary tract ultrasonography in the evaluation of hematuria—a report of over 100 cases. *Ann R Coll Surg Engl*. 2002;84:203–205.

David KA, Mallin K, Milowsky MI, et al. Surveillance of urothelial carcinoma: stage and grade migration, 1993-2005 and survival trends, 1993-2000. *Cancer*. 2009;115(7):1435–1447.

Davis BW, Hough AJ, Gardner WA. Renal pelvic carcinoma: morphological correlates of metastatic behavior. *J Urol*. 1987;137(5):857–861.

De Broe ME, Elseviers MM. Analgesic nephropathy. *N Engl J Med*. 1998;338(7):446–452.

De Stefani E, Boffetta P, Deneo-Pellegrini H, et al. Non-alcoholic beverages and risk of bladder cancer in Uruguay. *BMC Cancer*. 2007;7:57.

Dixon JS, Gosling JA. The musculature of the human renal calices, pelvis and upper ureter. *J Anat*. 1982;135(Pt 1):129–137.

Dragicevic D, Djokic M, Pekmezovic T, et al. Survival of patients with transitional cell carcinoma of the ureter and renal pelvis in Balkan endemic nephropathy and non-endemic areas of Serbia. *BJU Int*. 2007;99(6):1357–1362.

Ehdaie B, Chromecki TF, Lee RK, et al. Obesity adversely impacts disease specific outcomes in patients with upper tract urothelial carcinoma. *J Urol*. 2011;186(1):66–72.

El-Hakim A, Weiss GH, Lee BR, et al. Correlation of ureteroscopic appearance with histologic grade of upper tract transitional cell carcinoma. *Urology*. 2004;63(4):647–650 [discussion 50].

Fajkovic H, Cha EK, Jeldres C, et al. Prognostic value of extranodal extension and other lymph node parameters in patients with upper tract urothelial carcinoma. *J Urol*. 2012;187(3):845–851.

Favaretto RL, Bahadori A, Mathieu R, et al. Prognostic role of decreased E-cadherin expression in patients with upper tract urothelial carcinoma: a multi-institutional study. *World J*

Urol. 2017;35(1):113–120.

Favaretto RL, Shariat SF, Savage C, et al. Combining imaging and ureteroscopy variables in a preoperative multivariable model for prediction of muscle-invasive and non-organ confined disease in patients with upper tract urothelial carcinoma. *BJU Int*. 2012;109(1):77–82.

Fein AB, McClennan BL. Solitary filling defects of the ureter. *Semin Roentgenol*. 1986;21(3):201–213.

Fernández MI, Shariat SF, Margulis V, et al. Evidence-based sex-related outcomes after radical nephroureterectomy for upper tract urothelial carcinoma: results of large multicenter study. *Urology*. 2009;73(1):142–146.

Fritsche H-M, Novara G, Burger M, et al. Macroscopic sessile tumor architecture is a pathologic feature of biologically aggressive upper tract urothelial carcinoma. *Urol Oncol*. 2012;30(5):666–672.

Gadzinski AJ, Roberts WW, Faerber GJ, et al. Long-term outcomes of immediate versus delayed nephroureterectomy for upper tract urothelial carcinoma. *J Endourol*. 2012;26(5):566–573.

Geiger J, Fong Q, Fay R. Transitional cell carcinoma of renal pelvis with invasion of renal vein and thrombosis of subhepatic inferior vena cava. *Urology*. 1986;28(1):52–54.

Godfrey MS, Badalato GM, Hruby GW, et al. Prognostic indicators for upper tract urothelial carcinoma after radical nephroureterectomy: the impact of lymphovascular invasion. *BJU Int*. 2012;110(6):798–803.

Grainger R, Gikas PW, Grossman HB. Urothelial carcinoma occurring within an inverted papilloma of the ureter. *J Urol*. 1990;143(4):802–804.

Green DA, Rink M, Xylinas E, et al. Urothelial carcinoma of the bladder and the upper tract: disparate twins. *J Urol*. 2013;189(4):1214–1221.

Greenlee RT, Murray T, Bolden S, et al. Cancer statistics, 2000. *CA Cancer J Clin*. 2000;50(1):7–33.

Grollman AP. Aristolochic acid nephropathy: harbinger of a global iatrogenic disease. *Environ Mol Mutagen*. 2013;54(1):1–7.

Grollman AP, Shibutani S, Moriya M, et al. Aristolochic acid and the etiology of endemic (Balkan) nephropathy. *Proc Natl Acad Sci USA*. 2007;104(29):12129–12134.

Guarnizo E, Pavlovich CP, Seiba M, et al. Ureteroscopic biopsy of upper tract urothelial carcinoma: improved diagnostic accuracy and histopathological considerations using a multi-biopsy approach. *J Urol*. 2000;163(1):52–55.

Guinan P, Vogelzang NJ, Randazzo R, et al. Renal pelvic cancer: a review of 611 patients treated in Illinois 1975-1985. Cancer Incidence and End Results Committee. *Urology*. 1992;40(5):393–399.

Guinan P, Volgelzang NJ, Randazzo R, et al. Renal pelvic transitional cell carcinoma. The role of the kidney in tumor-node-metastasis staging. *Cancer*. 1992;69(7):1773–1775.

Habuchi T, Takahashi R, Yamada H, et al. Metachronous multifocal development of urothelial cancers by intraluminal seeding. *Lancet*. 1993;342(8879):1087–1088.

Hafner C, Knuechel R, Stoehr R, et al. Clonality of multifocal urothelial carcinomas: 10 years of molecular genetic studies. *Int J Cancer*. 2002;101(1):1–6.

Hall MC, Womack JS, Roehrborn CG, et al. Advanced transitional cell carcinoma of the upper urinary tract: patterns of failure, survival and impact of postoperative adjuvant radiotherapy. *J Urol*. 1998;160(3 Pt 1):703–706.

Hanna MK, Jeffs RD, Sturgess JM, et al. Ureteral structure and ultrastructure. Part II. Congenital ureteropelvic junction obstruction and primary obstructive megaureter. *J Urol*. 1976;116(6):725–730.

Harris AL, Neal DE. Bladder cancer–field versus clonal origin. *New Engl J Med*. 1992;326(11):759–761.

Hartmann A, Dietmaier W, Hofstädter F, et al. Urothelial carcinoma of the upper urinary tract: inverted growth pattern is predictive of microsatellite instability. *Hum Pathol*. 2003;34(3):222–227.

Heney NM, Nocks BN, Daly JJ, et al. Prognostic factors in carcinoma of the ureter. *J Urol*. 1981;125(5):632–636.

Herr HW, Bar-Chama N, O'Sullivan M, et al. Paternity in men with stage I testis tumors on surveillance. *J Clin Oncol*. 1998;16(2):733–734.

Herr HW, Cookson MS, Soloway SM. Upper tract tumors in patients with primary bladder cancer followed for 15 years. *J Urol*. 1996;156(4):1286–1287.

Herr HW, Wartinger DD, Fair WR, et al. Bacillus Calmette-Guerin therapy for superficial bladder cancer: a 10-year followup. *J Urol*. 1992;147(4):1020–1023.

Hisataki T, Miyao N, Masumori N, et al. Risk factors for the development of bladder cancer after upper tract urothelial cancer. *Urology*. 2000;55(5):663–667.

Ho C-L, Tzai T-S, Chen J-C, et al. The molecular signature for urothelial carcinoma of the upper urinary tract. *J Urol*. 2008;179(3):1155–1159.

Holmäng S, Johansson SL. Synchronous bilateral ureteral and renal pelvic carcinomas: incidence, etiology, treatment and outcome. *Cancer*. 2004;101(4):741–747.

Holmäng S, Thomsen J, Johansson SL. Micropapillary carcinoma of the renal pelvis and ureter. *J Urol*. 2006;175(2):463–466 [discussion 6].

Huang A, Low RK, deVere White R. Nephrostomy tract tumor seeding following percutaneous manipulation of a ureteral carcinoma. *J Urol*. 1995;153(3 Pt 2):1041–1042.

Huang WT, Li LY, Pang J, et al. Fluorescence in situ hybridization assay detects upper urinary tract transitional cell carcinoma in patients with asymptomatic hematuria and negative urine cytology. *Neoplasma*. 2012;59(4):355–360.

Huben RP, Mounzer AM, Murphy GP. Tumor grade and stage as prognostic variables in upper tract urothelial tumors. *Cancer*. 1988;62(9):2016–2020.

Hubosky SG, Boman BM, Charles S, et al. Ureteroscopic management of upper tract urothelial carcinoma (UTUC) in patients with Lynch Syndrome (hereditary nonpolyposis colorectal cancer syndrome). *BJU Int*. 2013;112(6):813–819.

Hudson MA, Herr HW. Carcinoma in situ of the bladder. *J Urol*. 1995;153(3 Pt 1):564–572.

Huguet J. Follow-up after radical cystectomy based on patterns of tumour recurrence and its risk factors. *Actas Urol Esp*. 2013;37(6):376–382.

Hung RJ, Boffetta P, Brennan P, et al. GST, NAT, SULT1A1, CYP1B1 genetic polymorphisms, interactions with environmental exposures and bladder cancer risk in a high-risk population. *Int J Cancer*. 2004;110(4):598–604.

Hurel S, Rouprêt M, Seisen T, et al. Influence of preoperative factors on the oncologic outcome for upper urinary tract urothelial carcinoma after radical nephroureterectomy. *World J Urol*. 2015;33(3):335–341.

Igel TC, Engen DE, Banks PM, et al. Renal plasmacytoma: Mayo Clinic experience and review of the literature. *Urology*. 1991;37(4):385–389.

Inoue K, Kamada M, Slaton JW, et al. The prognostic value of angiogenesis and metastasis-related genes for progression of transitional cell carcinoma of the renal pelvis and ureter. *Clin Cancer Res*. 2002;8(6):1863–1870.

Ishikawa S, Abe T, Shinohara N, et al. Impact of diagnostic ureteroscopy on intravesical recurrence and survival in patients with urothelial carcinoma of the upper urinary tract. *J*

Urol. 2010;184(3):883–887.

Ito A, Shintaku I, Satoh M, et al. Prospective randomized phase II trial of a single early intravesical instillation of pirarubicin (THP) in the prevention of bladder recurrence after nephroureterectomy for upper urinary tract urothelial carcinoma: the THP Monotherapy Study Group Trial. *J Clin Oncol*. 2013;31(11):1422–1427.

Ito Y, Kikuchi E, Tanaka N, et al. Preoperative hydronephrosis grade independently predicts worse pathological outcomes in patients undergoing nephroureterectomy for upper tract urothelial carcinoma. *J Urol*. 2011;185(5):1621–1626.

Jeldres C, Sun M, Isbarn H, et al. A population-based assessment of perioperative mortality after nephroureterectomy for upper-tract urothelial carcinoma. *Urology*. 2010;75(2):315–320.

Jensen OM, Knudsen JB, McLaughlin JK, et al. The Copenhagen case-control study of renal pelvis and ureter cancer: role of smoking and occupational exposures. *Int J Cancer*. 1988;41(4):557–561.

Jeon HG, Jeong IG, Bae J, et al. Expression of Ki-67 and COX-2 in patients with upper urinary tract urothelial carcinoma. *Urology*. 2010;76(2):513 [e7-12].

Jeong IG, Kim SH, Jeon HG, et al. Prognostic value of apoptosis-related markers in urothelial cancer of the upper urinary tract. *Hum Pathol*. 2009;40(5):668–677.

Jitsukawa S, Nakamura K, Nakayama M, et al. Transitional cell carcinoma of kidney extending into renal vein and inferior vena cava. *Urology*. 1985;25(3):310–312.

Johannes JR, Nelson E, Bibbo M, et al. Voided urine fluorescence in situ hybridization testing for upper tract urothelial carcinoma surveillance. *J Urol*. 2010;184(3):879–882.

Johansson S, Angervall L, Bengtsson U, et al. Uroepithelial tumors of the renal pelvis associated with abuse of phenacetin-containing analgesics. *Cancer*. 1974;33(3):743–753.

Johansson S, Angervall L, Bengtsson U, et al. A clinicopathologic and prognostic study of epithelial tumors of the renal pelvis. *Cancer*. 1976;37(3):1376–1383.

Johansson S, Wahlqvist L. A prognostic study of urothelial renal pelvic tumors: comparison between the prognosis of patients treated with intrafascial nephrectomy and perifascial nephroureterectomy. *Cancer*. 1979;43(6):2525–2531.

Johnson DE, Babaian RJ. Conservative surgical management for noninvasive distal ureteral carcinoma. *Urology*. 1979;13(4):365–367.

Joung JY, Yang SO, Jeong IG, et al. Identification of immunohistochemical factors that predict the synchronous or metachronous development of bladder tumors in patients with upper urinary tract tumors. *Urol Int*. 2008;81(3):306–311.

Junker K, Wolf M, Schubert J. Molecular clonal analysis of recurrent bladder cancer. *Oncol Rep*. 2005;14(2):319–323.

Kakizoe T, Fujita J, Murase T, et al. Transitional cell carcinoma of the bladder in patients with renal pelvic and ureteral cancer. *J Urol*. 1980;124(1):17–19.

Kamai T, Takagi K, Asami H, et al. Prognostic significance of p27Kip1 and Ki-67 expression in carcinoma of the renal pelvis and ureter. *BJU Int*. 2000;86(1):14–19.

Kang C-H, Chiang P-H, Huang S-C. Correlation of COX-2 expression in stromal cells with high stage, high grade, and poor prognosis in urothelial carcinoma of upper urinary tracts. *Urology*. 2008;72(1):153–157.

Kang C-H, Yu T-J, Hsieh H-H, et al. The development of bladder tumors and contralateral upper urinary tract tumors after primary transitional cell carcinoma of the upper urinary tract. *Cancer*. 2003;98(8):1620–1626.

Kata SG, Aboumarzouk OM, Zreik A, et al. Photodynamic diagnostic ureterorenoscopy: a valuable tool in the detection of upper urinary tract tumour. *Photodiagnosis Photodyn Ther*. 2016;13:255–260.

Ke H-L, Wei Y-C, Yang S-F, et al. Overexpression of hypoxia-inducible factor-1alpha predicts an unfavorable outcome in urothelial carcinoma of the upper urinary tract. *Int J Urol*. 2008;15(3):200–205.

Keeley FX, Bibbo M, McCue PA, et al. Use of p53 in the diagnosis of upper-tract transitional cell carcinoma. *Urology*. 1997;49(2):181–186.

Keeley FX, Kulp DA, Bibbo M, et al. Diagnostic accuracy of ureteroscopic biopsy in upper tract transitional cell carcinoma. *J Urol*. 1997;157(1):33–37.

Kenney PJ, Stanley RJ. Computed tomography of ureteral tumors. *J Comput Assist Tomogr*. 1987;11(1):102–107.

Kikuchi E, Margulis V, Karakiewicz PI, et al. Lymphovascular invasion predicts clinical outcomes in patients with node-negative upper tract urothelial carcinoma. *J Clin Oncol*. 2009;27(4):612–618.

Kim HS, Jeong CW, Kwak C, et al. Association between demographic factors and prognosis in urothelial carcinoma of the upper urinary tract: a systematic review and meta-analysis. *Oncotarget*. 2017;8(5):7464–7476.

Kim JK, Moon KC, Jeong CW, et al. Variant histology as a significant predictor of survival after radical nephroureterectomy in patients with upper urinary tract urothelial carcinoma. *Urol Oncol*. 2017;35(7):458 [e9-e15].

Kondo T, Hashimoto Y, Kobayashi H, et al. Template-based lymphadenectomy in urothelial carcinoma of the upper urinary tract: impact on patient survival. *Int J Urol*. 2010;17(10):848–854.

Konety BR, Getzenberg RH. Urine based markers of urological malignancy. *J Urol*. 2001;165(2):600–611.

Kosaka T, Kikuchi E, Mikami S, et al. Expression of snail in upper urinary tract urothelial carcinoma: prognostic significance and implications for tumor invasion. *Clin Cancer Res*. 2010;16(23):5814–5823.

Krabbe L-M, Eminaga O, Shariat SF, et al. Postoperative nomogram for relapse-free survival in patients with high grade upper tract urothelial carcinoma. *J Urol*. 2017;197(3 Pt 1):580–589.

Krabbe L-M, Heitplatz B, Preuss S, et al. Prognostic value of PD-1 and PD-L1 expression in patients with high grade upper tract urothelial carcinoma. *J Urol*. 2017;198(6):1253–1262.

Ku JH, Moon KC, Jung JH, et al. External validation of an online nomogram in patients undergoing radical nephroureterectomy for upper urinary tract urothelial carcinoma. *Br J Cancer*. 2013;109(5):1130–1136.

Lamm SH, Engel A, Penn CA, et al. Arsenic cancer risk confounder in southwest Taiwan data set. *Environ Health Perspect*. 2006;114(7):1077–1082.

Lantz EJ, Hattery RR. Diagnostic imaging of urothelial cancer. *Urol Clin North Am*. 1984;11(4):567–583.

Li Q, Assel M, Benfante N, et al. Clinical outcomes in patients with panurothelial carcinoma treated with radical nephroureterectomy following cystectomy for metachronous recurrence. *J Urol*. 2017;198(3):546–551.

Li WM, Shen JT, Li CC, et al. Oncologic outcomes following three different approaches to the distal ureter and bladder cuff in nephroureterectomy for primary upper urinary tract urothelial carcinoma. *Eur Urol*. 2010;57(6):963–969.

Liaw KL, Linet MS, McLaughlin JK, et al. Possible relation between hypertension and cancers of the renal pelvis and ureter. *Int J Cancer*. 1997;70(3):265–268.

Lim DJ, Shattuck MC, Cook WA. Pyelovenous lymphatic migration of transitional cell carcinoma following flexible ureterorenoscopy. *J Urol*. 1993;149(1):109–111.

Lughezzani G, Burger M, Margulis V, et al. Prognostic factors in upper urinary tract urothelial carcinomas: a comprehensive review of the current literature. *Eur Urol*. 2012;62(1):100–114.

Lughezzani G, Jeldres C, Isbarn H, et al. A critical appraisal of the value of lymph node dissection at nephroureterectomy for upper tract urothelial carcinoma. *Urology*. 2010;75(1):118–124.

Lughezzani G, Sun M, Perrotte P, et al. Gender-related differences in patients with stage I to III upper tract urothelial carcinoma: results from the Surveillance, Epidemiology, and End Results database. *Urology*. 2010;75(2):321–327.

Lunec J, Challen C, Wright C, et al. C-erbB-2 amplification and identical p53 mutations in concomitant transitional carcinomas of renal pelvis and urinary bladder. *Lancet*. 1992;339(8790):439–440.

Lynch HT, Ens JA, Lynch JF. The Lynch syndrome II and urological malignancies. *J Urol*. 1990;143(1):24–28.

Madgar I, Goldwasser B, Czerniak A, et al. Leiomyosarcoma of the ureter. *Eur Urol*. 1988;14(6):487–489.

Mahadevia PS, Karwa GL, Koss LG. Mapping of urothelium in carcinomas of the renal pelvis and ureter. A report of nine cases. *Cancer*. 1983;51(5):890–897.

Mahoney JF, Storey BG, Ibanez RC, et al. Analgesic abuse: renal parenchymal disease and carcinoma of the kidney or ureter. *Aust N Z J Med*. 1977;7:463–469.

Marchioni M, Primiceri G, Cindolo L, et al. Impact of diagnostic ureteroscopy on intravesical recurrence in patients undergoing radical nephroureterectomy for upper tract urothelial cancer: a systematic review and meta-analysis. *BJU Int*. 2017;120(3):313–319.

Margulis V, Shariat SF, Matin SF, et al. Outcomes of radical nephroureterectomy: a series from the Upper Tract Urothelial Carcinoma Collaboration. *Cancer*. 2009;115(6):1224–1233.

Margulis V, Youssef RF, Karakiewicz PI, et al. Preoperative multivariable prognostic model for prediction of nonorgan confined urothelial carcinoma of the upper urinary tract. *J Urol*. 2010;184(2):453–458.

Markovic B. Endemic nephritis and urinary tract cancer in Yugoslavia, Bulgaria, and Romania. *J Urol*. 1972;107:212–219.

Masson-Lecomte A, Colin P, Bozzini G, et al. Impact of micropapillary histological variant on survival after radical nephroureterectomy for upper tract urothelial carcinoma. *World J Urol*. 2014;32(2):531–537.

Matsui Y, Utsunomiya N, Ichioka K. Risk factors for subsequent development of bladder cancer after primary transitional cell carcinoma of the upper urinary tract. *Urology*. 2005;54:279–283.

Matsumoto K, Novara G, Gupta A, et al. Racial differences in the outcome of patients with urothelial carcinoma of the upper urinary tract: an international study. *BJU Int*. 2011;108(8 Pt 2):E304–E309.

Matsuoka K, Lida S, Tomiyasu K, et al. Transurethral endoscopic management of upper urinary tract tumors using a holmium:YAG laser. *Lasers Surg Med*. 2003;32:336–340.

Maulard-Durdux C, Dufour B, Hennequin C, et al. Postoperative radiation therapy in 26 patients with invasive transitional cell carcinoma of the upper urinary tract: no impact on survival? *J Urol*. 1996;155(1):115–117.

Mazeman E. Tumours of the upper urinary tract calyces, renal pelvis and ureter. *Eur Urol*. 1976;2(3):120–126.

Mbeutcha A, Rouprêt M, Kamat AM, et al. Prognostic factors and predictive tools for upper tract urothelial carcinoma: a systematic review. *World J Urol*. 2017;35(3):337–353.

McCarron JP, Mills C, Vaughn ED. Tumors of the renal pelvic and ureter: current concepts and management. *Semin Urol*. 1983;1(1):75–81.

McCredie M, Stewart JH, Carter JJ, et al. Phenacetin and papillary necrosis: independent risk factors for renal pelvic cancer. *Kidney Int*. 1986;30(1):81–84.

McDougal WS, Cramer SF, Miller R. Invasive carcinoma of the renal pelvis following cyclophosphamide therapy for nonmalignant disease. *Cancer*. 1981;48(3):691–695.

McLaughlin JK, Gao YT, Gao RN, et al. Risk factors for renal-cell cancer in Shanghai, China. *Int J Cancer*. 1992;52(4):562–565.

McTavish JD, Jinzaki M, Zou KH, et al. Multi-detector row CT urography: comparison of strategies for depicting the normal urinary collecting system. *Radiology*. 2002;225(3):783–790.

Melamed MR, Reuter VE. Pathology and staging of urothelial tumors of the kidney and ureter. *Urol Clin North Am*. 1993;20(2):333–347.

Messer J, Shariat SF, Brien JC, et al. Urinary cytology has a poor performance for predicting invasive or high-grade upper-tract urothelial carcinoma. *BJU Int*. 2011;108(5):701–705.

Messer JC, Terrell JD, Herman MP, et al. Multi-institutional validation of the ability of preoperative hydronephrosis to predict advanced pathologic tumor stage in upper-tract urothelial carcinoma. *Urol Oncol*. 2013;31(6):904–908.

Mian C, Mazzoleni G, Vikoler S, et al. Fluorescence in situ hybridisation in the diagnosis of upper urinary tract tumours. *Eur Urol*. 2010;58(2):288–292.

Milestone B, Friedman AC, Seidmon EJ, et al. Staging of ureteral transitional cell carcinoma by CT and MRI. *Urology*. 1990;36(4):346–349.

Miyake H, Hara I, Arakawa S, et al. A clinicopathological study of bladder cancer associated with upper urinary tract cancer. *BJU Int*. 2000;85(1):37–41.

Miyata Y, Kanda S, Nomata K, et al. Expression of metalloproteinase-2, metalloproteinase-9, and tissue inhibitor of metalloproteinase-1 in transitional cell carcinoma of upper urinary tract: correlation with tumor stage and survival. *Urology*. 2004;63(3):602–608.

Morrison AS. Advances in the etiology of urothelial cancer. *Urol Clin North Am*. 1984;11(4):557–566.

Moussa S, Yafi FA, El-Hakim A, et al. Outcome of surgical treatment of patients with upper versus lower urinary tract urothelial carcinoma: stage-by-stage comparison. *Urol Int*. 2010;84(1):50–55.

Mufti GR, Gove JR, Riddle PR. Nephroureterectomy after radical cystectomy. *J Urol*. 1988;139(3):588–589.

Mullerad M, Russo P, Golijanin D, et al. Bladder cancer as a prognostic factor for upper tract transitional cell carcinoma. *J Urol*. 2004;172(6 Pt 1):2177–2181.

Munoz JJ, Ellison LM. Upper tract urothelial neoplasms: incidence and survival during the last 2 decades. *J Urol*. 2000;164(5):1523–1525.

Murphy DM, Zincke H, Furlow WL. Management of high grade transitional cell cancer of the upper urinary tract. *J Urol*. 1981;125(1):25–29.

Murphy WM, Soloway MS. Urothelial dysplasia. *J Urol*. 1982;127(5):849–854.

Musselman P, Kay R. The spectrum of urinary tract fibroepithelial polyps in children. *J Urol*. 1986;136(2):476–477.

Nakanishi K, Kawai T, Hiroi S, et al. Expression of telomerase mRNA component (hTR) in transitional cell carcinoma of the upper urinary tract. *Cancer*. 1999;86(10):2109–2116.

Ng CK, Shariat SF, Lucas SM, et al. Does the presence of hydronephrosis on preoperative axial CT imaging predict worse outcomes for patients undergoing nephroureterectomy for upper-tract urothelial carcinoma? *Urol Oncol*. 2011;29(1):27–32.

Nguyen L, Gandhi N, Sterling T, et al. Panurothelial cell carcinoma: lessons learned. *J Urol*. 2014;191:e893.

Nortier JL, Martinez MC, Schmeiser HH, et al. Urothelial carcinoma associated with the use of a Chinese herb (Aristolochia fangchi). *New Engl J Med*. 2000;342(23):1686–1692.

Notley RG. Ureteral morphology: anatomic and clinical considerations. *Urology*. 1978;12(1):8–14.

Novara G, De Marco V, Dalpiaz O, et al. Independent predictors of contralateral metachronous upper urinary tract transitional cell carcinoma after nephroureterectomy: multi-institutional dataset from three European centers. *Int J Urol*. 2009;16(2):187–191.

Novara G, Matsumoto K, Kassouf W, et al. Prognostic role of lymphovascular invasion in patients with urothelial carcinoma of the upper urinary tract: an international validation study. *Eur Urol*. 2010;57(6):1064–1071.

Ohtsuka Y, Kawakami S, Fujii Y, et al. Loss of uroplakin III expression is associated with a poor prognosis in patients with urothelial carcinoma of the upper urinary tract. *BJU Int*. 2006;97(6):1322–1326.

Oldbring J, Glifberg I, Mikulowski P, et al. Carcinoma of the renal pelvis and ureter following bladder carcinoma: frequency, risk factors and clinicopathological findings. *J Urol*. 1989;141(6):1311–1313.

Orsola A, Trias I, Raventós CX, et al. Renal collecting (Bellini) duct carcinoma displays similar characteristics to upper tract urothelial cell carcinoma. *Urology*. 2005;65(1):49–54.

Ouzzane A, Colin P, Xylinas E, et al. Ureteral and multifocal tumours have worse prognosis than renal pelvic tumours in urothelial carcinoma of the upper urinary tract treated by nephroureterectomy. *Eur Urol*. 2011;60(6):1258–1265.

Ouzzane A, Ghoneim TP, Udo K, et al. Small cell carcinoma of the upper urinary tract (UUT-SCC): report of a rare entity and systematic review of the literature. *Cancer Treat Rev*. 2011;37(5):366–372.

Oyasu R. World Health Organization and International Society of Urological Pathology classification and two-number grading system of bladder tumors. *Cancer*. 2000;88(7):1509–1512.

Palvio DH, Andersen JC, Falk E. Transitional cell tumors of the renal pelvis and ureter associated with capillarosclerosis indicating analgesic abuse. *Cancer*. 1987;59(5):972–976.

Park J, Habuchi T, Arai Y, et al. Reassessment of prognostic heterogeneity of pT3 renal pelvic urothelial carcinoma: analysis in terms of proposed pT3 subclassification systems. *J Urol*. 2014;192(4):1064–1071.

Park S, Hong B, Kim C-S, et al. The impact of tumor location on prognosis of transitional cell carcinoma of the upper urinary tract. *J Urol*. 2004;171(2 Pt 1):621–625.

Petkovic SD. Conservation of the kidney in operations for tumors of the renal pelvis and calyces: a report of 26 cases. *Br J Urol*. 1972;44:1–8.

Petkovic SD. Epidemiology and treatment of renal pelvic and ureteral tumors. *J Urol*. 1975;114:858–865.

Petrelli F, Yasser Hussein MI, Vavassori I, et al. Prognostic factors of overall survival in upper urinary tract carcinoma: a systematic review and meta-analysis. *Urology*. 2017;100:9–15.

Picozzi S, Ricci C, Gaeta M, et al. Upper urinary tract recurrence following radical cystectomy for bladder cancer: a meta-analysis on 13,185 patients. *J Urol*. 2012;188(6):2046–2054.

Pommer W, Bronder E, Klimpel A, et al. Urothelial cancer at different tumour sites: role of smoking and habitual intake of analgesics and laxatives. Results of the Berlin Urothelial Cancer Study. *Nephrol Dial Transplant*. 1999;14(12):2892–2897.

Raabe NK, Fosså SD, Bjerkehagen B. Carcinoma of the renal pelvis. Experience of 80 cases. *Scand J Urol Nephrol*. 1992;26(4):357–361.

Rabbani F, Perrotti M, Russo P, et al. Upper-tract tumors after an initial diagnosis of bladder cancer: argument for long-term surveillance. *J Clin Oncol*. 2001;19(1):94–100.

Radovanovic Z, Krajinovic S, Jankovic S, et al. Family history of cancer among cases of upper urothelial tumours in the Balkan nephropathy area. *J Cancer Res Clin Oncol*. 1985;110:181–183.

Raman JD, Messer J, Sielatycki JA, et al. Incidence and survival of patients with carcinoma of the ureter and renal pelvis in the USA, 1973-2005. *BJU Int*. 2011;107(7):1059–1064.

Raman JD, Ng CK, Scherr DS, et al. Impact of tumor location on prognosis for patients with upper tract urothelial carcinoma managed by radical nephroureterectomy. *Eur Urol*. 2010;57(6):1072–1079.

Raman JD, Shariat SF, Karakiewicz PI, et al. Does preoperative symptom classification impact prognosis in patients with clinically localized upper-tract urothelial carcinoma managed by radical nephroureterectomy? *Urol Oncol*. 2011;29(6):716–723.

Reddy M, Kader K. Follow-up management of cystectomy patients. *Urol Clin North Am*. 2018;45(2):241–247.

Redrow GP, Guo CC, Brausi MA, et al. Upper Urinary tract carcinoma in situ: current knowledge, future direction. *J*

Urol. 2017;197(2):287–295.

Remzi M, Haitel A, Margulis V, et al. Tumour architecture is an independent predictor of outcomes after nephroureterectomy: a multi-institutional analysis of 1363 patients. *BJU Int*. 2009;103(3):307–311.

Renfer LG, Kelley J, Belville WD. Inverted papilloma of the urinary tract: histogenesis, recurrence and associated malignancy. *J Urol*. 1988;140(4).

Resseguie LJ, Nobrega FT, Farrow GM, et al. Epidemiology of renal and ureteral cancer in Rochester, Minnesota, 1950-1974, with special reference to clinical and pathologic features. *Mayo Clin Proc*. 1978;53(8):503–510.

Richie JP. Carcinoma of the renal pelvis and ureter. Skinner DG, Lieskovsky G. *Diagnosis and management of genitourinary cancer*. Saunders: Philadelphia; 1988:323–336.

Rigola MA, Fuster C, Casadevall C, et al. Comparative genomic hybridization analysis of transitional cell carcinomas of the renal pelvis. *Cancer Genet Cytogenet*. 2001;127(1):59–63.

Rink M, Ehdaie B, Cha EK, et al. Stage-specific impact of tumor location on oncologic outcomes in patients with upper and lower tract urothelial carcinoma following radical surgery. *Eur Urol*. 2012;62(4):677–684.

Rink M, Robinson BD, Green DA, et al. Impact of histological variants on clinical outcomes of patients with upper urinary tract urothelial carcinoma. *J Urol*. 2012;188(2):398–404.

Rojas CP, Castle SM, Llanos CA, et al. Low biopsy volume in ureteroscopy does not affect tumor biopsy grading in upper tract urothelial carcinoma. *Urol Oncol*. 2013;31(8):1696–1700.

Ros MM, Bas Bueno-de-Mesquita HB, Büchner FL, et al. Fluid intake and the risk of urothelial cell carcinomas in the European Prospective Investigation into Cancer and Nutrition (EPIC). *Int J Cancer*. 2011;128(11):2695–2708.

Roscigno M, Cha EK, Rink M, et al. International validation of the prognostic value of subclassification for AJCC stage pT3 upper tract urothelial carcinoma of the renal pelvis. *BJU Int*. 2012;110(5):674–681.

Rosenthal DL, Wojcik EM, Kurtycz DFI. *The Paris system for reporting urinary cytology*. Springer International Publishing: New York; 2016:1–4.

Ross RK, Paganini-Hill A, Landolph J, et al. Analgesics, cigarette smoking, and other risk factors for cancer of the renal pelvis and ureter. *Cancer Res*. 1989;49(4):1045–1048.

Roupret M, Fromont G, Azzouzi AR, et al. Microsatellite instability as predictor of survival in patients with invasive upper urinary tract transitional cell carcinoma. *Urology*. 2005;65:1233.

Roupret M, Colin P, Yates DR. A new proposal to risk stratify urothelial carcinomas of the upper urinary tract (UTUCs) in a predefinitive treatment setting: low-risk versus high-risk UTUCs. *Eur Urol*. 2014;66:181–183.

Roupret M, Babjuk M, Comperat E, et al. European Association of Urology guidelines on upper urinary tract urothelial carcinoma: 2017 update. *Eur Urol*. 2018;73(1):111–122.

Roupret M, Hupertan V, Seisen T, et al. Prediction of cancer specific survival after radical nephroureterectomy for upper tract urothelial carcinoma: development of an optimized postoperative nomogram using decision curve analysis. *J Urol*. 2013;189:1662–1669.

Roupret M, Yates DR, Comperat E. Upper urinary tract urothelial cell carcinomas and other urological malignancies involved in the hereditary nonpolyposis colorectal cancer (Lynch syndrome) tumor spectrum. *Eur Urol*. 2008;54:1226–1236.

Roupret M, Zigeuner R, Palou J. European guidelines for the diagnosis and management of upper urinary tract urothelial cell carcinomas: update. *Eur Urol*. 2011;59:584–594.

Sakano S, Matsuyama H, Kamiryo Y, et al. Impact of variant histology on disease aggressiveness and outcome after nephroureterectomy in Japanese patients with upper tract urothelial carcinoma. *Int J Clin Oncol*. 2015;20(2):362–368.

Scarpini S, Rouprêt M, Renard-Penna R, et al. Impact of the expression of Aurora-A, p53, and MIB-1 on the prognosis of urothelial carcinomas of the upper urinary tract. *Urol Oncol*. 2012;30(2):182–187.

Scolieri MJ, Paik ML, Brown SL, et al. Limitations of computed tomography in the preoperative staging of upper tract urothelial carcinoma. *Urology*. 2000;56(6):930–934.

Seisen T, Colin P, Hupertan V, et al. Postoperative nomogram to predict cancer-specific survival after radical nephroureterectomy in patients with localised and/or locally advanced upper tract urothelial carcinoma without metastasis. *BJU Int*. 2014;114(5):733–740.

Seisen T, Granger B, Colin P, et al. A systematic review and meta-analysis of clinicopathologic factors linked to intravesical recurrence after radical nephroureterectomy to treat upper tract urothelial carcinoma. *Eur Urol*. 2015;67(6):1122–1133.

Seitz C, Gupta A, Shariat SF, et al. Association of tumor necrosis with pathological features and clinical outcome in 754 patients undergoing radical nephroureterectomy for upper tract urothelial carcinoma: an international validation study. *J Urol*. 2010;184(5):1895–1900.

Shariat SF, Favaretto RL, Gupta A, et al. Gender differences in radical nephroureterectomy for upper tract urothelial carcinoma. *World J Urol*. 2011;29(4):481–486.

Shariat SF, Godoy G, Lotan Y, et al. Advanced patient age is associated with inferior cancer-specific survival after radical nephroureterectomy. *BJU Int*. 2010;105(12):1672–1677.

Shinka T, Uekado Y, Aoshi H, et al. Occurrence of uroepithelial tumors of the upper urinary tract after the initial diagnosis of bladder cancer. *J Urol*. 1988;140(4):745–748.

Siegel R, Naishadham D, Jemal A. Cancer statistics, 2013. *CA Cancer J Clin*. 2013;63(1):11–30.

Siemens DR, Morales A, Johnston B, et al. A comparative analysis of rapid urine tests for the diagnosis of upper urinary tract malignancy. *Can J Urol*. 2003;10(1):1754–1758.

Simone G, Papalia R, Loreto A, et al. Independent prognostic value of tumour diameter and tumour necrosis in upper urinary tract urothelial carcinoma. *BJU Int*. 2009;103(8):1052–1057.

Simsir A, Sarsik B, Cureklibatir I, et al. Prognostic factors for upper urinary tract urothelial carcinomas: stage, grade, and smoking status. *Int Urol Nephrol*. 2011;43(4):1039–1045.

Singla N, Fang D, Su X, et al. A multi-institutional comparison of clinicopathological characteristics and oncologic outcomes of upper tract urothelial carcinoma in China and the United States. *J Urol*. 2017;197(5):1208–1213.

Skeldon SC, Semotiuk K, Aronson M, et al. Patients with Lynch syndrome mismatch repair gene mutations are at higher risk for not only upper tract urothelial cancer but also bladder cancer. *Eur Urol*. 2013;63(2):379–385.

Skolarikos A, Griffiths TRL, Powell PH, et al. Cytologic analysis of ureteral washings is informative in patients with grade 2 upper tract TCC considering endoscopic treatment. *Urology*. 2003;61(6):1146–1150.

Slaton JW, Swanson DA, Grossman HB, et al. A stage specific approach to tumor surveillance after radical cystectomy for transitional cell carcinoma of the bladder. *J Urol*. 1999;162(3 Pt 1):710–714.

Smith AK, Stephenson AJ, Lane BR, et al. Inadequacy of biopsy for diagnosis of upper tract urothelial carcinoma:

implications for conservative management. *Urology*. 2011;78(1):82–86.

Solsona E, Iborra I, Ricós JV, et al. Upper urinary tract involvement in patients with bladder carcinoma in situ (Tis): its impact on management. *Urology*. 1997;49(3):347–352.

Solsona E, Iborra I, Ricos JV, et al. Clinical panurothelial disease in patients with superficial bladder tumors: therapeutic implications. *J Urol*. 2002;167(5):2007–2011.

Soria F, Moschini M, Haitel A, et al. HER2 overexpression is associated with worse outcomes in patients with upper tract urothelial carcinoma (UTUC). *World J Urol*. 2017;35(2):251–259.

Soria F, Shariat SF, Lerner SP, et al. Epidemiology, diagnosis, preoperative evaluation and prognostic assessment of upper-tract urothelial carcinoma (UTUC). *World J Urol*. 2017;35(3):379–387.

Soukup V, Čapoun O, Cohen D, et al. Prognostic performance and reproducibility of the 1973 and 2004/2016 World Health Organization Grading Classification Systems in non-muscle-invasive bladder cancer: a European Association of urology non-muscle invasive bladder cancer guidelines panel systematic review. *Eur Urol*. 2017;72(5):801–813.

Spires SE, Banks ER, Cibull ML, et al. Adenocarcinoma of renal pelvis. *Arch Pathol Lab Med*. 1993;117(11):1156–1160.

Stefanovic V, Radovanovic Z. Balkan endemic nephropathy and associated urothelial cancer. *Nat Clin Pract Urol*. 2008;5(2):105–112.

Steffens J, Nagel R. Tumours of the renal pelvis and ureter. Observations in 170 patients. *Br J Urol*. 1988;61(4):277–283.

Stein A, Sova Y, Lurie M, et al. Adenocarcinoma of the renal pelvis. Report of two cases, one with simultaneous transitional cell carcinoma of the bladder. *Urol Int*. 1988;43(5):299–301.

Stewart JH, Hobbs JB, McCredie MR. Morphologic evidence that analgesic-induced kidney pathology contributes to the progression of tumors of the renal pelvis. *Cancer*. 1999;86(8):1576–1582.

Stower MJ, MacIver AG, Gingell JC, et al. Inverted papilloma of the ureter with malignant change. *Br J Urol*. 1990;65(1):13–16.

Streem SB, Pontes JE, Novick AC, et al. Ureteropyeloscopy in the evaluation of upper tract filling defects. *J Urol*. 1986;136(2):383–385.

Sundi D, Svatek RS, Margulis V, et al. Upper tract urothelial carcinoma: impact of time to surgery. *Urol Oncol*. 2012;30(3):266–272.

Sung HH, Cho J, Kwon GY, et al. Clinical significance of micropapillary urothelial carcinoma of the upper urinary tract. *J Clin Pathol*. 2014;67(1):49–54.

Sved PD, Gomez P, Nieder AM, et al. Upper tract tumour after radical cystectomy for transitional cell carcinoma of the bladder: incidence and risk factors. *BJU Int*. 2004;94(6):785–789.

Takahashi N, Glockner JF, Hartman RP, et al. Gadolinium enhanced magnetic resonance urography for upper urinary tract malignancy. *J Urol*. 2010;183(4):1330–1365.

Takahashi T, Habuchi T, Kakehi Y, et al. Molecular diagnosis of metastatic origin in a patient with metachronous multiple cancers of the renal pelvis and bladder. *Urology*. 2000;56(2):331.

Takahashi T, Kakehi Y, Mitsumori K, et al. Distinct microsatellite alterations in upper urinary tract tumors and subsequent bladder tumors. *J Urol*. 2001;165(2):672–677.

Tan L-B, Chen K-T, Guo H-R. Clinical and epidemiological features of patients with genitourinary tract tumour in a blackfoot disease endemic area of Taiwan. *BJU Int*.

2008;102(1):48–54.

Terakawa T, Miyake H, Muramaki M, et al. Risk factors for intravesical recurrence after surgical management of transitional cell carcinoma of the upper urinary tract. *Urology*. 2008;71(1):123–127.

Terrell RB, Cheville JC, See WA, et al. Histopathological features and p53 nuclear protein staining as predictors of survival and tumor recurrence in patients with transitional cell carcinoma of the renal pelvis. *J Urol*. 1995;154(4):1342–1347.

Terris MK. The effect of contrast material on transitional cell carcinoma viability. *Adv Exp Med Biol*. 2004;539:121.

Tomera KM, Leary FJ, Zincke H. Pyeloscopy in urothelial tumors. *J Urol*. 1982;127(6):1088–1089.

Tran W, Serio AM, Raj GV, et al. Longitudinal risk of upper tract recurrence following radical cystectomy for urothelial cancer and the potential implications for long-term surveillance. *J Urol*. 2008;179(1):96–100.

van der Post RS, Kiemeney LA, Ligtenberg MJ, et al. Risk of urothelial bladder cancer in Lynch syndrome is increased, in particular among MSH2 mutation carriers. *J Med Genet*. 2010;47(7):464–470.

Varela-Duran J, Urdiales-Viedma M, Taboada-Blanco F, et al. Neurofibroma of the ureter. *J Urol*. 1987;138(6):1425–1426.

Verhoest G, Shariat SF, Chromecki TF, et al. Predictive factors of recurrence and survival of upper tract urothelial carcinomas. *World J Urol*. 2011;29(4):495–501.

Villanueva CM, Silverman DT, Murta-Nascimento C, et al. Coffee consumption, genetic susceptibility and bladder cancer risk. *Cancer Causes Control*. 2009;20(1):121–127.

Vincente J, Pilar L, Sole-Balcells FJ. Transitional cell carcinoma of the upper urinary tract: diagnosis and management. *Urol Int*. 1995;2:7.

Volkmer BG, Schnoeller T, Kuefer R, et al. Upper urinary tract recurrence after radical cystectomy for bladder cancer–who is at risk? *J Urol*. 2009;182(6):2632–2637.

Waldert M, Karakiewicz PI, Raman JD, et al. A delay in radical nephroureterectomy can lead to upstaging. *BJU Int*. 2010;105(6):812–817.

Wheat JC, Weizer AZ, Wolf JS, et al. Concomitant carcinoma in situ is a feature of aggressive disease in patients with organ confined urothelial carcinoma following radical nephroureterectomy. *Urol Oncol*. 2012;30(3):252–258.

Williams AK, Kassouf W, Chin J, et al. Multifocality rather than tumor location is a prognostic factor in upper tract urothelial carcinoma. *Urol Oncol*. 2013;31(7):1161–1165.

Williams RD. Renal, perirenal, and ureteral neoplasms. Gillenwater JY, Grayhack JT, Howards SS, et al. *Adult and pediatric urology*. ed 2. Mosby–Year Book: St. Louis; 1991.

Witjes JA, Redorta JP, Jacqmin D, et al. Hexaminolevulinate-guided fluorescence cystoscopy in the diagnosis and follow-up of patients with non-muscle-invasive bladder cancer: review of the evidence and recommendations. *Eur Urol*. 2010;57(4):607–614.

Wright JL, Hotaling J, Porter MP. Predictors of upper tract urothelial cell carcinoma after primary bladder cancer: a population based analysis. *J Urol*. 2009;181(3):1035–1039 [discussion 9].

Xylinas E, Kluth LA, Rieken M, et al. Impact of smoking status and cumulative exposure on intravesical recurrence of upper tract urothelial carcinoma after radical nephroureterectomy. *BJU Int*. 2014;114(1):56–61.

Xylinas E, Rink M, Margulis V, et al. Multifocal carcinoma in situ of the upper tract is associated with high risk of bladder cancer recurrence. *Eur Urol*. 2012;61(5):1069–1070.

Yafi FA, Novara G, Shariat SF, et al. Impact of tumour location versus multifocality in patients with upper tract urothelial carcinoma treated with nephroureterectomy and bladder cuff excision: a homogeneous series without perioperative chemotherapy. *BJU Int*. 2012;110(2 Pt 2):E7–E13.

Yang M-H, Chen K-K, Yen C-C, et al. Unusually high incidence of upper urinary tract urothelial carcinoma in Taiwan. *Urology*. 2002;59(5):681–687.

Yates DR, Hupertan V, Colin P, et al. Cancer-specific survival after radical nephroureterectomy for upper urinary tract urothelial carcinoma: proposal and multi-institutional validation of a post-operative nomogram. *Br J Cancer*. 2012;106(6):1083–1088.

Yip SK, Peh WC, Tam PC, et al. Role of ultrasonography in screening for urological malignancies in patients presenting with painless haematuria. *Ann Acad Med Singapore*. 1999;28(2):174–177.

Yoo S, You D, Song C, et al. Risk of intravesical recurrence after ureteroscopic biopsy for upper tract urothelial carcinoma: does the location matter? *J Endourol*. 2017;31(3):259–265.

Zhang Z, Furge KA, Yang XJ, et al. Comparative gene expression profiling analysis of urothelial carcinoma of the renal pelvis and bladder. *BMC Med Genomics*. 2010;3:58.

Zigeuner R, Shariat SF, Margulis V, et al. Tumour necrosis is an indicator of aggressive biology in patients with urothelial carcinoma of the upper urinary tract. *Eur Urol*. 2010;57(4):575–581.

Zigeuner R, Tsybrovskyy O, Ratschek M, et al. Prognostic impact of p63 and p53 expression in upper urinary tract transitional cell carcinoma. *Urology*. 2004;63(6):1079–1083.

Zincke H, Aguilo JJ, Farrow GM, et al. Significance of urinary cytology in the early detection of transitional cell cancer of the upper urinary tract. *J Urol*. 1976;116(6):781–783.

Zincke H, Garbeff PJ, Beahrs JR. Upper urinary tract transitional cell cancer after radical cystectomy for bladder cancer. *J Urol*. 1984;131(1):50–52.

Zincke H, Neves RJ. Feasibility of conservative surgery for transitional cell cancer of the upper urinary tract. *Urol Clin North Am*. 1984;11(4):717–724.

Surgical Management of Upper Urinary Tract Urothelial Tumors

Thomas W. Jarret MD, Surena F. Matin MD, Armine K. Smith MD

Diagnosis

Ureteroscopic Evaluation and Biopsy

Although the diagnosis can be made in obvious cases with CT urogram, cystoscopy, and a positive urinary cytology (Potrezke et al., 2016), technical advances achieved in the realm of endoscopic equipment have made flexible and rigid ureteroscopy a key part of the evaluation (and treatment) of upper urinary tract tumors. **Diagnostic accuracy can be improved from approximately 75% with excretory or retrograde urography alone to 85% to 90% when it is combined with ureteroscopy** (Blute et al., 1989; Streem et al., 1986). Although pyelovenous and pyelolymphatic migration has been reported with ureteroscopy, this phenomenon appears to be uncommon and should not preclude its use (Guo et al., 2017; Lim et al., 1993). Generally the tumor is biopsied and the treatment is contingent on the patient factors along with the biopsy results. Occasionally, the tumor is biopsied and treated in the same setting. Percutaneous access to the renal pelvis and antegrade ureteroscopy may be required for diagnosis or treatment; examples include patients with urinary diversion. These techniques are described in more detail in later sections.

In addition to biopsy, ureteroscopy allows direct tumor visualization of areas that may have not been seen on imaging and provides information that may assist with treatment planning. **Preoperative ureteroscopy has clear benefits when there is a question of diagnosis and/or if conservative management is being considered.**

Because of the small size and shallow depth of ureteroscopic biopsy specimens, a precise correlation with eventual tumor stage is difficult. Therefore, in predicting the tumor stage, a combination of the radiographic studies, the visualized appearance of the tumor, and the tumor grade provides the surgeon with the best estimation for risk stratification.

Treatment Algorithm

The gold standard therapy for treatment of upper tract urothelial carcinoma (UTUC) is nephroureterectomy with a cuff of bladder, provided there is a normal contralateral kidney. The European Association of Urology (EAU) devised a risk-adapted protocol for kidney-sparing management (Box 99.1; Roupret, 2018).

Box 99.1

Risk-Adapted Protocol for Kidney-Sparing Management

High-Risk UTUC

- Clinical factors
  - Hydronephrosis
  - High grade
  - Tumor >1 cm
  - Invasive features on imaging
  - Multifocal disease
  - Failed endoscopic treatment
- Clinical factors
  - Smoking
  - Previous bladder UCC and/or cystectomy

Low-Risk UTUC

- Clinical factors
  - Low-grade biopsy
  - Low-grade cytology
  - Tumor <1 cm
  - No invasive features on imaging
  - Unifocal disease
  - Compliant patient

UCC, Urothelial cell carcinoma; *UTUC,* upper tract urothelial cancer.

Modified from Rouprêt M, Babjuk M, Compérat E, et al.: European Association of Urology Guidelines on Upper Urinary Tract Urothelial Carcinoma: 2017 Update. *Eur Urol* 73:111–122, 2018.

All patients with low-risk disease should be considered for kidney-sparing treatment irrespective of the contralateral kidney because of the lower morbidity of the procedures without compromising oncologic outcomes. Kidney-sparing surgery can also be considered in select patients with higher-risk situations such as (1) serious renal insufficiency, (2) solitary kidney, (3) bilateral tumors, and/or (4) poor surgical candidate. Certainly the treatment chosen must not significantly compromise oncologic outcomes. The risks of cancer control must be weighed against the preservation of renal function. In situations of high-grade disease, segmental resection should be considered over endoscopic management, which can only reliably treat surface tumors (Seisen, 2016).

Surgical Management

The treatment of upper tract urothelial tumors has undergone significant changes. **The relatively low frequency of these lesions and paucity of prospective randomized trials do not permit absolute conclusions about treatment impact on outcomes.** In the past, treatment recommendations were based, at least in part, on practical limitations in follow-up and detection of local disease recurrence. Technologic improvements in imaging and, most important, direct endoscopic visualization of all levels of the urinary tract allow earlier and more accurate initial diagnosis and treatment and improved follow-up. Treatment may be based primarily on the risk the tumor poses and on the efficacy of a specific treatment rather than on other considerations. The specific indications and techniques for each form of treatment (open vs. laparoscopic radical nephroureterectomy; open vs. retrograde endoscopic vs. percutaneous renal-sparing tumor ablation) are addressed later in this chapter. However, the following introductory considerations apply. The least invasive treatment necessary for safe control of the tumor is preferred, but never at the risk of compromising oncologic control. UTUC is unforgiving to surgical indiscretions, which usually cannot be salvaged by other modalities. Most upper tract urothelial tumors are not large or bulky. Thus laparoscopic surgery is ideal, at least for the renal portion of radical nephroureterectomy when the tumor warrants removal of the entire renal unit. A variety of approaches with various combinations of laparoscopic and open techniques are employed for distal ureterectomy. Select low-grade noninvasive upper tract tumors can be managed initially by ablative renal-sparing surgery. Retrograde ureteroscopy and ureteropyeloscopy are preferred when tumor size, number, and access allow complete tumor ablation. Percutaneous antegrade tumor ablation is chosen when the anatomy and the tumor do not allow complete ablation through a retrograde approach.

Radical Nephroureterectomy

Indications

Radical nephroureterectomy with excision of a bladder cuff is the gold standard for large, high-grade, suspected invasive tumors of the renal pelvis

and proximal ureter (Babaian and Johnson, 1980; Batata and Grabstald, 1976; Cummings, 1980; McCarron et al., 1983; Messing and Catalona, 1998; Murphy et al., 1981; Nocks et al., 1982; Richie, 1988; Skinner, 1978; Williams, 1991). Radical surgery also retains a role in treatment of low-grade, noninvasive tumors of the renal pelvis and upper ureter when they are large, multifocal, or rapidly recurring despite maximal efforts at conservative surgery.

Techniques

Open Radical Nephrectomy.

The choice among a variety of surgical approaches to open radical nephroureterectomy is dictated primarily by the surgeon's experience and patient's body habitus. Nephroureterectomy is one of the few multi-quadrant operations that urologists perform with a variety of approaches. The patient may be positioned supine or in modified flank position. In male patients the genitalia are included in the surgical field so that the bladder catheter may be accessed during the procedure. The midline approach gives the most optimal exposure to the retroperitoneal lymph nodes and bladder. This incision, however, may be limiting in exposure of the upper pole of the left kidney, especially in obese patients. Other incisions are flank, subcostal, and thoracoabdominal. The choice of these incisions necessitates using an additional Gibson, midline, or Pfannenstiel incision for bladder cuff removal (Fig. 99.1). After the white line of Toldt is incised, the ipsilateral colon is mobilized to expose the Gerota fascia. Ideally, the hilum is controlled before excessive manipulation of the kidney and ureter. The renal hilum is exposed, reflecting the duodenum medially on the right side. For left-sided tumors, care should be taken to avoid injury to the pancreatic tail and spleen. The renal artery and vein are secured and divided in a standard manner. The variety of options for ligating the vessels is used, including suture ligature, ties, and a combination of ties with clips and stapling devices using an endovascular load. The ureter is typically ligated at this time to prevent migration of tumor fragments into the bladder. The entire kidney is mobilized, taking care to stay outside of Gerota fascia. Attachments between liver and kidney on the right side and splenorenal ligament on the left side are incised, allowing mobility of the kidney. Adrenalectomy does not aid the oncologic control of UTUC, unless its direct involvement is suspected by preoperative imaging or intraoperative examination. Thus as a routine, concomitant adrenalectomy is unnecessary.

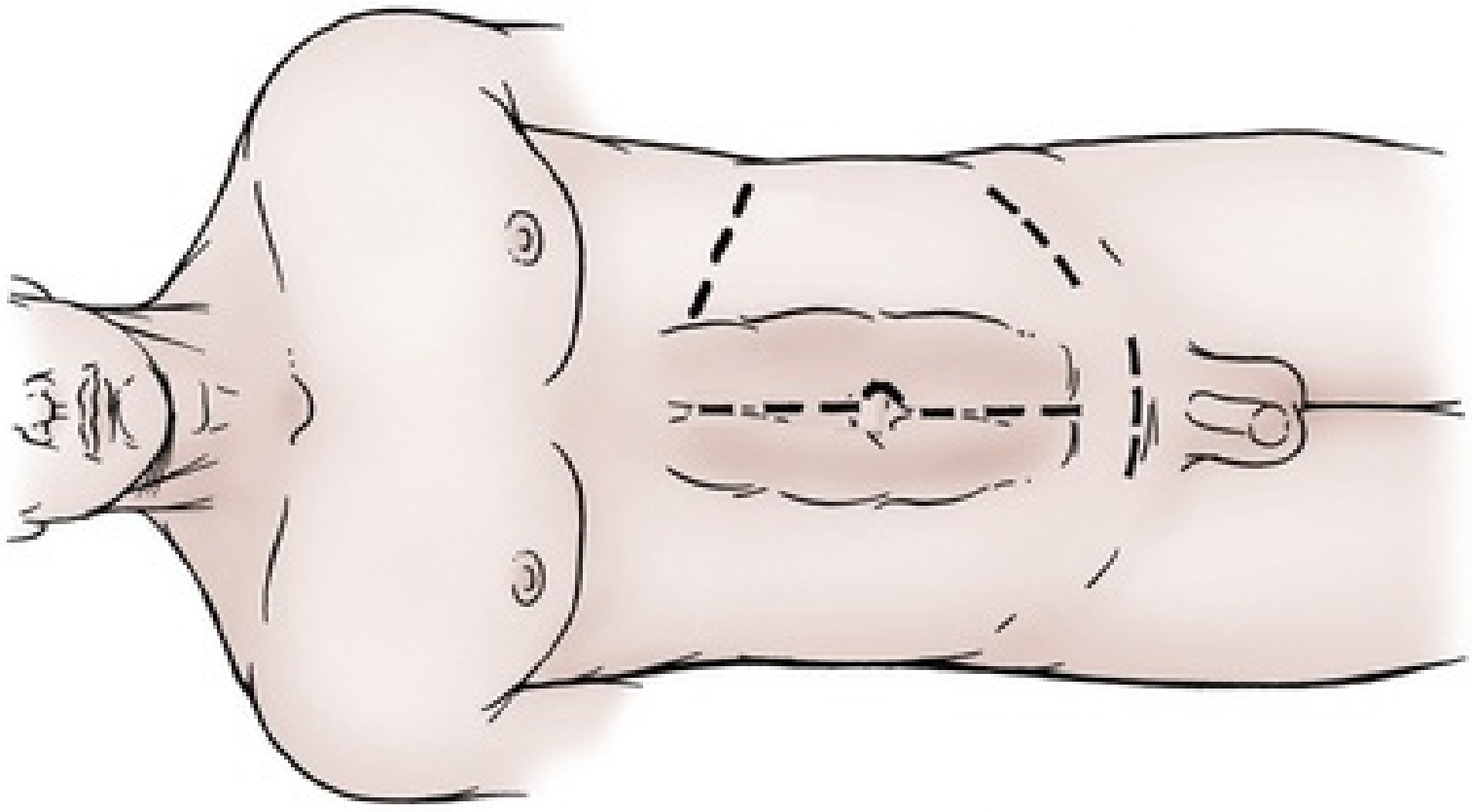

FIG. 99.1 Choice of incision for radical nephroureterectomy (midline, subcostal, flank, or thoracoabdominal) is dictated by the surgeon's preference and experience. Unless a midline incision is used, an additional Gibson, low midline, or Pfannenstiel incision is necessary for bladder cuff removal.

Management of Distal Ureter and Bladder Cuff.

Complete removal of the distal ureter and bladder cuff offers superior oncologic outcomes to incomplete resection. In addition, an adequate cystoscopic surveillance of a residual distal ureter stump after nephroureterectomy is almost impossible, contributing to high rates of local recurrence. **Therefore the entire distal ureter, including the intramural portion and the ureteral orifice, must be removed.** The kidney and proximal ureter may be kept in continuity with the distal segment; however, the bulk of the attached kidney makes its manipulation difficult, and, apart from helping the pathologist with specimen orientation, this technique is not necessary as long as the distal ureter is divided in the controlled manner between ties or clips at a location that is free of gross tumor. There are at least five different techniques described for distal ureterectomy, and most of these apply to open and laparoscopic surgery.

Traditional Open Distal Ureterectomy.

Using a Gibson, low midline or Pfannestiel incision, bladder cuff removal is performed by extravesical (Fig. 99.2), transvesical (Fig. 99.3), or combined approach. Either of these methods is acceptable, provided that the whole ureter, including the intramural portion and mucosa of ureteral orifice, is removed with the surgeon's visual confirmation of complete resection. For the extravesical approach, the distal ureter is freed toward the bladder to the point of the intramural ureter. Gentle traction on the ureter and full bladder may aid in this step and for adequate access to the entire intramural ureter, the lateral pedicle of the bladder (obliterated artery, superior, middle, and inferior vesical arteries) may be ligated and divided. Care must be taken to avoid uncontrolled entry to urinary tract. A cuff of bladder is removed en bloc with the ureter by applying a clamp to bladder wall and excising the full intramural portion of the ureter, taking care to stay away from the contralateral ureteral orifice. In the transvesical approach, anterior cystotomy is made, and intravesical dissection of ureter is performed, including a traditional 1-cm mucosal cuff around the orifice. A wider margin can be taken if a gross tumor is seen protruding from the orifice, and if an invasive intramural tumor is suspected, an en bloc partial cystectomy may be required to ensure negative margins. Cystotomy defects are closed in two layers with interrupted or running absorbable sutures: the first layer should incorporate mucosa, and the second layer should include detrusor muscle and adventitia. A Foley catheter is placed and maintained for 5 to 7 days, and a suction drain is left in the perivesical space.

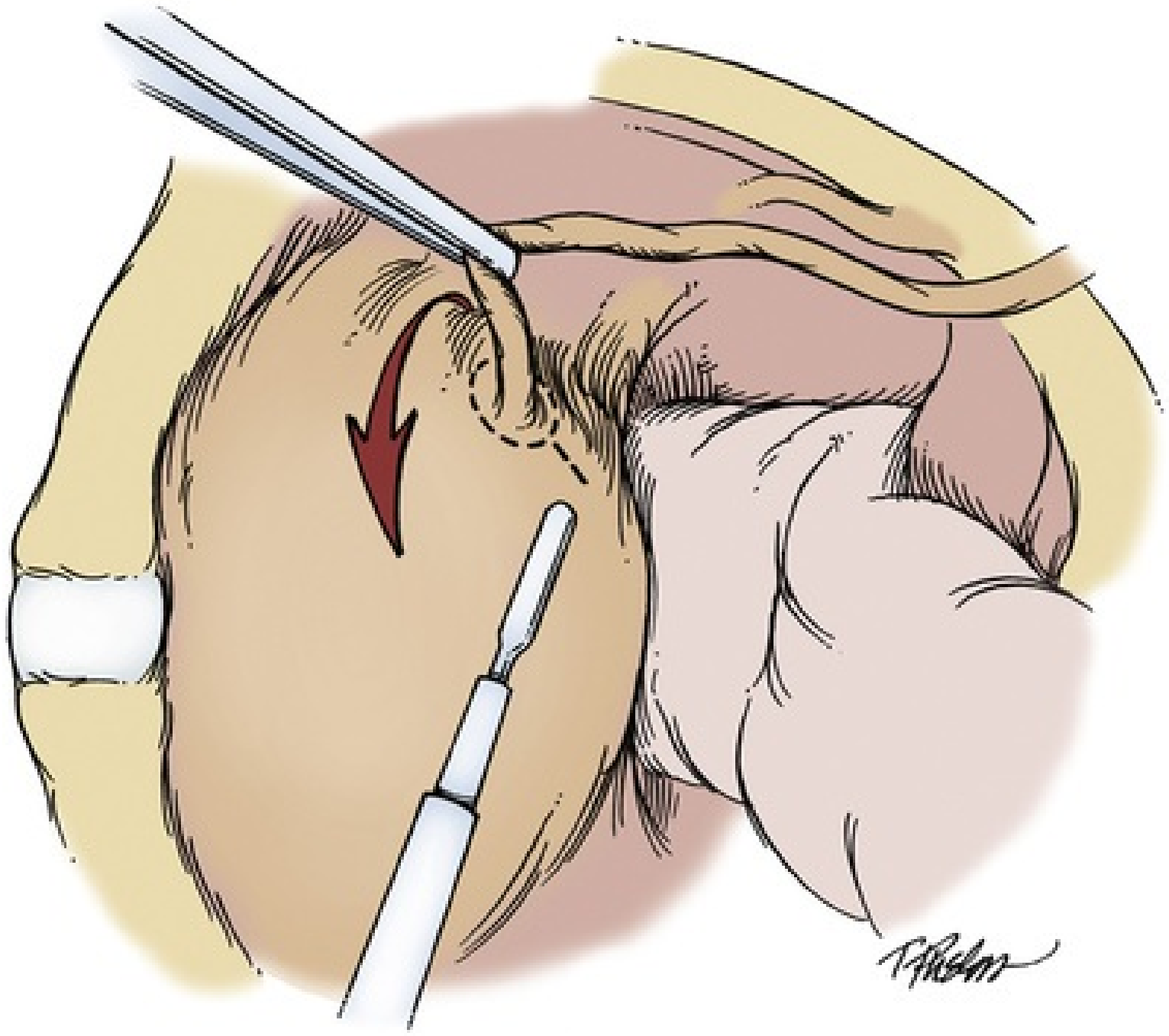

FIG. 99.2 Complete distal ureterectomy by extravesical approach. Traction is placed, everting the orifice outside the bladder. Care must be taken to ensure complete removal and to avoid injury to the contralateral ureteral orifice.

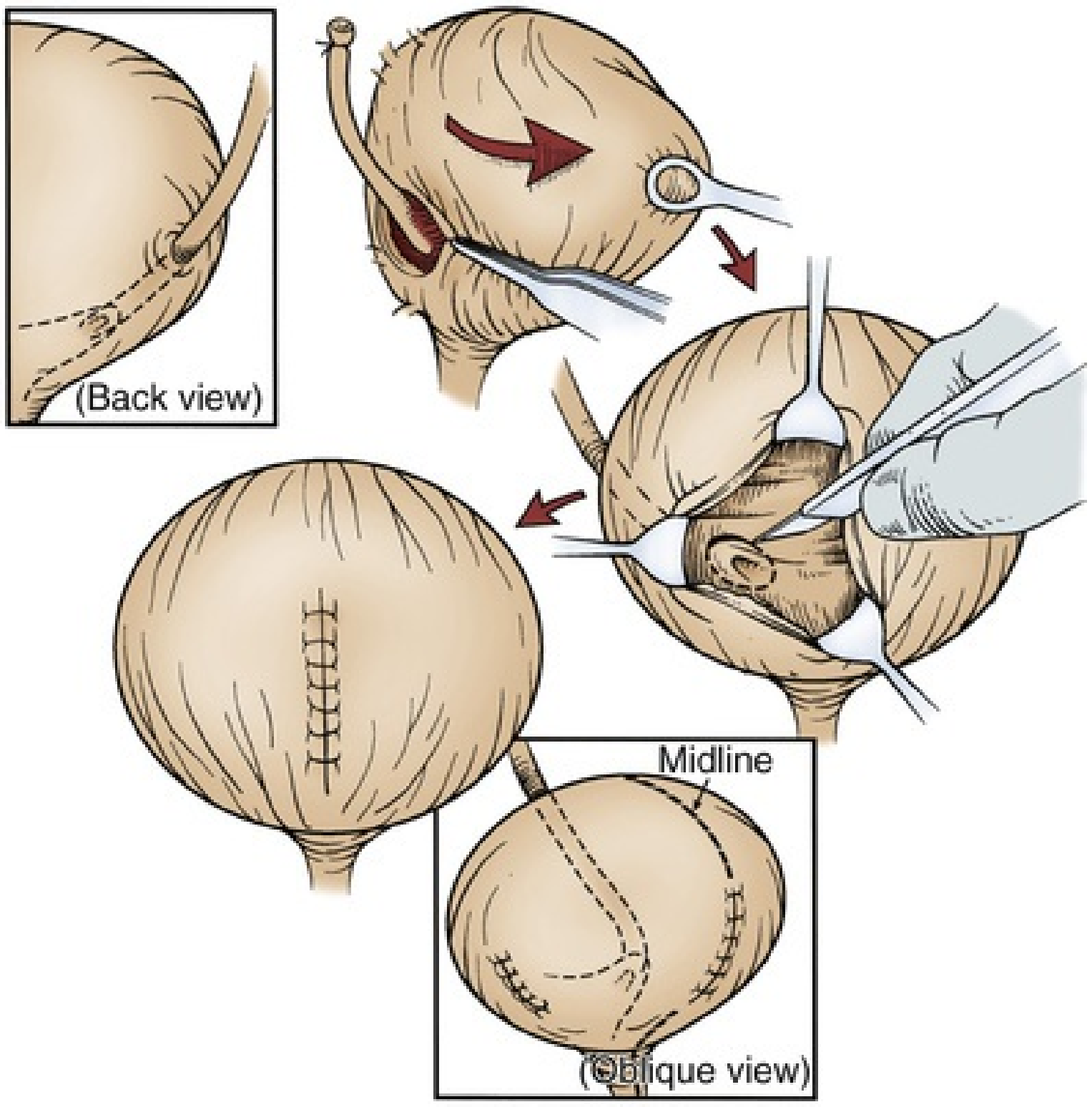

FIG. 99.3 Complete distal ureterectomy with bladder cuff is performed by combined extravesical and transvesical dissection.

Transvesical Ligation and Detachment Technique.

This technique mimics the open bladder cuff removal. Before nephrectomy portion, the patient is placed in low lithotomy position, the cystoscope is passed into the bladder and kept in place, and the bladder is filled. One or two 5-mm trocars are placed intravesically from the suprapubic area. An Endoloop is placed around the ureteral orifice, and a ureteral catheter is advanced into the ureter through the Endoloop. Using a Collins knife, the surgeon incises the bladder cuff, and this incision is carried into the extravesical space (Fig. 99.4). Retraction is provided by the grasper through the one of the trochars. Once the ureter is freed, the Endoloop is cinched around the ureter as the catheter is removed. This creates a “closed” urothelium with subsequent en bloc removal of specimen, and extravasation of fluid from the bladder is minimized by continuous suction from the second intravesical trocar. There has been excellent clinical success reported with this technique (Gill et al., 1999), but the learning curve is difficult, and repositioning of the patient for nephrectomy portion is required. Patients with distal ureteral tumors, disease in the bladder, or prior pelvic radiation are not candidates for this technique.

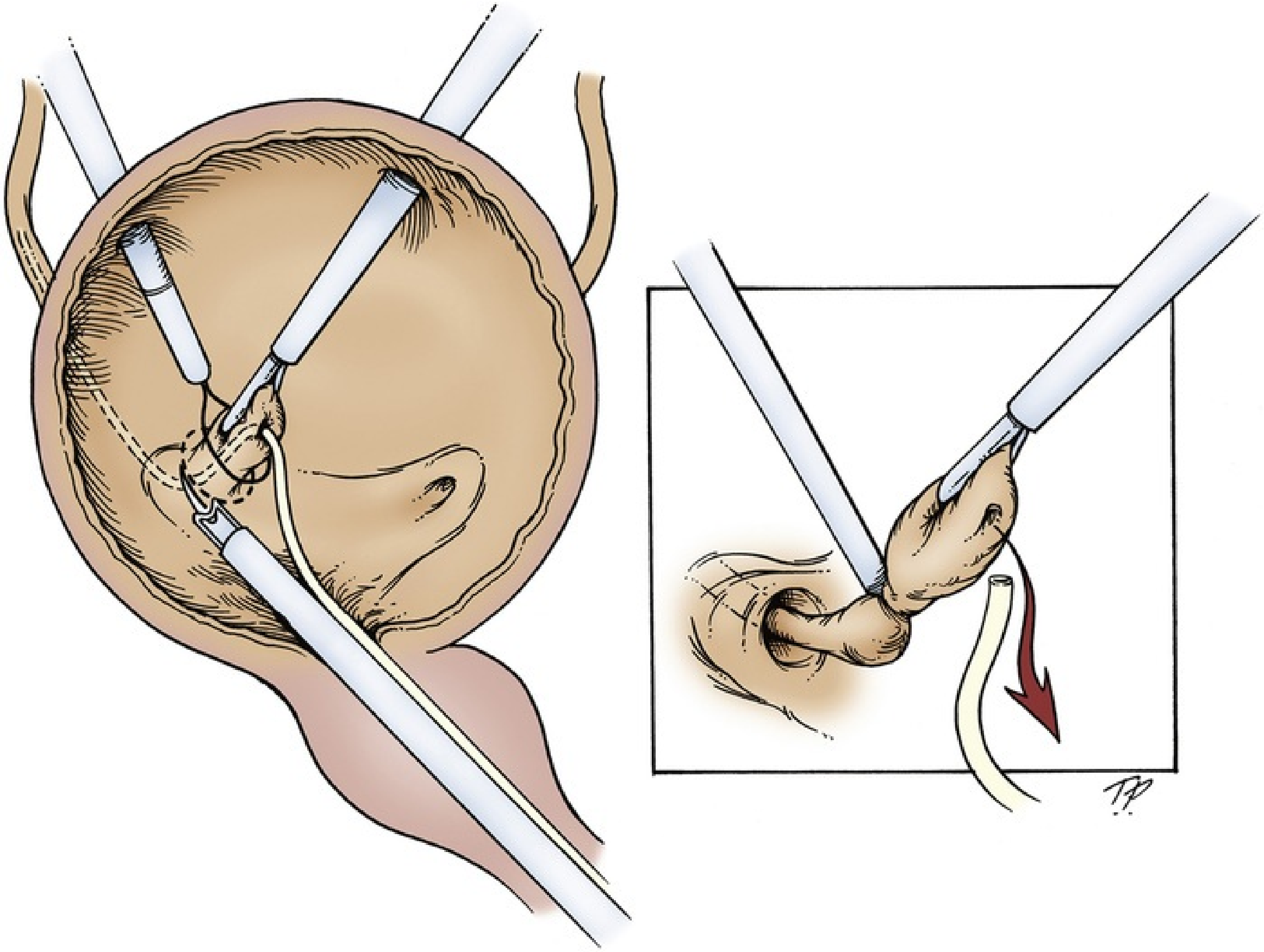

FIG. 99.4 A ureteral catheter is placed, and two laparoscopic ports are placed transvesically. The ureteral orifice is tented up; a loop is placed around the orifice to occlude the opening and to place traction on the ureter. A Collins knife then facilitates the dissection to the extravesical space.

Transurethral Resection of the Ureteral Orifice.

This approach is also referred to as a “pluck” technique and can be used in patients with proximal tumors and absence of bladder disease (Abercrombie et al., 1988; Palou et al., 1995). With the patient in the lithotomy position, the resectoscope is inserted into the bladder, and aggressive resection of ureteral orifice and intramural ureter is performed down to perivesical fat (Fig. 99.5). This facilitates the plucking of the distal ureter during the nephrectomy portion of the procedure. Even though equivalent oncologic outcomes were reported in limited studies (Walton et al., 2009), concerns about tumor seeding of extravesical space and the potential of leaving an incompletely resected ureter caused this technique to be largely abandoned (Arango et al., 1997; Jones and Moisey, 1993).

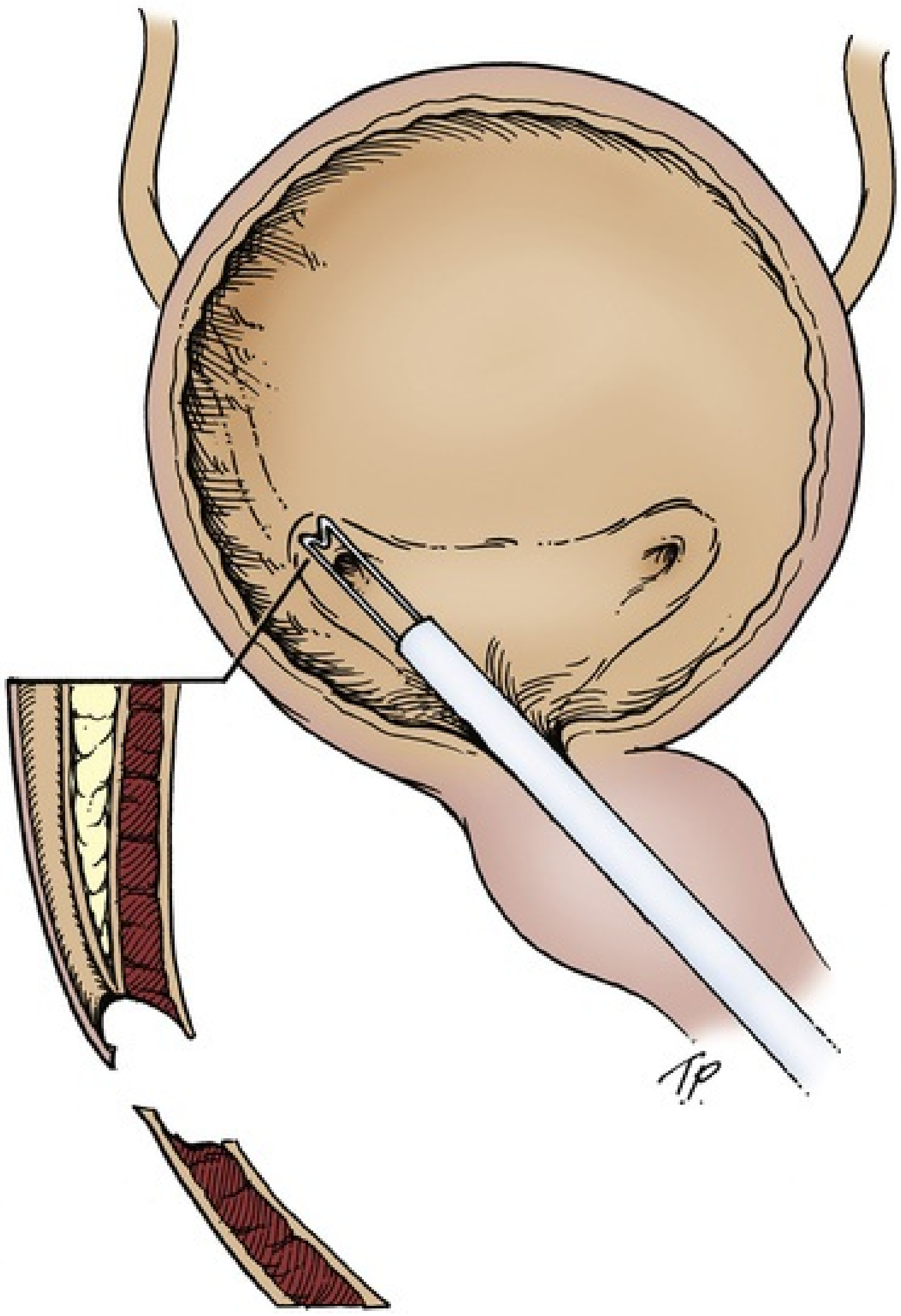

FIG. 99.5 The entire orifice and intramural ureter are resected transurethrally until the extravesical fat is seen. This portion is usually done at the beginning but can be done at the end of the procedure.

Intussusception (Stripping) Technique.

This technique was initially described in 1953, and several modifications have been described since then (Angulo et al., 1998; Clayman et al., 1983; McDonald, 1953; Roth et al., 1996). It is contraindicated in the presence of ureteral tumors. At the beginning of the procedure, a ureteral catheter is placed in the ureter, and nephrectomy is carried out as usual. The distal ureter is isolated extravesically, and a tie is placed around it, securing the catheter to the ureter (Fig. 99.6). After the nephrectomy portion is completed, the ureter is transected between ties, and the bladder cuff is incised cystoscopically using a Collins knife. Pulling on the ureteral catheter everts the distal ureter inside the bladder. The intussuscepted ureter is then removed by traction out of the urethra. The edges of the bladder mucosa can be fulgurated. The concerns with this technique include exposure of bladder urothelium to ureteral mucosa with extensive manipulation of ureter and the potential for incomplete intramural ureter excision. In addition, the failure rate of 18.7% has been described, in which there was disruption of the ureter during manipulation and the need for an additional surgical incision (Giovansili et al., 2004).

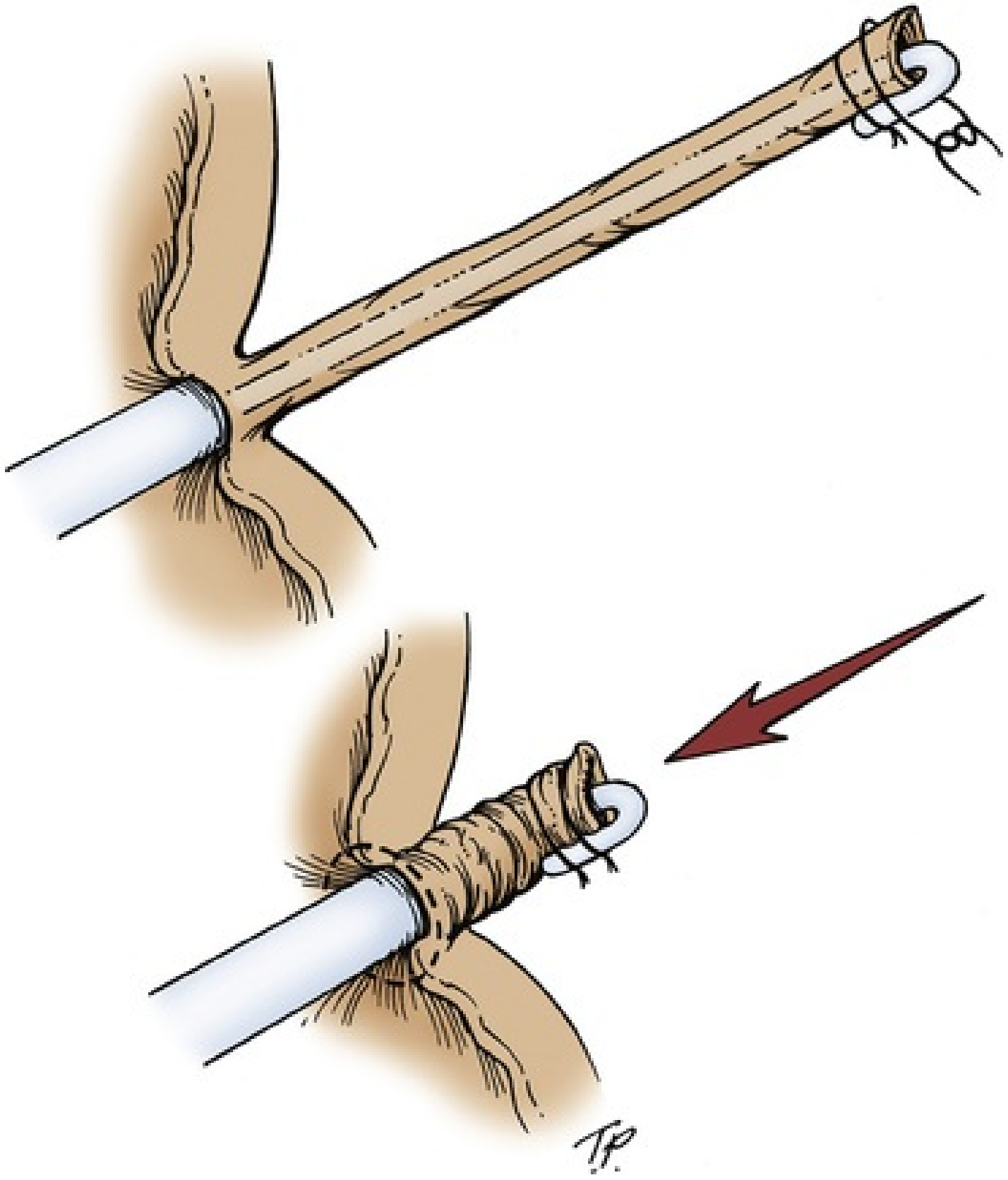

FIG. 99.6 With the intussusception technique, a ureteral catheter is placed at the beginning of the case. After nephrectomy the ureter is divided and the catheter is secured to the distal portion of the ureter. The patient is moved to the lithotomy position, and the ureter is intussuscepted into the bladder with retrograde traction. A resectoscope is used to excise the attached orifice.

Total Laparoscopic Technique.

This approach is attractive to many because it avoids incision into the urinary tract, and in experienced hands the operative time is reduced. Initially, cystoscopy may be performed and the ureteral orifice cauterized, which may be preceded by placement of a ureteral catheter and incision of intramural tunnel at the 12 o'clock position. The nephrectomy portion is performed as usual, and the distal ureter is traced to the detrusor muscle. The ureteral dissection is carried down to the bladder. The detrusor muscle is split and the ureter retracted in antegrade direction. The endovascular stapler is then used to place a staple line as distally as possible. The fulguration mark helps serve as an identifier of bladder cuff (Fig. 99.7). The concerns with this technique include the potential for leaving ureter mucosa within the staple line and inability for the pathologist to evaluate the distal margin because of the presence of staples. Laparoscopic stapling has been associated with a higher risk of positive margins, which in this disease is associated with significantly reduced survival (Matin and Gill, 2005; Steinberg and Matin, 2004). Contraindications include the presence of distal ureteral tumors.

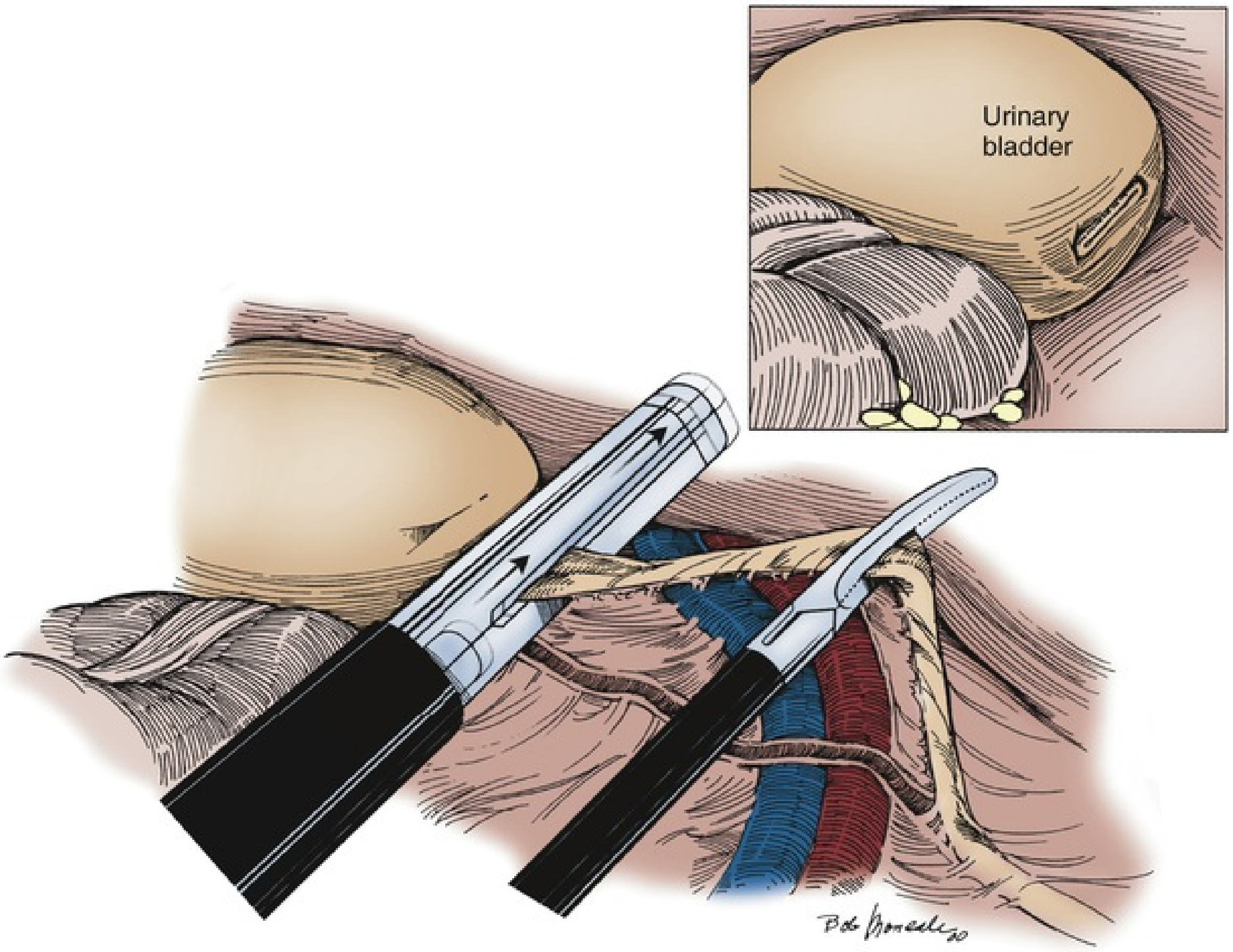

FIG. 99.7 The ureter is dissected extravesically to the ureteral orifice. Lateral traction is placed on the ureter, everting the orifice, and the endovascular stapling device is placed at the distal margin, providing simultaneous ligation and division of the distal ureter at the level of the bladder. A cystoscope can be placed to ensure that the entire ureter is removed.

Laparoscopic Radical Nephroureterectomy

Indications

The indications for laparoscopic nephroureterectomy are the same as those for open nephroureterectomy. Exceptions may include large bulky tumors with involvement of adjacent structures or those in which extended lymph node dissections may be considered. Laparoscopic nephroureterectomy can be performed by transperitoneal, retroperitoneal, hand-assisted (Ni et al., 2012), and robotic approaches. **The laparoscopic approach generally shows a significant decrease in morbidity compared with an open surgical approach for appropriately selected patients.** All laparoscopic techniques involve two distinct portions of the procedure: nephrectomy/proximal ureterectomy and excision of the distal ureter with intact specimen extraction for accurate staging. Management of the distal ureter was described previously in the chapter. Several factors must be considered with laparoscopic nephroureterectomy, including the risk of tumor seeding from the ureter and the bladder. For these reasons, removal of an intact specimen is desirable. The incision should be strategically placed for extraction of the specimen and dissection of the distal ureter. Because an incision is necessary regardless of the approach chosen, some techniques for avoidance of a second incision for the distal ureter described previously have less utility.

Technique

Transperitoneal Laparoscopic Nephroureterectomy

Laparoscopic Removal of Kidney Down to Mid-Ureter.

The patient is placed supine with the ipsilateral hip and shoulder rotated approximately 20 degrees (Fig. 99.8). The patient is secured to the table and can be easily moved from the flank position (nephrectomy portion) to the modified supine position (open portion) by rotating the operative table. The ipsilateral flank and urethra are prepared and draped, and a Foley catheter is placed before insufflation of the abdomen. The abdomen is insufflated, and three or four trocars are placed as outlined in Fig. 99.9, with the first usually being the lateral trocar. Subsequent trocars are placed under direct vision. With this configuration, the camera is kept at the umbilicus for the entire procedure. The upper midline and lateral trocars are used by the surgeon for the dissection of the kidney and the proximal half of the ureter. The lower midline and lateral trocars are used for the dissection of the distal ureter. A 3-mm trocar just below the xiphoid can be helpful in retracting the spleen and liver for left- and right-sided lesions, respectively. The exception is with obese patients, when shifting of the trocars may be necessary to provide optimal visualization (Fig. 99.10). If a hand-assist approach is chosen, the hand port site should be placed so that it can be used for the dissection of the distal ureter and open bladder cuff as indicated. The table is rotated so that the patient is in the flank position. The peritoneum is incised along the white line of Toldt from the level of the iliac vessels to the hepatic flexure on the right and to the splenic flexure on the left. The colon is moved medially by releasing the renocolic ligaments while leaving the lateral attachments of the Gerota fascia in place to prevent the kidney from “flopping” medially. The colon mesentery should be mobilized medial to the great vessels to facilitate dissection of the ureter, renal hilum, and local lymph nodes as needed.

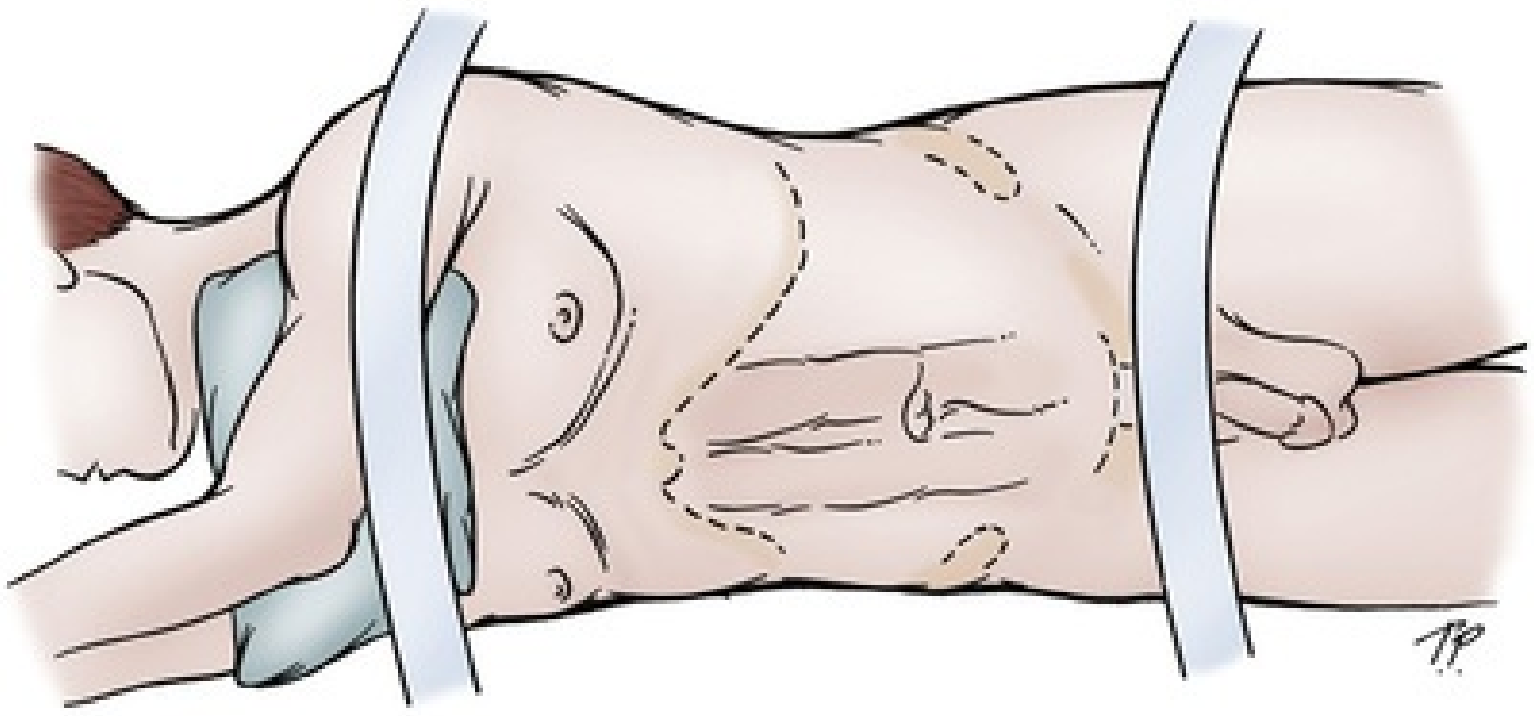

FIG. 99.8 The patient is positioned on the table in a modified lateral decubitus position with the ipsilateral flank rotated up 15 degrees. The patient is secured to the table at the chest, waist, and lower extremity. This setup allows the patient to be moved to the full flank or supine position with simple rotation of the operating table. (From Jarrett TW: Laparoscopic nephroureterectomy. In Bishoff JT, Kavoussi LR, editors: *Atlas of laparoscopic retroperitoneal surgery,* Philadelphia, 2000, Saunders, p 105.)

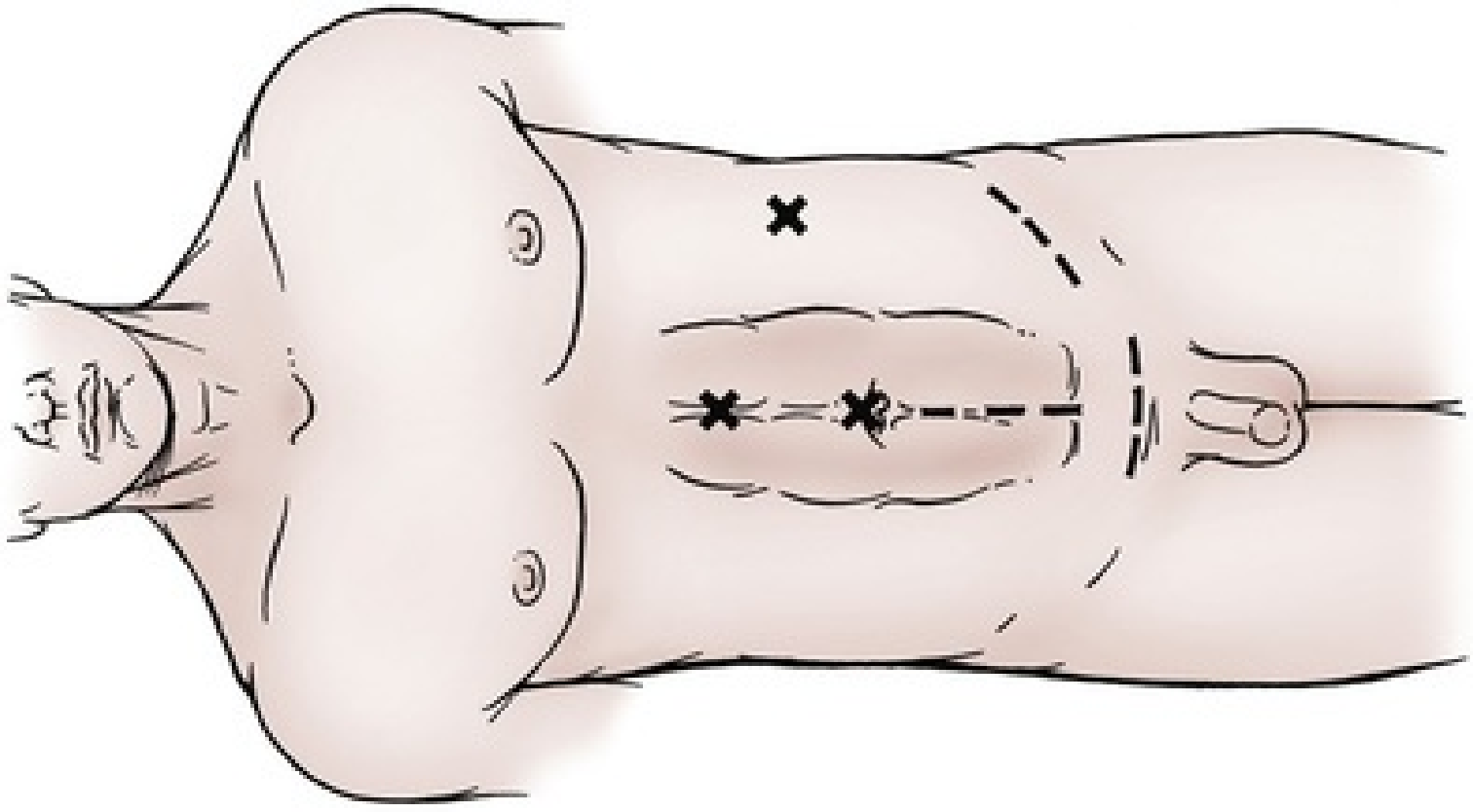

FIG. 99.9 Port configuration for laparoscopic-assisted nephroureterectomy. Three ports are typically used for the kidney and upper ureteral dissection. A fourth midline port between the umbilicus and symphysis can be placed, if needed, for further ureteral dissection. The incision is then strategically placed to allow the distal ureteral dissection and specimen removal. The choice of incision largely depends on patient factors and level of dissection reached during the laparoscopic portion of the procedure. A low abdominal (midline or Pfannenstiel) incision is favored if the dissection is below the iliac vessels. A Gibson-type incision will give exposure of the more proximal ureter, if necessary.

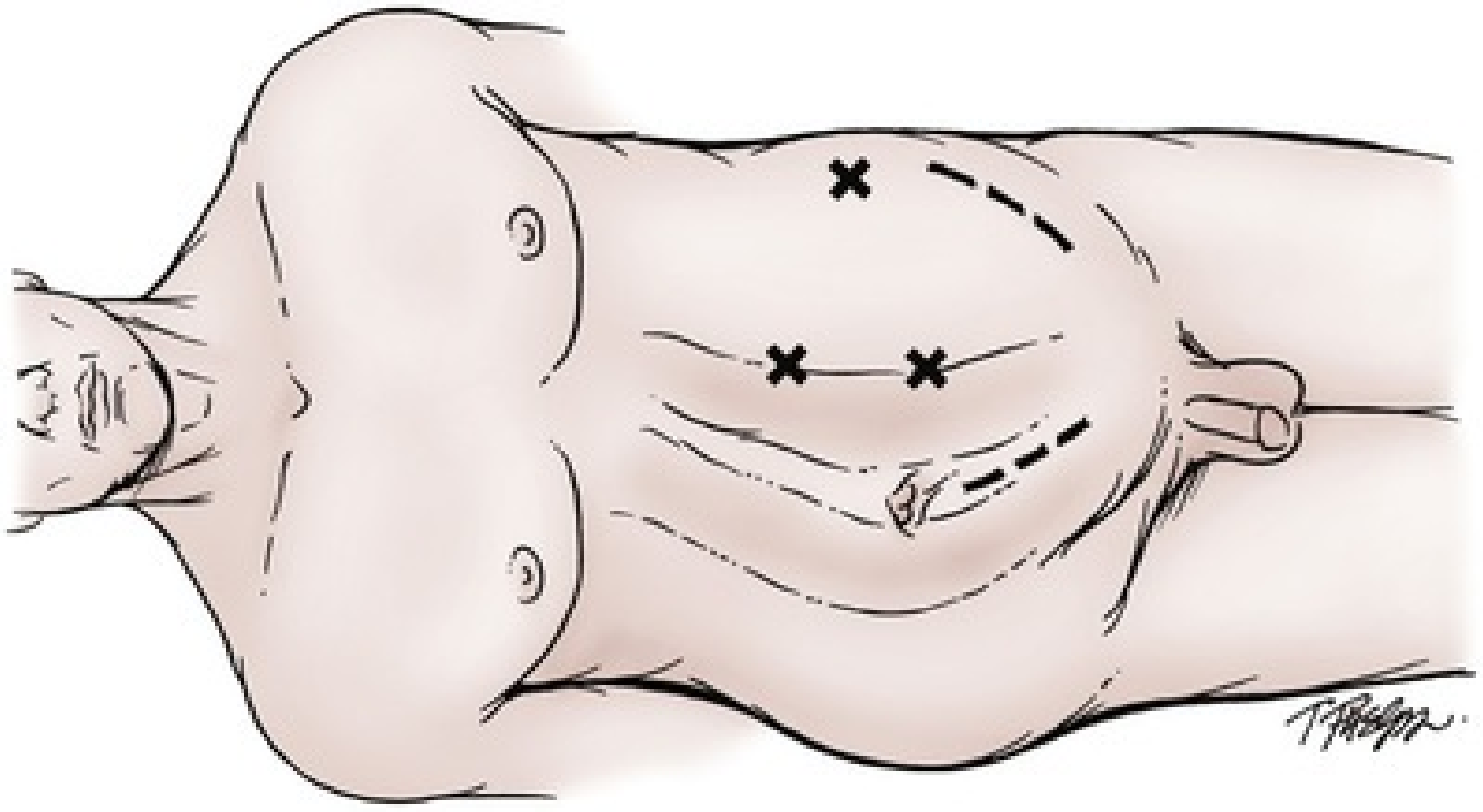

FIG. 99.10 For obese patients undergoing laparoscopic-assisted nephroureterectomy, the trocars are shifted laterally to accommodate the increased distance from the kidney.

Proximal Ureteronephrectomy.

The proximal ureter is identified, just medial to the lower pole of the kidney, and dissected toward the renal pelvis, avoiding skeletonization and maintaining copious periureteral fat if any tumor is located in this area. If an invasive ureteral lesion is suspected, the dissection should include a wide margin of tissue. The renal hilum is identified, and its vessels are exposed with a combination of blunt and sharp dissection. The artery is ligated and divided by use of a stapling device with a vascular load or multiple clips. The renal vein is then divided in a similar fashion (Fig. 99.11). With vascular control ensured, most prefer to ligate the ureter with a clip as previously described, and the kidney is dissected free outside the Gerota fascia. Similar as described for open nephroureterectomy, the adrenal gland does not have to be removed routinely. The ureteral dissection is continued distally, keeping in mind that the ureteral blood supply is generally anteromedially located in the proximal third, medially located in the middle third, and laterally located in the distal third. Dissection of the lower half may require placement of the fourth trocar. In the area of primary disease, surrounding tissue should be left to provide an adequate tumor margin. The ureteral dissection is continued as far as is technically feasible. If the distal limits of the dissection are below the level of the iliac vessels, the remainder of the procedure can easily be completed through a lower abdominal incision. The specimen is placed in the pelvis, and the renal bed is inspected meticulously for bleeding. At this time, the 10-mm port sites may be closed before proceeding to the open portion of the case.

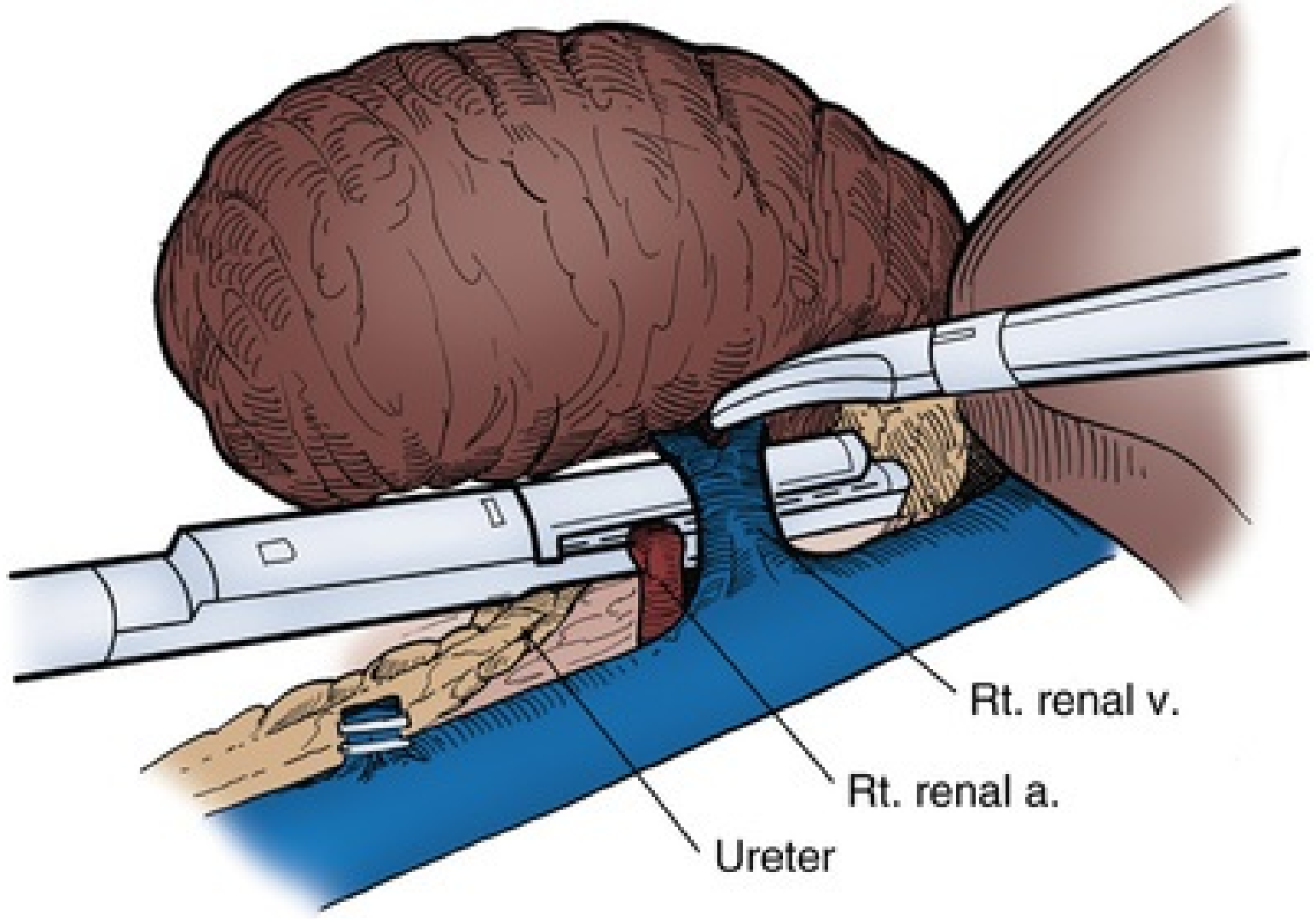

FIG. 99.11 The vessels of the renal hilum are carefully dissected, and the endovascular stapling device, with a vascular load, is used to simultaneously ligate and divide the vessels in a controlled environment. (From Jarrett TW: Laparoscopic nephroureterectomy. In Bishoff JT, Kavoussi LR, editors: *Atlas of laparoscopic retroperitoneal surgery,* Philadelphia, 2000, Saunders, p 112.)

Open Distal Ureterectomy With Excision of Bladder Cuff.

The patient is now moved to the supine position, which can usually be done without re-preparation, and a low midline Pfannenstiel or Gibson incision is made. The choice of incision largely depends on the tumor location, the body habitus of the patient, and the most caudal level of ureteral dissection attained during the laparoscopic portion. The Gibson incision is preferable when the distal ureter cannot be freed laparoscopically to the level of the iliac vessels.

Dissection of the Distal Ureter.

To consider a total laparoscopic procedure or to minimize the open distal portion, the ureteral dissection must continue to the level of the bladder. The patient is placed in the Trendelenburg position to move the bowel contents out of the pelvis. The peritoneal incision is extended from the level of the iliac vessels into the pelvis lateral to the bladder and medial to the medial umbilical ligament (Fig. 99.12). The vas deferens in male patients or the round ligament in female patients is clipped and divided if exposure is limited. The ureter can now be traced between the bladder and the medial umbilical ligament down to its origin at the bladder. Optimal exposure of the entire intramural ureter is gained by division of the lateral pedicle of the bladder, allowing medial rotation of the bladder, exposing the entire length of the ureter. The bladder cuff may be dissected extravesically, freeing the ureter from the surrounding detrusor muscle, or alternatively, opening the bladder immediately around the ureteral orifice allows direct visual confirmation for complete resection of the bladder cuff. Yet another alternative during a complete extravesical approach is flexible cystoscopy in confirming complete ureterectomy and patency of the contralateral ureteral orifice. The techniques for open distal ureterectomy and bladder cuff excision are described in the section on open techniques.

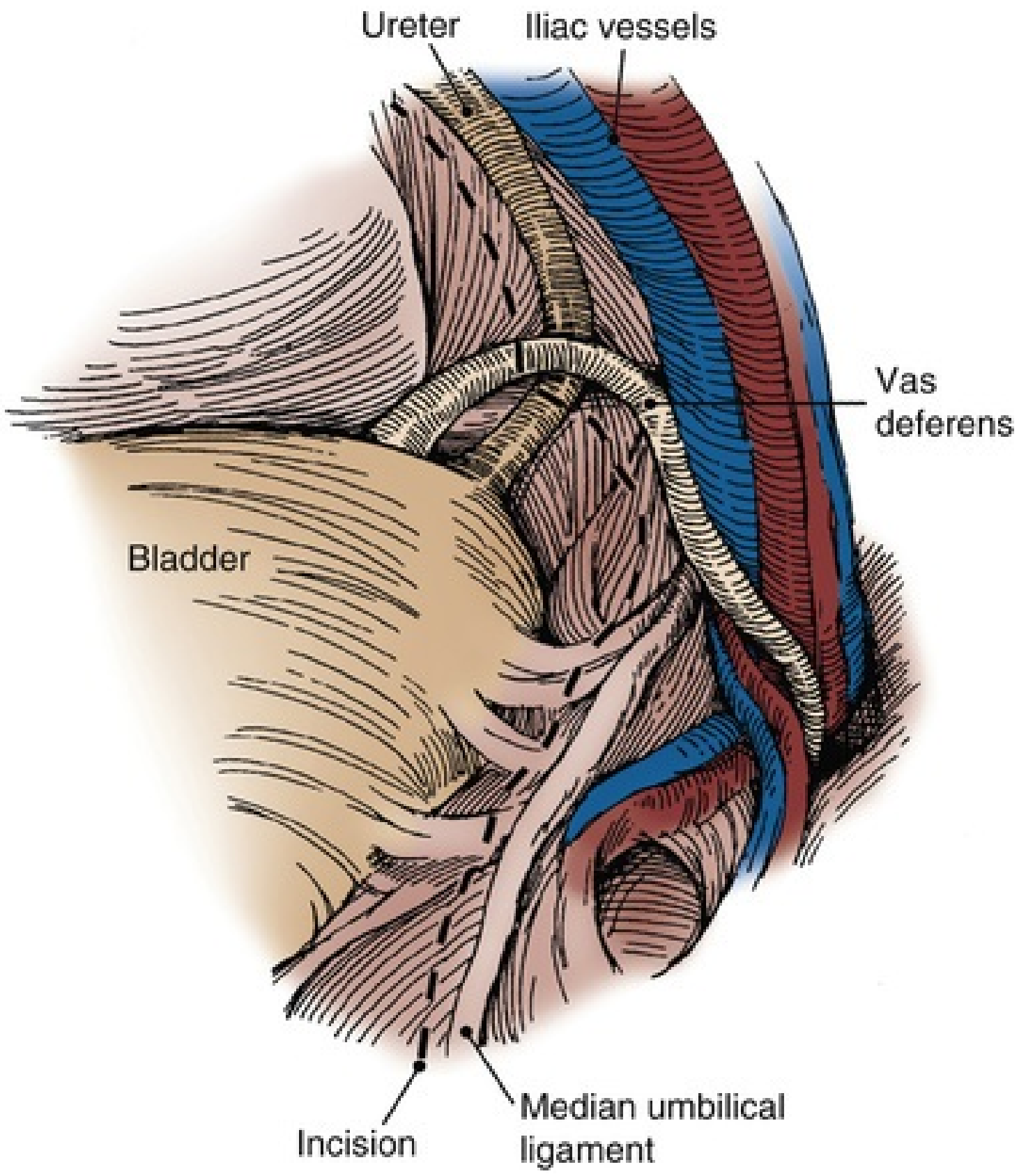

FIG. 99.12 The peritoneal incision is continued below the iliac vessels medial to the median umbilical ligament and lateral to the bladder. The vas deferens is divided between clips in the male patient. In the female patient the round ligament is divided, giving full exposure of the distal ureter to the bladder.

Robot-Assisted Laparoscopic Nephroureterectomy.

With the increased use of robots in urologic surgery, robot-assisted nephroureterectomy has become a feasible alternative to more traditional open or laparoscopic technique. The availability of da Vinci Xi system with longer instruments and improved range of motion with less arm clashing has allowed performance of the surgery without the need to re-dock the robot or reposition the patient for distal ureterectomy portion. Proper port positioning is paramount to the success of this technique (Fig. 99.13). The 12-mm camera port is placed at the level of umbilicus, lateral to rectus sheath, followed by placement of cephalad (port #1) and caudad (port #2) 8-mm robotic ports, both of which are positioned 7 to 8 cm away from the camera port on the same line. The third robotic port (port #3) is placed about 5 cm cranial to iliac crest, close to the anterior axillary line. The assistant port is placed in the midline in or around the umbilicus. Docking the robot, the left arm is placed in port #1, right arm in port #2, and the fourth arm is placed in port #3 and used for retraction. Once the nephrectomy portion is completed, the retraction instrument is moved to port #1 and left arm to port #3 for distal ureter and bladder cuff dissection. For extravesical dissection of the ureter, the distended bladder is helpful in tracing the ureterovesical junction. Once the distal ureter is dissected out of the detrusor, the bladder can be emptied. Placement of stay sutures medial and lateral to the incision site of ureterovesical junction aids in subsequent reconstruction of bladder. Bladder should be closed in two layers (Hemal et al., 2011). For the Xi system the robotic trocars position should be modified to a straight diagonal line starting with cephalad port at midline and the rest of the ports placed caudally and toward the iliac crest at 8-cm increments. The camera port is initially placed in the second port from the top and moved to the third port for the bladder cuff portion of the surgery.

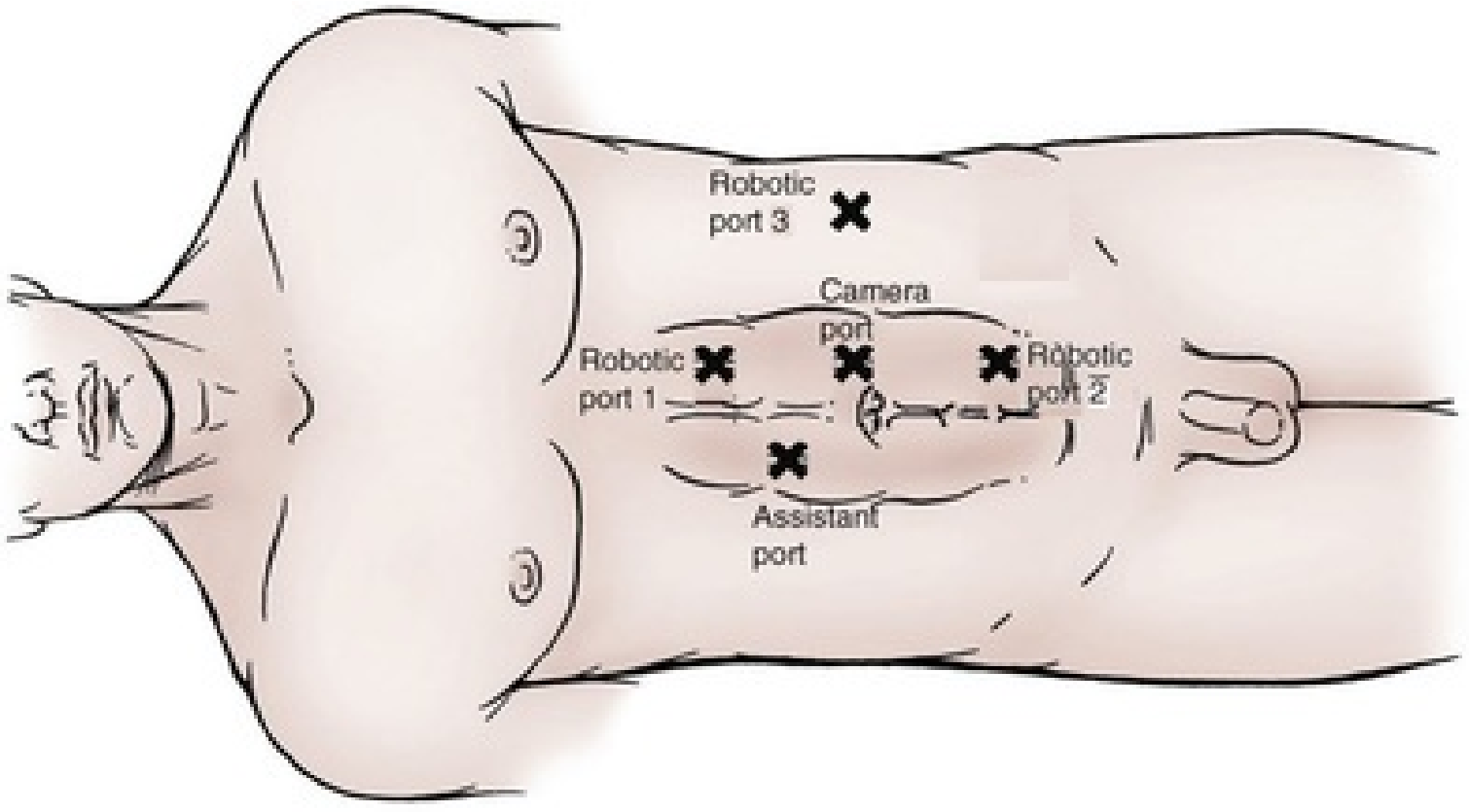

FIG. 99.13 Port configuration for robot-assisted laparoscopic nephroureterectomy. For nephrectomy and upper ureterectomy portion, the retraction instrument is placed in port 3, and for distal ureterectomy with bladder cuff removal, the retraction instrument is moved to port 1 and the left arm to port 3.

Results

The first laparoscopic nephroureterectomy was performed in 1991 by Clayman et al. Since that time the technical aspects and safety of laparoscopic procedures have been well established. There are multiple reviews and published series of laparoscopic nephroureterectomy with varying techniques (Bariol et al., 2004; Hsueh et al., 2004; Jarrett et al., 2001; Matin and Gill, 2005; Ni et al., 2012; Rai et al., 2012;, Stifleman et al., 2001; Wolf et al., 2005). Each varies with regard to approach (transperitoneal vs. retroperitoneal), management of the distal ureter by open removal, transurethral resection, and total laparoscopic management. As with other laparoscopic renal procedures, there is no clear-cut benefit of any one approach with regard to morbidity, cosmesis, or return to activity.

All, however, show a benefit with regard to morbidity compared with open surgery. The efficacy of laparoscopic nephroureterectomy is being established for cancer control. With intermediate and long-term follow-up, cancer-related outcomes appear comparable with those of the open counterpart (McNeill et al., 2000). El Fettouh et al. (2002), in a multi-institutional study with 116 patients, showed the local and bladder recurrence rates to be 2% and 24%, respectively. The rate of distant metastasis was 9%, and positive margins were seen in 4.5% of cases. Berger et al. (2008) showed a 5-year cancer-specific survival of 80%, 70%, 68%, 60%, and 0 for stage Ta/Tis, T1, T2, T3, and T4 lesions, respectively. Schatteman et al., (2007) similarly showed cancer-specific survival rates of 100%, 86%, 100%, 77%, and 0 for stage Ta, T1, Tis, T3, and T4 lesions. In both studies there was a worsening prognosis with increasing tumor stage. Long-term data are available from Muntener et al. (2007a), who studied 37 patients with follow-up of 60 to 148 months. In this study, 11 patients had disease progression and died 7 to 59 months after the operation. Tumor stage was the only factor significantly associated with disease recurrence. Ni et al. (2012) compared open with laparoscopic outcomes in a larger review of comparative studies. Although the results were not statistically significant, the study showed that laparoscopic surgery had a higher 5-year cancer-specific survival and lower bladder and overall recurrence rate compared with open surgery. With appropriate patient selection, a laparoscopic approach offers reliable safety and oncologic efficacy with the advantage of lower morbidity for well-selected patients. In the only surgical randomized controlled trial comparing laparoscopic and open extirpative surgery, Simone et al. (2009) showed no difference in metastasis-free and cancer-specific survival in patients with organ-confined disease. However, in this study, patients with high-grade disease or at least pT3 stage benefited from open nephroureterectomy.

Local recurrence and port-site seeding are major concerns. There have been a few reported instances of port-site seeding involving UTUC. Two of these cases were discovered after simple nephrectomy for presumed benign disease in which the principles of surgical oncology were inadvertently not followed (Ahmed et al., 1998; Otani et al., 1999). All were for high-grade disease. Muntener et al. (2007b) reported a single case of local recurrence among 166 cases. In this instance there was obvious violation of the ipsilateral urinary tract, noted perioperatively. Although the potential for seeding exists, it seems to be decreasing and does not appear any higher than that for the open surgical counterpart as long as good surgical principles are followed.

In summary, there does not appear to be a significant difference between laparoscopic and open nephroureterectomy when the principles of surgical oncology are followed. Management of the bladder cuff still has shown variability and a tendency toward higher recurrences with minimally invasive approaches. Lymphadenectomy can be performed laparoscopically and should be used based on the clinical situation. Even extended lymph node dissections can be considered in those with advanced laparoscopic skills.

Lymphadenectomy

There is still controversy surrounding the lymphadenectomy for UTUC. For renal pelvis and proximal or mid-ureteral tumors it most commonly includes the ipsilateral renal hilar nodes and the adjacent para-aortic or paracaval nodes, and pelvic nodes for distal ureteral tumors (Abe et al., 2008; Babaian and Johnson, 1980; Batata et al., 1975; Batata and Grabstald, 1976; Brausi et al., 2007, Cummings, 1980; Grabstald et al., 1971; Heney et al., 1981; Johansson and Wahlquist, 1979; Kondo et al., 2007; McCarron et al., 1983; Messing and Catalona, 1998; Richie, 1988; Skinner, 1978; Williams, 1991). This dissection adds little time or morbidity to the surgery. Kondo and Tanabe (2012) proposed an extended lymphadenectomy template based on the location of the tumor (Fig. 99.14). For tumors of renal pelvis this includes ipsilateral hilar, paracaval, retrocaval, and interaortocaval nodes up to the level of inferior mesenteric artery for right-sided tumors, and ipsilateral hilar and para-aortic up to the level of inferior mesenteric artery for left-sided tumors. For tumors of the upper two-thirds of the ureter (above crossing of inferior mesenteric artery to the common iliac artery), the template is similar, but the distal border of dissection is extended to the level of aortic bifurcation. For tumors of the lower one-third of the ureter, these include ipsilateral obturator, internal, external and common iliac, and presacral packets. A recent mapping study looked at the pattern of spread to lymph nodes based on the location and side of the primary tumor (Matin et al., 2015). For right-sided tumors of the renal pelvis and proximal ureter, lymphadenectomy of the hilar, paracaval, and retrocaval nodes captured 82.9% of metastases, and adding interaortocaval dissection increased this number to 95.8%. For left-sided tumors, dissection of hilar and para-aortic nodes captured 86.9% of metastases, and addition of interaortocaval nodes increased that number to 90.2%. Data for mid-ureteral and distal ureteral tumors were less conclusive.

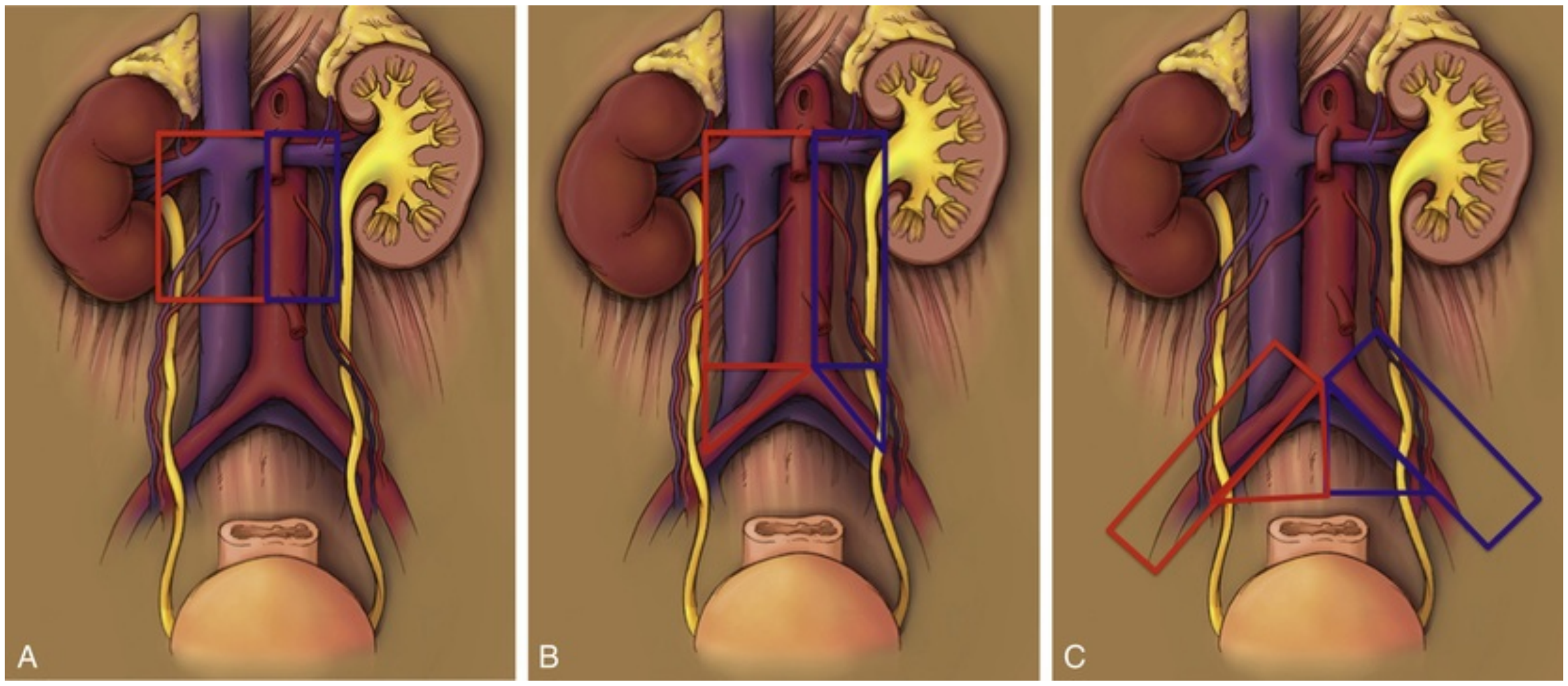

FIG. 99.14 (A) In addition to ipsilateral hilar nodes, the extended lymphadenectomy template for tumors of the renal pelvis includes paracaval, retrocaval, and interaortocaval lymph nodes for right-sided, and para-aortic lymph nodes for left-sided tumors. The inferior mesenteric artery marks the inferior boundary of the template. (B) For tumors of the upper two-thirds of the ureter, this template is extended to the level of bifurcation of aorta. (C) The extended lymphadenectomy template for tumors in the distal ureter includes ipsilateral common, external and internal iliac, obturator, and presacral nodes.

The analysis of the UTUC literature is complicated by a lack of uniformity in templates for lymphadenectomy and the inconsistent pattern of spread, especially for mid-ureteral and distal ureteral tumors. Lymph node involvement is reported in 12% to 25% of patients, although it increases with advanced stage and grade. The reported numbers are 0 to 3% in pTa/pTis, 0 to 6.3% in pT1, 0 to 40% in pT2, 19% to 47% in pT3, and 20% to 100% in pT4. However, the median number of nodes removed and boundaries of lymphadenectomy varied widely in these studies (Weight and Gettman, 2011). Multiple series of lymphadenectomy at the time of nephroureterectomy (Abe et al., 2010; Burger et al., 2011; Lughezzani et al., 2010; Roscigno et al., 2008, 2009; Secin et al., 2007) confirm than oncologic outcomes for patients with pN0 are better than pNx and worse for pN+ compared with pNx groups. The importance of the number of lymph nodes removed was addressed by Roscigno et al. (2009), reporting that removal of 8 or more nodes increased the chance of finding positive LNs by 49% and improved disease-specific survival for those with greater than pT1 disease. A 2017 study by Zareba et al. confirmed that an increase in lymph node yield was an independent predictor of overall survival. In another recent study from a single institution (Lenis et al., 2018), the type of surgical approach (open vs. robotic) did not appear to compromise the nodal yield. Kondo et al. (2010) stressed the importance of the dissection template over the nodal counts for survival difference. For patients with muscle invasive tumors of renal pelvis, template lymphadenectomy was an independent predictor of overall survival in multivariate analysis (Kondo et al., 2014a). Several other studies explored the effects of lymphadenectomy on survival, suggesting a potential therapeutic benefit (Brausi et al., 2007; Kondo et al., 2007, 2014b). The latter study also addressed the perioperative complications, citing 13% overall complication rate for renal pelvis disease and 15% for ureteral disease, including 5.2% incidence of lymphatic or chylous leak. These numbers were in line with other studies for open and laparoscopic surgery (Abe et al., 2015; Mitropoulos et al., 2017).

In summary, although prospective studies are needed to assess the role and optimal extent of lymphadenectomy in UTUC, emerging data validate its importance in the treatment of this cancer. It is safe and beneficial for accurate staging and appears to have prognostic and therapeutic value in patients with invasive disease (T2-T4), especially in the setting of tumors of renal pelvis and proximal ureter.

Results

Multiple series reported on strong correlation of outcome with tumor stage and grade. Recently, additional prognostic factors, such as tumor architecture, presence of carcinoma in situ (CIS), lymphovascular invasion, and lymph node positivity, were shown to correlate to oncologic outcomes (Cha et al., 2012; Margulis et al., 2009).

Complete ureterectomy with bowel cuff excision should accompany nephroureterectomy for UTUC. The risk of tumor recurrence in a remaining ureteral stump is 30% to 75% (Babaian and Johnson, 1980; Bloom et al., 1970; Johansson and Wahlquist, 1979; Kakizoe et al., 1980; McCarron et al., 1983; Mullen and Kovacs, 1980; Strong et al., 1976). Techniques such as simple extravesical dissection and tenting up of the ureter result in an incomplete removal of the distal ureter (Strong et al., 1976). Smith et al. (2009) presented data on a single-center experience comparing oncologic outcomes following variations in technique of distal ureterectomy. The techniques were divided into definitive, which included any approach that resulted in excision of distal ureter with bladder mucosal cuff, and nondefinitive, which included detachment of the ureter at or above the level of detrusor. **Nondefinitive management of the**

distal ureter was associated with a higher rate of local and distal recurrence and inferior disease-specific and overall survival. Complete ureterectomy with a bowel cuff should also be performed in the setting of a renal unit draining into a urinary diversion. Tumor recurrence rates up to 37.5% have been reported when ureteroenteric anastomosis was not removed (Mufti et al., 1988).

Multiple series recommend radical nephroureterectomy as a treatment that provides optimal oncologic control (Batata et al., 1975; Johansson and Wahlquist, 1979; McCarron et al., 1983; Murphy et al., 1980; Zungri et al., 1990). Margulis et al. (2009) conducted a retrospective review of 1363 patients from 12 tertiary care centers worldwide who underwent radical nephroureterectomy with curative intent. Although the data for open and laparoscopic cases were pooled together, the majority (77%) had open nephroureterectomy. The pT stage was evenly distributed between Ta, T1, T2, and T3, but less than 5% of patients had each T0, Tcis, or T4. Two-thirds of patients had high-grade tumors, and 28% had concomitant CIS. Around 10% of patients had lymph node positivity, and 16% received perioperative chemotherapy. Disease recurrence was observed in 28% of patients at a median of 10.4 months. During a median follow-up of 37.2 months, 30% of patients died, and 61% of deaths were attributable to their disease. In summary, radical nephroureterectomy provides reasonable oncologic control, with outcomes largely dependent on clinicopathological characteristics. It is warranted for patients with high-grade invasive organ confined or locally advanced disease (stage T1–4, N0–2, M0). **Comparative data of extirpative vs. conservative management are lacking because the population of the patients who undergo these surgeries is very diverse. Treatment decisions in patients with compromised renal function must balance the potential curative effect of radical surgery to the morbidity associated with dialysis.**

Segmental Ureteral Resection

For purposes of this section, segmental ureterectomy primarily indicates distal ureterectomy with ureteral reimplant. True segmental resection of the proximal ureter with primary uretero-ureterostomy is rarely indicated but is discussed in the technical portions of this chapter, as is total ureterectomy requiring ileal ureter replacement or autotransplantation. Several studies have compared results of nephroureterectomy with segmental ureteral resection, but because these are all retrospective and selection for these patients are very different, there is significant selection bias and the quality of the data remains poor. Segmental resection performed to preserve renal function in patients with compromised renal function must not compromise oncologic efficacy for the sake of avoiding the morbidity associated with dialysis. It is critical to evaluate the entire upper tract above the tumor with ureteroscopy to ensure there is no multifocality. In addition, if high-grade disease is present, many practitioners also do an ipsilateral pelvic lymph node dissection. Advantages to a segmental ureterectomy are the ability to preserve renal function while also providing a pathological specimen that can inform the need and extent of adjuvant therapy.

Open Segmental Ureterectomy

Ureteroureterostomy

Indications.

Segmental ureterectomy is indicated for tumors of the proximal ureter or mid-ureter that are not able to be removed endoscopically or for high-grade or invasive tumors when preservation of the renal unit is necessary. Achieving a clear margin and still being able to mobilize enough well-vascularized ureter to perform a tension-free anastomosis is paramount to the success of this procedure and the major limiting challenge. It is a rare and narrowly indicated procedure for when there is only a small tumor without any multifocality elsewhere, and not endoscopically manageable.

Technique.

The patient is positioned in full or modified flank position. A flank incision from the tip of the 12th rib provides access to the proximal ureter or mid-ureter. With use of an extraperitoneal approach, the ureter is identified, mobilized, and secured with vessel loops. The tumor is palpated, and the ureter is ligated 1 to 2 cm above and below the suspected tumor margin (Fig. 99.15). This location can be also verified by preoperative cross-sectional imaging. The diseased ureter is excised and clear margins ascertained by frozen pathology. After regional lymphadenectomy is performed, both ends of the ureter are spatulated and anastomosed with an interrupted 4-0 Vicryl suture. The success of reconstruction depends on preservation of the blood supply to the ureter and adequate mobilization of the ureteral edges to achieve a tension-free anastomosis. If a large segment of ureter is excised, mobilization and descensus of kidney may be performed to provide additional length to the proximal ureter. A ureteral stent is placed before completion of the anastomosis. Placement of a drain is up to the surgeon's preference. For laparoscopic or robotic approaches, the patient is also in flank position and the trocar placement is similar as to a pyeloplasty or nephrectomy. Extreme care is taken to follow oncologic principles to ensure nonviolation of tumor and obtain negative margins.

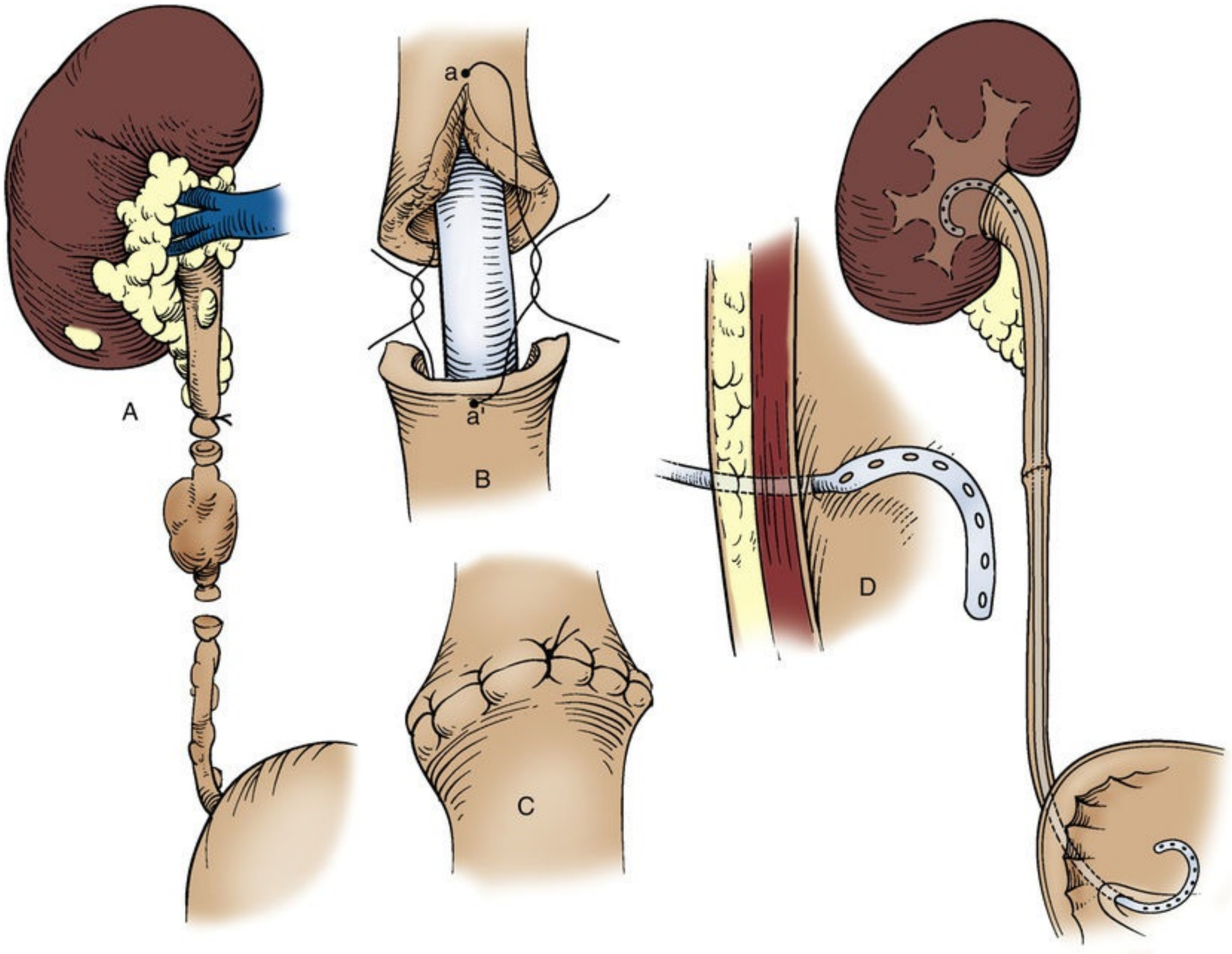

FIG. 99.15 (A) Segmental ureterectomy between ties for a large, invasive tumor of the mid-ureter. (B and C) Ureteroureterostomy of spatulated ends of the ureter. The repair is performed over an internal stent. (D) Completed repair with closed-suction drain in retroperitoneal space.

Distal Ureterectomy and Direct Neocystostomy or Ureteroneocystostomy With a Bladder Psoas Muscle Hitch or a Boari Flap.

The distal ureterectomy is performed as described in the prior section, with the exception that the entire distal ureter and bladder cuff must be excised, and the posterior cystotomy at the bladder cuff site is closed in two layers. For laparoscopic or robotic approaches, the patient is placed in dorsolithotomy or supine and in Trendelenburg position, similar to an approach for prostatectomy. The ureter is mobilized to achieve a tension-free anastomosis and spatulated. Ureterovesical anastomosis may be performed using an extravesical or intravesical approach. Whether to perform a refluxing or nonrefluxing anastomosis remains a matter of debate. The benefits of a nonrefluxing anastomosis include a limit of infection to the lower tract and the theoretic possibility of avoiding seeding of the upper tract. A refluxing anastomosis may make surveillance of the upper tracts easier. If an extravesical approach is desired, bladder detrusor muscle is incised, exposing the mucosa. A mucosal slit is performed at the distal aspect of this incision. An anastomosis is performed using continuous or interrupted 3-0 polyglactin or polydioxanone sutures through the full thickness of the ureter and bladder mucosa. At the distal portion of the anastomosis, two of these sutures are passed through the full thickness wall of the bladder to anchor the ureter and prevent sliding out of the tunnel. The bladder detrusor is then closed on the top of the ureter with interrupted absorbable sutures, such as 2-0 polyglactin, to achieve a nonrefluxing mechanism. A ureteral stent may be placed before completion of the anastomosis.

For the intravesical technique, an anterior cystotomy is made. An incision is made at the posterolateral wall of the bladder and a 2- to 3-cm submucosal tunnel is fashioned. The ureter is brought through this tunnel. After the ureter is spatulated, the anastomosis is performed with interrupted absorbable sutures.

If a long segment of distal ureter is excised and a tension-free anastomosis cannot be achieved by simple ureteroneocystostomy, an additional 5 cm in length can be gained by using a psoas hitch of the bladder. The bladder is mobilized anteriorly and laterally, and in women the round ligament is divided. The contralateral superior vesical artery and entire lateral pedicle can also be divided to gain further mobility. The ipsilateral dome of the bladder is sutured to the psoas tendon using several interrupted sutures. Care should be taken to avoid injury or entrapment of the nerve (Lenis et al., 2018). The ureterovesical anastomosis is then completed in a tension-free manner. If additional length is desired, a Boari flap can help gain another 10 to 15 cm in length and in some cases may be able to reach all the way to renal pelvis (Fig. 99.16). If a Boari flap is planned, it is advisable to obtain a preoperative cystogram to assess bladder capacity, because a small-capacity bladder, especially if radiated, is a contraindication to this technique. A U-shaped bladder wall flap or, if a longer segment is desired, an L-shaped segment, is developed. To ensure a good blood supply to the flap, the base of the flap should be at least 2 cm greater than the apex. To achieve adequate width of the tubularized segment, the width of the flap should be at least three times the diameter of the ureter. The tip of the flap is secured to the psoas muscle using interrupted absorbable suture, and the spatulated ureter is anastomosed to the flap in the end-to-end fashion. The flap is then tubularized and closed with two layers of absorbable sutures. A ureteral catheter is placed before closure of the flap. After all of these techniques, it is advisable to use a suction drain in the retroperitoneum and 5- to 7-day Foley drainage of the bladder. After extensive reconstruction, a cystogram should precede Foley removal.

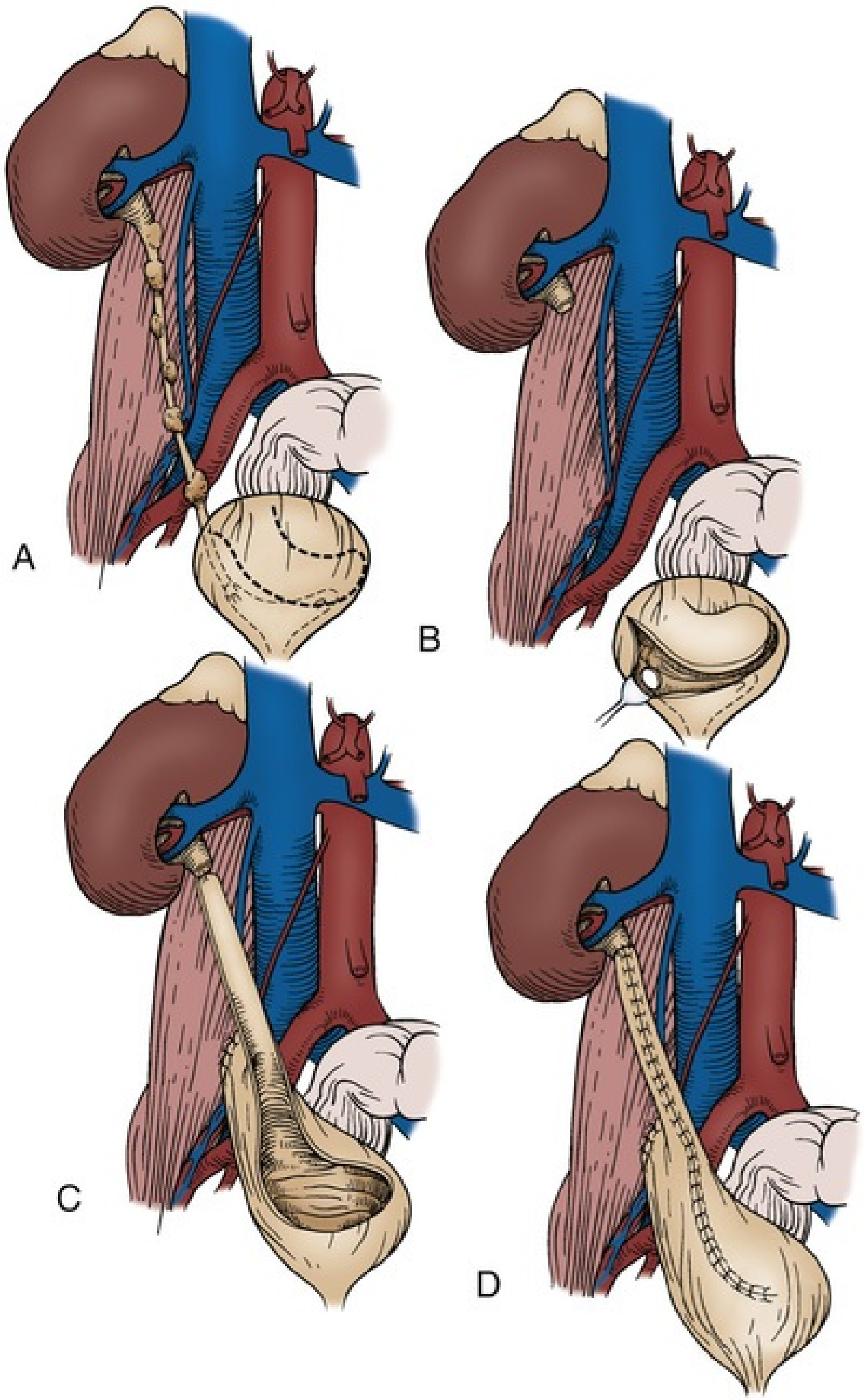

FIG. 99.16 (A) Subtotal ureterectomy required for nephron sparing in a patient with multiple diffuse ureteral tumors. (B) A spiral flap is fashioned from the anterior bladder wall. (C) The psoas hitch plus Boari flap reaches the remaining proximal ureter. (D) Completed anastomosis and bladder closure.

Ileal Ureteral Replacement

When a long segment of ureter is diseased, a segment of ileum can be used to reconstruct the urinary system. The appendix has also been used for segmental ureteral substitution (Goldwasser et al., 1994). Through a midline intraperitoneal incision, 20 to 25 cm of ileum is harvested at least 15 cm away from the ileocecal valve. Bowel continuity is re-established using a stapled anastomosis. With a running absorbable suture, the ileal segment is anastomosed to the renal pelvis proximally in an end-to-end fashion and an isoperistaltic direction. If the proximal portion of the ureter is healthy, the ileal segment can be anastomosed to it in an end-to-side fashion. A ureteral stent is placed before completion of the anastomosis. Distally, the segment is anastomosed to the posterior wall of the bladder in an end-to-side manner through an intravesical approach. This anastomosis is done in two layers. A suction drain is positioned in the retroperitoneum close to anastomotic sites. Optimal drainage is important for proper healing, so a large Foley catheter is inserted in the bladder and left for at least 1 week or longer postoperatively. It may have to be irrigated frequently. A nephrostomy tube may be used to drain the kidney. Before removal of the tubes, a cystogram and nephrostogram are obtained.

In skilled hands, renal autotransplantation is a feasible alternative to ileal replacement. Another approach that may help avoid ileal reconstruction involves mobilization of the kidney with subsequent nephropexy of the Gerota fascia to the cut edge of the peritoneum, placing traction in the caudal direction (Fig. 99.17). It may add up to 8 to 10 cm of length on the left side because of a longer left renal vein. This approach has been used laparoscopically, avoiding the need for a second flank incision (Sutherland et al., 2011).

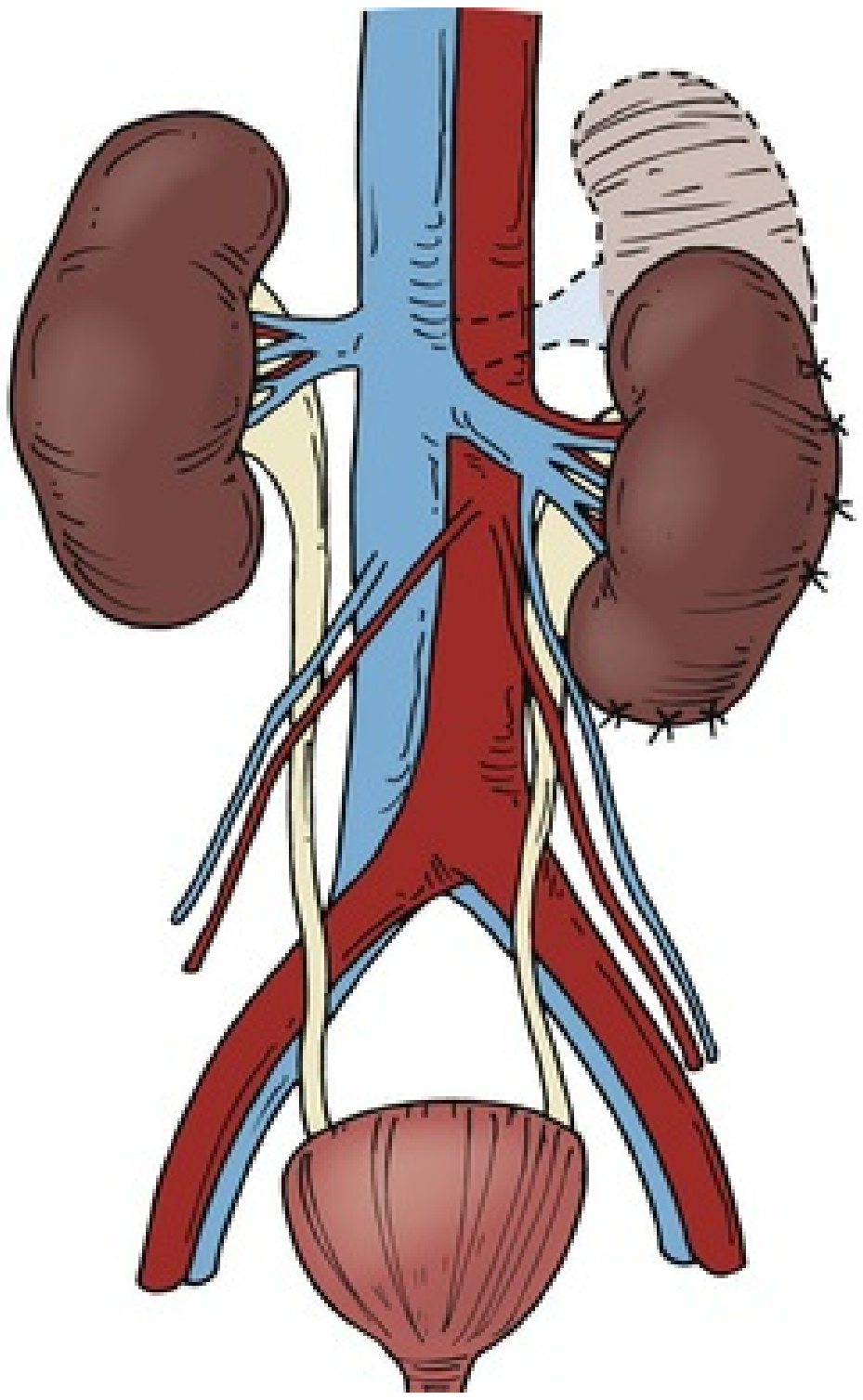

FIG. 99.17 Mobilization of the kidney with subsequent nephropexy of Gerota fascia to cut the edge of the peritoneum, placing traction in the caudal direction, may add up to 10 cm of length on the left side.

Laparoscopic or Robotic Distal Ureterectomy and Reimplantation

Various laparoscopic techniques for distal ureterectomy and reimplantation have been reported. The robotic approach may assist with the reconstruction portion of the procedure. The indications are the same as those for the open counterpart, and the techniques are reserved for low-risk distal tumors. The distal ureter is dissected down to the ureteral orifice, and the proximal end is anastomosed to the bladder using standard techniques. The early reports are encouraging, but strict adherence to oncologic principles must be followed.

Results

In the past, some authors recommended radical nephroureterectomy for all patients with upper tract urothelial tumors (Skinner, 1978). Others suggested segmental ureterectomy only for patients with low-grade, noninvasive tumors of the distal ureter (Babaian et al., 1980). Most ureteral cancers occur in the distal ureter, followed by mid-ureter and proximal ureter (Vaughn et al., 2009). Most studies show similar oncologic outcomes as nephroureterectomy with properly selected patients. The outcome of patients with UTUC of the ureter strongly correlates with tumor stage and grade regardless of the extent of surgical treatment (Table 99.1). A single-center study evaluating the prognostic factors in urothelial tumors of the ureter showed an 80% 10-year progression-free survival and 10% ipsilateral tumor recurrence (Lehmann et al., 2007), although the majority of these patients had non–muscle-invasive disease. Overall, 145 patients were evaluated, and 51 underwent segmental ureterectomy. When adjusted for clinicopathological characteristics, the outcomes were similar for patients who underwent nephroureterectomy versus segmental ureterectomy. The mean follow-up in this study was 96 months. Leitenberger et al. (1996) reported their experience with organ-sparing surgery for ureter cancer. Out of 40 patients, 13 underwent extirpative nephron-sparing surgery, and recurrence was observed in 4 patients, all of whom had invasive disease. Anderstrom et al. (1989) reported no tumor-related deaths and only 1 recurrence among 21 patients treated with segmental ureterectomy for low-grade, noninvasive ureteral tumors who were observed for a median of 83 months. McCarron et al. (1983) reported 5-year survival of 64% for patients with stage Ta tumors treated by either segmental ureterectomy or endoscopic tumor ablation. In the same series, 5-year tumor-free survival rates were 66% and 50% for stage T1 and T2 tumors, respectively, treated with segmental or distal ureterectomy. In the series by Grabstald et al. (1971), disease-specific survival rates were 64% and 100% for stage Ta to T1 and stage T2 disease, respectively. All deaths were from unrelated causes. In contrast, for patients with stage T3 disease, cancer-specific survival was only 7% and the rate of death caused by tumor was 87%. A recent Surveillance, Epidemiology, and End Results database review of 2044 patients with a mean follow-up of 30 months showed no difference in 5-year cancer-specific mortality in segmental ureterectomy versus nephroureterectomy, adjusted for pathological stage (Jeldres et al., 2010). A more recent single institution comparison of 112 patients with ureteral cancer treated either by radical nephroureterectomy or segmental ureterectomy found no significant differences in bladder, local, or distant recurrence and no difference in survival outcomes after a mean follow-up of 44 and 48 months (Hung et al., 2014).

TABLE 99.1

Literature Review of Overall Survival of Patients With Upper Tract Urothelial Tumors (Renal Pelvis or Ureter) by Stage and Grade

5-YEAR SURVIVAL (%)	
TUMOR GRADE	
1–2	40–87
3–4	0–33
TNM STAGE	
Ta, T1, Tcis	60–90
T2	43–75
T3	16–33
T4	0–5
N+	0–4
M+	0

TNM, Tumor node metastasis.

The risk of ipsilateral recurrence after conservative treatment of ureteral tumors is 33% to 55% (Babaian et al., 1980; Johnson et al., 1979; Mazeman, 1976; McCarron et al., 1983; Williams, 1991). Most recurrences are distal to the original lesion, but proximal recurrences are also seen (Strong et al., 1976). The risk for recurrence and the need for follow-up are lifelong (Herr, 1998), because late recurrence can be seen (Grossman, 1978). These historical studies also reflect results of when ureteroscopic evaluation was much more limited. If patients have a thorough ureteroscopic evaluation and are properly selected for ureterectomy, the results are probably more favorable (Hung et al., 2014). **Segmental ureterectomy is offered for low-grade, non–muscle-invasive disease of the proximal ureter or mid-ureter that is not amenable to complete ablation by endoscopic means because of tumor size or multiplicity. Distal ureterectomy and neocystostomy may be offered for low-grade, low-stage, or in select cases, high-grade, locally invasive tumors of the distal ureter when renal preservation is necessary. As mentioned previously, in the presence of high-grade disease, consideration should also be given for lymphadenectomy.**

Endourologic Management

Basic Attributes

Hugh Hampton Young described the first endoscopic evaluation of the upper urinary tract in 1912. Subsequent advances in technology allow us to reach all parts of the urinary tract with minimal morbidity through antegrade and retrograde approaches. Diagnosis and treatment of UTUC have become possible with these improvements because tumor biopsy and ablation by various energy sources are possible even through the smallest instruments. In addition, miniaturization has made follow-up surveillance of the upper tract more practical with the use of smaller ureteroscopes, which usually do not require previous stenting, or with active dilation of the distal ureter.

Tumors of the upper urinary tract can be approached in a retrograde or antegrade fashion. The approach chosen depends largely on the tumor location and size. In general, a retrograde ureteroscopic approach is used for low-volume ureteral and renal tumors. An antegrade percutaneous approach is preferred for larger tumors of the upper ureter or kidney and for those that cannot be adequately manipulated in a retrograde approach because of location (e.g., lower pole calyx) or previous urinary diversion. In cases with multifocal involvement, combined antegrade and retrograde approaches can be considered (Fig. 99.18).

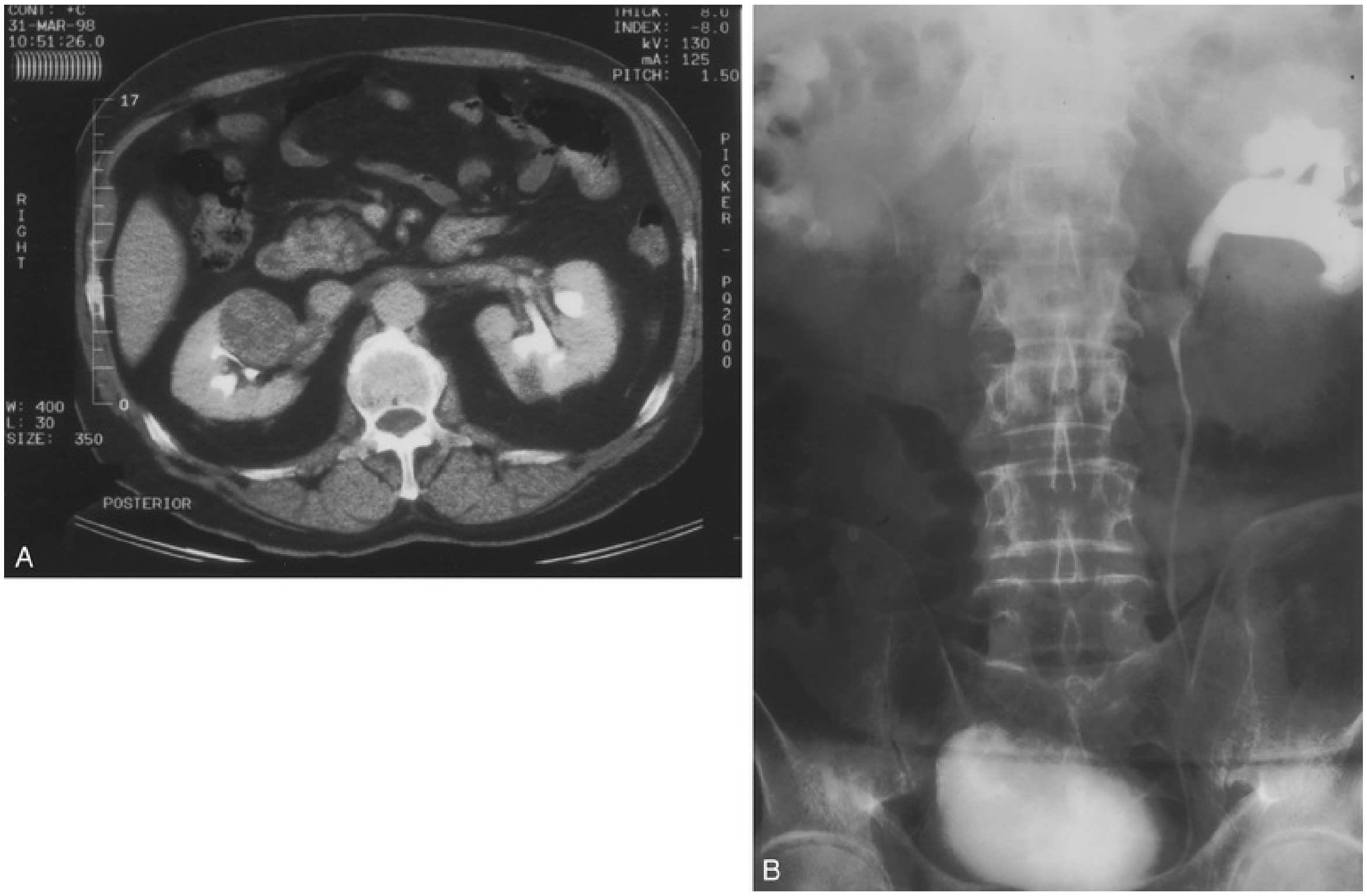

FIG. 99.18 Patient with synchronous bilateral tumors. (A) Right renal cell carcinoma that required radical nephrectomy. (B) Left proximal ureteral tumor that required combined ureteroscopic and antegrade percutaneous ablation.

The basic principles for treatment of UTUC are similar to those for the bladder counterpart (Fig. 99.19). The tumor is sampled and ablated by electrocautery or laser energy sources. Tumor grading is a valuable tool when considering a patient for endoscopic treatment. Almås et al. (2016) showed results indicating that endoscopic treatment of UTUC is safe and feasible for verified low-grade disease whereas its use for high-grade tumors has poor results. A staged procedure should be considered for high-volume disease or disease that is thought to represent high pathological grade or stage. In such cases, when subsequent nephroureterectomy most likely will be necessary for cure, only biopsy and partial ablation are performed to minimize the risks of perforation or major complications. Endoscopic management is completed only after the pathological examination shows that the patient is an acceptable candidate for continued minimally invasive endoscopic management. If the pathological process is unresectable, of high grade, or invasive, the patient should proceed immediately to nephroureterectomy. Segmental resection can be considered in cases of solitary kidney or significant renal insufficiency provided he or she is medically fit. Patients who undergo renal-sparing therapy must be committed to a lifetime of follow-up with radiographs and endoscopy.

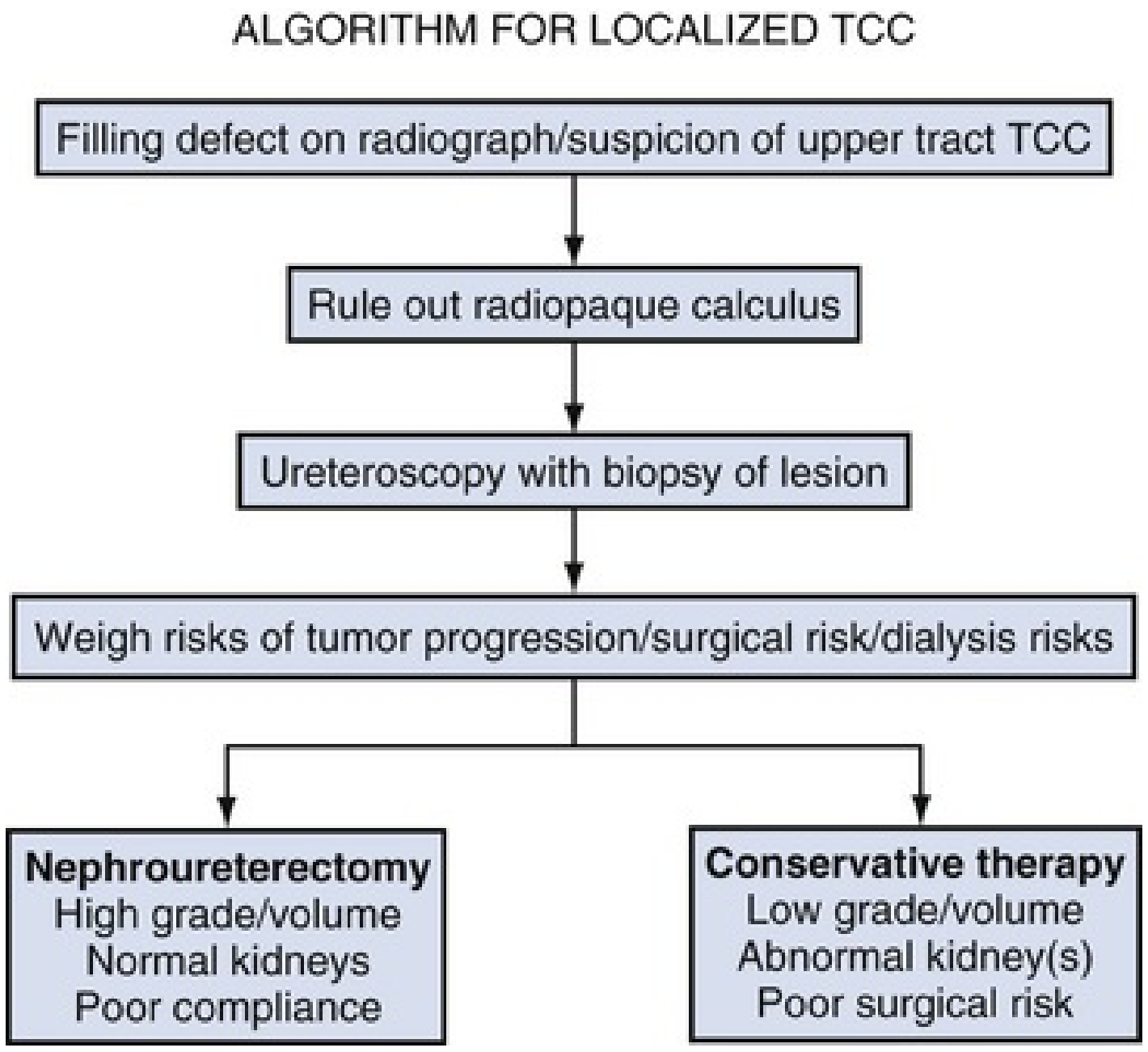
ALGORITHM FOR LOCALIZED TCC
Filling defect on radiograph/suspicion of upper tract TCC
Rule out radiopaque calculus
Ureteroscopy with biopsy of lesion
Weigh risks of tumor progression/surgical risk/dialysis risks
Nephroureterectomy
High grade/volume
Normal kidneys
Poor compliance
Conservative therapy
Low grade/volume
Abnormal kidney(s)
Poor surgical risk

FIG. 99.19 Algorithm for endoscopic approach to upper tract transitional cell carcinoma (TCC).

Retrograde Ureteroscopic

Ureteroscopy and Ureteropyeloscopy

The ureteroscopic approach to tumors was first described by Goodman in 1984 and is generally favored for ureteral and smaller renal tumors. With the advent of small-diameter rigid and flexible ureteroscopes, tumor location is less of a limiting factor than it used to be. **The advantage of a ureteroscopic approach is lower morbidity than that of the percutaneous and open surgical counterparts, with the maintenance of a closed system. With a closed system, nonurothelial surfaces are not exposed to the possibility of tumor seeding.**

The major disadvantages of a retrograde approach are related to the smaller instruments required. Smaller endoscopes have a smaller field of view and working channel. This limits the size of tumor that can be approached in a retrograde fashion. In addition, some portions of the upper urinary tract, such as the lower pole calyces, cannot be reliably reached with working instruments. Smaller instruments limit the ability to remove large tumors and to obtain deep specimens for reliable staging. In addition, retrograde ureteroscopy is difficult in patients with prior urinary diversion.

Technique and Instrumentation.

A wide variety of ureteroscopic instruments are available, each with its own distinct advantages and disadvantages. In general, rigid ureteroscopes are used primarily for the distal and mid-ureter. Access to the upper ureter and kidney with rigid endoscopy is unreliable, especially in the male patient. Larger, rigid ureteroscopes provide better visualization because of their larger field of view and better irrigation. Smaller rigid ureteroscopes (8 Fr) generally do not require active dilation of the ureteral orifice (Fig. 99.20A). Newer-generation, flexible ureteropyeloscopes are available in sizes smaller than 8 Fr to allow simple and reliable passage to most portions of the urinary tract (Abdel-Razzak and Bagley, 1993; Chen and Bagley, 2000; Chen et al., 2000; Grasso and Bagley, 1994). These are generally preferred in the upper ureter and kidney, where the rigid ureteroscope cannot be reliably passed. **Flexible ureteroscopes, however, have technical limitations, such as a small working channel, that limit irrigant flow and the diameter of working instruments. Further limitations of flexible ureteroscopy include reduced access to certain areas of the kidney, such as the lower pole, where the infundibulopelvic angle may limit passage of the scope, and prior urinary diversion** (Fig. 99.20B).

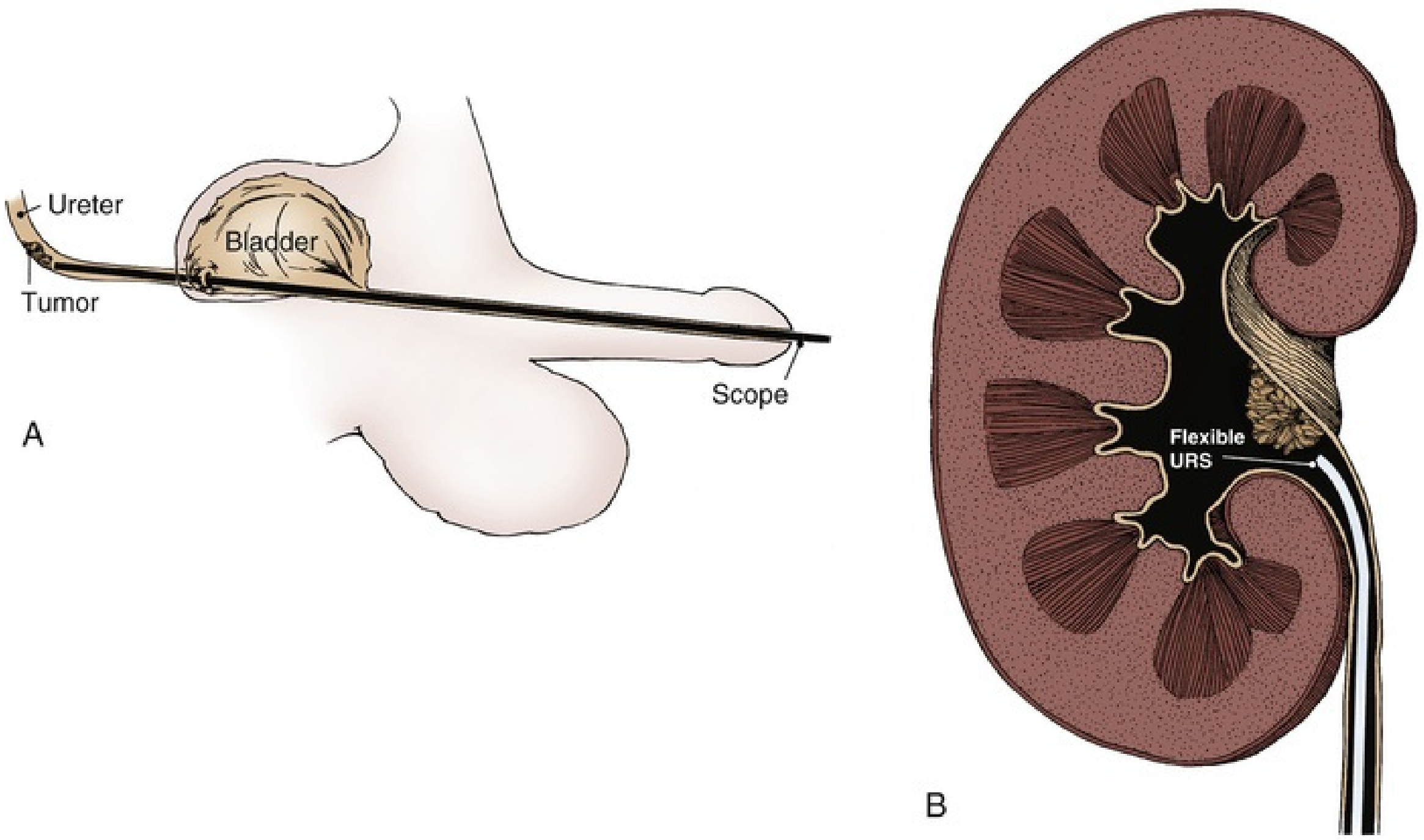

FIG. 99.20 (A) Rigid ureteroscopic approach. (B) Flexible ureteroscopic approach. *URS,* Ureteroscope.

Endoscopic Evaluation and Collection of Urine Cytology Specimen.

Cystoscopy is performed and the bladder inspected for concomitant bladder disease. The ureteral orifice is identified and inspected for lateralizing hematuria. A small-diameter (6.9 or 7.5 Fr) ureteroscope is passed directly into the ureteral orifice, and the distal ureter is inspected for any trauma from a previously placed guidewire or dilation. A guidewire is then placed through the ureteroscope and up the ureter to the level of the renal pelvis under fluoroscopic guidance. The flexible ureteroscope is used to visualize the remaining urothelium. All lesions are mapped. **When a lesion or suspicious area is seen, a normal saline washing of the area is performed before biopsy or intervention** (Bian et al., 1995). If the ureter does not accept the smaller ureteroscope, active dilation of the ureter is necessary.

There are no recommendations regarding the use of ureteral access sheaths. They provide the advantage of allowing for a low pressure system and allow for repeated access to the ureter. Larger specimens can be removed with less theoretical risk of downstream seeding because the lower ureter is bypassed during removal. The downside is the need for additional dilation of the ureteral orifice and the need for postprocedure stenting.

Tumor Confined to the Intramural Ureter

A second type of case is tumor in the intramural ureter. When a tumor protrudes from the ureteral orifice, complete ureteroscopic ablation of the tumor or aggressive transurethral resection of the entire most distal ureter can be done with acceptable results (Palou et al., 2000).

Biopsy and Definitive Treatment.

Three general approaches can be used for tumor ablation: bulk excision with ablation of the base, resection of the tumor to its base, and diagnostic biopsy followed by ablation with electrocautery or laser energy sources. Regardless of technique used, special attention to biopsy specimens is necessary. Specimens are frequently minute and should be placed in fixative at once and are specially labeled for either histologic or cytologic evaluation (Tawfiek et al., 1997).

Ureteroscopic Techniques.

The tumor is debulked by use of either biopsy forceps or a flat wire basket engaged adjacent to the tumor (Fig. 99.21A). Next, the tumor base is treated with either electrocautery or laser energy sources. This technique is especially useful for low-grade papillary tumor on a narrow stalk. The specimen is sent for pathological evaluation.

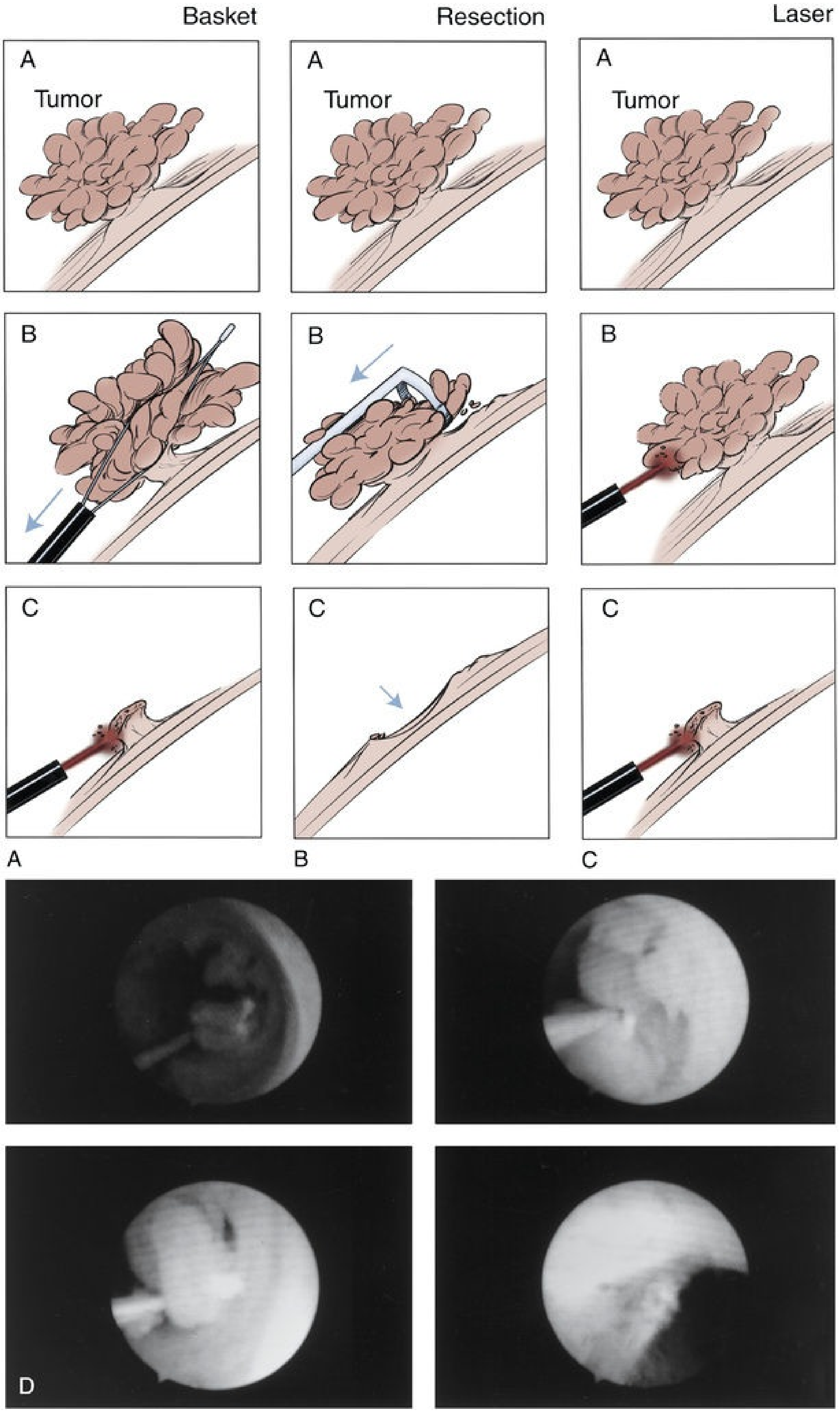
Basket
Resection
Laser
A
Tumor
A
Tumor
A
Tumor
B
B
B
C
C
C
A
B
C
D

FIG. 99.21 Techniques for ureteroscopic treatment of ureteral and renal tumors. (A) The tumor is identified and removed piecemeal by grasping forceps to its base. (B) Alternatively, a flat wire basket can be deployed alongside the tumor. The tumor is engaged and removed, with care taken not to avulse the adjacent ureter. With either of these techniques, the base is treated with electrocautery or a laser energy source. (C) The tumor is identified and removed by a ureteroscopic resectoscope. The technique differs from the technique for bladder tumors in that only intraluminal tumor is resected. No attempt is made to resect deep, as with a bladder tumor. The scope is not arching deep into the tissue. (D) The tumor is sampled for diagnostic purposes. The bulk of the tumor is then ablated with electrosurgical or laser energy. In general, laser energy is preferred because it has more reliable delivery of energy and depth of penetration. The two most commonly used energy sources are holmium:yttrium-aluminum-garnet and neodymium:yttrium-aluminum-garnet.

Alternatively, a ureteroscopic resectoscope is used to remove the tumor (Fig. 99.21B). Only the intraluminal tumor is resected, and no attempt is made to resect deep (beyond the lamina propria). Extra care is necessary in the mid-ureter and upper ureter, where the wall is thin and prone to perforation. With larger volume disease of the distal ureter, Jarrett et al. (1995a) described extensive dilation of the ureter followed by resection with a long standard resectoscope. **The tumor is adequately sampled with forceps and sent to the pathology laboratory for diagnostic evaluation. The tumor bulk is then ablated to its base with laser or electrosurgical energy** (Fig. 99.21C and D). Multiple biopsy specimens are often required when small, flexible 3-Fr biopsy forceps are used. Electrocautery delivered through a small Bugbee electrode (2 or 3 Fr) can be used to fulgurate tumors. However, the variable depth of penetration can make its use in the ureter dangerous, and circumferential fulguration should be avoided because of the high risk of stricture formation. More recently, laser energy with either neodymium:yttrium-aluminum-garnet (Nd:YAG) (Carson, 1991; Schilling et al., 1986; Schmeller and Hofstetter, 1989; Smith et al., 1984) or holmium:YAG (Ho:YAG; Bagley and Erhard, 1995; Matsuoka et al., 2003; Razvi et al., 1995; Suoka et al., 2003) sources has been popular. Each has characteristic advantages (Fig. 99.22) and can be delivered through small, flexible fibers (200 or 365 μm) that fit through small, flexible ureteroscopes without significant alteration of irrigant flow or scope deflection. The holmium:YAG laser is well suited for use in the ureter. The tissue penetration is less than 0.5 mm, which allows tumor ablation with excellent hemostasis and minimal risk of full-thickness injury to the ureter. Its shallow penetration may, however, make its use cumbersome with larger tumors, especially in the renal pelvis. Settings most commonly used for the holmium:YAG laser are energy of 0.6 to 1 J with frequency of 10 Hz. The Nd:YAG laser has a tissue penetration of up to 5 to 6 mm, depending on laser settings and duration of treatment. In contrast to the holmium:YAG laser, which ablates tumor, the Nd:YAG laser works by coagulative necrosis with subsequent sloughing of the necrotic tumor. The safety margin is significantly lower and can limit its use in the ureter, where the ureteral wall is thin. Settings most commonly used for the Nd:YAG laser are 15 W for 2 seconds for ablation of tumor and 5 to 10 W for 2 seconds for coagulation.

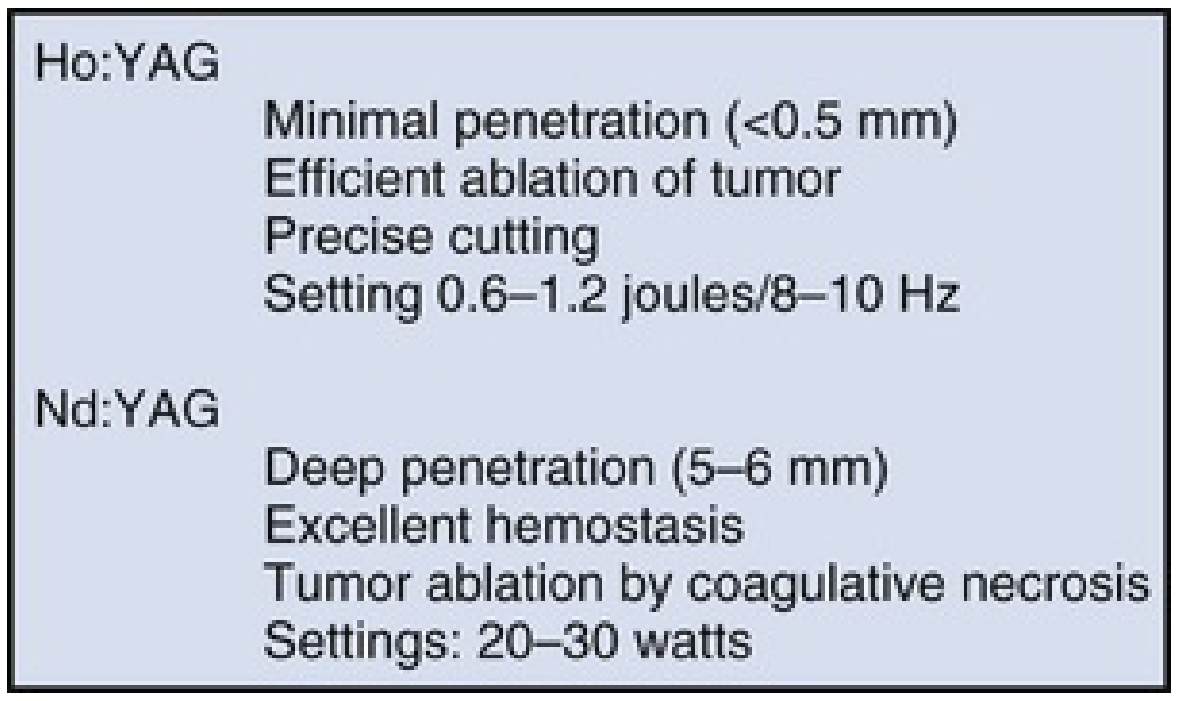

Ho:YAG

- Minimal penetration (<0.5 mm)
- Efficient ablation of tumor
- Precise cutting
- Setting 0.6–1.2 joules/8–10 Hz

Nd:YAG

- Deep penetration (5–6 mm)
- Excellent hemostasis
- Tumor ablation by coagulative necrosis
- Settings: 20–30 watts

FIG. 99.22 Characteristics of holmium:yttrium-aluminum-garnet (Ho:YAG) and neodymium:yttrium-aluminum-garnet (Nd:YAG) laser energy sources.

A ureteral stent is placed for a variable duration to aid with the healing process. Large tumors usually require multiple treatment sessions during several months.

Results

There are no published series of randomized controlled trials comparing endoscopic therapy and nephroureterectomy, and all are case series (level 4 evidence). Multiple series have shown the safety and efficacy of ureteroscopic treatment of UTUC (Cutress et al., 2012; Daneshmand et al., 2003; Gadzinski et al., 2010; Krambeck et al., 2007; Lucas et al., 2008; Thompson et al., 2008). See Table 99.2 for a summary of the largest current series. In a literature review of 736 patients (Cutress et al., 2012), the overall recurrence rates for upper tract was 53%, and the risk of bladder recurrence was 34%. Disease progression was present in 15% with 9% recurring with metastatic disease. The failure rate of ureteroscopic therapy was 24% with 19% undergoing subsequent nephroureterectomy. There was, however, considerable bias for favorable tumor characteristics (unifocal, low grade, and small tumor size). As with any urothelial cancer, the most important prognostic indicator for tumor recurrence was grade. Cutress et al. (2012) showed the upper tract recurrence rate for grades 1, 2, and 3 lesions to be 52%, 54%, and 76%, respectively. The upper tract recurrence rate and disease-free survival were worse with higher-grade tumors.

TABLE 99.2

Ureteroscopic Management

STUDY	NUMBER OF PATIENTS	FOLLOW-UP (mo)	UPPER TRACT RECURRENCE (%)	BLADDER RECURRENCE (%)	NEPHRO RATE (%
Martínez-Piñeiro et al., 1996	54	31	23	ND	10
Daneshmand et al., 2003	30	31	90	23	13
Johnson et al., 2005	35	52	68	ND	3
Gadzinski et al., 2010	34	18	31	15	ND
Pak et al., 2009	57	53	90	ND	19
Thompson et al., 2008	83	55	55	45	33
Cutress et al., 2012	73	54	69	43	19

ND, Not disclosed.

Modified from Cutress ML, Stewart GD, Zakikhani P, et al.: Ureteroscopic and percutaneous management of upper tract urothelial carcinoma (UTUC): systematic review. *BJU Int* 110:614–628, 2012.

The literature shows the long-term feasibility of the ureteroscopic approach, but concerns over the high rate of ipsilateral recurrences remain. Daneshmand et al. (2003) reported a large number of recurrences with an overall ipsilateral recurrence rate of 90% with three to four recurrences per patient. Cutress et al. (2012) reported 5-year recurrence-free survival of 13% to 54% in the largest series. This is important in considering patients with a normal contralateral kidney. Patients must be counseled in the need for lifetime follow-up and possible treatment of ipsilateral recurrence.

Complications were uncommon and usually related to the patient's comorbidities. Complications specific to ureteroscopic therapy were 14% (Cutress et al., 2012) and included ureteral perforation, which can be managed with indwelling ureteral stent; ureteral stricture occurred in 11%. The complication rates seemed to have dropped in more contemporary series, most likely related to smaller endoscopes, improved laser energy sources, and refinements in endoscopic techniques.

Two major concerns of the ureteroscopic approach are the accuracy of ureteroscopic biopsies and the limitations of biopsies, especially with regard to staging. Retrospective reviews of patients who underwent ureteroscopic biopsy followed by nephroureterectomy found the accuracy of ureteroscopic diagnosis to be 89% to 94% and the pathological grading to match the open surgical technique in 70% to 92% (Guarnizo et al., 2000; Keeley et al., 1997a; Smith et al., 2011). From prior studies, we know that there is a good correlation between grade of lesion and stage (Chasko et al., 1981; Heney et al., 1981). This holds true for the ureteroscopic approach (Keeley et al., 1997b) because 87% of patients with grade 1 or grade 2 tumors had noninvasive disease (stage Ta or T1), whereas 67% of patients with grade 3 tumors had invasive disease (stage T2 or T3). This information supports the notion that tumor grade is the most important prognostic factor and, although stage cannot be directly assessed, noninvasive disease can be expected in most cases of low-grade tumor.

A final concern is whether ureteroscopy promotes progression or spread of disease to other urothelial surfaces or metastatic sites. There have been reports of increased tumor appearance in refluxing ureters of patients with bladder tumors (de Torres Mateos et al., 1987) and in the ipsilateral urinary tract and bladder of patients after ureteroscopic treatment. However, Kulp and Bagley (1994) reported on 13 patients who underwent multiple ureteroscopic treatments followed by nephroureterectomy; they found no unusual propagation of cancer in the specimens. Concerns that ureteroscopy may promote metastatic spread were raised by Lim et al. (1993), who found tumor cells in renal lymphatics after ureteroscopy. However, Hendin et al. (1999) reported no increased risk of metastatic disease in a group of patients who underwent ureteroscopy before nephroureterectomy compared with a group undergoing nephroureterectomy alone.

Antegrade Nephroureteroscopic

The percutaneous approach was first described by Tomera et al. in 1982 and is generally favored for larger tumors located proximally in the renal pelvis or proximal ureter. **The main advantage of the percutaneous approach is the ability to use larger instruments that can remove a large volume of tumor** in any portion of the renal collecting system. The EAU recommends against endoscopic therapy for tumors greater than 1 cm (Roupret et al., 2018); however, multiple reports have shown successful treatment of larger tumors (Cutress et al., 2012). Because deeper biopsy specimens are obtained, tumor staging as well as grading is usually possible. In addition, a percutaneous approach may avoid the limitations of flexible ureteroscopy, especially in complicated calyceal systems or areas difficult to access, such as the lower pole calyx or the upper urinary tract of patients with urinary diversion. With a percutaneous approach, the established nephrostomy tract can be maintained for immediate postoperative nephroscopy and administration of topical adjuvant therapy.

The main disadvantages are the increased morbidity compared with ureteroscopy and the potential for tumor seeding outside the urinary tract. Establishment of the nephrostomy tract has inherent risks, and the procedure usually requires inpatient admission. Distinct risks related to a percutaneous approach are loss of urothelial integrity and exposure of nonurothelial surfaces to tumor cells. This open system provides the possibility of tumor implantation in the nephrostomy tract.

Technique and Instrumentation

Establishment of the Nephrostomy Tract.

Cystoscopy is performed, and an open-ended ureteral catheter is positioned in the pelvis. Contrast material is injected to define the calyceal anatomy, and a percutaneous nephrostomy tract is established through the desired calyx (Fig. 99.23). If the patient is in the prone split-leg position, a flexible ureteroscope can be passed to the desired area and renal access obtained under direct and fluoroscopic guidance. Tumors in peripheral calyces are best approached with direct puncture distal to the tumor (Fig. 99.24), avoiding trauma to or direct puncture into the tumor. Disease in the renal pelvis and upper ureter is best approached through an upper or middle pole access to allow scope maneuvering through the collecting system and down the ureteropelvic junction. The tract is dilated by either sequential (Amplatz) or balloon dilation to accommodate a 30-Fr sheath. Correct positioning of the nephrostomy tract is crucial to the success of the procedure and should be done by the urologist or by the radiologist after direct consultation with the operating surgeon. Some practitioners prefer to perform this in two stages, with establishment of a tract first and allowing this to mature over 1 to 2 weeks, followed by tract dilation and treatment. Alternatively, if only a diagnostic procedure must be performed, such as evaluation of a positive cytology after cystectomy and diversion, the initial smaller nephrostomy tract may be used to introduce a flexible ureteroscope. Otherwise, a nephroscope is inserted, and the ureteral catheter is grasped, brought out the tract, and exchanged for a stiff guidewire, thus providing antegrade and retrograde control. Complete nephroscopy is performed with rigid and flexible endoscopes when necessary. Any suspicion of upper ureteral involvement warrants antegrade ureteroscopy.

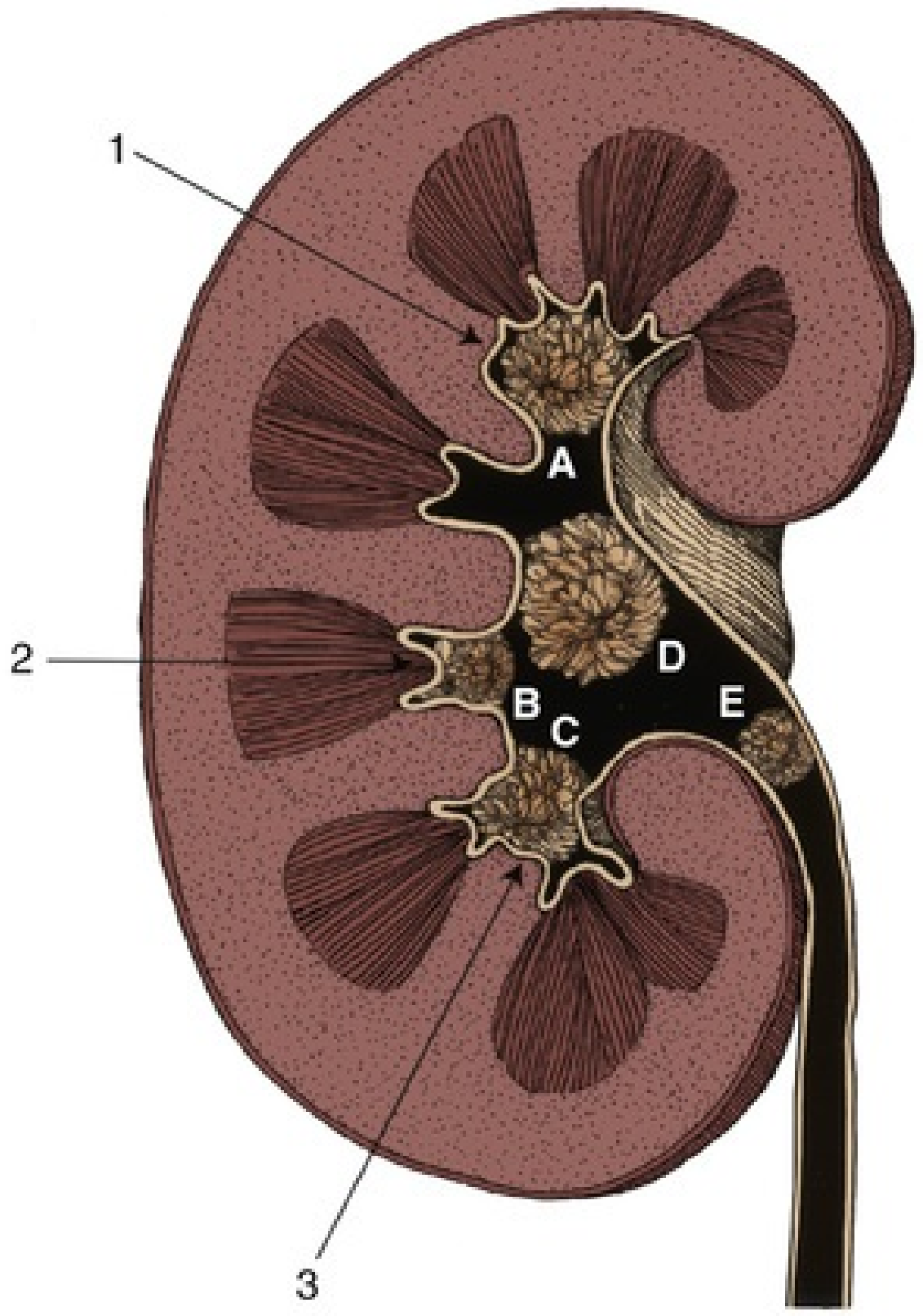

FIG. 99.23 Nephrostomy tract puncture site. Position of the nephrostomy is imperative for successful percutaneous resection of transitional cell carcinoma of the renal collecting system and upper ureter and requires careful preoperative evaluation of radiographs for tumor location. Tumors in

peripheral calyces (*A* to *C*) are best approached by direct puncture as far distally in the calyx as possible. Tumors in the renal pelvis *(D)* and upper ureter *(E)* are best approached by puncture to an upper *(1)* or middle *(2)* calyx, which allows the scope to be maneuvered in the renal pelvis and down the ureter. Tumors in the lower calyx are approached by lower calyx puncture *(3)*.

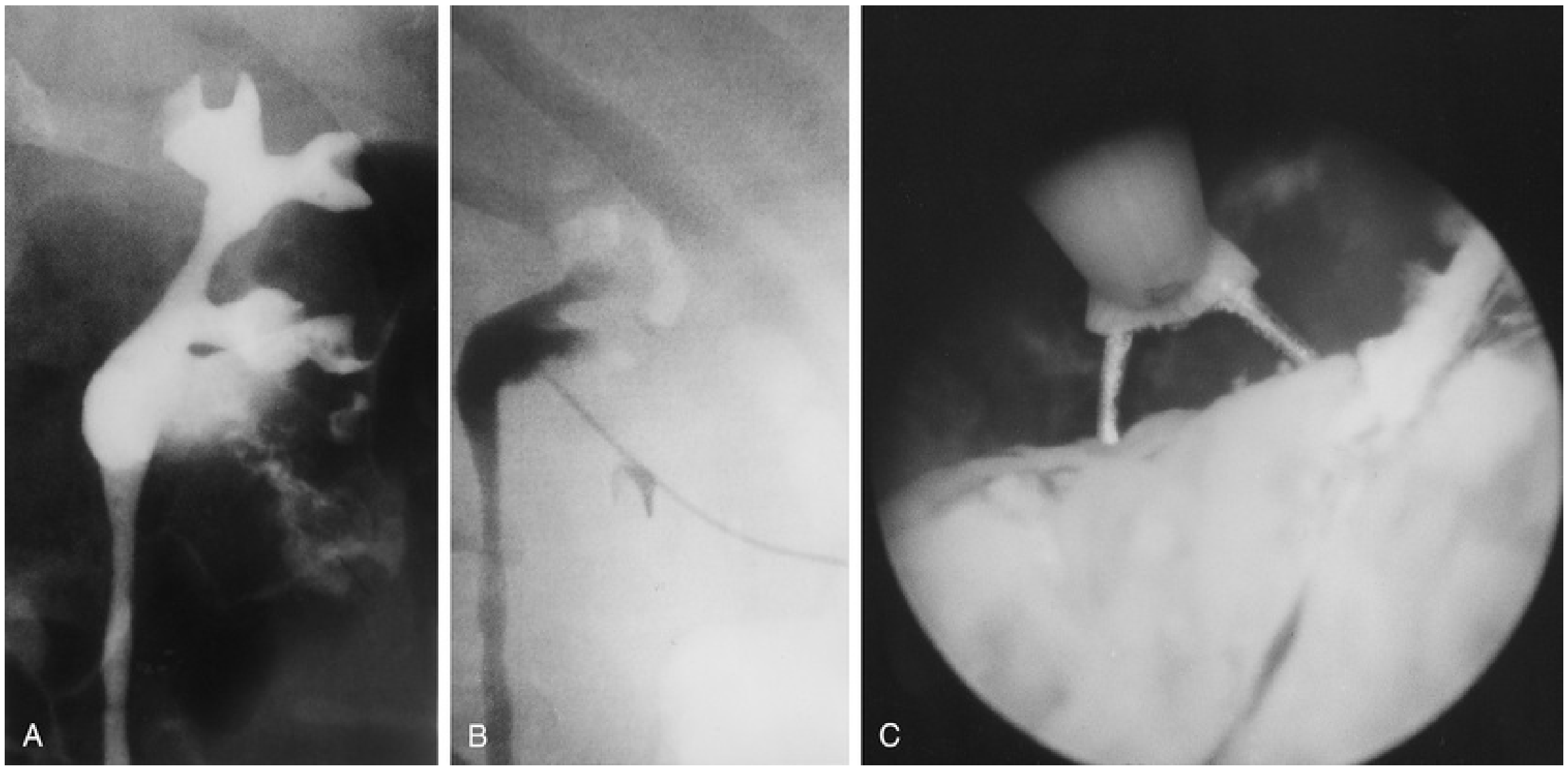

FIG. 99.24 (A) Retrograde pyelogram of a man with transitional cell carcinoma of the lower calyx in a solitary kidney. (B) Access distal in the calyx allows a clear view of the tumor. (C) Subsequent resection.

Biopsy and Definitive Therapy.

After identification, the tumors are removed by one of the following three techniques. In the first technique, which uses a cold-cup biopsy forceps through a standard nephroscope, the bulk of the tumor is grasped by forceps and removed in piecemeal fashion until the base is reached (Fig. 99.25A). A separate biopsy of the base is performed for staging purposes, and the base is cauterized with a Bugbee electrode and cautery. Low-grade papillary lesions on a thin stalk are easily treated in this manner with minimal bleeding.

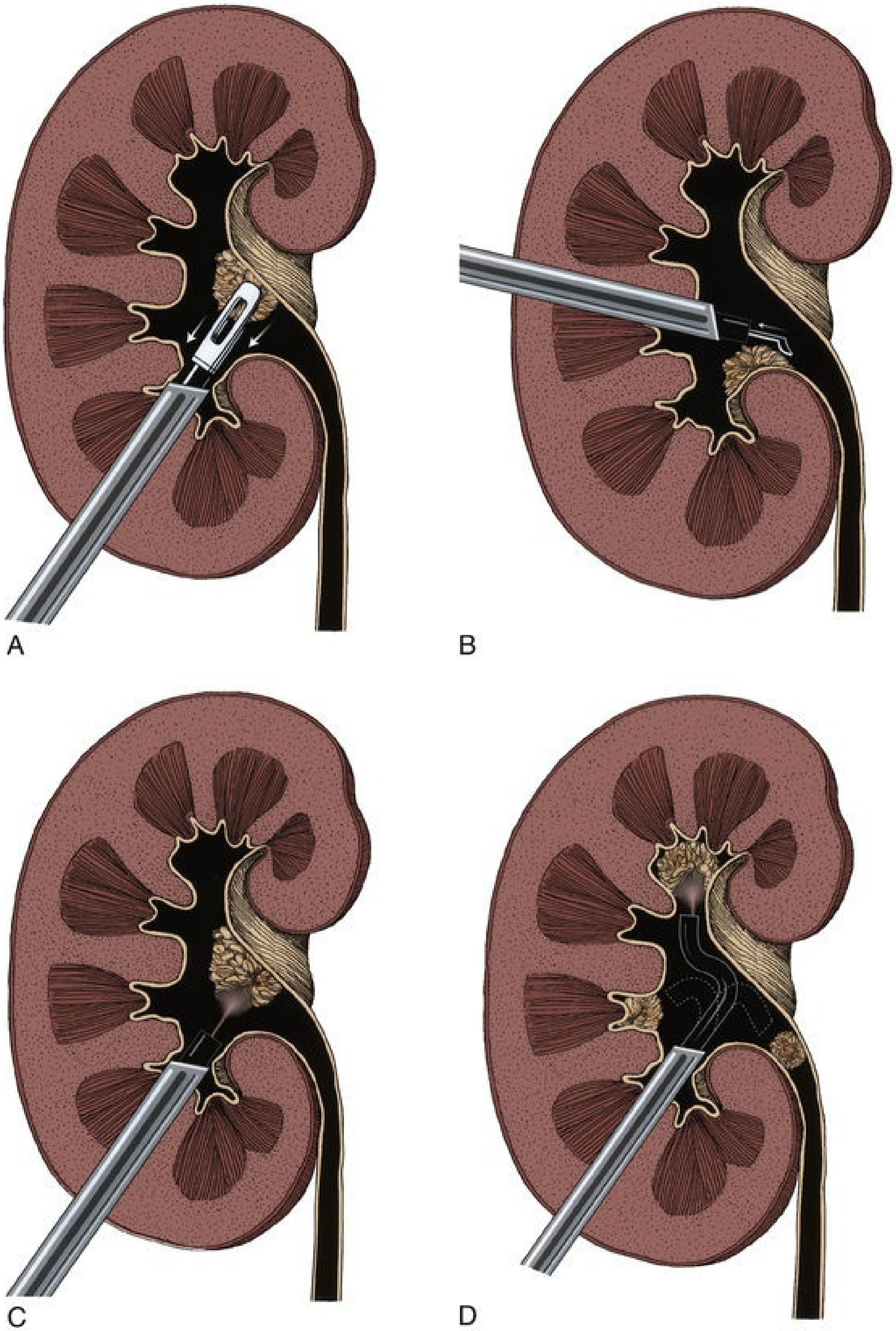

FIG. 99.25 Techniques for percutaneous removal of transitional cell carcinoma of the renal collecting system. (A) The tumor is identified and debulked by forceps to its base. The base is sampled and sent separately

for evaluation. This technique works well for papillary tumors on a narrow stalk. Broad-based tumors may cause excessive bleeding and are best approached with resection or laser therapy. (B) With use of a standard resectoscope, the tumor is identified and resected to its base. Special care should be taken to avoid resection into major renal vasculature. The tumor is identified, sampled for diagnostic purposes, and treated by holmium or neodymium laser sources. This can be done through a standard nephroscope (C) or with a flexible cystoscope (D).

Alternatively, a cutting loop from a standard resectoscope or bipolar resectocope is used to remove the tumor to its base (see Fig. 99.25B). A monopolar resection does carry the risk of absorption of large volumes of hypo-osmotic irrigant, and thus bipolar resection may be preferred. Once again, the base should be resected and sent separately for staging purposes. This approach is more effective for larger, broad-based tumors for which simple debulking to a stalk is not possible.

For the third technique, which uses flexible or rigid endoscopes, the tumor is sampled and treated with a holmium:YAG or Nd:YAG laser at 25 to 30 W (Fig. 99.25C and D). Tissue may also be obtained with a small snare used for gastrointestinal polyps.

Regardless of approach, a nephrostomy tube is left in place. This access can be used for second-look follow-up nephroscopy to ensure complete tumor removal (Fig. 99.26). Nephroureterectomy is indicated if the pathological examination shows high-grade or invasive disease.

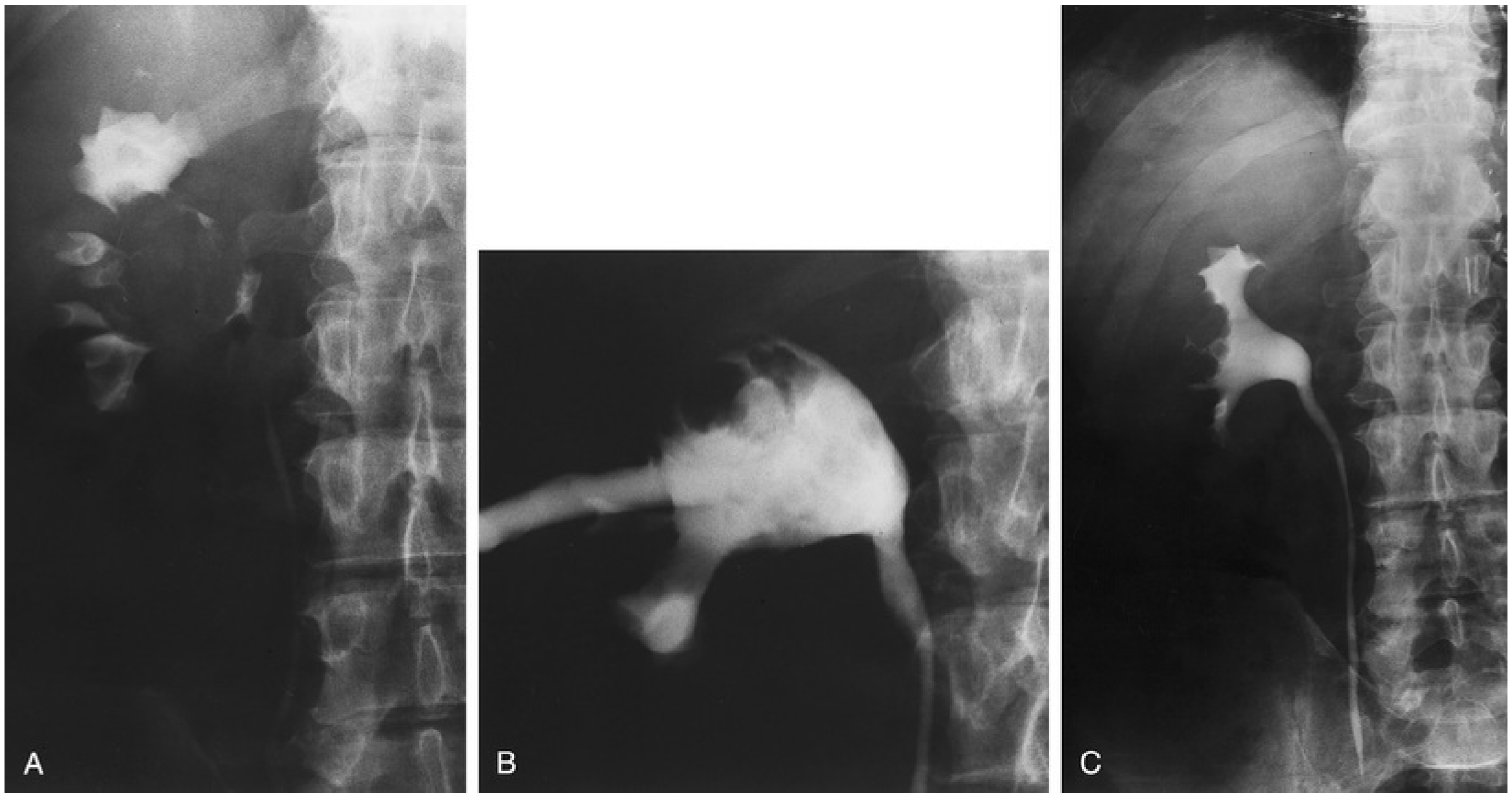

FIG. 99.26 (A) A 65-year-old man with a solitary kidney and a 5-cm renal pelvis tumor. (B) Nephrostogram after patient underwent staged resection. (C) Three-month follow-up retrograde pyelogram after completed resection. The patient showed grade 1 transitional cell carcinoma without invasion to submucosa.

Second-Look Nephroscopy.

Follow-up nephroscopy is performed 4 to 14 days later to allow adequate healing. The tumor resection site is identified, and any residual tumor is removed. If no tumor is identified, the base should be sampled and treated by cautery or the Nd:YAG laser (15 to 20 W and 3-second exposures). The nephrostomy tube can be removed several days later if all tumors have been removed. If the patient is being considered for adjuvant topical therapy, a small, 8-Fr nephrostomy tube is left to provide access for instillations. Some authors advocate third-look nephroscopy before removal of the nephrostomy tube (Jarrett et al., 1995b).

Results

As with the ureteroscopic approach, there are no randomized controlled trials and only limited contemporary case series (Table 99.3) with adequate numbers and follow-up from which to draw reasonable conclusions (Goel et al., 2003; Palou et al., 2004; Rastinehad et al., 2009; Roupret et al., 2007). In the longest series to date, Motamedinia et al. (2015) had an average follow-up of 76.9 months and had 87% for imperative conditions and 90% for elective conditions. In a literature review of 288 patients, Cutress et al. (2012) found an overall recurrence rate of upper tract recurrence rate of 26% and a bladder recurrence rate of 31%. Failed endoscopic management occurred in 32% with a nephroureterectomy rate of 22%. Disease progression occurred in 17% with 6% advancing to metastatic disease. As expected, tumor grade strongly predicted outcomes. Cutress et al. (2012) showed the upper tract recurrence rate for grades 1, 2, and 3 lesions to be 23%, 30%, and 40%, respectively. Lee et al. (1999) reviewed their 13-year experience with percutaneous management, comparing 50 patients who underwent percutaneous management with 60 patients who underwent nephroureterectomy and found no significant difference in overall survival. As expected, patients with low-grade disease did well regardless of modality and patients with high-grade disease did poorly regardless of treatment option.

TABLE 99.3

Percutaneous Management

STUDY	NUMBER OF PATIENTS (%)	FOLLOW-UP (mo)	UPPER TRACT RECURRENCE (%)	BLADDER RECURRENCE	NEPHROU RATE (%)
Jarrett et al., 1995b	36	55	33	ND	42
Patel et al., 1996	26	45	35	42	19
Goel et al., 2003	20	64	65	15	50
Palou et al., 2004	34	51	44	ND	26
Roupret et al., 2007	24	62	13	17	21
Rastinehad et al., 2009	89	61	33	ND	13

ND, Not disclosed.

Modified from Cutress ML, Stewart GD, Zakikhani P, et al.: Ureteroscopic and percutaneous management of upper tract urothelial carcinoma (UTUC): systematic review. *BJU Int* 110:614–628, 2012.

Most would agree from the literature that percutaneous management is acceptable in patients with low-grade (grade 1) disease regardless of the status of the contralateral kidney, provided the patient is committed to lifelong endoscopic follow-up. Patients with high-grade or grade 3 disease do poorly regardless of modality chosen but should probably undergo nephroureterectomy to maximize cancer therapy (provided they are medically fit). The largest area of controversy surrounds the use of percutaneous management for patients with grade 2 disease and a normal contralateral kidney. With more invasive lesions, the potential for disease progression and metastatic disease is significant and nephroureterectomy should be considered. Interestingly, there appears to be a lower rate of upper tract recurrence with a percutaneous approach when compared with the ureteroscopic approach. Cutress et al. (2012) showed a 52% upper tract recurrence compared with 37% for ureteroscopy when comparing pooled data.

Complications from percutaneous management of tumors are similar to those for benign renal processes and include bleeding, systemic absorption of hypo-osmotic irrigation (with monopolar resection), perforation of the collecting system, and secondary ureteropelvic junction obstruction. Cutress showed the overall complication rate to be 27%; transfusion, dialysis, and renal failure were the most significant. Complications increase in number and severity with higher tumor grade (Jarrett et al., 1995a). This finding is probably due to the more extensive pathological process and treatments necessary to eradicate the tumor. Unlike ureteroscopic resection, the percutaneous method can stage tumors and, as expected, stage increases with tumor grade.

A major concern of the percutaneous approach is the potential seeding of nonurothelial surfaces with tumor cells. There have been limited reports of nephrostomy tract infiltration with high-grade tumors. Schwartzmann et al. (2017) reported on their only instance and summarized 7 additional case reports. All were high-grade tumors with 5 of urothelial and 3 of squamous histology. Cutress et al. (2012), however, only showed a 0.3% overall rate of tumor seeding in a large review of the percutaneous approach. Tract seeding is a possibility but appears to be an uncommon event.

Consideration for Urinary Diversions

With cases of prior urinary diversion, identification of the ureteroenteric anastomosis is difficult and may require antegrade percutaneous passage of a guidewire down the ureter before endoscopy. For conduits and neobladders, a trial with flexible endoscopy into the diversion and identification of the ureteroenteric anastomosis is reasonable. Knowledge of the type of anastomosis is essential. For conduits, knowledge location of the ureters (i.e., Wallace vs. Bricker) is essential to location of the ureters. Similarly with a neobladder, identification is also possible provided the pouch anatomy is known (i.e., Studer). Identification of the ureters is usually not possible with a catheterizable continent urinary diversion. With all types of diversion, if the ureters are not identifiable, antegrade passage of a wire into the pouch may be necessary by the urologist or with the assistance of interventional radiology. The wire can be retrieved from the diversion, and the ureteroscope can be passed in a retrograde fashion. The nephrostomy tract does not have to be fully dilated in this setting. Wagner et al. (2008) described their experience with endoscopic monitoring of patients with ureteral carcinoma in situ (CIS) after radical cystectomy. If this is not possible, then dilation of the tract and antegrade uretero-nephroscopy may be necessary.

Management of Positive Upper Tract Urinary Cytology and Carcinoma in situ

Evaluation

An unequivocal positive voiding urinary cytology usually indicates the presence of urothelial carcinoma. Most cases are from a bladder source; however, extravesical sites may be involved, including the upper urinary tracts and the prostatic urethra in men. Often the diagnosis is difficult because of the limitations of radiographic evaluation of upper tracts and the complexity of upper tract endoscopy compared with the bladder. In addition, the interpretation of minute pathological specimens of the upper urinary tract makes precise histologic diagnosis and staging difficult. Fig. 99.27 outlines the algorithm for management of a positive urinary cytology as described by Schwalb et al. (1994). The cytology must be repeated to confirm the findings. The next step involves radiographic evaluation of the upper tracts, usually with CT urography and a complete bladder evaluation including bladder biopsies and tumor resection if tumor is present. If the bladder evaluation was positive for urothelial carcinoma, the initial treatment at that point is to treat the bladder with either intravesical therapy and/or tumor resection and follow the voided urinary cytologies. If these remain positive despite a negative bladder evaluation or after successful treatment of the bladder, then one should proceed to evaluating extravesical sites and consider repeat bladder evaluation at the same time. Evaluation of extravesical sites should include selective cytologies from each upper urinary tract, ensuring noncontamination of the specimen from the bladder or urethra, retrograde pyelograms (if not evaluated or visualized on CT urogram), as well as resection of a representative specimen of the prostatic urethra in men. Ureteroscopy can also be done at this time to allow for direct visualization of the upper urinary tracts, or done once the positive cytology is lateralized.

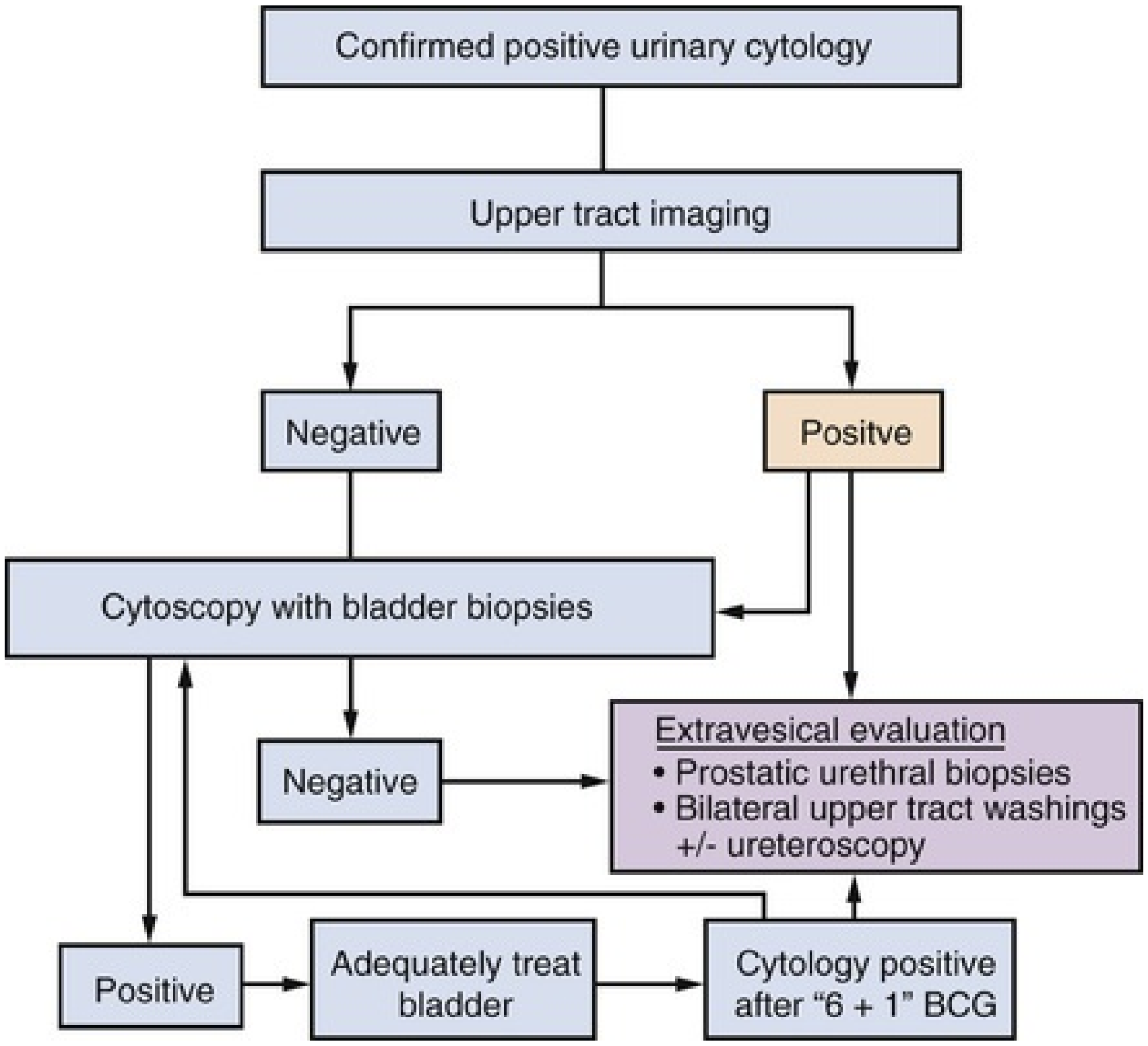
Confirmed positive urinary cytology
Upper tract imaging
Negative
Positve
Cytoscopy with bladder biopsies
Negative
Extravesical evaluation
• Prostatic urethral biopsies
• Bilateral upper tract washings +/- ureteroscopy
Positive
Adequately treat bladder
Cytology positive after "6 + 1" BCG

FIG. 99.27 Algorithm for management of a positive urinary cytology.

Carcinoma in situ of the Upper Urinary Tracts

The diagnosis of isolated CIS of the upper urinary tracts is a difficult one because of the inability to evaluate the urothelium of the upper tracts with adequate tissue samples. **In most cases the diagnosis is one of exclusion, wherein there is a persistent positive selective cytology in the absence of any ureteroscopic and radiographic findings** (Redrow et al., 2016). This is to be distinguished from cases in which CIS is coexistent with a high-grade papillary UTUC, in which case radical and possibly multimodal treatment is indicated, as the presence of CIS in addition to papillary tumors is associated with significantly worse recurrence-free and cancer-specific survival (Otto, 2011; Wheat, 2012). Treatment for isolated upper tract CIS is not well established: radical nephroureterectomy was performed in the past for a unilateral cytologic abnormality of the upper tract (Gittes, 1980; McCarron et al., 1983; Messing et al., 1998; Williams, 1991). This practice may not be recommended in the modern era. Upper tract cytology has the same limitations in specificity as bladder cytology. Furthermore, properly collected upper tract samples are of limited volume and cell count compared with bladder washings. Any source of inflammation, such as urinary infection or calculus, may produce a false-positive result. A subsequent cytologic abnormality from the contralateral side during follow-up is not rare in cases of true-positive results from early CIS (Khan et al., 1979; Murphy et al., 1974). There is one large series and many small series of topical therapy of the upper tract with immune therapy and chemotherapy via retrograde and antegrade approaches with variable response rates. Patients with CIS appear to do equally as well as their bladder counterparts in these limited, retrospective studies (Giannarini et al., 2011; Redrow et al., 2016) (see the section on topical therapy for results of topical therapy for upper tract CIS). Placement of a nephrostomy tube seems to be the more reliable delivery system; alternatively, a weekly cystoscopy can be performed and a ureteral catheter placed in the upper calyx (Metcalfe et al., 2017). Most would not intervene initially with surgical intervention in the absence of any histologic, radiographic, or endoscopic finding because of the limitations of cytology alone with false-positive results and the high risk for bilateral disease in the future. In addition, segmental resection is usually not effective in addressing the problem because of the field-effect nature of the disease. Nephroureterectomy is, however, indicated with radiographic or endoscopic confirmation that the patient has more than just surface disease. Frequent-interval re-evaluation with urinalysis, bladder and possible selective cytology, cystoscopy every 3 months, and retrograde pyelography or ureteropyeloscopy every 6 months are indicated for 1 to 2 years.

Another scenario is CIS of ureteral margins during radical cystectomy. There is controversy over the proper management of this finding, which definitely confers a risk of disease progression but may require a long follow-up time to demonstrate a recurrence. However, many do not progress, and when they do, recurrences may not be isolated to the distal ureteral margin. Wagner et al. (2008) studied a select group with serial endoscopy and found that recurrences were found at the site of the margin and at other sites. Herr et al. (1996) showed that many did not show any tumor at the margin site but did show a high risk of overall disease progression to death from metastatic disease. Whalen et al. (2015) performed 590 intraoperative ureteral frozen sections in 241 patients. These were positive in 12.9% of cases, and conversion to negative was accomplished in 82%. The authors showed that conversion from positive to negative was associated with improved survival.

Expectant Management

There is very little information on the role of active surveillance. UTUC was originally not thought to be amenable to active surveillance because of the risks of disease progression especially with high-risk disease, flank pain, chronic hematuria, and urinary tract obstruction. Some recent studies have shown that this approach can be considered in selected cases. Syed et al. (2018) reported on a group of patients diagnosed with UTUC but not treated and found a marked decrease overall survival in the untreated group (1.9 vs. 7.8). Thus for patients with a very short life expectancy, this approach may be chosen.

Adjuvant Topical Therapy

Adjuvant Intravesical Topical Chemotherapy After Nephroureterectomy to Decrease Bladder Recurrence.

Patients with upper urinary tract tumors have a 30% to 50% risk for development of bladder cancer after nephroureterectomy (Hisataki et al., 2000; Ito et al., 2013; Kakizoe et al., 1980; Kang et al., 2003; O'Brien et al., 2011). Most recurrences in the bladder are likely a result of seeding and occur within 2 years (Catto et al., 2006; Kang et al., 2003; Takahashi et al., 2001). Data already exist showing the efficacy of mitomycin-C, and most recently, gemcitabine (Messing et al., 2017) to reduce post-transurethral resection of bladder tumor (TURBT) recurrences. Two randomized controlled studies have definitively shown a decreased risk of recurrence with use of a single postoperative dose of topical chemotherapy after nephroureterectomy. O'Brien et al. (2011) first showed that a single intravesical dose of mitomycin-C was able to reduce the risk of bladder tumor from 28% in the control arm to 16% in the mitomycin arm within the first year after nephroureterectomy. In that study, mitomycin was given at variable times and biopsy confirmation of bladder recurrence was not required. Another randomized prospective study by Ito et al. (2013) using a single dose of intravesicular pirarubicin showed reduction of bladder recurrence at 2 years from 42% in the control arm to 17% in the pirarubicin arm. In the Ito et al. study, treatment was given consistently within 5 days and biopsy confirmation of disease was required. Interestingly, given the differences in study design and different drugs used, the results of both studies are remarkably similar at the 1-year mark. Finally and most importantly, both studies consistently showed a very low rate of adverse effects and good tolerance in patients. **Perioperative single-dose intravesical chemotherapy should now be considered as a standard of care for prevention of bladder cancer after nephroureterectomy.**

Technique

Within 3 to 7 days after nephroureterectomy and with the catheter still in place from surgery, patients undergo cystogram to confirm absence of leakage from the site of bladder cuff resection. If the scan is negative, a single dose of mitomycin, gemcitabine, or other proven chemotherapeutic is instilled into the bladder, and the catheter is clamped, allowing a dwell time of at least 1 and up to 2 hours. Patients should be instructed to arrive for treatment relatively dehydrated, and in the case of mitomycin, have been alkalinized with oral sodium bicarbonate starting the day prior (1 to 1.5 g sodium bicarbonate at night and in the morning on treatment day). Some of the authors have made two changes to the protocol as described in prior studies. Given the newer data on the efficacy of gemcitabine after TURBT (Messing et al., 2017), especially because of its efficacy for low- and high-grade disease, some have switched to the use of this compound instead of mitomycin. In addition, it does not require urinary alkalinization for optimized efficacy. Another major change has been to instill the gemcitabine *at the time of nephroureterectomy*. The rationale for this change is the following: (1) it does not require the patient to return for cystogram and an additional clinic visit; (2) it allows for possible earlier removal of the urinary catheter after surgery and before discharge; (3) it would preclude situations when leakage at the site of the bladder cuff would result in treatment being canceled; and (4) it is given, theoretically, at the most effective time period when seeding is thought to occur. In cases of intraoperative chemotherapy instillation, the following steps are taken. A 2- or 3-way urinary catheter is placed either on the sterile field or sterilely off the field, and the bladder is drained, after which the chemotherapy can be administered intravesically before the surgery is started. A clamp is placed on the outflow (also on inflow if using a 3-way catheter; we do this when the catheter is placed off the sterile field to allow the nursing circulator to easily irrigate the bladder using attached irrigation tubing). The anesthesia team is requested to minimize intravenous fluid administration because the bladder will be clamped for 1 to 2 hours. After surgery has started, once the ureter is clipped below the level of the tumor and after at least 1 and up to 2 hours of dwell time, the circulator can remove the clamp(s) and drain the bladder. By the time surgical dissection reaches the distal ureter and bladder cuff, the bladder has been fully drained of the chemotherapy. In addition, the use of the 3-way catheter allows additional bladder irrigation to wash out any possible residual chemotherapy, and after closure of the cystotomy, confirmation of a watertight closure of the cystotomy site.

After Organ-Sparing Therapy

Any procedure short of extirpative surgery has a higher local recurrence because of the established risk of ipsilateral recurrence. Several approaches are available to minimize these risks and that consist of reliable instillation of immunotherapeutic or chemotherapeutic agents to the upper tract.

Instillation Therapy.

Instillation therapy is used in two settings for treatment of UTUC, namely as primary treatment for CIS, and as adjuvant therapy after endoscopic or organ-sparing therapy. Delivery of the agents presents an additional challenge and can be accomplished in several ways. Accepted, reliable techniques include antegrade instillation through a nephrostomy tube (Fig. 99.28) and retrograde instillation directly via a ureteral catheter. Attempting to induce reflux in a patient using an indwelling ureteral stent or by iatrogenically created vesicoureteral reflux appears to be an unreliable method of effective drug administration to the upper tracts and is not recommended. Patel and Fuchs (1998) described a technique of outpatient instillation through a ureteral catheter placed suprapubically, but given the concern over tumor implantation, this technique is not recommended. Regardless of the technique chosen, administration to the upper urinary tract should be done under low pressure and in the absence of active infection to minimize the risk of bacterial sepsis or systemic absorption of the agent.

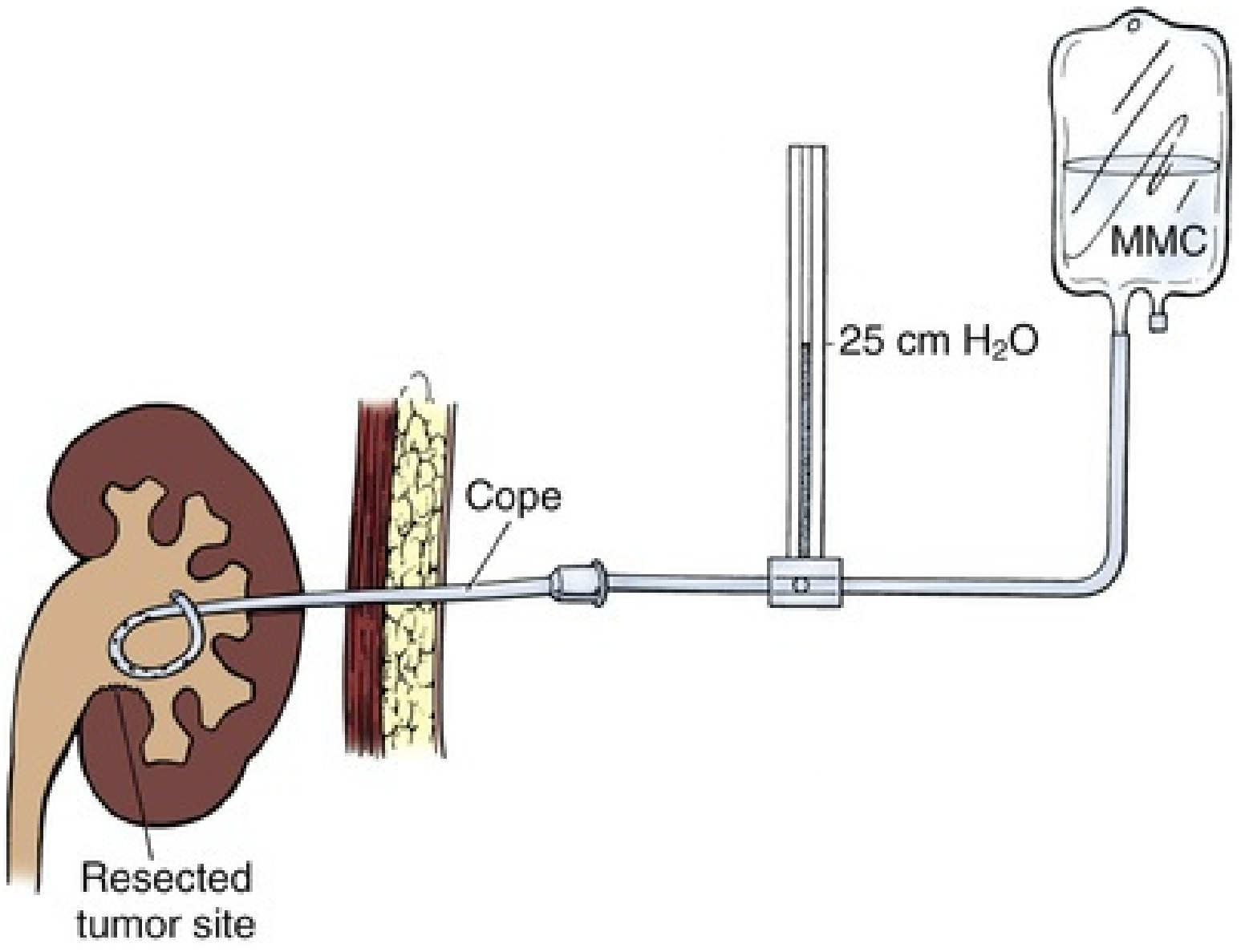

FIG. 99.28 Setup for administration of topical immunotherapy or chemotherapy to the upper urinary tract through a previously placed nephrostomy tube. Therapy is instilled by gravity with a mechanism that prevents excessive intrarenal pressures. High pressures have been linked to complications of systemic absorption and bacterial sepsis. *MMC,* Mitomycin C.

Results

The same agents used to treat urothelial carcinoma of the bladder are used to treat tumors of the upper urinary tract. Most historical studies are small, retrospective, uncontrolled series of patients undergoing therapy with thiotepa (Elliott et al., 1996; Patel et al., 1996), **mitomycin** (Cornu et al., 2010; Cutress et al., 2012), **and bacille Calmette-Guérin (BCG)** (Palou et al., 2004). See Table 99.4 for a summary.

TABLE 99.4

Adjuvant Upper Tract Instillation

AGENT	NO. OF PATIENTS	MEAN FOLLOW-UP (mo)	COMPLICATIONS (%)	BENEFIT SHOWN
THIOTEPA				
Elliot et al., 1996	4	60	ND	Benefit not evaluated
Patel et al., 1996	1	1	1 death from sepsis	No benefit
MMC				
Keeley et al., 1997a	19	30	10	Safety, no definite benefit
Martínez-Piñeiro et al, 1996	41	31	3 deaths from systemic absorption	14% recurrence compared with 25% without MMC
Cornu et al., 2010	35	24	9	Benefit not evaluated
Cutress et al., 2012	73	63	18	No benefit
BCG				
Clark et al., 1999	17	21	ND	No benefit

Palou et al., 2004	34	51	6	No benefit
Giannarini et al., 2011	22	42	201 deaths from sepsis	No benefit
Rastinehad et al., 2009	89	61	2 deaths from sepsis	No benefit

BCG, Bacille Calmette-Guérin; *MMC,* mitomycin C; *ND,* not disclosed.

Modified from Cutress ML, Stewart GD, Zakikhani P, et al.: Ureteroscopic and percutaneous management of upper tract urothelial carcinoma (UTUC): systematic review. *BJU Int* 110:614–628, 2012.

Gemcitabine has been used intravesically as an alternative to BCG with fewer side effects. We may see a larger role in the upper urinary tract. Although the cumulative experience appears encouraging, definitive conclusions are not easily reached. Possible reasons for this include (1) insufficient numbers to show clinical significance because of the relative rarity of the disease; (2) tumors of the upper urinary tract, which have a tumor biology different from that of their bladder counterparts; and (3) a nonstandardized and possibly inadequate delivery system that, unlike in the bladder, does not allow uniform delivery of the agent with adequate dwell time to enable a clinical response.

The largest experience is from use of BCG via a nephrostomy tube for primary treatment of CIS, and in this setting favorable responses are seen. In a recent update of this experience with 55 patients, a 57% 5-year recurrence-free survival was seen; on the other hand, patients treated in an adjuvant fashion after endoscopic ablation of papillary tumors had inferior results (Giannarini et al., 2011). The greatest experience with chemotherapy is with the use of mitomycin C, but because of the smaller numbers of patients and variable selection criteria, no definite conclusions can be reached, with the exception that mitomycin is very well tolerated and has a very low adverse event profile (Audenet et al., 2013). A recent single-institutional experience with use of mitomycin-c given as induction and maintenance therapy via nephrostomy tube or weekly cystoscopically placed ureteral catheter in 27 patients showed 60% recurrence-free, 80% progression-free, and 76% nephroureterectomy-free survival at a median follow-up of 19 months (range 7–92) (Metcalfe, 2016).

In the study with intrarenal perfusion of BCG, despite initial return of cytology results to normal, 50% of patients (5 of 10) developed disease recurrence after a mean follow-up of 50.9 months, and all of these had cancer-specific mortality (Hayashida et al., 2004). The initial results regarding response are encouraging; however, the recurrences with possible disease progression should not give the clinician optimism for long-term cure. Although removal of a renal unit for CIS alone is not urged, patients need to be followed vigilantly for disease progression.

One of the most promising avenues that may radically change the paradigm for how low-grade UTUC is endoscopically managed is undergoing clinical trial evaluation at the time of this writing. The Optimized DeLivery of Mitomycin for Primary UTUC Study (Olympus) is the first sponsored trial specifically for UTUC (https://clinicaltrials.gov/NCT02793128). The study is a phase 3, prospective, open-label, single-arm trial designed to assess the efficacy, safety, and tolerability of treatment with MitoGel. This compound is a unique reverse-polymer hydrogel admixed with mitomycin, which transitions from a viscous liquid to a gel when warmed to body temperature and subsequently dissolves at a constant rate in urine over the course of several hours, delivering mitomycin at a higher concentration and longer time period than conventional methods. The study is designed for low-grade, low-volume tumors. Although the study is ongoing and results are not yet available, the results of its use in the compassionate use setting were presented by Lin et al. (2017). Of 22 patients, 18 of whom had low-grade disease, 16 (73%) completed 6 weekly treatments and 9 (41% of total population, 59% of those who completed treatment) had a complete response. **If found effective, well-tolerated, and approved, Mitogel therapy will significantly change the endoscopic management of low-grade UTUC by providing a viable therapy for not only primary topical chemoablation but also adjuvant therapy.**

The most common complications of instillation therapy are bacterial sepsis and development of strictures. To minimize infections, patients must be evaluated for active infection before each treatment, and only a low-pressure delivery system should be used. Stricture formation may be related to prior endoscopy, ureteral catheter placement, or the agent used, or a combination of all these factors (Aboumarzouk et al., 2013; Metcalfe et al., 2017). Agent-specific complications of the various therapies include ramifications of systemic absorption of the agent Bellman et al. (1994) such as described upper urinary tract complications of percutaneous BCG instillation. Granulomatous involvement of the kidney in the absence of systemic signs of BCG infection was most commonly seen. Mukamel et al., (1991) saw an inordinate decrease in renal function for patients receiving BCG who had vesicoureteral reflux.

Systemic Chemotherapy.

The use of agents for UTUC has been extrapolated from chemotherapy regimens used in bladder urothelial cancer. In 2018 significant strides were made, with presentation of 2 separate prospective trials on the use of systemic chemotherapy, one a randomized adjuvant trial, the other a nonrandomized, GFR-stratified neoadjuvant trial.

The strongest current rationale for use of neoadjuvant therapy is the high proportion of significant baseline chronic kidney disease in patients with UTUC, which worsens after nephroureterectomy, rendering patients ineligible to receive the full-dose cisplatinum-based chemotherapy postoperatively (Lane et al., 2010). There are two reports on the use of neoadjuvant therapy. The initial data came from a small series of 15 patients who received MVAC (methotrexate, vinblastine, adriamycin, and cisplatin), MEC (methotrexate, etoposide, and cisplatin), or MVEC (methotrexate, vinblastine, epirubicin, and cisplatin) regimens before nephroureterectomy (Igawa et al., 1995). All of the patients had advanced disease, with 6 having clinical T2N0M0, 4 with T3N0-1M0, and 5 with T4N0-3M0 disease. Of these patients, 13% achieved complete, and 40% partial, pathological response. The authors reported a positive correlation between pathological response and disease-specific survival. Another larger retrospective case-control study (Matin et al., 2010) of 150 high-risk UTUC patients, 43 of whom received neoadjuvant therapy with a variety of regimens (MVAC, cisplatin-gemcitabine-ifosfamide, gemcitabine-paclitaxel-doxorubicin [GTA], cisplatin-gemcitabine [GC], and others), observed a significant incidence of pathological downstaging of tumors and a 14% complete response rate. A survival update of these patients showed significant improvement in 5-year survival in those receiving neoadjuvant chemotherapy versus a matched historical cohort (94% vs. 58%, $P < 0.001$) (Porten et al., 2013). **This data informed the development of the first collaborative prospective UTUC trial in the United States. The intergroup trial EA8141 was a phase 2, nonrandomized study of neoadjuvant chemotherapy for patients at high risk of recurrence after nephroureterectomy.** Patients were stratified based on kidney function, with those having a creatinine clearance of more than 50 receiving accelerated MVAC for 4 cycles before surgery, and those with clearance of 30 to 49 receiving carboplatin and gemcitabine for 4 cycles before surgery. The study was closed in 2017 after all 30 patients were enrolled in the MVAC arm and about half as many in the Carbo/Gem arm. Results were presented at the 2018 American Urological Association meeting, with the study meeting its predefined efficacy end point of pathological 14% complete remission and 60% downstaging to less than pT1N0, and no new safety concerns in patients with creatinine clearance of more than 50. **EA8141 confirms the efficacy of the neoadjuvant approach with pathological end points, which are well-accepted surrogates for survival. Once published in the peer-reviewed literature, it will be considered as an acceptable standard of care for patients with high-risk UTUC, and especially for those anticipated to have a postoperative creatinine clearance of less than 50.**

Adjuvant therapy has been used infrequently in the treatment of UTUC, and, until very recently, most publications are based on retrospective review of institutional experience. A study of 27 patients with pT3N0M0, 16 of whom received platinum-based therapy after nephroureterectomy, reported no significant difference in recurrence-free and disease-specific survival after 40 months of follow-up (Lee et al., 2006). Another study compared the outcomes of 24 patients with pT2-3N0M0 disease who received MVAC chemotherapy after nephroureterectomy with those of a similar group of patients who did not receive adjuvant therapy. The authors did not observe a significant difference in 10-year overall survival rates. A multi-institutional retrospective review of pT3-4N0M0 and N+ patients (Hellenthal et al., 2009) who did or did not receive platinum-based chemotherapy failed to show a significant difference in the overall or disease-specific survival rates. However, in this cohort, adjuvant therapy was more commonly used in patients with higher tumor grade and stage. In contrast, Kwak et al. (2006) showed a twofold decrease in recurrence of cancer and a significant reduction in disease-specific mortality (28.1% vs. 81.8%) in the pT2-3N0M0 patient population who received platinum-based chemotherapy. A recent large, multi-institutional retrospective study of 1544 patients with pT2-4 Nany M0 having nephroureterectomy from 15 centers treated between 2000 and 2015 was reported (Necchi et al., 2018). Patients receiving adjuvant therapy (n = 312) were compared with those not receiving adjuvant (n = 1232) using propensity score matching and inverse probability of treatment weighting to analyze overall survival. The authors found no improvement in overall survival. In retrospect, all of these studies were biased in one direction or another as a result of unmeasured selection biases, as became evident when prospective data were available.

In 2018 the results of the phase III randomized trial of Peri-Operative Chemotherapy Versus Surveillance in Upper Tract Urothelial Cancer (POUT) were presented after the trial was stopped early as a result of meeting predefined efficacy criteria (Birtle et al., 2018). This study randomized patients having undergone nephroureterectomy with high risk of recurrence (pT2-4 N0-3 M0) to adjuvant chemotherapy (n = 125) versus surveillance (n = 123). Patients in the adjuvant arm received gemcitabine and cisplatin if postoperative creatinine clearance was more than 50 and gemcitabine-carboplatin if clearance was 30 to 49. At a median follow-up of 17.6 months, 2-year disease-free survival was 51% for surveillance (95% confidence interval [CI] 39, 61) and 70% for chemotherapy (95% CI 58, 79). Progression-free survival favored chemotherapy, with hazard ratio (HR) = 0.49 (95% CI 0.30, 0.79, *P* = 0.003). **The POUT trial is the largest trial completed for UTUC, and once published, will establish adjuvant chemotherapy as a standard for patients with high risk of recurrence after nephroureterectomy.** Although the POUT data establish the efficacy of adjuvant therapy overall, more detailed information is needed to determine how many patients were precluded from the trial as a result of low kidney function, and the extent of efficacy of the gemcitabine-carboplatin arm, as carboplatin in the metastatic setting has limited efficacy (see the next section). Interestingly, the 2-year disease-free survival result from POUT (70%) is inferior to the 5-year cancer-specific survival obtained from neoadjuvant chemotherapy in the Matin et al. study (90%). Although the latter was retrospective, its results are similar to those obtained from the EA8141 trial. Further studies are needed to determine whether neoadjuvant or adjuvant therapy is superior; in the meantime, the consideration of post-nephroureterectomy kidney function remains paramount in planning a treatment course for the patient.

Treatment of Lymph Node–Positive and Metastatic Disease

Chemotherapy

There are limited data on efficacy of chemotherapy in lymph node positive and metastatic UTUC. Prospective randomized trials comparing chemotherapeutic regimens for UTUC are not feasible because of the rarity of these patients. Therefore other than the two recently completed prospective trials on neoadjuvant and adjuvant chemotherapy for localized or locally advanced UTUC, the data for chemotherapy response rates are extrapolated from observations in urothelial cancer, most of which do not stratify results by original location of tumor. In a study of 184 patients accrued over three consecutive time intervals from 1986 to 2004 at MD Anderson Cancer Center, the median recurrence-free survival was 2.4 years and did not improve over time (Brown et al., 2006). The decline in renal function after nephroureterectomy in these mostly elderly patients may compromise the ability to administer effective postoperative chemotherapy and is yet another reason to consider neoadjuvant chemotherapy for patients with high-risk upper tract tumors. **When there is evidence of regional lymph node metastases, initial chemotherapy should be given as the primary therapy, and surgery should be withheld until a good—ideally a complete—radiographic response is seen. Generally, two additional cycles after maximal response are given (usually a total of 6 cycles). At that time, consolidative surgery that includes lymphadenectomy can be offered, similar to the paradigm for bladder urothelial carcinoma.**

The MVAC regimen continues to have the highest response rate (Sternberg et al., 1989); however, its toxicity prohibits optimal dosage and duration in a large proportion of patients. In addition, complete responses are rare in the metastatic setting, and the duration of response is limited, with overall survival of 12 to 24 months. **A variation of standard MVAC is the dose-dense regimen, whereby all drugs are given at the same time with cell support, and this regimen has actually been shown to have a lower toxicity profile and may have better responses** (Sternberg et al., 2006). There is considerable ongoing investigation with newer agents, including paclitaxel, ifosfamide, carboplatin, gemcitabine, and vinflunine, used in various combinations and sequences (Bajorin et al., 1998; Bamias et al., 2006; Kaufman et al., 2000; Lorusso et al., 2000; Redman et al., 1998; Roth et al., 1994; Siefker-Radtke et al., 2013; Vaughn et al., 1998, 2009). Carboplatin is frequently substituted for cisplatin because of either limitations of renal function or concerns over toxicity with the latter, but the results with carboplatin remain inferior (Galsky et al., 2012). Many of these show initial overall response rates similar to the response rate to the MVAC regimen and lower toxicity. However, thus far, complete responses are rare, and there are no head-to-head comparison studies evaluating their durability or survival advantage compared with the MVAC regimen.

Results from a recent randomized phase III study comparing paclitaxel, cisplatin, and gemcitabine (PCG) versus GC in chemotherapy-naive patients with metastatic or locally advanced urothelial cancer (Bellmunt et al., 2012) showed that after a median follow-up of 4.6 years, with addition of paclitaxel, there was improvement in median overall survival (15.8 months vs. 12.7 months). The overall response rate was 55.5% with the use of PCG and 43.6 with GC, and both of the regimens were well tolerated. Of the 626 patients in this cohort, 82 had primary carcinoma of the renal pelvis or ureter; although there was no specific breakdown of the outcomes for this group of patients, on post hoc analysis the overall survival benefit was more pronounced in the group of patients with primary bladder tumors.

Another effective combination in patients with poor renal reserve is with gemcitabine, taxol, and doxorubicin (GTA). In many cases, patients can experience an improvement in kidney function after a few cycles, allowing for subsequent switching to a cisplatin regimen (Campbell et al., 2017).

There have been encouraging early results with cabozantinib, the inhibitor of MET and vascular endothelial growth factor pathways, in patients in whom previous chemotherapy has failed (Fig. 99.29). The patient accrual portion of a phase II trial is ongoing; it is hoped that this trial will provide further insight into the effects of this drug, which has shown clinical activity in multiple solid tumors.

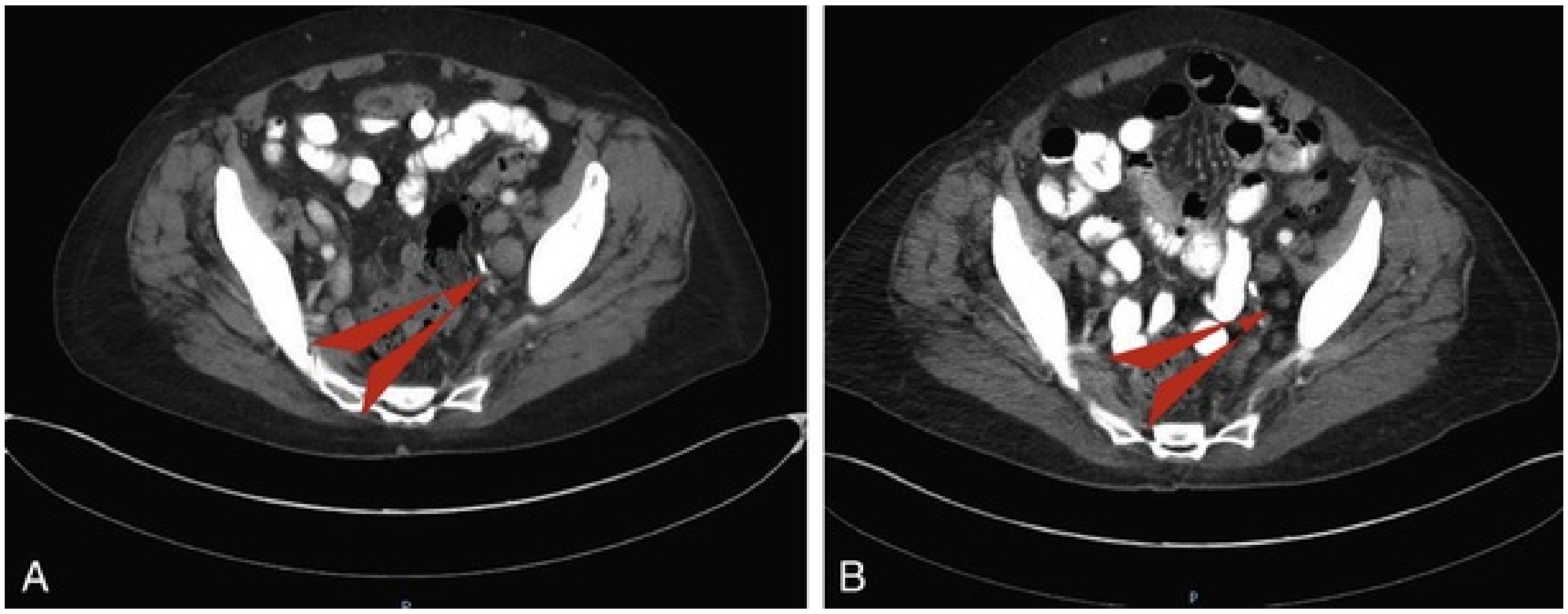

FIG. 99.29 (A) A patient with urothelial cell carcinoma of the kidney and left inguinal lymphadenopathy. (B) The patient had a sustained almost complete response at 9 weeks and 16 weeks after treatment with cabozantinib. *Red arrowhead* points to resolving adenopathy.

Immunotherapy

Recently, immune modulation using a variety of checkpoint inhibitors has shown promise in the treatment of multiple malignancies, including urothelial carcinoma, and it promises to significantly change the outcomes for patients with metastatic urothelial cancer. Until now, options for patients progressing after platinum chemotherapy were poor and this was a major area of unmet need.

Targeting the inhibitory surface receptor PD-1 (programmed death-1), activation of which by programmed cell death-ligand 1 (PD-L1) confers inhibition of T-cell proliferation and cytokine production, produced remarkable clinical activity in phase 1 clinical trials in metastatic urothelial carcinoma (Powles et al., 2014) with favorable side effect profile, and most importantly, infrequent renal impairment. These studies paved the way to tremendous success of new drugs approved for treatment of urothelial cancer, primarily PD-1, and PD-L1 inhibitors. UTUC patients may particularly derive a benefit from these treatments given the higher rates of microsatellite instability in UTUC than in bladder urothelial cancer, as high MSI appears to be particularly responsive to immune checkpoint inhibition. All of the following drugs are approved for patients with advanced urothelial cancer that has stopped responding or progressed after platinum chemotherapy.

Anti–PD-1 Approved Therapies.

Nivolumab is a PD-1 inhibitor approved in 2017 after a phase 2 trial with median follow-up of 7 months showed objective rates of 16.1%, 28.4%, and 23.8% in those with <1%, >1%, and >5%, respectively, PD-L1 expression (not statistically significant). Grades 3 and 4 adverse events occurred in 18%, and there were 3 of 270 patients who had treatment-related death. The authors concluded that nivolumab monotherapy provided meaningful clinical benefit with an acceptable safety profile (Sharma et al., 2017). Pembrolizumab is another monoclonal antibody directed against PD-1 approved in 2017. Results of the KEYNOTE-045 study showed after a median follow-up of 27.7 months a median overall survival of 10.3 months for patients treated with pembrolizumab versus 7.3 months for those treated with chemotherapy (HR = 0.70; *P* = 0.00017). Moreover, responses appear to remain durable even after completion of therapy (Bellmunt et al., 2017). Interestingly, and similar to the nivolumab trial, patients with higher PD-L1 staining in tumor and immune cells did not appear to have substantially better survival outcomes.

Anti–PD-L1 Approved Therapies.

Atezolizumab was the first PD-L1 inhibitor found to be active in urothelial cancer (Powles et al., 2014) and was approved in 2016 as first-line treatment for advanced or metastatic urothelial carcinoma ineligible for cisplatin chemotherapy. The IMvigor211 phase 3 trial showed similar objective response compared with chemotherapy (23% vs. 22%), but patients receiving atezolizumab had longer duration of response (15.9 months vs. 8.3 months), which was not statistically significant at the time, and had fewer high grade adverse events (Powles et al., 2018). Avelumab is unique in that it not only is a PD-L1 inhibitor but also acts via antibody-dependent cell-mediated toxicity, which directly lyses cells. It was approved for patients with platinum-refractory urothelial cancer, after initial results from a phase 1b trial showed an objective response from a nonrandomized clinical trial of 16.5% and a progression-free survival rate at 12 weeks of 35.6%. Adverse events occurred in 41% and 6% of patients died of treatment-related events. A subsequent pooled study of 2 cohorts (23.7% of which were UTUC patients) showed response rates of 17.6%, including 9 complete responses, and disease control rate of 41.2% (Patel et al., 2017). Durvalumab was shown in an open label phase 1/2 study in mostly previously treated urothelial cancer to have objective response rate of 17.8%, including 7 complete responses. Responses were early, durable, and were not related to expression of PD-L1 expression. Grade 3/4 treatment-related adverse events occurred in 6.8%, with 2 of 3 patients (1.6%) stopping treatment because of adverse events dying from immune-mediated events (Powles et al., 2017).

Molecular Alterations and Future of Genomic-Driven Therapy

Recent genomic studies are starting to improve our understanding of urothelial cancer in general, and specifically UTUC (Moss et al., 2017; Rouprêt et al., 2005); these show that despite phenotypic similarities, these cancers are genomically somewhat dissimilar. Microsatellite instability has been shown to be high in UTUC as compared with bladder cancer, which now has important implications for genomic-driven therapy with the approval of pembrolizumab for any solid tumor with high MSI (Le et al., 2015). In the first genomic study of UTUC, Sfakianos et al. (2015) compared tumor and germline DNA using a 300 cancer gene array. They found significant higher rate of mutations in *FGFR3* (35.6% vs. 21.6%; $P = 0.065$), *HRAS* (13.6% vs. 1.0%; $P = 0.001$), and *CDKN2B* (15.3% vs. 3.9%; $P = 0.016$) in high-grade UTUC than high-grade bladder cancer, and fewer mutations in TP53 (25.4% vs. 57.8%; $P < 0.001$) and RB1 (0 vs. 18.6%; $P < 0.001$). Mutations in chromatin-modifying genes were common, similar to bladder cancer. A second study by Moss et al. (Moss et al., 2017) reported a comprehensive genomic study of 31 UTUC samples using whole exome sequencing, RNA sequencing, and protein analysis. Of 2784 mutated genes, *FGFR3* was the most commonly mutated (74.1%), including in high-grade tumors (92% low-grade, 60% high-grade), followed by *KMT2D* (44.4%), *PIK3CA* (25.9%), and *TP53* (22.2%). Several patients had hypermutated genes, some of which were associated with deficient mismatch repair proteins associated with Lynch syndrome. APOBEC and CpG were the most common mutational signatures. RNA sequencing revealed clustering into 4 putative molecular subtypes with unique clinical behaviors, with one of the subtypes having highly upregulated expression of CTLA-4, PD-1, and PD-L1.

Relevant to these findings are the recent data showing activity of erdafitinib, a pan-FGFR inhibitor, for metastatic urothelial cancer, the first targeted agent for this indication. An ongoing phase 2 study showed a 42% response among 59 patients with metastatic urothelial cancer having specific *FGFR* mutations. The disease control rate was 73% to 74% for patients who received intermittent and continuous dosing (Loriot et al., 2018).

In summary, UTUC, like bladder cancer, is chemosensitive, but established chemotherapy regimens are toxic and lack sustained response. Unique to this population is the high rate of baseline chronic kidney disease, which worsens after nephroureterectomy. Immunotherapy with checkpoint inhibitors are starting to significantly improve the outlook for treatment-naive and platinum-refractory metastatic urothelial cancer, and the growing understanding of molecular alterations and genomic-driven therapy promises to continue expanding on this success.

Radiotherapy

There is a limited role for radiation outside treatment other than in the palliative setting. The proximity of the bowel to the upper urinary tract limits the dosing needed for effective primary therapy.

Follow-Up

Issues in Assessing for Recurrence

The propensity of upper tract tumors for multifocal recurrence and metastatic spread with more dysplastic lesions makes follow-up complicated. Postoperative evaluation must routinely include evaluation of the bladder, the ipsilateral (if organ-sparing therapy was chosen) and contralateral urinary tracts, and the extraurinary sites for local and metastatic spread. A follow-up regimen is thus dependent on the time from surgery, the approach chosen (organ sparing vs. radical), and the potential for metastatic spread. Conservative recommendations for time intervals are listed in Fig. 99.30. The European Association of Urology recommendations for follow-up are much less strict, particularly for those who have radical nephroureterectomy rather than kidney-sparing treatment. Cystoscopy is recommended only at 3 and 6 months and then annually, and computed tomography every 6 to 12 months for 2 years then annually, depending on risk. After kidney-sparing management, cytology and ureteroscopy are recommended at 3, 6, 12, 18, and 24 months and annually thereafter (Rouprêt et al., 2018). The later sections detail some of the considerations and issues that address the need for individualizing follow-up care.

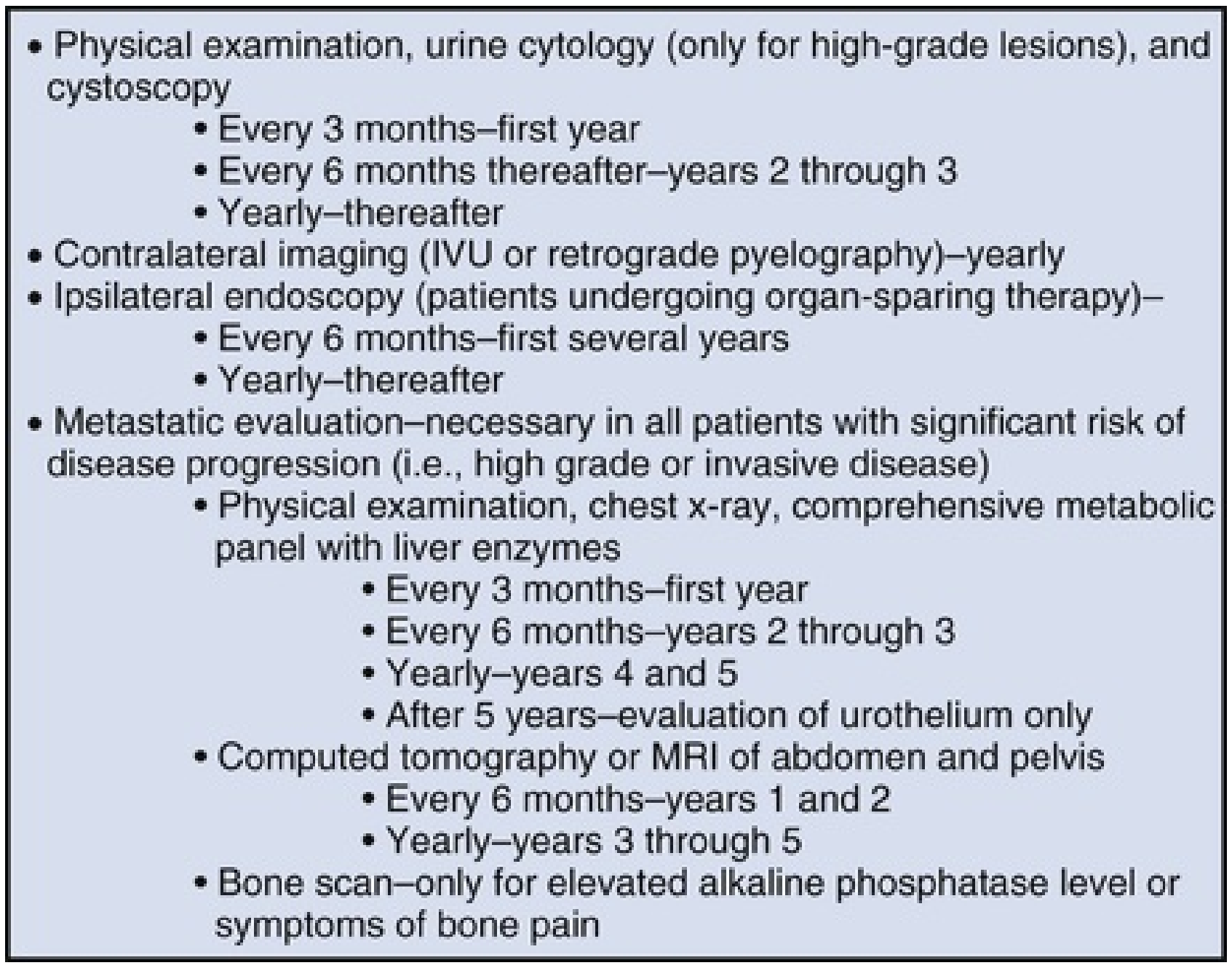

- Physical examination, urine cytology (only for high-grade lesions), and cystoscopy
    - Every 3 months–first year
    - Every 6 months thereafter–years 2 through 3
    - Yearly–thereafter
- Contralateral imaging (IVU or retrograde pyelography)–yearly
- Ipsilateral endoscopy (patients undergoing organ-sparing therapy)–
    - Every 6 months–first several years
    - Yearly–thereafter
- Metastatic evaluation–necessary in all patients with significant risk of disease progression (i.e., high grade or invasive disease)
    - Physical examination, chest x-ray, comprehensive metabolic panel with liver enzymes
        - Every 3 months–first year
        - Every 6 months–years 2 through 3
        - Yearly–years 4 and 5
        - After 5 years–evaluation of urothelium only
    - Computed tomography or MRI of abdomen and pelvis
        - Every 6 months–years 1 and 2
        - Yearly–years 3 through 5
    - Bone scan–only for elevated alkaline phosphatase level or symptoms of bone pain

FIG. 99.30 Follow-up begins after open surgery or when the patient is rendered tumor free by endoscopic management. The commencement of follow-up may be altered according to the potential for disease progression. *IVU,* Intravenous urography.

General Procedures

All patients should be assessed at regular intervals the first year after they are rendered tumor free by endoscopic or open surgical approaches (Keeley et al., 1997a). After the first year, this evaluation can be spaced out. This schedule is largely based on work with bladder urothelial carcinoma, showing that most tumor recurrences after bladder resection develop in the first year (Loening et al., 1980; Varkarakis et al., 1974). The upper urinary tract is more difficult to monitor, and delayed recognition of upper tract tumor recurrence may lead to disease progression and poor results (Mazeman, 1976). Evaluation should include history, physical examination, urinalysis, and office cystoscopy because of the high risk of bladder recurrences in patients treated conservatively and with nephroureterectomy (Mazeman, 1976). If the patient requires endoscopic evaluation of the upper urinary tract, cystoscopy can be done in conjunction with that procedure. Recent data suggest that patients treated for UTUC who do not develop a bladder recurrence in the first 6 to 12 months can have more rapid de-escalation of cystoscopic monitoring. As noted earlier, the European Association of Urology guidelines recommend a cystoscopy at 3 months and then annually (Rouprêt et al., 2018).

Urine cytology may be helpful in assessing for upper tract recurrence, especially for high-grade tumors (Murphy et al., 1981). The usefulness, however, is decreased with less dysplastic tumors (Grace et al., 1967; Sarnacki et al., 1971; Zincke et al., 1976). The same tumor markers under study for bladder urothelial carcinoma are promising for UTUC (Brown, 2000).

Specific Procedures

Bilateral disease, either synchronous or metachronous, is seen in 1% to 4% of patients (Babaian et al., 1980; Murphy et al., 1981; Petković, 1975), and thus imaging of the contralateral kidney is required on a regular basis. Yearly CT urography is usually sufficient, having replaced intravenous urography, and also can serve for metastatic surveillance. However, retrograde pyelography may be necessary if the patient is not a candidate for injection of iodinated contrast medium or if the urographic phase is not diagnostic. Magnetic resonance urography is another option for those unable to receive iodinated contrast, but patients with a creatinine clearance below 30 mg/dL may not receive gadolinium contrast because of concerns with development of nephrogenic systemic fibrosis. In these cases, MR urography with carefully performed and reformatted T2-weighted images can sometimes provide useful images. CT or ultrasonography is helpful in distinguishing stones from soft tissue densities. Further evaluation of filling defects on imaging studies usually requires ureteroscopic evaluation.

If an organ-sparing approach is chosen, the entire ipsilateral urinary tract must be assessed as well as the remainder of the urinary tract. The frequency and duration of the follow-up assessments depend largely on the grade and stage of the lesion, but they are usually every 6 months for several years and annually thereafter. Radiographic evaluation of the upper tracts alone may not be adequate because Keeley et al. (1997a) showed that 75% of early tumor recurrences were visible endoscopically and not radiographically. With tumors approached in a percutaneous fashion, early follow-up nephroscopy can be performed through the established nephrostomy tract.

In the past, the burden of repeated endoscopic evaluation of the upper urinary tracts was a major deterrent to conservative therapy. The use of smaller, 7.5-Fr flexible ureteroscopes has greatly eased the burden of follow-up because ureteroscopes can be reliably passed up the ureter without the need for dilation of the ureteral orifice or prior stenting. Others have advocated resection of the ureteral orifice to facilitate subsequent surveillance ureteroscopy in the office setting (Kerbl et al., 1993). Even though technology has somewhat facilitated follow-up, physician and patient must be committed to nephron-sparing treatment.

Metastatic Restaging

Metastatic restaging is required in all patients at significant risk for disease progression to local or distant sites and can be performed every 3 to 6 months in the first 2 years after surgery, because the majority of patients who recur with metastases do so within the first 2 to 3 years. This group includes those with high-grade or high-stage (>pT1) disease. Metastatic restaging is usually not necessary as frequently for low-grade disease when the risks of invasive and subsequent metastatic disease are negligible, and this can be done every 6 to 12 months in the first 2 years. Included in metastatic restaging is imaging of the ipsilateral renal bed for recurrence with cross-sectional imaging. Follow-up restaging includes chest radiography, liver function tests, cross-sectional body imaging, and selective use of bone scintigraphy based on symptoms or elevated serum markers. Follow-up of the upper tracts should be lifelong because of a lifetime risk of development of upper tract tumors in patients with prior bladder cancer (Herr et al., 1996).

References

Abdel-Razzak O, Bagley DH. The 6.9 F semirigid ureteroscope in clinical use. *Urology*. 1993;41:45–48.

Abe T, Shinohara N, Harabayashi T, et al. The role of lymph-node dissection in the treatment of upper urinary tract cancer: a multi-institutional study. *BJU Int*. 2008;102:576–580.

Abe T, Shinohara N, Muranaka M, et al. Role of lymph node dissection in the treatment of urothelial carcinoma of the upper urinary tract: multi-institutional relapse analysis and immunohistochemical re-evaluation of negative lymph nodes. *Eur J Surg Oncol*. 2010;36:1085–1091.

Abe T, Takada N, Matsumoto R, et al. Outcome of regional lymphadenectomy in accordance with primary tumor location on laparoscopic nephroureterectomy for urothelial carcinoma of the upper urinary tract: a prospective study. *J Endourol*. 2015;29:304–309.

Abercrombie GF, Eardley I, Payne SR, et al. Modified nephro-ureterectomy: long-term follow-up with particular reference to subsequent bladder tumours. *Br J Urol*. 1988;61:198–200.

Aboumarzouk O, Somani B, Ahmad S, et al. Mitomycin C instillation following ureterorenoscopic laser ablation of upper urinary tract carcinoma. *Urol Ann*. 2013;5(3):184–189.

Ahmed I, Shaikh NA, Kapadia CR. Track recurrence of renal pelvic transitional cell carcinoma after laparoscopic nephrectomy. *Br J Urol*. 1998;81:319.

Almås B, Halvorsen OJ, Gjengstø P, et al. Grading of urothelial carcinoma of the upper urinary tract according to the World Health Organization/International Society of Urological Pathology classification from 2004 is a valuable tool when considering whether a patient is suitable for endoscopic treatment. *Scand J Urol*. 2016;50(4):298–304.

Anderstrom C, Johansson SL, Pettersson S, et al. Carcinoma of the ureter: a clinicopathologic study of 49 cases. *J Urol*. 1989;142:280–283.

Angulo JC, Hontoria J, Sanchez-Chapado M. One-incision nephroureterectomy endoscopically assisted by transurethral ureteral stripping. *Urology*. 1998;52:203.

Arango O, Bielsa O, Carles J, et al. Massive tumor implantation in the endoscopic resected area in modified nephroureterectomy. *J Urol*. 1997;157:1839.

Audenet F, Traxer O, Bensalah K, et al. Upper urinary tract instillations in the treatment of urothelial carcinomas: a review of technical constraints and outcomes. *World J Urol*. 2013;31:45–52.

Babaian RJ, Johnson DE. Primary carcinoma of the ureter. *J Urol*. 1980;123:357–359.

Bagley D, Erhard M. Use of the holmium laser in the upper urinary tract. *Tech Urol*. 1995;1:25–30.

Bajorin D, McCaffrey J, Hilton S, et al. Treatment of patients with transitional cell carcinoma of the urothelial tract with ifosfamide, paclitaxel, and cisplatin: a phase II trial. *J Clin Oncol*. 1998;16:2722–2727.

Bamias A, Moulopoulos LA, Koutras A, et al. The combination of gemcitabine and carboplatin as first-line treatment in patients with advanced urothelial carcinoma. A phase II study of the Hellenic Cooperative Oncology Group. *Cancer*. 2006;106:297–303.

Bariol SV, Stewart GD, McNeill SA, et al. Oncological control following laparoscopic nephroureterectomy: 7-year outcome. *J Urol*. 2004;172(Pt 1):1805–1808.

Batata MA, Grabstald H. Upper urinary tract urothelial tumors. *Urol Clin North Am*. 1976;3:79–86.

Batata MA, Whitmore WF Jr, Hilaris BS, et al. Primary carcinoma of the ureter: a prognostic study. *Cancer*.

1975;35:1626–1632.

Bellman GC, Sweetser P, Smith AD. Complications of intracavitary bacillus Calmette-Guérin after percutaneous resection of upper tract transitional cell carcinoma. *J Urol*. 1994;51:13–15.

Bellmunt J, De Wit R, Vaughn DJ, et al. Pembrolizumab as second-line therapy for advanced urothelial carcinoma. *New Engl J Med*. 2017;376(11):1015–1026.

Bellmunt J, von der Maase H, Mead GM, et al. Randomized phase III study comparing paclitaxel/cisplatin/gemcitabine and gemcitabine/cisplatin in patients with locally advanced or metastatic urothelial cancer without prior systemic therapy: EORTC Intergroup Study 30987. *J Clin Oncol*. 2012;30:1107–1113.

Berger MA, Haber GP, Kamoi K, et al. Laparoscopic radical nephroureterectomy for upper tract transitional cell carcinoma: oncological outcomes at 7 years. *J Urol*. 2008;180:849–854.

Bian Y, Ehya H, Bagley DH. Cytologic diagnosis of upper urinary tract neoplasms by ureteroscopic sampling. *Acta Cytol*. 1995;39:733–740.

Birtle AJ, Chester JD, Jones RJ, et al. Results of POUT: a phase III randomised trial of perioperative chemotherapy versus surveillance in upper tract urothelial cancer (UTUC). *J Clin Oncol*. 2018;36:407.

Bloom NA, Vidone RA, Lytton B. Primary carcinoma of the ureter: a report of 102 new cases. *J Urol*. 1970;103:590–598.

Blute ML, Segura JW, Patterson DE, et al. Impact of endourology on diagnosis and management of upper urinary tract urothelial cancer. *J Urol*. 1989;141:1298.

Brausi M, Gavioli M, De Luca G, et al. Retroperitoneal lymph node dissection (RPLND) in conjunction with nephroureterectomy in the treatment of infiltrative transitional cell carcinoma (TCC) of the upper urinary tract: impact on survival. *Eur Urol*. 2007;52:1414–1420.

Brown FM. Urine cytology: is it still the gold standard for screening? *Urol Clin North Am*. 2000;27:25–37.

Brown GA, Busby JE, Wood CG, et al. Nephroureterectomy for treating upper urinary tract transitional cell carcinoma: time to change the treatment paradigm? *BJU Int*. 2006;98:1176–1180.

Burger M, Shariat SF, Fritsche HM, et al. No overt influence of lymphadenectomy on cancer-specific survival in organ-confined versus locally advanced upper urinary tract urothelial carcinoma undergoing radical nephroureterectomy: a retrospective international, multi-institutional study. *World J Urol*. 2011;29:465–472.

Campbell MT, Shah AY, Matin SF, et al: Optimizing management of upper tract urothelial carcinoma. Paper presented at the Urologic Oncology: Seminars and Original Investigations 2017.

Carson CC. Endoscopic treatment of upper and lower urinary tract lesions using lasers. *Semin Urol*. 1991;9:185–191.

Catto JW, Hartmann A, Stoehr R, et al. Multifocal urothelial cancers with the mutator phenotype are of monoclonal origin and require panurothelial treatment for tumor clearance. *J Urol*. 2006;175:2323–2330.

Cha EK, Shariat SF, Kormaksson M, et al. Predicting clinical outcomes after radical nephroureterectomy for upper tract urothelial carcinoma. *Eur Urol*. 2012;61:818–825.

Chasko SB, Gray GF, McCarron JP Jr. Urothelial neoplasia of the upper urinary tract. *Pathol Annu*. 1981;16(Pt 2):127–153.

Chen GL, Bagley DH. Ureteroscopic management of upper tract transitional cell carcinoma in patients with normal contralateral kidneys. *J Urol*. 2000;164:1173.

Chen GL, El-Gabry EA, Bagley DH, et al. Surveillance of upper urinary tract transitional cell carcinoma: the role of ureteroscopy, retrograde urography, cytology and urinalysis. *J Urol*. 2000;164:1901.

Clark PC, Streem SB, Geisinger MA. 13 year experience with percutaneous management of upper tract transitional cell carcinoma. *J Urol*. 1999;161:772–775.

Clayman RV, Garske GL, Lange PH. Total nephroureterectomy with ureteral intussusception and transurethral ureteral detachment and pull-through. *Urology*. 1983;21:482–486.

Cornu JN, Roupret M, Carpentier X, et al. Oncologic control obtained after exclusive flexible ureteroscopic management of upper urinary tract urothelial cell carcinoma. *World J Urol*. 2010;28:151–156.

Cummings KB. Nephroureterectomy: rationale in the management of transitional cell carcinoma of the upper urinary tract. *Urol Clin North Am*. 1980;7:569–578.

Cutress ML, Stewart GD, Zakikhani P, et al. Ureteroscopic and percutaneous management of upper tract urothelial carcinoma (UTUC): systematic review. *BJU Int*. 2012;110:614–628.

Daneshmand S, Quek ML, Huffman JL. Endoscopic management of upper urinary tract transitional cell carcinoma: long-term experience. *Cancer*. 2003;98:55–60.

De Torres Mateos JA, Banus Gassol JM, Palou Redota J, et al. Vesicorenal reflux and upper urinary tract transitional cell carcinoma after transurethral resection of recurrent superficial bladder carcinoma. *J Urol*. 1987;138:49–51.

El Fettouh HA, Rassweiler JJ, Schulze M, et al. Laparoscopic radical nephroureterectomy: results of an international multicenter study. *Eur Urol*. 2002;42:447–452.

Elliott DS, Blute ML, Patterson DE, et al. Long-term follow-up of endoscopically treated upper urinary tract transitional cell carcinoma. *Urology*. 1996;47:819–825.

Gadzinski AJ, Roberts WW, Faerber GJ, et al. Long-term outcomes of nephroureterectomy versus endoscopic management for upper tract urothelial carcinoma. *J Urol*. 2010;183:2148–2153.

Galsky MD, Chen GJ, Oh WK, et al. Comparative effectiveness of cisplatin-based and carboplatin-based chemotherapy for treatment of advanced urothelial carcinoma. *Ann Oncol*. 2012;23:406–410.

Giannarini G, Kessler TM, Birkhauser FD, et al. Antegrade perfusion with bacillus Calmette-Guérin in patients with non–muscle-invasive urothelial carcinoma of the upper urinary tract: who may benefit? *Eur Urol*. 2011;60:955–960.

Gill IS, Soble JJ, Miller SD, et al. A novel technique for management of the en bloc bladder cuff and distal ureter during laparoscopic nephroureterectomy. *J Urol*. 1999;161:430–434.

Giovansili B, Peyromaure M, Saighi D, et al. Stripping technique for endoscopic management of distal ureter during nephroureterectomy: experience of 32 procedures. *Urology*. 2004;64:448–452.

Gittes RF. Management of transitional cell carcinoma of the upper tract: case for conservative local excision. *Urol Clin North Am*. 1980;7:559–568.

Goel MC, Mahendra V, Roberts JG. Percutaneous management of renal pelvic urothelial tumors: long-term followup. *J Urol*. 2003;169:925–929.

Goldwasser B, Leibovitch I, Avigad I. Ureteral substitution using the isolated interposed vermiform appendix in a patient with a single kidney and transitional cell carcinoma of the ureter. *Urology*. 1994;44:437–440.

Goodman TM. Ureteroscopy with rigid instruments in the management of distal ureteral disease. *J Urol*. 1984;132(2):250–253.

Grabstald H, Whitmore WF Jr, Melamed MR. Renal pelvic tumors. *J Am Med Assoc*. 1971;218:845–854.

Grace DA, Taylor WN, Taylor JN, et al. Carcinoma of the renal pelvis: a 15-year review. *J Urol*. 1967;98:566–569.

Grasso M, Bagley A. 7.5/8.2 F actively deflectable, flexible ureteroscope: a new device for both diagnostic and therapeutic upper urinary tract endoscopy. *Urology*. 1994;43:435–441.

Grossman HB. The late recurrence of grade I transitional cell carcinoma of the ureter after conservative therapy. *J Urol*. 1978;120:251–252.

Guarnizo E, Pavlovich CP, Seiba M, et al. Ureteroscopic biopsy of upper tract urothelial carcinoma: improved diagnostic accuracy and histopathological considerations using a multi-biopsy approach. *J Urol*. 2000;163:52–55.

Hayashida Y, Nomata K, Noguchi M, et al. Long-term effects of bacille Calmette-Guérin perfusion therapy for treatment of transitional cell carcinoma in situ of upper urinary tract. *Urology*. 2004;63:1084–1088.

Hellenthal NJ, Shariat SF, Margulis V, et al. Adjuvant chemotherapy for high risk upper tract urothelial carcinoma: results from the Upper Tract Urothelial Carcinoma Collaboration. *J Urol*. 2009;182:900–906.

Hemal AK, Stansel I, Babbar P, et al. Robotic-assisted nephroureterectomy and bladder cuff excision without intraoperative repositioning. *Urology*. 2011;78:357–364.

Hendin BN, Streem SB, Levin HS, et al. Impact of diagnostic ureteroscopy on long-term survival in patients with upper tract transitional cell carcinoma. *J Urol*. 1999;161:783–785.

Heney N, Nocks B, Daly J, et al. Prognostic factors in carcinoma of the ureter. *J Urol*. 1981;125:632–636.

Herr HW, Cookson MS, Soloway SM. Upper tract tumors in patients with primary bladder cancer followed for 15 years. *J Urol*. 1996;156:1286–1287.

Herr HW. Long-term results of BCG therapy: concern about upper tract tumors. *Semin Urol Oncol*. 1998;16:13–16.

Hisataki T, Miyao N, Masumori N, et al. Risk factors for the development of bladder cancer after upper tract urothelial cancer. *Urology*. 2000;55:663–667.

Hsueh TY, Huang YH, Chiu AW, et al. A comparison of the clinical outcome between open and hand-assisted laparoscopic nephroureterectomy for upper urinary tract transitional cell carcinoma. *BJU Int*. 2004;94:798–801.

Hung SY, Yang WC, Luo HL, et al. Segmental ureterectomy does not compromise the oncologic outcome compared with nephroureterectomy for pure ureter cancer. *Int Urol Nephrol*. 2014;46(5):921–926.

Igawa M, Urakami S, Shiina H, et al. Neoadjuvant chemotherapy for locally advanced urothelial cancer of the upper urinary tract. *Urol Int*. 1995;55:74–77.

Ito A, Shintaku I, Satoh M, et al. Prospective randomized phase II trial of a single early intravesical instillation of pirarubicin (THP) in the prevention of bladder recurrence after nephroureterectomy for upper urinary tract urothelial carcinoma: the THP Monotherapy Study Group Trial. *J Clin Oncol*. 2013;31:1422–1427.

Jarrett TW, Chan DY, Cadeddu JA, et al. Laparoscopic nephroureterectomy for the treatment of transitional cell carcinoma of the upper urinary tract. *Urology*. 2001;57:448–453.

Jarrett TW, Lee CK, Pardalidis NP, et al. Extensive dilation of distal ureter for endoscopic treatment of large volume ureteral disease. *J Urol*. 1995;153:1214–1217.

Jarrett TW, Sweetser PM, Weiss GH, et al. Percutaneous management of transitional cell carcinoma of the renal collecting system: 9-year experience. *J Urol*. 1995;154:1629–1635.

Jeldres C, Sun M, Isbarn H, et al. A population-based assessment of perioperative mortality after nephroureterectomy for upper-tract urothelial carcinoma. *Urology*. 2010;75:315–320.

Johansson S, Wahlquist L. A prognostic study of urothelial renal pelvic tumors: comparison between the prognosis of patients treated with intrafascial nephrectomy and perifascial nephroureterectomy. *Cancer*. 1979;43:2525.

Johnson DE, Babaian RJ. Conservative surgical management for noninvasive distal ureteral carcinoma. *Urology*. 1979;13:365–367.

Johnson GB, Fraiman M, Grasso M. Broadening experience with the retrograde endoscopic management of upper urinary tract urothelial malignancies. *BJU Int*. 2005;95:110–113.

Jones DR, Moisey CU. A cautionary tale of the modified “pluck” nephroureterectomy. *Br J Urol*. 1993;71:486.

Kakizoe T, Fujita J, Murase T, et al. Transitional cell carcinoma of the bladder in patients with renal pelvic and ureteral cancer. *J Urol*. 1980;124:17–19.

Kang CH, Yu TJ, Hsieh HH, et al. The development of bladder tumors and contralateral upper urinary tract tumors after primary transitional cell carcinoma of the upper urinary tract. *Cancer*. 2003;98:1620–1626.

Kaufman D, Raghavan D, Carducci M, et al. Phase II trial of gemcitabine plus cisplatin in patients with metastatic urothelial cancer. *J Clin Oncol*. 2000;18:1921–1927.

Keeley FX, Bibbo M, Bagley DM. Ureteroscopic treatment and evaluation of the upper tract TCC. *J Urol*. 1997;157:1560.

Keeley FX, Kulp DA, Bibbo M, et al. Diagnostic accuracy of ureteroscopic biopsy in upper tract transitional cell carcinoma. *J Urol*. 1997;157:33–37.

Kerbl K, Clayman RV. Incision of the ureterovesical junction for endoscopic surveillance of transitional cell cancer of the upper urinary tract. *J Urol*. 1993;150:1440–1443.

Khan S, Farrow GM, Zincke H, et al. Primary carcinoma in situ of the ureter and renal pelvis. *J Urol*. 1979;121:681–683.

Kondo T, Hashimoto Y, Kobayashi H, et al. Template-based lymphadenectomy in urothelial carcinoma of the upper urinary tract: impact on patient survival. *Int J Urol*. 2010;17:848–854.

Kondo T, Nakazawa H, Ito F, et al. Impact of the extent of regional lymphadenectomy on the survival of patients with urothelial carcinoma of the upper urinary tract. *J Urol*. 2007;178:1212–1217.

Kondo T, Tanabe K. Role of lymphadenectomy in the management of urothelial carcinoma of the bladder and the upper urinary tract. *Int J Urol*. 2012;19:710–721.

Krambeck AE, Thompson RH, Lohse CM, et al. Endoscopic management of upper tract urothelial carcinoma in patients with a history of bladder urothelial carcinoma. *J Urol*. 2007;177:1721–1726.

Kulp DA, Bagley DH. Does flexible uretero-pyeloscopy promote local recurrence of transitional cell carcinoma? *J Endourol*. 1994;8:111–113.

Kwak C, Lee SE, Jeong IG, et al. Adjuvant systemic chemotherapy in the treatment of patients with invasive transitional cell carcinoma of the upper urinary tract. *Urology*. 2006;68:53–57.

Lane BR, Smith AK, Larson BT, et al. Chronic kidney disease after nephroureterectomy for upper tract urothelial carcinoma and implications for the administration of perioperative chemotherapy. *Cancer*. 2010;116:2967–2973.

Le DT, Uram JN, Wang H, et al. PD-1 Blockade in tumors with mismatch-repair deficiency. *New Engl J Med*. 2015;372(26):2509–2520.

Lee BR, Jabbour ME, Marshall FF, et al. 13-year survival comparison of percutaneous and open nephroureterectomy approaches for management of transitional cell carcinoma of renal collecting system: equivalent outcomes. *J Endourol*. 1999;13:289–294.

Lee SE, Byun SS, Park YH, et al. Adjuvant chemotherapy in the management of pT3N0M0 transitional cell carcinoma of the upper urinary tract. *Urol Int*. 2006;77:22–26.

Lehmann J, Suttmann H, Kovac I, et al. Transitional cell carcinoma of the ureter: prognostic factors influencing progression and survival. *Eur Urol*. 2007;51:1281–1288.

Leitenberger A, Beyer A, Altwein JE. Organ-sparing treatment for ureteral carcinoma? *Eur Urol*. 1996;29:272–278.

Lenis AT, Donin NM, Faiena I, et al. Role of surgical approach on lymph node dissection yield and survival in patients with upper tract urothelial carcinoma. *Urol Oncol*. 2018;36(1):9 [e1–e9].

Lim DJ, Shattuck MC, Cook WA. Pyelovenous lymphatic migration of transitional cell carcinoma following flexible ureterorenoscopy. *J Urol*. 1993;149:109–111.

Lin JS-J, Kleinmann N, Wirth GJ, et al. *Thermo reversible hydrogel based delivery of mitomycin C for treatment of upper tract urothelial carcinoma (UTUC): American Society of Clinical Oncology*. 2017.

Loening S, Narayana A, Yoder L, et al. Factors influencing the recurrence rate of bladder cancer. *J Urol*. 1980;123:29–31.

Loriot Y, Necchi A, Park SH, et al. Erdafitinib (ERDA; JNJ-42756493), a pan-fibroblast growth factor receptor (FGFR) inhibitor, in patients (pts) with metastatic or unresectable urothelial carcinoma (mUC) and FGFR alterations (FGFRa): phase 2 continuous versus intermittent dosing. *J Clin Oncol*. 2018;36:411.

Lorusso V, Manzione L, De Vita F, et al. Gemcitabine plus cisplatin for advanced transitional cell carcinoma of the urinary tract: a phase II multicenter trial. *J Urol*. 2000;164:53.

Lucas SM, Svatek RS, Olgin G, et al. Conservative management in selected patients with upper tract urothelial carcinoma compares favourably with early radical surgery. *BJU Int*. 2008;102:172–176.

Lughezzani G, Jeldres C, Isbarn H, et al. A critical appraisal of the value of lymph node dissection at nephroureterectomy for upper tract urothelial carcinoma. *Urology*. 2010;75:118–124.

Margulis V, Shariat SF, Matin SF, et al. Outcomes of radical nephroureterectomy: a series from the Upper Tract Urothelial Carcinoma Collaboration. *Cancer*. 2009;115:1224–1233.

Martínez-Piñeiro JA, García Matres MJ, Martínez-Piñeiro L. Endourological treatment of upper tract urothelial carcinomas: analysis of a series of 59 tumors. *J Urol*. 1996;156:377–385.

Matin SF, Gill IS. Recurrence and survival following laparoscopic radical nephroureterectomy with various forms of bladder cuff control. *J Urol*. 2005;173:395–400.

Matin SF, Margulis V, Kamat A, et al. Incidence of downstaging and complete remission after neoadjuvant chemotherapy for high-risk upper tract transitional cell carcinoma. *Cancer*. 2010;116:3127–3134.

Matin SF, Sfakianos JP, Espiritu PN, et al. Patterns of lymphatic metastases in upper tract urothelial carcinoma and proposed dissection templates. *J Urol*. 2015;194:1567–1574.

Matsuoka K, Lida S, Tomiyasu K, et al. Transurethral endoscopic treatment of upper urinary tract tumors using a holmium:YAG laser. *Lasers Surg Med*. 2003;32:336–340.

Mazeman E. Tumors of the upper respiratory tract calyces, renal pelvis, and ureter. *Eur Urol*. 1976;2:120–126.

McCarron JP Jr, Mills C, Vaughn ED Jr. Tumors of the renal pelvis and ureter: current concepts and management. *Semin Urol*. 1983;1:75–81.

McDonald DF. Intussusception ureterectomy: a method of removal of the ureteral stump at time of nephrectomy without an additional incision. *Surg Gynecol Obstet*. 1953;97:565.

McNeill SA, Chrisofos M, Tolley DA. The long-term outcome after laparoscopic nephroureterectomy: a comparison with open nephroureterectomy. *BJU Int*. 2000;86:619.

Messing E, Tangen C, Lerner S, et al. A Phase Iii blinded study of immediate post-Turbt instillation of gemcitabine versus saline in patients with newly diagnosed or occasionally recurring grade I/Ii non-muscle invasive bladder cancer: swog S0337. *J Urol*. 2017;197:E914–E915.

Messing EM, Catalona W. Urothelial tumors of the urinary tract. Walsh PC, Retik AD, Vaughan ED, et al. *Campbell's urology*. 7th ed. Saunders: Philadelphia; 1998:2327–2410.

Metcalfe M, Wagenheim G, Xiao L, et al. Induction and maintenance adjuvant mitomycin C topical therapy for upper tract urothelial carcinoma: tolerability and intermediate term outcomes. *J Endourol*. 2017;31(9):946–953.

Metcalfe M. *J Endou*. 2016.

Mitropoulos D, Artibani W, Biyani CS, et al. Validation of the Clavien-Dindo grading system in urology by the European Association of Urology Guidelines Ad Hoc Panel. *Eur Urol Focus*. 2017.

Moss TJ, Qi Y, Xi L, et al. Comprehensive genomic characterization of upper tract urothelial carcinoma. *Eur Urol*. 2017;72:641–649.

Motamedinia P, Keheila M, Leavitt DA, et al. The expanded use of percutaneous resection for upper tract urothelial carcinoma: a 30-year comprehensive experience. *J Endourol*. 2015;30:262–267.

Mufti GR, Gove JR, Riddle R. Nephroureterectomy after radical cystectomy. *J Urol*. 1988;139:588–589.

Mukamel E, Vilkovsky E, Hadar H, et al. The effect of intravesical bacillus Calmette-Guérin therapy on the upper urinary tract. *J Urol*. 1991;146:980–981.

Mullen JB, Kovacs D. Primary carcinoma of the ureteral stump: a case report and a review of the literature. *J Urol*. 1980;123:113–115.

Muntener M, Nielson ME, Romero FR, et al. Long-term oncologic outcome after laparoscopic radical nephrouretheretomy for upper tract transitional cell carcinoma. *Eur Urol*. 2007;51(6):1639–1644.

Muntener M, Schaeffer EM, Romero FR, et al. Incidence of local recurrence and port site metastasis after laparoscopic radical nephroureterectomy. *Urology*. 2007;70(5):864–868.

Murphy DM, Zincke H, Furlow WL. Management of high grade transitional cell cancer of the upper urinary tract. *J Urol*. 1981;125:25–29.

Murphy DM, Zincke H, Furlow WL. Primary grade I transitional cell carcinoma of the renal pelvis and ureter. *J Urol*. 1980;123:629–631.

Murphy WM, von Buiduigen RP, Poley RW. Primary carcinoma in situ of renal pelvis and ureter. *Cancer*. 1974;34:1126–1130.

Necchi A, Lo Vullo S, Mariani L, et al. Adjuvant chemotherapy after radical nephroureterectomy does not improve survival in patients with upper tract urothelial carcinoma: a joint study by the European Association of Urology-Young Academic Urologists and the Upper Tract Urothelial Carcinoma Collaboration. *BJU Int*. 2018;121:252–259.

Ni S, Tao W, Chen Q, et al. Laparoscopic versus open nephroureterectomy for the treatment of upper urinary tract urothelial carcinoma: a systematic review and cumulative analysis of comparative studies. *Eur Urol*. 2012;61:1142–1153.

Nocks BN, Heney NM, Daly JJ, et al. Transitional cell carcinoma of renal pelvis. *Urology*. 1982;14:472–477.

O'Brien T, Ray E, Singh R, et al. Prevention of bladder tumours after nephroureterectomy for primary upper urinary tract urothelial carcinoma: a prospective, multicentre, randomized clinical trial of a single postoperative intravesical dose of mitomycin C (the ODMIT-C Trial). *Eur Urol*. 2011;60:703–710.

Otani M, Irie S, Tsuji Y. Port site metastasis after laparoscopic nephrectomy: unsuspected transitional cell carcinoma within a tuberculous atrophic kidney. *J Urol*. 1999;162:486–487.

Otto W, Shariat SF, Fritsche HM, et al. Concomitant carcinoma in situ as an independent prognostic parameter for recurrence and survival in upper tract urothelial carcinoma: a multicenter analysis of 772 patients. *World J Urol*. 2011;29(4):487–494.

Pak RW, Moskowitz EJ, Bagley DH. What is the cost of maintaining a kidney in upper-tract transitional-cell carcinoma? An objective analysis of cost and survival. *J Endourol*. 2009;23:341–346.

Palou J, Caparros J, Orsola A, et al. Transurethral resection of the intramural ureter as the first step of nephroureterectomy. *J Urol*. 1995;154:43–44.

Palou J, Piovesan LF, Huguet J, et al. Percutaneous nephroscopic management of upper urinary tract transitional cell carcinoma: recurrence and long-term followup. *J Urol*. 2004;172:66–69.

Palou J, Salvador J, Millan F, et al. Management of superficial transitional cell carcinoma in the intramural ureter: what to do? *J Urol*. 2000;163:744–747.

Patel A, Fuchs GJ. New techniques for the administration of topical adjuvant therapy after endoscopic ablation of upper urinary tract transitional cell carcinoma. *J Urol*. 1998;159:71–75.

Patel A, Soonawalla P, Shepherd SF, et al. Long-term outcome after percutaneous treatment of transitional cell carcinoma of the renal pelvis. *J Urol*. 1996;155:868–874.

Patel MR, Ellerton JA, Infante JR, et al. Avelumab in patients with metastatic urothelial carcinoma: pooled results from two cohorts of the phase 1b JAVELIN Solid Tumor trial. *J Clin Oncol*. 2017;35:330.

Petković SD. Epidemiology and treatment of renal pelvic and ureteral tumors. *J Urol*. 1975;114(6):858–865.

Porten SP, Siefker-Radtke AO, Kamat AM, et al: Survival outcomes in patients undergoing neoadjuvant chemotherapy for upper tract urothelial cell carcinoma. Abstract no. 311. Presented at: 2013 Genitourinary Cancers Symposium; 2013 Feb 14-16; Orlando, FL.

Potrezke AM, et al. *Urology*. 2016.

Powles T, Eder JP, Fine GD, et al. MPDL3280A (anti-PD-L1) treatment leads to clinical activity in metastatic bladder cancer. *Nature*. 2014;515:558–562.

Powles T, Durán I, van der Heijden MS, et al. Atezolizumab versus chemotherapy in patients with platinum-treated locally advanced or metastatic urothelial carcinoma (IMvigor211): a multicentre, open-label, phase 3 randomised controlled trial. *Lancet*. 2018;391:748–757.

Powles T, O'Donnell PH, Massard C, et al. Efficacy and safety of durvalumab in locally advanced or metastatic urothelial carcinoma: updated results from a phase 1/2 open-label study. *JAMA Oncol*. 2017;3:e172411.

Rai BP, Shelley M, Coles B, et al. Surgical management for upper urinary tract transitional cell carcinoma (UUT-TCC): a systematic review. *BJU Int*. 2012;110:1426–1435.

Rastinehad AR, Vanderbrink BA, Greenberg KL, et al. A 20 year experience with percutaneous resection of upper tract transitional cell carcinoma: is there an oncologic benefit with adjuvant bacillus Calmette Guérin. *Urology*. 2009;73(1):27–31.

Razvi HA, Chun SS, Denstedt JD, et al. Soft-tissue applications of the holmium:YAG laser in urology. *J Endourol*. 1995;9:387–390.

Redman B, Smith D, Flaherty L, et al. Phase II trial of paclitaxel and carboplatin in the treatment of advanced urothelial carcinoma. *J Clin Oncol*. 1998;16:1844–1848.

Redrow GP, Matin SF. Upper tract urothelial carcinoma: epidemiology, high risk populations and detection. *Minerva Urol Nefrol*. 2016;68:350–358.

Richie JP. Carcinoma of the renal pelvis and ureter. Skinner DG, Lieskovsky G. *Diagnosis and management of genitourinary cancer*. Saunders: Philadelphia; 1988:323–336.

Roscigno M, Cozzarini C, Bertini R, et al. Prognostic value of lymph node dissection in patients with muscle-invasive transitional cell carcinoma of the upper urinary tract. *Eur Urol*. 2008;53:794–802.

Roscigno M, Shariat SF, Margulis V, et al. The extent of lymphadenectomy seems to be associated with better survival in patients with nonmetastatic upper-tract urothelial carcinoma: how many lymph nodes should be removed? *Eur Urol*. 2009;56:512–518.

Roth B, Dreicer R, Einhorn L, et al. Significant activity of paclitaxel in advanced transitional cell carcinoma of the urothelium: a phase II trial of the Eastern Cooperative Oncology Group. *J Clin Oncol*. 1994;12:2264–2270.

Roth S, van Ahlen H, Semjonow A, et al. Modified ureteral stripping as an alternative to open surgical ureterectomy. *J Urol*. 1996;155:1568.

Rouprêt M, Azzouzi AR, Cussenot O. Microsatellite instability and transitional cell carcinoma of the upper urinary tract. *BJU Int*. 2005;96(4):489–492.

Rouprêt M, Babjuk M, Compérat E, et al. European Association of Urology guidelines on upper urinary tract urothelial carcinoma: 2017 update. *Eur Urol*. 2018;73:111–122.

Roupret M, Harmon JD, Sanderson KM, et al. Laparoscopic distal ureterectomy and anastomosis for management of low-risk upper urinary tract transitional cell carcinoma: preliminary results. *BJU Int*. 2007;99(3):623–627.

Sarnacki CT, McCormack LJ, Kiser WS, et al. Urinary cytology and the clinical diagnosis of urinary tract malignancy: a clinicopathologic study of 1400 patients. *J Urol*. 1971;106:761–764.

Schatteman P, Chatzopoulos C, Assenmacher C. Laparoscopic nephroureterectomy for upper urinary tract transitional cell carcinoma: results of a Belgian retrospective multicentre survey. *Eur Urol*. 2007;51(6):1633.

Schilling A, Bowering R, Keiditsch E. Use of the neodymium:YAG laser in the treatment of ureteral tumors and urethral condylomata acuminata: clinical experience. *Eur Urol*. 1986;12(Suppl 1):30.

Schmeller NT, Hofstetter AG. Laser treatment of ureteral tumors. *J Urol*. 1989;141:840–843.

Schwalb MD, Herr HW, Sogani PC, et al. Positive urinary cytology following a complete response to intravesical bacillus Calmette-Guérin therapy: pattern of recurrence. *J Urol*. 1994;152:382–387.

Schwartzmann I, Pastore AL, Saccà A, et al. Upper urinary tract urothelial carcinoma tumor seeding along percutaneous nephrostomy track: case report and review of the literature. *Urol Int*. 2017;98(1):115–119.

Secin FP, Koppie TM, Salamanca JI, et al. Evaluation of regional lymph node dissection in patients with upper urinary tract urothelial cancer. *Int J Urol*. 2007;14:26–32.

Sfakianos JP, Cha EK, Iyer G, et al. Genomic characterization of upper tract urothelial carcinoma. *Eur Urol*. 2015;68:970–977.

Sharma P, Retz M, Siefker-Radtke A, et al. Nivolumab in metastatic urothelial carcinoma after platinum therapy (CheckMate 275): a multicentre, single-arm, phase 2 trial. *Lancet Oncol*. 2017;18:312–322.

Siefker-Radtke AO, Dinney CP, Shen Y, et al. A phase 2 clinical trial of sequential neoadjuvant chemotherapy with ifosfamide, doxorubicin, and gemcitabine followed by cisplatin, gemcitabine, and ifosfamide in locally advanced urothelial cancer: final results. *Cancer*. 2013;119:540–547.

Simone G, Papalia R, Guaglianone S, et al. Laparoscopic versus open nephroureterectomy: perioperative and oncologic outcomes from a randomized prospective study. *Eur Urol*. 2009;56:520–526.

Skinner D. Technique of nephroureterectomy with regional lymph node dissection. *Urol Clin North Am*. 1978;5:253–260.

Smith AK, Lane BR, Larson BT, et al. Does the choice of technique for management of the bladder cuff affect oncologic outcomes of nephroureterectomy for upper tract urothelial cancer? *J Urol*. 2009;181:133–134.

Smith AK, Stephenson AJ, Lane BR, et al. Inadequacy of biopsy for diagnosis of upper tract urothelial carcinoma: implications for conservative management. *Urology*. 2011;78:82–86.

Smith JA Jr, Lee RG, Dixon JA. Tissue effects of neodymium:YAG laser photoradiation of canine ureters. *J Surg Oncol*. 1984;27:168–171.

Steinberg JR, Matin SF. Laparoscopic radical nephroureterectomy: dilemma of the distal ureter. *Curr Opin Urol*. 2004;14:61–65.

Sternberg CN, de Mulder P, Schornagel JH, et al. Seven year update of an EORTC phase III trial of high-dose intensity M-VAC chemotherapy and G-CSF versus classic M-VAC in advanced urothelial tract tumours. *Eur J Cancer*.

2006;42:50–54.

Sternberg CN, Yagoda A, Scher HI, et al. Methotrexate, vinblastine, doxorubicin, and cisplatin for advanced transitional cell carcinoma of the urothelium: efficacy and patterns of response and relapse. *Cancer*. 1989;64:2448–2458.

Stifleman MD, Hyman MJ, Shichman S, et al. Hand-assisted laparoscopic nephroureterectomy versus open nephroureterectomy for the treatment of transitional-cell carcinoma of the upper urinary tract. *J Endourol*. 2001;15:391–395.

Streem SB, Pontes JE, Novick AC, et al. Ureteropyeloscopy in the evaluation of upper tract filling defects. *J Urol*. 1986;136:388.

Strong DW, Pearse HD, Tank ES, et al. The ureteral stump after nephroureterectomy. *J Urol*. 1976;115:654–655.

Suoka K, Lida S, Tomiyasu K, et al. Transurethral endoscopic management of upper urinary tract tumors using a holmium:YAG laser. *Lasers Surg Med*. 2003;32:336.

Sutherland DE, Williams SB, Jarrett TW. Laparoscopic renal descensus for upper tract reconstruction. *J Endourol*. 2011;25:271–272.

Syed JS, Nguyen KA, Suarez-Sarmiento A, et al. Survival outcomes for patients with localised upper tract urothelial carcinoma managed with non-definitive treatment. *BJU Int*. 2018;121(1):124–129.

Takahashi T, Kakehi Y, Mitsumori K, et al. Distinct microsatellite alterations in upper urinary tract tumors and subsequent bladder tumors. *J Urol*. 2001;165:672–677.

Tawfiek ER, Bibbo M, Bagley D. Ureteroscopic biopsy: technique and specimen preparation. *Urology*. 1997;50:117–119.

Thompson RH, Drambeck AE, Lohse CM, et al. Endoscopic management of upper tract transitional cell carcinoma in patients with normal contralateral kidneys. *Urology*. 2008;7:713–717.

Tomera KM, Leary FJ, Zincke H. Pyeloscopy in urothelial tumors. *J Urol*. 1982;127(6):1088–1089.

Varkarakis MJ, Gaeta J, Moore RH, et al. Superficial bladder tumor: aspects of clinical progression. *Urology*. 1974;4:414–420.

Vaughn D, Malkowicz S, Zoltick B, et al. Paclitaxel plus carboplatin in advanced carcinoma of the urothelium: an active and tolerable outpatient regimen. *J Clin Oncol*. 1998;16:255–260.

Vaughn DJ, Srinivas S, Stadler WM, et al. Vinflunine in platinum-pretreated patients with locally advanced or metastatic urothelial carcinoma: results of a large phase 2 study. *Cancer*. 2009;115:4110–4117.

Wagner KR, Schoenberg MP, Bianco FJ Jr, et al. Prospective intermediate follow-up of carcinoma in situ involving the distal ureter at cystectomy: is there a role for ureteroscopy? *J Endourol*. 2008;22(6):1241–1246.

Walton TJ, Sherwood BT, Parkinson RJ, et al. Comparative outcomes following endoscopic ureteral detachment and formal bladder cuff excision in open nephroureterectomy for upper tract transitional cell carcinoma. *J Urol*. 2009;181:532–539.

Weight CJ, Gettman MT. The emerging role of lymphadenectomy in upper tract urothelial carcinoma. *Urol Clin North Am*. 2011;38:429–437 [vi].

Whalen MJ, RiChard JL, Ghandour R, et al. Lessons learned from routine intraoperative ureteral margin frozen sections during radical cystectomy. *Urol Pract*. 2015;2:90–95.

Wheat JC, Weizer AZ, Wolf JS Jr, et al. Concomitant carcinoma in situ is a feature of aggressive disease in patients with organ confined urothelial carcinoma following radical nephroureterectomy. *Urol Oncol*. 2012;30(3):252–258.

Williams RD. Renal, perirenal, and ureteral neoplasms. Gillenwater JY, Grayhack JT, Howards SS, et al. *Adult and pediatric urology*. 2nd ed. Mosby–Year Book: St. Louis; 1991.

Wolf JS Jr, Dash A, Hollenbeck BK, et al. Intermediate followup of hand assisted laparoscopic nephroureterectomy for urothelial carcinoma: factors associated with outcomes. *J Urol*. 2005;173:1102–1107.

Zareba P, Rosenzweig B, Winer AG, et al. Association between lymph node yield and survival among patients undergoing radical nephroureterectomy for urothelial carcinoma of the upper tract. *Cancer*. 2017;123:1741–1750.

Zincke H, Aguilo JJ, Farrow GM, et al. Significance of urinary cytology in the early detection of transitional cell cancer of the upper urinary tract. *J Urol*. 1976;116:781–783.

Zungri E, Chechile G, Algaba F, et al. Treatment of transitional cell carcinoma of the ureter: is the controversy justified? *Eur Urol*. 1990;17:276–280.

Retroperitoneal Tumors

Timothy A. Masterson MD, K. Clint Cary MD, MPH, Richard S. Foster MD

Overview

The retroperitoneum (RP) is a common location for many pathologic conditions with which urologists must be familiar. Tumors within this region often involve adjacent structures including parts of the urinary tract, RP vasculature, and lymphatic circulation. Understanding the fundamental differences among a variety of tumors, both malignant and benign, that are unique to this location is important for making appropriate management decisions for patients. The origin of many tumors is primary to the RP, and for others it serves as a destination for metastatic deposits. In this chapter, we will review the anatomy of the RP, initial evaluation of the RP mass, differential diagnosis, and management strategies. Beyond this, we will discuss important perioperative management considerations, the surgical approach to the RP, and adjuvant therapies. Conditions unique to the kidneys and adrenal glands are discussed elsewhere.

Anatomic Considerations of the Retroperitoneum

Within the RP, an in-depth understanding of the anatomy is imperative. Borders include the diaphragm superiorly, inlet to the true pelvis inferiorly, insulation by the peritoneal contents anteriorly, the body wall posteriorly, and extension to the flank musculature laterally. Inclusive within the RP is the upper urinary tract (including the kidneys, renal pelvis, and proximal/middle portions of the ureter); adrenal glands; great vessels (infradiaphragmatic aorta and vena cava, common iliac vessels, lumbar branches); RP lymphatics and connective tissues (RP fat, Gerota fat, and fascia); and portions of the sensory, motor, and autonomic nervous systems (sympathetic chain of ganglia, postganglionic sympathetic and para-sympathetic nerve fibers). The close approximation of the peritoneal contents, including the second and third portions of the duodenum, ascending and descending colon, pancreas, and splenic hilum, warrant special consideration, as many of the conditions we will discuss present clinically as expansile tumors that distort and invade adjacent structures.

Specific to the right RP, tumors in the upper RP require attention not only regarding potential involvement of the kidney/ureter and adrenal gland, but more importantly the duodenum, vena cava, posterior diaphragm, and right segments of the liver. Involvement of the mesentery of the right colon can be difficult to assess on preoperative imaging, but indistinct tumor borders with loss of fat planes may raise concerns for its involvement. As for the left RP, involvement of the aorta, splenic hilum, and tail of the pancreas raise the greatest concerns. Similar to right-sided tumors, involvement of the diaphragm and mesentery of the left colon needs to be assessed. Similar to both, involvement/invasion of the posterior body wall and psoas muscle may be present. Depending on depth into the psoas muscle, trauma and/or disruption of sensory and motor nerves may be encountered. Paresthesias along the anterior and medial thigh may manifest as a result of transient or permanent injury to the genitofemoral nerve. Of greater concern, harm to the psoas muscle and femoral nerve can result in motor weakness and functional impairment with lower extremity flexion at the hip and extension from the knee.

Understanding in the preoperative setting the potential for involvement of any of these structures allows for a safer operation and better outcome.

Consultation with hepatobiliary, vascular, thoracic, and/or general surgeons may be necessary to facilitate optimal care depending on the tumor location. Additionally, this will help establish appropriate expectations as to the degree of convalescence and recovery for the patient in the postoperative period.

Key Point

- The confines of the RP represent a specific anatomic compartment that houses or borders portions of the urinary, vascular, hepatobiliary, gastrointestinal, neurologic, and lymphatic systems. Accordingly, tumors arising within this region often involve multiple organ systems and require careful consideration/planning before intervention.

Initial Evaluation of the Retroperitoneal Mass

Because of the insulation that the RP provides, tumors may grow to sizable dimensions without detection or symptoms. In a series of patients undergoing treatment for RP sarcoma, the average dimensions of tumors resected exceeded 15 cm (Fabre-Guillevin et al., 2006). Regardless of whether the mass is identified by incidental detection on routine imaging for other causes or by patient symptoms, understanding the next most appropriate steps in the evaluation is important.

Almost exclusively, computed tomography (CT) of the chest, abdomen, and pelvis represents the optimal initial imaging modality for characterizing masses occurring within the RP (National Comprehensive Cancer Network guidelines, 2018). **CT allows for detail of the lesion through demonstration of size, internal density, presence of calcifications, relation to adjacent organs, infiltration of borders, and presence of regional or distant spread. With intravenous contrast enhancement, identification of cystic changes or necrosis can be depicted.** Additionally, the use of oral contrast can aid in the assessment of duodenal, small bowel, and colonic involvement (Cohan et al., 1988; Katz et al., 2007; Tzeng et al., 2007). In the setting of fat-containing tumors, negative Hounsfield units can identify areas whose features can be pathognomonic in certain conditions such as liposarcomas, angiomyolipomas (AMLs), and myelolipomas. Limitations of CT imaging lies in the inability to discriminate histologic origin or malignant potential based on radiographic appearance alone. Magnetic resonance imaging (MRI) adds value in helping discriminate the degree of vascular involvement when central vessels are distorted, helps define the presence of cystic components or fat within masses, and provides greater resolution of internal characteristics when intravenous contrast administration cannot be provided in the setting of contrast allergy or poor renal function for enhancement during CT imaging. Positron emission tomography/computed tomography (PET/CT) increasingly has been used and plays an important role selectively in a handful of scenarios. Most notable would be assessing viability of postchemotherapy residual masses in the setting of advanced/metastatic seminoma to the RP, risk assessment and estimation of tumor grade/histologic subtypes of RP liposarcomas (Schwarzbach et al., 2001;

Brenner et al., 2006), and staging and treatment adaptation in certain subtypes of lymphoma (Tateishi et al., 2010; Hutchings and Barrington, 2009).

Laboratory testing certainly plays an important role, especially in the evaluation of young male patients with a newly discovered RP mass. Serum tumor marker assessment evaluating for elevations in α-fetoprotein (AFP) and human chorionic gonadotropin (hCG) remains a critical tool in the diagnosis, prognostication, and management of germ cell tumors (GCTs). Blood cell counts can identify dyscrasias that may suggest lymphoproliferative disorders, and metabolic panels provide assessment of kidney and liver function.

The role of diagnostic sampling of tumors via fine-needle aspiration (FNA) or core-needle biopsy remains an essential tool in guiding therapy. In the era of personalized medicine, much can be learned from tissue samples as far as histologic subtype and tumor grade. Additionally, when sequencing of various therapies may be altered based on the findings on biopsy, this information becomes essential. An excellent example would be the case of RP lymphoma, in which the initial therapy is systemic chemotherapy in all circumstances and regimen based on lymphoma subtype. In the case of many sarcomas, surgical therapy was the historical mainstay of initial treatment; therefore, surgical biopsy played little role in its initial evaluation. However, as discussed later in this chapter, multimodal therapies are now often employed in the setting of high-grade tumors (von Mehren et al., 2018; Gronchi et al., 2004; Grobmyer et al., 2010). **As such, biopsy may select certain patients for neoadjuvant therapies such as chemotherapy or radiation before surgical resection.** When a biopsy is indicated, how to approach (trans-peritoneal vs. RP) and type of biopsy (FNA vs. core) are often dictated by clinical presentation and limitations of access. At times, open or laparoscopic biopsies can be incorporated when larger tissue samples are needed to solidify the correct diagnosis, often in advanced or unresectable situations. In general, the incremental benefit of core biopsy (typically using a 14- or 16-gauge coaxial needle) over FNA in ensuring adequate tissue for diagnostic testing and discriminatory abilities by histopathology when cellular architecture is needed has been well documented (Bennert and Abdul-Karim, 1994; Domanski, 2007). Exceptions to the benefits of biopsy include liposarcoma, a tumor in which biopsy is often nondiagnostic and notoriously limited in guiding treatment decisions (Ikoma et al., 2015).

Key Points

- Many tumors of the RP grow silently over months or years, thus presenting with sizeable dimensions and adjacent organ involvement.
- Cross-sectional imaging offers the best means of assessing size and extent of disease. Serologic testing plays an important role, specifically in GCTs.
- FNA and/or core biopsy remain an important tool in the evaluation and management of many diseases, and its diagnostic value should be considered in the initial workup of all RP masses.

Differential Diagnosis

Tumors occurring in the RP need to be carefully evaluated to allow for categorization into specific groups, for which management can vary widely. These categories include both primary and metastatic tumors of germ cell/gonadal, mesodermal, neurologic, and hematologic origins. We will discuss each entity in terms of relative incidence and demographics, common clinical/radiographic/pathologic/histologic characteristics, genetic predispositions when present, and prognosis. Table 100.1 provides a comprehensive list of relevant immunohistochemical features and genetic associations of the most common entities included in the following sections.

TABLE 100.1

Immunohistochemical and Genetic Characteristics

	NOTABLE POSITIVES	NOTABLE NEGATIVE
Seminoma	Nuclear: OCT4/SALL4/NANOG Cytoplasmic: PLAP/CD117/D2-40	CD30/pan-keratin
Nonseminoma		Inhibin/calretinin
Embryonal	Nuclear: OCT4/SALL4/SOX2 Cytoplasmic: CD30/pan-keratin/CK7	CD117/D2-40
Yolk sac tumor	AFP/SALL4/glypican-3/pan-keratin	OCT4/CD30/CK7
Choriocarcinoma	hCG/pan-keratin	OCT4/CD30
Teratoma		
Sex cord stromal tumor		
Leydig cell tumor	Inhibin/calretinin	SALL4/PLAP
Sertoli cell tumor	Inhibin/calretinin/β-catenin (nuclear expression)[a]	SALL4/PLAP
Granulosa cell tumor	Inhibin/calretinin	SALL4/PLAP
Liposarcoma		
Well-differentiated/de-differentiated tumor	MDM2/CDK4/S100	

Pleomorphic tumor	S100	MDM2/CDK4
Leiomyosarcoma	SMA/desmin/H-Caldesmon	MDM2/CD117/HMB-45/DOG1
Undifferentiated pleomorphic sarcoma (i.e., malignant fibrous histiocytoma)	Variable, positive IHC usually not helpful	Negative for markers that would indicate lineage of differentiation
Synovial sarcoma	TLE1/CD99/EMA/pan-keratin	FLI1
Solitary fibrous tumor	STAT6/CD34	Desmin/S100/DOG1
Extraskeletal Ewing sarcoma	CD99/FLI1	TLE1/EMA/pan-keratin
Desmoplastic small round cell tumor	EMA/desmin/pan-keratin/WT1 (only the antibody directed against C-terminus of the protein)	
Perivascular epitheliod cell tumor (PEComa)	Variably positive for melanocytic markers (e.g., HMB-45 and melan A) and muscle markers (e.g., SMA and desmin)	
Fibromatosis (desmoid tumor)	β-catenin (nuclear expression)	
Ganglioneuroblastoma	CD56/chromogranin A/neurofilament/synaptophysin/neuron-specific enolase	
Paraganglioma	Synaptophysin/chromogranin A/GATA3	
Neurofibroma	S100	
Malignant peripheral nerve sheath tumor	S100 (patchy)	H3K27me3 (~50% of malignant peripheral nerve sheath tumor)

Lymphoma		
Hodgkin (classic Hodgkin lymphoma)	CD30/PAX5	CD45
Non-Hodgkin lymphoma	Variable depending on type, usually CD45	
Plasma cell neoplasm	CD138/CD38	CD45/CD20
Cystic lymphangioma	CD31/CD34/D2-40	
Cystic mesothelioma	Calretinin/pan-keratin	
RP cancer of unknown primary origin		

[a] 60% to 70% of Sertoli cell tumors demonstrate nuclear expression of β-catenin, which is very specific for Sertoli cell tumor, however lack of nuclear expression does not exclude Sertoli cell tumor as a possibility.

Germ Cell/Gonadal Origins

Tumors of germ cell or gonadal origin can occur in the RP as a primary tumor or as a metastatic deposit. Although uncommon in frequency as compared with other solid tumors, the presence of a RP mass in a young male patient should immediately raise concerns of this entity. Similarly, tumors arising from the stromal elements of the testis can also find the RP as a landing zone in a similarly predictable fashion. Classified as either seminomas or nonseminomas among GCT entities versus Leydig cell, Sertoli cell, or granulosa cell tumors among the greater category of sex cord stromal tumors, each of these cancers has a distinct biologic potential that dictates specific considerations in management.

Germ Cell Tumor

Although discussed in greater detail elsewhere in this book, these remain important considerations because of their propensity to metastasize to the RP, and occasionally arise within the RP as a primary tumor. The incidence of GCTs is increasing in the population, with Hispanics representing the ethnicity with the most rapid rise (Ghazarian et al., 2017). Most commonly they are discovered as an enlarging mass in the scrotum. Within the RP, they can develop as heterogeneous, circumscribed masses along the lymphatic chains of the RP lymph nodes. CT imaging provides the best means of characterizing RP disease, and scrotal ultrasonography can aid in the detection of primary disease within the testis when present. This general category is broken down into divergent pathways of pure seminomas and nonseminomas, which includes embryonal carcinoma, yolk sac tumor, choriocarcinoma, and teratoma. Important to this classification are the clinical differences that motivate variations in management, including the distribution and rate of developing distant disease, serologic assessments, susceptibility to chemotherapy, surgery and radiation, and the risk for long-term relapse.

Seminomatous GCTs arise from the germinal epithelium of the seminiferous tubules. Occurring in the third to fifth decades of life, they represent roughly one-half of all GCT cases at presentation. Serologic testing reveals an elevated hCG in 10% to 15% of cases, corresponding to the presence of syncytiotrophoblasts in the tumor. The presence of an elevated AFP when attributable to the tumor excludes the category of pure seminoma. The tumors themselves are fleshy and tan in appearance on the cut surface. Histologically, they appear as sheets of polygonal cells with abundant clear cytoplasm that are separated into nests by fibrous septae, with a lymphocytic infiltration being present in the majority of cases. A uniform, orderly distribution of prominent nucleoli is typical, contrasting the disorganized appearance in embryonal carcinoma. Additionally, the presence of mitotic figures is numerous. Immunohistochemistry (IHC) typically reveals nuclear staining for OCT4/SALL4/NANOG and cytoplasmic staining for PLAP/CD117/D2-40. Historically, seminoma has been classified into three entities including classic type, spermatocytic, and anaplastic. Although the spermatocytic entity rarely, if ever, metastasizes, the significance of subclassification into classic versus anaplastic variants has little prognostic value. The majority of these tumors remain confined to the testis and are cured with orchiectomy; however, when metastatic they are notably chemotherapy and radiotherapy sensitive. **Pure seminomas remain one of the most curable solid tumors, even in the metastatic setting, with cure rates approaching 98%.**

Nonseminomatous GCTs includes at least one the following histologies: embryonal carcinoma, yolk sac tumor, choriocarcinoma, and teratoma. These tumors usually present in the late teens thru early thirties, although later presentations can occur. Their radiographic characteristics are similar in the testicle and RP as seminomas; however, serologic differences exist. **The**

production of AFP is specific for yolk sac tumor and embryonal carcinoma elements, whereas hCG can be produced by choriocarcinoma, embryonal carcinoma, and seminoma. Depending on the components present within the tumor, variable degrees of hemorrhage, necrosis, cystic changes, and calcifications can be present. Histologically, each component within nonseminoma is distinct. Embryonal carcinoma consists of polygonadal cells in clusters with varying degrees of eosinophilic cytoplasm and prominent nucleoli. Typical IHC staining patterns include OCT4, SALL4, and SOX2 in the nucleus (Cao et al., 2009; Gopalan et al., 2009; Jones et al., 2004). Cytoplasmic and cell wall staining is positive for CD30, CK7, and pan-keratin in most, with AFP positivity in up to one-third. Yolk sac tumor, in contrast, can have a variable architectural pattern and is OCT4 and CD30 negative, weakly positive for AFP, but positive for SALL4, glypican-3, and pan-keratin. Choriocarcinomas are associated with extensive hemorrhage and necrosis, and diffusely contain syncytiotrophoblasts and mononuclear trophoblasts. IHC staining is diffusely positive for hCG and pan-cytokeratin, and similarly OCT4 and CD30 negative. Lastly, teratoma is composed of random distributions from multiple germ layers, ranging from squamous/glandular epithelium, to stromal tissues with smooth muscle/bone/cartilage, to mature and immature neural tissues. Occasionally, somatic transformation of teratomatous elements into sarcomas and carcinomas can be seen. Cystic changes are common as well. IHC plays little role in the characterization of teratoma because of its unique architectural features and marbling of elements. Genetically, GCTs demonstrate the characteristic presence of chromosome 12p abnormalities in the majority of cases. Clinically, the components of embryonal carcinoma, yolk sac tumor, and choriocarcinoma are chemosensitive, similar to seminomas. However, because of the common presence of teratomatous elements, which are resistant to chemotherapy and radiotherapy, surgery often plays a more significant role in the setting of advanced disease.

The incidence of truly extragonadal GCTs in the RP remains somewhat controversial. The presence of GCT elements localized primarily to the mediastinum or RP in the absence of a testicular primary tumor occurs in 3% to 5% of all reported cases of GCT. In a multicenter collaboration evaluating 635 patients with extragonadal GCTs, 45% were localized to the RP (Bokemeyer et al., 2002). **However, when extragonadal GCTs of the RP lateralize to the left or right landing zones, over 70% of cases in one series had histologic evidence of either teratoma (20%) or necrosis/fibrosis (80%) within the**

ipsilateral testicle at time of orchiectomy after chemotherapy (Brown et al., 2008). Regardless, when the presence of a GCT histology is identified serologically or pathologically to the RP, initial management is treatment with platinum-based chemotherapy. If known to be of nonseminomatous differentiation, resection of residual disease after chemotherapy is recommended in all cases (Albany and Einhorn, 2013).

Sex Cord Stromal Tumor

Sex cord stromal testicular tumors, which include Leydig, Sertoli, and granulosa cell types, compose less than 5% of all testicular neoplasms. Of the sex cord stromal tumors, Leydig cell tumors are the most common and generally occur between 30 and 60 years of age. The presence of Reinke crystals is a classic histologic finding, however, this is only present in roughly 30% of cases. Histologically, these tumors can be confused with tumors seen in congenital adrenal hyperplasia, which can be differentiated by an elevated adrenocorticotropic hormone level. Sertoli cell tumors compose less than 1% of testicular neoplasms. They are most common between 35 and 50 years of age. They can be associated with Peutz-Jeghers syndrome. They can be misinterpreted as seminomas, and therefore careful histologic assessment is important to guide therapy. A positive cytokeratin and inhibin stain with an absent PLAP stain favors Sertoli cell tumor over seminoma. Granulosa cell tumors are one of the rarest types. Two types exist: juvenile and adult. The juvenile type is benign and accounts for up to 7% of prepubertal testicular neoplasms. Most commonly, the juvenile type occurs before 6 months of age (Kao et al., 2015). Microscopically, the juvenile tumors typically show a lobular growth, punctuated by variably sized and shaped follicles. The adult type resembles that of granulosa tumors of the ovary. Twenty-five percent of patients present with infertility and gynecomastia. In general, these tumors are slow growing with limited reports of RP metastases.

Although most of these rare tumors are benign, approximately 10% will metastasize (Grem et al., 1986; Kim et al., 1985; Kratzer et al., 1997). These malignant tumors respond poorly to chemotherapy or radiotherapy. Similar to mixed GCTs, metastatic forms of sex cord stromal tumors will frequently spread to the retroperitoneum, and then to the lung. The ideal timing of surgery has been questioned because of high mortality rates for patients who develop metastasis while on surveillance, despite adequate resection. As a result, several studies have examined predictive pathologic and clinical factors to identify patients who would benefit from immediate retroperitoneal lymph node dissection (RPLND) in the clinical absence of metastatic disease to pathologically stage and hopefully prevent further nodal spread. **Although the presence of metastatic disease is the only reliable indicator of malignant phenotype, various primary tumor characteristics have been evaluated for their ability to predict aggressive behavior. These characteristics include older age, primary tumor size larger than 4 to 5 cm, necrosis, mitotic rate greater than 3 to 5 per 10 high-power fields, moderate-to-severe nuclear atypia, infiltrative tumor margins/invasion of adjacent structures, and lymphovascular invasion**. Although there are some reported cures with positive RP lymph nodes, the presence of radiologic enlarged lymph nodes is a poor prognostic sign (Mosharafa et al., 2003; Silberstein et al., 2014).

Mesodermal Origins

Tumors that arise from mesodermal origins compose the greater category of soft-tissue tumors including sarcoma and benign mesenchymal tumors. Among sarcomas, these most commonly include liposarcomas, leiomyosarcomas, malignant fibrous histiocytomas (MFHs), and, less commonly, angiosarcomas, rhabdomyosarcoma, and myxosarcomas. Tumors of the benign variety include lipomas, leiomyomas, fibromas, hemangiopericytomas, PEComas, chordomas, myelolipomas, xanthogranulomas, myxomas, and gastrointestinal stromal tumors. The following sections will discuss those entities that are more commonly associated with the RP, for which clinical decisions will be more relevant and impactful.

Soft tissue sarcomas represent approximately 1% of all solid cancers in adults, with tumors arising from the retroperitoneum in roughly 15% to 20% of those cases (Olimpiadi et al., 2015; Pisters, 2007; van Houdt et al., 2017). With as many as 50 different subtypes of sarcoma having been described, very few are likely to be discovered in the RP. With considerable overlap and varied histologic appearance, clinicopathologic characteristics and molecular diagnostics are often necessary to identify the true nature of these tumors. This requires more than ever the integration of IHC, molecular and cytogenetic characterization, as well as clinical details for the clinician and pathologist to render an accurate diagnosis.

Liposarcoma

Liposarcoma represents a malignant, locally aggressive tumor composed of adipocytes with nuclear atypia and hyperchromasia. These tumors can be classified as well-differentiated or de-differentiated, based on the presence or absence of higher-grade, nonlipogenic components within the tumor. Combined, these entities represent roughly 60% of all retroperitoneal sarcomas (Gronchi et al., 2016; Tan et al., 2016). Both typically present as painless masses, often found incidentally during a workup for other conditions or screening examinations. Growth rates of the de-differentiated tumors tend to be rapid, often drawing attention to a clinically more aggressive phenotype of liposarcoma. Radiographically, liposarcomas on CT have a low signal intensity but demonstrate mass-effect of the surrounding structures (Fig. 100.1). Areas of greater signal intensity internally within the tumor often reflect de-differentiated components (Fig. 100.2).

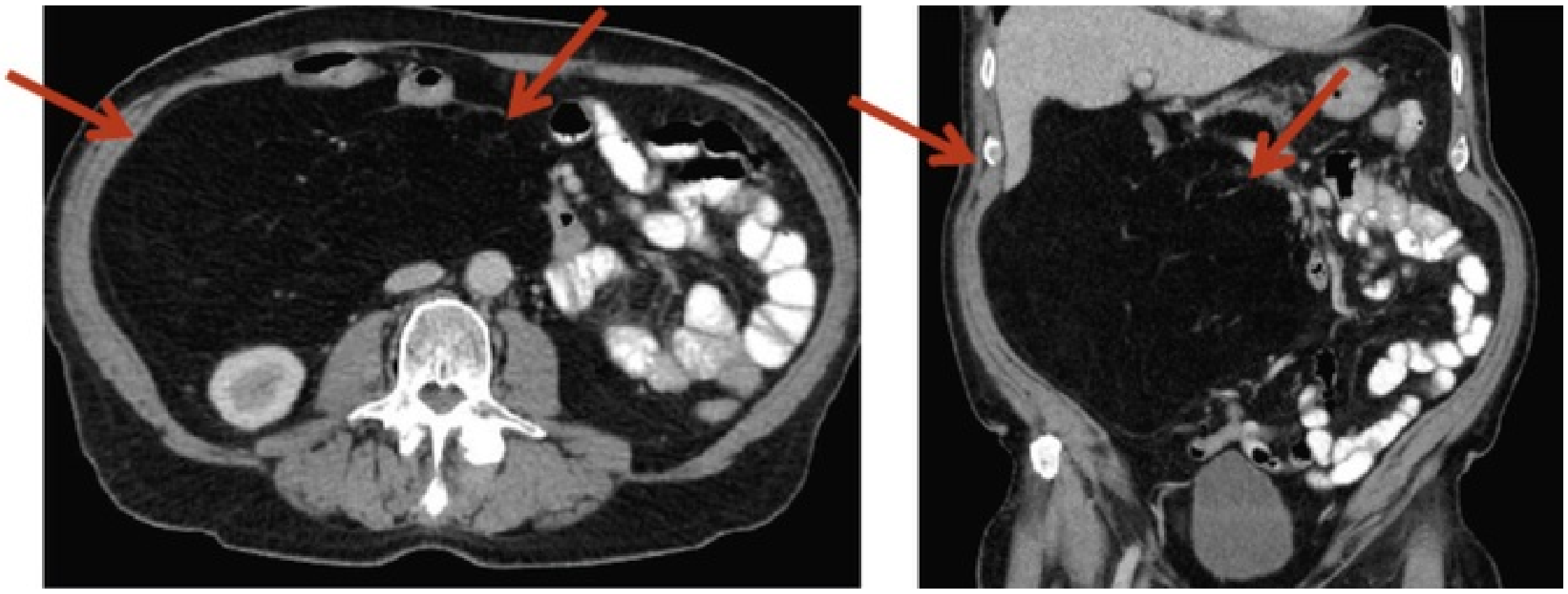

FIG. 100.1 Well-differentiated liposarcoma *(arrows).*

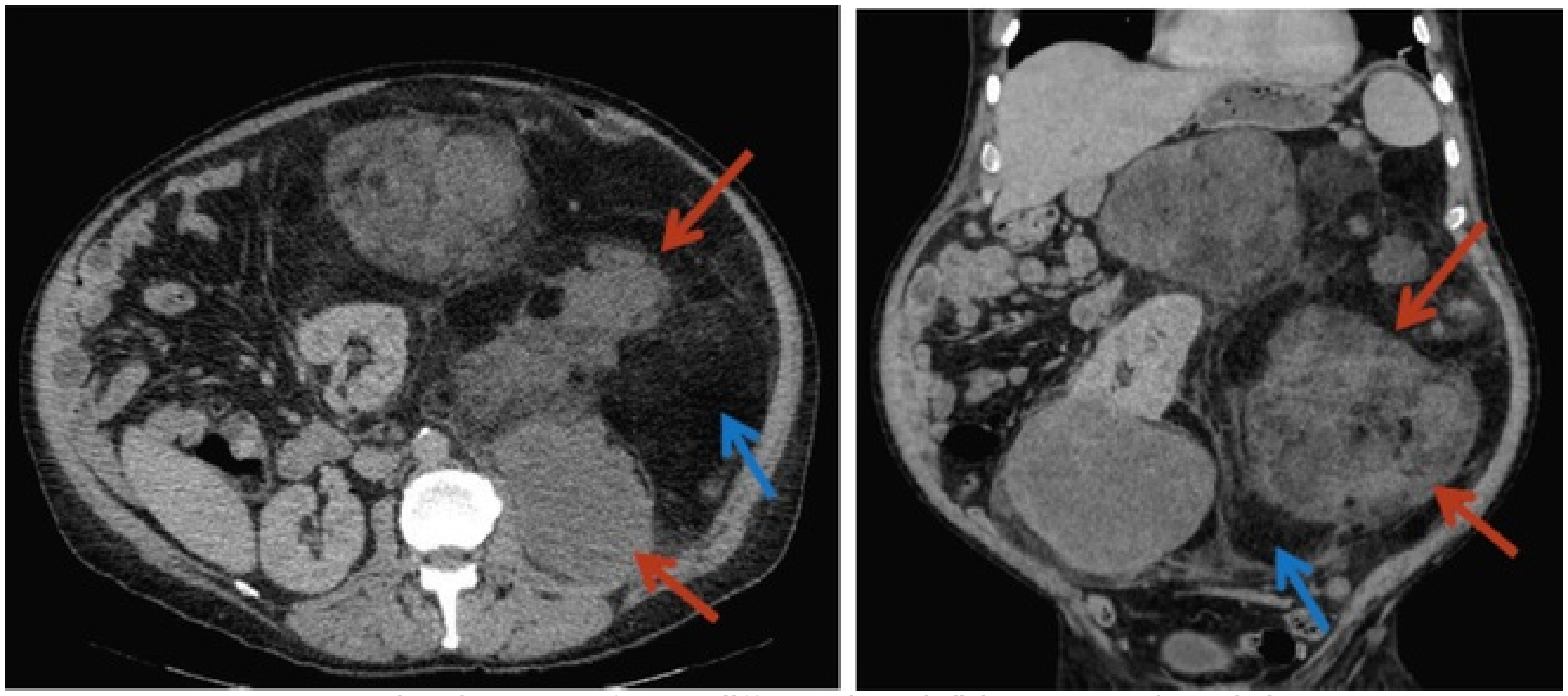

FIG. 100.2 Mixed tumor of well-differentiated *(blue arrows)* and de-differentiated liposarcoma *(red arrows).*

Histologically, well differentiated liposarcomas can be characterized into three distinct groups: adipocytic (lipoma-like), sclerosing, and inflammatory. Adipocytic tumors resemble lipomas morphologically, with hyperchromatic and atypical nuclei scantly distributed among fat lobules, often rendering core biopsies inconclusive. Sclerosing-type liposarcomas contain a hyalinized stroma intermixed with variable amounts of atypical adipocytes scattered throughout. Lastly, inflammatory-type liposarcomas have an inflammatory infiltrate interspersed among adipocytic changes. Depending on the degree of lymphoid aggregates within the tumor, these can sometimes be difficult to distinguish from a primary lymphoproliferative malignancy. **As with most cases of liposarcomas, a combination of histologic features along with clinical and anatomic presentation are often required to render the appropriate diagnosis.**

De-differentiated liposarcomas often arise from well differentiated components, therefore histologic appearance reveals atypical adipocytes surrounding regions of fleshy, nonlipogenic areas. Within these de-differentiated regions of the tumor, cells can have a mixture of patterns that appear similar to undifferentiated spindle cell sarcomas, myxoid tumors, and areas containing meningothelial and pleomorphic-like features. Not uncommonly, components of osteosarcoma, rhabdomyosarcoma, leiomyosarcoma, and small round cell morphologies can be seen within the tumor.

Cytologically, both well-differentiated and de-differentiated tumors demonstrate overexpression and/or amplification of genes localized to chromosome 12q (Sandberg, 2004), including MDM2, S100, and CDK4. Accordingly, monoclonal antibodies against these genes can be utilized through fluorescence in-situ hybridization or IHC to solidify the diagnosis of liposarcoma when suspected in otherwise limited tissue samples or in the presence of abundant stroma or inflammatory cells that obscure the diagnosis.

Prognostically, these tumors have a predilection for relapse. In well-differentiated tumors, up to 40% of tumors will recur locally (Fletcher et al., 1996; Gronchi et al., 2015b; Lucas et al., 1994; Singer et al., 2003; Tan et al., 2016; Tseng et al., 2014)**. Similar numbers have been reported for local relapse in de-differentiated tumors as well. However, unlike well-differentiated tumors, de-differentiated liposarcomas are associated with a higher rate of distant metastasis (up to 20% of cases) and a 5-year cancer-specific mortality of 30%** (Fletcher et al., 1996; Henricks et al., 1997; Lahat et al., 2008; Linehan et al., 2000; Tan et al., 2016; Tseng et al., 2014). The risk for local recurrence depends partly on tumor biology and surgical factors. Differing opinions with regard to the impact of surgical margin status (R0 vs. R1 resections) exist (Keung et al., 2014; Lahat et al., 2008; Neuhaus et al., 2005; Singer et al., 2003); however, most would agree that negative margins optimize outcomes for patients. Current strategies involving radical compartment resections for liposarcomas have been reported to improve local recurrence rates (Bonvalot et al., 2009; Gronchi et al., 2009, 2012, 2016; Raut et al., 2010). Average time reported for recurrent disease is roughly 2 years; therefore, long-term observation is needed (MacNeill et al., 2017). In the setting of unresectable or metastatic disease, use of anthracycline-based regimens has been associated with modest improvements in short-term survival (Jones et al., 2005). More recently, the safety and efficacy of immune checkpoint inhibitors (Pembrolizumab) was assessed in a phase II study, with objective responses seen in 2 of 10 patients (Tawbi et al., 2017).

Pleomorphic Liposarcoma

These tumors represent a very rare type of liposarcoma. They occur predominantly in adult patients, occurring more commonly in the extremities, but can be seen in the RP and along the spermatic cord (Hornick et al., 2004). They typically are fast-growing tumors, and histologically demonstrate pleomorphic lipoblasts that do *not* overexpress MDM2 or CDK4. Tissue samples often have frequent mitotic figures seen per high-power microscopic field, and can vary with the degree of spindle and epithelioid cells intermixed. These tumors can often resemble poorly differentiated carcinomas or renal cell carcinomas on needle biopsy. Ultimately, the identification of poorly differentiated lipoblasts on histologic sectioning is imperative for diagnosing these tumors. These tumors progress rapidly to widespread metastatic disease, with dissemination to the lungs being most common.

Leiomyosarcoma

Malignant tumors arising from smooth muscle cells are characterized as leiomyosarcomas. These tumors represent the second most common sarcoma type within the RP, occurring in about 20% of RP sarcoma cases (Gronchi et al., 2016; Tan et al., 2016). Arising from the media of RP blood vessels, muscularis of collecting system within the urinary tract, or other smooth muscle–containing structures of the RP, these tumors can grow silently until mass-effect or obstruction presents itself, often leading to problems of venous return, urinary drainage and function, or impingement of the gastrointestinal system. In females, many RP leiomyosarcomas are of gynecologic origin. Similar to liposarcomas, many can be detected as incidental findings. **In rare circumstances, these tumors can develop in the setting of Epstein-Barr viral infections in immunosuppressed patients** (Deyrup et al., 2004; McClain et al., 1995).

Clinically, these tumors grow as homogeneous tumors that encase structures with fleshy bundles of tissue (Fig. 100.3). On occasion, necrosis or cystic areas can be seen. Cytologically, these tumors reveal fascicles of atypical smooth muscle bundles with varying amounts of nuclear atypia depending on the grade of the tumor. Although de-differentiation to other sarcoma types can be seen, this is a less common phenomenon. When a smooth muscle–containing tumor is identified, criteria have been proposed to distinguish malignant from benign entities. These parameters include location of the primary tumor (RP vs. somatic soft tissues), mitotic rate, nuclear and cellular atypia, and presence/absence of necrosis. With increasing degrees of atypia, necrosis, and mitoses, these tumors can be classified from leiomyomas, to smooth muscle tumors of low malignant potential (STUMP), to leiomyosarcomas. (Marušić and Billings, 2017). IHC plays a similarly important role in the characterization and differentiation from other soft-tissue tumors. Markers such as smooth muscle actin (SMA), desmin, and H-Caldesmon can suggest this diagnosis when staining positive, and MDM2, CD117, HMB-45, and DOG1 are typically negative.

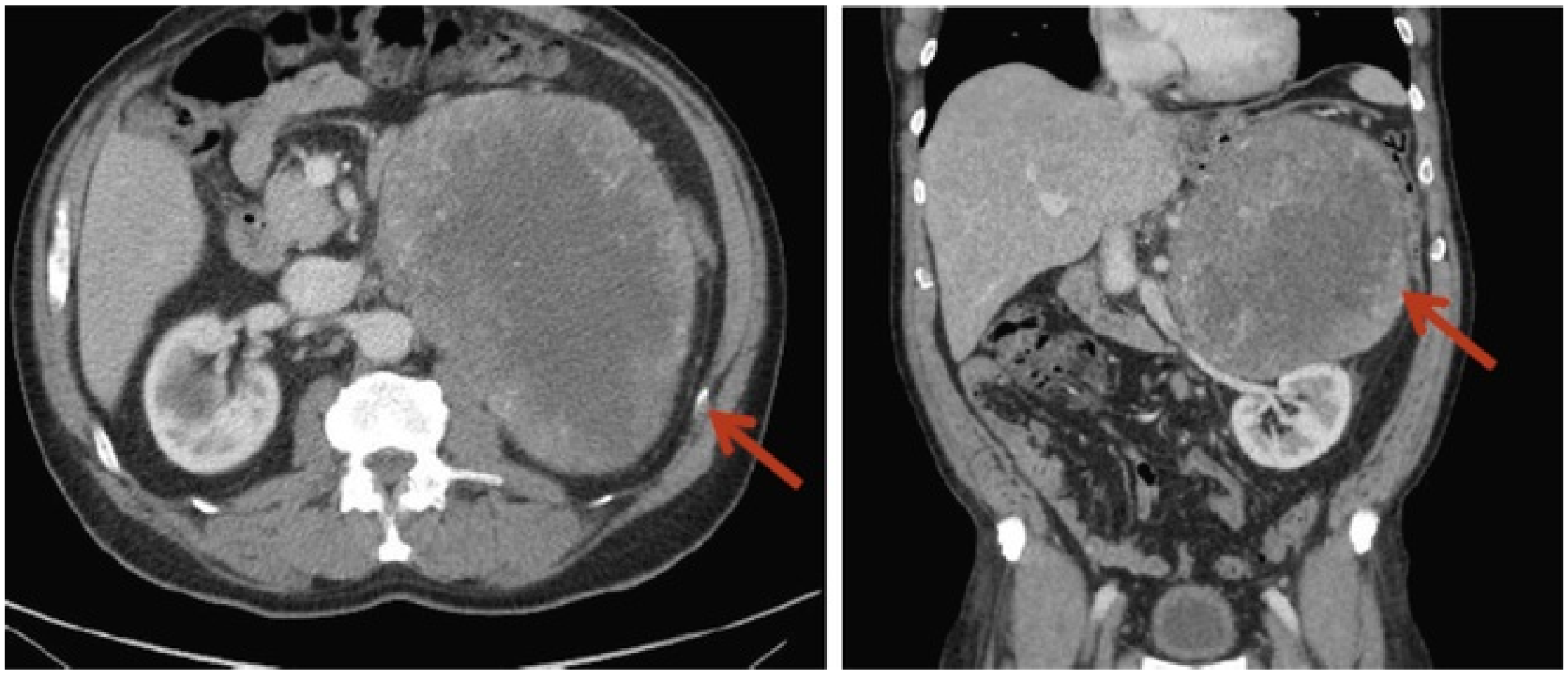

FIG. 100.3 Leiomyosarcoma *(arrows).*

Similar to de-differentiated liposarcomas, local and regional recurrences are common, with distant spread occurring frequently. Diagnosing these tumors on needle biopsy oftentimes underestimates the aggressiveness of disease, and an aggressive multimodal approach is often needed.

Malignant Fibrous Histiocytoma/Undifferentiated Pleomorphic Sarcoma

Tumors arising from fibroblastic and histiocyte-like cells compose the entity of malignant fibrous histiocytoma/undifferentiated pleomorphic sarcoma (MFH/UPS). Commonly occurring in the fifth and sixth decades of life, these tumors account for roughly one-fourth of soft-tissue sarcomas (Giménez Bachs et al., 2004; Ros et al., 1984; Schaefer and Fletcher, 2014). Often clinically silent, these tumors can reach large dimensions before being detected. Radiographic characteristics reveal heterogeneous soft-tissue masses caused by central necrosis, hemorrhage, and myxoid degeneration, typical of RP sarcomas (Fig. 100.4). The absence of fat within the tumor separates these tumors radiographically from liposarcomas, and rarely is there invasion of vascular structures. Peripheral nodular enhancement of a lobulated mass is common, with calcifications occurring in 10% of cases (Neville and Herts, 2004; Ros et al., 1984). Metastatic disease when present is typically to the lungs, liver, and bone. Tissue sampling is required to differentiate from other conditions, revealing spindle-shaped fibroblasts along with round histiocyte-like cells, lymphocytes, foamy cells, and giant cells. Histologic features also include a pseudoangiomatoid pattern, plasma and lymphocytic infiltrations, and a fibrous pseudocapsule (Grossman et al., 1996). Tumors most commonly stain positive for desmin, epithelial membrane antigen, CD68, and CD99 (García and Folpe, 2010). Gene translocations have been characterized in MFH/UPS tumors, resulting in the following gene fusion products: FUS/ATF1, EWSR1/ATF1, and EWSR1/CREB1 (Antonescu et al., 2007; Rossi et al., 2007; Waters et al., 2000). Among MFH/UPS, variations can exist and have been classified into distinct types: storiform-pleomorphic, myxoid, giant cell, angiomatoid, and inflammatory. The storiform-pleomorphic and myxoid tumors tend to represent high-grade sarcomas, whereas the others are often characterized as low-grade lesions. Treatment remains surgical in the absence of metastatic disease, with wide resection to achieve negative margins being associated with a risk reduction for local/distant relapse and improved survival (Yamaguchi et al., 2004). Limited data exist defining the benefits for adjuvant chemotherapy or radiotherapy in this disease. Overall 5-year survival in one series for MFH was 51% (Fabre-Guillevin et al., 2006).

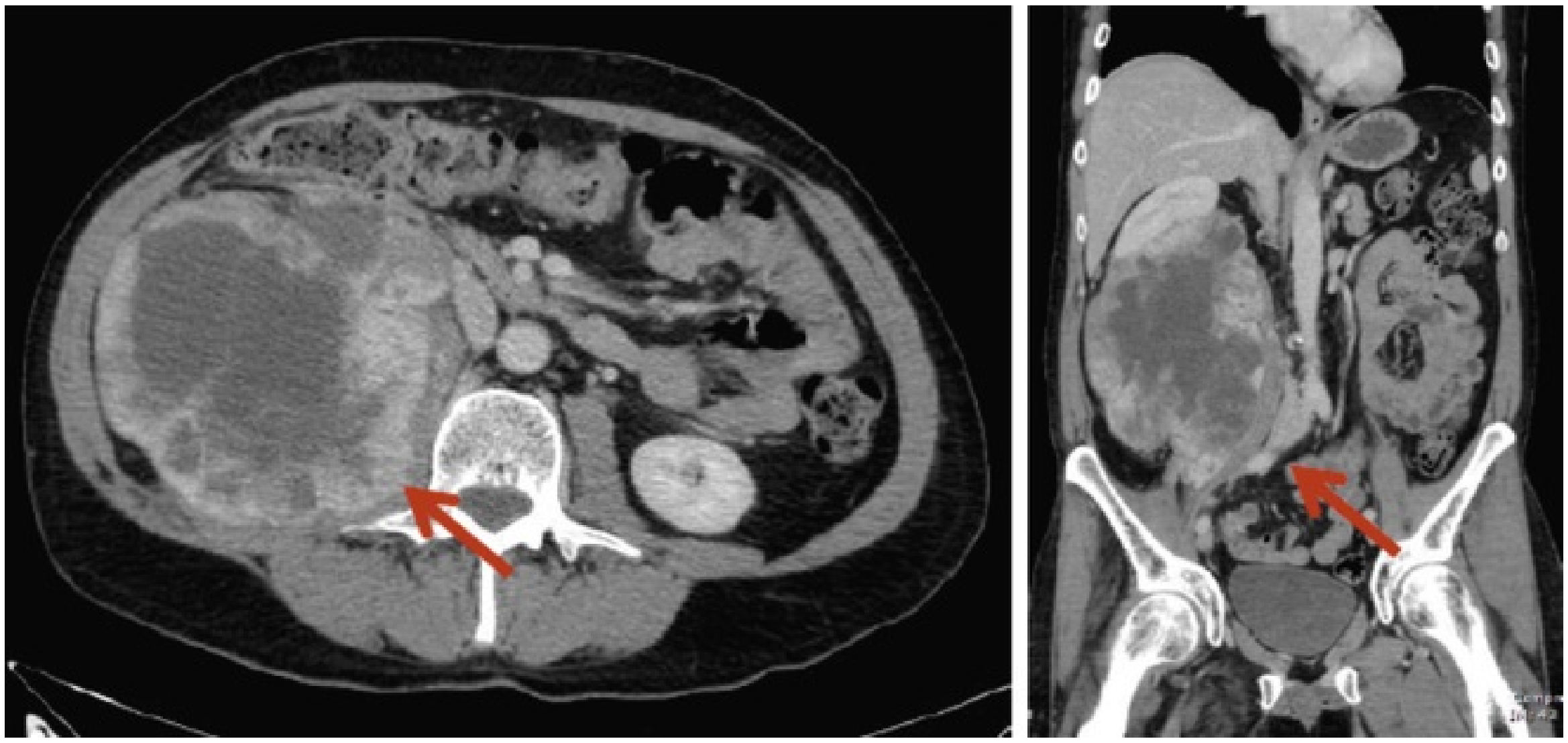

FIG. 100.4 Malignant fibrous histiocytoma *(arrows).*

Synovial Sarcoma

Although common in other locations, retroperitoneal synovial sarcomas are uncommon and occur across all age demographics (Chatzipantelis and Kafiri, 2008; Sultan et al., 2009). These mesenchymal tumors can arise from a variety of sources such as kidneys, adrenal glands, or other viscera (Fig. 100.5). Confusion can occur when arising from nerve structures, leading clinicians to suspect malignant peripheral nerve sheath tumors (Chrisinger et al., 2017). **They can grow to large sizes without symptoms within the RP, developing intratumoral calcifications that can hint at the diagnosis. Although rare, a history of prior radiation can be associated with development of these tumors** (van de Rijn et al., 1997).

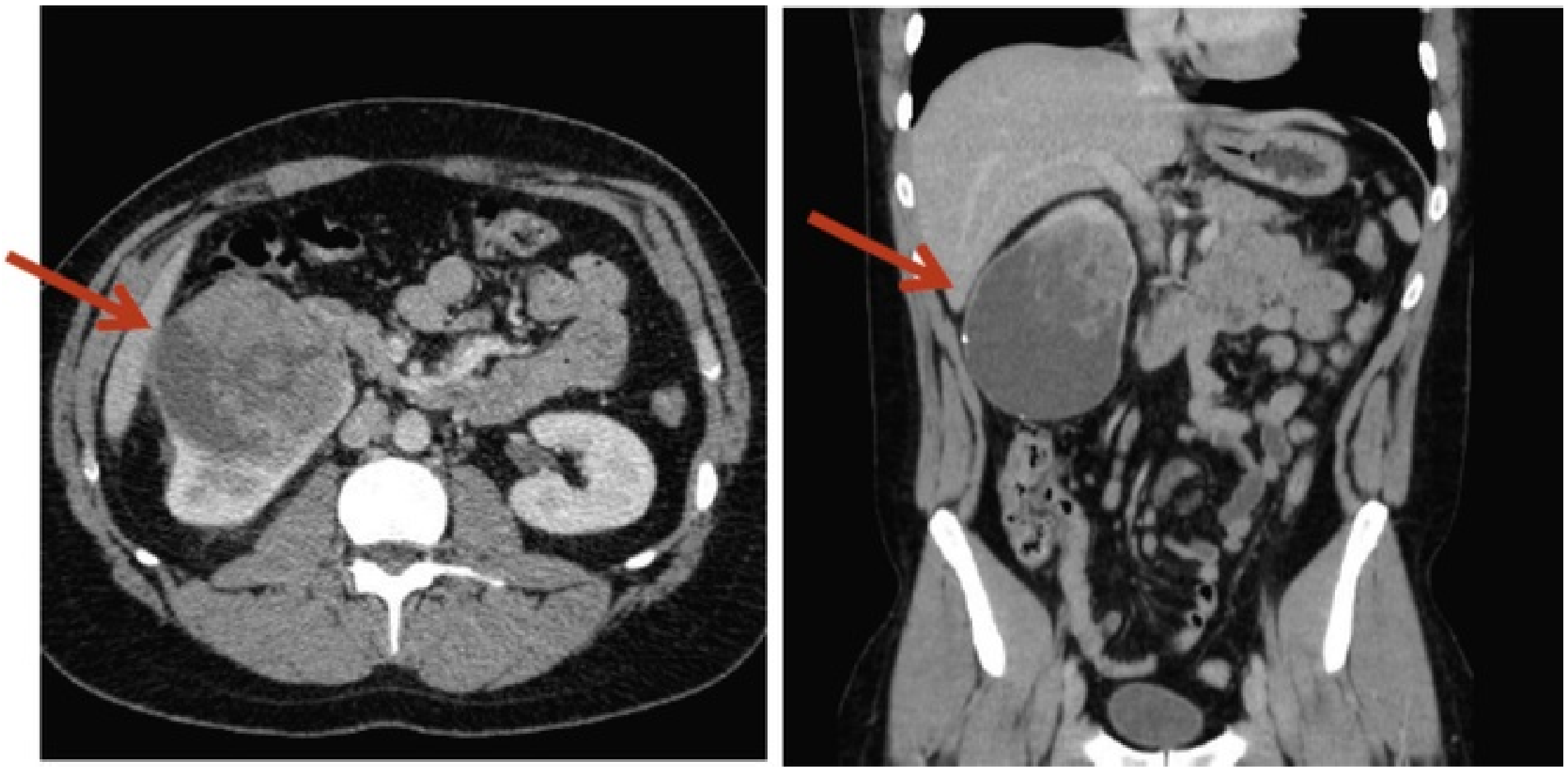

FIG. 100.5 Synovial sarcoma of the kidney *(arrows).*

The majority are encapsulated tumors, with cystic degeneration being present in many. Microscopically, they appear in a herringbone pattern with spindle cells. Mitotic activity is variable and correlates with tumor grade. They can demonstrate areas of differentiation into glandular, cystic, and undifferentiated round cell morphologies, rendering them often confused with other tumors. IHC testing for TLE1 is positive in 90% of cases, but is not exclusive (Terry et al., 2007). Molecular changes typical for synovial sarcomas include their translocations of X;18, which is present in the majority of cases. (Turc-Carel et al., 1986).

Outcomes are dependent on grade of tumor. Favorable characteristics include younger age at presentation and presence of diffuse calcifications (Soule, 1986).

Solitary Fibrous Tumor

Previously referred to as *hemangiopericytomas*, these fibroblastic tumors can occur throughout the body. Occurring predominantly in younger patients, they can grow to very large sizes before clinical symptoms develop (Fig. 100.6). **In rare occasions, a paraneoplastic phenomenon associated with hypoglycemia has been described, resulting from oversecretion of insulin-like growth factor (Doege-Potter Syndrome)** (Han et al., 2017).

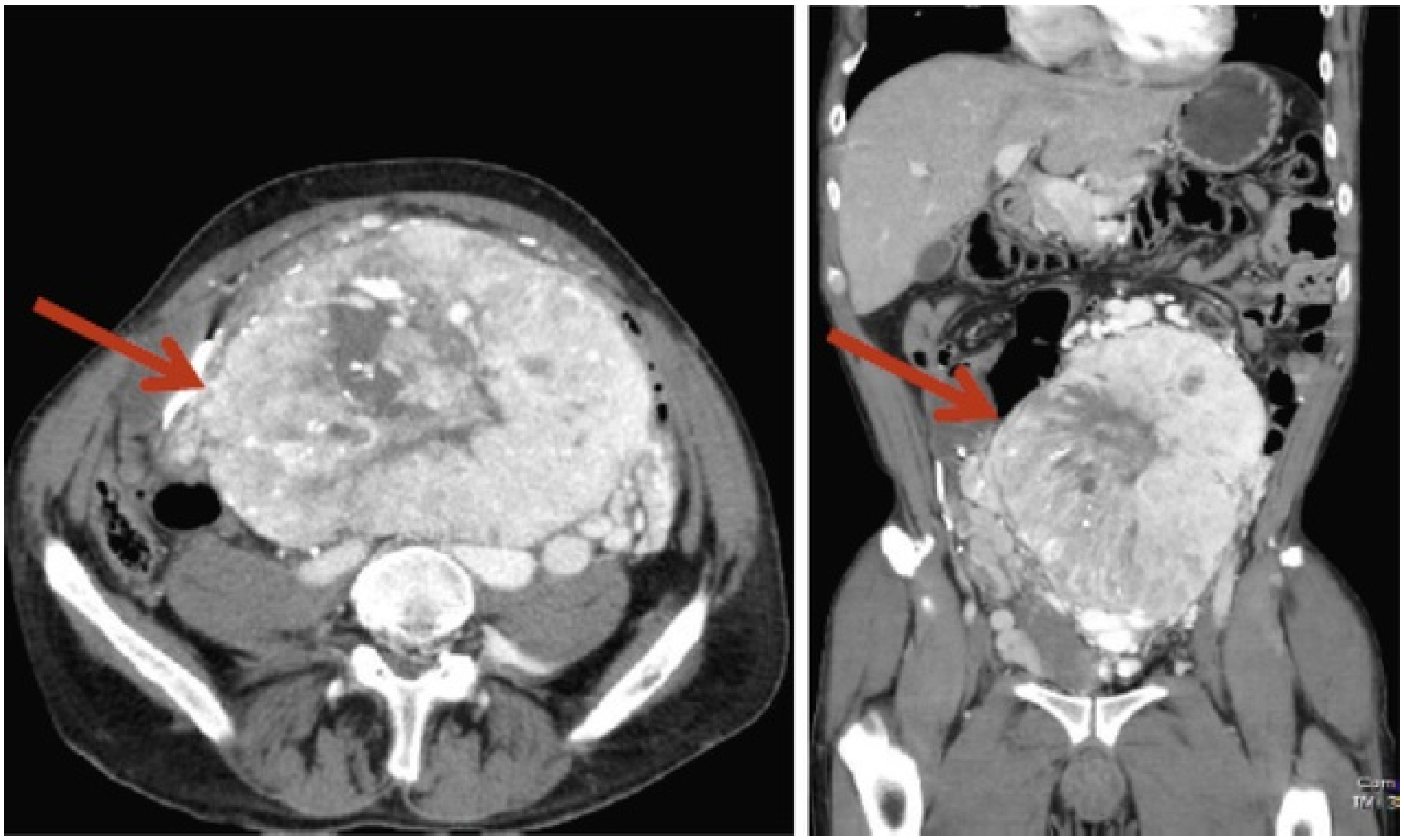

FIG. 100.6 Solitary fibrous tumor *(arrows).*

Solitary fibrous tumors can be characterized by a “patternless” architecture, with myxoid degeneration and fatty differentiation occurring in some tumors (Demicco et al., 2012). Tumors with high mitotic indices and greater pleomorphism represent biologically more aggressive tumor behavior, with one-third of cases demonstrating these malignant features. (England et al., 1989; Demicco et al., 2017; Morimitsu et al., 2000). Unique to these tumors is near-uniform positivity for the *NAB2-STAT6* gene fusion product (Robinson et al., 2013).

Prognosis is variable, as the majority of these follow an indolent course. Unfortunately, clinico-pathologic features reflect tumor biology poorly, with a subset of cases demonstrating relatively benign features developing regional and distant metastases. Criteria have been established to further risk-stratify patients including advancing age, high mitotic rate, necrosis, and tumor size as signatures for more aggressive tumors (Demicco et al., 2017). Overtly malignant cases are associated with a poor prognosis. Overall survival rates for all cases of solitary fibrous tumor at 8 years have been reported in the 75% range for most series. (Ardoino et al., 2010; Gronchi et al., 2013, 2015a, 2016; Pasquali et al., 2016; Raut et al., 2016; Wang et al., 2014). Complete en bloc resection is standard management, noting that preservation of adjacent organs is recommended when feasible, as wide margins are not routinely needed (Pasquali et al., 2016; Trans-Atlantic RPS Working Group, 2015). **Perioperative radiotherapy can be used as an adjunct to treatment, as these tumors are radiosensitive** (Kawamura et al., 2007; Liu et al., 2014; Saynak et al., 2010).

Ewing and Ewing-Like Sarcoma

Primarily tumors of bone origin, these malignant small, round, blue tumors can rarely occur in soft tissues of the RP (Fig. 100.7). **Ewing sarcomas are associated with *EWSR1* translocations with the ETS transcription factor family.** Typically a disease of young adult Caucasian males, neuropathic pain can be a presenting symptom when tumors develop adjacent to peripheral nerves. Unlike other sarcomas, these tumors tend to be infiltrative in their margins, rendering primary surgery alone unlikely to cure patients. Current standards recommend chemotherapy in combination for management, with cure rates exceeding 50% with multimodal therapies. Presence of larger tumor size, presence of metastatic disease, and relative absence of tumor necrosis after chemotherapy are poor prognostic features. Among Ewing-like sarcomas, the presence of the *CIC*-gene rearrangement is also considered to be associated with a poor outcome (Antonescu et al., 2017).

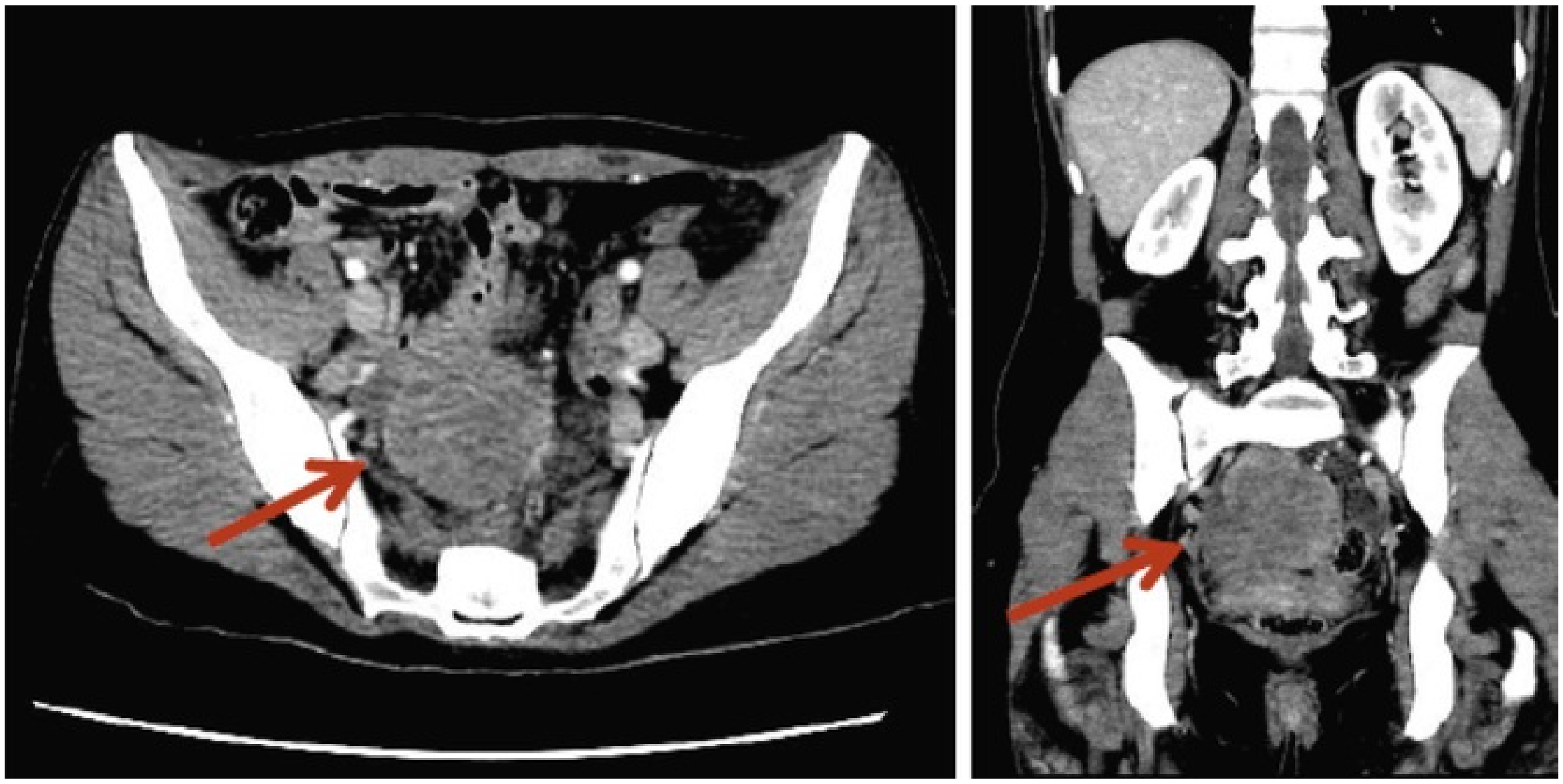

FIG. 100.7 Ewing sarcoma *(arrows).*

Desmoplastic Small Round Cell Tumors

Another translocation-associated sarcoma, these morphologically small round cell tumors are characterized by the t(11;22)(p13;q12) *WT1-EWSR1* gene fusion protein. Occurring mostly in young males, these tumors present with multifocal peritoneal implantations of tumor. Abdominal pain and distention is the most common complaint. Imaging often reveals heterogeneous enhancement of the mass with central necrosis being common (Pickhardt et al., 1999). The presence of abdominal ascites is typical, given the predilection for liver involvement. Histologic staining of the EWSR1-WT1 fusion product is diagnostic for these tumors. Prognosis is universally poor, despite multimodal therapy to address widespread disease.

Unclassified Sarcomas

These tumors with no distinct characteristics that would define a particular line of differentiation serve as a diagnosis of exclusion and occur in up to 20% of cases. This category of tumor is associated with a history of prior radiation therapy in one-fourth of patients (Gladdy et al., 2010). Typically associated with a rapid growth rate and aggressive clinical course, prognosis is universally poor. Important for these patients is to rule out the presence of de-differentiated liposarcoma through *MDM2* screening to avoid misclassification.

Perivascular Epitheliod Cell Tumor

Perivascular epitheliod cell tumor (PEComa) represents a broad range of neoplasms with perivascular epithelioid cell differentiation. This category of tumors includes renal and extrarenal angiomyolipoma (AML), extrapulmonary clear-cell sugar tumor, clear cell myomelanocytic tumor, pigmented melanotic tumor, lymphangioleiomyomatosis (LAM), and malignant PEComa (Fletcher, 2014). Accordingly, clinical presentation and behavior is quite diverse. Features associated with a malignant phenotype include large tumor size (>5 cm), high cellularity and atypia, mitotic index greater than 1/hpf, tumor necrosis, and vascular invasion. (Folpe et al., 2005). **Most PEComas are sporadic in nature, with inherited conditions such as tuberous sclerosis being responsible for the remainder.** In a distinct subset of cases, *TFE3* gene rearrangements can be identified, typically occurring in younger patients (Argani et al., 2010; Malinowska et al., 2012; Tanaka et al., 2009). Surgical management with wide local excision is indicated in tumors demonstrating adverse features, as PEComas are largely chemoresistant tumors. In unresectable or metastatic cases, use of mTOR inhibitors such as temsirolimus, everolimus, rapamycin, or sirolimus has been shown to demonstrate responses and prolonged survival (Bissler et al., 2008; Curatolo and Moavero, 2012; Dickson et al., 2013; Kenerson et al., 2007; Wagner et al., 2010).

Desmoid Tumor

These fibroblastic tumors are locally advanced tumors that demonstrate rapid growth and disruption of fascial planes, resulting in adjacent organ involvement leading to ureteral or bowel obstruction (Fig. 100.8). With a peak incidence in the third decade of life, these tumors are radiographically heterogeneous and difficult to differentiate from sarcomas. Histologically, they are composed of spindle-shaped cells, extracellular collagen, and myxoid matrix (Dinauer et al., 2007; Rajiah et al., 2011). Although not known for distant spread or metastasis, they recur locally in up to one-half of patients despite wide resection (Dinauer et al., 2007).

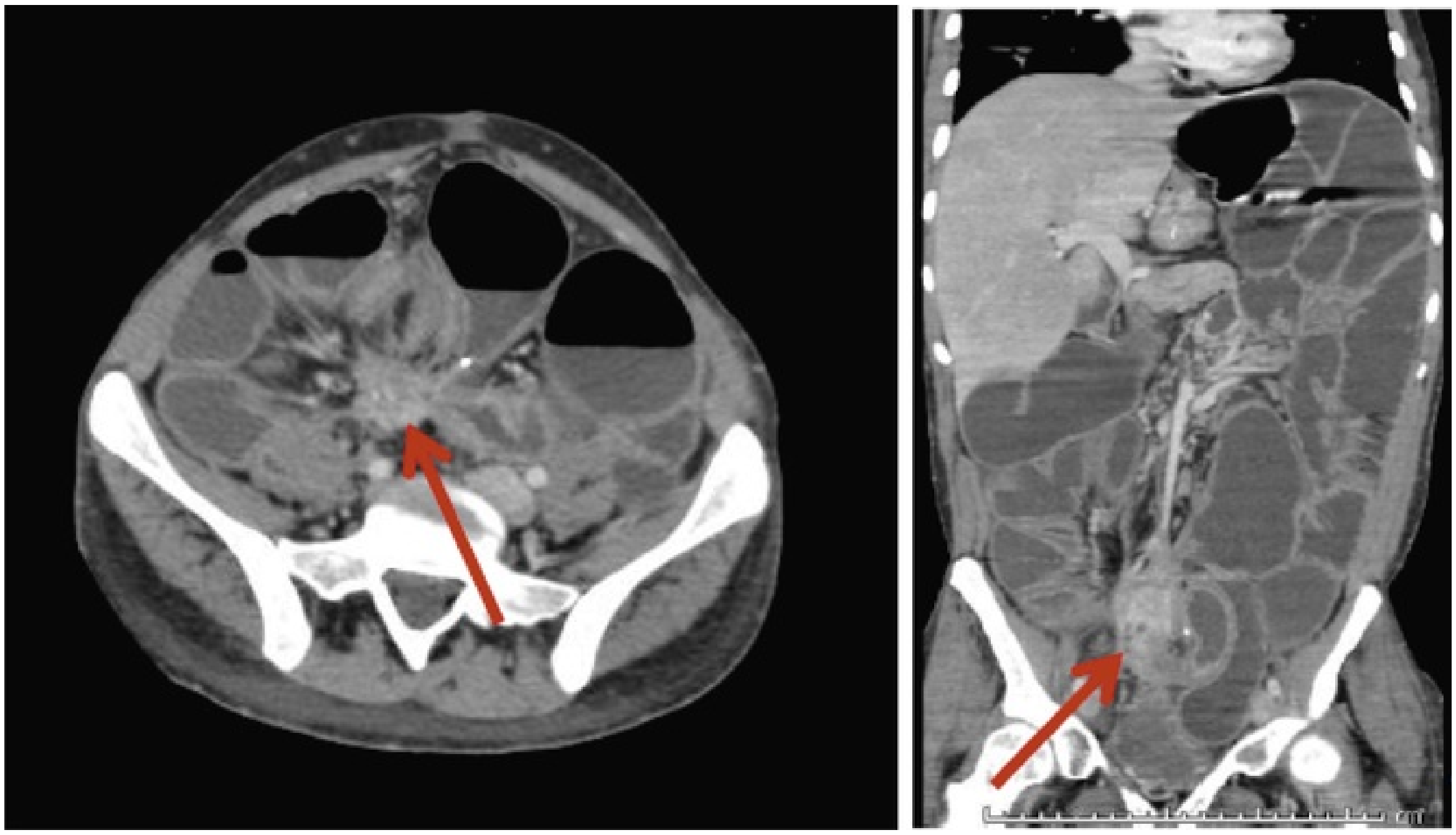

FIG. 100.8 Desmoid tumor with secondary bowel obstruction *(arrows)*.

Neurogenic Origins

Tumors arising from neurogenic origins such as ganglion cells, paraganglionic tissues, and peripheral nerve sheaths compose roughly 10% of RP primary tumors. Distribution of tumors occur along sympathetic ganglia posterior to the great vessels, within the adrenal glands, or in the location of the organ of Zuckerkandl. Prognosis for these tumors tends to be much improved compared with sarcomas, with many representing benign tumors.

Tumors of Sympathetic Ganglia

Tumors arising from the sympathetic neural tissue fall within this class of retroperitoneal pathology. These include ganglioneuromas, neuroblastomas, and ganglioneuroblastomas. These tumors can arise from the adrenal medulla or along the course of the sympathetic chain of ganglia. Although most have a relatively benign course, some behave aggressively with regional and distant dissemination.

Ganglioneuromas are benign tumors arising from the nerve cells of the sympathetic ganglia. Commonly seen in the third or fourth decades, they occur equally among men and women. **When originating from the adrenal medulla,**

secretion of catecholamines, vasoactive intestinal peptide, or androgenic proteins can be seen (Otal et al., 2001; Rha et al., 2003). Usually discovered incidentally, they are well circumscribed tumors radiographically, with calcifications being present in up to 30% of tumors (Rajiah et al., 2011). Prognosis is excellent with local removal.

Neuroblastomas are malignant tumors arising from primitive neuroblasts found within the adrenal medulla and sympathetic chain. These tumors occur largely within the first decade of life, with two-thirds originating from the adrenal medulla. These are heterogeneous tumors radiographically with course calcifications seen in the majority of cases. Most have evidence of metastatic disease at the time of presentation, and local invasion with encasement of adjacent organs, making local therapy challenging.

Ganglioneuroblastomas have features of both ganglioneuromas and neuroblastomas (Fig. 100.9). Also seen primarily in the pediatric population, they occur most commonly in the 2- to 4-year-old age group. However, cases in the adult population do occur between the late second to early fourth decades of life (Jrebi et al., 2014). Presenting with abdominal or back pain, these tumors often metastasize to regional lymph nodes, bone, brain, liver, and skin (Smith et al., 2013). **Staging imaging studies most useful include MRI and metaiodobenzylguanidine (MIBG) scanning to assess for bony involvement and local extent of the tumor.** Diagnosis is made on histologic assessment, which typically reveals IHC staining that is positive for CD-56, chromogranin A, neurofilament, synaptophysin, neuron-specific enolase, and LOH at 11q and 1p (Jrebi et al., 2014; Park et al., 2010). **Additionally, *n-Myc* gene amplification, when present, represents a negative prognostic feature**. Although treatment of these tumors is surgical resection when localized with or without adjuvant chemotherapy, they tend to disseminate widely. In one series, over one-half of patients at presentation had distant metastatic disease at the time of presentation (Jrebi et al., 2014). Therefore, neoadjuvant chemotherapy is recommended utilizing pediatric regimens that often include a combination of several drugs, such as cyclophosphamide, cisplatin, ifosfamide, vincristine, doxorubicin, etoposide, cis-retinoic acid, and carboplatin. Overall, prognosis is quite poor for these rare adult tumors.

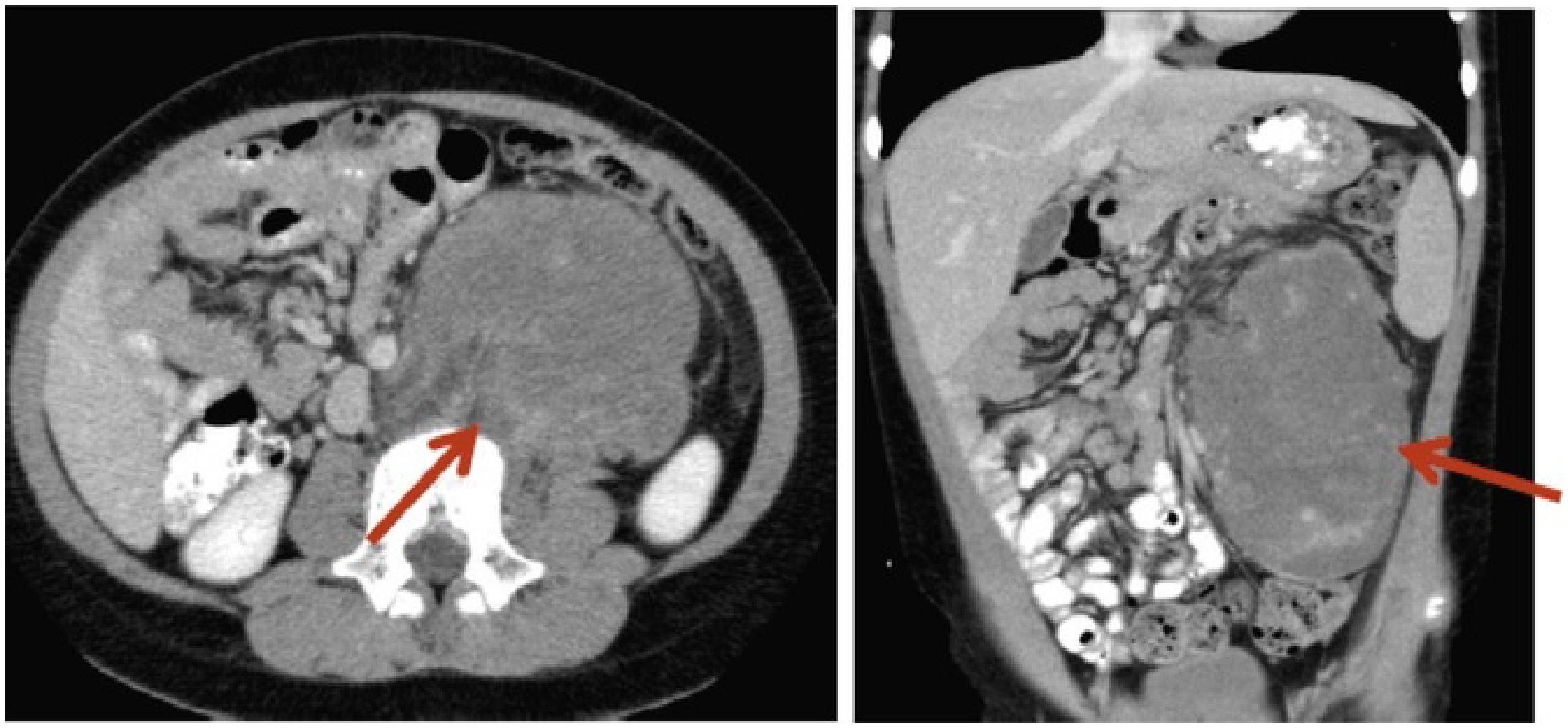

FIG. 100.9 Ganglioneuroblastoma *(arrows).*

Tumors of Paraganglionic System

Also derived from neural tissues found in the adrenal medulla and RP ganglia, these tumors arise from specialized neural crest cells (Neville and Herts, 2004). **When occurring from the neural crest cells found within the adrenal gland, they are referred to as pheochromocytomas. Extra-adrenal locations are classified as paragangliomas** (Rajiah et al., 2011).

Extra-adrenal paragangliomas occur most commonly in the third to fourth decades of life and are gender-neutral. Although they can occur anywhere within the RP, the most common location is within the organ of Zuckerkandl, which is located anteriorly along the aorta below the takeoff of the inferior mesenteric artery near the aortic bifurcation (Fig. 100.10). Radiographically, they demonstrate similar characteristics as pheochromocytomas, including the characteristic high–signal intensity appearance on T2-weighed MRI images (Rha et al., 2003). Also similar to pheochromocytomas, production of catecholamines is common, with elevations occurring in roughly 40% of cases (Neville and Herts, 2004; Tohme et al., 2006). Immunohistologic characteristics include a yellow-gray appearing tumor grossly, with large polygonal and pleomorphic cells that stain positive for synaptophysin and chromogranin A (Sun et al., 1998). Features of necrosis, high mitotic index, atypical nucleoli, infiltrative borders, and vascular invasion again poorly predict malignant potential, with metastases occurring in 20% to 50% of cases (Neville and Herts, 2004). Management is surgical in nature, as tumors respond poorly to other therapies. **Genetic**

predispositions for these tumors can be seen in patients with neurofibromatosis type 1 (**NF-1**; Kimura et al., 2002) **and multiple endocrine neoplasia type 2a** (Gullu et al., 2005).

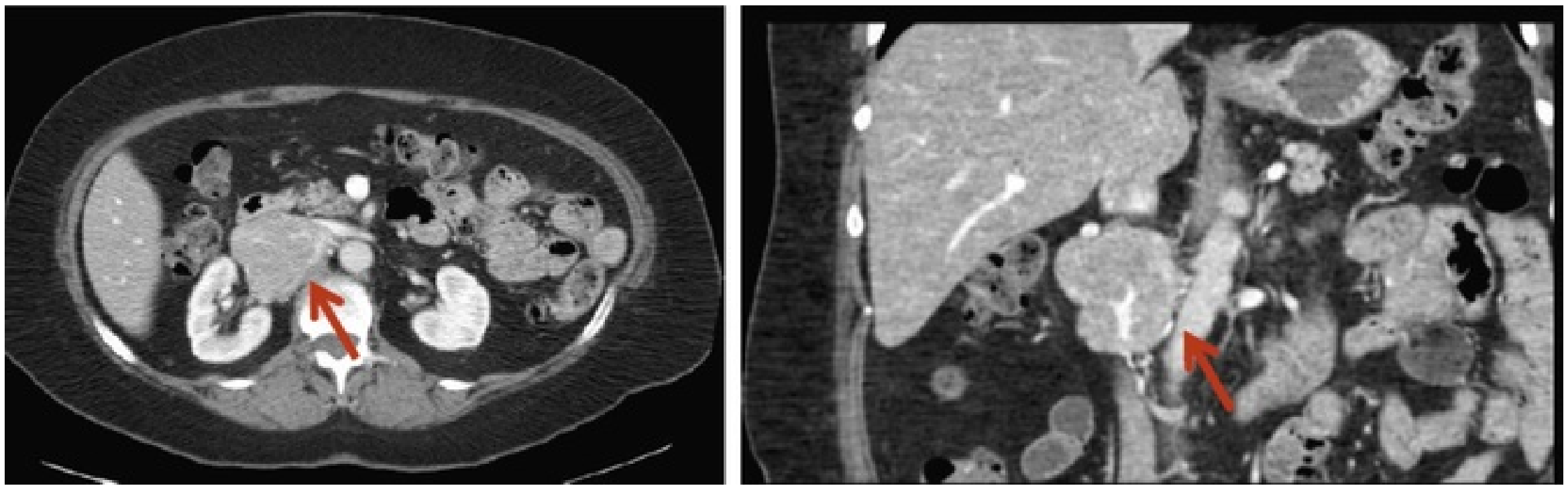
FIG. 100.10 Paraganglioma *(arrows).*

Tumors of Nerve Sheath Origin

Schwannomas, neurofibromas, and malignant peripheral nerve sheath tumors represent this class of tumor. Schwannomas are benign tumors arising from the Schwann cells responsible for myelinating peripheral nerves. Slow growing in nature, they typically occur in the paravertebral location, and patients present with symptoms related to nerve compression. They appear homogeneous and circumscribed on cross-sectional imaging when small, but can develop cystic degeneration and calcifications as they grow. As they arise from neural crest cells, they stain positive for S-100 on IHC. They are encapsulated tumors, and complete local resection is usually curative.

Neurofibromas are similarly benign tumors of the nerve sheath. However, they originate from nonmyelinating Schwann cells. **Commonly associated with NF-1, an autosomal dominant genetically inherited condition, sporadic tumors can also occur in the RP.** With a male predilection, these tumors occur mostly in the third to fifth decade of life (Neville and Herts, 2004). Radiographically, they are well-circumscribed with homogeneous appearance on CT. Treatment is surgical, as malignant transformation can occur in up to 20% of cases, most commonly occurring in patients with NF-1 and those exposed to radiation (Neville and Herts, 2004; Isler et al., 1996).

Malignant peripheral nerve sheath tumors are rare among soft-tissue sarcomas, representing less than 10% of cases in the RP (Deger et al., 2015;

Gronchi et al., 2016; Le Guellec et al., 2016; Tan et al., 2016). Arising from cellular components of peripheral nerves along the sacral or lumbar nerve plexus, roughly one-half are associated with genetic predisposing conditions (most commonly NF-1), with the remainder representing sporadic tumor development (Le Guellec et al., 2016). Among sporadic cases, a history of prior radiation has been reported and is likely causative (Gladdy et al., 2010). Clinical presentations often relate to symptoms related to nerve irritation, pain, paresthesias, or paralysis (Fig. 100.11). Among patients with NF-1, discovery of these tumors often occurs in adolescence. Radiographically indistinguishable from schwannomas or neurofibromas, biopsy remains the gold standard for diagnosis.

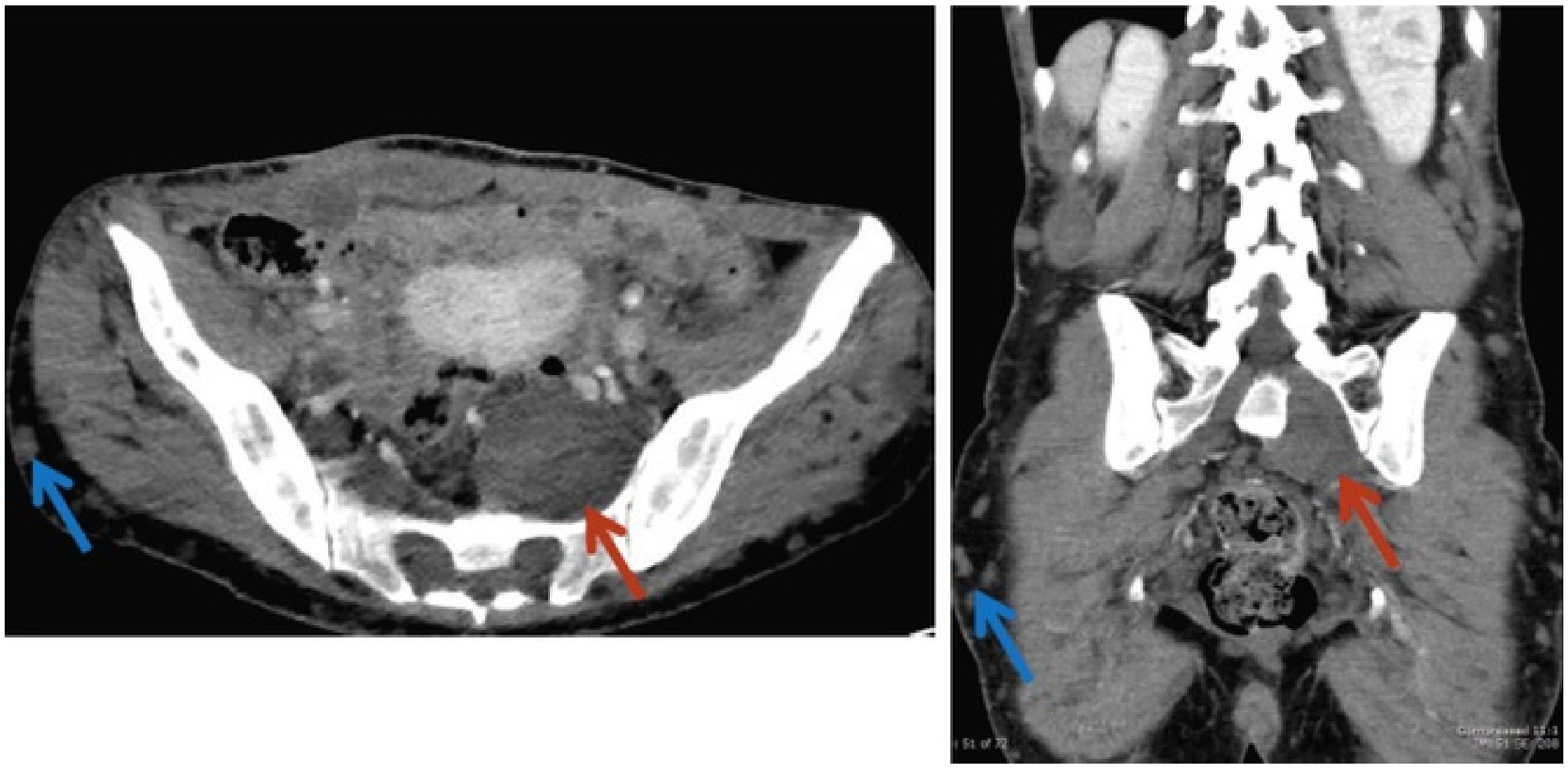

FIG. 100.11 Malignant peripheral nerve sheath tumor *(red arrows)* in patient with neurofibromas (indicated by *blue arrows*).

Malignant peripheral nerve sheath tumors are similarly fleshy tumors, often associated with hemorrhage or necrosis. Microscopically, they demonstrate spindle-shaped cells with herringbone orientation. Not uncommonly, heterogeneous areas of tumor may have a benign component of neurofibromas adjacent to areas of malignant peripheral nerve sheath tumors, rendering diagnosis challenging in limited samples. Immunohistochemical staining can help with diagnosis, with roughly one-half of cases staining positive for S100, along with loss of H3K27me3 expression. A clinical history of prior radiation, NF1, or clinical/radiographic evidence of peripheral nerve origin help key in on this clinical entity.

Management remains surgical for all cases. Preoperative chemotherapy and radiation remain ineffective at eradicating disease, but both have shown to improve complete surgical resection rates (Anghileri et al., 2006). Although infiltration into adjacent structures is uncommon, extension along nerve roots can occur. Prognosis is closely associated with achieving negative margins. As these tumors arise from peripheral nerves, complete resection of those nerves is required, and loss of neurologic function is inevitable. Among malignant peripheral nerve sheath tumor patients with negative margins, 5-year survival rates approach 70%, compared with roughly 20% for those with positive margins at time of resection (Wong et al., 1998). In unresectable tumors, anthracycline-based chemotherapy and palliative radiation should be considered (Kroep et al., 2011).

Hematologic Conditions/Lymphomas of the Retroperitoneum

Hematologic conditions represent a significant number of the masses that develop within the RP. Lymphomas being the most common, other conditions such as extramedullary myeloma/plasmacytomas and other lymphoproliferative diseases can occur as well.

Lymphomas

Constituting almost one-third of primary RP tumors, lymphomas represent hematologic cancers of lymphoid tissues occurring throughout the body. They can be categorized into Hodgkin and non-Hodgkin varieties, with prognostic differences separating the two. Radiographically, lymphomas are circumscribed, confluent, commonly homogeneous masses located typically along the RP and pelvic lymph node chains (Fig. 100.12). The issue of greatest importance to the urologist is their relative similarity to other RP tumors. Hence the importance of tissue sampling with FNA and/or core needle biopsy, as these tumors rarely, if ever, warrant surgical intervention and are best managed with chemotherapy.

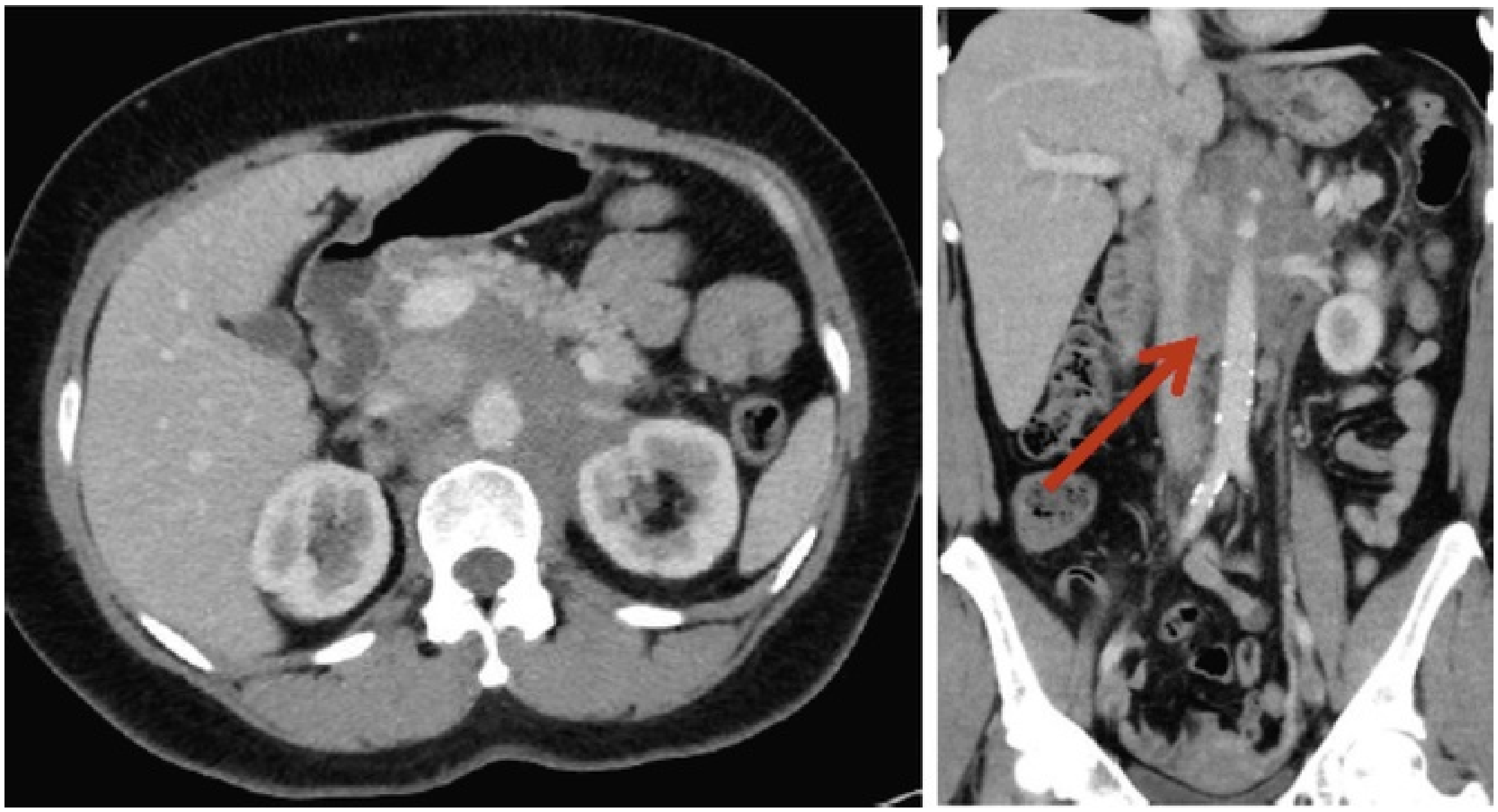

FIG. 100.12 Lymphoma *(arrows).*

Plasmacytoma

The spectrum of plasma cell infiltration on one end and multiple osseous and extramedullary lesions on the other reflects the range of clinical presentations that are characterized as plasmacytoma when focal and multiple myeloma when diffuse. Although multiple myeloma represents the most common primary osseous malignancy in adults, extramedullary manifestations of the disease occur in <10% of newly diagnosed patients (Hanrahan et al., 2010; Touzeau and Moreau, 2016). Locations of disease outside of bone include the abdomen/pelvis, skin and soft tissues, and paraspinous regions (Ames et al., 2017; Usmani et al., 2012). In a comprehensive review of the literature by Ames et al., the RP was the location for extraosseous lesions in 23 of 2538 cases reported at the time of the 2017 article (Ames et al., 2017). Serologic testing during the initial evaluation is typically positive for elevated IgG levels, and serum electrophoresis can reveal the finding of an “M spike,” suggestive of elevated levels of the myeloma protein, which can lead to impaired immune function, clotting, and kidney damage. Percutaneous biopsy with FNA or core-needle biopsy is often needed to diagnose. When suspected, a bone marrow aspiration and skeletal survey are recommended. Conventional radiographs for detection of bone disease have been supplanted by whole-body CT, with PET/CT imaging serving as the main imaging modality to assess response to therapy (Cavo et al., 2017; Rajkumar et al., 2014; Regelink et al., 2013). These tumors on histopathologic assessment reveal a monoclonal plasma cell infiltration of polygonal cells with homogeneous amphophilic cytoplasm and asymmetric nuclei. IHC typically reveals positivity for CD138 and Bcl-2. In the setting of isolated RP disease, case reports of complete response to wide surgical excision (Hong et al., 2009; Sharma et al., 2004), radiation, and chemotherapy have been reported (Chao et al., 2005; Chen et al., 1998; Saito et al., 2003).

Cystic Masses

Cystic masses occurring alone in the RP are rare. However, several entities that present as asymptomatic, predominantly cystic lesions can occur. Among these include cystic lymphangioma, cystic teratoma, cystadenoma, cystadenocarcinoma, cystic mesothelioma, and cystic changes of solid neoplasms. Given the fact that treatment strategies vary greatly depending on the nature of the lesion, clinical diagnostics based on presentation, radiographic findings, and serologic testing are imperative. This is particularly relevant given the general cautionary recommendations against percutaneous biopsy or aspiration of lesions because of the risk for rupture and/or sampling limitations.

Cystic Lymphangioma

Arising from acquired loss or abnormal congenital communication of lymphatic ducts with upstream channels, these represent uncommon RP masses. They are seen most frequently in the pediatric population, but can present in adulthood and occur most frequently in men. (Davidson and Hartman, 1990; Munechika et al., 1987). **Resulting in progressive accumulation of cystic masses, these appear radiographically as thin-walled, multiseptated lesions, often crossing the midline into several** compartments (Fig. 100.13). Histologically, lymphangiomas can be classified into three distinct patterns (cystic, cavernous, and capillary), with the cystic type representing the most common (Casadei et al., 2003). The cystic spaces are lined with a single layer of endothelium, containing clear or milky lymphatic fluid within them. Immunohistochemical markers for lymphatic endothelium include CD31, CD34, and D2-40 (Gui et al., 2003). Treatment is complete surgical removal for symptomatic relief and exclusion of other entities. More conservative measures such as cyst aspiration or marsupialization have been abandoned because of high rates of recurrence (Surlin et al., 2011).

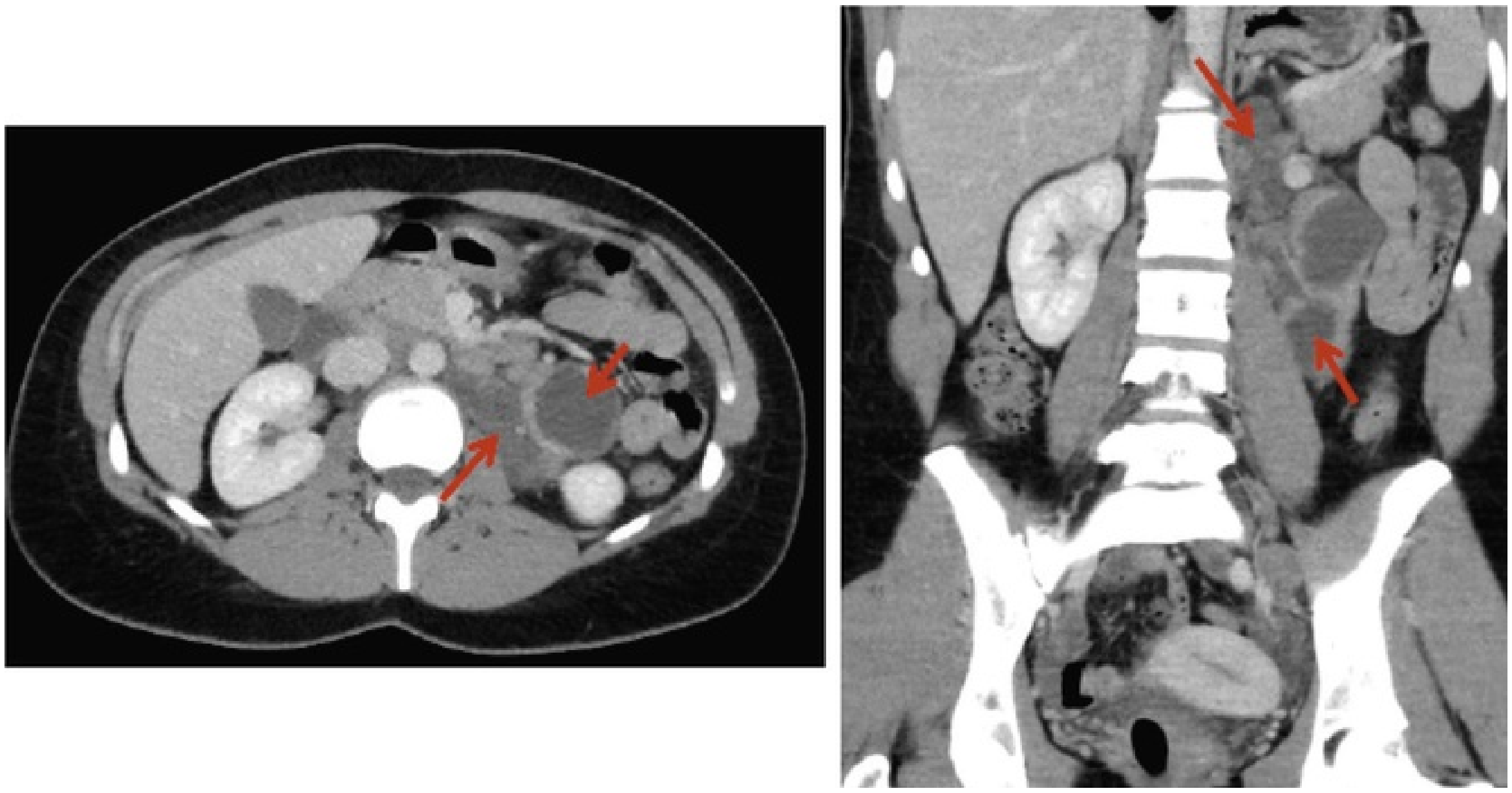

FIG. 100.13 Cystic lymphangioma *(arrows).*

Mucinous Cystadenoma

Predominantly a tumor in women, these present as a unilocular cyst with homogeneous features. Although the true etiology of these lesions remains unclear, some hypothesize these represent invaginations of the peritoneal mesothelial layer resulting in cyst formation. Subsequent mucinous metaplasia develops, which can result in eventual malignant transformation in some cases (Pennell and Gusdon, 1989). Diagnostics are limited, and aspiration of fluid for cytologic analysis often provides little information. Management is complete surgical removal for histologic confirmation and treatment. On histopathology, the cyst is lined by a single layer of columnar epithelium with basal nuclei and pale cytoplasm.

Cystic Mesothelioma

Arising from the serous lining of the pleural, pericardial, or peritoneal spaces, cystic mesothelioma can occur rarely in the RP space. **Unlike malignant**

mesothelioma of the pleura, cystic mesothelioma is not associated with prior asbestos exposure. Usually presenting with vague abdominal pain, they appear radiographically similar to lymphangiomas with multilocular, thin-walled cysts (Lee et al., 2009). Unlike lymphangiomas, these occur more commonly in women. Wide surgical resection is the treatment of choice, as local recurrences can occur.

Cystic Change of Solid Retroperitoneal Tumors

There remains a variety of tumors in which cystic changes can occur either arising from serous or mucinous production within the lesion, or with degenerative changes in response to treatments such as chemotherapy or radiation. A detailed history is paramount in evaluating these patients, paying particular attention to a history of prior treatment of cancer, presence of constitutional symptoms at time of presentation, and family history. In patients with a history of GCT, cystic teratoma can predominate within the RP. This is especially relevant after chemotherapy in the setting of growing tumor or late relapse. Similarly, paragangliomas can develop central areas of low attenuation on CT imaging, possibly resulting from internal hemorrhage and subsequent liquefaction (Yang et al., 2005). Other tumors demonstrating similar features include leiomyosarcomas, neurilemmomas, and gastrointestinal stromal tumors.

Retroperitoneal Cancer of Unknown Primary Origin

In the setting of a newly discovered tumor, the goal is to identify the site of origin and provide disease-specific therapy. However, when the primary origin of disease cannot be identified, determining what type of therapy to administer becomes uncertain. Cancer of an unknown primary origin presents several challenges to the treating clinician, representing up to 5% of new cancer diagnoses worldwide (Greco and Hainsworth, 1992; Levi et al., 2002; Miura et al., 1995). The median age at presentation is approximately 60 years of age, with a slight male predominance. Presenting clinically in a variety of patterns, radiographic distribution and immunohistochemical characterization through tissue biopsy samples become the mainstay of their evaluation. **Among all sites of disease, adenocarcinomas are the most common histologic subtype (50% of cases), followed by undifferentiated carcinomas (30%), squamous**

carcinomas (15%), and undifferentiated neoplasms (Greco et al., 1997). In the RP, poorly differentiated carcinomas predominate, oftentimes presenting as soft-tissue masses encompassing the great vessels. Molecular and genetic analysis may reveal aberrancies of chromosomes 1 and 12, along with overexpression of Bcl-2 and p53 detected in up to one-half of patients (Bar-Eli et al., 1993; Briasoulis et al., 1998). IHC may also reveal increases of c-myc, ras, and c-erB-B2 protein expression (Hainsworth et al., 2001; Pavlidis and Fizazi, 2005). **Assessment for isochromosome i(12)p when assessing young male patients may identify patients with RP primary GCTs** (Abbruzzese et al., 1993; Bell et al., 1989). Additionally, serologic testing of tumor markers including AFP/B-hCG in young males and PSA in older men should be incorporated into the clinical workup. Despite several advances in immunohistochemical and genetic characterizations, less than 20% of cases historically will have a primary origin of disease identified. Completion of the workup includes whole-body imaging to stage and aid in identification of a primary tumor. Although CT imaging has been the mainstay of initial radiographic assessment, PET/CT scans have come into prominence to help in the workup of these lesions (Lassen et al., 1999; Rades et al., 2001).

Initial therapies are based on grouping or classifications according to the histologic characterizations and radiographic distribution. For tumors predominantly localized to the central/midline RP, especially when tissue analysis reveals i(12)p positivity, platinum-based combination chemotherapy is recommended. Response rates are reported in up to 50% of patients, with complete radiographic response rates occurring in 15% to 25% of cases (Greco et al., 1986; van der Gaast et al., 1990). Among those with poorly differentiated neuroendocrine carcinomas of the RP, again platinum-based regimens are recommended (Greco and Hainsworth, 1997; Pavlidis et al., 2003). Lastly, for those rare cases in which a cancer of unknown primary origin presents as a single, small, localized metastasis, considerations for local therapy with surgical extirpation and/or focused radiotherapy can be considered (Pavlidis et al., 2003).

Future horizons in this set of difficult-to-characterize tumors include gene expression profiles and whole-genome–based analysis. These technologies will hopefully provide a greater ability to characterize these tumors accurately according to the tissue of origin and individualize therapies with greater efficacy.

Key Point

- A multitude of histologic entities can exist within the RT that present with an infiltrative or expanding mass. Using a multidisciplinary approach with radiographic staging, consideration for pretreatment biopsy when indicated, specialized serologic and immunohistochemical characterization, and multimodal therapy including surgery, systemic therapies, and radiotherapy are pivotal for optimizing outcomes.

Surgical Management of the Retroperitoneal Tumor

Preoperative Considerations

We do not recommend bowel preparation or dietary modifications before RP surgery. For GCTs, serum tumor markers should be checked within 7 to 10 days of surgery. Increased quantities of blood products should be considered for patients requiring more complex resections. **Preoperative sperm banking should be offered to patients who desire future paternity if retroperitoneal masses are in the path of the postganglionic sympathetic nerve fibers.** It is important for the urologist to have a medical oncology partner who possesses the clinical ability to assess bleomycin toxicity, to limit the dose when necessary, and to obtain pulmonary function testing when appropriate before sending the patient to surgery to minimize risk for postoperative acute respiratory distress syndrome. Additionally, the surgeon should ensure that the anesthesia provider is aware of any prior receipt of bleomycin and that he or she is familiar and comfortable with management of these patients. Specifically, low fraction of inspired oxygen (FiO_2) and conservative intraoperative fluid resuscitation are important in minimizing the risk for postoperative lung toxicity (Donat and Levy, 1998; Goldiner et al., 1978). Preoperative CT of the abdomen and pelvis should be thoroughly reviewed at initial consultation and immediately before surgery. A current CT scan of the chest is also required in patients with a history of pulmonary masses, planned concurrent resection of thoracic disease, or other radiographic/serologic evidence of disease progression. We prefer that preoperative imaging be performed within 6 weeks of the surgery date. **Careful inspection of imaging can usually prevent unplanned intraoperative consultations of other surgical specialists.** Preoperative identification of total inferior vena cava (IVC) thrombosis is important because the operation is made simpler by resection of the IVC (Beck and Lalka, 1998). Patients with incomplete occlusion requiring IVC resection may require reconstruction with a cadaveric allograft.

Surgical Technique

An orogastric tube is sufficient for intraoperative gastric decompression. Nasogastric tubes are generally reserved for patients with duodenal involvement that requires resection/repair, or high-volume retroperitoneal masses that require complete mobilization of the mesentery and placement of the bowels on the patient's chest for the duration of the surgery. The patient is placed in the supine position, and a ventral midline incision is made. When the peritoneal cavity is entered, a thorough inspection of abdominal viscera is performed. The falciform ligament is identified, ligated, and divided to minimize the risk for hepatic retraction injury. A self-retaining retractor is then placed.

Exposure of the Retroperitoneum

For smaller paracaval and interaortocaval masses, the root of the mesentery is opened from the inferior tip of the cecum to the medial aspect of the inferior mesenteric vein (Fig. 100.14, *green dotted line*). In the case of large right RP, interaortocaval, and/or paracaval masses, the mesenteric incision can be continued around the inferior portion of the cecum to the right white line of Toldt and up to the foramen of Winslow to permit placement of the bowels on the chest (see Fig. 100.14, *green and purple line*). In the case of larger left RP and para-aortic masses, the inferior mesenteric vein is often ligated and divided to improve exposure of the left retroperitoneum. Alternatively, in the case of a small-volume disease in the left RP, the mass and/or para-aortic lymphatics can be approached through the left white line of Toldt (see Fig. 100.14, *red dotted line*).

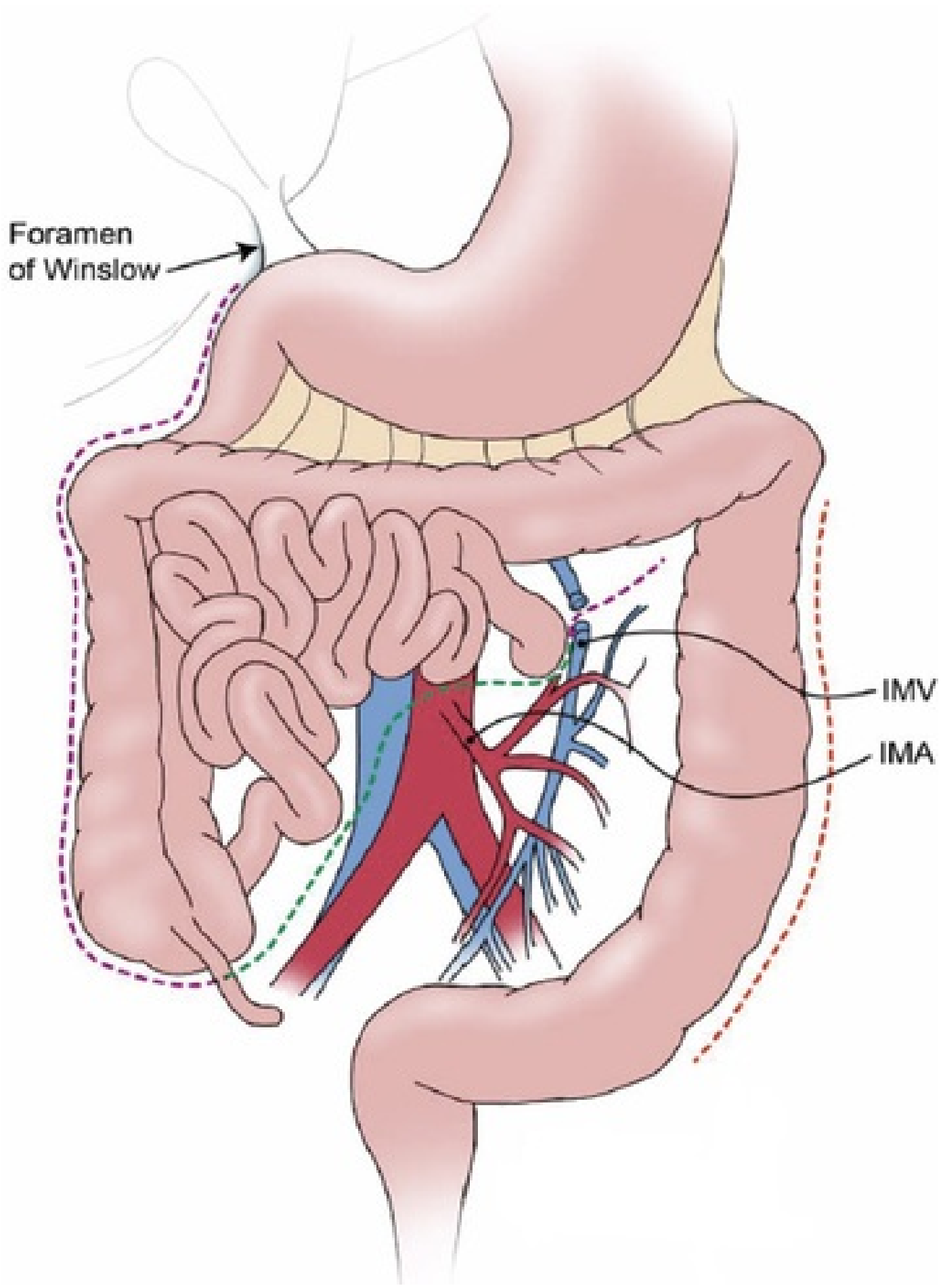

FIG. 100.14 Exposure of the retroperitoneum. *IMA,* Inferior mesenteric artery; *IMV,* inferior mesenteric vein. (Image courtesy of Indiana University School of Medicine, 2014.)

The plane between the mesentery and the retroperitoneal fat is developed by identifying the gonadal vein and developing the plane along its anterior surface. The duodenum is dissected off of the IVC and left renal vein. Before placing retractors in this region, the superior mesenteric artery must be identified (usually by palpation). The blades of the retractors should then be placed on either side of the superior mesenteric artery.

Approach to the Retroperitoneum

Split-and-Roll Technique.

Central within the RP are the vena cava and aorta. Accordingly, the surgical technique to manage any RP mass requires a thoughtful approach to exposing these structures. The large lymphatics coursing over the left renal vein should be ligated and divided. When the chosen template includes splitting over both great vessels, we prefer to perform the split on the aorta first rather than the IVC to avoid precaval right-sided accessory lower pole renal arteries. The advantage of performing the IVC split first is that the right-sided postganglionic sympathetic nerve fibers can be identified and traced to the superior hypogastric plexus, minimizing risk for injury during the aortic split. The split is started at the 12 o'clock position of the aorta, immediately inferior to the left renal vein (Fig. 100.15), and continued caudally, taking care to identify prospectively the inferior mesenteric artery and (1) preserve it in cases of a right RP procedure or (2) doubly ligate and divide this structure to expose the left para-aortic region in cases of a bilateral RP dissection. If a nerve-sparing technique is to be performed, the split should be stopped at the inferior mesenteric artery, and postganglionic sympathetic fibers should be identified before proceeding caudally.

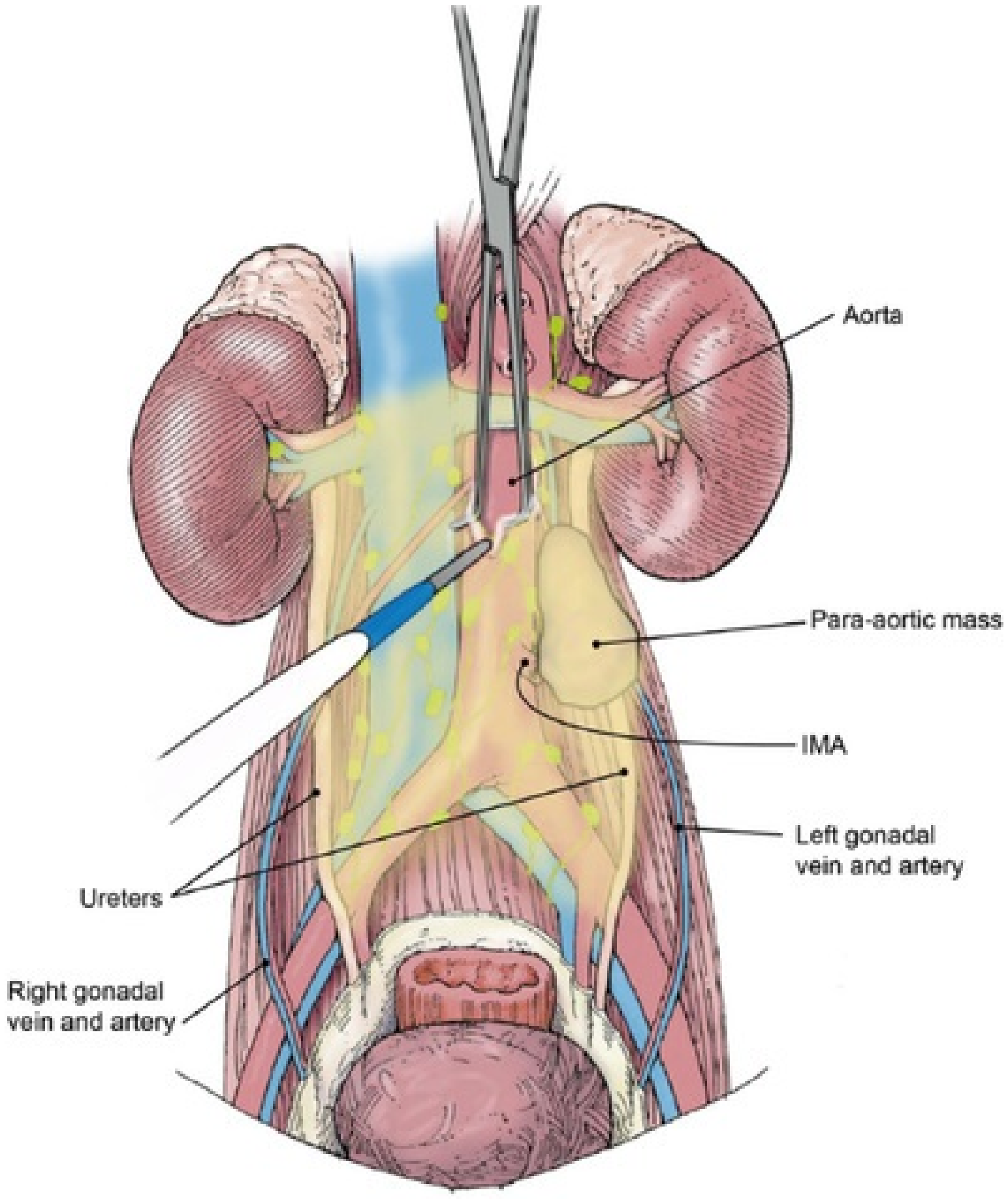

FIG. 100.15 The split-and-roll technique. *IMA,* Inferior mesenteric artery.

Left Para-Aortic Region.

As mentioned previously, the left RP can be approached laterally through the left white line of Toldt or medially through the mesenteric root depending on the distribution of disease. The left gonadal vein is doubly ligated and divided where it crosses the left ureter. The ureter is swept laterally and placed behind a retractor to minimize the risk for subsequent injury. The split is continued down the 12 o'clock position of the aorta and left common iliac artery until the left ureter is reached. The lymphatic tissue is rolled laterally off of the aorta and left common iliac artery. The three left-sided lumbar arteries located between the renal hilum and aortic bifurcation are identified, doubly ligated, and divided.

The mass and surrounding lymphatics are rolled inferiorly off of the left renal vein. The left gonadal and lumbar vein (when present) are doubly ligated and divided where they drain into the left renal vein. The lateral aspect of the packet is dissected off of the lower pole of the kidney and ureter.

The caudal extent of the packet is rolled superiorly off of the posterior body wall. The left genitofemoral nerve and sympathetic trunk should be identified and preserved when possible. The lumbar veins and body wall ends of the divided lumbar arteries should be identified and controlled. The packet is rolled up to the crus of the diaphragm. Lymphatics should be ligated as they course through the crus and into the retrocrural region. When the para-aortic resection is complete, tension on the ureteral retractor should be released to prevent prolonged ischemia.

Interaortocaval Region.

If a right-sided nerve-sparing technique is to be performed, the IVC split and roll is performed next. Otherwise, the medial side of the aorta can be controlled first. The IVC split is performed from the renal hilum to the crossover of the right common iliac artery, where it is continued inferolaterally until the right ureter is reached. The right gonadal vein is doubly ligated and divided at the IVC. The lymphatic tissue is rolled medially off of the IVC. The nerves are visible, running obliquely along the lateral edge of the packet as it is peeled off the medial border of the IVC. The lumbar veins located between the renal hilum and the common iliac veins are identified, doubly ligated, and divided. In contrast with the lumbar arteries, the number and positions of the veins are unpredictable. When the medial aspect of the IVC has been controlled, lymphatic tissue is rolled laterally off of the IVC, and any lumbar veins encountered are ligated and divided. Before harvesting the interaortocaval mass, the right gonadal vein is ligated and divided where it crosses the right ureter. The ureter is placed behind a retractor to keep it out of the field of dissection.

Lymphatic tissue is rolled medially off of the aorta. The medial three lumbar arteries are identified, ligated, and divided. The interaortocaval mass and lymphatic tissue are harvested off of the anterior spinous ligament. The right sympathetic trunk is encountered at the right lateral border of the interaortocaval packet and should be preserved when possible. As the tumor is rolled off of the anterior spinous ligament, the cut ends of the lumbar vessels should be controlled as they enter and exit the body wall. The superior aspect of the packet is rolled inferiorly off of the renal vessels exposing the crus of the diaphragm. Taking care to avoid injury to the renal artery, the lymphatics coursing into the retrocrural region must be ligated to prevent postoperative lymph leak and chylous ascites.

Right Paracaval Region.

The right paracaval lymphatics tend to be the smallest of the three major lymph node packets because the right kidney and ureter are located very close to the lateral border of the IVC. Masses in this location can be approached similarly to those in the interaortocaval region. The lymphatic tissue is rolled laterally and superiorly off of the right common iliac artery until the crossover of the right ureter is reached. The tissue is rolled superiorly off of the psoas fascia, taking care to preserve the right sympathetic trunk and the genitofemoral nerve. This roll is continued superiorly toward the right renal hilum and crus of the diaphragm. This packet often tapers to nothing and crosses under the IVC before the actual renal hilum is reached.

Surgical Modifications

Template Considerations for Management of Metastatic Germ Cell Tumors

Primary Retroperitoneal Lymph Node Dissection.

In the 1970s and 1980s, the development of curative cisplatin-based chemotherapeutic regimens (Einhorn and Donohue, 1977), elucidation of distinct lymphatic spread for right-sided versus left-sided testicular tumors (Donohue et al., 1982; Ray et al., 1974; Weissbach and Boedefeld, 1987), and description of surgical techniques to preserve the postganglionic sympathetic nerve fibers involved in seminal emission and antegrade ejaculation (Colleselli et al., 1990; Donohue et al., 1990; Jewett et al., 1988) significantly altered management of the retroperitoneum in patients with testicular GCT. In 1974, Ray et al. presented a series of 283 patients undergoing RPLND at Memorial Sloan Kettering Cancer Center (MSKCC) from 1944 to 1971. Dissections were predominantly infrahilar and evolved from a full bilateral dissection to a "modified bilateral" dissection as the primary landing zones of right-sided versus left-sided primaries became apparent. These modified bilateral templates were very similar to modified unilateral templates with the exception that lymphatic tissue below the inferior mesenteric artery (IMA) was routinely resected. The detailed description of distinct templates based on the laterality of the testicular primary was the first of its kind and set the stage for further refinement.

Donohue et al. (1982) published a pathologic lymph node mapping study performed at Indiana University on 104 patients found to have pathologically positive nodes (pN+) at primary RPLND. Full bilateral dissections to include bilateral suprahilar dissections were performed on every patient. **Investigators found that left-sided tumors were most likely to metastasize to the left para-aortic lymph nodes, whereas right-sided tumors were most likely to metastasize to interaortocaval and precaval regions. Spread to contralateral retroperitoneum and suprahilar regions was rare but increased with tumor bulk.** Metastasis to the interiliac region was rare. This study confirmed the relatively predictable pattern of the lymphatic spread of testicular GCTs and provided strong pathologic evidence for the use of "modified bilateral" templates proposed by Ray et al. (1974) in patients with low-stage retroperitoneal disease. Omission of the contralateral retroperitoneum and interiliac regions resulted in the preservation of antegrade ejaculation in most patients. Omission of suprahilar regions decreased the risk for postoperative chylous ascites, renovascular injuries, and pancreatic complications.

In 1987, Weissbach and Boedefeld reported a multi-institutional retrospective review of 214 patients with nonbulky pathologic stage II disease (Weissbach and Boedefeld, 1987). The authors recommended a more reduced left-sided template including the para-aortic and upper preaortic nodes. The authors also proposed that a frozen section be sent from the primary landing zone; if the section was positive, a full bilateral infrahilar RPLND should be performed.

The end result of these template studies has been a more efficient, less morbid, and maximally effective RPLND. There is still significant debate among experts regarding the ideal extent of surgical templates. Most experts agree that suprahilar/retrocrural and interiliac resections can safely be omitted from the standard RPLND template. However, controversy exists regarding the need to resect the contralateral retroperitoneal lymphatic tissue. The boundaries of the modified unilateral templates and a full bilateral template are demonstrated in Fig. 100.16.

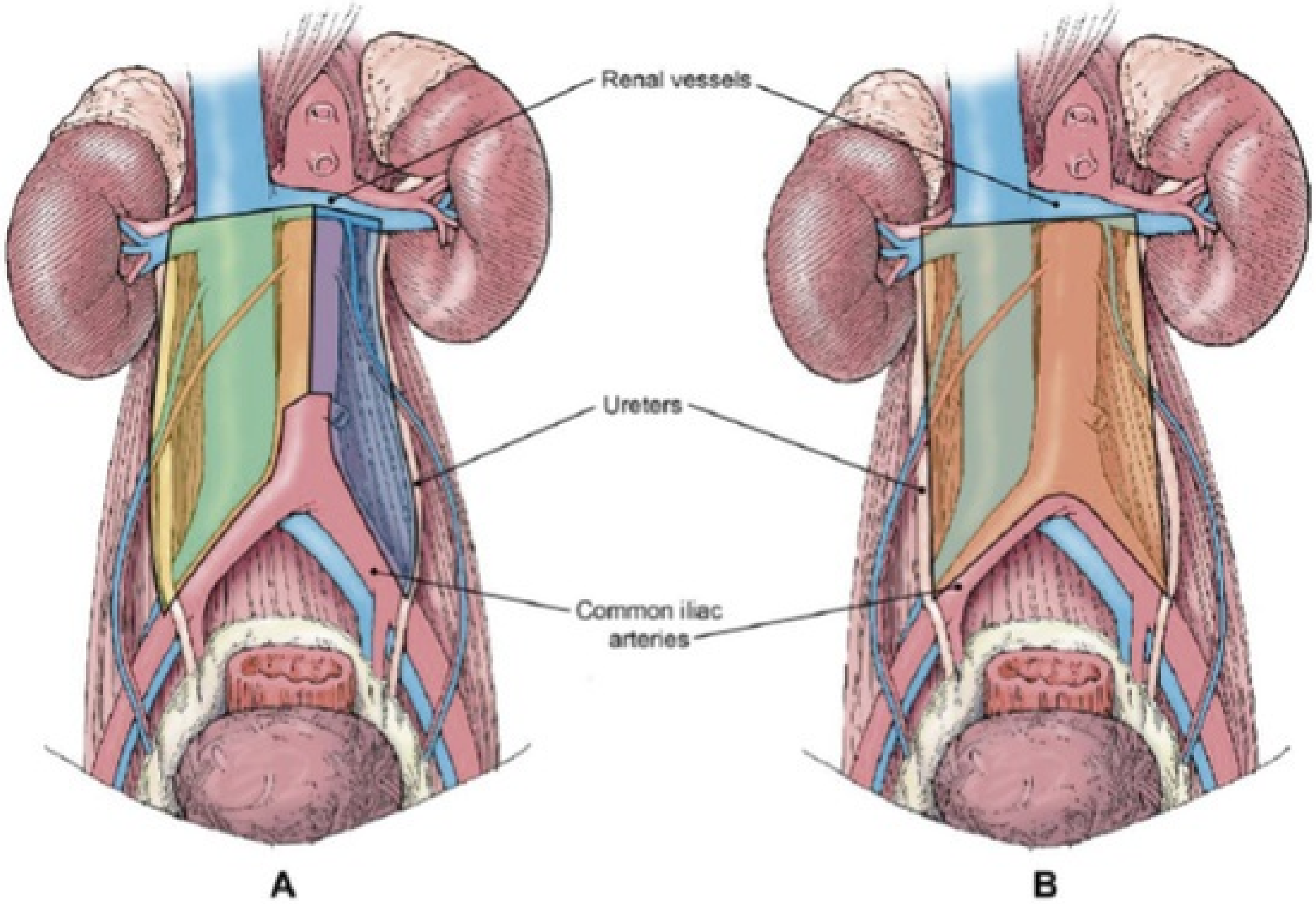

FIG. 100.16 Template modifications in retroperitoneal lymph node dissection templates. (A) Modified unilateral templates—right-sided shaded in yellow, left-sided shaded in purple. (B) Modified bilateral template—shaded area. (Image courtesy of Indiana University School of Medicine, 2014.)

Eggener et al. (2007) reviewed a series of 500 patients undergoing primary RPLND for clinical stage I or IIA testicular cancer at MSKCC. Bilateral infrahilar dissection was usually performed. The authors analyzed the 191 patients (38%) with pathologic stage II disease for the anatomic distribution of positive-node packets and applied five modified templates to these results. They reported that 3% to 23% of patients with pathologically positive nodes were found to have disease outside of the modified unilateral template, depending on which one was applied. Extratemplate disease was seen more commonly with right-sided than left-sided tumors. Given these results, the authors recommended full bilateral infrahilar nerve–sparing RPLND for patients with clinical stage I or IIA testicular cancer.

To date, no prospective or retrospective studies have compared the modified unilateral templates with the full bilateral templates. Cancer-specific and overall survival approach 100% in all published series. Expanding the templates cannot be expected to improve either of these outcomes. The question is whether performance of a full bilateral infrahilar RPLND would prevent retroperitoneal relapses that would occur after a properly performed modified unilateral template. When comparing series from centers that use the modified unilateral templates with series from centers that use the bilateral infrahilar templates, outcomes are very similar (Table 100.2) (Donohue et al., 1993; Hermans et al., 2000; Nicolai et al., 2004; Stephenson et al., 2005). Although the MSKCC series reported an increased proportion of patients being cured by surgery alone, patients with pN2 disease routinely receive adjuvant postoperative chemotherapy at that center (Stephenson et al., 2005). In the first Indiana study, most of the node-positive patients were randomly assigned to observation versus adjuvant chemotherapy on protocol (Donohue et al., 1993). In the more recent Indiana study, pN1 patients and most pN2 patients were observed with chemotherapy reserved for patients who experienced recurrence and pN3 patients (Hermans et al., 2000).

TABLE 100.2

Selected Primary Retroperitoneal Lymph Node Dissection Series

STUDY	NO. OF PATIENTS	NO. pN+ (%)	RECURRENCE RATE FOR pN0 (%)	RECURRENCE RATE FOR pN+ MANAGED WITH RPLND ALONE (%)	FOLLOW-UP (YEARS)	CSS (%)
Donohue et al., 1993	378	112 (29.6)	31 (12)	22 (34)	6.2	99.2
Hermans et al., 2000	292	66 (22.4)	23 (10.2)	7 (22.6)	3.8	100
Nicolai et al., 2004	322	60 (20)	NR	NR	7.2	98.8
Stephenson et al., 2005	308	91 (29.5)	NR (7)	NR (34)	4.9	99.7

CSS, Cancer-specific survival; *RPLND,* retroperitoneal lymph node dissection.

The appropriate boundaries of the primary RPLND template are controversial. Use of the templates recommended in the studies by Ray, Donohue, Weissbach, and Eggener and their colleagues will undoubtedly result in excellent survival outcomes. The question of which template offers greatest balance of oncologic control and minimization of morbidity remains unanswered.

Postchemotherapy Retroperitoneal Lymph Node Dissection.

Donohue et al. first reported their experience performing consolidative RPLND after cisplatin-based chemotherapy in 1982. Most tumors containing teratoma and/or viable malignancy were located in their respective primary landing zones. However, given the frequent contralateral crossover in the setting of bulky disease and the inability to obtain reliable confirmation of histology intraoperatively, the authors stressed the importance of the PC-RPLND being "as complete as possible" (Donohue et al., 1982). The standard PC-RPLND became resection of all macroscopic disease along with a full bilateral infrahilar dissection. This approach provides excellent local control of the RP, but is associated with significant morbidity including anejaculation in patients in whom a nerve-sparing technique is not possible.

Several groups investigated whether modified unilateral templates can safely be applied to appropriately selected patients in the postchemotherapy setting (Beck et al., 2007; Carver et al., 2007; Ehrlich et al., 2006; Heidenreich et al., 2009; Herr, 1997; Rabbani et al., 1998; Steiner et al., 2008; Wood et al., 1992). When bilateral dissections were performed, rates of disease outside the unilateral template are reported to range from 18% to 32% (Carver et al., 2007). However, rates of disease outside of the unilateral template and outside of macroscopic disease ranged from 2% to 18.6%. Variability in these percentages is likely a function of patient selection and the specific template used. Safe use of the unilateral modified templates in the postchemotherapy setting relies on selection of the correct template and appropriate patient selection. Patients meeting the following criteria may be considered for modified unilateral template PC-RPLND according to data emerging from centers performing the following surgeries:

- Well-defined lesion measuring 5 cm or less confined to the primary landing zone of the primary tumor on imaging before and

after chemotherapy
- Normal postchemotherapy serum tumor markers
- International Germ Cell Cancer Collaborative Group (IGCCCG) good/intermediate risk

Use of these selection criteria has resulted in in-field retroperitoneal recurrence rates of 0% to 1%, antegrade ejaculation rates of 85% to 99%, and cancer-specific survival of 98% to 100% at postoperative follow-up times of 2.6 to 10 years (Cho et al., 2017; Heidenreich et al., 2009; Steiner et al., 2008). Although these data are encouraging with regard to the use of the modified unilateral templates in PC-RPLND, the standard of care for patients requiring postchemotherapy resection remains resection of all macroscopic disease and a full bilateral infrahilar template RPLND. To date, there have been no prospective studies comparing outcomes in patients undergoing bilateral versus modified unilateral template PC-RPLND. If unilateral modified templates are to be used at PC-RPLND, strict adherence to the above-listed selection criteria is important.

Nerve-Sparing RPLND.

The anatomy of the four postganglionic efferent sympathetic fibers (L1 to L4) involved in antegrade ejaculation demonstrates significant variability from patient to patient. The L2 and L3 fibers are usually fused. Although the L2 to L4 fibers tend to take a more anterior course along the aorta and common iliac vessels, the L1 fiber takes a more shallow, caudal, and oblique course, exiting the sympathetic trunk near the level of the ipsilateral renal hilum Fig. 100.17.

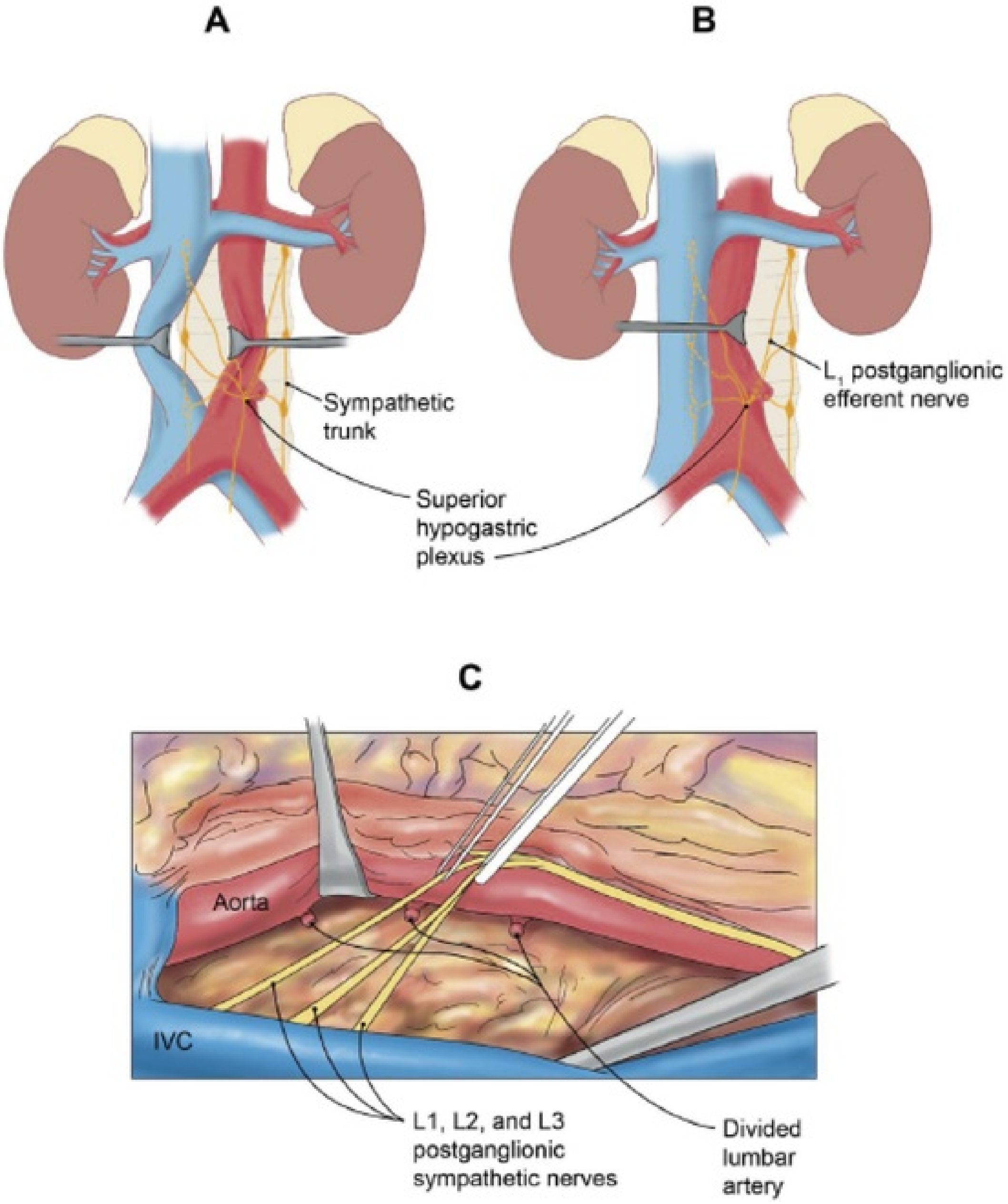
A
B
Sympathetic trunk
Superior hypogastric plexus
L_1 postganglionic efferent nerve
C
Aorta
IVC
L1, L2, and L3 postganglionic sympathetic nerves
Divided lumbar artery

FIG. 100.17 Nerve-sparing for ejaculatory function preservation. (A) Location of right-sided postganglionic sympathetic nerves. (B) Location of left-sided postganglionic sympathetic nerves. (C) Right-sided nerve-sparing technique with ligated lumbar arteries. *IVC,* Inferior vena cava. (Image courtesy of Indiana University School of Medicine, 2014.)

The left-sided postganglionic sympathetic nerves are first identified as they course along the lateral border of the aorta and left common iliac artery and onto the anterior surface of these vessels immediately caudal to the IMA (see Fig. 100.17). A Kittner sponge can be used to sweep the fatty connective tissue gently away revealing the shiny off-white nerve fibers running obliquely over the aorta and joining the contralateral postganglionic fibers in the superior hypogastric plexus. Fibers can be tagged with vessel loops to provide continued gentle traction as they are dissected to their origins at the sympathetic trunk. Alternatively, the left sympathetic trunk can be identified first distal to the level of the IMA and traced cranially until the postganglionic fibers are sequentially encountered.

The right-sided postganglionic nerve fibers are best identified as the precaval and interaortocaval lymphatic tissue is rolled medially off of the IVC. The postganglionic fibers can be seen coursing obliquely in an anterior and inferior direction toward the superior hypogastric plexus. These can be cleared of overlying tissue using a Kittner sponge. As described previously, the individual fibers should be encircled with vessel loops to place them on traction as they are traced down to their origins in the right sympathetic trunk.

When the nerve fibers have been dissected free for the entirety of their courses through the RPLND template, the lymphatic packets around the fibers should be dissected. The specimen must be sequentially passed through the web of postganglionic fibers as it is released from the body wall. Care must be taken to avoid injuring the fibers during specimen harvest and obtaining hemostasis. The nerve fibers often exit the sympathetic trunks in close proximity to the lumbar vessels, which puts them at particular risk for collateral injury if lumbar bleeding is encountered. Patients who undergo bilateral nerve-sparing or unilateral nerve-sparing with contralateral complete resection may experience an anejaculatory period postoperatively. This likely results from neuropraxia.

Auxiliary Procedures

The following discussion of auxiliary procedures applies to advanced-stage tumor of the RP because these procedures are rarely, if ever, required during treatment of smaller-volume disease. The most common auxiliary procedure is a nephrectomy, followed by vascular reconstruction or resection. As the volume of retroperitoneal disease increases, so does the likelihood of requiring resection of adjacent organs and/or structures.

Nephrectomy.

Nephrectomy at the time of PC-RPLND is the most commonly performed auxiliary procedure for GCTs. The incidence of nephrectomy at PC-RPLND ranges from 5% to 31% (Cary et al., 2013; Djaladat et al., 2012; Nash et al, 1998; Stephenson et al., 2006). **In the setting of sarcomas, the reported**

incidence of the nephrectomy in 1007 patients with primary RP sarcoma is upward of 55% (Gronchi et al., 2016).

Recognition of preoperative risk factors associated with nephrectomy at the time of RP surgery is vital for surgical planning and patient counseling. Nephrectomy is usually needed in high-risk settings such as salvage RPLND, desperation RPLND, resection of late relapse, or reoperative RPLND. Additional risk factors include retroperitoneal mass size and location of primary tumor (i.e., left vs. right testicle for GCTs). In the Indiana University study, men who had an RP mass size greater than 10 cm had a ninefold increase in odds of nephrectomy compared with men who had retroperitoneal mass less than 2 cm. Left-sided primary tumors with left para-aortic retroperitoneal masses had significantly increased odds of nephrectomy compared with right-sided tumors (odds ratio 5.44, P <.0001) (Cary et al., 2013).

It is important to consider postoperative renal function after nephrectomy because these patients may require postoperative adjuvant chemotherapy. Studies from Indiana University and MSKCC reported a decline in renal function after nephrectomy (Nash et al., 1998; Stephenson et al., 2006). However, this decreased renal function neither resulted in the need for renal replacement therapy nor compromised subsequent adjuvant or salvage chemotherapy when necessary. Despite changes in renal function, most patients can tolerate subsequent chemotherapy if needed and avoid renal replacement therapy. However, progression to chronic kidney disease is largely dependent on age and preoperative GFR.

Vascular Reconstruction

Aortic Replacement

In some cases, RP tumor encasement of the aorta requires en bloc aortic resection with reconstruction to remove the RP mass adequately. When this clinical situation occurs, it is crucial to alert additional surgical teams (i.e., vascular surgery) preoperatively to ensure successful clinical outcomes. It is ideal to anticipate the need for aortic replacement preoperatively to allow proper patient counseling and time to coordinate between surgical services. An aortic tube graft is most commonly used for reconstruction; however, an aortobi-iliac graft may be used depending on the extent of tumor involvement.

Several studies evaluated the indications for aortic resection and its morbidity. In 2001, Beck et al. reported 15 patients who underwent aortic replacement during PC-RPLND. Over a 30-year span involving more than 1200 patients, approximately 1% required this procedure**.** Two-thirds of these patients had received at least one course of salvage chemotherapy and/or had elevated serum tumor markers at the time of surgery. The indication for aortic replacement in these patients was tumor fixation to the aorta, with en bloc resection of the aorta deemed necessary for complete tumor removal. At a median follow-up of 34 months, 33% of these patients were disease-free. Given the chemoresistant nature of the disease and bulky tumor burden surrounding the aorta in most of these patients with advanced GCT and sarcoma, aortic resection is a worthwhile undertaking and may provide a therapeutic benefit in a significant proportion of patients.

When the decision for aortic resection has been made, the principles of the operation do not change substantially. The IVC should be dissected away from the mass and aorta using the split-and-roll technique with division of lumbar veins. The left ureter should be freed from the retroperitoneal mass. If the tumor does not encroach on the left renal hilum, this is also dissected free. The vascular surgery team assists with this dissection to ensure adequate length of the aorta cranial and caudal to the tumor, which allows for proximal and distal vascular control and ease of graft anastomoses. The aorta is cross-clamped and resected en bloc with the retroperitoneal mass. Lumbar arteries are divided during this process. Before cross-clamping, the patient is usually administered intravenous heparin to minimize the risk for arterial thrombosis. The graft is sewn into place using standard vascular surgery principles.

Vena Caval Resection

Most cases requiring IVC resection have bulky stage disease. The incidence of IVC resection reported in the literature for GCTs range from 5% to 10% (Beck and Lalka, 1998; Nash et al., 1998; Winter et al., 2012). In 1991, Donohue et al. reported on 40 patients who underwent IVC resection without reconstruction. In this study, the three indications for caval resection were necessity for tumor clearance (38%), vena caval scar occlusion (14%), and vena caval tumor thrombus (48%). The decision for en bloc caval resection was justified by the adverse nodal pathology, which included active cancer in 63% and teratoma in 31% of the specimens. For patients with lower-extremity edema and imaging concerning for IVC compression/occlusion, venacavography, ultrasonography, or magnetic resonance imaging is helpful to assess for flow through the IVC and guide intraoperative decision making.

Routine reconstruction of the vena cava after resection is not required. Data on 65 infrarenal IVC resections without reconstruction by Beck and Lalka (1998) support this approach. This study evaluated the long-term sequelae of IVC resection using a survey developed by an international consensus conference on chronic venous disease held by the American Venous Forum (Beebe et al., 1996). The median follow-up for these patients was 89 months. Of patients, 75% had a disability score of 0 to 1 (none or mild disability). Only one patient had the highest possible disability score. Although these patients are at higher risk for chylous ascites and other periprocedural complications (Baniel et al, 1993), long-term venous congestion seems to be less of an issue; this is particularly true if there is complete occlusion with development of collateral circulation present preoperatively. Slow progressive retroperitoneal tumor growth with accompanying desmoplastic reaction to chemotherapy likely results in a gradual occlusion of caval blood flow allowing for adequate development of venous collateral circulation. The development of this collateral venous return likely results in less morbidity from caval resection in patients with testicular cancer compared with patients with acute IVC occlusion.

In the sarcoma population, caval resection with or without reconstruction is well described as well. The necessity of this mirrors the indications in GCTs with the ultimate goal of obtaining negative margins. Different techniques have been described for vena caval reconstruction (e.g., Dacron, PTFE, homografts) in the sarcoma population. Late morbidity of vena caval reconstruction in this group with a prosthesis results in graft thrombosis in 10% to 40% of cases (Fiore et al, 2012; Quinones-Baldrich et al, 2012).

Tumor Thrombectomy

Intraluminal thrombi occur infrequently in GCTs and sarcoma, but has been reported most commonly in the vena cava. Additional locations are reported in the renal vein and least commonly in the aorta. The largest published series of this phenomenon comes from the Indiana group. Johnston et al. (2013) reported on 89 patients with 98 intraluminal thrombi. Seventy-three percent of these occurred in the vena cava and were managed with either cavectomy, partial cavectomy, or thrombectomy. Of the renal vein thrombi, 90% were managed with nephrectomy. The histology of these resected thrombi was bland thrombus in 32%, necrosis in 23%, teratoma in 29%, and residual cancer in 16%.

Complications

Ejaculatory Function

Early studies on ejaculatory outcomes after modified unilateral template RPLND without nerve-sparing technique reported postoperative antegrade ejaculation in 75% to 87% of patients (Fossa et al, 1985; Pizzocaro et al, 1985; Weissbach et al, 1985) However, in a more recent series, Beck et al. (2010) reported preservation of antegrade ejaculation in 97% of men undergoing modified unilateral template dissection without ipsilateral nerve–sparing technique. Additionally, 99.2% of men undergoing modified unilateral template dissection with ipsilateral nerve sparing maintained antegrade ejaculation in this series. These superior outcomes likely reflect improved understanding of the anatomy of postganglionic sympathetic nerve fibers allowing for the avoidance of damage to contralateral fibers caudal to the IMA.

Nerve-sparing RPLND results in preservation of antegrade ejaculation in 90% to 100% of patients (Beck et al., 2010; Donohue et al., 1990; Heidenreich et al., 2003; Jewett and Torbey, 1988). Although Jewett and Torbey reported temporary postoperative anejaculation in most patients, Donohue observed no such anejaculatory period (Donohue et al., 1993; Jewett and Torbey, 1988). In the study by Jewett and Torbey, bilateral template RPLND was performed in all patients, whereas ipsilateral nerve–sparing and modified unilateral template dissections were performed in most patients in the study by Donohue (Donohue et al., 1993; Jewett and Torbey, 1988). Neuropraxia likely accounted for the temporary anejaculation reported by Jewett and Torbey (1988).

Vascular

Retroperitoneal tumors requiring major vascular resection have a modest increase in vascular morbidity. In a recent series of 65 patients who required vena caval reconstruction, the incidence of perioperative thrombosis was 22%, including 9% with deep venous thrombosis and 12% with pulmonary embolus (Hicks et al, 2016).

Venous thromboembolism (VTE) rates reported after primary RPLND and PC-RPLND for GCTs are consistently low; this is likely the result of a young, otherwise healthy patient population. The rate of pulmonary embolism after primary RPLND has been reported to be less than 1% (Baniel et al., 1994; Heidenreich et al., 2003; Subramanian et al., 2010). After PC-RPLND, the rates range from 0.1% to 3.1% (Baniel et al., 1995; Subramanian et al., 2010). The incidence of deep venous thrombosis is more difficult to determine because these cases are not consistently reported in the literature and are likely most often asymptomatic. Reported rates range from 0% to 1% in primary RPLND and PC-RPLND (Heidenreich et al., 2003; Subramanian et al., 2010).

Lymphatic

Lymphocele.

The incidence of subclinical lymphocele after RPLND is unknown. However, it is thought that lymphoceles are relatively common and clinically insignificant in most cases. Symptomatic retroperitoneal lymphoceles are extremely rare, with reported rates ranging from 0% to 1.7% (Baniel et al., 1994, 1995; Heidenreich et al., 2003; Subramanian et al., 2010). Symptoms can be related to ureteral compression, displacement of abdominal viscera (if very large), or secondary infection. CT scan demonstrates a thin-walled cystic lesion in the resection bed. Air within the lymphocele and/or rim enhancement should raise concern for an infection. Meticulous attention to ligation of large-caliber lymphatics during resection likely decreases the risk for developing a symptomatic lymphocele. Treatment of symptomatic and/or infected lymphoceles includes percutaneous drainage with systemic antibiotics reserved for infected lymphoceles. Additionally, in the setting of infected lymphocele, one should consider leaving an indwelling drain rather than simple percutaneous aspiration.

Chylous Ascites.

Chylous ascites refers to the accumulation of chylomicron-containing lymphatic fluid in the peritoneal cavity. Chylous ascites has been reported to occur in 0.2% to 2.1% of patients undergoing primary RPLND and 2% to 7% of patients undergoing PC-RPLND (Baniel et al., 1994, 1995; Evans et al., 2006; Heidenreich et al., 2003; Subramanian et al., 2010). Patients typically present with complaints of increasing abdominal fullness, anorexia, nausea, vomiting, abdominal pain, and dyspnea. Patients often have a fluid wave on abdominal examination, which can help distinguish ascites from an ileus. Additionally, accumulated peritoneal fluid results in significant weight gain. Fluid has a milky color if paracentesis is performed. **Chylous ascites is alkaline, stains positive for Sudan black, and demonstrates a triglyceride concentration greater than that of serum. However, these tests are usually unnecessary because clinical examination and/or gross inspection of aspirating fluid should be enough to**

confirm the diagnosis.

Suprahilar resections are thought to carry a higher risk for chylous ascites because of disruption of the cisterna chyli and its contributing lymphatics. The cisterna chyli is located at the level of the L1-L2 vertebral bodies, medial to the posterior surface of the aorta in the retrocrural space. The association of IVC resection and chylous ascites is thought to be related to increased venous pressure below the level of the IVC producing increased capillary leak and ultimately third-spacing of lymphatic fluid into the retroperitoneum (Baniel et al., 1993). In a review of the MD Anderson Cancer Center experience, Evans et al. (2006) found an increased number of preoperative cycles of chemotherapy, increased estimated blood loss, and longer operative time to be associated with development of chylous ascites.

We recommend a graduated approach to the management of chylous ascites. In general, patients with symptomatic chylous ascites should first be managed with paracentesis. Although an indwelling drain can be left, we recommend simple paracentesis with consideration of low-fat/medium-chain triglyceride diet and intramuscular octreotide. If ascites reaccumulates, an indwelling drain should be placed. If these dietary modifications have already been instituted, patients should be given nothing by mouth, and total parenteral nutrition should be initiated. Although the use of octreotide in the setting of chylous ascites has not been studied in the urologic literature, it has demonstrated efficacy in minimizing chylous leaks after hepaticopancreaticobiliary surgery (Shapiro et al., 1996; Kuboki et al., 2013). Persistent high-volume chylous drainage (>100 mL/24 hr) despite these modifications is exceedingly rare. When it does occur, options include continued observation with conservative management, placement of a peritoneovenous (LeVeen) shunt, or surgical exploration with attempted ligation of the lymphatic leak. The latter two options should be reserved as last resorts. Peritoneovenous shunts have been reported to be associated with a significant incidence of occlusion and/or malfunction often requiring revision after placement, sepsis, and potentially fat embolization (Evans et al., 2006). Regardless of treatment modality that ultimately results in resolution of chylous ascites, consideration should be given to a continued low-fat diet with medium-chain triglycerides for 1 to 3 months after resolution of lymph leak.

Neurologic

In the Indiana PC-RPLND review, no cases of paraplegia were noted. Seven cases of peripheral nerve injury were reported (Baniel et al., 1995). All of these cases were secondary to patient positioning and potentially retractor placement (femoral neuropraxia). Careful attention to appropriate patient positioning by the surgical and anesthesia teams is important in minimizing peripheral nerve damage. In a review of 268 patients undergoing postchemotherapy resection of mediastinal disease for testicular or primary retroperitoneal GCT, Kesler et al. (2003) reported 6 patients (2.2%) with paraplegia. Patients with bulky mediastinal and retroperitoneal disease are at an increased risk for developing paraplegia. The likelihood of neurologic complications increases with the scale of para-aortic resection.

Approximately 5% of patients with primary retroperitoneal sarcomas will require major lumbar nerve resections (Mullen and van Houdt, 2018). This most commonly results from the sarcoma arising from the nerve root itself. The most commonly affected nerves are the femoral and obturator nerves. There are also several sensory nerves that can be affected, such as the genitofemoral, ilioinguinal, and so forth. The femoral nerve is the most functionally important nerve of this group affecting ipsilateral knee extension requiring a hinged knee brace in severe cases.

Postoperative Care

Surgical drains are not routinely placed. However, large-volume retroperitoneal, retrocrural, or duodenal resections may require a drain. We leave a Penrose drain for large-volume resections, given the propensity of postoperative abdominal third spacing. This drain is typically removed after the patient has resumed a regular diet and drainage remains serous and less than 100 mL for 24 hours.

In the absence of bowel repair/anastomoses, patients are given sips of ice chips on the evening of surgery. On postoperative day 1, patients are advanced to unlimited clear liquids, and they are encouraged to spend most of the day in a chair and ambulating. If patients tolerate clear liquids, they are advanced to a regular diet and transitioned off of intravenous pain medications on postoperative day 2. Patients are typically discharged between postoperative days 2 and 5 depending on how quickly they are able to tolerate a regular diet. Patients undergoing larger resections tend to have longer inpatient stays.

Key Point

- Surgical preparation and management of the RP mass requires careful consideration of all potential risks and obstacles, need for a thoughtful approach to surgical exposure and mobilization of the mass, preparation in advance and coordination of consultation for the possibility of auxiliary procedures when indicated, and a keen understanding of the short- and long-term complications that come along with RP surgery.

Disease-Specific Neoadjuvant and Adjuvant Therapies

Radiation

The use of multimodal therapy has increased among cancer management strategies over time. Among RP tumors, focusing mostly on sarcoma-based treatments, the use of radiation as an adjunct to surgical extirpation has become more prevalent over time with the goal of reducing local recurrences. Extrapolating from experiences in extremity soft-tissue sarcomas, the incorporation of perioperative radiotherapy in RP soft-tissue sarcoma has demonstrated improvements in survival outcomes (Nussbaum et al., 2016). However, long-term data on associated toxicities and impact on recurrence patterns requires more investigation. Controversies as to the timing of radiation, overall radiotherapy dose, and overall distribution continue to evolve. In one of the first prospective clinical trials using perioperative radiotherapy in RP sarcoma, 35 patients were randomized to receive either intraoperative (20 Gy)/postoperative (35–40 Gy) combination radiotherapy versus postoperative (50–55 Gy) radiotherapy alone (control group) (Sindelar et al., 1993). Local control with regard to locoregional relapse was higher in the intraoperative group (40% vs. 80%), and overall survival was similar (45 vs. 52 months). However, radiation-related toxicities were significant in both groups, with disabling radiation enteritis occurring more often in the control group (50% vs. 13%) and radiation-related peripheral neuropathy more frequent in the intraoperative cohort (60% vs. 5%). Interestingly, use of adjunctive chemotherapy offered no perceivable benefit with a regimen of cyclophosphamide, adriamycin, and methotrexate. The use of low-dose brachytherapy has been assessed in a phase I/II trial as an adjunct to preoperative radiotherapy, but severe toxicity was reported and the trial was closed accordingly (Jones et al., 2002). Two prospective trials hoping to compare preoperative radiotherapy to surgery alone have been initiated (NCT00091351 & NCT1344018), but results are still awaited.

In the absence of robust prospective data, large observational studies have been performed that offer some insight into the value of perioperative radiotherapy. In a case-control, propensity score-matched cohort study involving more than 9000 patients included in the National Cancer Database, the use of preoperative (563 patients), postoperative (2215 patients), and no-radiotherapy (6290 patients) was compared (Nussbaum et al., 2016). Results demonstrated a survival advantage for the use of any radiotherapy in the management of RP sarcoma patients (hazard ratio [HR] = 0.70 for preoperative; HR = 0.78 for postoperative). Similar assessment of survival benefits using postoperative radiotherapy using the Surveillance, Epidemiology, and End Results (SEER) database have been published with disparate results. Bates et al. (2018) assessed outcomes from 1973 to 2010 among 480 patients with RP sarcoma; 30% received adjuvant radiotherapy with a survival advantage at 3 years (HR = 0.79, $P = 0.023$). Conversely, in a larger cohort from the SEER database (1535 patients), Tseng et al. (2011) reported on 5-year overall survival and disease-specific survival outcomes. No differences were seen among those receiving or not receiving adjuvant radiotherapy, with the exception of those being treated for malignant fibrous histiocytoma. **Limitations for all of these retrospective studies include the inability to assess local control rates, toxicity-related differences, variations in radiotherapy dose administered, timing of treatment, or control for differences in patient selection.** Others have attempted to identify thresholds for radiation-related toxicity based on dose administered. Rates of late complications associated with 50–60 Gy range from 5% at 10 years up to 40% at 3.5 years, largely related to bowel-associated toxicity (Ballo et al., 2007; Bishop et al., 2015; Gilbeau et al., 2002; Le Péchoux et al., 2013; Pezner et al., 2011; Zlotecki et al., 2005). Most of the toxicity is attributable to the use of adjuvant radiotherapy, with preoperative radiotherapy having fewer issues reported.

Overall, the optimal role of perioperative radiotherapy in the setting of RP sarcoma remains uncertain. Although the incorporation of radiotherapy seems to improve local control rates, this comes at the expense of greater toxicity, particularly when used in the postoperative setting, with marginal improvements in overall survival. If radiotherapy is to be considered, its use in the preoperative setting seems to have the most promise. Results from the prospective European Organization for Research and Treatment of Cancer-STBSG trial are being eagerly awaited to clarify the benefits and risks associated with preoperative therapy. Intraoperative electron beam or brachytherapy as adjuncts to surgical resection remain investigational and warrant further assessment in the setting of a clinical trial.

Chemotherapy and Systemic Therapies

Outside of platinum-based chemotherapy used in the management of metastatic GCTs, data supporting the use of systemic therapies in localized RP sarcomas are limited. The majority of RP sarcomas identified largely represent chemotherapy-resistant entities, such as liposarcomas and leiomyosarcomas. However, there remain certain histologic subtypes for which chemotherapy represents the primary modality of treatment (i.e., lymphomas); therefore, the importance of accurate characterization of the primary tumor remains pivotal. In the absence of metastatic disease, the question at time of diagnosis is whether neoadjuvant systemic therapy impacts the risk for distant spread, improves resectability, and reduces positive surgical margins.

Although prospective studies enrolling large numbers of patients are lacking, several retrospective analyses have been published in soft-tissue sarcoma. However, heterogeneity of RP tumor subtypes limits their impact. **Table 100.3 summarizes the relative response rates of the various RP sarcoma subtypes as reported in the literature.** Overall, selective tumors have demonstrated responses to systemic therapies. Most notable examples include myxoid liposarcomas, synovial sarcomas, and Ewing sarcoma. Although standard use of neoadjuvant chemotherapy is recommended only in Ewing sarcoma based on response rates in extremity locations, its role among other entities remains uncertain. In the setting of a resectable tumor, the benefits of neoadjuvant chemotherapy remain uncertain. For tumors in which resectability is a concern or if regional or distant spread is documented, then multimodal therapy including induction chemotherapy should be considered. In RP tumors for which minimal response to chemotherapy has been recorded (i.e., well-differentiated liposarcoma, leiomyosarcoma), resection of local, regional, and/or systemic disease when feasible can be recommended in select cases. Otherwise, enrollment into clinical trials serves as the only alternative option for these patients. Some early successes have been reported with targeted therapies, particularly with MDM2 and CDK4 inhibitors in liposarcomas (Constantinidou et al., 2012; Dickson et al., 2013, 2016; Ray-Coquard et al., 2012), tyrosine kinase inhibitors in refractory soft-tissue sarcomas (Mahmood et al., 2011; Nakayama et al., 2016; van der Graaf et al., 2012), and immune-modulating therapies (Tseng et al., 2015).

TABLE 100.3

Chemotherapy Trials in Sarcoma

	NUMBER OF PATIENTS	PRIMARY RP LOCATION (%)	INTENT FOR CT	REGIMEN USED	RESPONSE RATES
RETROPERITONEAL SARCOMA NOS					
Miura et al., 2015	8653	100%	NAC:11% None: 89%	NR	NAC (yes/no) 40 vs. 52 mont
Bremjit et al., 2014	132	100%	NAC: 21% None: 79%	NR	No improveme in OS with NA (HR = 1.6)
Gronchi et al., 2016	1007	100%	NAC: 15% Adjuvant: 3% None: 82%	NR	No improveme in OS with NA (HR = 1.17)
Movva et al., 2015	16,370	22%	Metastatic: 100%	NR	82.7 vs. 51.3 months (CT vs. not), HR = 0.8
LIPOSARCOMA					
Jones et al., 2005	88	43%	Metastatic: 100%	Variable (Doxy/Ifos)	Well-differentiat 0% De-differentiat 25% Myxoid 48

Italiano et al., 2012	208	77.5%	Metastatic: 100%	Antracycline-based regimen (85%)	1% CR 11% PR 48% stable disease 39% no response
MYXOID LIPOSARCOMA					
Katz et al., 2012	37	4%	NAC: 70% Metastatic: 30%	Doxy/Ifos	0% CR 38% PR 62% Stable
SYNOVIAL SARCOMA					
Wu et al., 2017	89		NAC: 84%		NAC >> Adj
Chakiba et al., 2014	65	42%	NAC: 69%		
Vlenterie et al., 2016	313	17%	Metastatic: 100%		Improved PFS (6.3 vs. 3.7 months) for SS vs. other histology
MALIGNANT PERIPHERAL NERVE SHEATH TUMOR					
Hirbe et al., 2017	5	1 patient	NAC	Ifosphamide Epirubicin	80% response i tumor

CT, Chemotherapy; *HR,* hazard ratio; *NA,* not applicable; *NAC,* neoadjuvant chemotherapy; *NOS,* not otherwise specified; *NR,* not reported; *OS,* overall survival; *RP,* retroperitoneal; *SS,* synovial sarcoma; *XRT,* x-ray therapy.

Key Points

- Adjuvant and neoadjuvant therapies will continue to be expanded and incorporated as part of the multimodal approach to cancer treatment.

- No disease process has exemplified this more than the management approach for testicular cancer patients.
- In sarcoma, the heterogeneity across the spectrum of histologic entities and their biologic differences in response to radiation and systemic therapies restrict one's ability to make sweeping recommendations as to the timing and sequencing of different therapies.
- Accordingly, using a multidisciplinary team to explore all available options to ensure optimal management of the RP mass offers patients the greatest chance of a favorable outcome.

Conclusions

The evaluation, diagnostics, and therapeutic management strategies of the RP mass requires careful initial consideration. Although many entities discovered are managed with surgical excision, some follow divergent therapies that warrant accurate characterization up front to facilitate these decisions. For metastatic GCT, clinical pathways have been standardized, and referral to experienced centers for coordination of care is recommended. Similar recommendations exist for the presence of RP sarcomas, given their uncommon nature, variable clinical behavior, and need for multidisciplinary care. Multimodal therapy can be considered, but limited data exist regarding the role and impact of neoadjuvant or adjuvant therapies with chemotherapy or radiation in RP sarcoma treatment. Given that the majority of lesions occurring in the RP ultimately require surgical intervention, having an in-depth familiarity of these clinical entities, their radiographic and histologic features, and perioperative needs is essential for the optimization of care for these patients.

References

Abbruzzese JL, Lenzi R, Raber MN, et al. The biology of unknown primary tumors. *Semin Oncol*. 1993;20(3):238–243.

Albany C, Einhorn LH. Extragonadal germ cell tumors: clinical presentation and management. *Curr Opin Oncol*. 2013;25(3):261–265.

Ames J, Al-Samaraee A, Takahashi T. Extraosseous multiple myeloma: case report of presentation in the lower extremity soft tissues with literature review. *Case Rep Radiol*. 2017;2017:9159035–9159039.

Anghileri M, Miceli R, Fiore M, et al. Malignant peripheral nerve sheath tumors: prognostic factors and survival in a series of patients treated at a single institution. *Cancer*. 2006;107(5):1065–1074.

Antonescu CR, Dal Cin P, Nafa K, et al. EWSR1-CREB1 is the predominant gene fusion in angiomatoid fibrous histiocytoma. *Genes Chromosomes Cancer*. 2007;46(12):1051–1060.

Antonescu CR, Owosho AA, Zhang L, et al. Sarcomas With CIC-rearrangements are a distinct pathologic entity with aggressive outcome: a clinicopathologic and molecular study of 115 cases. *Am J Surg Pathol*. 2017;41(7):941–949.

Ardoino I, Miceli R, Berselli M, et al. Histology-specific nomogram for primary retroperitoneal soft tissue sarcoma. *Cancer*. 2010;116(10):2429–2436.

Argani P, Aulmann S, Illei PB, et al. A distinctive subset of PEComas harbors TFE3 gene fusions. *Am J Surg Pathol*. 2010;34(10):1395–1406.

Ballo MT, Zagars GK, Pollock RE, et al. Retroperitoneal soft tissue sarcoma: an analysis of radiation and surgical treatment. *Int J Radiat Oncol Biol Phys*. 2007;67(1):158–163.

Baniel J, Foster RS, Rowland RG, et al. Management of chylous ascites after retroperitoneal lymph node dissection for testicular cancer. *J Urol*. 1993;150(5 Pt 1):1422–1424.

Baniel J, Foster RS, Rowland RG, et al. Complications of primary retroperitoneal lymph node dissection. *J Urol*. 1994;152(2 Pt 1):424–427.

Baniel J, Leibovitch I, Foster RS, et al. Hyperamylasemia after post-chemotherapy retroperitoneal lymph node dissection for testis cancer. *J Urol*. 1995;154(4):1373–1375.

Bar-Eli M, Abbruzzese JL, Lee-Jackson D, et al. p53 gene mutation spectrum in human unknown primary tumors. *Anticancer Res*. 1993;13(5A):1619–1623.

Bates JE, Dhakal S, Mazloom A, et al. The benefit of adjuvant radiotherapy in high-grade nonmetastatic retroperitoneal soft tissue sarcoma: a SEER analysis. *Am J Clin Oncol*. 2018;41(3):274–279.

Beck SD, Bey AL, Bihrle R, et al. Ejaculatory status and fertility rates after primary retroperitoneal lymph node dissection. *J Urol*. 2010;184(5):2078–2080.

Beck SD, Foster RS, Bihrle R, et al. Is full bilateral retroperitoneal lymph node dissection always necessary for postchemotherapy residual tumor? *Cancer*. 2007;110(6):1235–1240.

Beebe HG, Bergan JJ, Bergqvist D, et al. Classification and grading of chronic venous disease in the lower limbs. A consensus statement. *Eur J Vasc Endovasc Surg*. 1996;12(4):487–491.

Bell CW, Pathak S, Frost P. Unknown primary tumors: establishment of cell lines, identification of chromosomal abnormalities, and implications for a second type of tumor progression. *Cancer Res*. 1989;49(15):4311–4315.

Bennert KW, Abdul-Karim FW. Fine needle aspiration cytology vs. needle core biopsy of soft tissue tumors. A comparison.

Acta Cytol. 1994;38(3):381–384.

Bishop AJ, Zagars GK, Torres KE, et al. Combined modality management of retroperitoneal sarcomas: a single-institution series of 121 patients. *Int J Radiat Oncol Biol Phys*. 2015;93(1):158–165.

Bissler JJ, McCormack FX, Young LR, et al. Sirolimus for angiomyolipoma in tuberous sclerosis complex or lymphangioleiomyomatosis. *N Engl J Med*. 2008;358(2):140–151.

Bokemeyer C, Nichols CR, Droz J-P, et al. Extragonadal germ cell tumors of the mediastinum and retroperitoneum: results from an international analysis. *J Clin Oncol*. 2002;20(7):1864–1873.

Bonvalot S, Rivoire M, Castaing M, et al. Primary retroperitoneal sarcomas: a multivariate analysis of surgical factors associated with local control. *J Clin Oncol*. 2009;27(1):31–37.

Bremjit PJ, Jones RL, Chai X, et al. A contemporary large single-institution evaluation of resected retroperitoneal sarcoma. *Ann Surg Oncol*. 2014;21(7):2150–2158.

Brenner W, Eary JF, Hwang W, et al. Risk assessment in liposarcoma patients based on FDG PET imaging. *Eur J Nucl Med Mol Imaging*. 2006;33(11):1290–1295.

Briasoulis E, Tsokos M, Fountzilas G, et al. Bcl2 and p53 protein expression in metastatic carcinoma of unknown primary origin: biological and clinical implications. A Hellenic Co-operative Oncology Group study. *Anticancer Res*. 1998;18(3B):1907–1914.

Brown JA, Bihrle R, Foster RS. Delayed orchiectomy at postchemotherapy retroperitoneal lymph node dissection due to laterality of retroperitoneal metastatic pattern consistent with testicular primary: assessment of pathologic findings. *Urology*. 2008;71(5):911–914.

Cao D, Li J, Guo CC, et al. SALL4 is a novel diagnostic marker for testicular germ cell tumors. *Am J Surg Pathol*. 2009;33(7):1065–1077.

Carver BS, Shayegan B, Eggener S, et al. Incidence of metastatic nonseminomatous germ cell tumor outside the boundaries of a modified postchemotherapy retroperitoneal lymph node dissection. *J Clin Oncol*. 2007;25(28):4365–4369.

Cary C, Beck SDW, Bihrle R, et al. Clinical and pathological features predictive of nephrectomy at post-chemotherapy retroperitoneal lymph node dissection. *J Urol*. 2013;189(3):812–817.

Casadei R, Minni F, Selva S, et al. Cystic lymphangioma of the pancreas: anatomoclinical, diagnostic and therapeutic considerations regarding three personal observations and review of the literature. *Hepatogastroenterology*. 2003;50(53):1681–1686.

Cavo M, Terpos E, Nanni C, et al. Role of 18F-FDG PET/CT in the diagnosis and management of multiple myeloma and other plasma cell disorders: a consensus statement by the International Myeloma Working Group. *Lancet Oncol*. 2017;18(4):e206–e217.

Chakiba C, Lagarde P, Pissaloux D, et al. Response to chemotherapy is not related to chromosome instability in synovial sarcoma. *Ann Oncol*. 2014;25(11):2267–2271.

Chao MW, Gibbs P, Wirth A, et al. Radiotherapy in the management of solitary extramedullary plasmacytoma. *Intern Med J*. 2005;35(4):211–215.

Chatzipantelis P, Kafiri G. Retroperitoneal synovial sarcoma: a clinicopathological study of 6 cases. *J BUON*. 2008;13(2):211–216.

Chen TC, Wu JH, Ng KF, et al. Solitary extramedullary plasmacytoma in the retroperitoneum. *Am J Hematol*.

1998;58(3):235–238.

Cho JS, Kaimakliotis HZ, Cary C, et al. Modified retroperitoneal lymph node dissection for post-chemotherapy residual tumour: a long-term update. *BJU Int*. 2017;120(1):104–108.

Chrisinger JSA, Salem UI, Kindblom L-G, et al. Synovial sarcoma of peripheral nerves: analysis of 15 cases. *Am J Surg Pathol*. 2017;41(8):1087–1096.

Cohan RH, Baker ME, Cooper C, et al. Computed tomography of primary retroperitoneal malignancies. *J Comput Assist Tomogr*. 1988;12(5):804–810.

Colleselli K, Poisel S, Schachtner W, et al. Nerve-preserving bilateral retroperitoneal lymphadenectomy: anatomical study and operative approach. *J Urol*. 1990;144(2 Pt 1):293–297.

Constantinidou A, Pollack SM, Jones RL. MDM2 inhibition in liposarcoma: a step in the right direction. *Lancet Oncol*. 2012;13(11):1070–1071.

Curatolo P, Moavero R. mTOR inhibitors in tuberous sclerosis complex. *Curr Neuropharmacol*. 2012;10(4):404–415.

Davidson AJ, Hartman DS. Lymphangioma of the retroperitoneum: CT and sonographic characteristic. *Radiology*. 1990;175(2):507–510.

Deger AN, Bayar MA, Caydere M, et al. Retroperitoneal malignant peripheral nerve sheath tumour: a rare case report. *J Clin Diagn Res*. 2015;9(9):ED9–ED11.

Demicco EG, Park MS, Araujo DM, et al. Solitary fibrous tumor: a clinicopathological study of 110 cases and proposed risk assessment model. *Mod Pathol*. 2012;25(9):1298–1306.

Demicco EG, Wagner MJ, Maki RG, et al. Risk assessment in solitary fibrous tumors: validation and refinement of a risk stratification model. *Mod Pathol*. 2017;30(10):1433–1442.

Deyrup AT, Montgomery E, Fisher C. Leiomyosarcoma of the kidney: a clinicopathologic study. *Am J Surg Pathol*.

2004;28(2):178–182.

Dickson MA, Mahoney MR, Tap WD, et al. Phase II study of MLN8237 (Alisertib) in advanced/metastatic sarcoma. *Ann Oncol*. 2016;27(10):1855–1860.

Dickson MA, Schwartz GK, Antonescu CR, et al. Extrarenal perivascular epithelioid cell tumors (PEComas) respond to mTOR inhibition: clinical and molecular correlates. *Int J Cancer*. 2013;132(7):1711–1717.

Dinauer PA, Brixey CJ, Moncur JT, et al. Pathologic and MR imaging features of benign fibrous soft-tissue tumors in adults. *Radiographics*. 2007;27(1):173–187.

Djaladat H, Nichols C, Daneshmand S. Adjuvant surgery in testicular cancer patients undergoing postchemotherapy retroperitoneal lymph node dissection. *Ann Surg Oncol*. 2012;19(7):2388–2393.

Domanski HA. Fine-needle aspiration cytology of soft tissue lesions: diagnostic challenges. *Diagn Cytopathol*. 2007;35(12):768–773.

Donat SM, Levy DA. Bleomycin associated pulmonary toxicity: is perioperative oxygen restriction necessary? *J Urol*. 1998;160(4):1347–1352.

Donohue JP, Foster RS, Rowland RG, et al. Nerve-sparing retroperitoneal lymphadenectomy with preservation of ejaculation. *J Urol*. 1990;144(2 Pt 1):287–291.

Donohue JP, Thornhill JA, Foster RS, et al. Primary retroperitoneal lymph node dissection in clinical stage A non-seminomatous germ cell testis cancer. Review of the Indiana University experience 1965-1989. *Br J Urol*. 1993;71(3):326–335.

Donohue JP, Zachary JM, Maynard BR. Distribution of nodal metastases in nonseminomatous testis cancer. *J Urol*. 1982;128(2):315–320.

Eggener SE, Carver BS, Sharp DS, et al. Incidence of disease outside modified retroperitoneal lymph node dissection templates in clinical stage I or IIA nonseminomatous germ cell testicular cancer. *J Urol*. 2007;177(3):937–942.

Ehrlich Y, Brames MJ, Beck SD, et al. Long-term follow-up of Cisplatin combination chemotherapy in patients with disseminated nonseminomatous germ cell tumors: is a postchemotherapy retroperitoneal lymph node dissection needed after complete remission? *J Clin Oncol*. 2010;28(4):531–536.

Einhorn LH, Donohue J. Cis-diamminedichloroplatinum, vinblastine, and bleomycin combination chemotherapy in disseminated testicular cancer. *Ann Intern Med*. 1977;87(3):293–298.

England DM, Hochholzer L, McCarthy MJ. Localized benign and malignant fibrous tumors of the pleura. A clinicopathologic review of 223 cases. *Am J Surg Pathol*. 1989;13(8):640–658.

Evans JG, Spiess PE, Kamat AM, et al. Chylous ascites after post-chemotherapy retroperitoneal lymph node dissection: review of the M.D. Anderson experience. *J Urol*. 2006;176(4 Pt 1):1463–1467.

Fabre-Guillevin E, Coindre JM, Somerhausen Nde S, et al. Retroperitoneal liposarcomas: follow-up analysis of dedifferentiation after clinicopathologic reexamination of 86 liposarcomas and malignant fibrous histiocytomas. *Cancer*. 2006;106(12):2725–2733.

Fiore M, Colombo C, Locati P, et al. Surgical technique, morbidity, and outcome of primary retroperitoneal sarcoma involving inferior vena cava. *Ann Surg Oncol*. 2012;19(2):511–518.

Fletcher CD. The evolving classification of soft tissue tumours—an update based on the new 2013 WHO classification. *Histopathology*. 2014;64(1):2–11.

Fletcher JA. Cytogenetics and molecular biology of soft tissue tumors. *Monogr Pathol*. 1996;38:37–64.

Folpe AL, Mentzel T, Lehr HA, et al. Perivascular epithelioid cell neoplasms of soft tissue and gynecologic origin: a clinicopathologic study of 26 cases and review of the literature. *Am J Surg Pathol*. 2005;29(12):1558–1575.

Fosså SD, Ous S, Abyholm T, et al. Post-treatment fertility in patients with testicular cancer. I. Influence of retroperitoneal lymph node dissection on ejaculatory potency. *Br J Urol*. 1985;57(2):204–209.

García JJ, Folpe AL. The impact of advances in molecular genetic pathology on the classification, diagnosis and treatment of selected soft tissue tumors of the head and neck. *Head Neck Pathol*. 2010;4(1):70–76.

Ghazarian AA, Kelly SP, Altekruse SF, et al. Future of testicular germ cell tumor incidence in the United States: forecast through 2026. *Cancer*. 2017;123(12):2320–2328.

Gilbeau L, Kantor G, Stoeckle E, et al. Surgical resection and radiotherapy for primary retroperitoneal soft tissue sarcoma. *Radiother Oncol*. 2002;65(3):137–143.

Giménez Bachs JM, Salinas Sánchez A, Lorenzo Romero J, et al. [Large retroperitoneal malignant fibrohistiocytoma: report of one case]. *Arch Esp Urol*. 2004;57(2):172–174.

Gladdy RA, Qin LX, Moraco N, et al. Do radiation-associated soft tissue sarcomas have the same prognosis as sporadic soft tissue sarcomas? *J Clin Oncol*. 2010;28(12):2064–2069.

Goldiner PL, Carlon GC, Cvitkovic E, et al. Factors influencing postoperative morbidity and mortality in patients treated with bleomycin. *Br Med J*. 1978;1(6128):1664–1667.

Gopalan A, Dhall D, Olgac S, et al. Testicular mixed germ cell tumors: a morphological and immunohistochemical study using stem cell markers, OCT3/4, SOX2 and GDF3, with emphasis on morphologically difficult-to-classify areas. *Mod*

Pathol. 2009;22(8):1066–1074.

Greco FA, Hainsworth JD. Tumors of unknown origin. *CA Cancer J Clin*. 1992;42(2):96–115.

Greco FA, Hainsworth JD. One-hour paclitaxel, carboplatin, and extended-schedule etoposide in the treatment of carcinoma of unknown primary site. *Semin Oncol*. 1997;24(6 Suppl 19) [S19-101–S19-105].

Greco FA, Vaughn WK, Hainsworth JD. Advanced poorly differentiated carcinoma of unknown primary site: recognition of a treatable syndrome. *Ann Intern Med*. 1986;104(4):547–553.

Grem JL, Robins HI, Wilson KS, et al. Metastatic Leydig cell tumor of the testis. Report of three cases and review of the literature. *Cancer*. 1986;58(9):2116–2119.

Grobmyer SR, Wilson JP, Apel B, et al. Recurrent retroperitoneal sarcoma: impact of biology and therapy on outcomes. *J Am Coll Surg*. 2010;210(5):602–608 [608–610].

Gronchi A, Casali PG, Fiore M, et al. Retroperitoneal soft tissue sarcomas: patterns of recurrence in 167 patients treated at a single institution. *Cancer*. 2004;100(11):2448–2455.

Gronchi A, Vullo Lo S, Fiore M, et al. Aggressive surgical policies in a retrospectively reviewed single-institution case series of retroperitoneal soft tissue sarcoma patients. *J Clin Oncol*. 2009;27(1):24–30.

Gronchi A, Miceli R, Colombo C, et al. Frontline extended surgery is associated with improved survival in retroperitoneal low- to intermediate-grade soft tissue sarcomas. *Ann Oncol*. 2012;23(4):1067–1073.

Gronchi A, Miceli R, Shurell E, et al. Outcome prediction in primary resected retroperitoneal soft tissue sarcoma: histology-specific overall survival and disease-free survival nomograms built on major sarcoma center data sets. *J Clin Oncol*. 2013;31(13):1649–1655.

Gronchi A, Miceli R, Allard MA, et al. Personalizing the approach to retroperitoneal soft tissue sarcoma: histology-specific patterns of failure and postrelapse outcome after primary extended resection. *Ann Surg Oncol*. 2015;22(5):1447–1454.

Gronchi A, Collini P, Miceli R, et al. Myogenic differentiation and histologic grading are major prognostic determinants in retroperitoneal liposarcoma. *Am J Surg Pathol*. 2015;39(3):383–393.

Gronchi A, Strauss DC, Miceli R, et al. Variability in patterns of recurrence after resection of primary retroperitoneal sarcoma (RPS): a report on 1007 patients from the Multi-institutional Collaborative RPS Working Group. *Ann Surg*. 2016;263(5):1002–1009.

Grossman LD, White RR, Arber DA. Angiomatoid fibrous histiocytoma. *Ann Plast Surg*. 1996;36(6):649–651.

Gui L, Bigler SA, Subramony C. Lymphangioma of the pancreas with “ovarian-like” mesenchymal stroma: a case report with emphasis on histogenesis. *Arch Pathol Lab Med*. 2003;127(11):1513–1516.

Gullu S, Gursoy A, Erdogan MF, et al. Multiple endocrine neoplasia type 2A/localized cutaneous lichen amyloidosis associated with malignant pheochromocytoma and ganglioneuroma. *J Endocrinol Invest*. 2005;28(8):734–737.

Hainsworth JD, Burris HA 3rd, Calvert SW, et al. Gemcitabine in the second-line therapy of patients with carcinoma of unknown primary site: a phase II trial of the Minnie Pearl Cancer Research Network. *Cancer Invest*. 2001;19(4):335–339.

Han G, Zhang Z, Shen X, et al. Doege-Potter syndrome: a review of the literature including a new case report. *Medicine (Baltimore)*. 2017;96(27):e7417.

Hanrahan CJ, Christensen CR, Crim JR. Current concepts in the evaluation of multiple myeloma with MR imaging and FDG PET/CT. *Radiographics*. 2010;30(1):127–142.

Heidenreich A, Albers P, Hartmann M, German Testicular Cancer Study Group, et al. Complications of primary nerve sparing retroperitoneal lymph node dissection for clinical stage I nonseminomatous germ cell tumors of the testis: experience of the German Testicular Cancer Study Group. *J Urol*. 2003;169(5):1710–1714.

Heidenreich A, Pfister D, Witthuhn R, et al. Postchemotherapy retroperitoneal lymph node dissection in advanced testicular cancer: radical or modified template resection. *Eur Urol*. 2009;55(1):217–226.

Henricks WH, Chu YC, Goldblum JR, et al. Dedifferentiated liposarcoma: a clinicopathological analysis of 155 cases with a proposal for an expanded definition of dedifferentiation. *Am J Surg Pathol*. 1997;21(3):271–281.

Hermans BP, Sweeney CJ, Foster RS, et al. Risk of systemic metastases in clinical stage I nonseminoma germ cell testis tumor managed by retroperitoneal lymph node dissection. *J Urol*. 2000;163(6):1721–1724.

Herr HW. Does necrosis on frozen-section analysis of a mass after chemotherapy justify a limited retroperitoneal resection in patients with advanced testis cancer? *Br J Urol*. 1997;80(4):653–657.

Hicks CW, Glebova NO, Piazza KM, et al. Risk of venous thromboembolic events following inferior vena cava resection and reconstruction. *J Vasc Surg*. 2016;63(4):1004–1010.

Hirbe AC, Kaushal M, Sharma MK, et al. Clinical genomic profiling identifies TYK2 mutation and overexpression in patients with neurofibromatosis type 1-associated malignant peripheral nerve sheath tumors. *Cancer*. 2017;123(7):1194–1201.

Hong W, Yu XM, Jiang MQ, et al. Solitary extramedullary plasmacytoma in retroperitoneum: a case report and review of the literature. *World J Gastroenterol*. 2009;15(19):2425–2427.

Hornick JL, Bosenberg MW, Mentzel T, et al. Pleomorphic liposarcoma: clinicopathologic analysis of 57 cases. *Am J Surg Pathol*. 2004;28(10):1257–1267.

Hutchings M, Barrington SF. PET/CT for therapy response assessment in lymphoma. *J Nucl Med*. 2009;50(Suppl 1):21S–30S.

Ikoma N, Torres KE, Somaiah N, et al. Accuracy of preoperative percutaneous biopsy for the diagnosis of retroperitoneal liposarcoma subtypes. *Ann Surg Oncol*. 2015;22(4):1068–1072.

Isler MH, Fogaça MF, Mankin HJ. Radiation induced malignant schwannoma arising in a neurofibroma. *Clin Orthop Relat Res*. 1996;325:251–255.

Italiano A, Toulmonde M, Cioffi A, et al. Advanced well-differentiated/dedifferentiated liposarcomas: role of chemotherapy and survival. *Ann Oncol*. 2012;23(6):1601–1607.

Jewett MA, Kong YS, Goldberg SD, et al. Retroperitoneal lymphadenectomy for testis tumor with nerve sparing for ejaculation. *J Urol*. 1988;139(6):1220–1224.

Johnston P, Beck SD, Cheng L, et al. Incidence, histology and management of intraluminal thrombus at post-chemotherapy retroperitoneal lymph node dissection. *J Urol*. 2013;190(3):874–877.

Jones JJ, Catton CN, O'Sullivan B, et al. Initial results of a trial of preoperative external-beam radiation therapy and postoperative brachytherapy for retroperitoneal sarcoma. *Ann Surg Oncol*. 2002;9(4):346–354.

Jones TD, Ulbright TM, Eble JN, et al. OCT4 staining in testicular tumors: a sensitive and specific marker for seminoma and embryonal carcinoma. *Am J Surg Pathol*. 2004;28(7):935–940.

Jones RL, Fisher C, Al-Muderis O, et al. Differential sensitivity of liposarcoma subtypes to chemotherapy. *Eur J Cancer*. 2005;41(18):2853–2860.

Jrebi NY, Iqbal CW, Joliat GR, et al. Review of our experience with neuroblastoma and ganglioneuroblastoma in adults. *World J Surg*. 2014;38(11):2871–2874.

Kao CS, Cornejo KM, Ulbright TM, et al. Juvenile granulosa cell tumors of the testis: a clinicopathologic study of 70 cases with emphasis on its wide morphologic spectrum. *Am J Surg Pathol*. 2015;39(9):1159–1169.

Katz D, Boonsirikamchai P, Choi H, et al. Efficacy of first-line doxorubicin and ifosfamide in myxoid liposarcoma. *Clin Sarcoma Res*. 2012;2(1):2.

Katz MH, Choi EA, Pollock RE. Current concepts in multimodality therapy for retroperitoneal sarcoma. *Expert Rev Anticancer Ther*. 2007;7(2):159–168.

Kawamura S, Nakamura T, Oya T, et al. Advanced malignant solitary fibrous tumor in pelvis responding to radiation therapy. *Pathol Int*. 2007;57(4):213–218.

Kenerson H, Folpe AL, Takayama TK, et al. Activation of the mTOR pathway in sporadic angiomyolipomas and other perivascular epithelioid cell neoplasms. *Hum Pathol*. 2007;38(9):1361–1371.

Kesler KA, Brooks JA, Rieger KM, et al. Mediastinal metastases from testicular nonseminomatous germ cell tumors: patterns of dissemination and predictors of long-term survival with surgery. *J Thorac Cardiovasc Surg*. 2003;125(4):913–923.

Keung EZ, Hornick JL, Bertagnolli MM, et al. Predictors of outcomes in patients with primary retroperitoneal dedifferentiated liposarcoma undergoing surgery. *J Am Coll Surg*. 2014;218(2):206–217.

Kim I, Young RH, Scully RE. Leydig cell tumors of the testis. A clinicopathological analysis of 40 cases and review of the literature. *Am J Surg Pathol*. 1985;9(3):177–192.

Kimura N, Watanabe T, Fukase M, et al. Neurofibromin and NF1 gene analysis in composite pheochromocytoma and tumors associated with von Recklinghausen's disease. *Mod Pathol*. 2002;15(3):183–188.

Kratzer SS, Ulbright TM, Talerman A, et al. Large cell calcifying Sertoli cell tumor of the testis: contrasting features of six malignant and six benign tumors and a review of the literature. *Am J Surg Pathol*. 1997;21(11):1271–1280.

Kroep JR, Ouali M, Gelderblom H, et al. First-line chemotherapy for malignant peripheral nerve sheath tumor (MPNST) versus other histological soft tissue sarcoma subtypes and as a prognostic factor for MPNST: an EORTC soft tissue and bone sarcoma group study. *Ann Oncol*. 2011;22(1):207–214.

Kuboki S, Shimizu H, Yoshidome H, et al. Chylous ascites after hepatopancreatobiliary surgery. *Br J Surg*. 2013;100(4):522–527.

Lahat G, Anaya DA, Wang X, et al. Resectable well-differentiated versus dedifferentiated liposarcomas: two different diseases possibly requiring different treatment approaches. *Ann Surg Oncol*. 2008;15(6):1585–1593.

Lassen U, Daugaard G, Eigtved A, et al. 18F-FDG whole body positron emission tomography (PET) in patients with unknown primary tumours (UPT). *Eur J Cancer*. 1999;35(7):1076–1082.

Le Guellec S, Decouvelaere AV, Filleron T, et al. Malignant peripheral nerve sheath tumor is a challenging diagnosis: a systematic pathology review, immunohistochemistry, and molecular analysis in 160 patients from the French Sarcoma Group Database. *Am J Surg Pathol*. 2016;40(7):896–908.

Le Péchoux C, Musat E, Baey C, et al. Should adjuvant radiotherapy be administered in addition to front-line aggressive surgery (FAS) in patients with primary retroperitoneal sarcoma? *Ann Oncol*. 2013;24(3):832–837.

Lee KH, Yoon HS, Choi SJ, et al. Asbestos exposure and malignant mesothelioma in Korea. *Asian Pac J Cancer Prev*. 2009;10(4):707–710.

Levi F, Te VC, Erler G, et al. Epidemiology of unknown primary tumours. *Eur J Cancer*. 2002;38(13):1810–1812.

Linehan DC, Lewis JJ, Leung D, et al. Influence of biologic factors and anatomic site in completely resected liposarcoma. *J Clin Oncol*. 2000;18(8):1637–1643.

Liu M, Liu B, Dong L, et al. Recurrent intrathoracic solitary fibrous tumor: remarkable response to radiotherapy. *Ann Thorac Med*. 2014;9(4):245–247.

Lucas DR, Nascimento AG, Sanjay BK, et al. Well-differentiated liposarcoma. The Mayo Clinic experience with 58 cases. *Am J Clin Pathol*. 1994;102(5):677–683.

MacNeill AJ, Miceli R, Strauss DC, et al. Post-relapse outcomes after primary extended resection of retroperitoneal sarcoma: a report from the Trans-Atlantic RPS Working Group. *Cancer*. 2017;123(11):1971–1978.

Mahmood ST, Agresta S, Vigil CE, et al. Phase II study of sunitinib malate, a multitargeted tyrosine kinase inhibitor in patients with relapsed or refractory soft tissue sarcomas. Focus on three prevalent histologies: leiomyosarcoma, liposarcoma and malignant fibrous histiocytoma. *Int J Cancer*. 2011;129(8):1963–1969.

Malinowska I, Kwiatkowski DJ, Weiss S, et al. Perivascular epithelioid cell tumors (PEComas) harboring TFE3 gene rearrangements lack the TSC2 alterations characteristic of conventional PEComas: further evidence for a biological distinction. *Am J Surg Pathol*. 2012;36(5):783–784.

Marušić Z, Billings SD. Histopathology of spindle cell vascular tumors. *Surg Pathol Clin*. 2017;10(2):345–366.

McClain KL, Leach CT, Jenson HB, et al. Association of Epstein-Barr virus with leiomyosarcomas in young people with AIDS. *N Engl J Med*. 1995;332(1):12–18.

Miura JT, Charlson J, Gamblin TC, et al. Impact of chemotherapy on survival in surgically resected retroperitoneal sarcoma. *Eur J Surg Oncol*. 2015;41(10):1386–1392.

Miura S, Mii Y, Miyauchi Y, et al. Efficacy of slow-releasing anticancer drug delivery systems on transplantable osteosarcomas in rats. *Jpn J Clin Oncol*. 1995;25(3):61–71.

Morimitsu Y, Nakajima M, Hisaoka M, et al. Extrapleural solitary fibrous tumor: clinicopathologic study of 17 cases and molecular analysis of the p53 pathway. *APMIS*. 2000;108(9):617–625.

Mosharafa AA, Foster RS, Bihrle R, et al. Does retroperitoneal lymph node dissection have a curative role for patients with sex cord-stromal testicular tumors? *Cancer*. 2003;98(4):753–757.

Movva S, von Mehren M, Ross EA, et al. Patterns of chemotherapy administration in high-risk soft tissue sarcoma and impact on overall survival. *J Natl Compr Canc Netw*. 2015;13(11):1366–1374.

Mullen JT, van Houdt W. Soft tissue tumors of the pelvis: technical and histological considerations. *J Surg Oncol*. 2018;117(1):48–55.

Munechika H, Honda M, Kushihashi T, et al. Computed tomography of retroperitoneal cystic lymphangiomas. *J Comput Assist Tomogr*. 1987;11(1):116–119.

Nakayama R, Zhang YX, Czaplinski JT, et al. Preclinical activity of selinexor, an inhibitor of XPO1, in sarcoma. *Oncotarget*. 2016;7(13):16581–16592.

Nash PA, Leibovitch I, Foster RS, et al. En bloc nephrectomy in patients undergoing post-chemotherapy retroperitoneal lymph node dissection for nonseminomatous testis cancer: indications, implications and outcomes. *J Urol*. 1998;159(3):707–710.

Neuhaus SJ, Barry P, Clark MA, et al. Surgical management of primary and recurrent retroperitoneal liposarcoma. *Br J Surg*. 2005;92(2):246–252.

Neville A, Herts BR. CT characteristics of primary retroperitoneal neoplasms. *Crit Rev Comput Tomogr*. 2004;45(4):247–270.

Nicolai N, Miceli R, Artusi R, et al. A simple model for predicting nodal metastasis in patients with clinical stage I nonseminomatous germ cell testicular tumors undergoing retroperitoneal lymph node dissection only. *J Urol*. 2004;171(1):172–176.

Nussbaum DP, Rushing CN, Lane WO, et al. Preoperative or postoperative radiotherapy versus surgery alone for retroperitoneal sarcoma: a case-control, propensity score-matched analysis of a nationwide clinical oncology database. *Lancet Oncol*. 2016;17(7):966–975.

Olimpiadi Y, Song S, Hu JS, et al. Contemporary management of retroperitoneal soft tissue sarcomas. *Curr Oncol Rep*. 2015;17(8):39.

Otal P, Mezghani S, Hassissene S, et al. Imaging of retroperitoneal ganglioneuroma. *Eur Radiol*. 2001;11(6):940–945.

Park SJ, Park CJ, Kim S, et al. Detection of bone marrow metastases of neuroblastoma with immunohistochemical staining of CD56, chromogranin A, and synaptophysin. *Appl Immunohistochem Mol Morphol*. 2010;18(4):348–352.

Pasquali S, Gronchi A, Strauss D, et al. Resectable extra-pleural and extra-meningeal solitary fibrous tumours: a multi-centre prognostic study. *Eur J Surg Oncol*. 2016;42(7):1064–1070.

Pavlidis N, Briasoulis E, Hainsworth J, et al. Diagnostic and therapeutic management of cancer of an unknown primary. *Eur J Cancer*. 2003;39(14):1990–2005.

Pavlidis N, Fizazi K. Cancer of unknown primary (CUP). *Crit Rev Oncol Hematol*. 2005;54(3):243–250.

Pennell TC, Gusdon JP Jr. Retroperitoneal mucinous cystadenoma. *Am J Obstet Gynecol*. 1989;160(5 Pt 1):1229–1231.

Pezner RD, Liu A, Chen YJ, et al. Full-dose adjuvant postoperative radiation therapy for retroperitoneal sarcomas. *Am J Clin Oncol*. 2011;34(5):511–516.

Pickhardt PJ, Fisher AJ, Balfe DM, et al. Desmoplastic small round cell tumor of the abdomen: radiologic-histopathologic correlation. *Radiology*. 1999;210(3):633–638.

Pisters PW. Retroperitoneal sarcomas—an SOS to colleagues in Europe. *Ann Surg Oncol*. 2007;14(6):1787–1789.

Pizzocaro G, Salvioni R, Zanoni F. Unilateral lymphadenectomy in intraoperative stage I nonseminomatous germinal testis cancer. *J Urol*. 1985;134(3):485–489.

Quinones-Baldrich W, Alktaifi A, et al. Inferior vena cava resection and reconstruction for retroperitoneal tumor excision. *J Vasc Surg*. 2012;55(5):1386–1393 [discussion 1393].

Rabbani F, Goldenberg SL, Gleave ME, et al. Retroperitoneal lymphadenectomy for post-chemotherapy residual masses: is a modified dissection and resection of residual masses sufficient? *Br J Urol*. 1998;81(2):295–300.

Rades D, Kühnel G, Wildfang I, et al. Localised disease in cancer of unknown primary (CUP): the value of positron emission tomography (PET) for individual therapeutic management. *Ann Oncol*. 2001;12(11):1605–1609.

Rajiah P, Sinha R, Cuevas C, et al. Imaging of uncommon retroperitoneal masses. *Radiographics*. 2011;31(4):949–976.

Rajkumar SV, Dimopoulos MA, Palumbo A, et al. International Myeloma Working Group updated criteria for the diagnosis of multiple myeloma. *Lancet Oncol*. 2014;15(12):e538–e548.

Raut CP, Miceli R, Strauss DC, et al. External validation of a multi-institutional retroperitoneal sarcoma nomogram. *Cancer*. 2016;122(9):1417–1424.

Raut CP, Swallow CJ. Are radical compartmental resections for retroperitoneal sarcomas justified? *Ann Surg Oncol*. 2010;17(6):1481–1484.

Ray B, Hajdu SI, Whitmore WF Jr. Proceedings: distribution of retroperitoneal lymph node metastases in testicular germinal tumors. *Cancer*. 1974;33(2):340–348.

Ray-Coquard I, Blay JY, Italiano A, et al. Effect of the MDM2 antagonist RG7112 on the P53 pathway in patients with MDM2-amplified, well-differentiated or dedifferentiated liposarcoma: an exploratory proof-of-mechanism study. *Lancet Oncol*. 2012;13(11):1133–1140.

Regelink JC, Minnema MC, Terpos E, et al. Comparison of modern and conventional imaging techniques in establishing multiple myeloma-related bone disease: a systematic review. *Br J Haematol*. 2013;162(1):50–61.

Rha SE, Byun JY, Jung SE, et al. Neurogenic tumors in the abdomen: tumor types and imaging characteristics. *Radiographics*. 2003;23(1):29–43.

Robinson DR, Wu YM, Kalyana-Sundaram S, et al. Identification of recurrent NAB2-STAT6 gene fusions in solitary fibrous tumor by integrative sequencing. *Nat Genet*. 2013;45(2):180–185.

Ros PR, Viamonte M, Rywlin AM. Malignant fibrous histiocytoma: mesenchymal tumor of ubiquitous origin. *AJR*

Am J Roentgenol. 1984;142(4):753–759.

Rossi S, Szuhai K, Ijszenga M, et al. EWSR1-CREB1 and EWSR1-ATF1 fusion genes in angiomatoid fibrous histiocytoma. *Clin Cancer Res*. 2007;13(24):7322–7328.

Saito M, Tsuchiya N, Iinuma M, et al. [A case of retroperitoneal extramedullary plasmacytoma]. *Hinyokika Kiyo*. 2003;49(12):735–739.

Sandberg AA. Updates on the cytogenetics and molecular genetics of bone and soft tissue tumors: liposarcoma. *Cancer Genet Cytogenet*. 2004;155(1):1–24.

Saynak M, Bayir-Angin G, Kocak Z, et al. Recurrent solitary fibrous tumor of the pleura: significant response to radiotherapy. *Med Oncol*. 2010;27(1):45–48.

Schaefer IM, Fletcher CD. Myxoid variant of so-called angiomatoid “malignant fibrous histiocytoma”: clinicopathologic characterization in a series of 21 cases. *Am J Surg Pathol*. 2014;38(6):816–823.

Schwarzbach MH, Dimitrakopoulou-Strauss A, Mechtersheimer G, et al. Assessment of soft tissue lesions suspicious for liposarcoma by F18-deoxyglucose (FDG) positron emission tomography (PET). *Anticancer Res*. 2001;21(5):3609–3614.

Shapiro AM, Bain VG, Sigalet DL, et al. Rapid resolution of chylous ascites after liver transplantation using somatostatin analog and total parenteral nutrition. *Transplantation*. 1996;61(9):1410–1411.

Sharma LM, Biswas G, Rai SS, et al. Retro-peritoneal plasmacytoma: a case report and review of literature. *Indian J Cancer*. 2004;41(3):133–134.

Silberstein JL, Bazzi WM, Vertosick E, et al. Clinical outcomes of local and metastatic testicular sex cord-stromal tumors. *J Urol*. 2014;192(2):415–419.

Sindelar WF, Kinsella TJ, Chen PW, et al. Intraoperative radiotherapy in retroperitoneal sarcomas. Final results of a prospective, randomized, clinical trial. *Arch Surg*. 1993;128(4):402–410.

Singer S, Antonescu CR, Riedel E, et al. Histologic subtype and margin of resection predict pattern of recurrence and survival for retroperitoneal liposarcoma. *Ann Surg*. 2003;238(3):358–370 [discussion 371].

Smith L, Minter S, O'Brien P, et al. Neuroblastoma in an adult: case presentation and literature review. *Ann Clin Lab Sci*. 2013;43(1):81–84.

Soule EH. Synovial sarcoma. *Am J Surg Pathol*. 1986;10(Suppl 1):78–82.

Steiner H, Peschel R, Bartsch G. Retroperitoneal lymph node dissection after chemotherapy for germ cell tumours: is a full bilateral template always necessary? *BJU Int*. 2008;102(3):310–314.

Stephenson AJ, Bosl GJ, Motzer RJ, et al. Retroperitoneal lymph node dissection for nonseminomatous germ cell testicular cancer: impact of patient selection factors on outcome. *J Clin Oncol*. 2005;23(12):2781–2788.

Stephenson AJ, Tal R, Sheinfeld J. Adjunctive nephrectomy at post-chemotherapy retroperitoneal lymph node dissection for nonseminomatous germ cell testicular cancer. *J Urol*. 2006;176(5):1996–1999.

Subramanian VS, Nguyen CT, Stephenson AJ, et al. Complications of open primary and post-chemotherapy retroperitoneal lymph node dissection for testicular cancer. *Urol Oncol*. 2010;28(5):504–509.

Sultan I, Rodriguez-Galindo C, Saab R, et al. Comparing children and adults with synovial sarcoma in the Surveillance, Epidemiology, and End Results program, 1983 to 2005: an analysis of 1268 patients. *Cancer*. 2009;115(15):3537–3547.

Sun Z, Wang Y, Li Z. [Recurrent pheochromocytoma].

Zhonghua Wai Ke Za Zhi. 1998;36(1):59–60.

Surlin V, Georgescu E, Dumitrescu C, et al. Retropancreatic cystic lymphangioma: considerations upon a case. *Rom J Morphol Embryol*. 2011;52(1 Suppl):493–496.

Tan MC, Brennan MF, Kuk D, et al. Histology-based classification predicts pattern of recurrence and improves risk stratification in primary retroperitoneal sarcoma. *Ann Surg*. 2016;263(3):593–600.

Tanaka M, Kato K, Gomi K, et al. Perivascular epithelioid cell tumor with SFPQ/PSF-TFE3 gene fusion in a patient with advanced neuroblastoma. *Am J Surg Pathol*. 2009;33(9):1416–1420.

Tateishi U, Terauchi T, Inoue T, et al. Nodal status of malignant lymphoma in pelvic and retroperitoneal lymphatic pathways: PET/CT. *Abdom Imaging*. 2010;35(2):232–240.

Tawbi HA, Burgess M, Bolejack V, et al. Pembrolizumab in advanced soft-tissue sarcoma and bone sarcoma (SARC028): a multicentre, two-cohort, single-arm, open-label, phase 2 trial. *Lancet Oncol*. 2017;18(11):1493–1501 [Erratum in: Lancet Oncol. 2017;18(12):e711. *Lancet Oncol* 2018;19(1):e8].

Terry J, Saito T, Subramanian S, et al. TLE1 as a diagnostic immunohistochemical marker for synovial sarcoma emerging from gene expression profiling studies. *Am J Surg Pathol*. 2007;31(2):240–246.

Tohme CA, Mattar WE, Ghorra CS. Extra-adrenal composite pheochromocytoma-ganglioneuroma. *Saudi Med J*. 2006;27(10):1594–1597.

Touzeau C, Moreau P. How I treat extramedullary myeloma. *Blood*. 2016;127(8):971–976.

Trans-Atlantic RPS Working Group. Management of primary retroperitoneal sarcoma (RPS) in the adult: a consensus approach from the Trans-Atlantic RPS Working Group. *Ann*

Surg Oncol. 2015;22(1):256–263.

Tseng WW, Madewell JE, Wei W, et al. Locoregional disease patterns in well-differentiated and dedifferentiated retroperitoneal liposarcoma: implications for the extent of resection? *Ann Surg Oncol*. 2014;21(7):2136–2143.

Tseng WW, Malu S, Zhang M, et al. Analysis of the intratumoral adaptive immune response in well differentiated and dedifferentiated retroperitoneal liposarcoma. *Sarcoma*. 2015;2015:547460.

Tseng WH, Martinez SR, Do L, et al. Lack of survival benefit following adjuvant radiation in patients with retroperitoneal sarcoma: a SEER analysis. *J Surg Res*. 2011;168(2):e173–e180.

Turc-Carel C, Dal Cin P, Limon J, et al. Translocation X;18 in synovial sarcoma. *Cancer Genet Cytogenet*. 1986;23(1):93.

Tzeng CW, Smith JK, Heslin MJ. Soft tissue sarcoma: preoperative and postoperative imaging for staging. *Surg Oncol Clin N Am*. 2007;16(2):389–402.

Usmani SZ, Heuck C, Mitchell A, et al. Extramedullary disease portends poor prognosis in multiple myeloma and is over-represented in high-risk disease even in the era of novel agents. *Haematologica*. 2012;97(11):1761–1767.

van de Rijn M, Barr FG, Xiong QB, et al. Radiation-associated synovial sarcoma. *Hum Pathol*. 1997;28(11):1325–1328.

van der Gaast A, Verweij J, Henzen-Logmans SC, et al. Carcinoma of unknown primary: identification of a treatable subset? *Ann Oncol*. 1990;1(2):119–122.

van der Graaf WT, Blay JY, Chawla SP, EORTC Soft Tissue and Bone Sarcoma Group; PALETTE study group, et al. Pazopanib for metastatic soft-tissue sarcoma (PALETTE): a randomised, double-blind, placebo-controlled phase 3 trial. *Lancet*. 2012;379(9829):1879–1886.

van Houdt WJ, Zaidi S, Messiou C, et al. Treatment of retroperitoneal sarcoma: current standards and new developments. *Curr Opin Oncol*. 2017;29(4):260–267.

Vlenterie M, Litière S, Rizzo E, et al. Outcome of chemotherapy in advanced synovial sarcoma patients: review of 15 clinical trials from the European Organisation for Research and Treatment of Cancer Soft Tissue and Bone Sarcoma Group; setting a new landmark for studies in this entity. *Eur J Cancer*. 2016;58:62–72.

von Mehren M, Randall RL, Benjamin RS, et al. Soft tissue sarcoma, version 2.2018, NCCN clinical practice guidelines in oncology. *J Natl Compr Canc Netw*. 2018;16(5):536–563.

Wagner AJ, Malinowska-Kolodziej I, Morgan JA, et al. Clinical activity of mTOR inhibition with sirolimus in malignant perivascular epithelioid cell tumors: targeting the pathogenic activation of mTORC1 in tumors. *J Clin Oncol*. 2010;28(5):835–840.

Wang H, Chen P, Zhao W, et al. Clinicopathological findings in a case series of abdominopelvic solitary fibrous tumors. *Oncol Lett*. 2014;7(4):1067–1072.

Waters BL, Panagopoulos I, Allen EF. Genetic characterization of angiomatoid fibrous histiocytoma identifies fusion of the FUS and ATF-1 genes induced by a chromosomal translocation involving bands 12q13 and 16p11. *Cancer Genet Cytogenet*. 2000;121(2):109–116.

Weissbach L, Boedefeld EA. Localization of solitary and multiple metastases in stage II nonseminomatous testis tumor as basis for a modified staging lymph node dissection in stage I. *J Urol*. 1987;138(1):77–82.

Weissbach L, Boedefeld EA, Oberdörster W. Modified RLND as a means to preserve ejaculation. *Prog Clin Biol Res*. 1985;203:323–334.

Winter C, Pfister D, Busch J, et al. Residual tumor size and IGCCCG risk classification predict additional vascular procedures in patients with germ cell tumors and residual tumor resection: a multicenter analysis of the German Testicular Cancer Study Group. *Eur Urol*. 2012;61(2):403–409.

Wong WW, Hirose T, Scheithauer BW, et al. Malignant peripheral nerve sheath tumor: analysis of treatment outcome. *Int J Radiat Oncol Biol Phys*. 1998;42(2):351–360.

Wood DP Jr, Herr HW, Heller G, et al. Distribution of retroperitoneal metastases after chemotherapy in patients with nonseminomatous germ cell tumors. *J Urol*. 1992;148(6):1812–1815.

Wu Y, Bi W, Han G, et al. Influence of neoadjuvant chemotherapy on prognosis of patients with synovial sarcoma. *World J Surg Oncol*. 2017;15(1):101.

Yamaguchi S, Nagasawa H, Suzuki T, et al. Sarcomas of the oral and maxillofacial region: a review of 32 cases in 25 years. *Clin Oral Investig*. 2004;8(2):52–55.

Yang SY, Jin YJ, Park SH, et al. Paragangliomas in the cauda equina region: clinicopathoradiologic findings in four cases. *J Neurooncol*. 2005;72(1):49–55.

Zlotecki RA, Katz TS, Morris CG, et al. Adjuvant radiation therapy for resectable retroperitoneal soft tissue sarcoma: the University of Florida experience. *Am J Clin Oncol*. 2005;28(3):310–316.

Open Surgery of the Kidney

Aria F. Olumi MD, Michael L. Blute MD

Historical Perspective

Kidney-related diseases have significantly helped our understanding of the normal physiology of the kidney. As a result of better understanding of the pathophysiology and anatomic structures of the kidney, surgical approaches to management of renally related disease have evolved. From the first successful nephrectomy in 1869 for management of ureterovaginal fistula to the first radical nephrectomy, renal vasculature and caval reconstructions and advances made in retroperitoneal and transabdominal approaches for renal surgery have all stemmed from improved understanding of the surgical anatomy of the kidney and its surrounding structures. Therefore, for appropriate decision making in the perioperative period, detailed knowledge of the renal anatomy is paramount. Renal anatomy has been discussed in detail in the anatomy chapters of this book, and it will not be repeated here. The reader is referred to those chapters for review and understanding of the important surgical anatomic landmarks necessary for renal surgery.

Preoperative Evaluation and Preparation

Before any renal surgery, a global assessment of the patient's renal function is important. Routinely, preoperative urinalysis, urine culture, and serum creatinine (SCr) and hemoglobin are evaluated. Patients with locally advanced or metastatic disease should be screened for hepatic dysfunction (Stauffer syndrome) and any associated coagulopathy. Renal function can be evaluated by estimating the **glomerular filtration rate (GFR) using the Modification of Diet in Renal Disease Study equation** (Levey et al., 1999):

$$\text{GFR}\ (\text{mL/min}/1.73\ \text{m}^2) = 186 \times (\text{SCr})^{-1.154} \times (\text{Age})^{-0.203} \times \\ (0.742\ \text{if female}) \times (1.212\ \text{if African-American})$$

Those in good health with two normally functioning kidneys are at low risk for requiring postoperative dialysis following open renal surgery; however, patients with GFR less than 60 mL/min or significant proteinuria are at increased risk for requiring dialysis. As a result, perioperative consultation with a nephrologist can be most useful in optimizing a patient's renal function pre- and postoperatively.

Assessment of cardiac and pulmonary status is important before any surgery, but because of the potential for significant cardiopulmonary compromise resulting from intraoperative positioning, potential for blood loss, and possible fluid shifts, particular care needs to be taken to maximize cardiopulmonary function preoperatively (Fleisher et al., 2007a, 2007b).

In the modern era, cross-sectional imaging is a necessary step before any renal surgery (Bradley et al., 2011). Computed tomography (CT) and/or magnetic resonance imaging (MRI) studies are useful for proper surgical planning and assessment of renal parenchyma, renal pelvis and ureter, and renal vasculature (Fig. 101.1) (Derweesh et al., 2003; Herts, 2005).

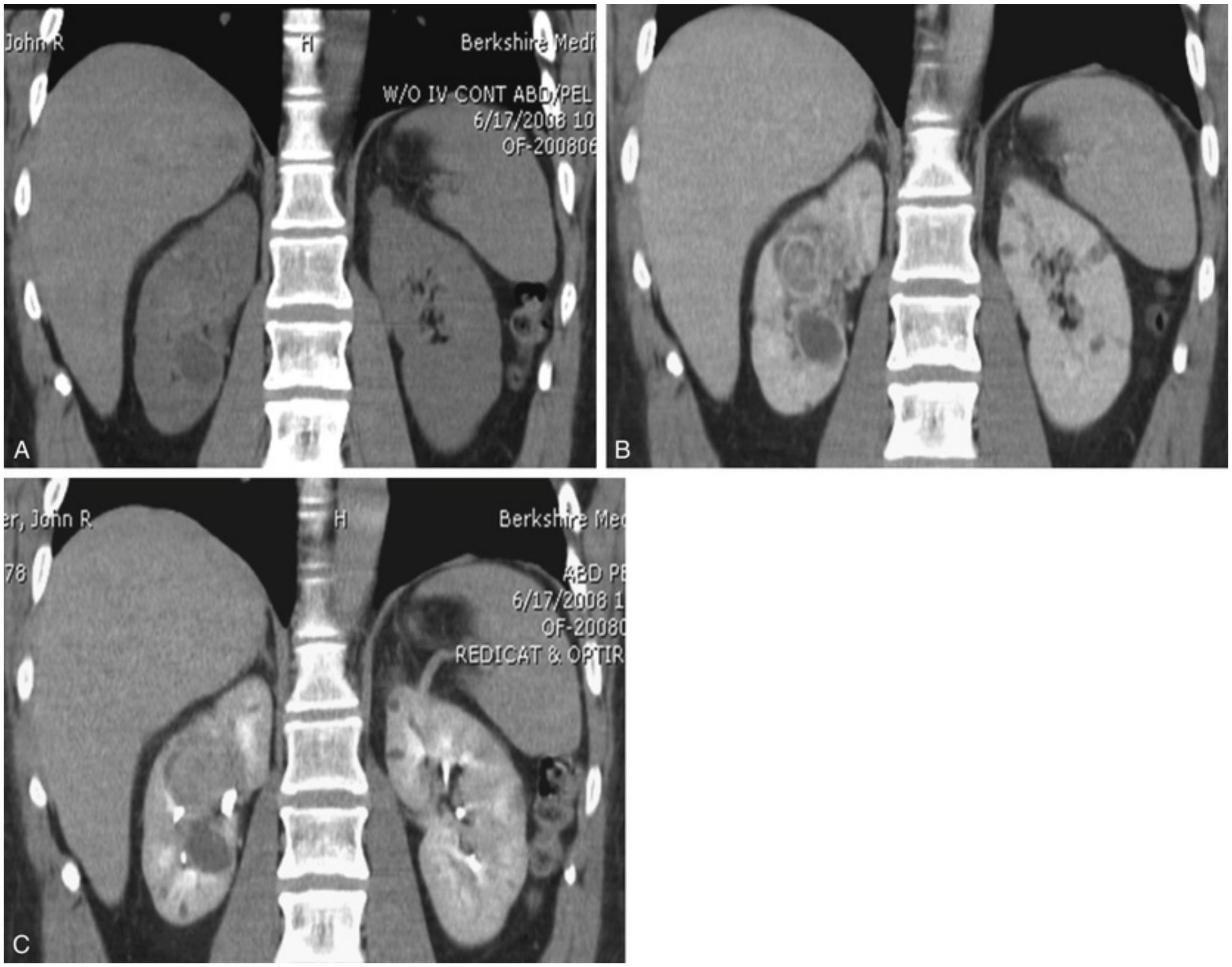

FIG. 101.1 (A) Preoperative computed tomography imaging demonstrates a large (4-cm) hilar lesion during a noncontrast film in a patient with a history of von Hippel-Lindau disease. (B) Contrast administration demonstrates enhancement of a large intrarenal mass and nearby simple cyst. (C) Delayed images depict close proximity to collecting system.

Renal artery embolization (RAE) has been employed for palliation of inoperable renal tumors to control bleeding for large locally advanced renal tumors (eFig. 101.2) (Klimberg et al., 1985). In addition, RAE has been utilized to aid in surgical dissection of large renal tumors (Wszolek et al, 2008). Possible benefits of RAE before nephrectomy include shrinkage of an arterialized tumor thrombus to ease surgical removal, reduced blood loss, facilitation of dissection as a result of tissue plane edema, and ability to ligate the renal vein before the renal artery. However, because postinfarction syndrome, which includes flank pain, nausea, and fever, occurs in approximately three-fourths of patients, RAE is not utilized by all surgeons, and in some retrospective series RAE is associated with high blood loss, possibly secondary to the increased edema associated with the infarcted renal tissue (Schwartz et al., 2007).

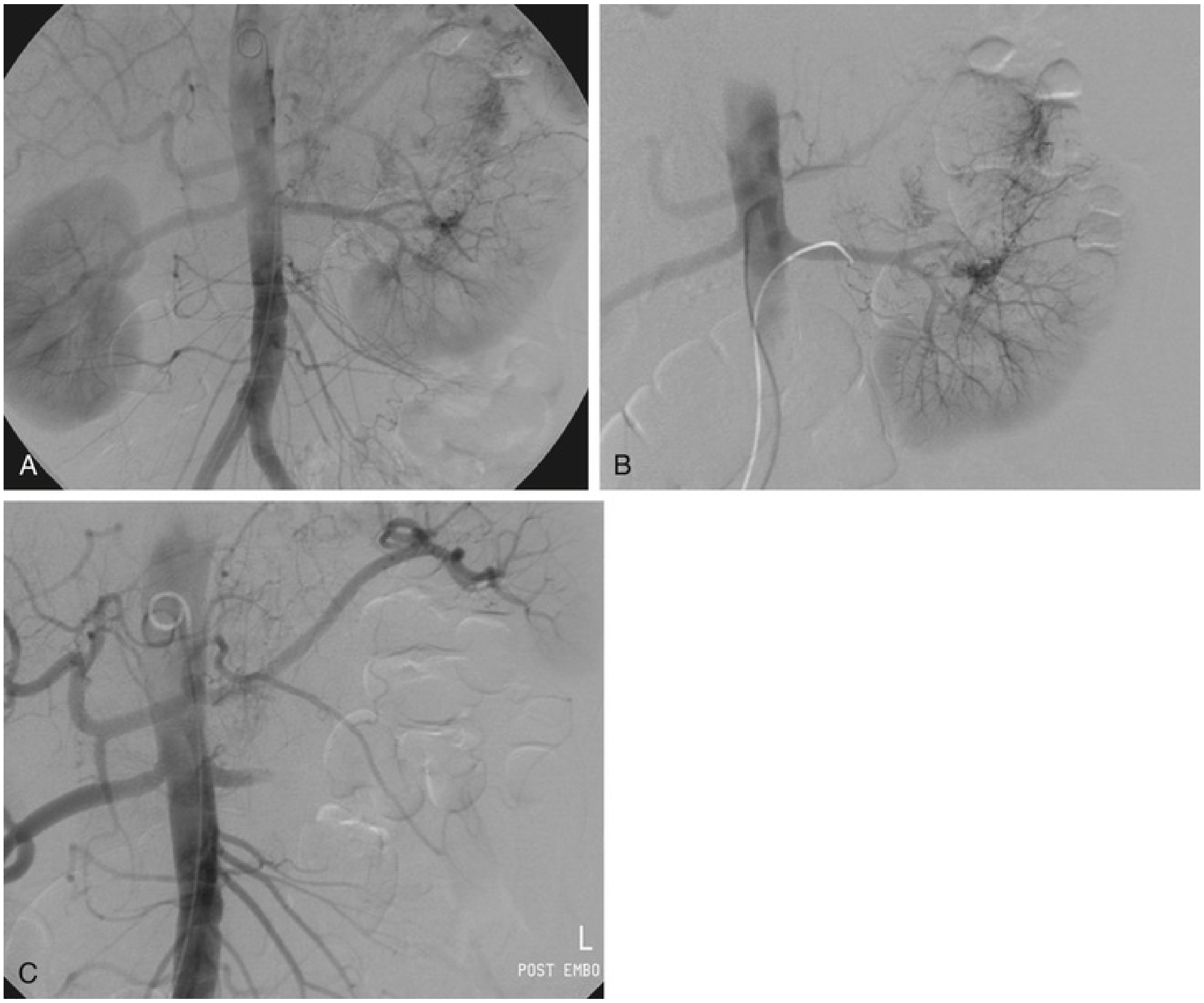

EFIG. 101.2 (A) Aortogram in a patient with a left hypervascular renal mass. Note the pooling of contrast medium in the upper pole. (B) Left selective artery angiogram before coil placement. (C) Aortogram after coil placement demonstrating abrupt cutoff of flow from the left renal artery.

Surgical site infection can be minimized by following the American Urological Association's guidelines (Wolf et al., 2008). A single dose of cefazolin or clindamycin for patients undergoing renal surgery with negative urine culture is prescribed. Any active urinary tract infection should be treated preoperatively.

Prophylactic Measures

Mechanical bowel preparation is not indicated for open renal surgery unless there is concern about intestinal involvement of a pathologic process or iatrogenic intestinal trauma is likely because of multiple prior abdominal surgeries, with likely requirement of extensive lysis of adhesions. When bowel preparation is utilized, potential adverse effects need to be considered, including chronic renal deficiency, particularly in older adults (Heher et al., 2008). For renal surgeries that may require long postoperative care and management in the intensive care unit, prophylaxis with proton pump inhibitors or sucralfate has been shown to reduce gastric stress ulcers (Bredenoord et al., 2013).

Although there is little evidence to support the use of thromboembolic prophylaxis for renal surgery, extrapolation from other similar surgeries suggests that routine use of intermittent pneumatic compression devices is useful to reduce the risk for postoperative deep venous thrombosis. The American College of Chest Physicians advises pharmacologic therapy once the bleeding risk has diminished (Geerts et al., 2008). The American Urological Association recommends use of mechanical prophylaxis in all patients undergoing open surgery and consideration of pharmacologic prophylaxis in patients with elevated risk for deep venous thrombosis.

For cigarette smokers who are anticipating elective open renal surgery, if time permits, a 4- to 6-week preoperative smoking cessation program has been shown to reduce postoperative complications. Other strategies to reduce postoperative respiratory complications include the use of incentive spirometry in high-risk patients or simply deep breathing exercises in low-risk individuals (Overend et al., 2001).

Surgical Instruments

Self-retaining retractors (Omni-Tract, Omni-Tract Surgical, St. Paul, MN; Bookwalter, Codman & Shurtleff, Raynham, MA; or Balfour, Sklar Surgical Instruments, West Chester, PA), long genitourinary surgical instruments, bulldog and/or Satinsky vascular pedicle clamps, surgical clips, and a suction drain are common instruments available and used for most open renal surgeries.

Surgical Approaches

Adequate exposure is the hallmark of effective open renal surgery. Anatomic knowledge and consideration of adjacent visceral organs during the surgical approach are critical for safe surgical management. For right kidney surgery, the liver, colon, and duodenum serve as critical landmark structures, and for left kidney surgery, the spleen, tail of the pancreas, and colon need to be heeded. Proper incision and exposure minimize the amount of required retraction and minimize the likelihood of retractor-related injuries. The ideal surgical approach is tailored not only to the operation being performed but also to the anatomy as defined on preoperative imaging, previous surgical history, body habitus, and presence of limiting factors such as kyphoscoliosis or pulmonary disease (Wotkowicz and Libertino, 2007).

Flank Approaches

For a flank incision, with the patient in the lateral decubitus position, the table is flexed between the iliac crest and costal margin. With the kidney bar raised, the structures of the retroperitoneum are better exposed; however, care needs to be taken to avoid injury to a previously repaired contralateral kidney.

Flank approaches may not be ideal in patients with preexisting cardiopulmonary deficits because exaggerated lateral decubitus positioning may compromise pulmonary function and venous return to the heart. In patients with severe kyphosis, the flank approach may not allow proper exposure of the retroperitoneum and may lead to unanticipated pressure on the flank and vertebral bones. Therefore, the surgeon needs to be familiar with other approaches and tailor the incision for each individual case.

Subcostal Flank Approach

The subcostal approach provides excellent exposure to the proximal ureter and renal parenchyma. It is well suited for approaches to the lower renal pole, ureteropelvic junction, and proximal ureter. However, access to the renal hilum is poor, making the subcostal approach somewhat limiting for management of large renal masses. In addition, it is not an ideal approach for partial nephrectomy because excellent exposure and access to the renal hilum are required (Fig. 101.3).

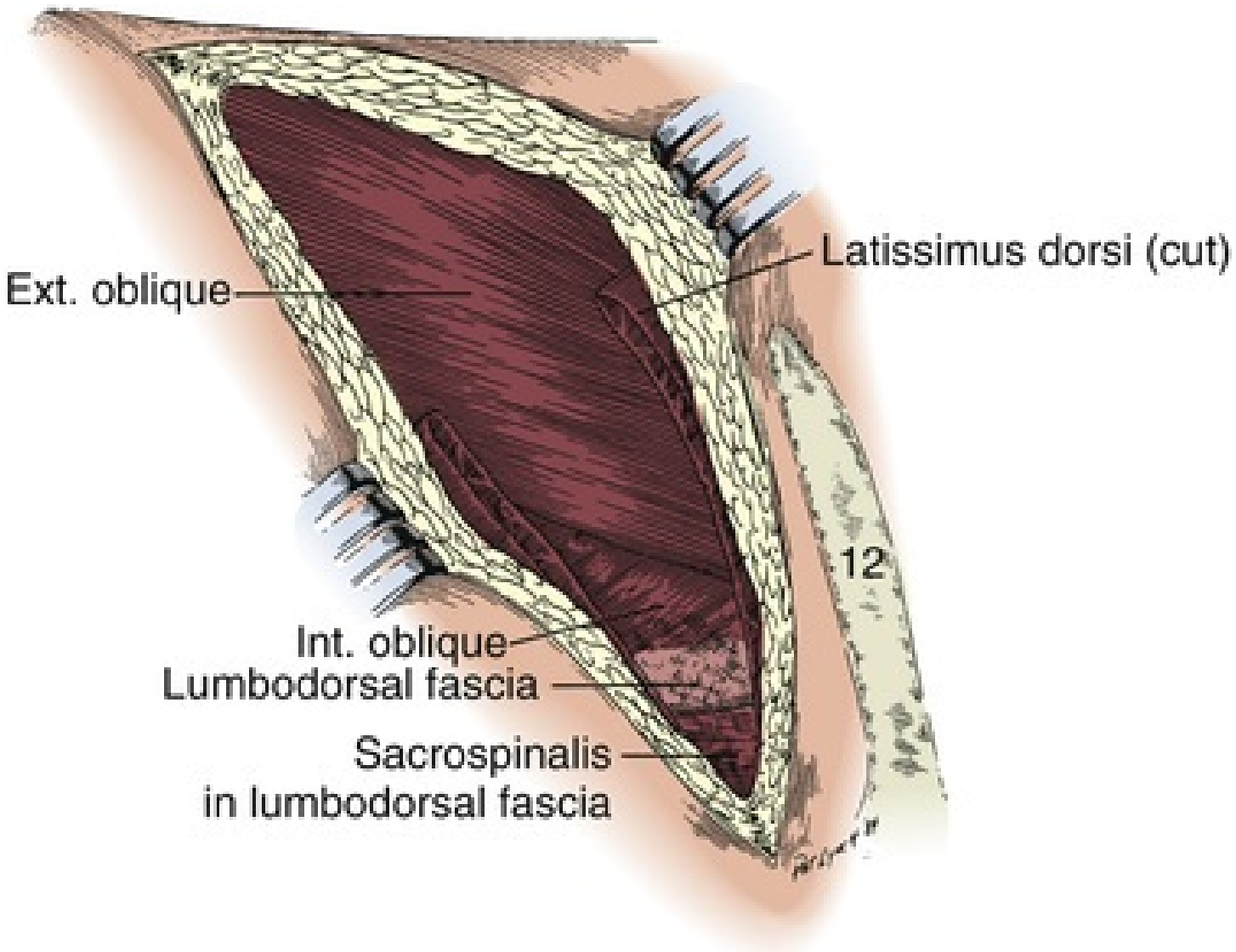

FIG. 101.3 Left subcostal incision. The latissimus dorsi muscle has been divided to expose the lumbodorsal fascia and the posterior aspects of the abdominal muscles.

After induction of anesthesia, insertion of an endotracheal tube, and introduction of a Foley catheter into the urinary bladder to monitor urine output, the patient is placed in the lateral decubitus position. The head is supported to avoid excess flexion at the cervical spine. A kidney bar can be employed if necessary; the tip of the 12th rib should be positioned over the kidney bar (eFig. 101.4). The patient's back is supported by a rolled blanket or surgical beanbag. To preserve stability and prevent forward roll, the dependent leg is flexed at the hip and knee, and the top leg is kept straight. A pillow is placed between the knees. An axillary roll is deployed just caudal to the axilla to prevent compression or injury of the axillary neurovascular bundle. Other pressure points, including the upper foot, are padded with foam. The nondependent arm should be placed on a padded Mayo stand so that the arm is horizontal with slight forward rotation at the shoulder. The bed is flexed until the flank muscles are under stretch. The bed is placed in the Trendelenburg position so that the flank is rendered parallel to the floor. The patient is secured to the mobile part of the operating table with 2-inch-wide adhesive tape, which fixes the patient in place while allowing adjustment of flexion.

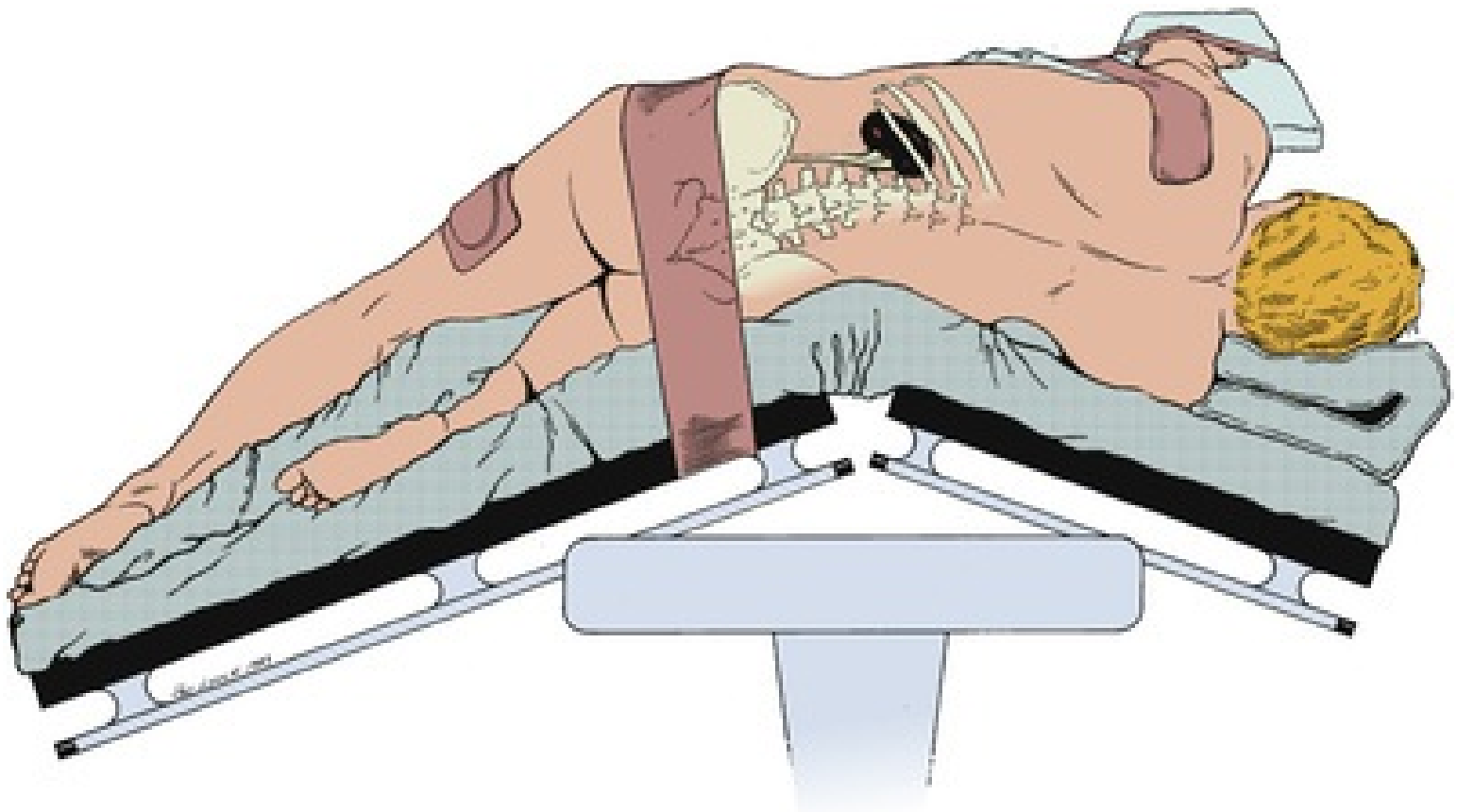

EFIG. 101.4 Position of the patient for the flank approach. Note the axillary pad. The kidney bar may be elevated if further lateral extension is needed.

After sterile preparation and draping, the skin incision begins at the costovertebral angle, approximately at the lateral border of the sacrospinalis muscle just inferior to the 12th rib. The incision is made a fingerbreadth below and parallel to the 12th rib and is carried onto the anterior abdominal wall. In an attempt to avoid the subcostal nerve, the incision can be curved gently downward at the midaxillary line. If needed, the incision can be extended caudally or medially to the lateral border of the rectus abdominis.

The incision is carried sharply through the subcutaneous tissue, exposing the fascia of the latissimus dorsi and external oblique muscles. Electrocautery is used to incise the muscles in the line of the incision, starting with the latissimus dorsi posteriorly (eFig. 101.5). The posterior inferior serratus muscles, which insert into the lower four ribs, are also encountered in the posterior portion of the wound and transected. In the anterior aspect of the wound, the external oblique muscle is divided. These maneuvers expose the fused lumbodorsal fascia, which gives rise to the internal oblique and transversus abdominis muscles. The lumbodorsal fascia and internal oblique muscle are divided (Fig. 101.6). By using two fingers inserted into an opening created in the lumbodorsal fascia at the tip of the 12th rib, the peritoneum is swept medially as the transversus abdominis is split digitally. The subcostal nerve should be identified between the internal oblique and transversus abdominis muscles and spared (Figs. 101.7 and 101.8).

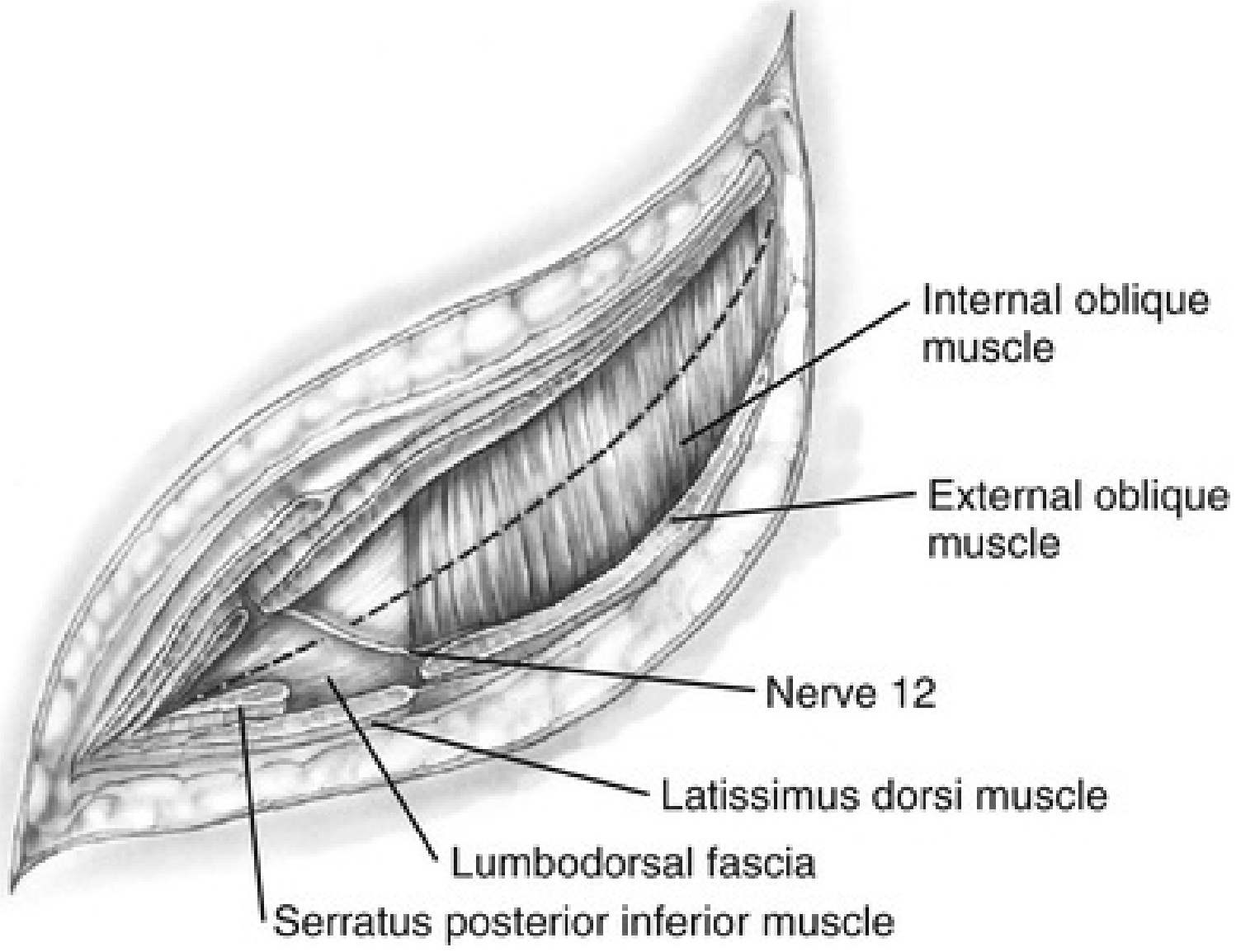
Internal oblique muscle
External oblique muscle
Nerve 12
Latissimus dorsi muscle
Lumbodorsal fascia
Serratus posterior inferior muscle

FIG. 101.6 Dissection through flank muscles. (From Libertino JA, ed. *Reconstructive urologic surgery.* 3rd ed. Philadelphia, PA: Mosby; 1998.)

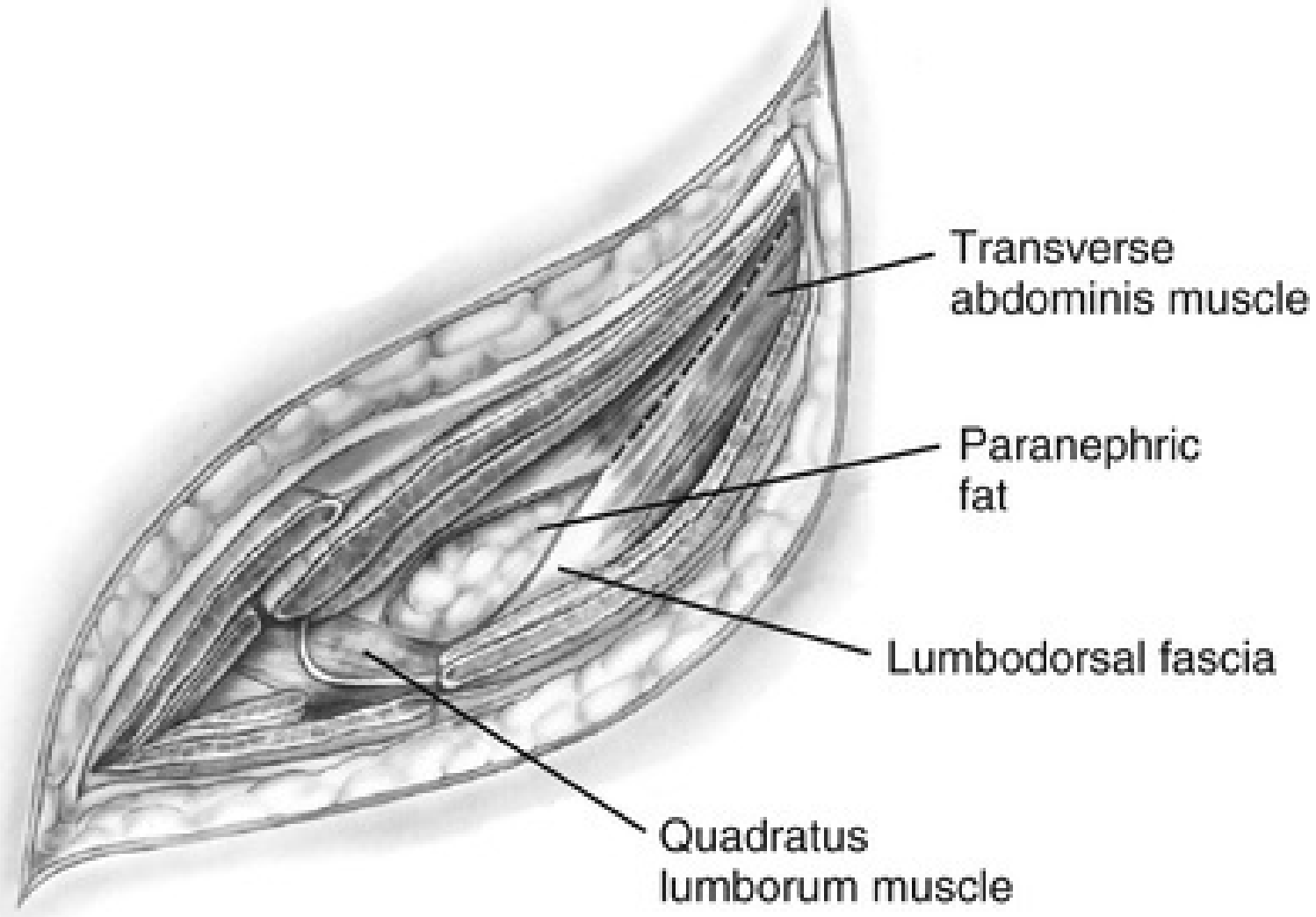
Transverse abdominis muscle
Paranephric fat
Lumbodorsal fascia
Quadratus lumborum muscle

FIG. 101.7 Opening lumbodorsal fascia to gain entrance to retroperitoneum. (From Libertino JA, ed. *Reconstructive urologic surgery.* 3rd ed. Philadelphia, PA: Mosby; 1998.)

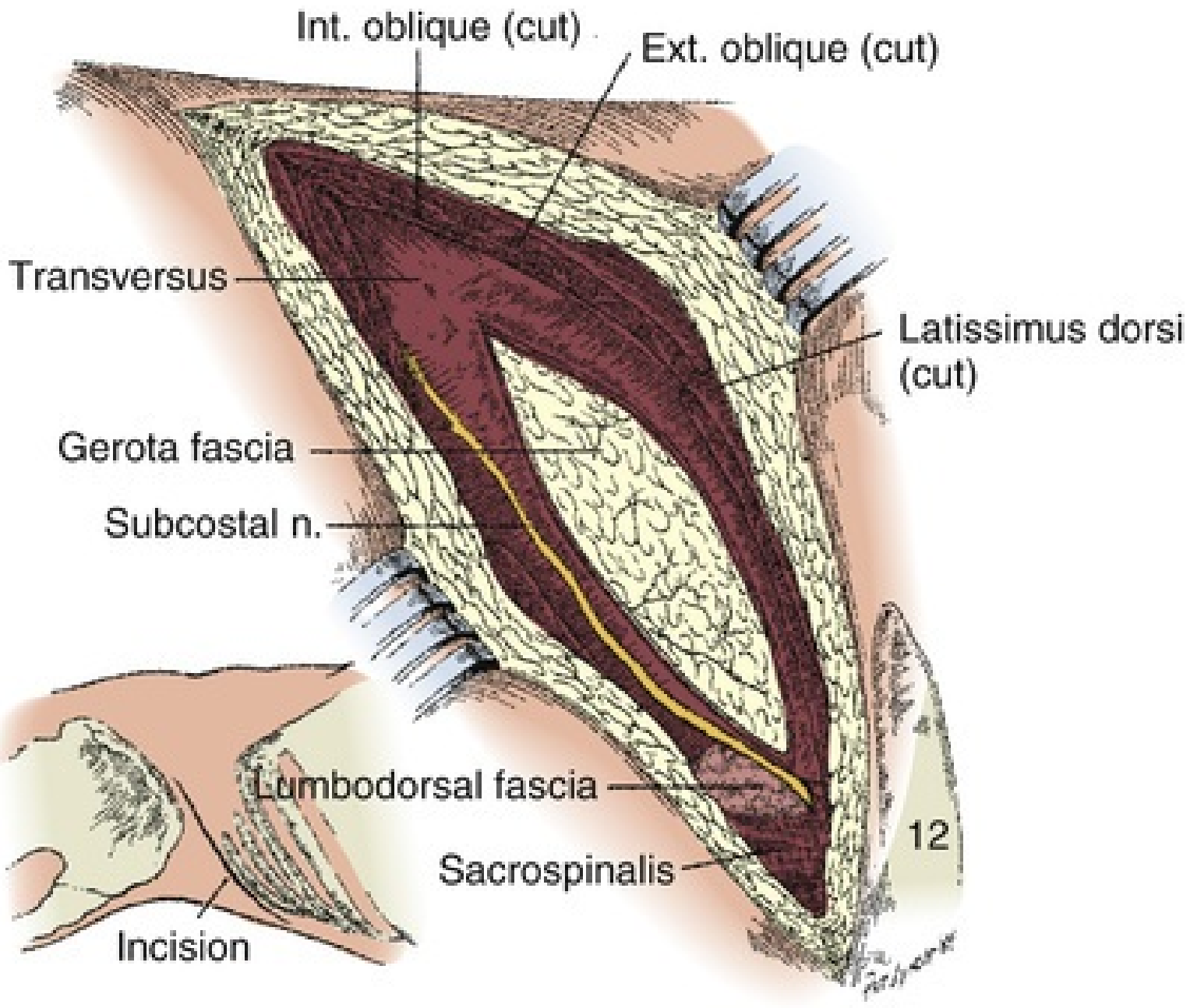
Int. oblique (cut)
Ext. oblique (cut)
Transversus
Latissimus dorsi (cut)
Gerota fascia
Subcostal n.
Lumbodorsal fascia
Sacrospinalis
12
Incision

FIG. 101.8 The lumbodorsal fascia and transverse abdominal muscle have been divided to expose the Gerota fascia. The subcostal nerve and vessels pierce the lumbodorsal fascia posteriorly and course forward on the transverse abdominal muscle.

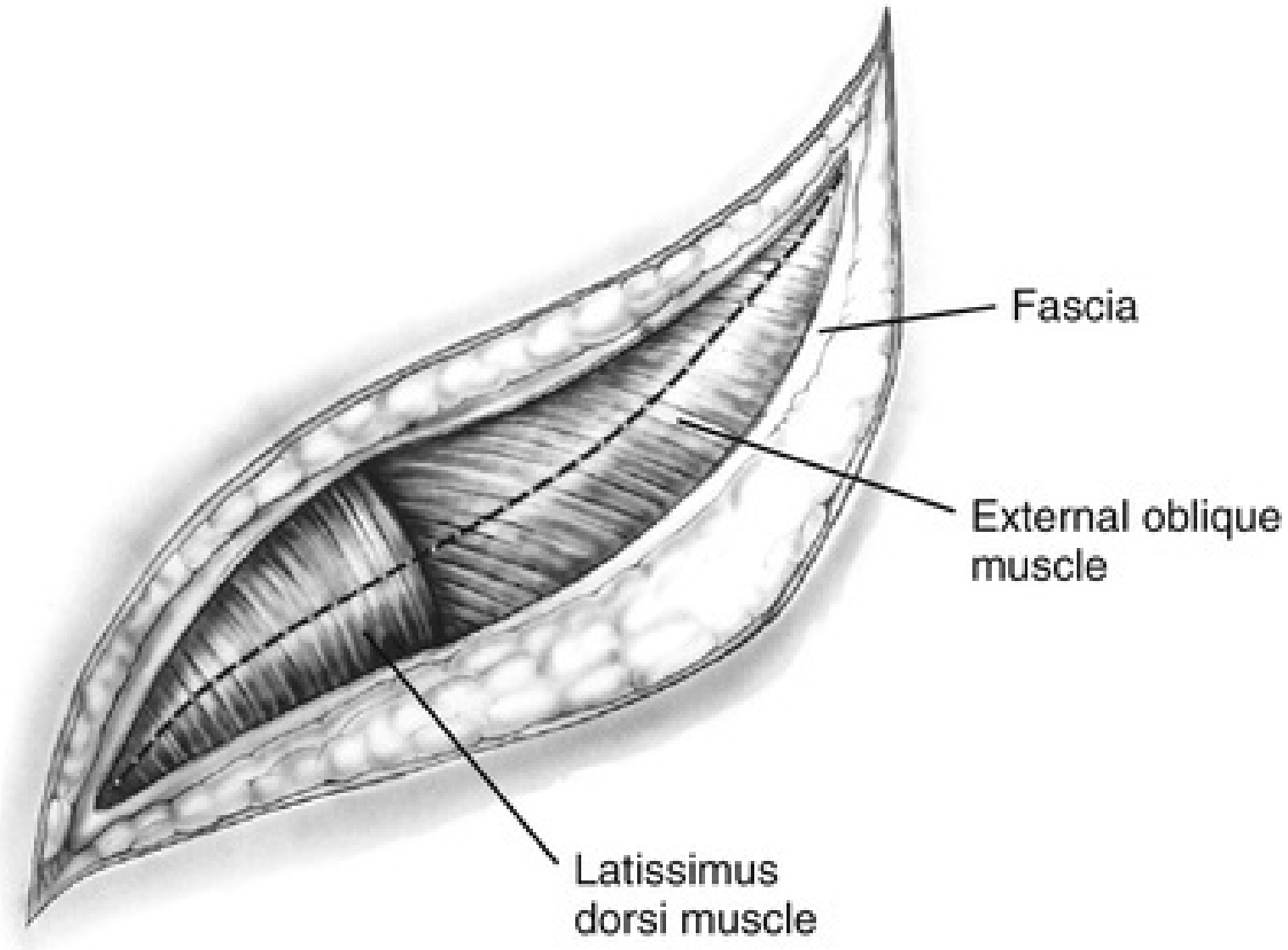
Fascia
External oblique muscle
Latissimus dorsi muscle

EFIG. 101.5 Superficial incision through flank. (From Libertino JA, ed. *Reconstructive urologic surgery.* 3rd ed. Philadelphia, PA: Mosby; 1998.)

To maximize exposure in the posterior aspect of the incision, one may incise the posterior angle of the lumbodorsal fascia, exposing the sacrospinalis and quadratus lumborum muscles. Dividing the costovertebral ligament permits superior retraction of the 12th rib if enhanced exposure is deemed necessary. A Bookwalter flank retractor is used for exposure.

Supracostal Flank Approach

The supracostal flank incision (above the 11th or 12th rib) is favored by many open renal surgeons. An extraperitoneal, extrapleural approach can potentially minimize postoperative complications and lead to a more rapid recovery. Turner Warwick (1965), who popularized the approach, believed that the supracostal approach provides maximal posterior exposure, simplifies wound closure, and is less morbid than a transcostal incision requiring rib resection. More recently, an 8-cm modified mini-flank supra–11th rib incision has been described as a safe, effective approach to radical or partial nephrectomy for renal cortical tumors (Diblasio et al., 2006).

The level of the incision is determined by the patient's anatomy, the location of the lesion, and the planned procedure. Positioning is similar to that described for the subcostal flank approach.

A skin incision at the superior aspect of the 11th or 12th rib is made, beginning at the lateral border of the sacrospinalis muscle and continuing to the lateral border of the ipsilateral rectus abdominis muscle. The incision is carried through the subcutaneous tissue. The latissimus dorsi and posterior inferior serratus muscles are transected in the posterior aspect of the wound, revealing the intercostal muscles.

The external and internal oblique muscles are divided. The lumbodorsal fascia is opened at the tip of the rib to avoid both peritoneum and pleura. Moving medially, the transversus abdominis muscle is divided carefully while sweeping the peritoneum medially and inferiorly. The diaphragm is exposed by transection of the transversalis muscle. The pleura is identified between the divided transversus abdominis muscle and the diaphragm and can be mobilized superiorly.

The lateral aspect of the sacrospinalis is identified and is either incised or retracted to permit access to the neck of the rib and its attachments. Division of the intercostal muscles should start at the most distal aspect of the rib and proceed toward the spine. The corresponding intercostal nerve is identified and spared. To avoid the neurovascular bundle, the intercostal muscles are divided in close proximity to the superior aspect of the rib. The plane between the chest wall and pleura is developed by entering the investing fascia surrounding the intercostal nerve, which allows an extrapleural dissection (eFig. 101.9). The slips of the diaphragm attached to the inferior ribs are transected.

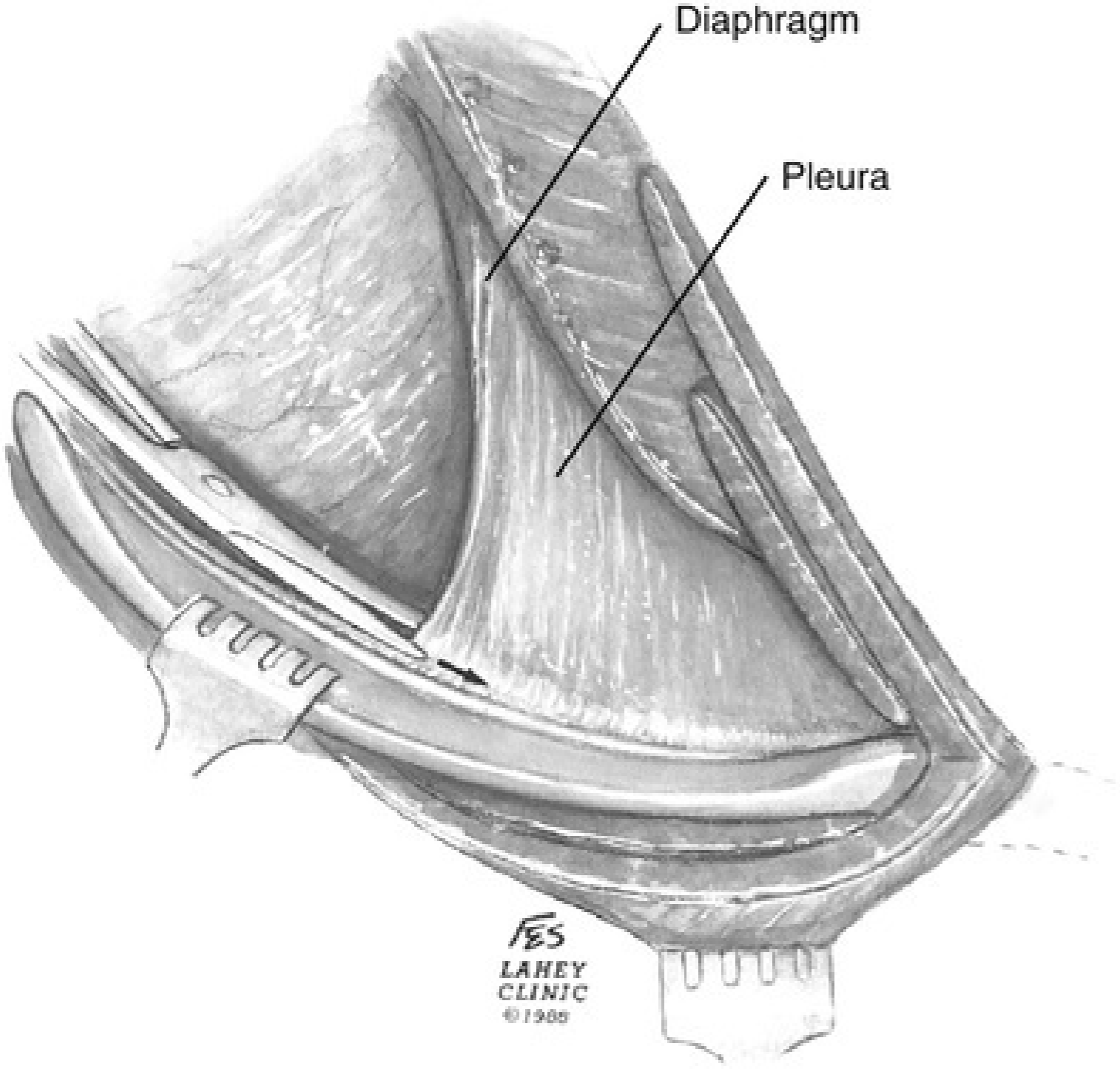

EFIG. 101.9 Following the intercostal nerve to remain extrapleural back to the intercostal ligament. (© The Lahey Clinic.)

Dorsal Lumbotomy Approach

This approach is typically reserved for pediatric patients and for thin adults requiring bilateral nephrectomy. The advantage to this approach is low morbidity because no muscle is transected. The main disadvantage is lack of exposure, particularly to the renal hilum and its vessels, making this approach very challenging, particularly for obese and muscular individuals and patients with high-riding enlarged kidneys (Andaloro and Lilien, 1975; Gardiner et al., 1979; Novick, 1980).

The patient is first anesthetized and intubated in the supine position. The patient is then rolled into the prone position (ventral decubitus/ventral recumbent position) with the help of several operating room personnel, and the operating table is flexed approximately 10 degrees. The arms may be tucked inward or positioned and supported cranially in an overhead swimming position. To protect the face and endotracheal tube, a *C*-shaped face support or doughnut-shaped foam pad may be used. The head can be rotated sideways or face downward. Eyes and ears are appropriately padded. To avoid axillary plexus injury, the humerus should not be forced into the axilla. The elbow should be flexed approximately 90 degrees and padded to prevent ulnar nerve injury. The knees should be padded and, to avoid pressure injury to the toes, the ankles should be supported and raised so that the toes do not touch the operating table. If necessary, the breasts should be displaced medially and cranially. Women who are pregnant or lactating, have breast implants, are obese, or have enlarged breasts are at risk for trauma to their breasts. The penis and scrotum should not be compressed by the body weight. In cases in which there are bowel/urinary abdominal stomas, extreme care should be taken to avoid excess pressure on these structures. In such cases, longitudinal torso frames/rolls should be used to minimize pressure from the anterior chest/abdominal structures.

The prone position may be poorly tolerated by older adults, patients with cervical spine pathology, patients with unstable chest walls following trauma, and patients with a known thoracic outlet syndrome. From a cardiovascular standpoint, the thoracic outlet syndrome (resulting from an anomalous cervical rib or some other anatomic reason) can occur particularly when the arms are located in the swimmer's position and the head is turned to one side. Because of increased pressure on the sternum, unanticipated pressure may be generated on the mediastinum, reducing coronary blood flow. Hemodynamically, the central venous pressure may rise, resulting in venous engorgement and potentially increased bleeding. From a respiratory standpoint, an increased amount of work is required to breathe when prone, an endotracheal tube can be displaced accidentally, and the risk for venous air embolism from central lines is increased. From a neurologic standpoint, rotation of the head can modify the cerebral blood flow and place the patient at risk for cerebral ischemia.

The dorsal lumbotomy approach is an anatomic approach to the kidney, with incision of fascial planes rather than muscle (Fig. 101.10). A vertical skin incision is made from the inferior border of the 12th rib to the iliac crest, in line with the lateral border of the sacrospinalis muscle. The subcutaneous tissues are divided, exposing the latissimus dorsi muscle. The aponeurosis of the latissimus dorsi is separated from the posterior layer of the lumbodorsal fascia where it overlies the sacrospinalis muscle. The posterior layer of the lumbodorsal fascia, a strong fascial covering, is incised, which allows the sacrospinalis muscle to be retracted medially. The costovertebral ligament is divided, which permits superolateral retraction of the 12th rib, which improves access superiorly. The fused middle and anterior layers of the lumbodorsal fascia are divided, permitting the quadratus lumborum muscle to be retracted medially. The ilioinguinal nerve should be identified and spared. Entry into the paranephric space is achieved by incising the transversalis fascia. Division of the perinephric fascia reveals the kidney.

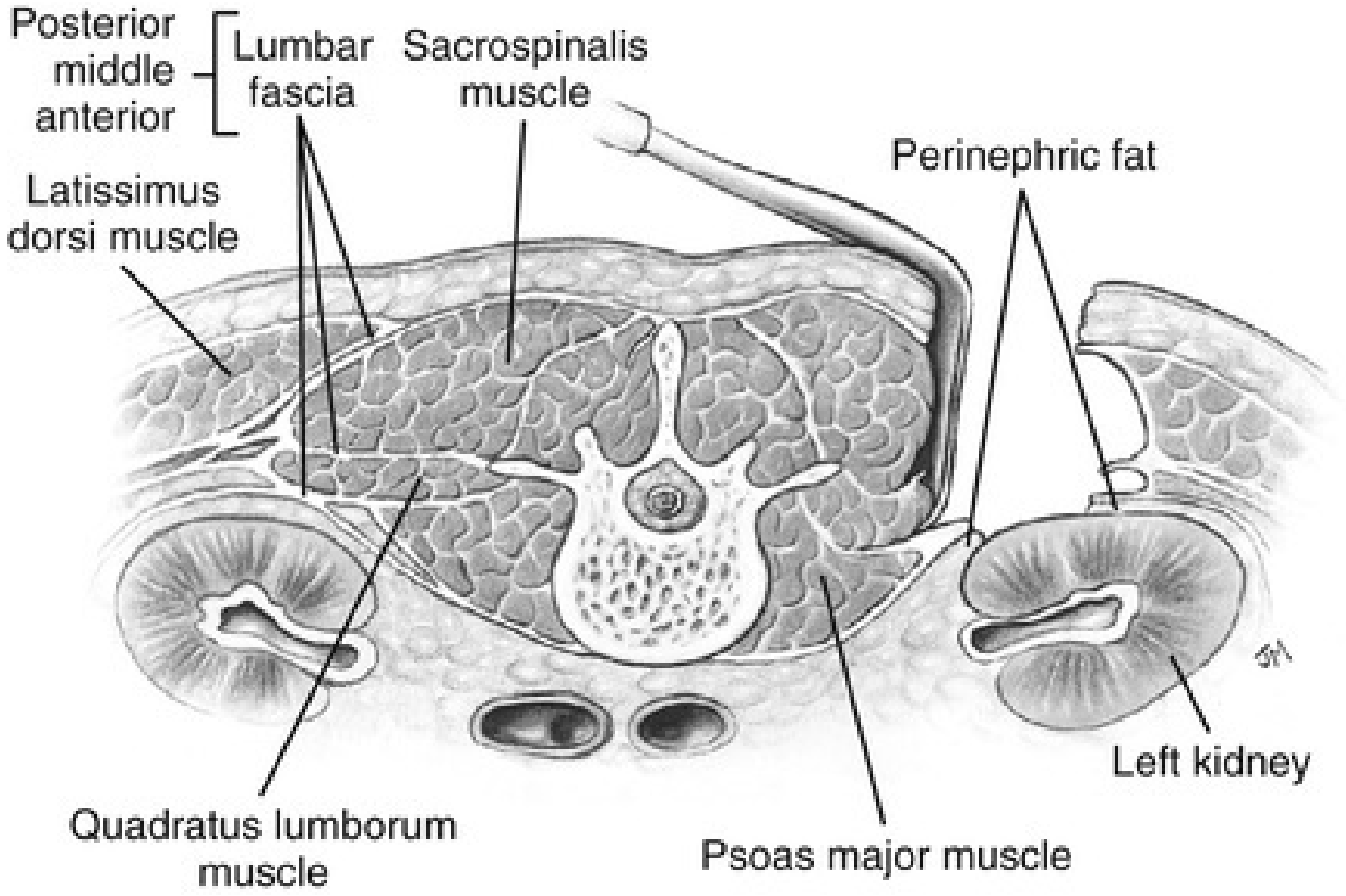
Posterior
middle
anterior
Lumbar fascia
Sacrospinalis muscle
Perinephric fat
Latissimus dorsi muscle
Left kidney
Quadratus lumborum muscle
Psoas major muscle

FIG. 101.10 Cross-sectional view of Gil-Vernet approach. (From Libertino JA, ed. *Reconstructive urologic surgery.* 3rd ed. Philadelphia, PA: Mosby; 1998.)

Thoracoabdominal Approach

The thoracoabdominal approach (Fig. 101.11) is ideal for the management of large renal masses, suprarenal or upper pole masses, renal tumors with venous extension, and tumors involving adjacent structures.

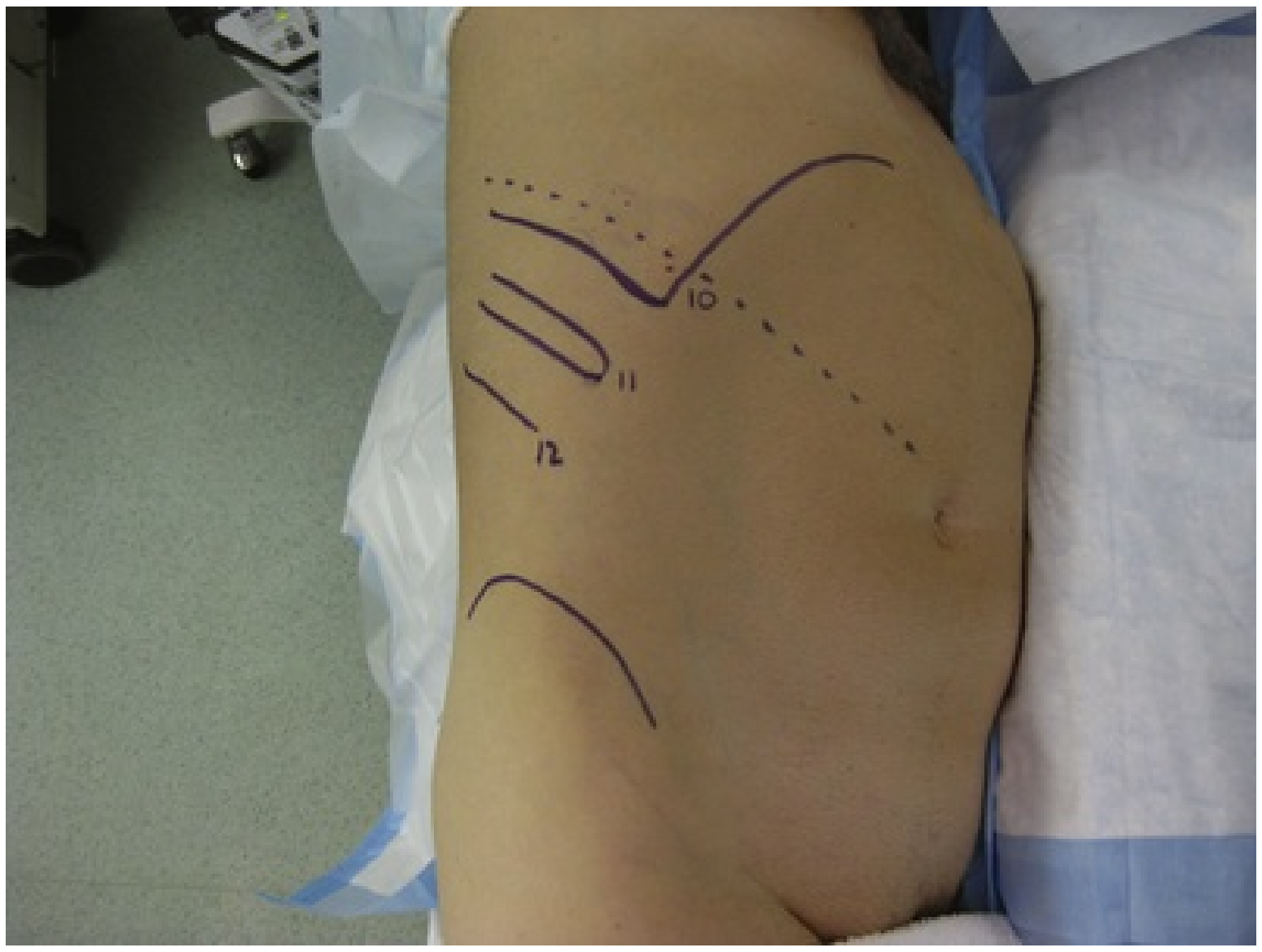

FIG. 101.11 Thoracoabdominal incision at the supra–10th rib border with the patient in the lateral decubitus position.

The patient is positioned in a semioblique manner as described earlier for the flank approaches, with a rolled blanket or beanbag supporting the flank. The legs are positioned similarly to the traditional flank position. The pelvis is rotated to a more horizontal position than for the flank incisions, at an angle of approximately 45 degrees.

The level of the incision is determined by the nature of the tumor, including size and relationship to surrounding structures. Depending on the location of the tumor, access is gained through the 8th, 9th, 10th, or 11th intercostal space. The skin incision begins at the lateral aspect of the sacrospinalis muscle over the 10th or 11th rib and can travel as far as the contralateral rectus abdominis muscle or caudally toward the symphysis pubis.

The internal oblique and transversus abdominis muscles are transected. The underlying peritoneum is opened, and the peritoneal cavity and chest are entered. Staying close to the superior border of the rib, the intercostal muscles are divided, which exposes the underlying pleura and diaphragm. The pleura is opened sharply, taking care to avoid the lung. The costovertebral ligament is divided. The diaphragm is opened from its thoracic surface. Starting anteriorly and proceeding posteriorly, the diaphragm is opened in a curvilinear fashion staying about two fingerbreadths from the chest wall to avoid injuring the more central phrenic nerve.

The liver or spleen is gently retracted upward. Additional hepatic mobility can be obtained by dividing the coronary ligament and the right triangular ligament of the liver (Fig. 101.12, eFig. 101.13; Video 101.1). For right-sided tumors, the kidney and great vessels are approached by mobilizing the colon medially and kocherizing the duodenum (Fig. 101.14 and eFig. 101.15, Fig. 101.16). For left-sided tumors, the colon and the tail of the pancreas are mobilized (eFig. 101.17, Fig. 101.18).

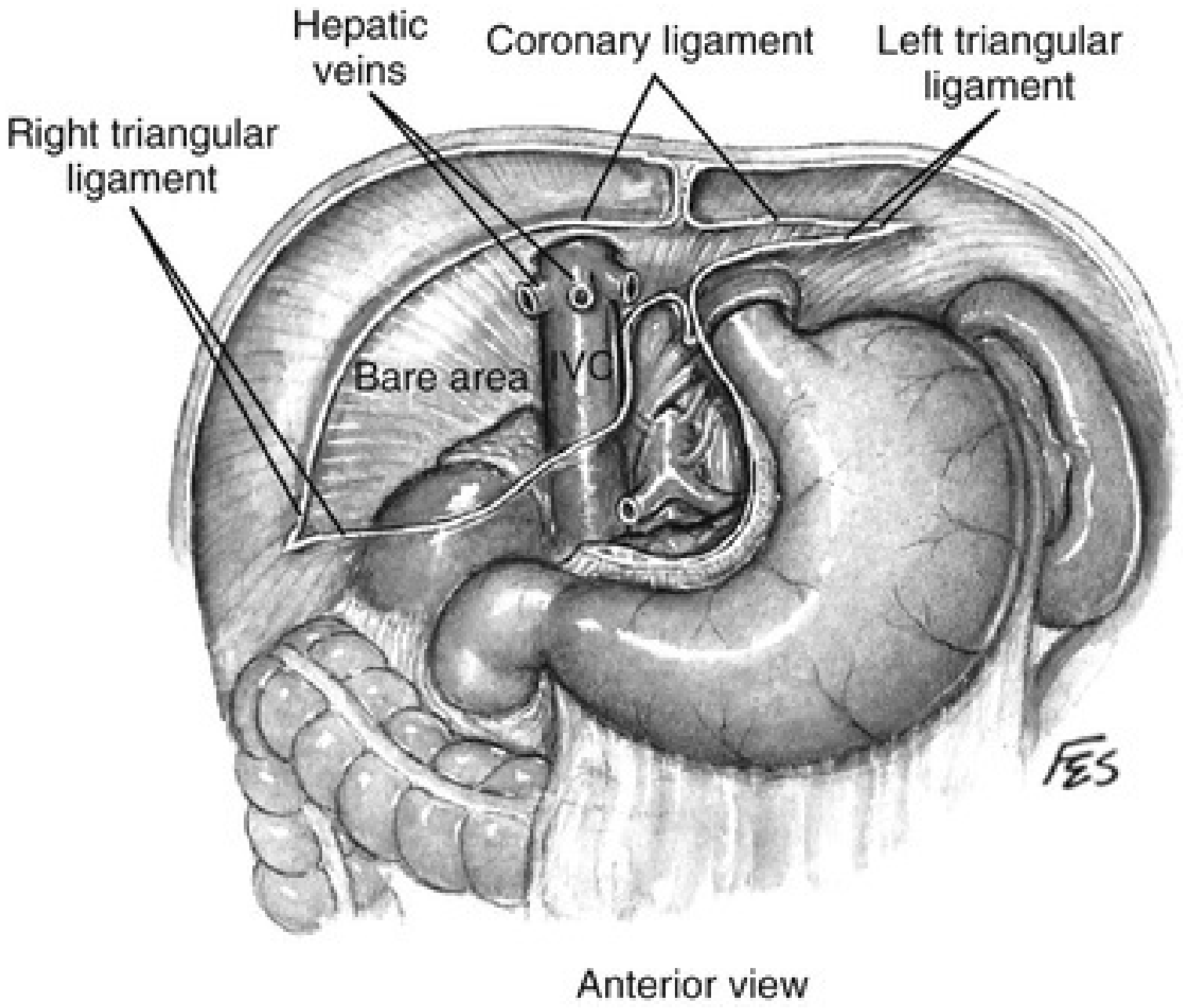
Hepatic veins
Coronary ligament
Left triangular ligament
Right triangular ligament
Bare area
IVC
FES
Anterior view

FIG. 101.12 Relationship of the liver and triangular and coronary ligaments to the inferior vena cava *(IVC).* (© The Lahey Clinic.)

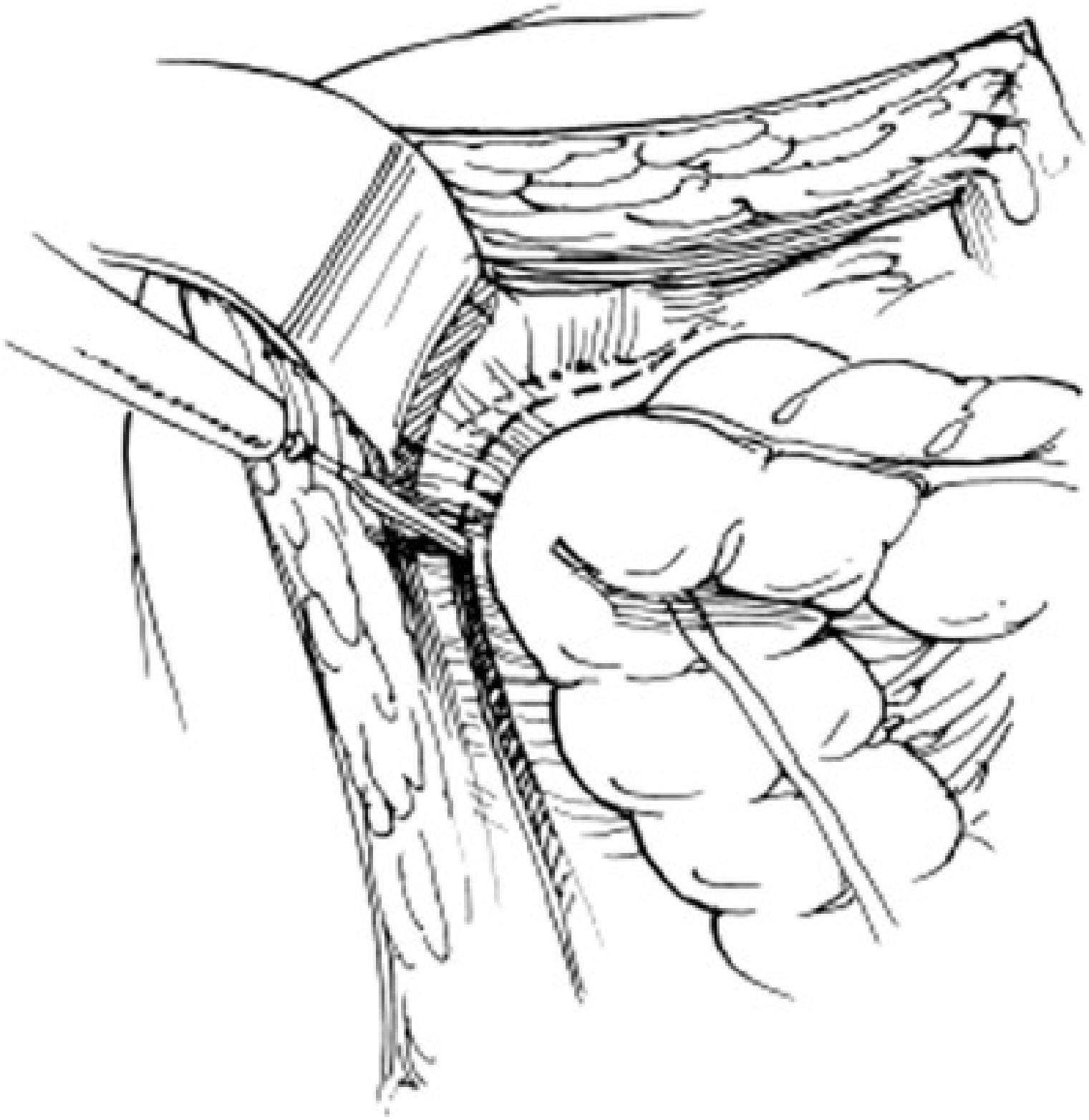

FIG. 101.14 The white line of Toldt is incised from the hepatic flexure to the common iliac artery, and the ascending colon is reflected medially. (From Smith JA Jr, Howards SS, Preminger GM, eds. *Hinman's atlas of urologic surgery.* 3rd ed. Philadelphia, PA: Saunders; 2012.)

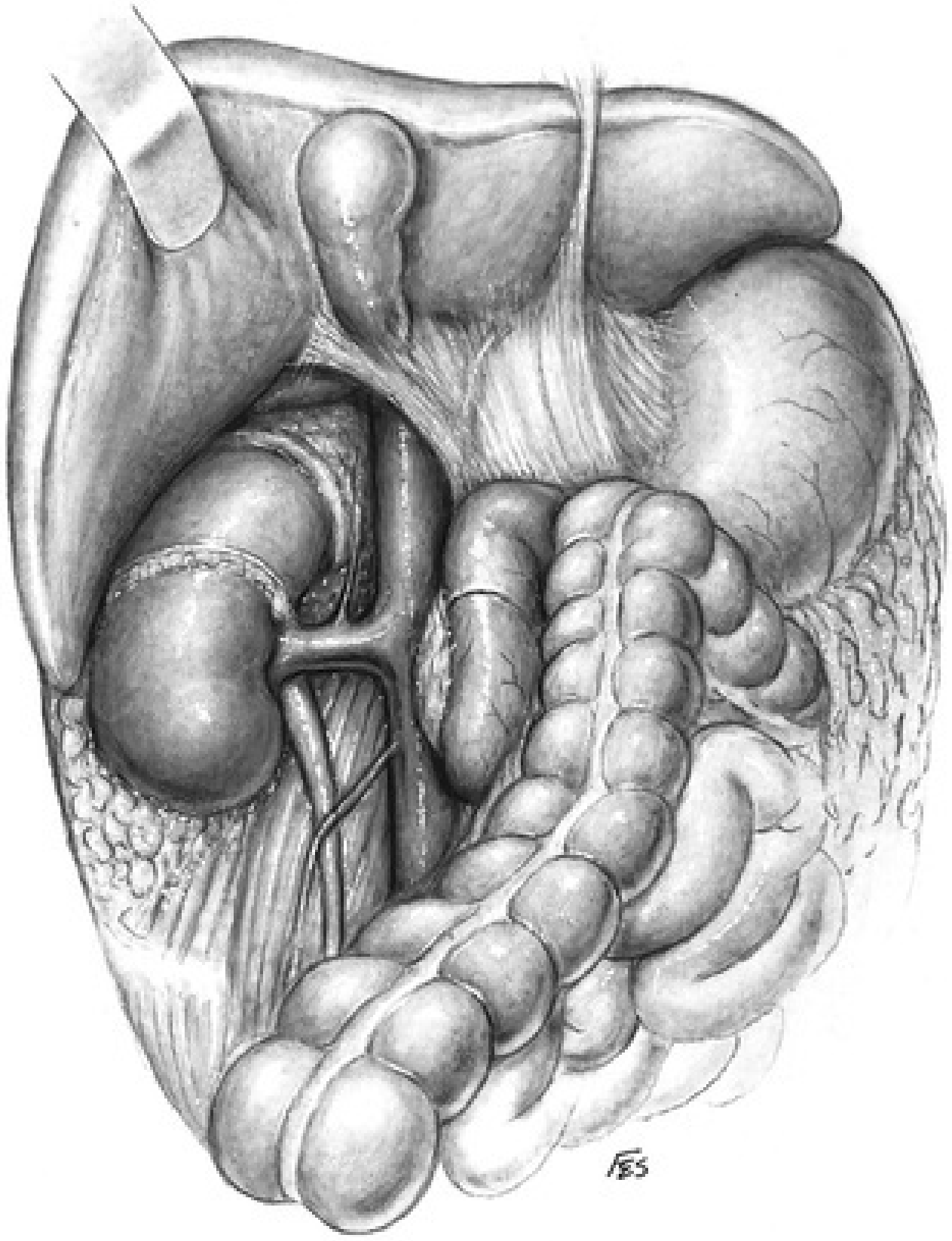

FIG. 101.16 Access to the vena cava can be achieved using the Langenbeck maneuver whereby the right triangular and coronary ligaments of the liver are divided, permitting the right lobe of the liver to be rotated medially and cephalad, exposing the retrohepatic inferior vena cava up to the diaphragms. (© The Lahey Clinic.)

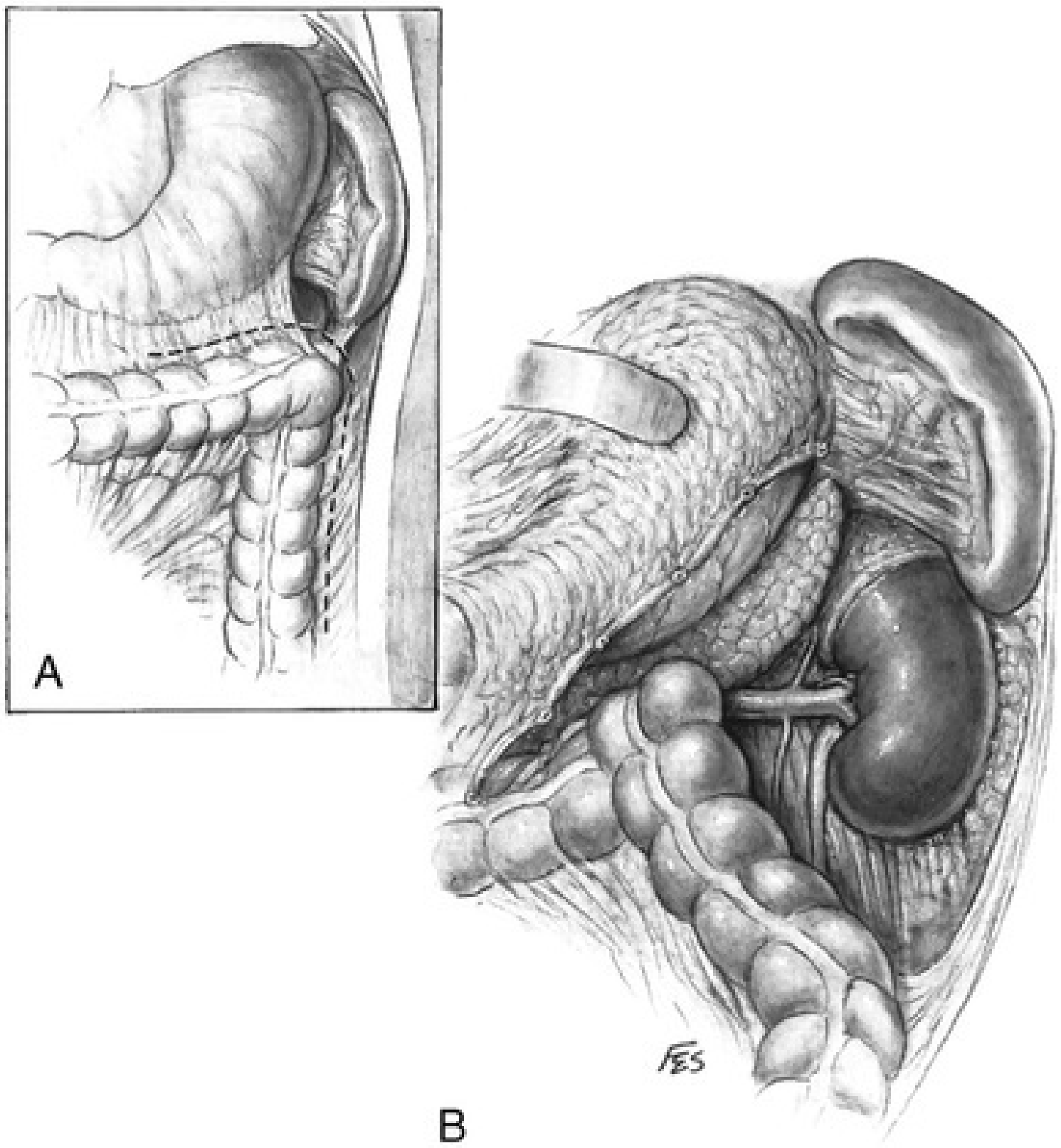

FIG. 101.18 (A) The left gastrocolic, phrenocolic, and lateral peritoneal attachments are divided. (B) The stomach, pancreas, and spleen are gently retracted upward without mobilizing the kidney. (© The Lahey Clinic.)

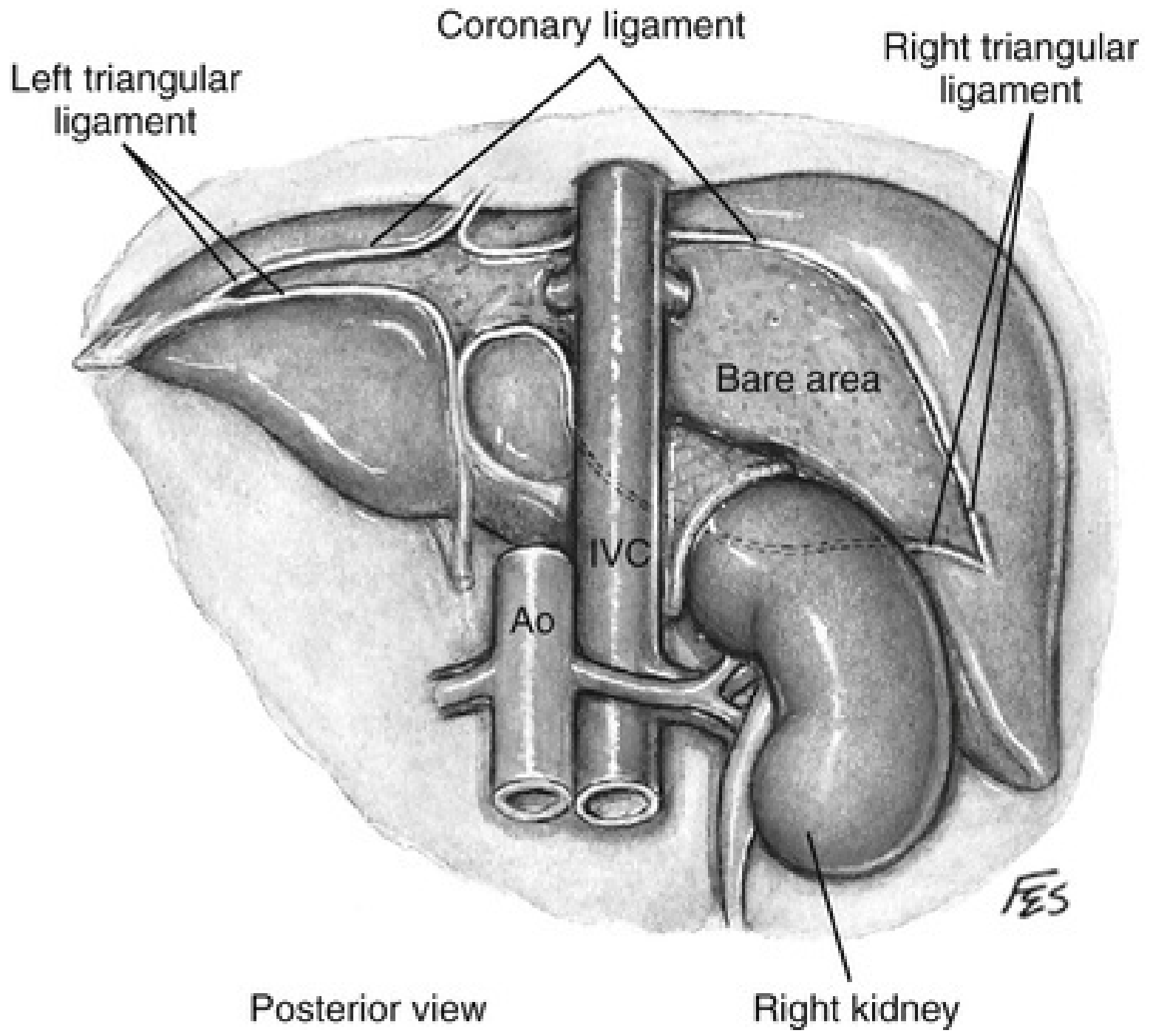
Coronary ligament
Left triangular ligament
Right triangular ligament
Bare area
IVC
Ao
FES
Posterior view
Right kidney

EFIG. 101.13 Posterior view of relationship of liver and triangular and coronary ligaments to inferior vena cava *(IVC). Ao,* Aorta. (© The Lahey Clinic.)

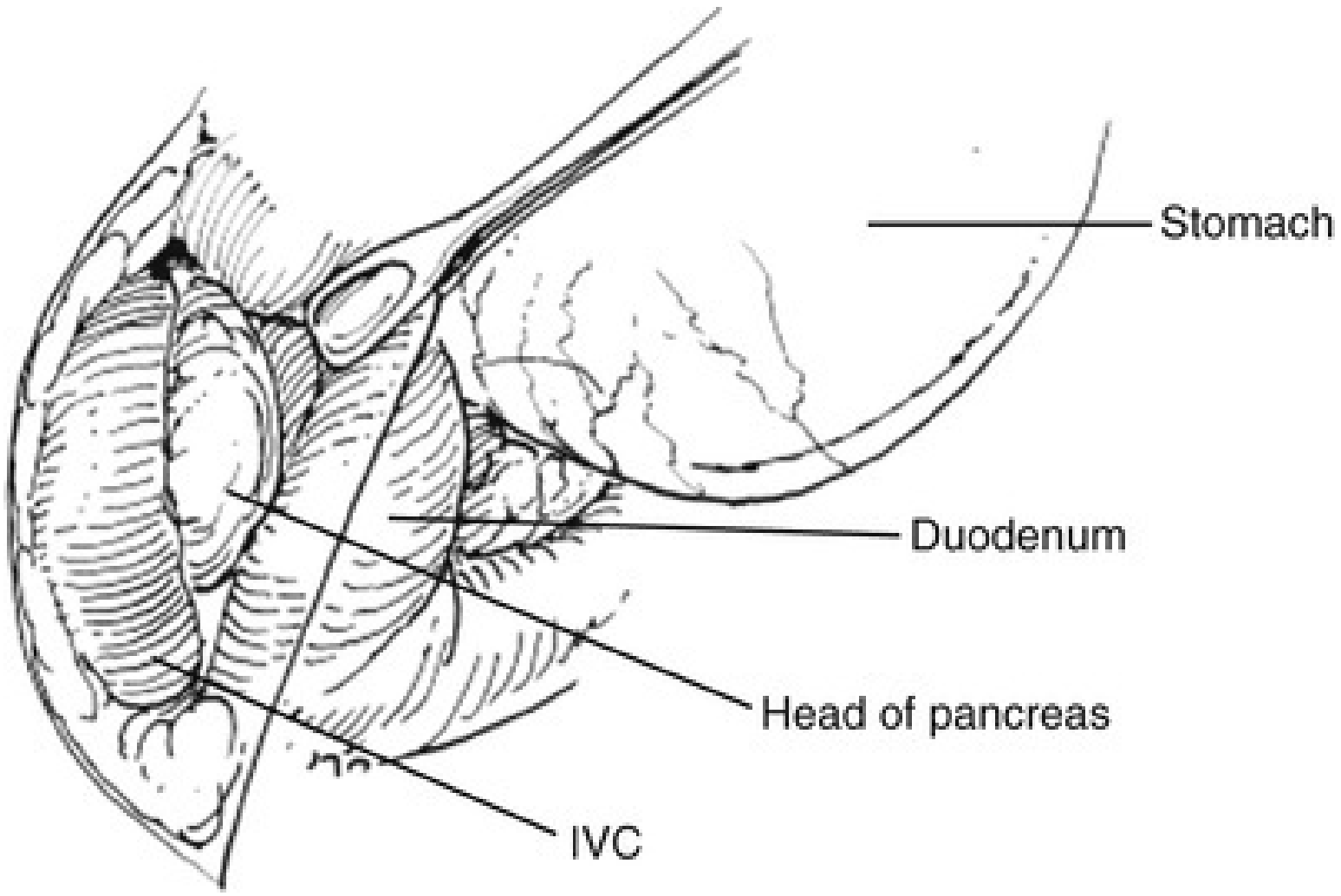
Stomach
Duodenum
Head of pancreas
IVC

EFIG. 101.15 For right-sided tumors, the duodenum is exposed and then reflected medially by means of the Kocher maneuver. *IVC,* Inferior vena cava. (From Smith JA Jr, Howards SS, Preminger GM, eds. *Hinman's atlas of urologic surgery.* 3rd ed. Philadelphia, PA: Saunders; 2012.)

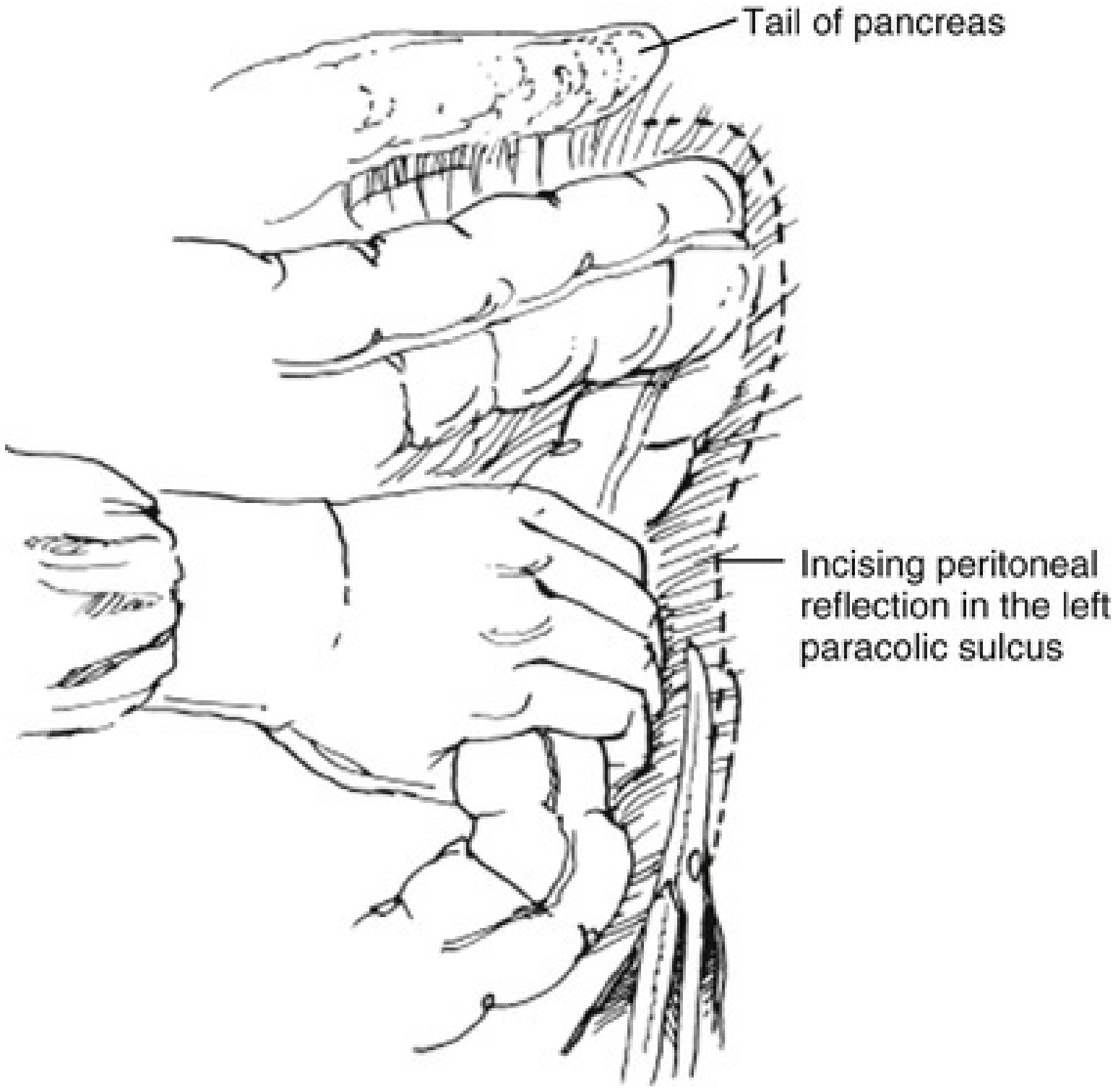

EFIG. 101.17 For left-sided tumors, the white line of Toldt is incised from the splenic flexure to the common iliac artery, and the descending colon is reflected medially. (From Smith JA Jr, Howards SS, Preminger GM, eds. *Hinman's atlas of urologic surgery.* 3rd ed. Philadelphia, PA: Saunders; 2012.)

Anterior Approaches

Anterior Midline Approach

An anterior midline incision is the incision of choice for management of renal trauma because it permits exploration for associated intraperitoneal injuries. It can also be employed for renovascular surgery, for reconstructive procedures, including ileal ureteral replacement, and for bilateral renal procedures.

With the patient in the supine position, a midline skin incision is carried out between the xiphoid process and the symphysis pubis. After dividing the subcutaneous tissues with electrocautery, the linea alba is sharply incised to expose the underlying preperitoneal fat and peritoneum. The peritoneum is grasped with two smooth forceps and incised. The ligamentum teres should be divided and suture-ligated.

Control of the renal pedicle can be obtained directly through the posterior parietal peritoneum or by medial reflection of the colon. On the left, the approach involves a vertical incision in the posterior peritoneum below the ligament of Treitz. This space contains the anterior surface of the aorta, the crossing left renal vein, and often the inferior mesenteric vein (IMV) and gonadal vessels. The superior mesenteric artery (SMA) should be on the anterior surface of the aorta and is usually 1 to 2 cm cephalad to the left renal vein. Gentle dissection along the hilum at this level provides good vascular control. A second approach to the left renal hilum is through the lesser sac. In this approach, the gastrocolic omentum is divided and entered. The transverse colon can then be retracted inferiorly. The peritoneum below the pancreas can be incised. The vessels are identified. This permits access to the renal pedicle both anteriorly and posteriorly. The artery can be isolated posteriorly and the venous system identified and controlled anteriorly.

Similarly, the right kidney can be reached directly by incision of the hepatic flexure and the Kocher maneuver to free the duodenum and reflect it medially. Further incision along the white line of Toldt frees the colon, permitting exposure of the anterior Gerota fascia. After the duodenum is reflected, the anterior surface of the vena cava is exposed. Care is taken not to injure the pancreas, gonadal vein, adrenal vein, or accessory renal vessels. The main renal vein is mobilized. Posterior to the renal vein along its superior margin lies the renal artery (eFig. 101.19), which normally runs a retrocaval course. The renal artery can be isolated here or between the vena cava and aorta when greater length is required.

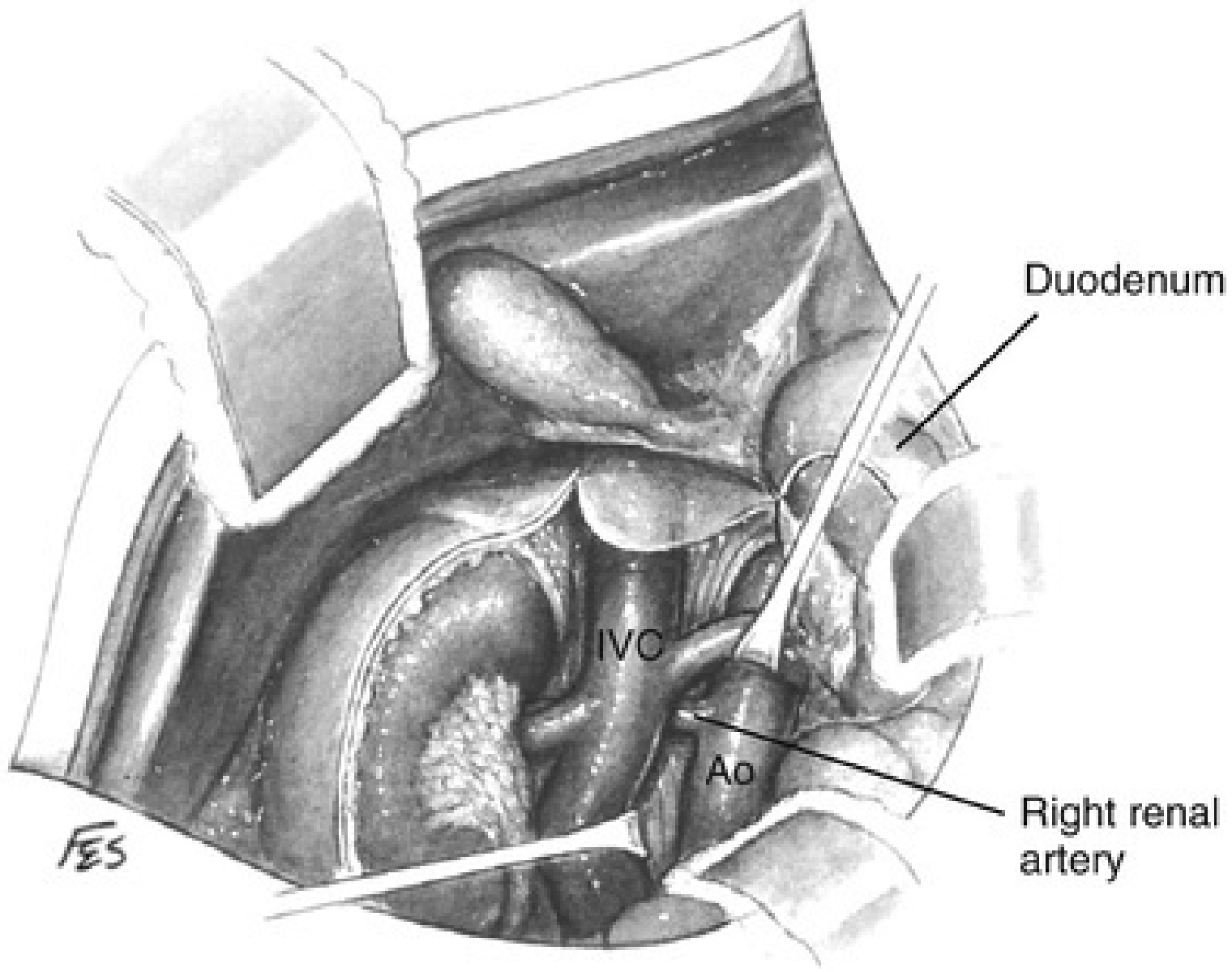

EFIG. 101.19 Exposure of the right renal artery behind the overlying left renal vein. *Ao,* Aorta; *IVC,* inferior vena cava. (© The Lahey Clinic.)

Anterior Subcostal Approach

For the anterior subcostal approach, the patient is placed in the supine position. Some surgeons choose to place a rolled blanket under the lumbar spine to facilitate exposure with hyperlordosis. However, **excessive hyperlordosis can lead to excessive unwanted tension on the great vessels, minimizing blood flow. Also, excessive hyperlordosis may lead to postoperative lower back pain. In patients with spinal stenosis, hyperlordosis is not recommended.** In the supine position, the arms can be tucked at the side or abducted at 90 degrees while supported on arm pads. The elbows should be well protected with adequate padding to avoid ulnar nerve injury.

The supine position can cause several important problems; therefore care should be taken to avoid complications from positioning. The pressure points (occiput, dorsal torso, sacrum, dorsal legs, and heels) should be well padded. From a cardiovascular perspective, supine positioning can result in supine hypotension (aortocaval syndrome) if excess adiposity or abdominal masses compress the great vessels. From a musculoskeletal perspective, low back pain is frequent, particularly in patients with scoliotic and kyphotic spine deformities. Artificial hip and knee joints may also be placed under stress.

Chevron Incision (Bilateral Anterior Subcostal Approach)

The chevron incision, which is composed of bilateral anterior subcostal incisions, is ideal for renovascular surgery and radical nephrectomy with inferior vena cava (IVC) tumor thrombectomy. Exposure of the renal pedicles and great vessels is outstanding. The incision starts at the tip of the 11th rib, extends approximately two fingerbreadths below and parallel to the costal margin, curves superiorly in the midline, travels parallel to the contralateral costal margin, and terminates at the tip of the contralateral 11th rib.

Surgery for Benign Diseases

Simple Nephrectomy

Simple nephrectomy—removal of the kidney within the Gerota fascia—is used to manage nonmalignant diseases of the kidney (eFig. 101.20). Indications for simple nephrectomy include durable nonfunction or poor function of a kidney as a result of obstruction, infection, trauma, stones, nephrosclerosis, vesicoureteral reflux, polycystic kidney, or congenital dysplasia. Simple nephrectomy of a functional kidney may be employed to relieve intractable symptoms or associated problems, such as bleeding, pain, hypertension, or persistent infection.

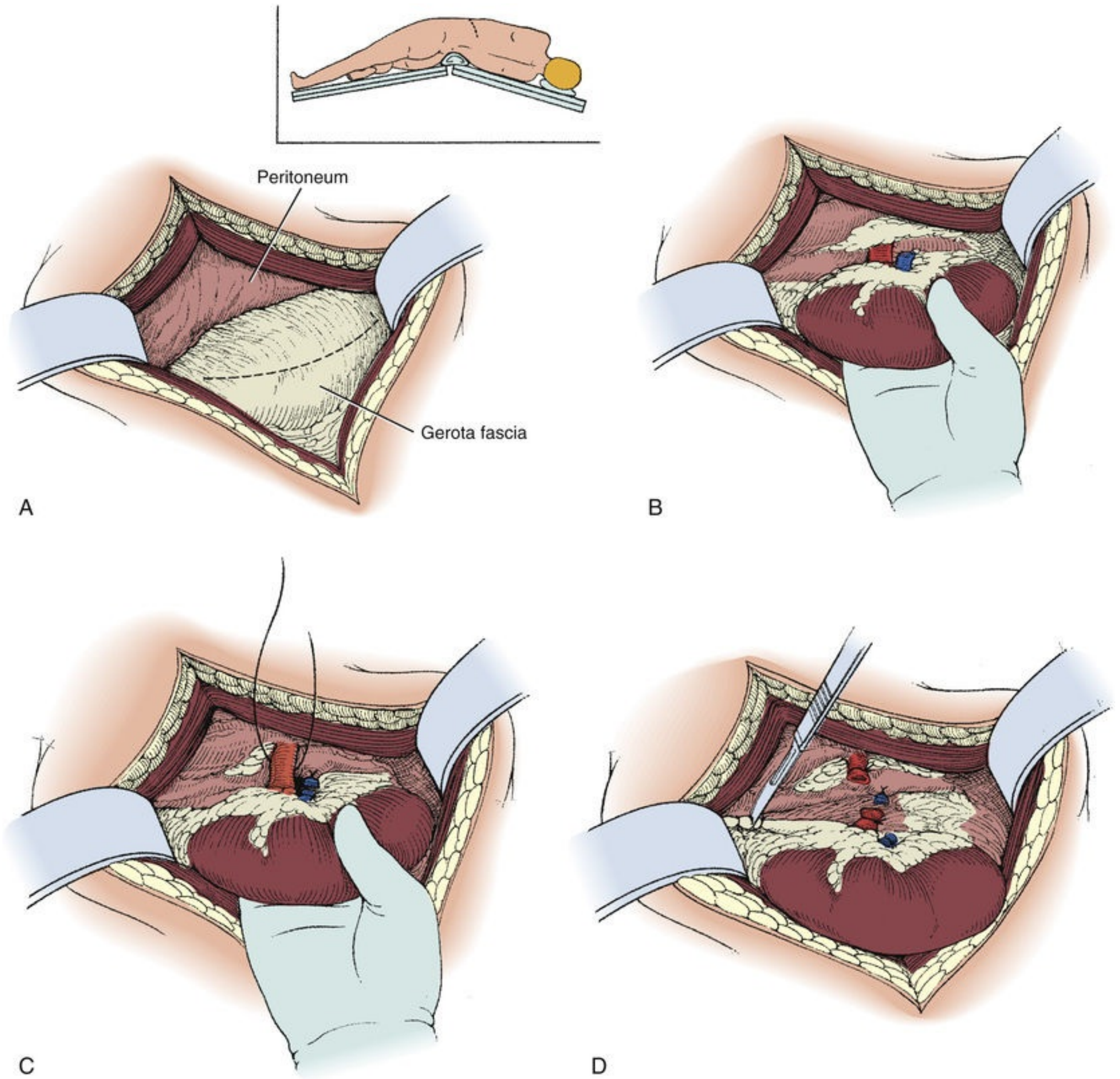

EFIG. 101.20 (A to D) Technique of simple left nephrectomy through an extraperitoneal flank incision.

Using one of the incisions described earlier, typically a flank incision, access to the retroperitoneal cavity is obtained. A self-retaining retractor (Finochietto, Bookwalter, or Omni-Tract retractor) is used to expose the visceral organs. The posterior layer of the renal fascia is bluntly dissected from the muscles of the posterior abdominal wall. The anterior layer of renal fascia is dissected from the colonic mesentery and peritoneum, leaving a fascial compartment in which the kidney, adrenal gland, and perirenal fat lie. The renal fascia is incised, and the perirenal fat is separated from the kidney using a combination of blunt dissection and electrocautery. Improper entry into the subrenal capsule must be avoided as this can lead to additional bleeding and difficulty in identifying the appropriate surgical planes. The surgeon must beware of aberrant vessels, typically found near the poles and in areas resistant to blunt dissection. In cases in which posterior dissection is difficult because of adherence of the kidney to the psoas muscle, inclusion of the psoas fascia in the dissection may be helpful and necessary. In cases of a large hydronephrotic kidney, in which exposure can be difficult, puncture and aspiration of the renal pelvic contents may decompress and aid mobilization of the kidney. Next, the adrenal gland is dissected from the upper pole of the kidney by maintaining the dissection plane directly on the renal capsule. The superior attachments of the kidney to the spleen, pancreas, and liver are freed to allow safe caudal retraction of the kidney.

Next, the lower pole of the kidney is mobilized and the ureter isolated, and the gonadal vein, usually found adjacent to the ureter, is identified. Care should be taken to mobilize the gonadal vein medially to avoid traction injury and avulsion of the vein. Once the inferior pole is mobilized, the ureter can be divided in between surgical clips or 2-0 silk ties. Division of the ureter provides access to the posterior part of the kidney and better exposure of the renal hilar structures. From a caudocranial approach, the renal vein is usually identified after division of the ureter. Combination of blunt and sharp dissections will allow identification of the renal artery posterior to the renal vein (Fig. 101.21).

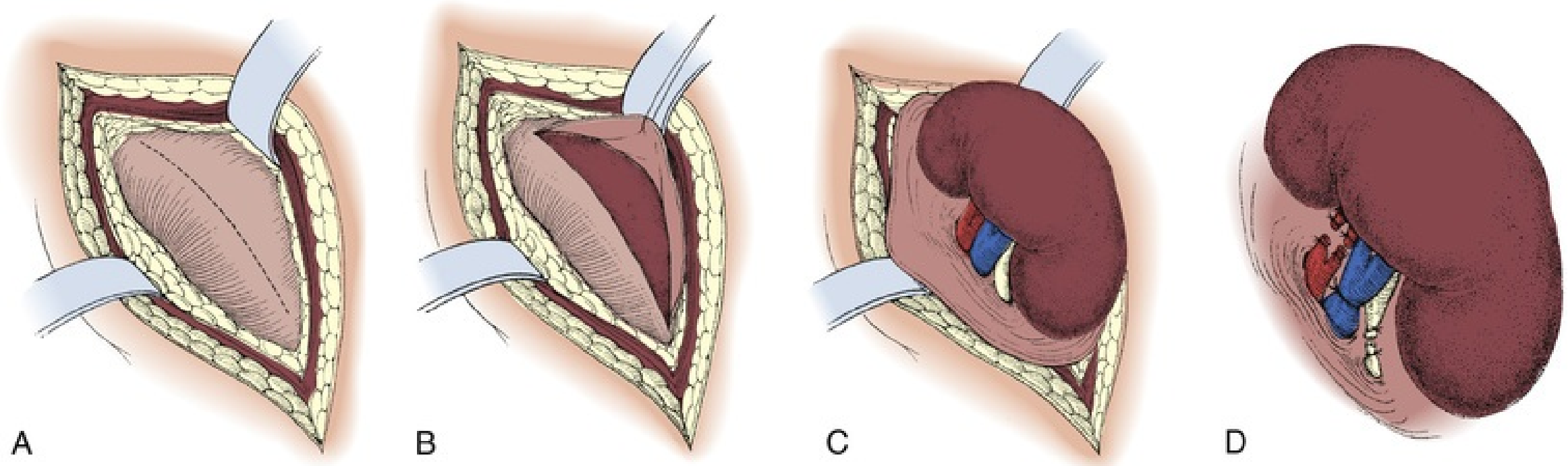

FIG. 101.21 (A to D) Technique of subcapsular nephrectomy.

Partial Nephrectomy for Benign Disease

Partial nephrectomy, in addition to its common utilization for treatment of small-sized renal cancer, can sometime be used for benign diseases. Some clinical scenarios in which partial nephrectomy may be indicated in benign diseases include hydronephrosis with parenchymal atrophy, atrophic pyelonephritis in a duplicated kidney, infected calyceal diverticulum, segmental traumatic renal injury with irreversible damage, and removal of benign renal tumors (angiomyolipoma or oncocytoma).

Partial nephrectomy for benign disease entities can be approached by excision of the renal capsule from the diseased site. The excised renal capsule can be successfully used for renorrhaphy (Fig. 101.22). Further details and techniques of partial nephrectomy are described in the Partial Nephrectomy for Malignant Disease section later in this chapter.

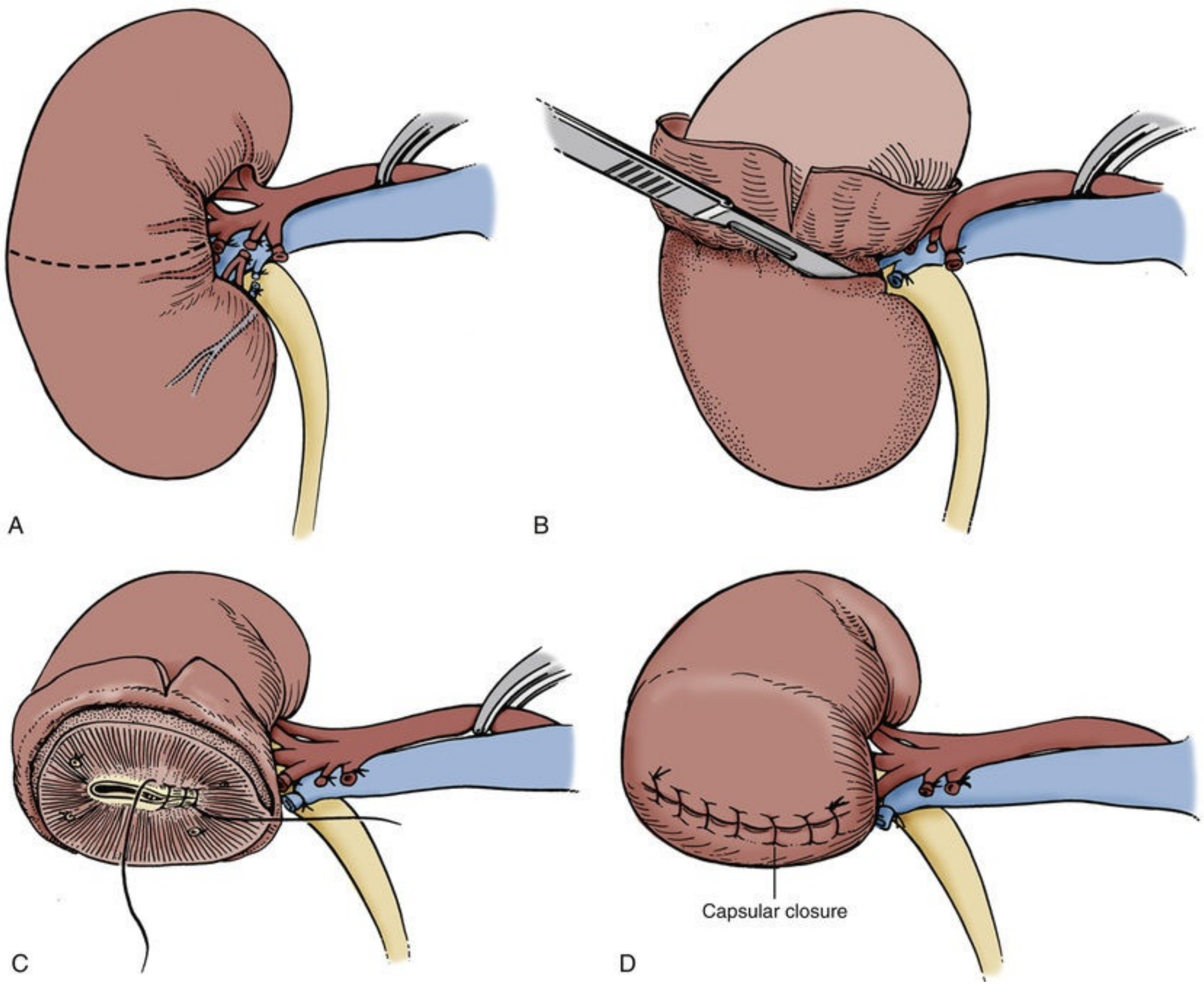

FIG. 101.22 (A to D) Technique of transverse renal resection for a benign disorder. The renal capsule from the diseased parenchyma is preserved and used to cover the transected renal surface.

Open Nephrostomy

With the advancement in percutaneous nephrostomy tube placements, open surgical insertion of nephrostomy tubes is rare. However, when percutaneous nephrostomy tube placement is not technically feasible and endoscopic placement of a ureteral stent is not an option, open surgical placement of a nephrostomy tube can be a lifesaving procedure (eFig. 101.23).

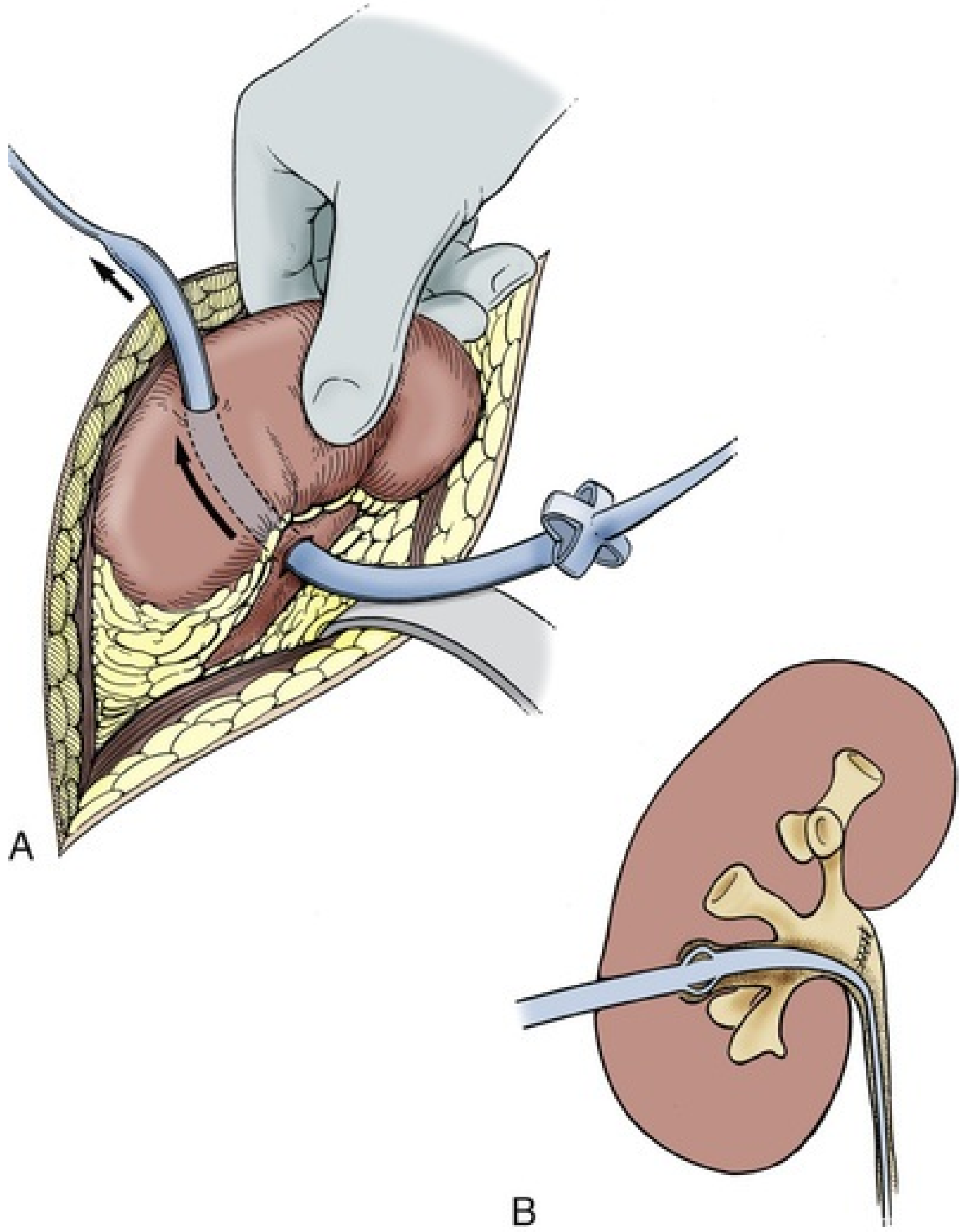

EFIG. 101.23 (A and B) Technique of open nephrostomy tube placement.

Through a retroperitoneal flank incision, the Gerota fascia is identified and incised. The kidney is mobilized within the Gerota fascia to expose the posterior surface, and the ureter is identified inferiorly. The ureter is followed superiorly to identify the renal pelvis. The renal pelvis is incised after placement of two 2-0 absorbable Vicryl (Ethicon, Cincinnati, OH) holding sutures away from the ureteropelvic junction. Using a hooked scalpel or sharp tenotomy scissors, a 2-cm incision is made parallel to the long axis of the kidney between the holding sutures. Next, a stone forceps is passed through the pyelotomy incision into the lower pole calyx. The tip of the forceps is aimed at the convex border of the kidney, because a nephrostomy on the anterior or posterior surface of the kidney has a higher risk for hemorrhage from damage to intrarenal vessels. While pressure is applied with the forceps, the tip of the forceps is palpated at the convex border of the kidney. A radial capsulotomy is made over the tip of the forceps. The tract through the parenchyma is widened. From the exterior surface of the kidney, a Malecot catheter with a threaded 0 silk suture at the tip is guided through the renal parenchyma; the tip is placed in the renal pelvis, and the guiding 0 silk suture is removed. The Malecot catheter is secured to the renal capsule using a 3-0 absorbable purse-string suture, the pyelotomy is closed with 4-0 Vicryl sutures, and then the holding sutures are removed. The distal end of the Malecot catheter is externalized through a stab incision from the anterior flank, avoiding kinking of the tube to ensure proper drainage. The Malecot catheter is secured to the skin externally using a drain stitch (2-0 silk or 3-0 nylon). A Penrose drain or Jackson-Pratt drain (Cardinal Health, Dublin, OH) is placed in the perinephric area, and the flank incision is closed.

Extracorporeal Renal Surgery

Extracorporeal renal surgery (ECRS) with autotransplantation is an operative technique that is rarely used in contemporary urologic practice because open in situ renal exposure with vascular clamping and hypothermia provides excellent access to the kidney for nearly all forms of renal surgery. The advantages of ECRS are better exposure and illumination, a bloodless surgical field, the ability to protect the kidney from prolonged ischemia, and the opportunity to use an operating microscope (Husberg et al., 1975; Ota et al., 1967; Putnam et al., 1975). Currently, ECRS is reserved for reconstruction of complex renal pathologies in cases of a solitary kidney, when percutaneous approaches are not appropriate or possible, and when routine in situ operative exposure is inadequate (Fig. 101.24). Additionally, ECRS is used when addressing anatomic problems in a donated kidney that is destined for allogeneic transplantation. Specific indications for which ECRS may be a valid option are as follows:

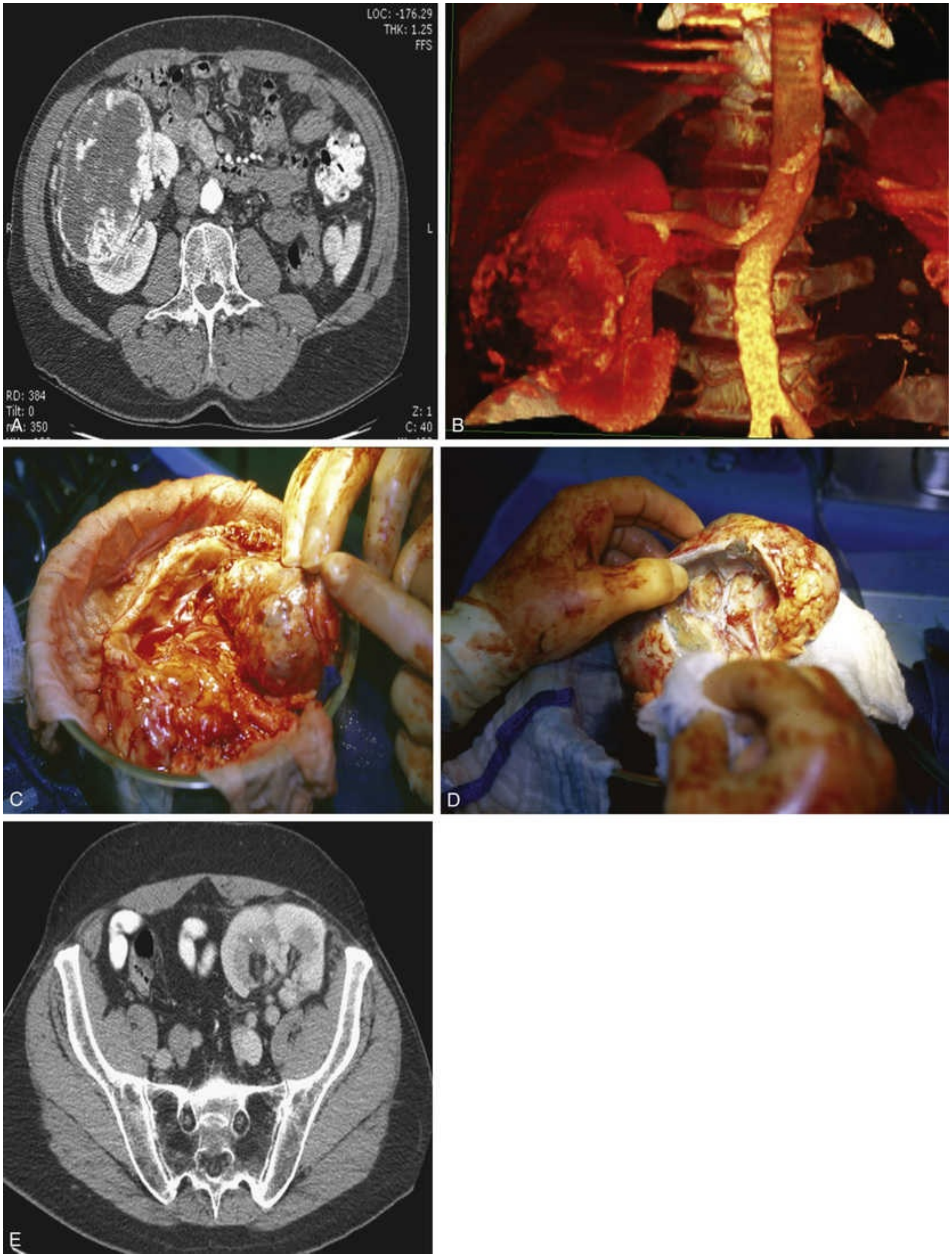
LOC: -176.29
THK: 1.25
FFS
R
L
RD: 384
Tilt: 0
mA: 350
Z: 1
C: 40
A
B
C
D
E

FIG. 101.24 Extracorporeal renal surgery. (A) Computed tomography (CT) scan demonstrating larger midpolar tumor in a solitary right kidney. (B) Three-dimensional arterial reconstruction. (C) Kidney on back table in hypothermic solution before tumor excision. (D) Mass excised with

preservation of collecting system and intrarenal arterial tree. (E) Contrast-enhanced CT scan 4 years later demonstrating no evidence of recurrence.

Renovascular diseases
- Prolonged ischemia (>45 minutes) is anticipated
- Segmental renal artery disease
- Multivessel disease
- Arteriovenous malformations refractory to embolization
- Large intrarenal arterial aneurysms

Renal transplantation
- Repair of vascular anomaly
- Repair of collecting system anomaly

Malignancy in solitary kidney
- Large, central mass encroaching on the renal pedicle
- Large, central renal pelvic tumor
- Multiple subcortical neoplasms

Preoperative Considerations

Thorough abdominal imaging studies (CT scan and/or magnetic resonance angiogram) should be obtained to fully evaluate the renal parenchyma, collecting system, and vasculature. In select cases, digital subtraction arteriography may be used to evaluate the vascular anatomy.

The patient's renal function is assessed by serum creatinine level. Strong consideration should be given to obtaining a preoperative nephrology consultation to help maximize renal function preoperatively and to make necessary preparations in case of hemodialysis postoperatively.

A seated operative bench should be available with ice slush, renal transplant preservation solution (e.g., Euro-Collins or UW solution), and microvascular instruments.

Surgical Procedure

Because access to both the retroperitoneum and iliac fossa (for autotransplantation) is required, a number of different single- or double-incision approaches are possible. Following incision and abdominal exploration, the kidney is exposed as for a living related donor nephrectomy. When the kidney is mobilized and the only remaining attachments are the ureter, renal vein, and renal artery, 12.5 g of mannitol and 20 mg of furosemide are rapidly infused intravenously. The ureter is ligated as far distally as possible and transected, preserving as much periureteral tissue as possible. Although the ureter can be preserved intact, we do not favor this approach because it limits positioning the autotransplanted kidney in the opposite iliac fossa, and the long length of ureter is prone to ischemia and kinking, leading to obstruction. Vascular clamps are applied to each renal vessel directly where they exit the aorta and IVC (a C-shaped clamp is useful to gain length on the right renal vein), and the renal vessels are transected directly on the clamps.

Immediately after dividing the renal vessels, the kidney is placed on the workbench in a pan of ice slush covered with a towel. The kidney is flushed intra-arterially by gravity flow with renal preservation solution at 6° C. Flushing the kidney should continue until it is cooled and the renal effluent is clear (~500 to 1000 mL). The kidney is kept in the ice slush basin during the procedure to maintain hypothermia.

For renovascular disease, the vasculature of the renal hilum is dissected and vascular repair is done. For neoplasms, the Gerota fascia and the perirenal fat are removed and partial nephrectomy is undertaken. After reconstruction of the renal vasculature or the nephrectomy parenchymal defect is achieved, the renal artery and vein are flushed independently with preservation solution to assess for potential sites of bleeding. Retrograde flushing of the ureter is done to assess for collecting system leaks, which should be repaired if identified.

The kidney may be transplanted into either lower quadrant. The kidney is transferred to the iliac fossa, and the renal vein is anastomosed to the external iliac vein. The renal artery anastomosis can be achieved by either end-to-end anastomosis to the hypogastric artery or end-to-side anastomosis with the external iliac artery. During the anastomosis, the vessels should be irrigated with heparin solution (10,000 units of heparin in 100 mL of normal saline), and the surgeon should consider injecting 10 mg of verapamil into the renal artery following the anastomosis to help vasodilation. The ureter is implanted into the dome of the bladder with a tension-free anastomosis. Before completion of the ureteral anastomosis, a ureteral stent is placed. Finally, a closed suction drain is placed.

Surgery for Malignancy

Radical Nephrectomy

Radical nephrectomy refers to complete removal of the kidney outside the Gerota fascia together with the ipsilateral adrenal gland and complete regional lymphadenectomy from the crus of the diaphragm to the aortic bifurcation, as described by Robson et al. (1969) **for management of renal malignancy. Today, the adrenal gland is typically spared when technically possible because removal of the adrenal gland, when not involved by tumor, has not been shown to improve survival of patients with renal cancer.** Extensive lymphadenectomy is only done in select cases when it is strongly felt that it may contribute to improved patient survival without adding complications to the patient's recovery.

Radical nephrectomy is reserved for renal tumors that are not amenable to partial nephrectomy. Indications for radical nephrectomy include tumors in nonfunctional kidneys, large tumors replacing the majority of renal parenchyma, tumors associated with detectable regional lymphadenopathy, or tumors associated with renal vein thrombus.

All renal tumors suspicious of malignancy should be staged with abdominopelvic CT or MRI and chest imaging with chest radiograph or chest CT (Fig. 101.25) (Bradley et al., 2011; Chen and Uzzo, 2011). If any sign of metastatic disease is present, a bone scan and head CT should also be obtained. The cross-sectional imaging should be closely evaluated for tumor thrombus, enlarged retroperitoneal nodes, and any embryologic abnormalities of the renal collecting system and vasculature.

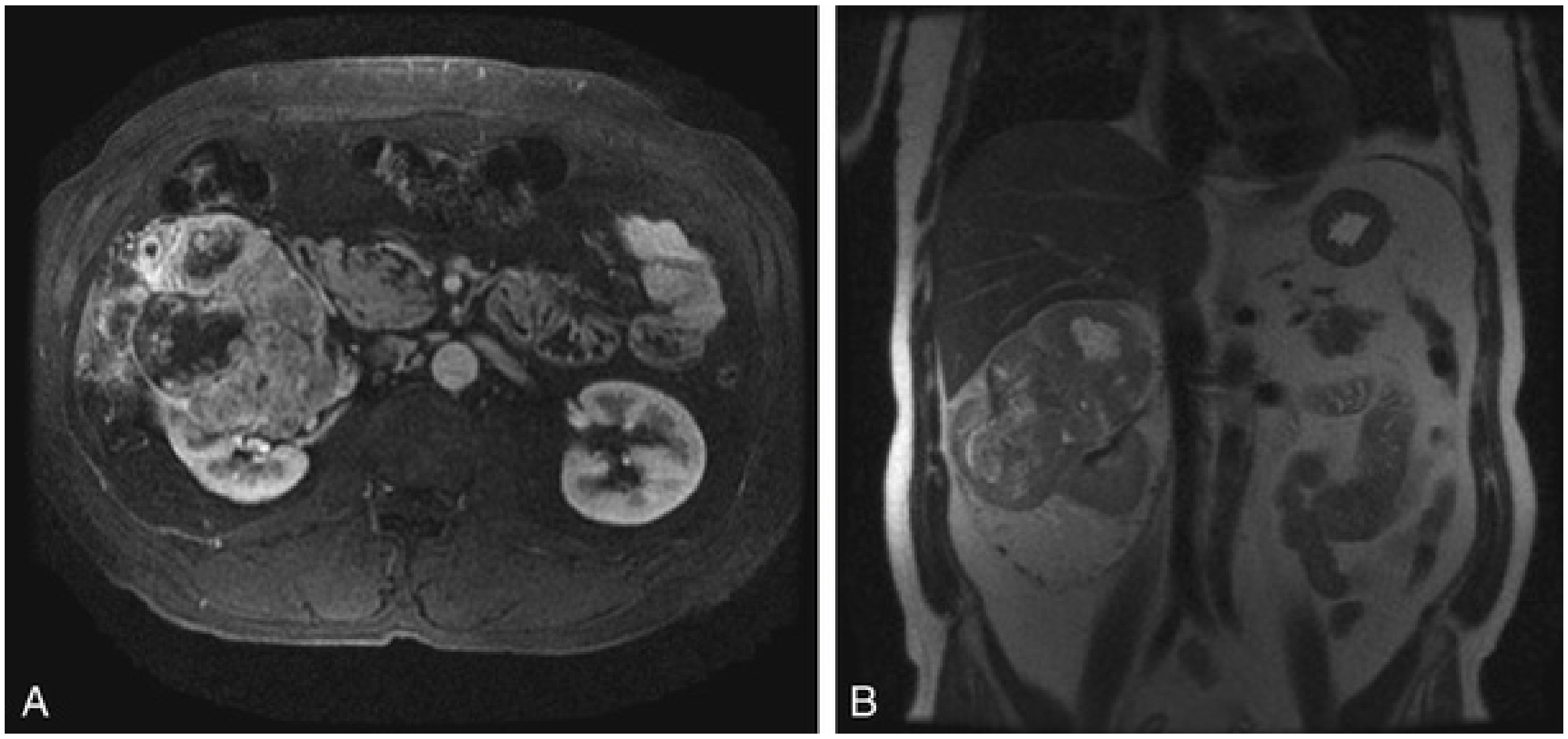

FIG. 101.25 Axial (A) and coronal (B) magnetic resonance images of a right-sided renal mass.

Before surgery, percutaneous renal biopsy can be considered in patients with another malignancy to evaluate for potential metastatic disease, to evaluate for the possibility of lymphoma in cases of infiltrative-appearing renal masses on imaging studies and solid masses that will be managed nonoperatively with percutaneous modalities (radiofrequency or cryotherapy), or in nonoperative cases when the histology may dictate the type of systemic therapy (Pandharipande et al., 2010; Psutka et al., 2013;Volpe et al., 2007). In cases of bilateral renal tumors, percutaneous renal biopsy should be considered to guide management (Blute et al., 2000).

At times, preoperative angioembolization is undertaken for the kidney with a large renal mass and regional lymphadenopathy (Schwartz et al., 2007). Potentially, angioembolization can reduce the amount of intraoperative blood loss and provide the ability to ligate the renal vein before the renal artery, which may be necessary as a result of extensive hilar lymphadenopathy. Angioembolization may also reduce the size of the primary tumor, thereby technically improving the feasibility of nephrectomy. Disadvantages of angioembolization include postinfarction painful syndrome, risk for tumor lysis syndrome, risk for embolization of tumor thrombi, and risk for vascular trauma.

Ipsilateral adrenalectomy should be considered in large upper pole tumors when the surgical plane between the kidney and adrenal gland may be compromised. Otherwise, routine adrenalectomy is not required because the overall incidence of adrenal metastasis is less than 5%. Because preoperative CT and MRI may miss 20% to 25% of adrenal metastases, one must consider clinical indicators of adrenal involvement to guide surgical practice (Siemer et al., 2004). Typically, adrenalectomy is indicated when there is diffuse involvement by tumor, large tumor size (>10 cm), extrarenal tumor extension, tumor thrombus, lymphadenopathy and regional metastasis, or an adrenal mass on imaging.

Regional lymphadenectomy is not required in every radical nephrectomy because the overall incidence of lymph node disease is about 5%. Regional lymphadenectomy should be considered in patients who may have a reasonable chance of benefiting from the added surgery. Blute et al. and Crispen et al. discussed the probability of regional nodal involvement (Blute et al, 2004a; Crispen et al., 2011). Indications for regional lymphadenectomy include enlarged lymph nodes on imaging, cytoreductive surgery for metastatic disease, tumor size greater than 10 cm, nuclear grade 3 or greater, sarcomatoid histology, presence of tumor necrosis on imaging, extrarenal tumor extension, and tumor thrombus and direct tumoral invasion of adjacent organs.

In cases of adjacent organ involvement (colon and/or spleen), preoperative planning for splenectomy and/or partial colectomy is important (Blute et al., 2004a). Because of the presence of its bilaminar capsule, the liver is not usually directly invaded by renal tumors despite preoperative imaging studies that may suggest extension of right-sided renal tumors to the liver. However, in rare circumstances when a right-sided renal tumor does directly invade into the liver, appropriate preoperative surgical planning is essential.

Surgical Procedure

The most commonly used incisions for radical nephrectomy are subcostal flank incisions, which are described earlier in this chapter. In brief, for a subcostal approach, the patient is placed in a modified lateral decubitus position. After incising through the skin and muscular layers, a Balfour, Bookwalter, or Omni-Tract retractor is placed, and, for a right-sided approach, the liver and gallbladder are packed away superiorly. When additional mobilization of the liver is required, the avascular right triangular ligament is incised. The posterior parietal peritoneum on the white line of Toldt is incised from the pelvis (region of the iliac artery) to the right upper quadrant (region of hepatic flexure). The anterior pararenal space is developed by dissecting in the plane between the anterior renal fascia and the mesentery of the ascending colon. With large inflammatory masses, the anterior pararenal space may be difficult to develop. It is important to avoid injury to the ascending mesocolon because injury to the right colic and ileocolic arteries may devitalize this segment of colon. It is important to resect the renal fascia in its entirety for the best chance of surgical cure and to avoid intra-abdominal tumor spillage.

After mobilizing the hepatic flexure of the colon using sharp and blunt dissection, the second part of the duodenum is mobilized medially using the Kocher maneuver (Fig. 101.26). With medially located tumors, mobilization of the duodenum should be performed with extreme care to avoid injury.

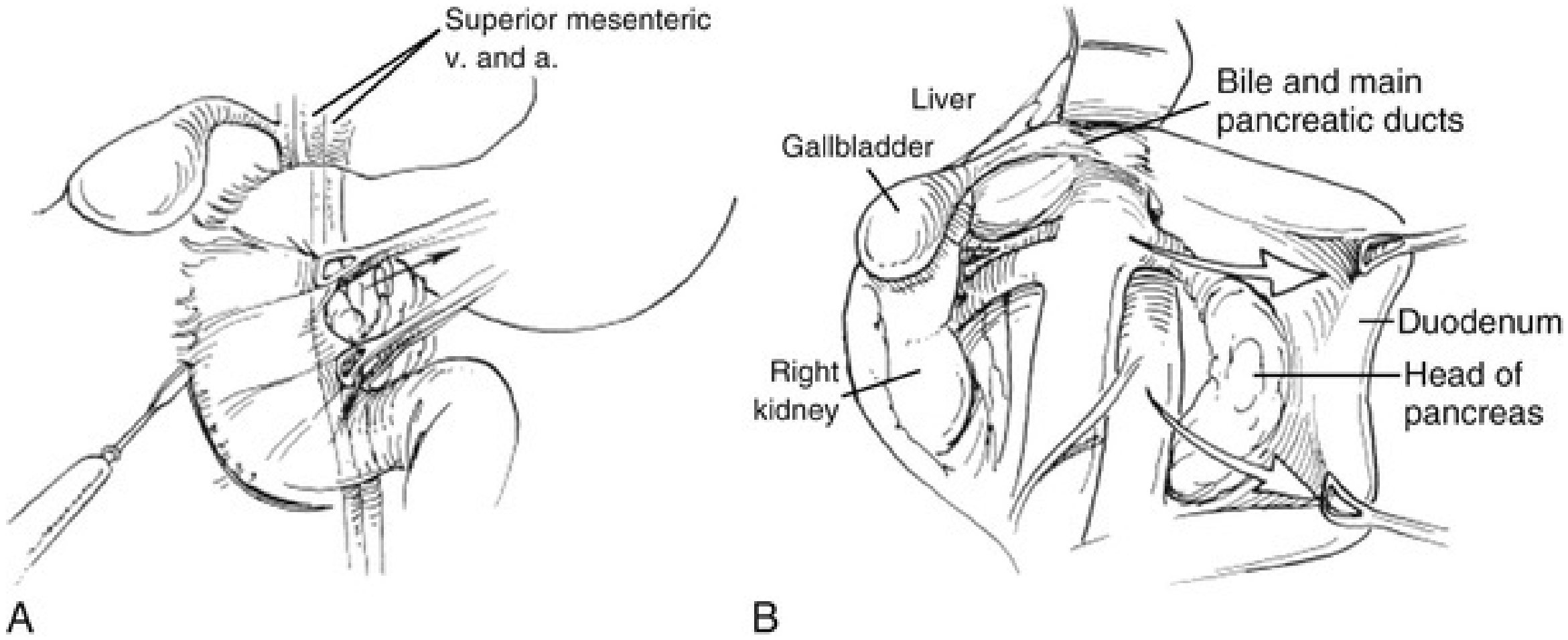

FIG. 101.26 (A and B) Kocher maneuver. (From Smith JA Jr, Howards SS, Preminger GM, eds. *Hinman's atlas of urologic surgery.* 3rd ed. Philadelphia, PA: Saunders; 2012.)

After mobilization of the duodenum, the IVC is identified posteriorly. Dissection anterior to the IVC will enable identification of the renal vein and gonadal vein (on the right side). Placement of a vessel loop will enable gentle traction of the renal vein. The renal vein is palpated for any tumor thrombus. Next the renal artery is identified posterior to the renal vein. If identification of the renal artery is difficult, attention is turned to the lower pole of the kidney to identify the ureter and gonadal vein. If technically feasible, the gonadal vein is spared. However, often because of the large size of the renal tumor, the gonadal vein cannot be safely left intact without the risk for avulsion from the IVC (right side) or left renal vein. With ligation of the ureter, the kidney is lifted from a posterior to an anterior position to aid in identification of the renal artery posterior to the kidney.

Another option for identifying the right renal artery in difficult hilar dissections is to dissect in the interaortocaval region at its takeoff from the

aorta (Fig. 101.27). The right renal artery can be ligated with a 0 silk suture or in emergent cases with a surgical clip. With the renal artery controlled, the right kidney and tumor will decrease in size and engorgement, easing the dissection of the kidney at the hilum and the remaining sites. The right renal vein, which should now be flaccid, is examined for any tumor thrombus and subsequently doubly ligated with a 0 silk tie and 2-0 silk suture ligature and divided. Identification of the renal artery should be technically much easier lateral to the IVC, which can now be doubly ligated and divided. Attention should be given to the lumbar veins, which enter the IVC (eFig. 101.28). If avulsed, bleeding should be controlled with suture ligatures and not surgical clips because surgical clips do not provide adequate hemostasis for the lumbar veins. These veins can retract, thereby exacerbating the degree of retroperitoneal bleeding, which will be difficult to access and control.

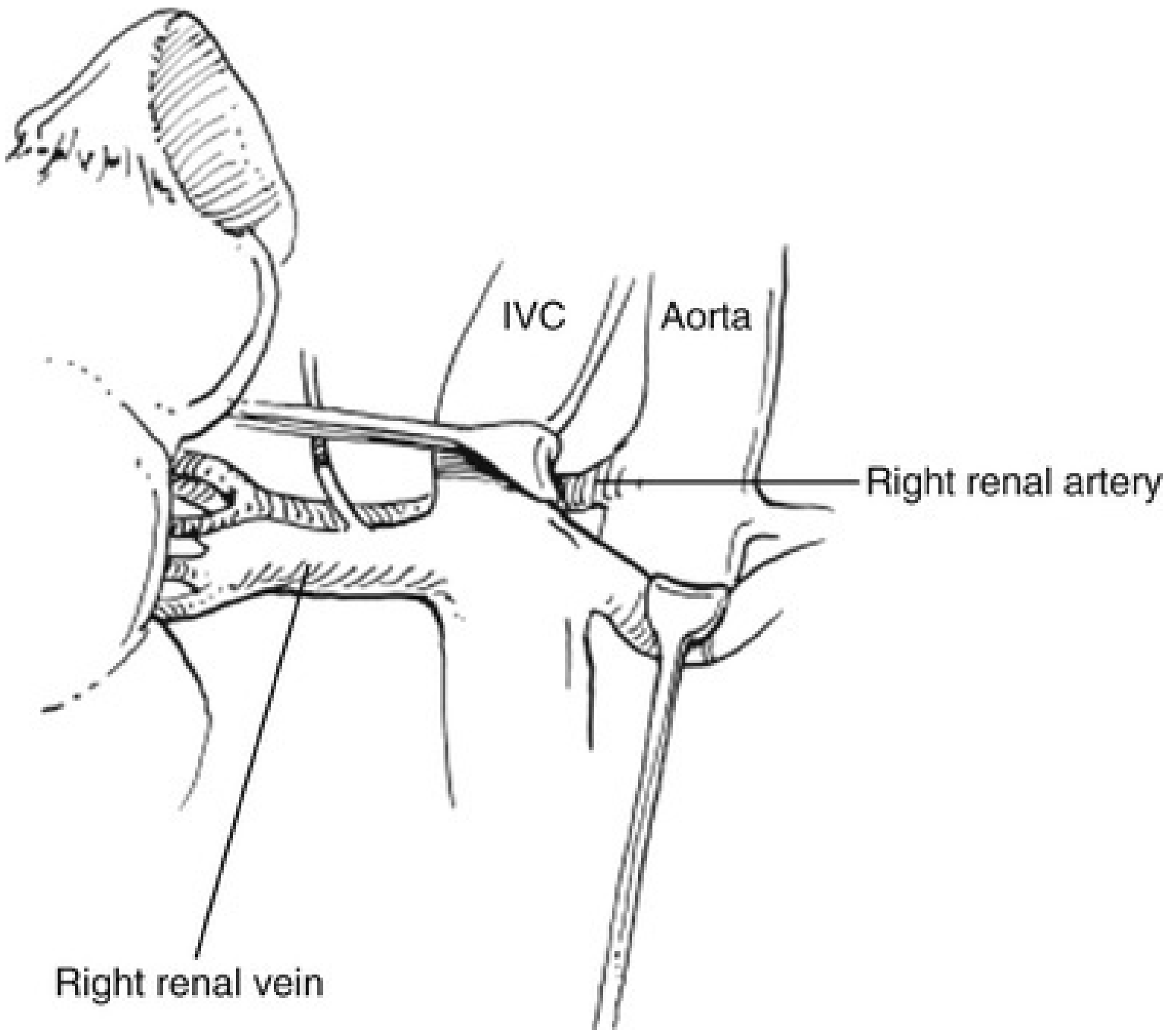

FIG, 101.27 The anteromedial surface of the inferior vena cava *(IVC)* can be used as a guide to identify the short right renal vein. The right renal artery is usually located deep to the right renal vein and is sometimes easier to identify in the interaortocaval groove. (From Smith JA Jr, Howards SS, Preminger GM, eds. *Hinman's atlas of urologic surgery.* 3rd ed. Philadelphia, PA: Saunders; 2012.)

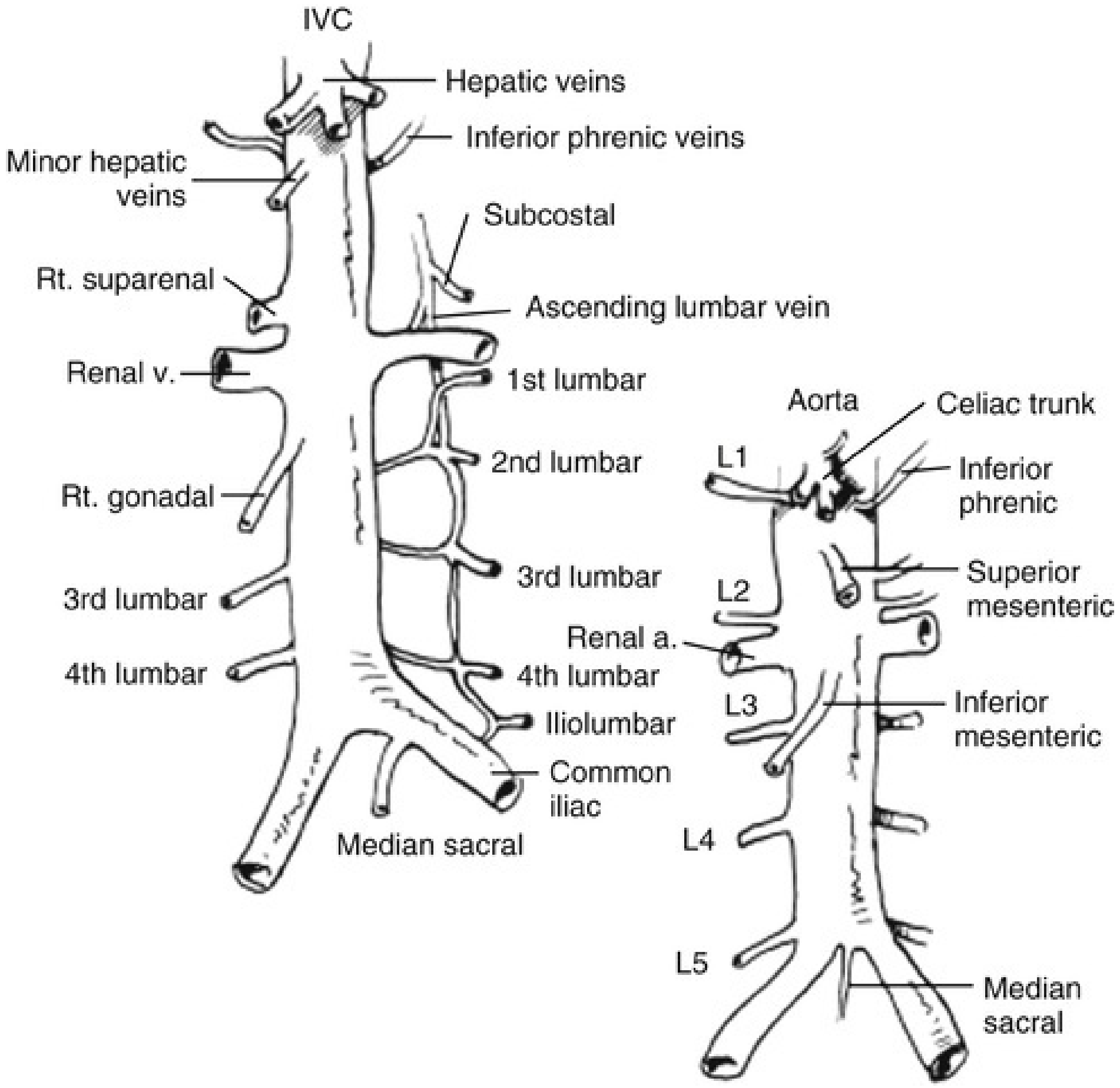
IVC
Hepatic veins
Inferior phrenic veins
Minor hepatic veins
Subcostal
Rt. suparenal
Ascending lumbar vein
Renal v.
1st lumbar
2nd lumbar
Rt. gonadal
3rd lumbar
3rd lumbar
4th lumbar
4th lumbar
Iliolumbar
Common iliac
Median sacral
Aorta
Celiac trunk
L1
Inferior phrenic
L2
Superior mesenteric
Renal a.
L3
Inferior mesenteric
L4
L5
Median sacral

EFIG. 101.28 Branches of the inferior vena cava *(IVC)* and aorta. (From Smith JA Jr, Howards SS, Preminger GM, eds. *Hinman's atlas of urologic surgery.* 3rd ed. Philadelphia, PA: Saunders; 2012.)

For left radical nephrectomy, after incision of the white line of Toldt from the splenic flexure to the common iliac artery, the descending colon is reflected medially. The renocolic ligament is divided, and extreme care is taken to avoid injury to the tail of the pancreas. The left renal vein is identified using the anterior surface of the aorta as a guide. The left renal artery is usually located cranial and posterior to the left renal vein. After further mobilization of the lower pole of the kidney, the left ureter and the left gonadal vein are identified. The left gonadal vein can be traced to its insertion to help identify the left renal vein. Depending on the size and location of the tumor, the surgeon determines whether the left gonadal vein should be left intact or tied off and transected to help with mobilization of the kidney. The ureter is divided, and the inferior and posterior surface of the kidney is mobilized to identify the left renal artery. Once the left renal artery and vein are identified, the renal artery is ligated with two right-angle clamps and divided. Preferably, the proximal end of the renal artery is clamped with two right-angle clamps and the distal end with one right-angle clamp. The renal artery is divided using a fine scalpel. The proximal end is ligated with a 0 silk suture and further secured with a 2-0 silk suture ligature; the distal end is tied with a 0 silk tie. With the renal artery secured and divided, the renal vein is secured and divided in a similar fashion.

At times, the renal artery and vein cannot be separated individually because of significant hilar lymphadenopathy. Then, a whole-pedicle clamp technique may be utilized to control the hilar vessels (eFig. 101.29). Although the risk for arteriovenous fistula may be associated with en bloc ligation of the whole renal pedicle (Lacombe, 1985)**, some small clinical series have not found any evidence of such fistulas in patients undergoing nephrectomy who have been managed with en bloc stapling of the renal hilum** (Chung et al, 2013; Ou et al, 2008). The vascular pedicle is bluntly dissected until the pedicle has a 2- to 3-cm diameter. Long curved vascular clamps (e.g., Satinsky clamps) or renal pedicle clamps (e.g., Crawford, Young, Mayo) are used to clamp the renal artery and vein together. The pedicle is pinched, and the first clamp is placed at the lowermost aspect of the pedicle to ensure adequate length for ligation of the pedicle and that the clamp extends far enough beyond the structures within the pedicle to engage the suture. A second clamp is placed above and adjacent to the first under direct vision. A third clamp is placed on the pedicle near the renal parenchyma. The pedicle is divided between the second and the third clamps, leaving vascular stumps protruding. A 0 silk suture is looped below the lower clamp to tie off. It is prudent to tie the pedicle twice and also use suture ligature to minimize the risk with silk ties, which may slip off the vascular pedicle. Various other techniques can be utilized for controlling the vascular pedicles (Figs. 101.30 and 101.31).

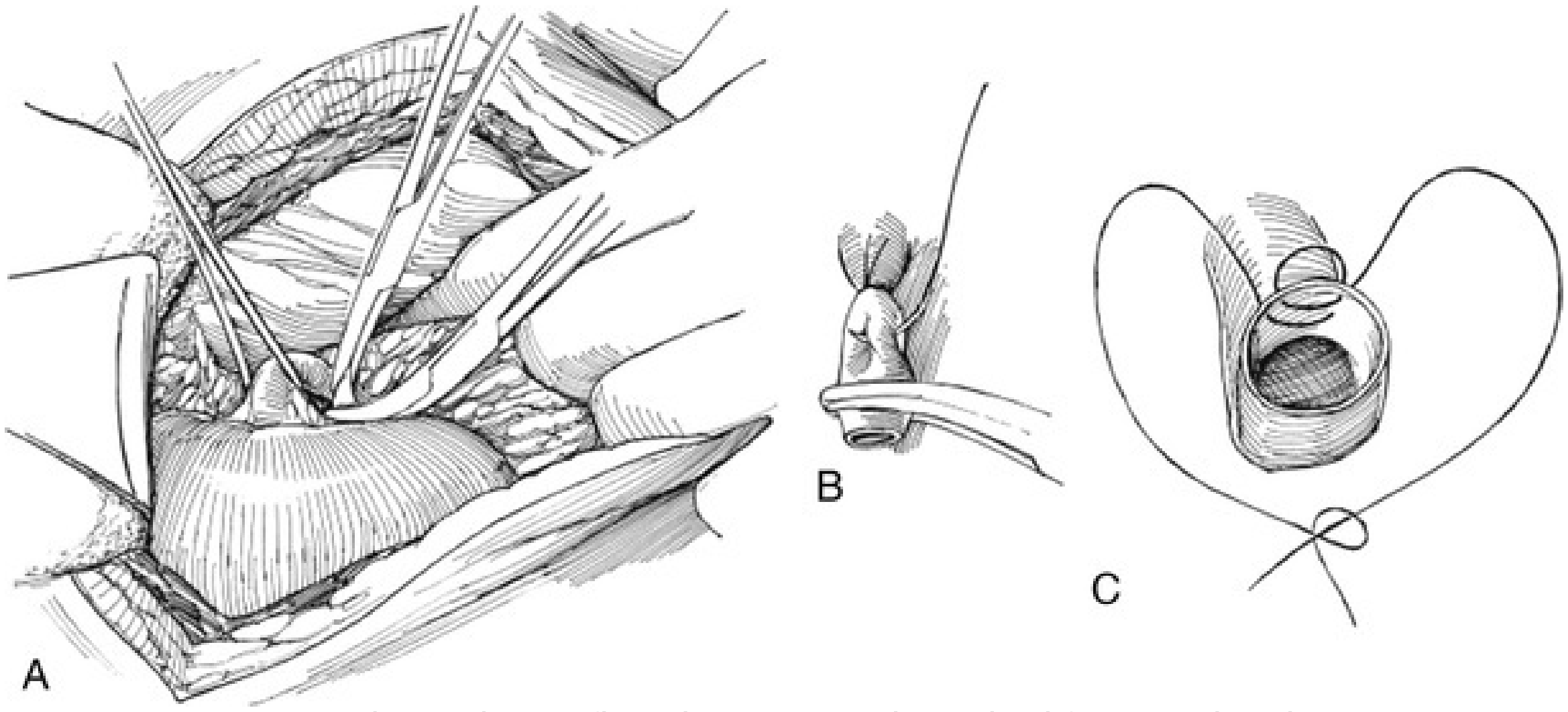

FIG. 101.30 (A to C) “Cut first, ligate second” method for securing the renal hilum. (From Smith JA Jr, Howards SS, Preminger GM, eds. *Hinman‘s atlas of urologic surgery.* 3rd ed. Philadelphia, PA: Saunders; 2012.)

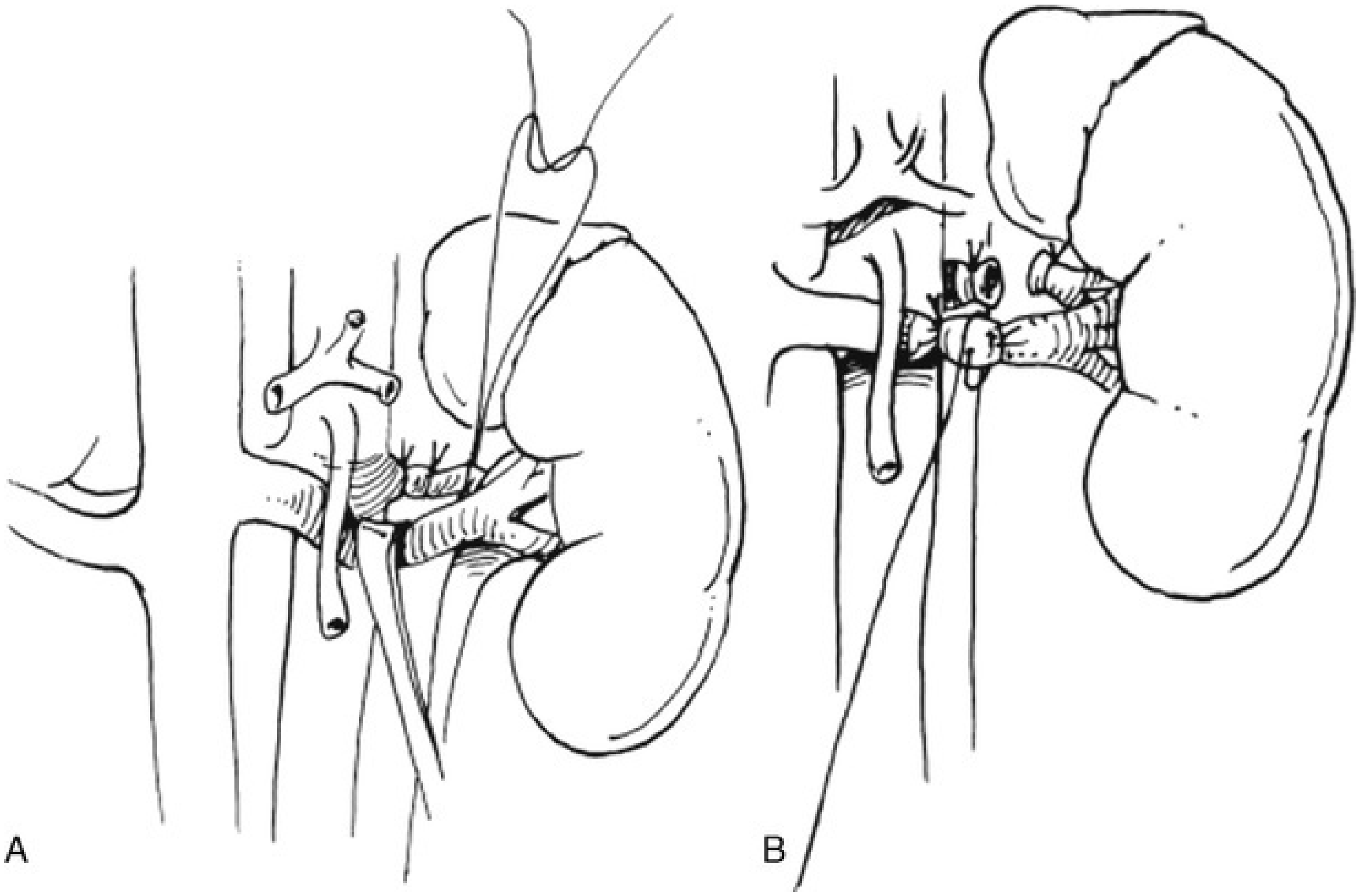

FIG. 101.31 (A and B) “Ligate first, cut second” method for securing the renal hilum. (From Smith JA Jr, Howards SS, Preminger GM, eds. *Hinman‘s atlas of urologic surgery.* 3rd ed. Philadelphia, PA: Saunders; 2012.)

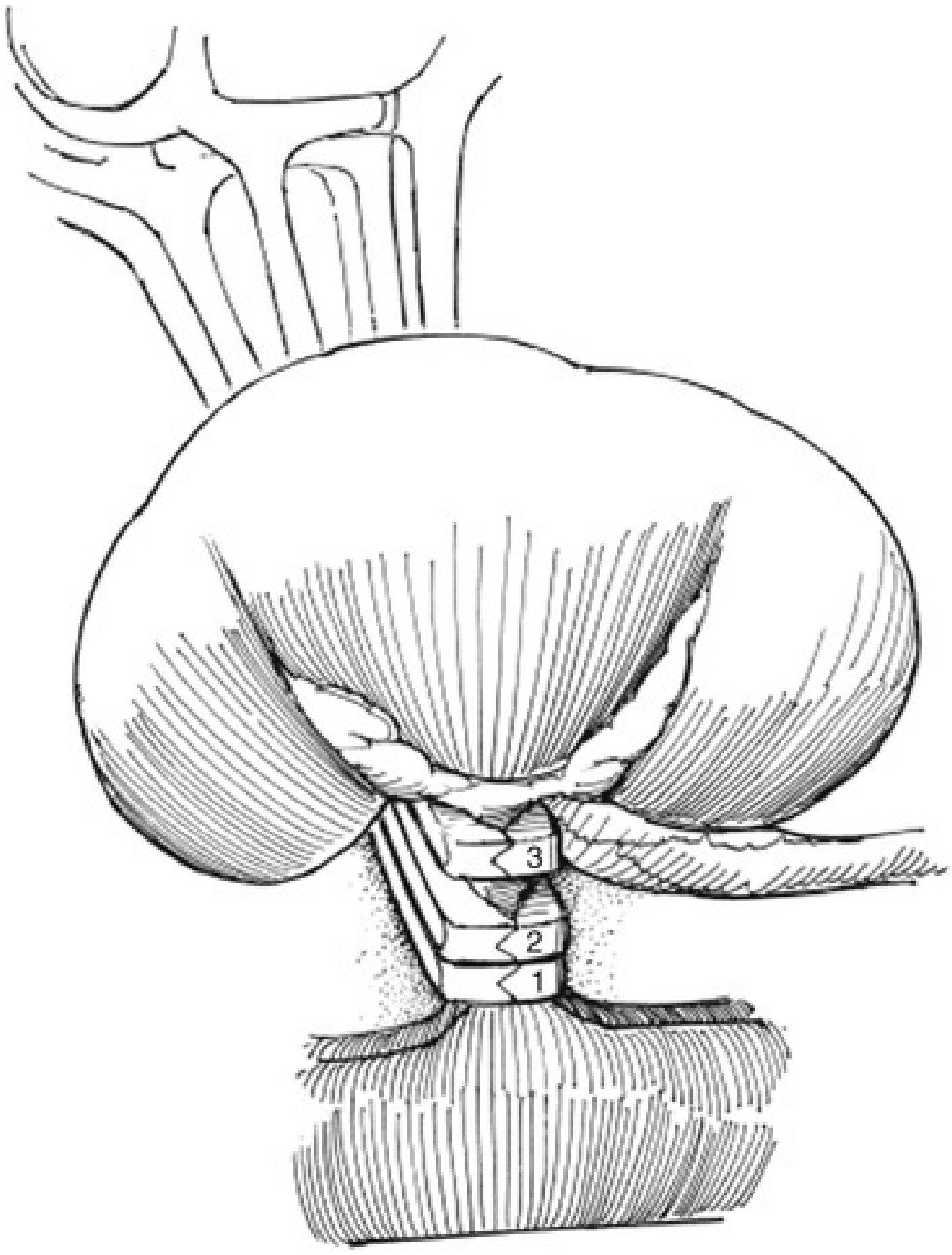

EFIG. 101.29 Whole-pedicle clamp method for securing the renal hilum. (From Smith JA Jr, Howards SS, Preminger GM, eds. *Hinman's atlas of urologic surgery.* 3rd ed. Philadelphia, PA: Saunders; 2012.)

In the emergent condition of loss of control of the renal hilar vascular pedicle, it is important to stay calm. The surgeon must inform the anesthesiologist and all operating room personnel of major bleeding and request aggressive hydration and availability of blood products. Compression can be applied using a fingertip or sponge stick to achieve hemostasis as best as possible so that the rest of the operating room staff can prepare. Compression can also be applied on the IVC and/or aorta to control bleeding. Two Yankauer suction tubes can be used to clear the surgical wound. Vascular occlusion clamps are used to clamp and ligate actively bleeding vessels. Clamping should not be done blindly; rather, one should suction, pack, retract, and dissect to get better exposure. If the bleeding is occurring from the renal artery, the surgeon can compress the aorta above the renal artery, clamp the arterial stump with a vascular clamp, and repair the defect with two layered running vascular sutures. If the bleeding is occurring from the IVC because of an avulsed or lacerated renal vein, or avulsed gonadal or lumbar vein, a finger can be placed on the hole until the hole can be grasped with an Allis clamp (Scanlan International, St. Paul, MN). Pulling up on the clamp will normally stop the bleeding, allowing the defect to be visualized for repair.

For repair, polypropylene (Prolene) sutures (Ethicon, Cincinnati, OH)—typically 30 inch or 36 inch (75 cm or 90 cm)—are used; 3-0 or 4-0 sutures can be used for IVC or aortic repairs, and 4-0 or 5-0 sutures can be used for renal vessel repairs. We recommend using double-armed sutures with tapered needles—⅜-circle BB (17 mm) for arterial repair (they are less likely to fracture a calcific arterial plaque) and ½-circle RB-1 (17 mm) or SH (26 mm) for venous repair.

Regional Lymphadenectomy for Renal Cancer

The role of regional lymphadenectomy for renal cell carcinoma (RCC) has remained controversial. Multiple retrospective studies have suggested a possible benefit to regional lymphadenectomy for carefully selected patients (Blute et al., 2004a; Crispen et al., 2011; Capitanio et al., 2013; Kim et al, 2004; Lam et al., 2004, 2006; Sun et al., 2014). A prospective randomized trial that was carried out by the European Organization for Research and Treatment of Cancer included 772 patients. Patients were randomly assigned to two groups—one that underwent regional lymphadenectomy and one that did not. Although no overall survival benefit was shown for patients who underwent regional lymphadenectomy for management of RCC, the study included a high percentage of patients with localized small and low-stage tumors who may not have benefited from lymphadenectomy at all (Blom et al., 2009).

For right-sided renal masses when lymphadenectomy is considered, the paracaval, precaval, retrocaval, and interaortocaval nodes from the right crus of the diaphragm to the bifurcation of the IVC are sampled (Fig. 101.32). A right-angle clamp and electrocautery are used to split the lymphatic tissue from the anterior surface of the IVC. The lymphatic tissue is cleared cranially from the right crus of the diaphragm (located 3 to 4 cm above the right renal vein) and caudally until the bifurcation of the IVC. The right gonadal vein is ligated at its insertion into the IVC with a 2-0 silk suture, to avoid avulsion of the vein. Next the lymphatic tissue is cleared off the lateral aspect of the IVC (paracaval nodes). The IVC is gently elevated with a vein retractor to expose the lumbar branches. The lumbar veins (typically four or five branches on either side of the IVC) are carefully ligated with 3-0 silk ties and transected. The lymphatic trunks located above the renal vein are ligated with surgical clips. Care to adequately ligate the lymphatic trunks is essential because large quantities of lymph and chyle drain through the cisterna chyli and thoracic duct, and failure to appropriately control them can result in chylous ascites (eFig. 101.33). Once the lumbar veins are secured and the superior aspect of the lymphatic trunk above the renal vein is secured, the assistant rolls the IVC medially with gentle pressure using two sponge sticks. Next the lymphatic tissue is cleared off the retrocaval region. The nodal tissue overlying the anterior surface of the aorta is then split and divided to the superior border of the left renal vein. Division of the nodal packet is followed to the medial border of the IVC, and the aortocaval nodal packet is cleared to the level of the common iliac vessels.

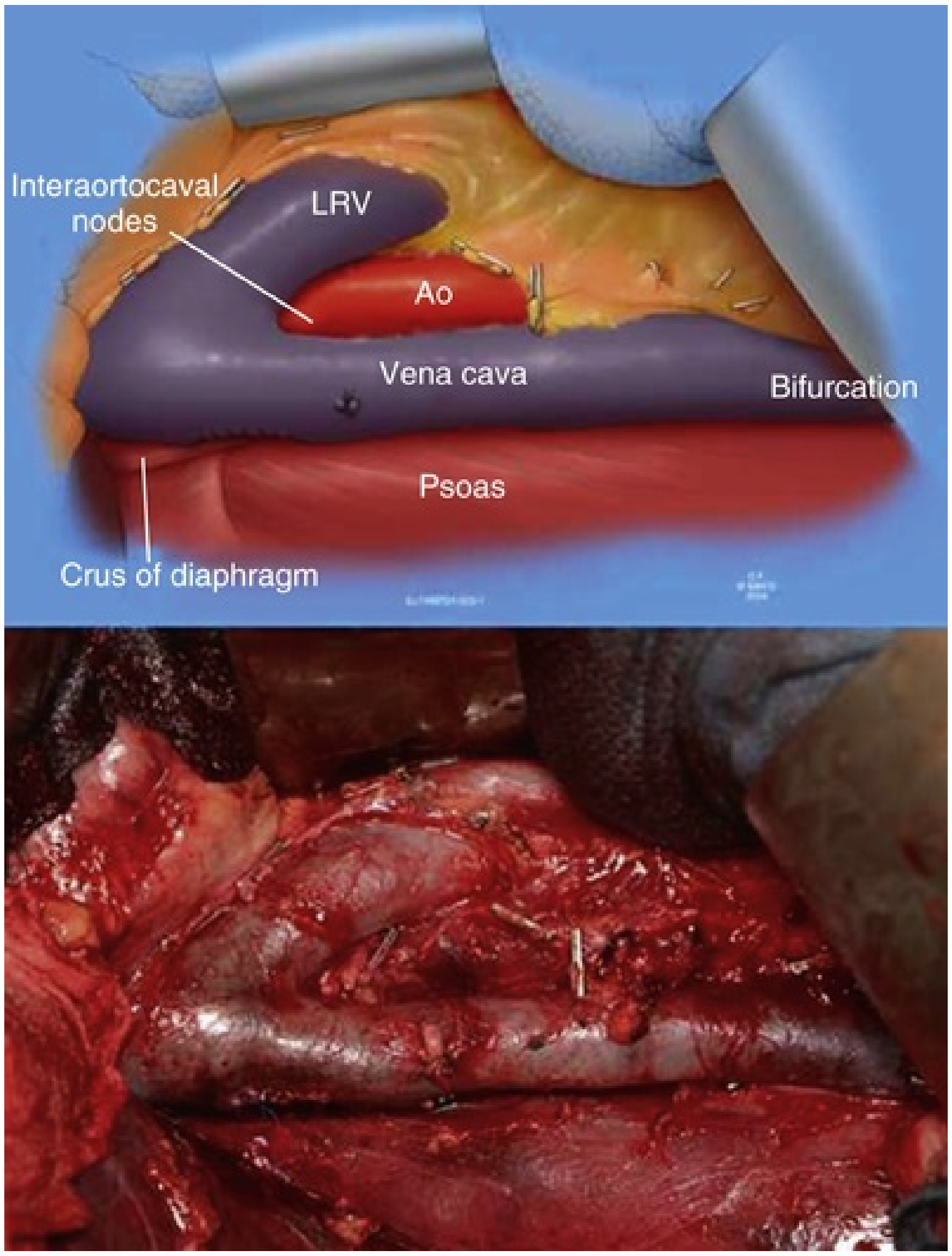
Interaortocaval nodes
LRV
Ao
Vena cava
Bifurcation
Psoas
Crus of diaphragm

FIG. 101.32 Extended lymphadenectomy for right-sided renal masses. *Ao,* aorta; *LRV,* left renal vein.

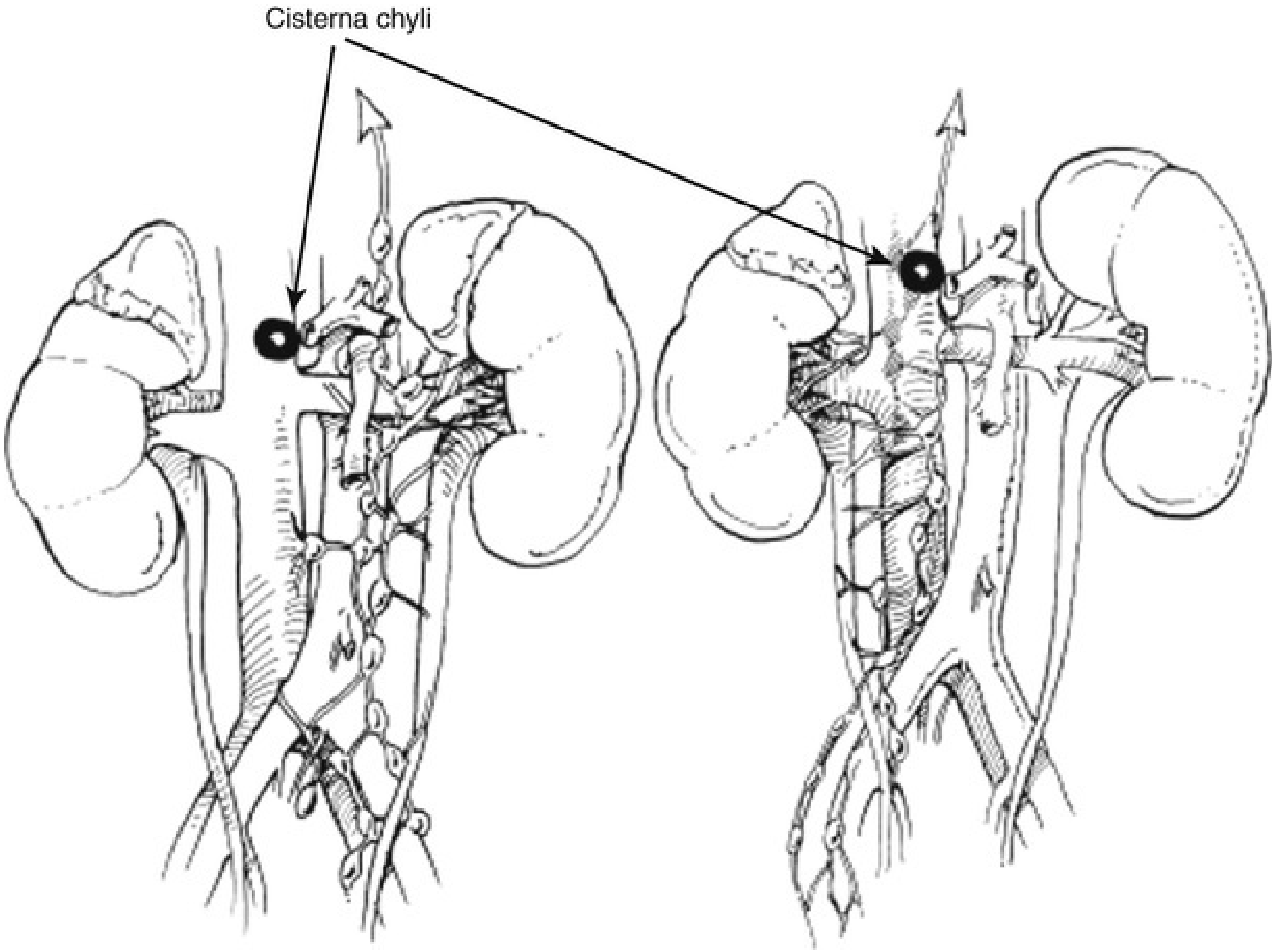

EFIG. 101.33 Renal lymphatic drainage and location of the cisterna chyli. (From Smith JA Jr, Howards SS, Preminger GM, eds. *Hinman's atlas of urologic surgery.* 3rd ed. Philadelphia, PA: Saunders; 2012.)

For left-sided renal masses, the lymphatic tissue on the anteromedial surface of the aorta is clipped and divided, and then rolled laterally (Fig. 101.34). The split is continued cranially along the aorta to the level of the SMA and caudally past the inferior mesenteric artery (IMA) to the bifurcation of the aorta. Although the IMA and the celiac trunk have to be preserved, the IMA can be tied and divided in case of involved lymphadenopathy. Once the lymphatics are dissected off the anterior and lateral surface of the aorta, the assistant gently elevates the aorta on either side to expose, secure, and divide the lumbar arteries. Once the lumbar arteries are properly secured, the aorta is rolled medially and the tissue between the anterior longitudinal vertebral ligament and the aorta (retroaortic lymph nodes) is resected. The interaortocaval nodes are resected only if they are palpable or visualized on preoperative imaging, or if there is extensive nodal involvement around the aorta.

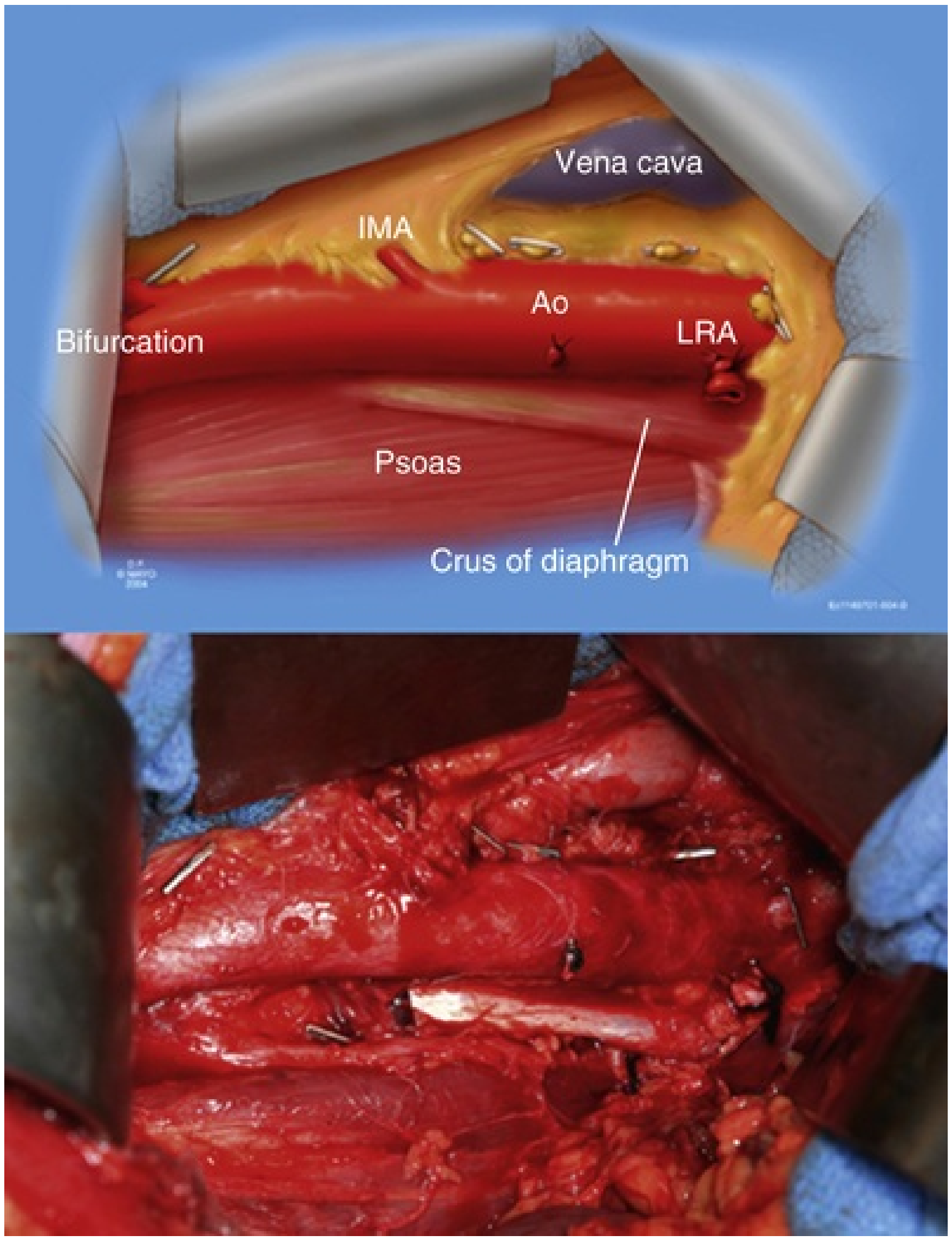

FIG. 101.34 Extended lymphadenectomy for left-sided renal masses. *Ao,* Aorta; *IMA,* inferior mesenteric artery; *LRA,* left renal artery.

Wound Closure

Once the surgical procedure is completed, the surgeon should investigate for hemostasis and evaluate adjacent organs for any signs of injury. The diaphragm and pleura are tissues that can be inadvertently injured secondary to retraction during radical open renal surgery. To test for pleural injury, the retroperitoneum is filled to the level of the flank incision with saline. The anesthesiologist then inflates the lungs with high inspiratory volumes. Bubbling of saline irrigation in the retroperitoneum with deep inspiration would suggest a pneumothorax. In case of a small pleural injury, the pleural cavity can be closed with running nonabsorbable sutures. Before complete closure of the pleura, the tip of a 14-Fr red rubber catheter is placed in the pleural cavity. The end of the catheter is placed in a saline-filled bowl. The anesthesiologist provides a deep inspiratory breath to evacuate any air from the pleural cavity through the red rubber catheter and into the saline bowl. Once the air is evacuated from the pleural cavity as evidenced by bubbles in the saline bowl, the red rubber catheter is removed and the assistant cinches the pleural incision tight for an airtight closure. A postoperative chest radiograph is essential to assess for any significant pneumothorax, even in cases when pneumothorax is not suspected.

The fascial layers are approximated typically in two layers—the transversus abdominis and internal oblique fasciae are approximated together, and the external oblique fascia is approximated as a separate layer. A 1 : 1 mixture of bupivacaine (0.5%) and lidocaine (1%) solutions is injected into the wound for pain control. The subcutaneous tissue is approximated using 3-0 absorbable sutures. The skin is approximated with skin staples or a subcuticular 4-0 poliglecaprone 25 (Monocryl) suture (Ethicon, Cincinnati, OH).

Intra- and Postoperative Complications

Damage During Suprahilar and Retrocrural Lymphadenectomy.

Dissecting the lymphatic tissue located above the left renal vein (suprahilar and retrocrural nodes) in the interaortocaval space should be undertaken with great caution and care because the duodenum, pancreas, SMA, celiac trunk, superior mesenteric autonomic plexus, and cisterna chyli can all be easily damaged in this area with serious sequelae. In general, we consider dissecting this area if the nodes are noticeably palpable or enlarged on preoperative imaging.

Injury to the Vasculature of the Gut.

During radical nephrectomy, a number of important gastrointestinal blood vessels may be encountered that have become involved by tumor, resulting in iatrogenic injury. **The IMA provides the blood supply to the distal transverse, descending, and sigmoid colon. It can be safely ligated as long as the marginal artery of the colon (marginal artery of Drummond, arch of Riolan) is patent and can supply blood from the SMA to the left colonic arcades.** The SMA provides the blood supply to the entire small bowel and to the cecum and ascending and transverse colon, whereas the celiac trunk feeds the esophagus, stomach, pancreas, liver, spleen, and part of the duodenum. **Ligation of either the SMA or the celiac trunk is a catastrophic event that occurs predominantly with left-sided nephrectomy and that must be rapidly**

reversed if the patient is to survive. A vascular surgeon should be immediately called to the operating room and the vessel in question should be repaired.

The IMV is found in the mesentery of the descending colon, immediately lateral to the ligament of Treitz. It is a useful landmark for mobilization of the right colon and small bowel mesentery to access the retroperitoneum, because the posterior peritoneum is incised immediately medial to the IMV. The IMV can be safely ligated during surgery without consequence.

In contrast, the superior mesenteric vein (SMV) should not be ligated unless that is the only surgical option. It runs in the root of the small bowel mesentery and joins the splenic vein and IMV to form the portal vein. Repair of an SMV laceration is done by first clipping the small venous branches entering the SMV and then isolating the injury with atraumatic vascular clamps. Venorrhaphy using 6-0 Prolene is usually adequate to repair the vein. If the vein has been ligated and transected, serious bowel edema and venous engorgement will result, which can impair venous return through the portal venous system. The net result is the development of systemic hypotension/splanchnic hypertension syndrome, which is characterized by venous thrombosis, bowel ischemia, and necrosis. If possible, a ligated SMV should be reanastomosed primarily or repaired using autologous venous grafting. Gore-Tex vascular grafts (W. L. Gore & Associates, Flagstaff, AZ) should only be used when autologous veins are not available because the thrombosis rate is high. The abdomen should not be closed primarily in cases of SMV injury because abdominal compartment syndrome will occur.

Injury to the Liver and Spleen.

Small hepatic injuries (capsular tears and minor lacerations) can usually be managed effectively with argon beam coagulation or electrocautery. Fibrin glue and topical hemostatic meshes (e.g., Surgicel Absorbable Hemostat, Ethicon, Cincinnati, OH) are useful adjuncts. More serious splenic injuries can be managed with splenorrhaphy or splenectomy. Minor hepatic lacerations can be repaired using the same basic principles as for partial nephrectomy closure, with a synthetic absorbable suture on a ½-circle tapered needle and Nu-Knit pledgets (Ethicon, Cincinnati, OH), as described in the Enucleation for Small Cortical Tumors section later in this chapter.

Injury to the Duodenum.

Most intramural hematomas of the duodenum are managed expectantly. However, if the hematoma is large and narrowing the duodenal lumen, incision of the serosa and muscularis (but not the mucosa) can be performed to drain the hematoma and achieve hemostasis. The defect should be closed in one layer with interrupted 3-0 silk sutures. The involved segment may initially appear nonviable; however, no resection should be performed because the initial perception is false. Consultation with a general surgeon or gastrointestinal surgeon can be very helpful.

Minor electrocautery or laceration injuries should be managed with careful debridement of the nonviable tissue and closure in two layers, the mucosal layer with continuous 4-0 chromic or Vicryl suture on a ½-circle tapered needle, and the serosa and muscularis layer with a 3-0 silk interrupted suture on a ½-circle tapered needle. An omental flap is placed over the injury, and a closed suction drain is inserted.

Injury to the Pancreas.

The first step in management of pancreatic injury is a thorough inspection of the organ. Superficial lacerations and contusions can usually be managed by applying fibrin glue and inserting a closed suction drain. The drain is monitored for an alkaline pH and lipase/amylase levels to determine whether a pancreatic fistula is developing. If the injury to the pancreas is deep and/or involves the pancreatic duct, consultation with a gastrointestinal surgeon is essential for appropriate repair and management.

Pulmonary Complications.

Large postoperative pleural effusions can be managed with aspiration initially, followed by chest tube drainage if necessary.

Partial Nephrectomy for Malignant Disease

When technically feasible, partial nephrectomy is the preferred method of choice for managing most renal masses to preserve maximum renal function (Fig. 101.35). Although in the past partial nephrectomy was reserved for specific conditions (bilateral tumors, tumor in a solitary kidney, patient at high risk for future renal failure) and small tumors less than 4 cm in diameter (Novick et al., 1991), indications for partial nephrectomy have considerably widened to include most renal masses that can be safely and completely removed independent of their size (Blute and Inman, 2012; Blute et al., 2003; Gill et al., 2007).

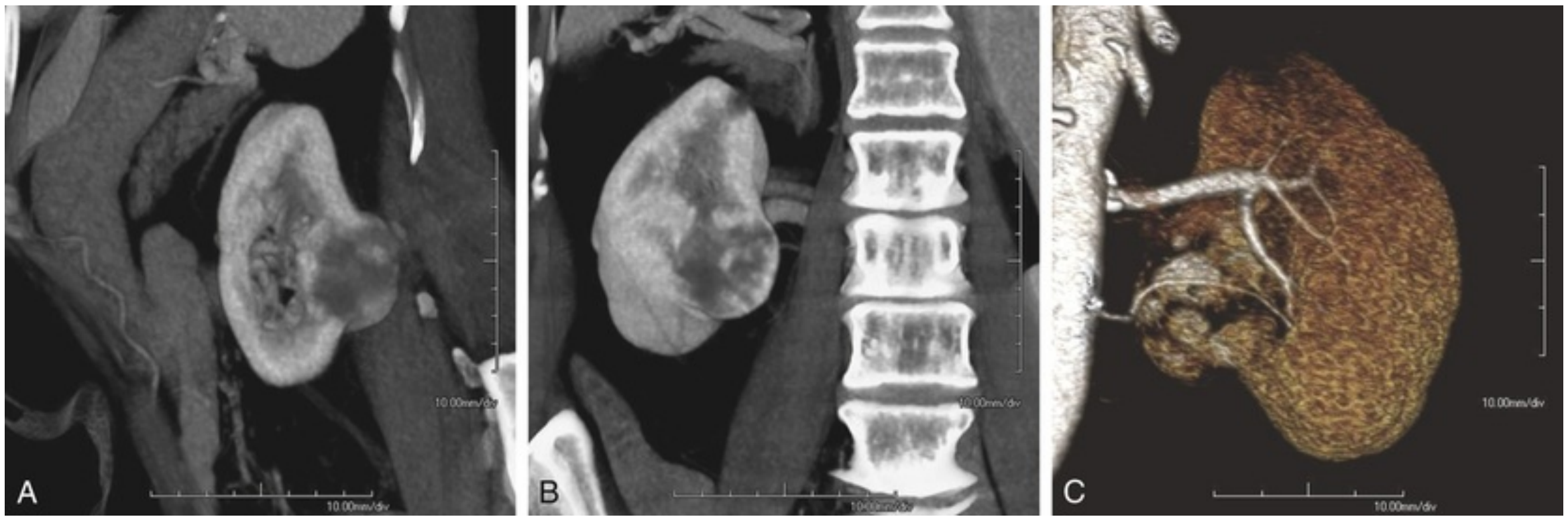

FIG. 101.35 (A) Contrast-enhanced computed tomography scan demonstrating right renal mass. (B) Three-dimensional reconstruction demonstrates a large intrarenal component to the mass. (C) Arterial reconstruction shows lower pole renal artery in close proximity to the renal mass.

Relative contraindications to partial nephrectomy include the following:

Technical issues
- Cold ischemia time greater than 45 minutes (consider extracorporeal approach)
- Less than 20% of global nephron mass retained

Cancer-related issues
- Diffuse encasement of renal pedicle by tumor
- Diffuse invasion of central collecting system
- Tumor thrombus involving major renal veins
- Adjacent organ invasion (stage cT4)
- Regional lymphadenopathy (stage cTxN1)

Preoperative Considerations

In addition to the preoperative considerations for radical nephrectomy, there are additional concepts to consider related to partial nephrectomy.

Hyperfiltration Injury.

When a significant portion of renal parenchyma is removed, the renal blood flow is delivered to a smaller number of nephrons, which can lead to increased glomerular capillary perfusion pressure that results in an increased single-nephron glomerular filtration rate called *hyperfiltration* (Goldfarb, 1995; Steckler et al., 1990). Over decades, the hyperfiltration can injure the remaining nephrons, resulting in focal segmental glomerulosclerosis and the clinical manifestations of proteinuria and progressive renal failure. Hyperfiltration injury is most common when the total nephron mass of both kidneys is reduced by more than 80%.

Renal Ischemia and Hypothermia.

To minimize blood loss and allow for adequate surgical visibility, it is often necessary to employ vascular compression during partial nephrectomy. Options include manual compression, a renal compression clamp (Kaufmann clamp), selective clamping of the renal artery, and en bloc clamping of the entire renal pedicle. Manual and clamp compression of renal parenchyma is preferable because vascular clamping is associated with a higher incidence of renal complications (Fig. 101.36). It is unclear whether leaving the renal vein unclamped for retrograde renal perfusion offers any tangible benefit. Attempting to limit warm ischemia to 20 minutes and cold ischemia to 35 minutes helps maintain renal function (Thompson et al., 2007).

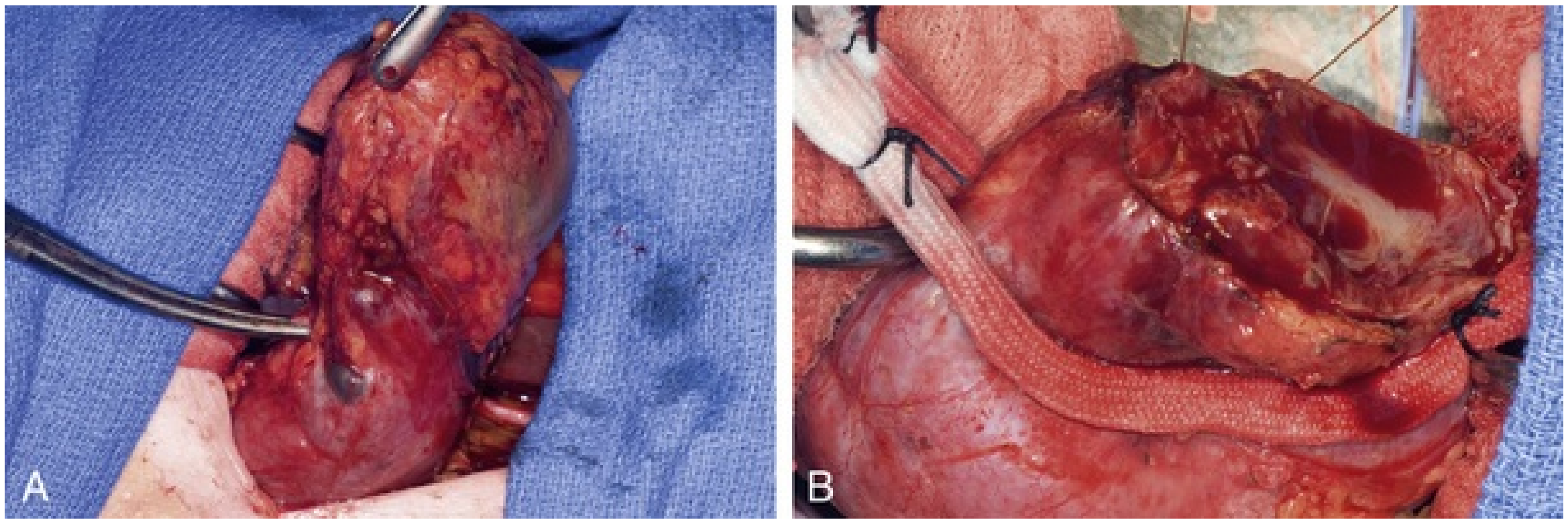

FIG. 101.36 (A and B) Partial nephrectomy for a large polar tumor using a Satinsky clamp on the renal parenchyma for ischemia.

Adequate renal hypothermia (core renal temperature of 20° C) takes at least 15 minutes to achieve if the kidney is packed with ice slush. To help prevent acute postoperative renal failure, intravenous mannitol (12.5 g) and furosemide (20 mg) should be infused about 15 minutes before renal artery clamping (Hanley and Davidson, 1981; Tiggeler et al., 1985). Although evidence supporting this practice is somewhat limited, both drugs are quite safe as long as the patient is well hydrated (Novick et al., 1991).

Enucleation and Surgical Margin.

Simple tumor enucleation can be safely conducted in small renal tumors while preserving a small rim of normal tissue and a negative surgical margin (Carini et al., 2006).

Multifocality and Tumor Size.

The incidence of multifocality is approximately 2% for clear cell and chromophobe RCC and 10% for papillary RCC (Fig. 101.37). Multifocal tumors are also more common as the primary tumor size increases (Blute et al., 2003). Careful inspection of the entire renal surface should be done at the time of partial nephrectomy to ensure that intraoperative findings corroborate preoperative imaging studies. If additional unanticipated renal mass(es) are encountered intraoperatively, partial nephrectomy is still the treatment of choice for multifocal tumors as long as they can be safely resected with clear surgical margins.

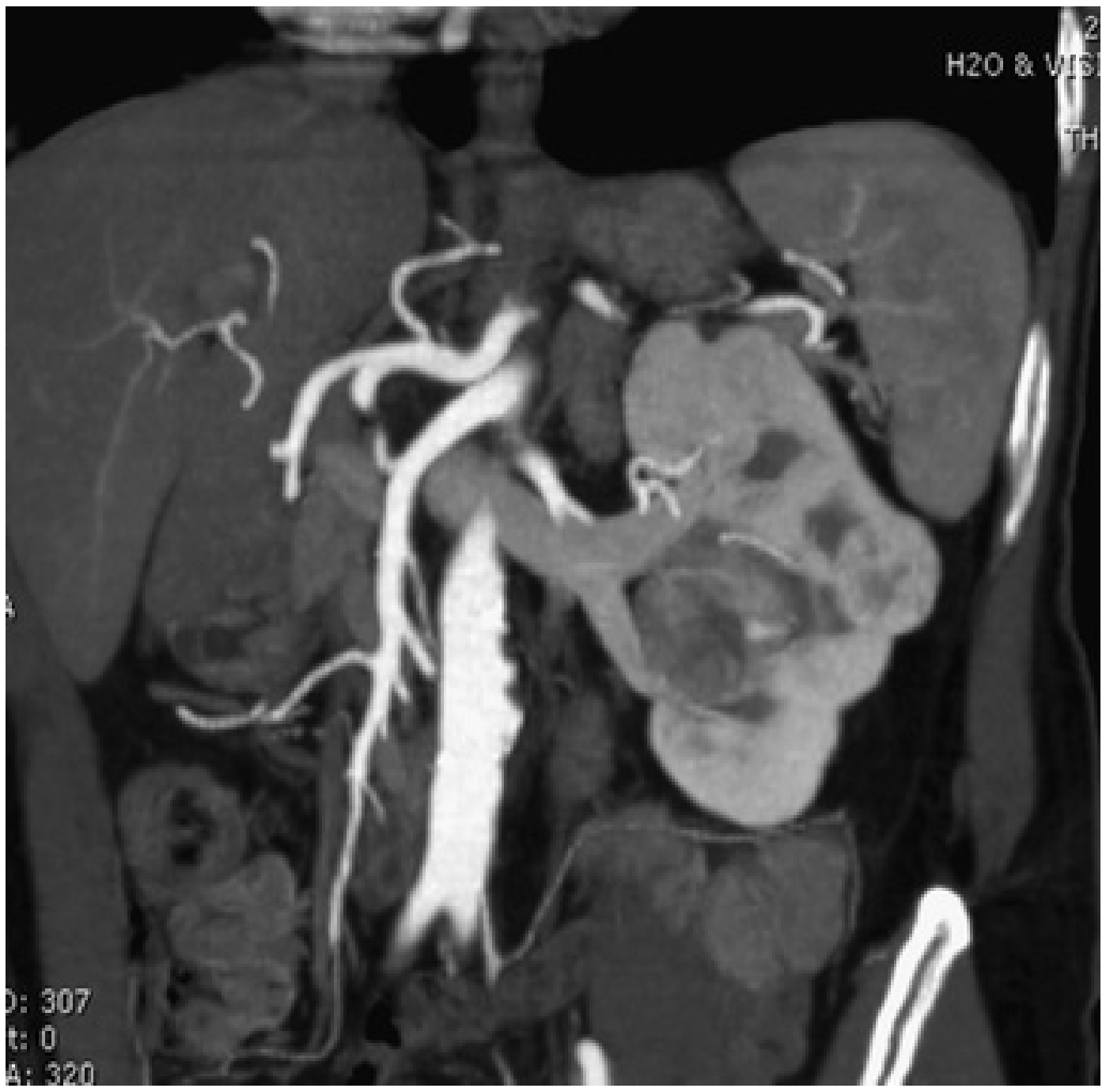

FIG. 101.37 Three-dimensional computed tomography reconstruction demonstrating a hilar tumor and peripheral tumor.

Hereditary Renal Malignancy.

Hereditary renal tumors are usually multifocal and bilateral, with high likelihood of recurrence. Except for patients with hereditary leiomyomatosis and RCC who should be aggressively treated with wide excision, most patients with hereditary syndromes can be safely observed with little chance of metastasis until the renal tumors reach 3 cm in size (Maher et al., 1991; Seizinger, 1991; Richards et al., 1993). When partial nephrectomy is performed, the perirenal fat and renal fascia should be preserved. The entire renal surface should be visualized, and all visible tumors should be resected. Intraoperative ultrasound can be used to identify any subcortical tumors that could also be resected (eFig. 101.38). Hypothermia is advisable to minimize injury to the renal parenchyma.

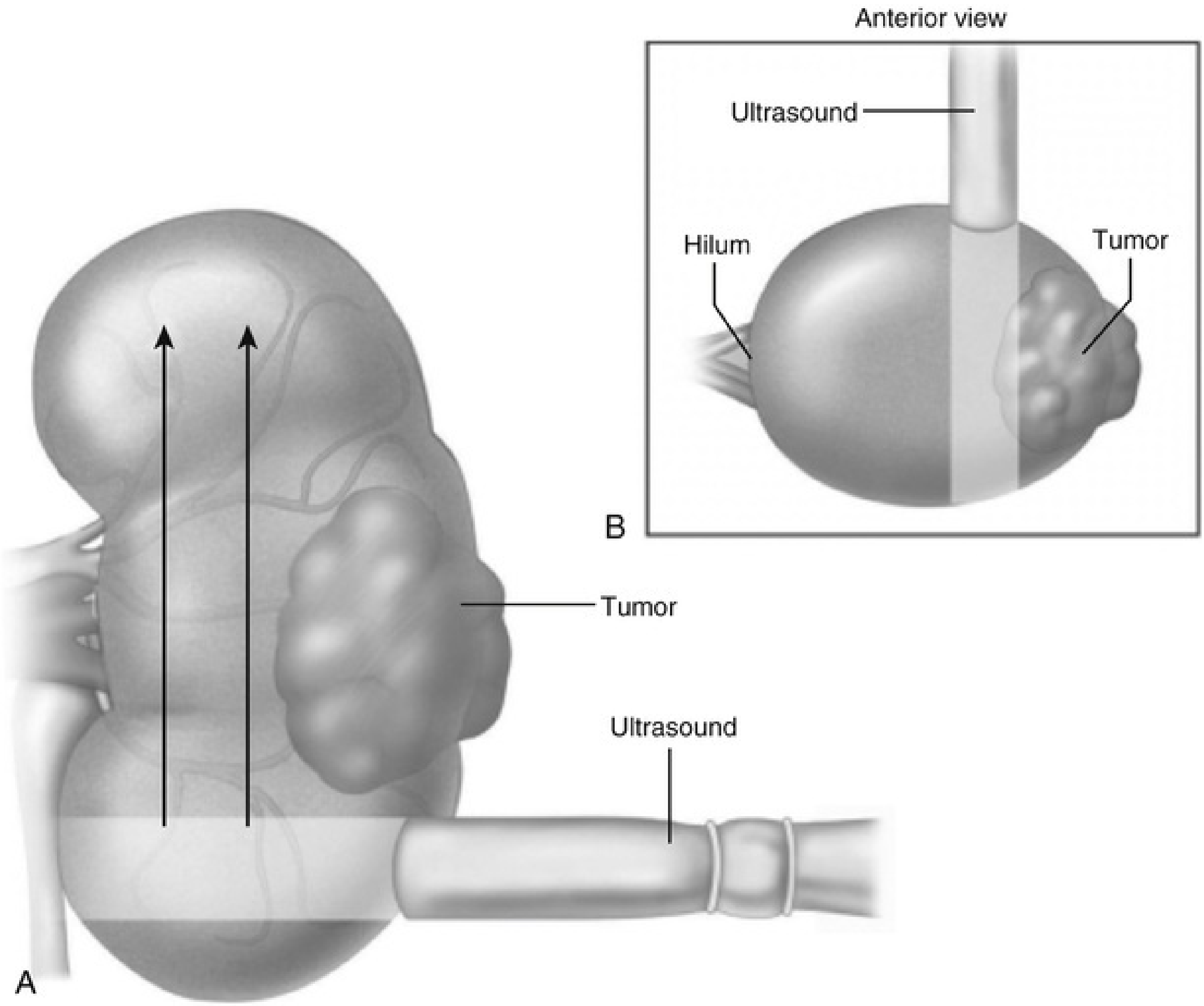

EFIG. 101.38 (A and B) When performing intraoperative ultrasonography for assessment of a renal tumor, the probe is passed over the kidney in radial angles to the center of the tumor. This allows assessment of the subcortical extent of the tumor in each angle by assessing the transition from normal kidney to tumor interface in multiple planes. On the basis of this assessment, the position and line of incision are selected. (From Graham SD Jr, Keane TE, eds. *Glenn's urologic surgery.* 7th ed. Philadelphia, PA: Lippincott Williams & Wilkins; 2010.)

Enucleation for Small Cortical Tumors

The surgeon should ensure that renal cooling is available, even though ischemia time seldom exceeds 30 minutes. Two cylinder-shaped cigarette-like bolsters are prepared by rolling Nu-Knit Absorbable Hemostat and tying each end with absorbable sutures. Two pledgets are prepared by folding Nu-Knit into a double-layer strip 5 to 10 cm wide and 1 cm long. We prefer Nu-Knit because it is absorbable and it maintains its integrity without immediate shrinkage when wet. In addition, it has excellent tensile strength when sutured.

The kidney is exposed using either the anterior subcostal or flank approach as described earlier. The entire surface of the kidney is freed of perirenal fat, with the exception of the perirenal fat overlying the tumor. While removing the perirenal fat, special care should be taken to avoid injury to the ureter, particularly for lower pole tumors. Intravenous mannitol and furosemide are administered and the renal pedicle is exposed sufficiently to allow safe application of a vascular clamp if necessary. Vessel loops are placed around the renal vein and artery individually.

The renal cortex surrounding the tumor is marked circumferentially using electrocautery. The plane outside the tumor pseudocapsule and within the normal parenchyma is identified and bluntly dissected with small closed Metzenbaum scissors. For enucleation of small lesions, renal occlusion is usually not necessary. However, if there is excessive bleeding that hampers proper visualization of the resection margin, then manual compression of the kidney or clamping of the renal pedicle can help. When small vessels within the kidney are encountered, they are divided sharply with scissors. The tumor is excised, and the margins are examined for gross evidence of a positive surgical margin; the deep margin of the excised tumor is assessed by frozen-section analysis. Small bleeding vessels in the renal parenchyma are controlled with 4-0 absorbable figure-of-eight sutures on a tapered needle or by coagulation with an argon beam coagulator or bipolar electrocautery. The integrity of the collecting system is verified by checking for injury and repairing with absorbable suture if necessary (Fig. 101.39).

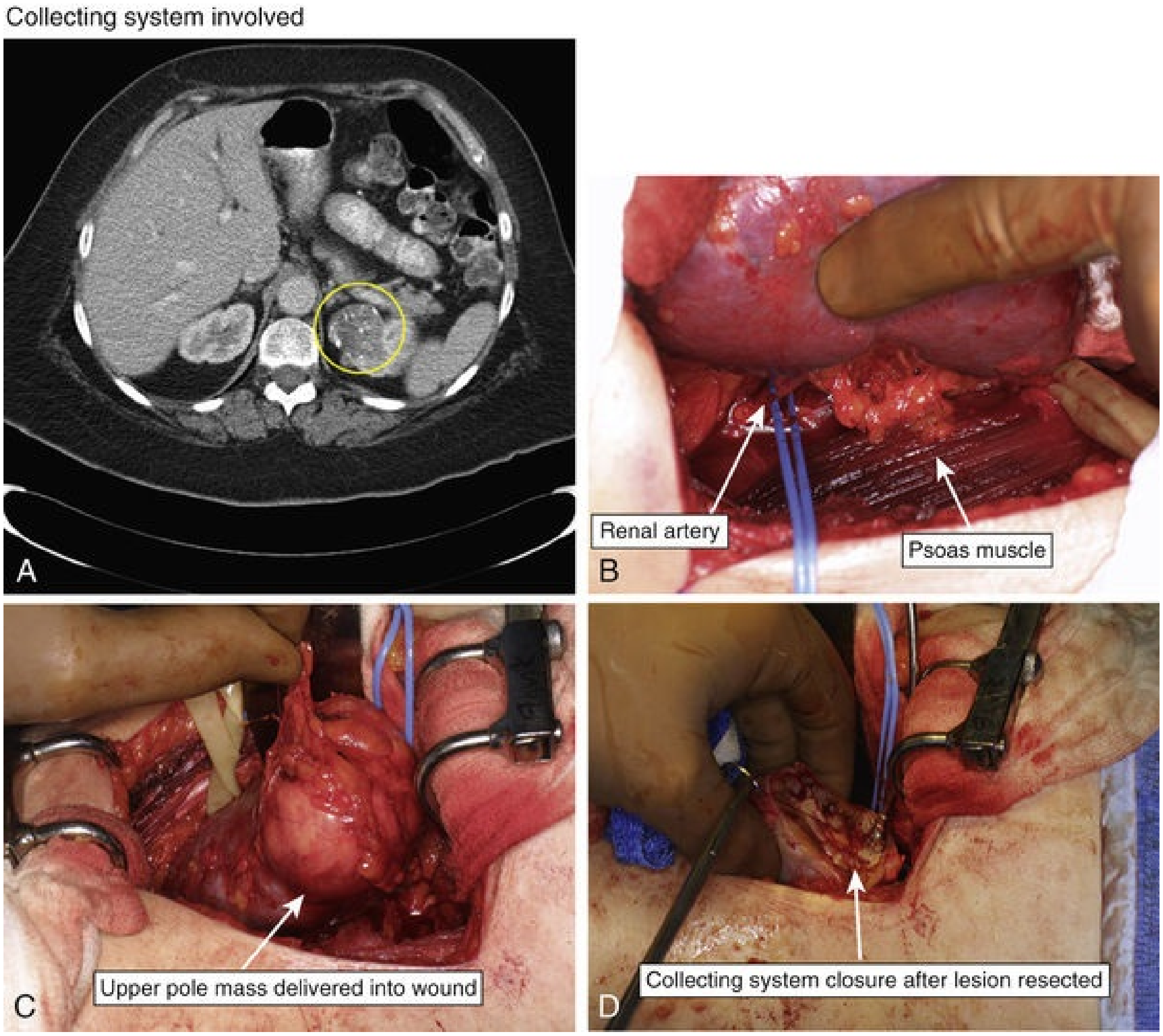
Collecting system involved
A
Renal artery
Psoas muscle
B
Upper pole mass delivered into wound
C
Collecting system closure after lesion resected
D

FIG. 101.39 (A) Renal tumor involving the collecting system demonstrated on computed tomography scan. (B) Securing the renal artery. (C) Identifying the upper pole mass. (D) Repair of the collecting system after lesion is resected.

A Nu-Knit pledget that was prepared earlier is placed along each border of the excised renal parenchyma and in the bottom of the excised parenchyma (Fig. 101.40). The defect is closed with 2-0 absorbable horizontal mattress sutures on a long ½ -circle tapered needle. The suture is placed through the pledget and about 1 to 2 cm into the renal parenchyma to prevent capsular and parenchymal tearing. The pledgets allow even distribution of tension along the renal capsule, reducing the likelihood of tearing the capsule. If clamping was used, the pedicle is unclamped and inspection is done for bleeding, ischemia, or urine leakage of the kidney and for adjacent organ trauma.

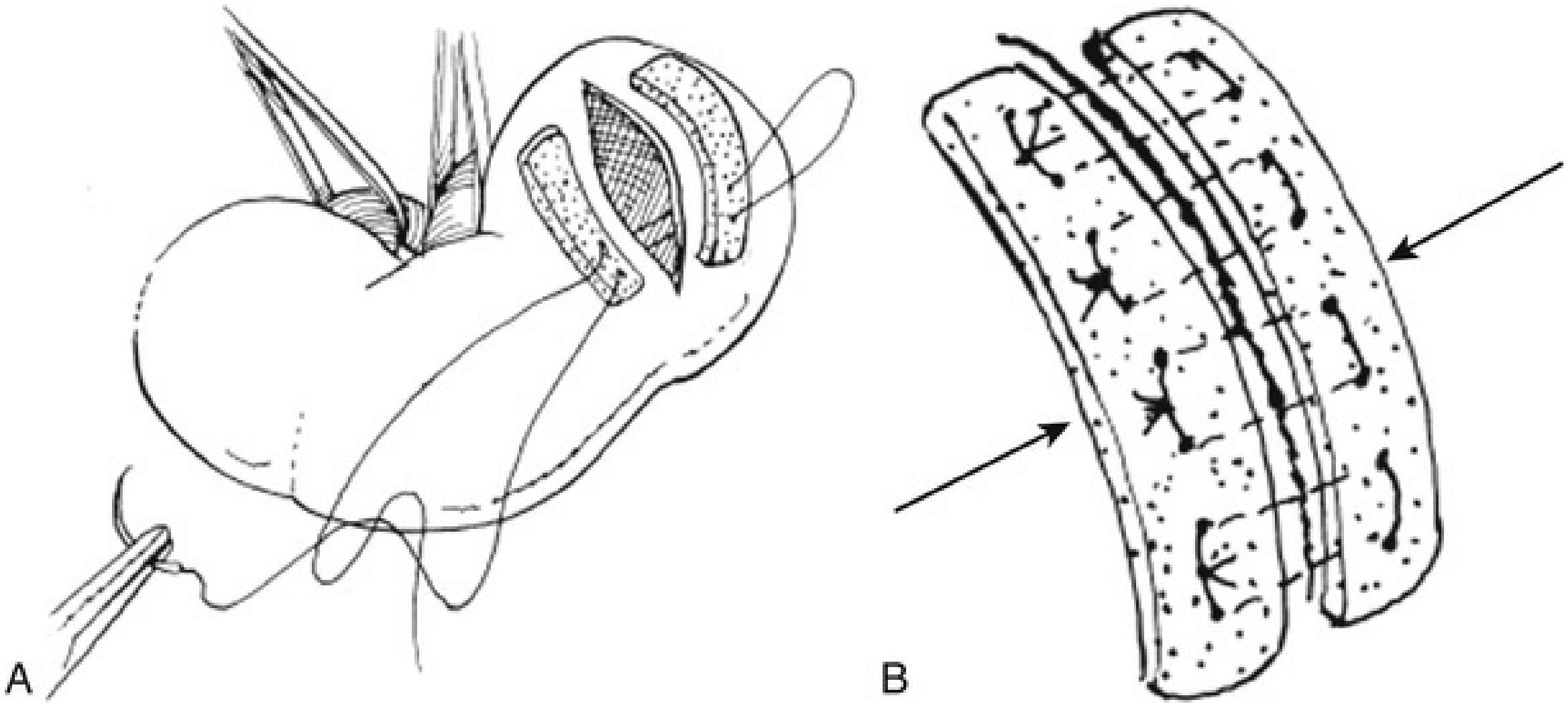

FIG. 101.40 (A and B) A Nu-Knit pledget is placed along each border of the crater, and a Nu-Knit bolster is placed into the bottom of the crater (not required if the defect is very small). The defect is closed with a 2-0 absorbable horizontal mattress suture. (From Smith JA Jr, Howards SS, Preminger GM, eds. *Hinman's atlas of urologic surgery.* 3rd ed. Philadelphia, PA: Saunders; 2012.)

The perirenal fat and renal fascia are replaced around the kidney. A closed suction drain in the pararenal space is placed to monitor for bleeding and urine leaks. The closed suction drain is removed after 2 to 5 days when the output is minimal. A Foley catheter is used to monitor the urine output. Unless there is a large renal collecting system defect, a ureteral stent is not typically required.

Wedge Resection for Large Cortical Tumors

For large tumors, intravenous mannitol and furosemide are administered, and then the renal artery is clamped with a vascular bulldog clamp. Based on the surgeon's preference, when partial nephrectomy is being performed for larger tumor sizes or lesions that are close to the renal hilum, the renal vein may also be clamped after clamping the renal artery to provide better hemostasis during partial nephrectomy (Fig. 101.41). A plastic bag or sheet is placed around the kidney and filled with ice slush. The kidney is allowed to cool to 20° C (approximately 15 minutes).

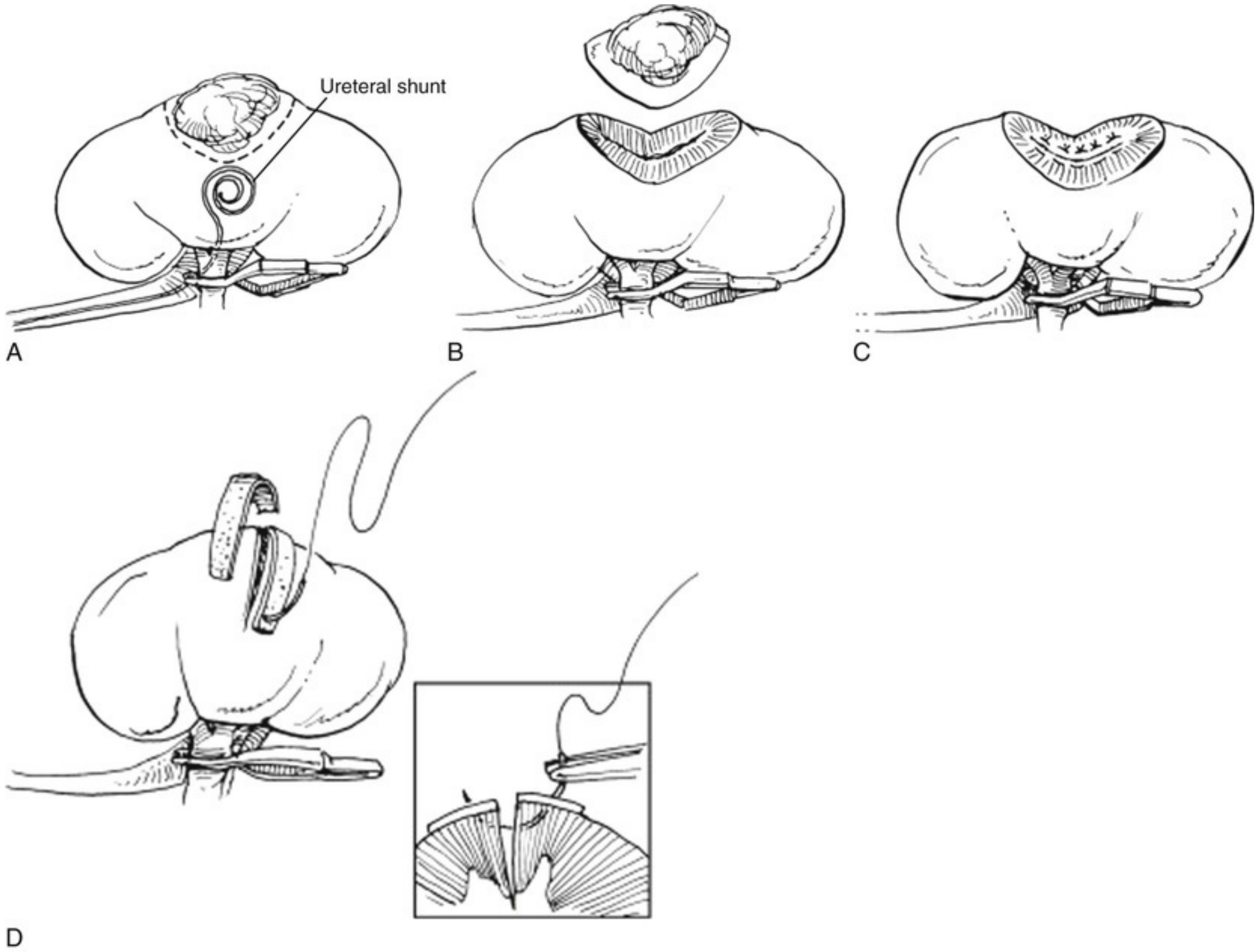

FIG. 101.41 (A) The renal capsule is circumferentially incised 5 to 10 mm peripheral to the tumor with electrocautery. (B) A combination of blunt and sharp dissection with Metzenbaum scissors is used to excise the tumor with a small rim of normal parenchyma. (C) Bleeding vessels are controlled, and the collecting system is closed. (D) The defect is reconstructed using Nu-Knit bolsters and pledgets. (From Smith JA Jr, Howards SS, Preminger GM, eds. *Hinman's atlas of urologic surgery.* 3rd ed. Philadelphia, PA: Saunders; 2012.)

The renal capsule is circumferentially incised 5 to 10 mm peripheral to the tumor with electrocautery. Using a combination of blunt and sharp dissection with Metzenbaum scissors, the tumor is excised with a small rim of normal parenchyma. The specimen is inspected for visible tumor at the resection margin, then submitted for frozen-section analysis.

Bleeding vessels are controlled with figure-of-eight sutures or with argon beam or bipolar electrocautery. The deep resection margin of the kidney must be inspected for any residual tumor or any sign of collecting system injury. If there is any doubt about collecting system injury, 10 to 20 mL of diluted indigo carmine is injected into the renal pelvis while occluding the ureter to assess for leaks. The collecting system is closed with a 4-0 absorbable suture on a tapered needle.

The renal parenchymal defect is reconstructed using Nu-Knit bolsters and pledgets as described earlier. Fibrin glue is applied to the renal parenchymal defect. Finally, the renal vessels are unclamped—if the renal vein and the renal artery is clamped, the renal vein is unclamped first, followed by unclamping the renal artery.

Segmental Nephrectomy for Large Polar Tumors

Intravenous mannitol and furosemide are administered, and the renal pedicle is completely dissected, including the segmental branches (Fig. 101.42, eFig. 101.43). A bulldog clamp is applied to the apical segmental artery (or basilar segmental artery for lower pole tumors), and the line of ischemia is observed. The avascular line can be further demarcated by injecting 5 mL of indigo carmine directly into the clamped artery (eFig. 101.44). The line of ischemia is the optimal site for transection of the kidney and should be lightly marked with electrocautery. The apical segmental artery is ligated, then the renal pedicle is clamped en bloc with a curved Satinsky clamp. A plastic bag or sheet is placed around the kidney and filled with ice slush to cool the kidney to 20° C (approximately 15 minutes). The renal capsule is incised along the line of ischemia with electrocautery. Using blunt dissection, the pole of the kidney is excised (Fig. 101.45). Bleeding vessels are controlled, working expeditiously and accurately. The clamp is released to check for uncontrolled bleeders. If hemostasis is adequate, collecting system repair is begun; otherwise the pedicle is reclamped and vascular control resumed.

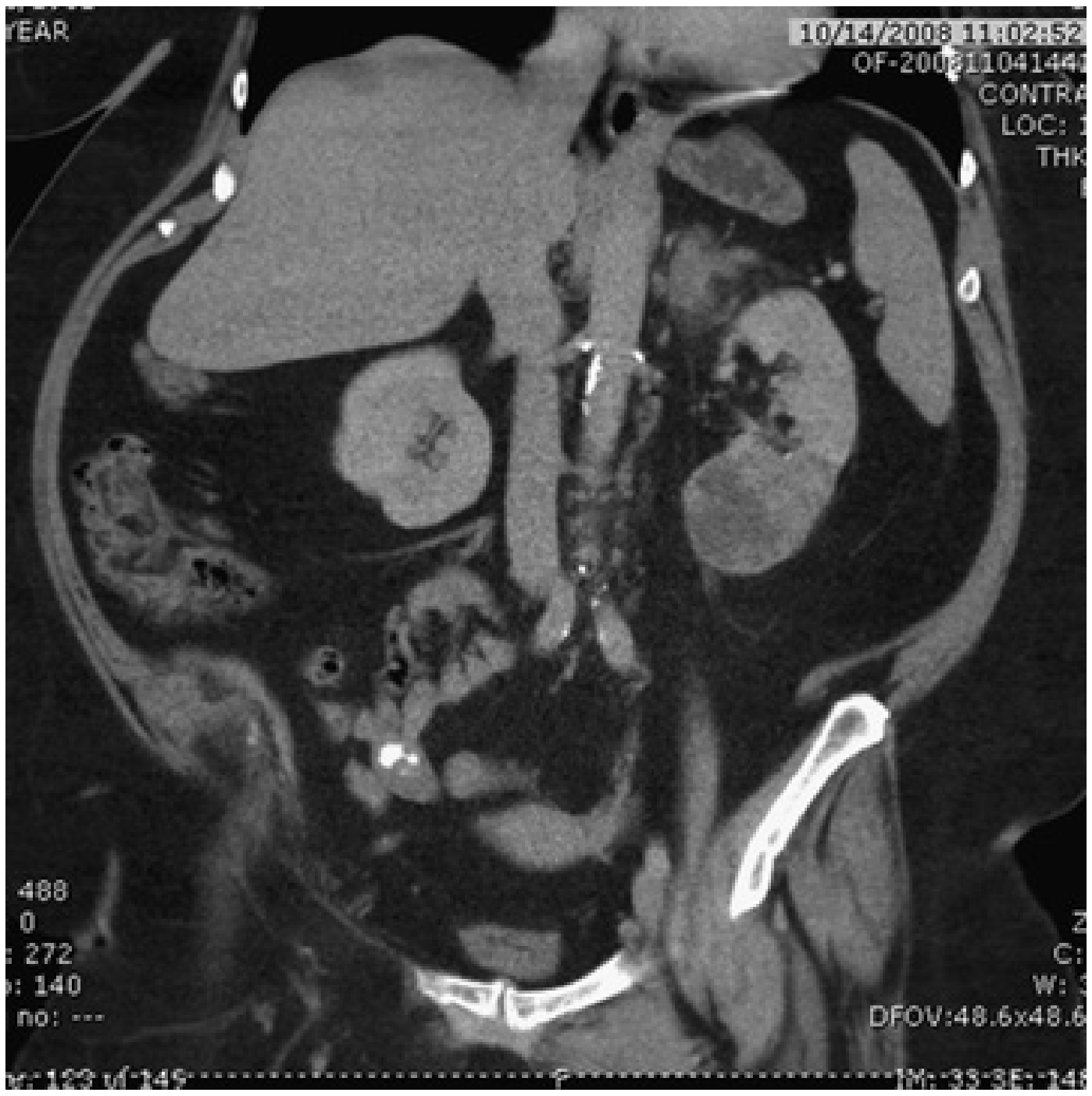
EAR
10/14/2008 11:02:52
OF-20081104144
CONTRA
LOC:
THK
488
0
: 272
: 140
no: ---
Z
C:
W:
DFOV:48.6x48.6

FIG. 101.42 Left renal mass in the lower pole on computed tomography scan.

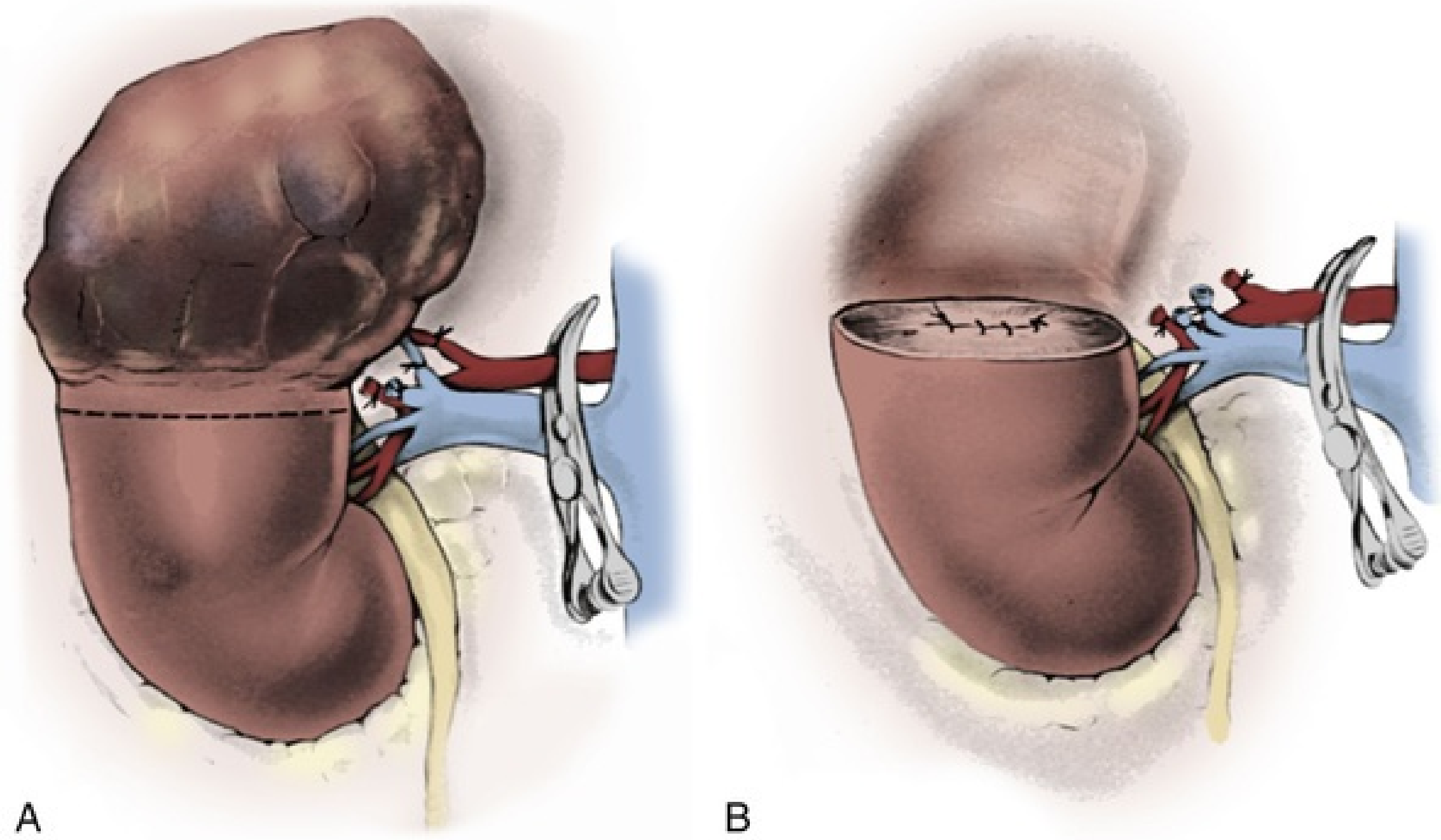

FIG. 101.45 (A and B) Technique of transverse resection for a tumor involving the upper half of the kidney. (From Novick AC: Partial nephrectomy for renal cell carcinoma. *Urol Clin North Am* 14:419, 1987.)

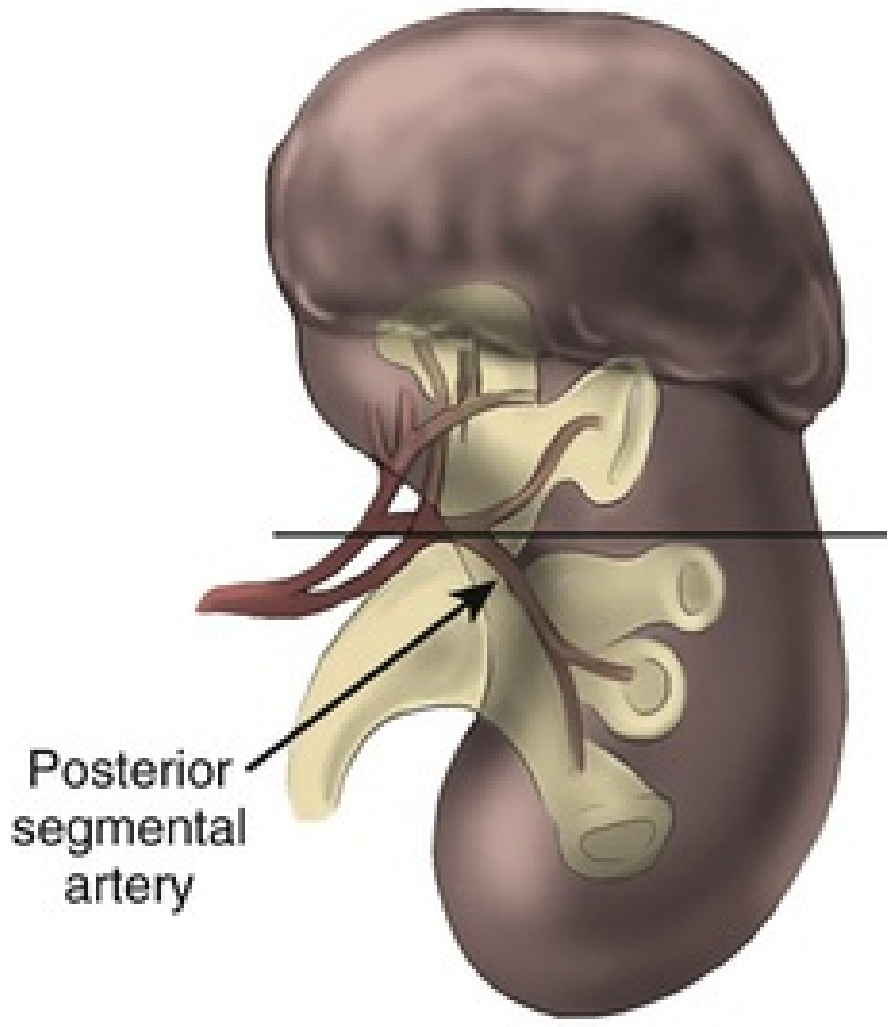

EFIG. 101.43 Injury to the posterior segmental artery must be avoided.

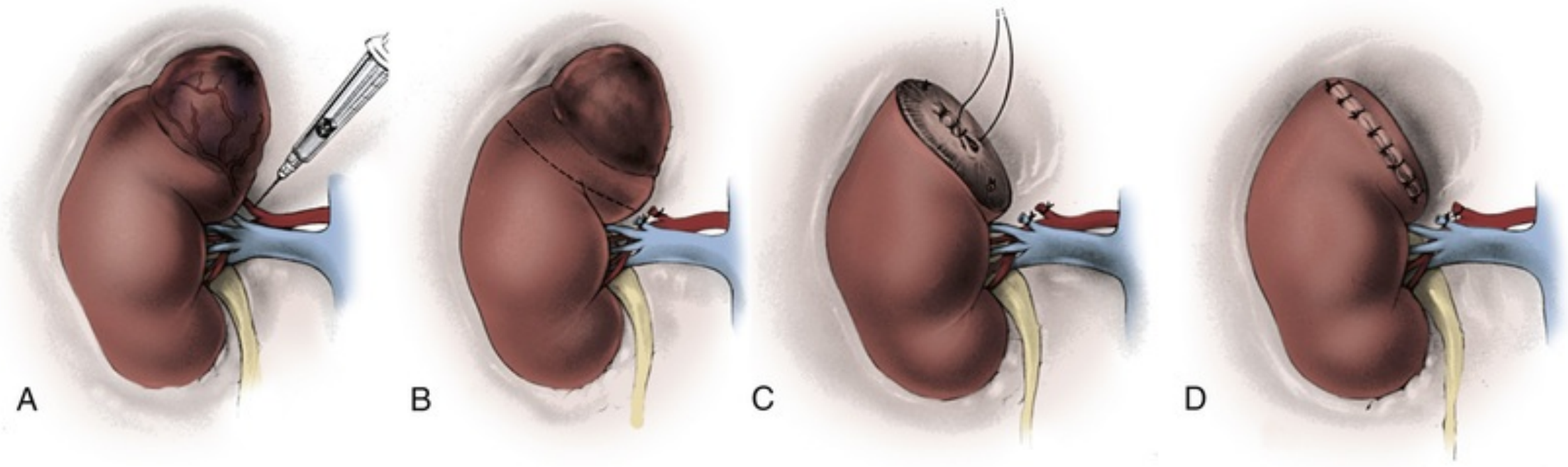

EFIG. 101.44 (A to D) Technique of segmental (apical) polar nephrectomy with preliminary ligation of apical arterial and venous branches. (From Novick AC. Partial nephrectomy for renal cell carcinoma. *Urol Clin North Am* 14:419, 1987.)

The collecting system is inspected for injury. If the defect in the collecting system is large, a guidewire is inserted into the defect and manually guided into the ureter and bladder. A 6-Fr double-J ureteral stent is inserted over the guidewire with the proximal coil in the renal pelvis. The collecting system is closed with a running 4-0 absorbable noncutting suture.

The renal capsule is closed using Nu-Knit pledgets and horizontal mattress sutures as described earlier. Because the defect is large, we use a larger needle (e.g., XLH, GS-27) for segmental polar nephrectomies and heminephrectomies than for enucleation and wedge resections. Nephropexy should be considered if the kidney is quite mobile; however, injury to retroperitoneal nerves overlying the psoas and quadratus lumborum muscles must be avoided (eFig. 101.46). The kidney is covered with perirenal fat and renal fascia, and a closed suction drain is placed to monitor output postoperatively. The indwelling Foley catheter is removed when the patient is mobile and stable. Depending on the output of the closed suction drain, it can be removed 5 to 10 days postoperatively. If a ureteral stent is used, it should not be removed for 4 to 6 weeks postoperatively. After removal of the indwelling Foley catheter, if the output of the closed suction drain is increased, the transurethral indwelling Foley catheter is reinserted to reduce the intrapelvic urine pressure, which should minimize the output from the closed suction drain.

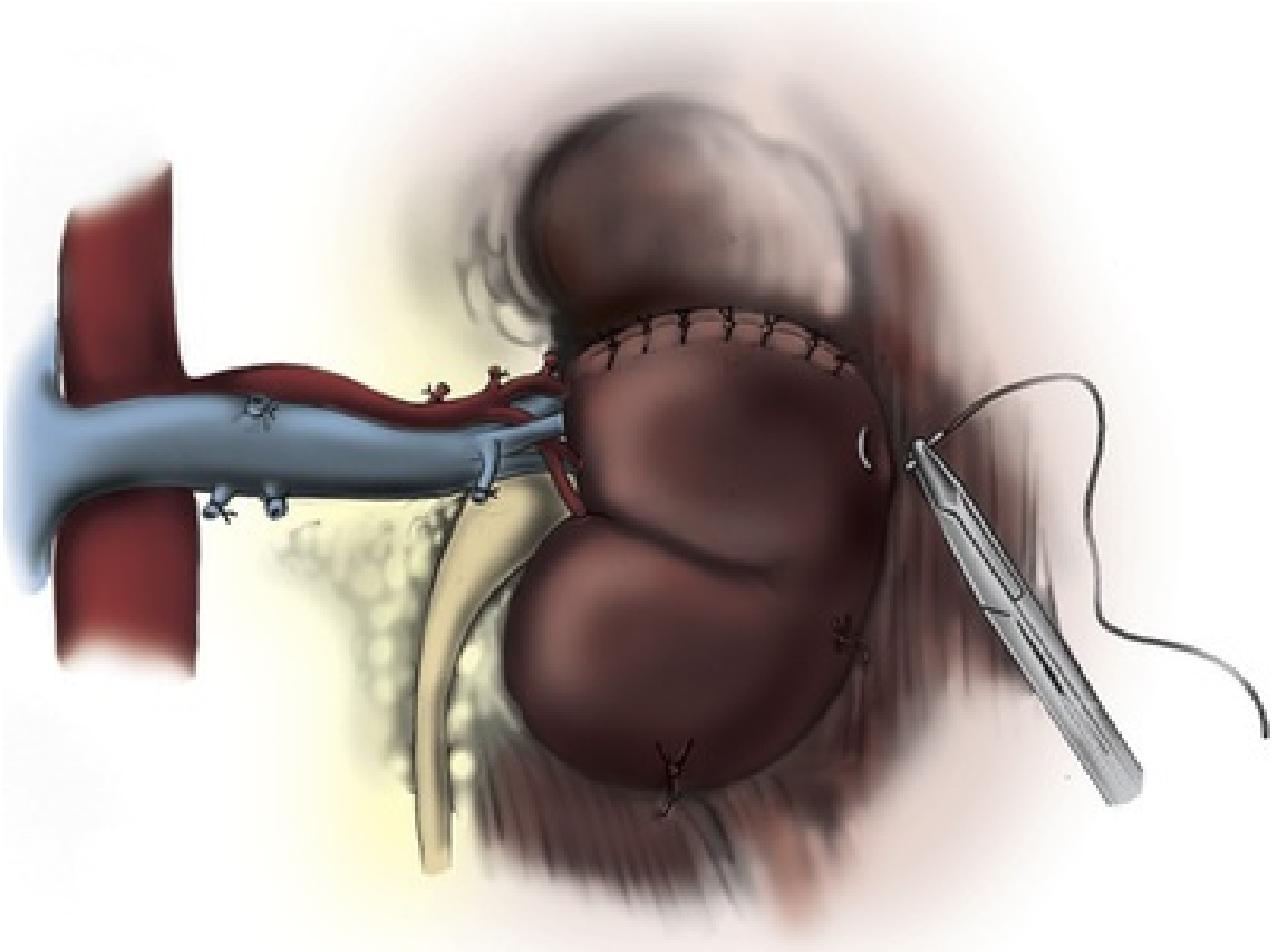

EFIG. 101.46 Nephropexy of the remnant kidney to the retroperitoneum is achieved with several interrupted sutures.

Complications Associated With Partial Nephrectomy

Urinary Fistulae.

Partial nephrectomies that involve incision of the collecting system, because of the size and location of the tumor, increase the possibility of urinary leakage. Most urinary fistulae present themselves in about 1 week postoperatively. Therefore, in cases of deep renal resections, it is advisable to keep the closed suction abdominal drain in place for 7 to 10 days. If a urinary fistula is suspected, the diagnosis is confirmed by checking the effluent for creatinine, which will be present at a level manyfold higher than the serum creatinine level. Alternatively, an intravenous ampule of indigo carmine, when injected and collected in the closed suction drain, can also confirm the diagnosis.

If a closed suction drain is not present and a urinary fistula is suspected, a urinary collection in the retroperitoneum can become symptomatic. Abdominal imaging is used to confirm the diagnosis. The treatment of urinary fistulae requires three tubes: (1) a retroperitoneal closed suction drain to collect the urinoma, (2) a double-J ureteral stent that is placed after retrograde pyelography, and (3) a Foley catheter to keep the entire collecting system at low pressure. Most fistulas resolve within 4 to 6 weeks with conservative management, and reoperation is rarely required.

Postoperative Bleeding.

Delayed bleeding can occur following partial nephrectomy, particularly in patients who require postoperative anticoagulation therapy. If a drain is in place, initial management is conservative and consists of bed rest, hydration, close clinical monitoring, and serial evaluations of blood counts. In situations in which more than 1 to 2 units of transfused blood products are required, renal angioembolization should be attempted. Usually, bleeding segmental and subsegmental arteries can be selectively embolized and the kidney salvaged without need for complete nephrectomy. Life-threatening hemorrhage can also occur and require complete angioinfarction of the kidney or reoperative exploration.

Renal Insufficiency.

Acute renal failure may follow partial nephrectomy in a solitary kidney, related to large size of the tumor, excessive removal of renal parenchyma, and prolonged ischemic time. Obstruction of the collecting system, drug toxicity, vascular thrombosis, and vascular disruption are other causes that should be considered. Although most cases of postoperative renal insufficiency are mild and temporary, some cases require hemodialysis for electrolyte and fluid management. Hyperfiltration injury can also cause a gradual decrease in renal function over time, typically associated with proteinuria.

Vena Caval Thrombectomy

Tumor thrombus within the venous drainage system of the kidney can occur with many retroperitoneal tumors. In children, Wilms tumor, clear cell sarcoma of the kidney, adrenocortical carcinoma, and neuroblastoma can all be associated with IVC thrombi. In adults, urothelial carcinoma of the renal pelvis, lymphoma, retroperitoneal sarcoma, adrenocortical carcinoma, pheochromocytoma, and angiomyolipoma are all potential sources of an IVC thrombus. RCC is the most common cause associated with IVC tumor thrombus, accounting for 18% of all tumors that have venous thrombi (Blute et al., 2004b). The two components associated with IVC thrombi are tumor thrombus (tumor cells contained within bland thrombus) and bland thrombus (blood coagulum without tumor cells). Venous drainage is hampered by venous thrombus encouraging formation of bland thrombus. Distinction between these two forms of venous thrombus is critical and forms the basis of operative management for IVC thrombi.

Management of a tumor with an associated IVC thrombus can be technically challenging. In the case of RCC with venous thrombus, 10% have associated positive regional lymph nodes, 25% have associated metastases, and 50% have perirenal fat invasion. Usually, IVC thrombectomy is accompanied by radical nephrectomy and regional lymph node dissection.

Preoperative Considerations

Pulmonary Embolism, Anticoagulation, and IVC Filters.

Patients with renal tumors are at increased risk for pulmonary embolism as a result of malignancy-associated hypercoagulability and venous thrombus embolization. We suggest anticoagulation with intravenous or low-molecular-weight heparin to be started as soon as tumor thrombus is detected. Although evidence supporting the use of preoperative anticoagulation is limited, several potential benefits include reduced risk for pulmonary embolism, tumor thrombus shrinkage, and bland thrombus shrinkage and/or prevention. Temporary suprarenal IVC filters are also an option for patients with level 0, I, and II tumor thrombi. However, because of the risk for contralateral renal and hepatic vein thrombosis, the risk for provoking embolization, and the impediment that these devices can pose to future IVC thrombectomy, we do not recommend use of suprarenal IVC filters. Given the risk for intraoperative thrombus detachment and the possibility of interval thrombus growth in the period immediately preceding surgery, we recommend the use of transesophageal echocardiography (TEE) for level II to IV thrombi.

Preoperative angioembolization can be considered because tumor thrombi have an independent blood supply arising from the renal artery and/or aorta in one-third of cases. Angiographic infarction of the blood supply to the tumor thrombus can help shrink a large thrombus to a more manageable size, potentially avoiding the need for bypass or extensive mobilization of the liver. Angioembolization can be considered when caval thrombi appear to invade the IVC, when the thrombus invades the intrahepatic or suprahepatic veins and cannot be excised, when the thrombus is associated with a bleeding kidney, and when deep hypothermic arrest is planned because the patency of the coronary arteries can be simultaneously assessed. The optimal timing for angioembolization is unknown, but it is usually performed 1 day before surgery at most centers. There is a potential risk for causing iatrogenic pulmonary embolization of the tumor thrombus when angiography is performed; however, this risk appears to be minimal. We seldom use angioembolization, but it is associated with ischemia-related flank pain and tumor lysis syndrome.

Urologists who do not routinely handle the IVC and aorta should consult a vascular surgeon for level II and III thrombi to aid in vena caval control and reconstruction. Consultation with a cardiothoracic surgeon preoperatively for all level III and IV thrombi is essential because access to the mediastinal compartment for vascular bypass and thrombus removal may be required. Involvement of a cardiologist or cardiac anesthesiologist is essential for level II to IV thrombi to allow for intraoperative TEE.

Tumor Thrombus Level.

Traditionally, IVC thrombi have been defined and managed according to the cranial extent of the tumor thrombus (Fig. 101.47). MRI provides excellent overall assessment of the level of tumor thrombus involvement; however, reconstructed CT angiograms can also produce excellent images to determine the level of the tumor thrombus. Assessment of the bland thrombus, a grouping system that complements the traditional tumor thrombus levels, can help with intraoperative decision making (Tables 101.1 and 101.2). The key addition of this grouping system is the consideration of the location and extent of bland thrombus and its impact on IVC management (Fig. 101.48).

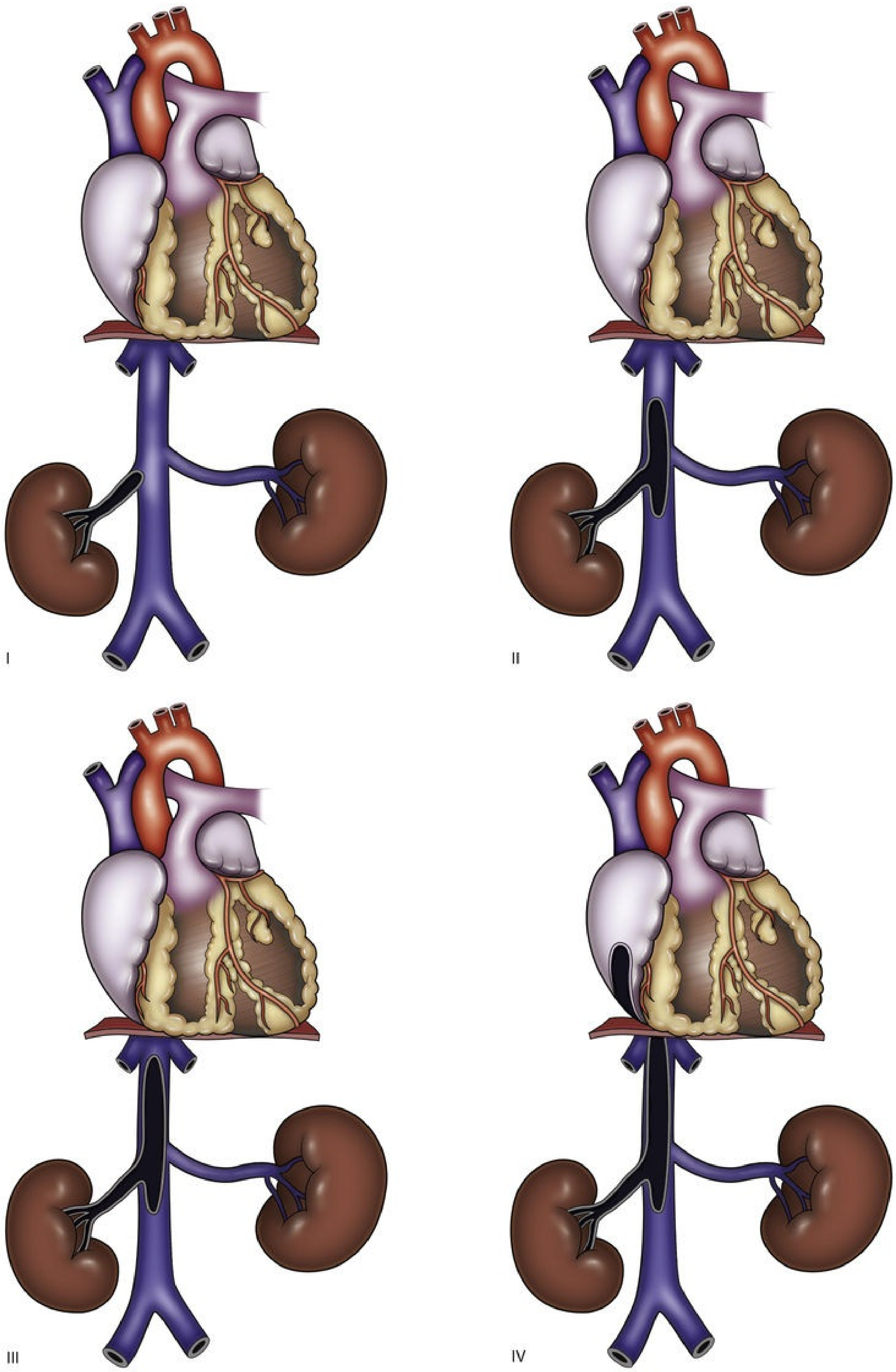
I
II
III
IV

FIG. 101.47 (I to IV) Classification of venous tumor thrombus extension. (From Wang GJ, Carpenter JP, Fairman RM, et al. Single-center experience of caval thrombectomy in patients with renal cell carcinoma with tumor thrombus extension into the inferior vena cava. *Vasc Endovasc Surg* 42:335–40, 2008.)

TABLE 101.1

Traditional Staging and Management of Inferior Vena Caval Thrombi

THROMBUS LEVEL	INCIDENCE RATE IN RCC	PROPORTION OF THROMBI	CRANIAL EXTENT OF THROMBUS	MANAGEMENT OF TUMOR THROMBUS
0	12%	65%	Confined to renal vein	Radical nephrectomy
I	2%	10%	Within 2 cm of renal vein ostium	IVC milking, partial IVC occlusion, ostial cavotomy
II	3%	15%	Below hepatic veins	Complete IVC mobilization/control, infrahepatic cavotomy
III	1%	5%	Between hepatic veins and diaphragm	Complete occlusion: suprahepatic IVC clamping, infrahepatic cavotomy
				Partial occlusion: venovenous bypass, infrahepatic cavotomy
IV	1%	5%	Above diaphragm	Deep hypothermic arrest, infrahepatic cavotomy, right atriotomy

IVC, Inferior vena cava; *RCC,* renal cell carcinoma.

Data from Blute ML, Leibovich BC, Lohse CM, et al. The Mayo Clinic experience with surgical management, complications and outcome for patients with renal cell carcinoma and venous tumour thrombus. *BJU Int* 94:33–41, 2004.

TABLE 101.2

The Mayo Clinic Thrombus Grouping System for Inferior Vena Caval

Thrombi

MAYO THROMBUS GROUP	INCIDENCE RATE IN RCC	PROPORTION OF THROMBI	ASSOCIATED BLAND THROMBUS	ADDITIONAL IVC MANAGEMENT
A	17%	90%	None	None
B	<1%	1%	At or below common iliac veins	Infrarenal IVC filter (e.g., Greenfield)
C	1%	5%	Infrarenal IVC, separate from tumor thrombus	Infrarenal IVC interruption with vena caval clip
D	0.5%	4%	Infrarenal IVC, mixed with tumor thrombus	Infrarenal IVC resection

IVC, Inferior vena cava; *RCC,* renal cell carcinoma.

Data from Blute ML, Leibovich BC, Lohse CM, et al. The Mayo Clinic experience with surgical management, complications and outcome for patients with renal cell carcinoma and venous tumour thrombus. *BJU Int* 94:33–41, 2004.

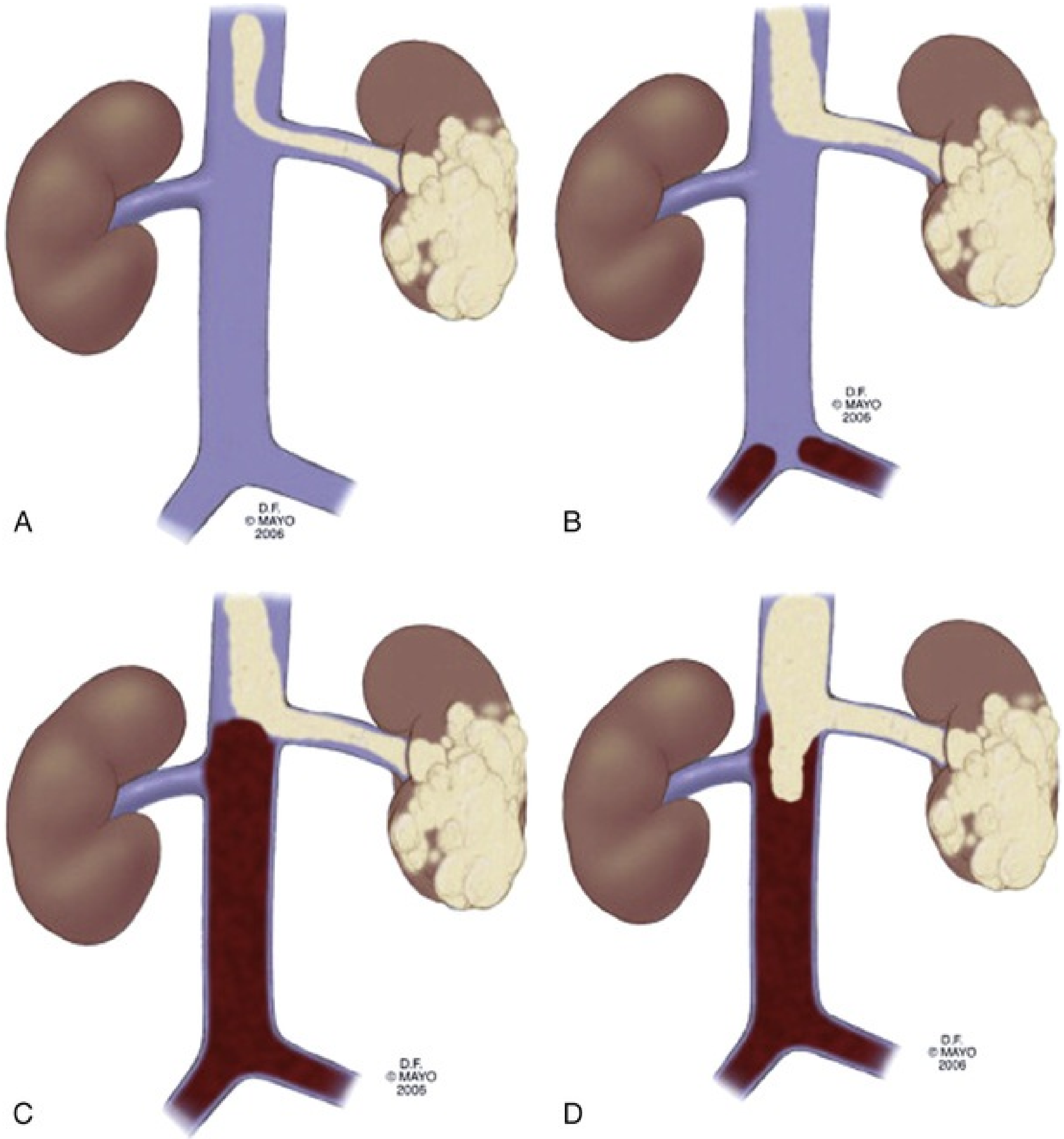

FIG. 101.48 (A to D) Mayo Clinic classification scheme for IVC interruption based on degree of venous occlusion and bland thrombus. (From Blute ML, Boorjian SA, Leibovich BC, et al. Results of inferior vena caval interruption by Greenfield filter, ligation or resection during radical nephrectomy and tumor thrombectomy. *J Urol* 178:440-5, 2007. Reprinted with permission of Mayo Foundation for Medical Education and Research. All rights reserved.)

Level I Vena Caval Thrombectomy: Right-Sided Tumor

Usually, level I thrombi are partially occlusive, are nonadherent, and do not require extensive IVC dissection or any form of bypass. Some groups mobilize the kidney after the thrombectomy is complete, to minimize the risk for embolization, while others mobilize the kidney first followed by thrombectomy.

Using an anterior midline, anterior subcostal, or modified flank incision, access is gained to the kidney as previously described. The great vessels and the renal hilum are exposed. Using care not to manipulate the renal vein or IVC too much, the renal artery is identified in the interaortocaval region and secured with a 0 silk ligature or a large clip. Ligating the renal artery early will help reduce the blood flow to the kidney and minimize the amount of potential blood loss. The kidney is mobilized outside the renal fascia, and the IVC is dissected above the right renal vein. The left renal vein, suprarenal IVC, and infrarenal IVC are identified and secured with vessel loops. To help with temporary ligation of these vessels, 3- to 6-inch portions of an 18-Fr red rubber catheter are passed through the vessel loop and used as Rummel tourniquets (eFig. 101.49). Although this degree of vascular control may not be necessary for all level I thrombi, it is prudent to have adequate vascular control if there is any doubt about the extension of the level of thrombus. Starting cranially, the IVC is gently pinched closed, and then the Rummel tourniquets are applied so that the infrarenal IVC, left renal vein, and suprarenal IVC are closed in that order. The IVC is milked with the left hand toward the ostium of the right renal vein. A C-shaped Satinsky vascular clamp is placed around the ostium of the right renal vein partially occluding the IVC (Fig. 101.50), ensuring that the thrombus is located within the jaws of the clamp before complete closure. The IVC is palpated for evidence of any other thrombus. Suction and two sponge sticks (to compress the IVC if necessary) are readied, and laparotomy sponges are placed around the renal vein to collect any spillage of tumor thrombus after opening of the renal vein. The renal ostium is circumferentially incised using a scalpel or fine-tipped Metzenbaum or Potts scissors. At least one-half of the width of the IVC must be maintained for proper closure.

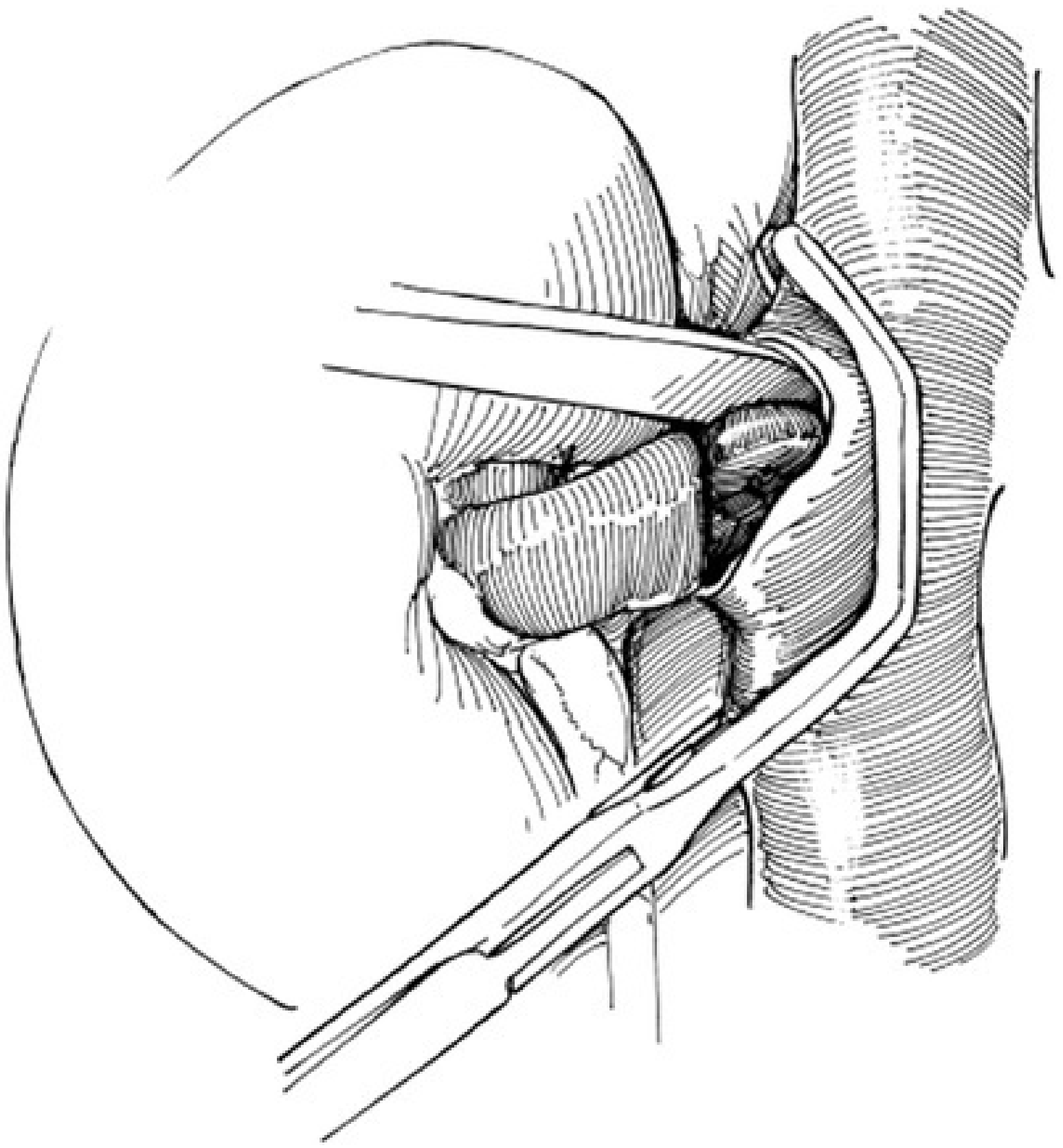

FIG. 101.50 Right-sided level I tumor thrombus. A C-shaped Satinsky vascular clamp is placed around the ostium of the right renal vein, partially occluding the inferior vena cava. (From Smith JA Jr, Howards SS, Preminger GM, eds. *Hinman's atlas of urologic surgery.* 3rd ed. Philadelphia, PA: Saunders; 2012.)

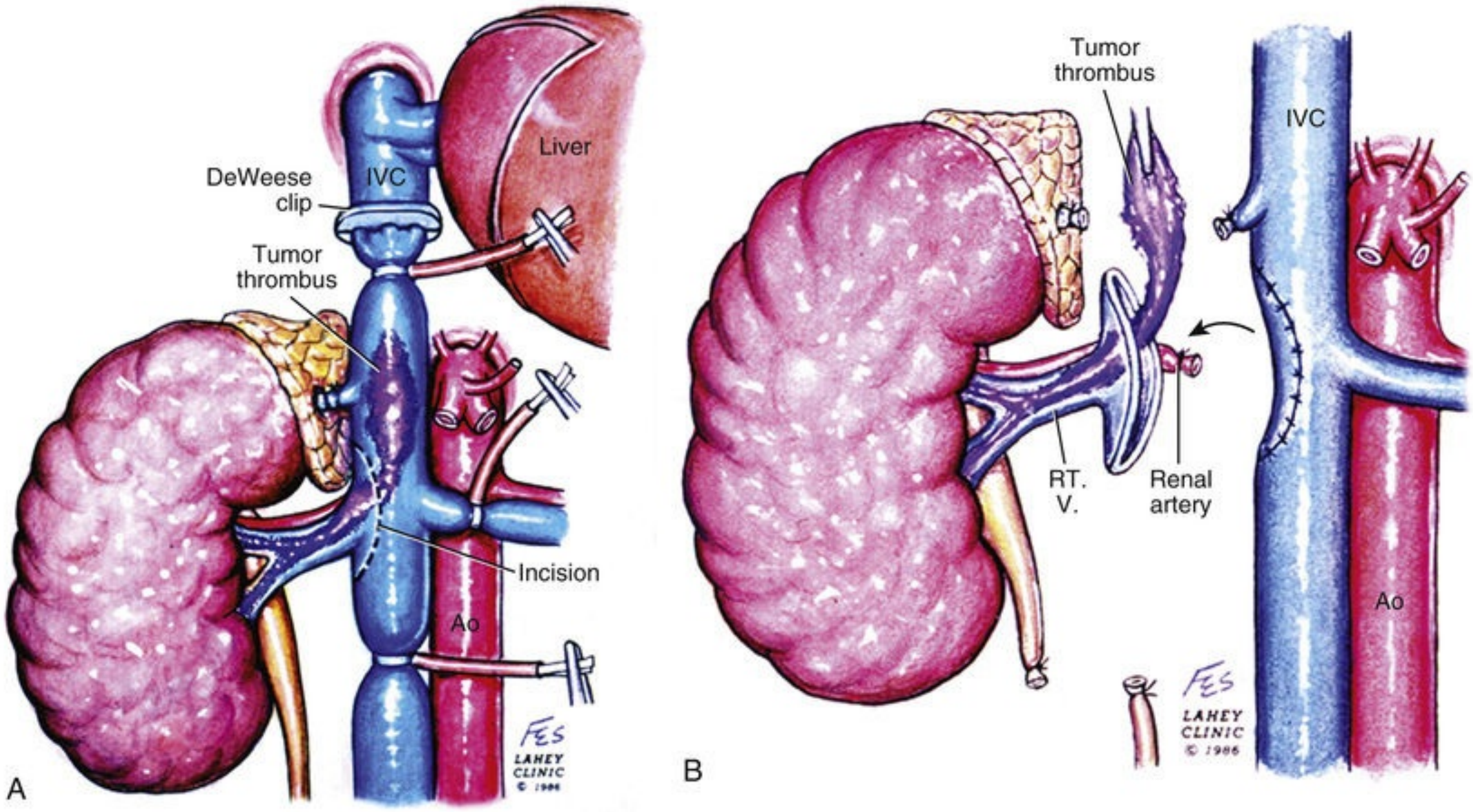
DeWeese clip
IVC
Liver
Tumor thrombus
Incision
Ao
FES LAHEY CLINIC © 1986
A
Tumor thrombus
IVC
RT. V.
Renal artery
Ao
FES LAHEY CLINIC © 1986
B

EFIG. 101.49 (A and B) Technique for removing infrahepatic tumor thrombus with assistance of Rummel tourniquets, avoiding cardiopulmonary bypass. *Ao,* Aorta; *IVC,* inferior vena cava; *RT. V.* right vein. (© The Lahey Clinic.)

The thrombus is extracted by gentle downward traction on the renal vein. A gauze is wrapped around the renal vein stump and secured with a silk ligature to prevent tumor spillage (Fig. 101.51). The medial attachments of the kidney are dissected, ligating the renal artery again before division.

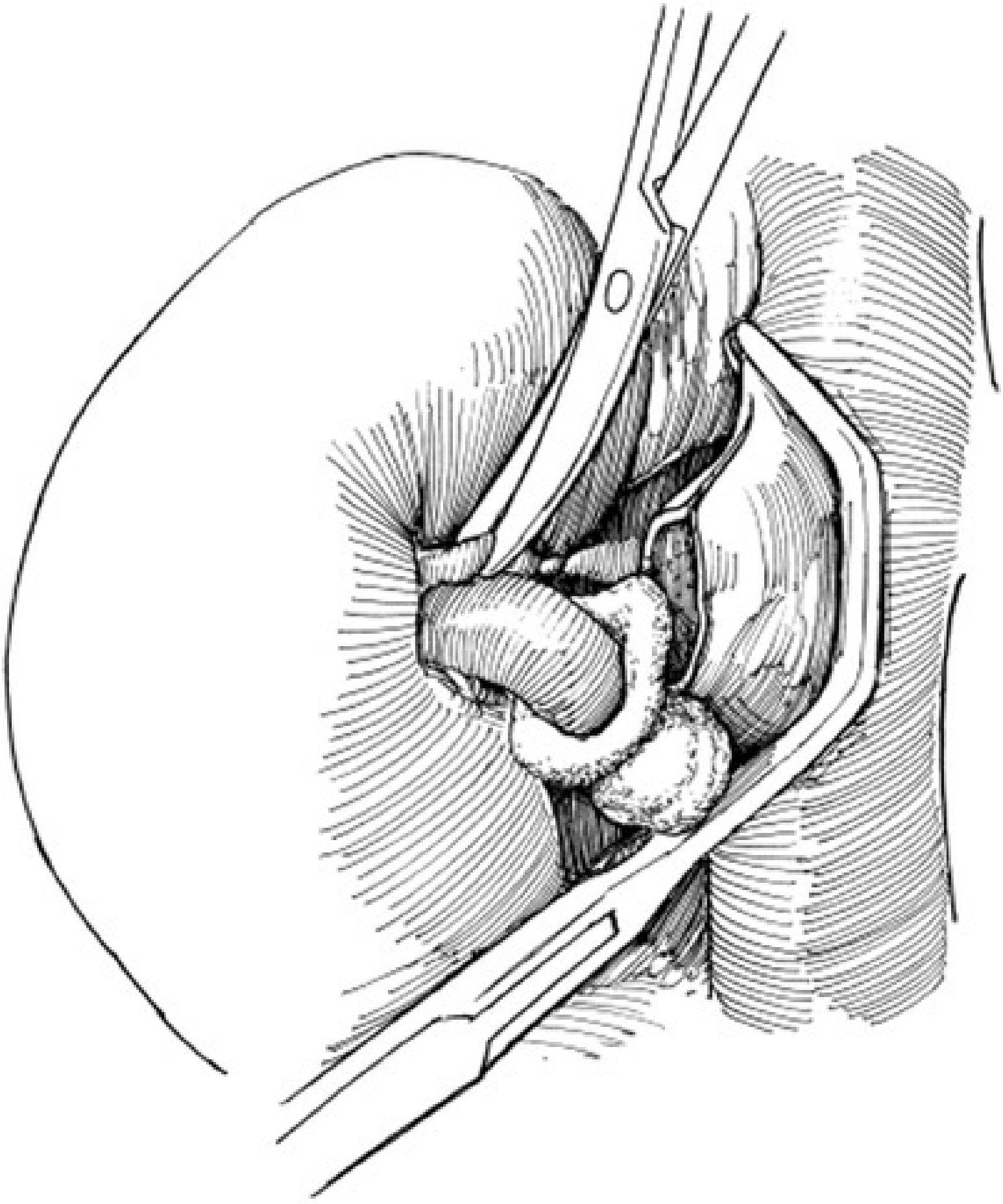

FIG. 101.51 Right-sided level I tumor thrombus. Preventing tumor spillage. (From Smith JA Jr, Howards SS, Preminger GM, eds. *Hinman's atlas of urologic surgery.* 3rd ed. Philadelphia, PA: Saunders; 2012.)

The IVC is inspected for evidence of residual thrombus, irrigating its lumen with heparinized saline solution (100 units/mL) for improved visualization. The IVC defect is closed with a running closure using a 4-0 Prolene suture on a BB vascular needle (Fig. 101.52). Before tying the knot, the anesthesiologist should apply positive airway pressure, pinch the infrarenal IVC closed, and then release the Satinsky clamp. The surgeon should allow 5 to 10 mL of blood to escape from the caval defect to flush out any residual thrombus fragments and debris before pulling the suture tight and tying the closure. A right regional lymphadenectomy is performed, irrigating the wound copiously with sterile water. The surgeon may consider placement of a closed suction catheter to monitor for bleeding.

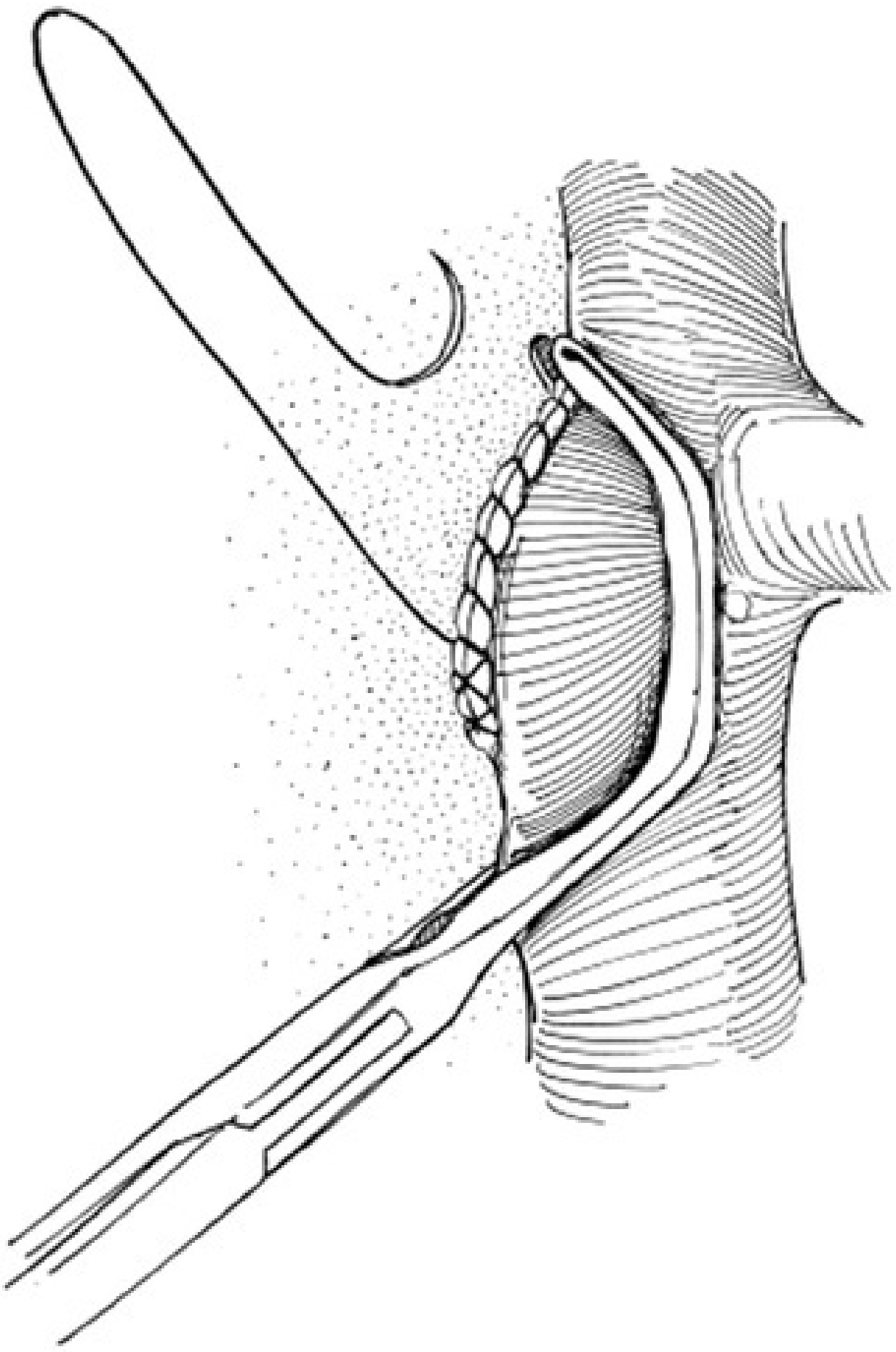

FIG. 101.52 Right-sided level I tumor thrombus. Closing the inferior vena cava defect. (From Smith JA Jr, Howards SS, Preminger GM, eds. *Hinman's atlas of urologic surgery.* 3rd ed. Philadelphia, PA: Saunders; 2012.)

Level II Vena Caval Thrombectomy: Left-Sided Tumor

Exposure for a tumor thrombus associated with a left-sided tumor is more difficult because the IVC is best accessed from the right retroperitoneum. Both the right and the left colon must be mobilized to get adequate exposure. The anterior midline and chevron incisions provide the best access for left-sided tumors associated with tumor thrombi in the IVC.

After a subcostal chevron incision is made, the left colon is mobilized and the left anterior pararenal space is developed. The left renal artery is then identified and ligated near its origin close to the aorta. The adrenal, lumbar, and gonadal branches of the left renal vein are ligated and divided. These branches are often dilated and friable and occasionally contain thrombi. The kidney is mobilized outside the renal fascia, and the ureter is divided.

The right colon and small bowel are mobilized, the Kocher maneuver is performed, and the right anterior space is developed and the great vessels are exposed. The IVC is carefully dissected to its bifurcation, ligating the right gonadal vein on its anterior surface. Vascular control is obtained sequentially in the following order: (1) the ipsilateral (left) renal artery is ligated, (2) the infrarenal IVC is clamped, (3) the contralateral (right) renal vein is clamped, (4) the suprarenal IVC is clamped, and (5) accessory hepatic veins are ligated to the caudate lobe (this is an optional maneuver to gain 2 to 3 cm of extra infrahepatic IVC exposure) (eFig. 101.53). Optionally, one can clamp the contralateral renal artery to prevent renal engorgement while the venous outflow is temporarily clamped. This is more of an issue for left-sided tumors because the right kidney does not have significant venous collateralization to shunt blood when the right renal vein is clamped. While obtaining vascular control, one must be very gentle to avoid dislodging the thrombus. The lumbar veins are ligated and divided as required. Before clamping, some may use 0.5 mg/kg of intravenous heparin to prevent clamp-related thrombotic complications. Our experience has been that bleeding, not clotting, is the principal problem encountered with vena caval thrombectomy, and we do not routinely heparinize our patients.

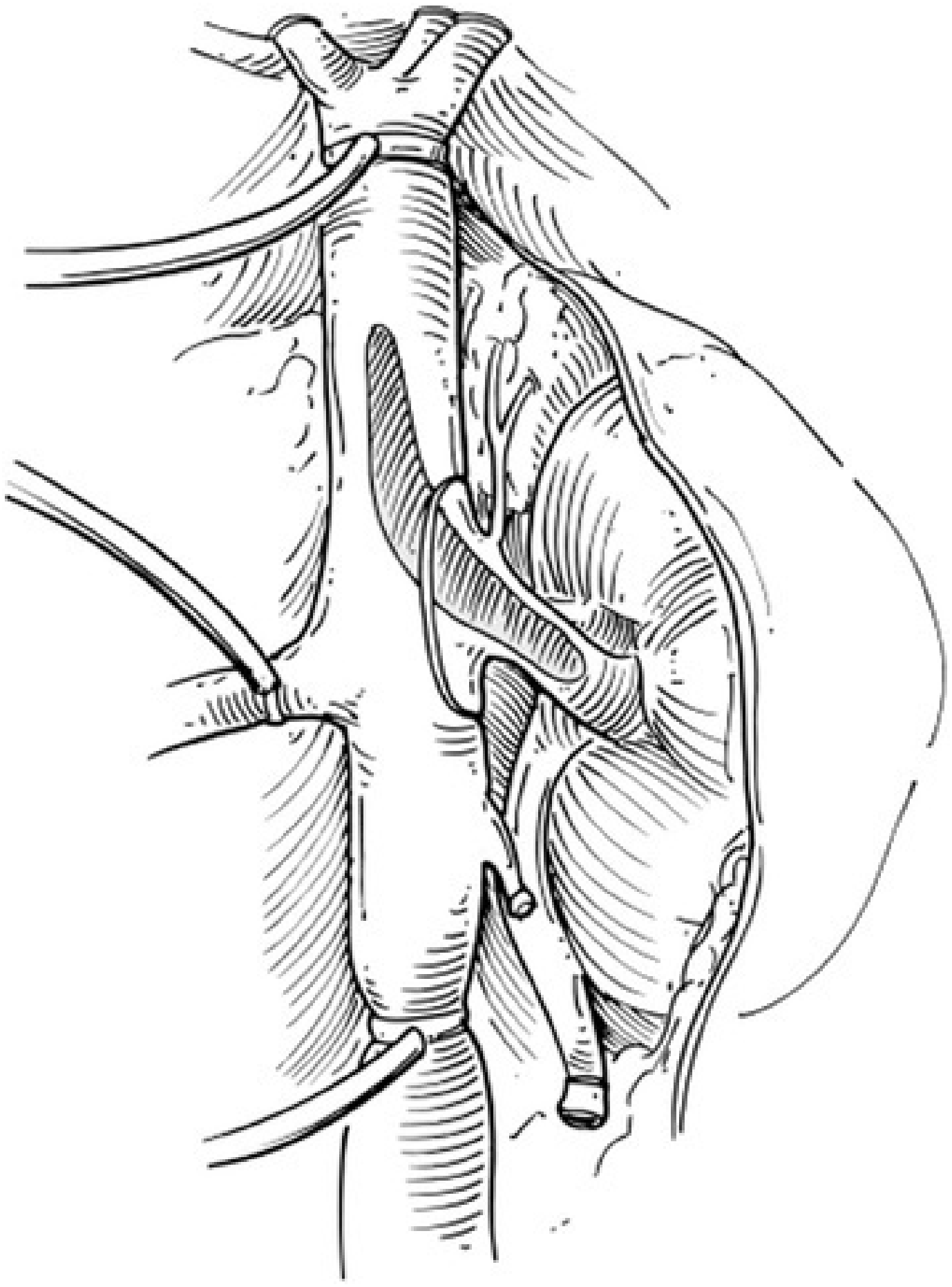

EFIG. 101.53 Left-sided level II tumor thrombus. (From Smith JA Jr, Howards SS, Preminger GM, eds. *Hinman's atlas of urologic surgery.* 3rd ed. Philadelphia, PA: Saunders; 2012.)

The renal vein ostium is circumferentially excised, and the incision is extended superiorly onto the anterior surface of the IVC using Potts scissors (Fig. 101.54). A Penfield dissector is used to carefully extract the tumor thrombus from the IVC. Lumbar veins can be a source of troublesome bleeding at this stage and should be ligated or sutured as needed. The gross tumor thrombus and kidney are removed en bloc. The IVC is flushed with heparinized saline solution, and the intima is inspected for signs of caval invasion. Any suspicious areas should be biopsied or resected. The IVC lumen can be safely narrowed to about 50% of its preoperative size without requiring special measures. The caval defect is closed with a running 4-0 Prolene suture. Before tying the knot, the infrarenal clamp is released and 5 to 10 mL of blood is allowed to seep from the cavotomy to clear the IVC of air and debris. After tying the suture, the contralateral renal clamp is released followed by the suprarenal IVC clamp. Regional lymphadenectomy is performed, consideration is given to leaving a closed suction drain, and the wound is irrigated and the incision closed.

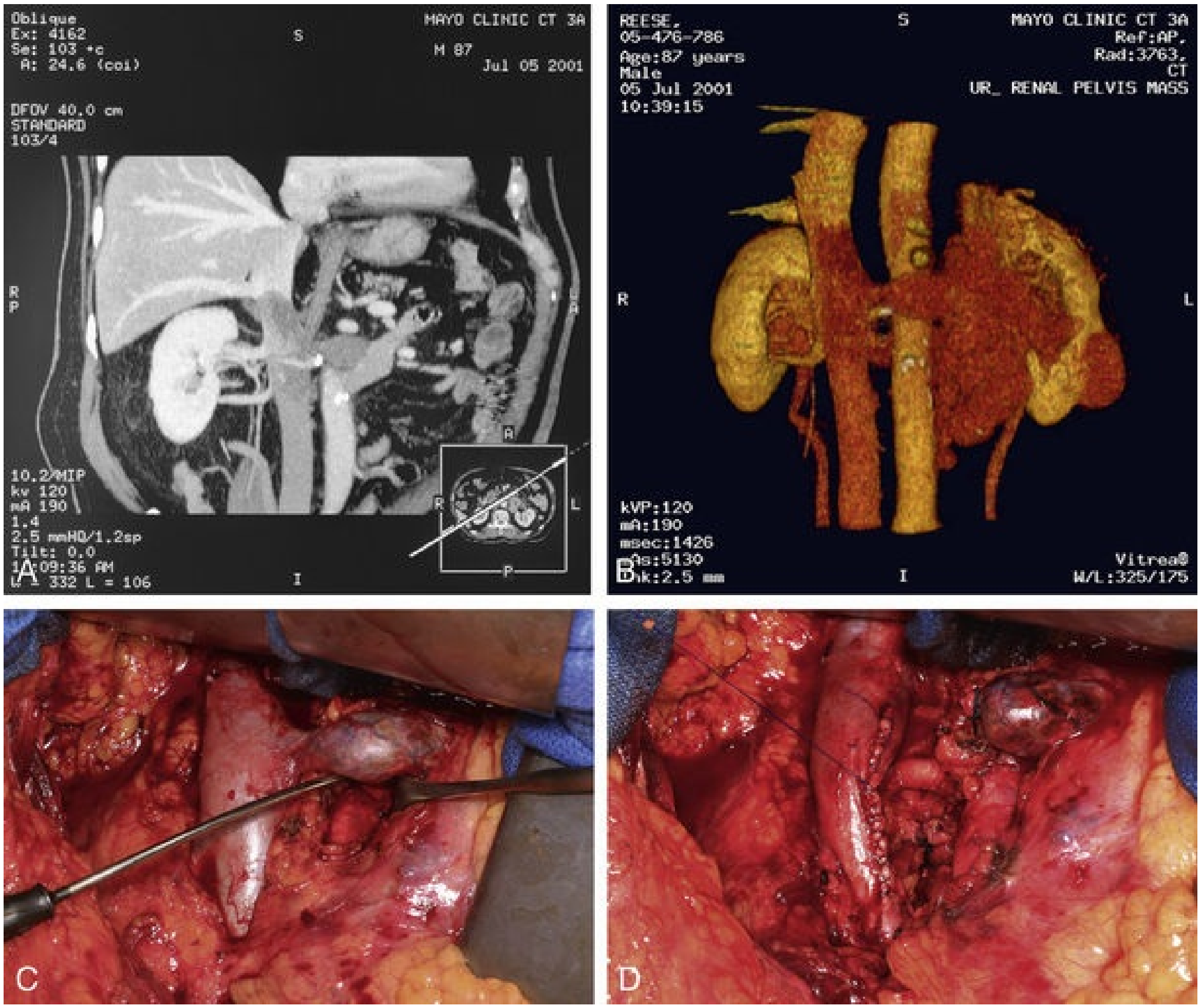
Oblique
Ex: 4162
Se: 103 +c
A: 24.6 (coi)
S
MAYO CLINIC CT 3A
M 87
Jul 05 2001
DFOV 40.0 cm
STANDARD
103/4
R
P
10.2/MIP
kv 120
mA 190
1.4
2.5 mmHQ/1.2sp
Tilt: 0.0
10:09:36 AM
W = 332 L = 106
I
A
R
L
P
REESE,
05-476-786
Age:87 years
Male
05 Jul 2001
10:39:15
S
MAYO CLINIC CT 3A
Ref:AP.
Rad:3763.
CT
UR_ RENAL PELVIS MASS
R
L
kVP:120
mA:190
msec:1426
mAs:5130
Thk:2.5 mm
I
Vitrea®
W/L:325/175
A
B
C
D

FIG. 101.54 Coronal computed tomography scan (A) and three-dimensional reconstruction (B) of a level II left-sided tumor thrombus. (C) Securing vascular control. (D) Repair of inferior vena caval defect.

Level III-IV Vena Caval Thrombectomy: Intra-Abdominal Approach

Intrahepatic tumor thrombi are very challenging cases to treat. The operating room should be set up for possible cardiopulmonary bypass (CPB), including deep hypothermic arrest. Intraoperative TEE should be available to measure the cranial extent of the thrombus and to monitor the thrombus for fracture and embolization (Fig. 101.55). Cardiac function is evaluated with TEE so that the anesthesiologist can appropriately manage the patient's hemodynamics.

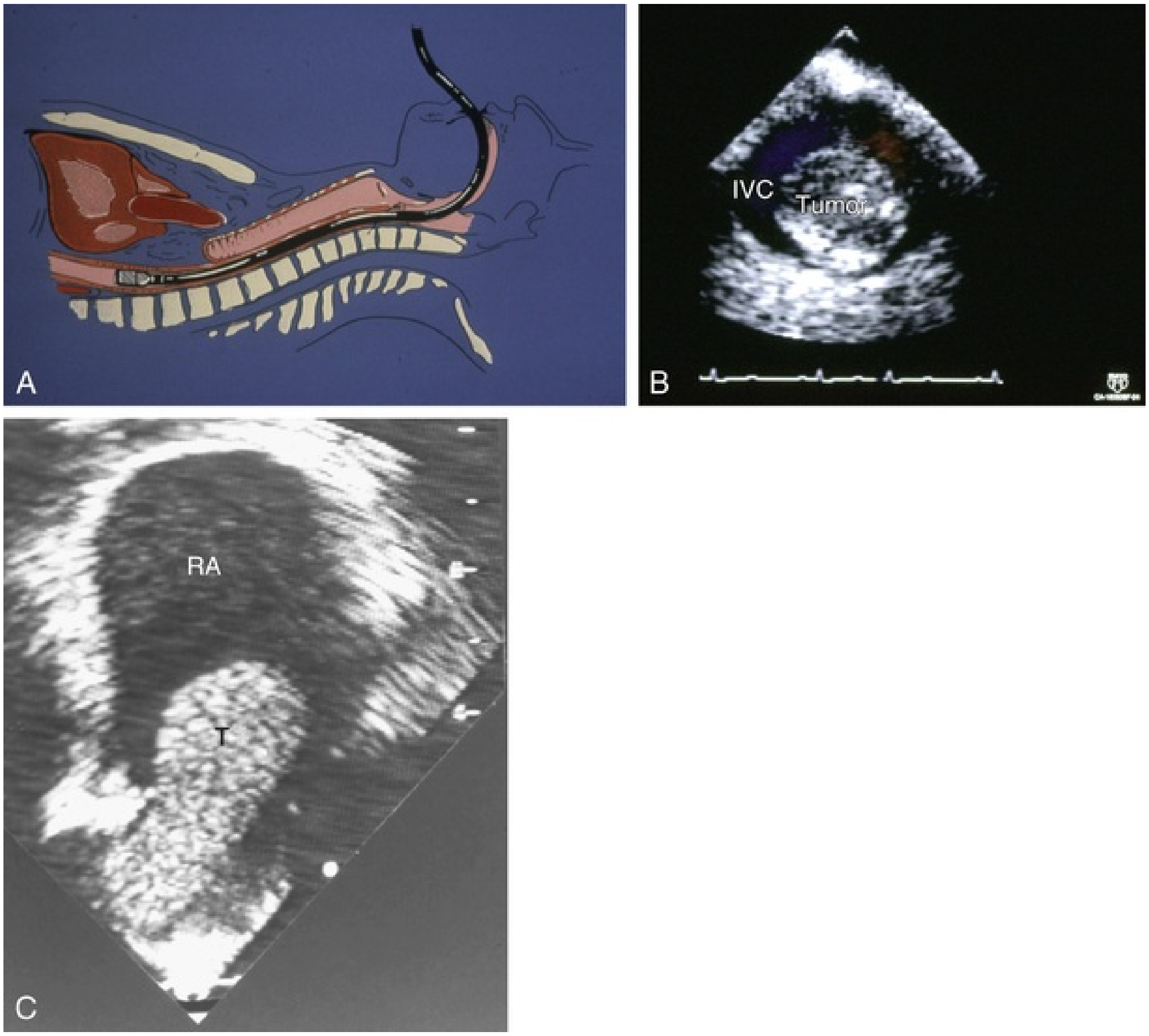

FIG. 101.55 Transesophageal echocardiogram (A) demonstrating a tumor thrombus in the inferior vena cava (B) and right atrium (C). *IVC,* Inferior vena cava; *RA,* right atrium.

The key decision for level III thrombi is whether to attempt an intra-abdominal thrombus extraction with complete hepatic mobilization or use a combined intrathoracic/intra-abdominal approach with bypass. This decision can only be made intraoperatively, after the renal artery is ligated, the liver is mobilized, and the IVC is exposed and evaluated. If the IVC can be clamped below the hepatic veins, this is preferable because the venous return from the liver is significant. As a rule of thumb, patents with free-floating partially occlusive thrombi will not tolerate suprahepatic clamping very well and should probably undergo bypass. Contrarily, patients with completely occlusive thrombi will typically have developed extensive collateral venous drainage networks and therefore tolerate clamping much better (Fig. 101.56). Occasionally, a level IV thrombus can be milked into the abdomen through a small diaphragmatic incision and treated intra-abdominally. It is crucial that IVC control not compromise the operation because bleeding and hypotension can lead to an incomplete tumor resection, a result that is universally fatal. Techniques of bypass are discussed in a later section.

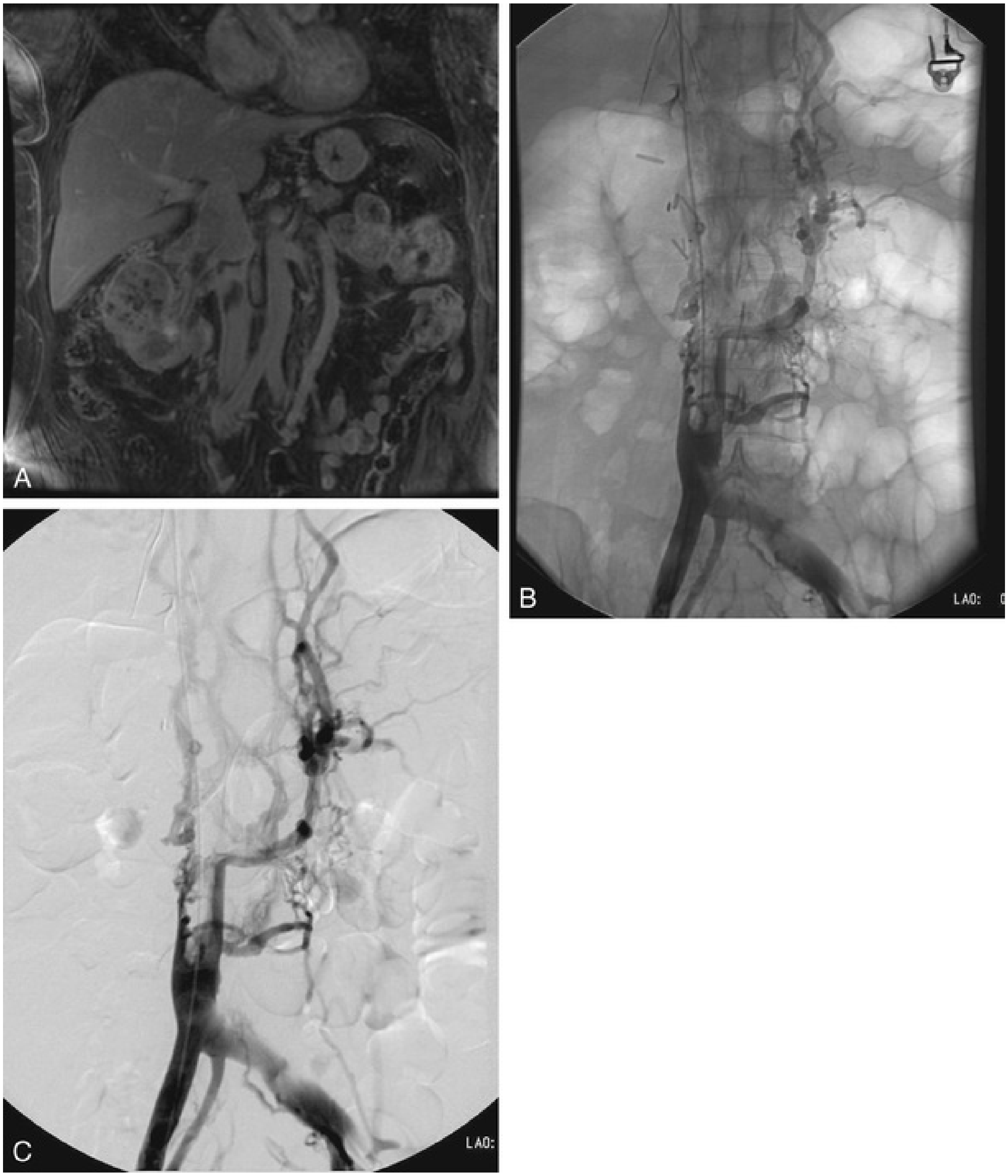

FIG. 101.56 Renal cell carcinoma tumor thrombus causing complete

inferior vena caval occlusion with extensive collateralization to the azygous system demonstrated on computed tomography scan (A) and angiogram (B and C).

We prefer the anterior midline incision for level III and IV thrombi; however, a chevron incision with added sternotomy can also be used. The right kidney and great vessels are exposed as described for a level I thrombus, and the right renal artery is ligated in the interaortocaval area. The infrahepatic IVC is gently dissected. The infrarenal IVC and left renal vein are isolated, and Rummel tourniquets are placed around them.

The liver is mobilized by ligating and dividing the ligamentum teres, the remnant of the obliterated left umbilical vein that is located at the lower free border of the falciform ligament. The falciform ligament is divided with electrocautery up to the upper border of the liver, where it branches into the coronary ligament on the right and the left triangular ligament on the left (see Fig. 101.12). The superior layer of the coronary ligament is divided with scissors or electrocautery, taking care not to injure the liver or the IVC, which is located just behind the ligament in the bare area of the liver. Division of the superior layer of the coronary ligament continues along the right border of the liver until it forms the right triangular ligament (the fused superior and inferior layers of the coronary ligament), which should also be divided. Mobilization of the right lobe of the liver is completed by dividing the inferior layer of the coronary ligament, the attachment that ties the liver to the diaphragm, upward toward the IVC.

The left triangular ligament is divided anteriorly, and hepatic mobilization is completed by dividing the posterior aspects of the left triangular ligament toward the IVC. The right lobe of the liver can now be safely and gently rotated toward the midline so that the IVC can be evaluated on the posterior surface of the liver (Fig. 101.57). For tumors of the left kidney, it may be necessary to divide the diaphragmatic attachments of the spleen so that it can be rotated toward the midline with the pancreas without being traumatized.

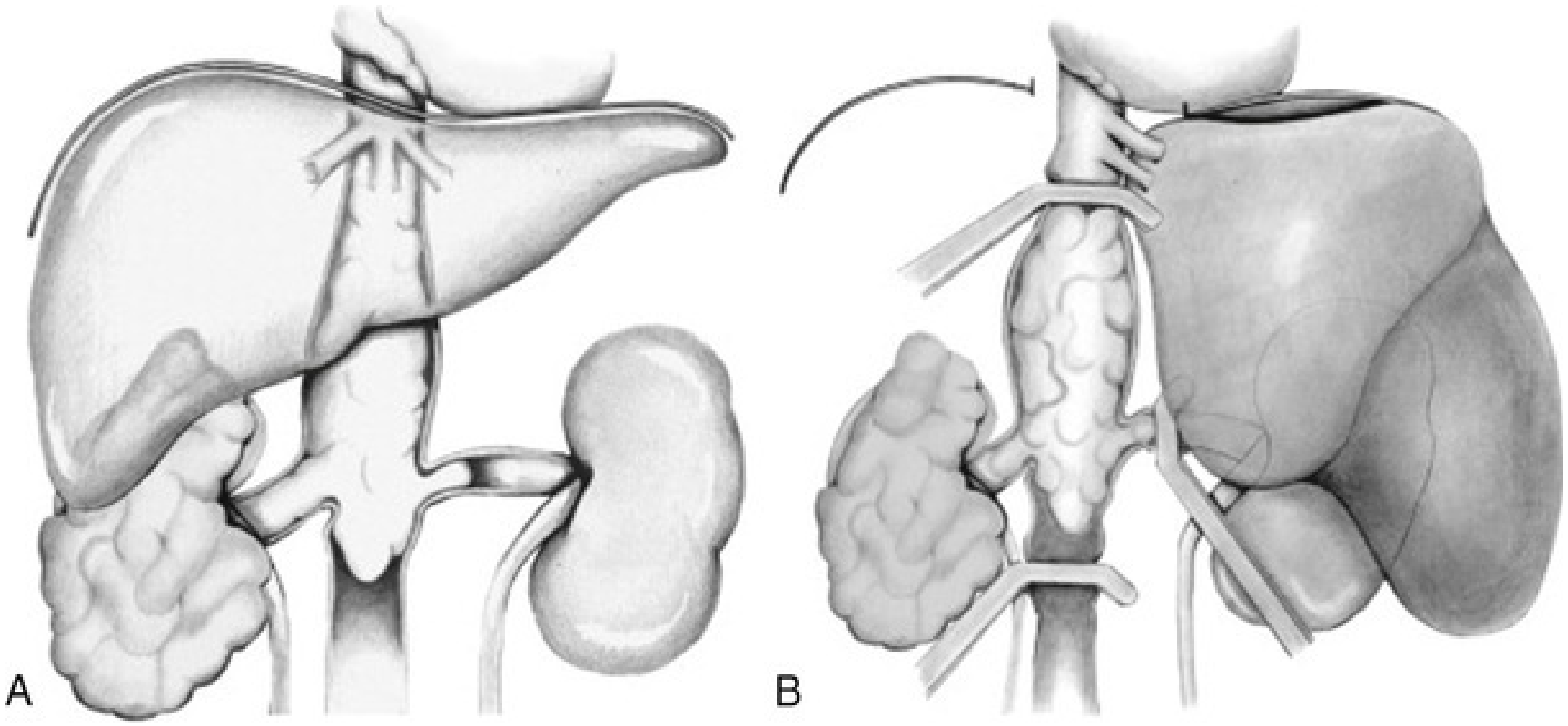

FIG. 101.57 (A and B) Mobilizing the liver to expose the inferior vena cava for management of tumor thrombus. (From Ciancio G, Livingstone AS, Soloway M. Surgical management of renal cell carcinoma with tumor thrombus in the renal and inferior vena cava: the University of Miami experience in using liver transplantation techniques. *Eur Urol* 51:988–95, 2007.)

The plane between the posterior surface of the liver and the anterior surface of the IVC is developed. The help of a hepatic surgeon with this portion of the procedure should be considered. This plane contains venous branches from the liver that are divided into upper and lower groups. The most important group is the upper group that contains the right, middle, and left hepatic veins, the principal outflow from the liver, and therefore cannot be divided. Tumor thrombus can extend into these veins, and they must be carefully inspected and cleared of any thrombus during thrombectomy. Obstruction of these three veins leads to the Budd-Chiari syndrome. The lower group of hepatic veins (the accessory hepatic veins) drain blood principally from the caudate lobe (with a small contribution from the right lobe) and can be safely divided. The accessory hepatic veins are ligated with 2-0 silk, and the plane between the IVC and the liver is developed. Additionally, the lumbar veins are ligated with 2-0 silk, and the plane between the IVC and the posterior abdominal wall is developed. The IVC should now be fully mobilized.

A window is created in the lesser omentum, and the porta hepatis (also called the *portal triad* or *hepatic pedicle*), which contains the portal vein, common hepatic artery, and common bile duct, is encircled with a Rummel tourniquet. Clamping the porta hepatis (the Pringle maneuver) is necessary to prevent massive blood loss if the IVC is clamped above the major hepatic veins (eFig.

101.58). Clamping the IVC above and below the hepatic veins while performing the Pringle maneuver is called *total hepatic vascular occlusion.* If the IVC is clamped below the major hepatic veins and the accessory hepatic veins are ligated, the Pringle maneuver may not be necessary. Under normothermic conditions, the porta hepatis can be clamped for up to 60 minutes, although a clamping time of 20 minutes or less is preferred because ischemic hepatic injury and portal vein thrombosis can ensue. Another complication of the Pringle maneuver is splenic engorgement and rupture as a result of backup of venous drainage from the splenic vein, which normally empties into the portal vein.

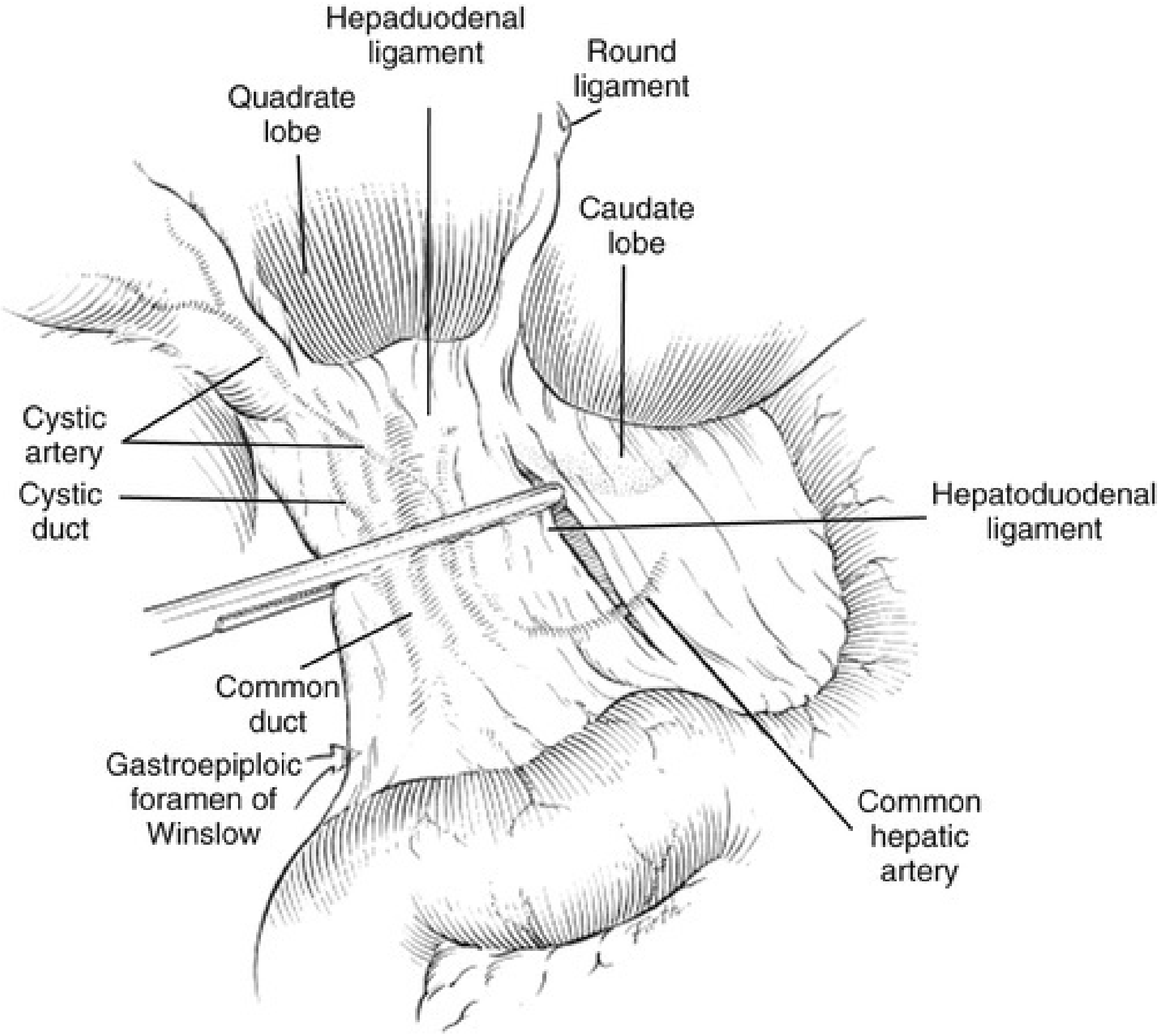
Hepaduodenal ligament
Round ligament
Quadrate lobe
Caudate lobe
Cystic artery
Cystic duct
Hepatoduodenal ligament
Common duct
Gastroepiploic foramen of Winslow
Common hepatic artery

EFIG. 101.58 The Pringle maneuver. (From Asensio J, Trunkey D. *Current therapy of trauma and surgical critical care.* Philadelphia, PA: Mosby; 2008.)

The resectability of the tumor and thrombus is determined using TEE and a thorough intraoperative assessment of the anatomy. If the thrombus is below the hepatic veins or can be milked below these veins, it is usually safe to proceed without bypass. If the thrombus involves the hepatic veins or extends above the liver, bypass is often required (Fig. 101.59). The IVC is occluded above the liver and thrombus, and the patient's hemodynamic response is observed over 2 to 5 minutes. Clamping the suprahepatic IVC results in a 60% reduction in cardiac preload, an 80% increase in peripheral vascular resistance, a 50% increase in heart rate, a 40% drop in cardiac output, and a 10% to 20% drop in mean arterial blood pressure. If the cardiac output drops more than 50% or the mean arterial blood pressure drops more than 30%, the patient will not tolerate suprahepatic IVC clamping. Options for managing this situation include bypass (our preference) and clamping of the supraceliac aorta. If the IVC clamping trial is tolerated and the thrombus can be removed in less than 30 minutes, it is safe to proceed with the intra-abdominal procedure.

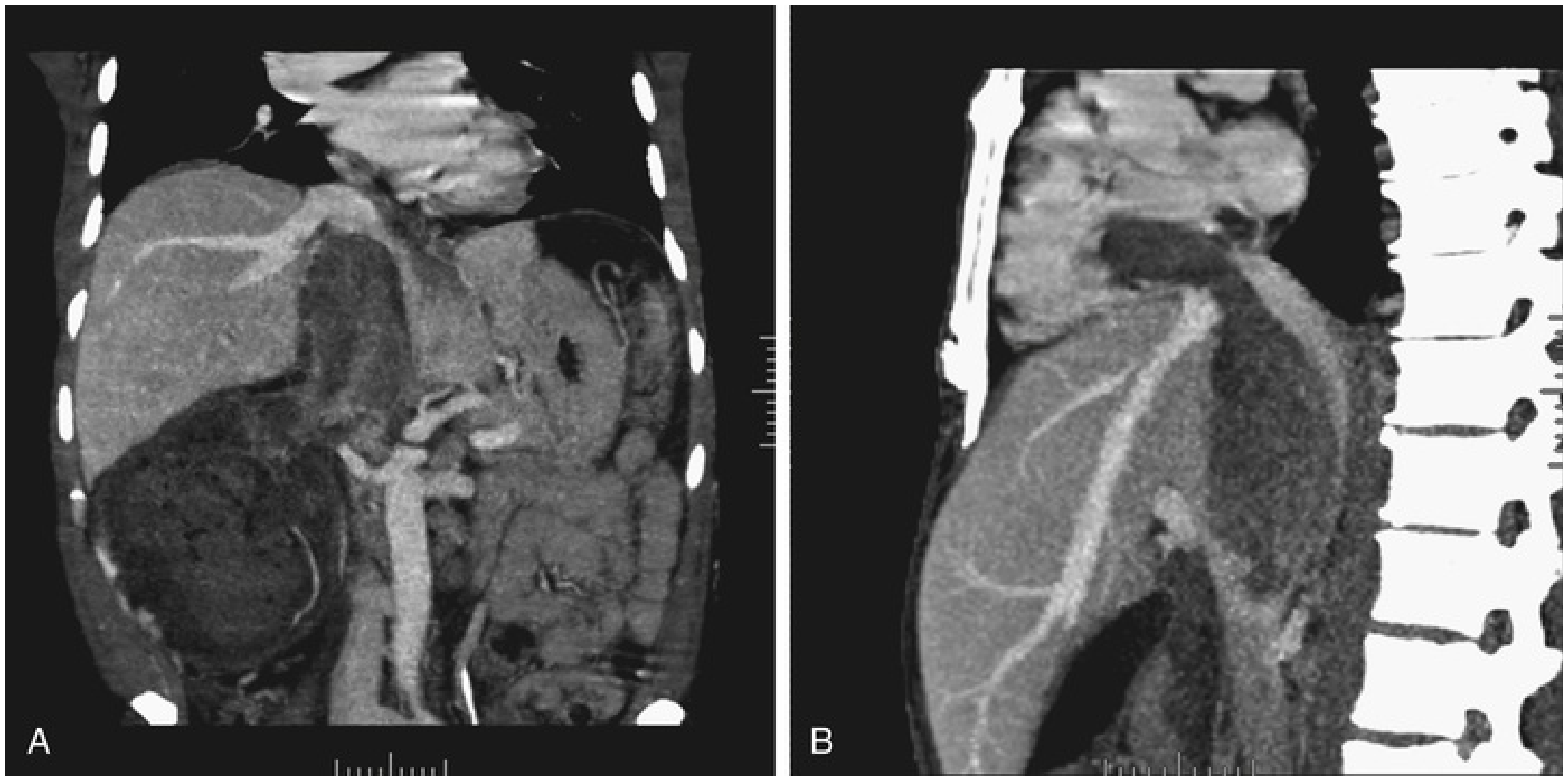

FIG. 101.59 (A) Coronal magnetic resonance image demonstrates tumor extending to the level of the diaphragm. (B) Sagittal magnetic resonance reconstruction demonstrates thrombus that extends farther into the right atrium. The patient would eventually require cardiopulmonary bypass and deep hypothermic circulatory arrest.

In sequence, the infrarenal IVC, the contralateral (left) renal vein, the porta hepatis, and the suprahepatic IVC are clamped. For left-sided tumors, the right renal artery should be clamped before the right renal vein because there is no good collateral venous drainage for the right kidney. The ostium of the right renal vein is circumferentially incised, and the incision is extended upward toward the intrahepatic IVC. The incision should be large enough to permit extraction of all of the tumor thrombus and careful inspection of the intima of the IVC. The thrombus and kidney are excised (Fig. 101.60). With the help of a Penfield dissector, the IVC is cleared of adherent thrombus. A Fogarty balloon catheter (Edwards Lifesciences Corporation, Irvine, CA) or 20-Fr Foley catheter can be used as an embolectomy catheter if the thrombus is out of reach. If involved with tumor that cannot be scraped away, the IVC should be completely or partially resected and reconstructed (see the Patching, Replacing, and Interrupting the Inferior Vena Cava section later in this chapter). During deep hypothermic arrest, a cystoscope can be used to inspect the hepatic veins and suprahepatic IVC, which allows for a smaller caval incision. The IVC is closed as described for level II thrombus. The hepatic ligaments are tacked back into place to prevent torsion of the liver. A regional lymphadenectomy is performed, and a closed suction drain is inserted.

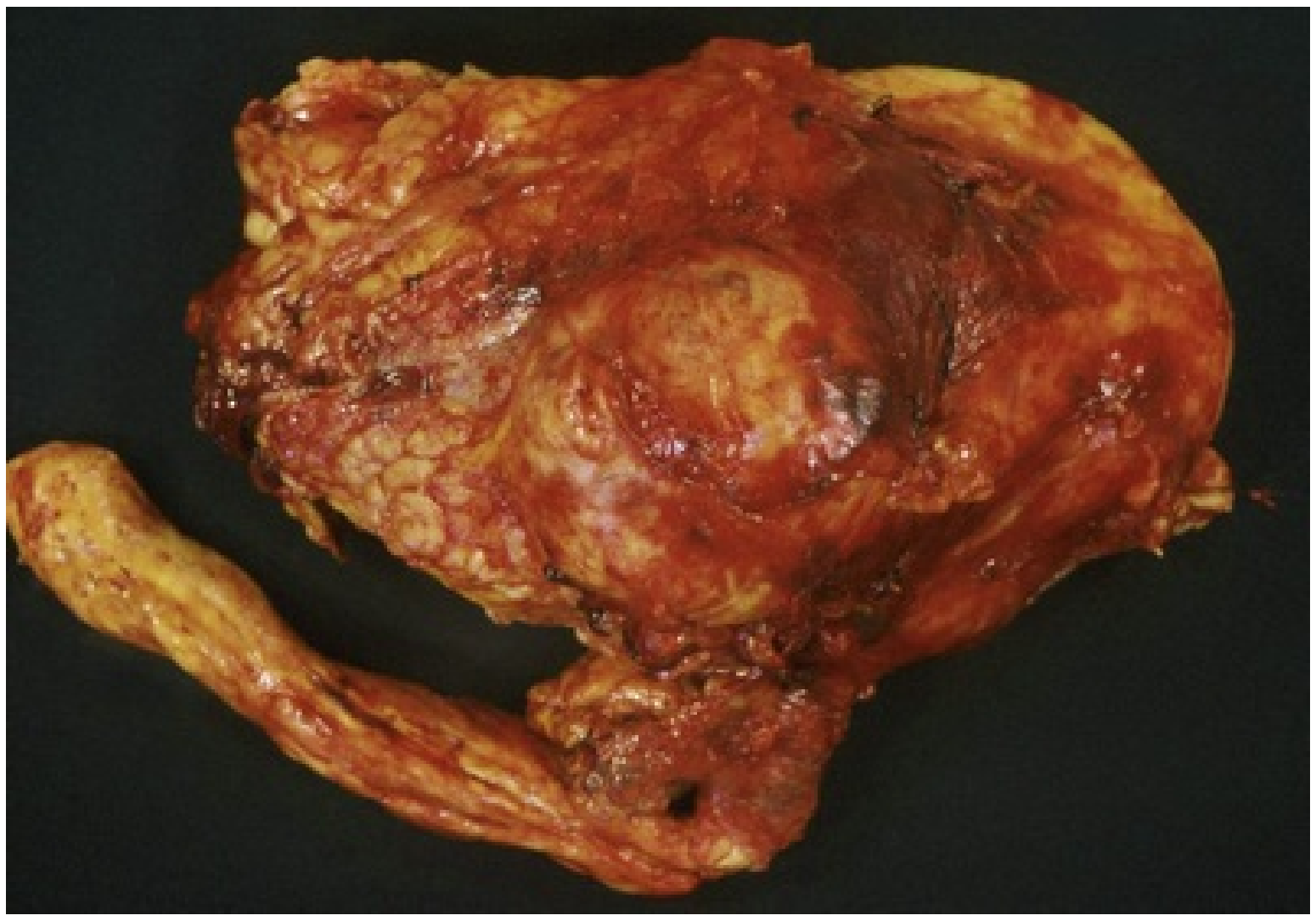

FIG. 101.60 Resected renal mass and intact inferior vena caval thrombus.

Level III-IV Vena Caval Thrombectomy: Combined Intra-Abdominal and Intrathoracic Approach

Level III thrombi that cannot be removed intra-abdominally and most level IV thrombi are managed with a combined intra-abdominal and intrathoracic approach. Thoracoabdominal, chevron laparotomy with sternotomy, and anterior midline laparotomy with sternotomy incisions can be used to provide access to the chest and abdomen (eFig. 101.61). We prefer the anterior midline laparotomy with sternotomy. A cardiothoracic surgeon needs to participate with the planned operation.

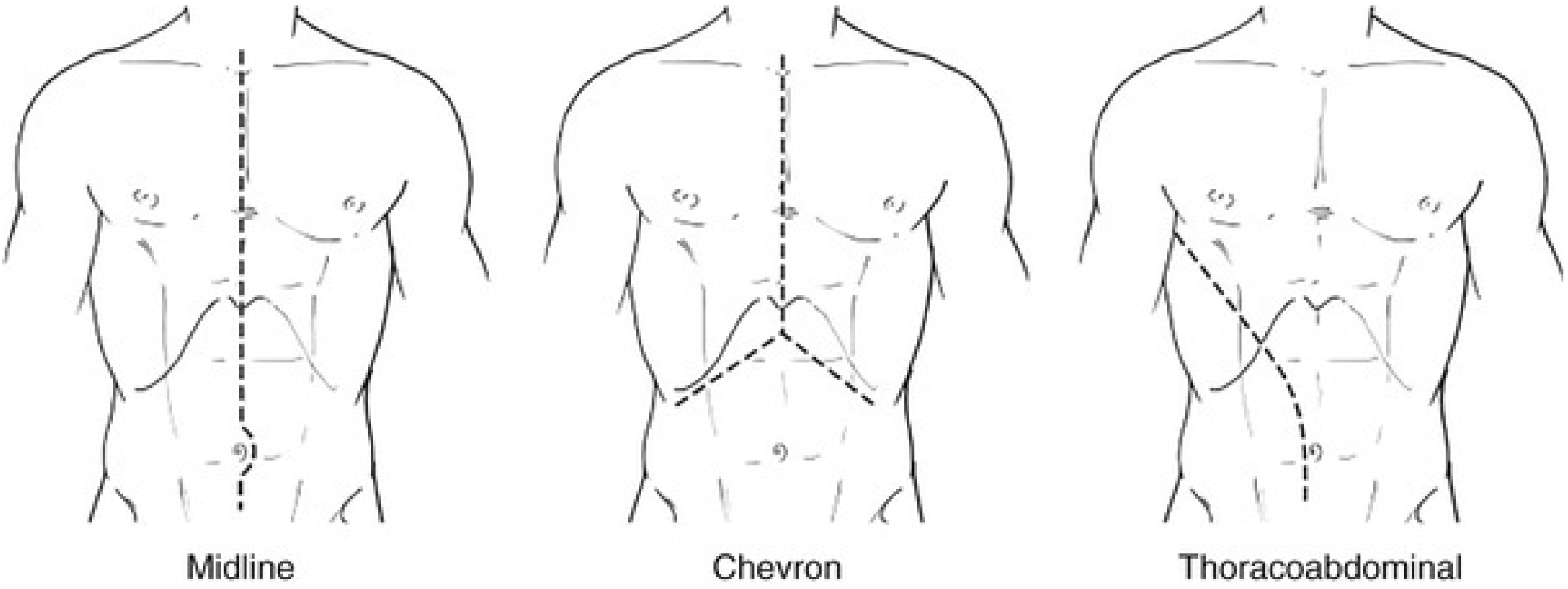

EFIG. 101.61 Surgical incisions for combined intra-abdominal and intrathoracic approach to vena caval tumor thrombi. (From Smith JA Jr, Howards SS, Preminger GM, eds. *Hinman's atlas of urologic surgery.* 3rd ed. Philadelphia, PA: Saunders; 2012.)

The abdominal portion of the case is identical to the intra-abdominal approach described earlier. Once the abdominal phase is completed, the cardiothoracic surgeon is called to the operating room and a median sternotomy is performed. The pericardium is opened, and the right heart is exposed. Often, mobilization of the liver and IVC is easier once the sternotomy is completed (Fig. 101.62).

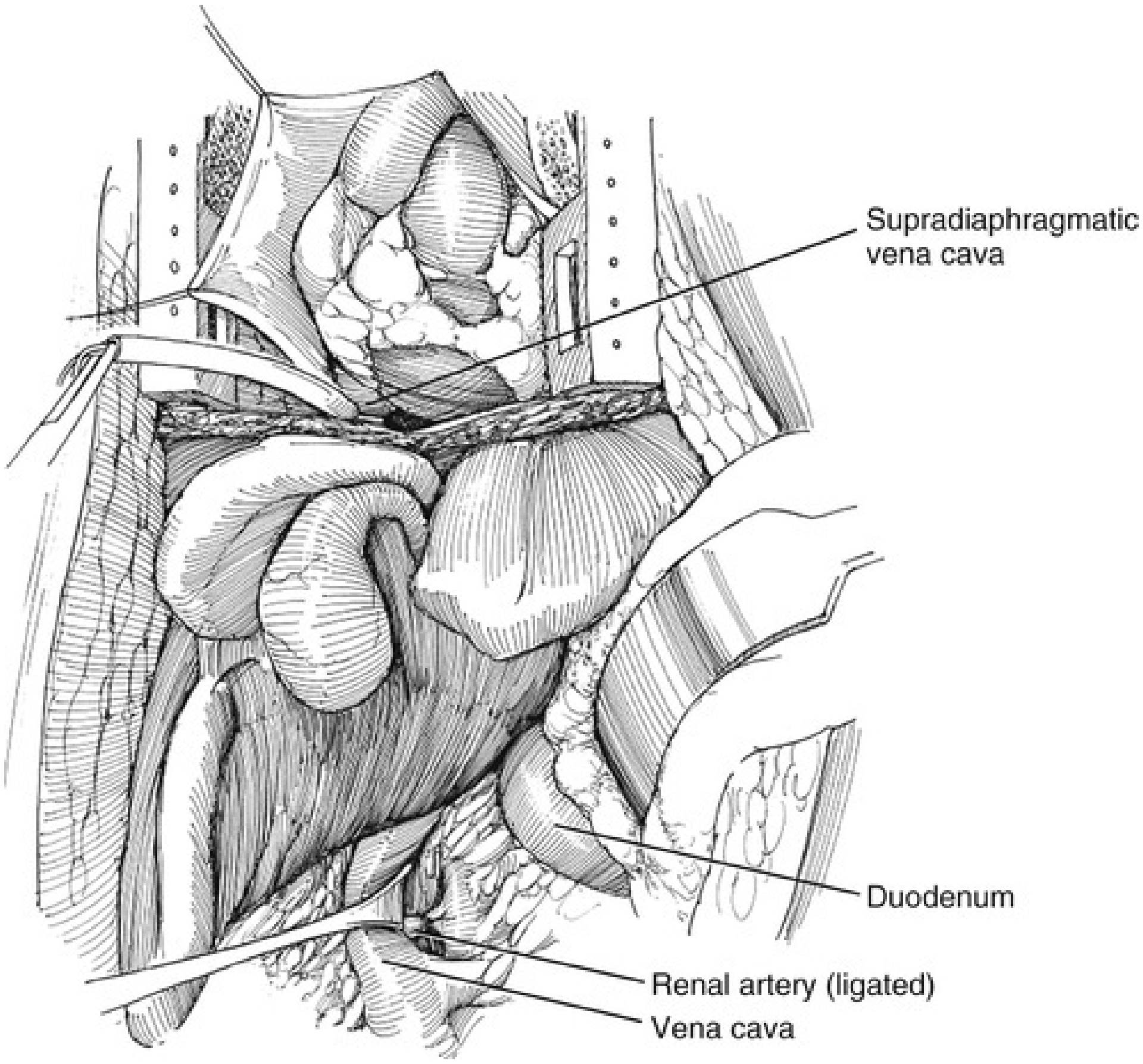

FIG. 101.62 Median sternotomy with pericardium opened exposing the right heart. (From Smith JA Jr, Howards SS, Preminger GM, eds. *Hinman's atlas of urologic surgery.* 3rd ed. Philadelphia, PA: Saunders; 2012.)

The blood supply is bypassed using one of the techniques described in the following sections. Once on bypass, the ostium of the renal vein is circumferentially excised, the incision is extended cranially on the IVC, and the thrombus is extracted. A right atriotomy is usually performed to help remove the suprahepatic thrombus. The atrium and IVC are then closed. The patient is taken off bypass and thoracotomy tubes, and closed suction abdominal drains are placed. The hepatic ligaments are tacked back into place to prevent torsion of the liver, and regional lymphadenectomy is performed.

Bypass Techniques for Inferior Vena Caval Surgery

The requirement of bypass significantly complicates and prolongs IVC thrombectomy. However, bypass is often critical to performing the procedure safely and completely and should be used whenever required. Bypass should be considered in patients in whom the IVC cross-clamping trial causes significant hypotension, and in patients in whom there is preoperative cardiac or hepatic dysfunction, contralateral renal dysfunction, or portal venous hypertension, and when there is major intraoperative bleeding that is difficult to control.

Venovenous Bypass.

This is the least invasive bypass technique for IVC thrombi and involves shunting the venous blood from below the renal veins to the venous return of the heart with the aid of a pump. Venovenous bypass (VVB) can be done without opening the chest, which is a key advantage that it has over traditional CPB. Two main options are available for infrarenal cannulation: a percutaneous approach through the femoral vein or a direct intraoperative approach through the IVC just above its bifurcation. When cannulating the IVC, it is important to position the tip of the cannula as far from the tumor thrombus as possible to avoid dislodging it, which can cause a massive pulmonary embolism, and to avoid aspirating and recirculating tumor cells. Several options are available for delivering the shunted blood back to the heart: a percutaneous approach via the internal jugular vein, a cutdown approach to the brachial/axillary vein, and a direct intraoperative approach through the right atrium. One advantage of VVB is that full heparinization is not required, which may help minimize postoperative bleeding problems. However, a key disadvantage is that the blood flow to the intercostal and lumbar arteries and the intercostal and lumbar veins is not interrupted during VVB, a problem that can lead to major bleeding once the cavotomy is performed to extract the thrombus. VVB should not be used when atrial thrombi cannot be completely milked into the IVC, when there is extensive bland thrombus in the iliac veins or infrarenal IVC, or when there is preexisting Budd-Chiari syndrome.

For percutaneous VVB, immediately following intubation, the anesthesiologist should insert an 8- to 18-Fr heparin-bonded arterial cannula into the internal jugular vein using the Seldinger technique (Fig. 101.63). A 6-cm, 18-gauge hollow needle is inserted into the femoral vein, a guidewire is placed, the tract is dilated, and a 14- to 20-Fr heparin-bonded arterial cannula is advanced into the common iliac vein. Both cannulae are connected to a perfusion pump using heparin-bonded tubing. The portal vein can also be cannulated with a 20-Fr cannula and its venous flow returned to the pump, although this is usually not necessary. The incision is performed, and the kidney and IVC are dissected. Once all the vessels are clamped, the perfusion pump is started and the thrombectomy is performed under pump, ligating any troublesome lumbar and intercostal veins. Once thrombectomy and IVC repair are complete, the vessels are unclamped in the same order they were clamped.

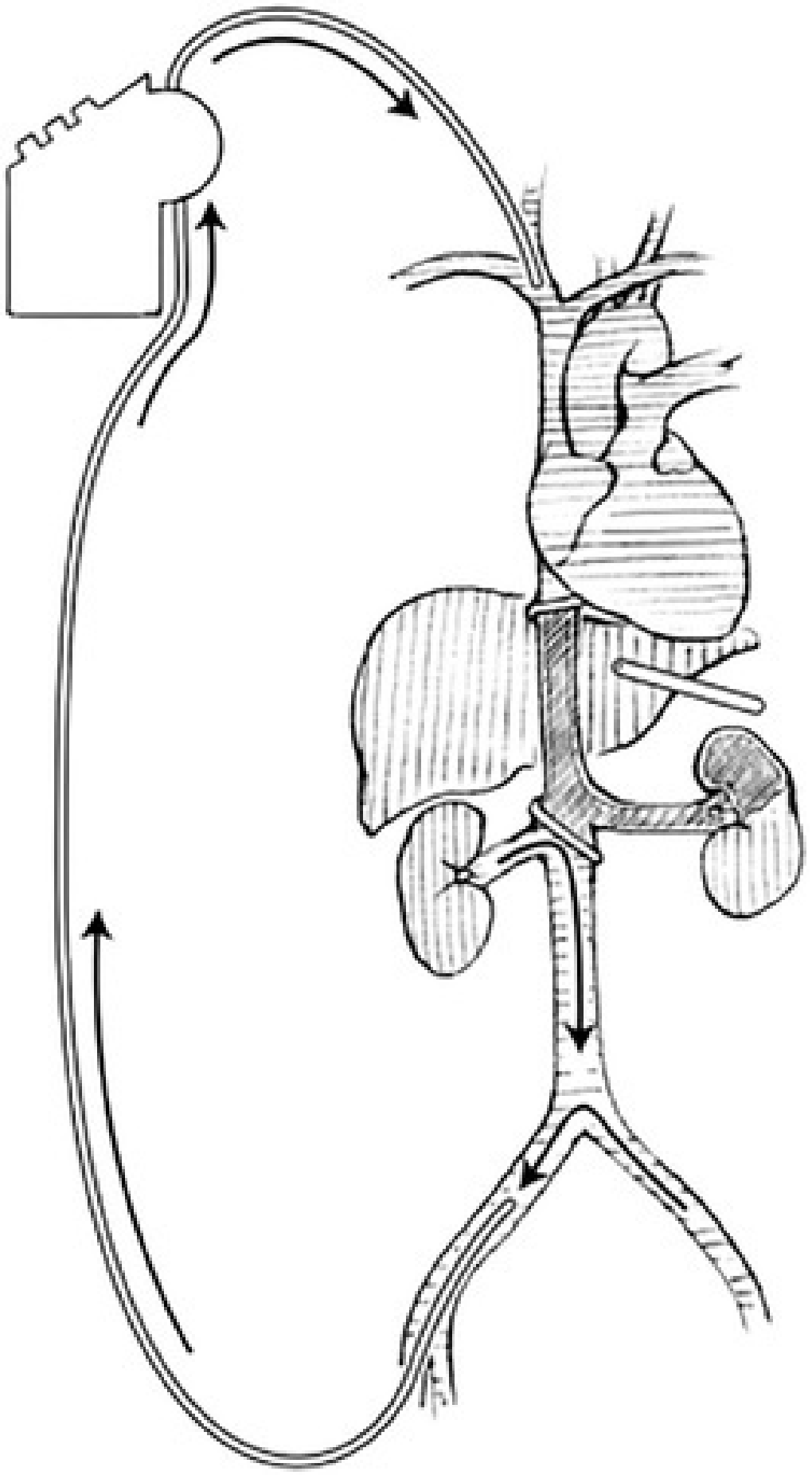

FIG. 101.63 Percutaneous venovenous bypass. (From Smith JA Jr, Howards SS, Preminger GM, eds. *Hinman's atlas of urologic surgery.* 3rd ed. Philadelphia, PA: Saunders; 2012.)

For open VVB, the kidney and IVC are dissected, the liver is mobilized, and a sternotomy is performed (eFig. 101.64). A 20-Fr cannula is inserted into the infrarenal IVC well away from the tumor thrombus, and then a 14- to 20-Fr cannula is inserted into the auricle of the right atrium. The infrarenal IVC, renal vein, porta hepatis, and suprarenal IVC are clamped, and then bypass is started. Thrombectomy is performed as quickly as possible.

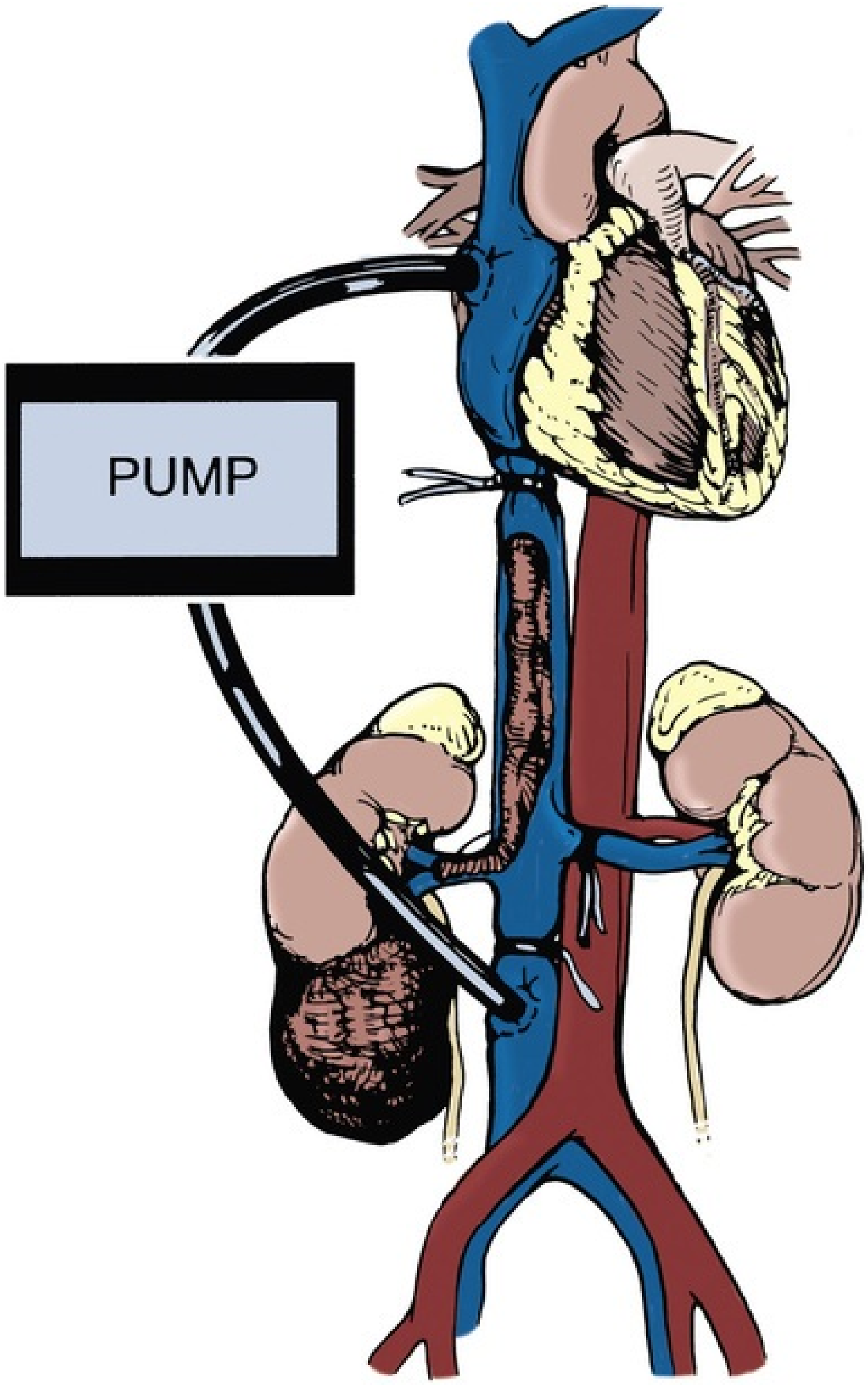

EFIG. 101.64 Technique of open venovenous bypass for removal of supradiaphragmatic vena caval tumor thrombus.

Cardiopulmonary Bypass With and Without Deep Hypothermic Arrest.

CPB can be performed with or without deep hypothermic arrest (Fig. 101.65). CPB with hypothermic arrest involves stopping the heart and starting bypass, cooling the patient to 16° C to 18° C, and draining all of the blood from the patient. Although very invasive, CPB with hypothermic arrest offers several benefits. First, it can be used in cases in which the thrombus cannot be milked below an intrapericardial IVC clamp. Second, there is no need to clamp the aorta or porta hepatis or to ligate as many lumbar and hepatic veins because blood flow to these structures is no longer present. However, all vessels that have been traumatized or transected must be controlled because they will bleed once the patient is taken off bypass. Third, the absence of active blood flow allows for complete inspection of the IVC and hepatic veins, thereby aiding in achieving a complete thrombectomy. Fourth, the risk for embolization during thrombectomy is lower. Fifth, the surgeon is allowed up to 60 minutes to perform thrombectomy (although <40 minutes is certainly a better target), whereas IVC clamping without bypass is only tolerated for about 30 minutes.

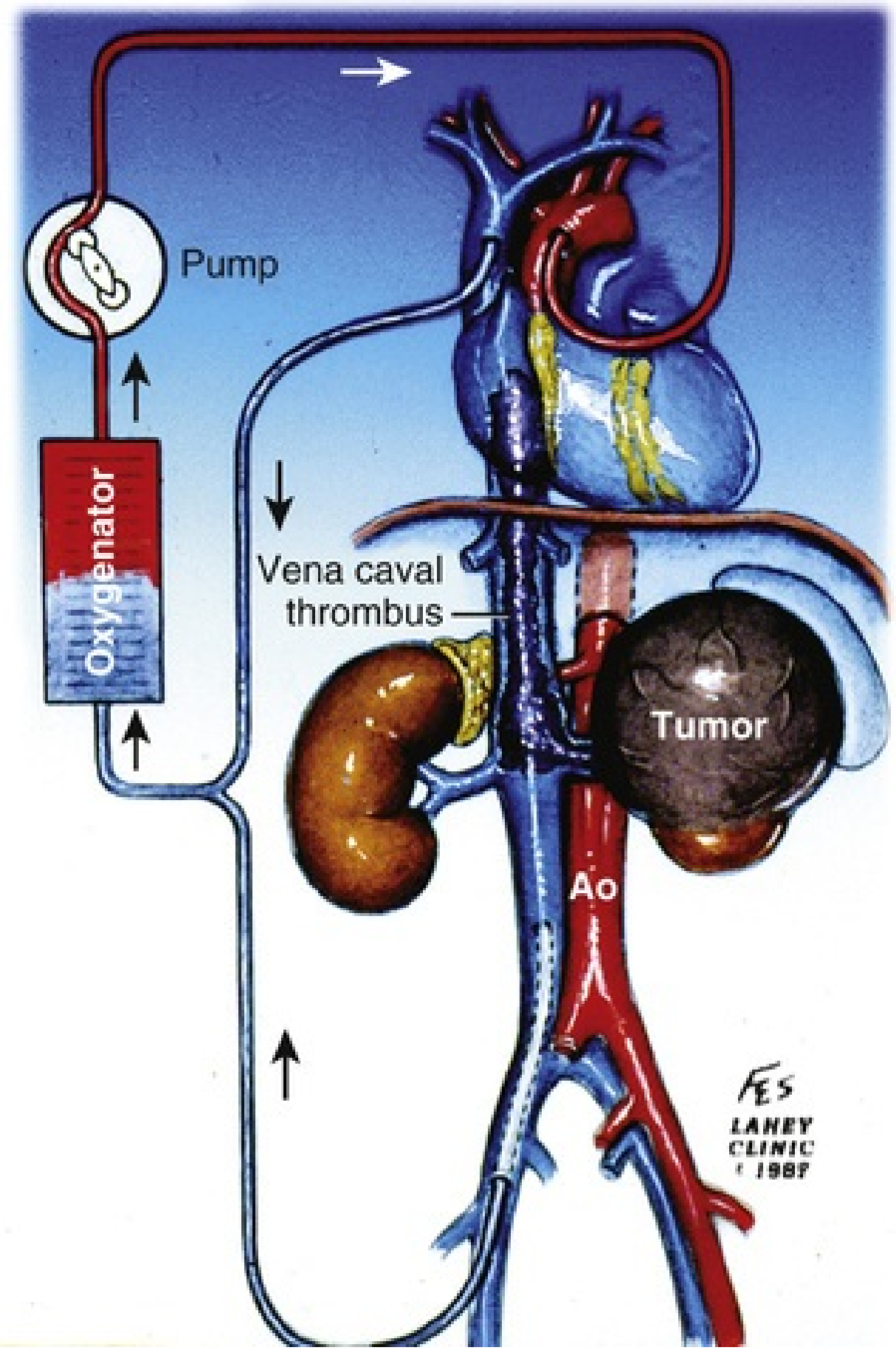

FIG. 101.65 Traditional median sternotomy approach with cannulation of the aortic arch, superior vena cava, and right femoral vein for cardiopulmonary bypass. *Ao,* Aorta. (© The Lahey Clinic.)

For CPB with deep hypothermia, the kidney and IVC are dissected and the liver is mobilized. The cardiothoracic surgeon performs the sternotomy, opens the pericardium, and exposes the heart and its vessels. Heparin-bonded cannulae are placed in the infrarenal IVC and the right atrium to collect venous blood, and a cannula is placed into the aortic arch for outflow. The patient is heparinized, and bypass is started. The aorta is clamped, and cardioplegia solution is administered. The temperature of the recirculated blood is dropped to 10° C to 14° C, and the patient is cooled for 15 to 30 minutes until a core temperature of 16° C to 18° C is reached. Intraoperative electroencephalography should be performed to determine when the brain has been adequately cooled. When sufficient cooling has been achieved, the perfusion pump is stopped and 95% of the patient's blood volume is drained into the pump reservoir. Tumor thrombectomy should be performed as quickly as possible, taking great care to ligate all potential bleeders (Fig. 101.66 and eFig. 101.67). If the patient has known coronary artery disease, coronary artery bypass can be performed at the same time. If the resection is taking longer than anticipated, the surgeon should consider allowing a 10-mL/kg/min trickle of blood to flow to the organs or using retrograde cerebral perfusion.

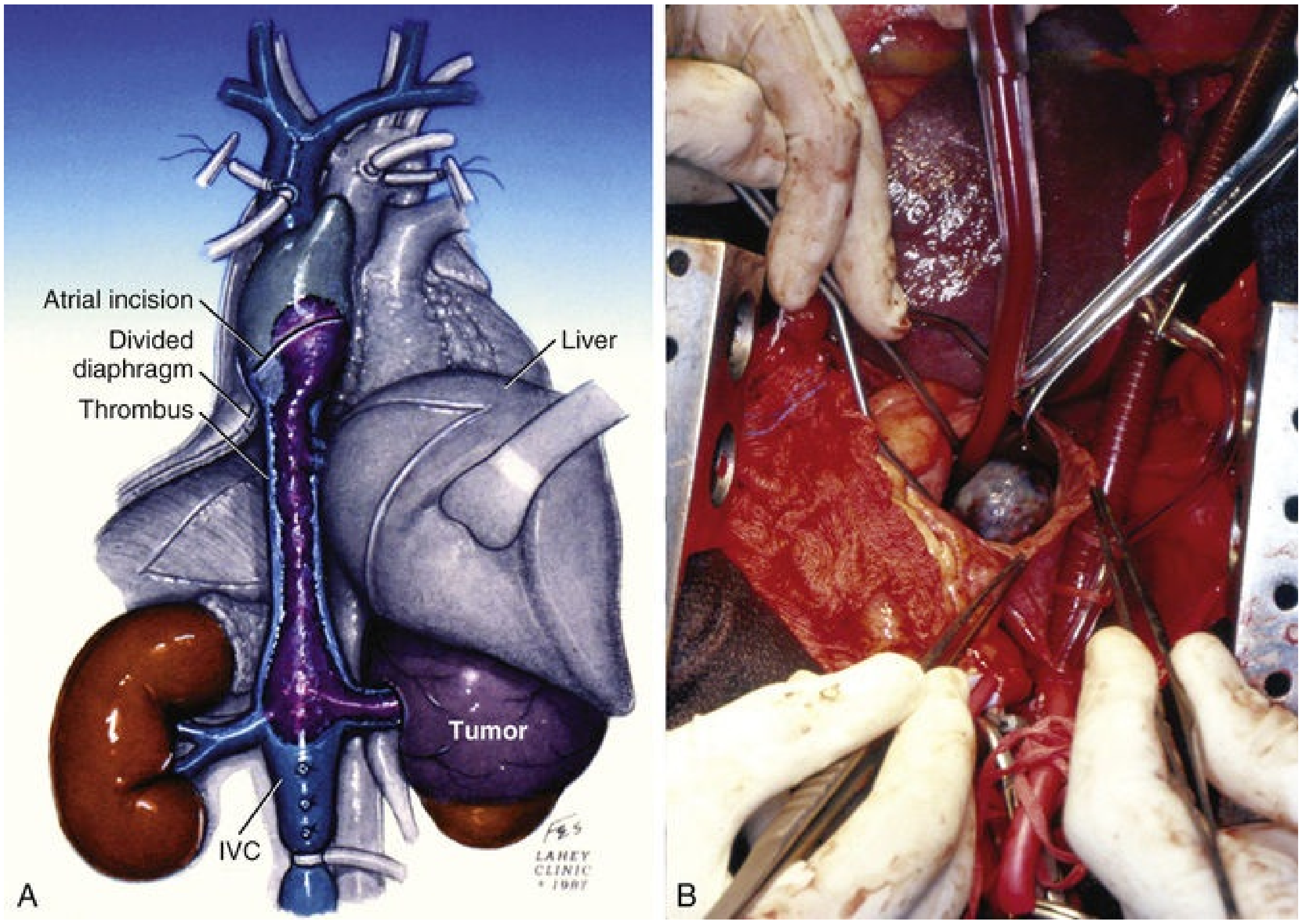

FIG. 101.66 (A and B) Tumor thrombus extension into the right atrium is removed using a traditional median sternotomy approach and an atriotomy for retrieval of the thrombus. *IVC,* Inferior vena cava. (A, © The Lahey

Clinic; B, from Wotkowicz C, Libertino JA, Sorcini A, et al. Management of renal cell carcinoma with vena cava and atrial thrombus: minimal access vs. median sternotomy with circulatory arrest. *BJU Int* 98:289–97, 2006.)

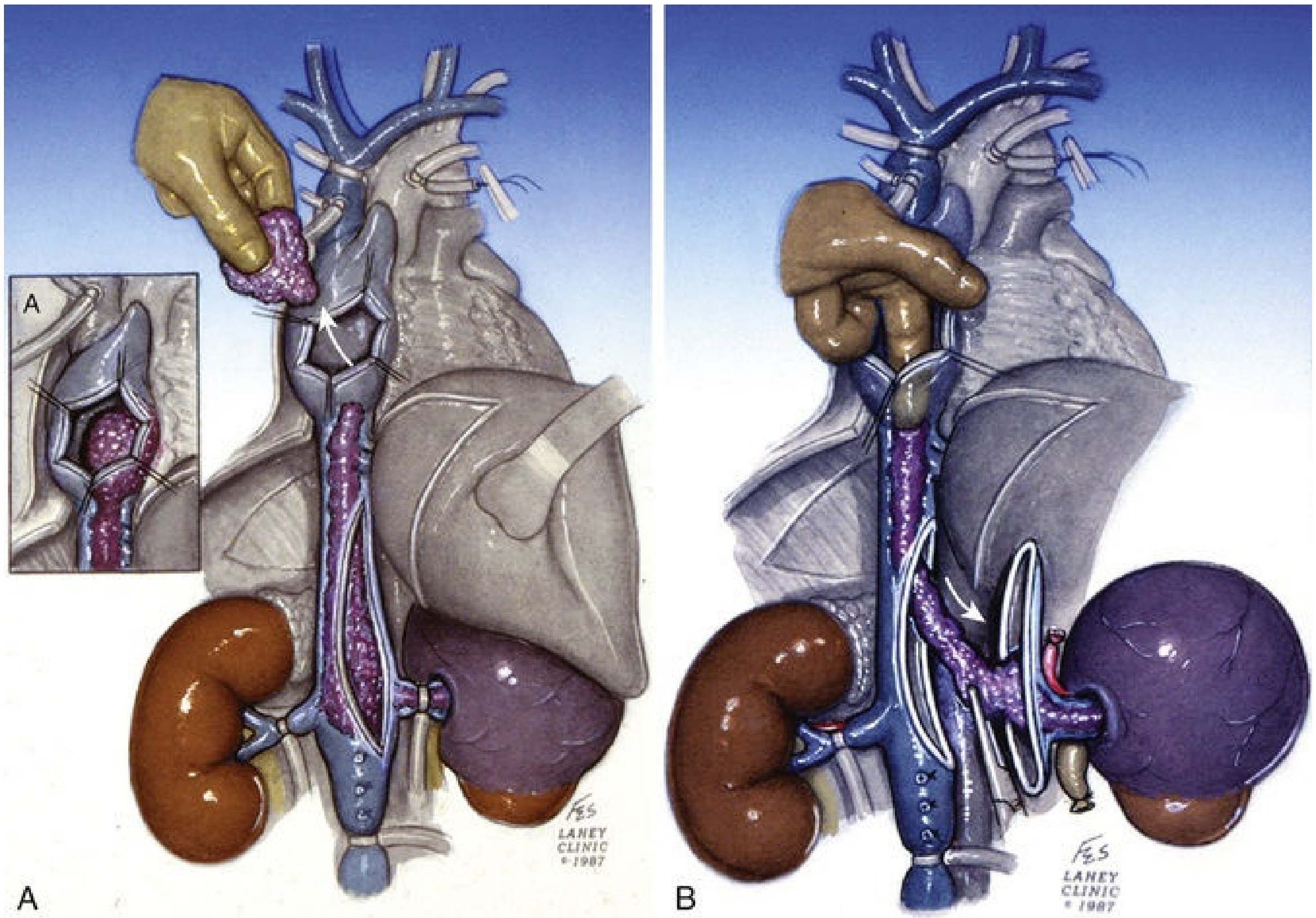

EFIG. 101.67 A and B, Tumor thrombus finger fracture and removal after formal atriotomy with retraction sutures *(inset A).* Manual displacement from atrium through diaphragm and removal through anterior cavotomy. (© The Lahey Clinic.)

Once the IVC and right atrium are repaired, warm blood is reinfused from the pump reservoir and CPB is restarted. Hemostasis is performed while the patient warms to 37° C over the next 30 to 45 minutes. Once the heart has restarted pumping, bypass is stopped, the cannulae are removed, and protamine sulfate is administered. Coagulopathy is common, and fresh frozen plasma, platelets, and packed red blood cells should be available to administer. Thoracostomy tubes and closed suction abdominal drains are inserted.

Patching, Replacing, and Interrupting the Inferior Vena Cava

Patch Cavoplasty.

If the IVC is expected to be less than 50% of its original size, a patch cavoplasty is necessary to prevent IVC stenosis and thrombosis-related events (Fig. 101.68). Autologous and bovine pericardium, polytetrafluoroethylene (PTFE), collagen-impregnated Dacron (DuPont, Wilmington, DE), and autologous saphenous vein are materials that can be used for patch cavoplasty.

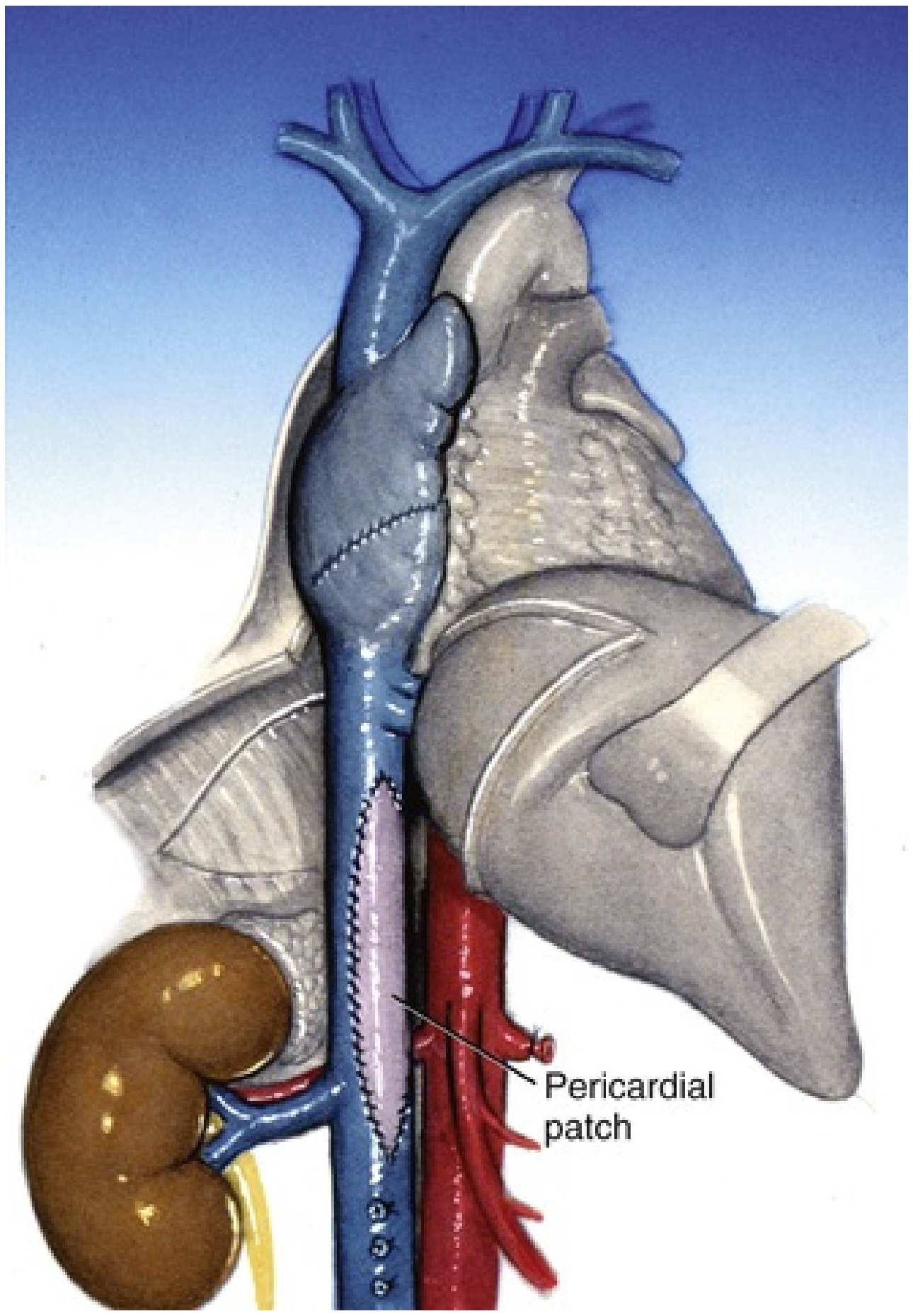

FIG. 101.68 Vena caval reconstruction using a pericardial patch graft.

The patch is sized to a bit larger dimension than the caval defect, typically configured to an oval shape. A double-armed 5-0 Prolene suture on a BB needle is used to sew the patch in place. Small and regular suture bites will assure a tight closure. Intraluminal inversion of the edges of the patch should be avoided to prevent excess thrombogenesis. Some surgeons prefer tacking both apices of the defect first and then running a strand of suture from each apex to the midpoint between the apices, which requires four knots. Alternatively, the graft can be parachuted into position and sewn into place circumferentially, requiring only one knot. Minimal manipulation of the patch is helpful to prevent inadvertent damage to the patch and caval edge. Liberal use of heparinized saline solution can help with visualization. Before final closure of the cava, the caudal IVC clamp should be released and 5 to 10 mL of venous blood allowed to escape from the cavotomy, providing for removal of air, debris, and clot before unclamping the cranial caval clamp.

Vena Caval Replacement.

In situations in which a circumferential section of IVC has been removed or if a vena cava defect is too large for simple patching, vena caval replacement is necessary (Fig. 101.69). Typically, we use PTFE grafts to replace the IVC, although others have described spiraled saphenous vein, superficial femoral vein, and tubularized pericardium as options (Helfand et al., 2011; Hyams et al., 2011; Pulitano et al., 2013; Quinones-Baldrich et al., 2012). Typically a graft size of 16 to 20 mm in diameter is required. The large diameter of the graft reduces the risk for thrombosis.

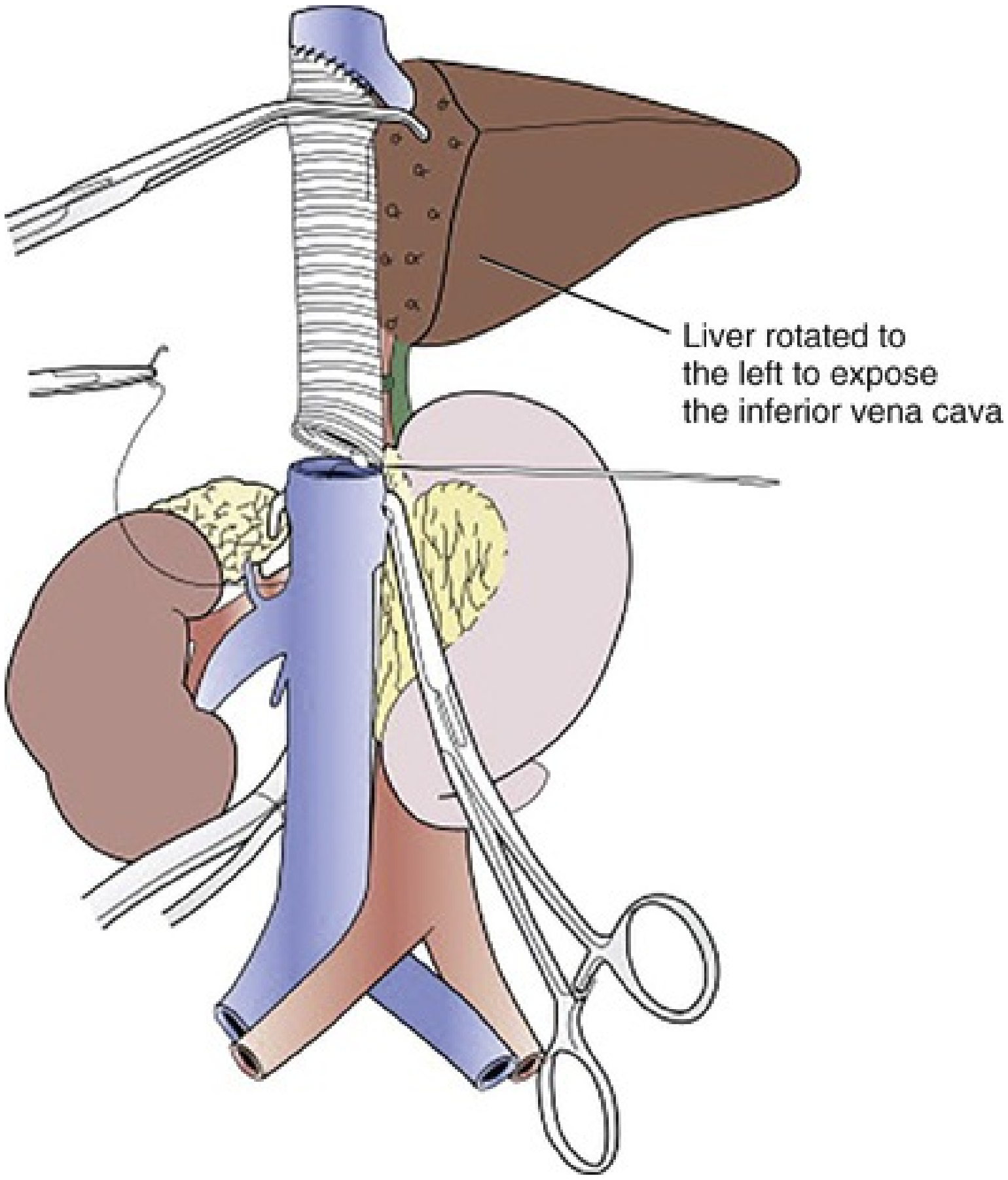

FIG. 101.69 Vena caval replacement with polytetrafluoroethylene graft. (From Bower TC, Nagorney DM, Toomey BJ, et al. Vena cava replacement for malignant disease: is there a role? *Ann Vasc Surg* 7:51–62, 1993.)

The liver is mobilized, and the IVC is exposed completely. Vascular bypass is used if clinically indicated, and 5000 units of intravenous heparin is administered. The IVC is clamped, and the affected portion is excised. The cranial IVC-patch anastomosis is completed first. Subsequently, the graft is clamped followed by releasing the cranial IVC clamp to test the upper IVC-patch anastomosis. Next the graft is sized and cut to fit the IVC defect and the caudal IVC-patch anastomosis is completed. Before closure of the lower IVC anastomosis, the graft is unclamped and 5 to 10 mL of blood is allowed to escape from the graft through the cavotomy. The graft is then reclamped and the infrarenal IVC is unclamped, and 5 to 10 mL of blood is allowed to escape from the infrarenal IVC. Closure of the anastomosis is completed by tying the final knot, and the IVC is unclamped. The graft is wrapped with omentum or retroperitoneal fat, and then the hepatic ligaments are reapproximated to prevent torsion of the IVC graft.

Postoperatively, low-dose intravenous heparin or a reduced dosage of low-molecular-weight heparin is given. Once the patient's bowel function has recovered, lifelong oral warfarin is used with a target international normalized ratio of 2 to 3.

Inferior Vena Cava Filtration and Permanent Interruption for Bland Thrombus

Occasionally, a patient with an infrarenal bland thrombus requires management at the time of tumor thrombectomy. For bland thrombus that is limited to the pelvic veins, intraoperative placement of an infrarenal vena caval filter is indicated. When the bland thrombus diffusely involves the infrarenal IVC, the optimal management is permanent interruption of the IVC. Necessary intraoperative care is required to preserve the collateral lumbar venous drainage because these vessels provide a “release valve” for the impaired caval blood flow. When the infrarenal IVC is occluded with bland thrombus that is distinct and separate from the tumor thrombus, the best form of management is usually permanent interruption without resection because attempts at complete removal of diffuse organized bland thrombus are almost always unsuccessful and often result in vascular injury. Options for permanent interruption of the IVC include serrated vena caval clips (e.g., Adams-DeWeese clip, Moretz clip), cross-stapling with a vascular GIA stapler (Covidien Ltd., Mansfield, MA), suture plication, and suture ligation. Serrated vena caval clips and vascular staplers offer the advantage of easy application, while serrated vena caval clips allow partial blood flow through the IVC.

When the bland thrombus in the infrarenal IVC is admixed with tumor thrombus that has undergone retrograde growth, segmental resection of the IVC with permanent interruption of the IVC will maximize the chance of cure. Because it is not possible to accurately dissect tumor thrombus from bland thrombus and assure complete resection of tumor, resection of the IVC below the level of the contralateral renal vein ostium is recommended. Resection should be as close to the renal vein ostium as possible to prevent turbulent and thrombogenic flow in the upper stump. In addition, maximal preservation of the lumbar veins in the lower stump is important to ensure good collateral drainage.

Perioperative Complications

Air Embolism.

Air embolism to the right heart and pulmonary arteries is a serious and potentially lethal complication associated with caval thrombectomy. Risk for air embolism can be significantly reduced by releasing the caudal IVC clamp first and allowing air and some blood (5 to 10 mL) to escape from the IVC repair site before removing the cranial clamp.

Acute Pulmonary Embolism.

Tumor and bland thrombus can embolize during and after surgery. Minimizing intraoperative manipulation of the kidney and IVC before vascular control helps reduce the likelihood of acute thrombotic pulmonary embolism. Early preoperative or intraoperative placement of a Greenfield filter (Boston Scientific, Natick, MA) in a patient with pelvic bland thrombus can also help reduce the risk for pulmonary embolism. If respiratory distress is encountered during surgery, strong consideration should be given to prompt thoracotomy, pulmonary arteriotomy, and extraction of the thrombus.

Massive Hemorrhage.

Major bleeding can occur during and after the surgery. If uncontrolled major bleeding occurs in a patient who is not on bypass, the surgeon should consider clamping the aorta above the celiac trunk or initiating deep hypothermic CPB. However, CPB can also lead to major coagulopathy, potentially worsening the degree of hemorrhage. Fresh frozen plasma, platelets, and red blood cells should be transfused liberally as indicated. Using a Cell Saver (Haemonetics Corporation, Braintree, MA) is not recommended for oncologic surgery because tumor cells can be disseminated.

Hepatic Dysfunction.

Temporary hepatic dysfunction, characterized by elevated transaminases and alkaline phosphatase, is common in patients with levels III and IV thrombi that require suprahepatic IVC clamping and/or bypass. Minimizing clamping of the porta hepatis as much as possible can reduce hepatic ischemia and thereby the degree of postoperative hepatic dysfunction. Liver enzymes typically peak 2 to 3 days postoperatively and slowly resolve thereafter.

Organ Ischemia.

Cardiac ischemia is most common in patients undergoing suprahepatic IVC clamping without bypass. Patients with poor preoperative cardiac function are probably best managed with CPB. Renal and intestinal ischemia can also result during thrombectomy, requiring close postoperative monitoring.

Key Points

- The origin of the right renal artery is posterior to the left renal vein and the IVC. During a difficult right radical nephrectomy, the right renal artery may be more accessible posterior and medial to the IVC, near the site of origin from the aorta.
- Although the right gonadal and adrenal veins drain into the IVC, the drainage of the left gonadal and left adrenal veins is different as they drain into the left renal vein.
- Simple nephrectomy, removal of the kidney within the Gerota fascia, is used for management of benign renal entities.
- The key elements of radical nephrectomy are early ligation of the renal artery and vein and removal of the kidney outside of the Gerota fascia. When technically feasible, the ipsilateral adrenal gland should be spared.
- For left radical nephrectomy, particularly for upper pole renal masses, identification of the left renal artery from the posterior approach is recommended to avoid inadvertent ligation of the SMA, which is on the anterior surface of the aorta 1 to 2 cm cephalad to the left renal vein.
- Regional lymphadenectomy extending from the crus of the diaphragm to the aortic bifurcation is employed in select cases of advanced local disease and when technically feasible.
- The impact of lymphadenectomy on progression-free and overall survival is controversial.
- To maintain the maximum number of functioning nephrons, partial nephrectomy is the treatment of choice for stage T1 renal tumors when technically feasible, even in the absence of identifiable renal insufficiency.
- The goal of partial nephrectomy is complete excision of the tumor with negative surgical margins and maximal preservation of benign adjacent parenchyma. Various techniques have been used, including enucleation, polar segmental nephrectomy, transverse resection, wedge resection, and extracorporeal partial nephrectomy with renal autotransplantation.

- In patients with known IVC tumor thrombus, intraoperative TEE should be utilized after the patient is anesthetized and intubated to appropriately assess the distal extent of the tumor thrombus before initiating the surgical procedure.
- When performing right radical nephrectomy with tumor thrombectomy, the suprarenal IVC can be resected, but only if the left renal vein has been ligated distal to its venous tributaries (i.e., gonadal, lumbar, and adrenal veins).
- Given the lack of venous tributaries on the right side, the suprarenal IVC should not be resected for a left-sided tumor unless one provides alternative venous drainage for the right kidney with autotransplantation or a saphenous vein graft to the splenic, portal, or inferior mesenteric vein.
- Alternatives to CPB may include venovenous bypass and extensive liver mobilization.
- When reconstructing the IVC, the lumen can be safely narrowed by half and closed primarily. To maintain the lumen in larger resections, the cava can be reconstructed with a pericardial graft or PTFE.

Videos 101.2, 101.3, and 101.4 ▶▶▶ show procedures related to this chapter.

Suggested Readings

Blom JH, van Poppel H, Marechal JM, et al. Radical nephrectomy with and without lymph-node dissection: final results of European Organization for Research and Treatment of Cancer (EORTC) randomized phase 3 trial 30881. *Eur Urol*. 2009;55:28–34.

Blute ML, Amling CL, Bryant SC, et al. Management and extended outcome of patients with synchronous bilateral solid renal neoplasms in the absence of von Hippel-Lindau disease. *Mayo Clin Proc*. 2000;75:1020–1026.

Blute ML, Leibovich BC, Cheville JC, et al. A protocol for performing extended lymph node dissection using primary tumor pathological features for patients treated with radical nephrectomy for clear cell renal cell carcinoma. *J Urol*. 2004;172:465–469.

Blute ML, Leibovich BC, Lohse CM, et al. The Mayo Clinic experience with surgical management, complications and outcome for patients with renal cell carcinoma and venous tumour thrombus. *BJU Int*. 2004;94:33–41.

Crawford ED, Skinner DG. Intercostal nerve block with thoracoabdominal and flank incisions. *Urology*. 1982;19:25–28.

Gill IS, Kavoussi LR, Lane BR, et al. Comparison of 1,800 laparoscopic and open partial nephrectomies for single renal tumors. *J Urol*. 2007;178:41–46.

Hanley MJ, Davidson K. Prior mannitol and furosemide infusion in a model of ischemic acute renal failure. *Am J Physiol*. 1981;241:F556–F564.

Novick AC, Gephardt G, Guz B, et al. Long-term follow-up after partial removal of a solitary kidney. *N Engl J Med*. 1991;325:1058–1062.

Novick AC, Jackson CL, Straffon RA. The role of renal autotransplantation in complex urological reconstruction. *J Urol*. 1990;143:452–457.

Psutka SP, Feldman AS, McDougal WS, et al. Long-term oncologic outcomes after radiofrequency ablation for T1 renal cell carcinoma. *Eur Urol*. 2013;63:486–492.

Schwartz MJ, Smith EB, Trost DW, et al. Renal artery embolization: clinical indications and experience from over 100 cases. *BJU Int*. 2007;99:881–886.

Siemer S, Lehmann J, Kamradt J, et al. Adrenal metastases in 1635 patients with renal cell carcinoma: outcome and indication for adrenalectomy. *J Urol*. 2004;171:2155–2159 [discussion 2159].

Stormont TJ, Bilhartz DL, Zincke H. Pitfalls of "bench surgery" and autotransplantation for renal cell carcinoma. *Mayo Clin Proc*. 1992;67:621–628.

Volpe A, Kachura JR, Geddie WR, et al. Techniques, safety and accuracy of sampling of renal tumors by fine needle aspiration and core biopsy. *J Urol*. 2007;178:379–386.

Zincke H, Sen SE. Experience with extracorporeal surgery and autotransplantation for renal cell and transitional cell cancer of the kidney. *J Urol*. 1988;140:25–27.

References

Andaloro VA, Lilien OM. Posterior approach to the kidney. *Urology*. 1975;5:600–605.

Blom JH, van Poppel H, Marechal JM, et al. Radical nephrectomy with and without lymph-node dissection: final results of European Organization for Research and Treatment of Cancer (EORTC) randomized phase 3 trial 30881. *Eur Urol*. 2009;55:28–34.

Blute M, Thibault GP, Leibovich BC, et al. Multiple ipsilateral renal tumors discovered at planned nephron sparing surgery: importance of tumor histology and risk of metachronous recurrence. *J Urol*. 2003;170:760–763.

Blute ML Sr, Inman B. Partial nephrectomy. Smith JA Jr, Howards SS, Preminger GM. *Hinman's atlas of urologic surgery*. ed 3. Saunders: Philadelphia, PA; 2012:1001–1008.

Blute ML, Amling CL, Bryant SC, et al. Management and extended outcome of patients with synchronous bilateral solid renal neoplasms in the absence of von Hippel-Lindau disease. *Mayo Clin Proc*. 2000;75:1020–1026.

Blute ML, Leibovich BC, Cheville JC, et al. A protocol for performing extended lymph node dissection using primary tumor pathological features for patients treated with radical nephrectomy for clear cell renal cell carcinoma. *J Urol*. 2004;172:465–469.

Blute ML, Leibovich BC, Lohse CM, et al. The Mayo Clinic experience with surgical management, complications and outcome for patients with renal cell carcinoma and venous tumour thrombus. *BJU Int*. 2004;94:33–41.

Bradley AJ, Lim YY, Singh FM. Imaging features, follow-up, and management of incidentally detected renal lesions. *Clin Radiol*. 2011;66:1129–1139.

Bredenoord AJ, Pandolfino JE, Smout AJ. Gastro-oesophageal reflux disease. *Lancet*. 2013;381:1933–1942.

Capitanio U, Abdollah F, Matloob R, et al. When to perform lymph node dissection in patients with renal cell carcinoma: a novel approach to the preoperative assessment of risk of lymph node invasion at surgery and of lymph node progression during follow-up. *BJU Int*. 2013;112:E59–E66.

Carini M, Minervini A, Masieri L, et al. Simple enucleation for the treatment of PT1a renal cell carcinoma: our 20-year experience. *Eur Urol*. 2006;50:1263–1268 [discussion 1269–1271].

Chen DY, Uzzo RG. Evaluation and management of the renal mass. *Med Clin North Am*. 2011;95:179–189.

Chung JH, Lee SW, Lee KS, et al. Safety of en bloc ligation of the renal hilum during laparoscopic radical nephrectomy for renal cell carcinoma: a randomized controlled trial. *J Laparoendosc Adv Surg Tech A*. 2013;23:489–494.

Crispen PL, Breau RH, Allmer C, et al. Lymph node dissection at the time of radical nephrectomy for high-risk clear cell renal cell carcinoma: indications and recommendations for surgical templates. *Eur Urol*. 2011;59:18–23.

Derweesh IH, Herts B, Novick AC. Three-dimensional image reconstruction for preplanning of renal surgery. *Urol Clin North Am*. 2003;30:515–528.

Diblasio CJ, Snyder ME, Russo P. Mini-flank supra-11th rib incision for open partial or radical nephrectomy. *BJU Int*. 2006;97:149–156.

Fleisher LA, Beckman JA, Brown KA, et al. ACC/AHA 2007 guidelines on perioperative cardiovascular evaluation and care for noncardiac surgery: executive summary: a report of the American College of Cardiology/American Heart Association Task Force on Practice Guidelines (Writing Committee to Revise the 2002 Guidelines on Perioperative

Cardiovascular Evaluation for Noncardiac Surgery). *Circulation*. 2007;116:1971–1996.

Fleisher LA, Beckman JA, Brown KA, et al. ACC/AHA 2007 guidelines on perioperative cardiovascular evaluation and care for noncardiac surgery: a report of the American College of Cardiology/American Heart Association Task Force on Practice Guidelines (Writing Committee to Revise the 2002 Guidelines on Perioperative Cardiovascular Evaluation for Noncardiac Surgery). *Circulation*. 2007;116:e418–e499.

Gardiner RA, Naunton-Morgan TC, Whitfield HN, et al. The modified lumbotomy versus the oblique loin incision for renal surgery. *Br J Urol*. 1979;51:256–259.

Geerts WH, Bergqvist D, Pineo GF, et al. Prevention of venous thromboembolism: American College of Chest Physicians Evidence-Based Clinical Practice Guidelines. 8th ed. *Chest*. 2008;133:381S–453S.

Gill IS, Kavoussi LR, Lane BR, et al. Comparison of 1,800 laparoscopic and open partial nephrectomies for single renal tumors. *J Urol*. 2007;178:41–46.

Goldfarb DA. Preservation of renal function and the risk of hyperfiltration nephropathy. *Semin Urol Oncol*. 1995;13:292–295.

Hanley MJ, Davidson K. Prior mannitol and furosemide infusion in a model of ischemic acute renal failure. *Am J Physiol*. 1981;241:F556–F564.

Heher EC, Thier SO, Rennke H, et al. Adverse renal and metabolic effects associated with oral sodium phosphate bowel preparation. *Clin J Am Soc Nephrol*. 2008;3:1494–1503.

Helfand BT, Smith ND, Kozlowski JM, et al. Vena cava thrombectomy and primary repair after radical nephrectomy for renal cell carcinoma: single-center experience. *Ann Vasc Surg*. 2011;25:39–43.

Herts BR. Role of three-dimensional imaging in surgical planning for kidney surgery. *BJU Int*. 2005;95(Suppl 2):16–20.

Husberg BS, Bakshandeh K, Lilly J, et al. Five cases and five unusual indications for autogenic renal transplantation. *Acta Chir Scand*. 1975;141:557–563.

Hyams ES, Pierorazio PM, Shah A, et al. Graft reconstruction of inferior vena cava for renal cell carcinoma stage pT3b or greater. *Urology*. 2011;78:838–843.

Kim HL, Lam JS, Belldegrun AS. The role of lymphadenectomy in renal cell carcinoma. *Curr Urol Rep*. 2004;5:25–29.

Klimberg I, Hunter P, Hawkins IF, et al. Preoperative angioinfarction of localized renal cell carcinoma using absolute ethanol. *J Urol*. 1985;133:21–24.

Lacombe M. Renal arteriovenous fistula following nephrectomy. *Urology*. 1985;25:13–16.

Lam JS, Belldegrun AS, Pantuck AJ. Long-term outcomes of the surgical management of renal cell carcinoma. *World J Urol*. 2006;24:255–266.

Lam JS, Shvarts O, Pantuck AJ. Changing concepts in the surgical management of renal cell carcinoma. *Eur Urol*. 2004;45:692–705.

Levey AS, Bosch JP, Lewis JB, et al. A more accurate method to estimate glomerular filtration rate from serum creatinine: a new prediction equation. Modification of Diet in Renal Disease Study Group. *Ann Intern Med*. 1999;130:461–470.

Maher ER, Bentley E, Yates JR, et al. Mapping of the von Hippel-Lindau disease locus to a small region of chromosome 3p by genetic linkage analysis. *Genomics*. 1991;10:957–960.

Novick AC, Gephardt G, Guz B, et al. Long-term follow-up after partial removal of a solitary kidney. *N Engl J Med*. 1991;325:1058–1062.

Novick AC. Posterior surgical approach to the kidney and ureter. *J Urol*. 1980;124:192–195.

Ota K, Mori S, Awane Y, et al. Ex situ repair of renal artery for renovascular hypertension. *Arch Surg*. 1967;94:370–373.

Ou CH, Yang WH, Tzai TS. En bloc stapling of renal hilum during hand-assisted retroperitoneoscopic nephroureterectomy in dialysis patients. *Urology*. 2008;72:589–592.

Overend TJ, Anderson CM, Lucy SD, et al. The effect of incentive spirometry on postoperative pulmonary complications: a systematic review. *Chest*. 2001;120:971–978.

Pandharipande PV, Gervais DA, Hartman RI, et al. Renal mass biopsy to guide treatment decisions for small incidental renal tumors: a cost-effectiveness analysis. *Radiology*. 2010;256:836–846.

Psutka SP, Feldman AS, McDougal WS, et al. Long-term oncologic outcomes after radiofrequency ablation for T1 renal cell carcinoma. *Eur Urol*. 2013;63:486–492.

Pulitano C, Crawford M, Ho P, et al. The use of biological grafts for reconstruction of the inferior vena cava is a safe and valid alternative: results in 32 patients in a single institution. *HPB (Oxford)*. 2013;15:628–632.

Putnam CW, Halgrimson CG, Stables DP, et al. Ex vivo renal perfusion and autotransplantation in treatment of calculous disease or abdominal aortic aneurysm. *Urology*. 1975;5:337–342.

Quinones-Baldrich W, Alktaifi A, Eilber F, et al. Inferior vena cava resection and reconstruction for retroperitoneal tumor excision. *J Vasc Surg*. 2012;55:1386–1393 [discussion 1393].

Richards FM, Maher ER, Latif F, et al. Detailed genetic mapping of the von Hippel-Lindau disease tumour suppressor gene. *J Med Genet*. 1993;30:104–107.

Robson CJ, Churchill BM, Anderson W. The results of radical nephrectomy for renal cell carcinoma. *J Urol*. 1969;101(3):297–301.

Schwartz MJ, Smith EB, Trost DW, et al. Renal artery embolization: clinical indications and experience from over 100 cases. *BJU Int*. 2007;99:881–886.

Seizinger BR. Toward the isolation of the primary genetic defect in von Hippel-Lindau disease. *Ann N Y Acad Sci*. 1991;615:332–337.

Siemer S, Lehmann J, Kamradt J, et al. Adrenal metastases in 1635 patients with renal cell carcinoma: outcome and indication for adrenalectomy. *J Urol*. 2004;171:2155–2159 [discussion 2159].

Steckler RE, Riehle RA Jr, Vaughan ED Jr. Hyperfiltration-induced renal injury in normal man: myth or reality. *J Urol*. 1990;144:1323–1327.

Sun M, Trinh QD, Bianchi M, et al. Extent of lymphadenectomy does not improve the survival of patients with renal cell carcinoma and nodal metastases: biases associated with the handling of missing data. *BJU Int*. 2014;113:36–42.

Thompson RH, Frank I, Lohse CM, et al. The impact of ischemia time during open nephron sparing surgery on solitary kidneys: a multi-institutional study. *J Urol*. 2007;177:471–476.

Tiggeler RG, Berden JH, Hoitsma AJ, et al. Prevention of acute tubular necrosis in cadaveric kidney transplantation by the combined use of mannitol and moderate hydration. *Ann Surg*. 1985;201:246–251.

Turner Warwick RT. The supracostal approach to the renal area. *Br J Urol*. 1965;37:671–672.

Volpe A, Kachura JR, Geddie WR, et al. Techniques, safety and accuracy of sampling of renal tumors by fine needle aspiration and core biopsy. *J Urol*. 2007;178:379–386.

Wolf JS Jr, Bennett CJ, Dmochowski RR, et al. Best practice policy statement on urologic surgery antimicrobial prophylaxis. *J Urol*. 2008;179:1379–1390.

Wotkowicz C, Libertino JA. Renal cell cancer: radical nephrectomy. *BJU Int*. 2007;99:1231–1238.

Wszolek MF, Wotkowicz C, Libertino JA. Surgical management of large renal tumors. *Nat Clin Pract Urol*. 2008;5:35–46.

Laparoscopic and Robotic Surgery of the Kidney

Daniel M. Moreira MD, MHS, Louis R. Kavoussi MD, MBA

The first laparoscopic nephrectomy was described by Ralph Clayman and colleagues at Washington University in St. Louis in 1991. Subsequently, minimally invasive techniques have been applied to all surgical renal pathology. Expanding surgical experience has shown equivalent long-term outcomes and improved recovery compared with open surgery. The introduction of ”robotic” technology has led to a widespread adoption of minimally invasive renal surgery; laparoscopic radical nephrectomy has become the most common approach for renal tumors not amenable to partial nephrectomy (Kerbl et al., 2011). **Multiple studies have demonstrated that minimally invasive renal surgery provides less incisional pain, shorter convalescence, and better cosmesis compared with open surgery** (Gill et al., 2007; Lane et al., 2008; Tan et al., 2011). This chapter discusses indications, present techniques, and results and outlines potential complications of laparoscopy and robotic-assisted laparoscopic surgery as applied to the kidney.

Patient Evaluation and Preparation

Patient selection and preparation for laparoscopic and robotic renal surgery follow the same principles of general laparoscopic surgery and comparable open renal surgery, which are discussed in Chapters 9 and 101, respectively. **Relevant history and physical exam are important to identify potential issues that could arise during surgery.** For example, body habitus should be taken into consideration when positioning the patient on the surgical table and obtaining access**.** Prior abdominal and/or retroperitoneal surgery may influence trocar placement and surgical approach (e.g., transperitoneal vs. extraperitoneal access) (Cadeddu et al., 1999; Chenet al., 1998).

Anesthetic Considerations for Laparoscopy

Laparoscopic renal surgery requires general anesthesia. **The patient's pulmonary and cardiac function must tolerate this approach; the pneumoperitoneum can compromise ventilation and venous return.** For example, patients with severe chronic pulmonary disease may not be able to compensate for the pneumoperitoneum-induced hypercarbia. In these cases, lower insufflation pressures, use of helium insufflation, or conversion to open surgery may be required (Whalley and Berrigan, 2000).

Considerations in Obese Patients

Although not a contraindication to laparoscopic or robotic surgery, obesity frequently poses a challenge to the surgical team. **Difficulties include the distorted or hidden anatomy resulting from the excess adipose tissue, limited range of trocar and instrument motion, need for longer instruments, and higher pneumoperitoneum pressures.** These challenges may translate into higher complication rates and conversion to open surgery (Mendoza et al., 1996).

Considerations in Elderly Patients

The benefits of minimally invasive renal surgery have been demonstrated in all patient groups irrespective of age. **Some of the minimally invasive renal**

surgery benefits are particularly advantageous in the elderly population, including reduced postoperative pain and minimization of narcotic use leading to early mobilization (Salami et al., 2013).

Surgical Approaches and Obtaining Access

The minimally invasive approaches to renal surgery can be broadly divided into categories: transperitoneal, retroperitoneal, hand-assisted, robotic, laparoendoscopic single-site surgery (LESS), and natural orifice transluminal endoscopic surgery (NOTES). Although each approach has specific situational advantages, data from randomized clinical trials and retrospective studies suggest these approaches have comparable outcomes with only potential cosmetic differences. **Thus the choice of surgical approach should be based on availability of resources, surgeon's experience, and patient as well as disease characteristics.**

Transperitoneal Approach

This is the most traditional and widely used surgical approach. Its advantages include the largest working space, familiar anatomic landmarks, and several options for trocar and instrument placement.

Patient Positioning and Trocar Placement

After intravenous access, anesthesia induction, endotracheal intubation, bladder catheter, sequential compression stockings, and orogastric tube placement, the patient is placed in the modified flank position (from 30- to 45-degree flank up). If desired, table flexion to increase the distance between the ribs and iliac crest may facilitate trocar placement. All pressure points should be carefully padded and the patient secured to the table to allow lateral tilting of the table (Fig. 102.1). Arms may be secured on pillows or arm rest. The operating room is configured to maximize the use of space and allow all members of the surgical team to view the procedure (Fig. 102.2). The entire abdomen and flank are included in the field of skin preparation and draping, in case conversion to open surgery is required. After pneumoperitoneum is achieved, three to five trocars are placed (Fig. 102.3). A wide variety of trocar configurations are effective for renal surgery. The following is a guide for trocar placement, and adaptations may be required on a case-by-case basis.

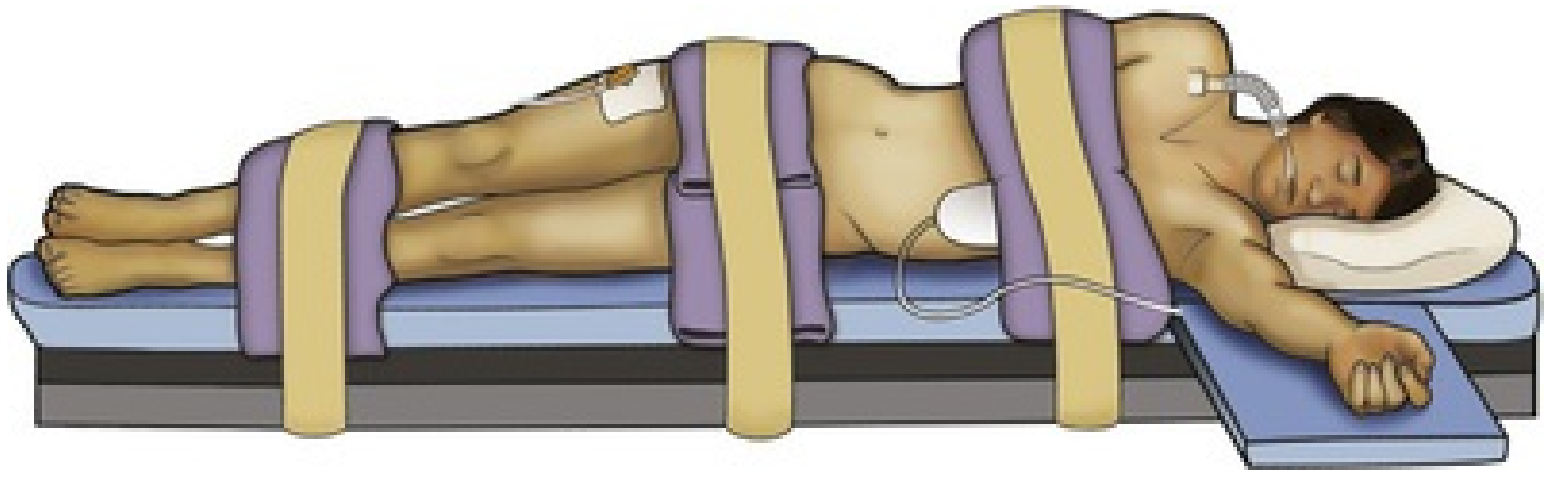

FIG. 102.1 The patient is placed in a modified flank position with the operative side tilted up 30 to 45 degrees using a gel roll or a rolled blanket supporting the back. The lower arm is placed on a padded arm rest, and the other arm is flexed at the elbow and rested over the chest. Wide cloth or silk tape is used to secure the patient to the operating table to allow for table rotation during the surgery.

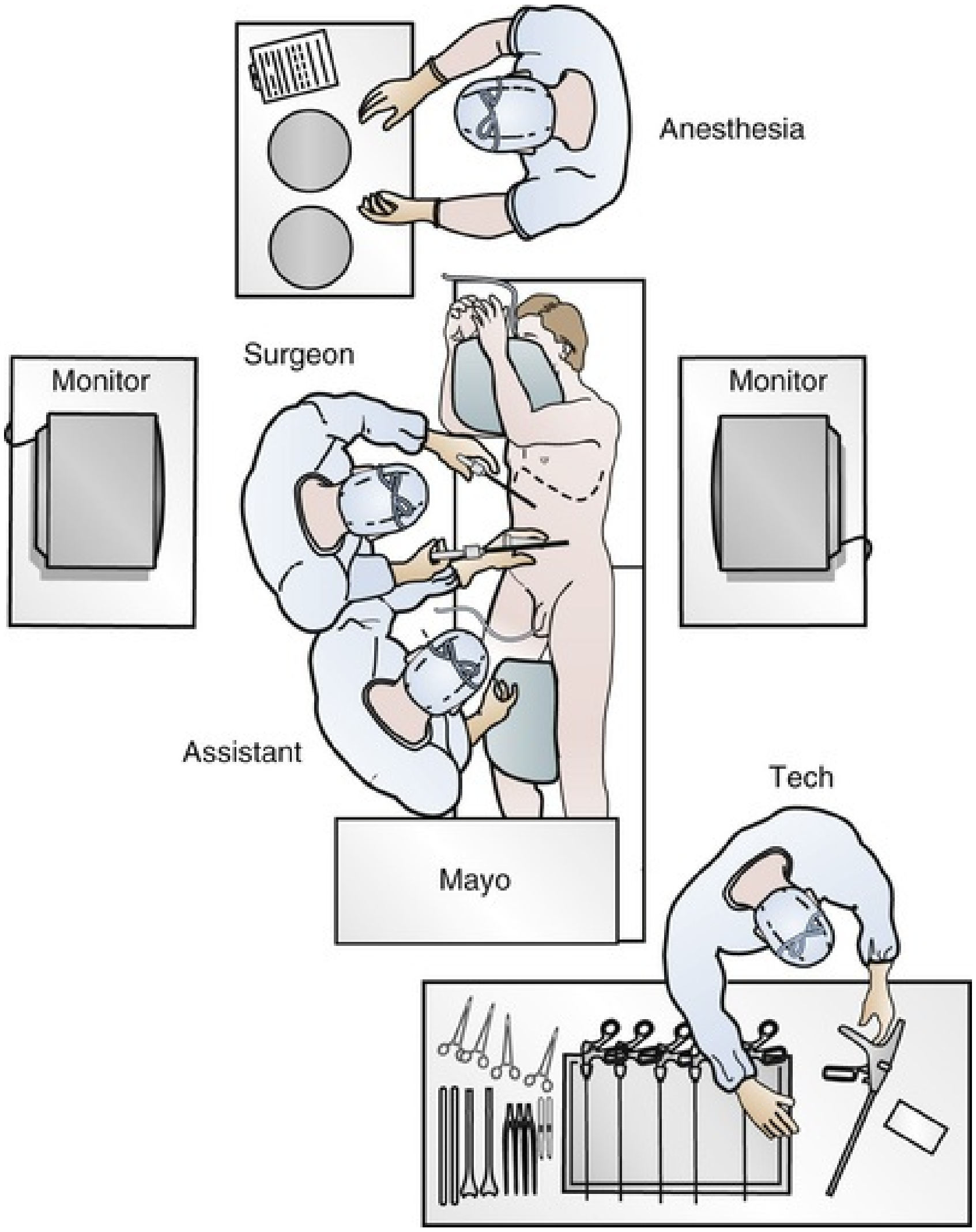

FIG. 102.2 The operating room configured for left nephrectomy. Two monitors allow the assistant to follow the procedure. The scrub technician

(tech) is positioned to easily assist with instrument passage and exchange.

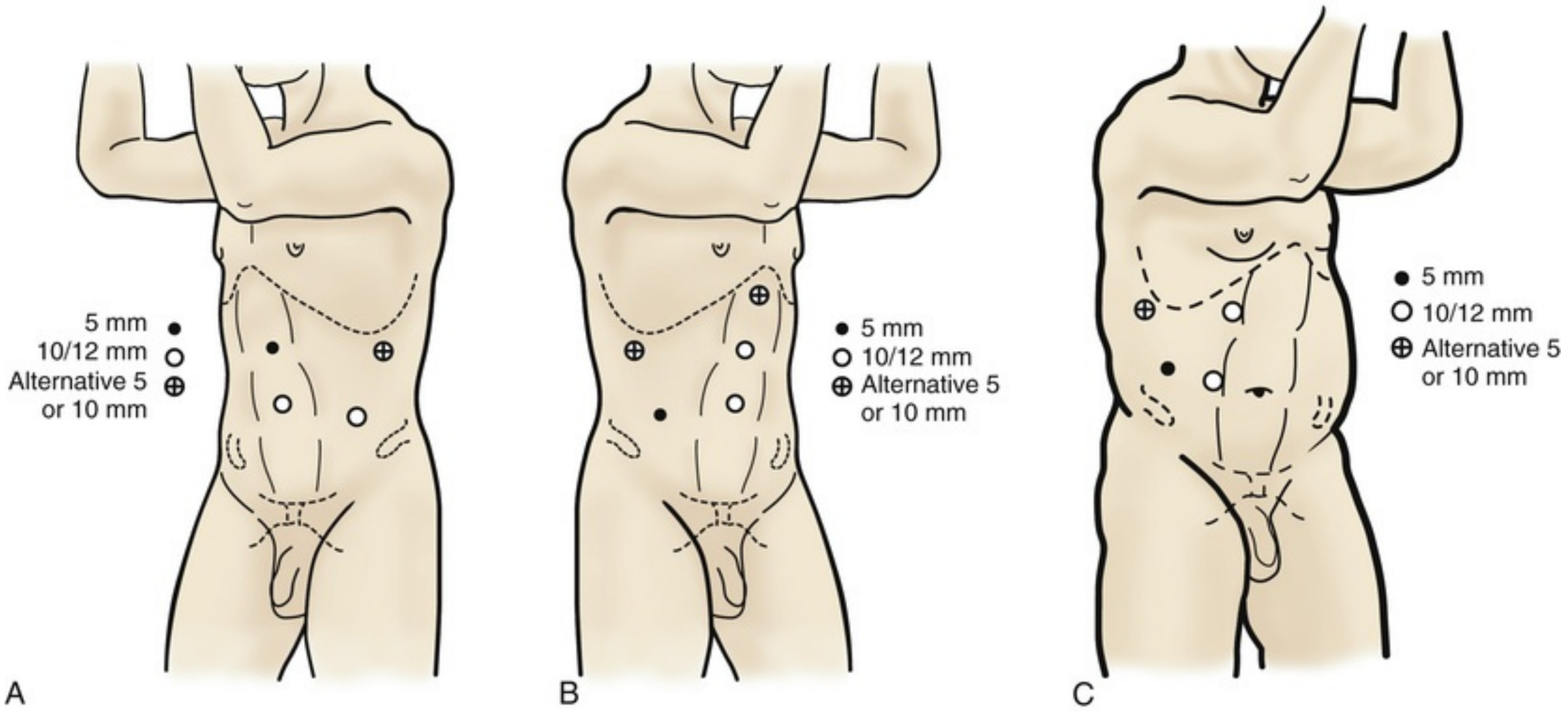

FIG. 102.3 Trocar sites for left-sided (A) and right-sided (B) procedures. A 12-mm trocar is placed lateral to the rectus at the level of the umbilicus, a second 10-mm trocar is placed at the umbilicus, and a 5-mm trocar is inserted in the midline between the umbilicus and the xiphoid process. (C) In obese patients, all trocars are shifted laterally. Optional accessory subcostal, subxiphoid, and low midline trocar positions, which may be helpful for retraction, are also shown.

A 10-mm camera port is inserted at the umbilicus, and a 5- or 10-mm trocar is placed in the midline about 2 cm below the xiphoid process. A 12-mm trocar is inserted in the anterior axillary line at the level of the umbilicus. This trocar is used for instrumentation and the passage of sutures, clamps, or staplers. In short patients, the 12-mm trocar may be placed in the midline, halfway between the umbilicus and pubis. In obese patients, all trocar sites are laterally shifted (see Fig. 102.3). Additional trocars may be placed for the use of retractors to assist visualization or exposure (Fig. 102.4), including a low midline 10- or 12-mm trocar for colon retraction and a 5-mm subxiphoid for liver retraction.

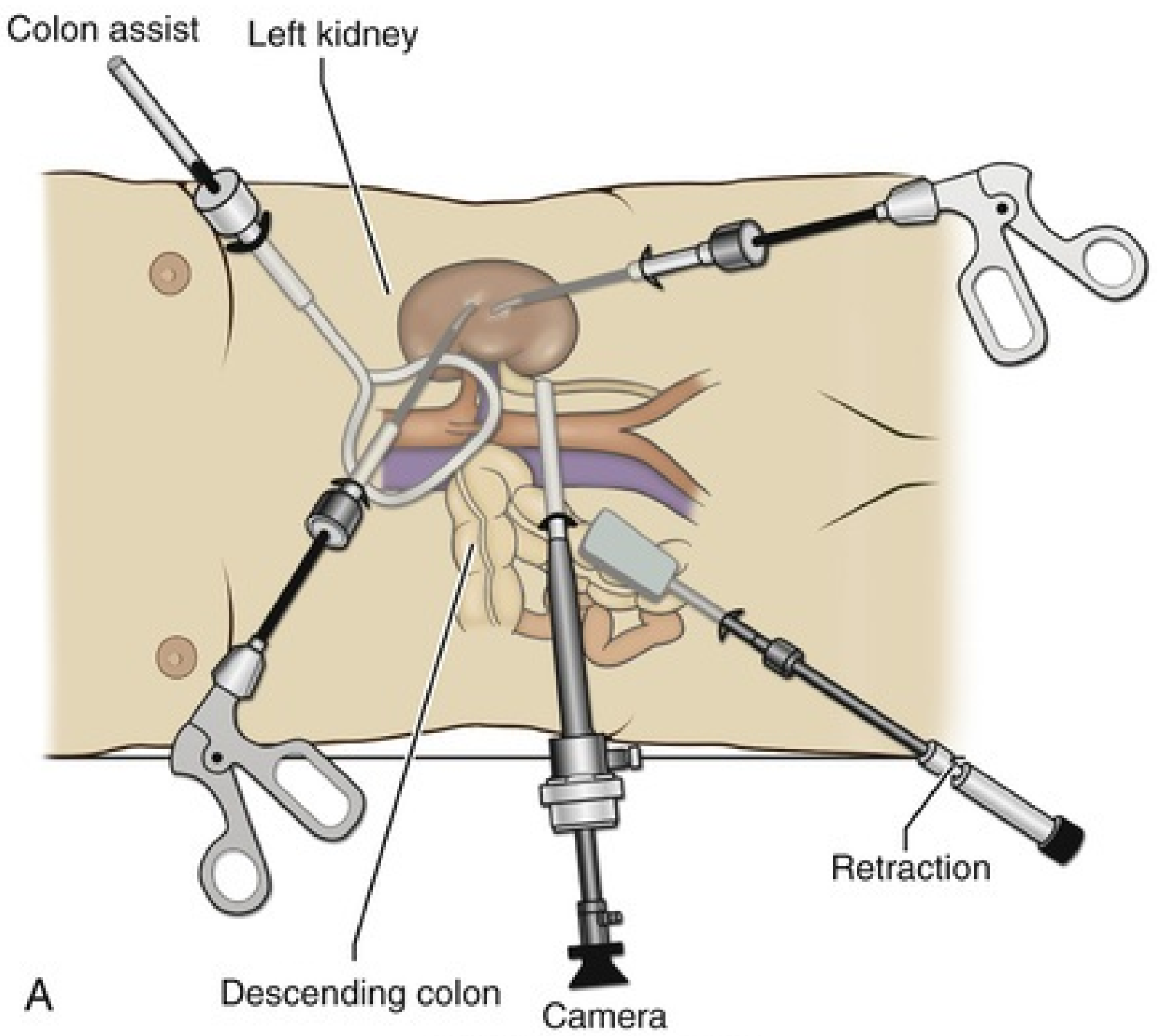
Colon assist
Left kidney
Retraction
A
Descending colon
Camera

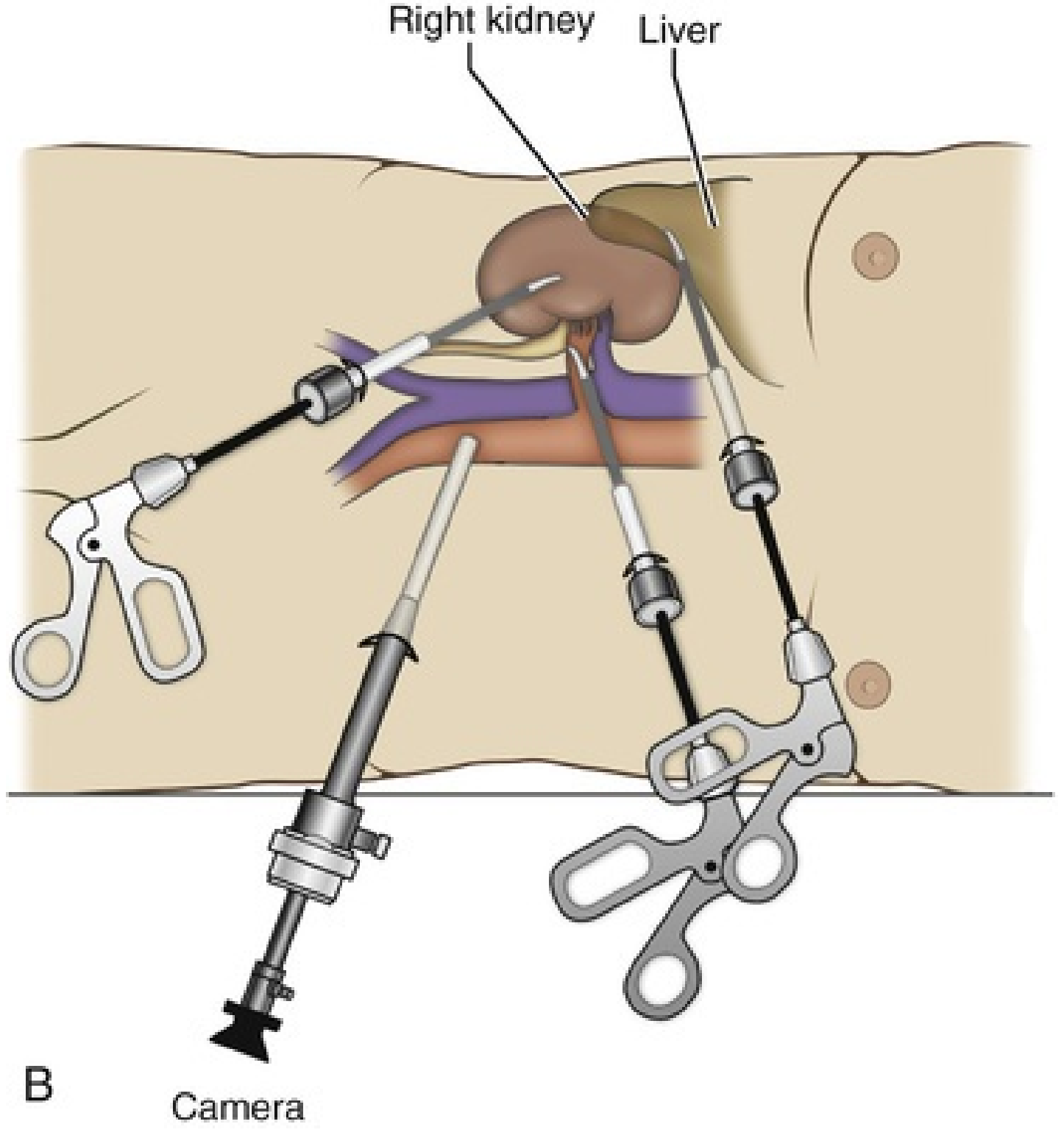
Right kidney
Liver
B
Camera

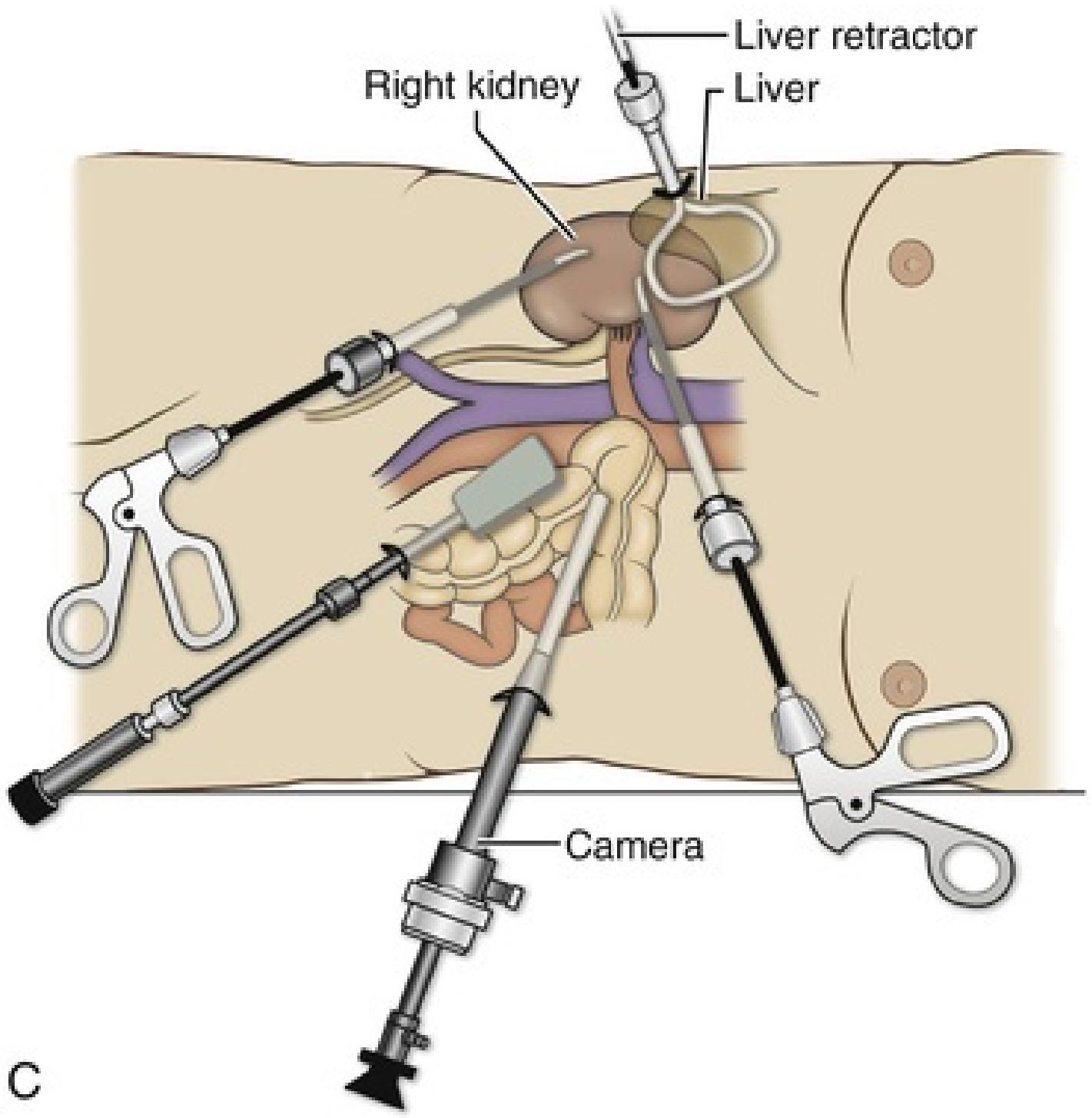

FIG. 102.4 Options for additional trocar placement and instrumentation. (A) Additional retraction during left-sided procedures can be accomplished with the use of a blunt instrument passed through a 5- or 10-mm trocar placed above the symphysis pubis or a 5-mm instrument and retractor passed through a subcostal incision. (B) In right-sided procedures, the liver and bowel can be retracted through a 3- or 5-mm trocar placed in the midline. (C) In right-sided procedures, the liver and bowel can be retracted through a 5-mm trocar with a 5-mm instrument. An optional 10-mm lower midline trocar may also be placed for retraction, freeing the two other working hands for dissection.

Retroperitoneal Approach

This approach resembles the open surgical technique in which the peritoneal cavity is not violated. It may be preferred for select cases of partial nephrectomy, pyeloplasty, cyst marsupialization, or renal biopsies. Moreover, this may be preferred especially in instances of extensive intraperitoneal adhesions. **In appropriately selected partial nephrectomy cases such as those with posterior tumors, the retroperitoneal approach may be faster and equally safe compared with the transperitoneal approach** (Fan et al., 2013). **The main limitations of the retroperitoneal approach include the following: limited working space leading to limited distance between trocars and decreased triangulation; less familiar anatomic landmarks; and surgical**

dissection being much closer to the lens, which may cause frequent smudging of the image.

Patient Positioning and Trocar Placement

The patient is placed in a full flank position. Table flexion is used to increase the distance between the ribs and iliac crest to facilitate trocar placement. An axillary roll is placed to protect the lower arm. All pressure points should be carefully padded and the patient secured to the table to allow lateral tilting of the table. Arms may be secured on pillows or an arm rest. A trocar transverse incision is made in the posterior axillary line, halfway between the tip of the 12th rib and the iliac crest (Fig. 102.5A). After the lumbodorsal fascia is divided and the retroperitoneum is entered, a working space is developed using blunt dissection with the laparoscope through a visual obturator or the finger. When manual dissection is used, a finger is placed in the space between the psoas muscle and the kidney (Fig. 102.5B). A balloon dilator is introduced in the cavity and distended with gas or fluid. This displaces the adjacent fat and peritoneum to create a suitable working space (Fig. 102.5C). A simple balloon can be constructed using two fingers of a size 8 or 9 glove (Gaur, 1992). A blunt tip trocar (US Surgical, Norwalk, CT) is then passed through the incision, and the trocar cuff is expanded and cinched to the skin to prevent gas leakage (Fig. 102.5D). Care must be taken to place the balloon completely in the retroperitoneum to avoid dilating the muscle and causing postoperative flank hernia. Alternatively, a 0-degree lens and visual obturator through the initial incision can be used to enter the retroperitoneal space (Fig. 102.6A). The appearance of the characteristic yellow retroperitoneal fat confirms the correct trocar placement. Insufflation is initiated, and blunt dissection using the laparoscope or a laparoscope with a working channel is performed to further develop the working space (Fig. 103.6B). Caution must be taken to avoid entering too anteriorly, which may cause inadvertent peritoneal violation or colon injury, or too posteriorly, which may result in bleeding from the quadratus lumborum or psoas muscles. Once the working space is fully established, the anatomic structures should be identified for orientation and additional trocar placement. Typically, a 5-mm trocar is placed just off the tip of the 12th rib, and a 12-mm trocar is placed posteriorly and superiorly relative to the camera port, both under laparoscopic visualization (see Fig. 103.5A). In cases in which the retroperitoneal approach does not allow the safe completion of the procedure, an initial retroperitoneal access can be expanded to a transperitoneal approach by opening the peritoneum under direct vision.

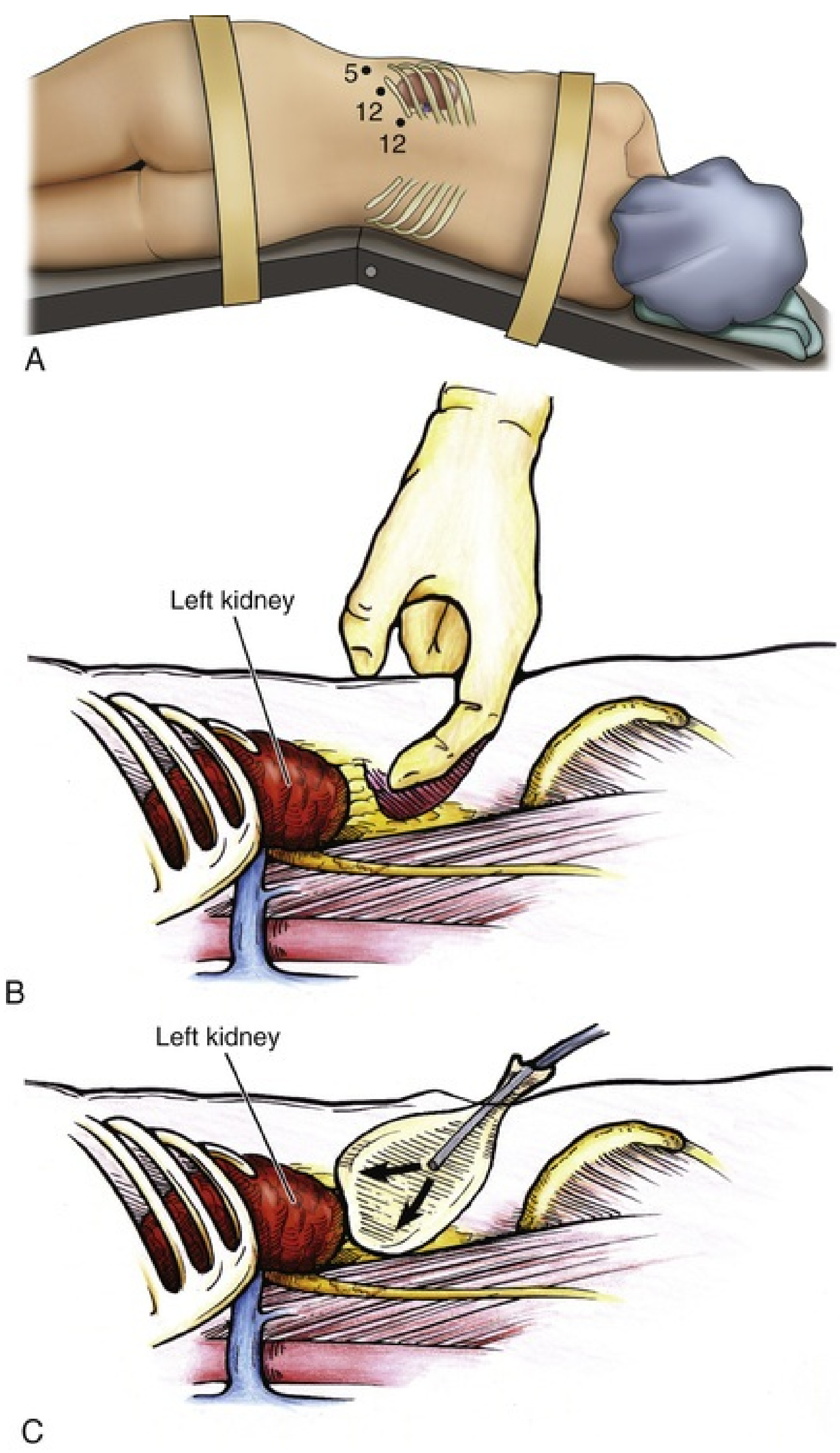
5
12
12
A
Left kidney
B
Left kidney
C

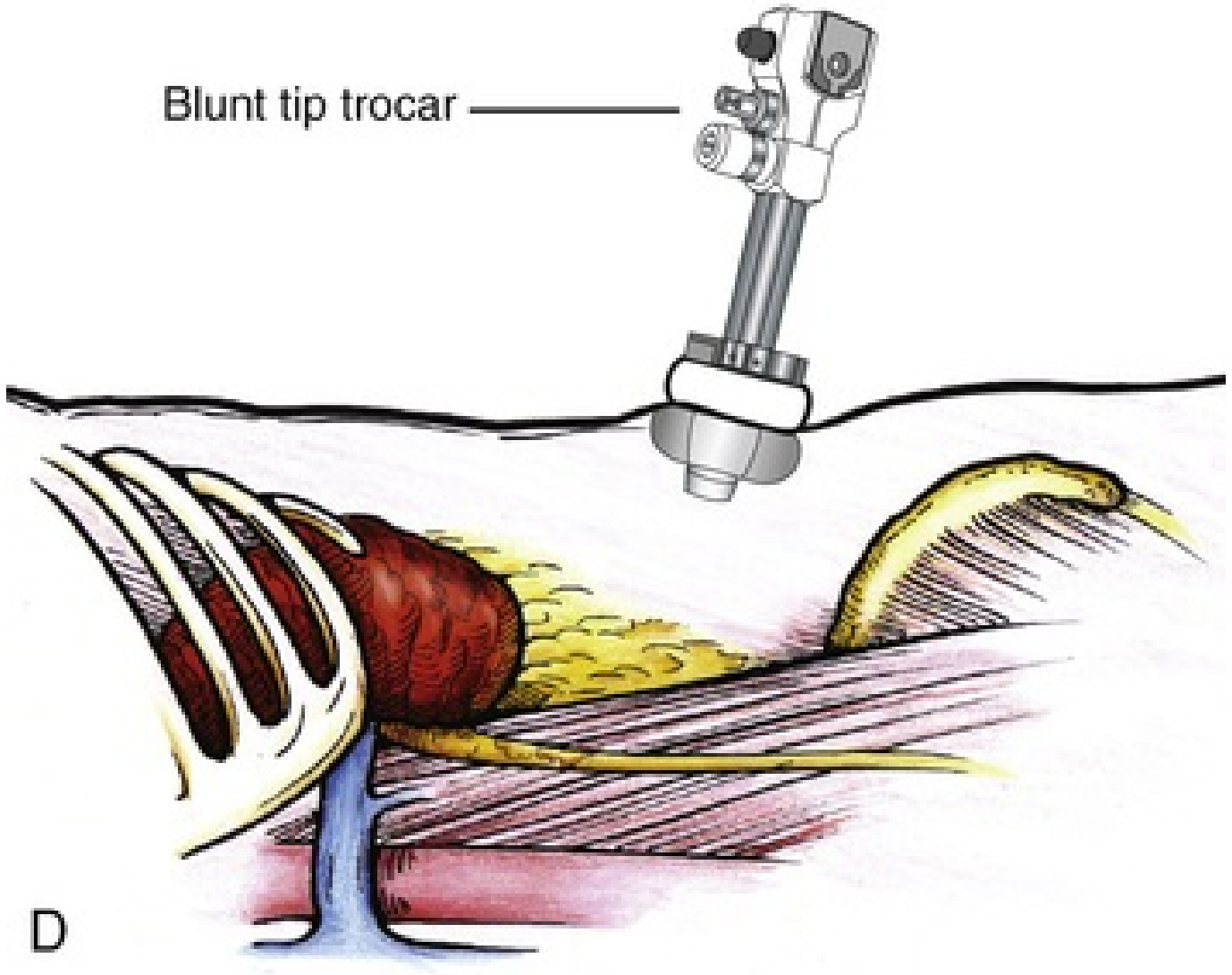

FIG. 102.5 Trocar placement for retroperitoneal kidney surgery. (A) With the patient in the full lateral position, the hips flexed, and the kidney rest elevated, a 15-mm incision is made 2 cm below the tip of the 12th rib, between the rib and the anterior superior iliac spine. (B) The index finger is inserted through the incision and used for blunt dissection to create a hole from the skin through the muscle into the retroperitoneal space. If the finger is in the correct position, the surgeon should feel the smooth surface of psoas muscle and the lower pole of the kidney covered by Gerota fascia. (C) To quickly create the working space, insert a balloon created from the finger of a size 8 or 9 glove, secured with silk suture over a simple red rubber catheter. The balloon is then filled with 600 to 800 mL of saline. (D) A blunt tip trocar (US Surgical, Norwalk, CT) is used to seal the trocar site. Because of its low profile, it will not obstruct the view or take up useful space in the retroperitoneum. The balloon and collar configuration eliminates the need for sutures and allows 360-degree rotation.

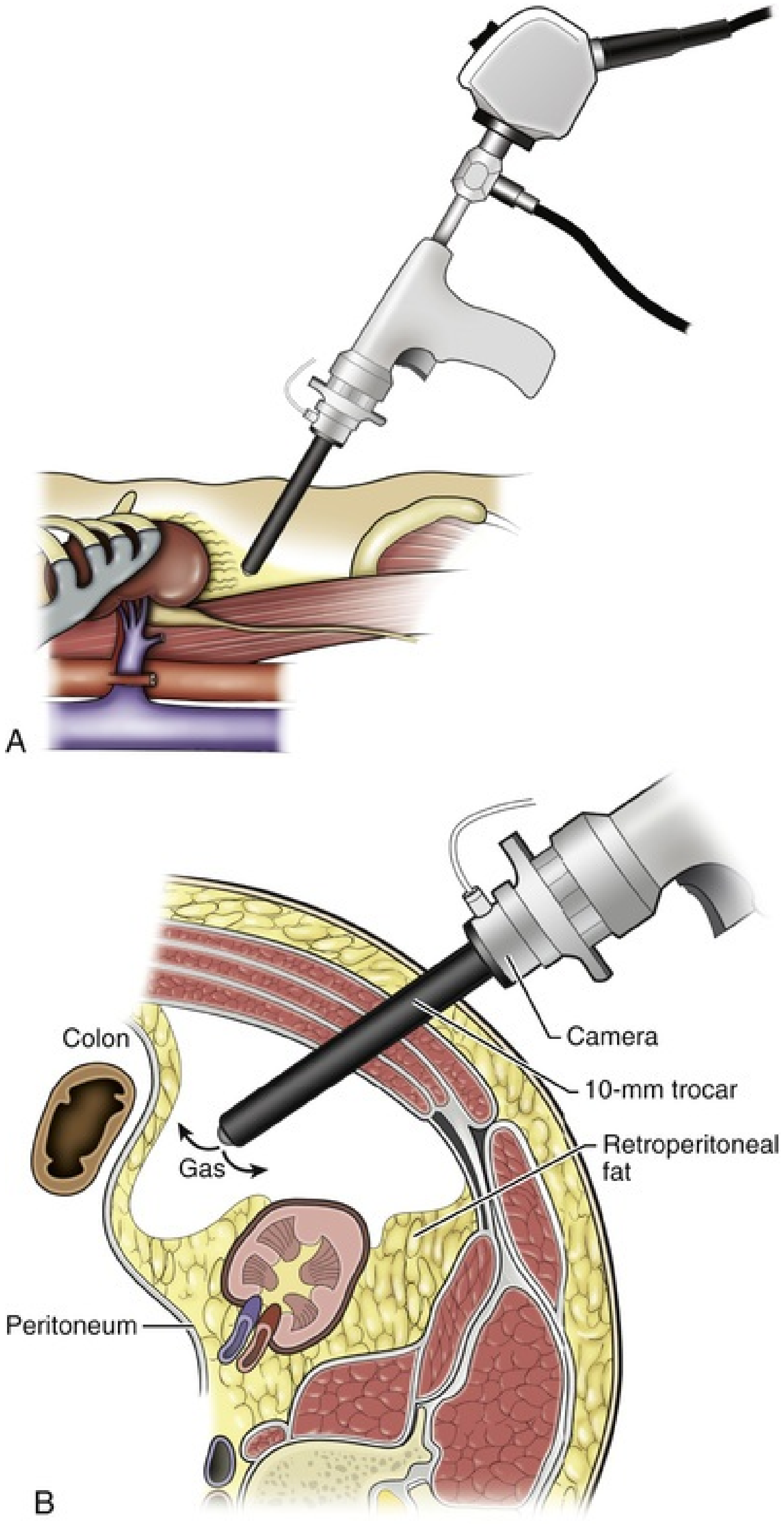
A
Colon
Camera
10-mm trocar
Retroperitoneal fat
Gas
Peritoneum
B

FIG. 102.6 (A) Standing behind the patient, the surgeon initially develops a space bluntly between the psoas muscle and the kidney using the visual obturator with the 0-degree laparoscope through it. (B) Together, they are used to bluntly push the peritoneum medially, creating a working space large enough to allow placement of additional trocars.

Hand-Assisted Laparoscopy

The hand-assisted approach combines some of the benefits of pure laparoscopy, such as improved visualization and smaller incisions, with the advantages of open surgery, including the use of the surgeon's hand for dissection, retraction, and hemostasis, while maintaining tactile feedback. In addition, the same incision, large enough for the hand, is also used to extract the surgical specimen. This approach is attractive for the novice laparoscopic surgeon particularly and in cases of significant scarring around the kidney, when difficult dissection is anticipated. Hand assistance may also be used in the event of an emergency, such as bleeding, by extending a trocar site and placing a hand port to assist in vascular control and repair.

Patient Positioning and Trocar Placement

The patient is posited for a transperitoneal approach (see earlier). First, the hand port incision is made through the skin and fascia and into the peritoneal cavity. The hand port location depends on the operative side, patient's body habitus, surgeon's handedness, and personal preferences (Figs. 102.7 and 102.8). The incision should not be too large given this may cause leakage of gas and difficulty to maintain an adequate pneumoperitoneal pressure. After the hand port is placed, the pneumoperitoneum is established, and additional trocars are placed under direct laparoscopic visualization. Care must be taken in the port placement to avoid the hand getting in the way of the laparoscope or other instruments. The surgeon should be aware of the increased pressure in the arm (from 30 to 100 mm Hg), which may cause tingling, numbness, and pain in the hand and forearm (Monga et al., 2004; Ost et al., 2006).

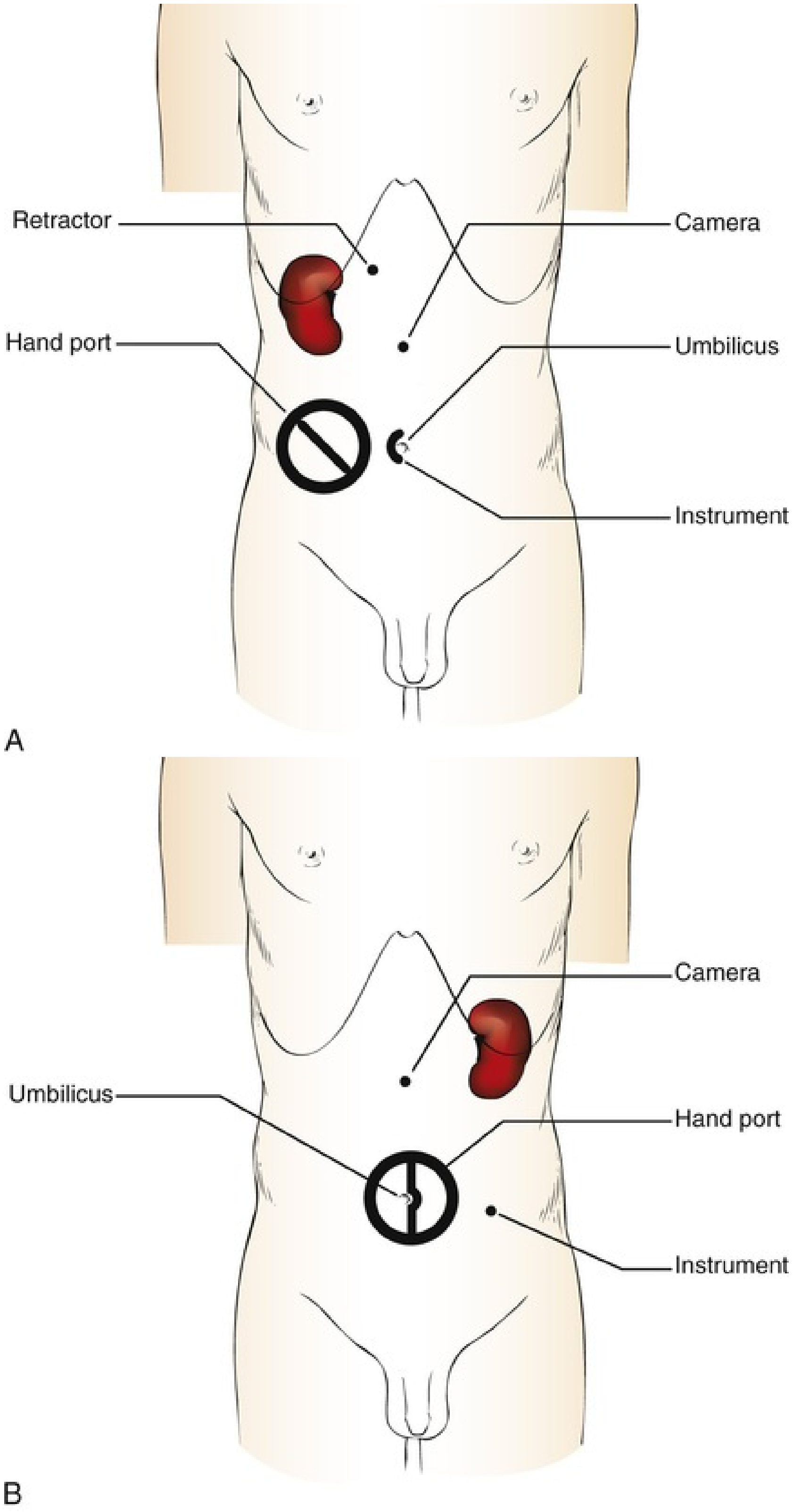
Retractor
Camera
Hand port
Umbilicus
Instrument
A
Camera
Umbilicus
Hand port
Instrument
B

FIG. 102.7 Port placement for a right-handed surgeon for hand assistance. (A) For a right-sided kidney, the hand-assisted device is placed in the right lower quadrant for insertion of the left hand, and dissection is

performed with instruments in the right hand placed through an umbilical trocar. The camera is placed several centimeters above the umbilicus in the midline. On the right side, retraction of the liver is usually necessary to allow visualization and dissection of the renal hilum. A liver or bowel retractor can be placed through a subcostal trocar to assist with visualization or irrigation and aspiration. (B) For the left kidney, the hand-assisted device and left hand are placed though a periumbilical incision, and dissection is performed with the right hand using an instrument placed in the subcostal margin just medial to the nipple. The camera is placed several centimeters lateral to the edge of the actual hand-assisted device (not the edge of the incision). Additional assistance can be delivered through the most lateral trocar site.

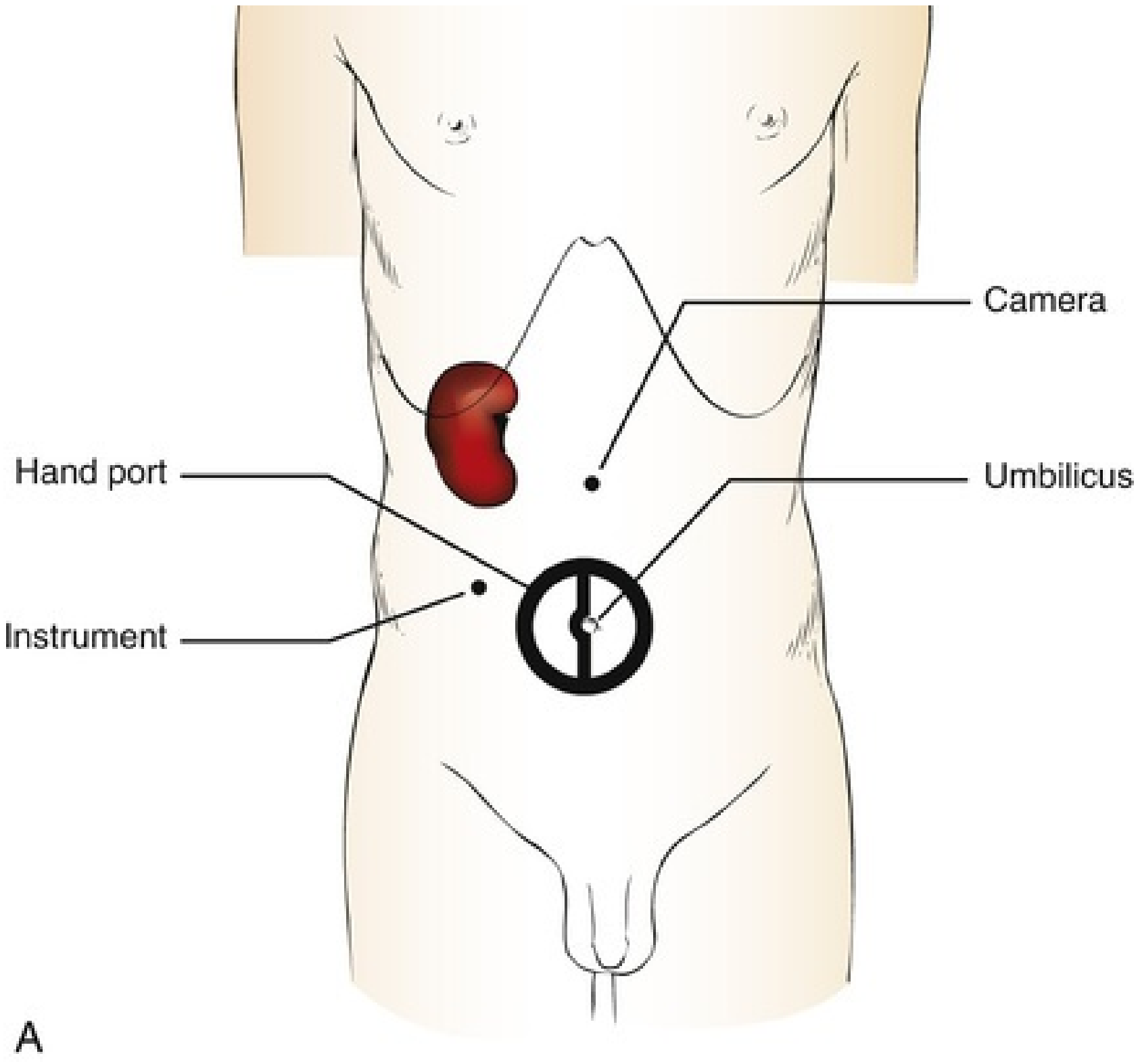

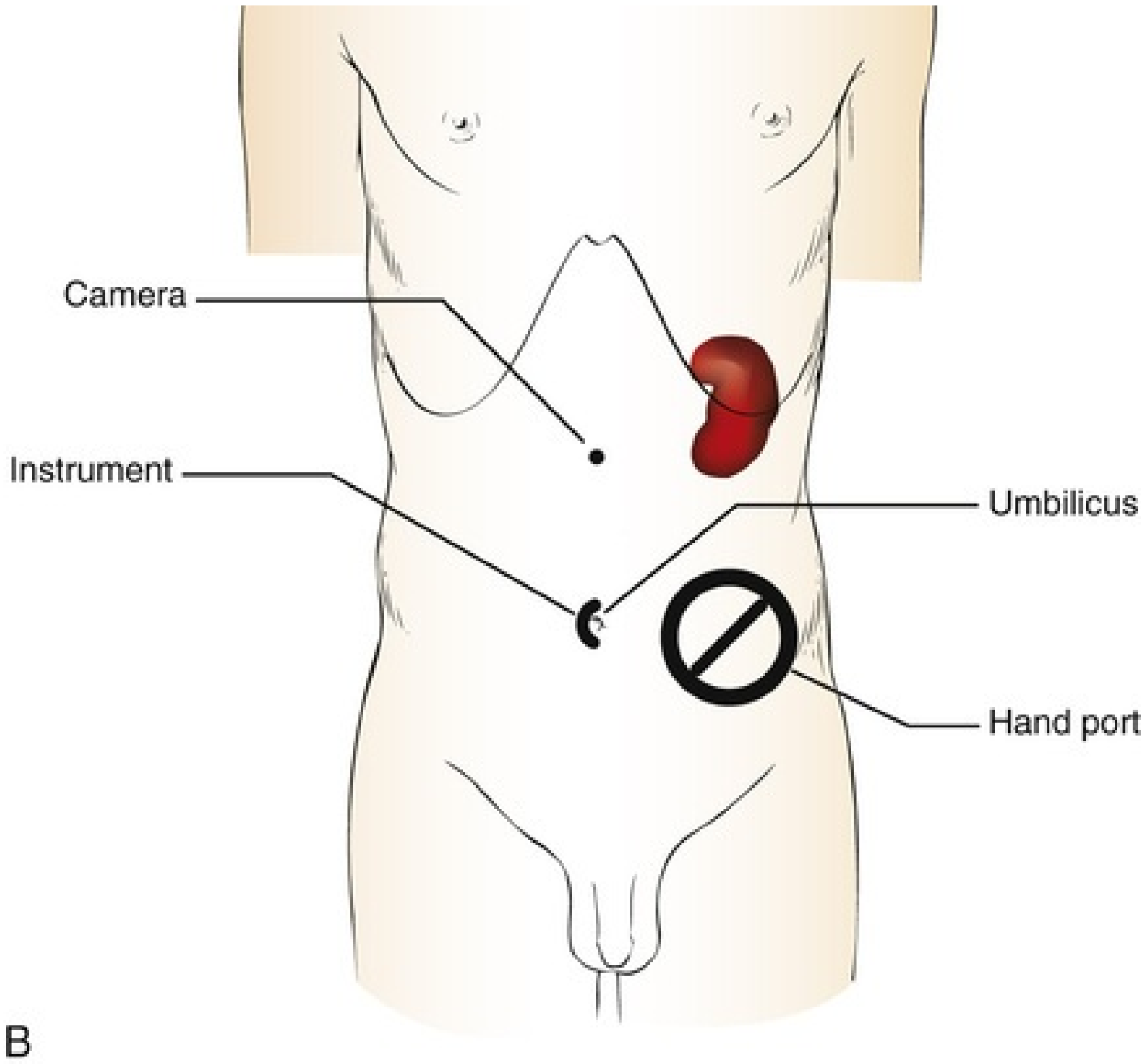

FIG. 102.8 Port placement for a left-handed surgeon for hand assistance. (A) When operating on the right kidney, a left-handed surgeon places the hand-assisted port in the periumbilical location for insertion of the right hand. The working port for the left hand is placed lateral to the rectus muscle, in line with or just inferior to the level of the umbilicus. The camera is placed through a lateral trocar in the anterior axillary line. Additional assistance with retraction of the liver can be accomplished through a subcostal trocar. (B) For a left-handed surgeon operating on the left kidney, the hand-assisted port is placed in the left lower quadrant for insertion of the right hand. The left hand works with the instrument passed through an umbilical trocar, and the camera is placed midway between the umbilicus and the xiphoid process. Additional assistance with retraction or aspiration can be accomplished through a fourth trocar placed at the subcostal margin.

Robotic-Assisted Laparoscopy

The robotic approach allows surgeons with limited laparoscopic skills to perform minimally invasive reconstructive renal surgery. It has the advantages of a three-dimensional view of the surgical field, greater degree of instrument motion, elimination of tremor, ergonomic position, and the ability to scale motions. The robotic kidney surgery can be done transperitoneally or retroperitoneally via multiple or single-site ports.

Patient Positioning and Trocar Placement

Patient positioning depends on the surgical approach (transperitoneal or retroperitoneal), number of robotic arms used, and tumor location (in cases of partial nephrectomy) (Fig. 102.9). In most cases, the patient is positioned in the flank position with or without table flexion and secure to the table as previously described. In a three-arm configuration, the camera port is placed in the periumbilical area and two robotic trocars in the anterior axillary line, one above the iliac crest and a second one subcostal. A 12-mm assistant trocar is inserted in the low midline to allow passage of sutures, clamps, stapler devices, suction, or retraction. An additional 5- or 12-mm subxiphoid trocar may be used, if necessary (Fig. 102.10A). In a four-arm configuration an additional robotic trocar is placed in the lower quadrant (Fig. 102.10B). Attention must be paid to avoid robotic arm collision, especially in short patients. Lateral port placement shift may be required in obese patients.

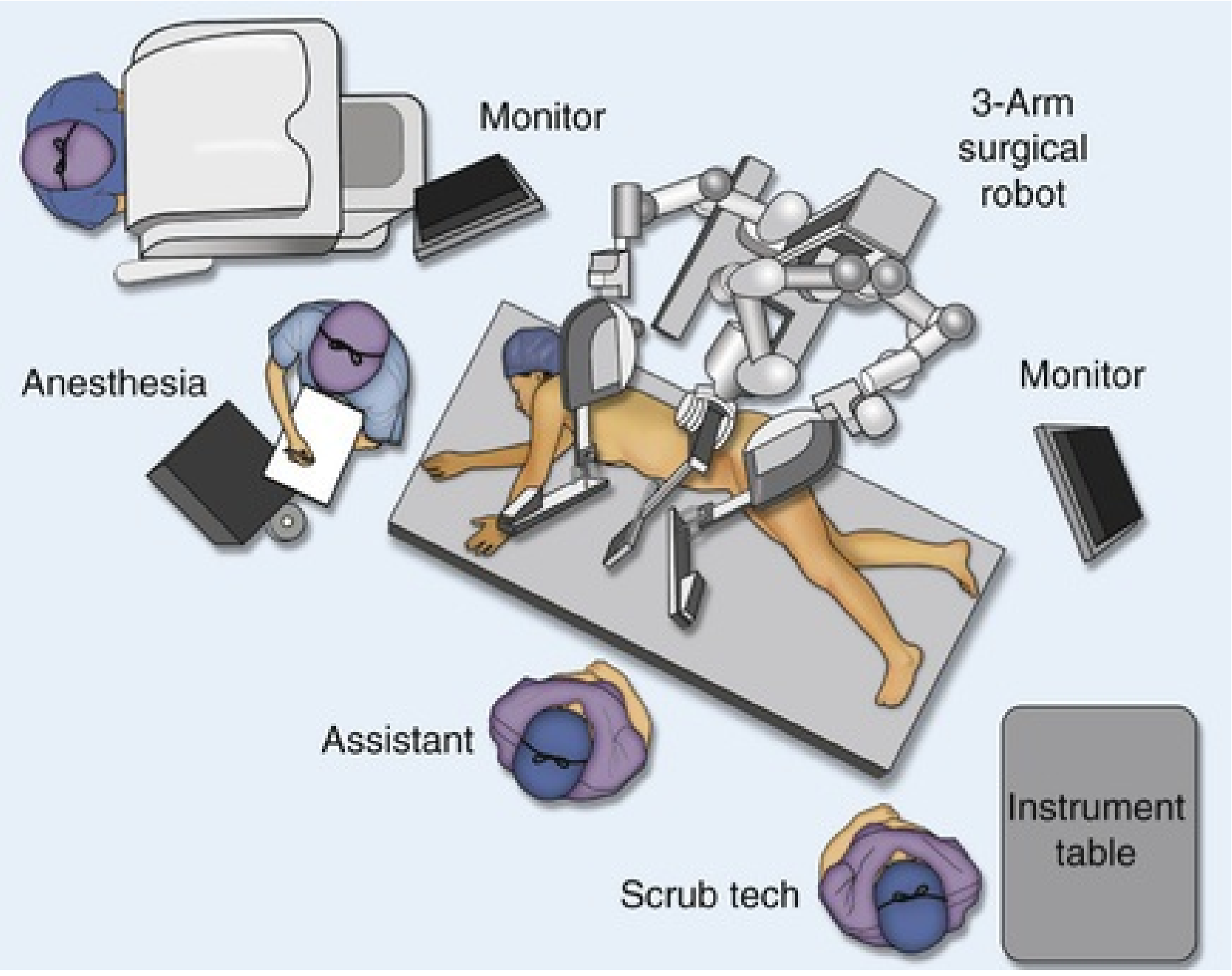

FIG. 102.9 Operating room configured for left-sided robotic-assisted laparoscopic partial nephrectomy.

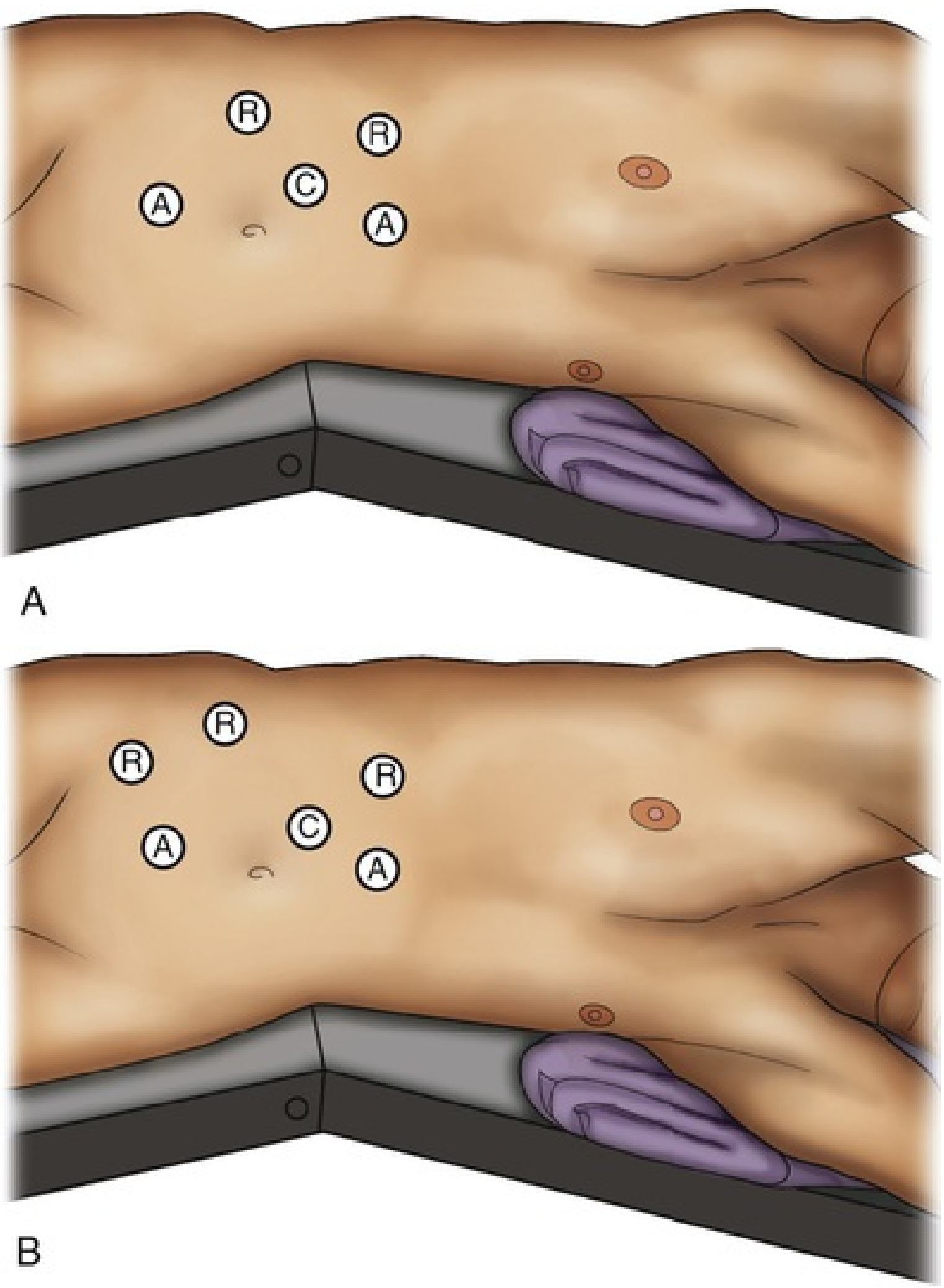

FIG. 102.10 Trocar placement for robotic-assisted laparoscopic renal surgery. (A) Three-arm system configuration. (B) Four-arm system configuration. *A,* Assistant trocar; *C,* camera port; *R,* robotic trocar.

Laparoendoscopic Single-Site Surgery and Natural Orifice Transluminal Endoscopic Surgery

LESS consolidates all laparoscopic ports in a single skin incision (Box et al., 2008)**. NOTES uses one or more patent natural orifices of the body for access. These approaches have evolved with the goal of further improving cosmesis and reducing postoperative pain**. Virtually all renal procedures have now been performed via LESS, whereas the experience with pure NOTES is limited to a small number of procedures (Autorino et al., 2010; Kaouk et al., 2010). However, hybrid NOTES with standard laparoscopic approaches, using the vagina as an access and extraction site during nephrectomy, have been reported by several authors (Alcaraz et al., 2011; Branco et al., 2008; Gill et al., 2002; Xue et al., 2015).

Patient Positioning and Trocar Placement

A variety of accepted LESS methods of positioning and trocar use have been described and are currently used. Most approaches involve the placement of a multichannel access in the umbilicus or below the waistline to minimize visible scars. Modified flank and full flank positions have been described, mirroring positioning for standard transperitoneal or retroperitoneal laparoscopic kidney surgery, respectively. After the pneumoperitoneum is established, multiple traditional low-profile trocars close together within a single, small extraction incision (Fig. 102.11) or a purpose-specific access device (Fig. 102.12) are placed. Conventional laparoscopic instrumentation can be used; however, flexible or articulated instruments provide extra degrees of motion. Moreover, a single-site surgical version of the daVinci device has been developed. Characteristics of various single-site access options are described in Table 102.1. **LESS approaches can be technically challenging, largely because of the limited triangulation afforded by the clustering of instruments entering the intracorporal working space.**

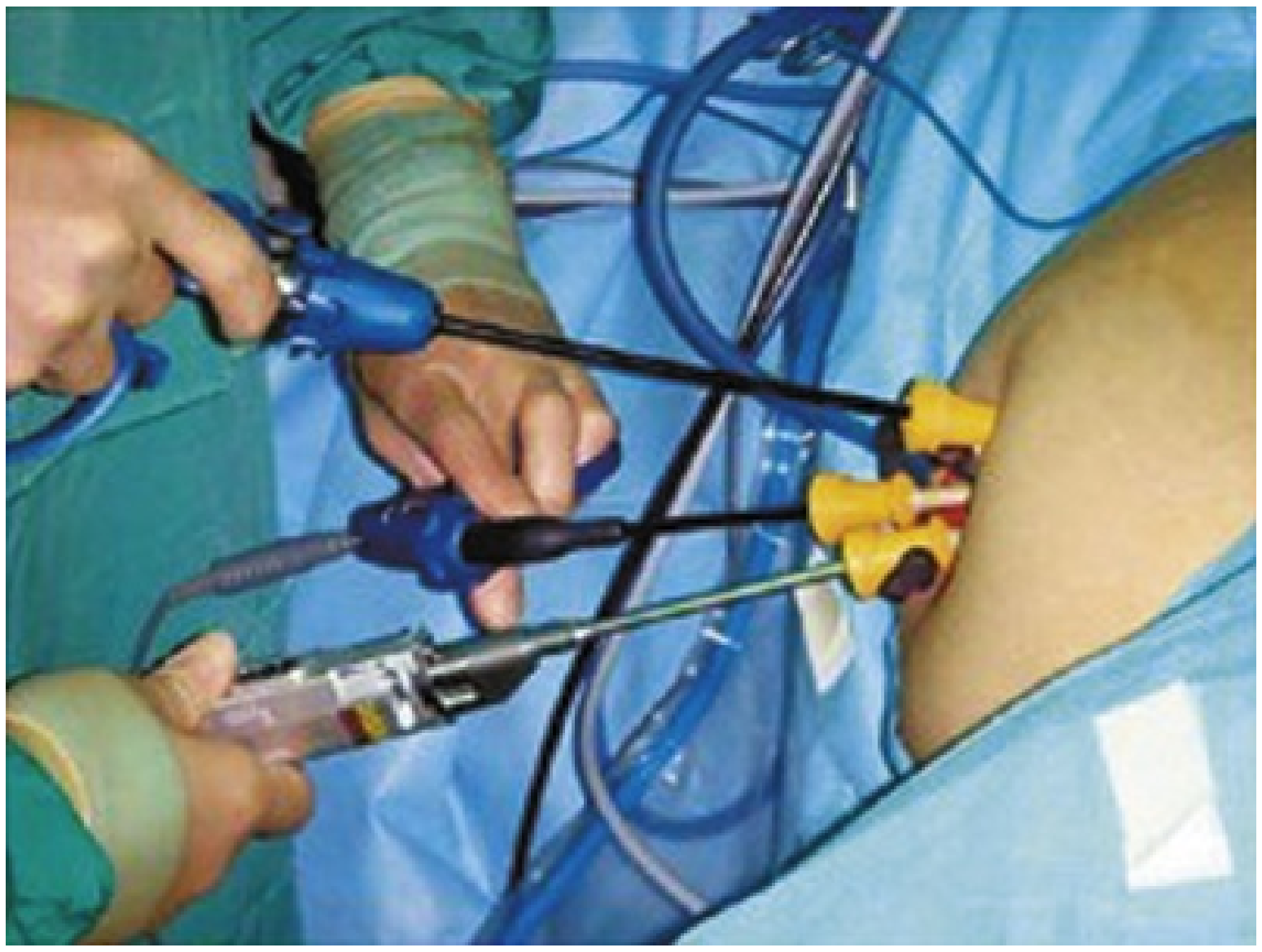

FIG. 102.11 Laparoendoscopic single-site surgery performed using three low-profile trocars inserted through a single small extraction incision. A

flexible laparoscope and flexible instrumentation may be used. (From Tracy CR, Raman JD, Cadeddu JA, et al.: Laparoendoscopic single-site surgery in urology: where have we been and where are we heading? *Nat Clin Pract Urol* 5:561–568, 2008.)

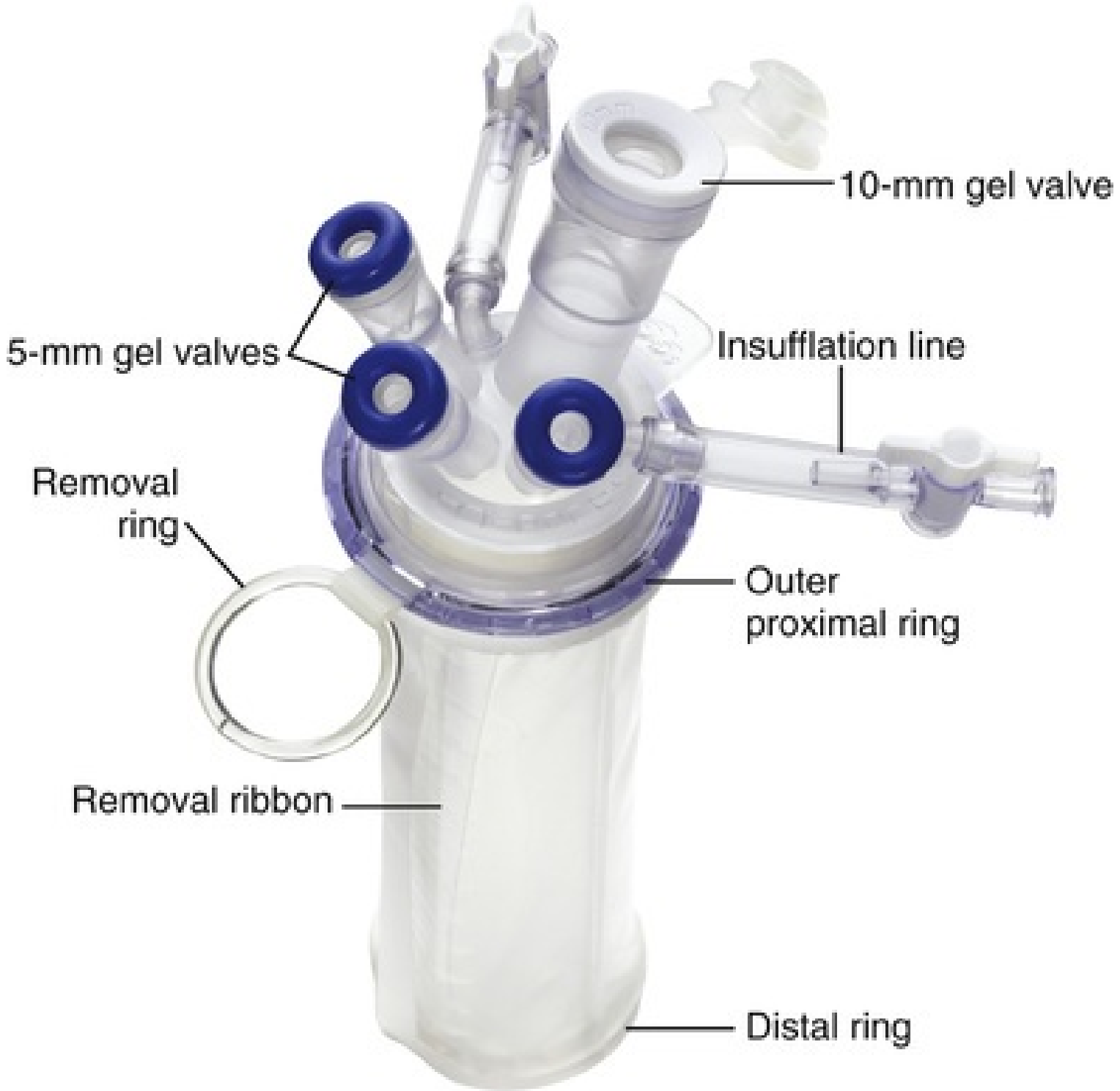
10-mm gel valve
5-mm gel valves
Insufflation line
Removal ring
Outer proximal ring
Removal ribbon
Distal ring

FIG. 102.12 Purpose-specific device for laparoendoscopic single-site surgery. The TriPort system (Advanced Surgical Concepts, Bray, Ireland) allows for passage of multiple instruments through a single incision.

TABLE 102.1

Access Options for Laparoendoscopic Single-Site Surgery (LESS)

ACCESS TYPE	DESCRIPTION
Keyhole	Use of three closely approximated periumbilical trocars placed side by side in a single skin incision or three separate incisions.
	No additional purpose-built device required.
	Typically used with articulating camera and specialized instrumentation.
	Insufflation through one of the trocars.

TriPort +/TriPort 15/QuadPort + (Advanced Surgical Concepts, Bray, Ireland)	Open or closed access, may be used with multiple incision sizes, typically 2.5- to 5-cm fascial incision.
	Anchored by inner (intra-abdominal) and outer rings drawn together with cylindric sleeve.
	Three-port (one 12-mm and two 5-mm) and four-port (two 12-mm and two 5-mm) configurations available.
	Insufflation through valve housing.
Uni-X (Pnavel Systems, Cleveland, OH)	Open access technique, requires 2-cm fascial incision.
	Anchored with preplaced fascial sutures.
	Single port encompassing three 5-mm access ports.
	Typically used with articulating camera and specialized instrumentation.
	Insufflation through valve housing.
GelPort/GelPoint (Applied Medical, Rancho Santa Margarita, CA)	Open access technique, requires 2.5- to 5-cm fascial incision.
	Anchored by inner and outer rings drawn together with cylindric sleeve.
	Can accommodate all trocar sizes.
	May allow for wider spacing of trocars.
	Insufflation through trocar placed through device.
AirSeal (SurgiQuest, Milford, CT)	Various trocar sizes up to 27 mm, oval-shaped trocar accommodating multiple instruments.
	High-velocity CO_2 recycling system to maintain pneumoperitoneum pressures without mechanical valve.
SILS (Covidien, Mansfield, MA)	Single biconcave piece of foam with a valve for insufflation and three holes to accommodate trocars (three 5-mm low-profile trocars or two 5-mm trocars and one 10- to 12-mm trocar).
	Inserted via open Hasson technique through minimum 2-cm fascial incision with the aid of a Péan clamp.
SPIDER (TransEnterix, Morrisville, NC)	Single-access device allowing for the use of flexible instruments passed through articulating instrument delivery tubes.
	Additional working channels allow for use of conventional laparoscopic instruments as well.
Homemade port (using Applied Medical [Rancho Santa Margarita, CA] wound retractor)	Similar to GelPoint trocar using a wound retractor from the same company in addition to a sterile surgical glove.
	Surgical glove secured to the wound retractor using suture or sterile rubber bands.
	Trocars can be passed through each of the fingers of the surgical glove portion of the access device.

OCTO Port (DalimSurgNET, Seoul, Korea)	Available in two base sizes requiring fascial incisions ranging from 1.5 to 5 cm.
	Uses a wound retractor and multiple attachments allowing for up to four ports.
Single Site Laparoscopy (SSL) Access System (Ethicon Endo-Surgery, Somerville, NJ)	Similar to other access devices in using a wound retractor base with an attachment cap.
	Integrates channels (two 5-mm instruments and a 10- to 12-mm instrument) with no trocar components protruding above the low-profile cap that can rotate.
	Placed through 2- to 4-cm fascial openings and able to traverse abdominal wall thickness up to 7 cm.

Simple Nephrectomy

Laparoscopic simple nephrectomy is indicated in the treatment of many benign renal diseases, including chronic pyelonephritis, obstructive or reflux nephropathy, renal tuberculosis, multicystic dysplastic kidney, renovascular hypertension, acquired renal cystic disease in dialysis patients, nephrosclerosis, symptomatic autosomal dominant polycystic kidney disease (ADPKD), and post–kidney transplantation hypertension (Gupta and Gautam, 2005). Chronic refractory pyelonephritis, including xanthogranulomatous pyelonephritis, can be managed laparoscopically; however, these conditions are usually associated with dense perinephric adhesions, loss of tissue planes, and a higher risk for complication and conversion to open surgery (Gupta et al., 1997). In some cases, the use of hand assistance or subcapsular nephrectomy technique may be needed to safely complete the procedure.

Procedure

Reflection of the Colon

For right and left transperitoneal renal surgery, the colon should be reflected medially. For a left nephrectomy, an incision of the peritoneum at the level of the line of Toldt is carried from below the lower pole of the kidney inferiorly to above the upper pole superiorly lateral to the spleen (Fig. 102.13). Care must be taken to avoid injury to the diaphragm. The inferior limit is extended as needed to obtain adequate reflection of the colon. Dissection of the lateral attachments of the kidney should be avoided at this time given these will prevent the kidney from rolling over and obscuring the hilum. The lienocolic ligament should be incised to allow the spleen to fall medially along with the pancreas and the colon (see Fig. 102.13). The thin colorenal attachments are incised and the colon is medially retracted (Fig. 102.14). Identification of the plane between the mesenteric fat, which has brighter yellow hue, and the pale yellow retroperitoneal or Gerota fat is key for a proper dissection and to avoid making an incision in the mesocolon or Gerota fascia. If the mesocolon is accidentally opened, it should be repaired to prevent the development of an internal hernia (Regan et al., 2003). A paddle retractor may be placed through an additional lower midline trocar to aid in retracting the colon, pancreas, and spleen medially (see Fig. 102.4A).

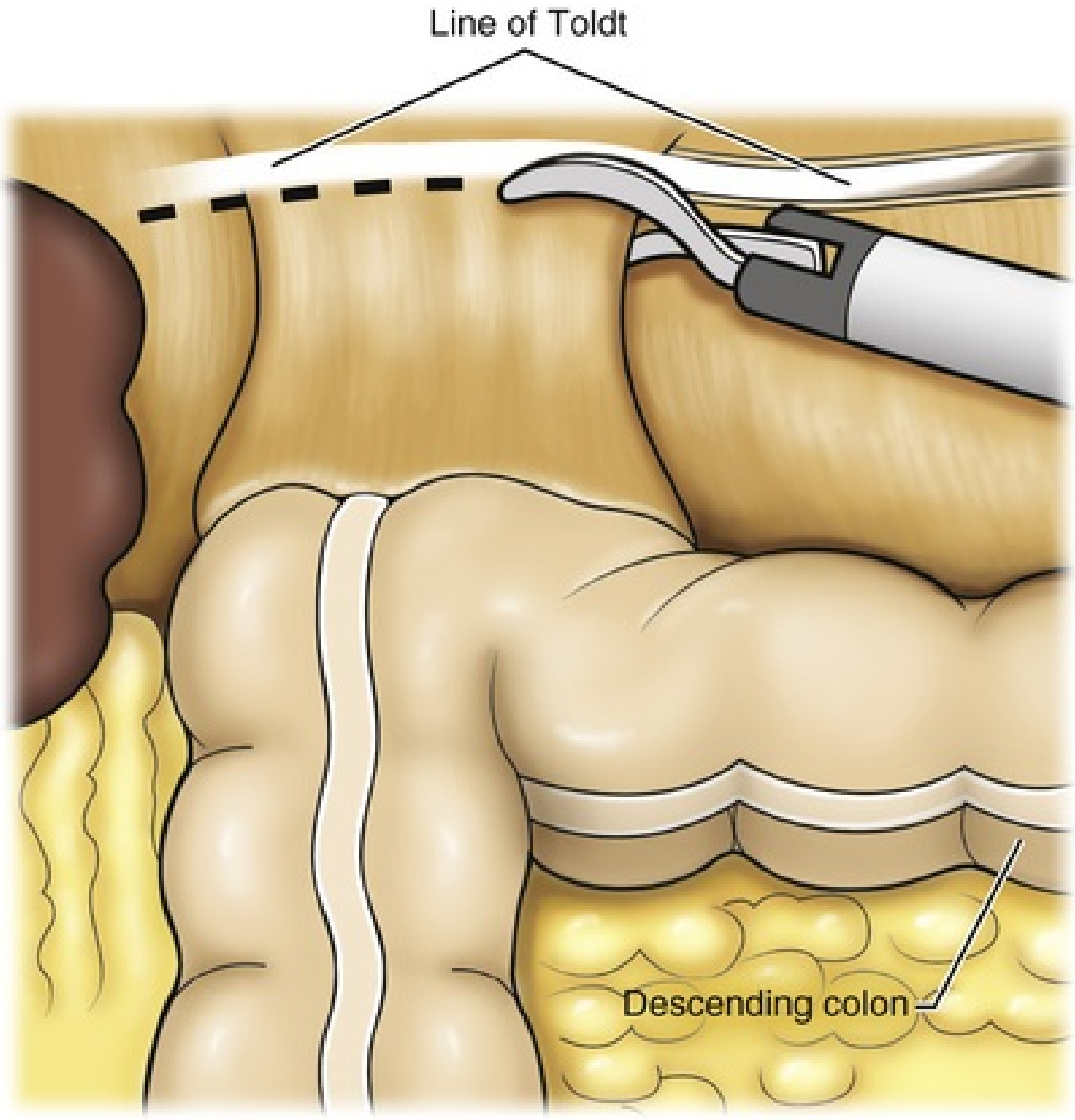

FIG. 102.13 Incision of the white line of Toldt with endoshears, bipolar cautery, or ultrasonic energy allows reflection of the colon. Continuing superiorly allows incision of the lienocolic ligament, facilitating reflection of the spleen, pancreas, and colon.

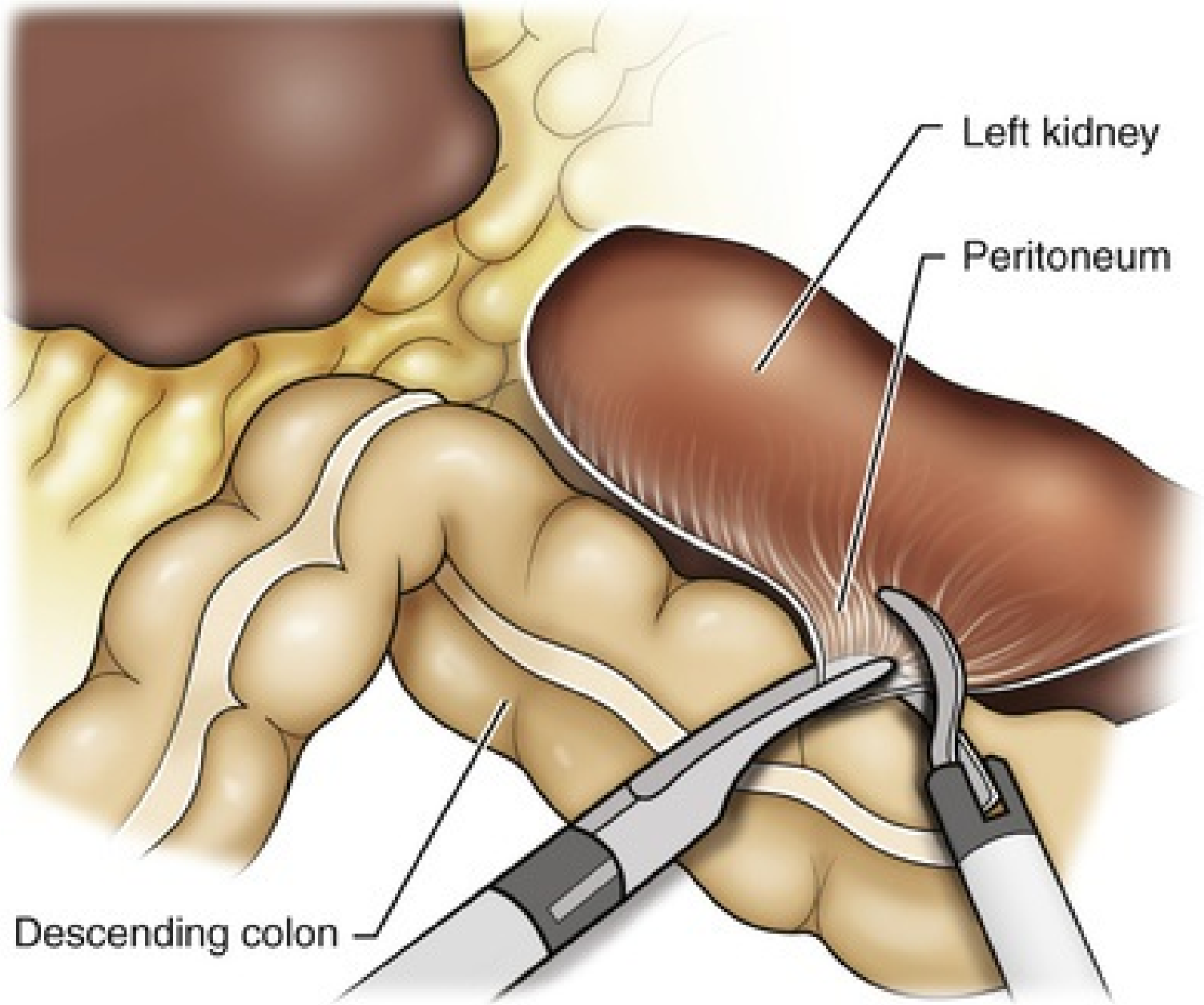

FIG. 102.14 Medial traction on the colon helps identify additional colorenal attachments and assists in differentiating the undersurface of the large bowel mesentery. Care must be taken at this step to avoid creating a mesenteric window.

For a right nephrectomy, a liver retractor inserted through an anterior axillary line or high midline port may be needed to expose the upper pole of the kidney (see Fig. 102.4B and C). After the peritoneal incision as described earlier, medial traction on the colon reveals colorenal attachments that must be divided to complete the colon reflection. Care must be taken to avoid thermal injury to the duodenum. Again, a low midline retractor may be helpful for visualization. Lateral dissection of the duodenum (Kocher maneuver) may be required to fully expose the medial aspect of the kidney and the connective tissue overlying the renal hilum and inferior vena cava (IVC) (Fig. 102.15). This should be done without electrocautery adjacent to the duodenum.

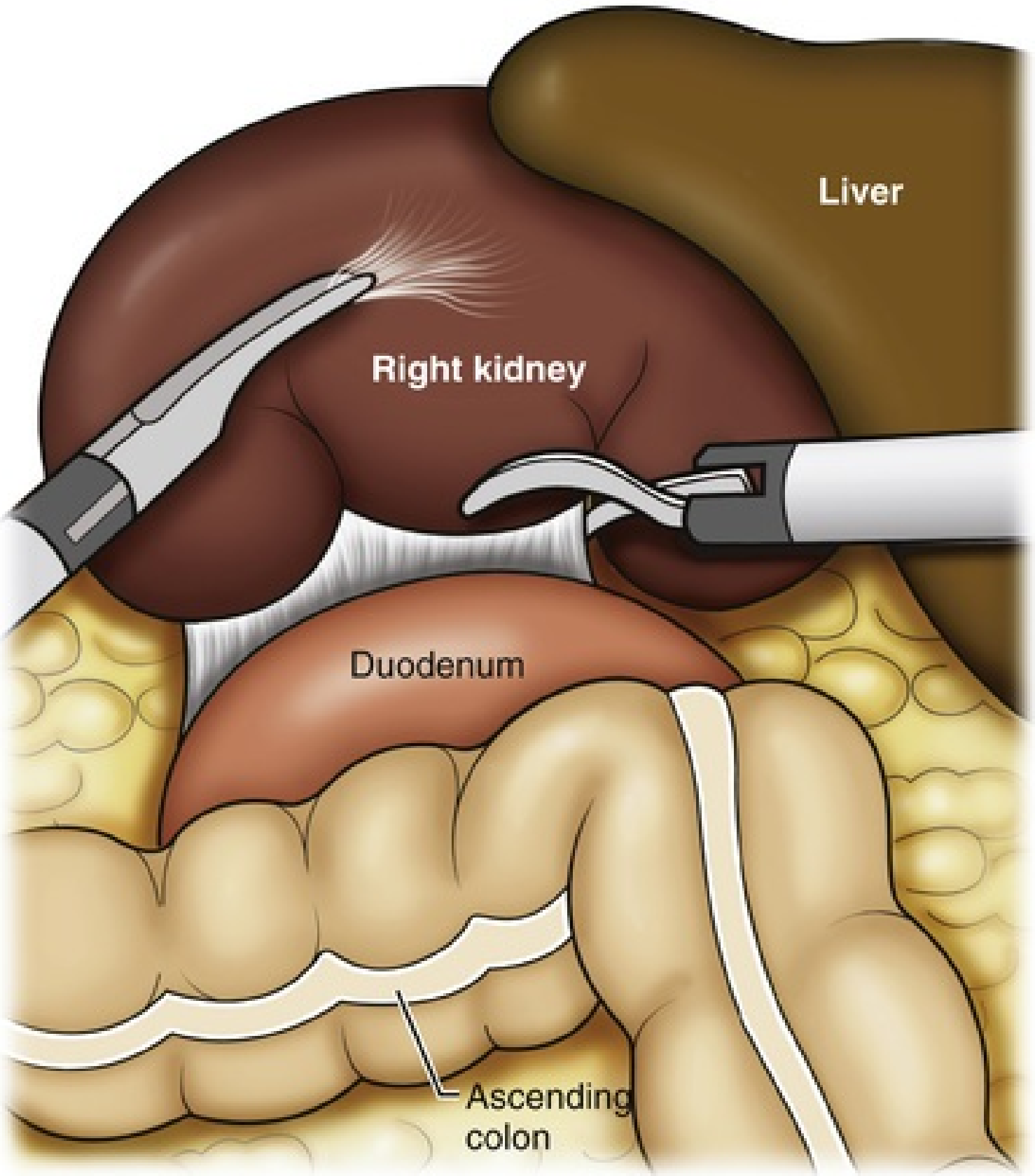

FIG. 102.15 On the right side, the colon is reflected, and a Kocher maneuver may be performed to completely expose the kidney and the renal hilum.

Dissection of the Ureter

Once the colon is medially reflected, the psoas muscle and tendon should be identified inferior to the lower pole of the kidney. Following the psoas medially, the gonadal vessels are usually encountered first, and the ureter is usually located just posterior to these vessels. Ureteral peristalsis can help differentiate the ureter from adjacent vascular structures. Once identified, the ureter is elevated, the gonadal vessels are swept medially, and the dissection is carried up proximally to the lower pole of the kidney. The ureter is not divided at this time, because it can be used to help elevate the kidney (Fig. 102.16). The tissue posterior to the ureter and lower pole of the kidney is swept anteriorly to further expose the anterior surface of the psoas muscle. Care should be taken to stay above the psoas fascia to minimize injury to cutaneous nerves, which would result in postoperative thigh numbness.

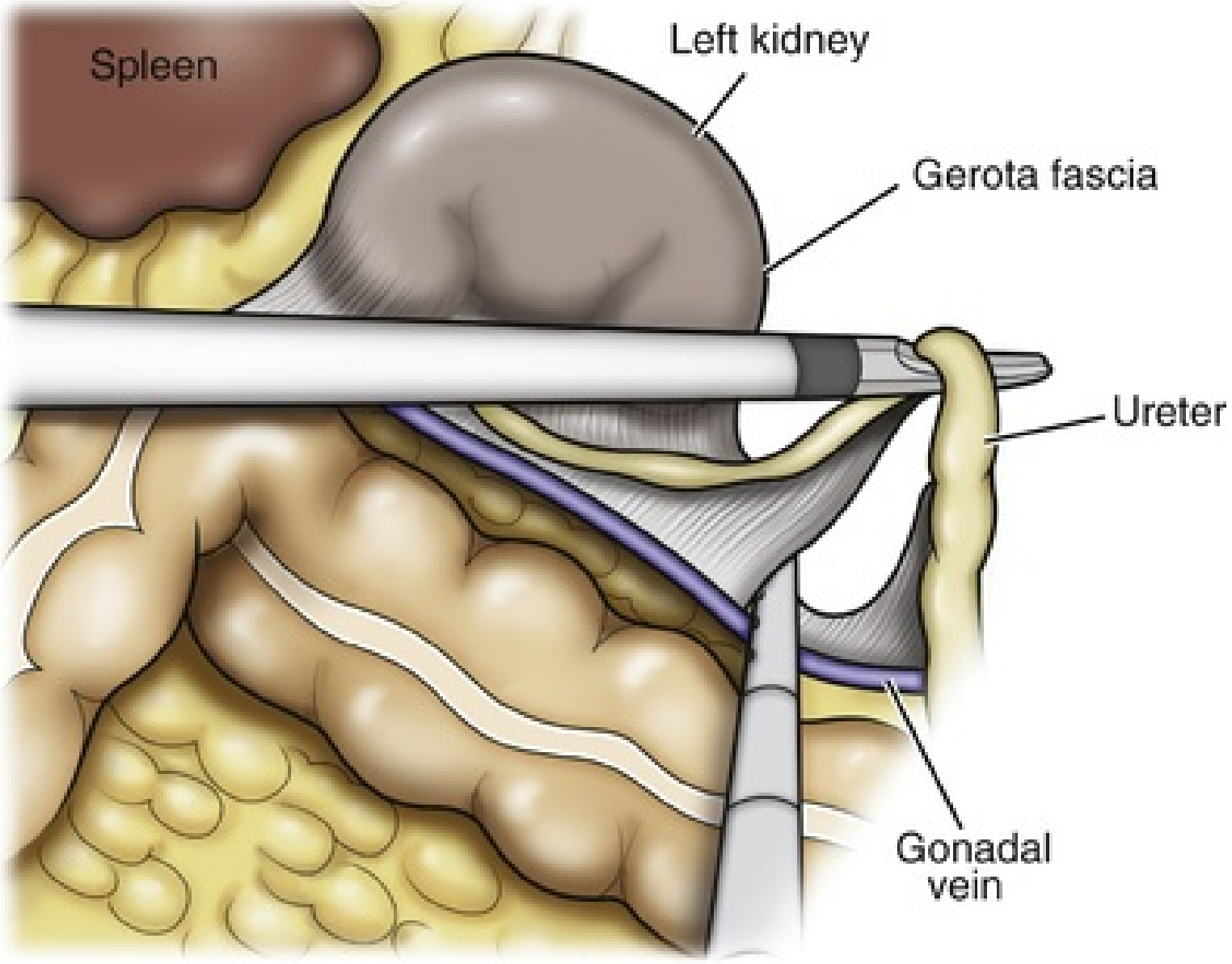

FIG. 102.16 A curved dissector, in the left hand, is placed beneath the ureter and used to provide anterolateral elevation. On the right side the angle of insertion from the gonadal vein to the vena cava can be a source of significant bleeding if torn during elevation.

Identification of the Renal Hilum

Safe dissection of the renal hilum requires adequate exposure by medial retraction of the colon and small bowel by gravity or the lower midline retractor, as well as anterior-lateral retraction of the kidney by lifting it out of the renal fossa (Fig. 102.17). The hilar dissection is facilitated by keeping the hilum on traction with firm anterior-lateral retraction of the kidney. This can be accomplished by gently placing the lateral grasper under the ureter and kidney until it abuts the abdominal sidewall. Care must be taken to avoid placing the grasper into the renal parenchyma. With the ureter and lower pole of the kidney elevated, vessels entering the renal hilum can be identified and bluntly dissected. A gentle, layer-by-layer dissection is performed until the renal vein is identified. Gonadal, lumbar, and accessory venous branches can be clipped and divided as needed. Clips should not be placed in the anticipated staple line to prevent stapler misfire.

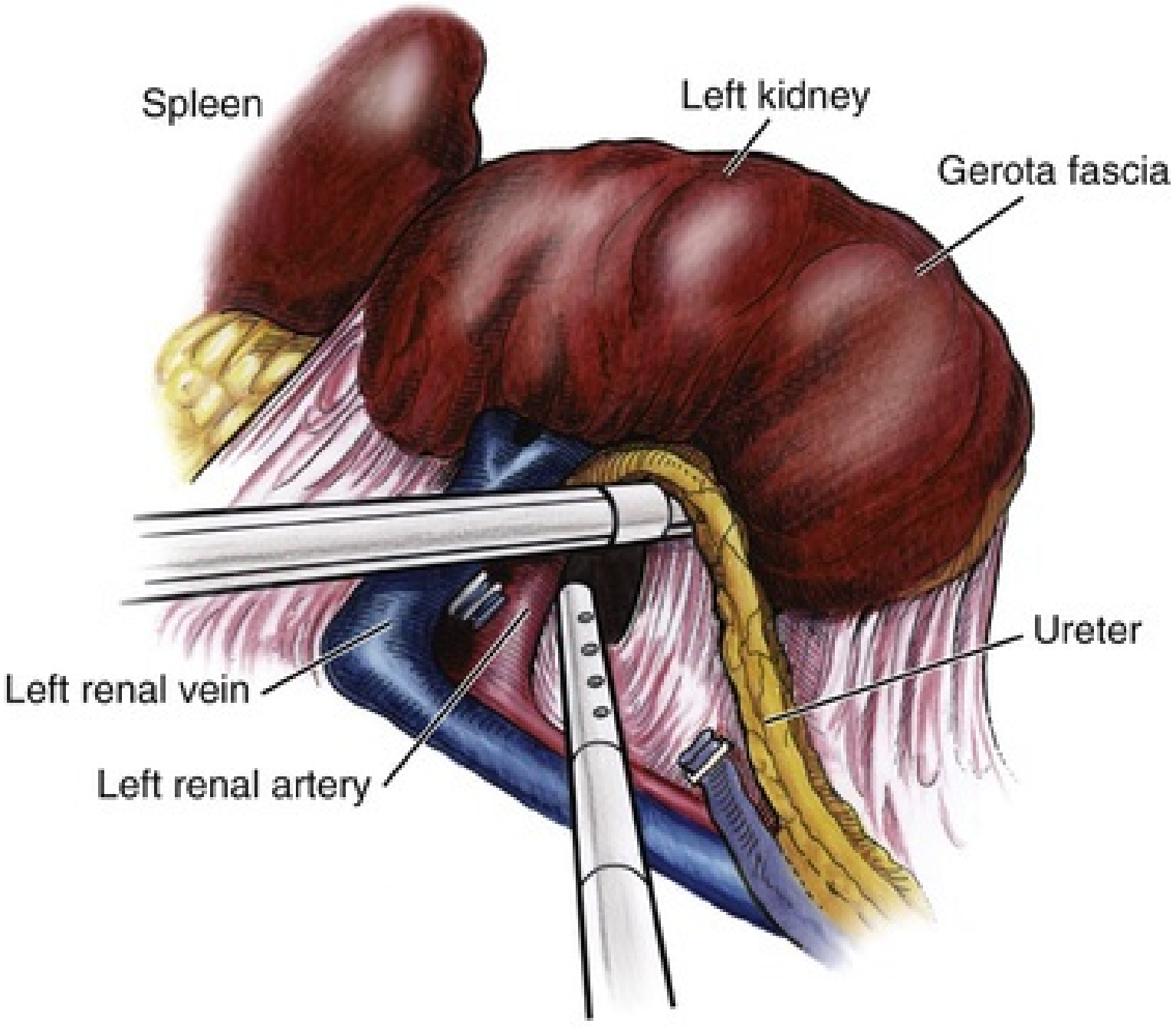

FIG. 102.17 The lower pole of the kidney and ureter are firmly retracted anterolaterally, placing the hilum on stretch. The left gonadal vein has been ligated and divided.

Securing the Renal Blood Vessels

Once the hilum is exposed and kept under traction, the renal artery should be identified typically posterior to the vein. Preoperative imaging is usually helpful to identify the location and number of renal vessels. Meticulous dissection of the vein and artery can be accomplished with a combination of blunt and sharp dissection using irrigator-aspirator tip, hook electrode, scissors, or laparoscopic forceps. With an endoscopic vascular stapler, first the artery is ligated and divided, then the vein (Fig. 102.18). It is important to ensure that the stapler covers the entire vessel. En bloc renal hilar vascular staple ligation appears to be a safe alternative to individual vessel ligation (Lai and Rais-Bahrami, 2017). In some cases, additional clips may be needed for complete hemostasis. Plastic clips alone are contraindicated for the ligation of the renal artery because of reports of fatal cases of clip failure (Hsi et al., 2007).

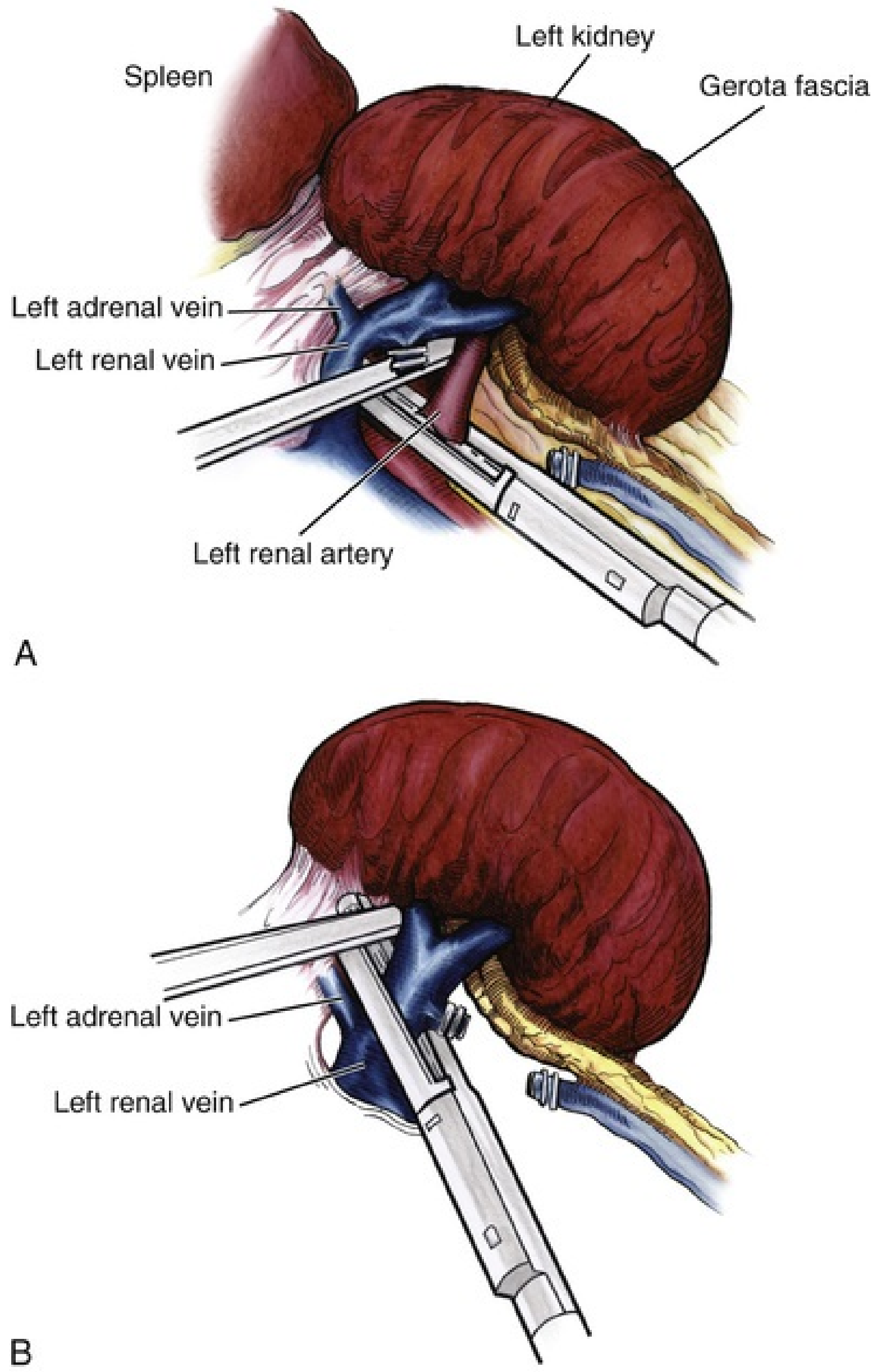
Spleen
Left kidney
Gerota fascia
Left adrenal vein
Left renal vein
Left renal artery
A
Left adrenal vein
Left renal vein
B

FIG. 102.18 (A) First, the renal artery is stapled using an endovascular gastrointestinal anastomosis (GIA) stapler. (B) The renal vein is secured lateral to the adrenal vein with the GIA stapler. If clips are used on the gonadal or adrenal vessels, the surgeon must be careful to exclude them from the jaws of the stapler.

Dissection of the Upper Pole

After the hilar vessels are divided, the dissection continues posteriorly and superiorly to the upper pole. The adrenal gland is preserved by carrying the dissection on to the upper pole of the kidney (Fig. 102.19). This can be accomplished by incising the Gerota fascia anteriorly, just above the hilum. The perinephric fat is then gently peeled off circumferentially above the upper pole of the kidney. The ureter is then clipped and divided, and the lateral attachments of the kidney are divided. This allows the kidney to be rotated anteriorly above the liver (on the right) or spleen (on the left) to facilitate incision of the uppermost attachments under direct vision. In cases of extreme fibrosis, a subcapsular nephrectomy can be performed once the artery and vein have been controlled (Moore et al., 1998). Care should be taken to avoid a diaphragmatic injury.

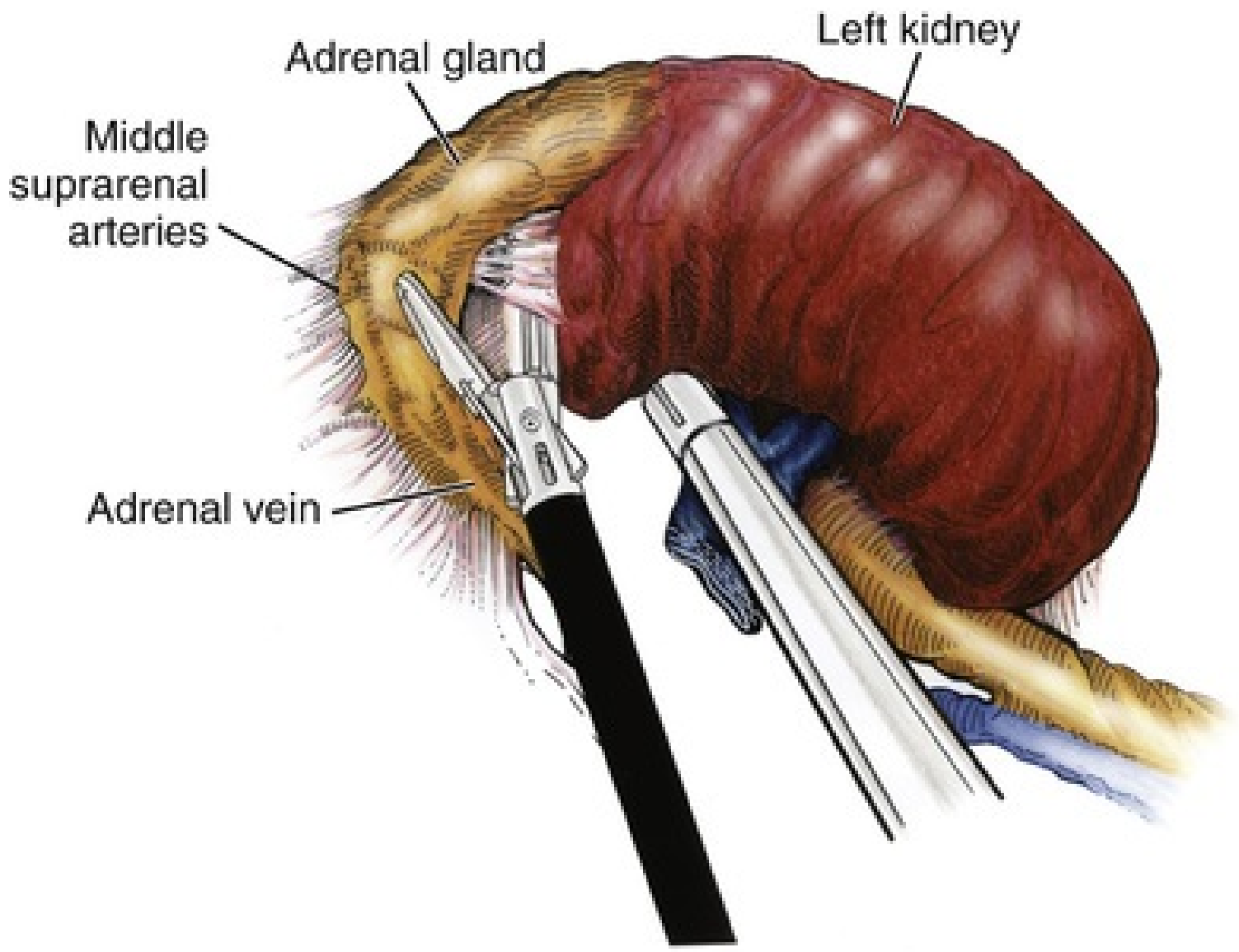

FIG. 102.19 The adrenal gland can be preserved during simple nephrectomy or radical nephrectomy as indicated by dissecting it from the superior pole of the kidney.

Organ Entrapment and Extraction

The kidney can be removed intact or piecemeal after morcellation. The specimen is placed in an extraction bag and removed intact through an extended trocar site or Pfannenstiel incision (Fig. 102.20). Morcellation can be accomplished using ring forceps and Kocher clamp (Fig. 102.21) or using a purpose-built morcellator system.

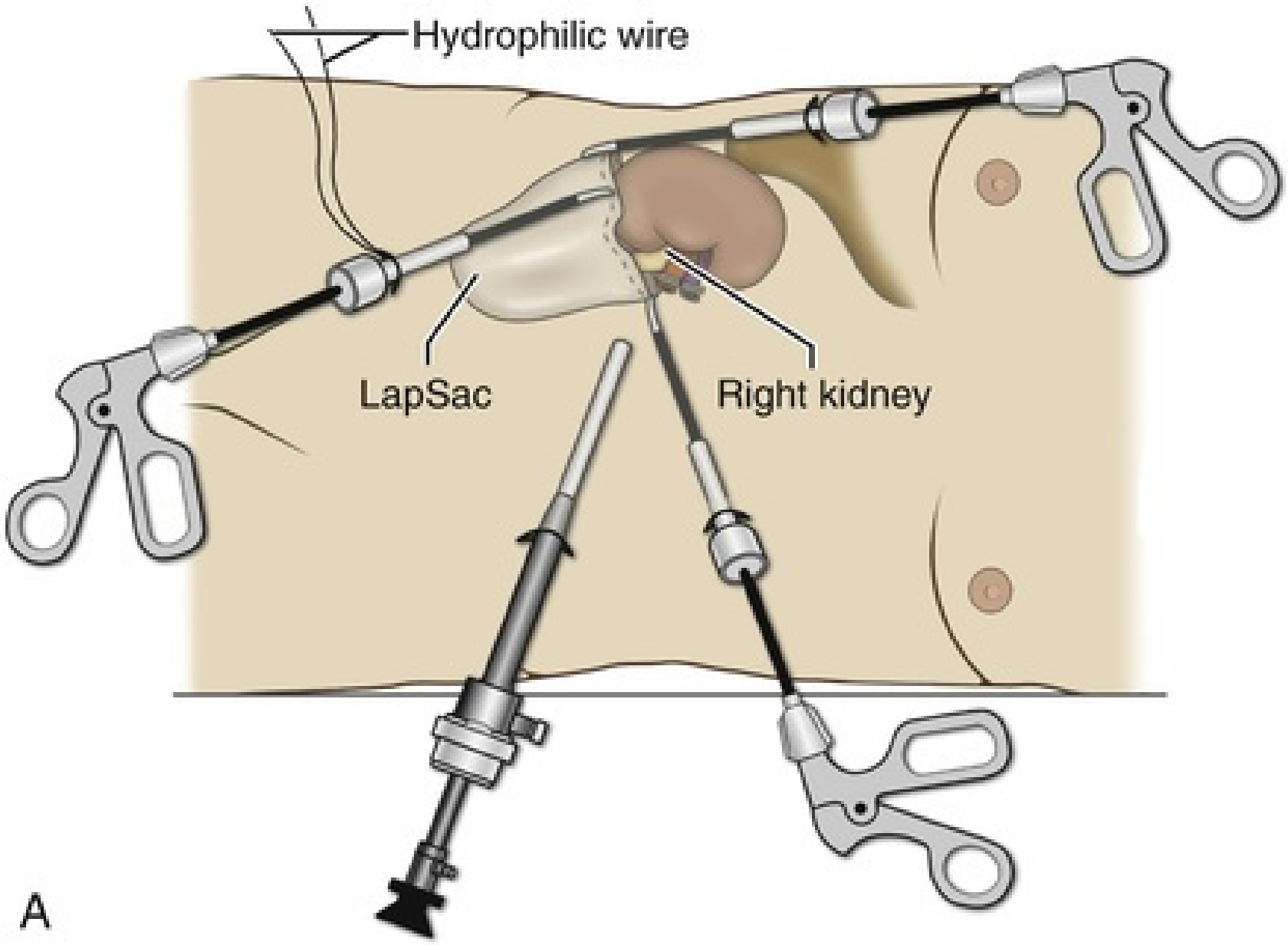
Hydrophilic wire
LapSac
Right kidney
A

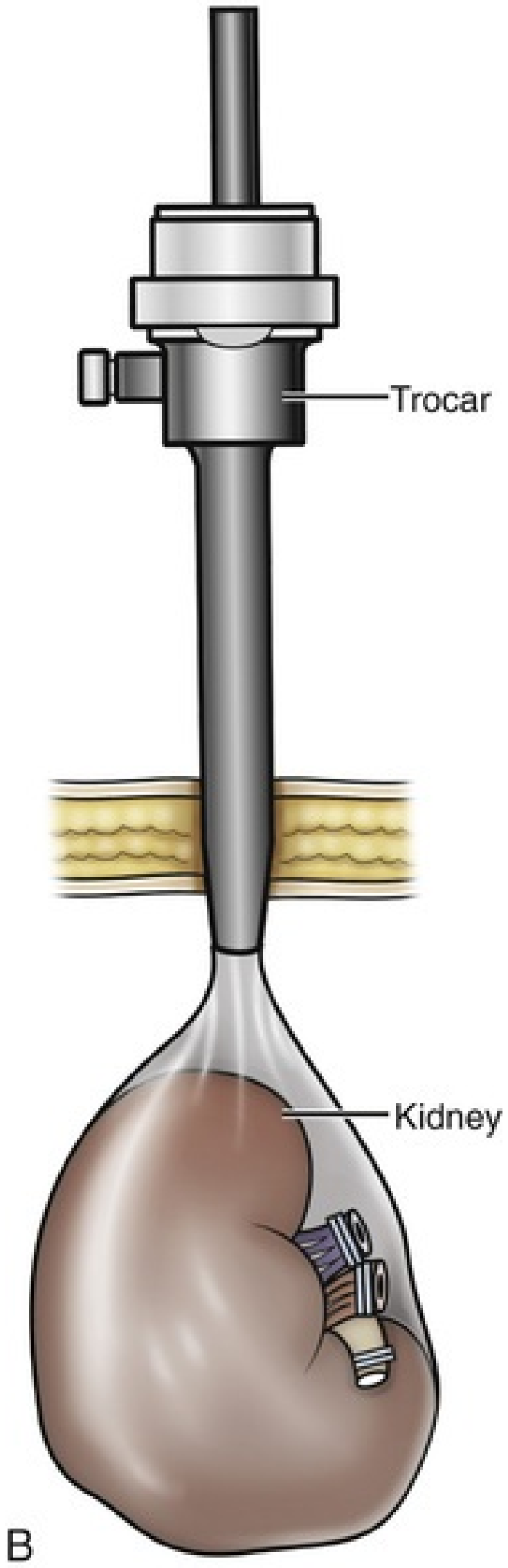
Trocar
Kidney
B

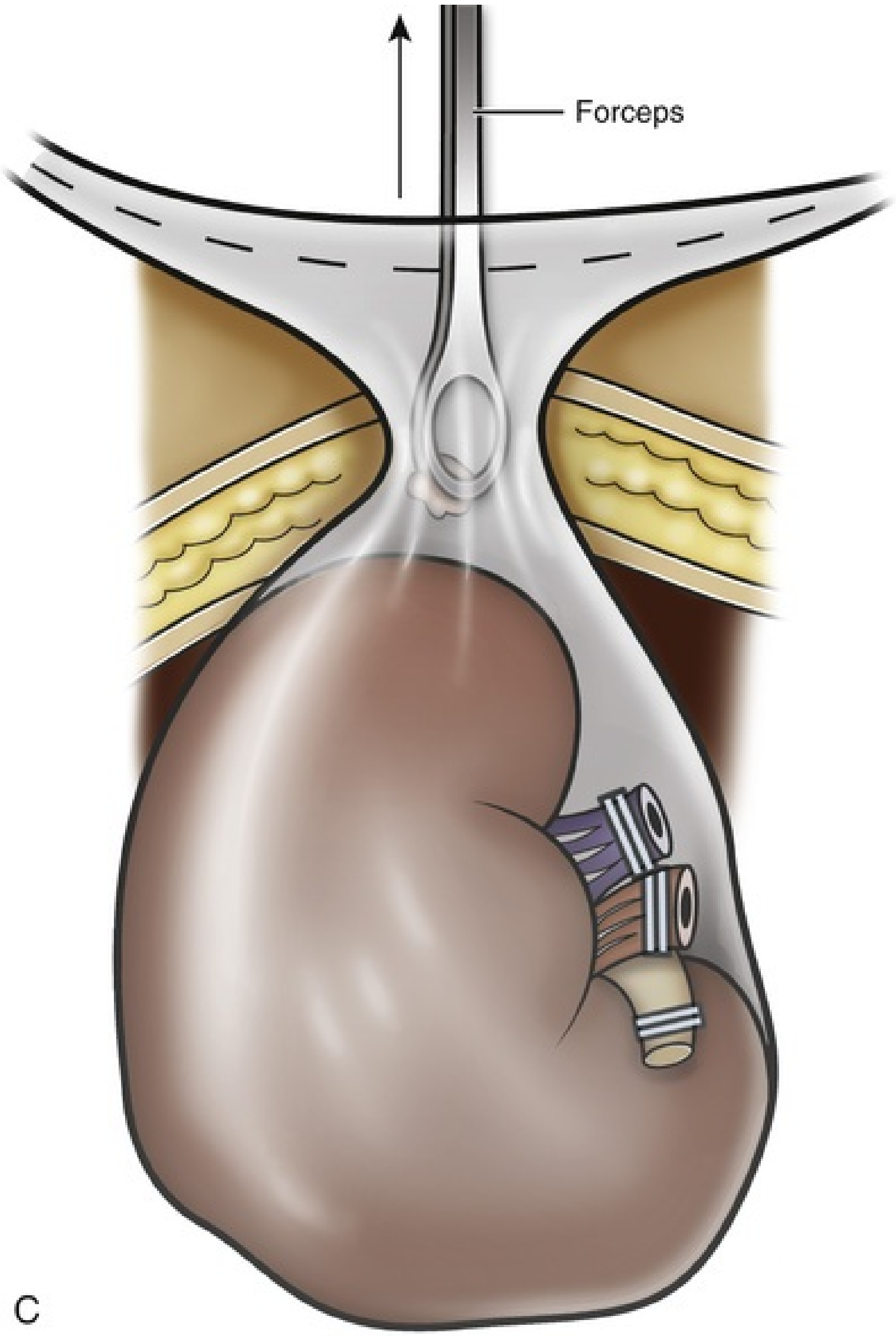
Forceps
C

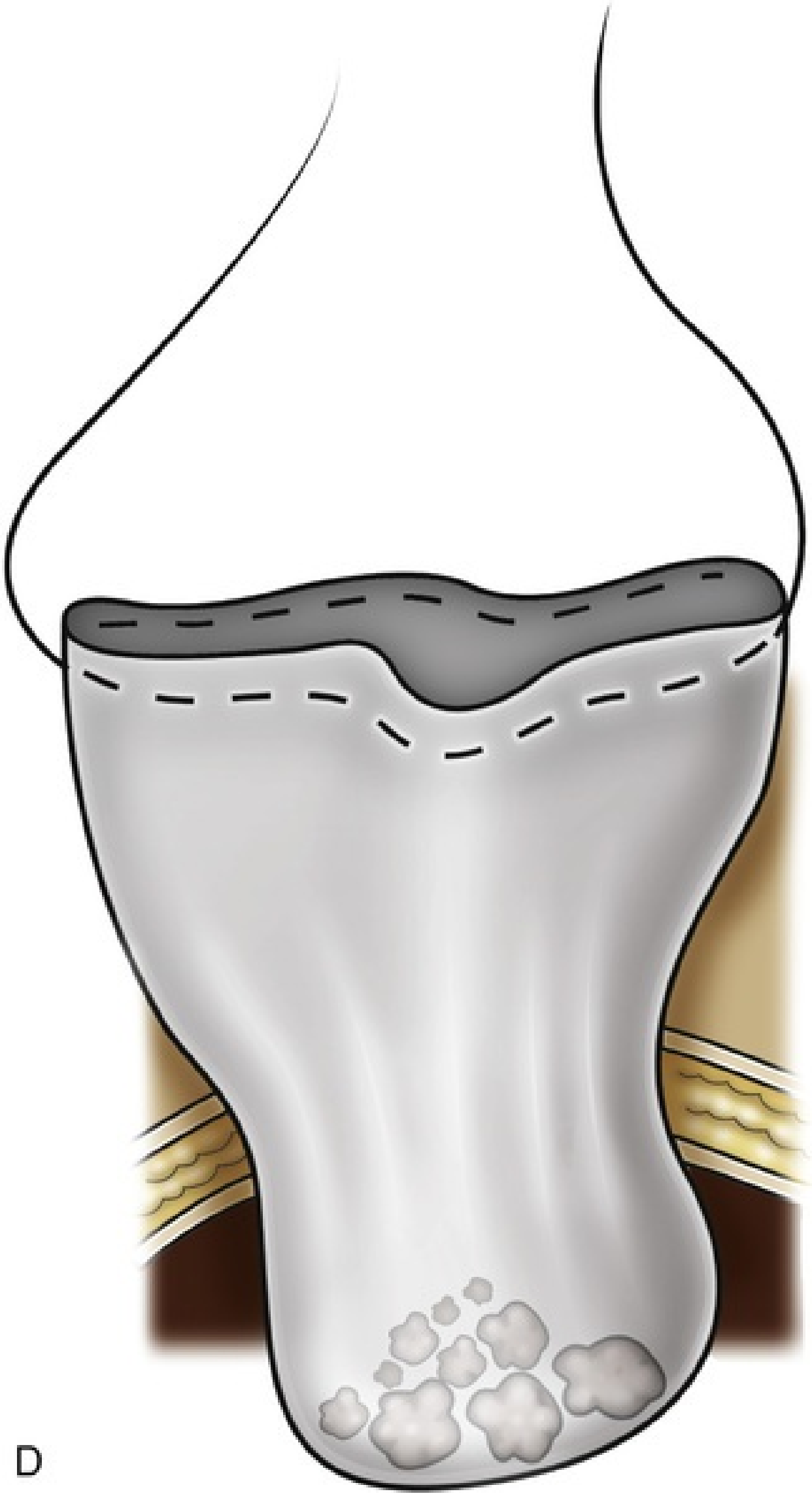

FIG. 102.20 Removal of the intact specimen. (A) The camera is moved to the lateral port site and an Endo Catch device (Covidien, Dublin, Ireland) is placed through the umbilical trocar site to entrap the specimen. (B) Alternatively, the specimen may be extracted through a Pfannenstiel incision. To accomplish this, the Endo Catch device is brought in through a separate 10-mm suprapubic incision. (C) The trocar is then removed, bringing the Endo Catch device with it through the trocar site, and the suture is cut and clamped. (D) A 4- to 6-cm incision is made including one of the trocar sites. The surgeon's finger protects the specimen and underlying structures from injury.

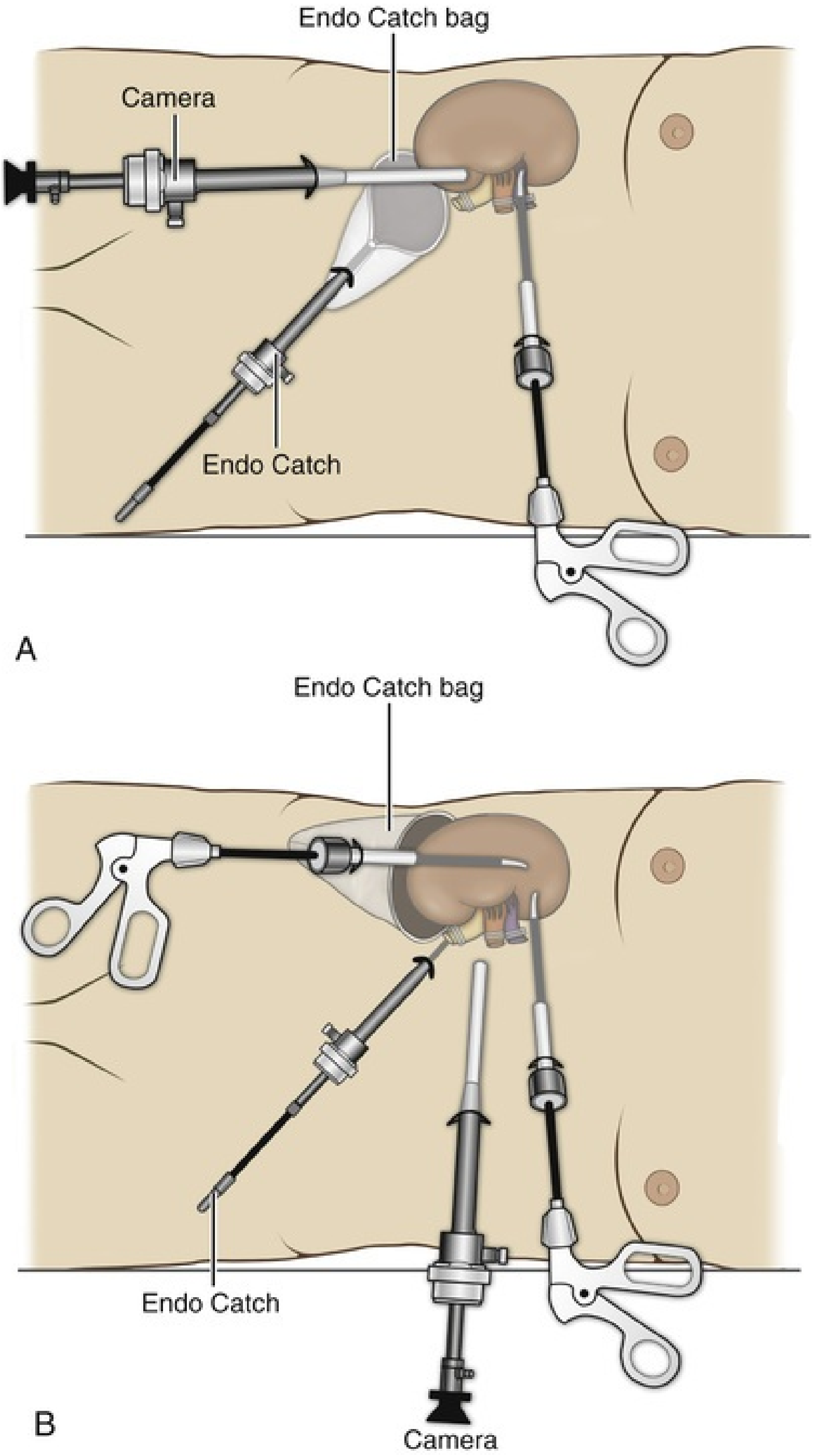
Endo Catch bag
Camera
Endo Catch
A
Endo Catch bag
Endo Catch
B
Camera

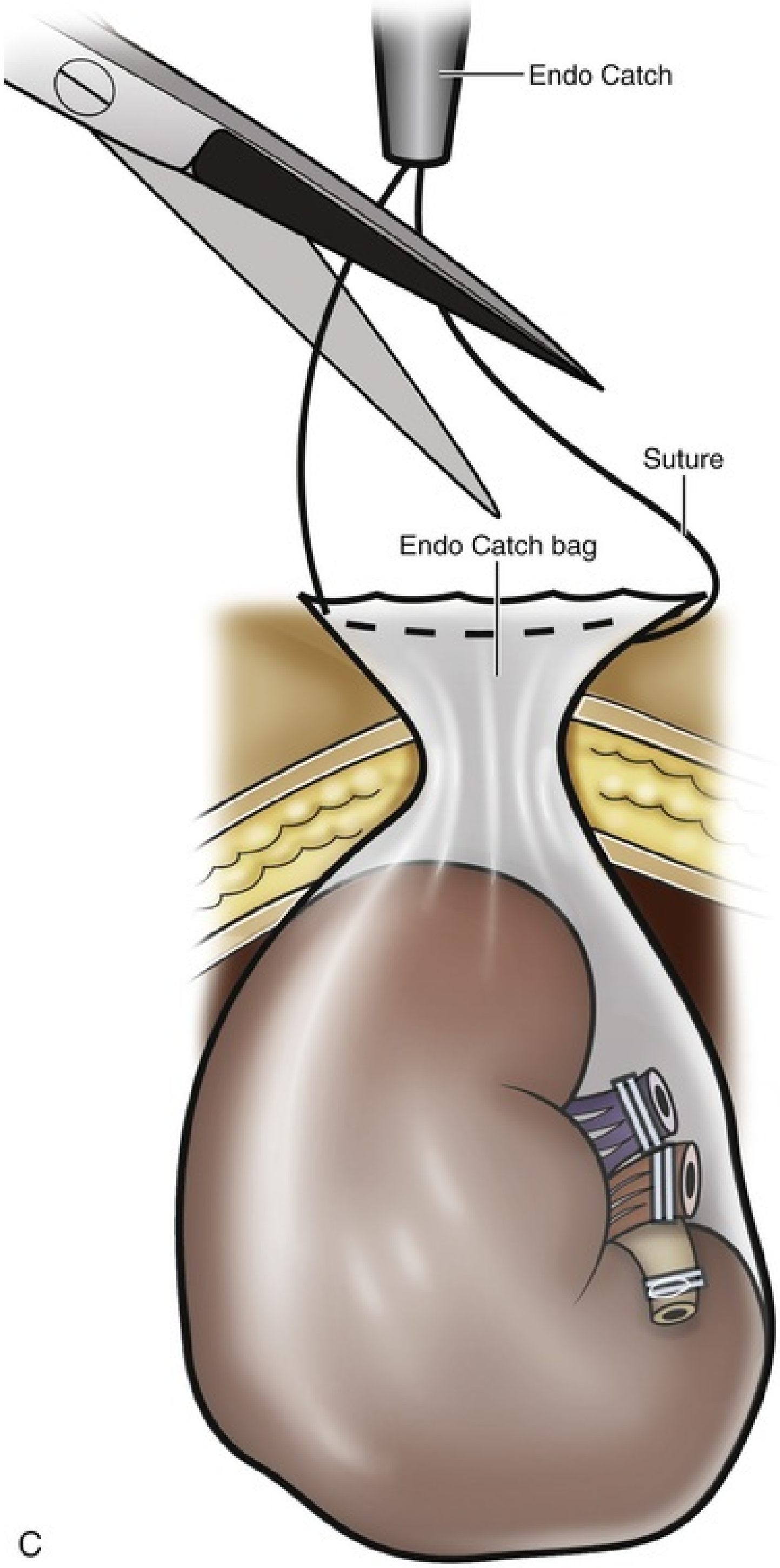
Endo Catch
Suture
Endo Catch bag
C

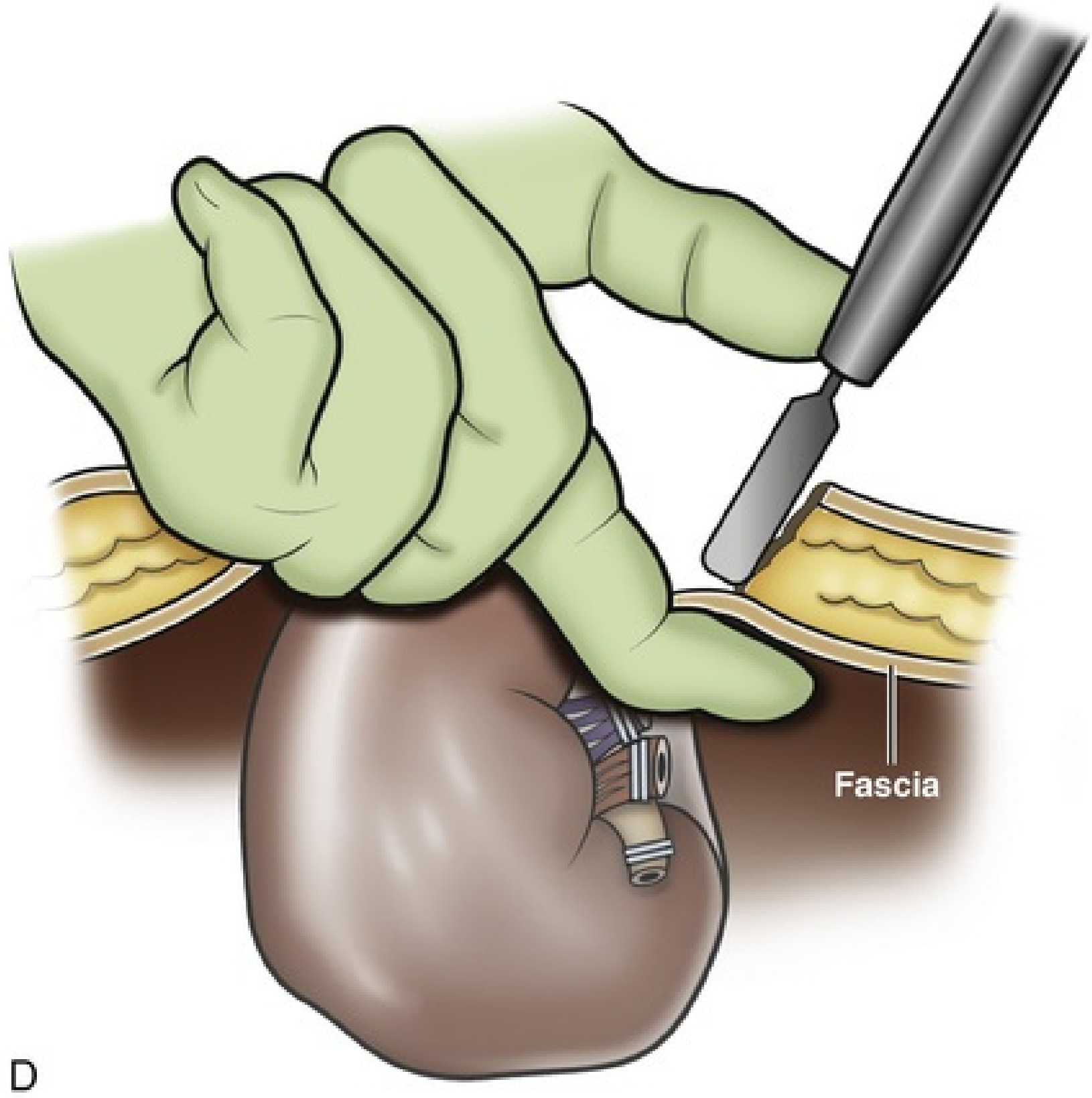

FIG. 102.21 Removal of the morcellated specimen. (A) The LapSac (Cook Urological, Spencer, IN) entrapment sac is introduced through the lateral 10-mm trocar site after passage of a hydrophilic wire through the opening of the LapSac. The entrapment sac is then released within the abdomen. The wire facilitates opening of the bag and placement of the specimen. A lateral 5- or 3-mm port may be necessary to assist with holding placement of the specimen inside the LapSac. (B) Once the specimen is within the LapSac, the wire is removed, the bag cinched closed, and the opening withdrawn through the 10-mm trocar site. (C) The entrapment sac is pulled tightly up against the abdominal wall, with two hands pushing part of the specimen to appear through the opening of the LapSac. After the site is carefully draped, manual morcellation with ring forceps or a Kelly clamp can be used. (D) The entrapment sac is removed once the remaining specimen fragments are small enough to be extracted through the trocar site. Only the tissue visible from the opening is grasped. Blind passes into the bag may injure surrounding bowel segments.

Postoperative Management

The orogastric tube is removed at the end of the procedure. Diet can be resumed as tolerated, and the Foley catheter can be removed once the patient is comfortably ambulating. Unrestricted activity can usually be resumed as tolerated. Heavy lifting should be deferred for 4 to 6 weeks in those cases with an extraction incision.

Results

The postoperative results of laparoscopic nephrectomy are comparable with those of open surgery, with less pain, less blood loss, shorter hospital stay, quicker return to normal activity, and comparable complication rates (Dunn et al., 2000; Fornara et al. 2001; Wolf et al., 2001). In spite of the higher operating room and supply costs associated with the laparoscopic approach, laparoscopic nephrectomy is cost effective compared with open surgery because of short operating times and brief lengths of stay (Lotan et al., 2002).

Surgery for Renal Cystic Disease

Although common, renal cysts rarely require surgical intervention. **Indications for operative treatment include cyst-associated pain, infection, obstruction, or concerns for malignancy.** The evaluation of renal cysts is discussed in Chapter 96. Symptomatic benign cysts can be initially managed with percutaneous needle aspiration. A sclerosing agent may be used to potentially reduce the risk of recurrence (Rane, 2004; Fig. 102.22). Caution should be taken to avoid extravasation of these agents into the collecting system because of the risk of fibrosis. Benign cysts not amenable to percutaneous treatment can be managed with cyst decortication, marsupialization, or unroofing (Okeke et al., 2003). Multiple and bilateral cysts can be treated in the same operation (Roberts et al., 2001). Laparoscopic cyst decortication has been shown to be an effective treatment for cyst-related pain in individuals with ADPKD. In cases of end-stage renal disease, bilateral synchronous laparoscopic nephrectomy may be performed in patients with enlarged, symptomatic, or infected kidneys. Renal cysts suspicious to harbor malignancy can be explored, biopsied, and treated laparoscopically with cryoablation, enucleation, or partial or radical nephrectomy (Wehle and Grabstald, 1986).

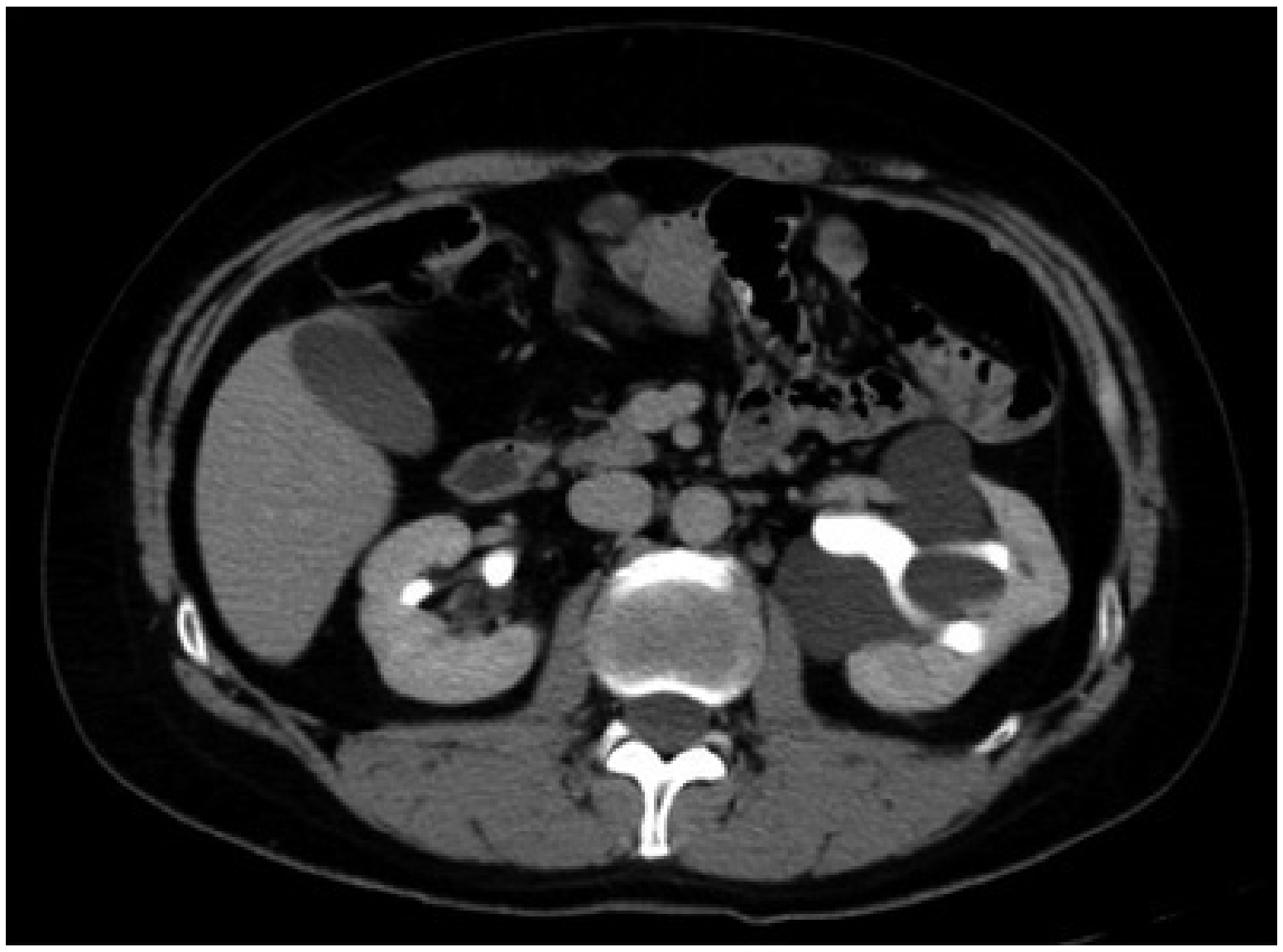

FIG. 102.22 Axial computed tomography scan in delayed phase after intravenous contrast administration, demonstrating peripelvic cysts in a patient with left flank pain.

Procedure

The kidney is mobilized as previously described. After Gerota fascia is incised and the renal capsule exposed, the cyst is identified. Intraoperative ultrasound can be used to assist in locating the cyst. Hilar control is usually not required. Dissection of the cyst wall from surrounding structures is done before draining the cyst's contents. The wall of the cyst can be grasped and excised, cutting along the junction between the cyst wall and the renal parenchyma (Fig. 102.23). Lesions suspicious for malignancy can be biopsied. The cyst wall may be fulgurated with either electrocautery or argon beam coagulator. Care should be taken when ablating the surface, because inadvertent or occult entry into the collecting system can easily occur. Packing with hemostatic agents or suturing may be necessary. In cases in which the collecting system is entered, it is recommended to leave a drain (Fig. 102.24). If malignancy is noted, extirpative surgery or cryoablation may be used to treat the remainder of the lesion or kidney.

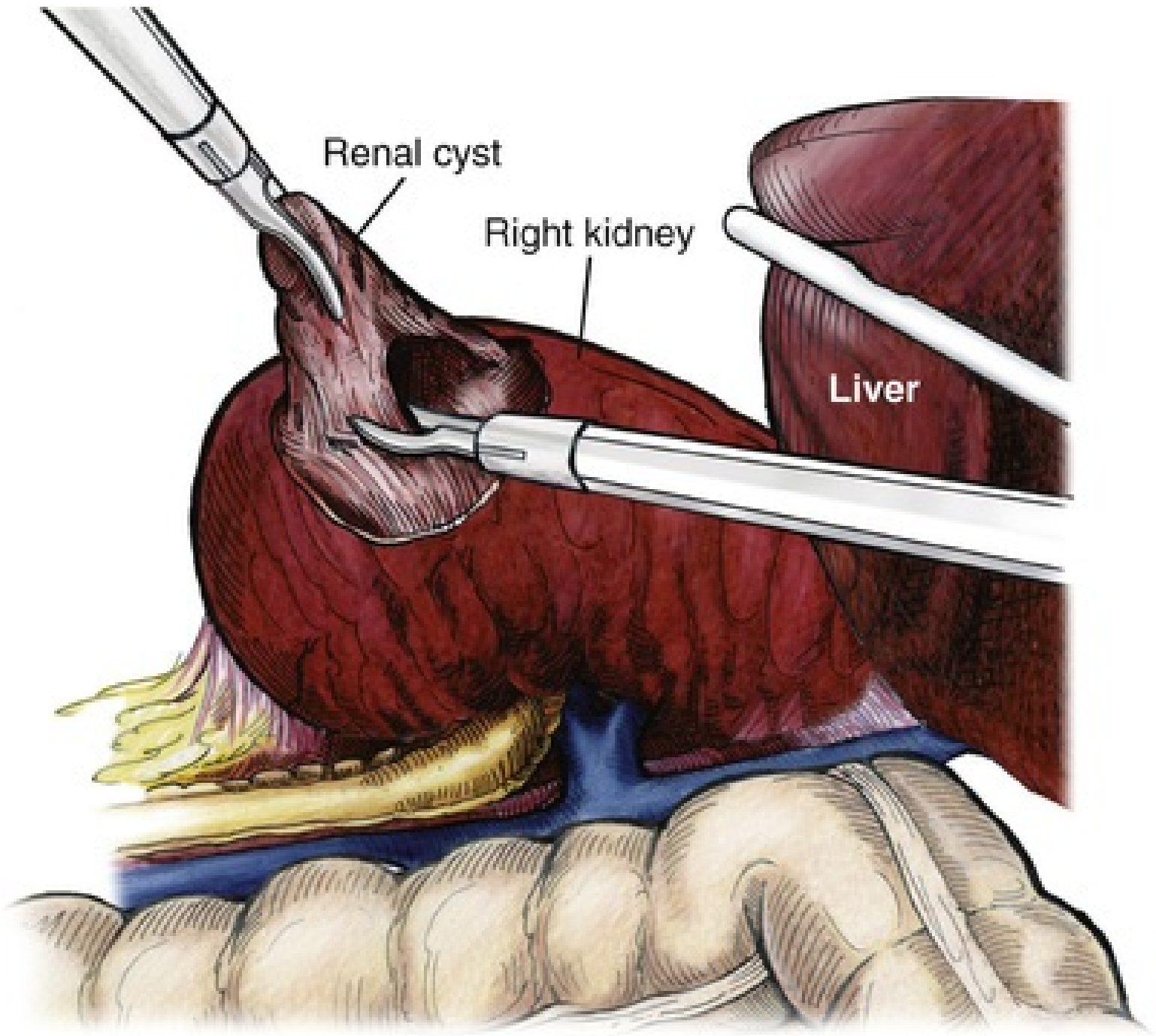

FIG. 102.23 The cyst fluid is aspirated with a laparoscopic aspiration needle. After decompression of the cyst, the wall can easily be grasped and manipulated. The cyst is elevated with a grasper and scissors or ultrasonic shears to circumferentially excise the cyst wall. The edge of the

cyst is carefully inspected, and biopsies are performed using the 5-mm laparoscopic biopsy forceps as needed.

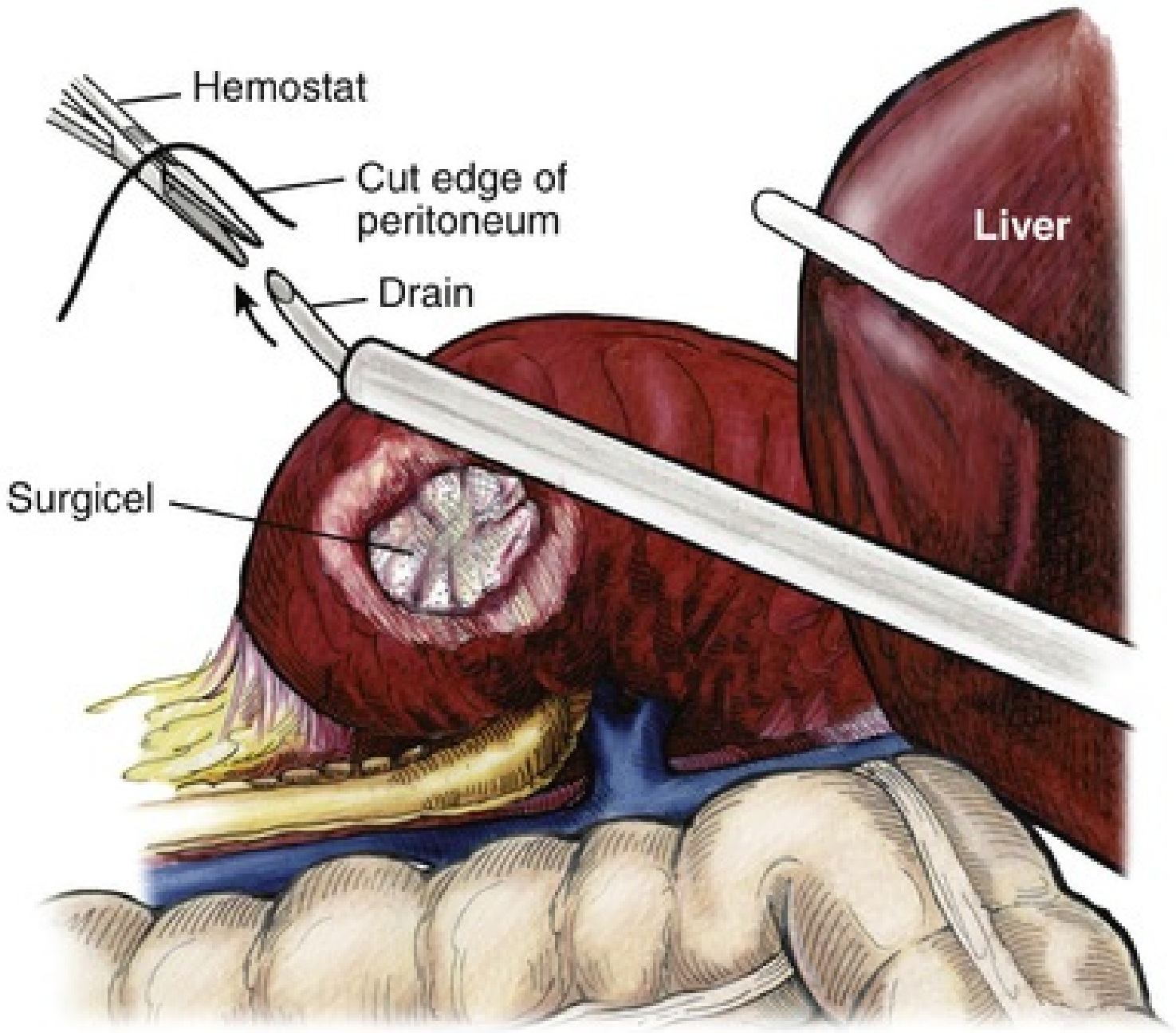

FIG. 102.24 Drain placement after renal cyst excision. If the collecting system has been entered, it is closed and a drain placed. To insert the drain, a hemostat is passed through a small stab incision in the side and advanced into the abdominal cavity under direct vision. A drain is placed through a trocar site and advanced toward the open hemostat using the trocar to direct the drain. The colon is brought back over the kidney and attached to the sidewall to “reperitonealize” the kidney and drain.

Results

Laparoscopic management of symptomatic renal cysts is highly effective. Retrospective studies suggest a greater than 90% postoperative symptom improvement (Atug et al., 2006; Lee et al., 2003; Thwaini et al., 2007). In a series of 45 laparoscopic cyst decortications, the mean operative time was 89 minutes, mean estimated blood loss 85 mL, and a major complication was observed in only 1 case requiring conversion to open surgery as a result of bleeding. A total of 95% of patients achieved radiographic resolution of the cyst, and 91% were pain free after a median follow-up of 39 months (Thwaini et al., 2007).

Renal Biopsy for Medical Renal Disease

Renal biopsy plays a central role in the diagnosis and management of patients with hematuria and proteinuria of glomerular origin and/or unexplained renal failure. **Although renal biopsy is typically done percutaneously under CT or ultrasound guidance, there are circumstances in which a laparoscopic biopsy may be preferred, including failed previous attempts at percutaneous biopsy, renal anatomic abnormalities, bleeding diathesis, morbid obesity, multiple renal cysts, or a solitary kidney.**

Procedure

The patient is positioned, and access is obtained based on the chosen technique as previously described. Although LESS approaches have been described (Micali et al., 2014), a two-port retroperitoneal technique is typically preferred. A 10-mm trocar is placed above the iliac crest in the posterior axillary line, and a 5-mm trocar is placed at the same level at the anterior axillary line. Blunt dissection is used to open Gerota fascia to expose the lower pole of the kidney. The use of a balloon dilator can help develop the working space. Ultrasound can facilitate the localization of the kidney in cases of abundant retroperitoneal and perinephric adipose tissue. A 5-mm biopsy forceps is used to take samples of the cortical parenchyma (Fig. 102.25). Alternatively, an 18-gauge Trucut needle can be used for deeper tissue sampling. This can be passed percutaneously under visual guidance. Electrocautery or an argon beam coagulator is used to achieve hemostasis (Gimenez et al., 1998).

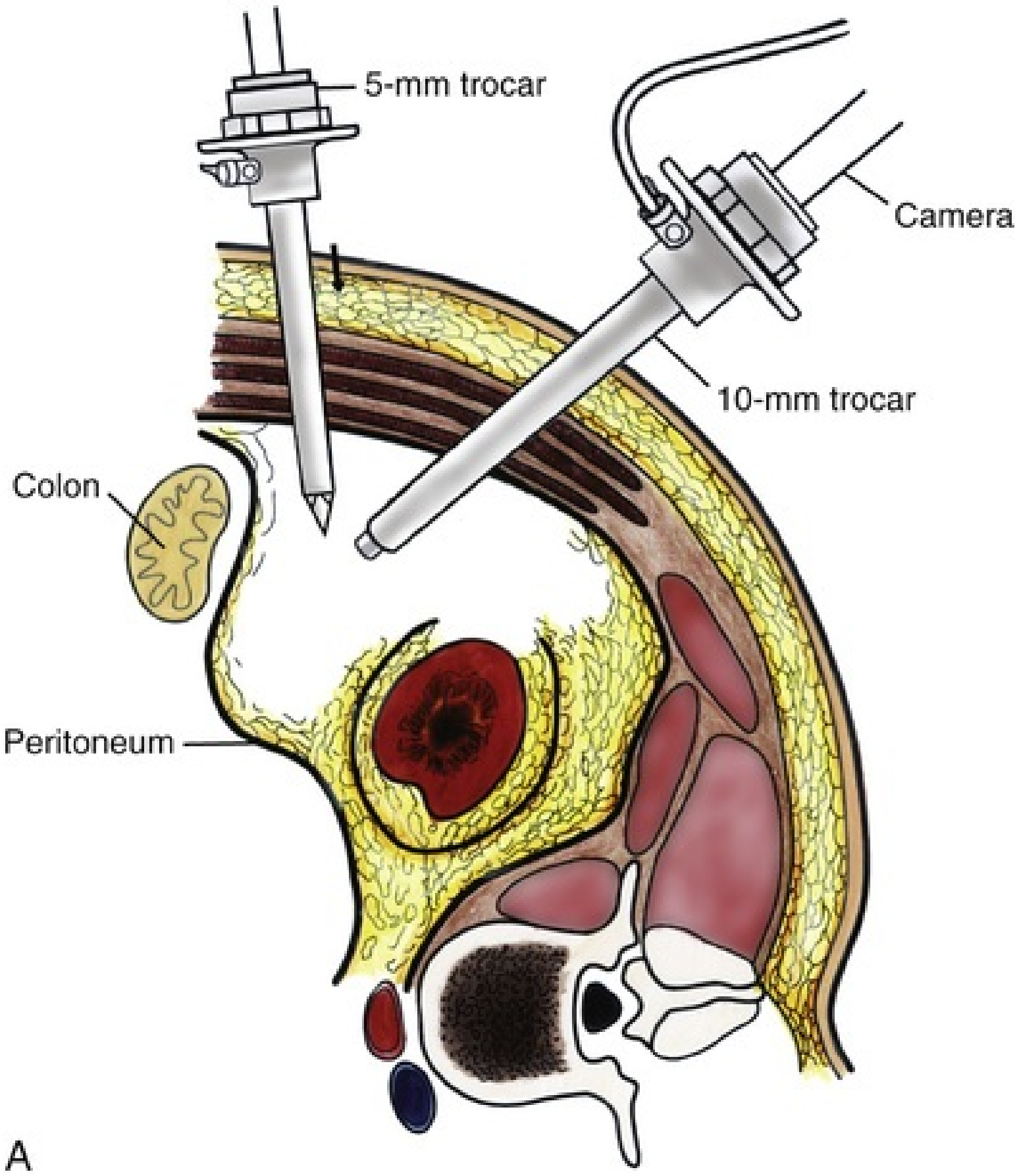
5-mm trocar
Camera
10-mm trocar
Colon
Peritoneum
A

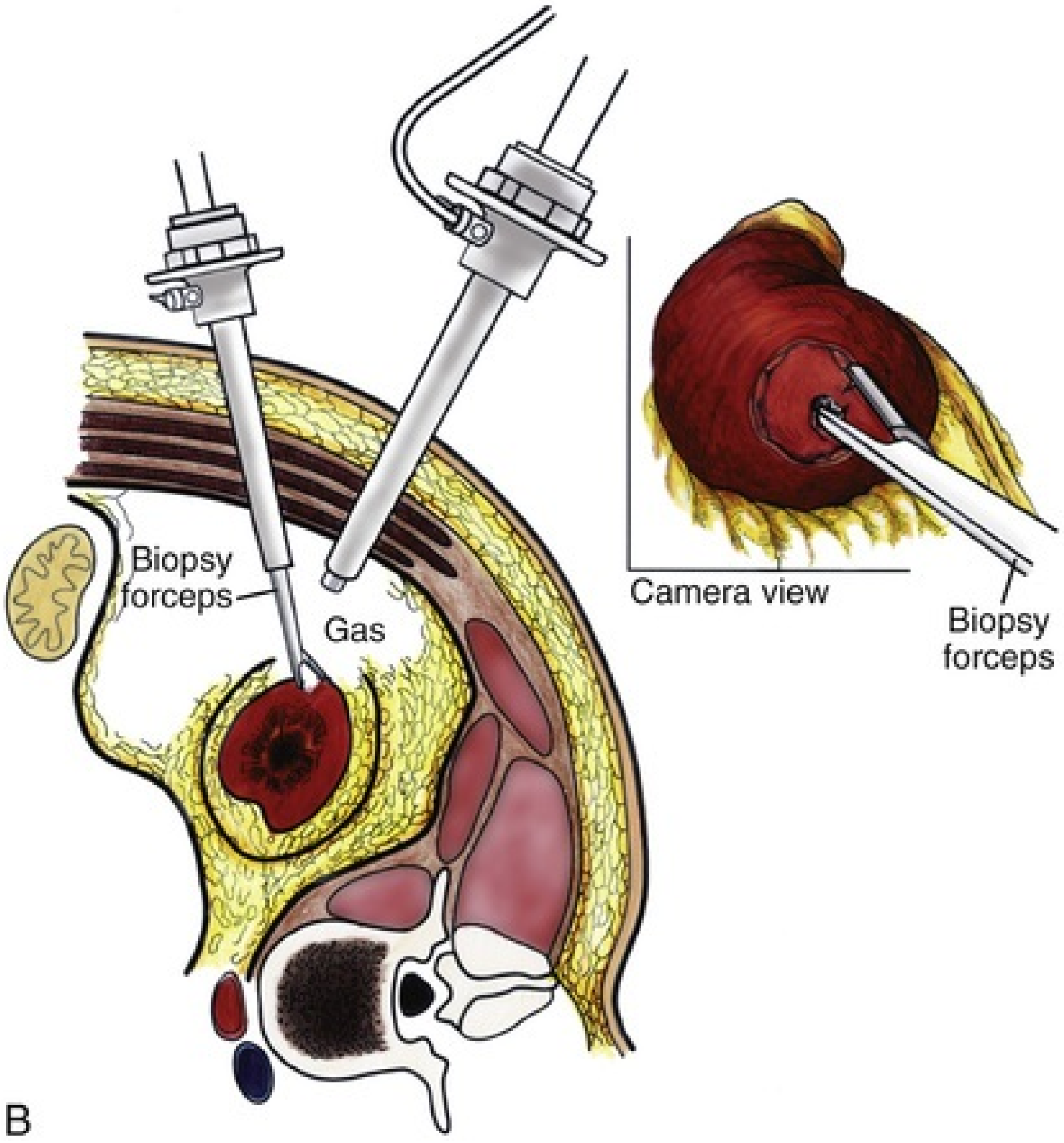

FIG. 102.25 (A) After establishment of a working space, a 5-mm trocar is placed under direct vision. The working instruments are passed through this port. The camera can be used to assist with dissection and is frequently cleaned to maintain adequate visualization. (B) Gerota fascia is opened with the use of the scissors. With 5-mm two-tooth laparoscopic biopsy forceps, two or three samples are taken from the lower pole of the kidney.

Results

The largest laparoscopic renal biopsy series including 74 patients showed a mean operative time of 123 minutes and mean estimated blood loss of 76 mL. Nearly 60% and 75% of the patients were discharged within 24 and 48 hours, respectively, with the remainder staying longer as a result of preexisting medical conditions. The most common complication was bleeding in 3 cases, followed by nonrenal tissue biopsy in 2 cases and inability to obtain a specimen in 2 cases. A series of 14 LESS renal biopsies showed a mean operative time of 53 minutes, estimated blood loss less than 50 mL, and hospital stay less than 24 hours in all cases. Patients did not require additional analgesia postoperatively, and no complications were observed (Micali et al., 2014).

Nephropexy

Nephropexy is the surgical fixation of a mobile (ptotic) kidney. Anatomically, nephroptosis is defined as a significant descent (>5 cm or two vertebral bodies on an intravenous urography) of the kidney as the patient moves from supine to erect (Fig. 102.26; Srirangam et al., 2009). Nephropexy is usually indicated in cases of nephroptosis associated with pain (longer than 3 months duration), evidence of restricted blood flow, and/or urinary drainage on intravenous urography, nuclear medicine scan, or color Doppler imaging.

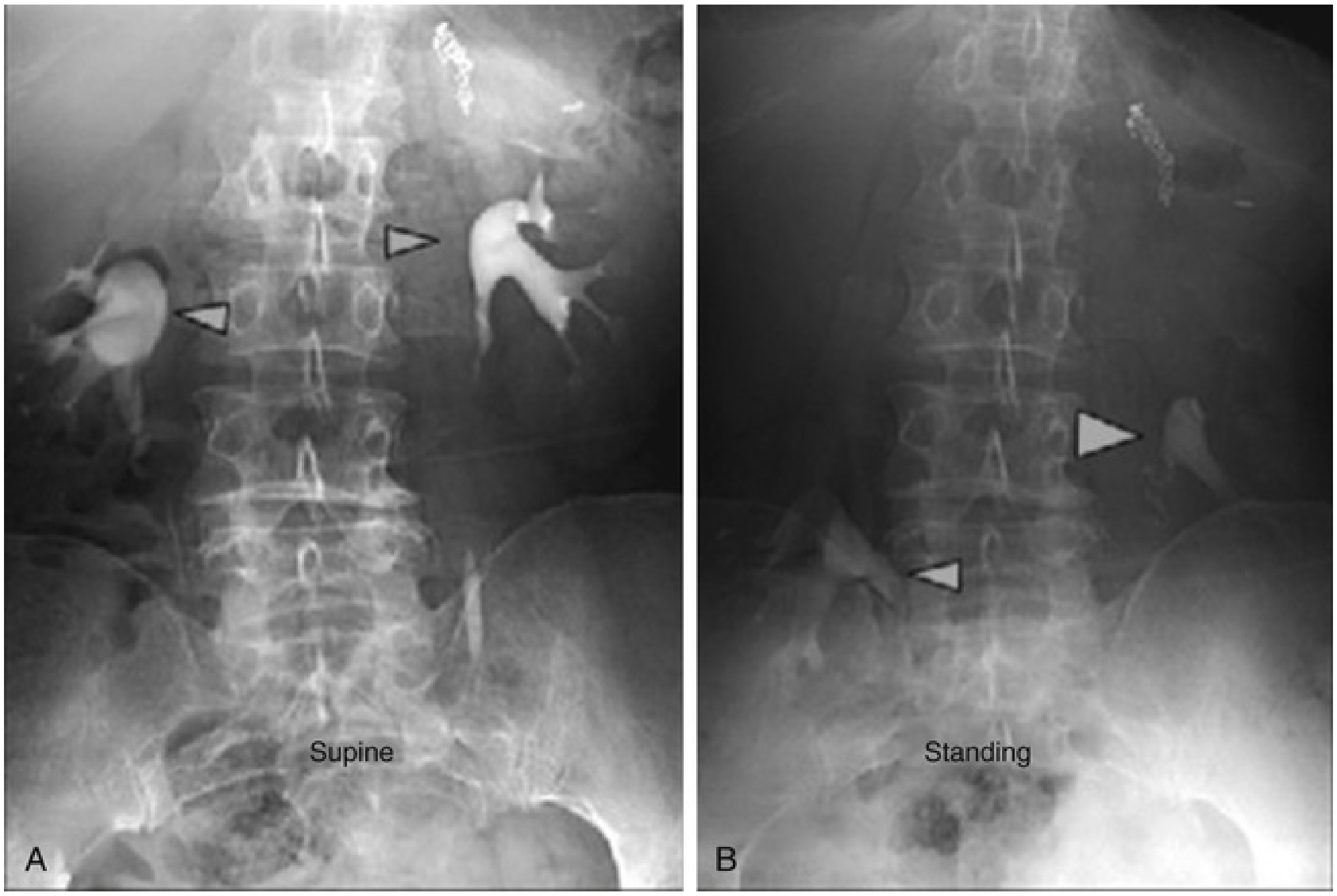

FIG. 102.26 Intravenous pyelogram demonstrating bilateral ptotic kidneys in the supine (A) and standing (B) positions. (From El-Moula MG, Izaki H, Kishimoto T, et al.: Laparoscopic nephropexy. *J Laparoendosc Adv Surg Tech A* 18:230–236, 2008.)

Procedure

Dissection is performed to mobilize the entire affected kidney and expose the underlying psoas and quadratus lumborum fascia (Fig. 102.27). Renal fixation can be accomplished either by suture fixation or with use of foreign material, such as mesh or tissue adhesive. For suture fixation, interrupted nonabsorbable sutures securing the lateral edge of the renal capsule to the underlying muscle fascia are placed starting at the upper pole moving down to the lower pole (Fig. 102.28). Additional sutures between the anterior renal capsule and the parietal peritoneum can be placed for additional support. Alternatively, a tension-free tape or mesh can be used to trap the kidney against the dorsal abdominal wall. In this technique, after the kidney is mobilized, the needle attached to the tape is directed below the lower pole and pushed through the abdominal wall. The tape is guided just over the lateral margin of the kidney and pushed through the abdominal wall, so the kidney is trapped by the tape. The sling is tightened until the kidney is securely fixed to the dorsal abdominal wall (Hubner et al., 2004).

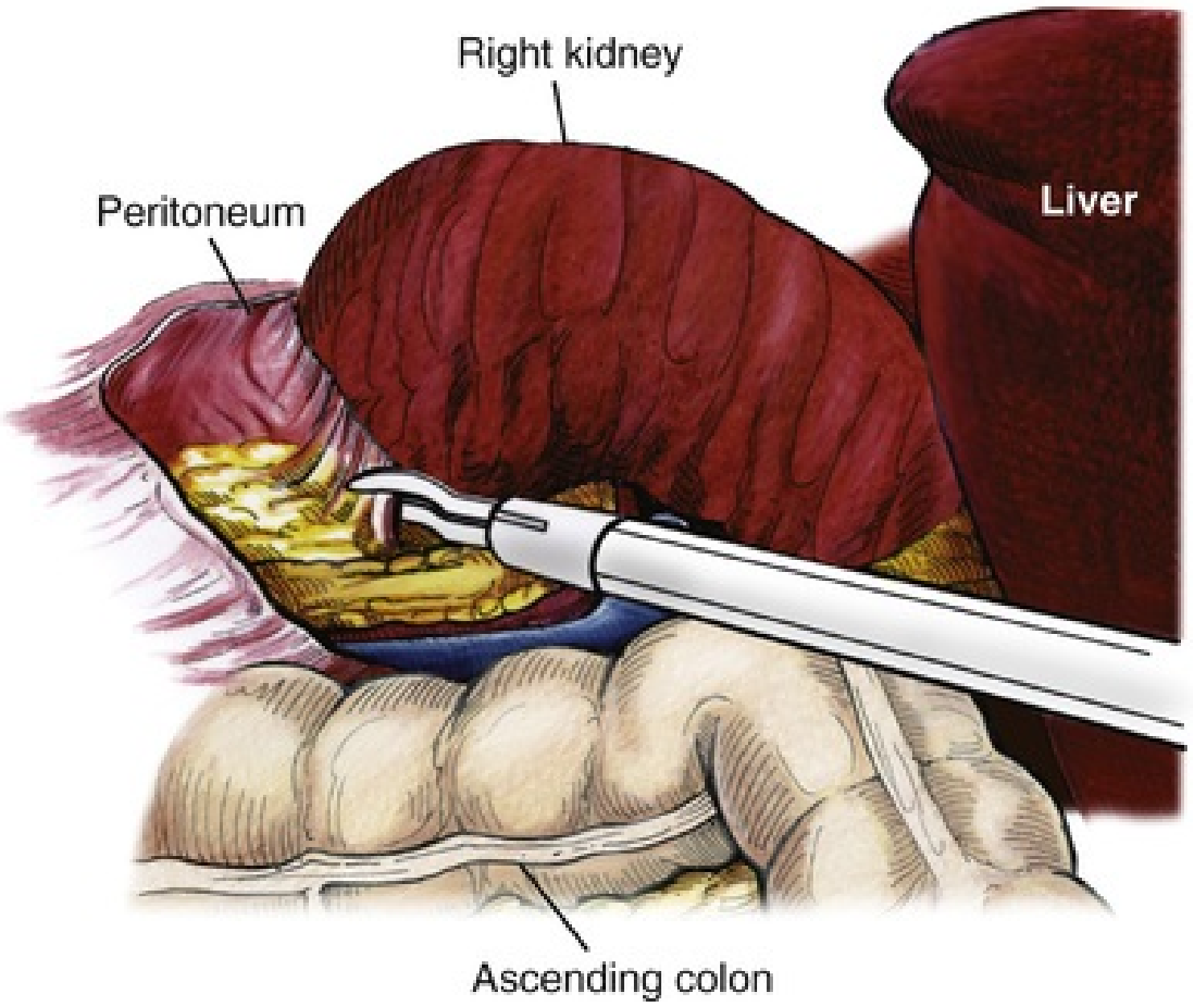

FIG. 102.27 The kidney is stripped of overlying Gerota fascia down to the surface of the renal capsule. All remaining attachments are divided, allowing full mobility for repositioning.

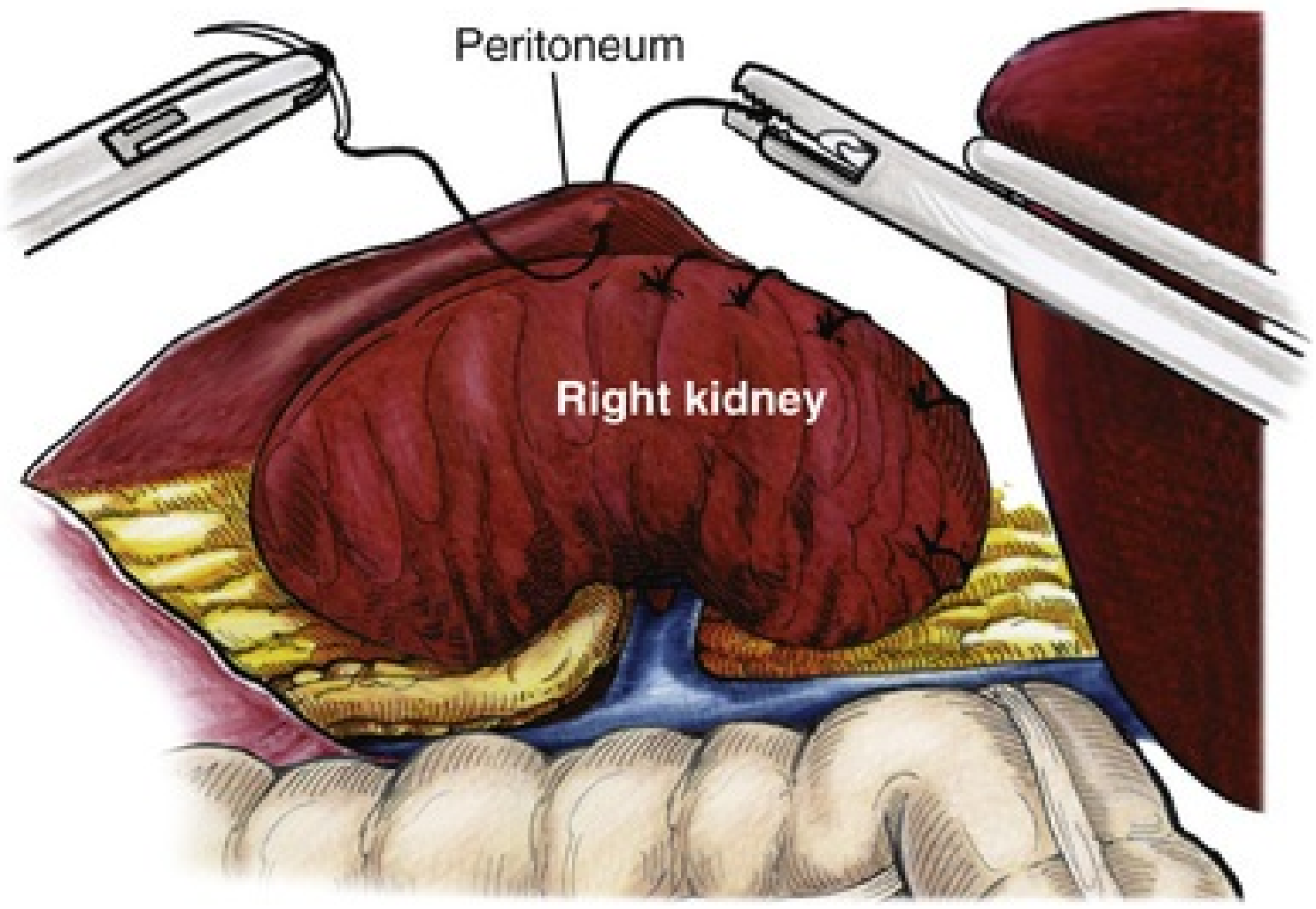

FIG. 102.28 Nephropexy. Once the kidney is free of lateral and posterior attachments, multiple 2-0 sutures are placed into the capsule and the lateral edge of the fascia overlying the abdominal wall. Sutures may also be placed between the anterior renal capsule and the parietal peritoneum for additional support.

Results

Retrospective series of laparoscopic nephropexy suggest a 90% to 100% pain improvement, 80% to 95% resolution of the 5-cm renal descent, and 90% improvement in renal function measured by nuclear medicine scan (Elashry et al., 1995; Fornara et al., 1997; Plas et al., 2001). In a series of 48 laparoscopic nephropexies, the median estimate blood loss was 50 mL, mean operative time was 95 minutes, and there were no major complications (Gozen et al., 2008). Nearly 90% of patients were satisfied and would undergo the operation again.

Calyceal Diverticulectomy

Several laparoscopic techniques to treat calyceal diverticula have been described, including unroofing, excision, ablation, and obliteration of the diverticulum as well as partial nephrectomy. **Indications for operative intervention include chronic pain, recurrent urinary tract infection, gross hematuria, and decline in renal function** (Waingankar et al., 2014). The modern principles of treatment include the removal of stones and widening of the infundibular drainage to prevent urinary stasis or complete ablation of the diverticula cavity.

Procedure

The kidney is dissected as previously described. After Gerota fascia is incised and the renal capsule exposed, there is usually a divot noted on the parenchyma overlying the diverticulum. The overlying parenchyma is incised with electrocautery revealing the diverticula cavity. Hilar control is usually not required unless a partial excision of the kidney is planned. Intraoperative ultrasound and/or injection of dye via a preoperatively placed externalized ureteral catheter can be used to assist in locating the diverticulum as well as os. Stones should be removed with a grasper and placed in an extraction bag. The diverticulum cavity is obliterated with argon beam coagulation or monopolar cautery. The infundibulum in communication with the collecting system may be closed with suture. Perirenal fat may be placed into the defect to further decrease the likelihood of recurrence. A drain is usually left in place after closure of the collecting system defect.

Results

Although only small series and case reports of laparoscopic calyceal diverticulectomy are available, authors have reported excellent results with this treatment modality, including 50% to 100% pain resolution, and 90% to 100% stone-free rate. In an analysis of 31 cases, only 1 complication (urinary leak) was observed (Gonzalez et al., 2011). In a series of 6 minimally invasive calyceal diverticulectomies, the mean operative time was 162 minutes, mean estimated blood loss was 150 mL, and mean hospital stay was 2 days

(Taylor and Thiel, 2015).

Nephrolysis

Nephrolysis consists of the renal mobilization with skeletonization of the hilar vessels and upper ureter with ligation of the lymphatic channels. It is indicated in select cases of loin pain hematuria syndrome and chyluria. There are very limited data on nephrolysis for the management of loin pain hematuria syndrome. Nephrolysis is an effective treatment for severe refractory chyluria, where there is lymphatic rupture and/or fistulous connections into the pyelocaliceal system (Fig. 102.29).

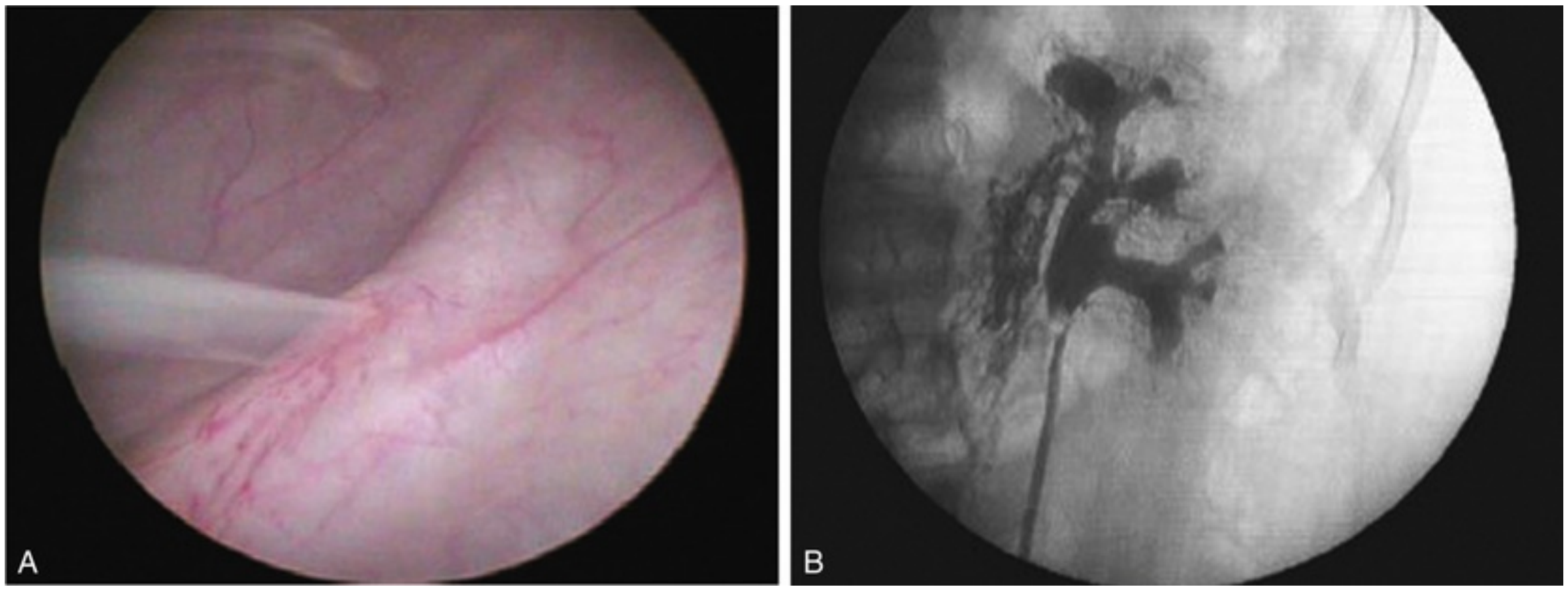

FIG. 102.29 Chyluria. (A) Cystoscopy demonstrating milky white efflux from the left ureteral orifice. (B) Retrograde pyelogram demonstrating lymphorenal fistula. (From Eisner BH, Tanrikut C, Dahl DM: Chyluria secondary to lymphorenal fistula. *Kidney Int* 76:126, 2009.)

Procedure and Results

Traditionally, the affected kidney is fully mobilized, ensuring complete lymphatic dissociation. A recent study suggests the dissection of the upper pole may be safely omitted in cases of chyluria (Zhang et al., 2016). The use of an omental wrap around the hilum has been described and may provide an additional barrier against recurrence of chyluria (Dalela et al., 2004). In a series of 59 laparoscopic nephrolysis for chyluria, the mean operative time was 79 minutes, estimated blood loss was 49 mL, and only 1 patient developed disease recurrence (Zhang et al., 2012).

Radical Nephrectomy

The indications for minimally invasive radical nephrectomy are similar to those for open surgery. Renal tumors as large as 25 cm have been successfully removed laparoscopically. Complex kidney cancers such as those involving the IVC, lymph nodes, and adjacent or distant organs may also be managed using minimally invasive techniques (Berger et al., 2009; Rabets et al., 2004; Simmons et al., 2007; Steinnerd et al., 2007).

Transperitoneal

Procedure

The patient is positioned and trocars are placed for transperitoneal access as described earlier in the chapter. Additional trocars or a hand port are placed as needed, especially in cases of larger tumors, IVC involvement, or adjacent organ invasion. Laparoscopic radical nephrectomy is essentially identical to laparoscopic simple nephrectomy except that the Gerota fascia and fat are left intact during dissection. When indicated, the adrenal gland can be removed en bloc with the kidney (Fig. 102.30A). This can be accomplished by ligating the renal vein medial to the take-off of the adrenal vein. For adrenal-sparing nephrectomy, the fascia is opened over the upper medial aspect of the kidney (Fig. 102.30B). Regional lymph nodes may be removed, and a full hilar or retroperitoneal dissection can be carried out if deemed necessary. Excision of part of the adjacent organs, such as the diaphragm, pancreas, liver, spleen, and bowel, can be accomplished if needed (Molina et al., 2004; O'Malley et al., 2009).

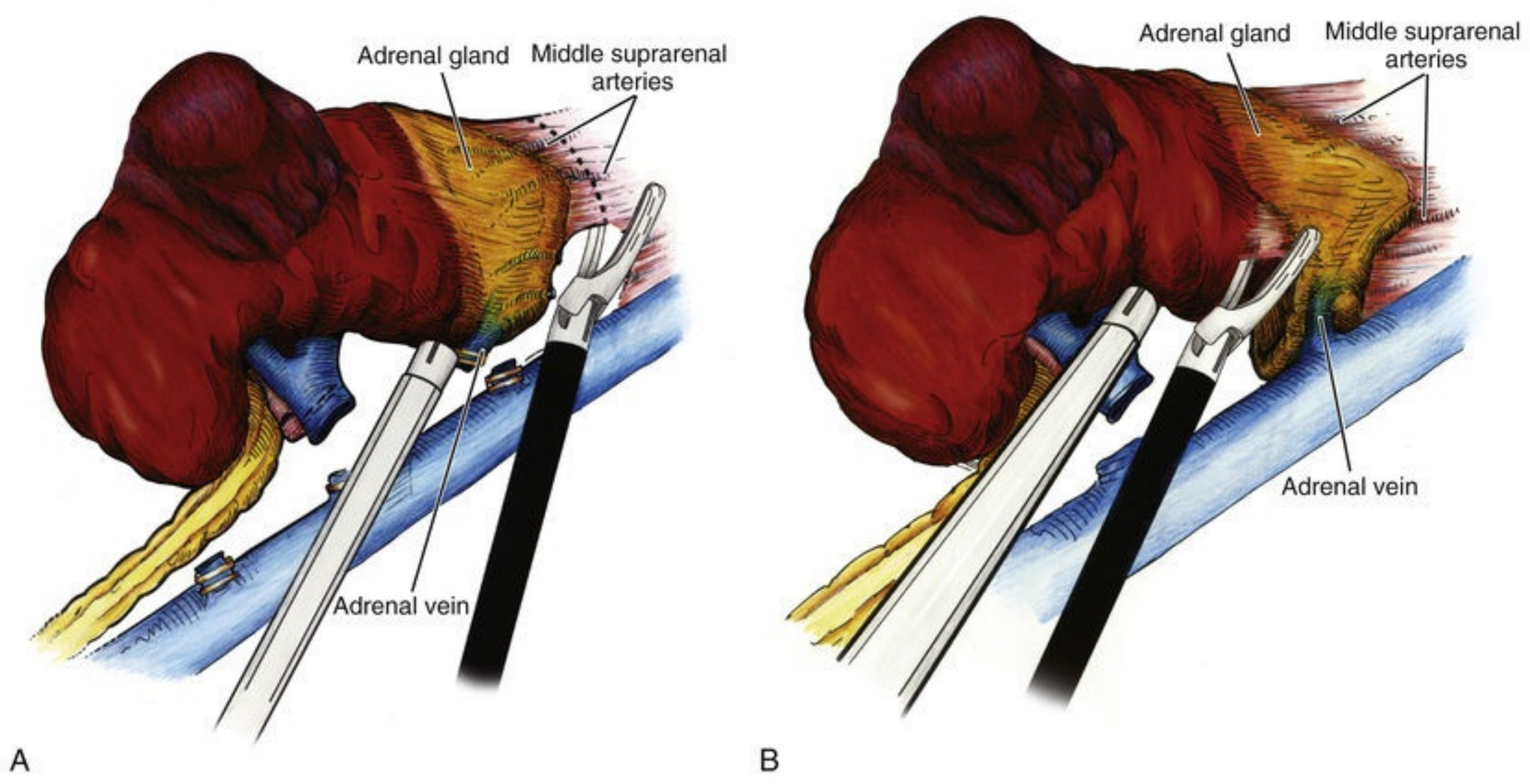

FIG. 102.30 (A) Inclusion of the adrenal gland during right laparoscopic radical nephrectomy can be readily accomplished using ultrasonic or bipolar shears to control the multiple arterial branches to the adrenal gland. Inferior retraction of the specimen facilitates exposure of this surgical plane. (B) Adrenal-sparing, right radical nephrectomy. Use of a blunt instrument above the hilum to put anterior and inferior traction on the kidney helps to expose the correct plane and place the connective tissue on stretch. Ultrasonic or bipolar shears are again useful to avoid any bleeding that may be encountered in this plane.

Results

Laparoscopic radical nephrectomy offers minimally invasive advantages with similar long-term oncologic outcomes compared with open surgery (Campbell et al., 2017; EAU Guidelines: http://uroweb.org/guideline/renal-cell-carcinoma/). **Laparoscopic radical nephrectomy is associated with shorter hospital stay, time to start oral intake, and convalescence time; less estimated blood loss, lower blood transfusion rate, fewer analgesic requirements, and improved cosmesis compared with the open approach** (Fornara et al., 2001; Rassweiler et al., 1998; Tan et al., 2011; Wolf et al., 2001). A systematic review and meta-analysis of 37 prospective and retrospective studies comparing laparoscopic to open radical nephrectomy showed the laparoscopic approach was associated with a 29% lower risk of postoperative complications (Liu et al., 2017). There were no significant differences in cancer-specific mortality, tumor recurrence, or intraoperative complications. A large multi-institutional study including 1555 patients comparing laparoscopic with open radical nephrectomy demonstrated equivalent 5-year overall (laparoscopic: 93.5% vs. open: 89.8%) and recurrence-free (laparoscopic: 94.0% vs. open: 92.8%) survival rates (Jeon et al., 2011). Similar results were observed in studies with long-term follow-up in which the 10-year recurrence-free, cancer-specific, and overall survivals were 94%, 97%, and 76% for laparoscopic nephrectomy compared with 87%, 86%, and 58% for open surgery, respectively (Permpongkosol et al., 2005). Similarly, a study of laparoscopic nephrectomy for renal cell carcinoma followed for 10 years or more showed a 10-year recurrence-free, cancer-specific, and overall survival of 86%, 92%, and 65%, respectively (Berger et al., 2009).

Retroperitoneal

Procedure

The patient is positioned, and trocars are placed for retroperitoneal access as previously described. After identification of the psoas muscle and tendon, the retroperitoneal space anterior to the muscle is developed. Medial dissection in this plane will reveal the ureter. Elevation of the ureter allows the visualization and subsequent elevation of the lower pole of the kidney. This places the renal vessels on stretch, facilitating their dissection. The arterial pulsation may be indirectly visualized through overlying connective tissue. A gentle layer-by-layer dissection allows the renal vessels to come more directly into view. Use of the right-angle dissector allows the artery and vein to be circumferentially freed from the surrounding tissue, and the endovascular stapler or clips are used to divide the artery and vein sequentially. During surgery on the left kidney, a lumbar vein typically requires dissection, ligation, and division to allow direct access to the renal hilum. Once the renal hilum is ligated, the posterior dissection is carried in a cephalad direction to the upper pole followed by dissection of the lateral and anterior aspects of the kidney. Continuous identification of anatomic landmarks is key to avoid disorientation.

Results

Retroperitoneal radical nephrectomy has comparable complication rates, analgesic requirements, hospital course, convalescence, and oncologic outcomes compared with transperitoneal surgery. Three randomized clinical trials compared pure transperitoneal with retroperitoneal laparoscopic nephrectomy. In the first study with 40 patients, no significant differences in estimated blood loss, operative time, complication rates, and hospital stay were noted (Nambirajan et al., 2004). A second study including 52 transperitoneal and 50 retroperitoneal radical nephrectomies found no significant difference in estimated blood loss, narcotic use, hospital stay, or complication rate (Desai et al., 2005). However, retroperitoneal surgery was associated with shorter operative time (150 vs. 207 minutes). A third study including 62 patients found retroperitoneal nephrectomy was associated with shorter operative time (120 vs. 140 minutes), lower pain scores, lower analgesic requirements, shorter convalescence, and lower complication rate (13% vs. 6%) (Garg et al., 2014). A meta-analysis of 12 studies comparing the two approaches showed the retroperitoneal was associated with shorter operative time, and lower intraoperative complication rate (Fan et al., 2013). No significant differences in time to oral intake, postoperative analgesic requirement, postoperative complications, blood transfusion, or oncologic outcomes were observed.

Hand-Assisted

Procedure

Patient positioning, hand port, and trocar placement are done as described earlier in the chapter. The steps in hand-assisted laparoscopic nephrectomy are similar to those of standard laparoscopic surgery, but the nondominant hand is used throughout for retraction and blunt dissection. The line of Toldt is incised while the hand retracts the colon medially (Fig. 102.31). The surgeon's hand and fingers may be used to simultaneously place lateral traction on the kidney and medial traction on the bowel, helping to demonstrate the plane posterior to the mesocolon and anterior to the Gerota fascia. On the left side, the hand may also be used to retract the spleen and pancreas medially while dividing the lienorenal attachments. On the right, the hand is used to retract the liver anteriorly to expose the upper pole. After the colon is mobilized, the psoas muscle is identified, and the ureter is elevated. On the left, the gonadal vein is typically elevated in the packet along with the ureter while, on the right, the gonadal vein is reflected medially. With the ureter elevated, the hand can bluntly dissect and elevate the entire kidney off the psoas muscle, and the ureter is then followed to the renal hilum. The fingers are then used to place anterolateral traction on the kidney, while the thumb pushes the bowel and mesentery medially to expose the hilum. Once the renal vessels are sufficiently skeletonized, the endovascular stapler or clips are used to ligate and divide the artery and vein (Fig. 102.32). The lateral and superior attachments may then be divided, using a LigaSure device or Harmonic scalpel (Ethicon), while the hand keeps them on traction. The hand should not be used to bluntly dissect the adrenal gland free from the upper pole because this typically results in bleeding. A rolled laparotomy sponge placed through the hand port at the beginning of the procedure may assist with retraction and hemostasis. The previously made hand-port incision allows rapid removal of sponge and the specimen. However, because hand-port metastases have been reported, it is recommended to place the specimen in a removal device before extraction (Chen et al., 2003). At the conclusion of the procedure, the hand-port incision is irrigated and closed.

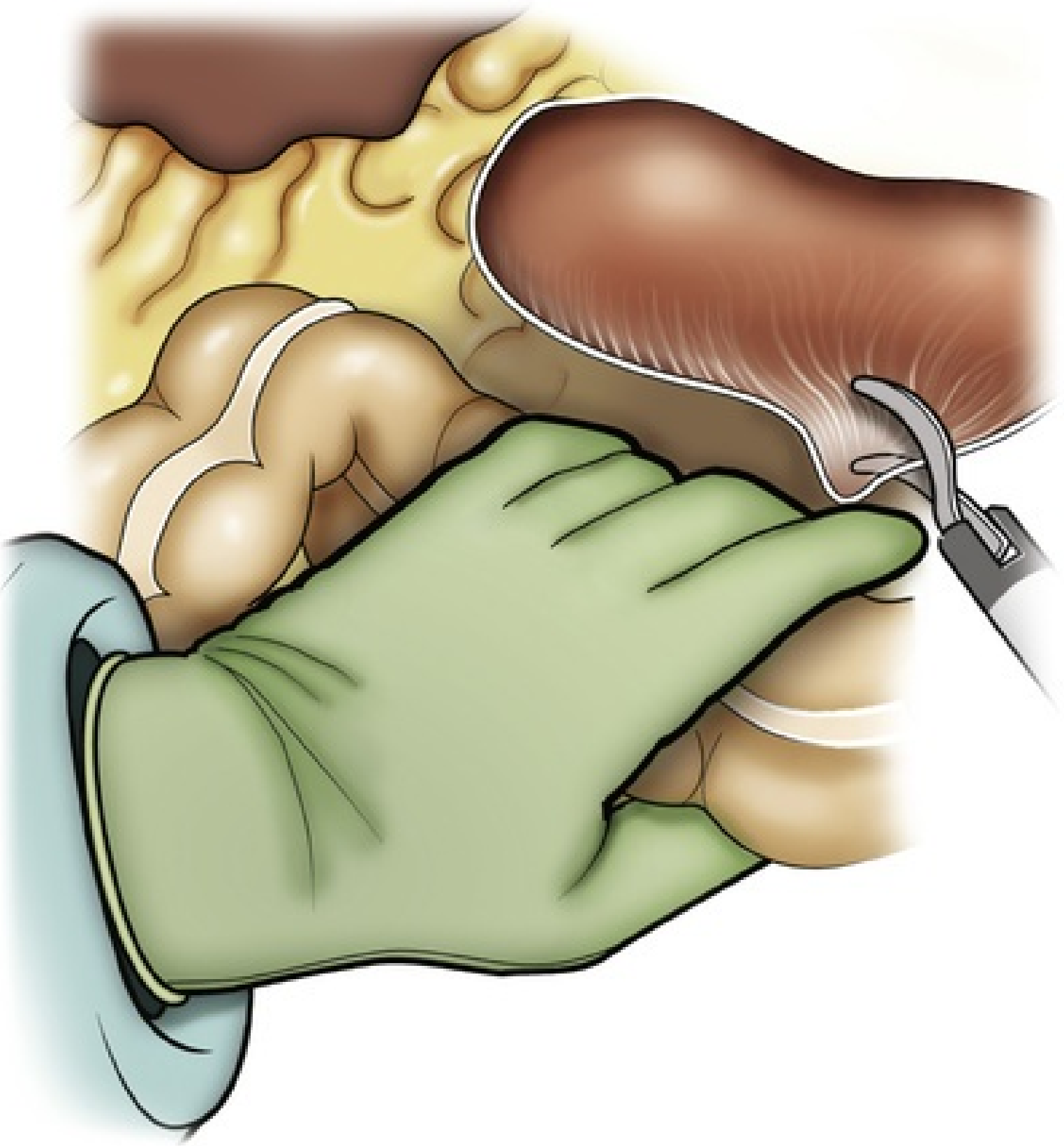

FIG. 102.31 The nondominant hand is used to retract the colon medially and to dissect tissue planes, while the dominant hand uses endoscopic scissors to divide colon attachments.

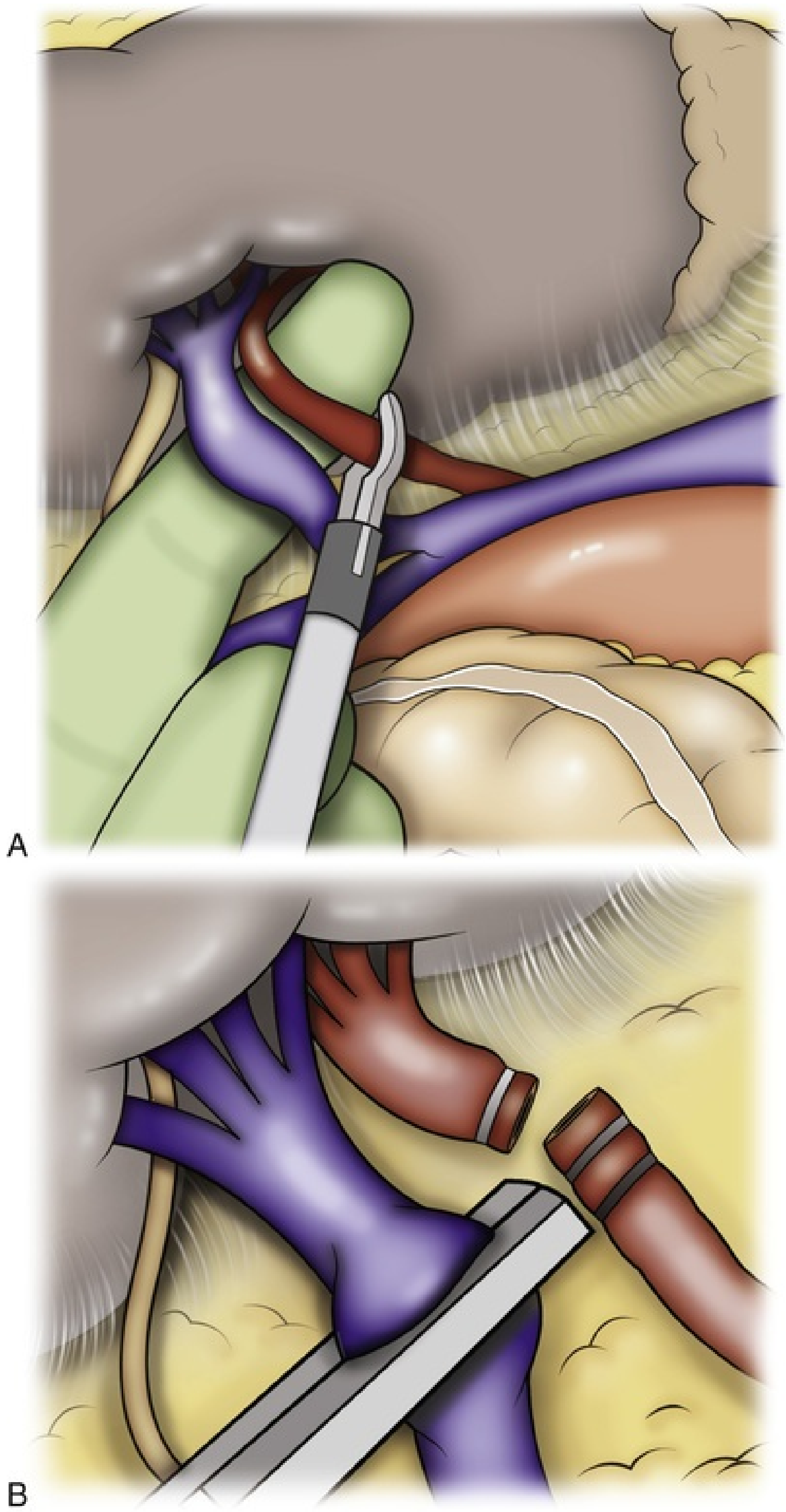

FIG. 102.32 (A) With the renal hilum on stretch and the bowel retracted medially to expose the vessels, the fingers can be used to palpate the renal artery and guide a stapler or clip applier to secure and divide the artery. (B) Once the artery is divided, the renal vein is freed circumferentially and divided with an endovascular stapler.

Results

Hand-assisted laparoscopic radical nephrectomy offers recovery, morbidity, and cost that are comparable with those of pure laparoscopy surgery. A study of 22 hand-assisted and 16 standard laparoscopic radical nephrectomies found comparable operative times and no difference in the complication rate, hospital costs or stay, return to activity, or overall pain score (Nelson and Wolf, 2002). In two separate studies the rate of wound-related complications such as wound infection and incisional hernia was slightly higher in hand-assisted approach compared with pure laparoscopy (Nadler et al., 2006; Okeke et al., 2002). Oncologic outcomes seem comparable with the ones achieved with pure laparoscopy or open surgery (Chung et al., 2007; Gabr et al., 2009; Kawauchi et al., 2007). A study of 147 standard and 108 hand-assisted laparoscopic radical nephrectomies found comparable operative times and conversion to open surgery and complication rates (Gabr et al., 2009). After a median follow-up of 35 months, recurrence-free, cancer-specific, and overall survivals were similar between surgical techniques.

Special Considerations

Large Tumors

Although renal masses larger than 7 cm pose a surgical challenge, minimally invasive techniques have been shown to be a feasible and safe treatment option in most cases of large renal masses (Luciani et al., 2013; Stewart et al., 2012). A study of 200 laparoscopic radical nephrectomies for tumors larger than 7 cm showed a conversion rate to open surgery of 5% and complication rate of 20% (Pierorazio et al., 2012). **Because of the bulk of the tumor, the working space can be reduced and normal anatomic landmarks distorted, potentially leading to disorientation.** In some cases, the hilum may be obscured by large perihilar collateral vascularity or the kidney may fall over the hilum. Continuous intraoperative reference to preoperative imaging as well as use of intraoperative ultrasonography is helpful. It may be beneficial to use a hand port or additional trocars to assist in the lateral distraction of the kidney and allow for more widely distributed retraction of the kidney.

En Bloc Hilar Vessel Stapling

In spite of previous concerns of arteriovenous fistula formation in cases of

en bloc hilar vessel stapling, this approach has been shown to be a safe alternative. A meta-analysis of 595 cases of en bloc stapling followed for an average of 2 years did not reveal any cases of arteriovenous fistula. Moreover, en bloc stapling was associated with almost identical complication rates and a significant reduction in operative time by an average of 43 minutes (Lai and Rais-Bahrami, 2017).

Tumor Seeding and Port-Site Recurrence

Tumor seeding is a rare complication of laparoscopic renal surgery. In a multi-institutional survey including nearly 11,000 laparoscopic urologic surgeries for cancer, tumor seeding was observed in 13 cases (0.1%), of which 10 were port-site recurrences (Micali et al., 2004). In another study of 1098 laparoscopic urologic procedures for malignancy, two port-site recurrences (0.18%) were identified (Rassweiler et al., 2003). Tumor aggressiveness, patient immune status, local wound factors, surgical technique, and tumor spillage are potential factors associated with tumor seeding. **Pneumoperitoneum, aerosolization of tumor cells, insufflation gas type, and laparoscopic wound closure techniques have been studied and have been shown to be noncontributory** (Halpin et al., 2005)**. Sound surgical technique avoiding tumor spillage and careful tumor extraction with the assistance of an impermeable retrieval bag are recommended to minimize the risk of tumor seeding.**

Specimen Extraction

Specimen extraction can be accomplished by removing it intact or after morcellation. Although morcellation can achieve smaller extraction incisions with better cosmesis, and potentially shorter recovery, it is surrounded by controversy because of concerns of inadequate pathological evaluation and the risk of tumor seeding. A study of 57 laparoscopic nephrectomies in which 23 specimens were removed intact and 33 after morcellation found the mean incision length for morcellated specimens was 1.2 cm compared with 7.1 cm in the intact extraction group (Hernandez et al., 2003). No significant differences in operative time, pain, or hospital stay were observed. In a multi-institutional study of 188 radical nephrectomies in which specimens were removed after morcellation, one port site recurrence was identified (Wu et al., 2009). The authors concluded intracorporal mechanical morcellation after radical nephrectomy is a safe and effective way of specimen extraction. A study of 9 pathological evaluations before and after ex vivo morcellation showed morcellation did not affect the of histologic diagnosis, grade, or stage (Landman et al., 2000). Only tumor size was not assessable after morcellation. Conversely, in a study of 23 renal specimens after morcellation, tumor size, renal capsule involvement, and renal vein involvement could not be adequately evaluated for renal cell carcinoma and invasion could not be properly assessed for urothelial carcinoma of the renal pelvis (Rabban et al., 2001). Thus morcellation can be used in select cases, but it is not considered standard of care. **If the specimen is to be morcellated, the surgeon should strictly adhere to proper technique including the use of a purpose-built sac, adequate draping, and change of gowns, gloves, and instruments after morcellation.** The LapSac (Cook Urological, Spencer, IN) has been shown to be impermeable to bacteria and tumor cells, even after its use for morcellation (Urban et al., 1993). The sac is prepared by passing a moistened hydrophilic wire alternating through every third hole in the sac, which is then rolled from the bottom up and passed through a 12-mm trocar site. The trocar is replaced, leaving the wire and drawstrings outside the trocar. Graspers are used to place the specimen in the sac, which is held open by the wire, and the wire is removed (Wakabayashi et al., 2003). The drawstrings are grasped and brought through the periumbilical incision along with the neck of the sac, which is held tightly against the abdomen. Enlarging the trocar site by 1 cm allows small amounts of tissue to protrude through the mouth of the sac. The morcellation process is performed with a ring forceps, working with alternating bites on the protruding tissue. Deep passes with the forceps should be avoided to prevent unintentional incorporation of bowel into the forceps. Pneumoperitoneum and direct laparoscopic visualization should also be maintained during the process to allow monitoring of the sac intracorporeally to avoid injury to structures resting against the sac or sac perforation.

Lymphadenectomy

Routine retroperitoneal lymphadenectomy at the time of nephrectomy remains controversial. Although the removal of retroperitoneal lymph nodes allows for better disease staging and prognostication, the oncologic benefit of this procedure remains unclear (Blom et al., 2009; Gershman et al., 2017). Moreover, there is no consensus on the extent of node dissection to be performed. A study of 50 laparoscopic radical nephrectomies alone and 50 laparoscopic nephrectomies with lymphadenectomy showed that 10% of the cases had positive nodes (Chapman et al., 2008). Estimated blood loss, length of hospitalization, and complication rates were similar between groups. These results suggest that minimally invasive lymphadenectomy is feasible and a safe procedure. However, currently only 6% of the laparoscopic nephrectomies are accompanied by lymphadenectomy (Filson et al., 2012). For right-sided tumors, lymphadenectomy involved sampling the paracaval, precaval, retrocaval, and interaortocaval nodes from the crus of the diaphragm to the bifurcation of the IVC. For left renal masses, the paraaortic and preaortic nodes are sampled from the crus of the diaphragm to the bifurcation of the aorta; the interaortocaval nodes are removed when suspicious for malignant involvement.

Local Recurrence

Isolated local recurrence is defined as recurrence in the ipsilateral retroperitoneal lymph nodes, renal fossa, or adrenal gland without evidence of distant metastasis (Fig. 102.33). Its incidence after radical nephrectomy is approximately 2% (Itano et al., 2000; Margulis et al., 2009). A study of 54 isolated local recurrence treated with open resection showed median recurrence-free and cancer-specific survival rates of 11 and 61 months, respectively (Margulis et al., 2009). Given its rarity, only a few series of cases of minimally invasive excision of isolated local recurrence after nephrectomy have been published. A series of 5 patients (1 open conversion resulting from IVC invasion) undergoing hand-assisted excision of isolated local recurrence showed cancer-specific and disease-free survival rates were 60% and 20%, respectively, after a mean follow-up of 43 months (Bandi et al., 2008). The robotic approach has also been described to manage isolated local recurrence (Gilbert and Abaza, 2015).

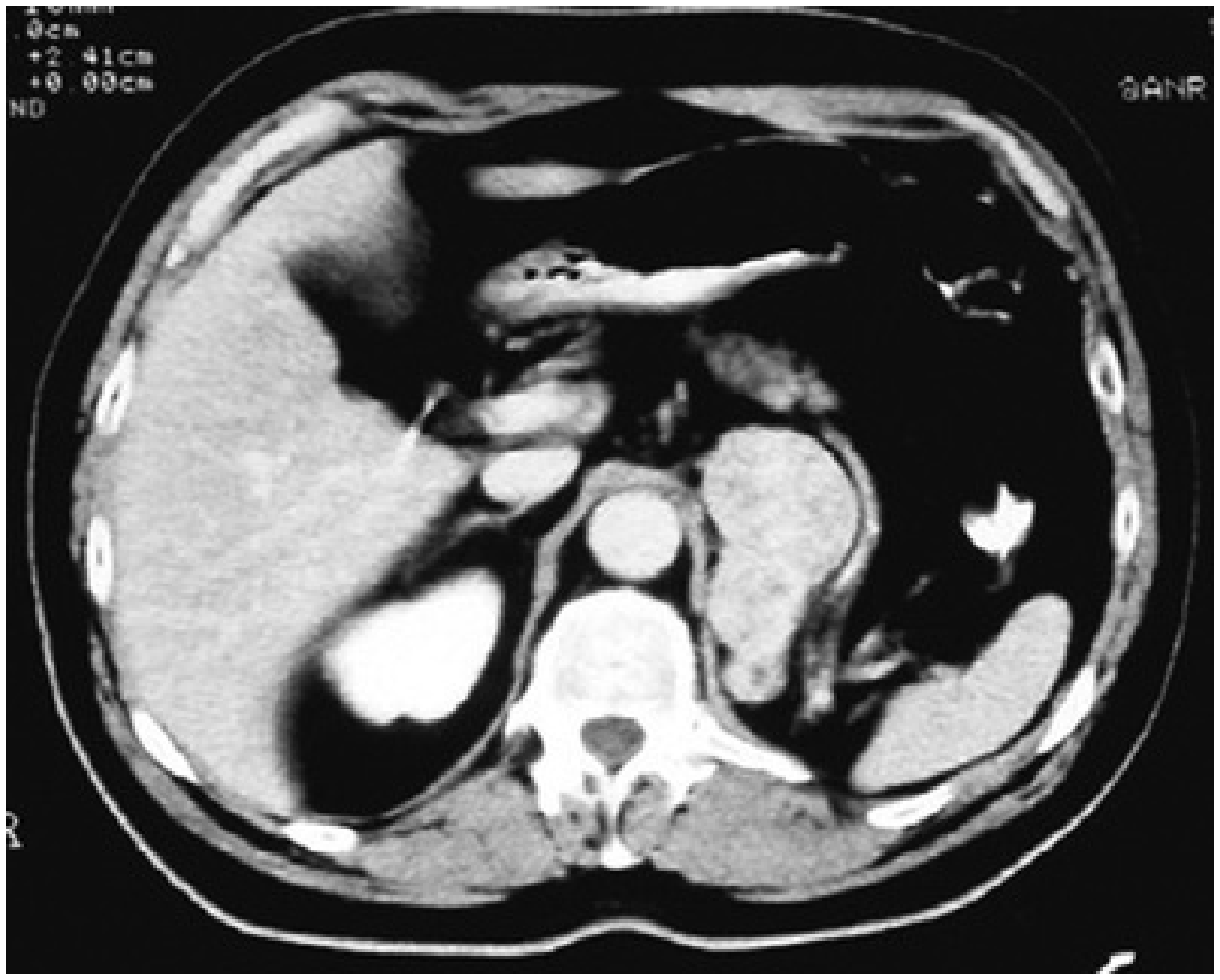

FIG. 102.33 Renal fossa recurrence. (From Nóbrega de Jesus CM, Silva Casafus FA, et al.: Surgical treatment of renal cell carcinoma recurrence at the renal fossa following radical nephrectomy. *Sao Paulo Med J* 126:194–196, 2008.)

Renal Vein and Caval Tumor Thrombus

With the evolution of minimally invasive techniques and increasing surgical experience, laparoscopic surgery is now used to manage complex renal tumors, including those associated with renal vein and caval thrombus (Abaza et al., 2016; Desai et al., 2003). In a study of 37 laparoscopic radical nephrectomies for renal masses with renal vein thrombus, the median estimated blood loss was 200 mL, median length of hospital stay was 3 days, and complication rate was 14% (Guzzo et al., 2009). **The authors concluded laparoscopic radical nephrectomy in the setting of renal vein thrombus is feasible but complex and requires significant laparoscopic skills.** Management of renal vein thrombus usually involves complete laparoscopic mobilization of the kidney and ligation of the renal artery followed by use of a laparoscopic DeBakey, vessel loop, or hand-assistance to “milk” the tumor thrombus back toward the kidney. This allows either the endovascular stapler to be deployed on the renal vein excluding the thrombus, or a laparoscopic Satinsky clamp to be placed to isolate a cuff of the IVC so that the cuff may be excised to allow intact specimen extraction without tumor at the margin. In cases in which a cuff of the IVC is excised en bloc with the renal vein stump, the cavotomy may be oversewn using Prolene suture mirroring the open procedure. Intraoperative ultrasonography can aid in assessing the location and extent of the thrombus (Hsu et al., 2003). A tangential clamping of the IVC using a laparoscopic Satinsky clamp can be used to manage short caval thrombi. Long caval thrombi require circumferential dissection of the IVC above and below the thrombus to allow the placement of Rommel tourniquets or vascular clamps. The contralateral renal vein should also be controlled and lumbar veins ligated as needed. The IVC is open after the blood flow is interrupted. The thrombus is excised, and the IVC is closed using Prolene sutures and flushed with heparinized saline before reestablishing blood flow. A study of robotic-assisted radical nephrectomy in 30 level II and 2 level III IVC thrombus cases showed a need for IVC cross-clamping in 24 cases, and 1 case required synthetic patch cavoplasty (Abaza et al., 2016). Mean operative time was 292 minutes, mean blood loss was 400 mL, with no conversions to open surgery or aborted procedures. Three patients required transfusions and no Clavien grades III through V complications were observed. **The authors concluded robotic nephrectomy in the setting of IVC thrombus is feasible in selected patients. Given the complexity of the procedure and potential for catastrophic complications, these should be performed by experienced surgeons.**

Cytoreductive Nephrectomy

Cytoreductive nephrectomy has been shown to provide survival benefits in metastatic renal cell carcinoma. A study of 22 laparoscopic and 42 open cytoreductive nephrectomies showed shorter length of stay (2.3 vs. 6.1 days), less estimated blood loss (300 vs. 1,200 mL), and shorter interval from surgery to the initiation of systemic therapy (36 vs. 61 days) in the laparoscopic group, but the overall survival at 1 year was similar between groups (61% vs. 65%) (Rabets et al., 2004). Similar results have been reported in separate studies (Eisenberg et al., 2006; Matin et al., 2006; Nunez Bragayrac et al. 2016), although the shorter interval to systemic therapy has not been consistently observed.

Surgical Salvage After Failed Ablative Therapies

Several studies have shown the feasibility of the minimally invasive nephrectomy in the management after failed ablative therapies (Breda et al., 2010; Kowalczyk et al., 2009; Nguyen et al., 2008). However, the surgery can be technically challenging as a result of perinephric fibrosis causing loss of tissue planes around the lesion. A report of 10 patients undergoing salvage surgery showed that laparoscopic nephrectomy was only possible in four patients, and the remainder required either open partial or radical nephrectomy (Nguyen et al., 2008).

Partial Nephrectomy

Partial nephrectomy is increasingly used for the management of renal masses. The preservation of renal function with reduced morbidity and equivalent oncologic outcomes led to a paradigm shift away from radical nephrectomy. The minimally invasive approach has emerged as a management option that reduces operative time, blood loss, and hospital stay (Gill et al., 2007; Lane and Gill, 2010).

Indications

The first laparoscopic partial nephrectomy was reported in 1993 by Winfield et al., with the retroperitoneal approach introduced 1 year later (Gill et al., 1994). Initially, laparoscopic partial nephrectomy (▶Video 102.1) was used in the management of small exophytic renal masses (clinical stage T1a) (Fig. 102.34). With increasing experience, the indications of minimally invasive partial nephrectomy have expanded to include large and complex renal tumors. Tumor complexity can be characterized using RENAL nephrometry score, which takes into consideration tumor Radius, Exophytic/endophytic appearance, Nearness to the collecting system, Anterior/posterior position, and Location relative to the polar line (Kutikov and Uzzo, 2009). Anatomic complexity measured by RENAL nephrometry has been shown to correlate with risk of complications, warm ischemia time, operative time, hospital stay, estimated blood loss, and risk of recurrence after surgery (Hayn et al., 2011; Nagahara et al., 2016; Watts et al., 2017).

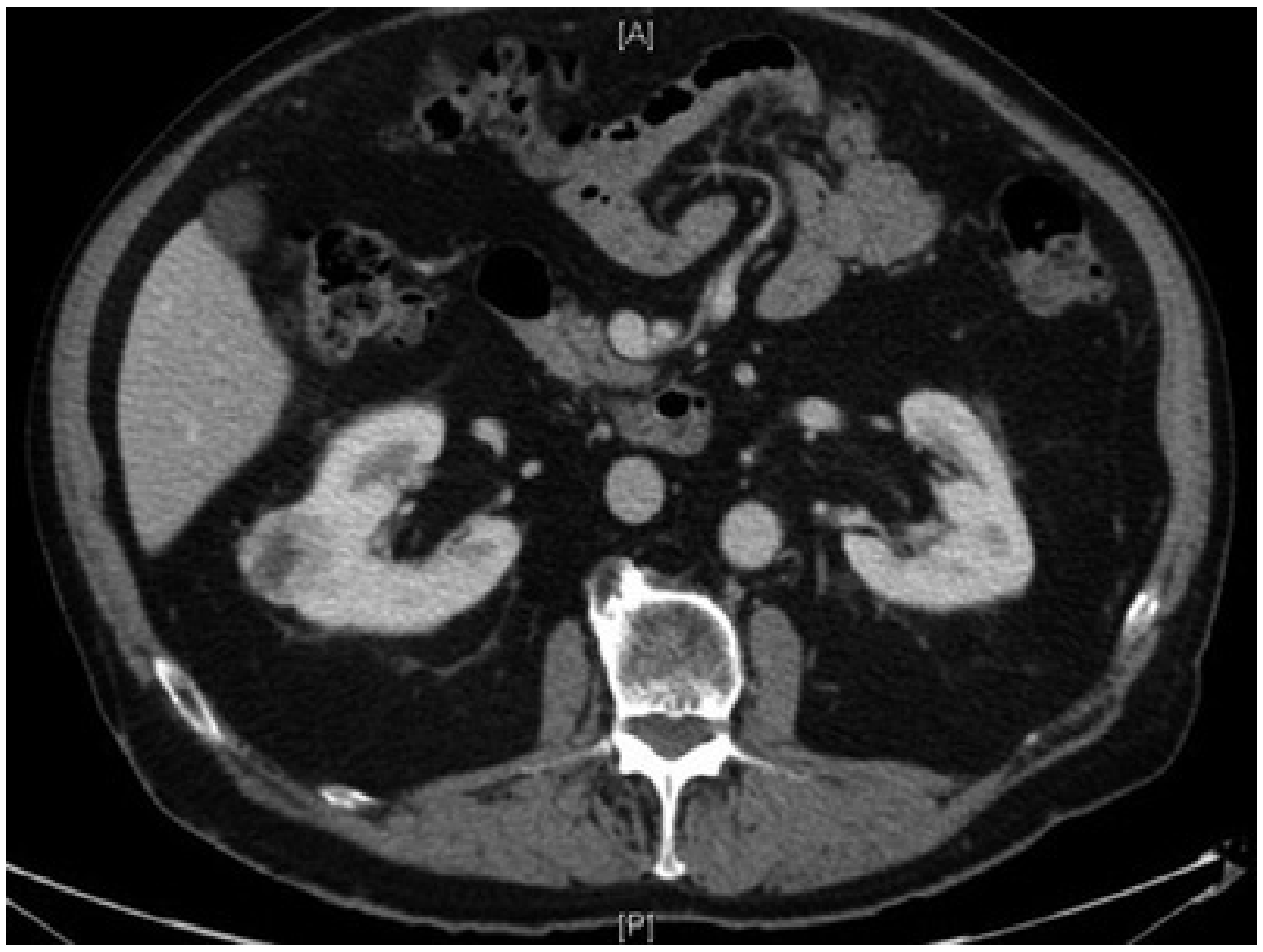

FIG. 102.34 Computed tomography scan with intravenous contrast demonstrating a partially exophytic mid-pole clinical T1a lesion in the right kidney.

Clinical Stage T1b and Greater Tumors

With the increasing experience of minimally invasive nephron-sparing surgery for the management of small renal masses and advances in laparoscopic techniques, select larger renal masses can be treated with minimally invasive partial nephrectomy. Although there are no randomized clinical trials comparing partial with radical nephrectomy in the management of large renal masses, retrospective studies have shown feasibility and safety of nephron-sparing surgery for large renal tumors. A study of 35 laparoscopic partial and 75 radical nephrectomies for tumors larger than 4 cm (clinical stage pT1b or greater) showed similar negative margin rates, overall and cancer-specific and disease-free survival between groups (Simmons et al., 2009). A 2-stage worsening in chronic kidney disease stage occurred in 12% vs. 0 of the radical and partial nephrectomy groups. A similar study found longer operative times and higher estimated blood loss in the laparoscopic partial nephrectomy group, but the rate of complications and oncologic outcomes was similar between laparoscopic partial and radical nephrectomies (Deklaj et al., 2010). Radical nephrectomy was associated with a nearly 30% decline in estimated glomerular filtration rate compared with only 12% in the partial nephrectomy group. **These studies suggest with adequate laparoscopic experience and appropriate patient selection, the perioperative outcomes of laparoscopic**

partial nephrectomy for clinical T1b tumors appear comparable with those achieved by radical nephrectomy. A multi-institutional study of robotic partial nephrectomy for the treatment of 1358 T1a, 379 T1b, and 41 T2a renal masses showed comparable complication rates, negative surgical margins, length of stay, and renal function decline across all three groups (Delto et al., 2018). However, larger tumors were associated with increased operative (T1a: 160, T1b: 190, and T2a: 224 minutes) and ischemia time (T1a: 15, T1b: 18, and T2a: 20 minutes), increased estimated blood loss (T1a: 100, T1b: 150, and T2a: 200 mL), and higher risk of recurrence at 1 year (T1a: 1%, T1b: 0, and T2a: 8%). A study of 133 open, 57 laparoscopic, and 95 robot-assisted partial nephrectomies for the management of pT1b renal tumors showed comparable perioperative complications, negative surgical margins, and ischemia time across all three surgical approaches (Porpiglia et al., 2016). Shah et al. (2016) looked at 1250 partial nephrectomies and found a 27% rate of upstaging in patients with clinical t1b compared with 4.4% in patients with clinical t1a disease. Furthermore, 33% of these recurred. Coupling this with the fact that medical renal disease is much different than surgically induced renal disease, caution should be taken in applying partial nephrectomy to larger tumors and indications for sparing parenchyma should be well defined.

Laparoscopic Heminephrectomy

Heminephrectomy involves the excision of 30% or more of the renal parenchyma. Specific technical considerations include deeper parenchymal resection, transection of large intraparenchymal blood vessels with potential need for clipping or suturing, and intentional entry into the pelvicalyceal system, in some cases, requiring surgical repair. A study of 41 laparoscopic heminephrectomies compared with 41 matched partial nephrectomies showed similar estimated blood loss, operative time, hospital stay, overall complication rate, and postoperative serum creatinine (Finelli et al., 2005). Heminephrectomy was associated with larger parenchymal resections, pelvicalyceal system repair, and longer warm ischemia time (39 vs. 33 minutes). Similar findings have been reported by other authors (Sobey et al., 2012).

Central and Hilar Tumors

Central tumors are defined as those abutting or invading the central renal sinus fat and/or the collecting system. These tumors deeply infiltrate the renal parenchyma, and their excision frequently requires intraoperative ultrasound guidance, intentional entry into and potentially suture-repair of the pelvicalyceal system along with complex parenchymal reconstruction, all within the time constraints of renal ischemia. A study of 154 central and 209 peripheral tumors undergoing laparoscopic partial nephrectomy showed comparable estimated blood loss, complication rates, surgical margins, and postoperative creatinine levels. Central tumors were associated with longer warm ischemia time (33.5 vs. 30 minutes), operative time (3.5 vs. 3.0 hours), and hospital stay (67 vs. 60 hours) (Frank et al., 2006). A similar analysis of laparoscopic partial nephrectomy for 53 central and 159 peripheral tumors showed similar estimated blood loss, operative time, and complication rates (Nadu et al., 2009). Central tumors were associated with longer warm ischemia time (37 vs. 28 minutes), lower conversion rate to open surgery (1% vs 6%), and less positive surgical margins (0 vs. 5%). **Hilar tumors are defined as tumors located in the renal hilum in direct contact with the renal artery and/or vein.** Preoperative three-dimensional reconstruction of triphasic spiral CT assists surgical planning by detailing the number, interrelationship, anatomic course, and position of the renal vessels in relation to the tumor (Gill et al., 2005). A study of 43 hilar tumors treated with laparoscopic partial nephrectomy found no significant differences in any perioperative parameter investigated, including warm ischemia time, surgical margins, and postoperative renal functional outcomes at 6 months' follow-up (George et al., 2014). **These authors conclude minimally invasive partial nephrectomy for central and hilar tumors can be performed safely by an experienced surgeon with perioperative outcomes comparable with those of peripheral tumors.**

Tumor in a Solitary Kidney

Partial nephrectomy in a solitary kidney poses a challenge regardless of the surgical approach. A multi-institutional study of 74 patients undergoing robotic partial nephrectomy for renal mass in a solitary kidney showed a mean warm ischemia time of 15.5 minutes, 24% 3-month complication rate, 95% negative surgical margins, and only one conversion to radical nephrectomy (Arora et al., 2018). These results are comparable with previous reports of partial nephrectomy in solitary kidneys (Reynolds et al., 2017; Zargar, et al. 2014). **These authors concluded that minimally invasive partial nephrectomy for management of tumors in a solitary kidney is safe and offered reliable preservation of renal function and comparable outcomes with open surgery.**

Multiple Tumors

Nephron-sparing surgery is an attractive treatment option for multifocal ipsilateral tumors because of the potential for contralateral recurrence. In a matched analysis of 33 patients undergoing partial nephrectomy for multiple tumors, resection of multiple tumors was associated with long operative time and hospitalization with comparable blood loss, complication rates, and renal functional outcomes (Abreu et al., 2013). Bilateral laparoscopic partial nephrectomies can be performed in a staged or single-setting fashion. In a study of 13 cases of bilateral renal masses, 11 (85%) were successfully treated in a single setting (Reisiger et al., 2005). The authors concluded that bilateral single-setting surgery is feasible and should only be performed in select cases when the primary procedure has been completed expeditiously and without complications.

Repeat Partial Nephrectomy

Repeat renal surgery can pose a technical challenge and result in higher blood loss and complication rates compared with first-time renal surgery. Studies of patients with hereditary kidney cancers showed repeat laparoscopic and robotic partial nephrectomy to be safe and feasible in select cases (Johnson et al., 2008). A study of 26 repeat robotic partial nephrectomies showed significantly higher estimated blood loss and longer hospitalization and a trend toward higher complication rates in the repeat surgery group with similar renal functional outcomes (Watson et al., 2016).

Other Indications

Minimally invasive partial nephrectomy has been performed in multiple clinical scenarios including in combination with adrenalectomy for upper pole tumor (Ramani et al., 2003), in patients with renal artery disease (Steinberg et al., 2003), tumors in congenitally anomalous kidney, such as horseshoe kidney (Tsivian et al., 2007), obese patients (Romero et al., 2008), and hereditary renal cell carcinoma (Watson et al., 2016). Although each of these scenarios poses different challenges, the minimally invasive partial nephrectomy in most clinical settings should realistically be able to safely remove the tumor while sparing normal renal parenchyma, minimizing ischemia and operative times, and minimizing postoperative complications.

Procedure

The primary goal of partial nephrectomy is complete tumor excision with negative margins and adequate hemostasis while paying attention to warm ischemia time. Successful minimally invasive partial nephrectomy requires an in-depth understanding of three-dimensional (3D) renal anatomy, real-time intraoperative appreciation of visual anatomic cues, and precise and efficient intracorporal suturing.

Transperitoneal Laparoscopic Partial Nephrectomy

The advantages of the transperitoneal approach include a large working space, familiar landmarks, greater versatility of instrument angles, and technical ease of suturing. The initial portion of the procedure is performed as previously described for transperitoneal access to the kidney.

Retroperitoneal Laparoscopic Partial Nephrectomy

The advantages of the retroperitoneal approach include no need for bowel mobilization and a more direct access to the posterior aspect of kidney and the renal hilum at the cost of a smaller working space and less familiar landmarks. After the retroperitoneum is entered and the working space established as previously described, the psoas muscle should be identified, and the kidney may be lifted anteriorly off the psoas muscle to allow visualization of the arterial pulsation. The dissection of the renal hilum can then proceed to facilitate bulldog clamp placement when deemed necessary. A meta-analysis of 8 retrospective studies comparing transperitoneal to retroperitoneal laparoscopic partial nephrectomy indicated the retroperitoneal approach was associated with shorter operative time, lower estimated blood loss, and a shorter length of hospital stay (Ren et al., 2014). Complication rates and conversion to open surgery were comparable between the two approaches. A study comparing 100 transperitoneal and 63 retroperitoneal laparoscopic partial nephrectomies found that 77% of the posterior tumors were managed via retroperitoneal approach, whereas 97% of the anterior tumors were managed with transperitoneal surgery (Ng et al., 2005). The retroperitoneal approach was associated with smaller lesions, less pyelocaliceal system repair, shorter operative time, shorter warm ischemia time, and a shorter length of hospital stay. The choice of transperitoneal or retroperitoneal approach mainly relies on tumor location and the surgeon's preference. Other factors that may influence the decision include tumor size, number of tumors, number of arteries supplying the kidney, amount of visceral fat surrounding the kidney, and prior abdominal surgeries.

Robotic-Assisted Laparoscopic Partial Nephrectomy

Robotics have facilitated the diffusion of minimally invasive partial nephrectomy by reducing difficulty of intracorporal tumor resection and suturing, resulting in a shorter learning curve for individuals not skilled in pure laparoscopic techniques (Alameddine et al., 2018; Pierorazio et al., 2011). A meta-analysis of 23 nonrandomized studies of beginning laparoscopic surgeons comparing robotic with laparoscopic partial nephrectomy found the robotic-assisted approach was associated with a lower rate of conversion to open surgery and radical nephrectomy, shorter warm ischemia time, smaller changes in estimated glomerular filtration rate, and shorter length of hospital stay (Choi et al., 2015). Complication rate, operative time, estimated blood loss, and surgical margins were comparable between groups. Although robotic-assisted retroperitoneal laparoscopic partial nephrectomy techniques have been described, the transperitoneal approach is the one most commonly used (Ludwig et al., 2017). The initial portion of the procedure is performed as previously described for robotic-assisted laparoscopy. The beginning of the case can be done with conventional laparoscopy and the robot docked at any time, usually for tumor resection and renorrhaphy, or the robotic assistance can be used throughout the case, starting immediately after trocar insertion. Depending on the technique and instrumentation used, the responsibilities of the bedside assistant may include aiding in clamping the renal hilum, providing suction and retraction to maintain a clean operative field, delivery and cutting of sutures, clip placement, and the operation of the intraoperative ultrasound.

Tumor Localization and Excision

Once the initial dissection is complete, tumor localization can be achieved by directed inspection of the kidney and intraoperative ultrasonography, which can estimate tumor size and depth (Fig. 102.35). The Gerota fascia is entered away from the lesion to expose the renal capsule. In some cases in which the adherent fat is not easily dissecting off the renal capsule, a subcapsular dissection to visually identify the borders of the tumor before resection may be needed (Davidiuk et al., 2014). Using the monopolar scissors, the capsule is scored circumferentially around the tumor (Fig. 102.36), and the hilum is clamped (Fig.

102.37). The scored line may be incised using cold scissors (Fig. 102.38), and with the assistance of a grasper or suction device to provide countertraction and a clear operative field, the tumor excision is completed. Tumor excision can be accomplished with (standard partial nephrectomy) or without a rim of normal parenchyma (tumor enucleation). Standard partial nephrectomy and tumor enucleation seem to have comparable surgical margins and perioperative outcomes (Blackwell et al., 2017; Longo et al., 2014; Minervini et al. 2011; Takagi et al., 2017). A retrospective review of 982 standard partial nephrectomies and 537 tumor enucleations found comparable progression-free and cancer-specific survivals in the two groups after a 10-year follow-up (Minervini et al., 2011). Tumor enucleation should be considered in patients with familial renal cell carcinoma, multifocal disease, or severe renal dysfunction to optimize parenchymal mass preservation (Campbell et al., 2017). After complete excision, the tumor should be placed in a bag for later extraction.

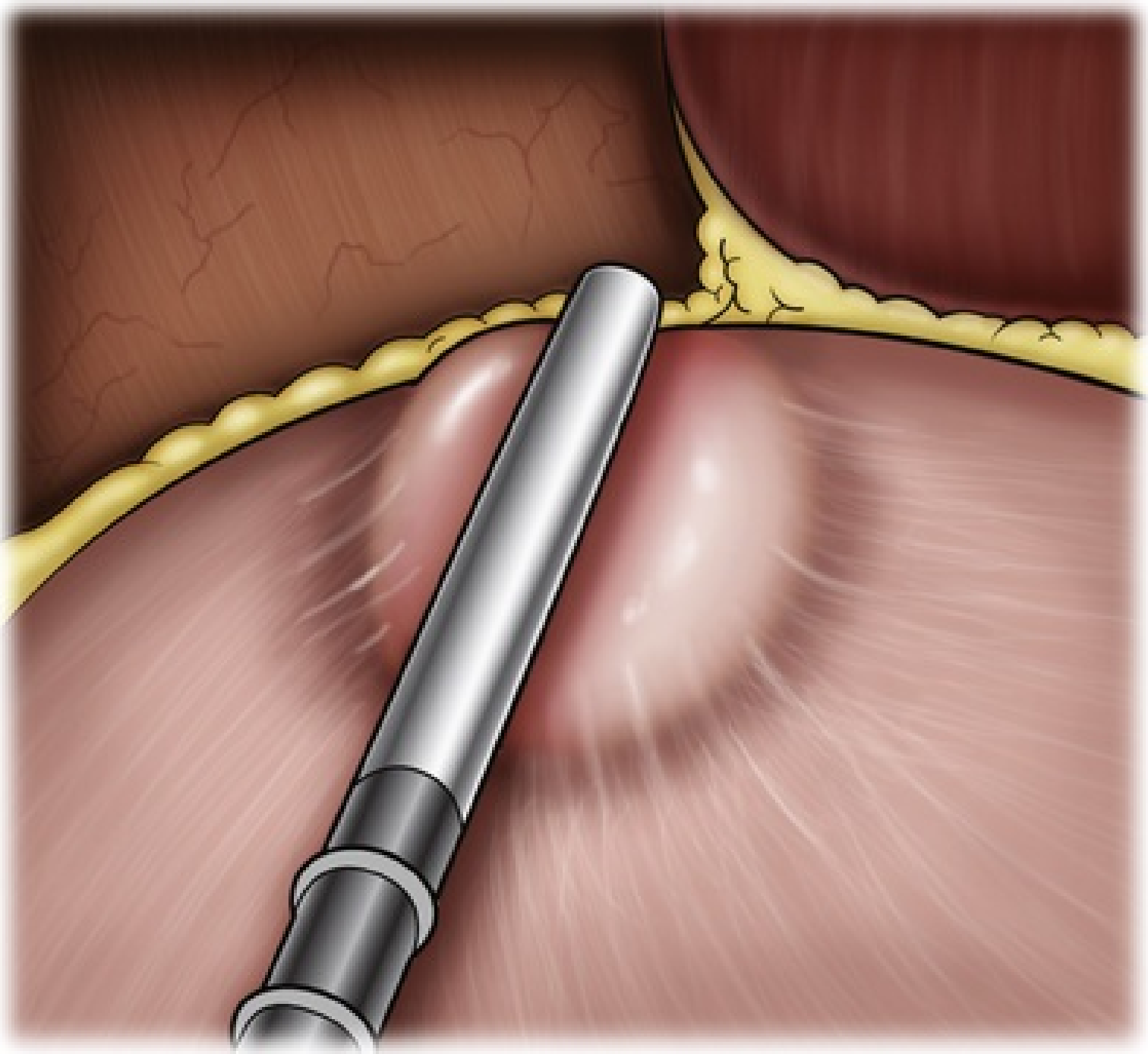

FIG. 102.35 Intraoperative ultrasonography is used to confirm location, width, and depth of the tumor.

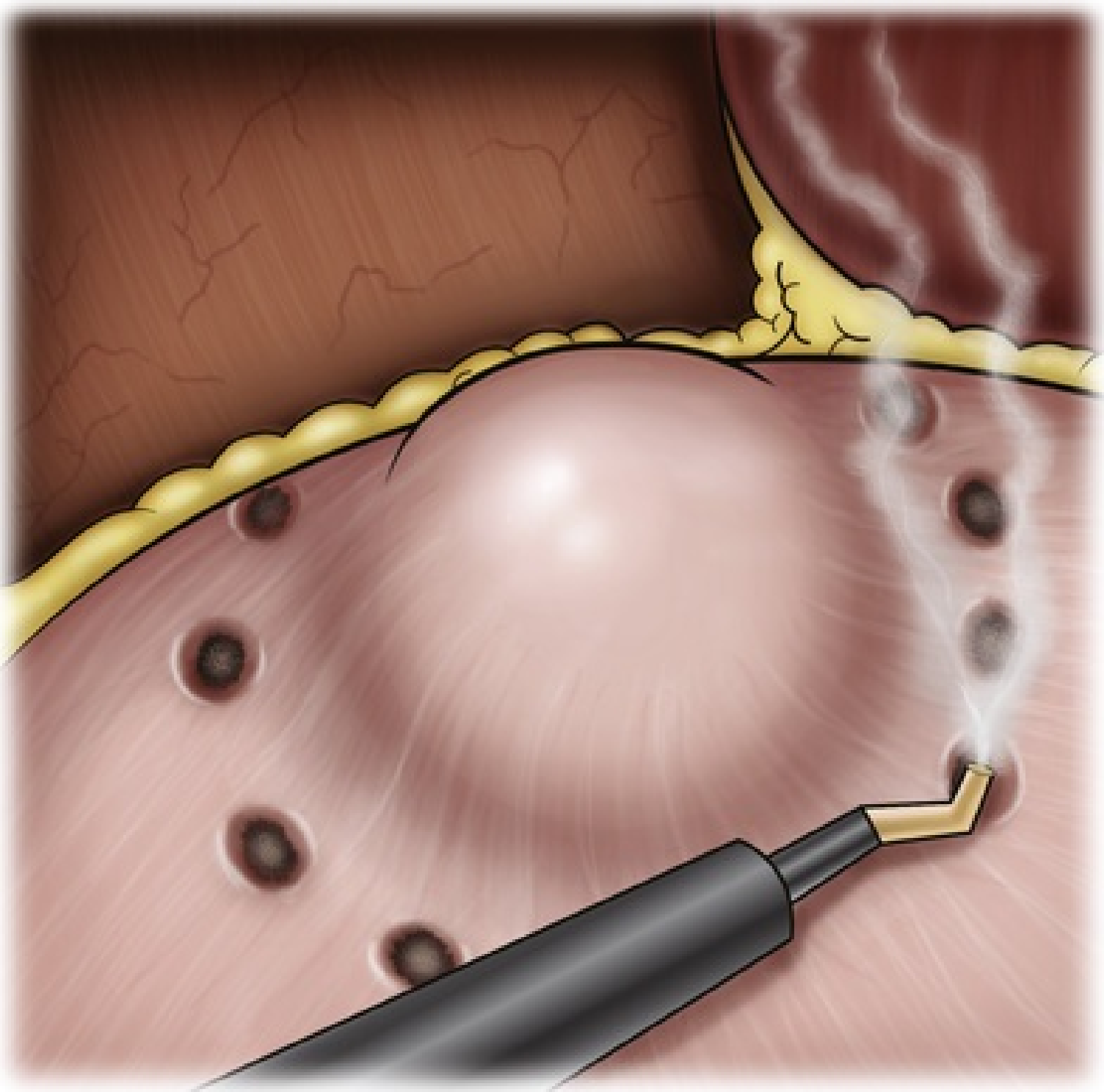

FIG. 102.36 After the Gerota fascia is cleared to expose the lesion and the renal capsule, with use of monopolar scissors or hook cautery, the capsule is scored circumferentially around the tumor.

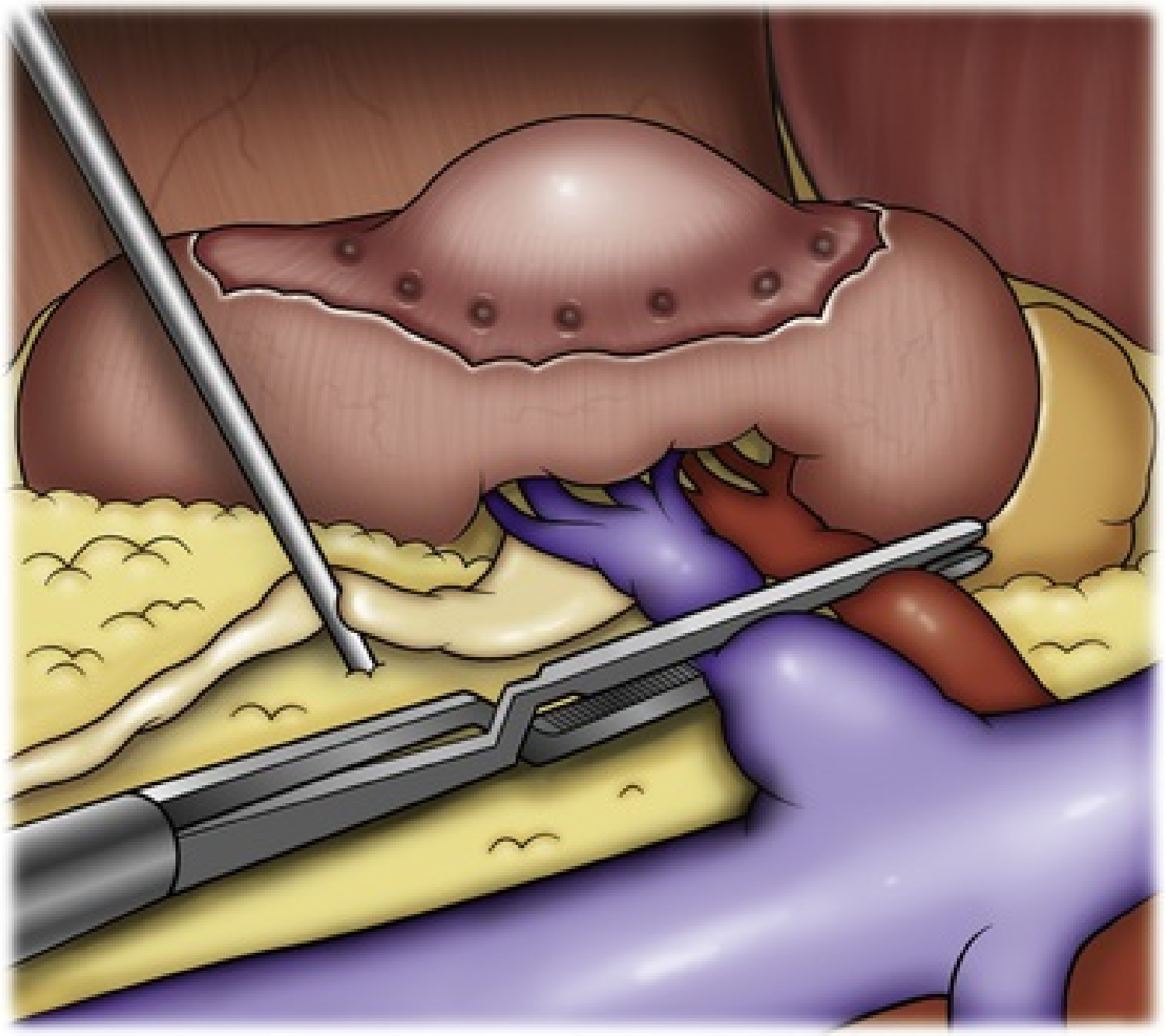

FIG. 102.37 Once the margin around the tumor has been scored, the hilum is clamped en bloc using a laparoscopic Satinsky clamp, or the artery and vein are clamped separately using bulldog clamps.

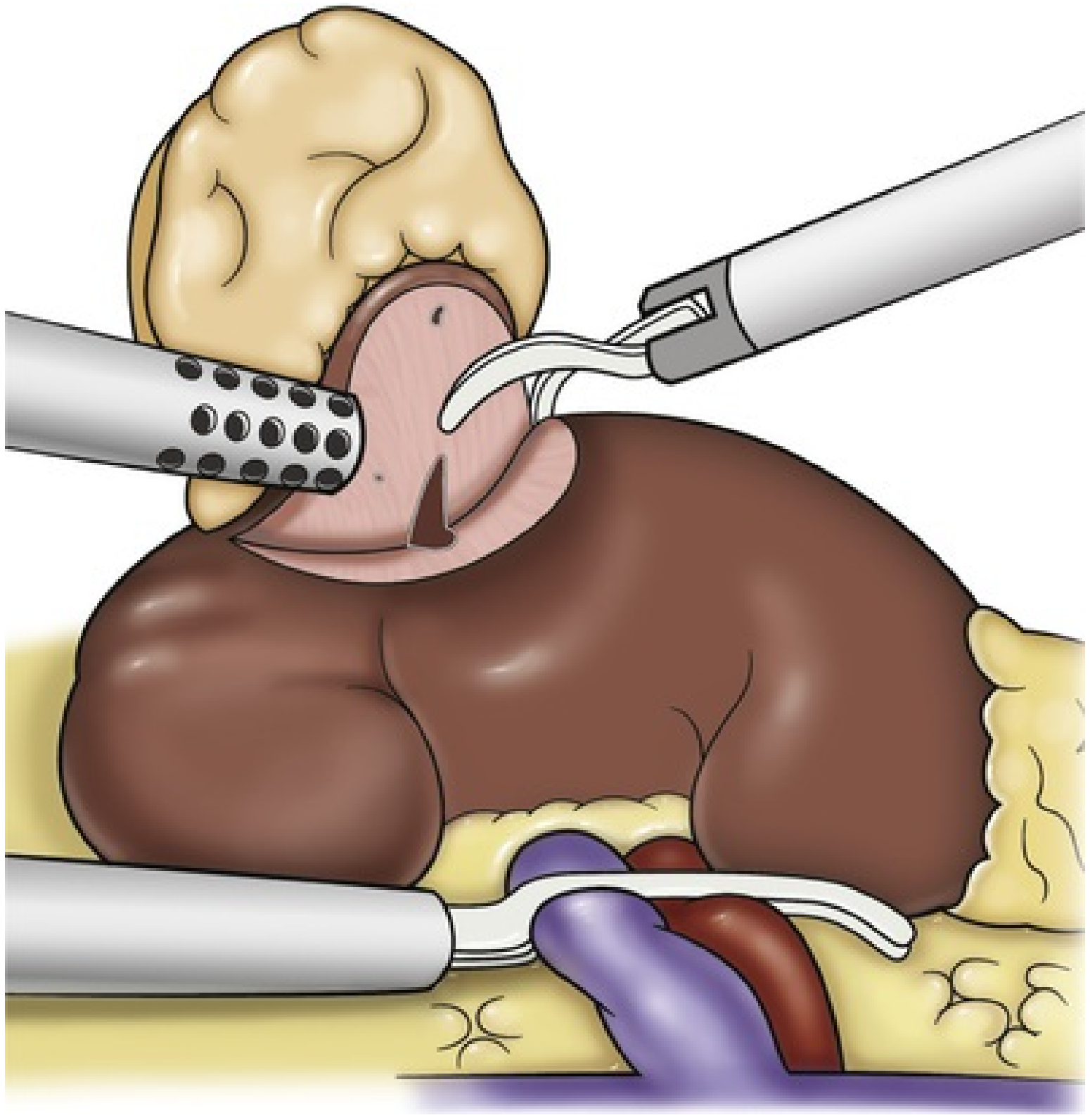

FIG. 102.38 The scored margin around the tumor is incised using cold shears with the renal hilum clamped. The suction-irrigator provides countertraction and helps to maintain a clear operative field and adequate margin of normal renal tissue.

Hemostasis

Suture renorrhaphy is the most reliable technique to achieve hemostasis of the partial nephrectomy bed (Fig. 102.39). This can be accomplished with or without adjunctive hemostatic or sealing agents, or a Surgicel bolster (Johnson and Johnson, New Brunswick, NJ). A popular renorrhaphy technique involves the use of locking clips applied to the suture, which are then slid toward the renal capsule to keep the renal parenchyma under tension (Benway et al., 2009). Barbed suture run in a horizontal mattress is the authors' preferred choice. This eliminates the need for knot tying. In addition, suturing or clip ligation of individual vessels may be required to control large vessels in the nephrectomy bed. During extrication, surgical clips may also be used to ligate any visualized vessels while coming across the surface of the parenchyma. A number of tissue sealants are available and used based on surgeon preference: gelatin matrix thrombin sealant (Floseal; Baxter, Deerfield, IL), fibrin glue (Tisseel; Baxter), fibrin sealant (Evicel; Ethicon, Somerville, NJ), polyethylene glycol hydrogel (Coseal; Baxter), cyanoacrylate glue (Dermabond; Ethicon), and BioGlue (CryoLife; Atlanta, GA). No study published has clearly demonstrated a clear benefit of any of these agents.

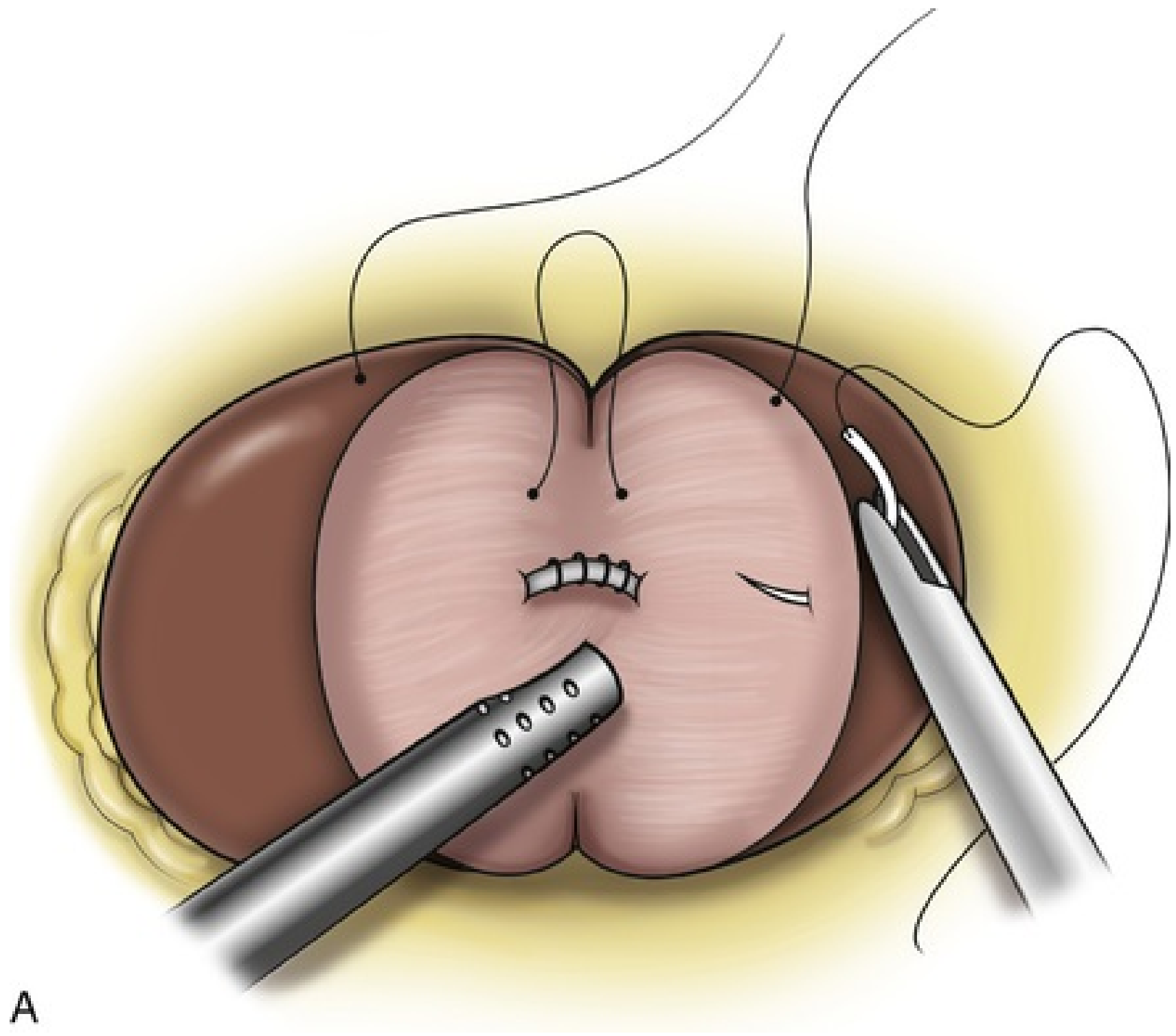

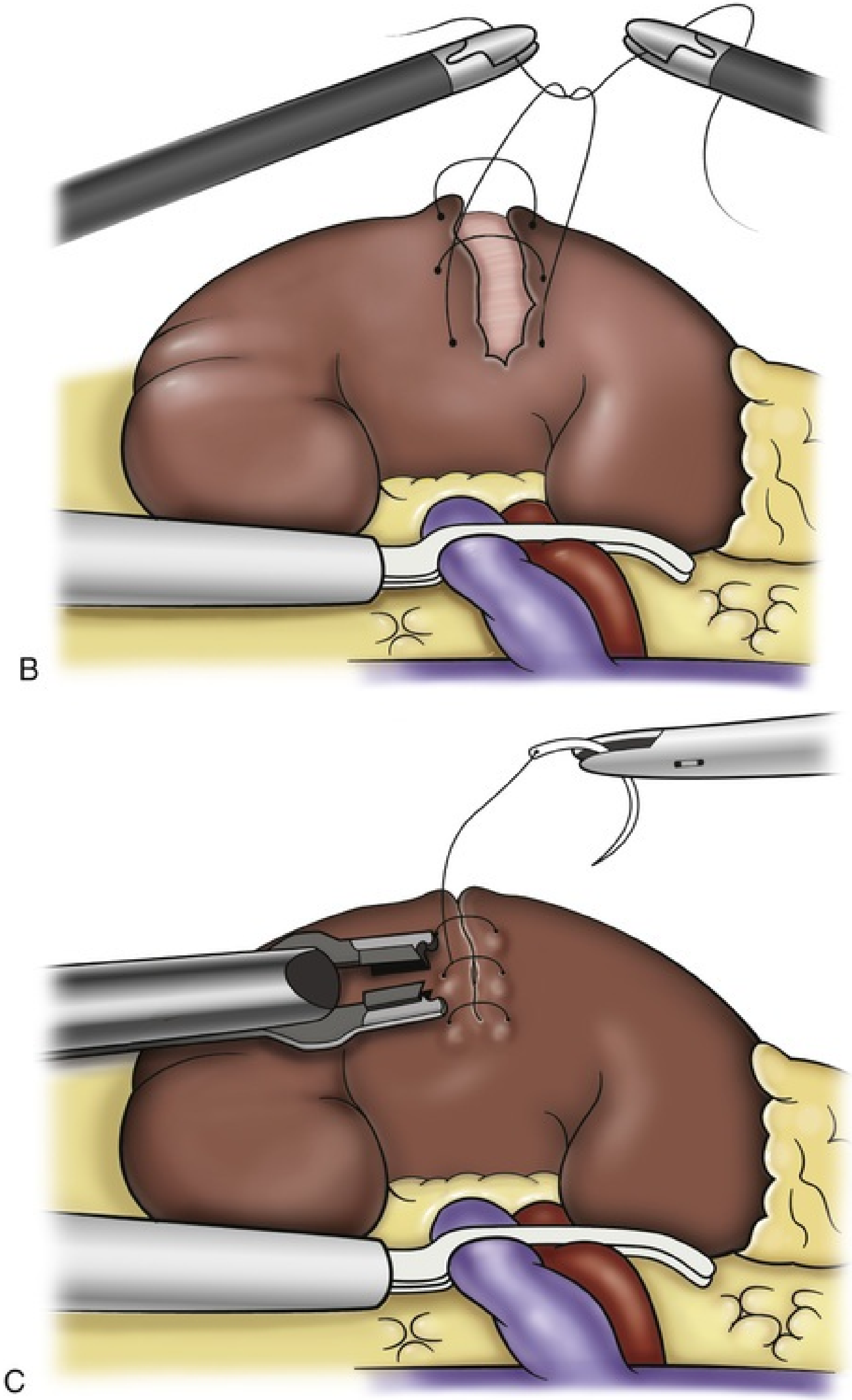

FIG. 102.39 (A) After use of the argon beam coagulator on the exposed parenchyma, interrupted absorbable sutures are placed for the renorrhaphy. The collecting system has already been repaired and the suction-irrigator provides countertraction and maintains a clear operative field. (B) The sutures may be laparoscopically tied with optional pledgets to help prevent capsular tearing during closure. (C) Alternatively, sutures with

preplaced Lapra-Ty clips (Ethicon, Cincinnati, OH) at the tail are used and secured with an additional Lapra-Ty clip after the needle is passed and tension on the closure is adjusted.

Collecting System Repair

Incision and resection of the pelvicalyceal system may be needed during an excision of tumors abutting or invading the collecting system. It is estimated that in 60% of the laparoscopic partial nephrectomies the pelvicalyceal system is violated. Risk factors for pelvicalyceal system violation include larger tumor sizes, endophytic lesions, and solid tumors (Meeks et al., 2008; Shikanov et al., 2009; Zorn et al., 2007). Suture repair of the pelvicalyceal system can be done with running 3-0 or 4-0 polyglactin (Fig. 102.40). Alternatively, the renal parenchyma and capsule can be closed over the defect without primary pelvicalyceal system repair. In either case, a drain should be placed to reduce the risk of perinephric urinoma. Several nonrandomized studies comparing suture repair of the pelvicalyceal system versus no repair showed increased in mean operative time and was ischemia time in the repair group without any differences in postoperative renal function or complication rates including urinary fistula (Desai et al., 2003; Williams et al., 2017; Zorn et al., 2007).

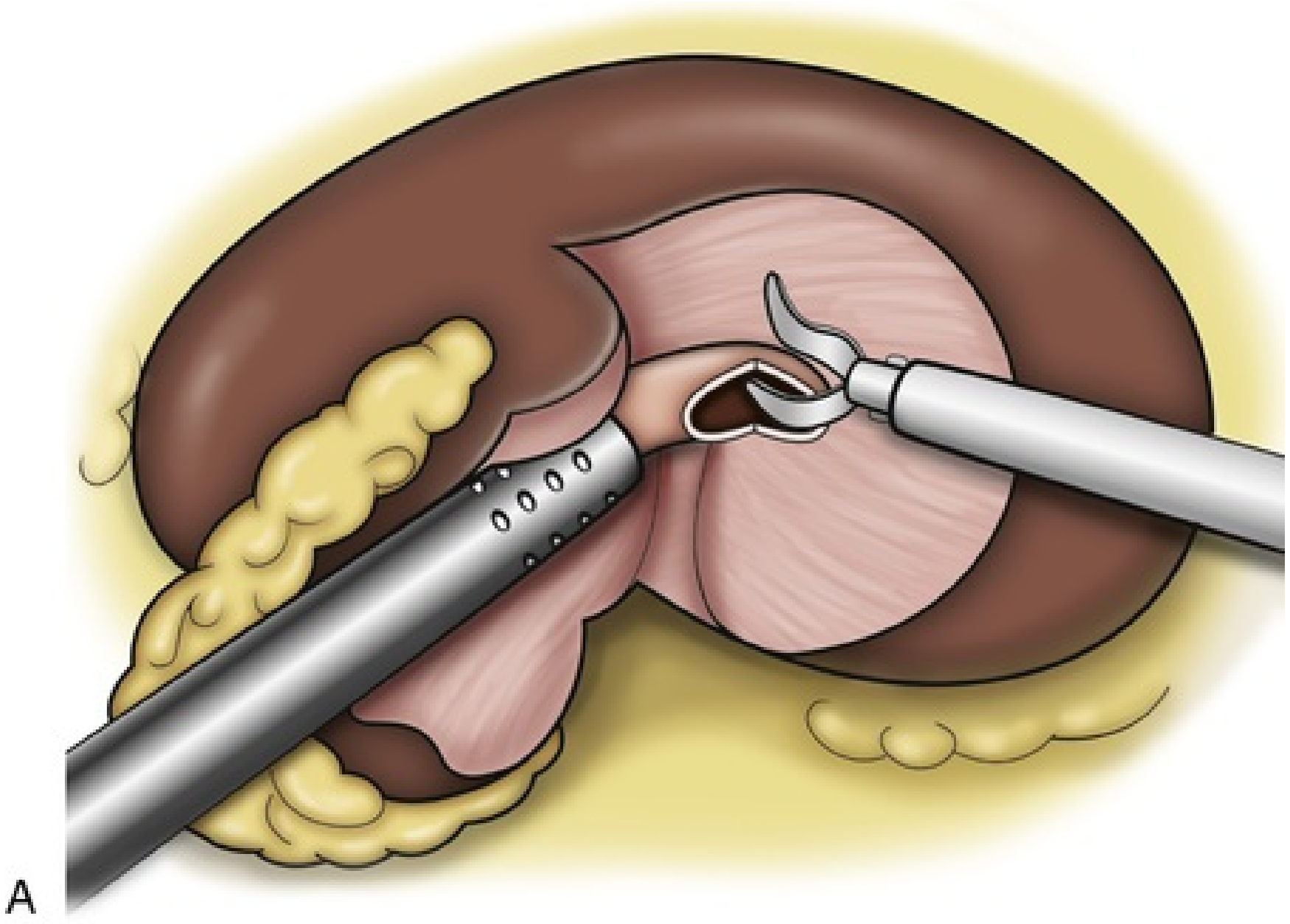

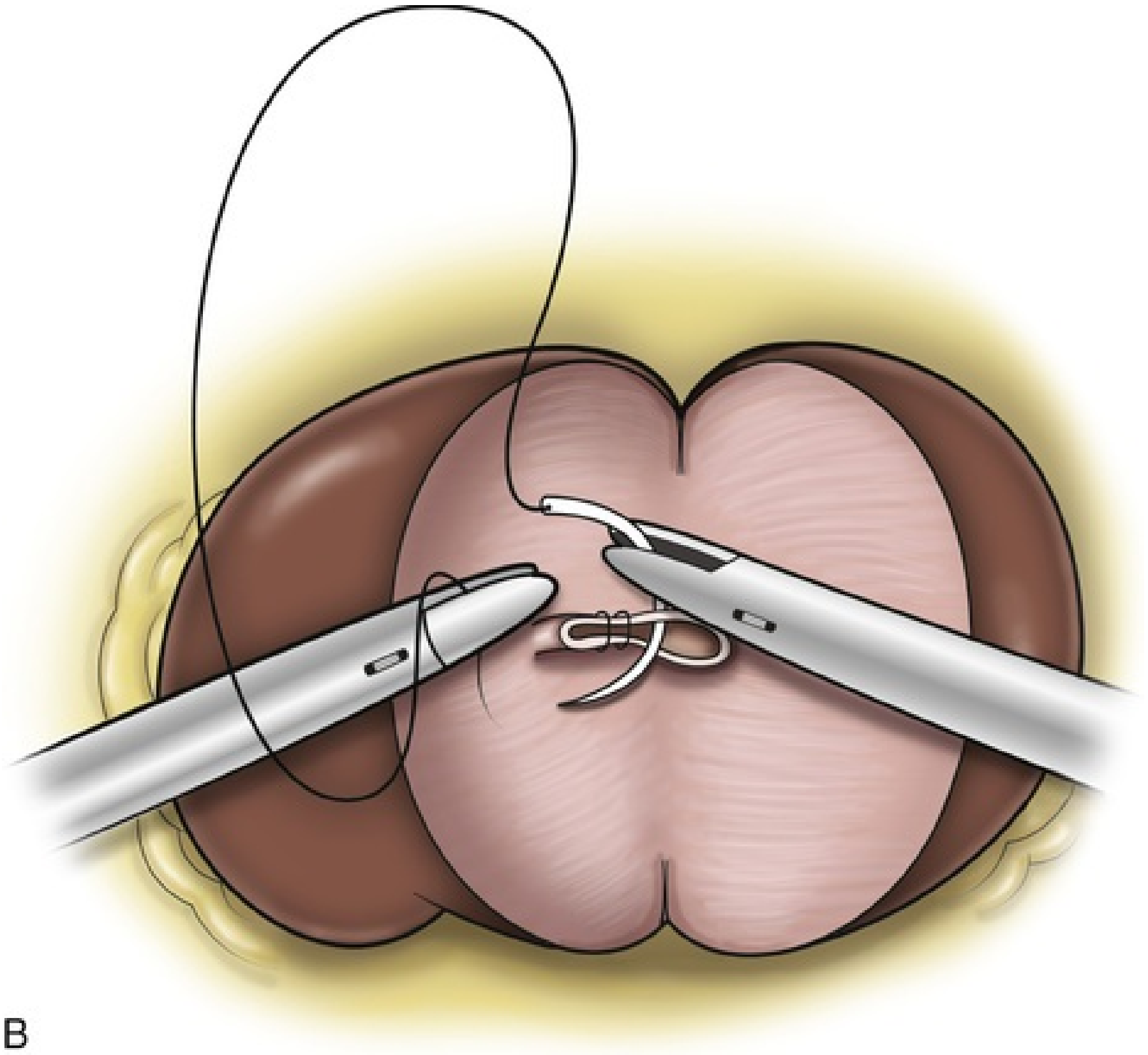

FIG. 102.40 (A) When deep resection is required, the collecting system will often be transected. With occlusion of the renal vessels, these defects can easily be identified and closed using absorbable sutures. The cut edge of the collecting system is identified with the tip of the needle and elevated. (B) An interrupted figure-of-eight suture or running suture is used to completely close the collecting system. The integrity of the repair can be determined by intravenous indigo carmine administration or retrograde instillation, if a ureteral catheter was placed at the beginning of the case. Care must be taken not to destroy the suture, if argon beam coagulation of the parenchyma surface will be performed.

Renal Hypothermia

Several minimally invasive renal hypothermia techniques that have been described in the literature include surface cooling with ice slush, instillation of cold saline via retrograde ureteral catheter, and intra-arterial cold perfusion (Gill et al., 2003; Kijvikai et al., 2010; Landman et al., 2003). Although these techniques are feasible, their effects on preserving renal function have not been established (Arai et al., 2011; Abe et al., 2012; Ramirez et al., 2016). Moreover, most tumors subjected to partial nephrectomy do not require an inordinately extended period of warm ischemia for resection and reconstruction.

Hypothermic techniques may be considered in cases of a solitary kidney or significant renal insufficiency, depending on surgeon preference, tumor complexity, and anticipated long ischemia time.

Warm Ischemia and Hilar Control

Hilar control can be accomplished by using bulldog clamps on the renal artery with or without venous clamping, or a laparoscopic Satinsky clamp for en bloc hilar clamping. In a case-control study of patients undergoing laparoscopic partial nephrectomy with artery-only clamping (N = 25) versus combined clamping of the artery and vein (N = 53), artery-only clamping was associated with lower postoperative creatine rise, whereas both techniques had comparable estimated blood loss, warm ischemia time, and complication rates (Gong et al., 2008). Traditionally, the entire tumor excision and renorrhaphy is done while the hilum is clamped. The limit of safe renal warm ischemia time has historically been 30 minutes. However, there are conflicting data suggesting that up to 90 minutes may be reasonably safe, whereas other studies suggest every minute of warm ischemia counts toward worse renal damage (Orvieto et al., 2005; Thompson et al., 2010). Modifications of the surgical technique to accomplish shorter ischemia times have been described, including early unclamping, before the completion of the renorrhaphy (Nguyen and Gill, 2008). A study of 430 laparoscopic partial nephrectomies comparing early unclamping to the conventional technique found early unclamping to be associated with shorter warm ischemia time and comparable estimated blood loss and complication rates (Peyronnet et al., 2014). A similar study with 70 patients found early hilar unclamping was associated with improved postoperative renal function (Campbell et al., 2017).

Off-Clamp Partial Nephrectomy.

Select tumors, especially small, exophytic, and noninfiltrating lesions, can be excised without hilar clamping (Novak et al., 2012). Even larger, deeper, central, or hilar tumors, which may require more substantial dissection and reconstruction, can be safely excised off-clamp with adequate experience (Kreshover et al., 2013; Simone et al., 2013). A meta-analysis of 10 studies including 728 off-clamp and 1267 on-clamp partial nephrectomies found that off-clamp surgery had a higher blood transfusion rate but lower overall postoperative complication rate, lower positive margin rate, and better preservation of renal function than the on-clamp approach (Liu et al., 2014).

Similarly, a retrospective review of 289 on-clamp and 150 off-clamp laparoscopic partial nephrectomies found the off-clamp technique to be associated with lower reduction in estimated glomerular filtration rate (GFR) immediately postoperatively and at 6 months, slightly lower complication rates, and increased estimated blood loss (George et al., 2013). Other perioperative outcomes were comparable between groups. A 5-year follow-up study of the same cohort found no differences in GFR beyond the early postoperative period (Shah et al., 2016). A similar study including only partial nephrectomy in solitary kidneys found the off-clamp technique to be associated with improved estimated GFR in the early and late postoperative periods (Wszolek et al., 2011).

Selective Arterial Clamping.

Selective arterial clamping techniques by interrupting single or multiple arterial branches supplying the area of the tumor without causing global renal ischemia have been described (Patil and Gill, 2011). The theoretic advantages of this approach include a relatively bloodless field for tumor resection, without compromising blood flow to the entire kidney. A retrospective study of 121 partial nephrectomies comparing selective arterial clamping with hilar clamping found selective clamping to be associated with improved postoperative renal function, longer operative times, higher transfusion rates, and comparable perioperative complication rates and length of hospital stay (Desai et al., 2014). The use of duplex ultrasound and near-infrared fluorescence imaging can facilitate selective arterial clamping during partial nephrectomy (Borofsky et al., 2013; Rao et al., 2013).

Parenchymal Compression.

Another alternative to hilar clamping is the compression of renal parenchyma that can be accomplished by hand compression (in hand-assisted surgery) or by using a laparoscopic clamp. Reports using these techniques have demonstrated their feasibility and safety in selected cases, especially in cases of peripherally located tumors (Simon et al., 2009; Verhoest et al., 2007).

Results

The feasibility, safety, and effectiveness of minimally invasive partial nephrectomy have been demonstrated by several authors (Gill et al., 2010; Lane and Gill, 2010; Permpongkosol et al., 2006; Saika et al., 2003). **Studies**

comparing laparoscopic and open partial nephrectomy with radical nephrectomy suggest that nephron-sparing surgery is associated with equivalent oncologic outcomes in properly selected patients and improved overall survival, likely resulting from reduced rates of renal insufficiency and cardiovascular morbidity (Huang et al., 2006; Thompson et al., 2008). However, the only randomized trial comparing open partial with open radical nephrectomy found nephron-sparing surgery was associated with slightly worse overall survival and comparable progression-free survival (Van Poppel et al., 2011). The authors acknowledge that their findings contradict those of prior retrospective studies and encourage a minimally invasive nephron-sparing approach when feasible**. A multitude of observational studies compared laparoscopic with open partial nephrectomy showing consistent results, including shorter operative time, lower estimated blood loss, and shorter hospital stay in patients treated with laparoscopy** (Abdelhafez et al., 2017; Gill et al., 2007; Gong et al., 2008; Marszalek et al., 2009). In a study including 771 laparoscopic and 1028 open partial nephrectomies for clinical T1 renal masses, the laparoscopic approach was associated with lower shorter operative time, decreased estimated blood loss, shorter hospital stay and comparable intraoperative complications (1.8% vs. 1%), positive surgical margins (1.6% vs. 1%), and 3-year oncologic and functional outcomes (Gill et al., 2007). Laparoscopy was also associated with slightly higher overall postoperative complications (25% vs. 19%) and longer warm ischemia time (30 vs. 20 minutes).

Comparative series of laparoscopic and open partial nephrectomy have shown the two approaches have similar long-term oncologic outcomes (Springer et al., 2013). A study of 200 laparoscopic and 200 open partial nephrectomies for clinical T1 renal masses matched for age, sex, and tumor size found comparable 5-year local recurrence-free survival (laparoscopic: 97% vs. open 98%), metastasis-free survival (laparoscopic: 99% vs open: 96%), and overall survival (laparoscopic: 96% vs. open: 85%) (Marszalek et al., 2009). The 10-year oncologic outcomes were evaluated in a larger study including 625 laparoscopic and 916 open partial nephrectomies for clinical stage T1 renal tumors (Lane et al., 2013). Subjects in the open nephrectomy groups had significantly larger tumors, more malignant tumors, and worse baseline renal function. At 5 years, both surgical approaches had comparable recurrence-free survival in the pT1a (laparoscopic: 98% vs. open: 97%) and pT1b (laparoscopic: 93% vs. open: 93%) subgroups. At 10 years, the overall survival for laparoscopic and open approaches were 78% and 72%, respectively. The recurrence rate in the open partial nephrectomy cohort was higher likely because of inherent differences between the cohorts. On multivariable analysis, predictors of metastasis included larger tumor size, absolute indication, and comorbidity but not surgical approach. **The authors concluded that laparoscopic and open partial nephrectomy provide equivalent long-term overall and recurrence-free survival for pT1 tumors.**

Multiple authors compared robot-assisted partial nephrectomy with open nephrectomy showing similar benefits of the robot-assisted approach, including less estimated blood loss, shorter hospital stay, and lower complications rates with comparable warm ischemia times and positive margin rates (Ficarra et al., 2014; Kara et al., 2016; Oh et al., 2016; Wang et al., 2017). Two meta-analyses, one including 8 retrospective studies and 3418 surgeries and another including 16 studies and 3024 surgeries, comparing robot-assisted to open partial nephrectomy demonstrated that the robot-assisted approach was associated with a lower rate of perioperative complications, less estimated blood loss, and shorter length of hospital stay with comparable conversion to radical nephrectomy, warm ischemia time, estimated GFR changes, margin status, and overall cost (Shen et al., 2016; Wu et al., 2014).

Positive Surgical Margins

Complete tumor excision with negative surgical margins should always be the goal in any oncologic procedure. Unfortunately, positive margins are observed in 0 to 7% of the minimally invasive partial nephrectomy series (Borghesi et al., 2013; Shah et al., 2016; Tabayoyong et al., 2015). Several studies failed to demonstrate worse oncologic outcomes among patients with positive surgical margins (Kang et al., 2016; Permpongkosol et al., 2006; Sutherland et al., 2002). Indeed, a study of 1390 partial nephrectomies with a positive margin rate of 5.5% showed 93% disease-free survival at 10 years regardless of margins status (Yossepowitch et al., 2008). More recently, a multi-institutional review of 1240 partial nephrectomies with a positive margins rate of 7.8% showed a twofold increase in the risk of recurrence among all patients and a 7.5-fold increase among high-risk tumors (pT2-3 or nuclear grade 3–4) (Shah et al., 2016). The increased risk of recurrence was not observed among low-risk tumors.

Laparoscopic Ablative Techniques

Renal ablative treatments use extremes of temperature to cause apoptosis in cancer cells. **Their primary goals are complete tumor destruction with minimal or no morbidity. Compared with partial nephrectomy, the potential advantages of thermal ablation include less blood loss, short operative time, decreased need for dissection, and fewer complications** (Long et al., 2017). Thermal ablation can be administered percutaneously or laparoscopically. The percutaneous approach is preferred for treatment of small renal masses because of its lower morbidity. **However, the laparoscopic approach offers certain advantages such as direct tumor visualization, mobilization of the kidney, and dissection and retraction of surrounding structures** (Zargar et al., 2015). Although thermal ablation can be used to treat most small renal masses, most common indications include lesions in patients with significant comorbidities, solitary kidney, and hereditary renal cell carcinoma. Multiple energy-delivery systems have been described including cryoablation, radiofrequency ablation (RFA), and microwave therapy. Cryoablation and RFA are the most widely used and studied thermal ablation techniques and are discussed in the next sections.

Cryoablation

Transperitoneal or retroperitoneal approaches can be used for laparoscopic cryoablation, depending on tumor location. The kidney is dissected as previously described, Gerota fascia is incised, and the tumor is exposed. The fat overlying the tumor may be excised. Biopsy samples of the tumor may also be taken with a 14- or 18-gauge biopsy needle for histopathologic diagnosis. Cryoprobes may be placed percutaneously and maneuvered into the tumor using direct visualization and laparoscopic ultrasonography guidance. The number of and spacing between probes are dictated by probe-specific ablative shape and diameter and tumor size. Probes are typically arranged parallel to each another in a triangular or quadrangular configuration ensuring cryolesion overlap. The tip of the probes should be advanced just beyond the deepest margin of the tumor. The progress of the iceball formation may be monitored in real time using intraoperative ultrasonography, and the iceball should extend approximately 0.5 to 1 cm beyond the edge of the tumor. Because the progress of the iceball cannot be abruptly stopped, caution should be exercised to avoid contact of the iceball with the renal collecting system, ureter, renal vasculature, or adjacent organs. After two consecutive freeze-thaw cycles are completed, the probes are removed with a gentle twisting motion. If any bleeding occurs, it can usually be controlled by applying pressure or, if necessary, hemostatic agents such as fibrin glue or Floseal (Schiffman et al., 2014).

Radiofrequency Ablation

RFA can also be delivered laparoscopically via the transperitoneal or retroperitoneal approaches. After the kidney is dissected, Gerota fascia is open and the tumor exposed, the RFA probe is introduced into the tumor, and the tines are deployed to a diameter that ensures ablation of the tumor and a 1-cm margin of normal renal tissue. The diameter of the ablation zone varies according to the length, diameter, surface area, and temperature of the electrode. Thermal damage occurs through frictional heating resulting from ionic oscillation by a monopolar or bipolar high-frequency alternating current, which can induce temperatures between 60° and 100°C throughout the tumor (Gervais et al., 2005; Goldberg et al., 2000). Temperatures above 105°C should be avoided to prevent tissue vaporization. Unfortunately, there is no current imaging technique that effectively monitors the progress of RFA lesions intraoperatively, and most of the treatment is based on direct temperature measurement or measurement of electrical impedance.

Results

Laparoscopic thermal ablation is an effective treatment for small renal masses. A retrospective review of 167 tumors treated with laparoscopic cryoablation, with a medium tumor size of 2.4 cm, showed a recurrence-free and overall survival of 79% and 86% at 5 years (Kim et al., 2014). Similarly, a study of 79 patients with 111 small renal masses undergoing laparoscopic RFA, with median tumor size of 2.2 cm and mean follow-up of 59 months, demonstrated a recurrence-free survival of 93.3% (Ramirez et al., 2014). Larger tumor size, endophytic lesions, and hilar location are associated with higher treatment failure rates (Tsivian et al., 2010). Indeed, a study of 31 patients with renal masses from 4 to 7 cm in diameter treated with percutaneous and laparoscopic cryoablation showed a recurrence-free survival of nearly 70% at 2 years compared with 100% among those treated with partial nephrectomy (Caputo et al., 2017). In a meta-analysis of 788 patients treated with laparoscopic and 687 with percutaneous cryoablation, laparoscopic cryoablation had less incomplete ablation and higher cancer-specific survival, whereas the percutaneous group had shorter hospital stays and lower costs (Aboumarzouk et al., 2018). There are no direct comparisons between laparoscopic cryoablation and RFA. A meta-analysis comparing percutaneous and laparoscopic cryoablation with RFA showed similar efficacy and complication rates (El Dib et al., 2012). However, a review of 47 studies including predominantly laparoscopic cryoablation and percutaneous RFA demonstrated fewer retreatments (8.5% vs. 1.3%), improved local tumor control, and lower risk of metastatic progression in the cryoablation group (Kunkle and Uzzo, 2008). There are no randomized trials comparing thermal ablation with other treatment modalities, including partial nephrectomy. A meta-analysis of 13 observational studies comparing laparoscopic cryoablation with laparoscopic partial nephrectomy for the treatment of small renal tumors showed laparoscopic cryoablation had better perioperative outcomes (operative times, estimated blood loss, length of stay, and complication rates) but higher local and metastatic tumor progression (Klatte et al., 2014). Another meta-analysis including 99 studies and 6471 tumors demonstrated increased local progression rates in the cryoablation and RFA groups compared with partial nephrectomy, with similar metastatic progression rates (Kunkle et al., 2008). Conversely, a study of 1424 small renal masses showed comparable recurrence-free survival between laparoscopic partial nephrectomy and percutaneous ablation. Metastases-free survival was superior for partial nephrectomy and percutaneous cryoablation compared with RFA (Thompson et al., 2015).

Complications

Laparoscopic renal ablation is generally well tolerated. A review of 148 laparoscopic cryoablations showed an overall complication rate of 15.5%, with 3.1% considered major complications. The risk factors for complications included larger tumor size, preexisting heart disease, and female gender (Laguna et al., 2009). Similarly, a series of 139 laparoscopic cryoablations and 133 RFAs showed an overall complication rate of 11%, with 1.8% classified as major and 9.2% as minor. Major complications included significant hemorrhage, ileus, ureteropelvic junction obstruction requiring nephrectomy, urinoma, conversion to open surgery, and death. The most common complication was pain or paresthesia at the ablation probe insertion site (Johnson et al., 2004). A meta-analysis including 457 laparoscopic ablations did not find any significant difference in complication rates between cryoablation and RFA (El Dib et al., 2012). Likewise, an analysis of 118 patients undergoing laparoscopic cryoablation or laparoscopic partial nephrectomy for tumor in a solitary kidney revealed comparable complication rates (Bhindi et al., 2018).

Laparoendoscopic Single-Site Surgery of the Kidney

LESS approaches have been successfully used in a wide range of renal procedures, including pyeloplasty, simple nephrectomy, donor nephrectomy, radical nephrectomy, nephroureterectomy, partial nephrectomy, renal cyst decortication, and renal cryoablation.

Renal Laparoendoscopic Single-Site Surgery

The surgical techniques used in LESS are similar to the ones of the conventional laparoscopy, usually following the same steps described previously for conventional laparoscopy. However, adaptations of the surgical equipment and techniques to overcome the limited triangulation and the clustering of instruments is frequently needed. For example, the use of flexible scopes and articulating instruments may facilitate the dissection (Fig. 102.41). **In addition, the use of offset optics, custom hand piece, and instruments and scopes of variable length may help prevent instrument collision.** In a multi-institutional review of 1076 urologic LESS procedures, an additional port was used in 23% (Kaouk et al., 2011). The overall conversion rate was 21%, with 20% of the cases converted to conventional laparoscopy and 1% to open surgery. Peri- and intraoperative complication rates were 9.5% and 3%, respectively. In a randomized trial comparing upper urinary tract LESS with laparoscopy including 60 patients found similar operative time, estimated blood loss, complication rate, and hospital stay between the two approaches (Abdel-Karim et al., 2017). However, LESS was associated with fewer analgesic requirements. A meta-analysis of 3 randomized clinical trials including 179 patients comparing LESS donor nephrectomy with conventional laparoscopic nephrectomy found no difference in hospital stay, time to return to normal activities, blood transfusions, conversion rates, or total analgesic requirement (Gupta et al., 2016). LESS was associated with lower postoperative pain scores. A retrospective study of 141 patients comparing LESS with conventional laparoscopic nephrectomy for renal mass found comparable perioperative outcomes and disease-free and overall survivals (Antonelli et al., 2013). **Thus the main advantages of LESS over conventional laparoscopy include**

improved pain and cosmesis without compromising perioperative or long-term outcomes.

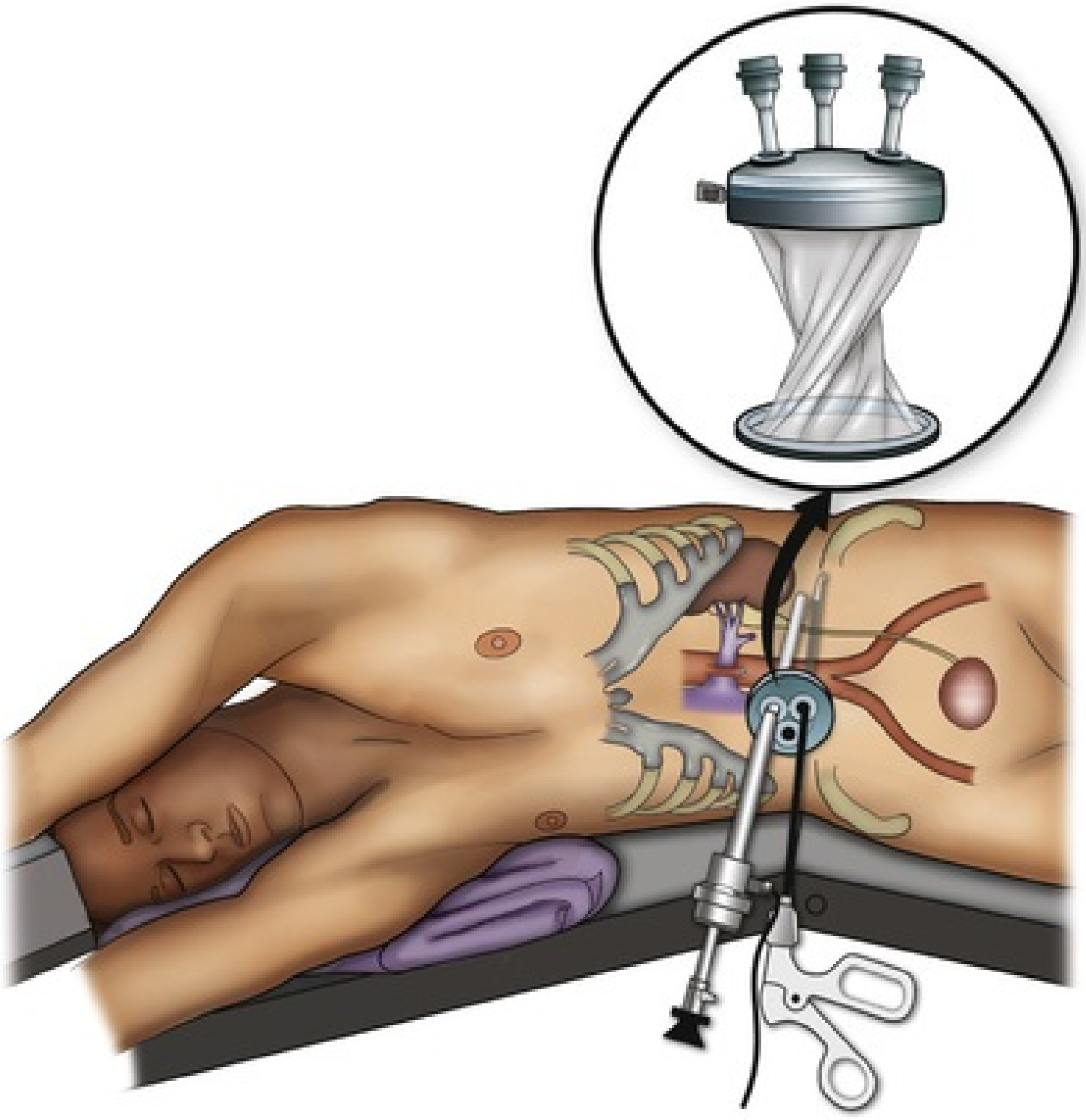

FIG. 102.41 Laparoendoscopic single-site surgery donor nephrectomy using a purpose-specific device with multichannel instrument access. A 2-mm instrument is also used to aid in retraction, hilar dissection, and extraction.

Robotic Laparoendoscopic Single-Site Surgery

Robotic laparoendoscopic single-site (R-LESS) surgery has the potential to minimize the morbidity of multiport approaches while overcoming some of the technical challenges of LESS. In a retrospective study of 89 conventional robotic partial nephrectomy and 78 R-LESS partial nephrectomies, R-LESS was associated with longer operative time, longer warm ischemia time, and greater decline in estimated GFR (Komninos et al., 2014). Hospital stay, estimated blood loss, surgical margins, and perioperative complication rates were comparable between the two approaches. In another study of 80 conventional robotic partial nephrectomies and 79 R-LESS partial nephrectomies, R-LESS was associated with longer operative time and warm ischemia, lower postoperative pain scores, similar surgical margins, postoperative renal function, and perioperative complication rates (Shin et al., 2014). **Thus, similar to LESS, the main advantages of R-LESS are reduced pain and improved cosmesis. However, increased technical challenges result in longer operative times.** New robotic platforms to overcome these technical challenges are being assessed.

Complications ff Laparoscopic Renal Surgery

Complications are deviations from the normal postoperative course. Knowledge of each procedure and its potential pitfalls is key for preventing adverse events. Patient education about the potential risks of surgery is also essential. A study of 16,869 laparoscopic renal surgeries revealed an overall complication rate of 14.7% with 3.5% intraoperative and 12.1% postoperative complications. Most commonly reported intraoperative complications were bleeding (1.7%); bowel (0.3%), spleen (0.3%), and liver (0.1%) injuries; and pneumothorax (0.3%). Postoperative complications included bleeding (1.6%), wound infection (1.4%), pneumonia (1.2%), and prolonged ileus (1.1%). Reported complication rates were higher after partial nephrectomy (18.6%) compared with radical nephrectomy (15.4%) and simple nephrectomy (11.0%) (Henderson et al., 2016). Surgical approach may also correlate with complications. In a meta-analysis including 2240 partial nephrectomies, although the risk of complications was similar between robotic and laparoscopic approaches, robotic partial nephrectomy was associated with a nearly 50% lower risk of conversion to open surgery (Choi et al., 2015). Several patient-level factors including obesity and other comorbidities and prior abdominal surgery are associated with a higher complication risk (Zaid et al., 2017). Advanced age does not seem to be a major risk factor for complications. Several studies showed comparable morbidity of laparoscopic renal surgery in young and elderly patients (Thomas et al., 2009; Varkarakis et al., 2004). Although previous surgery is not a contraindication to laparoscopic renal surgery, it requires special consideration given the resulting intra-abdominal adhesions and increased possibility of bowel injury during insufflation, trocar placement, or dissection. Placement of the Veress needle and initial trocar away from previous scars and surgical fields, open trocar placement, or retroperitoneal approach may be needed to minimize access injuries and avoid adhesions (Hasson, 1971). Disease-related factors such as large tumors, and centrally located renal lesions also correlate with a higher complication rate (Simhan et al., 2011). Indeed, in a retrospective review of 482 laparoscopic nephrectomies most of the conversions to open surgery occurred in cases of infectious cause such as chronic pyelonephritis (Rassweiler et al., 1998). Finally, surgeon-related factors such as surgical experience also play a role. A multi-institutional study of 185 laparoscopic nephrectomies showed that 70% of the complications occurred during the first 20 cases at each institution. A learning curve of approximately 20 laparoscopic nephrectomy cases is also supported by other reports (Fahlenkamp et al., 1999; Keeley and Tolley, 1998; Rassweiler et al., 1998). In a series of laparoscopic partial nephrectomies, the complication rate continued to decrease even after 750 cases, implying a longer learning curve for more complex procedures (Gill et al., 2010). **When complications occur, early recognition and appropriate intervention can often minimize their morbid consequences.** Laparoscopic renal surgeries share several potential risks with traditional open approaches. However, there are differences in the type and presentation of these complications. All situations are individual, and unique problems may arise and require innovative actions.

Vascular Complications

Vascular injuries are the most common complication of urologic laparoscopic surgery (Fahlenkamp et al., 1999; Permpongkosol et al., 2007). **Major vascular injuries during laparoscopic surgery are rare, with an incidence of less than 1 in 1000** (Simforoosh et al., 2014). Although intraoperative vascular injuries can occur at any step of the procedure, most of the life-threatening vascular complications occur during the access phase of laparoscopy, including insertion of a Veress needle or the first trocar, or during the dissection of the renal hilum. Direct injury to the aorta, IVC, renal artery, or vein as well as their branches can result in significant bleeding, quickly leading to hemodynamic instability. Injuries to the renal hilum usually occur when structures are not fully identified before transection, during hilar dissection with a sharp instrument, or when the stapler does not completely cover the vessel or misfires (Meraney et al., 2002). If an arterial injury is identified, adequate hemostasis can be achieved with the use of clips, sutures, cautery, or vascular stapler depending on the location, size, and nature of the injury as well as surrounding structures. A hand may be placed in a lower abdominal midline incision to hold pressure if bleeding is brisk. In this manner, laparoscopic suturing or conversion to open surgery can be done in a controlled manner. Mild to moderate venous bleeding can frequently be controlled by applying direct pressure with a gauze for several minutes. Dissection may continue with the gauze in place. If a hole is visible, placement of a clip or suture may be attempted once a grasper has controlled the bleeding. Blind clip placement or suturing can lead to a worsening of the situation and additional complications.

Cases of inadvertent ligation of important vascular structures have been reported, including IVC, aorta, contralateral renal vessels, and inferior mesenteric vessels. Most of these injuries occurred during retroperitoneal procedures and unfortunately most were only diagnosed postoperatively (McAllister et al. 2004; Simforoosh et al., 2014). Equipment malfunction can also result in bleeding. Most reported cases of hemostatic device failure in laparoscopic renal surgery are related to vascular staplers (63%), nonlocking titanium clips (33%), and locking clips (4%) (Hsi et al., 2007). Most stapler failures are missing or malformed staple line, stapler locking up, or partial or no cutting. Clip failures include jamming or difficulty feeding clips, inability to close clips, and clip dislodgement, especially with locking clips (Hsi et al., 2009). A review of vascular stapler malfunction showed blood loss from 200 to 1200 mL and 20% conversion to open surgery (Chan et al., 2000). A 2% mortality rate was associated with hemostatic device failure (Hsi et al., 2007). Preventable causes of stapler malfunction include stapling over clips or incomplete transection resulting from incorrect placement. **Proper anatomic orientation, identification of vascular structures, and meticulous surgical dissection are important to prevent vascular complications.** At the end of surgery, the abdominal cavity should be inspected for bleeding. Reducing the intraperitoneal insufflation pressures may unmask occult venous bleeding. **Common areas of postoperative bleeding include the bed of the dissection, adrenal gland, mesentery, gonadal vessels, and ureteral stump.** Postoperative hemorrhage can occur after laparoscopic renal surgery. Hypotension associated with tachycardia and decreasing hematocrit suggest postoperative bleeding. CT scanning may be appropriate in identifying the site of bleeding. Only a small fraction require surgical intervention because most cases respond to conservative measures. For hemorrhage originating from the renal artery, most cases can be successfully managed with angiography and embolization (Jeon et al., 2016). Gross hematuria after partial nephrectomy may indicate the renal artery pseudoaneurysm. Pseudoaneurysm occurs in 2% after partial nephrectomy. Most patients present within 30 days after surgery with gross hematuria. Almost all patients with renal artery pseudoaneurysm can be successfully treated with angiography and embolization (Jain et al., 2013).

Although the risk of deep vein thrombosis (DVT) after laparoscopic renal surgery is low (Montgomery and Wolf, 2005), the decision on when and how to use prophylaxis for DVT must be based on the patient's stratification risks. Several prophylactic methods have been proposed, including unfractioned heparin, fractioned heparin, low-molecular-weight heparin, sequential compressive stocking devices (SCDs), and combination therapy, but the optimal prophylaxis is still controversial. For low-risk patients, SCDs are usually the recommended option, whereas high-risk individuals may require pharmacologic prophylaxis (Forrest et al., 2009).

Urinary Complications

Persistent urine leakage is a potential complication of any renal surgery in which the pelvicalyceal system is violated. The reported incidence of urinary leak after partial nephrectomy varies from 0.8% to 10% after laparoscopic and robotic partial nephrectomy, but it is occasionally seen after cyst or tumor ablation (Meeks et al., 2008; Potretzke et al., 2016). Factors associated with urinary leak include large tumor size, hilar location, pelvicalyceal repair, prolonged operative, and warm ischemia time. Most cases of urinary leak require no intervention other than percutaneous drainage. When conservative management fails or there is evidence of distal obstruction, additional intervention may be required, such as ureteral stenting and bladder decompression (Kundu et al., 2010).

Visceral and Bowel Complications

One of the most significant complications of laparoscopic surgery is unrecognized bowel injury (Fig. 102.42), **which has a mortality rate of about 3%. The incidence of bowel injury in the urologic literature varies from 0.1% to 0.8%** (Bishoff et al., 1999; Schwartz et al., 2010). Bowel injuries can occur at any point during the procedure, including access in 32% of the cases. The most common cause of unrecognized injury is the use of thermal energy adjacent to the bowel, responsible for nearly 50% of the cases. When recognized intraoperatively, superficial thermal injuries may be oversewn with 3-0 silk suture to imbricate the affected area. In addition, given only a small portion of the laparoscopic instrument is in the visual field, injuries can occur out of the surgeon's view during introduction or retraction of instruments. The presentation of unrecognized bowel injury after laparoscopic surgery is variable but typically includes persistent and increased trocar site pain at the site closest to the bowel injury without significant erythema or purulent drainage. Thermal injuries usually present later than nonthermal bowel injuries. Patients may develop abdominal distention, nausea, diarrhea, anorexia, low-grade fever, persistent bowel sounds, and low or normal white blood cell count. The patient's condition can rapidly deteriorate to hemodynamic instability and death if the injury is not recognized and appropriately treated (Bishoff et al., 1999).

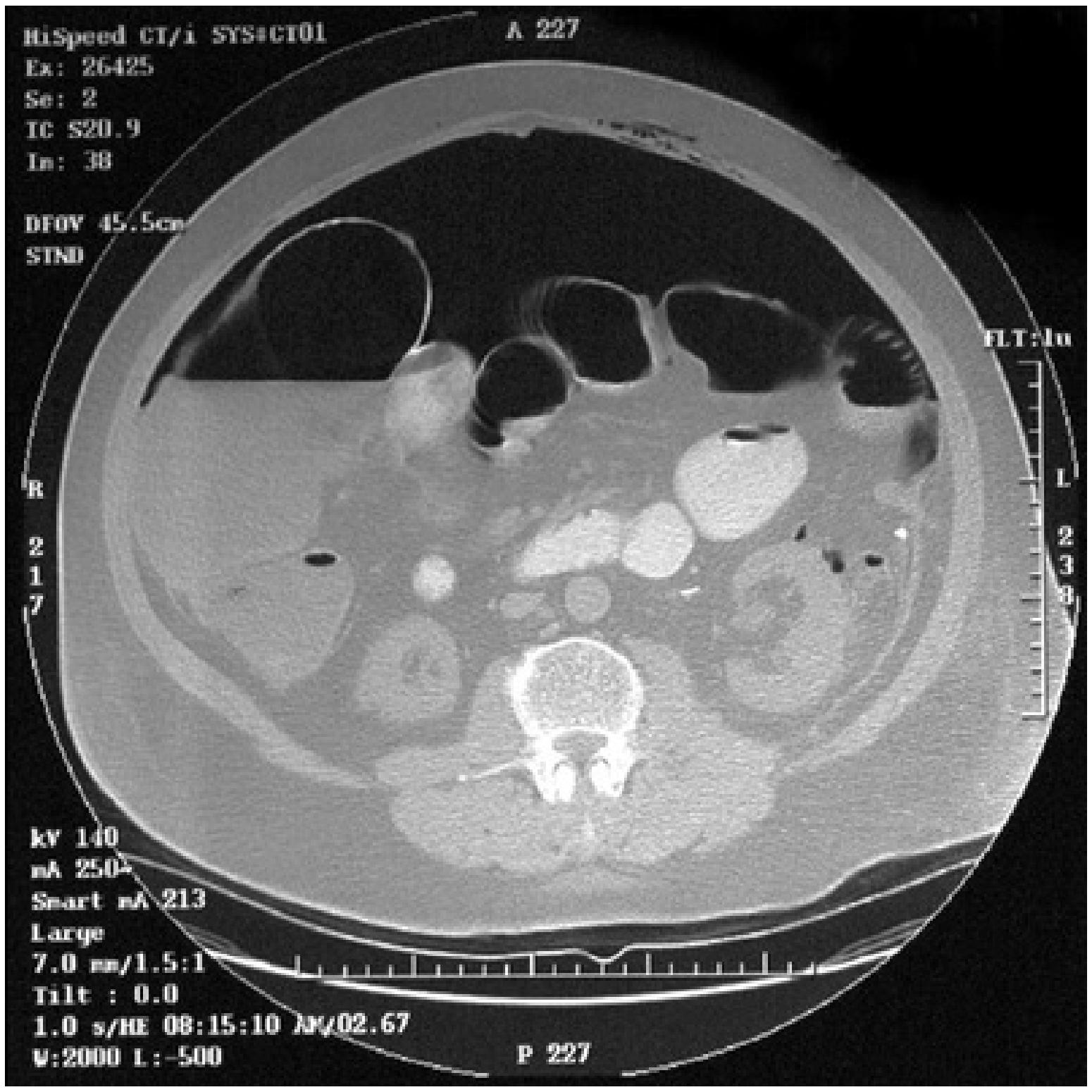
HiSpeed CT/i SYS#CT01
Ex: 26425
Se: 2
IC S20.9
Im: 38
DFOV 45.5cm
STND
A 227
FLT:1u
R
217
L
238
kV 140
mA 250
Smart mA 213
Large
7.0 mm/1.5:1
Tilt : 0.0
1.0 s/HE 08:15:10 AM/02.67
W:2000 L:-500
P 227

FIG. 102.42 Computed tomography (CT) scan taken 9 days after partial nephrectomy when the patient visited the clinic for routine follow-up complaining of distention and worsening abdominal pain for the previous 3 days, low-grade fever, leukopenia, and pain out of proportion at a single trocar site. CT shows dilated loops of large bowel and significant amounts of free air. Exploration revealed a small perforation in the cecum.

CT with oral contrast is the initial diagnostic modality of choice (Cadeddu et al., 1997), and open exploration is usually required to evacuate bowel spillage and perform the necessary repair. In rare cases, when a controlled fistula develops, conservative management with bowel rest and parenteral nutrition may be used, but this may take several months to resolve. When reflecting the colon, the surgeon must take care to avoid making a hole in the mesentery, especially on the left side. Any mesenteric defects should be closed because of the possibility of bowel herniation (Regan et al., 2003). During closure of the mesentery, care should be taken to avoid compromising the vascular supply to the colon. The incidence of splenic and pancreatic injury during laparoscopic left renal surgery varies from 0 to 0.5% (Canby-Hagino et al., 2000; Varkarakis et al., 2004). Splenic injuries are most commonly caused by vigorous traction on splenic ligaments. Most cases of splenic bleeding can be controlled with argon beam coagulation and topical hemostatic agents; however, some cases require splenectomy (Biggs et al., 2005; Canby-Hagino et al., 2000). Injuries to the pancreas may be insidious, and careful inspection at the end of surgery is advisable. Capsular pancreatic injuries can be managed by closing the defect with nonabsorbable suture and/or drain placement. Deeper injuries can cause pancreatic leak and usually require formal repair or isolation of the segment with a stapler (Varkarakis et al., 2004). Intraoperative general surgery consultation is advisable. Injury to the liver or gallbladder can occur during right renal surgery. Most liver injuries can be managed with topical hemostatic therapy and argon beam coagulation. Gallbladder injuries are best managed by cholecystectomy.

Other Complications

Diaphragmatic injuries can occur during the upper pole renal dissection on either side. Most significant diaphragmatic injuries with resulting pneumothorax are immediately recognized because of a sudden increase in peak airway pressures, and the patient becomes difficult to ventilate. Immediate treatment is needed to prevent tension pneumothorax. These injuries can be repaired by suturing the hole in the diaphragm while a central line catheter is placed into the ipsilateral anterior second intercostal space and placed to a water seal. A chest radiograph should be obtained at the end of the procedure to ensure the pneumothorax is resolved and the catheter can be safely removed. When significant pneumothorax persists, a chest tube insertion is advisable (Aron et al., 2007; Del Pizzo et al., 2003). The incidence of unrecognized pneumothorax after laparoscopic nephrectomy is approximately 0.3%, and routine postoperative chest radiograph for asymptomatic patients with low suspicion for diaphragmatic injury is not recommended (Simon et al., 2005). Neuromuscular injuries occur in 2.7% of laparoscopic urologic surgeries and include abdominal wall neuralgia, motor and sensory deficit, rhabdomyolysis, orchialgia, and others. Most of these are caused by direct surgical trauma or the anatomic stress of positioning. Although most of these complications occur with similar frequency compared with open surgery, the risk of rhabdomyolysis may be increased with the laparoscopic approach. Shorter operative times and positioning patients in a partial rather than full flank position may reduce the incidence of rhabdomyolysis (Wolf et al., 2000). Thigh paresthesias may be avoided by preserving the psoas fascia during posterior renal dissection. Additional reported complications associated with minimally invasive renal surgery include incisional hernia, prolonged ileus, pulmonary embolus, and pneumonia.

Minimally Invasive Renal Surgery in Urologic Practice

Since its inception, the adoption of minimally invasive renal surgery has progressively increased. Data from Surveillance, Epidemiology and End Results-Medicare indicate laparoscopic nephrectomy use increased from 1.5% in 1995 to 45% in 2005 (Filson et al., 2011). Similarly, the use of laparoscopic partial nephrectomy for small renal masses increased from 15% in 2004 to 22% in 2009 (Banegas et al., 2016). More recently with the introduction of robotic technology, the use of robotic radical nephrectomy has increased from 1.5% to 27% from 2003 to 2015 (Jeong et al., 2017). This was accompanied by a decrease in laparoscopic radical nephrectomies, which raised some concerns regarding cost effectiveness because robot radical nephrectomy was associated with higher costs but similar outcomes compared with laparoscopic surgery (Yang et al. 2014). Data from the National Cancer Database indicate an increase in the use of robotic partial nephrectomy from 41% in 2010 to 63% in 2013 (Alameddine et al., 2018). Although the adoption of minimally invasive techniques in renal surgery is increasing, this has been occurring at slow pace. A complex array of reasons may account for this observation, including the differential incidence of kidney and prostate cancer, marketing of robotics, referral patterns, and consumer demand (Richstone and Kavoussi, 2008).

Summary

Minimally invasive surgery is the preferred treatment approach for many renal diseases. **Patients have undoubtedly gained from the benefits of minimally invasive surgery: less perioperative morbidity without sacrificing therapeutic outcomes.** As surgical tools continue to evolve, even more minimally invasive options may become more pervasive and potentially offer additional benefits to patients.

Key Points: Laparoscopic and Robotic Surgery of the Kidney

- Minimally invasive renal surgery provides less incisional pain, shorter convalescence, and better cosmesis compared with open surgery with comparable efficacy and long-term outcomes.
- The indications for minimally invasive renal surgery are generally similar to those for open renal surgery.
- The basic principles of oncologic surgery including complete tumor excision with negative margins associated with maximization of renal parenchyma preservation when feasible should be followed when using minimally invasive approaches to treat renal tumors.
- Familiarity with the anatomic landmarks, surgical techniques, instrumentation, and knowledge of each procedure and its potential pitfalls are key for successful minimally invasive surgery.

Suggested Readings

AUA guidelines on Renal Mass and Localized Renal Cancer. Available from: http://www.auanet.org/guidelines/renal-mass-and-localized-renal-cancer-new-(2017).

Berger A, Brandina R, Atalla MA, et al. Laparoscopic radical nephrectomy for renal cell carcinoma: oncological outcomes at 10 years or more. *J Urol*. 2009;182(5):2172–2176.

Blom JH, van Poppel H, Marechal JM, et al. Radical nephrectomy with and without lymph-node dissection: final results of European Organization for Research and Treatment of Cancer (EORTC) randomized phase 3 trial 30881. *Eur Urol*. 2009;55(1):28–34.

Choi JE, You JH, Kim DK, et al. Comparison of perioperative outcomes between robotic and laparoscopic partial nephrectomy: a systematic review and meta-analysis. *Eur Urol*. 2015;67(5):891–901.

EAU guidelines on Renal Cell Carcinoma. Available from: http://uroweb.org/guideline/renal-cell-carcinoma/.

Fahlenkamp D, Rassweiler J, Fornara P, et al. Complications of laparoscopic procedures in urology: experience with 2,407 procedures at 4 German centers. *J Urol*. 1999;162(3 Pt 1):765–770 [discussion 770–761].

Gill IS, Kavoussi LR, Lane BR, et al. Comparison of 1,800 laparoscopic and open partial nephrectomies for single renal tumors. *J Urol*. 2007;178(1):41–46.

Kaouk JH, Autorino R, Kim FJ, et al. Laparoendoscopic single-site surgery in urology: worldwide multi-institutional analysis of 1076 cases. *Eur Urol*. 2011;60(5):998–1005.

Permpongkosol S, Link RE, Su LM, et al. Complications of 2,775 urological laparoscopic procedures: 1993 to 2005. *J Urol*. 2007;177(2):580–585.

Shah PH, Moreira DM, Okhunov Z, et al. Positive surgical margins increase risk of recurrence after partial nephrectomy for high risk renal tumors. *J Urol*. 2016;196(2):327–334.

References

Abaza R, Shabsigh A, Castle E, et al. Multi-institutional experience with robotic nephrectomy with inferior vena cava tumor thrombectomy. *J Urol*. 2016;195(4 Pt 1):865–871.

Abdel-Karim AM, El Tayeb MM, Yahia E, et al. Evaluation of the role of laparoendoscopic single-site surgery vs minilaparoscopy for treatment of upper urinary tract pathologies: prospective randomized comparative study. *J Endourol*. 2017;31(12):1237–1242.

Abdelhafez M, Bastian A, Rausch S, et al. Laparoscopic versus open partial nephrectomy: comparison of overall and subgroup outcomes. *Anticancer Res*. 2017;37(1):261–265.

Abe T, Sazawa A, Harabayashi T, et al. Renal hypothermia with ice slush in laparoscopic partial nephrectomy: the outcome of renal function. *J Endourol*. 2012;26(11):1483–1488.

Aboumarzouk OM, Ismail M, Breen DJ, et al. Laparoscopic vs percutaneous cryotherapy for renal tumors: a systematic review and meta-analysis. *J Endourol*. 2018;32:177–183.

Abreu AL, Berger AK, Aron M, et al. Minimally invasive partial nephrectomy for single versus multiple renal tumors. *J Urol*. 2013;189(2):462–467.

Alameddine M, Koru-Sengul T, Moore KJ, et al. Trends in utilization of robotic and open partial nephrectomy for management of cT1 renal masses. *Eur Urol Focus*. 2018 [S2405_4569(17), Jan 8, 2018].

Alcaraz A, Musquera M, Peri L, et al. Feasibility of transvaginal natural orifice transluminal endoscopic surgery-assisted living donor nephrectomy: is kidney vaginal delivery the approach of the future? *Eur Urol*. 2011;59(6):1019–1025.

Antonelli JA, Bagrodia A, Odom C, et al. Laparoendoscopic single-site nephrectomy compared with conventional laparoscopic nephrectomy: a 5-year, single-surgeon experience. *Eur Urol*. 2013;64(3):412–418.

Arai Y, Kaiho Y, Saito H, et al. Renal hypothermia using ice-cold saline for retroperitoneal laparoscopic partial nephrectomy: evaluation of split renal function with technetium-99m-dimercaptosuccinic acid renal scintigraphy. *Urology*. 2011;77(4):814–818.

Aron M, Colombo JR Jr, Turna B, et al. Diaphragmatic repair and/or reconstruction during upper abdominal urological laparoscopy. *J Urol*. 2007;178(6):2444–2450.

Arora S, Abaza R, Adshead JM, et al. 'Trifecta' outcomes of robot-assisted partial nephrectomy in solitary kidney: a Vattikuti Collective Quality Initiative (VCQI) database analysis. *BJU Int*. 2018;121(1):119–123.

Atug F, Burgess SV, Ruiz-Deya G, et al. Long-term durability of laparoscopic decortication of symptomatic renal cysts. *Urology*. 2006;68(2):272–275.

Autorino R, Haber GP, White MA, et al. Pure and hybrid natural orifice transluminal endoscopic surgery (NOTES): current clinical experience in urology. *BJU Int*. 2010;106(6 Pt B):919–922.

Bandi G, Wen CC, Moon TD, et al. Single center preliminary experience with hand-assisted laparoscopic resection of isolated renal cell carcinoma fossa recurrences. *Urology*. 2008;71(3):495–499 [discussion 499–500].

Banegas MP, Harlan LC, Mann B, et al. Toward greater adoption of minimally invasive and nephron-sparing surgical techniques for renal cell cancer in the United States. *Urol Oncol*. 2016;34(10) [433 e439–433 e417].

Benway BM, Wang AJ, Cabello JM, et al. Robotic partial nephrectomy with sliding-clip renorrhaphy: technique and outcomes. *Eur Urol*. 2009;55(3):592–599.

Berger A, Brandina R, Atalla MA, et al. Laparoscopic radical nephrectomy for renal cell carcinoma: oncological outcomes at 10 years or more. *J Urol*. 2009;182(5):2172–2176.

Bhindi B, Mason RJ, Haddad MM, et al. Outcomes after cryoablation versus partial nephrectomy for sporadic renal tumors in a solitary kidney: a propensity score analysis. *Eur Urol*. 2018;73(2):254–259.

Biggs G, Hafron J, Feliciano J, et al. Treatment of splenic injury during laparoscopic nephrectomy with BioGlue, a surgical adhesive. *Urology*. 2005;66(4):882.

Bishoff JT, Allaf ME, Kirkels W, et al. Laparoscopic bowel injury: incidence and clinical presentation. *J Urol*. 1999;161(3):887–890.

Blackwell RH, Li B, Kozel Z, et al. Functional implications of renal tumor enucleation relative to standard partial nephrectomy. *Urology*. 2017;99:162–168.

Blom JH, van Poppel H, Marechal JM, et al. Radical nephrectomy with and without lymph-node dissection: final results of European Organization for Research and Treatment of Cancer (EORTC) randomized phase 3 trial 30881. *Eur Urol*. 2009;55(1):28–34.

Borghesi M, Brunocilla E, Schiavina R, et al. Positive surgical margins after nephron-sparing surgery for renal cell carcinoma: incidence, clinical impact, and management. *Clin Genitourin Cancer*. 2013;11(1):5–9.

Borofsky MS, Gill IS, Hemal AK, et al. Near-infrared fluorescence imaging to facilitate super-selective arterial clamping during zero-ischaemia robotic partial nephrectomy. *BJU Int*. 2013;111(4):604–610.

Box G, Averch T, Cadeddu J, et al. Nomenclature of natural orifice translumenal endoscopic surgery (NOTES) and laparoendoscopic single-site surgery (LESS) procedures in urology. *J Endourol*. 2008;22(11):2575–2581.

Branco AW, Branco Filho AJ, Kondo W, et al. Hybrid transvaginal nephrectomy. *Eur Urol*. 2008;53(6):1290–1294.

Breda A, Anterasian C, Belldegrun A. Management and outcomes of tumor recurrence after focal ablation renal therapy. *J Endourol*. 2010;24(5):749–752.

Cadeddu JA, Chan DY, Hedican SP, et al. Retroperitoneal access for transperitoneal laparoscopy in patients at high risk for intra-abdominal scarring. *J Endourol*. 1999;13(8):567–570.

Cadeddu JA, Regan F, Kavoussi LR, et al. The role of computerized tomography in the evaluation of complications after laparoscopic urological surgery. *J Urol*. 1997;158(4):1349–1352.

Campbell J, Chan G, Luke PP. Early clamp release during laparoscopic partial nephrectomy: implications for preservation of renal function. *Can Urol Assoc J*. 2017;11(7):E261–E265.

Campbell S, Uzzo RG, Allaf ME, et al. Renal mass and localized renal cancer: AUA guideline. *J Urol*. 2017;198(3):520–529.

Canby-Hagino ED, Morey AF, Jatoi I, et al. Fibrin sealant treatment of splenic injury during open and laparoscopic left radical nephrectomy. *J Urol*. 2000;164(6):2004–2005.

Caputo PA, Zargar H, Ramirez D, et al. Cryoablation versus partial nephrectomy for clinical T1b renal tumors: a matched group comparative analysis. *Eur Urol*. 2017;71(1):111–117.

Chan D, Bishoff JT, Ratner L, et al. Endovascular gastrointestinal stapler device malfunction during laparoscopic nephrectomy: early recognition and management. *J Urol*. 2000;164(2):319–321.

Chapman TN, Sharma S, Zhang S, et al. Laparoscopic lymph node dissection in clinically node-negative patients undergoing laparoscopic nephrectomy for renal carcinoma. *Urology*. 2008;71(2):287–291.

Chen RN, Moore RG, Cadeddu JA, et al. Laparoscopic renal surgery in patients at high risk for intra-abdominal or retroperitoneal scarring. *J Endourol*. 1998;12(2):143–147.

Chen YT, Yang SS, Hsieh CH, et al. Hand port-site metastasis of renal-cell carcinoma following hand-assisted laparoscopic radical nephrectomy: case report. *J Endourol*. 2003;17(9):771–775.

Choi JE, You JH, Kim DK, et al. Comparison of perioperative outcomes between robotic and laparoscopic partial nephrectomy: a systematic review and meta-analysis. *Eur Urol*. 2015;67(5):891–901.

Chung SD, Huang KH, Lai MK, et al. Long-term follow-up of hand-assisted laparoscopic radical nephrectomy for organ-confined renal cell carcinoma. *Urology*. 2007;69(4):652–655.

Clayman RV, Kavoussi LR, Soper NJ, et al. Laparoscopic nephrectomy. *N Engl J Med*. 1991;324(19):1370–1371.

Dalela D, Gupta VP, Goel A, et al. Omental wrap around the renal pedicle: an adjunctive step to minimize morbidity and recurrence after lymphorenal disconnection for chyluria. *BJU Int*. 2004;94(4):673–674.

Davidiuk AJ, Parker AS, Thomas CS, et al. Mayo adhesive probability score: an accurate image-based scoring system to predict adherent perinephric fat in partial nephrectomy. *Eur Urol*. 2014;66(6):1165–1171.

Deklaj T, Lifshitz DA, Shikanov SA, et al. Laparoscopic radical versus laparoscopic partial nephrectomy for clinical T1bN0M0 renal tumors: comparison of perioperative, pathological, and functional outcomes. *J Endourol*. 2010;24(10):1603–1607.

Del Pizzo JJ, Jacobs SC, Bishoff JT, et al. Pleural injury during laparoscopic renal surgery: early recognition and management. *J Urol*. 2003;169(1):41–44.

Delto JC, Paulucci D, Helbig MW, et al. Robotic partial nephrectomy for large renal masses: a multi-institutional series. *BJU Int*. 2018;121:908–915.

Desai MM, de Castro Abreu AL, Leslie S, et al. Robotic partial nephrectomy with superselective versus main artery clamping: a retrospective comparison. *Eur Urol*. 2014;66(4):713–719.

Desai MM, Gill IS, Kaouk JH, et al. Laparoscopic partial nephrectomy with suture repair of the pelvicaliceal system. *Urology*. 2003;61(1):99–104.

Desai MM, Gill IS, Ramani AP, et al. Laparoscopic radical nephrectomy for cancer with level I renal vein involvement. *J Urol*. 2003;169(2):487–491.

Desai MM, Strzempkowski B, Matin SF, et al. Prospective randomized comparison of transperitoneal versus retroperitoneal laparoscopic radical nephrectomy. *J Urol*. 2005;173(1):38–41.

Dunn MD, Portis AJ, Shalhav AL, et al. Laparoscopic versus open radical nephrectomy: a 9-year experience. *J Urol*. 2000;164(4):1153–1159.

Eisenberg MS, Meng MV, Master VA, et al. Laparoscopic versus open cytoreductive nephrectomy in advanced renal-cell carcinoma. *J Endourol*. 2006;20(7):504–508.

El Dib R, Touma NJ, Kapoor A. Cryoablation vs radiofrequency ablation for the treatment of renal cell carcinoma: a meta-analysis of case series studies. *BJU Int*. 2012;110(4):510–516.

Elashry OM, Nakada SY, McDougall EM, et al. Laparoscopic nephropexy: Washington University experience. *J Urol*. 1995;154(5):1655–1659.

Fahlenkamp D, Rassweiler J, Fornara P, et al. Complications of laparoscopic procedures in urology: experience with 2,407 procedures at 4 German centers. *J Urol*. 1999;162(3 Pt 1):765–770 [discussion 770–761].

Fan X, Xu K, Lin T, et al. Comparison of transperitoneal and retroperitoneal laparoscopic nephrectomy for renal cell carcinoma: a systematic review and meta-analysis. *BJU Int*. 2013;111(4):611–621.

Ficarra V, Minervini A, Antonelli A, et al. A multicentre matched-pair analysis comparing robot-assisted versus open partial nephrectomy. *BJU Int*. 2014;113(6):936–941.

Filson CP, Banerjee M, Wolf JS Jr, et al. Surgeon characteristics and long-term trends in the adoption of laparoscopic radical nephrectomy. *J Urol*. 2011;185(6):2072–2077.

Filson CP, Miller DC, Colt JS, et al. Surgical approach and the use of lymphadenectomy and adrenalectomy among patients undergoing radical nephrectomy for renal cell carcinoma. *Urol Oncol*. 2012;30(6):856–863.

Finelli A, Gill IS, Desai MM, et al. Laparoscopic heminephrectomy for tumor. *Urology*. 2005;65(3):473–478.

Fornara P, Doehn C, Friedrich HJ, et al. Nonrandomized comparison of open flank versus laparoscopic nephrectomy in 249 patients with benign renal disease. *Eur Urol*. 2001;40(1):24–31.

Fornara P, Doehn C, Jocham D. Laparoscopic nephropexy: 3-year experience. *J Urol*. 1997;158(5):1679–1683.

Forrest JB, Clemens JQ, Finamore P, et al. AUA Best Practice Statement for the prevention of deep vein thrombosis in patients undergoing urologic surgery. [the; A. American Urological] *J Urol*. 2009;181(3):1170–1177.

Frank I, Colombo JR Jr, Rubinstein M, et al. Laparoscopic partial nephrectomy for centrally located renal tumors. *J Urol*. 2006;175(3 Pt 1):849–852.

Gabr AH, Gdor Y, Strope SA, et al. Approach and specimen handling do not influence oncological perioperative and long-term outcomes after laparoscopic radical nephrectomy. *J Urol*. 2009;182(3):874–880.

Garg M, Singh V, Sinha RJ, et al. Prospective randomized comparison of transperitoneal vs retroperitoneal laparoscopic simple nephrectomy. *Urology*. 2014;84(2):335–339.

Gaur DD. Laparoscopic operative retroperitoneoscopy: use of a new device. *J Urol*. 1992;148(4):1137–1139.

George AK, Herati AS, Rais-Bahrami S, et al. Laparoscopic partial nephrectomy for hilar tumors: oncologic and renal functional outcomes. *Urology*. 2014;83(1):111–115.

George AK, Herati AS, Srinivasan AK, et al. Perioperative outcomes of off-clamp vs complete hilar control laparoscopic partial nephrectomy. *BJU Int*. 2013;111(4 Pt B):E235–E241.

Gershman B, Thompson RH, Moreira DM, et al. Radical nephrectomy with or without lymph node dissection for nonmetastatic renal cell carcinoma: a propensity score-based analysis. *Eur Urol*. 2017;71(4):560–567.

Gervais DA, Arellano RS, Mueller PR. Percutaneous radiofrequency ablation of renal cell carcinoma. *Eur Radiol*. 2005;15(5):960–967.

Gilbert D, Abaza R. Robotic excision of recurrent renal cell carcinomas with laparoscopic ultrasound assistance. *Urology*. 2015;85(5):1206–1210.

Gill IS, Abreu SC, Desai MM, et al. Laparoscopic ice slush renal hypothermia for partial nephrectomy: the initial experience. *J Urol*. 2003;170(1):52–56.

Gill IS, Cherullo EE, Meraney AM, et al. Vaginal extraction of the intact specimen following laparoscopic radical nephrectomy. *J Urol*. 2002;167(1):238–241.

Gill IS, Colombo JR Jr, Frank I, et al. Laparoscopic partial nephrectomy for hilar tumors. *J Urol*. 2005;174(3):850–853 [discussion 853–854].

Gill IS, Delworth MG, Munch LC. Laparoscopic retroperitoneal partial nephrectomy. *J Urol*. 1994;152(5 Pt 1):1539–1542.

Gill IS, Kamoi K, Aron M, et al. 800 Laparoscopic partial nephrectomies: a single surgeon series. *J Urol*. 2010;183(1):34–41.

Gill IS, Kavoussi LR, Lane BR, et al. Comparison of 1,800 laparoscopic and open partial nephrectomies for single renal tumors. *J Urol*. 2007;178(1):41–46.

Gimenez LF, Micali S, Chen RN, et al. Laparoscopic renal biopsy. *Kidney Int*. 1998;54(2):525–529.

Goldberg SN, Gazelle GS, Mueller PR. Thermal ablation therapy for focal malignancy: a unified approach to underlying principles, techniques, and diagnostic imaging guidance. *Am J Roentgenol*. 2000;174(2):323–331.

Gong EM, Orvieto MA, Zorn KC, et al. Comparison of laparoscopic and open partial nephrectomy in clinical T1a renal tumors. *J Endourol*. 2008;22(5):953–957.

Gong EM, Zorn KC, Orvieto MA, et al. Artery-only occlusion may provide superior renal preservation during laparoscopic partial nephrectomy. *Urology*. 2008;72(4):843–846.

Gonzalez RD, Whiting B, Canales BK. Laparoscopic calyceal diverticulectomy: video review of techniques and outcomes. *J Endourol*. 2011;25(10):1591–1595.

Gozen AS, Rassweiler JJ, Neuwinger F, et al. Long-term outcome of laparoscopic retroperitoneal nephropexy. *J Endourol*. 2008;22(10):2263–2267.

Gupta A, Ahmed K, Kynaston HG, et al. Laparoendoscopic single-site donor nephrectomy (LESS-DN) versus standard laparoscopic donor nephrectomy. *Cochrane Database Syst Rev*. 2016;(5) [CD010850].

Gupta NP, Agrawal AK, Sood S. Tubercular pyelonephritic nonfunctioning kidney–another relative contraindication for laparoscopic nephrectomy: a case report. *J Laparoendosc Adv Surg Tech A*. 1997;7(2):131–134.

Gupta NP, Gautam G. Laparoscopic nephrectomy for benign non functioning kidneys. *J Minim Access Surg*.

2005;1(4):149–154.

Guzzo TJ, Schaeffer EM, McNeil BK, et al. Laparoscopic radical nephrectomy for patients with pathologic T3b renal-cell carcinoma: the Johns Hopkins experience. *J Endourol*. 2009;23(1):63–67.

Halpin VJ, Underwood RA, Ye D, et al. Pneumoperitoneum does not influence trocar site implantation during tumor manipulation in a solid tumor model. *Surg Endosc*. 2005;19(12):1636–1640.

Hasson HM. A modified instrument and method for laparoscopy. *Am J Obstet Gynecol*. 1971;110(6):886–887.

Hayn MH, Schwaab T, Underwood W, et al. RENAL nephrometry score predicts surgical outcomes of laparoscopic partial nephrectomy. *BJU Int*. 2011;108(6):876–881.

Henderson JM, Fabricius MJ, Fowler S, et al. The complications of laparoscopic renal surgery: a review of 10 years of audit data in the UK. *J Clin Urol*. 2016;9(1):23–31.

Hernandez F, Rha KH, Pinto PA, et al. Laparoscopic nephrectomy: assessment of morcellation versus intact specimen extraction on postoperative status. *J Urol*. 2003;170(2 Pt 1):412–415.

Hsi RS, Ojogho ON, Baldwin DD. Analysis of techniques to secure the renal hilum during laparoscopic donor nephrectomy: review of the FDA database. *Urology*. 2009;74(1):142–147.

Hsi RS, Saint-Elie DT, Zimmerman GJ, et al. Mechanisms of hemostatic failure during laparoscopic nephrectomy: review of Food and Drug Administration database. *Urology*. 2007;70(5):888–892.

Hsu TH, Jeffrey RB Jr, Chon C, et al. Laparoscopic radical nephrectomy incorporating intraoperative ultrasonography for renal cell carcinoma with renal vein tumor thrombus. *Urology*. 2003;61(6):1246–1248.

Huang WC, Levey AS, Serio AM, et al. Chronic kidney disease after nephrectomy in patients with renal cortical tumours: a retrospective cohort study. *Lancet Oncol*. 2006;7(9):735–740.

Hubner WA, Schlarp O, Riedl C, et al. Laparoscopic nephropexy using tension-free vaginal tape for symptomatic nephroptosis. *Urology*. 2004;64(2):372–374.

Itano NB, Blute ML, Spotts B, et al. Outcome of isolated renal cell carcinoma fossa recurrence after nephrectomy. *J Urol*. 2000;164(2):322–325.

Jain S, Nyirenda T, Yates J, et al. Incidence of renal artery pseudoaneurysm following open and minimally invasive partial nephrectomy: a systematic review and comparative analysis. *J Urol*. 2013;189(5):1643–1648.

Jeon CH, Seong NJ, Yoon CJ, et al. Clinical results of renal artery embolization to control postoperative hemorrhage after partial nephrectomy. *Acta Radiol Open*. 2016;5(8) [2058460116655833].

Jeon SH, Kwon TG, Rha KH, et al. Comparison of laparoscopic versus open radical nephrectomy for large renal tumors: a retrospective analysis of multi-center results. *BJU Int*. 2011;107(5):817–821.

Jeong IG, Khandwala YS, Kim JH, et al. Association of robotic-assisted vs laparoscopic radical nephrectomy with perioperative outcomes and health care costs, 2003 to 2015. *J Am Med Assoc*. 2017;318(16):1561–1568.

Johnson A, Sudarshan S, Liu J, et al. Feasibility and outcomes of repeat partial nephrectomy. *J Urol*. 2008;180(1):89–93 [discussion 93].

Johnson DB, Solomon SB, Su LM, et al. Defining the complications of cryoablation and radio frequency ablation of small renal tumors: a multi-institutional review. *J Urol*. 2004;172(3):874–877.

Kang HW, Lee SK, Kim WT, et al. Surgical margin does not influence recurrence rate in pT1 clear cell renal cell carcinoma after partial nephrectomy: a multicenter study. *J Surg Oncol*. 2016;114(1):70–74.

Kaouk JH, Autorino R, Kim FJ, et al. Laparoendoscopic single-site surgery in urology: worldwide multi-institutional analysis of 1076 cases. *Eur Urol*. 2011;60(5):998–1005.

Kaouk JH, Haber GP, Goel RK, et al. Pure natural orifice translumenal endoscopic surgery (NOTES) transvaginal nephrectomy. *Eur Urol*. 2010;57(4):723–726.

Kara O, Maurice MJ, Malkoc E, et al. Comparison of robot-assisted and open partial nephrectomy for completely endophytic renal tumours: a single centre experience. *BJU Int*. 2016;118(6):946–951.

Kawauchi A, Yoneda K, Fujito A, et al. Oncologic outcome of hand-assisted laparoscopic radical nephrectomy. *Urology*. 2007;69(1):53–56.

Keeley FX, Tolley DA. A review of our first 100 cases of laparoscopic nephrectomy: defining risk factors for complications. *Br J Urol*. 1998;82(5):615–618.

Kerbl DC, McDougall EM, Clayman RV, et al. A history and evolution of laparoscopic nephrectomy: perspectives from the past and future directions in the surgical management of renal tumors. *J Urol*. 2011;185(3):1150–1154.

Kijvikai K, Viprakasit DP, Milhoua P, et al. A simple, effective method to create laparoscopic renal protective hypothermia with cold saline surface irrigation: clinical application and assessment. *J Urol*. 2010;184(5):1861–1866.

Kim EH, Tanagho YS, Saad NE, et al. Comparison of laparoscopic and percutaneous cryoablation for treatment of renal masses. *Urology*. 2014;83(5):1081–1087.

Klatte T, Shariat SF, Remzi M. Systematic review and meta-analysis of perioperative and oncologic outcomes of laparoscopic cryoablation versus laparoscopic partial nephrectomy for the treatment of small renal tumors. *J Urol*. 2014;191(5):1209–1217.

Komninos C, Shin TY, Tuliao P, et al. R-LESS partial nephrectomy trifecta outcome is inferior to multiport robotic partial nephrectomy: comparative analysis. *Eur Urol*. 2014;66(3):512–517.

Kowalczyk KJ, Hooper HB, Linehan WM, et al. Partial nephrectomy after previous radio frequency ablation: the National Cancer Institute experience. *J Urol*. 2009;182(5):2158–2163.

Kreshover JE, Kavoussi LR, Richstone L. Hilar clamping versus off-clamp laparoscopic partial nephrectomy for T1b tumors. *Curr Opin Urol*. 2013;23(5):399–402.

Kundu SD, Thompson RH, Kallingal GJ, et al. Urinary fistulae after partial nephrectomy. *BJU Int*. 2010;106(7):1042–1044.

Kunkle DA, Egleston BL, Uzzo RG. Excise, ablate or observe: the small renal mass dilemma–a meta-analysis and review. *J Urol*. 2008;179(4):1227–1233 [discussion 1233–1224].

Kunkle DA, Uzzo RG. Cryoablation or radiofrequency ablation of the small renal mass: a meta-analysis. *Cancer*. 2008;113(10):2671–2680.

Kutikov A, Uzzo RG. The R.E.N.A.L. nephrometry score: a comprehensive standardized system for quantitating renal tumor size, location and depth. *J Urol*. 2009;182(3):844–853.

Laguna MP, Beemster P, Kumar V, et al. Perioperative morbidity of laparoscopic cryoablation of small renal masses with ultrathin probes: a European multicentre experience. *Eur Urol*. 2009;56(2):355–361.

Lai WS, Rais-Bahrami S. Safety and efficacy of en bloc renal hilar vascular staple ligation: a meta-analysis. *J Urol*. 2017;197(1):175–181.

Landman J, Lento P, Hassen W, et al. Feasibility of pathological evaluation of morcellated kidneys after radical nephrectomy.

J Urol. 2000;164(6):2086–2089.

Landman J, Venkatesh R, Lee D, et al. Renal hypothermia achieved by retrograde endoscopic cold saline perfusion: technique and initial clinical application. *Urology*. 2003;61(5):1023–1025.

Lane BR, Campbell SC, Gill IS. 10-year oncologic outcomes after laparoscopic and open partial nephrectomy. *J Urol*. 2013;190(1):44–49.

Lane BR, Gill IS. 7-year oncological outcomes after laparoscopic and open partial nephrectomy. *J Urol*. 2010;183(2):473–479.

Lane BR, Novick AC, Babineau D, et al. Comparison of laparoscopic and open partial nephrectomy for tumor in a solitary kidney. *J Urol*. 2008;179(3):847–851 [discussion 852].

Lee DI, Andreoni CR, Rehman J, et al. Laparoscopic cyst decortication in autosomal dominant polycystic kidney disease: impact on pain, hypertension, and renal function. *J Endourol*. 2003;17(6):345–354.

Liu G, Ma Y, Wang S, et al. Laparoscopic versus open radical nephrectomy for renal cell carcinoma: a systematic review and meta-analysis. *Transl Oncol*. 2017;10(4):501–510.

Liu W, Li Y, Chen M, et al. Off-clamp versus complete hilar control partial nephrectomy for renal cell carcinoma: a systematic review and meta-analysis. *J Endourol*. 2014;28(5):567–576.

Long JA, Bernhard JC, Bigot P, et al. Partial nephrectomy versus ablative therapy for the treatment of renal tumors in an imperative setting. [the; C. French association of Urology Cancerology] *World J Urol*. 2017;35(4):649–656.

Longo N, Minervini A, Antonelli A, et al. Simple enucleation versus standard partial nephrectomy for clinical T1 renal masses: perioperative outcomes based on a matched-pair comparison of 396 patients (RECORd project). *Eur J Surg Oncol*. 2014;40(6):762–768.

Lotan Y, Gettman MT, Roehrborn CG, et al. Cost comparison for laparoscopic nephrectomy and open nephrectomy: analysis of individual parameters. *Urology*. 2002;59(6):821–825.

Luciani LG, Porpiglia F, Cai T, et al. Operative safety and oncologic outcome of laparoscopic radical nephrectomy for renal cell carcinoma >7 cm: a multicenter study of 222 patients. *Urology*. 2013;81(6):1239–1244.

Ludwig WW, Gorin MA, Pierorazio PM, et al. Frontiers in robot-assisted retroperitoneal oncological surgery. *Nat Rev Urol*. 2017;14(12):731–741.

Margulis V, McDonald M, Tamboli P, et al. Predictors of oncological outcome after resection of locally recurrent renal cell carcinoma. *J Urol*. 2009;181(5):2044–2051.

Marszalek M, Meixl H, Polajnar M, et al. Laparoscopic and open partial nephrectomy: a matched-pair comparison of 200 patients. *Eur Urol*. 2009;55(5):1171–1178.

Matin SF, Madsen LT, Wood CG. Laparoscopic cytoreductive nephrectomy: the M. D. Anderson Cancer Center experience. *Urology*. 2006;68(3):528–532.

McAllister M, Bhayani SB, Ong A, et al. Vena caval transection during retroperitoneoscopic nephrectomy: report of the complication and review of the literature. *J Urol*. 2004;172(1):183–185.

Meeks JJ, Zhao LC, Navai N, et al. Risk factors and management of urine leaks after partial nephrectomy. *J Urol*. 2008;180(6):2375–2378.

Mendoza D, Newman RC, Albala D, et al. Laparoscopic complications in markedly obese urologic patients (a multi-institutional review). *Urology*. 1996;48(4):562–567.

Meraney AM, Samee AA, Gill IS. Vascular and bowel complications during retroperitoneal laparoscopic surgery. *J Urol*. 2002;168(5):1941–1944.

Micali S, Celia A, Bove P, et al. Tumor seeding in urological laparoscopy: an international survey. *J Urol*. 2004;171(6 Pt 1):2151–2154.

Micali S, Zordani A, Galli R, et al. Retroperitoneoscopic single site renal biopsy surgery: right indications for the right technique. *BMC Urol*. 2014;14:80.

Molina WR, Desai MM, Ng CS, et al. Retroperitoneoscopic radical nephrectomy with concomitant distal pancreatectomy: case report. *J Endourol*. 2004;18(7):665–667.

Monga M, Premoli J, Skemp N, et al. Forearm compression by laparoscopic hand-assist devices. *J Endourol*. 2004;18(7):654–656.

Montgomery JS, Wolf JS Jr. Venous thrombosis prophylaxis for urological laparoscopy: fractionated heparin versus sequential compression devices. *J Urol*. 2005;173(5):1623–1626.

Moore RG, Chen RN, Hedican SP. Laparoscopic subcapsular nephrectomy. *J Endourol*. 1998;12(3):263–264.

Nadler RB, Loeb S, Clemens JQ, et al. A prospective study of laparoscopic radical nephrectomy for T1 tumors–is transperitoneal, retroperitoneal or hand assisted the best approach? *J Urol*. 2006;175(4):1230–1233 [discussion 1234].

Nadu A, Kleinmann N, Laufer M, et al. Laparoscopic partial nephrectomy for central tumors: analysis of perioperative outcomes and complications. *J Urol*. 2009;181(1):42–47 [discussion 47].

Nagahara A, Uemura M, Kawashima A, et al. R.E.N.A.L. nephrometry score predicts postoperative recurrence of localized renal cell carcinoma treated by radical nephrectomy. *Int J Clin Oncol*. 2016;21(2):367–372.

Nambirajan T, Jeschke S, Al-Zahrani H, et al. Prospective, randomized controlled study: transperitoneal laparoscopic versus retroperitoneoscopic radical nephrectomy. *Urology*. 2004;64(5):919–924.

Nelson CP, Wolf JS Jr. Comparison of hand assisted versus standard laparoscopic radical nephrectomy for suspected renal cell carcinoma. *J Urol*. 2002;167(5):1989–1994.

Ng CS, Gill IS, Ramani AP, et al. Transperitoneal versus retroperitoneal laparoscopic partial nephrectomy: patient selection and perioperative outcomes. *J Urol*. 2005;174(3):846–849.

Nguyen CT, Lane BR, Kaouk JH, et al. Surgical salvage of renal cell carcinoma recurrence after thermal ablative therapy. *J Urol*. 2008;180(1):104–109 [discussion 109].

Nguyen MM, Gill IS. Halving ischemia time during laparoscopic partial nephrectomy. *J Urol*. 2008;179(2):627–632 [discussion 632].

Novak R, Mulligan D, Abaza R. Robotic partial nephrectomy without renal ischemia. *Urology*. 2012;79(6):1296–1301.

Nunez Bragayrac L, Hoffmeyer J, Abbotoy D, et al. Minimally invasive cytoreductive nephrectomy: a multi-institutional experience. *World J Urol*. 2016;34(12):1651–1656.

O'Malley RL, Godoy G, Kanofsky JA, et al. The necessity of adrenalectomy at the time of radical nephrectomy: a systematic review. *J Urol*. 2009;181(5):2009–2017.

Oh JJ, Lee JK, Kim K, et al. Comparison of the width of peritumoral surgical margin in open and robotic partial nephrectomy: a propensity score matched analysis. *PLoS ONE*. 2016;11(6):e0158027.

Okeke AA, Mitchelmore AE, Keeley FX, et al. A comparison of aspiration and sclerotherapy with laparoscopic de-roofing in the management of symptomatic simple renal cysts. *BJU Int*. 2003;92(6):610–613.

Okeke AA, Timoney AG, Keeley FX. Hand-assisted laparoscopic nephrectomy: complications related to the hand-port site. *BJU Int*. 2002;90(4):364–367.

Orvieto MA, Tolhurst SR, Chuang MS, et al. Defining maximal renal tolerance to warm ischemia in porcine laparoscopic and open surgery model. *Urology*. 2005;66(5):1111–1115.

Ost MC, VanderBrink BA, Rastinehad AR, et al. Hand pain during hand assisted laparoscopic nephrectomy–an ischemic event? *J Urol*. 2006;176(1):149–154.

Patil MB, Gill IS. Zero-ischaemia robotic and laparoscopic partial nephrectomy (PN). *BJU Int*. 2011;108(5):780–792.

Permpongkosol S, Bagga HS, Romero FR, et al. Laparoscopic versus open partial nephrectomy for the treatment of pathological T1N0M0 renal cell carcinoma: a 5-year survival rate. *J Urol*. 2006;176(5):1984–1988 [discussion 1988–1989].

Permpongkosol S, Chan DY, Link RE, et al. Long-term survival analysis after laparoscopic radical nephrectomy. *J Urol*. 2005;174(4 Pt 1):1222–1225.

Permpongkosol S, Colombo JR Jr, Gill IS, et al. Positive surgical parenchymal margin after laparoscopic partial nephrectomy for renal cell carcinoma: oncological outcomes. *J Urol*. 2006;176(6 Pt 1):2401–2404.

Permpongkosol S, Link RE, Su LM, et al. Complications of 2,775 urological laparoscopic procedures: 1993 to 2005. *J Urol*. 2007;177(2):580–585.

Peyronnet B, Baumert H, Mathieu R, et al. Early unclamping technique during robot-assisted laparoscopic partial nephrectomy can minimise warm ischaemia without increasing morbidity. *BJU Int*. 2014;114(5):741–747.

Pierorazio PM, Hyams ES, Lin BM, et al. Laparoscopic radical nephrectomy for large renal masses: critical assessment of perioperative and oncologic outcomes of stage T2a and T2b tumors. *Urology*. 2012;79(3):570–575.

Pierorazio PM, Patel HD, Feng T, et al. Robotic-assisted versus traditional laparoscopic partial nephrectomy: comparison of outcomes and evaluation of learning curve. *Urology*. 2011;78(4):813–819.

Plas E, Daha K, Riedl CR, et al. Long-term followup after laparoscopic nephropexy for symptomatic nephroptosis. *J Urol*. 2001;166(2):449–452.

Porpiglia F, Mari A, Bertolo R, et al. Partial nephrectomy in clinical T1b renal tumors: multicenter comparative study of open, laparoscopic and robot-assisted approach (the RECORd Project). *Urology*. 2016;89:45–51.

Potretzke AM, Knight BA, Zargar H, et al. Urinary fistula after robot-assisted partial nephrectomy: a multicentre analysis of 1 791 patients. *BJU Int*. 2016;117(1):131–137.

Rabban JT, Meng MV, Yeh B, et al. Kidney morcellation in laparoscopic nephrectomy for tumor: recommendations for specimen sampling and pathologic tumor staging. *Am J Surg Pathol*. 2001;25(9):1158–1166.

Rabets JC, Kaouk J, Fergany A, et al. Laparoscopic versus open cytoreductive nephrectomy for metastatic renal cell carcinoma. *Urology*. 2004;64(5):930–934.

Ramani AP, Abreu SC, Desai MM, et al. Laparoscopic upper pole partial nephrectomy with concomitant en bloc adrenalectomy. *Urology*. 2003;62(2):223–226.

Ramirez D, Caputo PA, Krishnan J, et al. Robot-assisted partial nephrectomy with intracorporeal renal hypothermia using ice slush: step-by-step technique and matched comparison with warm ischaemia. *BJU Int*. 2016;117(3):531–536.

Ramirez D, Ma YB, Bedir S, et al. Laparoscopic radiofrequency ablation of small renal tumors: long-term oncologic outcomes. *J Endourol*. 2014;28(3):330–334.

Rane A. Laparoscopic management of symptomatic simple renal cysts. *Int Urol Nephrol*. 2004;36(1):5–9.

Rao AR, Gray R, Mayer E, et al. Occlusion angiography using intraoperative contrast-enhanced ultrasound scan (CEUS): a novel technique demonstrating segmental renal blood supply to assist zero-ischaemia robot-assisted partial nephrectomy. *Eur Urol*. 2013;63(5):913–919.

Rassweiler J, Fornara P, Weber M, et al. Laparoscopic nephrectomy: the experience of the laparoscopy working group of the German Urologic Association. *J Urol*. 1998;160(1):18–21.

Rassweiler J, Frede T, Henkel TO, et al. Nephrectomy: a comparative study between the transperitoneal and retroperitoneal laparoscopic versus the open approach. *Eur Urol*. 1998;33(5):489–496.

Rassweiler J, Tsivian A, Kumar AV, et al. Oncological safety of laparoscopic surgery for urological malignancy: experience with more than 1,000 operations. *J Urol*. 2003;169(6):2072–2075.

Regan JP, Cho ES, Flowers JL. Small bowel obstruction after laparoscopic donor nephrectomy. *Surg Endosc*. 2003;17(1):108–110.

Reisiger K, Tran V, Figenshau RS, et al. Single-setting bilateral laparoscopic renal surgery: assessment of single-stage procedure. *Urology*. 2005;65(5):892–897 [discussion 897].

Ren T, Liu Y, Zhao X, et al. Transperitoneal approach versus retroperitoneal approach: a meta-analysis of laparoscopic partial nephrectomy for renal cell carcinoma. *PLoS ONE*. 2014;9(3):e91978.

Reynolds CR, Delto JC, Paulucci DJ, et al. Comparison of perioperative and functional outcomes of robotic partial nephrectomy for cT1a vs cT1b renal masses. *BJU Int*. 2017;120(6):842–847.

Richstone L, Kavoussi LR. Barriers to the diffusion of advanced surgical techniques. *Cancer*. 2008;112(8):1646–1649.

Roberts WW, Bluebond-Langner R, Boyle KE, et al.

Laparoscopic ablation of symptomatic parenchymal and peripelvic renal cysts. *Urology*. 2001;58(2):165–169.

Romero FR, Rais-Bahrami S, Muntener M, et al. Laparoscopic partial nephrectomy in obese and non-obese patients: comparison with open surgery. *Urology*. 2008;71(5):806–809.

Saika T, Ono Y, Hattori R, et al. Long-term outcome of laparoscopic radical nephrectomy for pathologic T1 renal cell carcinoma. *Urology*. 2003;62(6):1018–1023.

Salami SS, George AK, Rais-Bahrami S. Outcomes of minimally invasive urologic surgery in the elderly patient population. *Curr Transl Geriatr Exp Gerontol Rep*. 2013;2(2):84–90.

Schiffman M, Moshfegh A, Talenfeld A, et al. Laparoscopic renal cryoablation. *Semin Intervent Radiol*. 2014;31(1):64–69.

Schwartz MJ, Faiena I, Cinman N, et al. Laparoscopic bowel injury in retroperitoneal surgery: current incidence and outcomes. *J Urol*. 2010;184(2):589–594.

Shah PH, George AK, Moreira DM, et al. To clamp or not to clamp? Long-term functional outcomes for elective off-clamp laparoscopic partial nephrectomy. *BJU Int*. 2016;117(2):293–299.

Shah PH, Moreira DM, Okhunov Z, et al. Positive surgical margins increase risk of recurrence after partial nephrectomy for high risk renal tumors. *J Urol*. 2016;196(2):327–334.

Shen Z, Xie L, Xie W, et al. The comparison of perioperative outcomes of robot-assisted and open partial nephrectomy: a systematic review and meta-analysis. *World J Surg Oncol*. 2016;14(1):220.

Shikanov S, Lifshitz DA, Deklaj T, et al. Predicting collecting system transection at laparoscopic partial nephrectomy: analysis of tumor parameters. *J Endourol*. 2009;23(11):1863–1866.

Shin TY, Lim SK, Komninos C, et al. Laparoendoscopic single-site (LESS) robot-assisted partial nephrectomy (RAPN) reduces postoperative wound pain without a rise in complication rates. *BJU Int*. 2014;114(4):555–561.

Simforoosh N, Basiri A, Ziaee SA, et al. Major vascular injury in laparoscopic urology. *JSLS*. 2014;18(3).

Simhan J, Smaldone MC, Tsai KJ, et al. Objective measures of renal mass anatomic complexity predict rates of major complications following partial nephrectomy. *Eur Urol*. 2011;60(4):724–730.

Simmons MN, Kaouk J, Gill IS, et al. Laparoscopic radical nephrectomy with hilar lymph node dissection in patients with advanced renal cell carcinoma. *Urology*. 2007;70(1):43–46.

Simmons MN, Weight CJ, Gill IS. Laparoscopic radical versus partial nephrectomy for tumors >4 cm: intermediate-term oncologic and functional outcomes. *Urology*. 2009;73(5):1077–1082.

Simon J, Bartsch G Jr, Finter F, et al. Laparoscopic partial nephrectomy with selective control of the renal parenchyma: initial experience with a novel laparoscopic clamp. *BJU Int*. 2009;103(6):805–808.

Simon SD, Castle EP, Ferrigni RG, et al. Routine postoperative chest x-ray following laparoscopic nephrectomy. *JSLS*. 2005;9(2):205–207.

Simone G, Ferriero M, Papalia R, et al. Zero-ischemia minimally invasive partial nephrectomy. *Curr Urol Rep*. 2013;14(5):465–470.

Sobey S, Hakimi AA, Faleck D, et al. Minimally invasive heminephrectomy: feasibility and outcomes. *J Endourol*. 2012;26(7):866–870.

Springer C, Hoda MR, Fajkovic H, et al. Laparoscopic vs open partial nephrectomy for T1 renal tumours: evaluation of long-term oncological and functional outcomes in 340 patients. *BJU Int*. 2013;111(2):281–288.

Srirangam SJ, Pollard AJ, Adeyoju AA, et al. Nephroptosis: seriously misunderstood? *BJU Int*. 2009;103(3):296–300.

Steinberg AP, Abreu SC, Desai MM, et al. Laparoscopic nephron-sparing surgery in the presence of renal artery disease. *Urology*. 2003;62(5):935–939.

Steinnerd LE, Vardi IY, Bhayani SB. Laparoscopic radical nephrectomy for renal carcinoma with known level I renal vein tumor thrombus. *Urology*. 2007;69(4):662–665.

Stewart GD, Ang WJ, Laird A, et al. The operative safety and oncological outcomes of laparoscopic nephrectomy for T3 renal cell cancer. *BJU Int*. 2012;110(6):884–890.

Sutherland SE, Resnick MI, Maclennan GT, et al. Does the size of the surgical margin in partial nephrectomy for renal cell cancer really matter? *J Urol*. 2002;167(1):61–64.

Tabayoyong W, Abouassaly R, Kiechle JE, et al. Variation in surgical margin status by surgical approach among patients undergoing partial nephrectomy for small renal masses. *J Urol*. 2015;194(6):1548–1553.

Takagi T, Kondo T, Tachibana H, et al. Comparison of surgical outcomes between resection and enucleation in robot-assisted laparoscopic partial nephrectomy for renal tumors according to the surface-intermediate-base margin score: a propensity score-matched study. *J Endourol*. 2017;31(8):756–761.

Tan HJ, Wolf JS Jr, Ye Z, et al. Complications and failure to rescue after laparoscopic versus open radical nephrectomy. *J Urol*. 2011;186(4):1254–1260.

Tan HJ, Wolf JS Jr, Ye Z, et al. Population-level comparative effectiveness of laparoscopic versus open radical nephrectomy for patients with kidney cancer. *Cancer*. 2011;117(18):4184–4193.

Taylor AS, Thiel DD. Laparoscopic and robotic calyceal diverticulectomy: outcomes and modifications of technique. *J Laparoendosc Adv Surg Tech A*. 2015;25(5):406–410.

Thomas AA, Aron M, Hernandez AV, et al. Laparoscopic partial nephrectomy in octogenarians. *Urology*. 2009;74(5):1042–1046.

Thompson RH, Atwell T, Schmit G, et al. Comparison of partial nephrectomy and percutaneous ablation for cT1 renal masses. *Eur Urol*. 2015;67(2):252–259.

Thompson RH, Boorjian SA, Lohse CM, et al. Radical nephrectomy for pT1a renal masses may be associated with decreased overall survival compared with partial nephrectomy. *J Urol*. 2008;179(2):468–471 [discussion 472–463].

Thompson RH, Lane BR, Lohse CM, et al. Every minute counts when the renal hilum is clamped during partial nephrectomy. *Eur Urol*. 2010;58(3):340–345.

Thwaini A, Shergill IS, Arya M, et al. Long-term follow-up after retroperitoneal laparoscopic decortication of symptomatic renal cysts. *Urol Int*. 2007;79(4):352–355.

Tsivian A, Shtricker A, Benjamin S, et al. Laparoscopic partial nephrectomy for tumour excision in a horseshoe kidney. *Eur Urol*. 2007;51(4):1132–1133.

Tsivian M, Lyne JC, Mayes JM, et al. Tumor size and endophytic growth pattern affect recurrence rates after laparoscopic renal cryoablation. *Urology*. 2010;75(2):307–310.

Urban DA, Kerbl K, McDougall EM, et al. Organ entrapment and renal morcellation: permeability studies. *J Urol*. 1993;150(6):1792–1794.

Van Poppel H, Da Pozzo L, Albrecht W, et al. A prospective, randomised EORTC intergroup phase 3 study comparing the oncologic outcome of elective nephron-sparing surgery and radical nephrectomy for low-stage renal cell carcinoma. *Eur*

Urol. 2011;59(4):543–552.
Varkarakis I, Neururer R, Harabayashi T, et al. Laparoscopic radical nephrectomy in the elderly. *BJU Int*. 2004;94(4):517–520.
Varkarakis IM, Allaf ME, Bhayani SB, et al. Pancreatic injuries during laparoscopic urologic surgery. *Urology*. 2004;64(6):1089–1093.
Verhoest G, Manunta A, Bensalah K, et al. Laparoscopic partial nephrectomy with clamping of the renal parenchyma: initial experience. *Eur Urol*. 2007;52(5):1340–1346.
Waingankar N, Hayek S, Smith AD, et al. Calyceal diverticula: a comprehensive review. *Rev Urol*. 2014;16(1):29–43.
Wakabayashi Y, Kataoka A, Koizumi S, et al. A simple technique for facilitating kidney entrapment using a laparoscopic sack during retroperitoneal laparoscopic radical nephrectomy. *Urology*. 2003;61(4):828–829.
Wang Y, Shao J, Ma X, et al. Robotic and open partial nephrectomy for complex renal tumors: a matched-pair comparison with a long-term follow-up. *World J Urol*. 2017;35(1):73–80.
Watson MJ, Sidana A, Diaz AW, et al. Repeat robotic partial nephrectomy: characteristics, complications, and renal functional outcomes. *J Endourol*. 2016;30(11):1219–1226.
Watts KL, Ghosh P, Stein S, et al. Value of nephrometry score constituents on perioperative outcomes and split renal function in patients undergoing minimally invasive partial nephrectomy. *Urology*. 2017;99:112–117.
Wehle MJ, Grabstald H. Contraindications to needle aspiration of a solid renal mass: tumor dissemination by renal needle aspiration. *J Urol*. 1986;136(2):446–448.
Whalley DG, Berrigan MJ. Anesthesia for radical prostatectomy, cystectomy, nephrectomy, pheochromocytoma, and laparoscopic procedures.

Anesthesiol Clin North America. 2000;18(4):899–917 [x].

Williams RD, Snowden C, Frank R, et al. Has sliding-clip renorrhaphy eliminated the need for collecting system repair during robot-assisted partial nephrectomy? *J Endourol*. 2017;31(3):289–294.

Winfield HN, Donovan JF, Godet AS, et al. Laparoscopic partial nephrectomy: initial case report for benign disease. *J Endourol*. 1993;7(6):521–526.

Wolf JS Jr, Marcovich R, Gill IS, et al. Survey of neuromuscular injuries to the patient and surgeon during urologic laparoscopic surgery. *Urology*. 2000;55(6):831–836.

Wolf JS Jr, Merion RM, Leichtman AB, et al. Randomized controlled trial of hand-assisted laparoscopic versus open surgical live donor nephrectomy. *Transplantation*. 2001;72(2):284–290.

Wszolek MF, Kenney PA, Lee Y, et al. Comparison of hilar clamping and non-hilar clamping partial nephrectomy for tumours involving a solitary kidney. *BJU Int*. 2011;107(12):1886–1892.

Wu SD, Lesani OA, Zhao LC, et al. A multi-institutional study on the safety and efficacy of specimen morcellation after laparoscopic radical nephrectomy for clinical stage T1 or T2 renal cell carcinoma. *J Endourol*. 2009;23(9):1513–1518.

Wu Z, Li M, Liu B, et al. Robotic versus open partial nephrectomy: a systematic review and meta-analysis. *PLoS ONE*. 2014;9(4):e94878.

Xue Y, Zou X, Zhang G, et al. Transvaginal natural orifice transluminal endoscopic nephrectomy in a series of 63 cases: stepwise transition from hybrid to pure NOTES. *Eur Urol*. 2015;68(2):302–310.

Yang DY, Monn MF, Bahler CD, et al. Does robotic assistance confer an economic benefit during laparoscopic radical nephrectomy? *J Urol*. 2014;192(3):671–676.

Yossepowitch O, Thompson RH, Leibovich BC, et al. Positive surgical margins at partial nephrectomy: predictors and oncological outcomes. *J Urol*. 2008;179(6):2158–2163.

Zaid HB, Parker WP, Lohse CM, et al. Patient factors associated with 30-day complications after partial nephrectomy: a contemporary update. *Urol Oncol*. 2017;35(4):153 e151–153 e156.

Zargar H, Bhayani S, Allaf ME, et al. Comparison of perioperative outcomes of robot-assisted partial nephrectomy and open partial nephrectomy in patients with a solitary kidney. *J Endourol*. 2014;28(10):1224–1230.

Zargar H, Samarasekera D, Khalifeh A, et al. Laparoscopic vs percutaneous cryoablation for the small renal mass: 15-year experience at a single center. *Urology*. 2015;85(4):850–855.

Zhang T, Wang J, Yu D, et al. It is unnecessary to completely mobilize the kidney in retroperitoneoscopic renal pedicle lymphatic disconnection for intractable chyluria. *Int Urol Nephrol*. 2016;48(10):1565–1569.

Zhang Y, Zeng J, Zhang K, et al. Surgical management of intractable chyluria: a comparison of retroperitoneoscopy with open surgery. *Urol Int*. 2012;89(2):222–226.

Zorn KC, Gong EM, Orvieto MA, et al. Impact of collecting-system repair during laparoscopic partial nephrectomy. *J Endourol*. 2007;21(3):315–320.

103

Nonsurgical Focal Therapy for Renal Tumors

Chad R. Tracy MD, Jeffrey A. Cadeddu MD

The incidence of localized renal cell carcinoma (RCC) is rising as a result of the increasing use of cross-sectional imaging. Along with the increasing incidence in the diagnosis of renal masses, there has been a parallel down-staging of newly detected renal masses such that more than 70% are small and organ confined (clinical stage T1) (Chen and Uzzo, 2011; Volpe et al., 2004). The overall result is a paradigm shift in management over the last decade, with an increasing focus on minimally invasive treatment and nephron-sparing surgery. Accordingly, in addition to cancer-specific survival (CSS), emphasis is now placed on preservation of renal function and avoidance of treatment-related morbidity in the management of early stage RCC. Therefore the 2017 American Urological Association (AUA) guidelines for the management of clinical stage 1 renal masses recommends nephron-sparing surgery as standard of care, with consideration of ablative therapies as valid alternatives for patients with cT1a tumors less than 3 cm in diameter or for those with substantial comorbidities (Campbell et al., 2017).

Partial nephrectomy is the gold standard for the treatment of small renal tumors because it provides comparable oncologic outcomes (>95% CSS) compared with radical nephrectomy and is associated with improved preservation of renal function, superior cardiac outcomes, and improved overall survival (Huang et al., 2009; Pierorazio et al., 2016; Zini et al., 2009). However, irrespective of an open or laparoscopic/robotic surgical approach, nephron-sparing surgery is underused because of the comparative risks and attendant technical demands associated with the procedure (Abouassaly et al., 2009). Recent Surveillance, Epidemiology, and End Results (SEER) data found that partial nephrectomy use is increasing, yet many patients with localized renal tumors still undergo radical nephrectomy (Smaldone et al., 2012). Thus, to increase the number of patients offered nephron-sparing surgery and broaden the minimally invasive treatment options available to patients with small renal tumors, energy-based systems, including cryoablation (CA) and radiofrequency ablation (RFA), were introduced in the 1990s.

Focal ablative therapies offer several advantages compared with extirpative surgery. First, these modalities are less technically demanding than open, laparoscopic, or robotic partial nephrectomy, because renorrhaphy and hilar dissection are not obligatory. Consequently, renal tumor ablation is associated with shorter convalescence and fewer complications than extirpative surgery (Desai et al., 2005; Pierorazio et al., 2016). Equally important, several studies clearly demonstrated minimal impact on postablation renal function, with comparable or better postoperative renal function found when compared with that of partial nephrectomy (Bhindi et al., 2017; Lucas et al., 2008; Raman et al., 2008b; Ross et al., 2017; Woldu et al., 2015). Finally, all of the ablation modalities offer treatment versatility because they can be deployed in open, laparoscopic, or percutaneous procedures. Given these advantages, well-recognized indications for CA and RFA include patients with small renal tumors who are either poor surgical candidates or at risk for renal insufficiency, including patients with solitary kidneys, bilateral renal tumors, and hereditary syndromes such as von Hippel-Lindau disease. However, because of the excellent long-term published results, there is now growing experience with the treatment of the sporadic small renal tumors in healthy patients (Stern et al., 2009). Together with more robust operator experience and improved patient selection, renal CA and RFA technologies are now a viable treatment alternative for small renal tumors, in particular for those patients presenting with cT1a tumors less than 3 cm in diameter (2017 AUA guidelines). Experience with less mature (microwave ablation [MWA]) or novel technologies (irreversible electroporation [IRE] and stereotactic radiotherapy) are promising and hint at an expanding repertoire of minimally invasive modalities for renal tumor management in the near future.

Cryoablation

Background and Mode of Action

CA, or cryotherapy, is the practice of using extreme cold temperatures to treat a wide variety of pathological conditions. The use of cold therapy in medicine can be traced to the early Egyptians, who used cold to treat inflammatory conditions as early as 2500 BCE. However, CA was not used with a goal of tissue destruction until the mid-1800s, when an English physician, Dr. James Arnott, described using a combination of ice and salt to obtain temperatures (−18°C to −24°C) sufficient to treat breast, cervical, and skin cancers (Arnott, 1850). Over the course of the ensuing decades, multiple investigators described the use of cooled gases for treatment of various skin conditions, beginning with liquified air (−190°C), followed by solidified carbon dioxide (−78.5°C), liquid oxygen (−182.9°C), and then eventually liquid nitrogen (−196°C) (Freiman and Bouganim, 2005). In 1963 Cooper and Lee developed the first modern cryoprobe using pressurized liquid nitrogen passed through a three-channel probe (one inflow and two outflow) to achieve controlled temperatures of −196°C (Cooper, 1963). This revolutionary probe opened the possibility of treating less accessible areas rather than relegating cryotherapy solely to superficial areas such as the skin.

Although Cooper's design allowed for intra-abdominal treatment of large volumes, its use was limited by an inability to control or monitor the extent of the cryolesion. Without the availability of intraoperative imaging to visualize the expanding frozen tissue or “iceball,” physicians were forced to rely on physical examination to monitor treatment, such as digital rectal examination during prostate cryotherapy, which often led to excessive ablation and irreparable collateral damage (Weber and Lee, 2005). In the mid-1980s, Onik et al. (1984, 1985) discovered that the cryogenic ice-tissue interface was highly echogenic on ultrasonography, which allowed for real-time guidance for treating intra-abdominal malignancies. Further animal studies confirmed a close correlation between the sonographically visible iceball and the zone of cell death, providing a reliable and reproducible method of targeting and destroying tumors without attendant collateral damage (Campbell et al., 1998; Steed et al., 1997; Weber et al., 1998).

After nitrogen-based cryoprobes and ultrasound guidance, the next significant breakthrough in the use of CA came with the development of argon gas–based probes, which rely on the Joule-Thomson principle (low temperatures are achieved by the rapid expansion of high-pressure, inert gas) to generate temperatures of −185.7°C within the target tissues. In addition to providing a reliable target temperature, argon-based systems are more efficient than nitrogen-based probes, with target temperatures reached faster and with a steeper internal thermal gradient (Rewcastle et al., 1999). The majority of commercially available CA units now employ argon gas–based systems (CryoHit, Galil Medical, Plymouth Meeting, PA; CryoCare, CryoCare CS, Endocare, Irvine, CA; SeedNet, Oncura, Philadelphia, PA).

Tissue destruction during CA occurs during the freezing and thawing processes. Rapid freezing in the area closest to the cryoprobe forms ice crystals within the intracellular space that cause direct cellular injury through mechanical trauma to plasma membranes and organelles, leading to subsequent cell death mediated by ischemia and apoptosis (Baust and Gage, 2005; Hoffmann and Bischof, 2002; Ishiguro and Rubinsky, 1994; Mazur, 1977). As the freezing process expands further from the cryoprobe, the cooling process is slower, which encourages extracellular ice crystals to form, leading to a depletion of extracellular water and an osmotic gradient that causes further intracellular damage through dehydration and membrane rupture. During the thawing phase, extracellular osmolarity decreases as ice crystals melt, which leads to cellular edema and further disruption of cell membranes resulting from the rapid influx of water back into cells (Erinjeri and Clark, 2010). In addition to direct cellular damage, injury to blood vessel endothelium during the freezing process results in platelet activation, vascular thrombosis, and tissue ischemia (Kahlenberg et al., 1998; Rupp et al., 2002; Weber et al., 1997). The summative pathological consequence of treatment is coagulative necrosis, cellular apoptosis, and eventual fibrosis and scar formation.

Treatment Temperature

Tissue destruction during CA requires a certain threshold temperature, which is unique to the cell type and cellular environment of the target tissue. Whereas normal renal parenchyma is typically destroyed at −19.4°C, small animal models of CA indicate that temperatures as low as −50°C may be necessary to guarantee complete cellular death of cancerous tissue because of its more fibrous nature (Chosy et al., 1998; Gage and Baust, 1998; Larson et al., 2000). **Therefore the preferred target tissue temperature during CA is at or below −40°C.**

Importantly, the temperature of the progressing iceball is not uniform, with temperatures increasing the further the distance from the cryoprobe. Campbell et al. (1998) measured intrarenal temperatures during CA and referenced these to the leading edge of the ice-tissue interface. At the edge of the iceball, the temperature was measured at 0°C, correlating with the onset of the freezing process, whereas temperatures consistently below −20°C were not reached until 3.1 mm inside. Based on these findings, most authors advocate creating an iceball treatment zone that is at least 5 to 10 mm beyond the edge of the target lesion. Alternatively, small temperature probes may be positioned around the tumor periphery to ensure that adequate treatment temperatures (−40°C) are achieved (Rukstalis et al., 2001), which may be especially important for complex tumors or more challenging anatomy (Vernez et al., 2017). Depending on the size of the lesion and the type and size of probe used, reaching the appropriate target temperature within the entire mass may require the use of multiple cryoprobes (Breen et al., 2013). In addition, freezing is subject to the “heat sink” phenomenon, in which large blood vessels adjacent to the tumor may dissipate ice formation and require more extreme temperatures or longer periods of cooling (see the section on radiofrequency ablation and heat sink).

Freeze-Thaw Cycles

In vivo animal studies initially demonstrated adequate cell kill in normal tissue employing a single freeze-thaw cycle (Weber et al., 1997). However, further studies on implanted tumor cells in mice, then in dogs, found that multiple freeze-thaw cycles promoted a larger and more adequate area of liquefactive necrosis, improving subsequent cure rates (Neel et al., 1971; Woolley et al., 2002). **Therefore, in treatment of renal malignancies, the current recommendation is to perform a double freeze-thaw cycle to ensure complete cellular death.** The thawing process is also instrumental in cellular death and may be performed in a passive or active manner. Passive thawing, which relies on the iceball melting without any intervention after the cessation of argon gas through the cryoprobe, is more time consuming than active thawing, in which helium gas (rather than argon) is forced through the cryoprobe, creating a warming effect secondary to the Joule-Thomson principle. Although clearly more efficient, there are conflicting data on whether an active thaw is as effective as a passive thaw, leading to variation in practice patterns between centers (Klossner et al., 2007; Woolley et al., 2002). Some authors advocate a passive thaw between cycles and an active thaw at the end of treatment so that post-treatment bleeding may be more rapidly addressed (White and Kaouk, 2012).

Duration of Treatment

The duration of treatment to produce complete cellular death in humans is unknown. Auge et al. (2006) performed a prospective study in nine female farm pigs with CA performed for 5, 10, or 15 minutes. Although all lesions demonstrated complete cellular necrosis 5 mm from the probe, only animals treated for 10 or 15 minutes had necrosis extending 10 mm or more beyond the probes. Furthermore, animals treated for only 5 minutes had excessive bleeding, whereas those treated for 15 minutes had an increased risk for tumor fracture and subsequent hemorrhage. **Based on these findings, most contemporary series use a freeze cycle of 8 to 10 minutes** (Breen et al., 2013; Kim et al., 2013)**.**

Key Points: Cryoablation

- CA employs argon gas–based systems to achieve treatment temperatures of less than −40°C through the Joule-Thomson principle.
- CA of renal tumors should be performed under real-time imaging, with the treatment area approximately 5 to 10 mm beyond the margin of the tumor.
- A double freeze-thaw cycle, each 8 to 10 minutes in duration, is currently the standard of care during renal tumor CA.

Radiofrequency Ablation

Background and Mode of Action

RFA is the use of radiofrequency energy to heat tissue to the point of cellular death. RFA uses monopolar alternating electric current that is delivered directly into the target tissue at a frequency of 450 to 1200 kHz, leading to vibration of ions within tissue and resulting in molecular friction and heat production. Increasing temperature within the target tissue leads to cellular protein denaturation and cell membrane disintegration (Hsu et al., 2000; Tracy et al., 2010). Importantly, heat is not directly supplied by the probe, but rather by the agitation of ions within the tissue (Cosman et al., 1984). Study of the effect of radiofrequency energy dates back more than100 years to 1891 when d'Arsonval described the ability of radiofrequency waves to heat living tissue. Without a clear understanding of the technology and an inability to effectively control the energy, the use of radiofrequency energy in surgery did not become more mainstream until 1928, when Cushing and Bovie developed the electrocautery knife. Using radiofrequency energy, they described an ability to cauterize or cut tissue, ushering in the development of the modern-day electrocautery probe, which desiccates tissue at the point of contact when alternating current passes through the patient and then dissipates to a remotely placed grounding pad on the patient's lower extremities.

In 1990 two individual groups of researchers simultaneously reported the development of probes that could be used for percutaneous ablation (McGahan et al., 1990; Rossi et al., 1990). These probes consisted of a layer of insulation down to an exposed metal tip, which allowed for percutaneous passage of the needle to deeper target tissues. Using these needles, the amount of tissue destruction could be controlled along the central axis of the lesion by adjusting the length of the exposed, uninsulated portion of the needle. Although effective in ablating along the long axis of the lesion, these initial probes were limited in their ability to create circumferential tissue damage, preventing their use in lesions greater than 1.5 cm. Further refinements using these initial designs led to the development of modern RFA generators and probes, which are capable of treating larger and more complex lesions.

Variations in Radiofrequency Ablation Equipment

RFA can be performed with either a temperature-based or impedance-based monitoring system. Temperature-based systems work by measuring tissue temperatures at the tip of the electrode and are based on achieving a specific temperature for a given period. These systems accurately measure the temperature of the tissue at the electrode tip; however, they do not measure the temperature of the surrounding parenchyma. Alternatively, impedance-based systems measure the tissue impedance (resistance to alternating current) at the electrode tip and are based on achieving a predetermined impedance level at the tissue-probe interface that indicates complete tissue desiccation and thereby ablation. **There are no explicit clinical data that support the superiority of impedance or temperature-based systems.**

The original ablation probes, which were designed as single-electrode monopolar probes controlled by varying the exposed uninsulated tip, were capable of treating tumors no greater than 2 cm (McGahan et al., 1993). Therefore the treatment of larger tumors or the acquisition of an adequate tumor margin often required additional probes or treatment of overlapping regions. To achieve a larger overall treatment volume, LeVeen (1997) introduced an insulated monopolar probe (Boston Scientific, Natick, MA) with 12 deployable tines that function as radiofrequency antennas for the wider dispersion of current. These tines are deployed in an umbrella shape to create a spherical lesion. When high impedance is encountered at one prong, current is redirected to areas of lower impedance. The similar starburst–shaped RITA device (AngioDynamics, Queensbury, NY) uses thermistors embedded in five of the nine electrical tines to modulate energy based on the aggregate average temperature of the electrodes. An alternative monopolar system, by Covidien (Boulder, CO) uses an impedance-based system composed of a single 17-gauge (“cool tip”) electrode that is cooled internally with chilled saline to prevent charring of tissue adjacent to the probe. A direct comparison of these systems in the porcine liver demonstrated larger zones of ablation with the “cool tip” systems, more spheric ablation volumes with the 12-tine electrodes, and better reproducibility with the 9-tine electrodes (Pereira et al., 2004). Clinical validation studies have suggested more complete necrosis, better lesion accuracy, and superior treatment outcomes with multitine electrodes (Curley et al., 2000; Rehman et al., 2004; Rossi et al., 1998).

Another major classification in RFA technology is the differentiation between “dry” and “wet” RFA. As tissue desiccation increases in the target lesion, the charring effect (carbonization) on tissue leads to increased impedance and resistance to the alternating current of the electrode, limiting the size of the ablation zone with a single electrode to less than 4 cm. "Wet" RFA probes deliver a constant saline infusion into the tissue and in proximity to the probe to lower the temperature at the probe tip, thus mitigating the charring effect and corresponding premature rise in impedance, allowing for larger zones of ablation (Collyer et al., 2001; Goldberg et al., 1996; Lorentzen et al., 1997; Pereira et al., 2004). In addition, interstitial hypertonic saline infusion forms a virtual "liquid electrode" beyond the metal electrode so that the total electrode surface area is augmented (Ni et al., 1999). **Although lesions tend to be larger using "wet" RFA, there is less control of the exact size of ablation, which may lead to overtreatment of the target zone and disruption of adjacent normal parenchyma** (Frich et al., 2005).

Radiofrequency energy also can be delivered through bipolar electrodes. These devices generate current between two separate electrodes (one active and one negative), within the target tissue. The purported advantage of bipolar energy is that significantly higher temperatures are induced compared with those of monopolar devices (Nakada et al., 2003). In addition, heat is generated not only at the active probe but also adjacent to the ground needle and between the two electrodes (McGahan et al., 1996), resulting in a focus of coagulation necrosis that is larger than with a conventional monopolar electrode. The use of two separate electrodes, however, produces an elliptical area of coagulation necrosis rather than spherical; because most renal tumors are spherical, this technology has not been widely adapted for RFA of renal masses. In addition, clinical studies have revealed that the bipolar probes are less accurate than monopolar-based probes, with a wider variability in desired and actual target size (Rathke et al., 2014).

Treatment Temperature

The ability of RFA to ablate the target tissue relies on power delivered to the probe, the maximum temperature obtained, and the duration of the ablation (McGahan and Dodd, 2001). As stated, alternating radiofrequency current creates cellular agitation and, as a result of electrical impedance of the tissue, local heating. Provided that electrical impedance remains low, an expanding sphere of tissue damage emanates outward from the treatment probe. If current is administered too rapidly, charring occurs, which dessicates the tissue at the probe-tissue interface. This may lead to increased electrical impedance, blocking energy transfer and halting the heating process (Djavan et al., 2000;

Finelli et al., 2003). To prevent this phenomenon, which may lead to incomplete or nonuniform ablation, temperatures during RFA are generally kept at or below 105°C. It is also important to reach a minimum target temperature at which cellular death occurs. In in vitro studies using human prostate tissue, Bhowmick et al. (2004a, 2004b) achieved irreversible cell injury when benign and malignant cell lines were heated to 45°C for 60 minutes, 55°C for 5 minutes, and 70°C for 1 minute. Similarly, Walsh et al. (2007) found that even short exposures at temperatures higher than 70°C are lethal to human RCC in vitro. **To maximize cellular death without carbonization, modern temperature-based generators are programmed to reach a target temperature of 90°C to 105°C, and ablation should not be considered successful unless a minimum of 70°C is uniformly reached during the treatment cycle. Impedance-based systems are typically started at 40 to 80 W and increased at 10 W/min to a maximum of 130 to 200 W until an impedance of 200 to 500 ohms is reached.**

The ability of the thermal technology to reach its target temperature within the tissue depends not only on the probe itself and the energy delivered but also on the surrounding treatment environment (Goldberg et al., 2000). In particular, **when the target zone is highly vascularized or is adjacent to large vessels, thermal energy is preferentially dispersed to the comparatively cooler blood within these vessels. This heat sink effect may therefore spare tumor cells in proximity to large blood vessels and lead to treatment failures.** Temporary renal ischemia during RFA experimentally increases the size of the initial treatment lesion and shortens the time to reach target temperature (Corwin et al., 2001). However, hilar occlusion is not currently recommended because of the risk for arterial thrombosis and ischemia-reperfusion injury to normal parenchyma. To prevent complications of vascular clamping, some authors advocate selective arterial embolization when performing RFA (Hall et al., 2000). The authors have successfully employed this approach for a few central or large (>4 cm) tumors to reduce the circulatory heat sink.

Although most studies show cellular death with a single RFA treatment, studies in animals using CA have demonstrated improved cell death with multiple cycles. Therefore, when employing a temperature-based system, we typically recommend using two separate RFA cycles separated by a minimum 30-second cool-down period (Park et al., 2006a).

Intraoperative Monitoring

Although it is possible to visualize placement of the RFA probe using ultrasonography, magnetic resonance imaging (MRI), or CT guidance, there is currently no reliable manner to evaluate the zone of treatment radiographically (Rendon et al., 2001; Renshaw, 2004). In contrast to CA, in which the expanding iceball indicates the zone of treatment, the RFA treatment zone is determined solely by the probe choice, accurate placement, and measurement of electrical impedance or temperature. An alternative method, which also may be used with CA, is to place nonconducting temperature probes around the periphery of the tumor or at the deep margin to measure real-time treatment temperatures independent of the RFA device. Using this method, Carey and Leveillee (2007) demonstrated 100% clinical success in treating tumors up to 5 cm in diameter. Experimental imaging modalities, including real-time contrast-enhanced ultrasonography (Chen et al., 2013; Johnson et al., 2005), magnetic resonance thermometry (Ertürk et al., 2016), and magnetic resonance elastography (Li et al., 2013), have shown some promise experimentally but have not been properly evaluated in the clinical setting. **The successful ablation of a renal lesion with RFA therefore is highly dependent on precise probe placement, and outcome is typically determined only by feedback from the generator, thermal probes, and the absence of contrast enhancement during percutaneous axial image-guided RFA.**

Key Points: Radiofrequency Ablation

- Transfer of radiofrequency energy generates ionic friction and agitation within tissue that results in heating. When temperatures exceed 70°C for 1 minute or more, irreversible coagulative necrosis and tissue desiccation occur.
- Treatment may be either temperature-based or impedance-based.
- Real-time monitoring of ablation depends on measurement of electrical impedance and temperature rather than visual or radiographic cues.

Surgical Technique

Transperitoneal and Retroperitoneal Laparoscopic Renal Cryoablation and Radiofrequency Ablation

See Chapter 61 for these modalities.

Percutaneous Renal Cryoablation and Radiofrequency Ablation (See Video 103.1)

Depending on treating physician preference, percutaneous tumor ablation is performed under either conscious sedation with local anesthesia or general endotracheal anesthesia on an outpatient basis or with 23-hour observation. General endotracheal anesthesia enables control of respiration during probe placement and tumor biopsy that may translate into more accurate targeting and improved overall outcomes (Gupta et al., 2009). Conversely, conscious sedation minimizes the morbidity and time of the procedure. After administration of intravenous prophylactic antibiotics, the patient is positioned in either a prone or modified flank position on the CT gantry, with the choice of position largely dictated by the tumor location. CT guidance is by far the preferred and most common targeting technique, although ultrasound and magnetic resonance guidance also have been reported (Dong et al., 2016; vanOostenbrugge et al., 2017).

A noncontrast CT image is obtained first to confirm tumor size and position in the prone or lateral position, and a contrast-enhanced CT image is then often obtained to better delineate the tumor. A radiographic grid placed on the patient's skin can help localize placement of the needle. A 20-gauge “finder needle” or access sheath may be inserted under CT guidance near the expected location of the tumor, with position confirmed through repeated imaging. Using this finder needle as a guide, the ablation probe(s) is then positioned to treat the tumor. The number of probes and the duration of treatment are determined based on lesion size in accordance with the manufacturer's recommendations. Serial imaging is used to confirm the placement of all treatment probes/tines. **Before a thermal ablation is scheduled, needle biopsy confirming malignancy is strongly**

recommended to confirm the need for treatment and dictate follow-up (Campbell et al., 2017). However, if a tumor biopsy has not been performed preprocedure, an 18-gauge core biopsy needle should be obtained and sent for permanent section before the initiation of therapy. Importantly, the treatment probes should be placed into the tumor before the biopsy is obtained because perinephric hematoma formation may obscure visualization of the tumor. Probe and biopsy needle positioning and adjustments are performed with breath holding to standardize the position of the mobile kidney with each sequential pass of the needle.

Monitoring of treatment efficacy during CA employs imaging of the ablation zone. **Although each cryoprobe tip reaches temperatures of −140°C to −190°C, there is a steep temperature gradient that falls to 0°C at the edge of the iceball.** Temperatures of less than −20°C are achieved at a distance of 3.1 mm inside the edge of the iceball (Campbell et al., 1998). **Because tumor cell death is reliably achieved at target temperatures of −40°C** (Campbell et al., 1998)**, the iceball should propagate 5 to 10 mm beyond the tumor margin to ensure complete treatment.** The iceball appears as a distinct hypodense zone on CT imaging (Fig. 103.1). As previously mentioned in the section on mechanism of action, two freeze-thaw cycles are performed to obtain more complete tissue necrosis (Woolley et al., 2002). Unlike RFA, with which lesions are typically treated for a predetermined period, there is no standard duration for a freeze cycle as long as the intended ablation zone size is attained. Ten minutes is commonly used during the initial cycle, and the second cycle is generally shorter (6 to 8 minutes) based on animal evidence demonstrating inadequate necrosis at 5 minutes and increased tissue fracture at 15 minutes. Thus 10-minute freeze cycles represent an optimal compromise with adequate tumor necrosis and fewer complications (Auge et al., 2006). Each freeze cycle is followed by either an active (helium-based) or passive thaw. Although there is conflicting evidence regarding an active versus passive thaw, some authors suggest an active thaw during at least the second thaw cycle to decrease operative time and allow the surgeon to more rapidly address post-treatment bleeding (White and Kaouk, 2012). After the second cycle thaw, the probe is gently twisted, and, if there is no resistance, it is removed atraumatically. A contrast-enhanced CT is repeated after treatment to assess completeness of ablation and rule out complications.

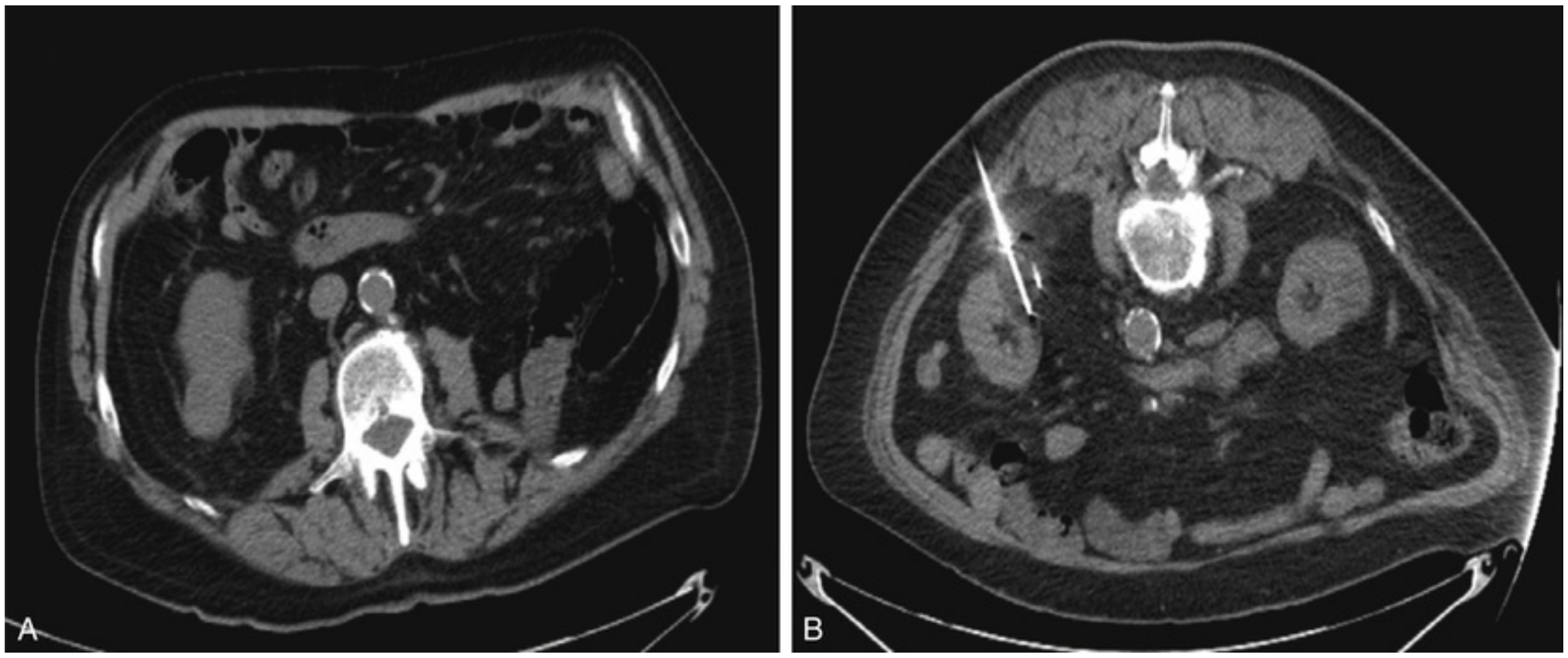

FIG. 103.1 Percutaneous cryoablation. (A) Preoperative imaging demonstrates a 2.6-cm exophytic renal cell carcinoma on the posterior aspect of the right kidney. (B) Intraoperative image during percutaneous ablations shows low attenuation area corresponding to the iceball. (Courtesy Ardeshir Rastinehad, MD, Department of Urology, North Shore-Long Island Jewish Health system.)

Monitoring of treatment efficacy during RFA employs measurement of tissue temperature or impedance, using either single multitined probes (with incorporated thermistors) or multiple single-shaft probes that measure tissue impedance as the end point. At our institutions, a 14-gauge Starburst XL (AngioDynamics, Queensbury, NY) **RFA probe is deployed, and its position is adjusted to ensure complete lesion coverage plus a peritumoral margin of at least 5 mm** (Fig. 103.2). To limit radiation exposure to the patient, confirmatory scans should be limited to 3 to 4 3-mm images centered around the target lesion at a lower current than standard helical imaging (70 mA vs. 150 mA) (Tracy et al., 2015). Ablation cycles of 5, 7, and 8 minutes at a target temperature of 105°C are then delivered for tine deployments of less than 2 cm, 2 to 3 cm, and 3 to 4 cm, respectively. After a 30-second cool-down, a second cycle of similar duration is performed. During the initial and secondary cool-down cycles, the passive tissue temperature in each quadrant should be at least 70°C, confirming the absence of a large heat sink. Contrast-enhanced helical CT is repeated after treatment to assess completeness of ablation and rule out complications. If inadequately treated areas are identified, the radiofrequency probe is repositioned and the treatment is repeated in a similar fashion. Depending on the manufacturer, the probe tract is ablated during probe withdrawal. For ablation of larger lesions, some authors have described the use of nonconducting temperature probes placed at the peripheral and deep margins of the tumor for active temperature monitoring (Carey and Leveillee, 2007). Rather than multitined probes, multiple individual probes also can be used in overlapping ablations (Karam et al., 2011). Patients who undergo percutaneous CA or RFA under general anesthesia or conscious sedation are discharged in a same-day fashion, whereas those with significant comorbidities or complication typically are admitted overnight.

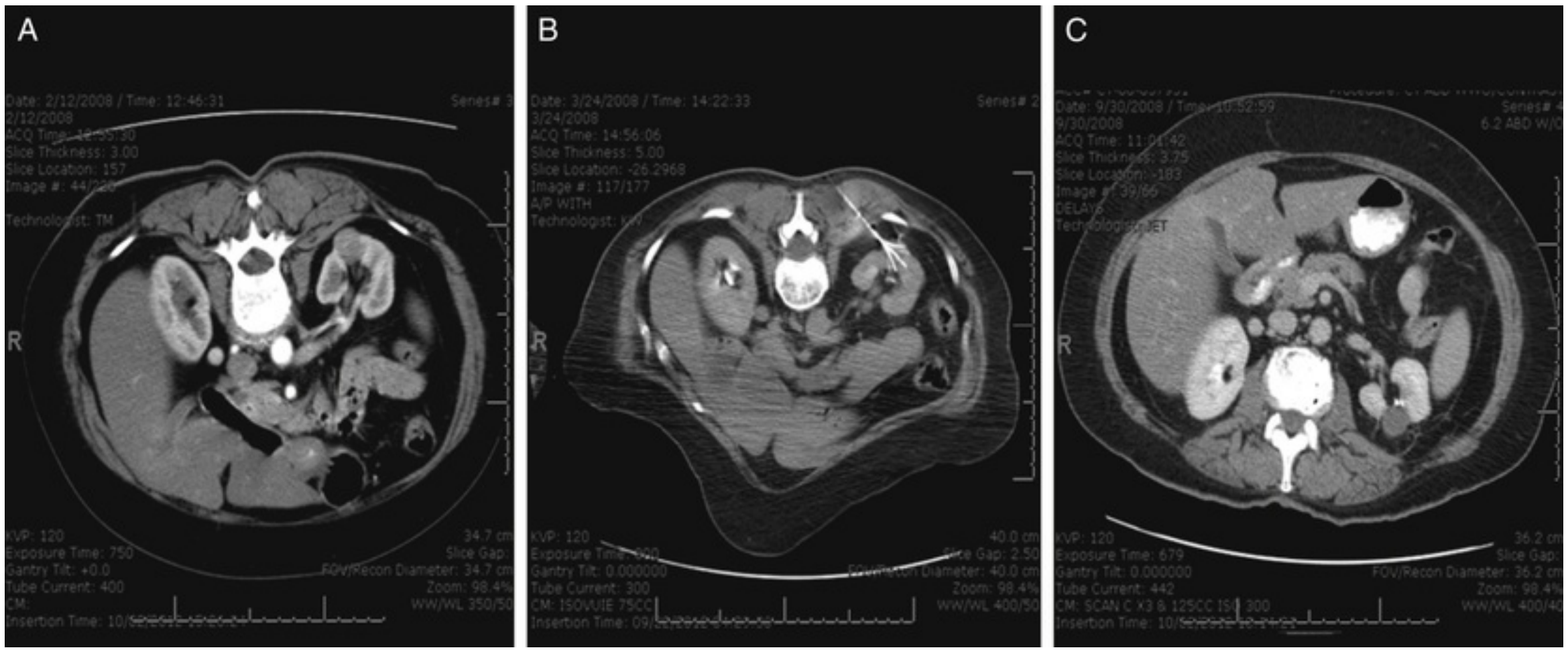

FIG. 103.2 Radiofrequency ablation (RFA) probe positioning and postablation findings. (A) Posterior left renal tumor before ablation. (B) RFA probe positioned. (C) Six months after ablation imaging with characteristic periablation halo sign.

Treatment Success and Follow-Up Protocol After Tumor Ablation

Interpretation of treatment success after renal tumor ablation had been a controversial subject, but with maturing experience and standardization of follow-up protocols, **radiographic cross-sectional imaging is the accepted measure of treatment efficacy** (Donat et al., 2013; Matin et al., 2006). Routine postablative biopsy is not recommended because the interpretation of biopsy findings after ablation is highly contentious and unresolved. When enhancement and involution are incongruent or recurrence is suspected, multisite-directed core biopsies are appropriate.

Radiographic Interpretation of Success

No pathological margins are rendered with in situ ablation; therefore imaging characteristics serve as a surrogate marker of treatment efficacy. In general, the **complete loss of contrast enhancement on follow-up CT or MRI is considered evidence of thorough tissue destruction and attendant treatment success** (Matsumoto et al., 2004; McAchran et al., 2005). At most centers, the first postablation CT or MRI image is obtained at 6 to 12 weeks. **If persistent enhancement is identified in any portion of the treated lesion on initial imaging, it is classified as an incomplete ablation and repeat ablation is scheduled** (Fig. 103.3)**. Conversely, if a lesion demonstrates an initial complete loss of contrast enhancement and later demonstrates enlargement of the lesion and/or contrast enhancement, this is considered local tumor recurrence or progression** (Matin, 2010)**.**

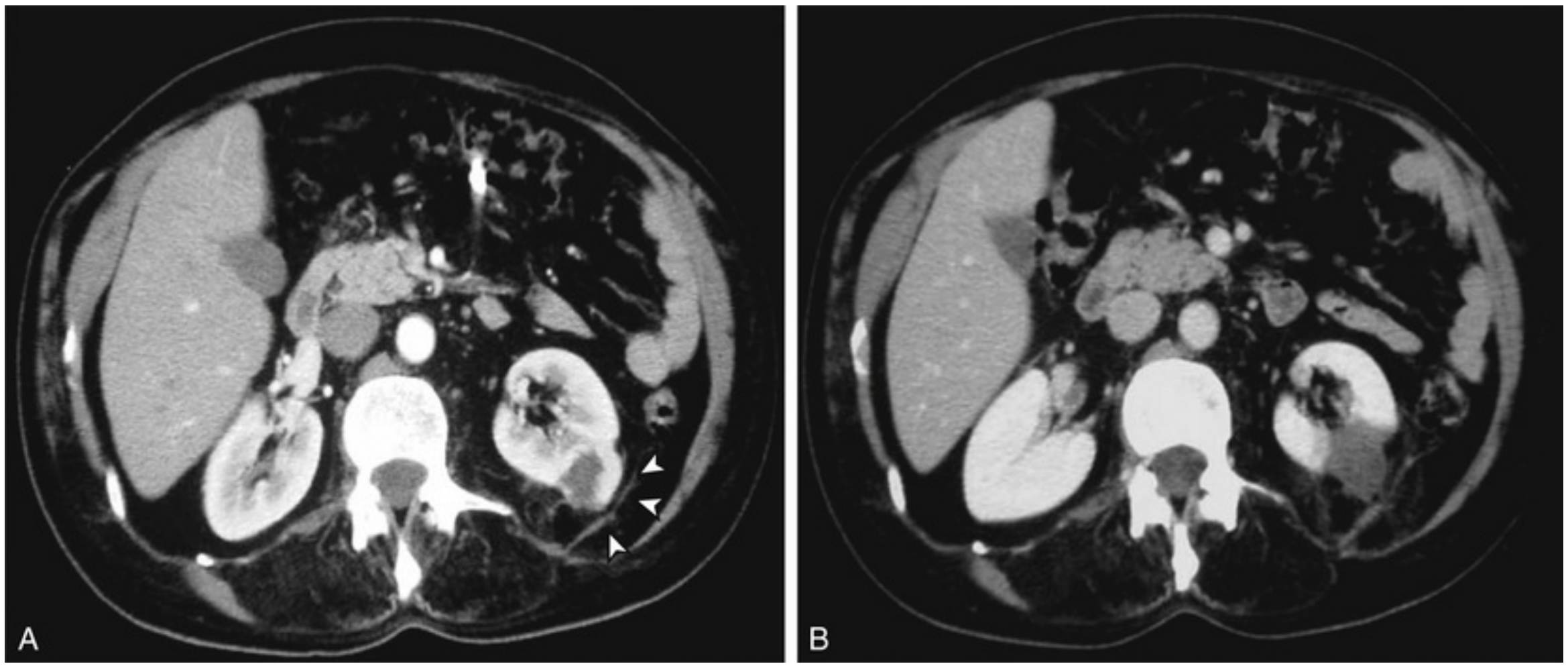

FIG. 103.3 Incomplete ablation with radiofrequency ablation. (A) Six-week follow-up computed tomography scan shows contrast enhancement of a left renal cell carcinoma indicative of an incomplete ablation *(arrowheads).* (B) After repeat ablation, the tumor shows no further enhancement on subsequent 6-week follow-up.

In addition to contrast-related characteristics, lesions that undergo CA or RFA demonstrate characteristic but strikingly different appearances on follow-up imaging. **The majority of lesions treated with CA demonstrate a greater than 50% reduction in size in the first year after treatment** (Deane and Clayman, 2006; Kawamoto et al., 2009). This contraction is due to cellular breakdown and phagocytosis. Conversely, **lesions treated with RFA often demonstrate minimal postablative contraction and a have a distinctive fibrotic halo or circular demarcation around the treatment zone when performed percutaneously** (see Fig. 103.2C), representing a foreign-body giant cell fibrotic response (Park et al., 2006b). **Enlargement of a lesion, regardless of the treatment modality or the enhancement characteristics, should be considered a tumor recurrence,** and biopsy and/or treatment (observation vs. repeat ablation vs. extirpative surgery) should be strongly considered.

Recommended Radiographic Follow-Up Protocol

The AUA guidelines for the follow-up of an ablated renal tumor recommend that **CT or MRI with and without intravenous contrast should be performed at 3 to 6 months after ablation and then annually thereafter for 5 years** (Donat et al., 2013). There are no available data suggesting the superiority of MRI or CT in routine follow-up. Ultrasonography should not be routinely employed to evaluate lesions after ablation unless specific protocols are in place for contrast-enhanced ultrasonography.

Role of Preablation and Postablation Biopsy

To establish a diagnosis and provide uniformity and improved outcomes-based data, the AUA Small Renal Mass and the Follow-up for Clinically Localized Renal Neoplasms Guidelines Panels recommend that tumor biopsy be universally performed before ablation (Campbell et al., 2017; Donat et al., 2013). The diagnostic accuracy in specimen interpretation is high (Schmidbauer et al., 2008) and will help define the frequency of postablation follow-up. Conversely, one of the chief criticisms of in situ renal ablation has been the inability to render definitive pathological evidence of treatment success. Efficacy with ablative technologies is therefore predicated solely on indirect radiographic interpretation, as previously discussed. The role of a routine postablation biopsy has yielded conflicting data on its utility given questions surrounding the oncologic accuracy of the histologic interpretation, inherent sampling error, and poor correlation with long-term oncologic results (Klingler et al., 2007; Lin et al., 2004; Matlaga et al., 2002; Raman et al., 2008a; Weight et al., 2008). Considering the dual limitations of imaging studies and biopsy findings, **a multi-institutional study on the incidence and patterns of recurrence after energy ablative therapy concluded that radiographic detection of residual or recurrent disease is the current state of the art when performed correctly** (Matin, 2010).

Key Points: Follow-Up After Tumor Ablation

- Complete loss of contrast enhancement on follow-up CT or MRI is considered evidence of complete tissue destruction and treatment success.
- The majority of lesions treated with CA demonstrate a greater than 50% reduction in size in the first year after treatment. Lesions treated with RFA demonstrate minimal postablative contraction and a have a distinctive fibrotic halo or circular demarcation around the treatment zone. Enlargement of a lesion, regardless of the treatment modality or the enhancement characteristics, should be construed as an ominous sign of

local tumor recurrence.

- The AUA Guidelines Panel recommends that a pretreatment tumor biopsy be universally performed before ablation.
- The same Guidelines Panel recommends that a CT or MRI scan with intravenous contrast should be performed at 3 and 6 months after ablation and then annually thereafter for 5 years.

Oncologic Outcomes

Several confounding variables in the literature complicate the interpretation and comparison of oncologic success after thermal ablation, including small cohort sizes, short follow-up, inclusion of patients with benign masses, lack of preablation biopsy, inclusion of patients with confounding features for RCC recurrence such as hereditary cancer syndromes, use of various (and evolving) technologies, and variable definitions of recurrence. Fortunately, as the ablative literature continues to mature, the quality of evidence has continued to improve, with the majority of series now controlling for most of these variables. Tables 103.1 and 103.2 summarize RCC-specific outcomes for RFA and CA, respectively, in select series with intermediate- to long-term follow-up. Although a direct comparison between ablation and partial nephrectomy is limited by patient, tumor, and surgeon selection biases, as well as inconsistent definitions of postablation recurrence, **data suggest that progression-free survival and disease-specific survival are similar for energy ablative therapy and extirpative therapy in the intermediate term, exceeding 90% in each case.** In a head-to-head comparison of RFA and partial nephrectomy in patients with sporadic unilateral T1a RCC, 5-year actual local recurrence-free survival (LRFS), overall disease-free survival (DFS), and progression-free survival were statistically similar between cohorts when including patients who may have required a second ablation for incomplete primary treatment (Olweny et al., 2012). Similarly, a separate comparison of TA (CA and RFA) to partial nephrectomy showed no difference in recurrence-free survival (RFS) among the varying modalities at 3 years of follow-up (Thompson et al., 2015).

TABLE 103.1

Intermediate-Term to Long-Term Outcomes After Radiofrequency Ablation of Biopsy-Proved Renal Cell Carcinoma

AUTHOR	NO. PATIENTS (NO. TUMORS)	FOLLOW-UP (yr) (RANGE)	TUMOR SIZE (cm) (RANGE)	TECHNIQUE	% LOCAL RECURRENCE-FREE SURVIVAL	% M R
Psutka et	185 (185)	Median	Median 3	Perc	5-yr: 95.2	5-

al., 2013		6.43 (0.5–13.4)	(1–6.5)			
Tracy et al., 2010	160 (179)	Mean 2.25 (0.13–7.5)	Mean 2.4 (1.0–5.4)	Perc and Lap	5-yr: 90	5-
Zagoria et al., 2011	41 (48)	Median 4.67 (IQR 3–5.3)	Median 2.6 (0.7–8.2)	Perc	5-yr: 88	5-
Olweny et al., 2012	37 (37)	Median 6.5 (IQR 5.8–7.1)	Median 2.1 (IQR 1.8-2.8)	Perc and Lap	5-yr: 91.7	5-
Levinson et al., 2008	18 (18)	Mean 4.8 (3.4–6.7)	Mean 2.1 (1–4)	Perc	5-yr: 79.9	5-
Wah et al., 2014	165 (200)	Mean 3.8 (0.2–8)	Mean 2.9 (1–5.6	Perc	5-yr: 93.5	
Atwell et al., 2013	222 (256)	Mean 2.8 (1.2–4.1)	Mean 1.9 (0.6–3)	Perc	5-yr: 98.1	5

[a] Overall survival for entire cohort, including 22% with nondiagnostic or benign histology.

[b] No recurrences observed in patients with tumors less than 4 cm in size.

[c] Patients with no history of RCC.

CSS, Cancer-specific survival; *DFS,* disease-free survival; *IQR,* interquartile range; *Lap,* laparoscopic; *MFS,* metastasis-free survival; *OS,* overall survival; *Perc,* percutaneous; *RCC,* renal cell carcinoma.

TABLE 103.2

Intermediate-Term to Long-Term Outcomes After Cryoablation for Biopsy-Proved Renal Cell Carcinoma

AUTHOR	NO. PATIENTS (NO. TUMORS)	FOLLOW UP (yr) (RANGE)	TUMOR SIZE (cm) (RANGE)	APPROACH	% LOCAL RECURRENCE-FREE SURVIVAL	% M R
Caputo et al., 2015	100	Mean 8.2	Mean 2.4 (0.5–5.2)	Lap	97	–
Guazzoni et al., 2010	44	Mean 5.1	Median 2.14 (0.5–4)	Lap	93.2[a]	9
Johnson et al., 2014	67	Mean 8.2	Mean 2.3	Lap	91.4	9

			(0.86–7)			
Nielsen et al., 2017	514	Median (IQR) 3 (1.2–4.7)	Median (IQR) 2.5 (2.0–3.0)	Lap	93.8	—
Tanagho et al., 2012	35	Mean 6.3 (SD 3.3)	Mean 2.5 (SD 0.98)	Lap	6-yr LRFS 80	6

[a] Although these patients received salvage therapy by radiofrequency ablation or radical nephrectomy, the authors did not include them in their analysis of recurrences.

CSS, Cancer-specific survival; *DFS,* disease-free survival; *IQR,* interquartile range; *Lap,* laparoscopic; *LRFS,* local recurrence-free survival; *MFS,* metastasis-free survival; *OS,* overall survival; *RFS,* recurrence-free survival.

Altogether, intermediate and long term results of CA and RFA demonstrate the durability of ablation for the treatment of small cortical neoplasms, allowing for expanding indications. **The AUA guidelines now recommend that physicians consider thermal ablation as an alternative approach for the management of cT1a renal masses less than 3 cm in diameter** (Campbell et al., 2017), with an understanding that tumor recurrence or persistence may be more likely and that repeat ablation may be required.

Local Recurrence-Free Survival

The definition of local recurrence-free survival is likely the most contested point with regard to comparing CA, RFA, and partial nephrectomy. In addition to varying time points for defining success ranging from days to months, surgical approach may confound initial success rates. In particular, compared with partial nephrectomy and cryotherapy, which has been generally reported in the literature using either an open or laparoscopic technique, the majority of RFA cases are performed percutaneously. Because percutaneous treatments are considered to be easily repeatable, physicians performing the procedure may be less aggressive with their initial treatment compared with those approaching a malignancy in an open or laparoscopic fashion. Surgeons performing percutaneous ablation therefore may be more accepting of persistent disease on short-term follow-up, presuming that the tumor may be completely ablated with a second, minimally invasive procedure. Indeed, several studies have demonstrated similar recurrence-free survival rates between CA and RFA when taking into account the percutaneous versus laparoscopic approach (Matin et al., 2006; Permpongkosol et al., 2006, Zargar et al., 2015).

Local recurrence is most often defined as any evidence of residual disease remaining in the treated kidney after the primary ablation procedure. Using this definition, **the 2009 AUA Guidelines Panel examined 10 studies of CA and 10 studies of RFA and determined a local recurrence-free survival of 90.6% (83.8% to 94.7%) for CA and 87.0% (83.2% to 90%) for RFA** (Campbell et al., 2017)**. When compared with alternative extirpative treatments, the 2017 AUA guidelines recognized that CA and RFA demonstrated significantly higher rates of local recurrence but no significant difference in local recurrence-free survival when considering repeat ablation.** Importantly, in a more recent meta-analysis, El Dib et al. (2012) reviewed 31 case series (20 CA, 11 RFA) and found no difference in the clinical efficacy (89% vs. 90%) between CA and RFA, respectively.

Several recent meta-analysis have investigated the risk for local tumor recurrence after TA compared with extirpative surgery. In an analysis of 147 studies on the management of localized renal masses, Pierorazio et al. (2016) found that at a median of 60 months in the extirpative cohorts and 48.6 months in thermal ablation cohorts, there was an increased local recurrence-free survival (LRFS) with partial nephrectomy compared with TA (98.9% vs. 93%). However, this difference became insignificant when considering the LRFS after a subsequent salvage ablative procedure, which increased the efficacy of TA to 97% to 100%. Likewise, Katsanos et al. (2014) found that in 587 patients with small renal tumors who underwent TA versus nephrectomy, there was no difference in local recurrence rate (3.6% vs. 3.6%) at 5 years. A cohort study using data from the SEER registry found that patients undergoing nephron-sparing surgery had a 5-year disease-specific survival that was incrementally improved (1.7%) over ablation (Whitson et al., 2012), although there was no significant difference in the risk for death when comparing the two treatments. Interestingly, the authors noted that the difference in disease-specific survival between nephron-sparing surgery and ablation has decreased over time, possibly indicating improved outcomes from ablative procedures as a result of increased experience, improved patient selection, and technical modifications.

In addition to surgical factors and their influence on outcomes after ablative procedures, long-term follow-up data suggest that tumor size is a significant indicator of ablation success. Best et al. (2012) found that in patients undergoing RFA, the 5-year overall local recurrence-free survival in 108 biopsy-proved RCCs was 95% for those with tumors smaller than 3 cm but only 78% for those with tumors 3 cm or larger ($P = 0.002$). This was similar to a subsequent study by Psutka et al. (2013), which demonstrated a 5-year LRFS and overall disease-free survival after RFA of 96.1% and 91.5% with tumors smaller than 4 cm (T1a) compared with 91.9% and 74.5% in tumors larger than 4 cm (T1b). Tanagho et al. (2012) demonstrated a 6-year overall disease-free survival of 80% after CA, with tumor size 2.6 cm or greater the only predictor of oncologic failure on multivariate analysis. Expanding on this observation, a more recent publication by Caputo et al. (2017) evaluated their experience treating T1b tumors (>4 and <7 cm) with CA vs. partial nephrectomy and found a 23% recurrence rate with CA compared with PN despite a modest overall tumor size in the CA and PN cohorts (4.3 cm vs. 4.6 cm, $P = 0.07$).

Metastatic Recurrence-Free Survival

Metastatic recurrence-free survival is generally defined as any disease present in the body other than in the treated kidney or associated renal fossa after primary treatment. Based on this definition, **recent meta-analyses have found no difference in metastasis-free survival when comparing extirpative surgery and TA** (Katsanos et al., 2014; Pierorazio et al., 2016).

As seen in Tables 103.1 and 103.2, multiple centers have reported on their intermediate- to long-term outcomes, including multiple series with more than 5 years of follow-up for RFA (Best et al., 2012; Olweny et al., 2012; Psutka et al., 2013; Tracy et al., 2010; Zagoria et al., 2011) and CA (Aron et al., 2010; Tanagho et al., 2012). Although the presence of confounding factors precludes meaningful comparisons among these studies, **these data seem to support the fact that outcomes for ablative procedures are durable beyond 5 years and up to 10 years**.

Cancer-Specific Survival

The AUA meta-analysis published in 2009 evaluated the risk for dying from RCC after CA or RFA and concluded that **CSS was 95.2% (89.2% to 97.9%) with CA and 98.1% (95.2% to 99.2%) with RFA with no significant difference in CSS between CA and RFA.** Although selection bias and short duration of follow-up may confound these results, more recent publications reporting on long-term outcomes have verified a CSS ranging from 80% to 100% at up to 10 years for CA (Caputo et al., 2017; Tanagho et al., 2012; Zargar et al., 2015) and approximately 98% for RFA (Olweny et al., 2012; Psutka et al., 2013; Zagoria et al., 2011). **Recent meta-analyses have found no difference in CSS when comparing extirpative surgery and TA** (Katsanos et al., 2014; Pierorazio et al., 2016).

Overall Survival

Patients undergoing ablative procedures tend to be older and have more comorbidities than those undergoing extirpative surgery (Campbell et al., 2017). Thus the mean overall survival rate after ablative procedures is typically 75% to 85% at 5 years, decreasing to 54% to 64% at 10 years (Caputo et al., 2015; Nielsen et al, 2017; Psutka et al., 2013; Tracy et al., 2010).

Cryoablation Versus Radiofrequency Ablation

No data directly compare percutaneous and laparoscopic CA to its respective RFA counterparts. Beyond issues of ill-defined radiologic and pathological end points, there is considerable variability in patient selection, tumor size and location, technique, and approach (laparoscopic vs. percutaneous), as well as inherent bias for a particular ablative modality.

Two large single-institution studies with significant experience with CA and RFA have reported comparable oncologic outcomes, impact on renal function, and complication rates. In 2006 Hegarty et al. compared outcomes in a somewhat disparate cohort of 164 laparoscopic CA procedures and 82 percutaneous RFA procedures. Although there was no significant difference in tumor size between the two groups, the RFA cohort contained more patients with central tumors and tumors in solitary kidneys, which likely accounted for the higher radiographic evidence of disease persistence or recurrence noted in patients who underwent percutaneous RFA (11% vs. 2% for laparoscopic CA). Importantly, there was no significant impact on renal function with either modality, and the short-term CSS for CA and RFA were comparable at 98% and 100%, respectively. More recently, Atwell et al. (2013) reported their single-institution contemporary outcomes comparing percutaneous ablation using either RFA or CA. Overall, in their experience with 445 tumors 3 cm or smaller over a 10-year period (256 RFA, 189 CA), the local tumor recurrence rate was 3.2% for

RFA at a mean of 2.8 years and 2.8% for CA at a mean of 0.9 year. In patients with biopsy-proved RCC, there was no difference in local recurrence-free survival at 1 (100% vs. 97.3%), 3 (98.1% vs. 90.6%), and 5 years (98.1% vs. 90.6%), when comparing RFA and CA, respectively.

Ultimately, the result of multiple meta-analyses offers the most insight into the comparative oncologic merit and potential limitations of CA and RFA (Campbell et al., 2017; El Dib et al., 2012; Kunkle and Uzzo, 2008). **It appears that there is no significant difference in the risk for local tumor recurrence, disease progression/metastasis, CSS, and overall survival between CA and RFA, leading more recent studies to combine the two modalities into one category when comparing outcomes with extirpative procedures** (Pierorazio et al., 2016)**. Currently, RFA and CA are recognized options for patients who elect thermal ablation** (Campbell et al., 2017)**, with choice of therapy type dependent on institutional preference as well as tumor characteristics.**

Laparoscopic Versus Percutaneous Renal Tumor Ablation

One limitation when comparing series of renal tumor ablation to each other is the variability in technique. The assumption that the success of a laparoscopic and percutaneous ablation is comparable remains debatable. Indeed, until recently the vast majority of published CA series were approached laparoscopically, whereas more than 95% of RFA procedures were performed percutaneously. Zargar et al. (2015) retrospectively compared 275 patients undergoing laparoscopic cryoablation (LCA) to 137 undergoing percutaneous cryoablation (PCA) at their institution. Despite an increase in tumor complexity in the percutaneous cohort, the authors found no difference in 5-year recurrence-free survival (RFS) for LCA vs. PCA (79% vs. 80%) at a median of 4.4 and 3.1 years, respectively. Likewise there was no difference in incomplete treatment (6.9% vs. 6.6%) or local recurrence based on approach for LCA versus PCA (13.1% vs. 14.6%). Similarly, Leveillee et al. (2013) reported their experience with laparoscopic and percutaneous RFA in 274 patients with 292 tumors. The radiographic recurrence rate for either approach was only 4%. **Given morbidity and cost advantages, the percutaneous approach for thermal ablation is preferred** (Campbell et al., 2017). Similar studies comparing laparoscopic and percutaneous tumor ablation have confirmed these findings for RFA and CA (Derweesh et al., 2008; Hinshaw et al., 2008; Hui et al., 2008; O'Malley et al.,

2006).

Key Points: Oncologic Outcomes

- The interpretation of oncologic outcomes after renal tumor ablation is subject to confounding variables such as the inclusion of nonmalignant tumors.
- When compared with alternative extirpative treatments, CA and RFA demonstrate significantly higher rates of local recurrence, albeit they can be salvaged with repeat ablation or surgery.
- There is no apparent significant difference in metastatic recurrence-free survival when comparing RFA and CA to each other or against extirpative treatments.
- Any discussion of oncologic efficacy regarding ablative technologies must focus on long-term markers of success, such as metastasis-free survival, CSS, renal function preservation, and quality-of-life outcomes.

Complications

A meta-analysis comparing urologic and nonurologic complications after CA, RFA, and alternative extirpative approaches (Campbell et al., 2017) revealed that **the incidence of major urologic complications with renal CA and RFA was 4.9% (range 3.3% to 7.4%) and 6.0% (4.3% to 8.2%), respectively. Major nonurologic problems occurred in 5% (3.5% to 7.2%) of patients undergoing CA and 4.5% (3.2% to 6.2%) of those undergoing RFA. The risk for major urologic complications was lower with ablative techniques than with either laparoscopic or open partial nephrectomy. There was no significant difference in urologic complications with CA versus RFA.** Likewise, the more recent meta-analysis by Katsanos et al. (2014) also showed significantly fewer overall and major complications with TA compared with nephrectomy (7.4% vs. 11.1% and 2.3% vs. 5%, respectively).

The majority of complications that occur with renal ablation are minor, with major complications occurring in approximately 2% of cases (Katsanos et al., 2014). However, up to 20% of complications may require hospital readmission, procedural intervention, or transfusion (Johnson et al., 2004). **Laparoscopic ablation tends to have a higher rate of complications than percutaneous ablation, with an estimated one-third of laparoscopic ablation complications occurring as a result of laparoscopic technique** (Johnson et al., 2004)**.** Complications decrease significantly, regardless of surgical approach, with increasing operative experience.

Several authors have attempted to objectively determine the risk for complications using patient and tumor characteristics. Using the findings of prior studies on extirpative surgery for renal malignancy that demonstrated that the RENAL nephrometry score (Kutikov and Uzzo, 2009) can predict surgeon preference and postoperative complications (Canter et al., 2011; Rosevear et al., 2012), most authors have now started to include this variable in their outcomes. In a retrospective review of 77 laparoscopic CAs performed at three high-volume centers, Okhunov et al. (2012) reported their complication rates based on low (4 to 6), moderate (7 to 19), or high (10 to 12) nephrometry scores. Overall, their cohort had a complication rate of 19.5%, including 9.5% with major complications. There was a significant association with tumor complexity and complications, with no complications in the low complexity cohort compared with 35% and 100% of those with moderate or high nephrometry scores, respectively. Similarly, Schmit et al. (2013) reported their extensive experience with 679 percutaneous tumor ablations, stratifying patients by renal complexity based on nephrometry score to predict outcomes and complications of percutaneous ablation (CA and RFA). In their series, 5.6% of patients developed major complications, including 7.8% of CAs and 2.7% of RFAs. Patients with complications had a higher mean nephrometry score than those who did not experience complications (8.1 vs. 6.8), and patients with high-complexity tumors (nephrometry score 10 to 12) had a 14.3% risk for major complications. Although there was a clear difference between complications with regard to ablative technology (CA vs. RFA), the results were difficult to compare because the authors typically performed CA on larger, more complex lesions and RFA on more exophytic and smaller lesions. Seidman et al. (2013) evaluated their experience with percutaneous and laparoscopic RFA and identified an overall complication rate of 7.5%, with a major complication rate of 2%, neither of which were predicted based on nephrometry complexity. Importantly, mean tumor complexity was less than 8 for all of the cohorts, which likely limited the ability to discern among risk categories. Accordingly, the authors subsequently suggested a modification to the scoring system, where the R score was modified to 1 if less than 3 cm, 2 if 3 to 4 cm, or 3 if greater than 4 cm. Using this scoring system, they were able to accurately predict initial treatment failure and DFS at 3 years (Gahan et al., 2015).

In addition to tumor factors, various patient factors also influence the risk of complications as well as success of ablation. In the multi-institutional EuRECA study, which evaluated 808 patients undergoing laparoscopic CA across eight European institutions, 16.6% of patients had a complication, 3.2% of which were considered major. Although nephrometry score was not included, multivariable analysis showed that an American Society of Anesthesiology (ASA) score of more than 3 was associated with a threefold increased risk of overall complications (Nielsen et al., 2017).

Historically, the most common complication after renal tumor ablation was pain or paresthesia at the percutaneous probe insertion site, occurring in up to 8% of patients (Farrell et al., 2003b). However, current generation cryoprobes are thermally insulated along the shaft, which has led to a decrease in freezer burns as were seen with prior generations. The active portion of the RFA probe is only along the most distal aspect. However, with RFA, to prevent inadvertent nerve damage, tract ablation should be performed only long enough to remove the probe from the kidney and surrounding the Gerota fascia. Electrical skin burns after RFA, which may occur at the site of the grounding pads, should be incredibly rare and can be avoided by placing the pads at the exact same level on the patient's posterior thigh (McDougal et al., 2005). Because energy returning to the generator travels in the shortest arc, the pads should be placed perpendicular to the long axis of the thigh to increase surface area for energy dissipation.

Currently, **the most common perioperative complication from percutaneous ablation is intraoperative or postoperative hemorrhage**, which may occur in up to 11% to 27% of patients undergoing ablative renal procedures (Finley et al., 2008), with transfusion rates of 3.2% (2% to 4.9%) with CA and 2.4% (1.4% to 4%) with RFA (Campbell et al., 2017). As experience matures, the risk of postoperative blood transfusion continues to decline with more recent series reporting rates between 0 and 2% (Nielsen et al., 2017; Okhunov et al., 2017). **The primary risk factor for hemorrhage is the use of multiple probes for treatment of larger renal masses** (Okhunov et al., 2017)**. To decrease the risk for tumor fracture during CA, probes should be given adequate time to thaw because premature removal increases the risk for tumor fracture and hemorrhage. Bleeding during needle placement may be controlled by initiating the ablation, especially with the coagulative nature of RFA.** Bleeding during laparoscopic ablation can be managed with the use of hemostatic agents combined with direct pressure. If bleeding continues after ablation, consideration should be given to selective angioembolization. As with any percutaneous needle placement, percutaneous ablation risks damage to the abdominal wall vasculature, and thus care should be taken to avoid intercostal arteries. When injury does occur, it is typically visualized during the procedure with routine imaging. The expanding hematoma may be observed with serial imaging (if rapidly expanding) or serial hematocrit levels (if stable), with only the rare case requiring angiographic embolization.

Complications from damage to surrounding intra-abdominal organs can be minimized through appropriate patient selection, preoperative planning, and good surgical technique. Cross-sectional preoperative imaging is essential to determine if a tumor should be managed with a laparoscopic or percutaneous approach. For patients in whom there may be a concern regarding adjacent organs, additional imaging can be obtained with the patient in various positions to plan an appropriate needle path. Patients with anterior tumors, tumors close to the collecting system, or without a suitable access tract on preoperative imaging should be scheduled for laparoscopic ablation or have consideration for displacement of organs using intraprocedural hydrodissection. **Ideal patients for**

percutaneous treatment are those with posterior or lateral tumors, those with tumors located more than 0.5 cm from the ureteropelvic junction or renal pelvis, and those with tumors at least 1 cm from surrounding bowel.

Urothelial damage may manifest as minor hematuria, hematuria with significant clots, or urinary tract obstruction. Patients with hematuria should be managed conservatively, unless they present with significant hemorrhage, at which time they can be managed with selective angioembolization. There have been several reports of urinary fistula or collecting system injury after RFA as well as CA (Brown and Bhayani, 2007; Gervais et al., 2005a, 2005b; Janzen et al., 2005). **Permanent urothelial damage may manifest as either calyceal obstruction or ureteral obstruction if damage occurs at the ureteropelvic junction or distally** (Johnson et al., 2003)**.** In extreme cases, damage to the urinary tract may result in perirenal urinoma formation or cutaneous urinary fistula. Patients with ureteral obstruction or urine leakage from the collecting system may be managed conservatively or with insertion of an indwelling ureteral stent (Fig. 103.4). Patients with significant urinoma accumulation should have a percutaneous drain placed.

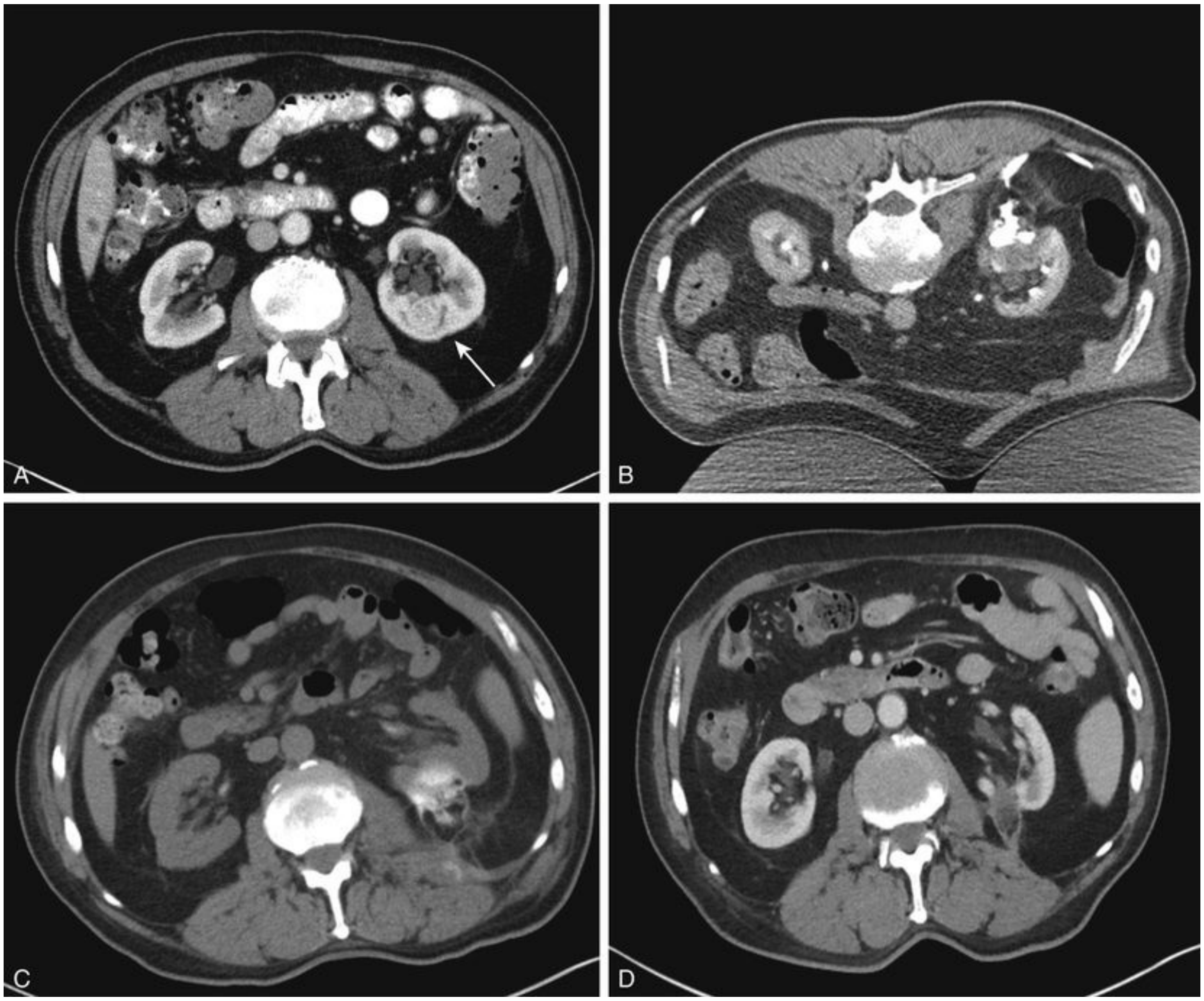

FIG. 103.4 Urine leak after percutaneous radiofrequency ablation (RFA). (A) Preoperative imaging shows 2.5-cm endophytic left renal mass *(arrow).* (B) Immediate postoperative image after ablation shows urinary extravasation at the site of RFA. (C) Postoperative day 1 computed tomography (CT) image shows no change in the fluid collection. (D) Three-year follow-up CT shows involution of the treated area with postoperative halo.

Injury to the pleural cavity resulting in pneumothorax or hemothorax can occur if probes are placed above the twelfth rib to treat upper pole lesions. These complications are typically recognized either during the procedure as breathing difficulties or with percutaneous access on routine imaging during tumor treatment. If a simple pneumothorax is identified, it may be treated by aspiration using a small needle inserted into the pleural space at the conclusion of the case. In the absence of a large or persistent pneumothorax, placement of a chest tube should be performed sparingly. Postoperatively, chest pain or shortness of breath should trigger suspicion of pneumothorax and prompt performance of an upright chest radiograph.

Colon injury after renal mass ablation is exceedingly rare and should be largely preventable with appropriate surgical technique. During percutaneous access, tumors within close proximity to bowel may be dissected free from the treatment area by injecting saline to hydrodissect tissues and develop a safe working space around the tumor (Clark et al., 2006; Farrell et al., 2003a; Lee et al., 2006; Fig. 103.5). However, reproducibility and surgeon familiarity with the patient's anatomy may make these lesions more suitable for the laparoscopic approach by which the bowel can be safely removed from the operative field. Patients with colon damage should be managed along with a general surgical consultation. Patients with a controlled colon-nephric fistula should be initially managed with placement of a ureteral stent, whereas those with a persistent fistula or with colon-cutaneous fistulas may require surgical diversion or a trial of total peripheral nutrition (Vanderbrink et al., 2007). Patients with frank colon perforation and signs of peritonitis should be managed with prompt surgical exploration.

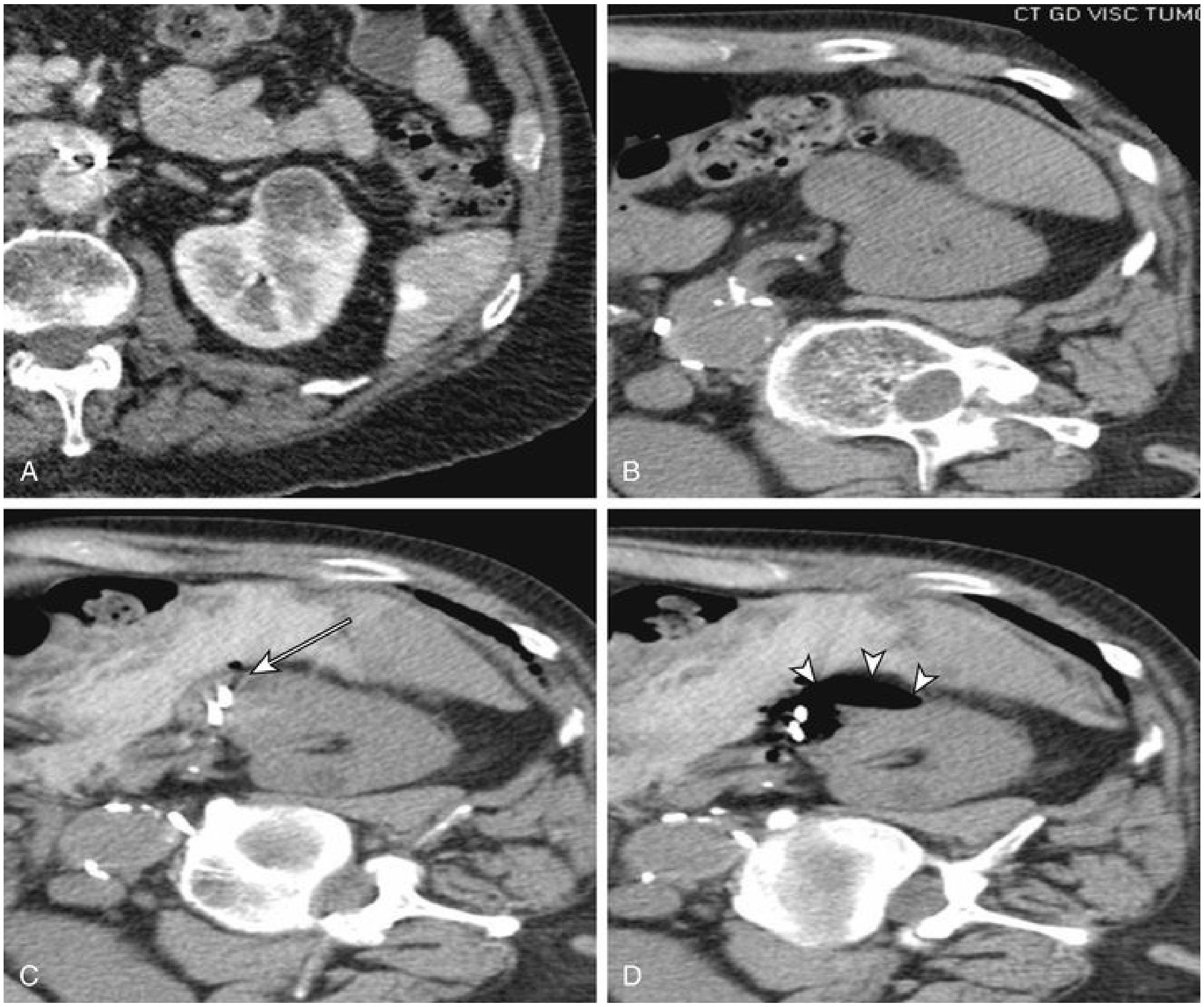

FIG. 103.5 Intraoperative hydrodissection for anterior tumor. (A) Preoperative imaging shows a 3-cm anterior renal mass. (B) Intraoperative imaging demonstrates large bowel anterior to the lesion. (C) D5 + contrast is injected percutaneously to hydrodissect bowel and create a window for placement of two cryoprobes *(arrow).* (D) Iceball is demonstrated by hypodense lesion adjacent to the cryoprobes *(arrowheads).* (Courtesy Fred Lee Jr, MD, University of Wisconsin.)

When posterior tumors are treated percutaneously, damage to the nerves running along the posterior abdominal wall can lead to self-limiting neuralgia or neuroapraxias (Baker et al., 2007; Lee et al., 2006)**.** This complication can be avoided by positioning the patient so that the tumor falls away from the body wall or by hydrodissecting the plane between kidney and body wall (Lee et al., 2006). For patients with multiple posterior tumors or with limited perinephric fat between the kidney and body wall, strong consideration should be given to the laparoscopic approach in which the kidney can be physically relocated away from the body wall.

Postoperative infection after tumor ablation, in the absence of a large hematoma or urinoma, is exceedingly rare but may be lethal (Schmit et al., 2013). Patients at risk for infection are those with chronic colonization of the urinary tract (e.g., ileal conduit) or active infection at the time of procedure (Bandi et al., 2007; Brown and Bhayani, 2007). When infectious complications do occur, they typically manifest from 1 to 6 months later as a chronic drainage or retroperitoneal abscess. Patients at risk for urinary tract infection (UTI) should be screened by urine culture and treated appropriately before their ablation procedure. Whereas we routinely administer perioperative prophylactic antibiotics at the time of the surgery, some authors suggest broad-spectrum coverage 2 days before and 2 weeks after surgery for patients at high risk for infection (Wah et al., 2008).

Key Points: Complications After Tumor Ablation

- The risk for major urologic complications is lower with ablative techniques (~5%) than with either laparoscopic or open partial nephrectomy. There is no significant difference in urologic complications between CA and RFA.
- For CA, postoperative hemorrhage is the most commonly cited major adverse risk.
- Bleeding is less common with RFA than CA and may be ideally suited for those at risk for postoperative hemorrhage.
- The risk for complications with CA may be predicted by tumor complexity.
- Commonly cited minor complications with CA and RFA include pain and paresthesia at the probe insertion site, UTIs, damage to surrounding structures, and self-limited hematuria.

New Ablation Modalities

High-Intensity Focused Ultrasonography

As an acoustic wave is propagated through tissue, a portion of its energy is absorbed and converted into heat (Madersbacher et al., 1995; Vricella et al., 2009). When the ultrasound waves are focused with an appropriately shaped transducer, the temperature at the focal point can exceed the threshold for cell death, while adjacent tissue is spared. At sufficiently high intensities (>3500 W/cm^3), cavitation and microbubble formation occur that yield extremely high temperatures and a mechanically disrupting "shock wave" effect similar to that seen with extracorporeal shock wave lithotripsy (Kieran et al., 2007). Termed high-intensity focused ultrasound (HIFU), it is a unique thermal ablation technology in that it can be administered in an entirely noninvasive, extracorporeal fashion minimizing or eliminating the risk for tumor seeding, hemorrhage, or urinary extravasation.

HIFU employs a transducer used for treatment and monitoring. Under real-time guidance, the HIFU beam is focused on the treatment zone and a defined area is ablated. The transducer is then refocused to ablate overlapping volumes and "paint" a larger overall volume of tissue. Treatment times can be lengthy, with a mean reported duration of nearly 5.5 hours (1.5 to 9 hours) (Häcker et al., 2006; Köhrmann et al., 2002; Marberger et al., 2005). A myriad of parameters, including focal length, type of transducer employed, and type of treatment system have been investigated and are beyond the scope of this chapter.

Although early clinical trials have established the feasibility of transcutaneous HIFU, based on the data available and the existing clinical hurdles, it should be considered only investigational at this time. Two important ablate-and-resect studies have noted incomplete treatment in all specimens, highlighting the challenge of accurate targeting (Marberger et al., 2005; Vallancien et al., 1993). Ritchie et al. (2010) reported a very limited experience with transcutaneous HIFU ablation and subsequent intermediate-term radiographic follow-up. MRI 2 weeks after treatment suggested viable tumor in 8 of 15 treated tumors. Of 14 patients with at least 6 months' follow-up, 10 appeared to have tumor involution with loss of enhancement and shrinkage (mean follow-up 36 months). Purported explanations for these collective incomplete treatments have included poor targeting secondary to respiratory movement and acoustic interference (acoustic shadowing, reverberation, and refraction) and lack of effective intraoperative monitoring of treatment progress. To circumvent these issues, laparoscopic HIFU has been investigated, and although results are favorable, its viability as a treatment modality is questionable because it would compete with established laparoscopic CA and RFA techniques (Klingler et al., 2008). **In summary, outcomes with renal HIFU have stagnated and proved inferior to alternative ablative technologies, and its use in this regard should be considered investigational.**

Radiation Therapy

Historically, radiation therapy was considered ineffective in the treatment of RCC. It remains unclear whether poor outcomes with conventional external-beam linear accelerator radiation systems were due to an inherent resistance to radiation or to limitations with radiation delivery (Camphausen and Coia, 2008). There are many technical challenges associated with treatment of kidney tumors, including limited radiation tolerance of the normal parenchyma, significant scatter with attendant damage to the surrounding tissues, and difficulty of target localization.

Stereotactic body radiation therapy (SBRT) is a “treatment method to deliver a high dose of radiation to the target, using either a single dose or a small number of fractions with a high degree of precision within the body” (Potters et al., 2010). As opposed to conventional radiation delivery techniques, modern stereotactic treatment systems employ three-dimensional coordinates to target and compensate for respiratory movement and radiation scatter by automatically tracking, detecting, and correcting for tumor and/or organ movement without interrupting the treatment or repositioning the patient. This tracking system is image guided and dependent on a constant reference point (e.g., fiducial marker) that is continually recognized by the linear accelerator. High-dose radiation beams move in real time with the respiratory cycle and are therefore extremely accurate (Ponsky et al., 2007). Not only is radiation scatter minimized but also higher doses may be applied in a focal manner that effectively ablates masses in the kidney without compromising overall renal function. Ponsky et al. (2003) first evaluated stereotactic radiosurgery in the porcine kidney using the CyberKnife (Accuray, Palo Alto, CA) treatment system. Treatment doses between 24 to 40 Gy resulted in complete necrosis in the treatment zone with no collateral damage to adjacent tissue. Building on this initial animal experience, Ponsky et al. (2007) subsequently performed a phase I study on three human patients with a mean renal tumor size of 2 cm. A total of 16 Gy was administered in a fractionated fashion. Patients were followed for 8 weeks, after which a partial nephrectomy was performed. No adverse events or radiation toxicities were noted. Histopathology demonstrated residual RCC in two patients and no evidence of viable tumor in the remaining patient.

Svedman et al. (2006) performed a retrospective study evaluating the efficacy and safety of stereotactic radiosurgery in the management of inoperable or metastatic primary RCC. Thirty patients with 82 lesions underwent treatment with varied dose/fractionation schedules. At a median follow-up of 52 months, complete response was noted in 21% of patients, with another 58% demonstrating a partial/stable response.

A critical and systematic review of SBRT for primary RCC recently identified 10 studies consisting of 126 patients treated with between one and six fractions (Siva et al., 2012). The most common treatment regimen was 40 Gy over five fractions. Median or mean follow-up ranged from 9 to 57 months. Local control was defined only radiologically and was estimated at 94% at 2 years. The weighted rate of grade 3 or higher adverse effects was only 3.8%; the most common was radiation dermatitis and enteritis.

Most recently, Sun et al. (2016) clarified the expected radiographic appearance of RCC ablated with SBRT using a fixed body frame rather than fiducial markers. They treated 41 renal tumors (all but 8 biopsy-confirmed carcinomas) with SBRT (21–48 Gy over 3 treatments) with a mean follow-up of 1.5 years. Unlike thermal ablation wherein successful treatment is characterized by complete loss of enhancement and gradual involution of the mass, it appears that the early 1-year response to SBRT is unique and may be clinically challenging to interpret. There was no statistical change in tumor enhancement during follow-up, and 75% were stable in size (though previously growing), 20% demonstrated a partial response, and a complete response occurred in only 1 patient. No tumor was biopsied during follow-up. Staehler et al. (2016) reported a success rate of 98% at 2 years with a convenient single treatment (25 Gy) for 45 tumors all less than 4 cm in diameter.

Certainly, the responsiveness of RCC to stereotactic radiosurgery in the aforementioned trials argues against its radioresistant reputation. **Presently its use should be considered experimental because there is no consensus for dose fractionation, technique (with or without fiducial markers), or appropriate criteria for imaging interpretation. With improved treatment**

protocols and well-designed prospective trials, SABR ultimately may play a significant role in the treatment of RCC.

Microwave Ablation

Microwave ablation (MWA) delivers energy through semiflexible probes that are inserted directly into the target lesion and functions in a similar fashion to RFA. Medical applications of microwave energy operate in the 900-MHz to 2.45-GHz range of the electromagnetic spectrum and create rapid water ion oscillation in the tissue and frictional heat. The degree of tissue penetration and heat produced is related to the water content of the target tissue, which can be more difficult to predict in the heterogeneous kidney parenchyma environment (Moore et al., 2010; Rehman et al., 2004). MWA is capable of achieving treatment temperatures (>60°C) with greater rapidity than RFA and is not limited by tissue charring and desiccation as experienced with RFA. These qualities may translate into more efficient treatment times and may make MWA less susceptible to the heat sink phenomenon (Cornelis et al., 2017; Liang and Wang, 2007).

MWA technology was initially designed for the percutaneous treatment of liver tumors and has enjoyed considerable success in this capacity. Its use in the management of renal tumors remains immature. Clark et al. (2007) performed a phase I study in which 10 patients underwent MWA of suspected RCC at the time of radical nephrectomy. When examined pathologically, lesions as large as 5.7 cm × 4.7 cm × 3.8 cm were achieved with complete and uniform tissue necrosis. Following the initial data, MWA has continued to expand in the clinical realm. Although there was initially some concern for high treatment failures (Castle et al., 2011), more contemporary series have reported a success rate greater than 90% for pT1a and pT1b tumors (Lin et al., 2014; Wells et al., 2016). The only direct comparison of MWA to partial nephrectomy reported comparable 3-year recurrence-free survival of 90% and 97%, respectively (Guan et al., 2012). Although there are several theoretical advantages of MWA over CA and RFA, there are insufficient follow-up data and further study is required (Cornelis et al., 2017).

At this point, MWA offers considerable promise as an alternative thermal ablative technology. However, larger prospective studies with longer follow-up are necessary to better understand the optimal tumor characteristics, risks, and morbidity.

Irreversible Electroporation

Irreversible electroporation (IRE), is a novel nonthermal method for ablation of living tissue that potentially offers advantages over RFA and CA. Electroporation is a process whereby an electric field applied across cells generates nanoscale pores within cellular membranes that can be either reversible or lethally irreversible depending on the magnitude of voltage applied. IRE is produced through a series of electrical pulses delivered by a single (bipolar) or multiple (monopolar) electrodes. With appropriate modulation it is able to ablate a substantial and reproducible amount of tissue by increasing cell membrane permeability that ultimately leads to cell death (Edd et al., 2006). The result is a nonthermal effect that preserves the extracellular matrix, tissue scaffolding, ductal structures, and large blood vessels (Deodhar et al., 2011; Edd et al., 2006).

Because of the potential to avoid the shortcomings of thermal ablation, there is a great deal of interest in applying IRE to ablation of renal tumors. Although IRE has been shown to be effective in ablating liver and prostate tissue, these results cannot be readily extrapolated to the kidney, which is substantially different given the vigorous arterial blood supply, complex collecting system, and presence of urinary solutes in varying concentrations. The efficacy of IRE ablation of renal parenchyma was first described by Tracy et al. (2011). When IRE bipolar and monopolar electrodes (Angiodynamics, Queensbury, NY) were used to perform laparoscopic ablations on porcine kidneys, histopathological evaluation revealed absence of cellular viability immediately after IRE treatment that evolved to diffuse cellular necrosis by 7 days and chronic inflammation, cellular contraction, and fibrosis by day 14. In addition to its effect on the parenchyma, IRE appeared to provide some urothelial sparing with initial ulceration followed by signs of early repair and viability. Other authors subsequently confirmed these findings using image-guided percutaneous placement of IRE electrodes (Deodhar et al., 2011).

There is very limited clinical experience with percutaneous IRE. In a series of five patients Diehl et al. (2016) demonstrated the safety of IRE in treating SRM in solitary kidneys, although oncologic outcomes were not reported. Most recently, Canvasser et al. (2017) reported on 36 tumors in 35 patients who underwent IRE. Mean tumor size was 2.0 cm with a median R.E.N.A.L nephrometry score of 5. No major (Clavien grade II or higher) intraoperative or postoperative complications occurred and initial treatment success rate was 92%.

The 2-year actuarial local recurrence-free survival was 78% for patients with biopsy-confirmed RCC, 85% with biopsy-confirmed or a history of RCC, and 89% for the intent-to-treat cohort.

In summary, the experience with IRE ablation of renal tumors is very limited, and its use in this regard should be considered investigational.

Targeted Embolization and Ablation

Because of the heat sink phenomenon with RFA, highly vascular central lesions or lesions positioned adjacent to the renal hilum are often inadequately ablated. Studies estimate treatment failures to be as high as 40%. In an attempt to address conductive heat loss, investigators have performed selective arterial embolization before CA and RFA (Gebauer et al., 2007; Mahnken et al., 2009; Moynagh et al., 2015; Yamakado et al., 2006). Theoretically, selective embolization should allow for more homogeneous heating and improved tissue necrosis. **Clinical reports are sporadic and anecdotal. Therefore the use of targeted angioembolization before RFA remains investigational.**

Key Points: New Ablation Technologies

- Although there are a number of promising ablation modalities on the horizon, the majority of these should be considered investigational.
- The most promising future ablation modalities appear to be stereotactic radiosurgery, microwave thermotherapy, and IRE. However, significant study is required to further determine their potential benefits compared with the well-established methods of CA and RFA.

Conclusion

Once considered experimental and appropriate only for patients with significant comorbidities, CA and RFA are currently considered viable alternatives to extirpative management of cT1a renal carcinoma. In situ ablation confers less treatment-related morbidity than either open or laparoscopic partial nephrectomy and offers comparable renal function preservation compared with partial nephrectomy. CA and RFA are technically less challenging than other nephron-sparing approaches, although learning curves exist for patient selection, tumor targeting, probe deployment, and generator use. Results from recent meta-analyses demonstrate modestly inferior local tumor control compared with partial and radical nephrectomy, but with equivalent cancer-specific and overall survival when salvage ablation is considered. No prospective literature currently exists that addresses the superiority of CA or RFA. Ultimately, the decision to treat a small renal mass with an ablative technology should take into account tumor-related characteristics, patient demographics and comorbidities, and the values and desires of the patient.

Suggested Readings

Atwell TD, Schmit GD, Boorjian SA, et al. Percutaneous ablation of renal masses measuring 3.0 cm and smaller: comparative local control and complications after radiofrequency ablation and cryoablation. *AJR Am J Roentgenol*. 2013;200:461–466.

Best SL, Park S, Yaacoub RF, et al. Long-term outcomes of renal tumor radiofrequency ablation stratified by tumor diameter: size matters. *J Urol*. 2012;187:1183.

Carraway WA, Raman JD, Cadeddu JA. Current status of renal radiofrequency ablation. *Curr Opin Urol*. 2009;19:143–147.

Davenport MS, Caoili EM, Cohan RH, et al. MRI and CT characteristics of successfully ablated renal masses: imaging surveillance after radiofrequency ablation. *AJR Am J Roentgenol*. 2009;192:1571–1578.

Karam JA, Ahrar K, Matin SF. Ablation of kidney tumors. *Surg Oncol Clin N Am*. 2011;20:341–353.

Kunkle DA, Egleston BL, Uzzo RG. Excise, ablate or observe: the small renal mass dilemma—a meta-analysis and review. *J Urol*. 2008;179:1227–1234.

Miller DC, Saigal CS, Banerjee M, et al. Diffusion of surgical innovation among patients with kidney cancer. *Cancer*. 2008;112:1708–1717.

Novick AC, Campbell SC, Belldegrun A, et al. *Guideline for management of the clinical stage 1 renal mass*. [(website); Available from:] http://www.auanet.org/content/guidelines-and-quality-care/clinical-guidelines/main-reports/renalmass09.pdf; 2009.

Ponsky LE, Crownover RL, Rosen MJ, et al. Initial evaluation of Cyberknife technology for extracorporeal renal tissue ablation. *Urology*. 2003;61:498–501.

Weight CJ, Kaouk JH, Hegarty NJ, et al. Correlation of radiographic imaging and histopathology following cryoablation and radio frequency ablation for renal tumors. *J Urol*. 2008;179:1277–1281.

References

Abouassaly R, Finelli A, Timilshina N, et al. Treatment trends for renal cell carcinoma in a population-based tumor registry: the potential underuse of partial nephrectomy. *J Urol*. 2009;181:76.

Aron M, Kamoi K, Remer E, et al. Laparoscopic renal cryoablation: 8-year, single surgeon outcomes. *J Urol*. 2010;183:889–895.

Arnott J. Practical illustrations of the remedial efficacy of a very low or anaesthetic temperature in cancer. *Lancet*. 1850;2:257–259.

Atwell TD, Schmit GD, Boorjian SA, et al. Percutaneous ablation of renal masses measuring 3.0 cm and smaller: comparative local control and complications after radiofrequency ablation and cryoablation. *AJR Am J Roentgenol*. 2013;200:461–466.

Auge BK, Santa-Cruz RW, Polascik TJ. Effect of freeze time during renal cryoablation: a swine model. *J Endourol*. 2006;20:1101–1105.

Baker M, Anderson JK, Jaffer O, et al. Pain after percutaneous radiofrequency ablation of renal tumors. *J Endourol*. 2007;21:606–609.

Bandi G, Wen CC, Hedican SP, et al. Cryoablation of small renal masses: assessment of the outcome at one institution. *BJU Int*. 2007;100:798–801.

Baust JG, Gage AA. The molecular basis of cryosurgery. *BJU Int*. 2005;95:1187–1191.

Best SL, Park SK, Yaacoub RF, et al. Long-term outcomes of renal tumor radio frequency ablation stratified by tumor diameter: size matters. *J Urol*. 2012;187:1183–1189.

Bhindi B, Mason RJ, Haddad MM, et al. Outcomes after cryoablation versus partial nephrectomy for sporadic renal tumors in a solitary kidney: a propensity score analysis. *Eur Urol*. 2017;73:254–259.

Bhowmick P, Coad JE, Bhowmick S, et al. In vitro assessment of the efficacy of thermal therapy in human benign prostatic hyperplasia. *Int J Hyperthermia*. 2004;20:421–439.

Bhowmick S, Coad JE, Swanlund DJ, et al. In vitro thermal therapy of AT-1 Dunning prostate tumours. *Int J Hyperthermia*. 2004;20:73–92.

Breen D, Bryant TJ, Abbas A, et al. Percutaneous cryoablation of renal tumours: outcomes from 171 tumours in 147 patients. *BJU Int*. 2013;112:758–765.

Brown DB, Bhayani SB. Persistent urine leak after cryoablation of a renal tumor in a patient with an ileal conduit. *J Vasc Interv Radiol*. 2007;18:1324–1327.

Campbell SC, Krishnamurthi V, Chow G, et al. Renal cryosurgery: experimental evaluation of treatment parameters. *Urology*. 1998;52:29–33.

Campbell S, Uzzo RG, Mollaf ME, et al. *Renal mass and localized renal cancer: AUA Guideline*. [(website); Available from:] https://www.auanet.org/guidelines/renal-cancer-renal-mass-and-localized-renal-cancer-guideline; 2017.

Camphausen KA, Coia LR, et al. Principles of radiation therapy. Pazdur R, Wagman LD, Camphausen KA. *Cancer management: a multidisciplinary approach*. ed 11. CMP Medica: Lawrence (KS); 2008.

Canter D, Kutikov A, Manley B, et al. Utility of the R.E.N.A.L.-Nephrometry Scoring System in objectifying treatment decision-making of the enhancing renal mass. *Urology*. 2011;78:1089–1094.

Caputo Peter A, Zargar Homayoun, Ramirez Daniel, et al. Cryoablation versus partial nephrectomy for Clinical T1b Renal tumors: a matched group comparative analysis. *Eur*

Urol. 2017;71(1):111–117.

Canvasser N, Lay A, Morgan MSC, et al. Irreversible electroporation of small renal masses: suboptimal oncologic efficacy in an early series. *World J Urol*. 2017;35:1549–1555.

Carey RI, Leveillee RJ. Direct real-time temperature monitoring for laparoscopic and CT-guided radiofrequency ablation of renal tumors between 3 and 5 cm. *J Endourol*. 2007;21:807–813.

Castle SM, Salas N, Leveillee RJ. Initial experience using microwave ablation therapy for renal tumor treatment: 18-month follow-up. *Urology*. 2011;77:792–797.

Chen DY, Uzzo RG. Evaluation and management of the renal mass. *Med Clin North Am*. 2011;95:179–189.

Chen Y, Huang J, Xia L, et al. Monitoring laparoscopic radiofrequency renal lesions in real time using contrast-enhanced ultrasonography: an open-label, randomized, comparative pilot trial. *J Endourol*. 2013;27:697–704.

Chosy SG, Nakada SY, Lee FT Jr, et al. Monitoring renal cryosurgery: predictors of tissue necrosis in swine. *J Urol*. 1998;159:1370–1374.

Clark PE, Woodruff RD, Zagoria RJ, et al. Microwave ablation of renal parenchymal tumors before nephrectomy: phase I study. *AJR Am J Roentgenol*. 2007;188:1212–1214.

Clark TW, Malkowicz B, Stavropoulos SW, et al. Radiofrequency ablation of small renal cell carcinomas using multitined expandable electrodes: preliminary experience. *J Vasc Interv Radiol*. 2006;17:513–519.

Collyer WC, Landman J, Olweny EO, et al. Comparison of renal ablation with cryotherapy, dry radiofrequency, and saline augmented radiofrequency in a porcine model. *J Am Coll Surg*. 2001;193:505–513.

Cooper IS. A new method of destruction of extirpation of benign and malignant tissues. *N Engl J Med*. 1963;263:741–

749.

Cornelis FH, Marcelin C, Bernhard JC. Microwave ablation of renal tumors: a narrative review of technical considerations and clinical results. *Diagn Interv Imaging*. 2017;98:287–297.

Corwin TS, Lindberg G, Traxer O, et al. Laparoscopic radiofrequency thermal ablation of renal tissue with and without hilar occlusion. *J Urol*. 2001;166:281–284.

Cosman ER, Nashold BS, Ovelman-Levitt J. Theoretical aspects of radiofrequency lesions in the dorsal root entry zone. *Neurosurgery*. 1984;15:945–950.

Curley SA, Izzo F, Ellis LM, et al. Radiofrequency ablation of hepatocellular cancer in 110 patients with cirrhosis. *Ann Surg*. 2000;232:381–391.

Cushing H, Bovie WT. Electro-surgery as an aid to the removal of intracranial tumors. *Surg Gynecol Obstet*. 1928;47:751–784.

d'Arsonval MA. Action physiologique des courants alternatifs. *CR Soc Biol*. 1891;43:283–286.

Deane LA, Clayman RV. Review of minimally invasive renal therapies: needle-based and extracorporeal. *Urology*. 2006;68:26–37.

Deodhar A, Monette S, Single GW Jr, et al. Renal tissue ablation with irreversible electroporation: preliminary results in a porcine model. *Urology*. 2011;77:754–760.

Derweesh IH, Malcolm JB, Diblasio CJ, et al. Single center comparison of laparoscopic cryoablation and CT-guided percutaneous cryoablation for renal tumors. *J Endourol*. 2008;22:2461–2467.

Desai MM, Aron M, Gill IS. Laparoscopic partial nephrectomy versus laparoscopic cryoablation for the small renal tumor. *Urology*. 2005;66:23–28.

Diehl SJ, Rathmann N, Kostrzewa M, et al. Irreversible electroporation for surgical renal masses in solitary kidneys:

short-term interventional and functional outcome. *J Vasc Interv Radiol*. 2016;27:1407–1413.

Djavan B, Partin AW, Hoey MF, et al. Transurethral radiofrequency therapy for benign prostatic hyperplasia using a novel saline-liquid conductor: the virtual electrode. *Urology*. 2000;55:13–16.

Donat SM, Diaz M, Bishoff JT, et al. Follow-up for clinically localized renal neoplasms: AUA guideline. *J Urol*. 2013;190:407–416.

Dong XL, Jie Y, Ming-an Y, et al. Complications of ultrasound-guided percutaneous microwave ablation of renal cell carcinoma. *Onco Targets Ther*. 2016;9:5903–5909.

Edd JF, Horowitz L, Davalos RV, et al. In vivo results of a new focal tissue ablation technique: irreversible electroporation. *IEEE Trans Biomed Eng*. 2006;53:1409–1415.

El Dib R, Touma NJ, Kapoor A. Cryoablation vs radiofrequency ablation for the treatment of renal cell carcinoma: a meta-analysis of case series studies. *BJU Int*. 2012;110:510–516.

Erinjeri JP, Clark TW. Cryoablation: mechanism of action and devices. *J Vasc Interv Radiol*. 2010;21(8 Suppl):S187–S191.

Ertürk MA, Sathyanarayana HS, Bottomley PA. Radiofrequency ablation, MR thermometry, and high-spatial-resolution MR parametric imaging with a single, minimally invasive device. *Radiology*. 2016;281:927–932.

Farrell MA, Charboneau JW, Callstrom MR, et al. Paranephric water instillation: a technique to prevent bowel injury during percutaneous renal radiofrequency ablation. *AJR Am J Roentgenol*. 2003;181:1315–1317.

Farrell MA, Charboneau WJ, DiMarco DS, et al. Imaging-guided radiofrequency ablation of solid renal tumors. *AJR Am J Roentgenol*. 2003;180:1509–1513.

Finelli A, Rewcastle JC, Jewett MAS. Cryotherapy and radiofrequency ablation: pathophysiologic basis and laboratory studies. *Curr Opin Urol*. 2003;13:187–191.

Finley DS, Beck S, Box G, et al. Percutaneous and laparoscopic cryoablation of small renal masses. *J Urol*. 2008;180:492–498.

Freiman A, Bouganim N. History of cryotherapy. *Dermatol Online J*. 2005;11:9.

Frich L, Edwin B, Brabrand K, et al. Percutaneous saline-enhanced radiofrequency ablation of colorectal liver metastases in a patient with adhesions in the peritoneal cavity. *AJR Am J Roentgenol*. 2005;16:83–88.

Gage AA, Baust J. Mechanisms of tissue injury in cryosurgery. *Cryobiology*. 1998;37:171–186.

Gahan JC, Richter MD, Seideman CA, et al. The performance of a modified RENAL nephrometry score in predicting renal mass radiofrequency ablation success. *Urology*. 2015;85:125–129.

Gebauer B, Werk M, Lopez-Hänninen E, et al. Radiofrequency ablation in combination with embolization in metachronous recurrent renal cancer in solitary kidney after contralateral tumor nephrectomy. *Cardiovasc Intervent Radiol*. 2007;30:644–649.

Gervais DA, Arellano RS, McGovern FJ, et al. Radiofrequency ablation of renal cell carcinoma. II. Lessons learned with ablation of 100 tumors. *AJR Am J Roentgenol*. 2005;185:72–80.

Gervais DA, McGovern FJ, Arellano RS, et al. Radiofrequency ablation of renal cell carcinoma. I. Indications, results, and role in patient management over a 6-year period and ablation of 100 tumors. *AJR Am J Roentgenol*. 2005;185:64–71.

Goldberg SN, Gazelle GS, Halpern EF, et al. Radiofrequency tissue ablation: importance of local temperature along the electrode tip exposure in determining lesion shape and size. *Acad Radiol*. 1996;3:212–218.

Goldberg SN, Gazelle GS, Mueller PR. Thermal ablation therapy for focal malignancy: a unified approach to underlying principles, techniques, and diagnostic imaging guidance. *AJR Am J Roentgenol*. 2000;174:323–331.

Guan W, Bai J, Liu J, et al. Microwave ablation versus partial nephrectomy for small renal tumors: intermediate-term results. *J Surg Oncol*. 2012;106:316–321.

Guazzoni G, Cestari A, Buffi N, et al. Oncologic results of laparoscopic renal cryoablation for clinical T1a tumors: 8 years of experience in a single institution. *Urology*. 2010;76:624–629.

Gupta A, Raman JD, Leveillee RJ, et al. General anesthesia and contrast-enhanced computed tomography to optimize renal percutaneous radiofrequency ablation: multi-institutional intermediate-term results. *J Endourol*. 2009;23:1099–1105.

Häcker A, Michel MS, Marlinghaus E, et al. Extracorporeally induced ablation of renal tissue by high-intensity focused ultrasound. *BJU Int*. 2006;97:779–785.

Hall WH, McGahan JP, Link DP, et al. Combined embolization and percutaneous radiofrequency ablation of a solid renal tumor. *AJR Am J Roentgenol*. 2000;174:1592–1594.

Hegarty NJ, Gill IS, Desai MM, et al. Probe-ablative nephron-sparing surgery: cryoablation versus radiofrequency ablation. *Urol*. 2006;68:7–13.

Hinshaw JL, Shadid AM, Nakada SY, et al. Comparison of percutaneous and laparoscopic cryoablation for the treatment of solid renal mass. *AJR Am J Roentgenol*. 2008;191:1159–1168.

Hoffmann NE, Bischof JC. The cryobiology of cryosurgical injury. *Urology*. 2002;60:40–49.

Hsu TH, Fidler ME, Gill IS. Radiofrequency ablation of the kidney: acute and chronic histology in the porcine model. *Urology*. 2000;56:872–875.

Huang WC, Elkin EB, Levey AS, et al. Partial nephrectomy versus radical nephrectomy in patients with small renal tumors: is there a difference in mortality and cardiovascular outcomes? *J Urol*. 2009;181:55–62.

Hui GC, Tuncali K, Tatli S, et al. Comparison of percutaneous and surgical approaches to renal tumor ablation: metaanalysis of effectiveness and complication rates. *J Vasc Interv Radiol*. 2008;19:1311–1320.

Ishiguro H, Rubinsky B. Mechanical interactions between ice crystals and red-blood cells during directional solidification. *Cryobiology*. 1994;31:483–500.

Janzen NK, Perry KT, Han KR, et al. The effects of intentional cryoablation and radio frequency ablation of renal tissue involving the collecting system in a porcine model. *J Urol*. 2005;173:1368–1374.

Johnson DB, Duchene DA, Taylor GD, et al. Contrast-enhanced ultrasound evaluation of radiofrequency ablation of the kidney: reliable imaging of the thermolesion. *J Endourol*. 2005;19:248–252.

Johnson J, Pham KN, See W, et al. Laparoscopic cryoablation for clinical stage T1 renal masses: long-term oncologic outcomes at the Medical College of Wisconsin. *Urology*. 2014;84:613–618.

Johnson DB, Saboorian MH, Duchene DA, et al. Nephrectomy after radiofrequency ablation-induced ureteropelvic junction obstruction: potential complication and long-term assessment of ablation adequacy. *Urology*. 2003;62:351–352.

Johnson DB, Solomon SB, Su LM, et al. Defining the complications of cryoablation and radio frequency ablation of small renal tumors: a multi-institutional review. *J Urol*. 2004;172:874–877.

Kahlenberg MS, Volpe C, Klippenstein DL, et al. Clinicopathologic effects of cryotherapy on hepatic vessels and bile ducts in a porcine model. *Ann Surg Oncol*. 1998;5:713–718.

Karam JA, Ahrar K, Matin SF. Ablation of kidney tumors. *Surg Oncol Clin N Am*. 2011;20:341–353.

Katsanos K, Mailli L, Krokidis M, et al. Systematic review and meta-analysis of thermal ablation versus surgical nephrectomy for small renal tumors. *Cardiovasc Intervent Radiol*. 2014;37:427–437.

Kawamoto S, Solomon SB, Bluemke DA, et al. Computed tomography and magnetic resonance imaging appearance of renal neoplasms after radiofrequency ablation and cryoablation. *Semin Ultrasound CT MR*. 2009;30:67–77.

Kieran K, Hall TL, Parsons JE, et al. Refining histotripsy: defining the parameter space for the creation of nonthermal lesions with high intensity, pulsed focused ultrasound of the in vitro kidney. *J Urol*. 2007;178:672–676.

Kim EH, Tanagho YS, Bhayani SB, et al. Percutaneous cryoablation of renal masses: Washington University experience of treating 129 tumours. *BJU Int*. 2013;111:872–879.

Klingler HC, Marberger M, Mauermann J, et al. ‘Skipping’ is still a problem with radiofrequency ablation of small renal tumours. *BJU Int*. 2007;99:998–1001.

Klingler HC, Susani M, Seip R, et al. A novel approach to energy ablative therapy of small renal tumours: laparoscopic high-intensity focused ultrasound. *Eur Urol*. 2008;53:810–816.

Klossner DP, Robilotto AT, Clarke DM, et al. Cryosurgical technique: assessment of the fundamental variables using human prostate cancer model systems. *Cryobiology*. 2007;55:189–199.

Köhrmann KU, Michel MS, Gaa J, et al. High intensity focused ultrasound as noninvasive therapy for multilocal renal cell carcinoma: case study and review of the literature. *J Urol*. 2002;167:2397–2403.

Kunkle DA, Uzzo RG. Cryoablation or radiofrequency ablation of the small renal mass. *Cancer*. 2008;113:2671–2680.

Kutikov A, Uzzo RG. The R.E.N.A.L. Nephrometry Score: a comprehensive standardized system for quantitating renal tumor size, location and depth. *J Urol*. 2009;182:844–853.

Larson TR, Robertson DW, Corica A, et al. In vivo interstitial temperature mapping of the human prostate during cryosurgery with correlation to histopathology outcome. *Urology*. 2000;55:547–552.

Lee SJ, Choyke LT, Locklin JK, et al. Use of hydrodissection to prevent nerve and muscular damage during radiofrequency ablation of kidney tumors. *J Vasc Interv Radiol*. 2006;17:1967–1969.

LeVeen RF. Laser hyperthermia and radiofrequency ablation of hepatic lesions. *Semin Interv Radiol*. 1997;14:313–324.

Leveillee RJ, Castle SM, Gorbatiy V, et al. Oncologic outcomes using real-time peripheral thermometry-guided radiofrequency ablation of small renal masses. *J Endourol*. 2013;27:480–489.

Levinson AW, Su L, Agarwal D, et al. Long-term oncological and overall outcomes of percutaneous radio frequency ablation in high risk surgical patients with a solitary small renal mass. *J Urol*. 2008;180:499–504.

Li BN, Shen ZH, Chui CK, et al. Evaluation of radiofrequency ablation using magnetic resonance elastography. *IFMBE Proc*. 2013;39:2134–2137.

Liang P, Wang Y. Microwave ablation of hepatocellular carcinoma. *Oncology*. 2007;72:124–131.

Lin CH, Moinzadeh A, Ramani AP, et al. Histopathologic confirmation of complete cancer-cell kill in excised specimens after renal cryotherapy. *Urology*. 2004;64:590.

Lin Y, Liang P, Yu XL, et al. Percutaneous microwave ablation of renal cell carcinoma is safe in patients with a solitary kidney. *Urology*. 2014;83(2):357–363.

Lorentzen T, Christensen NE, Nolsoe CP, et al. Radiofrequency tissue ablation with a cooled needle in vitro: ultrasonography, dose response, and lesion temperature. *Acad Radiol*. 1997;4:292–297.

Lucas SM, Stern JM, Adibi M, et al. Renal function outcomes in patients treated for renal masses smaller than 4 cm by ablative or extirpative techniques. *J Urol*. 2008;179:75.

Madersbacher S, Vingers L, Marberger M, et al. Effect of high-intensity focused ultrasound on human prostate cancer in vivo. *Cancer Res*. 1995;55:3346–3351.

Mahnken AH, Penzkofer T, Bruners P, et al. Interventional management of a renal cell carcinoma by radiofrequency ablation with tagging and cooling. *Korean J Radiol*. 2009;10:523–526.

Marberger M, Schatzl G, Cranston D, et al. Extracorporeal ablation of renal tumors with high intensity focused ultrasound. *BJU Int*. 2005;95:52–55.

Matin SF. Determining failure after renal ablative therapy for renal cell carcinoma: false-negative and false-positive imaging findings. *Urology*. 2010;75:1254.

Matin SF, Ahrar K, Cadeddu JA, et al. Residual and recurrent disease following renal energy ablative therapy: a multi-institutional study. *J Urol*. 2006;176:1973–1977.

Matlaga BR, Zagoria RJ, Woodruff RD, et al. Phase II trial of radiofrequency ablation of renal cancer: evaluation of the kill zone. *J Urol*. 2002;168:2401–2405.

Matsumoto ED, Watumull L, Johnson DB, et al. The radiographic evolution of radio-frequency ablated renal tumors. *J Urol*. 2004;172:45–48.

Mazur P. The role of intracellular freezing in the death of cells cooled at supraoptimal rates. *Cryobiology*. 1977;14:251–272.

McAchran SE, Lesani OA, Resnick MI. Radiofrequency ablation of renal tumors: past, present, and future. *Urology*. 2005;66(5 Suppl):15–22.

McDougal WS, Gervais DA, McGovern FJ, et al. Long-term follow-up of patients with renal cell carcinoma treated with radiofrequency ablation with curative intent. *J Urol*. 2005;174:61–63.

McGahan JP, Browning PD, Brock JM, et al. Hepatic ablation using radiofrequency electrocautery. *Invest Radiol*. 1990;25:267–270.

McGahan JP, Dodd GD 3rd. Radiofrequency ablation of the liver: current status. *AJR Am J Roentgenol*. 2001;176:3–16.

McGahan JP, Scheider P, Brock JM, et al. Treatment of liver tumors by percutaneous radiofrequency electrocautery. *Semin Interv Radiol*. 1993;10:143–149.

McGahan JP, Wei-Zhong G, Brock JM, et al. Hepatic ablation using bipolar radiofrequency electrocautery. *Acad Radiol*. 1996;3:418–422.

Moore C, Salas N, Zaias J, et al. Effects of microwave ablation of the kidney. *J Endourol*. 2010;24:439.

Moynagh MR, Schmit GD, Thompson RH, et al. Percutaneous cryoablation of clinical T2 (4 7 cm) renal masses: technical considerations, complications, and short-term outcomes. *J Vasc Interv Radiol*. 2015;26:800–806.

Nakada SY, Jerde TJ, Warner TF, et al. Bipolar radiofrequency ablation of the kidney: comparison with monopolar radiofrequency ablation. *J Endourol*. 2003;17:927–933.

Neel HB, Ketcham AS, Hammond WG. Requisites for successful cryogenic surgery of cancer. *Arch Surg*. 1971;102:45–48.

Ni Y, Miao Y, Mulier S, et al. A novel “cooled-wet” electrode for radiofrequency ablation. *Eur Radiol*. 1999;10:852–854.

Nielsen TK, Lagerveld BW, Keeley F, et al. Oncological outcomes and complication rates after laparoscopic-assisted cryoablation: a European Registry for Renal Cryoablation (EuRECA) multi-institutional study. *BJU Int*. 2017;119:390–395.

Okhunov Z, Moreira DM, del Junco M, et al. Predictors of complications after percutaneous image-guided renal cryoablation for T1a renal cortical neoplasms. *J Endourol*. 2017;31:7–13.

Okhunov Z, Shapiro EY, Moreira DM, et al. RENAL nephrometry score accurately predicts complications following laparoscopic renal cryoablation. *J Urol*. 2012;188:1796–1800.

Olweny EO, Park SK, Tan YK, et al. Radiofrequency ablation versus partial nephrectomy in patients with solitary clinical T1a renal cell carcinoma: comparable oncologic outcomes at a minimum of 5 years of follow-up. *Eur Urol*. 2012;61:1156–1161.

O'Malley RL, Berger AD, Kanofsky JA, et al. A matched-cohort comparison of laparoscopic cryoablation and laparoscopic partial nephrectomy for treating renal masses. *BJU Int*. 2006;99:395–398.

Onik G, Cooper C, Goldberg HI, et al. Ultrasonic characteristics of frozen liver. *Cryobiology*. 1984;21:321–328.

Onik G, Gilbert J, Hoddick W, et al. Sonographic monitoring of hepatic cryosurgery in an experimental animal model. *AJR Am J Roentgenol*. 1985;144:1043–1047.

Park S, Anderson JK, Matsumoto ED, et al. Radiofrequency ablation of renal tumors: intermediate-term results. *J Endourol*. 2006;20:569–573.

Park S, Strup SE, Saboorian H, et al. No evidence of disease after radiofrequency ablation in delayed nephrectomy specimens. *Urology*. 2006;68:964–967.

Pereira PL, Trubenbach J, Schenk M, et al. Radiofrequency ablation: in vivo comparison of four commercially available devices in pig livers. *Radiology*. 2004;232:482–490.

Permpongkosol S, Link RE, Kavoussi LR, et al. Percutaneous computerized tomography guided cryoablation for localized renal cell carcinoma: factors influencing success. *J Urol*. 2006;176:1963.

Pierorazio PM, Johnson MH, Patel HD, et al. Management of renal masses and localized renal cancer: systematic review and meta-analysis. *J Urol*. 2016;196:989–999.

Ponsky LE, Crownover RL, Rosen MJ, et al. Initial evaluation of Cyberknife technology for extracorporeal renal tissue ablation. *Urology*. 2003;61:498–501.

Ponsky LE, Mahadevan A, Gill IS, et al. Renal radiosurgery: initial clinical experience with histological evaluation. *Surg Innov*. 2007;14:265–269.

Potters L, Kavanagh B, Galvin JM, et al. American Society for Therapeutic Radiology and Oncology (ASTRO) and American College of Radiology (ACR) practice guideline for the performance of stereotactic body radiation therapy. *Int J Radiat Oncol Biol Phys*. 2010;76:326–332.

Psutka SP, Feldman AS, McDougal WS, et al. Long-term oncologic outcomes after radiofrequency ablation for T1 renal cell carcinoma. *Eur Urol*. 2013;63:486–492.

Raman JD, Stern JM, Zeltser I, et al. Absence of viable renal carcinoma in biopsies performed more than 1 year following radio frequency ablation confirms reliability of axial imaging. *J Urol*. 2008;179:2142.

Raman JD, Thomas J, Lucas SM, et al. Radiofrequency ablation for T1a tumors in a solitary kidney: promising intermediate oncologic and renal function outcomes. *Can J Urol*. 2008;15:3980–3985.

Rathke H, Hamm B, Güttler F, et al. Comparison of four radiofrequency ablation systems at two target volumes in an ex vivo bovine liver model. *Diagn Interv Radiol*. 2014;20:251–258.

Rehman J, Landman J, Lee D, et al. Needle-based ablation of renal parenchyma using microwave, cryoablation, impedance and temperature based monopolar and bipolar radiofrequency, and liquid and gel chemoablation: laboratory studies and review of the literature. *J Endourol*. 2004;18:83–104.

Rendon RA, Gertner MR, Sherap MD, et al. Development of a radiofrequency based thermal therapy technique in an in vivo porcine model for the treatment of small renal masses. *J Urol*. 2001;166:292–298.

Renshaw A. The natural history of incidentally detected small renal masses. *Cancer*. 2004;101:650–652.

Rewcastle JC, Sandison GA, Saliken JC, et al. Considerations during clinical operation of two commercially available cryomachines. *J Surg Oncol*. 1999;71:106–111.

Ritchie RW, Leslie T, Phillips R, et al. Extracorporeal high-intensity focus ultrasound for renal tumors: a 3 year follow-up. *BJU Int*. 2010;106:1004–1009.

Rosevear HM, Gellhaus PT, Lightfoot AJ, et al. Utility of the RENAL nephrometry scoring system in the real world: predicting surgeon operative preference and complication risk. *BJU Int*. 2012;109:700–705.

Ross J, Mason RJ, Atwell TD, et al. Renal functional outcomes in patients undergoing percutaneous cryoablation or partial nephrectomy for a solitary renal mass. *BJU Int*. 2017;120(4):544–549.

Rossi S, Buscarini E, Garbagnati F, et al. Percutaneous treatment of small hepatic tumors by an expandable RF needle electrode. *AJR Am J Roentgenol*. 1998;170:1015–1022.

Rossi S, Fornari F, Paties C, et al. Thermal lesions induced by

480-KHz localized current field in guinea pig and in pig livers. *Tumori*. 1990;76:54–57.

Rukstalis DB, Khorsandi M, Garcia FU, et al. Clinical experience with open renal cryoablation. *Urology*. 2001;57:34–39.

Rupp CC, Hoffmann NE, Schmidlin FR, et al. Cryosurgical changes in the porcine kidney: histologic analysis with thermal history correlation. *Cryobiology*. 2002;45:167–182.

Schmidbauer J, Remzi M, Memarsadeghi M, et al. Diagnostic accuracy of computed tomography-guided percutaneous biopsy of renal masses. *Eur Urol*. 2008;53:1003–1011.

Schmit GD, Thompson RH, Kurup AN, et al. Usefulness of RENAL nephrometry scoring system for predicting outcomes and complications of percutaneous ablation of 751 renal tumors. *J Urol*. 2013;189:30–35.

Seidman CA, Gahan J, Weaver M, et al. Renal tumor nephrometry score does not correlate with the risk of radiofrequency ablation complications. *BJU Int*. 2013;112:1121–1124.

Siva S, Pham D, Gill S, et al. A systematic review of stereotactic radiotherapy ablation for primary renal cell carcinoma. *BJU Int*. 2012;110:E737–E743.

Smaldone MC, Kutikov A, Egleston B, et al. Assessing performance trends in laparoscopic nephrectomy and nephron-sparing surgery for localized renal tumors. *Urology*. 2012;80:286–291.

Staehler M, Bader M, Schlenker B, et al. Single fraction radiosurgery for the treatment of renal tumors. *J Urol*. 2016;193:771–775.

Steed J, Saliken JC, Donnelly BJ, et al. Correlation between thermosensor temperature and transrectal ultrasonography during prostate cryoablation. *Can Assoc Radiol J*. 1997;48:186–190.

Stern JM, Gupta A, Raman JD, et al. Radiofrequency ablation of small renal cortical tumours in healthy adults: renal function preservation and intermediate oncological outcome. *BJU Int*. 2009;104:786–789.

Sun MRM, Brook A, Powell MF, et al. Effect of stereotactic body radiotherapy on the growth kinetics and enhancement pattern of primary renal tumors. *AJR Am J Roentgenol*. 2016;206:544–553.

Svedman C, Sandström P, Pisa P, et al. A prospective Phase II trial of using extracranial stereotactic radiotherapy in primary and metastatic renal cell carcinoma. *Acta Oncol*. 2006;45:870–875.

Tanagho YS, Roytman TM, Bhayani SB, et al. Laparoscopic cryoablation of renal masses: single-center long-term experience. *Urology*. 2012;80:307–314.

Thompson RH, Atwell T, Schmit G, et al. Comparison of partial nephrectomy and percutaneous ablation for cT1 renal masses. *Eur Urol*. 2015;67:252–259.

Tracy CR, Kabbani W, Cadeddu JA. Irreversible electroporation (IRE): a novel method for renal tissue ablation. *BJU Int*. 2011;107:1982–1987.

Tracy CR, Kogan P, Gupta A, et al. Radiation exposure during percutaneous ablation of small renal masses: a multi-institutional multimodality analysis. *J Endourol*. 2015;29:1314–1320.

Tracy CR, Raman JD, Donnally C, et al. Durable oncologic outcomes after radiofrequency ablation: experience from treating 243 small renal masses over 7.5 years. *Cancer*. 2010;116:3135–3142.

Vallancien G, Chartier-Kastler E, Bataille N, et al. Focused extracorporeal pyrotherapy. *Eur Urol*. 1993;23:48–52.

Vanderbrink BA, Rastinehad A, Caplin D, et al. Successful conservative management of colorenal fistula after percutaneous cryoablation of renal-cell carcinoma. *J Endourol*. 2007;21:726–729.

van Oostenbrugge TJ, Langenhuijsen JF, Overduin Christiaan G, et al. Percutaneous MR imaging–guided cryoablation of small renal masses in a 3-T closed-bore MR imaging environment: initial experience. *J Vasc Interv Radiol*. 2017;28:1098–1107.

Vernez SL, Okhunov Z, Kaler K, et al. Skin-to-tumor distance predicts treatment failure of T1A renal cell carcinoma following percutaneous cryoablation. *Urology*. 2017;108:195–200.

Volpe A, Panzarella T, Rendon RA, et al. The natural history of incidentally detected small renal masses. *Cancer*. 2004;15:738–745.

Vricella GJ, Ponsky LE, Cadeddu JA. Ablative technologies for urologic cancers. *Urol Clin North Am*. 2009;36:163–178.

Wah TM, Irving HC. Infectious complications after percutaneous radiofrequency ablation of renal cell carcinoma in patients with ileal conduit. *J Vasc Interv Radiol*. 2008;19:1382–1385.

Wah TM, Irving HC, Gregory W, et al. Radiofrequency ablation (RFA) of renal cell carcinoma (RCC): experience in 200 tumours. *BJU Int*. 2014;113:416–428.

Walsh LP, Anderson JK, Baker MR, et al. In vitro assessment of the efficacy of thermal therapy in human renal cell carcinoma. *Urology*. 2007;70:380.

Weber SM, Lee FT Jr. Cryoablation: history, mechanism of action, and guidance modalities. van Sonnenberg E, McMullen W, Solbiati L. *Tumor ablation: principles and practice*. Springer: New York; 2005:250–265.

Weber SM, Lee FT, Chinn DO, et al. Perivascular and intralesional tissue necrosis after hepatic cryoablation: results in a porcine model. *Surgery*. 1997;122:742–747.

Weber SM, Lee FT, Warner TF, et al. Hepatic cryoablation: US monitoring of extent of necrosis in normal pig liver. *Radiology*. 1998;207:73–77.

Weight CJ, Kaouk JH, Hegarty NJ, et al. Correlation of radiographic imaging and histopathology following cryoablation and radio frequency ablation for renal tumors. *J Urol*. 2008;179:1277–1281.

Wells SA, Wheeler KM, Mithqal A, et al. Percutaneous microwave ablation of T1a and T1b renal cell carcinoma: short-term efficacy and complications with emphasis on tumor complexity and single session treatment. *Abdom Radiol*. 2016;41:1203–1211.

White WM, Kaouk JH, et al. Ablative therapy for renal tumors. Kavoussi LR, Novick AC, Partin AW. *Campbell-Walsh urology*. ed 10. Saunders: Philadelphia; 2012:1672–1682.

Whitson JM, Harris CR, Meng MV. Population-based comparative effectiveness of nephron-sparing surgery vs ablation for small renal masses. *BJU Int*. 2012;110:1438–1443.

Woldu SL, Thoreson GR, Okhunov Z, et al. Comparison of renal parenchymal volume preservation between partial nephrectomy, cryoablation, and radiofrequency ablation using 3D volume measurements. *J Endourol*. 2015;29:948–955.

Woolley ML, Schulsinger DA, Durand DB, et al. Effect of freezing parameters (freeze cycle and thaw process) on tissue destruction following renal cryoablation. *J Endourol*. 2002;16:519–522.

Yamakado K, Nakatsura A, Kobayashi S, et al. Radiofrequency ablation combined with renal arterial embolization for the treatment of unresectable renal cell carcinoma larger than 3.5 cm: initial experience. *Cardiovasc Intervent Radiol*. 2006;29:389–394.

Zagoria RJ, Pettus JA, Rogers M, et al. Long-term outcomes after percutaneous radiofrequency ablation for renal cell carcinoma. *Urology*. 2011;77:1393–1397.

Zargar H, Samarasekera D, Khalifeh A, et al. Laparoscopic vs percutaneous cryoablation for the small renal mass: 15-year experience at a single center. *Urology*. 2015;85:850–855.

Zini L, Perrotte P, Capitano U, et al. Radical versus partial nephrectomy. *Cancer*. 2009;115:1465–1471.

Treatment of Advanced Renal Cell Carcinoma

Ramaprasad Srinivasan MD, PhD, W. Marston Linehan MD

***Renal cell carcinoma* (RCC) is a term that includes a variety of cancers arising in the kidney and encompasses several histologically, biologically, and clinically distinct entities** (Linehan et al., 2007, 2009). An estimated 65,340 new cases of cancer arising in the kidney or renal pelvis were diagnosed in 2018 in the United States (Siegel et al., 2018). **Approximately one-third of all patients with newly diagnosed RCC are seen initially with synchronous metastatic disease, and an additional 20% to 40% of patients with clinically localized disease at diagnosis eventually develop metastases** (Bukowski et al., 1997; Rabinovitch et al., 1994; Skinner et al., 1971). Metastatic RCC is almost always fatal, with 10-year survival rates of less than 5% (Bukowski et al., 1997; Motzer et al., 1999, 2000; Motzer and Russo, 2000; Negrier et al., 2002); patients with metastatic disease account for the majority of deaths (approximately 13,860 a year in the United States) related to RCC (Siegel et al., 2018).

Advances in our understanding of the genetic and molecular changes underlying the individual subtypes of RCC have led to the development of novel agents designed to reverse or modulate aberrant pathways contributing to renal oncogenesis. Over the past decade, these “targeted” therapeutic strategies have become an integral component in the management of metastatic clear cell kidney cancer. However, surgery, irradiation, and cytokine therapy remain appropriate choices in the management of selected patients with advanced clear cell RCC. More recently, the recognition that agents modulating T-cell function may have activity against a variety of solid tumors, including RCC, has reinvigorated interest in immunotherapy strategies; the efficacy of several immune “checkpoint” inhibitors in clear cell RCC has been clearly demonstrated in the front-line setting and in patients who have progressed on therapy directed against the vascular endothelial growth factor (VEGF) axis. Although the optimal management of patients with advanced clear cell RCC remains to be determined, the standard of care is evolving rapidly, with emerging data from a variety of strategies, including dual immune checkpoint inhibition and combinations of agents targeting the PD1/PDL1 interaction and those targeting VEGF or VEGF receptors beginning to demonstrate superiority over previously accepted standards. Last, the advent of techniques that allow comprehensive interrogation of the cancer genome has allowed identification of hitherto unrecognized alterations affecting diverse cellular functions, including carbohydrate and amino acid metabolism as well as chromatin remodeling in clear cell RCC. Although the precise contribution of these changes to the genesis and progression of kidney cancer remains to be determined, it is likely that a better understanding of these pathways will spawn additional strategies to combat what remains a largely incurable group of malignancies.

Although agents effective in clear cell RCC are often used in patients with other subtypes of RCC, there is scant evidence from prospective studies to justify their utility in non–clear cell RCC variants. Elucidation of aberrant oncogenic pathways in papillary, chromophobe, and other variants of RCC has paved the way for evaluation of targeted therapeutic approaches in these histologic subtypes (Linehan, 2009; Ricketts et al., 2016).

Prognostic Factors

Patients with metastatic RCC generally have a poor prognosis: the majority succumb to their disease. Ten-year survival in patients diagnosed with metastatic disease was estimated to be less than 5% in the era of cytokine therapy and is unlikely to change significantly with targeted therapy. It is hoped that newer immunotherapeutic strategies may be associated with a higher proportion of complete and/or durable responders, but longer follow-up of patients treated with these emerging strategies is required to better quantify long-term benefit. However, **several clinical features, such as a long time interval between initial diagnosis and appearance of metastatic disease and presence of fewer sites of metastatic disease, have been associated with better outcome. Conversely, poor performance status and the presence of lymph node and/or liver metastases have long been recognized to be associated with shorter survival.**

Investigators at the Memorial Sloan Kettering Cancer Center evaluated a variety of clinical and laboratory parameters in 670 patients enrolled on various clinical trials of chemotherapy or cytokine therapy (most treated with interferon-α) in an effort to identify those pretreatment factors that were able to best predict outcome (Motzer et al., 1999). **In a multivariate analysis, a poor performance status (Karnofsky score <80), an elevated serum lactate dehydrogenase (LDH) level (>1.5 times upper limit of normal), a low hemoglobin (less than the lower limit of normal), an elevated corrected calcium concentration (>10 g/dL), and lack of prior nephrectomy were independent predictors of a poor outcome** (Table 104.1). **Patients could be stratified into three distinct prognostic groups based on these five poor prognostic factors** (Table 104.2). **The overall survival (OS) times in patients with no adverse factors (favorable-risk group), one to two risk factors (intermediate-risk group), and more than three risk factors (poor-risk group) were 20 months, 10 months, and 4 months, respectively** (Fig. 104.1; Motzer et al., 1999). Subsequently, the same group identified poor performance status, high serum calcium, low hemoglobin, elevated LDH, and a short time interval from initial diagnosis to initiation of systemic therapy (<1 year) as factors that could best predict a poor outcome in 463 patients receiving interferon-based therapy in the first-line setting (Motzer et al., 2002). This prognostic model was found to be predictive of survival in an independent data set derived from patients treated at the Cleveland Clinic, providing independent, external validation of the proposed model (Mekhail et al., 2005). Similar prognostic schemes have also been proposed by the Groupe Français d'Immunotherapie, by the International Kidney Cancer Working Group, and by investigators from the University of California, Los Angeles (Manola et al., 2011; Negrier et al., 2002; Tsui et al., 2000).

TABLE 104.1

Adverse Prognostic Factors in 670 Patients Treated With Chemotherapy or Immunotherapy at the Memorial Sloan Kettering Cancer Center

- Karnofsky performance score < 80%
- Elevated lactate dehydrogenase (>1.5 times upper limit of normal)
- Low hemoglobin (<lower limit of normal)
- Elevated corrected calcium (>10 mg/dL)
- Absence of prior nephrectomy

TABLE 104.2

Risk Stratification Based on Adverse Prognostic Factors in 670 Patients Treated With Chemotherapy or Immunotherapy at the Memorial Sloan Kettering Cancer Center

RISK GROUP	NO. OF ADVERSE PROGNOSTIC FACTORS	MEDIAN OVERALL SURVIVAL
Good	0	20 months
Intermediate	1–2	10 months
Poor	3–5	4 months

Data from Motzer RJ, Mazumdar M, Bacik J, et al.: Survival and prognostic stratification of 670 patients with advanced renal cell carcinoma. *J Clin Oncol* 17:2530–2540, 1999.

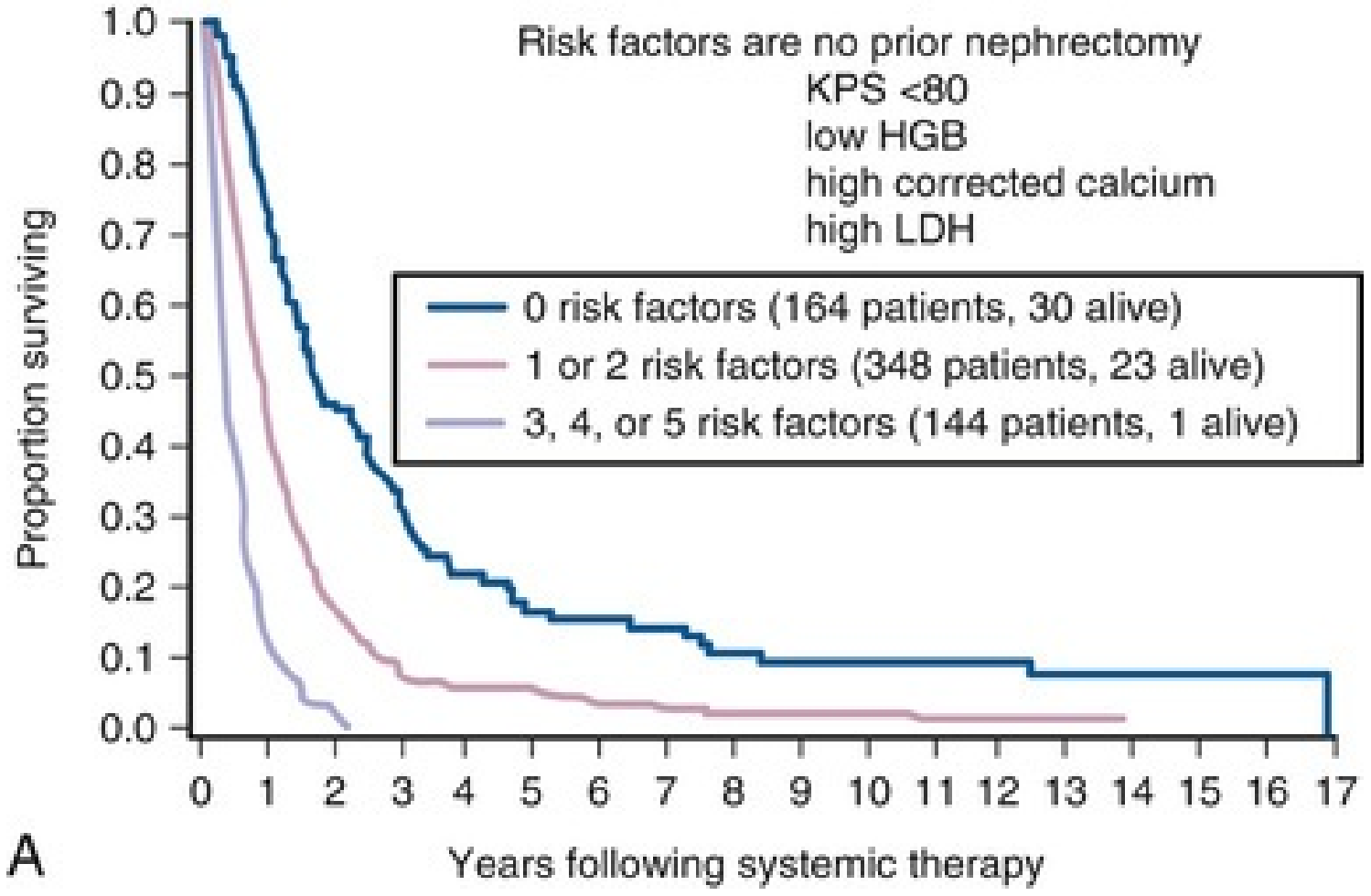

(A) Survival analysis stratified according to risk group in 670 patients treated with chemotherapy or immunotherapy at the Memorial Sloan Kettering Cancer Center (*n* = 656; 14 patients missing one or more of the five risk factors were excluded). *HGB,* hemoglobin; *KPS,* Karnofsky performance score; *LDH,* lactate dehydrogenase. (Data from Motzer RJ, Mazumdar M, Bacik J, et al.: Survival and prognostic stratification of 670 patients with advanced renal cell carcinoma. *J Clin Oncol* 17:2530–2540, 1999.)

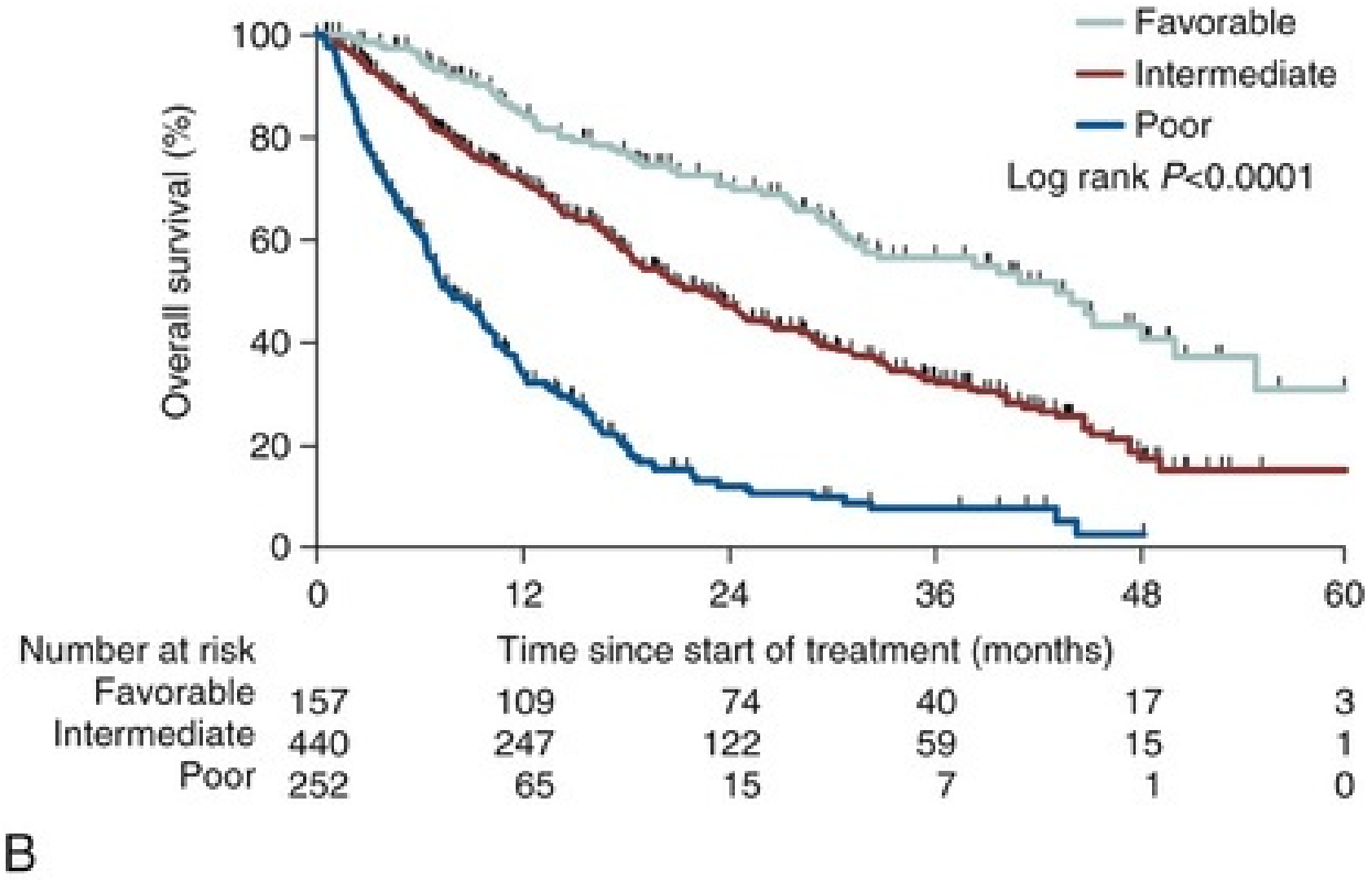

(B) Survival analysis stratified according to risk group in 849 patients treated with first-line VEGF-targeted therapy. (IMDC Prognostic Criteria; data from Heng D, Xie W, Regan M, et al.: External validation and comparison with other models of the International Metastatic Renal Cell-Carcinoma Database Consortium prognostic model: a population-based study. Lancet Oncol 14[2]:141–148, 2013.)

FIG. 104.1

Modifications of these prognostic schemes as well as identification of reliable molecular markers are under investigation as suitable predictors of response to and survival after therapy with newer targeted agents against VEGF and mammalian target of rapamycin (mTOR) pathway components (Choueiri et al., 2007, 2008; Motzer et al., 2008). The most comprehensive effort to define prognostic factors in patients undergoing therapy with VEGF-pathway antagonists was undertaken by the International Metastatic Renal Cell Carcinoma Database Consortium (IMDC). **Using data from a group of 645 patients treated with first-line VEGF-targeted agents at several US and Canadian centers, the IMDC investigators confirmed the prognostic relevance of several components of the Memorial Sloan Kettering Cancer Center model (performance status, hypercalcemia, anemia, and time from diagnosis to treatment); in addition, neutrophilia and thrombocytosis were identified as additional, independent predictors of poor outcome. Patients were divided into three risk categories based on the number of adverse prognostic factors associated with their disease** (Heng et al., 2009). This model was validated by the same group in an independent cohort of 849 patients and shown to be comparable with other prognostic models such as the MSKCC model. In their updated analysis, median OS was 43.2 months in patients with no risk factors, 22.5 months in those with 1 or 2 risk factors, and 7.8 months in those with 3 or more risk factors (Fig. 104.1B and Tables 104.3 and 104.4; Heng et al., 2013). **Validated prognostic models are used in clinical practice to help make appropriate management decisions as well as in the design and interpretation of clinical trials.**

TABLE 104.3

Adverse Prognostic Factors in 849 Patients Treated With First-Line VEGF-Targeted Therapy

- Karnofsky performance score <80%
- Neutrophilia (>upper limit of normal)

- Low hemoglobin (<lower limit of normal)
- Elevated corrected calcium (>upper limit of normal)
- Thrombocytosis (>upper limit of normal)
- <1 yr from diagnosis to VEGF-targeted therapy

TABLE 104.4

Risk Stratification Based on Adverse Prognostic Factors in 849 Patients Treated With First-Line VEGF-Targeted Therapy

RISK GROUP	NO. OF ADVERSE PROGNOSTIC FACTORS	MEDIAN OVERALL SURVIVAL
Good	0	43.2 months
Intermediate	1–2	22.5 months
Poor	3–6	7.8 months

Data from Heng DY, Xie W, Regan MM, et al.: External validation and comparison with other models of the International Metastatic Renal-Cell Carcinoma Database Consortium prognostic model: a population-based study. *Lancet Oncol* 14(2):141–148, 2013.

Surgical Management of Metastatic Renal Cell Carcinoma

Debulking or Cytoreductive Nephrectomy in Patients With Metastatic Renal Cell Carcinoma

The role of cytoreductive nephrectomy preceding systemic therapy has been extensively studied in the era of cytokine therapy. The impetus for exploring this approach in metastatic RCC came from the perception that bulky tumors may inhibit key components of the immune system critical for combating cancer, and from observations suggesting that removal of large primary tumors may provide clinical benefit. To support this practice, early proponents of cytoreductive nephrectomy had cited (1) the rare but well-described occurrence of spontaneous regression of metastatic lesions after nephrectomy (Bloom, 1973; Marcus et al., 1993; Middleton, 1980; Snow and Schellhammer, 1982); (2) preclinical data suggesting that large primary tumors may inhibit T-cell function (Bukowski et al., 1998; Kudoh et al., 1997; Ling et al., 1998; Uzzo et al., 1999a,b); and (3) the inability of systemic agents, particularly cytokines, to induce meaningful responses in primary renal tumors in most patients (Rackley et al., 1994; Sella et al., 1993; Wagner et al., 1999). However, the risk of perioperative morbidity and mortality and the inability of a significant proportion of patients undergoing nephrectomy to subsequently receive systemic therapy clearly underlined the need for unequivocal evidence of clinical benefit as well as the ability to identify patients likely to benefit from this approach.

Nephrectomy as the sole therapeutic intervention in the context of metastatic disease is unlikely to alter outcome, as suggested by small retrospective analyses (deKernion et al., 1978). However, several retrospective studies have demonstrated the feasibility of a combined modality approach in which nephrectomy is followed by cytokine therapy, with some suggesting that this approach may favorably affect response and survival. Investigators from the National Cancer Institute (NCI) reported their experience in 195 patients undergoing nephrectomy followed by high-dose interleukin-2 (IL-2) therapy between the years 1985 and 1996 (Walther et al., 1997). An overall response rate of 18% (including a complete response rate of 4%) after IL-2 therapy was observed in this study. A notable finding that emerged from this study was that, although the majority of patients underwent successful resection of the primary tumor, only 107/195 (55%) went on to receive IL-2 therapy. Rapid postoperative disease progression and perioperative surgical and medical morbidity were the most common factors preventing delivery of systemic therapy, suggesting that careful patient selection may play an important role in the successful application of this combined modality approach.

The impact of patient and/or disease characteristics on outcome was further highlighted by a retrospective study addressing this issue. In a 1995 series by Bennet et al. of 30 patients, including several patients with unfavorable performance status (Eastern Cooperative Oncology Group [ECOG] 2) and multiple metastatic sites including patients with brain or liver metastases, only 7 (23%) were able to proceed with IL-2 after nephrectomy. Conversely, in a series that included only patients with favorable clinical/prognostic factors (e.g., good performance status, minimal comorbidity, no liver or brain metastases), the majority of patients were able to proceed to systemic therapy after nephrectomy, with high response rates (35% to 40%) and OS (median 20 to 22 months) after cytokine-based treatment (Fallick et al., 1997; Figlin et al., 1997). More recently, in a population based analysis of more than 5000 patients with metastatic kidney cancer identified in the Surveillance, Epidemiology, and End Results database, cytoreductive nephrectomy appeared to be associated with a better OS and cancer-specific survival (Zini et al., 2009). **Although these retrospective analyses and small single-arm prospective studies confirmed the feasibility of a tandem surgical/systemic therapy approach, their major contribution was in laying the foundation for controlled, prospective studies to determine if outcomes with systemic therapy could be improved by prior nephrectomy.**

The most compelling evidence in support of cytoreductive nephrectomy is provided by two randomized phase III studies conducted by the Southwest Oncology Group (SWOG) and the European Organization for Research and Treatment of Cancer (EORTC). The larger of the two studies, SWOG 8949, randomized 241 patients with metastatic RCC to receive interferon-α-2b either as initial therapy or after cytoreductive nephrectomy (Flanigan et al., 2001). Salient eligibility criteria included a histologic diagnosis of kidney cancer (all histologic subtypes were allowed); good performance status (ECOG 0 or 1); presence of a resectable primary renal tumor; no prior chemotherapy, irradiation, or immunotherapy; and adequate organ function. **Although there were no significant differences in the response rates to interferon observed in the**

two study arms, OS was improved in the surgery plus interferon arm (median 11.1 vs. 8.1 months for interferon alone, *P* = 0.05) (Fig. 104.2). These data were recapitulated in a smaller EORTC trial (a total of 85 patients randomized to interferon alone or interferon after nephrectomy) that used a similar design and reported a survival advantage favoring the surgery plus interferon arm (median OS 17 vs. 7 months, *P* = 0.03) (Mickisch et al., 2001). A combined analysis of both trials revealed data that were consistent with those reported in the individual trials (Flanigan et al., 2004). **These data supported the use of cytoreductive nephrectomy in carefully selected patients with metastatic RCC who are likely candidates for subsequent cytokine therapy** (data summarized in Table 104.5). Although some patients with non–clear cell histologic subtypes of RCC were included in the aforementioned trials, the role of nephrectomy before systemic therapy in these patients is unclear.

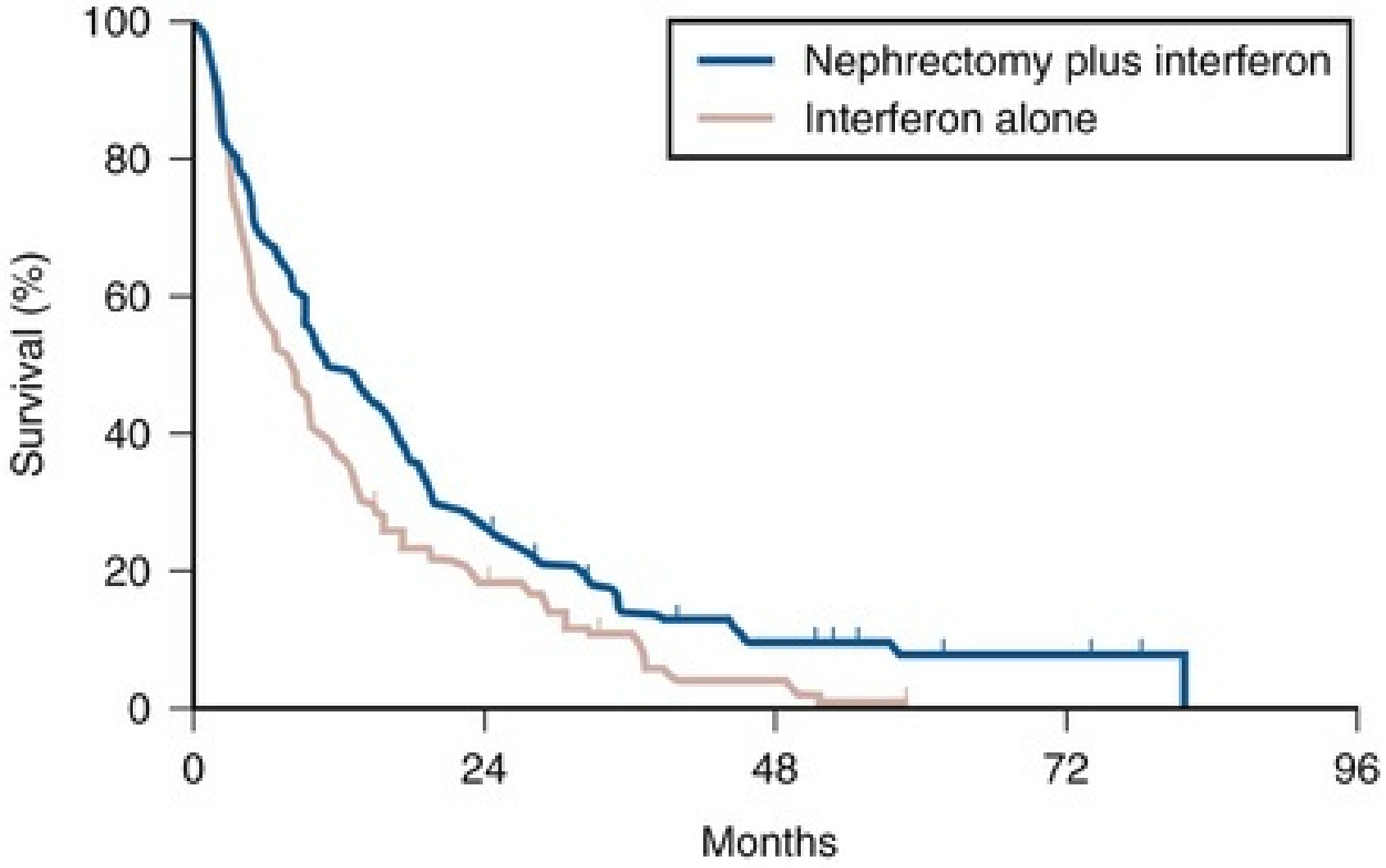

No. at risk

Interferon alone	121	21	4	0	
Nephrectomy plus interferon	120	29	9	3	0

FIG. 104.2 Actuarial survival among 241 patients with metastatic renal cell carcinoma randomized to either interferon-α alone or interferon-α after cytoreductive nephrectomy. (Modified from Flanigan RC et al.: Nephrectomy followed by interferon alfa-2b compared with interferon alfa-2b alone for metastatic renal-cell cancer. *N Engl J Med* 345:1655–1659, 2001.)

TABLE 104.5

Summary of Outcome in Randomized Studies of Interferon-α Alone

or Interferon-α After Cytoreductive Nephrectomy in Patients With Metastatic Kidney Cancer

STUDY	NO. OF ELIGIBLE PATIENTS			RESPONSE RATE AFTER IFN (%)			MEDIAN OVERALL SURVIVAL (MO)		
	TOTAL	IFN	Nx Plus IFN	IFN	Nx Plus IFN	*P*	IFN	Nx Plus IFN	*P*
Flanigan et al., 2001	241	121	120	3.6	3.3	NS	8.1	11.1	.05
Mickisch et al., 2001	83	42	41	12	19	.38	7	17	.03
Flanigan et al., 2004	331	163	161	5.7	6.9	.60	7.8	13.6	.002

IFN, Interferon-α; *Nx,* cytoreductive nephrectomy.

Since the advent of VEGFR-targeted therapy, cytoreductive nephrectomy had remained the practice, based largely on data generated in the era of cytokine therapy and supported by retrospective series and outcome analysis from a national cancer database. Several retrospective series suggest that patients with metastatic clear cell RCC benefited from undergoing cytoreductive nephrectomy before initiation of systemic therapy with tyrosine kinase inhibitors targeting VEGFR. In one early series of 314 patients who had received VEGF-pathway antagonists, 201 underwent prior cytoreductive surgery, and the remainder (n = 113) proceeded to systemic therapy without surgical debulking of their primary tumor. In a univariate analysis, cytoreductive surgery was associated with a more favorable outcome (median OS 19.8 vs 9.4 months, HR 0.44; 95% CI 0.32–0.59; $P < 0.01$), a difference that persisted after adjusting for confounding prognostic/risk factors (HR 0.68; 95% CI 0.46–0.99; $P = 0.04$) (Choueiri et al., 2011). Data from the National Cancer Database also suggested that cytoreductive nephrectomy was used more frequently at academic centers and associated with a survival advantage (Hanna et al., 2016). Although these data were subject to the inherent bias associated with analyses of this nature, they nonetheless provided some justification for clinicians who continued the practice of cytoreductive nephrectomy in the era of targeted systemic therapy.

The French Association of Urology and Urogenital Tumors Study Group undertook the CARMENA study (Cancer du Rein Metastatique Nephrectomie et Antiangiogéniques) in a bid to provide more definitive, prospective data to address this issue (Mejean et al., 2018). A total of 576 patients with metastatic clear cell RCC were randomized equally to one of two arms: cytoreductive nephrectomy followed by sunitinib or sunitinib alone. The primary objective was to ascertain the noninferiority of sunitinib alone, with OS as the primary end point. The study was hampered by low accrual, with only 450 patients accrued at 79 centers across Europe over 9 years, leading to premature closure of the trial. With a median follow-up of 50.9 months, the OS in the nephrectomy arm was 13.9 months (95% CI 11.8–18.3) versus 18.4 months in the sunitinib arm (95% CI 14.7–23.0; HR 0.89; 95% CI 0.76–1.10), leading the authors to conclude that sunitinib alone was not inferior to cytoreductive nephrectomy followed by sunitinib in patients with intermediate or poor prognosis (Fig. 104.3).

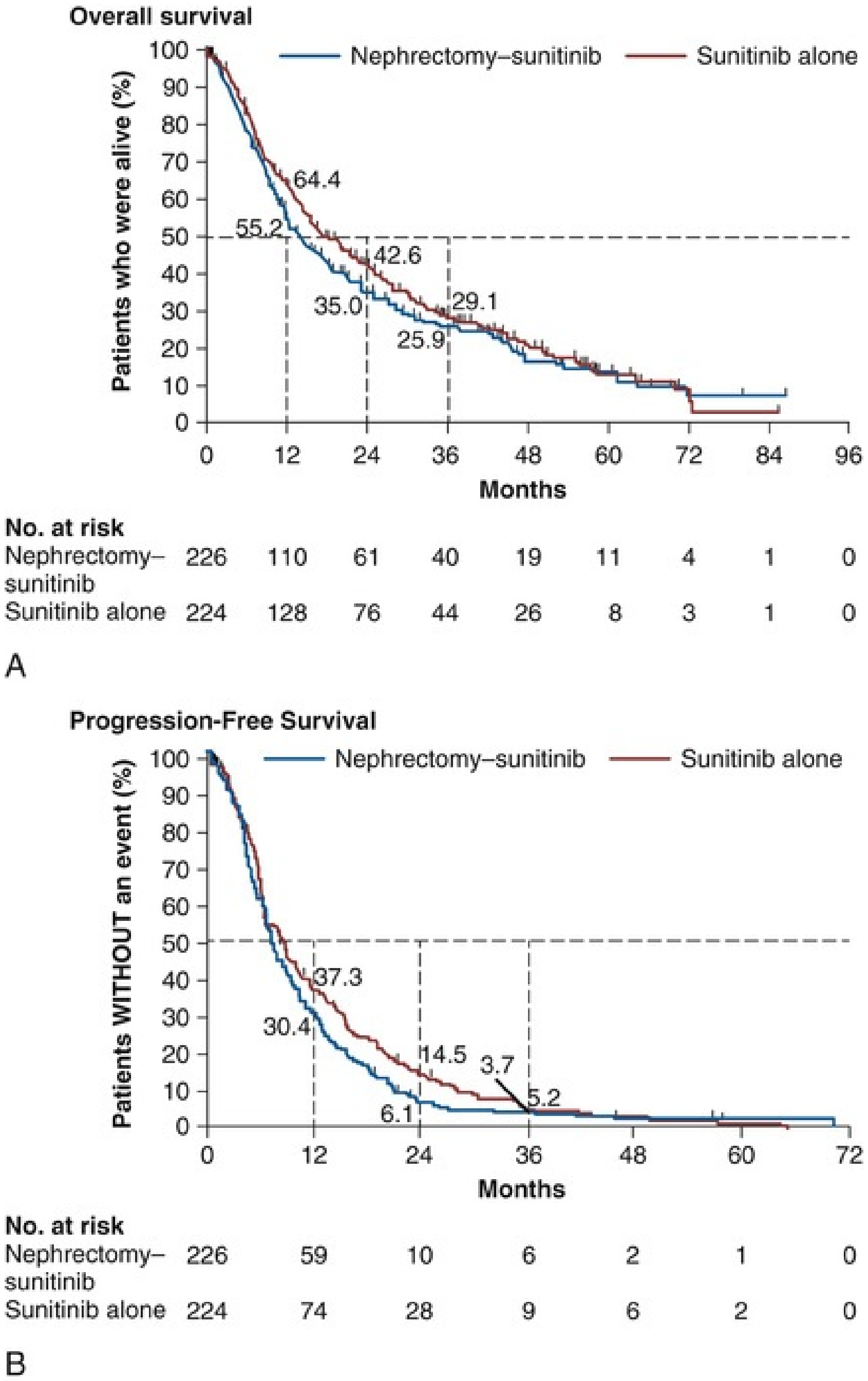

FIG. 104.3 Kaplan-Meier Curves for Overall Survival (A) and Progression Free Survival (B) among 450 patients with metastatic clear cell cancer treated with either sunitinib alone or sunitinib following cytoreductive nephrectomy. (Mejean et al., *N Engl J Med* 379 : 417-427, 2018.)

To evaluate the impact of these data on clinical practice, several aspects of this study merit further attention. First, almost 45% of the patients randomized were characterized as having poor prognosis by MSKCC criteria, a group that is typically not offered cytoreductive nephrectomy. Consequently, approximately

25% of patients assigned to the nephrectomy arm did not receive the intended treatment, including 7% who did not undergo nephrectomy and 18% who did not receive sunitinib after a nephrectomy. Conversely, 17% of patients who received sunitinib as initial therapy underwent a subsequent cytoreductive nephrectomy. When the survival analysis was limited to patients who received the intended treatment, it was no longer clear that sunitinib alone was non-inferior (upper limit of 95% CI crossed the preset boundary for non-inferiority). Second, a population most likely to benefit from cytoreductive nephrectomy may have been underrepresented because investigators screening patients were allowed to exclude patients with low metastatic burden at their discretion. Third, the study was stopped prematurely with far fewer events than originally planned, reducing statistical power. In fact, a planned interim analysis at the time the study halted further accrual failed to meet statistical parameters for stopping the study early, and the outcome may have been different had the study been allowed to meet the original accrual goal. **Although findings from this study reiterate that patients with poor prognosis are not likely to benefit from cytoreductive nephrectomy, the impact of these data on current clinical practice (i.e., the use of cytoreductive surgery in appropriately selected patients with low metastatic burden and other favorable features) remains uncertain. Furthermore, the relevance of data from the CARMENA study in the current era also requires careful consideration, because sunitinib is no longer the standard initial therapy in most newly diagnosed patients.**

Key Points: Cytoreductive Nephrectomy in Metastatic Renal Cell Carcinoma

- Two randomized studies have demonstrated improved survival in carefully selected metastatic RCC patients undergoing cytoreductive nephrectomy followed by cytokine therapy (interferon-α) compared with those receiving cytokine therapy alone.
- Several patient and/or disease characteristics appear to influence outcome; for example, patients with poor performance status, medical comorbidity, rapidly progressive disease, and presence of brain metastases are unlikely to benefit from this approach.
- Although several retrospective studies suggested that cytoreductive

nephrectomy may be of benefit in the era of VEGFR-targeted therapy, a randomized study failed to demonstrate an advantage in patients with intermediate and poor prognoses. These data, however, do not specifically address the utility of nephrectomy in patients with relatively low metastatic burden and other favorable features who may benefit from this approach.

Resection of Metastases

Most patients with metastatic RCC will not achieve a cure or long-term disease remission with currently available systemic agents. **However, resection of limited metastatic disease has been reported by several groups to be associated with long disease-free intervals and OS in some patients. Metastasectomy has not been evaluated systematically in a prospective, randomized fashion, and the favorable outcome ascribed to resection in patients with solitary metastatic disease may reflect patient selection bias, inherent differences in tumor biology, and natural history or other confounding factors.**

Most studies detailing outcome after metastasectomy are retrospective series. In most series, isolated pulmonary metastases were the lesions most commonly amenable to resection with curative intent. The OS of patients undergoing complete resection of limited metastatic disease is impressive, with reported median 5-year survival rates of 35% to 50% in many series (Friedel et al., 1999; Kierney et al., 1994; Middleton, 1967; Murthy et al., 2005; O'Dea et al., 1978; Pogrebniak et al., 1992; Russo et al., 2007; Skinner et al., 1971; Tolia and Whitmore, 1975). The larger of these studies have also attempted to identify patients most likely to benefit from this approach. In a series of 278 patients with recurrent RCC treated at the Memorial Sloan Kettering Cancer Center, 211 were reported to have undergone either complete (141 patients) or incomplete (70 patients) resection of recurrent tumor from a variety of metastatic sites (Kavolius et al., 1998). **In this series, complete or "curative" resection was associated with a longer OS (44% 5-year survival vs. 14% in patients undergoing incomplete resection); multivariate analysis also identified the presence of a solitary metastatic lesion, age younger than 60 years, and a disease-free interval of more than 1 year as favorable prognostic indicators. In addition, some studies have suggested that pulmonary metastases, smaller tumor size (<4 cm in one series), and metachronous lesions are predictors of better outcome after metastasectomy** (Friedel et al., 1999; Murthy et al., 2005; Piltz et al., 2002). In a retrospective single institution study of 125 patients who had one or more metastatic lesions surgically removed, Alt et al. (2011) confirmed that patients who underwent complete metastatectomy had improved outcomes; furthermore, complete metastasectomy appeared to be feasible and predictive of improved cancer-specific survival even in patients with multiple metastatic lesions. **Although not supported by convincing evidence of survival benefit from prospective studies, resection of isolated metastatic lesions is a reasonable and widely employed practice in well-selected patients with RCC.**

Key Points: Metastasectomy

- Resection of isolated metastatic lesions is appropriate in selected patients.
- Several retrospective studies have suggested that patients undergoing complete resection of isolated metastatic foci may experience long disease-free intervals with median overall survival rates of 35% to 50% in some reports.
- Several factors are associated with an improved outcome after metastasectomy, including complete resection, presence of solitary metastatic lesions, age younger than 60 years, smaller tumor size, presence of pulmonary metastases, and development of metachronous metastatic disease.
- There are no prospective, randomized studies demonstrating a favorable outcome with metastasectomy. It is therefore possible that the favorable outcome after resection of limited metastatic disease may be a reflection of patient selection bias, differences in tumor biology and natural history, or other confounding factors not related to resection.

Palliative Surgery

Cytoreductive nephrectomy can be performed with palliative intent in patients with intractable pain, hematuria, constitutional symptoms, or a variety of paraneoplastic manifestations such as hypercalcemia, erythrocytosis, secondary thrombocytosis, or hypertension. Symptoms such as pain and laboratory abnormalities including hypercalcemia can often be effectively managed medically, whereas symptoms such as hematuria may be amenable to alternative treatment approaches (e.g., angioembolization). Furthermore, **resection of the primary renal tumor does not always result in clinical benefit;** for instance, in one series, only a little more than half the patients (7/12) with hypercalcemia experienced clinically meaningful reductions in serum calcium levels (Walther et al., 1997). **Cytoreductive nephrectomy with palliative intent is therefore performed relatively infrequently but is appropriate in some patients.**

Resection of metastases to alleviate pain or to forestall potentially life-threatening or debilitating complications is often indicated in a variety of situations. Patients who may benefit from noncurative resection of metastatic lesions include those with solitary brain metastases, metastatic lesions in weight-bearing bones or joints, or vertebral metastatic lesions with impending spinal cord or radicular compromise (Kollender et al., 2000; Sheehan et al., 2003; Sundaresan et al., 1986). Surgical resection is often combined with radiation and/or systemic therapy in many of the aforementioned situations.

It is our current practice to offer cytoreductive nephrectomy to well-selected patients with metastatic clear cell RCC.

Key Points: Palliative Surgery in Advanced Renal Cell Carcinoma

- In some patients with advanced RCC, cytoreductive nephrectomy may help alleviate symptoms related to the primary tumor (e.g., intractable pain, hematuria) or paraneoplastic manifestations.
- However, nonsurgical options are often effective in palliating symptoms associated with RCC; cytoreductive nephrectomy is hence infrequently performed with purely palliative intent.
- Resection of metastatic lesions (often in combination with radiation or systemic therapy) is sometimes performed for relief of symptoms or to prevent life-threatening or disabling sequelae.

Immunologic Approaches in the Management of Advanced Clear Cell Renal Cell Carcinoma

The host immune system has long been believed to play an important role in the causation and control of renal cell cancer. A report detailing spontaneous regression of metastatic lesions after radical nephrectomy provides perhaps the earliest evidence implicating the immune system in the regulation of kidney cancer. The phenomenon of spontaneous regression, thought to represent T- or B-cell mediated antitumor immunity, has sparked great enthusiasm over the years and generated several reports describing this phenomenon (Braren et al., 1974; Edwards et al., 1996; Kavoussi et al., 1986; Marcus et al., 1993; Middleton, Jr., 1980; Robson, 1982; Silber et al., 1975; Snow and Schellhammer, 1982). Although rare **(it is estimated that the true incidence of spontaneous regression is less than 1%)** and often transient, the presumed immunologic mechanisms underlying this event have nonetheless played an important part in the development of immunotherapeutic approaches in kidney cancer. The presence of immune cells, notably cytotoxic T lymphocytes, in resected tumors and the identification of tumor-associated antigens that can serve as human leukocyte antigen (HLA)-restricted targets on tumor cells for T cell–mediated cytotoxicity have also kindled interest in immune-based strategies in renal cell cancer (Ada, 1999; Boon et al., 1997; Finke et al., 1994; Rosenberg, 1999; Takahashi et al., 2008). Early clinical studies explored the efficacy of agents believed to act as nonspecific stimulators of the host immune system, such as cytokines, with or without adoptive cellular therapy. More recently, investigators have evaluated a variety of novel approaches, including allogeneic immunotherapy, vaccines, and modulators of T-cell function. Most immunotherapy strategies have been directed at clear cell RCC, and the utility of these approaches in non–clear cell variants remains to be explored.

Interferons

The interferons are a group of proteins with diverse biologic functions, including immunomodulatory properties. Interferon-α was one of the earliest cytokines to be evaluated for activity in RCC. Initial trials with interferon used leukocyte-derived interferon. The subsequent availability of recombinant interferon-α in the early to mid-1980s allowed investigators to evaluate higher doses of this cytokine in a series of phase II trials. **Initial trials demonstrated overall response rates of 16% to 26% in patients treated with interferon-α, and several subsequent trials have confirmed the activity of this agent, with response rates generally in the 10% to 15% range** (deKernion et al., 1983; Figlin et al., 1988; Minasian et al., 1993; Motzer et al., 2002; Muss et al., 1987; Quesada, 1989; Quesada et al., 1983, 1985; Rosenberg et al., 1987; Umeda and Niijima, 1986). **The limited long-term survival data available suggest that durable complete responses with this agent are relatively rare (<2%).** A variety of dosing schedules and routes have been evaluated to determine the optimal interferon regimen; no single mode of administration or dosing schedule has so far demonstrated superiority over others (Kirkwood et al., 1985; Minasian et al., 1993; Muss et al., 1987; Umeda and Niijima, 1986). Similarly, the addition of chemotherapy or other cytokines to interferon-α has failed to improve the outcomes seen with single-agent therapy (Ellerhorst et al., 1997; Negrier et al., 2000a,b; Ravaud et al., 1994, 1998; Rosenberg et al., 1989; Sella et al., 1992; Tourani et al., 1998, 2003).

Several prospective, randomized trials evaluating the efficacy of interferon-α have demonstrated a modest but statistically significant improvement in outcome after treatment with this agent. A randomized phase III study that assigned 335 patients to receive either interferon-α or medroxyprogesterone demonstrated a higher response rate (14% vs. 2%) and OS (median 8.5 vs. 6 months, hazard ratio 0.72, $P = 0.017$), favoring the interferon arm of the study (Medical Research Council Renal Cancer, 1999). A second study randomized 160 patients with metastatic RCC to receive vinblastine alone or in combination with interferon-α; a higher response rate (16% vs. 2.5%) and improved OS (median 16 vs. 9 months, $P = 0.0049$) with the addition of interferon was observed in this study (Table 104.6; Pyrhonen et al., 1999). Two additional randomized studies suggested that vinblastine is unlikely to have contributed significantly to the activity of this combination by showing that survival was not improved with the addition of vinblastine to interferon-α (Fossa et al., 1992; Neidhart et al., 1991). Last, a meta-analysis of randomized trials of interferon against a variety of agents suggested that interferon-based therapy conferred a survival advantage (Coppin et al., 2005). **Despite its relatively modest activity, based on the just-described data and relative ease of administration compared with IL-2, interferon was commonly the agent of choice in the initial treatment of**

metastatic RCC until the advent of VEGF pathway antagonists.

TABLE 104.6

Summary of Results From Selected Randomized Trials of Interferon-α in Metastatic Renal Cell Carcinoma

STUDY	AGENT(S)	PHASE	NO. OF PATIENTS TOTAL (RANDOMIZED)	OVERALL RESPONSE RATE (%)	OVERALL SURVIVAL	
					MEDIAN (mo)	*P*
Medical Research Council, 1999	IFN vs. MPA	III	335 (167 vs. 168)	13 vs. 7	8.5 vs. 6.0	<0.01
Pyrhonen et al., 1999	IFN + vinblastine vs. vinblastine	III	160 (79 vs. 81)	16 vs. 2.5	15.8 vs. 8.8	<0.01
Neidhart et al., 1991	IFN vs. IFN + vinblastine	III	165 (82 vs. 83)	13 vs. 13	NA	NS
Fossa et al., 1992	IFN vs. IFN + vinblastine	III	178 (87 vs. 91)	11 vs. 24	12 vs. 12	NS

IFN, Interferon; *MPA,* medroxyprogesterone acetate; *NA,* not available; *NS,* not significant.

Interleukin-2

Clinical trials in the early 1980s initially identified IL-2 as an active agent in RCC, with some IL-2–based regimens leading to objective response rates in excess of 30% (Rosenberg et al., 1989, 1993). In a subsequent report detailing 255 patients treated on a series of phase II trials at the NCI, a more modest overall response rate of 15% (37/255 patients) was noted (Fyfe et al., 1996). **Several trials conducted by the NCI and the Cytokine Working Group as well as meta-analyses of published data have consistently demonstrated response rates in the range of 15% to 20%** (Dutcher et al., 1997; Fisher et al., 1988; Lotze et al., 1986; Rosenberg et al., 1987, 1989, 1993). **More importantly, 7% to 9% of patients receiving high-dose IL-2 are reported to have achieved complete regression of all metastatic tumors, with the**

majority of complete responders (>80%) demonstrating no evidence of disease recurrence on long-term follow-up (Fisher et al., 1997, 2000; Rosenberg et al., 1998). There have also been reports of long-term disease-free remission in partial responders whose limited disease burden after IL-2 therapy rendered them amenable to resection of localized metastases. **High-dose IL-2 was approved by the US Food and Drug Administration (FDA) for the treatment of metastatic kidney cancer in 1992, based largely on its ability to induce durable complete responses in some patients.**

The initial studies with IL-2 were conducted using an intravenous bolus regimen with doses of 600,000 or 720,000 IU/kg administered every 8 hours as tolerated to a maximum of 15 doses. A major limitation of this dosing regimen is the considerable associated toxicity that has limited its widespread use. Vascular leak syndrome, and the resulting hypotension, third-space fluid retention, respiratory compromise, and multiorgan damage are some of the more problematic concomitants of IL-2 therapy and led to an unacceptably high treatment-related mortality rate (2% to 5%) in early studies with this agent (Kammula et al., 1998; Rosenberg et al., 1987). Subsequently, careful patient selection, intensive monitoring schemes, and early interventions with IV fluids, vasopressors, and antibiotics have significantly reduced mortality associated with IL-2 (Kammula et al., 1998). However, the significant morbidity and expense associated with delivering bolus high-dose IL-2 have led several investigators to explore alternative regimens aimed at reducing toxicity without compromising efficacy. Numerous single-arm phase II studies have evaluated a variety of alternative regimens, including daily subcutaneous administration and continuous intravenous infusion (Atkins et al., 2001; Escudier et al., 1994a,b, 1995; Negrier et al., 2000, 2005, 2008). Many of these studies have reported overall response rates of 10% to 30%, suggesting comparable efficacy with high-dose bolus administration based on data from historical controls. However, two randomized studies have demonstrated that, although well tolerated, lower-dose regimens are associated with lower overall response rates, as well with fewer durable, complete responses (Table 104.7; McDermott et al., 2005; Yang et al., 2003). **Based on these data, we only recommend high-dose IL-2 regimens in patients being considered for cytokine therapy.**

TABLE 104.7

Summary of Results From Selected Randomized Trials of Interleukin-2 in Metastatic Renal Cell Carcinoma

STUDY	TREATMENT ARMS	NO. OF PATIENTS	DOSE, ROUTE, AND SCHEDULE	RESPONSE		OVERALL SURVIVAL	
				ORR	*P*	MEDIAN (mo)	*P*
Négrier et al., 1998	IL-2	138	18 × 10^6 IU/m^2/d × 5 days, CIV	6.5		12	
	IFN	147	18 × 10^6 IU three times a week, SC	7.5		13	0.5
	IL-2 + IFN	140	18 × 10^6 IU/m^2/d × 5 days, CIV + 6 × 10^6 IU three times a week, SC	18.6	0.01	17	
Yang et al., 2003b	IL-2	156	720,000 U/kg every 8 hours × 5 days, IV bolus	21		NA	
	IL-2	150	72,000 U/kg every 8 hours × 5 days, IV bolus	13	0.048	NA	0.4
	IL-2	94	250,000 U/d × 5 days, SC, week 1 125,000 U/d × 5 days, SC, weeks 2 to 6	10	0.033	NA	0.3
McDermott et al., 2005	IL-2	96	600,000 U/kg every 8 hours × 5 days, IV bolus	23		17	
	IL-2+ IFN	96	5 × 10^6 IU/m^2 every 8 hours × 3, then 5 ×	10	0.018	13	0.2

			10^6 IU/m^2/d × 5 days/week, SC + 5 × 10^6 IU three times a week, SC				

CIV, Continuous intravenous infusion; *IFN,* interferon-α; *IL-2,* interleukin-2; *IV,* intravenous; *NA,* not available; *ORR,* overall response rate; *SC,* subcutaneous.

Attempts to enhance the efficacy of IL-2 therapy have led investigators to explore combination therapy with other cytokines, cytotoxic chemotherapy, and adoptive cellular immunotherapy. Early experience with combination cytokine therapy was promising: one study reported a 31% overall response rate in patients treated with high-dose bolus IL-2 and interferon (Rosenberg et al., 1989). However, subsequent studies have indicated that this combination is more toxic and no more effective than IL-2 alone (Bukowski et al., 1997; Dutcher et al., 1997; Ravaud et al., 1994; Tourani et al., 1998, 2003). A multicenter, randomized phase III study compared the efficacy of intermediate-dose IL-2 administered by continuous intravenous infusion with interferon-α or the combination in 425 patients with metastatic clear cell RCC (Negrier et al., 1998). **Although the combination of IL-2 and interferon resulted in a higher response rate (18.6%) and 1-year event-free survival (EFS; 20%) compared with IL-2 (overall response rate 6.5%, 1-year EFS 15%) or interferon (overall response rate 7.5%, 1-year EFS 12%) alone, there was no significant difference in survival between the groups.** Combination therapy also resulted in higher toxicity than either agent given alone. Regimens combining IL-2 and cytotoxic chemotherapy (particularly 5-fluorouracil [5-FU]) have been the subject of numerous studies. Unfortunately, reports of high response rates in initial studies (49% in a study using IL-2, interferon, and 5-FU) could not be reproduced in later studies (Atzpodien et al., 1993; Dutcher et al., 2000; Ellerhorst et al., 1997; Negrier et al., 2000). Similarly, despite the promise of preclinical and early clinical studies, the addition of ex vivo expanded tumor-infiltrating lymphocytes or lymphokine-activated killer cells to high-dose IL-2 has not reliably demonstrated improved clinical benefit, and these approaches have been largely abandoned (Figlin et al., 1999; Law et al., 1995; Rosenberg et al., 1993).

Given the considerable toxicity associated with high-dose IL-2 and the relatively small proportion of patients who derive benefit from this therapy, identification of predictors of response and long-term outcome has received considerable attention. The predictive value of a variety of histologic, clinical, laboratory, and molecular parameters has been studied. **Patients with clear cell RCC appear most likely to benefit from IL-2 therapy,** although the exceedingly small number of patients with non–clear cell histologies typically enrolled in studies of IL-2 makes it difficult to draw definitive conclusions about efficacy in this subgroup of patients. **Patient performance status, number of metastatic sites, site of metastases, prior nephrectomy, and time from nephrectomy to systemic therapy are some of the factors that may affect outcome.** In one study, patients with more than one site of metastasis, those with metastatic disease within 1 year of diagnosis, and those with liver metastases had the worst outcome, with a median survival of 6 months (Negrier et al., 2002). Overexpression of carbonic anhydrase IX (CAIX or G250) has been observed in a retrospective analysis to be associated with a higher probability of response to IL-2 (Atkins et al., 2005); however, a prospective trial of 120 advanced kidney cancer patients designed to evaluate the impact of prespecified “good-risk” clinical features or biomarkers (i.e., CAIX) on outcome revealed that CAIX expression was not predictive of response (McDermott et al., 2015). **The role of cytokine therapy in the current management of kidney cancer has changed with the availability of novel inhibitors of VEGF and mTOR pathways, as well as immune checkpoint inhibitors with activity in clear cell RCC. Single-agent interferon, once the standard in many institutions, is no longer used in the treatment of clear cell RCC. However, given the inability of newer targeted agents to induce durable responses, high-dose intravenous IL-2 remains a reasonable option in most carefully selected patients with metastatic clear cell RCC.**

Allogeneic Hematopoietic Stem Cell Transplantation

Allogeneic hematopoietic stem cell transplantation allows the replacement of host or recipient immune and hematopoietic systems with those of a healthy, HLA-compatible donor. The therapeutic potential of hematopoietic stem cell transplantation lies largely in the ability of the transplanted donor graft to generate an allogeneic antitumor immune response known as the graft-versus-tumor effect. This approach has been used successfully with curative intent in a variety of hematologic malignancies (Thomas et al., 1977; Weiden et al., 1979, 1981). The ability of a variety of immune-based approaches to induce remissions in patients with RCC and evidence suggesting that the host immune system in these patients may be compromised and/or tolerant to tumor cells have led several investigators to evaluate allogeneic hematopoietic stem cell transplantation in kidney cancer.

The approach was initially studied by investigators at the National Heart, Lung and Blood Institute exploring the efficacy of reduced intensity hematopoietic stem cell transplantation in patients with treatment-refractory metastatic RCC. Eligible patients underwent reduced intensity conditioning with cyclophosphamide (120 mg/kg) and fludarabine (125 mg/m^2) followed by infusion of a granulocyte colony-stimulating factor–mobilized peripheral blood stem cell graft from a 5/6 or 6/6 HLA-matched sibling donor. The initial experience with hematopoietic stem cell transplantation in metastatic RCC was published by Childs et al. (2000). Ten of the first 19 patients treated with this transplant approach had tumor shrinkage, including 3 who had a complete response and 7 who had a partial response. As more recently reported, 74 patients have undergone hematopoietic stem cell transplantation for RCC at the National Institutes of Health. Of these, 73 patients have demonstrated durable engraftment, achieving 100% donor T cell chimerism by day 100 post-transplant. Twenty-nine of 74 (39%) patients have had a disease response, including 7 complete (9%) and 22 partial responders (30%) (Takahashi et al., 2008). In one responder, T cells recognizing an endogenous retroviral element (HERV-E) were identified and believed to mediate antitumor responses. **Preliminary data suggest that disease response after hematopoietic stem cell transplantation is a clinically meaningful phenomenon because regression of metastatic RCC appears to be associated with a trend toward improved survival. Survival in nonresponders has been less than 6 months, in contrast to those achieving a partial response who survived a median 2.5 years post-transplant. Several durable responses have been noted, and the first patient who underwent a transplant remains in complete remission more than 10 years after the procedure.**

Hematopoietic stem cell transplantation is associated with a variety of adverse events typically associated with conditioning chemotherapy (e.g., pancytopenia), a variety of opportunistic infections, and graft-versus-host disease (GVHD). Eight patients in the aforementioned series died of transplant-related causes (transplant-related mortality of 11%), most because of GVHD and its attendant infectious complications. Several other trials have since confirmed the efficacy of this approach in RCC (Table 104.8; Artz et al., 2005; Barkholt et al., 2006; Bregni et al., 2002; Rini et al., 2001, 2002). However, a Cancer and Leukemia Group B (CALGB) intergroup trial evaluating the feasibility of performing hematopoietic stem cell transplantation for metastatic RCC in a multi-institutional setting in the United States reported no responses in 22 patients undergoing hematopoietic stem cell transplantation from an HLA-matched sibling donor after cyclophosphamide/fludarabine–based conditioning (Rini et al., 2006). Median OS was only 5½ months, with most patients dying of disease progression (median time to progression of 3 months). Inclusion of a number of patients with multiple adverse prognostic factors, sparing use of donor lymphocyte infusions (only 2/22 patients received donor lymphocyte infusions despite disease progression in the majority), and inclusion of patients with non–clear cell histology are some of the factors that may account for the poor outcome observed in this trial. This trial clearly highlights the importance of appropriate patient selection and the need for identifying prognostic factors likely to predict for a favorable outcome. In a European multicenter study of 106 patients undergoing transplantation, chronic GVHD, good performance status (Karnofsky score = 80), administration of donor lymphocyte infusions, and fewer than three sites of metastatic disease were identified as factors favorably affecting survival (Barkholt et al., 2006). Given the high morbidity and mortality with this approach, careful patient selection is of great importance. With the advent of agents targeting the VEGF pathway and immune checkpoint inhibitors, **hematopoietic stem cell transplantation is no longer being explored as a viable therapeutic approach in RCC. However, the recognition that specific RCC-associated antigens may serve as targets for cytotoxic T cell responses provides the basis for exploring antigen-specific adoptive cellular therapy approaches.**

TABLE 104.8

Summary of Results From Selected Trials of Allogeneic Hematopoietic Stem Cell Transplantation in Metastatic Renal Cell Carcinoma

STUDIES	CONDITIONING AGENTS	GVHD PROPHYLAXIS	aGVHD (II–IV)	cGVHD	TRM	RESPON (PR OR

						CR)
Childs et al., 2000; Takahashi et al., 2008	Cy + Flu	CSP (First 25 patients) CSP + MMF (subsequent patients)	55%	21%	11%	39%
Artz et al., 2005; Rini et al., 2001, 2002	Cy + Flu	Tacro + MMF	22%	39%	14%	22%
Bregni et al., 2002	Cy + Flu + Thiotepa	CSP + MTX	86%	71%	0%	57%
Barkholt et al., 2006	Multiple fludarabine-based regimens	CSP ± MMF or MTX	40%	33%	16%	32%
Rini et al., 2006	Flu + Cy	Tacro + MTX	32%	23%	9%	0%

aGVHD, Acute graft-versus-host disease; *ATG,* antithymocyte globulin; *cGVHD,* chronic graft-versus-host disease; *CR,* complete response; *CSP,* cyclosporine; *Cy,* cyclophosphamide; *GVHD,* graft-versus-host disease; *MMF,* mycophenolate mofetil; *MTX,* methotrexate; *PR,* partial response; *Tacro,* tacrolimus; *TRM,* treatment-related mortality.

Immune “Checkpoint” Inhibitors

The host immune response to tumors is a highly complex process that is regulated at multiple levels. The interplay between multiple stimulatory and inhibitory processes determines the nature and extent of the antitumor response generated by the host immune system. Over the last few years, it has become increasingly evident that several inhibitory receptors on effector immune cells such as CD8+ T-lymphocytes play a key role in tightly regulating the immune response to tumors; furthermore, antitumor responses can be downregulated by activation of T cell receptors such as cytotoxic T-lymphocyte–associated antigen (CTLA-4) and those mediating programmed cell death (PD-1).

Pharmacologic targeting of immune checkpoints such as CTLA-4 and the PD-1 axis has been successfully explored in many solid tumors, including RCC. A single-arm phase II study of ipilimumab, a monoclonal antibody targeting CTLA-4, demonstrated activity in patients with clear cell activity, including in some who had previously progressed after IL-2 therapy (Yang et al., 2007). The most notable side effects associated with this agent included autoimmune events such as enteritis and hypophysitis. Although autoimmune adverse events were highly predictive of response, they were sufficiently severe (grade 3–4 in up to one-third of the patients), dampening enthusiasm for further development of this agent in RCC.

More recently, PD-1 and its ligands (PD-L1, PD-L2) have attracted attention as potential antitumor targets. Although PD-1 is expressed on CD+ T cells, PD-L1 and PD-L2 are expressed on the surface of tumor cells, macrophages, and other cells; patients whose tumors contain PD-1–positive tumor-infiltrating lymphocytes (TIL) are more likely to have larger tumors, higher-grade tumors, advanced-stage RCC, and sarcomatoid differentiation than patients without PD-1–positive TILs (Thompson et al., 2007). Engagement of PD-1 on T cells by its ligand leads to downregulation of antigen-driven immune responses (Fife et al., 2009; Sznol and Chen, 2013).

A number of antibodies targeting the PD-1/PD-L1 checkpoint have been evaluated clinically with several approved for use in a variety of malignancies by the FDA. In a large phase I study with multiple expansion cohorts, patients with advanced melanoma, non–small-cell lung cancer, castration-resistant prostate cancer, colorectal cancer, or renal cancer were treated with nivolumab (anti-PD-1 antibody) (Topalian et al., 2012). A total of 33 RCC patients were enrolled, and 9 patients (27%) had an objective response. Despite the fairly short follow-up, several durable responses were evident, with 5 patients demonstrating a response lasting 1 year or more. Furthermore, stable disease lasting 24 weeks or more was seen in an additional 9 patients (27%). Interestingly, pretreatment tumor specimens from 42 patients (5 RCC) were analyzed for PD-L1 expression on the surface of tumor cells. None of the 17 patients with PD-L1 negative tumors experienced a response, whereas 9/25 (36%) with PD-L1 expression had an objective response, suggesting that PD-L1 expression should be further evaluated as a predictive biomarker. As anticipated, several patients experienced adverse events of possible autoimmune cause, including diarrhea, hypophysitis, and vitiligo.

A second phase I, dose-escalating study evaluating inhibition of the PD-1 checkpoint was conducted with BMS-936559, a PD-L1 specific monoclonal antibody, in patients with advanced solid tumors (Brahmer et al., 2012). Out of 75 patients, 17 had RCC. Two out of 17 RCC patients (12%) had an objective response, lasting 4 and 17 months, respectively. Seven additional patients (41%) had stable disease lasting at least 24 weeks.

Based on the encouraging data from early phase studies, nivolumab has been evaluated in large randomized phase III studies in treatment-naive patients with metastatic clear cell RCC and in those who have progressed on prior therapy targeting the VEGF/VEGFR axis. The first of these studies (CheckMate 025), enrolled 821 patients with advanced RCC with a clear cell component who had progressed on treatment with one or two antiangiogenic agents (Motzer et al., 2015). Patients were randomized to receive either 3 mg/kg of nivolumab every 2 weeks or 10 mg of everolimus daily. The primary end point of the study was overall survival, whereas secondary objectives included evaluation of progression-free survival (PFS), overall response rate, and safety. Although the PFS was not different between the two arms [4.6 months (95% CI 3.7–5.4) with nivolumab and 4.4 months (95% CI 3.7–5.5) with everolimus (hazard ratio, 0.88; 95% CI 0.75–1.03; $P = 0.11$)], nivolumab was associated with a higher response rate (25% vs. 5%; odds ratio 5.98; 95% CI 3.68–9.72; $P < 0.001$) and improved OS. **The median OS was 25 months (95% CI 21.8–not estimable) for nivolumab and 19.6 months (95% CI 17.6–23.1) for everolimus (HR 0.73; 98.5% CI 0.57–0.93; $P = 0.002$) (Fig. 104.4).** Nivolumab was generally well tolerated, with 19% of the patients experiencing a grade 3 to 4 adverse event compared with 37% in patients treated with everolimus. The adverse event profile was consistent with that seen in other studies of similar checkpoint inhibitors and included a variety of autoimmune phenomena and fatigue. **Based on these data, nivolumab as a single agent is a reasonable option in patients who have progressed on prior therapy with inhibitors of the VEGF axis. These data also provided the impetus for evaluating PD-1/PD-L1 checkpoint inhibitors in the front-line setting, largely in combination with other immune checkpoint inhibitors and antagonists of the VEGF axis.**

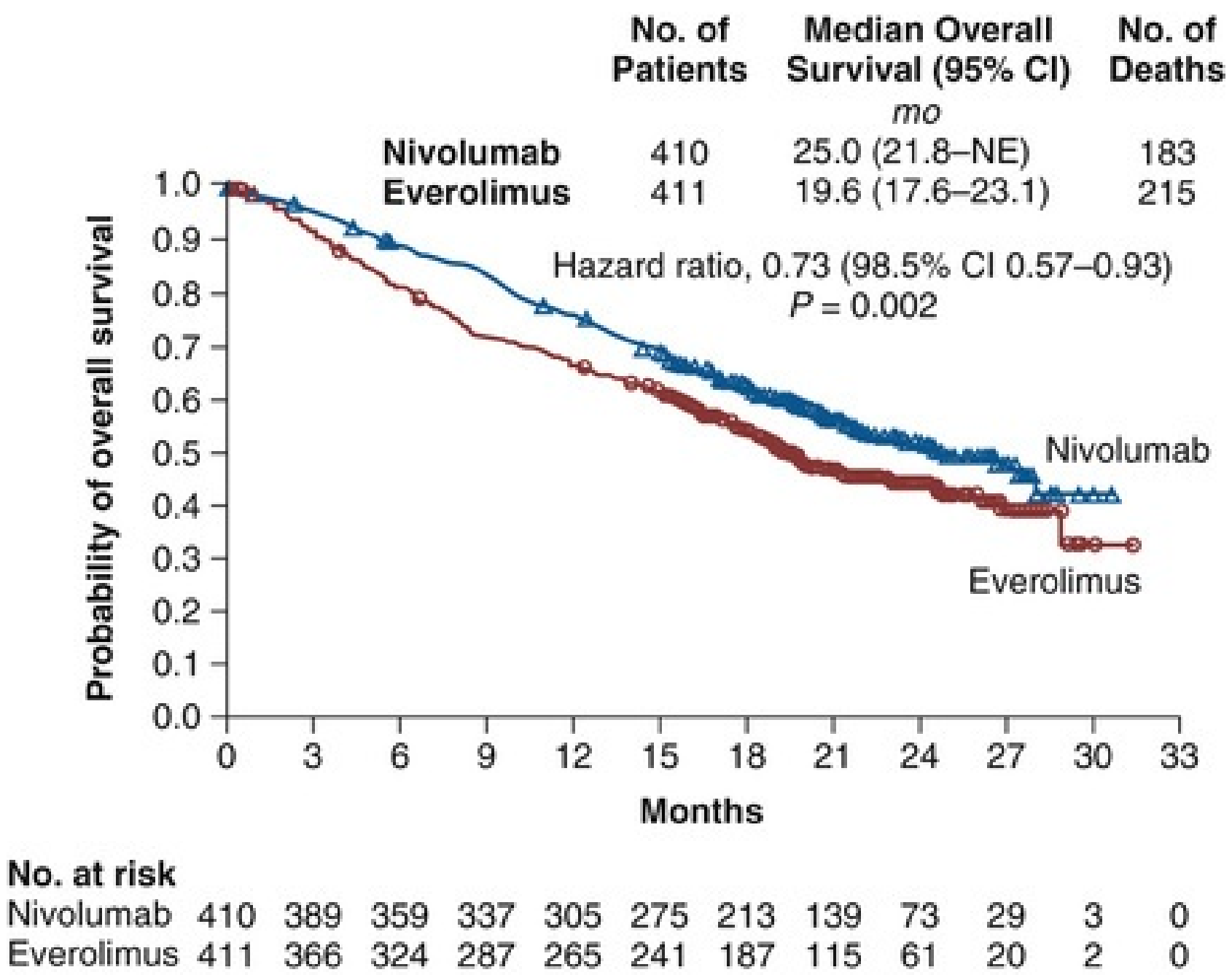

FIG. 104.4 Kaplan-Meier estimates of overall survival in 821 previously treated patients with metastatic clear cell renal cell cancer receiving either nivolumab or everolimus. (Motzer RJ, Escudier B, McDermott D, et al.: Nivolumab versus everolimus in advanced renal-cell carcinoma. *N Engl J Med* 373:1803–1813, 2015.)

Molecular Basis for Targeted Approaches in Clear Cell Renal Cell Carcinoma

The development of antagonists of the VEGF pathway in the treatment of clear cell RCC is an often-cited paradigm in the evolution of rational targeted therapeutic strategies and represents a logical progression from identification of an oncogenic cellular pathway to rational drug design and structured clinical evaluation. The earliest clues to the central role played by VEGF in renal oncogenesis came from studies attempting to identify the genetic basis of the von Hippel-Lindau familial kidney cancer syndrome. **In the early 1990s, investigators at the National Cancer Institute studying families with von-Hippel-Lindau disease used genetic linkage analysis to identify germline mutations or deletions in the *VHL* gene as the basis for this disease** (Latif et al., 1993). Individuals carrying germline *VHL* mutations are at increased risk for developing tumors in multiple organs, including bilateral, multifocal clear cell kidney cancer. **The *VHL* gene is a classic tumor suppressor gene, with inactivation of the normal *VHL* allele in affected tissues by a somatic "second hit" required for tumor formation.**

The *VHL* gene resides on the short arm of chromosome 3 and encodes the VHL protein, which can be synthesized as two alternatively spliced variants (Gnarra et al., 1996; Iliopoulos et al., 1998; Latif et al., 1993; Linehan, 2003). One of the better understood functions of the VHL protein is its association with elongins B and C and CUL2 to form a protein complex that tags certain cellular proteins for delivery to and degradation by the ubiquitin system (Duan et al., 1995; Kaelin, 2004; Linehan, 2003; Pause et al., 1997; Stebbins et al., 1999). Proteins targeted for ubiquitin-mediated degradation include the α subunits of a group of transcriptionally active proteins known as hypoxia-inducible factors (HIFs) (Cockman et al., 2000; Iliopoulos et al., 1996; Ivan et al., 2001; Jaakkola et al., 2001; Maxwell et al., 1999; Ohh et al., 2000; Pause et al., 1997). In cells with intact VHL function, HIF levels are controlled primarily by ambient oxygen tension. In normoxic conditions, hydroxylation of key proline residues on HIF promotes its association with the VHL/elongin/CUL complex and subsequent degradation; conversely, hypoxia impedes prolyl hydroxylation of HIF and its subsequent degradation, leading to intracellular accumulation of HIF α subunits. **Mutations in *VHL* interfere with its binding to either HIF or elongin/CUL2 and promote HIF accumulation even under normoxia. HIF accumulation, in turn, leads to the upregulation of a variety of proangiogenic and growth factors, including VEGF, platelet-derived growth factor (PDGF), transforming growth factor-α, Glut-1, and erythropoietin, which are believed to play critical roles in the development and progression of clear cell RCC** (Fig. 104.5; Duan et al., 1995; Iliopoulos et al., 1996; Kaelin, 2004; Linehan et al., 2007)**. Although originally identified as a germline defect in von Hippel-Lindau families, evidence of somatic *VHL* inactivation by mutation or promoter hypermethylation has been observed in a high proportion of sporadic clear cell tumors (91% in one series)** (Gnarra et al., 1996; Herman et al., 1994; Nickerson et al., 2008; Zhuang et al., 1996a,b). The recognition of VHL loss as a central event in renal oncogenesis has paved the way for the development of novel agents targeting components of this pathway in the management of metastatic clear cell RCC.

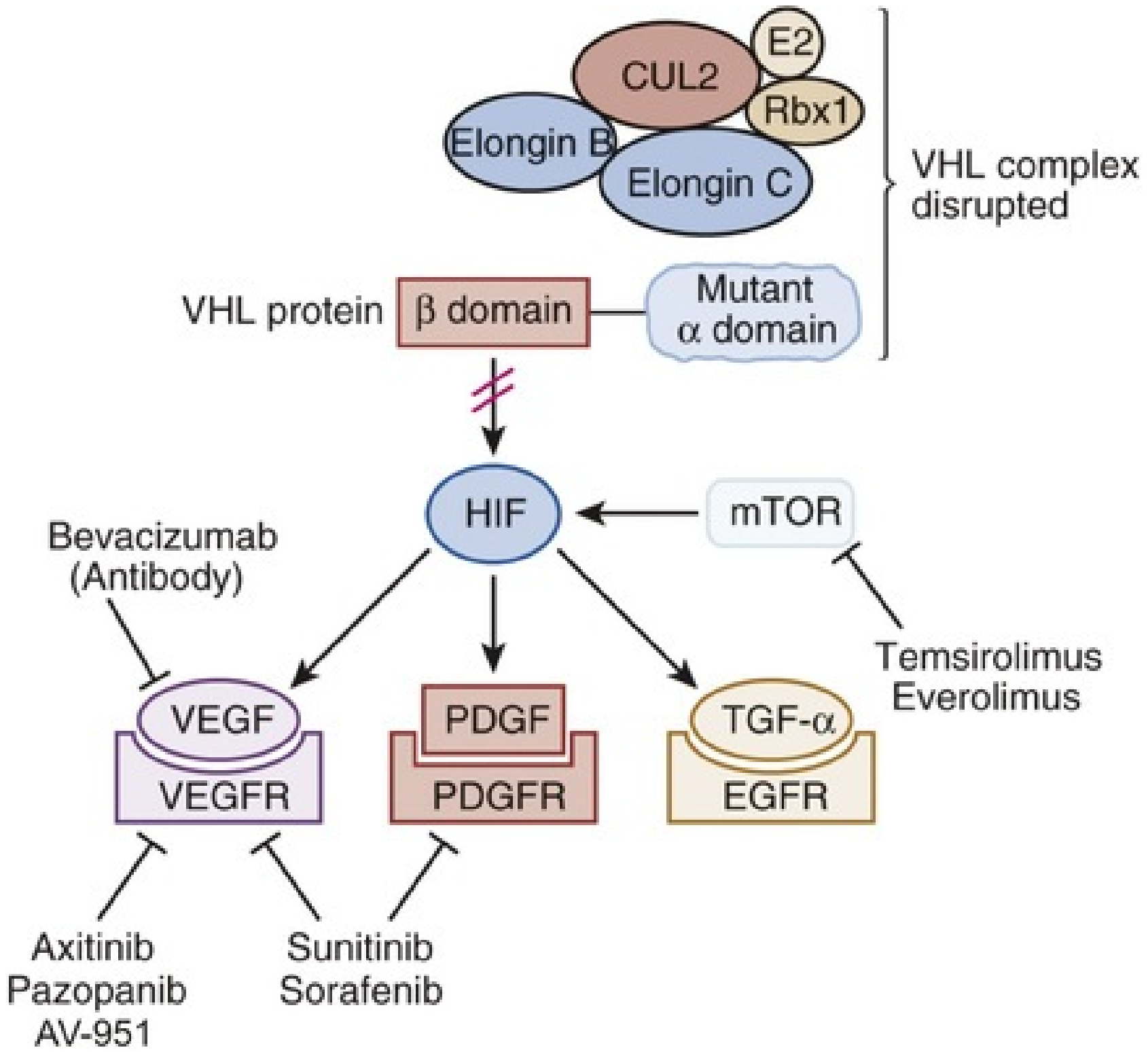
CUL2
E2
Rbx1
Elongin B
Elongin C
VHL complex disrupted
VHL protein
β domain
Mutant α domain
HIF
mTOR
Bevacizumab (Antibody)
Temsirolimus
Everolimus
VEGF
VEGFR
PDGF
PDGFR
TGF-α
EGFR
Axitinib
Pazopanib
AV-951
Sunitinib
Sorafenib

FIG. 104.5 Targeting the VHL pathway in clear cell renal cell carcinoma. Loss of VHL activity leads to accumulation of HIF and several proangiogenic and growth factors that can serve as targets for anticancer

drugs. HIF can also be upregulated by mTOR, which promotes HIF translation. (Modified from Linehan WM, Bratslavsky G, Pinto PA, et al.: Molecular diagnosis and therapy of kidney cancer. *Annu Rev Med* 61:329–343, 2010.)

Targeted Molecular Agents in Clear Cell Renal Cell Carcinoma

Antagonists of the Vascular Endothelial Growth Factor Pathway

Bevacizumab

Bevacizumab, a humanized monoclonal antibody against VEGF-A, was the first VEGF pathway antagonist used in clinical trials to test the hypothesis that modulation of aberrantly expressed components of the VHL pathway would be associated with clinical activity in clear cell RCC. In a three-arm phase II study, patients with metastatic clear cell RCC whose disease had progressed after prior cytokine therapy were randomized to receive either one of two dose levels of bevacizumab (10 mg/kg or 3 mg/kg administered every 2 weeks intravenously) or placebo (Table 104.9; Yang et al., 2003). **An interim efficacy analysis performed after 116 patients (of a planned 240 patients) were enrolled in the study demonstrated a significantly longer PFS in patients assigned to 10 mg/kg bevacizumab compared with those receiving placebo (4.8 vs 2.5 months, $P < 0.001$)**. There was no corresponding improvement in OS, although the crossover design used in this trial (patients progressing on placebo were allowed to cross over to the bevacizumab arm) may have influenced this outcome. The overall response rate in patients receiving bevacizumab was modest (objective response rate of 10%, all in patients assigned to the 10-mg/kg dose). The agent was well tolerated; bleeding, hypertension, fatigue, and proteinuria were some of the more common adverse events reported. Single-agent bevacizumab has not been compared with either cytokines (often used in first-line treatment before the advent of VEGF pathway antagonists) or other VEGF pathway antagonists such as sunitinib in prospective trials.

TABLE 104.9

Summary of Selected Studies of Bevacizumab-Based Regimens in Metastatic Renal Cell Carcinoma

	STUDY	NO. OF	OVERALL RESPONSE	ME

STUDY	AGENT(S)	PHASE	POPULATION	PATIENTS	RATE (RECIST)	PFS (M
Yang et al., 2003a	Bev (10 mg/kg) vs. Bev (3 mg/kg) vs. placebo	Randomized, 3-arm phase II	Cytokine-refractory clear cell	116	10% vs. 0 vs. 0	4.8 vs.
Escudier et al., 2007b	Bev + IFN-α vs. IFN-α	Randomized phase III	Previously untreated clear cell	649	31% vs. 13%	10.2 5.4
Rini et al., 2008a	Bev + IFN-α vs. IFN-α	Randomized phase III	Previously untreated clear cell	732	26% vs. 13%	8.5 5.2
Bukowski et al., 2007	Bev + Erlotinib vs. Bev	Randomized phase II	Previously untreated clear cell	104	14% vs. 13%	9.9

Bev, Bevacizumab; *IFN-*α*;* interferon-α; *NA,* not available; *NR,* not reached; *OS,* overall survival; *PFS,* progression-free survival.

Several strategies for improving the efficacy of bevacizumab have been explored, including combination with cytokines (interferon-α) and other targeted agents (e.g., erlotinib, a small molecule inhibitor of epidermal growth factor receptor tyrosine kinase activity). A single-arm phase II study of bevacizumab plus erlotinib showed promising activity with an overall response rate of 25% (higher than would be expected with bevacizumab alone based on historical data) and median PFS of 11 months (Hainsworth et al., 2005). However, a subsequent randomized phase II study failed to demonstrate the superiority of this combination (median PFS 9.9 months) over bevacizumab alone (median PFS 8.5 months, $P = 0.58$) in patients with advanced clear cell RCC (Bukowski et al., 2007). Two large randomized phase III studies have compared the combination of bevacizumab and interferon-α to interferon-α alone (see Table 104.9). **In a Cancer and Leukemia Group B study (CALGB 90206) of 752 patients with previously untreated metastatic clear cell RCC randomized to one of two treatment arms, a higher response rate (25.5% vs. 13.1%, $P < 0.0001$) and PFS (8.5 months vs. 5.2 months, $P < 0.0001$) were observed in patients assigned to bevacizumab plus interferon-α compared with those receiving interferon-α alone** (Rini et al., 2008). **A multicenter European trial (AVOREN) with a similar design also reported similar results with PFS (10.2 vs. 5.4 months, $P = 0.0001$) and objective response rate (31% vs. 13%)**

favoring the combination arm (Escudier et al., 2007). Updated survival data from both trials were recently reported, demonstrating no improvement in OS associated with the addition of bevacizumab to interferon (Escudier et al., 2010; Rini et al., 2010).

Although neither study permitted crossover of patients assigned to interferon-α at progression, a significant number of patients (>60%) subsequently received anticancer therapy off protocol, potentially confounding OS analysis. Both trials reported a higher incidence of some grade 3 adverse events, such as hypertension, fatigue, anorexia, and asthenia in patients receiving combination therapy. The CALGB and Avoren trials were large, well-designed, and well-conducted multicenter studies that suggest that the addition of bevacizumab to interferon may be associated with clinical benefit (i.e., improvement in PFS). However, these trials did not include an arm with bevacizumab alone (because insufficient evidence of single-agent activity at the time these trials were designed to justify a bevacizumab-only arm), making it difficult to determine if inclusion of interferon in this regimen, with its attendant toxicities, adds meaningful clinical benefit. Interestingly, the median PFS observed in the combination arm of the CALGB trial (8½ months) is similar to that observed with bevacizumab alone in a phase II trial of previously untreated patients with clear cell RCC (Bukowski et al., 2007). Last, bevacizumab (either alone or in combination with interferon) has not been compared prospectively with VEGF receptor (VEGFR) antagonists such as sunitinib or pazopanib. **Bevacizumab was not widely used as a single agent in the initial therapy for metastatic clear cell RCC but is being explored in combination studies with other agents, including inhibitors of the PD-1/PD-L1 checkpoint, because of its favorable toxicity profile. Ongoing and future trials may help determine the best use of this agent in the overall management of patients with clear cell RCC.**

Sorafenib

Sorafenib is an oral receptor kinase inhibitor with activity against VEGFR2, PDGF receptor-β, and raf-1. A phase II trial using a randomized discontinuation design provided initial evidence that sorafenib is active in RCC (see Table 104.10; Ratain et al., 2006). Subsequently, a global, multicenter, placebo-controlled randomized phase III trial with 903 patients (the TARGET study) was undertaken to evaluate the efficacy of sorafenib in patients with metastatic RCC who had previously received cytokine therapy (Escudier et al., 2007). **This trial echoed the results seen in the phase II trial, with patients randomized to receive sorafenib experiencing a longer PFS (median 5.5 months) versus those receiving placebo (2.8 months, $P < 0.01$) at a planned interim analysis. Mature survival data from this trial were subsequently presented and demonstrated no significant difference in OS between the two groups (17.8 months for sorafenib vs. 15.3 months with placebo, $P = 0.146$) in an intent-to-treat analysis** (Escudier et al., 2009). The side effect profile of sorafenib is comparable to that of other agents in this class and includes hypertension, fatigue, rash, hand-foot syndrome, and diarrhea. The efficacy of sorafenib in the first-line setting was investigated in a randomized phase II study that assigned 189 previously untreated patients with metastatic clear cell RCC to receive either sorafenib or interferon-α (Escudier et al., 2009). Although patients receiving sorafenib had a higher likelihood of achieving tumor regression (68% vs. 39%), PFS in the two groups was nearly identical (median 5.7 months for sorafenib vs. 5.6 months for interferon, P = NS) (Table 104.10). **Although sorafenib is FDA-approved for the treatment of advanced kidney cancer, it is infrequently, if ever, used in the management of these patients in view of the plethora of more effective treatment options available.**

TABLE 104.10

Summary of Selected Studies of Sorafenib in Metastatic Renal Cell Carcinoma

STUDIES	AGENT(S)	PHASE	STUDY POPULATION	NO. OF PATIENTS	OVERALL RESPONSE RATE (RECIST)	M P (
Ratain et al., 2006	Sorafenib vs. placebo	Phase II randomized discontinuation	Treatment-refractory, all histologic subtypes	202		6
Escudier et al., 2007a, 2009a	Sorafenib vs. placebo	Randomized phase III	Cytokine-refractory clear cell	903	10% vs. 2%	5
Escudier et al., 2009b	Sorafenib vs. IFN-α	Randomized phase II	Previously untreated clear cell	189	5% vs. 9%	5

IFN-α, Interferon-α; *NA,* not available; *NR,* not reached; *OS,* overall survival; *PFS,* progression-free survival.

Sunitinib

Sunitinib is an oral VEGFR kinase inhibitor widely used until recently in the initial treatment of metastatic clear cell RCC. It is a potent inhibitor of VEGFR2, PDGFR-β, c-*KIT*, and fms-like tyrosine kinase-3. As with sorafenib, simultaneous targeting of VEGF and PDGF pathways by this agent is likely to act synergistically in inhibiting tumor angiogenesis, by directly disrupting VEGF-mediated vascular endothelial development and proliferation and by interfering with vascular pericyte function, which is dependent on the integrity of PDGF signaling. Initial evaluation of sunitinib was undertaken with two single-arm open-label phase II trials in patients with metastatic RCC, most of whom had previously received cytokine therapy (Motzer et al., 2006a,b). Sunitinib was administered orally at a dose of 50 mg/d during the first 4 weeks of a 6-week cycle on both trials (Table 104.11). Remarkably high overall response rates (30% to 40%) with a median PFS of more than 8½ months were observed in these trials, leading to the approval of this agent for treatment of advanced RCC by the FDA.

TABLE 104.11

Summary of Selected Studies of Sunitinib in Metastatic Renal Cell Carcinoma

STUDIES	AGENT(S)	PHASE	STUDY POPULATION	NO. OF PATIENTS	OVERALL RESPONSE RATE (RECIST)	ME PFS (M
Motzer et al., 2007, 2009	Sunitinib vs. IFN-α	Randomized phase III	Previously untreated clear cell	750	31% vs. 6%	11 v
Motzer et al., 2006a	Sunitinib	Single-arm phase II	Cytokine-refractory clear cell	63	40%	8.7
Motzer et al., 2006b	Sunitinib	Single-arm phase II	Cytokine-refractory clear cell	106	44%	8.1

NA, Not available; *OS,* overall survival; *PFS,* progression-free survival.

A landmark phase III randomized trial comparing sunitinib with interferon-α as first-line therapy in patients with metastatic clear cell RCC further demonstrated the activity of sunitinib in this patient population (Motzer et al., 2007). In this study, 750 patients were randomized to receive either sunitinib or interferon-α. **An interim analysis based on independent, third-party radiologic assessment demonstrated a significantly superior PFS (median 11 months vs. 5 months, *P* = 0.001) and overall response rate (31% vs. 6%, *P* = 0.001) favoring the sunitinib arm** (Fig. 104.6). **Gastrointestinal events, particularly diarrhea, dermatologic manifestations such as rash and hand-foot syndrome, constitutional symptoms such as fatigue and asthenia, and hypertension were the most commonly adverse events associated with sunitinib, whereas bone marrow suppression and hypothyroidism were other notable side effects. Sunitinib also performed better than interferon in a quality-of-life assessment conducted as part of the study. Mature survival data from this study were subsequently reported and demonstrated a clear trend toward superior OS in the sunitinib study arm based on an intent-to-treat analysis (median OS 26.4 vs. 21.8 months, *P* = 0.051)** (Motzer et al., 2009). **Based on these data, sunitinib was widely used in the initial management of metastatic clear cell RCC patients in the United States. However, recent studies have demonstrated the superiority of PD-1/PD-L1 checkpoint inhibitor–based combinations over sunitinib in the first-line setting, particularly in patients with intermediate and poor prognosis RCC. Currently, sunitinib is largely used in the treatment of good prognosis patients or those unable to receive checkpoint inhibitor-based therapy.**

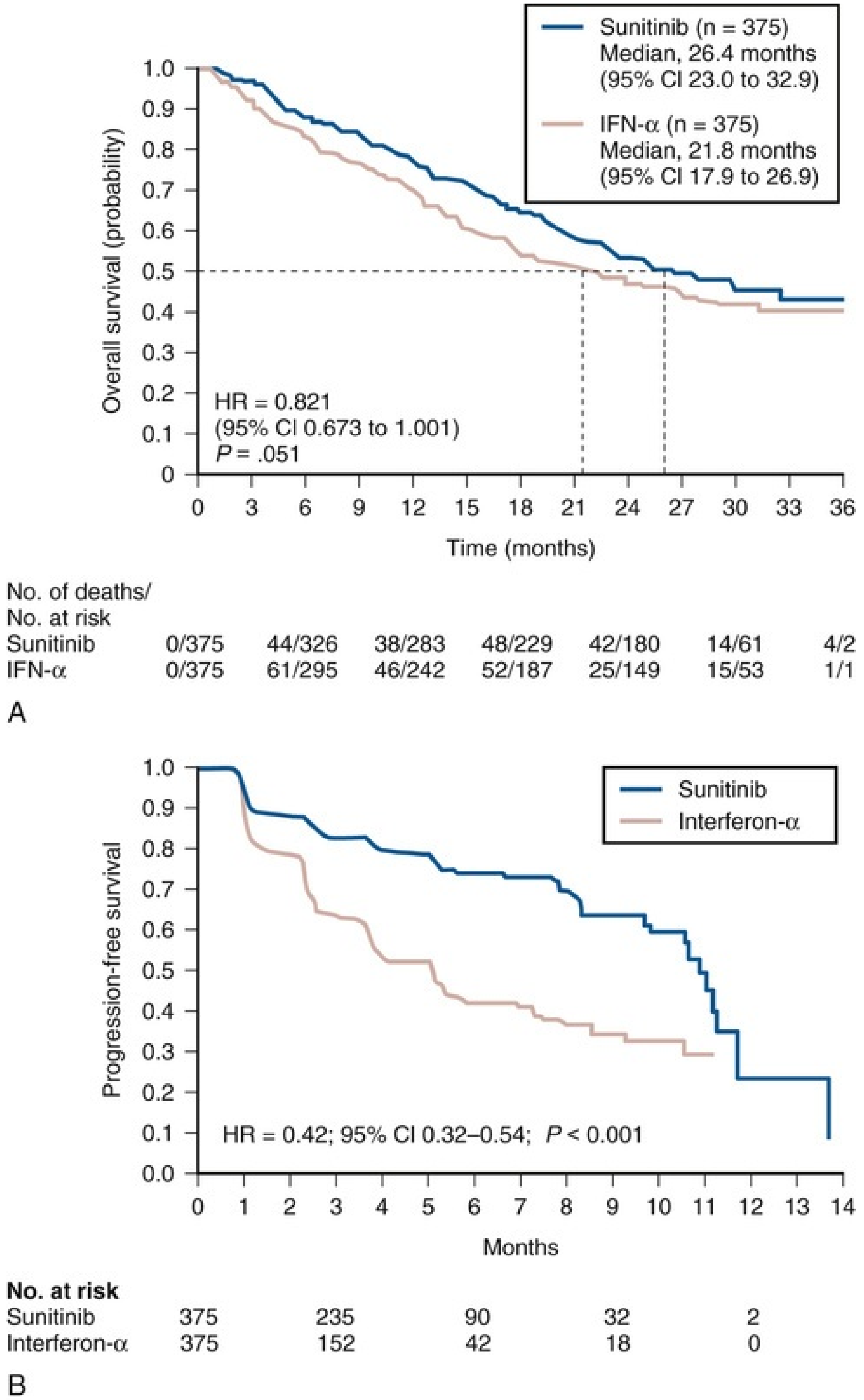

FIG. 104.6 Kaplan-Meier analysis of overall survival (A) and progression-free survival (B) in 750 previously untreated patients with metastatic renal cell carcinoma receiving either sunitinib or interferon-α. (Data from Motzer RJ, Hutson TE, Tomczak P, et al.: Overall survival and updated results for sunitinib compared with interferon alfa in patients with metastatic renal cell

carcinoma. *J Clin Oncol* 27:3584–3590, 2009; and Motzer RJ, Hutson TE, Tomczak P, et al.: Sunitinib versus interferon alfa in metastatic renal-cell carcinoma. *N Engl J Med* 356:115–124, 2007.)

Pazopanib

Agents such as sunitinib and sorafenib have activity against a wide array of targets, some of which may not be relevant in clear cell RCC. Although these agents are relatively well tolerated when compared with conventional cytotoxic chemotherapy, dose reductions and termination of treatment resulting from toxicity are not infrequently warranted in patients receiving these drugs. A variety of newer agents with selective activity against the VEGFR family were evaluated as a possible means of diminishing the side effects associated with therapy without compromising efficacy (Table 104.12). One agent in this class, pazopanib, is a potent inhibitor of the VEGF receptors but retains activity against PDGFR. Pazopanib was evaluated in a randomized, double-blind, placebo-controlled phase III trial in patients with metastatic clear cell RCC who had received no or one prior cytokine-based therapy (Sternberg et al., 2010). **In the 435 patients randomized (2 : 1) to receive either pazopanib or placebo, PFS (median 9.4 months vs. 4.2 months, P = 0.0000001) and response rates (30% vs. 3%) clearly favored the pazopanib study arm. Pazopanib was associated with superior outcomes in the treatment-naive (N = 233; median PFS 11.1 vs. 2.8 months; HR 0.40; 95% CI 0.27–0.60; P < 0.0001), and the cytokine-pretreated subpopulations (N = 202; median PFS, 7.4 vs. 4.2 months; HR 0.54; 95% CI 0.35–0.84; P < 0.001). Furthermore, reported toxicities were mild, with very few grade 3 and 4 adverse events encountered.** However, mature survival data from this trial demonstrated OS was not significantly better in the pazopanib arm compared with placebo (median OS 22.9 vs. 20.5 months, respectively; hazard ratio [HR] = 0.91; 95% confidence interval [CI], 0.71–1.16; one-sided P = 0.224) (Sternberg et al., 2013).

TABLE 104.12

Summary of Selected Studies of Selective VEGFR Antagonists in Metastatic Renal Cell Carcinoma

	STUDY	NO. OF	OVERALL RESPONSE	MED

STUDY	AGENT(S)	PHASE	POPULATION	PATIENTS	RATE (RECIST)	PFS (MO
Sternberg et al., 2010 Sternberg et al., 2013	Pazopanib vs. placebo	Randomized phase III	Metastatic clear cell RCC patients with 0-1 prior cytokine therapy	435	30% vs. 3%	9.2 v
Motzer et al., 2013	Tivozanib vs. Sorafenib	Randomized phase III	Metastatic clear cell RCC; 0-1 prior therapies	517	33% vs. 23%	11.9 9.1
Rini et al., 2011; Motzer et al., 2013	Axitinib vs. Sorafenib	Randomized phase III	Second-line clear cell RCC	723	19% vs. 9%	6.7 v
Motzer et al., 2013	Pazopanib vs. Sunitinib	Randomized phase III	Previously untreated clear cell RCC	1110	31% vs. 25%	10.5 10.2

NA, Not available; *OS,* overall survival; *PFS,* progression-free survival; *RCC,* renal cell carcinoma.

The efficacy and/or tolerability of pazopanib and sunitinib were subsequently compared in at least two studies. In a recently published multicenter phase III randomized trial (COMPARZ) of 1110 patients with previously untreated metastatic clear cell kidney cancer comparing the efficacy and safety of the two agents, patients were randomized to receive either pazopanib 800 mg once daily (N = 557) or a standard sunitinib regimen (50 mg once daily for 4 weeks followed by 2 weeks with no treatment, N = 553) (Motzer et al., 2013). The primary end point was PFS, and the study was powered to evaluate non-inferiority of pazopanib versus sunitinib. Secondary end points included OS, quality of life, and safety. Median PFS in patients treated with pazopanib was 8.4 months compared with 9.5 for sunitinib. Based on predefined criteria, PFS with pazopanib was determined to be noninferior to sunitinib (HR 1.05; 95% CI 0.90–1.22). Overall survival was comparable in the two groups with a median OS of 28.4 months in the pazopanib group versus 29.3 months in the sunitinib group (HR 0.91; 95% CI 0.76–1.08). However, differences were noted in the adverse event profile and patient tolerability between the two groups. Patients treated with sunitinib had a higher incidence of fatigue (63% vs. 55%), thrombocytopenia (78% vs. 41%), and hand-foot syndrome (50% vs. 29%), whereas increased levels of alanine aminotransferase were more common in the pazopanib group (60% vs. 43%). Quality-of-life assessments related to fatigue or soreness in the mouth, throat, and hands or feet during the first 6 months of treatment favored pazopanib.

Results from a second, smaller study evaluating patient preference between pazopanib and sunitinib (PISCES) also demonstrated that pazopanib was generally better tolerated (Escudier et al., 2014). One hundred and sixty eight previously untreated patients with metastatic clear cell RCC were randomized to receive pazopanib for 10 weeks followed by a 2-week washout and then sunitinib for 10 weeks (on a 4 week on/2 week off schedule) or vice versa. After completing 22 weeks of therapy, the patients were asked to complete a questionnaire assessing which agent they preferred. Pazopanib was preferred by 70% of the patients, although sunitinib was preferred by 22% of the patients (8% had no specific preference between the agents). **Based on these data, pazopanib is a reasonable alternative to sunitinib in those cases in which the latter would be a suitable therapeutic option. Although pazopanib appears to be better tolerated than sunitinib by the majority of patients, it appears to be associated with an increased incidence of hepatotoxicity and must be used with caution in patients at risk for this complication. At least some patients found sunitinib more tolerable than pazopanib. With the advent of effective combination therapies containing immune checkpoint inhibitors, the role of single-agent pazopanib is limited, particularly in the first-line setting, largely to good-risk patients.**

Axitinib

Axitinib is a highly selective oral small molecule tyrosine kinase inhibitor of VEGFR1, VEGFR2, and VEGFR3. In a phase II trial of axitinib in 52 patients with advanced kidney cancer, an overall response rate of 44%, including two complete responses (4%), and a median time to progression of 15.7 months were reported (Rixe et al., 2007). Most patients treated on this study displayed some degree of tumor shrinkage, and many had been pretreated with either IL-2 or interferon. Diarrhea, fatigue, and hypertension were the most commonly encountered grade 3 and 4 events and were amenable to medical management in most patients. Axtinib was the subject of a phase III trial that compared its efficacy to that of sorafenib (a first-generation VEGFR and RAF inhibitor) in the second-line setting (Motzer et al., 2013; Rini et al., 2011; see Table 104.12). **In this study, 723 patients with clear cell RCC who progressed on one first-line therapy containing sunitinib, bevacizumab, temsirolimus, or cytokines were**

randomized to receive axitinib (starting dose of 5 mg PO BID, *N* = 361) or sorafenib (400 mg PO BID, *N* = 362). Patients on the axitinib arm were allowed to receive higher doses (up to 10 mg PO twice daily) if lower dose levels were well tolerated; there was no dose-escalation in the sorafenib arm. Median progression-free survival (PFS), as measured by response criteria in solid tumors (RECIST), was 6.7 months in the axitinib arm compared with 4.7 months in the sorafenib arm (HR 0.665; 95% CI 0.544–0.812; *P* < 0.0001). The benefit from axitinib was most pronounced in patients who had previously received cytokines (median PFS 12·1 months for axitinib vs 6.5 months for sorafenib; HR 0.464; 95% CI 0.318–0.676; *P* < 0.0001). Patients previously treated with a VEGF pathway antagonist also appeared to benefit, although the improvement in PFS was modest. For instance, in patients who had received sunitinib in the first-line setting, median PFS was 4 to 8 months with axitinib and 3 to 4 months with sorafenib (HR 0.741; 95% CI 0.573–0.958; *P* = 0.0107). OS in the two arms was comparable with a median OS of 20.1 months with axitinib (95% CI 16.7–23.4) and 19.2 months (17.5–22.3) with sorafenib (HR 0.969; 95% CI 0.800–1.174; one-sided *P* = 0.3744). **Based on the improved PFS compared with sorafenib in the AXIS trial, axitinib was approved by the FDA for use in the second-line setting in patients with advanced RCC. Axitinib is also being explored in combination with PD-1 or PD-L1 inhibitors, with available data suggesting that these regimens are well tolerated and highly effective.**

Newer VEGFR-Based Targeted Therapy Strategies

Attempts to improve on outcomes associated with conventional angiogenesis inhibitors such as sunitinib and pazopanib have led to the development of agents that target VEGFR and other specific pathways believed to play a role in clear cell RCC. This has led to the development and successful clinical evaluation of strategies targeting Met and related pathways as well as those targeting FGFR.

Cabozantinib

Despite advances in our ability to target the VEGF pathway in a clinically meaningful manner, most patients with clear cell RCC eventually progress and die from their disease. Identifying mechanisms mediating primary and acquired or adaptive resistance to VEGF pathway inhibition is an area of active investigation. The Met pathway appears to be important in clear cell RCC, with preclinical models suggesting that HIF-mediated overexpression of Met may engender resistance to agents targeting the VEGF axis (Koochekpour et al., 1999). Moreover, Met and a related kinase, Axl, are overexpressed in clear cell RCC and appear to portend worse prognosis. Cabozantinib is a multityrosine kinase inhibitor with activity against VEGFR, Met, and Axl. After demonstration of activity in a single-arm phase II study in clear cell RCC patients who had received multiple prior lines of therapy, cabozantinib was evaluated in a randomized phase III study (METEOR) (Choueiri et al., 2015, 2016). A total of 658 clear cell RCC patients who had received prior therapy with VEGF or VEGFR-targeted therapy were randomized to receive either cabozantinib (60 mg PO every day) or everolimus (10 mg PO every day). Cabozantinib was associated with a higher response rate (21% with cabozantinib vs. 5% with everolimus; $P < 0.001$), and superior PFS (median PFS 7.4 months with cabozantinib vs. 3.8 months with everolimus; HR 0.58; 95% CI 0.45–0.75; $P < 0.001$). A subsequent analysis, after 430 deaths (198 for cabozantinib and 232 for everolimus), showed that cabozantinib was also associated with better OS (median OS was 21.4 months with cabozantinib and 17.1 months with everolimus; HR 0.70; 95% CI 0.58–0.85; $P = 0.0002$) (Fig. 104.7). Although cabozantinib therapy was associated with significant toxicity (60% of patients required a dose reduction, mostly because of fatigue, diarrhea, or palmar plantar erythrodysesthesia), most patients were managed with dose reductions, with only 10% requiring permanent discontinuation because of toxicity. **These data established cabozantinib as a reasonable option in patients who had received a prior angiogenesis inhibitor.**

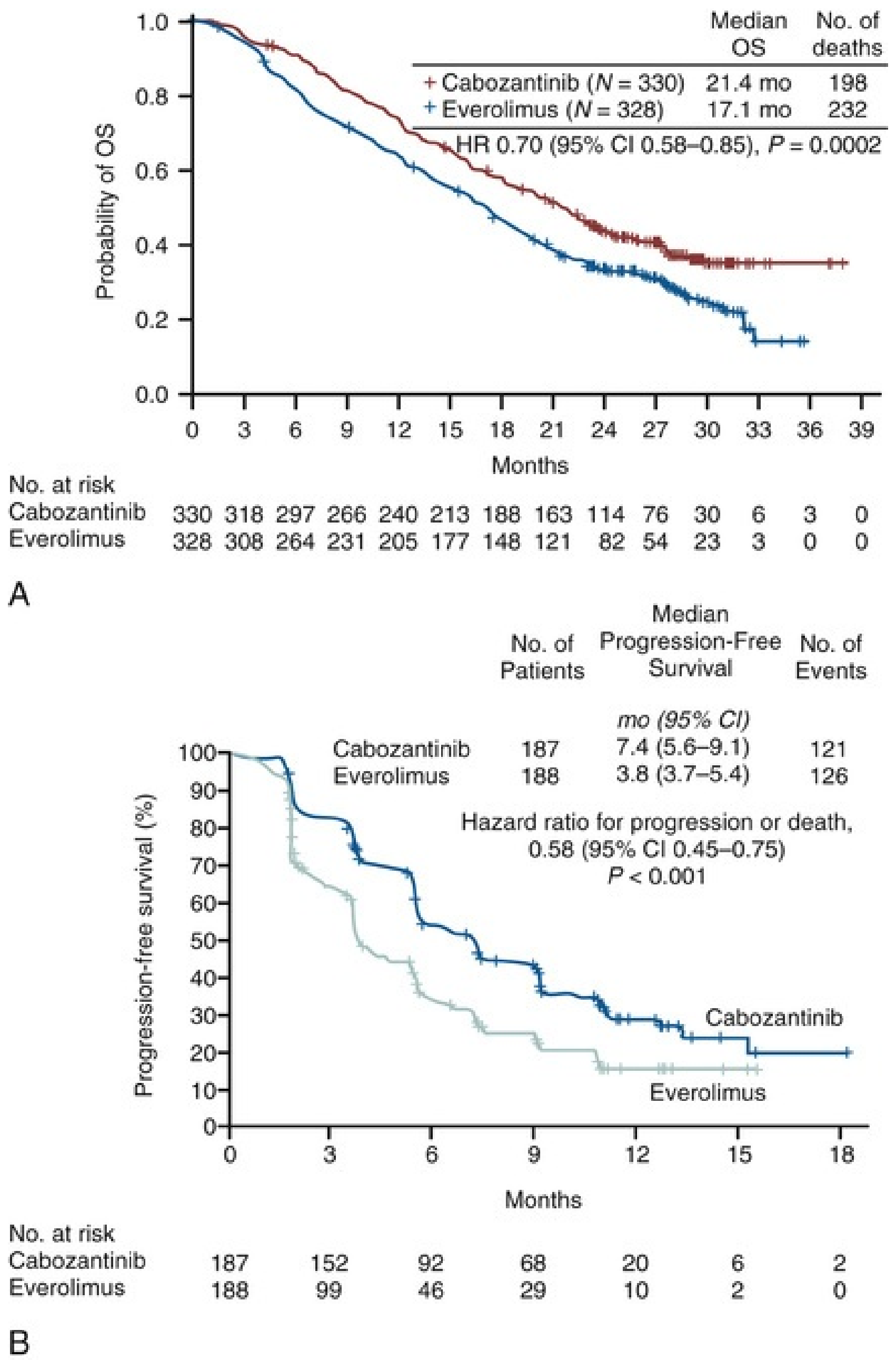

FIG. 104.7 Kaplan-Meier estimates of (A) overall survival (OS) and (B) progression-free survival in 658 patients with metastatic clear cell RCC receiving either cabozantinib or everolimus. (Modified from Motzer RJ, Escudier B, Powles T, et al.: Long-term follow-up of overall survival for cabozantanib versus everolimus in advanced renal cell carcinoma. *Br J Cancer* 118:1176–1178, 2018 and Choueiri TK, Escudier B, Powles T, et al.: Cabozantinib versus everolimus in advanced renal-cell carcinoma. *N Engl J Med* 373:1814–1823, 2015.)

Subsequent attempts to ascertain the efficacy of cabozantinib in the front-line setting led to a randomized phase II study (CABOSUN); 157 patients with intermediate or poor-risk clear cell RCC (based on IMDC criteria) were randomized to receive either sunitinib or cabozantinib at standard doses (Choueiri et al., 2017; Table 104.13). Treatment with cabozantinib was associated with a significant improvement in the primary end point, PFS (median PFS 8.2 vs. 5.6 months with sunitinib; adjusted HR 0.66; 95% CI 0.46–0.95; one-sided *P* = 0.012). Cabozantinib was also associated with a better ORR (46% [95% CI 34–57] vs. 18%; 95% CI 10–28] for sunitinib) (Fig. 104.8). **Based on these data, the FDA expanded the approval of cabozantinib to include patients with untreated advanced RCC.**

TABLE 104.13

Summary of Selected Studies of Newer Targeted Multikinase Inhibitors in Metastatic Renal Cell Carcinoma

STUDY	AGENT(S)	PHASE	STUDY POPULATION	NO. OF PATIENTS	OVERALL RESPONSE RATE (RECIST)	M P (
METEOR (Choueiri et al., 2015; Motzer et al., 2018)	Cabozantinib vs. Everolimus	Randomized phase III	Metastatic clear cell RCC patients who had progressed on anti-VEGFR therapy	658	31% vs. 5%	7.
CABOSUN Choueiri et al., 2017	Cabozantinib vs. Sunitinib	Randomized phase II	Untreated intermediate or poor risk metastatic clear cell RCC	157	33% vs. 12%	8.
Everolimus with or without Lenvatinib (Motzer et al., 2015)	Lenvatinb plus Everolimus vs. Everolimus	Randomized phase II	Metastatic clear cell RCC patients who had progressed on anti-VEGFR therapy	101	43% vs. 6%	14 5.

RCC, Renal cell carcinoma.

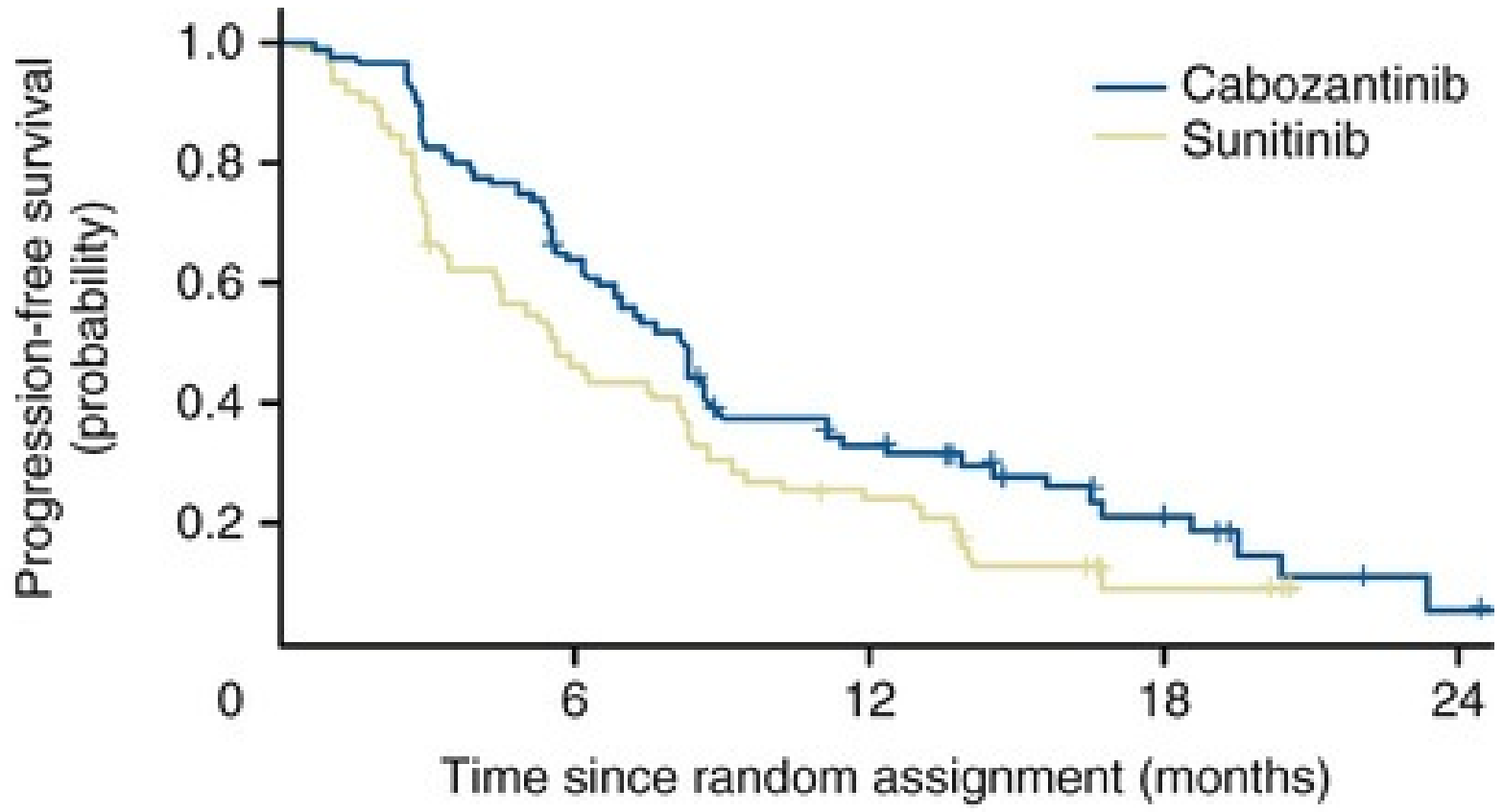

No. at risk					
Cabozantinib	79	49	22	9	1
Sunitinib	78	32	15	3	0

FIG. 104.8 Kaplan Meier estimate of progression-free survival in 157 previously untreated patients with metastatic clear cell renal cell carcinoma receiving either sunitinib or cabozantinib. (Choueiri TK, Halabi S, Sanford BL, et al.: Cabozantinib versus sunitinib as initial targeted therapy for patients with metastatic renal cell carcinoma of poor or intermediate risk: the Alliance A031203 CABOSUN trial. *J Clin Oncol* 35[6]:591–597.)

Lenvatinib

Activation of alternative means of promoting and supporting angiogenesis in the face of VEGF inhibition has emerged as a possible contributor to resistance in preclinical models. FGF receptors (FGFR1 and FGFR2) have been proposed as important mediators of resistance after effective VEGF pathway inhibition in some models (Korc and Friesel, 2009; Welti et al., 2011). A randomized phase II study evaluated the use of sunitinib and nintedanib, a small angiokinase inhibitor with activity against VEGFR-1–3, PDGFR-α/β, FGFR-1–3, RET, and Flt3 and found modest activity and no discernible advantage to nintedanib (Eisen et al., 2015). A subsequent phase III study with dovitinib, an oral inhibitor of VEGFR, PDGFR, and FGFR also dampened enthusiasm for further evaluating this class of drugs as a single agent in RCC. In this open-label randomized phase III trial, 570 patients with clear cell RCC who had received one prior VEGF and one prior mTOR therapy were randomized 1 : 1 to dovitinib or sorafenib with PFS as the primary end point (Motzer et al., 2014). PFS was comparable, with a median of 3.7 and 3.6 months (HR 0.86; 95% CI 0.72–1.94, P = 0.063) in the dovitinib and sorafenib arms, respectively. Median OS (HR 0.96; 95% CI 0.75–1.22; P = 0.357) was also similar (11.1 and 11 months in the dovitinib and sorafenib arms, respectively).

Lenvatinib is a newer multikinase inhibitor of VEGFR1, VEGFR2, and VEGFR3, with **additional** inhibitory activity against fibroblast growth factor receptors (FGFR1, FGFR2, FGFR3, and FGFR4), PDGFRα, RET, and KIT. **In a three-arm randomized phase II study of 153 patients with clear cell RCC who had progressed on prior VEGF-targeted therapy, lenvatinib (24 mg/d) was compared with everolimus (10 mg/d) alone or with a combination of lenvatinib (18 mg/d) plus everolimus (5 mg/d)** (Motzer et al., 2015) (see Table 104.13)**.** The combination of lenvatinib and everolimus significantly prolonged PFS compared with everolimus alone (median 14.6 months [95% CI 5.9–20.1] vs. 5.5 months [3.5–7.1]; HR 0.40; 95% CI 0.24–0.68; *P* = 0.0005)**; single-agent lenvatinib also significantly prolonged PFS compared with everolimus alone (HR 0.61; 95% CI 0.38–0.98; *P* = 0.048). However, there was no significant difference in outcome between the combination and** lenvatinib alone (**median PFS** 7.4 months [95% CI 5.6–10.2]; HR 0.66; 95% CI 0.39–1.10; *P* = 0.12). **Although these data should be confirmed in a larger study, they formed the basis for approval of the combination of lenvatinib and everolimus in patients who had progressed on prior anti-angiogenesis therapy. This combination is the subject of an ongoing randomized phase III study in previously untreated patients with clear cell RCC and is being compared to sunitinib and a combination of lenvatinib and pembrolizumab.**

Inhibitors of the Mammalian Target of Rapamycin

mTOR is a key intracellular protein that is a component of several signaling cascades including those mediating the effects of some growth factors. **It appears to play a role in regulating translation and stability of HIF-1α, and preclinical models have suggested that growth inhibition occurring in response to mTOR inhibitors correlates with a block in HIF-1α translation** (Hudson et al., 2002; Thomas et al., 2006). Two analogues of sirolimus, **temsirolimus** and **everolimus,** have been clinically evaluated with demonstrable activity in RCC.

A phase II trial of **temsirolimus** evaluated three different doses (25 mg, 75 mg, and 250 mg per week administered intravenously) in 111 patients assigned randomly to one of the dose levels (see Table 104.13). The overall response rate observed on this trial was modest (7%, including one patient with a complete response), and the median PFS was 15 months (Atkins et al., 2004). Responses and PFS appeared to be independent of temsirolimus dose. An exploratory subgroup analysis based on stratification of patients according to MSKCC risk groups revealed that patients in the poor-risk group had a longer median OS compared with historical controls receiving interferon-α (8.2 vs. 4.9 months). Based on this observation, a three-arm randomized phase III trial of 626 patients with three or more predefined poor-risk features was undertaken (Hudes et al., 2007). Patients with previously untreated metastatic kidney cancer of all histologic subtypes were eligible and randomized to receive temsirolimus alone (25 mg intravenously every week), interferon-α alone (up to 18 million units subcutaneously three times a week), or temsirolimus (15 mg intravenously every week) plus interferon-α (6 million units subcutaneously three times a week). PFS was superior in both temsirolimus-containing arms compared with interferon alone (median 3.8 months vs. 1.9 months). **Importantly, the trial also demonstrated a significantly higher OS in the temsirolimus arm compared with the interferon-only arm (median OS 10.9 vs. 7.3 months, $P = 0.008$), whereas the addition of temsirolimus did not appear to significantly alter OS compared with interferon alone (median OS 8.4 vs. 7.3 months, $P = 0.70$)** (Fig. 104.9). Temsirolimus was fairly well tolerated, and most common adverse events such as mucositis, fatigue, rash, hyperglycemia, hypophosphatemia, hypercholesterolemia, and pulmonary complications were amenable to medical and/or supportive measures. **Based on these data, temsirolimus was approved by the FDA for the treatment of patients with metastatic RCC, and the agent is a reasonable front-line choice in patients presenting with poor-risk features. However, its utility as well as relative efficacy in this patient population compared with immune checkpoint inhibitor therapy has not been evaluated.**

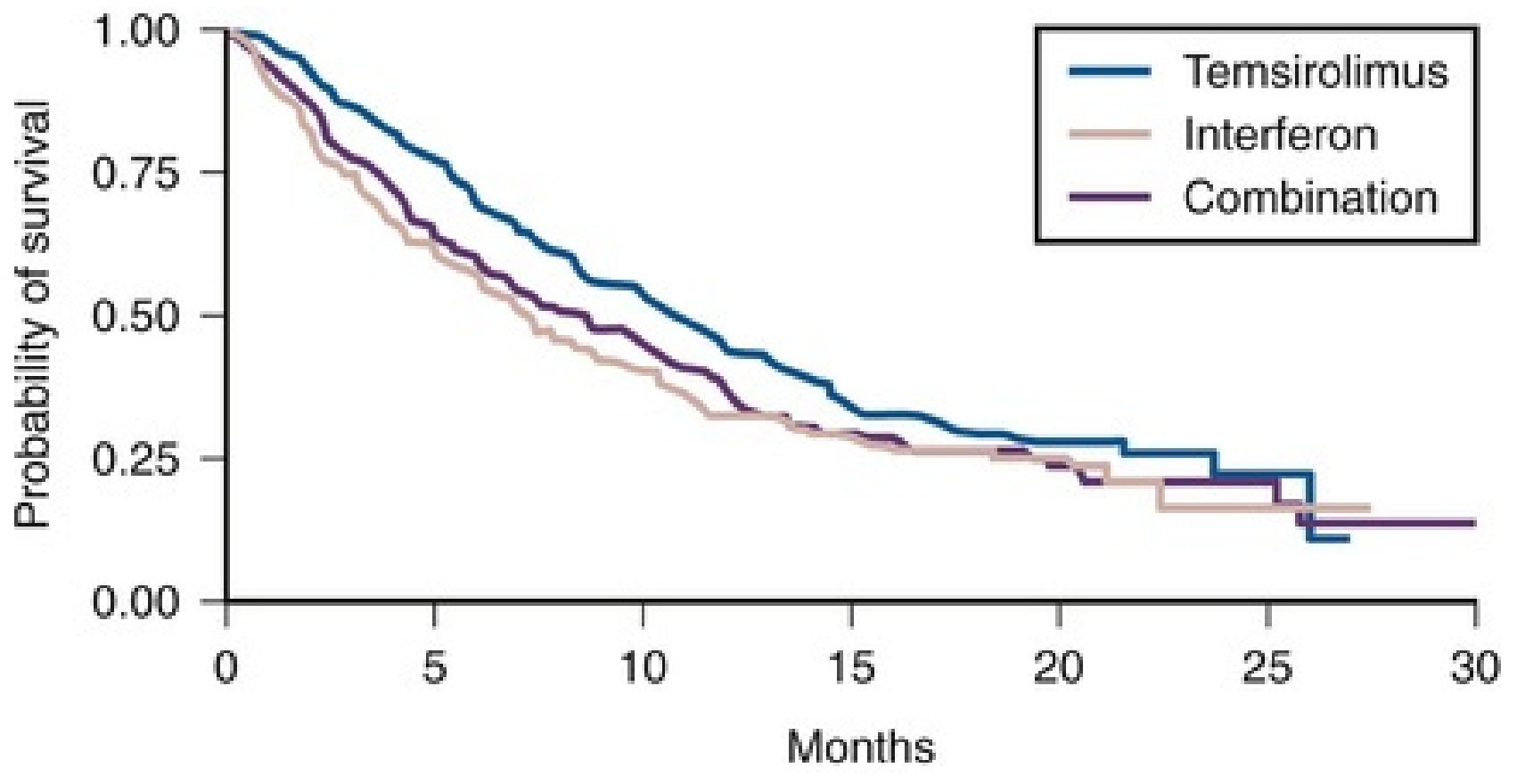

No. at risk							
Interferon	207	126	80	42	15	3	0
Temsirolimus	209	159	110	56	19	3	0
Combination	210	135	93	50	17	7	2

FIG. 104.9 Kaplan-Meier estimates of overall survival in 626 metastatic renal cell carcinoma patients with adverse prognostic features randomized to receive temsirolimus alone, interferon-α alone, or combination therapy. (From Hudes G, Carducci M, Tomczak P, et al.: Temsirolimus, interferon alfa, or both for advanced renal-cell carcinoma. *N Engl J Med* 356:2271–2281, 2007.)

Everolimus is an orally bioavailable inhibitor of mTOR. It was the subject of a phase III trial in patients with metastatic clear cell RCC whose disease had progressed after therapy with sunitinib, sorafenib, or both (Motzer et al., 2008). Patients were randomized to receive either everolimus, 10 mg once daily (n = 272), or placebo (n = 138) (Table 104.14). **The trial was stopped after an interim analysis demonstrated superior PFS in the everolimus arm (median 4 months) compared with the placebo arm (median 1.9 months)** (Fig. 104.10). At the time of this analysis, median survival had not been reached in the everolimus group and was 8.8 months for the placebo group; OS was not significantly different in the two groups. **Everolimus has been supplanted by other agents including nivolumab, and cabozantinib in the post-front-line setting. However, it is a reasonable option when used in combination with lenvatinib.**

TABLE 104.14

Summary of Selected Studies of mTOR Inhibitors in Metastatic Renal Cell Carcinoma

	OVERALL	MEDI

STUDY	AGENT(S)	PHASE	STUDY POPULATION	NO. OF PATIENTS	RESPONSE RATE (RECIST)	PFS (MO)
Hudes et al., 2007	Tem vs. IFN-α vs. tem/IFN-α	Randomized phase III	Poor prognosis, previously untreated, all histologic subtypes	626	8.6% vs. 4.8% vs. 8.1%	5.5 vs. vs. 4.7
Motzer et al., 2008b	Everolimus vs. placebo	Randomized phase III	Clear cell RCC refractory to VEGF-targeted therapy	410	1% vs. 0	4.0 vs.

IFN-α, Interferon-α; *NR,* not reached; *OS,* overall survival; *PFS,* progression-free survival; *RCC,* renal cell carcinoma; *tem,* temsirolimus.

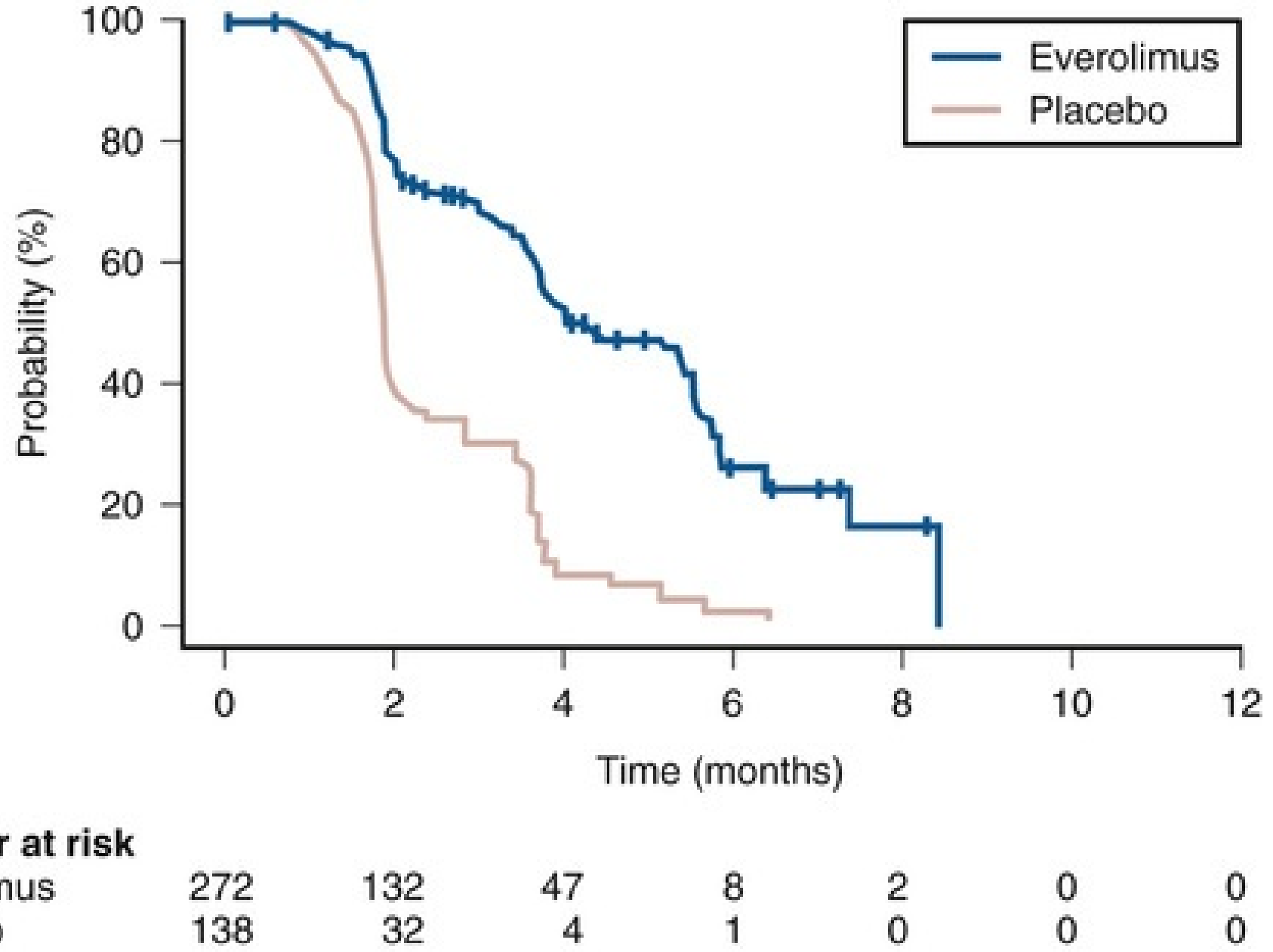

Number at risk

Everolimus	272	132	47	8	2	0	0
Placebo	138	32	4	1	0	0	0

FIG. 104.10 Kaplan-Meier estimates of progression-free survival in 410 patients with metastatic renal cell carcinoma randomized to everolimus or placebo. (From Motzer RJ et al.: Efficacy of everolimus in advanced renal cell carcinoma: a double-blind, randomised, placebo-controlled phase III trial. *Lancet* 372:449–456, 2008b.)

Combination and Sequential Therapy With Agents Targeting the VHL Pathway

Combinations of two or more classes of agents with activity centered on different components of the VHL pathway provide an attractive strategy that may increase efficacy as well as eliminating potential mechanisms of resistance. **A major limitation of this approach is the overlapping toxicity profile of several drugs, necessitating significant dose reductions of individual drugs** (Feldman et al., 2009; Patel et al., 2009). Several combinations of mTOR and VEGF-pathway antagonists have been evaluated in phase I trials. In general, combinations of first generation VEGFR inhibitors such as sunitinib, with an mTOR inhibitor are associated with significant toxicity discouraging their evaluation in phase 2/3 studies (Hainsworth et al., 2013; Patel et al., 2009). However, bevacizumab-based combinations appear to be better tolerated and have been evaluated in several trials.

The activity of bevacizumab in combination with everolimus was evaluated in a phase II trial of metastatic clear cell RCC patients (n = 80); both treatment-naive patients (n = 50) and patients who had previously received sunitinib and/or sorafenib were eligible (Hainsworth et al., 2010). Median PFS in the treatment-naive and previously treated populations was 9.1 and 7.1 months, respectively. The combination was further evaluated in a phase III trial (RECORD-2), which compared its efficacy with that of bevacizumab plus interferon-α (Ravaud et al., 2015). This study demonstrated similar median PFS, OS, and safety profiles in both groups, which suggests no additional advantage to replacing interferon-α with everolimus in combination with bevacizumab. The INTORACT trial compared the combination of either temsirolimus or interferon-α to bevacizumab (Rini et al., 2014): 791 patients with previously untreated metastatic clear cell RCC were randomized to one of the aforementioned groups; the primary end point of the trial was PFS. There was no significant difference between the temsirolimus and interferon-α groups in median PFS (9.1 months vs. 9.3 months, HR 1.1; 95% CI 0.9–1.3; P = 0.80), OS (25.8 months vs. 25.5 months, HR 1.0; 95% CI 0.9–1.3; P = 0.6) or objective response rates (27.0% vs. 27.4%, RR 1.0; 95% CI 0.8–1.3; P = 1.0). The combination of temsirolimus plus bevacizumab, however, appeared to be better tolerated, with superior symptom scores, as assessed by the validated Functional Assessment of Cancer Therapy-Kidney Symptom Index (FKSI)-15 and FKSI-Disease Related Symptoms, without a significant difference in global health outcomes. Based on these studies, **combinations of bevacizumab with a mTOR inhibitor do not appear to offer additional activity compared with previously established standard of care options in the first-line setting and are unlikely to be evaluated against**

newer standards.

Immune “Checkpoint” Inhibitor–Based Combination Strategies

Although the advent of inhibitors of PD1/PD-L1 has led to improved outcomes in patients with advanced clear cell RCC, a significant proportion of patients do not appear to benefit from these agents. In addition, complete responses, a potential surrogate for long-term disease-free interval, occur in less than 10% of patients treated with nivolumab or other checkpoint inhibitors given as a single agent. Consequently, there has been significant interest in evaluating combination strategies using inhibitors of the PD1/PD-L1 interaction in a bid to improve outcomes.

Cytotoxic T-lymphocyte associated protein 4 (CTLA-4) is a CD28 homolog expressed on T cells. Binding of B7 costimulatory molecules to CTLA-4 suppresses antigen-dependent T cell stimulation, and inhibitors of this interaction have demonstrable clinical activity in advanced cancer, including melanoma and RCC. Ipilimumab, a CTLA-4 inhibitor, is FDA-approved in melanoma, and the combination of PD-1/CTLA-4 blockade appears to be synergistic in the treatment of metastatic melanoma but is associated with significant toxicity. Consequently, a phase I study evaluating various doses of nivolumab and ipilimumab in combination was conducted in patients with advanced RCC (CheckMate 016) and led to the identification of nivolumab 3 mg/kg every 3 weeks and ipilimumab 1 mg/kg every 3 weeks for 4 doses as the combination associated with the most acceptable level of adverse events (<40% grade 3–4 adverse events, compared with more than 60% grade 3–4 events in regimens containing higher doses of ipilimumab) (Hammers et al., 2017).

This regimen was subsequently studied in previously untreated patients with metastatic clear cell RCC (CheckMate 214) in a phase III study with sunitinib as the comparator (Motzer et al., 2018). A total of 1096 patients were randomized 1 : 1 to receive either sunitinib or nivolumab plus ipilimumab. Of these, 847 patients were classified as having intermediate or poor risk based on IMDC prognostic criteria and constituted the population that was the subject of the primary end point analysis; OS, PFS, and overall response rate were the co-primary end points. With a median follow-up of 25.6 months, the combination of nivolumab and ipilimumab was determined to be superior to sunitinib. The median OS was not reached with nivolumab plus ipilimumab versus 26.0 months with sunitinib (HR for death, 0.63; $P < 0.001$), while the objective response rate was 42% versus 27% ($P < 0.001$) with a complete response rate of 9% versus 1% (Fig. 104.11). The median PFS was 11.6 months and 8.4 months, respectively (HR for disease progression or death, 0.82; $P = 0.03$, not significant per the prespecified 0.009 threshold). As anticipated, a significant proportion of patients treated with the combination experienced grade 3 to 4 adverse events (46%); immune-related side effects requiring high-dose glucocorticoid therapy were seen in 35% of patients, and 22% of patients had their treatment permanently discontinued because of toxicity. A total of 249 patients with good prognostic features were also treated on this study; these patients tended to have better outcomes with sunitinib compared with the immunotherapy combination. In a study of patient-reported outcomes of patients with advanced renal cell carcinoma treated with nivolumab plus ipilimumab versus sunitinib (CheckMate 214), Cella et al. (2019) found that nivolumab plus ipilimumab leads to fewer symptoms and better HRQoL than sunitinib in patients with intermediate- or poor-risk disease. **Based on these data, the combination of nivolumab plus ipilimumab is now considered a reasonable standard of care option in the front-line therapy of patients with intermediate or poor-risk clear cell RCC.**

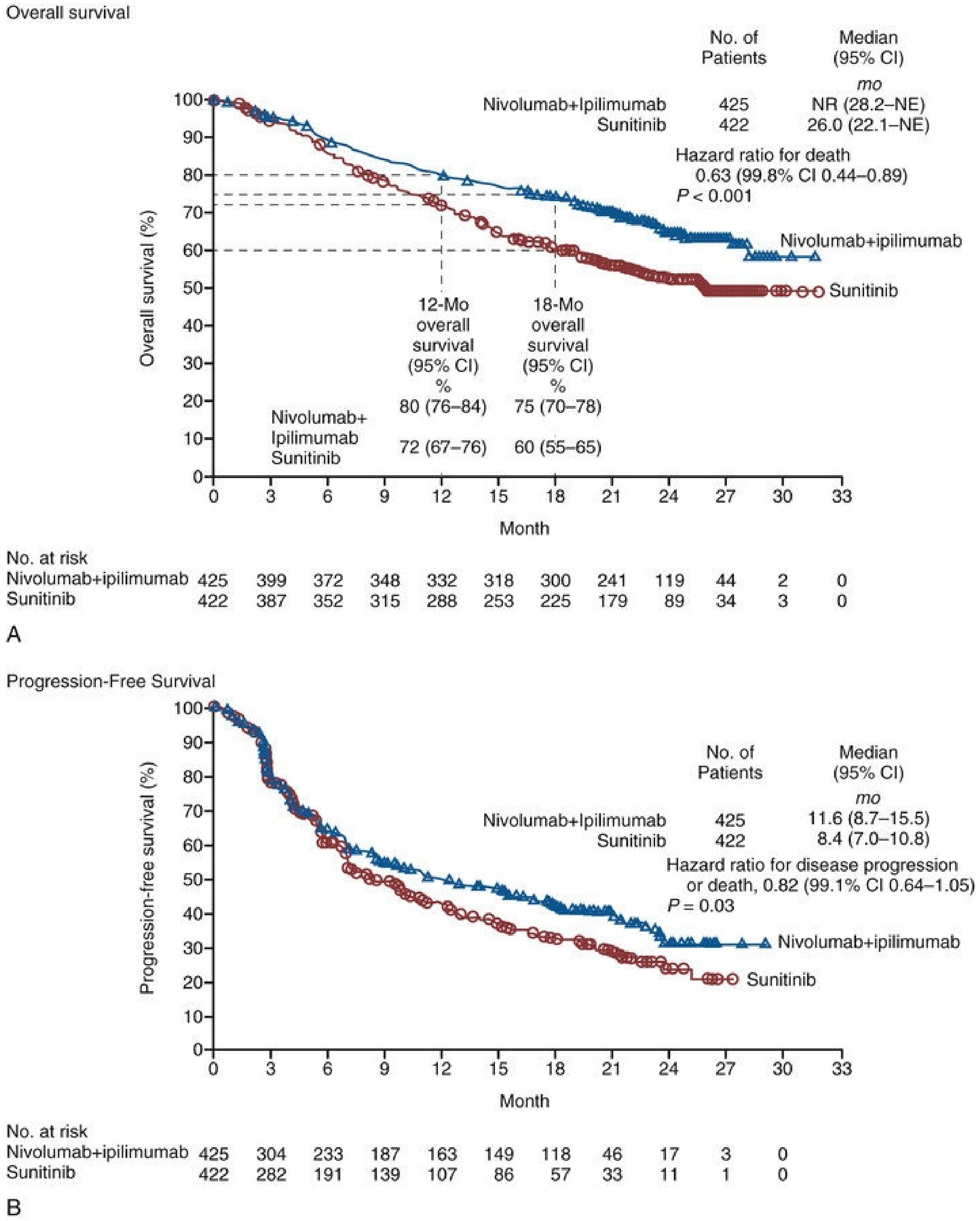

FIG. 104.11 Kaplan Meier analysis of overall survival (Panel A) and progression free survival (Panel B) in 847 patients with previously untreated intermediate or poor risk metastatic clear cell renal cell carcinoma receiving either nivolumab plus ipilimumab or sunitinib. (Motzer Tannir NM, McDermott DF, et al.: Nivolumab plus ipilimumab versus sunitinib in advanced renal-cell carcinoma. *N Engl J Med* 378:1277–1290, 2018.)

The addition of agents targeting the VEGF axis to immune checkpoint blockade is another strategy that is under investigation. In addition to the single agent activity of both classes of agents, there is ample preclinical evidence to suggest synergistic antitumor effect when VEGF pathway antagonists are combined with inhibitors of the PD1/PD-L1 interaction. Several studies suggest that VEGF-pathway inhibitors have an immunomodulatory effect. Sunitinib appears to decrease regulatory T cells, and sunitinib and sorafenib downregulate the function of suppressive tumor-associated macrophages, thereby enhancing an antitumor immune response (Ko et al., 2010; Lin et al., 2013; Porta et al., 2011). Although early studies combining nivolumab (2 mg/kg IV) and sunitinib (50 mg, 4 weeks on, 2 weeks off) or pazopanib (800 mg daily) in previously treated metastatic RCC demonstrated notable antitumor activity with an ORR of 52% in the sunitinib arm and 45% in the pazopanib arm, the associated toxicity was considered prohibitive (Amin et al., 2018).

Subsequent studies sought to mitigate the potential risk of combination therapy by using newer, more specific VEGF pathway antagonists. A number of these combinations are deemed safe and are the subject of phase III studies in untreated metastatic clear cell RCC patients. Pembrolizumab (an anti-PD1 antibody) and avelumab (an antibody directed against PD-L1) have been studied in combination with axitinib, demonstrating high response rates and manageable toxicity in phase I/II studies. Data from a phase III randomized study of avelumab and axitinib have been reported and demonstrate the superiority of this combination compared with sunitinib (JAVELIN Renal 101 Study) in 882 patients with previously untreated RCC, including 560 who had positive staining for PD-L1; specifically, the combination arm was associated with a higher PFS (13.8 vs. 7.2 months; HR 0.61; $P < 0.0001$) and overall response rate (55.2% [95% CI 49.9–61.2] vs. 25.5% [95% CI 20.6–30.9]) in the PD-L1 + population (Choueiri et al., 2017). Although grade 3 or greater toxicity was encountered in more than 70% of patients in both arms, the rate of permanent treatment discontinuation was much higher in the combination arm (22% vs. 13%). Similarly, the combination of bevacizumab and atezolizumab, another anti PD-L1 antibody, was also shown to be associated with a superior PFS compared with sunitinib in a randomized phase III study in previously untreated patients with metastatic RCC whose tumors expressed PD-L1 (Motzer et al., 2018). Other studies of similar design, including a phase III study comparing sunitinib against a combination of pembrolizumab and axitinib are ongoing. **Although**

mature overall survival data from these studies are not yet available, combinations of agents targeting the PD1 and VEGF axis appear to be associated with a better PFS and higher response rate compared with front-line VEGFR-targeted therapy. Although these combinations have not been compared directly to dual PD1/CTLA4 blockade, they appear to have at least comparable efficacy and a more favorable toxicity profile and are on the cusp of regulatory approval in the front-line setting.

Other Treatment Options in Patients With Clear Cell Renal Cell Carcinoma

Chemotherapy

Conventional cytotoxic chemotherapy has been largely ineffective in the management of clear cell RCC. Numerous chemotherapeutic agents including 5-FU, platinum compounds, gemcitabine, vinblastine, and bleomycin have been evaluated as single agents in this disease but have failed to demonstrate clinically meaningful activity; a wide array of combination chemotherapy regimens have fared little better (Amato, 2000; Haas et al., 1976; Hahn et al., 1977; Mertens et al., 1993, 1994; Rini et al., 2000, 2005; Stadler et al., 2006; Zaniboni et al., 1989). **Comprehensive meta-analyses of chemotherapy trials in RCC indicate the overall response rate is 5.5% to 6.0%** (Yagoda et al., 1995). Although the mechanisms underlying this profound chemoresistance have not been fully elucidated, overexpression of the multidrug resistance gene *(MDR)* has been proposed as one possible culprit (Fojo et al., 1987). However, the addition of MDR inhibitors such as toremifene, cyclosporine, and verapamil to conventional chemotherapeutic agents has failed to improve their efficacy, suggesting that other, as yet unrecognized, factors may be at play (Braybrooke et al., 2000). **Cytotoxic chemotherapy has no role in the current management of most patients with clear cell RCC.** One situation in which chemotherapy may bear further investigation is in patients whose tumors demonstrate a sarcomatoid component; a small case series has suggested promising activity for gemcitabine-based chemotherapy in this setting, prompting further study of this approach (Nanus et al., 2004).

Hormonal Therapy

Hormonal therapy had been the subject of trials in RCC in the 1970s and 1980s, preceding the advent of cytokines. These studies were prompted by the lack of effective therapies for kidney cancer and by the belief that a male preponderance (kidney cancer occurs approximately twice as frequently in males) implied a hormonal basis for this malignancy. Hormonal agents such as medroxyprogesterone have been noted to induce tumor regressions in a small minority of patients, but overall response rates are too low (approximately 2%) to have meaningful clinical impact in most patients (Braybrooke et al., 2000; Harris, 1983; Medical Research Council Renal Cancer, 1999; Schomburg et al., 1993). **Progestational and other hormonal agents have no role in the current management of renal cell cancer.**

Systemic Therapy for Non–Clear Cell Variants of Renal Cell Carcinoma

Non–clear cell subtypes of kidney cancer are relatively rare (constituting approximately 15% to 25% of all kidney cancer) and have been the subject of few prospective studies. Given the unavailability of agents of proven efficacy in papillary, chromophobe, and other rare histologic subtypes, patients with non–clear cell renal tumors often receive agents with activity in clear cell RCC.

VEGFR inhibitors active in clear cell RCC have only modest efficacy in papillary RCC. Sorafenib and sunitinib were shown to have minimal activity in retrospective studies of papillary RCC patients (Choueiri et al., 2008). Prospective phase II trials with sunitinib have demonstrated that this agent is associated with low response rates (5% to 10%) in papillary RCC. The Southwest Oncology Group reported an 11% overall response rate with erlotinib, an oral EGFR inhibitor, in 52 patients with metastatic papillary RCC with a 6-month PFS of only 29%.

An exploratory subgroup analysis of patients enrolled in large randomized phase III study evaluating the efficacy of temsirolimus versus interferon in “poor prognosis” patients suggests that mTOR inhibitors may have activity in some non–clear cell variants. Approximately 20% of the patients enrolled in this trial had non–clear cell histologies (predominantly papillary RCC). The outcome of 37 patients with non–clear cell RCC treated with temsirolimus (OS and PFS) was found to be better than that of 36 patients receiving interferon in this subgroup analysis. Although these data suggest that temsirolimus may have activity in some non–clear cell variants, these conclusions are limited by the fact that this is a subgroup analysis (Dutcher et al., 2009). Everolimus was evaluated in a relatively large open-labeled, multicenter phase II clinical trial evaluating as a first-line agent in patients with metastatic papillary RCC (RAPTOR) (Escudier et al., 2016). At the time of a preliminary intent-to-treat analysis (*n* = 83), median PFS was 3.7 months (95% CI 2.4–5.5), whereas median OS was 21 months (95% CI 15.4–28) by independent radiology review. Common grade 3 or 4 adverse events included asthenia (10.6%), fatigue (5.4%), and anemia (5.4%). Around 27.2% of the patients discontinued treatment because of adverse events. A second phase II trial of everolimus in patients with metastatic non–clear cell RCC was recently published. Of the 49 patients enrolled, 29 (59%) had papillary

RCC (Koh et al., 2013); 23 patients (47%) had prior anti-VEGF therapy. Partial response was noted in 5/49 (10%), stable disease in 25 (51%), and disease progression in 16 (32.7%) of the patients. Interestingly, 2 out of 5 patients with objective response to everolimus had chromophobe RCC, whereas 2 had pRCC and 1 had an unclassified RCC variant. The median PFS in this study was 5.2 months, and patients with chromophobe RCC had a trend toward longer PFS compared with other nccRCC patients (*P* = 0.084). Based on the two foregoing trials, everolimus appears to have modest activity in patients with papillary/non–clear cell RCC.

At least two phase II randomized studies have compared the activity of sunitinib and everolimus in patients with non–clear cell RCC. As was seen with single agent studies, both agents were associated with modest response rates and PFS (Armstrong et al., 2016; Tannir et al., 2016). Although neither agent was clearly superior, there was a trend toward better outcome with sunitinib.

Recent advances in our understanding of the genetic and molecular alterations underlying several RCC subtypes have begun to lead to a more rational and individualized approach to their management. As with clear cell RCC, hereditary forms of papillary and chromophobe RCC hold the key to the identification of critical molecular events leading to these tumors in familial and sporadic settings (Linehan, 2003, 2009). Hereditary papillary renal cancer (HPRC) is a familial condition characterized by the predisposition of affected individuals to develop bilateral, multifocal papillary type I RCC. **HPRC is characterized by the presence of activating germline mutations in the tyrosine kinase domain of the proto-oncogene *MET*, which is located on chromosome 7; this is usually accompanied by nonrandom duplication of the chromosome containing the mutated allele in the tumors** (Linehan, 2003, 2009; Schmidt et al., 1997, 1998, 1999, 2004; Zhuang et al., 1998). MET is a cell surface receptor that is normally activated on binding its ligand, hepatocyte growth factor (HGF) but is rendered constitutionally active in the presence of mutations in the kinase domain of this protein (Bottaro et al., 1991; Dharmawardana et al., 2004; Giubellino et al., 2009; Peruzzi and Bottaro, 2006). The HGF/MET pathway is involved in regulating a variety of biologic functions, including cell growth, proliferation, and motility (Fig. 104.12) (Giubellino et al., 2009; Jeffers et al., 1998). Somatic MET alterations have been noted in a proportion of patients with sporadic papillary RCC, with activating mutations identified in approximately 13% of papillary tumors in one series. Trisomy 7 (*HGF* and MET are located on chromosome 7) has been described in more than two-thirds of papillary tumors and may represent an alternative mechanism contributing to activation of the MET pathway in these tumors (Henke and Erbersdobler, 2002; Kovacs et al., 1991).

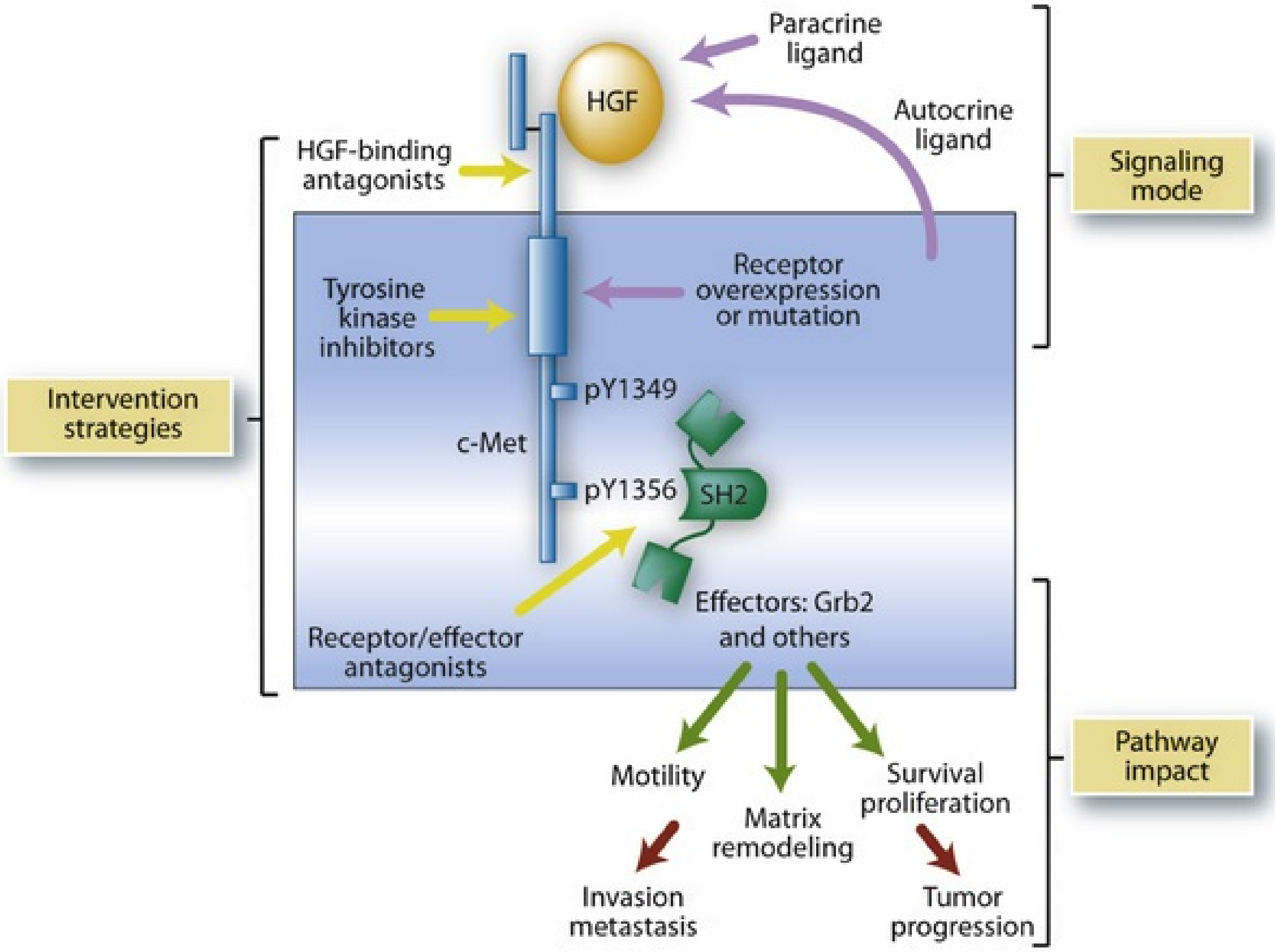
Paracrine ligand
HGF
Autocrine ligand
HGF-binding antagonists
Signaling mode
Tyrosine kinase inhibitors
Receptor overexpression or mutation
Intervention strategies
pY1349
c-Met
pY1356
SH2
Effectors: Grb2 and others
Receptor/effector antagonists
Motility
Matrix remodeling
Survival proliferation
Pathway impact
Invasion metastasis
Tumor progression

FIG. 104.12 MET oncogenic signaling pathway. Important downstream biochemical and biologic consequences of MET activation (by HGF binding or by constitutive activation of the receptor tyrosine kinase activity by mutation) are represented. The MET ligand (HGF), MET tyrosine kinase activity, and downstream effectors (such as Grb-2) are potential targets for drugs in tumors with aberrant pathway activation. (From Peruzzi B, Bottaro DP: Targeting the c-Met signaling pathway in cancer. *Clin Cancer Res* 12:3657–3660, 2006.)

The realization that MET activation may play an important role in some forms of papillary RCC has led to the evaluation of foretinib, a novel tyrosine kinase inhibitor with activity against *MET* and VEGFR2 in this RCC subtype. Two dosing regimens were evaluated in sequential patient cohorts: (1) an intermittent dosing regimen of 240 mg of foretinib given days 1 to 5 of every 14-day cycle (*n* = 37), and (2) a continuous daily dosing regimen of 80 mg/day (*n* = 37). The primary end point was ORR based on response evaluation criteria in solid tumors (RECIST). An ORR of 13.5% with a median PFS of 9.3 months was reported in the entire study population. A subgroup analysis was undertaken to determine if MET pathway activation was associated with treatment outcome. The presence of a germline *MET* mutation was associated with a high likelihood of response, with 5 of 10 patients (50%) demonstrating a PR in this group compared with 5 of 57 responders (9%) in the absence of germline alterations. The side effect profile for foretinib appeared similar to that of other anti-VEGFR agents; hypertension was the most commonly reported AE. Although the primary end point of ORR greater than 25% was not met, **foretinib has activity in pRCC, notably in the germline *MET* mutation cohort, indicating that MET inhibition may be a viable treatment option for a subset of patients with pRCC**. More selective inhibitors of Met, including savolitinib and crizotinib, which lack significant activity against the VEGF receptors, have also been evaluated in phase II studies; data from these studies appear to confirm the notion that inhibitors of Met may have activity against tumors that have Met activation (Choueiri et al., 2017; Schoffski et al., 2017). At least two ongoing randomized studies are evaluating the efficacy of Met inhibitors compared with sunitinib, in patients with advanced papillary RCC.

A second form of hereditary pRCC is associated with alterations in the *fumarate hydratase* gene *(FH)*, which encodes a tricarboxylic acid cycle enzyme that catalyzes the conversion of fumarate to malate. Germline *FH* mutations are seen in patients with hereditary leiomyomatosis and renal cell cancer (HLRCC), a condition associated with a highly aggressive variant of type II pRCC (Linehan et al., 2013; Ricketts et al., 2016; Shuch et al., 2013). It has long been recognized that accumulation of fumarate resulting from FH inactivation leads to a VHL-independent upregulation of intracellular HIF and transcriptional activation of downstream proangiogenic and growth factors (Isaacs et al., 2005). Loss of FH activity promotes a metabolic shift in these tumors, characterized by disruption of the Krebs cycle and a consequent reliance on aerobic glycolysis to satisfy cellular bioenergetic requirements.

Investigators at the National Cancer Institute have recently attempted to therapeutically exploit the exquisite sensitivity of this variant of papillary RCC to glucose deprivation (Yang et al., 2010). They hypothesized that a combination of bevacizumab, a monoclonal antibody to VEGF and erlotinib (inhibitor of EFGR kinase activity) would severely constrain glucose delivery to the tumor microenvironment and disrupt critical cellular processes. The combination of bevacizumab and erlotinib is currently being evaluated in patients with metastatic papillary RCC and interim data from his trial were recently presented (Srinivasan et al., 2014). This interim analysis included the first 41 individuals enrolled, of whom 21 had sporadic papillary RCC and 20 had HLRCC-associated kidney cancer. Sixteen patients had received at least one prior systemic therapy regimen. The overall RECIST response rate was 46% (19/41) in the entire cohort with a median PFS of 12.8 months; partial responses were seen in 13 out of 20 (65%) individuals with HLRCC and 6 out of 20 (29%) individuals with sporadic pRCC. After a median follow-up of 10.7 months, median PFS was 10.5 months (95% CI 7.4–18.6 months). **Although these results are promising and suggest that the combination of bevacizumab and erlotinib is highly active in some forms of papillary RCC, further follow-up is required to clearly define the efficacy of this regimen in this population.**

Cytotoxic chemotherapy has been used with modest success in collecting duct carcinoma, a rare kidney cancer variant with similarities to urothelial malignancies. In a series of 23 patients with metastatic collecting duct carcinoma, a response rate of 26% (including one complete response) was reported with a regimen comprising gemcitabine and carboplatin. Median PFS (7.1 months) and OS (10.5 months) were modest (Oudard et al., 2007).

In summary, there is no standard approach of proven efficacy for most patients with non–clear cell RCC, although some promising approaches are being evaluated. Enrollment in suitable trials should be considered for all patients with non–clear cell RCC.

Suggested Readings

Atkins MB, Dutcher J, Weiss G, et al. Kidney cancer: the Cytokine Working Group experience (1986-2001): part I. IL-2-based clinical trials. *Med Oncol*. 2001;18:197–207.

Choueiri TK, Escudier B, Powles T, et al. Cabozantinib versus everolimus in advanced renal-cell carcinoma. *N Engl J Med*. 2015;373:1814–1823.

Choueiri TK, Escudier B, Powles T, et al. Cabozantinib versus everolimus in advanced renal cell carcinoma (METEOR): final results from a randomised, open-label, phase 3 trial. *Lancet Oncol*. 2016;17:917–927.

Choueiri TK, Halabi S, Sanford BL, et al. Cabozantinib versus sunitinib as initial targeted therapy for patients with metastatic renal cell carcinoma of poor or intermediate risk: the Alliance A031203 CABOSUN Trial. *J Clin Oncol*. 2017;35:591–597.

Flanigan RC, Salmon SE, Blumenstein BA, et al. Nephrectomy followed by interferon alfa-2b compared with interferon alfa-2b alone for metastatic renal-cell cancer. *New Engl J Med*. 2001;345:1655–1659.

Fyfe GA, Fisher RI, Rosenberg SA, et al. Long-term response data for 255 patients with metastatic renal cell carcinoma treated with high-dose recombinant interleukin-2 therapy. *J Clin Oncol*. 1996;14:2410–2411.

Heng DY, Xie W, Regan MM, et al. External validation and comparison with other models of the International Metastatic Renal-Cell Carcinoma Database Consortium prognostic model: a population-based study. *Lancet Oncol*. 2013;14:141–148.

Hudes G, Carducci M, Tomczak P, et al. Temsirolimus, interferon alfa, or both for advanced renal-cell carcinoma.

New Engl J Med. 2007;356:2271–2281.

Mejean A, Ravaud A, Thezenas S, et al. Sunitinib alone or after nephrectomy in metastatic renal-cell carcinoma. *N Engl J Med*. 2018;379:417–427.

Motzer RJ, Hutson TE, Tomczak P, et al. Sunitinib versus interferon alfa in metastatic renal-cell carcinoma. *New Engl J Med*. 2007;356:115–124.

Motzer RJ, Mazumdar M, Bacik J, et al. Survival and prognostic stratification of 670 patients with advanced renal cell carcinoma. *J Clin Oncol*. 1999;17:2530–2540.

Motzer RJ, Escudier B, McDermott DF, et al. Nivolumab versus everolimus in advanced renal-cell carcinoma. *N Engl J Med*. 2015;373:1803–1813.

Motzer RJ, Tannir NM, McDermott DF, et al. Nivolumab plus ipilimumab versus sunitinib in advanced renal-cell carcinoma. *N Engl J Med*. 2018;378:1277–1290.

References

Ada G. The coming of age of tumour immunotherapy. *Immunol Cell Biol*. 1999;77:180–185.

Alt AL, Boorjian SA, Lohse CM, et al. Survival after complete surgical resection of multiple metastases from renal cell carcinoma. *Cancer*. 2011;117:2873–2882.

Amato RJ. Chemotherapy for renal cell carcinoma. *Sem Oncol*. 2000;27:177–186.

Amin A, Plimack ER, Ernstoff MS, et al. Safety and efficacy of nivolumab in combination with sunitinib or pazopanib in advanced or metastatic renal cell carcinoma: the CheckMate 016 study. *J Immunother Cancer*. 2018;6:109.

Armstrong AJ, Halabi S, Eisen T, et al. Everolimus versus sunitinib for patients with metastatic non-clear cell renal cell carcinoma (ASPEN): a multicentre, open-label, randomised phase 2 trial. *Lancet Oncol*. 2016;17:378–388.

Artz AS, Van Besien K, Zimmerman T, et al. Long-term follow-up of nonmyeloablative allogeneic stem cell transplantation for renal cell carcinoma: the University of Chicago Experience. *Bone Marrow Transplant*. 2005;35:253–260.

Atkins M, Regan M, McDermott D, et al. Carbonic anhydrase IX expression predicts outcome of interleukin 2 therapy for renal cancer. *Clin Cancer Res*. 2005;11:3714–3721.

Atkins MB, Dutcher J, Weiss G, et al. Kidney cancer: the Cytokine Working Group experience (1986-2001): part I. IL-2-based clinical trials. *Med Oncol*. 2001;18:197–207.

Atkins MB, Hidalgo M, Stadler WM, et al. Randomized phase II study of multiple dose levels of CCI-779, a novel mammalian target of rapamycin kinase inhibitor, in patients with advanced refractory renal cell carcinoma. *J Clin Oncol*. 2004;22:909–918.

Atzpodien J, Kirchner H, Hanninen EL, et al. Interleukin-2 in combination with interferon-alpha and 5-fluorouracil for metastatic renal cell cancer. *Eur J Cancer*. 1993;29A(Suppl 5):S6–S8.

Barkholt L, Bregni M, Remberger M, et al. Allogeneic haematopoietic stem cell transplantation for metastatic renal carcinoma in Europe. *Ann Oncol*. 2006;17:1134–1140.

Bennett RT, Lerner SE, Taub HC, et al. Cytoreductive surgery for stage IV renal cell carcinoma. *J Urol*. 1995;154:32–34.

Bloom HJ. Hormone-induced and spontaneous regression of metastatic renal cancer. *Cancer*. 1973;32:1066–1071.

Boon T, Coulie PG, Van den Eynde B. Tumor antigens recognized by T cells. *Immunol Today*. 1997;18:267–268.

Bottaro DP, Rubin JS, Faletto DL, et al. Identification of the hepatocyte growth factor receptor as the c-met proto-oncogene product. *Science*. 1991;251:802–804.

Brahmer JR, Tykodi SS, Chow LQ, et al. Safety and activity of anti-PD-L1 antibody in patients with advanced cancer. *N Engl J Med*. 2012;366:2455–2465.

Braren V, Taylor JN, Pace W. Regression of metastatic renal carcinoma following nephrectomy. *Urology*. 1974;III:777–778.

Braybrooke JP, O'Byrne KJ, Propper DJ, et al. A phase II study of razoxane, an antiangiogenic topoisomerase II inhibitor, in renal cell cancer with assessment of potential surrogate markers of angiogenesis. *Clin Cancer Res*. 2000;6:4697–4704.

Bregni M, Dodero A, Peccatori J, et al. Nonmyeloablative conditioning followed by hematopoietic cell allografting and donor lymphocyte infusions for patients with metastatic renal and breast cancer. *Blood*. 2002;99:4234–4236.

Bukowski RM, Olencki T, Wang Q, et al. Phase II trial of interleukin-2 and interferon-à in patients with renal cell carcinoma: clinical results and immunologic correlates of response. *J Immunother*. 1997;20:301–311.

Bukowski RM, Rayman P, Uzzo R, et al. Signal transduction abnormalities in T lymphocytes from patients with advanced renal carcinoma: clinical relevance and effects of cytokine therapy. *Clin Cancer Res*. 1998;4:2337–2347.

Bukowski RM, Kabbinavar FF, Figlin RA, et al. Randomized phase II study of erlotinib combined with bevacizumab compared with bevacizumab alone in metastatic renal cell cancer. *J Clin Oncol*. 2007;25:4536–4541.

Cella D, Grunwald V, Escudier B, et al. Patient-reported outcomes of patients with advanced renal cell carcinoma treated with nivolumab plus ipilimumab versus sunitinib (CheckMate 214): a randomised, phase 3 trial. *Lancet Oncol*. 2019;20:297–310.

Childs R, Chernoff A, Contentin N, et al. Regression of metastatic renal-cell carcinoma after nonmyeloablative allogeneic peripheral-blood stem-cell transplantation. *New Engl J Med*. 2000;343:750–758.

Choueiri TK, Garcia JA, Elson P, et al. Clinical factors associated with outcome in patients with metastatic clear-cell renal cell carcinoma treated with vascular endothelial growth factor-targeted therapy. *Cancer*. 2007;110:543–550.

Choueiri TK, Plantade A, Elson P, et al. Efficacy of sunitinib and sorafenib in metastatic papillary and chromophobe renal cell carcinoma. *J Clin Oncol*. 2008;26:127–131.

Choueiri TK, Xie W, Kollmannsberger C, et al. The impact of cytoreductive nephrectomy on survival of patients with metastatic renal cell carcinoma receiving vascular endothelial growth factor targeted therapy. *J Urol*. 2011;185:60–66.

Choueiri TK, Escudier B, Powles T, et al. Cabozantinib versus everolimus in advanced renal-cell carcinoma. *N Engl J Med*. 2015;373:1814–1823.

Choueiri TK, Escudier B, Powles T, et al. Cabozantinib versus everolimus in advanced renal cell carcinoma (METEOR): final results from a randomised, open-label, phase 3 trial. *Lancet Oncol*. 2016;17:917–927.

Choueiri TK, Halabi S, Sanford BL, et al. Cabozantinib versus sunitinib as initial targeted therapy for patients with metastatic renal cell carcinoma of poor or intermediate risk: the alliance A031203 CABOSUN Trial. *J Clin Oncol*. 2017;35:591–597.

Choueiri TK, Plimack E, Arkenau HT, et al. Biomarker-based phase II trial of savolitinib in patients with advanced papillary renal cell cancer. *J Clin Oncol*. 2017;35:2993–3001.

Choueiri TK, Rini BI, Larkin JMG, et al. Avelumab plus axitinib vs sunitinib as first-line treatment of advanced renal cell carcinoma: phase 3 study (JAVELIN Renal 101). *J Clin Oncol*. 2017;35.

Cockman ME, Masson N, Mole DR, et al. Hypoxia inducible factor-alpha binding and ubiquitylation by the von Hippel-Lindau tumor suppressor protein. *J Biol Chem*. 2000;275:25733–25741.

Coppin C, Porzsolt F, Awa A, et al. Immunotherapy for advanced renal cell cancer. *Cochrane Database Syst Rev*. 2005;(12) [CD001425].

deKernion JB, Ramming KP, Smith RB. The natural history of metastatic renal cell carcinoma: a computer analysis. *J Urol*. 1978;120:148–152.

deKernion JB, Sarna G, Figlin RA, et al. The treatment of renal cell carcinoma with human leukocyte alpha- interferon. *J Urol*. 1983;130:1063–1066.

Dharmawardana PG, Giubellino A, Bottaro DP. Hereditary papillary renal carcinoma type I. *Curr Mol Med*. 2004;4:855–868.

Duan DR, Humphrey JS, Chen DY, et al. Characterization of the

VHL tumor suppressor gene product: localization, complex formation, and the effect of natural inactivating mutations. *Proc Natl Acad Sci USA*. 1995;92:6459–6463.

Dutcher JP, Atkins M, Fisher R, et al. Interleukin-2-based therapy for metastatic renal cell cancer: the Cytokine Working Group experience, 1989-1997. *Cancer J Sci Am*. 1997;3(Suppl 1):S73–S78.

Dutcher JP, Fisher RI, Weiss G, et al. Outpatient subcutaneous interleukin-2 and interferon-alpha for metastatic renal cell cancer: five-year follow-up of the Cytokine Working Group Study [see comments]. *Cancer J Sci Am*. 1997;3:157–162.

Dutcher JP, Logan T, Gordon M, et al. Phase II trial of interleukin 2, interferon alpha, and 5-fluorouracil in metastatic renal cell cancer: a cytokine working group study. *Clin Cancer Res*. 2000;6:3442–3450.

Dutcher JP, de Souza P, McDermott D, et al. Effect of temsirolimus versus interferon-alpha on outcome of patients with advanced renal cell carcinoma of different tumor histologies. *Med Oncol*. 2009;26:202–209.

Edwards MJ, Anderson JA, Angel JR, et al. Spontaneous regression of primary and metastatic renal cell carcinoma. *J Urol*. 1996;155:1385.

Eisen T, Loembe AB, Shparyk Y, et al. A randomised, phase II study of nintedanib or sunitinib in previously untreated patients with advanced renal cell cancer: 3-year results. *Br J Cancer*. 2015;113:1140–1147.

Ellerhorst JA, Sella A, Amato RJ, et al. Phase II trial of 5-fluorouracil, interferon-à and continuous infusion interleukin-2 for patients with metastatic renal cell carcinoma. *Cancer*. 1997;80:2128–2132.

Escudier B, Farace F, Angevin E, et al. Immunotherapy with interleukin-2 (IL2) and lymphokine-activated natural killer cells: improvement of clinical responses in metastatic renal cell carcinoma patients previously treated with IL2. *Eur J Cancer*. 1994;30A:1078–1083.

Escudier B, Ravaud A, Fabbro M, et al. High-dose interleukin-2 two days a week for metastatic renal cell carcinoma: a FNCLCC multicenter study. *J Immunother Emphasis Tumor Immunol*. 1994;16:306–312.

Escudier B, Farace F, Theodore C, et al. [Treatment of metastatic kidney neoplasms with a new interleukin 2 protocol: the experience of the Gustave-Roussy Institute]. *Bull Cancer*. 1995;82:296–302.

Escudier B, Eisen T, Stadler WM, et al. Sorafenib in advanced clear-cell renal-cell carcinoma. *New Engl J Med*. 2007;356:125–134.

Escudier B, Pluzanska A, Koralewski P, et al. Bevacizumab plus interferon alfa-2a for treatment of metastatic renal cell carcinoma: a randomised, double-blind phase III trial. *Lancet*. 2007;370:2103–2111.

Escudier B, Eisen T, Stadler WM, et al. Sorafenib for treatment of renal cell carcinoma: final efficacy and safety results of the phase III treatment approaches in renal cancer global evaluation trial. *J Clin Oncol*. 2009;27:3312–3318.

Escudier B, Szczylik C, Hutson TE, et al. Randomized phase II trial of first-line treatment with sorafenib versus interferon Alfa-2a in patients with metastatic renal cell carcinoma. *J Clin Oncol*. 2009;27:1280–1289.

Escudier B, Bellmunt J, Negrier S, et al. Phase III trial of bevacizumab plus interferon alfa-2a in patients with metastatic renal cell carcinoma (AVOREN): final analysis of overall survival. *J Clin Oncol*. 2010;28:2144–2150.

Escudier B, Porta C, Bono P, et al. Randomized, controlled, double-blind, cross-over trial assessing treatment preference for pazopanib versus sunitinib in patients with metastatic renal cell carcinoma: PISCES Study. *J Clin Oncol*.

2014;32:1412–1418.

Escudier B, Molinie V, Bracarda S, et al. Open-label phase 2 trial of first-line everolimus monotherapy in patients with papillary metastatic renal cell carcinoma: RAPTOR final analysis. *Eur J Cancer*. 2016;69:226–235.

Fallick ML, McDermott DF, LaRock D, et al. Nephrectomy before interleukin-2 therapy for patients with metastatic renal cell carcinoma. *J Urol*. 1997;158:1691–1695.

Feldman DR, Baum MS, Ginsberg MS, et al. Phase I trial of bevacizumab plus escalated doses of sunitinib in patients with metastatic renal cell carcinoma. *J Clin Oncol*. 2009;27:1432–1439.

Fife BT, Pauken KE, Eagar TN, et al. Interactions between PD-1 and PD-L1 promote tolerance by blocking the TCR-induced stop signal. *Nat Immunol*. 2009;10:1185–1192.

Figlin RA, deKernion JB, Mukamel E, et al. Recombinant interferon alfa-2a in metastatic renal cell carcinoma: assessment of antitumor activity and anti-interferon antibody formation. *J Clin Oncol*. 1988;6:1604–1610.

Figlin RA, Pierce WC, Kaboo R, et al. Treatment of metastatic renal cell carcinoma with nephrectomy, interleukin-2 and cytokine-primed or CD8(+) selected tumor infiltrating lymphocytes from primary tumor. *J Urol*. 1997;158:740–745.

Figlin RA, Thompson JA, Bukowski RM, et al. Multicenter, randomized, phase III trial of CD8(+) tumor-infiltrating lymphocytes in combination with recombinant interleukin-2 in metastatic renal cell carcinoma [In Process Citation]. *J Clin Oncol*. 1999;17:2521.

Finke JH, Rayman P, Hart L, et al. Characterization of tumor-infiltrating lymphocyte subsets from human renal cell carcinoma: specific reactivity defined by cytotoxicity, interferon-gamma secretion, and proliferation. *J Immunother Emphasis Tumor Immunol*. 1994;15:91–104.

Fisher RI, Coltman CA, Doroshow JH, et al. Metastatic renal cancer treated with interleukin-2 and lymphokine-activated killer cells. *Ann Intern Med*. 1988;108:518–523.

Fisher RI, Rosenberg SA, Sznol M, et al. High-dose aldesleukin in renal cell carcinoma: Long-term survival update. *Cancer J Sci Am*. 1997;3:S70–S72.

Fisher RI, Rosenberg SA, Fyfe G. Long-term survival update for high-dose recombinant interleukin-2 in patients with renal cell carcinoma. *Cancer J Sci Am*. 2000;6(Suppl 1):S55–S57.

Flanigan RC, Salmon SE, Blumenstein BA, et al. Nephrectomy followed by interferon alfa-2b compared with interferon alfa-2b alone for metastatic renal-cell cancer. *New Engl J Med*. 2001;345:1655–1659.

Flanigan RC, Mickisch G, Sylvester R, et al. Cytoreductive nephrectomy in patients with metastatic renal cancer: a combined analysis. *J Urol*. 2004;171:1071–1076.

Fojo AT, Shen DW, Mickley LA, et al. Intrinsic drug resistance in human kidney cancer is associated with expression of a human multidrug-resistance gene. *J Clin Oncol*. 1987;5:1922–1927.

Fossa SD, Martinelli G, Otto U, et al. Recombinant interferon alfa-2a with or without vinblastine in metastatic renal cell carcinoma: results of a European multi-center phase III study. *Ann Oncol*. 1992;3:301–305.

Friedel G, Hurtgen M, Penzenstadler M, et al. Resection of pulmonary metastases from renal cell carcinoma. *Anticancer Res*. 1999;19:1593–1596.

Fyfe GA, Fisher RI, Rosenberg SA, et al. Long-term response data for 255 patients with metastatic renal cell carcinoma treated with high-dose recombinant interleukin-2 therapy [letter]. *J Clin Oncol*. 1996;14:2410–2411.

Giubellino A, Linehan WM, Bottaro DP. Targeting the Met signaling pathway in renal cancer. *Expert Rev Anticancer*

Ther. 2009;9:785–793.

Gnarra JR, Duan DR, Weng Y, et al. Molecular cloning of the von Hippel-Lindau tumor suppressor gene and its role in renal carcinoma. *Biochim Biophys Acta*. 1996;1242:201–210.

Haas CD, Coltman CA Jr, Gottlieb JA, et al. Phase II evaluation of bleomycin. A Southwest oncology Group study. *Cancer*. 1976;38:8–12.

Hahn DM, Schimpff SC, Ruckdeschel JC, et al. Single-agent therapy for renal cell carcinoma: CCNU, vinblastine, thioTEPA, or bleomycin. *Cancer Treat Rep*. 1977;61:1585–1587.

Hainsworth JD, Sosman JA, Spigel DR, et al. Treatment of metastatic renal cell carcinoma with a combination of bevacizumab and erlotinib. *J Clin Oncol*. 2005;23:7889–7896.

Hainsworth JD, Spigel DR, Burris HA 3rd, et al. Phase II trial of bevacizumab and everolimus in patients with advanced renal cell carcinoma. *J Clin Oncol*. 2010;28:2131–2136.

Hainsworth JD, Waterhouse DM, Penley WC, et al. Sorafenib and everolimus in advanced clear cell renal carcinoma: a phase I/II trial of the SCRI Oncology Research Consortium. *Cancer Invest*. 2013;31:323–329.

Hammers HJ, Plimack ER, Infante JR, et al. Safety and efficacy of nivolumab in combination with ipilimumab in metastatic renal cell carcinoma: the CheckMate 016 Study. *J Clin Oncol*. 2017;35:3851–3858.

Hanna N, Sun M, Meyer CP, et al. Survival analyses of patients with metastatic renal cancer treated with targeted therapy with or without cytoreductive nephrectomy: a national cancer data base study. *J Clin Oncol*. 2016;34:3267–3275.

Harris DT. Hormonal therapy and chemotherapy of renal-cell carcinoma. *Sem Oncol*. 1983;10:422–430.

Heng DY, Xie W, Regan MM, et al. Prognostic factors for overall survival in patients with metastatic renal cell carcinoma treated with vascular endothelial growth factor-targeted agents: results from a large, multicenter study. *J Clin Oncol*. 2009;27:5794–5799.

Heng DY, Xie W, Regan MM, et al. External validation and comparison with other models of the International Metastatic Renal-Cell Carcinoma Database Consortium prognostic model: a population-based study. *Lancet Oncol*. 2013;14:141–148.

Henke RP, Erbersdobler A. Numerical chromosomal aberrations in papillary renal cortical tumors: relationship with histopathologic features. *Virchows Arch*. 2002;440:604–609.

Herman JG, Latif F, Weng Y, et al. Silencing of the VHL tumor-suppressor gene by DNA methylation in renal carcinoma. *Proc Natl Acad Sci USA*. 1994;91:9700–9704.

Hudes G, Carducci M, Tomczak P, et al. Temsirolimus, interferon alfa, or both for advanced renal-cell carcinoma. *New Engl J Med*. 2007;356:2271–2281.

Hudson CC, Liu M, Chiang GG, et al. Regulation of hypoxia-inducible factor 1alpha expression and function by the mammalian target of rapamycin. *Mol Cell Biol*. 2002;22:7004–7014.

Iliopoulos O, Jiang C, Levy AP, et al. Negative regulation of hypoxia-inducible genes by the von Hippel-Lindau protein. *Proc Natl Acad Sci USA*. 1996;93:10595–10599.

Iliopoulos O, Ohh M, Kaelin WG Jr. pVHL19 is a biologically active product of the von Hippel-Lindau gene arising from internal translation initiation. *Proc Natl Acad Sci USA*. 1998;95:11661–11666.

Isaacs JS, Jung YJ, Mole DR, et al. HIF overexpression correlates with biallelic loss of fumarate hydratase in renal cancer: novel role of fumarate in regulation of HIF stability. *Cancer Cell*. 2005;8:143–153.

Ivan M, Kondo K, Yang H, et al. HIFalpha targeted for VHL-mediated destruction by proline hydroxylation: implications for O2 sensing. *Science*. 2001;292:464–468.

Jaakkola P, Mole DR, Tian YM, et al. Targeting of HIF-alpha to the von Hippel-Lindau ubiquitylation complex by O2-regulated prolyl hydroxylation. *Science*. 2001;292:468–472.

Jeffers M, Fiscella M, Webb CP, et al. The mutationally activated Met receptor mediates motility and metastasis. *Proc Natl Acad Sci USA*. 1998;95:14417–14422.

Kaelin WG Jr. The von Hippel-Lindau tumor suppressor gene and kidney cancer. *Clin Cancer Res*. 2004;10:6290S–6295S.

Kammula US, White DE, Rosenberg SA. Trends in the safety of high dose bolus interleukin-2 administration in patients with metastatic cancer. *Cancer*. 1998;83:797–805.

Kavolius JP, Mastorakos DP, Pavlovich C, et al. Resection of metastatic renal cell carcinoma. *J Clin Oncol*. 1998;16:2261–2266.

Kavoussi LR, Levine SR, Kadmon D, et al. Regression of metastatic renal cell carcinoma: a case report and literature review. *J Urol*. 1986;135:1005–1007.

Kierney PC, van Heerden JA, Segura JW, et al. Surgeon's role in the management of solitary renal cell carcinoma metastases occurring subsequent to initial curative nephrectomy: an institutional review. *Ann Surg Oncol*. 1994;1:345–352.

Kirkwood JM, Harris JE, Vera P. A randomized study of low and high doses of leukocyte alpha interferon in metastatic renal cell carcinoma: the American Cancer Society collaborative trial. *Cancer Res*. 1985;45:863.

Ko JS, Rayman P, Ireland J, et al. Direct and differential suppression of myeloid-derived suppressor cell subsets by sunitinib is compartmentally constrained. *Cancer Res*. 2010;70:3526–3536.

Koh Y, Lim HY, Ahn JH, et al. Phase II trial of everolimus for the treatment of nonclear-cell renal cell carcinoma. *Ann Oncol*. 2013;24:1026–1031.

Kollender Y, Bickels J, Price WM, et al. Metastatic renal cell carcinoma of bone: indications and technique of surgical intervention. *J Urol*. 2000;164:1505–1508.

Koochekpour S, Jeffers M, Wang PH, et al. The von Hippel-Lindau tumor suppressor gene inhibits hepatocyte growth factor/scatter factor-induced invasion and branching morphogenesis in renal carcinoma cells. *Mol Cell Biol*. 1999;19:5902–5912.

Korc M, Friesel RE. The role of fibroblast growth factors in tumor growth. *Curr Cancer Drug Targets*. 2009;9:639–651.

Kovacs G, Fuzesi L, Emanual A, et al. Cytogenetics of papillary renal cell tumors. *Genes Chromosomes Cancer*. 1991;3:249–255.

Kudoh S, Redovan C, Rayman P, et al. Defective granzyme B gene expression and lytic response in T lymphocytes infiltrating human renal cell carcinoma. *J Immunother*. 1997;20:479–487.

Latif F, Tory K, Gnarra JR, et al. Identification of the von Hippel-Lindau disease tumor suppressor gene. *Science*. 1993;260:1317–1320.

Law TM, Motzer R, Mazumdar M, et al. Phase III randomized trial of interleukin-2 with or without lymphokine activated killer cells in the treatment of patients with advanced renal cell carcinoma. *Cancer*. 1995;76:824–832.

Lin JC, Liu CL, Lee JJ, et al. Sorafenib induces autophagy and suppresses activation of human macrophage. *Int Immunopharmacol*. 2013;15:333–339.

Linehan WM. Molecular targeting of VHL gene pathway in clear cell kidney cancer. *J Urol*. 2003;170:593–594.

Linehan WM, Pinto PA, Srinivasan R, et al. Identification of the genes for kidney cancer: opportunity for disease-specific targeted therapeutics. *Clin Cancer Res*. 2007;13:671s–679s.

Linehan WM. Genetic basis of bilateral renal cancer: implications for evaluation and management. *J Clin Oncol*. 2009;27:3731–3733.

Linehan WM, Pinto PA, Bratslavsky G, et al. Hereditary kidney cancer: unique opportunity for disease-based therapy. *Cancer*. 2009;115:2252–2261.

Linehan WM, Srinivasan R, Garcia JA. Non-clear cell renal cancer: disease-based management and opportunities for targeted therapeutic approaches. *Semin Oncol*. 2013;40:511–520.

Ling W, Rayman P, Uzzo R, et al. Impaired activation of NFkappaB in T cells from a subset of renal cell carcinoma patients is mediated by inhibition of phosphorylation and degradation of the inhibitor, IkappaBalpha. *Blood*. 1998;92:1334–1341.

Lotze MT, Chang AE, Seipp CA, et al. High-dose recombinant interleukin 2 in the treatment of patients with disseminated cancer: responses, treatment-related morbidity and histologic findings. *J Am Med Assoc*. 1986;256:3117–3124.

Manola J, Royston P, Elson P, et al. Prognostic model for survival in patients with metastatic renal cell carcinoma: results from the international kidney cancer working group. *Clin Cancer Res*. 2011;17:5443–5450.

Marcus SG, Choyke PL, Reiter R, et al. Regression of metastatic renal cell carcinoma after cytoreductive nephrectomy. *J Urol*. 1993;150:463–466.

Maxwell PH, Wiesener MS, Chang GW, et al. The tumour suppressor protein VHL targets hypoxia-inducible factors for oxygen-dependent proteolysis. *Nature*. 1999;399:271–275.

McDermott DF, Regan MM, Clark JI, et al. Randomized phase III trial of high-dose interleukin-2 versus subcutaneous interleukin-2 and interferon in patients with metastatic renal cell carcinoma. *J Clin Oncol*. 2005;23:133–141.

McDermott DF, Cheng SC, Signoretti S, et al. The high-dose aldesleukin “select” trial: a trial to prospectively validate predictive models of response to treatment in patients with metastatic renal cell carcinoma. *Clin Cancer Res*. 2015;21:561–568.

Medical Research Council Renal Cancer C. Interferon-alpha and survival in metastatic renal carcinoma: early results of a randomised controlled trial. *Lancet*. 1999;353:14–17.

Mejean A, Ravaud A, Thezenas S, et al. Sunitinib alone or after nephrectomy in metastatic renal-cell carcinoma. *N Engl J Med*. 2018;379:417–427.

Mekhail TM, bou-Jawde RM, Boumerhi G, et al. Validation and extension of the Memorial Sloan-Kettering prognostic factors model for survival in patients with previously untreated metastatic renal cell carcinoma. *J Clin Oncol*. 2005;23:832–841.

Mertens WC, Eisenhauer EA, Moore M, et al. Gemcitabine in advanced renal cell carcinoma. A phase II study of the National Cancer Institute of Canada Clinical Trials Group. *Ann Oncol*. 1993;4:331–332.

Mertens WC, Eisenhauer EA, Jolivet J, et al. Docetaxel in advanced renal carcinoma. A phase II trial of the National Cancer Institute of Canada Clinical Trials Group. *Ann Oncol*. 1994;5:185–187.

Mickisch GH, Garin A, Van Poppel H, et al. Radical nephrectomy plus interferon-alfa-based immunotherapy compared with interferon alfa alone in metastatic renal-cell carcinoma: a randomised trial. *Lancet*. 2001;358:966–970.

Middleton AW Jr. Indications for and results of nephrectomy for metastatic renal cell carcinoma. *Urol Clin North Am*. 1980;7:711–717.

Middleton RG. Surgery for metastatic renal cell carcinoma. *J*

Urol. 1967;97:973–977.

Minasian LM, Motzer RJ, Gluck L, et al. Interferon alfa-2a in advanced renal cell carcinoma: treatment results and survival in 159 patients with long-term follow-up. *J Clin Oncol*. 1993;11:1368–1375.

Motzer RJ, Mazumdar M, Bacik J, et al. Survival and prognostic stratification of 670 patients with advanced renal cell carcinoma. *J Clin Oncol*. 1999;17:2530–2540.

Motzer RJ, Mazumdar M, Bacik J, et al. Effect of cytokine therapy on survival for patients with advanced renal cell carcinoma. *J Clin Oncol*. 2000;18:1928–1935.

Motzer RJ, Russo P. Systemic therapy for renal cell carcinoma. *J Urol*. 2000;163:408–417.

Motzer RJ, Bacik J, Murphy BA, et al. Interferon-alfa as a comparative treatment for clinical trials of new therapies against advanced renal cell carcinoma. *J Clin Oncol*. 2002;20:289–296.

Motzer RJ, Michaelson MD, Redman BG, et al. Activity of SU11248, a multitargeted inhibitor of vascular endothelial growth factor receptor and platelet-derived growth factor receptor, in patients with metastatic renal cell carcinoma. *J Clin Oncol*. 2006;24:16–24.

Motzer RJ, Rini BI, Bukowski RM, et al. Sunitinib in patients with metastatic renal cell carcinoma. *J Am Med Assoc*. 2006;295:2516–2524.

Motzer RJ, Hutson TE, Tomczak P, et al. Sunitinib versus interferon alfa in metastatic renal-cell carcinoma. *New Engl J Med*. 2007;356:115–124.

Motzer RJ, Bukowski RM, Figlin RA, et al. Prognostic nomogram for sunitinib in patients with metastatic renal cell carcinoma. *Cancer*. 2008;113:1552–1558.

Motzer RJ, Escudier B, Oudard S, et al. Efficacy of everolimus in advanced renal cell carcinoma: a double-blind, randomised, placebo-controlled phase III trial. *Lancet*. 2008;372:1432–1439.

Motzer RJ, Hutson TE, Tomczak P, et al. Overall survival and updated results for sunitinib compared with interferon alfa in patients with metastatic renal cell carcinoma. *J Clin Oncol*. 2009;27:3584–3590.

Motzer RJ, Escudier B, Tomczak P, et al. Axitinib versus sorafenib as second-line treatment for advanced renal cell carcinoma: overall survival analysis and updated results from a randomised phase 3 trial. *Lancet Oncol*. 2013;14:552–562.

Motzer RJ, Hutson TE, Cella D, et al. Pazopanib versus sunitinib in metastatic renal-cell carcinoma. *N Engl J Med*. 2013;369:722–731.

Motzer RJ, Porta C, Vogelzang NJ, et al. Dovitinib versus sorafenib for third-line targeted treatment of patients with metastatic renal cell carcinoma: an open-label, randomised phase 3 trial. *Lancet Oncol*. 2014;15:286–296.

Motzer RJ, Escudier B, McDermott DF, et al. Nivolumab versus everolimus in advanced renal-cell carcinoma. *N Engl J Med*. 2015;373:1803–1813.

Motzer RJ, Hutson TE, Glen H, et al. Lenvatinib, everolimus, and the combination in patients with metastatic renal cell carcinoma: a randomised, phase 2, open-label, multicentre trial. *Lancet Oncol*. 2015;16:1473–1482.

Motzer RJ, Powles T, Atkins MB, et al. IMmotion151: a randomized phase III study of atezolizumab plus bevacizumab vs sunitinib in untreated metastatic renal cell carcinoma (mRCC). *J Clin Oncol*. 2018;36.

Motzer RJ, Tannir NM, McDermott DF, et al. Nivolumab plus ipilimumab versus sunitinib in advanced renal-cell carcinoma. *N Engl J Med*. 2018;378:1277–1290.

Murthy SC, Kim K, Rice TW, et al. Can we predict long-term survival after pulmonary metastasectomy for renal cell carcinoma? *Ann Thorac Surg*. 2005;79:996–1003.

Muss HB, Costanzi JJ, Leavitt R, et al. Recombinant alfa interferon in renal cell carcinoma: a randomized trial of two routes of administration. *J Clin Oncol*. 1987;5:286–291.

Nanus DM, Garino A, Milowsky MI, et al. Active chemotherapy for sarcomatoid and rapidly progressing renal cell carcinoma. *Cancer*. 2004;101:1545–1551.

Negrier S, Escudier B, Lasset C, et al. Recombinant human interleukin-2, recombinant human interferon alfa-2a, or both in metastatic renal-cell carcinoma. Groupe Francais d'Immunotherapie [see comments]. *New Engl J Med*. 1998;338:1272–1278.

Negrier S, Caty A, Lesimple T, et al. Treatment of patients with metastatic renal carcinoma with a combination of subcutaneous interleukin-2 and interferon alfa with or without fluorouracil. Groupe Francais d'Immunotherapie, Federation Nationale des Centres de Lutte Contre le Cancer. *J Clin Oncol*. 2000;18:4009–4015.

Negrier S, Maral J, Drevon M, et al. Long-term follow-up of patients with metastatic renal cell carcinoma treated with intravenous recombinant interleukin-2 in Europe. *Cancer J Sci Am*. 2000;6(Suppl 1):S93–S98.

Negrier S, Escudier B, Gomez F, et al. Prognostic factors of survival and rapid progression in 782 patients with metastatic renal carcinomas treated by cytokines: a report from the Groupe Francais d'Immunotherapie. *Ann Oncol*. 2002;13:1460–1468.

Negrier S, Gomez F, Douillard JY, et al. Prognostic factors of response or failure of treatment in patients with metastatic renal carcinomas treated by cytokines: a report from the Groupe Francais d'Immunotherapie. *World J Urol*. 2005;23:161–165.

Negrier S, Perol D, Ravaud A, et al. Randomized study of intravenous versus subcutaneous interleukin-2, and IFNalpha in patients with good prognosis metastatic renal cancer. *Clin Cancer Res*. 2008;14:5907–5912.

Neidhart JA, Anderson SA, Harris JE, et al. Vinblastine fails to improve response of renal cancer to interferon alfa-n1: high response rate in patients with pulmonary metastases. *J Clin Oncol*. 1991;9:832–836.

Nickerson ML, Jaeger E, Shi Y, et al. Improved identification of von Hippel-Lindau gene alterations in clear cell renal tumors. *Clin Cancer Res*. 2008;14:4726–4734.

O'Dea MJ, Zincke H, Utz DC. The treatment of renal cell carcinoma with solitary metastasis. *J Urol*. 1978;120:540–542.

Ohh M, Park CW, Ivan M, et al. Ubiquitination of hypoxia-inducible factor requires direct binding to the beta-domain of the von Hippel-Lindau protein. *Nat Cell Biol*. 2000;2:423–427.

Oudard S, Banu E, Vieillefond A, et al. Prospective multicenter phase II study of gemcitabine plus platinum salt for metastatic collecting duct carcinoma: results of a GETUG (Groupe d'Etudes des Tumeurs Uro-Genitales) study. *J Urol*. 2007;177:1698–1702.

Patel PH, Senico PL, Curiel RE, et al. Phase I study combining treatment with temsirolimus and sunitinib malate in patients with advanced renal cell carcinoma. *Clin Genitourin Cancer*. 2009;7:24–27.

Pause A, Lee S, Worrell RA, et al. The von Hippel-Lindau tumor-suppressor gene product forms a stable complex with human CUL-2, a member of the Cdc53 family of proteins. *Proc Natl Acad Sci USA*. 1997;94:2156–2161.

Peruzzi B, Bottaro DP. Targeting the c-Met signaling pathway in cancer. *Clin Cancer Res*. 2006;12:3657–3660.

Piltz S, Meimarakis G, Wichmann MW, et al. Long-term results after pulmonary resection of renal cell carcinoma metastases. *Ann Thorac Surg*. 2002;73:1082–1087.

Pogrebniak HW, Haas G, Linehan WM, et al. Renal cell carcinoma: resection of solitary and multiple metastases. *Ann Thorac Surg*. 1992;54:33–38.

Porta C, Paglino C, Imarisio I, et al. Immunological effects of multikinase inhibitors for kidney cancer: a clue for integration with cellular therapies? *J Cancer*. 2011;2:333–338.

Pyrhonen S, Salminen E, Ruutu M, et al. Prospective randomized trial of interferon alfa-2a plus vinblastine versus vinblastine alone in patients with advanced renal cell cancer [In Process Citation]. *J Clin Oncol*. 1999;17:2859.

Quesada JR, Swanson DA, Trindade A, et al. Renal cell carcinoma: antitumor effects of leukocyte interferon. *Cancer Res*. 1983;43:940–947.

Quesada JR, Swanson DA, Gutterman JU. Phase II study of interferon alpha in metastatic renal-cell carcinoma: a progress report. *J Clin Oncol*. 1985;3:1086–1092.

Quesada JR. Role of interferons in the therapy of metastatic renal cell carcinoma. *Urology*. 1989;34:80–83.

Rabinovitch RA, Zelefsky MJ, Gaynor JJ, et al. Patterns of failure following surgical resection of renal cell carcinoma: implications for adjuvant local and systemic therapy. *J Clin Oncol*. 1994;12:206–212.

Rackley R, Novick A, Klein E, et al. The impact of adjuvant nephrectomy on multimodality treatment of metastatic renal cell carcinoma. *J Urol*. 1994;152:1399–1403.

Ratain MJ, Eisen T, Stadler WM, et al. Phase II placebo-controlled randomized discontinuation trial of sorafenib in patients with metastatic renal cell carcinoma. *J Clin Oncol*. 2006;24:2505–2512.

Ravaud A, Negrier S, Cany L, et al. Subcutaneous low-dose recombinant Interleukin 2 and alpha-interferon in patients with metastatic renal cell carcinoma. *Br J Cancer*. 1994;69:1111–1114.

Ravaud A, Audhuy B, Gomez F, et al. Subcutaneous interleukin-2, interferon alfa-2a, and continuous infusion of fluorouracil in metastatic renal cell carcinoma: a multicenter phase II trial. Groupe Francais d'Immunotherapie. *J Clin Oncol*. 1998;16:2728–2732.

Ravaud A, Barrios CH, Alekseev B, et al. RECORD-2: phase II randomized study of everolimus and bevacizumab versus interferon alpha-2a and bevacizumab as first-line therapy in patients with metastatic renal cell carcinoma. *Ann Oncol*. 2015;26:1378–1384.

Ricketts CJ, Crooks DR, Sourbier C, et al. SnapShot: renal cell carcinoma. *Cancer Cell*. 2016;29:610–610 e611.

Rini BI, Vogelzang NJ, Dumas MC, et al. Phase II trial of weekly intravenous gemcitabine with continuous infusion fluorouracil in patients with metastatic renal cell cancer. *J Clin Oncol*. 2000;18:2419–2426.

Rini BI, Zimmerman TM, Gajewski TF, et al. Allogeneic peripheral blood stem cell transplantation for metastatic renal cell carcinoma. *J Urol*. 2001;165:1208–1209.

Rini BI, Zimmerman T, Stadler WM, et al. Allogeneic stem-cell transplantation of renal cell cancer after nonmyeloablative chemotherapy: feasibility, engraftment, and clinical results. *J Clin Oncol*. 2002;20:2017–2024.

Rini BI, Weinberg V, Small EJ. A phase I trial of fixed dose rate gemcitabine and capecitabine in metastatic renal cell carcinoma. *Cancer*. 2005;103:553–558.

Rini BI, Halabi S, Barrier R, et al. Adoptive immunotherapy by allogeneic stem cell transplantation for metastatic renal cell carcinoma: a CALGB intergroup phase II study. *Biol Blood Marrow Transplant*. 2006;12:778–785.

Rini BI, Halabi S, Rosenberg JE, et al. Bevacizumab plus interferon alfa compared with interferon alfa monotherapy in patients with metastatic renal cell carcinoma: CALGB 90206. *J Clin Oncol*. 2008;26:5422–5428.

Rini BI, Halabi S, Rosenberg JE, et al. Phase III trial of bevacizumab plus interferon alfa versus interferon alfa monotherapy in patients with metastatic renal cell carcinoma: final results of CALGB 90206. *J Clin Oncol*. 2010;28:2137–2143.

Rini BI, Escudier B, Tomczak P, et al. Comparative effectiveness of axitinib versus sorafenib in advanced renal cell carcinoma (AXIS): a randomised phase 3 trial. *Lancet*. 2011;378:1931–1939.

Rini BI, Bellmunt J, Clancy J, et al. Randomized phase III trial of temsirolimus and bevacizumab versus interferon alfa and bevacizumab in metastatic renal cell carcinoma: INTORACT trial. *J Clin Oncol*. 2014;32:752–759.

Rixe O, Bukowski RM, Michaelson MD, et al. Axitinib treatment in patients with cytokine-refractory metastatic renal-cell cancer: a phase II study. *Lancet Oncol*. 2007;8:975–984.

Robson CJ. The natural history of renal cell carcinoma. *Prog Clin Biol Res*. 1982;100:447–452.

Rosenberg SA, Lotze MT, Muul LM, et al. A progress report on the treatment of 157 patients with advanced cancer using lymphokine-activated killer cells and interleukin-2 or high-dose interleukin-2 alone. *New Engl J Med*. 1987;316:889–897.

Rosenberg SA, Lotze MT, Yang JC, et al. Experience with the use of high-dose interleukin-2 in the treatment of 652 cancer patients. *Ann Surg*. 1989;210:474–484.

Rosenberg SA, Lotze MT, Yang JC, et al. Combination therapy with interleukin-2 and alpha-interferon for the treatment of patients with advanced cancer. *J Clin Oncol*. 1989;7:1863–1874.

Rosenberg SA, Lotze MT, Yang JC, et al. Prospective randomized trial of high-dose interleukin-2 alone or in conjunction with lymphokine-activated killer cells for the treatment of patients with advanced cancer. *J Natl Cancer Inst*. 1993;85:622–632.

Rosenberg SA, Yang JC, White DE, et al. Durability of complete responses in patients with metastatic cancer treated with high-dose interleukin-2: identification of the antigens mediating response. *Ann Surg*. 1998;228:307–319.

Rosenberg SA. A new era for cancer immunotherapy based on the genes that encode cancer antigens. *Immunity*. 1999;10:281–287.

Russo P, Synder M, Vickers A, et al. Cytoreductive nephrectomy and nephrectomy/complete metastasectomy for metastatic renal cancer. *Sci World J*. 2007;7:768–778.

Schmidt LS, Duh FM, Chen F, et al. Germline and somatic mutations in the tyrosine kinase domain of the MET proto-oncogene in papillary renal carcinomas. *Nat Genet*. 1997;16:68–73.

Schmidt LS, Junker K, Weirich G, et al. Two North American families with hereditary papillary renal carcinoma and identical novel mutations in the MET proto-oncogene. *Cancer Res*. 1998;58:1719–1722.

Schmidt LS, Junker K, Nakaigawa N, et al. Novel mutations of the MET proto-oncogene in papillary renal carcinomas. *Oncogene*. 1999;18:2343–2350.

Schmidt LS, Nickerson ML, Angeloni D, et al. Early onset hereditary papillary renal carcinoma: germline missense mutations in the tyrosine kinase domain of the Met proto-oncogene. *J Urol*. 2004;172:1256–1261.

Schoffski P, Wozniak A, Escudier B, et al. Crizotinib achieves long-lasting disease control in advanced papillary renal-cell carcinoma type 1 patients with MET mutations or amplification. EORTC 90101 CREATE trial. *Eur J Cancer*. 2017;87:147–163.

Schomburg A, Kirchner H, Fenner M, et al. Lack of therapeutic efficacy of tamoxifen in advanced renal cell carcinoma. *Eur J Cancer*. 1993;29A:737–740.

Sella A, Logothetis CJ, Fitz K, et al. Phase II study of interferon-alpha and chemotherapy (5-fluorouracil and mitomycin C) in metastatic renal cell cancer. *J Urol*. 1992;147:573–577.

Sella A, Swanson DA, Ro JY, et al. Surgery following response to interferon-alpha-based therapy for residual renal cell carcinoma. *J Urol*. 1993;149:19–21 [discussion 21–12].

Sheehan JP, Sun MH, Kondziolka D, et al. Radiosurgery in patients with renal cell carcinoma metastasis to the brain: long-term outcomes and prognostic factors influencing survival and local tumor control. *J Neurosurg*. 2003;98:342–349.

Shuch B, Linehan WM, Srinivasan R. Aerobic glycolysis: a novel target in kidney cancer. *Expert Rev Anticancer Ther*. 2013;13:711–719.

Siegel RL, Miller KD, Jemal A. Cancer statistics, 2018. *CA Cancer J Clin*. 2018;68:7–30.

Silber SJ, Chen CY, Gould F. Regression of metastases after nephrectomy for renal cell carcinoma. *Br J Urol*. 1975;47:259–261.

Skinner DG, Calvin RB, Vermillion CD, et al. Diagnosis and management of renal cell carcinoma. *Cancer*. 1971;28:1165–1177.

Snow RM, Schellhammer PF. Spontaneous regression of metastatic renal cell carcinoma. *Urology*. 1982;XX:177–181.

Srinivasan R, Su D, Stamatakis L, et al. Mechanism based targeted therapy for hereditary leiomyomatosis and renal cell cancer (HLRCC) and sporadic papillary renal cell carcinoma: interim results from a phase 2 study of bevacizumab and erlotinib. *Eur J Cancer*. 2014;50:8.

Stadler WM, Halabi S, Rini B, et al. A phase II study of gemcitabine and capecitabine in metastatic renal cancer: a report of Cancer and Leukemia Group B protocol 90008. *Cancer*. 2006;107:1273–1279.

Stebbins CE, Kaelin WG, Pavletich NP. Structure of the VHL-ElonginC-ElonginB complex: implications for VHL tumor suppressor function. *Science*. 1999;284:455–461.

Sternberg CN, Davis ID, Mardiak J, et al. Pazopanib in locally advanced or metastatic renal cell carcinoma: results of a randomized phase III trial. *J Clin Oncol*. 2010;28:1061–1068.

Sternberg CN, Hawkins RE, Wagstaff J, et al. A randomised, double-blind phase III study of pazopanib in patients with advanced and/or metastatic renal cell carcinoma: final overall survival results and safety update. *Eur J Cancer*. 2013;49:1287–1296.

Sundaresan N, Scher H, Whitmore WF. Spinal cord compression in kidney cancer. *Proc Am Soc Clin Oncol*. 1986;267.

Sznol M, Chen L. Antagonist antibodies to PD-1 and B7-H1 (PD-L1) in the treatment of advanced human cancer–response. *Clin Cancer Res*. 2013;19:5542.

Takahashi Y, Harashima N, Kajigaya S, et al. Regression of human kidney cancer following allogeneic stem cell transplantation is associated with recognition of an HERV-E antigen by T cells. *J Clin Invest*. 2008;118:1099–1109.

Tannir NM, Jonasch E, Albiges L, et al. Everolimus versus sunitinib prospective evaluation in metastatic non-clear cell renal cell carcinoma (ESPN): a randomized multicenter phase 2 trial. *Eur Urol*. 2016;69:866–874.

Thomas ED, Buckner CD, Banaji M, et al. One hundred patients with acute leukemia treated by chemotherapy, total body irradiation, and allogeneic marrow transplantation. *Blood*. 1977;49:511–533.

Thomas GV, Tran C, Mellinghoff IK, et al. Hypoxia-inducible factor determines sensitivity to inhibitors of mTOR in kidney cancer. *Nat Med*. 2006;12:122–127.

Thompson RH, Dong H, Kwon ED. Implications of B7-H1 expression in clear cell carcinoma of the kidney for prognostication and therapy. *Clin Cancer Res*. 2007;13:709s–715s.

Tolia BM, Whitmore WF. Solitary metastasis from renal cell carcinoma. *J Urol*. 1975;114:836–838.

Topalian SL, Hodi FS, Brahmer JR, et al. Safety, activity, and immune correlates of anti-PD-1 antibody in cancer. *N Engl J Med*. 2012;366:2443–2454.

Tourani JM, Pfister C, Berdah JF, et al. Outpatient treatment with subcutaneous interleukin-2 and interferon alfa administration in combination with fluorouracil in patients with metastatic renal cell carcinoma: results of a sequential nonrandomized Phase II study. *J Clin Oncol*. 1998;16:2505–2513.

Tourani JM, Pfister C, Tubiana N, et al. Subcutaneous interleukin-2 and interferon alfa administration in patients with metastatic renal cell carcinoma: final results of SCAPP III, a large, multicenter, phase II, nonrandomized study with sequential analysis design–the Subcutaneous Administration Propeukin Program Cooperative Group. *J Clin Oncol*. 2003;21:3987–3994.

Tsui KH, Shvarts O, Smith RB, et al. Prognostic indicators for renal cell carcinoma: a multivariate analysis of 643 patients using the revised 1997 TNM staging criteria. *J Urol*. 2000;163:1090–1095.

Umeda T, Niijima T. Phase II study of alpha interferon on renal cell carcinoma. Summary of three collaborative trials. *Cancer*. 1986;58:1231–1235.

Uzzo RG, Clark PE, Rayman P, et al. Alterations in NFkappaB activation in T lymphocytes of patients with renal cell carcinoma. *J Natl Cancer Inst*. 1999;91:718–721.

Uzzo RG, Rayman P, Kolenko V, et al. Mechanisms of apoptosis in T cells from patients with renal cell carcinoma. *Clin Cancer Res*. 1999;5:1219–1229.

Wagner JR, Walther MM, Linehan WM, et al. Interleukin-2 based immunotherapy for metastatic renal cell carcinoma with the kidney in place. *J Urol*. 1999;162:43–45.

Walther MM, Patel B, Choyke PL, et al. Hypercalcemia in patients with metastatic renal cell carcinoma: effect of nephrectomy and metabolic evaluation. *J Urol*. 1997;158:733–739.

Walther MM, Yang JC, Pass HI, et al. Cytoreductive surgery before high dose interleukin-2 based therapy in patients with metastatic renal cell carcinoma. *J Urol*. 1997;158:1675–1678.

Weiden PL, Flournoy N, Thomas ED, et al. Antileukemic effect of graft-versus-host disease in human recipients of allogeneic-marrow grafts. *N Engl J Med*. 1979;300:1068–1073.

Weiden PL, Sullivan KM, Flournoy N, et al. Antileukemic effect of chronic graft-versus-host disease: contribution to improved survival after allogeneic marrow transplantation. *N Engl J Med*. 1981;304:1529–1533.

Welti JC, Gourlaouen M, Powles T, et al. Fibroblast growth factor 2 regulates endothelial cell sensitivity to sunitinib. *Oncogene*. 2011;30:1183–1193.

Yagoda A, bi-Rached B, Petrylak D. Chemotherapy for advanced renal-cell carcinoma: 1983-1993. *Sem Oncol*. 1995;22:42–60.

Yang JC, Haworth L, Sherry RM, et al. A randomized trial of bevacizumab, an anti-vascular endothelial growth factor antibody, for metastatic renal cancer. *New Engl J Med*. 2003;349:427–434.

Yang JC, Sherry RM, Steinberg SM, et al. Randomized study of high-dose and low-dose interleukin-2 in patients with metastatic renal cancer. *J Clin Oncol*. 2003;21:3127–3132.

Yang JC, Hughes M, Kammula U, et al. Ipilimumab (Anti-CTLA4 Antibody) causes regression of metastatic renal cell cancer associated with enteritis and hypophysitis. *J Immunother*. 2007;30:825–830.

Yang Y, Valera VA, Padilla-Nash HM, et al. UOK 262 cell line, fumarate hydratase deficient (FH-/FH-) hereditary leiomyomatosis renal cell carcinoma: in vitro and in vivo model of an aberrant energy metabolic pathway in human cancer. *Cancer Genet Cytogenet*. 2010;196:45–55.

Zaniboni A, Simoncini E, Marpicati P, et al. Phase II trial of 5-fluorouracil and high-dose folinic acid in advanced renal cell cancer. *J Chemother*. 1989;1:350–351.

Zhuang Z, Emmert-Buck MR, Roth MJ, et al. von Hippel-Lindau disease gene deletion detected in microdissected sporadic human colon carcinoma specimens. *Human Pathol*. 1996;27:152–156.

Zhuang Z, Gnarra JR, Dudley CF, et al. Detection of von Hippel-Lindau disease gene mutations in paraffin-embedded sporadic renal cell carcinoma specimens. *Mod Pathol*. 1996;9:838–842.

Zhuang Z, Park WS, Pack S, et al. Trisomy 7 - harboring non-random duplication of the mutant MET allele in hereditary papillary renal carcinomas. *Nat Genet*. 1998;20:66–69.

Zini L, Capitanio U, Perrotte P, et al. Population-based assessment of survival after cytoreductive nephrectomy versus no surgery in patients with metastatic renal cell carcinoma. *Urology*. 2009;73:342–346.

Volume III

OUTLINE

Part XII The Adrenals
Part XIII Urine Transport, Storage, and Emptying
Part XIV Benign and Malignant Bladder Disorders
Part XV The Prostate

PART XII
The Adrenals

OUTLINE

105 Surgical and Radiographic Anatomy of the Adrenals

106 Pathophysiology, Evaluation, and Medical Management of Adrenal Disorders

107 Surgery of the Adrenal Glands

105

Surgical and Radiographic Anatomy of the Adrenals

Ravi Munver MD, FACS, John Stites MD

The adrenal glands are coupled retroperitoneal organs that are unique in their embryology, anatomy, and vital role in homeostasis. They produce mineralocorticoids, glucocorticoids, sex steroids, and catecholamines to continuously direct vital processes throughout the body. An understanding of adrenal anatomy is important for medical and surgical management of adrenal disease and is essential knowledge for the retroperitoneal surgeon. This chapter focuses on the surgical and radiographic anatomy of the adrenal glands (Fig. 105.1A to D).

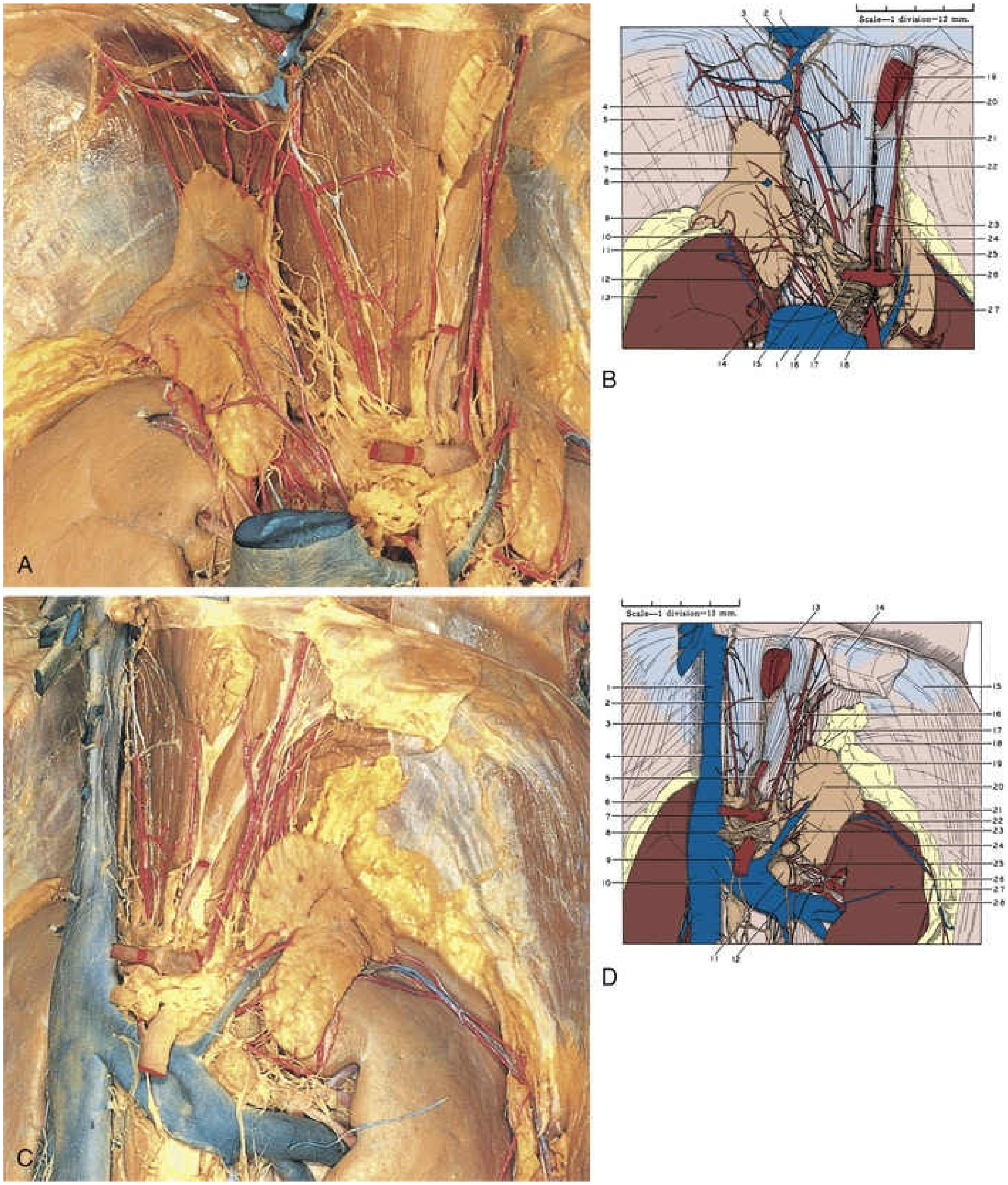
A
B
Scale—1 division=12 mm.
3
2
1
4
5
6
7
8
9
10
11
12
13
14
15
1
16
17
18
19
20
21
22
23
24
25
26
27
C
D
Scale—1 division=10 mm.
13
14
1
2
3
4
5
6
7
8
9
10
11
12
15
16
17
18
19
20
21
22
23
24
25
26
27
28

FIG. 105.1 Right and left adrenal glands dissected. (A) Right adrenal gland dissected. The inferior vena cava has been excised to fully expose the gland. The celiac arterial trunk, its branches, and associated autonomic nervous plexus are also well demonstrated. (B) *1,* Inferior vena cava (cut). *2,* Right inferior phrenic vein. *3,* Right phrenic nerve. *4,* Superior adrenal arteries (branching from right inferior phrenic artery). *5,* Diaphragm. *6,* Inferior phrenic ganglion. *7,* Right adrenal gland. *8,* Right adrenal vein (cut). *9,* Pararenal retroperitoneal fat. *10,* Autonomic nerves to adrenal gland. *11,* Middle adrenal artery (from aorta). *12,* Inferior adrenal artery (from renal artery). *13,* Right kidney. *14,* Branch of right renal artery. *15,* Celiac

ganglion. *16,* Common hepatic artery. *17,* Celiac autonomic nervous plexus. *18,* Superior mesenteric artery. *19,* Esophagus (cut). *20,* Branch of phrenic nerve. *21,* Upper pointer, right crus of diaphragm; lower pointer, vagus nerve. *22,* Right inferior phrenic artery. *23,* Upper pointer, left gastric artery; lower pointer, superior extension of celiac autonomic nervous plexus. *24,* Left inferior phrenic artery. *25,* Left adrenal gland. *26,* Splenic artery. *27,* Left adrenal vein. (C) Left adrenal gland dissected. (D) *1,* Inferior vena cava. *2,* Esophageal hiatus. *3,* Vagus nerve. *4,* Right inferior phrenic artery. *5,* Left gastric artery. *6,* Right celiac ganglion. *7,* Celiac artery. *8,* Left celiac ganglion. *9,* Superior mesenteric artery. *10,* Left renal vein. *11,* Renal hilar lymph node. *12,* Renal autonomic nervous plexus. *13,* Esophagus (cut). *14,* Peritoneum (cut). *15,* Diaphragm. *16,* Phrenic autonomic nervous plexus. *17,* Upper pointer, superior adrenal arteries (from inferior phrenic artery); lower pointer, superior margin of left adrenal gland. *18,* Perinephric fat. *19,* Upper pointer, left inferior phrenic artery; lower pointer, medial margin of left adrenal gland. *20,* Left adrenal gland. *21,* Left adrenal vein. *22,* Inferior adrenal artery (in this case branching from perinephric/capsular artery of kidney). *23,* Middle adrenal arteries (from aorta). *24,* Perinephric blood vessels within Gerota fascia. *25,* Inferior adrenal artery (from renal artery). *26,* Perinephric fat. *27,* Branch of left renal artery. *28,* Left kidney.

Anatomic Relationships

The adrenal glands are paired organs located cephalad to the kidneys in the retroperitoneum. The position of these glands varies from right to left. Both are located at the level of the 11th or 12th ribs, with the right gland located more superiorly and the left gland extending as low as the first lumbar space. The adrenals are enclosed within the perirenal (Gerota) fascia and are completely surrounded by perirenal adipose tissue. Each gland is separated from the upper pole of the ipsilateral kidney by a thin layer of connective tissue. Grossly, the adrenals are yellow-orange and noticeably more orange than the surrounding adipose tissue. The dimensions of the glands range from 2 to 3 cm in width and 4 and 6 cm in length (Mitty, 1988). **The weight of each the gland is approximately 5 g and ranges from 2 to 6 g, with no variation between genders** (Mills, 2007).

Surgical Landmarks

Dorsolaterally, the adrenal glands are in proximity to the crus of the diaphragm. The right gland is triangular and is located nearly directly cranial to the upper pole of the right kidney. The adjacent structures include the underside of the liver anterolaterally, the duodenum anteromedially, the lateral margin of the inferior vena cava (IVC) medially, and the psoas muscle posteriorly (Fig. 105.2A). The left adrenal gland is more crescenteric, and its lateral surface is in contact with the medial aspect of the upper pole of the left kidney. The adjacent structures include the splenic vessels and body of the pancreas anteriorly, the aorta medially, and the psoas muscle posteriorly (Fig. 105.2B).

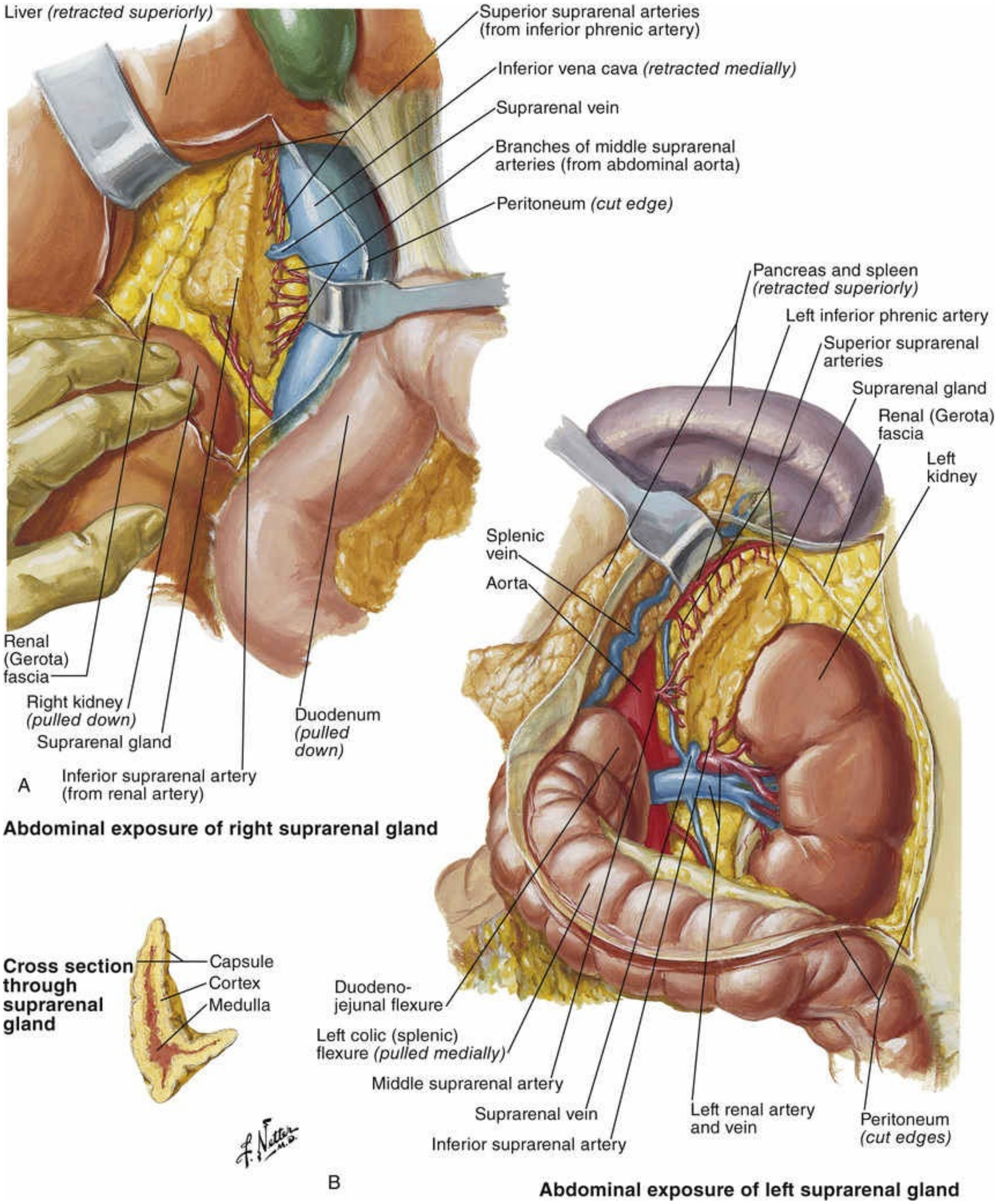
Liver (retracted superiorly)
Superior suprarenal arteries (from inferior phrenic artery)
Inferior vena cava (retracted medially)
Suprarenal vein
Branches of middle suprarenal arteries (from abdominal aorta)
Peritoneum (cut edge)
Renal (Gerota) fascia
Right kidney (pulled down)
Suprarenal gland
Duodenum (pulled down)
A
Inferior suprarenal artery (from renal artery)
Abdominal exposure of right suprarenal gland
Pancreas and spleen (retracted superiorly)
Left inferior phrenic artery
Superior suprarenal arteries
Suprarenal gland
Renal (Gerota) fascia
Left kidney
Splenic vein
Aorta
Cross section through suprarenal gland
Capsule
Cortex
Medulla
Duodeno-jejunal flexure
Left colic (splenic) flexure (pulled medially)
Middle suprarenal artery
Suprarenal vein
Inferior suprarenal artery
Left renal artery and vein
Peritoneum (cut edges)
B
Abdominal exposure of left suprarenal gland

FIG. 105.2 (A) Abdominal exposure of right adrenal gland. (B) Abdominal exposure of left adrenal gland. (Copyright 2016 Elsevier Inc. All rights reserved. www.netterimages.com.)

The anatomic relationships between the adrenal glands and the surrounding intra-abdominal and retroperitoneal organs are important when considering a surgical approach. The cross-sectional anatomy of the adrenal gland (Fig. 105.3) demonstrates the relationship of the right adrenal gland with the liver and IVC, and the left adrenal gland with the splenic vasculature and pancreas.

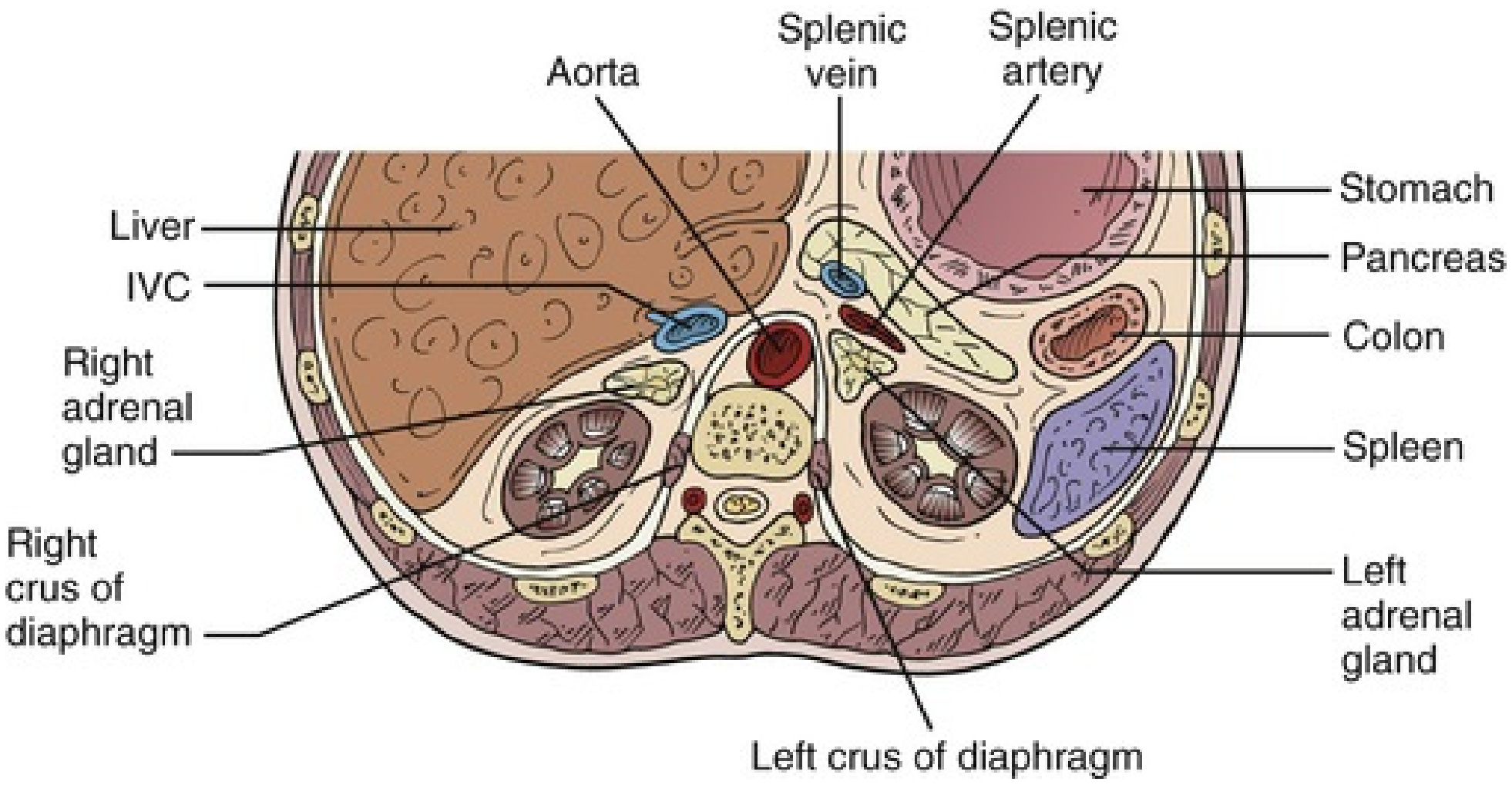
Aorta
Splenic vein
Splenic artery
Liver
IVC
Right adrenal gland
Right crus of diaphragm
Stomach
Pancreas
Colon
Spleen
Left adrenal gland
Left crus of diaphragm

FIG. 105.3 Cross-sectional anatomy of the adrenal glands and their relationships to nearby structures. *IVC,* Inferior vena cava. (Modified from Mitty HA: Embryology, anatomy, and anomalies of the adrenal gland. *Semin Roentgenol* 23:271–279, 1988.)

Adrenal Vasculature

The vasculature of the adrenal glands is unique: the arterial and venous anatomy is highly variable. **The arterial supply to the adrenal originates from three sources** (Fig. 105.4)**. Superiorly, the adrenal is typically supplied by the inferior phrenic artery and rarely by the aorta, celiac axis, or intercostal arteries. The middle adrenal artery typically arises from the lateral aspect of the aorta and rarely from the inferior phrenic artery or renal artery. The inferior adrenal artery typically arises from the superior aspect of the ipsilateral renal artery** (Toni and Mosca, 1988). The three main adrenal arteries each branch into cascades of 10 to 50 smaller arteries that then penetrate the adrenal capsule.

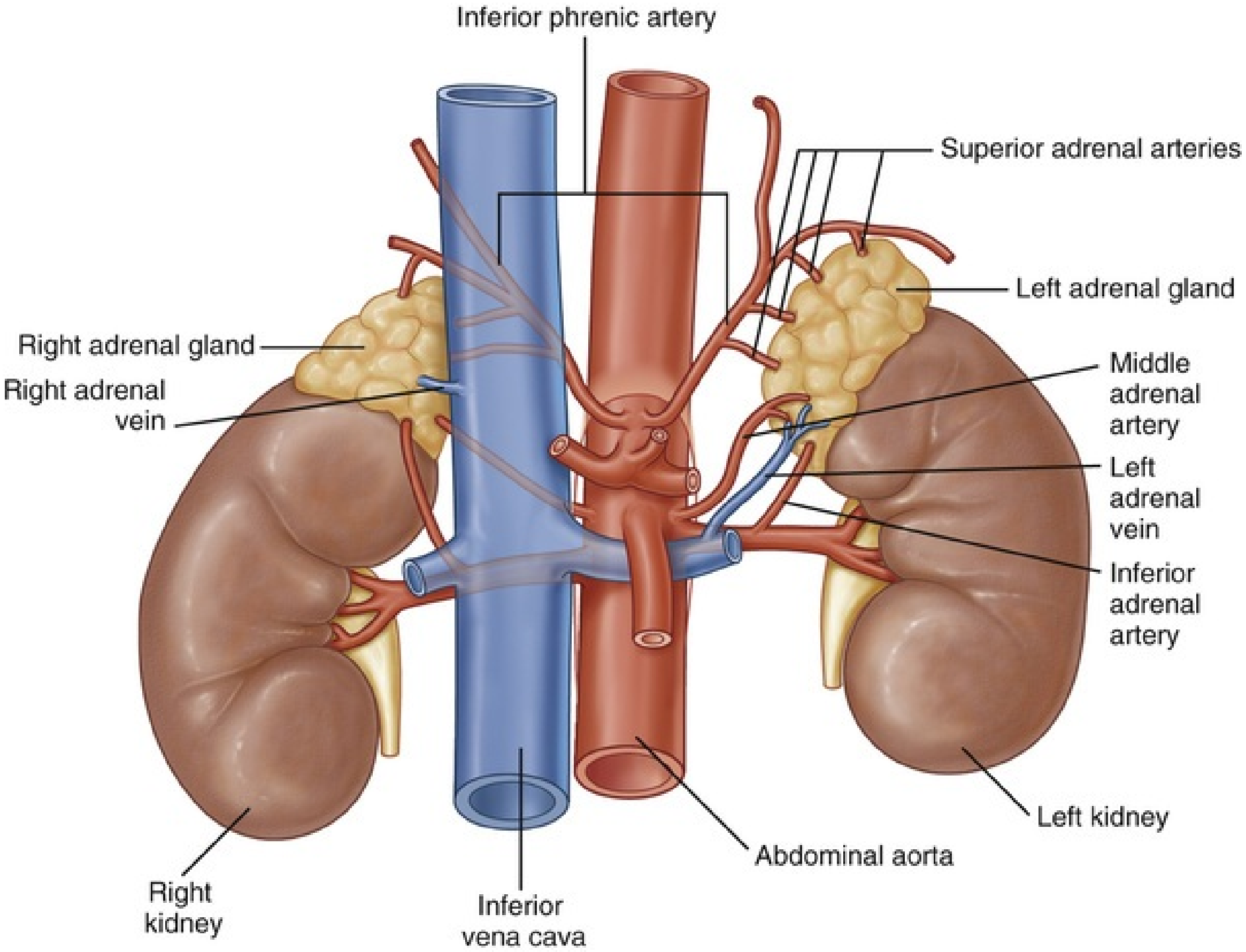
Inferior phrenic artery
Superior adrenal arteries
Left adrenal gland
Right adrenal gland
Right adrenal vein
Middle adrenal artery
Left adrenal vein
Inferior adrenal artery
Left kidney
Abdominal aorta
Right kidney
Inferior vena cava

FIG. 105.4 Arterial supply to the adrenal glands. (From Drake RL, Vogl W, Mitchell AWM: *Gray's anatomy for students,* Philadelphia, 2005, Elsevier, p 329.)

There are three patterns of blood distribution within the adrenal gland (Fig. 105.5). Capsular arteries only supply the adrenal capsule and do not penetrate any deeper into the tissue. Fenestrated cortical sinusoidal capillaries supply the cortex and then drain into fenestrated medullary capillary sinusoids. Medullary arterioles travel within the trabeculae of the adrenal gland to deliver blood to the medullary capillary sinusoids**. The medulla has two blood supplies: arterial blood from the medullary arterioles and venous blood from the cortical sinusoid capillaries that have already supplied the adrenal cortex with arterial blood** (Ross et al., 1995)**. This dual vascular supply is important for the medullary production of catecholamines.** As venous blood from the adrenal cortex reaches the medullary tissue, it contains a high concentration of glucocorticoids, which plays a role in epinephrine synthesis (Bloom and Fawcett, 1986). The complex vascular supply to the adrenal gland is composed of the cortical vascular supply (cortical sinusoids draining into the medullary capillaries, and the medullary vein) and the medullary vascular supply (medullary arterioles and cortical sinusoids) (Gray et al., 1995).

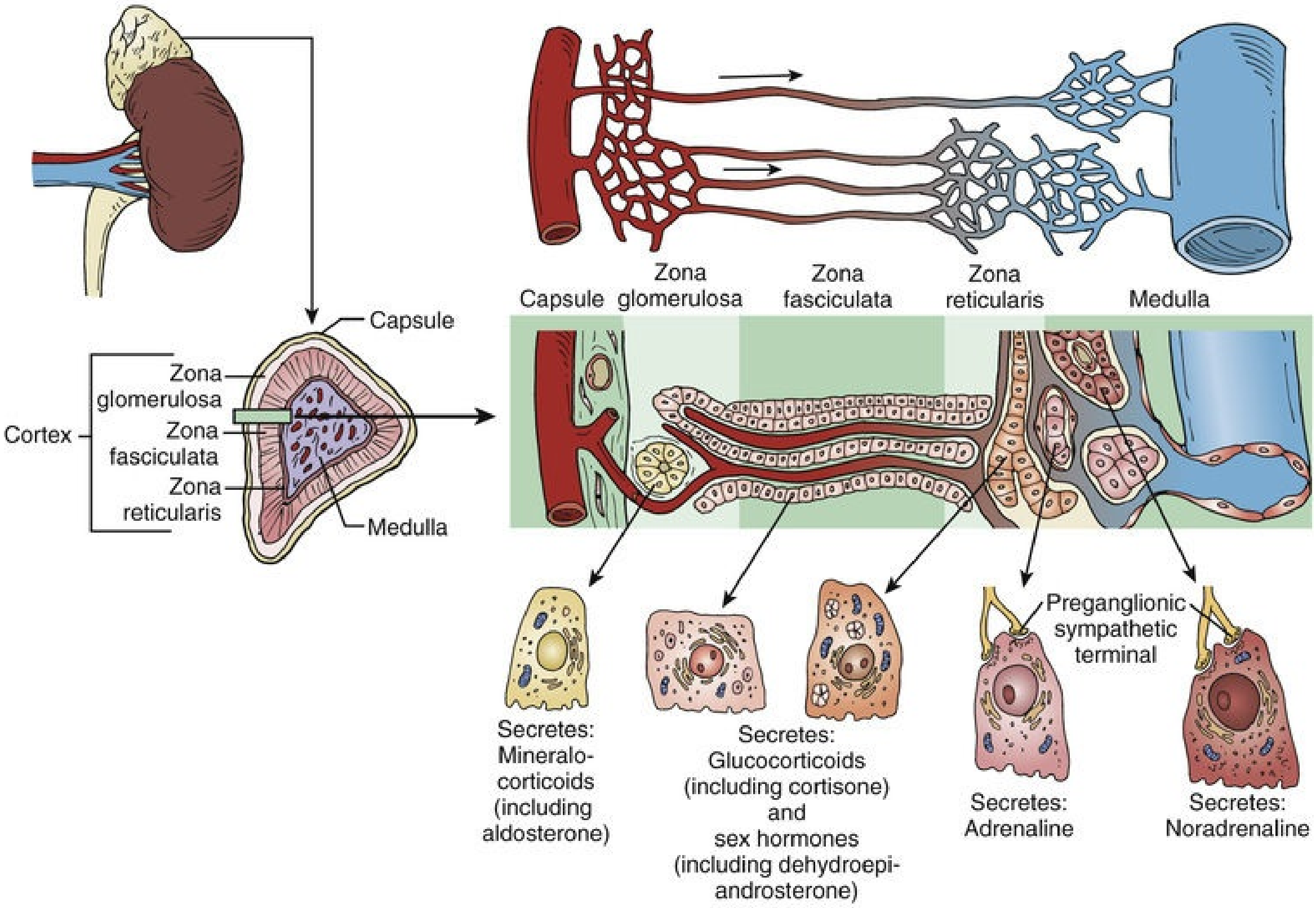
Capsule
Zona glomerulosa
Zona fasciculata
Zona reticularis
Medulla
Capsule
Cortex
Zona glomerulosa
Zona fasciculata
Zona reticularis
Medulla
Preganglionic sympathetic terminal
Secretes: Mineralo-corticoids (including aldosterone)
Secretes: Glucocorticoids (including cortisone) and sex hormones (including dehydroepi-androsterone)
Secretes: Adrenaline
Secretes: Noradrenaline

FIG. 105.5 The complex vascular supply of the adrenal gland. (From Gray

H, Williams PL, Bannister LH: *Gray's anatomy: the anatomical basis of medicine and surgery,* New York, 1995, Churchill Livingstone.)

The venous drainage of the adrenals varies by side, although both adrenal glands are drained by a single central vein that exits the adrenal anteromedially, with emissary veins connecting the central vein to the pericapsular adrenal arterial plexus (Mitty, 1988). The right adrenal vein is short and enters the posterior aspect of the IVC. The longer left adrenal vein joins with the inferior phrenic vein and enters the cranial aspect of the left renal vein (Fig. 105.6; ▶Videos 105.1 and ▶105.2; Avisse et al., 2000).

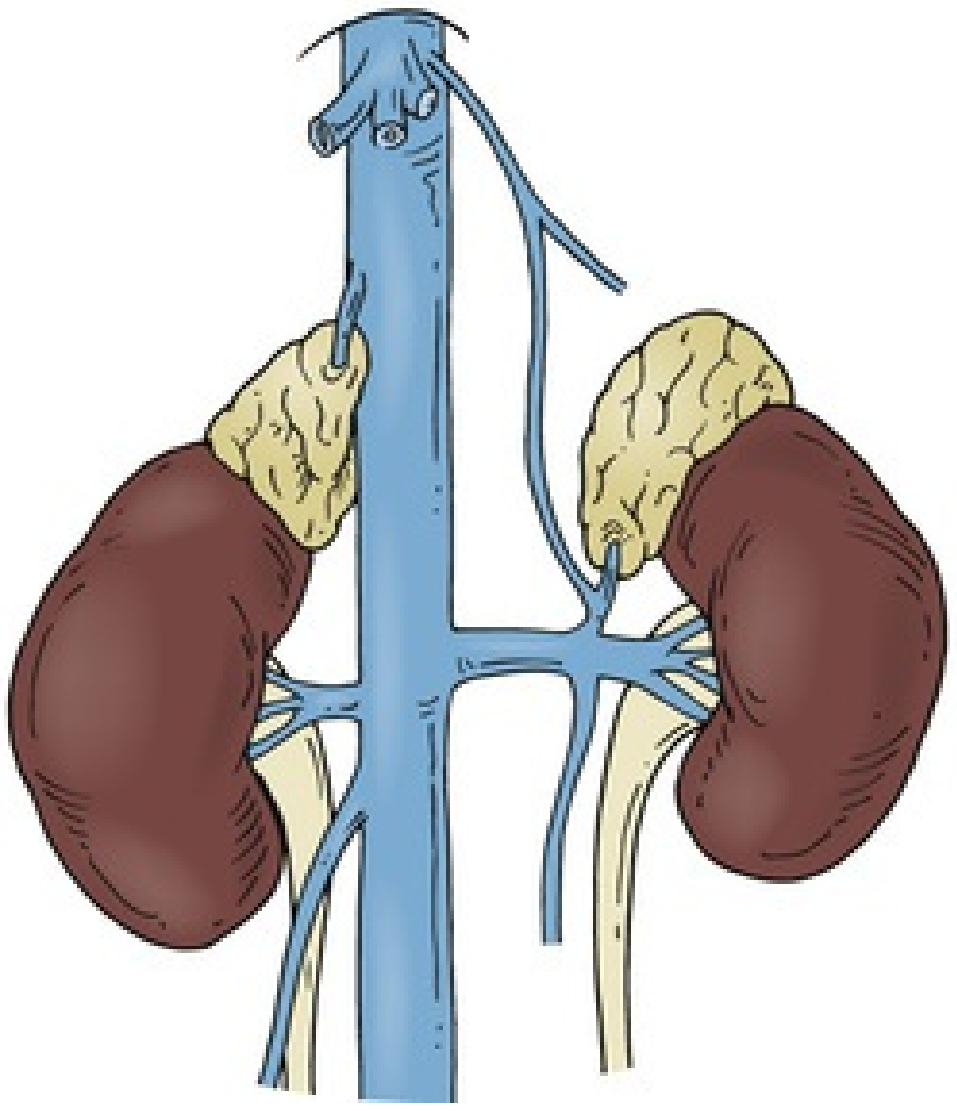

FIG. 105.6 Venous drainage of the right and left adrenal glands. The right adrenal vein enters the posterior aspect of the inferior vena cava. The left adrenal vein joins with the inferior phrenic vein and enters the cranial aspect of the left renal vein. (From Vaughan Jr ED, Carey RM, editors: *Adrenal disorders,* New York, 1989, Thieme Medical.)

Adrenal Nerves

Innervation of the adrenal gland is important for release of catecholamines from the chromaffin cells of the medulla (Fig. 105.7)**. Preganglionic sympathetic nerve fibers from the lower thoracic and lumbar spinal cord travel through the sympathetic chain to reach a nerve plexus at the adrenal capsule. These nerves then traverse the cortex to reach the medulla** (Bloom and Fawcett, 1986). The secretory products released from the adrenal medulla enter systemic circulation via fenestrated capillaries (Ross et al., 1995). Cholinergic innervation of the adrenal cortex has also been described, although it is not as well characterized as the innervation of the medulla (Charlton et al., 1991).

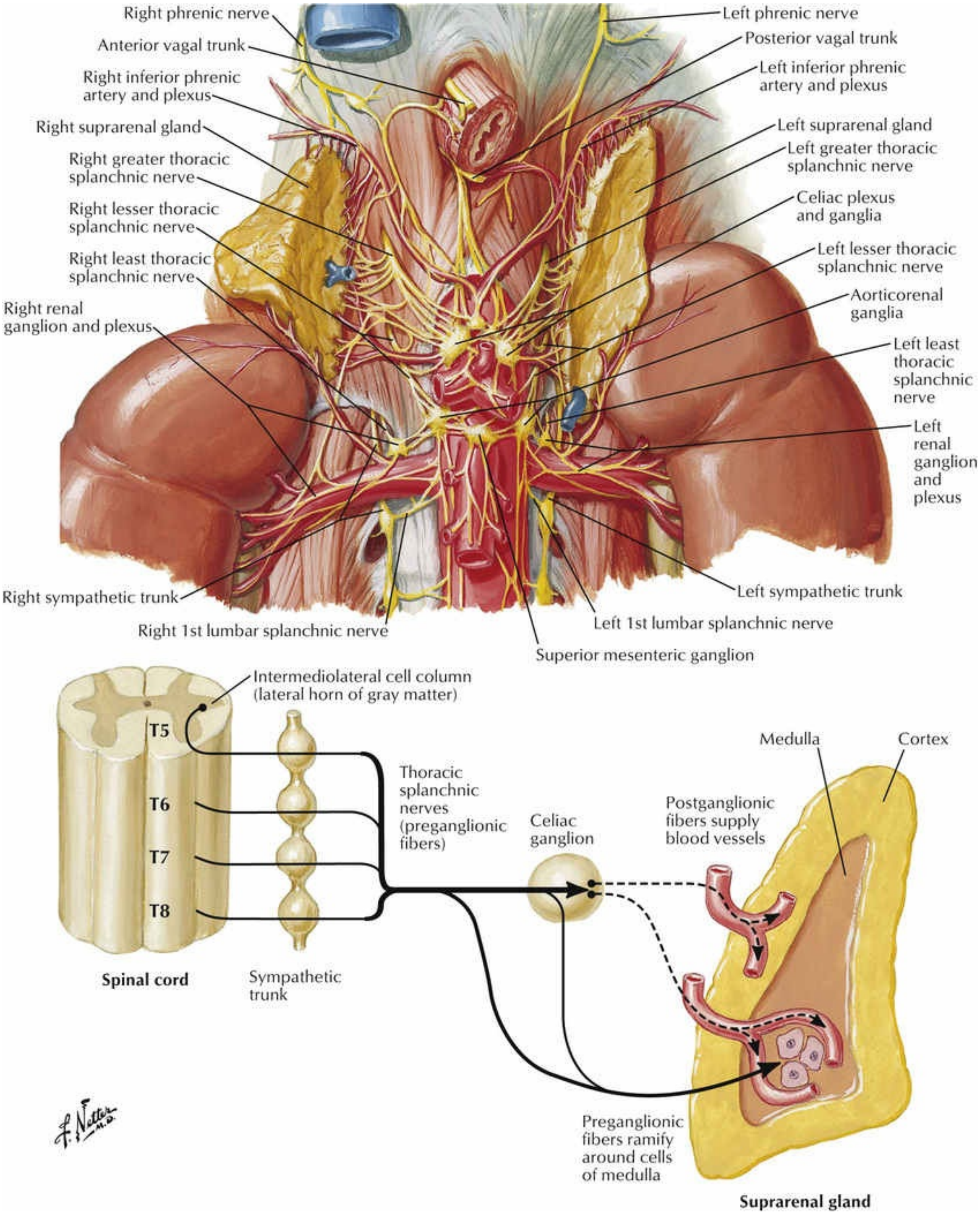
Right phrenic nerve
Anterior vagal trunk
Right inferior phrenic artery and plexus
Right suprarenal gland
Right greater thoracic splanchnic nerve
Right lesser thoracic splanchnic nerve
Right least thoracic splanchnic nerve
Right renal ganglion and plexus
Right sympathetic trunk
Right 1st lumbar splanchnic nerve
Left phrenic nerve
Posterior vagal trunk
Left inferior phrenic artery and plexus
Left suprarenal gland
Left greater thoracic splanchnic nerve
Celiac plexus and ganglia
Left lesser thoracic splanchnic nerve
Aorticorenal ganglia
Left least thoracic splanchnic nerve
Left renal ganglion and plexus
Left sympathetic trunk
Left 1st lumbar splanchnic nerve
Superior mesenteric ganglion
Intermediolateral cell column (lateral horn of gray matter)
T5
T6
T7
T8
Spinal cord
Sympathetic trunk
Thoracic splanchnic nerves (preganglionic fibers)
Celiac ganglion
Medulla
Cortex
Postganglionic fibers supply blood vessels
Preganglionic fibers ramify around cells of medulla
Suprarenal gland

FIG. 105.7 Innervation of the adrenal glands. (Copyright 2016 Elsevier Inc. All rights reserved. www.netterimages.com)

Embryology

The processes involved in the development of the adrenal glands were hypothesized until 1911 when the anatomy of adrenal glands from various stages of human development was initially described. The original illustration of the human fetal adrenal gland described an early fetal zone composed of immature cortical cells and groups of sympathogonia (Malendowicz, 2010). The fetal zone is an important part of development, and after birth this portion of the adrenal dramatically decreases in size.

The development of the adrenal gland begins at approximately the third or fourth week of fetal development, when columns of coelomic epithelium start to condense. During the next 2 weeks, these cells proliferate and begin to migrate to the cranial end of the mesonephros to form the adrenogonadal ridge, the common precursor to the adrenals and the gonads. The adrenal cortex arises from the cephalic portion of the ridge, whereas precursor cells of the future gonads arise from the caudal portion of the ridge (Fig. 105.8).

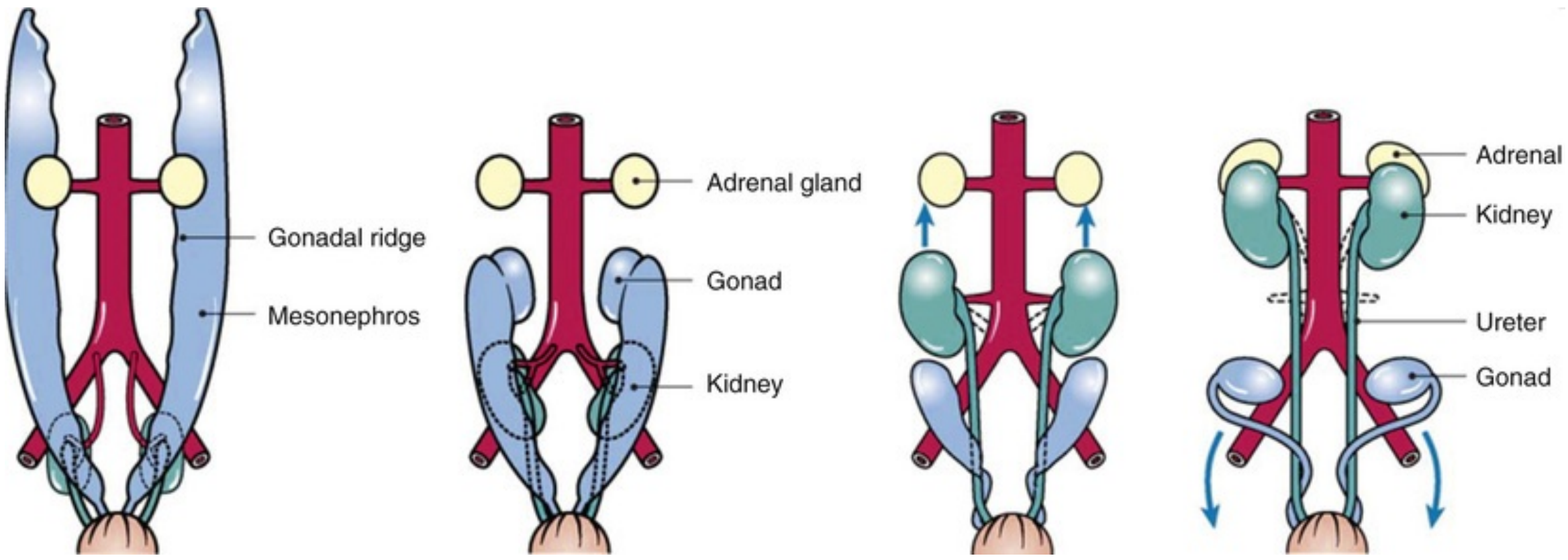

FIG. 105.8 Development of the adrenal gland. Note the close relationship between the gonadal ridge and the developing adrenal gland. (From Barwick TD, Malhotra A, Webb JA, et al.: Embryology of the adrenal gland and its relevance to diagnostic imaging. *Clin Radiol* 60:953–959, 2005.)

Morphologic differentiation into a definitive zone and fetal zone occurs between 8 and 10 weeks' development. Mesenchymal cells surrounding the fetal cortex form the adrenal capsule and neural crest-derived cells migrate to the medial region to form the eventual adrenal medulla. At this time, blood vessels and nerves of the adrenal gland develop.

At birth the adrenal glands are relatively large and weigh twice the weight of the adult glands (Kempna and Fluck, 2008). The fetal zone involutes during the first year of life and is replaced by the definitive zone. This zone develops into the adrenal cortex regions named the zona glomerulosa (ZG) and zona fasciculate (ZF), under the influence of adrenocorticotropic hormone (ACTH) secreted by the pituitary gland. With regression of the fetal zone, chromaffin cells that were scattered throughout the fetal zone aggregate to form the adrenal medulla (Ross et al., 1995). **The medulla is homologous to a sympathetic ganglion without postganglionic processes.** The zona reticularis (ZR), located between the ZF and the medulla, is a relatively minor component of the adrenal cortex until early childhood. Between 6 and 8 years of life, the ZR expands to its adult volume (Else and Hammer, 2005; Havelock et al, 2004; Kempna and Fluck, 2008; Sucheston and Cannon, 1968).

Several unique clinical findings occur with aberrant development of the adrenal glands and neighboring structures. The developing kidneys ascend from the pelvis to unite with the adrenal glands at approximately 8 weeks of development (Moore and Persaud, 1998). In the setting of renal agenesis, the adrenal glands will be found in their orthotopic positions, but they may be discoid instead of their normal triangular or crescent shapes (Mitty, 1988). Adrenal rests are ectopic tissue derived from either adrenal cortex or medulla. Adrenal rests are found in 1% of adults and are typically located in the vicinity of the adrenals in proximity to the celiac axis (Graham, 1953). These rests can also be found along the path of gonadal descent. Adrenal rests associated with the gonad are found in 7.5% to 15% of neonates and usually regress over time (Graham, 1953). In cases of congenital adrenal hyperplasia, these rests are sometimes seen as testes masses. The clinical significance of ectopic adrenal tissue may be important for compensatory hypertrophy after adrenalectomy, inadvertent excision of a heterotopic adrenal gland during unrelated surgery, or neoplastic transformation (Schechter, 1968).

Histology

The adult adrenal gland consists of an outer cortex, which makes up approximately 90% of the adrenal mass, and an inner medulla. The gland is surrounded by a capsule composed of hypocellular fibrous tissue (Mills, 2007). **The adrenal cortex consists of three concentric zones** (Fig. 105.9)**: the outer ZG, which makes up approximately 15% of the cortex; the middle ZF, which includes 80% of the cortex; and the inner ZR, which includes 5% to 7% of the cortex** (Ross et al., 1995). The zones are distinct, and each is identifiable by the typical appearance of the cells and tissue architecture.

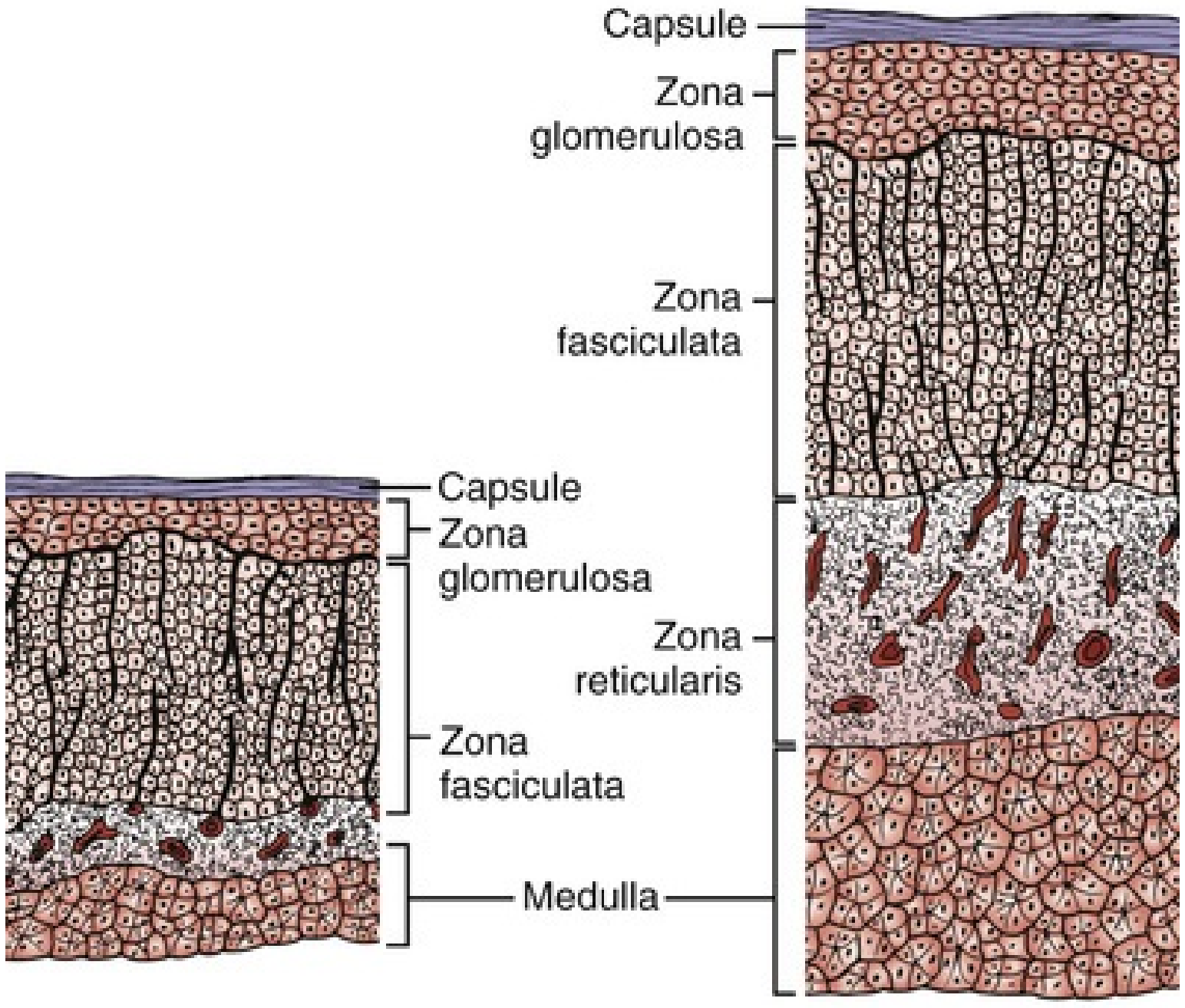

FIG. 105.9 Cross sections through the infant and adult adrenal gland. (From Bloom W, Fawcett DW: *Textbook of histology,* Philadelphia, 1986, Saunders.)

The ZG is composed of small, polyhedral cells arranged in ovoid clusters and curved columns, surrounded by sinusoidal capillaries. The cells are notable for less abundant cytoplasm and a large amount of lipid in the cytoplasm, which results in a vacuolated appearance. These cells are characterized by a higher nuclear-to-cytoplasmic ratio. Aldosterone is synthesized in these cells in the smooth endoplasmic reticulum and the mitochondria (Bloom and Fawcett, 1986;

Cormack, 1998; Mills, 2007; Ross et al., 1995). The ZF, which is the largest of the three cortical zones, contains large pale polyhedral cells arranged in long straight cords, separated by capillaries. These cells contain a higher amount of lipid than the other zones and are referred to as “clear cells” because of their histologic appearance (Mills, 2007). The ZR is composed of smaller cells arranged in anastomosing cords.

The adrenal medulla is composed of chromaffin cells arranged in ovoid clusters and cords. This portion of the adrenal gland provides 10% of the weight and volume of the total adrenal gland (Mills, 2007). The medullary cells are large and epithelioid in appearance and are closely associated with medullary capillaries. They are often poorly outlined and arranged in vague clusters, with nuclei of varying sizes (Mills, 2007). **Chromaffin cells are postganglionic sympathetic neurons that have lost their axons and dendrites** (Paulsen, 1996). Staining and electron microscopy of these cells can differentiate between those that secrete epinephrine and those that secrete norepinephrine (Bloom and Fawcett, 1986).

Radiology

Several imaging modalities are used to image the adrenal gland and its pathology. These include computed tomography (CT), magnetic resonance imaging (MRI), ultrasound (US), angiography, metaiodobenzylguanidine (MIBG) scan, and positron emission tomography (PET). Adrenal imaging is beneficial for the evaluation of abnormal adrenal morphology or function and is discussed in further detail in other chapters. This section reviews normal adrenal anatomy using CT, MRI, US, and angiography.

Computed Tomography

CT is the most widely used imaging modality for imaging the adrenal glands. The perinephric adipose tissue allows for the adrenal gland to be clearly visualized with outstanding resolution. Although CT provides excellent morphologic information, it does not provide functional data. On axial sections the adrenal glands have the appearance of an inverted V or Y. The limbs of the normal adrenal gland are usually thinner than the adjacent diaphragmatic crura with a width of approximately 3 to 6 mm. The right adrenal gland lies just superior to the upper pole of the right kidney and posterolateral to the IVC (Fig. 105.10A). The left adrenal gland is slightly more caudal and lies anterior and medial to the upper pole of the left kidney and posterior to the splenic vessels (Fig. 105.10B). **Normal adrenal tissue has a density of less than or equal to 10 Hounsfield units (HU) on noncontrast CT imaging.**

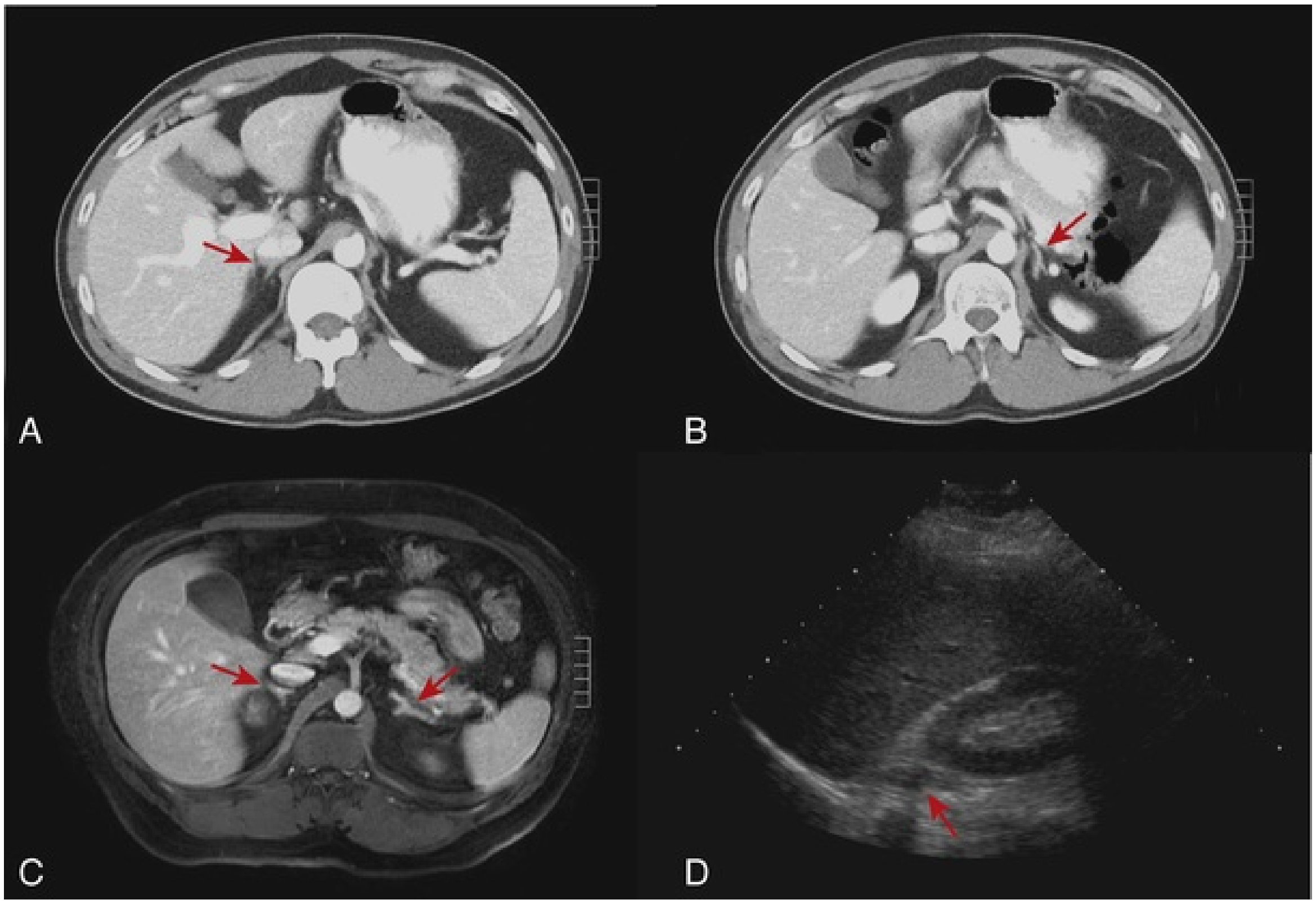

FIG. 105.10 Radiographic images of the adrenal glands. (A) Axial CT image of abdomen with *arrow* indicating right adrenal gland. (B) Axial CT image of abdomen with *arrow* indicating left adrenal gland. (C) T1-weighted axial MRI image of abdomen with *arrows* indicating right and left adrenal glands. (D) Ultrasound image of right upper quadrant with *arrow* indicating right adrenal gland.

Magnetic Resonance Imaging

MRI imaging of the adrenal glands is slightly inferior to CT in terms of spatial resolution but is a useful adjunct in selected cases of abnormal pathology. Coronal or sagittal images may confirm the adrenal origin of a mass when axial images are equivocal. **Contrast resolution of MRI via T1-weighted and T2-weighted images is superior to that of CT** and enables differentiation of adrenal masses. The technique of flow-related enhancement allows excellent evaluation of the arterial and venous vasculature. The transverse imaging plane is most commonly used to evaluate the adrenal gland at an MRI slice thickness of less than or equal to 3 mm. **On T1-weighted images, the normal adrenal gland has a uniform intermediate signal intensity that is slightly less intense than that of the liver and renal cortical tissue** (Fig. 105.10C)**. On T2-**

weighted images, the normal adrenal gland is difficult to distinguish from retroperitoneal adipose tissue because of the presence of intracellular lipid with the gland.

Ultrasonography

US imaging of the adrenal glands is typically performed to identify abnormalities. When the normal adrenal glands are visualized with this modality, they appear as hypoechoic structures (Fig. 105.10D). The retroperitoneal adipose tissue can make it difficult to differentiate normal adrenal tissue from the surrounding structures. As a result, **US imaging is more commonly used for differentiating between solid and cystic masses of the adrenal gland.**

Angiography

Adrenal venous sampling is performed to provide functional information by obtaining blood samples for metabolic assay. Inferior vena cavography can be performed to evaluate the intraluminal component of an adrenal malignancy when CT, MRI, and ultrasonography, are equivocal. Adrenal arteriography is rarely performed or required because CT and MRI nearly always provide the essential morphologic information required for surgical planning.

Conclusion

The one fundamental aspect of the adrenal glands is that they have unique anatomic, embryologic, and histologic characteristics. The adrenal gland's anatomic and histologic transformation from fetal development through adulthood is unlike any other organ. An appreciation of their vascular and anatomic relationships is critical for surgical approaches to the adrenal glands and to nearby organs. As radiographic imaging of the adrenal glands has evolved, normal and pathological adrenal anatomy can be better characterized.

Key Points: Adrenal Glands

- Embryologically, the adrenals are distinct from the kidney, and developmental abnormalities of one do not affect the other.
- The adrenal gland is divided into the cortex and the medulla.
- The adrenal cortex is composed of three distinct areas: the zona glomerulosa, zona fasciculata, and zona reticularis.
- The adrenal medulla receives preganglionic sympathetic input that stimulates the release of catecholamines from the medullary chromaffin cells.
- Arterial supply to the adrenal arises from branches of the inferior phrenic artery, aorta, and renal artery.
- Venous drainage of the adrenal varies by side, with the right adrenal vein entering the IVC and the left adrenal vein entering the left renal vein.

Suggested Readings

Avisse C, Marcus C, Patey M, et al. Surgical anatomy and embryology of the adrenal glands. *Surg Clin North Am*. 2000;80(1):403–415.

Mitty HA. Embryology, anatomy, and anomalies of the adrenal gland. *Semin Roentgenol*. 1988;23(4):271–279.

Toni R, Mosca S. Clinical anatomy of suprarenal arteries. *Surg Radiol Anat*. 1988;10:297–302.

References

Avisse C, Marcus C, Patey M, et al. Surgical anatomy and embryology of the adrenal glands. *Surg Clin North Am*. 2000;80(1):403–415.

Bloom W, Fawcett DW. *Textbook of histology*. Saunders: Philadelphia; 1986.

Charlton BG, Nkomazana OF, McGadey J, et al. A preliminary study of acetylcholinesterase-positive innervation in the human adrenal cortex. *J Anat*. 1991;176:99–104.

Cormack DH. *Clinically integrated histology*. Lippincott-Raven: Philadelphia; 1998.

Else T, Hammer GD. Genetic analysis of adrenal absence: agenesis and aplasia. *Trends Endocrinol Metab*. 2005;16(10):458–468.

Graham LS. Celiac accessory adrenal glands. *Cancer*. 1953;6:149–152.

Gray H, Williams PL, Bannister LH. *Gray's anatomy: the anatomical basis of medicine and surgery*. Churchill Livingstone: New York; 1995.

Havelock JC, Auchus RJ, Rainey WE. The rise in adrenal androgen biosynthesis: adrenarche. *Semin Reprod Med*. 2004;22:337–347.

Kempna P, Fluck CE. Adrenal gland development and defects: best practice and research. *Clin Endocrinol Metab*. 2008;22(1):77–93.

Malendowicz LK. 100th anniversary of the discovery of the human adrenal fetal zone by Stella Starkel and Leslaw Wegrzynowski: how far have we come? *Folia Histochem Cytobiol*. 2010;48(4):491–506.

Mills SE. *Histology for pathologists*. Lippincott Williams & Wilkins: Philadelphia; 2007.

Mitty HA. Embryology, anatomy, and anomalies of the adrenal gland. *Semin Roentgenol*. 1988;23(4):271–279.

Moore KL, Persaud TVN. *The developing human*. ed 6. Saunders: Philadelphia; 1998.

Paulsen DF. *Basic histology*. Appleton & Lange: Stamford; 1996.

Ross MH, Romrell LJ, Kaye GI. *Histology: a text and atlas*. Williams & Wilkins: Baltimore; 1995.

Schechter DC. Aberrant adrenal tissue. *Ann Surg*. 1968;167:421–426.

Sucheston ME, Cannon MS. Development of zonular patterns in the human adrenal gland. *J Morphol*. 1968;126:477–491.

Toni R, Mosca S. Clinical anatomy of suprarenal arteries. *Surg Radiol Anat*. 1988;10:297–302.

Pathophysiology, Evaluation, and Medical Management of Adrenal Disorders

---

Alexander Kutikov MD, FACS, Paul L. Crispen MD, Robert G. Uzzo MD, FACS

The adrenal glands are small and deceptively simple. Formerly known as the *suprarenal glands*, given their location above the kidneys, this paired triangular organ sits at an anatomic crossroads in the upper abdomen adjacent to major vessels, nerves, and other vital organs, which the adrenal glands help to monitor and regulate. The complexities of adrenal endocrine and neurocrine function only recently have been more fully recognized. Indeed, **adrenal glands are now known to be central to homeostasis.** Moreover, pathology involving the glands is responsible for major human ailments.

Given the varied systemic adrenal functions and dysfunctions, medical management is primarily within the purview of endocrinologists, nephrologists, and cardiologists. Similarly, surgical management of adrenal diseases historically has been divided among urologists, general surgeons, surgical oncologists, and, more recently, endocrine surgeons, with referral patterns often dependent on traditions established at individual institutions (Simhan et al., 2012b). With the urologist's advanced minimally invasive surgical skills, comfort with both retroperitoneal anatomy and surgical approaches to retroperitoneal organs, and the close relationship between renal and adrenal pathophysiology, **it is natural that the evaluation and surgical management of adrenal disorders remain firmly in the domain of practicing urologic surgeons.** This chapter strives for a comprehensive discussion of adrenal pathophysiology. **The last section, Evaluation of Adrenal Lesions in Urologic Practice, focuses on a practical discussion of clinical management of those patients with an adrenal mass who see a urologic specialist for consultation.**

Historical Background

The diminutive adrenal glands were easily overlooked by early physicians. Distinguished anatomists such as Galen, da Vinci, and Vesalius omitted the adrenal glands in their descriptions of the retroperitoneum. **Bartholomaeus Eustachius was the first to describe the organs in the mid-16th century** (Scott, 1990). Not until the mid-19th century was the critical importance of the adrenal gland recognized when **Thomas Addison,** an English physician, described a series of patients with the condition of **adrenal insufficiency** that now carries his name. He linked the disease to the adrenal glands on careful inspection of the organs at autopsy (Addison, 1855). Soon thereafter, **Charles Brown-Séquard,** through a series of animal experiments, demonstrated that **bilateral adrenalectomy uniformly resulted in death,** suggesting that the adrenal glands were indispensable to the survival of the host (Brown-Séquard, 1856). William Osler was the first to report treatment of Addison disease with hormonal replacement in 1896. He administered crude extract from the adrenal glands of pigs to a patient with Addison disease and produced significant weight gain in this one individual (Oliver and Sharpey-Schafer, 1895). In the ensuing half-century, *adrenaline* was discovered, and its production was localized to the adrenal medulla (Oliver and Sharpey-Schafer, 1895). The ability of adrenaline to produce a sustained rise in blood pressure was subsequently determined (Abell and Crawford, 1897). Moreover, the failure of this substance, later termed *epinephrine*, to sustain life after bilateral adrenalectomy underscored the complexity and multifunctionality of the adrenal gland and established Addison disease as an ailment of the adrenal cortex (Scott, 1990; Porterfield et al., 2008). Discovery and **isolation of cortisol from the adrenal gland** in the 1930s and subsequent work on its use to treat rheumatoid arthritis produced a **1950 Nobel Prize** in Physiology or Medicine for Edward Kendall, Philip Hench, and Tadeus Reichstein (Scott, 1990). Aldosterone was ultimately isolated from the bovine adrenal gland in 1952 (Grundy et al., 1952). The latter part of the 20th century witnessed a rapid transformation in our understanding and treatment of adrenal disorders led by pioneers such as Jerome Conn, Lawson Wilkins, Grant Liddle, and Earl Sutherland (Scott, 1990).

Adrenal Anatomy and Embryology

Overview

The adrenal glands are paired retroperitoneal organs composed of a cortex and medulla. Gross examination reveals a distinct spiculated mustard-yellow–colored cortex that is distinct from the surrounding perinephric fat and the inner medulla, which can be distinguished macroscopically on cross-section by its central brown color (Figs. 106.1 and 106.2). The normal adrenal glands weigh an average of 4 to 5 g each and range in size from 4 to 6 cm in length and 2 to 3 cm in width (Avisse et al., 2000; Mitty, 1988; Silverman and Lee, 1989). Morphologically, the right adrenal gland is triangular, whereas the left adrenal gland is crescent-shaped (Avisse et al., 2000). They may sit either immediately superior to the kidney, “capping” the upper pole, or superior medially to the upper pole, “cradled” by the kidney just above the renal vessels. Once understood, this difference can be appreciated through either computed tomography (CT) scan or magnetic resonance imaging (MRI) and is a relevant surgical distinction, particularly in patients with substantive perinephric fat and on the left side when identifying the adrenal vein.

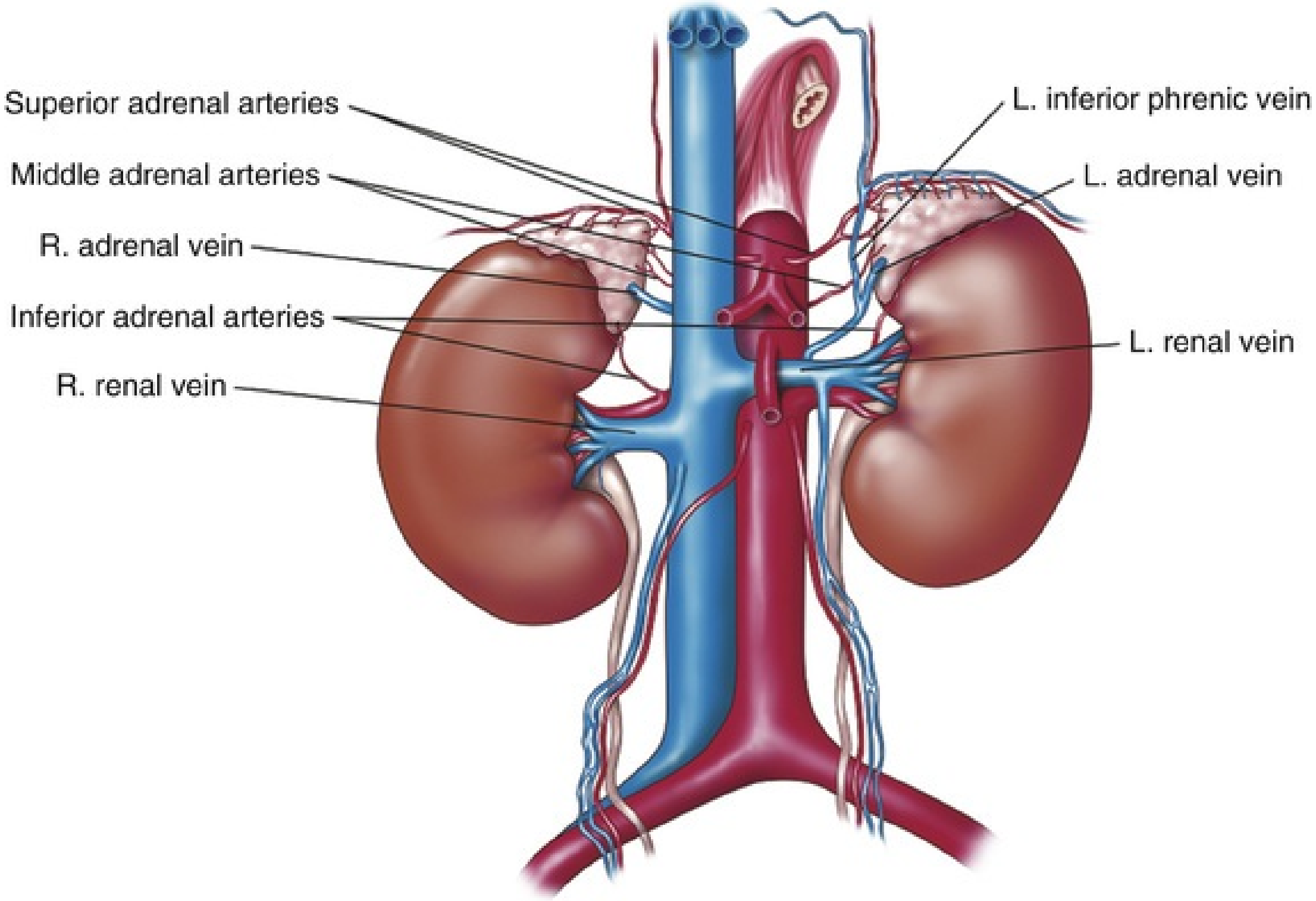
Superior adrenal arteries
Middle adrenal arteries
R. adrenal vein
Inferior adrenal arteries
R. renal vein
L. inferior phrenic vein
L. adrenal vein
L. renal vein

FIG. 106.1 Adrenal vascular supply demonstrating inflow from the superior, middle, and inferior adrenal arteries bilaterally. Whereas the right adrenal vein drains directly into the posterior inferior vena cava, the left adrenal vein often communicates with the inferior phrenic vein before draining into the left renal vein. (Courtesy of the University of Kentucky.)

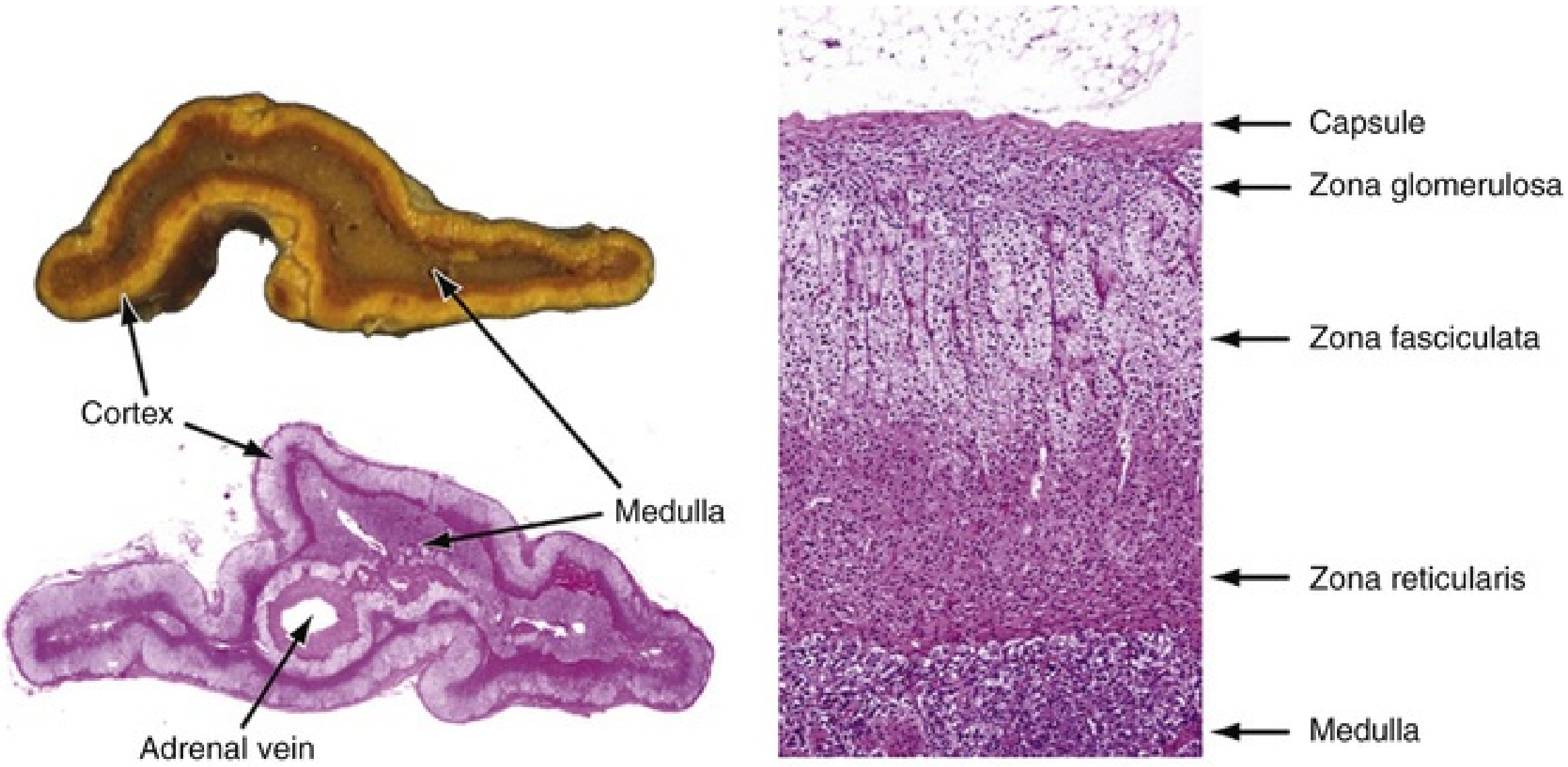
Cortex
Medulla
Adrenal vein
Capsule
Zona glomerulosa
Zona fasciculata
Zona reticularis
Medulla

FIG. 106.2 Normal adrenal gland histology. Macroscopic and low-power

microscopic views of the adrenal cortex and medulla. The three layers of the adrenal medulla (glomerulosa, fasciculata, and reticularis) produce mineralocorticoids (aldosterone), glucocorticoids (cortisol), and sex steroids (adrenal androgens and estrogens), respectively. The acronym *GFR = ACE* summarizes this relationship (glomerulosa, fasciculata, reticularis = aldosterone, cortisol, estrogen) nicely. (Courtesy of Dr. Thomas J. Sebo, Department of Laboratory Medicine and Pathology, Mayo Clinic, Rochester, MN.)

Embryology

The adrenal cortex and the medulla are two embryologically and functionally distinct units. The cortex is derived from the intermediate mesoderm of the urogenital ridge (Barwick et al., 2005; Mitty, 1988). Beginning in the fifth week of gestation, mesenchymal cells located at the urogenital ridge and the root of the mesentery proliferate and form the cortex of the fetal adrenal gland. During the sixth and seventh weeks of gestation, additional mesothelial cells surround the fetal adrenal cortex, which will later form the adult adrenal cortex (Barwick et al., 2005; Mitty, 1988). By the end of the eighth week of gestation, the mesothelial cells forming the cortex are encapsulated by connective tissue and have separated from the peritoneal mesothelium. After encapsulation, adult adrenocortical cells begin to replace the fetal adrenal gland cells (Walczak and Hammer, 2014). In distinction, the adrenal medulla is derived from neural crest cells, located in adjacent sympathetic ganglia, which migrate into the medial aspect of the fetal adrenal cortex by the ninth week of gestation (Kempna and Fluck, 2008). The neural crest cells continue to invade the adrenal cortex until they achieve a central position surrounding the adrenal vein by the 18th week of gestation. This embryologic relationship explains the brown stippling of the adrenal cortex.

At birth, the fetal adrenal gland is twice the weight of an adult adrenal gland but has not completed development. After birth, only a small rim of fetal cortex begins to atrophy and will be completely resorbed by 12 months of age (Mitty, 1988; Walczak and Hammer, 2014). As the fetal cortex is being resorbed, the zona glomerulosa and fasciculata of the adult cortex continue to develop, but the zona reticularis will not complete differentiation until 3 years of age, reflecting the relative late importance of sex steroid production by this part of the adrenal cortex (Barwick et al., 2005; Kempna and Fluck, 2008). In addition to the well-established roles of cells located within the three zones of the adrenal cortex, there is mounting data on the potential importance and role of adrenocortical stem cells in the normal development and hemostasis of the adrenal gland (Walczak and Hammer, 2014).

Cases of unilateral adrenal agenesis are rare and are often associated with unilateral renal agenesis (Else and Hammer, 2005; Nakada et al., 1988). However, because adrenal and renal development are separate processes, this association is likely spurious and is the result of limited radiographic evaluation of the ipsilateral adrenal gland in cases of renal agenesis. **Most often, adrenal gland development occurs normally in the absence of ipsilateral renal unit development, malrotation, or malascent. In these cases, the adrenal glands are often discoid in shape and located in their normal position within the retroperitoneum** (Mitty, 1988).

More common anomalies of adrenal gland development include accessory adrenal tissue and adrenal heterotopia. Accessory adrenal tissue, also known as *adrenal rests,* can be composed of cortical or medullary tissues. Because of the close proximity of the adrenal gland and genitourinary organ development, adrenal rests can be found anywhere along the path of gonadal descent within the retroperitoneum. Although adrenal rests can be found in up to 50% of neonates, the tissue typically atrophies and is found in only approximately 1% of adults (Barwick et al., 2005). **In cases of congenital adrenal hyperplasia (CAH), adrenal rest within the testis may become hyperplastic and manifest as a testicular mass. This is an important consideration before performance of an orchiectomy for a testicular mass in patients with CAH.** Adrenal heterotopia results from incomplete separation of primitive adrenal mesoderm from adjacent organs such as the liver or kidney, resulting in partial or complete incorporation of the gland into the adjacent organ.

Anatomy

The right and left adrenal glands are located within the Gerota fascia at the levels of the 11th and 12th ribs and share several important anatomic relationships, including being located cephalad to the upper pole of the kidneys and anterior to the crus of the diaphragm. The right adrenal gland is bounded medially by the inferior vena cava (IVC) and anteriorly by the liver; the left adrenal gland is bounded medially by the aorta and anteriorly by the stomach, pancreas, and splenic vessels. The close juxtaposition of these organs to the adrenal gland explains why lesions of adjacent organs, such as leiomyomas or diverticuli of the greater curvature of the stomach, may be confused for an adrenal lesion.

As with most endocrine organs, the blood supply to the adrenal gland is redundant. Although variable, the arterial supply of each adrenal gland may arise from three main sources: superior adrenal arteries (branches from the inferior phrenic arteries), middle adrenal arteries (direct visceral branches from the aorta), and inferior adrenal arteries (branches from the ipsilateral renal artery (see Fig. 106.1). The main adrenal arteries then branch to form a subcapsular plexus. From the subcapsular plexus, some branches continue directly to the medulla, and others form sinusoids supplying the adrenal cortex. On the venous side, medullary veins coalesce to form the adrenal vein, which is surrounded by medullary tissue within the adrenal gland. The short right adrenal vein drains directly into the vena cava. On the left side, the adrenal vein is long compared with the right and is joined by the inferior phrenic vein before draining into the left renal vein. The overlapping of both arterial and venous anatomy makes partial adrenalectomy possible with little risk for subsequent adrenal infarction. Anomalous venous drainage is noted in up to 9% of patients and is an important consideration when performing adrenal vein sampling (Ford et al., 2018). The principal lymphatic drainage of the adrenal glands is through the paracaval lymph nodes on the right and the para-aortic lymph nodes on the left.

The autonomic innervation of the adrenal glands includes predominantly preganglionic sympathetic fibers off the sympathetic trunk directly to the chromaffin cells of the adrenal medulla, whereas postganglionic fibers originating from the splanchnic ganglia provide innervation to the adrenal cortex. Parasympathetic innervation to the adrenal cortex and medulla is not well defined; however, animal models suggest that parasympathetic branches originating from the vagus nerve may be present.

Histology

Each adrenal gland is enclosed within a fibrous capsule (see Fig. 106.2). Directly beneath the capsule is the cortex, which consists of three zones: the zona glomerulosa, the zona fasciculata, and the zona reticularis. The zona glomerulosa consists of small polyhedral cells with scant eosinophilic cytoplasm and dark round nuclei. The essential function of the glomerulosa is the production of mineralocorticoids, predominantly aldosterone. The broad layer of large pale cells arranged in vertical columns beneath the zona glomerulosa is the zona fasciculata responsible for the production of glucocorticoids such as cortisol. The zona reticularis, the innermost layer of the cortex, consists of round dark-staining cells and predominantly produces sex steroids, such as adrenal estrogens and androgens (MacLennan et al., 2003; Mitty, 1988) (see Fig. 106.2).

Key Points: Anatomy and Embryology

- The adrenal glands are composed of two embryologically and functionally distinct components: the cortex and the medulla (the former endocrine, the latter neurocrine).
- The arterial supply of the adrenal glands is variable and can arise from several sources. However, the venous drainage is more predictable, with the right adrenal vein emptying into the IVC and the left adrenal vein draining into the left renal vein in the majority of patients.

Adrenal Physiology

Other than their juxtaposed anatomic associations, the adrenal cortex and the adrenal medulla are best conceptualized as two distinct organs, the former endocrine and the latter neurocrine.

Adrenal Cortex Physiology

As part of a multistep synthetic pathway, numerous enzymes of the adrenal cortex catalyze conversion of essential steroid hormones from the common precursor cholesterol. Low-density lipoprotein (LDL) serves as the primary source of cholesterol for the adrenal glands (Arlt and Stewart, 2005). **Ratios and types of enzymes in each zone of the adrenal cortex vary, resulting in different hormonal products for each region** (Fig. 106.3) (Rainey, 1999).

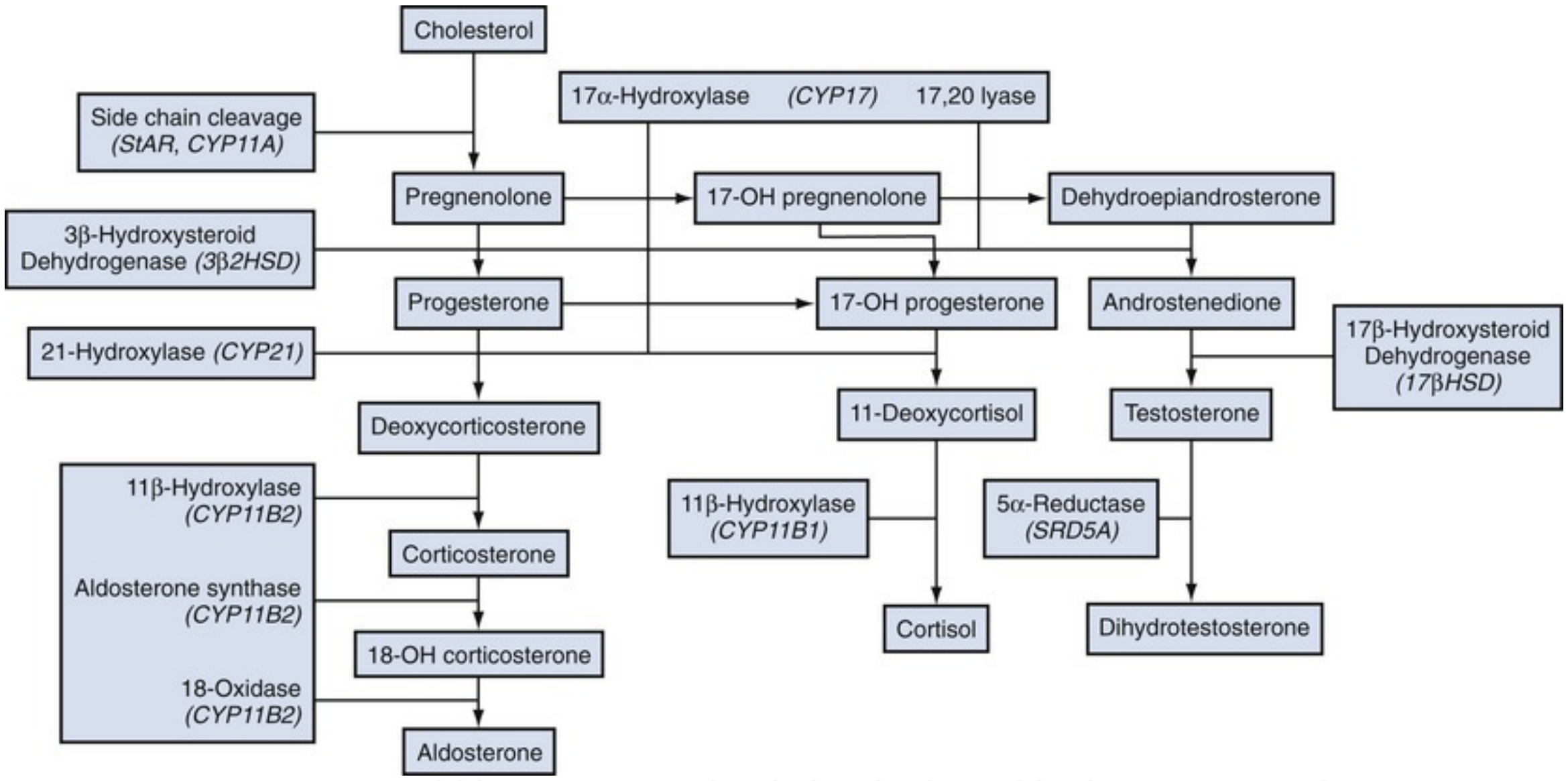
Cholesterol
17α-Hydroxylase (CYP17) 17,20 lyase
Side chain cleavage (StAR, CYP11A)
Pregnenolone
17-OH pregnenolone
Dehydroepiandrosterone
3β-Hydroxysteroid Dehydrogenase (3β2HSD)
Progesterone
17-OH progesterone
Androstenedione
17β-Hydroxysteroid Dehydrogenase (17βHSD)
21-Hydroxylase (CYP21)
Deoxycorticosterone
11-Deoxycortisol
Testosterone
11β-Hydroxylase (CYP11B2)
Aldosterone synthase (CYP11B2)
18-Oxidase (CYP11B2)
Corticosterone
18-OH corticosterone
Aldosterone
11β-Hydroxylase (CYP11B1)
Cortisol
5α-Reductase (SRD5A)
Dihydrotestosterone

FIG. 106.3 Steroid hormone synthesis beginning with cholesterol and resulting in mineralocorticoid, glucocorticoid, and androgen production in the adrenal cortex. Enzymes are listed in boxes and genes in parentheses. (From Hyun G, Kolon TF. A practical approach to intersex in the newborn period. *Urol Clin North Am* 31:435–443, 2004.)

Steroid hormone receptors are absent on cellular membranes of target tissues. Instead, steroids diffuse passively into the cell and bind to their respective receptors intracellularly. Gene transcription is then modulated by direct binding of the hormone receptor complex to target DNA (Arlt and Stewart, 2005). As discussed earlier, the three main zones of the adrenal cortex are the zona glomerulosa, zona fasciculata, and zona reticularis, with each zone primarily responsible for mineralocorticoid (100 to 150 µg/day), glucocorticoid (10 to 20 mg/day), and androgen (>20 mg/day) synthesis, respectively (Arlt and Stewart, 2005).

Zona Glomerulosa

The zona glomerulosa is the outermost region of the adrenal cortex and is the only zone of the adrenal gland that contains the enzyme aldosterone synthase (CYP11B2). As a result, the glomerulosa cells of this tissue are **the sole source of aldosterone**—the primary human mineralocorticoid (Rainey, 1999). Aldosterone regulates electrolyte metabolism by stimulating epithelial cells of the distal nephron to reabsorb Na^+ and Cl^-, while secreting H^+ and K^+. Although aldosterone levels have a profound effect on total body Na^+, concentration of the ion does not change, whereas reabsorption of sodium is accompanied by reuptake of free water. Therefore aldosterone primarily affects total body volume and not sodium concentration (Table 106.1) (White, 1994; Arlt and Stewart, 2005). Electrolyte balance in epithelial cells of the submaxillary salivary glands and the large intestine are also under mineralocorticoid control; however, the physiologic importance of this phenomenon is likely minimal (Bastl and Hayslett, 1992).

TABLE 106.1

Primary Effects of Mineralocorticoids

ACTION	EFFECT	SITE OF ACTION
Renal sodium reabsorption	Increased blood volume Increased blood pressure Decreased urine sodium	Distal tubule Connecting segment Collecting duct
Renal chloride reabsorption	Increased serum chloride Decreased urine chloride	Distal tubule Connecting segment Collecting duct
Renal potassium	Decreased serum	Distal tubule

secretion	potassium Increased urine potassium	Connecting segment Collecting duct
Renal proton secretion	Increased urine NH_4	Collecting duct—a result of sodium reabsorption

NH_4, Ammonia.

Aldosterone levels are primarily regulated by angiotensin II through the renin-angiotensin-aldosterone system (RAAS) and directly by serum potassium levels. A rise in adrenocorticotropic hormone (ACTH) can also increase aldosterone secretion, but this is a much less potent stimulus (White, 1994; Arlt and Stewart, 2005). For this reason, the zona glomerulosa is the only region of the adrenal cortex that does not atrophy on pituitary failure (Hubbard et al., 1990). Atrial natriuretic peptide is the main inhibitory regulator of aldosterone secretion, providing an important link among cardiac, adrenal, and renal function—although somatostatin, dopamine, and others may also play a role (Spat and Hunyady, 2004). A working knowledge of the RAAS is critical in understanding and managing hyperaldosteronism. The pathophysiology of this pathway is discussed in the Testing for Aldosterone Hypersecretion section later in this chapter.

Zona Fasciculata

The zona fasciculata is the site of glucocorticoid production as a result of zonal expression of 17α-hydroxylase, 21-hydroxylase, and 11β-hydroxylase enzymes (see Fig. 106.3) (Arlt and Stewart, 2005)**. Cortisol is the primary glucocorticoid in humans, and its secretion is under tight control of the ACTH.** Accordingly, cortisol and ACTH are a part of a classic hormonal negative feedback system that features the hypothalamus, the pituitary gland, and the adrenal glands. The physiology of this axis is discussed in more detail in the Cushing Syndrome section later in this chapter (Jacobson, 2005). Production of cortisol by the adrenal glands follows a strict circadian schedule, with the majority of the hormone being secreted in the early morning (Jacobson, 2005). Glucocorticoids are essential to life and modulate complex physiologic pathways that include metabolism, immunity, maintenance of intravascular volume, regulation of blood pressure, and complex modulation of the central nervous system (CNS) with significant effects on mood, sleep, and potentially memory (Arlt and Stewart, 2005) (Table 106.2).

TABLE 106.2

Primary Effects of Glucocorticoids

EFFECTS	CLINICAL IMPLICATIONS
Enhance skeletal and cardiac muscle contraction	Absence results in weakness.
Cause protein catabolism	Excess results in muscle wasting and weakness.
Inhibit bone formation	Excess decreases bone density.
Inhibit collagen synthesis	Excess causes thin skin and fragile capillaries.
Increase vascular contractility and decrease permeability	Absence makes it difficult to maintain blood pressure.
Have anti-inflammatory activity	Exogenous steroid is useful in treating inflammatory diseases.
Have anti–immune system activity	Exogenous steroids are useful in promoting transplant tolerance and in treating autoimmune disorders.
Maintain normal glomerular filtration rate	Absence reduces glomerular filtration rate.

From Howards SS, Carey RM. The adrenals. In: Gillenwater JY, Grayhack JT, Howards SS, et al., eds. *Adult and pediatric urology.* 2nd ed. Chicago, IL: Year Book; 1991.

Zona Reticularis

The zona reticularis is the innermost zone of the adrenal cortex. The presence of 17α-hydroxylase and 17,20-lyase results in the production of dehydroepiandrosterone (DHEA), sulfated DHEA (DHEA-S), and androstenedione to this region, although some androgen synthesis also occurs in the zona fasciculata. Adrenal androgen secretion appears to be under control of ACTH, and, like cortisol, exhibits circadian patterns (Arlt and Stewart, 2005). DHEA, DHEA-S, and androstenedione compose the greatest portion of steroid hormone that is produced by the adrenal glands (>20 mg/day), but appear to be the least important for adult physiologic homeostasis (Nguyen and Conley, 2008); however, **pharmacologic manipulation of adrenal androgen production remains a viable and increasingly targeted strategy for advanced prostate cancer (see Chapter 161).** Moreover, aberrations in production of these hormones during development are responsible for significant pathology and result in the clinical entity known as *congenital adrenal hyperplasia* (Finkelstein and Shaefer, 1979; Hubbard et al., 1990). CAH is discussed in detail in Chapter 149.

Adrenal Medulla Physiology

The **adrenal medulla** composes less than 10% of the total adrenal mass. Neither its function nor its embryology is related to the neighboring cortex. Instead, this portion of the adrenal gland, which **lies at the center of the gland, is an integral part of the autonomic nervous system.** Chromaffin cells of the medulla are innervated by preganglionic sympathetic fibers of T11 to L2, making them analogous to cells of the sympathetic ganglia. The medulla secretes epinephrine (80%), norepinephrine (19%), and dopamine (1%). These substances, collectively known as *catecholamines*, are produced from the amino acid tyrosine and modulate the systemic stress response (Fig. 106.4) (de Diego et al., 2008; Robertson, 1990). The effects of these catecholamines are mediated through their binding to adrenoreceptors located on target organs. The nature of these effects depends on the adrenoreceptor types or subtypes located and stimulated on a particular end organ (Table 106.3) (Guimaraes and Moura, 2001; Robertson, 1990). It is interesting to note that the enzyme phenylethanolamine-*N*-methyltransferase (PNMT), which catalyzes the conversion of norepinephrine to epinephrine, is relatively unique to the adrenal medulla (the brain and organ of Zuckerkandl also express this enzyme). The function of this enzyme is potentiated by the presence of glucocorticoids, thereby creating one of the few physiologic links between the adrenal cortex and the medulla. **Localization of PNMT to the adrenal medulla explains why the gland is the primary source of systemic epinephrine,** despite the presence of similar chromaffin cells elsewhere in the sympathetic nervous system (Robertson, 1990). Similar to the physiology that controls norepinephrine release at synaptic nerve terminals, the storage and release of adrenal catecholamines involves intracellular vesicles. Liberation of these vesicles through exocytosis results in release of adrenal catecholamines into the bloodstream (Eisenhofer et al., 2004b).

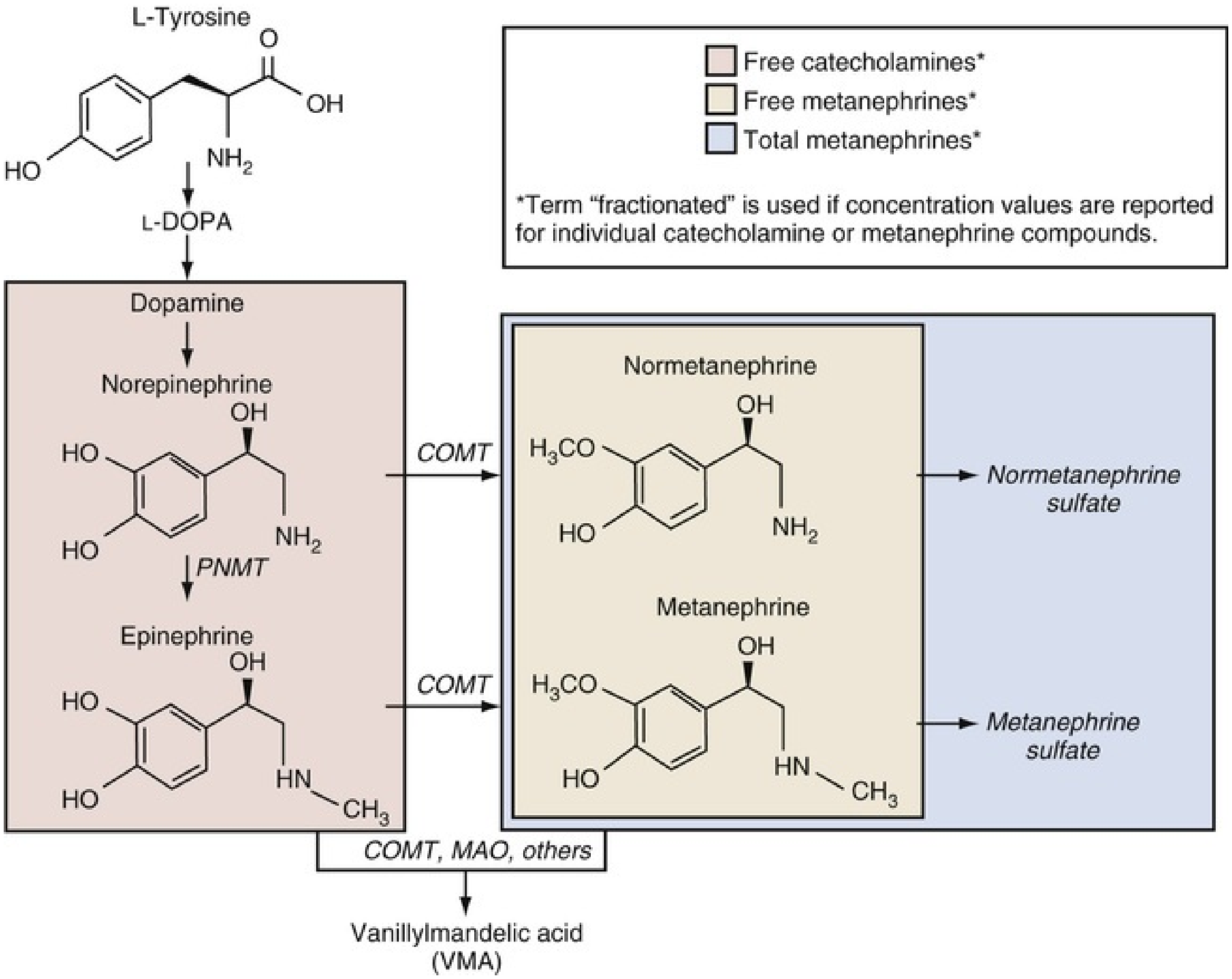
L-Tyrosine
L-DOPA
Dopamine
Norepinephrine
PNMT
Epinephrine
COMT
COMT
Normetanephrine
Metanephrine
Normetanephrine sulfate
Metanephrine sulfate
COMT, MAO, others
Vanillylmandelic acid (VMA)
Free catecholamines*
Free metanephrines*
Total metanephrines*
*Term "fractionated" is used if concentration values are reported for individual catecholamine or metanephrine compounds.

FIG. 106.4 Summary of catecholamine metabolism. The figure simplifies the metabolic pathway of norepinephrine and epinephrine degradation to highlight those metabolic products that play a role in routine clinical practice. Note: The central role that the monoamine oxidase (MAO) enzyme plays in catecholamine degradation is not fully reflected in this figure, because most metabolites that are produced by MAO catalysis are not routinely measured in laboratory assessments for pheochromocytoma. Key enzymes involved in catalysis of metabolic conversions are indicated in italic font. *COMT,* Catechol-*O*-methyltransferase; *PNMT,* phenylethanolamine-*N*-methyltransferase.

TABLE 106.3

Primary Effects of Catecholamines

EFFECTOR ORGANS	RECEPTOR TYPE	RESPONSES	MOST RELEVANT CLINICAL MANIFESTATIONS
Eye			

Radial muscle, iris	α_1	Contraction (mydriasis) ++	Blurry vision
Ciliary muscle	β_2	Relaxation for far vision +	
Heart			
SA node	β_1, β_2	Increase in heart rate ++	Palpitations, angina
Atria	β_1, β_2	Increase in contractility and conduction velocity ++	Palpitations, angina
AV node	β_1, β_2	Increase in automaticity and conduction velocity +++	Palpitations, angina
His-Purkinje system	β_1, β_2	Increase in automaticity and conduction velocity +++	Palpitations, angina
Ventricles	β_1, β_2	Increase in contractility, conduction velocity, automaticity, and rate of idioventricular pacemakers +++	Palpitations, angina
Arterioles			
Coronary	α_1, α_2, β_2	Constriction +; dilation ++	Angina
Skin and mucosa	α_1, α_2	Constriction +++	Pallor
Skeletal muscle	α, β_2	Constriction ++; dilation ++	Hypertension
Cerebral	α_1	Constriction (slight)	Stroke
Pulmonary	α_1, β_2	Constriction +; dilation ++	Edema
Abdominal viscera	α_1, β_2	Constriction +++; dilation +	For example, bowel ischemia
Salivary glands	α_1, α_2	Constriction +++	
Renal	α_1, α_2, β_1, β_2	Constriction +++; dilation +	Renal failure
Veins (systemic)	α_1, α_2, β_2	Constriction ++; dilation ++	Orthostatic hypotension
Lung			
Tracheal and bronchial muscle	β_2	Relaxation +	
Bronchial glands	α_1, β_2	Decreased secretion; increased secretion	
Stomach			
Motility and tone	α_1, α_2, β_2	Decrease (usually) +	Early satiety, discomfort
Sphincters	α_1	Contraction (usually) +	

Intestine			
Motility and tone	α_1, α_2, β_1, β_2	Decrease +	Constipation, ileus
Sphincters	α_1	Contraction (usually) +	
Secretion	α_2	Inhibition	Constipation
Gallbladder and ducts	β_2	Relaxation +	Gallstones
Kidney			
Renin secretion	α_1, β_2	Decrease +; increase ++	
Urinary bladder			
Detrusor	β_2	Relaxation (usually) +	Urinary retention
Trigone and sphincter	α_1	Contraction ++	Urinary retention
Ureter			
Motility and tone	α_1	Increase	
Uterus	α_1, β_2	Pregnant; contraction; relaxation	
		Nonpregnant; relaxation	
Sex organs, male	α_1	Ejaculation ++	
Skin			
Pilomotor muscles	α_1	Contraction ++	
Sweat glands	α_1	Localized secretion +	Sweating
Spleen capsule	α_1, β_2	Contraction +++; relaxation +	
Skeletal muscle	β_2	Increased contractility; glycogenolysis; K^+ uptake	Hyperglycemia, glycosuria
Pancreas			
Acini	α	Decreased secretion +	
Islets (β cells)	α_2	Decreased secretion +++	Hyperglycemia, glycosuria
	β_2	Increased secretion +	Hypoglycemia
Fat cells	α_2, β_1, β_2	Lipolysis +++ (thermogenesis)	Feeling warm
Salivary glands	α_1	K^+ and water secretion +	
	β	Amylase secretion +	
Lacrimal	α	Secretion +	Lacrimation

glands			
Pineal gland	β	Melatonin synthesis	
Posterior pituitary gland	β_1	Antidiuretic hormone secretion	Decreased diuresis

Highest (+++) to lowest (+) intensity of adrenergic nerve activity in the control of various organs and functions listed. Where (+) is not given, intensity is not specified.

AV, Atrioventricular; *SA,* sinoatrial.

Modified from Pacak K. Preoperative management of the pheochromocytoma patient. *J Clin Endocrinol Metab* 92:4069–4079, 2007.

The metabolism of catecholamines is complex, and some controversy exists about the physiologic relevance of each pathway (Eisenhofer et al., 2004b). The majority of adrenal catecholamine metabolism occurs at the scene of production in cells of the adrenal medulla themselves (Eisenhofer et al., 2003a). **For clinical purposes, three metabolites (metanephrine, normetanephrine, and vanillylmandelic acid [VMA]) and two enzymes (catechol-*O*-methyltransferase [COMT] and monoamine oxidase [MAO]) are important.** Metanephrine and normetanephrine result from respective methylation of epinephrine and norepinephrine by COMT. Although large amounts of this enzyme are present in the liver and kidneys, the majority of adrenal catecholamine metabolites are methylated by COMT within the cells of the adrenal medulla (Eisenhofer et al., 2003a). Indeed, **over 90% of metanephrine (epinephrine metabolite) and some 20% or more of normetanephrine (a norepinephrine metabolite) in the bloodstream are derived from the adrenal medulla.** Therefore, a measurable rise in the level of these metabolites is very useful when diagnosing potential pheochromocytomas (see Assessment of Function of Adrenal Masses section later in this chapter) (Eisenhofer et al., 1995). In the urine, most of these metabolites are excreted in a sulfonated form. Furthermore, MAO and other enzymes subsequently participate in the conversion of catecholamine metabolites to VMA, the primary catecholamine metabolic end product that is largely formed by the liver. Nonadrenal catecholamines from the sympathetic nervous system are similarly converted to VMA (Eisenhofer et al., 2004b). Fig. 106.4 summarizes the most clinically relevant aspects of the catecholamine metabolism pathway.

Key Points: Physiology

- The adrenal cortex and the adrenal medulla are best conceptualized as two distinct organs, the former endocrine and the latter neurocrine.
- Three main zones of the adrenal cortex are the zona glomerulosa, zona fasciculata, and zona reticularis, with each zone primarily responsible for mineralocorticoid, glucocorticoid, and androgen synthesis, respectively.
- Ratios and types of enzymes in each zone of the adrenal cortex vary, resulting in different hormonal products for each region.
- Aldosterone levels are primarily regulated by angiotensin II through the RAAS and directly by serum potassium levels. ACTH is less important in regulation of this region's function; therefore the zona glomerulosa is the only region of the adrenal cortex that does not atrophy on pituitary failure.
- Cortisol is the primary glucocorticoid in humans, and its secretion is under tight ACTH control.
- Pharmacologic manipulation of adrenal androgen production is an increasingly targeted strategy for treatment of advanced prostate cancer.
- Substances collectively known as *catecholamines*—epinephrine, norepinephrine, and dopamine—are produced from the amino acid tyrosine and modulate the systemic stress response.

Adrenal Disorders

Disorders of Increased Adrenal Function

Cushing Syndrome

Overview and Epidemiology.

Hypercortisolism secondary to excessive production of glucocorticoids by the adrenal cortex is defined as Cushing syndrome (Orth and Liddle, 1971). The disease is rare and occurs in 2 to 5 of every 1 million people per year (Lindholm et al., 2001; Findling and Raff, 2005). Diagnosis and treatment of Cushing syndrome is multifaceted, often requiring cooperation of internists, endocrinologists, neurosurgeons, and adrenal surgical experts (Newell-Price et al., 2006). The urologist must understand the comprehensive pathophysiology of hypercortisolism and have particularly advanced expertise in the aspects of this complex disease for which adrenalectomy is required.

Pathophysiology.

The zona fasciculata of the adrenal cortex secretes up to 20 mg of cortisol every day (Arlt and Stewart, 2005). Regulation of this secretion is controlled through the hypothalamic-pituitary-adrenal (HPA) axis (Jacobson, 2005). A fluent understanding of this classic neuroendocrine negative feedback system is critical for the successful management of the patient with Cushing syndrome.

Normal Hypothalamic-Pituitary-Adrenal Axis Physiology.

Corticotropic cells of the anterior pituitary gland secrete ACTH, also known as *corticotropin,* under the influence of neuronal innervations from the hypothalamus. Synthesis of ACTH is a result of cleavage of the pro-opiomelanocortin (POMC) precursor molecule. Physiologically, the most important promoter of ACTH release is corticotropin-releasing hormone (CRH), but oxytocin and vasopressin also play a role (Jacobson, 2005; Sam and Frohman, 2008). **Stress, whether physiologic or psychological, appears to be the most important variable in modulating activity of the HPA axis** (Jacobson, 2005).

ACTH not only is responsible for promoting production of glucocorticoids and androgens by the adrenal cortex, but it also plays a critical role in maintaining adrenal cortical vitality. Indeed, without ACTH (e.g., when its secretion is suppressed by exogenous steroid intake), all but the mineralocorticoid-producing cells of the adrenal cortex arrest hormone production and undergo apoptosis (Arlt and Stewart, 2005; Jacobson, 2005). In addition to ACTH, splanchnic nerves that innervate the adrenal glands also appear to affect glucocorticoid production (Jacobson, 2005).

Glucocorticoids bind receptors in the hypothalamus and the pituitary gland and complete the negative feedback loop by inhibiting production of CRH and ACTH by these structures, respectively (Jacobson, 2005). Fig. 106.5 summarizes the salient features of the HPA axis.

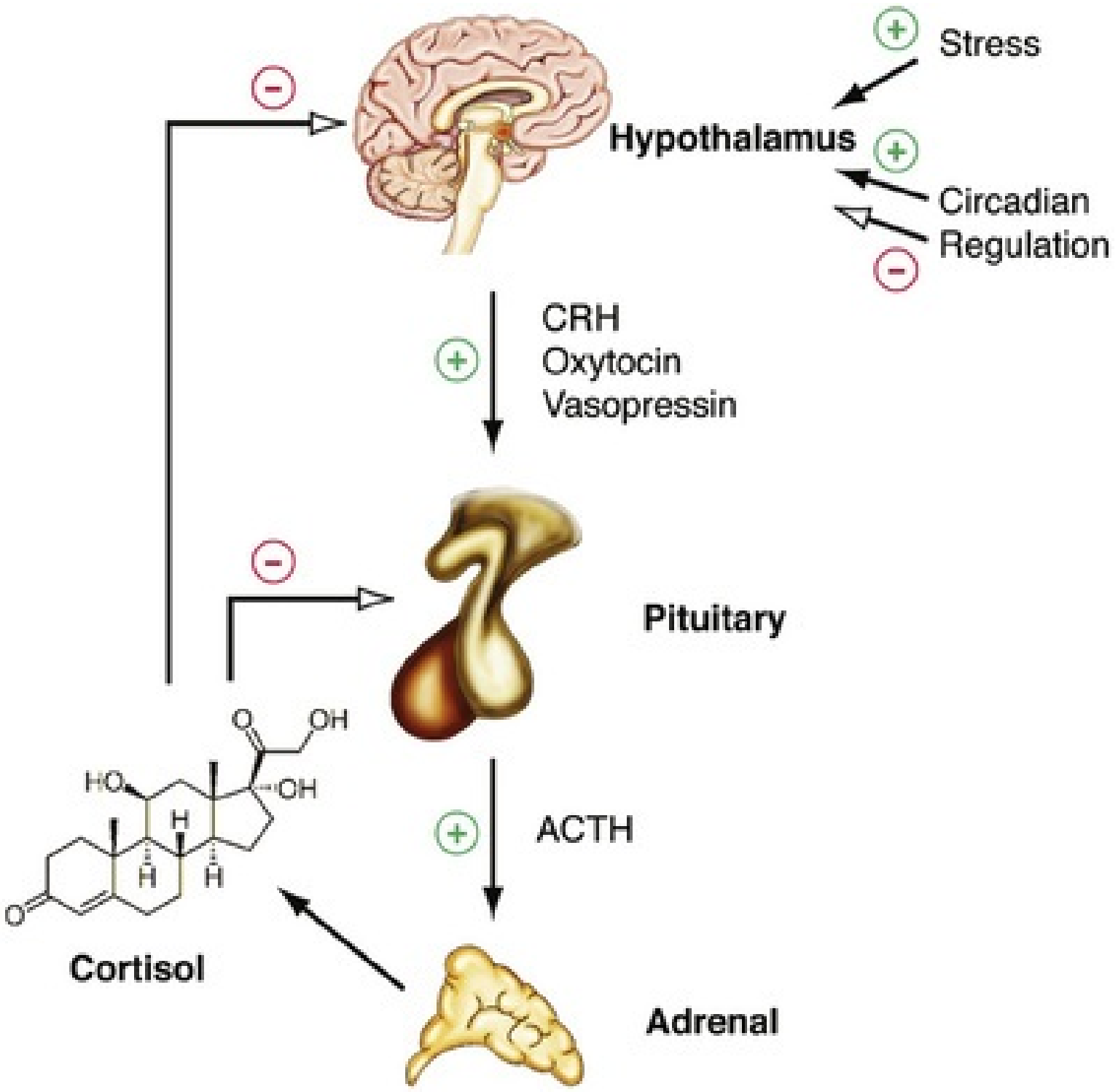

FIG. 106.5 The hypothalamic-pituitary-adrenal axis and feedback loop. *ACTH,* Adrenocorticotropic hormone; *CRH,* corticotropin-releasing hormone.

It is important to understand that CRH secretion is under tight control of the hypothalamic suprachiasmatic nucleus and follows circadian patterns. The highest level of cortisol in healthy subjects is detected in the mornings, and the nadir is observed at approximately 11 PM. Even small perturbations of this physiologic rhythm are considered pathologic (Jacobson, 2005; Sam and Frohman, 2008).

Overview of Cushing Syndrome.

Given the sophistication of the HPA axis, hypercortisolism can result from a number of different pathologies that result in oversecretion of cortisol by the adrenal glands. **Causes of Cushing syndrome can be divided into three main groups: (1) exogenous, (2) ACTH dependent, and (3) ACTH independent (Fig. 106.6).** Exogenous Cushing syndrome is a result of iatrogenic glucocorticoid administration. ACTH-dependent disease results from an elevated serum corticotropin level caused by pathology extrinsic to the adrenal gland and accounts for up to 85% of cases of endogenous Cushing syndrome. **ACTH-independent hypercortisolism, on the other hand, results from unregulated overproduction of glucocorticoids by the adrenal gland(s) and is relatively rare.** The adrenal surgeon has long been involved in management of ACTH-independent disease, but with the advent of laparoscopy, adrenal surgery for ACTH-dependent Cushing syndrome now also has a limited role (Porterfield et al., 2008).

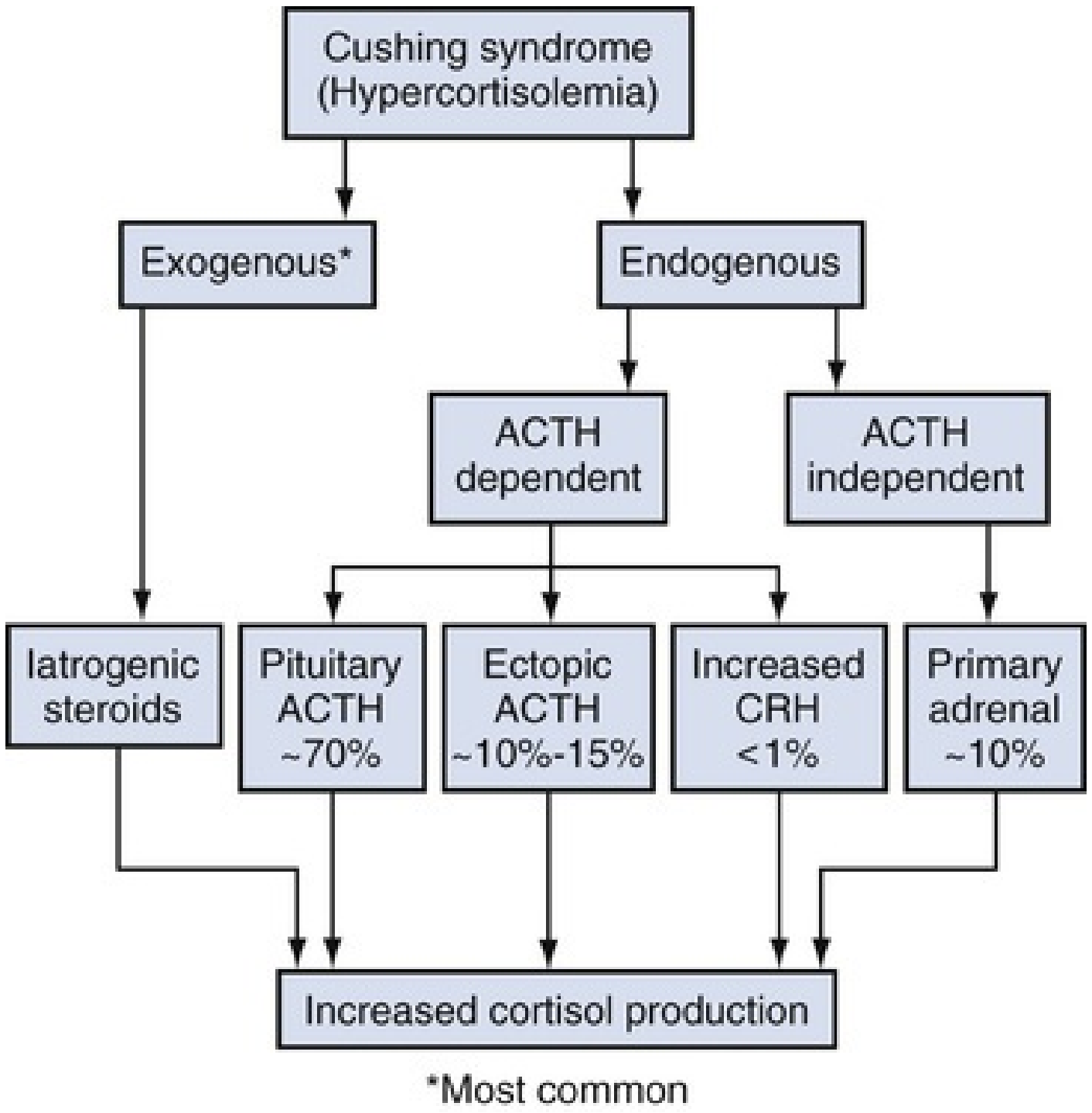
Cushing syndrome
(Hypercortisolemia)
Exogenous*
Endogenous
ACTH dependent
ACTH independent
Iatrogenic steroids
Pituitary ACTH ~70%
Ectopic ACTH ~10%-15%
Increased CRH <1%
Primary adrenal ~10%
Increased cortisol production
*Most common

FIG. 106.6 Clinically relevant causes of excess cortisol production. *ACTH,* Adrenocorticotropic hormone; *CRH,* corticotropin-releasing hormone.

Exogenous Cushing Syndrome.

Exogenous Cushing syndrome is the most common cause of hypercortisolism in patients of the Western world (Newell-Price et al., 2006). Synthetic glucocorticoids are frequently used in treatment of many conditions, and Cushing syndrome can result from the administration of even low doses of exogenous steroids orally, topically, or by inhaled preparations (Hopkins and Leinung, 2005; Newell-Price et al., 2006). A careful patient history is therefore essential in the evaluation of all patients with Cushing syndrome. The clinician also must be cognizant of the possibility that the patient either is unaware of his or her steroid use (e.g., use of herbal remedies, nasal sprays) or is surreptitiously self-administering glucocorticoids (e.g., for performance enhancement) (Hopkins and Leinung, 2005).

Adrenocorticotropic Hormone–Dependent Cushing Syndrome

Overview.

ACTH-dependent hypercortisolism accounts for 80% to 85% of endogenous Cushing syndrome. Approximately 80% of ACTH-dependent disease results from primary pituitary pathology and is known as *Cushing disease*. Ectopic ACTH production is the other main cause of ACTH-dependent hypercortisolism (Newell-Price et al., 2006). Ectopic CRH syndrome is a third cause of ACTH-dependent Cushing syndrome and is extremely uncommon (see Fig. 106.6) (Orth, 1995).

Cushing Disease.

Described by the neurosurgical pioneer Harvey Cushing in 1932, Cushing disease causes hypercortisolism through excessive secretion of ACTH by the pituitary gland (Cushing, 1932). The condition accounts for nearly 70% of endogenous Cushing syndrome. The most common culprit is a corticotropin-producing microadenoma. Large macroadenomas 1 cm or greater are found in only about 5% of cases (Newell-Price et al., 2006). Fifteen percent of functional pituitary adenomas exhibit the ability to secrete ACTH (Shimon and Melmed, 1998). Hyperplasia of ACTH-producing cells and pituitary carcinoma can also oversecrete ACTH but are extremely rare (Orth, 1995). Up to two-thirds of individuals with Cushing disease are female (Scott and Orth, 1990).

Ectopic Adrenocorticotropic Hormone Syndrome.

Production of ACTH by nonpituitary tumors can also result in

hypercortisolism. These corticotropin-producing tissues are nearly always malignant and account for approximately 10% of Cushing syndrome (Porterfield et al., 2008). Liddle et al. first described the phenomenon in the early 1960s and termed it *ectopic ACTH syndrome* (Meador et al., 1962; Scott and Orth, 1990). The timing and onset of hypercortisolism varies and can precede the diagnosis of an extra-adrenal malignancy by many years, resulting in diagnostic difficulties and the clinical conundrum wherein a subclinical pituitary adenoma is suspected but not radiographically identified (Aniszewski et al., 2001). Moreover, hypercortisolism in end-stage debilitated cancer patients is almost certainly underdiagnosed (Orth, 1995). As a result of higher ACTH levels, the adrenal glands of patients with ectopic ACTH syndrome are usually more markedly hyperplastic and thereby larger than those of patients with Cushing disease (Fig. 106.7) (Jenkins et al., 1999). Table 106.4 summarizes primary malignancies implicated in ectopic ACTH production, which notably includes pheochromocytoma.

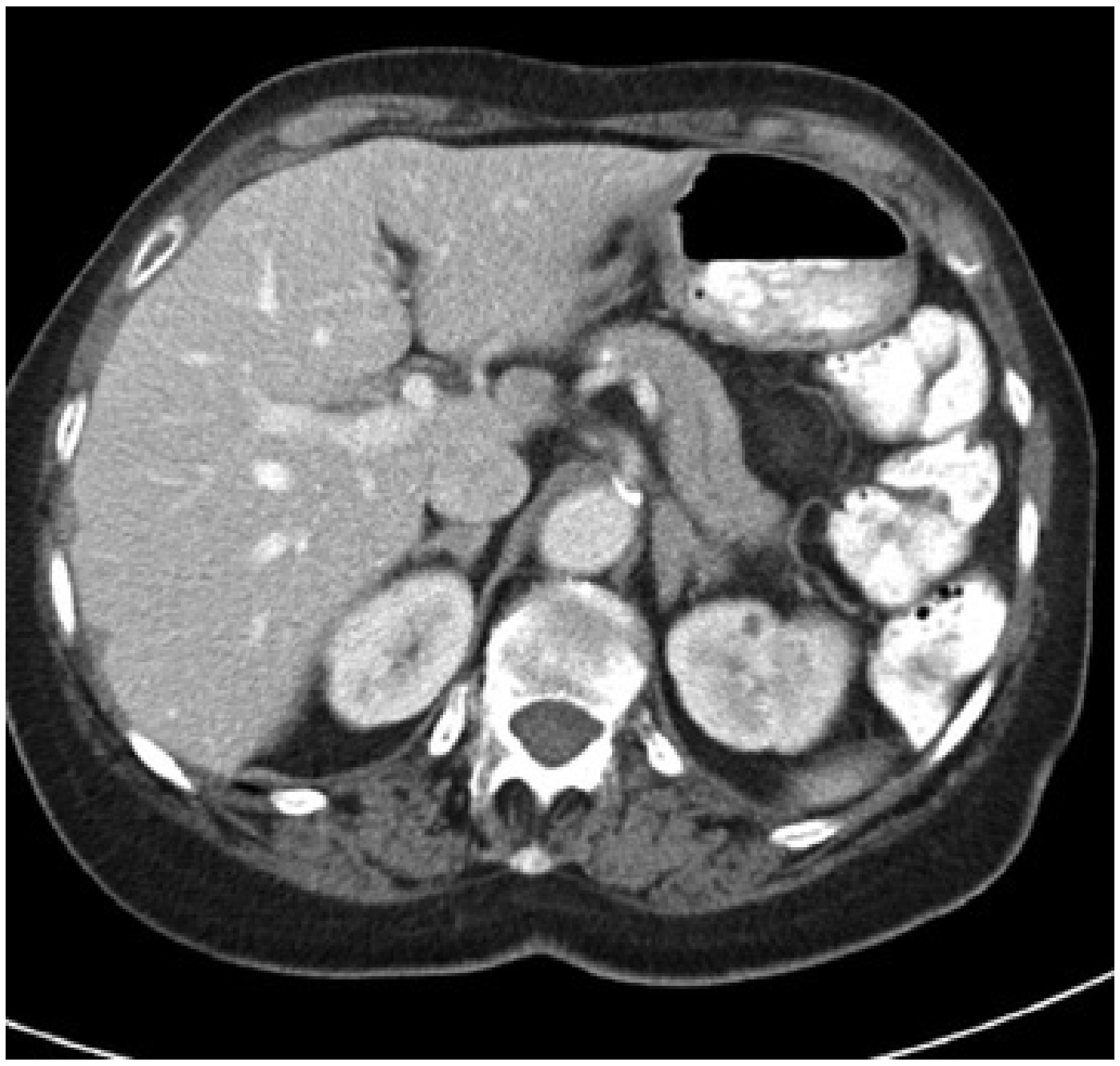

FIG. 106.7 Bilateral adrenal enlargement in a patient with advanced metastatic adenocarcinoma of the pancreas.

TABLE 106.4

Sources of Ectopic Adrenocorticotropic Hormone

PARAMETER	**CURRENT STUDY**	**FINDLING AND TYRRELL, 1986**[a]	**IMURA ET AL., 1975**	**DOPPMAN ET AL., 1989**	**HOWLETT ET AL., 1986**
Number of patients	106	49	30	28	16
No tumor found (%)	16	12		32	
Islet cell tumor (%)	16	4	7	11	13
Bronchial carcinoid tumor (%)	25	49	7	46	38
Thymic carcinoid tumor (%)	5	16			13
Medullary thyroid cancer (%)	8				
Disseminated neuroendocrine tumor (%)	7				
Disseminated gastrointestinal carcinoid tumor (%)	1				
Small cell lung cancer (%)	11	10	33		19
Miscellaneous (%)	8	6	17		13[b]
Pancreatic adenocarcinoma (%)		2			
Adenocarcinoma of the bronchus (%)			10		
Squamous cell carcinoma of the bronchus (%)			3		
Undifferentiated carcinoma of the bronchus (%)			10		
Malignant thymoma (%)			13		
Pheochromocytoma (%)	3			11	6
Total	100	100	100	100	100

[a] Includes a literature review.

[b] Carcinoid of the gallbladder and colon cancer.

Modified from Aniszewski JP, Young WF Jr, Thompson GB, et al. Cushing syndrome due to ectopic adrenocorticotropic hormone secretion. *World J Surg* 25(7):934–940, 2001.

Ectopic Corticotropin-Releasing Hormone.

Production of CRH by malignancies is extremely rare and is responsible for less than 1% of cases of Cushing syndrome. Bronchial carcinoma is the most common culprit, and concurrent ACTH secretion is not unusual (Carey et al., 1984; Orth, 1995).

Adrenocorticotropic Hormone–Independent Cushing Syndrome.

Uncontrolled hypersecretion of cortisol by adrenal tissues accounts for a minority of endogenous hypercortisolism and is classified as ACTH-independent Cushing syndrome. Adrenal neoplasms and rare forms of bilateral adrenal disease are responsible for this group of conditions (Lacroix and Bourdeau, 2005; Newell-Price et al., 2006).

Adrenal Tumors.

Cortisol-secreting benign adenomas of the adrenal gland are responsible for approximately 10% of Cushing syndrome and often result from a dominant unilateral hyperplastic nodule, although multifocal bilateral functional adrenal hyperplasia may also occur. Less than 10% of adrenal masses are bilateral and often present a diagnostic challenge (Lacroix and Bourdeau, 2005; Pasternak et al., 2015; Porterfield et al., 2008; Young et al., 2008). Radiographically undetectable benign adrenal cortisol-producing lesions may also be responsible for cases of subclinical Cushing syndrome (Rossi et al., 2000). Cortisol production by adrenocortical carcinomas (ACCs) accounts for approximately 8% of patients with Cushing syndrome and appears to be an independent predictor of poor outcome for patients with ACC (Berruti et al., 2014; Kim et al., 2016; Lindsay and Nieman, 2005a). The Cushingoid phenotype resolves for most patients within 7 to 9 months after adrenalectomy; however, it can persist for several years in some individuals (Sippel et al., 2008).

Adrenocorticotropic Hormone–Independent Macronodular Adrenal Hyperplasia.

ACTH-independent bilateral macronodular adrenal hyperplasia (AIMAH) gives rise to less than 1% of Cushing syndrome cases. The condition is characterized by multiple large (up to 4-cm) nodules replacing the glands, with each adrenal gland weighing over 60 g (Iacobone et al., 2008; Lacroix and Bourdeau, 2005).

Weights in excess of 200 g have been reported for each gland affected by AIMAH (Swain et al., 1998). It is essential that this disease entity be distinguished from adrenal enlargement caused by chronic adrenal stimulation in ACTH-dependent Cushing syndrome; radiographic images of the adrenal glands appear similar in both conditions. Bilateral macronodular hyperplasia is observed as a feature of the McCune-Albright syndrome, which also includes polyostotic fibrous dysplasia, dermatologic manifestations, and other endocrine abnormalities (Lacroix and Bourdeau, 2005).

Primary Pigmented Nodular Adrenocortical Disease.

Like AIMAH, primary pigmented nodular adrenocortical disease (PPNAD) is exceedingly rare, accounting for less than 1% of cases of Cushing syndrome. Unlike AIMAH, however, the adrenal glands in this condition remain normal in size and exhibit black or brown cortical nodules (Young et al., 1989). The cortical tissue surrounding the nodules is atrophic, and the adrenal medulla is free from disease (Lacroix and Bourdeau, 2005). Approximately one-half of PPNAD cases are found in patients with the autosomal dominant Carney complex, which is also responsible for spotty skin and mucous membrane lesions, and a variety of neoplasms that include Sertoli cell tumors. The other half of cases of PPNAD are nonhereditary with no known cause (Lacroix and Bourdeau, 2005).

Clinical Characteristics

Classical Cushing Syndrome.

Clinical characteristics of Cushing syndrome vary considerably among affected patients. Many of the classic symptoms of hypercortisolism, such as central obesity, moon facies, buffalo hump, proximal muscle weakness, easy bruisability, and abdominal striae, are nonspecific. It is the combination of these and other clinical signs that should raise suspicion and prompt potential screening for Cushing syndrome (Findling and Raff, 2005)**. Cushing syndrome also results in systemic symptomatology that is identical to the highly-prevalent metabolic syndrome, such as central obesity, dyslipidemia, insulin resistance, and hypertension** (Pivonello et al., 2005, 2008). Fig. 106.8 depicts the effects of glucocorticoids on organ systems, and Table 106.5 summarizes signs and symptoms of the disease and indicates their frequency. Screening for Cushing syndrome is usually beyond the scope of urologic practice; however, it is important for urologists to appreciate the **relatively common occurrence of hypogonadal hypogonadism in men with Cushing syndrome.** A low threshold for initiating a hypercortisolism workup should exist for these men with libido or erectile problems, low testosterone, and low gonadotropin levels (Findling and Raff, 2005; Pivonello et al., 2008). **Up to 50% of patients with Cushing syndrome exhibit urolithiasis;** therefore stone formers with cushingoid features also should receive a hypercortisolemia evaluation. It is interesting to note that definitive treatment of Cushing syndrome in these patients reduces the risk for stone formation but does not bring the risk back to that of the general population (Faggiano et al., 2003; Rahman et al., 2016).

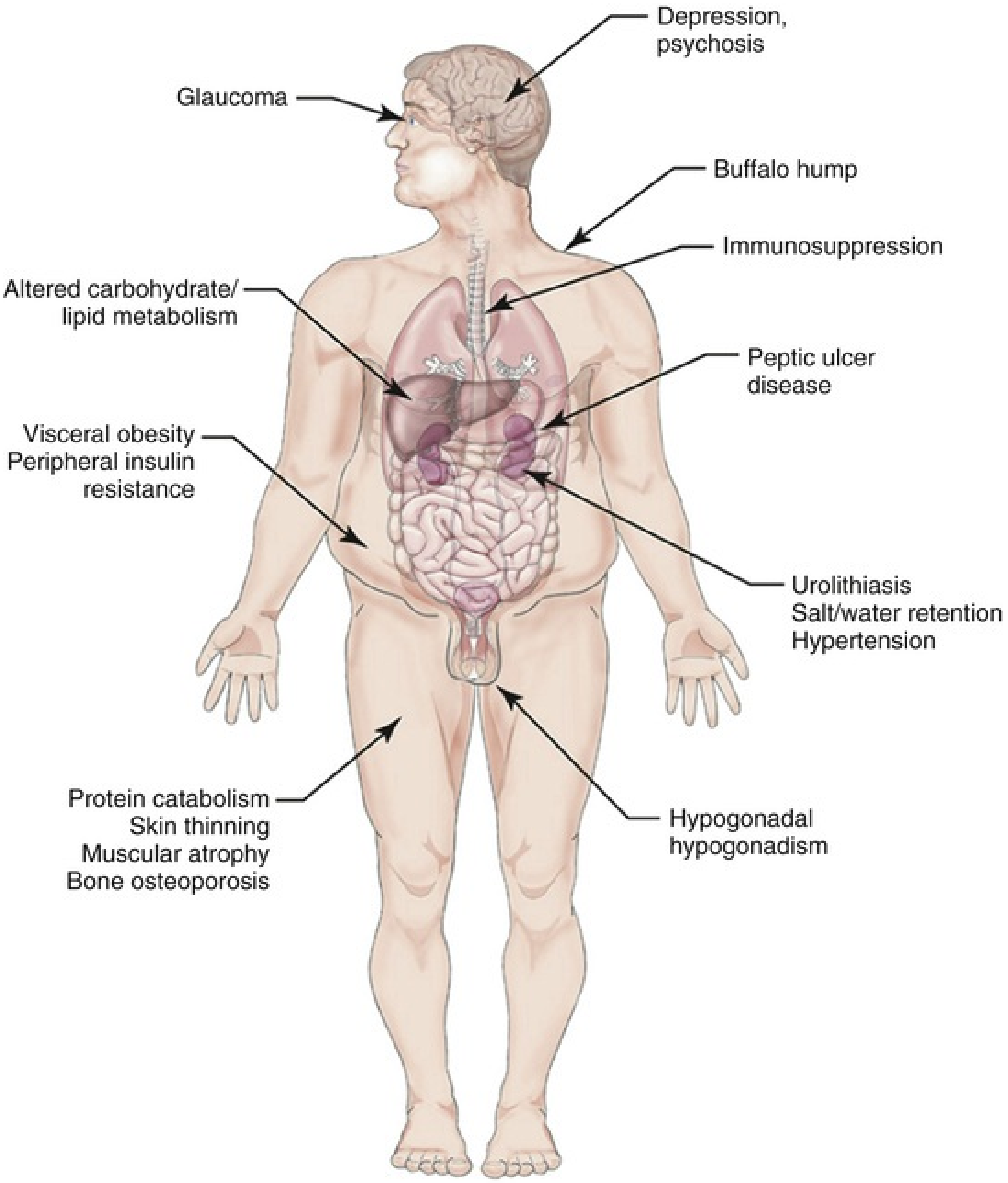
Depression, psychosis
Glaucoma
Buffalo hump
Immunosuppression
Altered carbohydrate/ lipid metabolism
Peptic ulcer disease
Visceral obesity
Peripheral insulin resistance
Urolithiasis
Salt/water retention
Hypertension
Protein catabolism
Skin thinning
Muscular atrophy
Bone osteoporosis
Hypogonadal hypogonadism

FIG. 106.8 Diverse effects of hypercortisolism on organ systems.

TABLE 106.5

Signs and Symptoms of Cushing Syndrome

SYMPTOMS AND SIGNS	PREVALENCE (%)
Central obesity	90–100
Rounded face (“moon face”)	
Facial plethora	
Decreased libido	

Purple striae	70–90
Menstrual disturbances	
Hirsutism	
Erectile dysfunction	
Hypertension	
Muscle weakness	50–70
Posterior neck fat deposit (“buffalo hump”)	
Body bruising	
Glucose intolerance, diabetes	
Osteopenia, osteoporosis	
Emotional lability, depression	
Headache	20–50
Backache	
Limb edema	
Recurrent infections	
Hypokalemic alkalosis	
Nephrolithiasis	
Acne	0–20
Alopecia	

Modified from Pivonello R, De Martino MC, De Leo M, et al. Cushing's syndrome. *Endocrinol Metab Clin North Am* 37(1):135–149, ix, 2008.

Autonomous Cortisol Secretion (Subclinical Cushing Syndrome).

Hypercortisolemia (>1.8 µg/dL AM cortisol on overnight low-dose dexamethasone suppression testing [LD-DST]) in the absence of an overt cushingoid phenotype classically has been termed *subclinical Cushing syndrome.* Obvious clinical signs of Cushing syndrome are absent, and the diagnosis is made when a metabolic workup for an incidentally discovered adrenal mass reveals hypercortisolemia (Sippel and Chen, 2004). In the past, the disease entity was referred to as *pre-Cushing syndrome, noncushingoid Cushing syndrome, preclinical Cushing syndrome, subclinical autonomous glucocorticoid hypersecretion,* and *subclinical Cushing syndrome;* however, in 2016 the Clinical Practice Guidelines from the European Society of Endocrinology and the European Network for the Study of Adrenal Tumors recommended the term *autonomous cortisol secretion* (Fassnacht, et al., 2016). Nevertheless, the term *subclinical Cushing syndrome* continues to be used in the literature (Yanase et al., 2018). Classically, the disease entity applies to patients who are found to have elevated cortisol levels on a metabolic workup of an adrenal incidentaloma.

Nearly 10% of patients in one large series of adrenal incidentalomas were found to have the condition (Mantero et al., 2000). Patients can also fall under the umbrella of this diagnosis when Cushing syndrome is discovered during screening. For instance, when patients with type 2 diabetes and poor glucose control are screened for hypercortisolism, some 2% have subclinical Cushing syndrome (Catargi et al., 2003).

Adrenalectomy in the setting of subclinical Cushing syndrome may improve glucose control and hypertension and result in weight loss (Midorikawa et al., 2001; Mitchell et al., 2007). However, patients with autonomous cortisol secretion are extremely unlikely to develop overt Cushing syndrome (Fassnacht, et al., 2016). Indeed, surgical indications and benefits for subclinical Cushing syndrome, however, are still a matter of debate (Sippel and Chen, 2004; Tsagarakis et al., 2006). Some authors have argued that adrenalectomy should be performed only in patients who are potentially symptomatic and exhibit clinical signs, such as hypertension, obesity, glucose intolerance, or osteopenia. Others propose that surgery must be offered to all patients to prevent the sequelae of hypercortisolism (Pivonello et al., 2005; Sippel and Chen, 2004; Tsagarakis et al., 2006). Recent Clinical Practice Guidelines from the European Society of Endocrinology and the European Network for the Study of Adrenal Tumors recommend an “individualized approach” to patients with this condition when considering adrenalectomy. The guidelines stress that the ACTH-independent nature of hypercortisolemia needs to be confirmed before extirpative surgery. Meanwhile, these patients should be screened for diabetes mellitus and vertebral fractures (Fassnacht, et al., 2016). Patients with subclinical Cushing syndrome may be at higher risk for postadrenalectomy adrenal insufficiency than patients with non–cortisol-secreting adrenal pathologies, because functionality of the contralateral gland may be suppressed (Tsagarakis et al., 2006).

Diagnostic Tests.

The diagnosis of Cushing syndrome is one of the most complex and difficult tasks in clinical endocrinology and most often falls outside of the realm of medical or surgical urologic practice (Findling and Raff, 2005). Nevertheless, the urologist must be familiar with these diagnostic strategies and how they relate to the etiology of hypercortisolism. Moreover, the urologist who offers adrenalectomy must be well-versed in the basic metabolic evaluation for Cushing syndrome in patients with adrenal masses.

Establishing the Diagnosis of Cushing Syndrome.

When the diagnosis of Cushing syndrome is suspected, the clinician can choose among several laboratory studies. **The two evaluations performed most frequently are the 24-hour urinary free cortisol (UFC) evaluation and the overnight LD-DST. The sensitivity of the former test, however, may not be adequate for screening patients with incidentalomas** (Nieman et al., 2008). Late-night salivary cortisol is also used. Second-line tests include the 2-day LD-DST and midnight plasma cortisol testing (Arnaldi et al., 2003; Newell-Price et al., 2006; Nieman et al., 2008; Pivonello et al., 2008). The physiologic principles underlying these tests are important to understand and are described in this section (Findling and Raff, 2005). The Evaluation of Adrenal Lesions in Urologic Practice section at the end of this chapter outlines practical algorithms for the metabolic evaluation of adrenal lesions. Tests such as random serum cortisol, plasma ACTH level, urinary 17-ketosteroid level, insulin tolerance testing, and loperamide testing have fallen out of favor and are no longer recommended (Nieman et al., 2008).

Administration of low-dose dexamethasone followed by measurement of serum cortisol the next morning probes the patient's glucocorticoid negative feedback system. In subjects without hypercortisolism, dexamethasone acts on the corticotropic cells of the anterior pituitary gland, suppresses ACTH production, and thereby results in a reduction of serum cortisol levels (Findling and Raff, 2005). A key element to understanding this test is that despite the “low-dose” designation, the dose of dexamethasone administered for this study corresponds to threefold to fourfold levels of physiologic glucocorticoid. It is important to note that the exogenous dexamethasone is not detected by the serum cortisol assay. The fact that patients with ACTH-independent Cushing syndrome and those with ectopic ACTH secretion fail to suppress cortisol production during such testing is intuitive; however, the reason for the failure of patients with ACTH-producing pituitary adenomas (Cushing disease) to suppress cortisol secretion after low-dose dexamethasone administration is less obvious. The phenomenon is best understood by the relative insensitivity of pituitary adenomas to the inhibitory effects of glucocorticoid stimulation (Raff and Findling, 2003). In summary, a patient's failure to suppress cortisol levels after an overnight low-dose dexamethasone administration is indicative of Cushing syndrome. See the Evaluation of Adrenal Lesions in Urologic Practice section later in this chapter for a discussion of proposed cortisol level cutoffs. This test does not delineate the cause of hypercortisolism, but simply suggests its presence. Administration of low-dose dexamethasone over a 48-hour period is less practical and is reserved for second-line testing.

The UFC evaluation is a 24-hour direct measurement of free bioavailable cortisol. Unlike serum cortisol testing, which measures both free and bound cortisol, urinary cortisol measurements are independent from the variables that influence corticosteroid-binding globulin levels (Arnaldi et al., 2003). Moreover, the test is an integrated measurement of cortisol secretion over a 24-hour period. This feature of the study is critical, because serum cortisol levels exhibit some circadian variation, even in many patients with Cushing syndrome (Orth, 1995). **The urologist must be cognizant that this test may not possess sufficient sensitivity for diagnosis of subclinical Cushing syndrome, and the Endocrine Society recommends against it for metabolic evaluation of adrenal incidentalomas** (Nieman et al., 2008).

Late-night salivary cortisol and midnight plasma cortisol measurements take advantage of a common feature of all causes of Cushing syndrome—a perturbation and in some cases complete disruption in the diurnal variation of cortisol levels. The abnormality, even in very mild cases of Cushing syndrome, is the inability to suppress cortisol levels at night. As previously mentioned, peak morning cortisol levels in patients with Cushing syndrome are often within the normal range; however, persistent elevation at night may signal the loss of diurnal variance associated with Cushing syndrome. Although midnight plasma cortisol measurements are clinically impractical in an outpatient setting, late-night salivary cortisol measurements are becoming a popular diagnostic tool for identification of hypercortisolism (Findling and Raff, 2005; Raff and Findling, 2003).

It is important to note that other conditions can stimulate the HPA axis and emulate Cushing syndrome (Box 106.1); therefore endocrinologic expertise is recommended when definitively diagnosing hypercortisolism (Nieman et al., 2008).

Box 106.1

Causes of Hypercortisolism in the Absence of Cushing Syndrome

Some clinical features of Cushing syndrome may be present:

    - Pregnancy
    - Depression
    - Alcohol dependence
    - Glucocorticoid resistance
    - Morbid obesity
    - Poorly controlled diabetes mellitus
- Unlikely to have any clinical features of Cushing syndrome:
    - Physical stress (hospitalization, surgery, pain)
    - Malnutrition, anorexia nervosa
    - Intense chronic exercise
    - Hypothalamic amenorrhea
    - Corticosteroid-binding globulin excess (increased serum but not in urine cortisol)

Although Cushing syndrome is unlikely in these conditions, it may rarely be present. If there is a high clinical index of suspicion, the patient should undergo testing, particularly those within the first group.

Modified from Nieman LK, Biller BM, Findling JW, et al. The diagnosis of Cushing's syndrome: an Endocrine Society clinical practice guideline. *J Clin Endocrinol Metab* 93(5):1526–1540, 2008.

Identifying the Cause of Cushing Syndrome.

Once Cushing syndrome has been diagnosed, its cause must be localized. Because of the nuanced complexity of this process, some authors believe that this is best done by endocrinologists at major referral centers (Newell-Price et al., 2006). Briefly, the algorithm is as follows.

First, ACTH-dependent disease must be distinguished from the ACTH-independent causes. This is done by measurement of serum ACTH. Low serum ACTH points to ACTH-independent pathology, and abdominal imaging is indicated to identify the adrenal source. If the adrenal glands are unremarkable on cross-sectional imaging, exogenous steroids as a cause of Cushing syndrome, or much less commonly PPNAD, must be suspected (Arnaldi et al., 2003). It is interesting to note that the presence of PPNAD often can be confirmed by a delayed “paradoxic rise” in the 24-hour urinary cortisol sampling after dexamethasone administration (Lacroix and Bourdeau, 2005). Up to 10% of patients with adrenal Cushing syndrome have bilateral adrenal lesions (Lacroix, 2008). Adrenal venous sampling (AVS) may be helpful in this setting (Young et al., 2008).

The true diagnostic difficulty lies in distinguishing Cushing disease from the ectopic ACTH syndrome for patients who have high serum ACTH levels. This problem stems from the fact that both pituitary microadenomas and ACTH-producing tumors can be very difficult to localize with modern imaging. Meanwhile, incidental imaging findings in the lungs, pancreas, and pituitary gland are relatively common, often clouding the diagnostic waters (Newell-Price et al., 2006). For instance, 10% of the general population exhibit an abnormality on imaging of the pituitary gland, whereas some 50% of patients with Cushing disease have no abnormality on pituitary MRI (Arnaldi et al., 2003; Porterfield et al., 2008).

Direct measurements of ACTH in a downstream venous plexus that drains the pituitary gland—the inferior petrosal sinus—after CRH stimulation has become the gold standard approach for distinguishing ectopic ACTH production from Cushing disease. High levels of ACTH in the inferior petrosal sinus, when compared with those in peripheral blood, indicate Cushing disease, whereas levels similar to peripheral plasma suggest an ectopic ACTH source (Findling and Raff, 2006; Porterfield et al., 2008).

High-dose dexamethasone suppression testing (HD-DST) was used in the past to differentiate pituitary and ectopic ACTH sources, but the value of this test is limited. The study is based on the principle that high enough doses of dexamethasone should suppress ACTH production by pituitary adenomas, whereas ectopic ACTH production continues despite the high-dose glucocorticoid administration (Arnaldi et al., 2003). Unfortunately, it is now clear that some nonpituitary ACTH-producing tumors possess the glucocorticoid receptor and also reduce ACTH production on high-dose dexamethasone administration (Aron et al., 1997; Raff and Findling, 2003). Currently, HD-DST is not routinely used (Fig. 106.9) (Findling and Raff, 2006; Porterfield et al., 2008).

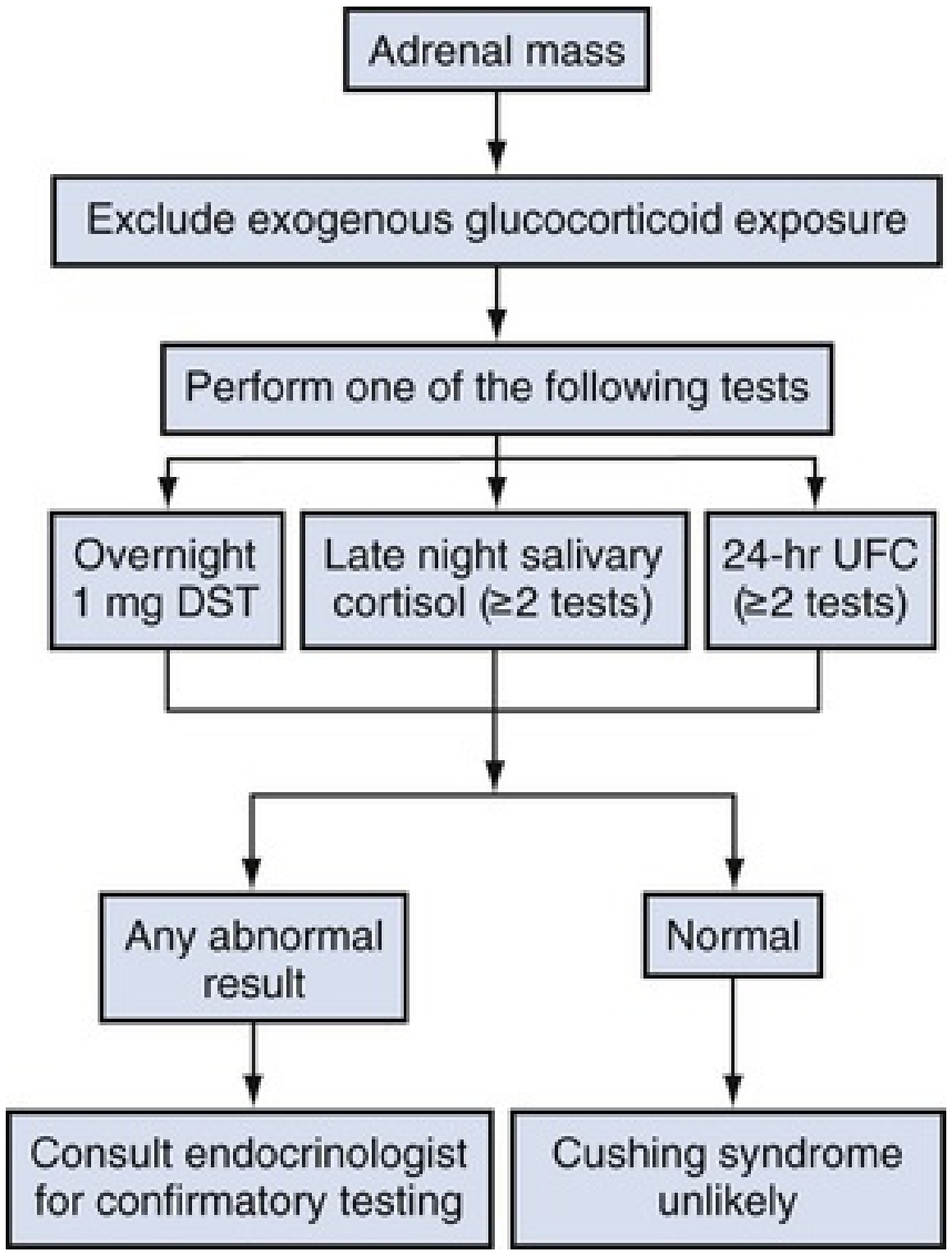
Adrenal mass
Exclude exogenous glucocorticoid exposure
Perform one of the following tests
Overnight 1 mg DST
Late night salivary cortisol (≥2 tests)
24-hr UFC (≥2 tests)
Any abnormal result
Normal
Consult endocrinologist for confirmatory testing
Cushing syndrome unlikely

FIG. 106.9 Testing algorithm for ruling out hypercortisolemia secondary to an adrenal mass. In case of a positive result during late-night salivary cortisol or 24-hour urinary free cortisol evaluations, repeat testing is often prudent. *DST,* Dexamethasone suppression test; *UFC,* urinary free cortisol.

Treatment.

The treatment of Cushing syndrome must be approached as a multidisciplinary endeavor. Primary care physicians, endocrinologists, neurosurgeons, and the adrenal surgical experts must effectively communicate not only with the patient but also with one another. Treatment goals involve correction of hypercortisolemia, restoration of the HPA axis, and management of Cushing syndrome sequelae (Porterfield et al., 2008).

Exogenous Cushing Syndrome.

Correction of exogenous Cushing syndrome, when appropriate, must be handled with proper care. Cessation of glucocorticoid administration must be gradual so that the HPA axis has ample time to recover. The process can take weeks to months and varies greatly from patient to patient. The physician must be aware of the clinical entity known as *steroid withdrawal syndrome*, wherein the patient cannot tolerate steroid dose reduction despite apparent normalization in HPA axis testing (Hopkins and Leinung, 2005).

Adrenocorticotropic Hormone–Dependent Disease

Cushing Disease.

The current standard of care for ACTH-secreting pituitary adenomas is trans-sphenoidal surgical resection (Fig. 106.10). Unfortunately, cure is seen in only 60% to 80% of patients (Newell-Price et al., 2006; Pivonello et al., 2008)**. Furthermore, long-term follow-up is necessary, because up to 25% of individuals relapse** (Patil et al., 2008). In addition, macroadenomas are resistant to neurosurgical treatment, and less than 15% of patients are cured after excision of tumors 1 cm or larger (Newell-Price et al., 2006). After resection, a severe addisonian state is common, and careful glucocorticoid replacement is necessary in the year after surgery (Utz et al., 2005). Hypopituitarism after resection of a pituitary adenoma is a known complication, with rates varying from less than 5% to more than 50% for the various pituitary metabolic products in various surgical series. Careful patient monitoring by expert endocrinologists is essential (Porterfield et al., 2008; Utz et al., 2005). Neurosurgical reoperation after initial failure is challenging, and success rates vary. Moreover, the risk for hypopituitarism also significantly rises with secondary resections (Porterfield et al., 2008; Utz et al., 2005). Salvage radiation therapy is an option, but the patient must be warned about significant delays in reduction of ACTH secretion and the possibility of hypopituitarism (Estrada et al., 1997; Porterfield et al., 2008; Utz et al., 2005).

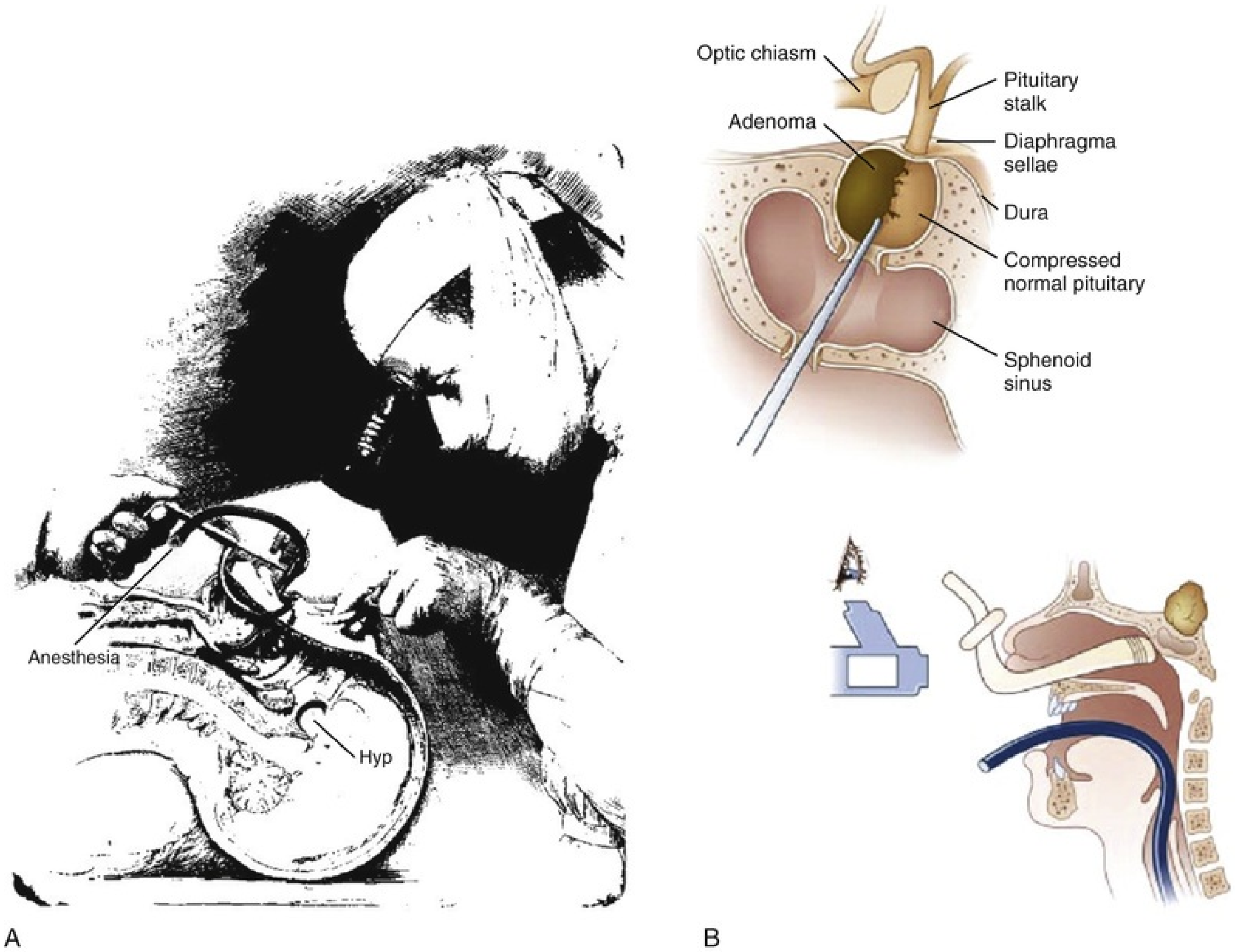

FIG. 106.10 (A) Harvey Cushing performing a trans-sphenoidal hypophysectomy. (B) Diagram of trans-sphenoidal access to the pituitary gland. *Hyp,* Hypothalamus. (From Schwartz SI, Fisher JE, Spencer FC, et al., eds. *Principles of surgery*. 7th ed. New York: McGraw-Hill; 1998; and Melmed S, Kronenberg HM. Anterior pituitary. In: Kronenberg HM, Melmed S, Polonsky KS, et al., eds. *Williams textbook of endocrinology*. 11th ed. Philadelphia, PA: Saunders; 2008.)

The urologist must be involved when adrenalectomy is contemplated or required. **Currently, bilateral adrenalectomy is most often recommended when at least one attempt to treat the primary tumor has failed. It is also necessary in rare instances when hypercortisolism is life-threatening and swift definitive treatment is mandatory.** The advantages of the procedure include a lack of postoperative hypopituitarism and an extremely high success rate with rapid resolution of hypercortisolism (Chow et al., 2008; Lacroix, 2008; Vella et al., 2001). Nevertheless, lifelong mineralocorticoid and glucocorticoid replacement is required in all patients. **Moreover, the patients are at risk for progressive growth of their pituitary adenoma, mainly resulting in complications such as ocular chiasm compression, oculomotor deficiencies,**

and, rarely, a rise in intracranial pressure (Assie et al., 2007)**. This is known as the Nelson-Salassa syndrome (also known as Nelson syndrome), which is found in 8% to 29% of patients who have undergone bilateral adrenalectomy in large series.** Prophylactic radiation therapy has been shown to prevent the phenomenon in some but not all published reports (Gil-Cárdenas et al., 2007). Routine use of prophylactic radiotherapy to prevent Nelson syndrome after bilateral adrenalectomy is controversial (Porterfield et al., 2008). **When counseling patients regarding bilateral adrenalectomy for ACTH-dependent Cushing syndrome, the urologist must also warn of the rare possibility of residual, functioning adrenal tissue remaining after the procedure** (Kemink et al., 1992).

Ectopic Adrenocorticotropic Hormone Syndrome.

Resection of the primary ACTH-producing tumor is the single best therapeutic approach to normalizing cortisol levels in patients with ectopic ACTH syndrome. In large series, however, primary tumor resection is possible in only approximately 10% of patients (Aniszewski et al., 2001). **For patients with unresectable primary tumors or whose primary ACTH-producing tissue cannot be identified (up to 35% of patients), bilateral adrenalectomy with lifelong replacement therapy is an excellent therapeutic option** (Aniszewski et al., 2001; Porterfield et al., 2008).

Adrenocorticotropic Hormone-Independent Disease.

Patients with unilateral cortisol-secreting adrenal masses are treated with ipsilateral adrenalectomy. Partial adrenalectomy is possible when preservation of adrenal tissue is deemed essential (Asher et al., 2011; Walz, 2004). Case reports of bilateral partial adrenalectomies for cortisol-producing masses exist in the literature (Inoue et al., 2006). The current standard of care for AIMAH and PPNAD patients is bilateral adrenalectomy with lifelong replacement therapy. Success with unilateral resection of the largest gland in AIMAH patients also has been reported (Iacobone et al., 2008).

Medical Treatment of Hypercortisolism.

Medical therapy for hypercortisolism is used for bridging a patient to surgery or when surgical intervention is not possible. Medications that block enzymes of steroid synthesis, such as metyrapone, aminoglutethimide trilostane, ketoconazole, and etomidate, are often used. Mitotane, a medication that is discussed in further detail in the Adrenal Carcinoma section later in this chapter, can also be used (Porterfield et al., 2008). Medical treatment of hypercortisolemia requires significant expertise and should be left to expert endocrinologists.

Prognosis.

Life expectancy for patients with Cushing syndrome falls short of that of patients with normal cortisol levels. Normalization of hypercortisolemia may reduce but not eradicate this risk (Pivonello et al., 2005; Swearingen et al., 1999). Aggressive management of cardiovascular risk factors under the watchful eyes of experienced medical experts is paramount, even in patients whose laboratory values return to normal after successful treatment.

Summary.

Cushing syndrome is a complex disorder that requires a multidisciplinary approach. The urologist plays a critical role in management of the hypercortisolemic patient when unilateral or bilateral adrenalectomy is required. A thorough understanding of relevant pathophysiology is necessary not only for diagnosis and treatment, but also for appropriate perioperative counseling of patients with Cushing syndrome.

Key Points: Cushing Syndrome

- Serum cortisol levels are under tight control. In healthy subjects, peaks occur in the morning, and the nadir is observed at approximately 11 PM.
- Adrenal tumors that secrete cortisol cause ACTH-independent Cushing syndrome and account for approximately 10% of Cushing syndrome cases that are not caused by steroid intake.
- Patients with undiagnosed Cushing syndrome can have hypogonadal hypogonadism or urolithiasis on presentation to the urologist.
- Testing of adrenal masses for cortisol hypersecretion is mandatory.

Primary Aldosteronism

Overview and Epidemiology.

Dr. Jerome Conn first described primary aldosteronism in 1955 in a 34-year-old woman with hypertension and hypokalemia (Conn, 1955). Urine assays demonstrated a markedly elevated level of mineralocorticoid activity. The patient's condition greatly improved after the removal of a 4-cm unilateral adrenal tumor. Since this initial case report, several subtypes of primary aldosteronism that require distinct evaluation and treatment have been identified. Primary aldosteronism is the most common form of secondary hypertension, with a prevalence ranging from 3% to 13% of hypertensive patients in the primary care setting and up to 30% of hypertensive patients at tertiary referral centers; thus, it is important for urologists to be familiar with appropriate diagnostic and management strategies (Funder et al., 2016; Kayser et al., 2016).

Pathophysiology.

The RAAS is a key regulator of blood pressure and extracellular fluid volume (Fig. 106.11). The release of renin from the juxtaglomerular cells is the rate-limiting step in the RAAS cascade. Under normal physiologic conditions, renin release is stimulated by low renal perfusion pressure, increased renal sympathetic nervous activity, and low sodium concentration sensed by the macula densa (Gibbons et al., 1984). Renin then cleaves angiotensinogen to angiotensin I, which in turn is cleaved by angiotensin-converting enzyme (ACE) to angiotensin II. Angiotensin II both functions as a potent vasoconstrictor and triggers the release of aldosterone from the zona glomerulosa. Additional regulators of aldosterone release include potassium and ACTH. **In primary aldosteronism, aldosterone secretion is independent of the RAAS, and plasma renin levels will be suppressed. This finding is in contrast with patients who have secondary hyperaldosteronism, in whom elevated renin levels are the cause of elevations in aldosterone secretion. This distinction between plasma renin levels in primary and secondary hyperaldosteronism is a critical concept used when screening for primary aldosteronism (see the Diagnostic Tests section later in this chapter).**

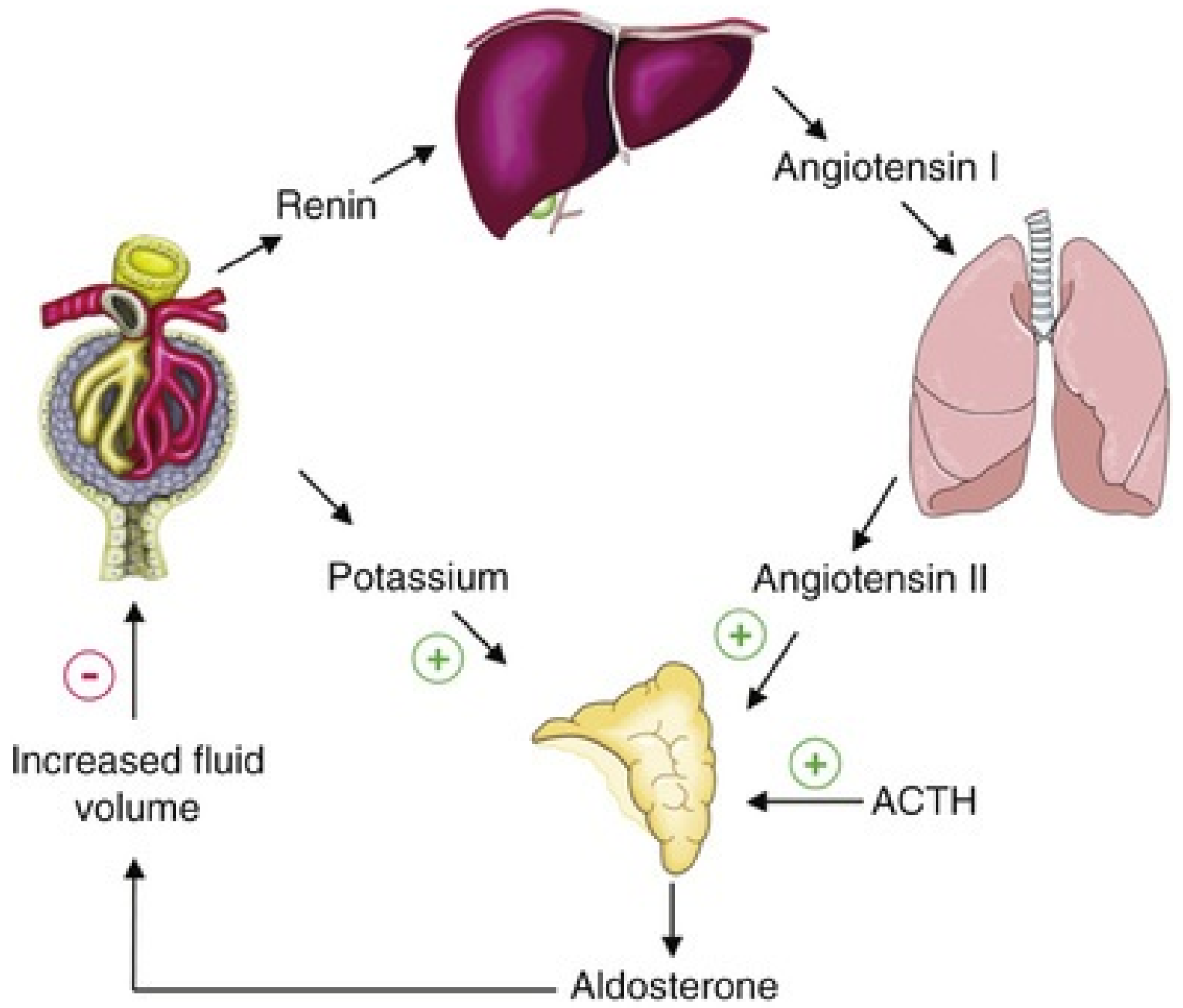

FIG. 106.11 Renin-angiotensin-aldosterone system. Under normal conditions, aldosterone secretion is under the control of angiotensin II, serum potassium levels, and adrenocorticotropic hormone (ACTH). In primary aldosteronism, aldosterone is autonomously released, resulting in decreased plasma renin levels.

After release from the adrenal cortex, aldosterone increases sodium reabsorption and potassium secretion in the distal nephron (Nyirenda and Padfield, 2007). Hypernatremia does not occur because sodium reabsorption is accompanied by water uptake, thereby maintaining isotonicity. The resultant volume expansion is limited by mineralocorticoid escape. Mineralocorticoid escape is mediated by pressure-natriuresis, atrial natriuretic peptide secretion, and changes in electrolyte transporters in the distal nephron, which result in limiting volume expansion to approximately 1.5 kg or less (Burnett et al., 1985; Knepper et al., 2003; Yokota et al., 1994).

Although the finding of increased plasma aldosterone and decreased plasma renin activity (PRA) is common to all patients with primary aldosteronism, individual subtypes of the disorder have distinct underlying pathophysiology. Differentiation between subtypes of primary aldosteronism is essential to ensure proper treatment. The causes of primary aldosteronism are presented in Fig. 106.12. Idiopathic hyperplasia and aldosterone-producing adenomas are by far the most common subtypes encountered, accounting for over 95% of cases. Although idiopathic hyperplasia is the most common subtype diagnosed, the prevalence of aldosterone-producing adenomas may be greater than previously thought because of a lack of routine lateralization studies in patients diagnosed with primary aldosteronism (Mulatero et al., 2004).

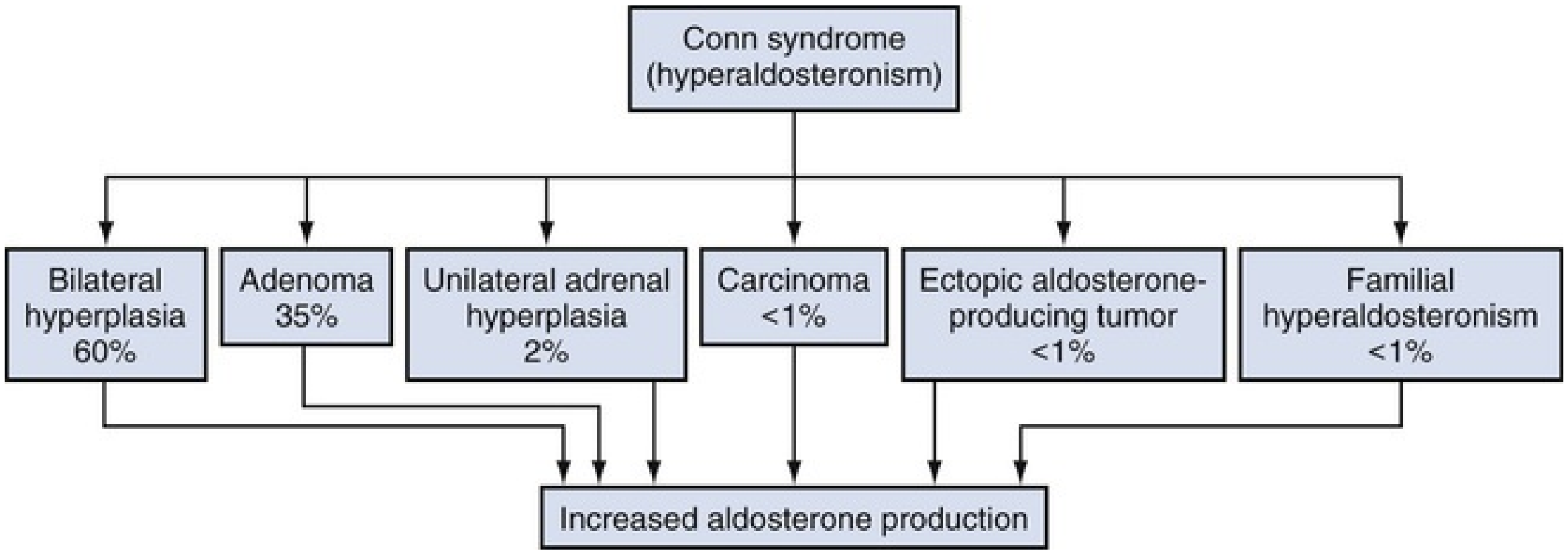
Conn syndrome (hyperaldosteronism)
Bilateral hyperplasia 60%
Adenoma 35%
Unilateral adrenal hyperplasia 2%
Carcinoma <1%
Ectopic aldosterone-producing tumor <1%
Familial hyperaldosteronism <1%
Increased aldosterone production

FIG. 106.12 Subtypes of primary aldosteronism. (Modified from Young WF. Primary aldosteronism: renaissance of a syndrome. *Clin Endocrinol [Oxf]* 66:607–618, 2007.)

The underlying pathophysiology of idiopathic hyperplasia, also referred to as *bilateral adrenal hyperplasia,* remains unknown. Macronodular hyperplasia is rare, with most cases attributed to micronodular hyperplasia (Schirpenbach and Reincke, 2007). Clinically, patients with idiopathic hyperplasia have less severe hypertension and are less likely to be hypokalemic compared with patients with aldosterone-producing adenomas (Rossi et al., 2006a). Whereas both adrenal glands are responsible for increased aldosterone production in idiopathic hyperplasia, unilaterally adrenalectomy is not therapeutic. Unilateral adrenal hyperplasia is distinctly uncommon but, when appropriately diagnosed, is potentially curable with adrenalectomy after confirmation of lateralizing aldosterone secretion (see the Subtype Differentiation section later in this chapter). In comparison with idiopathic hyperplasia, aldosterone-producing adenomas are associated with more profound hypertension and hypokalemia (Rossi et al., 2006a).

Less common causes of primary aldosteronism include ACCs, ectopic aldosterone-producing tumors, and familial hyperaldosteronism (FH). Primary aldosteronism associated with ACC is rare, representing less than 1% of primary aldosteronism cases and 2.5% to 5% of ACC cases (Ng and Libertino, 2003; Seccia et al., 2005). Ectopic aldosterone-producing tumors are extremely rare and should raise suspicion for the presence of accessory adrenal tissue or adrenal heterotopia (Abdelhamid et al., 1996).

Three types of FH have been described: type I, type II, and type III (Viola et al., 2013). FH type I, also known as glucocorticoid-remediable aldosteronism, is an autosomal dominant genetic disorder driven by the chimeric fusion of the promoter region of the 11β-hydroxylase gene *(CYP11B1)* and the coding region of the aldosterone synthase gene *(CYP11B2)*. This combination results in aldosterone synthase activity being controlled by ACTH. Thus aldosterone is secreted according to the circadian rhythm of ACTH instead of the RAAS (Lifton et al., 1992). Patients with FH type I will often have early-onset refractory hypertension and a family history of early-onset hypertension or cerebral vascular accidents (Litchfield et al., 1998; McMahon and Dluhy, 2004). FH type II is a genetically heterogeneous disease with an autosomal dominant inheritance pattern. Affected families will demonstrate either idiopathic hyperplasia or aldosterone-producing adenomas that are clinically and morphologically indistinguishable from sporadic cases of primary aldosteronism. Linkage analysis suggests that mutations in the 7p22 region are responsible for FH type II in some families (Mulatero et al., 2004; So et al., 2005). FH type III is characterized by bilateral adrenal hyperplasia, refractory hypertension, severe hypokalemia, and the overproduction of hybrid steroids (Geller et al., 2008). Genetic mutations of *KCNJ*, which encodes for a potassium channel, have been identified as the cause of FH type III (Charmandari et al., 2012; Mulatero et al., 2012). Genetic testing for FH type I is recommended for patients with a family history of primary aldosteronism or strokes at a young age, or with a diagnosis of primary aldosteronism at <20 years of age. Genetic testing for FH type III is recommended for patients diagnosed with primary aldosteronism at a very young age. Currently, there are no specific recommendations regarding indications for genetic testing for FH type II (Funder et al., 2016).

Clinical Characteristics.

The diagnosis of primary aldosteronism is usually made during the third to sixth decades of life in patients who are being evaluated for refractory hypertension. The degree of hypertension is typically graded as moderate to severe, with a mean blood pressure of 184/112 noted in a retrospective series of 262 patients with primary aldosteronism (Young and Klee, 1988). In the prospective series by Rossi et al., which evaluated the prevalence of primary aldosteronism in 1125 newly diagnosed hypertensive patients, the mean blood pressure (154/98) was significantly higher than in patients without primary aldosteronism (147/95) (Rossi et al., 2006a). The association between primary aldosteronism and the severity of hypertension has been demonstrated by Mosso et al., who noted a 2%, 8%, and 13% prevalence of primary aldosteronism in hypertensive patients stratified as stage 1 (140 to 159/90 to 99), stage 2 (160 to 179/100 to 109), and stage 3 (>180/>110) hypertension, respectively (Mosso et al., 2003).

Although hypokalemia has been classically described as a common finding in primary aldosteronism, in contemporary series 63% to 91% of newly diagnosed patients are normokalemic at the time of diagnosis (Mulatero et al., 2004). The incidence of hypokalemia has been associated with the subtype of primary aldosteronism, being noted in approximately 50% of patients with aldosterone-producing adenomas and only 17% of patients with idiopathic aldosteronism (Rossi et al., 2006a). In a minority of patients, hypokalemia is associated with symptoms including headache, polydipsia, palpitations, polyuria, nocturia, and muscle weakness (Young, 2007a). Because of mineralocorticoid escape, hypernatremia is an uncommon finding in primary aldosteronism, with serum sodium levels similar to those in other forms of hypertension (Rossi et al., 2006a; Young, 2007a).

Cardiovascular and renal damage is a concern for all patients with hypertension and underlies the need for treatment. The incidence and severity of target organ damage appears to be increased in patients with primary aldosteronism compared with other forms of hypertension (Mulatero et al., 2013). Cardiac abnormalities, including left ventricular filling and diastolic dysfunction, increased left ventricular mass measurement, and prolonged QT interval, have all been associated with primary aldosteronism (Rossi et al., 1996; Tanabe et al., 1997). These findings may help to explain the significant increase of cardiovascular events Milliez et al. (2005) noted in patients with primary aldosteronism. In a retrospective series of patients with hypertension, patients with primary aldosteronism were four times more likely to be diagnosed with stroke, 6.5 times more likely to be diagnosed with myocardial infarction, and 12 times more likely to be diagnosed with atrial fibrillation compared with patients with essential hypertension (Gonzaga and Calhoun, 2008; Milliez et al., 2005). The increased risk for cardiovascular disease may be associated with the increased prevalence of metabolic syndrome that has been noted in this patient population (Fallo et al., 2006). Fortunately, appropriate treatment of primary aldosteronism has been associated with left ventricular remodeling, which may decrease the risk for future cardiac events (Rossi et al., 2014). In addition, patients with primary aldosteronism demonstrate increased rates of proteinuria and development of type 2 diabetes when compared with patients who have essential hypertension (Fox et al., 2006; Mulatero et al., 2013; Rossi et al., 2006b).

Diagnostic Tests.

The diagnosis of primary aldosteronism requires screening, confirmatory testing, and subtype differentiation. Indications for screening are listed in Box 106.2. The accurate diagnosis and subtype differentiation of primary aldosteronism is critical because of the increased risk of target organ damage, proper selection of medical therapy, and potential for surgical cure in select patients.

Box 106.2

Indications for Primary Aldosterone Screening

Hypertension with hypokalemia
Resistant hypertension (three or more oral agents including a diuretic)
Controlled hypertension on four or more antihypertensives
Adrenal incidentaloma with hypertension
Hypertension with sleep apnea
Early-onset hypertension (<20 years) or stroke (<50 years)
Severe hypertension (≥150/≥100) measured on 3 different days
Whenever considering secondary causes of hypertension (i.e., pheochromocytoma or renovascular disease)
Unexplained hypokalemia (spontaneous or diuretic induced)
Evidence of target organ damage disproportionate to degree of hypertension
Hypertension with family history of primary aldosteronism

Modified from Funder JW, Carey RM, Mantero F, et al. The Management of Primary Aldosteronism: Case Detection, Diagnosis, and Treatment: An Endocrine Society Clinical Practice Guideline. *J Clin Endocrinol Metab* 101(5):1889–1916, 2016.

Screening.

Before screening is initiated, hypokalemia should be corrected and all contraindicated medications discontinued. Although patients can continue the majority of antihypertensive agents during screening, mineralocorticoid receptor antagonists are contraindicated and should be stopped at least 4 weeks before testing (Funder et al., 2016). Patients requiring these agents for control of severe hypertension should be transitioned to agents such as α_1-receptor blockers or long-acting calcium channel blockers, with minimal effects on screening test results (Rossi et al., 2008). Other antihypertensive agents can alter screening values, but not to the extent that mandates their discontinuation (see Fig. 106.32, later). Additionally, patients should be encouraged to liberalize sodium intake and avoid taking products derived from licorice root (chewing tobacco and licorice) (Funder et al., 2016; Li et al., 2016).

Screening for primary aldosteronism begins by obtaining a morning (between 8 and 10 AM) plasma aldosterone concentration (PAC) and PRA or direct renin concentration (DRC) (Funder et al., 2008). From these tests, the PAC and aldosterone-to-renin ratio (ARR) are used to screen for autonomous aldosterone secretion. Whereas the ARR is dependent on PRA/DRC, it is recommended that the lowest PRA/DRC value be set at 0.2 ng/mL/h to avoid falsely elevated ratios (Rossi et al., 2006a). The PACs and ARRs that define a positive screen and suggest the diagnosis of primary aldosteronism are subject to laboratory variability thus, standard thresholds have not been established. Reported sensitivities and specificities for use of ARRs in screening for primary aldosteronism range from 66% to 100% and 61% to 96%, respectively (Jansen et al., 2014; Li et al., 2016). The National Institutes of Health (NIH) consensus statement (2002) on the management of the clinically inapparent adrenal mass suggests cutoffs of greater than 30 ng/dL for the ARR and greater than 20 ng/dL for the PAC. However, other institutions have recommended lowering the cutoffs to greater than 20 ng/dL and greater than 15 ng/dL, respectively (Rossi et al., 2008; Young, 2007a). Although lowering the thresholds for a positive screening test result may increase the rate of false positives, all positive test results must be confirmed with further testing before the diagnosis of primary aldosteronism is made (Funder et al., 2016).

Confirmatory Testing.

After a positive screening test result, a confirmatory test should be performed before the diagnosis of primary aldosteronism is secured in most cases because of known variability of aldosterone and PRA levels secondary to day-to-day oscillation, posture, diet, and antihypertensives (Funder et al., 2016). Of patients with positive screening test results, only 50% to 87% will be diagnosed with primary aldosteronism on confirmatory testing (Giacchetti et al., 2006; Mosso et al., 2003; Nanba et al., 2012; Seiler et al., 2004). In cases of hypertension with spontaneous hypokalemia, plasma renin levels below the detection level, and PAC >20 ng/dL, confirmatory testing may be omitted (Funder et al., 2016). As with screening for primary aldosteronism, proper patient preparation is required, with the correction of hypokalemia and discontinuation of mineralocorticoid receptor antagonists. Of the confirmatory tests available, the majority evaluate the suppression of aldosterone after sodium loading. The underlying theory behind the sodium loading tests is that loading will decrease plasma renin and aldosterone production in patients without autonomous aldosterone secretion (Mattsson and Young, 2006). Additional confirmatory tests, including the captopril suppression test, furosemide-upright test, and ACTH stimulation test, have been described but are not widely accepted or used (Hirohara et al., 2001; Sonoyama et al., 2011). Selection of the confirmatory test used depends on individual patient characteristics and physician preferences as no single test has been demonstrated to be superior. Blood pressure should be monitored closely in all patients during confirmatory testing (Funder et al., 2016).

The fludrocortisone suppression test requires the administration of the synthetic mineralocorticoid fludrocortisone (0.1 mg every 6 hours) and sodium chloride (2 g every 8 hours) for 4 days. After 4 days of fludrocortisone and sodium loading, PAC is measured in the upright position. Failure to suppress PAC to less than 6 ng/dL is diagnostic of primary aldosteronism. Once considered the gold standard in the diagnosis of primary aldosteronism, the fludrocortisone suppression test has been supplanted by the oral sodium loading test and the intravenous infusion test because of the risk for severe hypertension and hypokalemia (Schirpenbach and Reincke, 2007).

The oral sodium loading test is conducted by administering a high-sodium diet for 3 days, followed by 24-hour urine measurements of aldosterone, sodium, and creatinine. Supplemental sodium chloride can be given to ensure the intake of at least 12.8 g of sodium per day. Twenty-four-hour sodium should be greater than 200 mmol to ensure adequate sodium loading. The diagnosis of primary aldosteronism is then made when the 24-hour aldosterone is greater than 12 μg/day.

The intravenous saline infusion test spares the patient from several days of sodium loading by the administration of 2 L of 0.9% sodium chloride intravenously over 4 hours. The infusion is performed in the morning after an overnight fast while the patient is in a recumbent position. After the intravenous infusion of saline, PAC is measured; a level greater than 5 ng/dL is diagnostic of primary aldosteronism, and levels greater than 10 ng/dL are suggestive of aldosterone-producing adenomas (Mulatero et al., 2005; Young, 2007a).

The captopril suppression test evaluates for the suppression of the ARR after the administration of an ACE inhibitor. Measurement of PAC is performed after administration of 25 to 50 mg of the ACE inhibitor captopril while the patient remains recumbent. Suppression of the RAAS should be noted in patients without primary aldosteronism after the administration of captopril, whereas those with autonomous aldosterone secretion will have persistently elevated PACs greater than 15 ng/dL (Young and Klee, 1988). Further standardization and validation of the captopril suppression test are needed before it is used routinely when sodium loading tests are available and not contraindicated as in patients with cardiac and renal disease, which largely prohibit sodium loading (Giacchetti et al., 2008).

Subtype Differentiation.

After diagnosis of primary aldosteronism, attention is then paid to defining the cause of autonomous aldosterone secretion. Subtype differentiation of primary aldosteronism is essential in selecting the appropriate therapy, because surgical therapy is successful for only select subtypes (Box 106.3). **In patients who are not surgical candidates, subtype differentiation is of little consequence because medical therapy will be instituted; thus these patients can forgo further evaluation, and medical management can be initiated** (Fig. 106.13)**. Given the rarity of familial primary aldosteronism, genetic screening should not be performed in all patients. However, patients with a family history of primary aldosteronism, early age of onset (<20 years) or with a family history of cerebral vascular accidents at a young age should be considered for genetic testing (Fig. 106.14)** (Funder et al., 2016). Cross-sectional abdominal imaging should be performed in all patients with primary aldosteronism who are potential surgical candidates.

Box 106.3

Subtypes of Primary Aldosteronism

Surgically Correctable

Aldosterone-producing adenoma
Primary unilateral adrenal hyperplasia
Ovarian aldosterone-secreting tumor
Aldosterone-producing carcinoma

Not Correctable by Surgery

Bilateral adrenal hyperplasia
Familial hyperaldosteronism type I
Familial hyperaldosteronism type II
Familial hyperaldosteronism type III

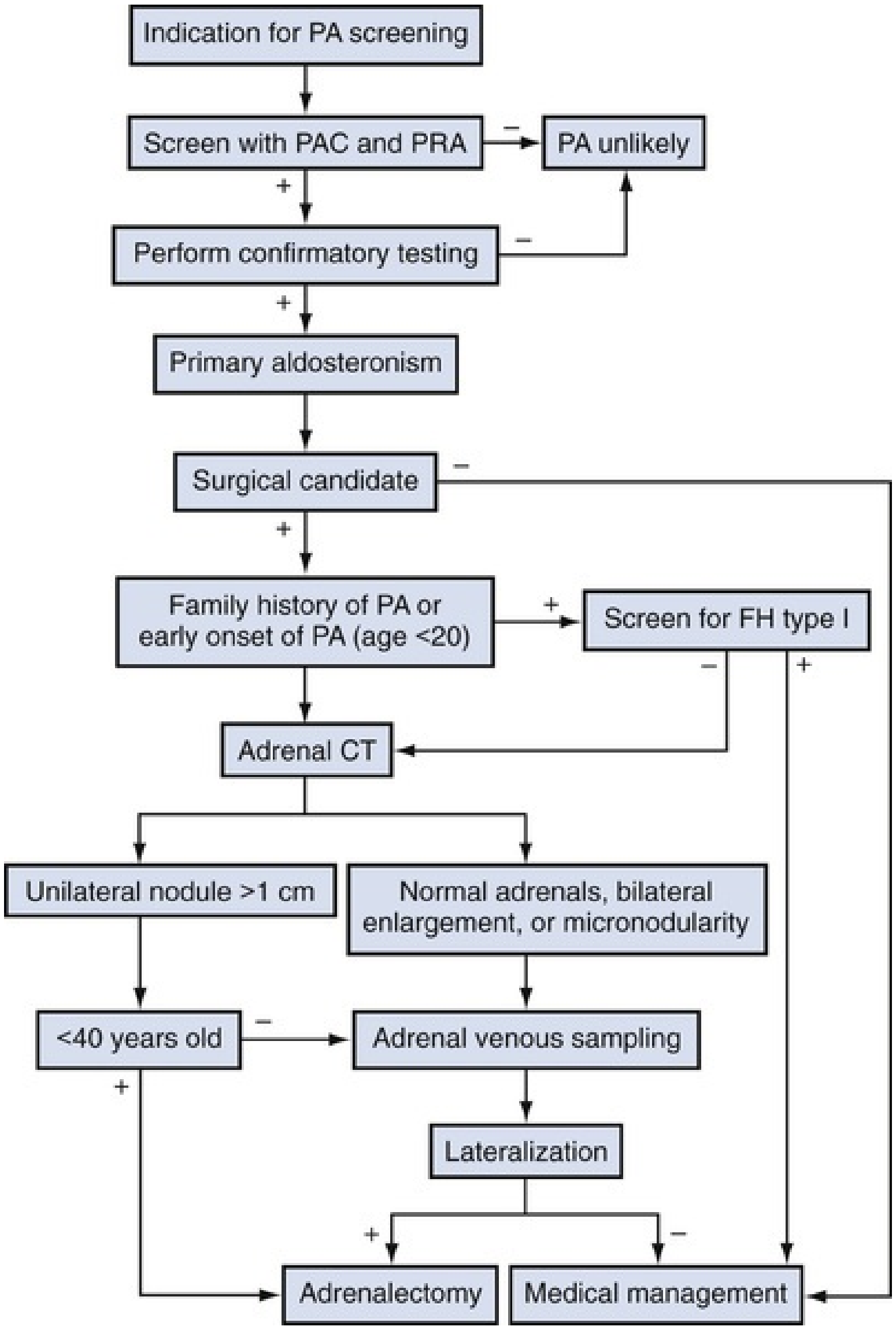
Indication for PA screening
Screen with PAC and PRA
PA unlikely
Perform confirmatory testing
Primary aldosteronism
Surgical candidate
Family history of PA or early onset of PA (age <20)
Screen for FH type I
Adrenal CT
Unilateral nodule >1 cm
Normal adrenals, bilateral enlargement, or micronodularity
<40 years old
Adrenal venous sampling
Lateralization
Adrenalectomy
Medical management
+
−

FIG. 106.13 Primary aldosteronism diagnosis and treatment algorithm. *CT,* Computed tomography; *FH,* familial hyperaldosteronism; *PA,* primary aldosteronism; *PAC,* plasma aldosterone concentration; *PRA,* plasma renin activity.

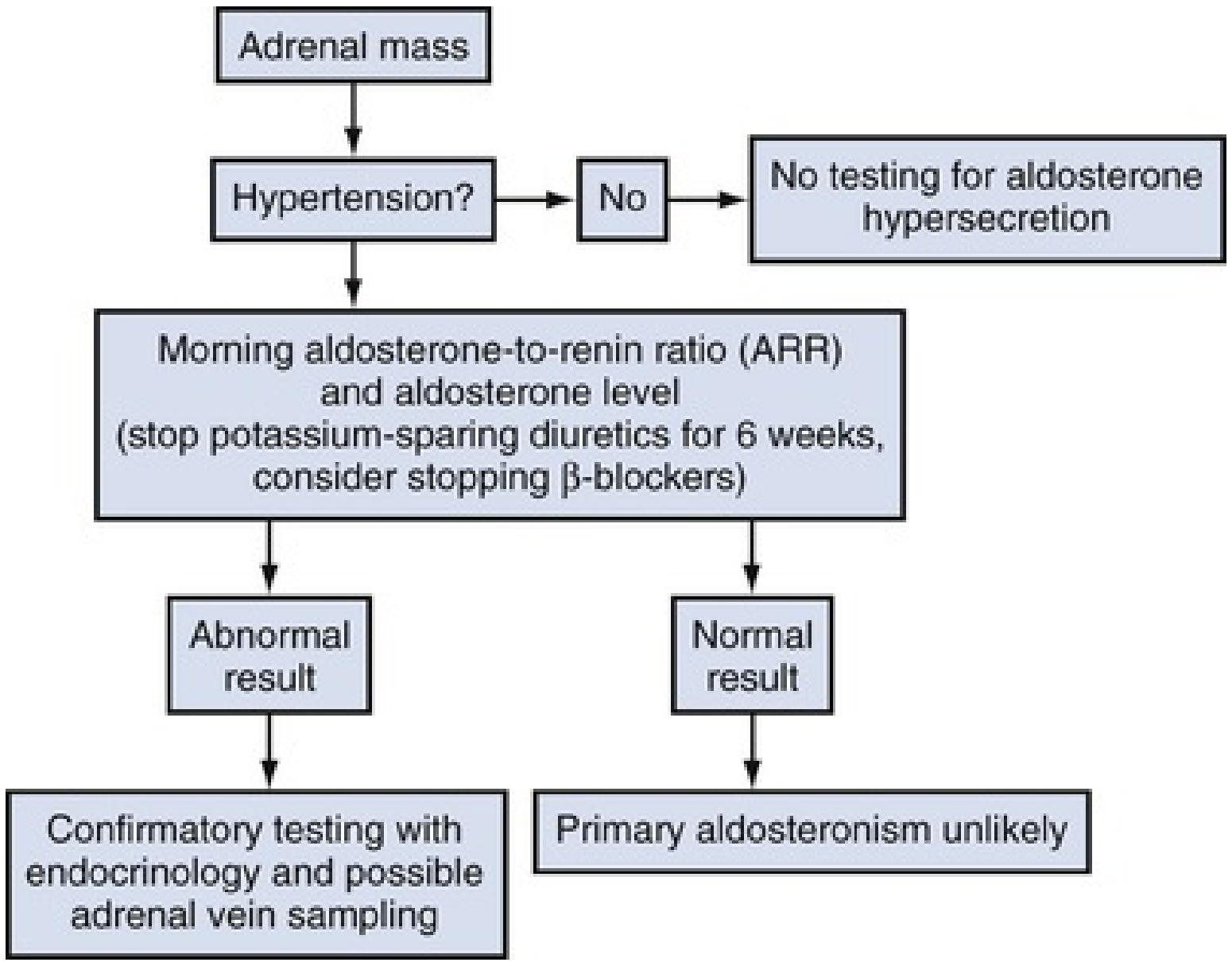
Adrenal mass
Hypertension?
No
No testing for aldosterone hypersecretion
Morning aldosterone-to-renin ratio (ARR) and aldosterone level (stop potassium-sparing diuretics for 6 weeks, consider stopping β-blockers)
Abnormal result
Normal result
Confirmatory testing with endocrinology and possible adrenal vein sampling
Primary aldosteronism unlikely

FIG. 106.14 Testing algorithm for aldosterone hypersecretion by an adrenal mass.

Although imperfect in delineating the subtype of primary aldosteronism, an adrenal CT scan should be obtained to evaluate for the presence of adrenal nodules. Radiographic characteristics of aldosterone-producing adenomas include the presence of a unilateral low-density nonenhancing lesion of less than 10 Hounsfield units (HU), with an average size of 1.6 to 1.8 cm and a normal-appearing contralateral adrenal gland. However, given that approximately 20% of aldosterone-producing adenomas will be smaller than 1 cm, lateralization is not based on CT findings alone (Simon and Palese, 2008). Radiographic characteristics of idiopathic hyperplasia can include the presence of multiple unilateral or bilateral adrenal nodules, bilateral adrenal enlargement with increased limb size, or the presence of normal-appearing glands. The combination of the small-size, aldosterone-producing adenomas and the potential for the presence of nonfunctional adrenal adenomas makes CT imaging flawed in delineating lateralization of aldosterone hypersecretion. Because MRI does not offer an advantage in delineating primary aldosteronism subtypes and is associated with increased cost, routine use is not currently recommended.

To establish lateralization of aldosterone secretion in surgical candidates, adrenal vein sampling should be performed. By establishing lateralization, one can differentiate between subtypes of primary aldosteronism and identify patients in whom adrenalectomy is potentially beneficial. **The value of adrenal vein sampling in evaluating the presence of lateralized aldosterone secretion**

was illustrated by Young et al. (2004), who noted that 22% of patients would have been incorrectly excluded from adrenalectomy and that 25% would have been inappropriately recommended to undergo adrenalectomy based on CT findings instead of adrenal vein sampling studies. As with all other evaluations performed for primary aldosteronism, proper patient selection, proper patient preparation, and an accurate interpretation of results are essential (Young and Stanson, 2009). A decision-making strategy when performing adrenal vein sampling is depicted in Fig. 106.15.

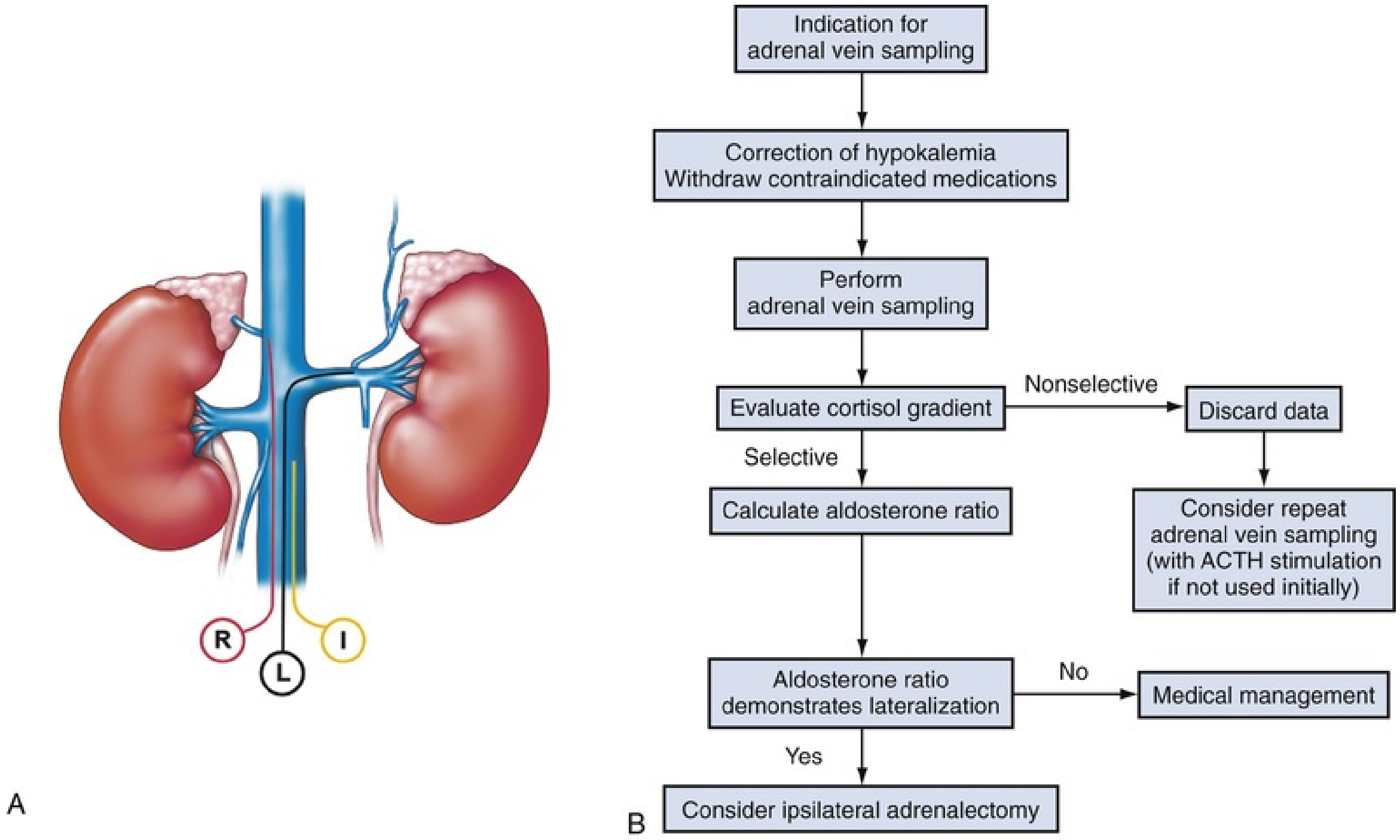
R
L
I
A
B
Indication for adrenal vein sampling
Correction of hypokalemia
Withdraw contraindicated medications
Perform adrenal vein sampling
Evaluate cortisol gradient
Nonselective
Discard data
Selective
Calculate aldosterone ratio
Consider repeat adrenal vein sampling (with ACTH stimulation if not used initially)
Aldosterone ratio demonstrates lateralization
No
Medical management
Yes
Consider ipsilateral adrenalectomy

FIG. 106.15 Adrenal vein sampling protocol. (A) Proper catheter positioning for sampling right adrenal vein sample *(R),* left adrenal vein sample *(L),* and inferior vena cava sample *(I)*. (B) After sample collection, the cortisol gradient is evaluated using the ratios $R_{cortisol}/I_{cortisol}$ and $L_{cortisol}/I_{cortisol}$. If the cortisol gradients confirm appropriate sample collection, lateralization of aldosterone secretion can be evaluated. Lateralization of aldosterone secretion is determined by the ratio of aldosterone secretion of the dominant to the nondominant adrenal gland while correcting for ipsilateral cortisol secretion using the formula $(A_{dominant}/C_{dominant})/(A_{nondominant}/C_{nondominant})$, where A = plasma aldosterone concentration and C = cortisol. *ACTH,* Adrenocorticotropic hormone.

Patients with confirmed PA should undergo adrenal vein sampling when adrenalectomy is being considered. Exceptions include patients younger than 40 years of age with a clear unilateral adrenal adenoma and normal contralateral adrenal gland on cross-sectional imaging and patients suspected of having an ACC (Funder et al., 2016; Rossi et al., 2014). Although adrenal vein sampling is advocated in most patients, a randomized trial comparing CT scan findings and adrenal vein sampling in directing therapy has been completed (Dekkers et al., 2016). The primary endpoint of this trial was intensity of hypertension medications at 1 year. No difference was noted in primary endpoint based on CT scan findings or adrenal vein sampling, challenging the recommended routine use of adrenal vein sampling. It is notable that lateralization of elevated aldosterone production was discordant in 50% of patients with both CT and AVS evaluation. Additionally, 20% of patients treated based on CT findings had persistent biochemical evidence of aldosteronism after adrenalectomy compared with 10% of patients treated based on AVS (Wolley and Stowasser, 2017).

Because multiple factors can affect the results of adrenal vein sampling, attention to preprocedural and procedural details is mandatory. Proper patient preparation is essential and includes 1 hour of recumbency, correction of hypokalemia, and discontinuation of antihypertensive agents, which may affect aldosterone and renin levels. After appropriate patient selection and preparation, adrenal vein sampling is performed in the morning after an overnight fast. Percutaneous access to the femoral vein is obtained, and catheter tips are positioned to collect samples from three sites: the right adrenal vein, left adrenal vein, and IVC (see Fig. 106.15A). Samples are then evaluated for aldosterone and cortisol concentrations. Appropriate specimen collection from the adrenal vein is determined by comparing the cortisol concentrations from the adrenal vein samples with the cortisol concentration from the IVC sample. The ratio of adrenal vein cortisol to IVC cortisol should be greater than 1.1 : 1 to 5 : 1, depending on the use of cosyntropin stimulation (Young and Stanson, 2009). If cosyntropin stimulation is used, a higher ratio is expected in properly collected samples. Adrenal vein sampling that demonstrates adrenal vein–to–IVC ratios below the cutoff, on either side, should be considered “nonselective” and discarded. An adrenal vein–to–IVC ratio above the cutoff, bilaterally, is considered “selective,” and comparisons between aldosterone concentrations can be made to determine the presence of lateralization.

Lateralization of aldosterone secretion is determined by comparing the aldosterone-to-cortisol ratios of the dominant to nondominant sides using the formula $(A_{dominant}/C_{dominant})/(A_{nondominant}/C_{nondominant})$. Aldosterone secretion is considered to be lateralized if the ratio is greater than 2 : 1 to 4 : 1, depending on the use of cosyntropin stimulation (Rossi et al., 2014; Young and Stanson, 2009). When performed and interpreted correctly, adrenal vein sampling has a sensitivity of 95% and a specificity of 100% in detecting lateralized autonomous aldosterone secretion (Young et al., 2004).

The routine use of cosyntropin stimulation during adrenal vein sampling is controversial. Potential advantages of cosyntropin stimulation include minimizing stress-induced fluctuations in aldosterone secretion, maximizing the cortisol gradient, and maximizing the aldosterone secretion from aldosterone-producing adenomas (Rossi et al., 2014; Young, 2007a; Young and Stanson, 2009). In a prospective study investigating these potential benefits, cosyntropin stimulation was noted to facilitate the ascertainment of proper specimen collection for evaluation of the cortisol gradient between adrenal and IVC specimens. However, the authors also noted that cosyntropin stimulation was also associated with a small risk (3% to 12%) of incorrectly assigning the side of lateralization of aldosterone-producing adenomas, and a moderate risk (36% to 37%) of incorrectly classifying aldosterone-producing adenomas as idiopathic hyperplasia (Seccia et al., 2009).

When adrenal vein sampling is inconclusive because of sampling error, alternative studies are available that may help guide treatment decisions, including nuclear scintigraphy, postural stimulation testing, and measurement of cortisol metabolites. Of these modalities, only nuclear scintigraphy can provide both functional and anatomic data, which are necessary when considering surgical intervention.

Iodine-131 (^{131}I)-6β-iodomethyl-norcholesterol (NP59) is a cortisol analogue that can label adrenal cortical cells to evaluate for areas of hypersecretion (Heinz-Peer et al., 2007). Before injection of the radiotracer, saturated potassium iodine (Lugol solution) is administered to protect the thyroid gland from uptake of free ^{131}I. In addition, suppression of ACTH with dexamethasone (1 mg every 6 hours for 7 days) is necessary. Evaluation of radiotracer uptake is begun 4 days after NP59 injection and may continue through day 10. Characteristics that suggest the presence of aldosterone-producing adenomas include unilateral uptake of radiotracer less than 5 days after injection, whereas bilateral uptake is suggestive of idiopathic hyperplasia (Simon and Palese, 2008). The ability to detect a hyperfunctioning adenoma using NP59 is directly proportional to tumor size and function, with a diminished ability to detect lesions smaller than 1.5 cm, and it is no longer available in the United States. (Funder et al., 2016; Hogan et al., 1976; Mansoor et al., 2002; Nomura et al., 1990). To overcome some of the known limitations of NP59 imaging, NP59 single-photon emission computed tomography (SPECT-CT) has been evaluated and has demonstrated improved sensitivity in detecting smaller adenomas (Yen et al., 2009).

The posture stimulation test is designed to distinguish between aldosterone-producing adenomas and idiopathic hyperplasia based on changes in PAC levels in response to changes in posture. The test is performed by comparing PAC levels after the patient has been recumbent overnight, and again after 4 hours of being upright. In theory, the increase of angiotensin induced with being upright leads to an increased PAC in normal patients that is twofold to fourfold greater when compared with recumbent levels. In comparison, patients with idiopathic hyperplasia will demonstrate an increase of at least 33% over baseline, and patients with aldosterone-producing adenomas or FH type I will not demonstrate an increase in PAC levels with changes in posture (Ganguly et al., 1973; Young, 2007a). Although the test can be helpful in distinguishing between aldosterone-producing adenomas and idiopathic hyperplasia, it does not provide information regarding the location of the adenoma (right vs. left). In addition, the reliability of the posture stimulation test is limited by the observation that 30% to 50% of aldosterone-producing adenomas demonstrate an increase in PAC, whereas 20% of idiopathic hyperplasia patients do not demonstrate any elevation with postural changes (Mulatero et al., 2004; Schirpenbach and Reincke, 2007).

Another potential method for differentiating aldosterone-producing adenomas from idiopathic hyperplasia is the measurement of 18-hydroxycorticosterone (18-OHB). 18-OHB is formed by the 18-hydroxylation of corticosterone and may be the immediate precursor of aldosterone (Mulatero et al., 2013). Elevated 18-OHB (>100 ng/dL) suggests an aldosterone-producing adenoma, whereas levels below 100 ng/dL suggest idiopathic hyperplasia (Biglieri and Schambelan, 1979). However, the accuracy of this test in distinguishing aldosterone production from an adenoma versus hyperplasia is thought to be less than 80%. In addition, the test does not provide information about tumor location (right vs. left) in cases of functional adenomas (Young and Klee, 1988).

A potential future study to evaluate for aldosterone-producing adenomas is $^{(11)}$C-Metomidate PET CT (Wolley and Stowasser, 2017). In an initial study of 25 patients with primary aldosteronism, $^{(11)}$C-Metomidate PET CT demonstrated 87% specificity and 76% sensitivity in detecting aldosterone-producing adenomas (Burton et al., 2012). Further evaluation and enhanced availability of $^{(11)}$C-Metomidate will be needed before routine use.

Treatment and Prognosis.

The goal of treatment in primary aldosteronism is to control and prevent the morbidity associated with mineralocorticoid access. Therefore the treatment strategies used in therapy aim to remove the source of mineralocorticoid access or block the effect of aldosterone on target organs (Young, 2007a). Treatment strategies for primary aldosteronism are primarily dependent on subtype classification and surgical candidacy (see Fig. 106.13). Patients who are acceptable surgical candidates and have been diagnosed with a surgically correctable subtype of primary aldosteronism can be offered unilateral adrenalectomy; other patients can be managed effectively with medical therapy.

In patients with confirmed lateralizing aldosterone secretion, adrenalectomy should be considered. Given the small size of aldosterone-producing adenomas, the majority of patients are candidates for a laparoscopic adrenalectomy. In patients suspected of having hypersecretion of aldosterone associated with ACC, an open procedure may be recommended (Gonzalez et al., 2005; Kebebew et al., 2002; Schlamp et al., 2007). **Improvements in blood pressure are noted in the majority of patients undergoing adrenalectomy for primary aldosteronism; however, a significant proportion of patients will require antihypertensive medications postoperatively** (Williams et al., 2017). A review of patient series using standardized criteria revealed that 37% to 52% of patients required no antihypertensive agents after adrenalectomy (Benham et al., 2016). Biochemical success, defined as correction of hypokalemia and normalization of ARR, was noted in 94% of patients in this series, suggesting additional conditions contributing to the continued requirement for antihypertensive agents after surgery. Several predictors of persistent hypertension after adrenalectomy for primary aldosteronism have been described, including age older than 50 years, male gender, high body mass index, preoperative ARR, the use of two or more antihypertensive agents preoperatively, having a first-degree relative with hypertension, prolonged duration of hypertension before adrenalectomy, degree of cardiovascular remodeling, and renal insufficiency (Benham et al., 2016; Celen et al., 1996; Rossi et al., 2014; Sawka et al., 2001; Wang et al., 2012). In patients younger than 40 years of age with a unilateral adenoma larger than 1 cm, a unilateral adrenalectomy can be performed without adrenal vein sampling because of the rarity of incidental adenomas in this population (Schirpenbach and Reincke, 2007; Young, 2007a; Zarnegar et al., 2008). In the immediate postoperative period, PAC and ARR should be evaluated to ensure biochemical cure. In addition, patients should maintain a high-sodium diet and be monitored for hyperkalemia for several weeks after surgery (Funder et al., 2008; Mattsson and Young, 2006). Continued changes in blood pressure after adrenalectomy for primary aldosteronism can be noted up to 6 months after surgery.

Medical treatment of primary aldosteronism is indicated in patients with nonsurgically correctable subtypes and those who are not surgical candidates. **The aldosterone receptor antagonists spironolactone and eplerenone are successful in lowering blood pressure and are the antihypertensive agents of choice in patients with primary aldosteronism.** Spironolactone therapy is initiated at doses of 25 to 50 mg/day and can be titrated up to 400 mg/day, depending on blood pressure, serum potassium levels, and side effects. Side effects of spironolactone include gynecomastia, impotence, and menstrual disturbances. Eplerenone may provide a more favorable side-effect profile compared with spironolactone because of increased selectivity for the aldosterone receptor. Treatment should be initiated with 25 mg/day and titrated up to 100 mg/day. Despite treatment with an aldosterone receptor antagonist, other antihypertensive agents will often be needed. In addition, several lifestyle modifications may contribute to the success of medical therapy, including weight loss, a low-sodium diet, and a regular exercise program (Young, 2007a).

Unlike other forms of primary aldosteronism, FH type I can be treated with oral glucocorticoids. Glucocorticoid administration will reduce ACTH release, leading to decreased aldosterone production in this select group of patients. In FH type I patients whose blood pressure is not controlled with glucocorticoids alone or in those who develop iatrogenic Cushing syndrome, the addition of an aldosterone receptor antagonist should be considered (Funder et al., 2008).

Summary.

Successful identification and treatment of primary aldosteronism is critical because of the increased risk for cardiovascular morbidity associated with the diagnosis. Because primary aldosteronism consists of several distinct subtypes that significantly affect management strategy, subtype differentiation is critical before surgical intervention.

Key Points: Primary Aldosteronism

- Most patients with primary aldosteronism in contemporary series are normokalemic.

- Primary aldosteronism is associated with an increased risk for end-organ damage compared with essential hypertension.
- Accurate subtype differentiation is essential to ensure appropriate treatment of primary aldosteronism.

Pheochromocytoma

Overview and Epidemiology.

Pheochromocytoma is a tumor of the catecholamine-producing cells of the adrenal medulla. Approximately 1 to 2 per 100,000 individuals are diagnosed annually with pheochromocytoma, albeit reports on incidence vary (Bravo and Tagle, 2003; Rijken et al., 2017). Given its rarity, it is estimated that pheochromocytoma is responsible for only approximately 0.5% of cases of hypertension (Lenders et al., 2005). **Among patients with incidental adrenal masses, approximately 5% will have a pheochromocytoma** (Mantero et al., 2000; Young, 2000). Indeed, incidentally discovered lesions account for 10% to 25% of all pheochromocytoma diagnoses (Bravo and Tagle, 2003; Lenders et al., 2005).

Some 1% to 25% of pheochromocytomas originate outside of the adrenal gland (Fig. 106.16). These extra-adrenal pheochromocytomas are known as *paragangliomas*, because they arise from paraganglia, a network of chromaffin-producing neural crest tissue that anatomically parallels the sympathetic and parasympathetic ganglia (Ilias and Pacak, 2004; Scott et al., 1990). Paragangliomas can arise in the head, neck, thorax, abdomen, and pelvis (including the bladder). The chromaffin bodies that lie between the aortic bifurcation and the root of the inferior mesenteric artery are known as the *organ of Zuckerkandl* and are a common site for paragangliomas (Scott et al., 1990). Of note, some authors reserve the term *paraganglioma* for tumors only in the head and neck, locations where extra-adrenal pheochromocytomas tend to be nonfunctional (Neumann et al., 2004).

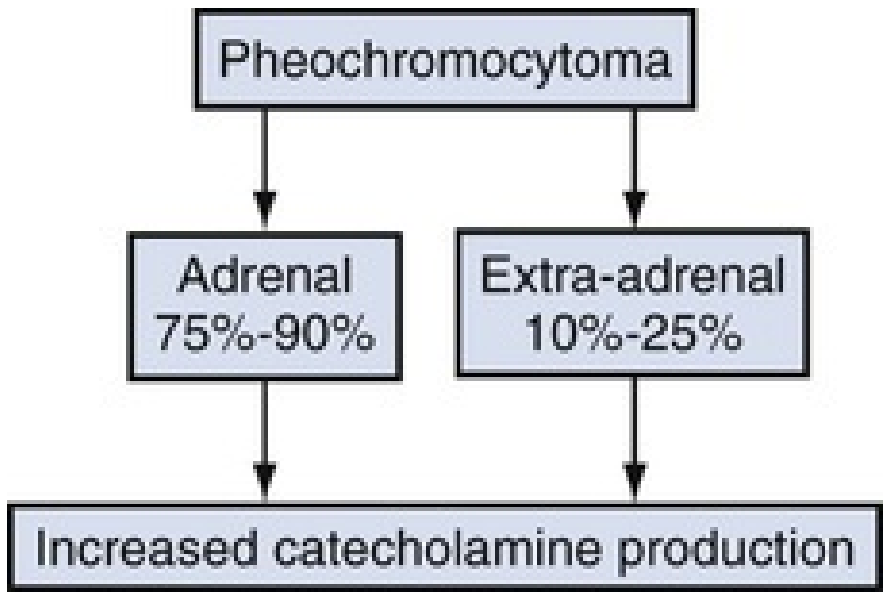

FIG. 106.16 Causes of excess catecholamines.

Pathophysiology

Overview.

As discussed in the Adrenal Physiology section earlier in this chapter, cells of the adrenal medulla are analogous to the chromaffin cells of the sympathetic ganglia. Unlike sympathetic ganglia cells, however, cells of the adrenal medulla, and therefore of adrenal pheochromocytomas, possess the enzyme PNMT, which gives them the ability to synthesize epinephrine from norepinephrine (Eisenhofer et al., 2004b). Pheochromocytomas vary in their enzymatic composition and in their ability to self-metabolize the catecholamines within each tumor's secretory vesicles. Therefore, there is great variability in the amount and ratio of catecholamines secreted by pheochromocytomas (Eisenhofer et al., 2001). Indeed, these differences in norepinephrine, epinephrine, and dopamine secretion explain the heterogeneity in clinical behavior of pheochromocytomas. For instance, patients with rare tumors that secrete primarily epinephrine (usually limited to those that arise from the adrenal glands or the organ of Zuckerkandl) tend to experience syncopal or hypotensive episodes because of epinephrine's vasodilatory action through the β_2 receptor, whereas patients with predominantly norepinephrine-secreting tumors (e.g., patients with von Hippel-Lindau [VHL] syndrome) have hypertension and sweating, given the compound's affinity for the vasoconstricting α adrenoreceptor (Pacak, 2007).

Pathophysiology of Hereditary Pheochromocytoma.

Familial cases account for nearly one-third of pheochromocytomas (Benn and Robinson, 2006). **Indeed, a significant percentage of cases that initially appear sporadic are later deemed hereditary on genetic testing. In a 2002 report, Neumann et al.** (2002) **demonstrated that 24% of patients (*n* = 271) with an isolated pheochromocytoma who lacked any significant family**

history exhibited a germline mutation that predisposed them to the disease. At least five genes—the rearranged transfection proto-oncogene *(RET)*, von Hippel-Lindau gene *(VHL)*, neurofibromatosis type 1 gene *(NF1)*, and mitochondrial succinate dehydrogenase subunits D and B genes *(SDHD, SDHB)*—are now associated with familial pheochromocytomas. Some investigators believe that these genetic abnormalities all modulate neuronal apoptosis and are related through signal transduction pathways downstream from the nerve growth factor (NGF) (Nakamura and Kaelin, 2006; Rijken et al., 2017). Nevertheless, the phenotypes produced by each gene mutation are quite diverse. Table 106.6 summarizes the clinical features associated with each gene mutation.

TABLE 106.6

Hereditary Forms of Pheochromocytoma

SYNDROME	CLINICAL CHARACTERISTICS	RISK FOR PHEOCHROMOCYTOMA	GENE	C A IN
Multiple endocrine neoplasia type 2A	Medullary cancer of thyroid Hyperparathyroidism Cutaneous lichen Amyloidosis	50%	*RET*	
Multiple endocrine neoplasia type 2B	Medullary cancer of thyroid Multiple neuromas Marfanoid body habitus Rare hyperparathyroidism	50%	*RET*	
von Hippel-Lindau syndrome type 2	Renal cell carcinomas and renal cysts CNS and retinal hemangioblastomas Pancreatic cysts Epididymal cystadenomas	10%–20%	*VHL*	

	Endolymphatic cyst tumors			
Neurofibromatosis type 1	Neurofibromas Café-au-lait skin spots	1%	*NF1*	
Familial paraganglioma syndrome type 4 (PGL-4)	Carotid body tumors (chemodectomas) Vagal, jugular, tympanic, abdominal, thoracic paragangliomas	Approximately 20%	*SDHB*	
Familial paraganglioma syndrome type 1 (PGL-1)	Carotid body tumors (chemodectomas) Vagal, jugular, tympanic, abdominal, thoracic paragangliomas	Approximately 20%	*SDHD*	

CNS, Central nervous system.

Data from Dluhy RG. Pheochromocytoma—death of an axiom. *N Engl J Med* 2002;346(19):1486–1488; and Lenders JW, Eisenhofer G, Mannelli M, et al. Phaeochromocytoma. *Lancet* 366(9486):665–675, 2005.

In general urologic practice, VHL and SDHB are the most relevant syndromes associated with pheochromocytoma, because these patients usually are already under urologic care because of their propensity to develop renal cell carcinoma (RCC). Patients with VHL and no family history of pheochromocytoma are classified as having the type 1 variant of the syndrome, whereas type 2 patients are those who carry a family history of pheochromocytoma. In addition, the type 2 variant of VHL is further subdivided. Type 2A patients are those without concomitant RCC, and type 2B patients are those who exhibit evidence of renal malignancy (Linehan and Ricketts, 2013). A type 2C variant is defined as patients with pheochromocytoma in the setting of a *VHL* mutation, but no other stigmata of the VHL syndrome (Hes et al., 2003). It is interesting to note that a genotype phenotype has been established with VHL-associated pheochromocytomas (type 2), wherein these patients are more likely to exhibit a missense mutation of the *VHL* gene (Walther et al., 1999). Whereas VHL type 2C patients appear to maintain hypoxia-inducible factor (HIF) regulation, pheochromocytoma pathogenesis may occur through HIF-independent pathways (Nakamura and Kaelin, 2006). Furthermore, pheochromocytomas in patients with VHL, unlike those in cases of sporadic or multiple endocrine neoplasia type

2 (MEN-2)–related disease, tend to produce less epinephrine. As a result, metanephrine (but not normetanephrine) levels in these patients are nearly always normal (Eisenhofer et al., 1999; Pacak, 2007; Walther et al., 1999). Meanwhile, estimated penetrance of developing a pheochromocytoma/paraganglioma in SDHB carriers appears to be 9% to 20% at 50 years of age when data are appropriately adjusted for ascertainment biases (Rijken et al., 2017).

Pathophysiology of Malignant Pheochromocytoma.

Malignant pheochromocytoma is an aggressive life-threatening neoplasm. **Currently, malignancy can only be defined by the presence of clinical metastases. Pathologic appearance and even local invasion are of only limited value in determining metastatic potential of a given lesion** (Scholz et al., 2007). A number of pathologic criteria to differentiate benign from malignant disease have been proposed, but to date there is no single histologic criterion agreed on (Kimura et al., 2005; Pacak et al., 2007; Scholz et al., 2007; Thompson, 2002). Some pathologic criteria use immunohistochemical strategies including Ki-67 staining, which may be the best indicator of malignancy thus far, although it has not yet been validated because of methodologic heterogeneity (Kimura et al., 2005; Pacak et al., 2007).

Malignant pheochromocytoma in patients with MEN-2 and VHL is exceedingly rare (see Table 106.6). The *SDHB* mutation is the single genetic abnormality most strongly associated with malignancy (Neumann et al., 2004; Rijken et al., 2017).

Clinical Characteristics

Overview.

Classically, pheochromocytoma has been called the “10% tumor”: 10% extra-adrenal, 10% familial, 10% bilateral, 10% pediatric, and 10% malignant (Dluhy, 2002; Lenders et al., 2005; Scott et al., 1990)**. However, this rule has been challenged repeatedly. As mentioned earlier, up to 25% of pheochromocytomas can be extra-adrenal** (Ilias and Pacak, 2004)**. Similarly, familial cases account for up to 30% of tumors at presentation** (Benn and Robinson, 2006)**. Malignancy is rare in both sporadic cases of adrenal pheochromocytoma (up to 5%) and in most cases of hereditary disease (see Table 106.6). However, for unclear reasons, it occurs in over one-third of**

patients with extra-adrenal disease (Lenders et al., 2005)**. Nonhereditary cases of pheochromocytoma are most often diagnosed in the fourth and fifth decades of life, whereas familial tumors tend to occur at a younger age** (Lenders et al., 2005). Despite being uncommon, pediatric pheochromocytoma is the most frequently encountered endocrine neoplasm in children. Up to 40% of such tumors are familial, and over 20% are bilateral (Havekes et al., 2009; Pacak et al., 2007). For reasons that are unclear, tumors arising from the right adrenal gland are more common, tend to be larger, and recur more frequently than those that arise in the left gland (Amar et al., 2005b).

Paroxysmal hypertension is the classic presenting sign in patients with pheochromocytoma. Nevertheless, such episodic spikes in blood pressure are documented in only approximately 30% to 50% of patients and can occur in the backdrop of baseline essential hypertension. The remainder of patients demonstrate persistently elevated blood pressure, and a minority are entirely normotensive (Scott et al., 1990). **The triad of headache, episodic sudden perspiration, and tachycardia is a classic hallmark of pheochromocytoma** (Bravo and Tagle, 2003). Table 106.7 lists common clinical signs and symptoms of pheochromocytoma. More than 20% of patients can be asymptomatic (Adler et al., 2008). Indeed, depending on the catecholamine milieu of each tumor, its ability to self-metabolize the catecholamine reserve, and patients' varied responses to catecholamine surges, symptomatology can drastically differ from patient to patient (Pacak, 2007). This heterogeneity in mode of presentation and symptomatology and the difficulty in establishing firm diagnostic criteria for pheochromocytoma are illustrated by an autopsy series that included 54 patients over a 50-year period from the Mayo Clinic, wherein more than 75% of tumors were not suspected before the patient's death (Sutton et al., 1981).

TABLE 106.7

Clinical Manifestations of Pheochromocytoma

MANIFESTATION	FREQUENCY (%)
Headache	60–90
Palpitations	50–70
Sweating	55–75
Pallor	40–45
Nausea	20–40
Flushing	10–20
Weight loss	20–40

Tiredness	25–40
Psychological symptoms (anxiety, panic)	20–40
Sustained hypertension	50–60
Paroxysmal hypertension	30
Orthostatic hypotension	10–50
Hyperglycemia	40

Modified from Lenders JW, Eisenhofer G, Mannelli M, et al. Phaeochromocytoma. *Lancet* 366(9486):665–675, 2005.

Clinical Characteristics of Hereditary Pheochromocytoma.

Hereditary pheochromocytomas occur at a younger age and tend to be multifocal and/or bilateral at presentation (Adler et al., 2008). Table 106.6 summarizes the clinical features of each gene mutation. Pheochromocytomas in patients with MEN-2 nearly always arise from the adrenal gland, whereas tumors in patients with VHL and neurofibromatosis type 1 (NF-1) are outside the adrenal gland in approximately 12% and 6% of cases, respectively (Benn and Robinson, 2006; Karagiannis et al., 2007; Lairmore et al., 1993; Walther et al., 1999). *SDHB* and *SDHD* mutations mostly result in extra-adrenal and often multifocal phenotypes; nevertheless, solitary adrenal masses, as a result of these genetic abnormalities, may also arise (Neumann et al., 2004; Pacak et al., 2007). Unlike other hereditary forms of pheochromocytoma, mutations in the *SDHB* gene are associated with a very high risk for malignancy (Neumann et al., 2004). As mentioned earlier, pheochromocytomas in patients with VHL mainly secrete norepinephrine and lack significantly elevated epinephrine secretion. As a result, normetanephrine, but not metanephrine, levels are elevated in these patients (Eisenhofer et al., 1999; Pacak, 2007; Walther et al., 1999).

Clinical Characteristics of Malignant Pheochromocytoma.

Metastatic disease is much more common in extra-adrenal lesions (Scholz et al., 2007). The *SDHB* mutation is the one genetic abnormality that is strongly associated with metastatic disease (see Table 106.6). Classically, the majority of patients with an *SDHB* abnormality exhibit extra-adrenal disease; however, a significant proportion of patients (28% of patients in one series) have adrenal lesions at presentation (Neumann et al., 2004). Malignant lesions are more likely to exhibit elevated dopamine levels and tend to be larger (>5 cm); however, as mentioned earlier, in the absence of metastatic deposits, a preclinical diagnosis of malignant potential is not possible (John et al., 1999; Lenders et al., 2005).

Bone, lungs, liver, and lymph nodes constitute the most common sites of metastases (Scholz et al., 2007).

Metastatic pheochromocytoma can be present at diagnosis or be detected during surveillance after excision of the primary tumor. Most metastases are discovered within 5 years of the original diagnosis, but metastatic spread more than 15 years after initial excision has been reported (Eisenhofer et al., 2004a; Lenders et al., 2005).

Diagnostic Tests.

Biochemical testing is the first step in the evaluation of patients suspected of having pheochromocytoma. If metabolic testing results are positive, appropriate imaging is undertaken to localize the source of the catecholamine excess (Adler et al., 2008). Timely and appropriate diagnosis of pheochromocytoma continues to be a clinical challenge (Harding et al., 2005; Yu et al., 2009; Zendron et al., 2004). In urologic practice, diagnosis of pheochromocytoma typically begins with the evaluation of an adrenal mass as a catecholamine-hypersecreting lesion. Given the potentially catastrophic consequences of misdiagnosis, the possibility of pheochromocytoma must also be considered in patients with a known history of malignancy, and with a solitary adrenal mass in those in whom a metastatic adrenal lesion is suspected (Weismann et al., 2006; Adler et al., 2007). Clinical evaluation depends on both radiographic imaging and, more important, biochemical testing.

Imaging.

Here we briefly discuss imaging of pheochromocytoma. Refer to the Imaging of Adrenal Masses section later in this chapter for further details on adrenal imaging.

Cross-Sectional Imaging.

On cross-sectional imaging, adrenal pheochromocytomas appear as well-circumscribed lesions. Given their rich vascularity and low lipid content, pheochromocytomas typically measure an attenuation of greater than 10 HU on unenhanced CT (mean approximately 35 HU). This property affords the ability to differentiate them from lipid-rich adenomas (Motta-Ramirez et al., 2005). Furthermore, pheochromocytomas can be distinguished from lipid-poor adenomas through use of CT contrast washout strategies. Although nonspecific, pheochromocytomas, unlike adenomas, do not exhibit rapid contrast washout on delayed imaging (Szolar et al., 2005); rare examples of low-density pheochromocytomas that exhibit an unenhanced attenuation of less than 10 HU and demonstrate brisk contrast washout have been reported (Blake et al., 2003, 2005). Such examples underscore the importance of a complete metabolic evaluation for every adrenal mass. In the past, iodinated intravenous contrast was believed to be a possible trigger for a hypertensive crisis. No evidence exists to support this misconception (Pacak, 2007).

Similar to CT, MRI is an excellent imaging modality for characterizing adrenal lesions. Again, differentiation of pheochromocytoma from adenoma centers on assessment of the lesion's lipid content. Unlike lipid-rich adenomas, pheochromocytomas do not exhibit signal dropout on out-of-phase sequences (Namimoto et al., 2001). Classically, bright signal intensity on T2-weighted imaging (best seen on fat suppression sequences)—termed the *light bulb sign*—was believed to be diagnostic for pheochromocytoma. It is now clear that this imaging characteristic is neither specific nor sensitive enough to secure a diagnosis and must be interpreted with caution (Elsayes et al., 2005; Varghese et al., 1997).

Functional Imaging

Positron Emission Tomography.

Fluorine-18 fluorodeoxyglucose positron emission tomography (^{18}F-FDG PET) recently has emerged as the gold standard imaging modality for definitive staging in patients with pheochromocytoma. Initially ^{18}F-FDG PET was shown to be a useful clinical tool for patients with the *SDHB* mutation (Timmers et al., 2007a, 2007b); however, a recent report of over 200 patients with adrenal and extra-adrenal pheochromocytoma from investigators from the NIH documented that ^{18}F-FDG PET has far superior test characteristics to CT, MRI, and metaiodobenzylguanidine (MIBG) scintigraphy. ^{18}F-FDG PET exhibited better accuracy than ^{123}I-MIBG in nearly all patients, especially for identification of metastatic disease. Notable exceptions were individuals with MEN-2 germline mutations for whom sensitivity of ^{18}F-FDG PET was low (<50%) and in whom the procedure was far inferior to ^{123}I-MIBG. It is interesting to note that PET avidity was independent of the tumor's biochemical vigor or “phenotype” (Timmers et al., 2012). More recently ^{68}Ga-DOTATATE PET/CT has been shown to exhibit superior signal-to-noise ratios and similar test characteristics when compared with ^{18}F-FDG PET, and is thus replacing ^{18}F-FDG PET for imaging of patients with pheochromocytoma at some centers (Chang et al., 2016).

Metaiodobenzylguanidine Scintigraphy.

MIBG is a small-molecule analog of norepinephrine. With MIBG tagged with either ^{131}I or ^{123}I, MIBG scintigraphy has been used since the 1980s to evaluate patients with pheochromocytoma. ^{123}I-MIBG—the preferred agent—affords a high sensitivity (83% to 100%) and superb specificity (95% to 100%) for identification of pheochromocytoma (Fig. 106.17) (Ilias and Pacak, 2004). Details regarding this imaging modality are discussed in the Imaging of Adrenal Masses section later in this chapter. Here, we review clinical applications of MIBG.

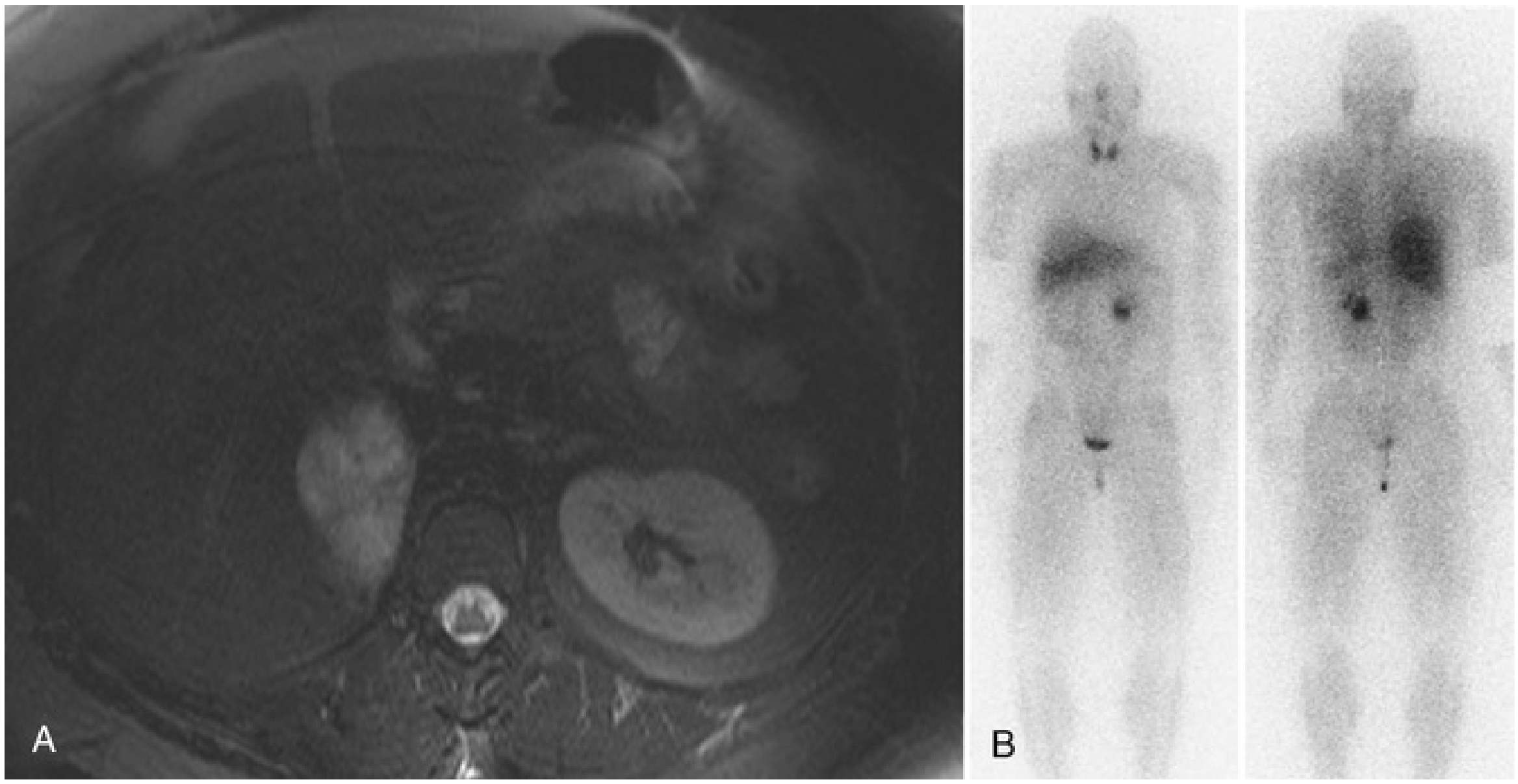

FIG. 106.17 Imaging of pheochromocytoma. (A) Axial T2-weighted magnetic resonance image of a right adrenal mass that proved to be pheochromocytoma. (B) Metaiodobenzylguanidine (MIBG) scan of a different patient with a localized left pheochromocytoma. Normal uptake can be seen in the liver, salivary glands, thyroid, and bladder. It is important to note that fluorodeoxyglucose positron emission tomography appears to be superior to the MIBG scan with a notable exception of patients with known multiple endocrine neoplasia type 2. (A, Courtesy of Dr. Rosaleen Parsons, Fox Chase Cancer Center, Philadelphia, PA. B, Courtesy of Dr. Michael Yu, Fox Chase Cancer Center, Philadelphia, PA.)

MIBG historically has been an integral part of a thorough workup for patients with extra-adrenal, metastatic, or recurrent pheochromocytoma; however, new data suggest that ^{18}F-FDG PET may be a superior modality for non–MEN-2 patients (Timmers et al., 2007b, 2012). MIBG is also often used to localize disease in patients with biochemical evidence of pheochromocytoma but negative cross-sectional imaging. Nevertheless, currently no consensus exists on the role of MIBG in the most common and urologically most relevant clinical scenario—a solitary adrenal mass on cross-sectional imaging in the setting of a biochemical evaluation indicative of pheochromocytoma (Koch, 2009; Pacak et al., 2007). Advocates for MIBG testing argue that in this context, MIBG affords the opportunity to verify that the mass in question is indeed a pheochromocytoma and that metastatic disease was not missed on cross-sectional imaging (Ilias and Pacak, 2004). Some clinical data, however, suggest that MIBG or ^{18}F-FDG PET in this situation can safely be omitted because these functional studies only serve to confirm what is already known and do not alter management (Bhatia et al., 2008; Greenblatt et al., 2008; Miskulin et al., 2003). Nevertheless, MIBG or ^{18}F-FDG PET imaging for large (>5 cm) tumors is likely prudent to assess for the presence of metastatic disease before surgery and thereby counsel the patient appropriately (Lenders et al., 2005). Rarely, MIBG scanning may also be used when a metabolic workup of an adrenal mass reveals exclusive excess of norepinephrine and normetanephrine but not epinephrine or metanephrine. In such unusual circumstances, MIBG scanning can at times demonstrate that the actual functioning lesion is extra-adrenal (Pacak et al., 2007).

Other Functional Imaging Modalities.

Whole-body functional imaging with MIBG has its limitations. For instance, tumors in patients with *VHL* and *SDHB* gene mutations may exhibit cold MIBG scans (Havekes et al., 2008; Timmers et al., 2007b). ^{18}F-FDG PET, nevertheless, is exquisitely sensitive in these individuals (Timmers et al., 2012). Furthermore, aggressive metastatic lesions may lose their ability to accumulate MIBG (Havekes et al., 2008). As discussed in the Imaging of Adrenal Masses section later in this chapter, several modalities using radiolabeled somatostatin analogues and PET radiopharmaceuticals have been developed to serve as alternatives to MIBG or standard PET imaging in these instances. Most have limited clinical usefulness; however, PET imaging with ^{18}F-dopamine has been explored at some institutions (Timmers et al., 2007a).

Biochemical Evaluation

Overview.

Catecholamines and their metabolites, including metanephrines, are conjugated with a sulfate moiety in the bloodstream. The term *free* refers to compounds that are not conjugated and lack this sulfate group. In the past, assays that measured “total” amounts of catecholamine metabolites were used. These assays were not able to discriminate between “free” and “sulfonated” compounds and were largely inferior in their test characteristics compared with current methods (Eisenhofer et al., 2003a). Moreover, in the past, assays did not always distinguish compound subtypes and reported the aggregate level of catecholamines or metanephrines. Today, the term *fractionated* is used when the laboratory report details not only the amount of each compound type (e.g., metanephrines), but also the relative concentrations of each compound (e.g., normetanephrine and metanephrine) (Eisenhofer et al., 2004b) (Table 106.8).

TABLE 106.8

Test Characteristics for Diagnosis of Pheochromocytoma From a Large Multicenter Cohort Study[a]

	SENSITIVITY (%)		SPECIFICITY (%)	
	HEREDITARY	SPORADIC	HEREDITARY	SPORADIC
Plasma free metanephrines	97 (74/76)	99 (137/138)	96 (326/339)	82 (249/305)
Catecholamines	69 (52/75)	92 (126/137)	89 (303/339)	72 (220/304)
Urinary fractionated metanephrines	96 (26/27)	97 (76/78)	82 (237/288)	45 (73/164)
Catecholamines	79 (54/68)	91 (97/107)	96 (312/324)	75 (159/211)
Total metanephrines	60 (27/45)	88 (61/69)	97 (91/94)	89 (79/89)
Vanillylmandelic acid	46 (30/65)	77 (66/86)	99 (310/312)	86 (132/153)

[a] N = 858: 214 patients with pheochromocytoma and 644 controls.

Data from Lenders J, Pacak K, Walther M, et al. Biochemical diagnosis of pheochromocytoma: which test is best? *JAMA* 287(11):1427–1434, 2002.

Catecholamine Testing.

Catecholamines—dopamine, norepinephrine, and epinephrine—are produced by pheochromocytomas in varying amounts. Release of these compounds into the bloodstream is often paroxysmal. In the past, measurement of both urinary and serum catecholamine levels was the mainstay for evaluation of pheochromocytoma. Because of the sensitivity (approximately 85%) and specificity (approximately 85%) of these tests, this strategy has been largely replaced by measurements of levels of metanephrines—the methylated metabolites of catecholamines (Lenders et al., 2002, 2005). Measurement of urinary catecholamines, nevertheless, is still generally obtained in conjunction with urinary fractionated metanephrine testing (Young, 2007b).

Metanephrine Testing.

O-methylation of catecholamines is catalyzed by the COMT enzyme. *O*-methylation of norepinephrine produces normetanephrine, whereas epinephrine's methylation results in formation of metanephrine. Together, normetanephrine and metanephrine are known as *metanephrines* (see Fig. 106.4) (Eisenhofer et al., 2001). Historically, formation of metanephrines was believed to take place by COMT in the liver and kidneys after catecholamines were released into the peripheral circulation by the tumor. Now it is clear that the vast majority of metanephrine synthesis occurs within the adrenal medulla and/or pheochromocytoma, and only then do metanephrines enter the bloodstream (Eisenhofer et al., 1998, 2004b). **Because this conversion of catecholamines to metanephrines is an uninterrupted process within pheochromocytomas, measurement of plasma concentration of metanephrines is a much more sensitive means of tumor detection than the measurement of rises in plasma catecholamines, which may be paroxysmal** (Eisenhofer et al., 2003a, 2003b). Today, measurement of metanephrine levels in plasma or urine represents the foundation for pheochromocytoma diagnosis and is extremely sensitive (Fig. 106.18). Controversy exists regarding whether measurement of plasma free metanephrines versus urinary fractionated metanephrines should be used as the initial test (Eisenhofer et al., 2008; Lenders et al., 2002; Sawka et al., 2003; Young, 2007b). Refer to the Testing for Catecholamine Hypersecretion section later in this chapter for a complete discussion of the two testing strategies. Traditionally, when tests for fractionated urine or total metanephrines are ordered, urine catecholamine levels are also obtained (Eisenhofer et al., 2003a).

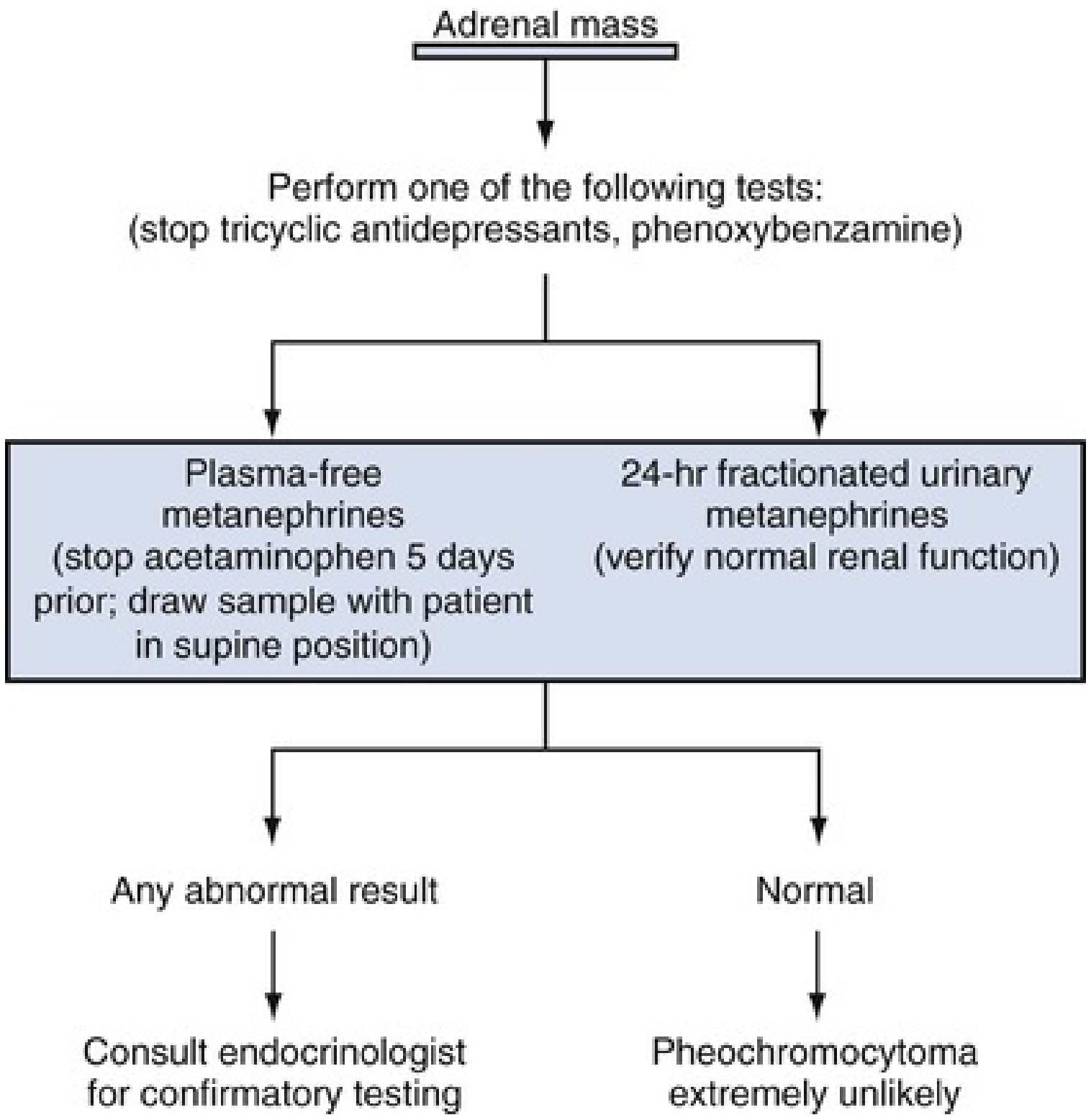
Adrenal mass
Perform one of the following tests:
(stop tricyclic antidepressants, phenoxybenzamine)
Plasma-free metanephrines (stop acetaminophen 5 days prior; draw sample with patient in supine position)
24-hr fractionated urinary metanephrines (verify normal renal function)
Any abnormal result
Normal
Consult endocrinologist for confirmatory testing
Pheochromocytoma extremely unlikely

FIG. 106.18 Testing algorithm to evaluate adrenal mass for catecholamine secretion.

Vanillylmandelic Acid Testing.

Because VMA is the primary end metabolite of catecholamines, its measurement in urine has long been used for diagnosis of pheochromocytoma. Nevertheless, synthesis of VMA requires deamination of catecholamines or their metabolites by the MAO enzyme and occurs not only in the adrenal medulla, but also in the sympathetic nervous system. Moreover, the sympathetic nervous system lacks the ability to produce epinephrine because of absence of the PNMT enzyme and therefore contributes to the serum level of only normetanephrine (from norepinephrine) but not metanephrine (from epinephrine). Therefore the relative rise of VMA levels in the presence of a pheochromocytoma is much less dramatic than the rise seen in the levels of metanephrines, and the sensitivity of urine VMA levels is therefore low (below 65% in some series) (Lenders et al., 2005). However, the specificity of the test is high, especially in nonfamilial cases (99%) (Lenders et al., 2002).

Clonidine Suppression Testing.

Clonidine, an α_2 agonist, suppresses catecholamine (specifically norepinephrine) production by the sympathetic nervous system but not by pheochromocytoma. Comparison of normetanephrine levels before and after clonidine administration has been shown to yield results with favorable test characteristics (Eisenhofer et al., 2003b). This evaluation is suggested by some experts for secondary testing in patients with pheochromocytoma who exhibit mild or borderline elevations in metanephrine levels. When embarking on clonidine suppression testing, one must be cognizant that clonidine administration can result in significant hypotension in certain patients (Eisenhofer et al., 2003b).

Chromogranin A Testing.

Chromogranin A belongs to a group of compounds known as *granins*, which exist in the secretory vesicles of the neuroendocrine and nervous systems. Elevation of serum chromogranin A levels has been documented in patients with pheochromocytoma. Although the sensitivity of the test for detecting pheochromocytoma is suboptimal (approximately 85%), some have suggested that the evaluation of chromogranin A level has a role in confirmatory testing in patients who have mild or moderate (less than a fourfold) elevation in free plasma metanephrine levels (Algeciras-Schimnich et al., 2008; Bravo and Tagle, 2003). Chromogranin A is renally cleared, and the specificity of the test decreases significantly in patients with glomerular filtration rates less than 80 mL/min (Bravo and Tagle, 2003).

Screening for Hereditary Pheochromocytoma.

A hereditary pattern is responsible for more than one-third of pheochromocytomas. Furthermore, nearly one-fourth of patients who appear to have sporadic nonfamilial disease at diagnosis demonstrate germline mutations on genetic testing (Benn and Robinson, 2006; Neumann et al., 2002). Despite this, the consensus of the First International Symposium on Pheochromocytoma in 2005 did not endorse universal genetic testing in all patients diagnosed with pheochromocytoma. Instead, this panel of experts established guidelines for screening and evaluation for pheochromocytoma. Fig. 106.19 summarizes how clinical history and disease characteristics at presentation should guide genetic testing. Others have suggested similar algorithms (Amar et al., 2005a). All patients younger than 50 years of age should receive genetic testing for the *RET*, *VHL*, *SDHB*, and *SDHD* gene mutations (Pacak, 2007). Routine testing for the *NF1* gene is not recommended in patients who do not meet clinical criteria for neurofibromatosis (Plouin and Gimenez-Roqueplo, 2006b). Before initiating genetic testing, the patient should be counseled about implications and benefits of genetic testing. Professional genetic counseling is strongly recommended (Gupta et al., 2017; Pacak, 2007).

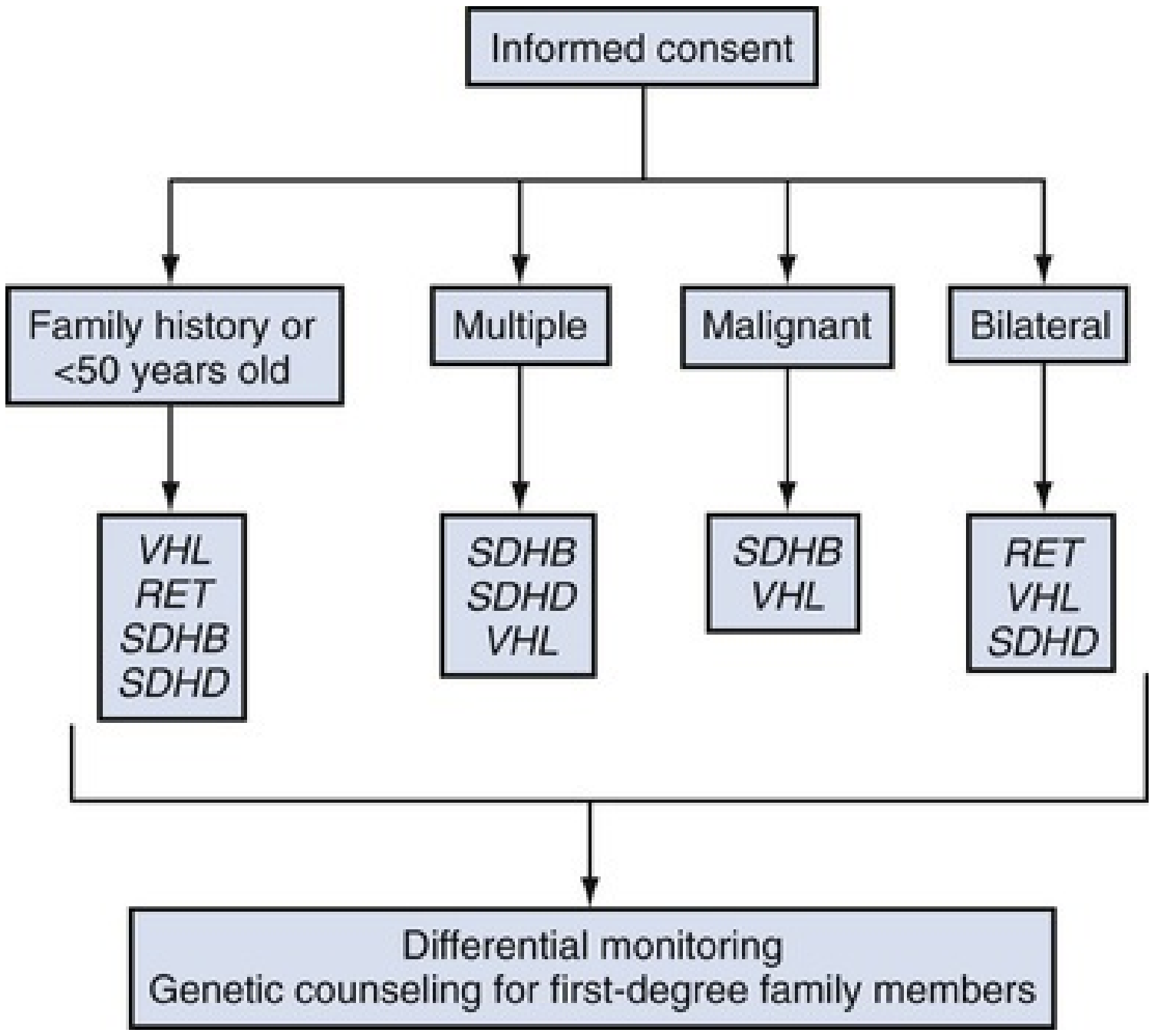
Informed consent
Family history or <50 years old
Multiple
Malignant
Bilateral
VHL
RET
SDHB
SDHD
SDHB
SDHD
VHL
SDHB
VHL
RET
VHL
SDHD
Differential monitoring
Genetic counseling for first-degree family members

FIG. 106.19 Algorithm for genetic screening of patients with pheochromocytoma with risk factors for hereditary disease. (From Pacak K. Preoperative management of the pheochromocytoma patient. *J Clin Endocrinol Metab* 92:4069–4079, 2007.)

Treatment

Overview.

Pheochromocytoma is a surgical disease. Complete resection of the tumor is advised whenever possible (Khorram-Manesh et al., 2005). Laparoscopic adrenalectomy constitutes the standard of care for most tumors, although open approaches have been advocated for large and/or surgically difficult lesions (Pacak et al., 2007). Please see Chapter 107 regarding surgical considerations when treating patients with pheochromocytoma. The urologist must be familiar with the perioperative management of catecholamine-producing tumors before taking the patient to the operating room. Lifelong follow-up is necessary for all patients. Patients with familial and malignant disease require a tailored approach that should include cardiology, endocrinology, and, if needed, medical oncology.

Preoperative Management

Overview.

Catecholamine release during intraoperative tumor manipulation can result in hazardous blood pressure elevation and cardiac arrhythmias. In the era before routine initiation of preoperative catecholamine blockade, some reported mortality rates as high as 50% (Pacak et al., 2001b). **In 2005, the First International Symposium on Pheochromocytoma recommended that all patients with pheochromocytoma and an abnormal metabolic evaluation undergo preoperative catecholamine blockade, including patients who do not exhibit evidence of blood pressure elevation and lack classic symptomatology** (Pacak, 2007; Waingankar, et al 2015). Contemporary series demonstrate mortality rates of less than 3%, which has been attributed in part to optimized anesthetic care and routine preoperative blockade (Lenders et al., 2005). In the absence of appropriately conducted clinical studies comparing preoperative management strategies, no level 1 evidence exists regarding optimal preoperative or perioperative management (Pacak, 2007). Here, we review preoperative blockade strategies relevant to aggressive α-blockade, a central theme recommended by the team from the NIH. Option 1 in Fig. 106.20 summarizes the team's approach. We also outline an alternative strategy (see Fig. 106.20, option 2) that focuses on calcium channel blockade and that has been popularized by other authors (Ulchaker et al., 1999). Other permutations on approaches to preoperative catecholamine blockade exist but are less widely discussed in the literature (Pacak, 2007). Some authors have published reports that advocate the safety of forgoing catecholamine blockade in select patients (Shao et al., 2011).

Thoughtful preoperative cardiac evaluation is paramount, because patients with pheochromocytoma are at risk for cardiomyopathy. Some experts recommend routine preoperative echocardiography (Kinney et al., 2002). We suggest that the patient undergo either a cardiology or anesthesia consultation before surgery.

α-Blockade.

Phenoxybenzamine is the most common α-blocker used for preoperative catecholamine blockade of pheochromocytoma. The agent irreversibly blocks the α receptor. Accordingly, intraoperative catecholamine surges typically do not override its actions, because reversal of the blockade is possible only through synthesis of new receptor molecules (Pacak, 2007). Phenoxybenzamine is started 7 to 14 days before surgery. Oral administration of 10 mg twice daily is initiated and titrated by increases of 10 to 20 mg to a blood pressure of 120 to 130/80 mm Hg in a seated position. Mild postural hypotension with systolic pressure greater than 80 mm Hg is acceptable (Kinney et al., 2002). Experience shows that a final dose of 1 mg/kg is usually sufficient to achieve adequate blockade (Pacak, 2007). In children, 0.2 mg/kg (maximum dose of 10 mg) four times daily with increases in 0.2-mg/kg increments is recommended (Lenders et al., 2005). Because of the irreversible nature of α-blockade, patients may require transient blood pressure support after tumor resection (Pacak, 2007).

Selective reversible α_1-blockers, such as terazosin, doxazosin, or prazosin, are used at some centers in lieu of or in combination with phenoxybenzamine. Although these agents may have fewer side effects than phenoxybenzamine, data regarding their efficacy are contradictory (Lenders et al., 2005; Pacak, 2007). **Moreover, recent compelling data are emerging that preoperative α-blockade may not be necessary in normotensive asymptomatic patients.** In one report, a large cohort of asymptomatic normotensive patients with incidentaloma and a metabolic workup suggestive of pheochromocytoma was offered either α-blockade with doxazosin (n = 38) or no preoperative blockade (n = 21) (Shao et al., 2011). No differences in blood pressure control or perioperative outcomes were seen between the two groups. The group that received doxazosin was more likely to require intraoperative administration of vasoactive agents (Shao et al., 2011). Although these data are provocative, they require validation from other centers, ideally in a prospective randomized fashion.

β-Blockade.

β-Blockade should be used with caution in patients with pheochromocytoma; however, its use is at times necessary because of reflex tachycardia and arrhythmias that can result on initiation of α-blockade. **It is important to understand that β-blockade should never be started before appropriate α-blockade.** Indeed, in the absence of α-blockade, β antagonists cause potentiation of the action of epinephrine on α_1 receptors resulting from blockade of the arteriolar dilation at the β_2 receptor. For this reason, selective β_1 adrenoreceptor blockers, such as atenolol and metoprolol, are usually preferred. Dosages for these agents are summarized in Fig. 106.20 (Pacak, 2007).

Catecholamine Synthesis Blockade.

α-Methyltyrosine, better known as *metyrosine,* blocks the rate-limiting step in the biosynthesis of catecholamines by inhibiting the tyrosine hydroxylase enzyme and thereby preventing the conversion of tyrosine to L-dihydroxyphenylalanine (L-DOPA) (see Fig. 106.4) (Pacak et al., 2001b). Approximately 3 days are necessary to achieve full clinical effect after initiation of this agent. Because blockade of catecholamine synthesis is incomplete, the use of metyrosine is usually coupled with α-blockade by phenoxybenzamine. Use of this agent largely depends on institutional preferences and availability. Some centers avoid routine use of this agent and reserve it for refractory or metastatic patients because of its central nervous system side effects, including sedation, mood depression, and galactorrhea. Extrapyramidal symptoms resembling parkinsonism can result and necessitate cessation of phenoxybenzamine use if present (Pacak et al., 2007). Dosage and titration strategies are summarized in Fig. 106.20.

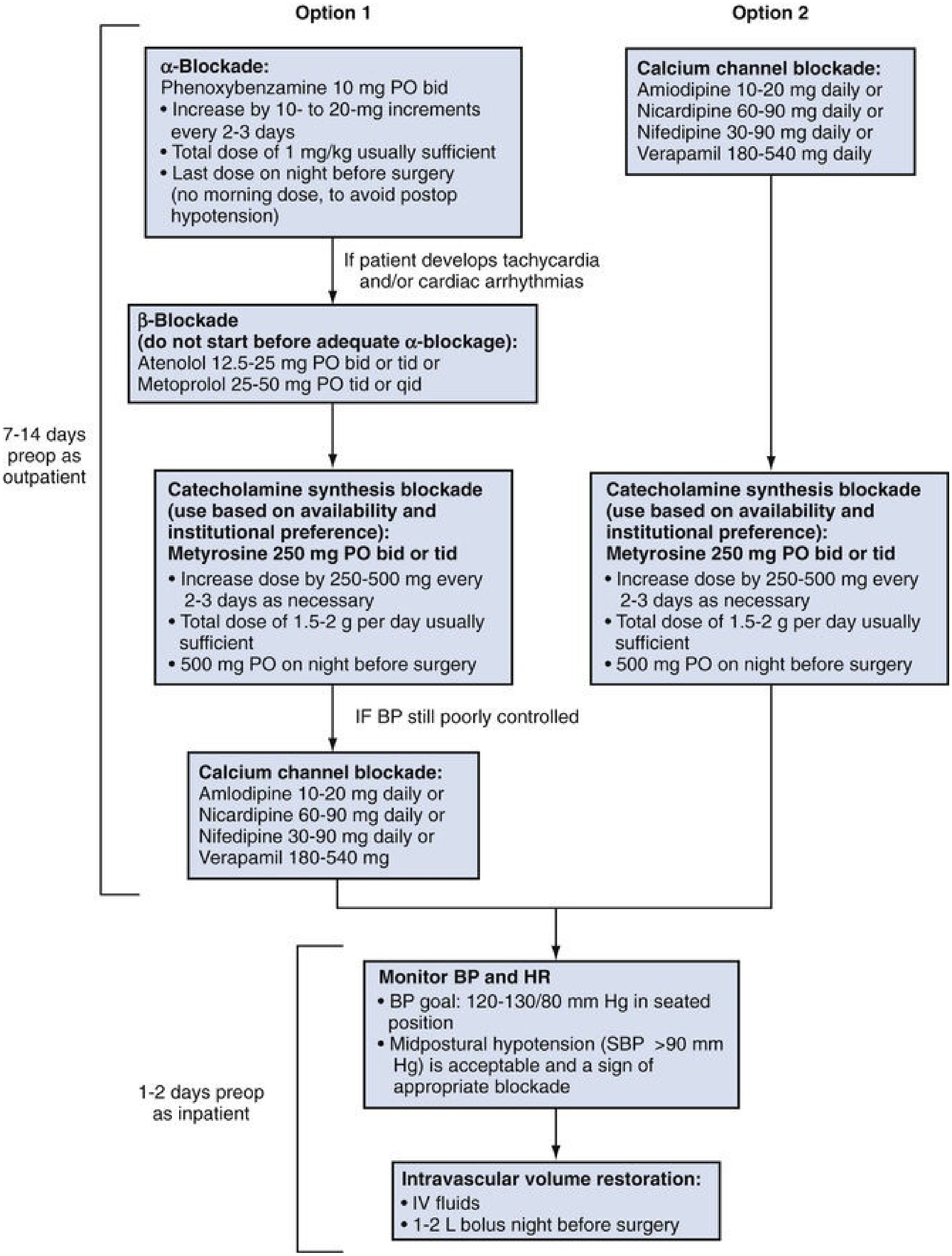
Option 1
Option 2
α-Blockade:
Phenoxybenzamine 10 mg PO bid
• Increase by 10- to 20-mg increments every 2-3 days
• Total dose of 1 mg/kg usually sufficient
• Last dose on night before surgery (no morning dose, to avoid postop hypotension)
If patient develops tachycardia and/or cardiac arrhythmias
β-Blockade (do not start before adequate α-blockage):
Atenolol 12.5-25 mg PO bid or tid or
Metoprolol 25-50 mg PO tid or qid
Calcium channel blockade:
Amiodipine 10-20 mg daily or
Nicardipine 60-90 mg daily or
Nifedipine 30-90 mg daily or
Verapamil 180-540 mg daily
7-14 days preop as outpatient
Catecholamine synthesis blockade (use based on availability and institutional preference):
Metyrosine 250 mg PO bid or tid
• Increase dose by 250-500 mg every 2-3 days as necessary
• Total dose of 1.5-2 g per day usually sufficient
• 500 mg PO on night before surgery
Catecholamine synthesis blockade (use based on availability and institutional preference):
Metyrosine 250 mg PO bid or tid
• Increase dose by 250-500 mg every 2-3 days as necessary
• Total dose of 1.5-2 g per day usually sufficient
• 500 mg PO on night before surgery
IF BP still poorly controlled
Calcium channel blockade:
Amlodipine 10-20 mg daily or
Nicardipine 60-90 mg daily or
Nifedipine 30-90 mg daily or
Verapamil 180-540 mg
Monitor BP and HR
• BP goal: 120-130/80 mm Hg in seated position
• Midpostural hypotension (SBP >90 mm Hg) is acceptable and a sign of appropriate blockade
1-2 days preop as inpatient
Intravascular volume restoration:
• IV fluids
• 1-2 L bolus night before surgery

FIG. 106.20 Preoperative medical management in patients with pheochromocytoma. *BP,* Blood pressure; *HR,* heart rate; *IV,* intravenous; *PO,* by mouth; *SBP,* systolic blood pressure. (Modified from Pacak K. Preoperative management of the pheochromocytoma patient. *J Clin Endocrinol Metab* 92:4069–4079, 2007.)

Calcium Channel Blockade.

Calcium channel blockade in the context of catecholamine excess lowers blood pressure by generating smooth muscle relaxation (Ulchaker et al., 1999). Some have suggested the use of agents such as nicardipine as an adjunct to traditional α-blockade therapy in refractory patients. Other groups, however, report that sole use of calcium channel blockers (see Fig. 106.20, option 2) is sufficient for safe pheochromocytoma resection (Lebuffe et al., 2005; Ulchaker et al., 1999). Indeed, advocates of this strategy argue that this approach avoids the reflex tachycardia and postoperative hypotension that are seen with use of phenoxybenzamine (Ulchaker et al., 1999). The team from the NIH suggests that this strategy (see Fig. 106.20, option 2) be reserved for patients with only mild symptomatology at presentation (Pacak, 2007).

Intravascular Volume Management.

Restoration of intravascular volume is perhaps the most important component of preoperative management of patients with pheochromocytoma. Intake of salt and fluid is encouraged once catecholamine blockade has been initiated (Lenders et al., 2005). Moreover, most centers admit patients the day before surgery and initiate aggressive intravenous fluid resuscitation. The last dose of phenoxybenzamine and/or metyrosine is usually given on the night before surgery, and the next morning's dose is withheld. This approach minimizes potentially prolonged hypotension after tumor resection (Pacak, 2007).

Postoperative Management.

In the immediate postoperative period, the patient must be actively monitored. If phenoxybenzamine was used for preoperative α-blockade, hypotension can occur, given the lasting effects of the agent (Pacak et al., 2001b). Moreover, in a high catecholamine state, α_2-adrenoreceptor stimulation inhibits insulin release. The withdrawal of this adrenergic stimulus after tumor resection may result in rebound hyperinsulinemia and subsequent hypoglycemia (Kinney et al., 2002; Waingankar et al., 2015). Hence, given the necessity for close monitoring, some experts advise overnight admission to the intensive care unit after pheochromocytoma resection (Lenders et al., 2005).

Follow-Up.

Repeat metabolic testing should be performed after adrenalectomy to document normalization of chromaffin cell function (Pacak et al., 2007). In patients in whom metanephrine levels remain elevated, MIBG imaging may be helpful. MIBG uptake by previously unseen metastases may be unveiled after resection of the primary tumor (Plouin and Gimenez-Roqueplo, 2006a).

Long-term vigilant postoperative follow-up of patients with pheochromocytoma is essential (Lenders et al., 2005; Pacak et al., 2007)**. Lifelong screening for recurrence is recommended by some experts, because 10-year recurrence rates are as high as 16% in some series of fully resected lesions** (Amar et al., 2005b; Plouin and Gimenez-Roqueplo, 2006a). Indeed, recurrent disease has been noted in patients more than 15 years after resection of the original tumor (Goldstein et al., 1999; Plouin et al., 1997). Annual biochemical follow-up is mandatory for all patients with resected pheochromocytoma (Eisenhofer et al., 2004a; Lenders et al., 2005). No consensus on follow-up protocols exists; however, biochemical testing at 6 months after surgery, followed by annual testing, has been suggested (Pacak et al., 2001b, 2007). Postoperative cross-sectional imaging is reasonable to document tumor resection and appropriate healing of the resection bed. Need for subsequent imaging should be guided by results of biochemical testing (Pacak et al., 2001b).

Treatment of Hereditary Pheochromocytoma.

Patients with hereditary pheochromocytoma require a unique approach. Given that for patients with MEN-2 and VHL, the risk for malignancy is low (see Table 106.6) whereas the risk for bilateral disease is significant, partial cortical-sparing adrenalectomy has been advocated. This strategy is used to avoid lifelong hormonal replacement, with its associated morbidity (Diner et al., 2005; Løvås et al., 2002; Yip et al., 2004). Successful surgical outcomes require advanced surgical expertise and careful preoperative radiographic planning (Mitterberger et al., 2006). Nevertheless, the patient must be counseled that hormonal replacement may still be necessary despite a seemingly successful cortex-sparing procedure. Life-threatening addisonian crisis can also occur despite close postoperative monitoring (Asari et al., 2006; Yip et al., 2004). Close long-term biochemical and radiographic follow-up is essential, whereas recurrence rates are poorly defined but appear to be significant (Asari et al., 2006; Yip et al., 2004).

Treatment of Malignant Pheochromocytoma.

Current therapy for metastatic pheochromocytoma is largely palliative. Surgical metastasectomy of resectable disease is the standard of care; however, little evidence exists to demonstrate that it prolongs patient survival or is more effective for symptomatic relief than medical treatment with α/β-blockade and α-methyl-*p*-tyrosine (Eisenhofer et al., 2004a; Lenders et al., 2005; Pacak, 2007). Local palliative tumor control using ablation techniques and embolization has also been described (Eisenhofer et al., 2004a; Pacak et al., 2001a).

Given the selective uptake of MIBG by pheochromocytoma cells, systemic treatment of metastatic disease with radioactive ^{131}I-MIBG may be instituted. Before initiation of therapy, MIBG uptake by tumor targets should be demonstrated with traditional MIBG imaging (Scholz et al., 2007). Symptomatic response is seen in up to 2 of 3 patients. Over 40% of patients exhibit a reduction in catecholamine levels. Tumor volume reduction occurs in approximately 30% of patients, but complete responses are seen in less than 5% (Loh et al., 1997; Scholz et al., 2007). High-dose therapy has been reported. Rose et al. (2003) described a multi-institutional study in which 12 patients were treated with ^{131}I-MIBG at 2 to 3.5 times its usual dose. Although toxicity was not trivial, 25% of patients ($n = 3$) exhibited a lasting complete response. Two of these patients had both bony and soft-tissue metastatic lesions. Given the significant toxicity, routine use of high-dose MIBG radiotherapy continues to be controversial (Lenders et al., 2005; Pacak et al., 2007; Scholz et al., 2007).

The best-studied chemotherapy regimen for malignant pheochromocytoma entails a combination of cyclophosphamide, vincristine, and dacarbazine (CVD). Although response rates can be significant (over 50% radiographic tumor response and nearly 75% biochemical response), they are typically short-lived (2 years) (Huang et al., 2008; Scholz et al., 2007). Chemotherapy is primarily used in patients in whom MIBG therapy has failed or in those whose tumors do not demonstrate MIBG uptake on initial MIBG imaging studies. Combination therapy with CVD and MIBG has been explored, but, to date, its risks and benefits remain poorly defined (Scholz et al., 2007). Emerging data utilizing novel peptide receptor radionuclide therapy are promising and appear superior to MIBG (Kong et al., 2017).

Prognosis.

After surgical resection, patients with pheochromocytoma typically do exceedingly well. Surgical mortality rates in the current era are less than 3%

(Lenders et al., 2005). Hypertension usually resolves after resection, but not in all cases (Plouin et al., 1997). **Despite an excellent prognosis, the disease can recur many years after resection in up to 16% of patients, necessitating vigilant lifelong follow-up** (Amar et al., 2005b; Eisenhofer et al., 2004a; Goldstein et al., 1999; Plouin et al., 1997). In one large series, patients with extra-adrenal disease (hazard ratio [HR] 11.2), hereditary pheochromocytomas (HR 3.4), right adrenal tumors (HR 3.1), bilateral tumors (HR 1.4), and larger tumors (HR 1.2 per centimeter of diameter) were more likely to demonstrate recurrence. **Some 50% of the recurrences were malignant** (Amar et al., 2005b).

In some patients, metastatic disease progresses rapidly, whereas others exhibit nonaggressive disease and can live in excess of 20 years (Huang et al., 2008). Bone metastases appear to carry the most benign prognosis (Pacak, 2007; Scholz et al., 2007). For all-comers, 5-year survival statistics vary but are believed to be approximately 50% (John et al., 1999; Lenders et al., 2005; Pacak et al., 2007; Scholz et al., 2007).

Summary.

Pheochromocytoma is a rare catecholamine-producing tumor. Awareness of its potential presence and familiarity with its management are critical for every urologist. Misdiagnosis or mismanagement is often associated with dire consequences. Pheochromocytoma must be considered in every adrenal mass and referral to a tertiary care facility made if the physician is unfamiliar with the care of these complex patients.

Key Points: Pheochromocytoma

- Nearly 25% of cases of pheochromocytoma that initially appear sporadic are later deemed hereditary on genetic testing.
- Testing for urinary or serum metanephrines (normetanephrine and metanephrine) represents the underpinning of modern biochemical testing for pheochromocytoma.
- Malignancy of pheochromocytoma can be defined only by presence of metastases. Pathologic appearance is unreliable. Long-term follow-up is paramount, because recurrences are reported even 15 years after initial

resection of a localized lesion.

- Familiarity with perioperative management of patients with pheochromocytoma is paramount.

Disorders of Decreased Adrenal Function

Overview and Epidemiology

Adrenal insufficiency, also known as *Addison disease,* is a condition whose management typically is beyond the scope of most urologic practices. Nonetheless, a working knowledge of the condition is essential for the urologic surgeon because the disease may result from either resection or pharmacologic inhibition of functioning adrenal tissues. Failure to consider and diagnose is potentially lethal and therefore warrants review. **Indeed, if the condition is not anticipated and appropriate proactive therapies are not instituted, addisonian crises after simultaneous or staged bilateral adrenalectomy can result in death** (Asari et al., 2006).

Adrenal insufficiency may be caused by primary adrenal failure or may occur secondary to extra-adrenal mechanisms. Its estimated prevalence is 39 to 60 per 1 million (Oelkers, 1996).

Pathophysiology

In the Western world, the most frequent cause of primary adrenal insufficiency is autoimmune adrenalitis. This condition can occur in isolation or as a constellation of pathologies known as *autoimmune polyendocrine syndrome (APS),* wherein adrenal insufficiency coexists with hypoparathyroidism, autoimmune thyroid disease, hypogonadism, diabetes, and other autoimmune conditions. Depending on the extent of endocrinologic involvement, APS is classified as either type 1 or the more common type 2 (Arlt and Allolio, 2003). In developing countries, as was true in the age of Thomas Addison, tuberculosis remains the major cause of adrenal failure (Løvås and Husebye, 2005). Other infectious causes, such as cytomegalovirus in the setting of human immunodeficiency virus (HIV) infection and rare fungal adrenalities, can also destroy the adrenal cortex. Bilateral adrenal hemorrhage or infiltrative diseases, such as amyloidosis, sarcoidosis, and hemochromatosis may also affect the function of the glands (Oelkers, 1996). Bilateral metastatic disease involving the adrenal glands, although classically described as a potential cause of adrenal insufficiency, is a very rare cause of clinically significant Addison disease (Lutz et al., 2000). In urologic practice, relevant clinical scenarios include simultaneous or staged surgical loss of bilateral adrenal tissue after treatment of adrenal or renal disease, and pharmacologic adrenalectomy with inhibitors of steroid hormone synthesis, such as ketoconazole, or new 17α-hydroxylase (CYP17) inhibitors such as abiraterone (Arlt and Allolio, 2003). Although low postoperative day 1 cortisol levels (<3.4 µg/dL) are not uncommon in patients after unilateral adrenalectomy, the clinical significance of such findings is unclear, and steroid replacement appears largely unnecessary for those without preoperative hypercortisolism (Mitchell et al., 2009; Shen et al., 2006). Nevertheless, a high index of suspicion for adrenal insufficiency must always remain in patients whose adrenal unit is removed.

Secondary adrenal insufficiency is caused by abnormalities in the pituitary gland or, less frequently, the hypothalamus. Tumors, radiation, autoimmune conditions, pituitary apoplexy (also known as *Sheehan syndrome* when it occurs peripartally), and trauma are less common causes of the condition. Rare congenital conditions marked by a metabolic error in the production of pituitary hormones, including ACTH, are rare causes of secondary Addison disease (Arlt and Allolio, 2003). Fig. 106.21 summarizes the major causes of Addison disease. It is important to note that, because aldosterone secretion by the adrenal glands does not depend on ACTH, the zona glomerulosa continues to function appropriately in patients with secondary adrenal insufficiency. **Mineralocorticoid deficiency is therefore present only in patients with primary Addison disease** (White, 1994).

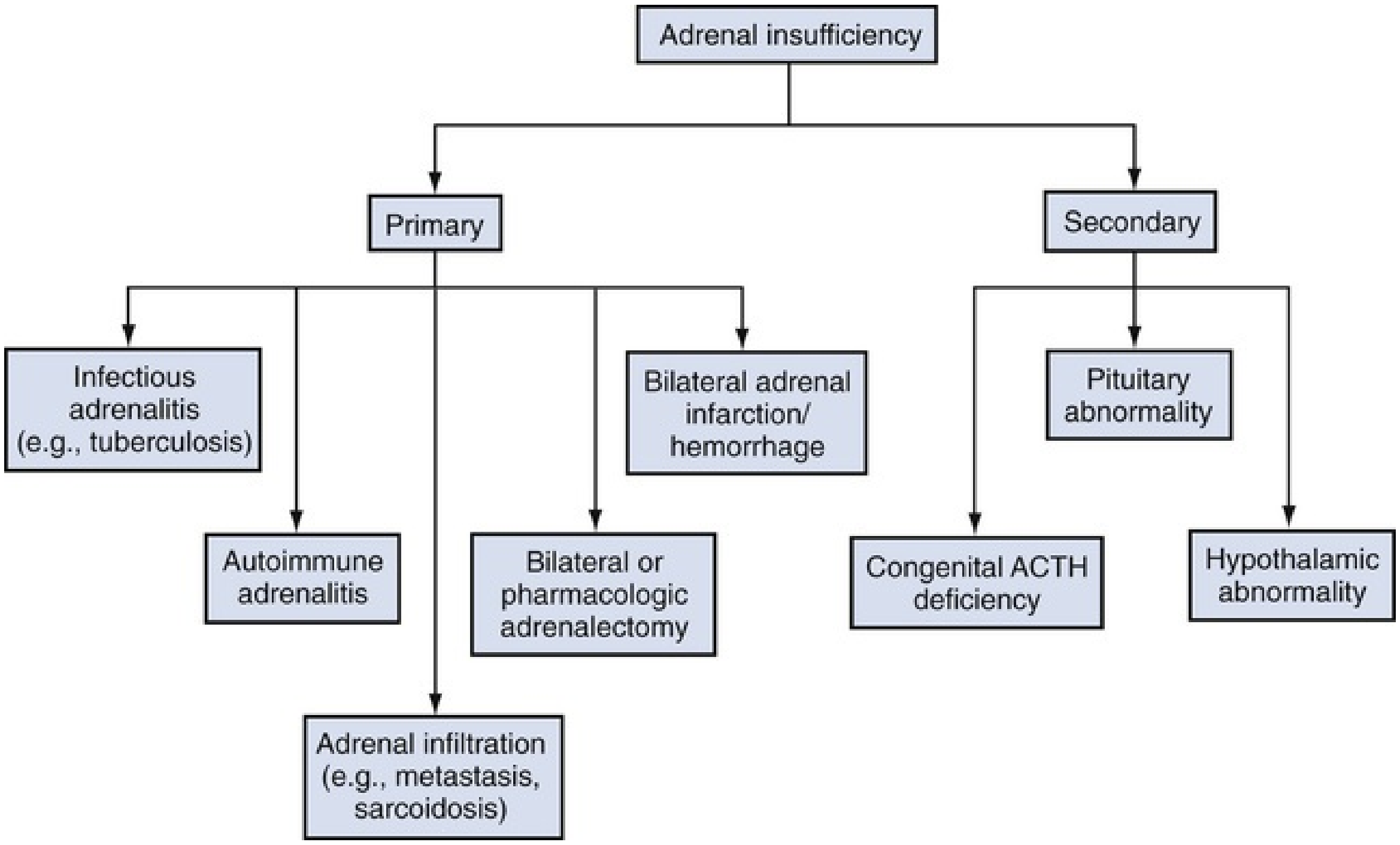
Adrenal insufficiency
Primary
Secondary
Infectious adrenalitis (e.g., tuberculosis)
Autoimmune adrenalitis
Adrenal infiltration (e.g., metastasis, sarcoidosis)
Bilateral or pharmacologic adrenalectomy
Bilateral adrenal infarction/ hemorrhage
Congenital ACTH deficiency
Pituitary abnormality
Hypothalamic abnormality

FIG. 106.21 Causes of adrenal insufficiency. *ACTH,* Adrenocorticotropic hormone.

Exogenous chronic administration of glucocorticoids accompanied by suppression of the HPA axis, resulting in secondary adrenal insufficiency, is particularly relevant to the surgeon (Krasner, 1999). Although overt adrenal crises caused by this clinical scenario are exceedingly rare, the possibility exists in surgical patients on chronic steroids (Axelrod, 2003). Postoperatively the urologist must also be cognizant of HPA axis failure in critically ill patients. This condition, recently termed *critical illness–related corticosteroid insufficiency*, is an important, albeit controversial, clinical entity (Marik, 2009; Marik et al., 2008).

Clinical Characteristics

Clinical signs and symptoms of Addison disease are usually nonspecific and constitutional in most outpatients, who may complain of profound fatigue and anorexia for many months before definitive diagnosis. Hyperpigmentation, a hallmark of primary adrenal insufficiency, results from high serum concentrations of ACTH in response to increased hypothalamic release of POMC-derived peptides that stimulate the melanocortin (MC1) receptor of the skin (Arlt and Allolio, 2003). Table 106.9 summarizes the clinical manifestations of adrenal insufficiency.

TABLE 106.9

Clinical Manifestations of Adrenal Insufficiency

SYMPTOMS	PATHOPHYSIOLOGY
Fatigue, lack of energy or stamina, reduced strength	Glucocorticoid deficiency, adrenal androgen deficiency
Anorexia, weight loss (in children, failure to thrive)	Glucocorticoid deficiency
Gastric pain, nausea, vomiting (more frequent in primary adrenal insufficiency)	Glucocorticoid deficiency, mineralocorticoid deficiency
Myalgia, joint pain	Glucocorticoid deficiency
Dizziness	Mineralocorticoid deficiency, glucocorticoid deficiency
Salt craving (primary adrenal insufficiency only)	Mineralocorticoid deficiency
Dry and itchy skin (in women)	Adrenal androgen deficiency
Loss or impairment of libido (in women)	Adrenal androgen deficiency
Skin hyperpigmentation (primary adrenal insufficiency only)	Excess of pro-opiomelanocortin–derived peptides
Alabaster-colored pale skin (secondary adrenal insufficiency only)	Deficiency of pro-opiomelanocortin–derived peptides
Fever	Glucocorticoid deficiency
Low blood pressure (systolic RR <100 mm Hg), postural hypotension (pronounced in primary adrenal insufficiency)	Mineralocorticoid deficiency, glucocorticoid deficiency
Raised serum creatinine (primary adrenal insufficiency only)	Mineralocorticoid deficiency
Hyponatremia	Mineralocorticoid deficiency, glucocorticoid deficiency (leading to syndrome of inappropriate antidiuretic hormone secretion [SIADH])
Hyperkalemia (primary adrenal insufficiency only)	Mineralocorticoid deficiency
Anemia, lymphocytosis, eosinophilia	Glucocorticoid deficiency
Increased thyroid-stimulating hormone (primary adrenal insufficiency only)	Glucocorticoid deficiency (or autoimmune thyroid failure)
Hypercalcemia (primary adrenal insufficiency only)	Glucocorticoid deficiency (mostly concurrent hyperthyroidism)

Hypoglycemia	Glucocorticoid deficiency
Loss of axillary or pubic hair (in women), absence of adrenarche or pubarche in children	Adrenal androgen deficiency

From Arlt W, Allolio B. Adrenal insufficiency. *Lancet* 361(9372):1881–1893, 2003.

Acute adrenal insufficiency, or adrenal crisis, is a life-threatening condition often preceded by hypotension unresponsive to fluid resuscitation. Patients are easily and often misdiagnosed with an acute abdomen, whereas abdominal pain, nausea, vomiting, and fever frequently accompany hypovolemia in these individuals. Pediatric patients can exhibit hypoglycemic seizures (Arlt and Allolio, 2003; Bouillon, 2006).

Adrenal insufficiency (an addisonian state) after adrenalectomy in the setting of a normally functioning contralateral adrenal gland is unlikely, but possible. This is especially true for patients who are undergoing adrenalectomy for a cortisol-secreting lesion, because functionality of the contralateral gland can be suppressed (Mitchell et al., 2009; Phitayakorn and McHenry, 2012; Shen et al., 2006; Tsagarakis et al., 2006)**. Furthermore, patients with a history of contralateral partial or radical nephrectomy clearly represent a high-risk group. The integrity of the adrenal gland on the side of previous surgery may be compromised, or that gland may be altogether absent. Close examination of preoperative imaging and review of old operative and pathology reports for information regarding the status of the adrenal gland in the previous surgical field are paramount.**

Diagnostic Tests

The diagnosis of primary adrenal insufficiency is primarily made on clinical grounds, with a high index of suspicion given a patient's history, examination findings, and laboratory evaluation. It is ultimately secured by measurements of morning serum cortisol and ACTH. Patients with primary Addison disease exhibit abnormal aldosterone and renin levels. Confirmatory testing involves assessing the adrenal response to ACTH stimulation in the form of the corticotropin test. The majority of patients with autoimmune adrenalitis demonstrate detectable levels of anti–21-hydroxylase antibodies (Arlt and Allolio, 2003; Oelkers et al., 1992).

The appropriate workup for secondary adrenal insufficiency often requires sophisticated probing of the HPA axis that goes beyond the scope of this text and requires endocrinologic expertise. In-depth reviews of the topic are available (Oelkers et al., 1992, 1996).

Treatment

The treatment of Addison disease involves adrenal hormonal repletion. Cortisol is replaced with hydrocortisone or with cortisone acetate. To mimic physiologic circadian glucocorticoid cycling, the majority (one-half or two-thirds) of the daily dose is given in the morning, with the rest administered in one or two doses later in the day (Arlt and Allolio, 2003). Mineralocorticoid replacement is required only for patients with primary adrenal insufficiency and is achieved with fludrocortisone (Løvås and Husebye, 2005). Supplementation of adrenal androgens is advised by some experts but is often limited to those who experience constitutional complaints despite adequate glucocorticoid and mineralocorticoid supplementation (Arlt and Allolio, 2003). Careful monitoring of patients on hormone replacement for adrenal insufficiency is required and is often best left to experienced endocrine experts.

The necessity of perioperative stress-dose steroid administration continues to be controversial. Although continuing the patient's usual steroid dose is usually sufficient, given the negligible downside of perioperative steroid coverage and the potential catastrophic consequences of failure to prevent adrenal crisis, surgeons continue to administer stress-dose steroids perioperatively. Tables 106.10 and 106.11 summarize contemporary recommendations (Axelrod, 2003; Krasner, 1999; Salem et al., 1994). Again, because aldosterone physiology is not altered in these patients, mineralocorticoid replacement is unnecessary (White, 1994).

TABLE 106.10

Perioperative Glucocorticoid Administration in Patients on Chronic Steroid Therapy

DEGREE OF SURGICAL STRESS	DEFINITION	GLUCOCORTICOID DOSE
Minor	Procedure under local anesthesia and less than 1 hour in duration (e.g.,	Hydrocortisone 25 mg or equivalent.

	inguinal hernia repair)	
Moderate	Procedure such as vascular surgery of a lower extremity or a total joint replacement	Hydrocortisone 50–75 mg or equivalent. This could be continuation of usual daily steroid dose (e.g., prednisone 10 mg/day) and hydrocortisone 50 mg intravenously during surgery.
Major	Procedure such as esophagogastrectomy or operation on cardiopulmonary bypass	Usual glucocorticoid (e.g., prednisone 40 mg or the parenteral equivalent within 2 h before surgery) and hydrocortisone 50 mg intravenously q8h after the initial dose for the first 48–72 h of postoperative period.

Data from Salem M, Tainsh RE Jr, Bromberg J, et al. Perioperative glucocorticoid coverage. A reassessment 42 years after emergence of a problem. *Ann Surg* 219(4):416–425, 1994; and Axelrod L. Perioperative management of patients treated with glucocorticoids. *Endocrinol Metab Clin North Am* 32(2):367–383, 2003.

TABLE 106.11

Relative Potency of Common Glucocorticoid Preparations

NAME	BIOLOGIC HALF-LIFE (HOURS)	RELATIVE ANTI-INFLAMMATORY POTENCY	APPROXIMATE ADULT PHYSIOLOGIC REPLACEMENT DOSE (MG/DAY)
Hydrocortisone (cortisol)	8–12	1	20
Cortisone acetate		0.8	25
Prednisone	18–36	4	5
Prednisolone		4	5
Methylprednisolone		5	4
Triamcinolone		5	4
Dexamethasone	36–54	25–50	0.5

Data from Krasner AS. Glucocorticoid-induced adrenal insufficiency. *JAMA* 282(7):671–676, 1999.

Prognosis

The impact on life expectancy in cases of primary adrenal insufficiency has not been established; however, a significant impact on a patient's quality of life has been demonstrated (Løvås et al., 2002). Many patients complain of decreased energy, loss of libido, and psychological maleffects (Arlt and Allolio, 2003).

Secondary adrenal insufficiency from hypopituitary disease is an established cause of premature death (Tomlinson et al., 2001).

Summary

In urologic practice, adrenal insufficiency can result from simultaneous or staged surgical excision or pharmacologic ablation with steroid hormone synthesis blockade agents. Diagnosis requires a high index of suspicion. Patients having undergone ipsilateral partial or radical nephrectomy who are to undergo contralateral surgery constitute an at-risk population. Obtaining old operative or pathology reports and examining cross-sectional imaging for the presence or absence of adrenal tissue are essential in this setting. Postoperative adrenal insufficiency must be considered in patients on chronic glucocorticoid therapy or in the critically ill. There should be a low threshold to consult advanced endocrinologic expertise, given the complexity and the potentially grave consequences of the condition.

Key Points: Adrenal Insufficiency

- Mineralocorticoid deficiency is present only in patients with primary Addison disease (e.g., autoimmune adrenalitis, surgical absence of adrenal tissue). Abnormalities in the pituitary gland or, less frequently, the hypothalamus (e.g., in patients with suppressed ACTH secretion from chronic steroid use) do not result in suppression of aldosterone production.
- Any patient who has undergone ipsilateral partial or radical nephrectomy and is undergoing contralateral renal or adrenal surgery is at risk for postoperative adrenal crisis. Obtaining old operative or pathology reports and examining cross-sectional imaging for the presence or absence of adrenal tissue are essential in this setting.

Disorders of Abnormal Adrenal Function

Congenital Adrenal Hyperplasia

CAH is a disorder that is characterized by low cortisol production caused by a metabolic enzymatic abnormality in the cholesterol-steroid biosynthesis pathway (see Fig. 106.3). The disorder is autosomal recessive and associated with a deficiency in the enzyme 21-hydroxylase in over 95% of cases. In the absence of negative feedback, ACTH production by the pituitary gland is increased, resulting in hyperplasia of the adrenal cortex and overproduction of adrenal androgens (Merke and Bornstein, 2005). Diagnosis of the condition is most often established in childhood. Patients with known CAH, as well as carriers of the *CAH* gene, appear to have a high propensity for developing benign adrenal cortical adenomas but are not at known increased risk for malignant adrenal lesions (Barzon et al., 2007; Jaresch et al., 1992). Patients with undiagnosed nonclassic 21-hydroxylase deficiency can develop adrenal neoplasms later in life (Nigawara et al., 2008; Ravichandran et al., 1996). Given the relatively low incidence, genetic screening of patients with adrenal incidentalomas has not demonstrated an increased incidence of undiagnosed CAH. Therefore screening of incidentaloma patients for CAH is not indicated (Barzon et al., 2003; Kjellman et al., 1999; Wagnerova et al., 2008).

Adrenal Lesions

Malignant

Adrenal Carcinoma

Overview and Epidemiology.

ACC is a rare malignancy with an incidence of 0.7 to 2 per 1 million (Allolio and Fasshacht, 2006; Aubert et al., 2002; Fassnacht et al., 2013; Kebebew et al., 2006; Roman, 2006). It has a bimodal age distribution that peaks in children during the first decade of life and in adults during the fourth to fifth decades of life, although most patients with ACC are adults, with a slight female predominance of 1.5 to 2.1 (Roman, 2006). Several important differences exist between the pediatric and adult ACC populations, including symptoms at presentation, staging systems used, and prognosis. Compared with the adult population, children with ACC on presentation will more often have lower-stage functional tumors associated with improved survival (Liou and Kay, 2000).

The majority of ACCs are sporadic and unilateral; however, 2% to 6% of patients will have bilateral disease that may be associated with a hereditary disorder (Ng and Libertino, 2003). Although the cause of sporadic ACC remains unknown, several syndromes are associated with an increased incidence of ACC, including Li-Fraumeni syndrome, Beckwith-Wiedemann syndrome, Lynch syndrome, Carney complex, MEN-1, neurofibromatosis type 1, familial adenomatous polyposis, and McCune-Albright syndrome (Else, 2012; Else et al., 2014a; Raymond et al., 2013). Although the underlying molecular defect of these syndromes has advanced our understanding of the tumorigenesis of ACC, significant improvements in treatment regimens and survival are yet to be realized. Currently, surgical resection remains the cornerstone of treatment and, when localized, offers the best chance of cure; however, multimodal therapy including systemic chemotherapy and radiation therapy are often required for locally advanced and metastatic disease. Over the past two decades, there has been a lack of stage and size migration in patients diagnosed with ACC, despite “incidental screening” of the adrenal gland that has resulted from rising rates of cross-sectional imaging. Furthermore, ACC survival rates have also failed to improve (Kutikov et al., 2011a).

Pathophysiology.

Two hereditary disorders, Li-Fraumeni syndrome and Beckwith-Wiedemann syndrome, have provided valuable insight into the tumorigenesis of sporadic ACC. Loss of TP53 function, as found in Li-Fraumeni syndrome, has been noted in 20% to 33% of sporadic ACC cases and 50% to 80% of pediatric ACC cases compared with 0% to 6% of adrenal cortical adenomas. Increased insulin-like growth factor (IGF) expression, as found in Beckwith-Wiedemann syndrome, has been noted in up to 90% of sporadic cases of ACC, compared with only 8.5% of adrenal cortical adenomas (Herbet et al., 2009; Wagner et al., 1994)**. These findings suggest that loss of *TP53* function and increased IGF expression represent late events in the tumorigenesis of sporadic ACC.** The Cancer Genome Atlas project evaluated 91 cases of ACC to improve our understanding of the molecular events involved with the development and outcomes of ACC (Zheng et al., 2016). The analysis evaluated clinical and pathologic features, genomic alterations, DNA-methylation profiles, and RNA and proteomic signatures. The genes altered most frequently by somatic mutations, DNA copy-number alterations, and epigenetic silencing were *TP53* (21%), *ZNRF3* (19%), *CDKN2A* (15%), *CTNNB1* (16%), *TERT* (14%), and *PRKAR1A* (11%). Cluster analysis identified three prognostic molecular subtypes based on DNA methylation signature; CpG island hypermethylated phenotype (CIMP) was categorized in low, intermediate, and high subtypes. Five-year survival was significantly associated with CIMP category and was 80% for CIMP-low, 43% for CIMP-intermediate, and 0% for CIMP-high. These results illustrate how molecular data, combined with traditional clinicopathologic assessment, may guide treatment decisions and ultimately improve outcomes. Furthermore, the diversity of genomic alterations suggests that targeting multiple altered pathways likely holds the key to success in improving systemic therapy for ACC.

Clinical Characteristics.

Incidental detection of ACC has increased with the routine use of cross-sectional imaging; however, the majority of patients still have advanced disease and tumor-related symptoms on presentation. Symptomatic presentation resulting from hypersecretion of adrenal hormones occurs in 40% to 60% of patients; 30% of patients present with symptoms of abdominal pain or fullness, and the remainder are incidentally detected (Else et al., 2014b). Fig. 106.22 shows a CT image of a large right-sided ACC. **Tumor-related symptoms of ACC can be**

secondary to local or systemic disease burden and/or hypersecretion of adrenal hormones, which has been noted in 50% to 79% of adult ACCs and 90% of pediatric ACCs (Fassnacht and Allolio, 2009; Roman, 2006). ACCs that are associated with the hypersecretion of adrenal hormones are characterized as being functional. However, the presence of a functional tumor does not always lead to clinical symptoms, as in the case of tumors that secrete high concentrations of steroid precursors. This is especially relevant given the increasing sensitivity of assays used when evaluating serum hormone levels. Furthermore, it is common to have several hormones secreted by a single tumor, and it has been theorized that a tumor's functional status and hormones secreted may change throughout the tumor's development and growth (Phan, 2007).

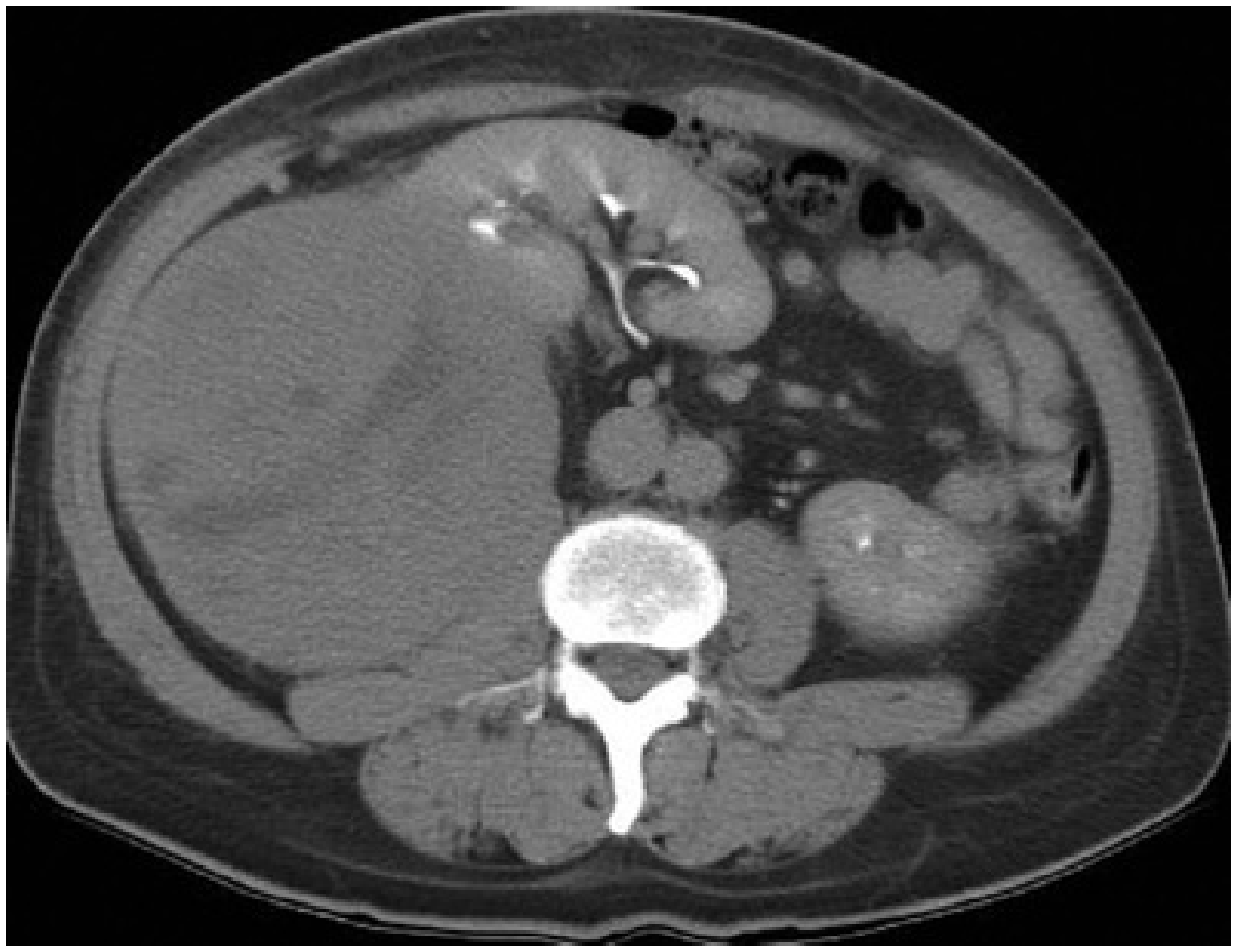

FIG. 106.22 Axial cut in excretory phase of a computed tomography scan demonstrating a large right adrenal carcinoma. The right kidney is shifted anteriorly and medially. Similar-sized masses that arise from the kidney itself usually do not displace the renal unit. Important even at this large size, the adrenal carcinoma appears relatively homogeneous and well circumscribed—features deceptively camouflaging its deadly biologic potential. Surgical resection demonstrated a 25-cm, stage II (pT2N0M0), localized adrenocortical carcinoma. (Courtesy of Dr. David Y.T. Chen, Fox Chase Cancer Center, Philadelphia, PA.)

The most common hormone secreted by ACC is cortisol, noted in 50% to 80% of functional tumors, resulting in the clinical manifestations of Cushing syndrome (Table 106.12) (Else et al., 2014). Hypercortisolism in ACC is ACTH-independent, and the Cushing-associated virilization has been noted to be more pronounced compared with that resulting from functional adenomas. Recent data suggest that symptomatic hypercortisolemia is an independent prognosticator of survival in patients with resected localized ACC (Berruti et al., 2014; Else et al., 2014b). Androgens are the second most common adrenal hormone produced by ACCs, accounting for 40% to 60% of functional tumors (Else et al., 2014a). The observed increase in virilization may be the result of increased rates of cosecretion of 17-ketosteroids and DHEA in patients with ACC (Roman, 2006). Androgen-secreting tumors in women can lead to virilization, characterized by male-pattern baldness, hirsutism, and oligomenorrhea, which are typically related to elevated 17-ketosteroids. When virilization is present in the absence of elevated 17-ketosteroids, free testosterone hypersecretion from an adrenal or ovarian source should be considered. Estrogen production can lead to feminization in men and is noted in 1% to 3% of patients. When present, feminization in men is characterized by testicular atrophy and gynecomastia, may result from peripheral conversion of androstenedione to estrogen, and is highly suggestive of malignancy. Combined hypercortisolism and androgen secretion is noted in up to 50% of patients with functional ACCs (Else et al., 2014a). Although hypersecretion of aldosterone is rarely associated with ACC, when present it is associated with profound hypertension and hypokalemia. Moreover, the symptoms of hypertension and hypokalemia are more likely secondary to other adrenal steroids produced by ACC, rather than the hypersecretion of aldosterone (Egoshi et al., 1998; Mussig et al., 2005). Although considered functional, ACCs can result in high levels of steroid precursors, such as androstenedione and 17α-hydroxyprogesterone, which may not cause any overt clinical symptoms (Fassnacht and Allolio, 2009). Nonfunctional ACCs may cause more generalized tumor-related symptoms, such as abdominal fullness, back pain, nausea, vomiting, or other constitutional symptoms.

TABLE 106.12

Functional Breakdown of Adrenal Cortical Carcinomas

Nonfunctional	21%–50%
Functional	50%–79%
Cushing syndrome	33%–53%
Cushing syndrome plus virilization	20%–24%
Virilization alone	10%–20%
Feminization	6%–10%

Hyperaldosteronism	2.5%–5%

Diagnostic Tests.

Suspicion for ACCs is based on clinical symptoms or radiographic findings and warrants the complete extent of disease evaluation, given the implications of this malignancy. Diagnosis should begin with a thorough history and physical examination focusing evaluation on signs and symptoms of adrenal hormone excess. Evaluating the functional status of adrenal tumors suspicious for ACC is essential, not only for making the diagnosis of ACC but also for consideration of postoperative cortisol replacement and the potential use of tumor-secreted hormones as markers during postoperative surveillance. **When considering the functional status of a tumor that raises suspicion for ACC, glucocorticoid, mineralocorticoid, catecholamine, sexual steroid, and steroid precursor excesses should be evaluated** as outlined in Table 106.13 (Else et al., 2014a).

TABLE 106.13

Functional Evaluation of Adrenal Tumors Suspected to Be Adrenocortical Carcinoma

TYPE OF ADRENAL HYPERSECRETION	FUNCTIONAL EVALUATION
Glucocorticoid excess	Low-dose dexamethasone suppression test (or late night salivary or 24-hour urine cortisol) ACTH
Sexual steroids and steroid precursors	DHEA-S Testosterone 17-OH-progesterone (optional) Androstenedione (optional) 17-OH-pregnenolone (optional) 11-deoxycorticosterone (optional) Progesterone (optional) Estradiol (optional) 17β-estradiol (only in men and postmenopausal women)
Catecholamine excess	Serum or urinary metanephrines
Mineralocorticoid excess	Aldosterone-to-renin ratio (only in patients with hypertension or hypokalemia)

ACTH, Adrenocorticotropic hormone; *DHEA-S,* dehydroepiandrosterone sulfate.

Data from Fassnacht M, Kenn W, Allolio B. Adrenal tumors: how to establish malignancy? *J*

Endocrinol Invest 27(4):387–399, 2004.

The radiographic characteristics of an adrenal tumor provide valuable information regarding the lesion's malignant potential and may be obtained using several modalities including CT, MRI, and ^{18}F-FDG PET imaging. **On cross-sectional imaging, ACCs tend to be larger than benign adrenal tumors, with an average size of 10 to 12 cm on presentation. Indeed, over 90% of ACCs are larger than 5 cm** (Fassnacht and Allolio, 2009; Ng and Libertino, 2003). In incidentally detected adrenal tumors, size is a relative indicator of malignancy, with 4% to 5% of tumors smaller than 4 cm, 10% of tumors larger than 4 cm, and 25% of tumors larger than 6 cm found to be adrenal carcinomas (Sturgeon and Kebebew, 2004; Walz et al., 2005). Given the relationship between adrenal tumor size and malignancy, it is currently recommended that adrenal tumors larger than 4 to 6 cm are considered for surgical extirpation (Schteingart et al., 2005). Although a complete metastatic evaluation should be obtained for all adrenal tumors that raise suspicion for ACC, the presence of lymphadenopathy and local tumor extension into the IVC and other adjacent organs are ominous indicators of locally advanced or distant metastatic disease. The most common sites of metastases in adrenal carcinoma are the lung and liver. Therefore metastatic evaluation at presentation should include cross-sectional imaging of the chest, abdomen, and pelvis. Evaluation for bone and central nervous system metastases need be performed only in patients with site-specific symptoms. **Common radiographic characteristics of adrenal carcinomas on CT imaging include the presence of irregular borders, irregular enhancement, calcifications, and necrotic areas with cystic degeneration. Mean attenuation on noncontrast CT scan in ACC is significantly higher (39 HU) compared with adenomas (8 HU).** Classically, ACC does not exhibit the brisk iodinated contrast washout characteristic of adenomas; however, these conclusions are based on limited data, and exceptions have been reported (Roman, 2006; Simhan et al., 2012a; Szolar et al., 2005) (Refer to the Imaging of Adrenal Masses section later in this chapter).

MRI provides valuable information for evaluating adrenal tumors. ACCs appear isointense relative to the liver or spleen on T1-weighted images and demonstrate intermediate to increased intensity on T2-weighted images. On gadolinium-enhanced images, adrenal carcinomas demonstrate marked contrast uptake (Ilias et al., 2007). In cases of suspicion for venous tumor thrombus, MRI can be an essential tool in detecting the presence of a tumor clot and delineating its extent.

Available data suggest that ACC tends to be ^{18}F-FDG PET avid (Boland et al., 2011; Leboulloux et al., 2006; Tenenbaum et al., 2004). The sensitivity and specificity of ^{18}F-FDG PET in diagnosing benign from malignant tumors was 97% and 91% in a meta-analysis (Sundin, 2012). However, ^{18}F-FDG PET cannot distinguish ACC from other malignancies and metastases.

In diagnosing ACCs, percutaneous needle biopsy is usually not performed before surgical excision because there is a clinically unacceptable risk for needle-tract seeding (Fassnacht et al., 2004; Schteingart et al., 2005). In cases of surgically resectable disease, the information obtained from biochemical and radiographic evaluation should be enough to justify extirpation. The primary indication for needle biopsy is in cases of unresectable, locally advanced, or metastatic disease to confirm the diagnosis before systemic medical therapy.

Pathologic Evaluation.

During the histologic evaluation of an adrenal tumor, tumor origin and malignancy are the two most important considerations. For cases in which tumor origin is questioned, SF1 expression can be evaluated, with positive staining suggesting adrenocortical origin (Fassnacht et al., 2013). Although the presence of distant metastasis and local invasion are clear indications of malignancy, the differentiation between benign and malignant neoplasms in organ-confined tumors can be pathologically challenging (Fig. 106.23). The Weiss criteria, developed in 1984, were established to distinguish benign from malignant adrenal tumors using nine pathologic features (Weiss, 1984). The classification system is based on tumor structure, cytology, and invasion (Box 106.4). The presence of three or more of the Weiss criteria is associated with malignancy, with a sensitivity of 100% and a specificity of 96% (Aubert et al., 2002). The mitotic rate can be used to classify ACCs as low grade and high grade. Of the Weiss criteria, grading based on mitotic rate has the greatest association with patient outcomes. In cases of pediatric adrenal tumors, and in adult adrenal tumors that demonstrate oncocytic features, the Weiss criteria should be used with caution, and alternative diagnostic criteria are recommended (Lau and Weiss, 2009, Margo et al., 2012; Weinke et al., 2003).

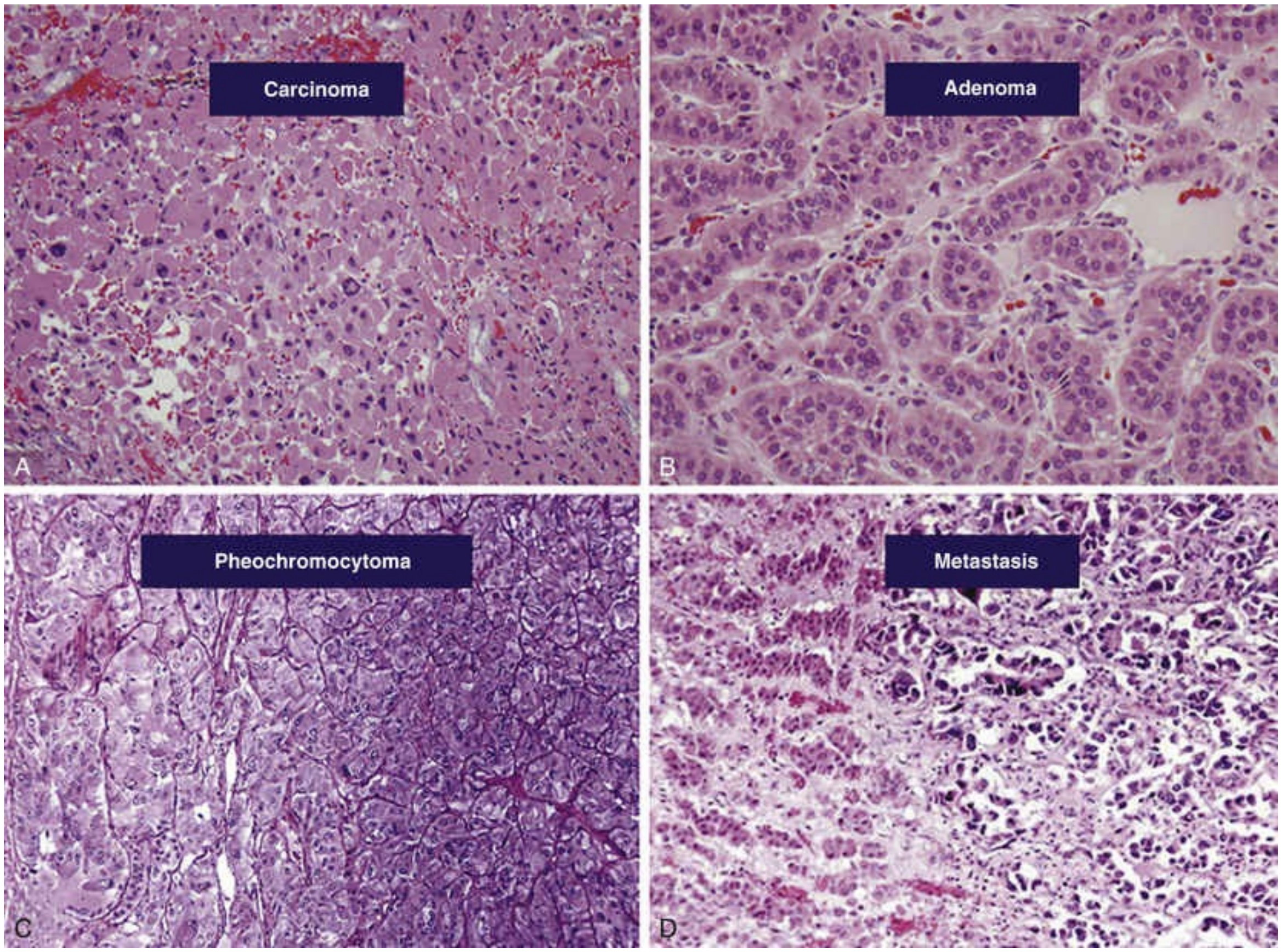

FIG. 106.23 Histologic appearance of adrenal tumors (hematoxylin and eosin staining). (A) Adrenocortical carcinoma: high-grade nuclear atypia with necrosis in other sections. (B) Adrenocortical adenoma: well-organized trabecular pattern with relatively uniform cells and minimal atypia. (C) Pheochromocytoma: alveolar and trabecular pattern, eosinophilic, and amphophilic finely granular cytoplasm. (D) Metastatic adenocarcinoma: hyperchromatic pleomorphic cells *(right)* compared with the eosinophilic cells with organized trabecular pattern *(left)* of the residual adrenal gland. (Courtesy of Tahseen Al-Saleem, MD, Department of Pathology, Fox Chase Cancer Center, Philadelphia, PA, and Dr. Thomas J. Sebo, Department of Laboratory Medicine and Pathology, Mayo Clinic, Rochester, MN.)

Box 106.4

Weiss Pathologic Criteria for Differentiating Benign and Malignant Adrenal Tumors

High nuclear grade (Furman grade 3 to 4)
High mitotic rate (greater than 5 mitoses per high-power field)

Presence of atypical mitoses
Character of cytoplasm (low percentage of clear cells)
Diffuse architecture of tumor cells
Presence of necrosis
Invasion of venous structures
Invasion of sinusoidal structures
Invasion of tumor capsule

From Weiss LM. Comparative histologic study of 43 metastasizing and nonmetastasizing adrenocortical tumors. *Am J Surg Pathol* 8(3):163–169, 1984.

Staging.

The American Joint Committee on Cancer (AJCC) staging of ACC is based on size of the primary tumor, degree of local invasion, and spread to regional lymph nodes or distant sites (Table 106.14). Stage I and II tumors are confined to the adrenal gland and are distinguished by a size cutoff of 5 cm. Stage III disease includes tumor extension into adjacent adipose tissue or the presence of regional lymph node involvement. Stage IV disease includes tumors invading adjacent organs and the presence of distant metastatic disease. The European Network for the Study of Adrenal Tumors (ENSAT) staging system of ACC is similar to the AJCC staging system; however, it differs in the grouping of patients with advanced disease. The ENSAT staging system maintains the tumor-node-metastasis (TNM) classifications used in the AJCC staging system (version 6); however, stage III disease includes patients with positive lymph nodes (N1), infiltration of surrounding tissues (T3 and T4), and venous tumor thrombus, whereas stage IV disease is reserved for any tumor associated with distant metastatic disease (Fassnacht et al., 2009).

TABLE 106.14

Staging of Adrenocortical Carcinoma Including Stage at Diagnosis and 5-Year Survival Data

STAGE	2004 UICC/WHO	AT DIAGNOSIS	5-YEAR SURVIVAL
I	T1N0M0	3%–4%	33%–66%
II	T2N0M0	29%–46%	20%–58%
III	T1-2N1M0 T3N0M0	11%–19%	18%–24%

IV	T1-4N0-1M1 T3N1M0 T4N0-1M0	39%–49%	<5%

T1, <5 cm; *T2,* >5 cm; *T3,* infiltration of surrounding adipose tissue; *T4,* invasion into adjacent organs; *UICC,* Union Internationale Contre Le Cancer; *WHO,* World Health Organization.

Management.

Unfortunately, the majority of patients with ACCs have advanced disease on presentation (see Table 106.14), and those who have localized disease are at a high risk for local recurrence and metastatic progression. For this reason, treatment of ACC often includes multimodal therapy directed by a team of surgeons, medical oncologists, endocrinologists, and radiation oncologists. **Despite aggressive surgical resection, adrenal carcinoma is associated with a high rate (60% to 80%) of recurrent disease** (Meyer et al., 2004; Pommier and Brennan, 1992; Stojadinovic et al., 2002). Thus, local and systemic adjuvant therapy is often administered, in spite of the lack of clear evidence demonstrating improved survival. Furthermore, given the low incidence of ACC, only one randomized trial has been completed evaluating the efficacy of current treatment regimens in patients with metastatic disease; thus, the remaining treatment strategies are based on the collective experience of nonrandomized retrospective series.

Surgery.

Complete surgical excision is essential in the management of ACC and offers the best chance of cure, control of symptoms secondary to hypersecretion of adrenal hormones, and other tumor-related symptoms in patients with localized disease (Else et al., 2014a). **Recent guidelines advocate preference for open surgery over laparoscopic resection in patients with tumors greater than 6 cm or those with evidence of local invasion, given emerging evidence for higher potential of peritoneal seeding with minimally invasive approaches** (Fassnacht et al., 2016; Miller et al., 2010; Payabyab et al., 2016). En bloc resection of surrounding organs involved with locally advanced disease should be performed whenever possible to achieve negative surgical margins. Regional retroperitoneal lymph node dissection can provide additional disease control and staging information. Cases of venous tumor thrombus involving the IVC may require vascular bypass techniques, IVC replacement, and/or IVC interruption. Given the extent of resection frequently required, open abdominal or retroperitoneal exploration is commonly performed. Smaller radiographically organ-confined disease can be approached laparoscopically, but the procedure should be performed with caution because there is a risk for tumor spillage, and data suggest improved outcomes with open surgery (Else et al., 2014; Gonzalez et al., 2005; Kebebew et al., 2002; Schlamp et al., 2007). **In cases of metastatic adrenal carcinoma, cytoreductive removal of the primary tumor and debulking metastasectomy should be considered if more than 90% of the disease burden can be removed** (Schteingart et al., 2005)**. Although debulking surgery may not improve survival, it may alleviate tumor-related side effects and facilitate additional therapies** (Fassnacht et al., 2004). **Local or distant disease recurrences after initial resection should be considered for surgical excision and have been associated with improved survival in retrospective series** (Datrice et al., 2012; Fassnacht et al., 2013; Meyer et al., 2004). Low-grade tumors with prolonged disease-free intervals may be the best candidates for surgical management of recurrent disease compared with high-grade tumors (Assie et al., 2007; Miller et al., 2010). Locally recurrent disease and select metastatic lesions may be treated with ablative therapy using radiofrequency ablation or angioembolization if surgical excision cannot be performed (Schteingart et al., 2005; Soga et al., 2009; Wood et al., 2003).

Follow-up should include cross-sectional imaging of the chest, abdomen, and pelvis every 3 months for the first 2 to 3 years. The value of routine PET imaging in disease surveillance has not been established and may be best reserved for indeterminate findings on CT or MRI. In patients with functional tumors, measurement of the initially elevated hormones postoperatively may help reveal early disease recurrence despite negative radiographic studies. After a disease-free interval of 2 to 3 years, surveillance should continue every 6 months until 5 years postsurgery (Fassnacht et al., 2013; Schteingart et al., 2005). Decisions for surveillance beyond 5 years is up to individual patients and providers as less than 3% of patients will demonstrate recurrence after 5 years of follow-up (Else et al., 2014a).

Radiation.

Currently there is a limited role for radiation therapy in the treatment of primary ACCs; however, radiation therapy remains the treatment of choice in the management of bone and CNS metastasis (Schteingart et al., 2005). Adjuvant radiation has been noted to decrease local recurrence rates after complete tumor resection, with reported 5-year local recurrence rates of 11% and 86%, without and with adjuvant radiation therapy, respectively (Fassnacht et al., 2006). Unfortunately, a significant improvement in disease-free or overall survival was not observed. Patients believed to benefit the most from adjuvant radiation therapy are those without evidence of metastatic disease and positive or indeterminate surgical margins.

Medical Therapy.

Mitotane is an oral synthetic derivative of the insecticide dichlorodiphenyltrichloroethane (DDT) and is the most commonly used chemotherapeutic agent in the treatment of ACC. The agent has demonstrated clinical benefit in the adjuvant setting after surgical resection and in patients with metastatic disease (Phan, 2007). Three mechanisms of action of mitotane against ACC have been proposed: direct cytotoxicity of cells in the adrenal cortex, oxidative damage through the production of free radicals, and/or inhibition of enzymes involved with steroid synthesis (Fassnacht and Allolio, 2009). Because of the adrenolytic effect of mitotane, steroid replacement is typically necessary during therapy. In addition to adrenal insufficiency, common side effects include gastrointestinal upset, lethargy, depression, feminization in males, rash, elevation of hepatic enzymes, elevation of hormone-binding globulins, hypothyroidism, dyslipidemia, and thrombocytopenia. Given its significant adverse-effect profile and its marginal therapeutic benefit, administration must be closely monitored and the dosage titrated according to patient tolerability and serum levels (Fassnacht and Allolio, 2009).

The efficacy of adjuvant mitotane after surgical resection has been evaluated by several small retrospective series with varying results. A more contemporary retrospective series by Berruti et al. (2017) evaluated the impact of adjuvant mitotane on recurrence-free survival and overall survival in 162 patients with ACC. A significant increase in recurrence-free survival and overall survival was noted in patients receiving mitotane compared with controls, after multivariate adjustments. In addition, treatment-related toxicity appeared acceptably low. Currently, significant questions remain regarding the routine use of adjuvant mitotane after surgical resection, including which patients will derive the greatest benefit from adjuvant therapy, and the optimal dosage and duration of adjuvant mitotane therapy (Else et al., 2014; Terzolo et al., 2007, 2009).

In patients who are not candidates for complete tumor debulking, surgery should not be performed because it will delay systemic therapy. Currently, mitotane remains the primary systemic therapy, either as a single agent or in combination with other cytotoxic drugs for ACCs. **As a single agent, overall responses to mitotane range from 14% to 36%, with few studies demonstrating a significant survival benefit** (Phan, 2007; Roman, 2006)**. In a series investigating the combination of mitotane and streptozotocin, Khan et al.** (2000) **noted a response rate of 36%. Berruti et al.** (2005) **noted a response rate of 49% with the combination of mitotane, etoposide, doxorubicin, and cisplatin.** The First International Randomized Trial in Locally Advanced and Metastatic Adrenocortical Carcinoma Treatment (FIRM-ACT) randomized patients to receive mitotane in combination with streptozotocin or etoposide, doxorubicin, and cisplatin (M-EDP) (Fassnacht et al., 2012). Overall survival was similar between groups; however, patients receiving M-EDP were noted to have improved objective response rates and progression-free survival. Based on the results of this trial, M-EDP is now being considered the first-line regimen of choice in patients requiring systemic therapy. With the known limited success of first-line therapy for advanced disease, salvage therapy is often required. Multiple ongoing trials are investigating targeted therapies and other agents in patients in whom the disease progresses after first-line systemic therapy (Fassnacht et al., 2013; Lebastchi et al., 2012; Roman, 2006).

Control of symptoms secondary to the hypersecretion of hormones is often necessary in patients with metastatic disease. Although mitotane has adrenolytic activity, given its delayed onset of action and associated toxicity, other agents are often necessary to help control symptoms of hormone hypersecretion. Adrenostatic drugs such as ketoconazole, metyrapone, aminoglutethimide, and etomidate, and mifepristone, a direct glucocorticoid antagonist, have been used to decrease symptoms related to glucocorticoid excess (Fassnacht et al., 2004; Fleseriu et al., 2012).

Prognosis.

Overall 5-year survival in ACCs is poor, ranging from 20% to 47% (Fassnacht and Allolio, 2009; Roman, 2006). The observed poor prognosis associated with ACC reflects the advanced stage frequently noted at presentation, the high rate of recurrent disease in patients with localized disease, and the limited efficacy of current systemic treatment regimens. Administrative datasets reveal that tumor size at resection in patients with localized disease fails to show a strong relationship with overall survival (Canter et al., 2013). Five-year survival based on tumor stage is presented in Table 106.14. In addition to advanced stage, several clinicopathologic features have been associated with decreased survival, including tumor size greater than 12 cm, age, positive surgical margins, high mitotic rate, cortisol production, tumor necrosis, atypical mitotic figures, and high Ki-67 staining (Ayala-Ramirez et al., 2013; Bilimoria et al., 2008; Else et al., 2014; Fassnacht and Allolio, 2009). The impact of a tumor's functional status on outcome has been widely debated and remains controversial (Chen et al., 2004; Favia et al., 2001; Luton et al., 1990; Vaughan, 2004).

Pediatric Adrenocortical Carcinoma.

The presentation, staging, and prognosis of pediatric ACC differ from those in adults (Liou and Kay, 2000). More than 90% of ACCs in children are functional at the time of presentation, with virilization being the most common clinical manifestation, occurring in 55% to 70% of patients (Marti et al., 2017). Unlike in adults, the female-to-male ratio is equal in children younger than 12 years of age; it sharply increases to 6 : 1 in children 13 to 20 years of age. Genetic syndromes should be considered in pediatric cases of adrenal carcinoma, particularly Li-Fraumeni syndrome, because a high rate of *TP53* mutations has been noted in prior series. The staging system in pediatric patients defines stage I and II tumors as being completely excised with negative margins and with a tumor weight of greater than 200 g differentiating stage I and II disease. Stage III disease is defined by the presence of microscopic or macroscopic residual disease after surgical resection or inoperable tumors; stage IV disease is defined by the presence of hematogenous metastasis. The overall 5-year survival rate is 54.2%, with several clinicopathologic features associated with diminished survival, including tumors weighing more than 400 g, stage, tumor size greater than 10.5 cm, necrosis, frequent and atypical mitotic bodies, and presentation after 5 years of age (Cecchetto et al., 2017; McAteer et al., 2013; Michalkiewicz et al., 2004).

Summary

ACC is a rare malignancy requiring multispecialty care. Given the aggressive natural history of the disease, ACC must be considered in the differential diagnosis in all patients with an adrenal tumor, particularly if larger than 6 cm. Evaluation of tumor functional status is critical for preoperative planning and supportive care, even in asymptomatic patients. Complete surgical resection of the primary tumor and any associated metastatic lesions should be performed whenever possible. Adjuvant therapy or enrollment into a clinical trial should be considered in most patients, given the high rate of local recurrence and metastatic progression despite complete surgical resection. Systemic therapy with mitotane therapy alone or in combination with other cytotoxic agents is recommended as first-line therapy in patients with metastatic ACC. Unfortunately, the prognosis for patients with ACC is poor, and improved therapeutic regimens are needed to improve outcomes.

Key Points: Adrenal Cortical Carcinoma

- Increasing adrenal tumor size is significantly associated with an increased risk for malignancy.
- The majority of ACCs will be functional at the time of presentation.
- Multimodal treatment, surgical resection, radiation therapy, and systemic chemotherapy are often necessary for patients with ACC.

Neuroblastoma.

Neuroblastoma, a malignancy derived from the cells of the neural crest, which give rise to the adrenal medulla and sympathetic ganglia, is the most common solid extracranial tumor of childhood (Park et al., 2008).

Metastases

Overview and Epidemiology.

The adrenal glands are a common site of metastases. Large autopsy series have demonstrated that over 25% of patients with melanoma and lung carcinoma have metastases to their adrenal glands (Bullock and Hirst, 1953). RCC, breast cancer, medullary thyroid carcinoma, contralateral ACC, gastrointestinal malignancies, prostate adenocarcinoma, cervical cancer, basal cell carcinoma, pancreatic tumors, cholangiocarcinoma, urothelial carcinoma, squamous cell carcinoma, seminoma, thymoma, chronic myelogenous leukemia, and other malignancies can all exhibit metastatic deposits within the adrenal glands (Bullock and Hirst, 1953; Lenert et al., 2001). Indeed, diagnostic challenges arise when an adrenal incidentaloma is discovered in patients with a known malignancy. **It has been estimated that in patients with a history of a previous malignancy, over 50% of newly discovered adrenal lesions are metastatic** (Frilling et al., 2004; Lenert et al., 2001). Current imaging modalities supplemented by adrenal biopsy, when necessary, can frequently differentiate metastases from a primary adrenal tumor.

RCC can involve the adrenal gland by direct invasion or systemic metastases (Antonelli et al., 2006; Lau et al., 2003). Yet, resection of the adrenal gland during radical or partial nephrectomy is only recommended for cases in which the gland is radiographically abnormal or a tumor thrombus extends to the level of the adrenal vein (Kutikov et al., 2011; Lane et al., 2009; O'Malley et al., 2009; Weight et al., 2011). Management of solitary metastases to the adrenal gland from RCC and other malignancies often falls within the purview of the practicing urologist. **Indeed, for some malignancies, specifically melanoma and non–small cell lung carcinoma, a survival benefit has been suggested in patients who undergo resection of an isolated adrenal metastasis** (Collinson et al., 2008; Mercier et al., 2005; Mittendorf et al., 2008; Tanvetyanon et al., 2008). Recently, prospective randomized data have emerged supporting metastatectomy in the lung cancer space (Gomez et al., 2016).

Pathophysiology and Clinical Characteristics.

Remarkably few patients with metastatic disease to the adrenal gland exhibit evidence of adrenal insufficiency. Indeed, although an addisonian state secondary to metastatic carcinoma was described by Addison in his original series, the scenario is exceedingly rare (Addison, 1855; Lutz et al., 2000). Some reports suggest that bulky (>4 cm) bilateral disease is necessary to produce biochemical evidence of adrenal insufficiency (Lutz et al., 2000). The statement that adrenal insufficiency exists in 20% of patients with metastatic RCC is, at times, quoted in the urologic literature. This supposition is based on an isolated report from the 1980s (involving a cohort of 15 patients) that, to our knowledge, has been published only in abstract form (Schorr et al., 1986). Indeed, patients with advanced malignancy may exhibit symptoms of an addisonian state (i.e., nausea, vomiting, fatigue, weight loss, and so on) in the absence of biochemical evidence of adrenal insufficiency (Lutz et al., 2000).

Diagnostic Tests.

Radiographically metastatic lesions, similar to benign adenomas, appear well circumscribed and homogeneous and most often lack areas of macroscopic necrosis (Boland et al., 2008). Nevertheless, metastatic disease often can be differentiated from the typical adrenal adenoma based on its lack of substantial lipid content. As discussed in the Imaging of Adrenal Masses section later in this chapter, metastatic lesions generally exhibit greater than 10 HU in attenuation on noncontrast imaging and fail to demonstrate significant contrast loss on adrenal washout studies (Fig. 106.24) (Boland et al., 2008). More recent literature, however, suggests that up to 7% of metastatic lesions may demonstrate attenuation of less than 10 HU, and washout characteristics of RCC and hepatocellular carcinoma metastases can mimic those of lipid-poor adenomas (Choi et al., 2013; Fassnacht et al., 2016). More recent emerging data suggest that increased signal intensity on MRI may be able to differentiate adrenal adenoma from RCC metastases (Schieda et al., 2017). Accordingly, when metastases from these primary tumor sites are suspected, adrenal nodule growth kinetics become critical in formulating clinical decision (Schieda et al., 2017). Furthermore, adrenal biopsy can be helpful with newly found adrenal lesions in the setting of a known history of malignancy (Delivanis et al., 2016). Unlike with metastases to the kidney, which are frequently associated with widespread metastatic disease, metastases to the adrenal glands can occur early and may be the sole focus of radiographically identifiable disease, making therapeutic resection feasible (see the Biopsy of Adrenal Masses section later in this chapter for more details).

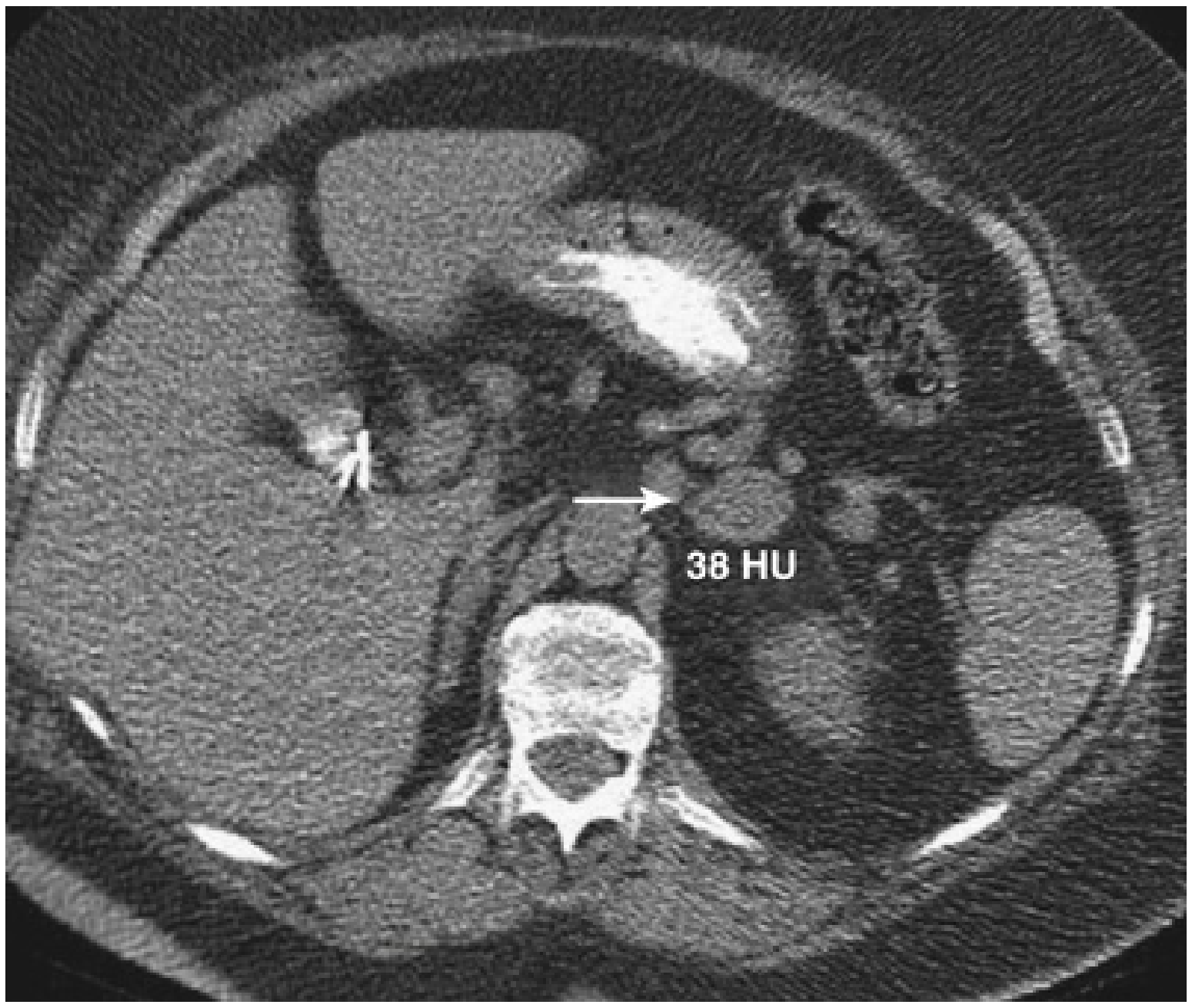

FIG. 106.24 Unenhanced computed tomography scan of a patient with a left adrenal metastasis from right-sided renal cell carcinoma (RCC) that had been resected several years earlier. At presentation, unenhanced imaging revealed a lesion with an attenuation of greater than 10 Hounsfield

units (HU), indicating that the adrenal mass was not a lipid-rich adenoma. Recent data reveal that RCC metastases may exhibit washout characteristics similar to lipid-poor adenomas. Metabolic evaluation ruled out pheochromocytoma. Laparoscopic adrenalectomy confirmed metastatic RCC.

Nonetheless, a standard metabolic workup is warranted to rule out functionality of any new adrenal lesion (Lenert et al., 2001). Indeed, some small series reported no difference in the incidence of metabolically active tumors when comparing patients with and without a history of extra-adrenal malignancy (Tsvetov et al., 2007). It is important to note that reports of pigmented pheochromocytomas being mislabeled as metastatic melanoma exist in the literature (Lenert et al., 2001).

Treatment and Prognosis.

Resection of metastases to the contralateral or ipsilateral adrenal gland from RCC is advocated in the context of a cytoreductive approach for a select group of patients. Nevertheless, benefits to adrenal metastasectomy are as yet unproven in a prospective fashion. Moreover, the role of resection may change with antiangiogenic targeted therapies and novel immunotherapies (Antonelli et al., 2006; Lau et al., 2003; O'Malley et al., 2009). **Treatment of metastatic disease of the adrenal glands in patients with nonurologic malignancies requires a multidisciplinary approach. The urologist must work closely with the patient's primary medical oncologist regarding the surgical and biologic prudence of resection.** Lenert et al. (2001) reported their experience with adrenalectomy for solitary adrenal metastases from over 20 separate primary malignancies. Currently, the best data regarding adrenal metastasectomy exist for patients with non–small cell lung carcinoma and melanoma (Branum et al., 1991; Mittendorf et al., 2008).

In patients with non–small cell lung cancer, adrenal metastases are most frequently encountered in the setting of systemic disease. An isolated adrenal metastasis is rare and may be the result of nonhematogenous lymphatic spread (Tanvetyanon et al., 2008). Surgical resection of solitary adrenal metastases has been associated with 5-year overall survival rates of over 25% (Mercier et al., 2005; Strong et al., 2007; Tanvetyanon et al., 2008). Although the prognosis after resection in patients with metachronous metastasis and longer disease-free intervals is thought to be better than in patients found to have an isolated adrenal metastasis at the time of their initial diagnosis, a meta-analysis from 2008 demonstrated that the 5-year overall survival is equivalent in both groups (Tanvetyanon et al., 2008). Moreover, recent level 1 evidence strongly supports metastatectomy in patients with non–small cell lung cancer (Gomez et al., 2016). In patients with metastatic melanoma, adrenalectomy has been reported to be associated with long-term survival and even rare regression of distant disease (Branum et al., 1991; Collinson et al., 2008). Nevertheless, data are limited to retrospective reports describing highly selected patient populations (Mittendorf et al., 2008).

Summary.

Metastatic disease to the adrenal gland is common and must be suspected when patients with a history of malignancy are found to have an adrenal incidentaloma. Radiographic and functional studies are essential and often secure the diagnosis. Percutaneous biopsy is safe, but its success depends on the size and location of the lesion and the technical aspects of the procedure. Adrenalectomy for patients with solitary adrenal metastasis is a viable option for a select group of individuals.

Key Points: Adrenal Metastases

- Metastatic disease to the adrenal glands is common, yet it appears that bilateral and bulky disease (>4 cm) is necessary to produce biochemical evidence of adrenal insufficiency.
- More than 50% of newly discovered adrenal lesions in patients with a history of previous malignancy represent metastatic disease; nevertheless, metabolic workup in these patients is recommended.

Malignant Pheochromocytoma.

Malignant pheochromocytomas are discussed in the Disorders of Increased Adrenal Function section earlier in this chapter.

Benign

Adenoma

Overview and Epidemiology.

Adenomas are the most common neoplasms arising from the adrenal gland and are most often associated with the cortex. These lesions are found in approximately 6% of patients at autopsy (Kloos et al., 1995). Clinically, adrenal adenomas are most often incidentally discovered on cross-sectional imaging obtained for other indications and are thus termed *incidentalomas*. More than 85% of adrenal neoplasms incidentally discovered on imaging are ultimately clinically proven to be adenomas (Young, 2000, 2007b). **The incidence of adenomas rises with age, as inferred from the observation that incidentalomas are found in less than 0.5% of individuals in their 20s and in up to 7% of those 70 years of age or older** (Young, 2000). Similar trends are observed in historical autopsy series (Commons and Callaway, 1948; Russell et al., 1972). Despite benign behavior, a small percentage of adrenal adenomas can exhibit metabolic activity and therefore can represent "surgical" lesions. The essential evaluation of the small adrenal mass requires differentiating the nonfunctional benign adenoma from functional or malignant lesions.

Pathophysiology and Clinical Characteristics.

Adenomas possess a yellowish color on gross pathologic examination as a result of the presence of abundant lipid. Histologically, they may be difficult to distinguish from adrenal adenocarcinomas. As discussed earlier (see Box 106.4), pathologists use a set of criteria proposed by Weiss along with modern immunohistochemical methods to differentiate the two clinical entities (Aubert et al., 2002; Sasano et al., 2006; Weiss, 1984).

Adrenal adenomas are by definition benign, and the vast majority are metabolically silent. An analysis of the 13 largest series of incidental adrenal masses ($N = 2005$) reveals that nearly 90% ($n = 1779$) of these lesions were clinically benign adenomas. Of these, only 127 lesions (7.1% of adenomas) exhibited metabolic activity, 107 (6% of adenomas) hypersecreted glucocorticoids, and 20 (1.1% of adenomas) were functioning hyperaldosteronomas. The overwhelming majority (93%) of adenomas displayed no evidence of metabolic activity (Young, 2000, 2007b). Hypersecretion of sex steroids by benign adrenal adenomas is exceedingly rare but has been reported. It is interesting to note that these rare lesions may secrete testosterone and possess Reinke crystals, normally identified in testosterone-producing Leydig cells of the testes (Ryan et al., 1995). The implications of glucocorticoid and mineralocorticoid hypersecretion by adrenal adenomas are discussed in detail in the sections Cushing Syndrome and Primary

Aldosteronism sections earlier in this chapter. Finally, it has been hypothesized that nonfunctional adrenal adenomas may be associated with physiologic derangements, such as insulin resistance and left ventricular dysfunction; however, such reports are isolated to small single-institution series and await confirmation (Ermetici et al., 2008; Midorikawa et al., 2001).

The growth kinetics of adrenal adenomas is reviewed later (see "Evaluation of Adrenal Lesions in Urologic Practice"). In brief, an analysis of 18 reported series following over 850 patients with adrenal incidentalomas revealed that the vast majority of these benign masses remained stable in size; however, approximately 9% of lesions increased by more than 1 cm in diameter over a mean follow-up of 3 years (Barzon et al., 2003). The size and growth of adrenal lesions are discussed in detail later in this chapter.

The current literature suggests that adenomas that are initially metabolically inert are unlikely to gain function. An analysis of 18 published series reporting more than 1100 incidental adrenal masses (not all of them adenomas) revealed that only 1.7% became metabolically active in follow-up, including 0.65% that developed subclinical Cushing syndrome, 0.3% with subsequent overt Cushing syndrome, and 0.05% that were identified as becoming functional secretors of catecholamines. No lesion produced new-onset hyperaldosteronism during endocrinologic reevaluation (Barzon et al., 2003).

Diagnostic Tests.

The evaluation of incidental adrenal lesions, the primary way that adenomas come to clinical attention, is discussed in detail elsewhere in this chapter. In this section, we review the salient points of the clinical workup as it relates to adenomas. The goal in evaluating any adrenal lesion is twofold: (1) rule out the possibility of malignancy and (2) document metabolic inactivity of the lesion in question.

Noncontrast CT scan is arguably the most valuable imaging study for the diagnosis of an adrenal adenoma. CT affords accurate measurements of a lesion's density, uniformity, and size. The vast majority of adrenal adenomas are smooth-bordered, homogeneous tumors that are less than 4 cm in diameter (Grumbach et al., 2003). High intracytoplasmic lipid content is unique to adenomas, and this attribute affords accurate differentiation of adenomas from other adrenal lesions on cross-sectional imaging. **According to an NIH 2002 consensus panel, an adrenal mass with an attenuation of less than 10 HU on unenhanced CT is "strongly suggest[ive of] a benign adrenal adenoma"**

(Grumbach et al., 2003). Indeed, a large contemporary series of resected adrenal masses from the Cleveland Clinic demonstrated 100% specificity when the threshold of less than 10 HU was applied to lesions in this cohort (Hamrahian et al., 2005). The 100% specificity for adenoma was retained if only masses equal to 4 cm were considered and the threshold was raised to 20 HU (Hamrahian et al., 2005). Nevertheless, not all adenomas have sufficient intracytoplasmic fat content to result in attenuation below 10 HU on noncontrast CT. Approximately 30% of adrenal adenomas register a density greater than 10 HU on unenhanced CT (Korobkin et al., 1998; Pena et al., 2000; Szolar et al., 2005). However, even in these cases a diagnosis of adenoma is still possible with use of the "washout" technique, whereby loss of attenuation of the lesion is noted on delayed contrast-enhanced CT imaging. Lesions that wash out more than 40% to 60% of gained enhancement can be identified as adenomas with extremely high specificity (Fig. 106.25) (Heinz-Peer et al., 2007; Korobkin et al., 1998; Pena et al., 2000; Szolar et al., 2005). The urologist must be aware, however, that RCC and hepatocellular carcinoma metastases may exhibit washout characteristics similar to lipid-poor adenomas (Choi et al., 2013). MRI also can be used to successfully characterize adrenal adenomas. Chemical shift ratios relating to in- and out-of-phase imaging substitute for CT attenuation values. Although, in general, adenomas do not exhibit significant FDG uptake on PET imaging, exceptions exist. Accordingly, increased standardized uptake values (SUVs) of an adrenal lesion with otherwise benign imaging characteristics must be interpreted in the context of each clinical scenario, especially when pretest probability of malignancy is low (Boland et al., 2011; Canter et al., 2011). Refer to the Imaging of Adrenal Masses section later in this chapter for further details on imaging of adrenal adenomas (Heinz-Peer et al., 2007; Hussain and Korobkin, 2004; Outwater et al., 1996).

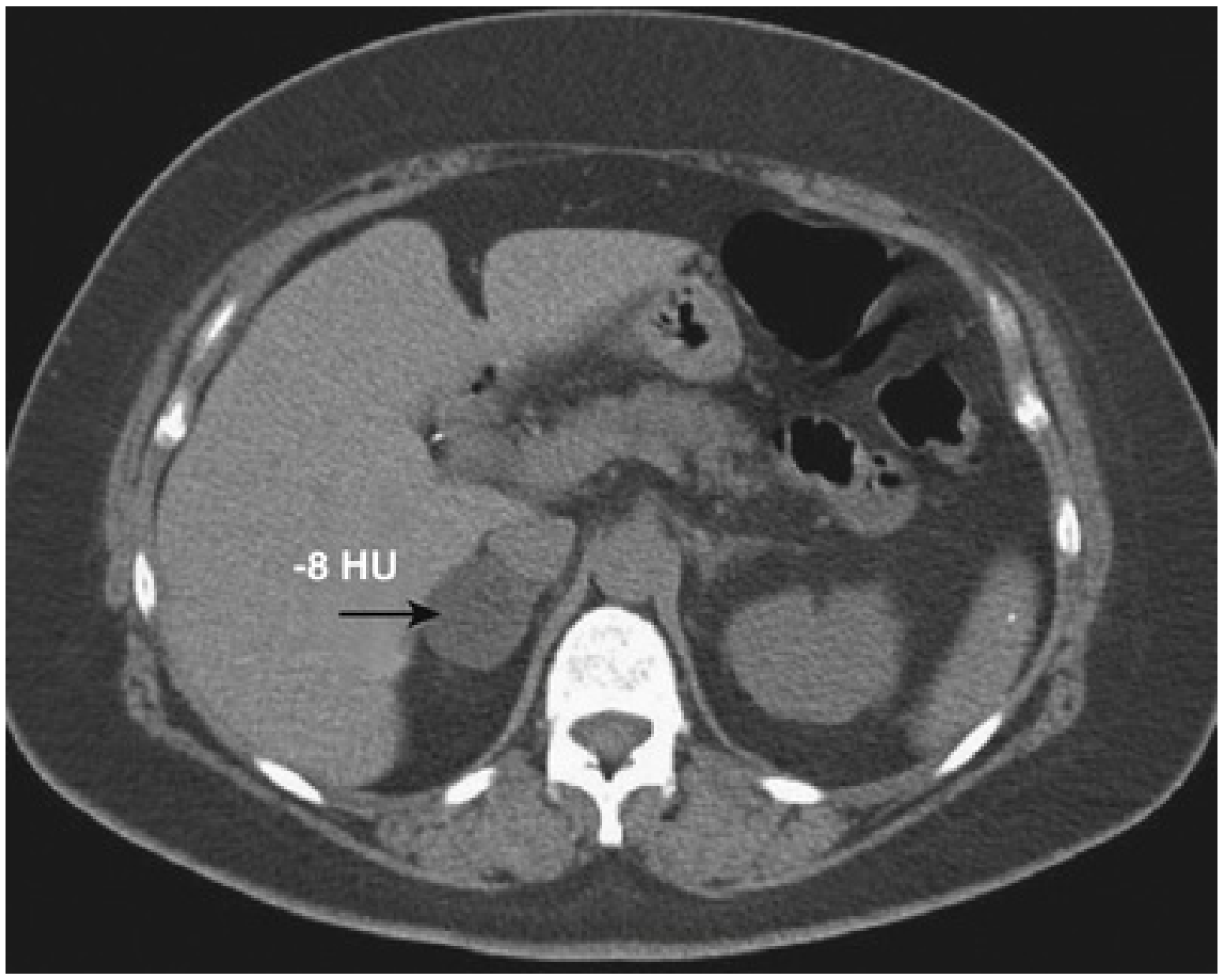

FIG. 106.25 Axial cut of an unenhanced computed tomography scan in a patient with a 3.5-cm, right, lipid-rich adrenal adenoma, demonstrating an attenuation of less than 10 Hounsfield units (HU).

Classically, incidentalomas are evaluated for excess cortisol and catecholamine secretion. In patients with a history of hypertension, hyperaldosteronemia also should be ruled out (Grumbach et al., 2003). Adenomas themselves have the potential to secrete only cortisol or aldosterone; therefore, strictly speaking, if a diagnosis of adenoma is unequivocal on imaging, metabolic workup for pheochromocytoma risks false-positive results given the imperfect specificity of testing. Nevertheless, current recommendations suggest serum or urine metanephrine testing for all adrenal lesions (Grumbach et al., 2003; Young, 2007b). Indeed, pheochromocytomas that mimic adenomas on imaging have been reported, validating the recommendation for metanephrine testing of all adrenal lesions (Blake et al., 2003). Despite the 2002 NIH consensus statement that all adrenal lesions larger than 1 cm should undergo a metabolic evaluation, current literature suggests that more than 80% of adrenal masses are not appropriately radiographically or functionally evaluated in routine clinical practice (Eldeiry and Garber, 2008).

Treatment.

Adenomas that are metabolically active should undergo resection in acceptable surgical candidates. In patients with nonfunctional adenomas, the size of the lesion and its growth characteristics generally dictate management.

Notwithstanding benign imaging features, experts suggest that resection of all adrenal masses larger than 6 cm is prudent, given that adenomas of this size are rare and the risk for malignancy is nontrivial. Nevertheless, there is growing enthusiasm to monitor even larger lesions when imaging features are benign and metabolic workup is unrevealing (Azoury et al., 2017; Fassnacht et al., 2016). Others argue that a cutoff of 4 cm should be used (Young, 2007b). Indeed, the latest guidelines suggest that metabolically silent lesions that meet radiographic criteria for adenoma and measure less than 4 cm in diameter require no further follow-up (Fassnacht et al., 2016). Lesions that are not resected but exhibit indeterminate imaging features should undergo at least initial radiographic follow-up to ascertain growth kinetics. Reimaging at 6, 12, and, potentially, 24 months has been recommended to verify benign clinical biology and indolent growth (Fassnacht et al., 2016; Grumbach et al., 2003; Young, 2007b). Suspicious and unusual tumors may necessitate imaging at earlier or more frequent intervals or removal (Young, 2007b). As already discussed, although reports in the literature vary, on average approximately 2% of incidentalomas that are initially metabolically silent result in superphysiologic hormone production during follow-up (Barzon et al., 2003). This rate may be higher in patients with bilateral adenomas (Pasternak et al., 2015). Despite this low rate of “metabolic transformation,” a panel of NIH-convened experts suggests that annual metabolic hormonal screening for the first 3 to 4 years after diagnosis is prudent, especially for masses that are equal to 3 cm in diameter (Grumbach et al., 2003). Nevertheless, given the lack of strong data supporting this recommendation, the need for metabolic reevaluation of adrenal adenomas in patients who show no clinical signs of hormonal hypersecretion remains controversial (Barry et al., 1998; Bulow et al., 2006; Young, 2007b), and the European Society of Endocrinology Clinical Practice Guideline in collaboration with the European Network for the Study of Adrenal Tumors suggests that repeat workup is unnecessary in the absence of new clinical signs of Cushing or Conn syndrome (e.g., new diabetes, worsening hypertenstion) (Fassnacht et al., 2016).

Prognosis.

Normalization of serum cortisol levels after resection of adenoma likely reduces but does not eradicate heightened cardiovascular risk in patients with Cushing syndrome (Pivonello et al., 2005; Swearingen et al., 1999). For patients with hyperaldosteronism, serum aldosterone and blood pressure often return to normal within 3 months of adrenalectomy (Young, 2007a), although those with baseline essential hypertension may remain medication-dependent. In general, patients with nonfunctional adrenal adenomas appear to be unaffected by their diagnoses. **A large surveillance series from the Mayo Clinic (*N* = 231) demonstrated that no patients died as a result of a condition that could be ascribed to adrenal pathology after a mean follow-up of 7 years** (Barry et al., 1998). However, a recent retrospective review suggested that patients with nonfunctional adenomas may be more susceptible to adverse endocrinologic and cardiovascular outcomes (Lopez et al., 2016).

Summary.

Adrenal adenomas account for more than 80% of incidental adrenal neoplasms. Because of their abundance of intracellular lipid, these lesions possess characteristic imaging features. More than 90% of these lesions are metabolically silent and require no treatment; however, all should be subjected to an initial metabolic evaluation. Lesions that are larger, have atypical radiographic features, and/or are metabolically active should be considered for resection in patients who are appropriate surgical candidates.

Key Points: Adenoma

- The incidence of adrenal adenoma rises with age.
- Approximately 7% of adrenal adenomas exhibit metabolic hyperactivity. Those that are metabolically inert at diagnosis only rarely (<2%) gain function on follow-up.
- Radiographic diagnosis of adrenal adenoma pivots on its high lipid content.

Oncocytoma

Overview and Epidemiology.

Oncocytomas are familiar to the urologist, given their relatively common renal origin (Chang and Harawi, 1992). Oncocytic tumors can also arise from the salivary gland and the endocrine organs. Adrenal lesions are exceedingly rare (Bisceglia et al., 2004), with approximately 50 cases reported in the literature (Juliano et al., 2008).

Pathophysiology and Clinical Characteristics.

Like oncocytic tumors in other organs, oncocytic adrenal lesions are characterized histologically by mitochondria-rich, large, eosinophilic cells with abundant granulations (Chang and Harawi, 1992). The pathogenesis of oncocytic neoplasias is poorly understood (Chang and Harawi, 1992). Females have been reported to be affected 2.5 times more frequently than males, and left-sided lesions outnumber those in the right adrenal gland 3.5 to 1. Tumors can grow up to 20 cm, and at least two cases have been reported in pregnancy (Bisceglia et al., 2004; Juliano et al., 2008). Most lesions that are documented in the literature are metabolically inactive; however, some oncocytic adrenal neoplasms ($n = 6$, or approximately 10% of all cases reported) hypersecrete sex steroids, cytokines, and/or cortisol (Akatsu et al., 2008; Juliano et al., 2008; Lee et al., 2008). Classically, these lesions have been considered benign (Vaughan and Blumenfeld, 2007); however, more than 30% of reported lesions have been classified as malignant, with an additional 23% having been designated as pathologically indeterminate (Juliano et al., 2008). These reports include a lesion that locally invaded the IVC (El-Naggar et al., 1991).

Diagnostic Tests and Treatment.

Because the diagnosis of adrenal oncocytic tumor is nearly always made on surgical resection, the evaluation and treatment of oncocytic lesions follow the same strategy as that of other adrenal masses. On imaging, adrenal oncocytic lesions are not reported to regularly possess the central stellate scar that may characterize such cases in the kidney (Lee et al., 2006). The optimal treatment for malignant oncocytic lesions is unknown; however, in at least one report, metastasectomy and radiation treatment for local recurrence may play a role (Juliano et al., 2008).

Prognosis.

Given the emerging appreciation for the heterogeneity of the biologic behavior of adrenal oncocytic lesions, the prognosis of patients with these lesions is uncertain but leans toward the more benign. Some reports suggest that even patients with widely metastatic disease can exhibit slow disease progression with long-term survival (Juliano et al., 2008).

Summary.

Adrenal oncocytic tumors are extremely rare neoplasms. Despite predominantly benign classical descriptions, a proportion of lesions can

exhibit malignant potential.

Key Point: Oncocytoma

- Unlike renal oncocytomas, a large proportion of adrenal lesions are malignant.

Myelolipoma

Overview and Epidemiology.

Myelolipomas are rare, benign, metabolically silent lesions that arise primarily from the adrenal gland and occur in all age groups (Han et al., 1997). Based on historical autopsy series, the incidence of these lesions is estimated at less than 0.1% (Bishop et al., 2006; Olsson et al., 1973). Some reports suggest that 15% of all myelolipomas are extra-adrenal, with up to one-half of these arising in the presacral area. Thoracic, retroperitoneal, pelvic, renal, hepatic, and gastric lesions have all been reported (Patel et al., 2006).

Pathophysiology.

Myelolipomas appear to result from clonal stem cell proliferation and are composed of an unusual mixture of mature adipose tissue and relatively normal trilineage hematopoietic elements (Bishop et al., 2006). Overabundance of megakaryocytes has been reported. Unlike in normal bone marrow, cellularity within myelolipomas varies greatly and does not decrease with increasing patient age. These lesions do not appear to contribute hematopoietic cells to the circulation, which may be a result of irregularities in stromal support and a lack of appropriate microvasculature. Specifically, normal capillary venous sinuses that are critical to functional bone marrow are nearly always absent in myelolipomas (Bishop et al., 2006).

Experimentally, myelolipoma generation has been induced in the adrenal glands of rats after injection with necrotic tumor tissues and ACTH (Seyle and Stone, 1950). This observation has resulted in the hypothesis that myelolipomas are a result of an adrenal stress response. Additional theories exist, and the cause of these unusual tumors remains unknown (Bishop et al., 2006; Han et al., 1997).

Clinical Characteristics.

Men and women are affected with relatively equal frequency. The tumor does not appear to have a predilection for either the right or left adrenal gland. Bilateral lesions have been reported (Bishoff et al., 1997; Han et al., 1997; Russell et al., 2000). Tumors vary greatly in size and can grow in excess of 10 cm. In a single institutional series of 21 lesions, the average tumor size was 5.1 cm (Han et al., 1997). As with most retroperitoneal tumors, these lesions are usually asymptomatic, although some patients do seek medical attention with abdominal or flank pain (Han et al., 1997). Spontaneous rupture of myelolipomas has been reported; however, this event is rare. Indeed, the mean tumor size of myelolipomas that have ruptured exceeds 10 cm (range 6.3 to 14.7 cm) (Russell et al., 2000).

Classically, myelolipomas are metabolically nonfunctional lesions. Nevertheless, the literature contains over two dozen cases in which myelolipomas are associated with adrenal metabolic hyperactivity. The most common abnormality appears to be hypercortisolemia (Hisamatsu et al., 2004). In the majority of patients, the myelolipoma is not the source of excess hormone production but coexists with a hyperfunctional adrenal adenoma. Indeed, some have suggested that these cases substantiate the early animal model wherein rat adrenal hyperstimulation with pituitary extract resulted in myelolipoma formation (Hisamatsu et al., 2004; Seyle and Stone, 1950).

Diagnostic Tests.

In the majority of cases, diagnosis of myelolipoma can be made accurately on cross-sectional imaging. CT reveals a well-circumscribed adrenal lesion with varying amounts of mature adipose tissue (less than 30 HU) interdigitated with higher-density myeloid components, which enhance on contrast administration (Fig. 106.26). Over one-fourth of the lesions may exhibit evidence of calcifications, and a large proportion have areas of hemorrhage (Kenney et al., 1998). Macroscopic adipose tissue can also be easily identified within myelolipomas on MRI (Cyran et al., 1996). The presence of macroscopic fat in an adrenal mass is virtually diagnostic of a myelolipoma. Nevertheless, exceedingly rare exceptions exist, and adrenal lipomas, teratomas, angiomyolipomas, metastases, and liposarcomas with macroscopic fat on imaging have been reported (Han et al., 1997; Lam and Lo, 2001). Careful interpretation of cross-sectional imaging is mandatory to distinguish an adrenal myelolipoma from an upper pole renal angiomyelolipoma. In contrast with the benign appearance of a myelolipoma, liposarcomas tend to be aggressive lesions that lack regular borders and have a propensity for infiltrating surrounding tissues (Schaeffer and Kavoussi, 2005). When the diagnosis is in doubt, some experts believe that percutaneous biopsy may be helpful (Han et al., 1997).

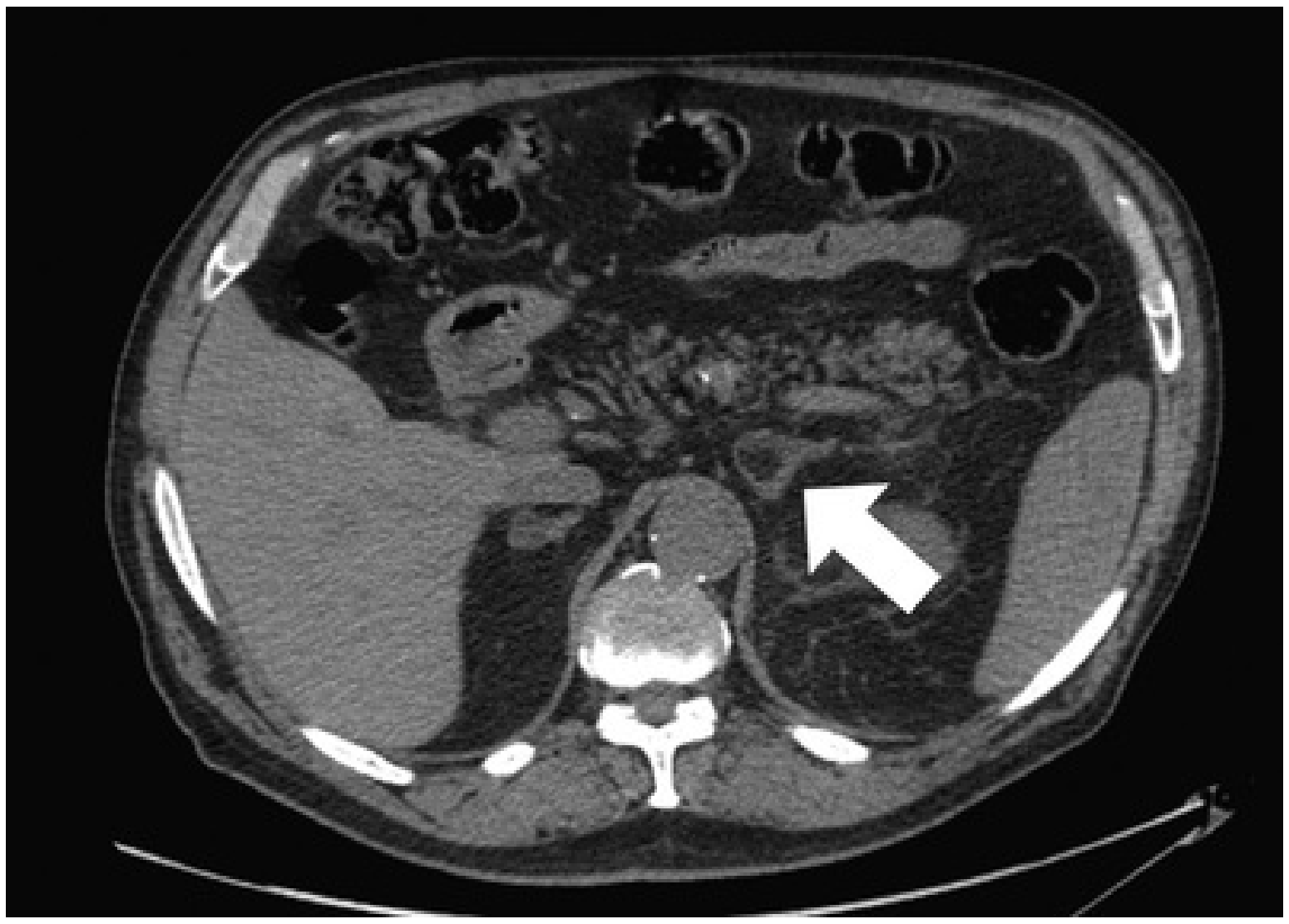

FIG. 106.26 79-year-old man with incidental finding of ~2 cm myelolipoma *(white arrow)* in the left adrenal gland. Macroscopic adipose tissue (~70 HU) within the mass on this noncontrast CT scan is clearly visible.

As discussed earlier, although myelolipomas are themselves metabolically silent, they have been associated with metabolically active adenomas and pheochromocytomas that may not be readily differentiated on imaging. Therefore it is not unreasonable to perform a standard adrenal metabolic workup in the rare patient who is diagnosed with a myelolipoma (Daneshmand and Quek, 2006; Patel et al., 2006). Nevertheless, some experts believe a metabolic workup is necessary only when the index of suspicion for a concomitant metabolically active tumor is high (Han et al., 1997). The NIH consensus panel on adrenal incidentaloma concluded that myelolipoma can be regarded as an exception to the mandatory metabolic workup of a newly discovered adrenal mass (Grumbach et al., 2003).

Treatment.

Classically asymptomatic myelolipomas are treated conservatively. No standard protocols for reimaging exist, but serial reevaluation with ultrasonography or CT every several years has been suggested (Han et al., 1997). **Surgery is usually reserved for symptomatic lesions** (Schaeffer and Kavoussi,

2005).

Prognosis.

Tumor growth rates vary. Not only do some lesions remain stable, but some may actually decrease in size over time (Han et al., 1997). Based on available literature, resections are considered definitive. As discussed earlier, although spontaneous rupture of myelolipomas has been reported, this event appears to be extremely rare and, on average, has been reported in lesions larger than 10 cm (range 6.3 to 14.7 cm) (Russell et al., 2000).

Summary.

Myelolipoma is a rare lesion of the adrenal gland that contains hematopoietic elements and mature adipose tissue. Extra-adrenal lesions have also been reported. In general, lesions do not require resection and follow a benign clinical course.

Key Points: Myelolipoma

- Myelolipomas possess tissue components identical to healthy bone marrow.
- The clinical course is benign, and surgery is indicated only for extremely large or symptomatic lesions.

Ganglioneuroma

Overview and Epidemiology.

Ganglioneuromas are extremely rare benign neuroectodermal neoplasms that are composed of ganglion and Schwann cells (Enzinger and Weiss, 1995). Although uncommon, the diagnosis must be considered during the evaluation of an adrenal mass (Maweja et al., 2007). In one large series (*N* = 88), 21% of cases arose from the adrenal gland itself. Other sites of origin included the mediastinum (39%) and retroperitoneum (31%), and isolated cases occurred in the pelvis and neck (Enzinger and Weiss, 1995). The tumor appears to have a predilection for the young, with only 20% of cases affecting individuals older than 40 years of age, and some 50% of cases found in patients 10 to 29 years of age (Enzinger and Weiss, 1995).

Pathophysiology/Clinical Characteristics.

Ganglioneuromas are benign, but isolated cases of ganglioneuromas undergoing malignant transformation have been reported (Enzinger and Weiss, 1995). Furthermore, cases of peripheral nerve sheath tumors (PNST) arising within ganglioneuromas, and composite tumors of ganglioneuroma and pheochromocytoma, also exist in the literature (Radin et al., 1997). It is interesting to note that reports of ganglioneuroma cells in lymph nodes surrounding an apparently benign tumor exist, and some authors presume that such cases represent neuroblastomas that have matured (Enzinger and Weiss, 1995).

Tumors can grow extremely large and have a propensity to encase vessels without impinging on the vessel lumen (Radin et al., 1997). Ganglioneuromas have been reported to secrete vasoactive intestinal polypeptide (VIP), and some patients complain of diarrhea (Enzinger and Weiss, 1995). Nevertheless, the majority of individuals with ganglioneuromas are largely asymptomatic (Radin et al., 1997).

Diagnostic Tests.

On both enhanced and unenhanced CT, ganglioneuromas exhibit attenuation less than that of muscle (Radin et al., 1997). Calcifications within the tumor are not uncommon and have been reported to be present in as many as one-third of ganglioneuromas (Enzinger and Weiss, 1995; Radin et al., 1997). Some authors have suggested that a metabolically silent adrenal mass with unenhanced attenuation of less than 40 HU and presence of stippled calcifications should raise suspicion for a ganglioneuroma (Maweja et al., 2007).

Treatment and Prognosis.

Because the diagnosis of ganglioneuroma is nearly always made on resection, natural history of unresected ganglioneuromas has not been clearly defined. Nevertheless, the urologist must be aware that the tumors can grow quite large and can surround critical structures such as retroperitoneal vessels (Radin et al., 1997).

Summary.

Ganglioneuromas are rare tumors that can arise from the adrenal gland. Diagnosis is largely pathologic, and the clinical course is nearly always benign.

Key Point: Ganglioneuroma

- Ganglioneuromas are rare, benign tumors that tend to occur in the young and can grow to encase critical structures.

Adrenal Cysts

Overview and Epidemiology.

Adrenal cysts have been noted in 0.064% to 0.18% of patients in autopsy series and account for 1% to 22% of incidentally detected adrenal lesions (Elsayes et al., 2004; Guo et al., 2007; Song et al., 2008; Wedmid and Palese; 2010). Cystic adrenal lesions can be diagnosed throughout life and as early as the prenatal period. Cyst size can range widely from several millimeters to greater than 20 cm, with either unilocular or multilocular components. Although the majority of adrenal cysts are unilateral, bilateral cysts have been noted in 8% to 10% of cases (Rozenblit et al., 1996). An increased incidence of adrenal cysts has been noted in women, with a peak incidence between the third and sixth decades of life (Sanal et al., 2006). Several medical conditions have been associated with adrenal cysts, including hypertension, polycystic renal disease, Klippel-Trénaunay-Weber syndrome, and Beckwith-Wiedemann syndrome (Carsote et al., 2017; Erickson et al., 2004).

Pathophysiology.

Four histologic types of adrenal cysts have been described: endothelial cysts (45%), pseudocysts (39%), epithelial cysts (9%), and parasitic cysts (7%). Among these, the most common are pseudocysts and endothelial adrenal cysts. Endothelial cysts lack proliferating endothelium and include lymphangiomatous and angiomatous subtypes. Adrenal pseudocysts do not possess a cellular lining and are believed to be the result of previous intra-adrenal hemorrhage or infarction in most cases. It has also been suggested that pseudocysts are closely related to endothelial cysts. Epithelial cysts are lined by a true epithelium and can be further characterized as glandular cysts, embryonal cysts, and cystic adenomas based on pathogenesis. Parasitic adrenal cysts may occur in association with disseminated *Echinococcus* infections; however, it is extremely rare for a parasitic adrenal cyst to be the only site of infection (Guo et al., 2007; Otal et al., 1999; Wedmid and Palese; 2010).

It can be difficult to distinguish a benign adrenal cyst from cystic adrenal neoplasms. This is especially true of adrenal neoplasms with associated hemorrhage or cystic degeneration, which may radiographically resemble an adrenal pseudocyst. In a series of 41 adrenal lesions macroscopically characterized as cysts, 7 were associated with adrenal neoplasms, including 2 ACCs, 2 adenomas, and 3 pheochromocytomas (Erickson et al., 2004). Furthermore, 6 of the 7 adrenal neoplasms in this series were associated with adrenal pseudocysts. **A review of multiple series accounting for 515 adrenal cysts noted that 7% of the lesions were associated with malignancy, all of which were pseudocysts** (Neri and Nance, 1999). In addition, cases of cystic adrenal carcinoma and pheochromocytomas have been reported (Rozenblit et al., 1996). Compared with benign cysts, cystic adrenal neoplasms tend to be larger (>7 cm) and have thicker walls. In considering the reported incidence of malignancy associated with adrenal cysts, it should be noted that histology in most series is based on surgical specimens, so the incidence of malignancy may be overestimated because small radiographically benign lesions likely remain unresected.

Clinical Characteristics.

Although most adrenal cysts are diagnosed incidentally, some become large in size and are symptomatic on presentation. The origin of large adrenal cysts is often difficult to distinguish from other organs, including the kidney, pancreas, spleen, and liver (Otal et al., 1999).

Diagnostic Tests.

Although the majority of adrenal cysts are benign and nonfunctional, routine endocrinologic evaluation should be performed to exclude active lesions. Because of the relative rarity of adrenal cysts, well-defined diagnostic criteria have not been established. The suggested radiographic criteria for diagnosing an adrenal cyst include a well-defined, sharply marginated mass of fluid attenuation without any evidence of enhancement (Fig. 106.27). Cysts with higher fluid attenuation (>30 HU) may be attributed to hemorrhage, intracystic debris, or calcification (Rozenblit et al., 1996; Sanal et al., 2006). The presence of peripheral calcifications has been noted in 15% to 70% of adrenal cysts (Song et al., 2008). Calcifications are typically rimlike, but occasionally will be nodular in appearance (Rozenblit et al., 1996). When evaluated with MRI, simple cysts will appear hypointense on T1-weighted images and hyperintense on T2-

weighted images. Unfortunately, radiographic criteria alone cannot rule out malignancy in adrenal cystic lesions; thus cyst aspiration or surgical excision is often performed to rule out malignancy. Aspiration of cystic adrenal lesions should be performed only after chemical evidence of pheochromocytoma has been excluded. Adrenal cyst aspiration may be both diagnostic and potentially therapeutic in select patients (Pradeep et al., 2006). If aspiration is performed, the collected fluid should be sent for Gram stain, cytology, triglycerides, cortisol, and amylase (for left-sided cysts). In addition, a contrast injection of the cyst cavity (cystogram) can be performed at the time of aspiration to evaluate the cyst wall texture.

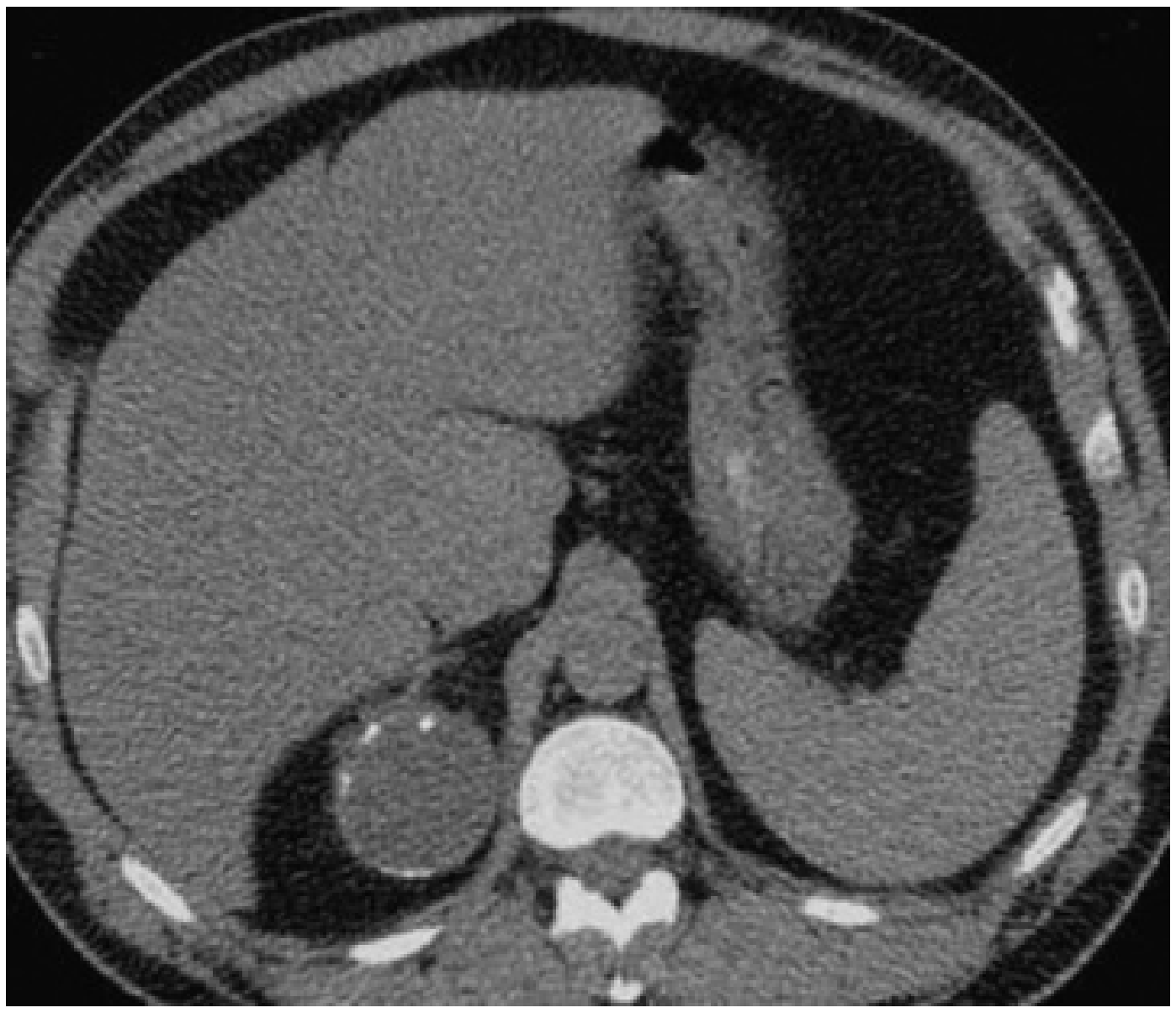

FIG. 106.27 Unenhanced computed tomography scan of a right adrenal cyst. Stippled calcifications within the cyst wall are not unusual in these lesions, as can be seen in this particular lesion.

Treatment.

Factors influencing the treatment of adrenal cysts include functional status, chances of incidental malignancy, and cyst-related symptoms. With the known, albeit low, risk for associated malignancy with cystic adrenal lesions, active surveillance must be done with caution. In small series, 60% of adrenal cysts were noted to increase in size and 25% decreased in size over time (Ricci et al., 2013). Small, asymptomatic thin-walled lesions containing homogeneous near-water attenuation may be safely observed (Rozenblit et al., 1996). The recent

European Society of Endocrinology Clinical Practice Guideline in collaboration with the European Network for the Study of Adrenal Tumors explicitly states that follow-up for metabolically silent lesions with benign radiographic features measuring less than 4 cm, which include adrenal cysts, is not required (Fassnacht et al., 2016). Adrenal cysts that are heterogeneous, larger than 5 cm, thick-walled, or symptomatic warrant further evaluation and surgical excision (Wedmid and Palese, 2010). Because of the known risk for associated malignancy, simple decortication is not advocated and should be undertaken with caution.

Prognosis.

The prognosis and subsequent follow-up after resection of an adrenal cyst are dependent on histology. Benign adrenal cysts warrant follow-up to monitor potential reaccumulation and warrant retreatment if symptoms return (Lyu et al., 2014). Adrenal cysts associated with malignancy require follow-up in accordance with the malignant histology detected.

Summary.

Adrenal cysts are rare, and their diagnosis can be challenging. Symptomatic adrenal cysts should be surgically removed, whereas small nonfunctional asymptomatic lesions with benign radiographic appearance may be treated conservatively with regular follow-up.

Key Point: Adrenal Cysts

- Because of the known chance of associated malignancy, observation of adrenal cysts must be done with caution.

Benign Pheochromocytoma.

Benign pheochromocytomas are discussed in the section on pheochromocytoma in the Disorders of Increased Adrenal Function section earlier in this chapter.

Evaluation of Adrenal Lesions in Urologic Practice

In urologic practice, the evaluation of adrenal pathology is typically in the setting of patients referred with a diagnosis of a new adrenal mass or in existing patients in whom a new adrenal mass is discovered incidentally. Occasionally, patients are identified by astute clinicians based on clinical symptoms in the absence of prior radiographic identification of an adrenal lesion. This section reviews clinically relevant evaluation and management of adrenal masses. It is important to note that the pregnant patient diagnosed with an adrenal mass requires a carefully planned, multidisciplinary, tailored approach. This subject matter is beyond the scope of this chapter; however, reviews on this topic are available (Harrington et al., 1999; Klibanski et al., 2006; Lindsay and Nieman, 2005b, 2006).

Overview of the Adrenal Incidentaloma

Adrenal incidentalomas are unsuspected adrenal masses greater than 1 cm in diameter identified on cross-sectional imaging performed for seemingly unrelated causes. Strictly speaking, patients who are undergoing a staging evaluation for another malignancy or who are later found to have symptoms relating to the adrenal lesion are excluded from the term *adrenal incidentaloma*, given the possible relationship of the primary indication for the study and the adrenal lesion (Mazzaglia and Monchik, 2009; Young, 2000, 2007b). **The frequency of adrenal incidentalomas is relatively high, with imaging series reporting an incidence of approximately 5%** (Song et al., 2008)**, similar to that found in historical autopsy data** (Commons and Callaway, 1948; Russell et al., 1972)**. The incidence of the incidental adrenal mass increases with age, with a risk of less than 0.5% in individuals in their 20s and up to 7% in those 70 years of age or older** (Young, 2000)**.**

It is important to emphasize that "incidental" does not mean "insignificant." Table 106.15 summarizes collective data available regarding pertinent clinical characteristics of over 2000 newly discovered adrenal lesions and demonstrates that **nearly 20% of adrenal incidentalomas are found to be potential surgical lesions.** The two characteristics of primary clinical relevance are imaging and metabolic activity or functional status. Biopsy is rarely indicated but can be a useful tool in specific clinical circumstances. This section describes in detail the clinical indications and processes of imaging, biopsy, and metabolic testing.

TABLE 106.15

Characteristics of Incidental Adrenal Masses as Described in a Systematic Review of Published Series of Adrenal Incidentalomas That Include 20 or More Patients

ADRENAL LESION	PERCENT OF TOTAL (*N* = 2005)
Metabolically active	11.2%
Cortisol-producing adenoma	5.3%
Aldosterone-producing adenoma	1.0%
Pheochromocytoma	5.1%
Malignant	7.2%
Adrenocortical carcinoma	4.7%
Metastasis	2.5%
Total potentially surgical lesions	18.4%

Data from Young WF Jr. Management approaches to adrenal incidentalomas. A view from Rochester, Minnesota. *Endocrinol Metab Clin North Am* 29(1):159–185, 2000; and Young WF Jr. The incidentally discovered adrenal mass. *N Engl J Med* 356(6):601–610, 2007.

Imaging of Adrenal Masses

Imaging Modalities

Appropriate management and follow-up of the adrenal incidentaloma largely depend on ordering the proper test, carrying out accurate image-acquisition protocols, and interpreting the information obtained. Urologists must be well versed in adrenal imaging modalities and limitations and be able to speak knowledgeably to their radiology colleagues. Numerous imaging modalities can be used to assess both morphologic and functional features of adrenal masses. This section summarizes the salient features of each imaging modality as it pertains to characterization of adrenal incidentalomas. Refer to the Adrenal Lesions section earlier in this chapter for details regarding imaging characteristics of each specific type of adrenal lesion.

Ultrasonography.

Ultrasonography is a suboptimal imaging modality for detecting and fully characterizing adrenal lesions. Nevertheless, many incidentalomas will be discovered on ultrasound imaging performed for unrelated reasons. Indeed, in parts of the world where ultrasonography is used as the primary imaging modality, the majority of adrenal incidentalomas are discovered through use of this modality (Bhargav et al., 2008). Moreover, in series wherein ultrasonography is responsible for identifying individuals with adenomas, right-sided lesions appear to be more common, whereas ultrasonography is less sensitive in identifying left-sided adrenal lesions than those in the right gland, based on anatomic differences. On the right, the IVC and liver provide a better window to the adrenal gland on ultrasonography, whereas on the left the adrenal gland can be overlooked or mistaken as part of the splenic, pancreatic, para-aortic lymphatic, or gastric anatomy (Barzon et al., 2003).

Computed Tomography and Magnetic Resonance Imaging.

CT and MRI permit cross-sectional and reconstructed anatomic image characterization of the adrenal glands and serve as the cornerstone for adrenal evaluation. Size, laterality, homogeneity, density, vascularity (enhancement and washout), and anatomic relationships can be accurately assessed using these modalities. Often the differential diagnosis of an adrenal lesion can be immediately narrowed based on the imaging characteristics. For instance, the presence of macroscopic fat identifies an adrenal myelolipoma, whereas large heterogeneous masses that invade surrounding structures are most indicative of adrenal adenocarcinomas (Cyran et al., 1996). Adrenal cysts and acute or subacute hemorrhage also exhibit characteristic imaging findings (Burks et al., 1992). **Nevertheless, most adrenal incidentalomas are small homogeneous masses with regular contours that cannot be immediately given a pathologic label. Further characterization of these common lesions relies on the ability of modern cross-sectional imaging to identify the presence of intracytoplasmic lipid that differentiates a benign adrenal adenoma from other adrenal pathology** (Fassnacht et al., 2016; Korobkin et al., 1996b). Although adenomas can be differentiated from nonadenomas based on this single imaging characteristic, the need for a metabolic workup is not eliminated based on identification of lipid within an adrenal mass. Radiographic differentiation between metabolically functional and nonfunctioning adenomas has been investigated, and, to date, no reliable radiographic test or characteristic is sensitive enough to obviate endocrinologic evaluation based solely on imaging

(Fujiyoshi et al., 2003; Hussain and Korobkin, 2004; Korobkin et al., 1996b).

Unenhanced Computed Tomography.

An unenhanced CT scan is the first, and perhaps single best, and most easily interpreted test for intracellular lipid and therefore can diagnose an adrenal adenoma in more than 70% of cases. Low attenuation (<10 HU) on unenhanced CT corresponds to high intracytoplasmic lipid content and is diagnostic for an adrenal adenoma (Korobkin et al., 1996b; Lee et al., 1991). Using a threshold of 0 HU or less, there is 100% specificity for an adrenal adenoma, meaning that if the lesion meets this criterion, it is always an adenoma. Unfortunately, the sensitivity of noncontrast CT density measurements is imperfect, meaning that not all adenomas will meet this criterion. Indeed only 41% of adenomas exhibit an attenuation of 0 HU (Boland et al., 1998), and therefore a threshold of 10 HU is currently used. This cutoff affords a sensitivity of 71% and a specificity of 98% for the diagnosis of adrenal adenomas (Boland et al., 1998, 2008). In other words, 98% of lesions that exhibit an attenuation of 10 HU or less on noncontrast CT are adrenal adenomas, whereas less than 30% of adrenal adenomas are lipid poor (also known as *atypical adenomas*) and exhibit an attenuation of greater than 10 HU. Similar test characteristics have been confirmed in purely surgical series (Hamrahian et al., 2005). It is important to note that the less than 10 HU threshold may have some limitations in patients with known malignancy. Authors of recent European Society of Endocrinology Clinical Practice Guideline in collaboration with the European Network for the Study of Adrenal Tumors indicates that review of available data reveals that up to 7% of adrenal metastases can exhibit attenuation of less than 10 HU on noncontrast imaging (Fassnacht et al., 2016). In urologic practice, the criterion on unenhanced CT is quite useful, because the vast majority of renal imaging for stones or lesions of the upper urinary tract includes an unenhanced precontrast phase. Despite the high specificity of the 10-HU cutoff, few low-density (<10 HU) pheochromocytomas have been reported, underscoring the importance of a metabolic workup for all adrenal lesions (Blake et al., 2003, 2005). It should be mentioned that in an era of digital radiology, density measurements of adrenal lesions can easily be undertaken at the time of evaluation, even when the interpreting radiologist may not provide the values in the dictation. Diligence in this regard by the clinician is essential to avoid additional unnecessary imaging tests, even if improperly recommended.

Enhanced Computed Tomography.

Some adrenal masses may be discovered on contrast-enhanced imaging without the benefit of precontrast films. Unfortunately, the diagnostic information that can be obtained from attenuation values of these single-phase studies (approximately 1 minute after the contrast bolus) is limited. Unlike unenhanced CT, there is tremendous overlap in postcontrast attenuation values of adenomas and nonadenomas (Korobkin et al., 1996a; Szolar and Kammerhuber, 1998).

Nevertheless, enhanced CT may contain diagnostic information that is helpful. Data reveal that morphologic features such as irregular margins and an enhancing rim can be quite specific for malignancy (Song et al., 2013). Furthermore, histogram analysis of the lesion's region of interest (ROI) may be useful in identifying lipid-rich adenomas on enhanced CT. This technique is available on most modern workstations, and it graphs the quantity of pixels in an ROI against their attenuation value (Boland et al., 2008). Some suggest that if more than 10% of pixels exhibit a density below 0 HU, the lesion is likely an adenoma (Bae et al., 2003; Boland et al., 2008). The combination of a histogram analysis and ^{18}FDG-PET CT also harbors promise (Perri et al., 2011).

Computed Tomography Washout Study.

Approximately 30% of adrenal adenomas exhibit an attenuation of greater than 10 HU on unenhanced CT because of their lower lipid content. These “atypical adenomas” are indistinguishable from nonadenomas on noncontrast CT density measurements alone (Boland et al., 1998)**. Fortunately, lipid-poor adenomas possess identical properties to lipid-rich adenomas regarding their rapid loss (washout) of enhancement after CT contrast load** (Caoili et al., 2000; Pena et al., 2000). Indeed, washout of contrast enhancement has become a routine technique to differentiate lipid-poor adenomas from other adrenal lesions (Fassnacht et al., 2016; Korobkin et al., 1998; Szolar and Kammerhuber, 1998; Szolar et al., 2005). An absolute percent washout (comparing noncontrast values with 15-minute postcontrast density values) of greater than 60%, or a relative percent washout (RPW) (comparing arterial phase density measurements with 15-minute postcontrast density values) of greater than 40% on delayed (washout) imaging, is indicative of adenoma (Fig. 106.28) (Boland et al., 2008; Caoili et al., 2002). Remarkably, test characteristics for these CT washout studies are highly sensitive and specific (Boland et al., 2008). Fig. 106.29 summarizes when CT washout studies should be used and how the percent washout is calculated. It is important to note, however, that washout characteristics may have limitations in differentiating lipid-poor adenomas from RCC and hepatocellular carcinoma metastases (Choi et al., 2013). Furthermore, data on washout characteristics of ACC are limited, largely because of the large size at presentation and lack of necessity in performing such studies. Although, classically, ACC can be differentiated from adenoma on 15-minute CT washout studies, some exceptions have been reported (Simhan et al., 2012a).

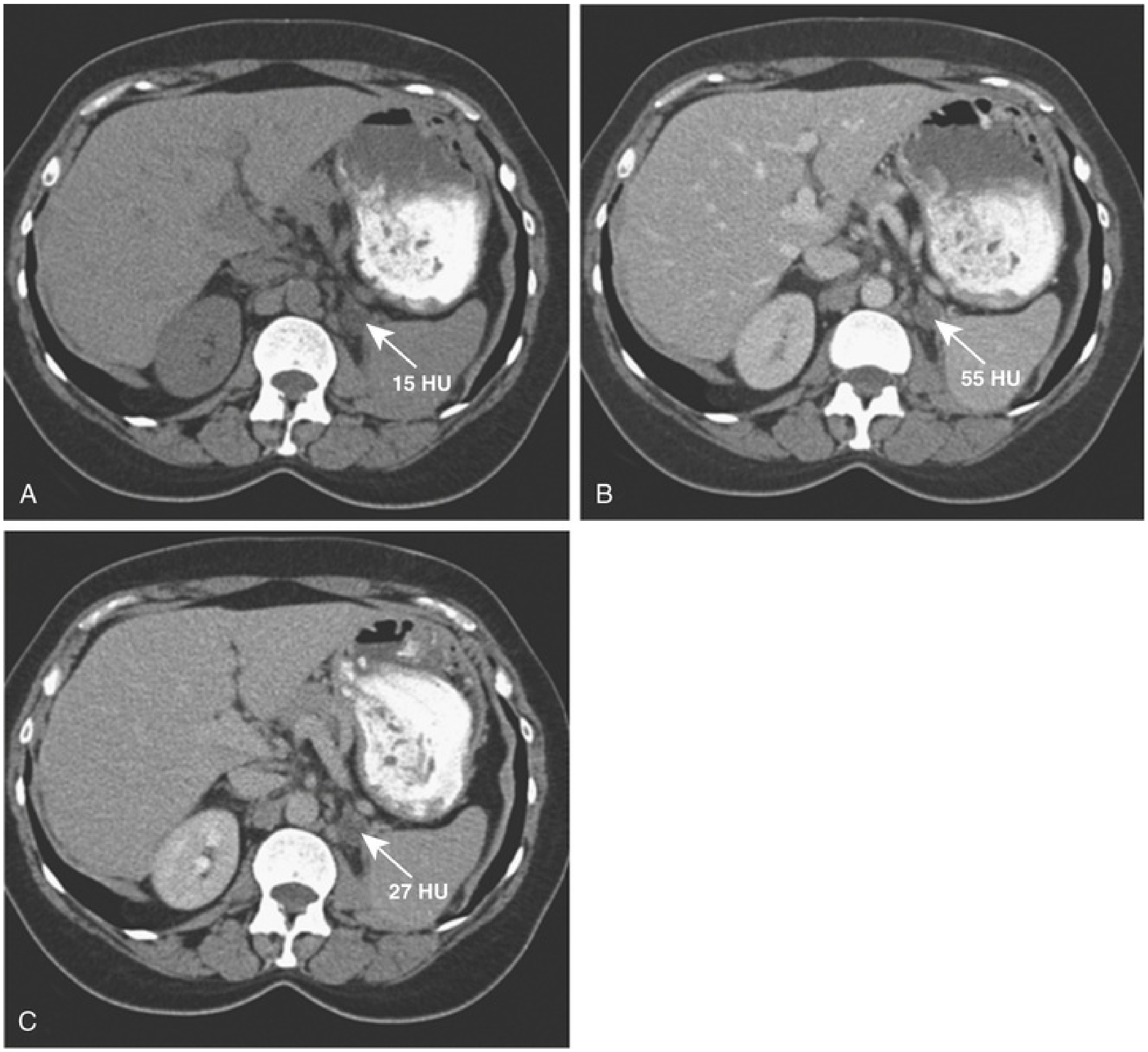

FIG. 106.28 (A) Computed tomography *(CT)* washout study performed to characterize a small, indeterminate, left adrenal lesion with an attenuation greater than 10 Hounsfield units *(HU)* on noncontrast CT. (B) CT demonstrating enhancement 60 seconds after an intravenous contrast bolus. (C) CT revealing attenuation of the lesion 15 minutes after the initial bolus after contrast washout. Because this lesion exhibits an absolute percent washout ([Enhanced − delayed]/[Enhanced − unenhanced] ×

100%) of greater than 60% (70% for this lesion), the lesion is a lipid-poor adenoma. If unenhanced imaging was not available, relative percent washout ([Enhanced − delayed]/Enhanced × 100%) of greater than 40% (60% for this lesion) would have been sufficient for diagnosis.

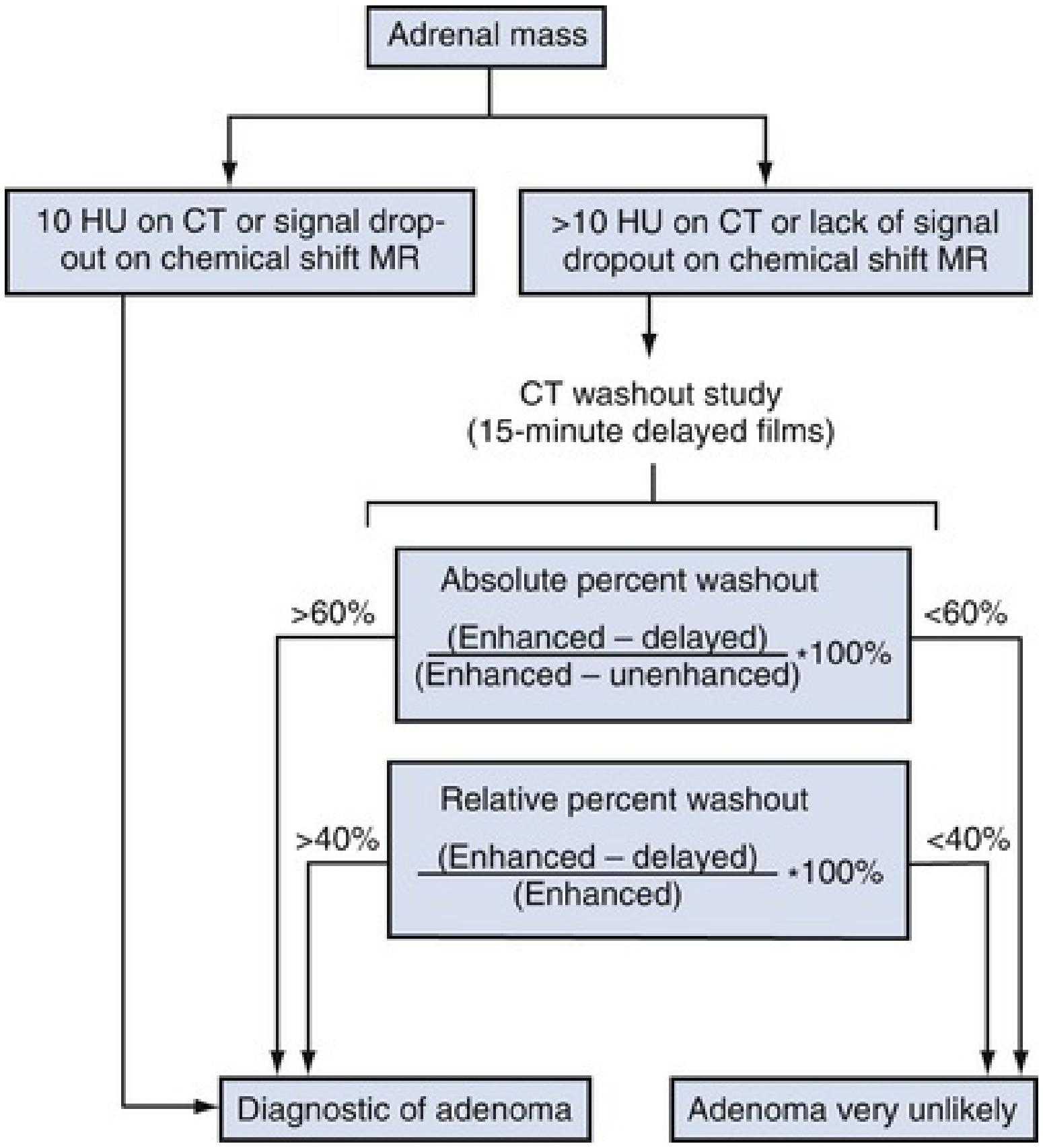
Adrenal mass
10 HU on CT or signal drop-out on chemical shift MR
>10 HU on CT or lack of signal dropout on chemical shift MR
CT washout study (15-minute delayed films)
>60%
Absolute percent washout
(Enhanced – delayed) / (Enhanced – unenhanced) *100%
<60%
>40%
Relative percent washout
(Enhanced – delayed) / (Enhanced) *100%
<40%
Diagnostic of adenoma
Adenoma very unlikely

FIG. 106.29 Summary of evaluation of adrenal mass using modern cross-sectional imaging. *CT,* Computed tomography; *HU,* Hounsfield units; *MR,* magnetic resonance.

Reports on washout studies using a 10-minute instead of a 15-minute delay exist. Originally, an RPW of greater than 50% was believed to be necessary to diagnose adenomas using such protocols (Pena et al., 2000). Although some reports suggest that just as with a 15-minute delayed study, an RPW of more than 40% is sufficient (Blake et al., 2005), imaging experts currently recommend use of 15-minute delayed protocols, despite the potential added efficiency of a 10-minute study (Boland et al., 2008, 2010b).

Given these data, it is imperative that the knowledgeable urologist order a proper adrenal CT study to include noncontrast 5-mm images through the adrenal gland with enhanced (1-minute postbolus imaging) and 15-minute washout imaging and that he or she speak to the radiologist to ensure that the test uses the proper protocol. In the absence of a properly performed test, nondiagnostic images may lead to a recommendation for subsequent unnecessary and anxiety-provoking tests.

Magnetic Resonance Imaging.

Similar to adrenal imaging by CT, MRI of the adrenal incidentaloma relies on its ability to accurately quantify the lesion's lipid content. **Whereas CT uses unenhanced attenuation to identify lipid-rich adenomas, MRI harnesses the interference between signal collected from fat and water tissue to evaluate for intracellular lipid content** (Hussain and Korobkin, 2004). **On such opposed-phase chemical shift imaging, signal intensity loss on out-of-phase sequences, when compared with in-phase imaging, signifies the presence of intracellular lipid and definitively identifies the lesions in question is an adenoma** (Korobkin et al., 1996b; Namimoto et al., 2001). The loss of signal intensity can be quantified by several methods (e.g., use of the spleen as an internal reference); however, in clinical practice, qualitative assessments are most often used (Boland et al., 2008; Fujiyoshi et al., 2003; Outwater et al., 1996). Most reports demonstrate that the test characteristics of chemical shift MRI are similar to those of unenhanced CT. Although some reports suggest that MRI may be superior to unenhanced CT in characterizing *lipid-poor* adenomas (Haider et al., 2004; Israel et al., 2004), most experts believe that the two modalities are largely equivalent (Boland, 2010b). **Nevertheless, CT washout studies appear to surpass opposed-phase chemical shift MRI in their sensitivity for identifying adenomas** (Boland, 2010a, 2010b; Boland et al., 2008; Caoili et al., 2000; Hussain and Korobkin, 2004; Park et al., 2007a)**. It is important to note that gadolinium-enhanced MRI washout studies do not exhibit the diagnostic strength of iodine-based CT washout studies and are not used in clinical practice.** This shortcoming of MRI is explained by the fact that gadolinium-induced signal intensity is less dose-dependent than enhancement from iodinated contrast on CT imaging (Hussain and Korobkin, 2004).

Functional Imaging.

The high diagnostic accuracy provided by biochemical evaluation and cross-sectional radiographic imaging of adrenal incidentalomas limits the indications for the routine use of functional imaging. However, functional adrenal imaging can provide valuable information when the origin of the adrenal tumor is unclear or when malignancy is highly suspected but has not been confirmed with other diagnostic modalities (Avram et al., 2006; Gross et al., 2009).

Radionuclide scintigraphy with the radiolabeled cholesterol analogue NP59 can help determine whether or not an adrenal lesion originated in the adrenal cortex or is from another source, because adrenocortical cells demonstrate increased uptake of the cholesterol analogue. Based on the pattern of NP59 uptake, adrenal adenomas can be distinguished from other space-occupying lesions of the adrenal gland with high sensitivity and specificity (Kloos et al., 1995, 1997). Although the characterization of lesions greater than 2 cm is limited with planar scintigraphy, the use of SPECT-CT may enhance the ability of NP59 to detect smaller lesions (La Cava et al., 2003). Despite the apparent benefits of NP59 scintigraphy in detecting adrenal adenomas, the test is time-consuming and is not currently approved by the US Food and Drug Administration. Moreover, it cannot reliably exclude the presence of ACC (Tauchmanova et al., 2004).

Additional radiotracers used to identify tumors of adrenocortical origin is carbon-11 (^{11}C)-metomidate and ^{123}I iodometomidate. Metomidate is an inhibitor of 11β-hydroxylase and aldosterone synthase that is preferentially taken up by adrenocortical cells (see Fig. 106.3). Although several studies have demonstrated the ability of ^{11}C-metomidate PET to correctly identify tumors of adrenocortical origin, the test is significantly limited by its inability to differentiate benign adrenal adenomas from ACCs and its short half-life (Hennings et al., 2006; Minn et al., 2004). An additional use for ^{11}C-metomidate PET may be in the evaluation of lateralization primary aldosteronism as mentioned earlier. ^{123}I iodometomidate has demonstrated an 89% sensitivity and an 85% specificity in differentiating adrenocortical tumors from tumors of nonadrenocortical origin (Hahner et al., 2013). With additional validation, ^{123}I iodometomidate may prove to be practical radiotracer when evaluating for the adrenocortical origin of tumors (Naruse et al., 2017).

The role of functional imaging for the diagnosis of pheochromocytoma is limited, given that most pheochromocytomas can be accurately diagnosed with cross-sectional imaging and metabolic evaluation for catecholamines and their metabolites. Therefore ^{131}I-MIBG imaging has a limited role in the routine evaluation of adrenal incidentalomas. MIBG is a functional and structural analogue of norepinephrine that is incorporated into catecholamine storage vesicles. Increased uptake of MIBG suggests the presence of a chromaffin tumor, such as a pheochromocytoma or paraganglioma. In a small series of 23 patients with nonfunctioning adrenal masses, ^{131}I-MIBG scintigraphy was performed before pathologic evaluation and demonstrated a sensitivity of 100% and a specificity of 94% in identifying the presence of pheochromocytomas and paragangliomas (Maurea et al., 2001). Although there are alternatives to MIBG imaging for the detection of pheochromocytomas, including ^{18}F-dopamine PET and the somatostatin analogue indium-111 (^{111}In)-octreotide, their usefulness in the routine evaluation of adrenal incidentalomas has not been evaluated to date (Mayo-Smith et al., 2001; Timmers et al., 2007a). As discussed earlier, ^{18}F-FDG PET is largely replacing MIBG in staging non–MEN-2 patients with known pheochromocytoma (Timmers et al., 2012). Meanwhile, ^{68}Ga-DOTATATE PET/CT exhibits superior signal-to-noise ratios and similar test characteristics when compared with ^{18}F-FDG PET and is gaining clinical traction at some centers (Chang et al., 2016).

The differentiation of benign and malignant adrenal tumors may be facilitated by the use of ^{18}F-FDG PET. Multiple reports have demonstrated that ^{18}F-FDG PET has a high sensitivity (93% to 100%) and specificity (80% to 100%) in identifying malignant adrenal tumors, including ACCs and metastatic lesions to the adrenal gland (Blake et al., 2006; Boland et al., 2011; Chong et al., 2006; Sundin, 2012). However, the use of ^{18}F-FDG PET is best reserved for cases in which CT imaging and clinical data are inconclusive (Boland et al., 2008, 2011). Indeed, some data suggest that CT washout studies are more helpful than ^{18}F-FDG PET in evaluating patients with an adrenal mass and known malignancy (Park et al., 2007b). Nevertheless, caution must be exercised in patients with known RCC and hepatocellular carcinoma, because adrenal metastases from these primary tumors can exhibit iodinated contrast washout characteristics similar to those of lipid-poor adenomas (Choi et al., 2013).

Key Points: Imaging

- Low attenuation on unenhanced CT (<10 HU) corresponds to high intracellular lipid and is extremely specific for identification of an adrenal adenoma.
- MRI is similar in its test characteristics to unenhanced CT.
- CT washout studies are considered the gold standard for adrenal imaging.

Rapid loss of contrast enhancement can differentiate even lipid-poor adenomas (approximately 30% of adenomas) from other lesions. Gadolinium-enhanced MRI washout studies do not exhibit the diagnostic strength of iodine-based CT washout studies and are not currently used in clinical practice.

- RCC metastases may exhibit imaging characteristics similar to those of lipid-poor adenomas.

Size and Growth

The retroperitoneal space allows for relatively asymptomatic growth of most adrenal lesions, which may reach beyond 20 cm in size before clinically manifesting. Nevertheless, at presentation the median radiographic diameter of an adrenal incidentaloma is approximately 3 cm (Mantero et al., 2000). **A relationship does exist between the size of an adrenal lesion and its malignant potential, with larger masses more likely to exhibit adverse clinical and pathologic features** (Angeli et al., 1997). Fig. 106.30 summarizes the relationship between adrenal mass size and its risk for malignancy in over 1300 reported incidentalomas (Barzon et al., 2003). Masses smaller than 4 cm are considered to possess low malignant potential (2% are adrenal carcinomas) and, if nonfunctional, can be observed safely (Cicala et al., 2008; Grumbach et al., 2003). **Classically, masses that exceed 6 cm have been considered malignant until proven benign; however, recent data suggest that benign imaging features appear to be more important for predicting tumor biology than size** (Azoury et al., 2017). For instance, in a large surgical series, all homogeneous lesions with imaging suggestive of adenoma proved to be benign upon resection, regardless of size (Azoury et al., 2017). In the intermediate size range of 4 to 6 cm, the rate of malignancy is estimated to be only 6% (Cicala et al., 2008). Nonetheless, in otherwise healthy individuals with an acceptable perioperative risk profile, most experts recommend 4 cm as the cutoff diameter where resection can be considered (Barry et al., 1998; Fassnacht et al., 2016; Mantero et al., 2000; Thompson and Young, 2003; Young, 2000; Young, 2007b). In the largest adrenal incidentaloma series to date (*N* = 1004), Mantero et al. reported that the 4-cm cutoff afforded a 93% sensitivity and a 42% specificity for detecting malignancy (Mantero et al., 2000). The sensitivity dropped to 74%, and the specificity rose to 73% when a 6-cm cutoff was applied. It is important to note that the relationship between the radiographic and pathologic size of an adrenal lesion is imperfect, with pathologic assessment usually resulting in a larger measurement (Cerfolio et al., 1993; Kouriefs et al., 2001). Furthermore, administrative data reveal only a weak relationship between tumor size at presentation and rates of concomitant metastatic disease in patients with ACC. Also, although analyses from administrative data sets must be interpreted with caution, a robust relationship between survival and size of localized ACC at resection is difficult to identify (Canter et al., 2013).

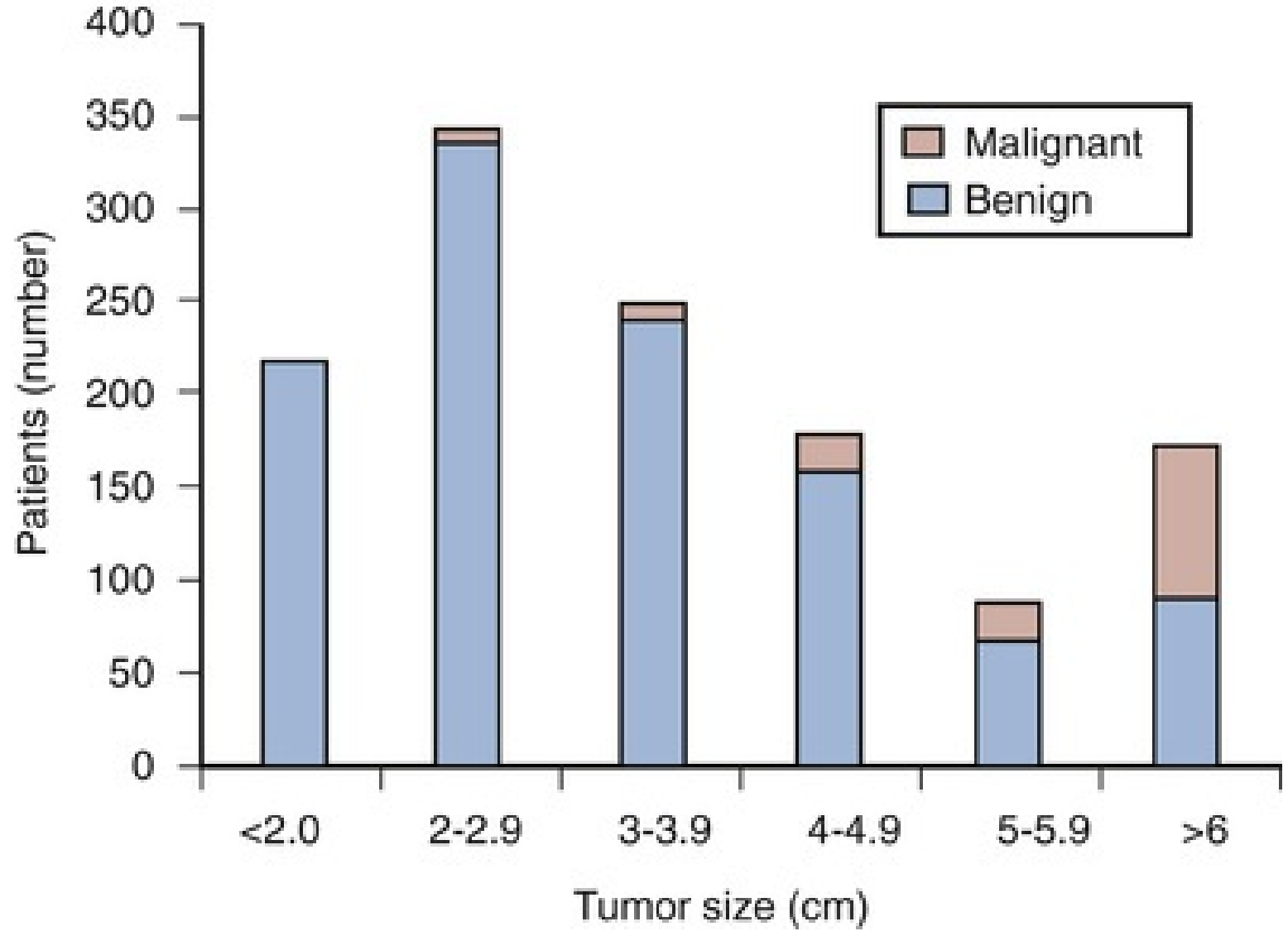

FIG. 106.30 Distribution of benign versus malignant adrenal masses based on lesion size ($N = 1322$). (Modified from Barzon L, Sonino N, Fallo F, et al. Prevalence and natural history of adrenal incidentalomas. *Eur J Endocrinol* 149:273–285, 2003.)

The urologic oncologist must remember that the incidence of benign adrenal adenomas increases with age; therefore, adrenal lesions in younger patients, even those smaller than 4 cm, must be managed with greater caution than similar lesions in an older patient. Likewise, lesions larger than 4 cm in older patients with significant comorbidities may be better served with observation than resection (Young, 2007b). Moreover, the radiographic characteristics of individual adrenal lesions (regularity of borders, lipid content, enhancement) must be considered in addition to the lesion's size when deciding whether to treat (Azoury et al., 2017). In the absence of level 1 evidence, large population-based reports must be integrated with sound clinical judgment.

The growth kinetics of unresected adrenal lesions should be followed, although most lesions that are resected because of increased growth kinetics ultimately prove benign. In a prospectively followed multi-institutional

Swedish cohort (*N* = 229, median follow-up 25 months), 7.4% (17) of masses grew at least 5 mm, with 5.2% (12) adding at least 1 cm to their diameter. All patients who underwent resection because of an increase in lesion size exhibited benign pathology (Libe et al., 2002). Similarly, an earlier review of the literature (*N* = 873) revealed that at a mean follow-up of 3 years, 9% of adrenal incidentalomas grew over 1 cm in diameter, and a smaller number decreased in size. In this series, only one lesion proved malignant. The authors concluded that the rate of malignant transformation of adrenal incidentalomas is approximately 1 in 1000 (Barzon et al., 2003). Nogueira et al. (2015) provided insight into the growth rate of malignant adrenal tumors in a series of 20 patients eventually diagnosed with ACC, in whom an average tumor growth rate of 1.9 cm per year was observed. Reimaging at 6, 12, and, as possible, 24 months was classically recommended to verify oncologic indolence (Grumbach et al., 2003; Young, 2007b). Suspicious and unusual tumors may require imaging at earlier or more frequent intervals (Young, 2007b). However, the European Society of Endocrinology Clinical Practice Guideline in collaboration with the European Network for the Study of Adrenal Tumors recommends no further follow-up in patients with less than 4 cm metabolically silent masses that exhibit benign imaging features. For other lesions, the panel recommended reimaging at 6 to 12 months (Fassnacht et al., 2016).

A rather arbitrary criterion of 1 cm of growth was classically proposed as an indication for resection; however, the patient must be counseled that the chance of malignancy is low if growth kinetics are flat (Young, 2007b). **The recent European Guideline Expert Panel suggested than an increase of greater than 20% in tumor diameter (and at least 5 mm growth) should be considered clinically concerning** (Fassnacht et al., 2016).

Key Points: Size and Growth

- Larger tumors are more likely to be malignant. Yet, even in large masses, imaging features can be informative. In otherwise healthy individuals, and especially in the young, masses 4 cm or larger should be resected or watched very closely.
- Kinetics of growth should be followed in lipid-poor masses or those greater than 4 cm in diameter that do not undergo resection.

Biopsy of Adrenal Masses

Overview

The role of adrenal biopsy has been limited for the following reasons: (1) modern imaging in the context of clinical characteristics affords superb diagnostic capabilities, (2) histologically, adenomas cannot be reliably differentiated from adrenal carcinomas, and (3) adrenal biopsy is not without risk (Thompson and Young, 2003; Young, 2007b). The latest European Society of Endocrinology Clinical Practice Guideline in collaboration with the European Network for the Study of Adrenal Tumors recommends against biopsy in patients without a history of malignancy (Fassnacht et al., 2016). Nevertheless, it is useful to review data that are available with regard to safety and diagnostic usefulness of adrenal biopsy, and the procedure can occasionally be a useful tool in the diagnostic armamentarium of the adrenal surgeon.

Test Characteristics of Biopsy

Welch et al. (1994) reported on 277 percutaneous biopsies performed at the Mayo Clinic. Most biopsies in the series were performed in patients with a known nonadrenal malignancy. The authors report a sensitivity of 81% and a specificity of 99%. The accuracy of right-sided biopsies was higher than those on the left side (94% vs. 87%). Larger biopsy needles (18 or 19 gauge) resulted in better diagnostic yield and equivalent complication rates when compared with biopsies performed with smaller needles.

The reported positive predictive value of adrenal biopsy is high, meaning that a positive biopsy for malignancy has a high correlation on final pathology. This is especially relevant in patients with a history of an unrelated primary malignancy and in whom an adrenal metastasis is suspected (Harisinghani et al., 2002; Silverman et al., 1993). Although the overall specificity is imperfect, in the same clinical scenario the test's negative predictive value is nevertheless impressive when nondiagnostic biopsies are excluded (Harisinghani et al., 2002; Silverman et al., 1993). In a series of 225 adrenal biopsies performed in patients with a known primary malignancy at Massachusetts General Hospital, 18% of biopsy specimens demonstrated adrenal tissue without evidence of malignancy. The authors reported the negative predictive value of these negative biopsy findings based on lack of tumor growth at follow-up, autopsy findings, or a rebiopsy result of 100%, although selection and research biases may have existed (Harisinghani et al., 2002). In skilled hands, nondiagnostic biopsies appear infrequent when the majority of sampling is performed with 18-gauge needles (Paulsen et al., 2004).

The probability of a positive adrenal biopsy for metastatic disease appears highest in patients with known lung carcinoma (>90%) and RCC (80%) (Mazzaglia and Monchik, 2009). In contrast, an adrenal mass in a patient without a previous history of malignancy and without evidence of a synchronous nonadrenal mass is highly unlikely to be present as a metastasis (Lutz et al., 2000). Biopsy in this setting is rarely helpful. Instead, other criteria, such as radiographic morphology and size, must be used to characterize adrenal masses in such patients (Mazzaglia and Monchik, 2009; Thompson and Young, 2003).

Complications of Biopsy

The complication rates of adrenal biopsies in some large series are as low as 2.8% (Welch et al., 1994). Bleeding is the most common postbiopsy issue, with pneumothoraces and hemothoraces also being reported (Quayle et al., 2007; Silverman et al., 1993; Welch et al., 1994). Needle-track seeding in patients with ACC remains a concern, and some authors suggest that biopsy should be avoided in patients in whom adrenal carcinoma is suspected (Quayle et al., 2007). Surgically, there has been a suggestion that biopsy, especially if followed by hemorrhage, can complicate or even prevent laparoscopic resection (Quayle et al., 2007).

The NIH consensus statement mandates that the possibility of pheochromocytoma be metabolically excluded before biopsy; percutaneous biopsies of pheochromocytomas have been reported to result in life-threatening hypertensive crises (Grumbach et al., 2003; Quayle et al., 2007). It is interesting to note that inadvertent biopsy of pheochromocytomas has resulted in no ill effects in some patients (Quayle et al., 2007); however, in real-world practice, due diligence to rule out pheochromocytoma before biopsy is prudent (Mazzaglia and Monchik, 2009).

Clinical Usefulness of Biopsy

Despite the fact that adrenal biopsies—when used to differentiate benign from metastatic disease—afford favorable accuracy, some clinicians argue that most adrenal biopsies performed today are unnecessary (Mazzaglia and Monchik, 2009; Quayle et al., 2007). For instance, Quayle et al. retrospectively reviewed their experience with patients who were sent to their tertiary referral center after an adrenal biopsy performed in the community. The researchers concluded that in no case did the biopsy affect the clinical management of these patients. Moreover, these and other investigators have raised the issue of radiology reports recommending adrenal biopsies or stating that the lesions are “amenable” to biopsy. The authors suggested that such language in radiology reports must be strongly discouraged, because it leads to unnecessary and, at times, deleterious procedures by physicians who are not familiar with standard management of the adrenal mass (Mazzaglia and Monchik, 2009; Quayle et al., 2007).

In conclusion, adrenal biopsy should be pursued only when limitations of imaging have been reached and when the physician and patient are certain that the result of biopsy will influence management. Indeed, perhaps the biggest role for adrenal mass biopsy is in patients with primary malignancies that have potentially recurred in the adrenal gland and whose management will be affected by the biopsy results (Fassnacht et al., 2016). Fig. 106.31 summarizes the salient points that must be considered when making a decision regarding whether to perform a biopsy of a patient's adrenal mass.


Adrenal mass
Can mass be characterized with imaging?
Yes
Is the mass metabolically active?
Yes
No role for biopsy
No
Will biopsy change management?
No
Yes
Is adrenocortical carcinoma strongly suspected?
Yes
No
Does benefit of biopsy justify risks including possibility of making laparoscopic adrenalectomy more difficult?
No
Yes
Perform biopsy (be certain pheochromocytoma is ruled out)

FIG. 106.31 Algorithm summarizing decision making regarding whether to subject the patient to an adrenal biopsy. Perhaps the most clinically valuable role for adrenal mass biopsy is in patients with primary malignancies that have potentially recurred in the adrenal gland and whose management will be affected by the biopsy results.

Key Points: Biopsy of Adrenal Masses

- When used to differentiate benign from metastatic disease, adrenal biopsy carries favorable test characteristics.
- Always exclude the possibility of pheochromocytoma before performing biopsy.

Assessment of Function of Adrenal Masses

Overview

The NIH consensus statement recommends metabolic testing for all adrenal incidentalomas (Grumbach et al., 2003)**. This recommendation is supported by the observation that more than 10% of adrenal incidentalomas are metabolically active (see Table 106.15). Current practice is to test all new adrenal masses for cortisol and catecholamine hypersecretion. In patients with a history of hypertension, aldosterone hypersecretion should also be assessed** (Grumbach et al., 2003; Young, 2007b). Despite this recommendation as a standard of care, routine clinical practice remains inadequate in this domain, whereas it is estimated that more than 80% of adrenal masses do not receive appropriate evaluation (Eldeiry and Garber, 2008).

Testing for Cortisol Hypersecretion

A systematic review of the literature reveals that 5% to 8% of adrenal incidentalomas produce excessive glucocorticoids (Barzon et al., 2003; Young, 2000). The NIH consensus guidelines state that all adrenal lesions should be tested for glucocorticoid hypersecretion (Grumbach et al., 2003). **Three first-line tests are available to screen patients with incidentalomas for Cushing syndrome: (1) LD-DST, (2) a late-night salivary cortisol test, and (3) a 24-hour UFC evaluation.** A meta-analysis of the published literature demonstrates that these tests afford relatively equivalent accuracy; however, the UFC and the LD-DST are supported by more abundant evidence than the late-night salivary cortisol approach (Elamin et al., 2008). **Nonetheless, reports suggest that UFC is not sufficiently sensitive to detect subclinical Cushing syndrome** (Mitchell et al., 2007; Tsagarakis et al., 2006). Indeed, recent practice guidelines from the Endocrine Society recommend the use of either the LD-DST or the late-night salivary cortisol test to screen patients with adrenal incidentalomas as part of a complete endocrinologic evaluation (Nieman et al., 2008). The Cushing Syndrome section earlier in this chapter reviews the physiologic rationale for both first-line testing discussed here and other testing that may be necessary. In this section, we review practical considerations of evaluating adrenal incidentalomas for excess glucocorticoid secretion within the scope of urologic practice. As mentioned earlier, the physician must verify that the patient is not using exogenous steroids, including creams and nasal sprays, before testing. Recent guidelines also recommend that a suppressed or low morning plasma ACTH should be confirmed prior to resection in patients with clinically significant hypercortisolemia and adrenal mass who elect to proceed with surgery (Fassnacht et al., 2016).

Overnight Low-Dose Dexamethasone Suppression Test.

Administration of low-dose dexamethasone followed by measurement of serum cortisol probes the patient's glucocorticoid negative feedback system (see the Cushing Syndrome section for a discussion of physiology). A patient's failure to suppress cortisol levels after low-dose dexamethasone administration is indicative of Cushing syndrome (Findling and Raff, 2005).

Despite the test's arguably complex physiologic considerations, its administration is remarkably simple. **The patient is given a prescription for 1 mg of dexamethasone and instructed to take it between 11 PM and 12 AM** (Newell-Price et al., 2006). The next **morning, serum cortisol is measured between 8 AM and 9 AM.** In patients without hypercortisolemia, the cortisol level should be suppressed below 5 µg/dL (140 nmol/L). Specificity at this threshold is greater than 95% (Nieman et al., 2008). The trade-off, however, is sensitivity. In some reports, up to 18% of patients with Cushing syndrome exhibited false-negative results (Findling et al., 2004). Therefore a threshold suppressed cortisol level of 1.8 µg/dL (50 nmol/L) has been suggested, raising the sensitivity to over 90% (Findling et al., 2004) with a specificity of 80% (Nieman et al., 2008). The test's performance is similar to that of other first-line tests used to diagnose Cushing syndrome and is recommended as an alternative to the late-night salivary cortisol test for initial screening of incidentalomas (Elamin et al., 2008; Nieman et al., 2008). Recent guidelines suggest repeat metabolic testing and a basal morning plasma ACTH draw in patients with LD-DST AM cortisol of greater than 1.8 µg/dL (Fassnacht et al., 2016).

Unlike 24-hour UFC testing, LD-DST is not affected by the patient's glomerular filtration rate (GFR). Box 106.5 lists the most common pharmacologic agents that can alter testing. **Most important, the urologist must be aware that the test can yield as high as a 50% false-positive rate in women using oral contraceptives, because the contraceptives increase total (but not bioavailable) cortisol levels by raising the patient's cortisol-binding globulin concentrations** (Nickelsen et al., 1989). Administration of low-dose dexamethasone over a 48-hour period is less practical but may improve accuracy and is preferred by some endocrinologists.

Box 106.5

Pharmaceuticals That Affect Testing for Cushing

Syndrome[a]

Drugs That Accelerate Dexamethasone Metabolism by Induction of Cyp3a4

Phenobarbital
Phenytoin
Carbamazepine
Primidone
Rifampin
Rifapentine
Ethosuximide
Pioglitazone

Drugs That Impair Dexamethasone Metabolism by Inhibition of Cyp3a4

Aprepitant, fosaprepitant
Itraconazole
Ritonavir
Fluoxetine
Diltiazem
Cimetidine

Drugs That Increase Cortisol-Binding Globulin and May Falsely Elevate Cortisol Results

Estrogens
Mitotane

Drugs That Increase Urine Free Cortisol Results

Carbamazepine
Fenofibrate (increase if measured by high-performance liquid chromatography)
Some synthetic glucocorticoids (immunoassays)
Drugs that inhibit 11β-hydroxysteroid dehydrogenase type 2 (licorice,

carbenoxolone)

---

[a] This should not be considered a complete list of potential drug interactions. Data regarding CYP3A4 obtained from http://medicine.iupui.edu/flockhart/table.htm.

From Nieman LK, Biller BM, Findling JW, et al. The diagnosis of Cushing's syndrome: an Endocrine Society clinical practice guideline. *J Clin Endocrinol Metab* 93:1526–1540, 2008.

Late-Night Salivary Cortisol.

Late-night cortisol measurements probe the perturbation or, in some cases, complete disruption in the diurnal variation of cortisol levels that is seen in Cushing syndrome. The abnormality, even in very mild cases of Cushing syndrome, is the inability to suppress cortisol levels at night (Findling and Raff, 2005; Raff and Findling, 2003). Because late-night serum cortisol measurements are impractical, salivary testing has gained acceptance, because salivary cortisol levels reflect near real-time serum cortisol levels. Measurements of cortisol in saliva samples collected between 11 PM and midnight or at bedtime should not exceed 145 ng/dL when the liquid chromatography–tandem mass spectrometry (LC-MS/MS) assay is used (Nieman et al., 2008). The sensitivity and specificity of the test exceed 90% and are similar to both UFC and LD-DST; however, a large meta-analysis concluded that the data supporting salivary cortisol testing, to date, are inferior to the data available for UFC and the LD-DST (Elamin et al., 2008; Nieman et al., 2008). Furthermore, the test's usefulness in diagnosing subclinical Cushing syndrome has been questioned (Nunes et al., 2009).

Unacceptably high false-positive rates may occur in patients with depression, altered sleep patterns, and chronic illness, because normal circadian variation in cortisol levels can be altered in these individuals. Tobacco use can affect salivary cortisol levels and should be avoided on the day of testing (Nieman et al., 2008). Some clinicians instruct patients to avoid oral food or liquid intake, brushing teeth, or undergoing stimulating activity within 30 minutes of salivary collection. Collection is rescheduled if the patient feels ill (Nunes et al., 2009). Some experts advise repeating salivary testing at least twice, regardless of the initial result (Nieman et al., 2008).

24-Hour Urinary Free Cortisol Evaluation.

The UFC evaluation is a 24-hour direct measurement of free bioavailable cortisol. This test is an integrated measurement of cortisol secretion over a 24-hour period and does not depend on variables that influence corticosteroid-binding globulin levels (e.g., oral contraceptives) (Arnaldi et al., 2003). This study has been recommended as an initial test to screen patients with incidentalomas for Cushing syndrome (Orth, 1995); however, some recent evidence suggests that the study may not be sensitive enough to detect subtle glucocorticoid metabolism perturbations in patients with cortisol-secreting adrenal lesions (Mitchell et al., 2007; Terzolo et al., 2005; Tsagarakis et al., 2006). **Practice guidelines issued by the Endocrine Society in 2008 recommend that the dexamethasone suppression test or the late-night salivary cortisol test supplant the 24-hour UFC evaluation in initial metabolic screening of patients with incidentalomas** (Nieman et al., 2008). Nevertheless, this test remains the test of choice in pregnant patients. In the second and third trimester, cutoff values twofold to threefold above the normal laboratory threshold must be used to account for the physiologic hormonal changes associated with pregnancy (Nieman et al., 2008).

As in all 24-hour urine collections, the patient is instructed to discard the morning's first voided urine and begin to collect all subsequent voided samples. The last sample that is collected is the first morning's void of the following day. Collection and analysis of two separate samples from each patient is advised. The test is most accurate in patients with a GFR greater than 60 mL/min because false-negative results may arise in patients with poor renal function (Nieman et al., 2008). Creatinine levels in the collection must be checked to verify completeness of the collection.

As for all tests, sensitivity and specificity of the UFC depend on the population that is being tested and the normal cutoff values that are selected. Normal cutoff values of approximately 50 µg to 100 µg per 24 hours of urine volume are usually used, but these vary depending on the laboratory where the test is performed and the assay used (Lin et al., 1997; Orth, 1995; Pecori Giraldi et al., 2007). Again, cutoff values in the second and third trimesters of pregnancy must be raised approximately threefold to account for physiologic changes. As stated earlier, the sensitivity of UFC for patients proven to exhibit hypercortisolism secondary to an adrenal adenoma has been reported to be as low as 85% (Invitti et al., 1999), whereas the specificity of the test in a population of patients with suspected Cushing syndrome appears to be in the

90% range (Pecori Giraldi et al., 2007).

Testing for Aldosterone Hypersecretion

Hypersecretion of aldosterone by adrenal masses is extremely rare, with only approximately 1% of adrenal adenomas responsible for Conn syndrome (Young, 2000). Nevertheless, data demonstrate that nearly 5% of newly hypertensive patients may harbor an aldosterone-secreting adenoma (Rossi et al., 2006a). Indeed, testing of hypertensive patients with adrenal lesions for hyperaldosteronemia is clinically recommended. Testing of nonhypertensive patients, however, currently is not recommended. The section on primary aldosteronism describes the physiologic rationale for each test. In this section, we review the practical implications of evaluating adrenal incidentalomas for excess aldosterone secretion.

In the past, low serum potassium level has been used as a screening tool to assess for the presence of aldosterone hypersecretion. Despite this prior teaching, contemporary series reveal that less than 40% of patients with hyperaldosteronism exhibit hypokalemia (Mulatero et al., 2004). **Today the screening test of choice for Conn syndrome is the ratio of morning plasma aldosterone (ng/dL) to renin (ng/mL/h). An ARR of 20 (some suggest 30) along with a concomitant aldosterone concentration above 15 ng/mL is indicative of Conn syndrome** (Grumbach et al., 2003; Mulatero et al., 2004; Vierhapper, 2007; Young, 2007b)**. The concurrent elevated aldosterone level appears important for cases in which the ARR is elevated simply because of a low renin level.** The test's characteristics have not been fully defined; however, sensitivities and specificities in the 90th percentile have been reported (Montori and Young, 2002; Young, 2007a).

Blood samples should be drawn between 8 AM and 10 AM, preferably with the patient in the sitting position. Note that this timing is also ideal for drawing the morning cortisol level for an LD-DST. Some experts believe that hypokalemia may result in false-positive results because of physiologic aldosterone elevation, and therefore patients with low potassium levels should undergo repletion before testing (Young, 2007a). **Potassium-sparing diuretics such as amiloride, and especially mineralocorticoid receptor blockers such as spironolactone, alter the RAAS and will affect test results. These agents should be stopped approximately 6 weeks before testing** (Young, 2007a). Also, historically, there has been great concern about ARR reliability in patients who are on other antihypertensive medications. Indeed, until recently, cessation of all antihypertensive therapy was recommended for a minimum of several days before ARR testing. Data now suggest that this may be unnecessary. Fig. 106.32 summarizes the effects of various antihypertensive agents on aldosterone and renin levels and on the ARR. The urologist must remember that patients on β-blockers who continue therapy through testing may show a false-positive rise in ARR. Interpretation in these cases should be unaffected because the concurrent aldosterone level remains within normal limits (Young, 2007a). Nevertheless, some experts recommend cessation of β-blockade before testing (Seifarth et al., 2002). ACE inhibitors and angiotensin receptor blockers (ARBs) can lower aldosterone levels while raising renin levels in normal individuals. The ARR in patients with and without hyperaldosteronism who are on these medications has been shown to fall. Cessation of ACE inhibitors and ARBs, however, is not required. First, aldosterone levels are unlikely to fall in patients with hypersecreting adrenal lesions in the setting of ACE inhibitor or ARB use, resulting from the fact that this hypersecretion is independent of the RAAS. Second, undetectable renin levels can be used as an additional screen for the diagnosis of hyperaldosteronism. Indeed, renin levels rise in normal individuals, and undetectable renin concentrations should be used as a trigger for secondary (confirmatory) testing, even in the setting of an ARR within the normal limits (Seifarth et al., 2002; Young, 2007a).

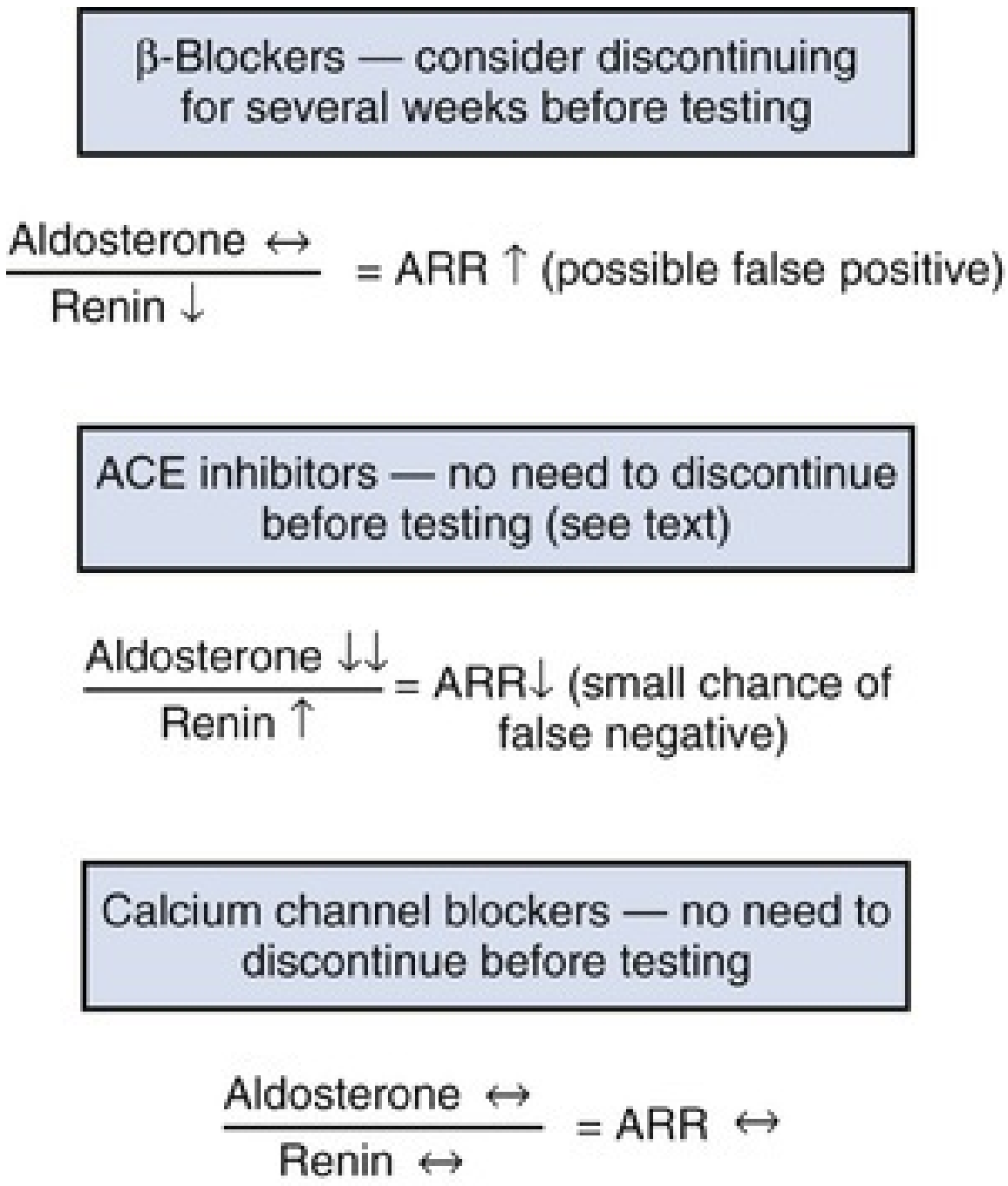
β-Blockers — consider discontinuing for several weeks before testing
Aldosterone ↔
Renin ↓
= ARR ↑ (possible false positive)
ACE inhibitors — no need to discontinue before testing (see text)
Aldosterone ↓↓
Renin ↑
= ARR↓ (small chance of false negative)
Calcium channel blockers — no need to discontinue before testing
Aldosterone ↔
Renin ↔
= ARR ↔

FIG. 106.32 Effect of antihypertensives on screening for

hyperaldosteronism. Potassium-sparing diuretics and mineralocorticoid receptor blockers are not included in the figure, because they greatly alter the renin-angiotensin-aldosterone axis and should be stopped at least 6 weeks before aldosterone-renin ratio *(ARR)* testing. The ARR must be interpreted in the context of the aldosterone and renin levels (see text). *ACE,* Angiotensin-converting enzyme.

Confirmatory testing is mandatory in patients who test positive during the initial screen for Conn syndrome. Briefly, this testing involves a 72-hour oral sodium challenge followed by measurements of a 24-hour urinary aldosterone level. The intravenous saline infusion test and the fludrocortisone suppression tests are also used for confirmatory testing by some experts, although the latter test has fallen out of favor (Mulatero et al., 2004; Young, 2007a). We strongly recommend that the patient be referred to an experienced endocrinologist at this point in his or her care. Once hyperaldosteronism is confirmed, further workup with adrenal vein sampling may be necessary. Refer to the Primary Aldosteronism section earlier in this chapter for further discussion.

Testing for Adrenal Sex Steroid Hypersecretion

Hypersecretion of adrenal sex steroids by adrenal masses, especially incidentalomas, is exceedingly rare. The most common adrenal mass that hypersecretes sex steroid is an adrenal carcinoma that concomitantly exhibits cortisol hypersecretion (Cordera et al., 2003; Wajchenberg et al., 2000). Tumors that exclusively hypersecrete androgens—testosterone and/or 17-ketosteroids—have been reported primarily in women. Approximately 50% of such lesions ultimately prove benign (Cordera et al., 2003; Moreno et al., 2004). **Routine testing of incidentalomas for sex hormones is currently not recommended** (Grumbach et al., 2003; Stanczyk, 2006; Young, 2007b); **however, adrenal androgen testing should be performed for patients in whom adrenal carcinoma is suspected** (Fassnacht et al., 2016).

Previously for patients with virilization, dexamethasone suppression testing was used to differentiate adrenal androgen excess from an ovarian androgen source; however, this approach has proven unreliable and has been largely replaced by radiographic imaging strategies (Cordera et al., 2003; Derksen et al., 1994).

Testing for Catecholamine Hypersecretion

Pheochromocytoma is found in approximately 5% of patients with adrenal incidentaloma. Therefore all patients, including those in whom metastatic disease is suspected, should undergo functional testing to rule out pheochromocytoma (Adler et al., 2007; Young, 2007b). The section on pheochromocytoma describes the physiologic rationale for each test. Here we discuss the practical details regarding testing.

Free fractionated plasma metanephrines and the 24-hour urinary fractionated metanephrine test constitute the mainstay for pheochromocytoma testing, given their superb sensitivity and suitable specificity. Indeed, the 2005 International Symposium on Pheochromocytoma concluded that one of these two tests should be used for initial diagnosis and screening for pheochromocytoma (Grossman et al., 2006; Pacak et al., 2007). Currently there is an ongoing debate regarding which one of these tests is superior (Eisenhofer et al., 2008; Young, 2007b).

Plasma Free Metanephrines.

The measurement of plasma free (fractionated) metanephrines has gained popularity because of ease of testing and excellent test characteristics. In a study of more than 850 patients (214 with pheochromocytoma, 644 without pheochromocytoma), Lenders et al. (2002) concluded that the test is superior to all other methods for diagnosing and excluding pheochromocytoma. Investigators in this multicenter study showed that the test affords nearly perfect sensitivity in cases of sporadic (99%) and familial (97%) pheochromocytoma. Specificity was reported to be 82% for sporadic cases and 96% for familial cases (Lenders et al., 2002). Indeed, the test's low specificity (reportedly as low as 77%) in patients older than 60 years of age may lead to false-positive results. For this reason, some experts advise against first-line use of plasma free metanephrines in all patients with incidentalomas (Sawka et al., 2003; Young, 2007b). Nevertheless, supporters of the test contend that the true specificity of the test is closer to 92% and that insufficient evidence exists to prove the superiority of urinary testing and to eliminate plasma free metanephrines from routine first-line use (Eisenhofer et al., 2008). Further arguments for and against the use of plasma free metanephrines are summarized in Table 106.16.

TABLE 106.16

Relative Merits for and Against Use of Plasma Free Metanephrines and Urinary Fractionated Metanephrines in Diagnosis of Pheochromocytoma

URINARY FRACTIONATED METANEPHRINES	**PLASMA FREE METANEPHRINES**
Well-established, widely available test.	Relatively new test with limited availability.
Urinary concentrations (200–2000 nmol) make analysis relatively easy.	Plasma concentrations (0.1–0.5 nmol) can make analysis difficult.
Easy for clinicians to implement with minimal expenditure of time and effort.	Blood collections require some time and effort by medical staff.
Twenty-four–hour collections can be inconvenient for patients.	Blood sampling relatively more convenient for patients.
Problems with reliability of incomplete timed urine collections.	Collection and handling of blood samples can be better regulated.
Difficult to control dietary and daily life influences on sympathoadrenal function.	Influences of diet and sympathoadrenal function more easily controlled.
In children, 24-hour collections are difficult to interpret without age-appropriate reference intervals.	In children, blood sampling may be stressful, but results are more easily interpreted without age-appropriate reference intervals.
Urine collections may be inappropriate in patients with renal failure.	Test is applicable in patients with renal failure.

From Grossman A, Pacak K, Sawka A, et al. Biochemical diagnosis and localization of pheochromocytoma: can we reach a consensus? *Ann N Y Acad Sci* 1073:332–347, 2006.

Ideally, patients should not consume food or liquids after midnight before the study. Caffeinated beverages must be avoided especially (Lenders et al., 2002). **Acetaminophen can produce a false-positive result because of cross-reactivity in the assay and should be stopped for at least 5 days before testing. Tricyclic antidepressants and phenoxybenzamine should also be stopped, because these have been shown to be responsible for false-positive results** (Eisenhofer et al., 2003b). Usual antihypertensive therapy can be continued. Although β-blockade can potentially result in a false-positive result, the current recommendation is to stop the medication only on repeat testing (Eisenhofer et al., 2003b). Ideally, the serum sample should be drawn with the patient in the supine position after at least 20 minutes of supine rest. Position is especially important if a positive result has been obtained and confirmatory testing is being performed (Grossman et al., 2006).

The upper limit of normal for the test is usually set at 0.61 nmol/L (112 ng/L) for normetanephrine and 0.31 nmol/L (61 ng/L) for metanephrine (Eisenhofer et al., 2003a, 2003b; Lenders et al., 2002; Pacak et al., 2007). Elevation beyond 2.2 nmol/L (400 ng/L) for normetanephrine and/or 1.2 nmol/L (236 ng/L) for metanephrine is substantial and is highly indicative of pheochromocytoma. Lesser elevation in plasma free metanephrine levels necessitates repeat testing (Eisenhofer et al., 2003b). No consensus exists regarding the best strategy for repeat testing; however, strategies such as repeating plasma free metanephrine under ideal conditions (i.e., supine for 20 minutes, off β-blockers, and so on), performing urinary fractionated metanephrine testing, evaluating for elevated chromogranin A levels, and subjecting the patient to clonidine suppression testing have all been suggested (Algeciras-Schimnich et al., 2008; Eisenhofer et al., 2003b; Lenders et al., 2005). At this point in the patient's care, we strongly suggest involving an experienced endocrinologist.

24-Hour Urinary Fractionated Metanephrines.

Some experts believe that 24-hour urinary fractionated metanephrines along with fractionated urinary catecholamine testing represent the best first-line test for pheochromocytoma (Perry et al., 2007; Young, 2007b). When measured with tandem mass spectrometry, and when an elevation in metanephrine (>1531 nmol/day), normetanephrine (>4001 nmol/day), or total metanephrine (>1563 nmol/day) level is considered as a positive result, sensitivity for detecting pheochromocytoma is reported to exceed 97%, with a specificity of approximately 91%. Supporters contend that given this specificity, the test is superior to plasma free metanephrines because it avoids unnecessary false-positive results, especially in patient populations with relatively low pretest probabilities, such as those with incidentaloma (Perry et al., 2007; Sawka et al., 2003; Young, 2007a, 2007b). Nevertheless, critics argue that high specificity is achieved by raising reference limits, potentially compromising sensitivity (Eisenhofer et al., 2008). Furthermore, they point to results of Lenders et al., which showed urinary fractionated metanephrine to be inferior to plasma free metanephrines (Lenders et al., 2002). Given strong opinions on both sides of the argument, the 2005 International Symposium on Pheochromocytoma failed to reach a consensus regarding the superiority of either test (Grossman et al., 2006; Pacak et al., 2007). Table 106.16 summarizes some additional arguments for and against urinary metanephrine testing.

As in all 24-hour urine collections, the patient is instructed to discard the morning's first voided urine and begin to collect all subsequent voided samples. The last sample that is collected is the first morning's void of the following day.

Creatinine levels in the collection must be checked to verify completeness of the collection. The test is most accurate in patients with normal renal function. Tricyclic antidepressants and phenoxybenzamine should be stopped.

Follow-Up

A small percentage (approximately 2%), of metabolically silent adrenal incidentalomas are reported to show new metabolic activity during follow-up evaluation (Barzon et al., 2003). In the past, annual metabolic hormonal screening for the first 3 to 4 years after diagnosis was recommended, especially for masses that are 3 cm in diameter (Grumbach et al., 2003). Given a lack of strong data for this recommendation, the need for metabolic re-evaluation of adrenal adenomas in patients who show no clinical signs of hormonal hypersecretion remained controversial (Barry et al., 1998; Bulow et al., 2006; Young, 2007b), **and recent guidelines recommend against repeat metabolic interrogation in patients with normal initial metabolic testing and no new signs of potential endocrine pathology (e.g., diabetes, hypertension)** (Fassnacht et al., 2016).

Key Points: Assessment of Function of Adrenal Masses

- All adrenal incidentalomas demand a metabolic evaluation.
- No repeat workup is necessary if the initial workup is normal and no new signs of endocrine-related pathology (e.g., hypertension, diabetes) arise.

Summary of Surgical Indications

Every urologist must clearly understand the indications for surgical intervention in patients with adrenal pathology. The decision-making and management algorithm for patients with adrenal incidentalomas is summarized in Fig. 106.33. Box 106.6 also details the major surgical indications for resection of the adrenal gland. The table also includes existing recommendations for adrenal resection during renal surgery (Kutikov et al., 2011b; Lane et al., 2009; O'Malley et al., 2009; Weight et al., 2011).

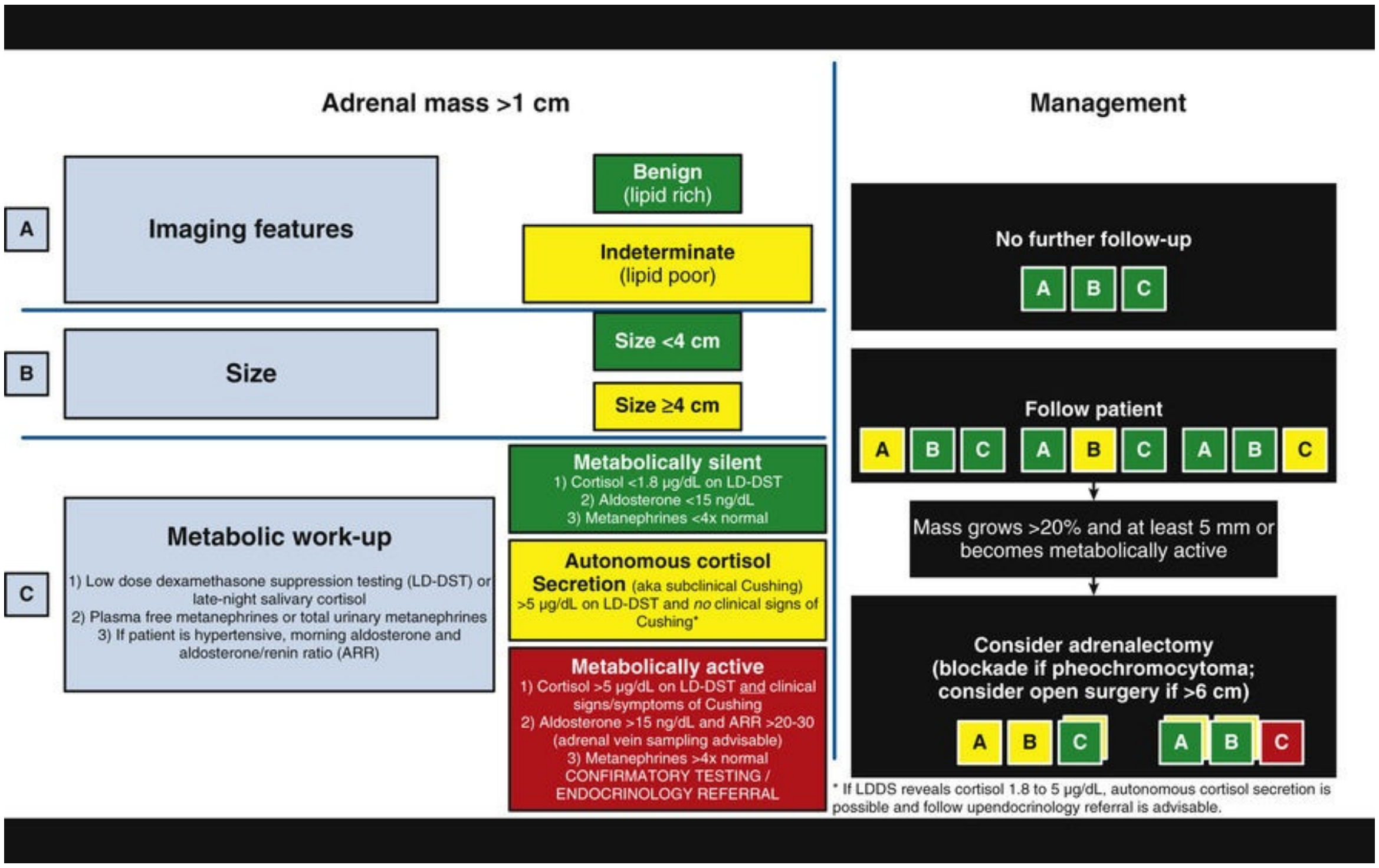
Adrenal mass >1 cm
Management
A
Imaging features
Benign
(lipid rich)
Indeterminate
(lipid poor)
B
Size
Size <4 cm
Size ≥4 cm
C
Metabolic work-up
1) Low dose dexamethasone suppression testing (LD-DST) or late-night salivary cortisol
2) Plasma free metanephrines or total urinary metanephrines
3) If patient is hypertensive, morning aldosterone and aldosterone/renin ratio (ARR)
Metabolically silent
1) Cortisol <1.8 μg/dL on LD-DST
2) Aldosterone <15 ng/dL
3) Metanephrines <4x normal
Autonomous cortisol Secretion (aka subclinical Cushing)
>5 μg/dL on LD-DST and *no* clinical signs of Cushing*
Metabolically active
1) Cortisol >5 μg/dL on LD-DST and clinical signs/symptoms of Cushing
2) Aldosterone >15 ng/dL and ARR >20-30 (adrenal vein sampling advisable)
3) Metanephrines >4x normal
CONFIRMATORY TESTING / ENDOCRINOLOGY REFERRAL
No further follow-up
A B C
Follow patient
A B C A B C A B C
Mass grows >20% and at least 5 mm or becomes metabolically active
Consider adrenalectomy
(blockade if pheochromocytoma;
consider open surgery if >6 cm)
A B C A B C

* If LDDS reveals cortisol 1.8 to 5 μg/dL, autonomous cortisol secretion is possible and follow upendocrinology referral is advisable.

FIG. 106.33 Management algorithm for newly diagnosed incidental adrenal mass.

Box 106.6

Summary of Surgical Indications for Adrenalectomy

- Functional adrenal mass
    - Cortisol hypersecretion
    - Pheochromocytoma
    - Aldosterone hypersecretion
- Mass >4 cm with the exception of myelolipoma (see discussion on size and growth under the Imaging of Adrenal Masses section in text)
- Mass with imaging findings that are suggestive of malignancy (e.g., lipid poor, heterogeneous, irregular borders, infiltrates surrounding structures)
- Adrenal incidentaloma that grows more than 1 cm on follow-up imaging
- Extremely large and/or symptomatic myelolipoma (see discussion on myelolipoma in the Adrenal Lesions section in text)
- Isolated adrenal metastasis (multidisciplinary decision making required)

- During renal surgery for renal cell carcinoma if:
    - Adrenal abnormal or not visualized because of large renal tumor size on imaging
    - Vein thrombus to level of adrenal vein
- Failed neurosurgical treatment of Cushing disease, necessitating bilateral adrenalectomy
- Select patients with ectopic adrenocorticotropic hormone (ACTH) syndrome, requiring bilateral adrenalectomy
- ACTH-independent macronodular adrenal hyperplasia (AIMAH)
- Primary pigmented nodular adrenocortical disease (PPNAD)

Conclusions

The adrenal glands have long been recognized for their essential role in regulation of critical homeostatic functions. Indeed, these deceptively simple glands are central to myriad essential life-sustaining human functions. Despite the frequency of incidental adrenal lesions, relative to other essential organs, the adrenal glands are infrequent primary initiators of human diseases. Nonetheless, clinically significant abnormalities of the adrenal gland require a systematic multidisciplinary approach. With the urologist's advanced minimally invasive surgical skills, his or her comfort with both retroperitoneal anatomy and surgical approaches to retroperitoneal organs, and the close relationship between renal and adrenal pathophysiology, it is natural that the urologist participate in the evaluation of adrenal disorders and provide primary surgical management for these patients.

Suggested Readings

Barzon L, Sonino N, Fallo F, et al. Prevalence and natural history of adrenal incidentalomas. *Eur J Endocrinol*. 2003;149(4):273–285.

Boland GW. Adrenal imaging: why, when, what and how? Part I. Why and when to image? *AJR Am J Roentgenol*. 2010;195:W377–W381.

Boland GW. Adrenal imaging: why when, what and how? Part II. What technique? *AJR Am J Roentgenol*. 2010;196:W1–W5.

Bratslavsky G, Linehan WM. Routine adrenalectomy in renal cancer—an antiquated practice. *Nat Rev Urol*. 2011;8(10):534–536.

Eisenhofer G, Siegert G, Kotzerke J, et al. Current progress and future challenges in the biochemical diagnosis and treatment of pheochromocytomas and paragangliomas. *Horm Metab Res*. 2008;40(5):329–337.

Else T, Kim AC, Sabolch A, et al. Adrenocortical carcinoma. *Endocr Rev*. 2014;35(2):282–326.

Fassnacht M, Kenn W, Allolio B. Adrenal tumors: how to establish malignancy? *J Endocrinol Invest*. 2004;27(4):387–399.

Fassnacht M, Terzolo M, Allolio B, et al. Combination chemotherapy in advanced adrenocortical carcinoma. *N Engl J Med*. 2012;366(23):2189–2197.

Funder JW, Carey RM, Mantero F, et al. The management of primary aldosteronism, case detection, diagnosis, and treatment: an Endocrine Society clinical practice guideline. *J Clin Endocrinol Metab*. 2016;101(5):1889–1916.

Grumbach MM, Biller BMK, Braunstein GD, et al. Management of the clinically inapparent adrenal mass (“incidentaloma”). *Ann Intern Med*. 2003;138(5):424–429.

Han M, Burnett AL, Fishman EK, et al. The natural history and treatment of adrenal myelolipoma. *J Urol*. 1997;157(4):1213–1216.

Kutikov A, Mallin K, Canter D, et al. Effects of increased cross-sectional imaging on the diagnosis and prognosis of adrenocortical carcinoma: analysis of the National Cancer Database. *J Urol*. 2011;186:805–810.

Lenders JW, Eisenhofer G, Mannelli M, et al. Phaeochromocytoma. *Lancet*. 2005;366(9486):665–675.

Mantero F, Terzolo M, Arnaldi G, et al. A survey on adrenal incidentaloma in Italy. Study Group on Adrenal Tumors of the Italian Society of Endocrinology. *J Clin Endocrinol Metab*. 2000;85(2):637–644.

Neri LM, Nance FC. Management of adrenal cysts. *Am Surg*. 1999;65(2):151–163.

Neumann H, Bausch B, McWhinney S, et al. Germ-line mutations in nonsyndromic pheochromocytoma. *N Engl J Med*. 2002;346(19):1459–1466.

Newell-Price J, Bertagna X, Grossman AB, et al. Cushing's syndrome. *Lancet*. 2006;367(9522):1605–1617.

Pacak K. Preoperative management of the pheochromocytoma patient. *J Clin Endocrinol Metab*. 2007;92(11):4069–4079.

Pacak K, Eisenhofer G, Ahlman H, et al. Pheochromocytoma: recommendations for clinical practice from the First International Symposium. October 2005. *Nat Clin Pract Endocrinol Metab*. 2007;3(2):92–102.

Porterfield J, Thompson G, Young W, et al. Surgery for Cushing's syndrome: an historical review and recent ten-year experience. *World J Surg*. 2008;32(5):659–677.

Salva M, Cicala M, Mantero F. Primary aldosteronism: the role of confirmatory tests. *Horm Metab Res*. 2012;44(3):177–180.

Young WF Jr. The incidentally discovered adrenal mass. *N Engl*

J Med. 2007;356(6):601–610.

References

Abdelhamid S, Muller-Lobeck H, Pahl S, et al. Prevalence of adrenal and extra-adrenal Conn syndrome in hypertensive patients. *Arch Intern Med*. 1996;156:1190.

Abell J, Crawford A. On the blood-pressure raising constituent of the suprarenal capsule. *Johns Hopkins Hosp Bull*. 1897;8:151–157.

Addison T. *On the constitutional and local effects of the disease of the supra-renal capsules*. Samuel Highley: London; 1855.

Adler JT, Mack E, Chen H. Isolated adrenal mass in patients with a history of cancer: remember pheochromocytoma. *Ann Surg Oncol*. 2007;14(8):2358–2362.

Adler JT, Meyer-Rochow GY, Chen H, et al. Pheochromocytoma: current approaches and future directions. *Oncologist*. 2008;13(7):779–793.

Akatsu T, Kameyama K, Araki K, et al. Functioning adrenocortical oncocytoma: the first documented case producing interleukin-6 and review of the literature. *J Endocrinol Invest*. 2008;31(1):68–73.

Algeciras-Schimnich A, Preissner CM, Young WF Jr, et al. Plasma chromogranin A or urine fractionated metanephrines follow-up testing improves the diagnostic accuracy of plasma fractionated metanephrines for pheochromocytoma. *J Clin Endocrinol Metab*. 2008;93(1):91–95.

Allolio B, Fasshacht M. Clinical Review: adrenocortical carcinoma: clinical update. *J Clin Endocrinol Metab*. 2006;91:2027–2037.

Amar L, Bertherat J, Baudin E, et al. Genetic testing in pheochromocytoma or functional paraganglioma. *J Clin Oncol*. 2005;23(34):8812–8818.

Amar L, Servais A, Gimenez-Roqueplo AP, et al. Year of diagnosis, features at presentation, and risk of recurrence in patients with pheochromocytoma or secreting paraganglioma. *J Clin Endocrinol Metab*. 2005;90(4):2110–2116.

Angeli A, Osella G, Ali A, et al. Adrenal incidentaloma: an overview of clinical and epidemiological data from the National Italian Study Group. *Horm Res*. 1997;47:279–283.

Aniszewski JP, Young WF Jr, Thompson GB, et al. Cushing syndrome due to ectopic adrenocorticotropic hormone secretion. *World J Surg*. 2001;25(7):934–940.

Antonelli A, Cozzoli A, Simeone C, et al. Surgical treatment of adrenal metastasis from renal cell carcinoma: a single-centre experience of 45 patients. *BJU Int*. 2006;97(3):505–508.

Arlt W, Allolio B. Adrenal insufficiency. *Lancet*. 2003;361(9372):1881–1893.

Arlt W, Stewart PM. Adrenal corticosteroid biosynthesis, metabolism, and action. *Endocrinol Metab Clin North Am*. 2005;34(2):293–313 [viii].

Arnaldi G, Angeli A, Atkinson AB, et al. Diagnosis and complications of Cushing's syndrome: a consensus statement. *J Clin Endocrinol Metab*. 2003;88(12):5593–5602.

Aron DC, Raff H, Findling JW. Effectiveness versus efficacy: the limited value in clinical practice of high dose dexamethasone suppression testing in the differential diagnosis of adrenocorticotropin-dependent Cushing's syndrome. *J Clin Endocrinol Metab*. 1997;82(6):1780–1785.

Asari R, Scheuba C, Kaczirek K, et al. Estimated risk of pheochromocytoma recurrence after adrenal-sparing surgery in patients with multiple endocrine neoplasia type 2A. *Arch Surg*. 2006;141(12):1199–1205.

Asher KP, Gupta GN, Boris RS, et al. Robot-assisted laparoscopic partial adrenalectomy for pheochromocytoma: the National Cancer Institute technique. *Eur Urol*. 2011;60(1):118–124.

Assie G, Antoni G, Tissier F, et al. Prognositic parameters of metastatic adrenocortical carcinoma. *J Clin Endocrinol Metab*. 2007;92:148–154.

Assie G, Bahurel H, Coste J, et al. Corticotroph tumor progression after adrenalectomy in Cushing's disease: a reappraisal of Nelson's syndrome. *J Clin Endocrinol Metab*. 2007;92(1):172–179.

Aubert S, Wacrenier A, Leroy X, et al. Weiss system revisited: a clinicopathologic and immunohistochemical study of 49 adrenocortical tumors. *Am J Surg Pathol*. 2002;26(12):1612–1619.

Avisse C, Marcus C, Patey M, et al. Surgical anatomy and embryology of the adrenal glands. *Surg Clin North Am*. 2000;80(1):403–415.

Avram AM, Fig LM, Gross MD. Adrenal gland scintigraphy. *Semin Nucl Med*. 2006;36(3):212–227.

Axelrod L. Perioperative management of patients treated with glucocorticoids. *Endocrinol Metab Clin North Am*. 2003;32(2):367–383.

Ayala-Ramirez M, Jasim S, Feng L, et al. Adrenocortical carcinoma: clinical outcomes and prognosis of 330 patients at a tertiary care center. *Eur J Endocrinol*. 2013;169(6):891–899.

Azoury SC, Nagarajan N, Young A, et al. Computed tomography in the management of adrenal tumors. *J Comput Assist Tomogr*. 2017;41(4):628–632.

Bae KT, Fuangtharnthip P, Prasad SR, et al. Adrenal masses: CT characterization with histogram analysis method. *Radiology*. 2003;228(3):735–742.

Barry MK, van Heerden JA, Farley DR, et al. Can adrenal incidentalomas be safely observed? *World J Surg*. 1998;22(6):599–604.

Barwick TD, Malhotra A, Webb JA, et al. Embryology of the adrenal glands and its relevance to diagnostic imaging. *Clin Radiol*. 2005;60(9):953–959.

Barzon L, Maffei P, Sonino N, et al. The role of 21-hydroxylase in the pathogenesis of adrenal masses: review of the literature and focus on our own experience. *J Endocrinol Invest*. 2007;30(7):615–623.

Barzon L, Sonino N, Fallo F, et al. Prevalence and natural history of adrenal incidentalomas. *Eur J Endocrinol*. 2003;149(4):273–285.

Bastl CP, Hayslett JP. The cellular action of aldosterone in target epithelia. *Kidney Int*. 1992;42(2):250–264.

Benham JL, Eldoma M, Khokar B, et al. Proportion of patients with hypertension resolution following adrenalectomy for primary aldosteronism: a systematic review and meta-analysis. *J Clin Hypertens*. 2016;18(12):1205–1212.

Benn DE, Robinson BG. Genetic basis of phaeochromocytoma and paraganglioma. *Best Pract Res Clin Endocrinol Metab*. 2006;20(3):435–450.

Berruti A, Terzolo M, Sperone P, et al. Etoposide, doxorubicin and cisplatin plus mitotane in the treatment of advanced adrenocortical carcinoma: a large prospective phase II trial. *Endocr Relat Cancer*. 2005;12(3):657–666.

Berruti A, Fassnacht M, Haak H, et al. Prognostic role of overt hypercortisolism in completely operated patients with adrenocortical cancer. *Eur Urol*. 2014;65(4):832–838.

Berruti A, Grisanti S, Pulzer A, et al. Long-term outcomes of adjuvant mitotane therapy in patients with radically resected adrenocortical carcinoma. *J Clin Endocrinol Metab*. 2017;102(4):1358–1365.

Bhargav P, Mishra A, Agarwal G, et al. Adrenal incidentalomas: experience in a developing country. *World J Surg*. 2008;32(8):1802–1808.

Bhatia KS, Ismail MM, Sahdev A, et al. 123I-metaiodobenzylguanidine (MIBG) scintigraphy for the detection of adrenal and extra-adrenal phaeochromocytomas: CT and MRI correlation. *Clin Endocrinol (Oxf)*. 2008;69(2):181–188.

Biglieri EG, Schambelan M. The significance of elevated levels of plasma 18-hydroxycorticosterone in patients with primary aldosteronism. *J Clin Endocrinol Metab*. 1979;49(1):87–91.

Bilimoria KY, Shen WT, Elaraj D, et al. Adrenocortical carcinoma in the United States: treatment utilization and prognostic factors. *Cancer*. 2008;88:3130–3136.

Bisceglia M, Ludovico O, Di Mattia A, et al. Adrenocortical oncocytic tumors: report of 10 cases and review of the literature. *Int J Surg Pathol*. 2004;12(3):231–243.

Bishoff JT, Waguespack RL, Lynch SC, et al. Bilateral symptomatic adrenal myelolipoma. *J Urol*. 1997;158(4):1517–1518.

Bishop E, Eble JN, Cheng L, et al. Adrenal myelolipomas show nonrandom X-chromosome inactivation in hematopoietic elements and fat: support for a clonal origin of myelolipomas. *Am J Surg Pathol*. 2006;30(7):838–843.

Blake MA, Kalra MK, Sweeney AT, et al. Distinguishing benign from malignant adrenal masses: multi-detector row CT protocol with 10-minute delay. *Radiology*. 2005;238(2):578–585.

Blake MA, Krishnamoorthy SK, Boland GW, et al. Low-density pheochromocytoma on CT: a mimicker of adrenal adenoma. *AJR Am J Roentgenol*. 2003;181(6):1663–1668.

Blake MA, Slattery JM, Kalra MK, et al. Adrenal lesions: characterization with fused PET/CT image in patients with proved or suspected malignancy—initial experience. *Radiology*. 2006;238(3):970–977.

Boland G, Lee M, Gazelle G, et al. Characterization of adrenal masses using unenhanced CT: an analysis of the CT literature. *AJR Am J Roentgenol*. 1998;171(1):201–204.

Boland GW, Blake MA, Hahn PF, et al. Incidental adrenal lesions: principles, techniques, and algorithms for imaging characterization. *Radiology*. 2008;249(3):756–775.

Boland GW, Dwamena BA, Sangwaiya MJ, et al. Characterization of adrenal masses by using FDG PET: a systematic review and meta-analysis of diagnostic test performance. *Radiology*. 2011;259(1):117–126.

Boland GW. Adrenal imaging: why when, what and how? Part II. What technique? *AJR Am J Roentgenol*. 2010;196:W1–W5.

Boland GW. Adrenal imaging: why, when, what and how? Part I. Why and when to image? *AJR Am J Roentgenol*. 2010;195:W377–W381.

Bouillon R. Acute adrenal insufficiency. *Endocrinol Metab Clin North Am*. 2006;35(4):767–775.

Branum GD, Epstein RE, Leight GS, et al. The role of resection in the management of melanoma metastatic to the adrenal gland. *Surgery*. 1991;109(2):127–131.

Bravo EL, Tagle R. Pheochromocytoma: state-of-the-art and future prospects. *Endocr Rev*. 2003;24(4):539–553.

Brown-Séquard C. Recherches experimentales sur la physiologie et la pathologie des capsules surrenales. *Arch Gen Med*. 1856;2:385–401.

Bullock WK, Hirst AE Jr. Metastatic carcinoma of the adrenal. *Am J Med Sci*. 1953;226(5):521–524.

Bulow B, Jansson S, Juhlin C, et al. Adrenal incidentaloma—follow-up results from a Swedish prospective study. *Eur J Endocrinol*. 2006;154(3):419–423.

Burks D, Mirvis S, Shanmuganathan K. Acute adrenal injury after blunt abdominal trauma: CT findings. *AJR Am J Roentgenol*. 1992;158(3):503–507.

Burnett JC Jr, Haas JA, Larson MS. Renal interstitial pressure in mineralocorticoid escape. *Am J Physiol*. 1985;249(3 Pt 2):F396–F399.

Burton TJ, Mackenzie IS, Balan K, et al. Evaluation of the sensitivity and specificity of (11)C-metomidate positron emission tomography (PET)-CT for lateralizing aldosterone secretion by Conn's adenomas. *J Clin Endocrinol Metab*. 2012;97:100–109.

Canter D, Simhan J, Wu KN, et al. Intensely positron emission tomography-avid benign adrenal adenoma. *Urology*. 2011;78(6):1307–1308.

Canter DJ, Mallin K, Uzzo RG, et al. Association of tumor size with metastatic potential and survival in patients with adrenocortical carcinoma: an analysis of the National Cancer Database. *Can J Urol*. 2013;20(5):6915–6921.

Caoili EM, Korobkin M, Francis IR, et al. Adrenal masses: characterization with combined unenhanced and delayed enhanced CT. *Radiology*. 2002;222(3):629–633.

Caoili EM, Korobkin M, Francis IR, et al. Delayed enhanced CT of lipid-poor adrenal adenomas. *AJR Am J Roentgenol*. 2000;175(5):1411–1415.

Carey RM, Varma SK, Drake CR Jr, et al. Ectopic secretion of corticotropin-releasing factor as a cause of Cushing's syndrome. A clinical, morphologic, and biochemical study. *N Engl J Med*. 1984;311(1):13–20.

Carsote M, Ghemigian A, Terzea D, et al. Cystic adrenal lesions: focus on pediatric population (a review). *Clujul Med*. 2017;90(1):5–12.

Catargi B, Rigalleau V, Poussin A, et al. Occult Cushing's syndrome in type-2 diabetes. *J Clin Endocrinol Metab*. 2003;88(12):5808–5813.

Cecchetto G, Ganarin A, Bien E, et al. Outcome and prognostic factors in high risk childhood adrenocortical carcinomas: a report from the European Cooperative Study Group on

Pediatric Rare Tumors (EXPeRT). *Pediatr Blood Cancer*. 2017;64(6).

Celen O, O'Brien MJ, Melby JC, et al. Factors influencing outcome of surgery for primary aldosteronism. *Arch Surg*. 1996;131(6):646–650.

Cerfolio RJ, Vaughan ED Jr, Brennan TG Jr, et al. Accuracy of computed tomography in predicting adrenal tumor size. *Surg Gynecol Obstet*. 1993;176(4):307–309.

Chang A, Harawi SJ. Oncocytes, oncocytosis, and oncocytic tumors. *Pathol Annu*. 1992;27(Pt 1):263–304.

Chang CA, Pattison DA, Tothill RW, et al. 68Ga-DOTATATE and 18F-FDG PET/CT in paraganglioma and pheochromocytoma: utility, patterns and heterogeneity. *Cancer Imaging*. 2016;16(1):1–12.

Charmandari E, Sertedaki A, Kino T, et al. A novel point mutation in the KCNJ5 gene causing primary hyperaldosteronism and early-onset autosomal dominant hypertension. *J Clin Endocrinol Metab*. 2012;97(8):e1532–e1539.

Chen DY, Sosa RE, Scherr DS. Treatment of adrenocortical carcinoma: contemporary outcomes. *Curr Urol Rep*. 2004;5(1):65–72.

Choi AH, Kim CK, Park BK, et al. Evaluation of adrenal metastases from renal cell carcinoma and hepatocellular carcinoma: use of delayed contrast-enhanced CT. *Radiology*. 2013;266(2):514–520.

Chong S, Lee KS, Kim HY, et al. Integrated PET-CT for the characterization of adrenal gland lesions in cancer patients: diagnostic efficacy and interpretation pitfalls. *Radiographics*. 2006;26(6):1811–1824 [discussion 24–26].

Chow JT, Thompson GB, Grant CS, et al. Bilateral laparoscopic adrenalectomy for corticotrophin-dependent Cushing's syndrome: a review of the Mayo Clinic experience. *Clin*

Endocrinol (Oxf). 2008;68(4):513–519.

Cicala MV, Sartorato P, Mantero F. Incidentally discovered masses in hypertensive patients. *Best Pract Res Clin Endocrinol Metab*. 2008;20(3):451–566.

Collinson FJ, Lam TK, Bruijn WM, et al. Long-term survival and occasional regression of distant melanoma metastases after adrenal metastasectomy. *Ann Surg Oncol*. 2008;15(6):1741–1749.

Commons RR, Callaway CP. Adenomas of the adrenal cortex. *Arch Med Interna*. 1948;81(1):37–41.

Conn JW. Presidential address. I. Painting background. II. Primary aldosteronism, a new clinical syndrome. *J Lab Clin Med*. 1955;45(1):3–17.

Cordera F, Grant C, van Heerden J, et al. Androgen-secreting adrenal tumors. *Surgery*. 2003;134(6):874–880 [discussion 80].

Cushing H. The basophil adenomas of the pituitary body and their clinical manifestations (pituitary basophilism). *Johns Hopkins Hosp Bull*. 1932;50:137–195.

Cyran KM, Kenney PJ, Memel DS, et al. Adrenal myelolipoma. *AJR Am J Roentgenol*. 1996;166(2):395–400.

Daneshmand S, Quek ML. Adrenal myelolipoma: diagnosis and management. *Urol J*. 2006;3(2):71–74.

Datrice N, Langan R, Ripley R, et al. Operative management for recurrent and metastatic adrenocortical carcinoma. *J Surg Oncol*. 2012;105(7):709–713.

de Diego AM, Gandía L, García AG. A physiological view of the central and peripheral mechanisms that regulate the release of catecholamines at the adrenal medulla. *Acta Physiol (Oxf)*. 2008;192(2):287–301.

Dekkers T, Prejbisz A, Kook LJS, et al. Adrenal vein sampling versus CT scan to determine treatment in primary aldosteronism: an outcome-based randomized diagnostic trial.

Lancet Diabetes Endocrinol. 2016;4(9):739–746.

Delivanis DA, Erickson D, Atwell TD, et al. Procedural and clinical outcomes of percutaneous adrenal biopsy in a high-risk population for adrenal malignancy. *Clin Endocrinol (Oxf)*. 2016;85(5):710–716.

Derksen J, Nagesser SK, Meinders AE, et al. Identification of virilizing adrenal tumors in hirsute women. *N Engl J Med*. 1994;331(15):968–973.

Diner EK, Franks ME, Behari A, et al. Partial adrenalectomy: the National Cancer Institute experience. *Urology*. 2005;66(1):19–23.

Dluhy RG. Pheochromocytoma—death of an axiom. *N Engl J Med*. 2002;346(19):1486–1488.

Doppman JL, Nieman L, Miller DL, et al. Ectopic adrenocorticotropic hormone syndrome: localization studies in 28 patients. *Radiology*. 1989;172:115.

Egoshi K, Masai M, Nagao K, et al. 11-Deoxycorticosterone-producing adrenocortical carcinoma. *Urol Int*. 1998;61:251–253.

Egoshi K, Masai M, Nagao K, et al. 11-deoxycorticosterone-producing adrenocortical carcinoma. *Urol Int*. 1998;61:251–253.

Eisenhofer G, Bornstein SR, Brouwers FM, et al. Malignant pheochromocytoma: current status and initiatives for future progress. *Endocr Relat Cancer*. 2004;11(3):423–436.

Eisenhofer G, Goldstein DS, Kopin IJ, et al. Pheochromocytoma: rediscovery as a catecholamine-metabolizing tumor. *Endocr Pathol*. 2003;14(3):193–212.

Eisenhofer G, Goldstein DS, Walther MM, et al. Biochemical diagnosis of pheochromocytoma: how to distinguish true- from false-positive test results. *J Clin Endocrinol Metab*. 2003;88(6):2656–2666.

Eisenhofer G, Huynh TT, Hiroi M, et al. Understanding catecholamine metabolism as a guide to the biochemical diagnosis of pheochromocytoma. *Rev Endocr Metab Disord*. 2001;2(3):297–311.

Eisenhofer G, Keiser H, Friberg P, et al. Plasma metanephrines are markers of pheochromocytoma produced by catechol-O-methyltransferase within tumors. *J Clin Endocr Metab*. 1998;83(6):2175–2185.

Eisenhofer G, Kopin IJ, Goldstein DS. Catecholamine metabolism: a contemporary view with implications for physiology and medicine. *Pharmacol Rev*. 2004;56(3):331–349.

Eisenhofer G, Lenders J, Linehan W, et al. Plasma normetanephrine and metanephrine for detecting pheochromocytoma in von Hippel-Lindau disease and multiple endocrine neoplasia type 2. *N Engl J Med*. 1999;340(24):1872–1879.

Eisenhofer G, Rundquist B, Aneman A, et al. Regional release and removal of catecholamines and extraneuronal metabolism to metanephrines. *J Clin Endocrinol Metab*. 1995;80(10):3009–3017.

Eisenhofer G, Siegert G, Kotzerke J, et al. Current progress and future challenges in the biochemical diagnosis and treatment of pheochromocytomas and paragangliomas. *Horm Metab Res*. 2008;40(05):329–337.

Elamin MB, Murad MH, Mullan R, et al. Accuracy of diagnostic tests for Cushing's syndrome: a systematic review and metaanalyses. *J Clin Endocrinol Metab*. 2008;93(5):1553–1562.

Eldeiry LS, Garber JR. Adrenal incidentalomas, 2003 to 2005: experience after publication of the National Institutes of Health consensus statement. *Endocr Pract*. 2008;14(3):279–284.

El-Naggar AK, Evans DB, Mackay B. Oncocytic adrenal cortical carcinoma. *Ultrastruct Pathol*. 1991;15(4–5):549–556.

Elsayes KM, Mukundan G, Narra VR, et al. Adrenal masses: MR imaging features with pathologic correlation. *Radiographics*. 2004;24(Suppl 1):S73–S86.

Elsayes KM, Narra VR, Leyendecker JR, et al. MRI of adrenal and extraadrenal pheochromocytoma. *AJR Am J Roentgenol*. 2005;184(3):860–867.

Else T, Hammer GD. Genetic analysis of adrenal absence: agenesis and aplasia. *Trends Endocrinol Metab*. 2005;16(10):458–468.

Else T, Kim AC, Sabolch A, et al. Adrenocortical carcinoma. *Endocr Rev*. 2014;35(2):282–326.

Else T, Williams A, Sabolch A, et al. Adjuvant therapies and patient and tumor characteristics associated with survival of adult patients with adrenocortical carcinoma. *J Clin Endocrinol*. 2014;99(2):455–461.

Else T. Association of adrenocortical carcinoma with familial cancer susceptibility syndromes. *Mol Cell Endocrinol*. 2012;351(1):66–70.

Enzinger F, Weiss S. *Primitive neuroectodermal tumors and related lesions. Soft tissue tumors*. Mosby: St. Louis; 1995:929–964.

Erickson LA, Lloyd RV, Hartman R, et al. Cystic adrenal neoplasms. *Cancer*. 2004;101(7):1537–1544.

Ermetici F, Dall'Asta C, Malavazos AE, et al. Echocardiographic alterations in patients with non-functioning adrenal incidentaloma. *J Endocrinol Invest*. 2008;31(6):573–577.

Estrada J, Boronat M, Mielgo M, et al. The long-term outcome of pituitary irradiation after unsuccessful transsphenoidal surgery in Cushing's disease. *N Engl J Med*. 1997;336(3):172–177.

Faggiano A, Pivonello R, Melis D, et al. Nephrolithiasis in Cushing's disease: prevalence, etiopathogenesis, and modification after disease cure. *J Clin Endocrinol Metab*. 2003;88(5):2076–2080.

Fallo F, Veglio F, Bertello C, et al. Prevalence and characteristics of the metabolic syndrome in primary aldosteronism. *J Clin Endocrinol Metab*. 2006;91(2):454–459.

Fassnacht M, Allolio B. Clinical management of adrenocortical carcinoma. *Best Pract Res Clin Endocrinol Metab*. 2009;23(2):273–289.

Fassnacht M, Arlt W, Bancos I, et al. Management of Adrenal Incidentalomas: European Society of Endocrinology Clinical Practice Guideline in collaboration with the European Network for the Study of Adrenal Tumors. *Eur J Endocrinol*. 2016;175(2):G1–G34.

Fassnacht M, Hahner S, Polat B, et al. Efficacy of adjuvant radiotherapy of the tumor bed on local recurrence of adrenocortical carcinoma. *J Clin Endocrinol Metab*. 2006;91:4501–4504.

Fassnacht M, Johanssen S, Quinkler M, et al. Limited prognostic value of the 2004 International Union Against Cancer staging classification for adrenocortical carcinoma: proposal for a Revised TNM Classification. *Cancer*. 2009;115(2):243–250.

Fassnacht M, Kenn W, Allolio B. Adrenal tumors: how to establish malignancy? *J Endocrinol Invest*. 2004;27(4):387–399.

Fassnacht M, Kroiss M, Allolio B. Update on adrenocortical carcinoma. *J Clin Endocrinol Metab*. 2013;98(12):4551–4564.

Fassnacht M, Terzolo M, Allolio B, et al. Combination chemotherapy in advanced adrenocortical carcinoma. *N Engl*

J Med. 2012;366(23):2189–2197.

Favia G, Lumachi F, D'Amico DF. Adrenocortical carcinoma: is prognosis different in nonfunctioning tumors? Results of surgical treatment in 31 patients. *World J Surg*. 2001;25(6):735–738.

Findling JW, Raff H, Aron DC. The low-dose dexamethasone suppression test: a reevaluation in patients with Cushing's syndrome. *J Clin Endocrinol Metab*. 2004;89(3):1222–1226.

Findling JW, Raff H. Cushing's syndrome: important issues in diagnosis and management. *J Clin Endocrinol Metab*. 2006;91(10):3746–3753.

Findling JW, Raff H. Screening and diagnosis of Cushing's syndrome. *Endocrinol Metab Clin North Am*. 2005;34(2):385–402 [ix–x].

Findling JW, Tyrrell JB. Occult ectopic secretion of corticotropin. *Arch Intern Med*. 1986;146:929.

Finkelstein M, Shaefer JM. Inborn errors of steroid biosynthesis. *Physiol Rev*. 1979;59(2):353–406.

Fleseriu M, Biller BM, Findling JW, et al. Mifepristone, a glucocorticoid receptor antagonist, produces clinical and metabolic benefits in patients with Cushing's syndrome. *J Clin Endocrinol Metab*. 2012;97:2039–2049.

Ford KM, Smolinski S, Perez Lozada JC. Anomalous adrenal vein anatomy complicating the evaluation of primary hyeraldosteronism. *Radiol Case Rep*. 2018;13:139–141.

Fox CS, Larson MG, Hwang SJ, et al. Cross-sectional relations of serum aldosterone and urine sodium excretion to urinary albumin excretion in a community-based sample. *Kidney Int*. 2006;69(11):2064–2069.

Frilling A, Tecklenborg K, Weber F, et al. Importance of adrenal incidentaloma in patients with a history of malignancy. *Surgery*. 2004;136(6):1289–1296.

Fujiyoshi F, Nakajo M, Fukukura Y, et al. Characterization of adrenal tumors by chemical shift fast low-angle shot MR imaging: comparison of four methods of quantitative evaluation. *AJR Am J Roentgenol*. 2003;180(6):1649–1657.

Funder JW, Carey RM, Fardella C, et al. Case detection, diagnosis, and treatment of patients with primary aldosteronism: an Endocrine Society clinical practice guideline. *J Clin Endocrinol Metab*. 2008;93(9):3266–3281.

Funder JW, Carey RM, Mantero F, et al. The management of primary aldosteronism, case detection, diagnosis, and treatment: an Endocrine Society clinical practice guideline. *J Clin Endocrinol Metab*. 2016;101(5):1889–1916.

Ganguly A, Dowdy AJ, Luetscher JA, et al. Anomalous postural response of plasma aldosterone concentration in patients with aldosterone-producing adrenal adenoma. *J Clin Endocrinol Metab*. 1973;36(2):401–404.

Geller D, Zhang J, Wisgerhof M, et al. A novel form of human mendelian hypertension featuring nonglucocorticoid-remediable aldosteronism. *J Clin Endocrinol Metab*. 2008;93(8):3117–3123.

Giacchetti G, Mulatero P, Mantero F, et al. Primary aldosteronism, a major form of low renin hypertension: from screening to diagnosis. *Trends Endocrinol Metab*. 2008;19(3):104–108.

Giacchetti G, Ronconi V, Lucarelli G, et al. Analysis of screening and confirmatory tests in the diagnosis of primary aldosteronism: need for a standardized protocol. *J Hypertens*. 2006;24(4):737–745.

Gibbons GH, Dzau VJ, Farhi ER, et al. Interaction of signals influencing renin release. *Annu Rev Physiol*. 1984;46:291–308.

Gil-Cárdenas A, Herrera MF, Díaz-Polanco A, et al. Nelson's syndrome after bilateral adrenalectomy for Cushing's disease. *Surgery*. 2007;141(2):147–152.

Goldstein RE, O'Neill JA Jr, Holcomb GW 3rd, et al. Clinical experience over 48 years with pheochromocytoma. *Ann Surg*. 1999;229(6):755–764 [discussion 64–66].

Gomez DR, Blumenschein GR, Lee JJ, et al. Local consolidative therapy versus maintenance therapy or observation for patients with oligometastatic non-small-cell lung cancer without progression after first-line systemic therapy: a multicenter, randomized controlled, phase 2 study. *Lancet Oncol*. 2016;17(12):1672–1682.

Gonzaga CC, Calhoun DA. Resistant hypertension and hyperaldosteronism. *Curr Hypertens Rep*. 2008;10(6):496–503.

Gonzalez RJ, Shapiro S, Sarlis N, et al. Laparoscopic resection of adrenal cortical carcinoma: a cautionary note. *Surgery*. 2005;138(6):1078–1085 [discussion 85–86].

Greenblatt DY, Shenker Y, Chen H. The utility of metaiodobenzylguanidine (MIBG) scintigraphy in patients with pheochromocytoma. *Ann Surg Oncol*. 2008;15(3):900–905.

Gross MD, Korobkin M, Assaly WB, et al. Contemporary imaging of incidentally discovered adrenal masses. *Nat Rev Urol*. 2009;6(7):363–373.

Grossman A, Pacak K, Sawka A, et al. Biochemical diagnosis and localization of pheochromocytoma: can we reach a consensus? *Ann N Y Acad Sci*. 2006;1073:332–347.

Grumbach MM, Biller BM, Braunstein GD, et al. Management of the clinically inapparent adrenal mass (“incidentaloma”). *Ann Intern Med*. 2003;138(5):424–429.

Grundy HM, Simpson SA, Tait JF. Isolation of a highly active mineralocorticoid from beef adrenal extract. *Nature*. 1952;169(4306):795–796.

Guimaraes S, Moura D. Vascular adrenoceptors: an update. *Pharmacol Rev*. 2001;53(2):319–356.

Guo YK, Yang ZG, Li Y, et al. Uncommon adrenal masses: CT and MRI features with histopathologic correlation. *Eur J Radiol*. 2007;62(3):359–370.

Gupta G, Pacak K. AACE Adrenal Scientific Committee. Precision Medicine: an update on genotype/biochemical phenotype relationships in pheochromocytoma/paraganglioma patients. *Endocr Pract*. 2017;23(6):690–704.

Hahner S, Kreissl MC, Fassnacht M, et al. Functional characterization of adrenal lesions using [123I]IMTO-SPECT/CT. *J Clin Endocrinol Metab*. 2013;98(4):1508–1518.

Haider MA, Ghai S, Jhaveri K, et al. Chemical shift MR imaging of hyperattenuating (>10 HU) adrenal masses: does it still have a role? *Radiology*. 2004;231(3):711–716.

Hamrahian AH, Ioachimescu AG, Remer EM, et al. Clinical utility of noncontrast computed tomography attenuation value (Hounsfield units) to differentiate adrenal adenomas/hyperplasias from nonadenomas: Cleveland Clinic experience. *J Clin Endocrinol Metab*. 2005;90(2):871–877.

Han M, Burnett AL, Fishman EK, et al. The natural history and treatment of adrenal myelolipoma. *J Urol*. 1997;157(4):1213–1216.

Harding JL, Yeh MW, Robinson BG, et al. Potential pitfalls in the diagnosis of phaeochromocytoma. *Med J Aust*. 2005;182(12):637–640.

Harisinghani MG, Maher MM, Hahn PF, et al. Predictive value of benign percutaneous adrenal biopsies in oncology patients. *Clin Radiol*. 2002;57(10):898–901.

Harrington JL, Farley DR, van Heerden JA, et al. Adrenal tumors and pregnancy. *World J Surg*. 1999;23(2):182–186.

Havekes B, Lai EW, Corssmit EP, et al. Detection and treatment of pheochromocytomas and paragangliomas: current standing of MIBG scintigraphy and future role of PET imaging. *Q J Nucl Med Mol Imaging*. 2008;52(4):419–429.

Havekes B, Romijn JA, Eisenhofer G, et al. Update on pediatric pheochromocytoma. *Pediatr Nephrol*. 2009;24(5):943–950.

Heinz-Peer G, Memarsadeghi M, Niederle B. Imaging of adrenal masses. *Curr Opin Urol*. 2007;17(1):32–38.

Hennings J, Lindhe O, Bergstrom M, et al. [11C]metomidate positron emission tomography of adrenocortical tumors in correlation with histopathological findings. *J Clin Endocrinol Metab*. 2006;91(4):1410–1414.

Herbet M, Feige JJ, Thomas M. Insights into the role of genetic alterations in adrenocortical tumorigenesis. *Mol Cell Endocrinol*. 2009;300(1–2):169–174.

Hes FJ, Hoppener JW, Lips CJ. Pheochromocytoma in von Hippel-Lindau disease. *J Clin Endocrinol Metab*. 2003;88(3):969–974.

Hirohara D, Nomura K, Okamoto T, et al. Performance of the basal aldosterone to renin ratio and of the renin stimulation test by furosemide and upright posture in screening for aldosterone-producing adenoma in low renin hypertensives. *J Clin Endocrinol Metab*. 2001;86(9):4292–4298.

Hisamatsu H, Sakai H, Tsuda S, et al. Combined adrenal adenoma and myelolipoma in a patient with Cushing's syndrome: case report and review of the literature. *Int J Urol*. 2004;11(6):416–418.

Hogan MJ, McRae J, Schambelan M, et al. Location of aldosterone-producing adenomas with 131I-19-iodocholesterol. *N Engl J Med*. 1976;294(8):410–414.

Hopkins RL, Leinung MC. Exogenous Cushing's syndrome and glucocorticoid withdrawal. *Endocrinol Metab Clin North Am*. 2005;34(2):371–384 [ix].

Howlett TA, Drury PL, Perry L, et al. Diagnosis and management of ACTH-dependent Cushing's syndrome:

comparison of the features in ectopic and pituitary ACTH production. *Clin Endocrinol (Oxf)*. 1986;24:699.

Huang H, Abraham J, Hung E, et al. Treatment of malignant pheochromocytoma/paraganglioma with cyclophosphamide, vincristine, and dacarbazine. *Cancer*. 2008;113(8):2020–2028.

Hubbard MM, Kulaylat MM, Abumrad NN. Adrenocorticoids—physiology, regulation, function, and metabolism. Scott WH. *Surgery of the adrenal glands*. JB Lippincott: Philadelphia, PA; 1990:39–54.

Hussain HK, Korobkin M. MR imaging of the adrenal glands. *Magn Reson Imaging Clin North Am*. 2004;12(3):515–544 [vii].

Iacobone M, Albiger N, Scaroni C, et al. The role of unilateral adrenalectomy in ACTH-independent macronodular adrenal hyperplasia (AIMAH). *World J Surg*. 2008;32(5):882–889.

Ilias I, Pacak K. Current approaches and recommended algorithm for the diagnostic localization of pheochromocytoma. *J Clin Endocrinol Metab*. 2004;89(2):479–491.

Ilias I, Sahdev A, Reznek RH, et al. The optimal imaging of adrenal tumours: a comparison of different methods. *Endocr Relat Cancer*. 2007;14(3):587–599.

Imura H, Matsukura S, Yamamoto H, et al. Studies on ectopic ACTH-producing tumors. II. Clinical and biochemical features of 30 cases. *Cancer*. 1975;35:1430.

Inoue T, Ishiguro K, Suda T, et al. Laparoscopic bilateral partial adrenalectomy for adrenocortical adenomas causing Cushing's syndrome: report of a case. *Surg Today*. 2006;36(1):94–97.

Invitti C, Giraldi FP, De Martin M, et al. Diagnosis and management of Cushing's syndrome: results of an Italian Multicentre Study. *J Clin Endocrinol Metab*.

1999;84(2):440–448.

Israel GM, Korobkin M, Wang C, et al. Comparison of unenhanced CT and chemical shift MRI in evaluating lipid-rich adrenal adenomas. *AJR Am J Roentgenol*. 2004;183(1):215–219.

Jacobson L. Hypothalamic-pituitary-adrenocortical axis regulation. *Endocrinol Metab Clin North Am*. 2005;34(2):271–292 [vii].

Jansen P, van den Born B, Fenkel W, et al. Test characteristics of the aldosterone-to-renin ratio as a screening test for primary aldosteronism. *J Hypertens*. 2014;32(1):115–126.

Jaresch S, Kornely E, Kley HK, et al. Adrenal incidentaloma and patients with homozygous or heterozygous congenital adrenal hyperplasia. *J Clin Endocrinol Metab*. 1992;74(3):685–689.

Jenkins PJ, Sohaib SA, Trainer PJ, et al. Adrenal enlargement and failure of suppression of circulating cortisol by dexamethasone in patients with malignancy. *Br J Cancer*. 1999;80(11):1815–1819.

John H, Ziegler WH, Hauri D, et al. Pheochromocytomas: can malignant potential be predicted? *Urology*. 1999;53(4):679–683.

Juliano JJ, Cody RL, Suh JH. Metastatic adrenocortical oncocytoma: a case report. *Urol Oncol*. 2008;26(2):198–201.

Karagiannis A, Mikhailidis DP, Athyros VG, et al. Pheochromocytoma: an update on genetics and management. *Endocr Relat Cancer*. 2007;14(4):935–956.

Kayser SC, Dekkers T, Groenewoud HJ, et al. Study heterogeneity and estimation of prevalence of primary aldosteronism: a systematic review and meta-regression analysis. *J Clin Endocrinol Metab*. 2016;101(7):2826–2835.

Kebebew E, Reiff E, Duh QY, et al. Extent of disease at presentation and outcome for adrenocortical carcinoma: have we made progress? *World J Surg*. 2006;30:872–878.

Kebebew E, Siperstein AE, Clark OH, et al. Results of laparoscopic adrenalectomy for suspected and unsuspected malignant adrenal neoplasms. *Arch Surg*. 2002;137(8):948–951 [discussion 952–953].

Kemink L, Hermus A, Pieters G, et al. Residual adrenocortical function after bilateral adrenalectomy for pituitary-dependent Cushing's syndrome. *J Clin Endocrinol Metab*. 1992;75(5):1211–1214.

Kempna P, Fluck CE. Adrenal gland development and defects. *Best Pract Res Clin Endocrinol Metab*. 2008;22(1):77–93.

Kenney PJ, Wagner BJ, Rao P, et al. Myelolipoma: CT and pathologic features. *Radiology*. 1998;208(1):87–95.

Khan TS, Imam H, Juhlin C, et al. Streptozocin and o,p'DDD in the treatment of adrenocortical cancer patients: long-term survival in its adjuvant use. *Ann Oncol*. 2000;11(10):1281–1287.

Khorram-Manesh A, Ahlman H, Nilsson O, et al. Long-term outcome of a large series of patients surgically treated for pheochromocytoma. *J Intern Med*. 2005;258(1):55–66.

Kim Y, Margonis GA, Prescott JD, et al. Nomograms to predict Recurrence-Free and overall survival after curative resection of adrenocortical carcinoma. *JAMA Surg*. 2016;151(4):365–373.

Kimura N, Watanabe T, Noshiro T, et al. Histological grading of adrenal and extra-adrenal pheochromocytomas and relationship to prognosis: a clinicopathological analysis of 116 adrenal pheochromocytomas and 30 extra-adrenal sympathetic paragangliomas including 38 malignant tumors. *Endocr Pathol*. 2005;16(1):23–32.

Kinney MA, Narr BJ, Warner MA. Perioperative management of pheochromocytoma. *J Cardiothorac Vasc Anesth*. 2002;16(3):359–369.

Kjellman M, Holst M, Backdahl M, et al. No overrepresentation of congenital adrenal hyperplasia in patients with adrenocortical tumours. *Clin Endocrinol (Oxf)*. 1999;50(3):343–346.

Klibanski A, Stephen AE, Greene MF, et al. Case records of the Massachusetts General Hospital. Case 36-2006. A 35-year-old pregnant woman with new hypertension. *N Engl J Med*. 2006;355(21):2237–2245.

Kloos RT, Gross MD, Francis IR, et al. Incidentally discovered adrenal masses. *Endocr Rev*. 1995;16(4):460–484.

Kloos RT, Gross MD, Shapiro B, et al. Diagnostic dilemma of small incidentally discovered adrenal masses: role for 131I-6beta-iodomethyl-norcholesterol scintigraphy. *World J Surg*. 1997;21(1):36–40.

Knepper MA, Kim GH, Masilamani S. Renal tubule sodium transporter abundance profiling in rat kidney: response to aldosterone and variations in NaCl intake. *Ann N Y Acad Sci*. 2003;986:562–569.

Koch CA. Should 123I-MIBG scintigraphy be part of the workup for pheochromocytomas? *Nat Clin Pract Endocrinol Metab*. 2009;5(2):76–77.

Kong G, Grozinsky-Glasberg S, Hofman MS, et al. Efficacy of peptide receptor radionuclide therapy for functional metastatic paraganglioma and pheochromocytoma. *J Clin Endocrinol Metab*. 2017;102(9):3278–3287.

Korobkin M, Brodeur F, Yutzy G, et al. Differentiation of adrenal adenomas from nonadenomas using CT attenuation values. *AJR Am J Roentgenol*. 1996;166(3):531–536.

Korobkin M, Brodeur FJ, Francis IR, et al. CT time-attenuation washout curves of adrenal adenomas and nonadenomas. *AJR Am J Roentgenol*. 1998;170(3):747–752.

Korobkin M, Giordano TJ, Brodeur FJ, et al. Adrenal adenomas: relationship between histologic lipid and CT and

MR findings. *Radiology*. 1996;200(3):743–747.

Kouriefs C, Mokbel K, Choy C. Is MRI more accurate than CT in estimating the real size of adrenal tumours? *Eur J Surg Oncol*. 2001;27(5):487–490.

Krasner AS. Glucocorticoid-induced adrenal insufficiency. *JAMA*. 1999;282(7):671–676.

Kutikov A, Mallin K, Canter D, et al. Effects of increased cross-sectional imaging on the diagnosis and prognosis of adrenocortical carcinoma: analysis of the National Cancer Database. *J Urol*. 2011;186:805–810.

Kutikov A, Piotrowski ZJ, Canter DJ, et al. Routine adrenalectomy is unnecessary during surgery for large and/or upper pole renal tumors when the adrenal gland is radiographically normal. *J Urol*. 2011;185(4):1198–1203.

La Cava G, Imperiale A, Olianti C, et al. SPECT semiquantitative analysis of adrenocortical (131)I-6 beta iodomethyl-norcholesterol uptake to discriminate subclinical and preclinical functioning adrenal incidentaloma. *J Nucl Med*. 2003;44(7):1057–1064.

Lacroix A, Bourdeau I. Bilateral adrenal Cushing's syndrome: macronodular adrenal hyperplasia and primary pigmented nodular adrenocortical disease. *Endocrinol Metab Clin North Am*. 2005;34(2):441–458 [x].

Lacroix A. Evaluation of bilateral laparoscopic adrenalectomy in adrenocorticotropic hormone–dependent Cushing's syndrome. *Nat Clin Pract Endocrinol Metab*. 2008;4(6):310–311.

Lairmore TC, Ball DW, Baylin SB, et al. Management of pheochromocytomas in patients with multiple endocrine neoplasia type 2 syndromes. *Ann Surg*. 1993;217(6):595–601 [discussion 601–603].

Lam KY, Lo CY. Adrenal lipomatous tumours: a 30-year clinicopathological experience at a single institution. *J Clin*

Pathol. 2001;54(9):707–712.

Lane BR, Tiong HY, Campbell SC, et al. Management of the adrenal gland during partial nephrectomy. *J Urol*. 2009;181(6):2430–2436.

Lau SK, Weiss LM. The Weiss system for evaluating adrenocortical neoplasms: 25 years later. *Hum Pathol*. 2009;40(6):757–768.

Lau WK, Zincke H, Lohse CM, et al. Contralateral adrenal metastasis of renal cell carcinoma: treatment, outcome and a review. *BJU Int*. 2003;91(9):775–779.

Lebastchi A, Kunstman J, Carling T. Adrenocortical carcinoma: current therapeutic state-of-the-art. *J Oncol*. 2012;2012:234726.

Leboulloux S, Dromain C, Bonniaud G, et al. Diagnostic and prognostic value of 18-fluorodeoxyglucose positron emission tomography in adrenocortical carcinoma: a prospective comparison with computed tomography. *J Clin Endocrinol Metab*. 2006;91:920–925.

Lebuffe G, Dosseh ED, Tek G, et al. The effect of calcium channel blockers on outcome following the surgical treatment of phaeochromocytomas and paragangliomas. *Anaesthesia*. 2005;60(5):439–444.

Lee MJ, Hahn PF, Papanicolaou N, et al. Benign and malignant adrenal masses: CT distinction with attenuation coefficients, size, and observer analysis. *Radiology*. 1991;179(2):415–418.

Lee R, Al-Ahmadie HA, Boorjian SA, et al. A case of incidental adrenocortical oncocytoma. *Nat Clin Pract Urol*. 2006;3(11):618–621.

Lee SS, Baek KH, Lee YS, et al. Subclinical Cushing's syndrome associated with an adrenocortical oncocytoma. *J Endocrinol Invest*. 2008;31(7):675–679.

Lenders JW, Eisenhofer G, Mannelli M, et al. Phaeochromocytoma. *Lancet*. 2005;366(9486):665–675.

Lenders JW, Pacak K, Walther MM, et al. Biochemical diagnosis of pheochromocytoma: which test is best? *JAMA*. 2002;287(11):1427–1434.

Lenert JT, Barnett CC, Kudelka AP, et al. Evaluation and surgical resection of adrenal masses in patients with a history of extra-adrenal malignancy. *Surgery*. 2001;130(6):1060–1067.

Li X, Goswami R, Yang S, et al. Aldosterone/direct renin concentration ratio as a screening test for primary aldosteronism: a meta-analysis. *J Renin Angiotensin Aldosterone Syst*. 2016;17(3).

Libe R, Dall'Asta C, Barbetta L, et al. Long-term follow-up study of patients with adrenal incidentalomas. *Eur J Endocrinol*. 2002;147(4):489–494.

Lifton RP, Dluhy RG, Powers M, et al. A chimaeric 11 beta-hydroxylase/aldosterone synthase gene causes glucocorticoid-remediable aldosteronism and human hypertension. *Nature*. 1992;355(6357):262–265.

Lin CL, Wu TJ, Machacek DA, et al. Urinary free cortisol and cortisone determined by high performance liquid chromatography in the diagnosis of Cushing's syndrome. *J Clin Endocrinol Metab*. 1997;82(1):151–155.

Lindholm J, Juul S, Jorgensen JO, et al. Incidence and late prognosis of Cushing's syndrome: a population-based study. *J Clin Endocrinol Metab*. 2001;86(1):117–123.

Lindsay JR, Nieman LK. Adrenal disorders in pregnancy. *Endocrinol Metab Clin North Am*. 2006;35(1):1–20 [v].

Lindsay JR, Nieman LK. Differential diagnosis and imaging in Cushing's syndrome. *Endocrinol Metab Clin North Am*. 2005;34(2):403–421 [x].

Lindsay JR, Nieman LK. The hypothalamic-pituitary-adrenal axis in pregnancy: challenges in disease detection and treatment. *Endocr Rev*. 2005;26(6):775–799.

Linehan WM, Ricketts CJ. The metabolic basis of kidney cancer. *Semin Cancer Biol*. 2013;23:46–55.

Liou LS, Kay R. Adrenocortical carcinoma in children. Review and recent innovations. *Urol Clin North Am*. 2000;27(3):403–421.

Litchfield WR, Anderson BF, Weiss RJ, et al. Intracranial aneurysm and hemorrhagic stroke in glucocorticoid-remediable aldosteronism. *Hypertension*. 1998;31(1 Pt 2):445–450.

Loh KC, Fitzgerald PA, Matthay KK, et al. The treatment of malignant pheochromocytoma with iodine-131 metaiodobenzylguanidine (131I-MIBG): a comprehensive review of 116 reported patients. *J Endocrinol Invest*. 1997;20(11):648–658.

Lopez D, Luque-Fernandez MA, Steele A, et al. “Nonfunctional” adrenal tumors and the risk for incident diabetes and cardiovascular outcomes: a cohort study. *Ann Intern Med*. 2016;165(8):533–542.

Løvås K, Husebye ES. Addison's disease. *Lancet*. 2005;365(9476):2058–2061.

Løvås K, Loge JH, Husebye ES. Subjective health status in Norwegian patients with Addison's disease. *Clin Endocrinol (Oxf)*. 2002;56(5):581–588.

Luton JP, Cerdas S, Billaud L, et al. Clinical features of adrenocortical carcinoma, prognostic factors, and the effect of mitotane therapy. *N Engl J Med*. 1990;322(17):1195–1201.

Lutz A, Stojkovic M, Schmidt M, et al. Adrenocortical function in patients with macrometastases of the adrenal gland. *Eur J Endocrinol*. 2000;143(1):91–97.

Lyu X, Liu L, Yang L, et al. Surgical management of adrenal cysts: a single-institution experience. *Int Braz J Urol*. 2014;40(5):656–665.

MacLennan GT, Resnick MI, Bostwick DG. *Pathology for* *urologists*. Saunders: Philadelphia, PA; 2003.

Mansoor GA, Malchoff CD, Arici MH, et al. Unilateral adrenal hyperplasia causing primary aldosteronism: limitations of I-131 norcholesterol scanning. *Am J Hypertens*. 2002;15(5):459–464.

Mantero F, Terzolo M, Arnaldi G, et al. A survey on adrenal incidentaloma in Italy. Study Group on Adrenal Tumors of the Italian Society of Endocrinology. *J Clin Endocrinol Metab*. 2000;85(2):637–644.

Margo G, Esposito G, Cecchetto G, et al. Pediatric adrenocortical tumors, morphological diagnostic criteria and immunohistochemical expression of matrix metalloproteinase type 2 and human leucocyte-associated antigen (HLA) class II antigens. *Hum Path*. 2012;43:31–39.

Marik PE, Pastores SM, Annane D, et al. Recommendations for the diagnosis and management of corticosteroid insufficiency in critically ill adult patients: consensus statements from an international task force by the American College of Critical Care Medicine. *Crit Care Med*. 2008;36(6):1937–1949.

Marik PE. Critical illness-related corticosteroid insufficiency. *Chest*. 2009;135(1):181–193.

Marti N, Malikova J, Galvan JA, et al. Androgen production in pediatric adrenocortical tumors may occur via both the classic and/or the alternative backdoor pathway. *Mol Cell Endocrinol*. 2017;5:64–73.

Mattsson C, Young WF Jr. Primary aldosteronism: diagnostic and treatment strategies. *Nat Clin Pract Nephrol*. 2006;2(4):198–208 [quiz, 1 p following 230].

Maurea S, Klain M, Mainolfi C, et al. The diagnostic role of radionuclide imaging in evaluation of patients with nonhypersecreting adrenal masses. *J Nucl Med*. 2001;42(6):884–892.

Maweja S, Materne R, Detrembleur N, et al. Adrenal ganglioneuroma. *Am J Surg*. 2007;194(5):683–684.

Mayo-Smith WW, Boland GW, Noto RB, et al. State-of-the-art adrenal imaging. *Radiographics*. 2001;21(4):995–1012.

Mazzaglia PJ, Monchik JM. Limited value of adrenal biopsy in the evaluation of adrenal neoplasm: a decade of experience. *Arch Surg*. 2009;144(5):465–470.

McAteer J, Huaco J, Gow K. Predictors of survival in pediatric adrenocortical carcinoma: a Surveillance, Epidemiology, and End Results (SEER) program study. *J Pediatr Surg*. 2013;48(5):1025–1031.

McMahon GT, Dluhy RG. Glucocorticoid-remediable aldosteronism. *Cardiol Rev*. 2004;12(1):44–48.

Meador CK, Liddle GW, Island DP, et al. Cause of Cushing's syndrome in patients with tumors arising from “nonendocrine” tissue. *J Clin Endocrinol Metab*. 1962;22:693–703.

Mercier O, Fadel E, de Perrot M, et al. Surgical treatment of solitary adrenal metastasis from non–small cell lung cancer. *J Thorac Cardiovasc Surg*. 2005;130(1):136–140.

Merke DP, Bornstein SR. Congenital adrenal hyperplasia. *Lancet*. 2005;365(9477):2125–2136.

Meyer A, Niemann U, Behrend M. Experience with the surgical treatment of adrenal cortical carcinoma. *Eur J Surg Oncol*. 2004;30(4):444–449.

Michalkiewicz E, Sandrini R, Figueiredo B, et al. Clinical and outcome characteristics of children with adrenocortical tumors: a report from the International Pediatric Adrenocortical Tumor Registry. *J Clin Oncol*. 2004;22(5):838–845.

Midorikawa S, Sanada H, Hashimoto S, et al. The improvement of insulin resistance in patients with adrenal incidentaloma by surgical resection. *Clin Endocrinol (Oxf)*. 2001;54(6):797–804.

Miller BS, Ammori JB, Gauger PG, et al. Laparoscopic resection is inappropriate in patients with known or suspected adrenocortical carcinoma. *World J Surg*. 2010;34(6):1380–1385.

Miller BS, Gauger PG, Hammer GD, et al. Proposal for modification of the ENSAT staging system of adrenocortical carcinoma using tumor grade. *Langenbecks Arch Surg*. 2010;395:955–961.

Milliez P, Girerd X, Plouin PF, et al. Evidence for an increased rate of cardiovascular events in patients with primary aldosteronism. *J Am Coll Cardiol*. 2005;45(8):1243–1248.

Minn H, Salonen A, Friberg J, et al. Imaging of adrenal incidentalomas with PET using (11)C-metomidate and (18)F-FDG. *J Nucl Med*. 2004;45(6):972–979.

Miskulin J, Shulkin BL, Doherty GM, et al. Is preoperative iodine 123 meta-iodobenzylguanidine scintigraphy routinely necessary before initial adrenalectomy for pheochromocytoma? *Surgery*. 2003;134(6):918–922.

Mitchell IC, Auchus RJ, Juneja K, et al. “Subclinical Cushing's syndrome” is not subclinical: improvement after adrenalectomy in 9 patients. *Surgery*. 2007;142(6):900–905 [discussion 905.e1].

Mitchell J, Barbosa G, Tsinberg M, et al. Unrecognized adrenal insufficiency in patients undergoing laparoscopic adrenalectomy. *Surg Endosc*. 2009;23:248–254.

Mittendorf EA, Lim SJ, Schacherer CW, et al. Melanoma adrenal metastasis: natural history and surgical management. *Am J Surg*. 2008;195(3):363–368 [discussion 8–9].

Mitterberger M, Pinggera GM, Peschel R, et al. The use of three-dimensional computed tomography for assessing patients before laparoscopic adrenal-sparing surgery. *BJU Int*. 2006;98(5):1068–1073.

Mitty HA. Embryology, anatomy, and anomalies of the adrenal gland. *Semin Roentgenol*. 1988;23(4):271–279.

Montori VM, Young WF Jr. Use of plasma aldosterone concentration-to-plasma renin activity ratio as a screening test for primary aldosteronism. A systematic review of the literature. *Endocrinol Metab Clin North Am*. 2002;31(3):619–632 [xi].

Moreno S, Montoya G, Armstrong J, et al. Profile and outcome of pure androgen-secreting adrenal tumors in women: experience of 21 cases. *Surgery*. 2004;136(6):1192–1198.

Mosso L, Carvajal C, Gonzalez A, et al. Primary aldosteronism and hypertensive disease. *Hypertension*. 2003;42(2):161–165.

Motta-Ramirez GA, Remer EM, Herts BR, et al. Comparison of CT findings in symptomatic and incidentally discovered pheochromocytomas. *AJR Am J Roentgenol*. 2005;185(3):684–688.

Mulatero P, Dluhy RG, Giacchetti G, et al. Diagnosis of primary aldosteronism: from screening to subtype differentiation. *Trends Endocrinol Metab*. 2005;16(3):114–119.

Mulatero P, Monticone S, Bertello C, et al. Long-term cardio- and cerebrovascular events in patients with primary aldosteronism. *J Clin Endocrinol Metab*. 2013;98(12):4826–4833.

Mulatero P, Stowasser M, Loh KC, et al. Increased diagnosis of primary aldosteronism, including surgically correctable forms, in centers from five continents. *J Clin Endocrinol Metab*. 2004;89(3):1045–1050.

Mulatero P, Tauber P, Zennaro M, et al. KCNJ5 mutations in European families with nonglucocorticoid remediable familial hyperaldosteronism. *Hypertension*. 2012;59(2):235–240.

Mussig K, Wehrmann M, Horger M, et al. Adrenocortical carcinoma producing 11-deoxycorticosterone: a rare cause of mineralocorticoid hypertension. *J Endocrinol Invest*.

2005;28:61–65.

Nakada T, Furuta H, Kazama T, et al. Unilateral renal agenesis with or without ipsilateral adrenal agenesis. *J Urol*. 1988;140(5):933–937.

Nakamura E, Kaelin WG Jr. Recent insights into the molecular pathogenesis of pheochromocytoma and paraganglioma. *Endocr Pathol*. 2006;17(2):97–106.

Namimoto T, Yamashita Y, Mitsuzaki K, et al. Adrenal masses: quantification of fat content with double-echo chemical shift in-phase and opposed-phase FLASH MR images for differentiation of adrenal adenomas. *Radiology*. 2001;218(3):642–646.

Nanba K, Tamanaha T, Nakao K, et al. Confirmatory testing in primary aldosteronism. *J Clin Endocrinol Metab*. 2012;97(5):1688–1694.

Naruse M, Umakoshi H, Tsuiki M, et al. The latest developments of functional molecular imaging in the diagnosis of primary aldosteronism. *Horm Metab Res*. 2017;49:929–935.

Neri LM, Nance FC. Management of adrenal cysts. *Am Surg*. 1999;65(2):151–163.

Neumann H, Bausch B, McWhinney S, et al. Germ-line mutations in nonsyndromic pheochromocytoma. *N Engl J Med*. 2002;346(19):1459–1466.

Neumann HP, Pawlu C, Peczkowska M, et al. Distinct clinical features of paraganglioma syndromes associated with SDHB and SDHD gene mutations. *JAMA*. 2004;292(8):943–951.

Newell-Price J, Bertagna X, Grossman AB, et al. Cushing's syndrome. *Lancet*. 2006;367(9522):1605–1617.

Ng L, Libertino JM. Adrenocortical carcinoma: diagnosis, evaluation and treatment. *J Urol*. 2003;169(1):5–11.

Nguyen AD, Conley AJ. Adrenal androgens in humans and nonhuman primates: production, zonation and regulation.

Endocr Dev. 2008;13:33–54.

Nickelsen T, Lissner W, Schoffling K. The dexamethasone suppression test and long-term contraceptive treatment: measurement of ACTH or salivary cortisol does not improve the reliability of the test. *Exp Clin Endocrinol*. 1989;94(3):275–280.

Nieman LK, Biller BM, Findling JW, et al. The diagnosis of Cushing's syndrome: an Endocrine Society clinical practice guideline. *J Clin Endocrinol Metab*. 2008;93(5):1526–1540.

Nigawara T, Kageyama K, Sakihara S, et al. A male case of nonclassical 21-hydroxylase deficiency first manifested in his sixties with adrenocortical incidentaloma. *Endocr J*. 2008;55(2):291–297.

2002. NIH state-of-the-science statement on management of the clinically inapparent adrenal mass (“incidentaloma”). *NIH Consens State Sci Statements*. 2002;19(2):1–25.

Nogueira TM, Lirov R, Caoili EM, et al. Radiographic characteristics of adrenal masses preceding the diagnosis of adrenocortical cancer. *Horm Cancer*. 2015;6(4):176–181.

Nomura K, Kusakabe K, Maki M, et al. Iodomethylnorcholesterol uptake in an aldosteronoma shown by dexamethasone-suppression scintigraphy: relationship to adenoma size and functional activity. *J Clin Endocrinol Metab*. 1990;71(4):825–830.

Nunes ML, Vattaut S, Corcuff JB, et al. Late-night salivary cortisol for diagnosis of overt and subclinical Cushing's syndrome in hospitalized and ambulatory patients. *J Clin Endocrinol Metab*. 2009;94(2):456–462.

Nyirenda MJ, Padfield PL. Aldosterone and refractory hypertension. *Curr Opin Endocrinol Diabetes Obes*. 2007;14(3):213–218.

Oelkers W, Diederich S, Bahr V. Diagnosis and therapy surveillance in Addison's disease: rapid adrenocorticotropin

(ACTH) test and measurement of plasma ACTH, renin activity, and aldosterone. *J Clin Endocrinol Metab*. 1992;75(1):259–264.

Oelkers W. Adrenal insufficiency. *N Engl J Med*. 1996;335(16):1206–1212.

Oliver G, Sharpey-Schafer E. The physiological effects of extracts on the suprarenal capsules. *J Physiol*. 1895;18:230–276.

Olsson CA, Krane RJ, Klugo RC, et al. Adrenal myelolipoma. *Surgery*. 1973;73(5):665–670.

O'Malley RL, Godoy G, Kanofsky JA, et al. The necessity of adrenalectomy at the time of radical nephrectomy: a systematic review. *J Urol*. 2009;181(5):2009–2017.

Orth DN, Liddle GW. Results of treatment in 108 patients with Cushing's syndrome. *N Engl J Med*. 1971;285(5):243–247.

Orth DN. Cushing's syndrome. *N Engl J Med*. 1995;332(12):791–803.

Otal P, Escourrou G, Mazerolles C, et al. Imaging features of uncommon adrenal masses with histopathologic correlation. *Radiographics*. 1999;19(3):569–581.

Outwater EK, Siegelman ES, Huang AB, et al. Adrenal masses: correlation between CT attenuation value and chemical shift ratio at MR imaging with in-phase and opposed-phase sequences. *Radiology*. 1996;200(3):749–752.

Pacak K, Eisenhofer G, Ahlman H, et al. Pheochromocytoma: recommendations for clinical practice from the First International Symposium. October 2005. *Nat Clin Pract Endocrinol Metab*. 2007;3(2):92–102.

Pacak K, Fojo T, Goldstein DS, et al. Radiofrequency ablation: a novel approach for treatment of metastatic pheochromocytoma. *J Natl Cancer Inst*. 2001;93(8):648–649.

Pacak K, Linehan W, Eisenhofer G, et al. Recent advances in genetics, diagnosis, localization, and treatment of pheochromocytoma. *Ann Intern Med*. 2001;134(4):315–329.

Pacak K. Preoperative management of the pheochromocytoma patient. *J Clin Endocrinol Metab*. 2007;92(11):4069–4079.

Park BK, Kim CK, Kim B, et al. Comparison of delayed enhanced CT and chemical shift MR for evaluating hyperattenuating incidental adrenal masses. *Radiology*. 2007;243(3):760–765.

Park BK, Kim CK, Kim B, et al. Comparison of delayed enhanced CT and 18F-FDG PET/CT in the evaluation of adrenal masses in oncology patients. *J Comput Assist Tomogr*. 2007;31(4):550–556.

Park JR, Eggert A, Caron H. Neuroblastoma: biology, prognosis, and treatment. *Pediatr Clin North Am*. 2008;55(1):97–120.

Pasternak JD, Seib CD, Seiser N, et al. Differences between bilateral adrenal incidentalomas and uliateral lesions. *JAMA Surg*. 2015;150(10):974–978.

Patel VG, Babalola OA, Fortson JK, et al. Adrenal myelolipoma: report of a case and review of the literature. *Am Surg*. 2006;72(7):649–654.

Patil CG, Prevedello DM, Lad SP, et al. Late recurrences of Cushing's disease after initial successful transsphenoidal surgery. *J Clin Endocrinol Metab*. 2008;93(2):358–362.

Paulsen SD, Nghiem HV, Korobkin M, et al. Changing role of imaging-guided percutaneous biopsy of adrenal masses: evaluation of 50 adrenal biopsies. *AJR Am J Roentgenol*. 2004;182(4):1033–1037.

Payabyab EC, Balasubramaniam S, Edgerly M, et al. Adrenocortical cancer: a molecularly complex disease where surgery matters. *Clin Cancer Res*. 2016;22(20):4989–5000.

Pecori Giraldi F, Ambrogio AG, De Martin M, et al. Specificity of first-line tests for the diagnosis of Cushing's syndrome: assessment in a large series. *J Clin Endocrinol Metab*.

2007;92(11):4123–4129.

Pena CS, Boland GW, Hahn PF, et al. Characterization of indeterminate (lipid-poor) adrenal masses: use of washout characteristics at contrast-enhanced CT. *Radiology*. 2000;217(3):798–802.

Perri M, Erba P, Volterrani D, et al. Adrenal masses in patients with cancer: PET/CT characterization with combined CT histogram and standardized uptake value PET analysis. *AJR Am J Roentgenol*. 2011;197:209–216.

Perry CG, Sawka AM, Singh R, et al. The diagnostic efficacy of urinary fractionated metanephrines measured by tandem mass spectrometry in detection of pheochromocytoma. *Clin Endocrinol (Oxf)*. 2007;66(5):703–708.

Phan AT. Adrenal cortical carcinoma—review of current knowledge and treatment practices. *Hematol Oncol Clin North Am*. 2007;21(3):489–507 [viii–ix].

Phitayakorn R, McHenry CR. Perioperative considerations in patients with adrenal tumors. *J Surg Oncol*. 2012;106:604–610.

Pivonello R, De Martino MC, De Leo M, et al. Cushing's syndrome. *Endocrinol Metab Clin North Am*. 2008;37(1):135–149 [ix].

Pivonello R, Faggiano A, Lombardi G, et al. The metabolic syndrome and cardiovascular risk in Cushing's syndrome. *Endocrinol Metab Clin North Am*. 2005;34(2):327–339 [viii].

Plouin PF, Chatellier G, Fofol I, et al. Tumor recurrence and hypertension persistence after successful pheochromocytoma operation. *Hypertension*. 1997;29(5):1133–1139.

Plouin PF, Gimenez-Roqueplo AP. Initial work-up and long-term follow-up in patients with phaeochromocytomas and paragangliomas. *Best Pract Res Clin Endocrinol Metab*. 2006;20(3):421–434.

Plouin PF, Gimenez-Roqueplo AP. The genetic basis of pheochromocytoma: who to screen and how? *Nat Clin Pract Endocrinol Metab*. 2006;2(2):60–61.

Pommier RF, Brennan MF. An eleven-year experience with adrenocortical carcinoma. *Surgery*. 1992;112(6):963–970 [discussion 970–971].

Porterfield J, Thompson G, Young W, et al. Surgery for Cushing's syndrome: an historical review and recent ten-year experience. *World J Surg*. 2008;32(5):659–677.

Pradeep PV, Mishra AK, Aggarwal V, et al. Adrenal cysts: an institutional experience. *World J Surg*. 2006;30(10):1817–1820.

Quayle FJ, Spitler JA, Pierce RA, et al. Needle biopsy of incidentally discovered adrenal masses is rarely informative and potentially hazardous. *Surgery*. 2007;142(4):497–504.

Radin R, David CL, Goldfarb H, et al. Adrenal and extra-adrenal retroperitoneal ganglioneuroma: imaging findings in 13 adults. *Radiology*. 1997;202(3):703–707.

Raff H, Findling JW. A physiologic approach to diagnosis of the Cushing syndrome. *Ann Intern Med*. 2003;138(12):980–991.

Rahman SH, Papadakis GZ, Keil MF, et al. Kidney stones as an underrecognized clinical sign in pediatric cushing disease. *J Pediatr*. 2016;170:273–277.e1.

Rainey WE. Adrenal zonation: clues from 11beta-hydroxylase and aldosterone synthase. *Mol Cell Endocrinol*. 1999;151(1–2):151–160.

Ravichandran R, Lafferty F, McGinniss MJ, et al. Congenital adrenal hyperplasia presenting as massive adrenal incidentalomas in the sixth decade of life: report of two patients with 21-hydroxylase deficiency. *J Clin Endocrinol Metab*. 1996;81(5):1776–1779.

Raymond V, Everett J, Furtado LV, et al. Adrenocortical carcinoma is a lynch syndrome-associated cancer. *J Clin Oncol*. 2013;31(24):3012–3018.

Ricci Z, Chernyak V, Hsu K, et al. Adrenal cysts: natural history by long-term imaging follow-up. *AJR Am J Roentgenol*. 2013;201:1009–1016.

Rijken JA, Neimeijer ND, Jonker MA, et al. The penetrance of paraganglioma and pheochromocytoma in SDHB germline mutation carriers. *Clin Genet*. 2017;93(1):60–66.

Robertson D. The adrenal medulla and adrenomedullary hormones. Scott WH. *Surgery of the adrenal glands*. JB Lippincott: Philadelphia, PA; 1990:55–68.

Roman S. Adrenocortical carcinoma. *Curr Opin Oncol*. 2006;18(1):36–42.

Rose B, Matthay KK, Price D, et al. High-dose 131I-metaiodobenzylguanidine therapy for 12 patients with malignant pheochromocytoma. *Cancer*. 2003;98(2):239–248.

Rossi G, Auchus R, Brown M, et al. An expert consensus statement on use of adrenal vein sampling for the subtyping of primary aldosteronism. *Hypertension*. 2014;63(1):151–160.

Rossi GP, Bernini G, Caliumi C, et al. A prospective study of the prevalence of primary aldosteronism in 1,125 hypertensive patients. *J Am Coll Cardiol*. 2006;48(11):2293–2300.

Rossi GP, Bernini G, Desideri G, et al. Renal damage in primary aldosteronism: results of the PAPY Study. *Hypertension*. 2006;48(2):232–238.

Rossi GP, Pessina AC, Heagerty AM. Primary aldosteronism: an update on screening, diagnosis and treatment. *J Hypertens*. 2008;26(4):613–621.

Rossi GP, Sacchetto A, Visentin P, et al. Changes in left ventricular anatomy and function in hypertension and primary aldosteronism. *Hypertension*. 1996;27(5):1039–1045.

Rossi R, Tauchmanova L, Luciano A, et al. Subclinical

Cushing's syndrome in patients with adrenal incidentaloma: clinical and biochemical features. *J Clin Endocrinol Metab*. 2000;85(4):1440–1448.

Rozenblit A, Morehouse HT, Amis ES Jr. Cystic adrenal lesions: CT features. *Radiology*. 1996;201(2):541–548.

Russell C, Goodacre BW, vanSonnenberg E, et al. Spontaneous rupture of adrenal myelolipoma: spiral CT appearance. *Abdom Imaging*. 2000;25(4):431–434.

Russell RP, Masi AT, Richter ED. Adrenal cortical adenomas and hypertension. A clinical pathologic analysis of 690 cases with matched controls and a review of the literature. *Medicine (Baltimore)*. 1972;51(3):211–225.

Ryan JJ, Rezkalla MA, Rizk SN, et al. Testosterone-secreting adrenal adenoma that contained crystalloids of Reinke in an adult female patient. *Mayo Clin Proc*. 1995;70(4):380–383.

Salem M, Tainsh RE Jr, Bromberg J, et al. Perioperative glucocorticoid coverage. A reassessment 42 years after emergence of a problem. *Ann Surg*. 1994;219(4):416–425.

Sam S, Frohman LA. Normal physiology of hypothalamic pituitary regulation. *Endocrinol Metab Clin North Am*. 2008;37(1):1–22 [vii].

Sanal HT, Kocaoglu M, Yildirim D, et al. Imaging features of benign adrenal cysts. *Eur J Radiol*. 2006;60(3):465–469.

Sasano H, Suzuki T, Moriya T. Recent advances in histopathology and immunohistochemistry of adrenocortical carcinoma. *Endocr Pathol*. 2006;17(4):345–354.

Sawka A, Jaeschke R, Singh R, et al. A comparison of biochemical tests for pheochromocytoma: measurement of fractionated plasma metanephrines compared with the combination of 24-hour urinary metanephrines and catecholamines. *J Clin Endocrinol Metab*. 2003;88(2):553–558.

Sawka AM, Young WF, Thompson GB, et al. Primary aldosteronism: factors associated with normalization of blood pressure after surgery. *Ann Intern Med*. 2001;135(4):258–261.

Schaeffer EM, Kavoussi LR. Adrenal myelolipoma. *J Urol*. 2005;173(5):1760.

Schieda N, Krishna S, McInnes MDF, et al. Utility of MRI to differentiate clear cell renal cell carcinoma adrenal metastases from adrenal adenomas. *AJR Am J Roentgenol*. 2017;209(3):W152–W159.

Schirpenbach C, Reincke M. Primary aldosteronism: current knowledge and controversies in Conn's syndrome. *Nat Clin Pract Endocrinol Metab*. 2007;3(3):220–227.

Schlamp A, Hallfeldt K, Mueller-Lisse U, et al. Recurrent adrenocortical carcinoma after laparoscopic resection. *Nat Clin Pract Endocrinol Metab*. 2007;3(2):191–195.

Scholz T, Eisenhofer G, Pacak K, et al. Current treatment of malignant pheochromocytoma. *J Clin Endocrinol Metab*. 2007;92(4):1217–1225.

Schorr A, Conrol JG, Garofano CD, et al. 20% incidence of adrenocortical insufficiency in metastatic hypernephroma. *Clin Res*. 1986;34(1):200A.

Schteingart DE, Doherty GM, Gauger PG, et al. Management of patients with adrenal cancer: recommendations of an international consensus conference. *Endocr Relat Cancer*. 2005;12(3):667–680.

Scott WH, Orth DN. Hypercortisolism (Cushing's syndrome). Scott WH. *Surgery of the adrenal glands*. JB Lippincott: Philadelphia, PA; 1990:115–151.

Scott WH, Van Way C, Gray GF, et al. Pheochromocytoma. Scott WH. *Surgery of the adrenal glands*. JB Lippincott: Philadelphia, PA; 1990:187–223.

Scott WH. Historical background of the adrenal glands. Scott WH. *Surgery of the adrenal glands*. JB Lippincott:

Philadelphia, PA; 1990:1–16.

Seccia TM, Fassina A, Nussdorfer GG, et al. Aldosterone-producing adrenocortical carcinoma: an unusual cause of Conn's syndrome with an ominous clinical course. *Endocr Relat Cancer*. 2005;12(1):149–159.

Seccia TM, Miotto D, De Toni R, et al. Adrenocorticotropic hormone stimulation during adrenal vein sampling for identifying surgically curable subtypes of primary aldosteronism: comparison of 3 different protocols. *Hypertension*. 2009;53(5):761–766.

Seifarth C, Trenkel S, Schobel H, et al. Influence of antihypertensive medication on aldosterone and renin concentration in the differential diagnosis of essential hypertension and primary aldosteronism. *Clin Endocrinol (Oxf)*. 2002;57(4):457–465.

Seiler L, Rump LC, Schulte-Monting J, et al. Diagnosis of primary aldosteronism: value of different screening parameters and influence of antihypertensive medication. *Eur J Endocrinol*. 2004;150(3):329–337.

Seyle H, Stone H. Hormonally induced transformation of the adrenal into myeloid tissue. *Am J Pathol*. 1950;23:211–233.

Shao Y, Chen R, Shen Z, et al. Preoperative alpha blockade for normotensive pheochromocytoma: is it necessary? *J Hypertens*. 2011;29:2429–2432.

Shen WT, Lee J, Kebebew E, et al. Selective use of steroid replacement after adrenalectomy. *Arch Surg*. 2006;141:771–776.

Shimon I, Melmed S. Management of pituitary tumors. *Ann Intern Med*. 1998;129(6):472–483.

Silverman ML, Lee AK. Anatomy and pathology of the adrenal glands. *Urol Clin North Am*. 1989;16(3):417–432.

Silverman SG, Mueller PR, Pinkney LP, et al. Predictive value of image-guided adrenal biopsy: analysis of results of 101 biopsies. *Radiology*. 1993;187(3):715–718.

Simhan J, Canter D, Teper E, et al. Adrenocortical carcinoma masquerading as a benign adenoma on computed tomography washout study. *Urology*. 2012;79(2):e19–e20.

Simhan J, Smaldone MC, Canter DJ, et al. Trends in regionalization of adrenalectomy to higher volume surgical centers. *J Urol*. 2012;188:377–383.

Simon DR, Palese MA. Noninvasive adrenal imaging in hyperaldosteronism. *Curr Urol Rep*. 2008;9(1):80–87.

Sippel RS, Chen H. Subclinical Cushing's syndrome in adrenal incidentalomas. *Surg Clin North Am*. 2004;84(3):875–885.

Sippel RS, Elaraj DM, Kebebew E, et al. Waiting for change: symptom resolution after adrenalectomy for Cushing's syndrome. *Surgery*. 2008;144:1054–1061.

So A, Duffy DL, Gordon RD, et al. Familial hyperaldosteronism type II is linked to the chromosome 7p22 region but also shows predicted heterogeneity. *J Hypertens*. 2005;23(8):1477–1478.

Soga H, Takenaka A, Ooba T, et al. A twelve-year experience with adrenal cortical carcinoma in a single institution: long-term survival after surgical treatment and transcatheter arterial embolization. *Urol Int*. 2009;82(2):222–226.

Song JH, Chaudhry FS, Mayo-Smith WW. The incidental adrenal mass on CT: prevalence of adrenal disease in 1,049 consecutive adrenal masses in patients with no known malignancy. *AJR Am J Roentgenol*. 2008;190(5):1163–1168.

Song JH, Grand DJ, Beland MD, et al. Morphologic features of 211 adrenal masses at initial contrast enhanced CT: can we differentiate benign from malignant lesions using imaging features alone? *AJR Am J Roentgenol*. 2013;201:1248–1253.

Sonoyama T, Sone M, Miyashita K, et al. Significance of adrenocorticotropin stimulation test in the diagnosis of an aldosterone-producing adenoma. *J Clin Endocrinol Metab*.

2011;96(9):2771–2778.

Spat A, Hunyady L. Control of aldosterone secretion: a model for convergence in cellular signaling pathways. *Physiol Rev*. 2004;84(2):489–539.

Stanczyk FZ. Diagnosis of hyperandrogenism: biochemical criteria. *Best Pract Res Clin Endocrinol Metab*. 2006;20(2):177–191.

Stojadinovic A, Ghossein RA, Hoos A, et al. Adrenocortical carcinoma: clinical, morphologic, and molecular characterization. *J Clin Oncol*. 2002;20(4):941–950.

Strong VE, D'Angelica M, Tang L, et al. Laparoscopic adrenalectomy for isolated adrenal metastasis. *Ann Surg Oncol*. 2007;14(12):3392–3400.

Sturgeon C, Kebebew E. Laparoscopic adrenalectomy for malignancy. *Surg Clin North Am*. 2004;84(3):755–774.

Sundin A. Imaging of adrenal masses with emphasis on adrenocortical tumors. *Theranostics*. 2012;2:516–522.

Sutton MG, Sheps SG, Lie JT. Prevalence of clinically unsuspected pheochromocytoma. Review of a 50-year autopsy series. *Mayo Clin Proc*. 1981;56(6):354–360.

Swain JM, Grant CS, Schlinkert RT, et al. Corticotropin-independent macronodular adrenal hyperplasia: a clinicopathologic correlation. *Arch Surg*. 1998;133(5):541–546.

Swearingen B, Biller BM, Barker FG 2nd, et al. Long-term mortality after transsphenoidal surgery for Cushing disease. *Ann Intern Med*. 1999;130(10):821–824.

Szolar DH, Kammerhuber FH. Adrenal adenomas and nonadenomas: assessment of washout at delayed contrast-enhanced CT. *Radiology*. 1998;207(2):369–375.

Szolar DH, Korobkin M, Reittner P, et al. Adrenocortical carcinomas and adrenal pheochromocytomas: mass and enhancement loss evaluation at delayed contrast-enhanced

CT. *Radiology*. 2005;234(2):479–485.

Tanabe A, Naruse M, Naruse K, et al. Left ventricular hypertrophy is more prominent in patients with primary aldosteronism than in patients with other types of secondary hypertension. *Hypertens Res*. 1997;20(2):85–90.

Tanvetyanon T, Robinson LA, Schell MJ, et al. Outcomes of adrenalectomy for isolated synchronous versus metachronous adrenal metastases in non–small-cell lung cancer: a systematic review and pooled analysis. *J Clin Oncol*. 2008;26(7):1142–1147.

Tauchmanova L, Colao A, Marzano LA, et al. Andrenocortical carcinomas: twelve-year prospective experience. *World J Surg*. 2004;28(9):896–903.

Tenenbaum F, Groussin L, Foehrenbach H, et al. 18F-fluorodeoxyglucose positron emission tomography as a diagnostic tool for malignancy of adrenocortical tumours? Preliminary results in 13 consecutive patients. *Eur J Endocrinol*. 2004;150(6):789–792.

Terzolo M, Angeli A, Fassnacht M, et al. Adjuvant mitotane treatment for adrenocortical carcinoma. *N Engl J Med*. 2007;356(23):2372–2380.

Terzolo M, Bovio S, Reimondo G, et al. Subclinical Cushing's syndrome in adrenal incidentalomas. *Endocrinol Metab Clin North Am*. 2005;34(2):423–439.

Terzolo M, Fassnacht M, Ciccone G, et al. Adjuvant mitotane for adrenocortical cancer—working through uncertainty. *J Clin Endocrinol Metab*. 2009;94(6):1879–1880.

Thompson GB, Young WF Jr. Adrenal incidentaloma. *Curr Opin Oncol*. 2003;15:84–90.

Thompson LD. Pheochromocytoma of the Adrenal gland Scaled Score (PASS) to separate benign from malignant neoplasms: a clinicopathologic and immunophenotypic study of 100 cases. *Am J Surg Pathol*. 2002;26(5):551–566.

Timmers HJ, Carrasquillo JA, Whatley M, et al. Usefulness of standardized uptake values for distinguishing adrenal glands with pheochromocytoma from normal adrenal glands by use of 6-18F-fluorodopamine PET. *J Nucl Med*. 2007;48(12):1940–1944.

Timmers HJ, Chen CC, Carrasquillo JA, et al. Staging and functional characterization of pheochromocytoma and paraganglioma by 18F-fluorodeoxyglucose (18F-FDG) positron emission tomography. *J Natl Cancer Inst*. 2012;104(9):700–708.

Timmers HJ, Kozupa A, Chen CC, et al. Superiority of fluorodeoxyglucose positron emission tomography to other functional imaging techniques in the evaluation of metastatic SDHB-associated pheochromocytoma and paraganglioma. *J Clin Oncol*. 2007;25(16):2262–2269.

Tomlinson JW, Holden N, Hills RK, et al. Association between premature mortality and hypopituitarism. *Lancet*. 2001;357(9254):425–431.

Tsagarakis S, Vassiliadi D, Thalassinos N. Endogenous subclinical hypercortisolism: diagnostic uncertainties and clinical implications. *J Endocrinol Invest*. 2006;29(5):471–482.

Tsvetov G, Shimon I, Benbassat C. Adrenal incidentaloma: clinical characteristics and comparison between patients with and without extraadrenal malignancy. *J Endocrinol Invest*. 2007;30(8):647–652.

Ulchaker JC, Goldfarb DA, Bravo EL, et al. Successful outcomes in pheochromocytoma surgery in the modern era. *J Urol*. 1999;161(3):764–767.

Utz AL, Swearingen B, Biller BM. Pituitary surgery and postoperative management in Cushing's disease. *Endocrinol Metab Clin North Am*. 2005;34(2):459–478 [xi].

Varghese JC, Hahn PF, Papanicolaou N, et al. MR differentiation of phaeochromocytoma from other adrenal lesions based on qualitative analysis of T2 relaxation times. *Clin Radiol*. 1997;52(8):603–606.

Vaughan DE, Blumenfeld JD. Pathophysiology, evaluation, and medical management of adrenal disorders. Wein AJ, Kavoussi LR, Novick AC. *Campbell-walsh urology*. Elsevier: Philadelphia, PA; 2007:144–157.

Vaughan ED Jr. Diseases of the adrenal gland. *Med Clin North Am*. 2004;88(2):443–466.

Vella A, Thompson GB, Grant CS, et al. Laparoscopic adrenalectomy for adrenocorticotropin-dependent Cushing's syndrome. *J Clin Endocrinol Metab*. 2001;86(4):1596–1599.

Vierhapper H. Determination of the aldosterone/renin ratio in 269 patients with adrenal incidentaloma. *Exp Clin Endocrinol Diabetes*. 2007;115(08):518–521.

Viola A, Tizzani D, Monticone S, et al. Diagnosis and treatment of unilateral forms of primary aldosteronism. *Curr Hypertens Rev*. 2013;9(2):156–165.

Wagner J, Portwine C, Rabin K, et al. High frequency of germline p53 mutations in childhood adrenocortical cancer. *J Natl Cancer Inst*. 1994;86:1707–1710.

Wagnerova H, Lazurova I, Habalova V, et al. The prevalence of 21-hydroxylase deficiency in adrenal incidentalomas—hormonal and mutation screening. *Exp Clin Endocrinol Diabetes*. 2008;116(5):272–275.

Waingankar N, Bratslavsky G, Jimenez C, et al. Pheochromocytoma in urologic practice. *Eur Urol Focus*. 2015;1–10.

Wajchenberg BL, Albergaria Pereira MA, Medonca BB, et al. Adrenocortical carcinoma. *Cancer*. 2000;88(4):711–736.

Walczak EM, Hammer GD. Regulation of the adrenocortical stem cell niche: implications for disease. *Nat Rev Endocrinol*. 2014;11(1):14–28.

Walther MM, Reiter R, Keiser HR, et al. Clinical and genetic characterization of pheochromocytoma in Von Hippel-Lindau families: comparison with sporadic pheochromocytoma gives insight into natural history of pheochromocytoma. *J Urol*. 1999;162(3):659–664.

Walz MK, Petersenn S, Koch JA, et al. Endoscopic treatment of large primary adrenal tumours. *Br J Surg*. 2005;92(6):719–723.

Walz MK. Extent of adrenalectomy for adrenal neoplasm: cortical sparing (subtotal) versus total adrenalectomy. *Surg Clin North Am*. 2004;84(3):743–753.

Wang W, Hu W, Zhang X, et al. Predictors of successful outcome after adrenalectomy for primary aldosteronism. *Int Surg*. 2012;97(2):104–111.

Wedmid A, Palese M. Diagnosis and treatment of the adrenal cyst. *Curr Urol Rep*. 2010;11(1):44–50.

Weight CJ, Kim SP, Lohse CM, et al. Routine adrenalectomy in patients with locally advanced renal cell cancer does not offer oncologic benefit and places a significant portion of patients at risk for an asynchronous metastasis in a solitary adrenal gland. *Eur Urol*. 2011;60(3):458–464.

Weinke JA, Thompson LD, Heffess CS. Adrenal cortical neoplasms in the pediatric population: a clinicopathologic and immunophenotypic analysis of 83 patients. *Am J Surg Pathol*. 2003;27:867–881.

Weismann D, Fassnacht M, Schubert B, et al. A dangerous liaison—pheochromocytoma in patients with malignant disease. *Ann Surg Oncol*. 2006;13(12):1696–1701.

Weiss LM. Comparative histologic study of 43 metastasizing and nonmetastasizing adrenocortical tumors. *Am J Surg Pathol*. 1984;8(3):163–169.

Welch TJ, Sheedy PF 2nd, Stephens DH, et al. Percutaneous adrenal biopsy: review of a 10-year experience. *Radiology*.

1994;193(2):341–344.

White PC. Disorders of aldosterone biosynthesis and action. *N Engl J Med*. 1994;331(4):250–258.

Williams TA, Lenders JWM, Mulatero P, et al. Outcome of adrenalectomy for unilateral primary aldosteronism: international consensus and remission rates. *Lancet Diabetes Endocrinol*. 2017;5(9):689–699.

Wolley MJ, Stowasser M. New advances in the diagnostic workup of primary aldosteronism. *J Endocr Soc*. 2017;1(3):149–161.

Wood BJ, Abraham J, Hvizda JL, et al. Radiofrequency ablation of adrenal tumors and adrenocortical carcinoma metastases. *Cancer*. 2003;97(3):554–560.

Yanase T, Oki Y, Katabami T, et al. New diagnostic criteria of adrenal subclinical Cushing's syndrome: opinion from the Japan Endocrine Society. *Endocr J*. 2018;65(4):383–393.

Yen R, Wu V, Liu K, et al. 131I-6beta-iodomethyl-19-norcholesterol SPECT/CT for primary aldosteronism patients with inconclusive adrenal venous sampling and CT results. *J Nucl Med*. 2009;50(10):1631–1637.

Yip L, Lee JE, Shapiro SE, et al. Surgical management of hereditary pheochromocytoma. *J Am Coll Surg*. 2004;198(4):525–534.

Yokota N, Bruneau BG, Kuroski de Bold ML, et al. Atrial natriuretic factor significantly contributes to the mineralocorticoid escape phenomenon. Evidence for a guanylate cyclase–mediated pathway. *J Clin Invest*. 1994;94(5):1938–1946.

Young WF Jr, Carney JA, Musa BU, et al. Familial Cushing's syndrome due to primary pigmented nodular adrenocortical disease. Reinvestigation 50 years later. *N Engl J Med*. 1989;321(24):1659–1664.

Young WF Jr, du Plessis H, Thompson GB, et al. The clinical conundrum of corticotropin-independent autonomous cortisol secretion in patients with bilateral adrenal masses. *World J Surg*. 2008;32(5):856–862.

Young WF Jr, Klee GG. Primary aldosteronism. Diagnostic evaluation. *Endocrinol Metab Clin North Am*. 1988;17(2):367–395.

Young WF Jr. Management approaches to adrenal incidentalomas. A view from Rochester, Minnesota. *Endocrinol Metab Clin North Am*. 2000;29(1):159–185 [x].

Young WF, Stanson AW, Thompson GB, et al. Role for adrenal venous sampling in primary aldosteronism. *Surgery*. 2004;136(6):1227–1235.

Young WF, Stanson AW. What are the keys to successful adrenal venous sampling (AVS) in patients with primary aldosteronism? *Clin Endocrinol (Oxf)*. 2009;70(1):14–17.

Young WF. Primary aldosteronism: renaissance of a syndrome. *Clin Endocrinol (Oxf)*. 2007;66(5):607–618.

Young WF Jr. The incidentally discovered adrenal mass. *N Engl J Med*. 2007;356(6):601–610.

Yu R, Nissen NN, Chopra P, et al. Diagnosis and treatment of pheochromocytoma in an academic hospital from 1997 to 2007. *Am J Med*. 2009;122(1):85–95.

Zarnegar R, Bloom AI, Lee J, et al. Is adrenal venous sampling necessary in all patients with hyperaldosteronism before adrenalectomy? *J Vasc Interv Radiol*. 2008;19(1):66–71.

Zendron L, Fehrenbach J, Taverna C, et al. Pitfalls in the diagnosis of phaeochromocytoma. *BMJ*. 2004;328(7440):629–630.

Zheng S, Cherniack AD, Dewal N, et al. Comprehensive pan-genomic characterization of adrenocortical carcinoma. *Cancer Cell*. 2016;29:723–736.

107

Surgery of the Adrenal Glands

Sey Kiat Lim MBBS, MRCS (Edinburgh), MMed (Surgery), FAMS (Urology),
Koon Ho Rha MD, PhD, FACS

Surgery of the adrenal gland is usually performed to control endocrine derangement after failed medical management or to treat malignancies. The first open adrenal surgery was performed in the late 19th century, and over the last century various operative techniques and surgical approaches had been developed and refined. The late 20th and early 21st centuries ushered the entrance of minimally invasive techniques for surgery of the adrenal gland. Although minimally invasive techniques have largely supplanted the open approach, the essential surgical principles of adrenal surgery remain unchanged, and the open approach is still vital in the management of large, invasive adrenal carcinoma. Moreover, all urologic surgeons must be familiar with open techniques in case emergent open conversion is necessary.

The evolution of adrenal surgery continues, and its future is exciting. Virtual reality (VR), computer simulation, and three- or four-dimensional reconstruction techniques, with their incorporation into existing robotic platforms, promise to push adrenal surgery to greater heights. In addition, minimally invasive nonsurgical approaches such as percutaneous ablative techniques may obviate not only scars but also the skills of the surgeon. Nevertheless, it is important that the urologist remain in the treatment team, either as a direct practitioner of the technique or in direct consultation guiding therapy.

Evolution of Adrenal Surgery

The early history of adrenal surgery is obscure because of the confusing nomenclature, the rarity of adrenal neoplasms, the lack of accurate diagnosis, and the ignorance of hormonal presentations associated with adrenal disorders. Indeed, the commonly used term *hypernephroma* was first proposed by Grawitz (1883), who erroneously believed that these neoplasms arose from adrenocortical tissue within the kidney.

Knowsly Thornton was credited with performing the first successful adrenal surgery in 1889 on a 36-year-old hirsute woman with a large abdominal mass (Thornton, 1890). Although Thornton was unaware of the adrenal origin of the patient's tumor, a 20-pound left adrenal malignant tumor was resected en bloc with her left kidney. Despite a difficult postoperative recovery complicated by subphrenic abscesses, she survived 2 years before tumor recurrence. Sargent performed the first planned adrenalectomy in 1914 for a large adrenal adenoma. The first adrenalectomy was performed via a T-shaped subcostal incision, and most of these early adrenal surgeries employed incisions used for renal surgeries. Consequently, these incisions were usually too low for optimal access to the adrenal gland. Therefore surgeons began to site their incisions progressively higher, usually involving resection of the 11th or 12th ribs. In 1927 Charles Mayo performed the first flank adrenalectomy for a tumor from a retroperitoneal nerve, which was subsequently found to be a pheochromocytoma (Mayo, 1927). In 1932 Broster used a transpleural, transdiaphragmatic approach through a long, posterior intercostal incision, providing excellent access for adrenalectomy (Broster et al., 1932).

The anterior approach permits a full exploration of the abdominal cavity and is helpful in surgeries involving large tumors but has associated disadvantages resulting from entry into the peritoneum. Lateral or flank incisions provide excellent access, but bilateral pathology such as Cushing syndrome caused by adrenal hyperplasia requires patient repositioning to access the contralateral side. Young (1936) described a “hockey stick” posterior approach in 1936 to access both adrenal glands simultaneously. Although excellent for resecting smaller bilateral tumors, surgical access was difficult for larger lesions. The thoracoabdominal incision for large retroperitoneal masses was first described by Chute et al. (1949).

The year 1991 marked the beginning of the era of minimally invasive adrenal surgery when Gagner performed the first laparoscopic transperitoneal adrenalectomy (Gagner et al., 1992). In 1992 Gaur developed the first device for balloon dilation of the retroperitoneum, and in 1995 Mercan reported the first case of retroperitoneoscopic adrenalectomy. The first robot-assisted laparoscopic adrenalectomies were reported by Piazza et al. (1999) and Hubens et al. (1999). In recent years, several techniques such as laparoendoscopic single-site (LESS) adrenalectomy and natural orifice transluminal endoscopic surgery (NOTES)–assisted laparoscopic adrenalectomy have moved to the forefront of the quest for smaller incisions or even “scarless” adrenal surgery.

Surgical Anatomy

The adrenal glands are paired retroperitoneal organs situated within the Gerota fascia, residing on the superomedial aspect of each kidney. The adrenal cortex can be readily differentiated from the surrounding adipose tissue by its characteristic bright chrome yellow color with a finely granular surface and firm consistency.

The right adrenal gland is pyramidal and is usually more cephalad than the left. It is bordered by the bare area of the right lobe of the liver anteriorly, the vena cava medially, the duodenum anteromedially, the diaphragm and pleura posteriorly, and the upper pole of right kidney inferiorly (Fig. 107.1). Unlike the left adrenal gland, the right is often fixed in its position and does not move down when the kidney is retracted downward. The right adrenal gland derives its arterial supply through the superior, middle, and inferior adrenal arteries from the inferior phrenic artery, the abdominal aorta, and the renal artery, respectively. The right adrenal vein takes a short (1-cm) transverse route at an angle of 45 degrees to empty into the posterior segment of the inferior vena cava and is usually not exposed until the adrenal gland is mobilized. **Consequently, meticulous dissection of the right adrenal vein is essential to avoid nicking the inferior vena cava.** The right inferior phrenic vein and aberrant smaller veins found in 5% to 10% of right adrenal glands may drain into the right hepatic or renal vein. These veins should be recognized intraoperatively to avoid accidental ligation of the right renal vein (Fig. 107.2).

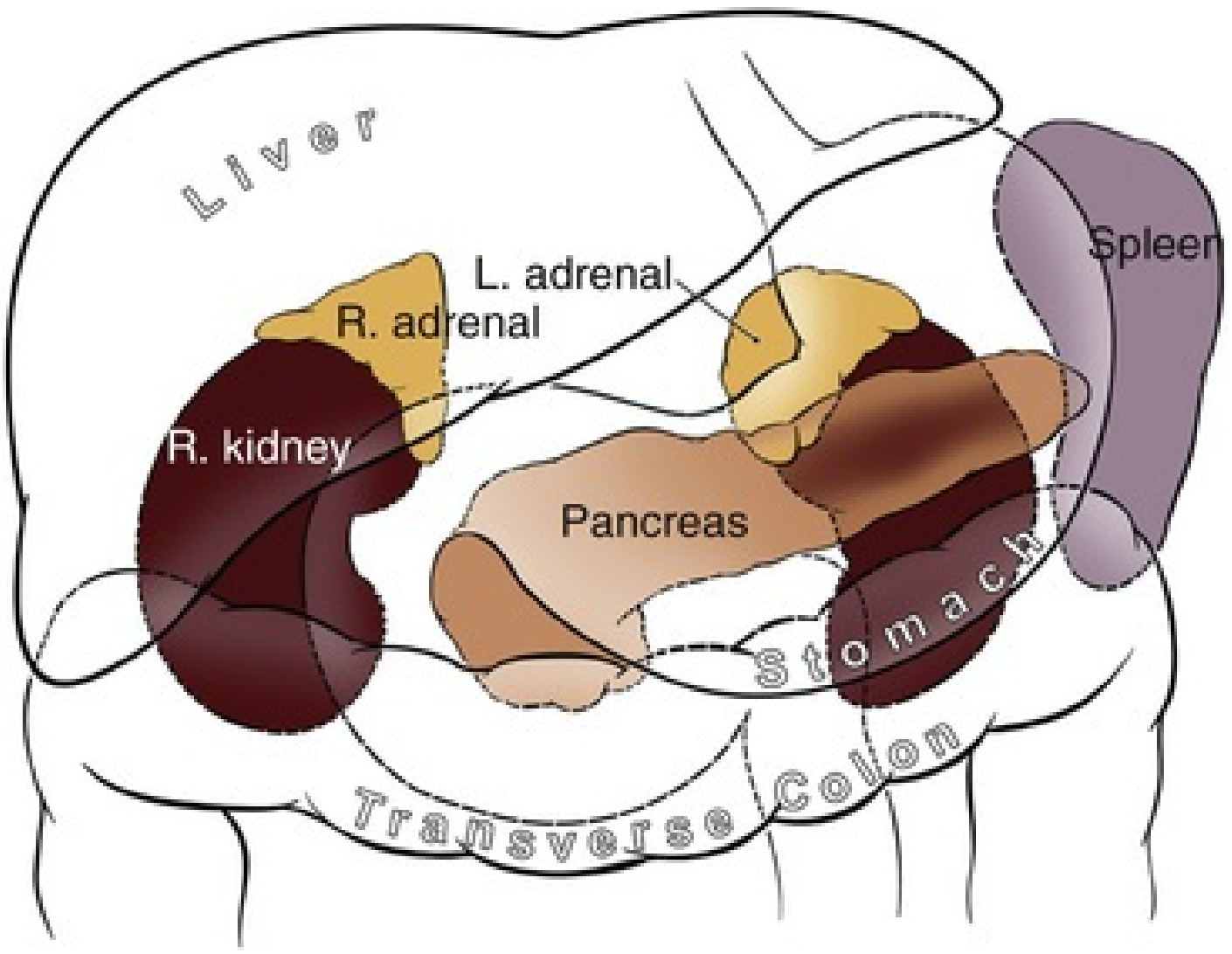
Liver
L. adrenal
R. adrenal
Spleen
R. kidney
Pancreas
Stomach
Transverse Colon

FIG. 107.1 Regional anatomy of adrenal glands. *L,* Left; *R,* right.

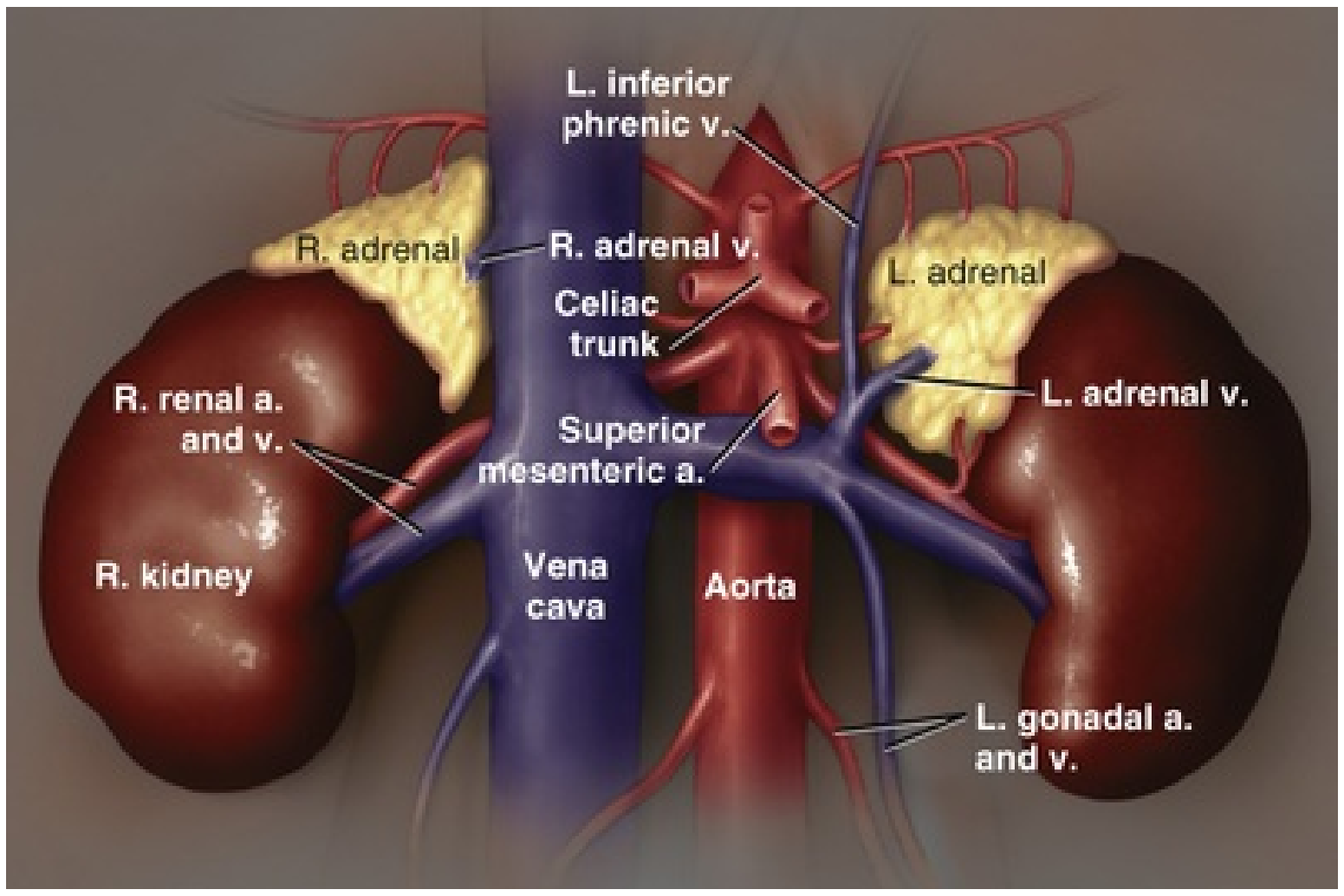
L. inferior phrenic v.
R. adrenal
R. adrenal v.
Celiac trunk
L. adrenal
L. adrenal v.
R. renal a. and v.
Superior mesenteric a.
R. kidney
Vena cava
Aorta
L. gonadal a. and v.

FIG. 107.2 Vascular supply of adrenal glands. *a,* Artery; *L,* left; *R,* right; *v,* vein.

The left adrenal gland is crescentic and is bordered by the abdominal aorta medially, the cardiac part of the stomach and the body of the pancreas anteriorly, the spleen superiorly, the kidney inferiorly, and the diaphragm and pleura posteriorly. The arterial supply of the left adrenal gland is identical to its right counterpart. The left adrenal vein takes a longer course of 2 to 3 cm, passing downward from the lower medial aspect of the gland, receiving the left inferior phrenic vein before draining into the left renal vein. Occasionally, the left adrenal vein empties into the left inferior phrenic vein before entering the left renal vein or courses over the aorta to enter the inferior vena cava directly. The longer course of the left adrenal vein facilitates venous control during left adrenalectomy.

The lymphatic drainage from the adrenal glands empties into the lateral aortic lymph node chain extending from the diaphragm to the ipsilateral renal artery and may end in the thoracic duct or the posterior mediastinal nodes after piercing the crura of the diaphragm.

Clinical Indications for Adrenalectomy

In general, adrenalectomy is indicated in functional adrenal masses or suspected adrenal malignancy (Fig. 107.3**), either primary adrenal cortical carcinoma or solitary metastasis from nonadrenal sources,** the most common being lungs, breasts, kidneys, and skin (melanomas). The indications for adrenalectomy are summarized in Box 107.1.

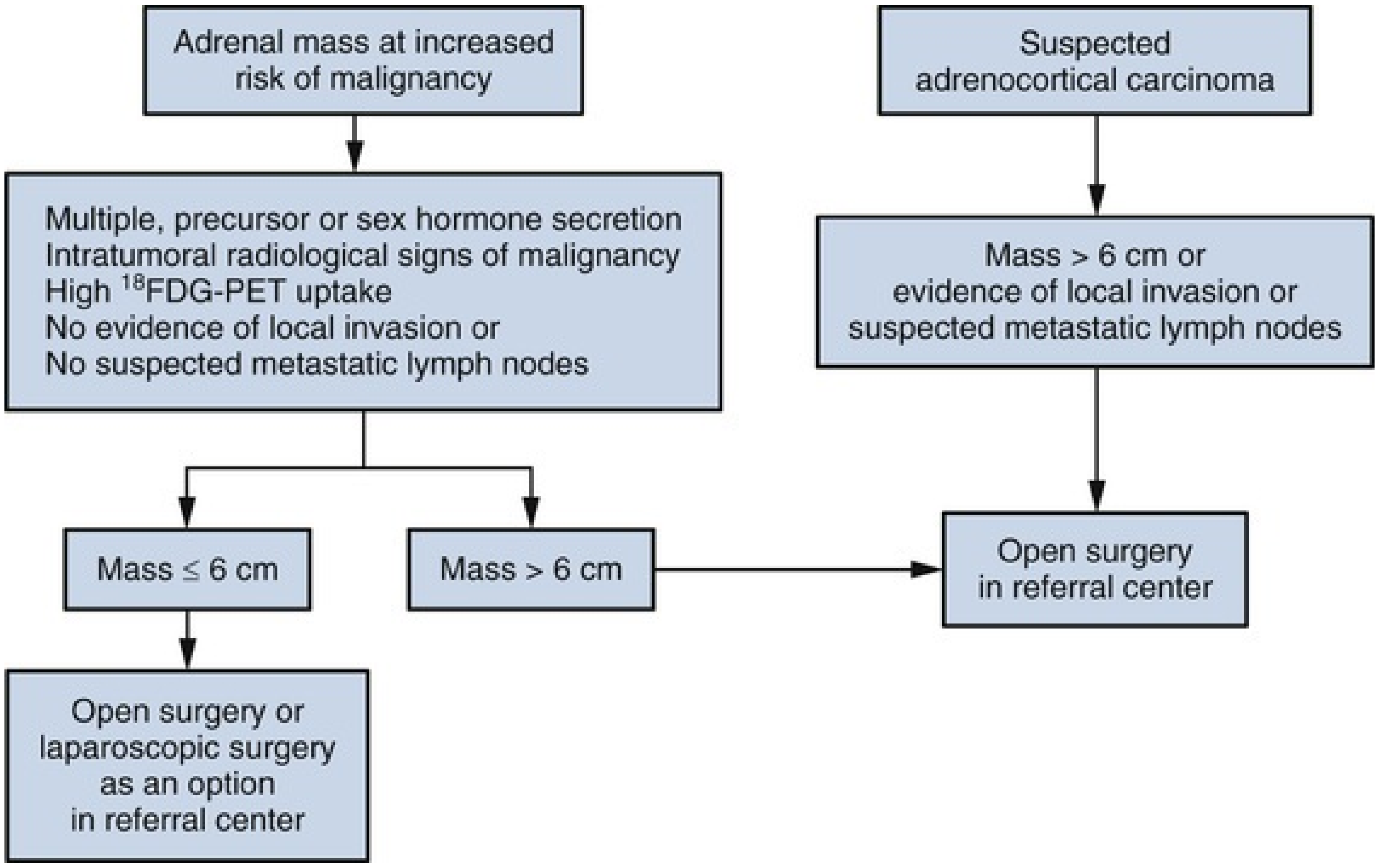
Adrenal mass at increased risk of malignancy
Multiple, precursor or sex hormone secretion
Intratumoral radiological signs of malignancy
High ^{18}FDG-PET uptake
No evidence of local invasion or
No suspected metastatic lymph nodes
Mass ≤ 6 cm
Mass > 6 cm
Open surgery or laparoscopic surgery as an option in referral center
Suspected adrenocortical carcinoma
Mass > 6 cm or evidence of local invasion or suspected metastatic lymph nodes
Open surgery in referral center

FIG. 107.3 Recommended surgical approach for nonmetastatic primary adrenocortical carcinoma. ^{1}*8FDG,* [18F]fluorodeoxyglucose. (From Gaujoux S, Mihai R; Joint Working Group of ESES and ENSAT: European Society of Endocrine Surgeons (ESES) and European Network for the Study of Adrenal Tumours (ENSAT) recommendations for the surgical management of adrenocortical carcinoma, *Br J Surg* 104(4):358–376, 2017.)

Box 107.1

Indications for Adrenalectomy

Functional Adrenal Tumors

Aldosterone-secreting adenomas (Conn syndrome)
Cortisol-secreting adenomas (Cushing syndrome)
Pituitary-dependent Cushing disease unsuccessfully managed by transsphenoidal surgery
Bilateral adrenal hyperplasia
Pheochromocytomas
Adrenal androgens/estrogen-producing tumors causing virilization/feminization

Nonfunctional Adrenal Tumors

Histologically confirmed adrenal cortical carcinoma
Symptomatic adrenal masses such as cysts, myelolipomas
Incidentally discovered adrenal tumors (adrenal incidentalomas)
Size criteria:
- Incidentaloma ≥6 cm
- Incidentaloma between 4 and 6 cm with suspicious features such as irregular margins and heterogenous enhancement
- Incidentaloma <4 cm and enlarging by >20% (in addition to at least a 5-mm increase in maximum diameter)

Radiologic imaging criteria:
- >10 HU in an unenhanced CT scan
- Enhancement washout of <50% and delayed attenuation of >35 HU on contrasted CT
- MRI – chemical shift not consistent with lipid rich adenoma (loss of signal intensity on outphase imaging)
- 18F-FDG-PET showing presence of FDG uptake or uptake more than the liver

Solitary adrenal metastasis from nonadrenal primary

CT, Computed tomography; *HU,* Hounsfield units; *MRI,* magnetic resonance imaging; *18F-FDG PET,* fluorine-18-fluorodeoxyglucose positron emission tomography.

The increased use of abdominal imaging such as ultrasonography or computed tomography (CT) has led to increased diagnosis of incidental adrenal masses. These adrenal “incidentalomas,” defined as any adrenal mass 1 cm or greater in diameter detected on radiologic imaging performed for indications other than primary adrenal disease, are reported in up to 4% of CT scans of the abdomen, with incidence increasing with age (Young, 2007). It is recommended that additional diagnostic workup should be performed only in lesions at least 1 cm in size unless clinical signs and symptoms suggestive of adrenal hormone excess are present. **Besides a functional incidentaloma, the size of an incidentaloma is a major determinant for surgical excision.** Twenty-five percent of adrenal lesions larger than 6 cm are adrenal cortical carcinomas, and these larger lesions should be resected (NIH state-of-the-science statement, 2002). Risk of malignancy in lesions smaller than 4 cm is 2% and, if deemed low risk by imaging criteria, these lesions could be monitored. Approximately 6% of adrenal lesions between 4 and 6 cm are malignant, and most guidelines recommend surgical resection if the lesions show features suspicious of malignancy (AACE-AAES Guidelines, 2009; ACR Incidental Findings Committee, 2010; ESE-ENSAT Guidelines, 2016; National Comprehensive Cancer Network, 2017). Increase in lesion size by more than 20% in addition to at least a 5-mm increase in maximum diameter is another consideration for adrenalectomy (ESE-ENSAT Guidelines).

Indications and Contraindications for Laparoscopic Adrenalectomy

Over the last decade, there has been a slow paradigm shift from open adrenalectomy toward laparoscopic adrenalectomy (Video 107.1) for most adrenal lesions. A growing body of evidence from literature published by major laparoscopic centers around the world indicates that laparoscopic adrenalectomy is replacing open adrenalectomy as the standard of care for surgical management of most adrenal lesions. The indications for laparoscopic adrenalectomy are summarized in Box 107.2.

Box 107.2

Indications and Contraindications for Laparoscopic Adrenalectomy

Indications

Functional adrenal tumors
- Aldosterone-secreting adenoma
- Cortisol-secreting adenoma
- Bilateral adrenal hyperplasia
- Pheochromocytoma

Symptomatic benign adrenal cyst or myelolipoma
Small incidentaloma without clinical or radiologic evidence of malignancy and local invasion

Contraindications

Relative

Large tumor
Localized adrenal cortical carcinoma without evidence of local invasion, adrenal vein, or vena caval involvement or lymph node metastases (>12 cm)
Morbid obesity

- Malignant pheochromocytoma
- Virilizing adrenal tumor (70%–80% of these tumors are actually functional adrenal cortical carcinoma)
- Significant abdominal adhesion
- History of recurrent pyelonephritis
- Pregnancy

Absolute

- Local recurrence of a previously resected adrenal mass
- Invasive adrenal cortical carcinoma with evidence of invasion of neighboring organs or renal vessels or vena caval involvement
- Severe cardiopulmonary disease

Contraindications to laparoscopic adrenalectomy would be indications for open adrenalectomy (see Box 107.2). Although the current indications for open adrenalectomy are few, the choice of open approach over laparoscopic approach is dictated by the surgeon's experience and expertise. A review of the Nationwide Inpatient Sample reported that in the United States, between 1998 to 2006, the majority of adrenalectomies (83%) were still performed using the open approach, which occurred mainly in smaller nonteaching hospitals with an annual case volume of fewer than six cases per year (Murphy et al., 2010). A more recent review on the national trends for adrenalectomy in America reported that of 58,948 adrenalectomies performed between 2002 and 2011, a minimally invasive approach was used in 20% of these operations, and there was a 4% increase in minimally invasive adrenalectomy throughout the study period (Monn et al., 2015).

Absolute contraindications to adrenalectomy include extensive metastatic disease, uncorrected coagulopathy, and severe cardiopulmonary disease that precludes anesthesia.

Past Surgical and Medical History

Previous abdominal surgeries may lead to intra-abdominal adhesions and scarring, which may render the laparoscopic approach difficult if not impossible. Siddiqui et al. (2010) reported an overall adhesiolysis rate of about 23% after any previous abdominal surgeries. However, this problem may be circumvented by modifying the laparoscopic approach according to the patient's past surgical history. A retroperitoneal laparoscopic approach may be ideal in a patient with history of transperitoneal surgery, whereas a transperitoneal laparoscopic approach may be the approach of choice in a patient with a previous flank, retroperitoneal surgery. Furthermore, Gill et al. (2001) have demonstrated the feasibility of a transthoracic laparoscopic approach that involves entering the thoracic cavity thoracoscopically and incising the diaphragm to approach the adrenal superiorly.

Conventionally, laparoscopic surgeries required the establishment of pneumoperitoneum that may lead to hemodynamic, metabolic, and neurologic adverse effects in patients with significant cardiopulmonary and neurologic diseases. Contraindications to establishment of pneumoperitoneum include patients with severe cardiac insufficiency, advanced chronic obstructive bronchitis, renal function insufficiency, acute glaucoma, recurrent spontaneous pneumothorax, vascular endocranial malformation, and hypertensive retinopathy. As surgeons gain more experience in laparoscopy and the introduction of specialized laparoscopic access ports, allowing maintenance of constant low pneumoperitoneal pressure of less than 7 mm Hg, mild to moderate cardiovascular disease could be considered a relative contraindication to laparoscopy, especially when laparoscopic adrenalectomy is performed with low pressure pneumoperitoneum, short operative time, and extraperitoneal approaches. Giraudo et al. (2009) have even described a gasless technique that made it possible for such patients to undergo laparoscopic adrenalectomy instead of the open approach.

Tumor Size

Large tumor size is considered a relative contraindication to laparoscopic adrenalectomy. A larger size increases the chance that the tumor is malignant and distorts the regional anatomy, making laparoscopic resection more difficult. Although most laparoscopic surgeons are comfortable with tumor sizes of up to 6 to 7 cm, there is no clear upper limit to the size at which the laparoscopic approach would be contraindicated. However, available literature seems to suggest an arbitrary upper limit of about 10 to 12 cm in diameter (Henry et al., 2002; MacGillivray et al., 2002; Zografos et al., 2010). The studies by MacGillivray et al. (2002) and Zografos et al. (2010) showed no difference in short-term morbidity in patients with larger tumor sizes (≥6 to 8 cm) compared with those with smaller tumors. CT can underestimate the size of adrenal tumors by as much as 12% to 23% compared with actual size determined by pathological examination (Lau et al., 1999).

In contrast, Hobart et al. (2000) noted increased operative time, blood loss, complication rates, and open conversion rates in larger tumors removed laparoscopically (mean 8 cm vs. 2.2 cm). However, they reported that operative time, blood loss, hospital stay, and complication rates were lower with laparoscopic adrenalectomy compared with open surgery. More recently, Bittner et al. (2013) reported similar findings in favor of laparoscopic adrenalectomy over the open approach in a larger cohort. Hence rather than an absolute size cutoff for laparoscopic adrenalectomy, it is mandatory to consider that surgeon experience, hospital volume, and a multidisciplinary approach to patients, which comprises surgeons, anesthesiologists, and endocrinologists, are three important parameters in the selection of patients.

Conversion to open surgery has been found to be associated with size of tumor and infiltrative adrenal cortical carcinoma. MacGillivray et al. (2002) concluded that preoperative CT scanning can identify those infiltrative tumors likely to be invasive carcinoma. Bittner et al. (2013) found that a tumor size of greater than 8 cm increases the risk of open conversion during laparoscopic adrenalectomy significantly (by 14 times). Maurice et al. (2017) noted a higher risk of positive surgical margins in adrenocortical carcinomas more than 10 cm or pT3 diseases in favor of open adrenalectomy over minimally invasive approaches.

Adrenal Cortical Carcinoma

Laparoscopic adrenalectomy in adrenal cortical carcinoma is currently controversial. In a consensus statement from the Third International Adrenal Cancer Symposium, the oncologic principles for resection of adrenal cortical carcinoma were outlined as summarized in Box 107.3 (Porpiglia et al., 2011). Strict adherence to these principles of resection is difficult during laparoscopic adrenalectomy, and thus the open approach seems to be the technique of choice. The thin tumor capsule is prone to rupture during inevitable manipulation of tumor during dissection, resulting in tumor spillage and subsequent recurrence. Furthermore, en bloc dissection of the retroperitoneal fat around the tumor is more difficult using laparoscopic techniques. However, this is often necessary because microscopic tumor extension cannot be accurately identified pre- and intraoperatively, and there are currently no effective adjuvant treatments if margins are positive. Reibetanz et al. (2012) showed that adrenal cortical carcinoma was associated with a 73% lymph node invasion rate and suggested that resection with clearing of at least 5 lymph nodes was associated with a reduction in the risk of local recurrence and cancer-specific mortality. A lymph node dissection should include at least the periadrenal fat, perirenal fat, and renal hilum. It is currently still controversial if there is value to a latero-aortic and inter-aorto-caval nodal dissection.

Box 107.3

Oncologic Principles of Resection for Adrenal Cortical Carcinoma

1. No touch technique
2. Preservation of the intact peritoneum on the anterior surface of the adrenal gland if no evidence of invasion through the overlying peritoneal layer
3. En bloc resection of tumor with a wide margin of surrounding benign tissue outside the tumor capsule
4. Strict preservation of an intact tumor capsule
5. Exclusion of the remainder of the peritoneal cavity as much as possible using barriers such as laparotomy pads, plastic barriers, or drapes
6. Minimizing of bleeding and fluid spillage into the peritoneal cavity
7. Extraction of specimen in a bag
8. Change of gloves, gowns, and instruments after removal of the tumor and before closure of the abdomen

Modified from Porpiglia F, Miller BS, Manfredi M, et al.: A debate on laparoscopic versus open adrenalectomy for adrenocortical carcinoma. *Horm Cancer* 2:372–377, 2011.

To determine whether the surgical approach for adrenal cortical carcinoma is a risk factor for peritoneal carcinomatosis, Leboulleux et al. (2010) reviewed 64 patients with stages I to IV disease with a median follow-up of 35 months. Of these, 58 patients underwent open adrenalectomy and 6 underwent laparoscopic adrenalectomy. The 4-year rate of peritoneal carcinomatosis was 67% for laparoscopic adrenalectomy and 27% for the open approach, with surgical approach being identified as the only risk factor. Data reported from the MD Anderson Cancer Center in 2005 showed similar outcomes with regard to increased risk of peritoneal carcinomatosis after laparoscopic adrenalectomy (Gonzalez et al., 2005). Miller et al. (2010) demonstrated in a retrospective review that 17 patients who underwent laparoscopic adrenalectomy showed significantly faster local recurrence time and higher rates of tumor spillage and positive surgical margins when compared with 71 patients who underwent open adrenalectomy. Although the local and overall recurrence rates were similar in both groups, they concluded that laparoscopic resection should not be attempted in patients with tumors suspicious for or known to be adrenal cortical carcinoma. More recently, a meta-analysis comprising nine studies published between 2010 and 2014 reported a higher risk of peritoneal carcinomatosis associated with laparoscopic adrenalectomy, although there were no statistical differences in overall recurrence, time to recurrence, and cancer-specific mortality when compared with open adrenalectomy (Autorino et al., 2016).

In contrast, a study from the German Adrenocortical Carcinoma Registry Group comparing 117 patients undergoing open adrenalectomy and 35 patients undergoing laparoscopic adrenalectomy for stages I to III adrenal cortical carcinoma showed no significant difference in disease-specific and recurrence-free survivals, tumor capsule violation, and peritoneal carcinomatosis (Brix et al., 2010). However, this study was limited by having more patients with higher-stage tumors in the open adrenalectomy group, short follow-up duration, and incomplete data, especially on resection margin status. Similarly, a recent multi-institutional study of 201 patients with adrenal cortical carcinoma reported no difference in 30-day mortality, intraoperative tumor rupture rates, and R0 resection rates between the minimally invasive approach and open approach (Lee et al., 2017). However, in this study, the median tumor size was 5.5 cm in the minimally invasive group compared with 10.9 cm in the open group. Porpiglia et al. (2010) concluded that open and laparoscopic adrenalectomy may be comparable in terms of recurrence-free survival for patients with stages I and II adrenal cortical carcinoma based on a retrospective analysis of 43 patients. A major limitation of this study was that patients who had macroscopically incomplete resection, tumor capsule violation, open conversion from laparoscopic approach, and microscopic periadrenal fat invasion on postoperative pathological examination were excluded, introducing significant selection bias. In addition, the follow-up period of less than 1 year in some patients is relatively short for diagnosis of tumor recurrence. Indeed, a recent review by the European Society of Endocrinology concluded that there were no differences in perioperative mortality or morbidity, completeness of resection, and recurrence-free and overall survival rates between open and minimally invasive adrenalectomy (Fassnacht et al., 2016).

There is currently no consensus opinion on the role of laparoscopic adrenalectomy in adrenal cortical carcinoma. The 2017 National Comprehensive Cancer Network (NCCN) and AACE-AAES (2009) guidelines recommended open adrenalectomy for adrenal cortical carcinoma. The Third International Adrenal Cancer Symposium (Porpiglia et al., 2011) suggested that laparoscopic adrenalectomy can be considered in small incidentalomas, indeterminate large incidentalomas without necrosis or evidence of invasion, and small adrenal cortical carcinoma only if surgery is limited to referral centers with at least 20 cases of laparoscopic adrenalectomy per year and oncologic principles are adhered to, with avoidance of tumor violation and extraction of tumor without fragmentation. Similarly, a recent joint guideline (2017) European Society of Endocrinology (ESE), European Society of Endocrine Surgeons (ESES), and European Network for the Study of Adrenal Tumours (ENSAT) suggested that **the laparoscopic approach for a suspected malignant adrenal mass with a diameter of less than 6 cm (ENSAT stage I or II) without evidence of local invasion or suspected metastatic lymph nodes, as an option, should be restricted to high-volume centers. If a laparoscopic approach is used, the transperitoneal approach in the flank position may be preferable.**

Preoperative and Perioperative Management

In general, preoperative management for adrenal surgery is similar to most general abdominal surgeries. Preoperative anesthetic consultation and optimization of the patient's medical conditions are essential. Mechanical bowel preparation and orogastric/nasogastric tube insertion are recommended in open or laparoscopic transperitoneal surgery and are optional for retroperitoneal approaches. The placement of a urinary catheter before surgery is helpful to measure urine output and to decompress the bladder. For functional tumors, special considerations are required (Box 107.4).

Box 107.4

Preparation of Patients for Adrenal Surgery

Primary Aldosteronism

Magnesium and potassium repletion
Normalization of intravascular fluid status
Blood pressure control
Stress dose of cortisol

Cushing Syndrome

Inhibition of glucocorticoid production with metyrapone when there is severe manifestation
Control of diabetes
Preoperative antibiotics
Cardiopulmonary workup
Operative steroid administration

Incidentalomas

Anesthetic preparation for pheochromocytoma; 5% have normal

diagnostic studies
Full endocrinology workup

Adrenal Carcinoma

Consent for adjacent organ removal
Failure to identify vena cava involvement

Pheochromocytoma

Preoperative catecholamine blockade
Consider beta-blockers if necessary
Volume expansion
Anesthetic consultation

Modified from Vaughn ED: Complications of adrenal surgery. In Taneja SS, Smith RB, Ehrlich RM, editors: *Complications of urologic surgery: prevention and management*, ed 3, Philadelphia, 2001, Saunders, p 363.

Pheochromocytoma

Excessive secretion of catecholamines from chromaffin tissue may result in tachycardia, diaphoresis, headache, hypertension, cardiac arrhythmias, left ventricular dysfunction, and impaired glucose tolerance. Preoperative cardiac workup, including electrocardiography and echocardiography, and assessment of hypertension-induced end-organ dysfunction are indicated. Preoperative sympatholytic therapy with α-adrenergic blockers for at least 2 weeks before surgery helps in hemodynamic and glucose control and should be continued until the day of surgery. Phenoxybenzamine is time proven to be safe and effective but has its associated problems. Its nonselective nature may lead to rebound tachycardia and β-adrenergic blockade may be necessary. Being an irreversible noncompetitive α-adrenergic blocker, prolonged hypotension in the immediate postoperative period and central nervous system effects such as somnolence may be expected. Newer selective and competitive α_1-adrenergic blockers such as doxazosin, prazosin, and terazosin are associated with less rebound tachycardia and less systemic side effects. **β-Adrenergic blockade, if needed, must be given with caution in patients with myocardial depression and started only**

after phenoxybenzamine therapy (generally 3 to 4 days after).

Intraoperatively, hypertensive episodes should be anticipated and can be controlled with intravenous drugs with rapid onset and short half-life, such as nitroprusside, phentolamine, nitroglycerin, and nicardipine. Temporary cessation of surgical manipulation of the pheochromocytoma may be necessary. Short-acting beta-blockers such as labetalol and esmolol are also good choices. Aggressive fluid management with volume repletion is necessary after removal of pheochromocytoma because hypotension can occur as a result of sudden loss of tonic vasoconstriction.

Postoperatively, fluid administration and use of vasopressors such as phenylephrine, guided by invasive monitoring, are useful to manage hypotension. Electrolyte abnormalities and hypoglycemia should be corrected. It is not uncommon for patients to remain hypertensive postoperatively, and antihypertensive management may have to be continued.

Conn Syndrome

Primary hyperaldosteronism can lead to electrolyte and acid-base disturbances such as hypokalemia, and alkalosis; fluid depletion or retention; refractory hypertension; and cardiac dysfunction and arrhythmias. Hypertension and hypokalemia should be corrected preoperatively, and this may occasionally require an aldosterone antagonist (spironolactone) (Funder et al., 2016; Winship et al., 1999). If concomitant excess cortisol production is diagnosed (subclinical Cushing syndrome), a stress dose of cortisol should be considered preoperatively and continued for 24 hours before reassessing the need for further doses.

Postoperatively, monitoring of electrolytes should be continued regularly because rebound hyperkalemia may occur up to 1 month after surgery. Persistent hypertension requires pharmacologic treatment with conventional antihypertensive medications.

Cushing Syndrome

Hypercortisolism can lead to numerous complications such as obesity, hypertension, diabetes, myopathy, hypokalemia, fluid retention, venous thromboembolic events, and cardiac dysfunction. Hence risk of perioperative complications may be high, depending on the degree of hypercortisolism. Obesity is associated with obstructive sleep apnea and may result in airway and ventilatory problems during anesthesia. Myopathy and intestinal motility abnormalities can result in postoperative respiratory problems and aspiration pneumonia. Preoperative anesthetic and cardiopulmonary consultations should be sought. Preoperative optimization of fluid status, blood pressure, and glucose control and correction of electrolyte abnormalities are necessary. Prophylactic antithrombotic therapy should be considered. Use of inhibitors of steroid production such as ketoconazole or metyrapone may be considered. Proton pump inhibitors and prokinetics such as metoclopramide can be considered to reduce risk of aspiration.

Postoperatively, patients must be monitored for respiratory depression. Epidural analgesia is recommended to minimize use of systemic opiate analgesia, which can lead to respiratory depression. Breathing exercises should be initiated early, and nonsteroidal analgesics can be considered. In all patients, steroid replacement therapy should be initiated at the time of tumor resection and continued postoperatively because the patients will be adrenal insufficient until recovery of the contralateral adrenal gland. Cardiovascular instability and electrolyte abnormalities may occur, and patients should be closely monitored.

Open Adrenalectomy

Open adrenalectomy can be broadly classified into transperitoneal and retroperitoneal approaches. Transperitoneal approaches include the anterior transabdominal and thoracoabdominal approaches, in which the main advantages lie in excellent surgical exposure and better access to the hilum and great vessels, at the expense of higher risk of intra-abdominal organ injury and ileus. Retroperitoneal approaches include the flank and posterior lumbodorsal approaches, which result in a smaller operative field but are associated with less ileus and shorter hospitalization. In addition, the retroperitoneal approach is ideal for the morbidly obese patient in whom the abdominal panniculus will fall forward in a flank or prone position.

Flank Retroperitoneal Approach

Positioning

The patient is placed in the lateral decubitus position with the side with adrenal pathology up. The table is flexed at the level of the costal margin, and a kidney rest is employed to maximize the distance between the costal margin and the iliac crest. An axillary roll is placed under the axilla with the arm closest to the table extended secured on an armboard and the upper arm slightly flexed at the elbow and placed on an elevated arm rest. The lower leg is flexed and the upper leg straight with pillows placed between them. All bony prominences are padded and the patient is secured to the operating table.

Incision

The course of the 11th rib is palpated, and the incision is made along the rib as shown in Fig. 107.4. The latissimus dorsi, external and internal oblique, and transversus abdominis muscles overlying the rib are divided until the anterior surface of the rib is exposed (Fig. 107.5).

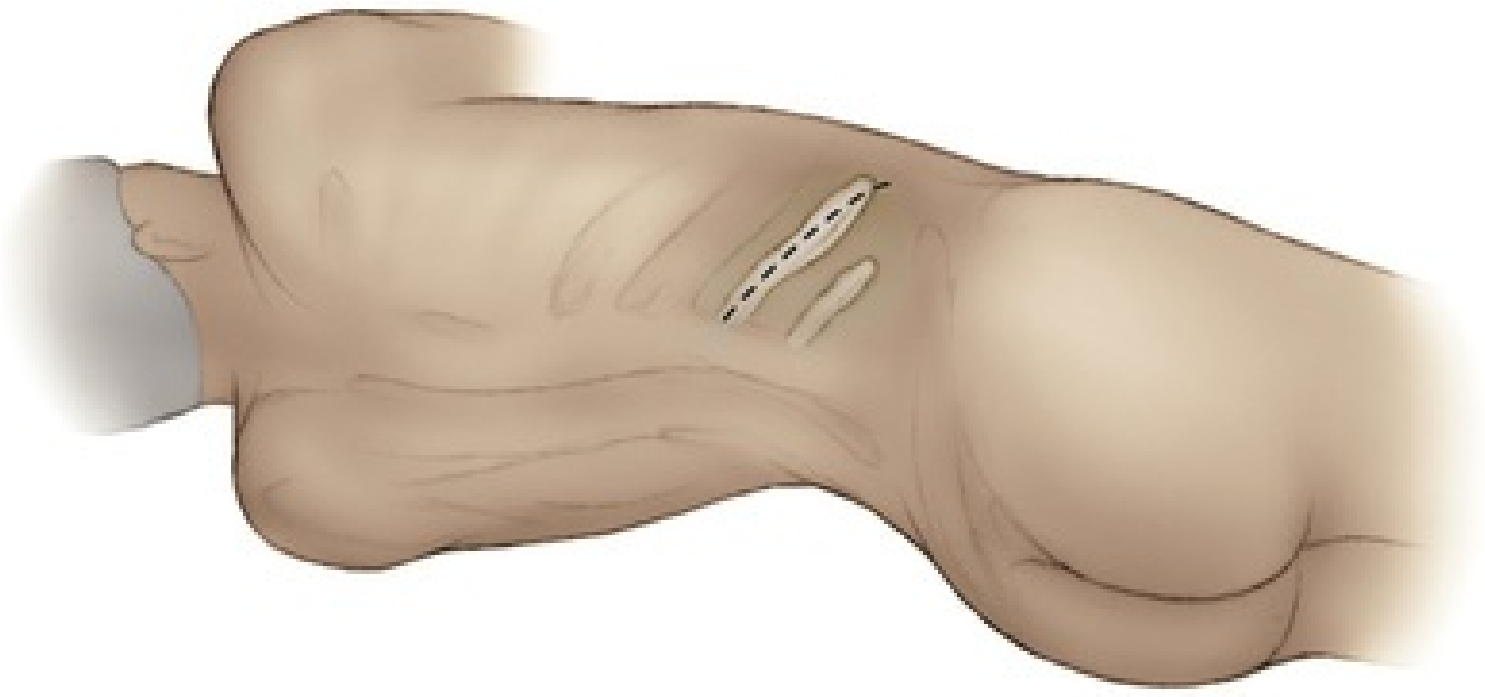

FIG. 107.4 Surgical incision over 11th rib for flank adrenalectomy. The patient is in flexion, with the kidney rest deployed to maximally expose the right retroperitoneum.

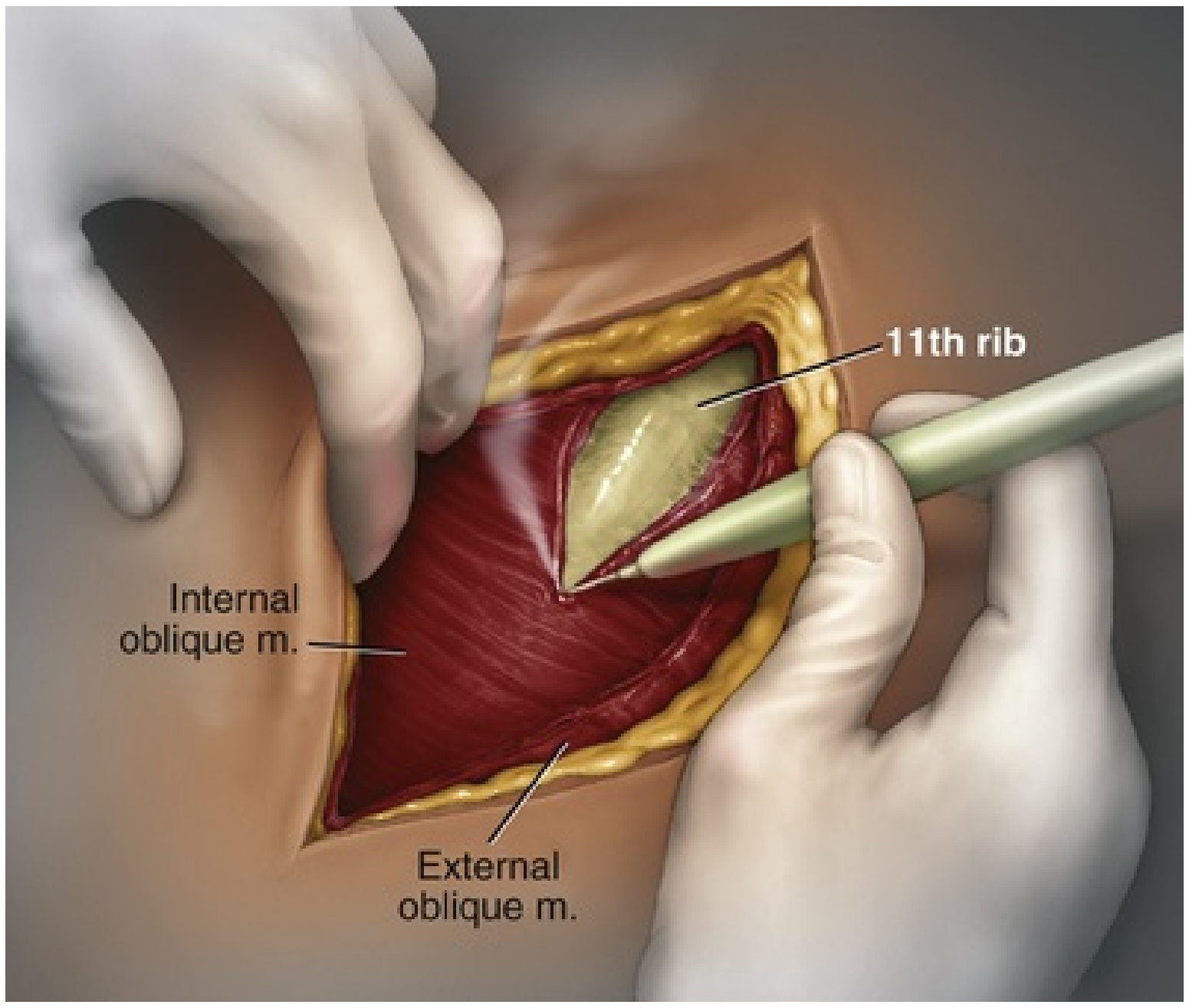

FIG. 107.5 Flank approach. Incision of muscle overlying 11th rib.

11th Rib Excision

The anterior periosteum of the rib is scraped off using the periosteal elevator, and the periosteum on the superior and inferior aspects of the rib is visualized. The periosteum posterior to the rib can be scraped off in a similar manner with the periosteal elevator, taking care not to injure the neurovascular bundle that runs along the inferior aspect of the rib. After stripping the periosteum from the tip of the rib back to the paraspinal muscles, the surgeon cuts the 11th rib with the rib cutter (Fig. 107.6). The rib stump is then smoothed with a rongeur, and hemostasis is secured with the aid of cautery or bone wax. The neurovascular bundle is then freed athermally to avoid injury during subsequent dissection and closure (Fig. 107.7).

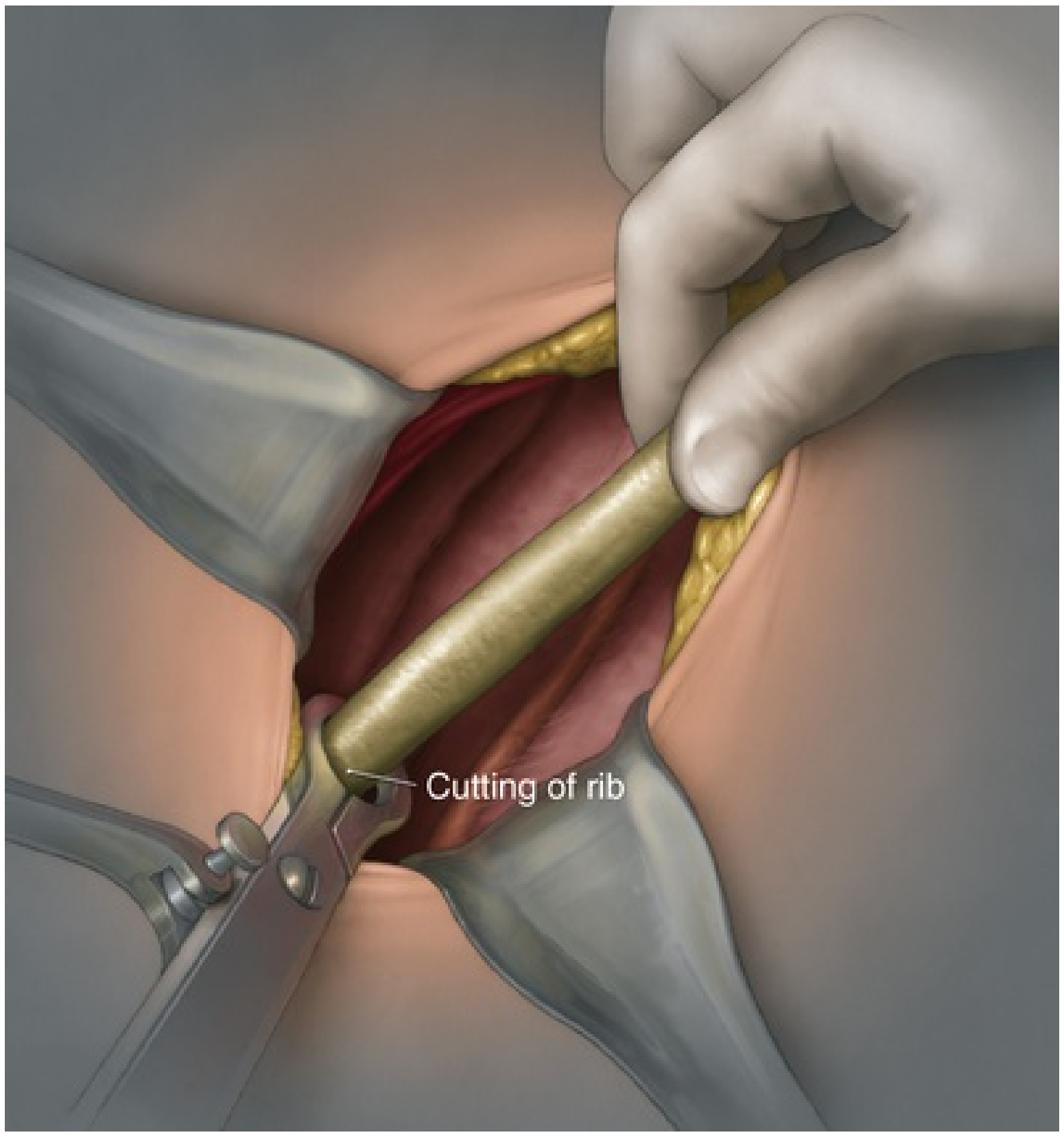

FIG. 107.6 Flank approach. Excision of 11th rib.

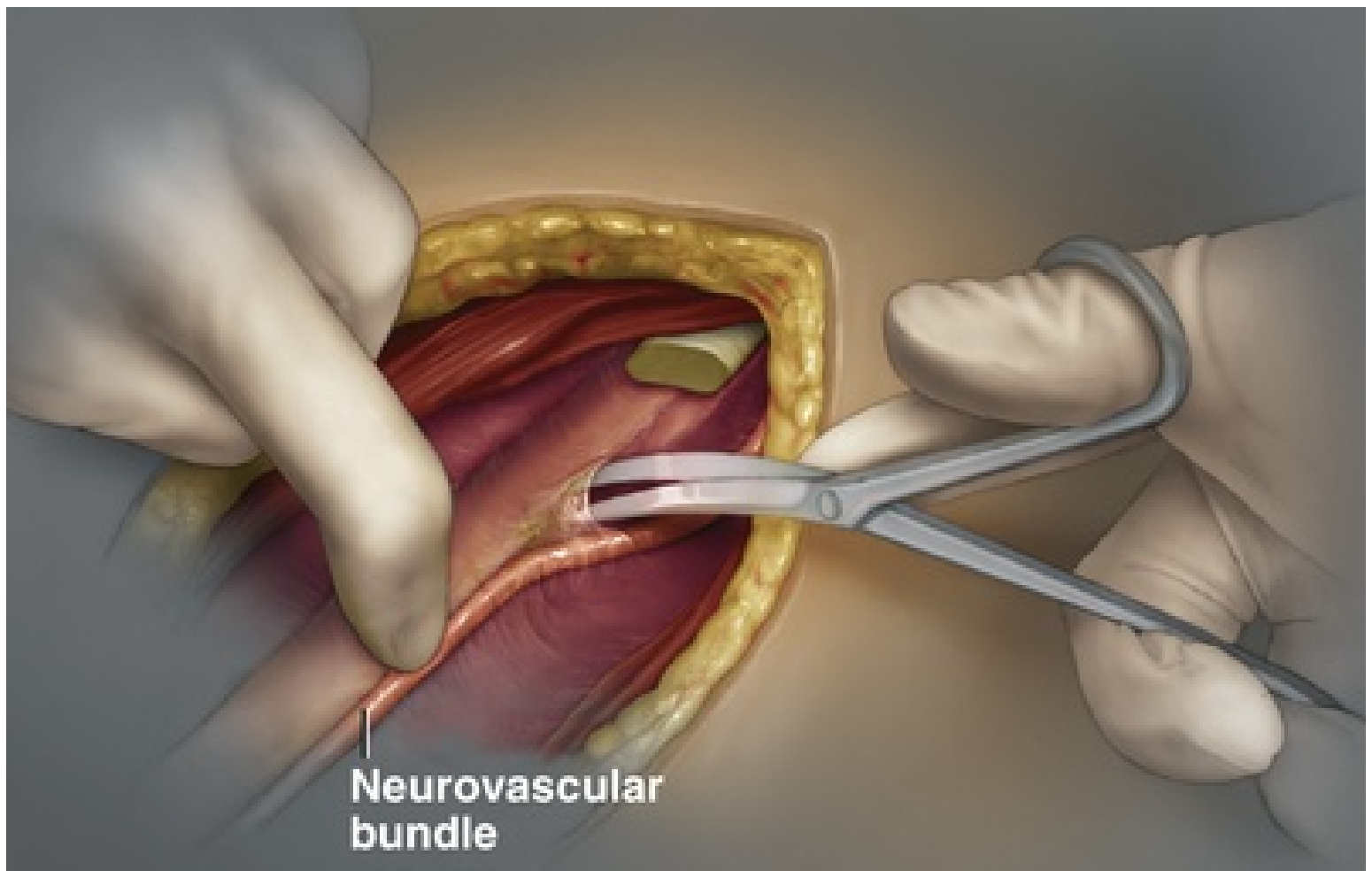

FIG. 107.7 Flank approach. Mobilization of the intercostal neurovascular bundle from the 11th rib. This is performed with a combination of blunt dissection with a Kittner dissector and sharp dissection with Metzenbaum scissors.

Creating the Retroperitoneal Space

The lumbodorsal fascia is entered and blunt dissection is used to dissect the peritoneum off the transverse fascia anteriorly. The muscles are divided and the plane between the Gerota fascia and the peritoneum is identified. This plane is then maximally developed with blunt dissection, reflecting the peritoneum anteromedially. A plane between the diaphragm and retroperitoneum is then developed, facilitating entry into the retroperitoneal space. Once the peritoneum is fully mobilized, the vena cava or aorta can be visualized. Further cephalad dissection will expose the adrenal gland and renal vein. Self-retaining retractors can be placed at this point with maximal exposure.

Dissection of Adrenal Gland

On the right side, dissection typically starts with the division of the peritoneal layer overlying the vena cava, along the medial border of the gland. The plane between the medial surface of the adrenal gland and the lateral vena cava is then bluntly dissected to expose the adrenal vein. The adrenal vein is then isolated with the aid of a right-angle instrument such as a Mixter forceps. The adrenal vein can then be ligated between silk ties or surgical clips. In the event of accidental avulsion of the vein resulting in hemorrhage from the vena cava, vascular control of the vena cava proximal and distal to the tear by vessel clamps or sponged forceps can be applied. The tear can then be repaired in the usual manner with 4-0 or 5-0 Prolene sutures (Ethicon, Cincinnati, OH).

The adrenal gland can then be dissected out starting with its superior attachments. Care must be taken to handle the friable adrenal gland via its surrounding adventitia to avoid tissue spillage, seeding, or autotransplantation. Actual arterial branches to the gland usually are not identified but can be safely cauterized during dissection of the gland. Clips or surgical ties should be employed if any vessels are identified. Inferomedial attachments to the kidney are then taken with sharp dissection or cautery, and the freed adrenal gland is removed from the surgical field. Dissection of the left adrenal gland is similar except that the aorta is encountered and the left adrenal vein runs a longer course, typically originating from the renal vein.

Closure

After ensuring good hemostasis of the adrenal bed, the surgeon closes the incision in two layers with a running looped polydioxanone suture. The deeper layer consists of the transverse abdominal and internal oblique muscles and fascia, and the outer layer consists of the external oblique muscle and fascia. Skin closure can be completed with staplers or absorbable/nonabsorbable sutures.

Posterior Lumbodorsal Approach

The posterior approach is the most direct route to the adrenal glands and no major muscles are divided, thus reducing dissection required to expose the adrenal glands. The prone position allows for ready access to both adrenal glands through two separate incisions. However, surgical exposure is limited; therefore surgery is usually reserved for smaller tumors or bilateral adrenal hyperplasia. In addition, access to the adrenal vein and great vessels is more difficult, which may be problematic in the event of excessive intraoperative bleeding. Finally, the prone position increases ventilatory difficulties. **This approach should not be used for large tumors or adrenal cortical carcinoma.**

Positioning

The patient is positioned in a prone position after intubation, with the operating table flexed at the level of the 12th rib. Pillows are placed under the abdomen and lower limbs, and care is taken to avoid compression on the eyes in the prone position.

Incision and Rib Excision

Incisions can be made along the course of the 11th or 12th rib, or a hockey-stick incision made about 5 cm lateral to the midline of the vertebral column, progressing downward and outward in a curvilinear fashion at the level of 10th rib, extending over or slightly below the 12th rib toward the iliac crest (Fig. 107.8). The technique of 12th rib excision on the right side is as follows. After the skin incision, division of the subcutaneous tissue and the latissimus dorsi and sacrospinalis muscles in layers exposes the 12th rib. The sacrospinalis is retracted medially and its attachment to the 12th rib is divided. Sequential division of the lumbodorsal fascia and then the posterior subcostal ligament releases the pleura from the 12th rib. The pleura dips below the 12th rib in the region of the costovertebral angle and may be perforated if the rib is elevated near the vertebral column. The 12th rib is then excised in a fashion similar to that described in the earlier section on the flank retroperitoneal approach, with careful preservation of the neurovascular bundle. The 11th rib is then retracted upward to expose the retroperitoneum. If a bilateral procedure is undertaken, a Finochietto retractor can be used to assist in bilateral exposure (Fig. 107.9).

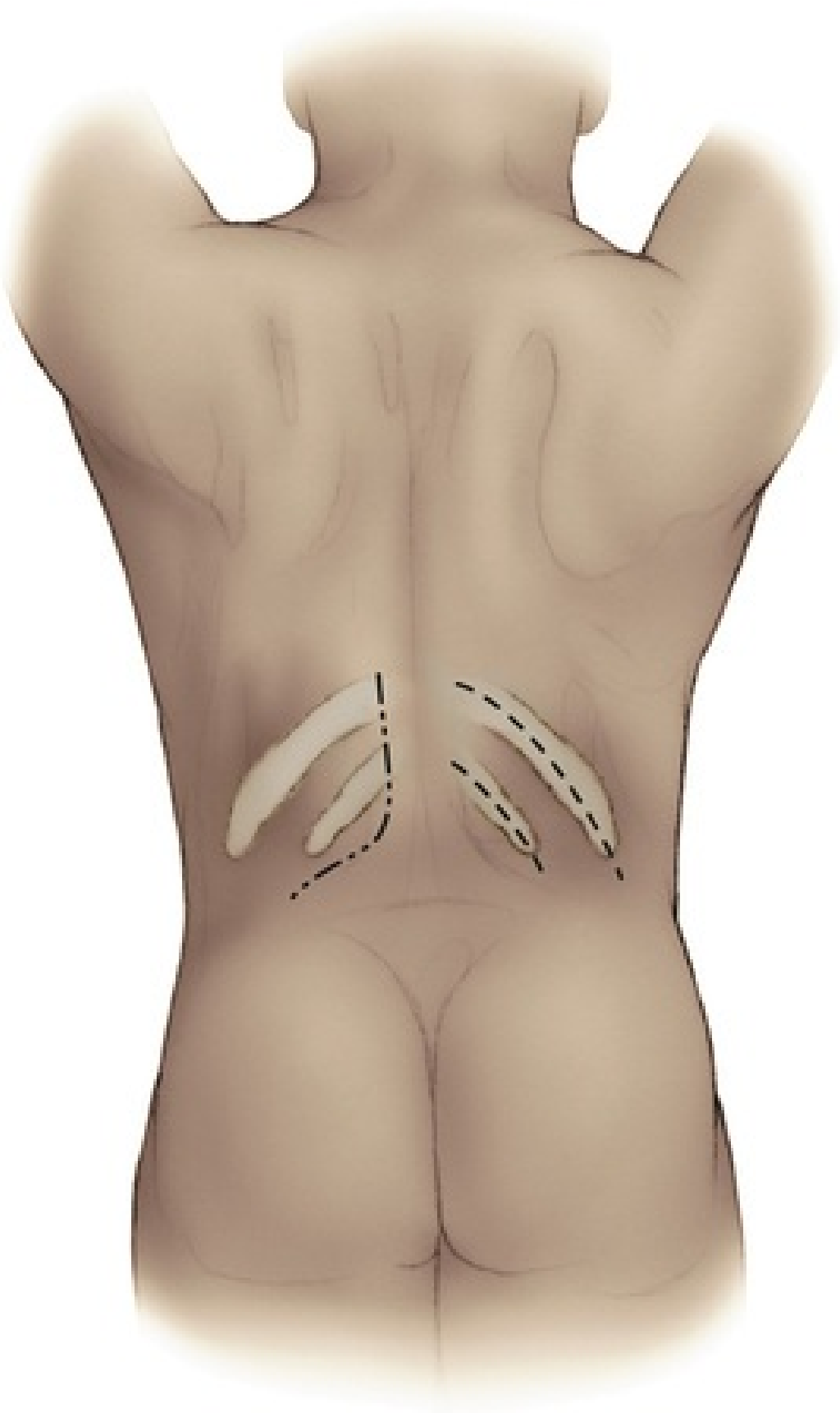

FIG. 107.8 Posterior approach—possible locations for lumbodorsal incisions.

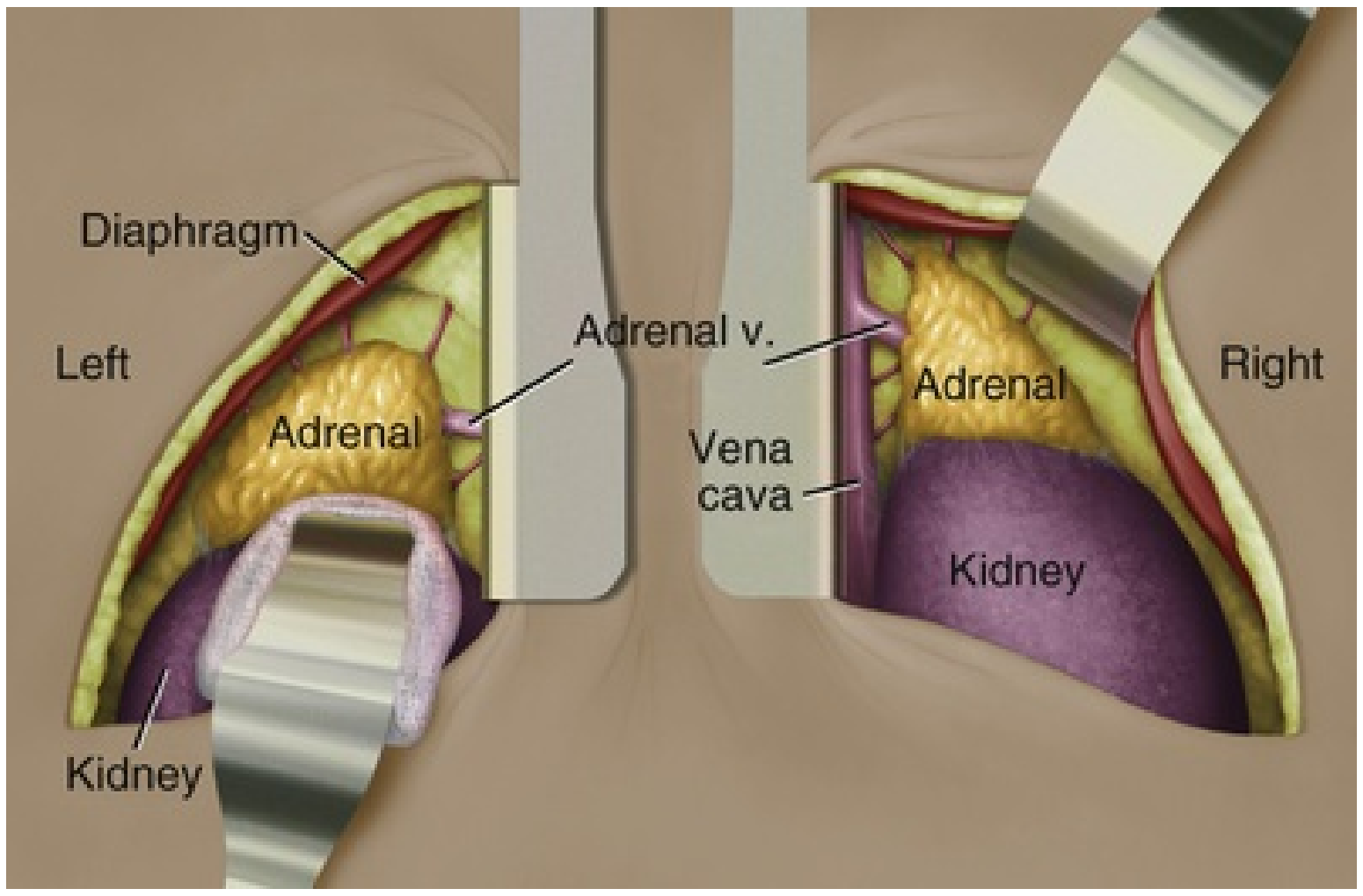
Diaphragm
Left
Adrenal
Kidney
Adrenal v.
Vena cava
Adrenal
Kidney
Right

FIG. 107.9 Bilateral posterior approach—anatomic relations to the adrenal gland as seen from behind. *v,* Vein.

Dissection of Adrenal Gland

With division of the final hepatic attachments, the adrenal gland and the vena cava are visualized. The right adrenal vein is identified at its posterolateral origin and ligated between clips or ties. The arterial branches are then ligated, and the adrenal gland is mobilized posteriorly away from the paraspinal muscles and dissected out, starting superiorly and progressing caudally.

Anterior Transabdominal Approach

The anterior transabdominal approach is indicated in cases of large or potentially malignant tumors for which adequate exposure for extensive dissection is needed. It is also mandatory in cases of inferior vena caval or extensive nodal involvement. The anterior transabdominal approach may be attempted through a subcostal, chevron, or midline approach (Fig. 107.10). The subcostal or chevron incision provides better exposure of the superior and lateral aspects of the adrenal gland than the midline approach. The midline approach is generally reserved for cases in which an extra-adrenal pheochromocytoma is suspected along the great vessels or in the pelvis.

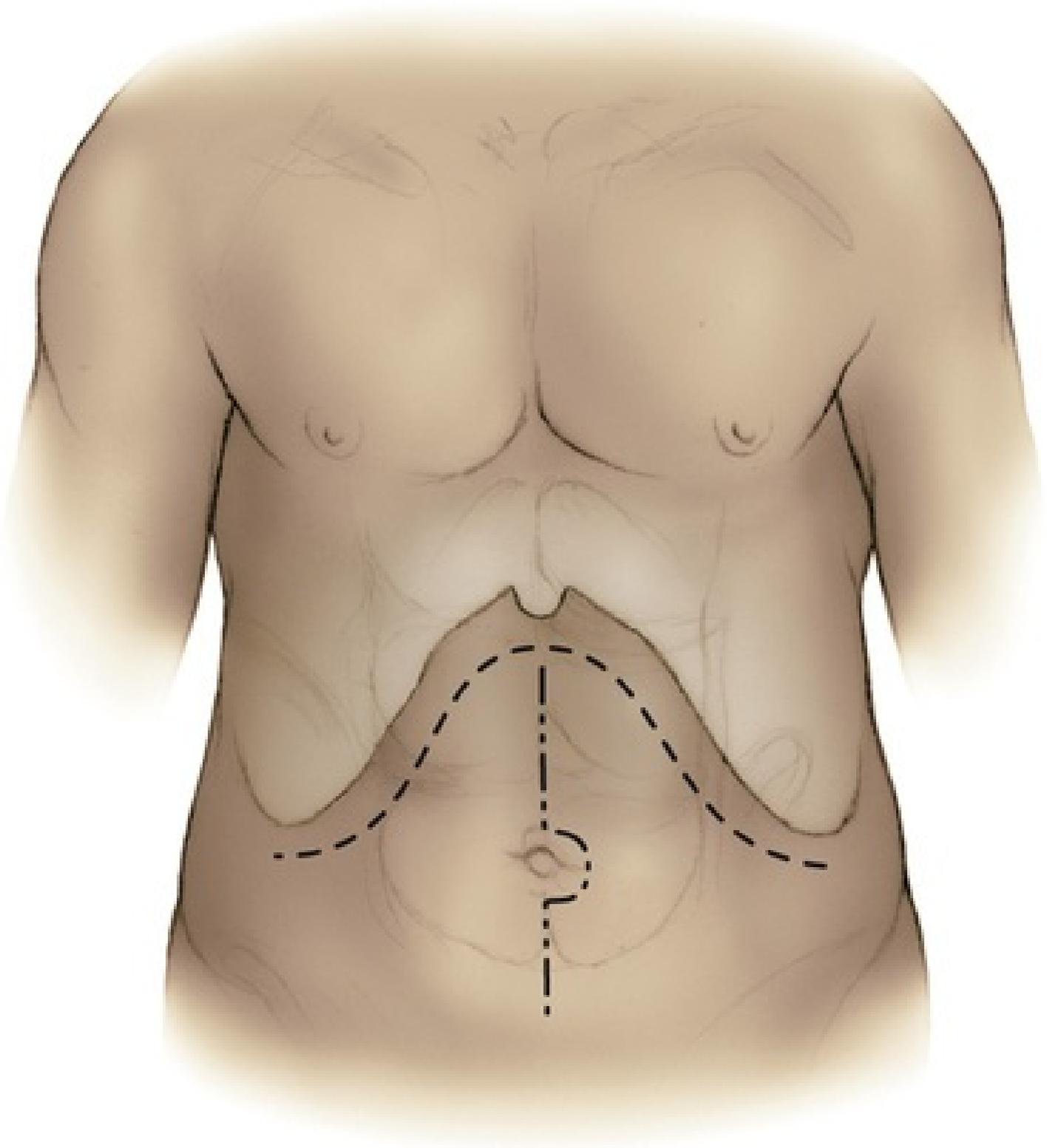

FIG. 107.10 Anterior approach. The transperitoneal approach may be attempted through a midline incision or subcostal incision. The subcostal incision can be extended into a full chevron for bilateral adrenalectomy or if a large unilateral tumor is encountered.

Left Adrenalectomy

Positioning and Incision.

The patient is positioned supine with a body roll placed under the back at the level of the costal margin to accentuate the costal margin. For left adrenalectomy, the skin incision is made two fingerbreadths below the costal margin and extends medially to the midline. The external oblique, internal oblique, and transverse abdominal muscles are divided laterally, and the rectus muscle and sheath are divided medially. The peritoneum is entered with sharp dissection, and the falciform ligament is ligated.

Approach to Left Adrenal Gland.

There are four different approaches to the left adrenal gland:

- Through the gastrocolic ligament
- Through the lienorenal ligament
- Through the transverse mesocolon
- Through the lesser omentum

The lienorenal ligament approach is described here. The line of Toldt is incised and the descending colon is mobilized medially. The splenic flexure is then taken down by dividing the splenocolic ligament (Fig. 107.11). Subsequent division of the lienorenal ligament and opening of the retroperitoneum along the inferior border of the pancreas will allow superior retraction of the spleen and pancreas with exposure of the left adrenal vein. The left adrenal vein is identified as it courses from the inferomedial border of the left adrenal gland into the left renal vein and is ligated and divided (Fig. 107.12). The medial attachments to the aorta can be taken at this point either with monopolar diathermy on a long right-angle instrument or with a harmonic scalpel while applying gentle lateral traction on the gland. The lateral and inferior attachments to the kidney are taken by blunt and sharp dissection off the renal capsule, taking care to avoid the vasculature to the renal upper pole.

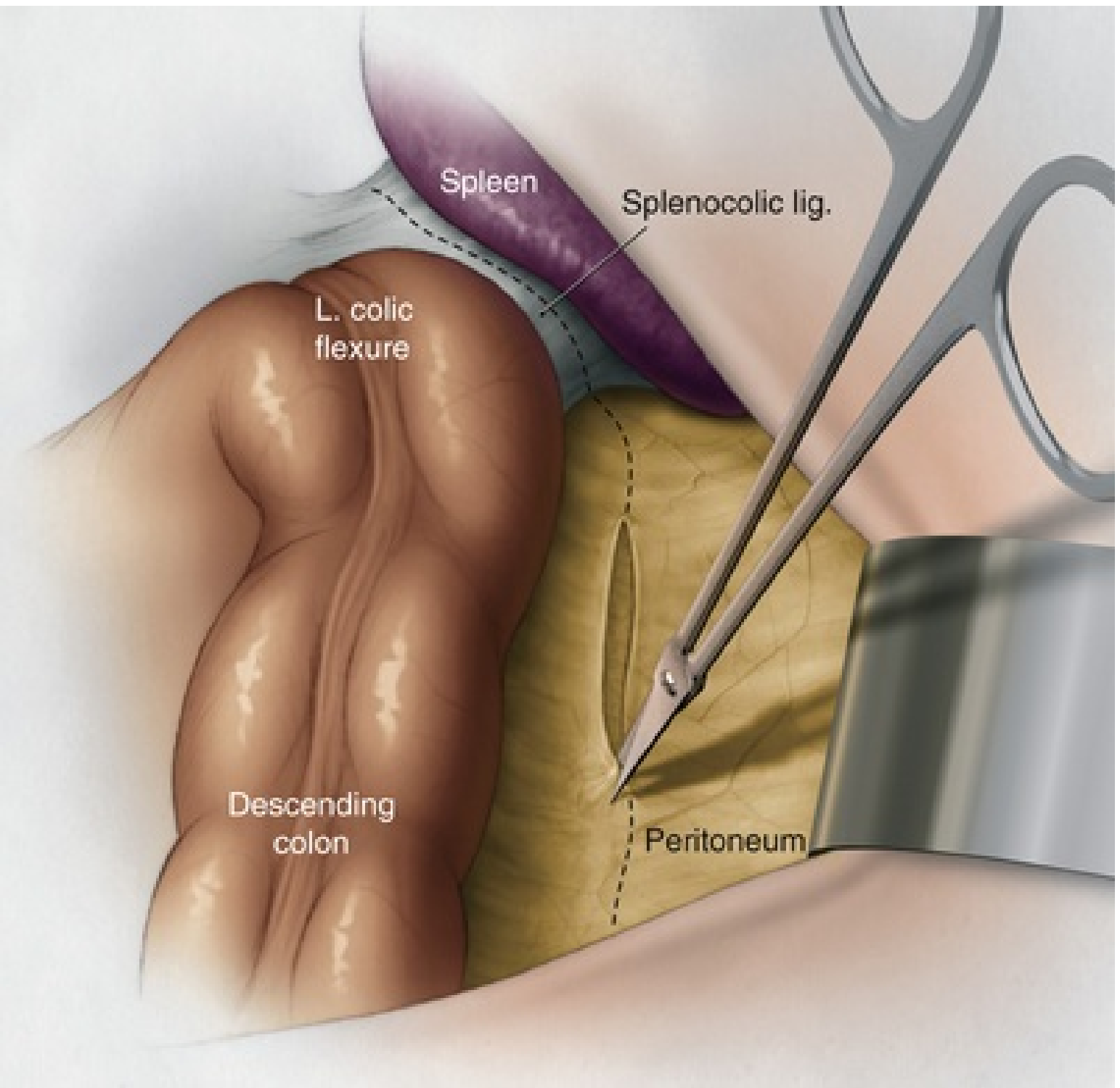

FIG. 107.11 Anterior approach. Peritoneum lateral to the left colon is

incised at the line of Toldt and extended cephalad to the splenocolic ligament and inferiorly. *L,* Left; *lig.,* ligament.

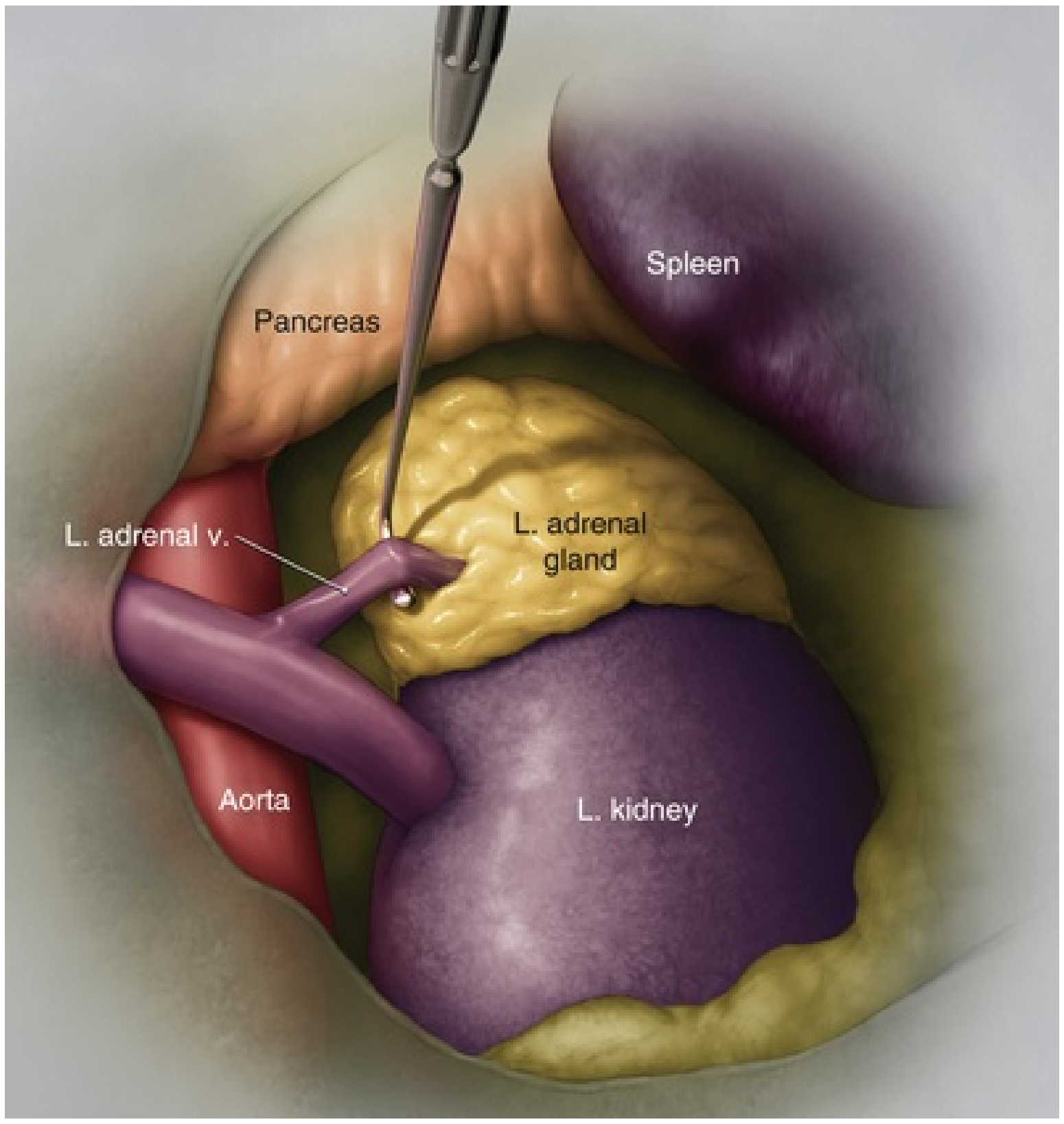

FIG. 107.12 Anterior approach. The left adrenal vein is dissected out and ligated. *L,* Left; *v,* vein.

Closure.

Closure of the incision is performed with a running No. 1 polydioxanone suture in two layers. The deep layer consists of the transverse abdominal muscle, transverse fascia, internal oblique muscle and fascia, and posterior rectus sheath. The superficial layer consists of the external oblique muscle and fascia and the anterior rectus sheath.

Right Adrenalectomy

After the peritoneum is entered, the hepatic flexure is mobilized inferiorly and the liver is retracted superiorly. The Kocher maneuver is performed to mobilize the second part of the duodenum sharply, and the inferior vena cava is exposed

(Fig. 107.13). The rest of the dissection is similar to that on the left side.

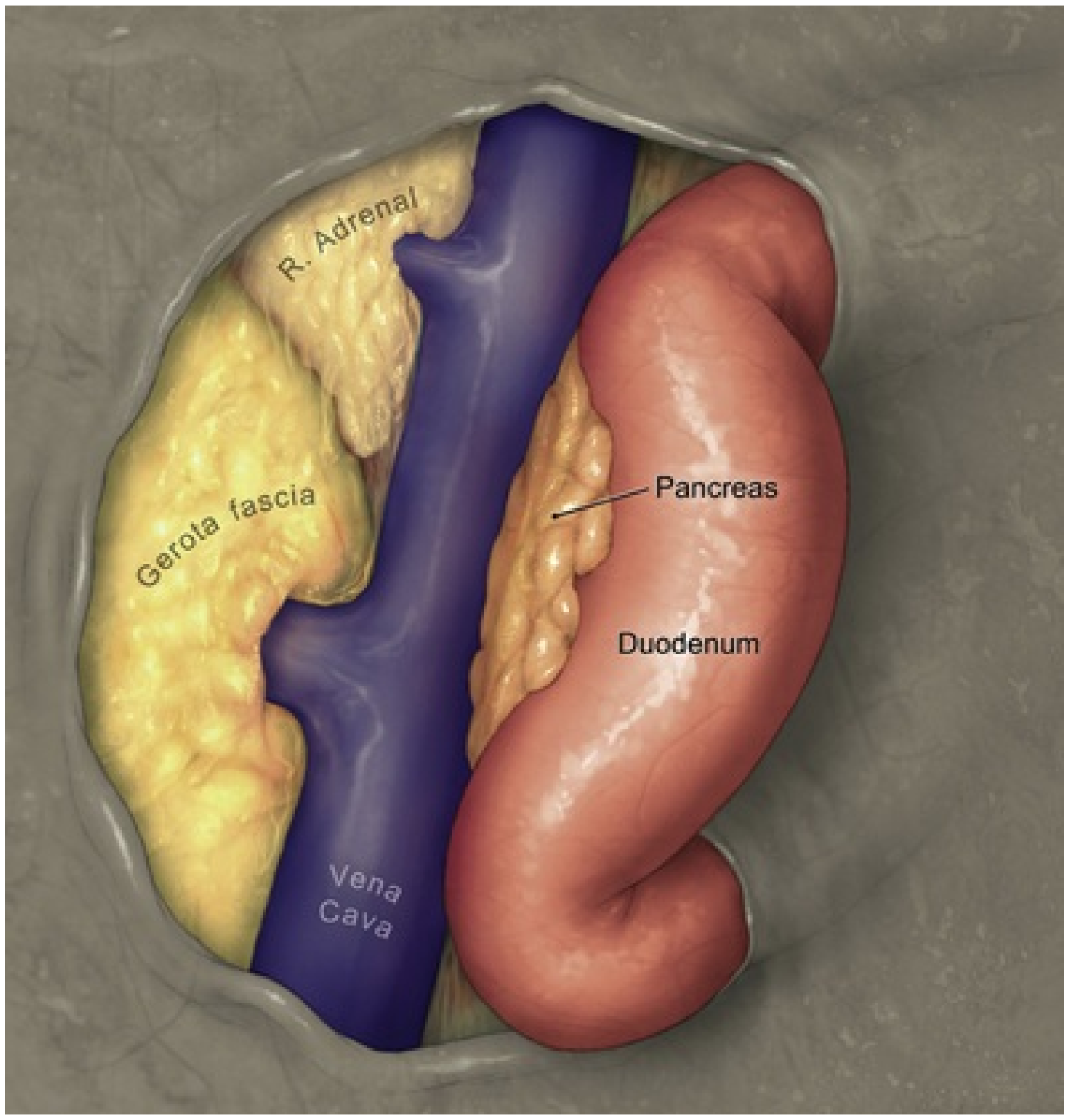

FIG. 107.13 Kocher maneuver. The peritoneum is incised, and sharp dissection and blunt dissection are used to mobilize the second stage of the duodenum away from the renal hilum. *R,* Right.

Thoracoabdominal Approach

The thoracoabdominal approach offers the best surgical exposure of the retroperitoneum, adrenal gland, and great vessels but may cause more morbidity, such as incisional pain, pulmonary morbidities, phrenic nerve injury during division of the diaphragm, and the need for a chest tube. **This approach is generally reserved for large and invasive tumors with extensive involvement of surrounding structures or vena cava that cannot be safely removed via the anterior transabdominal approach.** The thoracoabdominal approach is particularly useful in right-sided tumors because the liver and inferior vena cava can limit exposure, whereas, on the left side, the spleen and pancreas can generally be elevated to provide adequate exposure.

Positioning.

The patient is placed in a semioblique position at an angle of 45 degrees to the table with the operating side upward and the opposite side decubitus. A body roll or pillow is placed longitudinally along the hemithorax and flank to achieve and maintain this position. The ipsilateral arm is placed across the chest on a padded arm rest, and the other arm is secured to an armboard (Fig. 107.14).

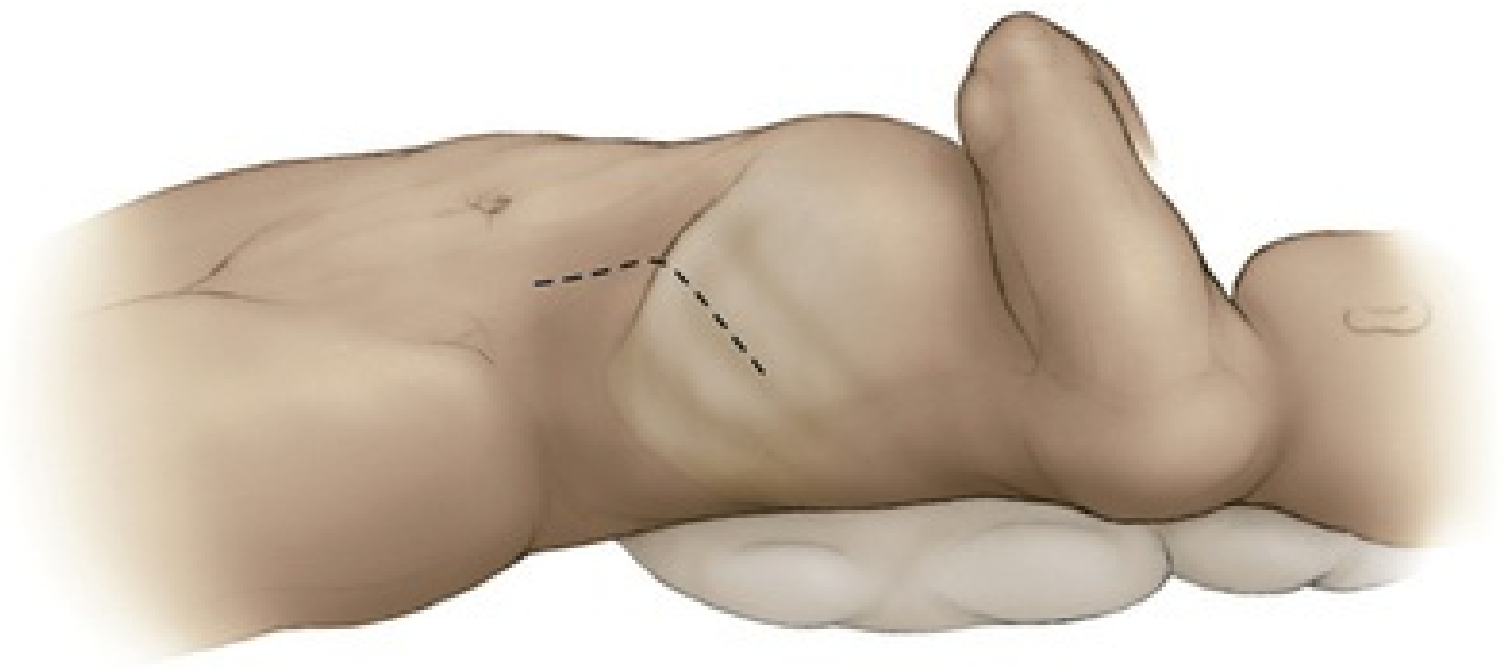

FIG. 107.14 Positioning for thoracoabdominal surgery. A body roll elevates the flank on the side of surgery, and the arm and shoulder are rotated away, supported by a sling.

Incision and Dissection of Adrenal Gland.

The incision is made along the eighth or ninth intercostal space extending from the posterior axillary line and curving over the costal margin into the abdomen (Fig. 107.15). The latissimus dorsi, serratus anterior, and intercostal muscles are divided. The costal cartilage is then divided with cautery, and the incision is carried through the anterior and posterior rectus sheaths and the rectus abdominis muscle. The pleura is entered along the superior margin of the rib to avoid injury to the neurovascular bundle, and the lung is packed away (Fig. 107.16). The diaphragm is divided in a circumferential fashion along its periphery. The surgeon must not cut directly to the center of the diaphragm because the phrenic nerve can be damaged. Marking sutures can be placed on either side of the divided diaphragm to aid alignment during closure. Once the diaphragm is divided, a Finochietto self-retaining retractor is placed. The rest of the dissection is similar to the previously described techniques. The relationship of the thoracoabdominal incision to the adrenal gland is illustrated in Figs. 107.17 and 107.18.

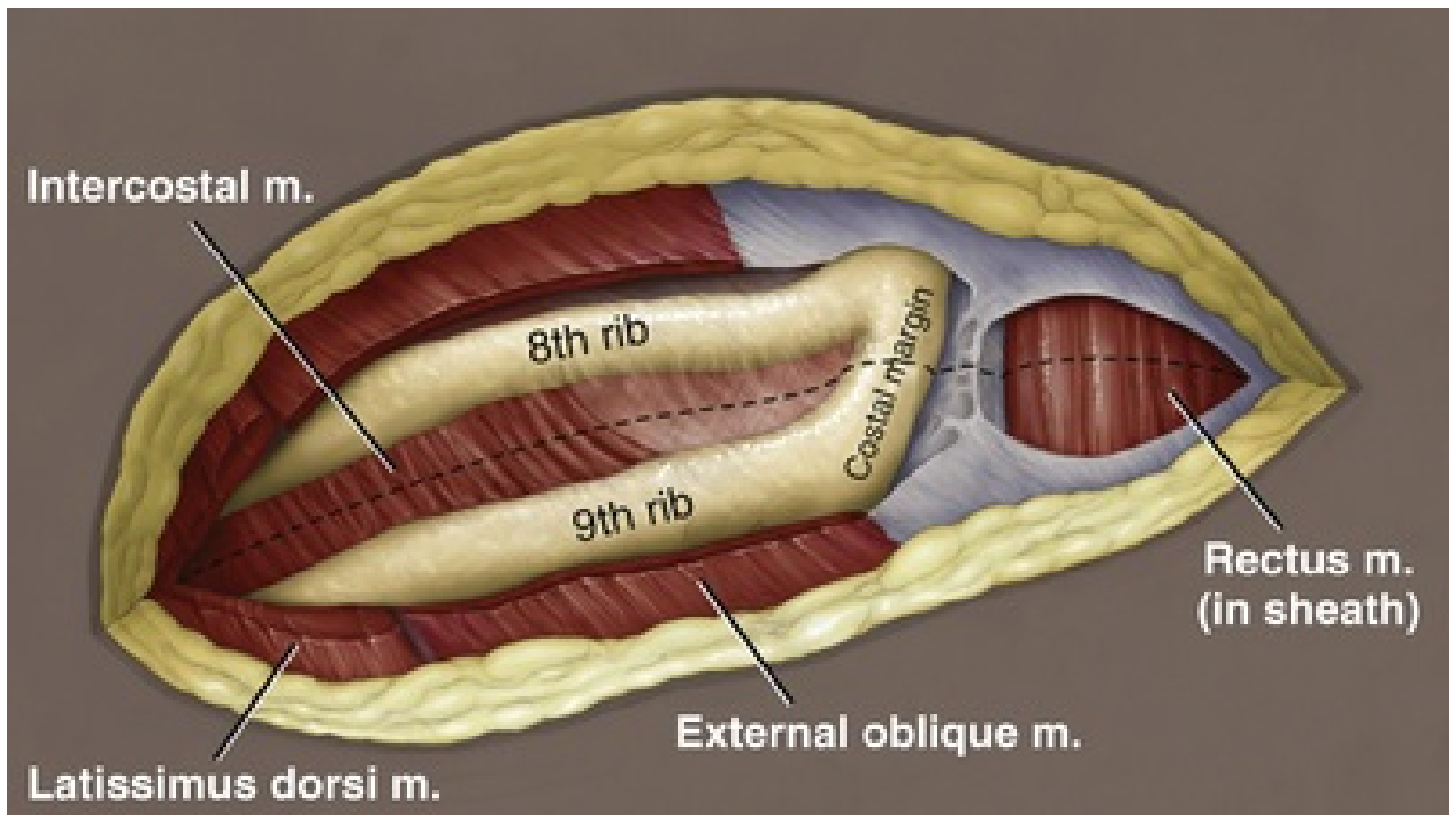
Intercostal m.
8th rib
Costal margin
9th rib
Rectus m.
(in sheath)
External oblique m.
Latissimus dorsi m.

FIG. 107.15 Thoracoabdominal approach. Incision at the eighth intercostal space. The costal margin, external intercostal muscle and fascia, and anterior rectus sheath are divided. *m,* Muscle.

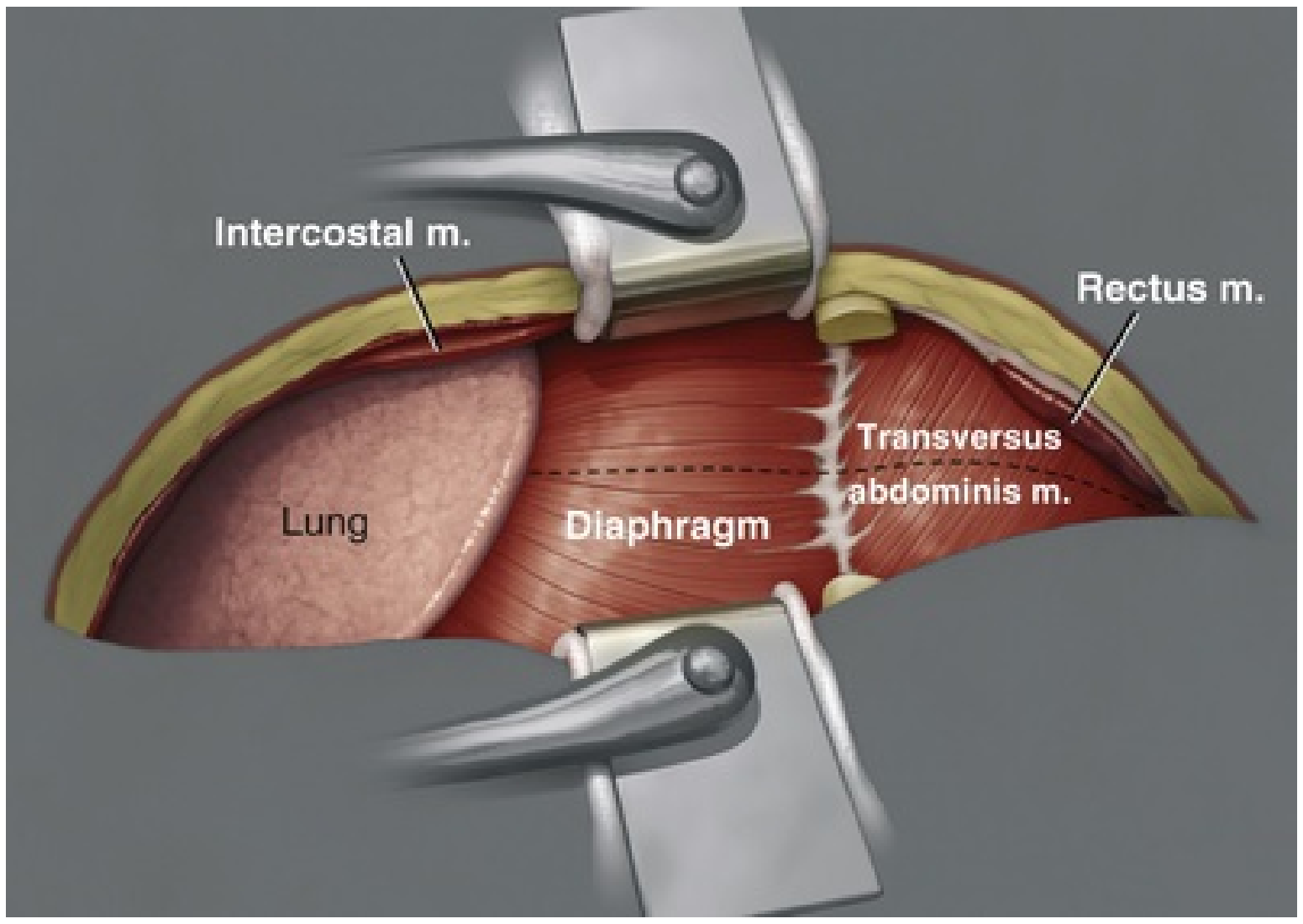
Intercostal m.
Rectus m.
Transversus
abdominis m.
Lung
Diaphragm

FIG. 107.16 Thoracoabdominal approach. The Finochietto retractor is placed to expose the anatomy. The lung visible in this view is packed away with laparotomy sponges. *m,* Muscle.

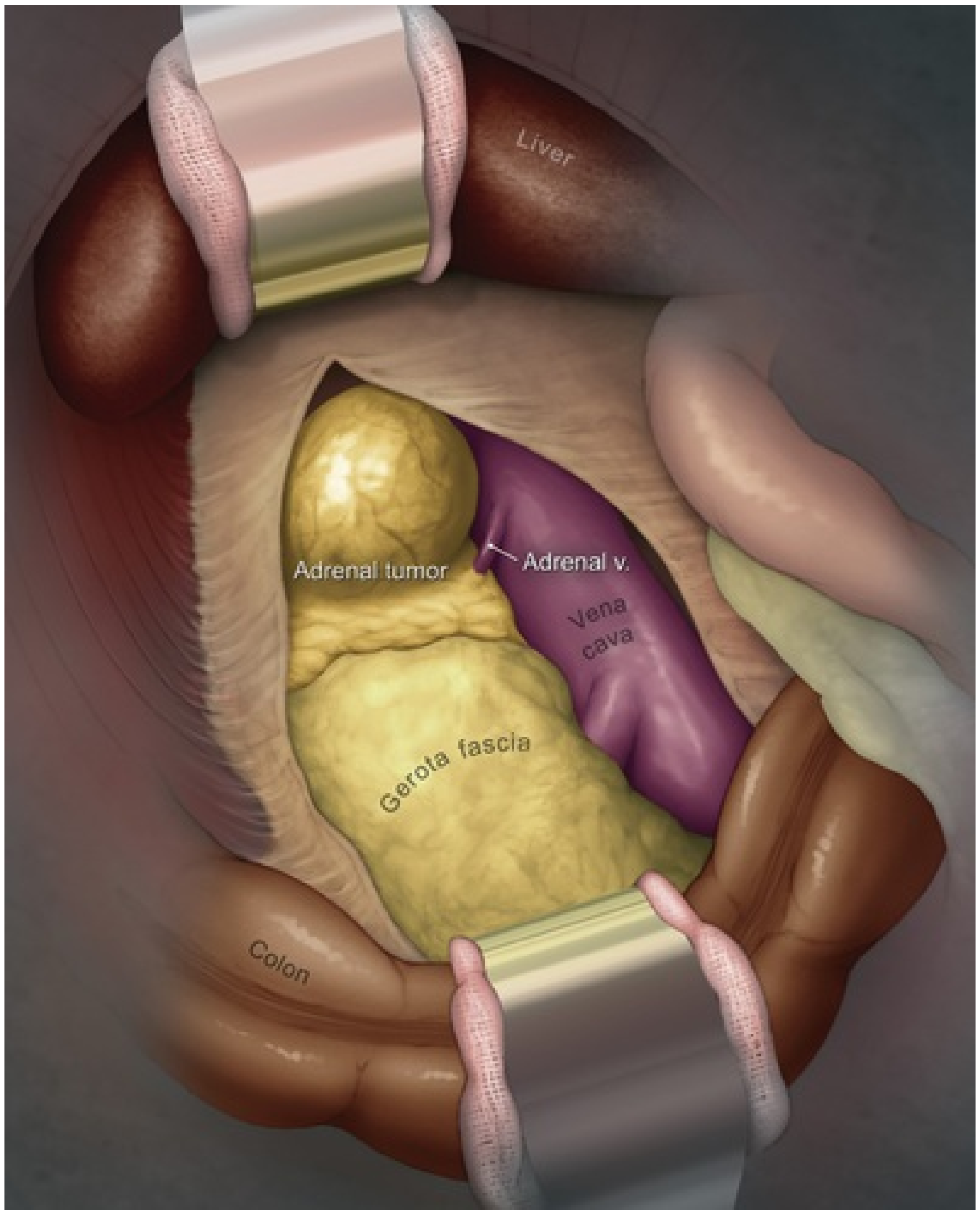
Liver
Adrenal tumor
Adrenal v.
Vena cava
Gerota fascia
Colon

FIG. 107.17 Thoracoabdominal approach. Exposure of the adrenal. *v,* Vein.

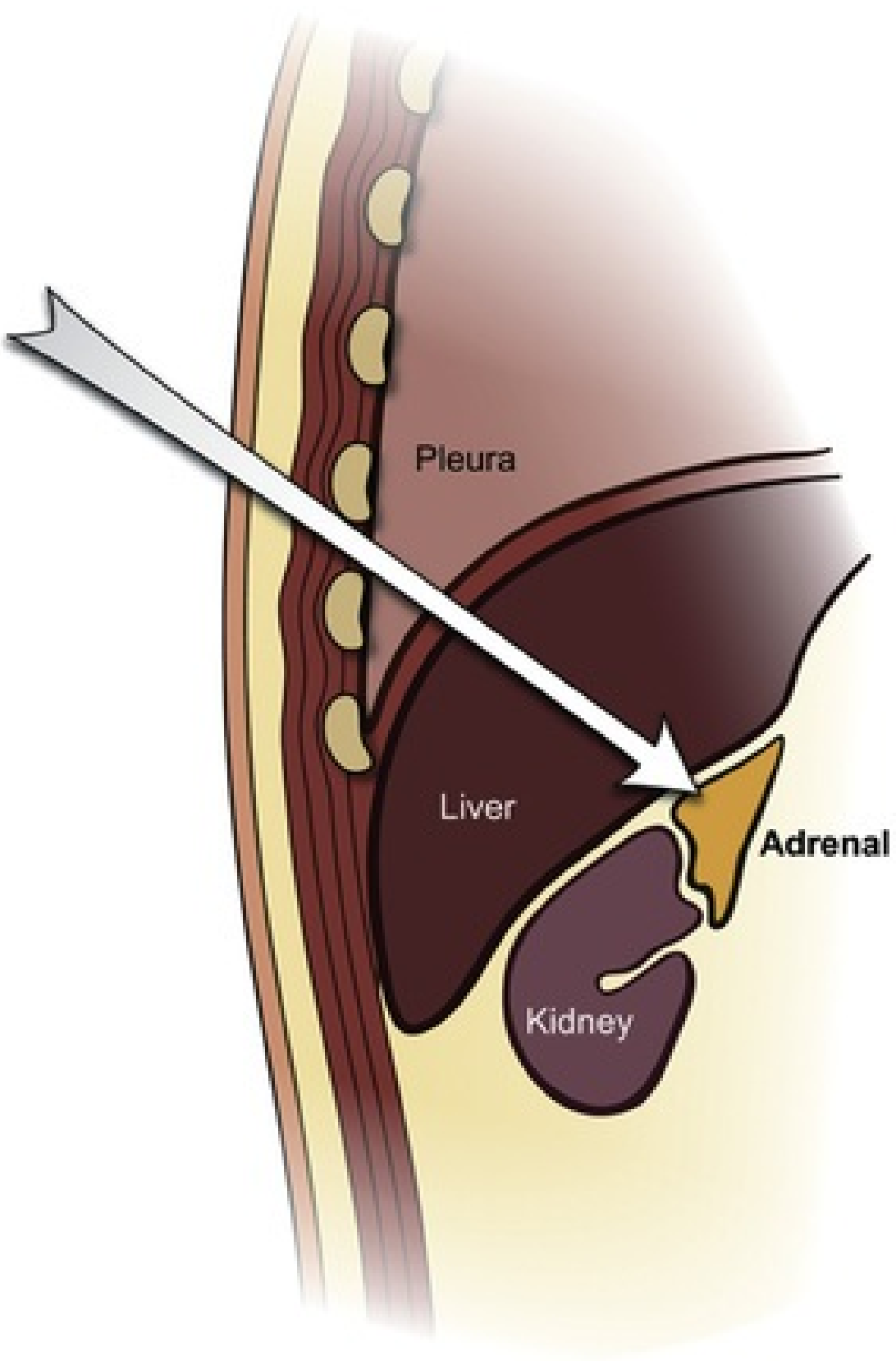

FIG. 107.18 Demonstration of the route of surgical dissection via thoracoabdominal incision.

Closure.

A chest tube is placed and the diaphragm is closed with either running suture or interrupted figure-of-eight stitches with nonabsorbable sutures. To take tension off the diaphragmatic closure, the ribs should be reapproximated with several interrupted No. 0 chromic sutures on blunt-tip liver needles around the superior border of the eighth rib and inferior border of the ninth rib. A No. 0 Prolene suture is placed through the cut costal cartilage to bring the costal margin together, followed by closure of the serratus anterior and latissimus dorsi muscles in two layers. The chest tube is then placed to a water seal and suction.

Laparoscopic Adrenalectomy

Transperitoneal Approach

Transperitoneal laparoscopic adrenalectomy can be performed with the patient in a supine or lateral position. In general, the transperitoneal approach allows for a greater working space and a better visualization of the operative field and surrounding anatomic structures than with the retroperitoneal approach. The lateral transperitoneal approach allows for a greater working space as gravity aids in moving the bowels away from the surgical field. The supine approach permits bilateral adrenalectomy without repositioning the patient. However, more dissection and retraction of surrounding organs are generally needed with the supine approach, so it is usually reserved for bilateral adrenalectomy.

Transperitoneal Lateral Approach: Left Adrenalectomy

Positioning and Ports Placement.

After general anesthesia, a urinary catheter and a nasogastric tube are inserted to decompress the bladder and the stomach. The patient can be positioned in either a full lateral position with the operating side upward or a modified lateral position angled at 45 to 60 degrees. The table can be straight or minimally flexed to increase the distance between the costal margins and the iliac crest. Care should be taken to avoid excessive flexion because this may lead to neuromuscular problems and decreased venous return. All bony prominences must be adequately padded and the patient strapped in position.

The initial 10-mm camera port can be inserted either with the open technique or with the aid of the Veress needle. After insufflation of the abdomen with CO_2, two or three other trocars are inserted under vision in the configuration shown in Fig. 107.19. The 5-mm port at the anterior axillary line can be replaced with a 10- to 12-mm port for larger instruments and ease of specimen retrieval. The splenic flexure may have to be mobilized before insertion of this port. The optional fourth 2- or 5-mm port may be inserted to aid retraction in difficult dissection.

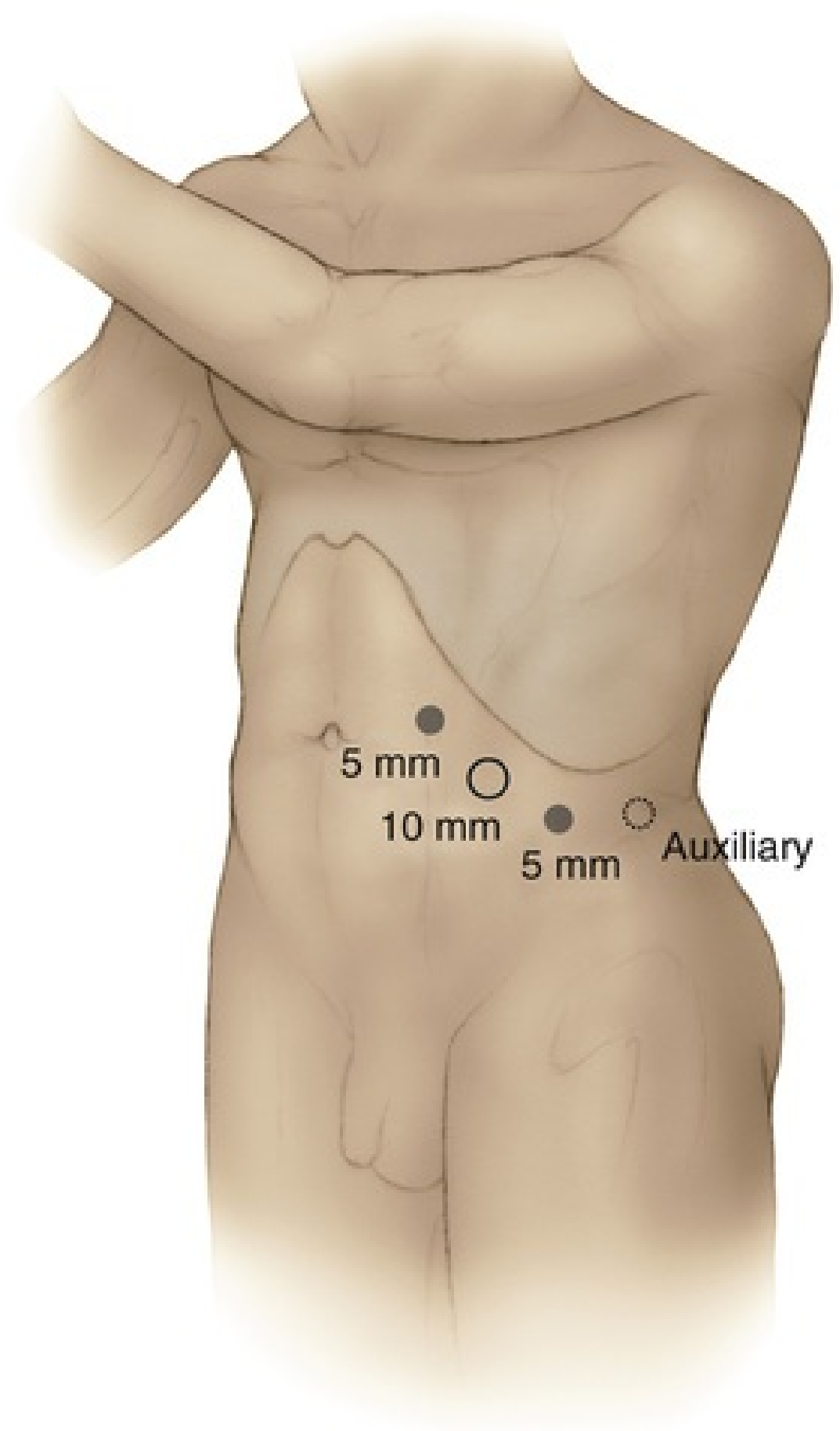

FIG. 107.19 Four-trocar configuration for left transperitoneal laparoscopic adrenalectomy.

Mobilization of Colon and Spleen.

The line of Toldt is incised and the colon is mobilized inferiorly (Fig. 107.20). The splenocolic and lienorenal ligaments are incised toward the diaphragm to the level of the gastric cardia, allowing for full medial rotation of the spleen away from the surgical field. Care should be taken to avoid injury to the stomach and diaphragm at this stage. A sudden loss of pneumoperitoneal pressure with increases in ventilation pressures may signify diaphragmatic perforation. With the spleen rotated away and the tail of the pancreas dissected off, the left adrenal gland will come into view. Occasionally, especially in patients with Cushing syndrome, dense retroperitoneal fat may obscure the adrenal gland. A laparoscopic ultrasound probe can be inserted through the 10- to 12-mm port for localization of the adrenal gland.

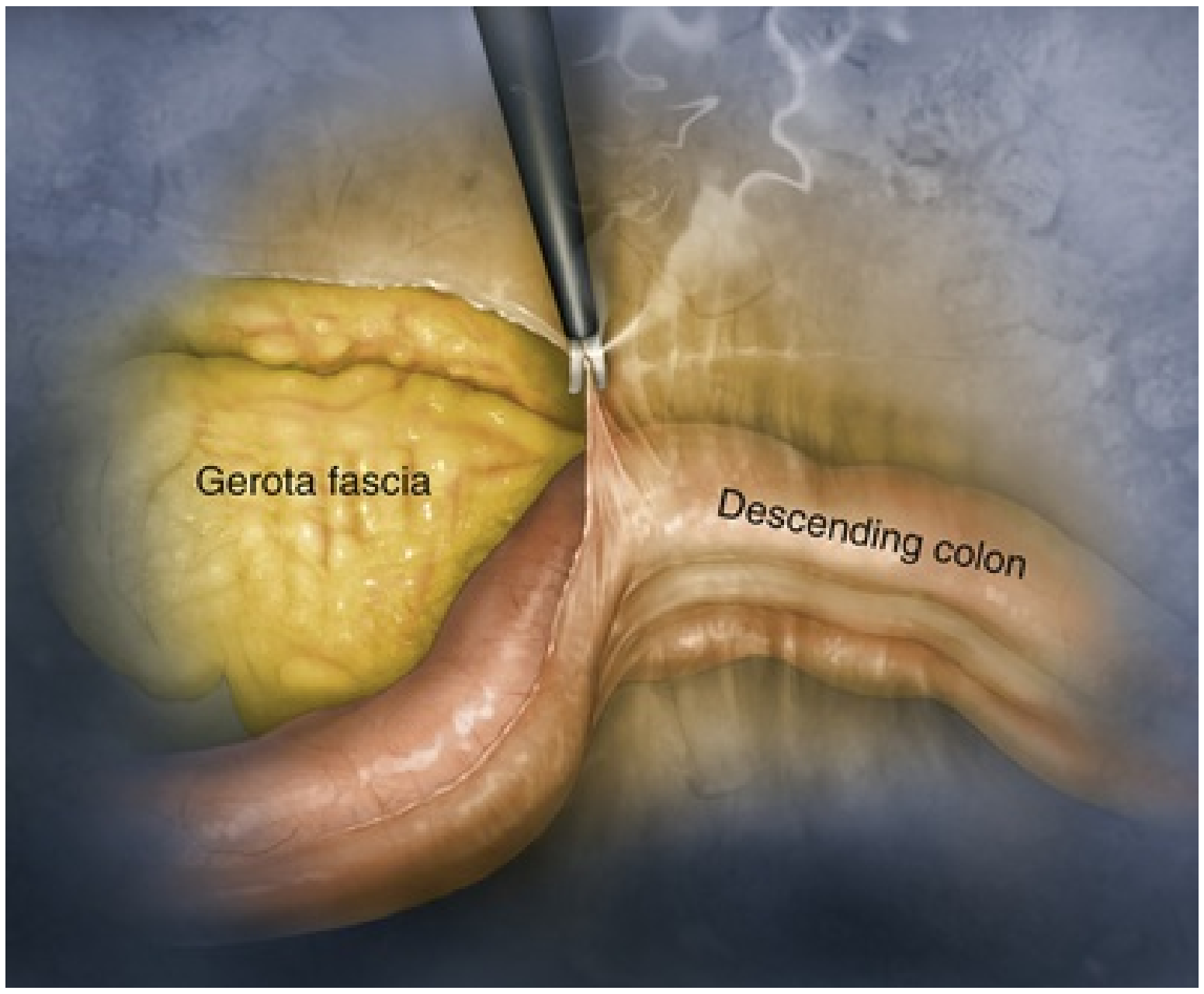

FIG. 107.20 Transperitoneal laparoscopic adrenalectomy. Incision of the line of Toldt and medial dissection of the left colon with cautery endoscopic scissors.

Ligation of Left Adrenal Vein and Mobilization of the Left Adrenal Gland.

The left renal vein is identified and traced along its superior border to reach the point of entry of the left adrenal vein (Fig. 107.21). The left adrenal vein is carefully isolated and ligated. It is advisable to place at least two clips on the stay side of the adrenal vein (Fig. 107.22). Care has to be taken to avoid any upper pole branch of the left renal artery, which may lie behind the adrenal vein. It is also important to recognize that the inferior phrenic vein may occasionally join the adrenal vein before its entry into the left renal vein. The adrenal arterial supply is divided with either cautery or a harmonic scalpel as the adrenal is dissected free (Figs. 107.23 and 107.24). **Grasping on the adrenal gland should be avoided because the gland is fragile and tears easily, leading to increased intraoperative bleeding.**

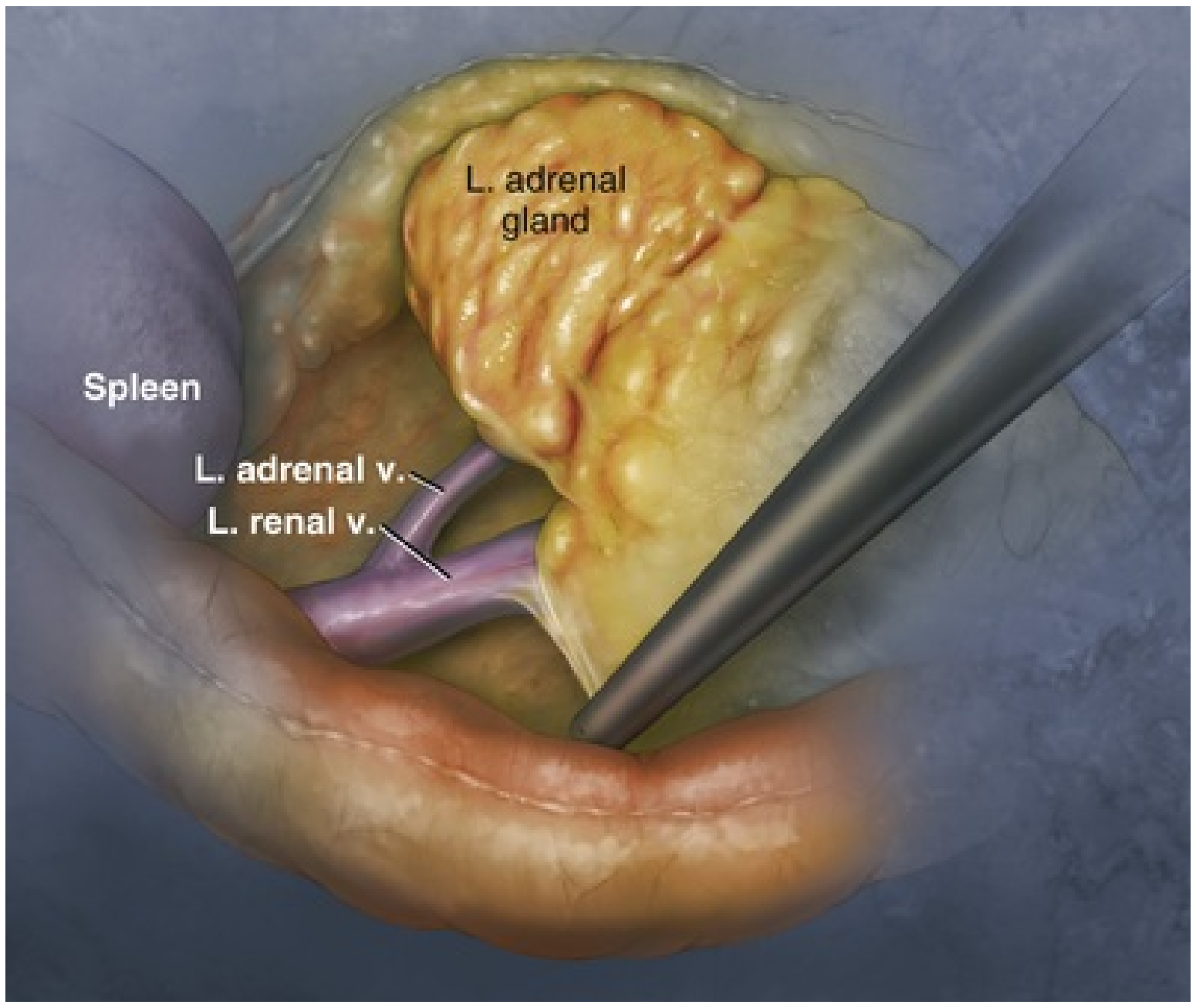
L. adrenal gland
Spleen
L. adrenal v.
L. renal v.

FIG. 107.21 Transperitoneal laparoscopic adrenalectomy. Exposure and dissection of the renal vein and left adrenal vein. *L,* Left; *v,* vein.

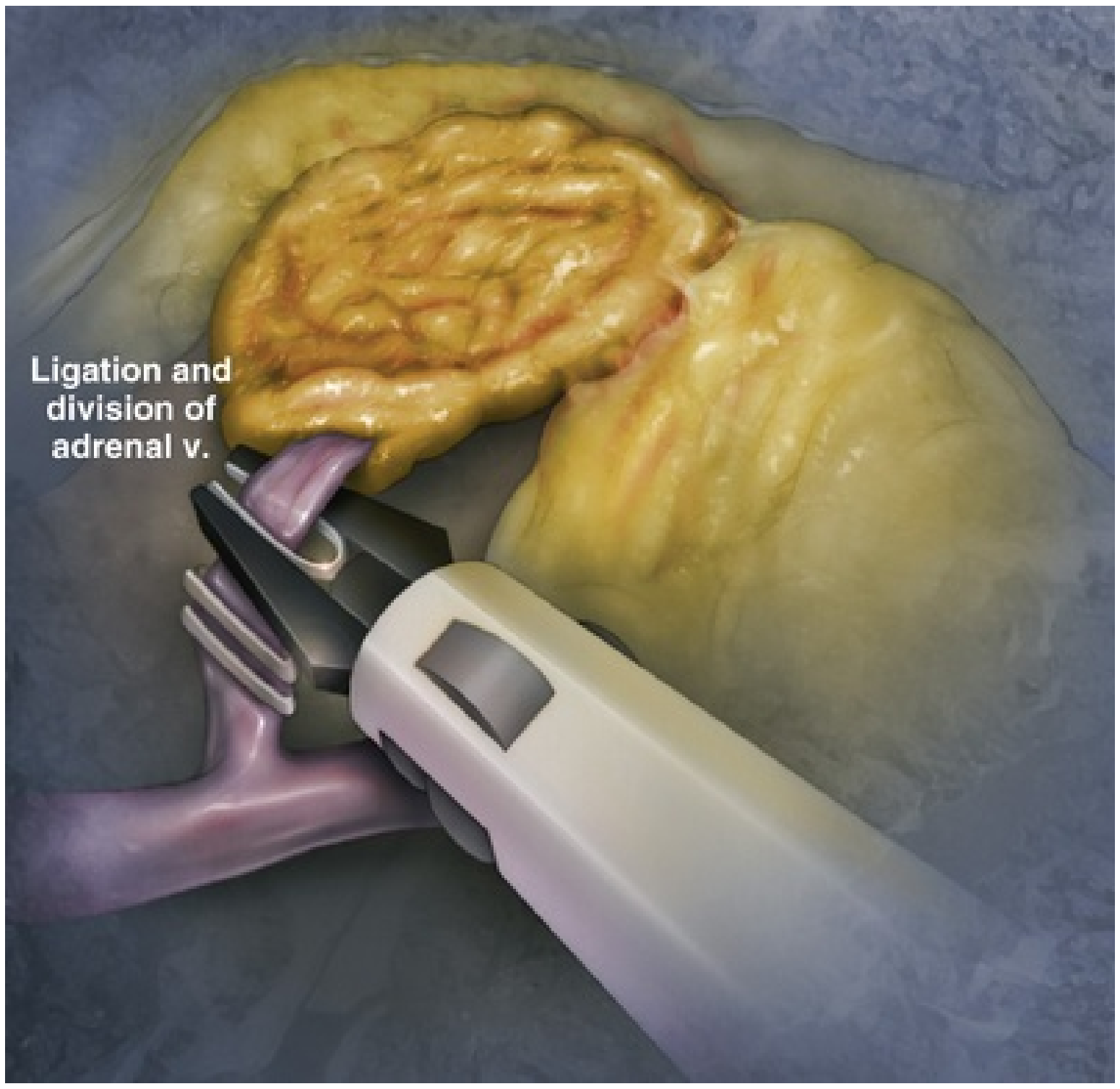
Ligation and division of adrenal v.

FIG. 107.22 Transperitoneal laparoscopic adrenalectomy. Ligation and division of left adrenal vein. *v,* Vein.

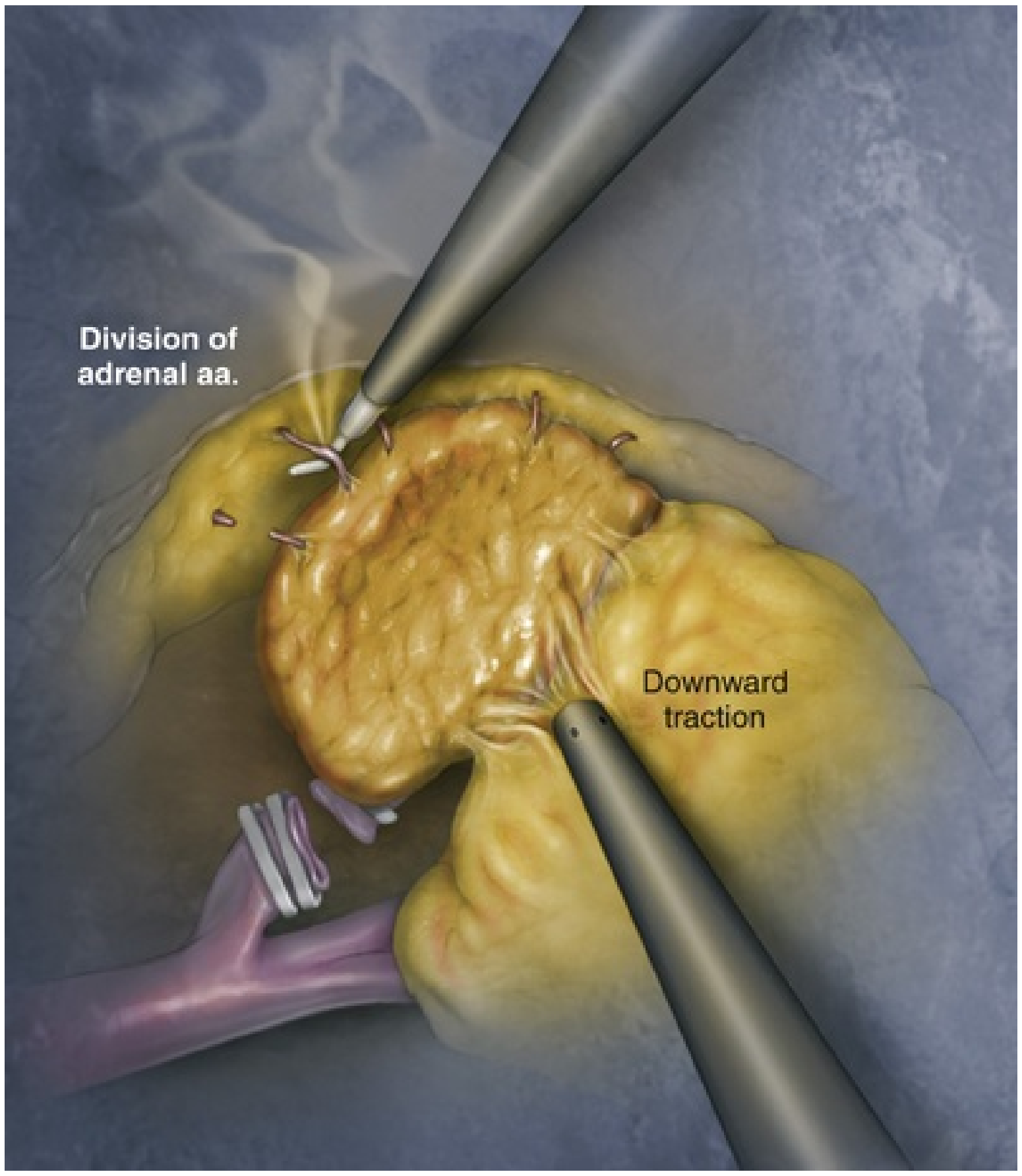
Division of adrenal aa.
Downward traction

FIG. 107.23 Transperitoneal laparoscopic adrenalectomy. Division of adrenal arterial supply and superomedial dissection with downward traction on the kidney. *aa,* Arteries.

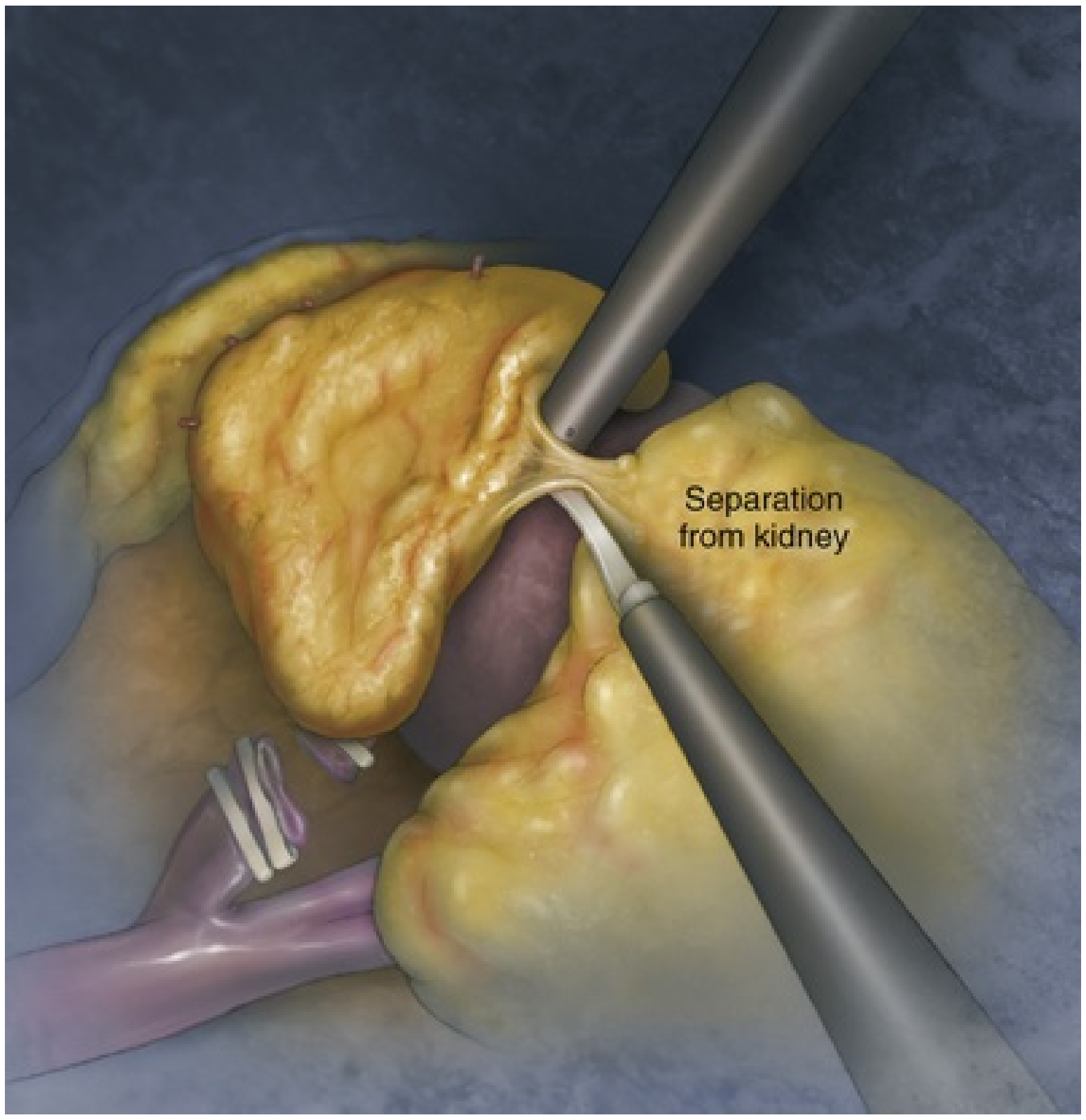

FIG. 107.24 Transperitoneal laparoscopic adrenalectomy. The adrenal gland is mobilized off the medial aspect of the kidney.

Closure.

Once the adrenal gland is freed, it is placed in an endoscopic bag and removed via the 10- to 12-mm port (Fig. 107.25). Pneumoperitoneal pressure is reduced to 5 mm Hg and the surgical bed inspected for hemostasis. All port sites larger than 5 mm are closed in layers with fascial approximation and skin closure.

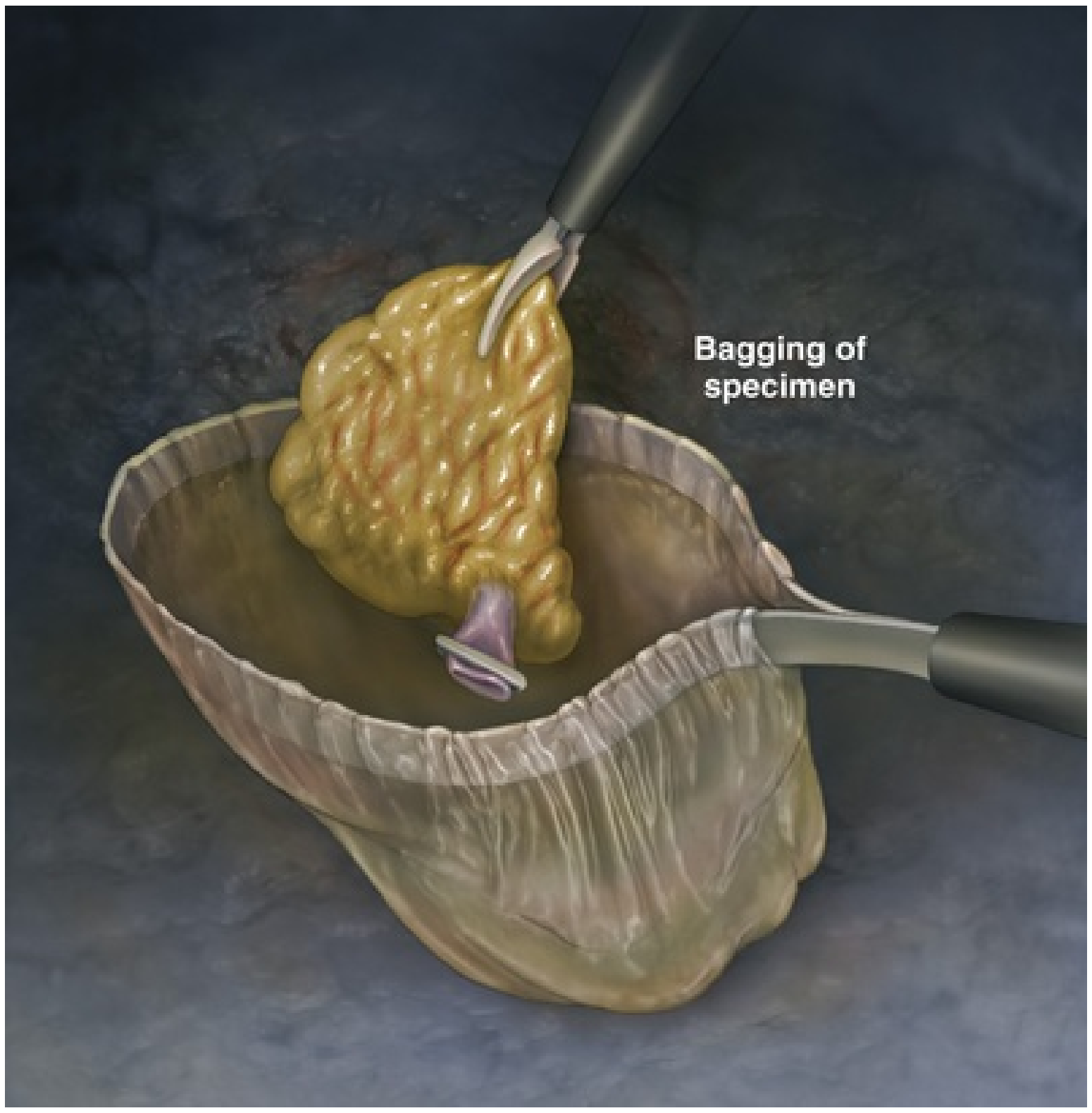

FIG. 107.25 Transperitoneal laparoscopic adrenalectomy. Placement of specimen in endoscopic extraction sac.

Transperitoneal Lateral Approach: Right Adrenalectomy

The port configuration for transperitoneal laparoscopic lateral right adrenalectomy is shown in Fig. 107.26. An additional 2- or 5-mm port sited most superomedially is used for liver retraction. After creation of pneumoperitoneum, the first step is to mobilize the liver by dividing the triangular ligament laterally and inferiorly. The liver is then retracted anterosuperiorly using the shaft of a 2- or 5-mm laparoscopic ratcheted locking forceps (Fig. 107.27). The lateral parietal peritoneum is grasped by the forceps, creating an assistant-free self-retaining retraction of the liver. A Kocher maneuver is then performed to mobilize the second part of the duodenum. This permits the visualization of the inferior vena cava and the right adrenal gland. The short right adrenal vein can be identified as it joins the inferior vena cava. The rest of the dissection is similar to that described on the left side.

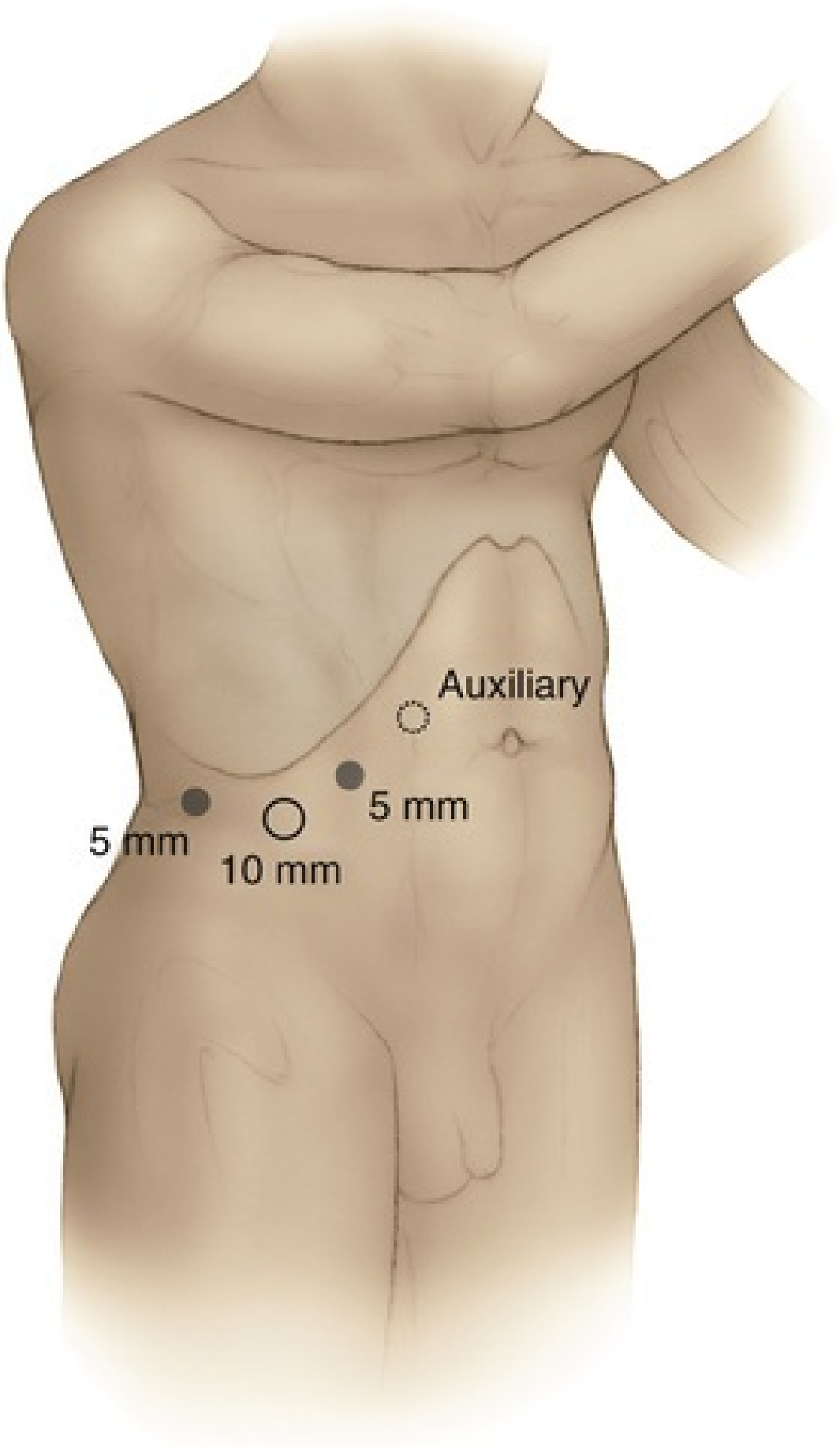
Auxiliary
5 mm
5 mm
10 mm

FIG. 107.26 Four-trocar configuration for right transperitoneal laparoscopic adrenalectomy. Auxiliary site can be used for liver retraction.

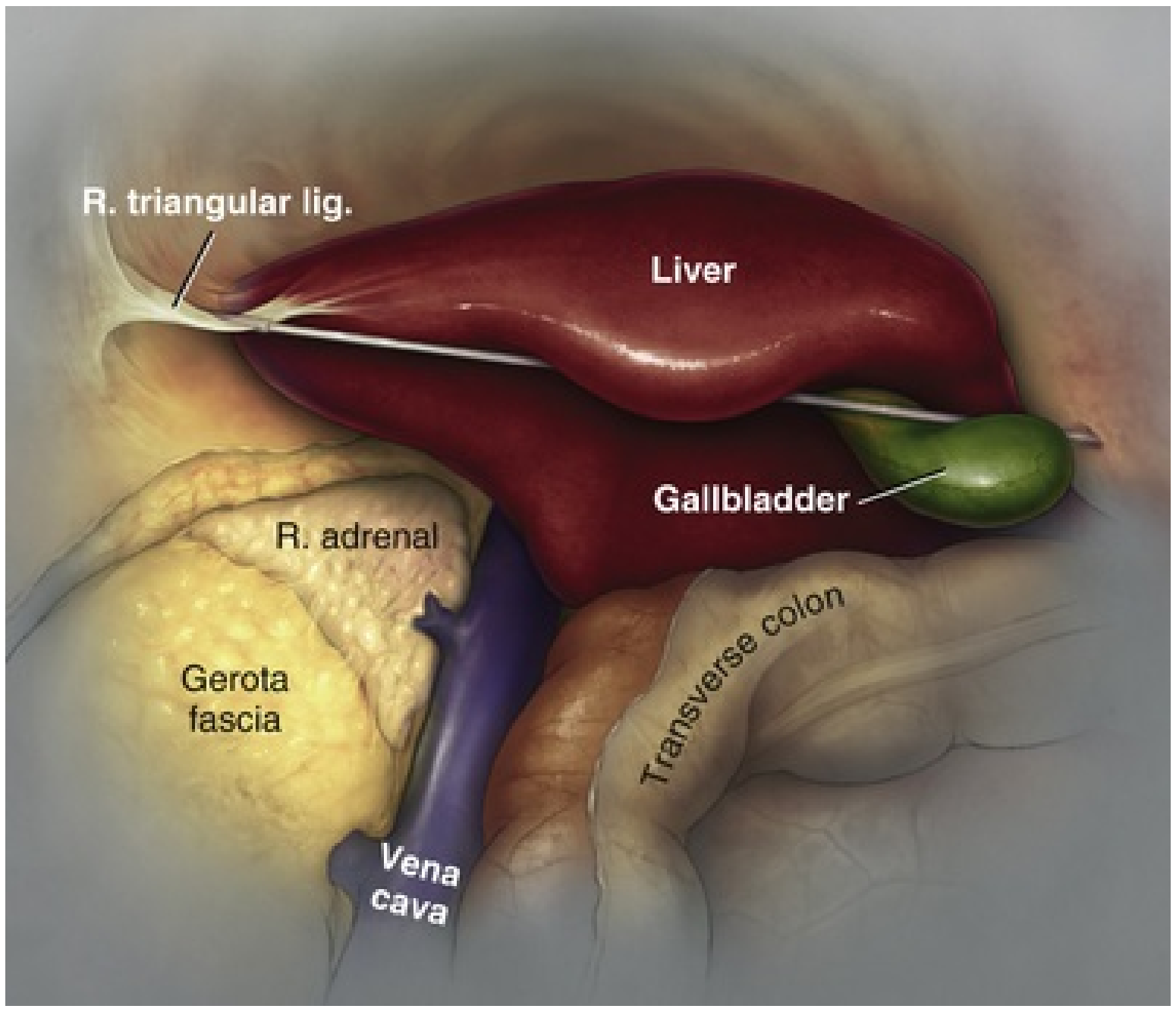

FIG. 107.27 A 2-mm trocar and locking grasping forceps can be used instead of a larger-caliber fan retractor to act as a self-retaining liver retractor. It is important that the trocar be placed just below the xiphoid process to ensure adequate retraction. *lig,* Ligament; *R,* right.

Gasless Laparoscopic Transperitoneal Approach

Pneumoperitoneum is associated with several negative hemodynamic, metabolic, neurologic, and humoral effects. These include decreased venous return and cardiac output, elevated systemic arterial blood pressure, increased inspiratory and expiratory airway pressures and end-tidal carbon dioxide levels, decreased renal blood flow, and possible gas embolism. Pneumoperitoneum is thus contraindicated in certain groups of patients with preexisting cardiac, pulmonary, or neurologic diseases.

Giraudo et al. (2009) described their gasless laparoscopic adrenalectomy techniques using an abdominal wall lifting platform. The LaparoTenser (L&T Lucini, Milan, Italy) (Fig. 107.28) is used as an abdominal wall retractor, with two curved needles placed in the subcutaneous tissue of the anterolateral abdominal wall. The intraperitoneal space is created by lifting the abdominal wall, which eliminates the need for pneumoperitoneum. Three or four trocars are then inserted and dissection of the adrenal gland proceeds in a manner similar to that described earlier. The main suggested benefit of this technique is that it allows laparoscopic transperitoneal adrenalectomy to be performed as an alternative to open surgery in patients with contraindications to pneumoperitoneum.

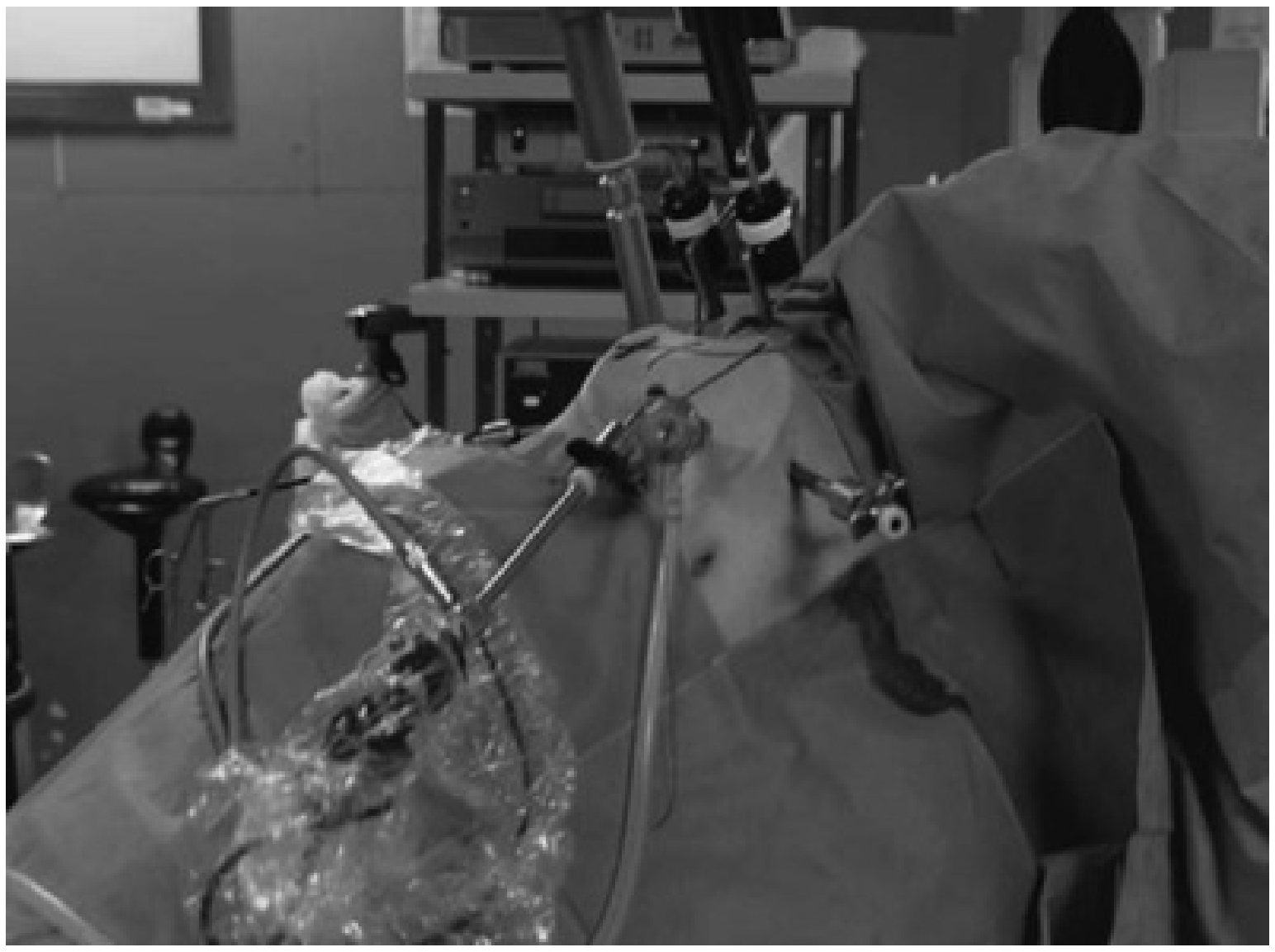

FIG. 107.28 The LaparoTenser (L&T Lucini, Milan, Italy). (From Giraudo G, Pantuso G, Festa F, et al.: Clinical role of gasless laparoscopic adrenalectomy. *Surg Laparosc Endosc Percutan Tech* 19:329–332, 2009.)

Retroperitoneal Approach

Laparoscopic retroperitoneal adrenalectomy can be performed using either the prone or the lateral approach. The main advantage of the retroperitoneal approach is that entry into the peritoneum is avoided and thus complications such as visceral and bowel injuries are minimized. In the absence of pneumoperitoneum, hemodynamic and respiratory morbidities are also reduced. In addition, dense intraperitoneal adhesions arising from previous surgery or inflammation are averted by operating in the retroperitoneum. The main disadvantage of the retroperitoneal approach is the limited working space that makes dissection of large tumors difficult. Furthermore, because of the smaller skin surface area for port placement, the risk of improper port placement leading to colonic injury is increased (Liapis et al., 2008). Finally, the lack of anatomic landmarks and the abundant retroperitoneal adipose tissues may pose a significant challenge to surgeons inexperienced with the retroperitoneum.

The main advantage of the lateral approach over the posterior approach is the ease of conversion into the transperitoneal approach should difficulties be encountered. In contrast, the prone retroperitoneal approach allows for bilateral adrenalectomy without patient repositioning.

Retroperitoneal Lateral Adrenalectomy: Left Adrenalectomy

Positioning and Ports Placement.

The patient is placed in the lateral position with the left side up with a kidney rest under the body and the operating table flexed to accentuate the left flank. A 1.5-cm incision is made near the tip of the 12th rib under the 11th rib. The underlying muscle and fasciae are divided with cautery until the lumbodorsal fascia is visible. This lumbodorsal fascia is then incised sharply and a finger is inserted to confirm access into the retroperitoneal space. The inner surface of the 12th or 11th rib should be palpable superiorly and the iliac crest felt inferiorly. Blunt finger dissection is used to create a plane between the psoas muscle and the posterior Gerota fascia by sweeping the kidney anteriorly and the peritoneum medially. This retroperitoneal space is then widened with a retroperitoneal dissection balloon inflated under direct vision by inserting the laparoscope into its transparent shaft. The balloon dissector is directed along the posterior abdominal wall in a cephalic direction. The psoas muscle is usually identifiable, and this serves as a landmark for longitudinal orientation. A balloon-tip trocar is secured in position into this space and insufflation of the retroperitoneum is generated. A 5- or 10-mm trocar is placed at the angle of the paraspinal muscle and the origin of the 12th rib. Another 5- or 10-mm trocar is placed about two fingerbreadths above the iliac crest near the anterior superior iliac spine (Fig. 107.29).

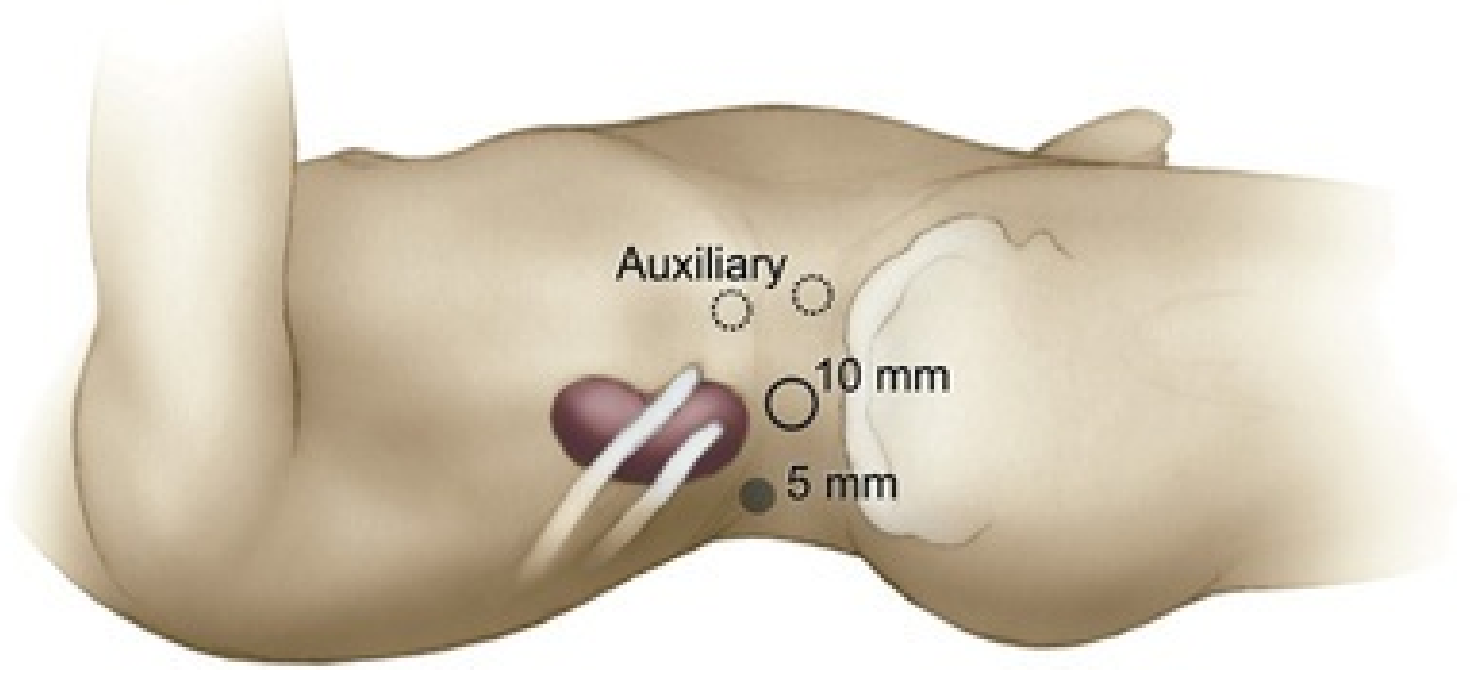

FIG. 107.29 Trocar placement for retroperitoneal laparoscopy. The *dotted circles* represent alternative sites for placement of a third port.

Ligation of Left Adrenal Vein and Mobilization of Left Adrenal Gland.

With use of medial dissection, the great vessels can be identified by their pulsation and their course parallel to the psoas. The renal hilum is then identified by the pulsation of the posteriorly situated renal artery. The superior border of the renal artery is dissected to expose the left adrenal vein as it courses anterior and cephalad to the renal artery toward the inferomedial border of the left adrenal gland (Fig. 107.30). The left adrenal vein is subsequently doubly clipped and ligated (Fig. 107.31). Small arterial branches arising from the aorta are ligated with cautery or a harmonic scalpel, mobilizing the medial border of the gland. The inferior and lateral borders of the gland are then mobilized in a similar manner from the upper pole of the left kidney. Finally, the anterior and superior borders of the gland are freed. The inferior phrenic vein may course along the anteromedial border of the gland to join the left adrenal vein. If encountered, it could be clipped and ligated.

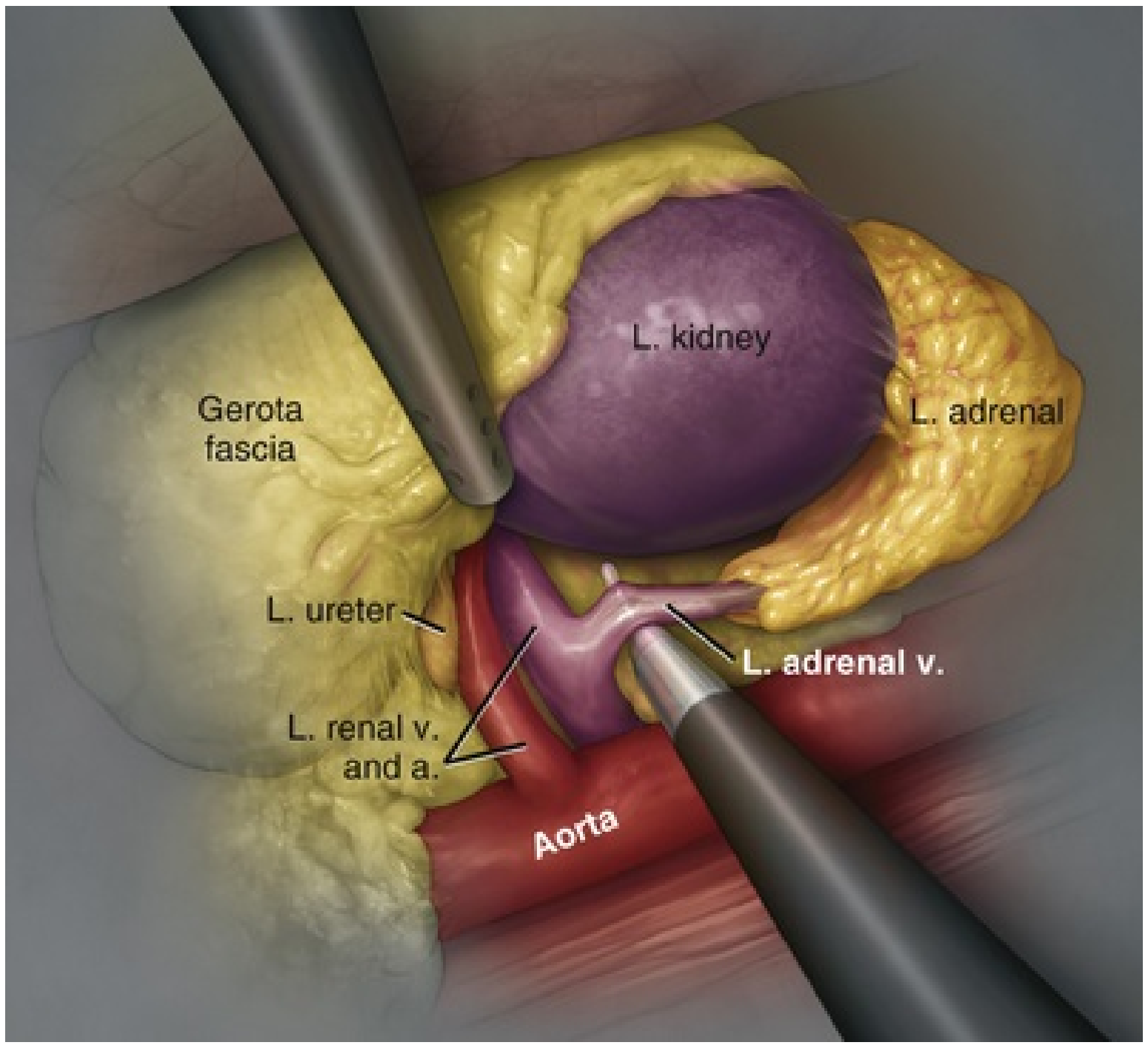

FIG. 107.30 Retroperitoneal laparoscopic adrenalectomy. Dissection of the left adrenal vein by the retroperitoneal approach. *a,* Artery; *L,* left; *v,* vein.

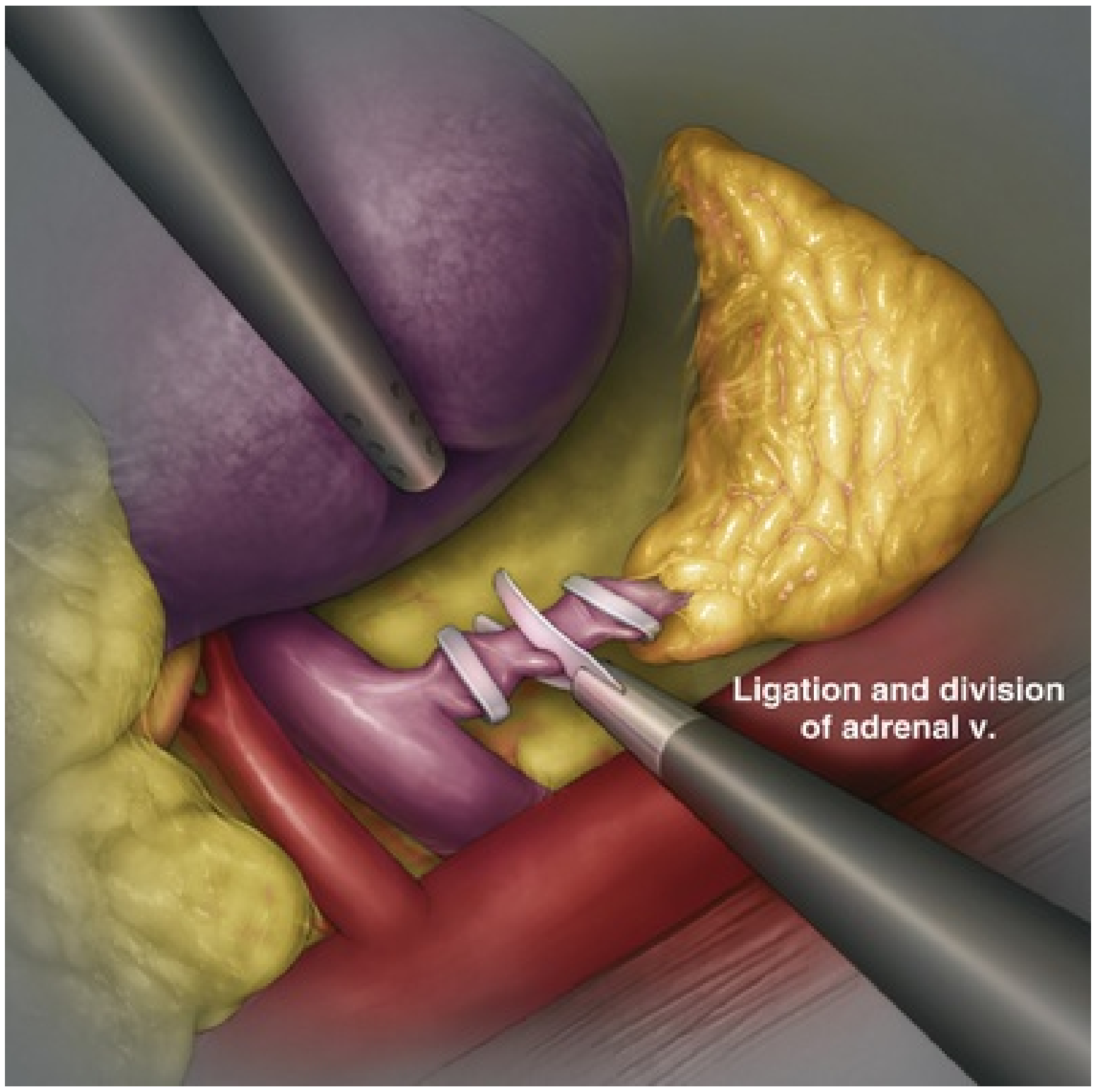

FIG. 107.31 Retroperitoneal laparoscopic adrenalectomy. Ligation and division of left adrenal vein. The kidney is dissected away from the adrenal gland. *v,* Vein.

Closure.

The specimen is placed in an endoscopic bag and extracted through a 10-mm port. After ensuring adequate hemostasis, the trocar sites are closed in the standard fashion as described earlier.

Retroperitoneal Lateral Adrenalectomy: Right Adrenalectomy

The right adrenalectomy is performed in a similar fashion, dissecting cephalad along the inferior vena cava to reach the renal hilum and right adrenal vein. The anatomic relationships of this approach are illustrated in Fig. 107.32.

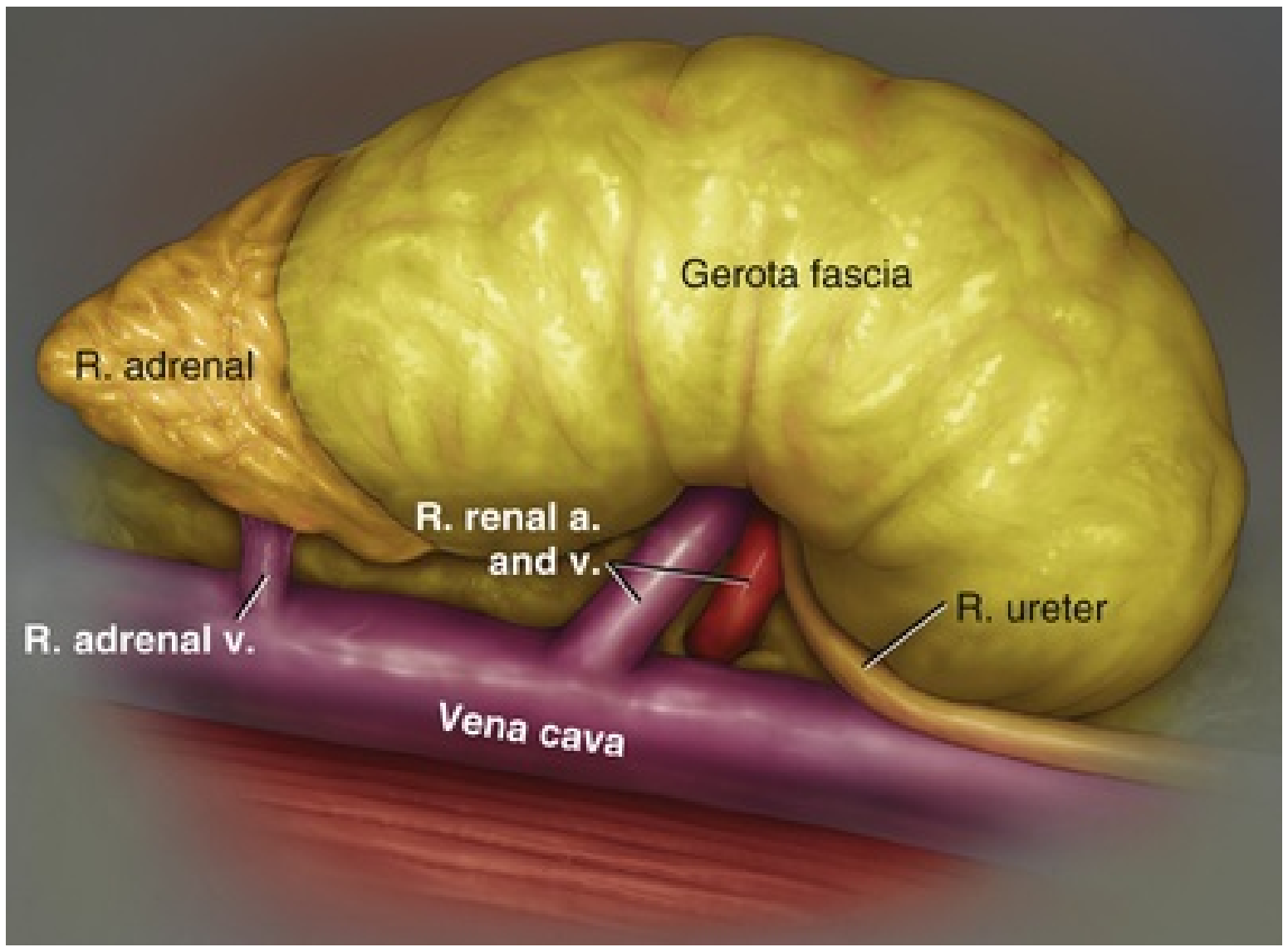
Gerota fascia
R. adrenal
R. renal a.
and v.
R. ureter
R. adrenal v.
Vena cava

FIG. 107.32 Anatomic view of right adrenal gland from laparoscopic retroperitoneal approach. *a,* Artery; *R,* right; *v,* vein.

Robot-Assisted Adrenalectomy

Currently, the da Vinci Surgical System (Intuitive Surgical, Sunnyvale, CA) is the dominant commercially available platform for robotic surgery, and the majority of adrenalectomies were performed using the da Vinci Surgical System. Since the first robot-assisted adrenalectomy in 1999, many centers around the world have jumped onto the bandwagon of robot-assisted adrenalectomy. The main benefits of the robotic system over conventional laparoscopy lie in superior ergonomics, three-dimensional (3D) magnification of the operative field, tremor filtering, and enhanced degrees of freedom of the EndoWrist (Intuitive Surgical, Sunnyvale, CA) instruments. These advantages of the robotic platform render it ideal in handling the fragile adrenal gland in a deep narrow space surrounded by major vessels and viscera, where injury may lead to catastrophic consequences.

Robot-Assisted Lateral Transperitoneal Adrenalectomy

After insertion of a nasogastric tube and urinary catheter, the patient is positioned in an oblique lateral position with the affected side elevated on a kidney rest at an angle of 30 to 45 degrees from the table. The bony prominences are padded and the patient is strapped securely onto the table. The table is then tilted in the opposite direction to achieve a supine position for port placement. A longitudinal 1.2-cm supraumbilical incision is made and pneumoperitoneum is established with a Veress needle. A 12-mm optical port is inserted for the camera for the S/Si model. The 12-mm port is replaced by a 8-mm robotic port in the Xi model. Two 8-mm robotic ports and a 12-mm assistant port are inserted under vision in the configuration shown in Fig. 107.33. For right adrenalectomy, an additional 5-mm port is inserted just inferior to the xiphoid process for liver retraction (Fig. 107.34). In general, the distance between the camera and each robotic port should be at least 8 cm to reduce instrument clashing internally and robotic arms clashing externally. The table is now tilted so that the patient lies in a full lateral position with the affected side upward. To facilitate access to the upper areas of the retroperitoneum, the robot is docked at an angle at the head of the table for the S/Si model as outlined in Fig. 107.35. For the Xi model, because of the rotating boom technology, there is more flexibility for the docking of the robot depending on the user's operating room setup.

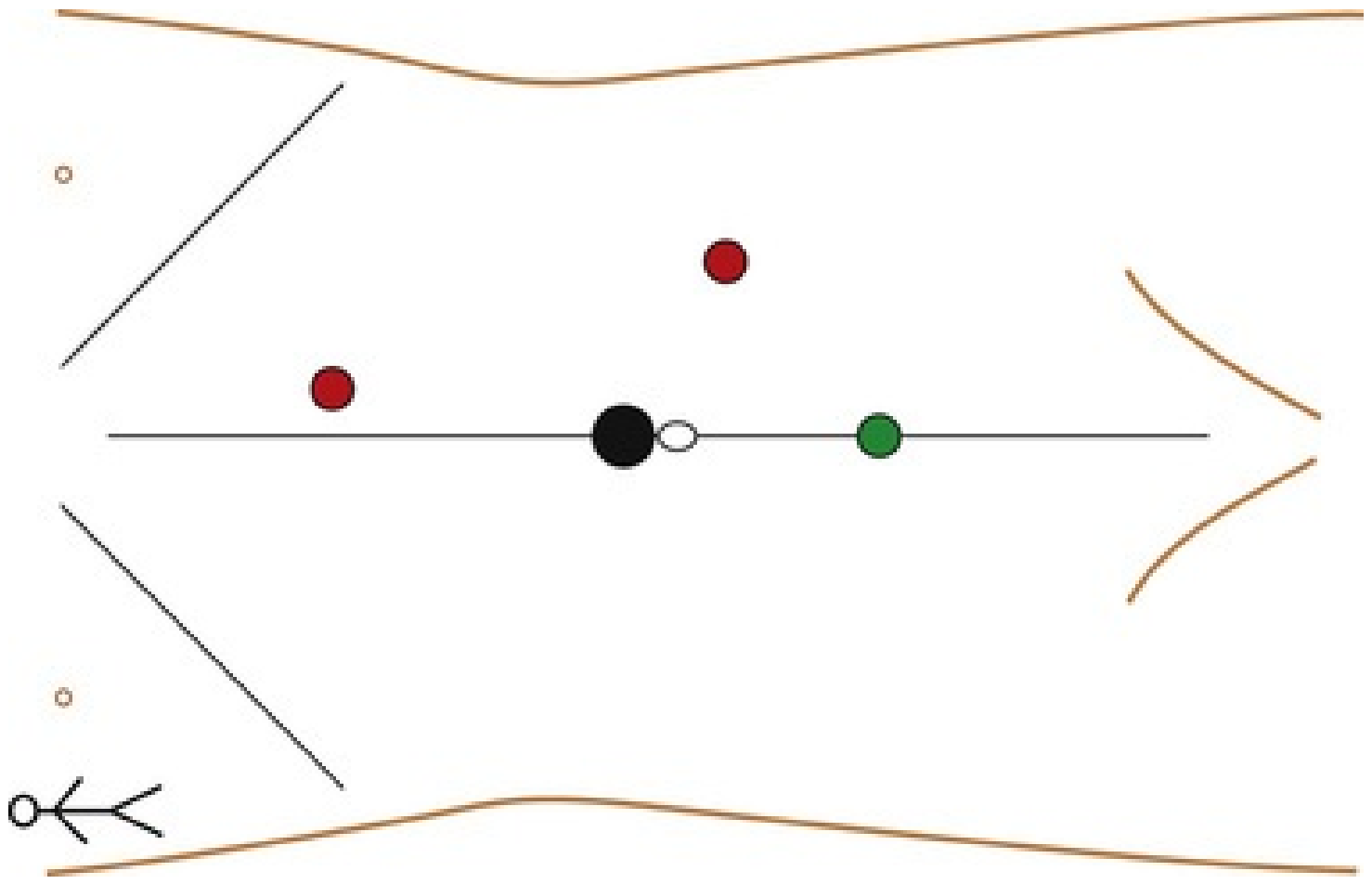

FIG. 107.33 Left robotic adrenalectomy trocar placement. A total of four ports are placed: one 12-mm camera port (●), one 12-mm assistant port (🟢), and two 8-mm robotic arm ports (🔴). The distance between each port should be at least 8 cm.

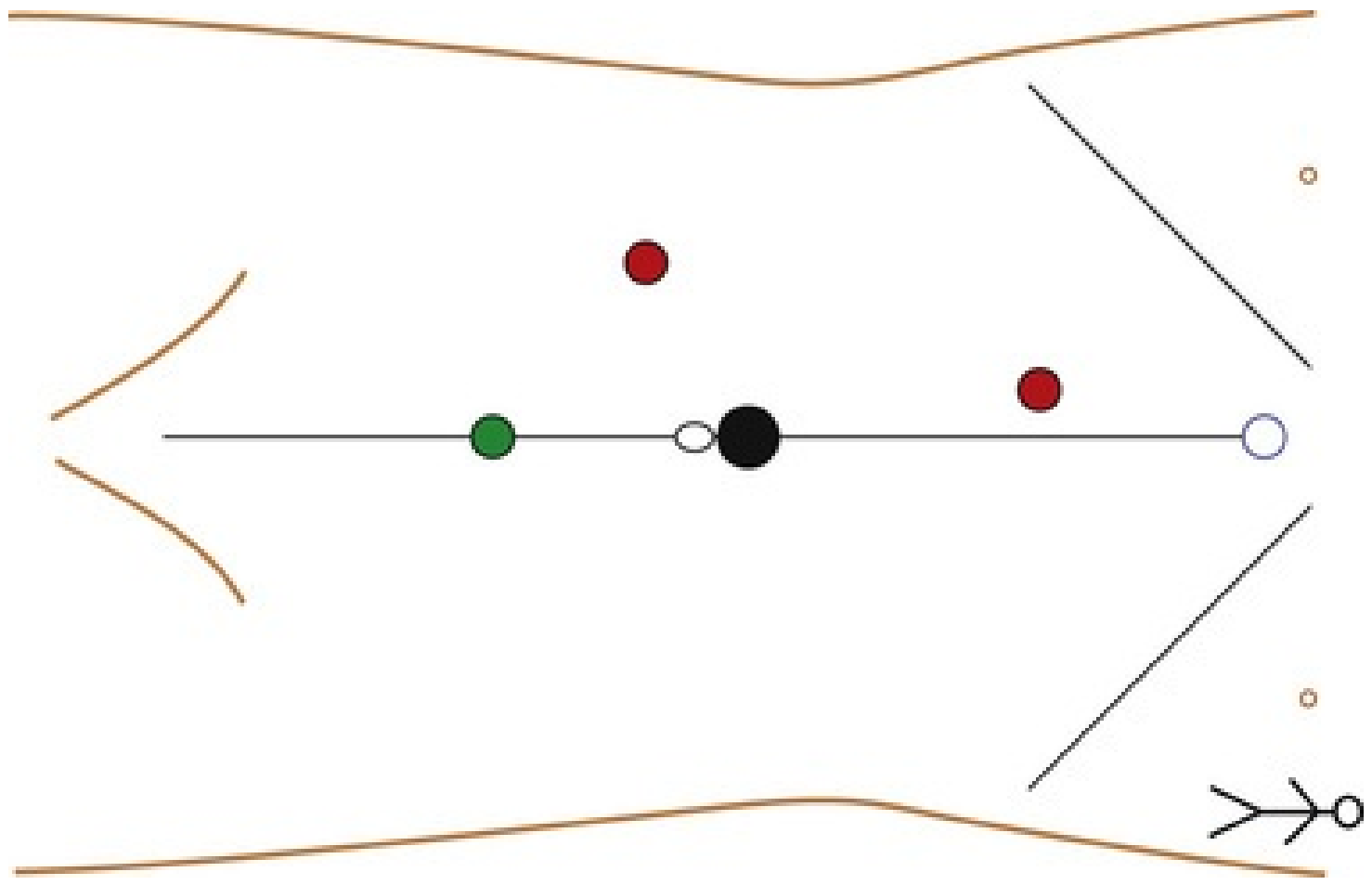

FIG. 107.34 Right robotic adrenalectomy trocar placement. A total of five ports are used: one 12-mm camera port (●), one 12-mm assistant port (🟢), two 8-mm robotic arm ports (🔴) are established, and to retract the liver, a 5-mm trocar (○) is placed with a retraction device.

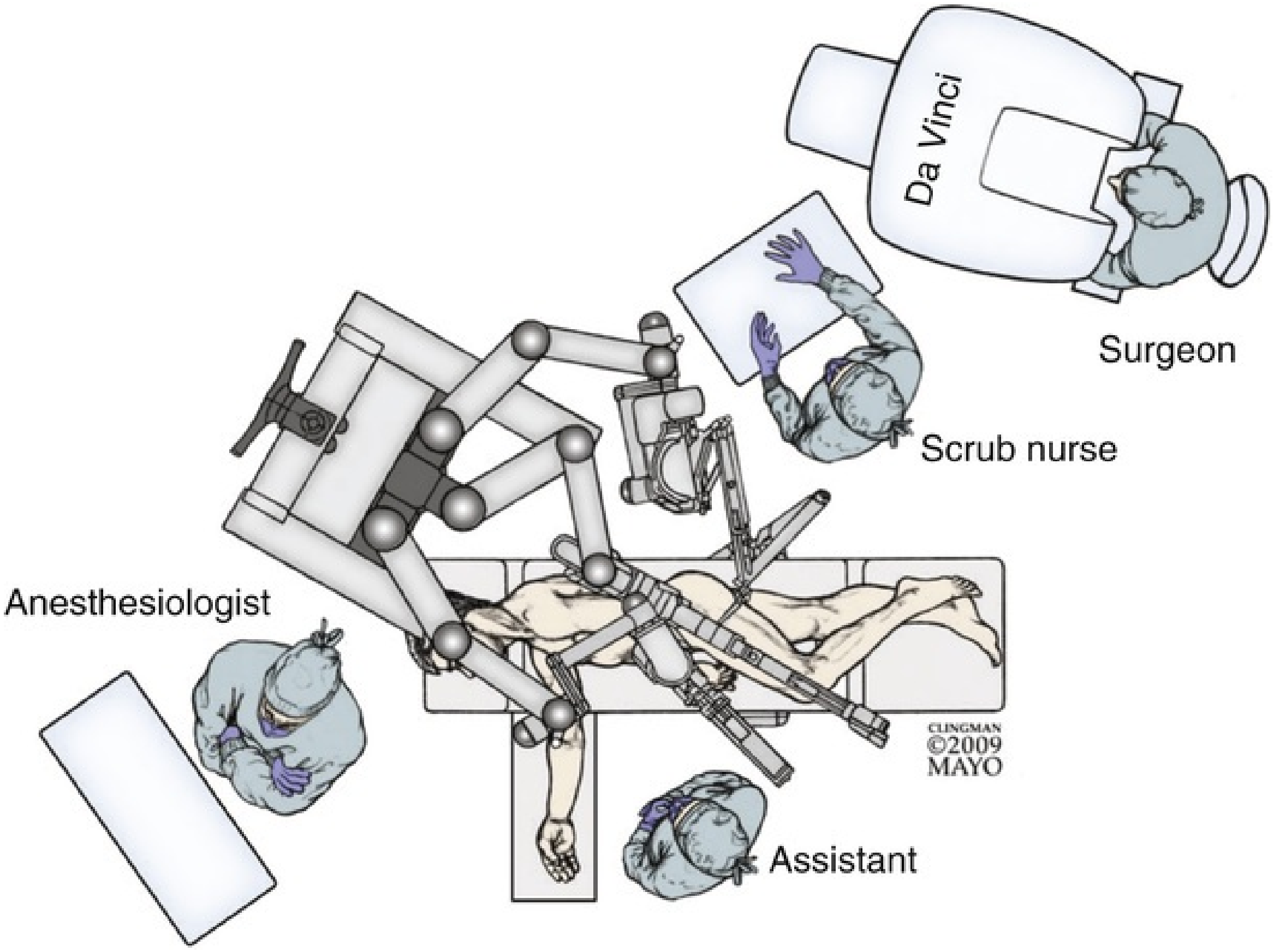
Da Vinci
Surgeon
Scrub nurse
Anesthesiologist
Assistant
CLINGMAN
©2009
MAYO

FIG. 107.35 Surgical room setup for left robotic adrenalectomy. The slave unit of the robot is brought in over the patient's left shoulder as indicated in the diagram. (By permission of Mayo Foundation for Medical Education and Research. All rights reserved.)

The dissection and mobilization of the adrenal gland are similar to the transperitoneal laparoscopic techniques described earlier.

Robot-Assisted Posterior Retroperitoneal Adrenalectomy

The patient is placed in a prone jackknife position using a Wilson frame. A small transverse incision is made just below the tip of the 12th rib and the retroperitoneal space is entered sharply. This space is further developed bluntly with a finger or with a dissecting balloon under vision if desired. A 12-mm optical port or 8-mm robotic port is designated as the camera port is anchored in place. Pneumoretroperitoneum was established with CO_2 insufflation. Two other 8-mm robotic ports were then placed on both sides of the camera port at least 8 cm apart, with the lateral port placed just below the line of 12th rib and the medial port in the subcostal location about 3 cm below the junction of the 12th rib and the paraspinous muscles. A 5-mm or 10- to 12-mm assistant port was placed lateral and inferior to the camera port (Fig. 107.36). The Gerota retroperitoneal fascia may have to be taken down carefully, avoiding injuring surrounding structures or violating the peritoneum laterally over the liver or spleen to create adequate space for ports placement. The surgical robot is docked from the patient's head.

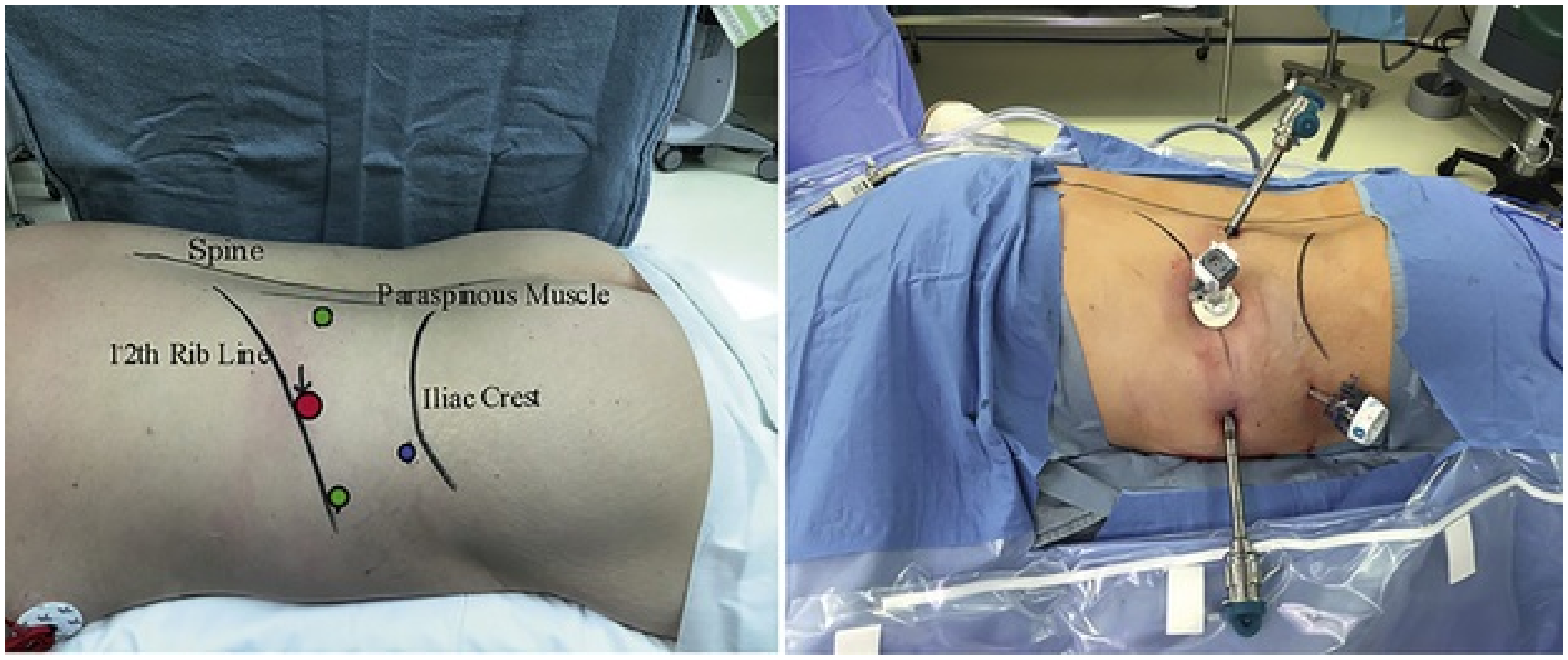

FIG. 107.36 Robot-assisted posterior retroperitoneal adrenalectomy. ● Camera port; ● 8-mm robotic ports; ● assistant port. (From Feng Z, Feng MP, Levine JW, et al.: Robotic retroperitoneoscopic adrenalectomy: useful modifications of the described posterior approach. *J Robot Surg* 11(4):409–414, 2017.)

With the 30-degree camera looking down, dissection began from lateral to medial, detaching the tissue above the kidney. A laparoscopic ultrasound can be used to help localize the adrenal gland. The kidney was retracted caudally by the assistant. The adrenal gland was mobilized from the superior aspect of the kidney, and the adrenal vein could be identified and clipped. Dissection of the adrenal gland can be complete by mobilizing it from the retroperitoneal attachments and removing it and placing it into a specimen bag.

Hand-Assisted Surgery

Hand assistance during laparoscopic surgery introduces enhanced tactile sensation and greater degrees of freedom of movement as compared with laparoscopic instruments. This may result in easier dissection, added security in the event of bleeding complications, and a shorter learning curve. With the introduction of the robotic system, hand-assisted adrenalectomy may have fallen out of favor in recent years, with publications limited to case reports and small case series published in the early 2000s. Hand-assisted adrenalectomy may be indicated in bilateral adrenalectomy or with large adrenal tumors that may require a larger incision for extraction. **There may also be a role for hand-assisted surgery as an alternative to open conversion should laparoscopic dissection prove difficult or for bleeding complications.**

Laparoendoscopic Single-Site Adrenalectomy

LESS surgery has recently been developed based on the principle that, with a smaller number of incisions and ports, enhancement of cosmesis and reduction of associated port site complications such as bleeding, organ injury, and incisional hernias can be attained. In general, all patients eligible for laparoscopic adrenalectomy can be considered for LESS depending on the surgeon's experience. However, because of the technical difficulties, LESS is most commonly performed for small (≤4 cm) and benign tumors.

Like conventional laparoscopic adrenalectomy, transperitoneal and retroperitoneal approaches for LESS adrenalectomy have been described. Single multiluminal access ports are commercially available for LESS access. The umbilicus is the most common location for LESS access because of the superior cosmetic results. However, the longer distance and the more tangential approach from the umbilicus to the adrenal gland render the surgery much more challenging. Alternative sites such as the subcostal margin or retroperitoneum have been described, albeit with less cosmetically appealing results. Moreover, the limited working space in the retroperitoneum makes the use of articulating and curved instruments more difficult when compared with the transperitoneal approach.

The inherent disadvantages of LESS surgery include reduced working space and loss of instrument triangulation leading to clashing, crossover, and paradoxic movement of instruments, as well as suboptimal approach to the adrenal gland and inadequate traction and countertraction. These disadvantages may translate into longer operative time and increased risk of tissue injuries and complications, especially during the early learning curve. Jeong et al. (2009) reported the first matched case-control study comparing 9 patients who underwent LESS adrenalectomy with 17 patients who underwent conventional laparoscopic adrenalectomy. Although the LESS adrenalectomy group required reduced postoperative analgesia, it was associated with a non–statistically significant longer operative time and a case of bowel injury. Similarly, Shi et al. (2011) and Walz et al. (2010) reported a longer median operative time and lower analgesic requirements after LESS adrenalectomy compared with conventional adrenalectomy. Ishida et al. (2013) showed that tissue regrasping was more frequently observed (16.2 vs. 2.2 times) during LESS than in conventional adrenalectomy. Hu et al. (2013) summarized in their meta-analysis comparing earlier studies of LESS adrenalectomy and conventional laparoscopic adrenalectomy that, although LESS adrenalectomy is associated with a longer operative time, estimated blood loss and complications are similar. In addition, patients who underwent LESS adrenalectomy had a shorter hospital stay and reduced requirement for analgesia.

The learning curve leading to a decrease in operative time for LESS adrenalectomy has been estimated by Fukumoto et al. (2017) to be about 30 cases. Many recent studies had reported no significant difference in operative time when comparing LESS adrenalectomy and conventional laparoscopic adrenalectomy. Indeed, a recent meta-analysis of 704 cases by Wu et al. (2016) reported that LESS adrenalectomy was associated with shorter length of hospital stay and lower postoperative pain scores with no significant difference in operative time, estimated blood loss, resumption of oral intake, dose of analgesic required, perioperative complications, conversion, transfusion, or pain medications required compared with conventional laparoscopic adrenalectomy.

Natural Orifice Transluminal Endoscopic Surgery–Assisted Laparoscopic Adrenalectomy

NOTES uses natural orifices such as the mouth, urethra, vagina, or anus as entry points to perform intra-abdominal surgeries. In pure NOTES, access points are strictly limited to natural orifices. Hybrid-NOTES allows for additional incisions to be made, usually around the umbilicus, to facilitate surgery. Like LESS, the aims of NOTES are to improve cosmetic outcomes and convalescence and reduce hospitalization stay and analgesia requirements without compromising safety and efficacy.

Fritscher-Ravens et al. (2008) were among the first to attempt NOTES adrenalectomy. By using the transesophageal or transgastric route with the aid of endoscopic ultrasonography, they failed to remove the adrenal gland in all procedures in which it was attempted. Perretta et al. (2009) successfully performed bilateral adrenalectomy in two female pigs and two female cadavers through a transvaginal retroperitoneal approach. The first report of hybrid-NOTES came from Zou et al. (2011), who presented their series of 11 female patients, with a median tumor size of 4.7 cm, who underwent transvaginal NOTES adrenalectomy. Injury to the spleen occurred in one patient, necessitating open conversion and splenectomy. Median estimated blood loss was 80 mL. Almost all published literature describes NOTES adrenalectomy via the transvaginal route. Eyraud et al. (2013) described their transrectal robot-assisted NOTES techniques in a male cadaver. The paucity of publications of NOTES adrenalectomy in the recent years may indicate a decline in interest in this approach. Currently, NOTES adrenalectomy is still in its infancy and should only be considered experimental.

Partial Adrenalectomy

Unilateral adrenalectomy is often well tolerated and should be considered as the gold standard in the treatment of functioning or malignant adrenal tumors. Patients with bilateral adrenalectomy require lifelong adrenal replacement therapy. Unfortunately, fixed daily dosing of steroids is associated with overdosing, which may result in osteoporosis, obesity, and Cushing syndrome, and with underdosing in times of stress. Life-threatening Addisonian crisis can occur. Patients after bilateral adrenalectomy continue to report poorer quality of life as compared with the general population (Hawn et al., 2002; van Aken et al., 2005): 30% reported constant tiredness with severe activity limitations; 48% of patients consider themselves to be handicapped (Debono M et al., 2009). Therefore partial adrenalectomy should be considered in patients with bilateral adrenal tumors, solitary adrenal gland, or familial syndromes such as von Hippel-Lindau disease, familial pheochromocytoma, and multiple endocrine neoplasia type IIA. Indications for partial adrenalectomy are summarized in Box 107.5. A review of 417 patients undergoing partial adrenalectomy published in 2010 by Kaye et al. found that the procedure was associated with minimal morbidity, a 3% recurrence rate, and the freedom from steroid replacement in 90% of patients.

Box 107.5

Indications for Partial Adrenalectomy

- Bilateral hereditary pheochromocytoma
  - Endocrine syndromes MEN I and II
  - von Hippel-Lindau syndrome
  - Neurofibromatosis type 1
  - Hereditary pheochromocytoma-paraganglioma syndrome (PGL)
  - Unilateral pheochromocytoma in documented genetic cases
- Primary aldosteronism resulting from unilateral adrenal adenoma with the opposite normal adrenal gland
- Unilateral adrenal adenoma in Cushing syndrome
- Pseudocyst or adrenal endothelial cyst

Partial adrenalectomy can be performed in any of the open, laparoscopic, or robot-assisted approaches described earlier. **A major and important difference is that the adrenal gland is exposed but not mobilized to preserve the arterial and venous blood supply, especially in cases in which the main adrenal vein has to be sacrificed.**

Accurate localization of the adrenal tumor in question is paramount for a successful partial adrenalectomy. In open surgery, the tumor can usually be visualized or palpated. In laparoscopic or robotic surgery, lesions larger than 1 cm can usually be visualized. In any of these approaches, the use of intraoperative ultrasonography can help accurately localize and identify the tumor. More recently, Manny et al. (2013) demonstrated use of fluorescent dye indocyanine green (ICG, IC-Green; Akorn Pharmaceuticals, Lake Forest, IL) during robotic surgery for better visualization of three different adrenal tumors (one pheochromocytoma, one lipoadenoma, and one benign nodular hyperplasia). Two milliliters of a 2.5 mg/mL solution were administered intravenously, and the robot (Intuitive Surgical, Sunnyvale, CA) was toggled to near-infrared (NIR) fluorescent mode. The adrenal parenchyma was seen to become fluorescent at an intensity only slightly less than the adjacent kidney but significantly less than the liver, while all three adrenal tumors were identified as hypofluorescent masses.

Once the lesion is identified, only the affected portion is mobilized. The arterial supply of the adrenal gland forms a plexus circumferentially around the gland and can usually be removed without fear of devascularizing the adrenal cortex. The gland will remain viable as long as it remains attached to the kidney or to an area of unmobilized connective tissue. The venous system drains into a central adrenal vein. Opinions are divided as to whether the main adrenal vein should be left intact during partial adrenalectomy. Some authors believe that removing the main adrenal vein will result in congested remnant adrenal tissues and difficult hemostasis, thus advocating its preservation (Imai et al., 1999; Janetschek et al., 1998). In our experience and as other authors concur, the main adrenal vein can be removed as long as the remnant adrenal gland remains in situ without mobilization (Kaouk et al., 2002; Walz et al., 1998). However, it would be prudent to preserve the main adrenal vein as long as it is safe and adequate margins can be obtained.

Partial adrenalectomy can be performed with either an endoscopic stapler (Imai et al., 1999), a harmonic scalpel (Sasagawa et al., 2000; Walz et al., 1998), or cautery or cold endoscissors with clips or suture ligation. The use of the endoscissors allows for clear identification of the tumor plane and precise dissection but may lead to more bleeding. Finally, the cut surface can be sealed with fibrin glue or Surgicel (Ethicon, Cincinnati, OH) to prevent delayed bleeding. Frozen section is recommended if available; if not, intraoperative ultrasonography can be performed to confirm gross complete resection.

The amount of adrenal tissue that must be left behind after partial adrenalectomy to avoid insufficiency is not known. It has been suggested previously that at least 20% of the adrenal gland should be preserved (Lee et al., 1996). However, Lee et al. were unable to correlate the amount of adrenal tissue preserved with the presence of adrenal insufficiency. More recent studies seem to suggest at least a third of the adrenal gland should be preserved (Brauckhoff M et al., 2003, 2008). Excision of tumor with a 3- to 5-mm margin is recommended.

Outcomes

Open Versus Laparoscopic Adrenalectomy

There has been only one randomized controlled trial comparing open with laparoscopic adrenalectomy. This was a small study consisting of 22 patients with pheochromocytoma, and the authors concluded that although laparoscopic adrenalectomy was associated with lower blood loss, shorter operative time and shorter hospital stay, there was an insignificant trend toward higher hemodynamic instability intraoperatively (Tiberio et al., 2008). It is highly doubtful that a large randomized controlled trial will ever be conducted because laparoscopic adrenalectomy is emerging as the gold standard technique for benign lesions, and surgeons are pushing the boundaries for laparoscopic management of malignant tumors. A cohort analysis performed using the Nationwide Inpatient Sample between 2002 and 2011 showed that of the nearly 60,000 adrenalectomies performed in the United States, 20% were performed with the minimally invasive approach with a 4% increase in the minimally invasive approach over the study period (Monn et al., 2015). Many large retrospective studies have consistently demonstrated superior outcomes of laparoscopic adrenalectomy over open surgery in terms of analgesia, hospital stay, blood loss, and complication rates. As surgeons gain more experience with laparoscopic surgeries, operative times have also decreased tremendously.

In an early meta-analysis of close to 100 studies comparing laparoscopic with open adrenalectomy, Brunt (2002) reported that, although the rate of bleeding complications was higher in laparoscopic (4.7%) than open (3.7%) adrenalectomy, total complication rates were lower in laparoscopic (10.9%) than open (25.2%) adrenalectomy. Open adrenalectomy was associated with significantly higher rates of associated organ injury and wound, pulmonary, cardiac, and infectious complications. There was also a higher non–statistically significant rate of mortality after open adrenalectomy (0.9% vs. 0.3%). Using the Veterans Affairs National Surgical Quality Improvement Program database to compare laparoscopic with open adrenalectomy, Lee et al. (2008) demonstrated that open procedures had increased operative times, transfusion requirements, reoperations, length of stay, and 30-day morbidity rates. Open adrenalectomy had also resulted in more pneumonia, unplanned intubation, unsuccessful ventilator wean, systemic sepsis, cardiac arrest, renal insufficiency, and wound infections. The 30-day morbidity rate was still higher even after adjusting for confounding factors.

Most recently, using a contemporary cohort from the American College of Surgeons National Surgical Quality Improvement Program (ACS-NSQIP) data, Elfenbein et al. (2013) concluded that patients undergoing laparoscopic adrenalectomy had significantly lower postoperative morbidity and shorter length of stay than patients undergoing an open procedure after adjustment for patient- and procedure-related factors, including malignancy. Similarly, a recent Nationwide Inpatient Sample from the United States involving close to 60,000 patients who underwent adrenalectomy echoed similar findings of fewer complications (8% vs. 13%) and shorter length of stay (2 days shorter) in patients who underwent laparoscopic adrenalectomy over their open adrenalectomy counterparts (Monn et al., 2015).

A recent network meta-analysis evaluation of open and minimally invasive adrenalectomy (Heger et al., 2017) yielded some interesting findings. In terms of complication rates, there was a significantly higher complication rate after open adrenalectomy than after laparoscopic surgery. The robotic approach was considered to have the lowest postoperative complication rate. Operating time was significantly shorter for open surgery than the retroperitoneoscopic and laparoscopic approaches, whereas intraoperative blood loss was significantly higher with open than with laparoscopic surgery with robotic approach resulting in the least blood loss. Finally, minimally invasive approaches were associated with a significantly shorter hospital stay than open surgery with the retroperitoneoscopic approach demonstrating the shortest length of hospital stay.

Laparoscopic Transperitoneal Versus Retroperitoneal Approach

Multiple retrospective studies have been performed that seem to suggest an advantage in terms of lesser blood loss and shorter convalescence time of the retroperitoneal approach over the transperitoneal approach. In a meta-analysis of 22 eligible studies (Constantinides et al., 2012), the laparoscopic retroperitoneal approach was associated with a significantly shorter hospital stay when compared with the transperitoneal approach. The authors attributed this to the decrease in postoperative pain and ileus associated with the retroperitoneal approach because the peritoneum is not breached. There were no differences in duration of operation, blood loss, time to ambulation and oral intake or complication rates between techniques. Another meta-analysis by Chen et al. (2013) identified nine eligible retrospective studies reporting that the retroperitoneal approach was associated with shorter operative time, less intraoperative blood loss, shorter hospital stay, and shorter time to first ambulation. There was no significant difference in open conversion rates, time to first oral intake, and major postoperative complication rates.

Three randomized prospective studies were carried out to compare these two approaches. Fernández-Cruz et al. (1996) randomized 21 laparoscopic adrenalectomy patients into transperitoneal and retroperitoneal approaches. They showed that the transperitoneal approach resulted in a greater rise in the $\mathrm{Pa}_{\mathrm{CO}_2}$ level compared with the retroperitoneal approach at 30 minutes, together with a significant increase in mean arterial pressure. However, operation time, blood transfusion and analgesia requirements, hospital stay, return to normal activities, and complication rates were similar between the two approaches. The authors concluded that the retroperitoneal approach may be a better option in patients with previous abdominal surgery and preexisting cardiopulmonary diseases. In another prospective randomized trial by Rubinstein et al. (2005) in which all baseline patient and operative factors were matched, the only significant difference was a shorter convalescence time in the retroperitoneal group. All other parameters such as blood loss, operative time, analgesia requirements, open conversion, and complication rates were similar. Finally, a prospective randomized study involving a more contemporary cohort concurred with the previous findings that the transperitoneal approach was comparable to the retroperitoneal approach in terms of operative time, estimated blood loss, time to ambulation, hospital stay, and analgesic requirement but was associated with longer time to oral intake resumption and longer convalescence period (Mohammadi-Fallah et al., 2013).

Ball et al. (2017) recently compiled an evidence-based systematic review on the use of minimally invasive adrenalectomy as part of the International Consultation on Urological Diseases (ICUD) and European Association of Urology (EAU) consultation. They concluded that transperitoneal and retroperitoneal approaches are equally effective, and one or the other should be chosen based on surgeon training and experience (Grade A).

Laparoscopic Versus Robot-Assisted Adrenalectomy

As described previously, the robotic platform offers several advantages over conventional laparoscopy, but current literature has yet to show conclusively that these advantages have translated into better clinical outcomes. A prospective randomized study comparing robot-assisted with laparoscopic adrenalectomy was published in the early years of robot-assisted surgeries. Morino et al. (2004) randomized 20 consecutive patients with benign adrenal tumors to either traditional laparoscopic or robotic surgery. The robot-assisted approach was associated with a longer operative time and higher 30-day complication rate compared with the laparoscopic approach. In addition, cost analyses revealed that robotic procedures were more expensive than laparoscopic procedures. The authors concluded that laparoscopic adrenalectomy was superior to robot-assisted adrenalectomy in terms of feasibility, morbidity, and cost. In separate studies, Brunaud et al. concurred that patients' quality of life after robotic surgery was similar to that after laparoscopic surgery (Brunaud et al., 2004), but robotic surgery was 2.3 times more expensive (Brunaud et al., 2008). However, this increase in cost can be mitigated in high-volume centers. Probst et al. (2016), in a recent paper comparing costs of robotic adrenalectomy and open adrenalectomy, demonstrated that the additional costs of robotic surgery were equalized if at least 150 cases of robotic procedures were performed per year based on certain health care cost assumptions within the health care system.

Robot-assisted surgery requires the insertion of more trocars and docking of the robotic arms when compared with conventional laparoscopy, and these additional steps may lead to longer operative time (Morino et al., 2004; Pineda-Solís et al., 2013; Wu et al., 2008). Robotic surgery is highly dependent on the expertise of the assistant and the whole robotic team, including the scrub nurses. As robotic teams go beyond the initial learning curve of 10 to 20 cases, operative times have been shown to approach those clocked by the conventional laparoscopic approach (Agcaoglu et al., 2012a; Brunaud et al., 2008; Karabulut et al., 2012). Karabulut et al. (2012) went further to time each individual step of adrenalectomy and reported similar timings for each step of robotic and laparoscopic adrenalectomy, except for shorter hemostasis time in the robotic group.

Multiple studies have demonstrated that perioperative outcomes such as estimated blood loss, hospital stay, postoperative analgesia, and complication and mortality rates are similar between the two approaches. In fact, robot-assisted adrenalectomy may be preferred in certain circumstances. For tumors greater than 5 cm, Agcaoglu et al. (2012b) reported shorter operative time and hospital stay and lower open conversion and morbidity rates in robot-assisted as compared with conventional laparoscopy. In a separate study by Karabulut et al. (2012), the morbidity was 10% in the laparoscopic and 2% in the robotic group despite the fact that tumors in the robotic group were significantly larger. For obese patients with body mass index 30 kg/m^2 or greater, Aksoy et al. (2013) found no differences in operative time, estimated blood loss, and hospital stay between robot-assisted and laparoscopic adrenalectomy. However, there was a lower conversion rate (0 vs. 5.2%) and a non–statistically significant lower 30-day morbidity rate (4.8% vs. 7%, $P = 0.06$) in favor of the robotic approach (Aksoy et al., 2013). Society of Gastrointestinal and Endoscopic Surgeons (SAGES) 2013 guidelines suggested that the use of robot-assisted adrenalectomy in patients with a high BMI as well those with larger tumors may be advantageous.

Being early in a surgeon's learning curve is associated with worse perioperative outcomes and increased complications. It has been estimated that the learning curve of laparoscopic adrenalectomy is between 20 and 40 cases, whereas that of robot-assisted transperitoneal adrenalectomy is only about half, ranging between 10 and 20 cases. Data for robot-assisted adrenalectomy are maturing in recent years as surgeons gain more experience in this approach. Three recent meta-analyses showed some benefits of robotic approach over the standard laparoscopic approach. In an analysis of nine studies (600 patients), Brandao et al. (2014) reported a shorter hospital stay, less blood loss, and lower occurrence of postoperative complications in patients who underwent robot-assisted adrenalectomy when compared with standard laparoscopic adrenalectomy. Tang et al. (2015) analyzed eight trials and showed that, although the robotic approach was associated with a longer operative time, it was associated with significantly less blood loss and shorter hospital stay over standard laparoscopy. Finally in the largest meta-analysis comprising 27 trials and 1162 patients (Economopoulos et al., 2017), it was demonstrated that there was no significant difference between the robotic and the laparoscopic groups for intraoperative complications, postoperative complications, mortality, conversion to laparotomy or laparoscopy, blood loss, and operative time. The only significant difference found was a shorter hospital stay in favor of robot-assisted adrenalectomy.

Complications

Intraoperative

Box 107.6 summarizes the intraoperative complications that can occur. As expected, adrenal surgery, both open and laparoscopic, can involve injury to adjacent organs. Hemorrhage is a potentially catastrophic complication of adrenal surgery. Bleeding can result from injury to the adrenal vein, inferior vena cava, lumbar vein, or renal vein. These injuries are managed initially by application of direct pressure to the injury. Grasping a small injury with an Allis clamp (Scanlan International, St. Paul, MN) and closing it with suture or by placement of a vascular clamp for a larger vena cava injury may be curative. In the early days of laparoscopic adrenalectomy, open conversion was the typical consequence of vascular injury. However, with increasing experience with laparoscopic suturing techniques, these injuries are often managed as in the open surgery.

Box 107.6

Intraoperative Complications of Adrenal Surgery

Access Related

Abdominal wall hemorrhage
Cutaneous nerve injury
Visceral injury by Veress needle or trocar

Hemorrhage

Inferior vena cava or aorta
Adrenal vein
Lumbar vein
Hepatic vein
Remnant adrenal gland after partial adrenalectomy

Ischemia

Ligation of renal artery or vein
Ligation of superior mesenteric artery and vein

Injury to Neighboring Organs as a Result of Thermal Energy or Incorrect Plane of Dissection

Lung—pneumothorax
Pancreas
Liver
Spleen
Stomach and bowel, especially duodenum
Kidney

Hemodynamic Instability

Pheochromocytoma

Modified from Vaughn ED: Complications of adrenal surgery. In Taneja SS, Smith RB, Ehrlich RM, editors: *Complications of urologic surgery: prevention and management*, ed 3, Philadelphia, 2001, p 366.

Ischemic injuries can occur as well. An upper pole renal artery branch can be divided inadvertently during dissection. If the branch is small and supplies a minimal portion of the kidney, it can be ignored. More substantial injuries may require a revascularization attempt. If the patient has a large tumor, there can be distortion of the regional anatomy, and inadvertent ligation of the superior mesenteric vein or artery is possible. This is a potentially fatal injury, and one must have a high index of suspicion to restore vascular supply to the bowel as soon as possible.

The adjacent organs can be injured during dissection of the adrenal gland. The liver can be injured during right adrenalectomy. Liver lacerations can be treated with argon beam coagulation and application of hemostatic agents such as methylcellulose. More serious injuries may require hemostatic sutures with a blunt-tip liver needle. The spleen can be injured during left adrenalectomy. As with hepatic injury, argon beam coagulation and hemostatic agents can be used to control bleeding. If this is not sufficient, splenorrhaphy can be attempted. If these measures are unsuccessful, splenectomy may be necessary. **It is important**

to remember to give pneumococcus, *Haemophilus influenzae* type B (Hib) and meningococcus vaccinations to these patients during postoperative care.

The pancreas can be injured during surgery on either the right or left adrenal gland. If an injury to the tail of the pancreas occurs, distal pancreatectomy may be performed. If the injury is to the pancreatic duct, this may be repaired and surgical drains left. If there is uncertainty of pancreatic injury, leaving closed-suction surgical drains behind is advisable. Postoperative drainage high in triglycerides is indicative of pancreas injury. Management consists of bowel rest with parenteral nutrition. The administration of octreotide can decrease pancreatic secretions while the pancreas heals.

The proximity of the kidney to the adrenal gland can be a problem in cases of large adrenal cortical carcinomas. **It is imperative for all patients undergoing surgery for large adrenal masses to be counseled about the possibility of concurrent en bloc nephrectomy.**

During 11th-rib or higher flank adrenalectomy, it is not unusual for pleural injury to be incurred. These injuries can be repaired with a purse-string chromic suture and a red rubber catheter to water seal. Expulsion of air from the pleura followed by cinching of the purse-string suture usually repairs the defect. Postoperative chest radiography should be routinely performed after flank or thoracoabdominal nephrectomy. If a significant pneumothorax is present, a chest tube should be placed.

With pheochromocytoma, blood pressure fluctuations can be life threatening. The anesthesiologist typically manages high blood pressure with short-acting β-blockade, alpha-blockers, or nitroprusside. Arrhythmias are usually treated with beta-blockers. When the adrenal vein is ligated, there can be a sudden drop in blood pressure. It is important to inform the anesthesiologist just before the adrenal vein is ligated to avoid any nasty surprises. Fluid repletion and vasopressors may be necessary to bring the pressure to normal.

With the emergence of minimally invasive surgery, access-related complications can occur. Bleeding from the abdominal wall can occur after trocar insertion. Care should be exercised to avoid visible superficial veins during trocar site insertion. Although bleeding usually stops from the tamponade effect of the trocar and pneumoperitoneum, it is imperative to inspect all trocar sites laparoscopically upon trocar withdrawal at end of surgery to ensure hemostasis. Cutaneous nerve injury is less likely to occur than in open surgery because of smaller incisions. Finally, visceral injury by the Veress needle can occur. Closed access technique using the Veress needle must be done with caution in patients with previous abdominal surgery because bowels may be adherent to the abdominal wall and can be injured. The open (Hasson) access technique can be a safer alternative in these cases.

Postoperative

The American College of Surgeons National Surgical Quality Improvement Program reported a 7.5% overall complication rate in 4844 patients who underwent adrenalectomy during the period of 2005 to 2012 (Sood et al., 2016). Of these, 43.2% occurred postdischarge. The overall blood transfusion, reintervention, readmission, and mortality rates were 3.9%, 2.0%, 6.4%, and 0.6%, respectively. The median time to major complications was 4 days, whereas for minor complications it was 9 days from surgery; most complications occurred within the first 2 weeks postadrenalectomy (Sood et al., 2016). A previous nationwide study by Park et al. using the Nationwide Inpatient Sample (NIS) reported an overall inpatient complication rate of 16% between 1999 and 2005. This improvement in overall complication rate is likely due to increased experience in adrenalectomies.

Box 107.7 summarizes the postoperative complications that can occur. Disease-specific complications must be accounted for to ensure an uneventful postoperative course. Risk factors associated with increased complication rates include larger tumor sizes, functional adrenocortical adenocarcinoma or adenoma, and conversion to open surgery (Thompson et al., 2017).

Box 107.7

Postoperative Complications of Adrenal Surgery

Primary Aldosteronism

Hypokalemia: secondary to continued potassium loss immediately postoperative

Hyperkalemia: secondary to failure of contralateral adrenal to secrete aldosterone

Cushing Syndrome

Inadequate steroid replacement leading to hypocorticism
Fracture secondary to osteoporosis
Hyperglycemia
Poor wound healing
Increased risk of infections

Pheochromocytoma

Hypotension secondary to α-adrenergic blockade after tumor removal

Generic Complications

Hemorrhage
Pneumothorax
Pancreatitis
Pneumonia
Prolonged ileus
Intra-abdominal collections

Modified from Vaughn ED: Complications of adrenal surgery. In Taneja SS, Smith RB, Ehrlich RM, editors: *Complications of urologic surgery: prevention and management*, ed 3, Philadelphia, 2001, Saunders, p 368.

Patients with primary hyperaldosteronism require close monitoring of potassium levels because they can be either hypokalemic or hyperkalemic. Hyperkalemia, secondary to contralateral adrenal zona glomerulosa suppression, should be managed medically with the typical hyperkalemia regimens. Hypokalemia can persist in the immediate period after adrenalectomy, and this should be corrected with potassium repletion. In patients who had only one adrenal gland to begin with, mineralocorticoid replacement with fludrocortisone is essential.

Patients with Cushing syndrome require steroid replacement after surgery until the contralateral gland recovers function. Measurements of plasma cortisol can be useful in determining when steroid replacement can be tapered. Furthermore, these patients have increased risk of fracture secondary to osteoporosis, hyperglycemia, and poor wound healing.

Patients with pheochromocytoma may have hypotension secondary to α-blockade. These patients need to be monitored closely until α-blockade wears off, often in the intensive care unit. If α-blockade was not used preoperatively, intensive care stay is unnecessary in most cases.

Ablative Therapy for Adrenal Tumors

Ablative therapies can be performed either percutaneously with imaging guidance or intraoperatively, usually laparoscopically. Current indications for ablative therapy for adrenal tumors include patients with small hyperfunctional tumors not keen on or suitable for surgery, treatment of oligometastatic lesions or palliation of metastases not amenable to resection. In such cases, the size of the lesion is an important factor to achieving complete tumor ablation. The smaller the size of the lesion, the greater the likelihood of complete treatment. Although the threshold size to expect therapeutic response has not been well evaluated, better results have been reported for adrenal tumors measuring 5 cm or smaller (Wood et al., 2003). In addition, patients with normal-appearing adrenal glands or with multiple nodules are not candidates for ablation because of the uncertainty of location of the hyperfunctioning nodule. Proximity of the nodule to the inferior vena cava may cause a heat sink effect, reducing the efficacy of the ablation.

The three major thermal ablative techniques currently used are radiofrequency ablation (RFA), cryoablation, and microwave ablation. RFA uses frictional energy created by oscillating tissue ions to supply destructive heat to target tissue, with target tissue temperature ranging from 60°C to 100°C, resulting in protein and enzymatic degradation and cell death. The advantages of RFA include a well-established safety profile, widespread availability, and predictable thermal volumes based on the probe type. Microwave ablation creates an alternating electric field that causes oscillation of surrounding water dipoles resulting in tissue heating. Some authors have suggested that advantages of microwave ablation include the ability to achieve higher local temperatures, the potential for larger ablation volumes in a shorter ablation time, decreased procedural pain, and the potential to treat cystic lesions (Simon et al., 2005). Cryoablation relies on rapid freezing and thawing to cause rupture of cell membranes resulting in cell death. The main advantage of this technique is the ability to follow iceball formation in real time with CT imaging, reducing the risk of injury to surrounding organs. The main limitations of cryoablation are the increased risk of hemorrhage caused by microvascular thrombosis and the inability to coagulate tissue during probe withdrawal such as can be done with RFA and microwave ablation, leading to a theoretical risk of tract seeding.

Planning the route of approach is very important to ensure complete ablation of the lesion and avoiding complications. The main complications are injury to neighboring organs such as the liver, spleen, bowels, or lungs and hemorrhage. To reduce the risk of hemorrhage, it is important to identify and consider any critical vascular structures that lie adjacent to the adrenal glands, including the inferior vena cava, aorta, renal arteries, and lumbar collateral vessels. If the lesions are hypervascular, such as metastases from hepatocellular carcinoma or renal cell carcinoma, combination therapy with adrenal arterial embolization and ablation therapy can be useful for preventing hemorrhagic complication and reinforcing antitumoral effects.

It is generally recommended to perform a biopsy of the tumor either before or at the same session as ablative therapy because histologic results may influence follow-up management. Systemic catecholamine release resulting in hypertensive crisis and cardiac arrest has been reported during ablative treatment of adrenal metastases, hyperfunctioning tumors, and pheochromocytomas (Chini et al., 2004; Mamlouk et al., 2009; Tsoumakidou et al., 2010). **Because catecholamine release can be caused by thermal injury to the adrenal in the absence of pheochromocytoma,** some authors advocate premedication with α-blockade before the ablation procedure. Welch et al. (2011) demonstrated a significant increase in systolic blood pressure, pulse pressure, and mean arterial pressures in patients undergoing adrenal cryoablation, even with prior α-blockade. Continuous blood pressure monitoring with an arterial line and general anesthesia with a rapid-acting vasodilatory drug on standby may be prudent.

Ablative therapy is most commonly performed for hyperfunctioning tumors. Mendiratta-Lala et al. (2011) treated 13 hyperfunctioning small adrenal tumors with RFA. At a mean follow-up of about 21 months, all patients experienced resolution of clinical symptoms or syndrome and normalization of biochemical markers. The majority of current literature on ablative therapy is centered on treatment of metastases in the adrenal gland. The largest of these studies by Wolf et al. (2012) reported that 19 of 23 tumors treated showed no evidence of local progression and tumor enhancement at mean follow-up of 45.1 months after RFA or microwave ablation. Other studies also mirrored excellent short-term local progression-free and enhancement-free rates ranging from 83% to 100% after RFA, microwave ablation, or cryoablation (Carrafiello et al., 2008; Mayo-Smith and Dupuy, 2004; Wang et al., 2009; Welch et al., 2011). When compared with laparoscopic adrenalectomy, no prospective randomized trial is available. Studies by Sarwar et al. (2016) and Yang et al. (2016) showed no statistically significant difference in treatment results when comparing ablation with adrenalectomy. However, Liu et al. showed lower rates of hypertension resolution with radiofrequency ablation compared with laparoscopic adrenalectomy (92% vs. 100%). Nonetheless, when compared with surgery in all three studies, radiofrequency ablation had a number of significant advantages including shorter operative time, shorter hospital stay, less analgesic requirements, less blood loss, lower complication rates, and earlier resumption of work. Evidence of long-term follow-up and outcomes are generally lacking. Liu et al. reported at long-term follow-up of about 6 years after RFA of aldosterone-producing adenoma, treatment success was maintained in 92% of patients, all of whom had biochemical markers in the normal range with a 0 recurrence rate.

In the treatment of malignant tumors, ablative therapy is more commonly used in the management of metastatic lesions than primary adrenocortical carcinomas. Using thermal ablation, the reported rates of residual or recurrent disease in treating adrenal malignancies are as low as 0 to 25%, with a mean follow-up of 10.3 to 37.7 months (Li et al., 2011; Welch et al., 2011; Wolf et al., 2012; Wood et al., 2003).

Future of Adrenal Surgery

Although the adrenal glands or adrenal tumors can usually be identified fairly easily intraoperatively in most cases, there are certain situations in which accurate localization of the gland or tumor is more difficult: for example, in patients with severe obesity, previous abdominal surgeries with dense intra-abdominal adhesions or small adrenal tumors in which partial adrenalectomy is to be attempted. The most widely used adjunct for this purpose currently is the intraoperative laparoscopic ultrasound and is associated with some limitations such as poor visualization at certain difficult angles, contributed partly by the fairly bulky probe and the limitations of degree of movement of the probe. Recently, the use of ICG and radionuclide isotopes such as ^{131}I-iodocholesterol with gamma probe had been tried in a few patients with encouraging success. DeLong et al. (2015) showed that with the help of ICG and near-infrared (NIR) fluorescence, they were able to perform four cases of laparoscopic adrenalectomy with lesser blood losses and shorter operative times. Sound et al. (2016) reported differentiated uptake of ICG under NIR depending on the adrenal pathologies. They found that primary hyperaldosteronism was associated with increased uptake of ICG, whereas adrenocortical carcinoma and pheochromocytoma were associated with little or no ICG uptake. These findings are potentially helpful in tumor localization especially during partial adrenalectomies. One limitation of ICG is for right adrenalectomies, the liver will have similar uptake with the adrenal gland, and this may potentially lead to difficulties in the identification of the right adrenal gland.

Contemporary computer-based image acquisition systems are able to perform accurate 3D reconstruction of an organ or body region. Surgeons are now able to manipulate these 3D images so that the organ or body region could be viewed from almost all angles, allowing surgeons to acquire a mental picture of the regional anatomy they will be dealing with before surgery. 3D printing technologies currently allow surgeons to have an exact, individualized replica of the adrenal gland to aid surgery (Srougi et al., 2016) Currently, virtual reality systems are being developed that will allow for the creation of a virtual environment in which organs and structures can be represented in a fully 3D manner and surgeons can interact with the images as though they truly exist and perform tasks and surgical manipulations (Marescaux et al., 2005). In addition, the differentiation between the structure of the normal gland and pathological lesions can be enhanced with high contrast and color, allowing for accurate localization of pathological lesions and their relationship with the surrounding structures.

There are a few potential clinical applications for these virtual reality systems (Marescaux et al., 2005). First, by integrating with surgical simulators, residents and junior surgeons are able to gain surgical experience in a completely safe environment where errors could be made without detrimental consequences to the patient. Second, the integrated system can allow the surgeon to have an individualized “dry run” of a patient's surgery before the actual procedure, allowing for better planning as well as anticipation of possible dangers and identification of the optimal plane for dissection or resection. Third, there are currently applications in initial clinical trials that allow 3D reconstruction images of an organ to be superimposed as an overlay onto the target organ on the operating field via the tile-pro technology of the da Vinci Surgical Robotic Platform, allowing surgeons to see in real time the surrounding vasculatures as well as the tumor during the surgery. This is especially helpful in partial adrenalectomies or in cases of complex adrenal or renal vasculatures. Finally, by integrating these virtual reality systems with advanced surgical robots in future, the digital data of the best simulated procedure performed by an expert could be recorded and transmitted to a distant remote location where a robot reproduces the surgery automatically on a patient. In fact, the first clinical application has already been developed by Kurenov et al. (2017). The system included a surgeon-authored virtual reality (VR) training module authored by surgeons using the Toolkit for Illustration of Procedures in Surgery (TIPS) and two 6 degrees of freedom haptic devices simulating laparoscopic instruments providing physical feedback to the training surgeon.

The future of adrenal surgery remains exciting and fascinating. Science fiction of today may become the reality of tomorrow.

Key Points: Surgery of the Adrenal Glands

- Adrenalectomy is indicated in functional adrenal masses or suspected adrenal malignancy, either primary adrenal cortical carcinoma or solitary metastasis from nonadrenal sources.
- Preoperative and postoperative medical management is essential for optimal surgical outcome for functional adrenal tumors.

- Laparoscopic adrenalectomy is the current standard of care for adrenal lesions with the exception of invasive adrenal cortical carcinoma or adrenal cortical carcinoma with caval thrombus. Robot-assisted adrenalectomy is emerging as an alternative approach especially in more complex cases such as obese patients or large tumors.
- Open adrenal surgery is indicated for lesions contraindicated for or not amendable to minimally invasive techniques (e.g., large invasive carcinomas, great vessel involvement, severe cardiopulmonary diseases).
- All patients undergoing surgery for large adrenal masses must be counseled about the possibility of concurrent en bloc nephrectomy.
- It is recommended to perform a biopsy of the tumor either before or at the same session as ablative therapy.

Suggested Readings

Brix D, Allolio B, Fenske W, et al. German Adrenocortical Carcinoma Registry Group. Laparoscopic versus open adrenalectomy for adrenocortical carcinoma: surgical and oncologic outcome in 152 patients. *Eur Urol*. 2010;58:609–615.

Lee J, El-Tamer M, Schifftner T, et al. Open and laparoscopic adrenalectomy: analysis of the National Surgical Quality Improvement Program. *J Am Coll Surg*. 2008;206:953–959 [discussion 959–61].

Murphy MM, Witkowski ER, Ng SC, et al. Trends in adrenalectomy: a recent national review. *Surg Endosc*. 2010;24:2518–2526.

National Comprehensive Cancer Network. *NCCN clinical practice guidelines in oncology: neuroendocrine tumors, version 1*. [2014 (website)] http://www.nccn.org/professionals/physician_gls/f_guidelines 2014.

NIH state-of-the-science statement on management of the clinically inapparent adrenal mass (“incidentaloma”). *NIH Consens State Sci Statements*. 2002;19(2):1–25.

References

Agcaoglu O, Aliyev S, Karabulut K, et al. Robotic vs laparoscopic posterior retroperitoneal adrenalectomy. *Arch Surg*. 2012;147:272–275.

Agcaoglu O, Aliyev S, Karabulut K, et al. Robotic versus laparoscopic resection of large adrenal tumors. *Ann Surg Oncol*. 2012;19:2288–2294.

Aksoy E, Taskin HE, Aliyev S, et al. Robotic versus laparoscopic adrenalectomy in obese patients. *Surg Endosc*. 2013;27:1233–1236.

American Association of Clinical Endocrinologists and American Association of Endocrine Surgeons Medical Guidelines for the Management of Adrenal Incidentalomas. *Endocr Pract*. 2009;15(5):450–453.

Autorino R, Bove P, Sio MD, et al. Open versus laparoscopic adrenalectomy for adrenocortical carcinoma: a meta-analysis of surgical and oncological outcomes. *Ann Surg Oncol*. 2016;23:1195–1202.

Ball MW, Hemal AK, Allaf ME. International Consultation on Urological Diseases and European Association of Urology International Consultation on Minimally Invasive Surgery in Urology: laparoscopic and robotic adrenalectomy. *BJU Int*. 2017;119:13–21.

Berland LL, Silverman SG, Gore RM, et al. Managing incidental findings on abdominal CT: white paper of the ACR Incidental Findings Committee. *J Am Coll Radiol*. 2010;7:754–773.

Bittner JG 4th, Gershuni VM, Matthews BD, et al. Risk factors affecting operative approach, conversion, and morbidity for adrenalectomy: a single-institution series of 402 patients. *Surg Endosc*. 2013;27:2342–2350.

Brandao LF, Autorino R, Zargar H, et al. Robot-assisted laparoscopic adrenalectomy: step-by-step technique and comparative outcomes. *Eur Urol*. 2014;66(5):898–905.

Brix D, Allolio B, Fenske W, German Adrenocortical Carcinoma Registry Group, et al. Laparoscopic versus open adrenalectomy for adrenocortical carcinoma: surgical and oncologic outcome in 152 patients. *Eur Urol*. 2010;58:609–615.

Brauckhoff M, Gimm O, Thanh PN, et al. Critical size of residual adrenal tissue and recovery from impaired early postoperative adrenocortical function after subtotal bilateral adrenalectomy. *Surgery*. 2003;134:1020–1027.

Brauckhoff M, Stock K, Stock S, et al. Limitations of intraoperative adrenal remnant volume measurement in patients undergoing subtotal adrenalectomy. *World J Surg*. 2008;32:863–872.

Broster LR, Hill HG, Greenfield JG. Adreno-genital syndrome and unilateral adrenalectomy. *Br J Surg*. 1932;19:557–570.

Brunaud L, Ayav A, Zarnegar R, et al. Prospective evaluation of 100 robotic-assisted unilateral adrenalectomies. *Surgery*. 2008;144:995–1001.

Brunaud L, Bresler L, Zarnegar R, et al. Does robotic adrenalectomy improve patient quality of life when compared to laparoscopic adrenalectomy? *World J Surg*. 2004;28:1180–1185.

Brunt LM. The positive impact of laparoscopic adrenalectomy on complications of adrenal surgery. *Surg Endosc*. 2002;16:252–257.

Carrafiello G, Lagana D, Recaldini C, et al. Imaging-guided percutaneous radiofrequency ablation of adrenal metastases: preliminary results at a single institution with a single device. *Cardiovasc Intervent Radiol*. 2008;31:762–767.

Chen W, Li F, Chen D, et al. Retroperitoneal versus transperitoneal laparoscopic adrenalectomy in adrenal tumor: a meta-analysis. *Surg Laparosc Endosc Percutan Tech*. 2013;23:121–127.

Chini EN, Brown MJ, Farrell MA, et al. Hypertensive crisis in a patient undergoing percutaneous radiofrequency ablation of an adrenal mass under general anesthesia. *Anesth Analg*. 2004;99:1867–1869.

Chute R, Soutter L, Kerr WS Jr. The value of the thoracoabdominal incision in the removal of kidney tumors. *N Engl J Med*. 1949;241:951–960.

Constantinides VA, Christakis I, Touska P, et al. Systematic review and meta-analysis of retroperitoneoscopic versus laparoscopic adrenalectomy. *Br J Surg*. 2012;99:1639–1648.

Debono M, Ross RJ, Newell-Proce J. Inadequacies of glucocorticoid replacement and improvements by physiological circadian therapy. *Eur J Endocrinol*. 2009;160:719–729.

DeLong JC, Chakedis JM, Hosseini A, et al. Indocyanine green (ICG) fluorescence-guided laparoscopic adrenalectomy. *J Surg Oncol*. 2015;112(6):650–653.

Economopoulos KP, Mylonas KS, Stamou AA, et al. Laparoscopic versus robotic adrenalectomy: a comprehensive meta-analysis. *Int J Surg*. 2017;38:95–104.

Elfenbein DM, Scarborough JE, Speicher PJ, et al. Comparison of laparoscopic versus open adrenalectomy: results from American College of Surgeons-National Surgery Quality Improvement Project. *J Surg Res*. 2013;184:216–220.

European Society of Endocrinology Clinical Practice Guideline in collaboration with the European Network for the Study of Adrenal Tumors. *Eur J Endocrinol*. 2016;175(2):G1–G34.

Eyraud R, Laydner H, Autorino R, et al. Robot-assisted transrectal hybrid natural orifice transluminal endoscopic surgery nephrectomy and adrenalectomy: initial investigation in a cadaver model. *Urology*. 2013;81:1090–1094.

Fassnacht M, Arlt W, Bancos I, et al. Management of adrenal incidentalomas: European Society of Endocrinology Clinical Practice Guideline in collaboration with the European Network for the Study of Adrenal Tumors. *Eur J Endocrinol*. 2016;175(2):G1–G34.

Fernández-Cruz L, Saenz A, Benarroch G, et al. Laparoscopic unilateral and bilateral adrenalectomy for Cushing's syndrome. Transperitoneal and retroperitoneal approaches. *Ann Surg*. 1996;224:727–734.

Fritscher-Ravens A, Ghanbari A, Cuming T, et al. Comparative study of NOTES alone vs. EUS-guided NOTES procedures. *Endoscopy*. 2008;40:925–930.

Fukumoto K, Miyajima A, Hattori S, et al. The learning curve of laparoendoscopic single-site adrenalectomy: an analysis of over 100 cases. *Surg Endosc*. 2017;31(1):170–177.

Funder JW, Carey RM, Mantero F, et al. The management of primary aldosteronism: case detection, diagnosis, and treatment: an endocrine society clinical practice guideline. *J Clin Endocrinol Metab*. 2016;101(5):1889–1916.

Gagner M, Lacroix A, Bolté E. Laparoscopic adrenalectomy in Cushing's syndrome and pheochromocytoma. *N Engl J Med*. 1992;327:1033.

Gaur DD. Laparoscopic operative retroperitoneoscopy: use of a new device. *J Urol*. 1992;148:1137–1139.

Gill IS, Merany AM, Thomas JC, et al. Thoracoscopic transdiaphragmatic adrenalectomy: the initial experience. *J Urol*. 2001;165(6 Pt 1):1875–1881.

Giraudo G, Pantuso G, Festa F, et al. Clinical role of gasless laparoscopic adrenalectomy. *Surg Laparosc Endosc Percutan Tech*. 2009;19:329–332.

Gonzalez RJ, Shapiro S, Sarlis N, et al. Laparoscopic resection of adrenal cortical carcinoma: a cautionary note. *Surgery*.

2005;138:1078–1085.

Grawitz P. Die sogenannten lipome der niere. *Virchows Arch Patholo Anat Physiol Klin Med*. 1883;xciii:121–124 [in German].

Hawn MT, Cook D, Deveney C, et al. Quality of life after laparoscopic bilateral adrenalectomy for Cushing's disease. *Surgery*. 2002;132:1064–1068.

Heger P, Probst P, Hüttner FJ, et al. Evaluation of open and minimally invasive adrenalectomy: a systematic review and network meta-analysis. *World J Surg*. 2017;41(11):2746–2757.

Henry JF, Sebag F, Iacobone M, et al. Results of laparoscopic adrenalectomy for large and potentially malignant tumors. *World J Surg*. 2002;26:1043.

Hobart MG, Gill IS, Schweizer D, et al. Laparoscopic adrenalectomy for large-volume (5 cm) adrenal masses. *J Endourol*. 2000;14:149.

Hu Q, Gou Y, Sun C, et al. A systematic review and meta-analysis of current evidence comparing laparoendoscopic single-site adrenalectomy and conventional laparoscopic adrenalectomy. *J Endourol*. 2013;27:676–683.

Hubens G, Ysebaert D, Vaneerdeweg W, et al. Laparoscopic adrenalectomy with the aid of the AESOP 2000 robot. *Acta Chir Belg*. 1999;99:125–127.

Imai T, Tanaka Y, Kikumori T, et al. Laparoscopic partial adrenalectomy. *Surg Endosc*. 1999;13:343–345.

Ishida M, Miyajima A, Takeda T, et al. Technical difficulties of transumbilical laparoendoscopic single-site adrenalectomy: comparison with conventional laparoscopic adrenalectomy. *World J Urol*. 2013;31:199–203.

Janetschek G, Finkenstedt G, Gasser R, et al. Laparoscopic surgery for pheochromocytoma: adrenalectomy, partial resection, excision of paragangliomas. *J Urol*. 1998;160:330–

334.

Jeong BC, Park YH, Han DH, et al. Laparoendoscopic single-site and conventional laparoscopic adrenalectomy: a matched case-control study. *J Endourol*. 2009;23:1957–1960.

Kaouk JH, Matin S, Bravo EL, et al. Laparoscopic bilateral partial adrenalectomy for pheochromocytoma. *Urology*. 2002;60:1100–1103.

Karabulut K, Agcaoglu O, Aliyev S, et al. Comparison of intraoperative time use and perioperative outcomes for robotic versus laparoscopic adrenalectomy. *Surgery*. 2012;151:537–542.

Kaye DR, Storey BB, Pacak K, et al. Partial adrenalectomy: underused first line therapy for small adrenal tumors. *J Urol*. 2010;184:18–25.

Kurenov S, Cendan J, Dindar S, et al. Surgeon-authored virtual laparoscopic adrenalectomy module is judged effective and preferred over traditional teaching tools. *Surg Innov*. 2017;24(1):72–81.

Lau H, Lo CY, Lam KY. Surgical indications of underestimation of adrenal tumour size by computed tomography. *Br J Surg*. 1999;86:385–387.

Leboulleux S, Deanderis D, Al Ghuzian A, et al. Adrenocortical carcinoma: is the surgical approach a risk factor of peritoneal carcinomatosis? *Eur J Endocrinol*. 2010;162:1147–1153.

Lee CW, Salem AI, Schneider DF, et al. Minimally invasive resection of adrenocortical carcinoma: a multi-institutional study of 201 patients. *J Gastrointest Surg*. 2017;21(2):352–362.

Lee J, Curley SA, Gagel RF, et al. Cortical-sparing adrenalectomy for patients with bilateral pheochromocytoma. *Surgery*. 1996;120:1064–1070.

Lee J, El-Tamer M, Schifftner T, et al. Open and laparoscopic adrenalectomy: analysis of the National Surgical Quality

Improvement Program. *J Am Coll Surg*. 2008;206:953–959 [discussion 959–61].

Li X, Fan W, Zhang L, et al. CT-guided percutaneous microwave ablation of adrenal malignant carcinoma: preliminary results. *Cancer*. 2011;117(22):5182–5188.

Liapis D, de la Taille A, Ploussard G, et al. Analysis of complications from 600 retroperitoneoscopic procedures of the upper urinary tract during the last 10 years. *World J Urol*. 2008;26:523–530.

MacGillivray DC, Whalen GF, Malchoff CD, et al. Laparoscopic resection of large adrenal tumors. *Ann Surg Oncol*. 2002;9:480–485.

Mamlouk MD, vanSonnenberg E, Stringfellow G, et al. Radiofrequency ablation and biopsy of metastatic pheochromocytoma: emphasizing safety issues and dangers. *J Vasc Interv Radiol*. 2009;20:670–673.

Manny TB, Pompeo AS, Hemal AK. Robotic partial adrenalectomy using indocyanine green dye with near-infrared imaging: the initial clinical experience. *Urology*. 2013;82:738–742.

Marescaux J, Rubino F, Soler L. Virtual reality and robotic technologies in adrenal surgery. Linos D, van Heerden JA. *Adrenal glands: diagnostic aspects and surgical therapy*. Springer-Verlag: Berlin; 2005:345–353.

Maurice MJ, Bream MJ, Kim SP, et al. Surgical quality of minimally invasive adrenalectomy for adrenocortical carcinoma: a contemporary analysis using the National Cancer Database. *BJU Int*. 2017;119:436–443.

Mayo CH. Paroxysmal hypertension with tumor of retroperitoneal nerve: report of case. *J Am Med Assoc*. 1927;89:1047–1050.

Mayo-Smith WW, Dupuy DE. Adrenal neoplasms: CT-guided radiofrequency ablation—preliminary results. *Radiology*.

2004;231:225–230.

Mendiratta-Lala M, Brennan DD, Brook OR, et al. Efficacy of radiofrequency ablation in the treatment of small functional adrenal neoplasms. *Radiology*. 2011;258:308–316.

Mercan S, Seven R, Ozarmagan S, et al. Endoscopic retroperitoneal adrenalectomy. *Surgery*. 1995;118:1071–1075.

Miller BS, Ammori JB, Gauger PG, et al. Laparoscopic resection is inappropriate in patients with known or suspected adrenocortical carcinoma. *World J Surg*. 2010;34:1380–1385.

Mohammadi-Fallah MR, Mehdizadeh A, Badalzadeh A, et al. Comparison of transperitoneal versus retroperitoneal laparoscopic adrenalectomy in a prospective randomized study. *J Laparoendosc Adv Surg Tech A*. 2013;23:362–366.

Monn MF, Calaway AC, Mellon MJ, et al. Changing USA national trends for adrenalectomy: the influence of surgeon and technique. *BJU Int*. 2015;115(2):288–294.

Morino M, Benincà G, Giraudo G, et al. Robot-assisted vs laparoscopic adrenalectomy: a prospective randomized controlled trial. *Surg Endosc*. 2004;18:1742–1746.

Murphy MM, Witkowski ER, Ng SC, et al. Trends in adrenalectomy: a recent national review. *Surg Endosc*. 2010;24:2518–2526.

National Comprehensive Cancer Network. *NCCN clinical practice guidelines in oncology: neuroendocrine tumors, version 3*. 2017.

NIH state-of-the-science statement on management of the clinically inapparent adrenal mass (“incidentaloma”). *NIH Consens State Sci Statements*. 2002;19(2):1–25.

Perretta S, Allemann P, Asakuma M, et al. Adrenalectomy using natural orifice transluminal endoscopic surgery (NOTES): a transvaginal retroperitoneal approach. *Surg Endosc*. 2009;23:1390.

Piazza L, Caragliano P, Scardilli M, et al. Laparoscopic robot-assisted right adrenalectomy and left ovariectomy (case reports). *Chir Ital*. 1999;51:465–466.

Pineda-Solís K, Medina-Franco H, Heslin MJ. Robotic versus laparoscopic adrenalectomy: a comparative study in a high-volume center. *Surg Endosc*. 2013;27:599–602.

Porpiglia F, Fiori C, Daffara F, et al. Retrospective evaluation of the outcome of open versus laparoscopic adrenalectomy for stage I and II adrenocortical cancer. *Eur Urol*. 2010;57:873–878.

Porpiglia F, Miller BS, Manfredi M, et al. A debate on laparoscopic versus open adrenalectomy for adrenocortical carcinoma. *Horm Cancer*. 2011;2:372–377.

Probst KA, Ohlmann CH, Saar M, et al. Robot-assisted vs. open adrenalectomy: evaluation of cost effectiveness and perioperative outcome. *BJU Int*. 2016;118(6):952–957.

Reibetanz J, Jurowich C, Erdogan I, et al. Impact of lymphadenectomy on the oncologic outcome of patients with adrenocortical carcinoma. *Ann Surg*. 2012;255:363–369.

Rubinstein M, Gill IS, Aron M, et al. Prospective, randomized comparison of transperitoneal versus retroperitoneal laparoscopic adrenalectomy. *J Urol*. 2005;174:442–445.

Sasagawa I, Suzuki H, Izumi T, et al. Posterior retroperitoneoscopic partial adrenalectomy using ultrasonic scalpel for aldosterone-producing adenoma. *J Endourol*. 2000;14:573–576.

Sarwar A, Brook OR, Vaidya A, et al. Clinical outcomes following percutaneous radiofrequency ablation of unilateral aldosterone-producing adenoma: comparison with adrenalectomy. *J Vasc Interv Radiol*. 2016;27:961–967.

Shi TP, Zhang X, Ma X, et al. Laparoendoscopic single-site retroperitoneoscopic adrenalectomy: a matched-pair comparison with the gold standard. *Surg Endosc*.

2011;25:2117–2124.

Siddiqui SA, Krane LS, Bhandari A, et al. The impact of previous inguinal or abdominal surgery on outcomes after robotic radical prostatectomy. *Urology*. 2010;75:1079–1082.

Simon CJ, Dupuy DE, Mayo-Smith WW. Microwave ablation: principles and applications. *Radiographics*. 2005;25:S69–S83.

Sood A, Majumder K, Kachroo N, et al. Adverse event rates, timing of complications, and the impact of specialty on outcomes following adrenal surgery: an analysis of 30-day outcome data from the American College of Surgeons National Surgical Quality Improvement Program (ACS-NSQIP). *Urology*. 2016;90:62–68.

Sound S, Okoh AK, Bucak E, et al. Intraoperative tumor localization and tissue distinction during robotic adrenalectomy using indocyanine green fluorescence imaging: a feasibility study. *Surg Endosc*. 2016;30(2):657–662.

Srougi V, Rocha BA, Tanno FY, et al. The use of three-dimensional printers for partial adrenalectomy: estimating the resection limits. *Urology*. 2016;90:217–220.

Tang K, Li H, Xia D, et al. Robot-assisted versus laparoscopic adrenalectomy: a systematic review and meta-analysis. *J Laparoendosc Adv Surg Tech A*. 2015;25(3):187–195.

Thompson LH, Nordenström E, Almquist M, et al. Risk factors for complications after adrenalectomy: results from a comprehensive national database. *Langenbecks Arch Surg*. 2017;402(2):315–322.

Thornton JK. Abdominal nephrectomy for large sarcoma of the left suprarenal capsule: recovery. *Trans Clin Soc Lond*. 1890;23:150.

Tiberio GA, Baiocchi GL, Arru L, et al. Prospective randomized comparison of laparoscopic versus open adrenalectomy for sporadic pheochromocytoma. *Surg Endosc*. 2008;22(6):1435–1439.

Tsoumakidou G, Buy X, Zickler P, et al. Life-threatening complication during percutaneous ablation of adrenal gland metastasis: Takotsubo syndrome. *Cardiovasc Intervent Radiol*. 2010;33:646–649.

van Aken MO, Pereira AM, Biermasz NR, et al. Quality of life in patients after long-term biochemical cure of Cushing's disease. *J Clin Endocrinol Metab*. 2005;90:3279–3286.

Walz MK, Groeben H, Alesina PF. Single-access retroperitoneoscopic adrenalectomy (SARA) versus conventional retroperitoneoscopic adrenalectomy (CORA): a case-control study. *World J Surg*. 2010;34:1386–1390.

Walz MK, Peitgen K, Saller B, et al. Subtotal adrenalectomy by the posterior retroperitoneoscopic approach. *World J Surg*. 1998;22:621–627.

Wang Y, Liang P, Yu X, et al. Ultrasound-guided percutaneous microwave ablation of adrenal metastasis: preliminary results. *Int J Hyperthermia*. 2009;25:455–461.

Welch BT, Atwell TD, Nichols DA, et al. Percutaneous image-guided adrenal cryoablation: procedural considerations and technical success. *Radiology*. 2011;258:301–307.

Winship SM, Winstanley JHR, Hunter JM. Anaesthesia for Conn's syndrome. *Anaesthesia*. 1999;54:564–574.

Wolf FJ, Dupuy DE, Machan JT, et al. Adrenal neoplasms: effectiveness and safety of CT-guided ablation of 23 tumors in 22 patients. *Eur J Radiol*. 2012;81:1717–1723.

Wood BJ, Abraham J, Hvizda JL, et al. Radiofrequency ablation of adrenal tumors and adrenocortical carcinoma metastases. *Cancer*. 2003;97(3):554–560.

Wu JC, Wu HS, Lin MS, et al. Comparison of robot-assisted laparoscopic adrenalectomy with traditional laparoscopic adrenalectomy—1 year follow-up. *Surg Endosc*.

2008;22:463–466.

Wu S, Lai H, Zhao J, et al. Laparoendoscopic single-site adrenalectomy versus conventional laparoscopic adrenalectomy: an updated meta analysis. *Urol J*. 2016;13(2):2590–2598.

Yang MH, Tyan YS, Huang YH, et al. Comparison of radiofrequency ablation versus laparoscopic adrenalectomy for benign aldosterone-producing adenoma. *Radiol Med*. 2016;121:811–819.

Young HH. A technique for simultaneous exposure and operation on the adrenals. *Surg Gynecol Obstet*. 1936;54:179.

Young WF Jr. Clinical practice. The incidentally discovered adrenal mass. *N Engl J Med*. 2007;356:601–610.

Zografos GN, Farfaras A, Vasiliadis G, et al. Laparoscopic resection of large adrenal tumors. *JSLS*. 2010;14:364–368.

Zou X, Zhang G, Xiao R, et al. Transvaginal natural orifice transluminal endoscopic surgery (NOTES)-assisted laparoscopic adrenalectomy: first clinical experience. *Surg Endosc*. 2011;25:3767–3772.

PART XIII

Urine Transport, Storage, and Emptying

OUTLINE

108 Surgical, Radiographic, and Endoscopic Anatomy of the Female Pelvis

109 Surgical, Radiographic, and Endoscopic Anatomy of the Male Pelvis

110 Physiology and Pharmacology of the Bladder and Urethra

111 Pathophysiology and Classification of Lower Urinary Tract Dysfunction Overview

112 Evaluation and Management of Women With Urinary Incontinence and Pelvic Prolapse

113 Evaluation and Management of Men With Urinary Incontinence

114 Urodynamic and Video-Urodynamic Evaluation of the Lower Urinary Tract

115 Urinary Incontinence and Pelvic Prolapse Epidemiology and Pathophysiology

116 Neuromuscular Dysfunction of the Lower Urinary Tract

117 Overactive Bladder

118 The Underactive Detrusor

119 Nocturia

120 Pharmacologic Management of Lower Urinary Tract Storage and Emptying Failure

121 Conservative Management of Urinary Incontinence Behavioral and Pelvic Floor Therapy, Urethral and Pelvic Devices

122 Electrical Stimulation and Neuromodulation in Storage and Emptying Failure

123 Retropubic Suspension Surgery for Incontinence in Women
124 Vaginal and Abdominal Reconstructive Surgery for Pelvic Organ Prolapse
125 Slings Autologous, Biologic, Synthetic, and Mid-urethral
126 Complications Related to the Use of Mesh and Their Repair
127 Additional Therapies for Storage and Emptying Failure
128 Aging and Geriatric Urology
129 Urinary Tract Fistulae
130 Bladder and Female Urethral Diverticula
131 Surgical Procedures for Sphincteric Incontinence in the Male

Surgical, Radiographic, and Endoscopic Anatomy of the Female Pelvis

Priya Padmanabhan MD, MPH

The female pelvis is vital to locomotion and childbirth. These conflicting demands are fulfilled by a complicated urosurgical anatomy (Palastanga et al., 2006). There has historically been controversy over terminology and the function of the structures. This anatomy is not easily understood with pictures and descriptions alone because of the variability between individuals and indistinctness of some structures. This chapter focuses on aspects unique to the female pelvis, including surgical, radiographic, and endoscopic anatomic features.

Surgical Anatomy of the Female Pelvis

Bony Pelvis

The foundation of the female pelvic anatomy is the bony pelvis (Fig. 108.1), which is divided into two continuous compartments (true and false pelvises).

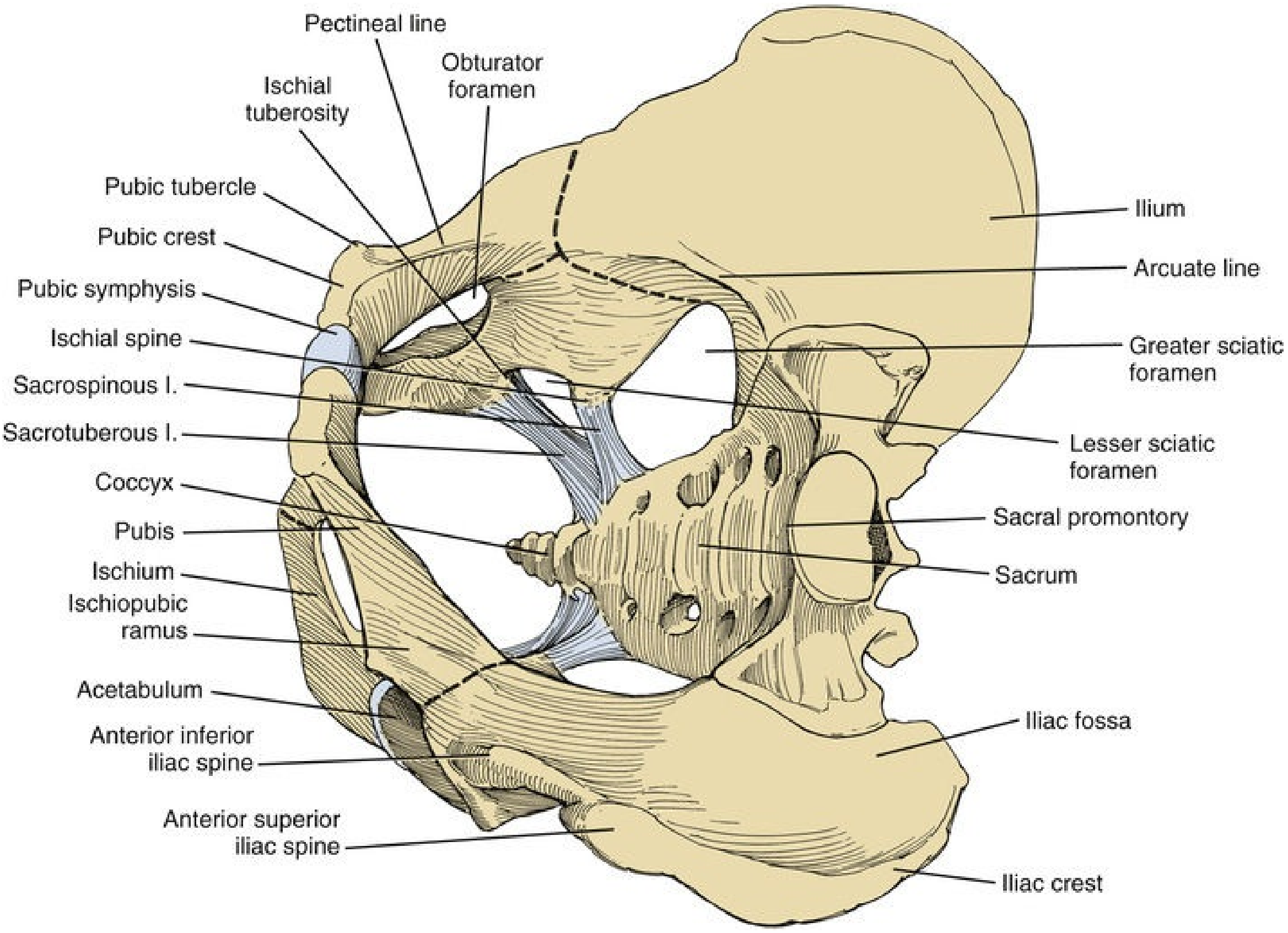
Pectineal line
Ischial tuberosity
Obturator foramen
Pubic tubercle
Pubic crest
Pubic symphysis
Ischial spine
Sacrospinous l.
Sacrotuberous l.
Coccyx
Pubis
Ischium
Ischiopubic ramus
Acetabulum
Anterior inferior iliac spine
Anterior superior iliac spine
Ilium
Arcuate line
Greater sciatic foramen
Lesser sciatic foramen
Sacral promontory
Sacrum
Iliac fossa
Iliac crest

FIG. 108.1 Bony pelvis. *l,* Ligament.

The true pelvis consists of four bones: two hip bones or innominate bones and the sacrum and coccyx. Each innominate bone is made up of the ilium, ischium, and the pubis. The ilium is the fan-shaped region of the hip bone that has a wing and body. The iliac crest is the rim between the anterior and posterior iliac spines. **During vaginal prolapse surgery, the ischial spine is an important landmark for identifying a safe location for fixation of apical suspension sutures.** The pubic rami, ischial spines, and sacrum are the main anchoring points for the ligamentous attachments supporting the pelvis. A line drawn between the ischial spines divides the anterior and posterior compartments.

The pelvis is divided into the true and false pelvis by an oblique line passing from the sacral promontory posterior to the superior margin of the pubic symphysis, corresponding with the iliopectineal line (Fig. 108.2). The pelvic brim defines the pelvic inlet. The true pelvis is the area below the pelvic brim, and the false pelvis is located above the brim.

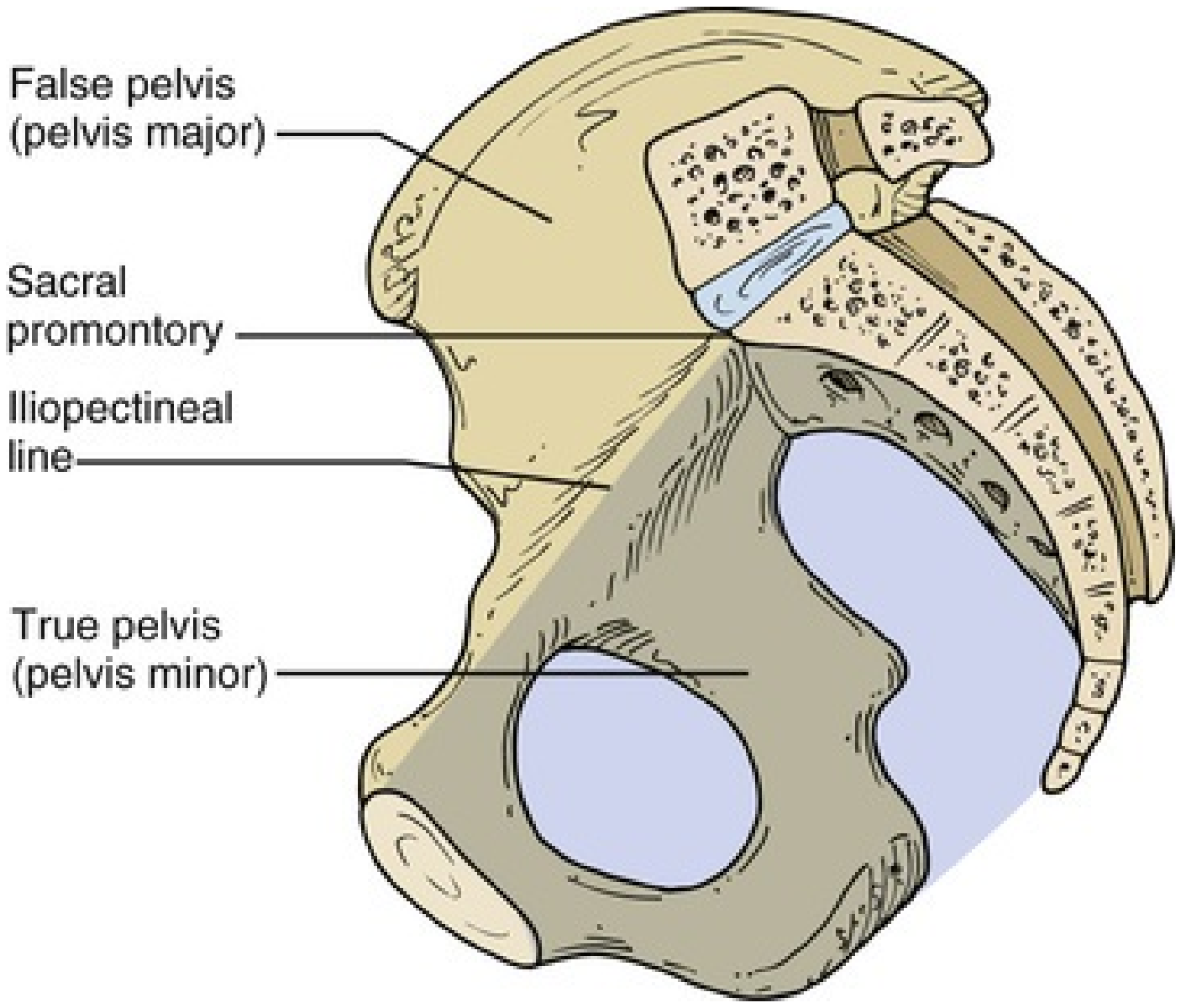

FIG. 108.2 Sagittal plane through the lateral pelvis. (From Goldstein C, Hagen-Ansert SL: *Textbook of diagnostic sonography,* ed 8, St. Louis, 2018, Mosby, pp 1049–1065.)

The principal differences in the female true and false pelvises include the following:

- The female pelvis is larger and broader with sides wider apart (Merry, 2005).
- The female inlet is oval (as compared with the heart-shaped male inlet) and wider, which contributes to the weakness of the pelvic floor (Herschorn, 2004).
- The angle between the inferior pubic rami is obtuse in women.
- The female sacrum is shorter and wider with a less pronounced sacral promontory (Schünke et al., 2006).

When a person is standing, the anterior superior iliac spine and pubic symphysis lie parallel to each other (Barber, 2005). **The pelvic inlet faces anteriorly, allowing pressure of the intra-abdominal and intrapelvic contents to be directed to the bony pelvis rather than the muscles and the fascia** (Fig. 108.3). This contrasts with surgical anatomy, which is commonly described in the lithotomy position.

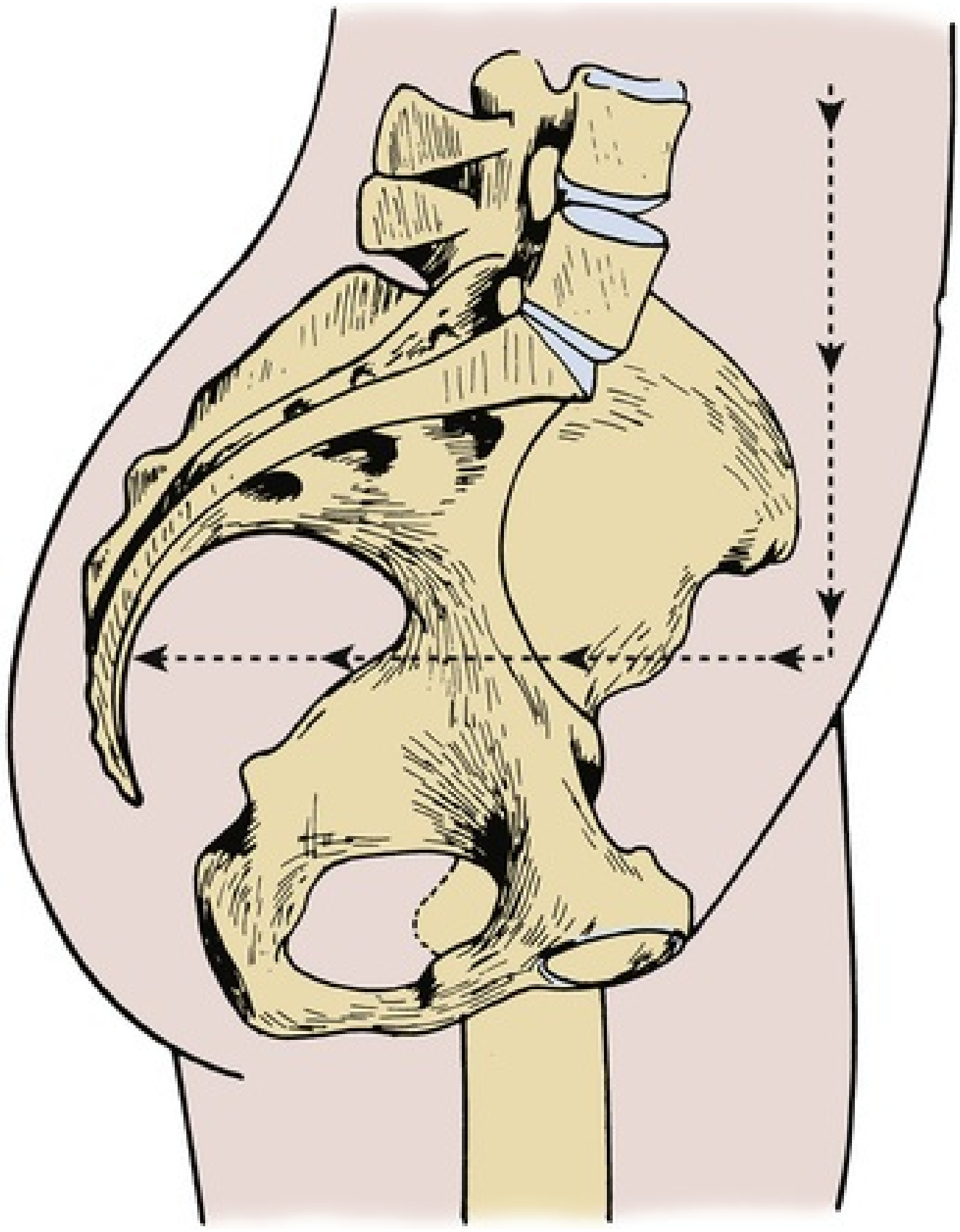

FIG. 108.3 Anterior-facing pelvic inlet.

Fascia and Peritoneum

The fascia is divided into three strata: inner, intermediate, and outer. Rectus fascia, which is part of the inner strata, covers the anterior and lateral rectal wall, vessels, and nerves forming part of Denonvilliers fascia. The intermediate strata surround the uterus and supporting vessels. Most of the support of the pelvic organs comes from the retroperitoneal connective tissue, which is derived from the intermediate stratum. This includes the pubovesical and pubocervical fascia that surround the vagina. Fascia attached to the uterus is called the parametrium, and the fascia surrounding the vagina is called the paracolpium (Wei and DeLancey, 2004; Fig. 108.4).

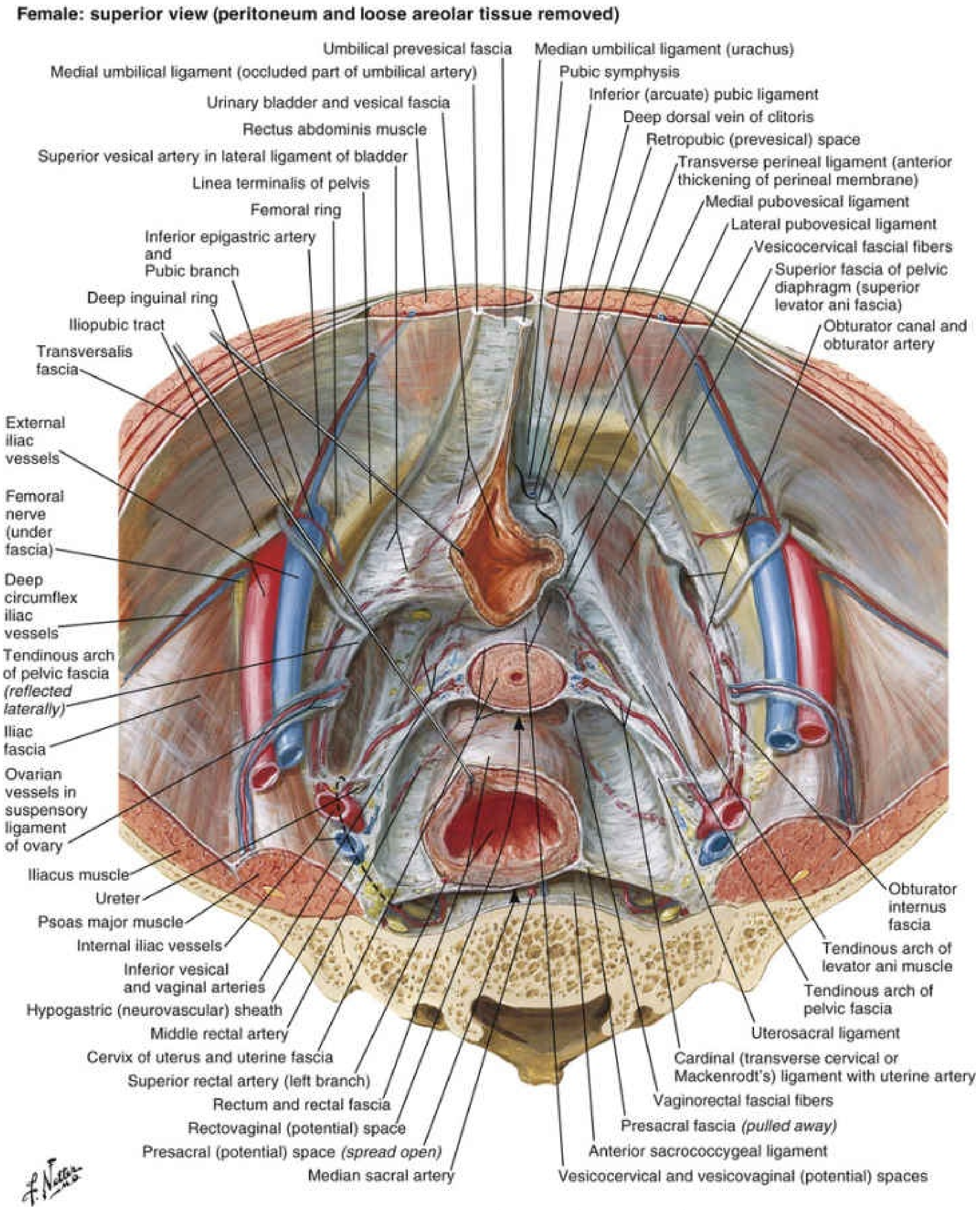
Female: superior view (peritoneum and loose areolar tissue removed)
Umbilical prevesical fascia
Medial umbilical ligament (occluded part of umbilical artery)
Urinary bladder and vesical fascia
Rectus abdominis muscle
Superior vesical artery in lateral ligament of bladder
Linea terminalis of pelvis
Femoral ring
Inferior epigastric artery and Pubic branch
Deep inguinal ring
Iliopubic tract
Transversalis fascia
External iliac vessels
Femoral nerve (under fascia)
Deep circumflex iliac vessels
Tendinous arch of pelvic fascia *(reflected laterally)*
Iliac fascia
Ovarian vessels in suspensory ligament of ovary
Iliacus muscle
Ureter
Psoas major muscle
Internal iliac vessels
Inferior vesical and vaginal arteries
Hypogastric (neurovascular) sheath
Middle rectal artery
Cervix of uterus and uterine fascia
Superior rectal artery (left branch)
Rectum and rectal fascia
Rectovaginal (potential) space
Presacral (potential) space *(spread open)*
Median sacral artery
Median umbilical ligament (urachus)
Pubic symphysis
Inferior (arcuate) pubic ligament
Deep dorsal vein of clitoris
Retropubic (prevesical) space
Transverse perineal ligament (anterior thickening of perineal membrane)
Medial pubovesical ligament
Lateral pubovesical ligament
Vesicocervical fascial fibers
Superior fascia of pelvic diaphragm (superior levator ani fascia)
Obturator canal and obturator artery
Obturator internus fascia
Tendinous arch of levator ani muscle
Tendinous arch of pelvic fascia
Uterosacral ligament
Cardinal (transverse cervical or Mackenrodt's) ligament with uterine artery
Vaginorectal fascial fibers
Presacral fascia *(pulled away)*
Anterior sacrococcygeal ligament
Vesicocervical and vesicovaginal (potential) spaces
F. Netter M.D.

FIG. 108.4 Fascia: parametrium and paracolpium.

The transversalis fascia is part of the outer stratum and is continuous with the endopelvic and lateral pelvic fascia, which both play a key role at the exit points of the pelvic organs. The endopelvic fascia extends down from the uterine artery to the fusion of the vagina and levator ani. The iliac fascia is part of the outer stratum and covers the iliacus and psoas muscles. This attaches to the iliac crest and runs down to the tendinous arch (white line) and is continuous with the posterior part of the inguinal ligament, pectineal fascia, and obturator fascia. The obturator internus and piriformis muscles are covered by the obturator fascia.

The arcus tendineus fascia pelvis (ATFP), or arcus tendineus, is the thickened band of pelvic fascia running from the ischial spine to the pubic bone and serves **as a key point for fascial layer attachment.** The ATFP originates from the pubic bone laterally, pubovesical ligaments medially, and the tendinous arch of the levator ani (Fritsch et al., 2012). **The muscles of the levator ani attach to the arcus tendineus levator ani (ATLA).** The ATLA is the aponeurotic portion of the obturator fascia covering the obturator internus muscle.

The inferior pelvic fascia is continuous with the obturator fascia and fascia of the pudendal canal and covers the levator ani surface. The superior pelvic fascia arises from the outer stratum and obturator fascia. It runs from the pubic symphysis laterally to the ischial spine. The fascia is thinner over the muscles and organs, which allows for more mobility.

Spaces Among Pelvic Organs

Six potential spaces exist among the female pelvic organs. The vesicovaginal and rectovaginal spaces are in the midline. The vesicovaginal space is contained by the bladder adventitia anteriorly and the vagina posteriorly. This space ends where the vagina fuses with the distal urethra and at the vesicocervical ligament (fusion of the bladder with the vagina and cervix). Another potential space is the prevesical space, which lies between the fascia covering the bladder and the endopelvic fascia behind the pubis. This space extends laterally to the obliterated umbilical artery. The retrorectal space is between the rectal fascia and the transversalis fascia over the sacrum. Laterally lie the paravesical and pararectal spaces, which are adjacent to their respective organs.

The pouch of Douglas, or rectouterine pouch, is formed by a fold of peritoneum (rectovaginal fold) that extends between the uterus and rectum. It is bound by the uterus, posterior vaginal fornix, rectum, and uterosacral ligaments.

The vesicouterine pouch is demarcated by a fold of peritoneum (uterovesical fold) reflected onto the bladder from the uterus at the junction of the uterine body and cervix. The peritoneum also forms the uterosacral folds between the pararectal and paravesical fossae.

Ligaments

The sacrospinous, sacrotuberous, and sacroiliac ligaments are significant to pelvic surgical anatomy. The sacrospinous ligament attaches from the ischial spine to the lateral border of the sacrum and crosses in front of the sacrotuberous ligament, fusing with it medially. The coccygeus muscle lies over the sacrospinous ligament. **The sciatic nerve and plexus cover the coccygeus muscle and must be avoided during vault suspension.** The sacrotuberous ligament runs from the posterior iliac spine along the sacral border and attaches to the ischial tuberosity. This attaches the ilium and ischium to the sacrum. The greater and lesser sciatic foramina run above and below the sacrotuberous ligament (Rosenblum et al., 2005). In addition, short and long dorsal sacroiliac ligaments connect the sacrum to the ilium posteriorly. The sacrospinous ligament lies in continuity with the sacrococcygeal ligament. The fifth lumbar vertebrae is connected to the ilium by the iliolumbar ligament (Fig. 108.5).

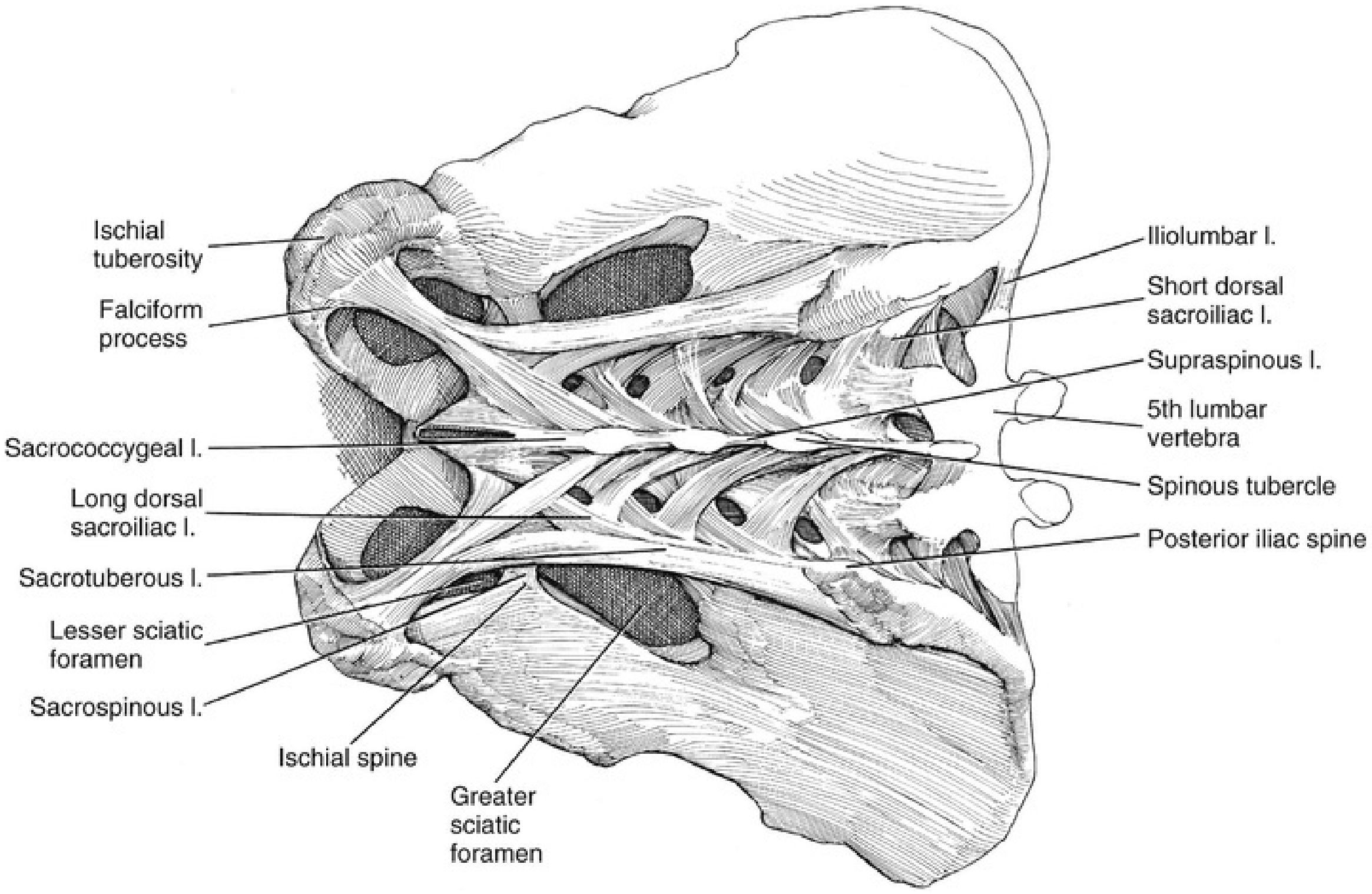
Ischial tuberosity
Falciform process
Sacrococcygeal l.
Long dorsal sacroiliac l.
Sacrotuberous l.
Lesser sciatic foramen
Sacrospinous l.
Ischial spine
Greater sciatic foramen
Iliolumbar l.
Short dorsal sacroiliac l.
Supraspinous l.
5th lumbar vertebra
Spinous tubercle
Posterior iliac spine

FIG. 108.5 Ligaments of the pelvis. *l,* Ligament. (From Maclenna GT: *Hinman's atlas of urosurgical anatomy,* ed 2, Philadelphia, 2012, Saunders.)

The pubovesical, vesicopelvic, cardinal, and uterosacral ligaments and pubocervical fascia are condensations of the transversalis fascia, which also help to support the pelvic organs. **The pubovesical ligaments (pubourethral ligaments) are analogous to the male puboprostatic ligaments and run from the pubic bone to the bladder neck, providing retropubic suspension.** They hold the bladder neck in place when it contracts and provide a hammock-like support for the mid-urethra in continuity with the anterior vaginal wall. The perivesical and endopelvic fascia fuse to form the vesicopelvic ligament or fascia. This extends from the base of the bladder and anterior vaginal wall and attaches to the tendinous arch. It is continuous with the periurethral fascia, cervix, and cardinal ligaments. **Defects in the vesicopelvic fascia can result in lateral cystocele defect** (Maclennan, 2012).

The broad ligament is formed by the peritoneum extending from the anterior and posterior surfaces of the uterus and contains the fallopian tube and ovary. It lies on the posterolateral surface of the uterus attaching it to the pelvic wall. The uterine artery, vein, and nerves lie within the mesometrium of the broad ligament. The mesosalpinx, a vascular network between the uterine tube and ovary, is also found within the broad ligament. **The round ligament exits at the internal inguinal ring and crosses over the external iliac artery, terminating in the mons pubis of the labium majus. The male homolog of the round ligament is the gubernaculum.** The round ligament attaches the lateral uterine body walls to the pelvic sidewalls and contains the ovarian ligaments. The infundibulopelvic ligament (suspensory ligament of the ovary) lies behind the broad ligament and runs from the ovary to the lateral surface of the uterus. This is beneath the entrance of the fallopian tube and contains the ovarian vessels (Fig. 108.6).

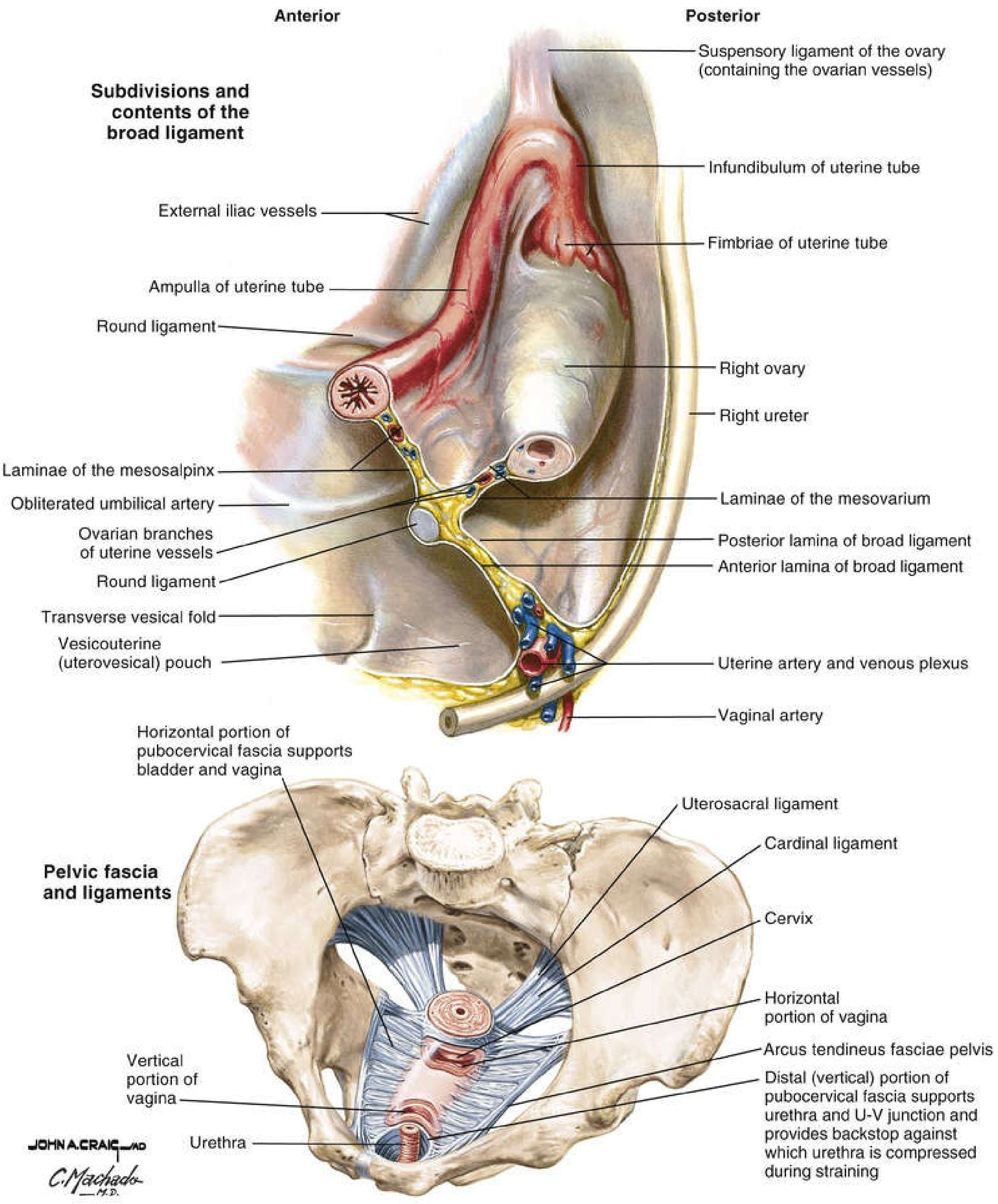
Anterior
Posterior
Subdivisions and contents of the broad ligament
Suspensory ligament of the ovary (containing the ovarian vessels)
Infundibulum of uterine tube
External iliac vessels
Fimbriae of uterine tube
Ampulla of uterine tube
Round ligament
Right ovary
Right ureter
Laminae of the mesosalpinx
Laminae of the mesovarium
Obliterated umbilical artery
Ovarian branches of uterine vessels
Posterior lamina of broad ligament
Anterior lamina of broad ligament
Round ligament
Transverse vesical fold
Vesicouterine (uterovesical) pouch
Uterine artery and venous plexus
Vaginal artery
Horizontal portion of pubocervical fascia supports bladder and vagina
Uterosacral ligament
Cardinal ligament
Pelvic fascia and ligaments
Cervix
Horizontal portion of vagina
Arcus tendineus fasciae pelvis
Vertical portion of vagina
Distal (vertical) portion of pubocervical fascia supports urethra and U-V junction and provides backstop against which urethra is compressed during straining
Urethra
JOHN A.CRAIG MD
C.Machado M.D.

FIG. 108.6 The broad ligament of the uterus and its contents.

The major supportive cardinal and uterosacral ligaments lie within the parametrium. Blood vessels, nerves, smooth muscle, adipose, and connective tissue lie near these ligaments. Nerves from the pelvic plexus travel with the vessels through the cardinal and uterosacral ligaments. **These structures are at risk during a hysterectomy and can lead to bladder dysfunction.** The uterosacral (sacrouterine ligaments) originate from the greater sciatic foramen and insert into the lateral aspect of the fascia encircling the cervix, isthmus of the uterus, and vaginal wall. They contain fibrous tissue and smooth muscle and are often used as anchoring structures in apical suspensions. **The ureter lies lateral to the anterior portion of the uterosacral ligament (closest at the cervix). There is potential for sacral nerve entrapment (S1 and S2 to S4 nerve trunks) during a suspension as the nerve crosses over the areas dorsally** (Ramanah et al., 2012).

The cardinal ligaments fuse posteriorly with the uterosacral ligaments and stabilize the uterus, cervix, and upper vagina (Fig. 108.7). They originate from S2 to S4 and insert into the posterolateral aspect of the pericervical fascia and lateral vaginal wall. Cardinal ligaments contain the major blood vessels form the internal iliac artery and run under the rectovaginal peritoneum.

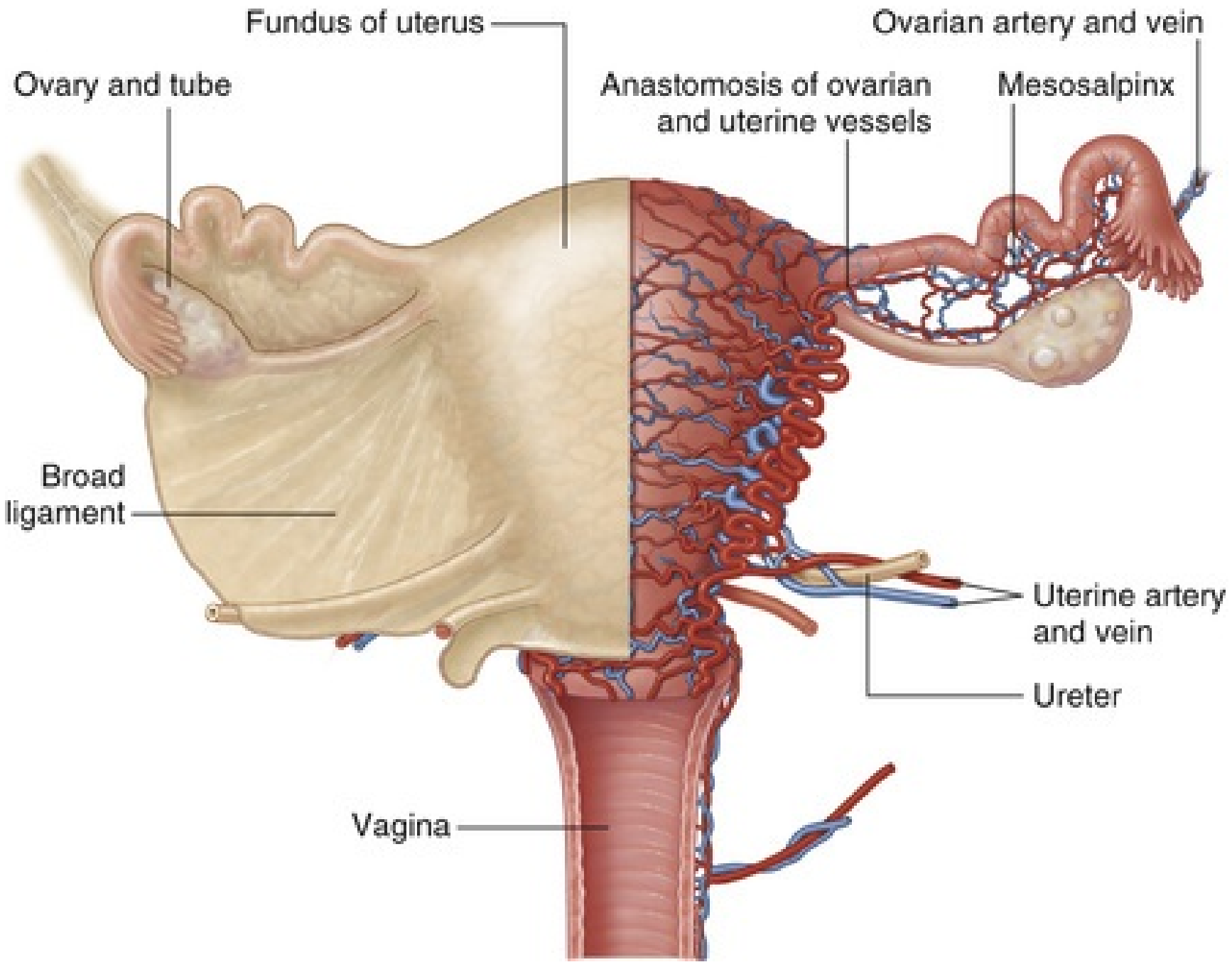
Fundus of uterus
Ovarian artery and vein
Ovary and tube
Anastomosis of ovarian and uterine vessels
Mesosalpinx
Broad ligament
Uterine artery and vein
Ureter
Vagina

FIG. 108.7 Ligaments and support of the vagina and uterus.

The ureter is susceptible to injury as it passes near the ligaments supporting the uterus and ovary (Fig. 108.8). It crosses the infundibulopelvic ligament under the ovarian artery and lies medial to the uterine artery. It also passes near the cardinal ligament and lies in proximity to the cervix.

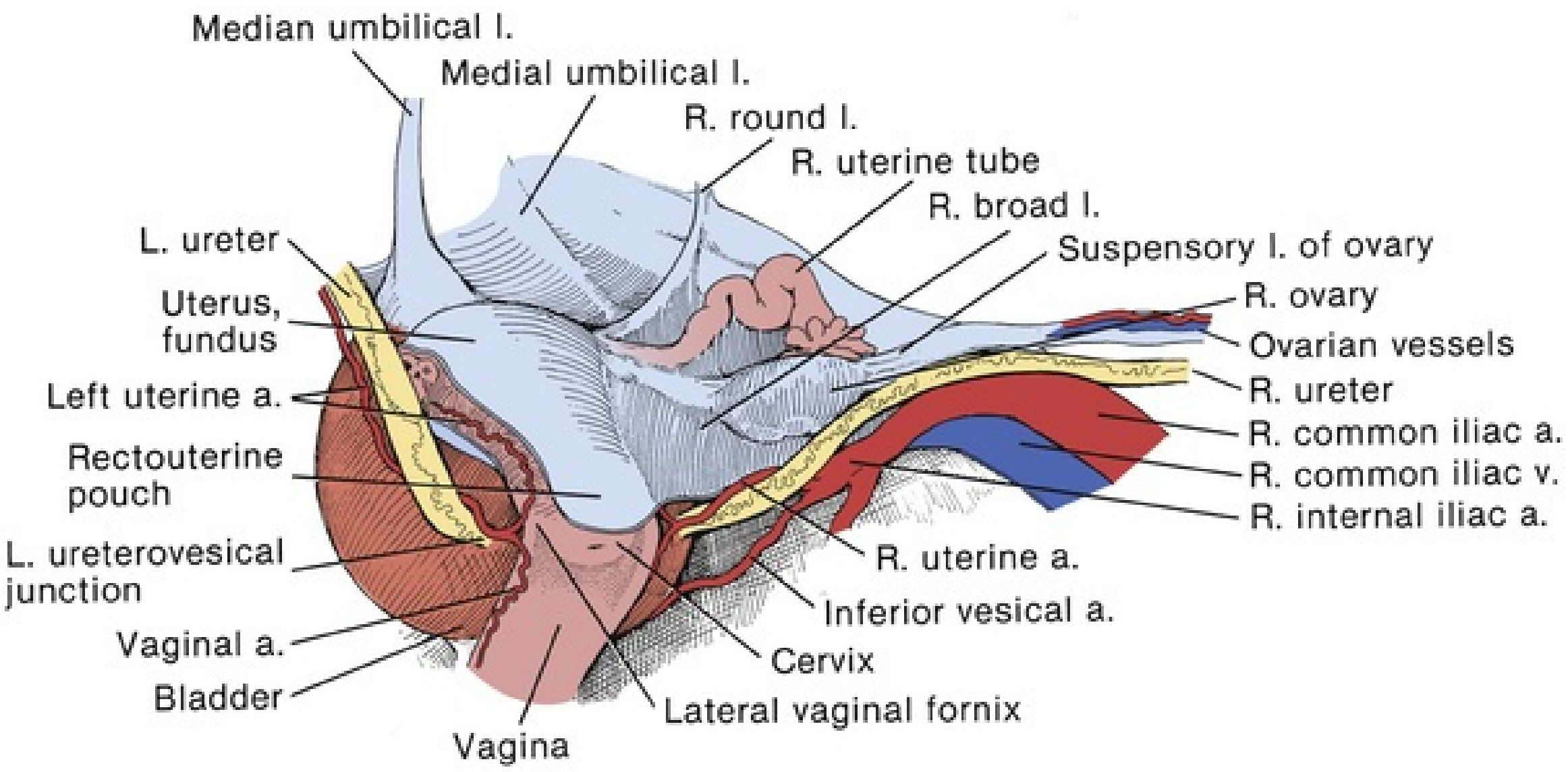
Median umbilical l.
Medial umbilical l.
R. round l.
R. uterine tube
R. broad l.
Suspensory l. of ovary
R. ovary
Ovarian vessels
R. ureter
R. common iliac a.
R. common iliac v.
R. internal iliac a.
R. uterine a.
Inferior vesical a.
Cervix
Lateral vaginal fornix
Vagina
Bladder
Vaginal a.
L. ureterovesical junction
Rectouterine pouch
Left uterine a.
Uterus, fundus
L. ureter

FIG. 108.8 Close relationship of ureter to the uterine structures. *a,* Artery; *l,* ligament; *L,* left; *R,* right; *v,* vein.

Muscles of the Pelvic Floor

Pelvic Sidewalls

The walls of the pelvis are formed by the obturator internus, iliacus, psoas major and minor, levator ani complex, and the coccygeus. The obturator internus covers most of the lateral pelvic sidewall and passes through the lesser sciatic foramen and attaches to the greater trochanter of the femur. The piriformis muscle covers and pads the pelvic side walls posteriolaterally. This passes through the greater sciatic foramen and attaches to the greater trochanter of the femur. The sacral plexus is found medially.

Pelvic Floor

The pelvic floor is composed of the pelvic diaphragm, which extends from the pubis anteriorly to the coccyx posteriorly. The pelvic floor muscles are made up of the levator ani muscles and puborectalis. **The greatest part of the pelvic cavity floor is created by the broad, thin levator ani muscle, which plays a crucial role in support and function of the urogenital viscera.** This consists of the **iliococcygeus, puborectalis, and pubococcygeus muscles** and is innervated by the fourth sacral nerve. The name of each of its components is derived from its attachments. **The puborectalis muscle arises from the back of the symphysis pubis and the superior fascia of the urogenital diaphragm**, **runs**

backward alongside the anorectal junction, and joins its paired muscle on the opposite side, to form a U-shaped loop behind the rectum that slings the anorectal junction to the pubis. The puborectalis and levator muscles have reciprocal action. **The pubococcygeus muscle originates at the posterior portion of the pubis and arcus tendineus** and attaches to the visceral organs and anococcygeal raphe**.** The pubococcygeus is important in visceral control by forming a sling around the vagina and urethra, called the *pubovaginal muscles*. **The iliococcygeus muscle (also called the *coccygeus*) arises from the ischial spine and posterior part of the obturator fossa** and inserts on the last two segments of the sacrum, coccyx, and anococcygeal raphe. It sits anterior to the sacrospinous ligament. The coccygeus and iliococcygeus were previously thought to be innervated by divisions of the pudendal nerve, inferior rectal nerve, and perineal nerve. However, recent studies describe the innervation solely from the levator ani nerve originating from S3, S4, and S5 and traveling medial to the ischial spine and the ATLA. The opening of the levator ani muscle group is referred to as the levator hiatus and allows passage of the urethra, vagina, and rectum. **The levator plate is created by the fusion of the levator ani muscles in the midline and serves as a shelf on which the viscera rests.** Weakening of the levator ani muscles may cause this plate to sag, opening the hiatus and predisposing to pelvic organ prolapse (Barber, 2005; Boutros and Gordon, 2017; Herschorn, 2004).

The sustained resting tone of the pelvic floor muscles supports pelvic viscera, resists increases in intra-abdominal pressure, and is crucial in passive control of urinary and fecal continence. With loss of tone from muscle or nerve injury, there is laxity in the urogenital hiatus, which lessens the horizontal orientation of the levator plate (Barber, 2005; Fig. 108.9).

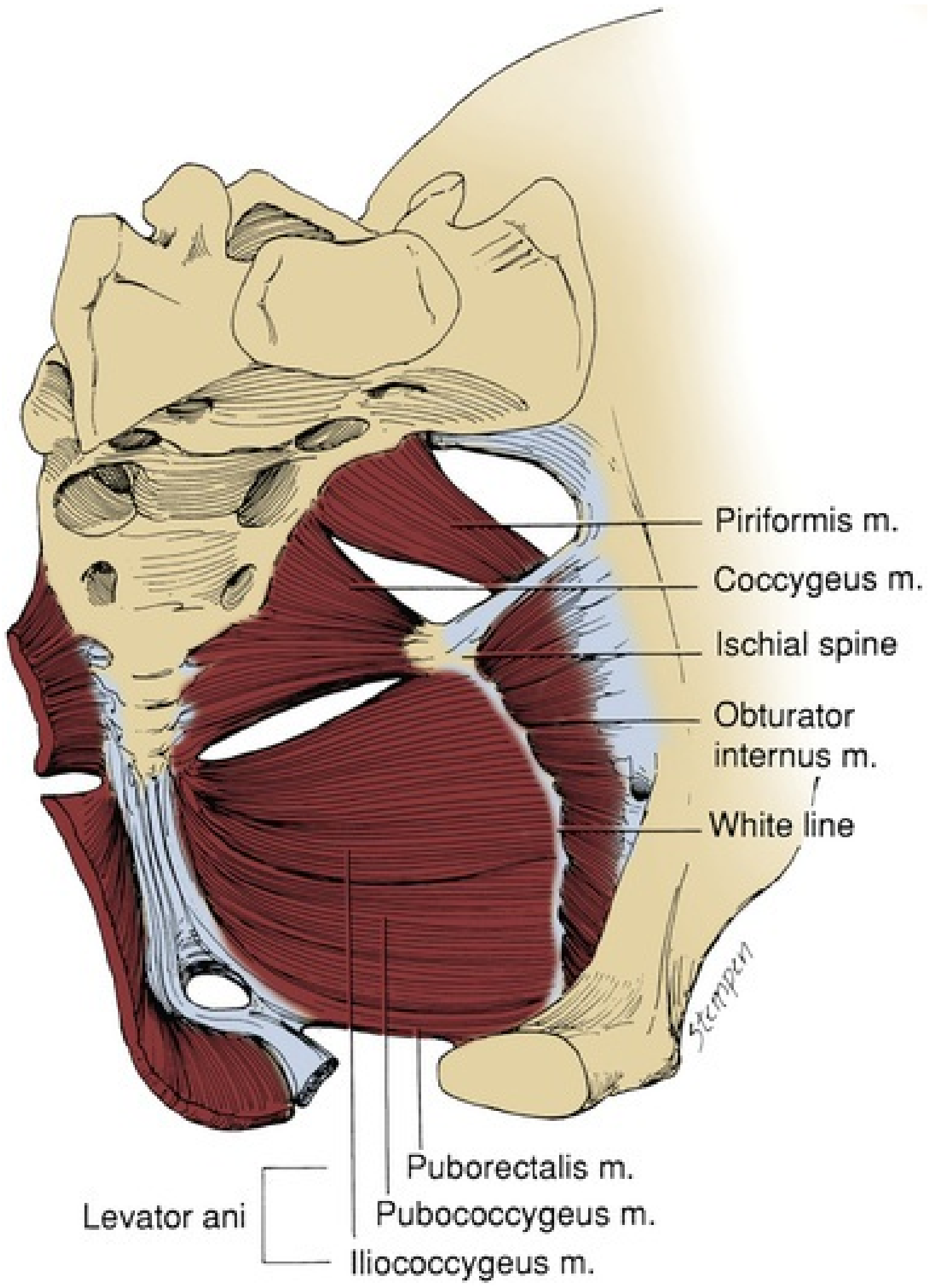
Piriformis m.
Coccygeus m.
Ischial spine
Obturator internus m.
White line
Puborectalis m.
Levator ani
Pubococcygeus m.
Iliococcygeus m.

FIG. 108.9 Muscles of the true pelvis (three-quarter view). *m,* Muscle.

Vasculature

Arterial Supply

The internal iliac arteries (hypogastric arteries) extend into the pelvic cavity, along the posterior wall, and provide multiple branches that perfuse the bladder, uterus, vagina, and rectum. The uterus is supplied by the uterine artery, which arises from the anterior branch of the iliac artery. From the internal iliac artery, the uterine artery crosses above and anterior to the ureter, extending medially in the base of the broad and cardinal ligaments to the uterus at the level of the cervix. The tortuous uterine artery spirals up the side of the uterus and branches to anastamose with the ovarian artery and descends to supply the cervix and vagina. **The uterine artery passes in front of the ureter, making the ureter**

vulnerable to injury during division of the uterine pedicle, during a hysterectomy (Goldstein and Hagen-Ansert, 2018a).

Venous Supply

There are corresponding veins, usually multiple, that course with each arterial branch and drain into the internal iliac veins or larger veins. **Extensive venous plexuses are associated with the bladder, rectum, vagina, and uterus, called the *pelvic plexus of veins.*** The obturator vein lies posterior to the artery and ureter and drains directly into the internal iliac vein. The superior and inferior gluteal veins, lateral sacral veins, and middle rectal and rectal venous plexus drain into the internal iliac vein. The clitoral veins drain into the retropubic plexus. The retropubic plexus drains through the vesical plexus, lying over the anterior portion of the bladder (in continuity with the uterine plexus) and eventually drains in the internal iliac vein. The external iliac vein is a continuation of the femoral vein and drains the inferior epigastric vein and deep circumflex iliac and pubic veins (Fig. 108.10).

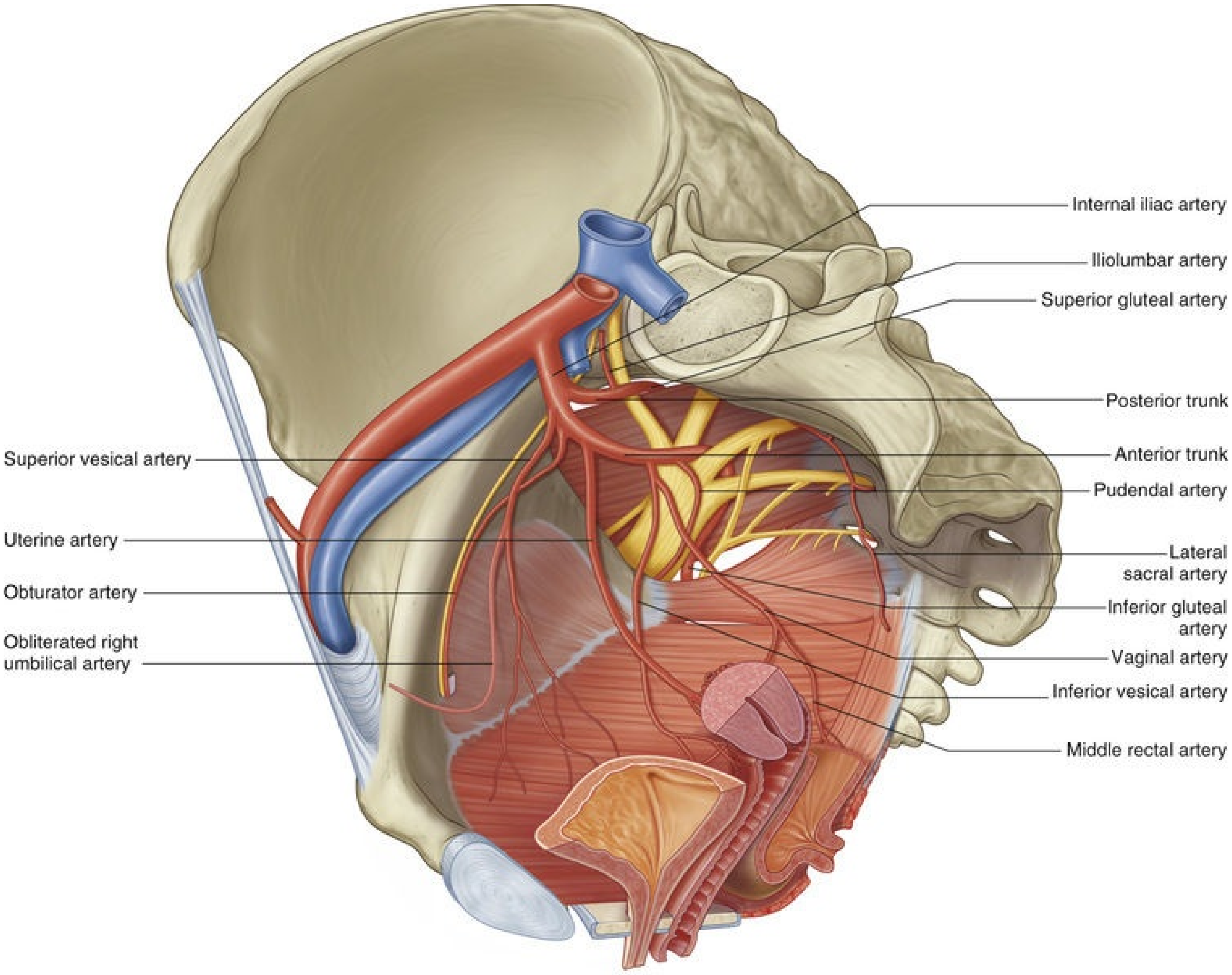
Internal iliac artery
Iliolumbar artery
Superior gluteal artery
Posterior trunk
Anterior trunk
Pudendal artery
Lateral sacral artery
Inferior gluteal artery
Vaginal artery
Inferior vesical artery
Middle rectal artery
Superior vesical artery
Uterine artery
Obturator artery
Obliterated right umbilical artery

FIG. 108.10 Arterial supply of the pelvis. (From Standring S: *Gray's anatomy: the anatomical basis of clinical practice,* ed 40, London, 2008, Churchill Livingstone.)

Lymphatic Drainage

Lymph nodes are difficult to appreciate on gross exam because they are hidden within the fatty and fibrous tissue of the intermediate stratum. Three major lymph node groups are associated with the pelvic vessels. **Most of the pelvic visceral lymphatic drainage passes through the internal iliac nodes and their branches: the presacral, obturator, and internal pudendal nodes.** The external iliac nodes are divided into three chains: external, middle, and internal. They lie lateral, anterior, and medial to the vessels. The external chain drains the anterior abdominal wall and clitoris. The bladder and vagina drain into the middle chain that lies over the external iliac artery. The internal chain drains the lower abdominal wall, superficial and deep inguinal nodes, bladder neck, and urethra. The inguinal nodes communicate directly with the internal and external iliac chains. The common iliac nodes receive efferent vessels from the external and internal iliac nodes and the pelvic ureter and drains in the lateral aortic nodes (Chung et al., 2016; Fig. 108.11).

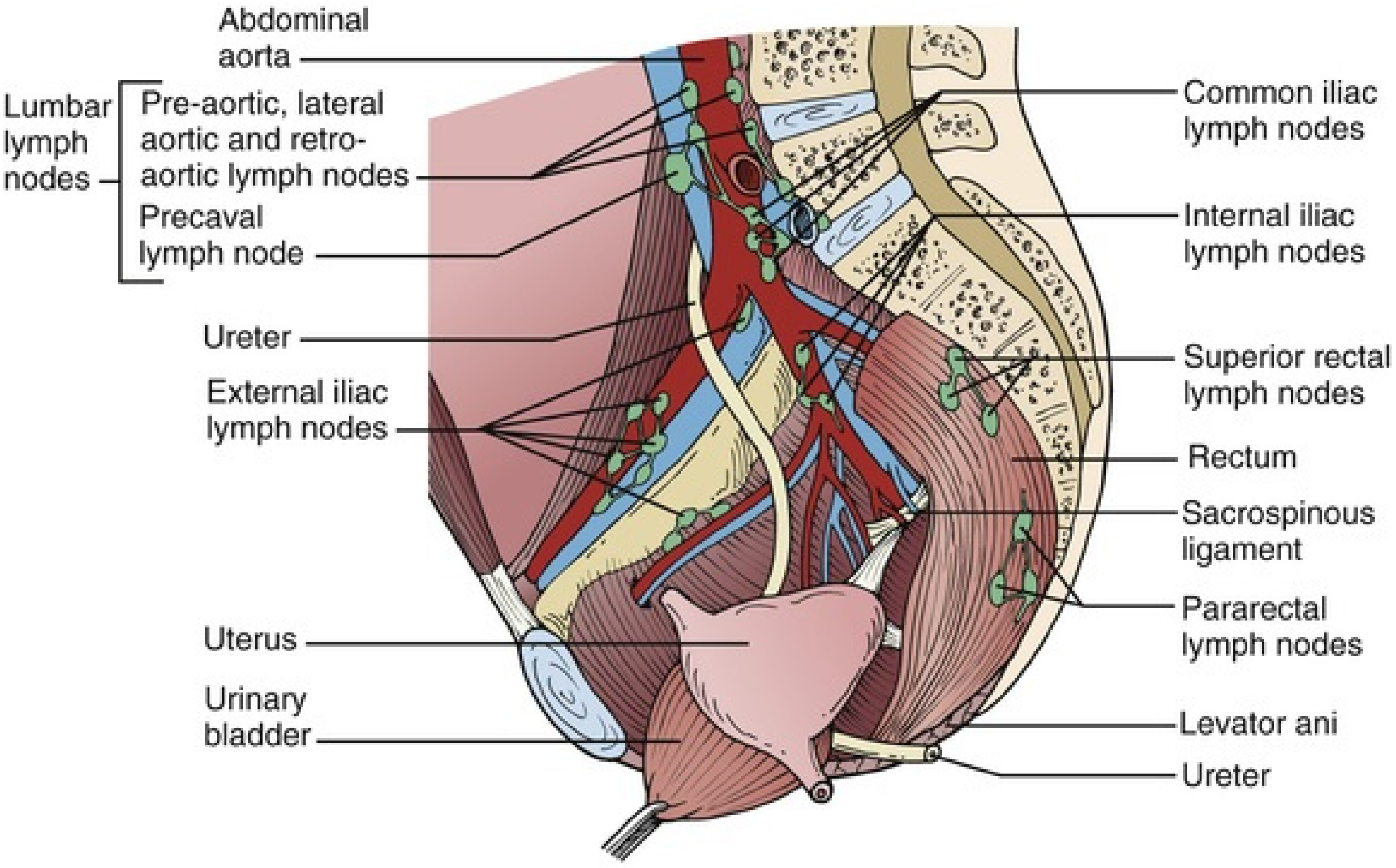
Abdominal aorta
Lumbar lymph nodes
Pre-aortic, lateral aortic and retro-aortic lymph nodes
Precaval lymph node
Ureter
External iliac lymph nodes
Uterus
Urinary bladder
Common iliac lymph nodes
Internal iliac lymph nodes
Superior rectal lymph nodes
Rectum
Sacrospinous ligament
Pararectal lymph nodes
Levator ani
Ureter

FIG. 108.11 Lymph vessels and nodes of the female pelvis. (In Paulsen F, Waschke J: *Sobotta Atlas of Human Anatomy,* ed 15, vol 2, München, 2013, Elsevier Urban & Fischer, pp 157–240.)

Nerves of the Pelvis

The pelvis and the pelvic organs have somatic and autonomic innervation. The somatic innervation includes sensory and motor functions and relates to the external genitalia and the pelvic floor. The autonomic innervation provides sympathetic and parasympathetic nerves supply to the pelvic organs.

Somatic Innervation

The sacral plexus is formed from the ventral rami of spinal nerves L4-L5 and S1-S4 and lies on the piriformis muscle deep to the endopelvic fascia and posterior to the internal iliac vessels. **The sacral plexus exits the pelvis through the greater sciatic foramen immediately posterior to the sacrospinous ligament (SSL) and can be injured during a sacrospinous ligament**

culposuspension. The sacral plexus supplies motor and sensory innervation to the posterior thigh and lower leg. **The exaggerated lithotomy position may stretch the tibialis anterior muscle, innervated by the L4-S1 roots, through the sciatic and ultimately deep peroneal nerves, which can lead to foot drop.**

Pelvic and perineal branches of the sacral plexus include the posterior femoral cutaneous nerve (S2-S3) that passes through the greater sciatic foramen and has a sensory branch to the perineum. It also includes the pelvic somatic afferent nerves (L4-S4) from the ventral rami. They travel on the pelvic surface of the levator ani, innervating these muscles as well as the striated urethral sphincter.

The pudendal nerve arises from S2-S4 just above the sacrotuberous ligament and ischiococcygeus, passes through the greater sciatic foramen, and crosses the piriformis, ischiococcygeus, and SSL close to where it attaches to the ischial spine. The pudendal nerve is vulnerable to injury during an SSLF. The pudendal nerve next runs medial to the internal pudendal vessels as they travel through the lesser sciatic foramen into Alcock canal. The pudendal nerve branches into the (1) inferior rectal nerve, (2) perineal nerve, and (3) dorsal nerve of the clitoris. The perineal branch divides into the posterior labial branch, supplying the labium majus, superficial and deep transverse perineal muscles, external and anal sphincter, and levator ani. The pudendal branches carry efferent impulses to muscles of the pelvic floor and proprioceptive afferent signals and sensation from the urethra. Additional cutaneous innervation of the mons and labia is derived from the ilioinguinal nerves (L1), the genitofemoral nerves (L1 and L2), and of the perineum through the posterior femoral cutaneous nerve form the sacral plexus (S1-S3). The ilioinguinal nerve is at increased risk of injury during inguinal hernia repair, open appendectomy, c-sections, and total abdominal hysterectomies. The genitofemoral nerve may also be injured at time of inguinal herniorraphy or may occur during standard and extended lymphadenectomy. Some common causes for injury to the posterior femoral cutaneous nerve include gluteal pressure injury and pelvic tumors. **The pudendal nerve mediates perineal pain.**

Autonomic Innervation

Sympathetic innervation arises from preganglionic fibers at the T10-T12 level and supplies the ovaries and fallopian tubes through sympathetic fibers traveling along the ovarian vessels. The body of the uterus and cervix receive sympathetic innervation through the hypogastric plexus, accompanying branches of the iliac vessels, with fibers signifying stretching. **The superior**

hypogastric plexus arises from the aortic plexus below the aortic bifurcation at L5. It bifurcates into the left and right hypogastric nerves that unite with pelvic splanchnic nerves. The right and left pelvic (hypogastric) plexi lie near the bladder base, yielding the vesical plexus and uterovaginal plexus, which sends fibers through the broad ligament. The broad ligament acts as sensory tissue during sexual intercourse and assists with sensory function in micturition. Uterine pain is mediated through sympathetic afferent nerves passing up to T11/T12 and L1/L2 and is felt in the lower abdomen and high lumber spine.

The parasympathetic fibers lie deeper to the sympathetic fibers within the intermediate stratum and arises from the S1-S3 segments. These fibers control smooth muscle function of the bladder and anal sphincter systems (smooth muscle of the internal anal sphincter and striated muscle of the external anal sphincter). Cervical pain is mediated through the parasympathetic afferent nerves passing backward to S1-S2 (DeCosta, 2013).

Perineum

The perineum is divided into **two adjacent triangles. The anterior urogenital triangle** is bound by the pubic symphysis, the pubic rami, ischial rami, and deep transverse perineal muscles spanning the ischial tuberosities. **The posterior anal triangle** lies behind a line between the ischial tuberosities and contains the anus. **The urogenital triangle is divided into deep and superficial spaces by the perineal membrane.** The **perineal membrane (previously called the urogenital diaphragm) is a sheet of fascia lying between the two sides of the pubic arch.** The urethra and vagina pass through the urogenital hiatus of the perineal membrane to exit at the vestibule.

The deep space of the urogenital triangle contains the urethral sphincter, urethrovaginalis, compressor urethrae, and deep transverse perineal muscles. Urethrovaginalis is another name for the female external sphincter. The inferior fascia of the urogenital diaphragm is what lays the groundwork for the deep space. **The superficial space is made up of the superficial perineal muscles, clitoris, vestibular bulbs, and Bartholin glands.** The vestibular bulbs or corpus spongiosum tissue are two elongated erectile bodies on either side of the urethra, close to the labia minora.

Colles fascia forms the roof of the superficial perineal space. Laterally, this fascia is firmly attached to the fascia lata of the thigh at the ischiopubic ramus and defines the perineal thigh crease. The apex is attached to the arcuate ligament of the pubis. Posteriorly, the fascia surrounds the superficial transverse perineal muscle and anchors to the inferior fascia of the urogenital diaphragm, fusing with the perineal body. Anteriorly, Colles fascia covers the clitoris similar to dartos in the male. The deep perineal fascia lies over the superficial muscles of the perineum and fuses with the suspensory ligaments of the clitoris and fascia of the rectus sheath and external oblique muscles.

The perineal body contains muscle and collagenous and elastic fibers and is at the central point of the perineum. **It is the convergence of the bulbospongiosus, external anal sphincter, and superficial and deep transverse perineal muscles.** The perineal body attaches to the posterior border of the perineal membrane. It is posterior to the vestibule of the vagina and anterior to the anal canal. Damage to the perineal body during parturition can cause damage to fibers of the external anal sphincter. Episiotomy is angled laterally to avoid damage to these fibers (Howard and Dickie, 2018).

The bulbospongiosus muscle splits to surround the introitus and attaches anteriorly to the clitoris. This muscle attaches to the perineal body and covers the vestibular bulbs. The bulbospongiosus muscle bodies contract to constrict the vaginal orifice and express vestibular gland secretions. The ischiocavernosus muscle also covers one crus of the clitoris and promotes its erection. The superficial transverse perineal muscles overlie the posterior portion of the vagina (Fig. 108.12).

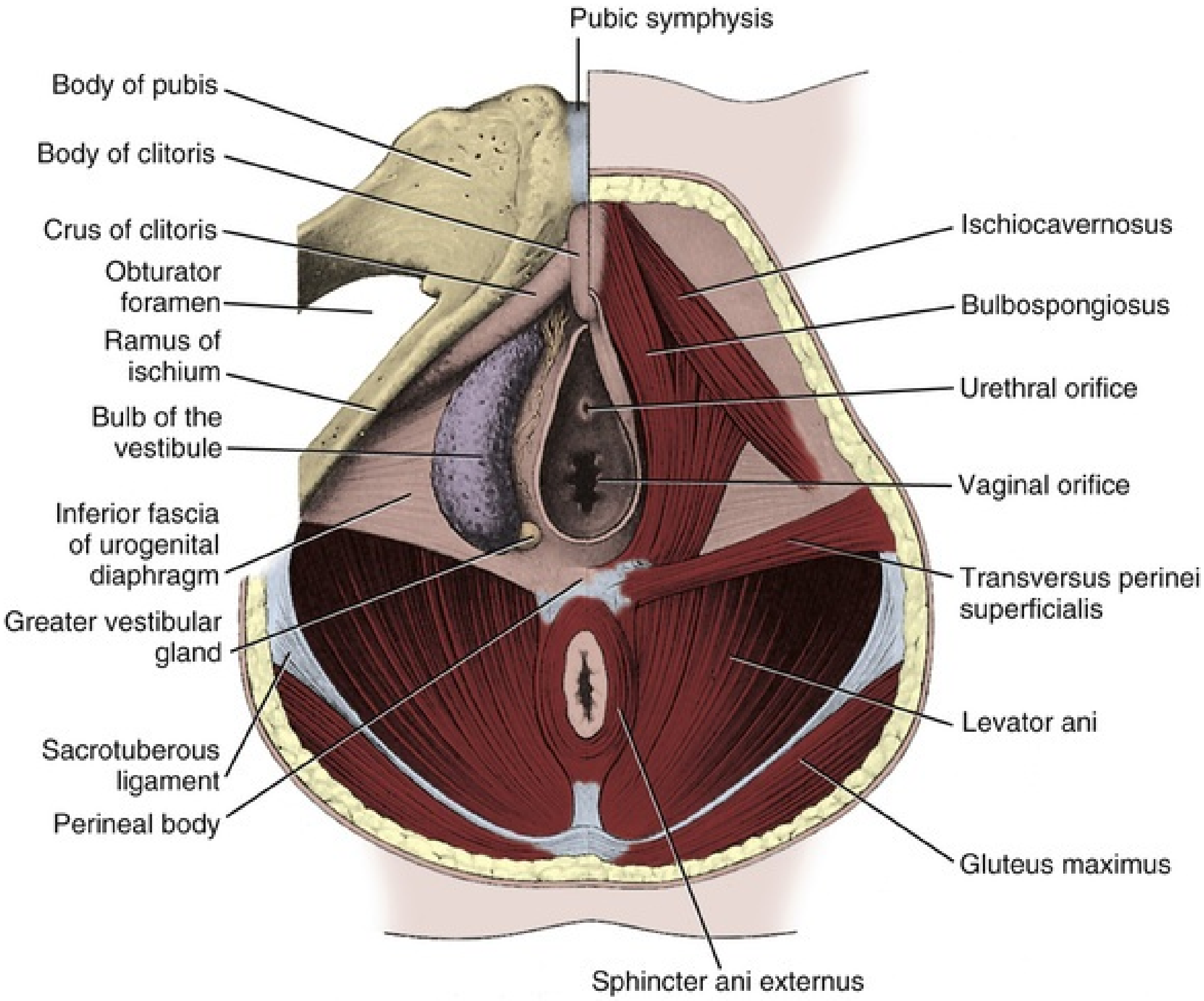
Pubic symphysis
Body of pubis
Body of clitoris
Crus of clitoris
Obturator foramen
Ramus of ischium
Bulb of the vestibule
Inferior fascia of urogenital diaphragm
Greater vestibular gland
Sacrotuberous ligament
Perineal body
Ischiocavernosus
Bulbospongiosus
Urethral orifice
Vaginal orifice
Transversus perinei superficialis
Levator ani
Gluteus maximus
Sphincter ani externus

FIG. 108.12 Female superficial perineal pouch. *Left,* The muscles have been removed to show the vestibular bulb and Bartholin glands. (From Williams PT, Warwick R: *Gray's anatomy,* ed 35 [British], Philadelphia, 1972, Saunders.)

Anal Perineum

The rectum is covered in pararectal fascia that attaches the anorectal junction to the sacrum. Anteriorly there is the rectovesical fascia and posterolaterally there are lateral ligaments of the rectum that run with the middle rectal vessels. The anococcygeal ligaments also provide anal canal support and run between the middle of the external anal sphincter and the coccyx.

The ischiorectal fossa contains fat and Colles fascia and is bound by the external anal sphincter, ischial tuberosity, urogenital diaphragm, and gluteus maximus. The internal pudendal vessels run along the lateral wall of the ischiorectal fossa inside Alcock canal. Alcock canal, also called the pudendal canal, is made up of fascia of the obturator internus muscle and contains the internal pudendal vessels and pudendal nerve. The internal rectal venous plexus lies between the rectum, puborectalis, and levator ani muscles. The external plexus lies deep to the sphincters. They both drain into the middle rectal vein. The superior rectal vein drains into the inferior mesenteric vein, and the inferior rectal vein drains into the pudendal vein.

The longitudinal muscles of the rectum continue into the anus as the intersphincteric plane demarcating the line between the internal sphincter and external sphincter fibers. **The external anal sphincter is composed of striated muscles and has three parts.** From distal to proximal, these components include the subcutaneous external anal sphincter, the superficial external sphincter, and the deep external sphincter. The deep external anal sphincter is adjacent to the deep transverse perineal muscles and the levator ani. The external anal sphincter is innervated by the inferior rectal nerve and by branches of the pudendal nerve. **The internal anal sphincter is circular nonstriated muscle lying outside the internal rectal venous plexus.** It receives autonomic innervation from iliohypogastric plexus branches. Fecal incontinence is complex and depends on the integrated function of the internal and external anal sphincters, the puborectalis muscle, intact neurosensory pathways, rectal compliance, anorectal sensation, and anal sphincter resting tone (Lin, 2013; Fig. 108.13).

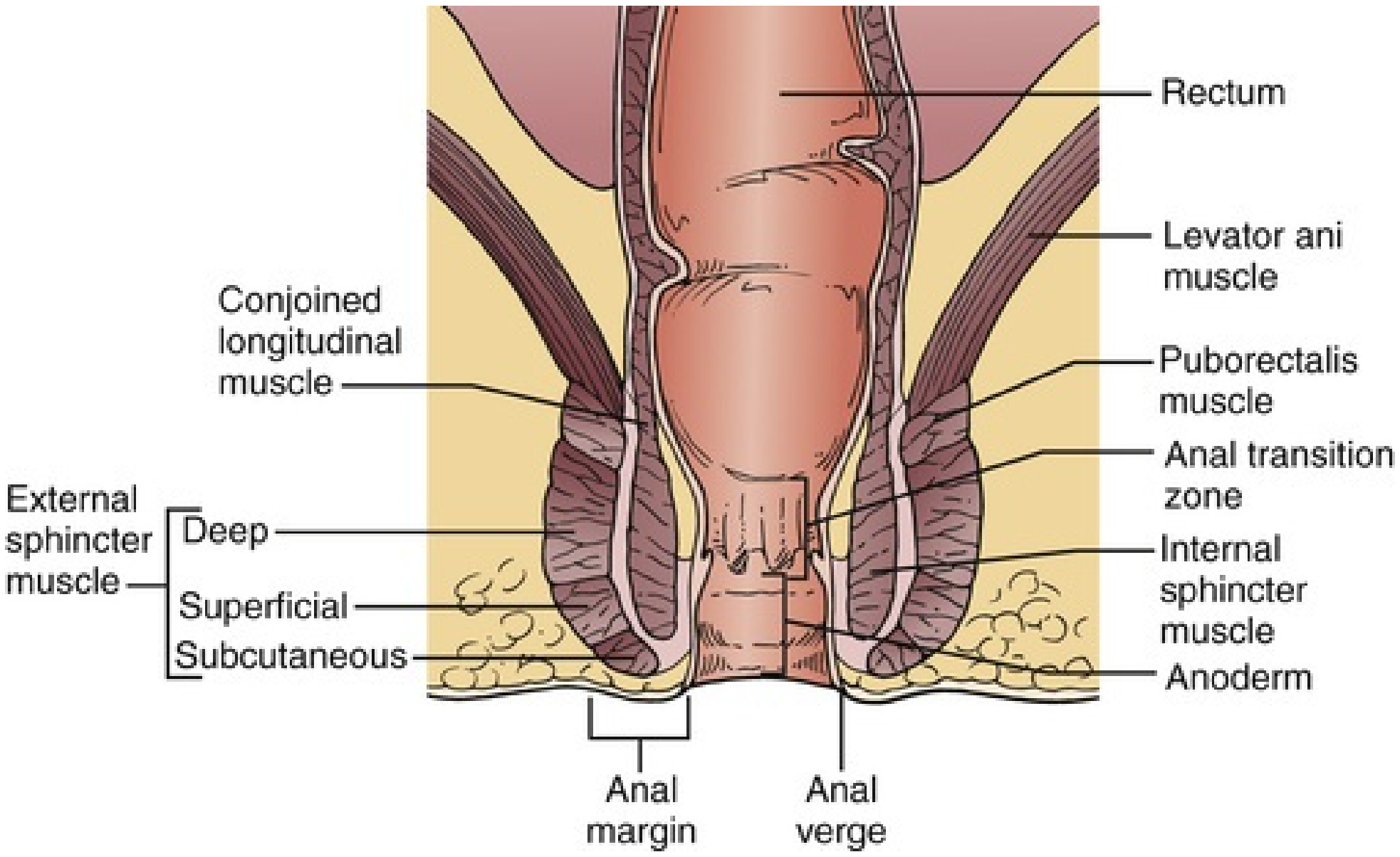
Rectum
Levator ani muscle
Conjoined longitudinal muscle
Puborectalis muscle
Anal transition zone
External sphincter muscle
Deep
Superficial
Subcutaneous
Internal sphincter muscle
Anoderm
Anal margin
Anal verge

FIG. 108.13 The anal canal musculature and pelvic floor muscles. (From Merchea A, Larson D: In Anus. In Townsend C, Beauchamp RD, Evers BM, et al.: *Sabiston textbook of surgery*, ed 20, Philadelphia, 2017, Elsevier.)

External Genitalia

The perineal membrane is pierced by the vagina and urethra. **The crura of the clitoris and the bulbs of the vestibule are covered by the ischiocavernosus and bulbospongiosus muscles, respectively.** The crura and vestibular bulbs make up the erectile tissue, which attaches to the inferior surface of the perineal membrane. The right and left crura attach to the medial margins of the ischiopubic rami to form the shaft of the clitoris. These bodies turn downward and backward to the urethral opening and are capped by the glans of the clitoris. The paired vestibular bulbs surround the urethral and vaginal openings. They taper and fuse in the midline, terminating with the glans. The posterior end of each bulb is expanded and covers the greater vestibular (Bartholin) gland. This gland can be the site of cyst formation (Bartholin gland cyst) or become infected (Bartholin abscess), requiring surgical intervention.

The skin folds, labia majora, are the most superficial parts of the female external genitalia. These meet anteriorly at the mons pubis. The mons pubis is a pad of fat overlying the pubis symphysis and covering most of the clitoris. The two labia minora lie between the labia majora and become more prominent anteriorly. **The labia minora fuse in the midline, forming two folds of skin around the glans of the clitoris. The hoodlike anterior fold becomes the prepuce of the clitoris, and the smaller posterior fold forms the frenulum.** Posteriorly, the labia minora come together at the fourchette, which is usually torn during vaginal delivery. **The labia minora encloses a cleft, the vestibule, into which the vagina and urethral meatus open.** The vaginal opening or introitus, is an anteroposterior slit, surround by a fringe of skin, the hymen. The external urethral meatus lies 1 cm anterior to the vaginal opening.

The term *vulva* describes the mons pubis, the labia major and minora, clitoris, and vestibule (Gosling et al., 2017). The vulva has lymphatic drainage into the superficial inguinal glands, which drain to the deep inguinal nodes that travel to the pelvic nodes. The clitoris and labia minora drain to the deep inguinal nodes and may pass to the internal iliac nodes.

The innervation of the anterior labium majus derives from branches of the ilioinguinal nerve, which arises from T12. Branches from the perineal nerve innervate the posterior two-thirds of the labia. Laterally, there is also innervation from the perineal branch of the cutaneous nerve of the thigh. Parasympathetic stimulation leads to increased vaginal secretions, erection of the clitoris, and engorgement of the erectile tissues (Figs. 108.14 and 108.15).

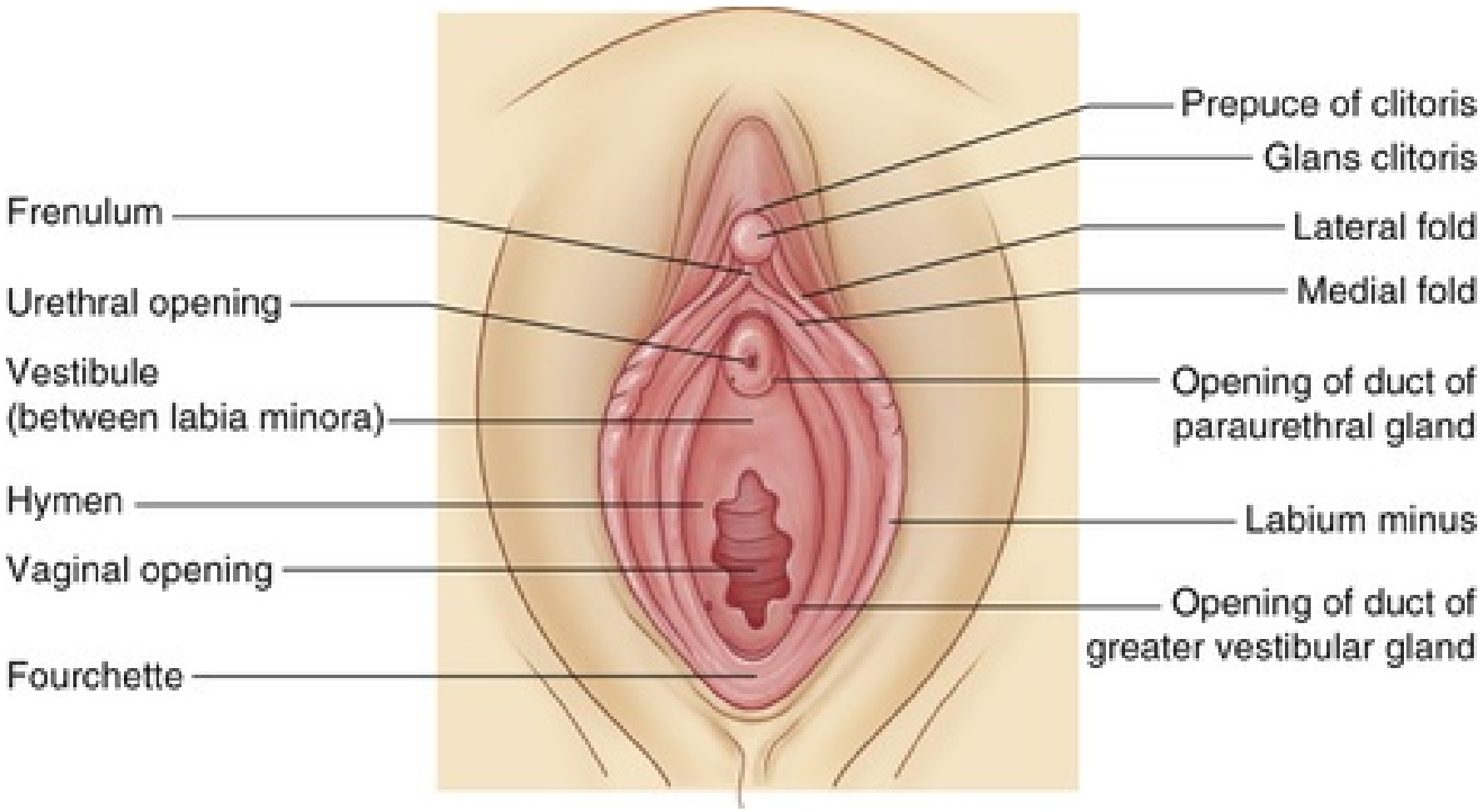
Prepuce of clitoris
Glans clitoris
Frenulum
Lateral fold
Medial fold
Urethral opening
Vestibule
(between labia minora)
Opening of duct of
paraurethral gland
Hymen
Labium minus
Vaginal opening
Opening of duct of
greater vestibular gland
Fourchette

FIG. 108.14 Female vulva and external genitalia. (From Standring S: *Gray's anatomy: the anatomical basis of clinical practice,* ed 40, London, 2008, Churchill Livingstone).

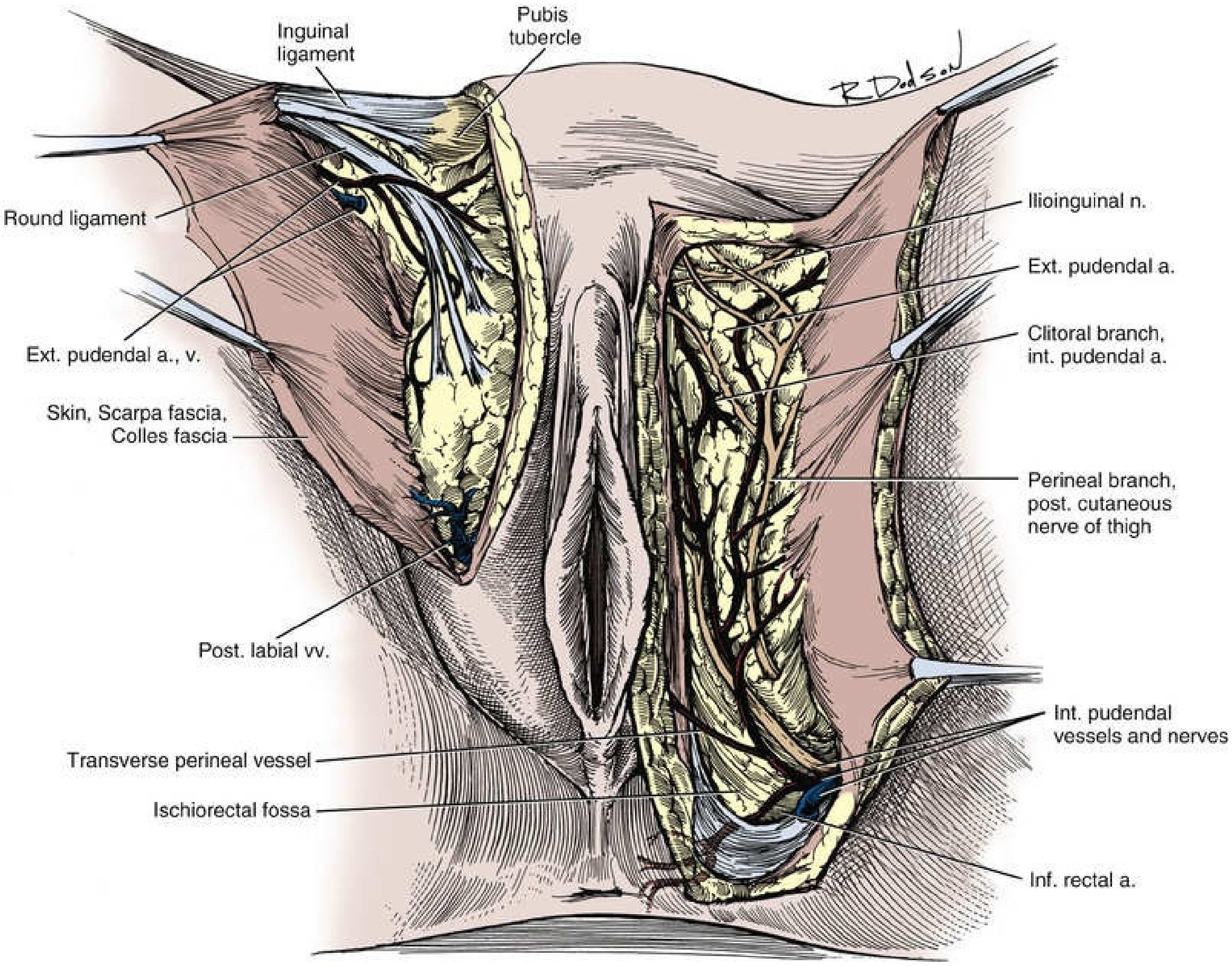
Inguinal ligament
Pubis tubercle
R Dodson
Round ligament
Ext. pudendal a., v.
Skin, Scarpa fascia, Colles fascia
Post. labial vv.
Transverse perineal vessel
Ischiorectal fossa
Ilioinguinal n.
Ext. pudendal a.
Clitoral branch, int. pudendal a.
Perineal branch, post. cutaneous nerve of thigh
Int. pudendal vessels and nerves
Inf. rectal a.

FIG. 108.15 Arteries and nerves of the female perineum. *a,* Artery; *Ext,* external; *Inf,* inferior; *Int,* internal; *n,* nerve; *Post,* posterior; *vv,* veins. (From Doherty MG: Clinical anatomy of the pelvis. In Copeland LJ, editor: *Textbook of gynecology,* Philadelphia, 1993, Saunders, p 51).

Female Pelvic Organs

The uterus is normally anteverted and anteflexed and composed of the uterine body and the cervix. The cervix terminates as the os into the vagina. It is surrounded by the vaginal wall that is shallow anteriorly (ventral fornix) and deeper posteriorly (dorsal fornix) along with lateral fornices. The cervix is usually 2.5 cm long, adjacent to the bladder, and separated by the parametrium. The body of the uterus is composed of three layers. **The outermost layers is the perimetrium, consisting of the peritoneum and thin connective tissue (parametrium). The myometrium is broken down into three additional layers: outer longitudinal layer continuous with the ovarian and round ligament, middle circular layer, and inner longitudinal layer. The blood**

vessels and nerves are located in this layer. The inner most layer of the uterus is the mucosal layer or endometrium.

The uterine artery branches off the anterior branch of the internal iliac artery. It crosses the ureter close to the cervix and provides a small branch to the ureter. The uterine artery passes through the broad ligament and feeds the fallopian tube and runs from lateral to medial to join the ovarian artery. The cervical branches terminate in the vaginal branches of the uterine artery or azygous arteries of the vagina. The uterus drains into a uterine plexus that runs in the broad ligament and joins the vaginal and ovarian plexuses to drain ultimately into the internal iliac vein. **The uterine innervation originates from the inferior hypogastric plexus. Uterine lymphatic drainage is complex.** The cervix drains into the external and internal iliac nodes and the sacral nodes. The upper part of the uterus and fallopian tubes follow the ovarian drainage into the lateral aortic and preaortic nodes. Around the round ligament, there is uterine drainage into the superficial inguinal nodes. The uterine body drains into the external iliac nodes. The fundus drains into the para-aortic and lateral aortic nodes (Fig. 108.16).

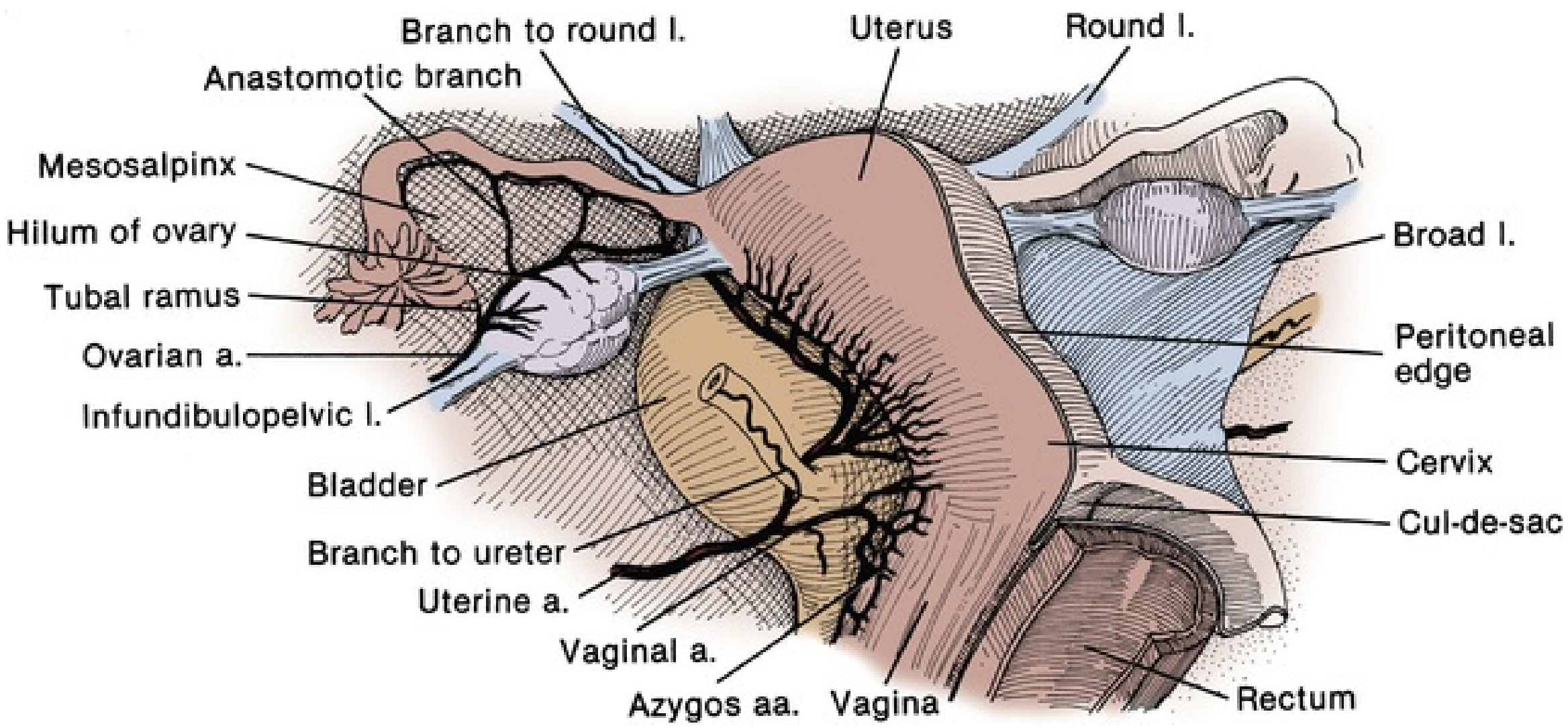
Branch to round l.
Uterus
Round l.
Anastomotic branch
Mesosalpinx
Hilum of ovary
Tubal ramus
Ovarian a.
Infundibulopelvic l.
Bladder
Branch to ureter
Uterine a.
Vaginal a.
Azygos aa.
Vagina
Rectum
Broad l.
Peritoneal edge
Cervix
Cul-de-sac

FIG. 108.16 Urethra and its supportive structures that help to maintain continence. *a,* Artery; *aa,* arteries; *l,* ligament. (From Maclenna GT: *Hinman's atlas of urosurgical anatomy,* ed 2, Philadelphia, 2012, Saunders.)

The fallopian tubes are 10 to 12 cm in length and are draped in the broad ligament. They open posteromedially and are divided into four parts:

uterine interstitial segment, isthmus, ampulla, and infundibulum. The fallopian tubes enter the uterus bilaterally at the uterine cornua (or horns) and terminate with fimbriae. The arterial blood supply is from the ovarian and uterine arteries. The lateral two-thirds of the fallopian tubes drain into the ovarian veins, and the medial portion drains into the uterine plexus. Lymphatic drainage is to the para-aortic nodes (ovarian vessels), internal iliac chain (uterine vessels), and inguinal nodes (round ligament). Innervation is by autonomic fibers from the ovarian and uterine plexuses.

The ovaries are supported by the mesovarium in the ovarian fossa within the posterior peritoneum, bordered by the obliterated umbilical artery, ureter, and internal iliac artery. The ovary is attached to the posterior aspect of the broad ligament and is suspended by the infundibulopelvic ligament, which contains the ovarian vessels. The ovary is also attached to the uterus by the ovarian ligament. The ovarian artery arises directly from the aorta and passes in the infundibulopelvic ligaments into the hilum of the ovary. The artery then passes through the broad ligament, supplying the fallopian tube, and joins the uterine artery. The venous drainage of the ovary is to a pampiniform plexus, merging into the ovarian vein. **The right ovarian vein drains directly into the vena cava below the renal vein, and the left ovarian vein drains into the left renal vein.** Innervation is from the ovarian and inferior mesenteric plexuses, following the path of the ovarian artery. The lymphatic drainage, like the testicle, is into the lateral aortic and preaortic nodes near the kidneys.

Columnae rugarum, or vaginal columns of mucosa, run along the anterior and posterior vaginal walls of the vagina, which terminate at the urethrovaginal ridge or carina. These ridges create an H shape on cross-section with rugae or folds. The vagina is composed of a mucous membrane and lamina propria that are fixed to the muscular layer. The muscle has an outer longitudinal and inner circular layer that are attached to the rectovesical fascia bilaterally. The muscle is lined by nonkeratinized, stratified squamous epithelium. **The vaginal wall is attached to the cervix higher on the posterior wall compared with the anterior wall; thus the anterior wall is 7.5 cm and the posterior wall is 9 cm on average. The vagina is attached anteriorly by the levator ani to the arcus tendineus and posteriorly to the rectovaginal septum.** The apex is covered by the peritoneum form the rectouterine pouch. The base of the bladder is tethered on the vaginal wall by smooth muscle fibers. These must be opened to access the vesicovaginal space, as needed for repair of a vesicovaginal fistula. **The ureters pass close to the lateral fornices of the**

vagina and are anterior to the vagina as they enter the bladder. Access to the retropubic space can be obtained by incising the anterior vaginal wall on either side of the urethra, which is the typical dissection for a retropubic sling.

The vaginal vessels (from the internal iliac artery) and nerves (branch of pudendal nerve called *deep perineal nerve*) lie on the anterolateral surface of the vagina deep to the ATFP. The uterine arteries supply the superior part of the vagina. The middle and inferior portion of the vagina are supplied by the vaginal arteries (branches of the uterine and middle rectal artery). The inferior portion is supplied by the internal pudendal artery. The vaginal venous plexus joins the uterine plexus to form the uterovaginal venous plexus. The lymphatic drainage into the internal and external iliac lymph nodes lies at the superior portion of the vagina. The middle portion drains into the internal iliac lymph nodes and the inferior portion into the sacral, common iliac, and superficial inguinal nodes.

The vagina has autonomic innervation from the uterovaginal plexus (sympathetic, parasympathetic, and visceral afferent fibers), which travels at the base of the broad ligament. **The lower one-fourth of the vagina has somatic innervation from the pudendal nerve and is sensitive to touch and temperature change.**

Pelvic Organ Support

The pubovesical ligaments help support the urethra and bladder neck but may also play a role in relaxation of the bladder neck during micturition (Herschorn, 2004). **The anterior vagina provides support to the urethra through its lateral attachments to the pubococcygeus and ATFP.** The pubocervical fascia that extends from the pubic symphysis to the cervix may provide additional support to the bladder base (Herschorn, 2004).

The parametrium and paracolpium provide support to the vagina and uterus. The cardinal ligaments and uterosacral ligaments provide additional support to the uterus, cervix, and vagina. This was described by DeLancey as Level 1 support (Wei and DeLancey, 2004), which supports the uterus and vaginal apex. The broad and round ligaments do not play a significant role in pelvic organ support (Barber, 2005). Weakness of the lateral attachments of the cardinal ligaments or vesicopelvic ligaments leads to lateral cystocele defects. The posterior vaginal wall is supported by the paracolpium that attaches to the rectovaginal fascia (Herschorn, 2004). This sheet of fascia at the medial aspect of the vagina is sometimes referred to as the rectal pillars (Ashton-Miller and

DeLancey, 2007). **Level II support runs from the paravaginal attachments to the ATFP and to the arcus tendineus rectovaginalis** (Barber, 2005)**. Anterior wall prolapse results from loss of level II support (anterior vaginal wall support). Level III support is created by the distal vagina attachments to the levator muscles laterally, anteriorly to the urethra, and posteriorly to the perineal body. Level III support provides foundation to the urethra, and disruption leads to urethral hypermobility** (Fig. 108.17).

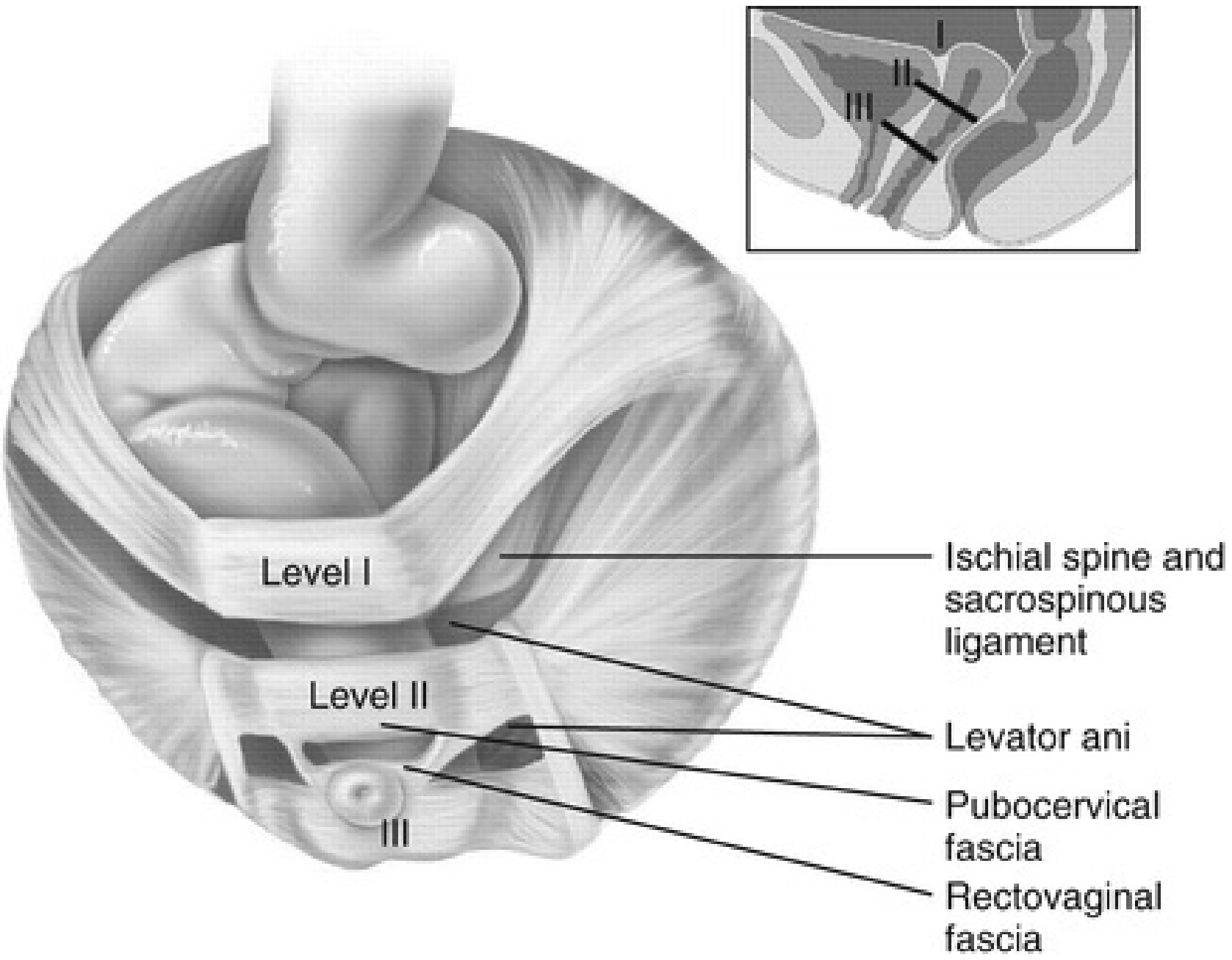

FIG. 108.17 Vaginal and visceral supportive structures as defined by Delancey. The fibers of level I support are oriented vertically and suspend the uterus and upper vagina. Level II support is more horizontal in its orientation and is attached to the mid-vagina. Distally, level III support fuses directly into support structures. (From Delancey JO: Anatomic aspects of vaginal eversion after hysterectomy. *Am J Obstet Gynecol* 166:1717–1728, 1992.)

Urethra

The adult female urethra is about 4 cm long and 6 mm in diameter. It runs anteroinferiorly behind the pubic symphysis, embedded in the anterior vaginal wall. It is suspended beneath the pubis by the posterior pubourethral ligaments and anteriorly by the suspensory ligaments of the clitoris. The urethra crosses the perineal membrane and ends at the external urethral orifice in the vestibule as an anteroposterior slit, anterior to the opening of the vagina and 2.5 cm behind the glans clitoris. Aside from urine passage, the anterior and posterior walls of the urethra are in apposition. Exceptions to this include congenital defects, such as hypospadias, when the urethra opens into the vagina and in epispadias, where there is a fissure in the upper wall of the urethra.

The wall of the female urethra consists of an outer, circular muscular layer and inner, longitudinal mucosal layer, which lines the lumen and is continuous with the bladder mucosa and constitutes the involuntary urethral sphincter. The female internal sphincter is a continuation of the detrusor muscle and is made of smooth muscle, which is under involuntary or autonomic control. The female external sphincter is anatomically separate from the adjacent periurethral striated muscles of the anterior pelvic floor. These muscle layers are surrounded by elastic tissue and collagen. The longitudinal fibers shorten the urethra and increase the diameter during voiding (Maclennan, 2012; Standring, 2016). **At the distal two-thirds of the urethra, the voluntary sphincter is present, composed of striated muscle. At the most proximal portion (mid-urethra) it forms a horseshoe around the urethra. This is where the closing pressure is highest.** There are muscle fibers on the lateral sides of the urethra, which are continuous with the anterior and lateral walls of the vagina (urethral compressor). When they contract, the urethra closes against the anterior vaginal wall. The additional fibers surrounding the urethra and vagina compose the urethrovaginal sphincter. When these fibers contract, they tighten the urogenital hiatus. The pubococcygeus runs along the urethra bilaterally and increases the resistance in the urethra.

There are many periurethral glands, which, when obstructed, may give rise to urethral diverticula or other cysts (see Fig. 108.23). The most prominent are Skene glands (homologous with the prostate), which open distally just inside the meatus.

The urethra is composed of three anatomic layers: (1) epithelium, (2) submucosa, and (3) mucosa. The lamina propria is a thin layer of connective tissue that forms part of the moist lining of the mucosa. The urethra is made up of transitional epithelium with multiple infoldings that allow distensibility and coaptation on closure. The epithelium transitions to pseudostratified and squamous epithelium at the most distal portion of the urethral. The epithelium is surrounded by spongy tissue of vascular networks that make up the submucosa. Surrounding the urethra is a thin periurethral fascia. An infected or ruptured paraurethral gland, disrupting the periurethral fascia leads to a urethral diverticulum. **The mucosa and submucosa are primarily responsible for urethral closure pressure and are estrogen dependent.**

The urethra is primarily supplied by the vaginal artery yet also receives some arterial supply from the inferior vesical artery and internal pudendal arteries. The venous drainage is carried through the inferior, middle, and superior vesical veins, as well as the clitoral plexus into the internal pudendal veins. The distal one-third of the urethra (anterior urethra) drains into the superficial and deep inguinal lymph nodes. The proximal two-thirds (posterior urethra) drains into the iliac and obturator lymph nodes (Fig. 108.18).

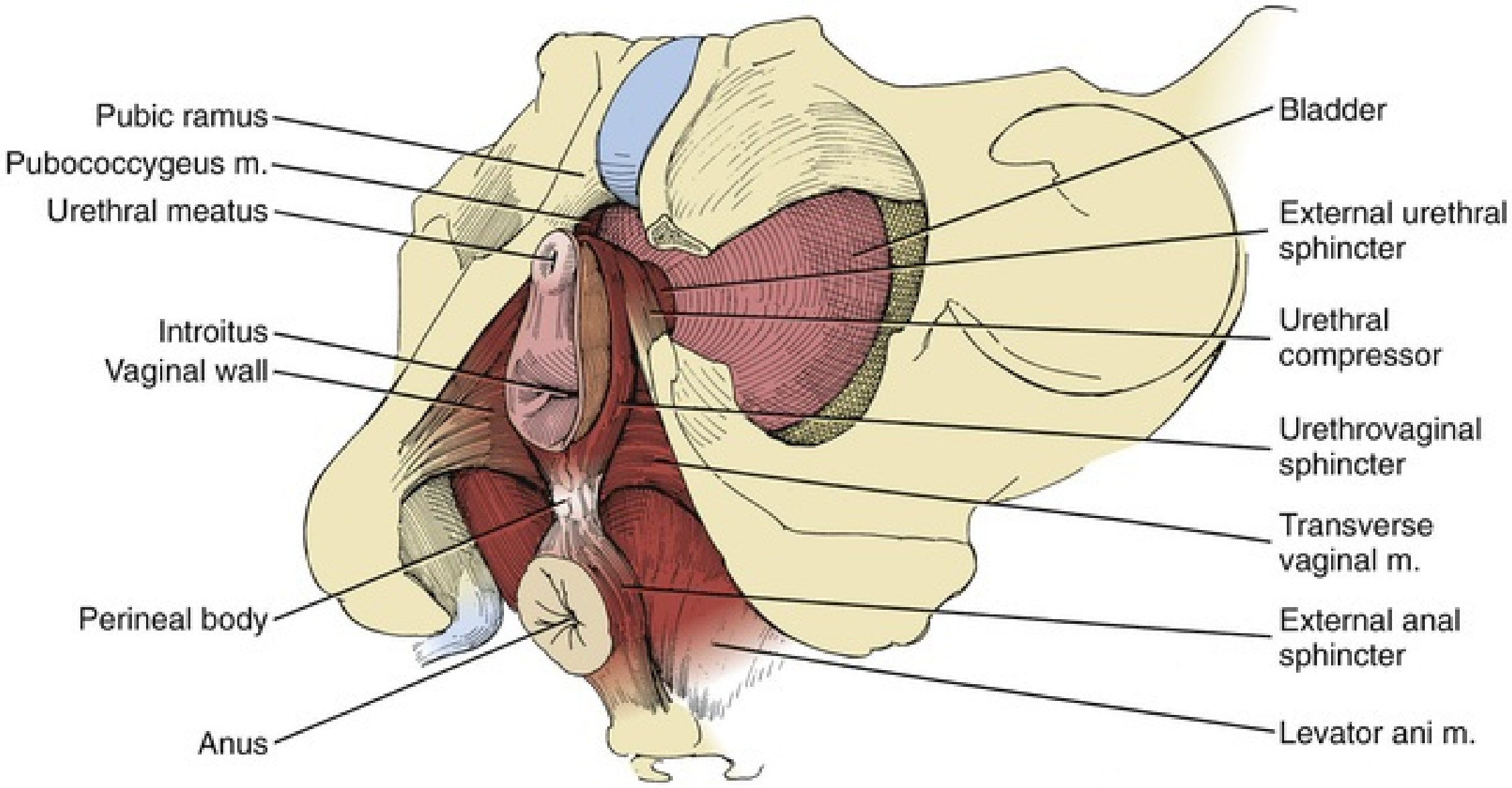
Pubic ramus
Pubococcygeus m.
Urethral meatus
Introitus
Vaginal wall
Perineal body
Anus
Bladder
External urethral sphincter
Urethral compressor
Urethrovaginal sphincter
Transverse vaginal m.
External anal sphincter
Levator ani m.

FIG. 108.18 Urethra and its supportive structures that help to maintain continence. *m,* Muscle. (From Maclenna GT: *Hinman's atlas of urosurgical anatomy,* ed 2, Philadelphia, 2012, Saunders.)

Key Points: Surgical Anatomy of the Female Pelvis

- The pelvic inlet faces anteriorly, allowing pressure of the intra-abdominal and intrapelvic contents to be directed to the bony pelvis rather than the muscles and the fascia. The bony pelvis should be visualized in the supine position.
- The ATFP and ATLA are two distinct structures serving as key players in fascial attachment. ATFP is the main point for fascial attachment. The

levator ani muscles attach to the ATFP and cover the obturator internus.

- The ischial spine and sacrospinous ligament are important landmarks during vault suspension to avoid injury to the sacral plexus and pudendal nerve.
- The sustained resting tone of the pelvic floor muscles (pubococcygeus, puborectalis, and iliococcygeus) supports pelvic viscera, resists increases in intra-abdominal pressure, and is crucial in passive control of urinary and fecal continence.

Radiographic Anatomy of the Female Pelvis

Different modalities are used to visualize female pelvic anatomy and its contents.

Ultrasound

Ultrasound (US) is a readily available, important diagnostic tool for evaluation of pelvic anatomy and pathology in adult and pediatric populations. It is a noninvasive, high-resolution imaging technique with ability to separate fluid from soft tissue (Goldstein and Hagen-Ansert, 2018b). Transabdominal, transperineal, transrectal, translabial, and transvaginal approaches have been used (Dietz, 2008).

Transperineal or translabial US is often used because of its noninvasive approach, which does not distort or compress underlying structures. The pubic symphysis, urethra, bladder neck, vagina, rectum, and anal canal are commonly seen on translabial US (Fig. 108.19). The levator plate and pubovisceral muscles are a hyperechogenic area behind the anorectal junction (Dietz, 2004). The cul-de-sac contains fluid, fat, or small bowel. Bladder neck mobility may be assessed via real-time imaging while performing a Valsalva maneuver in the supine position. Bladder wall thickness and pelvic organ prolapse can be measured via translabial US (Dietz, 2004). **Other common uses of ultrasound include visualization of transvaginal mesh, urethral bulking agents, and urethral implants.** Newer probes have allowed for three-dimensional imaging reconstruction, which provides the added benefit of visualizing structures in the axial view rather than only the midsagittal view (Fig. 108.20).

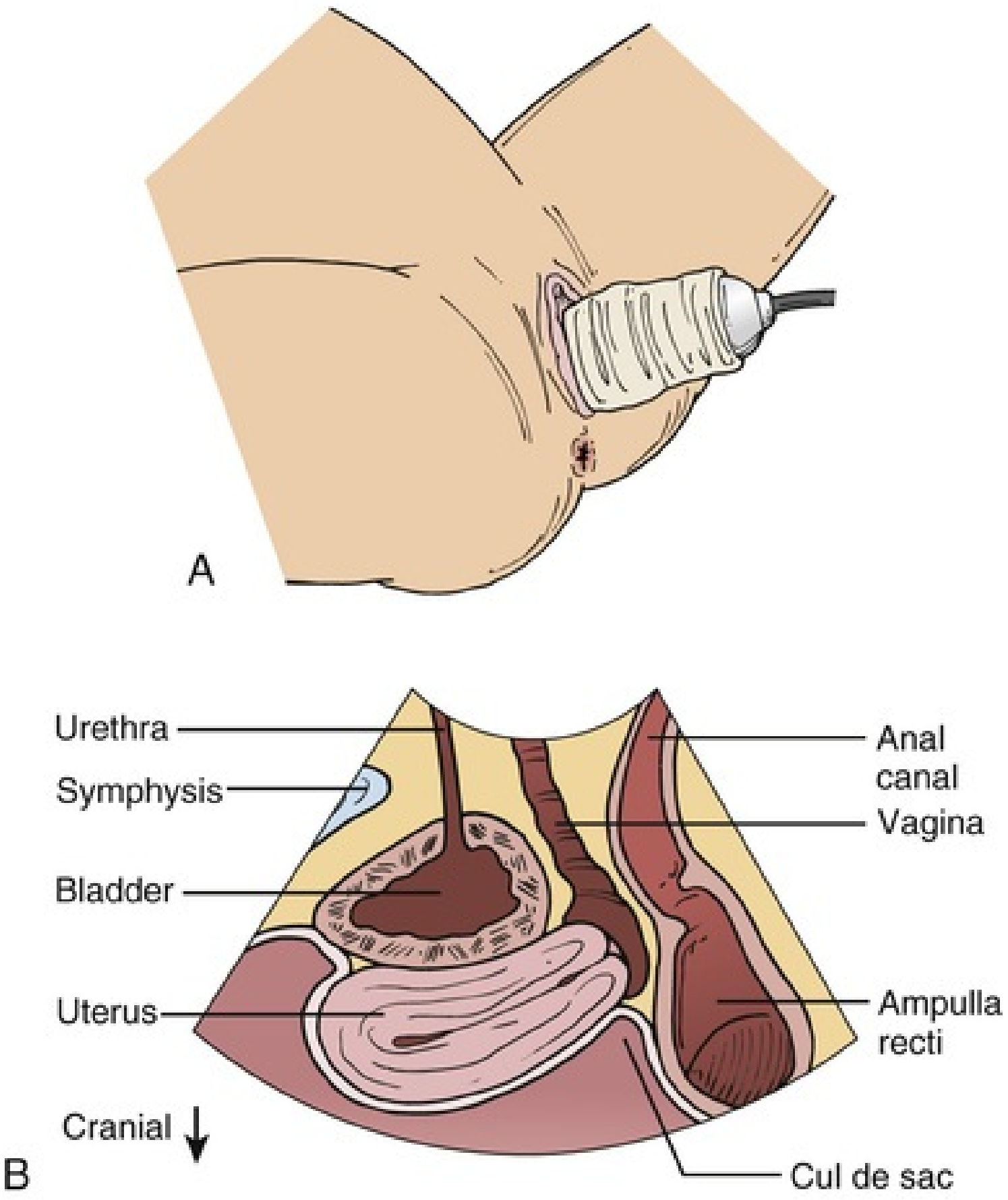
A
Urethra
Symphysis
Bladder
Uterus
Cranial
B
Anal canal
Vagina
Ampulla recti
Cul de sac

FIG. 108.19 Translabial ultrasound. Transducer placement (A) and field of vision (B). (From Dietz HP: The role of 2D and 3D dynamic US in pelvic organ prolapse. *J Minim Invas Gynecol* 17:282–294, 2010).

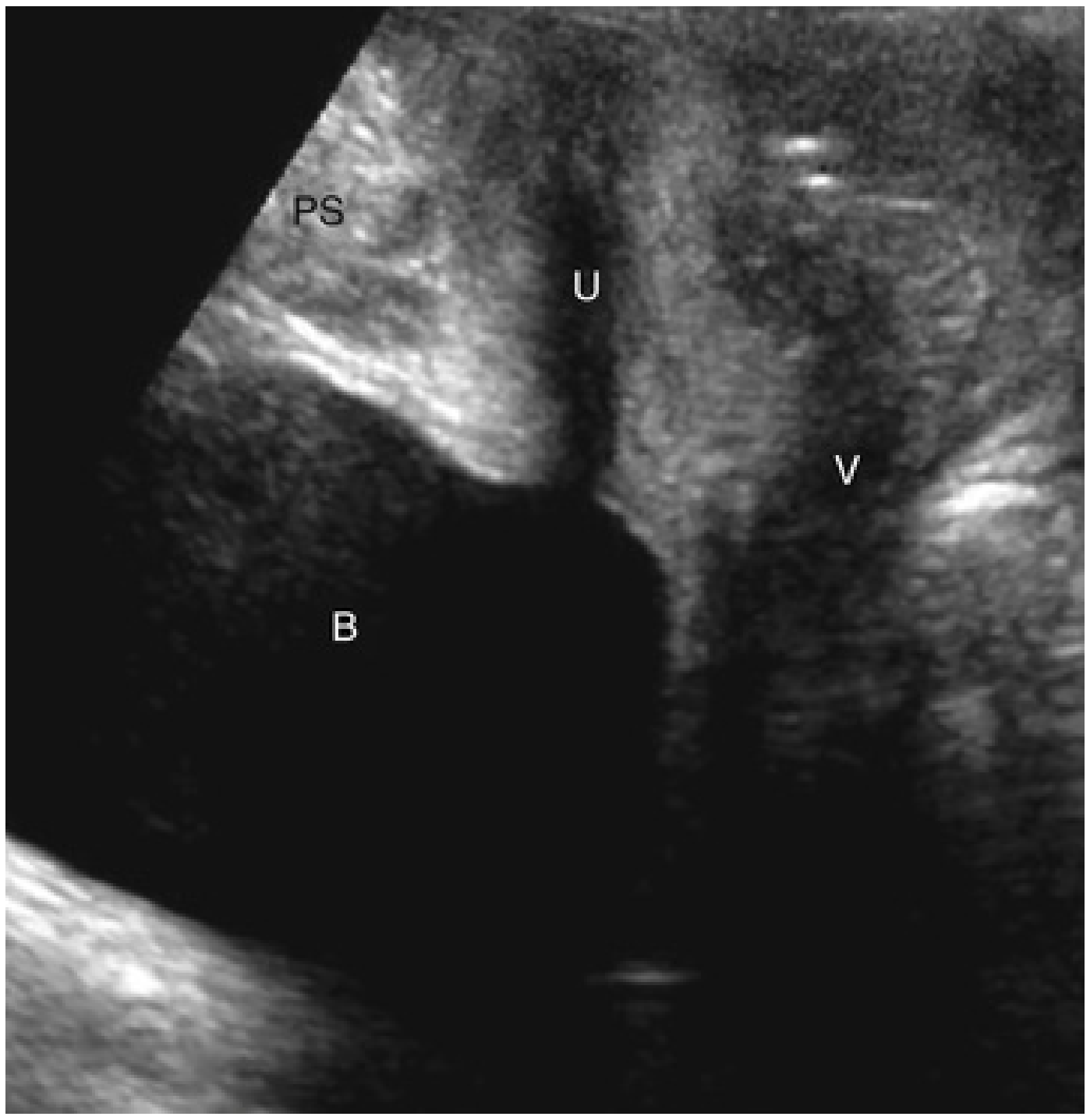

FIG. 108.20 Two-dimensional translabial ultrasound; image in the midsagittal plan. *B,* Bladder; *PS,* pubic symphysis; *U,* urethra; *V,* vagina.

Anorectal ultrasonography is useful for evaluation of anal sphincter defects in associated fecal incontinence. Internal sphincter defects are seen as an echogenic discontinuity in the hypoechoic muscle between the vagina and the rectum (Hull and Zutshi, 2008). External sphincteric injury appears as a hypoechoic lesion in a normally echogenic structure. A sphincter in spasm or that is hypertrophied (as in obstructed defecation) can appear thickened (Fig. 108.21).

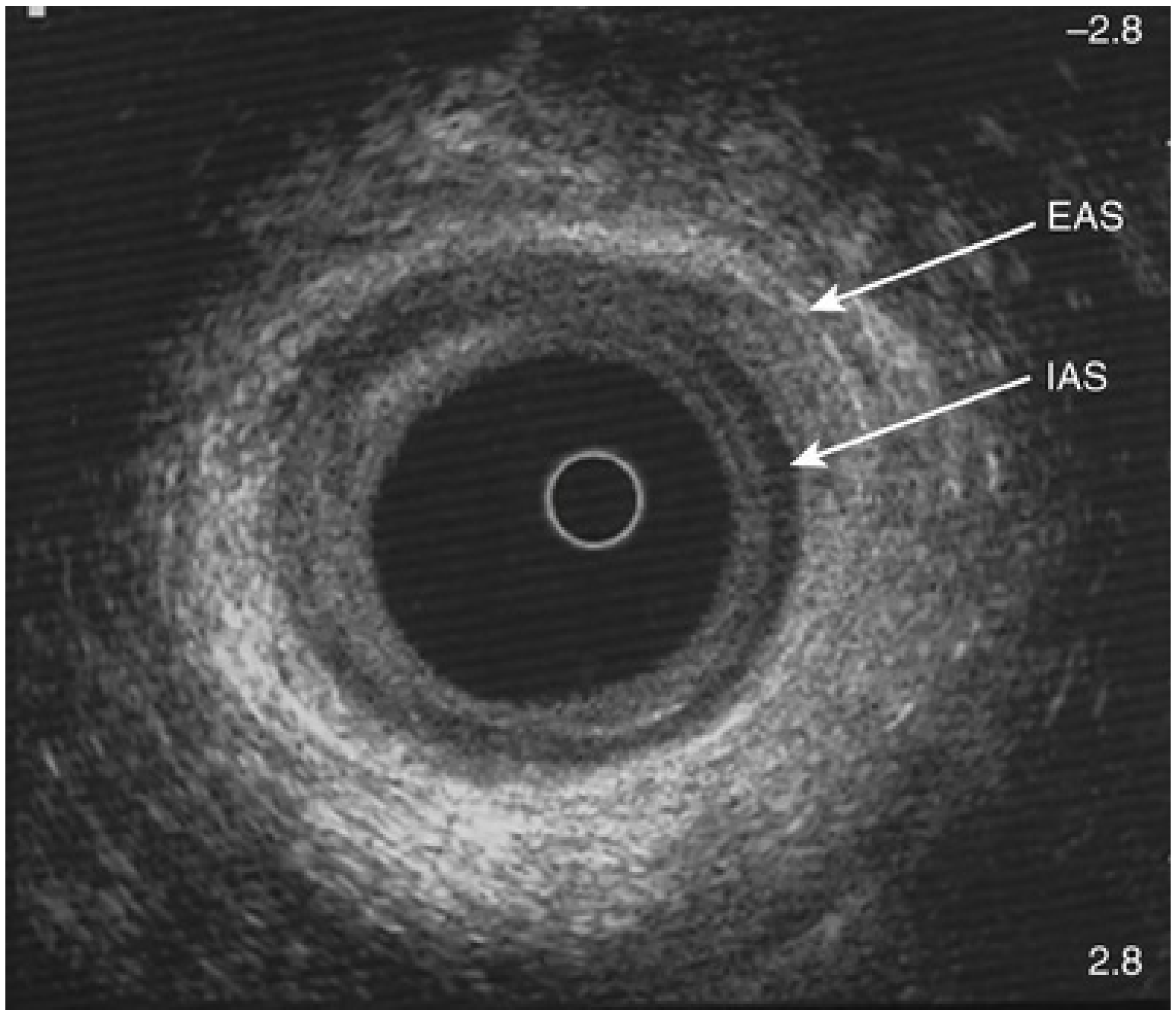

FIG. 108.21 Endoanal ultrasound imaging in a normal female. *EAS,* External anal sphincter; *IAS,* internal anal sphincter.

Pelvic Magnetic Resonance Imaging

Magnetic resonance imaging (MRI) is the most comprehensive and conclusive imaging modality available to image the female pelvis without the use of radiation. This modality provides well-delineated images of tissue based on different water content, such as muscle, fat, fluid, and blood (Roth and Deshmukh, 2018). For pelvic floor imaging, the half-Fourier acquisition single-shot turbo spin-echo (HASTE) or single-shot fast spin-echo (SSFSE) T2-weighted sequences are often used. These provide quick, noninvasive multiplanar surveys of the abdomen and pelvis and dynamic studies of the pelvic floor during relaxed or strained states (Raman and Boyadzhyan, 2008a). The obturator internus and levator ani muscles are well visualized by MRI (Fig. 108.22). T1-weighted imaging with gadolinium contrast is useful for visualization of the kidneys and ureters. T2-weighted imaging is useful to differentiate and assess masses, cysts, and tissue parenchyma.

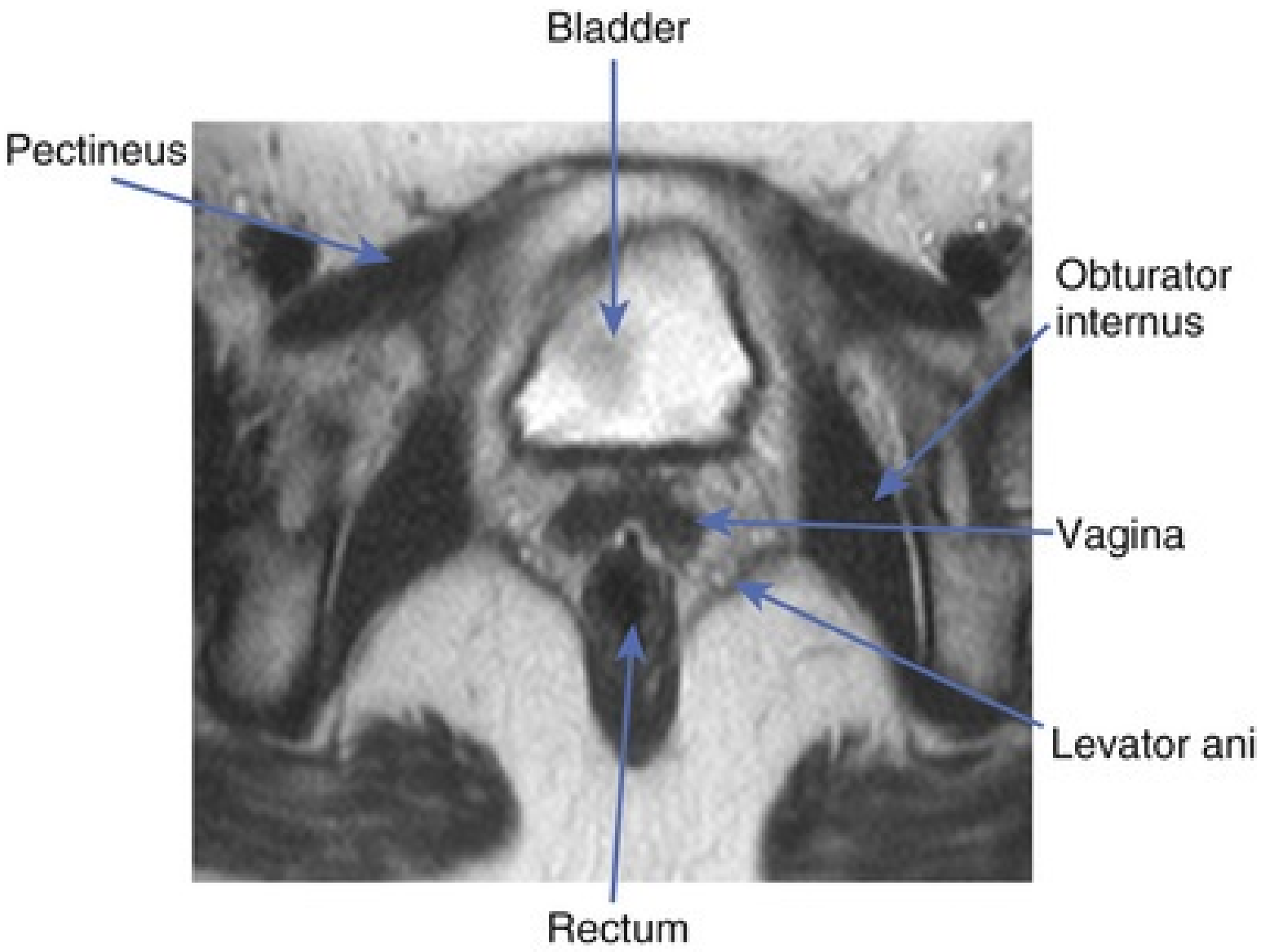
Bladder
Pectineus
Obturator internus
Vagina
Levator ani
Rectum

FIG. 108.22 Axial T2 half-Fourier acquisition single-shot turbo spin-echo magnetic resonance imaging of normal female pelvic anatomy.

Pelvic MRI can differentiate cystic lesions in the vagina and urethra. Common benign vaginal cysts include müllerian cysts, epidermal inclusion cysts, Gartner duct cysts, Bartholin gland cysts, and Skene gland cysts (Fig. 108.23). **T2-weighted MRI is the best imaging technique to visualize and localize urethral diverticula and to differentiate them from other benign vaginal masses** (Walker et al., 2011).

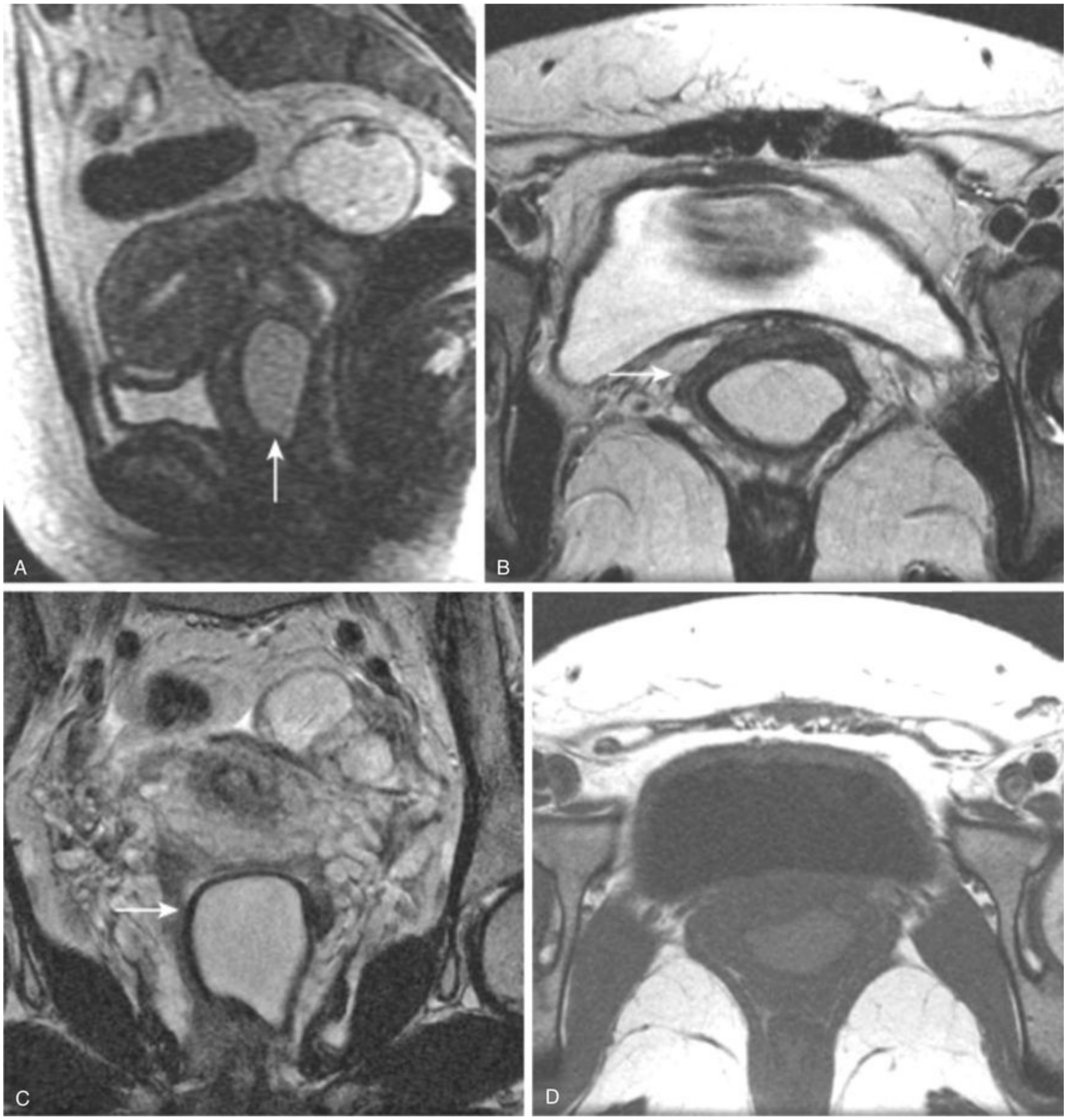

FIG. 108.23 Benign cystic lesions. (A) Garner duct cyst (T2-weighted image with uniformly hyperintense lesion in upper vagina). (B) Bartholin gland cyst (T1-weighted hyperintense lesion in lateral vagina). (C) Müllerian duct cyst (T2-weighted fat suppressed image shows a large septated cystic lesion in the upper vagina). (D) Skene gland cyst (T2-weighted image; a small cystic structure abutting the distal urethra). (In MRI of the Uterus, Cervix and Vagina in Fundamentals of the Uterus, Cervix and Vagina In Fundamentals of Body MRI. Chapter 9. 2018; pp 334–395.)

On T2-weighted MRI, the uterus is delineated into three zones; endometrium, junctional zone and myometrium (Fig. 108.24). The endometrium and uterine cavity have high signal, whereas the junctional zone has low signal. The outer myometrium has medium to high signal. The most common indications for MRI include identification and characterization of leiomyomata, assessment of leiomyoma treatment response, and for staging of endometrial and cervical malignancies (Roth and Deshmukh, 2018).

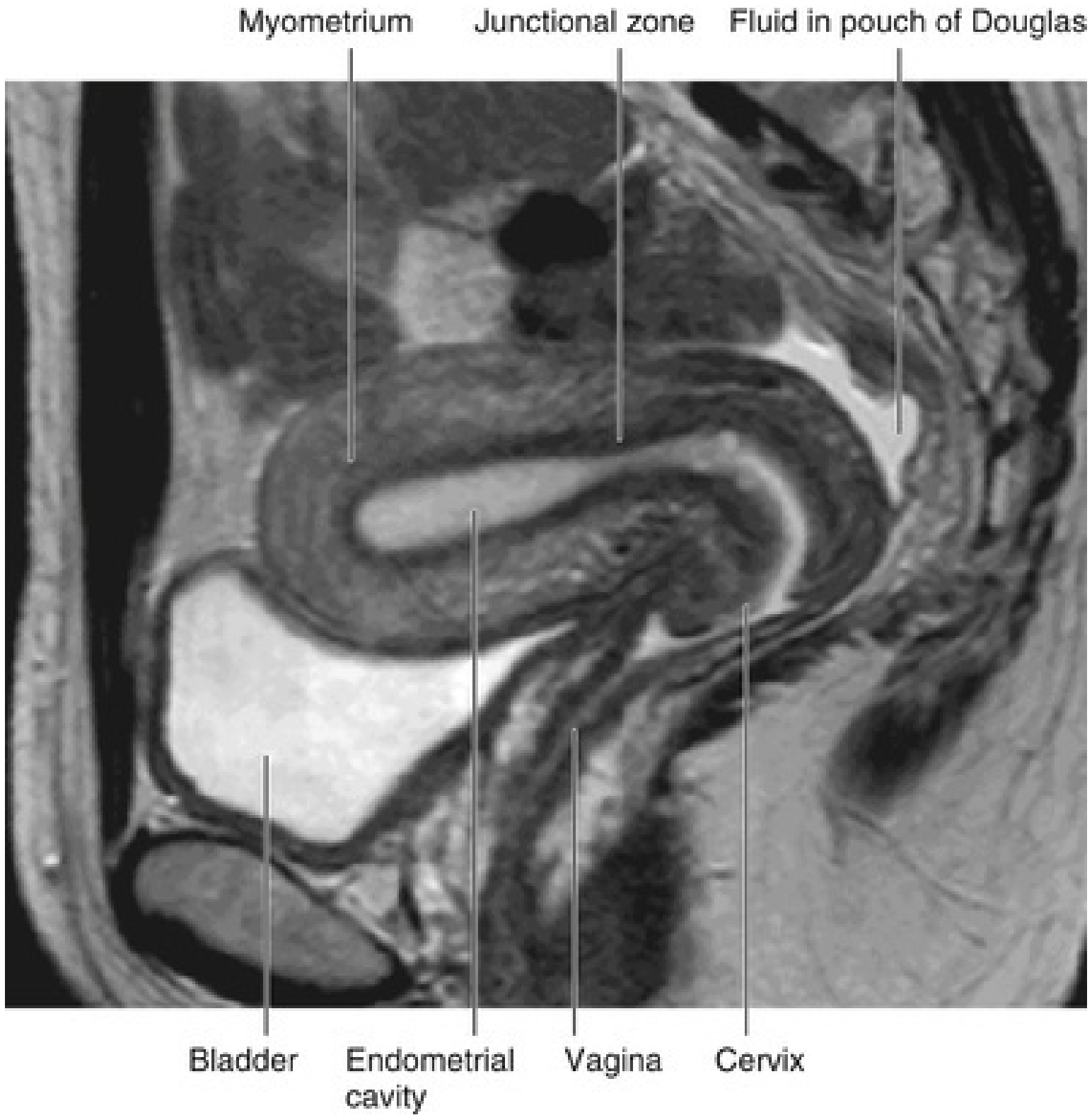

FIG. 108.24 Normal anatomy of the pelvic structures on T2-weighted magnetic resonance image showing the zonal anatomy of the uterus. (From Standring S: *Gray's anatomy: the anatomical basis of clinical practice,* ed 40, London, 2008, Churchill Livingstone.)

MRI can be used for the diagnosis and staging of pelvic organ prolapse. Midsagittal and parasagittal resting and straining supine views are obtained for evaluating the different compartments, pelvic floor muscles, and pelvic organs (Fig. 108.25). These images are often looped as a cine stack and are measured to fixed anatomic landmarks to determine the grade of pelvic organ prolapse and pelvic floor relaxation (Comiter, 2005). Measurements obtained include the “H-line,” or levator hiatus width, measured from the pubis to the posterior anal canal. The “M-line” (muscular pelvic floor relaxation) runs perpendicular from the pubococcygeal line (PCL) to the lowest aspect of the H line and relates to the descent of the levator hiatus from the PCL. The "O" classification is then assigned to the degree of prolapse beyond the "H-line" as 0, 1, 2, or 3 (no, mild, moderate, or severe). The midpubic line is the line drawn through the midline longitudinal axis of the pubic symphysis (Comiter, 1999; Fig. 108.26).

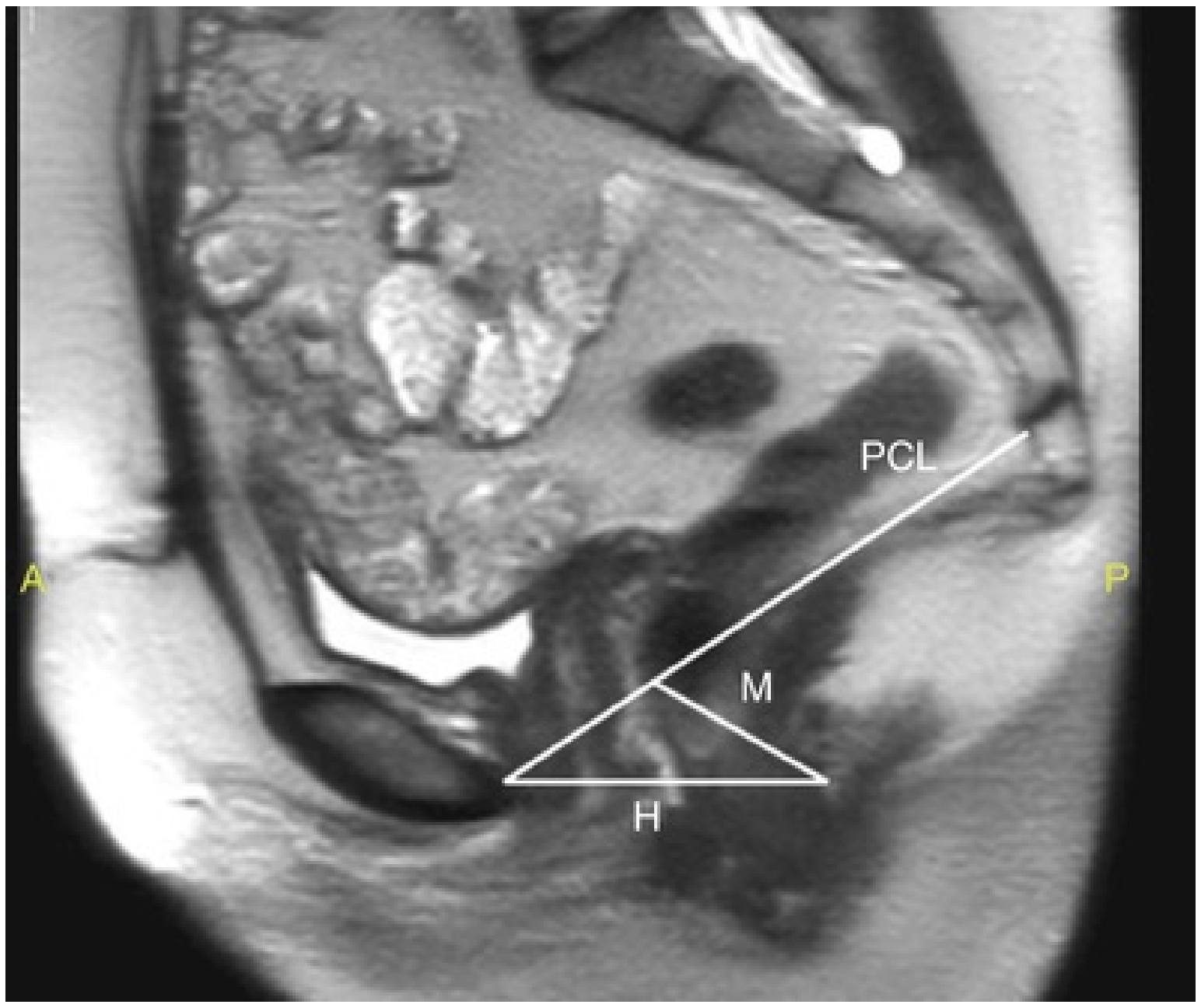

FIG. 108.25 Dynamic half-Fourier acquisition single-shot turbo spin-echo sequence T2-weighted magnetic resonance image in a patient with minor prolapse. H-line measures levator hiatus, M-line measures descent of the levator plate, and PCL measures pubococcygeus line. *A,* Anterior; *P,* posterior.

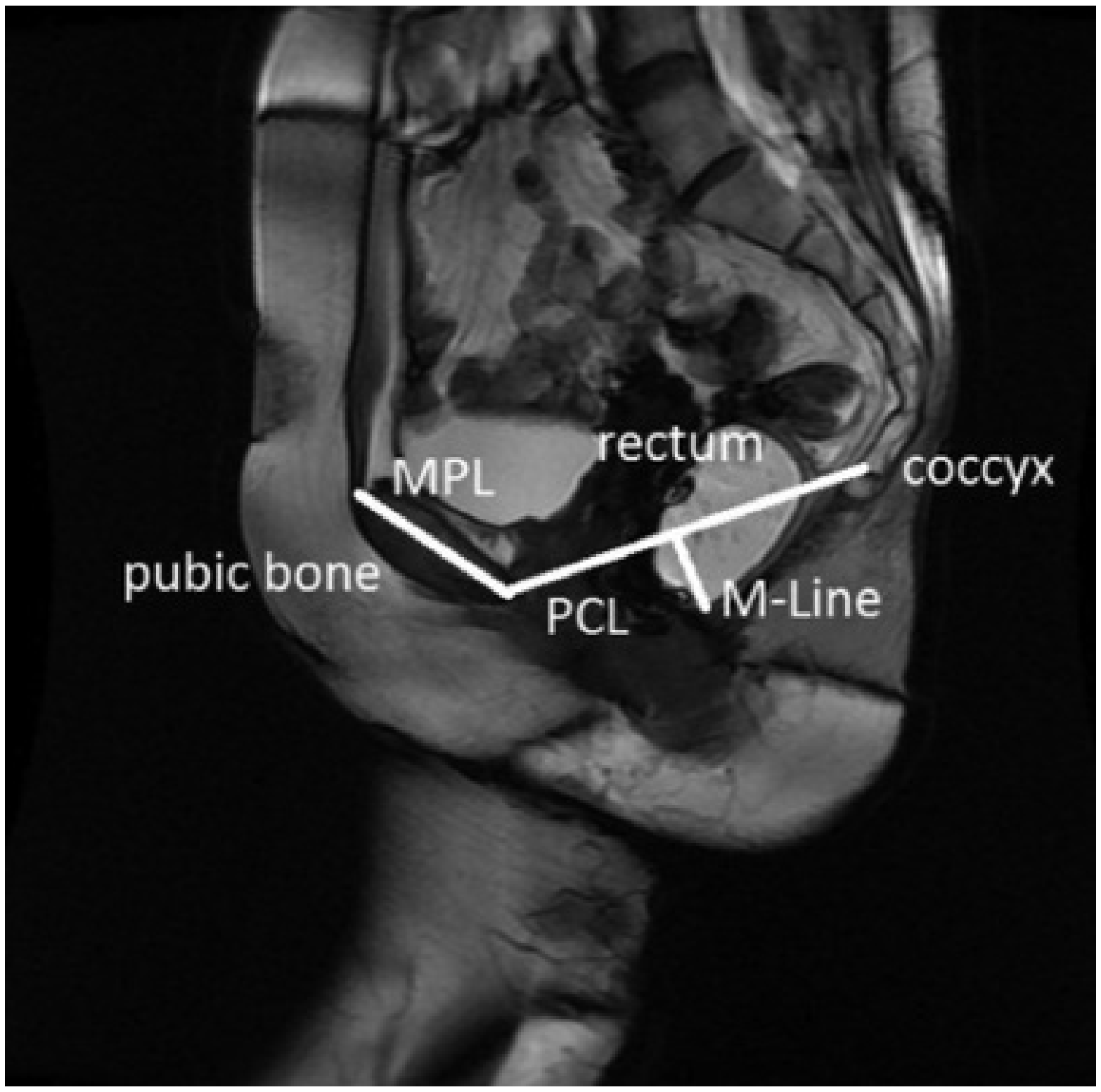

FIG. 108.26 Prolapse classification in magnetic resonance image. *1,* Perineal line; *2,* midpubic line; *3,* H-line; *4,* pubococcygeus line. (From Onal S, Lai-Yen S, Bao P, Weitzenfeld A: Image-based measurements for evaluation of pelvic organ prolapse. *J Biomed Eng* 6(1):45–55, 2013.)

Fluoroscopy

Fluoroscopy is often used to obtain real-time imaging, especially to capture dynamics pictures of the bladder and urethra during voiding. A low-dose radiographic beam passes to an image intensifier (Raman and Boyadzhyan, 2008b) and high-resolution monitor to create the image. **A cystogram is performed by taking static images of the bladder in different views after contrast is instilled and followed with a postdrainage picture. This modality may be used to diagnose bladder perforations, intravesical filling defects, and diverticula.** Low-pressure fistulae of the bladder may also be visualized (Fig. 108.27).

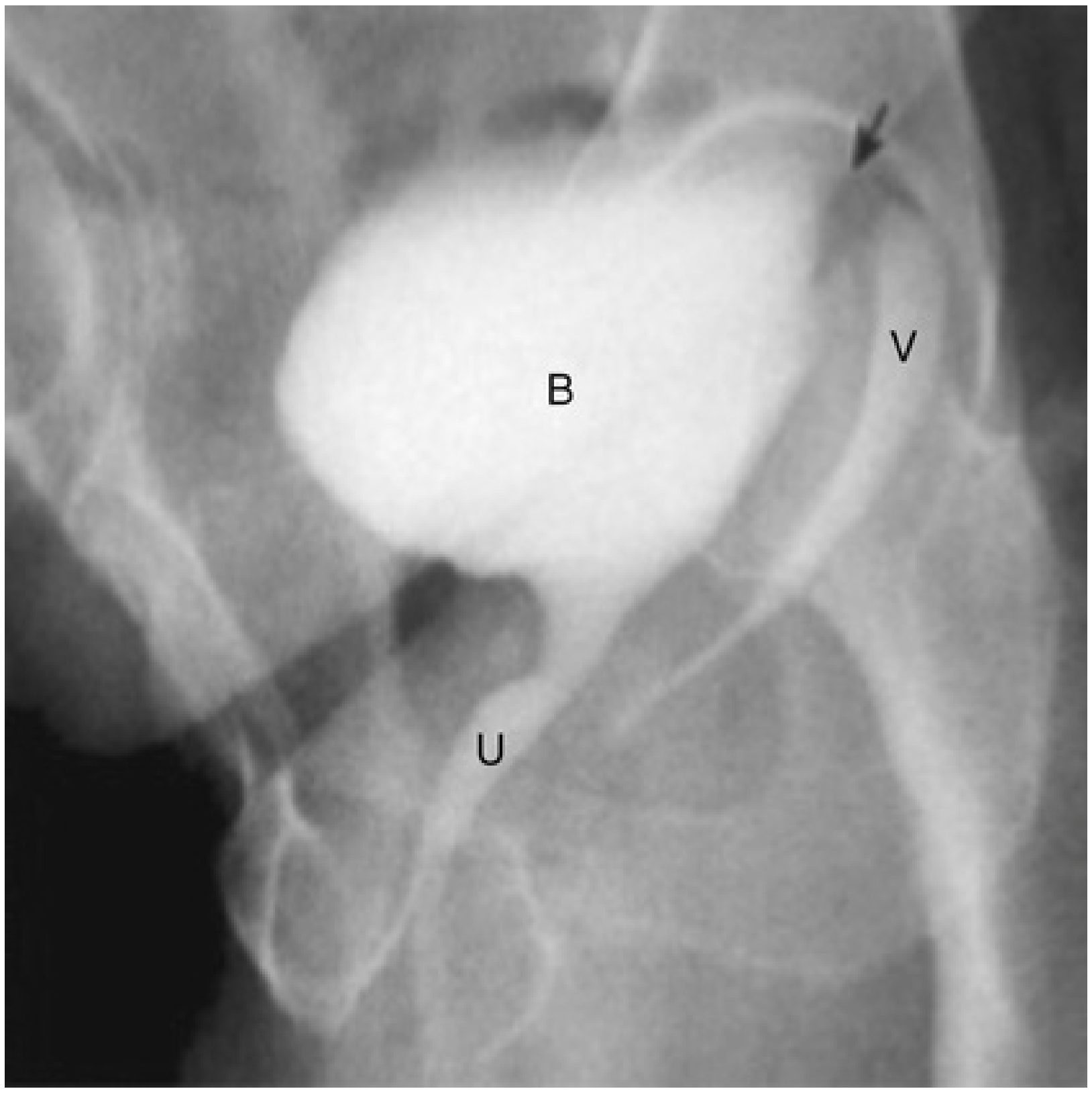

FIG. 108.27 Cystogram of vesicovaginal fistula. *B,* bladder; *U,* urethra; *V,* vagina.

A voiding cystourethrogram (VCUG) takes dynamic pictures during filling and voiding, postcontrast instillation into the bladder, and after subsequent catheter removal. This modality may be used concurrently with urodynamics to dynamically correlate with radiographic findings. VCUG imaging is especially helpful to evaluate the urethra and bladder outlet anatomy during voiding. **Vesicoureteral reflux, vesical fistulas, urethral obstruction, urethral diverticulae, and high-grade cystoceles may also be diagnosed with a VCUG.**

Endoscopic Anatomy

The normal urethra, typically 14 to 20 Fr in caliber (Keegan et al., 2008), may be evaluated with a rigid or flexible cystoscope. Translabial, transrectal, and transvaginal ultrasound has been used for diagnosis of urethral injury and stricture. The entire urethra, external sphincter, and bladder neck should be visualized in a retrograde and antegrade fashion, with a 0 or 30-degree lens, while irrigation is flowing to distend the urethra. The urethra is closely evaluated in women with recurrent urinary tract infections, dysuria, or obstruction. Cystoscopy is valuable for visualization of foreign bodies, stones, and the ostia of a urethral diverticulum.

The entire bladder mucosa, ureteral orifices, and trigone may be visualized with an additional 70-degree lens. At the trigone and base of the bladder, premenopausal women exhibit normal signs of squamous metaplasia (Clouston and Lawrentschuk, 2013). This is nonkeratinizing metaplasia or vaginal metaplasia that is hormonally responsive and is a normal variant. Cystoscopy is additionally useful for identifying tumors, masses, foreign bodies, fistula openings, trabeculation, or stones (Fig. 108.28A and B).

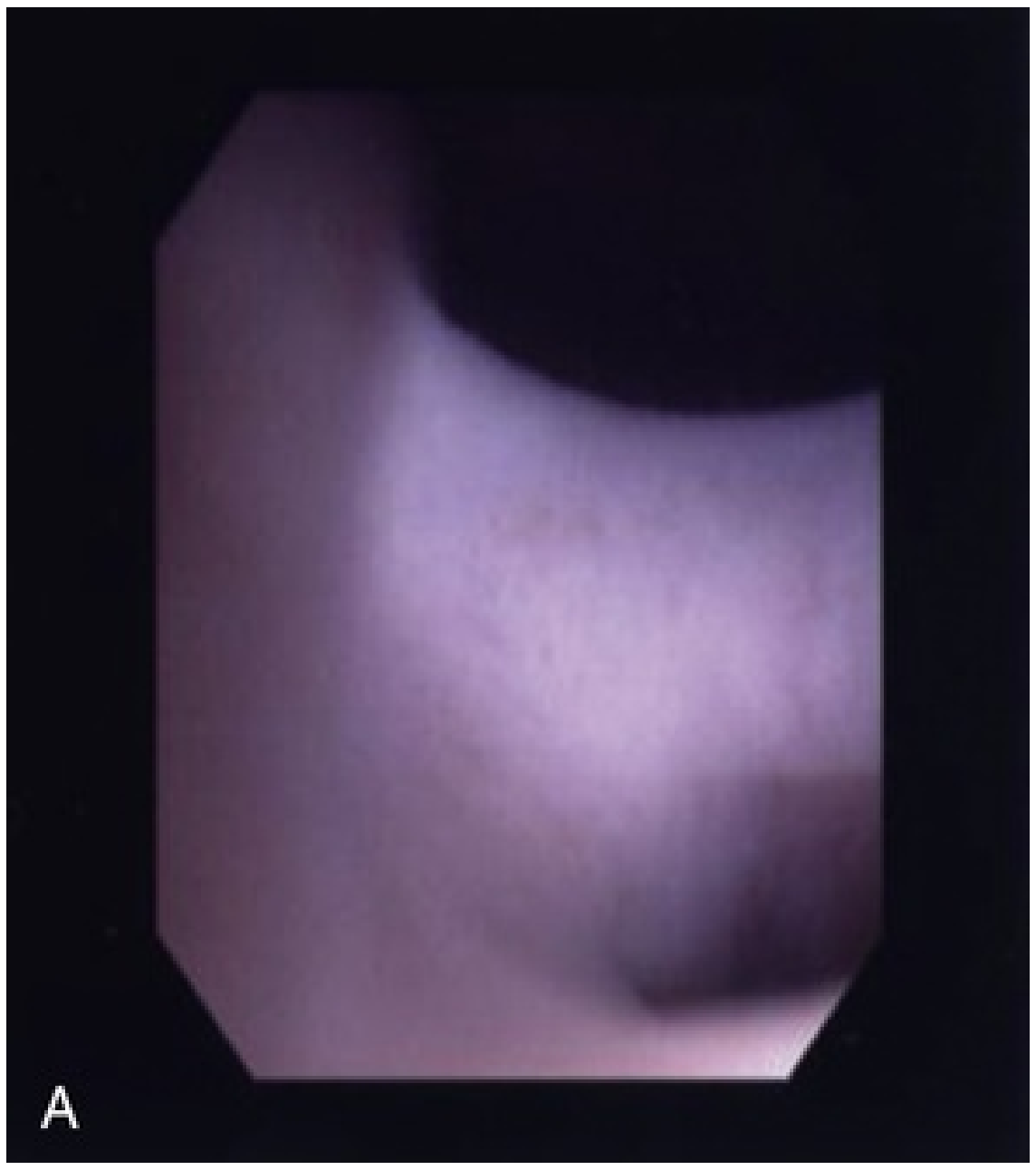

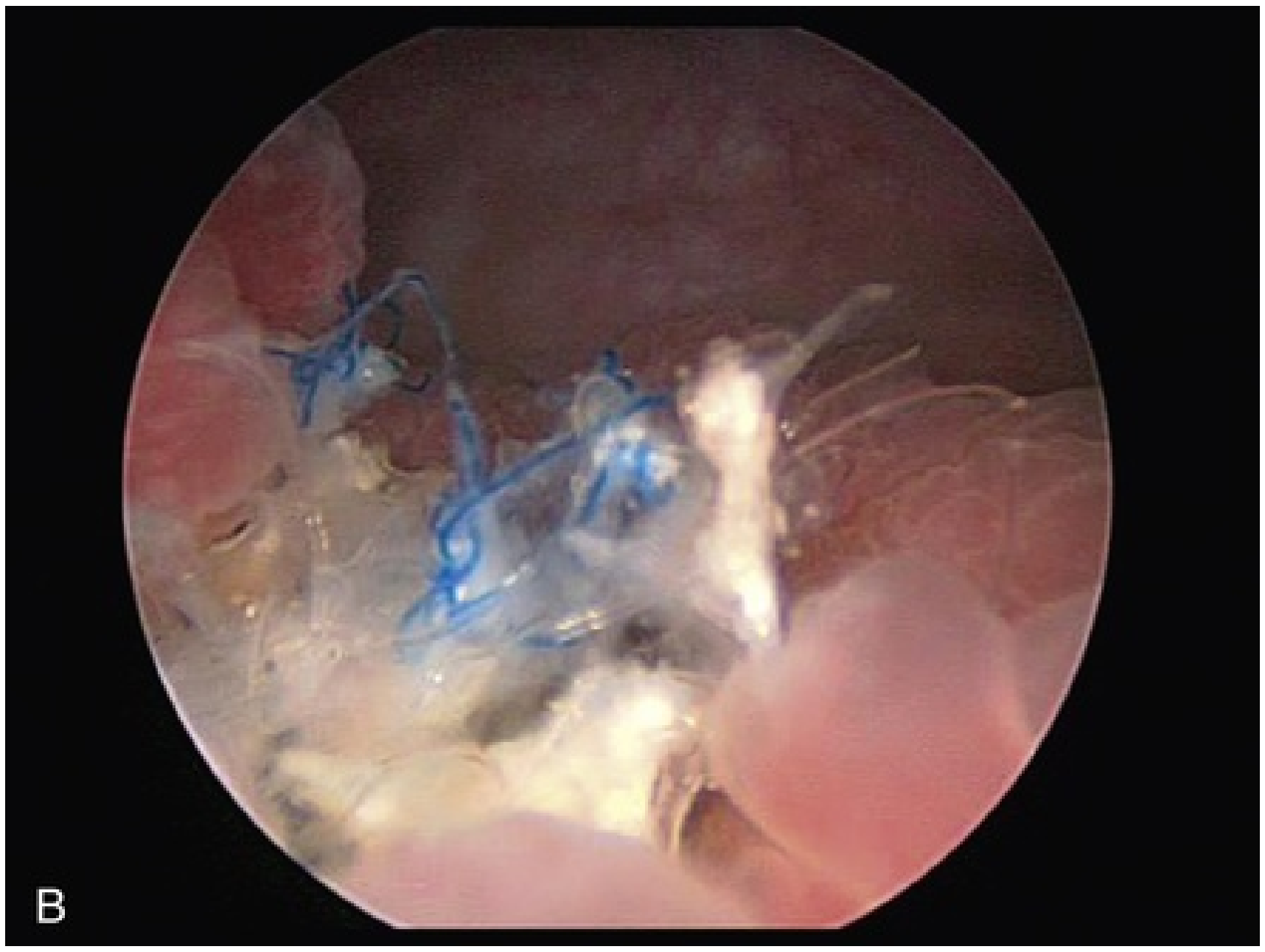

FIG. 108.28 Cystoscopic images. (A) Proximal urethral fistula. (B) Retropubic mid-urethral sling erosion.

Key Points: Radiographic and Endoscopic Anatomy

- Translabial ultrasound is useful for visualization of transvaginal mesh, urethral bulking agents, and urethral implants.
- MRI is the most comprehensive and conclusive imaging modality available to image the female pelvis without the use of radiation.
- T2-weighted MRI is the best imaging technique to visualize and localize urethral diverticula and to differentiate them from other benign vaginal masses.

References

Ashton-Miller JA, DeLancey JOL. Functional anatomy of the female pelvic floor. *Ann N Y Acad Sci*. 2007;266–296.

Barber M. Contemporary views on female pelvic anatomy. *Cleve Clin J Med*. 2005;72(Suppl 4):s3–s11.

Boutros M, Gordon PH. Pelvic floor muscles – anatomy and physiology of the colon, rectum, and anal canal. *Curr Ther Colon Rectal Surg*. 2017;1:3–11.

Chung BI, Sommer G, Brooks JD. Surgical radiographic and endoscopic anatomy of the male pelvis. ed 11. 2016:1611–1630. Wein AJ, Kavoussi LR, Partin AW. *Campbell-Walsh urology*. vol 68.

Clouston D, Lawrentschuk N. Metaplastic conditions of the bladder. *BJU Int*. 2013;112(Suppl 2):27–31.

Comiter CV, et al. Radiographic evaluation of pelvic organ prolapse. Vasavada SP, Appell RA, Sand PS. *Female urology, urogynecology and voiding dysfunction*. Marcel Dekker: New York; 2005:507–523.

Comiter CV, Vasavada SP, Barbaric ZL, et al. Grading pelvic prolapse and pelvic floor relaxation using dynamic magnetic resonance imaging. *Urology*. 1999;54:454–457.

DeCosta C. Anatomy of the female pelvis. *Essential obstetrics and gynecology*. 2013:3–11.

Dietz HP. Pelvic floor ultrasound. Raz S, Rodriguez LR. *Female urology*. ed 3. Saunders: Philadelphia; 2008:100–124.

Dietz HP. Ultrasound imaging of the pelvic floor. Part I: two-dimensional aspects. *Ultrasound Obstet Gynecol*. 2004;23:80–92.

Fritsch H, Zwiezina M, Riss P. Accuracy and concepts in female pelvic floor anatomy: facts and myths. *World J Urol*. 2012;30:429–435.

Goldstein C, Hagen-Ansert L. Sonographic and Doppler evaluation of the female pelvis. *Textbook of diagnostic sonography*. ed 8. Mosby: St Louis; 2018:1066–1088.

Goldstein C, Hagen-Ansert S. Pelvic vasculature – normal anatomy and physiology of the female pelvis. Hagen_Ansert SL. *Textbook of diagnostic sonography*. Mosby: St. Louis; 2018:1049–1065.

Gosling JA, Harris PF, Humpherson JR, et al. Female external genitalia- pelvis and perineum. Gosling J, Harris P, Humpherson J. *Human anatomy, color atlas and textbook*. ed 6. Elsevier: New York; 2017:213–252.

Herschorn S. Female pelvic floor anatomy: the pelvic floor supporting structures and pelvic organs. *Rev Urol*. 2004;6(Suppl S):S2–S10.

Howard MA, Dickie SR. Female perineum: comprehensive trunk anatomy. 2018:218–236. *Plastic surgery*. vol 4 [p].

Hull T, Zutshi M. Pathophysiology, diagnosis and treatment of defecatory dysfunction. Ras S, Rodriguez LR. *Female urology*. ed 3. Saunders: Philadelphia; 2008:761–771.

Keegan KA, Nawigian DK, Stone AR. Female urethral stricture disease. *Curr Urol Rep*. 2008;9:419–423.

Lin AY. Perineal proctectomy for prolapse. Townsend C, Evers BM. *Atlas of surgical techniques for colon, rectum and anus*. Elsevier: Philadelphia; 2013:250–261.

Maclennan GT. *Hinmans atlas of urosurgical anatomy*. ed 2. Saunders: Philadelphia; 2012.

Merry CV. *“Pelvic Shape” Mind-Primary Cause of Human Evolution*. 2005.

Palastanga N, Field D, Soames R. *Anatomy and human movement; structure and function*. Butterworth Heinemann Elsevier: Philadelphia; 2006.

Raman SS, Boyadzhyan L. Imaging in the diagnosis of pelvic organ prolapse. Raz S, Rodriguez LR. *Female urology*. ed 3.

Saunders: Philadelphia; 2008:564–578.

Raman SS, Boyadzhyan L. Imaging of the female genitourinary tract. Raz S, Rodriguez LR. *Female urology*. ed 3. Saunders: Philadelphia; 2008:86–99.

Ramanah R, Berger MB, Parratte BM, et al. Anatomy and histology of apical support. A literature review concerning cardinal and uterosacral ligaments. *Int Urogynecol J*. 2012;23:1483–1494.

Rosenblum N, Eilber K, Rodriguez L, et al. Anatomy of pelvic support. Vasavada SP, Appell RA, Sand PS, et al. *Female urology, urogynecology and voiding dysfunction*. Marcel Dekker: New York; 2005:1–21.

Roth CG, Deshmukh S. MRI of the uterus, cervix and vagina. Roth CG, Deshmukh S. *Fundamentals of body MRI*. Elsevier: Philadelphia; 2018:334–395.

Standring S. Bladder prostate and urethra. Standring S. *Gray's anatomy*. ed 41. Elsevier: Philadelphia; 2016:1255–1271.

Schünke M, Ross LM, Schulte E, et al. *Thieme atlas of anatomy: general anatomy and musculoskeletal system*. Thieme: New York; 2006.

Walker DK, Salibian RA, Salibian AD, et al. Overlooked diseases of the vagina: a directed anatomic pathologic approach for imaging assessment. *Radiographics*. 2011;31:1583–1598.

Wei JT, DeLancey JOL. Functional anatomy of the pelvis floor and lower urinary tract. *Clin Obstet Gynecol*. 2004;47:3–17.

109

Surgical, Radiographic, and Endoscopic Anatomy of the Male Pelvis

---

Jen-Jane Liu MD, Bryan Foster MD, Christopher L. Amling MD, FACS

Bony Pelvis

The bony pelvis consists of the sacrum posteriorly and the paired innominate bones anteriorly and laterally. **The innominate bones consist of three fused bones: the ilium, ischium, and pubis.** This fusion is centered at the acetabulum with the ilium forming the upper acetabulum, the ischium forming the posterior inferior acetabulum, and the pubis forming the anterior acetabulum. The innominate bones ("hip bones") articulate with the sacrum posteriorly at the sacroiliac (SI) joint and come together anteriorly to form a cartilaginous joint at the pubic symphysis. The sacrum is further fixed to the hip bones by two very strong ligaments, the sacrotuberous and sacrospinous ligaments. The more posterior sacrotuberous ligament extends from the sacrum/coccyx to the ischial tuberosity, and the more anterior sacrospinous ligament connects the sacrum/coccyx to the ischial spine (Fig. 109.1). These ligaments stabilize the sacrum, allowing only limited upward movement and thus providing resilience to the SI joint when the vertebral column sustains sudden weight increases. These bridging ligaments also create foramina, the sacrotuberous ligament the common sciatic foramen and the sacrospinous ligament bisects the sciatic foramen and forms the greater and lesser sciatic foramina. In the standing position, the pelvis curves obliquely backward relative to the trunk and abdominal cavity. The whole pelvis is tilted forward, with the plane of the pelvic brim making an angle 50 to 60 degrees with the horizontal.

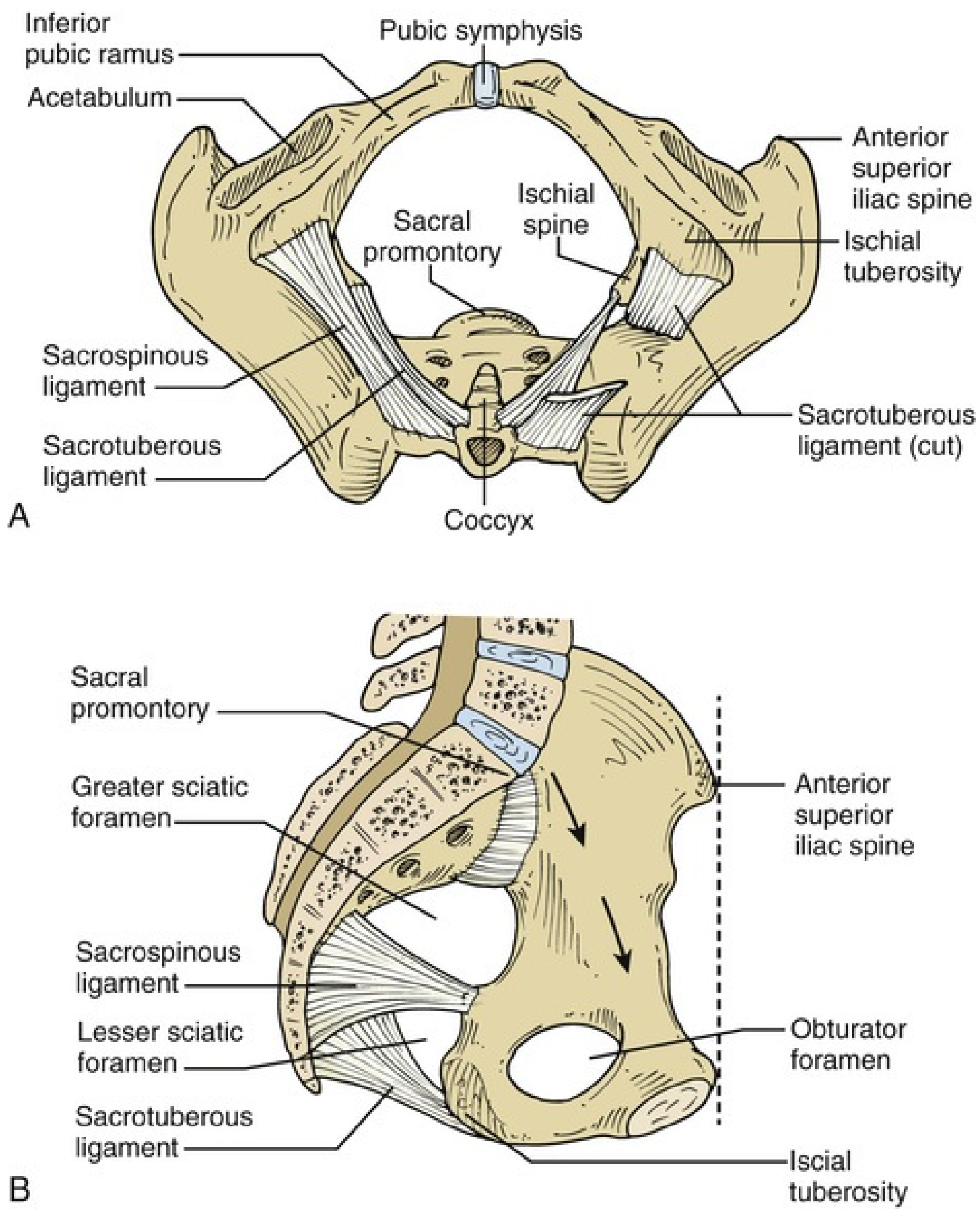
Inferior pubic ramus
Acetabulum
Pubic symphysis
Anterior superior iliac spine
Ischial spine
Sacral promontory
Ischial tuberosity
Sacrospinous ligament
Sacrotuberous ligament
Sacrotuberous ligament (cut)
A
Coccyx
Sacral promontory
Greater sciatic foramen
Anterior superior iliac spine
Sacrospinous ligament
Lesser sciatic foramen
Obturator foramen
Sacrotuberous ligament
Iscial tuberosity
B

FIG. 109.1 (A and B) Bony pelvis and its ligaments. (From Stepp KJ, Walters MD: *Urogynecology and reconstructive pelvic surgery,* 4th ed Philadelphia, Elsevier, 2015, pp 19–31, Figure 2.1 AB.)

The pelvis is classically divided into the greater (false) pelvis, formed by the iliac fossa with the cephalad extent being the iliac crest and the lesser (true) pelvis, which contains the urogenital organs. **The true and false pelvises are separated by the arcuate line, which extends from the sacral promontory posteriorly to the pubis anteriorly, where it becomes continuous with the pectineal line of the pubis**. The pelvic outlet or inferior pelvic aperture is an incomplete bony line roughly forming a circle with its boundaries being the lower aspect of the symphysis pubis, ischiopubic rami, ischial tuberosities, sacrotuberous ligaments, and coccyx. Bony landmarks commonly encountered during urologic surgery include the pubic arch and pubic symphysis, the ischial tuberosities, and the bony iliac crest, which lies at the level of the L4 vertebra and can be easily palpated as it extends posteriorly from the anterior superior iliac spine. During inguinal hernia repair or urethral suspension procedures, sutures are often placed in the Cooper (pectineal) ligament, which overlies the pectineal line of the pubis. Pelvic x-rays and fluoroscopy show pelvic bony landmarks with high resolution and detail (Fig. 109.2A and B).

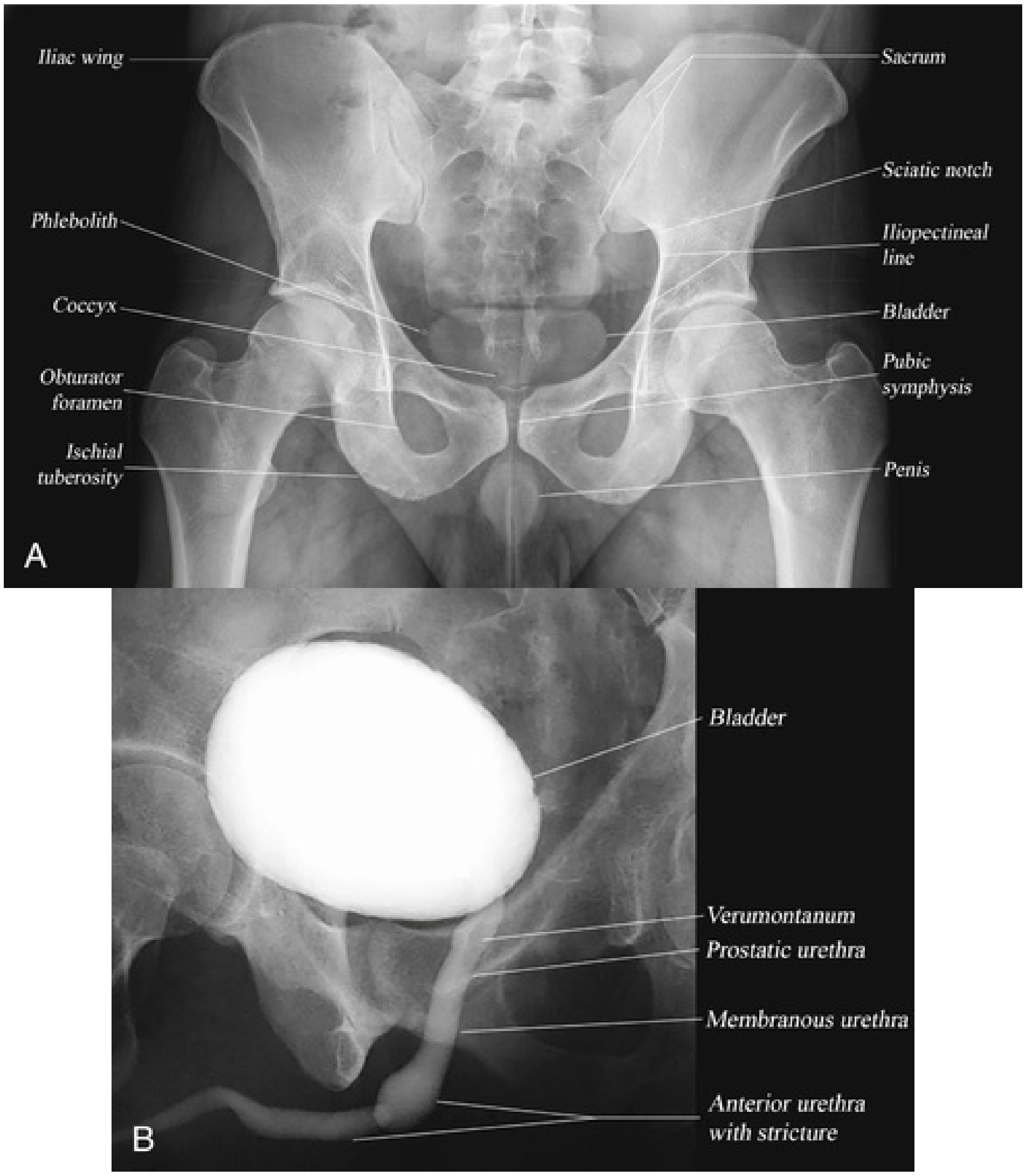
Iliac wing
Sacrum
Sciatic notch
Phlebolith
Iliopectineal line
Coccyx
Bladder
Obturator foramen
Pubic symphysis
Ischial tuberosity
Penis
A
Bladder
Verumontanum
Prostatic urethra
Membranous urethra
Anterior urethra with stricture
B

FIG. 109.2 (A) AP radiograph of the pelvis showing bony and soft-tissue anatomy. (B) Oblique spot image of the pelvis obtained during voiding cystourethrography showing bladder and urethral and bony anatomy.

Lower Abdominal Wall

Skin and Subcutaneous Fascia

The umbilicus indicates the level of the T10 dermatome and is typically at the level of the L3 vertebrae, although its position varies with the amount of fat in the subcutaneous tissue of the abdominal wall. In individuals with good muscle definition, curved skin grooves called the *semilunar lines* demarcate the lateral borders of the rectus abdominis and rectus sheath. These semilunar lines extend from the inferior costal margin near the ninth costal cartilages to the pubic tubercles bilaterally. Three transverse skin grooves may overlie the tendinous intersections of the rectus abdominis muscle. A skin crease, the inguinal groove, indicates the site of the inguinal ligament, and the groove located just inferior and parallel to this ligament marks the division between the anterior abdominal wall and the thigh.

The subcutaneous tissue of the lower abdominal wall is composed of two layers: a superficial fatty layer (Camper fascia) and a deep membranous layer (Scarpa fascia). The superficial circumflex iliac, external pudendal, and superficial inferior epigastric vessels branch from the femoral vessels and run in the loose fatty layer of Camper fascia. The superficial inferior epigastric vessels may be encountered during inguinal incisions or placement of laparoscopic trocars. **Scarpa fascia forms a distinct layer deep to Camper fascia but blends superficially and laterally with Camper fascia. Inferiorly, Scarpa fascia fuses with the deep fascia of the thigh (fascia lata) along a line approximately 1 cm inferior and parallel to the inguinal ligament. Medially, it is continuous with Colles fascia of the perineum, which fuses to the ischiopubic rami laterally and the posterior edge of the perineal membrane**. **Colles fascia is also continuous with dartos fascia of the penis and scrotum** (Fig. 109.3). These fascial layers limit of the spread of necrotizing soft-tissue infections of the scrotum and the extent of urinary extravasation and/or bleeding after anterior urethral injury. After anterior urethral injury, blood can accumulate in the scrotum and penis deep to the dartos fascia. This hematoma is limited by the fusions of Colles fascia to the ischiopubic rami laterally, resulting in a “butterfly” hematoma. Although these fascia also prevent bleeding, infection, or urinary extravasation from extending down the leg or into the buttock, they do not limit spread cephalad in the space deep to Scarpa fascia, thus allowing extension up the abdominal wall around the flank to the back.

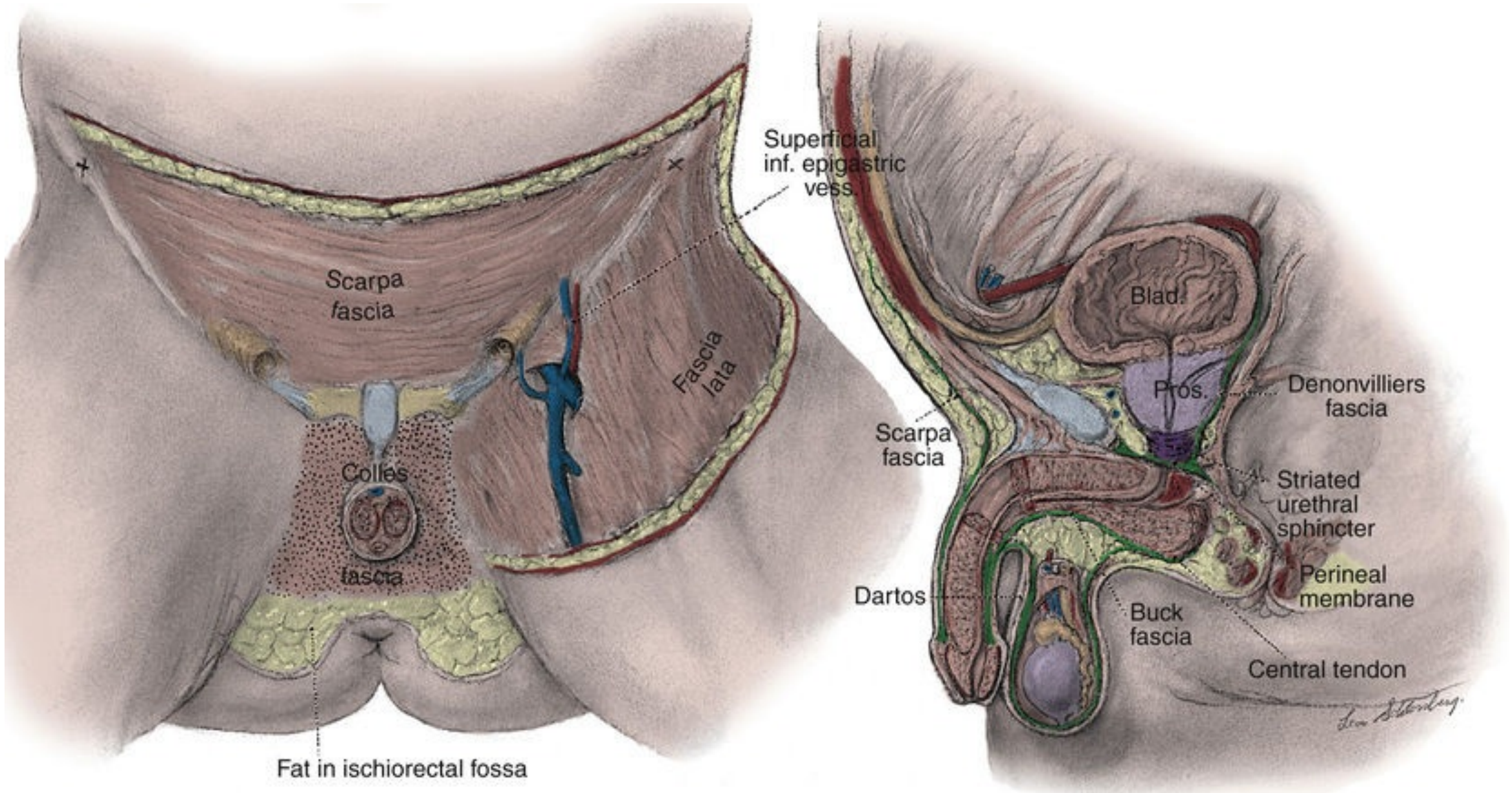
Superficial inf. epigastric vess.
Scarpa fascia
Fascia lata
Colles fascia
Fat in ischiorectal fossa
Blad.
Pros.
Denonvilliers fascia
Scarpa fascia
Striated urethral sphincter
Perineal membrane
Dartos
Buck fascia
Central tendon

FIG. 109.3 *Left,* Anterior view of the deep fasciae of the abdomen, perineum, and thigh. Note the superficial inferior epigastric artery passing superiorly in Camper fascia. *Right,* Midline sagittal view of the pelvic fasciae and their attachments.

Musculature

The lower abdominal wall musculature lies deep to Scarpa fascia. From the origins of the external oblique, internal oblique, and transversus abdominis muscles, these muscles terminate medially on the anterior abdominal wall as aponeurotic sheets that fuse in the midline at the linea alba, a convenient landmark for lower abdominal incisions. These three muscles also form the rectus sheath. Superior to the arcuate line, about one-third of the distance from the umbilicus to the pubic crest, the rectus abdominis is enveloped by the anterior and posterior rectus sheath. At this level, the anterior rectus sheath is formed by the aponeurosis of the external oblique muscle and a portion of the internal oblique muscle. The posterior sheath is derived from the remaining internal oblique aponeurosis and the transverses abdominis aponeurosis. **Below the arcuate line, all aponeurotic layers pass anterior to the rectus abdominis so that at this lower level, the rectus abdominis is covered only by the transversalis fascia and peritoneum posteriorly** (Fig. 109.4).

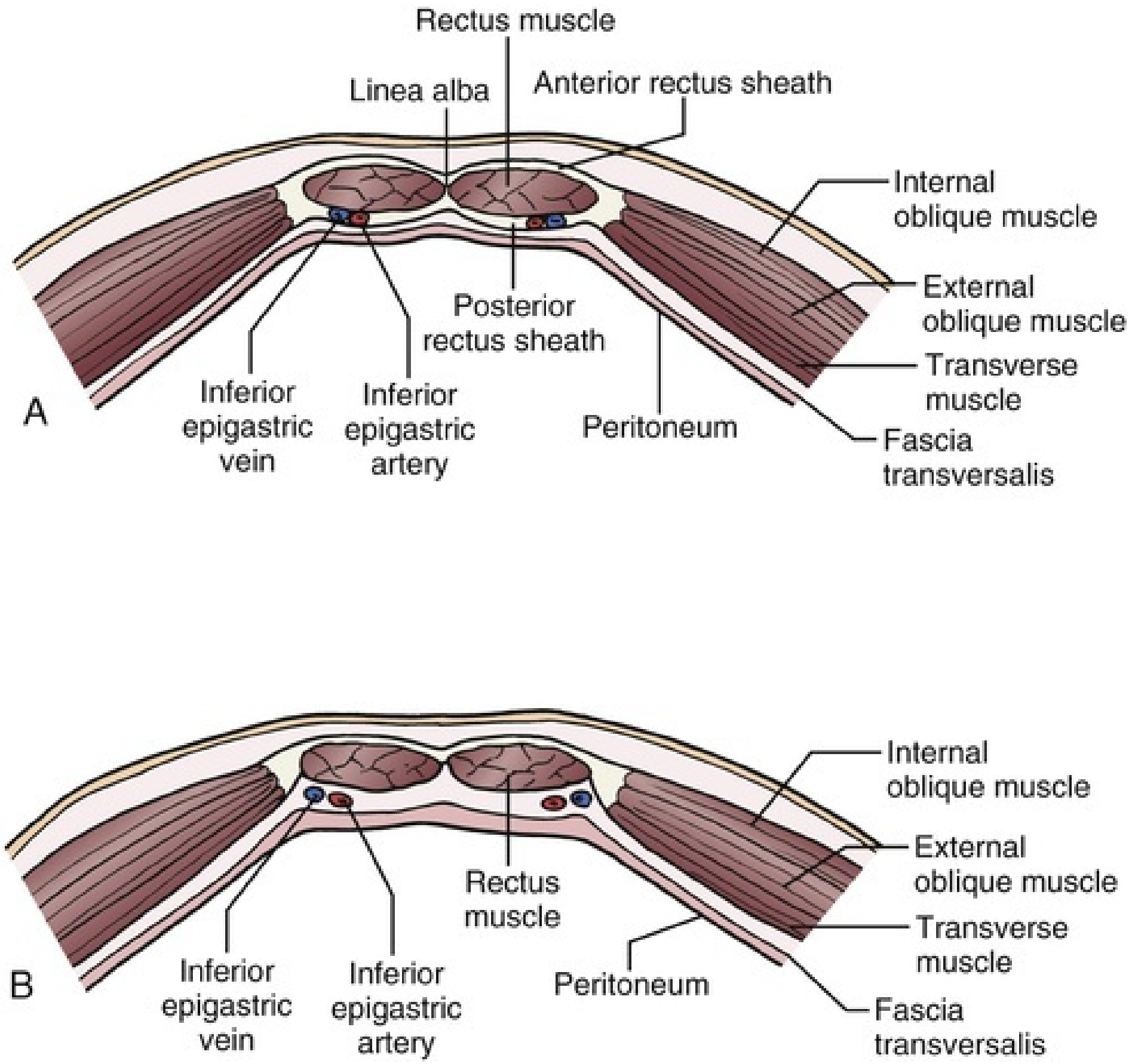
Rectus muscle
Linea alba
Anterior rectus sheath
Internal oblique muscle
External oblique muscle
Transverse muscle
Posterior rectus sheath
A
Inferior epigastric vein
Inferior epigastric artery
Peritoneum
Fascia transversalis
Internal oblique muscle
External oblique muscle
Rectus muscle
Transverse muscle
B
Inferior epigastric vein
Inferior epigastric artery
Peritoneum
Fascia transversalis

FIG. 109.4 Abdominal fascial layers above the arcuate line *(top)* and below it *(bottom).* (From Dohan A, Darnige L, Sapoval M, et al.: Spontaneous soft tissue hematomas. *Diagn Intervent Imag* 96[7–8]:789–796. Copyright 2015. Fig 5A.)

The rectus abdominis attaches to the pubis medial to the pubic tubercle and extends to its insertion on the xiphoid process and adjacent costal cartilages. The muscle fibers of the rectus do not run the length of the muscle. Rather, they run between three or more tendinous intersections, which are typically located at the level of the xiphoid process of the sternum, the umbilicus, and a level halfway between these points. Each intersection is firmly attached to the anterior layer of the rectus sheath. Thus the rectus abdominis muscle can be divided transversely without significant retraction. Its nerve supply is derived from thoracic segmental nerves that entered laterally. Division of these nerves during a paramedian incision lateral to the rectus may cause atrophy of the rectus and predispose to ventral hernia. The pyramidalis muscle is a small triangular muscle (absent in about 20% of people) that lies anterior to the rectus muscle but within its sheath. It arises from the pubic crest and inserts into the linea alba, which tenses with contraction (Fig. 109.5).

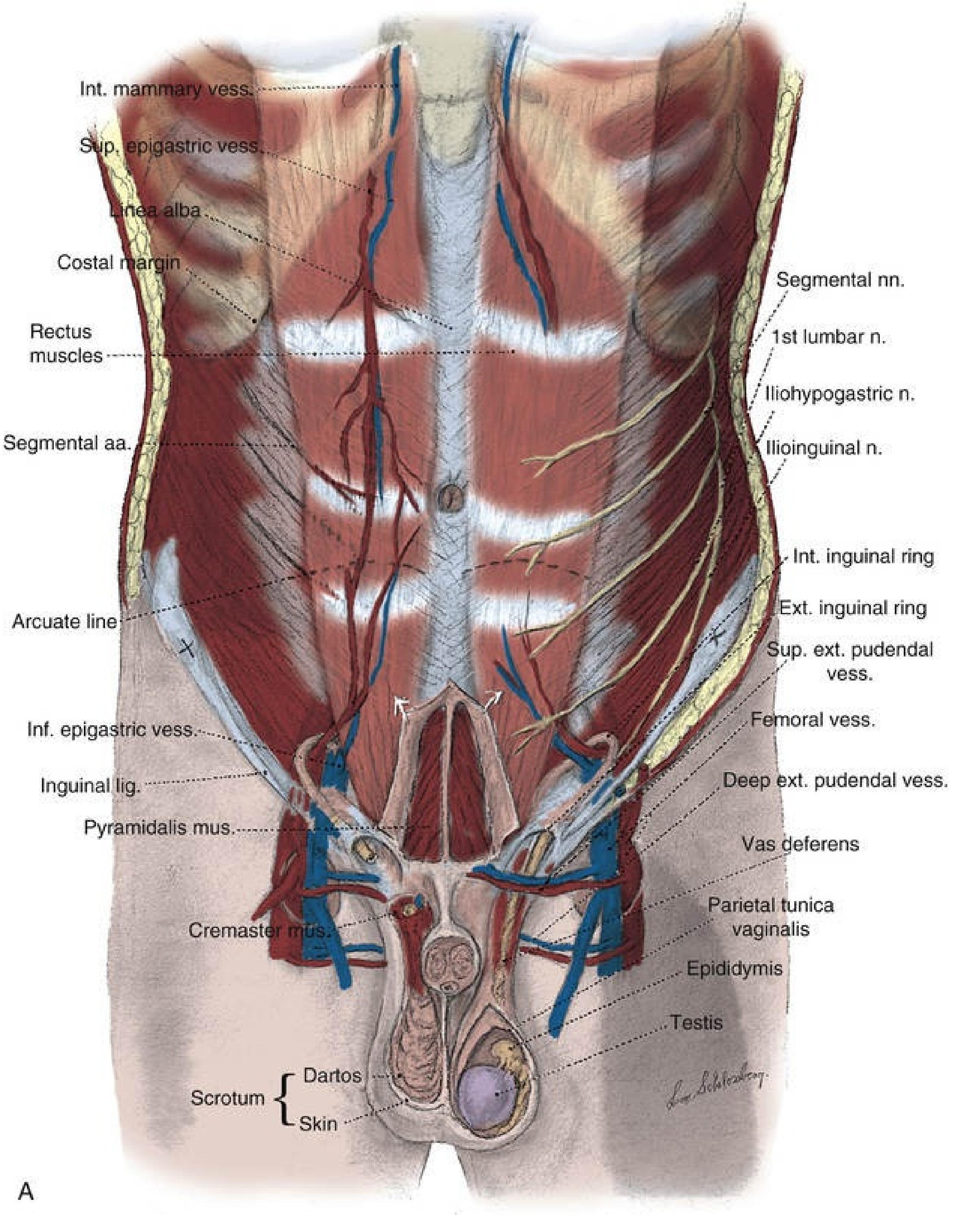
Int. mammary vess.
Sup. epigastric vess.
Linea alba
Costal margin
Rectus muscles
Segmental aa.
Arcuate line
Inf. epigastric vess.
Inguinal lig.
Pyramidalis mus.
Cremaster mus.
Scrotum
Dartos
Skin
Segmental nn.
1st lumbar n.
Iliohypogastric n.
Ilioinguinal n.
Int. inguinal ring
Ext. inguinal ring
Sup. ext. pudendal vess.
Femoral vess.
Deep ext. pudendal vess.
Vas deferens
Parietal tunica vaginalis
Epididymis
Testis
A

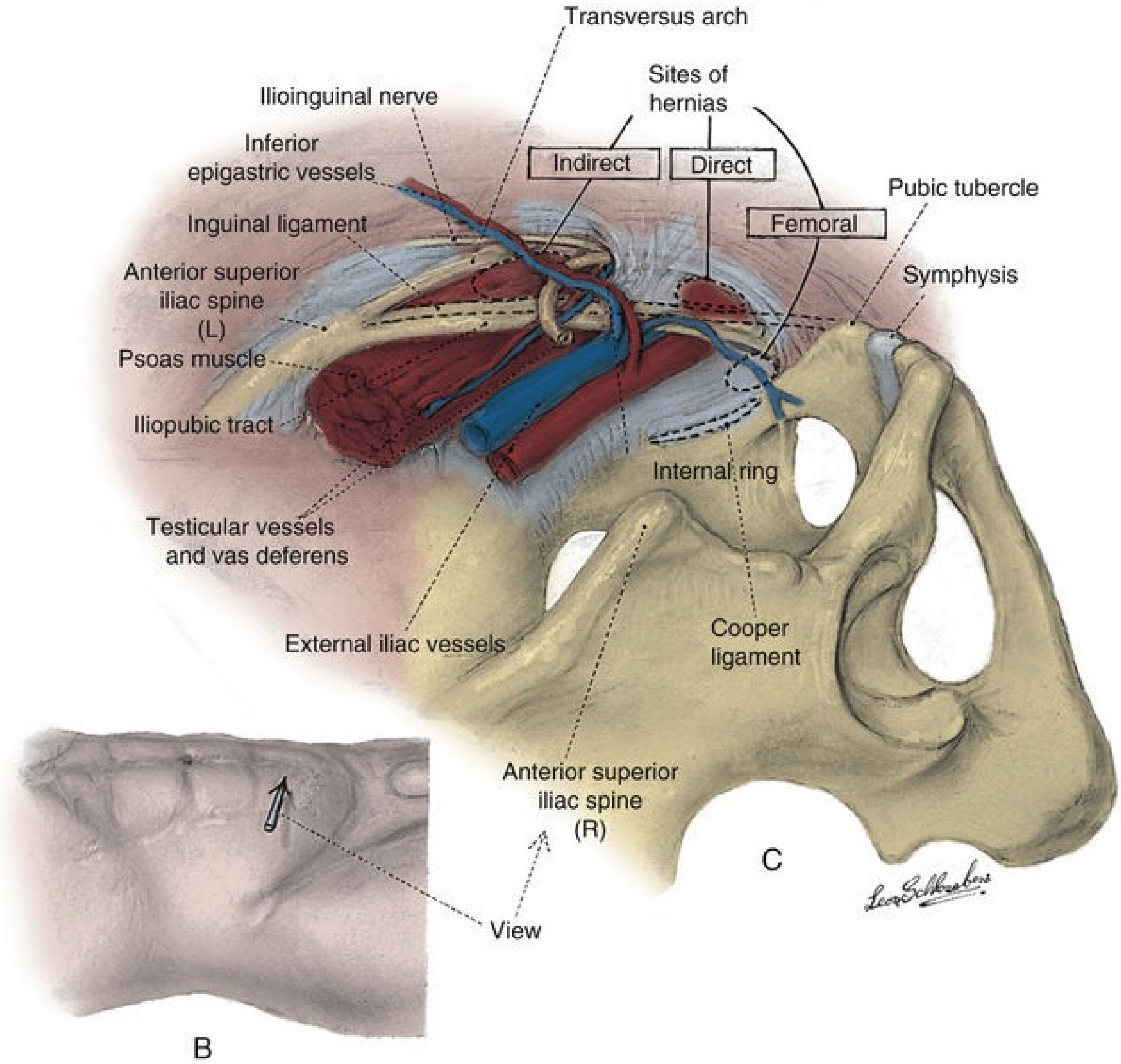
Transversus arch
Sites of hernias
Ilioinguinal nerve
Inferior epigastric vessels
Indirect
Direct
Pubic tubercle
Femoral
Inguinal ligament
Anterior superior iliac spine (L)
Symphysis
Psoas muscle
Iliopubic tract
Internal ring
Testicular vessels and vas deferens
Cooper ligament
External iliac vessels
Anterior superior iliac spine (R)
C
View
B

FIG. 109.5 (A) Muscles, vessels, and nerves of the anterior abdominal wall. Topography (B) and posterior wall (C) of the left inguinal canal, viewed from the preperitoneal space. The location of three types of inguinal hernia is demonstrated. *a,* Artery; *aa,* arteries; *ext,* external; *inf,* inferior; *int,* internal; *L,* left; *lig,* ligament; *mus,* muscle; *n,* nerve; *nn,* nerves; *R,* right; *vess,* vessel. (From Schlegel PN, Walsh PC: Simultaneous preperitoneal hernia repair during radical pelvic surgery. *J Urol* 137:1180–1183, 1987.)

Inguinal Canal

In adults, the inguinal canal is an inferior-medially directed oblique passage (approximately 4 cm long) that runs through the inferior part of the anterior abdominal wall. **The inguinal canal transmits the spermatic cord and the ilioinguinal nerve. It has a deep (internal) and superficial (external) inguinal**

ring. The deep ring serves as the internal entrance to the inguinal canal and is an evagination of the transversalis fascia superior to the inguinal ligament and lateral to the inferior epigastric vessels (Fig. 109.5B and C). The external inguinal ring is a slitlike opening in the aponeurosis of the external oblique, superior-lateral to the pubic tubercle, serving as the exit from the inguinal canal. The internal inguinal ring lies midway between the anterior superior iliac spine and the pubic tubercle, above the inguinal ligament and 4 cm lateral to the external ring.

The anterior wall of the inguinal canal is formed by the external oblique aponeurosis throughout the length of the canal but is reinforced laterally by the lower most fibers of the internal oblique muscle. The posterior wall is formed by transversalis fascia with the posterior medial part of the canal reinforced by the merging of the internal oblique and transversus abdominis aponeurosis into a common tendon, the inguinal falx (conjoint tendon). This tendon reinforces the posterior wall of the inguinal canal at the external ring (Fig. 109.6). The roof of the inguinal canal is also formed by internal oblique and transversus abdominis fibers, which arch over the canal before fusing at the conjoint tendon. The floor of the canal is formed laterally by the iliopubic tract, centrally by the superior surface of the “gutter-like” inguinal ligament, and medially by the lacunar ligament. With contraction of the internal oblique and transversus muscles, the roof of the canal closes against the floor, preventing herniation of intra-abdominal contents into the canal. Hernias into the canal may occur medial (direct) or lateral (indirect) to the inferior epigastric vessels (see Fig. 109.5B and C).

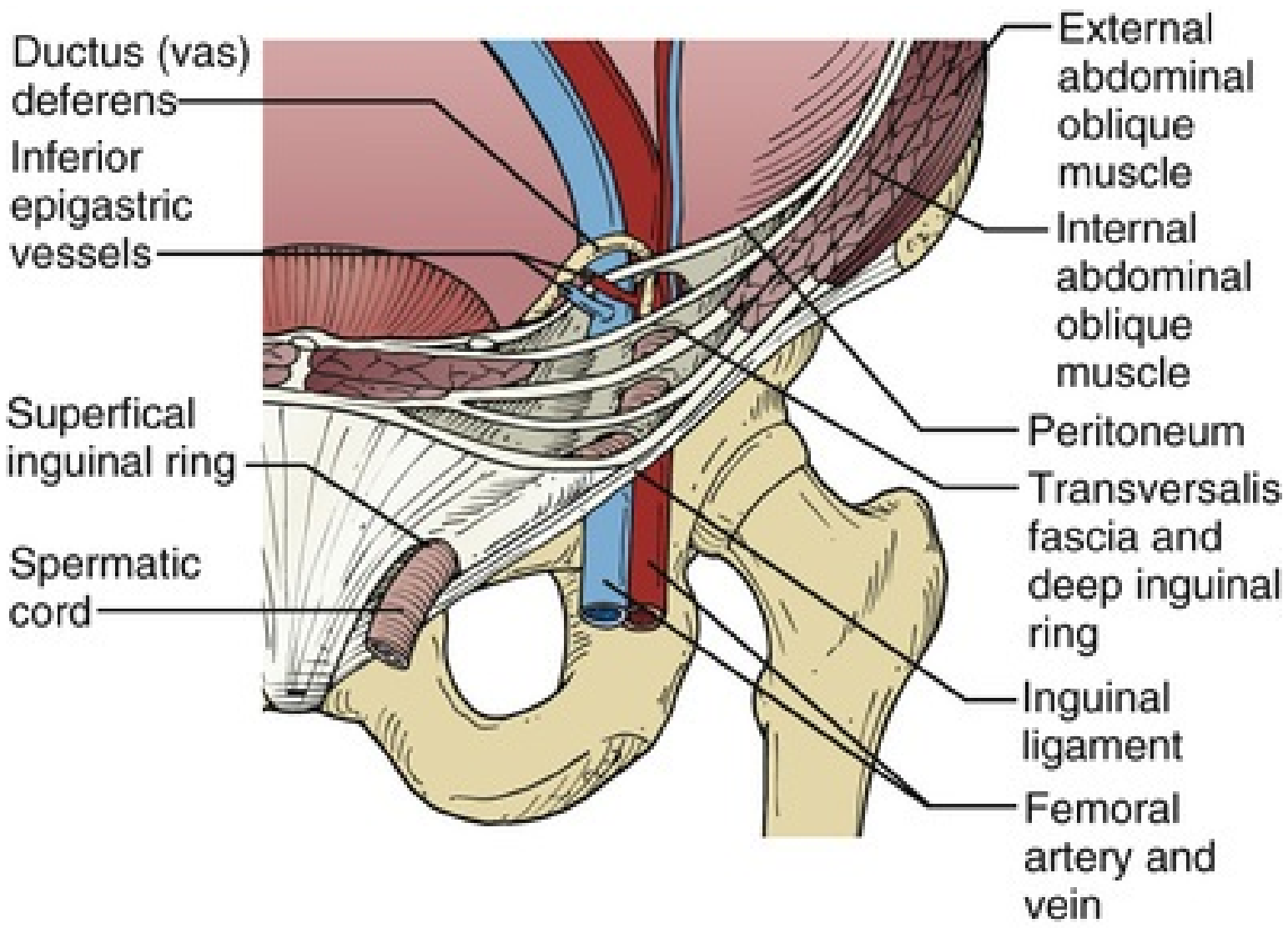
Ductus (vas) deferens
Inferior epigastric vessels
Superfical inguinal ring
Spermatic cord
External abdominal oblique muscle
Internal abdominal oblique muscle
Peritoneum
Transversalis fascia and deep inguinal ring
Inguinal ligament
Femoral artery and vein

FIG. 109.6 Diagram of the fascial layers that make up the inguinal canal. (From Chopra A, Robinson P: Imaging athletic groin pain. *Radiol Clin North Am* 54[5]:865–873, 2016. Fig. 5.)

Internal Peritoneal Elevations

The internal surface of the lower abdominal wall is covered with transversalis fascia, a variable amount of extraperitoneal fat, and parietal peritoneum. Below the umbilicus, the abdominal wall exhibits several peritoneal folds, some of which contain remnants of fetal vessels. These folds are identified easily during peritoneal laparoscopic/robotic surgery (Fig. 109.7). The median umbilical fold, extending from the apex of the bladder to the umbilicus, covers the median umbilical ligament, the remnant of the urachus that joined the apex of the fetal bladder to the umbilicus. The two medial umbilical folds lateral to the median umbilical fold cover the medial umbilical ligaments formed by the obliterated umbilical arteries. These ligaments, which can be traced to their origin from the internal iliac artery, serve as important landmarks for the surgeon. During transperitoneal laparoscopic surgery, access to the obturator fossa and space of Retzius is gained by incising the peritoneum lateral to these ligaments. The two lateral umbilical folds, which lie lateral to the medial umbilical folds, cover the inferior epigastric vessels as they ascend in the abdominal wall to supply the rectus abdominis muscle.

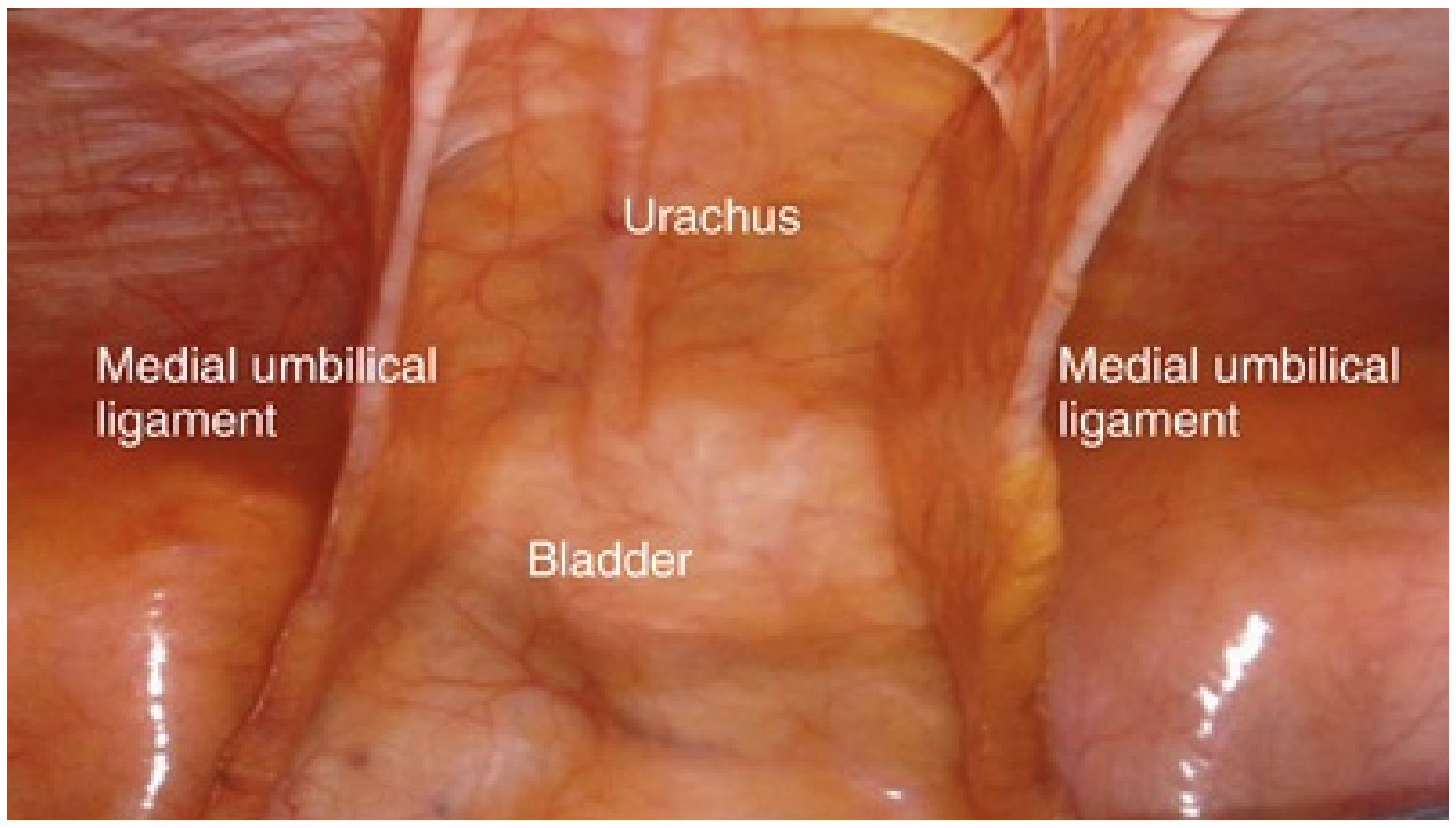
Urachus
Medial umbilical ligament
Medial umbilical ligament
Bladder

FIG. 109.7 Internal view of peritoneal elevations.

Key Points: Pelvis

- The bony pelvis consists of three fused bones: the ilium, ischium, and pubis.
- The true and false pelvises are separated by the arcuate line.
- The inguinal canal transmits the spermatic cord and the ilioinguinal nerve.

Soft Tissues of the Pelvis

Musculature

The lateral pelvic sidewalls are covered and padded by the obturator internus muscles, which exit the pelvis through the lesser sciatic foramen to insert on the femur. The medial surface of these muscles is covered by obturator fascia, which is thickened centrally as a tendinous arch extending from the ischial spine to the lower half of the pubis. **This tendinous arc of the levator ani serves as the origin of the muscular attachments of the bowl-shaped pelvic diaphragm, which consists of the levator ani and coccygeus muscles** (Fig. 109.8). The most posterior muscle of this pelvic diaphragm and the smallest part of it, the coccygeus muscle, extends from the ischial spine to the inferior end of the sacrum and coccyx. In addition to providing support for pelvic viscera, this muscle also flexes the coccyx. The bulk of the pelvic diaphragm is composed of the three muscular parts of the levator ani, the puborectalis, pubococcygeus, and iliococcygeus muscles. The most anterior of these, the puborectalis, forms a U-shaped muscular sling that passes posterior to the anorectal junction, playing a major role in maintaining fecal continence.

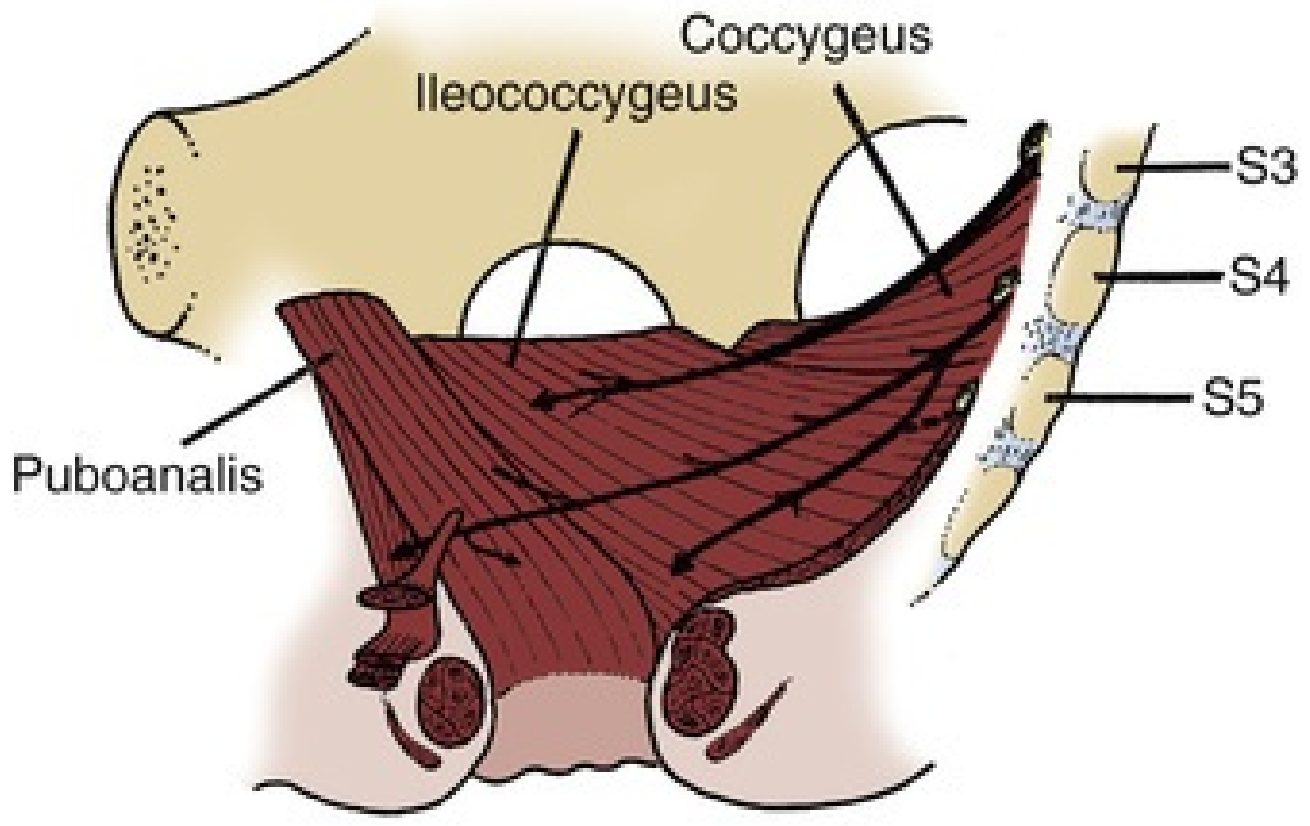

FIG. 109.8 Muscles of the pelvic floor. (From Lawson JO: Pelvic anatomy. I. Pelvic floor muscles. *Ann R Coll Surg Engl* 54:244–252, 1974.)

The levator ani muscles are under somatic control, providing a dynamic pelvic floor that is tonically contracted to support the pelvic viscera and to maintain urinary and fecal continence. They contain both type I (slow-twitch) and type II (fast-twitch) fibers (Gosling et al., 1981). Together, the muscles of the levator ani relax to allow defecation and urination and then contract to raise the pelvic floor. Further contraction occurs with Valsalva maneuvers to resist the increased intra-abdominal pressure that would otherwise force the abdominopelvic contents through the pelvic outlet. Kegel exercises to regain or maintain urinary continence after pelvic surgery are focused on increasing the tonic contraction of these muscles.

Pelvic Fascia

The pelvic fascia is connective tissue that is a continuation of retroperitoneal fascia and fascia that lies between the muscular and peritoneum layers of the lower abdominal wall. It can be divided into the parietal pelvic fascia, which forms the coverings of the pelvic muscles, and the visceral pelvic fascia, which forms a covering of the pelvic organs and their neurovascular supply. The parietal pelvic fascia is a membranous layer of variable thickness that lines the pelvic aspect of muscles forming the walls and floor of the pelvis. This layer is continuous superiorly with the transversalis fascia of the abdominal wall. It is fixed to the arcuate line of the pelvis, Cooper ligament, the sacrospinous ligament, the ischial spine, and tendinous arch of the levator ani. On the superomedial aspect of the upper parietal fascia over the levator ani, a thick white band of condensed connective tissue extends from the puboprostatic ligament to the superior margin of the ischial spine. This arcus tendineus fascia forms a junction between parietal and visceral fascia and provides attachment for the condensations of visceral fascia that provide support to the urethra and bladder. The visceral pelvic fascia directly ensheaths the pelvic organs, forming the adventitial layer of each. The lateral attachments of the pelvic organs to the pelvic sidewalls are referred to as the endopelvic fascia. These connections allow a conduit for conducting neurovascular structures from the pelvic sidewall to the organs and provide attachments that hold pelvic organs in place. The loose connective tissue associated with these mesenteries extend to the midline, separating the bladder, prostate, and seminal vesicles from the rectum. All pelvic vascular structures and some pelvic nerves travel in this fascial layer.

Perineum

Perineal Fascia

The perineal fascia consists of a superficial fatty layer and a deep membranous layer (Colles fascia). The subcutaneous layer is greatly diminished in males, being replaced altogether in the penis and scrotum with smooth (dartos) muscle. It is continuous between the penis or scrotum and thighs with the subcutaneous fatty layer of the abdominal wall. The membranous layer of the superficial perineal fascia (Colles fascia) is attached posteriorly to the posterior margin of the perineal membrane and laterally to the fascia lata of the medial thigh. It is continuous anteriorly with the dartos fascia of the penis and scrotum and the membranous layer of subcutaneous tissue of the abdomen (Scarpa fascia). **The urogenital triangle is enclosed by a thin sheet of tough, deep fascia referred to as the perineal membrane. The perineal membrane has a triangular shape and spans between the right and left pubic arch (inferior ischiopubic rami) extending from the pubis to the ischial tuberosities** (Fig. 109.9). It is perforated by the urethra. The anterior aspect of the perineal membrane supports the urethral sphincter, and the external genitalia attach to its inferior surface. The superficial and deep transverse perineal muscles run along its posterior edge to converge in the midline at the perineal body. **The perineal body is not a structure itself but instead an aggregation of fibromuscular tissue located in the midline at the junction between the urogenital and anal triangles.** Anteriorly, the perineal body blends with the posterior border of the perineal membrane and superiorly with the rectovesical septum, which is contiguous with Denonvilliers fascia. The perineal body is the focal point of pelvic support with nearly every pelvic muscle and fascia inserting into it. Disruption or injury to the perineal body during perineal prostatectomy risks postoperative urinary, and possibly fecal, incontinence.

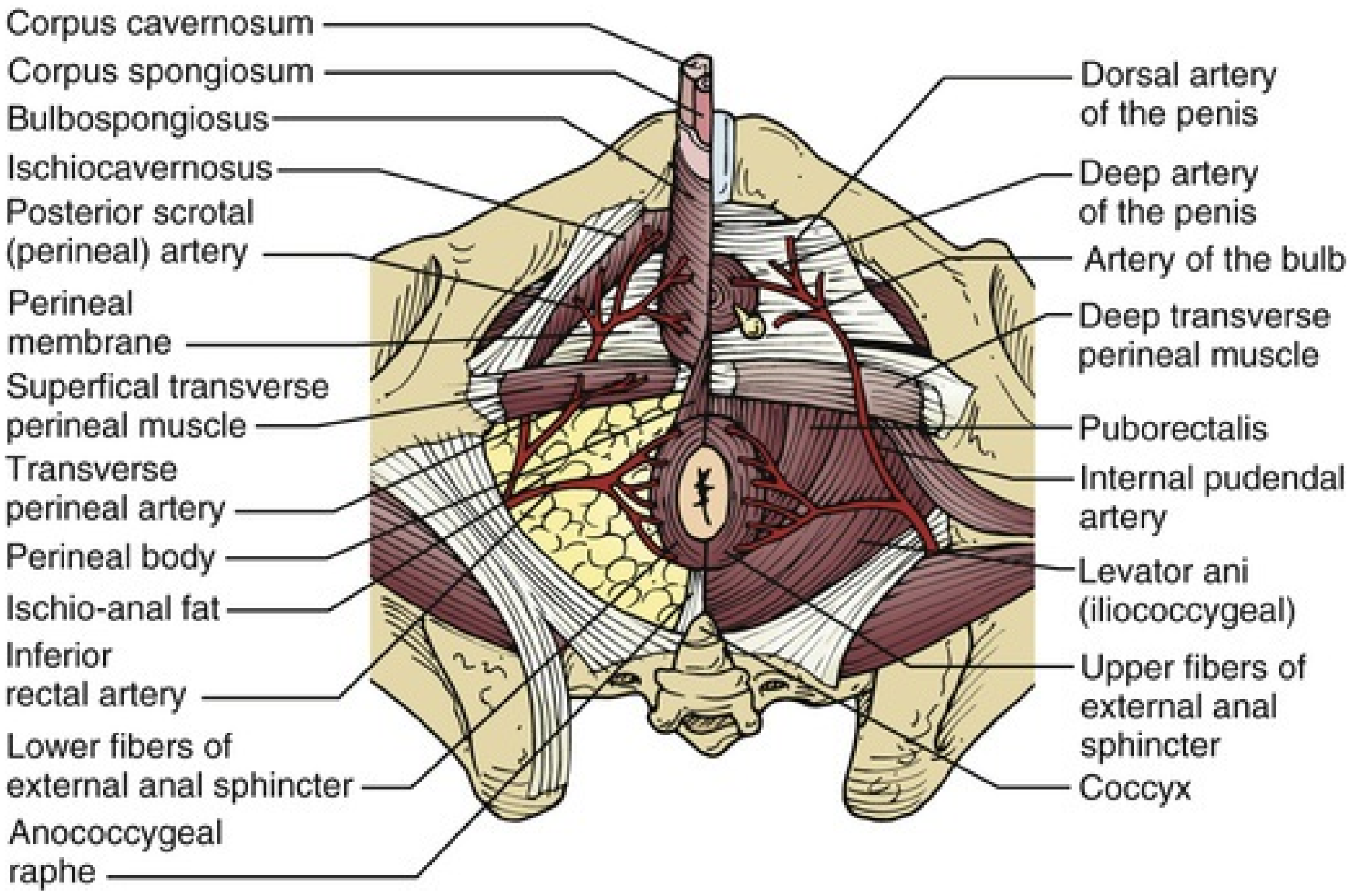
Corpus cavernosum
Corpus spongiosum
Bulbospongiosus
Ischiocavernosus
Posterior scrotal (perineal) artery
Perineal membrane
Superfical transverse perineal muscle
Transverse perineal artery
Perineal body
Ischio-anal fat
Inferior rectal artery
Lower fibers of external anal sphincter
Anococcygeal raphe
Dorsal artery of the penis
Deep artery of the penis
Artery of the bulb
Deep transverse perineal muscle
Puborectalis
Internal pudendal artery
Levator ani (iliococcygeal)
Upper fibers of external anal sphincter
Coccyx

FIG. 109.9 Muscles and fascia of the male perineum. (Modified from Standring S: *Gray's anatomy: the anatomical basis of clinical practice,* ed 41, Philadelphia, 2016, Elsevier, Fig. 73-12.)

The term "perineum" is used to refer to an external surface area (perineal region) and shallow compartment of the body limited superiorly by the pelvic diaphragm, the bowl-shaped fibromuscular layer formed by the levator ani and coccygeus muscles. The osseofibrous structures marking the boundaries of the perineal compartment include the symphysis pubis anteriorly, the ischiopubic rami anterolaterally, ischial tuberosities laterally, sacrotuberous ligaments posterolaterally, and the coccyx posteriorly. By convention, the perineum is divided into two triangles (anal and urogenital triangle) by a transverse line joining the anterior ends of the ischial tuberosities) (Fig. 109.9).

Anal Triangle

The anal triangle contains the anal canal and its sphincters and the ischiorectal fossa and its contained nerves and vessels. It is lined by superficial and deep fascia. The subcutaneous fatty tissue of the anal triangle surrounds the anus and is continuous with the subcutaneous fat of the urogenital triangle, buttocks, and thigh. The ischiorectal fossa, bounded by the levator ani medially and the obturator internus and sacrotuberous ligament laterally, is filled with fat and extends anteriorly to a recess above the urogenital diaphragm. It also extends posteriorly into the pelvis through the sciatic foramina. This continuity with the pelvis allows extension of perirectal infections between the perineum and pelvic cavity.

The anal canal begins where the ampulla of the rectum abruptly narrows at the level of the U-shaped sling formed by the puborectalis muscle. The anal canal is surrounded by the internal and external anal sphincters. The internal sphincter is an involuntary sphincter surrounding the upper two-thirds of the anal canal. It represents a thickening of the inner circular smooth muscle layer of the rectum. Its tonic contraction is maintained by sympathetic nerves and lessened by parasympathetic nerves, allowing it to expand passively during defecation. The external anal sphincter is a large voluntary sphincter forming bands of muscle around the inferior two-thirds of the anal canal and has subcutaneous, superficial, and deep parts. The subcutaneous portion attaches to the perineal body by collagenous and muscular fibers referred to as the central tendon of the perineum. The superficial part is attached to the perineal body and coccyx, and the deep portion blends with the puborectalis sling of the levator ani. Disruption of this muscular band results in fecal incontinence. During perineal prostatectomy, the prostate can be approached either by dividing the central tendon and sphincteric attachments to the perineum, leaving the external sphincter on the rectum (Young procedure), or by going under the external sphincter along the anterior rectal wall (Belt procedure).

Urogenital Triangle

The male urogenital triangle is enclosed by the scrotum anteriorly and the perineal body posteriorly. The skin and subcutaneous fat overlie Colles fascia, which attaches posteriorly to the perineal membrane (with the perineal body in the center), forming a superficial pouch. Deep to this pouch lies the root of the penis, with the paired corpora cavernosa attaching to the inferior ischiopubic rami and perineal membrane and the corpus spongiosum of the bulbar urethra attaching to the perineal membrane. The bulb of the penis is surrounded by the bulbospongiosus muscle, and the corpora cavernosa are surrounded by the ischiocavernosus muscles. Contraction of these muscles compresses the corpora cavernosa during penile erection.

The internal pudendal artery and its branches supply the perineum. After branching from the internal iliac artery, the internal pudendal artery travels through the lesser sciatic foramen, medial to the obturator internus in Alcock canal. It sends branches to the anus and then travels through Colles fascia into the superficial pouch of the urogenital triangle and posterior scrotum before terminating as the dorsal artery of the penis (Figs. 109.10 and 109.11).

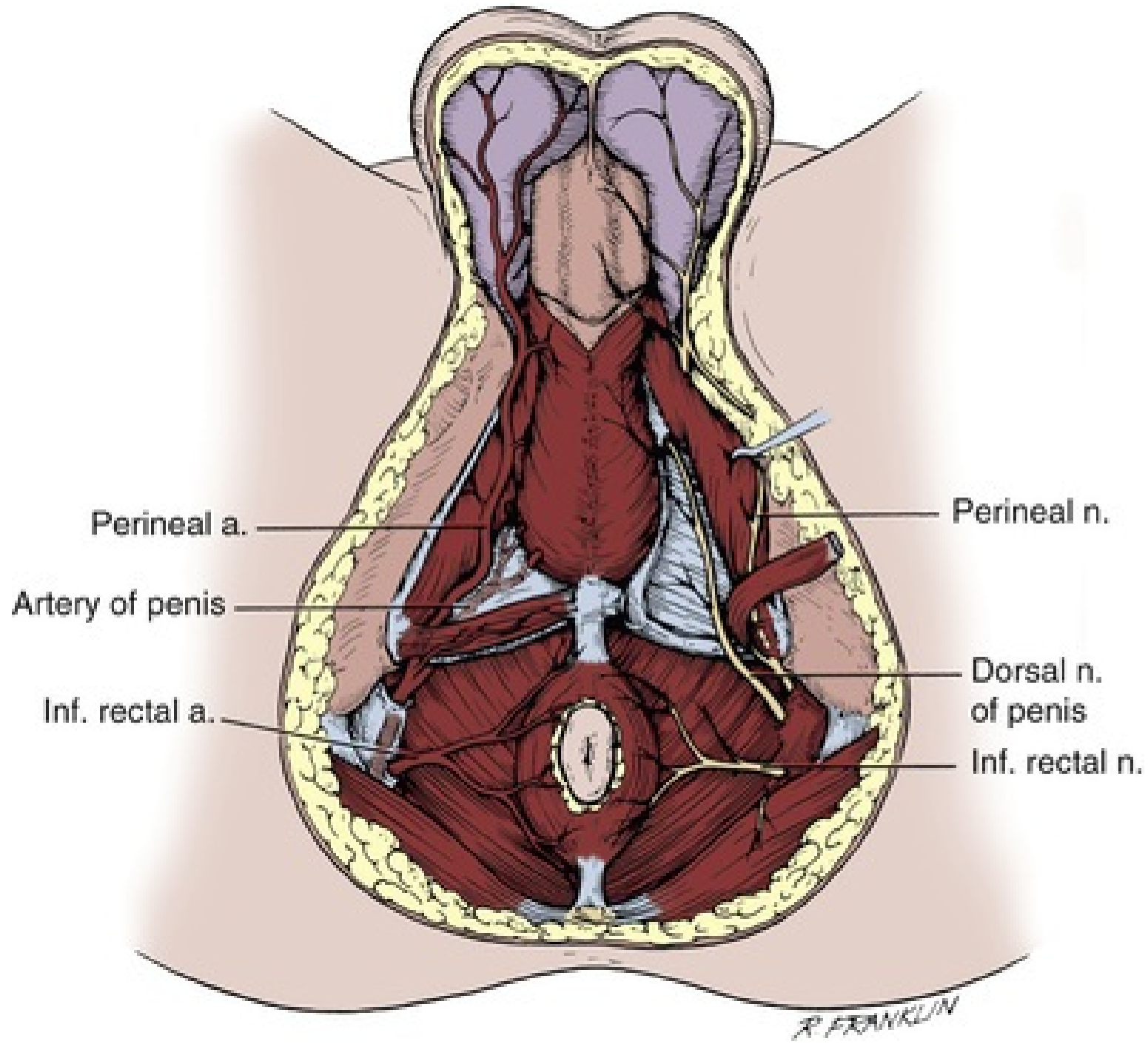
Perineal a.
Artery of penis
Inf. rectal a.
Perineal n.
Dorsal n. of penis
Inf. rectal n.
R FRANKLIN

FIG. 109.10 Male perineum, illustrating the internal pudendal artery and its branches on the left and the pudendal nerve and its branches on the right. *Inf,* inferior; *n,* nerve.

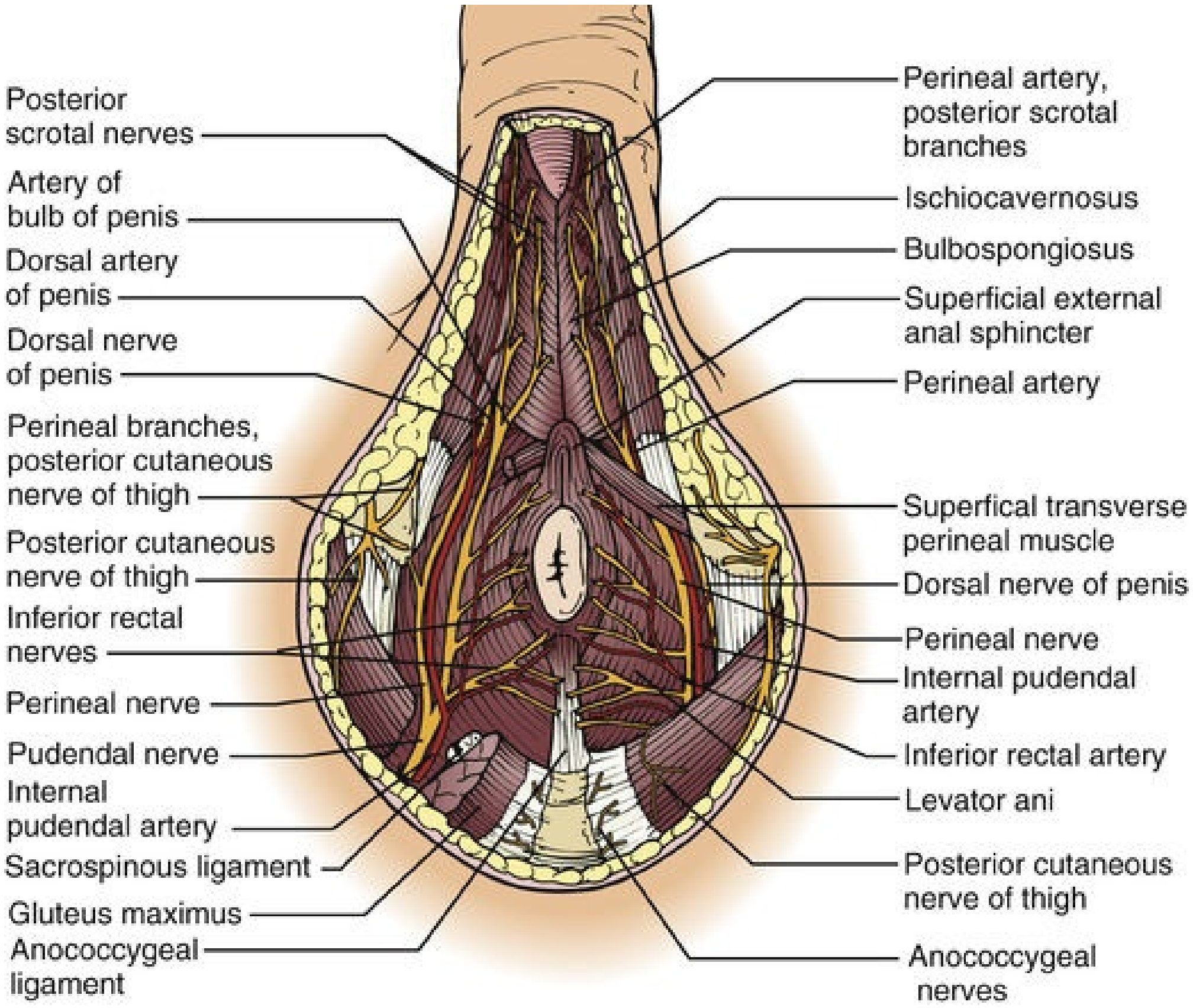
Posterior scrotal nerves
Artery of bulb of penis
Dorsal artery of penis
Dorsal nerve of penis
Perineal branches, posterior cutaneous nerve of thigh
Posterior cutaneous nerve of thigh
Inferior rectal nerves
Perineal nerve
Pudendal nerve
Internal pudendal artery
Sacrospinous ligament
Gluteus maximus
Anococcygeal ligament
Perineal artery, posterior scrotal branches
Ischiocavernosus
Bulbospongiosus
Superficial external anal sphincter
Perineal artery
Superfical transverse perineal muscle
Dorsal nerve of penis
Perineal nerve
Internal pudendal artery
Inferior rectal artery
Levator ani
Posterior cutaneous nerve of thigh
Anococcygeal nerves

FIG. 109.11 Blood vessels and nerves of the male perineum and external genitalia. (Modified from Standring S: *Gray's anatomy: the anatomical basis of clinical practice,* ed 41, Philadelphia, 2016, Elsevier, 2016, Fig. 76.24.)

The internal pudendal veins anastomose with the dorsal venous complex in the pelvis via a plexus on the lateral surface of the prostate that can cause bleeding during prostatic dissection. The inferior rectal veins arise from the internal pudendal vein and anastomose with the middle and superior rectal veins, which eventually drain to the inferior mesenteric vein. Obstruction of either the portal circulation from the inferior mesenteric vein or the systemic circulation from the inferior rectal veins can result in dilation of the venous plexus and hemorrhoid formation.

The pudendal nerve travels with the internal pudendal vessels in Alcock canal to innervate the perineum. Anteriorly, its first branch is the dorsal nerve of the penis, followed by branches that supply the ischiocavernosus and bulbospongiosus muscles, as well as sensory nerves to the posterior scrotum (Fig. 109.11). Perineal branches supply the striated urethral sphincter and levator ani. Posteriorly, the rectal branches supply the external sphincter and provide sensation to the perianal skin.

Key Points: Perineum

- The perineum is bordered by the symphysis pubis, ischiopubic rami, ischial tuberosities, sacrotuberous ligaments, and coccyx.
- The perineum is composed of two triangles: the urogenital triangle and anal triangle.
- The blood supply to the perineum is the internal pudendal artery and its branches, and its innervation is the pudendal nerve.

Pelvic Circulation

Arterial Supply

At the aortic bifurcation the middle sacral artery travels to the anterior sacrum, where it supplies the rectum and sacral foramina (Table 109.1). It may be encountered during dissection of the presacral space. **The common iliac arteries course anteriorly to the common iliac veins and split into an external and internal branch at the level of the sacroiliac joint.** The external iliac artery sits anterolateral to the vein and on top of the iliopsoas muscle. It eventually crosses under the inguinal ligament, where it becomes the femoral artery. Distal branches of the external iliac artery may be encountered during pelvic lymph node dissection, including the inferior epigastric artery (which leaves the artery proximal to the inguinal ligament and travels to the rectus muscle) and the deep circumflex iliac and pubic branches. The cremasteric artery also branches from the inferior epigastric artery, where it travels with the spermatic cord. Accessory obturator vessels may be encountered during pelvic lymph node dissection as they branch from the inferior epigastric vessels and travel into the obturator fossa.

TABLE 109.1

Arteries of the Pelvis

ARTERY NAME	ORIGIN	SUPPLIES
Middle sacral	Aorta	Sacral nerves and sacrum
EXTERNAL ILIAC BRANCHES		
Inferior epigastric	External iliac	Rectus abdominis muscle and overlying skin and fascia
Deep circumflex iliac	Inferior epigastric	Inguinal ligament and surrounding structures laterally
Pubic	Inferior epigastric	Inguinal ligament and surrounding structures medially
Cremasteric	Inferior epigastric	Vas deferens and testis
INTERNAL ILIAC BRANCHES		
Superior gluteal	Posterior	Gluteus muscles and overlying skin

	trunk	
Ascending lumbar	Posterior trunk	Psoas and quadratus lumborum muscles and adjacent structures
Lateral sacral	Posterior trunk	Sacral nerves and sacrum
Superior vesical	Anterior trunk	Bladder, ureter, vas deferens, and seminal vesicle
Middle rectal	Anterior trunk	Rectum, ureter, and bladder
Inferior vesical	Anterior trunk	Bladder, seminal vesicle, prostate, ureter, and the neurovascular bundle
Internal pudendal	Anterior trunk	Rectum, perineum, and external genitalia
Obturator	Anterior trunk	Adductor muscles of the leg and overlying skin
Inferior gluteal	Anterior trunk	Gluteus muscles and overlying skin

The internal iliac (hypogastric) artery travels posteriorly after branching from the common iliac artery to supply the deep pelvis. It is divided into an anterior and posterior trunk. The anterior trunk gives off several branches: the umbilical artery, the obturator artery, the middle rectal and inferior vesical artery, the internal pudendal artery, and then the inferior gluteal.

The umbilical artery is typically obliterated after its take off from the internal iliac artery and becomes the medial umbilical ligament along the anterior abdominal wall (see Fig. 109.7), which is an important landmark in pelvic surgery when entering the extraperitoneal space. **The superior vesical artery arises from the umbilical artery proximally and supplies the bladder along with the inferior vesical artery.** The artery of the vas deferens also comes from a branch of the umbilical artery and joins the cremasteric and testicular arteries in the spermatic cord, providing an additional blood supply to the testicle. The obturator artery supplies the adductor muscles of the thigh and travels through the obturator foramen and can be encountered deep and medial to the obturator nerve, particularly during pelvic lymph node dissection (Fig. 109.12).

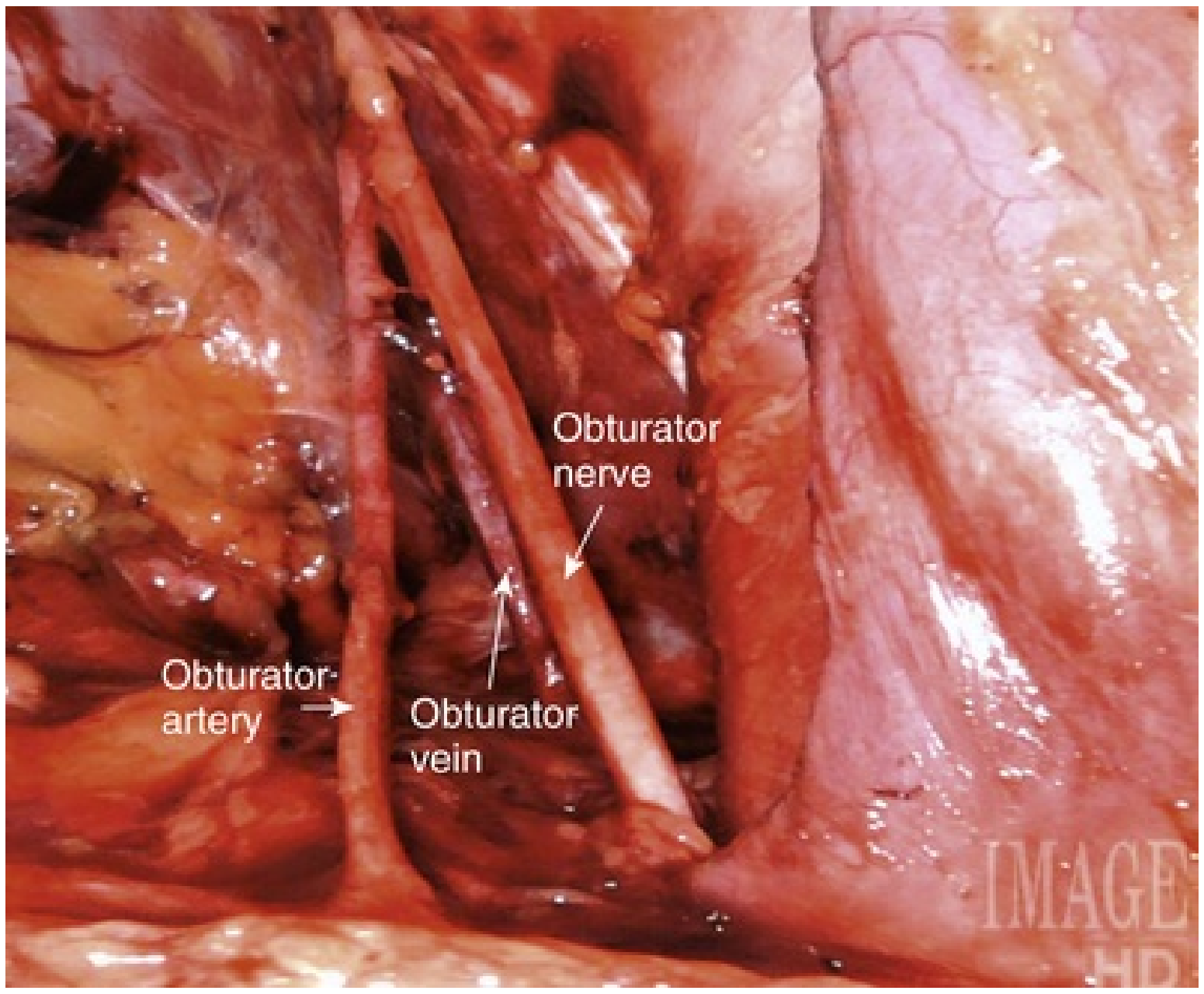

FIG. 109.12 Intraoperative photo of obturator fossa after lymph node dissection.

Venous Supply

The pelvis has a rich venous network. The external and internal iliac veins course inferior and medial to their corresponding arteries and join together behind the internal iliac artery, where they can be injured during pelvic lymph node dissection, resulting in significant bleeding. An accessory obturator vein may drain into the external iliac vein, which may also be encountered during lymph node dissection.

The dorsal venous complex drains the penis and enters the pelvis beneath the pubic symphysis in the midline anterior to the striated sphincter and then divides into a central superficial branch and a deeper plexus (Fig. 109.13). It is important to control when performing prostatectomy to minimize bleeding; however, this maneuver can damage the sphincter, particularly laterally. The prostatic venous plexus (Santorini plexus) drains the prostate and part of the rectum and may be encountered when entering the lateral prostatic fascia during radical prostatectomy. It eventually drains into the internal iliac vein, along with several inferior vesical veins.

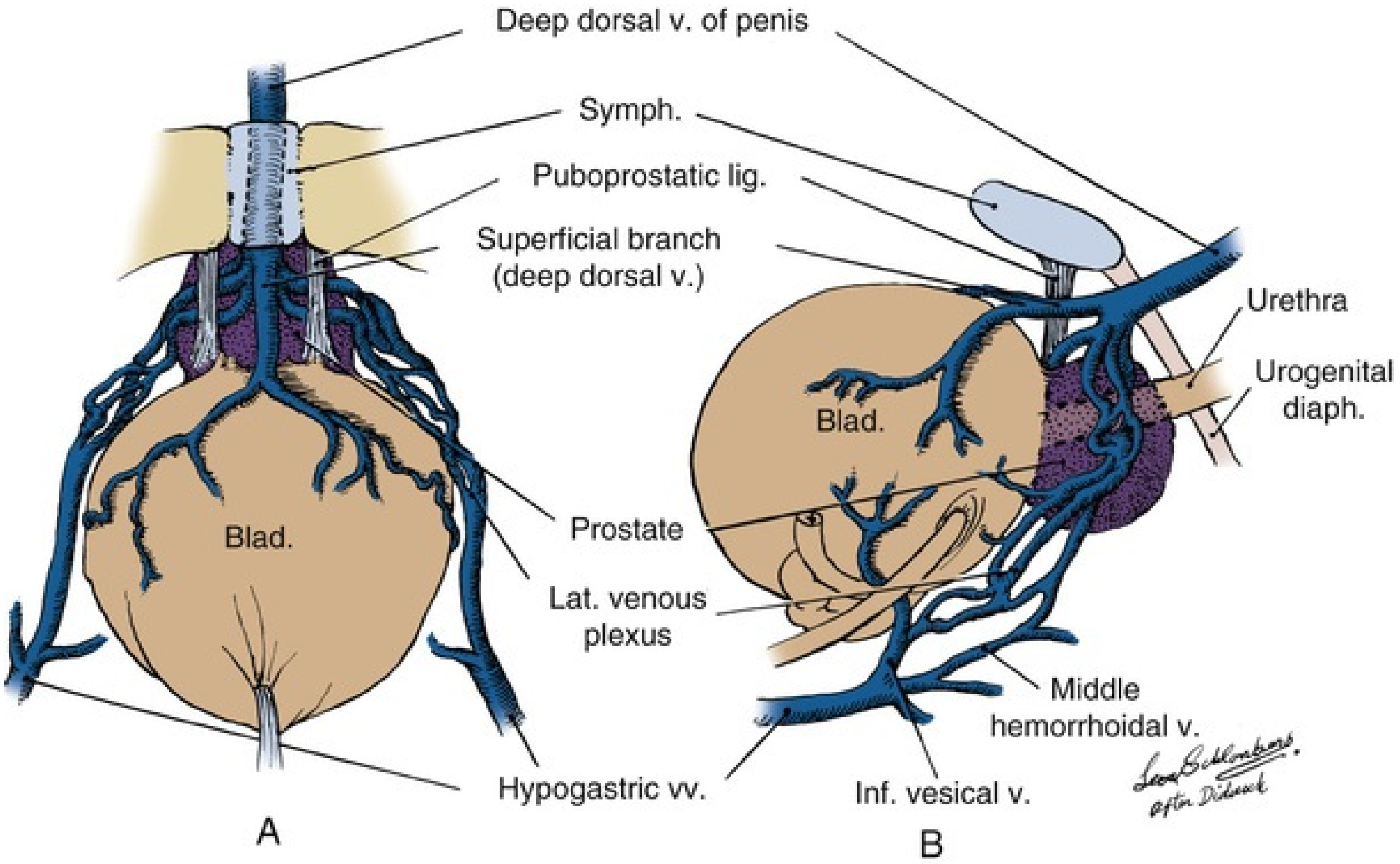
Deep dorsal v. of penis
Symph.
Puboprostatic lig.
Superficial branch (deep dorsal v.)
Urethra
Urogenital diaph.
Blad.
Blad.
Prostate
Lat. venous plexus
Middle hemorrhoidal v.
Hypogastric vv.
Inf. vesical v.
Leon Schlossberg after Didusch
A
B

FIG. 109.13 Pelvic venous plexus. (A) Trifurcation of the dorsal vein of the penis, viewed from the retropubic space. The relationship of the venous branches to the puboprostatic ligaments is shown. (B) Lateral view of the pelvic venous plexus after removal of the lateral pelvic fascia. Normally these structures are difficult to see because they are embedded in pelvic fascia. *Blad,* Bladder; *lig,* ligament; *v,* vein. (From Reiner WG, Walsh PC: An anatomical approach to the surgical management of the dorsal vein and Santorini's plexus during radical retropubic surgery. *J Urol* 121:198–200, 1979.)

Pelvic Lymphatics

The drainage from the pelvic viscera includes the iliac lymph nodes and its tributaries. There is frequent cross drainage between the right and left side of the pelvis. The external iliac lymph nodes extend from the top of the external iliac artery distally to just over the pelvic brim. They drain the anterior abdominal wall, urachus, and bladder. The most distal portion of the lymph node packet as the external iliac artery exits the femoral canal is referred to as the node of Cloquet and serves as the distal limit of pelvic lymph node dissection. The internal iliac lymph nodes receive drainage from the prostate and bladder. The presacral and obturator lymph nodes also drain into the internal iliac lymph node chain. The lymphatic drainage for the external genitalia is the inguinal lymph nodes, which then drain into the iliac lymph nodes.

Pelvic Innervation

The sensation to the pelvis and genitalia comes from the lumbosacral plexus. The iliohypogastric nerve originates from L1 to supply the anterior abdominal wall. The ilioinguinal nerve also originates from L1 and travels through the inguinal canal, providing sensation to the anterior scrotal skin. The genitofemoral nerve arises from L1 and L2 and splits into genital and femoral branches. It travels over the anterior surface of the psoas muscle. The genital branch travels through the inguinal canal to supply the cremaster muscle and anterior scrotum. The femoral branch provides sensation from the anterior thigh (Table 109.2).

TABLE 109.2

Somatic and Autonomic Nerves of the Pelvis

NERVE	SOURCE	SUPPLIES	ANATOMIC COURSE
Iliohypogastric	L1	Anterior abdominal wall and pubis	Between internal oblique and transversus muscle
Ilioinguinal	L1	Anterior scrotum	Through inguinal canal
Genitofemoral	L1, L2	Genital branch: cremaster muscle and anterior scrotum Femoral branch: anterior thigh	Combined nerve travels on anterior surface of psoas. Genital branch: through inguinal canal Femoral branch: along with external iliac under inguinal ligament
Lateral cutaneous femoral nerve	L2, L3	Lateral to psoas on iliacus	Lateral thigh
Posterior femoral cutaneous	S2, S3	Perineum and posterior scrotum	Greater sciatic foramen
Pudendal	S2, S3, S4	Sensation: perineum, scrotum, penis Motor: levator ani, urinary and anal sphincters	Follows internal pudendal artery
Pelvic somatic efferents	S2, S3, S4	Motor supply to levator ani and striated urethral sphincter	Branches from pudendal nerve into perineum
Nervi	S2, S3, S4	Parasympathetic fibers from	From sacral cord to bladder

erigentes		the sacral cord that supply the pelvic viscera	and rectum

Motor Nerves

The femoral nerve comprises branches from L2-L4 and contributes sensation to the anterior thigh and motor innervation to the extensors of the thigh. It travels deep within the psoas muscle but can be injured during psoas hitch, by pressure from retractor blades during laparotomy, or during inguinal lymph node dissection. The obturator nerve also originates from L2-L4 and is first apparent between the internal iliac vessels and the pelvic side wall at the bifurcation of the common iliac vessels; it travels anteriorly through the obturator canal (Fig. 109.14). Damage to this structure can occur during pelvic lymph node dissection, resulting in difficulty with adduction of the thigh.

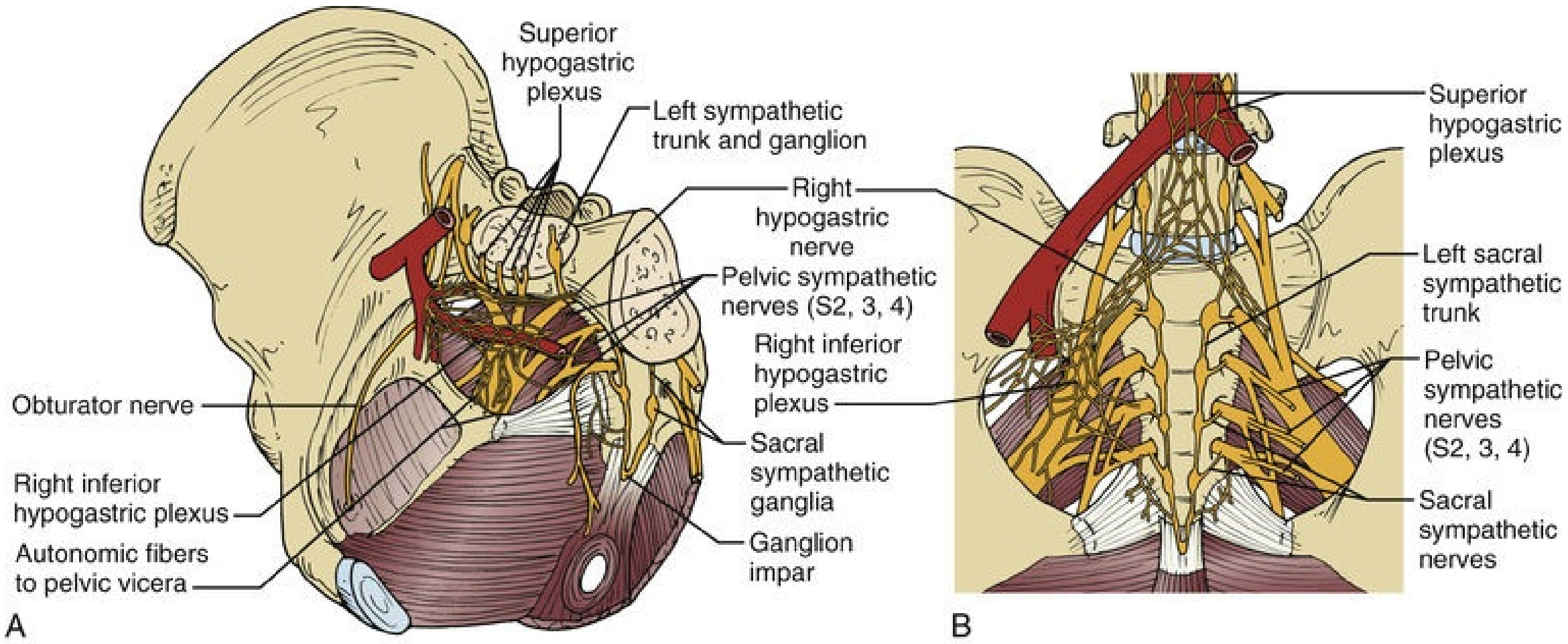
Superior hypogastric plexus
Left sympathetic trunk and ganglion
Right hypogastric nerve
Pelvic sympathetic nerves (S2, 3, 4)
Right inferior hypogastric plexus
Obturator nerve
Right inferior hypogastric plexus
Autonomic fibers to pelvic vicera
Sacral sympathetic ganglia
Ganglion impar
A
Superior hypogastric plexus
Left sacral sympathetic trunk
Pelvic sympathetic nerves (S2, 3, 4)
Sacral sympathetic nerves
B

FIG. 109.14 (A and B) Innervation of the pelvis. (Modified from Standring S: *Gray's anatomy: the anatomical basis of clinical practice,* ed 41, Philadelphia, 2016, Elsevier, 2016.)

The sacral plexus is formed by the lumbosacral trunk (L4, L5) and the sacral segmental nerves and is located between the internal iliac vessels and the piriformis muscle. It then travels through the greater sciatic foramen to innervate the lower leg and posterior thigh. The sensory branches to the pelvis are listed in Table 109.2.

Autonomic Nerves of the Pelvis

The sympathetic nerves of the pelvis originate in the lateral horn of the thoracic and lumbar spinal cord (T10-L2) and then travel to the pelvis via the superior hypogastric plexus and the sympathetic chain (Fig. 109.15). The hypogastric plexus is a continuation of nerve fibers from the celiac plexus and lumbar sympathetic nerves. It eventually becomes two discrete hypogastric nerves that travel anterior to the aorta and medial to the internal iliac artery into the pelvis beneath the endopelvic fascia. The sympathetic trunks are located lateral to the vertebral bodies and continue behind the iliac vessels to terminate in front of the coccyx.

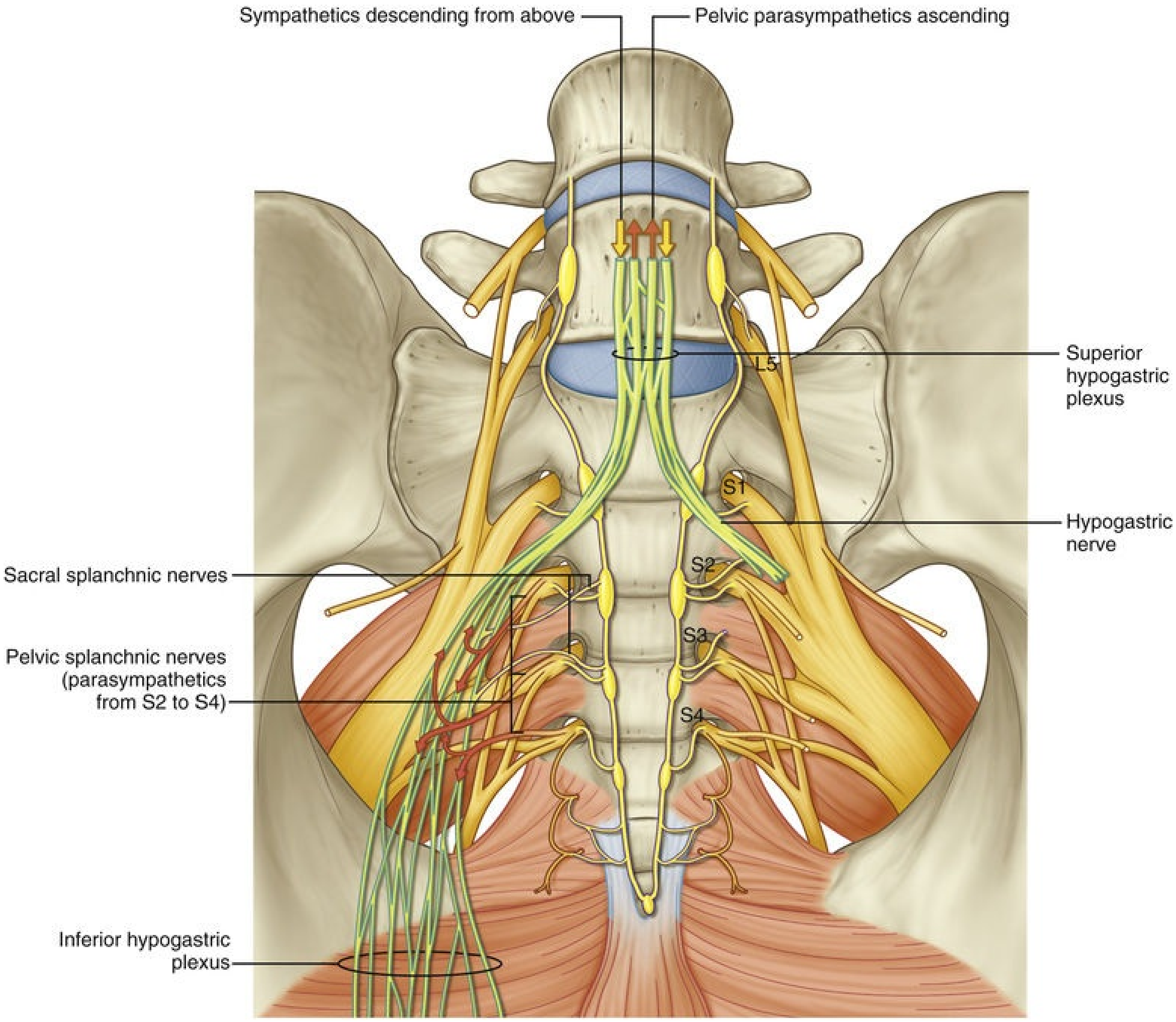
Sympathetics descending from above
Pelvic parasympathetics ascending
Superior hypogastric plexus
L5
S1
Hypogastric nerve
S2
Sacral splanchnic nerves
S3
Pelvic splanchnic nerves (parasympathetics from S2 to S4)
S4
Inferior hypogastric plexus

FIG. 109.15 Sympathetic and parasympathetic contributions to the pelvic autonomic nervous plexus.

Parasympathetic nerves in the pelvis come from the lateral horns of the sacral spinal cord (S2-S4) and join the sympathetic hypogastric plexus to form the pelvic plexus. The pelvic plexus is on either side of the rectum, centered around the seminal vesicles (Fig. 109.16), innervating the rectum, bladder neck, and distal ureter. Distally, the pelvic plexus innervates the prostate and continues as cavernosal nerves that run posterolateral to the prostate on the surface of the rectum outside of Denonvillier fascia. Prostatic arteries and veins travel with the nerve fibers forming a neurovascular bundle. **The neurovascular bundle continues between the 5 and 7 o'clock position at the apex of the prostate and then sends branches to the striated sphincter and corpora cavernosa to supply erectile tissue.** Damage to the neurovascular bundle or pelvic plexus during prostatectomy or rectal resection results in erectile dysfunction.

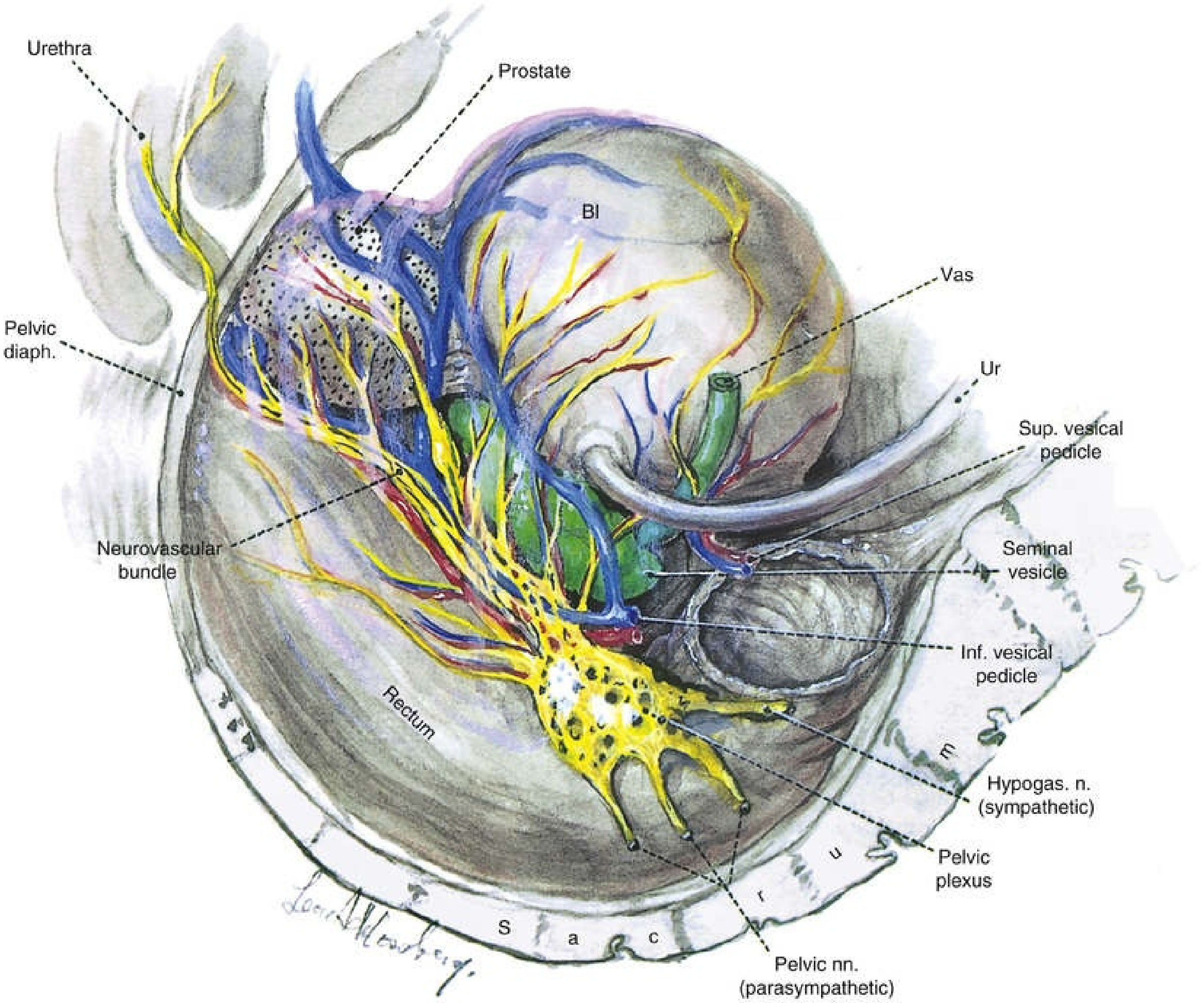
Urethra
Prostate
Bl
Vas
Ur
Sup. vesical pedicle
Pelvic diaph.
Seminal vesicle
Neurovascular bundle
Inf. vesical pedicle
Rectum
Hypogas. n. (sympathetic)
Pelvic plexus
S a c r u m
Pelvic nn. (parasympathetic)

FIG. 109.16 Lateral view showing the left pelvic autonomic nervous plexus and its relation to the pelvic viscera. *Bl,* Bladder; *Hypogas,* hypogastric; *Inf,* inferior; *n,* nerve; *nn,* nerves; *Sup,* superior; *Ur,* urethra. (From Schlegel PN, Walsh PC: Neuroanatomical approach to radical

cystoprostatectomy with preservation of sexual function. *J Urol* 138:1402–1406, 1987.)

Key Points: Pelvic Circulation and Innervation

- The vascular supply to the pelvis derives from the common iliac vessels and its branches, with the deep pelvis supplied by the internal iliac vessels.
- There is frequent cross-drainage between lymphatics to both sides of the pelvis.
- Prostatic arteries, veins, and the cavernosal nerves form the neurovascular bundle, which supplies erectile tissue.

Pelvic Viscera

Rectum

The rectum starts at the level of S3 and follows the curvature of the sacrum through the pelvic floor and terminates in the perineum as the anus. The anterior portion of the rectum is covered with peritoneum distally up to the rectovesical pouch. Incision of this peritoneum allows access to the seminal vesicles posterior to the bladder as is commonly performed in the “posterior approach” to robotic prostatectomy. **Beyond the rectovesical pouch Denonvillier fascia separates the rectum from the prostate.** The rectal blood supply derives from the middle rectal artery (from the internal iliac artery) and the inferior rectal artery (from the internal pudendal artery). The pelvic plexus is located laterally and provides autonomic innervation. The most distal portion of the rectum is the ampulla, where the rectourethralis muscle can be found. This portion of the rectum is in proximity to the striated urethral sphincter and prostate and is the most common location of rectal injury at the time of prostatectomy.

Bladder

Covered by peritoneum superiorly, the bladder is mostly an extraperitoneal organ. The superior portion (e.g., dome) is in continuity with the urachus, which is a fibrous embryologic structure typically lined with epithelium, but obliterated. The urachus continues along the midline of the anterior abdominal wall and terminates in the umbilicus. The urachus can be a source of adenocarcinomas of the bladder, and persistent communication to the urinary tract may result in fistulas or cysts. **Anterior to the bladder is the space of Retzius, a potential extraperitoneal space that lies deep to the transversalis fascia and is often developed by surgical dissection to access the bladder or prostate**. Laterally, the bladder is surrounded by loose connective and adipose tissue, and posteriorly the ureters enter alongside the seminal vesicles and vasa deferentia (Fig. 109.17). Posterior to these structures lies the rectum. The adult bladder rests in the true pelvis. The bladder neck is firmly attached to the base of the prostate and the urothelium of the bladder is in continuity with the prostatic urethra. In infants, the bladder is intraabdominal and migrates into the true pelvis during puberty.

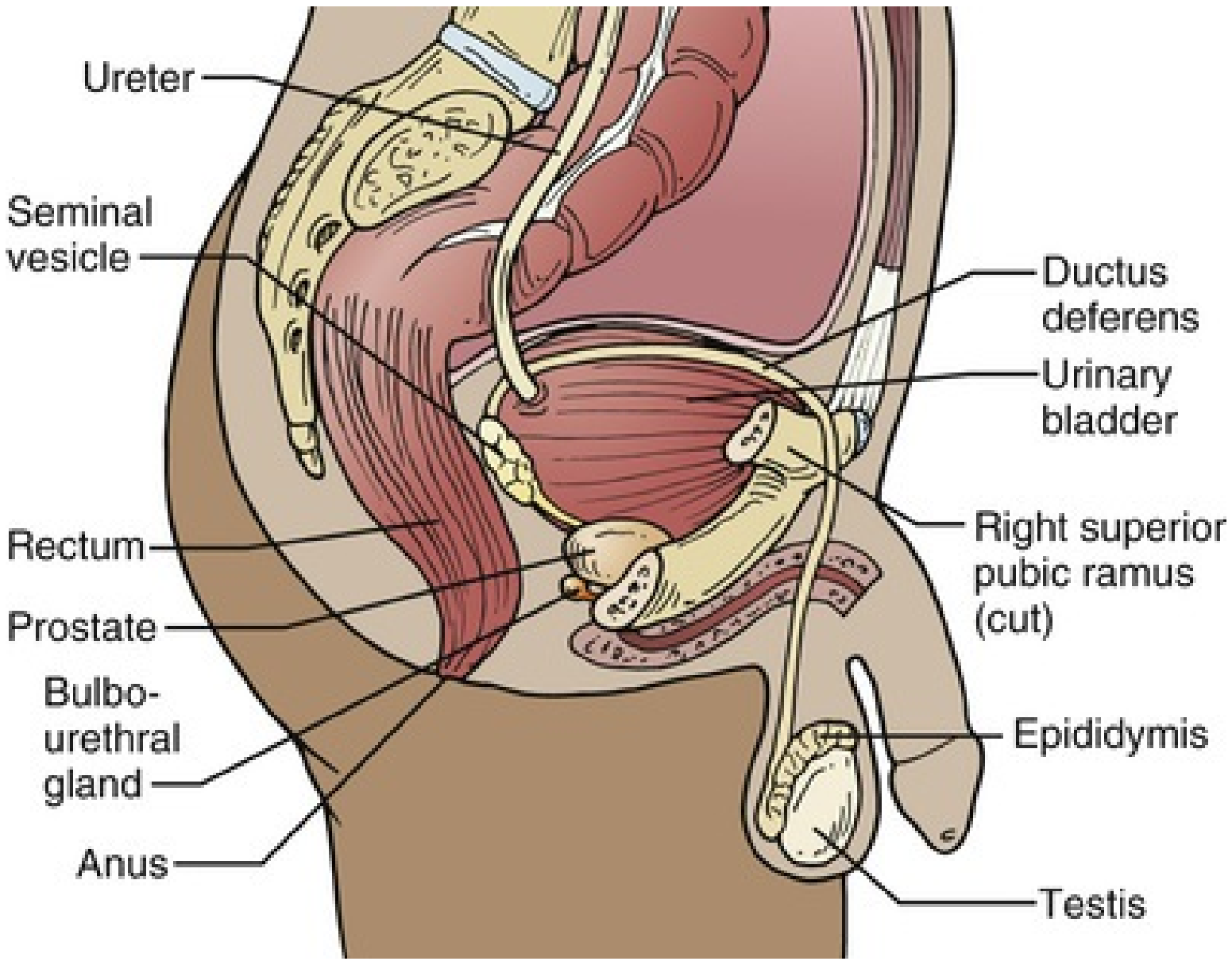

FIG. 109.17 Viscera of the male pelvis. (From Moses KP, Banks JC: Pelvic viscera. In Moses KP, Banks JC, Nava PB, Petersen DK, editors: *Atlas of clinical gross anatomy,* ed 2, Philadelphia, Elsevier, 2013, pp 460–477, Fig. 37.1.)

The bladder consists of several layers. The lining is a relatively impermeable transitional epithelium that is made up of several layers of cells with a superficial layer of umbrella cells. These cells are adherent to the connective tissue of the lamina propria and smooth muscle called the muscularis mucosae. Deep to this is the muscularis propria, which is composed of smooth muscle oriented in three separate layers (from inner to outer): longitudinal, circular, and longitudinal again. These fibers form a network that enables coordinated emptying of the bladder. These layers continue into the bladder neck, where the longitudinal fibers are continuous with the prostatic urethra. The circular fibers form the internal urethral sphincter (Brooks et al., 1998), which is an important component of continence in men. The role of this sphincter in continence is apparent post-prostatectomy, when these fibers may be damaged, resulting in urinary incontinence. The bladder neck is innervated by adrenergic nerve fibers, which enable it to close, allowing antegrade ejaculation. The trigone is the thickest portion of the detrusor muscle, and the outer longitudinal muscle fibers provide a strong muscular backing. Anteriorly, the longitudinal fibers are continuous with the puboprostatic ligaments.

Ureterovesical Junction

The ureters are encased by fibrous tissue (Waldeyer sheath) as they enter the trigone (Fig. 109.18). The entrance is cephalad and lateral, and the ureter travels 1.5 to 2 cm before reaching the ureteral orifice, which is located caudad and medial to its insertion into the bladder. The intramural ureter that travels through the detrusor is narrow and can be a site of obstruction in the setting of ureteral stones or significant bladder wall thickening. Because of the strong detrusor muscle backing, the intramural ureter is occluded during bladder filling, acting as a one-way valve for urine flow. Vesicoureteral reflux is thought to occur in part because of weak or shortened muscular backing of the intramural ureter. The entry point of the ureter is a point of weakness in the detrusor muscle and can form diverticula ("Hutch") from elevated intravesical pressures (Hutch et al., 1961). The superficial portion of the trigone is a triangular shape and formed from the joining of the longitudinal muscle fibers from the ureters, terminating at the verumontanum. The continuation of Waldeyer sheath and the detrusor muscle of the bladder form the outer layers of the trigone, anchoring the ureters to the bladder. The resultant fixation of the ureters to the detrusor allows for compression of the intramural ureter during bladder filling and helps prevent vesicoureteral reflux.

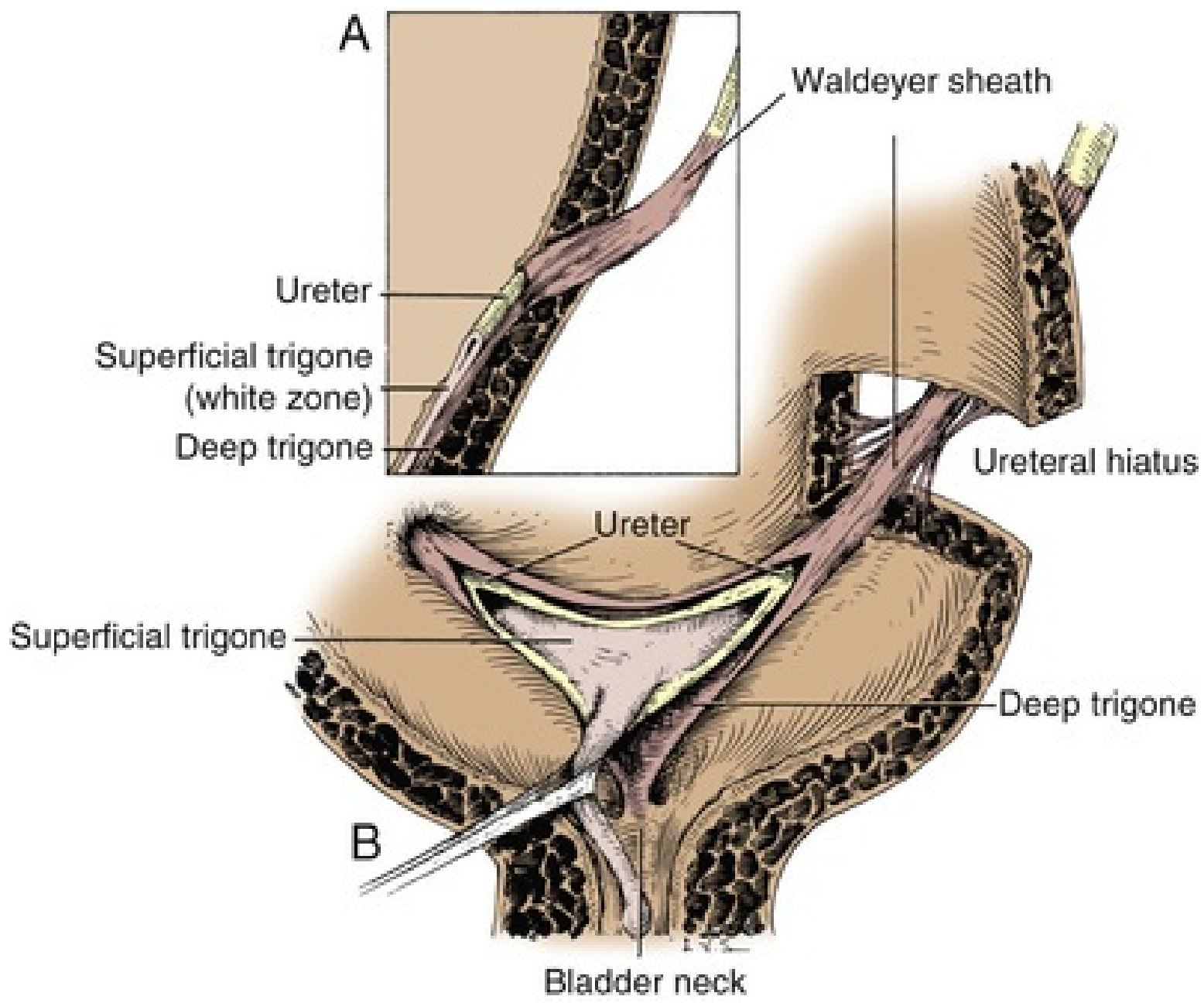

FIG. 109.18 Normal ureterovesical junction and trigone. (A) Section of the bladder wall perpendicular to the ureteral hiatus shows the oblique passage of the ureter through the detrusor and also shows the submucosal ureter with its detrusor backing. Waldeyer sheath surrounds the prevesical

ureter and extends inward to become the deep trigone. (B) Waldeyer sheath continues in the bladder as the deep trigone, which is fixed at the bladder neck. Smooth muscle of the ureter forms the superficial trigone and is anchored at the verumontanum. (From Tanagho EA, Pugh RCB: The anatomy and function of the ureterovesical junction. *Br J Urol* 35:151–165, 1963.)

Blood Supply and Lymphatic Drainage of the Bladder

In addition to the vesical branches, there are multiple other branches arising from the hypogastric artery that contribute to the vascular pedicles of the bladder, which can be found posterior and lateral to the bladder. The veins form a plexus within these pedicles and drain to the internal iliac vein. There are some lymph nodes in the perivesical space, but the lymphatics from the bladder start in the lamina propria layer and then drain largely to the external iliac lymph nodes, with some drainage to the internal iliac and obturator lymph nodes as well. **There is significant cross-drainage of lymphatics from the bladder, with drainage to both sides of the pelvis.**

Innervation of the Bladder

Efferent fibers come from the anterior portion of the pelvic plexus**. The bladder has a high density of parasympathetic cholinergic nerve endings, with relatively little sympathetic innervation.** There are also nonadrenergic, noncholinergic (NANC) fibers that innervate the bladder and are thought to use purines as neurotransmitters (Yoshida et al., 2001). Although their contribution to normal bladder contraction is relatively small, in pathological situations these receptors may be pharmacologic targets for intervention. The bladder neck has dense α1-receptors in males, enabling closure of the bladder neck for antegrade ejaculation and aiding continence. Nitric oxide synthase containing neurons can also be found in the bladder neck and trigone, which may promote relaxation during micturition. The afferent nerves from the bladder travel with the hypogastric plexus to reach the dorsal root ganglia in the spine.

Pelvic Ureter

The pelvic ureter begins as it crosses the common iliac artery. The proximity of the pelvic ureter to the iliac vessels results in a relative narrowing that can obstruct stone passage. The pelvic ureter can also become obstructed by extrinsic compression, such as by the gravid uterus or pathologically enlarged iliac lymphadenopathy. The structure of the ureter is reviewed in detail in Chapter 84. **After crossing the iliac vessels, the ureters travel laterally toward the pelvic side walls and then beneath the umbilical artery branch of the internal iliac artery. Then they turn medially behind the vas deferens to insert into the bladder.** The pelvic ureter is a retroperitoneal structure, although its peristalsis can be seen through the peritoneum in thin patients, particularly at the level of the iliac vessels.

The blood supply to the pelvic ureter derives from the common iliac artery, and multiple branches from the internal iliac artery (see Table 109.2), which enter the ureter laterally. Leaving the lateral attachments when dissecting around the ureter prevents devascularization. There are intramural blood vessels in the adventitia of the ureter that allow for circumferential dissection if needed. However, the quality of the blood supply is variable, and the ureter can be prone to stricture formation after circumferential dissection or ligation. The lymphatics of the ureter drain to the common, external, and internal iliac lymph nodes.

Key Points: Pelvic Viscera

- The rectum is separated from the bladder by a fascial layer (Denonvillier).
- The bladder is mostly extraperitoneal except for the dome.
- The anterior extraperitoneal space (Retzius) is an access point to the bladder and prostate.
- The ureters are anchored to the strong muscular backing of the trigone, which prevents reflux of urine.

Endoscopic Anatomy

The male bladder and urethra are easily visualized endoscopically in awake patients with local analgesia. Flexible fiberoptic cystoscopes enable complete visualization of the bladder, including the ureteral orifices and trigone, which can identify sources of hematuria and localize bladder tumors. At the bladder neck, retroflexion of the cytoscope can be performed to assess for intravesical protrusion of the prostate and to more readily identify small bladder tumors that lie just inside the bladder neck (Fig. 109.19A). The prostatic urethra can be visualized with the verumonatum located posteriorly and the ejaculatory ducts at the top (Fig. 109.19B). Withdrawing the cystoscope distally reveals the bulbar urethra, with coaptation of the extrinsic urethral sphincter evident just beyond the verumontanum (Fig. 109.19C). This anatomic landmark is important during transurethral resection of the prostate for benign prostatic enlargement, because deep resection in this area can damage the sphincter and result in incontinence.

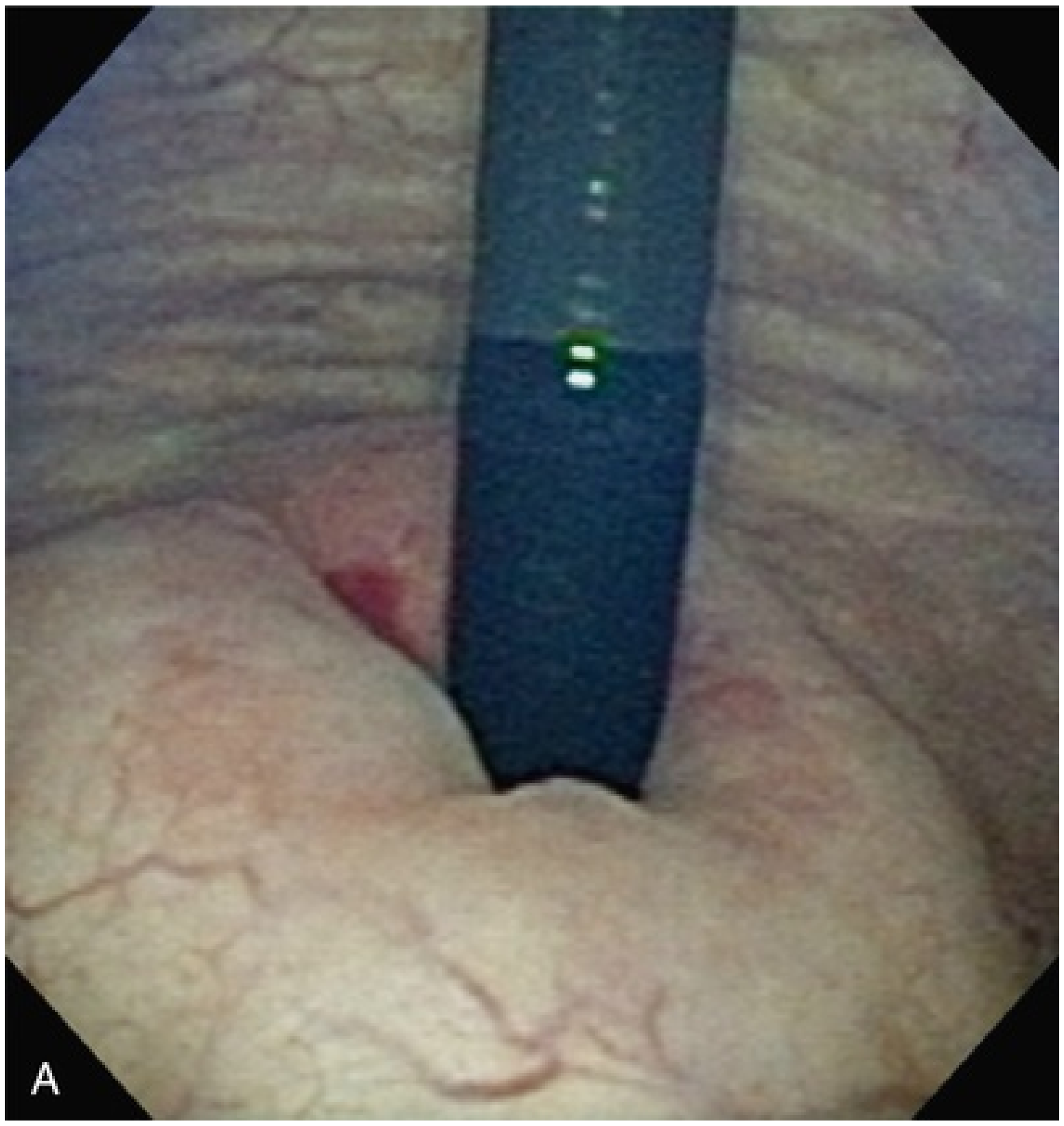

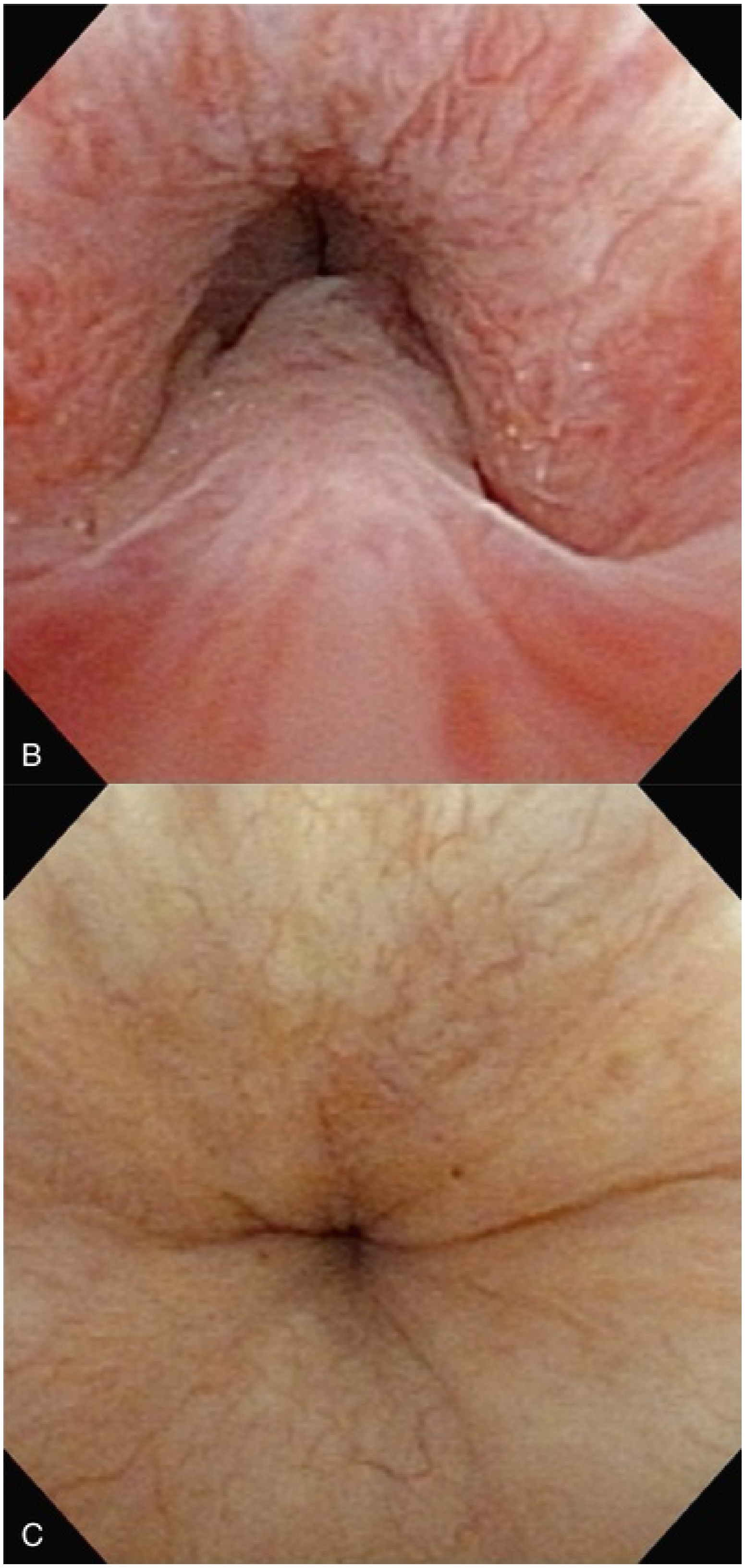

FIG. 109.19 Endoscopic view of (A) bladder neck with intravesical protrusion of prostate, (B) prostatic urethra with verumontanum, and (C) urethra showing good coaptation of the sphincter.

Radiographic Anatomy

Pelvic Radiographs and Fluoroscopy

Although pelvic radiographs and fluoroscopy show pelvic bony landmarks with high resolution and detail, the individual pelvic organs are generally poorly depicted by x-rays because of their similar densities. The bladder, for instance, can sometimes be seen when at least partially full as a faint line and rounded density in the middle of the pelvic ring, superior to the pubic symphysis. The rectum and sigmoid may be visualized and their size and location inferred by identification of gas bubbles or stool within the lumen outlining the wall. Calcifications are well seen in the pelvis, and the phlebolith (a calcification within a pelvic vein lumen) is essentially a normal finding, seen in up to 44% of pelvic x-rays (Mattsson, 1980). They have no clinical relevance but are important to recognize as they can mimic a distal ureter or bladder stone.

During fluoroscopic cystograms the empty bladder lies at or just above the pubic symphysis. As the bladder progressively fills with instilled contrast material, the bladder extends superiorly into the false pelvis (see Fig. 109.2B). Generally, the bladder stretches to occupy the lateral and anterior false pelvis extending toward the lateral pelvic sidewalls. Lack of bladder distention laterally may indicate space-occupying pelvic masses or fluid collections, classically resulting from extraperitoneal pelvic hematomas in the setting of pelvic trauma or lymphocele or hematoma after radical prostatectomy. Upon voiding the posterior urethra should be seen as a well-distended tube resulting from complete relaxation of the involuntary and voluntary urethral sphincter.

The posterior urethra is best imaged by retrograde urethrogram optimally performed in the oblique position. The posterior urethra comprises the membranous urethra, which passes through the urogenital diaphragm, and the prostatic urethra, extending from bladder base to the urogenital diaphragm. The membranous segment is the shortest segment and can be identified by its relationship just proximal to the cone of the bulbous urethra. The membranous segment is the narrowest part of the urethra and should not be mistaken for a stricture. It can be difficult to opacify the membranous and prostatic urethra with contrast because of voluntary external urethral sphincter contraction, but it is usually accomplished with steady injection pressure. The prostatic urethra is often tubular or somewhat flattened and is easy to identify because the verumontanum is seen as an oval central filling defect (see Fig. 109.2B). Once the prostatic urethra is opacified, contrast should flow freely into the bladder and show a triangular shape in the decompressed bladder or a vague, diluted pattern in a full bladder. Occasionally normal periurethral glands of Litre and Cowper ducts opacify alongside the posterior urethra, and these should not be mistaken for injuries or fistulae.

Computed Tomography

Modern computed tomography (CT) scans are acquired as a volumetric data set and can be reconstructed in any plane for viewing, although most commonly they are viewed in the axial, coronal, and sagittal planes. The inherent high spatial resolution of CT shows, in high anatomic detail, the pelvic organs and their relationships and allows for detection of various pathological conditions. Compared with magnetic resonance imaging (MRI), CT has a relatively low contrast resolution because most soft tissue organs and muscles are similar in density and consequently attenuate the x-ray beam similarly. Therefore most CT scans require injection of intravenous contrast to raise the attenuation of the organs to accentuate soft tissue contrast. The general exception to this rule is in imaging urolithiasis, in which intravenous contrast is unnecessary because the stones attenuate the x-ray beam strongly, resulting in high-contrast differences compared with the soft tissues. In the male, pelvis CT is primarily used for evaluating pain, infectious disease, stone disease, and postoperative complications and staging known malignancy. Detection of primary urologic malignancy is limited with most urologic tumors only seen at advanced local stage.

An important understanding of the peritoneal and extraperitoneal spaces is required to understand surgical anatomy, patterns of disease spread, and differential diagnosis of lesions. The abdominal wall peritoneum reflects over the dome of the bladder, and much of the bladder is surrounded by extraperitoneal spaces. The space of Retzius is seen at CT anterior to the bladder and communicates with lateral perivesicular spaces, both of which contain fat and vessels. Leaked urine accumulates in these spaces in the setting of extraperitoneal bladder rupture, and advanced bladder cancer may infiltrate these spaces. The peritoneum continues from the dome of the bladder into the retrovesical space as a pelvic peritoneal reflection of variable depth between the bladder and rectum. The retrovesical space is a common site of fluid accumulation or postoperative abscess formation because it is the most dependent portion of the peritoneum.

Lymph node evaluation is an important role of CT in patients with urologic malignancy. **Lymph nodes are well visualized by CT because of its spatial resolution. Normal lymph nodes appear as smooth, oval or elongated, homogenous soft-tissue density and may show fat density in the hilum where the vessels traverse.** Pelvic lymph nodes are found in specific locations adjacent to the major pelvic arterial divisions and are identified by named groups (Fig. 109.20). Size is the most commonly used criteria for abnormal lymph nodes with generally the highest specificity obtained at least 1 cm short axis. However, morphology is another criterion by which nodal metastasis can be assessed. Malignant nodes generally are rounded, heterogeneous, or hypervascular. Irregular and lobulated borders may be seen when there is extranodal extension of tumor.

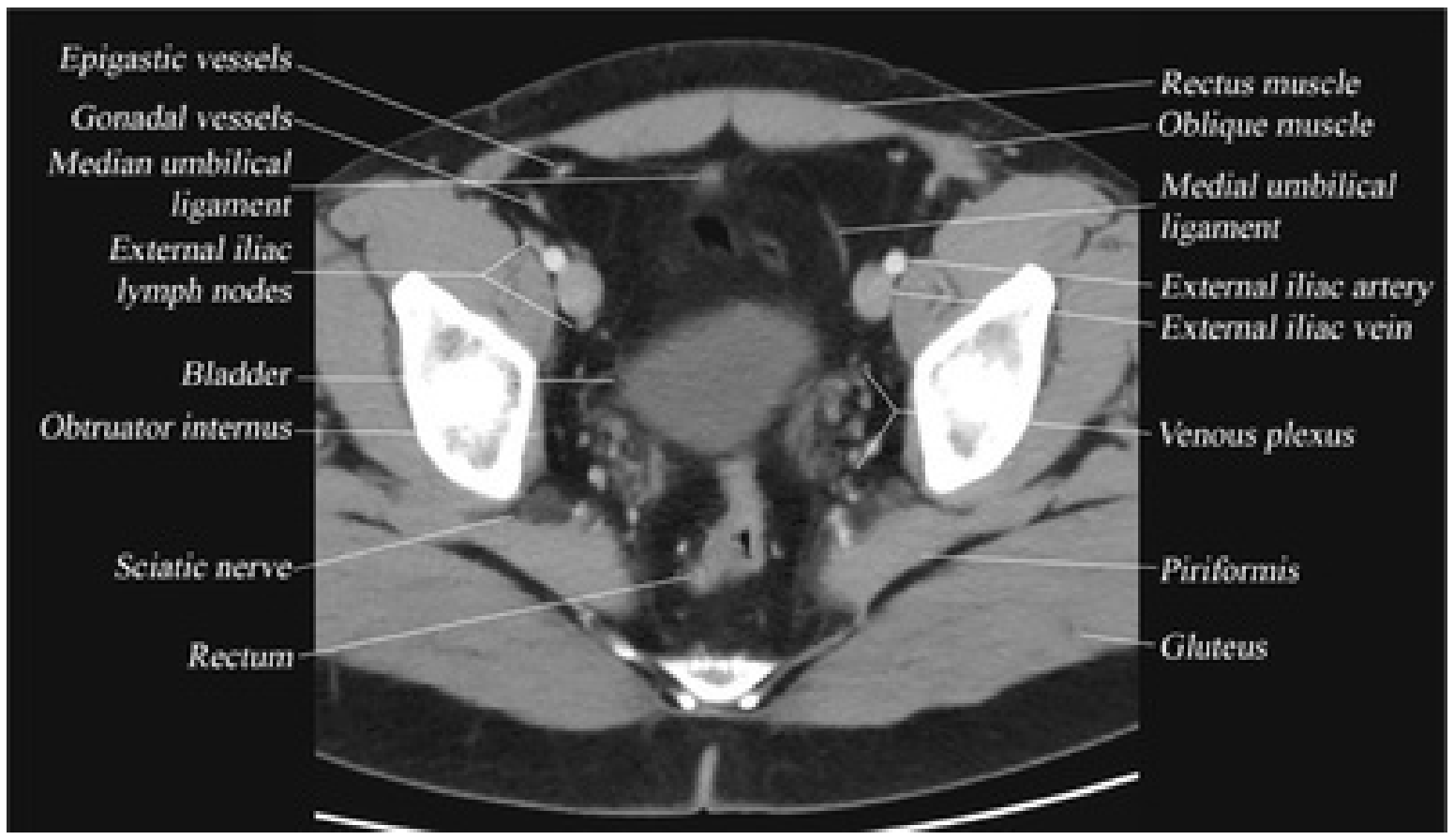
Epigastric vessels
Gonadal vessels
Median umbilical ligament
External iliac lymph nodes
Bladder
Obturator internus
Sciatic nerve
Rectum
Rectus muscle
Oblique muscle
Medial umbilical ligament
External iliac artery
External iliac vein
Venous plexus
Piriformis
Gluteus

FIG. 109.20 Axial contrast-enhanced CT through the mid-pelvis showing organ, vascular, lymph node, and muscle anatomy.

Contrast-enhanced CT can be performed as a multiphasic examination taking advantage of physiologic intravenous contrast dynamics. Because iodinated contrast is excreted almost exclusively through the kidneys, delayed imaging in the pelvis can be performed to show the ureters and bladder. These structures are filled with contrast typically at 7 to 10 minutes after injection, allowing for better visualization of the ureter course and wall, the bladder wall, and contents. Typically, this is accomplished with a CT urogram protocol, which allows for evaluation of the entire collecting system in one exam. The pelvic ureter is identified entering the pelvis as it crosses anteriorly and obliquely to the common or external iliac artery near the bifurcation (Fig. 109.21). A physiologic narrowing on CT urogram or pyelography can be seen at this point resulting from the vascular compression and turn as it passes over the pelvic brim. Further, it is not uncommon to identify undulations in the ureter diameter throughout its length resulting from normal peristaltic activity. Likewise, some segments of ureter may be unopacified with contrast because of peristalsis, and this should not be confused with disease. Continuing into the pelvis the ureter courses laterally along the pelvic sidewall and then takes an abrupt medial and anterior turn to enter the bladder at the ureterovesical junction (UVJ). On noncontrast axial images with thin-slice, modern CT, the ureter can almost always be followed along its entire course from the ureteropelvic junction (UPJ) to the bladder. Occasionally pelvic veins and other small structures can mimic the ureter, but if they are followed on subsequent slices, they will branch, disappear, or follow the incorrect anatomic course, unlike the ureter.

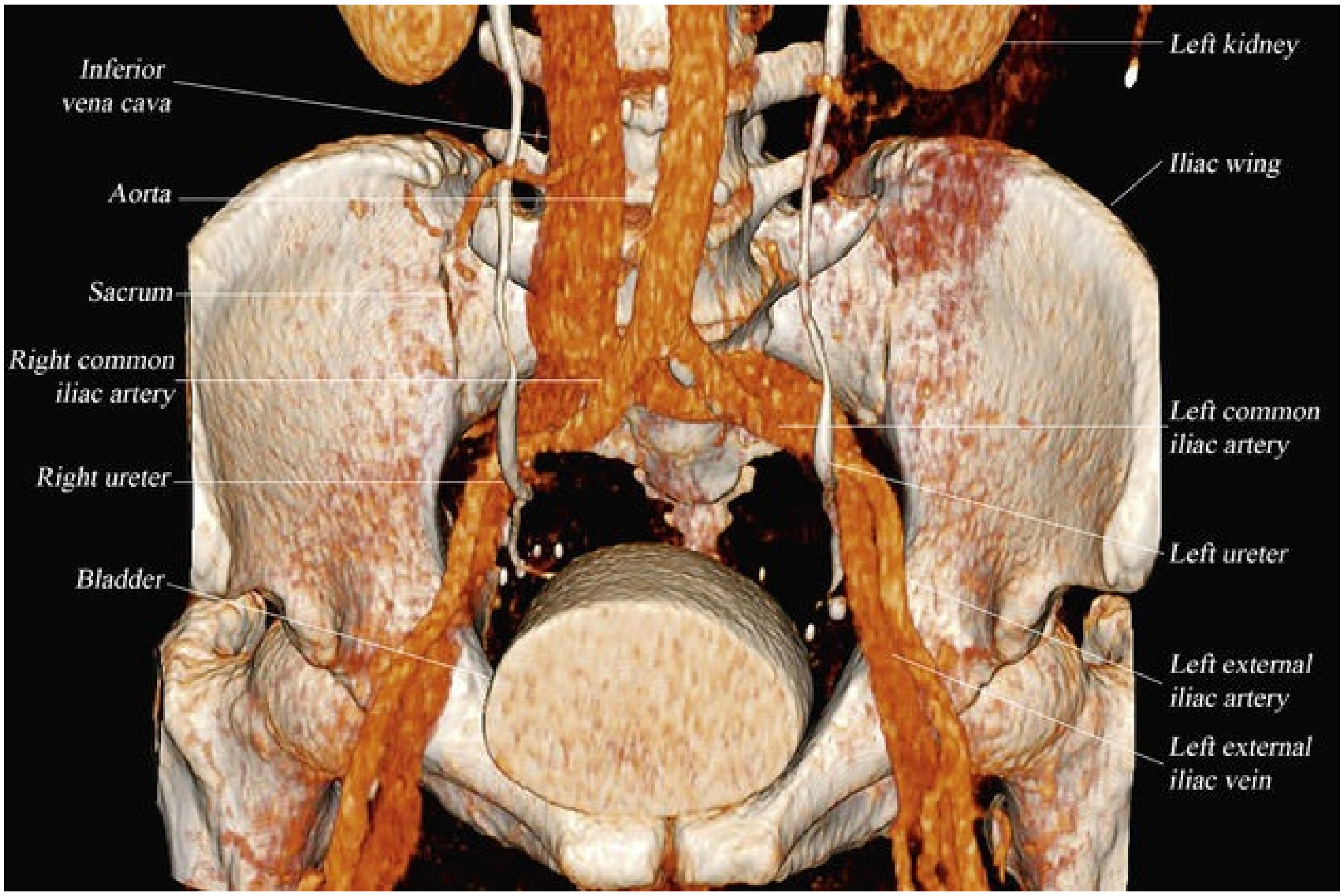
Inferior vena cava
Aorta
Sacrum
Right common iliac artery
Right ureter
Bladder
Left kidney
Iliac wing
Left common iliac artery
Left ureter
Left external iliac artery
Left external iliac vein

FIG. 109.21 Three-dimensional (3D) reformatted anteroposterior (AP) view of the pelvis from a CT urogram showing the ureter relationship to vascular and bony anatomy.

Magnetic Resonance Imaging

Although the resolution of CT and magnetic resonance imaging (MRI) can be similar, MRI shows more detailed muscle and soft-tissue anatomy in the male pelvis because of its higher soft-tissue contrast resolution, compared with CT. The pelvic organs, pelvic floor muscles, intervening fascia, vessels, and nerves are well depicted. Most MRIs are performed in multiple anatomic planes, using a combination of T1- and T2-weighted images with and without fat saturation pulses applied. **In general, T1-weighted images are best for evaluating osseous structures and muscles and to show post-contrast enhancement;** gadolinium contrast agents affect T1-weighted images much more than T2. T2-weighted images show detailed organ anatomy and muscles and are very sensitive to fluid, thereby showing edema, inflammation, and fluid collections well. In general, MRI images are best interpreted as a set, integrating the appearance of a lesion or organ across multiple T1 and T2 and post-contrast sequence types.

At pelvic MRI, the bladder is typically filled with urine, which is T2 hyperintense, whereas the wall is T2 dark. The bladder wall changes in thickness depending on the degree of distention. Generally, a normal, well-distended bladder has a wall thickness of less than 3 mm, whereas greater than 3 mm represents nonspecific pathologic thickening. The urethra can generally be followed throughout the course of the prostate gland, best identified on axial and sagittal images, usually traversing the midline posterior one-third of the gland (Fig. 109.22). In the mid-prostatic urethra the verumontanum is seen on axial images as a focal triangular or rounded bulge or filling defect within lumen (Fig. 109.23). This is the site where the ejaculatory ducts empty into the urethra, although generally the ducts are diminutive and cannot be seen by MRI in this location. The prostatic ducts, which empty throughout the urethra, are also not seen by MRI. The external urethral sphincter within the urogenital diaphragm lies just inferior to the apex of the prostate and is seen on axial images as a T2 dark donut-shaped structure of variable thickness (Fig. 109.24). Cowper glands within the urogenital diaphragm are normally not visualized unless enlarged or cystic.

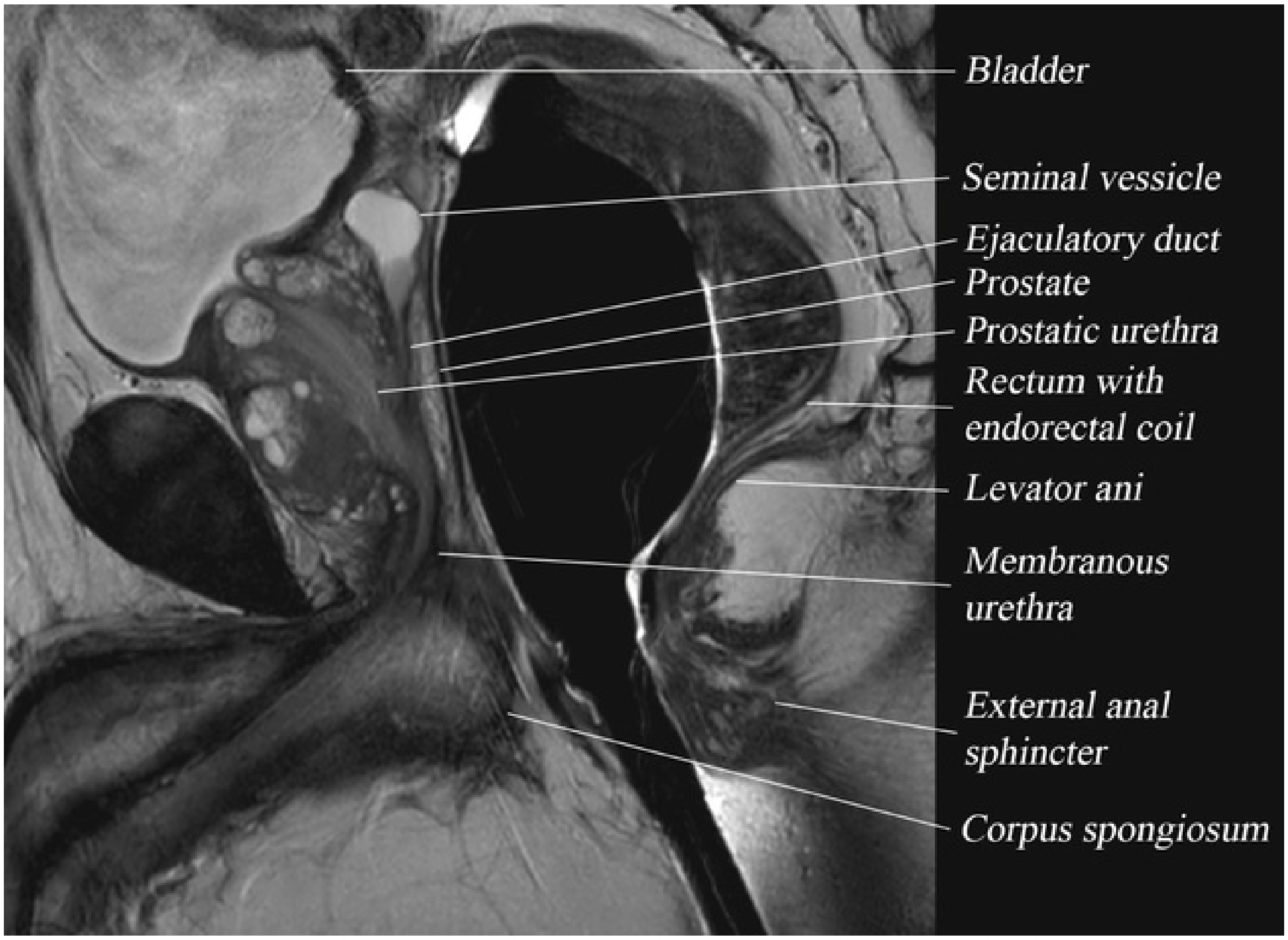
Bladder
Seminal vessicle
Ejaculatory duct
Prostate
Prostatic urethra
Rectum with
endorectal coil
Levator ani
Membranous
urethra
External anal
sphincter
Corpus spongiosum

FIG. 109.22 Sagittal T2-weighted MRI through the midline pelvis shows organ and urethral anatomy.

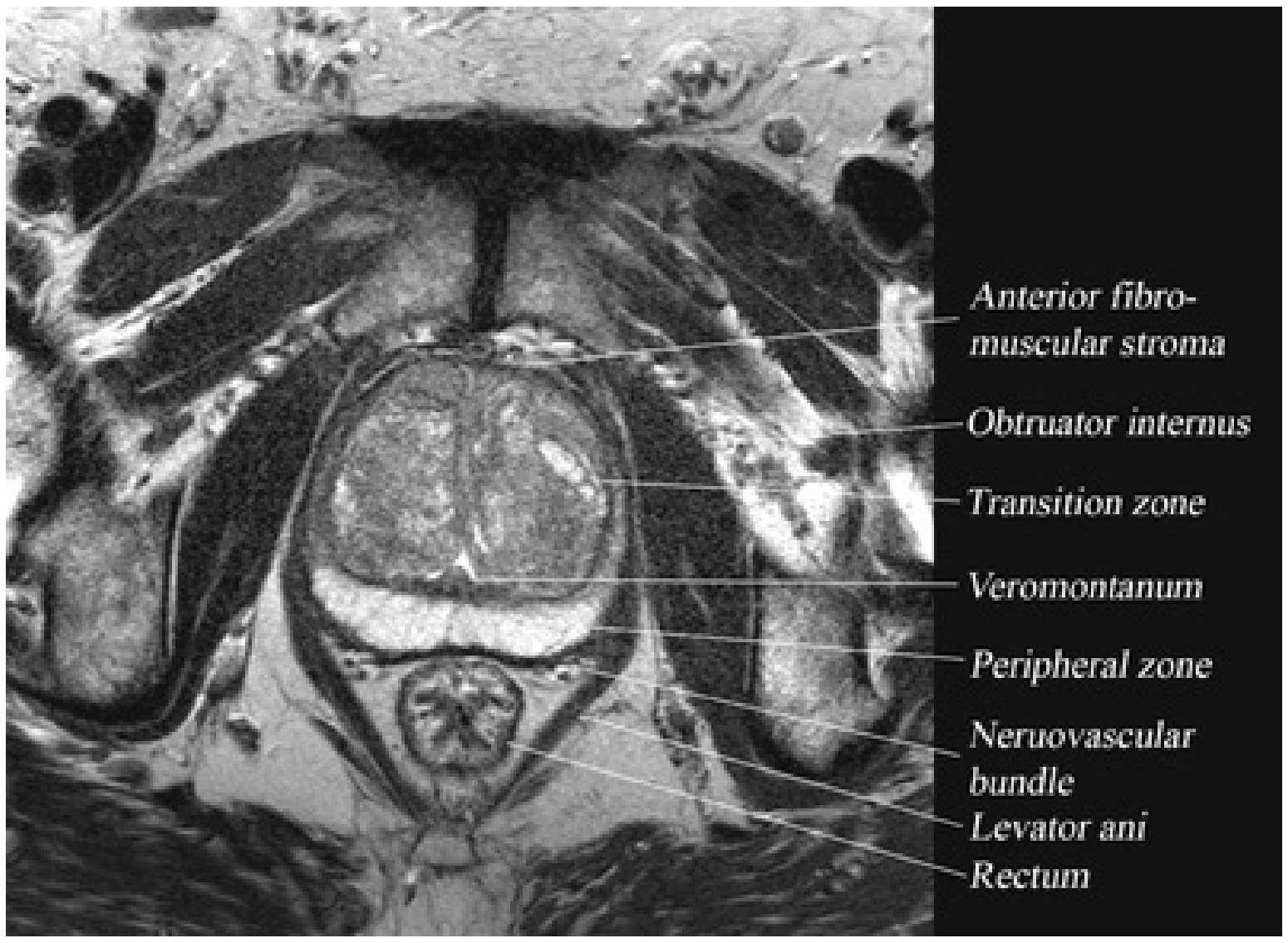
Anterior fibro-
muscular stroma
Obtruator internus
Transition zone
Veromontanum
Peripheral zone
Neruovascular
bundle
Levator ani
Rectum

FIG. 109.23 Axial T2-weighted MRI through the mid-prostate shows zonal prostate anatomy.

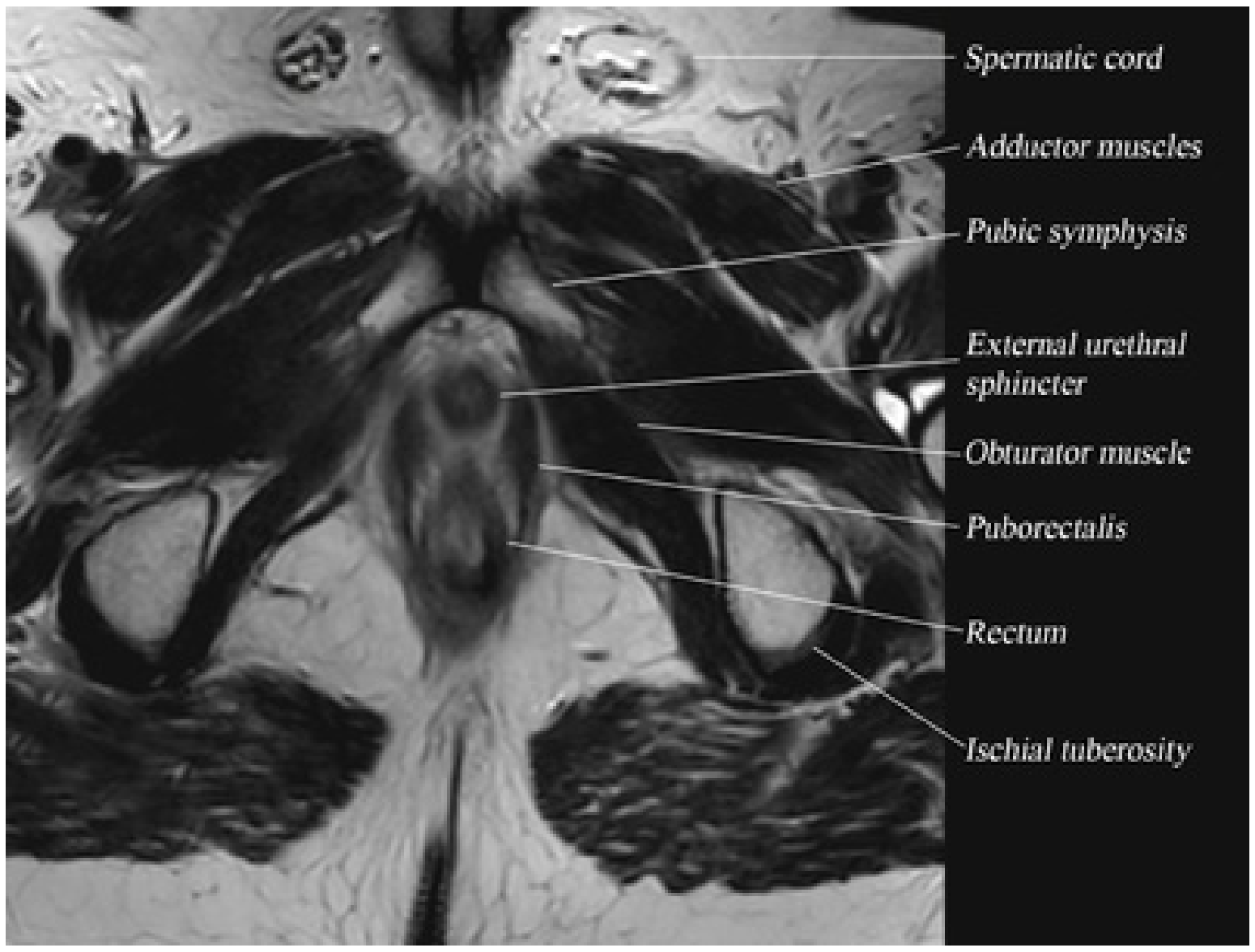

FIG. 109.24 Axial T2-weighted MRI through the pelvic floor shows the relationship of pelvic floor muscle and organ anatomy.

T2-weighted MRIs afford the best anatomic imaging assessment of the prostate gland, seminal vesicles, and supporting structures.

The pelvic organs are supported by the pelvic floor, a broad shelf or muscular plate comprising the levator ani complex, which is made up of three main muscles: puborectalis, pubococcygeus, and iliococcygeus. Puborectalis is a U-shaped muscle, best seen on axial images immediately superior to the external anal sphincter, passing from the inferoposterior aspect of the pubic bone, posteriorly, forming a sling around the anorectal junction (see Fig. 109.24). The muscle is important in the maintenance of voluntary urinary and fecal continence, and its function can be assessed at dynamic pelvic floor MRI. The pubococcygeus and iliococcygeus are thin, broad muscles extending from the pubic bone and lateral pelvic walls posteriorly to the coccyx, best seen on coronal images. Generally, they can be traced on MRI, but the individual fibers and insertions on pelvic organs are poorly depicted because of their small size. The pelvic organs are surrounded by endopelvic fascia, which also acts to support the organs. Endopelvic fascia generally appears as fat intensity on T1 or T2 images, and faint strands can be seen within representing connective tissue.

Below the pelvic floor, posteriorly, the internal and external anal sphincters are seen as separate structures at T2-weighted imaging, because the thick, donut-shaped smooth muscle fibers of the internal sphincter are more hyperintense compared with the thin, more vertically oriented external sphincter fibers (Fig. 109.25). Anteriorly below the urogenital diaphragm or triangle, the base of the penis is seen with the corpus cavernosa bodies appearing as T2-bright, almost fluid intensity structures because of their vascular contents. The midline corpus spongiosum appears similar, and generally the bulbous urethra wall can be seen as a faint T2-dark outline within. Thin, linear T2-dark fibers of the ischiocavernosus and bulbospongiosus muscles are seen adjacent to the corpus cavernosum and spongiosum, respectively (see Fig. 109.25).

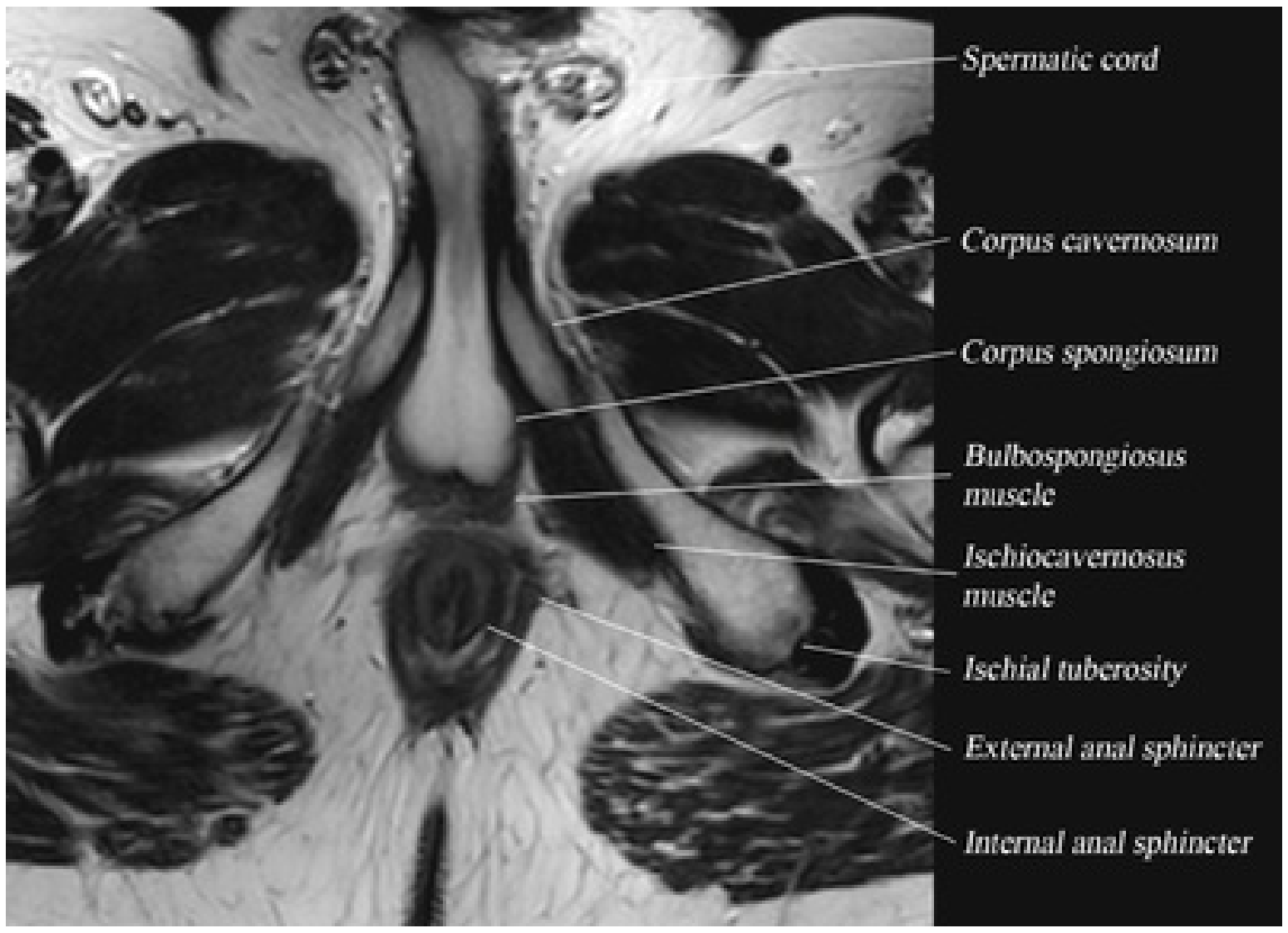
Spermatic cord
Corpus cavernosum
Corpus spongiosum
Bulbospongiosus muscle
Ischiocavernosus muscle
Ischial tuberosity
External anal sphincter
Internal anal sphincter

FIG. 109.25 Axial T2-weighted MRI through the perineum, below the pelvic floor, shows relationship of the base of the penis to muscle and the anal sphincter.

Key Points: Radiographic Imaging of the Pelvis

- Radiographs provide high-resolution images of the bony pelvis.
- The urethra is best imaged by fluoroscopy.
- CT is better for urolithiasis, lymph nodes, and the urinary system.
- MRI has better soft-tissue resolution for the prostate and pelvic floor.

References

Begg RC. The urachus: its anatomy, histology and development. *J Anat*. 1930;64:170–183.

Breza J, Aboseif SR, Ovis BR, et al. Detailed anatomy of penile neurovascular structures: surgical significance. *J Urol*. 1989;141:437–443.

Brooks JD, Chao W-M, Kerr J. Male pelvic anatomy reconstructed from the visible human data set. *J Urol*. 1998;159:868–872.

Brooks JD, Eggener SE, Chow W-M. Anatomy of the male rectourethralis muscle. *Eur Urol*. 2002;41:94–100.

Burnett AL. Nitric oxide control of lower genitourinary tract functions: a review. *Urology*. 1995;45:1071–1083.

Catalona WJ. Modified inguinal lymphadenectomy for carcinoma of the penis with preservation of the saphenous veins: technique and preliminary results. *J Urol*. 1988;140:306–310.

DeCaro R, Aragona F, Herms A, et al. Morphometric analysis of the fibroadipose tissue of the female pelvis. *J Urol*. 1998;160:707–713.

DeLancey JOL. The pubovesical ligament: a separate structure from the urethral supports (“pubo-urethral ligaments”). *Neurourol Urodyn*. 1989;8:53–62.

Golimbu M, Al-Askari S, Morales P. Transpubic approach for lower urinary tract surgery: a 15-year experience. *J Urol*. 1990;143:72–76.

Gosling JA, Dixon JS, Critchley HOD, et al. A comparative study of human external sphincter and periurethral levator ani muscles. *Br J Urol*. 1981;53:35–41.

Hinman F Jr. *Atlas of urosurgical anatomy*. Saunders: Philadelphia; 1993.

Hutch JA, Ayers RD, Loquvam GS. The bladder musculature with special reference to the ureterovesical junction. *J Urol*. 1961;85:531–539.

Lawson JON. Pelvic anatomy: pelvic floor muscles. *Ann R Coll Surg Engl*. 1974;54:244–252.

Lepor H, Gregerman M, Crosby R, et al. Precise localization of the autonomic nerves from the pelvic plexus to the corpora cavernosa: a detailed anatomical study of the adult male pelvis. *J Urol*. 1985;133:207–212.

Lue TF, Zeineh SJ, Schmidt RA, et al. Neuroanatomy of penile erection: its relevance to iatrogenic impotence. *J Urol*. 1984;131:273–280.

Mattsson T. Frequency and location of pelvic phleboliths. *Clin Radiol*. 1980;31(1):115–118 https://doi.org/10.1016/S0009-9260(80)80095-X.

Myers RP, Cahill DR, Devine RM, et al. Anatomy of radical prostatectomy as defined by magnetic resonance imaging. *J Urol*. 1998;159:2148–2158.

Netter F. *Atlas of human anatomy*. ed 6. Elsevier: Philadelphia.; 2014.

Reiner WG, Walsh PC. An anatomical approach to the surgical management of the dorsal vein and Santorini's plexus during radical retropubic surgery. *J Urol*. 1979;121:198–200.

Schlegel PN, Walsh PC. Neuroanatomical approach to radical cystoprostatectomy with preservation of sexual function. *J Urol*. 1987;138:1402–1406.

Shafik A. A study of the arterial pattern of the normal ureter. *J Urol*. 1972;107:720–722.

Tanagho EA. Anatomy of the lower urinary tract. Walsh PC, Retik AB, Stamey TA, et al. *Campbell's urology*. ed 6. Saunders: Philadelphia; 1992:40–69.

Thomson AS, Dabhoiwala NF, Verbeek FJ, et al. The functional anatomy of the ureterovesical junction. *Br J Urol*.

1994;73:284–291.
Uhlenhuth E. *Problems in the anatomy of the pelvis*. JB Lippincott: Philadelphia; 1953.
Walsh PC, Donker PJ. Impotence following radical prostatectomy: insight into etiology and prevention. *J Urol*. 1982;128:492–497.
Walsh PC, Lepor H, Eggleston JC. Radical prostatectomy with preservation of sexual function: anatomical and pathological considerations. *Prostate*. 1983;4:473–485.
Waterhouse K, Abrahams JI, Gruber H, et al. The transpubic approach to the urinary tract. *J Urol*. 1973;109:486–490.
Yoshida M, Homma Y, Inadome A, et al. Age-related changes in cholinergic and purinergic neurotransmission in human isolated bladder smooth muscles. *Exp Gerontol*. 2001;39:99.
Zvara P, Carrier S, Kour N-W, et al. The detailed neuroanatomy of the human striated urethral sphincter. *Br J Urol*. 1994;74:182–187.

Physiology and Pharmacology of the Bladder and Urethra

Toby C. Chai MD, Lori A. Birder PhD

This chapter reviews physiologic mechanisms that regulate lower urinary tract (LUT) function. The LUT is composed of the bladder and urethra, and the two defining functions of the LUT are urinary storage and emptying. Although not the focus of this chapter, another LUT function is protection of the kidneys from ascending pathogenic microorganisms, which involves appropriate functioning of the urothelium and presence of a community of microorganisms (microbiome).

Urinary storage (continence) and urinary emptying (micturition) depend on the integrated function of many components, including the central nervous system (CNS), the peripheral nervous system, bladder smooth muscle, bladder stroma, suburothelial and intradetrusor interstitial cells, bladder urothelium, urethral smooth muscle, pelvic floor striated muscles, and the external urethral sphincter (EUS). An understanding of LUT physiology is essential for management of lower urinary tract dysfunction (LUTD), such as urinary incontinence, lower urinary tract symptoms (LUTS), overactive bladder (OAB), nocturia, neurogenic bladder, and underactive bladder. Improvements in physiologic understanding will improve diagnostic and phenotyping abilities and help discover the next generation of LUTD treatments.

Laboratory investigations into LUT physiology have used animal models, and most of the data discussed in this chapter are from animal studies. This is reasonable because interventions or experiments in human subjects are limited. **However, several reasons may mitigate the relevance of animal findings to humans.** The first consideration is use of lower-order mammals (i.e., mice and rats) as a model for human LUT function. Rodents are nocturnally active and their circadian rhythm is opposite of humans. Micturition is a behavior in which some animals mark their territory, a conduct that does not apply to humans. Whereas the clinical management of LUTS is almost entirely symptom based, LUTS are difficult (if not impossible) to quantify in animals, so surrogate parameters (such as micturition frequency and volume, urodynamics) that may not relate to symptoms have been used. Another consideration is whether research data were obtained from anesthetized or awake animals, because anesthesia can alter continence and micturition reflexes. However, animal models, no matter the potential drawbacks, will always be needed to improve our understanding of human LUTS. Novel findings can arise from findings in animal models (Gillespie, 2005). However, the importance of translational research, which seeks a bidirectional link between the bedside and bench, whether it is validating animal findings in humans or replicating a human phenotype in animals, is crucial in improving the treatment of LUTD.

The process of control of urinary storage and emptying is classically summarized as a complex of neural circuits in the brain and spinal cord that coordinate the activity of smooth and striated muscles in the bladder and urethra (de Groat and Booth, 1993; de Groat et al., 1993; Torrens and Morrison, 1987; Yoshimura and de Groat, 1997). These neural circuits act as switches that enable the bladder to alternate between urinary storage and elimination. Although this concept is important, translating physiologic understanding of LUT function into improved care for LUTD should be the ultimate goal. Furthermore, LUTD may not always arise from primary defects in nerves and/or muscles. Other biologic mechanisms can adversely affect LUT function, such as endocrine dysregulation (e.g., metabolic syndrome and obesity), inflammation (e.g., urothelial response to microorganisms), bladder or urethral fibrosis, and ischemia. Therefore LUTD can be a manifestation of mechanisms arising separately from the LUT.

The mechanisms underlying control of detrusor contractility and LUT sensation remain two major areas that would benefit from continued research because of the potential for clinical impact. Many conditions encountered in LUTD relate to these two parameters. A complexity of normal LUT function is that the bladder and urethra function necessarily in an opposite manner, thus making treatments that target only the bladder or only the urethra potentially ineffective and/or causing them to have unwanted side effects. For example, treatments directed at increasing bladder contractility for detrusor underactivity may not work if the treatments do not concomitantly relax the urethra. On the other hand, an example of how a more complete understanding of a single area can improve storage and emptying disorders is in the area of sensory (afferent) function. Modulation of sensory mechanisms could serve two purposes: reducing afferent signals could help those with LUTS, whereas augmenting afferent signals could help those with detrusor underactivity (Eastham and Gillespie, 2013; Suskind and Smith, 2009). Thus manipulation of the sensory pathway could preserve the requirement of coordinated yet simultaneously opposite bladder and urethral functions.

Although the management of LUTD is primarily symptom based at this time, use of biomarkers may come into play based on better physiologic understanding of the LUT. Ultimately, we should look forward to a time when targeted therapies and even prevention strategies may be incorporated into the management of LUTD patients.

Lower Urinary Tract Anatomy

The bladder can be divided into several parts: a **body** lying above the ureteral orifices and a **base** consisting of the trigone and bladder neck; the two areas are different but homogeneous within themselves regarding neuromorphology and neuropharmacology (el-Badawi and Schenk, 1966). The bladder base has a laminar architecture with a superficial longitudinal layer lying beneath the trigone (Fig. 110.1). A muscle layer deep to the superficial layer is continuous with the detrusor (Dixon and Gosling, 1987; Tanagho, 1982; Zderic and Levin, 1996). The smaller muscle bundles of the deep muscle layer in the bladder base exhibit a predominantly circular orientation. Histology of the full-thickness bladder is shown in Fig. 110.2A. A complete and competent ring of smooth muscle at the male bladder neck has been described (Gosling, 1999). No such collar of muscle is identified in the female. The bladder neck serves an important function in reproduction. **In men, closure of the bladder neck facilitates antegrade ejaculation. This is accompanied through a rich noradrenergic innervation by sympathetic nerves that actively contract the bladder neck during ejaculation. However, in women the density of adrenergic innervation in the bladder neck is reportedly less than that in men** (de Groat and Booth, 1993).

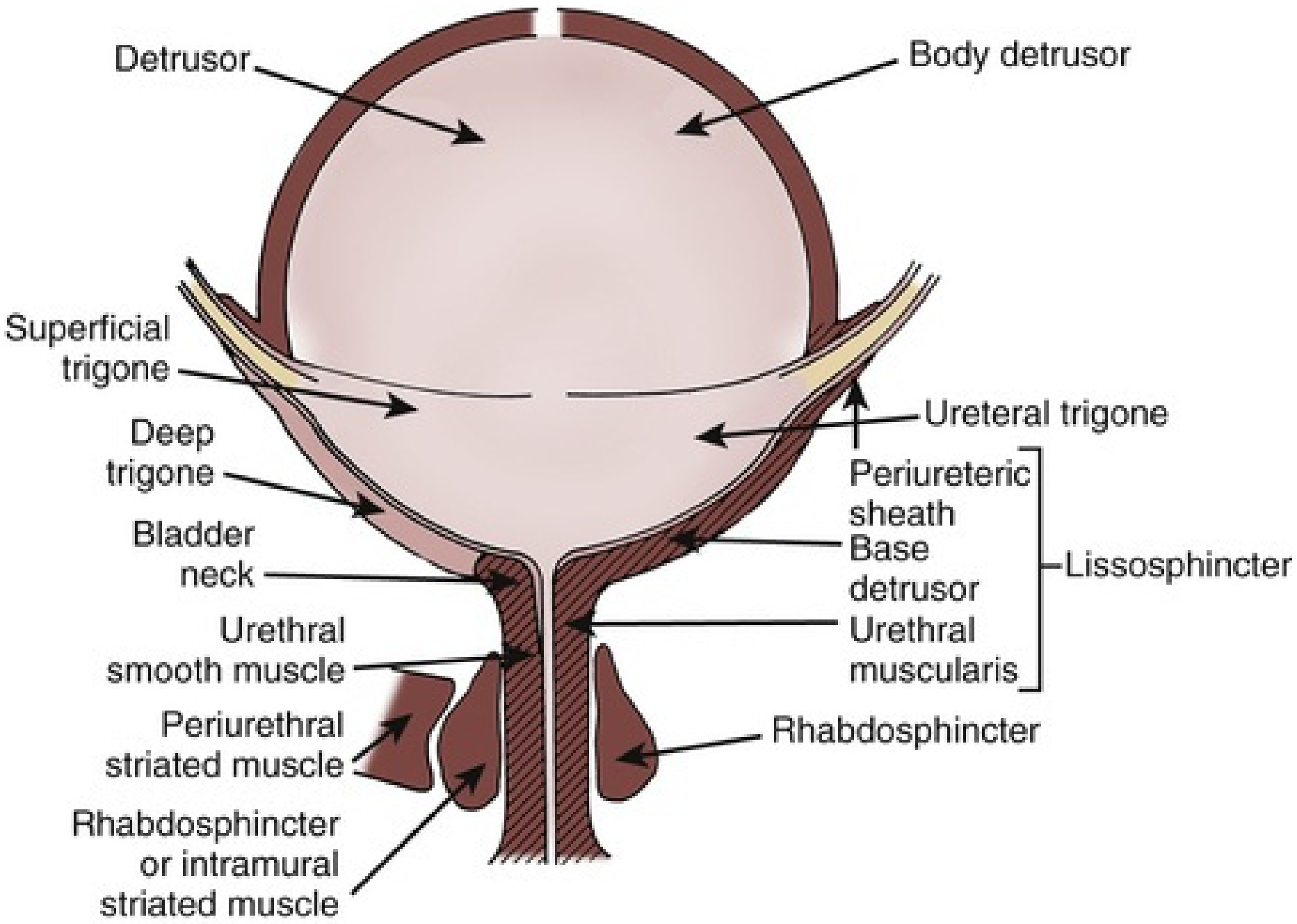
Detrusor
Body detrusor
Superficial trigone
Ureteral trigone
Deep trigone
Periureteric sheath
Base detrusor
Lissosphincter
Bladder neck
Urethral muscularis
Urethral smooth muscle
Rhabdosphincter
Periurethral striated muscle
Rhabdosphincter or intramural striated muscle

FIG. 110.1 Anatomy of the bladder and its outlet, as defined by Gosling and Dixon *(left)* versus Elbadawi et al. *(right).* (From Torrens M, Morrison JF: *The physiology of the urinary bladder,* New York, 1987, Springer-Verlag.)

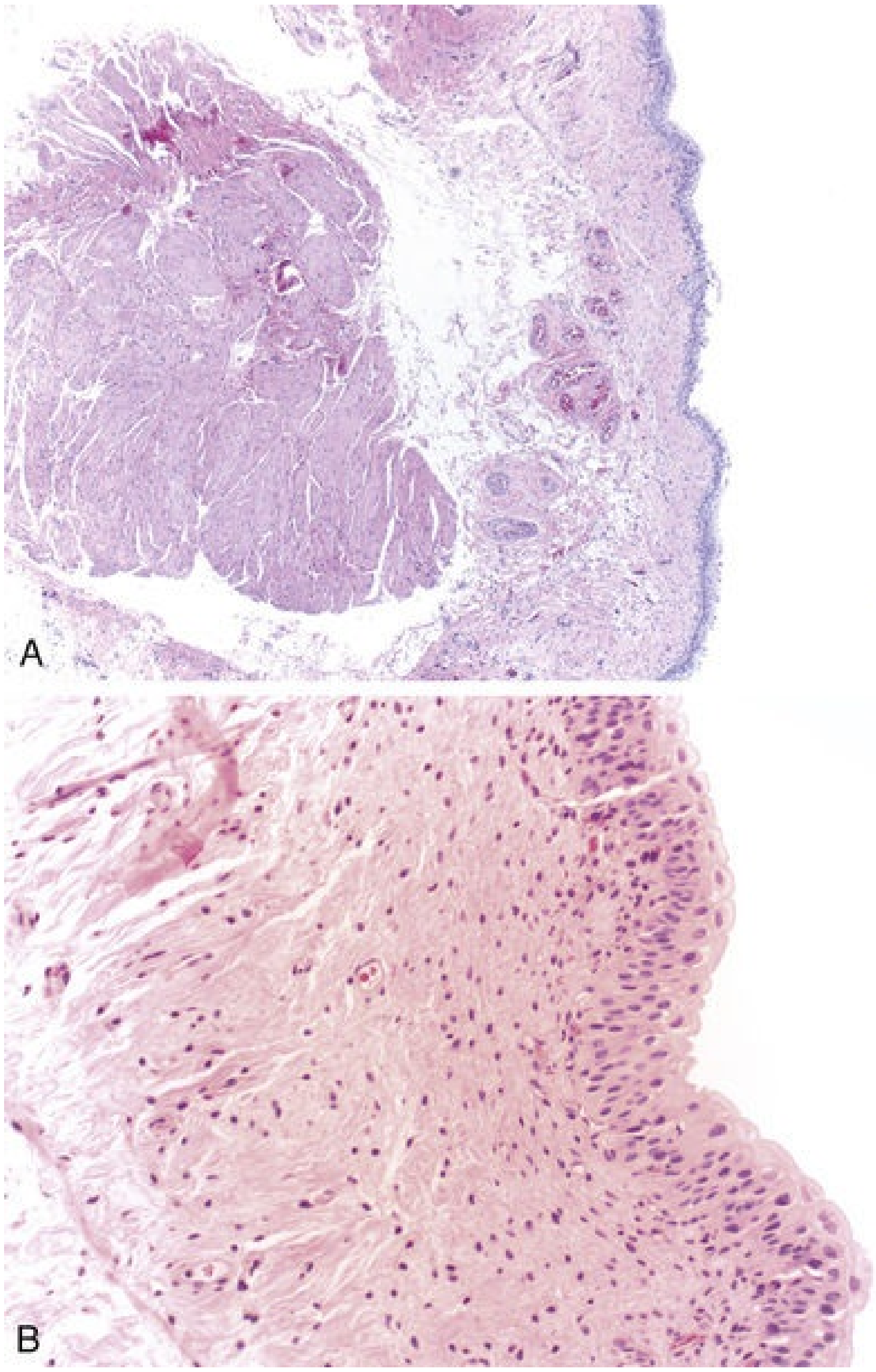

FIG. 110.2 Histologic sections from a human bladder obtained from cystectomy. (A) The entire bladder wall including urothelium, lamina propria, and muscularis propria (40× magnification). (B) The urothelium and lamina propria (200× magnification). (Courtesy Adebowale Adeniran, MD, Yale Department of Pathology.)

The urethra is part of the bladder outlet, along with the pelvic floor musculature. The urethra has components of smooth muscle and striated muscled (rhabdosphincter or EUS) (see Fig. 110.1). The periurethral striated muscle is part of the pelvic floor muscle complex.

Bladder Compartments

Urothelium

The urothelium is a multilayered epithelium with a basal, intermediate, and apical layer of cells. The apical cells (umbrella cells) make up the layer that is in contact with urine and microorganisms. The histology of the polarized urothelium is shown in Fig. 110.2B; the urothelium is about seven layers thick, with the largest cells being the apical (umbrella) cells, which are sometimes multinucleated. Although the anatomy of the urothelium is relatively straightforward, there are several physiologic functions, including barrier function (impermeability) and urothelial-afferent signaling, which are covered in later sections.

A scanning electron microscope (SEM) image of human apical urothelium, viewed from the luminal surface, is shown in Fig. 110.3. The SEM image was obtained from a biopsy forceps cystoscopic biopsy. Note the hexagonal shape of the apical urothelial cells and the microvilli on the surface. The apical cells are also unique in their expression of an assembly of a specialized class of proteins called *uroplakins*. The uroplakins are assembled within the apical membrane of the apical urothelial cells within specialized areas called *plaques*. The plaques have a membrane outer leaflet that is thicker than the inner leaflet, resulting in asymmetry. Thus the plaque region is also termed the *asymmetrical unit membrane* (AUM). The areas between the plaques are symmetrical in terms of the outer and inner leaflet thickness; this area is called the *hinge region*. Inside the AUM are chainmail-like ultrastructural hexagonal particles composed of uroplakins (Fig. 110.4). These ultrastructural particles are important in barrier function. The attachment of *Escherichia coli* type 1 fimbriae to uroplakins also initiates the host-pathogen interaction, initiating a cascade of host events (Mulvey et al., 1998; Thumbikat et al., 2009; Wu et al., 1996). More details of barrier function and urothelial-afferent crosstalk of the urothelium is described in later sections.

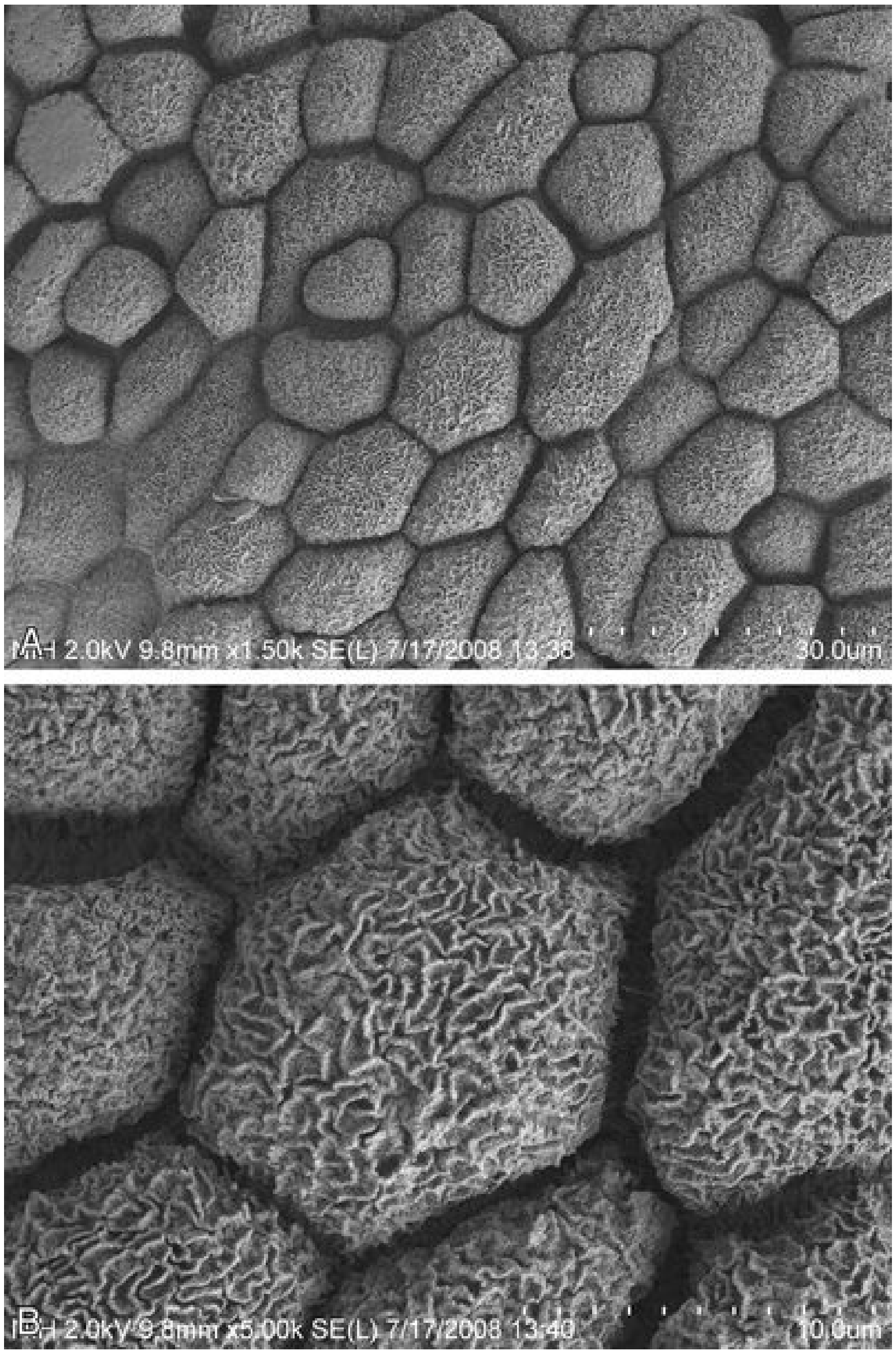
A
MH 2.0kV 9.8mm x1.50k SE(L) 7/17/2008 13:38
30.0um
B
MH 2.0kV 9.8mm x5.00k SE(L) 7/17/2008 13:40
10.0um

FIG. 110.3 Scanning electron microscope image of human apical urothelial cells: (A) 1500× magnification; (B) 5000× magnification.



FIG. 110.4 Hexagonal chainmail-like ultrastructural units composed of uroplakins. *H,* Hinge area; *P,* plaque area. (From Kachar B, Liang F, Lins U, et al.: Three-dimensional analysis of the 16 nm urothelial plaque particle: luminal surface exposure, preferential head-to-head interaction, and hinge formation. *J Mol Biol* 285:595–608, 1999.)

Lamina Propria and Vasculature

The lamina propria has been theorized to be the "functional center" for localized control of the bladder, coordinating the activities of the urothelium and detrusor smooth muscle (Andersson and McCloskey, 2014). Within the lamina propria, there is a diffuse plexus of unmyelinated nerve fibers making contact with urothelium, blood vessels, and detrusor smooth muscle. TRPV1 and $P2X_3$ receptors exist on nerve fibers that traverse the muscularis layer (Yiangou et al., 2001). In addition to the nerve fibers, other important structures in the lamina propria include interstitial cells (myofibroblasts) and microvasculature. The role of suburothelial myofibroblasts in detrusor contractility is discussed in a later section. These myofibroblasts positioned in the lamina propria are primed to modulate physiologic interactions between the urothelium and detrusor smooth muscle.

The anatomy of the microvasculature of the bladder in human and rabbit was studied using corrosion cast studies (Hossler and Monson, 1995; Miodonski and Litwin, 1999). The corrosion technique "fixes" the blood vessels by immediate vascular perfusion of the excised whole bladder with a fixative (e.g., a resin). Then all other tissue components of the bladder (smooth muscle, nerves, urothelium, stromal cells) were chemically digested, leaving only the vascular tree cast, which was imaged with scanning electron microscopy. The human bladder tissue studies showed a large horizontal plexus of blood vessels located in the lamina propria (termed the *mucosal plexus*) and another plexus just under the basal urothelial layer (termed the *subepithelial plexus*). Scanning electron microscopy of the mucosal vascular anatomy is shown in Fig. 110.5A, which shows a dense and rich submucosal plexus of vessels that lie immediately underneath the urothelium, the subepithelial capillary plexus. These are the vessels that would be typically seen during cystoscopy. Fig. 110.5B shows a schematic of what happens to the bladder vasculature during bladder filling and emptying. Blood flow through the subepithelial plexus may also be, in part, regulated by the urothelium. Furthermore, the subepithelial plexus could play a role for substances transported through or secreted by the urothelium.

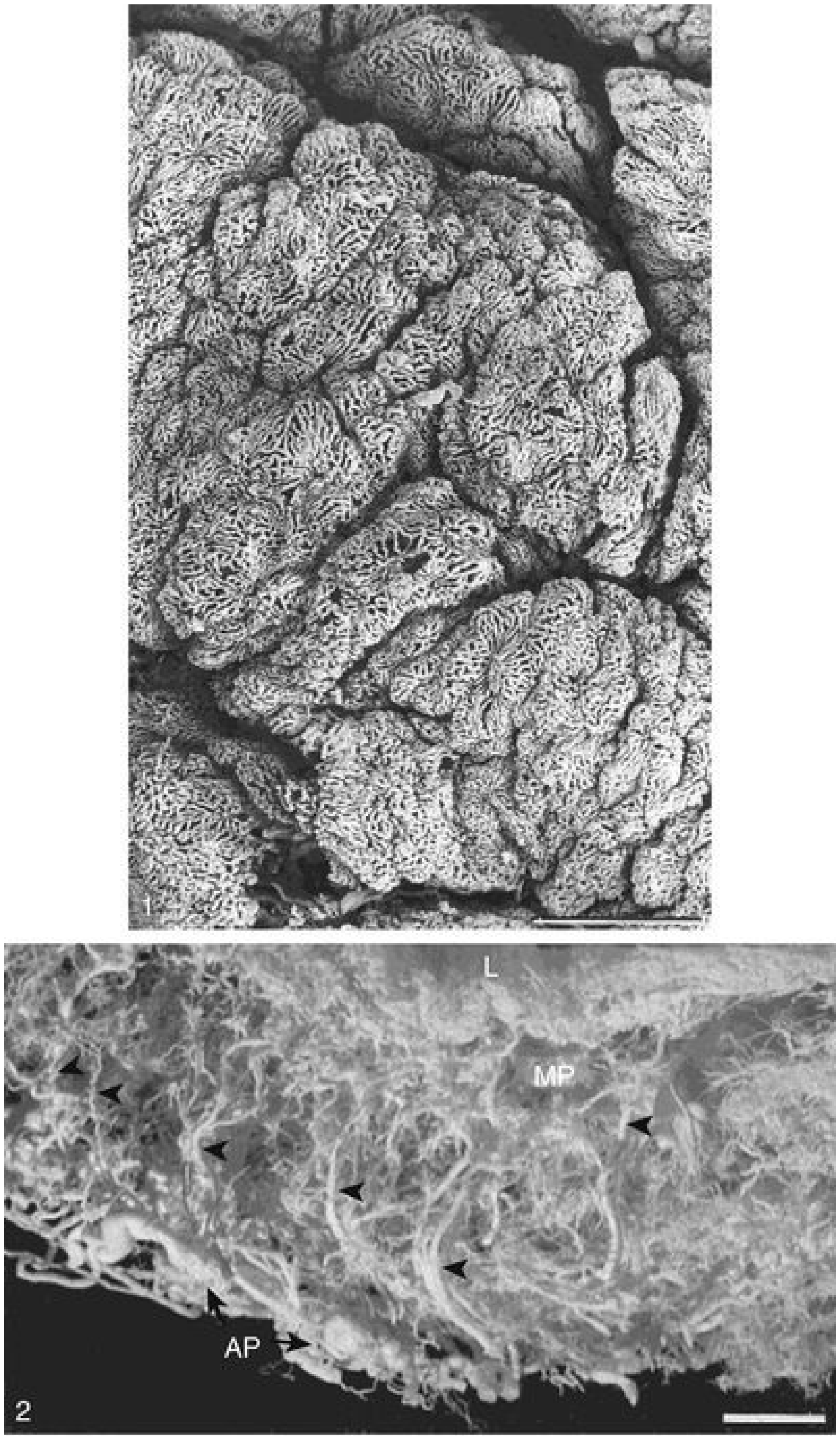

A

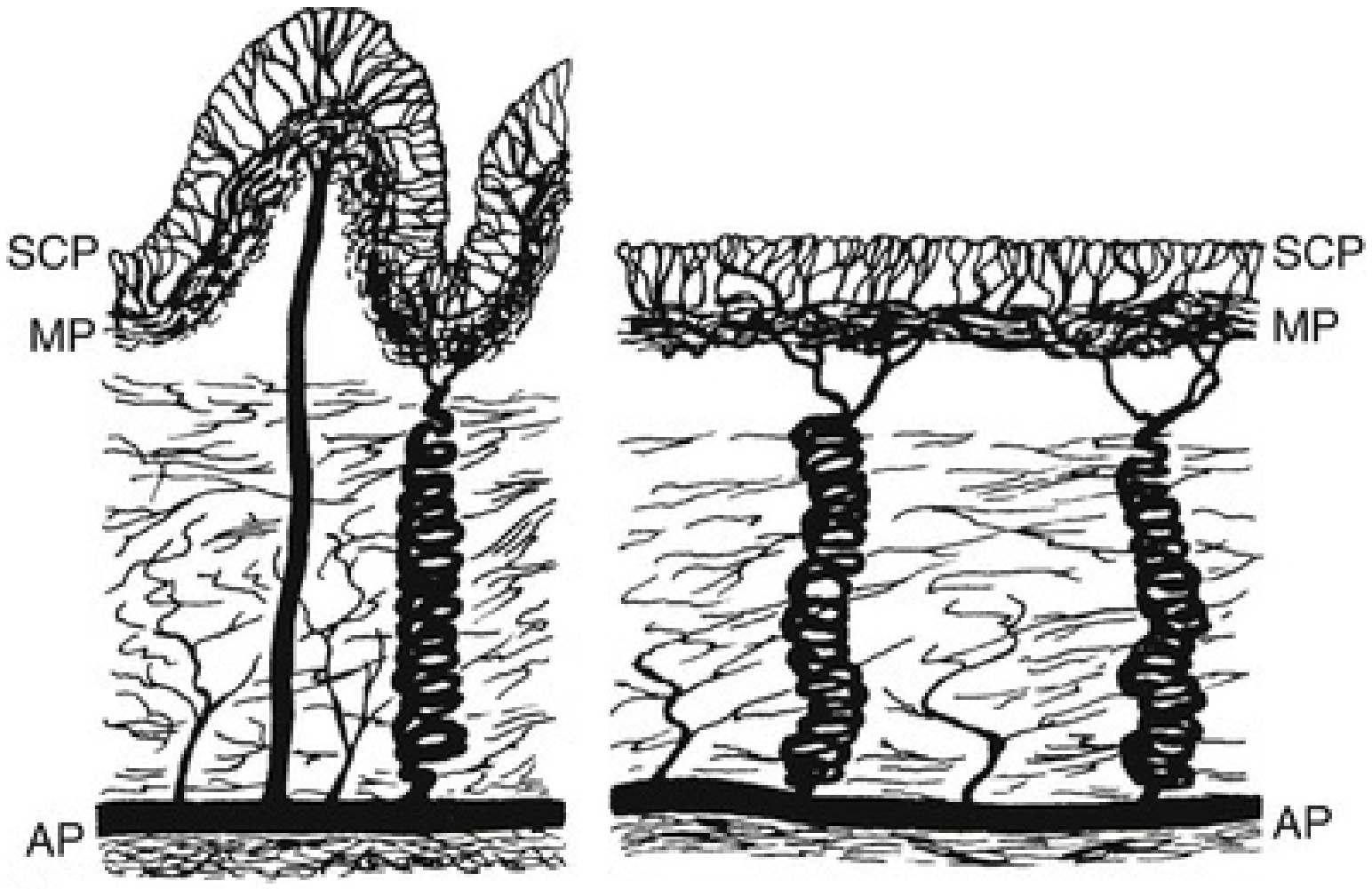

B

FIG. 110.5 (A) Scanning electron microscope image of human bladder blood vessels after corrosion cast preparation (see text). This is viewed from the luminal side and shows the high density of the vessels that comprise the subepithelial capillary network (scale = 1000 µm). (B) Schematic of vasculature of empty bladder *(left)* and full bladder *(right).* Mucosal plexus (MP) and subepithelial capillary plexus (SCP) are in lamina propria. *AP,* Adventitial plexus. (From Miodoński AJ, Litwin JA: Microvascular architecture of the human urinary bladder wall: a corrosion casting study. *Anat Rec* 254:375–381, 1999.)

Because of the large increase in surface area of the bladder wall during filling, the blood vessels must be able to change length considerably. To maintain good blood flow, mechanisms may be needed to ensure that the overall resistance of the vessels, as they lengthen, does not increase sufficiently to reduce the effective perfusion of the tissue. Several groups have investigated the effects of bladder filling on the blood flow. The majority of reports have shown that the blood flow is reduced by distention (Batista et al., 1996; Greenland and Brading, 1996). In patients with low bladder compliance, there is a marked increase in the intravesicular pressure and a more pronounced decrease in bladder blood flow compared with normal controls (Ohnishi et al., 1994). **The principal determinant of blood flow in the bladder wall seems to be intramural tension. During normal filling, the blood flow is able to adapt to the large increase in surface area until the pressure in the bladder increases** (Greenland and Brading, 1996).

When the detrusor is deprived of oxygen or a metabolic substrate, as would occur in ischemia, its contractile ability rapidly declines (Levin et al., 1982, 2003; Pessina et al., 1997; Zhao et al., 1991). It has been suggested that ischemia and reperfusion may lead to damage to intramural neurons and result in the patchy denervation and altered smooth muscle function seen in bladders of patients with detrusor overactivity (DO) (Brading, 1997a). Investigators have also modeled pelvic ischemia (and thus bladder ischemia) in animals by inducing balloon injury to the internal iliac artery intima followed by high cholesterol diet to induce plaque formation. The ischemia led to changes in bladder function including detrusor overactivity and structural changes in the bladder (Azadzoi et al., 2010).

Stroma

The main constituents of bladder wall stroma are collagen and elastin in a matrix composed of proteoglycans. The main cells are fibroblasts. **The passive mechanical properties of the bladder wall depend on the viscoelastic properties of the stroma and of the relaxed detrusor muscle** (Cortivo et al., 1981). The stroma has commonly been considered a passive low-metabolic tissue that fills out the space among muscle bundles, vessels, and nerves. There has been increased appreciation for the role of the stroma in the adaptation of the bladder to pathophysiologic conditions (Macarak and Howard, 1999). Bladder hypertrophy is likely to involve an interaction of stroma and smooth muscle. In arteries, disruption of elastin in the stroma can stimulate proliferation of smooth muscle (Li et al., 1998). Although no such mechanisms are yet known in the bladder, it is possible that there could be a more intimate relationship between changes in the composition of the stroma and muscle function and growth than is appreciated at present.

Bladder Wall Collagen

Most of the bladder wall collagen is found in the connective tissue outside the muscle bundles. Changes in the relative amounts of muscle and nonmuscle tissue in the bladder wall would therefore influence collagen concentration. A number of different collagen types have been identified. In the bladder, **types I, III, and IV are the most common** (Andersson and Arner, 2004; Macarak et al., 1995). Investigators (Landau et al., 1994) developed morphometric and histochemical techniques to determine the percentage volume of connective tissue in the bladder wall and to measure the two major types (I and III) of collagen. These methods quantitate three parameters of bladder ultrastructure: percentage volume of connective tissue, ratio of connective tissue to smooth muscle, and ratio of type III to type I collagen. These parameters have been shown to be abnormally elevated in patients with bladder disease compared with normal patients. Landau et al. (1994) further studied the ultrastructural changes that occur in the wall of dysfunctional bladders to determine the ability of new urodynamic techniques to reliably detect the clinical effect of these histologic changes. The study included 29 consecutive patients undergoing bladder augmentation. Preoperative urodynamic evaluation included measurement of the total bladder capacity, assessment of pressure-specific bladder volume, and dynamic analysis of bladder compliance. Full-thickness bladder biopsy specimens were obtained from the dome of the bladders during augmentation. The percentage of connective tissue and the ratio of connective tissue to smooth muscle were determined for all patients. These histologic results were compared with previously established normal values. All 29 patients had decreased bladder compliance, even though 9 had a normal bladder capacity. **The ratio of connective tissue to smooth muscle was significantly increased in poorly compliant versus normal bladders. The ratio of type III to type I collagen was also significantly elevated. One can conclude that the poor storage function of poorly compliant bladders is secondary to an alteration in the connective tissue content of the bladder wall, especially increased collagen type III.**

In the rat, infravesical obstruction or bladder denervation induces hypertrophy of the detrusor smooth muscle and, in turn, a decrease in the collagen concentration (Uvelius and Mattiasson, 1984, 1986). Aging is associated with a relative decrease in smooth muscle in men and women, relative to collagen content (Lepor et al., 1992; Susset et al., 1978). This could perhaps be related to the decreased packing density of submucosal collagen during aging (Levy and Wight, 1990).

Perhaps the most comprehensive work on bladder collagen was performed by these investigators (Macarak and Howard, 1999), who speculated that connections must exist between the tension-generating elements (i.e., the smooth muscle cells) and the other components of the bladder. In bladders that become noncompliant (e.g., from spinal cord injury), it is likely that there is some interference with the ability of the collagen fibers to alter their tortuosity. This, predictably, would reduce total bladder capacity. Further studies are required to establish the relationship between compliance changes and the passive mechanical elements of the bladder wall that make up its structural protein matrix.

Bladder Wall Elastin and Matrix

Elastic fibers are amorphous structures composed of elastin and a microfibrillar component located mainly around the periphery of the amorphous component (Rosenbloom et al., 1995). In the mature fiber, the amorphous component makes up about 90%. The microfibrils contain a number of glycoproteins. Elastin fibers are sparse in the bladder compared with collagen but are found in all layers of the bladder wall (Murakumo et al., 1995). In spinal cord–injured rats, the elastin-to-collagen ratio increases over the first 6 weeks after injury. During this 6 weeks, the bladder compliance increases and the bladder becomes overdistended. Then the ratio is reduced as bladder compliance is decreased as a result of the emergence of DO 10 weeks after injury, suggesting a potential role for elastin in the modulation of bladder compliance (Nagatomi et al., 2005; Toosi et al., 2008).

The nonfibrillar matrix in the stroma is largely composed of a gel of proteoglycans and water. Proteoglycans are glycoproteins with glycosaminoglycans (GAGs) covalently attached. The arrangement of the proteoglycans in the matrix creates a compartment of tissue water that has a viscous behavior when it is subjected to deformation.

Smooth Muscle

Histologic examination of the bladder body reveals that myofibrils are arranged into fascicles (bundles) in random directions (Donker et al., 1982). The individual cells within a bundle are connected to form a functional syncytium. This architecture differs from the discrete circular and longitudinal smooth muscle layers in the ureter or gastrointestinal (GI) tract.

Bladder smooth muscles have no cross striations visible under the microscope. Each detrusor smooth muscle cell contains a single nucleus. The individual smooth muscle cells in the bladder wall are small spindle-shaped cells with a central nucleus; fully relaxed, they are several hundred micrometers long with a 5- to 6-µm maximum diameter (Smet et al., 1996). The cell membranes of smooth muscle contain caveolae—flask-shaped invaginations of the membrane—and elements of the intracellular sarcoplasmic reticulum (SR) are often associated with caveolae.

The motor innervation of the bladder smooth muscle is from the postganglionic parasympathetic nerve fibers, although intramural ganglia can exist within the bladder wall. Fig. 110.6 shows the varicosities (rounded nodes) that wrap around the smooth muscle fiber. Varicosities can release a variety of neurotransmitters including acetylcholine (ACh) and adenosine triphosphate (ATP). It is unlikely that every smooth muscle cell receives direct synaptic contact; the presence of gap junctions allows excitation to propagate throughout the smooth muscle syncytium. Postjunctional receptors, such as muscarinic and purinergic receptors, are present on the smooth muscle cell. When activated by their respective agonists, these receptors initiate the excitation-contraction events (see later section) of the smooth muscle. Some investigators have found that the detrusor smooth muscle has afferent innervation that could mediate afferent signals related to smooth muscle activity (Gillespie et al., 2006).

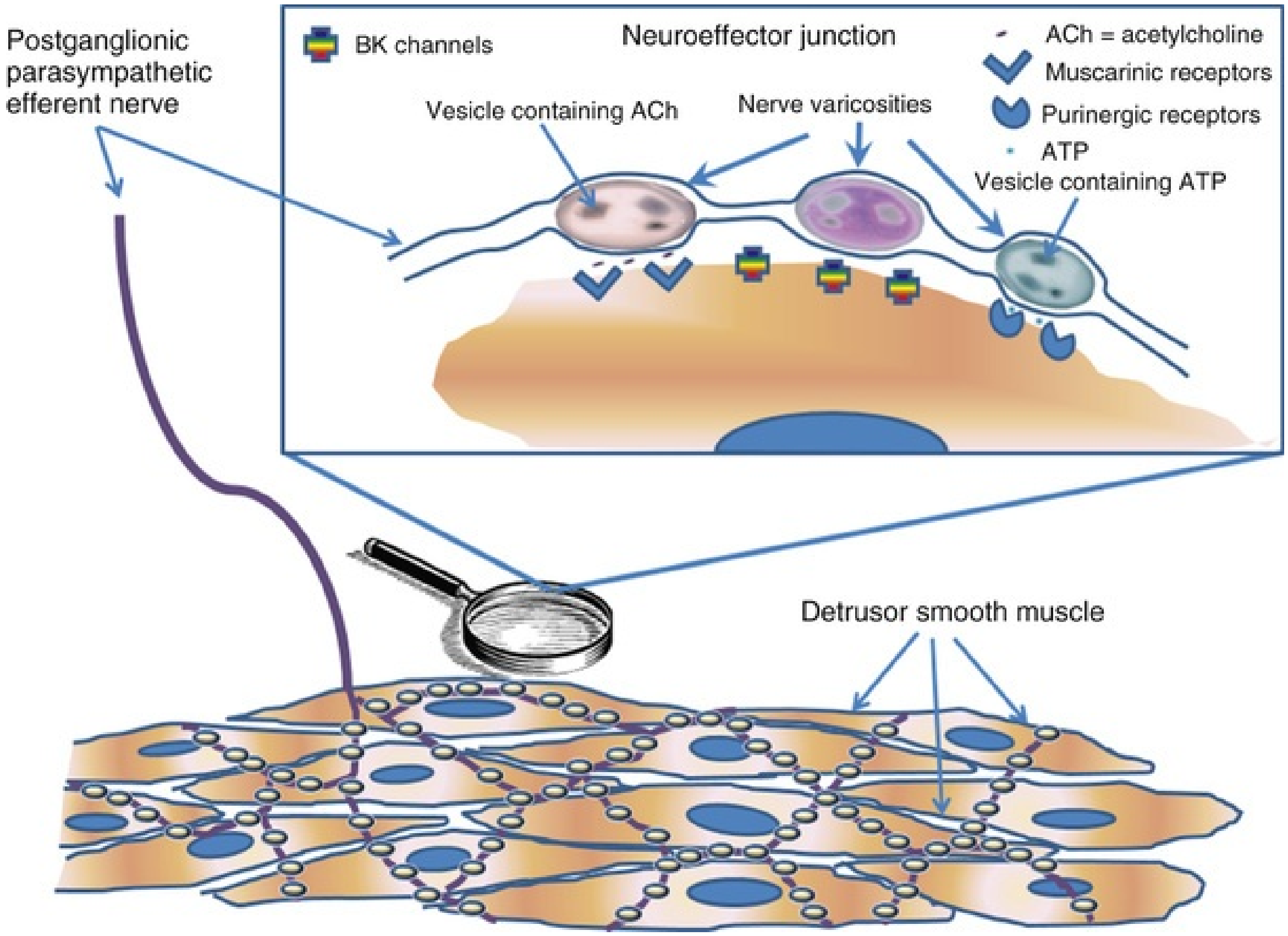
Postganglionic parasympathetic efferent nerve
BK channels
Neuroeffector junction
ACh = acetylcholine
Muscarinic receptors
Purinergic receptors
ATP
Vesicle containing ACh
Nerve varicosities
Vesicle containing ATP
Detrusor smooth muscle

FIG. 110.6 Motor nerve innervation of a detrusor muscle fascicle. See text for description.

Overview of the Urethra

Male Urethra

The urethra begins at the bladder neck and extends to the external meatus and is composed of striated and smooth muscle. In the male, four segments are readily identified. The first is the preprostatic portion, or the bladder neck. The prostatic urethra then extends throughout the length of the gland, terminating at the prostatic apex. The membranous urethra extends from the prostatic apex through the pelvic floor musculature (including the EUS) until it becomes the bulbous and penile urethra at the base of the penis (Fig. 110.7). The male EUS covers the ventral surface of the prostate as a crescent shape proximal to the verumontanum, then assumes a horseshoe shape distal to the verumontanum, and is crescent shape at the bulbar urethra.

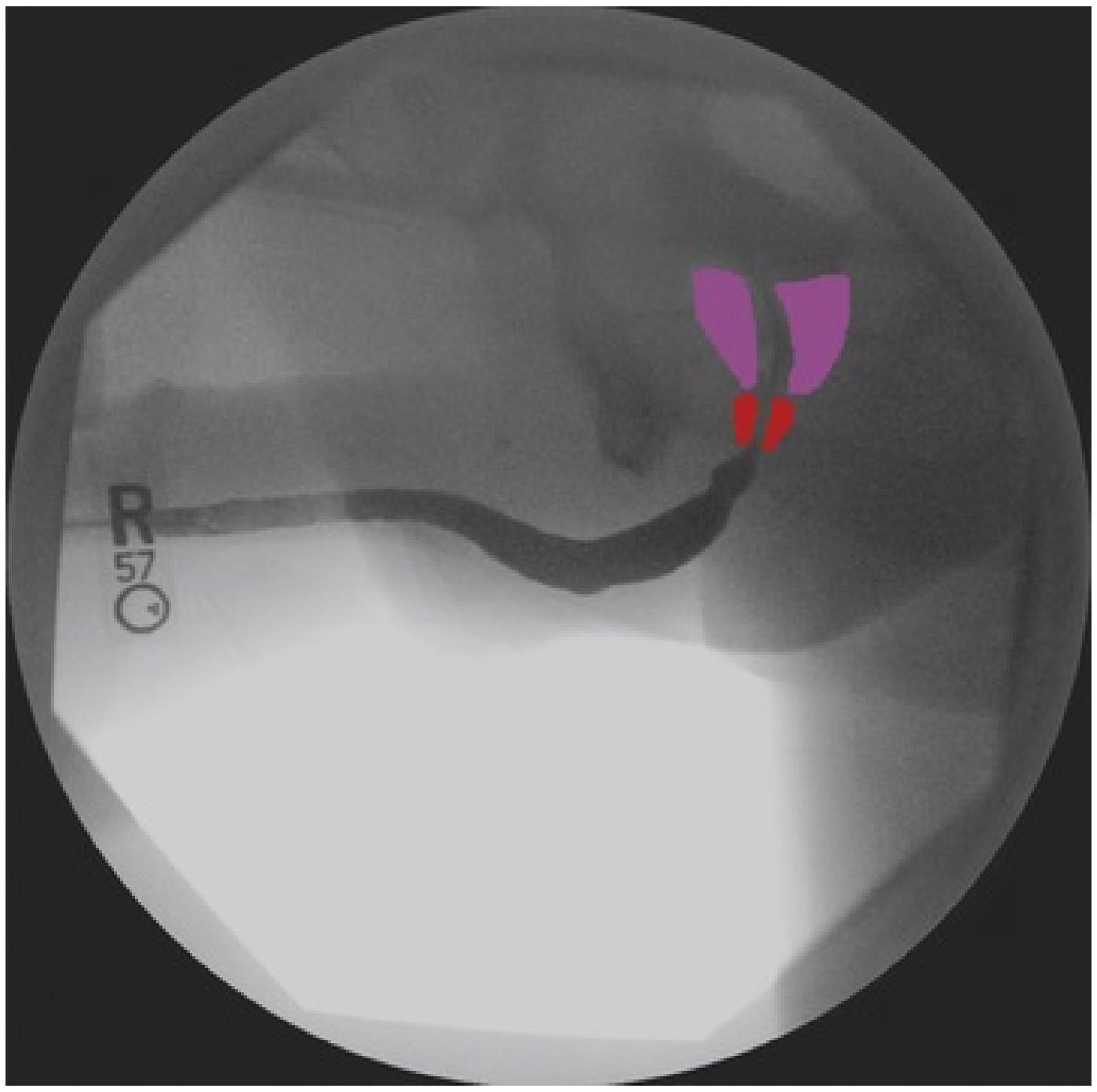

FIG. 110.7 Anatomy of male urethra seen on retrograde urethrogram with patient in lateral oblique position. The *red area* is the external urethral sphincter, and the *purple area* is the prostate.

Female Urethra

In women, the urethra extends throughout the distal third of the anterior vaginal wall from the bladder neck to the meatus. Detailed anatomic descriptions of structures along the female urethra are shown in Fig. 110.8. The urethra is composed of tissues that aid continence in addition to the urethral sphincter. **A network of vascular subepithelial tissue in women contributes to a urethral seal effect and promotes continence.** The EUS or rhabdosphincter (striated muscle) is under voluntary control and is part of the pelvic floor musculature. The female EUS covers the ventral surface of the urethra in a horseshoe configuration.

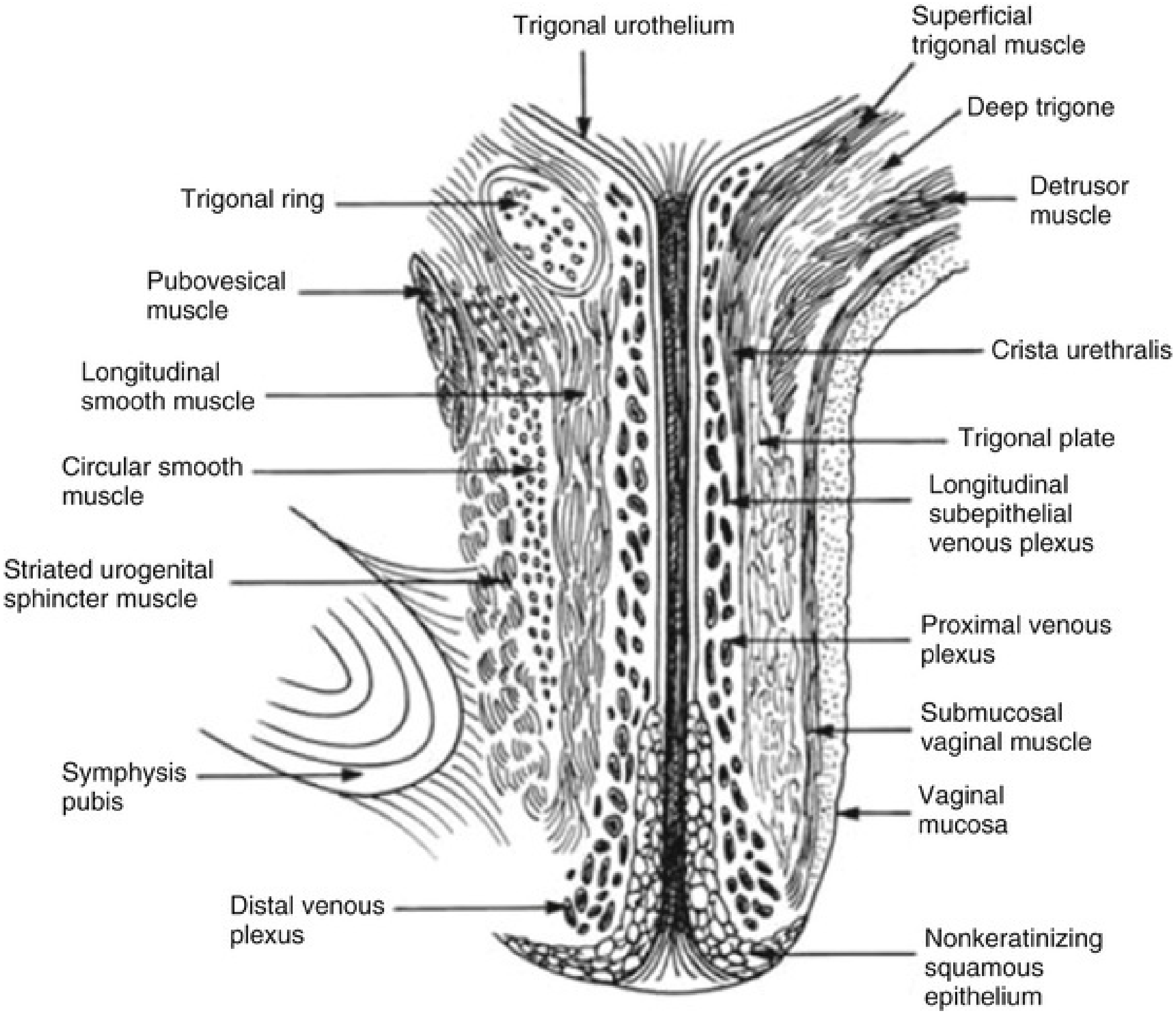
Trigonal urothelium
Superficial trigonal muscle
Deep trigone
Detrusor muscle
Trigonal ring
Pubovesical muscle
Longitudinal smooth muscle
Circular smooth muscle
Striated urogenital sphincter muscle
Symphysis pubis
Distal venous plexus
Crista urethralis
Trigonal plate
Longitudinal subepithelial venous plexus
Proximal venous plexus
Submucosal vaginal muscle
Vaginal mucosa
Nonkeratinizing squamous epithelium

FIG. 110.8 Female urethra showing importance of the multiple tissues in aid of continence including striated sphincter, smooth sphincter, and subepithelial venous plexus. (From Ashton-Miller JA, DeLancey JO: Functional anatomy of the female pelvic floor. *Ann N Y Acad Sci* 1101:266–

296, 2007.)

Urinary continence is maintained during elevations in intra-abdominal pressure by three processes. First, there is passive transmission of abdominal pressure to the proximal urethra. A guarding reflex involving an active contraction of striated muscle of the EUS can transiently help continence (Enhorning, 1961; Tanagho, 1982). However, mere transmission of abdominal pressure to the proximal urethra does not account for the entire increase in urethral pressure (Constantinou and Govan, 1982). Urethral pressure rises before cough transmission. These findings implicate an active urethral continence (neural) mechanism in women (Constantinou and Govan, 1982). DeLancey proposed the "hammock hypothesis"—that abdominal pressure transmitted through the proximal urethra presses the anterior wall against the posterior wall. The posterior wall remains rigid if there is adequate pelvic support from muscle and connective tissues. More distally, based on morphologic data, DeLancey and colleagues (DeLancey, 1989, 1997; Sampselle and DeLancey, 1998) postulated that the urethral attachments to the pubis (pubourethral) and vaginal connections to pelvic muscles and fascia actively change the position of the bladder neck and proximal urethra with voiding. This arrangement compresses the urethra against the pubis during bladder filling and straining. These attachments contain fascia and smooth muscle (Delancey, 1988; DeLancey, 1989; Oelrich, 1983). Thus urinary continence results from the combination of active muscle tone and passive anatomic coaptation.

Anatomy Common to Both Genders

Normal pelvic dissections of human urethral sphincters during different phases of gestational development were studied anatomically (Yucel and Baskin, 2004). The findings of this study were that development of the urethral sphincteric complex is similar in both genders. The urethral complex is derived from musculature from bladder detrusor, bladder trigone, and urethral muscles, each of different embryonic origin. These investigators found that the levator ani pelvic floor muscle does not surround the ventral aspect of the urethra in either gender, and the role of the levator ani in continence was questioned.

Fiber Types of Urethral Striated Muscle

Striated muscles are characterized as slow type and twitch type. Twitch-type myofibrils can be further classified as slow and fast on the basis of functional and metabolic characteristics (Padykula and Gauthier, 1967). Slow-twitch fibers seem ideally suited to maintaining sphincter tone for prolonged periods, whereas fast-twitch fibers may be needed to add to sphincter tone rapidly to maintain continence when intra-abdominal pressure is abruptly increased. Similar to smooth muscle, contraction of striated muscle fibers is governed by intracellular calcium, through interactions with troponin.

The fast-twitch fibers can be recruited rapidly but also fatigue rapidly and perform predominantly anaerobic metabolism (Markwardt and Isenberg, 1992). Fast-twitch fibers exhibit rapid bursts of contractile force and are rich in myosin ATPase that catalyzes the actin-myosin interaction. The speed of contraction may be correlated with the histochemical reaction of this ATPase and alkaline pH. In addition, fast-twitch muscles are supplied with a fast isoform of the Ca^{2+}-ATPase, which translocates the cytosolic calcium into the abundant SR to allow rapid relaxation.

In contrast, slow-twitch fibers are found in greater percentage in muscles that require sustained tension, such as the pelvic levators and urethral sphincter. These muscle fibers are recruited and fatigue slowly and can perform high rates of oxidative metabolism because they possess less of the myosin ATPase activity and contain an increased expression of a slow isoform of the Ca^{2+}-ATPase (Markwardt and Isenberg, 1992). These fibers give rise to the background electromyographic activity seen during a urodynamic evaluation.

The rhabdosphincter (EUS) is a skeletal muscle that is present in the walls of the urethra and is separate from the periurethral skeletal muscle of the pelvic floor. The muscle cells are smaller than ordinary skeletal muscle: 15 to 20 µm in diameter. **The EUS is composed of two parts. The periurethral striated muscle of the pelvic floor contains fast-twitch and slow-twitch fibers. The striated muscle of the distal sphincter mechanism contains predominantly slow-twitch fibers** (Elbadawi, 1984) **and provides more than 50% of the static resistance** (Tanagho et al., 1989). **Gosling et al.** (2000) **presented histochemical evidence in humans that striated muscle within the distal urethra is composed primarily of slow-twitch myofibrils in contrast to the periurethral striated muscles of the pelvic floor, which contain fast-twitch and slow-twitch fibers. In the male, the rhabdosphincter consists of 35% fast-twitch and 65% slow-twitch fibers** (Padykula and Gauthier, 1970). **In the female, the ratio of slow-twitch to fast-twitch fibers is 87% slow-twitch and 13% fast-twitch fibers.**

The majority of the fast-twitch fibers and about a fourth of the slow-twitch fibers in the intramural striated muscle of the human membranous urethral sphincter show positive staining for nitric oxide (NO) synthase (NOS) in the sarcolemma (Ho et al., 1998). Moreover, the striated periurethral muscles of the pelvic floor are adapted for the rapid recruitment of motor units required during increases in abdominal pressure. **It has been speculated that the successful treatment of stress incontinence by pelvic floor exercises or electrostimulation is caused by the conversion of fast-twitch to slow-twitch striated muscle fibers** (Bazeed et al., 1982).

In addition to striated muscle, the external sphincter appears to contain smooth muscle, which receives noradrenergic innervation. Investigators have shown that stimulation of the hypogastric nerve elicits myogenic potentials in the EUS (Kakizaki et al., 1991). Whether this activity is the result of smooth or striated muscle is unclear. Because these potentials persist after α-adrenergic blockade, investigators postulate that the activity arises from striated muscle.

Urothelial Physiology

Although the primary role of the urothelium is to form a relatively impermeable barrier to protect the underlying stroma of the bladder, other roles of the bladder urothelium include sentinel defense against uropathogenic bacterial infections, afferent signaling, and modulation of detrusor smooth muscle contractility.

Barrier Function

Epithelial permeability, including that of the urothelium, depends on a number of factors. These are passive diffusion, osmotically driven diffusion, active transport, and inertness of the membrane to the solutes to which it is exposed.

Descriptions of finite passage of substances across the urothelium are well known. In 1856 Kaupp reported that the composition and volume of urine were altered with 12-hour voiding patterns instead of hourly voiding. These changes in volume have also been noted in rats during isovolumetric cystometrograms during 3-hour periods (Sugaya et al., 1997), and the rate of water loss has also been estimated by direct measurement of passive water diffusion in vitro in the rabbit (Negrete et al., 1996). There is a passive permeability to most substances in the blood or urine (Hicks, 1975). In studies using an in vivo rat model, the bladder urothelium was permeable to urea, sodium, potassium, and chloride (Spector et al., 2011, 2013). The authors of these studies contend that the bladder modifies the final urinary concentration of these solutes and that this modification depends on the hydration status and dietary protein (Spector et al., 2012).

The human bladder urothelium is also permeable to water because of expression of the water transport protein aquaporin (Rubenwolf et al., 2009, 2012). Water permeability value in humans was measured at 6.5×10^{-5} cm/sec (Fellows and Marshall, 1972). This value was obtained by estimating the absorption of tritiated water into the plasma after instillation of the tritiated water into the bladder of volunteers. A direct measurement of urothelial diffusive permeability in the human has not yet been made. A measurement tool may help better phenotype LUTD that may be associated with increased urothelial permeability.

Breakdown of the apical (umbrella) cells in animal models of cystitis has shown increased water and urea permeability. Presumably, leakage of urinary solutes into the lamina propria is also responsible for the symptoms of cystitis (Lavelle et al., 1998, 2000). This increase in urothelial permeability with cystitis is increased further by distention of the bladder. The hypothesis is that with distention of the bladder, the weakened urothelium with denuded apical umbrella cells and no real barrier in the intermediate or basal cells is further disrupted, thus allowing further egress of urine constituents into the detrusor. Similar breakdown of the apical cells is thought to occur in most forms of infectious cystitis and also in radiation cystitis.

Direct measurements of the osmotic effect on permeability have not been performed on urothelium. However, the urothelium maintains an osmotic gradient between plasma (approximately 300 mOsm/kg) and urine (100 to 1500 mOsm/kg), depending on the level of water balance and diuresis of the individual. In the normal bladder, the osmotic effects of the urine appear to go unnoticed, and the patients have few or no symptoms. However, once the bladder is inflamed, as in bladder pain syndrome and interstitial cystitis (BPS/IC), the effects of osmotic gradients become important (Gao et al., 1994).

Patients with spinal cord injury or with myelodysplasia tend to have chronic cystitis with bacteriuria and inflamed urothelium. When detrusor activity was increased in the rat by instillation of hyperosmolar compounds, this was accompanied by neurogenic inflammation, including plasma extravasation of Evans blue that could be decreased by pretreatment with the C-fiber afferent neurotoxin capsaicin (Maggi et al., 1990), indicating that hyperosmolar solutions excite afferent nerves. With increased osmolality, detrusor contractions were much stronger and accompanied by blood pressure elevations. These effects were enhanced when the bladder was pretreated with dimethyl sulfoxide to simulate cystitis conditions (Hohlbrugger, 1987; Hohlbrugger and Lentsch, 1985).

Tight junction (TJ) proteins also contribute to the impermeability of the bladder urothelium. TJ proteins include zona occludens-1 (ZO-1), occludin, claudin-4, claudin-8, and claudin-12 (Acharya et al., 2004). TJs are present between cells to prevent paracellular (between the cell) permeability (Fig. 110.9). These TJ proteins adapt to stretch of the urothelium during filling and voiding without affecting permeability (of small molecules biotin, fluorescein, and ruthenium red), although there was a 10-fold drop in transepithelial resistance (TER) during urothelial stretch (Carattino et al., 2013). This drop in TER reflected increased ionic paracellular transport via claudin permeation pathway. In addition to these physiologic functions (barrier function, host response to pathogens) of the urothelium, the roles of urothelial-afferent signaling and modulation of smooth muscle contractility are covered in later sections.

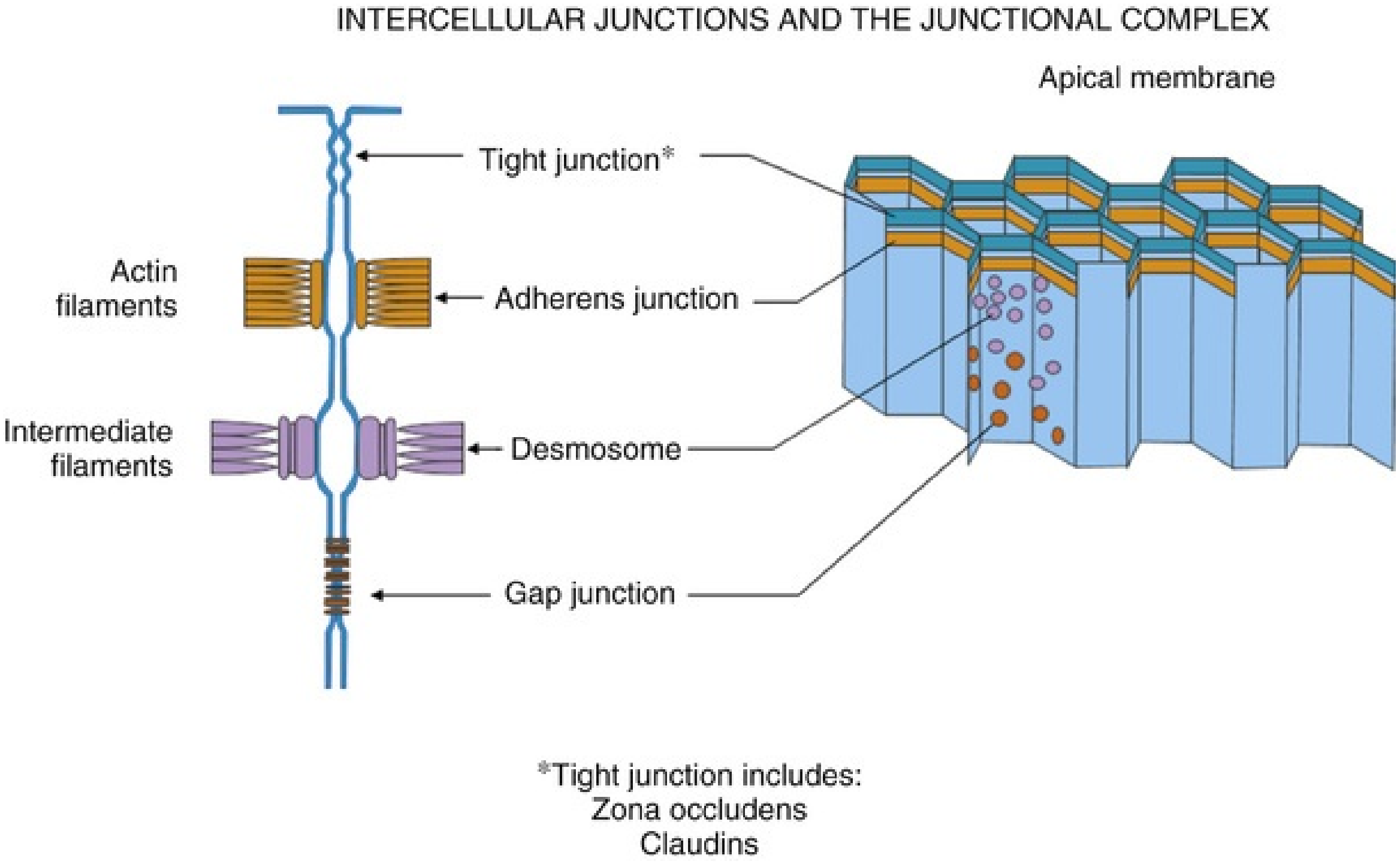
INTERCELLULAR JUNCTIONS AND THE JUNCTIONAL COMPLEX
Apical membrane
Tight junction*
Actin filaments
Adherens junction
Intermediate filaments
Desmosome
Gap junction
*Tight junction includes:
Zona occludens
Claudins

FIG. 110.9 Junctional complexes between cells include tight junctions, adherens, desmosomes, and gap junctions. Gap junctions include proteins such as zona occludens and claudins.

The GAG layer, which has been described to be located on the luminal surface of the apical urothelial cell, has been a controversial subject of research into urothelial barrier function. *GAG* refers to a structure composed of 100% carbohydrate (polysaccharide). GAG is not produced through a template reaction as a protein is (DNA → RNA → protein), but rather through a series of enzymatic reactions within the cell. For this reason, GAG can be highly heterogeneous in molecular weight and composition. This GAG theory arose from findings of increased bacterial adherence to rabbit bladder urothelium after topical acid treatment and return to normal function with decreased adherence within 24 hours after acid injury, suggesting a “secretory” factor produced by the urothelium protecting the urothelium against bacterial adherence (Parsons et al., 1975). The secretory factor was reported to be GAG, based on the histology of rabbit bladders (Mulholland et al., 1976). However, using a different approach, it was found that the secretory factor was a glycoprotein (mucin glycoprotein MUC-1) rather than a polysaccharide (GAG) (Buckley et al., 1996; Higuchi et al., 2000). In an indirect method of examining the role of the GAG layer, Madin-Darby canine kidney (MDCK) cells were transfected with MUC-1. After this treatment, no difference in the transcellular water and urea permeability was found (Lavelle et al., 1997). Immunofluorescence study of human urothelium showed that chondroitin sulfate was the main GAG component, although the role of GAG in creating impermeability was studied in monolayer of cultured pig urothelial cells (Janssen et al., 2013). In summary, the GAG layer may have importance in bacterial antiadherence and in prevention of urothelial damage by large macromolecules. However, there is no definite evidence that the GAG layer acts as the primary impermeability barrier between urine and plasma in the human urothelium.

There seems to be no apparent difference between the urothelium of the trigone compared with the detrusor, in contrast to luminal cells lining the proximal urethra (Sun, 2006). In this urethral region, there is a transition from urothelium to a stratified or columnar epithelium accompanied by a lack of urothelial-specific differentiation markers. In addition, specialized chemosensory neuroendocrine cells are distributed within the urethral epithelia. These cells are often exposed to the lumen and may share similarities to GI enterochromaffin cells or chemosensory cells of the trachea or respiratory tract (termed “brush” cells or paraneurons) (Deckmann et al., 2014; Kullmann et al., 2018), including expression of microvilli. These urethral specialized chemosensory cells or “paraneurons” are able to respond to detect potential noxious stimuli (using the classic taste transduction pathway) by releasing mediators such as acetylcholine and even serotonin. Similar to urothelial cells in the bladder, these urethral chemosensory cells are also in proximity to sensory nerve fibers, whereby intraurethral stimulation can lead to activation of underlying cells, including bladder smooth muscle and sensory afferents. In this regard, evidence has shown that in vivo intraurethral administration of serotonin augments abdominal muscle wall activity termed a viscero-motor response (VMR) as well as afferent nerve activation. In addition, there are also reports that have identified functional properties of sacral afferents able to respond to changes in fluid flow through the urethra (Snellings et al., 2012). Although the functional significance of these findings and the number of distinct chemosensory cell types may not yet be fully appreciated, it is clear that such “sentinel” type cells are able to recognize potentially harmful stimuli (including bacteria) in the urethral lumen and in turn, alter bladder function.

Urethral Tone

There is controversy about the relative roles of the urethral smooth and striated circular muscles and the lamina propria in generating the urethral pressure profile, but it seems likely that both contribute (Thind, 1995). **Blocking striated sphincter activity with nicotinic neuromuscular blocking agents has variable effects and may reduce urethral tone but rarely by more than 40%, suggesting that the smooth muscles are important. Blocking sympathetic tone with α-adrenoceptor blockers may also reduce urethral pressure by about a third** (Torrens and Morrison, 1987). There is little evidence for the involvement of the cholinergic innervation in generating urethral pressure.

Despite the horseshoe configuration with the open end in the posterior direction, urethral pressure recording at the external sphincter during bladder filling increases uniformly along the entire circumference like an iris (Morita and Tsuchida, 1984). Norepinephrine or hypogastric nerve stimulation augments this pressure, suggesting a role for adrenergic receptors and sympathetic nerves in the function of the EUS (Kakizaki et al., 1991).

The urethral stroma contains primarily longitudinally arranged collagen fibers and elastin fibers (Hickey et al., 1982; Huisman, 1983). The vascular filling of the urethral lamina propria is known to be of importance for urinary continence, although the magnitude of its contribution to continence is still not understood (Rud et al., 1980). Estrogen is known to increase the urethral blood flow, resulting in increased distention of the lamina propria blood vessels (Brading, 1997a).

Impaired arterial blood supply to the urethra decreases the intraluminal pressure (Rud et al., 1980), but at present it is not known whether it is the decrease in vascular filling or the urethral hypoxia that mediates the decrease in urethral pressure. It has been suggested that both these mechanisms may be involved because it was shown that the initial drop in urethral pressure was mediated through decreased vascular filling, whereas the later phase was the result of a hypoxic effect on the urethral smooth muscle (Greenland and Brading, 1996).

Results are divergent regarding the clinical significance of connective tissue outside the urethra. Paraurethral tissue biopsy specimens from premenopausal women with stress incontinence contain 30% more collagen, and the diameter of the fibrils is 30% larger than in controls (Falconer et al., 1998a). Postmenopausal stress-incontinent women, on the other hand, have no difference in collagen concentration compared with their age-matched controls (Falconer et al., 1998b). Others, however, have found a decreased periurethral collagen concentration (Rechberger et al., 1993) and a decreased ratio of collagen I to collagen III (Keane et al., 1997) in patients with stress incontinence.

Ionic Transport

The apical membrane of the urothelium has a high electrical resistance (Lavelle et al., 1998, 2000), whereas the basolateral membrane resistance is approximately 10-fold lower (Clausen et al., 1979). Active sodium transport across the urothelium has been demonstrated (Lewis and Diamond, 1976; Wickham, 1964). Na^+ channels that exist on the apical surface of the umbrella cells and in the cytoplasmic vesicles below the apical surface are primarily amiloride sensitive (inhibition) and aldosterone responsive. However, amiloride-insensitive, cation-selective, as well as amiloride-insensitive, unstable cation channels have also been identified. Both of these channels were found to be degradation products of the amiloride-sensitive Na^+ channel. The amiloride-sensitive Na^+ channel is hydrolyzed by serine proteases such as kallikrein and urokinase and plasmin (normally found in the urine but produced by the kidney) (Lewis et al., 1995). Studies of rat bladders have shown that urea, sodium, potassium, and chloride can cross the bladder urothelium and be taken up by suburothelial blood vessels (Spector et al., 2011, 2012, 2013).

Sodium that is transported into the cell is removed at the basolateral membrane by an Na^+-K^+ exchanger. This leaves the cell with a negative intracellular charge. The basolateral membrane contains K^+ and Cl^- channels, Na^+-H^+ exchangers, and Cl^--HCO_3^- exchangers. These channels and exchangers are important in recovery of cell volume during an increase in serosal osmolality (Donaldson and Lewis, 1990). Unfortunately, the precise role of the Na^+ channel in the apical membrane of the umbrella cell is unknown. It is possible that the degradation of the channel may follow the filling of the bladder and that the changes in conductance of sodium may be a signaling factor for the bladder and micturition when it reaches capacity. Alternatively, it may be involved in the signaling pathway that allows insertion or removal of apical membrane on expansion of the bladder.

Sensor-Transducer Function of the Urothelium

Whereas the urothelium has historically been viewed primarily as a barrier, there is increasing evidence that urothelial cells display a number of properties similar to sensory neurons (nociceptors and mechanoreceptors) and that both types of cells use diverse signal-transduction mechanisms to detect physiologic stimuli. Examples of “sensor molecules” (i.e., receptors and ion channels) associated with neurons that have been identified in urothelium include receptors for bradykinin (Chopra et al., 2005), neurotrophins (TrkA and p75) (Murray et al., 2004), purines (P2X and P2Y) (Birder et al., 2004; Chopra et al., 2008; Hu et al., 2002; Lee et al., 2000; Sun and Chai, 2004; Tempest et al., 2004), norepinephrine (α and β) (Birder and de Groat, 1998; Birder et al., 1998, 2002), ACh (nicotinic and muscarinic) (Beckel et al., 2006; Chess-Williams, 2002; Kullmann et al., 2008b) protease-activated receptors, amiloride-mechanosensitive Na$^+$ channels such as ENaC (Araki et al., 2004; Smith et al., 1998; Wang et al., 2003), and a number of transient receptor potential (TRP) channels (TRPV1, TRPV2, TRPV4, TRPM8) (Birder and de Groat, 1998; Birder et al., 2001, 2002, 2007a, 2007b; Gevaert et al., 2007; Stein et al., 2004).

When urothelial cells are activated through these receptors and ion channels in response to mechanical as well as chemical stimuli, they can, in turn, release chemical mediators such as NO, ATP, ACh, and substance P (SP) (Birder and de Groat, 1998; Birder et al., 1998, 2003; Burnstock, 2001a, 2001b; Chess-Williams, 2004; Ferguson et al., 1997). These agents are known to have excitatory and inhibitory actions on afferent nerves that are close to or in the urothelium (Bean et al., 1990; Birder et al., 2001; Yoshimura et al., 2008). Video 110.1 ▶ shows urothelial cells responding to increasing doses of extracellular carbachol, a nonselective muscarinic agonist, with increasing concentrations of intracellular Ca^{2+} (fura-2 ratio).

Chemicals released from urothelial cells may act directly on afferent nerves or indirectly through an action on suburothelial interstitial cells (also referred to as *myofibroblasts*) that lie in close proximity to afferent nerves. Myofibroblasts are extensively linked by gap junctions and can respond to chemicals that in turn modulate afferent nerves (Fowler et al., 2008). Thus it is believed that urothelial cells and myofibroblasts can participate in sensory mechanisms in the urinary tract by chemical coupling to the adjacent sensory nerves.

NO can be released by the urothelium, particularly during inflammation (Birder and de Groat, 1998; Birder et al., 1998). The release of NO may be evoked by the calcium ionophore A-23187, norepinephrine, and capsaicin. SP also acts on receptors on urothelial cells to release NO. The adrenergic release of NO from bladder strips was reduced by 85% after removal of the urothelium. Denervation of the bladder did not completely block the release of capsaicin-induced NO production, suggesting other sites of production. This is consistent with the observations that capsaicin released NO from cultured rat, cat, rabbit, and human urothelial cells and that the TRPV1 capsaicin receptor is expressed in cultured urothelial cells. NOS expression in afferent neurons is also increased in chronic bladder inflammation. Given that NO does not have much effect on the detrusor muscle but does inhibit Ca^{2+} channels in rat bladder afferent neurons (Yoshimura et al., 2001), **the role of NO in the urothelium has still to be clarified.** However, **NO released locally in the bladder appears to have an inhibitory effect on afferent activity in the bladder** because suppression of endogenous NO by intravesical oxyhemoglobin, an NO scavenger, or L-NAME, a NOS inhibitor, enhances bladder activity in rats (Masuda et al., 2007; Pandita et al., 2000).

ATP released from urothelial cells during stretch can activate a population of suburothelial bladder afferents expressing $P2X_3$ receptors, signaling changes in bladder fullness and pain (Burnstock, 2001a; Ferguson et al., 1997). Accordingly, $P2X_3$ null mice exhibit a urinary bladder hyporeflexia, suggesting that this receptor, as well as neural-epithelial interactions, are essential for normal bladder function (Cockayne et al., 2000). This type of regulation may be similar to epithelium-dependent secretion of mediators in airway epithelial cells, which are thought to modulate submucosal nerves and bronchial smooth muscle tone and may play an important role in inflammation (Homolya et al., 2000; Jallat-Daloz et al., 2001). Thus it is possible that activation of bladder nerves and urothelial cells can modulate bladder function directly or indirectly by the release of chemical factors in the urothelial layer. ATP released from the urothelium or surrounding tissues may also play a role in the regulation of membrane trafficking. This is supported by studies in the urinary bladder in which urothelium-derived ATP release purportedly acts as a trigger for exocytosis, in part by autocrine activation of urothelial purinergic (P2X, P2Y) receptors (Wang et al., 2005). These findings suggest a mechanism whereby urothelial cells sense or respond to ATP and thereby translate extracellular stimuli into functional processes.

A study showed that human bladder urothelial tissue behaved similarly to guinea pig bladder urothelium. Both urothelia released ATP in response to muscarinic and purinergic stimulation (Sui et al., 2014). The released ATP induced contraction of the urothelial mucosal tissue. Aging was associated with increased ATP release. These findings continue to support the hypothesis that the urothelium is capable of sensing and transducing signals and likely modulates overall bladder function.

Prostaglandins are also released from the urothelium. These are assigned two possible functions: regulation of detrusor muscle activity and cytoprotection of the urothelium, based on effective treatment of hemorrhagic cystitis by prostaglandins (Jeremy et al., 1987). The predominant forms found in human urothelium from biopsy specimens are 6-oxo–prostaglandin $F_{2\alpha}$ ($PGF_{2\alpha}$) more than PFE_2 more than $PGF_{2\alpha}$ more than thromboxane B_2. PGI_2 (prostacyclin) is also produced. These findings were confirmed and further developed in the guinea pig, in which it was found that the major production of prostaglandins occurred in the urothelium. The production of prostaglandins also increased greatly with inflammation (Saban et al., 1994). Prostaglandin synthesis also occurs in the ureter, where it is speculated to be important in the regulation of ureteral peristalsis and also in reducing the development of blood clots in the lumen of the ureter (Ali et al., 1998).

Evidence also suggests that the involvement of the muscarinic receptor in bladder function extends beyond detrusor contractility and into afferent sensory functioning. Muscarinic receptors are found on the urothelium at high density (Hawthorn et al., 2000), and there is a basal release of ACh from the urothelium that is increased by stretch and aging (Yoshida et al., 2006). Thus activation of the muscarinic receptors in the urothelium releases substances that modulate afferent nerves and smooth muscle activity (de Groat, 2004; Hawthorn et al., 2000; Kullmann et al., 2008a).

The urothelium also releases substances called *urothelium-derived inhibitory factors,* which decrease the force of detrusor muscle contraction in response to muscarinic stimulation (Hawthorn et al., 2000; Kumar et al., 2005). The molecular identity of this factor is not known; however, pharmacologic studies suggest that it is not NO, a prostaglandin, prostacyclin, adenosine, catecholamine, γ-aminobutyric acid (GABA), or a factor that acts through apamine-sensitive, small-conductance K^+ channels. It has been shown that an inhibitory response through this factor is attenuated in a fetal model of bladder outlet obstruction (BOO) (Thiruchelvam et al., 2003). Further studies are required to clarify the identity of this substance and its role in bladder function.

Suburothelial Interstitial Cells

In the human bladder, subepithelial interstitial cells, which are also called **myofibroblasts,** are located just below the basal layer of the urothelium. These myofibroblasts stain for vimentin and α-smooth muscle actin but not for desmin (Fry et al., 2004). These cells are linked by gap junctions consisting of connexin 43 (Cx43) proteins and make close appositions with C-fiber nerve endings in the submucosal layer of the bladder, suggesting that **there is a network of functionally connected interstitial cells immediately below the urothelium that may be modulated by other nerve fibers** (Fry et al., 2004; Fig. 110.10). ATP can induce inward currents associated with elevated intracellular Ca^{2+} in isolated suburothelial interstitial cells (Fry et al., 2007).

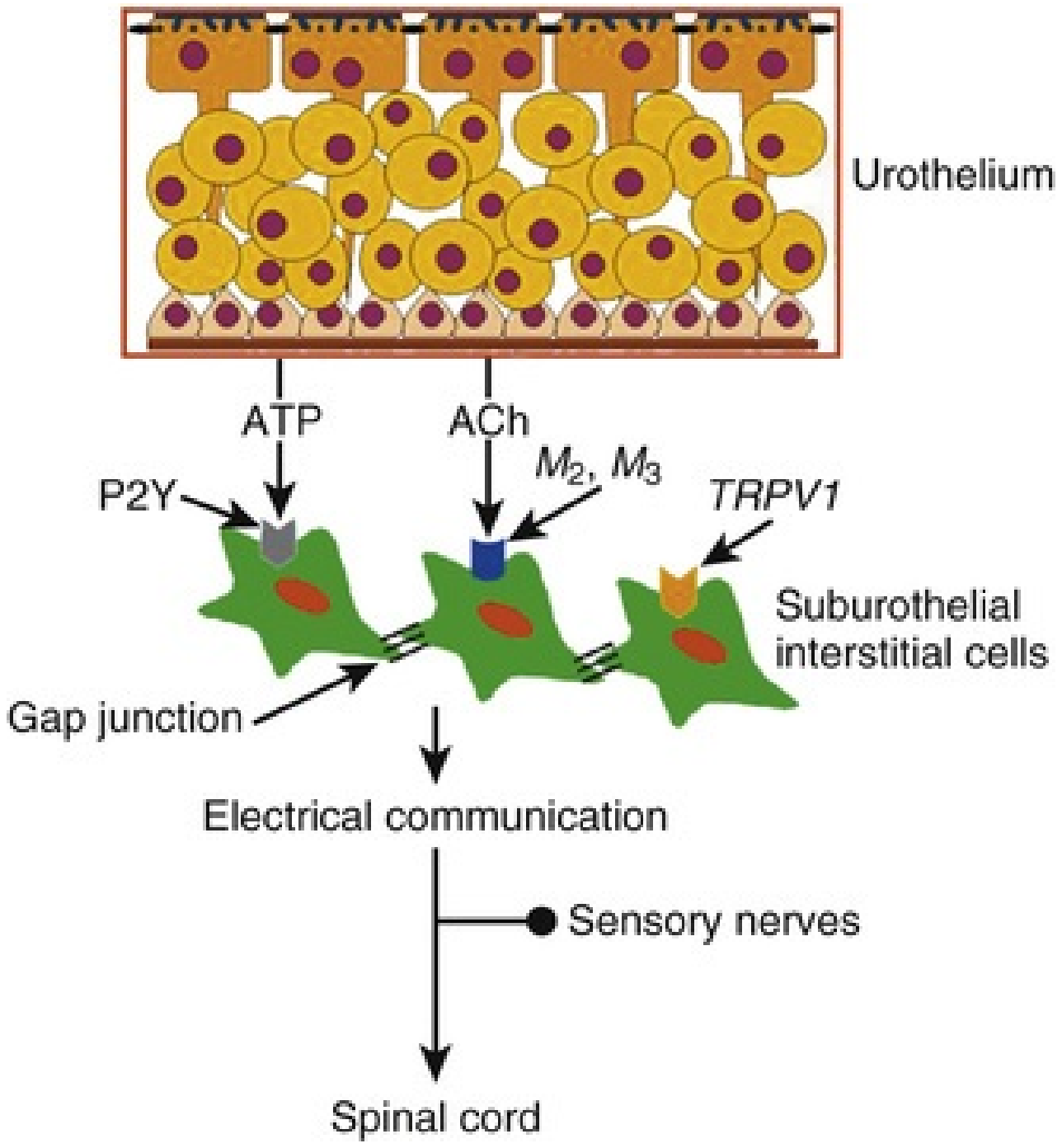

FIG. 110.10 Schematic representation of suburothelial interstitial cells, which are also called *myofibroblasts.* Substances released from the basolateral surface during stretch, such as adenosine triphosphate (ATP) and acetylcholine (ACh), activate afferents in the suburothelial layer through the intermediation of suburothelially located interstitial cells, which express purinergic P2Y receptors, muscarinic M_2 and M_3 receptors, or capsaicin TRPV1 receptors, and are connected to one another by gap-junction proteins.

Immunohistochemical studies show the expression of P2Y receptors, most notably $P2Y_6$ receptors, and M_3 muscarinic receptors in suburothelial interstitial cells from guinea pigs (Fry et al., 2007; Grol et al., 2009). In the human bladder, increased expression of muscarinic M_2 and M_3 receptors in vimentin-stained suburothelial interstitial cells is found and correlates with the urgency score in humans with idiopathic detrusor overactivity (IDO) (Mukerji et al., 2006). Because ATP or ACh is known to be released from the urothelium during bladder stretch, **suburothelial interstitial cells are in an ideal position between the urothelium and nerve endings to modify a sensory feedback mechanism.** Application of an NO donor sodium nitroprusside (SNP) also attenuates an increase in intracellular Ca^{2+} and current responses to ATP in guinea pig interstitial cells, suggesting the cyclic guanosine monophosphate (cGMP)–dependent inhibition of cell activity (Sui et al., 2008).

Key Points: Urothelium

- Uroplakin proteins and TJ proteins play key parts in urothelial barrier function.
- Uroplakins have also been shown to act as the primary attachment site of type 1 piliated uropathogenic *E. coli*.
- The GAG layer may have importance in bacterial antiadherence, but there is no definite evidence that the GAG layer serves impermeability function.
- Urothelial cells can release and respond to neurotransmitters.
- Myofibroblasts mediate interaction between urothelial cells and afferent nerves.

Smooth Muscle Physiology

Studies on bladder smooth muscle physiology have been a mainstay for understanding micturition function, because the detrusor smooth muscle must contract for the bladder to empty efficiently and normally. Understanding the factors that regulate smooth muscle quiescence could be applicable to clinical conditions characterized by DO such as OAB, neurogenic bladder, and underactive detrusor. Function of the smooth muscle, like striated muscle, is regulated by motor nerves (although autonomic rather than somatic), but unlike striated muscle, smooth muscle function can also be modulated by circulating hormones, local paracrine factors such as NO, and factors released by the urothelium. Although the coordinated and efficient contractions of the detrusor smooth muscle require neural control, detrusor muscle can generate spontaneous and rhythmic activity without neural input. The differences between smooth muscle versus striated muscle properties are shown in Table 110.1 (Chacko et al., 1999). The next several sections address physiologic aspects of detrusor smooth muscle function starting at the individual smooth muscle cell and moving to the whole organ level.

TABLE 110.1

Comparison of the Properties of Skeletal and Smooth Muscle

PROPERTY	SKELETAL MUSCLE	SMOOTH MUSCLE
Cell characteristics	Long cylindric cells with many nuclei	Spindle-shaped cells with a single nucleus
Maximum cell size (length × diameter)	30 cm × 100 µm	200 µm × 5 µm
Visible striations	Yes	No
Ultrastructure	Sarcomere pattern	No sarcomere pattern
	No immediate filaments	Intermediate filaments
		Dense bodies
Motor innervation	Somatic	Autonomic
Type of contracture	Phasic	Mostly tonic, some phasic
Contractile activity	Disinhibition of tropomyosin	Active myosin phosphorylation
	Sliding filaments	? Sliding filaments
	Rapid contraction	Formation of “latch state”

Calcium regulation	Rapid Ca^{2+} influx via T tubule	Voltage- and receptor-operated Ca^{2+} channels
		Release from internal stores
Basic muscle tone	Neural activity	Intrinsic, extrinsic factors
Force of contraction regulated by hormone	No	Yes

Contractile Proteins

Bladder (detrusor) smooth muscle cells contract by the interaction of thick and thin filaments within the intracellular cytoskeletal network. Thick filaments (15-nm diameter) are composed of myosin. Thin filaments (6- to 8-nm diameter) are composed mainly of actin. Bound to actin are tropomyosin (TM) and caldesmon (CaD), both of which are important in regulation of contraction. Intermediate filaments (10 nm in diameter) are composed of desmin and vimentin. Whereas contraction of smooth muscle cells is caused by the cross-bridge cycling between the thick and thin filaments, intermediate filaments can modulate the contractile response (see review by Tang [2008]). The thin and thick filaments of smooth muscle fibers are arranged as myofibrils that cross the fibers obliquely in a lattice-like arrangement, rather than the organized linear fashion of the sarcomere in striated muscle fibers. The thin and intermediate filaments attach to multiple sites within the cytoplasm (sarcoplasm) at locations called *dense bodies* (Fig. 110.11). The filaments of contractile proteins are also attached to the plasma membrane at junctional complexes between neighboring cells, which allow smooth muscle cells to contract as a syncytium.

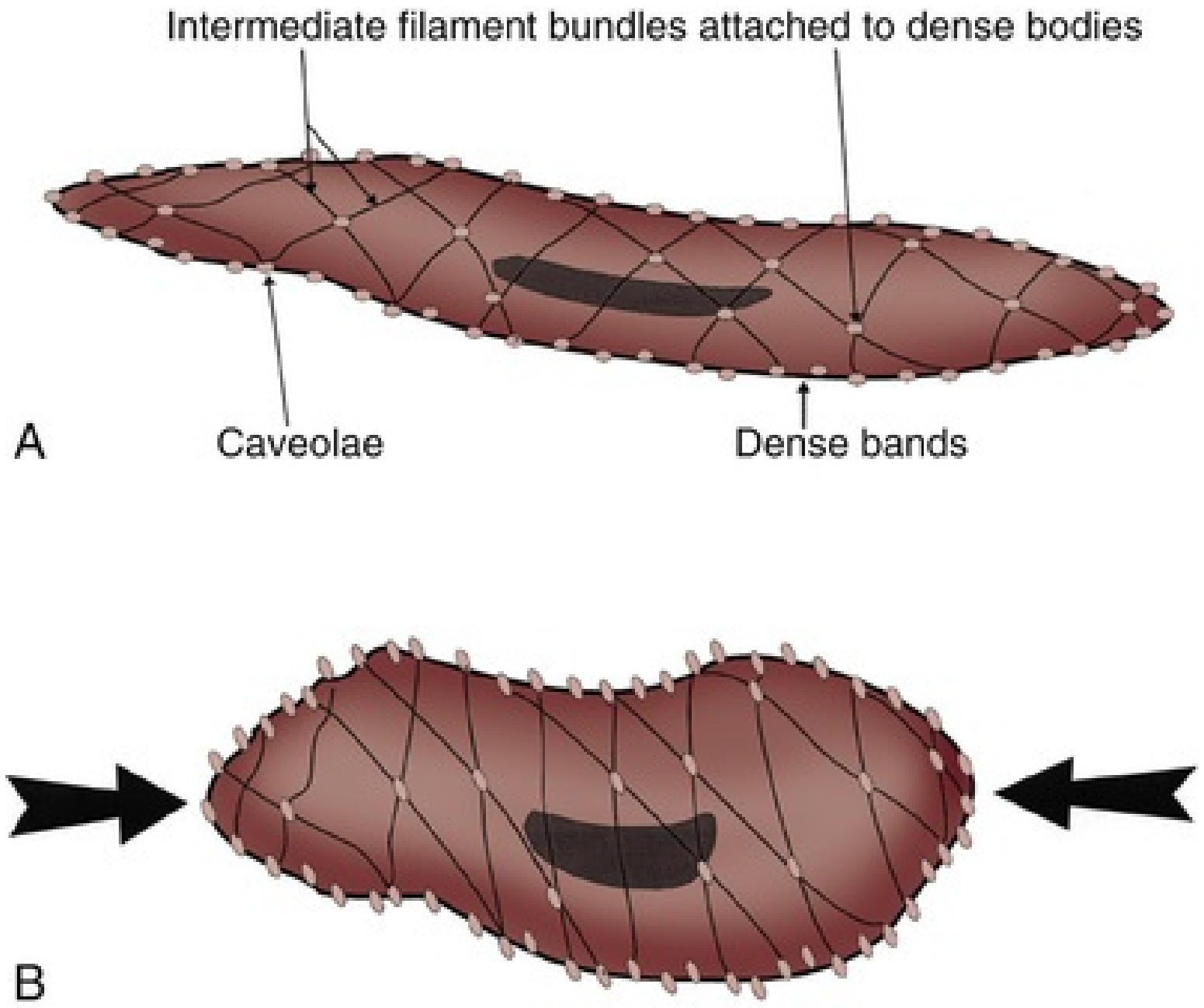

FIG. 110.11 The organization of the contractile elements of smooth muscle fibers by a simple model of the contraction of smooth muscle. (A) Relaxed smooth muscle cell. (B) Contracted smooth muscle cell. Intermediate filaments, dense bodies, and dense bands of smooth muscle fibers harness the pull generated during myosin cross-bridge activity. Intermediate and thin filaments attach to dense bodies scattered throughout the sarcoplasm and occasionally anchor to the dense bands situated between caveolae (invaginations of the sarcolemma). As the obliquely running contractile elements contract, the muscle shortens.

Thick filaments are made up of myosin II—two intertwined myosin heavy chains (MHCs) (Fig. 110.12) (as opposed to myosin I, which contains only one MHC). There are two areas of myosin II: the rod portion, which contains the coil region, and the head region, which contains globular domains of the two MHCs with an intervening hinge region between the coil and head. Alternative splicing of MHCs pre-mRNA at the 5′-end produces SM-A and SM-B isoforms of MHC, whereas alternative splicing at the 3′-end produces SM-1 and SM-2 isoforms of MHC. The bladder smooth muscle contains almost 100% SM-B. SM-B has a higher ATPase activity than SM-A; therefore SM-B can move actin filaments faster in an in vitro assay (Rovner et al., 1997).

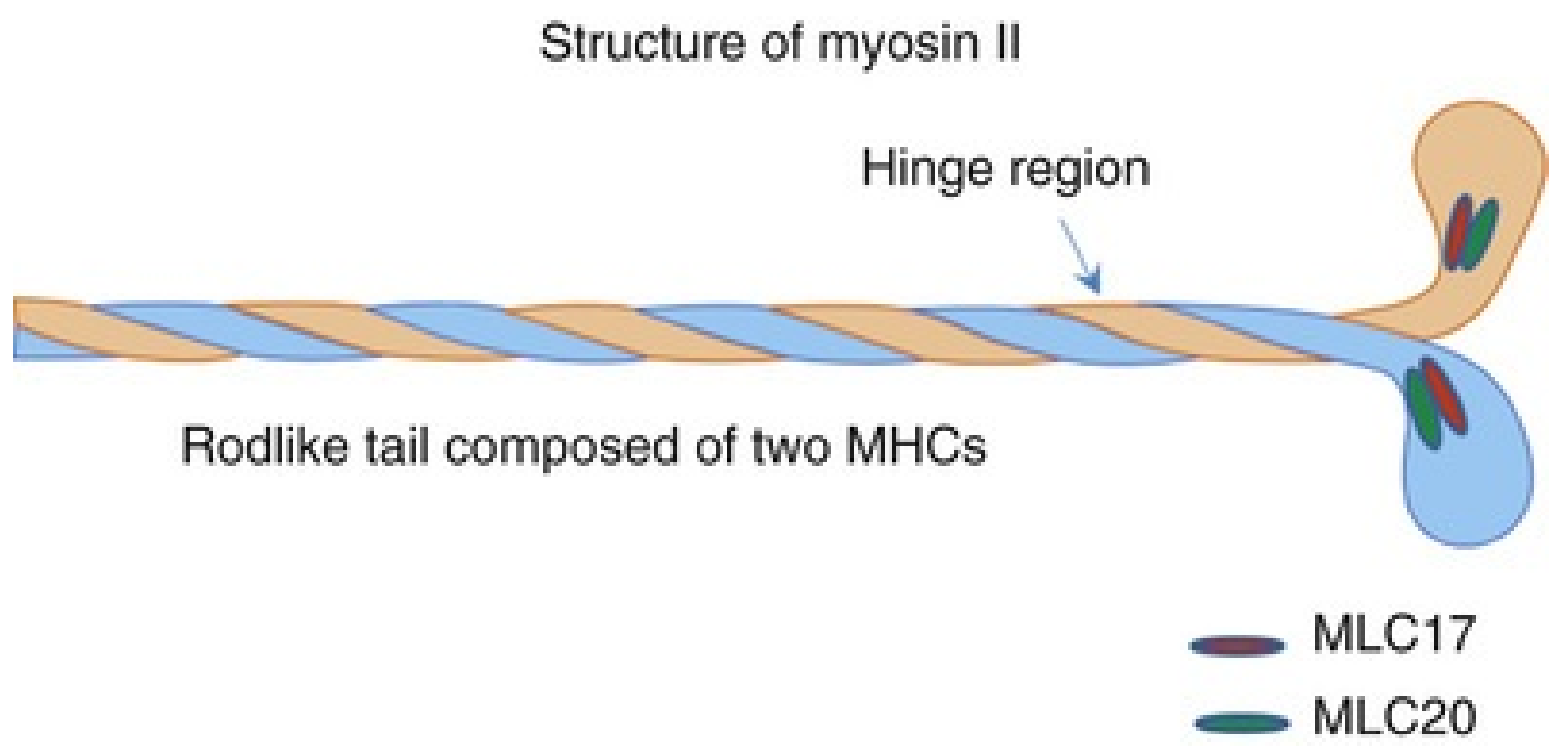

FIG. 110.12 Structure of myosin II composed of two intertwined myosin heavy chains (MHCs). MLC17 and MLC20 are two myosin light chains located on heads of myosin II.

Contained within each globular region of the MHC are two myosin light chains (MLCs), MLC20 (20 kDa) and MLC17 (17 kDa). These two MLC isoforms are encoded by different genes, but only one relates to contractility. Two MLC17 variants occur as a result of alternative splicing of a single MLC17 gene. **Cross-bridge cycling depends on the phosphorylation of MLC20, which increases the activity of an enzyme, myosin ATPase.**

Although studies of interactions between actin and myosin in cross-bridge cycling have been canonical in understanding smooth muscle contractility, the unique role of actin has been recognized and reviewed (Gunst and Zhang, 2008). The structure and organization of filamentous actin was thought to remain relatively constant during a contractile event. Furthermore, it was assumed that actin filaments anchored at adhesion sites at the plasma membrane and at dense bodies within the cytosol (see Fig. 110.11), which provides a fixed and stable network on which the myosin or thick filaments move during shortening and tension development. However, intracellular actin polymerization is now recognized as a seminal event in smooth muscle contraction. This actin polymerization also catalyzes recruitment of structural proteins that connect actin filaments and transmembrane integrin proteins to adhesion junctions (Fig. 110.13).

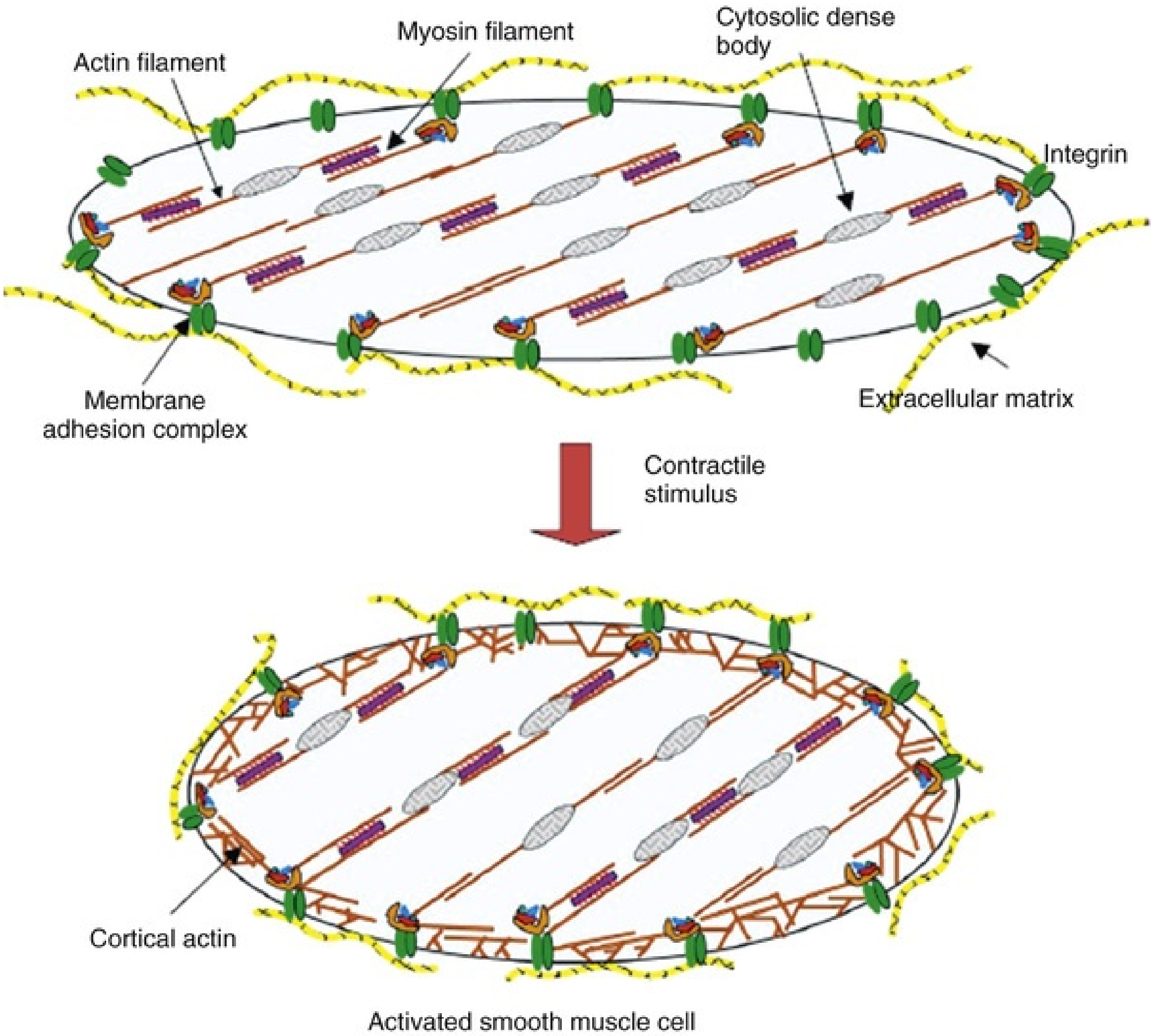
Actin filament
Myosin filament
Cytosolic dense body
Integrin
Membrane adhesion complex
Extracellular matrix
Contractile stimulus
Cortical actin
Activated smooth muscle cell

FIG. 110.13 Figure shows a single myocyte going from relaxation to contraction. The importance of actin polymerization at the periphery of the cell is that this network strengthens the membrane for force transmission from the actinomyosin cross-bridges. The regulation of actin polymerization is distinct and separate from actinomyosin cross-bridge cycling. (From Gunst SJ, Zhang W: Actin cytoskeletal dynamics in smooth muscle: a new paradigm for the regulation of smooth muscle contraction. *Am J Physiol Cell Physiol* 295:C576–C587, 2008.)

The interaction between actin and myosin in smooth muscle contractions is modulated by the actin-binding (actin-associated) proteins caldesmon (CaD) and tropomyosin (TM) (Fig. 110.14). These two proteins control access points on the actin filament to allow myosin II heads to form cross-bridges. Fig. 110.14 shows that CaD interacts with all of the contractile proteins and also calmodulin (CaM). CaD was first isolated from chicken gizzard smooth muscle in 1981 (Sobue et al., 1981). There are two isoforms of CaD: heavy CaD (h-CaD), which is associated with all smooth muscle, and light CaD (l-CaD), which is found in non–smooth muscle cells. CaD is an inhibitor of actinomyosin ATPase and motility, and actin binding and CaD inhibition are greatly enhanced in the presence of TM. Detailed descriptions of CaD functions have been reviewed (Wang, 2008). CaD is modulated by another protein, CaM. Although CaM is technically not a contractile protein, CaM is the protein that interacts with intracellular Ca^{2+} to initiate the contraction.

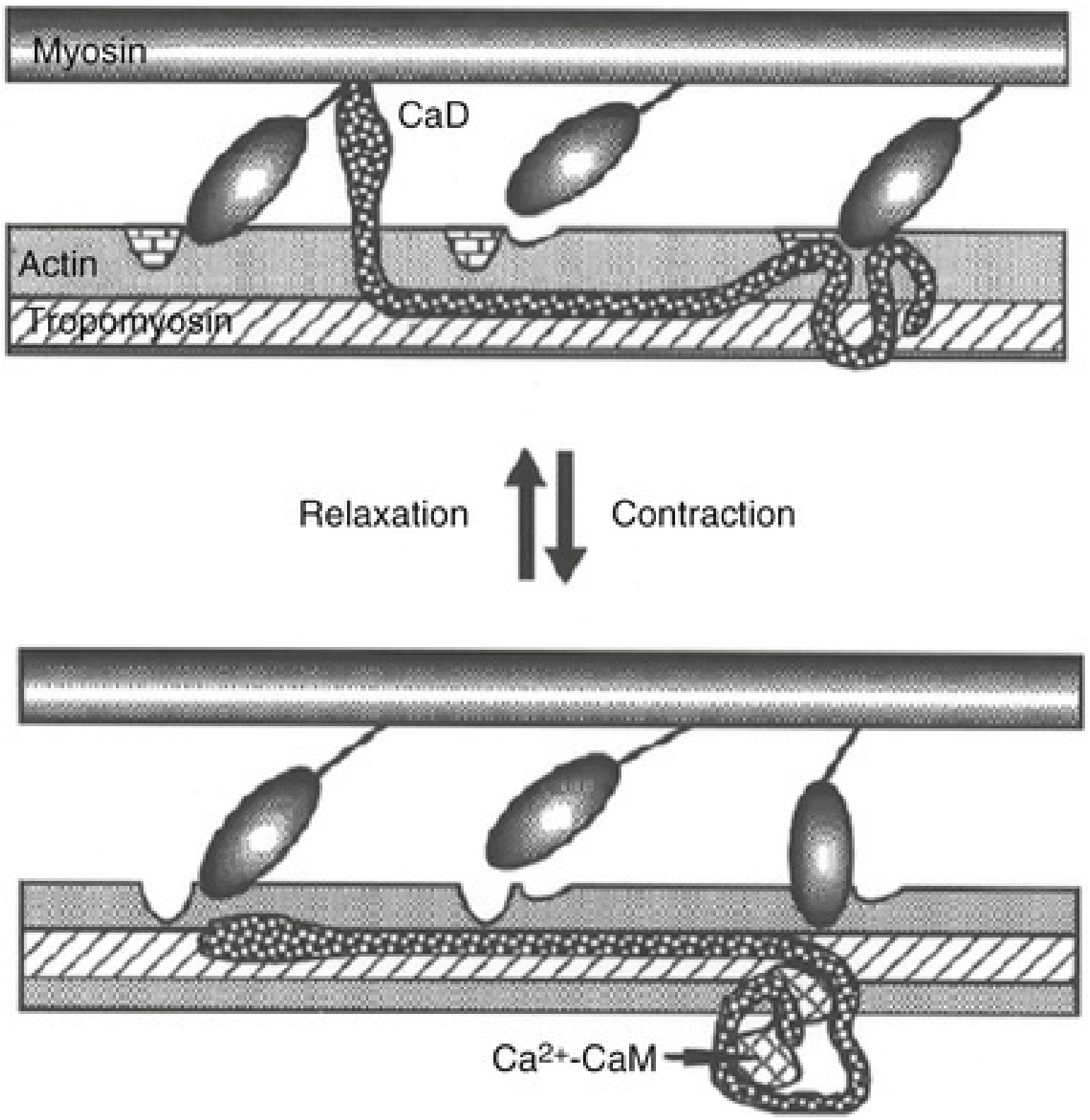

FIG. 110.14 Caldesmon (CaD) and tropomyosin are actin-bound proteins that regulate actinomyosin cross-bridging. CaD and tropomyosin move along the actin filament to expose actin binding sites for the head region of myosin II to generate contraction. (From Shirinsky VP, Vorotnikov AV, Gusev NB: Caldesmon phosphorylation and smooth muscle contraction. In Kohama K, Sasaki Y, editors: *Molecular mechanisms of smooth muscle contraction,* Austin, TX, 1999, RG Landes Company.)

Actinomyosin Cross-Bridge Cycling

The key step in smooth muscle cellular contraction is cross-bridge formation of myosin II heads to actin, which is dependent on rise of intracellular Ca^{2+}. When an action potential (AP) occurs in the smooth muscle cell, there is a rise in intracellular Ca^{2+}, which then binds to CaM, thereby activating myosin light chain kinase (MLCK) (Andersson and Arner, 2004; Gunst et al., 1993; Hai and Murphy, 1989). MLCK phosphorylates MLC20, which is in the head region of myosin II, cleaving a phosphate moiety in ATP, thus converting ATP to adenosine diphosphate (ADP) in the process. Phosphorylated MLC20 forms cross-bridges with (i.e., binds to) actin, leading to force generation (Andersson and Arner, 2004; Chacko et al., 1994; Gunst et al., 1993; Hai and Murphy, 1989; White et al., 1993). Dephosphorylation of MLC20 is catalyzed by myosin light chain phosphatase (MLCP), leading to detachment of the myosin II heads from actin and relaxation. An animation of these interactions is shown on the Expert Consult website. Key points in the smooth muscle contraction sequence are also presented in Box 110.1.

Box 110.1

Detrusor Smooth Muscle Contraction Sequence

- Ca^{2+} binds to calmodulin (CaM), activating it.
- CaM activates the kinase enzyme (myosin light chain kinase).
- The kinase enzyme catalyzes phosphate transfer from adenosine triphosphate to myosin, allowing myosin to interact with actin of the thin filaments.
- Smooth muscle relaxes with intracellular decrease in Ca^{2+} levels.

The determination of smooth muscle tone is therefore dependent on the balance of intracellular Ca^{2+} and the balance between MLCK and MLCP activities. Although Ca^{2+} is needed for MLCK activity, regulation of MLCP activity plays an important role in smooth muscle contractility. **Inhibition of MLCP activity promotes contractility and tone in the smooth muscle cell in the absence of increases in intracellular Ca^{2+} changes *(calcium sensitization)*. It has been shown that MLCP activity is under control of a series of complex molecular events related to two proteins, RhoA and Rho kinase (ROK).**

RhoA is part of a family of proteins known as *small GTPases*. The activity of RhoA (active vs. inactive forms) is based on the form of guanine phosphate bound to RhoA. Inactive RhoA is bound to guanosine diphosphate (GDP) (Rho-GDP), and active RhoA is bound to guanosine triphosphate (GTP) (Rho-GTP). Three classes of regulatory proteins control the cycling between active RhoA and inactive RhoA forms: (1) guanine nucleotide exchange factors (GEFs), which convert RhoA-GDP to Rho-GTP; (2) GTPase-activating proteins (GAPs), which convert Rho-GTP to Rho-GDP; and (3) guanine nucleotide dissociation inhibitors (GDIs), which bind to RhoA-GDP and prevent action of GEFs and prevent RhoA-GDP from translocating from cytosol to cellular membrane, which inhibits the activity of RhoA (Puetz et al., 2009).

Activated RhoA, RhoA-GTP, binds to ROK at the cellular membrane to activate ROK. **Activated ROK phosphorylates MLCP, inactivating MLCP, thus tipping the balance toward contraction of the smooth muscle cell.** Another mechanism in which activated ROK can inactivate MLCP is via phosphorylation of another protein, CPI-17 (Eto et al., 1997). Phosphorylated CPI-17 then can directly phosphorylate MLCP, thus inactivating MLCP. **Thus RhoA and ROK promote smooth bladder contractility by inactivation of MLCP** (Fig. 110.15).

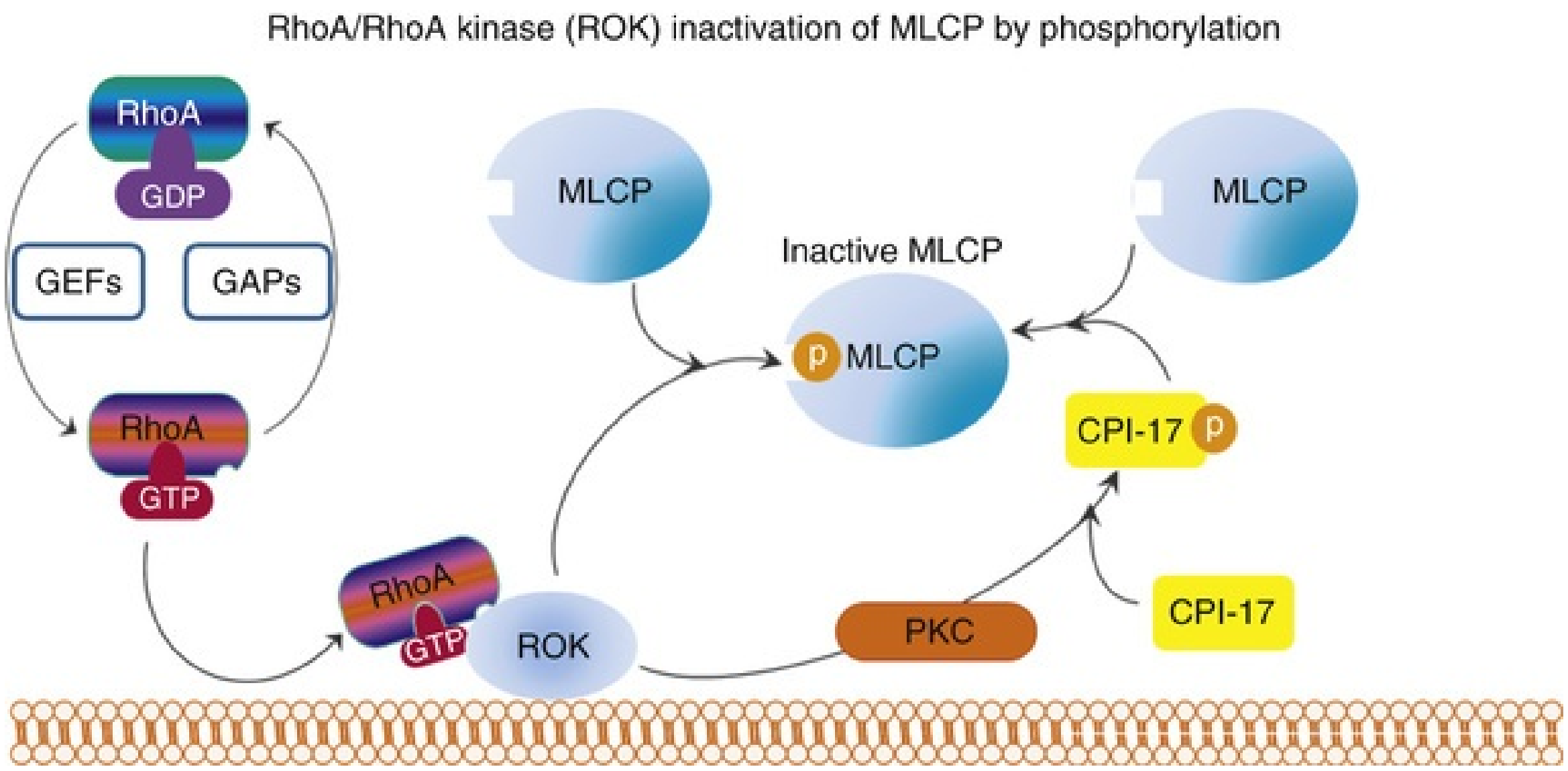

FIG. 110.15 Pathways for RhoA and Rho kinase (ROK) interaction with myosin light chain phosphatase (MLCP) in regulating smooth muscle contractility. See text for details. *GAPs,* GTPase-activating proteins; *GDP,* guanosine diphosphate; *GEFs,* guanine nucleotide exchange factors; *GTP,* guanosine triphosphate; *PKC,* protein kinase C.

Membrane Electrical Properties and Action Potentials

Smooth muscle cellular membrane potential is critical in regulating contraction because smooth muscle cells are excitable (can generate APs) and contractility is dependent on the membrane potential. One must keep in mind that studies of membrane properties of single smooth muscle cells do not take into account that the detrusor functions as a syncytium of cells involving gap junctions that allow electrical coupling among the cells. Furthermore, it is likely that in certain species, detrusor muscle interstitial cells, with their own intrinsic pacemaker activities, modulate smooth muscle cell excitability. Therefore, although single cell smooth muscle studies allow the ability to perform patch-clamp electrophysiologic experiments to study membrane properties, these findings are not necessarily reflective of the behavior of the syncytium of smooth muscle cells.

The membrane potential of a cell, in millivolts (mV), is created primarily by concentration differences between intracellular and extracellular spaces of the ions Na^+, K^+, and Cl^-. The approximate concentrations of these ions are as follows:

Ion Concentration (mEq/L)	**Na^+**	**K^+**	**Cl^-**
Intracellular	5–15 (low)	130–140 (high)	4–30 (low)
Extracellular	130–140 (high)	3–5 (low)	105–115 (high)

The equation for calculating membrane potential is determined by the Goldman-Hodgkin-Katz voltage equation, as follows:

$$Em = \frac{RT}{F} \ln\left(\frac{PNa[Na]o + PK[K]o + PCl[Cl]i}{PNa[Na]i + PK[K]i + PCl[Cl]o}\right)$$

where

Em = membrane potential
R = universal gas constant
T = absolute temperature
F = Faraday constant
PNa, PK, or PCl = permeability to that ion in arbitrary units

[…]o = concentration of that ion, outside (extracellular)
[…]i = concentration of that ion, inside (intracellular).

At rest, most cells are permeable to K^+ but impermeable to Na^+ and Cl^- (PNa and PCl = 0); thus the aforementioned equation for resting membrane potential essentially becomes the reversal potential for K^+, which is −62 mV. However, if the membrane becomes permeable Na^+ and Cl^-, the membrane potential will reflect the contribution of the electrochemical gradient of all these ions. The reversal potentials for Na^+ and Cl^- are approximately +65 mV and −85 mV, respectively. The resting membrane potential of human detrusor muscle cells varies and has been measured at −50 to −60 mV (Fry et al., 2002; Montgomery and Fry, 1992), although measurements in cultured human detrusor smooth muscle cells were more depolarized at −28 mV (Hristov et al., 2011).

Guinea pig smooth muscle cell APs were studied in detail by Klöchner (Klöchner and Isenberg, 1985). Pulse current (current passed from inside the cell to outside) via a patch electrode induced an AP, and continuous current resulted in a train of repetitive APs. The morphology of the AP tracings was typical of that of excitable cells, with four phases: phase 0, slow depolarization; phase 1, fast upstroke; phase 2, repolarization; and phase 3, hyperpolarization (Fig. 110.16). With use of voltage clamping techniques and pharmacologic channel blockers or changes in ion concentrations in extracellular buffer, the types of ionic currents that make up the phases of smooth muscle AP tracing were determined (see Fig. 110.16). Phase 1 fast upstroke of the AP is composed of a Ca^{2+} inward current (abbreviated I_{Ca}). Phases 2 repolarization and 3 hyperpolarization of AP are the result of a K^+ outward current (abbreviated I_K). These ionic currents are mediated by various ion channels.

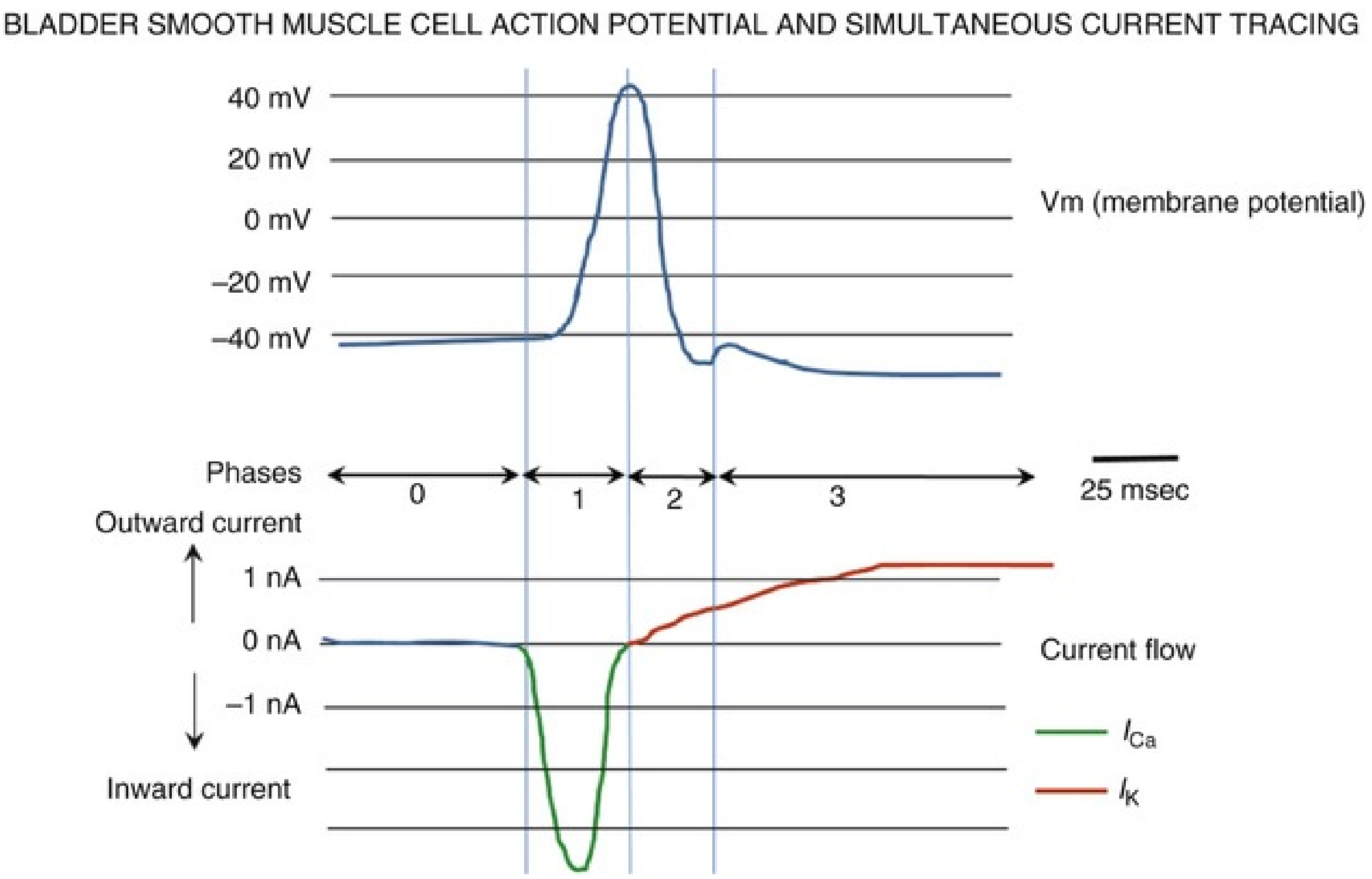

FIG. 110.16 The membrane potential *(upper panel)* and the current flow *(lower panel)* in a detrusor myocyte action potential (AP). There are four phases of the AP, and each phase is mediated by a different ionic current. Phase 0 is slow depolarization. Phase 1 is the fast upstroke of the AP mediated by Ca^{2+} inward current (I_{Ca}). Phases 2 and 3 are hyperpolarization of the AP mediated by K^+ outward current (I_K).

The I_K that occurs during phases 2 and 3 of the AP is the result of K^+ flowing out of the cell through different K^+ channels including small and large conductance calcium-activated K^+ channels (SK and BK, respectively) and voltage-gated K^+ channels (Kv) (Heppner et al., 1997; Hristov et al., 2011). **Blockage or inhibition of any of these K^+ channels would promote myocyte contractility and increase the propensity for spontaneous myocyte activity. Of these different types of K^+ channels, BK is the most critical.** BK regulates myocyte contractility by regulating the membrane potential, which in turn determines activity of the L-type voltage-dependent calcium channel (VDCC), which in turns determines $(Ca^{2+})_i$ and therefore the contractility of the myocyte.

Excitation-Contraction Coupling

When ACh, released by postganglionic parasympathetic nerve terminals, activates smooth muscle muscarinic M_3 receptors, smooth muscle intracellular Ca^{2+} concentration increases through two mechanisms: extracellular entry through VDCC L-type Ca^{2+} channels (Andersson and Arner, 2004; Andersson and Wein, 2004; Nausch et al., 2010; Schneider et al., 2004a, 2004b) and release of intracellular Ca^{2+} stores via G-protein activation with resultant inositol triphosphate (IP_3) production (Braverman et al., 2006a; Eglen et al., 1994; Fry et al., 2002; Harriss et al., 1995; Hashitani et al., 2000; Iacovou et al., 1990). Because the M_3 receptor is a canonical G_q-coupled protein (seven transmembrane domains), the downstream mechanisms after M_3 activation resulting in release of intracellular Ca^{2+} are reviewed in detail (Fig. 110.17). Other canonical receptors that share the same G_q-activated downstream mechanisms include all the odd muscarinic receptor subtypes (M_1, M_3, M_5), α_1-adrenoreceptors, angiotensin II receptors, histamine H_1 receptors, and 5-HT_2 serotonin receptors, although this is not the complete list (the 2012 Nobel Prize in Chemistry was awarded to Drs. Brian Kobilka and Robert Lefkowitz for their work in unraveling how G-coupled receptors work). Once the M_3 receptor is activated by ACh, it activates the α subunit of the G_q protein. The activated G protein then activates the membrane-bound enzyme, phospholipase C (PLC). Activated PLC cleaves a membrane phospholipid, PIP_2 (phosphatidylinositol 4,5-bisphosphate), to form cytosolic IP_3 (inositol triphosphate). IP_3 binds to its receptor at the SR, which causes stored Ca^{2+} to be released. The other product of PIP_2 cleavage is diacylglycerol (DAG), which remains membrane bound. DAG binds to protein kinase C (PKC), which is bound to the membrane, thereby activating PKC. PKC is a protein kinase that goes on to phosphorylate myriad proteins to induce secondary signals. Fig. 110.17 shows a diagram of the two categories of secondary messenger pathway that all G-coupled receptors follow: One pathway is the IP_3/PKC pathway, and the other is the cyclic adenosine monophosphate/protein kinase A (cAMP/PKA) pathway. The M_2 receptor subtype is coupled to $G_{i/o}$ and results in increased cAMP and activation of PKA. It has been shown in transgenic animals, in which selective deletion of either M_2 or M_3 receptors is created, that M_3 is the subtype that mediates the bladder contractions in the mouse and humans (Fetscher et al., 2002; Matsui et al., 2000; Stengel et al., 2002).

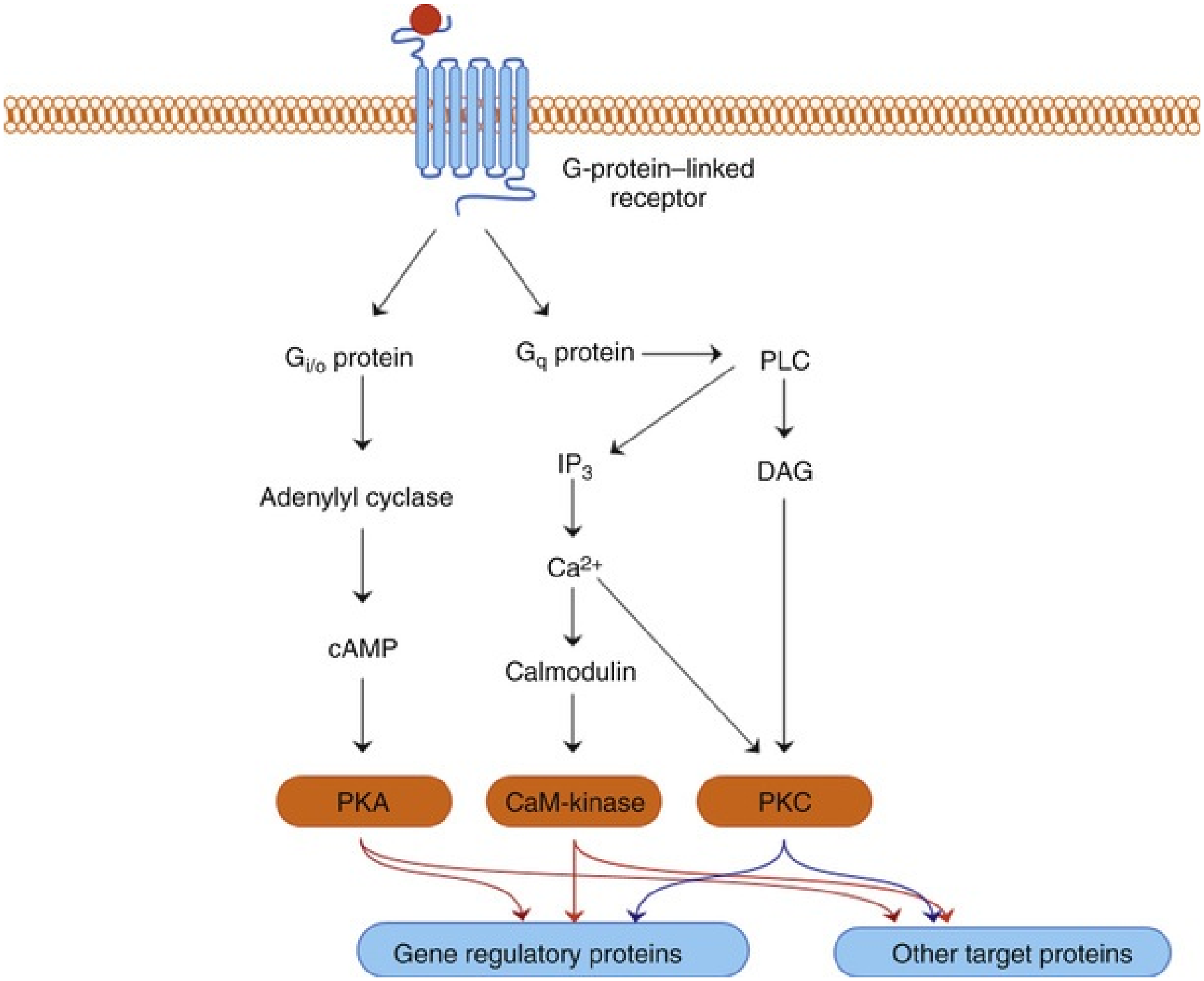
G-protein–linked receptor
$G_{i/o}$ protein
G_q protein
PLC
Adenylyl cyclase
IP_3
DAG
Ca^{2+}
cAMP
Calmodulin
PKA
CaM-kinase
PKC
Gene regulatory proteins
Other target proteins

FIG. 110.17 Paradigm for G-protein–linked receptor downstream mechanisms. Even muscarinic subtype receptors (M_2, M_4) are $G_{i/o}$-protein coupled. Odd muscarinic subtype receptors (M_1, M_3, M_5) are G_q protein coupled. *CaM,* Calmodulin; *cAMP,* cyclic adenosine monophosphate; *DAG,* diacylglycerol; *IP_3,* inositol triphosphate; *PKA,* protein kinase A; *PKC,* protein kinase C; *PLC,* phospholipase C.

The dogma that the release of intracellular stores of Ca^{2+} is the main driver for nerve-induced smooth muscle contraction has been challenged. Investigators have shown in **mouse detrusor smooth muscle that Ca^{2+} entering through L-type VDCCs is the only driver of contraction** (Nausch et al., 2010) after nerve stimulation with electric field stimulation (EFS), which causes efferent nerves to release neurotransmitters. EFS-induced smooth muscle contraction was reduced with an anticholinergic (atropine) and VDCC blocker (diltiazem), but EFS-induced contractions were not reduced by blocking IP_3-mediated signaling or inhibition of PLC. In this study, all purinergic components were blocked by using α,β-methylene ATP in the experiments, so only the muscarinic component was being studied.

Although the normal contraction in the human detrusor smooth muscle is mediated by ACh, in disease states the excitation neurotransmitter could possibly be caused by ATP. Human bladders from obstructed and OAB subjects were studied and found to have atropine-resistant contractions that were blocked by the ATP-receptor blocker α,β-methylene ATP, suggesting a purinergic excitatory component to the pathologic bladder contractions (Bayliss et al., 1999). In this study, normal human bladders had no purinergic excitation-coupling signaling. Investigations in mouse smooth bladder revealed that $P2X_1$ and M_3 receptors contribute to the muscle contractions. However, there appeared to be an element of suppression of the muscarinic excitation-contraction coupling by purinergic activation (Heppner et al., 2009). This observation supports a hypothesis of how DO (LUTS) and bladder underactivity can occur simultaneously in a patient, as with detrusor hyperactivity with impaired contractility (DHIC) (Resnick and Yalla, 1987). It has already been shown that purinergic signaling is increased in the human aging bladder (Yoshida et al., 2001). Furthermore, if the interplay between purinergic and muscarinic signaling occurs in human as it does in mice, then this increased purinergic signaling detected in elderly human bladders can explain the occurrence of LUTS and overactivity (through increased purinergic-activated afferent activity; see later) with simultaneous incomplete bladder emptying (detrusor underactivity or impaired contractility through suppression of muscarinic signaling). This describes DHIC. Furthermore, this interplay gives rise to the possibility of treating DHIC by blocking purinergic signaling.

Calcium Signaling in Detrusor Myocyte

Because contractility of the smooth muscle is dependent on Ca^{2+}, there are many control mechanisms regulating intracellular Ca^{2+}. I_{Ca} (Ca^{2+} inward current) occurring during the phase 1 fast upstroke of APs is mediated by voltage-dependent Ca^{2+} channels (gene name is *CaV* or *CACNA1*). As discussed in the previous section, Ca^{2+} entry through the VDCC is likely the main contributor to the contraction. There are several types of VDCCs, but the two types that are important in bladder smooth muscle contraction are L-type (*L* = long lasting) and T-type (*T* = transient). The classic VDCC, the L-type, which is blocked by traditional Ca^{2+} blockers such as nifedipine (a dihydropyridine), diltiazem (a nondihydropyridine), and verapamil (a phenylalkylamine), is present on smooth muscle cells and is activated by AP-induced depolarization (Nausch et al., 2010; Rivera and Brading, 2006). T-type VDCCs responded to lower magnitudes of depolarization, had smaller conductance, and have no highly specific blockers yet (Fry and Jabr, 2014). The participation of T-type VDCCs in bladder smooth muscle physiology may allow a finer control of the excitation coupling and/or be important in detrusor contractile pathologies. Calcium imaging is a technique whereby one can visualize changes in single-cell intracellular Ca^{2+} concentrations ($[Ca^{2+}]_i$) by using calcium dyes that fluoresce with intensities directly correlated with $(Ca^{2+})_i$. Calcium imaging during the course of a smooth muscle cell contraction reveals a “calcium flash” caused by a sudden large increase in $(Ca^{2+})_i$ followed by mechanical contraction with shortening of the cell. This influx of Ca^{2+} through both types of VDCC initiates the actinomyosin cross-bridge cycling as detailed in the previous section.

When $(Ca^{2+})_i$ rises via entry through VDCCs during the AP, this causes the SR to release its stores of Ca^{2+} (internal stores) through ryanodine receptors (RyRs)—a phenomenon called *calcium-induced calcium release* (CICR). Internal stores of Ca^{2+} released are visualized as “calcium sparks” (from microfluorometry) that were first discovered in arterial smooth muscle (Nelson et al., 1995). These calcium sparks activate (open) the nearby membrane-associated calcium-activated large conductance potassium channel (BK or gene name *KCNMA1*), which lets potassium out of the cell, thus hyperpolarizing the cell and relaxing the smooth muscle cell (see prior section about I_k portion of the AP and Fig. 110.16). These calcium sparks are the cause of the spontaneous transient outward currents (STOCs) of K^+ mediated by the BK channel. Calcium sparks were studied in detrusor smooth muscle (Collier et al., 2000; Herrera et al., 2001). In bladder myocytes, the calcium sparks (e.g., RyR openings) were not tightly linked to the gating of L-type VDCCs, as in cardiac myocytes, because the SR is not as physically close to the VDCC in the bladder myocytes as in the cardiac myocytes. Similar to arterial myocytes, the calcium sparks in detrusor myocytes also activate BK channels. These interactions are shown in the animation on the ExpertConsult.com.

Intracellular Ca^{2+} also activates a variety of cellular responses when it enters the cytoplasm of a cell. To be effective as a signal, its concentration must be returned to submicromolar levels, driven by ATP pumps. The Ca^{2+} pump is a membrane-bound, Ca^{2+}-activated ATPase, similar to the Na^+-K^+ pump that controls ion balance and membrane potential in all animal cells. These pumps belong to a superfamily of ATPases known as *P type*, because they depend on the autophosphorylation of a conserved aspartic acid residue using ATP. The rise in intracellular Ca^{2+} can be lowered by pumping Ca^{2+} back into the SR or mitochondria or out into the extracellular space (Fig. 110.18).

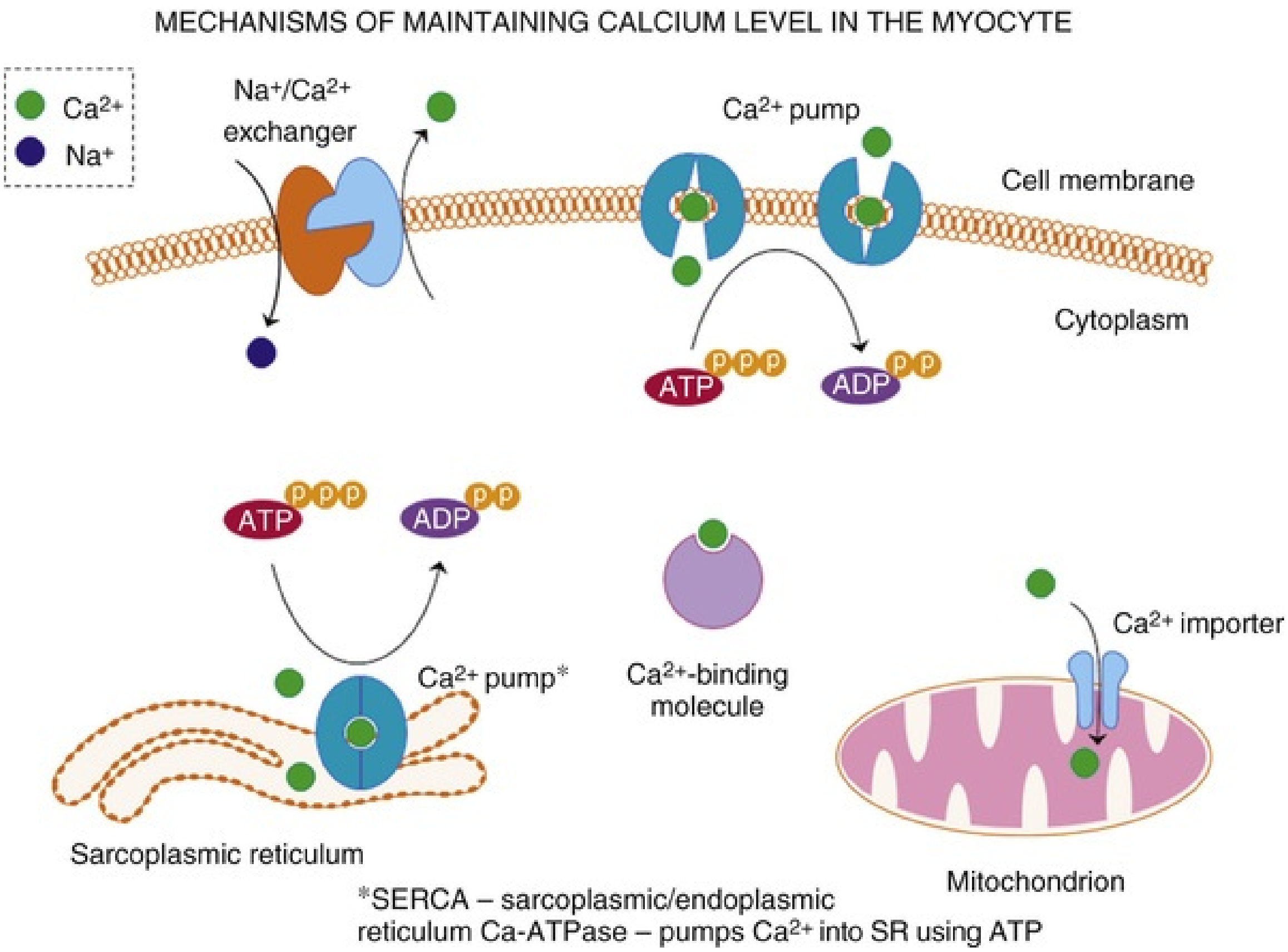
MECHANISMS OF MAINTAINING CALCIUM LEVEL IN THE MYOCYTE

● Ca^{2+}
● Na^+
Na^+/Ca^{2+} exchanger
Ca^{2+} pump
Cell membrane
Cytoplasm
ATP
ADP
P P P
P P
Ca^{2+} pump*
Ca^{2+}-binding molecule
Ca^{2+} importer
Sarcoplasmic reticulum
Mitochondrion

*SERCA – sarcoplasmic/endoplasmic reticulum Ca-ATPase – pumps Ca^{2+} into SR using ATP

FIG. 110.18 Intracellular calcium *(green circles)* in the detrusor myocyte can be regulated by various mechanisms: (1) exchanging for Na^+ ion; (2) pumping out of cell using adenosine triphosphate (ATP); (3) pumping into sarcoplasmic reticulum (SR) with SERCA/ATP; (4) binding to calcium-binding molecule; (5) pumping into mitochondria. *ADP,* Adenosine diphosphate.

When intracellular stores of Ca^{2+} within the SR are depleted, the myocyte has a mechanism by which another type of Ca^{2+} channel (ORAI) opens, thus allowing influx of extracellular Ca^{2+} to refill the SR stores. This process is called the *store-operated* Ca^{2+} *entry* (SOCE) or capacitive Ca^{2+} entry. The sensor for

SR Ca^{2+} concentration is the protein called STIM (stromal interaction molecule) (Roos et al., 2005). When STIM senses low Ca^{2+} concentrations, STIM proteins aggregate to form discrete membrane clusters that tether the plasma membrane protein ORAI, allowing tetramers of ORAI to form a pore for extracellular Ca^{2+} entry into the cell (Penna et al., 2008). This Ca^{2+} channel composed of multiunits of ORAI is called *CRAC* (calcium release–activated channel). The electrophysiologic current measured from Ca^{2+} entry through CRAC is denoted I_{CRAC}. Although SOCE has been shown to be present in various other smooth muscles, SOCE has not been measured yet in detrusor myocytes but is likely to exist.

Propagation of Electrical Responses

Specialized proteins called **connexin 43 (gap-junction proteins)** are expressed between the membranes of connected smooth muscle cells. The basic unit (monomer) of Cx43 is composed of four transmembrane domains with the carboxy-terminal and amino-terminal intracellular (Fig. 110.19). Six monomers of Cx43 are arranged as a hexamer unit with a central pore channel. The hexameric unit Cx43 of two neighboring myocytes will have to dock to align the central pore so that ions can flow from one myocyte to another. The electrically coupled myocytes can be measured using double whole-cell patch (DWCP) electrophysiology. This technique was performed on cultured human myocytes and gap junction currents were detected; also, Western blots confirmed the presence of Cx43 (Wang et al., 2006).

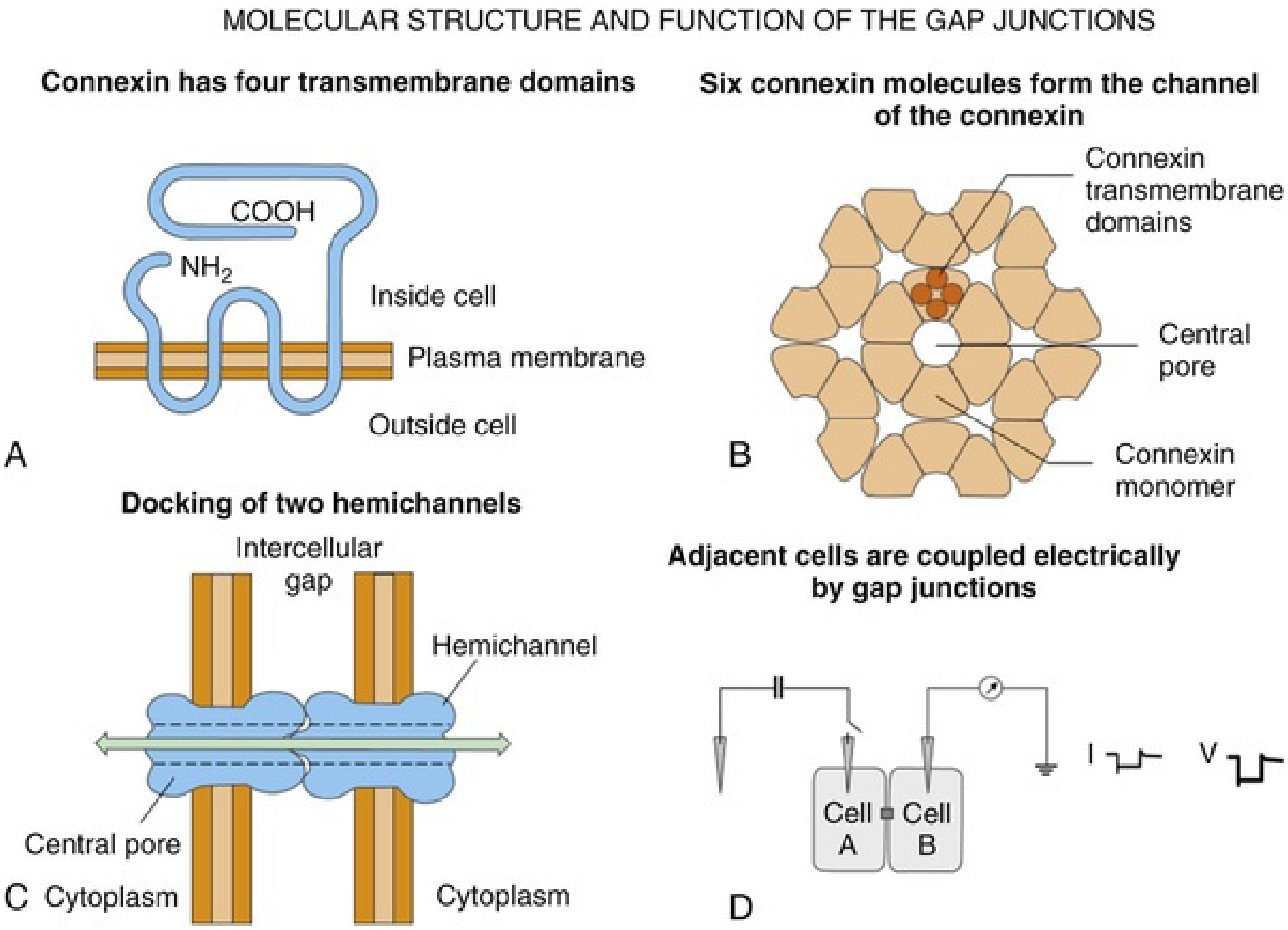
MOLECULAR STRUCTURE AND FUNCTION OF THE GAP JUNCTIONS
Connexin has four transmembrane domains
COOH
NH2
Inside cell
Plasma membrane
Outside cell
A
Six connexin molecules form the channel of the connexin
Connexin transmembrane domains
Central pore
Connexin monomer
B
Docking of two hemichannels
Intercellular gap
Hemichannel
Central pore
C
Cytoplasm
Cytoplasm
Adjacent cells are coupled electrically by gap junctions
Cell A
Cell B
I
V
D

FIG. 110.19 The molecular structure of a gap junction (e.g., connexin 43 [Cx43]). (A) Each connexin unit (monomer) has four transmembrane domains. (B) Six connexin units (monomers) form a hemichannel with a central pore. (C) Two hemichannels dock together to form a channel that allows passage of ions between cells. (D) Patch clamp can reveal electrically coupled cells.

However, lack of fused tetanic contractions in normal detrusor smooth muscle strips suggests that there is poor electrical coupling between smooth muscle cells (Uvelius and Gabella, 1980). **Measurements of tissue impedance support the observation that the detrusor is less well coupled electrically than other smooth muscles** (Brading and Mostwin, 1989; Parekh et al., 1990). **Poor coupling could be a feature of a normal detrusor that prevents synchronous activation of the smooth muscle cells during bladder filling.** Nevertheless, some degree of coupling within a muscle bundle clearly does exist, because it is possible to measure the length constant of a bundle (Seki et al., 1992). There is also evidence for gap-junction coupling between detrusor cells in humans and guinea pigs, detected by whole-cell patch clamp recordings (Wang et al., 2006) and Ca^{2+} imaging (Neuhaus et al., 2002), respectively. Significant expression of Cx43 and Cx45 gap-junction proteins is found in human detrusor muscles (John et al., 2003; Wang et al., 2006). However, electrical couplings between detrusor cells seem to be reduced during postnatal development because coordinated, large-amplitude, low-frequency contractile activity as seen in the neonate rat bladder declines and is replaced by low-amplitude, high-frequency, more irregular activity in older rats, which appears to depend on the disruption of the intercellular smooth muscle communication (Szell et al., 2003). It has also been suggested that a change in the properties of the cell coupling may underlie the generation of the uninhibited detrusor contractions occurring in overactive and aging bladders (Brading, 1997b, 2006; Seki et al., 1992).

Detrusor Interstitial Cells

Evidence suggests that the “normal” bladder may be spontaneously active and that exaggerated spontaneous contractions could contribute to the development of DO. In a rat model for DO, local areas of spontaneous contractions are increased and more coordinated in rat bladders with partial outlet obstruction (Drake et al., 2003). However, it is still not clear which cells generate spontaneous activity in the bladder. As mentioned before, detrusor myocytes could be spontaneously active, and electrical coupling through gap junctions could trigger spontaneous contractions (Brading, 1997b, 2006). Alternatively, another population of cells in the bladder known as *interstitial cells* or *myofibroblasts* has been proposed for a pacemaking role in spontaneous activity of the bladder (Andersson and Arner, 2004; Kumar et al., 2005). Interstitial cells have been identified in the human and guinea pig ureter, urethra, and bladder body (Fry et al., 2007; Hashitani, 2006; Kumar et al., 2005).

Interstitial cells, in addition to being located in the suburothelial layer, are also found in the detrusor layer and have been shown to be spontaneously active (Kumar et al., 2005). These cells are stained for c-KIT and located along both boundaries of muscle bundles in the guinea pig bladder (Hashitani, 2006; Hashitani et al., 2004; McCloskey and Gurney, 2002). These cells can fire Ca^{2+} waves in response to cholinergic stimulation by M_3 muscarinic receptor activation and can be spontaneously active, suggesting that they could act as pacemakers or intermediaries in transmission of nerve signals to smooth muscle cells (Johnston et al., 2008; McCloskey and Gurney, 2002; Fig. 110.20). However, Hashitani et al. (2004) have also suggested that interstitial cells in the detrusor may be more important for modulating the transmission of Ca^{2+} transients originating from smooth muscle cells than for being the pacemaker of spontaneous activity because spontaneous Ca^{2+} transients occur independently in smooth muscles and interstitial cells. It has also been demonstrated that the c-KIT tyrosine kinase inhibitor imatinib (Glivec) decreased the amplitude of spontaneous contractions in the guinea pig bladder (Kubota et al., 2004, 2006) and in muscle strips from the overactive human bladder, in which c-KIT–positive cells were increased compared with normal subjects (Biers et al., 2006), suggesting that targeting these receptors expressed in intradetrusor interstitial cells may provide a new approach for treating OAB. In addition, after application of SNP (an NO donor), interstitial cells throughout the bladder, but not detrusor muscle cells, demonstrate cGMP immunoreactivity (Gillespie et al., 2004; Smet et al., 1996). Thus increased levels of cGMP found in interstitial cells by using phosphodiesterase-5 (PDE5) inhibitors, for example, may diminish synchronicity between detrusor muscle bundles (Hashitani, 2006). These cells are also a source of prostaglandin E_2 (PGE_2) because of their expression of cyclooxygenase (COX) and a reduction in spontaneous activity of bladder muscle strips by use of PGE_2 receptor (EP) antagonists in rabbits (Collins et al., 2009).

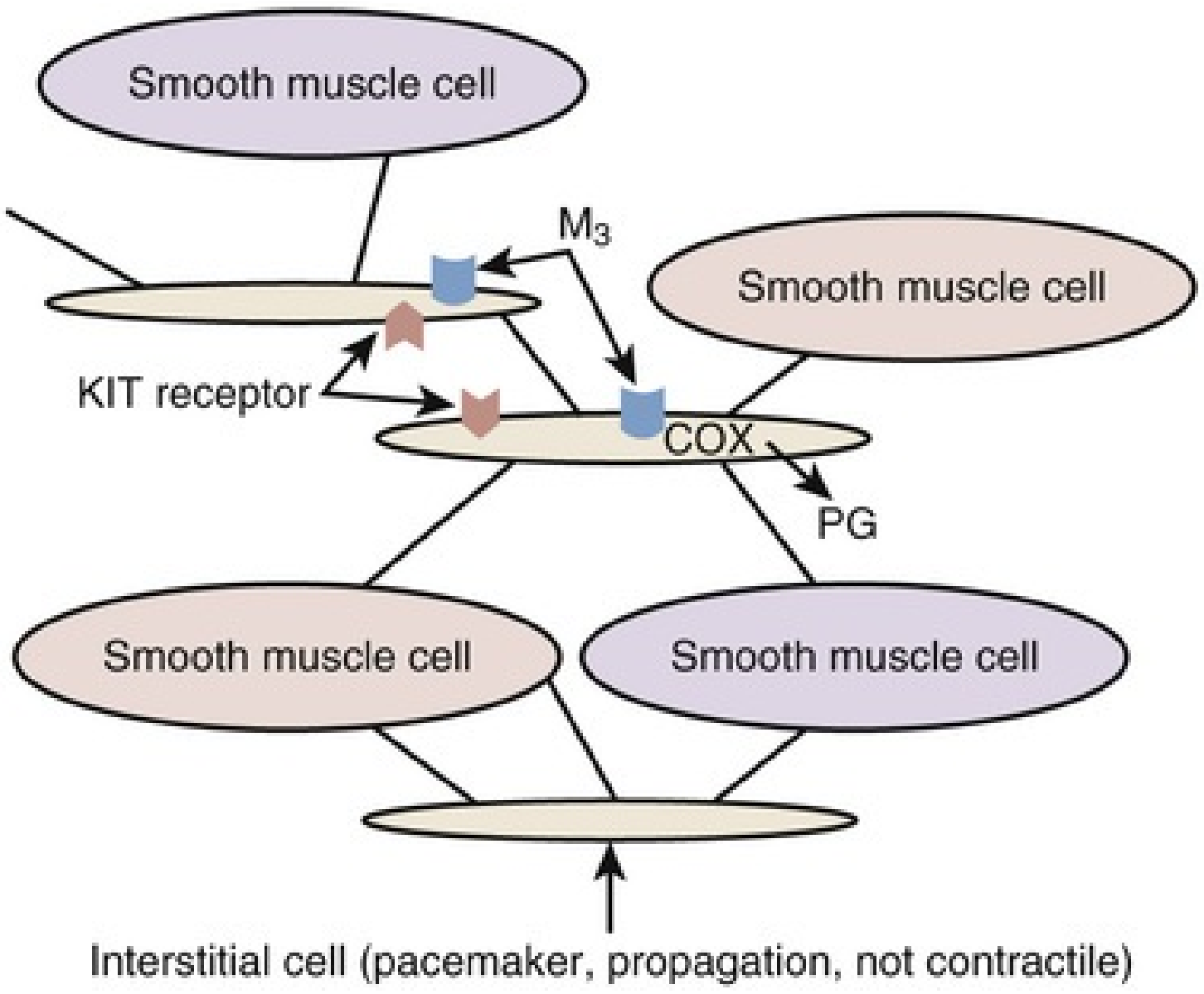

FIG. 110.20 Schematic representation of interstitial cells in the detrusor muscle layers. These cells are not contractile but may be pacemakers with spontaneous activity and propagate signals between detrusor muscles. They also express KIT receptors and muscarinic M_3 receptors, and can produce prostaglandins (PG), such as PGE_2, through activation of

cyclooxygenase (COX).

Investigators have found a new class of intradetrusor cells with pacemaker-like properties (Koh et al., 2012; Lee et al., 2014). These cells were not c-KIT positive, but rather expressed platelet-derived growth factor receptor (PDGFR)-α. The reason these investigators searched for this type of cell in the bladder was because the PDGFR-α–positive cells in the gastrointestinal tract have been found to inhibit neurotransmission in the myenteric neural plexus (Cobine et al., 2011; Kurahashi et al., 2011). Although purines such as ATP induce initial contraction of the bladder muscle (see the section on excitation-contraction coupling), there is also a prolonged relaxation that could be related to the suppression of the muscarinic excitation-coupling (Heppner et al., 2009). However, investigators found that the detrusor PDGFR-α cells, through $P2Y_1$ signaling, were the reason for the prolonged relaxation induced by purines (Lee et al., 2014). These investigators theorized that a “dual receptive field”—an excitatory field via $P2X_1$ on the smooth muscle and one inhibitory field via $P2Y_1$ on the PDGFR-α cells—provides finer regulation of detrusor contractility.

Further research is required to fully understand the role of suburothelial and intradetrusor interstitial cells and their contribution to spontaneous contractions or DO.

Key Points: Smooth Muscle Mechanics

- Muscarinic receptors induce detrusor contraction in response to ACh released from parasympathetic nerve terminals by calcium entry through Ca^{2+} channels.
- Although calcium serves the same triggering role in all muscle types, the mechanism of activation is different in smooth muscle. The contractile response is slower and longer lasting than that of skeletal and cardiac muscle.
- Evidence suggests that the “normal” bladder may be spontaneously active and that exaggerated spontaneous contractions could contribute to the development of an OAB. A population of cells within the detrusor layer, known as *interstitial cells* or *myofibroblasts*, has been proposed to have a pacemaking role in spontaneous activity of the bladder.

Bladder Mechanics

Urinary Storage (Filling)

During urine filling of the bladder, the viscoelastic behavior of the bladder depends on neuromuscular and mechanical properties. Mechanical properties are extremely sensitive to tissue structure and composition of the bladder wall. **In addition to smooth muscle, the human bladder is composed of roughly 50% collagen and 2% elastin. With injury, obstruction, or denervation, collagen content increases** (Macarak and Howard, 1999). When contractile protein content exceeds collagen, greater distensibility is achieved (compliance). **Conversely, when collagen levels increase, compliance falls.** The changes in the thickness of the lamina propria and the detrusor are mechanical requirements for the bladder to accommodate increasing urine volume. During filling, the lamina propria thins at a faster rate than the muscle wall. It has been proposed that bladder wall thinning during filling is the result of a rearrangement of the muscle bundles and also alteration of collagen coil structure (Macarak and Howard, 1999). A combination of muscle and connective tissue spatial changes is required to accommodate urine at low intravesical pressures (Chang et al., 1999). During filling, the detrusor reorganizes and muscle bundles shift position from a top-to-bottom to a side-to-side configuration. During reorganization, the coiled type III collagen fibers connecting the muscle bundles orthogonally become extended, longer, and taut and assume an orientation such that the fibers become oriented parallel to the lumen.

Bladder compliance *(C)* is defined as the change in volume *(V)* relative to the corresponding change in intravesical pressure *(P):*

$$C = DV/DP$$

Filling the bladder at a slow physiologic rate maintains an intravesical pressure of less than 10 cm H_2O (Klevmark, 1974). However, the compliance of the bladder is dependent on the rate at which fluid is instilled into the bladder (Coolsaet, 1985). This phenomenon can be seen in urodynamics when the intravesical pressure can drop when filling is slowed or stopped. The pressure-volume curve during filling of the bladder is dependent on several factors including (1) collagen, elastin, and smooth muscle as passive structures; (2) active properties of the smooth muscle; and (3) geometry of the bladder. Therefore, when there is decreased compliance of the bladder (steep filling curve), it may be the result of multiple factors including (1) fast filling rate; (2) change in composition of the bladder wall (e.g., more collagen, less elastin); (3) hyperactivity of the smooth muscle; and (4) a combination of any of these factors. The compliance of a typical bladder in 559 women with stress incontinence was measured with standardized urodynamics (50 mL/min filling rate). The data showed that the mean maximum cystometric capacity (MCC) was 392 mL; intravesical pressure (Pdet) rose from 2 cm H_2O at the beginning of fill to 6 cm H_2O at MCC (Nager et al., 2007).

Acute spinal transection of the bladder did not alter bladder compliance, although pelvic nerve transection did decrease compliance (Langley and Whiteside, 1951). **However, animal studies have suggested that central neural input is required for bladder compliance and that this is an active afferent neural process** (Smith et al., 2012b). These investigators theorized that afferent signals arising from the bladder wall during filling of the bladder are relayed to the CNS, which in turn inhibits spontaneous smooth muscle contractility, thus maintaining high bladder compliance during filling. In other words, the nervous system, in addition to viscoelastic properties of the bladder wall, has a role in maintaining bladder compliance during filling.

The bladder muscle has a broad length-tension relationship, allowing tension to be developed over a large range of resting muscle lengths (Uvelius and Gabella, 1980). The tissue shows viscoelasticity that influences muscle tension and manifests as total bladder wall tension (Venegas, 1991). Isolated detrusor strips show spontaneous mechanical activity to a variable extent. It is more frequently seen in bladders from small mammals (Sibley, 1984) but can also be seen in muscle strips from human detrusor. However, spontaneous fused tetanic contractions, such as those commonly seen in smooth muscles from the gastrointestinal tract and uterus, are almost never seen in normal bladders.

Voiding Mechanics

Intravesical pressure reflects the combined factors of abdominal (Pabd) and detrusor (Pdet) pressures. Therefore

$$Pdet = Pves - Pabd$$

Micturition relies on a neurally mediated detrusor contraction, causing Pdet to rise without a significant change in Pabd. To assess the strength of a detrusor contraction, Pdet alone is an insufficient measure. A muscle can use energy either to generate force or to shorten its length. Because the bladder is a hollow viscus, the force developed contributes to Pdet, whereas the velocity of shortening relates to urine flow (Q). There is a trade-off between generating Pdet and urine flow. This has been reviewed by Griffiths (1988). **If urethral resistance is low, as in women with sphincter insufficiency and even in normal continent women, Pdet may be almost undetectable; however, these women with modest Pdet would have normal flow rates.** In a population of 384 stress-incontinent women, the mean Pdet at Qmax on pressure-flow urodynamics study was 19 cm H_2O (Nager et al., 2007). In a group of 30 healthy men who underwent ambulatory urodynamics, Pdet at Qmax ranged from 60 to 70 cm H_2O (Schmidt et al., 2004). **The trade-off between Pdet and Q resembles a curve for constant mechanical power (W) in which**

$$W = Pdet \times Q$$

The equation explains why a woman could have normal detrusor contractility and normal detrusor power despite low voiding pressure. During micturition, Pdet reflects outlet resistance. When the urethra opens widely with a high flow (Q), little Pdet is needed to achieve the work necessary to empty the bladder. **The key message is that low voiding pressure in a woman does not equate with impaired detrusor contractility; she may simply be able to open her urethra widely. Moreover, pressure-flow nomograms developed for men for diagnosis of obstruction should not be applied to women without validation.**

Motor Sensory Network in Detrusor Muscle

Based on anatomic immunohistochemical localization studies of nerve fibers in the guinea pig, Gillespie has proposed a “motor sensory” network within the detrusor muscle wall (Gillespie et al., 2006; Fig. 110.21). This network involves the presence of sensory fibers (*green* and *red lines* in Fig. 110.21) next to detrusor myocytes and intradetrusor interstitial cells. Because the detrusor has spontaneous activity (as micromotions and/or nonvoiding contractions), the spontaneous smooth muscle contractions trigger sensory signals to the host. An increase in spontaneous activity of the detrusor smooth muscle could be interpreted as an urgency episode. Certainly, this model could help explain how decreasing smooth muscle spontaneous activity (e.g., with antimuscarinics) could decrease sensory input. The effect of tolterodine (antimuscarinic) and mirabegron (β_3 agonist) in decreasing nonvoiding contractions in a partial urethral obstruction animal model has been shown (Gillespie et al., 2012). However, the investigators did not measure the pelvic afferent output to determine whether that was reduced with the reduction of the nonvoiding contractions. Bladder wall micromotions were measured in women with sensory urgency, although the sample size was small (N = 6) (Drake et al., 2005). **This motor sensory network ties in the concept that it is not easy to separate the function of the bladder organ into simple efferent and afferent activities, because these two events are inexorably linked.**

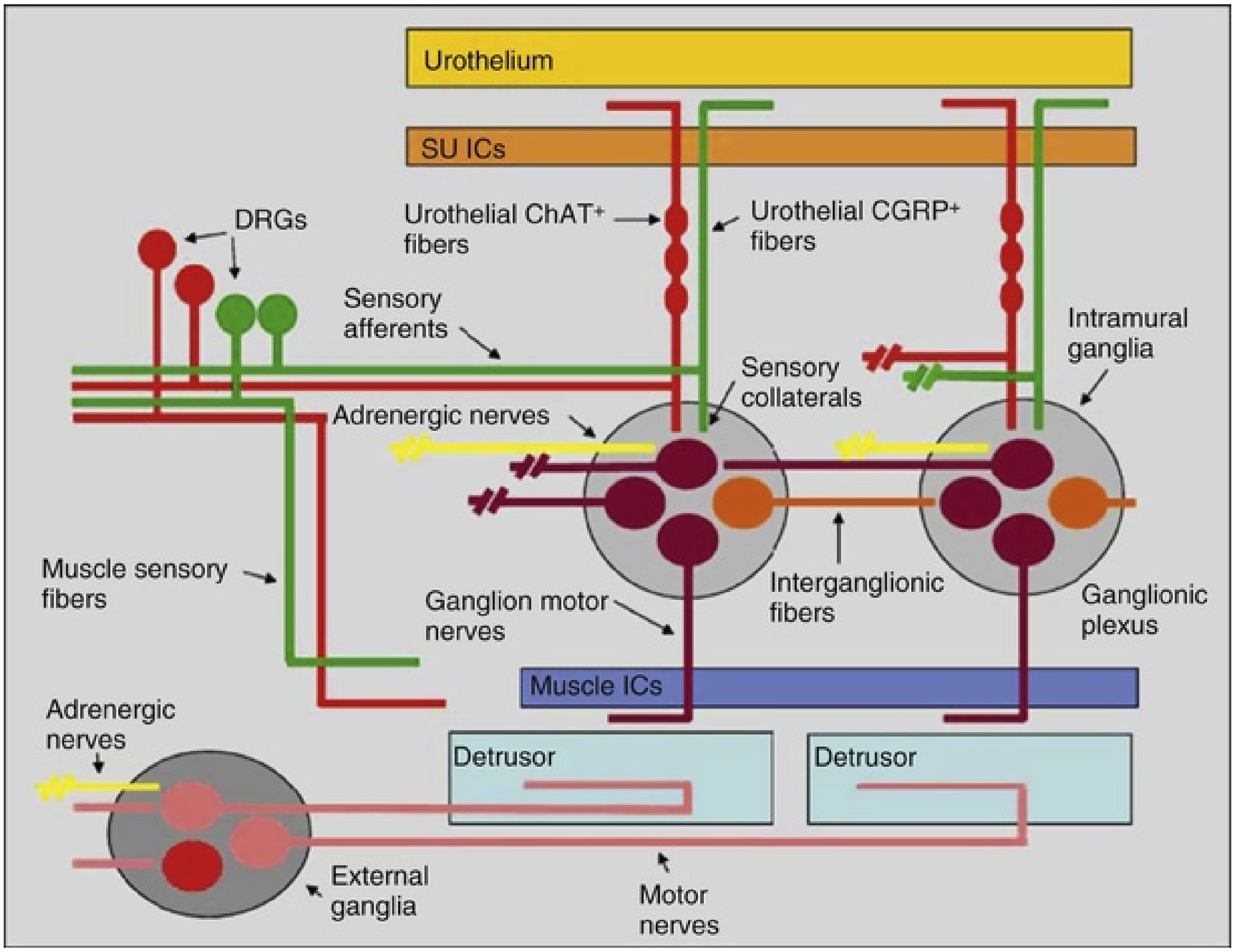
Urothelium
SU ICs
DRGs
Urothelial ChAT+ fibers
Urothelial CGRP+ fibers
Sensory afferents
Intramural ganglia
Sensory collaterals
Adrenergic nerves
Muscle sensory fibers
Ganglion motor nerves
Interganglionic fibers
Ganglionic plexus
Muscle ICs
Adrenergic nerves
Detrusor
Detrusor
External ganglia
Motor nerves

FIG. 110.21 Motor sensory network within the detrusor muscle wall.

Sensory afferents surround detrusor myocytes. *Gray circles* represent (1) intradetrusor ganglia that supply postganglionic efferents to detrusor muscle and (2) external ganglia. Detrusor myocyte spontaneous activity can trigger sensory afferents. *CGRP,* Calcitonin gene–related peptide; *ChAT,* choline acetyltransferase; *DRGs,* dorsal root ganglia; *ICs,* interstitial cells; *SU,* suburothelial.

Neural Control of the Lower Urinary Tract

Peripheral Nervous System

The LUT is innervated by three sets of peripheral nerves involving the parasympathetic, sympathetic, and somatic nervous systems (Fig. 110.22). Pelvic parasympathetic nerves arise at the sacral level of the spinal cord, excite the bladder, and relax the urethra. Lumbar sympathetic nerves inhibit the bladder body and excite the bladder base and urethra. Pudendal nerves excite the EUS. These nerves contain afferent (sensory) as well as efferent axons (de Groat and Booth, 1993; de Groat et al., 1993; Sugaya et al., 1997; Wein, 1992; Yoshimura et al., 2008).

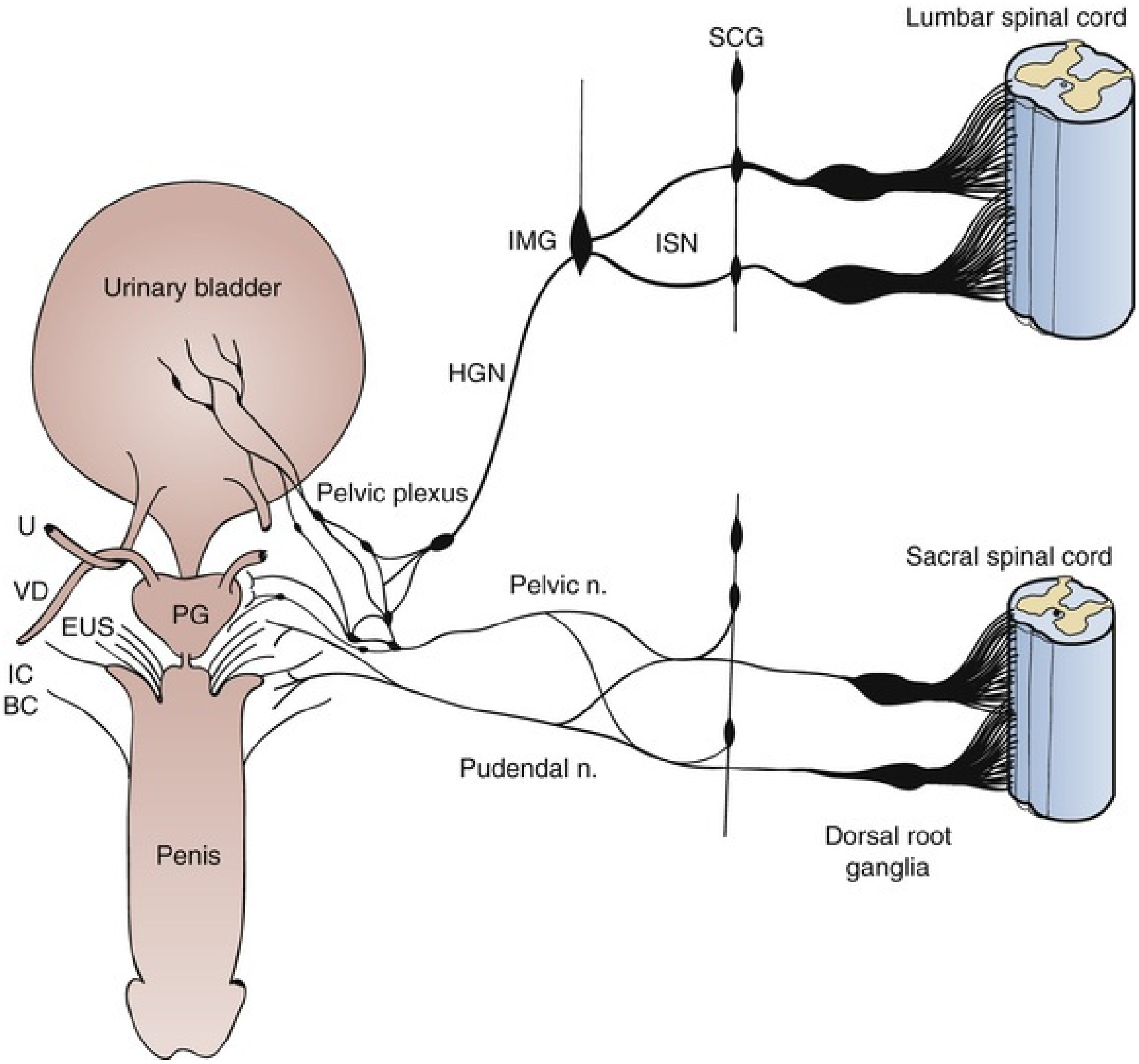
Lumbar spinal cord
SCG
IMG
ISN
Urinary bladder
HGN
Pelvic plexus
U
VD
EUS
PG
IC
BC
Pelvic n.
Sacral spinal cord
Pudendal n.
Penis
Dorsal root ganglia

FIG. 110.22 Diagram showing the sympathetic, parasympathetic, and somatic innervation of the urogenital tract of the male cat. Sympathetic preganglionic pathways emerge from the lumbar spinal cord and pass to the sympathetic chain ganglia (SCG) and then through the inferior splanchnic nerves (ISN) to the inferior mesenteric ganglia (IMG). Preganglionic and postganglionic sympathetic axons then travel in the hypogastric nerve (HGN) to the pelvic plexus and the urogenital organs. Parasympathetic preganglionic axons that originate in the sacral spinal cord pass in the pelvic nerve to ganglion cells in the pelvic plexus and to distal ganglia in the organs. Sacral somatic pathways are contained in the pudendal nerve, which provides an innervation to the penis and the ischiocavernosus (IC), bulbocavernosus (BC), and external urethral sphincter (EUS) muscles. The pudendal and pelvic nerves also receive postganglionic axons from the caudal sympathetic chain ganglia. These three sets of nerves contain afferent axons from the lumbosacral dorsal root ganglia. *PG,* Prostate gland; *U,* ureter; *VD,* vas deferens.

Parasympathetic Pathways

Parasympathetic preganglionic neurons innervating the LUT are located in the lateral part of the sacral intermediate gray matter in a region termed the *sacral parasympathetic nucleus* (de Groat and Booth, 1993; de Groat et al., 1993, 1996; Morgan et al., 1981, 1993; Nadelhaft et al., 1980). Parasympathetic preganglionic neurons send axons through the ventral roots to peripheral ganglia, where they release the excitatory transmitter ACh (de Groat and Booth, 1993). **Parasympathetic postganglionic neurons in humans are located in the detrusor wall layer as well as in the pelvic plexus. This is an important fact to remember because patients with cauda equina or pelvic plexus injury are neurologically decentralized but may not be completely denervated. Cauda equina injury allows possible afferent and efferent neuron interconnection at the level of the intramural ganglia** (de Groat and Booth, 1993; de Groat et al., 1993, 1996).

Sympathetic Pathways

Sympathetic outflow from the rostral lumbar spinal cord provides a noradrenergic excitatory and inhibitory input to the bladder and urethra (Andersson, 1993). Activation of sympathetic nerves induces relaxation of the bladder body and contraction of the bladder outlet and urethra, which contribute to urine storage in the bladder. **The peripheral sympathetic pathways follow a complex route that passes through the sympathetic chain ganglia to the inferior mesenteric ganglia and then through the hypogastric nerves to the pelvic ganglia.**

Somatic Pathways

The EUS motoneurons are located along the lateral border of the ventral horn, commonly referred to as the *Onuf nucleus* (Fig. 110.23; Thor et al., 1989). Sphincter motoneurons also exhibit transversely oriented dendritic bundles that project laterally into the lateral funiculus, dorsally into the intermediate gray matter, and dorsomedially toward the central canal.

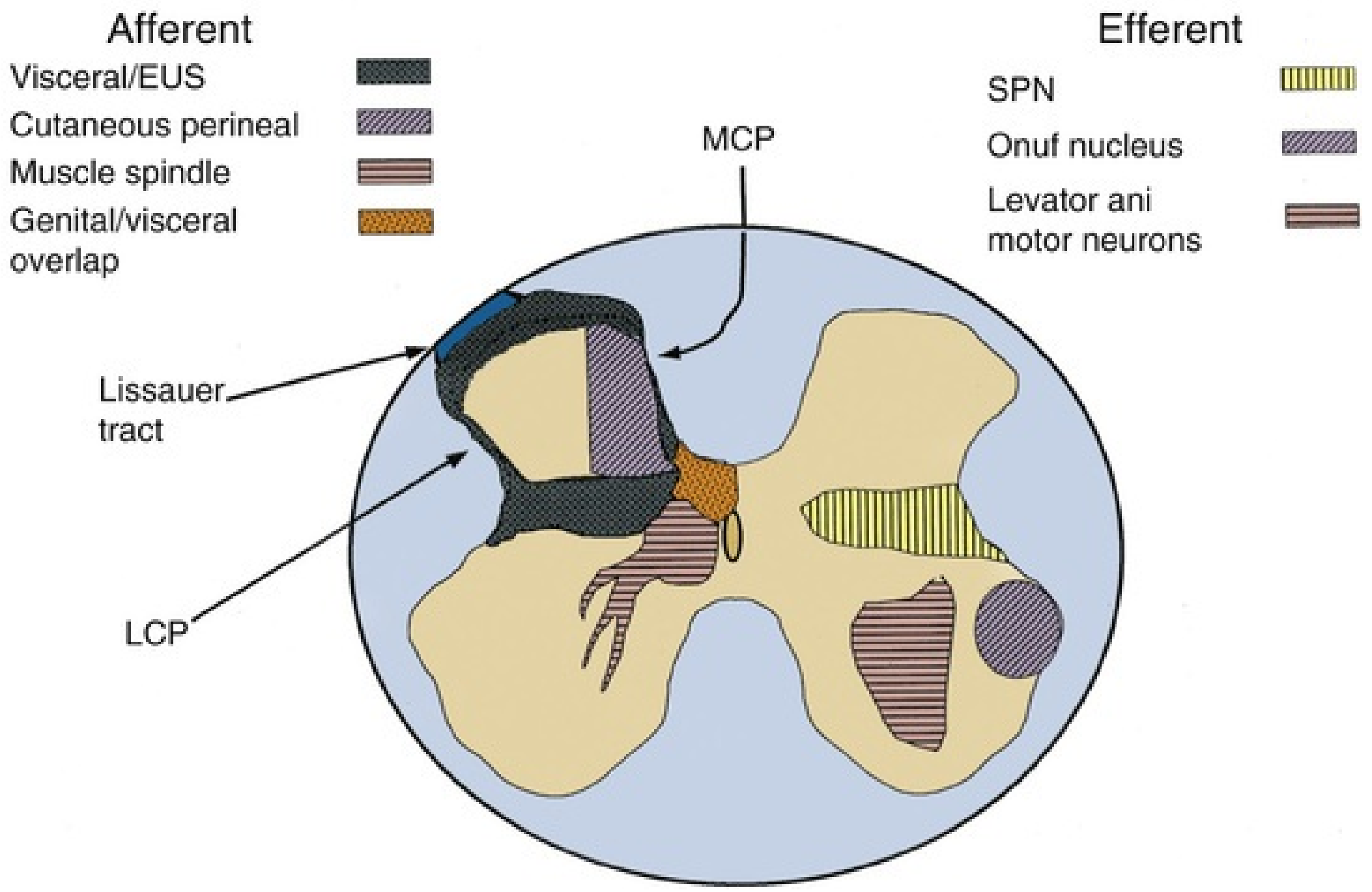

FIG. 110.23 Cross section of sacral spinal cord; neuroanatomic distribution of primary afferent and efferent components of storage and micturition reflexes. For purposes of clarity, afferent components are shown only on the left, and efferent components are shown only on the right. Both components are, of course, distributed bilaterally and thus overlap extensively. Visceral afferent components represent bladder, urethral, and genital (glans penis or clitoris) afferent fibers contained in the pelvic and pudendal nerves. Cutaneous perineal afferent components represent afferent fibers that innervate the perineal skin contained in the pudendal nerve. Muscle spindle afferent components represent Ia/b afferent fibers contained in the levator ani nerve that innervate muscle spindles in the levator ani muscle. *EUS,* External urethral sphincter; *LCP,* lateral collateral projection; *MCP,* medial collateral projection; *SPN,* sacral parasympathetic nucleus.

Afferent Pathways

Overview: Properties of Afferent Neurons.

The bladder and LUT store and evacuate urine and are controlled by a complex interaction of neural mechanisms organized by local, spinal, and brain circuits. The majority of time is spent in storage mode, during which the bladder accommodates urine and maintains continence via reflexes that prevent contraction of bladder smooth muscle and promote contraction of the urethral sphincter. This switches during micturition when the bladder contracts and the sphincter relaxes to facilitate voiding. This switch relies on sensory signals, which provide the input to the reflex circuits that control bladder filling and emptying and are also the source of nonpainful sensations of fullness and pain. Dysfunction leads to a number of disorders such as OAB syndrome and BPS/IC, with symptoms including urgency, pain, and urinary incontinence. Currently available therapeutic approaches are aimed primarily at reducing bladder contraction to relieve intravesical pressure and maintain continence. Interest in bladder afferent signaling has been driven by the realization that symptoms are a feature of dysregulated storage sensations rather than exaggerated contractile responses and therefore targeting afferent mechanisms may be a rational approach to treatment.

Pathways to the Spinal Cord.

Afferent fibers innervate the LUT via pelvic, hypogastric (lumber splanchnic), and pudendal nerves. These nerves are mixed nerves that also contain the efferent parasympathetic, sympathetic, and motor fibers supplying the bladder, urethra, and sphincters. Axonally transported dyes taken up by afferent nerves are transported to the afferent cell bodies in the lumbosacral dorsal root ganglia (DRG) and the afferent terminations in the dorsal horn of the spinal cord. The primary afferent neurons of the pelvic and pudendal nerves are contained in sacral DRG, whereas afferent innervation in the hypogastric nerves arises in the rostral lumbar DRG. The central axons of the DRG neurons carry the sensory information from the LUT to second-order neurons in the spinal cord (De Groat, 1986; de Groat et al., 1996; Morgan et al., 1981; Thor et al., 1989). These second-order neurons provide the basis for spinal reflexes and ascending pathways to higher brain regions involved in micturition, continence, and mediation of sensation.

Pelvic nerve afferents, which monitor the volume of the bladder and the amplitude of the bladder contraction, consist of myelinated (Aδ) and unmyelinated (C) axons (Table 110.2, Fig. 110.24). During neuropathic conditions (spinal cord injury) and possibly inflammatory conditions, there is recruitment of C fibers that form a new functional afferent pathway that can cause urgency incontinence and possibly bladder pain (Fig. 110.25).

TABLE 110.2

Bladder Afferent Properties

FIBER TYPE	**LOCATION**	**NORMAL FUNCTION**	**INFLAMMATION EFFECT**
	Smooth muscle	Sense bladder fullness (wall tension)	Increase discharge at lower pressure threshold
C fiber (unmyelinated axons)	Mucosa	Respond to stretch (bladder volume sensors)	Increase discharge at lower threshold
C fiber (unmyelinated axons)	Mucosa muscle	Nociception to overdistention	Sensitive to irritants
		Silent afferent	Become mechanosensitive and unmask new afferent pathway during inflammation

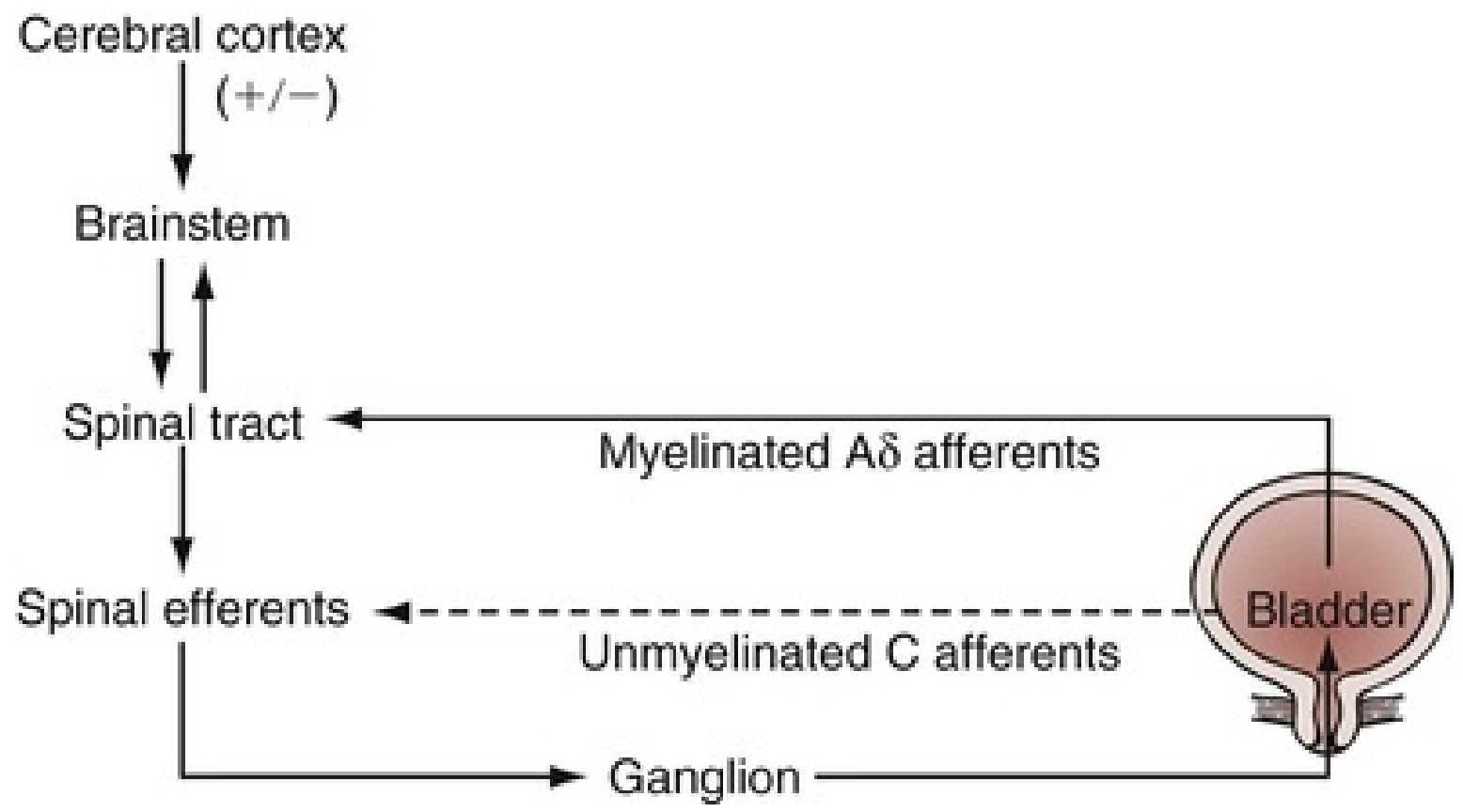
Cerebral cortex
(+/−)
Brainstem
Spinal tract
Myelinated Aδ afferents
Spinal efferents
Unmyelinated C afferents
Bladder
Ganglion

FIG. 110.24 Illustration depicting the predominant Aδ afferent contribution to the normal micturition reflex. C-fibers *(dotted line)* are normally silent unless turned on by pathology.

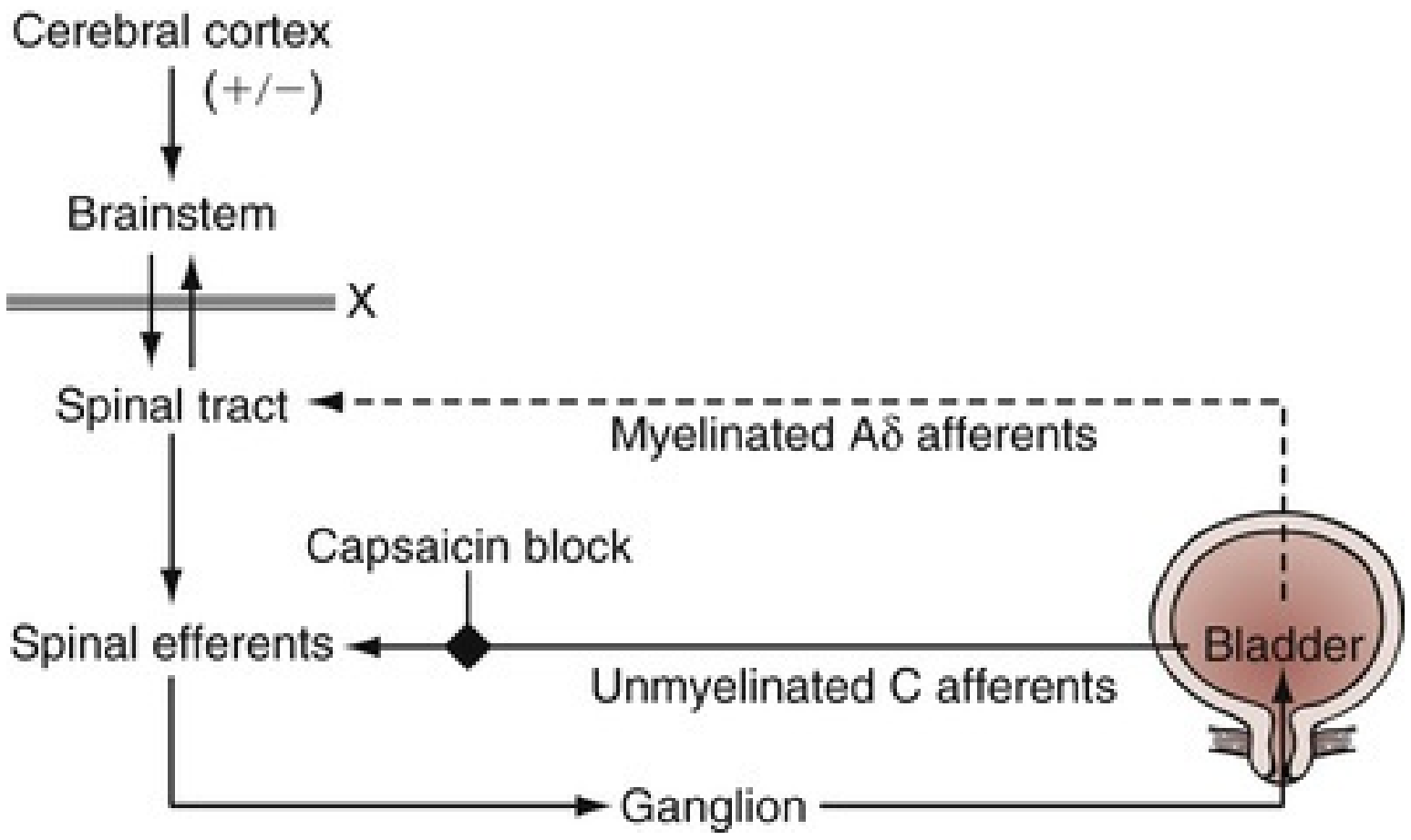

FIG. 110.25 Illustration depicting the switch in afferent contribution to the micturition reflex from Aδ-fiber predominant to C-fiber predominant with neurologic diseases, aging, and possibly inflammatory disease. Note that capsaicin (and other vanilloids) can block the C-fiber contribution under these conditions.

There is great interest in understanding the nature and origins of bladder sensation. “Sensing” bladder volume is of particular relevance during bladder storage. Nathan (1956) described the sensations of awareness and desire to micturate involving bladder distention (stretch) and contraction and suggested that these could be mapped to the urinary bladder. In contrast, the sensation of imminent micturition may originate not in the urinary bladder, but rather from the urethra. Ideas have been promulgated that link bladder filling with episodic bursts of sensation (correlating with afferent discharge) that increase in intensity during filling, with the final episodes being the most intense and often described as “urgency” (Chapple and Wein, 2005). Afferent discharges that occur during a bladder contraction have an important reflex function and appear to reinforce the central drive that maintains the detrusor contraction. Afferent nerves that respond to distention and contraction—that is, “in-series tension receptors”—have been identified in the pelvic and hypogastric nerves of cats and rats (Floyd et al., 1976; Iggo, 1955; Morrison, 1997). Afferents that respond only to bladder distention have been identified in the rat bladder (Morrison et al., 1998) and appear to be volume receptors, possibly sensitive to stretch of the urothelium. In the cat bladder, the presence of in-series tension receptors has also been reported (Downie and Armour, 1992). In the rat, there is evidence that many C bladder afferents are stretch receptors that do not respond to bladder contractions, a property that distinguishes them from in-series tension receptors (Morrison et al., 1998).

Functional Properties of Bladder Afferents.

In the human bladder, ultrastructural studies have identified only unmyelinated nerves in the urothelium and immediate suburothelial layer, with small myelinated nerves being closely associated with the smooth muscle layers (Wiseman et al., 2002). The plexus of afferent nerves in the lamina propria is thickest in bladder neck and in the initial portion of the urethra and becomes progressively less dense in adjacent regions such that the cranial region of the bladder has no afferent axons. In contrast, the afferent innervation of the musculature is more uniform throughout the bladder.

Recording from bladder afferents has revealed the diversity of afferent populations described earlier based on morphology, receptive field site, mechanical and chemical sensitivity, and electrophysiologic characteristics. **Conduction velocity measurements confirm the predominance of fibers conducting APs in the Aδ and C-fiber range. The majority of these fibers are mechanosensitive, responding with a range of thresholds from volumes that would be encountered under normal bladder filling to extreme levels of distention that would be considered noxious and give rise to pain.** Those with lower activation thresholds have small myelinated axons, whereas unmyelinated fibers in general have higher thresholds for activation. In addition, other afferents do not respond to bladder filling but can be activated by intraluminal chemicals such as hypertonic saline, capsaicin, or ATP, suggesting they may function as chemoreceptors. Still other subpopulations may be so-called silent afferents that have been described elsewhere, including the gastrointestinal tract. These afferents can be sensitized during inflammation, suggesting a role in signaling pain.

In the mouse pelvic nerve, four classes of bladder afferents (serosal, muscular, muscular/urothelial, and urothelial) have been identified based on responses to receptive field stimulation with different mechanical stimuli, including probing, stretch, and stroking the urothelium. Low-threshold, representing 65% to 80% of the total population, and high-threshold stretch-sensitive muscular afferents are present (Daly et al., 2007; Xu and Gebhart, 2008). The muscular afferents can be sensitized by application of a combination of inflammatory mediators (bradykinin, serotonin, prostaglandin, and histamine at pH 6.0) (Xu and Gebhart, 2008).

A series of studies have used open-sheet preparations of guinea pig bladder to examine the diversity of bladder afferents and to attempt to correlate structure with function. Low-threshold afferents have terminals in the muscle, described as “antenna-like” endings, and are referred to as *stretch-sensitive muscular mechanoreceptors* (Zagorodnyuk et al., 2006, 2007). These afferents, termed *tension receptors*, also respond to contraction of the detrusor muscle as well as tension generated by elongation during stretch and shortening during contraction. High-threshold afferents are also likely to terminate in the deeper muscle layers or in the serosa. These mechanosensitive endings have receptive fields (located by mechanical probing) associated with blood vessels. Thus high-threshold afferents respond to high levels of bladder stretch but may also become sensitized in response to inflammation.

Species differences, as well as differences in nomenclature, may account for some of the variations in reported properties of bladder afferents. For example, the conduction velocity that differentiates Aδ and C fibers is 2 m/sec in the cat, whereas it is 1.3 m/sec in the rat (Waddell et al., 1989). In the cat, bladder Aδ afferents appear to be low-threshold mechanoreceptors (Habler et al., 1993), whereas bladder C afferents (Habler et al., 1990) are, in general, mechano-insensitive (“silent C fibers”) (see Table 110.2). Some of the latter may be nociceptive and found to be sensitized by intravesical administration of chemicals (such as high potassium), low pH, high osmolality, and irritants such as capsaicin (Maggi et al., 1987; McMahon and Abel, 1987; Wen and Morrison, 1995; Zagorodnyuk et al., 2009; Fig. 110.26). After exposure to these substances, the sensitivity of bladder mechanoreceptors to distention increases, and some silent afferents become mechanoreceptive.

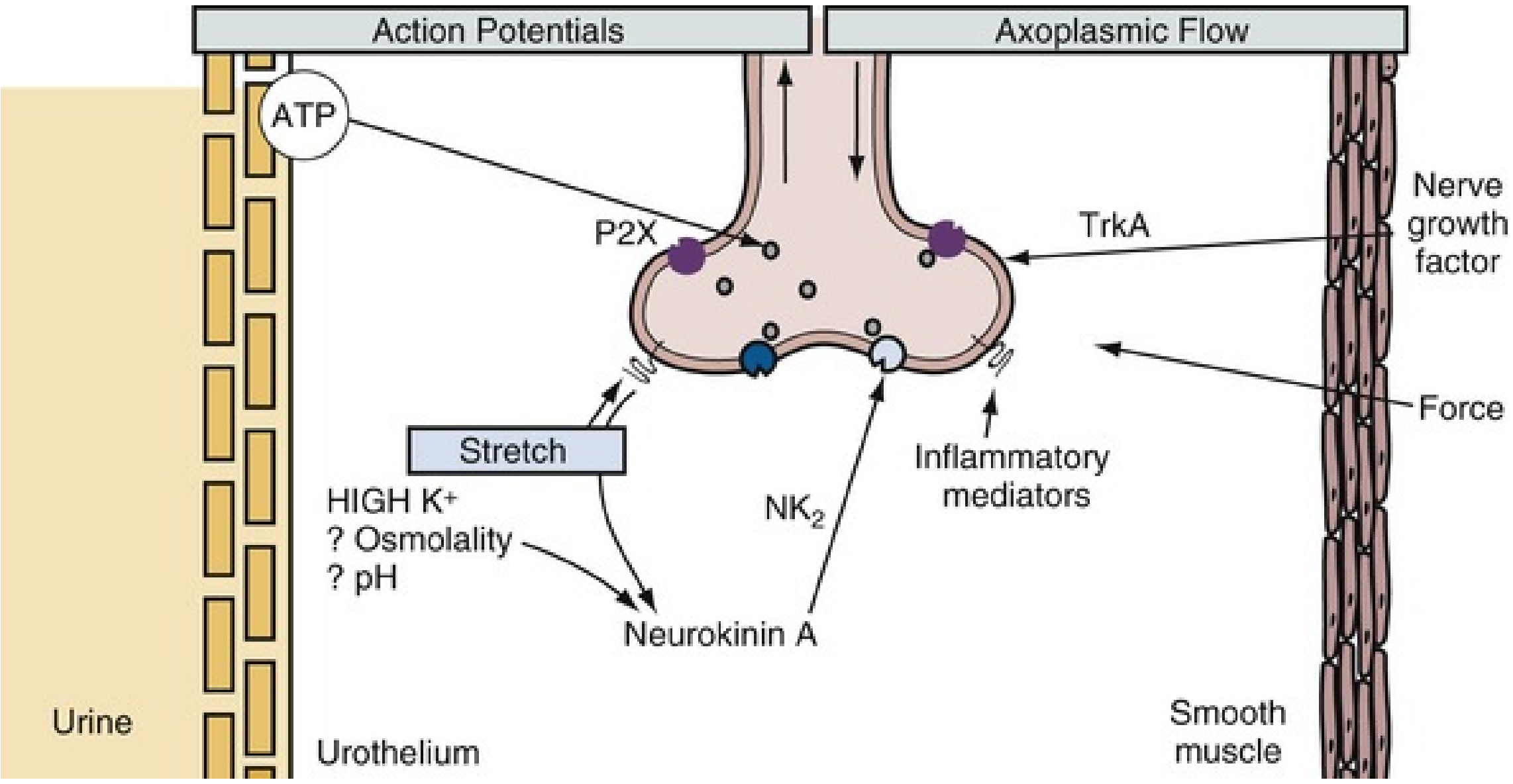

FIG. 110.26 Actions of chemical mediators that may sensitize

mechanosensory nerve endings in the bladder mucosa. Adenosine triphosphate (ATP) can be released from the urothelium and may sensitize the mechanoreceptors, which respond to stretch of the mucosa during bladder distention. P2X is the purinergic receptor subtype that binds ATP. Neuropeptides transported to the sensory ending by axoplasmic transport may be released during distention and chemical stimulation, and neurokinin A can act on NK_2 autoreceptors, which sensitize the mechanosensitive endings. This mechanism can be induced by high urinary potassium concentrations and possibly by other sensitizing solutions within the bladder lumen, such as those with high osmolality or low pH; the presence in the tissues of inflammatory mediators may also sensitize the endings. The smooth muscle can generate force that may influence some mucosal endings, and the production of nerve growth factor is another mechanism that can influence the mechanosensitivity of the sensory ending through the tyrosine kinase (TrkA) receptor.

The bladder neck and proximal urethra contain the largest density of bladder nerves (Gabella and Davis, 1998; Yokokawa et al., 1985). In the urethra, afferent nerves have been reported between the muscle fibers, surrounding blood vessels, within the urothelium, and in a dense suburothelial plexus (Crowe et al., 1986; Fahrenkrug and Hannibal, 1998; Tainio, 1993). The striated sphincter muscle surrounding the urethra receives a very sparse afferent innervation that is localized primarily to nerve bundles passing between the muscle bundles. Specialized tension receptors (muscle spindles) that are innervated by large-diameter myelinated group IA afferents and that are prominent in most striated muscles are absent (Gosling et al., 1981) or are present in low density (Lassmann, 1984) in striated sphincter muscles.

Afferent nerves may extend in some species to the luminal surface of the urothelium. In contrast, the urethral epithelium is likely to be part of a signaling system involving projections of neuroendocrine cells, interstitial cells, and sensory nerve endings. There is speculation that these urethral-neuroendocrine cells (often termed *paraneurons*) (Hashimoto et al., 1999) could release mediators such as neuropeptides or serotonin, which via activation of adjacent sensory nerves can stimulate urethral reflexes. Such types of cells are not unlike those in other types of epithelia, such as the trachea, in which a cell type termed *brush cells* has been described, which are likely chemoreceptive and make contact with nearby sensory nerve fibers (Saunders et al., 2013). In addition, there are also reports that have identified and characterized functional properties of sacral afferents responding to flow through the urethra (Snellings et al., 2012). These are important observations whereby properties of these flow-responsive afferents seem to parallel those of cutaneous afferents. This could be important in terms of restoration of bladder emptying after spinal cord injury.

Modulators of Afferent Sensitivity.

A number of parameters including stimulus-response function can be used to define the features of the various subpopulations of afferents that supply the LUT. The relationship between stimulus and response can be altered or modified according to the mechanical and chemical environment of the sensory ending. For example, bladder contractions can distort the afferent ending, whereas connective tissue elements will transmit or dissipate stimulus energy within the tissue, determining whether a response is rapidly or slowly adapting to maintained stretch. Similarly, a number of chemical mediators released from a variety of cells within the bladder wall, such as the urothelium and underlying lamina propria, will influence afferent firing.

Many mediators are released during inflammation, injury, and ischemia, as well as from a number of cell types such as mast cells, fibroblasts, and neurons. Some mediators act directly on sensory nerve terminals, whereas others act indirectly, causing release of yet other agents from nearby cells. Thus this can lead to augmented sensitivity of nerve endings to mechanical and chemical stimuli and may also contribute to chronic pain states. Examples of local mediators include neurotrophins, purines, proteases, prostanoids, and cytokines. They produce their effects on visceral afferent nerves by three distinct processes. First, they can act directly, by opening ion channels on the nerve terminals. Second, they can sensitize endings without causing direct stimulation but causing hyperexcitability to other chemical and mechanical stimuli. Third, as is the case with neurotrophins, they can change the phenotype of the afferent nerve over long periods. For example, they may alter expression of channels, receptors, or mediators in the sensory neuron (Vergnolle, 2008). The result of sensitization is a leftward shift in the stimulus-response function. This means that for any given level of stimulation, a greater afferent barrage is generated. Peripheral sensitization normally develops rapidly and is relatively short lived. However, in the presence of maintained injury or inflammation, the sensitization can be prolonged by changes in gene expression. Genes influenced in this way include those that determine the amount and pattern of neurotransmitter release by central nerve terminals in the brain and spinal cord. This alters the way that sensory signals are processed within the CNS and contributes to central sensitization (Woolf, 2011).

In contrast, ineffective or inefficient bladder emptying may be caused by several changes including damage or injury to bladder (afferent) pathways. Although mechanisms underlying detrusor underactivity are not well explored or defined, conditions including diabetes mellitus, classically referred to as a *diabetic cystopathy,* have been linked with impaired sensory function and increased residual urine (Ellenberg, 1980; Xiao et al., 2013). Factors including ischemia, altered glucose metabolism, and/or free radical formation may play a role in diabetic neuropathy and decreased sensation. Studies in aged rats have revealed a decreased afferent sensitivity to changes in bladder volume and a decreased level of afferent neuropeptide expression (Hotta et al., 1995; Mohammed and Santer, 2002). Also, studies in humans have revealed an age-related decreased response to bladder filling in brain regions that play a role in bladder sensation (Griffiths et al., 2007). Therefore **decreased afferent sensitivity or excitability in a number of conditions in addition to normal aging may be an important factor leading to impaired voiding** (Miyazato et al., 2013; Smith, 2010).

Nitric Oxide.

NO has been identified as a **major inhibitory transmitter mediating relaxation of the urethral smooth muscle during micturition** (Andersson, 1993; Andersson and Persson, 1995; Andersson et al., 1992; Bennett et al., 1995). In addition, **NO is also involved in controlling bladder afferent nerve activity.** Inhibitors of NOS, given systemically or intrathecally, do not affect normal micturition in conscious or anesthetized rats. However, DO that accompanies irritation is ameliorated by spinal application of NOS inhibitors (Kakizaki and de Groat, 1996; Lagos and Ballejo, 2004; Rice, 1995). Aizawa et al. (2011) examined the effect of NO on sensory signaling by directly recording afferent activity arising from the bladder in vivo. Release of NO can be inhibited using nonmetabolizable analogues that compete with L-arginine as substrate for NOS. On such inhibitor, L-NAME, increased the afferent response to bladder filling by about 50%, which was reversed by activation of NO pathways with L-arginine. These data suggest that **NO is able to inhibit afferent activity,** an observation consistent with earlier cystometric analysis of the effect of activating the NO pathway (Ozawa et al., 1999). In addition to studying NO mechanisms in the normal bladder, Aizawa et al. also showed that application of L-arginine significantly inhibited hypersensitivity induced by the cyclophosphamide metabolite acrolein, which is used experimentally as a model for BPS/IC.

The actions of NO are mediated through elevation of the intracellular

second messenger cGMP (Fig. 110.27). The second messengers cAMP and cGMP are synthesized from the corresponding nucleoside triphosphates by their respective membrane-bound or soluble adenylate or guanylate cyclases. cAMP and cGMP are inactivated by phosphodiesterases (PDEs) by hydrolytic cleavage of the 3′-ribose phosphate bond. Therefore **the level of intracellular second messengers can be regulated by PDE isoenzymes** (Truss et al., 1999, 2001). For example, PDE5 terminates the action of NO, and PDE inhibitors can be used therapeutically to prolong the action of NO at a number of sites including the bladder, prostate, and blood vessels. Behr-Roussel et al. (2011) found that inhibition of PDE5 attenuated bladder afferent activity in a rat model of spinal cord injury. Thus, in addition to an important role for PDEs in regulation of smooth muscle tone, available data suggest that these agents may represent a target for treatment of hypersensitivity disorders of the bladder such as BPS/IC and OAB.

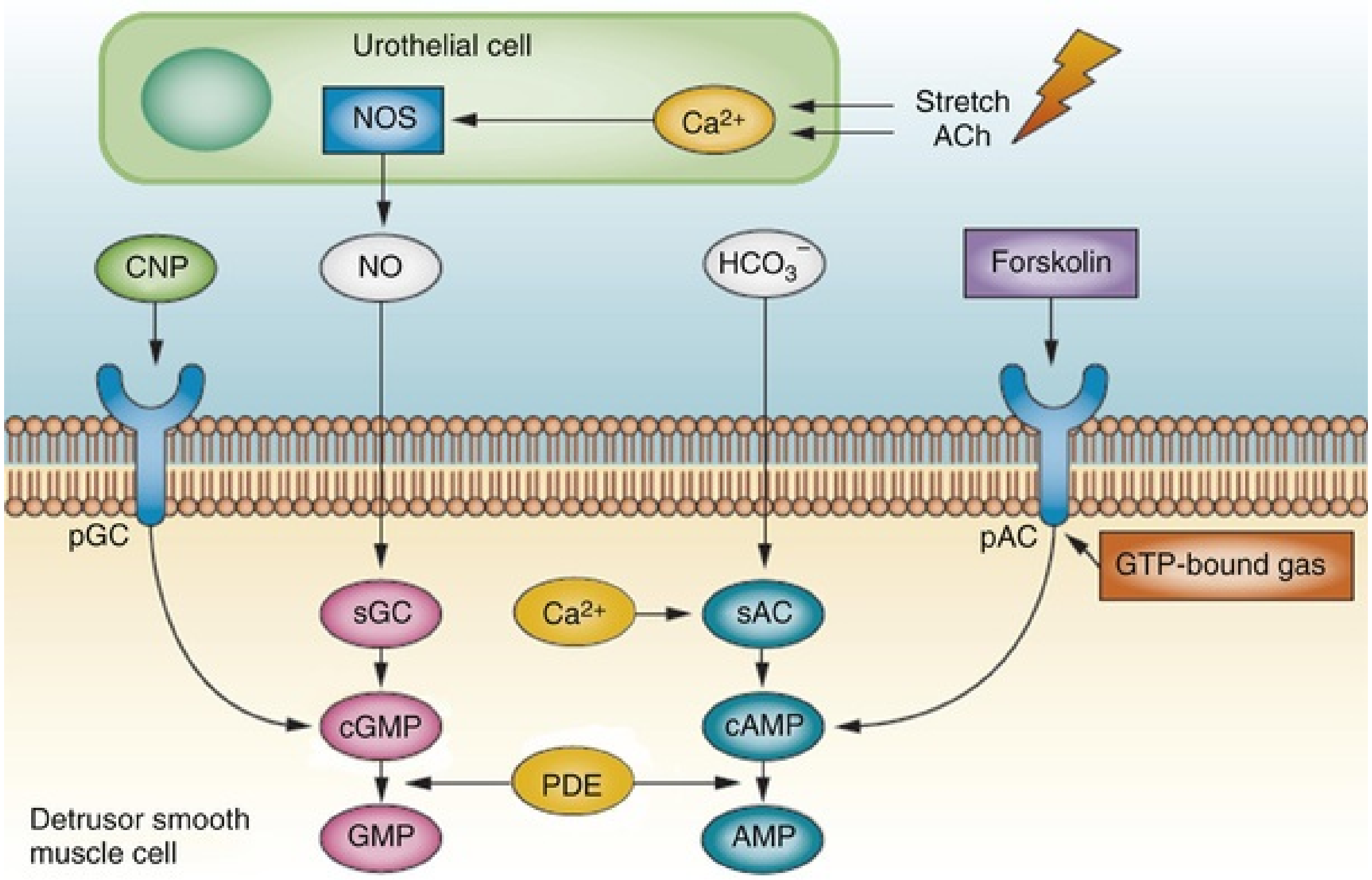

FIG. 110.27 Schematic diagram of the cyclic nucleotide signaling pathways. Stretch stimuli, or acetylcholine (ACh) release, increase internal Ca^{2+} levels in nitric oxide synthase (NOS)–expressing urothelial cells. NOS produces nitric oxide (NO), which signals to detrusor smooth muscle cells. NO is thought to have a modulatory role in the lower urinary tract, including the relaxation of urethral smooth muscle, modulation of neurotransmitter

release from efferent nerves, regulation of urothelial permeability, and modulation of afferent nerve activity. Moreover, a pathophysiologic role of NO has been suggested because injury or chronic inflammation can upregulate the expression of inducible NOS. Guanylyl cyclases located in the cytoplasm or plasma membrane synthesize cyclic guanosine monophosphate (cGMP) in response to NO or C-like natriuretic peptide (CNP), respectively. Cyclic adenosine monophosphate (cAMP) is synthesized by adenylyl cyclases, either associated with G protein–coupled receptors in the plasma membrane or in the cytoplasm. Membrane-associated adenylyl cyclases are activated by guanosine triphosphate (GTP)–bound $G_s\alpha$ and forskolin, whereas cytoplasmic adenylyl cyclases are regulated by HCO^{3-} and Ca^{2+} but insensitive to forskolin or activated $G_s\alpha$. cAMP and cGMP are hydrolyzed to AMP and GMP, respectively, by phosphodiesterases (PDEs). *pAC,* Particulate (plasma membrane) adenyl cyclase; *pGC,* particulate (plasma membrane) guanylyl cyclase; *sAC,* soluble (cytoplasmic) adenyl cyclase; *sGC,* soluble guanylyl cyclase. (From Rahnama'i MS, Ückert S, Hohnen R, et al.: The role of phosphodiesterases in bladder pathophysiology. *Nat Rev Urol* 10:414–424, 2013.)

Purinergic Signaling.

It is well established that the urothelium releases ATP in response to stretch and that this acts in a paracrine fashion to influence the function of myofibroblasts and bladder afferent nerves (Fig. 110.28). $P2X_2$ and $P2X_3$ receptors are expressed on unmyelinated afferent fibers innervating the bladder, and thus the hypothesis has been put forward that mechanosensitivity, at least in those afferents in proximity to the urothelium, involves ATP release by stretch and activation of $P2X_2$ and $P2X_{2/3}$ receptors on the afferents (Ferguson et al., 1997; Vlaskovska et al., 2001). In the normal bladder, it is believed that a balance between the excitatory effects of ATP and inhibitory effects of NO may determine micturition thresholds and urinary frequency and that this balance may be disturbed in bladder disorders. Elevated ATP levels have been demonstrated in patients with DO and BPS/IC (Kumar et al., 2007). Munoz et al. (2010), using a rat model of DO (diabetic bladder), found increased levels of ATP but normal levels of NO. Conversely in an underactive bladder model induced by chronic sugar intake, NO levels were increased whereas ATP remained normal. This suggests that the balance between ATP and NO is altered in bladder dysfunction.

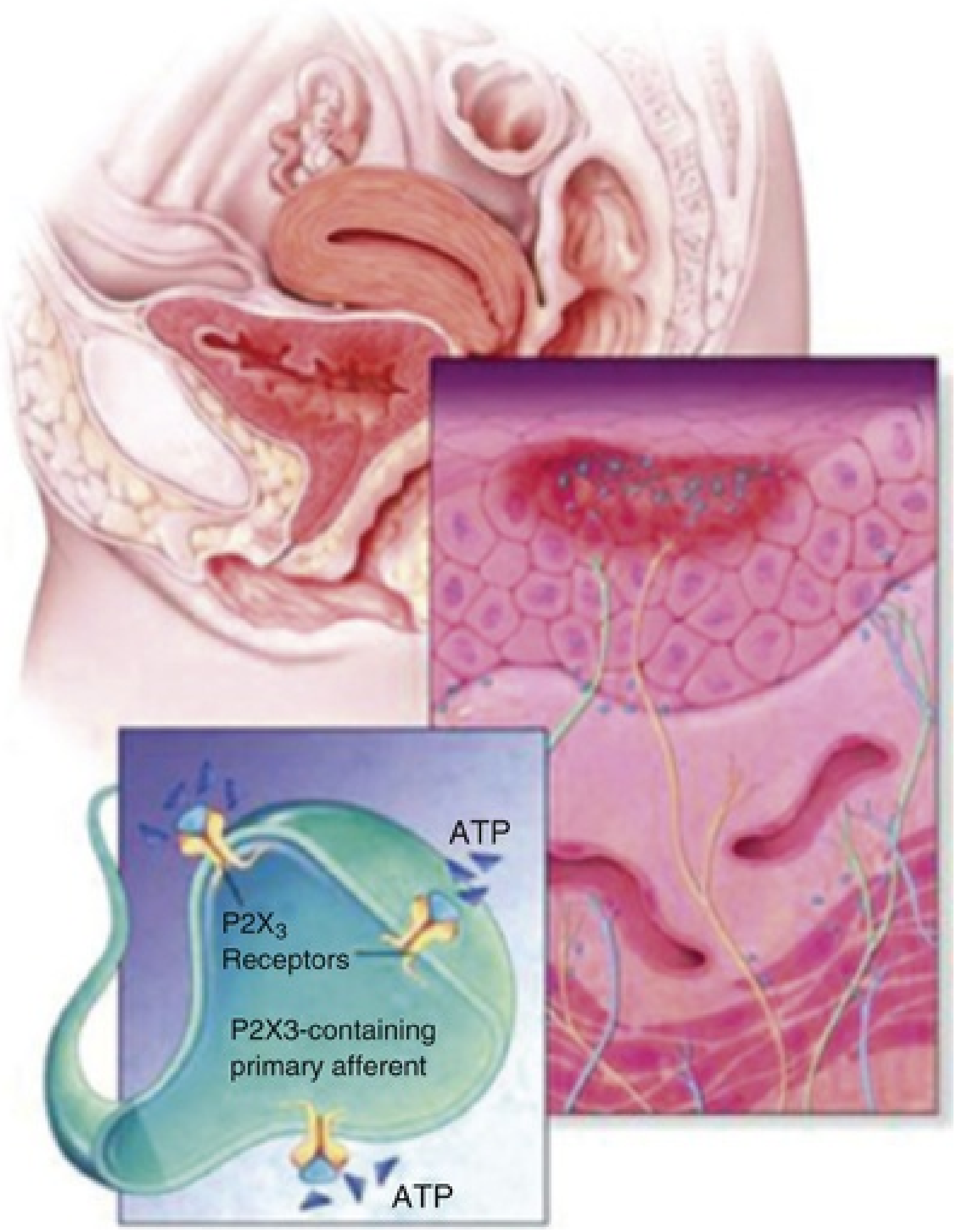

FIG. 110.28 Morphology and wiring of the lower urinary tract (LUT). In the LUT, adenosine triphosphate (ATP) (shown as *blue triangles*) is present in large extracellular concentrations, is released by various cells including epithelia, fibroblasts, and smooth muscles, and can activate C-fiber afferent and promote sensitization. Release of ATP is augmented in conditions of stress, injury, inflammation, and infection. (From Ford AP, Undem BJ: The therapeutic promise of ATP antagonism at P2X3 receptors in respiratory and urological disorders. *Front Cell Neurosci* 7:267, 2013.)

Transient Receptor Potential Cation Channels.

A number of different members of the transient receptor potential (TRP) channel family are expressed in the bladder, mostly in association with sensory nerve fibers involved in mechanotransduction and nociception. TRPV1, TRPV2, TRPV4, TRPM8, and TRPA1 are expressed in varying levels within the bladder. TRPV1, the most extensively studied TRP channel, is expressed on capsaicin-sensitive afferent pathways, predominantly C-fiber nociceptors, and responds to increases in temperature to the noxious range (>43°C) and to protons, suggesting that it functions as a transducer of painful thermal stimuli and acidity in vivo. Thus C fibers signal inflammatory or noxious events in the bladder. TRPV1 has been shown to play an integral role in modulating the excitability of bladder afferents and the generation of hypersensitivity, induced by bladder inflammation (Apostolidis et al., 2005a; Birder et al., 2002). It is through desensitization of this receptor that agents such as resiniferatoxin (RTX) act to treat symptoms in OAB (Kissin and Szallasi, 2011). TRPV1 is predominantly expressed on sensory nerves and has been identified within nerve plexuses running in the muscle layer and suburothelium as well as within the urothelium.

RTX is the principal active ingredient in the drug euphorbium, which is derived from the air-dried latex (resin) of the cactus-like plant *Euphorbia resinifera*. In 1975 the principal active ingredient in euphorbium was isolated and named *resiniferatoxin* (Hergenhahn et al., 1975). In 1989, RTX was recognized as an ultrapotent analog of capsaicin; however, it has unique pharmacologic effects as well (Szallasi and Blumberg, 1990), such as desensitization without prior excitation of the pulmonary chemoreflex pathway (Szolcsanyi, 1990). In patients with spinal cord injury–induced DO, clinical response to intravesical therapy with RTX showed changes in nerve fiber staining as well as marked improvements on cystometry and other parameters (Brady et al., 2004). Furthermore, it has also been shown that intravesical application of high-dose capsaicin as well as RTX is effective for treating painful symptoms in IC patients (Lazzeri et al., 1996, 2000), although a prospective, randomized clinical trial using intravesical RTX application showed no effect in patients with IC (Payne et al., 2005).

TRPV4 is a member of vanilloid TRPV channels and a nonselective cation channel activated by mechanical pressure, osmolarity (hypotonicity), moderate warmth (>27°C), and chemical stimuli such as phorbol esters. Interest in TRPV4 has been fueled by the observation of impaired voiding behavior in knockout mice (Gevaert et al., 2007). This channel shows mechanosensitivity and is proposed to play a role in the micturition reflex by activating C-fiber afferents (Aizawa et al., 2012). However, the site of action of TRPV4 agonists may in fact be the urothelium, which expresses the TRPV4 channel (Birder et al., 2007a), particularly in association with adherence junctions, where they may be preferentially activated by stretch and lead to the release of ATP (Yamada et al., 2009). Inhibition of TRPV4 has been shown to improve symptoms in a model of experimental cystitis (Everaerts et al., 2010).

TRPA1 is the only member of the ankyrin TRP channel and a receptor for several pungent chemicals that evoke pain, such as allyl isothiocyanate (the pungent compound in mustard oil), allicin (garlic), cinnamaldehyde (in cinnamon), and acrolein (a metabolite of cyclophosphamide). TRPA1 also functions as a receptor-operated channel that can be activated by growth factors or proinflammatory peptides such as bradykinin, which increases intracellular Ca^{2+} levels using G protein–coupled receptors. TRPA1 is also expressed in the bladder and is particularly associated with C-fiber endings in the suburothelium that co-localize calcitonin gene–related peptide (CGRP). Agonists acting at the receptor cause bladder overactivity and are suggested to play a role in mechanotransduction and in signaling pain. TRPA1 has also been demonstrated in the urothelium at transcriptional and protein levels. Expression is increased in a spinal cord injury model, and pharmacologic blockade and RNA knockdown of TRPA1 were effective in normalizing bladder reflex function (Andrade et al., 2011).

TRPM8 is a member of the temperature-sensitive TRP channels that responds to cold temperature of less than 23°C. Pharmacologic agents that evoke cool sensation, such as menthol and ilicin, can activate TRPM8. Interest in its role in the bladder stems from the observation that instillation of cold saline into the bladder elicits a contractile response (at pressures or volumes below the threshold for normal voiding). This response to a cooling stimulus (which has been referred to as the *bladder cooling reflex*) was originally thought to indicate a supraspinal neurologic lesion, and the test (termed the *ice-water test*) has been used in the diagnosis of bladder disorders such as OAB and BOO (Chai et al., 1998). Expression of TRPM8 has been identified on bladder afferent fibers and on the cell bodies in the DRG, where it co-localizes with nociceptive markers such as CGRP and IB4 (Hayashi et al., 2009a). Previously Lashinger et al. (2008) showed that application of a TRPM8 channel blocker decreased voiding frequency and abdominal motor responses in the rat, suggesting that in addition to cold sensing, TRPM8 may also be involved in the afferent control of micturition and nociception.

Cannabinoids.

The multicenter Cannabinoids in Multiple Sclerosis (CAMS) study reported that the use of cannabis-based extracts significantly improved symptoms of urge incontinence and DO in patients with multiple sclerosis. This observation has provoked interest in the study of expression and function of cannabinoid (CB) receptors in the bladder. In the human bladder, both receptors could be identified in the urothelium and detrusor, where CB1 receptors were more abundant than CB2 (Tyagi et al., 2009). In patients with BPS/IC and IDO, a significant increase in nerve fibers expressing CB1 in the urothelium was observed, strongly suggesting a role for CB1 in OAB (Mukerji et al., 2010). Functional experiments also found a reduction in distention-evoked afferent firing in response to application of a CB1 agonist. In particular, high-threshold afferents typically associated with noxious stimuli were directly affected. In contrast, Gratzke et al. (2009) found CB2 receptors predominated in the urothelium and suburothelium and on sensory nerve fibers and found that CB2 agonists inhibited nerve-induced contractions of the bladder, providing evidence that CB2 receptors are important in micturition. **Taken together, these studies suggest that CB receptors in the bladder may have a modulatory role in sensory afferent signaling,** a greater understanding of which could lead to new therapeutic strategies for treatment of bladder disorders.

Opioid Peptides.

The risk of opioid-related bladder dysfunction (urinary retention) is an important issue and has been well studied in postoperative patients for analgesia. Opiates and their analogues (mainly because of µ-opioid receptor agonism) not only decrease bladder sensation but also can increase sphincter tone, resulting in increased outlet resistance (Durant and Yaksh, 1988). Both effects increase the risk of urinary retention. There are also reports in animals of increased bladder capacity and compliance after intravenous or intrathecal tramadol. Although no prospective studies have been done, the half-life of the opioid may also affect risk of retention: orthopedic patients receiving fentanyl (which exhibits a short half-life) reported less risk for retention compared with those receiving morphine (Gallo et al., 2008). Studies have also evaluated whether reducing the dose of opioid by combining with nonsteroidal anti-inflammatory drugs could lead to less retention. Most have concluded that although concurrent use of COX-2 inhibitors led to less opioid consumption and even decreased risk of associated nausea and constipation, the risk of acute urinary retention was not affected (Marret et al., 2005; Romsing et al., 2005).

Pelvic Organ Interactions: Crosstalk Between Bladder and Bowel.

Patients with irritable bowel syndrome (IBS) often report LUTS, including nocturia, frequent and urgent micturition, and incomplete emptying (Whorwell et al., 1986). The counterpart is also true with patients with BPS/IC who have bowel symptoms (Alagiri et al., 1997). These observations are consistent with the concept of **cross-organ sensitization,** which extends to different abdominal and pelvic structures and contributes to a more generalized chronic pelvic pain syndrome (Brumovsky and Gebhart, 2010). In experimental models, colonic inflammation has been shown to lead to increased frequency of bladder contractions and altered micturition reflexes (Pezzone et al., 2005). Similarly, experimental bladder inflammation has been reported to sensitize the bowel to distention (Bielefeldt et al., 2006). Such cross-organ sensitization has also been demonstrated among the uterus, pelvic urethra, and vagina. In men there is the potential for cross-organ sensitization between the prostate and other pelvic organs.

The mechanisms underlying cross-organ sensitization have not been fully elucidated, but there are potentially several levels at which the sensory innervation to the different pelvic structures can interact. In terms of peripheral mechanisms there is evidence that afferent fibers branch extensively to innervate multiple target structures. Axonal tracing studies using different retrograde tracers injected into the bladder and bowel reveal a number of DRG neurons carrying both labels, although the numbers are low. Similarly, dichotomizing afferents have been shown to innervate the colon and uterus with DRGs expressing TRPV1 and $P2X_3$ receptors, implying a role in nociception. Sensitization of the endings in one organ by local inflammation would likely affect overall sensitivity after upregulation in excitability in all terminal receptive fields. Central sensitization may also contribute to cross-organ sensitization. Excitability of spinal neurons receiving afferent input from the bladder has been shown to respond to afferent input from other pelvic structures such as the colon (Fig. 110.29; Clemens et al., 2008; Malykhina, 2007). Second-order neurons in the spinal cord therefore receive convergent input from various visceral structures as well as somatic inputs. The latter explains the phenomenon of referred pain, wherein sensations from the viscera are experienced in the associated somatic sensory field, the classic example being angina. Such viscerosomatic convergence has been extensively investigated, and viscerovisceral referral has received attention. Nevertheless, convergent inputs would explain the poor localization of pelvic pain and the difficulty in diagnosis and treatment.

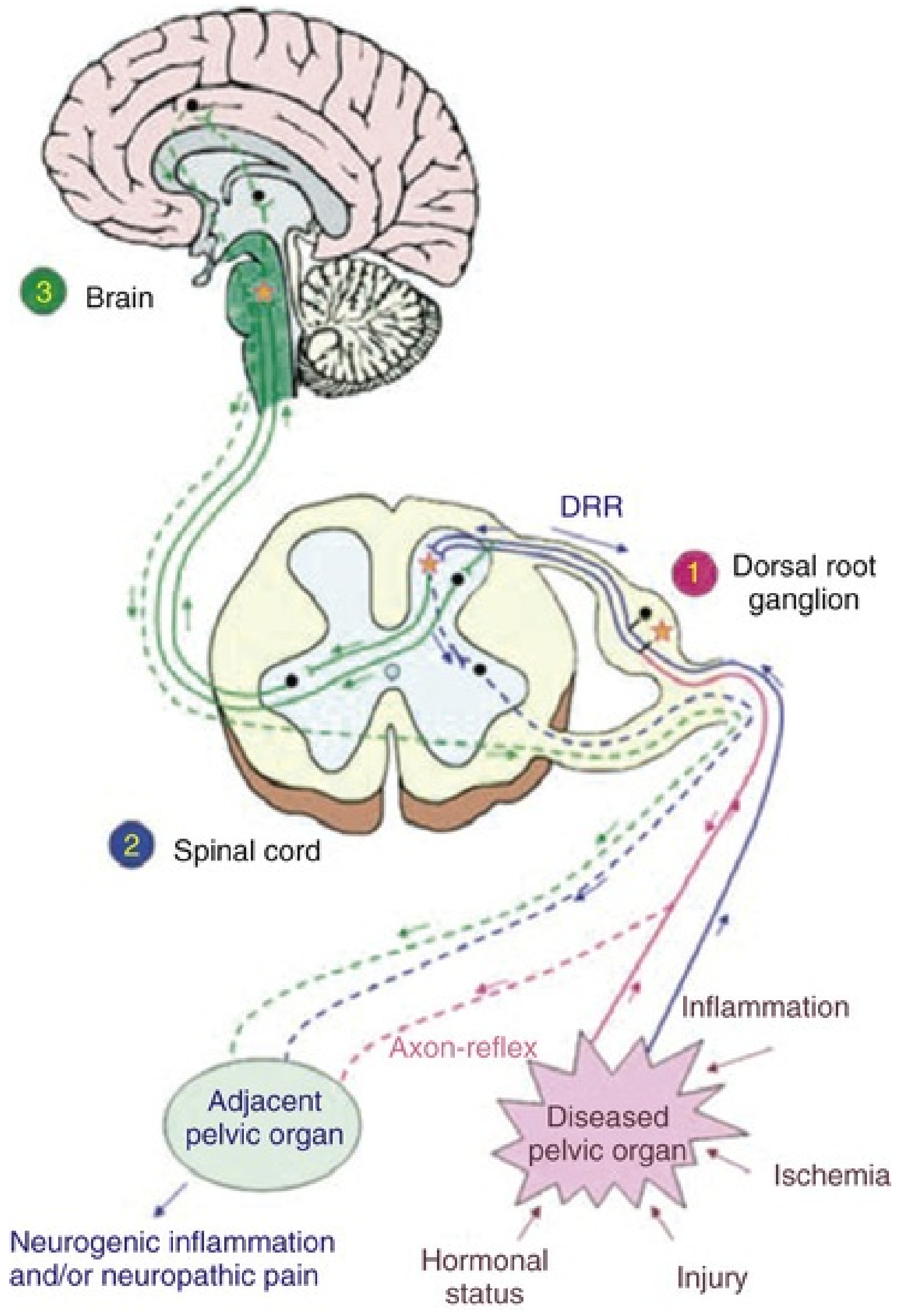
3 Brain
DRR
1 Dorsal root ganglion
2 Spinal cord
Inflammation
Axon-reflex
Adjacent pelvic organ
Diseased pelvic organ
Ischemia
Neurogenic inflammation and/or neuropathic pain
Hormonal status
Injury

FIG. 110.29 Schematic representation of convergent afferent pathways. *1,* Convergence of sensory neural pathways within a dorsal root ganglion *(red route).* The propagation of noxious stimulus from a diseased pelvic organ to a normal adjacent structure occurs via dichotomizing afferents as a result of an "axon-reflex" mechanism. Axon-reflex–antidromic propagation of action potentials (APs) from dorsal root ganglion to the periphery. *2,* Convergence of afferent information in the spinal cord *(blue route).* DRR refers to dorsal root reflexes (antidromic conductance via sensory fibers from the spinal cord to the periphery). Note that an output neuron belongs to the population of intermediolateral neurons (not motoneurons) localized mostly in laminae VI to VII. *3,* Convergence of afferent inputs from two different pelvic organs in the brain *(green route).* Convergent neurons within the dorsal root ganglion, in the spinal cord, and in the brain are shown by *star* symbol. Orthodromic propagation of APs from pelvic organs to the points of convergence is depicted by *solid lines* and *arrows* in respective color for each route. Anterograde AP propagation

from the brain, the spinal cord, and the dorsal root ganglion to the periphery is shown by *dotted lines.* (From Malykhina AP: Neural mechanisms of pelvic organ cross-sensitization. *Neuroscience* 149:660–672, 2007.)

Key Points: Afferent Pathways

- Studies of the properties of bladder afferents in the pelvic nerve, particularly in the rat, indicate that in-series tension receptors, volume receptors, and silent afferents (including nociceptors) are present.
- Intravesical irritant chemicals reduce the pressure thresholds of most of these endings, including the high-threshold receptors.
- A substantial proportion of the C-fiber afferent population is silent (i.e., insensitive to normal distention). However, these fibers become mechanosensitive after the action of various chemical mediators.
- During inflammation and possibly other pathologic conditions, there is recruitment of mechanosensitive C fibers that form a new functional afferent pathway. This is the rationale for intravesical C-fiber neurotoxin capsaicin and RTX therapy (Chancellor and de Groat, 1999).

Efferent Pathways to the Bladder

Three main neural pathways regulate LUT efferent activity: (1) **sacral parasympathetic** (pelvic) nerves provide excitatory input to the bladder; (2) **thoracolumbar sympathetic** (hypogastric) nerves provide inhibitory input to the bladder and excitatory input to the bladder neck and urethra; and (3) **sacral somatic** (pudendal) nerves innervate the striated muscles of the sphincters and pelvic floor (Fig. 110.30; Kluck, 1980). Parasympathetic postganglionic fibers terminate predominantly at the detrusor muscle and release ACh, resulting in detrusor contraction during voiding. Studies in animals have shown that sympathetic postganglionic fibers release noradrenaline (NA) and contribute to bladder relaxation during storage (via stimulation of β-adrenergic receptors expressed in detrusor).

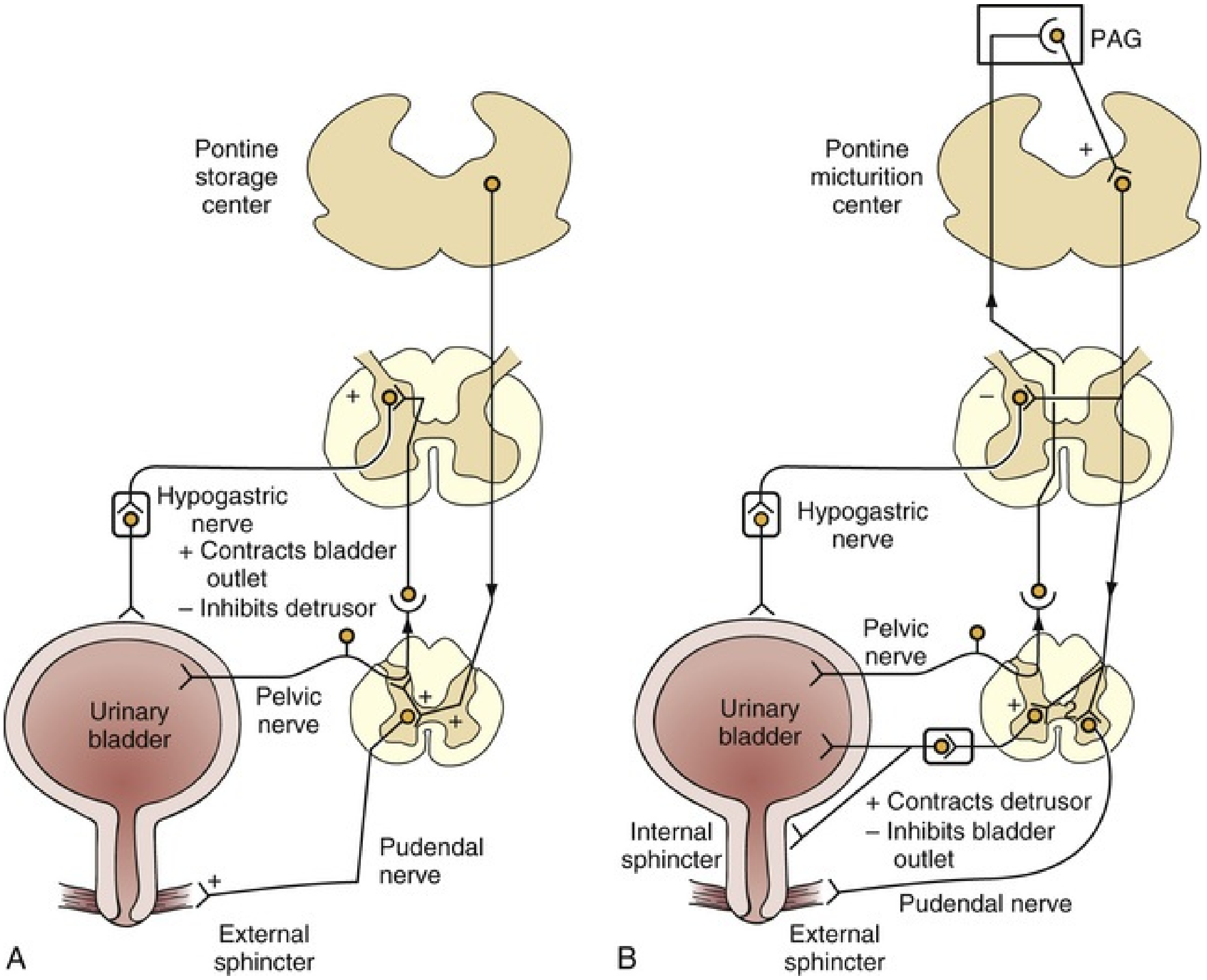
Pontine storage center
Hypogastric nerve
+ Contracts bladder outlet
– Inhibits detrusor
Urinary bladder
Pelvic nerve
Pudendal nerve
External sphincter
A
PAG
Pontine micturition center
Hypogastric nerve
Pelvic nerve
Urinary bladder
Internal sphincter
+ Contracts detrusor
– Inhibits bladder outlet
Pudendal nerve
External sphincter
B

FIG. 110.30 Mechanism of storage and voiding reflexes. (A) Storage reflexes. During the storage of urine, distention of the bladder produces low-level bladder afferent firing. Afferent firing, in turn, stimulates the sympathetic outflow to the bladder outlet (base and urethra) and pudendal outflow to the external urethral sphincter. These responses occur by spinal reflex pathways and represent "guarding reflexes," which promote continence. Sympathetic firing also inhibits detrusor muscle and transmission in bladder ganglia. (B) Voiding reflexes. At the initiation of micturition, intense vesical afferent activity activates the brainstem micturition center, which inhibits the spinal guarding reflexes (sympathetic and pudendal outflow to the urethra). The pontine micturition center also stimulates the parasympathetic outflow to the bladder and internal sphincter smooth muscle. Maintenance of the voiding reflex is through ascending afferent input from the spinal cord, which may pass through the periaqueductal gray matter (PAG) before reaching the pontine micturition center.

Terminal Nerve Fibers.

Smooth muscle cells in the bladder are grouped into fascicles, several of which make up a muscle bundle. They receive a dense innervation, which runs in line with the axis of the fascicle and is derived from coarse nerve trunks in the connective tissue around the fascicles and bundles. This innervation mediates the widespread coordinated detrusor contraction accompanying voiding. The nerve supply is illustrated in Fig. 110.6 (Maas et al., 2005), and the anatomic relationship between the preterminal innervation and the muscle fascicles has been described in a serial sectioning study in the human bladder (Kluck, 1980).

The majority of nerves innervating the detrusor express acetylcholinesterase and vesicular acetylcholine transferase (VAChT) (Dixon et al., 1983; Ek et al., 1977; Maas et al., 2005) and are thought to be parasympathetic. EFS studies have been used to elucidate the neurotransmitter content from muscle strips (with or without the mucosa). ACh and ATP appear to provide the majority of the excitatory input, because EFS responses are blocked by muscarinic receptor antagonists combined with purinergic antagonists. Both transmitters are released in the innervated muscle layer and persist after mucosal removal. Apart from ACh and ATP, there are additional substances present in parasympathetic efferents (vasoactive intestinal polypeptide [VIP], NOS, galanin), which allow immunohistochemical subclassification of nerve fibers and raise the question as to whether additional transmitters (other than ACh and ATP) have a role in normal micturition function or disease pathophysiology. In addition, cholinergic nerves are also present in the suburothelium, where most also contain neuropeptide Y (NPY) and tyrosine hydroxylase, and some also contain NOS. In the muscle of the trigone, the most common axons contain VIP and NPY, with noradrenergic axons forming only a sparse supply. Indeed, noradrenergic neurons are rare in the detrusor and absent in the urothelium (Wanigasekara et al., 2003).

Parathyroid hormone-related protein (PTHrP) released from detrusor smooth muscle (DSM) upon stretch may act as an endogenous DSM relaxant during bladder filling (Steers et al., 1998). A study in the rat bladder demonstrated that PTHrP potently suppressed spontaneous phasic contractions, while exerting only a modest inhibitory effect on carbachol-induced contractions (Nishikawa et al., 2013). PTH1R, a PTHrP receptor, predominantly locates in the muscular layers of the bladder wall (Lee et al., 2016; Nishikawa et al., 2015), and the concurrent expression of PTHrP in DSM indicated that PTHrP may function as a relaxing factor in an autocrine or paracrine fashion. Bath-applied PTHrP largely suppresses spontaneous contractions, whereas little affects cholinergic-induced contractions, indicating that PTHrP appears important for normal bladder function as well as a therapeutic target for overactive bladder. Endogenous and exogenously administrated PTHrP may not disturb neutrally mediated detrusor contractions during the voiding phase, while effectively suppressing spontaneous contractions that could stimulate afferent nerve firing. In contrast, downregulation of PTHrP mediated stabilization of DSM contractility may result in overactive bladder or reduced bladder capacity. Indeed, specimens taken from patients who have undergone bladder augmentation invariably show negative PTH1R staining in their DSM (Nishikawa et al., 2015). Because the detrusor has a 10-fold higher sensitivity to PTHrP compared with the muscularis mucosae and they are separated by layers of connective tissue, PTHrP may function as autocrine relaxant of DSM without suppressing mucosa contractility (Lee et al., 2016). In other smooth muscles, PTHrP acts via the adenylyl cyclase-cyclic AMP-PKA pathway. However, the involvement of this pathway in detrusor relaxation has not been established. Further studies are needed to explore the mechanism of PTHrP-induced suppression of spontaneous DSM contractions.

Spinal Ascending and Descending Influences: Transmitters

Glutamate.

Glutamate is present in the terminals of primary afferent neurons in the spinal cord along with interneurons and fibers originating in the medulla oblongata. In general, **glutamatergic neurons tend to be excitatory**, contrasting with generally inhibitory effects of glycinergic neurons; however, excitatory and inhibitory effects of transmitters can be reversed by the nature of the postsynaptic neuron. Thus glutamatergic neurons can indirectly have an inhibitory effect if an inhibitory neuron is interposed before the ultimate target (de Groat and Yoshimura, 2001). Glutamate acts on spinal neurons through a variety of receptor subtypes including *N*-methyl-D-aspartate (NMDA) receptors, which are important in controlling polysynaptic reflex pathways at the lumbosacral levels (Fig. 110.31). With aging, there is a decrease in the density of glutamatergic synaptic inputs, which may influence urinary tract function (Ranson et al., 2007).

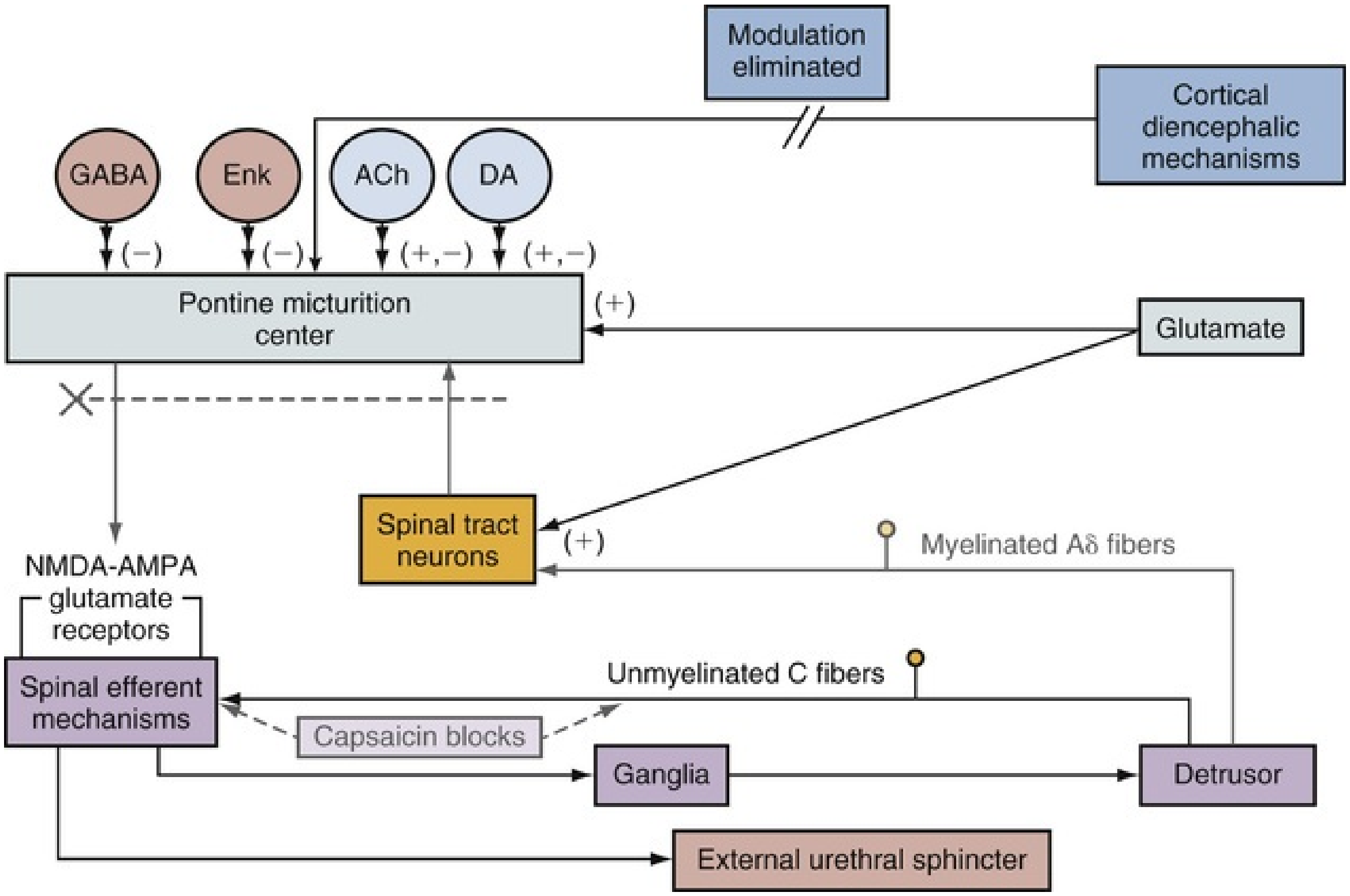
Modulation eliminated
Cortical diencephalic mechanisms
GABA
Enk
ACh
DA
(−)
(−)
(+,−)
(+,−)
Pontine micturition center
(+)
Glutamate
Spinal tract neurons
(+)
Myelinated Aδ fibers
NMDA-AMPA glutamate receptors
Spinal efferent mechanisms
Unmyelinated C fibers
Capsaicin blocks
Ganglia
Detrusor
External urethral sphincter

FIG. 110.31 Diagram of the central reflex pathways that regulate micturition in the cat. Normally, micturition is initiated by a supraspinal reflex pathway passing through the pontine micturition center (PMC) in the brainstem. The pathway is triggered by myelinated afferents (Aδ) connected to tension receptors in the bladder wall (detrusor). Spinal tract neurons carry information to the brain. During micturition, pathways from the PMC activate the parasympathetic outflow to the bladder and inhibit the somatic outflow to the urethral sphincter. Transmission in the PMC is modulated by cortical-diencephalic mechanisms. Interruption of these mechanisms leads to bladder instability. In spinal cord–transected animals, connections between the brainstem and the sacral spinal cord are interrupted and micturition is initially blocked. In animals with chronic spinal cord injury, a spinal micturition reflex emerges that is triggered by unmyelinated (C-fiber) bladder afferents. The C-fiber reflex pathway is usually weak or undetectable in animals with an intact nervous system. Stimulation of the C-fiber bladder afferents by instillation of ice water into the bladder (cold stimulation) activates voiding reflexes in patients with spinal cord injury. Capsaicin (20 to 30 mg/kg subcutaneously) blocks the C-fiber reflexes in cats with chronic spinal cord injury but does not block micturition reflexes in intact cats. Intravesical capsaicin also suppresses bladder instability and cold-evoked reflexes in patients with neurogenic bladder dysfunction. Glutamic acid is the principal excitatory transmitter in the ascending and descending limbs of the micturition reflex pathway, as well as in the reflex pathway controlling sphincter function. Glutamate acts on *N*-methyl-D-aspartate (NMDA) and α-amino-3-hydroxy-5-methylisoxazole-4-propionic acid (AMPA) glutamatergic receptors. Other neurotransmitters that regulate transmission in the micturition reflex

pathway include γ-aminobutyric acid (GABA), enkephalins (Enk), acetylcholine (ACh), and dopamine (DA). ACh and dopamine have excitatory and inhibitory effects on the pathway: excitatory (+) and inhibitory (−) synapse.

Glycine and γ-Aminobutyric Acid.

Glycinergic and GABAergic interneurons have a major role in neural control processes mediating bladder function (Shefchyk, 2002). **Glycinergic and GABAergic projections to the lumbosacral cord inhibit the micturition reflex and also inhibit glutamatergic neurons** (Miyazato et al., 2013). Clinically, DO can be inhibited by GABA receptor activation (Miyazato et al., 2008b, 2008c). Rectal distention prolongs the interval, decreases the amplitude, and shortens the duration of bladder contractions in rats; this effect is not seen after simultaneous intrathecal injection of low-dose strychnine (a selective glycine-receptor antagonist) and bicuculline (GABA-A receptor antagonist), suggesting that the inhibitory rectovesical reflex involves glycinergic and GABAergic mechanisms in the lumbosacral spinal cord, which may be synergistic (Miyazato et al., 2004).

Serotonin.

Spinal reflex circuits involved in voiding function have a dense serotonergic (5-hydroxytryptamine [5-HT]) innervation (de Groat, 2002). Immunocytochemical studies in rats, cats, and primates show that lumbosacral sympathetic and parasympathetic autonomic nuclei receive serotonergic inputs from the raphe nuclei (Kojima et al., 1983; Mizukawa, 1980; Rajaofetra et al., 1992; Skagerberg and Bjorklund, 1985). **Activation of the central serotonergic system can suppress voiding by inhibiting the parasympathetic excitatory input to the urinary bladder,** and 5-HT elicits a prolonged activation of thoracic sympathetic preganglionic neurons. Stimulation of the raphe nuclei in the cat inhibits reflex bladder activity (Chen et al., 1993; McMahon and Spillane, 1982; Sugaya et al., 1998). 5-HT$_{1A}$ and 5-HT$_2$ receptors are present in the sacral parasympathetic nucleus. However, in different species, serotonin (5-HT) may have varying functions in the central nervous control of bladder activity. For example, activation of 5-HT$_{1A}$ receptors facilitates reflex bladder activity in rats (de Groat, 2002; Lecci et al., 1992) and has been used to reverse the effects of diabetes mellitus (Gu et al., 2012).

Duloxetine, a combined norepinephrine and 5-HT reuptake inhibitor

(Sharma et al., 2000), **has been shown, in a bladder-irritated model, to increase the neural activity of the urethral sphincter and the bladder** (Cannon et al., 2003; Thor and Donatucci, 2004; Thor and Katofiasc, 1995). Duloxetine appears to have effects on the bladder and the sphincter and has been proposed for treatment of stress incontinence and urgency incontinence (Cannon et al., 2003; Thor and Donatucci, 2004). Duloxetine increases the neural activity to the EUS and decreases bladder activity through effects on the CNS in cats (Thor and Donatucci, 2004). In a rat study, duloxetine also enhances the urethral continence reflex during sneezing as evidenced by an increase in sneeze-induced pressure responses at the middle urethra, although the effect appears to be mainly mediated by α_1-adrenoceptors (Miyazato et al., 2008a).

Adrenergic Transmitters.

Descending catecholaminergic neurons are primarily located in the upper medulla or pons (Ranson et al., 2003). In clinical use, nonselective α_1-adrenergic antagonists influence urine flow and LUTS; the two effects probably occur by different mechanisms, and central or peripheral locations may be responsible (Somogyi et al., 1995). Reflex bladder activity is modulated by at least two spinal α_1-adrenergic mechanisms. First, there is inhibitory control of reflex bladder contractions, probably by modulation of afferent processing. Second, there is excitatory modulation of the amplitude of bladder contractions as a result of regulation of the descending glutamatergic limb of the spinobulbospinal bladder reflex pathway (de Groat et al., 1999; Yoshiyama et al., 2000). α_{1A}-Adrenoceptors constitute 70% and α_{1B}-adrenoceptors constitute 30% of the α-adrenergic receptors in the rat lumbar spinal cord (Wada et al., 1996), whereas α_{1D}-adrenoceptors do not appear to have a significant role.

Blood pressure, vascular resistance, and tissue blood flow are also regulated by α-adrenergic receptors. Aging is thought to affect pelvic blood flow and thus bladder function. Pharmacologic blockade of the vascular α_{1B} adrenoceptor may increase pelvic blood flow and contribute to an improvement in bladder dysfunctions associated with aging and/or hypertension (Yono et al., 2011). β_3-Adrenoceptors, although well documented peripherally, are also present at a number of sites peripherally as well as in the rat sacral spinal cord. A number of studies have demonstrated that these agonists (via effects on bladder afferents and detrusor smooth muscle) may be a promising treatment for OAB (Chapple et al., 2014).

Purinergic Transmitters.

ATP acting via purinergic receptors modulates bladder function mediated by afferent and efferent pathways involved in urine storage and emptying. ATP is released together with NA and NPY from sympathetic nerves. It is also released as a cotransmitter with ACh from parasympathetic nerves supplying the bladder. Cotransmission likely offers subtle, local variations in neurotransmission and neuromodulation mechanisms (Burnstock, 2009). Purinergic contribution to parasympathetic stimulation has been shown to exist in a variety of species including rat, rabbit, and guinea pig (Burnstock, 1996; Burnstock et al., 1972; Chancellor et al., 1992). In contrast, there is less evidence that purinergic neurotransmission exists in humans, at least regarding normal responses to stimulation, but it may play a role in pathological conditions such as DO or BOO (Burnstock, 2001b; O'Reilly et al., 2001a; Palea et al., 1993).

ATP acts on two families of purinergic receptors: an ion channel family (P2X) and a G protein–coupled receptor family (P2Y) (Inoue and Brading, 1990; Inoue and Gabella, 1991; McMurray et al., 1998). Seven P2X subtypes and eight P2Y subtypes have been identified. Analysis of the structure-activity relationships of a series of excitatory purinergic agonists on the guinea pig bladder revealed an order of potency consistent with $P2X_1$ or $P2X_2$ receptors (Burnstock, 2001a; Zhong et al., 2001). In other species various studies suggested that multiple purinergic excitatory receptors are present in the bladder (Burnstock, 2001b).

Immunohistochemical experiments with specific antibodies for different P2X receptors showed that $P2X_1$ receptors are the dominant subtype in membranes of rat detrusor muscle and vascular smooth muscle in the bladder (Lee et al., 2000). The predominant expression of $P2X_1$ receptors has also been confirmed in the human bladder (O'Reilly et al., 2001a, 2001b). Investigators also found that the amount of $P2X_1$ receptors was increased in the obstructed bladder compared with the control bladder, suggesting upregulated purinergic mechanisms mediating OAB resulting from BOO (O'Reilly et al., 2001a).

Key Points: Spinal Circuitry Neurotransmitters

- Glutamate plays an important role in the spinal efferent circuitry supporting micturition.
- The spinal noradrenergic system, mediated by α_1-adrenoceptors, has a

modulatory role in controlling micturition by inhibiting afferent inputs from the bladder and facilitating the descending limb of the spinal micturition reflex to increase bladder contractility.

- Transmitters such as 5-HT, purines, glycine, and GABA appear to selectively modulate the volume threshold by actions in the sacral spinal cord. The role of other potential excitatory transmitters remains to be examined.
- These mechanisms seem to be favorable for development of novel drug therapies.
- Glutamate appears to be involved as an excitatory transmitter in the supraspinal circuitry controlling micturition.
- Glutamate may also be a mediator of DO after neural injury.
- Several substances can exert significant modulatory influences on the supraspinal circuits (see Fig. 110.31) and can have dramatic influences on micturition.
- The receptors for these substances represent potential sites for therapeutic intervention.

Reflex Circuitry Controlling Continence and Micturition.

Multiple reflex pathways organized in the brain and spinal cord mediate coordination between the urinary bladder and the urethra. The central pathways controlling LUT function are organized as simple on-off switching circuits (Fig. 110.32) that maintain a reciprocal relationship between the urinary bladder and the urethral outlet (De Groat, 1975; de Groat and Booth, 1993; de Groat et al., 1993). Some reflexes promote urine storage, whereas others facilitate voiding (see Fig. 110.30). It is also possible that individual reflexes may be linked together in a serial manner to create complex feedback mechanisms. For example, **the bladder-to-EUS guarding reflex that triggers sphincter contractions during bladder filling could, in turn, activate sphincter muscle afferents that initiate an inhibition of the parasympathetic excitatory pathway to the bladder. Thus a bladder-to-sphincter-to-bladder reflex pathway could, in theory, contribute to the suppression of bladder activity during urine storage. Alterations in these primitive reflex mechanisms may contribute to neurogenic bladder dysfunction.** Direct activation of these reflexes by electric stimulation of the sacral spinal roots very likely contributes to therapeutic effects of sacral nerve root neuromodulation (Chancellor and

Chartier-Kastler, 2000; Dijkema et al., 1993).

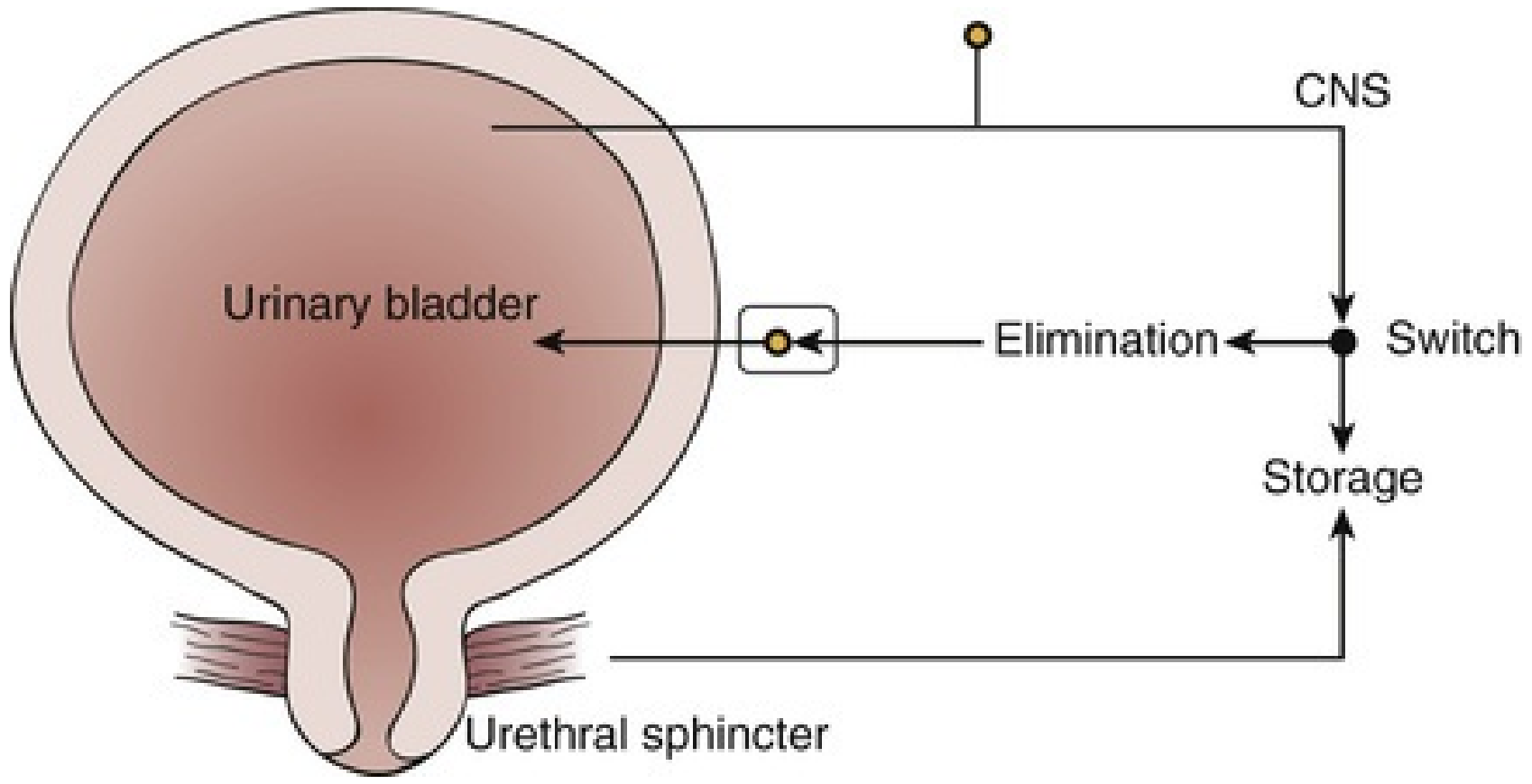

FIG. 110.32 Diagram illustrating the anatomy of the lower urinary tract and the "switchlike" function of the micturition reflex pathway. During urine storage, a low level of afferent activity activates efferent input to the urethral sphincter. A high level of afferent activity induced by bladder distention activates the switching circuit in the central nervous system (CNS), producing firing in the efferent pathways to the bladder, inhibition of the efferent outflow to the sphincter, and urine elimination.

Storage Phase of the Bladder.

Intravesical pressure measurements during bladder filling in humans and animals reveal low and relatively constant bladder pressures when bladder volume is below the threshold for inducing voiding (Fig. 110.33). **The accommodation of the bladder to increasing volumes of urine is dependent on the intrinsic properties of the vesical smooth muscle and stroma, as well as the quiescence of the parasympathetic efferent pathway** (de Groat and Booth, 1993; de Groat et al., 1993; Torrens and Morrison, 1987; Yoshimura et al., 2008). In addition, the urothelium also plays an important role in accommodating urine storage via changes in the apical (umbrella) cell membrane and release of a number of neuromediators that can influence bladder smooth muscle tone (Wang et al., 2005). **The bladder sympathetic reflex also contributes as a negative feedback or urine storage mechanism that promotes closure of the urethral outlet and inhibits neurally mediated contractions of the bladder during bladder filling** (de Groat and Theobald, 1976; Table 110.3). Reflex activation of the sympathetic outflow to the LUT can be triggered by afferent activity induced by distention of the urinary bladder (de

Groat and Booth, 1993; de Groat and Theobald, 1976; de Groat et al., 1993). This reflex response is organized in the lumbosacral spinal cord and persists after transection of the spinal cord at the thoracic levels (Fig. 110.34). **However, this bladder sympathetic mechanism to suppress bladder contractions during urine storage may be weak in humans,** given that bilateral retroperitoneal lymph node dissection, in which the sympathetic chains are destroyed, results in no discernible alteration of filling or storage function in humans.

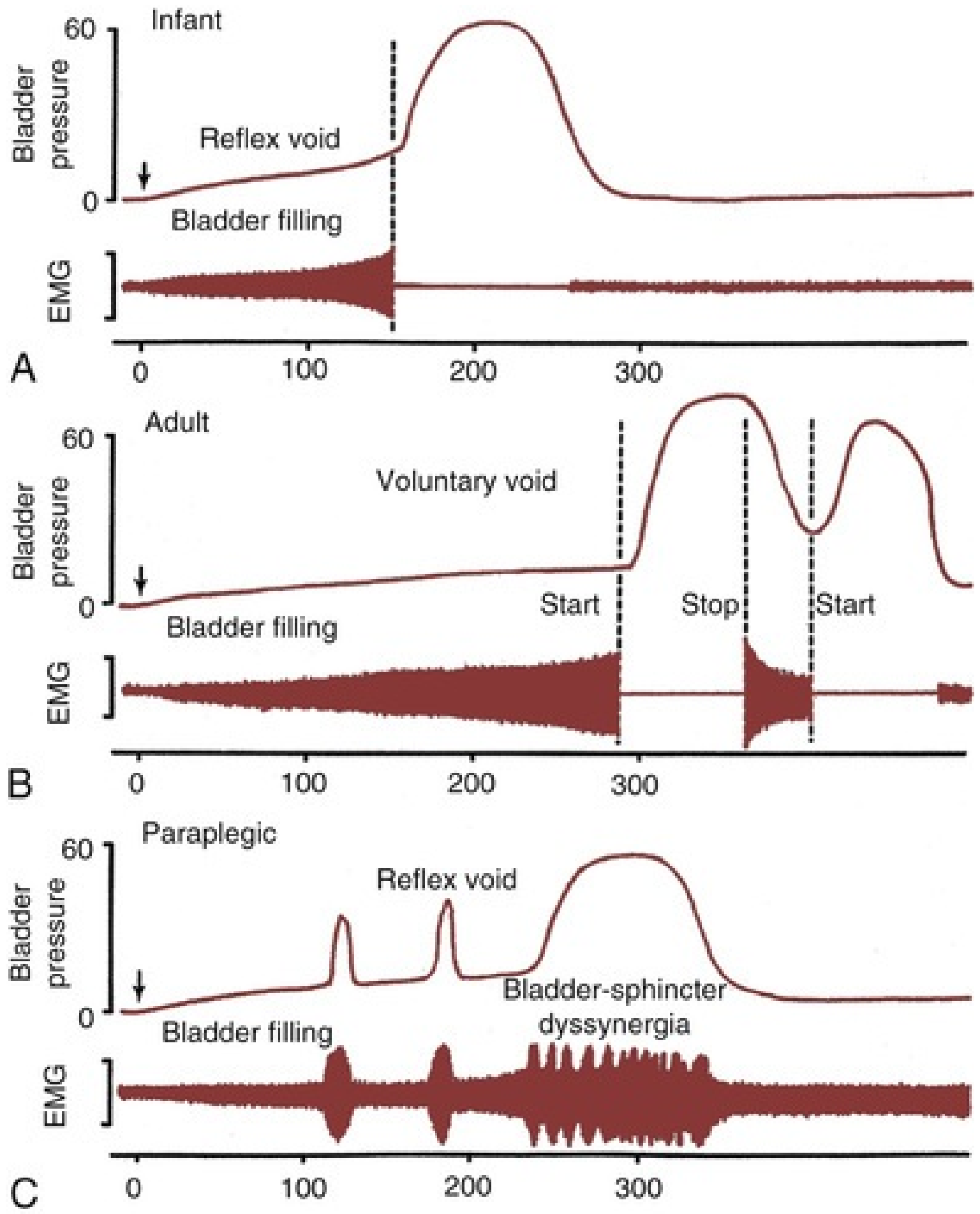

FIG. 110.33 Combined cystometrogram and sphincter electromyogram (EMG) comparing reflex voiding responses in an infant (A) and in a paraplegic patient (C) with a voluntary voiding response in an adult (B). The x-axis in all records represents bladder volume in milliliters, and the y-axis represents bladder pressure in centimeters of water and electrical activity of the electromyographic recording. On the left side of each trace, the *arrows* indicate the start of a slow infusion of fluid into the bladder (bladder filling). Vertical *dashed lines* indicate the start of sphincter relaxation that precedes by a few seconds the bladder contraction in A and

B. In B, note that a voluntary cessation of voiding (stop) is associated with an initial increase in sphincter electromyographic activity followed by a reciprocal relaxation of the bladder. A resumption of voiding is again associated with sphincter relaxation and a delayed increase in bladder pressure. On the other hand, in the paraplegic patient (C), the reciprocal relationship between bladder and sphincter is abolished. During bladder filling, transient uninhibited bladder contractions occur in association with sphincter activity. Further filling leads to more prolonged and simultaneous contractions of the bladder and sphincter (bladder-sphincter dyssynergia). Loss of the reciprocal relationship between bladder and sphincter in paraplegic patients interferes with bladder emptying. (From de Groat WC: Basic neurophysiology and neuropharmacology. In Abrams P, Khoury S, Wein A, editors: *Incontinence,* Plymouth, UK, 1999, Health Publications, p 112.)

TABLE 110.3

Reflexes to the Lower Urinary Tract

AFFERENT PATHWAY	EFFERENT PATHWAYS	CENTRAL PATHWAY
URINE STORAGE		
Low-level vesical afferent activity (pelvic nerve)	External sphincter contraction (somatic nerves)	Spinal reflexes
	Internal sphincter contraction (sympathetic nerves)	
	Detrusor inhibition (sympathetic nerves)	
	Ganglionic inhibition (sympathetic nerves)	
	Sacral parasympathetic outflow inactive	
MICTURITION		
High-level vesical afferent activity (pelvic nerve)	Inhibition of external sphincter activity	Spinobulbospinal reflex
	Inhibition of sympathetic outflow	
	Activation of parasympathetic outflow to the bladder	
	Activation of parasympathetic outflow to the urethra	

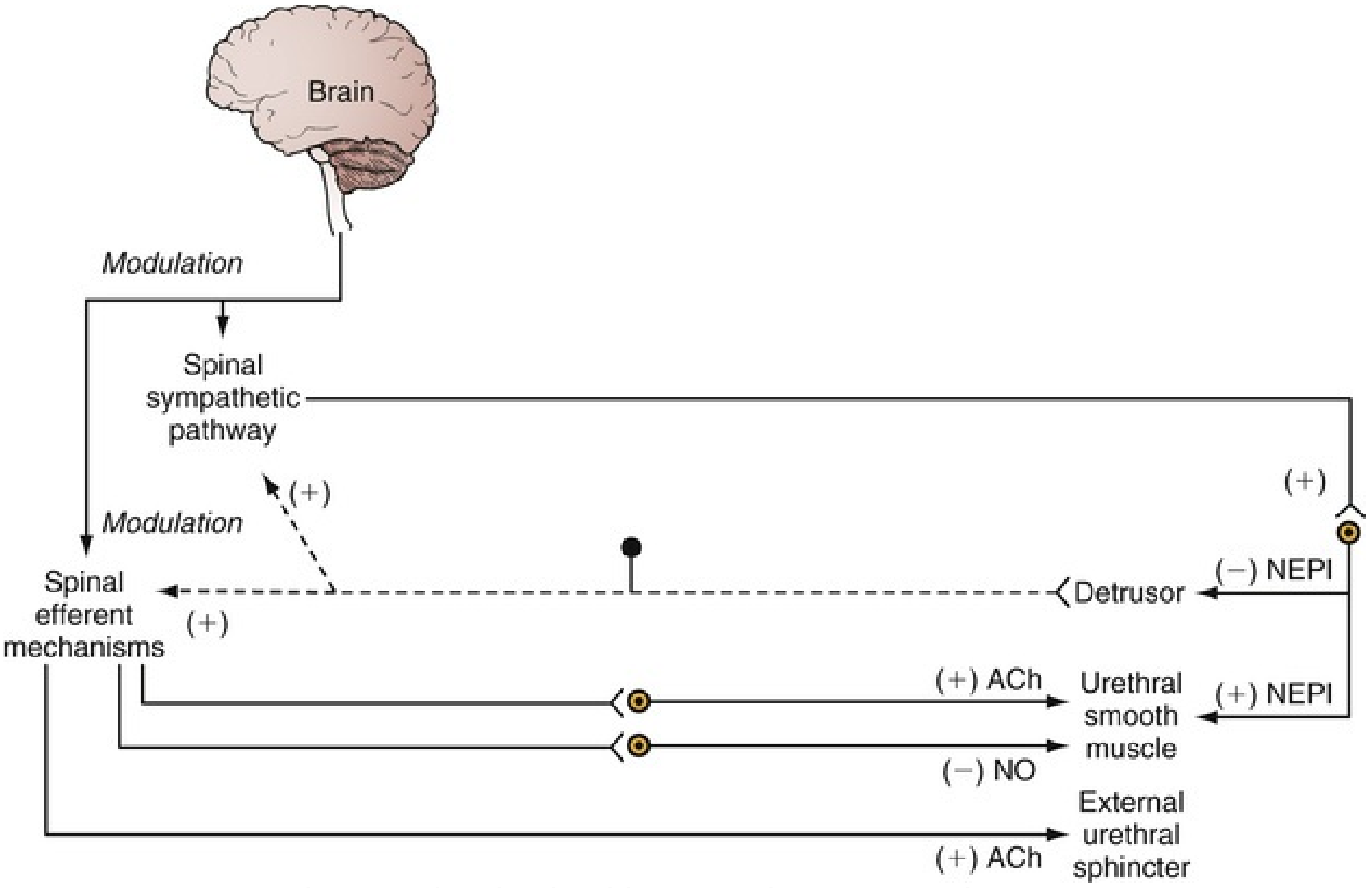

FIG. 110.34 Diagram showing bladder to urethra reflex pathways. Afferent pathway *(dashed line)* from the detrusor activates spinal reflex mechanisms that induce firing in somatic cholinergic nerves to the external urethral sphincter, sympathetic adrenergic nerves to the urethral smooth muscle, and cholinergic and nitrergic nerves to the urethral smooth muscle. Bulbospinal pathways from the brain can modulate these spinal reflex mechanisms. *ACh,* Acetylcholine; *NEPI,* norepinephrine; *NO,* nitric oxide; +, excitatory mechanism; −, inhibitory mechanism.

During bladder filling, the activity of the sphincter electromyogram also increases (see Fig. 110.33), reflecting an increase in efferent firing in the pudendal nerve and an increase in outlet resistance that contributes to the maintenance of urinary continence. Pudendal motoneurons are activated by bladder afferent input (the guarding reflex) (Park et al., 1997), whereas during micturition the motoneurons are reciprocally inhibited (de Groat and Booth, 1993; de Groat et al., 1993). EUS motoneurons are also activated by urethral or perineal afferents in the pudendal nerve (Fedirchuk and Hochman, 1992). This reflex may represent, in part, a continence mechanism that is activated by proprioceptive afferent input from the urethra or pelvic floor and that induces closure of the urethral outlet. These excitatory sphincter reflexes are organized in the spinal cord. Inhibition of EUS reflex activity during micturition is dependent, in part, on supraspinal mechanisms, because it is weak or absent in chronically spinalized animals and humans, resulting in simultaneous contractions of bladder and sphincter (i.e., detrusor-sphincter dyssynergia) (Blaivas, 1982; Rossier and Ott, 1976).

Sphincter to Bladder Reflexes.

It is well known that stimulation of somatic afferent pathways projecting in the pudendal nerve to the caudal lumbosacral spinal cord can inhibit voiding function. The inhibition can be induced by activation of afferent input from various sites, including the penis, vagina, rectum, perineum, urethral sphincter, and anal sphincter (de Groat and Booth, 1979, 1993; de Groat et al., 1979, 1993, 2001; de Groat and Yoshimura, 2001). Electrophysiologic studies in cats showed that the inhibition was mediated by suppression of interneuronal pathways in the sacral spinal cord and also by direct inhibitory input to the parasympathetic preganglionic neurons (De Groat et al., 1982).

On the basis of experiments in the laboratory and the review of medical literature, contractions of the EUS, and possibly other pelvic floor striated muscles, are likely to stimulate firing in muscle proprioceptive afferents, which then activate central inhibitory mechanisms to suppress the micturition reflex (see Fig. 110.33). A similar inhibitory mechanism has been identified in monkeys by directly stimulating the anal sphincter muscle (McGuire et al., 1983). In monkeys, at least part of the inhibitory mechanism must be localized in the spinal cord, because it persisted in T4 chronically paraplegic animals.

It is well known that stimulation of somatic afferent pathways projecting in the pudendal nerve to the caudal lumbosacral spinal cord can inhibit voiding function. The inhibition can be induced by activation of afferent input from various sites, including the penis, vagina, rectum, perineum, urethral sphincter, and anal sphincter (de Groat and Booth, 1979, 1993; de Groat and Yoshimura, 2001; de Groat et al., 1993, 2001). Electrophysiologic studies in cats showed that the inhibition was mediated by suppression of interneuronal pathways in the sacral spinal cord and also by direct inhibitory input to the parasympathetic preganglionic neurons (De Groat et al., 1982).

On the basis of laboratory experiments and review of the medical literatures, it is likely that contractions of the EUS, and possibly other pelvic floor striated muscles, stimulate firing in muscle proprioceptive afferents, which then activate central inhibitory mechanisms to suppress the micturition reflex (Fig. 110.35). A similar inhibitory mechanism has been identified in monkeys by directly stimulating the anal sphincter muscle (McGuire et al., 1983). In monkeys, at least part of the inhibitory mechanism must be localized in the spinal cord, because it persisted in T4 chronically paraplegic animals.

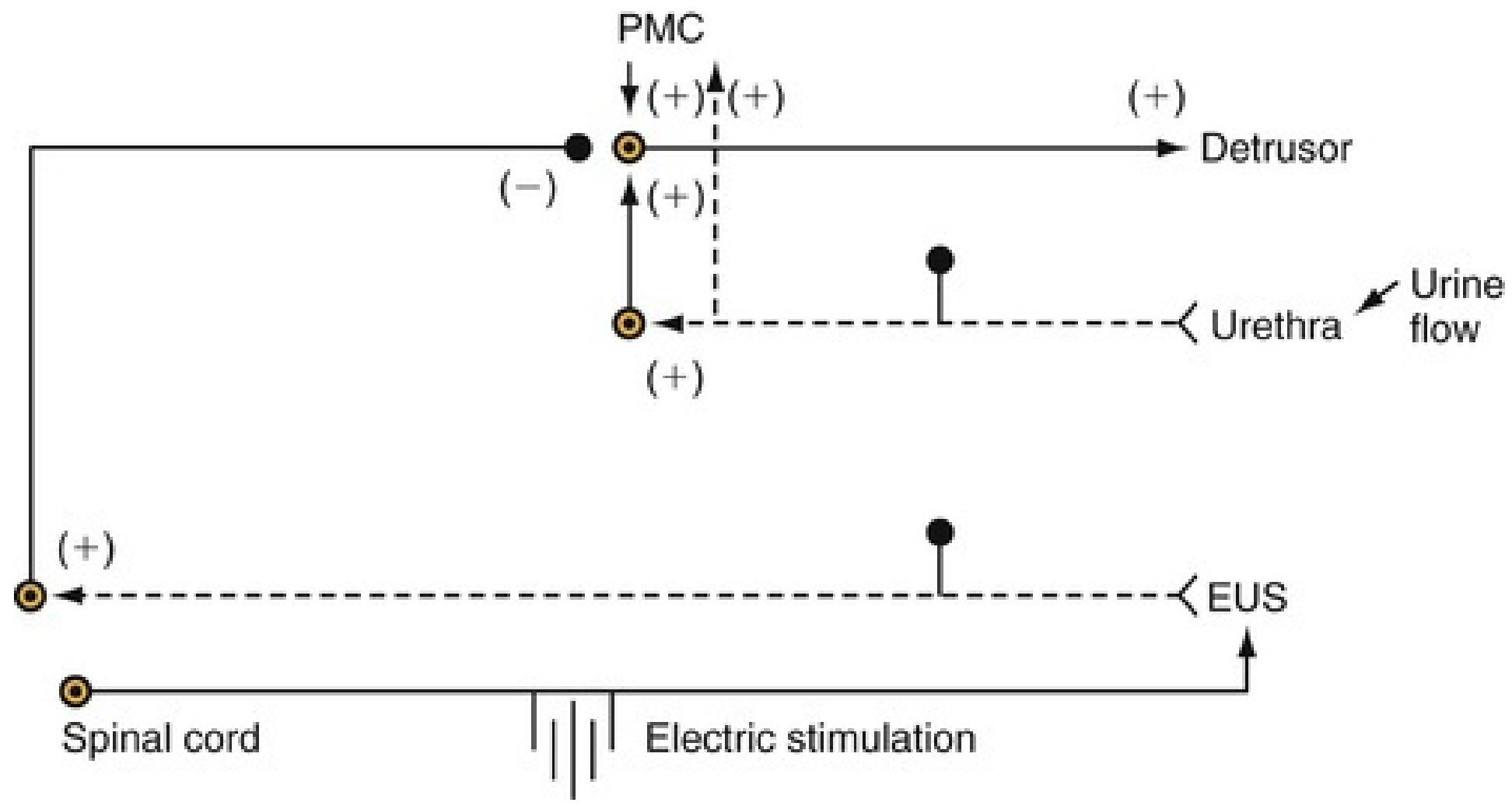

FIG. 110.35 Urethra to bladder reflexes. Activity in afferent nerves *(dashed lines)* from the urethra can facilitate parasympathetic efferent outflow to the detrusor by means of a supraspinal pathway passing through the pontine micturition center (PMC), as well as a spinal reflex pathway. Afferent input from the external urethral sphincter (EUS) can inhibit parasympathetic outflow to the detrusor through a spinal reflex circuit. Electric stimulation of motor axons in the S1 ventral root elicits an EUS contraction and EUS afferent firing that, in turn, inhibits reflex bladder activity. +, Excitatory mechanism; −, inhibitory mechanism.

Somatic to Visceral Reflexes.

There is evidence that stimulation of the sacral nerve roots using implanted electrodes (sacral neuromodulation) may be effective in patients with refractory OAB as well as in nonobstructive urinary retention, in patients refractory to conventional methods. Although the specific site of action is still unknown, various mechanisms have been described, including the modulation of CNS pathways (including somatic afferent inhibition of sensory processing) and the restoration of brainstem autoregulation (Leng and Chancellor, 2005; Thompson et al., 2010). Although more comprehensive evaluation is needed, another method that has been used as effective treatment for OAB and nonobstructive urinary retention is posterior tibial nerve stimulation (PTNS). Studies in anesthetized cats revealed that continuous tibial nerve stimulation (TNS) inhibited bladder activity that persisted after termination of the stimulus (Tai et al., 2011a,b), suggesting a role for treatment in bladder overactivity. In addition, this group also found evidence that an interaction between opioid and metabotropic glutamate receptor mechanisms may play a role in mechanisms underlying TNS-induced inhibition of bladder overactivity (Matsuta et al., 2013).

Emptying Phase of the Bladder.

The storage phase of the bladder can be switched to the voiding phase either involuntarily (reflexively) or voluntarily. The former is readily demonstrated in the human infant or in patients with neuropathic bladder when the bladder wall tension caused by increased volume of urine exceeds the micturition threshold. At this point, increased afferent firing from tension receptors in the bladder reverses the pattern of efferent outflow, producing firing in the sacral parasympathetic pathways and inhibition of sympathetic and somatic pathways. The expulsion phase consists of an initial relaxation of the urethral sphincter (see Fig. 110.33) followed in a few seconds by a contraction of the bladder, an increase in bladder pressure, and the flow of urine. Relaxation of the urethral smooth muscle during micturition is mediated by activation of a parasympathetic pathway to the urethra that triggers the release of NO, an inhibitory transmitter (Andersson, 1993), and by removal of excitatory inputs to the urethra. Secondary reflexes elicited by flow of urine through the urethra facilitate bladder emptying (de Groat and Booth, 1993; de Groat et al., 1993; Jung et al., 1999; Torrens and Morrison, 1987). These reflexes require the integrative action of neuronal populations at various levels of the neuraxis. The parasympathetic outflow to the detrusor and urethra has a more complicated central organization involving spinal and spinobulbospinal pathways passing through a micturition center in the pons (pontine micturition center [PMC]).

Urethra to Bladder Reflexes.

A landmark in the historical progress of neurobiology is the contribution of Barrington. Using his keen observational skills, Barrington (1931, 1941) reported that urine flow or mechanical stimulation of the urethra with a catheter could excite afferent nerves that, in turn, facilitated reflexive bladder contractions in the anesthetized cat (see Fig. 110.35). **He proposed that this facilitatory urethra-to-bladder reflex could promote complete bladder emptying.** Barrington identified two components of this reflex. One component was activated by a somatic afferent pathway in the pudendal nerve and produced facilitation by a supraspinal mechanism involving the PMC (see Fig. 110.35;

Barrington, 1931). Studies have confirmed the existence of this type of reflex by the pudendal nerve because low-frequency electric stimulation of afferent axons in the pudendal nerve in humans, or the deep perineal nerve (a caudal branch of the pudendal nerve) in cats, can initiate reflexive bladder contractions and voiding (Boggs et al., 2005; Shefchyk and Buss, 1998). The other component was activated by a visceral afferent pathway in the pelvic nerve and produced facilitation by a spinal reflex mechanism (Barrington, 1941).

Studies in the anesthetized rat have also provided additional support for Barrington's findings (Dokita et al., 1991). Measurements of reflexive bladder contractions, under isovolumetric conditions during continuous urethral perfusion (0.075 mL/min), revealed that the frequency of micturition reflexes was significantly reduced when urethral perfusion was stopped or after infusion of lidocaine (1%) into the urethra. Intraurethral infusion of NO donors (*S*-nitroso-*N*-acetylpenicillamine [SNAP] or nitroprusside, 1 to 2 mM) markedly decreased urethral perfusion pressure (approximately 30%) and decreased the frequency of reflex bladder contractions (45% to 75%) but did not change the amplitude of bladder contractions (Fig. 110.36). Desensitization of the urethral afferent with intraurethral capsaicin also dramatically altered the micturition reflex (Fig. 110.37). It was concluded that activation of urethral afferents during urethral perfusion could modulate the micturition reflex in the rat.

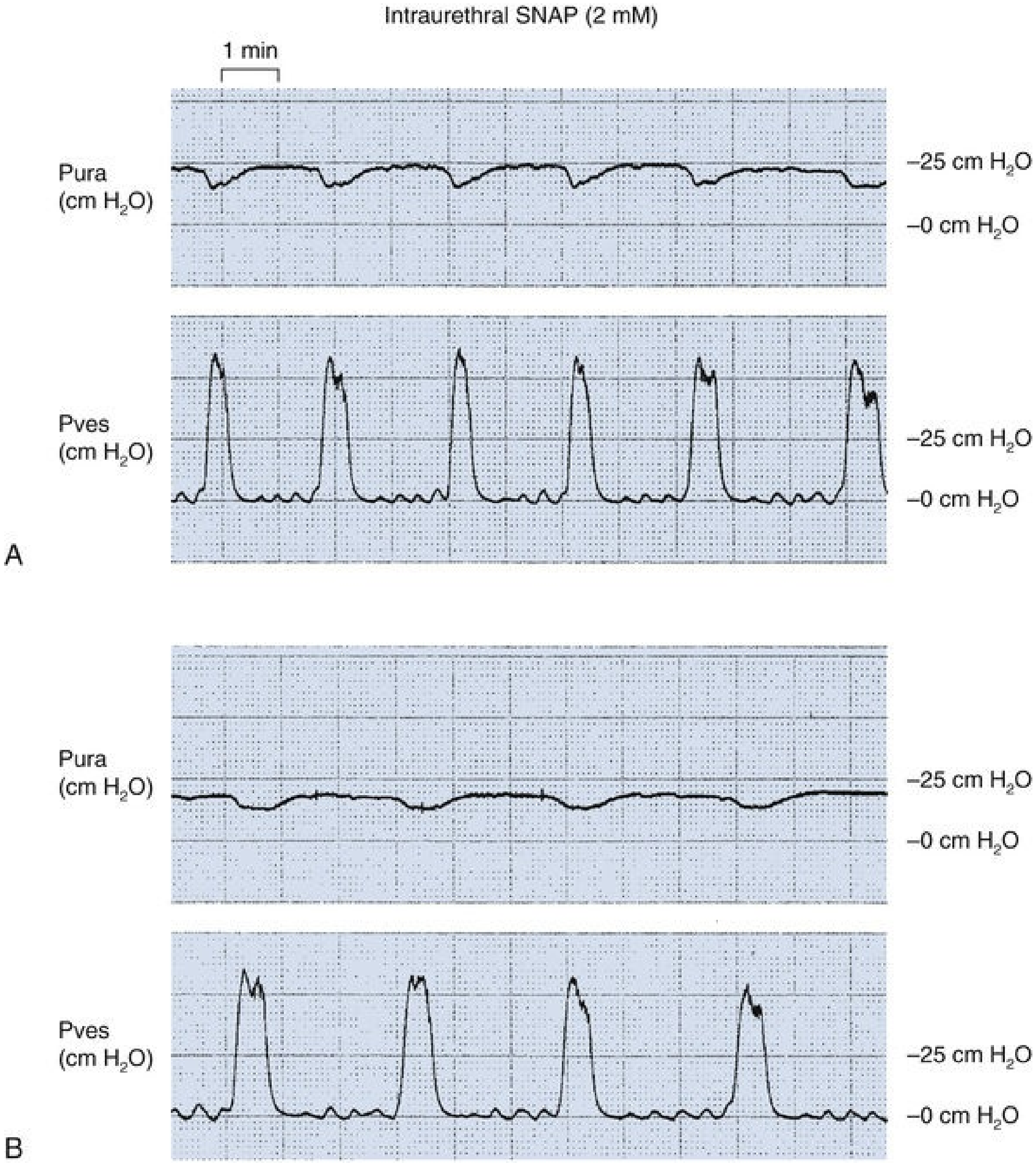

FIG. 110.36 Effects of intraurethral *S*-nitroso-*N*-acetylpenicillamine (SNAP) on the bladder pressure (Pves) and urethral pressure (Pura) in normal female rats. (A) Before treatment. (B) After intraurethral administration of SNAP (2 mM). Urethral perfusion pressure immediately decreased. In addition, bladder contraction frequency was significantly decreased. The duration of reflexive urethral relaxation was increased. (From Jung SY, Fraser MO, Ozawa H, et al.: Urethral afferent nerve activity affects the micturition reflex: implication for the relationship between stress incontinence and detrusor instability. *J Urol* 162:204–212, 1999.)

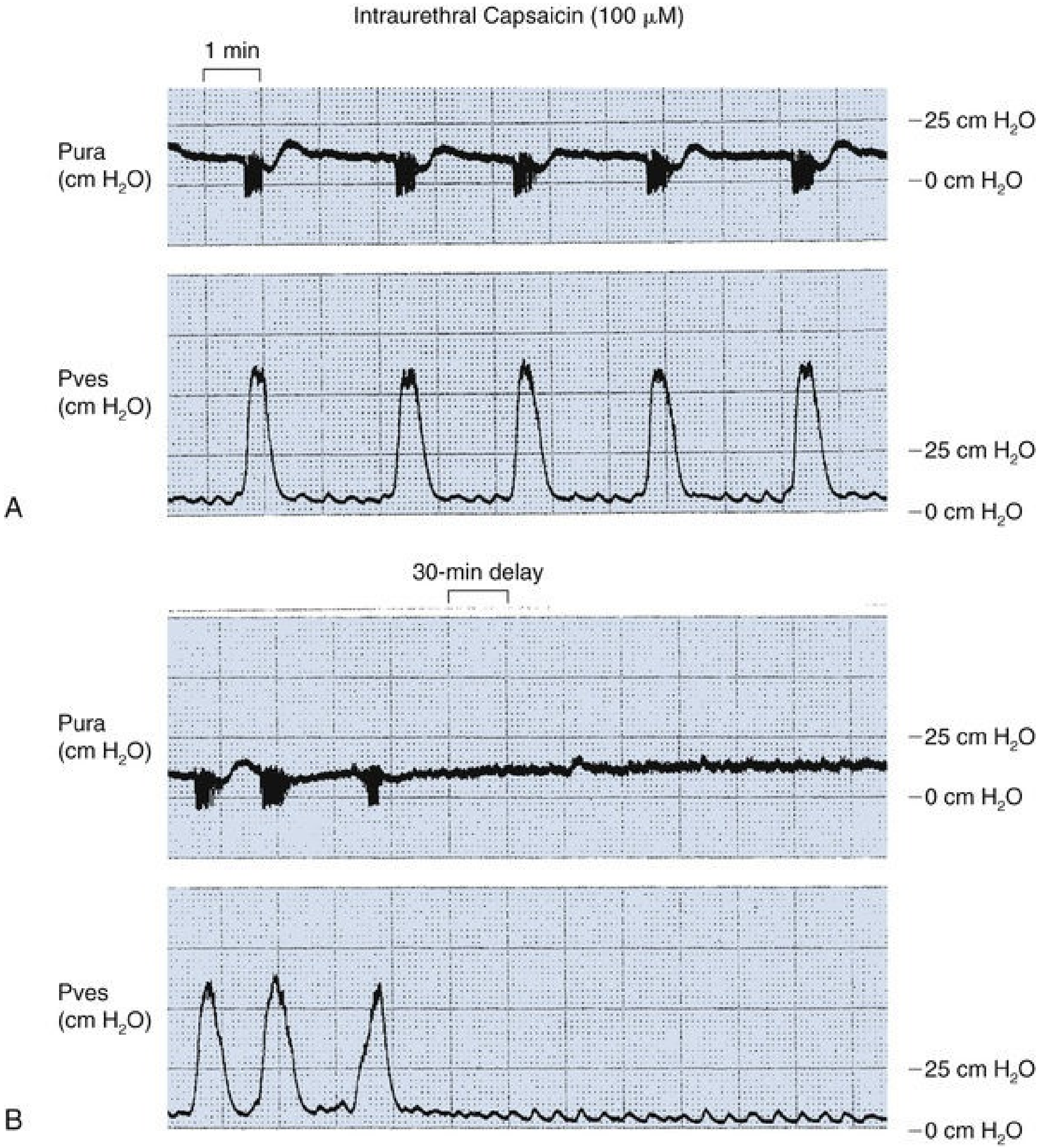

FIG. 110.37 Effects of intraurethral capsaicin on the bladder pressure (Pves) and urethral pressure (Pura) in normal female rats. (A) Before treatment. (B) After intraurethral administration of capsaicin (100 µM). Initially, intraurethral capsaicin instillation increased the bladder contraction frequency, but 30 minutes after continuous infusion, the activity was blocked. (From Jung SY, Fraser MO, Ozawa H, et al.: Urethral afferent nerve activity affects the micturition reflex: implication for the relationship between stress incontinence and detrusor instability. *J Urol* 162:204–212, 1999.)

Supraspinal Pathways

Pontine Micturition Center and Brainstem Modulatory Mechanisms.

The integral role of the brainstem in bladder function was initially realized by the demonstration in cats that micturition was abolished by lesions at the level of the inferior colliculus, whereas lesions anterior to the colliculus facilitated micturition, presumably by removing inhibitory influences (Barrington, 1921, 1925). Anatomic and physiologic studies in the rat and the cat have delineated midbrain–pontine–spinal cord circuits in reflexes controlling filling, storing, and emptying of the bladder (Fig. 110.38). The roles of pontine nuclei revealed by animal models translate well to humans as indicated by brain imaging during micturition (Blok and Holstege, 1997; Blok et al., 1997; Fukuyama et al., 1996; Kershen et al., 2003) and clinical cases showing that specific pontine lesions can result in either bladder continence or incontinence problems (Charil et al., 2003; Fukuyama et al., 1996; Sakakibara et al., 1996).

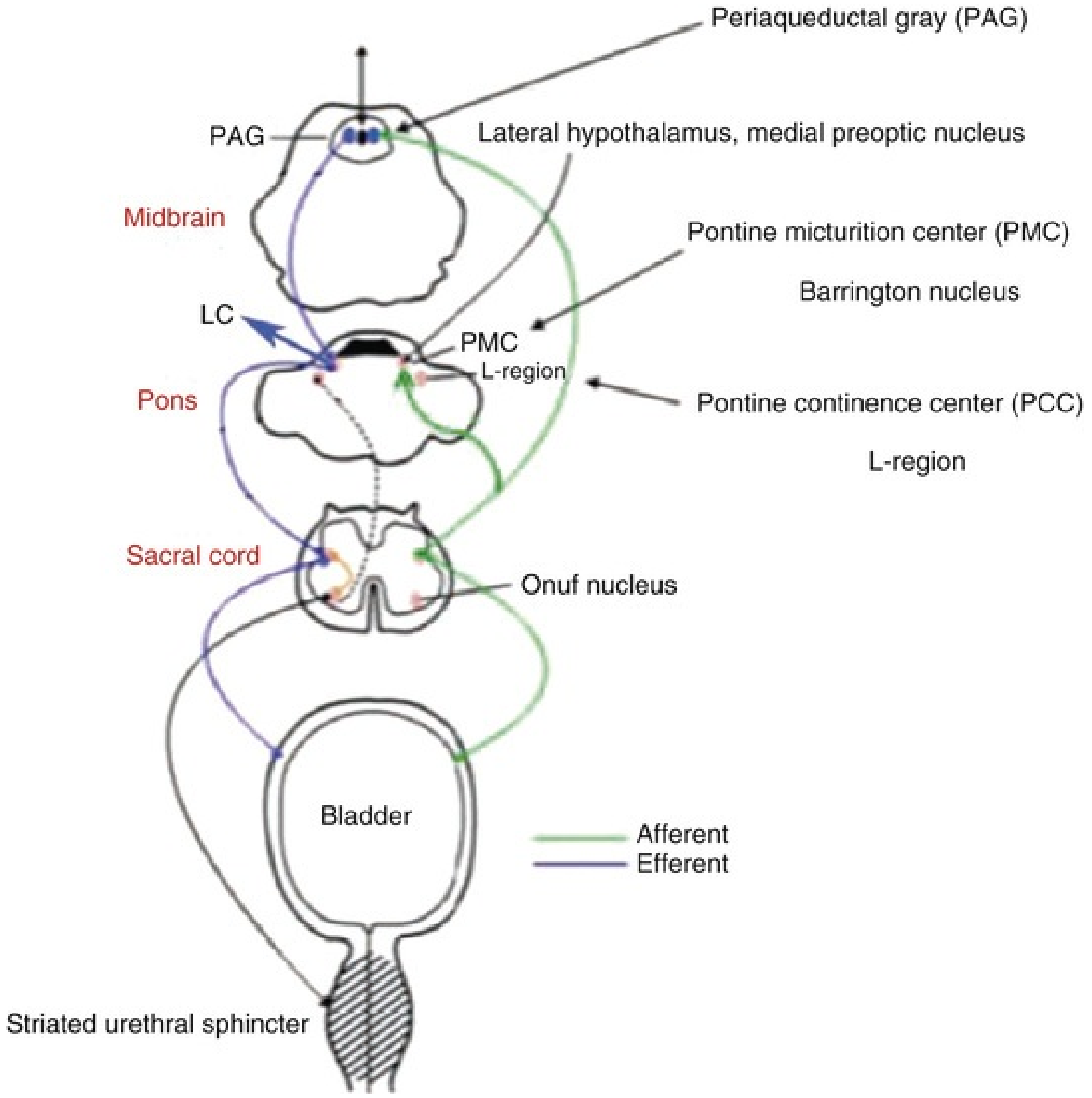
Periaqueductal gray (PAG)
PAG
Lateral hypothalamus, medial preoptic nucleus
Midbrain
Pontine micturition center (PMC)
Barrington nucleus
LC
PMC
L-region
Pons
Pontine continence center (PCC)
L-region
Sacral cord
Onuf nucleus
Bladder
Afferent
Efferent
Striated urethral sphincter

FIG. 110.38 Schematic depicting information flow among the bladder, spinal cord, and brain. In the rat, spinal cord interneurons relay information about the bladder to the pontine micturition center (PMC), Barrington nucleus, and PAG. The PMC also gets input from the PAG, lateral hypothalamus, and medial preoptic nucleus. PMC neurons project to the locus ceruleus (LC) and preganglionic parasympathetic neurons of the lumbosacral spinal cord that innervate the detrusor. There are also projections to premotor neurons in the dorsal gray commissure that innervate Onuf nucleus, which projects to the urethral sphincter. A pontine continence center (PCC) has been proposed in the cat and is localized to the L-region of the pons. Neurons here project to the Onuf nucleus.

The dorsal pontine tegmentum has been firmly established as an essential control center for micturition in normal subjects. First described by Barrington (1921), it has subsequently been called the *Barrington nucleus*, the *pontine micturition center* (Blok and Holstege, 1997), or the *M region* (Blok and Holstege, 1996; Holstege et al., 1996) because of its medial location. In 1925

Barrington was the first to describe a pontine control center for micturition in the cat after lesion studies (Barrington, 1921, 1925). This region was better localized to a nucleus in the dorsal pons (now termed the *Barrington nucleus)* using more discrete lesions that abolished micturition and caused urinary retention in cats and rats (Satoh et al., 1978; Tang, 1955). Lesions in humans as a result of stroke or multiple sclerosis in an analogous region similarly result in urinary retention (Komiyama et al., 1998).

Physiologic studies have confirmed the role of the Barrington nucleus in micturition. Electrical and chemical activation of Barrington nucleus neurons in rats and cats initiates bladder contractions and relaxes the urethral sphincter (Holstege et al., 1986; Mallory et al., 1991; Pavcovich and Valentino, 1995; Tanaka et al., 2003). Precise mapping of sites at which chemical stimulation elicits bladder contractions demonstrates a well-defined area localized to the Barrington nucleus (Pavcovich and Valentino, 1995). Single-unit recordings in rat pons revealed three types of responses to bladder contraction: an excitation that occurred only before contraction, an excitation that occurred before and was maintained during contraction, and an inhibition during contraction (Tanaka et al., 2003). Neurons that were activated just before contraction and that maintained activation during contraction were found in Barrington nucleus, whereas the other two types of neurons were scattered throughout the pontine tegmentum.

Micturition also requires an inhibition of the urethral sphincter to be coordinated with detrusor contraction. The striated urethral sphincter (rhabdosphincter) is controlled by the interaction between upper moto neurons and the lower motoneurons of the Onuf nucleus. Barrington nucleus neurons do not project to Onuf nucleus. Rather, in the cat a diffuse region ventrolateral to Barrington nucleus, termed the *L-region*, is thought to provide pontine control of sphincter function through its projections to Onuf nucleus (Holstege et al., 1979). For coordination between the detrusor and sphincter, there should be some form of reciprocal communication between these regions. However, a lack of connections between Barrington nucleus and the L-region is the reason for argument against sphincter regulation by Barrington nucleus through this route (Blok and Holstege, 1999). Rather, it has been proposed that Barrington nucleus indirectly inhibits Onuf nucleus neurons though excitatory projections to GABA premotor interneurons in the dorsal gray commissure (Blok and Holstege, 1999). In addition, Barrington nucleus projections onto inhibitory interneurons located in the intermediolateral cell column at the sacral segmental level have been described and may provide an inhibitory influence over Onuf nucleus; glycine and GABA are thought to play a role here (Blok and Holstege, 1998; Sie et al., 2001). Together, the anatomic and physiologic findings just described point to Barrington nucleus as being the command center for initiating and orchestrating the act of bladder emptying.

Central Circuitry Regulating Bladder Function by Transneuronal Tracing.

Transneuronal retrograde tracing from end organs with pseudorabies virus (PRV) has been an invaluable tool in delineating the central circuitry that regulates visceral function (Loewy, 1998). The population of rat brain neurons labeled from PRV injections in either the bladder wall or urethra of the rat exhibits an overlap and similar time course of labeling, supporting a close coordination of detrusor and urethral muscle function by brain circuits as previously suggested (Marson, 1997; Nadelhaft and Vera, 1996; Nadelhaft et al., 1992; Vizzard et al., 1995). The first neurons to be labeled in brain from bladder or urethra and therefore the most direct links to the spinal efferents are the ventral medullary raphe, parapyramidal reticular formation, A5, and Barrington nucleus. The periaqueductal gray (PAG), hypothalamus, and medial preoptic nucleus, which are prominent afferents to Barrington nucleus, are labeled at a slightly later time when the locus ceruleus (LC), cortex, and red nucleus are also labeled. PRV labeling from other pelvic viscera, including the distal colon, yields a similar pattern and time course, suggesting a certain degree of central coordination of these functions (Marson and Carson 3rd, 1999; Rouzade-Dominguez et al., 2003).

The PRV studies provide information regarding some hierarchy of neurons that is anatomically linked to the bladder and/or urethra. However, the PRV technique does not imply precise information about connectivity or functionality. This must be delineated by additional tract tracing between putatively connected brain nuclei and physiologic studies. For example, studies in humans indicate that voluntary control of voiding is dependent on connections between the frontal cortex and the septal-preoptic region of the hypothalamus, as well as on connections between the paracentral lobule and the brainstem. Lesions to these areas of cortex appear to directly increase bladder activity by removing cortical inhibitory control (de Groat and Booth, 1993; de Groat et al., 1993). Of the brain regions that are initially labeled with PRV from the bladder or urethra, most anatomic, electrophysiologic, and imaging studies have implicated the

Barrington nucleus as pivotal in regulating bladder function in animals and humans.

Neurotransmitters and Modulators Within Brainstem Networks.

Knowledge of the neurochemical signals within the central circuits controlling micturition is important for understanding how these circuits function and how they can be manipulated for the treatment of bladder dysfunctions. These were reviewed in detail by Holstege (2005) and by Fowler et al. (2008). Much of the current knowledge is based on studies using cats; less is known regarding rats and primates. **Glutamate is thought to be the primary neurotransmitter within Barrington nucleus neurons that innervate the preganglionic parasympathetic neurons responsible for detrusor contraction.** NMDA and non-NMDA receptors have been implicated in this response (Matsumoto et al., 1995a, 1995b; Yoshiyama et al., 1995; Yoshiyama and de Groat, 2005).

Barrington nucleus neurons express corticotropin-releasing factor (CRF) mRNA and protein, and a dense CRF terminal field is present in the region of preganglionic parasympathetic neurons of the rat lumbosacral spinal cord (Imaki et al., 1992; Valentino et al., 2000). Findings suggest that CRF has an inhibitory influence in this same pathway (Pavcovich and Valentino, 1995). Thus discrete chemical activation of Barrington nucleus neurons elicits bladder contraction that is enhanced by blocking the CRF influence in the lumbosacral spinal cord with a CRF antagonist. Serotonin appears to affect nervous control of bladder function at multiple levels, including sensory processing of bladder wall afferents within the dorsal horn of the spinal cord and at the level of the spinal motoneurons. In all cases this appeared to be an inhibitory influence on detrusor muscle activity but excitatory on urethral sphincter (Burgard et al., 2003). It was proposed that 5-HT$_{1A}$ receptors were located on the terminals of sensory afferent fibers to depress neurotransmitter release.

Human Brain Imaging Studies.

In the last decade, the areas of the brain involved in the control of micturition have been examined in human brain imaging studies using single-photon emission computed tomography (SPECT), positron emission tomography (PET), and functional magnetic resonance imaging (fMRI) (DasGupta et al., 2007; Griffiths and Tadic, 2008; Fig. 110.39). All these methods provide indirect measures of regional blood flow, assumed to be related to local neuronal activity, but PET is good for measuring long-lasting states of a system, whereas fMRI is better for following relatively fast events. SPECT has rather poor temporal and spatial resolution.

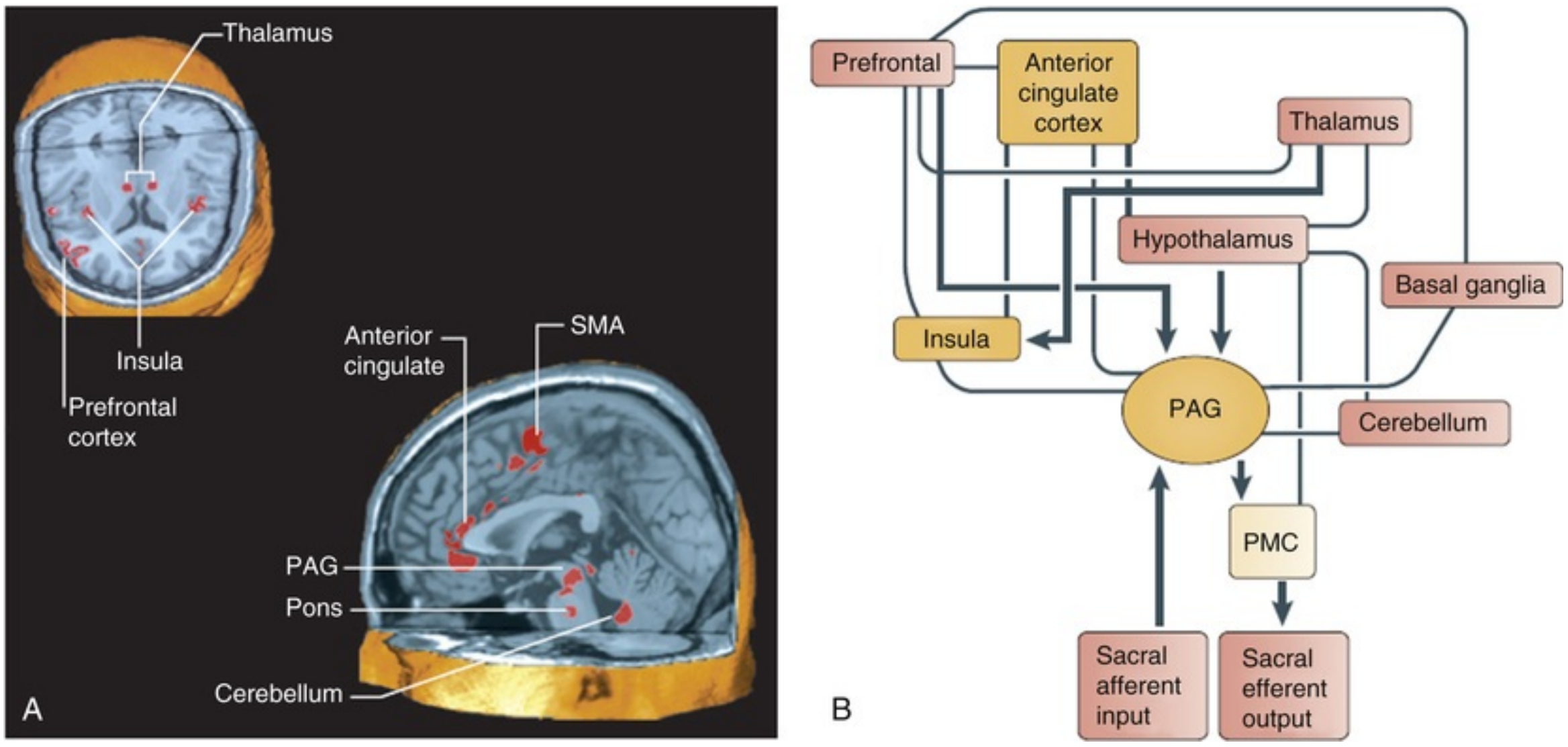
Thalamus
Insula
Prefrontal cortex
Anterior cingulate
SMA
PAG
Pons
Cerebellum
A
Prefrontal
Anterior cingulate cortex
Thalamus
Hypothalamus
Basal ganglia
Insula
PAG
Cerebellum
PMC
Sacral afferent input
Sacral efferent output
B

FIG. 110.39 Brain areas involved in the regulation of urine storage. (A) A meta-analysis of positron-emission tomography and functional magnetic resonance imaging studies that investigated which brain areas are involved in the regulation of micturition reveals that the thalamus, the insula, the prefrontal cortex, the anterior cingulate, the periaqueductal gray (PAG), the pons, the medulla, and the supplementary motor area (SMA) are activated during urinary storage. (B) A preliminary conceptual framework, based on functional brain-imaging studies, suggesting a scheme for the connections among various forebrain and brainstem structures that are involved in the control of the bladder and the sphincter in humans. *Arrows* show probable directions of connectivity but do not preclude connections in the opposite direction. *PMC,* Pontine micturition center. (From Fowler CJ, Griffiths D, de Groat WC: The neural control of micturition. *Neuroscience* 6:453–466, 2008.)

Cerebral Control of Voiding.

During human voiding the urethral sphincter relaxes, facilitating urine flow, and the detrusor contracts to expel urine. This coordinated relaxation and contraction of urethra and bladder respectively is driven by a long-loop spinobulbospinal reflex (Fowler et al., 2008). As the bladder fills, increasingly strong bladder afferents travel via synapses in the sacral cord to the brainstem and midbrain, where they synapse in the central PAG and possibly Barrington nucleus or PMC. Although there are differing views about how the brainstem circuitry is organized, regardless, if the trigger level is exceeded, efferent signals from the

PMC descend to the sacral cord, where they excite an indirect inhibitory pathway via the nucleus of Onuf that leads to sphincter relaxation (Blok and Holstege, 1998) and an excitatory pathway to the bladder that leads to detrusor contraction; thus voiding occurs. Therefore the spinobulbospinal voiding-reflex pathway functions as a switch, either “off” (storage) or “on” (voiding). In the absence of higher control, this switching behavior would lead to involuntary bladder emptying (i.e., incontinence) whenever the bladder volume reached a critical level sufficient to trigger the brainstem switch.

White-matter damage that causes permanent incontinence appears to do so by disrupting a pathway (from medial frontal cortex to brainstem, either direct or via the thalamus) carrying the signal that maintains continence by tonically inhibiting the voiding reflex during storage. Imaging studies using PET (Athwal et al., 2001; Blok and Holstege, 1997, 1998; Blok et al., 1997, 1998; Matsuura et al., 2002; Nour et al., 2000) or MRI (Blok et al., 2006; Di Gangi Herms et al., 2006; Griffiths et al., 2005; Kunze et al., 2006) are in agreement that during bladder filling, storage, and withholding of urine, there is activity in the right inferior frontal or dorsolateral prefrontal cortex, perhaps extending into the lateral part of the superior frontal cortex. There is some right-sided predominance. In contrast, there is little evidence for activation of the medial parts of the frontal cortex during storage. These observations are consistent with the concept that functional imaging reveals gray-matter activation or deactivation, whereas lesions may damage critical links in white-matter connecting pathways also.

Additional Regions.

PET scan studies in normal men and women revealed that, during voiding, two cortical areas (the dorsolateral prefrontal cortex and anterior cingulated gyrus) were active (i.e., exhibited increased blood flow). The hypothalamus, including the preoptic area, as well as the pons and the PAG also showed activity in concert with voluntary micturition (Blok and Holstege, 1997, 1998; Blok et al., 1997, 1998). Another PET study during voiding also confirmed that micturition was associated with increased activity in the pons, inferior frontal gyrus, hypothalamus, and PAG, while also showing activity in several other cortical areas (postcentral gyrus, superior frontal gyrus, thalamus, insula, and globus pallidus) and the cerebellar vermis (Nour et al., 2000).

Many functional imaging studies have observed responses (mostly activations) in ACG to bladder filling, storage, or withholding (Athwal et al., 2001; Blok and Holstege, 1997, 1998; Blok et al., 1997, 1998; Griffiths et al., 2005; Komesu et al., 2011; Matsuura et al., 2002; Yin et al., 2006). Response to bladder filling in the dorsal ACG and adjacent supplementary motor area (SMA) is abnormally pronounced in patients with urge incontinence (Griffiths et al., 2007) when, with full bladder but without any actual bladder contraction, they experience the abnormal sensation of urgency (a compelling desire to void that is difficult to inhibit [Abrams et al., 2002], also associated with fear of leakage, i.e., embarrassment) (Abrams et al., 1988). Thus urgency is a powerful homeostatic and social emotion that provides strong motivation to void together with motor output aimed at suppressing incontinence until a socially acceptable location can be reached. fMRI observations in rats confirm activation in the cingulate cortex during bladder filling (Tai et al., 2009), although whether this region is homologous with the human dorsal anterior cingulate cortex (dACC) and whether rats ever experience urgency are not known.

The demonstration by Barrington (1925) in the cat that a center necessary for activation of micturition existed at the level of the pons provided the background for recognizing a comparable center in humans and the early report of the association of difficulty with micturition with posterior fossa tumors. Later histories of individual cases of discrete pontine lesions (Betts et al., 1992; Komiyama et al., 1998; Manente et al., 1996; Sakakibara et al., 1996) and reports of difficulties with micturition or retention as a feature of brainstem gliomas in children (Renier and Gabreels, 1980; Ueki, 1960) or vascular lesions (Sakakibara et al., 1996) confirmed the likely existence of a comparable center in humans. Studies using MRI to visualize the precise location of the responsible lesions sited this in the dorsolateral pons, including the pontine reticular nucleus and the reticular formation, adjacent to the medial parabrachial nucleus and locus ceruleus (Sakakibara et al., 1996). Lesions in this location are frequently associated with disturbances of consciousness and respiration, and bladder symptoms may therefore be overlooked.

Other regions relevant to bladder control and revealed only by functional imaging include parts of parietal and frontoparietal cortices, posterior cortex (precuneus, posterior cingulate cortex), parts of the limbic system (hippocampal complex, amygdala), and the cerebellum. Functional imaging has occasionally shown activity in the basal ganglia, particularly the striatum and putamen (Griffiths et al., 2009). Correspondingly, dopamine pathways are thought to have a profound inhibitory effect on the PMC in health that is lost in Parkinson disease (Winge and Fowler, 2006).

Model of Brain-Bladder Control and Normal Continence Mechanism.

The brain regions involved in bladder control are believed to be organized in neural circuits that perform different tasks related to homeostasis, answering questions regarding the adequacy of bladder filling, and the safety and social appropriateness of voiding, as well as the reflex or mechanical aspects dealt with by the brainstem switch. We should therefore expect forebrain control of the switch to involve limbic circuits (concerned with basic emotion and safety) and cortical circuits (concerned with social propriety [Amodio and Frith, 2006] and conscious decision making). In the working model, the PAG and PMC form the brainstem switch (Fig. 110.40). The PMC is the final efferent brain nucleus involved in bladder control. The PAG receives numerous projections from forebrain regions (Mantyh, 1982; Mouton and Holstege, 2000) including the medial and orbital prefrontal cortex (An et al., 1998).

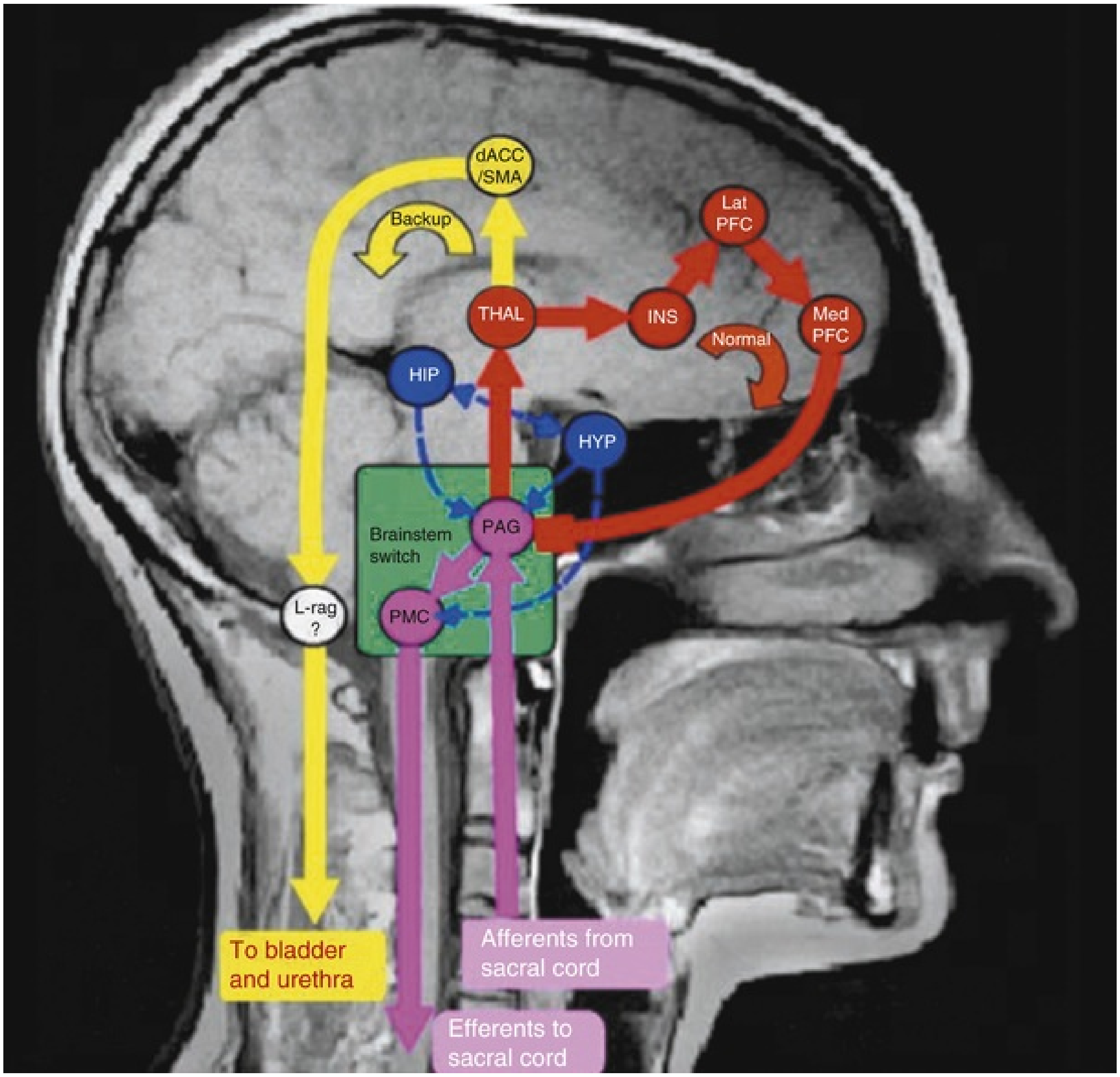
dACC
/SMA
Backup
Lat
PFC
THAL
INS
Med
PFC
Normal
HIP
HYP
Brainstem
switch
PAG
L-rag
?
PMC
To bladder
and urethra
Afferents from
sacral cord
Efferents to
sacral cord

FIG. 110.40 Working model of forebrain control of micturition showing the brainstem switch and neural circuits that mediate two possible continence mechanisms. The normal mechanism *(red)* operates when there is a normal sensation of bladder filling. It depends on tonic inhibition of the brainstem switch via a long return pathway from the medial prefrontal cortex to the brainstem switch (probably via the anterior thalamic radiation but shown for simplicity as a direct connection to the periaqueductal gray [PAG]). The inhibition is switched off for voiding. A backup mechanism *(yellow)* corresponds to the abnormal sensation or urgency. It may operate via brainstem nuclei such as an L-region (pontine storage center) or by modulating the sympathetic input to bladder and urethra. The *dashed blue arrows* show a possible circuit concerned with monitoring safety and/or maintaining continence without conscious sensation. *dACC,* Dorsal anterior cingulate cortex; *HIP,* (para)hippocampal complex (may include amygdala, inferior parts of temporal lobe and parts of posterior cortex); *HYP,* hypothalamus; *INS,* insula; *Lat,* lateral; *L-reg,* L-region; *med,* medial; *PFC,* prefrontal cortex; *PMC,* pontine micturition center; *SMA,* supplementary

motor area; *THAL,* thalamus.

During urine storage, as the bladder fills, it generates afferent signals that are transmitted to the brainstem switch but do not trigger it. They are relayed from the PAG via the thalamus to the insula (red circuit) and, if activation is strong enough, generate a desire to void. Propagation of this insular activity to the lateral and medial prefrontal cortex enables a conscious decision about voiding and an assessment of social propriety and possible embarrassment. If no voiding is planned, a return pathway from the medial frontal cortex to the brainstem tonically suppresses the voiding reflex. The pathway may run directly or via the thalamus in the anterior thalamic radiation. The result is postulated to be the normal continence mechanism. When there is a normal sensation of bladder filling, it exerts negative feedback on the brainstem switch, preventing incontinence. Interruption of the negative feedback—for example, by white-matter damage in the medial prefrontal cortex–periaqueductal gray (mPFC-PAG) pathway—leads to incontinence. During normal daily life, however, there is usually no conscious awareness of the bladder at all.

Pharmacology

Muscarinic Mechanisms

Detrusor strips from normal human bladders are contracted by cholinergic muscarinic receptor agonists and by electric stimulation of intrinsic cholinergic nerves. Contractile responses can be completely abolished by atropine (Sibley, 1984). **There are at least five receptor subtypes based on molecular cloning and four different receptor subtypes based on pharmacology (M_1 to M_5)** (Eglen et al., 1996; Hegde et al., 1997; Somogyi et al., 1994; Wang et al., 1995; Yamaguchi et al., 1996).

Pharmacologically, M_1, M_2, and M_3 receptor subtypes have been found in the human bladder by receptor binding assays (Kondo et al., 1995); **all M_1 to M_5 receptor mRNAs are detected by reverse transcription polymerase chain reaction assays** (Andersson and Wein, 2004; Mansfield et al., 2005). **Although ligand receptor binding studies revealed that M_2 receptors predominate, M_3 receptors mediate cholinergic contractions** (Eglen et al., 1994; Harriss et al., 1995; Hegde et al., 1997; Lai et al., 1998; Yamaguchi et al., 1996). **Stimulation of M_3 receptors by ACh leads to IP_3 hydrolysis as a result of PLC activation and then to the release of intracellular calcium and smooth muscle contraction** (Fry et al., 2002; Harriss et al., 1995) (see Figs. 110.15, 110.17, and 110.18). **The involvement of transmembrane flux of calcium ions through nifedipine-sensitive L-type Ca^{2+} channels has also been indicated in M_3 receptor–mediated detrusor muscle contractions** because the L-type Ca^{2+} channel inhibitor nifedipine strongly suppressed carbachol-induced detrusor contractions, whereas the PLC inhibitor or the store-operated Ca^{2+} channel inhibitor caused little inhibition in rats and humans (Andersson and Arner, 2004; Andersson and Wein, 2004; Frazier et al., 2008; Schneider et al., 2004a, 2004b) (see the earlier section on calcium signaling in detrusor myocyte). However, other studies have indicated the major contribution of the PLC-mediated mechanism to M_3 receptor–induced detrusor contractions, because PLC inhibitors significantly suppressed carbachol-induced detrusor contractions in rats (Braverman et al., 2006a, 2006b), and intracellular calcium elevation after carbachol application was observed without membrane depolarization in human bladders, which is required for the opening of L-type Ca^{2+} channels (Fry et al., 2002). Hashitani et al. (2000) reported that the stimulation of muscarinic receptors activates calcium influx through L-type Ca^{2+} channels and calcium release from intracellular calcium stores in guinea pig bladders.

It has also been proposed (Ehlert et al., 2005; Hegde et al., 1997) that **coactivation of M_2 receptors could enhance the response to M_3 stimulation by (1) inhibition of adenylate cyclase, thereby suppressing sympathetically mediated depression of detrusor muscle; (2) inactivation of K^+ channels; or (3) activation of nonspecific cation channels.** In addition, because the specific ROK inhibitor Y-27632 reportedly suppresses carbachol-induced detrusor contractions in rats and humans, **muscarinic receptor activation in detrusor smooth muscles is likely to stimulate the ROK pathway, leading to a direct inhibition of myosin phosphatase that induces calcium sensitization to enhance the ability of the muscle to generate the same contractile force with lower levels of intracellular calcium** (Andersson and Wein, 2004; Frazier et al., 2008; Schneider et al., 2004a, 2004b). Although the involvement of M_3 receptors for ROK activation has been suggested (Andersson and Arner, 2004; Andersson and Wein, 2004; Schneider et al., 2004a) (see Fig. 110.15), a study has also suggested the participation of M_2 receptors in this mechanism because Y-27632 not only suppressed carbachol-induced muscle contractions but also increased the affinity of darifenacin, an M_3 receptor antagonist with approximately a 30-fold selectivity for M_3 over M_2 receptors, for inhibiting carbachol-induced contractions of rat bladders (Braverman et al., 2006a, 2006b). It has also been reported that the muscarinic receptor subtype–mediated detrusor contractions shift from M_3 to M_2 receptor subtype in certain pathological conditions, such as obstructed or denervated hypertrophied bladders in rats (Braverman and Ruggieri, 2003; Braverman et al., 2006a, 2006b), as well as in bladder muscle specimens from patients with neurogenic bladder dysfunction (Pontari et al., 2004).

Studies using constructed mutant mice lacking the M_3 receptor or the M_2 and M_3 receptors have demonstrated that this subtype plays key roles in salivary secretion, pupillary constriction, and detrusor contractions (Igawa et al., 2004; Matsui et al., 2000, 2002). However, M_3-mediated signals in digestive and reproductive organs are dispensable, probably because of redundant mechanisms through other muscarinic ACh receptor subtypes or other mediators (Matsui et al., 2000). In addition, it has also been found that male M_3 knockout mice had a distended bladder and larger bladder capacity compared with females, indicating a considerable sex difference in the micturition mechanism (Igawa et al., 2004; Matsui et al., 2002). Thus M_3 or M_2 and M_3 double-knockout mice should provide a useful animal model for the DO pathophysiology and pharmacology.

The muscarinic receptor antagonists tolterodine and oxybutynin (Table 110.4) are widely prescribed drugs for urinary incontinence. Oxybutynin is a nonspecific muscarinic antagonist with additional smooth muscle relaxant properties. The smooth muscle relaxation properties of oxybutynin may be clinically relevant only with intravesical instillation of the drug. In addition, botulinum toxin A injections in children and adolescents diagnosed with neurogenic DO are associated with decreased muscarinic receptor muscular expression (Schulte-Baukloh et al., 2013). Thus, because new antimuscarinic and other therapies are continually being developed by the pharmaceutical industry, all urologists should be aware of the existence of muscarinic receptor subtypes and their distribution in the LUT and other organs.

TABLE 110.4

Drugs With Bladder Action

CLASSIFICATION	EXAMPLES	PHARMACOLOGIC ACTION
Anticholinergic agents	Atropine Glycopyrrolate Oxybutynin Propantheline Tolterodine	Inhibit muscarinic receptors, thus reducing the response to cholinergic stimulation; used to reduce pressure during bladder filling and for the treatment of unstable bladder contractions.
Smooth muscle relaxants	Dicyclomine Flavoxate	Direct smooth muscle relaxation reduces intravesical pressure during filling and reduces severity and presence of unstable bladder contractions; most of these agents have some degree of anticholinergic action.
Calcium antagonists	Diltiazem Nifedipine Verapamil	Used in the treatment of unstable bladder contractions to reduce the magnitude of the spikes by reducing the entrance of calcium during an action potential.
Potassium channel openers	Cromakalim Pinacidil	Act to increase the membrane potential and thus reduce the myogenic initiation of unstable bladder contractions.

Prostaglandin synthesis inhibitors	Flurbiprofen	Prostaglandins have been implicated in increased smooth muscle tone and in the induction of spontaneous activity. Inhibition of prostaglandin synthesis could promote relaxation of the bladder during filling and decrease spontaneous activity of the bladder.
β-Adrenergic agonists	Isoproterenol Terbutaline	Stimulation of β-receptors induces relaxation of the bladder body, resulting in a decrease in intravesical pressure during filling.
Tricyclic antidepressants	Amitriptyline Imipramine	These agents have anticholinergic, direct smooth muscle relaxant, and norepinephrine reuptake inhibition properties.
α-Adrenergic agonists	Ephedrine Phenylpropanolamine Midodrine Pseudoephedrine	Increase urethral tone and closure pressure by direct stimulation of α-adrenergic receptors.
Afferent nerve inhibitors	DMSO Capsaicin Resiniferatoxin	Reduce the sensory input from bladder and thereby increase bladder capacity and reduce detrusor overactivity.
Estrogen	Estradiol	Direct application to the vagina or oral therapy may increase the thickness of the urothelial mucosa, making a better seal and reducing the incidence of incontinence. Other actions may include increasing adrenergic effects on the urethra and increasing blood flow.

DMSO, Dimethyl sulfoxide.

We will briefly present two additional issues regarding the effect of antimuscarinic drugs on the bladder and salivary glands that have clinical relevancy. First, antimuscarinic drugs are metabolized, and their metabolites have pharmacologic effects. It has been shown that oxybutynin has less of a dry mouth effect than does its metabolite desethyloxybutynin (Gupta and Sathyan, 1999). Therefore the controlled-release formulation of oxybutynin maintains the efficacy of immediate-release oxybutynin but with significantly fewer side effects. Tolterodine and solifenacin have been shown in cats and rats, respectively, to have less activity on the salivary gland muscarinic receptors than on the bladder muscarinic receptors (Nilvebrant et al., 1997; Ohtake et al., 2004). Second, the site and speed of antimuscarinic metabolism appear to have profound effects in terms of clinical efficacy and side effects.

Muscarinic Selectivity

Pharmacologically defined subtype-selective drugs have been developed. Darifenacin and vamicamide have been demonstrated to be relatively selective for the M_3 subtype (Andersson, 1997; Steers, 2006; Yamamoto et al., 1995). However, they are not necessarily tissue selective, because salivary glands and other tissues also contain M_3 muscarinic receptors. Tolterodine appears to be a muscarinic antagonist that has selectivity for the bladder compared with the salivary gland, even though it may not be an M_3 subtype–selective antagonist (Andersson, 1998; Nilvebrant et al., 1997). Solifenacin has also shown selectivity to the bladder over the salivary gland; the receptor selectivity of solifenacin to M_3 receptors over M_2 receptors (10-fold) is similar to that of oxybutynin (Ikeda et al., 2002; Ohtake et al., 2004). Thus, therapeutically, it is more important to be tissue selective than subtype selective (Andersson, 1998; Nilvebrant et al., 1997). A truly bladder-selective antimuscarinic drug with *no* side effects is the “Holy Grail” of OAB drug therapy.

In addition, a number of studies have indicated that urothelial cells have the ability to release a variety of neurotransmitters including ACh and ATP. Mechanical stimuli and cholinergic agonists can evoke non-neuronal ACh release. Furthermore, stimulating ACh receptors leads to release of ATP, whereas blocking these receptors can reduce this release (Hanna-Mitchell et al., 2007; Mallory et al., 1991; McLatchie et al., 2014). These and other data suggest that release of ACh can modulate the release of additional transmitters that may help to explain in part the mechanism of action for muscarinic antagonists in reducing symptoms of bladder disorders.

Cognitive Impairment With Antimuscarinic Agents

It is well established that the efficacy of antimuscarinics and safety profiles depend upon interaction with a variety of muscarinic subtype receptors, which are expressed throughout the body. However, interactions with the M1 subtype in the CNS have the likelihood, especially in the older adult or those that have other comorbid disorders, that alter lipophilicity and ability to cross the blood-brain barrier, which can lead to cognitive impairment. In addition, combined use of antimuscarinics with drugs that also have anticholinergic activity (such as antihistamines, antispasmodics, and even muscle relaxants) can lead to confusion, mild cognitive deterioration (although not at risk for dementia), and even in some cases delirium in the older adult. Studies have revealed that anticholinergic withdrawal is likely to improve central side effects even after only a few weeks. It is important to be cautious with antimuscarinics in treating bladder symptoms in the elderly and frail patient, and even more so in those with pre-existing dementia (De Ridder, 2006; Moga et al., 2017; Wagg et al., 2010). This topic is discussed further in the section on aging as related to clinical relevance.

Key Points: Muscarinic Mechanisms

- There are at least five muscarinic receptor subtypes. Pharmacologically, M_1, M_2, and M_3 receptor subtypes have been found in the human bladder.
- Stimulation of M_3 receptors by ACh induces calcium influx through L-type Ca^{2+} channels, as well as IP_3 hydrolysis as a result of PLC activation, resulting in the release of intracellular calcium, both of which contribute to a smooth muscle contraction.
- Muscarinic receptor subtype–mediated detrusor contraction shift from M_3 to M_2 receptor subtype has been reported in bladder muscle specimens from neurogenic bladder dysfunction patients.

Adrenergic Mechanisms

β-Adrenergic Receptors

Stimulation of β_2- and β_3-adrenergic receptors that exist in the human detrusor results in the direct relaxation of the detrusor smooth muscle (Andersson, 1993; Levin and Wein, 1995; Morita et al., 1993; Nishimoto et al., 1995). In addition, β-adrenergic–stimulated relaxation is mediated through the stimulation of adenylate cyclase and the accumulation of cAMP (Andersson, 1993; Andersson and Arner, 2004; Levin et al., 1986). Because β-adrenoceptor–mediated relaxation of the human detrusor was not blocked by selective β_1– or β_2-adrenoceptor antagonists, such as dobutamine and procaterol, but was blocked by selective β_3-adrenoceptor antagonists, **the relaxation induced by adrenergic stimulation of the human detrusor is mediated mainly through β_3-adrenoceptor activation** (Andersson and Arner, 2004; Igawa et al., 1999; Yamaguchi, 2002). A quantitative analysis by reverse transcription polymerase chain reaction has also confirmed that the β_3-adrenergic receptor is the most highly expressed subtype among α- and β-adrenoceptor subtypes at the mRNA level in human bladders (Nomiya and Yamaguchi, 2003).

For these and other reasons, the β_3-receptor agonist mirabegron has been approved as a new treatment option for OAB with symptoms of urge incontinence (Andersson and Arner, 2004; Bridgeman et al., 2013). This agent has been shown to provide an alternative for patients with contraindications or intolerance to existing therapy, although combination therapy (mirabegron and the antimuscarinic solifenacin) has also been shown to be effective (Abrams et al., 2015). The mechanism of action may be related to effects on a number of cell types, including bladder afferent activity (Aizawa et al., 2015). Findings in rodents have revealed that β_3-adrenoceptor stimulation with mirabegron increased bladder compliance and shortened the intervoid interval; this regulation may be a result of the effect at a number of sites, including reduction of nonmicturition contractions and decreased afferent nerve activation (Aizawa et al., 2015; Sadananda et al., 2013).

A second pharmacologic method of increasing levels of cyclic nucleotide monophosphates (cAMP or cGMP) is use of PDE inhibitors. PDE enzymes catalyze the hydrolysis of cAMP or cGMP (Andersson, 1997; Longhurst et al., 1997; Rahnama'i et al., 2013). There are several classes of PDEs that have individual substrate affinities, specific species, tissue distributions, and pharmacologic selectivities (Longhurst et al., 1997; Truss et al., 1996). Currently, there is considerable research trying to identify the specific isoform of PDE present in the bladder as opposed to that in the penis (Truss et al., 1996). For example, in the isolated guinea pig bladder, the frequency of agonist-induced phasic activity is slowed by cAMP, and degradation of intracellular cAMP in the cells responsible for phasic activity appears to involve primarily PDE4 (Gillespie, 2004). PDE4 inhibitors are shown to suppress DO in a rat model of BOO induced by partial urethral ligation (Kaiho et al., 2008). Although a number of preclinical studies have been done, the PDE1 and PDE5 inhibitors have been used clinically for management of storage or voiding disorders.

α-Adrenergic Receptors

Although α-adrenergic stimulation is not prominent in the normal bladder, evidence indicates that under pathological conditions, such as DO associated with BOO, the α-adrenergic receptor density, especially the α_{1D}-receptor subtype, can increase to such an extent that the norepinephrine-induced responses in the bladder are converted from relaxation to contraction (Andersson and Arner, 2004). In rats with outflow obstruction, the proportion of α_{1D}-receptor subtype in the total α_1-receptor mRNA in the bladder is increased to 70% from 25% in normal rat bladders (Hampel et al., 2002), and urinary frequency is suppressed by an inhibition of α_{1D} and α_{1A} receptors by tamsulosin, whereas α_{1A}-receptor suppression by 5-methyl-urapidil has no effect. Moreover, α_{1D}-receptor knockout mice have larger bladder capacity and voided volumes than do their wild-type controls, which supports an important role of α_{1D} receptors in the control of bladder function (Chen et al., 2005). However, in humans, there is the predominant expression of α_{1D} receptors already in the normal bladder (Malloy et al., 1998), and the level of expression of α-adrenoceptor mRNA, which is considerably low compared with β_3 adrenoceptors in normal bladders, was not increased in the bladder with outflow obstruction (Nomiya and Yamaguchi, 2003). Thus the contribution of α_{1D} receptors to DO observed in a variety of pathological conditions, including obstructive uropathy and incontinence, still must be established (Andersson and Arner, 2004).

α-Adrenergic mechanisms are more important in urethral function. Substantial pharmacologic and physiologic evidence indicates that **urethral tone and intraurethral pressure are influenced by α-adrenergic receptors.** The presence of α_1 and α_2 adrenoceptors has been shown in the urethra of various species including humans. Among α_1 adrenoceptors, **the α_{1A} adrenoceptor is the major subtype expressed in urethral smooth muscle** at the mRNA and protein levels (Michel and Vrydag, 2006; Yono et al., 2004). Isolated human urethral smooth muscle contracts in response to α-adrenergic agonists (Awad et al., 1978; Mattiasson et al., 1984; Nordling et al., 1981; Yalla et al., 1977). It is also reported in the rabbit that the urethral contraction is mediated by the α_{1A}-adrenoceptor subtype (Michel and Vrydag, 2006; Testa et al., 1993). Likewise, **hypogastric nerve stimulation and α-adrenergic agonists raise intraurethral**

pressure, which is blocked by α_1-adrenergic antagonists (Awad et al., 1976; Yalla et al., 1977). These findings provide the rationale for use of α-adrenergic agonists to promote urine storage by increasing urethral resistance.

Conversely, α-adrenergic receptor antagonists facilitate urine release in conditions of functionally increased urethral resistance, such as benign prostatic hyperplasia (BPH). Although the α_{1A}-adrenoceptor is the major subtype in the prostate and urethra, highly selective α_{1A}-adrenoceptor antagonists (e.g., RS-17053) do not alter LUTS scores in men with BPH, but these agents are effective at relaxing prostate smooth muscle and increasing urine flow in men (Schwinn and Roehrborn, 2008). In contrast, α_1-adrenoceptor antagonists that contain α_{1D}-adrenoceptor blocking activity improve bladder-based symptoms in humans (Nishino et al., 2006), suggesting the important role of the α_{1D}-adrenoceptors for storage symptoms associated with BOO, receptors potentially located at the bladder or the spinal cord (Schwinn and Roehrborn, 2008).

α_2-Adrenergic antagonists increase the release of norepinephrine from urethral tissues through a presynaptic mechanism, but this does not affect the contractility of urethral smooth muscle in vitro (Mattiasson et al., 1984; Michel and Vrydag, 2006; Willette et al., 1990). The human urethra lacks postjunctional α_2-adrenergic receptors, although in vitro prejunctional activation of these receptors produces a feedback inhibition of norepinephrine release. Pharmacologic and electrophysiologic data suggest that adrenergic nerves influence excitatory cholinergic transmission in pelvic ganglia. Investigators (de Groat and Booth, 1993) have shown in the cat that hypogastric nerves inhibit excitatory cholinergic transmission in vesical ganglia by activation of α_2-adrenergic receptors (Fig. 110.41). Conversely, β-adrenergic agonists facilitate transmission in vesical ganglia.

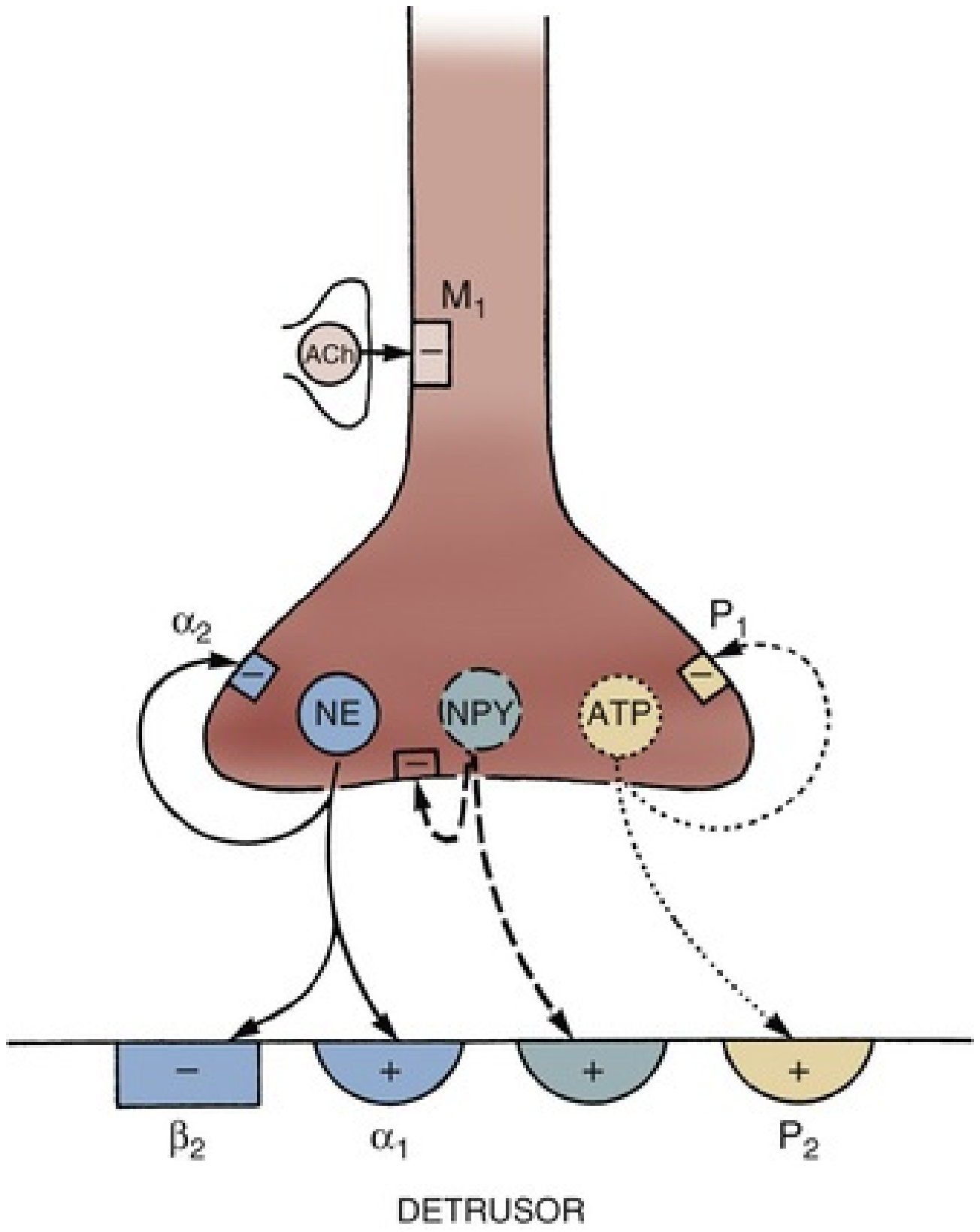

FIG. 110.41 Diagram of possible transmitters in an adrenergic terminal supplying the bladder or urethra. Norepinephrine (NE) release can activate α_1-adrenergic receptors and produce contraction (+) or β receptors and cause relaxation (−) of the detrusor. Feedback inhibition of NE release through α_2 receptors can also occur. Neuropeptide Y (NPY) can produce smooth muscle contraction (+) or inhibit acetylcholine (ACh) release (not shown), or feedback can inhibit NE release. Adenosine triphosphate (ATP) can activate P_2 receptors in the detrusor, which elicit contraction (+) or inhibit (−) further ATP release through P_1 prejunctional receptors. ACh release from terminals in synaptic contact with an adrenergic varicosity can inhibit firing of adrenergic axons by activation of M_1 receptors.

Key Points: Adrenergic Mechanisms

- β-Adrenergic–stimulated relaxation is mediated through the activation of adenylate cyclase and the accumulation of cAMP.
- The β_3-adrenergic receptor is the most highly expressed subtype among α- and β-adrenoceptor subtypes, and β_3-receptor agonists are in clinical trials for treatment of DO.

- In the human, there is a predominant expression of α_{1D}-receptors present in the normal bladder, and the level of expression of α-adrenoceptor mRNA, which is considerably low compared with β_3-adrenoceptors in normal bladders, was not increased in the bladder with outflow obstruction.
- Urethral tone and intraurethral pressure are influenced by α-adrenergic receptors. The α_{1A}-adrenoceptor is the major subtype in the prostate and urethra, and all three α_1-adrenoceptor subtypes (α_{1A}, α_{1B}, α_{1D}) are present in blood vessels.

Urethral Tone in Women

Taki et al. (1999) separated the entire length of the human female urethra into several parts and studied the regional contractile effect of norepinephrine, clonidine, ACh, and potassium chloride. Their findings suggest that sympathetic innervation helps maintain resting urethral tonus, mainly through α_1-adrenoceptors. With identification of at least three distinct subtypes of α_1 adrenoceptors with distinct pharmacologic profiles, it may be possible to develop urethra-specific adrenergic agonists for the treatment of stress urinary incontinence (SUI). A small-scale, placebo-controlled clinical study has demonstrated that activation of the $\alpha_{1A/1L}$-adrenoceptor subtype, which is a pharmacologic isoform of the α_{1A}-adrenoceptor gene product, was effective in reducing the number of incontinence episodes in women with mild-to-moderate SUI (Musselman et al., 2004), suggesting an important role of α_1-adrenoceptors in the urethral continence mechanism, although the data are still preliminary.

Afferent Neuropeptides

Afferent neurons innervating the LUT exhibit immunoreactivity for various neuropeptides, such as SP, CGRP, pituitary adenylate cyclase–activating polypeptide (PACAP), leucine enkephalin, CRP, and VIP (De Groat, 1986; Keast and De Groat, 1992; Maggi, 1993; Vizzard, 2001, 2006), as well as growth-associated protein-43 (GAP43), NOS (Vizzard et al., 1996), glutamic acid, and aspartic acid (Keast and Stephensen, 2000). These substances have been identified in many species and at one or more locations in the afferent pathways including (1) afferent neurons in lumbosacral DRG, (2) afferent nerves in the peripheral organs, and (3) afferent axons and terminals in the lumbosacral spinal cord (Kawatani et al., 1985, 1986, 1996; Morrison and Birder, 2005). The majority (>70%) of bladder DRG neurons in rats appear to contain multiple neuropeptides; CGRP, SP, and PACAP are the most common. In cats, VIP is also contained in a large percentage of bladder DRG neurons (de Groat, 1987).

Many of these peptides, which are contained in capsaicin-sensitive, C-fiber bladder afferents, are released in the bladder by noxious stimulation and contribute to inflammatory responses by triggering plasma extravasation, vasodilation, and alterations in bladder smooth muscle activity (Ishizuka et al., 1994, 1995; Maggi, 1993). These agents also function as transmitters at afferent terminals in the spinal cord.

Tachykinins

The tachykinins are a family of small peptides sharing a common C-terminal sequence, Phe-Xaa-Gly-Leu-Met-NH_2, whose main members are **SP, neurokinin A, and neurokinin B.** Tachykinins are found in central and peripheral nervous systems. In the peripheral nerves, tachykinins are predominantly located in the terminals of nonmyelinated, sensory C fibers. **The diverse biologic effects of the tachykinins are mediated through three receptors, designated NK_1, NK_2, and NK_3,** which belong to the superfamily of seven transmembrane-spanning G protein–coupled receptors (Khawaja and Rogers, 1996). SP is the most potent tachykinin for the NK_1 receptor, whereas neurokinin A exhibits the highest affinity for the tachykinin NK_2 receptor, and neurokinin B for the tachykinin NK_3 receptor (Table 110.5). All receptor subtypes have been identified in the bladder of humans and animals such as rats, mice, and dogs (Andersson and Arner, 2004; Lecci and Maggi, 2001).

TABLE 110.5

Tachykinins and Tachykinin Receptors

TACHYKININ	RECEPTOR
Substance P	NK_1
Neurokinin A	NK_2
Neurokinin B	NK_3

Tachykinins released from capsaicin-sensitive sensory C fibers in response to irritation in the bladder can act on (1) NK_1 receptors in blood vessels to induce plasma extravasation and vasodilation, (2) NK_2 receptors to stimulate bladder contractions, and (3) NK_2 receptors on primary afferent terminals to increase the excitability during bladder filling or during bladder inflammation (Andersson, 1993; de Groat, 1987; Lecci and Maggi, 2001; Morrison et al., 1995). A study by Kamo et al. (2005) also demonstrated that activation of NK_3 receptors on capsaicin-sensitive C-fiber afferents in the rat bladder can increase the excitability during bladder filling.

Intrathecal administration of NK_1 antagonists (RP 67580 and CP 96345) or systemic application of centrally acting NK_1 antagonists (GR 205171 and CP 99994) increased bladder capacity in normal rats and guinea pigs, respectively, without changing voiding pressure, whereas NK_2, NK_3, or peripherally acting NK_1 antagonists were ineffective (Lecci et al., 1993; Yamamoto et al., 2003). DO in rats induced by chemical cystitis, intravesical administration of capsaicin, or intravenous injection of L-dopa was also suppressed by intrathecal injection of NK_1 antagonists (Ishizuka et al., 1994, 1995; Lecci et al., 1994). DO induced by capsaicin was reduced by an NK_2 antagonist (SR 48965) that did not influence normal voiding (Lecci et al., 1997). In anesthetized guinea pigs, TAK-637, an NK_1 receptor antagonist, administered orally or intravenously also increased the volume threshold for inducing micturition and inhibited the micturition reflex induced by capsaicin applied topically to the bladder (Doi et al., 1999). In a clinical study, an NK_1 receptor antagonist, aprepitant, has also been shown to effectively decrease the average daily number of micturitions and urgency episodes compared with placebo at 8 weeks in women with idiopathic OAB (Green et al., 2006). These results indicate that **sensory input to the spinal cord from non-nociceptive bladder afferents is mediated by tachykinins acting on NK_1 receptors, whereas input from nociceptive afferents in the bladder can be mediated by NK_1, NK_2, and NK_3 receptors.** In addition, tachykinin NK_3 receptor activation in the spinal cord can inhibit the micturition reflex through an activation of the spinal opioid mechanism (Kamo et al., 2005).

Autofeedback mechanisms may also be important at afferent nerve terminals. As mentioned earlier, some stimuli are known to release neuropeptides from afferent nerves, and these neuropeptides may, in turn, sensitize the afferents. NK_2 agonists were found (Bushfield et al., 1995) to sensitize bladder mechanoreceptors by acting on NK_2 autoreceptors in the sensory endings in the bladder mucosa to produce the combination of effects found previously for other sensitizing agents (Morrison et al., 1998). The NK_2 receptor blocker SR 48968 decreases the sensitivity of bladder mechanoreceptors and also blocks the sensitization produced by NK_2 agonists and high urinary potassium levels. This suggests that the sensitization produced by intravesical chemical stimuli may be caused by a mechanism using the NK_2 receptor. On the basis of these findings, it could be hypothesized that high urinary potassium concentration or higher levels of bladder distention release neurokinin A from sensory endings, and that the sensitization is the result of the action of the peptide on local NK_2 autoreceptors on the sensory endings. It has also been shown that sensory neurons obtained from rat DRG can be excited by NK_2 agonists and inhibited by NK_3 agonists through modulation of Ca^{2+} channel activity mediated by PKC activation (Sculptoreanu and de Groat, 2003). NK_2 receptor activation also leads to PKC-induced phosphorylation of TRPV1 channels, resulting in an increase in capsaicin-evoked currents in rat DRG neurons (Sculptoreanu and de Groat, 2007; Sculptoreanu et al., 2008).

Prostanoids

Prostanoids (prostaglandins and thromboxanes), which make up a family of oxygenated metabolites of arachidonic acid, by the enzymatic activity of cyclooxygenases 1 and 2, are manufactured throughout the LUT and have been implicated in bladder contractility, inflammatory responses, and neurotransmission. Biopsy specimens of human bladder mucosa contain PGI_2, PGE_2, $PGE_{2\alpha}$, and thromboxane A. **In decreasing order of potency, $PGF_{2\alpha}$, PGE, and PGE_2 contract the human detrusor** (Andersson, 1993; Andersson and Arner, 2004). The actions of prostanoids are mediated by specific receptors on cell membranes. The receptors include the DP, EP, FP, IP, and TP receptors that preferentially respond to PGD_2, PGE_2, $PGF_{2\alpha}$, PGI_2, and thromboxane A_2, respectively. Furthermore, EP is subdivided into four subtypes: EP_1, EP_2, EP_3, and EP_4 (Breyer et al., 2001, 2003). **The slow onset of action for these substances suggests a modulatory role for prostaglandins. Some prostaglandins may affect neural release of transmitters, whereas others inhibit acetylcholinesterase activity.** These actions provide mechanisms whereby prostaglandins could potentially augment the amplitude of cholinergic-induced detrusor contractions (Borda et al., 1982).

Attempts to use prostaglandins to facilitate voiding have had mixed

results. Intravesical PGE_2 has been shown to enhance bladder emptying in women with urinary retention and patients with neurogenic voiding dysfunction (Bultitude et al., 1976; Tammela et al., 1987; Vaidyanathan et al., 1981). Others have failed to find PGE_2 useful to facilitate complete evacuation of the bladder (Delaere et al., 1981; Wagner et al., 1985). Intravesical PGE_2 does produce urgency and involuntary bladder contractions (Schussler, 1990). Consistent with this finding, inhibition of prostaglandin synthesis with indomethacin reduces DO (Cardozo and Stanton, 1980).

Endothelins

Endothelins (ETs), a family of 21–amino acid peptides (originally isolated from bovine aortic endothelial cells), include ET-1, ET-2, and ET-3, which are encoded by separate genes and mediate a variety of biologic actions through two distinct G protein–coupled receptor subtypes, the endothelin-A (ET_A) and the endothelin-B (ET_B) receptor (Masaki, 2004; Yanagisawa et al., 1988). The ET_A receptor subtype has a higher affinity for ET-1 and ET-2 than for ET-3; the ET_B receptor subtype binds all ETs with equal affinity (Rubanyi and Polokoff, 1994). ET-1, which is known to be primarily produced by human endothelial cells, can induce prolonged contractile responses in isolated urinary bladder muscle strips in various species (Khan et al., 1999; Maggi et al., 1990). In humans and rabbits, ET-like immunoreactivity is identified in almost all cell types in the bladder, including bladder epithelium, vascular endothelium, detrusor, and vascular smooth muscles, and fibroblasts; **it plays a role in control of bladder smooth muscle tone, regulation of local blood flow, and bladder wall remodeling in pathologic conditions** (Saenz de Tejada et al., 1992). In a rabbit model of BOO, ET-1 and ET_A receptor binding sites in detrusor smooth muscle and urothelium, as well as ET_B receptor binding sites in detrusor smooth muscle, were significantly increased (Khan et al., 1999). In addition, the ET-converting enzyme inhibitor WO-03028719, which suppresses ET-1 production, can improve voiding efficiency and suppress DO in a rat model of BOO (Schroder et al., 2004). YM598, a selective ET_A receptor antagonist, also reduces DO in urethral obstructed rats (Ukai et al., 2006). These results suggest that **the increase in ET-1 expression and ET receptors could be involved in detrusor hyperplasia and overactivity seen in patients with BOO resulting from BPH.**

There is also evidence that ETs have a role in modulation of sensory

function in the peripheral nervous system and CNS. The activation of ET_A receptors in capsaicin-sensitive C-fiber afferents in the bladder induces DO, whereas ET_A receptor activation in the spinal cord can inhibit the micturition reflex through activation of a spinal opioid mechanism in rats (Ogawa et al., 2004). In spinal cord–injured rats, the bladder ET-1 level was increased, and the application of ABT-627, an ET_A antagonist, suppressed C fiber–mediated DO. Accordingly, modulation of ET_A receptor activity in bladder afferent pathways or the spinal cord could be effective in treating bladder overactivity or painful conditions (Ogawa et al., 2008).

Sex Steroids

Differences in responses of human and animal bladders to the effect of drugs suggest that sex steroids play a role in detrusor contractility. It is not unusual for women to note changes in voiding, bladder pain, or continence at different times of their menstrual cycle. **Sex steroids do not directly affect bladder contractility, but they modulate receptors and influence growth of bladder tissues.** Estrogen receptors are expressed by the trigone in women (Iosif et al., 1981). Levin et al. (1980) noted that bladder body muscle from young female rabbits treated with estrogens exhibits increased responsiveness to α-adrenergic, cholinergic, and purinergic agonists. Others have seen a decreased density of adrenergic and muscarinic receptors in the bladder after estrogen administration (Batra and Andersson, 1989; Shapiro, 1986). In contrast to the study by Levin et al. (1980), Elliott et al. (1992) showed that bladder smooth muscle from estrogen-treated rats exhibited decreased contractions.

Estrogens also increase adrenergic receptors in the urethra (Callahan and Creed, 1985). Ekstrom et al. (1993) reported that estrogen administration to ovariectomized rabbits unmasked contractile responses to α-adrenergic agonists, whereas contracted and normal rabbit bladders demonstrated no response to these agents. Some clinicians have combined these agents to elevate urethral pressure in patients with stress incontinence (Wilson et al., 1987). However, the clinical efficacy of the combined use of estrogen with α-agonists has been questioned (Walter et al., 1990). **The effect of estrogens on urinary continence in females probably reflects the multiple actions of this hormone on adrenergic receptors, vasculature, and urothelium. In addition, progesterone increases electrical and cholinergic contractions of the**

bladder. Exogenous estrogens and progesterones also induce NOS activity in bladders of female guinea pigs (Ehren et al., 1995). This effect is postulated to contribute to relief of DO with hormonal treatment. However, the use of estrogens alone to treat either SUI or urgency incontinence has given disappointing results (Abrams et al., 2005), and studies have suggested that estrogen may be associated with an increase in urinary incontinence in postmenopausal women (Hendrix et al., 2005).

Androgen treatment in the male rat has been reported to have similar effects on synaptic connections, as well as effects on motoneuronal somatic and dendritic size in the androgen-sensitive motoneurons innervating the bulbocavernosus and levator ani muscles of the rat (Jordan, 1997; Matsumoto, 1997). Testosterone treatment can also influence the size of postganglionic neurons in the major pelvic ganglion of the male rat (Keast and Saunders, 1998). Thus further studies are needed to evaluate the influence of changes in hormonal environment on the neural pathways controlling the LUT.

Clinical Relevance

The following section discusses different LUTD conditions encountered by urologists that involve perturbation of the physiologic mechanisms presented in this chapter. Some of these conditions arise as a result of injuries to innervation, obstruction, or infection of the LUT. On a logical level, the ideal treatment for these conditions would be to reverse the neurologic injury, relieve the obstruction, or eradicate the infection. When LUTD, manifesting with LUTS, increased postvoid residual (PVR) volume, and/or DO, has no identifiable pathology, then the treatment becomes empirical and driven primarily by LUTS relief. A variety of diagnostic terms have been used to describe idiopathic LUTD conditions: OAB, IC/PBS, and underactive bladder to name a few. **Many of these idiopathic LUTD conditions reflect an increased or augmented sensory input from the LUT, leading to the term *afferent neurourology* in describing these conditions** (Clemens, 2013). Although idiopathic nonobstructive urinary retention (underactive detrusor) may be primarily a failure of efferent signaling, the resultant decreased motor sensory pathway (Eastham and Gillespie, 2013) could exacerbate or prolong this condition. **The ability to augment or inhibit sensory afferent mechanisms in treating these afferent neurourologic conditions could advance treatment for LUTD.**

One overarching paradigm to explain afferent neurourologic conditions involves C-fiber afferent activation via neurotrophic cytokine, such as nerve growth factor (NGF), signaling. Changes in bladder innervation orchestrated by neurotrophins manufactured by detrusor smooth muscle are temporally linked with DO (Fig. 110.42). The ability of local anesthetics, intravesical afferent neurotoxins, and destruction of afferent nerves in the bladder neck and prostate to reduce urgency, frequency, and urgency incontinence indicates an important role for afferent-evoked reflexes (Chalfin and Bradley, 1982). The development of a spinal reflex (ice-water test response) in patients with neurogenic bladders (Geirsson et al., 1999), as well as in patients with BOO (Chai et al., 1998; Hirayama et al., 2003, 2005), suggests a common underlying plasticity in nerves supplying the bladder. Moreover, the association between elevated blood pressure and LUTS in patients with BPH (Pool, 1994; Sugaya et al., 2003) provides a link between changes in sympathetic tone and voiding complaints.

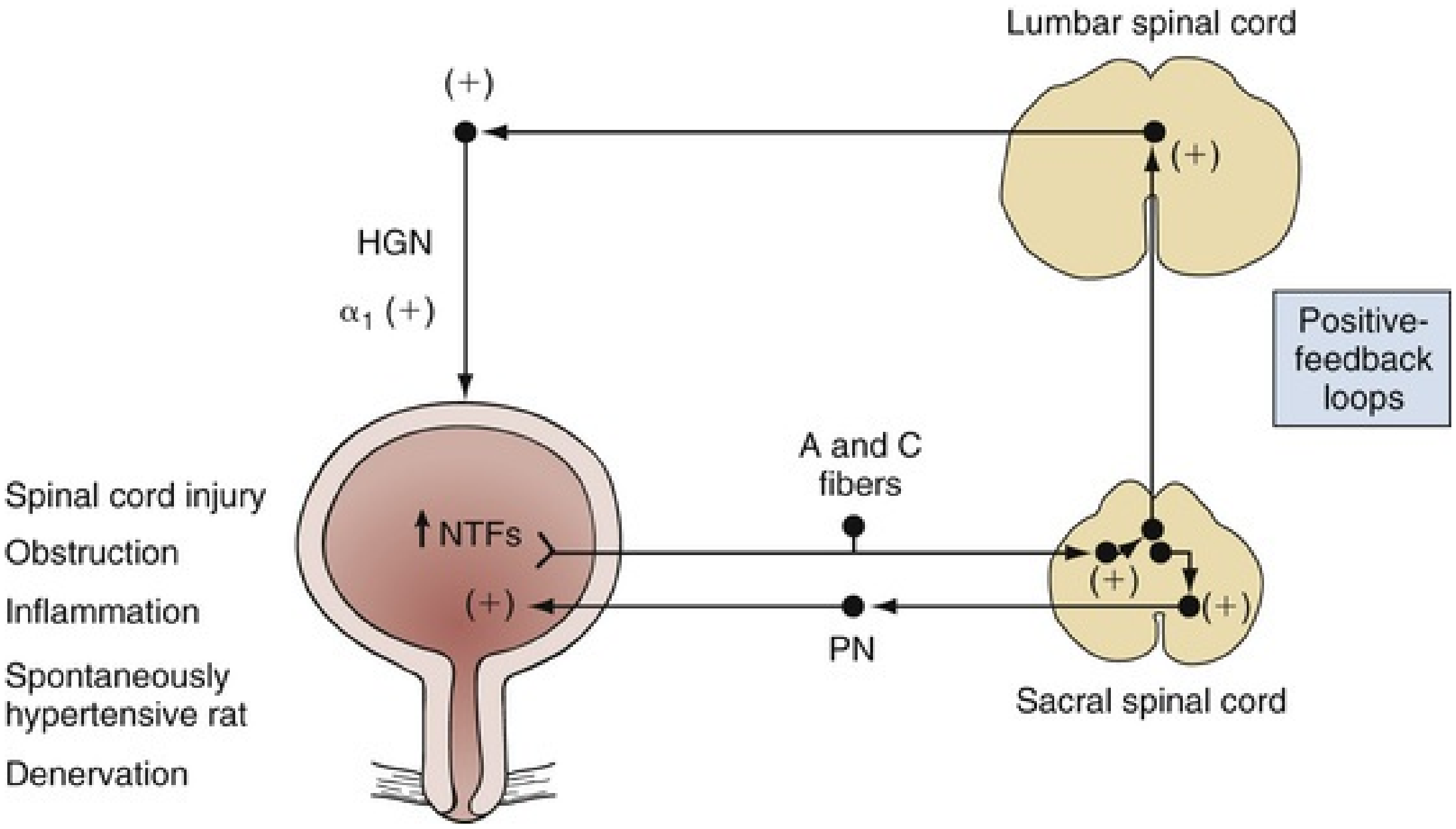
Lumbar spinal cord
(+)
(+)
HGN
α_1 (+)
Positive-feedback loops
A and C fibers
Spinal cord injury
Obstruction
Inflammation
Spontaneously hypertensive rat
Denervation
↑NTFs
(+)
(+)
(+)
PN
Sacral spinal cord

FIG. 110.42 Possible mechanisms underlying plasticity in bladder reflex pathways induced by various pathologic conditions. Bladders from rats with chronic spinal cord injury, urethral obstruction, chronic inflammation, and bladder denervation and those that are spontaneously hypertensive exhibit increased level of neurotrophic factors (NTFs), such as nerve growth factor. NTFs can increase the excitability of C-fiber bladder afferent neurons and alter reflex mechanisms in parasympathetic excitatory pathways in the pelvic nerve (PN), as well as in sympathetic pathways in the hypogastric nerve (HGN). These reflex circuits are organized in the spinal cord as positive-feedback loops that induce involuntary bladder activity. In certain situations, such as the spontaneously hypertensive rat, peripheral efferent mechanisms are also altered: excitatory α_1-adrenoceptor mechanisms are upregulated, providing an additional excitatory input to the bladder.

Mechanisms of Idiopathic Detrusor Overactivity and Overactive Bladder

The classic model of OAB is that of urodynamically demonstrated DO, although **DO was found in only 11% of a contemporary cohort of subjects with OAB symptoms** (Diamond et al., 2012). Nevertheless, various models have been used to explore the pathogenesis of DO and to formulate treatments for urgency incontinence associated with OAB. Animal models for DO that do not involve damage or injury to bladder, urethra, or spinal cord include the **spontaneously hypertensive rat** (Steers et al., 1999), **serotonin reuptake transporter knockout** (Cornelissen et al., 2005), **constitutive BK channel knockout**

(Meredith et al., 2004), **urothelially restricted NGF knock-in** (Schnegelsberg et al., 2010), and **urothelially restricted β_1-integrin knockout** (Kanasaki et al., 2013). Other molecular targets, using transgenic animals, have been used to study LUT function, although none of these models has specifically addressed the clinical problem of DO or OAB. These animal models include knockout mice lacking muscarinic receptors (M_1 to M_5) (Igawa et al., 2004; Matsui et al., 2002), purinergic receptors ($P2X_2$, $P2X_3$) (Cockayne et al., 2000, 2005), and TRPV1 (Birder et al., 2002). With some of these models, a mechanistic theme is alterations in growth factors leading to plasticity in micturitional neural and smooth muscle contractile pathways.

NGF has been a biomarker for LUTD since the description of NGF upregulation by bladder smooth muscle after BOO and increased diuresis (Steers and Tuttle, 2006; Steers et al., 1991). The role of increased urinary NGF as a biomarker for OAB has been studied (Liu and Kuo, 2012; Liu et al., 2009, 2011; Seth et al., 2013). Although the source of the urinary NGF is uncertain, it is less likely to come from the bladder stroma because of the necessity of NGF having to traverse the lamina propria and the entire urothelium. However, the role of increased NGF expressed by the bladder urothelium in mediating a change in bladder function was studied in transgenic mice with overexpression of NGF restricted to the urothelium (Schnegelsberg et al., 2010). These animals had increased urinary frequency, pelvic pain, and prominent neuronal hypertrophy in the lamina propria. Investigators failed to detect increased urothelial tissue NGF in DO subjects and paradoxically less urothelial tissue NGF in subjects with increased urinary frequency (Birder et al., 2007b). It remains to be seen how NGF can be used in evaluation, phenotyping, and/or treatment of OAB, and further studies are needed (Ochodnicky et al., 2011).

Urothelial dysfunction associated with idiopathic OAB has also been studied using human urothelial cells grown in culture. The findings from using human cells in these in vitro studies included increased urothelial polyamine signaling (Li et al., 2013) leading to block of urothelial BK channels (Li et al., 2009). Other findings include increased TRPV1 signaling in the cultured OAB cells (Li et al., 2011). Whether these urothelial abnormalities related to altered bladder urothelial-afferent signaling remains to be seen.

Investigators found that subjects with OAB and urgency incontinence had decreased urethral afferent function (Kenton et al., 2007, 2010) when measured with urethral current perception threshold (CPT) testing. Furthermore, 2 weeks after successful sacral neuromodulation treatment, urethral CPT measures did not change (Gleason et al., 2013). These findings are counterintuitive because augmented urethral afferent function would be expected in OAB. An animal model in which urethral afferent signaling can be selectively modulated (augmented or diminished) would help shed light on the impact of urethral afferent signaling on micturitional behavior.

The role of bladder smooth muscle pathophysiology in OAB and DO has also been studied. **In the constitutive BK knockout mouse, development of OAB micturitional behavior phenotype was seen** (Meredith et al., 2004). The ability to obtain detrusor smooth muscle strips in idiopathic urgency incontinence patients is limited, so confirmation of this phenomenon would be difficult, unlike the case of neurogenic DO (see the next section). Other investigators have examined derangements in regulation of $(Ca^{2+})_i$ from detrusor myocytes isolated from idiopathic and neurogenic DO subjects (Sui et al., 2009). These investigators found that myocytes from DO had increased resting $(Ca^{2+})_i$ and more spontaneous increases in $(Ca^{2+})_i$ arising from influx of extracellular Ca^{2+} from L-type and T-type VDCCs. There was a suggestion that neurogenic DO had greater dysregulation of $(Ca^{2+})_i$ than IDO.

The role of suburothelial myofibroblasts has been also explored in OAB. Immunofluorescent studies of these myofibroblasts from idiopathic and neurogenic DO subjects revealed increased gap junction (Cx43) expression in the myofibroblasts (Roosen et al., 2009). Furthermore, these changes were not reversed, even with successful treatment with onabotulinumtoxinA (OBTX). The links among myofibroblasts; detrusor myocytes; cytokines including interleukin-4 (IL-4), IL-6, IL-10; tumor necrosis factor-α (TNF-α); and transforming growth factor-β1 (TGF-β1); and Cx43 were investigated (Heinrich et al., 2011). These investigators found that these cytokines increased expression of Cx43 in myofibroblasts and myocytes, suggesting a mechanism for increased cellular connectivity in OAB (and IC/PBS) that is related to these cytokines. Although NGF was not tested in this study, investigators using PC12 cells (neuronal cells) found that NGF increased Cx43 connectivity in these cells (Cushing et al., 2005), which suggests that NGF could possibly also increase Cx43 expression in detrusor myocytes and myofibroblasts.

Stress Urinary Incontinence

Traditionally, SUI in women has been thought to be a urethral anatomic and not a urethral physiologic problem. The urethral integral theory of Petros and Ulmsten (1993) led to the development of the mid-urethral sling, the current standard surgical treatment for SUI. However, SUI in women is unlikely to be caused only by anatomic laxity of the anterior vaginal wall. **DeLancey** (2010) **presented data that showed intrinsic sphincteric function (physiologic function) to be more important for maintenance of stress continence than anatomic integrity (anatomic support)**. Pathophysiologic studies of urethral function in women have centered on the mechanisms surrounding urethral injury at time of childbirth using vaginal distention animal models, including pudendal nerve injuries (Damaser et al., 2007; Pan et al., 2009). Chemokines and receptors involved in stem cell homing, such as CCL7, CXCR4, CXCL12, CD195, and CD193, were upregulated with vaginal distention or after vaginal birth in rats (Lenis et al., 2013). Increased expression of monocyte chemotactic protein-3 (MCP-3) at the urethra after vaginal distention provides a homing signal for stem cells, because MCP-3 is a stem cell homing chemokine (Woo et al., 2007). A possible method to diminish SUI after childbirth is to maximize healing of urethral injuries (muscular and neurologic) soon after childbirth.

The ability to use biomarkers to predict success or failure after mid-urethral slings was studied (Chai et al., 2014). This study found that higher urinary NTx (N-telopeptide cross-linked collagen) was associated with a significantly higher failure rate after slings. NTx is a marker for bone metabolism; higher NTx levels reflect greater bone turnover and osteoporosis (Garnero, 2008). It remains to be seen whether leveraging this knowledge can reduce the failure rate of mid-urethral slings, which at 1 year is about 23% (Richter et al., 2010).

Serotonin-norepinephrine reuptake inhibitors, such as duloxetine, increase efferent output at the Onuf nucleus at the sacral spinal cord, thus increasing urethral smooth muscle tone and decreasing SUI (Thor and Katofiasc, 1995). Clinical trials of duloxetine have shown benefits over placebo in treating mild to moderate SUI (Millard et al., 2004; van Kerrebroeck et al., 2004). Duloxetine is approved in Europe, but not the United States, for use in SUI. Duloxetine has also been studied in male postprostatectomy SUI and was found to have statistically significant efficacy over placebo, although the sample size was small (Cornu et al., 2011).

Spinal Cord Injury and Neurogenic Detrusor Overactivity

Damage to the spinal cord above the sacral spinal level results in DO (Chancellor, 1997; Kaplan et al., 1991). Acute spinal cord injury disrupts normal supraspinal circuits that control urine storage and release. **After the spinal shock period of urinary retention** that typically lasts a few weeks, **neurogenic DO develops.** Electrophysiologic data reveal that **this DO is mediated by a spinal micturition reflex that emerges in response to a reorganization of synaptic connections in the spinal cord** (Araki and de Groat, 1997; De Groat, 1975; de Groat et al., 1981, 1990; Yoshimura, 1999). **In addition, bladder afferents that are normally unresponsive to low intravesical pressures become more mechanosensitive, leading to the development of DO.**

Normal micturition is associated with a spinobulbospinal reflex mediated by lightly myelinated Aδ afferents (de Groat and Booth, 1993; DeGroat et al., 1975; de Groat et al., 1993). **These fibers represent only 30% of bladder afferents in some species. Compared with Aδ fibers, the more prevalent unmyelinated C fibers are relatively insensitive to gradual distention of the urinary bladder, at least in the cat** (Habler et al., 1990). Most C fibers in this species remain silent during normal filling of the bladder, although in the rat, some studies indicate that C fibers can fire at low pressures (Sengupta and Gebhart, 1994). **After spinal cord injury, a capsaicin-sensitive C-fiber–mediated spinal reflex develops** (see Fig. 110.25)**. These C-fiber afferents are thought to play a role in the development of DO after spinal cord injury. Capsaicin-sensitive C fibers have also been implicated in DO after upper motoneuron diseases, such as spinal cord injury and multiple sclerosis** (Fowler et al., 1992, 1994; Geirsson et al., 1995; Szallasi and Fowler, 2002). Studies in multiple sclerosis and spinal cord–injured patients with DO also revealed an increased density of TRPV1 and $P2X_3$ immunoreactivity in suburothelial nerves, and increased TRPV1 immunoreactivity in the basal layer of the urothelium (Apostolidis et al., 2005b; Brady et al., 2004). Treatment of these patients with intravesical capsaicin or another C-fiber neurotoxin, RTX, reversed these abnormalities (Brady et al., 2004).

Insight into the mechanisms underlying the increased mechanosensitivity of C fibers after spinal cord injury has been gained by examination of the DRG cells innervating the bladder. Plasticity of these afferents manifests with enlargement of these DRG cells (Kruse et al., 1995) and increased electrical excitability (Yoshimura, 1999; Yoshimura and de Groat, 1997). Upregulation of tetrodotoxin (TTX)-sensitive Na^+ channels and downregulation of TTX-resistant Na^+ channels, as well as low-threshold A-type K^+ channels, occur after spinal cord injury (Yoshimura, 1999; Yoshimura and de Groat, 1997).

Plasticity in bladder afferents after spinal cord injury and upper motoneuron lesions may involve the retrograde transport of substances from either the spinal cord or the bladder to the DRG neuron. **NGF has been implicated as a chemical mediator of disease-induced changes in C-fiber afferent nerve excitability and reflex bladder activity** (Vizzard, 2000; Yoshimura, 1999). Chronic administration of NGF into bladder afferent pathways induced bladder overactivity and increased the firing frequency of dissociated bladder afferent neurons in rats (Vizzard, 2000; Yoshimura et al., 2006), and the production of neurotrophic factors, including NGF, increased in the bladder after spinal cord injury (Vizzard, 2000). Thus it seems that target organ–neural interactions mediated by neurotrophic factors, such as NGF, produced in the bladder may contribute to changes in C-fiber bladder afferent pathways that induce DO and detrusor-sphincter dyssynergia after spinal cord injury. In addition, increased NGF in the spinal cord after spinal cord injury is also responsible for inducing hyperexcitability of C-fiber bladder afferent pathways, and intrathecal application of NGF antibodies, which neutralizes NGF in the lumbosacral spinal cord and DRG, suppresses DO and detrusor-sphincter dyssynergia in spinal cord–injured rats (Seki et al., 2002). Intrathecal administration of NGF antibodies also blocks autonomic dysreflexia in paraplegic rats (Krenz et al., 1999). Thus NGF and its receptors in the bladder or the spinal cord are potential targets for new therapies to suppress DO and detrusor-sphincter dyssynergia after spinal cord injury.

Other neurogenic disorders associated with urgency incontinence respond to intravesical therapy with capsaicin or RTX, suggesting that plasticity in C-fiber afferents could form the neurogenic basis for DO (Fowler et al., 1994; Geirsson, 1993; Szallasi and Fowler, 2002). The emergence of a spinal reflex circuit activated by C-fiber bladder afferents represents a positive feedback mechanism (see Fig. 110.42) that may be unresponsive to voluntary control by higher brain centers and thereby be able to trigger involuntary voiding. **The bladder ice-water urodynamic test has been suggested as a method to assess the C-fiber–mediated micturition reflex.** Although the ice-water test is consistent in a strictly controlled research environment, it has not been adequately sensitive or specific in routine clinical use (Chai et al., 1998; Chancellor et al., 1998).

Neurogenic DO has also been associated with decreased expression and decreased activity of BK channels in the bladder smooth muscle (Hristov et al., 2013). BK channel activity (opening) underlies phase 2 and 3 hyperpolarization of the smooth muscle AP (see Fig. 110.16) and quells detrusor myocyte excitability. Therefore reduced expression and/or lessened function of the BK channels would necessarily lead to increased bladder contractions, hence DO. Although decreased BK expression and function in neurogenic DO help explain the mechanism behind neurogenic DO, the cause of decreased BK expression and function was not explored. This reference theorized that teleologically, decreased BK expression or function may be a consequence of a compensatory or adaptive mechanism in spinal cord injury patients that leads to increased detrusor smooth muscle contractility, allowing optimization of bladder emptying in the absence of normal innervation.

Key Points: Neurogenic Bladder

- Normal micturition is associated with a spinobulbospinal reflex mediated by lightly myelinated Aδ afferents.
- Unmyelinated C fibers are normally relatively insensitive to gradual distention of the urinary bladder.
- After spinal cord injury, a capsaicin-sensitive C-fiber–mediated spinal reflex develops and may play a role in the development of DO.
- Treatment of neurogenic DO patients with intravesical capsaicin or another C-fiber neurotoxin, RTX, produces symptomatic improvement in a subpopulation of these patients and reduces the density of TRPV1 immunoreactivity in nerve fibers and urothelium.
- The bladder ice-water urodynamic test has been suggested as a research method to assess the C-fiber–mediated micturition reflex but is not practiced clinically.

Nocturia

It is becoming recognized that nocturia, especially when occurring in isolation from other LUTS, represents a symptom with its own unique set of possible physiologic causes (Van Kerrebroeck and Andersson, 2014) including **global polyuria, nocturnal polyuria, reduced bladder capacity, sleep disorders, heart failure, and circadian clock disorders.** It has been shown that the **mouse bladder exhibits circadian rhythms in expression of Cx43** (Negoro et al.,

2012) and furthermore that Cx43 regulates bladder capacity in dark and light cycles of the mouse. During the light cycle, when the mouse is not active (equivalent to the human sleep cycle), Cx43 is downregulated, leading to increased bladder capacity (increased measure of volume voided per micturition). Conversely, during the dark cycle, when the mouse is awake and active, Cx43 is upregulated and bladder capacity is reduced (decreased volume voided per micturition). Transgenic animals with one of the circadian transcriptional regulators, Cry, knocked out developed loss of circadian oscillations of bladder capacity associated with loss of Cx43 expression oscillations. This study suggested that loss of the biologic clock mechanism in regulating Cx43 within the bladder may be a contributing mechanism to nocturia and nocturnal enuresis.

Bladder Outlet Obstruction

The bothersome symptoms of patients with urethral obstruction are in most cases caused by the bladder. BOO, such as that in patients with BPH, often produces detrusor hypertrophy and DO (Andersson and Wein, 2004; Gosling et al., 2000). After chronic partial obstruction of the urethra in rats, the bladder enlarges and is about 15 times heavier, but it has the same shape as in control rats; the growth is mainly accounted for by muscle hypertrophy. The outer surface of the hypertrophic bladder is increased sixfold over that of the controls; the muscle is increased threefold in thickness and is more compact. Mitoses are not found, but there is a massive increase in muscle cell size (Gabella and Uvelius, 1990). Obstruction-induced DO with irritative voiding symptoms has been attributed to denervation supersensitivity, because increased contractile responses of the bladder smooth muscle to cholinergic agonists have been observed (Andersson and Wein, 2004; Speakman et al., 1987). Alterations in detrusor contractility may also result from changes in contractile proteins (Chacko et al., 1999, 2004; Cher et al., 1990; Malmqvist et al., 1991). Changes in the contractile proteins occur in developing bladders and also during bladder hypertrophy (Sjuve et al., 1996; Wang et al., 1995; Wu et al., 1995). Obstructed bladders induced expression of SM-A (DiSanto et al., 2003). The obstructed bladder developed higher levels of force but with reduced cross-bridge cycling rates (Su et al., 2003). The ratio of SM1 to SM2 isoforms was also changed by BOO (Cher et al., 1996).

Brading and Turner (1994) proposed that all cases of DO have a common

feature—detrusor smooth muscle change that predisposes it to unstable contraction. They have demonstrated that DO, as shown in a pig model of obstruction, may occur without participation of a micturition reflex. Mills et al. (2000) have also implicated abnormalities in the detrusor muscle and its pattern of innervation in IDO. Compared with the bladder wall in control subjects, there was evidence in the detrusor smooth muscle of altered spontaneous contractile activity consistent with increased electrical coupling of cells, patchy denervation of the detrusor, and potassium supersensitivity (Mills et al., 2000). One of the manifestations of this abnormality is a partial denervation of the detrusor smooth muscle. In rats with BOO induced by partial urethral ligation, acetylcholine release during electric stimulation of obstructed bladder muscle strips was significantly decreased 3 to 6 months after obstruction, along with a reduction in the number of nerve fibers in the obstructed bladder compared with control rats (Murakami et al., 2008). Partial denervation in obstructed bladder leads to various functional changes in smooth muscles, including denervation supersensitivity of cholinergic (muscarinic) receptors (Speakman et al., 1987) and increases in purinergic receptor–mediated contractile responses as well as expression of purinergic receptors such as $P2X_1$ (Boselli et al., 2001; O'Reilly et al., 2001a). Changes in the cell-to-cell communication in detrusor muscles have also been indicated as a mechanism inducing DO, because there is an upregulation of Cx43, a gap-junction protein, in rats with DO induced by BOO (Christ et al., 2003; Imamura et al., 2009; Li et al., 2007; Mori et al., 2005). Increased expression of Cx43 is also identified in the bladders from patients with neurogenic DO (Haferkamp et al., 2004) or with urgency symptoms (Neuhaus et al., 2005). Thus increases in receptor-mediated muscle contractility and interaction among smooth muscle cells can result in coordinated myogenic contraction of the entire bladder and DO.

In addition, another population of cells in the bladder, known as *interstitial cells*, has been proposed to have a pacemaking role in spontaneous activity of the bladder (Andersson and Arner, 2004). **Because it has been reported that the number of interstitial cells is increased in a guinea pig model of BOO** (Kubota et al., 2008) **and that c-KIT tyrosine kinase inhibitors, which inhibit interstitial cell activity, decreased the amplitude of spontaneous contractions in the guinea pig and human bladder** (Biers et al., 2006; Kubota et al., 2006), **interstitial cells may also be involved in the emergence of DO as a result of enhanced autonomous detrusor muscle activity.**

Alterations also occur in neural networks in the CNS after obstruction of

the LUT. BOO in rats causes enhancement of a spinal reflex (Steers and De Groat, 1988). Similarly, in humans with obstruction, a capsaicin-sensitive spinal reflex can be detected by the ice-water test (Chai et al., 1998; Hirayama et al., 2003, 2005). Within the spinal cord, obstruction stimulates an increased expression of GAP43 that has been associated with axonal sprouting after injury (Steers et al., 1996). These observations suggest an enhancement or de novo development of new spinal circuits after obstruction. Similar to spinal cord injury, obstruction causes hypertrophy of bladder afferent and efferent neurons (Steers et al., 1990, 1991). A hypothesis proposed is that these newly formed spinal circuits (neuroplasticity), once formed, do not reverse easily even if obstruction is relieved because of persistent increased voiding frequency after relief of obstruction (Chai et al., 1999). An immunohistochemical analysis of the distribution and density of GAP43 showed that this protein was increased in the spinal cord in the region of the sacral parasympathetic nucleus in rats with BOO (Steers et al., 1996). Because this protein is a marker for axonal sprouting, its upregulation provides further indirect support for morphologic plasticity in afferent pathways after BOO. Nevertheless, these findings are not mutually exclusive of changes in the bladder smooth muscle, which are also likely to participate in the development of DO (Turner and Brading, 1997).

BOO appears to initiate the morphologic and electrophysiologic afferent plasticity through a mechanism involving NGF (see Fig. 110.42). NGF is responsible for the growth and maintenance of sympathetic and sensory neurons and has been shown to be responsible for neuronal regrowth after injury. NGF content is increased in obstructed bladders in animals and in humans (Steers et al., 1991). This increase in NGF content precedes the enlargement of bladder neurons and the developmental of urinary frequency (Steers et al., 1990, 1991). Moreover, blockade of NGF action with autoantibodies prevents the neural plasticity and urinary frequency after obstruction (Steers et al., 1996). In animals with persistent urinary frequency after relief of obstruction, NGF remains elevated in the bladder. These findings suggest a cause-and-effect relationship between NGF-mediated changes in bladder afferents and an enhanced spinal micturition reflex and urinary frequency associated with obstruction. Increased levels of urinary NGF have also been detected in BOO patients exhibiting OAB symptoms. Total urinary NGF levels were low in controls (0.5 pg/mL) and in patients with BOO without OAB symptoms (1 pg/mL), but considerably higher in patients with BOO and OAB symptoms (41 pg/mL) or BOO and DO (50 pg/mL). Investigators have examined urinary NGF before and after mid-urethral slings in females and found significantly increased NGF, corrected for creatinine, after mid-urethral slings (Chai et al., 2014), consistent with the finding that mid-urethral slings have a urodynamic cause of increased Pdet@Qmax (Kraus et al., 2011).

Key Points: Bladder Outlet Obstruction

- Obstruction-induced DO with irritative voiding symptoms has been attributed to denervation supersensitivity, because increased contractile responses of the bladder smooth muscle to cholinergic agonists have been observed. Alterations in detrusor contractility may also result from changes in contractile proteins.
- Increases in receptor-mediated muscle contractility and interaction among smooth muscle cells have been observed with BOO.
- BOO in rats causes enhancement of a spinal reflex.
- Bladder tissue and urine NGF content is increased in obstructed bladders in animals.

Underactive Bladder

Underactive bladder refers to LUTS suggesting diminished bladder contractility. Logically, these symptoms would be urinary emptying symptoms such as decreased force of stream, urinary hesitancy, interrupted stream, and straining to void. However, urinary storage symptoms such as urinary frequency, urgency, and nocturia often co-occur. Underactive bladder symptoms can also occur secondarily to bladder outlet obstruction, whether from prior suburethral sling in a female or BPH in a male. Therefore the symptoms of underactive bladder are nonspecific and furthermore do not denote a primary pathologic cause.

Decreased bladder contractility found during objective urodynamic testing is termed “detrusor underactivity.” The relationships between urodynamic finding of detrusor underactivity and lower urinary tract symptoms are not well understood. Although the concept of decreased detrusor contractility as the primary pathophysiology of detrusor underactivity seems appropriate, it is also important to consider that the afferent sensory mechanisms could be involved in detrusor underactivity. Decreased sensory input to the CNS may result in decreased detrusor contractility. Therefore detrusor underactivity may not just be due to pathophysiology of efferent mechanisms.

The utility of postvoid residual (PVR) volume determination in evaluation and management of patients who may have underactive bladder and/or detrusor underactivity is still not clear. An expert panel expert has made the recommendation of a PVR of at least 300 mL as the cutoff value before consideration of further evaluation (Stoffel et al., 2017). Furthermore, besides using this cutoff value, the presence of LUTS to moderately to severely affect quality of life or the presence of risk factors such as hydronephrosis, renal insufficiency, or urinary tract infections documented by positive cultures should prompt further evaluation and treatment. Also, a PVR of less than 300 mL does not imply that detrusor contractility is normal.

Bladder Pain Syndrome and Interstitial Cystitis

BPS/IC is a syndrome characterized primarily by pain attributable to the bladder associated with urinary frequency and urgency. This condition has no defined cause, although this section presents data from animal studies that offer some theoretical origins. **In Europe, the diagnosis of BPS/IC typically requires a bladder biopsy showing overt inflammation, so it is no surprise that histologic analysis of bladders from European patients with BPS/IC revealed marked edema, vasodilation, proliferation of nerve fibers, and infiltration of mast cells** (Johansson and Fall, 1997)**. However, the diagnosis of BPS/IC in the United States is driven primarily by symptoms of chronic bladder pain and urinary frequency and urgency in the absence of urinary tract infection (UTI).** In the United States, the diagnostic test, if performed, usually is hydrodistention of the bladder; and if a biopsy is performed, rarely is it a deep biopsy of the bladder stroma. The appearance of glomerulations (petechiae) after hydrodistention of the bladder as a diagnostic criterion for BPS/IC was first described by Messing and Stamey (1978), although the diagnostic specificity of glomerulations was questioned (Waxman et al., 1998). It appears that the diagnostic approach to BPS/IC varies between the United States and Europe.

Traditionally, BPS/IC is categorized as an inflammatory bladder disease, although the cause of the inflammation remains elusive (and some question whether BPS/IC is even an inflammatory disease). Cyclophosphamide-induced hemorrhagic cystitis has been used to model for BPS/IC, although there is no relationship between these two entities. Although the chemical cystitis model is important in understanding the neurobiologic response to inflammation, the relevance to BPS/IC remains to be validated in translational clinical trials.

Chemical cystitis resulted in sensitizing mechanosensitive afferents and/or recruitment of afferents normally unresponsive to mechanical stimulation (i.e., silent C fibers) (Dmitrieva and McMahon, 1996; Dmitrieva et al., 1997; Habler et al., 1990; Sengupta and Gebhart, 1994) and results in bladder inflammation. Proinflammatory agents, such as PGE_2, serotonin (5-HT), histamine, bradykinin, and adenosine, as well as neurotrophic factors such as NGF, which are released during chemical irritation, can induce bladder hyperactivity, as well as functional and chemical changes in C-fiber afferents that can lead to hyperexcitability (Dmitrieva and McMahon, 1996; Gold et al., 1996). For example, chronic chemical irritation of the bladder changes ion channel function in bladder afferent neurons and also increases the expression of various markers, including NOS (Vizzard et al., 1996), GAP43 (Vizzard and Boyle, 1999), PACAP, SP (Vizzard, 2001), and protease-activated receptors (Dattilio and Vizzard, 2005). The density of peptidergic afferent nerves also increases in the bladder mucosa and detrusor muscle (Dickson et al., 2006), and afferent peptidergic axons and parasympathetic efferent axons and varicosities are commonly observed in close contact, suggesting that sprouting of peripheral nerves occurs during chronic cystitis.

Cystitis also induces chemical changes in the spinal cord. Acute or chronic bladder irritation increases immediate early gene expression *(c-FOS)* in spinal neurons (Birder and de Groat, 1993), as well as increasing in GFRα1-IR in the spinal dorsal horn and in areas associated with autonomic neurons (Forrest and Keast, 2008). There was a much smaller increase in GFRα3-IR and no change in GFRα2-IR. Changes in spinal cord mitogen-activated protein (MAP) kinases (extracellular signal-related kinases 1 and 2 [ERK1 and ERK2]) may also play a role in the facilitation of reflex voiding after bladder inflammation. Immunohistochemical studies revealed that, in noninflamed rat bladders, noxious but not non-noxious stimulation significantly increased phospho-ERK immunoreactivity (Cruz et al., 2007). After bladder inflammation, innocuous and noxious bladder distention increased the number of spinal neurons exhibiting phospho-ERK immunoreactivity. ERK inhibition with intrathecal injection of PD98059 decreases reflex bladder activity and spinal c-FOS expression in animals with inflamed bladders but not in normal animals (Cruz et al., 2007). The results suggest that activation of spinal cord ERK contributes to acute and chronic inflammatory pain perception and mediates reflex bladder overactivity accompanying chronic bladder inflammation.

Direct evidence linking chronic bladder inflammation with functional changes in C-fiber afferents has been obtained in rat chronic cystitis models induced by cyclophosphamide or hydrochloric acid. In these models, the electrical properties of bladder afferent neurons (dissociated from L6 and S1 DRG), as well as the activity of the inflamed bladder, were measured. The majority of bladder afferent neurons from control and cyclophosphamide-treated rats are capsaicin sensitive and exhibit high-threshold TTX-resistant APs and Na^+ currents. However, neurons from rats with cystitis exhibit significantly lower thresholds for spike activation and show tonic rather than phasic firing characteristics (Hayashi et al., 2009b). Other significant changes in bladder afferent neurons from cystitis rats include increased somal diameter, increased input capacitance, and decreased density of slowly inactivating A-type K^+ (K_A) currents (Hayashi et al., 2009b; Yoshimura and de Groat, 1999). In addition, the reduction in K_A currents in the hydrochloric acid–induced cystitis model was associated with reduced expression of the Kv1.4 α-subunit protein (which can form K_A channels) in bladder afferent neurons (Hayashi et al., 2009b), suggesting that the Kv1.4 subunit may be a molecule responsible for reduced K_A currents and increased excitability of bladder afferent neurons after cystitis. Previous experiments using cats with naturally occurring feline-type IC have also demonstrated that capsaicin-sensitive dorsal root ganglion neurons exhibit an increase in cell size and increase in firing rates of depolarizing current pulses because of a reduction in low-threshold K^+ currents (Sculptoreanu et al., 2005). Accordingly, chronic inflammation in BPS/IC could induce cell hypertrophy and hyperexcitability of C-fiber bladder afferent neurons. If these changes in neuronal cell bodies also occur at C-fiber afferent terminals in the bladder wall, such hyperexcitability may represent an important mechanism for inducing pain in the inflamed bladder. This is supported by some clinical studies showing that C-fiber desensitization induced by intravesical application of capsaicin or RTX is effective for treating painful symptoms in patients with BPS/IC (Lazzeri et al., 1996, 2000), although a previous prospective, randomized clinical trial using intravesical RTX application was not effective in patients with BPS/IC (Payne et al., 2005).

There is little information available about the neuroplasticity of Aδ-fiber bladder afferents in BPS/IC. However, a previous study (Roppolo et al., 2005) using single nerve fiber recordings has documented that Aδ-fiber bladder afferents in cats with feline-type IC are more sensitive to bladder pressure changes than afferents in normal cats, suggesting that, in addition to neuroplasticity of C-fiber afferents, Aδ-fiber bladder afferents may also undergo functional changes in BPS/IC.

Chronic bladder inflammation can also induce changes in functional properties of chemosensitive receptors such as TRPV1 in sensory neurons. Sculptoreanu et al. (2005) reported that DRG neurons obtained from cats with feline IC exhibit capsaicin-induced responses that are larger in amplitude and desensitize more slowly compared with those obtained from normal cats, and that altered TRPV1 receptor activity in cats with feline IC is reversed by an application of an inhibitor of PKC, suggesting that BPS/IC can alter TRPV1 activity because of enhanced endogenous PKC activity. Because TRPV1 receptors are reportedly responsible, at least in part, for bladder overactivity elicited by cyclophosphamide-induced cystitis (Dinis et al., 2004), enhanced activity of TRPV1 receptors could contribute to bladder pain in BPS/IC. Studies in mice have also demonstrated a role of TRPV1 in cystitis. Systemic treatment with cyclophosphamide or intravesical administration of acrolein (the irritant metabolite of cyclophosphamide) produces not only bladder hyperactivity but also a sensitization of the paw withdrawal responses to mechanical stimulation of the paw (mechanical hyperalgesia). These responses do not occur in TRPV1 knockout mice (Charrua et al., 2007; Wang et al., 2008). In addition, GRC-6211, a new oral-specific TRPV1 antagonist, has been shown to decrease bladder overactivity and noxious bladder input in cystitis animal models (Charrua et al., 2009).

Afferent mechanisms can also explain the coexistence of pelvic organ hyperalgesia, such as BPS/IC and IBS. The animal model for this phenomenon is pelvic organ cross-sensitization. In this model, the rectum is exposed to a chemical irritant, with the resultant development of bladder afferent sensitivity, involvement of the C-fiber afferents, and bladder mast cell activation (Asfaw et al., 2011; Malykhina et al., 2013; Pan et al., 2010; Ustinova et al., 2006, 2010).

NGF has also attracted attention as a mediator in the link between experimentally induced inflammation and pain signaling in BPS/IC. NGF is expressed widely in various cells, including urothelial cells, smooth muscle cells, and mast cells, and can activate mast cells to degranulate and proliferate. In the cyclophosphamide-induced chronic cystitis model in rats, increased expression of neurotrophic growth factors, such as NGF, brain-derived neurotrophic factor (BDNF), and CNTF in the bladder, as well as phosphorylation of tyrosine kinase receptors (TrkA, TrkB) in bladder afferent neurons, has also been presented as direct evidence for increased neurotrophin-mediated signaling in chronic bladder inflammation (Qiao and Vizzard, 2002; Vizzard, 2000). The enhanced neurotrophic factor mechanisms are also associated with increased phosphorylated cAMP responsive element-binding protein (CREB) in bladder afferent neurons. Phosphorylated CREB, which is a transcription factor in the neurotrophin intracellular signaling pathway, is coexpressed with phosphorylated TrkA in a subpopulation of bladder afferent neurons (Qiao and Vizzard, 2004). RTX, a C-fiber neurotoxin, reduced cyclophosphamide-induced upregulation of phosphorylated CREB in DRG cells, suggesting that cystitis is linked with altered CREB phosphorylation in capsaicin-sensitive C-fiber bladder afferents (Qiao and Vizzard, 2004). These results suggest that upregulation of phosphorylated CREB may be mediated by a neurotrophin/TrkA signaling pathway, and that CREB phosphorylation may play a role as a transcription factor in LUT plasticity induced by chemical cystitis. In patients with BPS/IC, neurotrophins, including nerve growth factor, neurotrophin-3 (NT-3), and glial cell line–derived neurotrophic factor (GDNF), have been detected in the urine (Okragly et al., 1999). Increased expression of NGF is also present in bladder biopsy specimens from women with IC (Liu et al., 2014; Lowe et al., 1997).

Exogenous NGF can induce bladder nociceptive responses and bladder overactivity in rats when applied acutely into the bladder lumen (Chuang et al., 2001; Dmitrieva et al., 1997) or chronically to the bladder wall or intrathecal space (Lamb et al., 2004; Yoshimura et al., 2006; Zvara and Vizzard, 2007). Conversely, application of NGF-sequestering molecules (TrkA-IgG or REN1820) can reduce referred thermal hyperalgesia elicited by bladder inflammation induced by intravesically applied turpentine oil (Jaggar et al., 1999) or bladder overactivity elicited by cyclophosphamide-induced cystitis (Hu et al., 2005), suggesting that increased NGF expression is directly involved in the emergence of bladder-related nociceptive responses in cystitis. A urothelially restricted NGF expression transgenic animal has also been created (Schnegelsberg et al., 2010). This animal has increased voiding frequency and evidence of increased pelvic pain. The suburothelial nerve fibers also vastly expanded with hyperinnervation of the bladder with significantly increased mast cells in the bladder stroma, consistent with the trophic effects of NGF on this cell type. However despite these data, targeted treatment with monoclonal anti-NGF antibody, tanezumab, did not prove efficacious in BPS/IC patients (Evans et al., 2011). This may be a result of phenotyping issues in enrollment, and perhaps an entry criterion of threshold level of increased NGF would be required to show an effect. As discussed in a prior section, the use of NGF as a biomarker in evaluation and management of LUTD is still unresolved (Ochodnicky et al., 2011).

Purinergic mechanisms may also contribute to the bladder dysfunction in BPS/IC. ATP release from the urothelium is enhanced in patients and cats with BPS/IC (Birder et al., 2003; Sun et al., 2001). In conscious rats with cyclophosphamide-induced cystitis, purinergic receptor antagonists (pyridoxal-phosphate-6-azophenyl-2’,4’-disulfonic acid [PPADS] and A-317491) reduced nonvoiding contractions and decreased voiding frequency (Ito et al., 2008). In in vitro whole-bladder pelvic afferent nerve preparations from rats with cyclophosphamide-induced cystitis, afferent nerve firing induced by bladder distention or by direct electric stimulation was markedly increased compared with firing in normal rats (Yu and de Groat, 2008). Exogenous purinergic agonists mimic the facilitatory effects of cyclophosphamide treatment, and P2X purinergic receptor antagonists suppress the effects of purinergic agonists and cystitis. These results suggest that endogenous purinergic agonists released in the inflamed bladder can enhance the excitability of bladder afferent nerves by activating P2X receptors. Patch clamp studies on bladder afferent neurons from rats revealed that chronic cyclophosphamide treatment increases the currents induced by purinergic agonists in both thoracolumbar and lumbosacral neurons (Dang et al., 2008). Analysis of the kinetics of the currents indicated that increased receptor expression and/or properties of homomeric $P2X_3$ in thoracolumbar neurons and $P2X_{2/3}$ in lumbosacral neurons contributes to the enhanced responses during cystitis. Investigations with human BPS/IC bladder urothelial specimens found that stretch of cultured bladder urothelial cells resulted in significantly increased ATP release (Sun et al., 2001) and increased $P2X_3$ expression on the cells (Sun and Chai, 2004; Tempest et al., 2004). A $P2X_3$ antagonist, AF-219, has been tested in a proof-of-concept trial in treating symptoms associated with BPS/IC. In 36 and 38 BPS/IC women treated with AF-219 and placebo, respectively, patients treated with AF-219 had improvement in the key symptoms of BPS/IC: pain scores, urinary urgency, and general improvement in patient-reported symptoms, suggesting the potential efficacy of $P2X_3$ receptor antagonists for the treatment of BPS/IC symptoms

(Moldwin et al., 2015).

Another animal model for BPS/IC is chronic psychological stress inflicted by water avoidance stress (WAS) testing. In this model, a rat is placed on a narrow surface suspended over water. The rat becomes stressed because it must maintain balance to avoid getting wet. Changes in bladder neurophysiology then can be studied after chronic WAS. It was found that chronic WAS significantly enhanced visceral organ, including bladder, nociceptive responses (Bradesi et al., 2005; Robbins et al., 2007; Smith et al., 2011). Chronic WAS was noted to cause increased mast cell activity in the bladder, which was blocked with treatment with melatonin and montelukast (Cikler et al., 2005). Because stress mechanisms involve the brain, it could be theorized that the development of visceral hyperalgesia with chronic WAS involves brain mechanisms, which now can be imaged with fMRI in maintenance of the chronic pain state (Phillips and Clauw, 2011).

A search for urinary factors that may be a cause of BPS/IC resulted in discovery of antiproliferative factor (APF) by Keay et al. (1996, 1998). APF's structure was found to be a sialated glycol-nonapeptide with sequence homology to portion of the frizzled 8 protein of the Wnt signaling pathway (Keay et al., 2004). APF's receptor in the urothelial cell was found to be cytoskeletal-associated protein, CKAP4/p63 (Conrads et al., 2006). CKAP4/p63 is a palmitoylated protein that physically links the endoplasmic reticulum to the microtubules (Vedrenne et al., 2005). It is also a cell surface receptor for tissue plasminogen activator (Razzaq et al., 2003) and surfactant protein A (Gupta et al., 2006). CKAP4/p63 is a major substrate for a putative tumor suppressor enzyme, palmitoyl acyltransferase DHHC2 (Zhang et al., 2008), which may help explain APF's antiproliferative activity against urothelial cells. A mouse model in which intravesical application of APF resulted in similar bladder urothelial changes detected in human urothelium was published (Keay et al., 2012). Whether the understanding of APF biology can be integrated into care of BPS/IC patients remains to be seen.

Key Points: Bladder Pain Syndrome and Interstitial Cystitis

- Histologic analysis of bladders from patients with BPS/IC often revealed marked edema, vasodilation, proliferation of nerve fibers, and infiltration of mast cells.

- NGF appears to be a key player in the link between inflammation and altered pain signaling. NGF is expressed widely in various cells, including urothelial cells, smooth muscle cells, and mast cells, and can activate mast cells to degranulate and proliferate.
- Application of NGF-sequestering molecules can reduce bladder overactivity elicited by cyclophosphamide-induced cystitis.
- Direct evidence linking chronic bladder inflammation with functional changes in C-fiber afferents has been obtained in rat chronic cystitis models. Chronic bladder inflammation can also induce changes in functional properties of chemosensitive receptors, such as TRPV1 in sensory neurons.

Aging

LUTS, such as increased voiding frequency, urgency, urgency incontinence, and poor bladder emptying, are common and troublesome problems in older men and women (Naughton and Wyman, 1997; Nuotio et al., 2002; Resnick, 1995). Previous studies have reported various changes in LUT function, including a reduction in bladder capacity, increased bladder sensation, and DO (Diokno et al., 1986; Hald and Horn, 1998; Madersbacher et al., 1998, 1999; Nuotio et al., 2002). However, few studies have addressed the normal changes in the LUT that occur with aging. Studies by Pfisterer et al. (2006) have examined age-related changes in bladder function among 85 community-dwelling female volunteers and **demonstrated that detrusor contractility, bladder sensation, and urethral pressure decline with age** and that a reduction in bladder capacity associated with age may be related to DO rather than to aging, because bladder capacity did not decrease with age but was smaller in subjects with DO (Pfisterer et al., 2006). With aging, pelvic ischemia can occur as a result of vasculopathy, which can result in LUTS and detrusor overactivity (Azadzoi et al., 2010; Thurmond et al., 2016). Thus **aging appears to induce hypofunction of the bladder and urethra in humans.**

Epidemiologic studies have revealed that aging is the largest risk factor for lifestyle-related diseases or disorders, including bladder conditions; however, the underlying mechanisms that underlie the increased risk remain unclear. There is substantive evidence that cellular senescence and increased oxidative stress can contribute to changes in tissue perfusion, leading to a reduction in tactile and visceral hyposensitivity as well as abnormal urodynamic behavior in older adults. A report highlights how the TAME trial (Targeting Aging with Metformin) may help decrease age-related disease by targeting fundamental aging pathways including oxidative stress. Although metformin was originally introduced in clinical practice as an agent to treat diabetes, its use is being expanded to promote longevity and has been shown in mice to increase lifespan. Long-term caloric restriction may have effects on similar pathways and has also been shown to prevent age-related impairment of in vitro bladder dysfunction (Barzilai et al., 2016; Dai et al., 2014; Ito et al., 2015; Martin-Montalvo et al., 2013).

In animal studies, impaired bladder function, as evidenced by increased voided volume per micturition associated with a high micturition-pressure threshold, has also been demonstrated in aged rats compared with the young counterpart (Chai et al., 2000; Chun et al., 1988). In addition, aged rats exhibit reduced sensitivity of pelvic nerve afferents in response to increased bladder volume, but not pressure, and a reduction in the maximal bladder pressure generated during pelvic nerve stimulation (Hotta et al., 1995). In aging mice, bladder contractility was normal, but bladder afferent signaling was diminished (Smith et al., 2012a).

A significant linear reduction in the amount of acetylcholinesterase-positive nerve was observed with increasing age in the human bladder (Gilpin et al., 1986), suggesting reduced parasympathetic innervation of the aged bladder. It was also shown that expression of neuropeptides, such as CGRP and SP in lumbosacral DRG neurons, decreases with age (Mohammed and Santer, 2002) and that there is a marked reduction in the density of PACAP innervation of the subepithelial plexus and of the muscle layer of the bladder base, as well as slight reductions in CGRP and SP innervation of the muscle layer in old rats (Mohammed and Santer, 2002; Mohammed et al., 2002). Taken together, these results suggest that **impaired activity of the aged bladder is likely, at least in part, a result of reduced activity of efferent and afferent nerves innervating the bladder.**

Changes in the CNS in relation to LUT function have also been demonstrated in aged animals. Immunohistochemical analyses in aged rats revealed significant age-associated declines in the serotonergic (5-HT) and adrenergic innervation of various spinal cord regions, including the intermediolateral cell nucleus, sacral parasympathetic nucleus, dorsal gray commissure, and the ventral horn nucleus that contains the Onuf nucleus. However, 5-HT innervation of the sacral parasympathetic nucleus and tyrosine hydroxylase–like immunoreactivity in the ventral horn nucleus were maintained (Ranson et al., 2003). It was also shown that sympathetic preganglionic neurons in the L1-L2 spinal cord that project to the major pelvic ganglion exhibit a number of degenerative changes, such as reductions in the cell number, the length of their dendrites, and the synaptic contact made by glutamate-immunoreactive boutons onto the dendrites in aged rats, although these changes are not seen in parasympathetic preganglionic neurons in the L6-S1 spinal cord (Santer et al., 2002). Chai et al. (2000) also reported that frequent voiding produced by apomorphine-induced dopamine receptor activation is more pronounced in aged rats compared with young rats, suggesting that aged rats are more susceptible to altered central processing to induce bladder overactivity despite decline of baseline bladder function with aging. Hypoactivity of the bladder or the underactive bladder represents an unmet medical need moving forward in light of the aging populations in developed countries (Chancellor and Kaufman, 2008).

In contrast to altered nerve activity, there appears to be no significant change in detrusor contractile responses to cholinergic or electric stimulation between young and old animals (Chun et al., 1989; Lieu et al., 1997; Lin et al., 1997; Longhurst et al., 1992; Schneider et al., 2004b; Yu et al., 1996), although old rats have a reduced density of muscarinic receptors in the bladder (Schneider et al., 2004b). In contrast, there are some reports of age-related changes of the detrusor response to adrenergic stimulation (Latifpour et al., 1990). Most studies showed that detrusor contractile responses to α-adrenergic stimulation increased in old male and female rats (Lin et al., 1997; Nishimoto et al., 1995; Saito et al., 1991, 1993) in association with upregulation of α_{1D}-receptor expression in the bladder (Dmitrieva et al., 2008). However, another study showed no age-dependent changes in α_1-adrenoceptor properties, such as phenylephrine-induced contractile responses, total receptor density, and mRNA expression of α_1-adrenoceptor subtypes (α_{1A}, α_{1B}, and α_{1D}) in the rat bladder base and dome (Yono et al., 2006). The detrusor response to β-adrenergic stimulation is reduced in old male rats (Lin et al., 1997; Nishimoto et al., 1995), along with a reduction in the density of β-adrenergic receptors and decreased cAMP production (Nishimoto et al., 1995) in response to β-adrenergic stimulation. The combination of increased α-adrenergic excitatory response and decreased β-adrenergic inhibitory response results in a net contracting effect of norepinephrine on the aged bladder, in contrast to the relaxing effect of norepinephrine in the young bladder (Lin et al., 1997). However, the contribution of these changes in adrenoceptor properties to age-related alterations in LUT function is still to be determined.

Pharmacologic treatment of LUTS in the elderly often involves the use of antimuscarinic agents. The urologic use of antimuscarinics can increase risk of cognitive function decline (see the earlier section on cognitive impairment with antimuscarinic agents), especially because the elderly may be on several other medications with anticholinergic activity (increased anticholinergic burden). A case control study of approximately 40,000 cases (dementia) and 280,000 controls without dementia found that the risk for dementia increased with greater exposure to anticholinergics (oxybutynin and tolterodine) used for urologic indications (Richardson et al., 2018). However, it could not be determined from this study whether the increased dementia risk was increased because of anticholinergic side effects of oxybutynin/tolterodine or whether urologic symptoms being treated were prodromal for development for dementia.

Key Points: Aging

- Bladder sensation and urethral pressure decline with age, and a reduction in bladder capacity associated with age may be related to DO rather than to aging, because bladder capacity was not seen to decrease with age but was smaller in subjects with DO. Thus aging appears to induce hypofunction of the bladder and urethra in humans.
- In contrast to altered nerve activity, there appears to be no significant change in detrusor contractile responses to cholinergic or electric stimulation between young and old animals.
- Most studies have shown that detrusor contractile responses to α-adrenergic stimulation increase and that detrusor-relaxing responses to β-adrenergic stimulation decrease in old rats.

Neuromodulation

Hypothesis of Mechanism of Action of Sacral Neuromodulation

Neuromodulation of the sacral, pudendal, and posterior tibial nerves is now used for the treatment of refractory OAB and urinary retention relating to pelvic floor dysfunction (Das et al., 2004; Herbison and Arnold, 2009; Leng and Chancellor, 2005). Some have criticized the inconsistency that electric stimulation of the sacral nerve can paradoxically inhibit the OAB and conversely promote bladder emptying in patients with idiopathic nonobstructive urinary retention. The effects of sacral neuromodulation may depend on electric stimulation of afferent axons in the spinal roots, which in turn modulate voiding and continence reflex pathways in the CNS. The afferent system is the most likely target, because beneficial effects can be elicited at intensities of stimulation that do not activate movements of striated muscles (de Groat et al., 1997; Thon et al., 1991; Vodusek et al., 1986). Sacral neuromodulation activates somatic afferent axons that modulate sensory processing and micturition reflex pathways in the spinal cord. Urinary retention and dysfunctional voiding can be resolved by inhibition of the guarding reflexes. DO can be suppressed by direct inhibition of bladder preganglionic neurons. Inhibition of interneuronal transmission in the afferent limb of the micturition reflex can also block DO. Thus the principle behind sacral neuromodulation can be summarized as somatic afferent inhibition of sensory processing in the spinal cord.

Rationale for Neuromodulation to Facilitate Voiding

In adults, brain pathways are necessary to turn off sphincter and urethral guarding reflexes to allow efficient bladder emptying. Thus spinal cord injury produces bladder-sphincter dyssynergia and inefficient bladder emptying by eliminating the brain mechanisms involved (Fig. 110.43). This may also occur after more subtle neurologic lesions in patients with idiopathic urinary retention, such as after a bout of prostatitis or UTI. Before the development of brain control of micturition, at least in animals, the stimulation of somatic afferent pathways passing through the pudendal nerve from the perineum can initiate efficient voiding by activating bladder efferent pathways and turning off the excitatory pathways to the urethral outlet (de Groat and Booth, 1993; de Groat et al., 1993; Kruse and de Groat, 1993). Tactile stimulation of the perineum in the cat also inhibits the bladder–sympathetic reflex component of the guarding reflex mechanism. The sacral nerve stimulation may elicit similar responses in patients with urinary retention, and it may turn off excitatory outflow to the urethral outlet and promote bladder emptying. Because sphincter activity can generate afferent input to the spinal cord that can, in turn, inhibit reflex bladder activity, an indirect benefit of suppressing sphincter reflexes would be a facilitation of bladder activity.

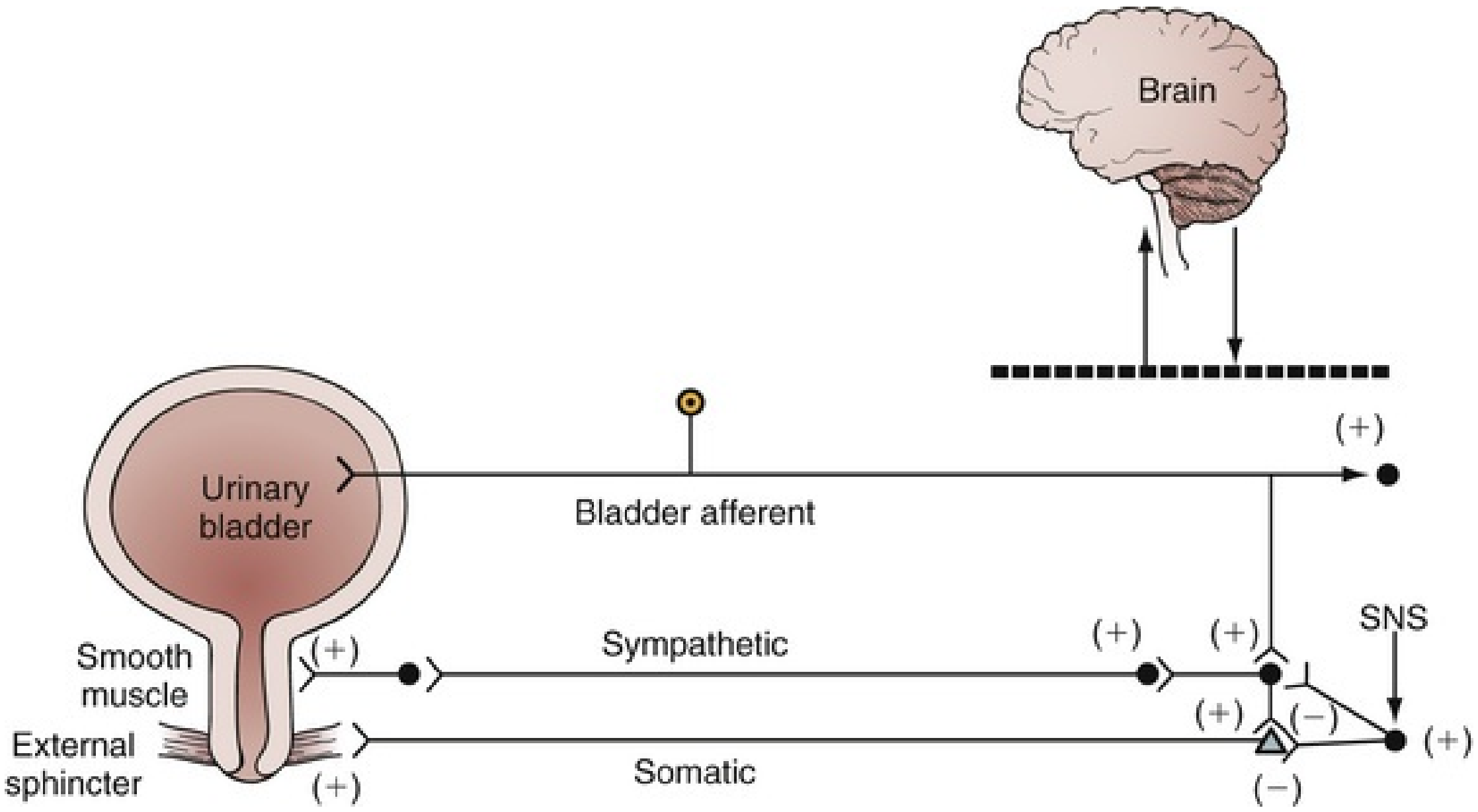

FIG. 110.43 When there is a sudden increase in intravesical pressure, such as during a cough, the urinary sphincter contracts by means of the spinal guarding reflex to prevent urinary incontinence (guarding reflex). The spinal guarding reflexes can be turned off by the brain for urination. In cases of neurologic diseases, the brain cannot turn off the guarding reflex, and retention can occur. Sacral nerve stimulation (SNS) restores voluntary micturition in cases of voiding dysfunction and urinary retention but inhibits the guarding reflex.

Rationale for Neuromodulation to Inhibit the Overactive Bladder

Several reflex mechanisms may be involved in the sacral neuromodulation suppression of DO. Afferent pathways projecting to the sacral cord can inhibit bladder reflexes in animals and humans. The source of afferent input may be from sphincter muscles, distal colon, rectum, anal canal, vagina, uterine cervix, and cutaneous afferents from the perineum (Fig. 110.44). As mentioned previously, two mechanisms have been identified in animals for somatic and visceral afferent inhibition of bladder reflexes. The most common mechanism is suppression of interneuronal transmission in the bladder reflex pathway (de Groat and Theobald, 1976; Kruse and de Groat, 1993; Kruse et al., 1990). It is assumed that this inhibition occurs, in part, on the ascending limb of the micturition reflex and therefore blocks the transfer of information from the bladder to the PMC. This action would prevent involuntary (reflex) micturition but not necessarily suppress voluntary voiding that would be mediated by descending excitatory efferent pathways from the brain to the sacral parasympathetic preganglionic neurons. A second inhibitory mechanism is mediated by a direct inhibitory input to the bladder preganglionic neurons. This can be induced by electric stimulation of the pudendal nerve or by mechanical stimulation of the anal canal and distal bowel. It is not elicited by tactile stimulation of penile or perineal afferents; this mechanism would be much more effective in turning off bladder reflexes, because it would directly suppress firing in the motor outflow from the spinal cord.

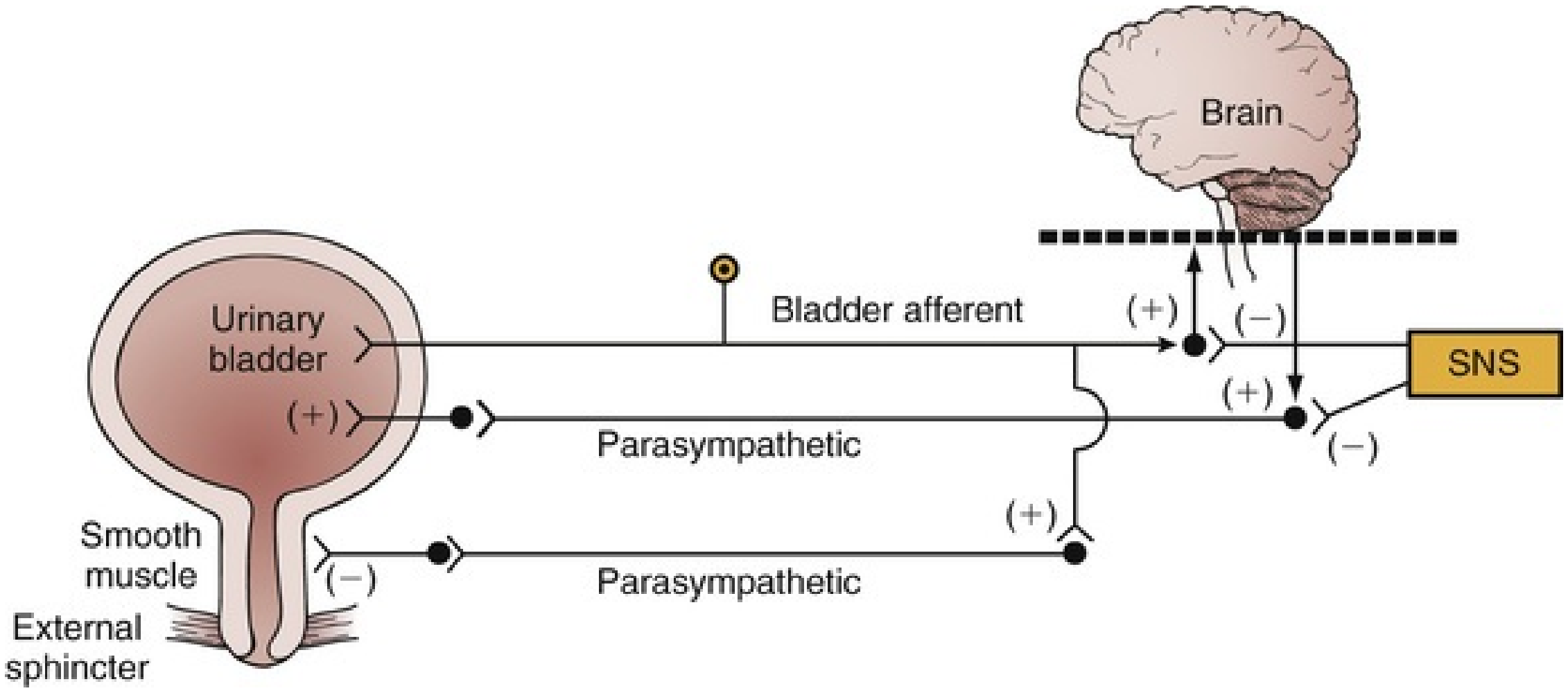

FIG. 110.44 The voiding reflex involves afferent neurons from the bladder that project on spinal tract neurons that ascend to the brain. Descending pathways connect to parasympathetic efferent nerves to contract the bladder (bladder-bladder reflex). A spinal bladder-urethra reflex is activated by a similar bladder afferent innervation. In cases of supraspinal dysfunction, overactive micturition reflexes occur. Sacral nerve stimulation (SNS) inhibits urinary urgency, frequency, and urge incontinence by inhibiting the bladder-bladder and bladder-urethra reflexes.

Pudendal Nerve Stimulation

The pudendal nerve is a peripheral branch of the sacral nerve roots, and stimulating the pudendal allows afferent stimulation to all three of the sacral nerve roots (S2, S3, S4), and that may raise the stimulation threshold needed for micturition and inhibit detrusor activity. Because this is a more peripheral nerve, it is less likely that stimulation of the sciatic and sural nerves will occur, thus decreasing the potential risk for discomfort in the thighs, calves, and feet as seen on occasion with sacral stimulation at the S3 nerve root. The pudendal nerve arises from the sacral plexus within the pelvis; it must go around the pelvic floor to reach the ischioanal fossa. In the pelvis, it runs on the piriformis and then passes laterally through the greater sciatic foramen to enter the gluteal region. Here it lies inferior to the piriformis as does the sciatic nerve, the inferior gluteal neurovascular bundle, and the nerve to the quadratus femoris. The pudendal nerve curls around the spine of the ischium, lying superficial to the sacrospinous ligament, and then passes into the lesser sciatic notch to enter the ischioanal fossa. The nerve then divides into the inferior rectal, the perineal, and the dorsal nerve of the penis or clitoris.

Afferent pudendal nerve stimulation has been demonstrated to inhibit the micturition reflex, abolish uninhibited detrusor contractions, and increase bladder capacity in animals and humans (Fall and Lindstrom, 1991). Peters et al. (2005) compared the effectiveness of sacral and pudendal nerve stimulation for voiding dysfunction in a prospective, single-blind, randomized crossover trial including 30 patients (22 with urgency or frequency, 5 with urgency incontinence, and 3 with urinary retention) scheduled for sacral implantation of a tined quadripolar lead who consented to the placement of a second pudendal lead. Twenty-four of the 30 patients demonstrated a significant clinical response and had an implantable pulse generator placed. Sacral nerve stimulation resulted in 46% improvement in symptoms, whereas pudendal nerve stimulation demonstrated 63% improvement in symptoms. Urgency-incontinence episodes were reduced by approximately 47%; however, this did not reach statistical significance because of small sample size (n = 5).

Inhibitory and Excitatory Stimulation Frequencies of the Pudendal-Bladder Reflexes

The exact mechanism of action of neuromodulation is unknown. In addition, there are no studies involving neuromodulation that look at programming parameters (pulse width, intensity, or frequency) and their impact on voiding function. The pudendal nerve may have a dual mechanism depending on the frequency and continuity of stimulation. A study by Tai et al. (2007) in anesthetized spinal cord–injured cats demonstrated that at 3 Hz, stimulation of the pudendal nerve inhibited bladder function and decreased bladder pressures, whereas intermittent stimulation at 20 Hz improved the efficiency of the bladder to empty (Tai et al., 2007). Furthermore, the clinical outcomes of continuous (which potentially can fatigue the urethral sphincter and accommodate the nerve) and intermittent stimulation have not been explored. It would directly suppress firing in the motor outflow from the spinal cord.

Activation of Somatic Afferents in the Foot

There is also evidence that using noninvasive transcutaneous stimulation of somatic nerves in the footpad of cats produced an inhibition of reflex bladder activity (Tai et al., 2011a,b). In this regard, a new treatment termed FootStim has been used as a noninvasive foot neuromodulation therapy for OAB. Using a wearable stimulator, the patient is able to use the device at home to activate nerves on the foot via skin surface electrodes. Results using FootStim (3 hours daily) showed decrease urgency urinary incontinence and urgency frequency in women with refractory OAB (Chermansky et al., 2017).

OnabotulinumtoxinA Neuromodulation

Botulinum toxins act by inhibiting ACh release at the presynaptic cholinergic nerve terminal, thereby inhibiting striated and smooth muscle contractions. The toxins are synthesized as single-chain polypeptides with a molecular weight of about 150 kD (DasGupta, 1994). Initially, the parent chain is cleaved into its active dichain polypeptide form, consisting of a heavy chain (approximately 100 kD) connected by a disulfide bond to a light chain (approximately 50 kD) with an associated zinc atom (Schiavo et al., 1992). Four steps are required for toxin-induced paralysis: binding of the toxin heavy chain to an as yet unidentified nerve terminal receptor, internalization of the toxin within the nerve terminal, translocation of the light chain into the cytosol, and inhibition of neurotransmitter release. Neurotransmitter release involves the ATP-dependent transport of the vesicle from the cytosol to the plasma membrane (Barinaga, 1993). Vesicle docking requires the interaction of various cytoplasm, vesicle, and target membrane proteins (i.e., soluble *N*-ethylmaleimide-sensitive factor attachment protein receptor [SNARE] proteins), some of which are specifically targeted with clostridial neurotoxins. For example, OBTX cleaves the cytosolic translocation protein SNAP-25, thus preventing vesicle fusion with the plasma membrane (Schiavo et al., 1993).

Although ACh release from bladder parasympathetic efferent terminals is a likely target of OBTX treatment, suppression of bladder afferent activity with

OBTX treatment is also evident because the reduction of urgency symptom in patients with neurogenic detrusor overactivity and IDO is associated with reduced expression of the capsaicin receptor (TRPV1) and the ATP receptor ($P2X_3$) in C fibers (Apostolidis et al., 2005a). In addition, in basic research, botulinum toxins are shown to suppress not only efferent nerve activity by inhibition of the release of ACh but also afferent nerve activity by release of inhibition of neurotransmitters, such as SP and CGRP, from sensory terminals (Chuang et al., 2004; Dressler et al., 2005; Ikeda et al., 2012). There is also evidence that the toxin can reduce the release of ATP (and possibly other mediators) from urothelial cells in control urothelial cells (Hanna-Mitchell et al., 2015) and in spinalized rats (Khera et al., 2004; Smith et al., 2005, 2008). A study using lipotoxin (liposomes as a carrier for OBTX) demonstrated that the urothelium is also a site of action for this treatment (Kuo et al., 2014). Thus the use of the toxins has been expanded to treat women with pelvic floor spasticity, as well as patients with non-neurogenic OAB and even BPS (Apostolidis and Fowler, 2008; Smith and Chancellor, 2004; Smith et al., 2003, 2005).

The use of intradetrusor OBTX injection versus oral antimuscarinics in idiopathic OAB with urgency incontinence was studied in a randomized comparative efficacy trial (Visco et al., 2012). Reduction in urgency incontinence episodes per day was not different between OBTX and antimuscarinics, but the rate of complete resolution of urgency incontinence was significantly higher in the OBTX-treated subjects. The antimuscarinic-treated subjects had a higher rate of dry mouth but lower rates of catheter use and UTI.

A randomized clinical trial comparing OBTX injection with sacral neuromodulation was conducted in women with refractory idiopathic, non-neurogenic, overactive bladder with 24-month follow-up data (Amundsen et al., 2016, 2018). These investigators found that the efficacy of the two treatments were comparable with higher complete dry rate with OBTX, although the OBTX dosage used was 200 units. There was higher UTI risk with OBTX injection.

Future Research

Research holds the key to advancing the evaluation, treatment, and prevention of LUTD. As research delves deeper into physiology and pharmacology of the lower urinary tract, it is vital to continually translate research findings into clinical advances. A continuing dialogue between the clinician and scientist must be maintained. Newer treatments such as OBTX, β_3-agonists, sacral neuromodulation, and posterior tibial neurostimulation have been implemented into our armamentarium, but what is next on the horizon? Although traditional physiologic, pharmacologic, and neurobiologic approaches will continue to be important, the field of LUTD will require innovations that have advanced other fields.

High throughput screening "omics" techniques—genomics, proteomics, transcriptomics, lipidomics, and metabolomics have been used in many other diseases and conditions. These "omics" techniques use evolving technologies to analyze the entire genome, every protein, every mRNA, every lipid, and/or every metabolite within a biologic specimen to find signature abnormalities that could point to biologic causes for the conditions being studied. Through the use of "omics" techniques, we will be able to describe a "deeper" phenotyping of patients with LUTD, moving beyond symptoms-based phenotyping. Phenotyping based on large sets of biologic markers may help prognosticate outcomes of LUTD treatment, identify causes for LUTD, and/or point to new biologic pathways involved in LUTD.

Pharmacogenomics is a field that seeks to identify individual genetic variations that influence drug effects (typically via alterations in pharmacokinetics). Knowing which genetic variations are associated with increased (or decreased) efficacy of a drug, coupled with genotyping of patients, would lead to individualized pharmacologic therapeutic approaches.

Tissue regeneration and stem cell research has undergone significant progress over the last decade and reviews relating this area of research to the lower urinary tract have been published (Chan et al., 2017). New methodologies, including advancement in material science, stem cell technology, and methods to promote antiogenesis and neural regeneration, have yielded possibilities that may translate into LUT applications, including ways to augment bladder storage and emptying and urethral closure function. Using stem cells (e.g. mesenchymal stem cells) to promote salutary mechanisms after injuries may prevent future organ dysfunction or accelerate process towards healthy organ function.

Continued studies into different forms of functional neuromodulation in treating the myriad of LUTD conditions appear warranted as the understanding of brain control of lower urinary tract function is better understood. Although stimulating a nerve root (S3) or peripheral nerve (posterior tibial nerve, foot nerve, saphenous nerve) (MacDiarmid et al., 2018) to modulate LUT function has been described, the future of brain stimulation to treat LUTD remains an area of research interest. With better understanding of the brain involvement in regulating lower urinary tract function through functional MRI techniques, future treatments to modulate the function and network connectivity of these brain areas using stimuli such as transcranial magnetic stimulation (TMS) require further research. TMS has already been applied to a wide variety of mental health and behavioral disorders such as depression (McClintock et al., 2018), schizophrenia (Aleman et al., 2018), addiction (Diana et al., 2017; Spagnolo and Goldman, 2017), and nonessential tremor (Kang and Cauraugh, 2017).

Investigations into the urinary microbiota are ongoing. Researchers have categorized the genera of bacteria that dwell are found in the urine from normal individuals (Wolfe et al., 2012) and subjects with overactive bladder/urgency urinary incontinence (Brubaker et al., 2014; Pearce et al., 2014) and IC/PBS (Nickel et al., 2016; Siddiqui et al., 2012). Although this chapter does not cover microbiome/bacterial biology, the urothelium, lamina propria, and afferent/efferent neural pathways are host biologic systems by which interactions occur with the urinary microbiota. Thus a more granular understanding of the role of urinary microbiota in LUTD symptoms would necessarily require an understanding of host responses to the urinary microbiota.

Questions for future research may include the following:

1. Can we prevent development of any form of LUTD based on our understanding of pathophysiologic mechanisms?
2. Will stratifying patients into treatment groups based on genotype lead to development of “personalized” pharmacotherapy?
3. Can we develop biomarkers to better phenotype different forms of LUTD?
4. Can the biomarkers be used to prognosticate treatment outcomes?
5. Can the biomarker search result in novel targets for treatment?

6. Can genomics studies point to susceptibility genes for the development of LUTD?
7. Can the afferent signals from the LUT be modulated to treat a variety of LUTD?
8. Is the bladder urothelium targetable to treat different forms of LUTD?
9. Will a pharmacologic or physiologic intervention be developed that will successfully treat the underactive detrusor so that self-catheterization is obsolete?
10. Will regenerative medicine technologies be shown to be clinically useful in LUTD?
11. How does the host respond to urinary microbiota in the normal and LUTD states?

Videos 110.1▶, 110.2▶, 110.3▶, and 110.4▶ show animations related to this chapter.

References

Abrams P, Blaivas JG, Stanton SL, et al. The standardisation of terminology of lower urinary tract function. The international continence society committee on standardisation of terminology. *Scand J Urol Nephrol Suppl*. 1988;114:5–19.

Abrams P, Cardozo L, et al. *World Health Organization 1st International Consultation on Incontinence*. World Health Organization: Paris, France; 2005.

Abrams P, Cardozo L, Fall M, et al. The standardisation of terminology of lower urinary tract function: report from the standardisation sub-committee of the international continence society. *Am J Obstet Gynecol*. 2002;187(1):116–126.

Abrams P, Kelleher C, Staskin D, et al. Combination treatment with mirabegron and solifenacin in patients with overactive bladder: efficacy and safety results from a randomised, double-blind, dose-ranging, phase 2 study (symphony). *Eur Urol*. 2015;67(3):577–588.

Acharya P, Beckel J, Ruiz WG, et al. Distribution of the tight junction proteins zo-1, occludin, and claudin-4, -8, and -12 in bladder epithelium. *Am J Physiol Renal Physiol*. 2004;287(2):F305–F318.

Aizawa N, Homma Y, Igawa Y. Effects of l-arginine, mirabegron, and oxybutynin on the primary bladder afferent nerve activities synchronized with reflexic, rhythmic bladder contractions in the rat. *Neurourol Urodyn*. 2015;34(4):368–374.

Aizawa N, Igawa Y, Nishizawa O, et al. Effects of nitric oxide on the primary bladder afferent activities of the rat with and without intravesical acrolein treatment. *Eur Urol*. 2011;59(2):264–271.

Aizawa N, Wyndaele JJ, Homma Y, et al. Effects of TRPV4 cation channel activation on the primary bladder afferent activities of the rat. *Neurourol Urodyn*. 2012;31(1):148–155.

Alagiri M, Chottiner S, Ratner V, et al. Interstitial cystitis: unexplained associations with other chronic disease and pain syndromes. *Urology*. 1997;49(5A Suppl):52–57.

Aleman A, Enriquez-Geppert S, Knegtering H, et al. Moderate effects of noninvasive brain stimulation of the frontal cortex for improving negative symptoms in schizophrenia: meta-analysis of controlled trials. *Neurosci Biobehav Rev*. 2018;89:111–118.

Ali M, Angelo-Khattar M, Thulesius L, et al. Urothelial synthesis of prostanoids in the ovine ureter. *Urol Res*. 1998;26(3):171–174.

Amodio DM, Frith CD. Meeting of minds: the medial frontal cortex and social cognition. *Nat Rev Neurosci*. 2006;7(4):268–277.

Amundsen CL, Komesu YM, Chermansky C, et al. Two-year outcomes of sacral neuromodulation versus onabotulinumtoxina for refractory urgency urinary incontinence: a randomized trial. *Eur Urol*. 2018.

Amundsen CL, Richter HE, Menefee SA, et al. Onabotulinumtoxina vs sacral neuromodulation on refractory urgency urinary incontinence in women: a randomized clinical trial. *J Am Med Assoc*. 2016;316(13):1366–1374.

An X, Bandler R, Ongur D, et al. Prefrontal cortical projections to longitudinal columns in the midbrain periaqueductal gray in macaque monkeys. *J Comp Neurol*. 1998;401(4):455–479.

Andersson KE, Arner A. Urinary bladder contraction and relaxation: physiology and pathophysiology. *Physiol Rev*. 2004;84(3):935–986.

Andersson KE, Garcia Pascual A, Persson K, et al. Electrically-induced, nerve-mediated relaxation of rabbit urethra involves nitric oxide. *J Urol*. 1992;147(1):253–259.

Andersson KE, McCloskey KD. Lamina propria: the functional center of the bladder? *Neurourol Urodyn*. 2014;33(1):9–16.

Andersson KE, Persson K. Nitric oxide synthase and the lower urinary tract: possible implications for physiology and pathophysiology. *Scand J Urol Nephrol Suppl*. 1995;175:43–53.

Andersson KE, Wein AJ. Pharmacology of the lower urinary tract: basis for current and future treatments of urinary incontinence. *Pharmacol Rev*. 2004;56(4):581–631.

Andersson KE. Pharmacology of lower urinary tract smooth muscles and penile erectile tissues. *Pharmacol Rev*. 1993;45(3):253–308.

Andersson KE. The concept of uroselectivity. *Eur Urol*. 1998;33(Suppl 2):7–11.

Andersson KE. The overactive bladder: pharmacologic basis of drug treatment. *Urology*. 1997;50(6A Suppl):74–84 [discussion 85–89].

Andrade EL, Forner S, Bento AF, et al. TRPA1 receptor modulation attenuates bladder overactivity induced by spinal cord injury. *Am J Physiol Renal Physiol*. 2011;300(5):F1223–F1234.

Apostolidis A, Brady CM, Yiangou Y, et al. Capsaicin receptor TRPV1 in urothelium of neurogenic human bladders and effect of intravesical resiniferatoxin. *Urology*. 2005;65(2):400–405.

Apostolidis A, Fowler CJ. The use of botulinum neurotoxin type a (bonta) in urology. *J Neural Transm (Vienna)*. 2008;115(4):593–605.

Apostolidis A, Popat R, Yiangou Y, et al. Decreased sensory receptors P2X3 and TRPV1 in suburothelial nerve fibers following intradetrusor injections of botulinum toxin for human detrusor overactivity. *J Urol*. 2005;174(3):977–982 [discussion 982–983].

Araki I, de Groat WC. Developmental synaptic depression underlying reorganization of visceral reflex pathways in the spinal cord. *J Neurosci*. 1997;17(21):8402–8407.

Araki I, Du S, Kamiyama M, et al. Overexpression of epithelial sodium channels in epithelium of human urinary bladder with outlet obstruction. *Urology*. 2004;64(6):1255–1260.

Asfaw TS, Hypolite J, Northington GM, et al. Acute colonic inflammation triggers detrusor instability via activation of TRPV1 receptors in a rat model of pelvic organ cross-sensitization. *Am J Physiol Regul Integr Comp Physiol*. 2011;300(6):R1392–R1400.

Athwal BS, Berkley KJ, Hussain I, et al. Brain responses to changes in bladder volume and urge to void in healthy men. *Brain*. 2001;124(Pt 2):369–377.

Awad SA, Downie JW, Kiruluta HG. Alpha-adrenergic agents in urinary disorders of the proximal urethra. Part I. Sphincteric incontinence. *Br J Urol*. 1978;50(5):332–335.

Awad SA, Downie JW, Lywood DW, et al. Sympathetic activity in the proximal urethra in patients with urinary obstruction. *J Urol*. 1976;115(5):545–547.

Azadzoi KM, Radisavljevic ZM, Golabek T, et al. Oxidative modification of mitochondrial integrity and nerve fiber density in the ischemic overactive bladder. *J Urol*. 2010;183:362–369.

Barinaga M. Secrets of secretion revealed. *Science*. 1993;260(5107):487–489.

Barrington FJF. The component reflexes of micturition in the cat. Part III1. *Brain*. 1941;64(4):239–243.

Barrington FJF. The component reflexes of micturition in the catparts I and II. *Brain*. 1931;54(2):177–188.

Barrington FJF. The effect of lesions of the hind- and mid-brain on micturition in the cat. *Q J Exp Physiol (1908)*. 1925;15(1):81–102.

Barrington FJF. The relation of the hind-brain to micturition1. *Brain*. 1921;44(1):23–53.

Barzilai N, Crandall JP, Kritchevsky SB, et al. Metformin as a tool to target aging. *Cell Metab*. 2016;23(6):1060–1065.

Batista JE, Wagner JR, Azadzoi KM, et al. Direct measurement of blood flow in the human bladder. *J Urol*. 1996;155(2):630–633.

Batra S, Andersson KE. Oestrogen-induced changes in muscarinic receptor density and contractile responses in the female rabbit urinary bladder. *Acta Physiol Scand*. 1989;137(1):135–141.

Bayliss M, Wu C, Newgreen D, et al. A quantitative study of atropine-resistant contractile responses in human detrusor smooth muscle, from stable, unstable and obstructed bladders. *J Urol*. 1999;162(5):1833–1839.

Bazeed MA, Thuroff JW, Schmidt RA, et al. Histochemical study of urethral striated musculature in the dog. *J Urol*. 1982;128(2):406–410.

Bean BP, Williams CA, Ceelen PW. Atp-activated channels in rat and bullfrog sensory neurons: current-voltage relation and single-channel behavior. *J Neurosci*. 1990;10(1):11–19.

Beckel JM, Kanai A, Lee SJ, et al. Expression of functional nicotinic acetylcholine receptors in rat urinary bladder epithelial cells. *Am J Physiol Renal Physiol*. 2006;290(1):F103–F110.

Behr-Roussel D, Oger S, Caisey S, et al. Vardenafil decreases bladder afferent nerve activity in unanesthetized, decerebrate, spinal cord-injured rats. *Eur Urol*. 2011;59(2):272–279.

Bennett BC, Kruse MN, Roppolo JR, et al. Neural control of urethral outlet activity in vivo: role of nitric oxide. *J Urol*. 1995;153(6):2004–2009.

Betts CD, Kapoor R, Fowler CJ. Pontine pathology and voiding dysfunction. *Br J Urol*. 1992;70(1):100–102.

Bielefeldt K, Lamb K, Gebhart GF. Convergence of sensory pathways in the development of somatic and visceral hypersensitivity. *Am J Physiol Gastrointest Liver Physiol*. 2006;291(4):G658–G665.

Biers SM, Reynard JM, Doore T, et al. The functional effects of a c-kit tyrosine inhibitor on guinea-pig and human detrusor. *BJU Int*. 2006;97(3):612–616.

Birder L, Kullmann FA, Lee H, et al. Activation of urothelial transient receptor potential vanilloid 4 by 4alpha-phorbol 12,13-didecanoate contributes to altered bladder reflexes in the rat. *J Pharmacol Exp Ther*. 2007;323(1):227–235.

Birder LA, Apodaca G, De Groat WC, et al. Adrenergic- and capsaicin-evoked nitric oxide release from urothelium and afferent nerves in urinary bladder. *Am J Physiol*. 1998;275(2 Pt 2):F226–F229.

Birder LA, Barrick SR, Roppolo JR, et al. Feline interstitial cystitis results in mechanical hypersensitivity and altered ATP release from bladder urothelium. *Am J Physiol Renal Physiol*. 2003;285(3):F423–F429.

Birder LA, de Groat WC. Contribution of c-fiber afferent nerves and autonomic pathways in the urinary bladder to spinal c-fos expression induced by bladder irritation. *Somatosens Mot Res*. 1998;15(1):5–12.

Birder LA, de Groat WC. Induction of c-fos expression in spinal neurons by nociceptive and nonnociceptive stimulation of LUT. *Am J Physiol*. 1993;265(2 Pt 2):R326–R333.

Birder LA, Kanai AJ, de Groat WC, et al. Vanilloid receptor expression suggests a sensory role for urinary bladder epithelial cells. *Proc Natl Acad Sci USA*. 2001;98(23):13396–13401.

Birder LA, Nakamura Y, Kiss S, et al. Altered urinary bladder function in mice lacking the vanilloid receptor TRPV1. *Nat Neurosci*. 2002;5(9):856–860.

Birder LA, Ruan HZ, Chopra B, et al. Alterations in p2x and p2y purinergic receptor expression in urinary bladder from normal cats and cats with interstitial cystitis. *Am J Physiol Renal Physiol*. 2004;287(5):F1084–F1091.

Birder LA, Wolf-Johnston A, Griffiths D, et al. Role of urothelial nerve growth factor in human bladder function. *Neurourol Urodyn*. 2007;26(3):405–409.

Blaivas JG. The neurophysiology of micturition: a clinical study of 550 patients. *J Urol*. 1982;127(5):958–963.

Blok BF, Groen J, Bosch JL, et al. Different brain effects during chronic and acute sacral neuromodulation in urge incontinent patients with implanted neurostimulators. *BJU Int*. 2006;98(6):1238–1243.

Blok BF, Holstege G. The central nervous system control of micturition in cats and humans. *Behav Brain Res*. 1998;92(2):119–125.

Blok BF, Holstege G. The neuronal control of micturition and its relation to the emotional motor system. *Prog Brain Res*. 1996;107:113–126.

Blok BF, Holstege G. Two pontine micturition centers in the cat are not interconnected directly: implications for the central organization of micturition. *J Comp Neurol*. 1999;403(2):209–218.

Blok BF, Holstege G. Ultrastructural evidence for a direct pathway from the pontine micturition center to the parasympathetic preganglionic motoneurons of the bladder of the cat. *Neurosci Lett*. 1997;222(3):195–198.

Blok BF, Sturms LM, Holstege G. Brain activation during micturition in women. *Brain*. 1998;121(Pt 11):2033–2042.

Blok BF, Willemsen AT, Holstege G. A pet study on brain control of micturition in humans. *Brain*. 1997;120(Pt 1):111–121.

Boggs JW, Wenzel BJ, Gustafson KJ, et al. Spinal micturition reflex mediated by afferents in the deep perineal nerve. *J Neurophysiol*. 2005;93(5):2688–2697.

Borda E, Contreras-Ortiz N, Gutnisky R, et al. In vitro effect of acetylcholine and bethanechol on the contractions of the human detrusor muscle. Influence of prostaglandins. *Arch Int Pharmacodyn Ther*. 1982;259(1):31–39.

Boselli C, Govoni S, Condino AM, et al. Bladder instability: a re-appraisal of classical experimental approaches and development of new therapeutic strategies. *J Auton Pharmacol*. 2001;21(5–6):219–229.

Bradesi S, Schwetz I, Ennes HS, et al. Repeated exposure to water avoidance stress in rats: a new model for sustained visceral hyperalgesia. *Am J Physiol Gastrointest Liver Physiol*. 2005;289(1):G42–G53.

Brading AF, Mostwin JL. Electrical and mechanical responses of guinea-pig bladder muscle to nerve stimulation. *Br J Pharmacol*. 1989;98(4):1083–1090.

Brading AF, Turner WH. The unstable bladder: towards a common mechanism. *Br J Urol*. 1994;73(1):3–8.

Brading AF. A myogenic basis for the overactive bladder. *Urology*. 1997;50(6A Suppl):57–67 [discussion 68–73].

Brading AF. Alterations in the physiological properties of urinary bladder smooth muscle caused by bladder emptying against an obstruction. *Scand J Urol Nephrol Suppl*. 1997;184:51–58.

Brading AF. Spontaneous activity of lower urinary tract smooth muscles: correlation between ion channels and tissue function. *J Physiol*. 2006;570(Pt 1):13–22.

Brady CM, Apostolidis AN, Harper M, et al. Parallel changes in bladder suburothelial vanilloid receptor TRPV1 and pan-neuronal marker PGP9.5 immunoreactivity in patients with neurogenic detrusor overactivity after intravesical resiniferatoxin treatment. *BJU Int*. 2004;93(6):770–776.

Braverman AS, Doumanian LR, Ruggieri MR Sr. M2 and M3 muscarinic receptor activation of urinary bladder contractile signal transduction. II. Denervated rat bladder. *J Pharmacol Exp Ther*. 2006;316(2):875–880.

Braverman AS, Ruggieri MR Sr. Hypertrophy changes the muscarinic receptor subtype mediating bladder contraction from M3 toward M2. *Am J Physiol Regul Integr Comp Physiol*. 2003;285(3):R701–R708.

Braverman AS, Tibb AS, Ruggieri MR Sr. M2 and M3 muscarinic receptor activation of urinary bladder contractile signal transduction. I. Normal rat bladder. *J Pharmacol Exp Ther*. 2006;316(2):869–874.

Breyer MD, Hebert RL, Breyer RM. Prostanoid receptors and the urogenital tract. *Curr Opin Investig Drugs*. 2003;4(11):1343–1353.

Breyer RM, Bagdassarian CK, Myers SA, et al. Prostanoid receptors: subtypes and signaling. *Annu Rev Pharmacol Toxicol*. 2001;41:661–690.

Bridgeman MB, Friia NJ, Taft C, et al. Mirabegron: beta3-adrenergic receptor agonist for the treatment of overactive bladder. *Ann Pharmacother*. 2013;47(7–8):1029–1038.

Brubaker L, Nager CW, Richter HE, et al. Urinary bacteria in adult women with urgency urinary incontinence. *Int Urogynecol J*. 2014;25(9):1179–1184.

Brumovsky PR, Gebhart GF. Visceral organ cross-sensitization—an integrated perspective. *Auton Neurosci*. 2010;153(1–2):106–115.

Buckley MS, Washington S, Laurent C, et al. Characterization and immunohistochemical localization of the glycoconjugates of the rabbit bladder mucosa. *Arch Biochem Biophys*. 1996;330(1):163–173.

Bultitude MI, Hills NH, Shuttleworth KE. Clinical and experimental studies on the action of prostaglandins and their synthesis inhibitors on detrusor muscle in vitro and in vivo. *Br J Urol*. 1976;48(7):631–637.

Burgard EC, Fraser MO, Thor KB. Serotonergic modulation of bladder afferent pathways. *Urology*. 2003;62(4 Suppl 1):10–15.

Burnstock G, Dumsday B, Smythe A. Atropine resistant excitation of the urinary bladder: the possibility of transmission via nerves releasing a purine nucleotide. *Br J Pharmacol*. 1972;44(3):451–461.

Burnstock G. P2 purinoceptors: historical perspective and classification. *Ciba Found Symp*. 1996;198:1–28 [discussion 29–34].

Burnstock G. Purine-mediated signalling in pain and visceral perception. *Trends Pharmacol Sci*. 2001;22(4):182–188.

Burnstock G. Purinergic signalling in lower urinary tract. Abbracchio MP, Williams M. *Purinergic and pyrimidinergic signalling I*. Springer: Berlin; 2001:151 [423–516].

Burnstock G. Purinergic signalling: past, present and future. *Braz J Med Biol Res*. 2009;42(1):3–8.

Bushfield M, Metcalfe M, Naylor AM. Activation of the micturition reflex by nk2 receptor stimulation in the anaesthetized guinea-pig. *Br J Pharmacol*. 1995;115(6):875–882.

Callahan SM, Creed KE. The effects of oestrogens on spontaneous activity and responses to phenylephrine of the mammalian urethra. *J Physiol*. 1985;358:35–46.

Cannon TW, Yoshimura N, Chancellor MB. Innovations in pharmacotherapy for stress urinary incontinence. *Int Urogynecol J Pelvic Floor Dysfunct*. 2003;14(6):367–372.

Carattino MD, Prakasam HS, Ruiz WG, et al. Bladder filling and voiding affect umbrella cell tight junction organization and function. *Am J Physiol Renal Physiol*. 2013;305(8):F1158–F1168.

Cardozo LD, Stanton SL. A comparison between bromocriptine and indomethacin in the treatment of detrusor instability. *J Urol*. 1980;123(3):399–401.

Chacko S, Chang S, Hypolite J, et al. Alteration of contractile and regulatory proteins following partial bladder outlet obstruction. *Scand J Urol Nephrol Suppl*. 2004;215:26–36.

Chacko S, DiSanto M, Menon C, et al. Contractile protein changes in urinary bladder smooth muscle following outlet obstruction. *Adv Exp Med Biol*. 1999;462:137–153.

Chacko S, Jacob SS, Horiuchi KY. Myosin i from mammalian smooth muscle is regulated by caldesmon-calmodulin. *J Biol Chem*. 1994;269(22):15803–15807.

Chai TC, Andersson KE, Tuttle JB, et al. Altered neural control of micturition in the aged f344 rat. *Urol Res*. 2000;28(5):348–354.

Chai TC, Gemalmaz H, Andersson KE, et al. Persistently increased voiding frequency despite relief of bladder outlet obstruction. *J Urol*. 1999;161(5):1689–1693.

Chai TC, Gray ML, Steers WD. The incidence of a positive ice water test in bladder outlet obstructed patients: evidence for bladder neural plasticity. *J Urol*. 1998;160(1):34–38.

Chai TC, Richter HE, Moalli P, et al. Inflammatory and tissue remodeling urinary biomarkers before and after mid urethral sling surgery for stress urinary incontinence. *J Urol*. 2014;191(3):703–709.

Chalfin SA, Bradley WE. The etiology of detrusor hyperreflexia in patients with infravesical obstruction. *J Urol*. 1982;127(5):938–942.

Chan YY, Sandlin SK, Kurzrock EA, et al. The current use of stem cells in bladder tissue regeneration and bioengineering. *Biomedicines*. 2017;5(1).

Chancellor MB, Chartier-Kastler EJ. Principles of sacral nerve stimulation (SNS) for the treatment of bladder and urethral sphincter dysfunctions. *Neuromodulation*. 2000;3(1):16–26.

Chancellor MB, de Groat WC. Intravesical capsaicin and resiniferatoxin therapy: spicing up the ways to treat the overactive bladder. *J Urol*. 1999;162(1):3–11.

Chancellor MB, Kaplan SA, Blaivas JG. The cholinergic and purinergic components of detrusor contractility in a whole rabbit bladder model. *J Urol*. 1992;148(3):906–909.

Chancellor MB, Kaufman J. Case for pharmacotherapy development for underactive bladder. *Urology*. 2008;72(5):966–967.

Chancellor MB, Lavelle J, Ozawa H, et al. Ice-water test in the urodynamic evaluation of spinal cord injured patients. *Tech Urol*. 1998;4(2):87–91.

Chancellor MB. Should we be using chili pepper extracts to treat the overactive bladder? *J Urol*. 1997;158(6):2097.

Chang SL, Chung JS, Yeung MK, et al. Roles of the lamina propria and the detrusor in tension transfer during bladder filling. *Scand J Urol Nephrol Suppl*. 1999;201:38–45.

Chapple CR, Cardozo L, Nitti VW, et al. Mirabegron in overactive bladder: a review of efficacy, safety, and tolerability. *Neurourol Urodyn*. 2014;33(1):17–30.

Chapple CR, Wein AJ. The urgency of the problem and the problem of urgency in the overactive bladder. *BJU Int*. 2005;95(3):274–275.

Charil A, Zijdenbos AP, Taylor J, et al. Statistical mapping analysis of lesion location and neurological disability in multiple sclerosis: application to 452 patient data sets. *Neuroimage*. 2003;19(3):532–544.

Charrua A, Cruz CD, Cruz F, et al. Transient receptor potential vanilloid subfamily 1 is essential for the generation of noxious bladder input and bladder overactivity in cystitis. *J Urol*. 2007;177(4):1537–1541.

Charrua A, Cruz CD, Narayanan S, et al. GRC-6211, a new oral specific TRPV1 antagonist, decreases bladder overactivity and noxious bladder input in cystitis animal models. *J Urol*. 2009;181(1):379–386.

Chen Q, Takahashi S, Zhong S, et al. Function of the lower urinary tract in mice lacking alpha1d-adrenoceptor. *J Urol*. 2005;174(1):370–374.

Chen SY, Wang SD, Cheng CL, et al. Glutamate activation of neurons in CV-reactive areas of cat brain stem affects urinary bladder motility. *Am J Physiol*. 1993;265(4 Pt 2):F520–F529.

Cher ML, Abernathy BB, McConnell JD, et al. Smooth-muscle myosin heavy-chain isoform expression in bladder-outlet obstruction. *World J Urol*. 1996;14(5):295–300.

Cher ML, Kamm KE, McConnell JD. Stress generation and myosin phosphorylation in the obstructed bladder. *J Urol*. 1990;143:355A [(Abstract)].

Chermansky CJ, Shen B, Okonski J, et al. Electrical stimulation of afferent nerves in the foot with transcutaneous adhesive pad electrodes in women with refractory overactive bladder: defining ideal stimulation duration. *J Urol*. 2017;197(4 Suppl):e1049 [PD54-11].

Chess-Williams R. Muscarinic receptors of the urinary bladder: detrusor, urothelial and prejunctional. *Auton Autacoid Pharmacol*. 2002;22(3):133–145.

Chess-Williams R. Potential therapeutic targets for the treatment of detrusor overactivity. *Expert Opin Ther Targets*. 2004;8(2):95–106.

Chopra B, Barrick SR, Meyers S, et al. Expression and function of bradykinin b1 and b2 receptors in normal and inflamed rat urinary bladder urothelium. *J Physiol*. 2005;562(Pt 3):859–871.

Chopra B, Gever J, Barrick SR, et al. Expression and function of rat urothelial p2y receptors. *Am J Physiol Renal Physiol*. 2008;294(4):F821–F829.

Christ GJ, Day NS, Day M, et al. Increased connexin43-mediated intercellular communication in a rat model of bladder overactivity in vivo. *Am J Physiol Regul Integr Comp Physiol*. 2003;284(5):R1241–R1248.

Chuang YC, Fraser MO, Yu Y, et al. The role of bladder afferent pathways in bladder hyperactivity induced by the intravesical administration of nerve growth factor. *J Urol*. 2001;165(3):975–979.

Chuang YC, Yoshimura N, Huang CC, et al. Intravesical botulinum toxin a administration produces analgesia against acetic acid induced bladder pain responses in rats. *J Urol*. 2004;172(4 Pt 1):1529–1532.

Chun AL, Wallace LJ, Gerald MC, et al. Effect of age on in vivo urinary bladder function in the rat. *J Urol*. 1988;139(3):625–627.

Chun AL, Wallace LJ, Gerald MC, et al. Effects of age on urinary bladder function in the male rat. *J Urol*. 1989;141(1):170–173.

Cikler E, Ercan F, Cetinel S, et al. The protective effects of melatonin against water avoidance stress-induced mast cell degranulation in dermis. *Acta Histochem*. 2005;106(6):467–475.

Clausen C, Lewis SA, Diamond JM. Impedance analysis of a tight epithelium using a distributed resistance model. *Biophys J*. 1979;26(2):291–317.

Clemens JQ, Meenan RT, O'Keeffe Rosetti MC, et al. Case-control study of medical comorbidities in women with interstitial cystitis. *J Urol*. 2008;179(6):2222–2225.

Clemens JQ. Afferent neurourology and urologic pain syndromes: current state of the art. *Curr Opin Urol*. 2013;23(6):552–553.

Cobine CA, Hennig GW, Kurahashi M, et al. Relationship between interstitial cells of cajal, fibroblast-like cells and inhibitory motor nerves in the internal anal sphincter. *Cell Tissue Res*. 2011;344(1):17–30.

Cockayne DA, Dunn PM, Zhong Y, et al. P2X2 knockout mice and P2X2/P2X3 double knockout mice reveal a role for the P2X2 receptor subunit in mediating multiple sensory effects of ATP. *J Physiol*. 2005;567(Pt 2):621–639.

Cockayne DA, Hamilton SG, Zhu QM, et al. Urinary bladder hyporeflexia and reduced pain-related behaviour in P2X3-deficient mice. *Nature*. 2000;407(6807):1011–1015.

Collier ML, Ji G, Wang Y, et al. Calcium-induced calcium release in smooth muscle: loose coupling between the action potential and calcium release. *J Gen Physiol*. 2000;115(5):653–662.

Collins C, Klausner AP, Herrick B, et al. Potential for control of detrusor smooth muscle spontaneous rhythmic contraction by cyclooxygenase products released by interstitial cells of cajal. *J Cell Mol Med*. 2009;13(9B):3236–3250.

Conrads TP, Tocci GM, Hood BL, et al. CKAP4/P63 is a receptor for the frizzled-8 protein-related antiproliferative factor from interstitial cystitis patients. *J Biol Chem*. 2006;281(49):37836–37843.

Constantinou CE, Govan DE. Spatial distribution and timing of transmitted and reflexly generated urethral pressures in healthy women. *J Urol*. 1982;127(5):964–969.

Coolsaet B. Bladder compliance and detrusor activity during the collection phase. *Neurourol Urodyn*. 1985;4(4):263–273.

Cornelissen LL, Brooks DP, Wibberley A. Female, but not male, serotonin reuptake transporter (5-HTT) knockout mice exhibit bladder instability. *Auton Neurosci*. 2005;122(1–2):107–110.

Cornu JN, Merlet B, Ciofu C, et al. Duloxetine for mild to moderate postprostatectomy incontinence: preliminary results of a randomised, placebo-controlled trial. *Eur Urol*.

2011;59(1):148–154.

Cortivo R, Pagano F, Passerini G, et al. Elastin and collagen in the normal and obstructed urinary bladder. *Br J Urol*. 1981;53(2):134–137.

Crowe R, Light K, Chilton CP, et al. Vasoactive intestinal polypeptide-, somatostatin- and substance p-immunoreactive nerves in the smooth and striated muscle of the intrinsic external urethral sphincter of patients with spinal cord injury. *J Urol*. 1986;136(2):487–491.

Cruz CD, Ferreira D, McMahon SB, et al. The activation of the ERK pathway contributes to the spinal c-*fos* expression observed after noxious bladder stimulation. *Somatosens Mot Res*. 2007;24(1–2):15–20.

Cushing P, Bhalla R, Johnson AM, et al. Nerve growth factor increases connexin43 phosphorylation and gap junctional intercellular communication. *J Neurosci Res*. 2005;82(6):788–801.

Dai DF, Chiao YA, Marcinek DJ, et al. Mitochondrial oxidative stress in aging and healthspan. *Longev Healthspan*. 2014;3:6.

Daly D, Rong W, Chess-Williams R, et al. Bladder afferent sensitivity in wild-type and TRPV1 knockout mice. *J Physiol*. 2007;583(Pt 2):663–674.

Damaser MS, Samplaski MK, Parikh M, et al. Time course of neuroanatomical and functional recovery after bilateral pudendal nerve injury in female rats. *Am J Physiol Renal Physiol*. 2007;293(5):F1614–F1621.

Dang K, Lamb K, Cohen M, et al. Cyclophosphamide-induced bladder inflammation sensitizes and enhances P2X receptor function in rat bladder sensory neurons. *J Neurophysiol*. 2008;99(1):49–59.

Das AK, Carlson AM, Hull M. Improvement in depression and health-related quality of life after sacral nerve stimulation therapy for treatment of voiding dysfunction. *Urology*.

2004;64(1):62–68.

DasGupta BR. Structures of botulinum neurotoxin, its functional domains, and perspectives on the crystalline type a toxin. Jankovic J, Hallett M. *Therapy with botulinum toxin*. Marcel Dekker: New York; 1994:15–39.

DasGupta R, Kavia RB, Fowler CJ. Cerebral mechanisms and voiding function. *BJU Int*. 2007;99(4):731–734.

Dattilio A, Vizzard MA. Up-regulation of protease activated receptors in bladder after cyclophosphamide induced cystitis and colocalization with capsaicin receptor (vr1) in bladder nerve fibers. *J Urol*. 2005;173(2):635–639.

de Groat WC, Booth AM, et al. Neural control of the urinary bladder and large intestine. Brooks CM, Koizumi K, Saito A. *Integrative functions of the autonomic nervous system*. Tokyo University Press: Tokyo; 1979:50–67.

De Groat WC, Booth AM, Milne RJ, et al. Parasympathetic preganglionic neurons in the sacral spinal cord. *J Auton Nerv Syst*. 1982;5(1):23–43.

de Groat WC, Booth AM, Yoshiyama M. Neurophysiology of micturition and its modification in animal models of human disease. Maggi CA. *The autonomic nervous system*. Harwood Academic Publishers: London; 1993:3 [227–90].

de Groat WC, Booth AM. Synaptic transmission in pelvic ganglia. Maggi CA. *The autonomic nervous system*. Harwood Academic Publishers: London; 1993:291–347.

de Groat WC, Fraser MO, Yoshiyama M, et al. Neural control of the urethra. *Scand J Urol Nephrol Suppl*. 2001;207:35–43 [discussion 106–125].

de Groat WC, Kawatani M, Hisamitsu T, et al. Mechanisms underlying the recovery of urinary bladder function following spinal cord injury. *J Auton Nerv Syst*. 1990;30(Suppl):S71–F77.

de Groat WC, Kruse MN, Vizzard MA, et al. Modification of urinary bladder function after spinal cord injury. *Adv Neurol*. 1997;72:347–364.

de Groat WC, Nadelhaft I, Milne RJ, et al. Organization of the sacral parasympathetic reflex pathways to the urinary bladder and large intestine. *J Auton Nerv Syst*. 1981;3(2–4):135–160.

de Groat WC, Theobald RJ. Reflex activation of sympathetic pathways to vesical smooth muscle and parasympathetic ganglia by electrical stimulation of vesical afferents. *J Physiol*. 1976;259(1):223–237.

de Groat WC, Yoshimura N. Pharmacology of the lower urinary tract. *Annu Rev Pharmacol Toxicol*. 2001;41:691–721.

de Groat WC, Yoshiyama M, Ramage AG, et al. Modulation of voiding and storage reflexes by activation of alpha1-adrenoceptors. *Eur Urol*. 1999;36(Suppl 1):68–73.

de Groat WC. Influence of central serotonergic mechanisms on lower urinary tract function. *Urology*. 2002;59(5 Suppl 1):30–36.

De Groat WC. Nervous control of the urinary bladder of the cat. *Brain Res*. 1975;87(2–3):201–211.

de Groat WC. Neuropeptides in pelvic afferent pathways. *Experientia*. 1987;43(7):801–813.

De Groat WC. Spinal cord projections and neuropeptides in visceral afferent neurons. *Prog Brain Res*. 1986;67:165–187.

de Groat WC. The urothelium in overactive bladder: passive bystander or active participant? *Urology*. 2004;64(6 Suppl 1):7–11.

De Ridder D. Antimuscarinics and cognitive function. *Eur Urol*. 2006;50(2):211–212.

Deckmann K, Filipski K, Krasteva-Christ G, et al. Bitter triggers acetylcholine release from polymodal urethral chemosensory cells and bladder reflexes. *Proc Natl Acad Sci USA*. 2014;111(22):8287–8292.

DeGroat WC, Douglas JW, Glass J, et al. Changes in somatovesical reflexes during postnatal development in the kitten. *Brain Res*. 1975;94(1):150–154.

deGroat WC, Vizzard MA, Araki I, et al. Spinal interneurons and preganglionic neurons in sacral autonomic reflex pathways. *Prog Brain Res*. 1996;107:97–111.

Delaere KP, Thomas CM, Moonen WA, et al. The value of intravesical prostaglandin E2 and F2 alpha in women with abnormalities of bladder emptying. *Br J Urol*. 1981;53(4):306–309.

DeLancey JO. Pubovesical ligament: a separate structure from the urethral supports ("pubo-urethral ligaments"). *Neurourol Urodyn*. 1989;8(1):53–61.

Delancey JO. Structural aspects of urethrovesical function in the female. *Neurourol Urodyn*. 1988;7(6):509–519.

DeLancey JO. The pathophysiology of stress urinary incontinence in women and its implications for surgical treatment. *World J Urol*. 1997;15(5):268–274.

Delancey JO. Why do women have stress urinary incontinence? *Neurourol Urodyn*. 2010;29(Suppl 1):S13–S17.

Di Gangi Herms AM, Veit R, Reisenauer C, et al. Functional imaging of stress urinary incontinence. *Neuroimage*. 2006;29(1):267–275.

Diamond P, Hassonah S, Alarab M, et al. The prevalence of detrusor overactivity amongst patients with symptoms of overactive bladder: a retrospective cohort study. *Int Urogynecol J*. 2012;23(11):1577–1580.

Diana M, Raij T, Melis M, et al. Rehabilitating the addicted brain with transcranial magnetic stimulation. *Nat Rev Neurosci*. 2017;18(11):685–693.

Dickson A, Avelino A, Cruz F, et al. Peptidergic sensory and parasympathetic fiber sprouting in the mucosa of the rat urinary bladder in a chronic model of cyclophosphamide-induced cystitis. *Neuroscience*. 2006;141(3):1633–1647.

Dijkema HE, Weil EH, Mijs PT, et al. Neuromodulation of sacral nerves for incontinence and voiding dysfunctions. Clinical results and complications. *Eur Urol*. 1993;24(1):72–76.

Dinis P, Charrua A, Avelino A, et al. Anandamide-evoked activation of vanilloid receptor 1 contributes to the development of bladder hyperreflexia and nociceptive transmission to spinal dorsal horn neurons in cystitis. *J Neurosci*. 2004;24(50):11253–11263.

Diokno AC, Brock BM, Brown MB, et al. Prevalence of urinary incontinence and other urological symptoms in the noninstitutionalized elderly. *J Urol*. 1986;136(5):1022–1025.

DiSanto ME, Stein R, Chang S, et al. Alteration in expression of myosin isoforms in detrusor smooth muscle following bladder outlet obstruction. *Am J Physiol Cell Physiol*. 2003;285(6):C1397–C1410.

Dixon J, Gosling J. Structure and innervation of human bladder. Torrens M, Morrison J. *The physiology of the lower urinary tract*. Springer-Verlag: New York; 1987:3–22.

Dixon JS, Gilpin SA, Gilpin CJ, et al. Intramural ganglia of the human urinary bladder. *Br J Urol*. 1983;55(2):195–198.

Dmitrieva N, McMahon SB. Sensitisation of visceral afferents by nerve growth factor in the adult rat. *Pain*. 1996;66(1):87–97.

Dmitrieva N, Shelton D, Rice AS, et al. The role of nerve growth factor in a model of visceral inflammation. *Neuroscience*. 1997;78(2):449–459.

Dmitrieva N, Zhang G, Nagabukuro H. Increased alpha1d adrenergic receptor activity and protein expression in the urinary bladder of aged rats. *World J Urol*. 2008;26(6):649–655.

Doi T, Kamo I, Imai S, et al. Effects of TAK-637, a tachykinin receptor antagonist, on lower urinary tract function in the guinea pig. *Eur J Pharmacol*. 1999;383(3):297–303.

Dokita S, Morgan WR, Wheeler MA, et al. Ng-nitro-l-arginine inhibits non-adrenergic, non-cholinergic relaxation in rabbit urethral smooth muscle. *Life Sci*. 1991;48(25):2429–2436.

Donaldson PJ, Lewis SA. Effect of hyperosmotic challenge on basolateral membrane potential in rabbit urinary bladder. *Am J Physiol*. 1990;258(2 Pt 1):C248–C257.

Donker P, Droes JP, Van Ulden BM, et al. Anatomy of the musculature and innovation of the bladder and urethra. Chisholm GD, Williams DI. *Scientific foundations of urology*. Heinemann Medical Books: London; 1982:404–441.

Downie JW, Armour JA. Mechanoreceptor afferent activity compared with receptor field dimensions and pressure changes in feline urinary bladder. *Can J Physiol Pharmacol*. 1992;70(11):1457–1467.

Drake MJ, Harvey IJ, Gillespie JI, et al. Localized contractions in the normal human bladder and in urinary urgency. *BJU Int*. 2005;95(7):1002–1005.

Drake MJ, Hedlund P, Harvey IJ, et al. Partial outlet obstruction enhances modular autonomous activity in the isolated rat bladder. *J Urol*. 2003;170(1):276–279.

Dressler D, Saberi FA, Barbosa ER. Botulinum toxin: mechanisms of action. *Arq Neuropsiquiatr*. 2005;63(1):180–185.

Durant PA, Yaksh TL. Drug effects on urinary bladder tone during spinal morphine-induced inhibition of the micturition reflex in unanesthetized rats. *Anesthesiology*. 1988;68(3):325–334.

Eastham JE, Gillespie JI. The concept of peripheral modulation of bladder sensation. *Organogenesis*. 2013;9(3):224–233.

Eglen RM, Hegde SS, Watson N. Muscarinic receptor subtypes and smooth muscle function. *Pharmacol Rev*. 1996;48(4):531–565.

Eglen RM, Reddy H, Watson N, et al. Muscarinic acetylcholine receptor subtypes in smooth muscle. *Trends Pharmacol Sci*. 1994;15(4):114–119.

Ehlert FJ, Griffin MT, Abe DM, et al. The m2 muscarinic receptor mediates contraction through indirect mechanisms in mouse urinary bladder. *J Pharmacol Exp Ther*. 2005;313(1):368–378.

Ehren I, Hammarstrom M, Adolfsson J, et al. Induction of calcium-dependent nitric oxide synthase by sex hormones in the guinea-pig urinary bladder. *Acta Physiol Scand*. 1995;153(4):393–394.

Ek A, Alm P, Andersson KE, et al. Adrenergic and cholinergic nerves of the human urethra and urinary bladder. A histochemical study. *Acta Physiol Scand*. 1977;99(3):345–352.

Ekstrom J, Iosif CS, Malmberg L. Effects of long-term treatment with estrogen and progesterone on in vitro muscle responses of the female rabbit urinary bladder and urethra to autonomic drugs and nerve stimulation. *J Urol*. 1993;150(4):1284–1288.

el-Badawi A, Schenk EA. Dual innervation of the mammalian urinary bladder. A histochemical study of the distribution of cholinergic and adrenergic nerves. *Am J Anat*. 1966;119(3):405–427.

Elbadawi A. Ultrastructure of vesicourethral innervation. II. Postganglionic axoaxonal synapses in intrinsic innervation of the vesicourethral lissosphincter: a new structural and functional concept in micturition. *J Urol*. 1984;131(4):781–790.

Ellenberg M. Development of urinary bladder dysfunction in diabetes mellitus. *Ann Intern Med*. 1980;92(2 Pt 2):321–323.

Elliott RA, Castleden CM, Miodrag A. The effect of in vivo oestrogen pretreatment on the contractile response of rat isolated detrusor muscle. *Br J Pharmacol*. 1992;107(3):766–770.

Enhorning G. Simultaneous recording of intravesical and intra-urethral pressure. A study on urethral closure in normal and stress incontinent women. *Acta Chir Scand Suppl*. 1961;276(Suppl):1–68.

Eto M, Senba S, Morita F, et al. Molecular cloning of a novel phosphorylation-dependent inhibitory protein of protein phosphatase-1 (CPI17) in smooth muscle: its specific localization in smooth muscle. *FEBS Lett*. 1997;410(2–3):356–360.

Evans RJ, Moldwin RM, Cossons N, et al. Proof of concept trial of tanezumab for the treatment of symptoms associated with interstitial cystitis. *J Urol*. 2011;185(5):1716–1721.

Everaerts W, Zhen X, Ghosh D, et al. Inhibition of the cation channel TRPV4 improves bladder function in mice and rats with cyclophosphamide-induced cystitis. *Proc Natl Acad Sci USA*. 2010;107(44):19084–19089.

Fahrenkrug J, Hannibal J. Pituitary adenylate cyclase activating polypeptide immunoreactivity in capsaicin-sensitive nerve fibres supplying the rat urinary tract. *Neuroscience*. 1998;83(4):1261–1272.

Falconer C, Blomgren B, Johansson O, et al. Different organization of collagen fibrils in stress-incontinent women of fertile age. *Acta Obstet Gynecol Scand*. 1998;77(1):87–94.

Falconer C, Ekman-Ordeberg G, Blomgren B, et al. Paraurethral connective tissue in stress-incontinent women after menopause. *Acta Obstet Gynecol Scand*. 1998;77(1):95–100.

Fall M, Lindstrom S. Electrical stimulation. A physiologic approach to the treatment of urinary incontinence. *Urol Clin North Am*. 1991;18(2):393–407.

Fedirchuk B, Hochman S, Shefchyk SJ. An intracellular study of perineal and hindlimb afferent inputs onto sphincter motoneurons in the decerebrate cat. *Exp Brain Res*. 1992;89(3):511–516.

Fellows GJ, Marshall DH. The permeability of human bladder epithelium to water and sodium. *Invest Urol*. 1972;9(4):339–344.

Ferguson DR, Kennedy I, Burton TJ. Atp is released from rabbit urinary bladder epithelial cells by hydrostatic pressure changes—a possible sensory mechanism? *J Physiol*. 1997;505(Pt 2):503–511.

Fetscher C, Fleichman M, Schmidt M, et al. M(3) muscarinic receptors mediate contraction of human urinary bladder. *Br J Pharmacol*. 2002;136(5):641–643.

Floyd K, Hick VE, Morrison JF. Mechanosensitive afferent units in the hypogastric nerve of the cat. *J Physiol*. 1976;259(2):457–471.

Forrest SL, Keast JR. Expression of receptors for glial cell line-derived neurotrophic factor family ligands in sacral spinal cord reveals separate targets of pelvic afferent fibers. *J Comp Neurol*. 2008;506(6):989–1002.

Fowler CJ, Beck RO, Gerrard S, et al. Intravesical capsaicin for treatment of detrusor hyperreflexia. *J Neurol Neurosurg Psychiatry*. 1994;57(2):169–173.

Fowler CJ, Griffiths D, de Groat WC. The neural control of micturition. *Nat Rev Neurosci*. 2008;9(6):453–466.

Fowler CJ, Jewkes D, McDonald WI, et al. Intravesical capsaicin for neurogenic bladder dysfunction. *Lancet*. 1992;339(8803):1239.

Frazier EP, Peters SL, Braverman AS, et al. Signal transduction underlying the control of urinary bladder smooth muscle tone by muscarinic receptors and beta-adrenoceptors. *Naunyn Schmiedebergs Arch Pharmacol*. 2008;377(4–6):449–462.

Fry CH, Ikeda Y, Harvey R, et al. Control of bladder function by peripheral nerves: avenues for novel drug targets. *Urology*.

2004;63(3 Suppl 1):24–31.

Fry CH, Jabr RI. T-type ca2+ channels and the urinary and male genital tracts. *Pflugers Arch*. 2014;466(4):781–789.

Fry CH, Skennerton D, Wood D, et al. The cellular basis of contraction in human detrusor smooth muscle from patients with stable and unstable bladders. *Urology*. 2002;59(5 Suppl 1):3–12.

Fry CH, Sui GP, Kanai AJ, et al. The function of suburothelial myofibroblasts in the bladder. *Neurourol Urodyn*. 2007;26(6 Suppl):914–919.

Fukuyama H, Matsuzaki S, Ouchi Y, et al. Neural control of micturition in man examined with single photon emission computed tomography using 99mtc-hmpao. *Neuroreport*. 1996;7(18):3009–3012.

Gabella G, Davis C. Distribution of afferent axons in the bladder of rats. *J Neurocytol*. 1998;27(3):141–155.

Gabella G, Uvelius B. Urinary bladder of rat: fine structure of normal and hypertrophic musculature. *Cell Tissue Res*. 1990;262(1):67–79.

Gallo S, DuRand J, Pshon N. A study of naloxone effect on urinary retention in the patient receiving morphine patient-controlled analgesia. *Orthop Nurs*. 2008;27(2):111–115.

Gao X, Buffington CA, Au JL. Effect of interstitial cystitis on drug absorption from urinary bladder. *J Pharmacol Exp Ther*. 1994;271(2):818–823.

Garnero P. Biomarkers for osteoporosis management: utility in diagnosis, fracture risk prediction and therapy monitoring. *Mol Diagn Ther*. 2008;12(3):157–170.

Geirsson G, Fall M, Sullivan L. Clinical and urodynamic effects of intravesical capsaicin treatment in patients with chronic traumatic spinal detrusor hyperreflexia. *J Urol*. 1995;154(5):1825–1829.

Geirsson G, Lindstrom S, Fall M. The bladder cooling reflex and the use of cooling as stimulus to the lower urinary tract. *J Urol*. 1999;162(6):1890–1896.

Geirsson G. Evidence of cold receptors in the human bladder: effect of menthol on the bladder cooling reflex. *J Urol*. 1993;150(2 Pt 1):427–430.

Gevaert T, Vriens J, Segal A, et al. Deletion of the transient receptor potential cation channel trpv4 impairs murine bladder voiding. *J Clin Invest*. 2007;117(11):3453–3462.

Gillespie JI, Markerink-van Ittersum M, de Vente J. cGMP-generating cells in the bladder wall: identification of distinct networks of interstitial cells. *BJU Int*. 2004;94(7):1114–1124.

Gillespie JI, Markerink-van Ittersum M, de Vente J. Sensory collaterals, intramural ganglia and motor nerves in the guinea-pig bladder: evidence for intramural neural circuits. *Cell Tissue Res*. 2006;325(1):33–45.

Gillespie JI, Palea S, Guilloteau V, et al. Modulation of non-voiding activity by the muscarinergic antagonist tolterodine and the beta(3)-adrenoceptor agonist mirabegron in conscious rats with partial outflow obstruction. *BJU Int*. 2012;110(2 Pt 2):E132–E142.

Gillespie JI. A developing view of the origins of urgency: the importance of animal models. *BJU Int*. 2005;96(Suppl 1):22–28.

Gillespie JI. Phosphodiesterase-linked inhibition of nonmicturition activity in the isolated bladder. *BJU Int*. 2004;93(9):1325–1332.

Gilpin SA, Gilpin CJ, Dixon JS, et al. The effect of age on the autonomic innervation of the urinary bladder. *Br J Urol*. 1986;58(4):378–381.

Gleason JL, Kenton K, Greer WJ, et al. Sacral neuromodulation effects on periurethral sensation and urethral sphincter activity. *Neurourol Urodyn*. 2013;32(5):476–479.

Gold MS, Shuster MJ, Levine JD. Characterization of six voltage-gated K+ currents in adult rat sensory neurons. *J Neurophysiol*. 1996;75(6):2629–2646.

Gosling J. Gross anatomy of the lower urinary tract. Abrams P, Khoury S. *Incontinence*. Health Publications: Plymouth, UK; 1999:23–56.

Gosling JA, Dixon JS, Critchley HO, et al. A comparative study of the human external sphincter and periurethral levator ani muscles. *Br J Urol*. 1981;53(1):35–41.

Gosling JA, Kung LS, Dixon JS, et al. Correlation between the structure and function of the rabbit urinary bladder following partial outlet obstruction. *J Urol*. 2000;163(4):1349–1356.

Gratzke C, Streng T, Park A, et al. Distribution and function of cannabinoid receptors 1 and 2 in the rat, monkey and human bladder. *J Urol*. 2009;181(4):1939–1948.

Green SA, Alon A, Ianus J, et al. Efficacy and safety of a neurokinin-1 receptor antagonist in postmenopausal women with overactive bladder with urge urinary incontinence. *J Urol*. 2006;176(6 Pt 1):2535–2540 [discussion 2540].

Greenland JE, Brading AF. Urinary bladder blood flow changes during the micturition cycle in a conscious pig model. *J Urol*. 1996;156(5):1858–1861.

Griffiths D, Derbyshire S, Stenger A, et al. Brain control of normal and overactive bladder. *J Urol*. 2005;174(5):1862–1867.

Griffiths D, Tadic SD, Schaefer W, et al. Cerebral control of the bladder in normal and urge-incontinent women. *Neuroimage*. 2007;37(1):1–7.

Griffiths D, Tadic SD. Bladder control, urgency, and urge incontinence: evidence from functional brain imaging. *Neurourol Urodyn*. 2008;27(6):466–474.

Griffiths D. Mechanics of micturition. Yalla SV, McGuire EJ, et al. *Neurourology and urodynamics: principles and practice*. Macmillan: New York; 1988:96–105.

Griffiths DJ, Tadic SD, Schaefer W, et al. Cerebral control of the lower urinary tract: how age-related changes might predispose to urge incontinence. *Neuroimage*. 2009;47(3):981–986.

Grol S, Essers PB, van Koeveringe GA, et al. M(3) muscarinic receptor expression on suburothelial interstitial cells. *BJU Int*. 2009;104(3):398–405.

Gu B, Wu G, Si J, et al. Improving voiding efficiency in the diabetic rat by a 5-HT1A serotonin receptor agonist. *Neurourol Urodyn*. 2012;31(1):168–173.

Gunst SJ, Wu MF, Smith DD. Contraction history modulates isotonic shortening velocity in smooth muscle. *Am J Physiol*. 1993;265(2 Pt 1):C467–C476.

Gunst SJ, Zhang W. Actin cytoskeletal dynamics in smooth muscle: a new paradigm for the regulation of smooth muscle contraction. *Am J Physiol Cell Physiol*. 2008;295(3):C576–C587.

Gupta N, Manevich Y, Kazi AS, et al. Identification and characterization of p63 (ckap4/ergic-63/climp-63), a surfactant protein a binding protein, on type ii pneumocytes. *Am J Physiol Lung Cell Mol Physiol*. 2006;291(3):L436–L446.

Gupta SK, Sathyan G. Pharmacokinetics of an oral once-a-day controlled-release oxybutynin formulation compared with immediate-release oxybutynin. *J Clin Pharmacol*. 1999;39(3):289–296.

Habler HJ, Janig W, Koltzenburg M. Activation of unmyelinated afferent fibres by mechanical stimuli and inflammation of the urinary bladder in the cat. *J Physiol*. 1990;425:545–562.

Habler HJ, Janig W, Koltzenburg M. Myelinated primary afferents of the sacral spinal cord responding to slow filling and distension of the cat urinary bladder. *J Physiol*.

1993;463:449–460.

Haferkamp A, Mundhenk J, Bastian PJ, et al. Increased expression of connexin 43 in the overactive neurogenic detrusor. *Eur Urol*. 2004;46(6):799–805.

Hai CM, Murphy RA. Ca2+, crossbridge phosphorylation, and contraction. *Annu Rev Physiol*. 1989;51:285–298.

Hald T, Horn T. The human urinary bladder in ageing. *Br J Urol*. 1998;82(Suppl 1):59–64.

Hampel C, Dolber PC, Smith MP, et al. Modulation of bladder alpha1-adrenergic receptor subtype expression by bladder outlet obstruction. *J Urol*. 2002;167(3):1513–1521.

Hanna-Mitchell AT, Beckel JM, Barbadora S, et al. Non-neuronal acetylcholine and urinary bladder urothelium. *Life Sci*. 2007;80(24–25):2298–2302.

Hanna-Mitchell AT, Wolf-Johnston AS, Barrick SR, et al. Effect of botulinum toxin a on urothelial-release of ATP and expression of snare targets within the urothelium. *Neurourol Urodyn*. 2015;34(1):79–84.

Harriss DR, Marsh KA, Birmingham AT, et al. Expression of muscarinic M3-receptors coupled to inositol phospholipid hydrolysis in human detrusor cultured smooth muscle cells. *J Urol*. 1995;154(3):1241–1245.

Hashimoto Y, Ushiki T, Uchida T, et al. Scanning electron microscopic observation of apical sites of open-type paraneurons in the stomach, intestine and urethra. *Arch Histol Cytol*. 1999;62(2):181–189.

Hashitani H, Bramich NJ, Hirst GD. Mechanisms of excitatory neuromuscular transmission in the guinea-pig urinary bladder. *J Physiol*. 2000;524(Pt 2):565–579.

Hashitani H, Yanai Y, Suzuki H. Role of interstitial cells and gap junctions in the transmission of spontaneous Ca2+ signals in detrusor smooth muscles of the guinea-pig urinary bladder. *J Physiol*. 2004;559(Pt 2):567–581.

Hashitani H. Interaction between interstitial cells and smooth muscles in the lower urinary tract and penis. *J Physiol*. 2006;576(Pt 3):707–714.

Hawthorn MH, Chapple CR, Cock M, et al. Urothelium-derived inhibitory factor(s) influences on detrusor muscle contractility in vitro. *Br J Pharmacol*. 2000;129(3):416–419.

Hayashi T, Kondo T, Ishimatsu M, et al. Expression of the TRPM8-immunoreactivity in dorsal root ganglion neurons innervating the rat urinary bladder. *Neurosci Res*. 2009;65(3):245–251.

Hayashi Y, Takimoto K, Chancellor MB, et al. Bladder hyperactivity and increased excitability of bladder afferent neurons associated with reduced expression of Kv1.4 alpha-subunit in rats with cystitis. *Am J Physiol Regul Integr Comp Physiol*. 2009;296(5):R1661–R1670.

Hegde SS, Choppin A, Bonhaus D, et al. Functional role of M2 and M3 muscarinic receptors in the urinary bladder of rats in vitro and in vivo. *Br J Pharmacol*. 1997;120(8):1409–1418.

Heinrich M, Oberbach A, Schlichting N, et al. Cytokine effects on gap junction communication and connexin expression in human bladder smooth muscle cells and suburothelial myofibroblasts. *PLoS ONE*. 2011;6(6):e20792.

Hendrix SL, Cochrane BB, Nygaard IE, et al. Effects of estrogen with and without progestin on urinary incontinence. *J Am Med Assoc*. 2005;293(8):935–948.

Heppner TJ, Bonev AD, Nelson MT. Ca(2+)-activated K+ channels regulate action potential repolarization in urinary bladder smooth muscle. *Am J Physiol*. 1997;273(1 Pt 1):C110–C117.

Heppner TJ, Werner ME, Nausch B, et al. Nerve-evoked purinergic signalling suppresses action potentials, Ca2+ flashes and contractility evoked by muscarinic receptor activation in mouse urinary bladder smooth muscle. *J*

Physiol. 2009;587(Pt 21):5275–5288.

Herbison GP, Arnold EP. Sacral neuromodulation with implanted devices for urinary storage and voiding dysfunction in adults. *Cochrane Database Syst Rev*. 2009;(2) [CD004202].

Hergenhahn M, Adolf W, Hecker E. Resiniferatoxin and other esters of novel polyfunctional diterpenes from euphorbia resinifera and unispina. *Tetrahedron Lett*. 1975;16(19):1595–1598.

Herrera GM, Heppner TJ, Nelson MT. Voltage dependence of the coupling of Ca(2+) sparks to BK(Ca) channels in urinary bladder smooth muscle. *Am J Physiol Cell Physiol*. 2001;280(3):C481–C490.

Hickey DS, Phillips JI, Hukins DW. Arrangements of collagen fibrils and muscle fibres in the female urethra and their implications for the control of micturition. *Br J Urol*. 1982;54(5):556–561.

Hicks RM. The mammalian urinary bladder: an accommodating organ. *Biol Rev Camb Philos Soc*. 1975;50(2):215–246.

Higuchi T, Xin P, Buckley MS, et al. Characterization of the rabbit homolog of human MUC1 glycoprotein isolated from bladder by affinity chromatography on immobilized jacalin. *Glycobiology*. 2000;10(7):659–667.

Hirayama A, Fujimoto K, Matsumoto Y, et al. Nocturia in men with lower urinary tract symptoms is associated with both nocturnal polyuria and detrusor overactivity with positive response to ice water test. *Urology*. 2005;65(6):1064–1069.

Hirayama A, Fujimoto K, Matsumoto Y, et al. Positive response to ice water test associated with high-grade bladder outlet obstruction in patients with benign prostatic hyperplasia. *Urology*. 2003;62(5):909–913.

Ho KM, McMurray G, Brading AF, et al. Nitric oxide synthase in the heterogeneous population of intramural striated muscle fibres of the human membranous urethral sphincter. *J Urol*. 1998;159(3):1091–1096.

Hohlbrugger G, Lentsch P. Intravesical ions, osmolality and pH influence the volume pressure response in the normal rat bladder, and this is more pronounced after DMSO exposure. *Eur Urol*. 1985;11(2):127–130.

Hohlbrugger G. Changes of hypo- and hypertonic sodium chloride induced by the rat urinary bladder at various filling stages. Evidence for an increased transurothelial access of urine to detrusor nerve and muscle cells with distension. *Eur Urol*. 1987;13(1–2):83–89.

Holstege G, Griffiths D, de Wall H, et al. Anatomical and physiological observations on supraspinal control of bladder and urethral sphincter muscles in the cat. *J Comp Neurol*. 1986;250(4):449–461.

Holstege G, Kuypers HG, Boer RC. Anatomical evidence for direct brain stem projections to the somatic motoneuronal cell groups and autonomic preganglionic cell groups in cat spinal cord. *Brain Res*. 1979;171(2):329–333.

Holstege G. Micturition and the soul. *J Comp Neurol*. 2005;493(1):15–20.

Holstege JC, Van Dijken H, Buijs RM, et al. Distribution of dopamine immunoreactivity in the rat, cat and monkey spinal cord. *J Comp Neurol*. 1996;376(4):631–652.

Homolya L, Steinberg TH, Boucher RC. Cell to cell communication in response to mechanical stress via bilateral release of ATP and UTP in polarized epithelia. *J Cell Biol*. 2000;150(6):1349–1360.

Hossler FE, Monson FC. Microvasculature of the rabbit urinary bladder. *Anat Rec*. 1995;243(4):438–448.

Hotta H, Morrison JF, Sato A, et al. The effects of aging on the rat bladder and its innervation. *Jpn J Physiol*. 1995;45(5):823–836.

Hristov KL, Afeli SA, Parajuli SP, et al. Neurogenic detrusor overactivity is associated with decreased expression and function of the large conductance voltage- and Ca(2+)-activated K(+) channels. *PLoS ONE*. 2013;8(7):e68052.

Hristov KL, Chen M, Kellett WF, et al. Large-conductance voltage- and Ca2+-activated KS+ channels regulate human detrusor smooth muscle function. *Am J Physiol Cell Physiol*. 2011;301(4):C903–C912.

Hu P, Meyers S, Liang FX, et al. Role of membrane proteins in permeability barrier function: uroplakin ablation elevates urothelial permeability. *Am J Physiol Renal Physiol*. 2002;283(6):F1200–F1207.

Hu VY, Zvara P, Dattilio A, et al. Decrease in bladder overactivity with ren1820 in rats with cyclophosphamide induced cystitis. *J Urol*. 2005;173(3):1016–1021.

Huisman AB. Aspects on the anatomy of the female urethra with special relation to urinary continence. *Contrib Gynecol Obstet*. 1983;10:1–31.

Iacovou JW, Hill SJ, Birmingham AT. Agonist-induced contraction and accumulation of inositol phosphates in the guinea-pig detrusor: evidence that muscarinic and purinergic receptors raise intracellular calcium by different mechanisms. *J Urol*. 1990;144(3):775–779.

Igawa Y, Yamazaki Y, Takeda H, et al. Functional and molecular biological evidence for a possible beta3-adrenoceptor in the human detrusor muscle. *Br J Pharmacol*. 1999;126(3):819–825.

Igawa Y, Zhang X, Nishizawa O, et al. Cystometric findings in mice lacking muscarinic M2 or M3 receptors. *J Urol*. 2004;172(6 Pt 1):2460–2464.

Iggo A. Tension receptors in the stomach and the urinary bladder. *J Physiol*. 1955;128(3):593–607.

Ikeda K, Kobayashi S, Suzuki M, et al. M(3) receptor antagonism by the novel antimuscarinic agent solifenacin in the urinary bladder and salivary gland. *Naunyn Schmiedebergs Arch Pharmacol*. 2002;366(2):97–103.

Ikeda Y, Zabbarova IV, Birder LA, et al. Botulinum neurotoxin serotype a suppresses neurotransmitter release from afferent as well as efferent nerves in the urinary bladder. *Eur Urol*. 2012;62(6):1157–1164.

Imaki T, Vale W, Sawchenko PE. Regulation of corticotropin-releasing factor mRNA in neuroendocrine and autonomic neurons by osmotic stimulation and volume loading. *Neuroendocrinology*. 1992;56(5):633–640.

Imamura M, Negoro H, Kanematsu A, et al. Basic fibroblast growth factor causes urinary bladder overactivity through gap junction generation in the smooth muscle. *Am J Physiol Renal Physiol*. 2009;297(1):F46–F54.

Inoue R, Brading AF. The properties of the ATP-induced depolarization and current in single cells isolated from the guinea-pig urinary bladder. *Br J Pharmacol*. 1990;100(3):619–625.

Inoue T, Gabella G. A vascular network closely linked to the epithelium of the urinary bladder of the rat. *Cell Tissue Res*. 1991;263(1):137–143.

Iosif CS, Batra S, Ek A, et al. Estrogen receptors in the human female lower urinary tract. *Am J Obstet Gynecol*. 1981;141(7):817–820.

Ishizuka O, Igawa Y, Lecci A, et al. Role of intrathecal tachykinins for micturition in unanaesthetized rats with and without bladder outlet obstruction. *Br J Pharmacol*. 1994;113(1):111–116.

Ishizuka O, Mattiasson A, Andersson KE. Effects of neurokinin receptor antagonists on l-dopa induced bladder hyperactivity in normal conscious rats. *J Urol*. 1995;154(4):1548–1551.

Ito H, Aizawa N, Fujita Y, et al. Long-term caloric restriction in rats may prevent age related impairment of in vitro bladder function. *J Urol*. 2015;193(6):2123–2130.

Ito K, Iwami A, Katsura H, et al. Therapeutic effects of the putative P2X3/P2X2/3 antagonist a-317491 on cyclophosphamide-induced cystitis in rats. *Naunyn Schmiedebergs Arch Pharmacol*. 2008;377(4–6):483–490.

Jaggar SI, Scott HC, Rice AS. Inflammation of the rat urinary bladder is associated with a referred thermal hyperalgesia which is nerve growth factor dependent. *Br J Anaesth*. 1999;83(3):442–448.

Jallat-Daloz I, Cognard JL, Badet JM, et al. Neural-epithelial cell interplay: in vitro evidence that vagal mediators increase PGE2 production by human nasal epithelial cells. *Allergy Asthma Proc*. 2001;22(1):17–23.

Janssen DA, van Wijk XM, Jansen KC, et al. The distribution and function of chondroitin sulfate and other sulfated glycosaminoglycans in the human bladder and their contribution to the protective bladder barrier. *J Urol*. 2013;189(1):336–342.

Jeremy JY, Tsang V, Mikhailidis DP, et al. Eicosanoid synthesis by human urinary bladder mucosa: pathological implications. *Br J Urol*. 1987;59(1):36–39.

Johansson S, Fall M. The pathology of interstitial cystitis. Sant GR. *Interstitial cystitis*. Lippincott-Raven: Philadelphia; 1997:143–151.

John H, Wang X, Wehrli E, et al. Evidence of gap junctions in the stable nonobstructed human bladder. *J Urol*. 2003;169(2):745–749.

Johnston L, Carson C, Lyons AD, et al. Cholinergic-induced Ca2+ signaling in interstitial cells of cajal from the guinea pig bladder. *Am J Physiol Renal Physiol*. 2008;294(3):F645–F655.

Jordan C. Androgen receptor (AR) immunoreactivity in rat pudendal motoneurons: implications for accessory proteins. *Horm Behav*. 1997;32(1):1–10.

Jung SY, Fraser MO, Ozawa H, et al. Urethral afferent nerve activity affects the micturition reflex; implication for the relationship between stress incontinence and detrusor instability. *J Urol*. 1999;162(1):204–212.

Kaiho Y, Nishiguchi J, Kwon DD, et al. The effects of a type 4 phosphodiesterase inhibitor and the muscarinic cholinergic antagonist tolterodine tartrate on detrusor overactivity in female rats with bladder outlet obstruction. *BJU Int*. 2008;101(5):615–620.

Kakizaki H, de Groat WC. Role of spinal nitric oxide in the facilitation of the micturition reflex by bladder irritation. *J Urol*. 1996;155(1):355–360.

Kakizaki H, Koyanagi T, Kato M. Urethral response to sympathetic nerve stimulation in the cat. *Nihon Hinyokika Gakkai Zasshi*. 1991;82(10):1664–1670.

Kamo I, Chancellor MB, de Groat WC, et al. Differential effects of activation of peripheral and spinal tachykinin neurokinin(3) receptors on the micturition reflex in rats. *J Urol*. 2005;174(2):776–781.

Kanasaki K, Yu W, von Bodungen M, et al. Loss of beta1-integrin from urothelium results in overactive bladder and incontinence in mice: a mechanosensory rather than structural phenotype. *FASEB J*. 2013;27(5):1950–1961.

Kang N, Cauraugh JH. Does non-invasive brain stimulation reduce essential tremor? A systematic review and meta-analysis. *PLoS ONE*. 2017;12(9):e0185462.

Kaplan SA, Chancellor MB, Blaivas JG. Bladder and sphincter behavior in patients with spinal cord lesions. *J Urol*. 1991;146(1):113–117.

Kawatani M, Nagel J, de Groat WC. Identification of neuropeptides in pelvic and pudendal nerve afferent pathways to the sacral spinal cord of the cat. *J Comp Neurol*. 1986;249(1):117–132.

Kawatani M, Rutigliano M, de Groat WC. Depolarization and muscarinic excitation induced in a sympathetic ganglion by vasoactive intestinal polypeptide. *Science*. 1985;229(4716):879.

Kawatani M, Suzuki T, de Groat WC. Corticotropin releasing factor-like immunoreactivity in afferent projections to the sacral spinal cord of the cat. *J Auton Nerv Syst*. 1996;61(3):218–226.

Keane DP, Sims TJ, Abrams P, et al. Analysis of collagen status in premenopausal nulliparous women with genuine stress incontinence. *Br J Obstet Gynaecol*. 1997;104(9):994–998.

Keast JR, De Groat WC. Segmental distribution and peptide content of primary afferent neurons innervating the urogenital organs and colon of male rats. *J Comp Neurol*. 1992;319(4):615–623.

Keast JR, Saunders RJ. Testosterone has potent, selective effects on the morphology of pelvic autonomic neurons which control the bladder, lower bowel and internal reproductive organs of the male rat. *Neuroscience*. 1998;85(2):543–556.

Keast JR, Stephensen TM. Glutamate and aspartate immunoreactivity in dorsal root ganglion cells supplying visceral and somatic targets and evidence for peripheral axonal transport. *J Comp Neurol*. 2000;424(4):577–587.

Keay S, Leitzell S, Ochrzcin A, et al. A mouse model for interstitial cystitis/painful bladder syndrome based on APF inhibition of bladder epithelial repair: a pilot study. *BMC Urol*. 2012;12:17.

Keay S, Zhang CO, Hise MK, et al. A diagnostic in vitro urine assay for interstitial cystitis. *Urology*. 1998;52(6):974–978.

Keay S, Zhang CO, Trifillis AL, et al. Decreased 3h-thymidine incorporation by human bladder epithelial cells following exposure to urine from interstitial cystitis patients. *J Urol*. 1996;156(6):2073–2078.

Keay SK, Szekely Z, Conrads TP, et al. An antiproliferative factor from interstitial cystitis patients is a frizzled 8 protein-related sialoglycopeptide. *Proc Natl Acad Sci USA*. 2004;101(32):11803–11808.

Kenton K, Lowenstein L, Brubaker L. Tolterodine causes measurable restoration of urethral sensation in women with urge urinary incontinence. *Neurourol Urodyn*. 2010;29(4):555–557.

Kenton K, Lowenstein L, Simmons J, et al. Aging and overactive bladder may be associated with loss of urethral sensation in women. *Neurourol Urodyn*. 2007;26(7):981–984.

Kershen RT, Kalisvaart J, Appell RA. Functional brain imaging and the bladder: new insights into cerebral control over micturition. *Curr Urol Rep*. 2003;4(5):344–349.

Khan MA, Dashwood MR, Thompson CS, et al. Up-regulation of endothelin (et(a) and et(b)) receptors and down-regulation of nitric oxide synthase in the detrusor of a rabbit model of partial bladder outlet obstruction. *Urol Res*. 1999;27(6):445–453.

Khawaja AM, Rogers DF. Tachykinins: receptor to effector. *Int J Biochem Cell Biol*. 1996;28(7):721–738.

Khera M, Somogyi GT, Kiss S, et al. Botulinum toxin a inhibits atp release from bladder urothelium after chronic spinal cord injury. *Neurochem Int*. 2004;45(7):987–993.

Kissin I, Szallasi A. Therapeutic targeting of trpv1 by resiniferatoxin, from preclinical studies to clinical trials. *Curr Top Med Chem*. 2011;11(17):2159–2170.

Klevmark B. Motility of the urinary bladder in cats during filling at physiological rates. I. Intravesical pressure patterns studied by a new method of cystometry. *Acta Physiol Scand*. 1974;90(3):565–577.

Klöchner U, Isenberg G. Action potentials and net membrane currents of isolated smooth muscle cells (urinary bladder of the guinea-pig). *Pflugers Arch*. 1985;405(4):329–339.

Kluck P. The autonomic innervation of the human urinary bladder, bladder neck and urethra: a histochemical study. *Anat Rec*. 1980;198(3):439–447.

Koh BH, Roy R, Hollywood MA, et al. Platelet-derived growth factor receptor-alpha cells in mouse urinary bladder: a new class of interstitial cells. *J Cell Mol Med*. 2012;16(4):691–700.

Kojima M, Takeuchi Y, Goto M, et al. Immunohistochemical study on the localization of serotonin fibers and terminals in the spinal cord of the monkey (macaca fuscata). *Cell Tissue Res*. 1983;229(1):23–36.

Komesu YM, Ketai LH, Mayer AR, et al. Functional MRI of the brain in women with overactive bladder: brain activation during urinary urgency. *Female Pelvic Med Reconstr Surg*. 2011;17(1):50–54.

Komiyama A, Kubota A, Hidai H. Urinary retention associated with a unilateral lesion in the dorsolateral tegmentum of the rostral pons. *J Neurol Neurosurg Psychiatry*. 1998;65(6):953–954.

Kondo S, Morita T, Tashima Y. Muscarinic cholinergic receptor subtypes in human detrusor muscle studied by labeled and nonlabeled pirenzepine, AFDX-116 and 4DAMP. *Urol Int*. 1995;54(3):150–153.

Kraus SR, Lemack GE, Richter HE, et al. Changes in urodynamic measures two years after burch colposuspension or autologous sling surgery. *Urology*. 2011;78(6):1263–1268.

Krenz NR, Meakin SO, Krassioukov AV, et al. Neutralizing intraspinal nerve growth factor blocks autonomic dysreflexia caused by spinal cord injury. *J Neurosci*. 1999;19(17):7405–7414.

Kruse MN, Bray LA, de Groat WC. Influence of spinal cord injury on the morphology of bladder afferent and efferent neurons. *J Auton Nerv Syst*. 1995;54(3):215–224.

Kruse MN, de Groat WC. Spinal pathways mediate coordinated bladder/urethral sphincter activity during reflex micturition in decerebrate and spinalized neonatal rats. *Neurosci Lett*. 1993;152(1–2):141–144.

Kruse MN, Noto H, Roppolo JR, et al. Pontine control of the urinary bladder and external urethral sphincter in the rat. *Brain Res*. 1990;532(1–2):182–190.

Kubota Y, Biers SM, Kohri K, et al. Effects of imatinib mesylate (glivec) as a c-kit tyrosine kinase inhibitor in the guinea-pig urinary bladder. *Neurourol Urodyn*. 2006;25(3):205–210.

Kubota Y, Hashitani H, Shirasawa N, et al. Altered distribution of interstitial cells in the guinea pig bladder following bladder outlet obstruction. *Neurourol Urodyn*. 2008;27(4):330–340.

Kubota Y, Kajioka S, Biers SM, et al. Investigation of the effect of the c-kit inhibitor glivec on isolated guinea-pig detrusor preparations. *Auton Neurosci*. 2004;115(1–2):64–73.

Kullmann FA, Artim DE, Birder LA, et al. Activation of muscarinic receptors in rat bladder sensory pathways alters reflex bladder activity. *J Neurosci*. 2008;28(8):1977–1987.

Kullmann FA, Artim D, Beckel J, et al. Heterogeneity of muscarinic receptor-mediated Ca2+ responses in cultured urothelial cells from rat. *Am J Physiol Renal Physiol*. 2008;294(4):F971–F981.

Kullmann FA, Chang HH, Gauthier C, et al. Serotonergic paraneurones in the female mouse urethral epithelium and their potential role in peripheral sensory information processing. *Acta Physiologica*. 2018;222(2):e12919.

Kumar V, Chapple CR, Surprenant AM, et al. Enhanced adenosine triphosphate release from the urothelium of patients with painful bladder syndrome: a possible pathophysiological explanation. *J Urol*. 2007;178(4 Pt 1):1533–1536.

Kumar V, Cross RL, Chess-Williams R, et al. Recent advances in basic science for overactive bladder. *Curr Opin Urol*. 2005;15(4):222–226.

Kunze A, Neuhaus J, Stolzenburg JU. Quantitative immunohistochemical study of the innervation of the guinea-pig lower urinary tract. *BJU Int*. 2006;98(2):424–429.

Kuo HC, Liu HT, Chuang YC, et al. Pilot study of liposome-encapsulated onabotulinumtoxina for patients with overactive bladder: a single-center study. *Eur Urol*. 2014;65(6):1117–1124.

Kurahashi M, Zheng H, Dwyer L, et al. A functional role for the ‘fibroblast-like cells’ in gastrointestinal smooth muscles. *J Physiol*. 2011;589(Pt 3):697–710.

Lagos P, Ballejo G. Role of spinal nitric oxide synthase-dependent processes in the initiation of the micturition hyperreflexia associated with cyclophosphamide-induced cystitis. *Neuroscience*. 2004;125(3):663–670.

Lai FM, Cobuzzi A, Spinelli W. Characterization of muscarinic receptors mediating the contraction of the urinary detrusor muscle in cynomolgus monkeys and guinea pigs. *Life Sci*. 1998;62(13):1179–1186.

Lamb K, Gebhart GF, Bielefeldt K. Increased nerve growth factor expression triggers bladder overactivity. *J Pain*. 2004;5(3):150–156.

Landau EH, Jayanthi VR, Churchill BM, et al. Loss of elasticity in dysfunctional bladders: urodynamic and histochemical correlation. *J Urol*. 1994;152(2 Pt 2):702–705.

Langley LL, Whiteside JA. Mechanism of accommodation and tone of urinary bladder. *J Neurophysiol*. 1951;14(2):147–152.

Lashinger ES, Steiginga MS, Hieble JP, et al. AMTB, a TRPM8 channel blocker: evidence in rats for activity in overactive bladder and painful bladder syndrome. *Am J Physiol Renal Physiol*. 2008;295(3):F803–F810.

Lassmann G. Muscle spindles and sensory nerve endings in the urethral sphincter. *Acta Neuropathol*. 1984;63(4):344–346.

Latifpour J, Kondo S, O'Hollaren B, et al. Autonomic receptors in urinary tract: sex and age differences. *J Pharmacol Exp Ther*. 1990;253(2):661–667.

Lavelle JP, Apodaca G, Meyers SA, et al. Disruption of guinea pig urinary bladder permeability barrier in noninfectious cystitis. *Am J Physiol*. 1998;274(1 Pt 2):F205–F214.

Lavelle JP, Meyers SA, Ruiz WG, et al. Urothelial pathophysiological changes in feline interstitial cystitis: a human model. *Am J Physiol Renal Physiol*. 2000;278(4):F540–F553.

Lavelle JP, Negrete HO, Poland PA, et al. Low permeabilities of MDCK cell monolayers: a model barrier epithelium. *Am J Physiol*. 1997;273(1 Pt 2):F67–F75.

Lazzeri M, Beneforti P, Benaim G, et al. Intravesical capsaicin for treatment of severe bladder pain: a randomized placebo controlled study. *J Urol*. 1996;156(3):947–952.

Lazzeri M, Beneforti P, Spinelli M, et al. Intravesical resiniferatoxin for the treatment of hypersensitive disorder: a randomized placebo controlled study. *J Urol*. 2000;164(3 Pt 1):676–679.

Lecci A, Giuliani S, Garret C, et al. Evidence for a role of tachykinins as sensory transmitters in the activation of micturition reflex. *Neuroscience*. 1993;54(3):827–837.

Lecci A, Giuliani S, Santicioli P, et al. Involvement of 5-hydroxytryptamine1a receptors in the modulation of micturition reflexes in the anesthetized rat. *J Pharmacol Exp Ther*. 1992;262(1):181–189.

Lecci A, Giuliani S, Santicioli P, et al. Involvement of spinal tachykinin NK1 and NK2 receptors in detrusor hyperreflexia during chemical cystitis in anaesthetized rats. *Eur J Pharmacol*. 1994;259(2):129–135.

Lecci A, Giuliani S, Tramontana M, et al. MEN 11,420, a peptide tachykinin NK2 receptor antagonist, reduces motor responses induced by the intravesical administration of capsaicin in vivo. *Naunyn Schmiedebergs Arch Pharmacol*. 1997;356(2):182–188.

Lecci A, Maggi CA. Tachykinins as modulators of the micturition reflex in the central and peripheral nervous system. *Regul Pept*. 2001;101(1–3):1–18.

Lee H, Koh BH, Peri LE, et al. Purinergic inhibitory regulation of murine detrusor muscles mediated by PDGFRalpha+ interstitial cells. *J Physiol*. 2014;592(6):1283–1293.

Lee HY, Bardini M, Burnstock G. Distribution of P2X receptors in the urinary bladder and the ureter of the rat. *J Urol*. 2000;163(6):2002–2007.

Lee K, Mitsui R, Kajioka S, et al. Role of PTHrP and sensory nerve peptides in regulating contractility of muscularis mucosae and detrusor smooth muscle in the guinea pig bladder. *J Urol*. 2016;196(4):1287–1294.

Leng WW, Chancellor MB. How sacral nerve stimulation neuromodulation works. *Urol Clin North Am*. 2005;32(1):11–18.

Lenis AT, Kuang M, Woo LL, et al. Impact of parturition on chemokine homing factor expression in the vaginal distention model of stress urinary incontinence. *J Urol*. 2013;189(4):1588–1594.

Lepor H, Sunaryadi I, Hartanto V, et al. Quantitative morphometry of the adult human bladder. *J Urol*. 1992;148(2 Pt 1):414–417.

Levin RM, High J, Wein AJ. Metabolic and contractile effects of anoxia on the rabbit urinary bladder. *J Urol*.

1982;128(1):194–196.

Levin RM, O'Connor LJ, Leggett RE, et al. Focal hypoxia of the obstructed rabbit bladder wall correlates with intermediate decompensation. *Neurourol Urodyn*. 2003;22(2):156–163.

Levin RM, Ruggieri MR, Hypolite J, et al. Beta-adrenergic stimulation of cyclic amp production in the rabbit urinary bladder. *Neurourol Urodyn*. 1986;5(2):227–233.

Levin RM, Shofer FS, Wein AJ. Estrogen-induced alterations in the autonomic responses of the rabbit urinary bladder. *J Pharmacol Exp Ther*. 1980;215(3):614–618.

Levin RM, Wein AJ. Neurophysiology and neuropharmacology. Krane R. *Bladder*. Churchill Livingstone: New York; 1995:47–70.

Levy BJ, Wight TN. Structural changes in the aging submucosa: new morphologic criteria for the evaluation of the unstable human bladder. *J Urol*. 1990;144(4):1044–1055.

Lewis SA, Berg JR, Kleine TJ. Modulation of epithelial permeability by extracellular macromolecules. *Physiol Rev*. 1995;75(3):561–589.

Lewis SA, Diamond JM. Na+ transport by rabbit urinary bladder, a tight epithelium. *J Membr Biol*. 1976;28(1):1–40.

Li DY, Brooke B, Davis EC, et al. Elastin is an essential determinant of arterial morphogenesis. *Nature*. 1998;393(6682):276–280.

Li L, Jiang C, Hao P, et al. Changes of gap junctional cell-cell communication in overactive detrusor in rats. *Am J Physiol Cell Physiol*. 2007;293(5):C1627–C1635.

Li M, Sun Y, Simard JM, et al. Augmented bladder urothelial polyamine signaling and block of bk channel in the pathophysiology of overactive bladder syndrome. *Am J Physiol Cell Physiol*. 2009;297(6):C1445–C1451.

Li M, Sun Y, Simard JM, et al. Increased transient receptor potential vanilloid type 1 (TRPV1) signaling in idiopathic overactive bladder urothelial cells. *Neurourol Urodyn*. 2011;30(4):606–611.

Li M, Sun Y, Tomiya N, et al. Elevated polyamines in urothelial cells from OAB subjects mediate oxotremorine-evoked rapid intracellular calcium rise and delayed acetylcholine release. *Am J Physiol Renal Physiol*. 2013;305(4):F445–F450.

Lieu PK, Sa'adu A, Orugun EO, et al. The influence of age on isometric and isotonic rat detrusor contractions. *J Gerontol A Biol Sci Med Sci*. 1997;52(2):M94–M96.

Lin AT, Yang CH, Chang LS. Impact of aging on rat urinary bladder fatigue. *J Urol*. 1997;157(5):1990–1994.

Liu BL, Yang F, Zhan HL, et al. Increased severity of inflammation correlates with elevated expression of TRPV1 nerve fibers and nerve growth factor on interstitial cystitis/bladder pain syndrome. *Urol Int*. 2014;92(2):202–208.

Liu HT, Chen CY, Kuo HC. Urinary nerve growth factor in women with overactive bladder syndrome. *BJU Int*. 2011;107(5):799–803.

Liu HT, Kuo HC. Increased urine and serum nerve growth factor levels in interstitial cystitis suggest chronic inflammation is involved in the pathogenesis of disease. *PLoS ONE*. 2012;7(9):e44687.

Liu HT, Tyagi P, Chancellor MB, et al. Urinary nerve growth factor level is increased in patients with interstitial cystitis/bladder pain syndrome and decreased in responders to treatment. *BJU Int*. 2009;104(10):1476–1481.

Loewy AD. Viruses as transneuronal tracers for defining neural circuits. *Neurosci Biobehav Rev*. 1998;22(6):679–684.

Longhurst PA, Briscoe JA, Rosenberg DJ, et al. The role of cyclic nucleotides in guinea-pig bladder contractility. *Br J Pharmacol*. 1997;121(8):1665–1672.

Longhurst PA, Eika B, Leggett RE, et al. Comparison of urinary bladder function in 6 and 24 month male and female rats. *J Urol*. 1992;148(5):1615–1620.

Lowe EM, Anand P, Terenghi G, et al. Increased nerve growth factor levels in the urinary bladder of women with idiopathic sensory urgency and interstitial cystitis. *Br J Urol*. 1997;79(4):572–577.

Maas CP, Kenter GG, Trimbos JB, et al. Anatomical basis for nerve-sparing radical hysterectomy: immunohistochemical study of the pelvic autonomic nerves. *Acta Obstet Gynecol Scand*. 2005;84(9):868–874.

Macarak EJ, Ewalt D, Baskin L, et al. The collagens and their urologic implications. *Adv Exp Med Biol*. 1995;385:173–177 [discussion 179–184].

Macarak EJ, Howard PS. The role of collagen in bladder filling. *Adv Exp Med Biol*. 1999;462:215–223 [discussion 225–233].

MacDiarmid SA, John MS, Yoo PB. A pilot feasibility study of treating overactive bladder patients with percutaneous saphenous nerve stimulation. *Neurourol Urodyn*. 2018;37(5):1815–1820.

Madersbacher S, Pycha A, Klingler CH, et al. Interrelationships of bladder compliance with age, detrusor instability, and obstruction in elderly men with lower urinary tract symptoms. *Neurourol Urodyn*. 1999;18(1):3–15.

Madersbacher S, Pycha A, Schatzl G, et al. The aging lower urinary tract: a comparative urodynamic study of men and women. *Urology*. 1998;51(2):206–212.

Maggi CA, Abelli L, Giuliani S, et al. Motor and inflammatory effect of hyperosmolar solutions on the rat urinary bladder in relation to capsaicin-sensitive sensory nerves. *Gen Pharmacol*. 1990;21(1):97–103.

Maggi CA, Giuliani S, Santicioli P, et al. Further studies on the mechanisms of the tachykinin-induced activation of micturition reflex in rats: evidence for the involvement of the capsaicin-sensitive bladder mechanoreceptors. *Eur J Pharmacol*. 1987;136(2):189–205.

Maggi CA. The dual, sensory and efferent function of the capsaicin-sensitive primary sensory nerves in the bladder and urethra. Maggi CA. *Nervous control of the urogenital system*. Harwood Academic Publishers: London; 1993:1 [383–422].

Mallory BS, Roppolo JR, de Groat WC. Pharmacological modulation of the pontine micturition center. *Brain Res*. 1991;546(2):310–320.

Malloy BJ, Price DT, Price RR, et al. Alpha1-adrenergic receptor subtypes in human detrusor. *J Urol*. 1998;160(3 Pt 1):937–943.

Malmqvist U, Amer A, Uvelius B. Cytoskeletal and contractile proteins in detrusor smooth muscle from bladders with outlet obstruction—a comparative study in rat and man. *Scand J Urol Nephrol*. 1991;25(4):261–267.

Malykhina AP, Qin C, Lei Q, et al. Differential effects of intravesical resiniferatoxin on excitability of bladder spinal neurons upon colon-bladder cross-sensitization. *Brain Res*. 2013;1491:213–224.

Malykhina AP. Neural mechanisms of pelvic organ cross-sensitization. *Neuroscience*. 2007;149(3):660–672.

Manente G, Melchionda D, Uncini A. Urinary retention in bilateral pontine tumour: evidence for a pontine micturition centre in humans. *J Neurol Neurosurg Psychiatry*. 1996;61(5):528–529.

Mansfield KJ, Liu L, Mitchelson FJ, et al. Muscarinic receptor subtypes in human bladder detrusor and mucosa, studied by radioligand binding and quantitative competitive RT-PCR: changes in ageing. *Br J Pharmacol*. 2005;144(8):1089–1099.

Mantyh PW. Forebrain projections to the periaqueductal gray in the monkey, with observations in the cat and rat. *J Comp Neurol*. 1982;206(2):146–158.

Markwardt F, Isenberg G. Gating of maxi K+ channels studied by Ca2+ concentration jumps in excised inside-out multi-channel patches (myocytes from guinea pig urinary bladder). *J Gen Physiol*. 1992;99(6):841–862.

Marret E, Kurdi O, Zufferey P, et al. Effects of nonsteroidal antiinflammatory drugs on patient-controlled analgesia morphine side effects: meta-analysis of randomized controlled trials. *Anesthesiology*. 2005;102(6):1249–1260.

Marson L, Carson CC 3rd. Central nervous system innervation of the penis, prostate, and perineal muscles: a transneuronal tracing study. *Mol Urol*. 1999;3(2):43–50.

Marson L. Identification of central nervous system neurons that innervate the bladder body, bladder base, or external urethral sphincter of female rats: a transneuronal tracing study using pseudorabies virus. *J Comp Neurol*. 1997;389(4):584–602.

Martin-Montalvo A, Mercken EM, Mitchell SJ, et al. Metformin improves healthspan and lifespan in mice. *Nat Commun*. 2013;4:2192.

Masaki T. Historical review: endothelin. *Trends Pharmacol Sci*. 2004;25(4):219–224.

Masuda H, Kim JH, Kihara K, et al. Inhibitory roles of peripheral nitrergic mechanisms in capsaicin-induced detrusor overactivity in the rat. *BJU Int*. 2007;100(4):912–918.

Matsui M, Motomura D, Fujikawa T, et al. Mice lacking M2 and M3 muscarinic acetylcholine receptors are devoid of cholinergic smooth muscle contractions but still viable. *J Neurosci*. 2002;22(24):10627–10632.

Matsui M, Motomura D, Karasawa H, et al. Multiple functional defects in peripheral autonomic organs in mice lacking muscarinic acetylcholine receptor gene for the M3 subtype. *Proc Natl Acad Sci USA*. 2000;97(17):9579–9584.

Matsumoto A. Hormonally induced neuronal plasticity in the adult motoneurons. *Brain Res Bull*. 1997;44(4):539–547.

Matsumoto G, Hisamitsu T, de Groat WC. Non-NMDA glutamatergic excitatory transmission in the descending limb of the spinobulbospinal micturition reflex pathway of the rat. *Brain Res*. 1995;693(1–2):246–250.

Matsumoto G, Hisamitsu T, de Groat WC. Role of glutamate and NMDA receptors in the descending limb of the spinobulbospinal micturition reflex pathway of the rat. *Neurosci Lett*. 1995;183(1–2):58–61.

Matsuta Y, Mally AD, Zhang F, et al. Contribution of opioid and metabotropic glutamate receptor mechanisms to inhibition of bladder overactivity by tibial nerve stimulation. *Am J Physiol Regul Integr Comp Physiol*. 2013;305(2):R126–R133.

Matsuura S, Kakizaki H, Mitsui T, et al. Human brain region response to distention or cold stimulation of the bladder: a positron emission tomography study. *J Urol*. 2002;168(5):2035–2039.

Mattiasson A, Andersson KE, Sjogren C. Adrenoceptors and cholinoceptors controlling noradrenaline release from adrenergic nerves in the urethra of rabbit and man. *J Urol*. 1984;131(6):1190–1195.

McClintock SM, Reti IM, Carpenter LL, et al. Consensus recommendations for the clinical application of repetitive transcranial magnetic stimulation (RTMS) in the treatment of depression. *J Clin Psychiatry*. 2018;79(1).

McCloskey KD, Gurney AM. Kit positive cells in the guinea pig bladder. *J Urol*. 2002;168(2):832–836.

McGuire E, Morrissey S, Zhang S, et al. Control of reflex detrusor activity in normal and spinal injured non-human primates. *J Urol*. 1983;129(1):197–199.

McLatchie LM, Young JS, Fry CH. Regulation of ach release from guinea pig bladder urothelial cells: potential role in bladder filling sensations. *Br J Pharmacol*.

2014;171(14):3394–3403.

McMahon SB, Abel C. A model for the study of visceral pain states: chronic inflammation of the chronic decerebrate rat urinary bladder by irritant chemicals. *Pain*. 1987;28(1):109–127.

McMahon SB, Spillane K. Brain stem influences on the parasympathetic supply to the urinary bladder of the cat. *Brain Res*. 1982;234(2):237–249.

McMurray G, Dass N, Brading AF. Purinoceptor subtypes mediating contraction and relaxation of marmoset urinary bladder smooth muscle. *Br J Pharmacol*. 1998;123(8):1579–1586.

Meredith AL, Thorneloe KS, Werner ME, et al. Overactive bladder and incontinence in the absence of the BK large conductance Ca2+-activated K+ channel. *J Biol Chem*. 2004;279(35):36746–36752.

Messing EM, Stamey TA. Interstitial cystitis: early diagnosis, pathology, and treatment. *Urology*. 1978;12(4):381–392.

Michel MC, Vrydag W. Alpha1-, alpha2- and beta-adrenoceptors in the urinary bladder, urethra and prostate. *Br J Pharmacol*. 2006;147(Suppl 2):S88–S119.

Millard RJ, Moore K, Rencken R, et al. Duloxetine vs placebo in the treatment of stress urinary incontinence: a four-continent randomized clinical trial. *BJU Int*. 2004;93(3):311–318.

Mills IW, Greenland JE, McMurray G, et al. Studies of the pathophysiology of idiopathic detrusor instability: the physiological properties of the detrusor smooth muscle and its pattern of innervation. *J Urol*. 2000;163(2):646–651.

Miodonski AJ, Litwin JA. Microvascular architecture of the human urinary bladder wall: a corrosion casting study. *Anat Rec*. 1999;254(3):375–381.

Miyazato M, Kaiho Y, Kamo I, et al. Effect of duloxetine, a norepinephrine and serotonin reuptake inhibitor, on sneeze-induced urethral continence reflex in rats. *Am J Physiol Renal Physiol*. 2008;295(1):F264–F271.

Miyazato M, Sasatomi K, Hiragata S, et al. Gaba receptor activation in the lumbosacral spinal cord decreases detrusor overactivity in spinal cord injured rats. *J Urol*. 2008;179(3):1178–1183.

Miyazato M, Sasatomi K, Hiragata S, et al. Suppression of detrusor-sphincter dysynergia by GABA-receptor activation in the lumbosacral spinal cord in spinal cord-injured rats. *Am J Physiol Regul Integr Comp Physiol*. 2008;295(1):R336–R342.

Miyazato M, Sugaya K, Nishijima S, et al. Rectal distention inhibits bladder activity via glycinergic and GABAergic mechanisms in rats. *J Urol*. 2004;171(3):1353–1356.

Miyazato M, Yoshimura N, Chancellor MB. The other bladder syndrome: underactive bladder. *Rev Urol*. 2013;15(1):11–22.

Mizukawa K. The segmental detailed topographical distribution of monoaminergic terminals and their pathways in the spinal cord of the cat. *Anat Anz*. 1980;147(2):125–144.

Moga DC, Abner EL, Wu Q, et al. Bladder antimuscarinics and cognitive decline in elderly patients. *Alzheimers Dement (N Y)*. 2017;3(1):139–148.

Mohammed H, Hannibal J, Fahrenkrug J, et al. Distribution and regional variation of pituitary adenylate cyclase activating polypeptide and other neuropeptides in the rat urinary bladder and ureter: effects of age. *Urol Res*. 2002;30(4):248–255.

Mohammed HA, Santer RM. Distribution and changes with age of calcitonin gene-related peptide- and substance p-immunoreactive nerves of the rat urinary bladder and lumbosacral sensory neurons. *Eur J Morphol*. 2002;40(5):293–301.

Moldwin R, Kitt M, Mangel J, et al. *A phase 2 study in women* *with interstitial cystitis/bladder pain syndrome (IC/BPS) of the novel P2X3 antagonist AF-219*. [(website)] https://www.ics.org/2015/abstract/23; 2015.

Montgomery BS, Fry CH. The action potential and net membrane currents in isolated human detrusor smooth muscle cells. *J Urol*. 1992;147(1):176–184.

Morgan C, Nadelhaft I, de Groat WC. The distribution of visceral primary afferents from the pelvic nerve to Lissauer's tract and the spinal gray matter and its relationship to the sacral parasympathetic nucleus. *J Comp Neurol*. 1981;201(3):415–440.

Morgan CW, De Groat WC, Felkins LA, et al. Intracellular injection of neurobiotin or horseradish peroxidase reveals separate types of preganglionic neurons in the sacral parasympathetic nucleus of the cat. *J Comp Neurol*. 1993;331(2):161–182.

Mori K, Noguchi M, Matsuo M, et al. Decreased cellular membrane expression of gap junctional protein, connexin 43, in rat detrusor muscle with chronic partial bladder outlet obstruction. *Urology*. 2005;65(6):1254–1258.

Morita T, Ando M, Kihara K, et al. Species differences in camp production and contractile response induced by beta-adrenoceptor subtypes in urinary bladder smooth muscle. *Neurourol Urodyn*. 1993;12(2):185–190.

Morita T, Tsuchida S. Stereographic urethral pressure profile. *Urol Int*. 1984;39(4):199–206.

Morrison J, Fowler CJ, Birder LA, et al. Neural control of the bladder. Abrams P, Cardozo L, et al. *3rd International Consultation on Incontinence*. Health Publications: Plymouth, UK; 2005:363–422.

Morrison J, Namasivayam S, et al. ATP may be a natural modulator of the sensitivity of bladder mechanoreceptors during slow distensions. Abrams P, Khoury S, Wein AJ. *1st*

International Consultation on Incontinence. Health Publication Ltd: Plymouth, UK; 1998.

Morrison JF, Sato A, Sato Y, et al. The influence of afferent inputs from skin and viscera on the activity of the bladder and the skeletal muscle surrounding the urethra in the rat. *Neurosci Res*. 1995;23(2):195–205.

Morrison JF. The physiological mechanisms involved in bladder emptying. *Scand J Urol Nephrol Suppl*. 1997;184:15–18.

Mouton LJ, Holstege G. Segmental and laminar organization of the spinal neurons projecting to the periaqueductal gray (PAG) in the cat suggests the existence of at least five separate clusters of spino-PAG neurons. *J Comp Neurol*. 2000;428(3):389–410.

Mukerji G, Yiangou Y, Agarwal SK, et al. Increased cannabinoid receptor 1-immunoreactive nerve fibers in overactive and painful bladder disorders and their correlation with symptoms. *Urology*. 2010;75(6):1514.e15–1514.e20.

Mukerji G, Yiangou Y, Grogono J, et al. Localization of M2 and M3 muscarinic receptors in human bladder disorders and their clinical correlations. *J Urol*. 2006;176(1):367–373.

Mulholland SG, Parsons CL, Shrom SH, et al. Bladder defense mechanism. *Trans Am Assoc Genitourin Surg*. 1976;68:83–86.

Mulvey MA, Lopez-Boado YS, Wilson CL, et al. Induction and evasion of host defenses by type 1-piliated uropathogenic Escherichia coli. *Science*. 1998;282(5393):1494–1497.

Munoz A, Gangitano DA, Smith CP, et al. Removal of urothelium affects bladder contractility and release of ATP but not release of NO in rat urinary bladder. *BMC Urol*. 2010;10:10.

Murakami S, Yoshida M, Masunaga K, et al. Change in acetylcholine release from rat bladder with partial outlet obstruction. *BJU Int*. 2008;101(5):633–639.

Murakumo M, Ushiki T, Abe K, et al. Three-dimensional arrangement of collagen and elastin fibers in the human urinary bladder: a scanning electron microscopic study. *J Urol*. 1995;154(1):251–256.

Murray E, Malley SE, Qiao LY, et al. Cyclophosphamide induced cystitis alters neurotrophin and receptor tyrosine kinase expression in pelvic ganglia and bladder. *J Urol*. 2004;172(6 Pt 1):2434–2439.

Musselman DM, Ford AP, Gennevois DJ, et al. A randomized crossover study to evaluate Ro 115-1240, a selective alpha1a/1l-adrenoceptor partial agonist in women with stress urinary incontinence. *BJU Int*. 2004;93(1):78–83.

Nadelhaft I, Degroat WC, Morgan C. Location and morphology of parasympathetic preganglionic neurons in the sacral spinal cord of the cat revealed by retrograde axonal transport of horseradish peroxidase. *J Comp Neurol*. 1980;193(1):265–281.

Nadelhaft I, Vera PL, Card JP, et al. Central nervous system neurons labelled following the injection of pseudorabies virus into the rat urinary bladder. *Neurosci Lett*. 1992;143(1–2):271–274.

Nadelhaft I, Vera PL. Neurons in the rat brain and spinal cord labeled after pseudorabies virus injected into the external urethral sphincter. *J Comp Neurol*. 1996;375(3):502–517.

Nagatomi J, DeMiguel F, Torimoto K, et al. Early molecular-level changes in rat bladder wall tissue following spinal cord injury. *Biochem Biophys Res Commun*. 2005;334(4):1159–1164.

Nager CW, Albo ME, Fitzgerald MP, et al. Reference urodynamic values for stress incontinent women. *Neurourol Urodyn*. 2007;26(3):333–340.

Nathan PW. Sensations associated with micturition. *Br J Urol*. 1956;28(2):126–131.

Naughton MJ, Wyman JF. Quality of life in geriatric patients with lower urinary tract dysfunction. *Am J Med Sci*. 1997;314(4):219–227.

Nausch B, Heppner TJ, Nelson MT. Nerve-released acetylcholine contracts urinary bladder smooth muscle by inducing action potentials independently of IP3-mediated calcium release. *Am J Physiol Regul Integr Comp Physiol*. 2010;299(3):R878–R888.

Negoro H, Kanematsu A, Doi M, et al. Involvement of urinary bladder connexin43 and the circadian clock in coordination of diurnal micturition rhythm. *Nat Commun*. 2012;3:809.

Negrete HO, Lavelle JP, Berg J, et al. Permeability properties of the intact mammalian bladder epithelium. *Am J Physiol*. 1996;271(4 Pt 2):F886–F894.

Nelson MT, Cheng H, Rubart M, et al. Relaxation of arterial smooth muscle by calcium sparks. *Science*. 1995;270(5236):633–637.

Neuhaus J, Pfeiffer F, Wolburg H, et al. Alterations in connexin expression in the bladder of patients with urge symptoms. *BJU Int*. 2005;96(4):670–676.

Neuhaus J, Wolburg H, Hermsdorf T, et al. Detrusor smooth muscle cells of the guinea-pig are functionally coupled via gap junctions in situ and in cell culture. *Cell Tissue Res*. 2002;309(2):301–311.

Nickel JC, Stephens A, Landis JR, et al. Assessment of the lower urinary tract microbiota during symptom flare in women with urologic chronic pelvic pain syndrome: a MAPP network study. *J Urol*. 2016;195(2):356–362.

Nilvebrant L, Andersson KE, Gillberg PG, et al. Tolterodine—a new bladder-selective antimuscarinic agent. *Eur J Pharmacol*. 1997;327(2–3):195–207.

Nishikawa N, Kanematsu A, Negoro H, et al. PTHrP is endogenous relaxant for spontaneous smooth muscle contraction in urinary bladder of female rat. *Endocrinology*. 2013;154(6):2058–2068.

Nishikawa N, Yago R, Yamazaki Y, et al. Expression of parathyroid hormone/parathyroid hormone-related peptide receptor 1 in normal and diseased bladder detrusor muscles: a clinico-pathological study. *BMC Urol*. 2015;15:2.

Nishimoto T, Latifpour J, Wheeler MA, et al. Age-dependent alterations in beta-adrenergic responsiveness of rat detrusor smooth muscle. *J Urol*. 1995;153(5):1701–1705.

Nishino Y, Masue T, Miwa K, et al. Comparison of two alpha1-adrenoceptor antagonists, naftopidil and tamsulosin hydrochloride, in the treatment of lower urinary tract symptoms with benign prostatic hyperplasia: a randomized crossover study. *BJU Int*. 2006;97(4):747–751 [discussion 751].

Nomiya M, Yamaguchi O. A quantitative analysis of MRNA expression of alpha 1 and beta-adrenoceptor subtypes and their functional roles in human normal and obstructed bladders. *J Urol*. 2003;170(2 Pt 1):649–653.

Nordling J, Meyhoff HH, Hald T. Neuromuscular dysfunction of the lower urinary tract with special reference to the influence of the sympathetic nervous system. *Scand J Urol Nephrol*. 1981;15(1):7–19.

Nour S, Svarer C, Kristensen JK, et al. Cerebral activation during micturition in normal men. *Brain*. 2000;123(Pt 4):781–789.

Nuotio M, Jylha M, Luukkaala T, et al. Urgency, urge incontinence and voiding symptoms in men and women aged 70 years and over. *BJU Int*. 2002;89(4):350–355.

Ochodnicky P, Cruz CD, Yoshimura N, et al. Nerve growth factor in bladder dysfunction: contributing factor, biomarker, and therapeutic target. *Neurourol Urodyn*. 2011;30(7):1227–1241.

Oelrich TM. The striated urogenital sphincter muscle in the female. *Anat Rec*. 1983;205(2):223–232.

Ogawa T, Kamo I, Pflug BR, et al. Differential roles of peripheral and spinal endothelin receptors in the micturition reflex in rats. *J Urol*. 2004;172(4 Pt 1):1533–1537.

Ogawa T, Sasatomi K, Hiragata S, et al. Therapeutic effects of endothelin-a receptor antagonist on bladder overactivity in rats with chronic spinal cord injury. *Urology*. 2008;71(2):341–345.

Ohnishi N, Kishima Y, Hashimoto K, et al. A new method of measurement of the urinary bladder blood flow in patients with low compliant bladder. *Hinyokika Kiyo*. 1994;40(8):663–667.

Ohtake A, Ukai M, Hatanaka T, et al. In vitro and in vivo tissue selectivity profile of solifenacin succinate (YM905) for urinary bladder over salivary gland in rats. *Eur J Pharmacol*. 2004;492(2–3):243–250.

Okragly AJ, Niles AL, Saban R, et al. Elevated tryptase, nerve growth factor, neurotrophin-3 and glial cell line-derived neurotrophic factor levels in the urine of interstitial cystitis and bladder cancer patients. *J Urol*. 1999;161(2):438–441 [discussion 441–442].

O'Reilly BA, Kosaka AH, Chang TK, et al. A quantitative analysis of purinoceptor expression in the bladders of patients with symptomatic outlet obstruction. *BJU Int*. 2001;87(7):617–622.

O'Reilly BA, Kosaka AH, Chang TK, et al. A quantitative analysis of purinoceptor expression in human fetal and adult bladders. *J Urol*. 2001;165(5):1730–1734.

Ozawa H, Chancellor MB, Jung SY, et al. Effect of intravesical nitric oxide therapy on cyclophosphamide-induced cystitis. *J Urol*. 1999;162(6):2211–2216.

Padykula H, Gauthier GF. Morphological and cytochemical characteristics of fiber types in mammalian skeletal muscle. Milhorat AT. *International congress series no. 147, explanatory concepts in neuromuscular dystrophy and related disorders: Proceedings of the international conference convened by Muscular Dystrophy Associations of America at Arden House, Harriman, New York, October 22-27, 1966*. Excerpta Medica Foundation: Amsterdam; 1967:117–131.

Padykula HA, Gauthier GF. The ultrastructure of the neuromuscular junctions of mammalian red, white, and intermediate skeletal muscle fibers. *J Cell Biol*. 1970;46(1):27–41.

Palea S, Artibani W, Ostardo E, et al. Evidence for purinergic neurotransmission in human urinary bladder affected by interstitial cystitis. *J Urol*. 1993;150(6):2007–2012.

Pan HQ, Kerns JM, Lin DL, et al. Dual simulated childbirth injury delays anatomic recovery. *Am J Physiol Renal Physiol*. 2009;296(2):F277–F283.

Pan XQ, Gonzalez JA, Chang S, et al. Experimental colitis triggers the release of substance p and calcitonin gene-related peptide in the urinary bladder via TRPV1 signaling pathways. *Exp Neurol*. 2010;225(2):262–273.

Pandita RK, Mizusawa H, Andersson KE. Intravesical oxyhemoglobin initiates bladder overactivity in conscious, normal rats. *J Urol*. 2000;164(2):545–550.

Parekh AB, Brading AF, Tomita T. Studies of longitudinal tissue impedance in various smooth muscles. *Prog Clin Biol Res*. 1990;327:375–378.

Park JM, Bloom DA, McGuire EJ. The guarding reflex revisited. *Br J Urol*. 1997;80(6):940–945.

Parsons CL, Greenspan C, Mulholland SG. The primary antibacterial defense mechanism of the bladder. *Invest Urol*. 1975;13(1):72–78.

Pavcovich LA, Valentino RJ. Central regulation of micturition in the rat the corticotropin-releasing hormone from Barrington's nucleus. *Neurosci Lett*. 1995;196(3):185–188.

Payne CK, Mosbaugh PG, Forrest JB, et al. Intravesical resiniferatoxin for the treatment of interstitial cystitis: a randomized, double-blind, placebo controlled trial. *J Urol*. 2005;173(5):1590–1594.

Pearce MM, Hilt EE, Rosenfeld AB, et al. The female urinary microbiome: a comparison of women with and without urgency urinary incontinence. *MBio*. 2014;5(4) [e01283-14].

Penna A, Demuro A, Yeromin AV, et al. The CRAC channel consists of a tetramer formed by Stim-induced dimerization of Orai dimers. *Nature*. 2008;456(7218):116–120.

Pessina F, McMurray G, Wiggin A, et al. The effect of anoxia and glucose-free solutions on the contractile response of guinea-pig detrusor strips to intrinsic nerve stimulation and the application of excitatory agonists. *J Urol*. 1997;157(6):2375–2380.

Peters KM, Feber KM, Bennett RC. Sacral versus pudendal nerve stimulation for voiding dysfunction: a prospective, single-blinded, randomized, crossover trial. *Neurourol Urodyn*. 2005;24(7):643–647.

Petros PE, Ulmsten UI. An integral theory and its method for the diagnosis and management of female urinary incontinence. *Scand J Urol Nephrol Suppl*. 1993;153:1–93.

Pezzone MA, Liang R, Fraser MO. A model of neural cross-talk and irritation in the pelvis: implications for the overlap of chronic pelvic pain disorders. *Gastroenterology*. 2005;128(7):1953–1964.

Pfisterer MH, Griffiths DJ, Schaefer W, et al. The effect of age on lower urinary tract function: a study in women. *J Am Geriatr Soc*. 2006;54(3):405–412.

Phillips K, Clauw DJ. Central pain mechanisms in chronic pain states–maybe it is all in their head. *Best Pract Res Clin*

Rheumatol. 2011;25(2):141–154.

Pontari MA, Braverman AS, Ruggieri MR Sr. The M2 muscarinic receptor mediates in vitro bladder contractions from patients with neurogenic bladder dysfunction. *Am J Physiol Regul Integr Comp Physiol*. 2004;286(5):R874–R880.

Pool JL. Role of the sympathetic nervous system in hypertension and benign prostatic hyperplasia. *Br J Clin Pract Suppl*. 1994;74:13–17.

Puetz S, Lubomirov LT, Pfitzer G. Regulation of smooth muscle contraction by small GTPases. *Physiology (Bethesda)*. 2009;24:342–356.

Qiao LY, Vizzard MA. Cystitis-induced upregulation of tyrosine kinase (TrkA, TrkB) receptor expression and phosphorylation in rat micturition pathways. *J Comp Neurol*. 2002;454(2):200–211.

Qiao LY, Vizzard MA. Up-regulation of phosphorylated CREB but not c-Jun in bladder afferent neurons in dorsal root ganglia after cystitis. *J Comp Neurol*. 2004;469(2):262–274.

Rahnama'i MS, Uckert S, Hohnen R, et al. The role of phosphodiesterases in bladder pathophysiology. *Nat Rev Urol*. 2013;10(7):414–424.

Rajaofetra N, Passagia JG, Marlier L, et al. Serotoninergic, noradrenergic, and peptidergic innervation of Onuf's nucleus of normal and transected spinal cords of baboons (papio papio). *J Comp Neurol*. 1992;318(1):1–17.

Ranson RN, Dodds AL, Smith MJ, et al. Age-associated changes in the monoaminergic innervation of rat lumbosacral spinal cord. *Brain Res*. 2003;972(1–2):149–158.

Ranson RN, Santer RM, Watson AH. Ageing reduces the number of vesicular glutamate transporter 2 containing immunoreactive inputs to identified rat pelvic motoneurons. *Exp Gerontol*. 2007;42(6):506–516.

Razzaq TM, Bass R, Vines DJ, et al. Functional regulation of tissue plasminogen activator on the surface of vascular smooth muscle cells by the type-ii transmembrane protein p63 (CKAP4). *J Biol Chem*. 2003;278(43):42679–42685.

Rechberger T, Donica H, Baranowski W, et al. Female urinary stress incontinence in terms of connective tissue biochemistry. *Eur J Obstet Gynecol Reprod Biol*. 1993;49(3):187–191.

Renier WO, Gabreels FJ. Evaluation of diagnosis and non-surgical therapy in 24 children with a pontine tumour. *Neuropediatrics*. 1980;11(3):262–273.

Resnick NM, Yalla SV. Detrusor hyperactivity with impaired contractile function. An unrecognized but common cause of incontinence in elderly patients. *J Am Med Assoc*. 1987;257(22):3076–3081.

Resnick NM. Urinary incontinence. *Lancet*. 1995;346(8967):94–99.

Rice AS. Topical spinal administration of a nitric oxide synthase inhibitor prevents the hyper-reflexia associated with a rat model of persistent visceral pain. *Neurosci Lett*. 1995;187(2):111–114.

Richardson K, Fox C, Maidment I, et al. Anticholinergic drugs and risk of dementia: case-control study. *BMJ*. 2018;361:k1315.

Richter HE, Albo ME, Zyczynski HM, et al. Retropubic versus transobturator midurethral slings for stress incontinence. *N Engl J Med*. 2010;362(22):2066–2076.

Rivera L, Brading AF. The role of Ca2+ influx and intracellular Ca2+ release in the muscarinic-mediated contraction of mammalian urinary bladder smooth muscle. *BJU Int*. 2006;98(4):868–875.

Robbins M, DeBerry J, Ness T. Chronic psychological stress enhances nociceptive processing in the urinary bladder in high-anxiety rats. *Physiol Behav*. 2007;91(5):544–550.

Romsing J, Moiniche S, Mathiesen O, et al. Reduction of opioid-related adverse events using opioid-sparing analgesia with cox-2 inhibitors lacks documentation: a systematic review. *Acta Anaesthesiol Scand*. 2005;49(2):133–142.

Roos J, DiGregorio PJ, Yeromin AV, et al. Stim1, an essential and conserved component of store-operated Ca2+ channel function. *J Cell Biol*. 2005;169(3):435–445.

Roosen A, Datta SN, Chowdhury RA, et al. Suburothelial myofibroblasts in the human overactive bladder and the effect of botulinum neurotoxin type a treatment. *Eur Urol*. 2009;55(6):1440–1448.

Roppolo JR, Tai C, Booth AM, et al. Bladder Adelta afferent nerve activity in normal cats and cats with feline interstitial cystitis. *J Urol*. 2005;173(3):1011–1015.

Rosenbloom J, Koo H, Howard PS, et al. Elastic fibers and their role in bladder extracellular matrix. *Adv Exp Med Biol*. 1995;385:161–172 [discussion 179–184].

Rossier AB, Ott R. Bladder and urethral recordings in acute and chronic spinal cord injury patients. *Urol Int*. 1976;31(1–2):49–59.

Rouzade-Dominguez ML, Miselis R, Valentino RJ. Central representation of bladder and colon revealed by dual transsynaptic tracing in the rat: substrates for pelvic visceral coordination. *Eur J Neurosci*. 2003;18(12):3311–3324.

Rovner AS, Freyzon Y, Trybus KM. An insert in the motor domain determines the functional properties of expressed smooth muscle myosin isoforms. *J Muscle Res Cell Motil*. 1997;18(1):103–110.

Rubanyi GM, Polokoff MA. Endothelins: molecular biology, biochemistry, pharmacology, physiology, and pathophysiology. *Pharmacol Rev*. 1994;46(3):325–415.

Rubenwolf PC, Georgopoulos NT, Clements LA, et al.

Expression and localisation of aquaporin water channels in human urothelium in situ and in vitro. *Eur Urol*. 2009;56(6):1013–1023.

Rubenwolf PC, Georgopoulos NT, Kirkwood LA, et al. Aquaporin expression contributes to human transurothelial permeability in vitro and is modulated by NaCl. *PLoS ONE*. 2012;7(9):e45339.

Rud T, Andersson KE, Asmussen M, et al. Factors maintaining the intraurethral pressure in women. *Invest Urol*. 1980;17(4):343–347.

Saban R, Undem BJ, Keith IM, et al. Differential release of prostaglandins and leukotrienes by sensitized guinea pig urinary bladder layers upon antigen challenge. *J Urol*. 1994;152(2 Pt 1):544–549.

Sadananda P, Drake MJ, Paton JF, et al. A functional analysis of the influence of beta3-adrenoceptors on the rat micturition cycle. *J Pharmacol Exp Ther*. 2013;347(2):506–515.

Saenz de Tejada I, Mueller JD, de Las Morenas A, et al. Endothelin in the urinary bladder. I. Synthesis of endothelin-1 by epithelia, muscle and fibroblasts suggests autocrine and paracrine cellular regulation. *J Urol*. 1992;148(4):1290–1298.

Saito M, Gotoh M, Kato K, et al. Influence of aging on the rat urinary bladder function. *Urol Int*. 1991;47(Suppl 1):39–42.

Saito M, Kondo A, Gotoh M, et al. Age-related changes in the response of the rat urinary bladder to neurotransmitters. *Neurourol Urodyn*. 1993;12(2):191–200.

Sakakibara R, Hattori T, Yasuda K, et al. Micturitional disturbance and the pontine tegmental lesion: urodynamic and MRI analyses of vascular cases. *J Neurol Sci*. 1996;141(1–2):105–110.

Sampselle CM, DeLancey JO. Anatomy of female continence. *J Wound Ostomy Continence Nurs*. 1998;25(2):63–70 [72–74].

Santer RM, Dering MA, Ranson RN, et al. Differential susceptibility to ageing of rat preganglionic neurones projecting to the major pelvic ganglion and of their afferent inputs. *Auton Neurosci*. 2002;96(1):73–81.

Satoh K, Shimizu N, Tohyama M, et al. Localization of the micturition reflex center at dorsolateral pontine tegmentum of the rat. *Neurosci Lett*. 1978;8(1):27–33.

Saunders CJ, Reynolds SD, Finger TE. Chemosensory brush cells of the trachea. A stable population in a dynamic epithelium. *Am J Respir Cell Mol Biol*. 2013;49(2):190–196.

Schiavo G, Rossetto O, Santucci A, et al. Botulinum neurotoxins are zinc proteins. *J Biol Chem*. 1992;267(33):23479–23483.

Schiavo G, Santucci A, Dasgupta BR, et al. Botulinum neurotoxins serotypes A and E cleave SNAP-25 at distinct COOH-terminal peptide bonds. *FEBS Lett*. 1993;335(1):99–103.

Schmidt F, Jorgensen TM, Djurhuus JC. Twenty-four-hour ambulatory urodynamics in healthy young men. *Scand J Urol Nephrol Suppl*. 2004;215:75–83.

Schnegelsberg B, Sun TT, Cain G, et al. Overexpression of NGF in mouse urothelium leads to neuronal hyperinnervation, pelvic sensitivity, and changes in urinary bladder function. *Am J Physiol Regul Integr Comp Physiol*. 2010;298(3):R534–R547.

Schneider T, Fetscher C, Krege S, et al. Signal transduction underlying carbachol-induced contraction of human urinary bladder. *J Pharmacol Exp Ther*. 2004;309(3):1148–1153.

Schneider T, Hein P, Michel MC. Signal transduction underlying carbachol-induced contraction of rat urinary bladder. I. Phospholipases and Ca2+ sources. *J Pharmacol Exp Ther*. 2004;308(1):47–53.

Schroder A, Tajimi M, Matsumoto H, et al. Protective effect of an oral endothelin converting enzyme inhibitor on rat detrusor function after outlet obstruction. *J Urol*. 2004;172(3):1171–1174.

Schulte-Baukloh H, Priefert J, Knispel HH, et al. Botulinum toxin a detrusor injections reduce postsynaptic muscular M2, M3, P2X2, and P2X3 receptors in children and adolescents who have neurogenic detrusor overactivity: a single-blind study. *Urology*. 2013;81(5):1052–1057.

Schussler B. Comparison of the mode of action of prostaglandin E2 (PGE2) and sulprostone, a PGE2-derivative, on the lower urinary tract in healthy women. A urodynamic study. *Urol Res*. 1990;18(5):349–352.

Schwinn DA, Roehrborn CG. Alpha1-adrenoceptor subtypes and lower urinary tract symptoms. *Int J Urol*. 2008;15(3):193–199.

Sculptoreanu A, Aura Kullmann F, de Groat WC. Neurokinin 2 receptor-mediated activation of protein kinase c modulates capsaicin responses in DRG neurons from adult rats. *Eur J Neurosci*. 2008;27(12):3171–3181.

Sculptoreanu A, de Groat WC, Buffington CA, et al. Protein kinase c contributes to abnormal capsaicin responses in DRG neurons from cats with feline interstitial cystitis. *Neurosci Lett*. 2005;381(1–2):42–46.

Sculptoreanu A, de Groat WC. Neurokinins enhance excitability in capsaicin-responsive DRG neurons. *Exp Neurol*. 2007;205(1):92–100.

Sculptoreanu A, de Groat WC. Protein kinase c is involved in neurokinin receptor modulation of N- and L-type Ca2+ channels in DRG neurons of the adult rat. *J Neurophysiol*. 2003;90(1):21–31.

Seki N, Karim OM, Mostwin JL. Changes in action potential kinetics following experimental bladder outflow obstruction in the guinea pig. *Urol Res*. 1992;20(6):387–392.

Seki S, Sasaki K, Fraser MO, et al. Immunoneutralization of nerve growth factor in lumbosacral spinal cord reduces bladder hyperreflexia in spinal cord injured rats. *J Urol*. 2002;168(5):2269–2274.

Sengupta JN, Gebhart GF. Mechanosensitive properties of pelvic nerve afferent fibers innervating the urinary bladder of the rat. *J Neurophysiol*. 1994;72(5):2420–2430.

Seth JH, Sahai A, Khan MS, et al. Nerve growth factor (NGF): a potential urinary biomarker for overactive bladder syndrome (OAB). *BJU Int*. 2013;111(3):372–380.

Shapiro E. Effect of estrogens on the weight and muscarinic cholinergic receptor density of the rabbit bladder and urethra. *J Urol*. 1986;135(5):1084–1087.

Sharma A, Goldberg MJ, Cerimele BJ. Pharmacokinetics and safety of duloxetine, a dual-serotonin and norepinephrine reuptake inhibitor. *J Clin Pharmacol*. 2000;40(2):161–167.

Shefchyk SJ, Buss RR. Urethral pudendal afferent-evoked bladder and sphincter reflexes in decerebrate and acute spinal cats. *Neurosci Lett*. 1998;244(3):137–140.

Shefchyk SJ. Spinal cord neural organization controlling the urinary bladder and striated sphincter. *Prog Brain Res*. 2002;137:71–82.

Sibley GN. A comparison of spontaneous and nerve-mediated activity in bladder muscle from man, pig and rabbit. *J Physiol*. 1984;354:431–443.

Siddiqui H, Lagesen K, Nederbragt AJ, et al. Alterations of microbiota in urine from women with interstitial cystitis. *BMC Microbiol*. 2012;12:205.

Sie JA, Blok BF, de Weerd H, et al. Ultrastructural evidence for direct projections from the pontine micturition center to glycine-immunoreactive neurons in the sacral dorsal gray commissure in the cat. *J Comp Neurol*. 2001;429(4):631–637.

Sjuve R, Haase H, Morano I, et al. Contraction kinetics and myosin isoform composition in smooth muscle from hypertrophied rat urinary bladder. *J Cell Biochem*. 1996;63(1):86–93.

Skagerberg G, Bjorklund A. Topographic principles in the spinal projections of serotonergic and non-serotonergic brainstem neurons in the rat. *Neuroscience*. 1985;15(2):445–480.

Smet PJ, Jonavicius J, Marshall VR, et al. Distribution of nitric oxide synthase-immunoreactive nerves and identification of the cellular targets of nitric oxide in guinea-pig and human urinary bladder by CGMP immunohistochemistry. *Neuroscience*. 1996;71(2):337–348.

Smith AL, Leung J, Kun S, et al. The effects of acute and chronic psychological stress on bladder function in a rodent model. *Urology*. 2011;78(4):967.e1–967.e7.

Smith CP, Chancellor MB. Emerging role of botulinum toxin in the management of voiding dysfunction. *J Urol*. 2004;171(6 Pt 1):2128–2137.

Smith CP, Franks ME, McNeil BK, et al. Effect of botulinum toxin a on the autonomic nervous system of the rat lower urinary tract. *J Urol*. 2003;169(5):1896–1900.

Smith CP, Gangitano DA, Munoz A, et al. Botulinum toxin type a normalizes alterations in urothelial ATP and no release induced by chronic spinal cord injury. *Neurochem Int*. 2008;52(6):1068–1075.

Smith CP, Vemulakonda VM, Kiss S, et al. Enhanced ATP release from rat bladder urothelium during chronic bladder inflammation: effect of botulinum toxin a. *Neurochem Int*. 2005;47(4):291–297.

Smith PP, DeAngelis A, Kuchel GA. Detrusor expulsive strength is preserved, but responsiveness to bladder filling and urinary sensitivity is diminished in the aging mouse. *Am J Physiol Regul Integr Comp Physiol*. 2012;302(5):R577–R586.

Smith PP, Deangelis AM, Kuchel GA. Evidence of central modulation of bladder compliance during filling phase. *Neurourol Urodyn*. 2012;31(1):30–35.

Smith PP. Aging and the underactive detrusor: a failure of activity or activation? *Neurourol Urodyn*. 2010;29(3):408–412.

Smith PR, Mackler SA, Weiser PC, et al. Expression and localization of epithelial sodium channel in mammalian urinary bladder. *Am J Physiol*. 1998;274(1 Pt 2):F91–F96.

Snellings AE, Yoo PB, Grill WM. Urethral flow-responsive afferents in the cat sacral dorsal root ganglia. *Neurosci Lett*. 2012;516(1):34–38.

Sobue K, Muramoto Y, Fujita M, et al. Purification of a calmodulin-binding protein from chicken gizzard that interacts with f-actin. *Proc Natl Acad Sci USA*. 1981;78(9):5652–5655.

Somogyi GT, Tanowitz M, de Groat WC. M1 muscarinic receptor-mediated facilitation of acetylcholine release in the rat urinary bladder. *J Physiol*. 1994;480(Pt 1):81–89.

Somogyi GT, Tanowitz M, de Groat WC. Prejunctional facilitatory alpha 1-adrenoceptors in the rat urinary bladder. *Br J Pharmacol*. 1995;114(8):1710–1716.

Spagnolo PA, Goldman D. Neuromodulation interventions for addictive disorders: challenges, promise, and roadmap for future research. *Brain*. 2017;140(5):1183–1203.

Speakman MJ, Brading AF, Gilpin CJ, et al. Bladder outflow obstruction—a cause of denervation supersensitivity. *J Urol*. 1987;138(6):1461–1466.

Spector DA, Deng J, Stewart KJ. Dietary protein affects urea transport across rat urothelia. *Am J Physiol Renal Physiol*. 2012;303(7):F944–F953.

Spector DA, Deng J, Stewart KJ. Hydration status affects sodium, potassium, and chloride transport across rat urothelia. *Am J Physiol Renal Physiol*. 2013;305(12):F1669–F1679.

Spector DA, Deng J, Stewart KJ. Hydration status affects urea transport across rat urothelia. *Am J Physiol Renal Physiol*. 2011;301(6):F1208–F1217.

Steers WD, Broder SR, Persson K, et al. Mechanical stretch increases secretion of parathyroid hormone-related protein by cultured bladder smooth muscle cells. *J Urol*. 1998;160(3 Pt 1):908–912.

Steers WD, Ciambotti J, Erdman S, et al. Morphological plasticity in efferent pathways to the urinary bladder of the rat following urethral obstruction. *J Neurosci*. 1990;10(6):1943–1951.

Steers WD, Clemow DB, Persson K, et al. Observations from the spontaneously hypertensive rat. Insight into ngf regulation and noradrenergic hyper-innervation in the lower urinary tract. *Adv Exp Med Biol*. 1999;462:283–292 [discussion 311–320].

Steers WD, Creedon DJ, Tuttle JB. Immunity to nerve growth factor prevents afferent plasticity following urinary bladder hypertrophy. *J Urol*. 1996;155(1):379–385.

Steers WD, De Groat WC. Effect of bladder outlet obstruction on micturition reflex pathways in the rat. *J Urol*. 1988;140(4):864–871.

Steers WD, Kolbeck S, Creedon D, et al. Nerve growth factor in the urinary bladder of the adult regulates neuronal form and function. *J Clin Invest*. 1991;88(5):1709–1715.

Steers WD, Tuttle JB. Mechanisms of disease: the role of nerve growth factor in the pathophysiology of bladder disorders. *Nat Clin Pract Urol*. 2006;3(2):101–110.

Steers WD. Darifenacin: pharmacology and clinical usage. *Urol Clin North Am*. 2006;33(4):475–482 [viii].

Stein RJ, Santos S, Nagatomi J, et al. Cool (TRPM8) and hot

(TRPV1) receptors in the bladder and male genital tract. *J Urol*. 2004;172(3):1175–1178.

Stengel PW, Yamada M, Wess J, et al. M(3)-receptor knockout mice: muscarinic receptor function in atria, stomach fundus, urinary bladder, and trachea. *Am J Physiol Regul Integr Comp Physiol*. 2002;282(5):R1443–R1449.

Stoffel JT, Peterson AC, Sandhu JS, et al. AUA white paper on nonneurogenic chronic urinary retention: consensus definition, treatment algorithm, and outcome end points. *J Urol*. 2017;198(1):153–160.

Su X, Stein R, Stanton MC, et al. Effect of partial outlet obstruction on rabbit urinary bladder smooth muscle function. *Am J Physiol Renal Physiol*. 2003;284(4):F644–F652.

Sugaya K, Kadekawa K, Ikehara A, et al. Influence of hypertension on lower urinary tract symptoms in benign prostatic hyperplasia. *Int J Urol*. 2003;10(11):569–574 [discussion 575].

Sugaya K, Ogawa Y, Hatano T, et al. Evidence for involvement of the subcoeruleus nucleus and nucleus raphe magnus in urine storage and penile erection in decerebrate rats. *J Urol*. 1998;159(6):2172–2176.

Sugaya K, Roppolo JR, Yoshimura N, et al. The central neural pathways involved in micturition in the neonatal rat as revealed by the injection of pseudorabies virus into the urinary bladder. *Neurosci Lett*. 1997;223(3):197–200.

Sui G, Fry CH, Malone-Lee J, et al. Aberrant Ca2+ oscillations in smooth muscle cells from overactive human bladders. *Cell Calcium*. 2009;45(5):456–464.

Sui G, Fry CH, Montgomery B, et al. Purinergic and muscarinic modulation of ATP release from the urothelium and its paracrine actions. *Am J Physiol Renal Physiol*. 2014;306(3):F286–F298.

Sui GP, Wu C, Roosen A, et al. Modulation of bladder myofibroblast activity: implications for bladder function. *Am J Physiol Renal Physiol*. 2008;295(3):F688–F697.

Sun TT. Altered phenotype of cultured urothelial and other stratified epithelial cells: implications for wound healing. *Am J Physiol Renal Physiol*. 2006;291(1):F9–F21.

Sun Y, Chai TC. Up-regulation of P2X3 receptor during stretch of bladder urothelial cells from patients with interstitial cystitis. *J Urol*. 2004;171(1):448–452.

Sun Y, Keay S, De Deyne PG, et al. Augmented stretch activated adenosine triphosphate release from bladder uroepithelial cells in patients with interstitial cystitis. *J Urol*. 2001;166(5):1951–1956.

Suskind AM, Smith PP. A new look at detrusor underactivity: impaired contractility versus afferent dysfunction. *Curr Urol Rep*. 2009;10(5):347–351.

Susset JG, Servot-Viguier D, Lamy F, et al. Collagen in 155 human bladders. *Invest Urol*. 1978;16(3):204–206.

Szallasi A, Blumberg PM. Resiniferatoxin and its analogs provide novel insights into the pharmacology of the vanilloid (capsaicin) receptor. *Life Sci*. 1990;47(16):1399–1408.

Szallasi A, Fowler CJ. After a decade of intravesical vanilloid therapy: still more questions than answers. *Lancet Neurol*. 2002;1(3):167–172.

Szell EA, Somogyi GT, de Groat WC, et al. Developmental changes in spontaneous smooth muscle activity in the neonatal rat urinary bladder. *Am J Physiol Regul Integr Comp Physiol*. 2003;285(4):R809–R816.

Szolcsanyi J. Effect of capsaicin, resiniferatoxin and piperine on ethanol-induced gastric ulcer of the rat. *Acta Physiol Hung*. 1990;75(Suppl):267–268.

Tai C, Shen B, et al. Prolonged poststimulation inhibition of bladder activity induced by tibial nerve stimulation in cats. *Am J Physiol Renal Physiol*. 2011;300:F385–F392.

Tai C, Shen B, Chen M, et al. Suppression of bladder overactivity by activation of somatic afferent nerves in the foot. *BJU Int*. 2011;107(2):303–309.

Tai C, Wang J, Jin T, et al. Brain switch for reflex micturition control detected by fMRI in rats. *J Neurophysiol*. 2009;102(5):2719–2730.

Tai C, Wang J, Wang X, et al. Bladder inhibition or voiding induced by pudendal nerve stimulation in chronic spinal cord injured cats. *Neurourol Urodyn*. 2007;26(4):570–577.

Tainio H. Neuropeptidergic innervation of the human male distal urethra and intrinsic external urethral sphincter. *Acta Histochem*. 1993;94(2):197–201.

Taki N, Taniguchi T, Okada K, et al. Evidence for predominant mediation of alpha1-adrenoceptor in the tonus of entire urethra of women. *J Urol*. 1999;162(5):1829–1832.

Tammela T, Kontturi M, Kaar K, et al. Intravesical prostaglandin f2 for promoting bladder emptying after surgery for female stress incontinence. *Br J Urol*. 1987;60(1):43–46.

Tanagho EA, Schmidt RA, Orvis BR. Neural stimulation for control of voiding dysfunction: a preliminary report in 22 patients with serious neuropathic voiding disorders. *J Urol*. 1989;142(2 Pt 1):340–345.

Tanagho EA. The ureterovesical junction: anatomy and physiology. Chisholm GD, Williams DI. *Scientific foundations of urology*. 2nd ed. Heinemann Medical Books: London; 1982:295–404.

Tanaka Y, Koyama Y, Kayama Y, et al. Firing of micturition center neurons in the rat mesopontine tegmentum during urinary bladder contraction. *Brain Res*. 2003;965(1–2):146–154.

Tang DD. Intermediate filaments in smooth muscle. *Am J Physiol Cell Physiol*. 2008;294(4):C869–C878.

Tang PC. Levels of brain stem and diencephalon controlling micturition reflex. *J Neurophysiol*. 1955;18(6):583–595.

Tempest HV, Dixon AK, Turner WH, et al. P2X and P2X receptor expression in human bladder urothelium and changes in interstitial cystitis. *BJU Int*. 2004;93(9):1344–1348.

Testa R, Guarneri L, Ibba M, et al. Characterization of alpha 1-adrenoceptor subtypes in prostate and prostatic urethra of rat, rabbit, dog and man. *Eur J Pharmacol*. 1993;249(3):307–315.

Thind P. The significance of smooth and striated muscles in the sphincter function of the urethra in healthy women. *Neurourol Urodyn*. 1995;14(6):585–618.

Thiruchelvam N, Wu C, David A, et al. Neurotransmission and viscoelasticity in the ovine fetal bladder after in utero bladder outflow obstruction. *Am J Physiol Regul Integr Comp Physiol*. 2003;284(5):R1296–R1305.

Thompson JH, Sutherland SE, Siegel SW. Sacral neuromodulation: therapy evolution. *Indian J Urol*. 2010;26(3):379–384.

Thon WF, Baskin LS, Jonas U, et al. Surgical principles of sacral foramen electrode implantation. *World J Urol*. 1991;9(3):133–137.

Thor KB, Donatucci C. Central nervous system control of the lower urinary tract: new pharmacological approaches to stress urinary incontinence in women. *J Urol*. 2004;172(1):27–33.

Thor KB, Katofiasc MA. Effects of duloxetine, a combined serotonin and norepinephrine reuptake inhibitor, on central neural control of lower urinary tract function in the chloralose-anesthetized female cat. *J Pharmacol Exp Ther*. 1995;274(2):1014–1024.

Thor KB, Morgan C, Nadelhaft I, et al. Organization of afferent and efferent pathways in the pudendal nerve of the female

cat. *J Comp Neurol*. 1989;288(2):263–279.
Thumbikat P, Berry RE, Zhou G, et al. Bacteria-induced uroplakin signaling mediates bladder response to infection. *PLoS Pathog*. 2009;5(5):e1000415.
Thurmond P, Yang JH, Azadzoi KM. LUTS in pelvic ischemia: a new concept in voiding dysfunction. *Am J Physiol Renal Physiol*. 2016;310(8):F738–F743.
Toosi KK, Nagatomi J, Chancellor MB, et al. The effects of long-term spinal cord injury on mechanical properties of the rat urinary bladder. *Ann Biomed Eng*. 2008;36(9):1470–1480.
Torrens M, Morrison JF. *The physiology of the lower urinary tract*. Springer-Verlag: New York; 1987.
Truss MC, Becker AJ, Uckert S, et al. Selective pharmacological manipulation of the smooth muscle tissue of the genitourinary tract: a glimpse into the future. *BJU Int*. 1999;83(Suppl 2):36–41.
Truss MC, Stief CG, Uckert S, et al. Phosphodiesterase 1 inhibition in the treatment of lower urinary tract dysfunction: from bench to bedside. *World J Urol*. 2001;19(5):344–350.
Truss MC, Uckert S, Stief CG, et al. Effects of various phosphodiesterase-inhibitors, forskolin, and sodium nitroprusside on porcine detrusor smooth muscle tonic responses to muscarinergic stimulation and cyclic nucleotide levels in vitro. *Neurourol Urodyn*. 1996;15(1):59–70.
Turner WH, Brading AF. Smooth muscle of the bladder in the normal and the diseased state: pathophysiology, diagnosis and treatment. *Pharmacol Ther*. 1997;75(2):77–110.
Tyagi V, Philips BJ, Su R, et al. Differential expression of functional cannabinoid receptors in human bladder detrusor and urothelium. *J Urol*. 2009;181(4):1932–1938.
Ueki K. Disturbances of micturition observed in some patients with brain tumor. *Neurol Med Chir (Tokyo)*. 1960;2(1–2):25–33.

Ukai M, Yuyama H, Noguchi Y, et al. Participation of endogenous endothelin and eta receptor in premicturition contractions in rats with bladder outlet obstruction. *Naunyn Schmiedebergs Arch Pharmacol*. 2006;373(3):197–203.

Ustinova EE, Fraser MO, Pezzone MA. Colonic irritation in the rat sensitizes urinary bladder afferents to mechanical and chemical stimuli: an afferent origin of pelvic organ cross-sensitization. *Am J Physiol Renal Physiol*. 2006;290(6):F1478–F1487.

Ustinova EE, Fraser MO, Pezzone MA. Cross-talk and sensitization of bladder afferent nerves. *Neurourol Urodyn*. 2010;29(1):77–81.

Uvelius B, Gabella G. Relation between cell length and force production in urinary bladder smooth muscle. *Acta Physiol Scand*. 1980;110(4):357–365.

Uvelius B, Mattiasson A. Collagen content in the rat urinary bladder subjected to infravesical outflow obstruction. *J Urol*. 1984;132(3):587–590.

Uvelius B, Mattiasson A. Detrusor collagen content in the denervated rat urinary bladder. *J Urol*. 1986;136(5):1110–1112.

Vaidyanathan S, Rao MS, Chary KS, et al. Enhancement of detrusor reflex activity by naloxone in patients with chronic neurogenic bladder dysfunction. Preliminary report. *J Urol*. 1981;126(4):500–502.

Valentino RJ, Kosboth M, Colflesh M, et al. Transneuronal labeling from the rat distal colon: anatomic evidence for regulation of distal colon function by a pontine corticotropin-releasing factor system. *J Comp Neurol*. 2000;417(4):399–414.

van Kerrebroeck P, Abrams P, Lange R, et al. Duloxetine versus placebo in the treatment of European and Canadian women with stress urinary incontinence. *BJOG*. 2004;111(3):249–

257.

Van Kerrebroeck P, Andersson KE. Terminology, epidemiology, etiology, and pathophysiology of nocturia. *Neurourol Urodyn*. 2014;33(Suppl 1):S2–S5.

Vedrenne C, Klopfenstein DR, Hauri HP. Phosphorylation controls CLIMP-63-mediated anchoring of the endoplasmic reticulum to microtubules. *Mol Biol Cell*. 2005;16(4):1928–1937.

Venegas JG. Viscoelastic properties of the contracting detrusor. I. Theoretical basis. *Am J Physiol*. 1991;261(2 Pt 1):C355–C363.

Vergnolle N. Postinflammatory visceral sensitivity and pain mechanisms. *Neurogastroenterol Motil*. 2008;20(Suppl 1):73–80.

Visco AG, Brubaker L, Richter HE, et al. Anticholinergic therapy vs. Onabotulinumtoxina for urgency urinary incontinence. *N Engl J Med*. 2012;367(19):1803–1813.

Vizzard MA, Boyle MM. Increased expression of growth-associated protein (GAP-43) in lower urinary tract pathways following cyclophosphamide (CYP)-induced cystitis. *Brain Res*. 1999;844(1–2):174–187.

Vizzard MA, Erdman SL, de Groat WC. Increased expression of neuronal nitric oxide synthase in bladder afferent pathways following chronic bladder irritation. *J Comp Neurol*. 1996;370(2):191–202.

Vizzard MA, Erickson VL, Card JP, et al. Transneuronal labeling of neurons in the adult rat brainstem and spinal cord after injection of pseudorabies virus into the urethra. *J Comp Neurol*. 1995;355(4):629–640.

Vizzard MA. Alterations in neuropeptide expression in lumbosacral bladder pathways following chronic cystitis. *J Chem Neuroanat*. 2001;21(2):125–138.

Vizzard MA. Changes in urinary bladder neurotrophic factor mRNA and NGF protein following urinary bladder dysfunction. *Exp Neurol*. 2000;161(1):273–284.

Vizzard MA. Neurochemical plasticity and the role of neurotrophic factors in bladder reflex pathways after spinal cord injury. *Prog Brain Res*. 2006;152:97–115.

Vlaskovska M, Kasakov L, Rong W, et al. P2X3 knock-out mice reveal a major sensory role for urothelially released ATP. *J Neurosci*. 2001;21(15):5670–5677.

Vodusek DB, Light JK, Libby JM. Detrusor inhibition induced by stimulation of pudendal nerve afferents. *Neurourol Urodyn*. 1986;5(4):381–389.

Wada T, Otsu T, Hasegawa Y, et al. Characterization of alpha 1-adrenoceptor subtypes in rat spinal cord. *Eur J Pharmacol*. 1996;312(2):263–266.

Waddell PJ, Lawson SN, McCarthy PW. Conduction velocity changes along the processes of rat primary sensory neurons. *Neuroscience*. 1989;30(3):577–584.

Wagg A, Verdejo C, Molander U. Review of cognitive impairment with antimuscarinic agents in elderly patients with overactive bladder. *Int J Clin Pract*. 2010;64(9):1279–1286.

Wagner G, Husslein P, Enzelsberger H. Is prostaglandin E2 really of therapeutic value for postoperative urinary retention? Results of a prospectively randomized double-blind study. *Am J Obstet Gynecol*. 1985;151(3):375–379.

Walter S, Kjaergaard B, Lose G, et al. Stress urinary incontinence in postmenopausal women treated with oral estrogen (estriol) and an alpha-adrenoceptor-stimulating agent (phenylpropanolamine): a randomised double-blind placebo-controlled study. *Int Urogynecol J*. 1990;1:74–79.

Wang CL. Caldesmon and the regulation of cytoskeletal functions. *Adv Exp Med Biol*. 2008;644:250–272.

Wang EC, Lee JM, Johnson JP, et al. Hydrostatic pressure-regulated ion transport in bladder uroepithelium. *Am J Physiol Renal Physiol*. 2003;285(4):F651–F663.

Wang EC, Lee JM, Ruiz WG, et al. Atp and purinergic receptor-dependent membrane traffic in bladder umbrella cells. *J Clin Invest*. 2005;115(9):2412–2422.

Wang HZ, Brink PR, Christ GJ. Gap junction channel activity in short-term cultured human detrusor myocyte cell pairs: gating and unitary conductances. *Am J Physiol Cell Physiol*. 2006;291(6):C1366–C1376.

Wang ZE, Gopalakurup SK, Levin RM, et al. Expression of smooth muscle myosin isoforms in urinary bladder smooth muscle during hypertrophy and regression. *Lab Invest*. 1995;73(2):244–251.

Wang ZY, Wang P, Merriam FV, et al. Lack of TRPV1 inhibits cystitis-induced increased mechanical sensitivity in mice. *Pain*. 2008;139(1):158–167.

Wanigasekara Y, Kepper ME, Keast JR. Immunohistochemical characterisation of pelvic autonomic ganglia in male mice. *Cell Tissue Res*. 2003;311(2):175–185.

Waxman JA, Sulak PJ, Kuehl TJ. Cystoscopic findings consistent with interstitial cystitis in normal women undergoing tubal ligation. *J Urol*. 1998;160(5):1663–1667.

Wein AJ. Neuromuscular dysfunction of the lower urinary tract. Walsh P, Retik A, et al. *Campbell's urology*. 6th ed. Saunders: Philadelphia; 1992.

Wen J, Morrison JF. The effects of high urinary potassium concentration on pelvic nerve mechanoreceptors and “silent” afferents from the rat bladder. *Adv Exp Med Biol*. 1995;385:237–239.

White S, Martin AF, Periasamy M. Identification of a novel smooth muscle myosin heavy chain CDNA: isoform diversity in the s1 head region. *Am J Physiol*. 1993;264(5 Pt 1):C1252–C1258.

Whorwell PJ, McCallum M, Creed FH, et al. Non-colonic features of irritable bowel syndrome. *Gut*. 1986;27(1):37–40.

Wickham JE. Active transport of sodium ion by the mammalian bladder epithelium. *Invest Urol*. 1964;2:145–153.

Willette RN, Sauermelch CF, Hieble JP. Role of alpha-1 and alpha-2 adrenoceptors in the sympathetic control of the proximal urethra. *J Pharmacol Exp Ther*. 1990;252(2):706–710.

Wilson PD, Faragher B, Butler B, et al. Treatment with oral piperazine oestrone sulphate for genuine stress incontinence in postmenopausal women. *Br J Obstet Gynaecol*. 1987;94(6):568–574.

Winge K, Fowler CJ. Bladder dysfunction in parkinsonism: mechanisms, prevalence, symptoms, and management. *Mov Disord*. 2006;21(6):737–745.

Wiseman OJ, Brady CM, Hussain IF, et al. The ultrastructure of bladder lamina propria nerves in healthy subjects and patients with detrusor hyperreflexia. *J Urol*. 2002;168(5):2040–2045.

Wolfe AJ, Toh E, Shibata N, et al. Evidence of uncultivated bacteria in the adult female bladder. *J Clin Microbiol*. 2012;50(4):1376–1383.

Woo LL, Hijaz A, Kuang M, et al. Over expression of stem cell homing cytokines in urogenital organs following vaginal distention. *J Urol*. 2007;177(4):1568–1572.

Woolf CJ. Central sensitization: implications for the diagnosis and treatment of pain. *Pain*. 2011;152(3 Suppl):S2–S15.

Wu C, Kentish JC, Fry CH. Effect of pH on myofilament Ca(2+)-sensitivity in alpha-toxin permeabilized guinea pig detrusor muscle. *J Urol*. 1995;154(5):1921–1924.

Wu XR, Sun TT, Medina JJ. In vitro binding of type 1-fimbriated Escherichia coli to uroplakins Ia and Ib: relation to urinary tract infections. *Proc Natl Acad Sci USA*. 1996;93(18):9630–9635.

Xiao N, Wang Z, Huang Y, et al. Roles of polyuria and hyperglycemia in bladder dysfunction in diabetes. *J Urol*. 2013;189(3):1130–1136.

Xu L, Gebhart GF. Characterization of mouse lumbar splanchnic and pelvic nerve urinary bladder mechanosensory afferents. *J Neurophysiol*. 2008;99(1):244–253.

Yalla SB, Rossier AB, Fam BA, et al. Functional contribution of autonomic innervation to urethral striated sphincter: studies with parasympathomimetic, parasympatholytic and alpha-adrenergic blocking agents in spinal cord injury and control male subjects. *J Urol*. 1977;117(4):494–499.

Yamada T, Ugawa S, Ueda T, et al. Differential localizations of the transient receptor potential channels TRPV4 and TRPV1 in the mouse urinary bladder. *J Histochem Cytochem*. 2009;57(3):277–287.

Yamaguchi O, Shishido K, Tamura K, et al. Evaluation of mRNAs encoding muscarinic receptor subtypes in human detrusor muscle. *J Urol*. 1996;156(3):1208–1213.

Yamaguchi O. Beta3-adrenoceptors in human detrusor muscle. *Urology*. 2002;59(5 Suppl 1):25–29.

Yamamoto T, Hanioka N, Maeda Y, et al. Contribution of tachykinin receptor subtypes to micturition reflex in guinea pigs. *Eur J Pharmacol*. 2003;477(3):253–259.

Yamamoto T, Honbo T, Tokoro K, et al. General pharmacology of the new antimuscarinic compound vamicamide. *Arzneimittelforschung*. 1995;45(12):1274–1284.

Yanagisawa M, Kurihara H, Kimura S, et al. A novel potent vasoconstrictor peptide produced by vascular endothelial cells. *Nature*. 1988;332(6163):411–415.

Yiangou Y, Facer P, Ford A, et al. Capsaicin receptor VR1 and ATP-gated ion channel P2X3 in human urinary bladder. *BJU Int*. 2001;87(9):774–779.

Yin Y, Shuke N, Okizaki A, et al. Cerebral activation during withholding urine with full bladder in healthy men using 99mtc-HMPAO spect. *J Nucl Med*. 2006;47(7):1093–1098.

Yokokawa K, Sakanaka M, Shiosaka S, et al. Three-dimensional distribution of substance p-like immunoreactivity in the urinary bladder of rat. *J Neural Transm*. 1985;63(3–4):209–222.

Yono M, Foster HE Jr, Shin D, et al. Doxazosin-induced up-regulation of alpha 1a-adrenoceptor mRNA in the rat lower urinary tract. *Can J Physiol Pharmacol*. 2004;82(10):872–878.

Yono M, Foster HE Jr, Weiss RM, et al. Age related changes in the functional, biochemical and molecular properties of alpha1-adrenoceptors in the rat genitourinary tract. *J Urol*. 2006;176(3):1214–1219.

Yono M, Tanaka T, Tsuji S, et al. Effects of age and hypertension on alpha1-adrenoceptors in the major source arteries of the rat bladder and penis. *Eur J Pharmacol*. 2011;670(1):260–265.

Yoshida M, Homma Y, Inadome A, et al. Age-related changes in cholinergic and purinergic neurotransmission in human isolated bladder smooth muscles. *Exp Gerontol*. 2001;36(1):99–109.

Yoshida M, Inadome A, Maeda Y, et al. Non-neuronal cholinergic system in human bladder urothelium. *Urology*. 2006;67(2):425–430.

Yoshimura N, Bennett NE, Hayashi Y, et al. Bladder overactivity and hyperexcitability of bladder afferent neurons after intrathecal delivery of nerve growth factor in rats. *J Neurosci*. 2006;26(42):10847–10855.

Yoshimura N, de Groat WC. Increased excitability of afferent neurons innervating rat urinary bladder after chronic bladder inflammation. *J Neurosci*. 1999;19(11):4644–4653.

Yoshimura N, de Groat WC. Neural control of the lower urinary tract. *Int J Urol*. 1997;4(2):111–125.

Yoshimura N, Kaiho Y, Miyazato M, et al. Therapeutic receptor targets for lower urinary tract dysfunction. *Naunyn Schmiedebergs Arch Pharmacol*. 2008;377(4–6):437–448.

Yoshimura N, Seki S, de Groat WC. Nitric oxide modulates Ca(2+) channels in dorsal root ganglion neurons innervating rat urinary bladder. *J Neurophysiol*. 2001;86(1):304–311.

Yoshimura N. Bladder afferent pathway and spinal cord injury: possible mechanisms inducing hyperreflexia of the urinary bladder. *Prog Neurobiol*. 1999;57(6):583–606.

Yoshiyama M, de Groat WC. Supraspinal and spinal alpha-amino-3-hydroxy-5-methylisoxazole-4-propionic acid and n-methyl-d-aspartate glutamatergic control of the micturition reflex in the urethane-anesthetized rat. *Neuroscience*. 2005;132(4):1017–1026.

Yoshiyama M, Roppolo JR, de Groat WC. Effects of GYKI 52466 and CNQX, AMPA/kainate receptor antagonists, on the micturition reflex in the rat. *Brain Res*. 1995;691(1–2):185–194.

Yoshiyama M, Yamamoto T, de Groat WC. Role of spinal alpha(1)-adrenergic mechanisms in the control of lower urinary tract in the rat. *Brain Res*. 2000;882(1–2):36–44.

Yu HJ, Wein AJ, Levin RM. Age-related differential susceptibility to calcium channel blocker and low calcium medium in rat detrusor muscle: response to field stimulation. *Neurourol Urodyn*. 1996;15(5):563–576.

Yu Y, de Groat WC. Sensitization of pelvic afferent nerves in the in vitro rat urinary bladder-pelvic nerve preparation by purinergic agonists and cyclophosphamide pretreatment. *Am J Physiol Renal Physiol*. 2008;294(5):F1146–F1156.

Yucel S, Baskin LS. An anatomical description of the male and female urethral sphincter complex. *J Urol*. 2004;171(5):1890–1897.

Zagorodnyuk VP, Brookes SJ, Spencer NJ, et al. Mechanotransduction and chemosensitivity of two major classes of bladder afferents with endings in the vicinity to the urothelium. *J Physiol*. 2009;587(Pt 14):3523–3538.

Zagorodnyuk VP, Costa M, Brookes SJ. Major classes of sensory neurons to the urinary bladder. *Auton Neurosci*. 2006;126–127 [390–397].

Zagorodnyuk VP, Gibbins IL, Costa M, et al. Properties of the major classes of mechanoreceptors in the guinea pig bladder. *J Physiol*. 2007;585(Pt 1):147–163.

Zderic S, Levin R, et al. Voiding function and dysfunction: relevant anatomy, physiology, pharmacology and molecular biology. Gillenwater J. *Adult and pediatric urology*. Mosby: Chicago; 1996:1159–1219.

Zhang J, Planey SL, Ceballos C, et al. Identification of CKAP4/p63 as a major substrate of the palmitoyl acyltransferase DHHC2, a putative tumor suppressor, using a novel proteomics method. *Mol Cell Proteomics*. 2008;7(7):1378–1388.

Zhao Y, Wein AJ, Bilgen A, et al. Effect of anoxia on in vitro bladder function. *Pharmacology*. 1991;43(6):337–344.

Zhong Y, Dunn PM, Burnstock G. Multiple P2X receptors on guinea-pig pelvic ganglion neurons exhibit novel pharmacological properties. *Br J Pharmacol*. 2001;132(1):221–233.

Zvara P, Vizzard MA. Exogenous overexpression of nerve growth factor in the urinary bladder produces bladder overactivity and altered micturition circuitry in the lumbosacral spinal cord. *BMC Physiol*. 2007;7:9.

Pathophysiology and Classification of Lower Urinary Tract Dysfunction

Overview

Elizabeth Timbrook Brown MD, MPH, Alan J. Wein MD, PhD (Hon), FACS, Roger R. Dmochowski MD, MMHC, FACS

The lower urinary tract (LUT) functions as a group of interrelated structures whose joint function in an adult is to bring about efficient and low-pressure bladder filling, low-pressure urine storage with perfect continence, and periodic complete voluntary urine expulsion also at low pressure. Appropriate sensation should accompany the function of the LUT, meaning that a sense of deferrable bladder fullness should gradually occur between voluntary voids up to a volume that is sufficient to prevent urinary frequency and without any pain or sudden compelling desires to void that are difficult to defer (urgency). Because the LUT in adults is normally under voluntary neural control, it is clearly different from other visceral organs innervated by the autonomic nervous system, whose regulation is solely by involuntary mechanisms.

For the purposes of description and teaching, the micturition cycle is best divided into two relatively discrete phases: bladder filling/urine storage and bladder emptying/voiding. The micturition cycle normally displays these two modes of operation in a simple on-off fashion. The cycle involves switching from inhibition of the voiding reflex and activation of the storage reflexes to inhibition of the storage reflexes and activation of the voiding reflex and back again. This chapter begins with a functional, physiologic, and pharmacologic overview of normal and abnormal LUT function. A simple way of looking at the pathophysiology of all types of voiding dysfunction is then presented, followed by a discussion of various systems of classification and categorization.

Consistent with prior attempts to make the understanding, evaluation, and management of voiding dysfunction as logical and simple as possible (Wein, 1981, 2002; Wein and Barrett, 1988), a functional and practical approach is favored.

Normal Lower Urinary Tract Function: Overview

Two-Phase Concept of Function: Filling/Storage and Emptying/Voiding

Whatever disagreements exist regarding the anatomic, morphologic, physiologic, pharmacologic, and mechanical details involved in the storage and the expulsion of urine by the LUT, "experts" would agree on several general points and guiding principles (Wein, 1981, 2007; Wein and Barrett, 1988; Wein and Moy, 2007). The first is that **the micturition cycle involves two relatively discrete processes: (1) bladder filling and urine storage and (2) bladder emptying or voiding.** The second is that, whatever the details involved, **one can succinctly summarize these processes from a conceptual point of view as follows:**

Bladder filling and urine storage require the following:

- Accommodation of increasing volumes of urine at a low detrusor pressure (normal compliance) and with appropriate sensation
- A bladder outlet that is closed at rest and remains so during increases in intra-abdominal pressure
- Absence of involuntary bladder contractions (detrusor overactivity [DO])

Bladder emptying and voiding require the following:

- A coordinated contraction of the bladder smooth musculature of adequate magnitude and duration
- A concomitant lowering of resistance at the level of the smooth and striated sphincter (no functional obstruction)
- Absence of anatomic (as opposed to functional) obstruction

The **smooth sphincter** refers to the smooth musculature of the bladder neck and proximal urethra. This is a physiologic but not an anatomic sphincter and one that is not under voluntary control. The **striated sphincter** refers to the striated musculature that is a part of the outer wall of the proximal urethra in males and females (this portion is often referred to as the **intrinsic or intramural striated sphincter or rhabdosphincter**). The **striated sphincter** also refers to the bulky skeletal muscle group that closely surrounds the urethra at the level of the membranous portion in males and primarily the middle segment in females (often referred to as the **extrinsic or extramural striated sphincter**). The extramural portion is the classically described **external urethral sphincter** and is under voluntary control (for a detailed discussion see Chapter 110) (Birder et al., 2013; Brading et al., 2001; DeLancey et al., 2002; Zderic et al., 2002).

Mechanisms Underlying the Two Phases of Function: Overview

This section briefly summarizes pertinent points regarding the physiology and pharmacology of the various mechanisms underlying normal bladder filling/storage and emptying/voiding that constitute the pathophysiologic mechanisms seen in the various types of dysfunction of the LUT. The general information is consistent with that detailed in Chapter 110 and in previous source materials and their supporting references (Andersson, 2014; Andersson and Arner, 2004; Andersson and Wein, 2004; Beckel and Holstege, 2011; Birder et al., 2013; de Groat, 2006; de Groat et al., 1993, 1999; de Groat and Yoshimura, 2001; Fowler et al., 2008; Koelbl et al., 2013; Michel and Barendrecht, 2008; Morrison et al., 2005; Mostwin et al., 2005; Ochodnicky et al., 2013; Wein and Barrett, 1988; Yoshimura and Chancellor, 2007; Zderic et al., 2002). Other specific references are provided only when particularly unique or applicable.

Bladder Response During Filling

The normal adult bladder response to filling at a physiologic rate is an almost imperceptible change in intravesical and detrusor pressure. During at least the initial stages of bladder filling, after unfolding of the bladder wall from its collapsed state, this high compliance (Δ volume/Δ pressure) of the bladder is due primarily to its elastic and viscoelastic properties. Elasticity allows the constituents of the bladder wall to stretch to a certain degree without any increase in tension. Viscoelasticity allows stretch to induce an increase in tension followed by a delay (“stress relaxation”) when the filling (stretch stimulus) slows or stops. The viscoelastic properties are considered to be primarily due to the characteristics of the extracellular matrix in the bladder wall. Andersson and Arner (2004) cite references demonstrating that the main extracellular components are elastic fibers and collagen fibrils present in the serosa, between muscle bundles, and between the smooth muscle cells in the muscle bundles. Brading et al. (1999) state that they believe there is continuous contractile activity in the smooth muscle cells to adjust their length during filling but without the type of synchronous activity that would increase intravesical pressure, would impede filling, and could cause urinary leakage. Neal et al. (2017) believe that intrinsic bladder compliance regulation is also dependent on the regulation of actomyosin cross-bridge activity. Clinically and urodynamically, the bladder seems “relaxed.” The urothelium also expands but must preserve its barrier function while doing so.

There may also be a non-neurogenic active component to the storage properties of the bladder. Hawthorn et al. (2000) have suggested that an as yet unidentifiable relaxing factor is released from the urothelium during filling and storage, and Andersson and Wein (2004) and Andersson (2014) have suggested that urothelium-released nitric oxide may have an inhibitory effect on afferent mechanisms as well.

The viscoelastic properties of the stroma (bladder wall less smooth muscle and epithelium) and the urodynamically noncontractile state of the detrusor muscle account for the passive mechanical properties and normal bladder compliance seen during filling. The main components of the stroma are collagen and elastin. In the usual clinical setting, filling cystometry seems to show a slight increase in intravesical pressure, but Klevmark (1974, 1999) elegantly showed that this pressure increase is a function of the fact that cystometric filling is carried out at a greater-than-physiologic rate and that, at physiologic filling rates, there is essentially no increase in bladder pressure until bladder capacity is reached.

When the collagen component of the bladder wall increases, compliance decreases. This can occur with chronic inflammation, bladder outlet obstruction, neurologic decentralization, and various other types of injury. Bladder muscle hypertrophy, which can result from outlet obstruction, can also result in decreased compliance because hypertrophic muscle is said to be less elastic than normal detrusor; it also can synthesize increased amounts of collagen (Mostwin, 2006). **Once decreased compliance has occurred because of a replacement**

by collagen of other components of the stroma, it is generally unresponsive to pharmacologic manipulation.

Does the nervous system affect the normal bladder response to filling? At a certain level of bladder filling, **spinal sympathetic reflexes** facilitatory to bladder filling/storage are clearly evoked in animals, a concept developed over the years by de Groat and others (see Chapter 110) (de Groat et al., 1993; de Groat and Yoshimura, 2001; Chancellor and Yoshimura, 2002; Yoshimura and Chancellor, 2007; Zderic et al., 2002), who have also cited indirect evidence to support such a role in humans. **This inhibitory effect is thought to be mediated primarily by sympathetic modulation of cholinergic ganglionic transmission.** Through this reflex mechanism, **two other possibilities exist for promoting filling and storage.** One is neurally mediated stimulation of the predominantly α-adrenergic receptors (α_1) in the area of the smooth sphincter, the net result of which would be to cause an increase in resistance in that area. The second is neurally mediated stimulation of the predominantly β-adrenergic receptors (β_3 inhibitory) in the bladder body smooth musculature, which would cause a decrease in bladder wall tension, promoting bladder relaxation. McGuire et al. (1983) have also proposed a direct inhibition of detrusor motor neurons in the sacral spinal cord during bladder filling related to increased afferent pudendal nerve activity generated by receptors in the striated sphincter. **Good evidence also seems to support an inhibitory effect of other neurotransmitters (e.g., glycine, γ-aminobutyric acid, opioids, purines, the noradrenergic system) on the micturition reflex at various levels of the neural axis.** Bladder filling and consequent wall distention may also result in the release of factors from the urothelium that may influence contractility (e.g., acetylcholine, adenosine triphosphate, nitric oxide, prostaglandins, other peptides, as yet unidentified inhibitory factors). Despite these findings, current urodynamic technology does not accurately measure underlying detrusor wall tension (Habteyer et al., 2017).

Outlet Response During Filling

There is a gradual increase in proximal urethral pressure during bladder filling, contributed to at least by the striated sphincteric element and perhaps by the smooth sphincteric element as well. The increase in urethral pressure seen during the filling/storage phase of micturition can be correlated with an increase in efferent pudendal nerve impulse frequency and in electromyographic activity of the striated sphincter. This constitutes the efferent limb of a spinal somatic reflex, the so-called guarding reflex, which results in a gradual increase in striated sphincter activity during normal bladder filling and storage. Although it seems logical and compatible with neuropharmacologic, neurophysiologic, and neuromorphologic data to assume that the muscular component of the smooth sphincter also contributes to the change in urethral response during bladder filling, probably through sympathetically induced contraction, it is extremely difficult to prove this experimentally or clinically. The direct and circumstantial evidence in favor of such a hypothesis has been summarized by Andersson (2014), Andersson and Wein (2004), Birder et al. (2013), Brading (1999), and Wein and Barrett (1988).

The passive properties of the urethral wall warrant mention because these undoubtedly play a role in the maintenance of continence (Brading, 1999; Zinner et al., 1983). Urethral wall tension develops within the outer layers of the urethra; however, urethral pressure is a product not only of the active characteristics of smooth and striated muscle but also of the passive characteristics of the elastic, collagenous, and vascular components of the urethral wall because this tension must be exerted on a soft or plastic inner layer capable of being compressed to a closed configuration—the **“filler material”** representing the submucosal portion of the urethra. The softer and more pliable this area is, the less pressure is required by the tension-producing area to produce continence. Finally, whatever the compressive forces, the lumen of the urethra must be capable of being obliterated by a watertight seal. This **“mucosal seal mechanism”** explains why a thin-walled rubber tube requires less pressure to close an open end when the inner layer is coated with a fine layer of grease than when it is not; the latter case is akin to scarred or atrophic urethral mucosa.

Voiding With a Normal Bladder Contraction

Although many factors are involved in the initiation of micturition, in adults, **increased intravesical pressure producing the sensation of distention is primarily responsible for the initiation of normal voluntarily induced emptying of the LUT. Although the origin of the parasympathetic neural outflow to the bladder, the pelvic nerve, is in the sacral spinal cord, the actual coordinating center for the micturition reflex in an intact neural axis is in the rostral brainstem.** The complete neural circuit for normal micturition includes the ascending and descending spinal cord pathways to and from this area and the facilitatory and inhibitory influences from other parts of the brain, particularly the cerebral cortex. **The final step in voluntarily induced micturition involves inhibition of the somatic neural efferent activity to the striated sphincter and an inhibition of all aspects of any spinal sympathetic reflexes evoked during filling. Efferent parasympathetic pelvic nerve activity is ultimately what is responsible for a highly coordinated contraction of the bulk of the bladder smooth musculature.**

A decrease in outlet resistance occurs with adaptive shaping or funneling of the relaxed bladder outlet. Besides the inhibition of any continence-promoting reflexes that have occurred during bladder filling, the change in outlet resistance may also involve an active relaxation of the smooth sphincter area through a noradrenergic noncholinergic mechanism, proposed to be mediated by nitric oxide (Andersson, 2014; Andersson and Arner, 2004; Andersson and Wein, 2004; Birder et al., 2013). The adaptive changes that occur in the outlet are probably also due at least in part to the anatomic interrelationships of the smooth muscle of the bladder base and proximal urethra. Longitudinal smooth muscle continuity (see Chapter 110) (Mostwin, 2006) would promote shortening and widening of the proximal urethra during a coordinated emptying bladder contraction. Other reflexes elicited by bladder contraction and by the passage of urine through the urethra may reinforce and facilitate complete bladder emptying. Superimposed on these autonomic and somatic reflexes are complex, modifying supraspinal inputs from other central neuronal networks. These facilitatory and inhibitory impulses, which originate from several areas of the nervous system, allow the full conscious control of micturition in the adult.

Urinary Continence During Abdominal Pressure Increases

During voluntarily initiated micturition, the bladder pressure becomes higher than the outlet pressure, and certain adaptive changes occur in the shape of the bladder outlet with consequent passage of urine into and through the proximal urethra. One could reasonably ask: **Why do such changes not occur with increases in intravesical pressure that are similar in magnitude but that are produced only by changes in intra-abdominal pressure such as straining or coughing?** First, a coordinated bladder contraction does not occur in response to such stimuli, emphasizing the fact that increases in total intravesical pressure are by no means equivalent to emptying ability. Second, for urine to flow into and through the proximal urethra in an individual who does not have sphincteric incontinence, there must be (1) an increase in intravesical/detrusor pressure that is primarily a product of a coordinated, neurally mediated bladder contraction and that is (2) associated with characteristic tension and conformational changes in the bladder neck and proximal urethral areas.

Assuming that the bladder outlet is competent at rest, a major factor required for the prevention of urinary leakage during increases in intra-abdominal pressure is the presence of **at least equal pressure transmission to the proximal urethra (the mid-urethra as well in women) during such activity.** This phenomenon was first described by Enhorning (1961) and has been confirmed in virtually every urodynamic laboratory since that time. **Failure of this mechanism is an invariable correlate of effort-related urinary incontinence in women and men. The urethral closure pressure increases with increments in intra-abdominal pressure, indicating that active muscular function related to a reflex increase in striated sphincter activity or other factors that increase urethral resistance is also involved in preventing such leakage.** Tanagho (1978) was the first to provide direct evidence of this. A more complete description of the factors involved in sphincteric incontinence can be found later in this chapter, in Chapter 110, and in the work of Koelbl et al. (2013).

Sensory Aspects

Most of the afferent input from the bladder and urethra reaches the spinal cord through the pelvic nerve and dorsal root ganglia, and some reaches the spinal cord through the hypogastric nerve. Afferent input from the striated muscle of the sphincter and pelvic floor travels in the pudendal nerve. The most important afferents for initiating and maintaining normal micturition are those in the pelvic nerve, relaying to the sacral spinal cord. These convey impulses from tension, volume, and nociceptive receptors located in the serosal, muscle, and urothelial and suburothelial layers of the bladder and urethra. In a neurologically normal adult, the sensation of filling and distention, but not urgency or pain, develops during normal filling/storage and initiates the reflexes responsible for emptying/voiding (see Chapter 110) (Birder et al., 2013; Chancellor and Yoshimura, 2002; de Groat and Yoshimura, 2001; Morrison et al., 2005). Alterations in this finely tuned pathway can be responsible for significant alterations in LUT function.

Micturition Cycle: Simplification and Overview

Filling/Storage

Bladder accommodation during filling is a primarily passive phenomenon dependent on the elastic and viscoelastic properties of the bladder wall and the lack of parasympathetic excitatory input. An increase in outlet resistance occurs by means of the striated sphincter somatic guarding reflex. In some species, a sympathetic reflex also contributes to storage by (1) increasing outlet resistance through increased tension in the smooth sphincter, (2) inhibiting bladder contractility through an inhibitory effect on parasympathetic ganglia, and (3) causing a decrease in tension of bladder body smooth muscle. Continence is maintained during increases in intra-abdominal pressure by the intrinsic competence of the bladder outlet (bladder neck and proximal urethra/mid-urethra) and the pressure transmission ratio to this area with respect to the intravesical contents. A further increase in striated sphincter activity, on a reflex basis, is also contributory.

Emptying/Voiding

Emptying/voiding can be voluntary or involuntary and involves an inhibition of the spinal somatic and sympathetic reflexes and activation of the vesical parasympathetic pathways, the organizational center for which is in the rostral brainstem. Initially, there is a decrease in outlet resistance, mediated not only by the cessation of the somatic and sympathetic spinal reflexes but possibly also by a relaxing factor released by parasympathetic stimulation or by some effect of bladder smooth muscle contraction. A highly coordinated, parasympathetically induced contraction of the bulk of the bladder smooth musculature occurs, with shaping or funneling of the relaxed outlet, at least partially because of smooth muscle continuity between the bladder base and the proximal urethra. With amplification and facilitation of the bladder contraction from other peripheral reflexes and from spinal cord supraspinal sources, and in the absence of anatomic or functional obstruction between the bladder and urethral meatus, complete emptying occurs.

Abnormalities of Filling/Storage and Emptying/Voiding: Overview of Pathophysiology

Excluding psychological reasons, the pathophysiology of failure of the LUT in an adult to fill with or store urine adequately or to empty adequately must logically be secondary to reasons related to the bladder, the outlet, or a combination (Wein, 1981; Wein and Barrett, 1988). This division provides a logical rationale for discussion and classification of all types of LUT dysfunction (Box 111.1).

Box 111.1

Simple Functional Classification of Lower Urinary Tract Dysfunction

Failure to Store

Because of the bladder
Because of the outlet

Failure to Empty

Because of the bladder
Because of the outlet

There are some types of dysfunction that represent combinations of filling/storage and emptying/voiding abnormalities (e.g., detrusor overactivity and sphincter dyssynergia in a patient with a suprasacral spinal cord injury; DO during filling/storage, detrusor underactivity during emptying). However, within this scheme these have become readily understandable and detectable, and the treatment dilemmas have been logically described. Failure in either category is not absolute but more often is relative. The system can be easily expanded and made more detailed to include etiologic or specific urodynamic connotations

(Box 111.2). However, the simplified system is perfectly workable and avoids argument in complex situations in which the exact cause or mechanism for a dysfunction cannot be established.

Box 111.2

Expanded Functional Classification of Lower Urinary Tract Dysfunction

- I. Failure to store
  - A. Because of the bladder
    - 1. Overactivity
      - a. Involuntary contractions (detrusor overactivity)
        - (1) Neurologic disease, injury, or degeneration
        - (2) Bladder outlet obstruction
        - (3) Increased afferent input or sensitivity
        - (4) Inflammation
        - (5) Increased neurotransmitter release
        - (6) Increased sensitivity to transmitter
        - (7) Decreased inhibitory pelvic floor activity
        - (8) Idiopathic
      - b. Decreased compliance
        - (1) Neurologic disease or injury
        - (2) Fibrosis
        - (3) Bladder muscle hypertrophy
        - (4) Idiopathic
      - c. Combination
    - 2. Hypersensitivity
      - a. Inflammatory/infectious
      - b. Neurologic
      - c. Increased neurotransmitter release or sensitivity
      - d. Psychological
      - e. Idiopathic
    - 3. Underactivity (with retention and overflow incontinence)
    - 4. Combination
  - B. Because of the outlet

    1. Genuine stress urinary incontinence
        a. Lack of suburethral support
        b. Pelvic floor laxity, hypermobility
    2. Intrinsic sphincter deficiency
        a. Neurologic disease or injury
        b. Fibrosis
    3. Combination (genuine stress urinary incontinence and intrinsic sphincter deficiency)
  C. Combination (bladder and outlet factors)
  D. Fistula

II. Failure to empty
  A. Because of the bladder (underactivity)
    1. Neurogenic (includes iatrogenic causes)
    2. Myogenic
    3. Psychogenic
    4. Idiopathic
  B. Because of the outlet
    1. Anatomic
        a. Prostatic obstruction
        b. Bladder neck contracture
        c. Urethral stricture
        d. Urethral compression, fibrosis
    2. Functional
        a. Striated sphincter dyssynergia (neurogenic)
        b. Smooth sphincter dyssynergia or dysfunction (bladder neck dysfunction)
        c. Dysfunctional voiding (non-neurogenic)
  C. Combination

Using this concept, all aspects of urodynamic and video-urodynamic evaluation can be conceptualized regarding exactly what they evaluate in terms of either bladder or outlet activity during filling/storage or emptying/voiding (Table 111.1). Treatments can be classified under these broad categories as to whether they facilitate filling/storage or emptying/voiding and whether they do so by acting primarily on the bladder or on one or more components of the bladder outlet (Boxes 111.3 and 111.4).

TABLE 111.1

Urodynamics Simplified

	BLADDER	OUTLET
Filling/storage phase	Pves[a] Pdet[b] (FCMG[c])	UPP[d]
	DLPP[e]	VLPP[f]
Emptying phase	Pves[g] Pdet[h] (VCMG)[i]	FLUORO[j]
		MUPP[k]
		FLUORO[l]
		EMG[m]
	(_________________ _________________)	
	_____________ FLOW[n] _______________	
	_____________ RU[o] ____________________	

[a,b] Total bladder (Pves) and detrusor (Pdet) pressures during a filling cystometrogram (FCMG).

[c] Filling cystometrogram.

[d] Urethral pressure profilometry.

[e] Detrusor leak point pressure.

[f] Valsalva leak point pressure.

[g,h] Total bladder and detrusor pressures during a voiding cystometrogram (VCMG).

[i] Voiding cystometrogram.

[j] Fluoroscopy of outlet during filling/storage.

[k] Micturitional urethral pressure profilometry.

[l] Fluoroscopy of outlet during emptying.

[m] Electromyography of periurethral striated musculature.

[n] Flowmetry.

[o] Residual urine.

This functional conceptualization of urodynamics categorizes each study as to whether it examines bladder or outlet activity during the filling/storage or emptying phase of micturition. In this scheme, uroflow and residual urine integrate the activity of the bladder and the outlet during the emptying phase.

Box 111.3

Functional Categorization of Therapy to Facilitate Urine Storage/Bladder Filling

I. Bladder related (decreasing intravesical pressure, inhibitors, detrusor contractility, increasing bladder capacity)
  A. Behavioral therapy (including any or all of the following)
    1. Education
    2. Bladder training
    3. Timed bladder emptying or prompted voiding
    4. Fluid restriction
    5. Pelvic floor physiotherapy ± biofeedback
  B. Pharmacologic therapy (oral, intravesical, intradetrusor)
    1. Antimuscarinic agents
    2. Drugs with mixed actions
    3. β-Adrenergic agonists
    4. Botulinum toxin
    5. Calcium antagonists
    6. Potassium channel openers
    7. Prostaglandin inhibitors
    8. α-Adrenergic antagonists
    9. Tricyclic antidepressants; serotonin and norepinephrine reuptake inhibitors
    10. Dimethyl sulfoxide
    11. Polysynaptic inhibitors
    12. Capsaicin, resiniferatoxin, and similar agents
  C. Bladder overdistention
  D. Electrical stimulation (sacral neuromodulation, posterior tibial and other peripheral nerve stimulation)
  E. Acupuncture and electroacupuncture
  F. Interruption of innervation
    1. Very central (subarachnoid block)
    2. Less central (sacral rhizotomy, selective sacral rhizotomy)
    3. Peripheral motor and/or sensory
  G. Augmentation cystoplasty (autoaugmentation, bowel, tissue engineering)

II. Outlet related (increasing outlet resistance)
  A. Behavioral therapy (see I. A.)
  B. Electrical stimulation
  C. Pharmacologic therapy

        1. α-Adrenergic agonists
        2. Tricyclic antidepressants; serotonin and norepinephrine reuptake inhibitors
        3. β-Adrenergic antagonists, agonists
    D. Vaginal and perineal occlusive and/or supportive devices; urethral plugs
    E. Nonsurgical periurethral bulking
        1. Synthetics
        2. Tissue engineering
    F. Retropubic vesicourethral suspension ± prolapse repair (female)
    G. Sling procedures ± prolapse repair (female)
    H. Mid-urethral tapes ± prolapse repair (female)
    I. Perineal sling procedure (male)
    J. Artificial urinary sphincter
    K. Myoplasty (muscle transposition)
    L. Bladder outlet closure

III. Circumventing the problem
    A. Absorbent products
    B. External collecting devices
    C. Antidiuretic hormone–like agents
    D. Short-acting diuretics
    E. Intermittent catheterization
    F. Continuous catheterization
    G. Urinary diversion

Box 111.4

Functional Categorization of Therapy to Facilitate Bladder Emptying and Voiding

I. Bladder related (increasing intravesical pressure or facilitating/augmenting bladder contractility)
    A. External compression, Valsalva
    B. Promotion or initiating of reflex contraction
        1. Trigger zones or maneuvers
        2. Bladder "training"; tidal drainage

- C. Pharmacologic therapy (oral, intravesical)
  - 1. Parasympathomimetic agents
  - 2. Prostaglandins
  - 3. Blockers of inhibition
    - a. α-Adrenergic antagonists
    - b. Opioid antagonists
- D. Electrical stimulation
  - 1. Directly to the bladder or spinal cord
  - 2. Directly to the nerve roots
  - 3. Intravesical (transurethral)
  - 4. Neuromodulation
- E. Reduction cystoplasty
- F. Bladder myoplasty (muscle wrap)
- G. Tissue engineering

II. Outlet related (decreasing outlet resistance)

- A. At a site of anatomic obstruction
  - 1. Pharmacologic therapy—decrease prostate size or tone
    - a. α-Adrenergic antagonists
    - b. α-Reductase inhibitors
    - c. Luteinizing hormone–releasing hormone agonists/antagonists
    - d. Antiandrogens
  - 2. Prostatectomy, prostatotomy (diathermy, heat, laser, stapling)
  - 3. Bladder neck incision or resection
  - 4. Urethral stricture repair or dilation
  - 5. Intraurethral devices
  - 6. Balloon dilation of stricture/contracture
- B. At level of smooth sphincter
  - 1. Pharmacologic therapy
    - a. α-Adrenergic antagonists
    - b. β-Adrenergic agonists
    - c. Botulinum toxin (injection)
  - 2. Transurethral resection or incision
  - 3. Reconstruction
- C. At level of striated sphincter
  - 1. Behavioral therapy ± biofeedback
  - 2. Pharmacologic therapy
    - a. Benzodiazepines

        - b. Baclofen
        - c. Dantrolene
        - d. α-Adrenergic antagonists
        - e. Botulinum toxin (injection)
    - 3. Surgical sphincterotomy
    - 4. Pudendal nerve interruption
- D. Circumventing the underlying problem
    - 1. Intermittent catheterization
    - 2. Continuous catheterization
    - 3. Urinary diversion (conduit or reservoir)

Filling and Storage Failure

Absolute or relative failure of the bladder to fill with and store urine adequately results from bladder overactivity (involuntary contraction and/or decreased compliance), decreased outlet resistance, heightened or altered sensation, or a combination.

Bladder Overactivity

Overactivity of the bladder during filling/storage can be expressed as phasic involuntary contractions, as low compliance, or as a combination. Involuntary contractions are most commonly seen in association with neurologic disease or injury, bladder outlet obstruction, stress urinary incontinence (perhaps because of sudden entry of urine into the proximal urethra, eliciting a reflex contraction), or aging (probably related to neural degeneration), or they may be truly idiopathic. These bladder abnormalities may also lead to the development of micromotions, which may generate afferent activity leading to DO (Vahabi and Drake, 2015). However, they may also be associated with increased afferent input related to inflammation or irritation of the bladder or urethral wall or an increased sensitivity (decreased threshold of activation to a normal amount of transmitter). Excitatory neurotransmitters may be released from the urothelium during filling/storage and activate afferent receptors/nerves, ultimately resulting, in some individuals, in involuntary contractions or altered (heightened) sensation: a premature sensation of distention or fullness, true urgency (a sudden compelling desire to void, which is difficult to defer), or pain. If an individual has urgency urinary incontinence, it can be assumed that an involuntary contraction (DO) has occurred. The symptom of urgency without incontinence suggests DO, but this is often not demonstrable on urodynamic study. Conversely, urodynamically demonstrable DO may not be associated with clinically troublesome filling/storage symptoms.

The possible pathophysiologies of the symptom syndrome "overactive bladder" (defined by the International Continence Society [ICS] as urgency with or without urge incontinence, usually with frequency and nocturia) can be summarized as (1) reduced supraspontine inhibition, (2) damaged axonal paths in the spinal cord, (3) damaged axonal paths in the periphery, (4) loss of peripheral inhibition, (5) enhancement of excitatory neurotransmission in the micturition reflex pathway, (6) increased LUT afferent input, or (7) idiopathic. Staskin (2001) and Mostwin et al. (2005) also hypothesized that decreased stimulation from the pelvic floor can contribute to phasic bladder overactivity. **Decreased compliance** during filling/storage may be secondary to neurologic injury or disease, usually at a sacral or infrasacral level but may result from any process that impairs or destroys the viscoelastic or elastic properties of the bladder wall. As such, a compliance abnormality can be seen with increased collagen deposition resulting from longstanding bladder outflow obstruction.

Filling and Storage Failure Resulting From Altered Sensation

Bladder-related storage failure may also occur in the absence of overactivity because of increased afferent input from inflammation, irritation, other causes of hypersensitivity, and pain. The causes may be chemical, psychological, or idiopathic. One classic example is termed *bladder pain syndrome* (also known as *interstitial cystitis*; see Chapter 57). Increased afferent activity can be responsible for true DO (an involuntary contraction), true urgency without DO, a premature feeling of fullness or distention without urgency or DO, or the sensation of pain during filling.

Outlet Underactivity

Decreased outlet resistance may result from any process that damages the innervation of structural elements of the smooth or striated sphincter, or both, or damages or impairs the support of the bladder outlet in women. This process may occur with neurologic disease or injury, surgical or other mechanical trauma, or aging. Classically, sphincteric incontinence in a woman was categorized into relatively discrete entities: (1) so-called genuine stress incontinence and (2) intrinsic sphincter deficiency (ISD), originally described as “type III stress incontinence” (DeLancey, 1994; Koelbl et al., 2013; Mostwin et al., 2005) (see Chapters 110). Genuine stress incontinence in women was described as associated with hypermobility of the bladder outlet because of poor pelvic support and with an outlet that was competent at rest but lost its competence only during increases in intra-abdominal pressure. ISD described a nonfunctional or poorly functional bladder neck and proximal urethra at rest. The implication of classic ISD was that a surgical procedure designed to correct only urethral hypermobility would have a relatively high failure rate, as opposed to one designed to improve urethral coaptation and compression. The contemporary view is that most cases of effort-related incontinence in women involve varying proportions of support-related factors and ISD. It is possible to have outlet-related incontinence that is due only to ISD but not due solely to hypermobility or poor support—some ISD must exist.

Stress or effort-related urinary incontinence is a symptom that arises primarily from damage to muscles, nerves, or connective tissue, or a combination, within the pelvic floor (DeLancey et al., 2002; Koelbl et al., 2013; Mostwin et al., 2005; Welk et al., 2015). Urethral support is important in women, the urethra normally being supported by the action of the levator ani muscles through their connection to the endopelvic fascia of the anterior vaginal wall. Damage to the connection between this fascia and this muscle, damage to the relevant nerve supply, or direct muscle damage can influence continence. Bladder neck function is likewise important, and loss of normal bladder neck closure can result in incontinence despite normal urethral support. Previously, the urethra was sometimes ignored as a factor contributing to continence in women, and the site of continence was thought to be exclusively the bladder neck. However, in approximately 50% of continent women, urine enters the urethra during increases in abdominal pressure. The continence point in these women (highest point of pressure transmission) is at the mid-urethra.

Urethral hypermobility implies weakness of the pelvic floor support structures. During increases in intra-abdominal pressure, there is descent of the bladder neck and proximal urethra. If the outlet opens concomitantly, stress urinary incontinence ensues. In the classic form of urethral hypermobility, there is rotational descent of the bladder neck and urethra. The urethra may also descend without rotation (it shortens and widens), or the posterior wall of the urethra may be pulled (sheared) open while the anterior wall remains fixed. However, urethral hypermobility is often present in women who are not incontinent, and the mere presence of urethral hypermobility is insufficient to make a diagnosis of a sphincter abnormality unless urinary incontinence is also demonstrated. The **“hammock hypothesis”** of DeLancey (1994) proposes that for stress incontinence to occur with hypermobility, there must be a lack of stability of the suburethral supportive layer. This theory proposes that the effect of abdominal pressure increases on the normal bladder outlet, if the suburethral supportive layer is firm, is to compress the urethra rapidly and effectively. If the supportive suburethral layer is lax and/or movable, compression is not as effective. **Intrinsic sphincter dysfunction** denotes an intrinsic malfunction of the urethral sphincter mechanism. In its most overt form, it is characterized by a bladder neck that is open at rest and a low abdominal leak point pressure and urethral closure pressure (see Chapter 114) and is usually the result of prior surgery, trauma with scarring, or a neurologic lesion.

Urethral instability refers to the rare phenomenon of episodic decreases in outlet pressure unrelated to increases in bladder or abdominal pressure. Although rarely seemingly demonstrable, many authors believe that the decrease in urethral pressure usually represents simply the urethral component of what would otherwise be a bladder contraction/urethral relaxation in an individual whose bladder does not measurably contract, for either myogenic or neurogenic reasons. There has been a paucity of new data since the last edition of this text.

In theory at least, categories of outlet-related incontinence in men are similar to the categories in women. However, sphincteric incontinence in men is not associated with hypermobility of the bladder neck and proximal urethra but is similar to what is termed *intrinsic sphincter dysfunction* in women. There is almost no information on the topic of urethral instability in men.

The treatment of filling/storage abnormalities is directed toward inhibiting bladder contractility, decreasing sensory output, mechanically increasing bladder capacity, or increasing outlet resistance, the last either continuously or just during increases in intra-abdominal pressure.

Emptying and Voiding Failure

Absolute or relative failure to empty the bladder results from decreased bladder contractility (a decrease in magnitude, coordination, or duration), increased outlet resistance, or a combination.

Bladder Underactivity

Absolute or relative failure of bladder contractility may result from temporary or permanent failure or impairment in one of the neuromuscular mechanisms necessary for initiating and maintaining a normal detrusor contraction. Inhibition of the voiding reflex in a neurologically normal individual may also occur; it may be by a reflex mechanism secondary to increased afferent input, especially from the pelvic and perineal areas, or may be psychogenic. Iatrogenic causes such as surgery for colorectal, urologic, and gynecologic pathology may also lead to underactive bladder (Osman et al., 2014). Non-neurogenic causes also include impairment of bladder smooth muscle function, which may result from overdistention, various centrally or peripherally acting drugs, severe infection, or fibrosis. Diabetes mellitus may lead to bladder underactivity resulting from a combination of neuromuscular and vascular causes (Osman et al., 2014).

Outlet Overactivity or Obstruction

The ICS defines bladder outflow obstruction as a reduced urine flow rate and/or presence of a raised postvoid residual and an increased detrusor pressure. Pathologically increased outlet resistance is much more common in men than in women. Although it is most often secondary to anatomic obstruction, it may be secondary to a failure of relaxation or active contraction of the striated or smooth sphincter during bladder contraction (see Chapter 116). **Striated sphincter dyssynergia** is a common cause of functional (nonanatomic as opposed to fixed anatomic) obstruction in patients with neurologic disease or injury. Except for the true smooth sphincter contraction, which occurs in conjunction with autonomic dysreflexia, true dyssynergia at the level of the bladder neck–proximal urethra is unusual. Incomplete opening of an anatomically normal bladder neck during voluntary or involuntary voiding is termed *bladder neck dysfunction* and is an uncommon entity found almost exclusively in young and middle-aged men (also sometimes known as *primary bladder neck obstruction* or *dysfunctional bladder neck*) (see Chapter 116). Common causes of **anatomic outlet obstruction in men** include prostatic enlargement, bladder neck contracture, and urethral stricture. A common cause of bladder **outlet obstruction (BOO) in women** is compression or fibrosis after surgery for sphincteric incontinence. Regardless of cause, the typical hallmark of BOO is the urodynamic identification of an elevated detrusor pressure to produce a diminished flow across the outlet.

The treatment of emptying failure generally consists of maneuvers to increase intravesical/detrusor pressure, facilitate the micturition reflex, decrease outlet resistance, or a combination of these. Prompt intervention is recommended because long-term obstruction can lead to anatomic and functional changes in the detrusor (hypertrophy, collagen deposition, bladder diverticuli, detrusor overactivity) as well as alteration in neural networks (de Groat et al., 2015). If other means fail or are impractical, intermittent (or continuous) catheterization is an effective way to circumvent emptying failure.

Classification Systems

On the basis of the data obtained from the neurourologic evaluation, a given LUT dysfunction can be categorized in an ever-increasing number of descriptive systems. The **purpose of any classification system** should be to facilitate understanding and management and to avoid confusion among those who are concerned with the problem for which the system was designed. A good classification system should serve as **intellectual shorthand** and should convey, in a few key words or phrases, the essence of a clinical situation. An ideal system for all types of voiding dysfunction would include or imply several factors: (1) the conclusions reached from urodynamic testing, (2) expected clinical symptoms, and (3) approximate site and type of a neurologic lesion or lack of one. If the various categories accurately portray pathophysiology, treatment options should be obvious, and a treatment "menu" should be evident. **Most classification systems for voiding dysfunction were formulated primarily to describe dysfunction secondary to neurologic disease or injury. The ideal system should be applicable to all types of voiding dysfunction.** On the basis of the data obtained from the neurourologic evaluation, a given voiding dysfunction can be categorized in many descriptive systems. **No one system is perfect.** The major systems or types of systems in use are reviewed here with their advantages and applicability. Understanding the rationale and shortcomings of each system significantly improves knowledge of LUT function and dysfunction.

Functional System

Classification of voiding dysfunction can be formulated on a simple functional basis, describing the dysfunction in terms of whether the deficit produced is primarily one of the filling/storage or the emptying/voiding phase of micturition (see Box 111.1) (Wein, 1981; Wein and Barrett, 1988). The genesis of such a system was proposed initially by Scott's group (Quesada et al., 1968). This simple scheme assumes only that, whatever their differences, all "experts" would agree on the two-phase concept of micturition (filling/storage and emptying/voiding), on the simple overall mechanisms underlying the normality of each phase (see previous discussion), and on the possibilities for dysfunction.

The expansion of this concept to encompass all types of LUT dysfunction

(see Box 111.2) **and categorize urodynamic and video-urodynamic studies** (see Table 111.1) **has been previously discussed. In addition, all known treatments for voiding dysfunction may be classified easily under the broad categories of whether they facilitate filling/storage and emptying/voiding and whether they do so by an action primarily on the bladder or on one or more of the components of the bladder outlet** (see Boxes 111.3 and 111.4).

Failure in either category generally is not absolute but more often is relative. Such a functional system can easily be "expanded" and made more complicated to include etiologic or specific urodynamic connotations (see Box 111.4). However, the simplified system is workable and avoids argument in complex situations in which the exact cause or urodynamic mechanism for a voiding dysfunction cannot be definitively identified.

Proper use of the functional system for a given voiding dysfunction requires a reasonably accurate notion of what the urodynamic data show. However, **an exact diagnosis is not required for treatment. Some patients do not have only a discrete storage or emptying failure, and the existence of combination deficits must be recognized to use this system classification properly.** For example, the "classic" T10 paraplegic patient after spinal shock generally exhibits a relative failure of storage because of involuntary bladder contraction and a relative failure to empty the bladder because of striated sphincter dyssynergia. With such a combination deficit, to use this classification system as a guide to treatment relies on the assumption that one of the deficits is primary and that significant improvement will result from its treatment alone or that the voiding dysfunction can be converted primarily to a disorder of either storage or emptying by means of nonsurgical or surgical therapy. The resultant deficit can then be treated or circumvented. Using this example, the combined deficit in a patient with T10 paraplegia can be converted primarily to a storage failure by procedures directed at the dyssynergic striated sphincter; the resultant storage failure (secondary to involuntary contraction) can be circumvented (in a man) with an external collecting device. Alternatively, the deficit can be converted primarily to an emptying failure by pharmacologic or surgical measures designed to abolish or reduce the involuntary contraction, and the resultant emptying failure can be circumvented with clean intermittent catheterization. Other examples of combination deficits include impaired bladder contractility or overactivity with sphincter dysfunction, BOO with DO, BOO with sphincter malfunction, and detrusor filling/storage overactivity with impaired emptying contractility.

One advantage of this functional classification is that it allows the clinician the liberty of "playing" with the system to suit his or her own preferences without an alteration in the basic concept of "keep it simple but accurate and informative." For instance, one could easily substitute the terms *overactive* or *oversensitive bladder* and *underactive outlet* for *because of the bladder* and *because of the outlet* under "Failure to Store" in Box 111.1. One could choose to categorize the bladder reasons for overactivity (see Box 111.2) further in terms of neurogenic, myogenic, or anatomic causes and subcategorize neurogenic further in terms of decreased inhibitory control, increased afferent activity, and increased sensitivity to efferent activity. The system is flexible.

The classification system proposed by the ICS (Box 111.5) is **an extension of a urodynamic classification system.** The storage and voiding phases of micturition are described separately, and, within each phase, various designations are applied to describe bladder and urethral function (Abrams et al., 1988, 1992). Some of the definitions were changed by the standardization subcommittee of the ICS in 2002, and the relevant changes are indicated here (Abrams et al., 2002, 2003). **Normal bladder function during filling/storage implies no significant increases in detrusor pressure (stability). Overactive detrusor function indicates the presence of "involuntary detrusor contractions during the filling phase, which may be spontaneous or provoked."** If the condition is caused by neurologic disease, the term ***neurogenic detrusor overactivity*** is applied. If not, the term ***idiopathic detrusor overactivity*** is applied. **Bladder sensation** can be categorized only in qualitative terms as indicated. **Bladder capacity and compliance** (Δ volume/Δ pressure) are cystometric measurements. Bladder capacity can refer to cystometric capacity, maximum cystometric capacity, or maximum anesthetic cystometric capacity (Abrams et al., 2002). **Normal urethral function during filling/storage indicates a positive urethral closure pressure (urethral pressure minus bladder pressure) even with increases in intra-abdominal pressure, although it may be overcome by DO. Incompetent urethral function during filling/storage** implies urine leakage in the absence of a detrusor contraction. This leakage may be due to genuine stress incontinence, intrinsic sphincter dysfunction, a combination, or an involuntary decrease in urethral pressure in the absence of detrusor contraction.

Box 111.5

International Continence Society Classification

STORAGE PHASE	VOIDING PHASE
BLADDER FUNCTION	**BLADDER FUNCTION**
Detrusor activity	Detrusor activity
Normal or stable	Normal
Overactive	Underactive
Neurogenic	Acontractile
Idiopathic	Areflexic
Bladder sensation	**URETHRAL FUNCTION**
Normal	Normal
Increased or hypersensitive	Abnormal
Reduced or hyposensitive	Mechanical obstruction
Absent	Overactivity
Bladder capacity	Dysfunctional voiding
Normal	Detrusor sphincter dyssynergia
High	Nonrelaxing urethral sphincter dysfunction
Low	
BLADDER COMPLIANCE	
Normal	
High	
Low	
URETHRAL FUNCTION	
Normal closure mechanism	
Incompetent closure mechanism	

Modified from Abrams P, Blaivas J, Stanton S, et al.: ICS standardization of terminology of LUT function. *Scand J Urol Nephrol* 114:5–19, 1988; Abrams P, Blaivas J, Stanton S, et al.: ICS 6th report on the standardization of terminology of LUT function. *Neurol Urodyn* 11:593–603, 1992; and Abrams P, Cardozo L, Fall M, et al.: The standardization of terminology in LUT function: report from the standardization subcommittee of the International Continence Society. *Neurol Urodyn* 21:167–178, 2002.

During the voiding/emptying phase of micturition, normal detrusor activity implies voiding by a voluntarily initiated sustained contraction that leads to complete bladder emptying within a normal time span. An **underactive detrusor** defines a contraction of inadequate magnitude or duration, or both, to empty the bladder within a normal time span. An **acontractile detrusor** is one that cannot be demonstrated to contract during urodynamic testing. **Areflexia** is defined as acontractility secondary to an abnormality of neural control, implying the complete absence of centrally coordinated contraction. **Normal urethral function** during voiding indicates a urethra that opens and is continuously relaxed to allow bladder emptying at a normal pressure. **Abnormal urethral function during voiding** may be due to either mechanical obstruction or urethral overactivity. **Dysfunctional voiding** describes an intermittent or fluctuating flow rate secondary to involuntary intermittent contractions of the periurethral striated muscle in neurologically normal individuals. **Detrusor sphincter dyssynergia** defines a detrusor contraction concurrent with an involuntary contraction of the urethral or periurethral striated muscle, or both. **Nonrelaxing urethral sphincter obstruction** usually occurs in individuals with a neurologic lesion and is characterized by a nonrelaxing obstructing urethra resulting in reduced urine flow.

LUT dysfunction in a patient with classic T10-level paraplegia after spinal shock has passed would be classified in the ICS system as follows:

- Storage phase: overactive neurogenic detrusor function, absent sensation, low capacity, normal compliance, normal urethral closure function
- Voiding phase: overactive obstructive urethral function, overactive detrusor function

The micturition dysfunction of a patient with stroke and urgency incontinence would most likely be classified during storage as overactive neurogenic detrusor function, normal sensation, low capacity, normal compliance, and normal urethral closure function. During voiding, the dysfunction would be classified as normal detrusor activity and normal urethral function, assuming that no anatomic obstruction existed.

Urodynamic Classification

As urodynamic techniques have become more accepted and sophisticated, systems of classification have evolved solely on the basis of objective urodynamic data (Box 111.6). Among the first to popularize this concept were Krane and Siroky (1984). When exact urodynamic classification is possible, such a system can provide an exact description of the voiding dysfunction that occurs. If a normal or overactive detrusor exists with coordinated smooth and striated sphincter function and without anatomic obstruction, normal bladder emptying should occur. Neurogenic **detrusor overactivity** is most commonly associated with neurologic lesions above the sacral spinal cord. **Striated sphincter dyssynergia** is most commonly seen after complete suprasacral spinal cord injury, following the period of spinal shock. **Smooth sphincter dyssynergia** is seen most classically in autonomic hyperreflexia (see Chapter 116) when it is characteristically associated with DO and striated sphincter dyssynergia. **Detrusor areflexia** (this category includes acontractile and areflexic bladder) may be secondary to bladder muscle decompensation or to various other conditions that produce inhibition at the level of the brainstem micturition center, the sacral spinal cord, bladder ganglia, or bladder smooth muscle. Patients with a voiding dysfunction secondary to detrusor areflexia generally attempt bladder emptying by abdominal straining, and their continence status and the efficiency of their emptying efforts are determined by the status of their smooth and striated sphincter mechanisms.

Box 111.6

Urodynamic Classification

Detrusor Hyperreflexia (or Normoreflexia)

Coordinated sphincters
Striated sphincter dyssynergia
Smooth sphincter dyssynergia
Nonrelaxing smooth sphincter

Detrusor Areflexia

Coordinated sphincters
Nonrelaxing striated sphincter
Denervated striated sphincter
Nonrelaxing smooth sphincter

Modified from Krane RJ, Siroky MB: Classification of voiding dysfunction: value of classification systems. In Barrett DM, Wein AJ, editors: *Controversies* *in neuro-urology,* New York, 1984, Churchill Livingstone, pp 223–238.

This classification system is easiest to use when detrusor overactivity or normoreflexia exists. A patient with typical T10-level paraplegia after spinal shock exhibits detrusor overactivity, smooth sphincter synergia, and striated sphincter dyssynergia. When a voluntary or a DO contraction cannot be elicited, the system is more difficult to use because it is not appropriate to speak of true sphincter dyssynergia in the absence of an opposing bladder contraction. There are many variations and extensions of such a system. **Such systems can work well only when total urodynamic agreement exists among classifiers. There are many dysfunctions that do not fit neatly into a urodynamic classification system that is agreed on by all experts. Compliance is not mentioned in this particular version, nor is sensation or the concept of deficient, but not absent, detrusor contractile function.** As sophisticated urodynamic technology and understanding improve, this type of classification system may be more commonly used. The ICS system (see previous discussion) is a logical and more complete extension of such a system.

Lapides Classification

Lapides (1970) contributed significantly to the classification and care of patients with neuropathic voiding dysfunction by slightly modifying and popularizing a system originally proposed by McLellan (1939) (Box 111.7). Lapides' classification differs from that of McLellan in only one respect, and that is the division of the group of "atonic neurogenic bladder" into sensory neurogenic and motor neurogenic bladder. This is a familiar system to urologists and nonurologists because it describes in recognizable shorthand the clinical and cystometric conditions of many types of neurogenic voiding dysfunction.

Box 111.7

Lapides Classification

Sensory neurogenic bladder
Motor paralytic bladder (motor neurogenic bladder)
Uninhibited neurogenic bladder
Reflex neurogenic bladder

Autonomous neurogenic bladder

A sensory neurogenic bladder results from disease that selectively interrupts the sensory fibers between the bladder and the spinal cord or the afferent tracts to the brain. **Diabetes mellitus, tabes dorsalis, and pernicious anemia** are the diseases most responsible. The first clinical changes are described as impaired sensation of bladder distention. Unless voiding is initiated on a timed basis, varying degrees of bladder overdistention can result with hypotonicity. If bladder decompensation occurs, significant amounts of residual urine result, and at that time the cystometric curve generally demonstrates a large-capacity bladder with a flat, high-compliance, low-pressure filling curve.

A **motor paralytic bladder** results from disease processes that destroy the parasympathetic motor innervation of the bladder. **Extensive pelvic surgery or trauma** may produce this. **Herpes zoster** has been listed as a cause as well, but more recent evidence suggests that the voiding dysfunction seen with herpes may be related more to a problem with afferent input (see Chapter 116). The early symptoms of a motor paralytic bladder may vary from painful urinary retention to only a relative inability to initiate and maintain normal micturition. Early cystometric filling is normal but without a voluntary bladder contraction at capacity. Chronic overdistention and decompensation may occur, resulting in a large-capacity bladder with a flat, low-pressure filling curve; a large amount of residual urine may result.

An **uninhibited neurogenic bladder** was described originally as resulting from injury or disease to the “corticoregulatory tract.” The sacral spinal cord was presumed to be the micturition reflex center, and this corticoregulatory tract was believed normally to exert an inhibitory influence on the sacral micturition reflex center. A destructive lesion in this tract would then result in overfacilitation of the micturition reflex. **Cerebrovascular accident, brain or spinal cord tumor, Parkinson disease, and demyelinating disease** were listed as the most common causes in this category. The voiding dysfunction is most often characterized symptomatically by frequency, urgency, and urge incontinence and urodynamically by normal sensation with involuntary contraction at low filling volumes. Residual urine is characteristically low unless anatomic outlet obstruction or true smooth or striated sphincter dyssynergia occurs. The patient generally can initiate a bladder contraction voluntarily but is often unable to do so during cystometry because sufficient urine storage cannot occur before involuntary contraction is stimulated.

Reflex neurogenic bladder refers to the post–spinal shock condition that exists after complete interruption of the sensory and motor pathways between the sacral spinal cord and the brainstem. Most commonly, this condition occurs in **traumatic spinal cord injury and transverse myelitis,** but it may occur with **extensive demyelinating disease or any process that produces significant suprasacral (cord) spinal cord destruction.** Typically, there is no bladder sensation, and there is inability to initiate voluntary micturition. Incontinence without sensation generally results from low-volume involuntary contraction. Striated sphincter dyssynergia is the rule. This type of lesion is essentially equivalent to a complete upper motor neuron (UMN) lesion in the Bors-Comarr system (see later in this chapter).

An autonomous neurogenic bladder results from complete motor and sensory separation of the bladder from the sacral spinal cord. This condition may be caused by **any disease that destroys the sacral cord or causes extensive damage to the sacral roots or pelvic nerves.** There is inability to initiate micturition voluntarily, no bladder reflex activity, and no specific bladder sensation. This type of bladder is equivalent to a complete lower motor neuron (LMN) lesion in the Bors-Comarr system and is the type of dysfunction seen in patients with spinal shock. The characteristic cystometric pattern is initially similar to the late stages of the motor or sensory paralytic bladder, with a marked shift to the right of the cystometric filling curve and a large bladder capacity at low intravesical pressure. However, decreased compliance may develop, secondary either to chronic inflammatory change or to the effects of denervation/decentralization with secondary neuromorphologic and neuropharmacologic reorganizational changes. Emptying capacity may vary widely, depending on the ability of the patient to increase intravesical pressure and on the resistance offered during this increase by the smooth and striated sphincters.

These classic categories in their usual settings are generally understood and remembered, and this is why this system provides an excellent framework for teaching some fundamentals of neurogenic voiding dysfunction to students and nonurologists. However, **many patients do not fit exactly into one or another category.** Gradations of sensory, motor, and mixed lesions occur, and the patterns produced after different types of peripheral denervation/defunctionalization may vary widely from the patterns that are classically described. **The system is applicable only to neuropathic dysfunction.**

Bors and Comarr (1971) made a remarkable contribution by logically deducing a classification system from clinical observation of their patients with traumatic spinal cord injury (Box 111.8). **This system, primarily of historical interest at present, applies only to patients with neurologic dysfunction and considers three factors: (1) the anatomic localization of the lesion, (2) the neurologic completeness or incompleteness of the lesion, and (3) whether LUT function is *balanced* or *unbalanced*.** The last terms are based solely on the percentage of residual urine relative to bladder capacity. **Unbalanced** signifies the presence of greater than 20% residual urine in a patient with a UMN lesion or 10% in a patient with an LMN lesion. This relative residual urine volume was ideally meant to imply coordination (synergy) or dyssynergia between the smooth and the striated sphincters of the outlet and the bladder during bladder contraction or during attempted micturition by abdominal straining or the Credé maneuver. The determination of the completeness of the lesion is made on the basis of a thorough neurologic examination.

Box 111.8

Bors-Comarr Classification

- Sensory neuron lesion
  - Incomplete, balanced
  - Complete, balanced
- Motor neuron lesion
  - Balanced
  - Imbalanced
- Sensorimotor neuron lesion
  - Upper motor neuron lesion
    - Complete, balanced
    - Complete, imbalanced
    - Incomplete, balanced
    - Incomplete, imbalanced
  - Lower motor neuron lesion
    - Complete, balanced
    - Complete, imbalanced
    - Incomplete, balanced

        Incomplete, imbalanced
    Mixed lesion
        Upper somatomotor neuron, lower visceromotor neuron
        Lower somatomotor neuron, upper visceromotor neuron
        Normal somatomotor neuron, lower visceromotor neuron

The system erroneously assumes that the sacral spinal cord is the primary reflex center for micturition. **LMN** implies collectively the preganglionic and postganglionic parasympathetic autonomic fibers that innervate the bladder and outlet and originate as preganglionic fibers in the sacral spinal cord. The term is used in an analogy to efferent somatic nerve fibers such as those of the pudendal nerve, which originate in the same sacral cord segment but terminate directly on pelvic floor striated musculature without the interposition of ganglia. **UMN** is used in a similar analogy to the somatic nervous system to describe the descending autonomic pathways above the sacral spinal cord (the origin of the motor efferent supply to the bladder).

In this system, **UMN bladder** refers to the pattern of micturition that results from an injury to the suprasacral spinal cord after the period of spinal shock has passed, assuming that the sacral spinal cord and the sacral nerve roots are intact and that the pelvic and pudendal nerve reflexes are intact. **LMN bladder** refers to the pattern resulting if the sacral spinal cord or sacral roots are damaged and the reflex pattern through the autonomic and somatic nerves that emanate from these segments is absent. This system implies that if skeletal muscle spasticity exists below the level of the lesion, the lesion is above the sacral spinal cord and is by definition a UMN lesion. This type of lesion is characterized by involuntary bladder contraction during filling. If flaccidity of the skeletal musculature below the level of a lesion exists, an LMN lesion is assumed to be present, implying that detrusor areflexia is present. Exceptions occur and are classified in a **“mixed lesion group”** characterized either by involuntary bladder contraction with a flaccid paralysis below the level of the lesion or by detrusor areflexia with spasticity or normal skeletal muscle tone neurologically below the lesion level.

The use of this system is illustrated as follows. A **“UMN lesion, complete, imbalanced”** implies a neurologically complete lesion above the level of the sacral spinal cord that results in skeletal muscle spasticity below the level of the injury. Involuntary bladder contraction occurs during filling, but a residual urine volume of greater than 20% of the bladder capacity is left after bladder contraction, implying obstruction in the area of the bladder outlet during the involuntary detrusor contraction. This obstruction is generally due to striated sphincter dyssynergia, typically occurring in patients who are paraplegic or quadriplegic with lesions between the cervical and the sacral spinal cord. Smooth sphincter dyssynergia may be seen as well in patients with lesions above the level of T6, usually associated with autonomic dysreflexia (see Chapter 116). An **“LMN lesion, complete, imbalanced”** implies a neurologically complete lesion at the level of the sacral spinal cord or of the sacral roots, resulting in skeletal muscle flaccidity below that level. Detrusor areflexia results, and whatever measures the patient may use to increase intravesical pressure during attempted voiding are insufficient to decrease residual urine to less than 10% of bladder capacity.

This classification system applies best to spinal cord injury patients with complete neurologic lesions after spinal shock has passed. It is difficult to apply to patients with multicentric neurologic disease and cannot be used at all for patients with non-neurologic disease. The system fails to reconcile the clinical and urodynamic variability exhibited by patients who, by neurologic examination alone, seem to have similar lesions. The period of spinal shock that immediately follows severe cord injury is generally associated with bladder areflexia, whatever the status of the sacral somatic reflexes. Temporary or permanent changes in bladder or outlet activity during filling/storage and emptying/voiding may occur as a result of numerous factors, such as chronic overdistention, infection, and reinnervation or reorganization of neural pathways after injury or disease; such changes make it **impossible to predict LUT activity accurately solely on the basis of the level of the neurologic lesion.** Finally, although the terms *balanced* and *imbalanced* are helpful in that they describe the presence or absence of a certain relative percentage of residual urine, they do not imply the true functional significance of a lesion, which depends on the potential for damage to the lower or upper urinary tracts and on the social and vocational disability that results.

Hald-Bradley Classification

Hald and Bradley (1982) described what they termed a simple *neurotopographic classification* (Box 111.9). The system is of historical interest only. A **supraspinal lesion** is characterized by synergy between detrusor contraction and the smooth and striated sphincters, but defective inhibition of the voiding reflex exists. Involuntary bladder contraction generally occurs, and sensation is usually preserved. However, depending on the site of the lesion, detrusor areflexia and defective sensation may be seen. A **suprasacral spinal lesion** is roughly equivalent to what is described as a UMN lesion in the Bors-Comarr classification. An **infrasacral lesion** is roughly equivalent to an LMN lesion. **Peripheral autonomic neuropathy** is most frequently encountered in patients with diabetes and is characterized by deficient bladder sensation, gradually increasing residual urine, and ultimate decompensation with loss of detrusor contractility. A **muscular lesion** can involve the detrusor, the smooth sphincter, or any portion, or all, of the striated sphincter. The resultant dysfunction depends on which structure is affected. Detrusor dysfunction is the most common and generally results from decompensation after long-standing bladder outlet obstruction. In my opinion, this system is as confusing as the word *neurotopographic* and adds little to the understanding of LUT dysfunction.

Box 111.9

Hald-Bradley Classification

Suprasacral lesion
Suprasacral spinal lesion
Infrasacral lesion
Peripheral autonomic neuropathy
Muscular lesion

Bradley Classification

Bradley's “loop system” of classification is a primarily neurologic system based on his conceptualization of central nervous system control of the LUT that identifies four neurologic “loops” (Hald and Bradley, 1982). Dysfunctions are classified according to the loop affected. Occasional reference is made to this system, primarily by nonurologists.

Loop 1 consists of neuronal connections between the cerebral cortex and the pontine mesencephalic micturition center; this coordinates voluntary control of the detrusor reflex. **Loop 1 lesions** are seen in conditions such as **brain tumor, cerebrovascular accident or disease, and cerebral atrophy with dementia.** The final result is characteristically **involuntary bladder contractions.**

Loop 2 includes the intraspinal pathway of detrusor muscle afferents to the brainstem micturition center and the motor impulses from this center to the sacral spinal cord. Loop 2 is thought to coordinate and provide for a detrusor reflex of adequate temporal duration to allow complete voiding. Partial interruption by spinal cord injury results in a detrusor reflex of low threshold and in poor emptying with residual urine. **Spinal cord transection of loop 2 acutely produces detrusor areflexia and urinary retention—spinal shock. After this has passed, involuntary bladder contractions result.**

Loop 3 consists of the peripheral detrusor afferent axons and their pathways in the spinal cord; these terminate by synapsing on pudendal motor neurons that ultimately innervate periurethral striated muscle. Loop 3 was thought to provide a neurologic substrate for coordinated reciprocal action of the bladder and striated sphincter. **Loop 3 dysfunction could be responsible for detrusor striated dyssynergia or involuntary sphincter relaxation.**

Loop 4 consists of two components. Loop 4A is the suprasacral afferent and efferent innervation of the pudendal motor neurons to the periurethral striated musculature. Loop 4B consists of afferent fibers from the periurethral striated musculature that synapse on pudendal motor neurons in Onuf nucleus—the segmental innervation of the periurethral striated muscle. Bradley conceptualized that, in contrast to the stimulation of detrusor afferent fibers, which produced inhibitory postsynaptic potentials in pudendal motor neurons through loop 3, pudendal nerve afferents produced excitatory postsynaptic potentials in those motor neurons through loop 4B. These provided for contraction of the periurethral striated muscle during bladder filling and urine storage. The related sensory impulses arise from muscle spindles and tendon organs in the pelvic floor musculature. **Loop 4 provides for volitional control of the striated sphincter.** Abnormalities of the suprasacral portion result in abnormal responses of the pudendal motor neurons to bladder filling and emptying, manifested as detrusor striated sphincter dyssynergia and/or loss of the ability to contract the striated sphincter voluntarily.

The Bradley system is sophisticated and reflects the ingenuity and neurophysiologic expertise of its originator, a neurologist. For neurologists, this method may be an excellent way to conceptualize the neurophysiology involved, assuming that there is agreement on the existence and significance of all four loops—a big assumption. Most urologists find this system difficult to use for many types of neurogenic LUT dysfunction and not applicable to non-neurogenic LUT dysfunction. Urodynamically, it may be extremely difficult to test the intactness of each loop system, and multicentric and partial lesions are difficult to describe.

Suggested Readings

Abrams P, Cardozo L, Fall M, et al. The standardization of terminology in LUT function. Report from the standardization subcommittee of the International Continence Society. *Neurourol Urodyn*. 2003;21:167–178 [61:37–9].

Andersson K-E. Relevant anatomy, physiology and pharmacology. Wein AJ, Andersson K-E, Drake MJ, et al. *Bladder dysfunction in the adult: the basis for clinical management*. Humana Press: New York; 2014:3–18.

Andersson K-E, Arner A. Urinary bladder contraction and relaxation: physiology and pathophysiology. *Physiol Rev*. 2004;84:935–988.

Andersson K-E, Wein AJ. Pharmacology of the LUT: basis for current and future treatments of urinary incontinence. *Pharmacol Rev*. 2004;56:581–631.

Birder L, Chai T, Griffiths D, et al. Neural control. Abrams P, Cardozo L, Khoury S, et al. *Incontinence*. ICUD-EAU: Paris; 2013:179–260.

Fowler CJ, Griffiths D, de Groat WC. The neural control of micturition. *Nat Rev Neurosci*. 2008;9:453–466.

Koelbl H, Igawa T, Salvatore S, et al. Pathophysiology of urinary incontinence, fecal incontinence and pelvic organ prolapse. Abrams P, Cardozo L, Khoury S, et al. *Incontinence*. ICUD-EAU: Paris; 2013:261–360.

Mostwin J, Bourcier A, Haab F, et al. Pathophysiology of urinary incontinence, fecal incontinence and pelvic organ prolapse. Abrams P, Cardozo L, Khoury S, et al. *Incontinence. Editions 21*. Health Publications Ltd: Paris; 2009:423–484.

Wein AJ, Barrett DM. *Voiding function and dysfunction: a logical and practical approach*. Year Book Medical

Publishers: Chicago; 1988.

References

Abrams P, Blaivas J, Stanton S, et al. ICS 6th report on the standardization of terminology of lower urinary tract function. *Neurol Urodyn*. 1992;11:593–603.

Abrams P, Blaivas J, Stanton S, et al. ICS standardization of terminology of lower urinary tract function. *Scand J Urol Nephrol*. 1988;114:5–19.

Abrams P, Cardozo L, Fall M, et al. The standardization of terminology in lower urinary tract function: report from the standardization subcommittee of the International Continence Society. *Neurol Urodyn*. 2002;21:167–178.

Abrams P, Cardozo L, Fall M, et al. The standardization of terminology in lower urinary tract function: report from the standardization subcommittee of the International Continence Society. *Urology*. 2003;61:37–49.

Andersson K-E, Arner A. Urinary bladder contraction and relaxation: physiology and pathophysiology. *Physiol Rev*. 2004;84:935–986.

Andersson K-E, Wein A. Pharmacology of the lower urinary tract: basis for current and future treatments of urinary incontinence. *Pharmacol Rev*. 2004;56:581–631.

Andersson K-E. Relevant anatomy, physiology and pharmacology. Wein AJ, Andersson K-E, Drake MJ, et al. *Bladder dysfunction in the adult: the basis for clinical management*. Humana Press: New York; 2014:3–18.

Beckel JM, Holstege G. Neurophysiology of the lower urinary tract. *Handb Exp Pharmacol*. 2011;202:149–169.

Birder L, Chai T, Griffiths D, et al. Neural control. Abrams P, Cardozo L, Khoury S. *Incontinence*. ICUD-EAU: Paris; 2013:179–260.

Bors E, Comarr A. *Neurological urology*. University Park Press:

Baltimore; 1971.

Brading A, Fry C, Maggi C, et al. Cellular biology. Abrams P, Khoury S, Wein A. *Incontinence. 1st International Consultation on Incontinence*. Health Publication, Ltd.: Plymouth (UK); 1999:57–104.

Brading A. The physiology of the mammalian outflow tract. *Exp Physiol*. 1999;84:215–221.

Brading AF, Teramoto N, Dass N, et al. Morphological and physiological characteristics of urethral circular and longitudinal smooth muscle. *Scand J Urol Nephrol Suppl*. 2001;207:12–18 [discussion 106–25].

Chancellor M, Yoshimura N. Physiology and pharmacology of the bladder and urethra. Walsh P, Retik A, Vaughan E Jr, et al. *Campbell's urology*. 8th ed. Saunders: Philadelphia; 2002:831–886.

de Groat W, Booth A, Yoshimura N. Neurophysiology of micturition and its modifications in animal models of human disease. Maggi C. *The autonomic nervous system*. Harwood Academic: London; 1993:227–290.

de Groat W, Downie J, Levin R, et al. Basic neurophysiology and neuropharmacology. Abrams P, Khoury S, Wein A. *Incontinence. 1st International Consultation on Incontinence*. Health Publication, Ltd.: Plymouth (UK); 1999:105–154.

de Groat W, Yoshimura N. Pharmacology of the lower urinary tract. *Ann Rev Pharmacol Toxicol*. 2001;41:691–721.

de Groat WC, Griffiths D, Yoshimura N. Neural control of the lower urinary tract. *Compr Physiol*. 2015;5(1):327–396.

de Groat WC. Integrative control of the lower urinary tract: preclinical perspective. *Br J Pharmacol*. 2006;147(Suppl 2):S25–S40.

DeLancey J, Gosling J, Creed K, et al. Gross anatomy and cell biology of the lower urinary tract. Abrams P, Cardozo L, Khoury S, et al. *Incontinence*. Health Publication, Ltd.:

Plymouth (UK); 2002:17–82.

DeLancey J. Structural support of the urethra as it relates to stress urinary incontinence: the hammock hypothesis. *Am J Obstet Gynecol*. 1994;170:1713–1717.

Enhorning G. Simultaneous recording of intravesical and intraurethral pressure. *Acta Chir Scand*. 1961;276(Suppl):1–68.

Fowler CJ, Griffiths D, de Groat WC. The neural control of micturition. *Nat Rev Neurosci*. 2008;9:453–466.

Habteyer FG, Komari SO, Nagle AS, et al. Modeling the influence of acute changes in bladder elasticity on pressure and wall tension during filling. *J Mech Behav Biomed Mater*. 2017;71:192–200.

Hald T, Bradley W. *The urinary bladder: neurology and dynamics*. Williams & Wilkins: Baltimore; 1982.

Hawthorn M, Chapple C, Cock M, et al. Urothelium-derived inhibitory factor(s) influences on detrusor muscle contractility in vitro. *Br J Pharmacol*. 2000;129:416–419.

Klevmark B. Motility of the urinary bladder in cats during filling at physiological rates: I. Intravesical pressure patterns studied by new methods of cystometry. *Acta Physiol Scand*. 1974;90:565–569.

Klevmark B. Natural pressure-volume curves and conventional cystometry. *Scand J Urol Nephrol Suppl*. 1999;201:1–4.

Koelbl H, Igawa T, Salvatore S, et al. Pathophysiology of urinary incontinence, fecal incontinence and pelvic organ prolapse. Abrams P, Cardozo L, Khoury S, et al. *Incontinence*. ICUD-EAU: Paris; 2013:261–360.

Krane R, Siroky M. Classification of voiding dysfunction: value of classification systems. Barrett D, Wein A. *Controversies in neuro-urology*. Churchill Livingstone: New York; 1984:223–238.

Lapides J. Neuromuscular, vesical and ureteral dysfunction.

Campbell M, Harrison J. *Urology*. Saunders: Philadelphia; 1970:1343–1379.

McGuire E, Shi-Chun Z, Horwinski E. Treatment for motor and sensory detrusor instability by electrical stimulation. *J Urol*. 1983;129:78–79.

McLellan F. *The neurogenic bladder*. Charles C. Thomas: Springfield; 1939:116–185.

Michel MC, Barendrecht MM. Physiological and pathological regulation of the autonomic control of urinary bladder contractility. *Pharmacol Ther*. 2008;117:297.

Morrison J, Birder L, Craggs M, et al. Neural control. Abrams P, Cardozo L, Khoury S, et al. *Incontinence*. Health Publication, Ltd.: Plymouth (UK); 2005:363–422.

Mostwin J, Bourcier A, Haab F, et al. Pathophysiology of urinary incontinence, fecal incontinence, and pelvic organ prolapse. Abrams P, Cardozo L, Khoury S, et al. *Incontinence*. Health Publication, Ltd.: Plymouth (UK); 2005:423–484.

Mostwin J. Clinical physiology of micturition. Cardozo L, Staskin D. *Textbook of female urology and urogynecology*. Informa Healthcare: Milton Park (UK); 2006:141–155.

Neal CJ, Lin JB, Hurley T, et al. Slowly cycling Rho kinase-dependent actomyosin cross-bridge “slippage” explains high compliance of detrusor smooth muscle. *Am J Physiol Renal Physiol*. 2017;313:F126–F134.

Ochodnicky P, Uvelius B, Andersson KE, et al. Autonomic nervous control of the urinary bladder. *Acta Physiol (Oxf)*. 2013;207:16–33.

Osman N, Chapple C, Abrams P, et al. Detrusor underactivity and the underactive bladder: a new clinical entity? a review of current terminology, definitions, epidemiology, aetiology, and diagnosis. *Eur Urol*. 2014;389–398.

Quesada E, Scott FB, Cardus D. Functional classification of neurogenic bladder dysfunction. *Arch Phys Med Rehabil*. 1968;49:692–697.

Staskin D. Classification of voiding dysfunction. Cardozo L, Stadskin D. *Textbook of female urology and urogynaecology*. Taylor & Francis: London; 2001:83–90.

Tanagho E. The anatomy and physiology of micturition. *Clin Obstet Gynecol*. 1978;5:3–9.

Vahabi B, Drake M. Physiological and pathophysiological implications of micromotion activity in urinary bladder function. *Acta Physiol (Oxf)*. 2015;213:360–370.

Wein A, Barrett D. *Voiding function and dysfunction: a logical and practical approach*. Year Book Medical Publishers: Chicago; 1988.

Wein A, Moy M. Voiding function and dysfunction; urinary incontinence. Hanno P, Malkowicz SB, Wein AJ. *Clinical manual of urology*. Saunders: Philadelphia; 2007:341–478.

Wein A. Pathophysiology and categorization of voiding dysfunction. Walsh P, Retik A, Vaughan E Jr, et al. *Campbell's urology*. 8th ed. Saunders: Philadelphia; 2002:887–899.

Wein A. Pathophysiology and categorization of voiding dysfunction. Wein A, Kavoussi L, Novick A, et al. *Campbell-Walsh urology*. 9th ed. Saunders: Philadelphia; 2007:1973–1985.

Wein AJ. Classification of neurogenic voiding dysfunction. *J Urol*. 1981;125:605–609.

Welk B, Al-Hothi H, Winick-Ng J, et al. The effect of pelvic fractures on future stress incontinence and pelvic organ prolapse surgery. *Int Urogynecol J*. 2015;26(6):805–811.

Yoshimura N, Chancellor M. Physiology and pharmacology of the bladder and urethra. Wein A, Kavoussi L, Novick A, et al. *Campbell-Walsh urology*. 8th ed. Saunders: Philadelphia; 2007:1922–1972.

Zderic S, Levin R, Wein A. Voiding function: relevant anatomy, physiology, pharmacology and molecular aspects. Gillenwater J, Grayhack J, Howards S, et al. *Adult and pediatric urology*. Lippincott, Williams & Wilkins: Philadelphia; 2002:1061–1113.

Zinner N, Sterling A, Ritter R. Structure and forces of continence. Raz S. *Female urology*. Saunders: Philadelphia; 1983:33–41.

Evaluation and Management of Women With Urinary Incontinence and Pelvic Prolapse

---

Alvaro Lucioni MD, Kathleen C. Kobashi MD

Definition and Impact of Pelvic Floor Disorders

Introduction

Pelvic floor disorders (PFDs) include urinary incontinence (UI), fecal incontinence, and pelvic organ prolapse (POP). With the increasing prevalence and health care costs related to evaluation and treatment of PFDs, understanding these disorders is of utmost importance.

The International Urogynecological Association (IUGA) and the International Continence Society (ICS) define urinary incontinence (UI) as the complaint of the involuntary loss of urine (Abrams et al., 2002; Haylen et al., 2010). There are a variety of different types of UI that include stress urinary incontinence (SUI), urgency urinary incontinence (UUI), mixed urinary incontinence (MUI), nocturnal enuresis, and postural, continuous, insensible, and coital incontinence. Table 112.1 lists the current IUGA/ICS nomenclature regarding urinary incontinence symptoms (Abrams et al., 2002; Abrams et al., 2009b; Haylen et al., 2010). The terminology continues to adjust to reflect the evolving understanding of the condition. The importance of this flexibility has been realized and acknowledged by leaders in the subspecialty of pelvic floor medicine (Chapple, 2009). Accordingly, the IUGA/ICS terminology has been updated since its inception and most recently has been expanded to include not only terminology for lower urinary tract (LUT) function and urodynamics (UDS), but also pelvic organ prolapse, lower urinary tract pain, sexual dysfunction, anorectal dysfunction, and pelvic imaging (Haylen et al., 2010).

TABLE 112.1

Standard International Urogynecological Association/International Continence Society Terminology of Urinary Incontinence Symptoms

TERMINOLOGY	DESCRIPTION
Urinary incontinence	Complaint of any involuntary leakage of urine
Stress urinary incontinence	Complaint of involuntary leakage on effort or exertion, or on sneezing or coughing
Urgency	Complaint of a sudden compelling desire to pass urine, which is

	difficult to defer
Urgency urinary incontinence	Complaint of involuntary leakage accompanied by or immediately preceded by urgency
Postural incontinence	Complaint of voluntary loss of urine associated with change of body position, for example, rising from a seated or lying position
Nocturnal enuresis	Complaint of involuntary loss of urine that occurs during sleep
Mixed incontinence	Complaint of involuntary leakage associated with urgency and also with exertion, effort, sneezing, or coughing
Continuous urinary incontinence	Complaint of continuous leakage
Insensible incontinence	Complaint of urinary incontinence when the woman has been unaware of how it occurred
Coital incontinence	Complaint of involuntary loss of urine with coitus

From Abrams P, Cardozo L, Fall M, et al. The standardisation of terminology of lower urinary tract function: Report from the Standardisation Sub-Committee of the International Continence Society. *Neurourol Urodyn* 21:167–178, 2002. (reprinted in *Urology* 61:37-49, 2003); Haylen BT, de Ridder D, Freeman RM, et al. An International Urogynecological Association (IUGA)/International Continence Society (ICS) joint report on the terminology for female pelvic floor dysfunction. *Neurourol Urodyn* 29:4–20, 2010.

UI is a common condition that affects all sectors of the population. The National Health and Nutrition Examination Survey of 2001 estimated the prevalence of SUI, UUI, MUI, and any type of incontinence to be 23.7%, 9.9%, 14.5%, and 49.2%, respectively (Minassian et al., 2008). The risk of UI increases with age, and with the aging population in the United States and worldwide, the impact of UI on society is expected to increase. UI is also prevalent in young women, with approximately 50% of adolescent and pregnant women younger than 25 years of age reporting some degree of UI (Jean-Michel et al., 2018). Women who participate in elite high-level sports have been noted to have three times the prevalence of urinary incontinence compared with controls (Carvalhais et al., 2018). Several studies have also implicated race as a potential risk factor for UI, with the odds of pure SUI being at least 2.5-fold higher in white and Mexican-American women than in black women (Dooley et al., 2008). Brazilian women have been reported to have an incidence of SUI of 39.3 × 1000 person-years (Tamanini et al., 2018). In Taiwan, 18.7% of women 29 to 59 years of age and 29.8% of women older than 60 years of age reported having SUI (Chang et al., 2017).

Pelvic organ prolapse (POP) refers to a falling, slipping, or downward displacement of a compartment or organ. Though the IUGA/ICS joint report on terminology establishes POP primarily as a definition of anatomic change, the diagnosis of POP requires clear clinical evidence that a woman is having symptoms related to the downward displacement of a pelvic organ (Haylen et al., 2016). Potential symptoms may include vaginal bulging, pelvic pressure, bleeding and/or discharge, need to splint or perform digitation for comfort or evacuation, and low backache. POP may have an effect on bladder, bowel, and sexual function. Lower urinary tract symptoms (LUTS) related to POP may vary from obstructive symptoms such as hesitancy, slow stream, intermittency, straining to void, feeling of incomplete bladder emptying, urgency, and position-dependent micturition to UI of a variety of types, such as SUI, UUI, and MUI. Anorectal dysfunction symptoms related to POP may include constipation, a sensation of incomplete bowel emptying, a need to splint or strain to evacuate, and fecal urgency with or without incontinence. Like incontinence, multiple risks factors for POP have been identified, including age, parity, genetics, estrogen deficiency, decreased pelvic floor muscle strength, smoking, cancer, and diabetes (Tamanini et al., 2018).

The impact of PFDs is far-reaching, carrying the potential to significantly affect a patient's quality of life (QoL), notwithstanding the psychological burden that can result from having any PFD. Additionally, PFDs can result in a tremendous cost to the individual and to society. Hu et al. estimated that the evaluation and management of UI and productivity lost as a result of the condition led to a $19.5 billion (year 2000 dollars) cost to society, although sensitivity analysis suggested a potential cost range of $9.32 to $28 billion (Hu et al., 2004). Reports have demonstrated that medical expenditures related to UI in the female Medicare population nearly doubled between 1992 and 1998, primarily as a result of increased outpatient expenditure from 9.1% to 27.3% of total Medicare costs in approximately the same timeframe (Anger et al., 2006a,b; Thom et al., 2005). The impact of PFDs on society goes further than evaluation and treatment costs. In a 2005 multinational study, the annual cost-of-illness estimate for UUI in the United States was $66 billion in 2007 US dollars (Milsom et al., 2014). In a retrospective study utilizing a 2001 to 2011 database, employees with UUI had 30% higher sick leave and 74% higher short-term disability costs (Kleinman et al., 2014). Work to mitigate this increase in cost is under way. Vermeulen et al. showed that a model in which primary care providers had an increased active role in the care of women 55 years of age or older demonstrated a significant improvement in the women's quality adjusted life-years (Vermeulen et al., 2016). Conversely, a mobile application that allowed for self-management of SUI with pelvic floor muscle training demonstrated a significant reduction in costs and improvement in quality adjusted life-years (Nyström et al., 2018).

The advent of social media and newer electronic tools has and will continue to dramatically increase the awareness of PFDs among affected populations and their health care providers. Additionally, a growing realization regarding the importance of QoL optimization has driven a new focus in the field of pelvic floor medicine. Tremendous research endeavors are under way to improve our understanding of the pathophysiology of PFDs in an effort to improve both diagnostic and therapeutic techniques. The importance of evidence-based medicine and meticulous follow-up of patients is driving improvement in the science on which advancements in this subspecialty of urology are being made.

Diagnostic Evaluation

General Considerations

A recent upsurge in research efforts has resulted in the emergence of new diagnostic and therapeutic techniques to address PFDs. As QoL impact has become a focus, much of current research efforts include detailed QoL assessment and attempts to quantify and assess the relationship between PFDs and their effects on QoL. Correlating the bother caused by a given PFD with the risks associated with available therapies is an important consideration. The purpose of evaluation of patients with UI includes documentation and characterization of the UI; consideration of the differential diagnosis; prognostication; and facilitation of treatment selection (Dmochowski et al., 2010). Additionally, proper evaluation helps assess symptom bother and establish a patient's expectations of potential outcomes so as to balance the degree of bother with the risks associated with available therapies for the individual patient (Kobashi et al., 2017).

The type of UI affecting an individual must be defined and quantified to guide proper treatment planning. Transient or unrelated conditions that can cause leakage should be identified before proceeding with definitive therapy. Table 112.2 contains a mnemonic of transient causes of UI (Resnick, 1984).

TABLE 112.2

Causes of Transient Incontinence (DIAPPERS)

Delerium
Infection (urinary tract infection)
Atrophic vaginitis/urethritis
Psychological (e.g., severe depression, neurosis)
Pharmacologic
Excess urine production
Restricted mobility
Stool impaction

From Resnick NM. Urinary incontinence in the elderly. *Medical Grand Rounds* 3:281–290, 1984.

The classification of POP is categorized according to the affected compartment. Simply put, anterior compartment prolapse (cystocele) generally involves descent of the bladder toward the vaginal lumen, posterior prolapse (rectocele) involves the rectum compressing the posterior vaginal wall into the vagina, and apical prolapse is associated with descent of the uterus (uterine procidentia) and/or the bowel (enterocele) at the top of the vagina. Several grading systems exist to quantify the severity of POP and are discussed later in this chapter and illustrated in Fig. 112.1.

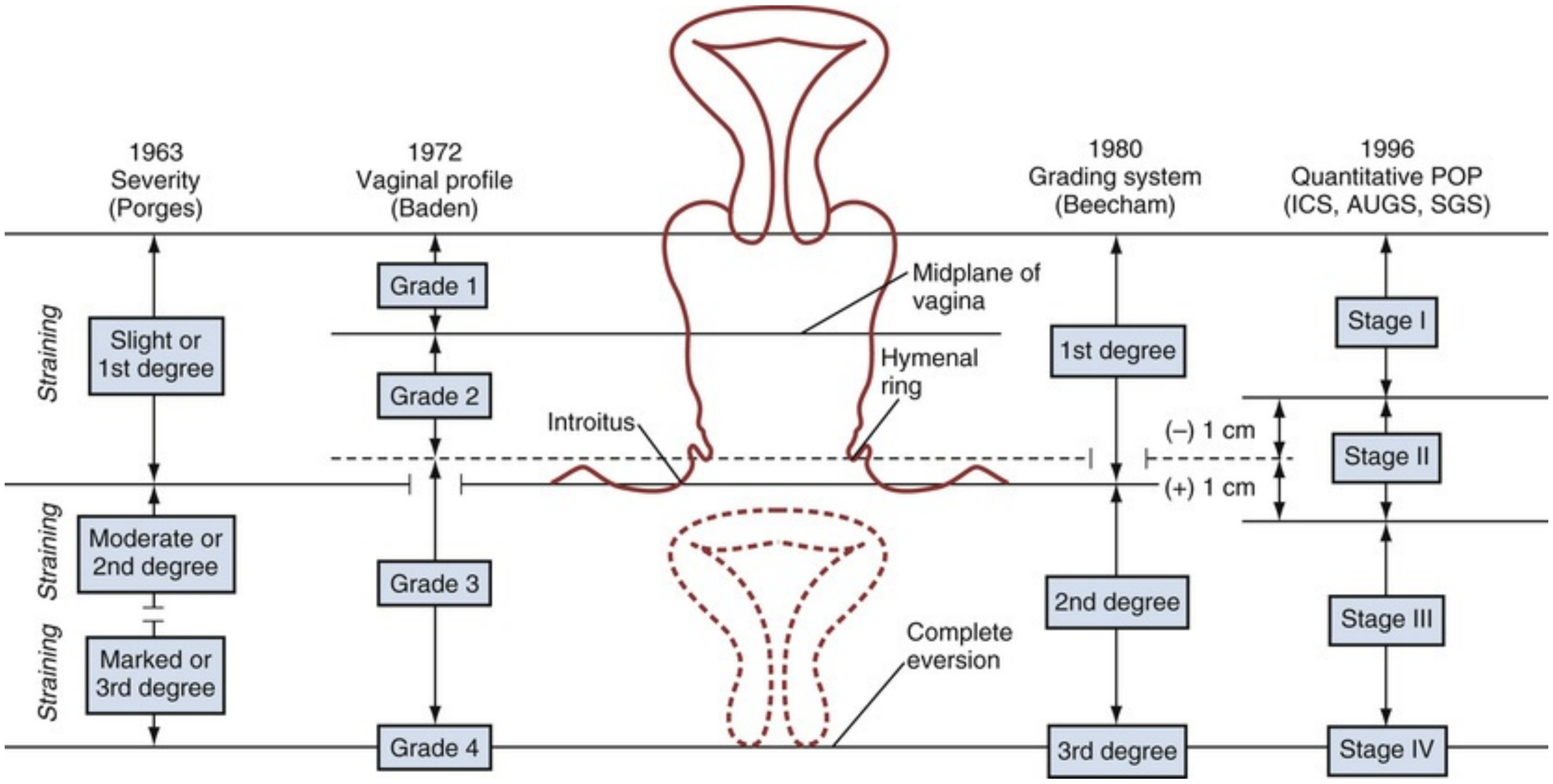
1963
Severity
(Porges)
1972
Vaginal profile
(Baden)
1980
Grading system
(Beecham)
1996
Quantitative POP
(ICS, AUGS, SGS)
Straining
Slight or 1st degree
Straining
Moderate or 2nd degree
Straining
Marked or 3rd degree
Grade 1
Grade 2
Grade 3
Grade 4
Midplane of vagina
Hymenal ring
Introitus
Complete eversion
1st degree
2nd degree
3rd degree
(–) 1 cm
(+) 1 cm
Stage I
Stage II
Stage III
Stage IV

FIG. 112.1 Visual comparison of systems used to quantify pelvic organ prolapse (POP). *AUGS,* American Urogynecologic Society; *ICS,* International Continence Society; *SGS,* Society of Gynecologic Surgeons. (From Theofrastous JP, Swift SE. The clinical evaluation of pelvic floor dysfunction. *Obstet Gynecol Clin North Am* 25:783–804, 1998.)

Regarding UI specifically, the substantiation of a proper diagnosis requires direct observation of urinary leakage by the clinician (Kobashi et al., 2017; Nitti and Blaivas, 2007). It is the belief of many experts that no patient should undergo invasive or irreversible therapies without definitive establishment of the cause of their incontinence and demonstration of leakage in the specific case of SUI. Complete and extensive evaluation can facilitate accurate diagnosis of

PFDs to promote optimal treatment planning and counseling of patients. Not only is it imperative that patients be aware of the risks, benefits, and alternatives of their treatment, but it has been shown that patients who understand their condition and the rationale behind their treatment have better outcomes (Kobashi et al., 2017).

Key Points

- PFDs are a prevalent worldwide health concern.
- Careful history and physical with objective demonstration of incontinence are integral in the proper evaluation of patient with PFDs.
- Supplementary evaluation including urinaylsis, postvoid residual, urodynamics, endoscopy, and radiologic imaging can be helpful in facilitating a complete and accurate diagnosis.
- A variety of surgical and nonsurgical options are available for treatment of urinary incontinence and pelvic organ prolapse.
- The degree of bother the symptoms of the PFDs are causing should be taken into account when considering treatment.

History

A careful history should always be obtained from the patient. However, several studies have indicated that patient history alone is not completely accurate as the sole determinant of incontinence type (Jensen et al., 1994; Summitt et al., 1992). In a systematic review of 3545 patients, women with a clinical history of SUI had 73% chance of having SUI, whereas women with no clinical history had a 16% chance of having SUI (Martin et al., 2006b). Bates et al. (1973) are credited with the dictum, “The bladder is an unreliable witness,” which has been corroborated by many investigators in various forms. Accordingly, all available information, including that which is obtained by supplementary examinations, should be integrated into the diagnosis.

History of Present Illness

A thorough history is imperative in the evaluation of incontinence. Several queries should be included in a continence and pelvic floor history to best portray the patient's symptoms (Holroyd-Leduc et al., 2008). ***The incontinence should first be characterized subjectively.*** Does the leakage occur: With physical activity? With a sense of urgency? Without sensory awareness? If the nature of the incontinence is mixed, does one component cause more bother or occur more frequently than the other? ***Second, the leakage should be quantified if possible.*** Appraisal of the degree of leakage before therapy can be helpful during postoperative assessment of treatment impact. For the purposes of routine outpatient assessment, this quantification can be achieved based on the number of pads used per day or the frequency of clothing changes resulting from urinary leakage. In the setting of research or an academic practice, more stringent and objective measures such as pad weight testing are often used (see “Supplemental Evaluation” later in this chapter). ***Third, the voiding pattern should be defined.*** What is the frequency of urination during the day? During the night? Are there any obstructive symptoms? Does the patient have to wait for the stream to start (hesitancy)? Does the patient feel as though he or she empties the bladder completely? Is the stream strong, or does it “trickle”? Does the stream fluctuate during the void (intermittency)? Is it necessary to push or strain or change posture to void or empty the bladder? ***Fourth, establishment of the duration of symptoms and any inciting events that contributed to the onset of leakage is important.*** Did the leakage follow a pregnancy or a vaginal delivery? How long ago? Did the leakage start after a strain, a fall, or trauma? Has the patient undergone pelvic or back surgery? In males, has there been any prostate or urethral surgery for benign or malignant disease? Has there been any lower urinary tract instrumentation? Are there any accompanying neurologic symptoms, such as numbness or tingling in the extremities, blurry/double vision, balance or coordination changes, or tremor? **It is helpful to determine the impact that the leakage has on the patient's daily life and activities.** Does the incontinence limit the individual's activity? Has the individual changed his or her lifestyle because of the threat of leakage? Questionnaires can be helpful adjuncts when assessing the impact the condition is having on an individual's QoL and the degree of bother the symptoms are causing him or her. **Finally, the American Urological Assocation (AUA) guidelines emphasize the importance of establishing patient expectation of treatment and an understanding of the balance between the benefits and risks/burden of available treatment options** (Kobashi et al., 2017).

Regarding pelvic prolapse specifically, important questions focus on

whether or not the patient is aware of any prolapse and what, if any, symptomatology and bother the prolapse may be causing. Does the patient feel that anything is falling down out of place in the vagina? Does she need to reduce the prolapse for comfort? Or to empty her bladder completely? Or to facilitate evacuation of her bowels? Patients with pelvic prolapse should also be assessed for presence of SUI given the high co-occurrence of these conditions (Roovers et al., 2007).

Past Medical and Surgical History

Past medical and surgical histories are vital to the assessment of incontinence insofar as medical conditions and surgeries can affect urinary tract function. Childhood and adult urologic history should be obtained, as should a neurologic history. **Neurologic conditions** such as Parkinson disease, multiple sclerosis, stroke, spinal cord injury, back surgery, and myelodysplasia can have a considerable impact on lower urinary tract (LUT) function. **Medical diagnoses**, such as diabetes mellitus and dementia, can affect continence. Similarly, a history of **radiation therapy** or neurologic or urologic **trauma** can affect LUT function, specifically with regard to outlet resistance and/or bladder contractility, stability, and compliance. Although outlet resistance may be compromised by trauma or LUT surgery, urethral strictures related to trauma or neurologic dysfunction that abnormally increase outlet resistance during voiding can cause obstruction and secondary symptoms related to the obstruction.

In women, the **gynecologic and obstetric history,** including gravity, parity, and hormonal status, is important. Determination of whether the patient is pre-, peri-, or postmenopausal, and whether or not she has used any exogenous hormones such as oral contraceptives or local or systemic hormone replacement therapy can be helpful in her overall assessment. As mentioned earlier, although beneficial effects of local hormone replacement therapy are well-established, there have been reports that exogenous systemic hormone therapy can actually increase the risk for SUI (Cody et al., 2012; Townsend et al., 2009; Waetjen et al., 2011).

Clearly, **previous pelvic surgery** can affect LUT function. Anti-incontinence surgery, POP repair, and hysterectomy can contribute to a variety of urinary symptoms in women. Similarly, a history of prostate surgery can give rise to voiding or leakage complaints in men. Abdominoperineal resection can result in neurologic injury that can affect the function of either the bladder or the sphincter (Petrelli et al., 1993), and back surgery can cause a variety of symptoms dependent on the level involved.

Medications

An accurate assessment of mediations is critical, particularly in the elderly patient population in whom polypharmacy is common. Many agents can affect urine production, LUT function, and mental status, all of which can have an impact on continence. Special attention should be focused on agents that can affect bladder/sphincteric function. Table 112.3 categorizes some commonly used classes of medications by mechanism of action and potential effect on the LUT.

TABLE 112.3

Pharmacologic Agents That Can Affect the Lower Urinary Tract

PHARMACOLOGIC EFFECTS	COMMON AGENTS	POTENTIAL EFFECTS ON URINARY TRACT
Sympathomimetics	Ephedrine, methylphenidate, cocaine, amohetamine	Can increase outlet resistance and exacerbate obstructive symptoms/overactive bladder symptoms
		Can decrease detrusor contractility and precipitate retention
Sympatholytics	Terazosin, doxazosin, tamsulosin, alfuzosin, silodosin	Can decrease outlet resistance and exacerbate stress incontinence
Anticholinergics	Oxybutynin, fesoteridine, solifenacin, trospium, darifenacin	Can contribute to urinary retention, particularly in patients with outlet obstruction
Diuretics	Furosemide, thiazides, spironolactone, triamterene, bumetanide	Do not affect bladder directly, but because of increased urine production, can aggravate incontinence problems

Other

As **genetics** can influence connective tissue integrity, it stands to reason that there may be a potential hereditary role in continence and POP (Richter et al., 2015; Twiss et al., 2007). Accordingly, inquiry about family history of POP may be helpful. Additionally, a thorough review of systems may reveal symptoms that suggest other conditions that could impact pelvic floor function.

Male incontinence, also a very prevalent health issue, should be assessed in much the same way as female incontinence, although specific consideration should be given to the impact of the anatomy specific to the male. **Benign prostatic hyperplasia**, the evaluation of which is covered in detail in Chapter 145, can cause secondary urgency and urgency incontinence in addition to more "typical" obstructive symptoms, such as a decreased force of stream, urinary hesitancy, intermittency, and incomplete bladder emptying. **Prostate surgery for benign or malignant disease** can contribute to SUI. With this in mind, full assessment of male LUTS should be performed to facilitate proper treatment planning.

Key Points

- A thorough history is essential in the diagnostic evaluation of patients with PFDs.
- Queries specific to the character, severity, duration, and quantity of incontinence and other symptoms related to pelvic floor function should be performed.
- Attention should be paid to the impact of PFD symptoms on QoL.
- When appropriate, the clinician should present questions specific to the female with potential pelvic organ prolapse and the male with potential prostate issues.
- Queries regarding past medical and surgical history, obstetric and gynecologic history, radiation therapy, trauma, and medications may provide important information.

Physical Examination

The general appearance of a patient, including details such as age, gait, stature, and fragility, can provide important information regarding performance status, neurologic status, and other factors that may direct proper treatment planning. Similarly, an abdominal examination evaluating incisions, hernias, organomegaly, bladder distension, and body habitus is important, particularly if abdominal surgery may be considered.

Frailty assessment of patients with PFDs, particularly if considering surgical intervention, is of utmost importance as frailty has been shown to affect surgical outcomes (Makary et al., 2010). The 5th International Consultation on Incontinence (ICI) presented a treatment algorithm that specifically addresses the management of the frail patient with UI (Wagg et al., 2015). Tools such as the "Timed up and Go" and the "FRAIL scale" have been developed for the assessment of frailty and can be useful in the evaluation of patients with PFDs (Morley et al., 2012; Pangilinan et al., 2017).

Per Medicare coding guidelines (Centers for Medicare and Medicaid Services, 1997), **a comprehensive female pelvic examination includes all bullet items listed in Table 112.4.** The **external genitalia** should be evaluated with regard to general appearance, **estrogen status,** lesions, and labial size and adhesions. Estrogen status can be evaluated based on the presence or absence of a urethral caruncle, urethral prolapse, and/or labial adhesions, all of which may indicate estrogen deficiency. Similarly, attention to the overall tissue appearance and color is important. Hormonally deficient vaginal tissue has a pale, flat, dry appearance with no rugae, as opposed to the healthy, pink rugaeted tissue of well-estrogenized tissue.

TABLE 112.4

Components of a Focused Pelvic Examination

Genitourinary Female
Pelvic examination (with or without specimen collection for smears and cultures), including: • Examination of external genitalia (e.g., general appearance, hair distribution, lesions) and vagina (e.g., general appearance, estrogen effect, discharge, lesions, pelvic support, cystocele, rectocele)

- Examination of urethra (e.g., masses, tenderness, scarring) Examination of bladder (e.g., fullness, masses, tenderness)
- Cervix (e.g., general appearance, lesions, discharge)
- Uterus (e.g., size, contour, position, mobility, tenderness, consistency, descent or support)
- Adnexa/parametria (e.g., masses, tenderness, organomegaly, nodularity)
- Anus and perineum

Note: At the time of this writing, all bullet points listed above are required to be considered a complete female genitourinary examination. However, other organ systems/body areas not limited to the genitourinary system may be included in a report to accomplish the requirements of various levels of examination.

From CMS 97 guidelines for focused female pelvic examination. Documentation Guidelines for Evaluation and Management (E/M) Services, jointly approved by the American Medical Association and HCFA with revisions November, 1997.

Consistent with prior iterations, the most recent AUA guidelines for surgical treatment of SUI recommend the objective demonstration of SUI (Kobashi et al., 2017). The most common methodology to document SUI on examination is the supine cough stress test, though this can also be performed in the standing position, particularly if SUI is not demonstrated in the recumbent position. A recent study evaluating the cough stress test showed that a bladder filled to one-half normal capacity (~200 mL) had a 90% specificity and 84% sensitivity (Henderson et al., 2018).

Urethral position and mobility should be assessed at rest and with straining and coughing. The **Q-tip test** was developed to objectify the evaluation of urethral mobility (Bergman and Bhatia, 1987; Walters and Diaz, 1987). The Q-tip is inserted into bladder through the urethra and the angle that the Q-tip moves from horizontal to its final position with straining is measured. Hypermobility is defined as a Q-tip angle of >30 degrees from horizontal. Insertion of the Q-tip can be uncomfortable, and this discomfort can be mitigated with the use of intraurethral lidocaine jelly.

DeLancey described the connective tissue support of the pelvis and the pelvic viscera in three levels. Levels I, II, and III represent the proximal, middle, and distal vaginal support, respectively, in this classification system that is utilized worldwide. Level I support depends on the uterosacral and cardinal ligaments and supports the vaginal vault; level II support applies to the mid-vagina and involves the attachment of the anterior and posterior endopelvic fascia to the lateral pelvic side walls; and level III support constitutes the fusion of the endopelvic fascia to the pubic symphysis and perineal body (DeLancey, 1992). **Assessment of prolapse should ideally be performed in both the lithotomy**

and standing positions, the latter facilitated by having the patient stand with one foot elevated on a short stool. Each compartment—the anterior, posterior, and apical (uterus/cervix or vaginal cuff) —should be evaluated methodically and the perineal body assessed for laxity. A complete systematic examination is performed using two posterior blades of a split Grave's speculum with and without straining. First, one blade is used to retract the posterior wall to facilitate anterior compartment examination. The blade is then repositioned to retract anteriorly for examination of the posterior compartment. Finally, both blades are inserted simultaneously, one anteriorly and one posteriorly, to isolate the vaginal apex and facilitate examination of the cervical or cuff support. The posterior blade is slowly withdrawn to examine the posterior wall. Next, with the posterior blade in place, the patient is asked to strain. Foreshortening of the posterior wall results in expulsion of the blade and suggests a compromise in the level I support (cardinal-uterosacral ligament complex) of the vault (DeLancey, 1992); if the blade remains in place, this could represent an isolated rectocele or enterocele without vault prolapse. Evaluation for occult SUI should be performed with the anterior wall supported. SUI can be masked if significant prolapse “kinks” the urethra and outlet.

Several classification systems are used to quantify POP, the most widely used of which are the **Baden-Walker classification** (Baden et al., 1968) **and the Pelvic Organ Prolapse-Quantification system, known as the “POP-Q”** (Bump et al., 1996). The two systems are juxtaposed in Fig. 112.1. **In the POP-Q system, which was created in an effort to provide objectivity to POP quantification, nine specific points of measurement are obtained in relation to the hymenal ring as illustrated in Fig. 112.2.** Six vaginal points labeled Aa, Ba, C, D, Ap, and Bp are measured during the Valsalva maneuver. Points above the hymen are considered negative, and points below the hymen are positive. The genital hiatus (gh) represents the size of the vaginal opening, and the perineal body (pb) represents the distance between the vagina and the anus. The total vaginal length (tvl) is measured by reducing the prolapse and measuring the depth of the vagina. Table 112.5 contains the **POP-Q staging criteria,** a simplified presentation of the POP-Q system, and Fig. 112.3 illustrates an example of the application of the system.

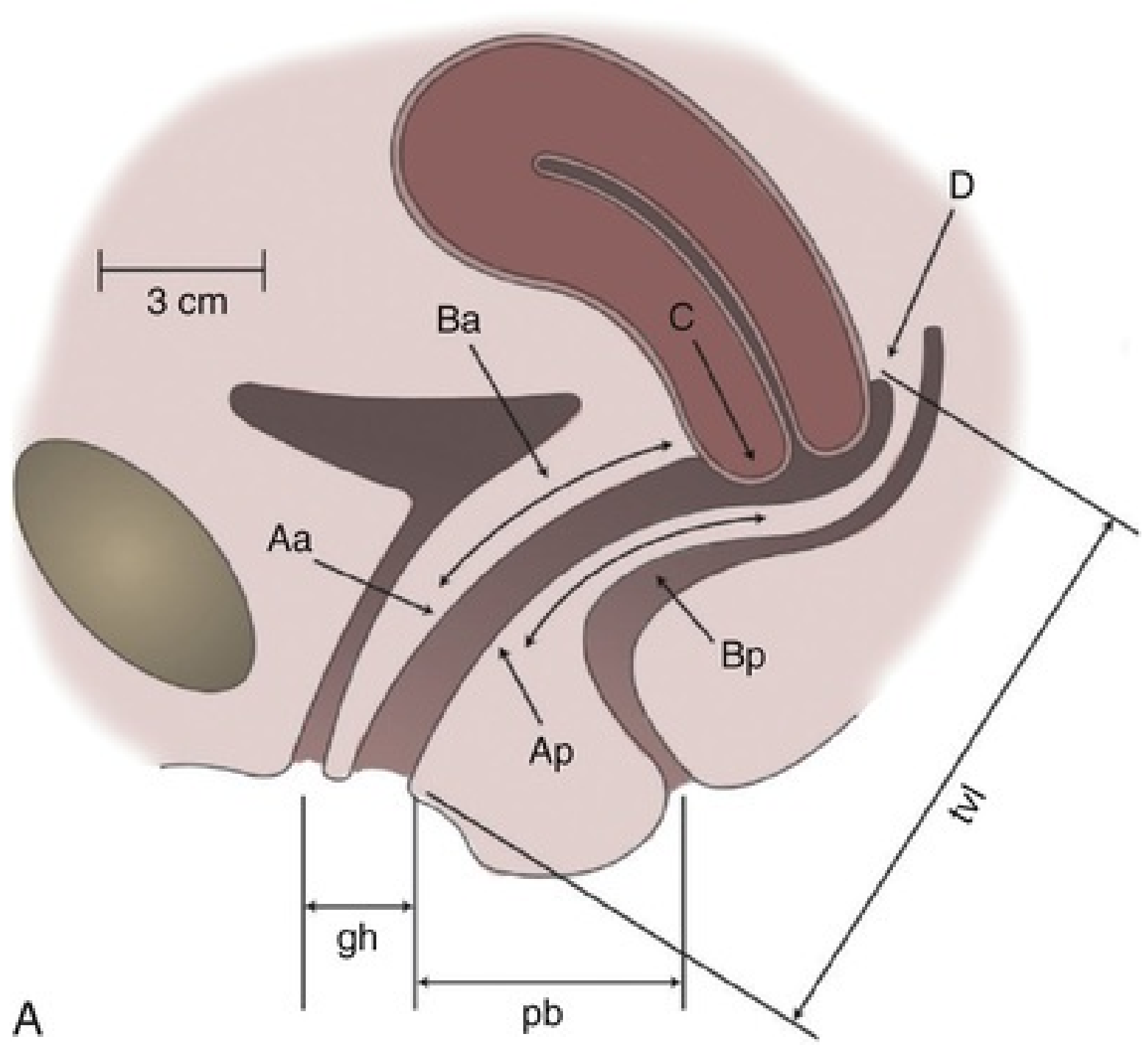

Point	Description	Range of values
Aa	Anterior vaginal wall 3 cm proximal to the hymen	–3 cm to +3 cm
Ba	Most distal position of remaining upper anterior vaginal wall	–3 cm to +tvl
C	Most distal edge of cervix or vaginal cuff scar	–
D	Posterior fornix (N/A if posthysterectomy)	–
Ap	Posterior vaginal wall 3 cm proximal to the hymen	–3 cm to +3 cm
Bp	Most distal position of remaining upper posterior vaginal wall	–3 cm to +tvl
gh (genital hiatus)	Measured from middle of external urethral meatus to posterior midline hymen	–
pb (perineal body)	Measured from posterior margin of gh to middle of anal opening	–
tvl (total vaginal length)	Depth of vagina when point D or C is reduced to normal position	–

B

FIG. 112.2 (A) Landmarks for the POP-Q system. (B) POP-Q points of reference. (A, From Bump RC, Mattiasson A, Bo K, et al. The standardization of terminology of female pelvic organ prolapse and pelvic floor dysfunction. *Am J Obstet Gynecol* 175:10–7, 1996.)

TABLE 112.5

POP-Q Staging Criteria

STAGE	CRITERIA
0	Aa, Ap, Ba, Bp at –3 cm and C or D ≤ – (tvl – 2) cm
I	Stage 0 criteria not met and leading edge < –1 cm
II	Leading edge ≥ –1 cm but ≤ +1 cm
III	Leading edge > +1 cm but < + (tvl – 2) cm
IV	Leading edge ≥ + (tvl – 2) cm

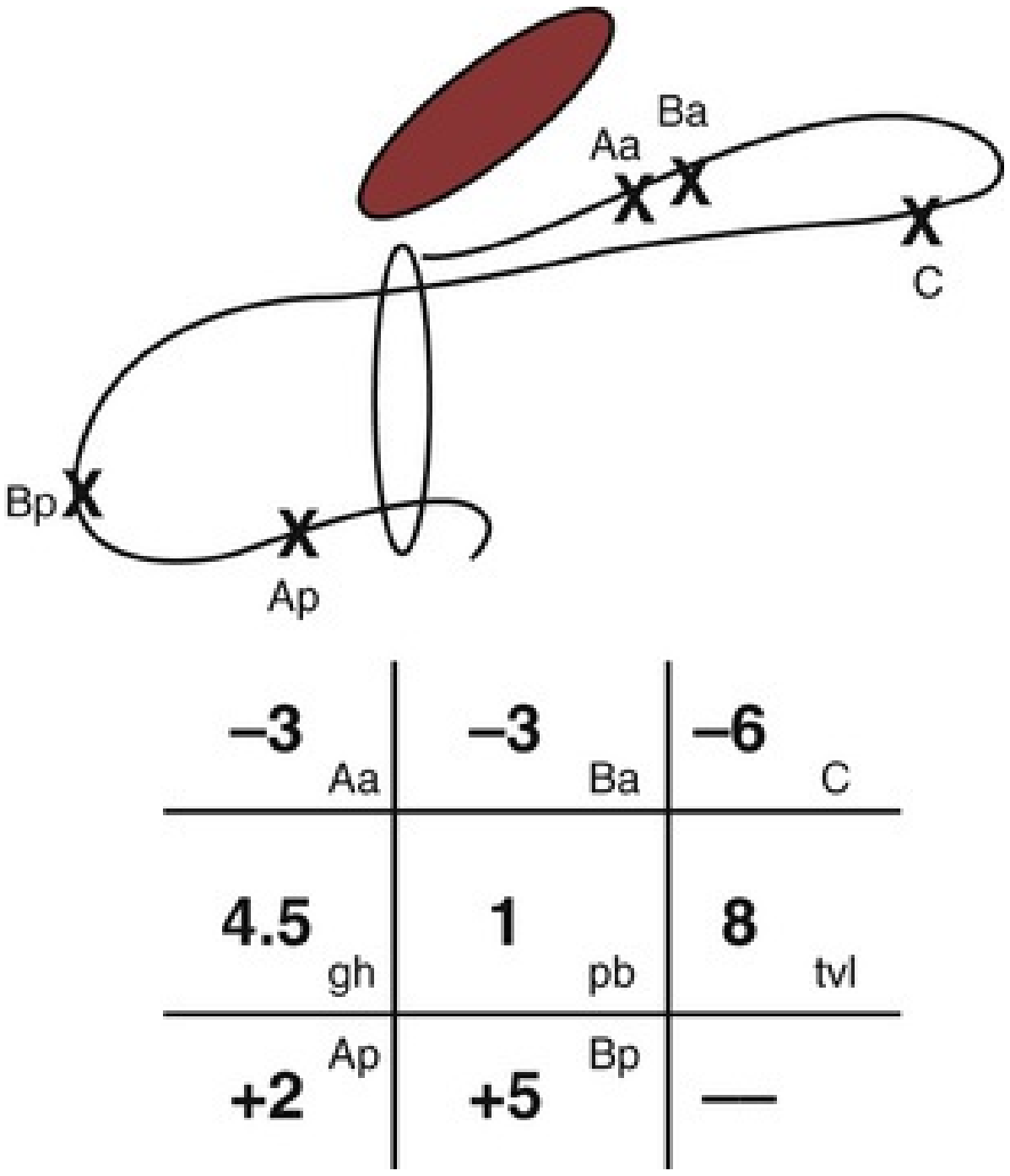

–3 Aa	–3 Ba	–6 C
4.5 gh	1 pb	8 tvl
+2 Ap	+5 Bp	—

FIG. 112.3 Line drawing example of posterior support defect. The anterior compartment is well supported. Bp is the leading point of the prolapse relative to the reference point of the hymen. At +5, Bp is 5 cm beyond the hymen. Point *C* designates the cuff position. Taking into consideration a total vaginal length (tvl) of 8 cm, the cuff has descended 2 cm. (From Bump RC, Mattiasson A, Bo K, et al. The standardization of terminology of female pelvic organ prolapse and pelvic floor dysfunction. *Am J Obstet Gynecol* 175:10–17, 1996.)

With the use of mesh in the surgical approach to PFDs, mesh-related complications have become more commonly encountered. Patients with these complications often present with symptoms, however, many can be asymptomatic. Consequently, patients who have undergone prior pelvic floor surgery with mesh that present with pain or voiding symptoms of any type should undergo a thorough history and examination. Pelvic examination should evaluate for the presence, location, and size of any mesh extrusion. Presence of tenderness, even in the absence of mesh exposure, should be documented. In 2011 IUGA and ICS developed joint terminology and classification of complications related directly to the use of prosthesis and grafts in female pelvic surgery (Haylen et al., 2011). Providers could refer to these classification when evaluating complications related to mesh used in pelvic floor surgery.

A **neurologic examination** is important in any patient with a known or suspected neurologic condition. Attention to the patient's gait, speech, cognitive status, facial symmetry, sensation in the lower extremities and perineal and perianal regions, lower extremity motor strength, and vaginal and pelvic floor strength can provide helpful information. Mobility and cognitive status can play a role in urinary continence insofar as both can affect a patient's ability to reach the facilities in a timely fashion. The **bulbocavernosus reflex (BCR)**, which is representative of sacral nerve root levels 2 to 4 (S2–S4), is present in 70% of normal females and 100% of normal males. The BCR is considered positive when squeezing of the glans penis or clitoris results in anal and pelvic floor contraction that can be detected visually or by rectal exam. Alternatively, applying traction to an indwelling Foley catheter to pull the balloon against bladder neck should also precipitate a BCR.

A **digital rectal examination (DRE)** is important in men to assess the prostate for size, nodularity, and tenderness. In the female, the DRE can facilitate assessment of the rectovaginal septum. Demonstration of a rectocele can be facilitated by applying anterior pressure with a finger placed in the rectum. Anal sphincter tone, which is a reflection of the function at S2–S4, is particularly important in neurologic patients with PFDs. Patients are asked to voluntarily tighten the pelvic floor as if attempting to stop the flow of urine midstream. Laxity in the rectal sphincter tone may suggest a possible neurologic defect, but one must also consider the possibility that it may be caused by a patient's lack of understanding regarding how to voluntarily control the specific muscle groups necessary for contraction.

In men, genitourinary examination as it pertains to voiding function should also include evaluation of the penis for meatal stenosis and, particularly in the post-prostatectomy patient, visible urinary leakage with coughing and straining. Examination for leakage is ideally performed with the patient in the standing position.

Key Points

- A properly performed physical examination is imperative in the evaluation of patients with PFDs.
- The Centers for Medicare and Medicaid Services require specific elements of both male and female genitourinary examination to meet coding guidelines (see Table 112.4).
- Assessment of POP should ideally be performed in both the supine and standing positions.
- Several classification and quantification systems are available for assessment of POP, and the most widely used systems (Baden-Walker and POP-Q) are illustrated in Figs. 112.1 and 112.2.
- A neurologic examination and rectal examination should be performed in appropriate patients to obtain complete clinical information important in the assessment of lower urinary tract and pelvic floor function.

Supplemental Evaluation

A variety of measures are available to supplement the history and physical examination in patients with PFDs. Instruments exist to quantify symptoms, their effects on QoL, and the degree of bother experienced by patients with PFDs. **Most experts concur that a urinalysis (UA) and postvoid residual (PVR) measurement should be considered in the majority of patients undergoing evaluation for incontinence. However, beyond this, there are no universally agreed-on standards regarding the roles of other studies, such as endoscopy, urodynamics (UDS), radiographic imaging, and various modalities of symptom quantification including voiding diaries, pad tests, and questionnaires** (Zimmern et al., 2010). In an effort to address this, the American Urological Association (AUA) and the Society of Female Pelvic Medicine and Reconstructive Surgery (SUFU) published guidelines based on the current literature (Gormley et al., 2012; Kobashi et al., 2017; Winters et al., 2012).

According to the guidelines, a urinalysis (UA) is part of the minimum proper evaluation of the overactive bladder (OAB) patient. Urine culture and PVR can be obtained at the discretion of the clinician. The guidelines state that UDS, cystoscopy, and renal ultrasonography should not be a part of the initial evaluation of the uncomplicated OAB patient (Gormley et al., 2012). For SUI, evaluation of the index patient who is considering treatment should include a UA and PVR assessment. UDS, pad tests, cystoscopy, and imaging can be considered (Kobashi et al., 2017) in specific situations such as those outlined in Table 112.6. In circumstances in which further investigation is considered, the value and accuracy (sensitivity and specificity) of the information provided by the given assessment method should be considered in relation to the cost and morbidity of the examination.

TABLE 112.6

Circumstances That Warrant Consideration of Supplemental Evaluation

- Inability to make definitive diagnosis based on symptoms and initial evaluation
- Inability to demonstrate stress urinary incontinence
- Known or suspected neurogenic lower urinary tract dysfunction
- Abnormal urinalysis, such as unexplained hematuria or pyuria

- Urgency-predominant mixed urinary incontinence
- Elevated post-void residual per clinician judgment
- High grade pelvic organ prolapse (POP-Q stage 3 or higher) if stress urinary incontinence not demonstrated with pelvic organ prolapse reduction
- Evidence of significant voiding dysfunction

Symptom Quantification Instruments

Voiding Diaries

Instruments such as voiding diaries, questionnaires, and pad tests, have been developed to aid in the quantification of urinary loss, both symptomatically and volumetrically. **Voiding diaries can provide valuable diagnostic and therapeutic information. The use of diaries often helps patients realize their pattern of urination and is more accurate than recall** (Larsson et al., 1984; McCormack et al., 1992; Siltberg et al., 1997)**. Furthermore, the diary can provide patients with insights into behaviors that can be altered to decrease urinary frequency** (Burgio, 2004)**. Despite its common use, the first validated voiding diary was only recently developed by the ICS in 2014 with the creation of a 3-day voiding diary called the ICIQ bladder diary** (Bright et al., 2014).

Several studies have demonstrated the adjunctive role that diaries can have in the diagnosis and management of incontinence. Diaries can be an adjunct to a routine subjective history as it has been demonstrated that patient recall is not often as accurate as a formal voiding diary in ascertaining urinary frequency. In a retrospective review of 601 patients who underwent sling surgery and completed bladder diaries, only 47% were accurate about their daytime frequency; 51% overestimated their diurnal frequency, and this overestimation was exaggerated in those who reported voiding more than 10 times per day (Stav et al., 2009). Overestimation rates were similar between patients with and without overactive bladder (OAB) symptoms. Interestingly, 93% of women in this study were accurate about their nighttime frequency. In another study of women with UI, it was noted that the overestimation of incontinence episode frequency occurred more often in those patients who were more bothered by their incontinence. Conversely, Ku et al. (2004) found a poor correlation between subjective nocturnal frequency and that noted by 164 patients on their frequency volume charts. Wyman similarly showed a higher correlation of diary-reported frequency in the daytime versus the night (Wyman et al., 1988).

Martin et al. (2006) performed a meta-analysis of 121 in 6099 papers that compared two or more diagnostic techniques for incontinence and showed that diaries are most cost-effective when used in conjunction with history, particularly in patients undergoing treatment for detrusor overactivity (DO). It should be noted, however, that diaries should not substitute for more formal studies in select patients. One study that retrospectively assessed the Larsson frequency/volume chart as compared with the cystometrogram in 216 patients demonstrated the sensitivity and specificity of the chart with regard to DO to be 52% and 70%, respectively, and with regard to SUI, 66% and 65%, respectively (Tincello and Richmond, 1998). For daily clinical practice, 24-hour diaries should suffice to obtain valuable clinical information regarding LUT function; in academic studies, longer diaries may be requested, but this should be balanced with the well-established knowledge that the more complex a given instrument is (i.e., the more data requested), the lower patient compliance will be in completing it (Groutz et al., 2000). In the current digital era, traditional paper voiding diaries are being replaced by electronic voiding diaries. Studies have demonstrated the benefit of the latter in preventing backfill and in a potential increase in patient compliance while maintaining good test reliability (Sussman et al., 2016).

Questionnaires and Quality of Life Instruments

Questionnaires can provide a helpful complement to the patient history and patient reported outcomes (PROs). A plethora of instruments to evaluate symptoms, degree of bother, and QoL in patients with incontinence and PFDs have been developed in an effort to provide optimal assessment of outcomes and to eliminate the confounding issue of physician bias; many have been validated. Table 112.7 contains validated questionnaires highly recommended by the ICI. One such instrument, the modular ICI questionnaire (ICIQ), was developed by the ICI in an effort to collaboratively develop a universally applicable instrument that could be utilized to assess pelvic floor function in both clinical practice and research settings (Abrams et al., 2005). To allow it to be used globally, the ICIQ has been translated in 38 languages. The short form of the ICIQ (ICIQ-SF) has been shown to correlate nicely with both the 1-hour (Franco et al., 2008) and 24-hour (Karantanis et al., 2004) pad test for evaluation of the severity of SUI. Another comparison of the 24-hour pad test, the ICIQ-SF, the International Prostate Symptom Score (IPSS), and the postoperative Patient Global

Impression of Improvement (PGI-I) score in 26 men after perineal sling placement confirmed the construct validity of these instruments (Twiss et al., 2007). There was a strong correlation demonstrated between the ICIQ-SF and PGI-I scores and the percentage reduction in 24-hour pad weight. At the time of this writing, available ICI modules include the ICIQ-MLUTS (male LUTS), ICIQ-FLUTS (female LUTS), ICIQ-SF, ICIQ-OAB, ICIQ-VS (vaginal symptoms), ICIQ-N, and the recently developed ICIQ-Bladder diary. Additional modules covering QoL, sexual function, pediatric LUTS, neurogenic LUTS, and bowel function are available or are in development and are or will be available through the ICI (Abrams et al., 2017).

TABLE 112.7

Instruments Highly Recommended by the International Consultation on Incontinence for Urinary Incontinence, Overactive Bladder, Lower Urinary Tract Symptoms, and Pelvic Organ Prolapse Patient Reported Outcomes

QUESTIONNAIRE	POPULATION	PURPOSE OF INSTRUMENT
Health-Related Quality Of Life		
BFLUTS (Bristol Female Lower Urinary Tract Symptoms Questionnaire) aka ICIQ-FLUTS (Jackson et al., 1996)	Women, incontinence	To assess female LUTS, particularly incontinence; measure impact on QoL; and evaluate treatment outcome
DAN-PSS-1 (Danish Prostatic Symptom Score) (Hansen et al., 1995)	Men, BPH	To evaluate males with LUTS suggestive of uncomplicated BPH
ICIQ-UI-SF (ICIQ Urinary Incontinence Short Form) (Avery et al., 2004)	Men and women, urinary symptoms	To assess symptoms and impact of urinary incontinence in clinical practice and research
ICSmale (ICIQ-MLUTS) (Donovan et al., 1996)	Men with LUTS and possible BPH	To provide evaluation of occurrence and bothersomeness of LUTS and their impact on the lives of men with BPH
ICS-LUTSqoL (Donovan et al., 1997)	Men with LUTS and possible BPH	To assess impact of LUTS on the lives of men with LUTS
IIQ (Incontinence Impact Questionnaire (Wyman et al., 1987)	Women, UUI, SUI	To assess impact of incontinence on HRQOL, primarily in patients with SUI

IIQ-7 (IIQ-short form) (Uebersax et al., 1995)	Women, UUI, SUI	To assess impact of urinary incontinence on HRQOL
I-QoL (ICIQ-UIqol) (Urinary incontinence-specific QoL instrument) (Wagner et al., 1996)	Women, UUI	To assess QoL of women with urinary incontinence
KHQ (King's Health Questionnaire) (ICIQ-LUTSqol) (Kelleher et al., 1997)	Men and women, OAB	To assess the impact of LUTS on HRQOL
N-QoL (ICIQ-Nqol; Nocturia QoL) (Abraham et al., 2004)	Men and women	To assess the impact of nocturia on QoL
OABq-SF (Coyne et al., 2002)	Men and women, OAB	Shortened version of OAB-q to evaluate both continence and incontinence symptoms of OAB and their impact on QoL
OAB-q (ICIQ-OABqol) (Coyne et al., 2002)	Men and women with OAB wet and OAB dry	To evaluate both OAB-wet and OAB-dry symptoms and their impact on HRQOL
PRAFAB (Protection, Amount Frequency, Adjustment, Body image) (Hendriks et al., 2007)	Women, UUI	To evaluate treatment effects for UUI in women
UISS (Urinary incontinence severity score) (Stach-Lempinen et al., 2001)	Women, UUI	To assess symptom severity and impact of urinary incontinence on everyday life
Urolife (BPH-QoL9) (Lukacs et al., 1997)	Men, BPH	To assess the impact of BPH and its treatment on the QoL of patients
Screeners		
B-SAQ (Bladder-Self-Assessment Questionnaire) (Basra et al., 2007)	Women	Screening tool for the presence of bothersome LUTS in women
LUSQ (Leicester Urinary Symptom Questionnaire) (Shaw et al., 2002)	Men and women, LUTS	Condition-specific screener of storage LUTS (urgency, frequency, nocturia, and incontinence)
OAB-SS (OAB Symptom Score) (Blaivas et al., 2007)	Men and women, LUTS with and without OAB	7-item tool to measure overall symptom severity due to the four index symptoms of OAB
OAB-V8 (OAB Awareness Tool) (Coyne et al., 2005)	Men and women, OAB	8-item screening tool for use in primary care setting to identify patients who may have OAB
QUID (Questionnaire for Urinary Incontinence Diagnosis)	Women, UUI and SUI	6-item tool to diagnose SUI and UUI

(Bradley et al., 2005)		
ICIQ Bladder diary (Bright et al., 2014)	Men and women, LUTS	3-day diary assessing volume, frequency, intake and incontinence episodes
Symptom bother		
PPBC (Patient perception of bladder condition) (Coyne et al., 2006)	Men and women	To assess patients' subjective impression of their current urinary problems. Developed as a global assessment of bladder condition.
UDI-6 (Urogenital Distress Inventory-6/short form) (Uebersax et al., 1995)	Women	To assess LUTS bother, including incontinence, in women
Urgency		
IUSS (Indevus Urgency Severity) (Nixon et al., 2005)	OAB with urgency incontinence, men and women	To quantify the level of urgency associated with each toilet void as measured during standard voiding diaries
POP symptoms and QoL		
PFDI (Pelvic floor distress inventory) (Barber et al., 2001)	Women	To quantify the symptoms caused by pelvic prolapse
PFIQ (Pelvic floor impact questionnaire) (Barber et al., 2001)	Women	To quantify the effects of pelvic prolapse on QoL
Sexual matters		
ICIQ-MLUTSsex; ICIQ-Bsex (McKown et al., 2010)	Men	Assessment of male sexual bother related to LUTS and bowel symptoms
ICIQ-FLUTSsex; ICIQ-Bsex	Women	Assessment of female sexual bother related to LUTS and bowel symptoms

BPH, Benign prostatic hypertrophy; *HRQOL,* health-related QoL; *ICIQ,* International Consultation on Incontinence Questionnaire; *ICS,* International Continence Society; *LUTS,* lower urinary tract symptoms; *MLUTS/FLUTS,* male/female lower urinary tract symptoms; *OAB,* overactive bladder; *PRO,* patient recorded outcomes; *QoL,* quality of life; *SF,* short form; *SUI,* stress urinary incontinence; *UUI,* urgency urinary incontinence.

A study examining the incontinence-related and non–incontinence-related pelvic floor symptoms evaluated by two widely utilized symptom tools, the Urogenital Distress Inventory (UDI)-6 and the ICIQ-UI, demonstrated that both symptom questionnaires were sound and correlated with each other and independently with the QoL scores, as measured by the IIQ-7 and IQOL (van de Vaart et al., 2010). This study also uncovered the interesting finding that the delay in time to consultation with a physician was associated with greater bother, emphasizing the importance of heightened awareness of PFDs in the female patient population.

In Martin's meta-analysis, two studies showed a high sensitivity (0.82 to 0.92) of question 3 in the Urogenital Distress Inventory for SUI; the specificity was 0.51 to 0.69 (Martin et al., 2006). In this study, history alone had a pooled sensitivity of 0.92 (95% CI) and a specificity of 0.56 for the diagnosis of SUI and a sensitivity of 0.61 and specificity of 0.87 for the diagnosis of DO. **It should be borne in mind, however, that for higher risk interventions such as surgery, the most accurate testing available remains multichannel UDS studies.**

Pad Tests

Pad tests are generally used for academic purposes. **The ICS recommends both a 3-day bladder diary and pad weight test as proper measures for symptom quantification in incontinence research** (Lose et al., 2001). However, although pad tests can be helpful in quantifying leakage, they are tedious and cumbersome for patients. Moreover, they do not provide information that is necessary for daily routine clinical practice. **The 5th ICI Committee on initial assessment did not recommend pad tests as part of the initial evaluation in the incontinent patient** (Abrams et al, 2013)**. From an *academic* standpoint, however, many investigators advocate pad tests in clinical trials, as pad tests can provide objective, precise information for assessment of actual volume of urine lost over an established period.**

According to the 3rd ICI, greater than 1.3 g of urine loss is considered a "positive" 24-hour pad test (Abrams et al., 2005a)**. Others consider up to 8 g of urine loss in 24 hours to be normal** (Lose et al., 1989). This variability poses a potential limitation on the utility of the pad test, however, many investigators utilize the test for research purposes. Vaginal secretions should also be taken into consideration, although the volume attributable to normal vaginal secretions may be as low as 0.3 g in 24 hours (Karantanis et al., 2003). O'Sullivan et al. (2004) evaluated 110 women with incontinence with two 1-hour pad tests and 7 consecutive days of 24-hour pad tests. The severity of the leakage was analyzed in relation to UDS parameters, age, parity, and pelvic floor muscle strength, showing increased severity with increasing age and parity and in those women who demonstrated DO. The authors proposed that a 24-hour loss of 1.3 to 20 g, 21 to 74 g, and greater than 75 g to signify “mild,” “moderate,” and “severe” incontinence, respectively. Another study of 144 randomly selected Danish women who underwent 24-hour pad testing revealed a similar loss of urine in the self-reported continent and incontinent groups or 3.1 and 3.3 g, respectively (Ryhammer et al., 1998).

It is generally agreed that the 24-hour pad test is a clinically more useful tool than the 1-hour pad test (Lose et al., 1989; Matharu et al., 2004); in fact, the test-retest reliability and the predictive value of the 1-hour test in the diagnosis of female incontinence has been shown to be poor (Constantini et al., 2008; Lose et al., 1986, 1988; Simons et al., 2001). Others have advocated the opposite extreme, suggesting that a 20-minute pad test with a standardized bladder volume of 250 cc instilled into the bladder via catheterization had superior sensitivity as compared with the 1-hour test conducted via the ICS standardized method of pad testing (Wu et al., 2006). The ICS method, described in 1988, requires the patient to drink 500 mL of sodium-free liquid in 15 minutes followed by a 30-minute resting period before proceeding with the recommended physical activity (Abrams et al., 1988). One potential concern about this method is the lack of standardization of bladder volume.

Parenthetically, pad use per day (PPD) obtained via patient history is a measure frequently used to quantify urine loss, but one study demonstrated that this is an unreliable measure of incontinence (Dylewski et al., 2007). In a retrospective chart review of 145 males and 116 females who underwent artificial urinary sphincter placement and sling surgery, respectively, and who had completed a self-reported pad-use query, the patients were asked to bring three pads into their clinic visit: one dry “reference” pad and the incontinence pads used for the 24-hour periods preceding and including the day of their visit. The pads were quantified and weighed to determine the grams of urine per pad (GPP). All patients also underwent a 24-hour pad weight test. Only a very weak correlation was found between reported pad usage and the 24-hour pad weight, with pad usage measuring only 38% of the variability of incontinence volume. Additionally, although the PPD decreased, the GPP increased with increasing age.

Dye Testing

Dye testing can be helpful to verify that the leakage represents urine versus another fluid such as vaginal discharge or peritoneal fluid and to substantiate the diagnosis of urinary tract fistulae. **Oral phenazopyridine** 100 mg or 200 mg three times a day colors the urine orange, and this simple test can confirm that the leaking fluid is indeed urine. Diagnosis of a vesicovaginal or urethrovaginal fistula can be supported by blue or orange staining of an intravaginal tampon after **intravesical instillation of methylene blue or pyridium dissolved in sterile water or saline.** In the case of a suspected *uretero*vaginal fistula, **intravesical methylene blue with concurrent oral pyridium** can elucidate the fistula location based on the staining pattern on the vaginal tampon. Orange staining suggests a ureteral communication, and blue staining connotes a bladder communication (Raghavaiah, 1974). The clinician must keep in mind that simultaneous vesicovaginal and ureterovaginal fistulae can occur.

Key Points

- It has been demonstrated that patient subjective history alone often does not reflect an accurate or complete picture of their symptomatology complex.
- Several instruments designed to facilitate symptom quantification have been developed and include tools such as voiding diaries, symptom and QoL questionnaires, and pad tests.
- Voiding diaries can be both diagnostic and therapeutic, as they can provide patients with insights into behaviors that may be contributing to their voiding symptoms.
- Pad tests may be helpful, particularly in the academic setting, to quantify incontinence symptoms. Loss of up to 8 g of urine in 24 hours may be considered normal, although the ICI considers loss of greater than 1.3 g to be a positive 24-hour test.
- Validated questionnaires are available to assess symptoms and quality of life in patients with PFDs.

Urinalysis

It is generally agreed that urinalysis plays a fundamental role in the evaluation of the incontinent patient or the patient with lower urinary tract symptoms (LUTS) (Abrams et al., 2009). The urinalysis provides information such as the presence of hematuria, pyuria, glucosuria, or proteinuria that can be indicative of conditions that can cause *secondary* incontinence. As indicated by the screening dipstick analysis, a microanalysis and/or culture should be performed that may provide guidance regarding further testing or therapy for conditions related to or independent of urinary incontinence.

Postvoid Residual

The volume of urine left in the bladder after routine voiding is termed the *postvoid residual (PVR),* and some authors have suggested that PVR should be evaluated in all incontinent patients (Gormley, 2007; Tubaro, 2005). This simple test, which can be performed via in-and-out catheterization or using noninvasive transabdominal ultrasonography, evaluates the bladder's emptying ability and can be helpful in the diagnosis of overflow incontinence. **The 2017 AUA/SUFU SUI guidelines state that clinicians considering invasive therapy in patients with SUI should assess PVR to evaluate bladder emptying as patients with elevated PVRs preoperatively are at increased risk of developing voiding difficulties postoperatively** (Kobashi et al., 2017). It is important to establish baseline bladder emptying, particularly in stress-incontinent patients who may be considered for an anti-incontinence procedure or patients with urinary urgency who may be candidates for therapies aimed at decreasing bladder contractility.

A number of studies have demonstrated that ultrasonography is comparable to catheterization in evaluating the PVR, although **there are no officially established volumes that define normal or impaired emptying.** The Agency for Healthcare Policy and Research (AHCPR) suggests that a PVR less than 50 cc represents adequate emptying and a PVR greater than 200 cc represents inadequate emptying (US Department of Health and Human Services, 1992). The International Continence Society considers a PVR greater than 200 to 300 mL concerning (Asimakopoulos et al., 2016). There is no consensus recommendation regarding the significance of PVR between 50 and 200 cc. In one study, Gehrich et al. (2007) enrolled 96 healthy women who presented for a routine “well-woman” checkup. Exclusion criteria included urinary incontinence more than twice per week, urinary retention, neurologic disease, or symptomatic POP. The mean and median PVRs were 19 cc (0 to 145 cc) and 24+/– 29 cc. 15% had PVR greater than 50 cc, and 95% had PVR less than 100 cc. Another study compared PVR measurements obtained by three-dimensional bladder scan versus catheterization in 170 women who were undergoing evaluation for SUI but who had never undergone previous pelvic surgery (Tseng et al., 2008). 35.5% had PVR greater than 50 cc, and 15.9% had PVR greater than 100 cc. Ultrasonography offered a sensitivity of 64.7% and a specificity of 94.3% in detecting PVR greater than 100 cc. Although several studies support the accuracy of the bladder scan (Al-Shaikh et al., 2009), some suggest that certain sonographic devices may provide more accurate information than others (Ghani et al., 2008).

Cystoscopy

Endoscopic examination of the bladder is important as a means to evaluate for intravesical or intraurethral pathology that may be contributing to the patient's symptomatology. Bladder tumors, bladder stones, cystitis, and intravesical or intraurethral foreign bodies such as mesh or suture can contribute to irritative voiding symptoms, recurrent urinary tract infections (UTIs), and incontinence. Patients with a history of previous pelvic floor reconstructive surgery should be evaluated for eroded materials into the LUT. The ureteral orifices should be identified and evaluated for morphology, position, number, and efflux. The bladder mucosa is examined for trabeculation (which can be suggestive of bladder outlet obstruction [BOO] and/or detrusor overactivity) and estrogen status, and the urethra is assessed for foreign bodies, stricture, diverticulum or fistula, and position.

The role of preoperative cystourethroscopy has been addressed by few authors. Anger et al. (2007) analyzed Medicare claims data to assess the effects of preoperative cystoscopy and UDS studies on sling outcomes. The data of a random 5% sample of Medicare beneficiaries during an established 18-month period were used to assess the likelihood of undergoing postoperative studies in those who did and did not undergo the same studies preoperatively. Although patients who underwent preoperative cystoscopy were less likely to undergo postoperative cystoscopy (23.4% vs. 35.2%, $P < 0.0001$) or UDS (19.3% vs. 34.0%, $P < 0.0001$), there were no significant differences in complications or repeat incontinence procedures between groups. However, Cundiff and Bent (1996) reported that cystoscopy changed the diagnosis and management in 6/84 women (7%) who underwent both cystoscopy and UDS for evaluation of LUT dysfunction. Findings included transitional cell carcinoma, cystitis glandularis, intravesical suture, and a urethral diverticulum.

Although the use of routine cystoscopy is not advocated in the evaluation

of the “index” stress urinary incontinence patient, it should be considered in patients who present with urinary urgency, hematuria, or other irritative symptoms, particularly if they have undergone a previous anti-incontinence procedure, pelvic radiation, or pelvic prolapse repair (Kobashi et al., 2017).

Urodynamics

Similar to cystourethroscopy, the routine use of UDS is the subject of much discussion; however, one should or may consider UDS in patients who are considering invasive, potentially morbid or irreversible surgery, have failed previous pelvic floor reconstruction, or who have mixed incontinence, urinary urgency, or obstructive symptoms, as well as in patients who have elevated PVRs or neurologic disease. UDS is also useful to confirm or refute a diagnosis and can facilitate patient selection and counseling. The benefit of UDS in these situations is to establish baseline bladder capacity, compliance, sensation, stability, and sphincter function before further surgical or therapeutic manipulation. A comprehensive review of UDS is presented in Chapter 114.

LUT function can be simply categorized into storage and emptying. Each of these categories is affected by the bladder (detrusor) and the outlet. **Two main questions should be considered in the evaluation of the incontinent patient: (1) Is the problem at hand a storage issue, an emptying issue, or a combination of the two?** ***and*** **(2) Is the etiology of #1 caused by a detrusor issue, an outlet issue, or a combination of both?**

“Eyeball UDS” is a simple economically favorable alternative to full multichannel UDS that can be helpful in selected patients. The study can determine bladder sensation, compliance, stability, and capacity as well as outlet competence and PVR. After voiding, the patient is placed in the lithotomy position and a Foley catheter is placed and the PVR measured. A 60-mL catheter tip syringe with the barrel removed is placed into the end of the catheter. With the syringe held upright, the bladder is filled with sterile fluid through the syringe. The height of the meniscus above the bladder represents the intravesical pressure. The volumes at first sensation and first desire, normal desire, and strong desire to void are recorded. During the filling phase, the meniscus in the syringe is observed for a rise and fall that may represent bladder overactivity or a consistent gradual rise that suggests compromised detrusor compliance. The absence of the abdominal pressure (Pabd) channel limits the ability to accurately determine any abdominal contribution to a change in the water volume in the syringe. The catheter is removed, and a cough stress test is performed by observing the urethra for incontinence during coughing and straining.

Multichannel UDS offers an extensive evaluation of LUT function. The degree of accuracy provided by multichannel UDS is important in a variety of circumstances, including when conservative treatment methods fail; when the diagnosis is unclear or previous diagnostic procedures are inconclusive; in patients with clinical pictures complicated by radiation therapy, neurologic disease, or prior failed pelvic floor reconstruction or anti-incontinence surgery; or when patients describe symptoms that cannot be confirmed by the clinician. A complete UDS study evaluates the ***filling/storage phase*** by filling cystometrogram and the ***voiding/emptying phase*** by uroflowmetry.

Catheters are placed into the bladder and the rectum. The bladder catheter measures the actual pressure within the bladder, termed the vesical pressure (Pves). The rectal catheter measures the abdominal pressure (Pabd). The detrusor pressure (Pdet) is a calculated value (Pves – Pabd) that represents the pressure created by the detrusor independent of the influences of intra-abdominal pressure. During the filling phase, the Pdet is expected to remain low and stable to allow for low-pressure bladder filling. Poorly compliant bladders will show a gradual steady rise in the Pdet as the bladder volume increases. Detrusor overactivity is manifest by intermittent and unpredictable rises in the Pdet. During the voiding phase, the Pdet may rise as the urine flows. Many women void normally with virtually no rise in Pdet. High Pdet with low flow during voiding suggests BOO. Inability to produce a flow with no Pdet, particularly when accompanied by abdominal straining (represented by an undulant Pabd), may indicate an atonic or hypotonic detrusor.

When making the diagnosis of urodynamic SUI, urethral function should be assessed (Winters et al., 2012). Quantitative measurements such as the Valsalva leak point pressure (VLPP) or maximal urethral closure pressure (MUCP) can be used to guide treatment decisions in patients suspected of having SUI who do not demonstrate leakage with stress maneuvers; stress testing should be repeated with urethral catheter removed. In patients with high-grade POP without symptoms of SUI, stress testing should be performed with the POP reduced to evaluate for occult SUI.

Electromyogram (EMG) and fluoroscopic imaging (“videourodynamics,” VURDS) are helpful adjuncts to the UDS study in selected patients and are covered in detail in Chapter 114. EMG activity is reflective of the activity of the striated muscles of the urethral and anal sphincters and the perineal musculature and can be measured using either surface electrodes or needle electrodes. Although the latter provides more accurate readings, the discomfort caused to the patient and the expertise required for the technique render it far less popular than surface electrodes. The coordination of the EMG and detrusor activity is most helpful during the voiding phase, when failure to relax the pelvic floor can be indicative of pathology. Similarly, recruitment of activity should be noted with BCR and increased abdominal pressure, such as occurs during coughing. VURDS can be useful in the demonstration of anatomy in the upright position, and because the bladder and outlet are visualized in real time, it can confirm incontinence in patients in whom the diagnosis is difficult and can provide an accurate measure of leak point pressure. It is also helpful to assess the bladder outlet in patients in whom dysfunctional voiding, primary bladder neck obstruction, or detrusor-sphincter dyssynergia are suspected. Patients can also be evaluated for vesicoureteral reflux (VUR) and bladder or urethral diverticula. Assessment of detrusor pressures in the face of reflux or a large bladder diverticulum can provide important information that would be missed without video-imaging.

Recent attention has been placed on scientifically establishing the role and clinical value of UDS. The VALUE study, a multi-institutional, randomized controlled trial published in 2012, demonstrated that UDS before mid-urethral sling placement for uncomplicated SUI did not change management (Nager et al., 2012). For the index patient with uncomplicated SUI and when incontinence is demonstrated on examination, physicians may omit urodynamic testing (Kobashi et al., 2017). However, it is important to note that the worth of a test is not solely in its diagnostic accuracy, but also in the improvement of the outcomes of subsequent interventions. UDS is frequently used in the evaluation of patients with PFDs and can be helpful in counseling. Suboptimal outcomes of anti-incontinence procedures are generally attributed to intrinsic sphincter deficiency (ISD), DO, or baseline dysfunctional voiding. The deliberation regarding the merit of these theories and the ability of UDS to accurately establish these conditions continues. In a study of 655 women with positive stress tests, 10% did not demonstrate urodynamic-SUI (UDS-SUI) (Nager et al., 2007). A meta-analysis based on a Medline search of the literature between 1975 and 1998 suggested that UDS has a positive predictive value (PPV) of only 56% and 79% for pure SUI and SUI with other abnormalities, respectively, and a positive cough test has a PPV for the same of 55% and 91%, respectively (Harvey and Versi, 2001). The Urinary Incontinence Treatment Network (UITN) reported that UDS did not predict postoperative voiding dysfunction or the risk of the need for postoperative surgical intervention (Lemack et al., 2008). In another retrospective study in women who underwent retropubic mid-urethral sling placement for treatment of mixed incontinence, the median opening detrusor pressure was higher in women with postoperative DO than in those with normal postoperative UDS (Panayi et al., 2009).

Much of the literature to date has been limited by the retrospective design and small cohorts of the available studies. The UITN found that the success of anti-incontinence surgery in patients who demonstrated UDS-SUI was nearly twice that of those with non–UDS-SUI, although this trend did not reach statistical significance (Nager et al., 2008). The same group showed that treatment outcomes at 1 year for women with uncomplicated demonstrable stress incontinence were not inferior in patients who did not undergo preoperative urodynamics as compared with those who did (Nager et al., 2009, 2012). Although a study by Anger et al. (2007) did not definitively establish an effect of preoperative UDS specifically on sling outcomes, there was a clear demonstration of a twofold (significant) increased likelihood of undergoing postoperative UDS studies in those patients who did not undergo the study preoperatively as compared with those who did.

With the implementation of health care reform in 2014, cost-effectiveness is at the forefront of discussion. Based on decision-analytic (hypothetical) models, one group deemed UDS not cost-effective relative to the basic office evaluation (Weber and Walters, 2000; Weber et al., 2002). However, one must remain mindful that UDS provides information, not only about the overall diagnosis, but also regarding important subtle findings that may direct the clinician in treatment planning and counseling (Patel and Chapple, 2008; Summitt et al., 1992). Although it has been suggested that UDS may not be necessary or useful in straightforward non-neurologic patients who would be considered for initial conservative management (Colli et al., 2003; National Institute for Health and Clinical Excellence, 2006, Winters et al., 2012), others have shown that as many as 20% of patients with presumed pure SUI may have UDS findings that might alter their treatment or outcomes (Digesu et al., 2009).

Reproducibility of UDS studies as well as the interpretation of the examination has been questioned by several studies (Gacci et al., 2007; Gupta et al., 2004; Van de Beek et al., 1997; Zimmern et al., 2006). Others have demonstrated that intraobserver interpretation (interpretation repeated by the same individual) is superior to interobserver interpretation (same study read by two different individuals) for both pressure-flow analyses (Digesu et al., 2003) and filling/voiding studies (Whiteside et al., 2006). Still others have demonstrated no difference in interobserver and intraobserver interpretation, but that live interpretation of a study provides different readings than post-hoc interpretation, suggesting that intangible experiential factors may play a role in the interpretation of UDS studies (Smith et al., 2009).

Approximately 40% of patients with POP describe SUI symptoms (Grody, 1998)**, and UDS-SUI is demonstrated in 70% to 75% of prolapse patients** (Roovers and Oelke, 2007)**. Occult SUI unmasked by reduction of prolapse is reported to be present in 36% to 80%** (Bergman et al., 1988; Chaikin et al., 2000; Richardson et al., 1983)**, and 11% to 50% of clinically continent patients will develop de novo SUI after repair of high-grade prolapse** (Bergman et al., 1988; Borstad and Rud, 1989; Gallantine and Cespedes, 2001). Women who demonstrated preoperative UDS-SUI before sacrocolpopexy were more likely to develop postoperative SUI irrespective of whether they received a concomitant Burch colposuspension (Visco et al., 2008). Conversely, following a retrospective review of the records of 76 patients who underwent POP repair, Roovers et al. (2007) reported that no UDS parameters predicted postoperative incontinence. In an effort to determine the need for prophylactic sling placement in patients undergoing surgery for high-grade POP, Ballert et al. (2009) followed a UDS protocol designed to address the urethra in a standardized fashion. They concluded that in patients who did not subjectively describe or urodynamically demonstrate SUI preoperatively, the risk for intervention resulting from BOO after sling placement was equivalent to the risk for intervention for SUI in patients who did not receive a sling. **The Colpopexy and Urinary Reduction Efforts (CARE) trial was designed to evaluate whether a Burch colpopsusension performed at the time of sacrocolpopexy for prolapse in *stress-continent* women reduced postoperative SUI. The large prospective randomized study was stopped after the first interim analysis at 3 months when 23.8% of the women in the Burch group and 44.1% of the control group met criteria for SUI ($p < 0.001$)** (Brubaker et al., 2006). The cohort was continued at 2 years and 7 years postoperatively, demonstrating a continued advantage of prophylactic Burch for SUI at both time points, though the failure rates of sacrocolpopexy increased in both groups by the 7-year follow up (Brubaker et al., 2008; Nygaard et al., 2013).

In select patients, particularly those with OAB symptoms and/or known neurogenic bladder, UDS can be helpful in determining the risk for progression to upper tract deterioration. DO, poor compliance, detrusor-external sphincter dyssynergia (DESD), high detrusor storage pressures, VUR, and BOO all represent potential risk factors or the development of upper tract disease, particularly in those patients with sustained Pdet greater than 40 cm H_2O (Blaivas and Barbalias, 1984; Ghoniem et al., 1989, 1990; McGuire et al., 1981).

Although multichannel UDS remains the most accurate tool with which to evaluate LUT function, it is clear that multi-institutional randomized prospective studies are of dire importance in addressing many of the unanswered questions regarding the role and contribution of UDS to patient care, counseling, and optimization of treatment modalities. Further evaluation of the accuracy of the study and most importantly, the impact of UDS on patients, treatments, and treatment outcomes must be pursued. The UDS guidelines provide parameters around the use of UDS based on an exhaustive review of the current literature.

Key Points

- UDS is the most accurate tool available for the assessment of LUT function and provides information regarding urine storage and emptying as they are affected by the bladder and the bladder outlet.
- Although the use of routine UDS for straightforward incontinence is a topic of discussion, UDS should be strongly considered before intervention in patients who have a complex clinical picture resulting from failed previous treatment or surgery, mixed incontinence, obstructive symptoms, significantly elevated PVR, neurologic disease, or other medical conditions that may contribute to LUT function, such as diabetes mellitus, pelvic prolapse, or history of radiation therapy.
- “Eyeball UDS” may provide an approximate picture of the bladder capacity, sensation, stability, compliance, and outlet resistance when formal UDS is not available.
- Multichannel UDS offers extensive evaluation of LUT function. It involves direct measurement of bladder and intraabdominal pressure (Pves and Pabd, respectively) and a calculated assessment of detrusor pressure that is independent of abdominal pressure (Pdet). Therefore,

$$Pves - Pabd = Pdet$$

- Fluoroscopic imaging provides useful adjunctive information, such as the position and status of the bladder base and bladder neck, the presence of vesicoureteral reflux, and direct visualization of urinary leakage under real-time circumstances. Video imaging should be considered when the diagnosis cannot be made with certainty without simultaneous understanding of the anatomy in conjunction with the functional findings.

Radiographic Imaging

Voiding Cystourethrogram

Standard imaging studies are not necessary in the initial evaluation of women with uncomplicated incontinence (Artibani and Cerruto, 2005; Artibani et al., 2002)**. However, upper and lower urinary tract imaging in patients in whom renal damage or pelvic pathology are suspected should be performed.** Voiding cystourethrogram (VCUG) is optional in patients with recurrent UTIs, but can be helpful in the diagnosis of a urethral diverticulum or VUR. VCUG can provide valuable information regarding the contour of the bladder, the presence of VUR, the position of the bladder base with and without straining with the patient in an upright posture, and the position and configuration of the bladder neck during voiding. Fluoroscopic imaging can also provide visualization of subtle leakage with coughing or Valsalva maneuver that may be difficult to detect with direct examination.

Ultrasonography

Upper tract imaging is recommended in patients with chronic urinary retention, suspected extraurethral incontinence, untreated severe POP, and neurogenic detrusor dysfunction considered to be at high risk for renal damage. Patients with high-grade POP can develop upper tract obstruction and hydroureteronephrosis related to ureteral “kinking” caused by the prolapse. **Ultrasonography** provides a noninvasive sensitive and specific method of assessing the upper tracts for hydronephrosis. Ultrasonic imaging of the bladder neck for urinary leakage and descent during stress has also been used to diagnose SUI with documented pooled sensitivity and specificity rates in the range of 0.84 to 0.89 and 0.82 to 0.89, respectively (Martin et al., 2006b).

Translabial ultrasonography has also been shown to be beneficial in the evaluation of patients who had previously placed mesh for pelvic floor reconstruction (Staack et al., 2014). In patients who have mesh-related complications such erosion or pain and for whom the physician is planning to do revision surgery, consideration should be given to translabial ultrasonography. It may help identify the location of mesh material in the pelvis, the proximity to the urethra, and any abnormality such as twisting of the mesh material. Further, in patients who have undergone previous revision surgery, this information and continuity of the mesh material may be important preoperative information.

Magnetic Resonance Imaging

Magnetic resonance imaging (MRI) has been proposed as an ideal method by which to evaluate the anatomy of the bladder neck and urethra with good correlation with functional studies (Macura, 2006; Macura and Genadry, 2008; Macura et al., 2008). MRI has also been advocated for evaluation of pelvic floor relaxation and POP (Boyadzhyan et al., 2008), particularly in patients undergoing evaluation for complex multicompartmental pelvic floor reconstruction (Boyadzhyan et al., 2008; Macura, 2006), and has been shown to identify changes related to the uterosacral ligaments before and after surgical repair of prolapse (Martin et al., 2006a). MRI may also be helpful in identifying those patients in whom a urethral diverticulum may be present. Although urethral diverticula can cause symptoms of urinary leakage, pelvic pain, obstructive voiding symptoms, recurrent UTIs, dyspareunia, and a multitude of nonspecific symptoms, up to 20% of diverticula may be completely asymptomatic (Rovner, 2007). In patients with complaints of SUI who are found to have a urethral diverticulum, a simultaneous anti-incontinence surgery may be considered, in which case proper radiographic imaging, such as that which can be obtained with MRI, can provide anatomic information germane to optimal surgical planning.

High-resolution MRI allows detailed visualization of the urethra, the external sphincter, and the supporting structures. MRI evaluation focusing specifically on the muscle volume of the sphincter, defects in the sphincteric musculature, funneling of the bladder neck, symmetry of the pubococcygeus muscle or urethral supporting ligaments, increase in the size of the retropubic space or urethrovesical angle, and abnormal vaginal shape may be helpful in the diagnosis of SUI caused by ISD or urethral hypermobility (Macura, 2006). To facilitate assessment of POP using MRI, the HMO (H-line, M-line, organ prolapse) system was developed (Pannu et al., 2000).

Evaluation is performed using rapid half-Fourier T2-weighted images in the midsagittal plane during maximal patient straining. There are three fixed points in the HMO system: ***A***, the inferior margin of the pubic symphysis, ***B***, the posterior levator plate, and ***C***, the junction between the first and second coccygeal segments. Two fixed reference points include point *B* and the pubococcygeal line ***(PCL),*** drawn between points *A* and *C*. ***Line H,*** drawn between *A* and *B*, represents the anterior-posterior hiatal dimension. ***Line M,*** which is the shortest distance between point *B* and the PCL, represents the degree of pelvic descent. The ***O component*** comprises the shortest distance between the H line and the most caudal aspect of the evaluated organ during the Valsalva maneuver. Prolapse is graded based on the organ location relative to the H-line in centimeters.

Dynamic MRI can provide integral information in the preoperative assessment of POP, particularly in patients in whom the pelvic examination is difficult and inconclusive. The sensitivity, specificity, and positive predictive value (PPV) of MRI for has been reported to be 70% to 100%, 83% to 100%, and 97% to 100%, respectively, for cystoceles; 42% to 100%, 54% to 81%, and 33% to 60%, respectively, for vaginal vault prolapse; 87% to 100%, 80% to 83%, and 75% to 91%, respectively, for enteroceles; 83%, 100%, and 100%, respectively, for uterine prolapse, and 87%, 72%, and 66%, respectively, for rectoceles (Deval et al., 2003; Gousse et al. 2000). Other authors have found that dynamic MRI does not correlate well with clinical findings in patients with middle compartment (i.e., apical) prolapse, and much of the literature suggests that the study should be used only as an adjunct to clarify anatomy in complex cases (Cortes et al., 2004) or under investigational circumstances (Tubaro, 2005). Similarly, many authors agree that the posterior compartment is not as easily visualized on dynamic MRI. A study using intrarectal air during MRI did not demonstrate any value of dynamic MRI for evaluation for rectoceles over videoproctography, the latter of which was more sensitive in identifying rectoceles (Matsuoka et al., 2001). For optimal visualization of rectoceles, intrarectal gel is used to provide hyperintensity on T2-weighted images (Boyadzhyan et al., 2008; Law and Fielding, 2008; Macura, 2006).

Management

Incontinence Treatment Overview

The approach to treatment of incontinence is contingent on a clear understanding of the etiology and pathophysiology underlying the patient's symptoms. The clinician must first determine whether the cause of the symptomatology complex is a bladder or an outlet problem, or, not uncommonly, a combination of both. Therapeutic options should be considered with the goal of providing an individualized patient-directed treatment plan based on patient goals and risk-benefit and cost-benefit ratios. Proper representative counseling is paramount to properly align patient expectations and goals and what is possible to achieve. Adjunctive studies such as UDS may be performed (and in select situations *should* be performed) to provide complete information on which clinical decisions can be made as outlines in the SUI, OAB, and UDS guidelines (Gormley et al., 2012; Kobashi et al., 2017; Winters et al., 2012).

Management of incontinence can be categorized into nonsurgical and surgical options. Underlying causes such as UTI, BOO, bladder stones, foreign body, or bladder tumor should be identified and addressed first.

Treatment of incontinence must be tailored to the patient's needs, goals, and expectations and requires proper counseling on the part of the clinician. Some patients may be satisfied with protective garments and/or urine-collection devices, such as indwelling or condom catheters, or barriers, such as urethral plugs or external occlusion devices. Intervention for patients with urgency incontinence may range from behavioral and dietary modification to biofeedback or pharmacotherapy. Per the OAB guidelines, behavioral therapy (e.g. fluid management, dietary modification, and bladder training) is considered to be the first line of therapy (Gormley et al., 2012). Medications can be added subsequently, but are technically considered to be second-line therapy. Sacral neuromodulation, onabotulinum toxin A detrusor injection, and enteric augmentation of the bladder may be considered in patients with refractory symptoms.

Similarly, patients with SUI may benefit variably from conservative measures using pelvic floor muscle exercises, biofeedback, electrical stimulation, and pharmacotherapy. Urethral bulking injection therapy can provide an intermediate option between nonsurgical and surgical therapies, but surgery remains the mainstay of treatment for SUI. Although needle suspensions remain only as a point of historic discussion, retropubic suspensions have persisted as a reasonable treatment option for SUI. However, slings, using a variety of materials, insertion approaches, and anchoring techniques, have effectively become the standard options for women with SUI. In 2011, the Food and Drug Administration released a safety communication (FDA website) regarding mesh placed transvaginally specifically for the repair of pelvic prolapse (FDA, 2011a, 2011b). Unfortunately, subsequent media communication regarding mesh litigation created patient confusion and concern prompting a joint response from the Society of Urodynamics, Female Pelvic Medicine and Urogenital Reconstruction (SUFU) and the American Urogynecology Society (AUGS) in 2014 (SUFU and AUGS websites). Then, in April 2019, the FDA ordered all manufacturers of surgical mesh intended for transvaginal repair of anterior compartment prolapse (cystocele) to stop selling and distributing their products immediately. SUFU and AUGS have since updated their communications to reflect this new FDA communication.

Injection therapy has not proven a particularly viable option for the treatment of male SUI (which occurs most commonly after prostatectomy for treatment of adenocarcinoma of the prostate), and follow-up of outcomes with male slings is still early. In a review of the literature, Cerruto et al. (2013) reported on a pooled cure rate from 160 studies, none of which were controlled). At a median follow-up of 15 months, 77.4% were “cured.” The artificial urinary sphincter (AUS) remains the prevailing treatment option for postprostatectomy incontinence. The AUS has also rarely been used for treatment of SUI in women. In the fortunately rare cases of complete urethral devastation, bladder neck closure or urinary diversion can be considered.

Pelvic Prolapse Treatment Overview

New techniques have been explored to improve on the traditional pelvic floor reconstructive approaches that depend on the inherently compromised tissues of the POP patient. The use of synthetic and biological graft materials to improve the integrity and durability of POP repairs have become popularized over the past decade, although graft use remains a point of robust discussion and debate. Novel anatomic approaches and “kits” have been developed and have resulted in a dramatic increase in the number of clinicians participating in pelvic floor reconstruction, but controversy surrounding the safety of synthetic mesh graft has quickly changed the landscape again.

The goal of POP repair is to restore the normal anatomy and function of the vagina and the lower urinary and GI tracts. The decision regarding whether to proceed with a transvaginal or a transabdominal approach is dependent on which of the three compartments is affected, the degree of prolapse, and patient and surgeon preference. Apical prolapse involving the uterus typically results in a hysterectomy, although uterine-sparing techniques can be performed. Posthysterectomy apical prolapse can be addressed transvaginally with a uterosacral ligament suspension or a sacrospinous ligament fixation. Several contemporary devices that aim to facilitate high prolapse reduction have been introduced, but follow up is early. Nevertheless, the sacrocolpopexy, a transabdominal approach that can be performed either open or minimally-invasively using laparoscopy or robotic assistance, remains the gold standard repair for apical prolapse. A *Y*-shaped mesh typically composed of polypropylene is attached to the apex of the vagina and bridged to the sacrum to return the vagina to its normal axis.

New techniques of pelvic floor reconstruction continue to emerge parallel with increasing efforts to understand pelvic floor anatomy and function. A comprehensive overview of current surgical management of pelvic prolapse is presented in Chapter 112.

Conclusion

The ultimate goal of pelvic floor reconstruction is to restore the normal anatomy and function of the vagina, bladder, and surrounding structures. Proper evaluation of the pelvic floor anatomy and function should theoretically maximize the probability of favorable outcomes. Additionally, with a growing emphasis on QoL enrichment and a simultaneously increasing cost of health care, along with implementation of the Affordable Care Act, economically sound and durable treatments are the aspiration. Accordingly, efforts to develop methods by which to evaluate and quantify symptoms and assess outcomes continue. New techniques designed to provide safe and successful options to achieve maximal symptom relief and QoL improvement continue to evolve, and tissue engineering is an exciting new frontier. As our comprehension of the pelvic floor advances, further approaches to treat PFDs will undoubtedly arise.

▶▶▶▶▶▶▶Videos 112.1 to 112.7 show procedures and discussions related to this chapter.

Suggested Readings

Abrams P, Cardozo L, Fall M, et al. The standardisation of terminology of lower urinary tract function: report from the Standardisation Sub-Committee of the International Continence Society. *Neurourol Urodyn*. 2002;21:167–178 [(reprinted in *Urology* 61:37–49, 2003)].

Abrams P, Cardozo L, Khoury S, et al. *Incontinence: 5th International Consultation on Incontinence, February 2012*. ICUD-EAU: Paris; 2013 [Print].

Andersson KE, Chapple CR, Cardozo L, et al. Pharmacological treatment of overactive bladder: report from the International Consultation on Incontinence. *Curr Opin Urol*. 2009;19:380–394.

Brubaker L, Cundiff GW, Fine P, et al. Abdominal sacrocolpopexy with Burch colposuspension to reduce urinary stress incontinence. [for; the Pelvic Floor Disorders Network] *N Engl J Med*. 2006;354(15):1557–1566.

Bump RC, Mattiasson A, Bo K, et al. The standardization of terminology of female pelvic organ prolapse and pelvic floor dysfunction. *Am J Obstet Gynecol*. 1996;175:10–17.

Chang KM, Hsieh CH, Chiang HS, et al. Trends in inpatient female urinary incontinence surgery and costs in Taiwan, 1997-2011. *Taiwan J Obstet Gynecol*. 2017;56(1):32–36.

CMS 97 guidelines for focused female pelvic examination. Documentation Guidelines for Evaluation and Management (E/M) Services, jointly approved by the American Medical Association and HCFA with revisions November, 1997.

DeLancey JO. Anatomic aspects of vaginal eversion after hysterectomy. *Am J Obstet Gynecol*. 1992;166(6 Pt 1):1717–1724 [discussion 1724–1728].

Kobashi KC, Albo ME, Dmochowski RR, et al. Surgical treatment of female stress urinary incontinence: AUA/SUFU Guideline. *J Urol*. 2017;198(4):875–883.

FDA. *Urogynecologic Surgical Mesh Implants*. https://www.fda.gov/medical-devices/implants-and-prosthetics/urogynecologic-surgical-mesh-implants; 2019.

FDA. *Considerations about Surgical Mesh for SUI*. http://www.fda.gov/MedicalDevices/ProductsandMedicalPro
2013.

Gormley EA, Lightner DJ, Burgio KL, et al. Diagnosis and treatment of overactive bladder (non-neurogenic) in adults: AUA/SUFU guideline. *J Urol*. 2012;188(6 Suppl):2455–2463.

Nygaard I, Barber MD, Burgio KL, et al. Prevalence of symptomatic pelvic floor disorders in US women. *JAMA*. 2008;300(111):1311–1316.

2014. *Society for Urodynamics, Female Pelvic Medicine and Reconstructive Urology, Position statement on mesh midurethral slings for stress urinary incontinence*. http://www.sufuorg.com/docs/news/AUGS-SUFU-MUS-Position-Statement-APPROVED-1-3-2014.aspx; 2014.

Winters JC, Dmochowski RR, Goldman HB, et al. Urodynamic studies in adults: AUA/SUFU guideline. *J Urol*. 2012;188(6 Suppl):2464–2472.

References

Abraham L, Hareendran A, Mills IW, et al. Development and validation of a quality-of-life measure for men with nocturia. *Urology*. 2004;63(3):481–486.

Abrams P, Blaivas JG, Stanton SL, et al. The standarisation of terminology of lower urinary tract function: the International Continence Society Committee on Standardisation of Terminology. *Scand J Urol Nephrol Suppl*. 1988;11:5–19.

Abrams P, Cardozo L, Fall M, et al. The standardisation of terminology of lower urinary tract function: report from the Standardisation Sub-Committee of the International Continence Society. *Neurourol Urodyn*. 2002;21:167–178.

Abrams P, Cardozo L, Khoury S, et al. *Incontinence. Proceedings from the 3rd International Consultation on Incontinence*. Health Publications: Paris; 2005.

Abrams P, Avery K, Gardener N, et al. The International Consultation on Incontinence modular questionnaire: www-iciq.net. [on behalf of; the ICIQ Advisory Board] *J Urol*. 2005;175:1063–1066.

Abrams P, Cardozo L, Wagg A, et al. *Incontinence*. ed 6. ICI-ICS: Bristol UK; 2017.

Abrams P, Chapple C, Khoury S, et al. Evaluation and treatment of lower urinary tract symptoms in older men. *J Urol*. 2009;181(4):1779–1787.

Abrams P, Ribani W, Cardozo L, et al. Reviewing the ICS 2002 Terminology report: the ongoing debate. *Neurourol Urodyn*. 2009;28:287.

Al-Shaikh G, Larochelle A, Campbell CE, et al. Accuracy of bladder scanning in the assessment of postvoid residual volume. *J Obstet Gynaecol Can*. 2009;31(6):526–532.

Anger JT, Saigal CS, Madison R, the Urologic Diseases of

America Project, et al. Increasing costs of urinary incontinence among female Medicare beneficiaries. *J Urol*. 2006;176:247–251.

Anger JT, Saigal CS, Stothers L, et al. Urologic Diseases of America Project: the prevalence of urinary incontinence among community dwelling men: results from the National Health and Nutrition Examination survey. *J Urol*. 2006;176(2):2103–2108.

Anger JT, Rodriguez LV, Wang Q, et al. The role of preoperative testing on outcomes after sling surgery for stress urinary incontinence. *J Urol*. 2007;178:1364–1369.

Artibani W, Andersen JT, Gajewski JB. Imaging and other investigations. Abrams P, Cardozo L, Khoury S, et al. *Incontinence*. Plymbridge Distributors: Plymouth; 2002:425–478.

Artibani W, Cerruto MA. The role of imaging in urinary incontinence. *BJU Int*. 2005;95(5):699–703.

Asimakopoulos AD, De Nunzio C, Kocjancic E, et al. Measurement of post-void residual urine. *Neurourol Urodyn*. 2016;35(1):55–57.

Avery K, Donovan J, Peters TJ, et al. ICIQ: a brief and robust measure for evaluating the symptoms and impact of urinary incontinence. *Neurourol Urodyn*. 2004;23(4):322–330.

Baden WF, Walker TA, Lindsay HJ. The vaginal profile. *Tex Med*. 1968;64:56–58.

Ballert KN, Biggs GY, Isenalumhe A, et al. Managing the urethra at transvaginal pelvic organ prolapse repair: a urodynamic approach. *J Urol*. 2009;181:679–684.

Barber MD, Kuchibhatla MN, Pieper CF, et al. Psychometric evaluation of 2 comprehensive condition-specific quality of life instruments for women with pelvic floor disorders. *Am J Obstet Gynecol*. 2001;185(6):1388–1395.

Basra R, Artibani W, Cardozo L, et al. Design and validation of a new screening instrument for lower urinary tract dysfunction: the bladder control self-assessment questionnaire (B-SAQ). *Eur Urol*. 2007;52(1):230–237.

Bates CP, Loose H, Stanton SL. The objective study for incontinence after repair operations. *Surg Gynecol Obstet*. 1973;136(1):17–22.

Bergman A, Bhatia NN. Urodynamic appraisal of the Marshal-Marchetti test in women with stress urinary incontinence. *Urology*. 1987;29(4):458–462.

Bergman A, Koonings PP, Ballard CA. Predicting postoperative urinary incontinence development in women undergoing operation for genitourinary prolapse. *Am J Obstet Gynecol*. 1988;158(5):1171–1175.

Blaivas JG, Barbalias GA. Detrusor-external sphincter dyssynergia in men with multiple sclerosis: an ominous urologic condition. *J Urol*. 1984;131(1):91–94.

Blaivas JG, Panagopoulos G, Weiss JP, et al. Validation of the overactive bladder symptom score. *J Urol*. 2007;178(2):543–547.

Borstad E, Rud T. The risk of developing urinary stress-incontinence after vaginal repair in continent women: a clinical and urodynamic follow-up study. *Acta Obstet Gynecol Scand*. 1989;68(6):545–549.

Boyadzhyan L, Raman SS, Raz S. Role of static and dynamic MR imaging in surgical pelvic floor dysfunction. *Radiographics*. 2008;28:949–967.

Bradley CS, Rovner ES, Morgan MA, et al. A new questionnaire for urinary incontinence diagnosis in women: development and testing. *Am J Obstet Gynecol*. 2005;192(1):66–73.

Bright E, Cotterill N, Drake M, et al. Developing and validating the International Consultation on Incontinence Questionnaire bladder diary. *Eur Urol*. 2014;66(2):294–300.

Brubaker L, Cundiff GW, Fine P, et al. Abdominal sacrocolpopexy with Burch colposuspension to reduce urinary stress incontinence. *N Engl J Med*. 2006;354(15):1557–1566.

Brubaker L, Nygaard I, Richter HE, et al. Two-year outcomes after sacrocolpopexy with and without Burch to prevent stress urinary incontinence. [for; the Pelvic Floor Disorders Network] *Obstet Gynecol*. 2008;112(1):49–55.

Bump RC, Mattiasson A, Bø K, et al. The standardization of terminology of female pelvic organ prolapse and pelvic floor dysfunction. *Am J Obstet Gynecol*. 1996;175:10–17.

Burgio KL. Current perspectives on management of urgency using bladder and behavioral training. *J Am Acad Nurse Pract*. 2004;16(10 Suppl):4–7.

Carvalhais A, Natal Jorge R, Bø K. Performing high-level sport is strongly associated with urinary incontinence in elite athletes: a comparative study of 372 elite female athletes and 372 controls. *Br J Sports Med*. 2018;52(24):1586–1590.

Centers for Medicare and Medicaid Services (CMS). *Single organ system exam—Genitourinary: 1997 Documentation Guidelines for Evaluation and Management (E/M) Services, jointly approved by the American Medical Association and HCFA with revisions November*. 1997.

Cerruto MA, D'alia C, Artibani W. Continence and complication rates after male slings as primary surgery for post-prostatectomy incontinence: a systematic review. *Arch Ital Urol Androl*. 2013;85(2):92–95.

Chaikin DC, Groutz A, Blaivas JG. Predicting the need for anti-incontinence surgery in continent women undergoing repair of severe urogenital prolapse. *J Urol*. 2000;163:531–534.

Chapple C. Old words revisited – the importance of standardisation. *Neurourol Urodyn*. 2009;28:267.

Cody JD, Jacobs ML, Richardson K, et al. Oestrogen therapy for urinary incontinence in post-menopausal women (Review). *Cochrane Database Syst Rev*. 2012;(10) [CD001405].

Colli E, Artibani W, Goka J, et al. Are urodynamic tests useful tools for the initial conservative management of non-neurogenic urinary incontinence? A review of the literature. *Eur Urol*. 2003;43(1):63–69.

Constantini E, Lazzeri M, Bini V, et al. Sensitivity and specificity of one-hour pad test as a predictive value for female urinary incontinence. *Urol Int*. 2008;81(2):153–159.

Cortes E, Reid WMN, Singh K, et al. Clinical examination and dynamic magnetic resonance imaging in vaginal vault prolapse. *Obstet Gynecol*. 2004;103:41–46.

Coyne K, Revicki D, Hunt T, et al. Psychometric validation of an overactive bladder symptom and health-related quality of life questionnaire: the OAB-q. *Qual Life Res*. 2002;11(6):563–574.

Coyne K, Zyczynski T, Margolis MK, et al. Validation of overactive bladder awareness tool for use in primary care settings. *Adv Ther*. 2005;22(4):381–394.

Coyne KS, Matza LS, Kopp Z, et al. The validation of the patient perception of bladder condition (PPBC): a single-item global measure for patients with overactive bladder. *Eur Urol*. 2006;49(6):1079–1086.

Cundiff GE, Bent AE. The contribution of urethrocystoscopy to evaluation of lower urinary tract dysfunction in women. *Int Urogynecol J Pelvic Floor Dysfunct*. 1996;7(6):307–311.

DeLancey JO. Anatomic aspects of vaginal eversion after hysterectomy. *Am J Obstet Gynecol*. 1992;166(6 Pt 1):1717–1724 [discussion 1724–1728].

Deval B, Vulierme MP, Poilpot S, et al. Imaging of pelvic floor prolapse. *J Gynecol Obstet Biol Reprod (Paris)*. 2003;32(1):22–29.

Digesu GA, Hendricken C, Fernando R, et al. Do women with pure stress urinary incontinence need urodynamics? *Urology*. 2009;74:278–282.

Digesu GA, Hutchings A, Salvatore S, et al. Reproducibility and reliability of pressure flow parameters in women. *BJOG*. 2003;110:774–776.

Dmochowski RR, Blaivas JM, Gormley EA, et al. Update of AUA guidelines on the surgical management of female stress urinary incontinence. *J Urol*. 2010;183(5):1906–1914.

Donovan JL, Abrams P, Peters TJ, et al. The ICS-“BPH” Study: the psychometric validity and reliability of the ICS male questionnaire. *Br J Urol*. 1996;77(4):554–562.

Donovan JL, Kay HE, Peters TH, et al. Using the ICSQoL to measure the impact of lower urinary tract symptoms on quality of life: evidence from the ICS-“BPH” Study. International Continence Society—Benign Prostatic Hyperplasia. *Br J Urol*. 1997;80(5):712–721.

Dooley Y, Kenton K, Cao G, et al. Urinary incontinence prevalence: results from the National Health and Nutrition Examination Survey. *J Urol*. 2008;179(2):656–661.

Dylewski DA, Jamison MG, Borawski KM, et al. A statistical comparison of pad numbers versus pad weights in the quantification of urinary incontinence. *Neurourol Urodyn*. 2007;26:3–7.

FDA, FDA Safety Communication. *UPDATE on Serious Complications Associated with Transvaginal Placement of Surgical Mesh for Pelvic Organ Prolapse*. http://wayback.archive-it.org/7993/20170111231226/http://www.fda.gov/MedicalDev 2011.

FDA, Urogynecologic Surgical Mesh. *Update on the Safety and Effectiveness of Vaginal Placement for Pelvic Organ Prolapse*.

https://www.fda.gov/downloads/medicaldevices/safety/alertsa
2011.

Franco AV, Lee F, Fynes MM. Is there an alternative to pad tests? Correlation of subjective variables of severity of urinary loss to the 1-h pad test in women with stress urinary incontinence. *BJU Int*. 2008;102(5):586–590.

Gacci M, Del Popolo G, Artibani W, et al. Visual assessment of uroflowmetry curves: description and interpretation by urodynamicists. *World J Urol*. 2007;25:333–337.

Gallantine ML, Cespedes RD. Occult stress urinary incontinence and the effect of vaginal vault prolapse on abdominal leak point pressures. *Urology*. 2001;57:40–44.

Gehrich A, Stany MP, Fischer JR, et al. Establishing a mean postvoid residual volume in asymptomatic perimenopausal and postmenopausal women. *Obstet Gynecol*. 2007;110(4):827–832.

Ghani KR, Pilcher J, Rowland D, et al. Portable ultrasonography and bladder volume accuracy—a comparative study using three-dimensional ultrasonography. *Urology*. 2008;72(1):24–28.

Ghoniem GM, Bloom DA, McGuire EJ, et al. Bladder compliance in meningomyelocele children. *J Urol*. 1989;141(6):1404–1406.

Ghoniem GM, Roach MB, Lewis VH, et al. The value of leak pressure and bladder compliance in the urodynamic evaluation of meningomyelocele patients. *J Urol*. 1990;144(6):1440–1442.

Gormley EA, Lightner DJ, Burgio KL, American Urological Association, Society of Urodynamics, Female Pelvic Medicine and Urogenital Reconstruction, et al. Diagnosis and treatment of overactive bladder (non-neurogenic) in adults: AUA/SUFU guideline. *J Urol*. 2012;188(6 Suppl):2455–2463.

Gormley EA. Evaluation of the patient with incontinence. *Can J Urol*. 2007;14(Suppl 1):58–62.

Gousse AE, Barbaric ZL, Safir MH, et al. Dynamic half-Fourier acquisition, single shot turbo spin echo magnetic resonance imaging for evaluating the female pelvis. *J Urol*. 2000;164(5):1606–1613.

Grody MH. Urinary incontinence and concomitant prolapse. *Clin Obstet Gyencol*. 1998;41:777–785.

Groutz A, Blaivas JG, Chaikin DC, et al. Noninvasive outcome measures of urinary incontinence and lower urinary tract symptoms: a multicenter study of micturition diary and pad tests. *J Urol*. 2000;164(3 Pt 1):698–701.

Gupta A, Defreitas GA, Lemack GE. The reproducibility of urodynamic findings in healthy female volunteers: results of repeated studies in the same setting and at short-term follow-up. *Neurourol Urodyn*. 2004;23:311–316.

Hansen BJ, Flyger H, Brasso K, et al. Validation of the self-administered Danish Prostatic Symptoms Score (DAN-PSS-1). Clinical assessment of indications and outcomes of transurethral prostatectomy for uncomplicated benign prostatic hyperplasia. *Br J Urol*. 1995;76(4):451–458.

Harvey MA, Versi E. Predictive value of clinical evaluation of stress urinary incontinence: a summary of the published literature. *Int Urogynecol J Pelvic Floor Dysfunct*. 2001;12(1):31–37.

Haylen BT, de Ridder D, Freeman RM, et al. An International Urogynecological Association (IUGA)/International Continence Society (ICS) joint report on the terminology for female pelvic floor dysfunction. *Neurourol Urodyn*. 2010;29:4–20.

Haylen BT, Freeman RM, Swift SE, et al. An International Urogynecological Association (IUGA)/International Continence Society (ICS) joint terminology and classification of the complications related directly to the insertion of prostheses (meshes, implants, tapes) and grafts in female pelvic floor surgery. *Neurourol Urodyn*. 2011;30:2–12.

Haylen BT, Maher CF, Barber MD, et al. An International Urogynecological Association (IUGA)/International Continence Society (ICS) joint report on the terminology for female pelvic organ prolapse (POP). *Int Urogynecol J*. 2016;27(4):655–684.

Henderson JW, Kane SM, Mangel JM, et al. A randomized comparative study evaluating various cough stress tests and 24-hour pad test with urodynamics in the diagnosis of stress urinary incontinence. *J Urol*. 2018;199(6):1557–1564.

Hendriks EJ, Bernards AT, Berghmans BC, et al. The psychometric properties of the PRAFAB-questionnaire: a brief assessment questionnaire to evaluate severity of urinary incontinence in women. *Neurourol Urodyn*. 2007;26(7):512–518.

Holroyd-Leduc JM, Tannenbaum C, Thorpe KE, et al. What type of urinary incontinence does this woman have? *JAMA*. 2008;299(12):1446–1456.

Hu TW, Wagner TH, Bentkover JD, et al. Costs of urinary incontinence and overactive bladder in the United States: a comparative study. *Urology*. 2004;63:461–465.

Jackson S, Donovan J, Brookers S, et al. The Bristol Female Lower Urinary Tract Symptoms questionnaire: development and psychometric testing. *Br J Urol*. 1996;77(6):805–812.

Jean-Michel M, Kroes J, Marroquin GA, et al. Urinary incontinence in pregnant young women and adolescents: an unrecognized at-risk group. *Female Pelvic Med Reconstr Surg*. 2018;24(3):232–236.

Jensen JK, Nielsen FR Jr, Ostergard DR. The role of patient history in the diagnosis of urinary incontinence. *Obstet Gynecol*. 1994;83(5 Pt 2):904–910.

Karantanis E, Fynes M, Moore KH, et al. Comparison of the ICIQ-SF and 24-hour pad test with other measures for evaluating the severity of urodynamic stress incontinence. *Int Urogynecol J Pelvic Floor Dysfunct*. 2004;15(2):111–116.

Karantanis E, O'Sullivan R, Moore KH. The 24-hour pad test in continence women and men: normal values and cyclical alternations. *BJOG*. 2003;110(6):567–571.

Kelleher CJ, Cardozo LD, Khullar V, et al. A new questionnaire to assess the quality of life of urinary incontinence women. *Br J Obstet Gynaecol*. 1997;104(12):1374–1379.

Kleinman NL, Odell K, Chen CI, et al. Persistence and adherence with urinary antispasmodic medications among employees and the impact of adherence on costs and absenteeism. *J Manag Care Spec Pharm*. 2014;20(10):1047–1056.

Kobashi KC, Albo ME, Dmochowski RR, et al. Surgical treatment of female stress urinary incontinence: AUA/SUFU Guideline. *J Urol*. 2017;198(4):875–883.

Ku JH, Hong SK, Kim HH, et al. Is questionnaire enough to assess number of nocturic episodes? Prospective comparative study between data from questionnaire and frequency-volume chart. *Urology*. 2004;64:966–969.

Larsson B, Andersson KE, Batra S, et al. Effects of estradiol on norepinephrine-induced contraction, alpha-adrenoreceptor number, and norephinephrine content in the female rabbit urethra. *J Pharmacol Exp Ther*. 1984;229(2):557–563.

Law YM, Fielding JR. MRI of pelvic floor dysfunction: review. *AJR Am J Roentgenol*. 2008;191(6 Suppl):S45–S53.

Lemack GE, Kraus S, Litman H, et al. Normal preoperative urodynamic testing does not predict voiding dysfunction after Burch colposuspension versus pubovaginal sling. [for; the Urinary Incontinence Treatment Network] *J Urol*. 2008;180:2076–2080.

Lose F, Gammelgaard J, Jorgensen TJ. The one-hour pad-weighing test: reproducibility and the correlation between the test result, the start volume in the bladder, and the diuresis. *Neurourol Urodyn*. 1986;5(1):17–21.

Lose G, Rosenkilde P, Gammelgaard J, et al. Pad-weighing test performed with standardized bladder volume. *Urology*. 1988;23(1):78–80.

Lose G, Jørgensen L, Thunedborg P. 24-hour pad weighing test versus 1-hour ward test in the assessment of mild stress incontinence. *Acta Obstet Gynecol Scand*. 1989;68(3):211–215.

Lose F, Fantl JA, Victor A, et al. Outcome measures for research in adult women with symptoms of lower urinary tract dysfunction. Standardization Committee of the International Continence Society. *Acta Obstet Gynecol Scand*. 2001;80:981–985.

Lukacs B, Comet D, Grange JC, et al. Construction and validation of a short-form benign prostatic hypertrophy health-related quality-of-life questionnaire. BPH Group in General Practice. *Br J Urol*. 1997;80(5):722–730.

Macura KJ, Genadry RR. Female urinary incontinence: pathophysiology, methods of evaluation and role of MR imaging. *Abdom Imaging*. 2008;33(3):371–380.

Macura KJ. Magnetic resonance imaging of pelvic floor defects in women. *Top Magn Reson Imaging*. 2006;17(6):417–426.

Makary MA, Segev DL, Pronovost PJ, et al. Frailty as a predictor of surgical outcomes in older patients. *J Am Coll Surg*. 2010;210(6):901–908.

Martin DR, Salman K, Wilmot CC, et al. MR imaging evaluation of the pelvic floor for the assessment of vaginal prolapse and urinary incontinence. *Magn Reson Imaging Clin N Am*. 2006;14(4):523–535.

Martin JL, Williams KS, Sutton AJ, et al. Systemic review and meta-analysis of methods of diagnostic assessment for urinary incontinence. *Neurourol Urodyn*. 2006;25(7):674–683.

Matharu GS, Assassa RP, Williams KS, et al. Objective assessment of urinary incontinence in women: comparison of the one-hour and 24 hour pad tests. *Eur Urol*. 2004;45(2):208–212.

Matsuoka H, Wexner SD, Desai MB, et al. A comparison between magnetic resonance imaging and videoproctography in patients with constipation. *Dis Colon Rectum*. 2001;44(4):571–576.

McCormack M, Infante-Rivard C, Schick E. Agreement between clinical methods of measurement of urinary frequency and functional bladder capacity. *Br J Urol*. 1992;69(1):17–21.

McGuire EJ, Woodside JR, Borden A, et al. Prognostic value of urodynamic testing in myelodysplastic patients. *J Urol*. 1981;126(2):205–209.

McKown S, Abraham L, Coyne K. Linguistic validation of the N-QOL (ICIQ), OAB-q (ICIQ), PPBC, OAB-S and ICIQ-MLUTSsex questionnaires in 16 languages. *Int J Clin Pract*. 2010;64(12):1643–1652.

Milsom I, Coyne KS, Nicholson S, et al. Global prevalence and economic burden of urgency urinary incontinence: a systemic review. *Eur Urol*. 2014;65(1):79–95.

Minassian VA, Stewart WF, Wood GC. Urinary incontinence in women: variation in prevalence estimates and risk factors. *Obstet Gynecol*. 2008;111(2 Pt 1):324–331.

Morley JE, Malmstrom TK, Miller DK. A simple frailty questionnaire (FRAIL) predicts outcomes in middle aged African Americans. *J Nutr Health Aging*. 2012;16(7):601–608.

Nager CW, Albo ME, FitzGerald MP, Urinary Incontinence

Treatment Network, et al. Reference urodynamic values for stress incontinent women. *Neurourol Urodyn*. 2007;26:333–340.

Nager CW, FitzGerald MP, Kraus SR, et al. Urodynamic measures do not predict stress continence outcomes after surgery for stress urinary incontinence in selected women. [for; the Urinary Incontinence Treatment Network] *J Urol*. 2008;179:1470–1474.

Nager CW, Brubaker L, Daneshgari F, et al. Design of the Value of Urodynamic Evaluation (ValUE) trial: a non-inferiority randomized trial of preoperative urodynamic investigations. [for; the Urinary Incontinence Network] *Contemp Clin Trials*. 2009;30(6):531–539.

Nager CW, Brubaker L, Litman HJ, et al. A randomized trial of urodynamic testing before stress-incontinence surgery. [for; the Urinary Incontinence Treatment Network] *N Engl J Med*. 2012;366:1987–1997.

National Institute for Health and Clinical Excellence. *The management of urinary incontinence in women*. RCOG press: London, UK; 2006 http://www.nice.org.uk/guidance/CG40/guidnance/pdf/E

Nitti VW, Blaivas JG. Urinary incontinence: epidemiology, pathophysiology, evaluation, and management overview. Wein AJ, Kavoussi LR, Novick AC, et al. *Campbell-Walsh urology*. ed 9. Saunders Elsevier: Philadelphia, PA; 2007:2059.

Nixon A, Colman S, Sabounjian L, et al. A validated patient reported measure of urinary urgency severity in overactive bladder for use in clinical trials. *J Urol*. 2005;174(2):604–607.

Nygaard I, Brubaker L, Zyczynski HM, et al. Long-term outcomes following abdominal sacrocolpopexy for pelvic organ prolapse. *JAMA*. 2013;309(19):2016–2024.

Nyström E, Asklund I, Sjöström M, et al. Treatment of stress urinary incontinence with a mobile app: factors associated with success. *Int Urogynecol J*. 2018;29(9):1325–1333.

O'Sullivan R, Karantanis E, Stevermuer TL, et al. Definition of mild, moderate and severe incontinence on the 24-hour pad test. *BJOG*. 2004;111(8):859–862.

Panayi DC, Duckett J, Digesu GA, et al. Pre-operative opening detrusor pressure is predictive of detrusor overactivity following TVT in patients with pre-operative mixed urinary incontinence. *Neurourol Urodyn*. 2009;28(1):82–85.

Pangilinan J, Quanstrom K, Bridge M, et al. The Timed Up and Go Test as a measure of frailty in urologic practice. *Urology*. 2017;106:32–38.

Pannu HK, Kaufman JS, Cundiff GW, et al. Dynamic MR imaging of pelvic organ prolapse: spectrum of abnormalities. *Radiographics*. 2000;20:1567–1582.

Patel AK, Chapple CR. Urodynamics in the management of female stress incontinence—which test and when? *Curr Opin Urol*. 2008;18:359–364.

Petrelli NJ, Nagel S, Rodruiguez-Bigas M, et al. Morbidity and mortality following abdominoperineal resection for rectal adenocarcinoma. *Am Surg*. 1993;59(7):400–404.

Raghavaiah NV. Double-dye test to diagnose various types of vaginal fistulas. *J Urol*. 1974;112(6):811–812.

Resnick NM. Urinary incontinence in the elderly. *Medical Grand Rounds*. 1984;3:281–290.

Richardson DA, Bent AE, Ostergard DR. The effect of uterovaginal prolapse on urethrovesical pressure dynamics. *Am J Obstet Gynecol*. 1983;146(8):901–905.

Richter HE, Whitehead N, Arya L, Pelvic Floor Disorders Network, et al. Genetic contributions to urgency urinary incontinence in women. *J Urol*. 2015;193(6):2020–2027.

Roovers JP, Oelke M. Clinical relevance of urodynamic investigation tests prior to surgical correction of genital prolapse: a literature review. *Int Urogynecol J Pelvic Floor Dysfunct*. 2007;18(4):455–460.

Roovers JP, van Laar JO, Loffeld C, et al. Does urodynamic investigation improve outcome in patients undergoing prolapse surgery? *Neurourol Urodyn*. 2007;26:170–175.

Rovner E. Bladder and urethral diverticula. Wein AJ, Kavoussi LR, Novick AC, et al. *Campbell-Walsh urology*. ed 9. Saunders Elsevier: Philadelphia, PA; 2007:2361–2390.

Ryhammer AM, Laurberg S, Djurhuus JC, et al. No relationship between subjective assessment of urinary incontinence and pad test weight gain in a random population sample of menopausal women. *J Urol*. 1998;159(3):800–803.

Shaw C, Matthews RJ, Perry SI, Leicestershire MRC Incontinence Study Team, et al. Validity and reliability of an interviewer-administered questionnaire to measure the severity of lower urinary tract symptoms of storage abnormality: the Leicester Urinary Symptoms Questionnaire. *BJU Int*. 2002;90(3):205–215.

Siltberg J, Larsson G, Victor A. Frequency/volume chart: the basic tool for investigating urinary symptoms. *Acta Obstet Gynecol Scand Suppl*. 1997;166:24–27.

Simons AM, Yoong WC, Buckland S, et al. Inadequate repeatability of the one-hour pad test: the need for a new incontinence outcome measure. *BJOG*. 2001;108(3):315–319.

Smith PP, Hurtado EA, Appell RA. Post hoc interpretation of urodynamic evaluation is qualitatively different than interpretation at the time of urodynamic study. *Neurourol Urodyn*. 2009;28(8):998–1002.

Staack A, Vitale J, Ragavendra N, et al. Translabial ultrasonography for evaluation of synthetic mesh in the vagina. *Urology*. 2014;83(1):68–74.

Stach-Lempinen B, Kujansuu E, Laippala P, et al. Visual analogue scale, urinary incontinence severity sore and 15 D—psychometric testing of three different health-related quality-of-life instruments for urinary incontinence women. *Scand J Urol Nephrol*. 2001;35(6):476–483.

Stav K, Dwyer PL, Rosamilia A. Women overestimate daytime urinary frequency: the importance of the bladder diary. *J Urol*. 2009;181(5):2176–2180.

Summitt RL Jr, Stovall TG, Bent AE, et al. Urinary incontinence: correlation of history and brief office evaluation with multichannel urodynamic testing. *Am J Obstet Gynecol*. 1992;166(6 Pt 1):1835–1840.

Sussman RD, Richter LA, Tefera E, et al. Utilizing technology in assessment of lower urinary tract symptoms: a randomized trial of electronic versus paper voiding diaries. *Female Pelvic Med Reconstr Surg*. 2016;22(4):224–228.

Tamanini JTN, Pallone LV, Sartori MGF, et al. A populational-based survey on the prevalence, incidence, and risk factors of urinary incontinence in older adults-results from the “SABE STUDY”. *Neurourol Urodyn*. 2018;37(1):466–477.

Thom DH, Nygaard IE, Calhoun EA. Urologic Diseases in America Project: urinary incontinence in women—national trends in hospitalizations, office visits, treatment and economic impact. *J Urol*. 2005;173:1295–1301.

Tincello DG, Richmond DH. The Larsson frequency/volume chart is not a substitute for cystometry in the investigation of women with urinary incontinence. *Int Urogynecol J Pelvic Floor Dysfunct*. 1998;9(6):391–396.

Townsend MK, Curhan GC, Resnick NM, et al. Oral contraceptive use and incident urinary incontinence in premenopausal women. *J Urol*. 2009;181(5):2170–2175.

Tseng LH, Liang CC, Chang YL, et al. Postvoid residual urine in women with stress incontinence. *Neurourol Urodyn*.

2008;27(1):48–51.

Twiss C, Triaca V, Rodriguez LV. Familial transmission of urogenital prolapse and incontinence. *Curr Opin Obstet Gynecol*. 2007;464–468.

Twiss CO, Fischer MC, Nitti NW. Comparison between reduction in 24-hour pad weight, International Consultation on Incontinence-Short Form (ICIQ-SF) score, International Prostate Symptom Score (IPSS), and post-operative Patient Global Impression of Improvement (PGI-I) score in patient evaluation after male perineal sling. *Neurourol Urodyn*. 2007;26:8–13.

Uebersax JS, Wyman JF, Shumaker SA, et al. Short forms to assess life quality and symptom distress for urinary incontinence in women: the Incontinence Impact Questionnaire and the Urogenital Distress Inventory, continence Program for Women Research Group. *Neurourol Urodyn*. 1995;14(2):131–139.

US Department of Health and Human Services. *Public Health Service, Agency for Health Care Policy and Research. Clinical practice guidelines: urinary incontinence in adults*. US Department of Health and Human Services: Washington, DC; 1992.

Van de Beek C, Stoevelaar HJ, McDonnell J, et al. Interpretation of uroflowmetry curves by urologists. *J Urol*. 1997;157:164–168.

Van de Vaart J, Falconer C, Quail D, et al. Patient reported outcomes tools in an observational study of female stress urinary incontinence. *Neurourol Urodyn*. 2010;29(3):348–353.

Vermeulen KM, Visser E, Messelink EJ, et al. Cost-effectiveness of a pro-active approach of urinary incontinence in women. *BJOG*. 2016;123(7):1213–1220.

Visco AG, Brubaker L, Nygaard I, Pelvic Floor Disorders

Network, et al. The role of preoperative urodynamic testing in stress-continent women undergoing sacrocolpopexy: the Colpopexy and Urinary Reduction Efforts (CARE) randomized surgical trial. *Int Urogynecol J Pelvic Floor Dysfunct*. 2008;19(5):607–614.

Waetjen LE, Johnson WO, Xing G, et al. Serum estradiol levels are not associated with urinary incontinence in midlife women transitioning through menopause. [for; The Study of Women's Health Across the Nation (SWAN)] *Menopause*. 2011;18(12):1283–1290.

Wagg A, Gibson W, Ostaszkiewicz J, et al. Urinary incontinence in frail elderly persons: report from the 5th International Consultation on Incontinence. *Neurourol Urodyn*. 2015;34(5):398–406.

Wagner TH, Patrick DL, Bavendam TG, et al. Quality of life of persons with urinary incontinence: development of a new measure. *Urology*. 1996;47(1):67–71.

Walters MD, Diaz K. Q-tip test: a study of continent and incontinent women. *Obstet Gynecol*. 1987;70(2):208–211.

Weber AM, Taylor RJ, Wei JT, et al. The cost-effectiveness of preoperative testing (basic office assessment vs. urodynamics) for stress urinary incontinence in women. *BJU Int*. 2002;89(4):356–363.

Weber AM, Walters MD. Cost-effectiveness of urodynamic testing before surgery for women with pelvic organ prolapse and stress urinary incontinence. *Am J Obstet Gynecol*. 2000;183(6):1338–1346.

Whiteside JL, Hijaz A, Imrey PB, et al. Reliability and agreement of urodynamics interpretations in a female pelvic medicine center. *Obstet Gynecol*. 2006;108:315–323.

Winters JC, Dmochowski RR, Goldman HB, American Urological Association; Society of Urodynamics, Female Pelvic Medicine and Urogenital Reconstruction, et al.

Urodynamic studies in adults: AUA/SUFU guideline. *J Urol*. 2012;188(6 Suppl):2464–2472.

Wu WY, Sheu BC, Lin HH. Comparison of 20-minute pad test versus one-hour pad test in women with stress urinary incontinence. *Urology*. 2006;68:764–768.

Wyman JF, Choi SC, Harkins SW, et al. The urinary diary in evaluation of incontinence women: a test-retest analysis. *Obstet Gynecol*. 1988;71(6 Pt 1):812–817.

Wyman JF, Harkins SW, Choi SC, et al. Psychosocial impact of urinary incontinence in women. *Obstet Gynecol*. 1987;70(3 Pt 1):278–281.

Zimmern P, Kobashi KC, Lemack GE. Outcome measures for stress urinary incontinence treatment (OMIT): results of two Society of Urodynamics and Female Urology (SUFU) surveys. *Neurourol Urodyn*. 2010;29:715–718.

Zimmern P, Nager CW, Albo M, et al. Urinary Incontinence Treatment Network: inter-rater reliability of filling cystometrogram interpretation in a multicenter study. *J Urol*. 2006;175:2174–2177.

113

Evaluation and Management of Men With Urinary Incontinence

Riyad Tasher Al-Mousa MBBS, SSCU, FEBU, MSHA, Hashim Hashim MBBS, MRCS (Eng), MD, FEBU, FRCS (Urol)

Urinary incontinence (UI) is defined by the International Continence Society as the complaint of any **involuntary loss of urine** (Abrams et al., 2002) or, in other words, any leakage of urine. It is part of storage lower urinary tract symptoms (LUTS). LUTS are classified into bladder storage, voiding, and post-micturition symptoms (Table 113.1). UI can result from a variety of causes. Potential risk factors for UI include increased age, infection, functional and cognitive impairment, neurologic disorders, diabetes, prostatectomy, and intake of drugs and alcohol. The acronym **DIAPPERS** can be used to list the most common causes of UI, especially in the elderly population, including delirium, infection, atrophic urethritis, pharmacologic agents, psychiatric illness, endocrine disorders, reduced mobility, and stool impaction (DuBeau, 2002). It is therefore important to understand the cause of the UI and to evaluate and assess appropriately the men who are suffering with UI to manage them accordingly, because this condition can be a social and hygienic problem that affects quality of life (QoL).

TABLE 113.1

Classification of Lower Urinary Tract Symptoms

STORAGE	VOIDING	POST-MICTURITION
• Urgency • Urinary incontinence • Increased daytime frequency • Nocturia	• Slow stream • Splitting/spraying • Intermittency • Hesitancy • Straining • Terminal dribbling	• Post-micturition dribbling • Feeling of incomplete emptying

UI should be **described by specifying relevant factors** such as type, frequency, severity, precipitating factors, social impact, effect on hygiene and QoL, the measures used to contain the leakage, and whether the individual seeks or desires help because of UI. The condition must be distinguished from sweating or urethral discharge.

UI in men is prevalent but less so than in women. It has not been well investigated and reported compared with the data available about UI in women, but Ancient Egyptian manuscripts detailed the existence of male incontinence 4000 years ago. UI in men is in a ratio of about 1 : 2 compared with UI in women. Prevalence in men varies from 1% to 39% depending on the definition used, variation in populations, response options, survey methods, and participation rates (Tikkinen et al., 2013). In a population survey in Canada, 5.4% of male respondents presented with UI (26% had stress urinary incontinence [SUI], 15% had mixed urinary incontinence [MUI], and 58% had urgency urinary incontinence [UUI]) (Bettez et al., 2012). In the EpiLUTS study (Coyne et al., 2012), the prevalence of UI in men was 46%. However, this included various forms of urinary symptoms, such as post-micturition incontinence, nocturnal enuresis, and urinary leakage with no definable cause. A total of 5.6% of men reported UUI only, 0.8% SUI only, 1.4% MUI, 6.3% UUI and another form of UI, and 1.2% SUI and another form of UI.

Prevalence has been shown to increase with age (Thom, 1998). Although UI was reported to be as low as 3% to 5% in young and middle-aged populations, it is estimated to range between 11% to 34% in old-aged population. However, some studies showed the racial and ethnic impact on UI in men (Wang et al., 2015). The National Health and Nutrition Examination Survey did not find any impact of race/ethnicity on prevalence of UI in men (Markland et al., 2010).

Key Points: Main Potential Risk Factors for Urinary Incontinence in Men

- Age
- Urologic infection
- Functional and cognitive impairment
- Neurologic diseases and comorbidities such as diabetes
- Drugs

- Surgery (e.g., prostatectomy)

Types of Urinary Incontinence

There are different types of UI (Abrams et al., 2002). Knowing the differences among them facilitates management of UI.

Stress Urinary Incontinence

SUI is the complaint of involuntary loss of urine on effort or physical exertion (e.g., sporting activities), or on sneezing, laughing, or coughing and not caused by a bladder contraction (Abrams et al., 2002). In other words, SUI is effort-related or activity-related incontinence, and this appellation may be preferred in some languages to avoid confusion with psychological stress. SUI occurs when the intra-abdominal pressure exceeds the intra-urethral pressure. SUI is more common in women (Haylen et al., 2010) than in men and usually occurs in men only after a prostatectomy, in which the external urethral sphincter is damaged.

Urgency Urinary Incontinence

UUI is the complaint of involuntary loss of urine associated with urgency. It was formerly known as urge urinary incontinence (Abrams et al., 2002). However, because it must be preceded by urgency, the terminology has changed to urgency urinary incontinence (Abrams et al., 2009; Toozs-Hobson et al., 2012). It is part of the **overactive bladder (OAB) syndrome,** and 90% of men who experience UUI will have detrusor overactivity (DO) on urodynamic studies, which leads to a rise in intravesical pressure that overcomes the outlet resistance (Hashim and Abrams, 2006). Patients who suffer with UUI have *wet OAB*.

Mixed Urinary Incontinence

MUI is the complaint of involuntary loss of urine associated with urgency and also associated with effort, physical exertion, sneezing, or coughing. Thus those with MUI experience UUI and SUI (Abrams et al., 2002). This condition is uncommon in men, although it may occur after prostatectomy.

Nocturnal Enuresis

Nocturnal enuresis is the **complaint of intermittent incontinence that occurs during periods of sleep** (Hashim et al., 2017). In other words, it is wetting the bed at night while asleep and not being aware of it.

Nocturnal enuresis has an estimated prevalence of nearly 10% in children aged 7 years. However, in 2% to 3% of children, it may persist into adulthood (Vande Walle et al., 2012). Nocturnal enuresis may also manifest later in life, and it is an important symptom, especially in men, because it may indicate that these men are in high-pressure chronic urinary retention, which can be associated with upper tract dilation and the risk of renal failure. Nocturnal enuresis is different from nocturia, which is **waking to pass urine during the main sleep period** (Hashim et al., 2017).

Continuous Urinary Incontinence

Continuous urinary incontinence describes the complaint of **continuous involuntary loss of urine** without normal voiding (Toozs-Hobson et al., 2012). This is a rare symptom and only exists when there is a fistula, for example, a prostate-rectal fistula, major sphincteric abnormalities such as exstrophy of the bladder or epispadias, or in cases with ectopic ureteral orifices. Sometimes men describe severe incontinence as continuous, when the underlying cause may be related to SUI, UUI, or MUI.

Incontinence Associated With Chronic Retention

It is commonly known as **overflow incontinence,** but this is no longer a recommended term by the International Continence Society (ICS). It is due to retention of urine and failure of the bladder to empty, and it may be dangerous in neurogenic patients because of the risk of autonomic dysreflexia in patients with spinal cord injuries above T10.

Other Types of Urinary Incontinence

Other relatively rare types of UI such as postural urinary incontinence are the **complaint of involuntary loss of urine associated with change of body position**, for example, seating after walking or rising from a seated or lying position. Insensible urinary incontinence is a complaint of UI when the patient is unaware of how it occurs but becomes aware that he is wet (Toozs-Hobson et al.,

2012).

Post-micturition leakage or dribble evokes complaints of **involuntary leakage of urine after the completion of micturition and occurring after the man has dressed himself, usually after he has left the toilet** (Abrams et al., 2002).

Functional incontinence is another type of UI. It is **the inability to reach the toilet properly because of cognitive, functional, or mobility problems in the absence of impaired lower urinary tract system.** This type of UI can happen in elderly or disabled patients. Also, UI may be situational; for example, the report of incontinence during sexual intercourse in women is termed coital incontinence. Giggle incontinence occurs when girls are giggling. Both of these types are rare in male patients.

Key Points: Types of Urinary Incontinence in Men

- SUI
- UUI
- MUI
- Nocturnal enuresis
- Continuous UI
- UI associated with chronic retention
- Others

Evaluation

History

Men with symptoms of UI must be evaluated with a **thorough history and directed physical examination.** It is important to enquire about the following:

- When do they leak? For example, when they cough, when they have urgency, at night while asleep, or at other times
- How often do they leak? For example, every night, daily, or another frequency
- Are there any precipitating factors that make leakage worse? For example, cold weather, putting the key in the door (latch-key incontinence), or other factors
- Was there any previous surgery to the prostate or bladder or was there major abdominal surgery that could have led to damage to the sacral plexus?
- How much do they leak? For example, wet the underwear, flood the outer clothing or floor, or other amounts
- Does the patient wear pads? If so, what type of pads, how many pads, what size of pads, or what other containment products are used, such as condom catheter or perhaps a change of underwear in the event of a leak?
- Has the patient tried any medications, and, if so, what medications does he take?
- Are there any neurologic problems and/or back pain that may suggest a neurologic cause for UI?
- How is the patient's sexual, erectile, and bowel function?
- What are his most bothersome symptoms?

A general medical, surgical, and social history must be obtained, including drug allergies, smoking habits, and quantifying any alcohol or caffeine intake.

Physical Examination

An examination, with the patient in a lying position, should include the following:

- The abdomen to check for surgical scars and to feel for any masses and especially for a distended bladder and hernias
- The external genitalia to examine the foreskin and external urethral meatus because some men may be suffering with *UI with chronic retention* resulting from a stenosis of the external urethral meatus or a severe phimosis
- The prostate via a digital rectal examination to feel the size and consistency of the prostate, assess if there is any pain on feeling the prostate to suggest prostatitis, as well as asking the patient to perform a pelvic squeeze to assess the strength of the pelvic floor
- The perineal skin, the anal canal and lower rectum to feel for anal tone and sensation and to assess rectal emptying
- Lower-limb neurologic examination to check reflexes, spasticity, muscle strength, gait, degree of mobility, and sensation
- Mental orientation
- Cough test: After the previous examinations are completed, ask the patient to cough to see if there is any leakage, and then ask the patient to stand and to cough again to check for SUI

First-Line Investigations

After the clinical examination is completed, bedside investigations must be performed.

Measurement of Height and Weight to Calculate Body Mass Index

The **body mass index** (BMI) is a good measure of obesity, and, in men who suffer with SUI, providing advice about weight loss may be helpful. However, there is little evidence that weight loss in men is useful; the evidence is extrapolated from women suffering with SUI. Also, related to men with SUI who have an artificial urinary sphincter (AUS), the less pressure there is intra-abdominally, and therefore the less pressure transmitted to the bladder, the less likely that these men would leak through the inflated artificial sphincter. This is because the AUS is a mechanical device, usually inserted with a pressure-regulating balloon of 61 to 70 cm H_20, and if the intra-abdominal pressure exceeds that, then the patient will leak.

Urinalysis

Urinalysis is usually performed using a dipstick with multiple parameters, including leukocytes and nitrites (to check for infection), glucose (to check for diabetes), blood (to check for hematuria), specific gravity (to ensure adequate fluid intake), pH (to see if the urine is basic or acidic), and ketones. Although false-positive and false-negative results may be encountered, the dipstick urine test is considered to be an inexpensive vital preliminary test (Roehrborn et al., 2001).

If there is any abnormality on the dipstick urinalysis, then the specimen is sent for microscopy, culture, and sensitivity. Appropriate investigations are also then initiated, such as urine cytology, a flexible cystoscopy, and ultrasound scan of the renal tract if there is hematuria.

Bladder Diary

The **bladder diary** (Fig. 113.1) is a vital investigational tool because it provides objective information on the number of episodes the patient is leaking and the number of pads being used, voiding pattern, and how many times the patient is passing urine during the day and night, the average and maximum voided volumes and therefore bladder capacity, the type and amount of fluid being consumed, assessment for nocturnal polyuria, and whether there is any urgency.

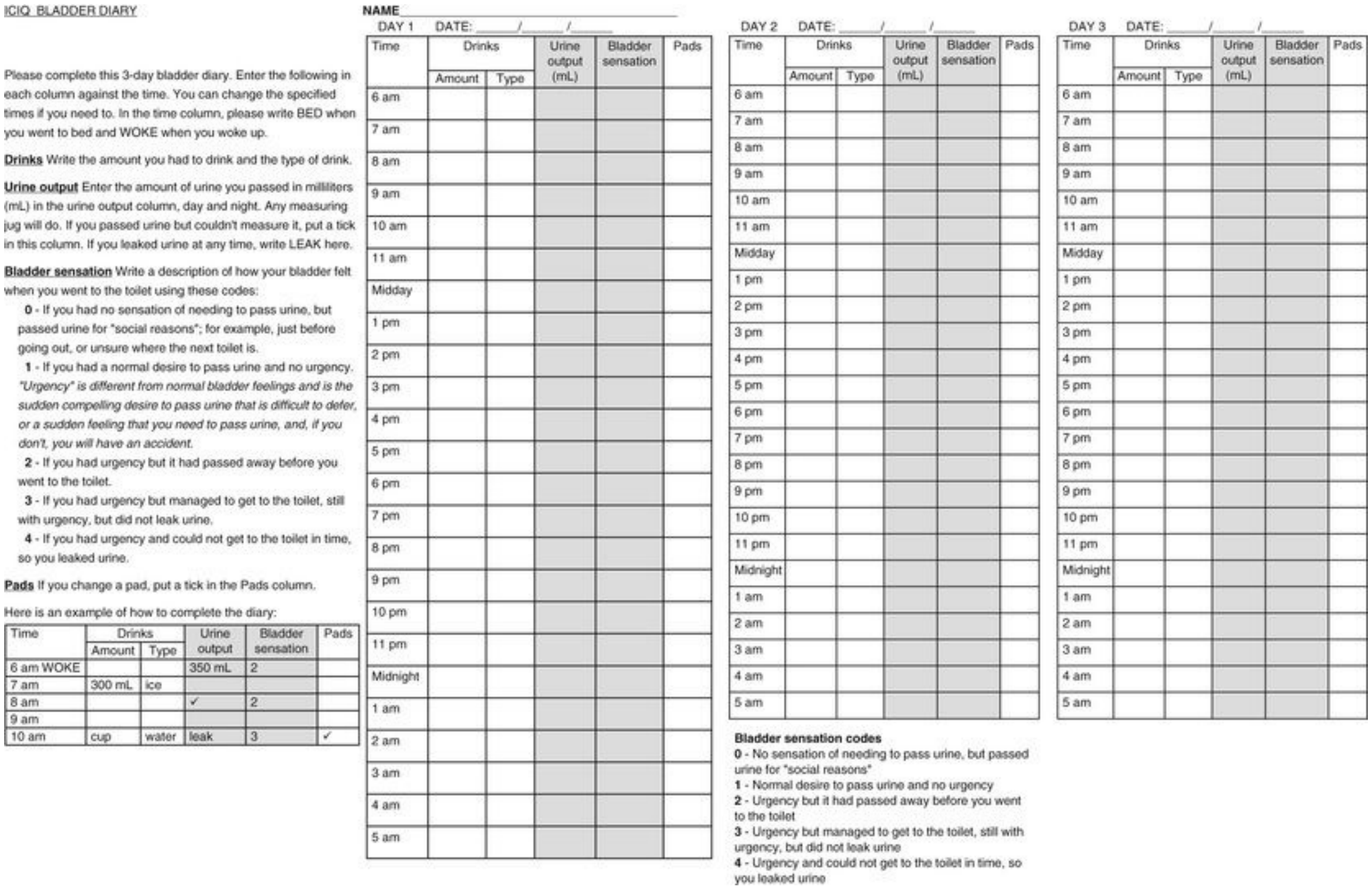

ICIQ BLADDER DIARY

Please complete this 3-day bladder diary. Enter the following in each column against the time. You can change the specified times if you need to. In the time column, please write BED when you went to bed and WOKE when you woke up.

Drinks Write the amount you had to drink and the type of drink.

Urine output Enter the amount of urine you passed in milliliters (mL) in the urine output column, day and night. Any measuring jug will do. If you passed urine but couldn't measure it, put a tick in this column. If you leaked urine at any time, write LEAK here.

Bladder sensation Write a description of how your bladder felt when you went to the toilet using these codes:

0 - If you had no sensation of needing to pass urine, but passed urine for "social reasons"; for example, just before going out, or unsure where the next toilet is.

1 - If you had a normal desire to pass urine and no urgency. *"Urgency" is different from normal bladder feelings and is the sudden compelling desire to pass urine that is difficult to defer, or a sudden feeling that you need to pass urine, and, if you don't, you will have an accident.*

2 - If you had urgency but it had passed away before you went to the toilet.

3 - If you had urgency but managed to get to the toilet, still with urgency, but did not leak urine.

4 - If you had urgency and could not get to the toilet in time, so you leaked urine.

Pads If you change a pad, put a tick in the Pads column.

Here is an example of how to complete the diary:

Time	Drinks		Urine output	Bladder sensation	Pads
	Amount	Type			
6 am WOKE			350 mL	2	
7 am	300 mL	ice			
8 am			✓	2	
9 am					
10 am	cup	water	leak	3	✓

NAME______________________

DAY 1 DATE: ____/____/____

Time	Drinks		Urine output (mL)	Bladder sensation	Pads
	Amount	Type			
6 am					
7 am					
8 am					
9 am					
10 am					
11 am					
Midday					
1 pm					
2 pm					
3 pm					
4 pm					
5 pm					
6 pm					
7 pm					
8 pm					
9 pm					
10 pm					
11 pm					
Midnight					
1 am					
2 am					
3 am					
4 am					
5 am					

DAY 2 DATE: ____/____/____

Time	Drinks		Urine output (mL)	Bladder sensation	Pads
	Amount	Type			
6 am					
7 am					
8 am					
9 am					
10 am					
11 am					
Midday					
1 pm					
2 pm					
3 pm					
4 pm					
5 pm					
6 pm					
7 pm					
8 pm					
9 pm					
10 pm					
11 pm					
Midnight					
1 am					
2 am					
3 am					
4 am					
5 am					

Bladder sensation codes

0 - No sensation of needing to pass urine, but passed urine for "social reasons"

1 - Normal desire to pass urine and no urgency

2 - Urgency but it had passed away before you went to the toilet

3 - Urgency but managed to get to the toilet, still with urgency, but did not leak urine

4 - Urgency and could not get to the toilet in time, so you leaked urine

DAY 3 DATE: ____/____/____

Time	Drinks		Urine output (mL)	Bladder sensation	Pads
	Amount	Type			
6 am					
7 am					
8 am					
9 am					
10 am					
11 am					
Midday					
1 pm					
2 pm					
3 pm					
4 pm					
5 pm					
6 pm					
7 pm					
8 pm					
9 pm					
10 pm					
11 pm					
Midnight					
1 am					
2 am					
3 am					
4 am					
5 am					

FIG. 113.1 International Consultation on Incontinence Questionnaire Bladder Diary (ICIQ-BD).

Several different bladder diaries are available. However, none of these diaries has been fully validated except for the International Consultation on Incontinence Questionnaire Bladder Diary **(ICIQ-BD)** (Bright et al., 2014).

The number of days a bladder diary must be completed has also been the subject of several publications, and the most recent recommendation is that a 3-day bladder diary would offer the same information as a 7-day one without being too exhaustive for patients (Dmochowski et al., 2005). It is important, however, to tell patients to try to complete the diary so that they include a combination of weekdays and weekends, and the entries should be representative of patients' day-to-day lifestyles. The ICIQ-BD validation has shown that 3 days is the appropriate length to include the day-to-day changes in frequency and so forth.

Quality-of-Life Questionnaires and Patient-Reported Outcome Measures

Patients are unlikely to suffer significant morbidity from most types of UI, but UI does cause significant impact on **QoL.** It is therefore prudent to assess the impact of UI on a patient's QoL with a validated questionnaire.

The International Prostate Symptom Score (IPSS or American Urological

Association-SI [AUA-SI]) is the most commonly used questionnaire for men. However, this questionnaire is useless for men with UI, simply because the IPSS does not measure incontinence.

The ICIQ-UI short form (**ICIQ-UI-SF**; Fig. 113.2) is a simple, short questionnaire that helps differentiate between SUI and UUI (Avery et al., 2004). The alternative is the longer form, ICIQ-male LUTS questionnaire (ICIQ-MLUTS; eFig. 113.3), which includes the advantages of asking about the storage and voiding symptoms covered by the IPPS and asking about the bother of each (Abrams et al., 2006).

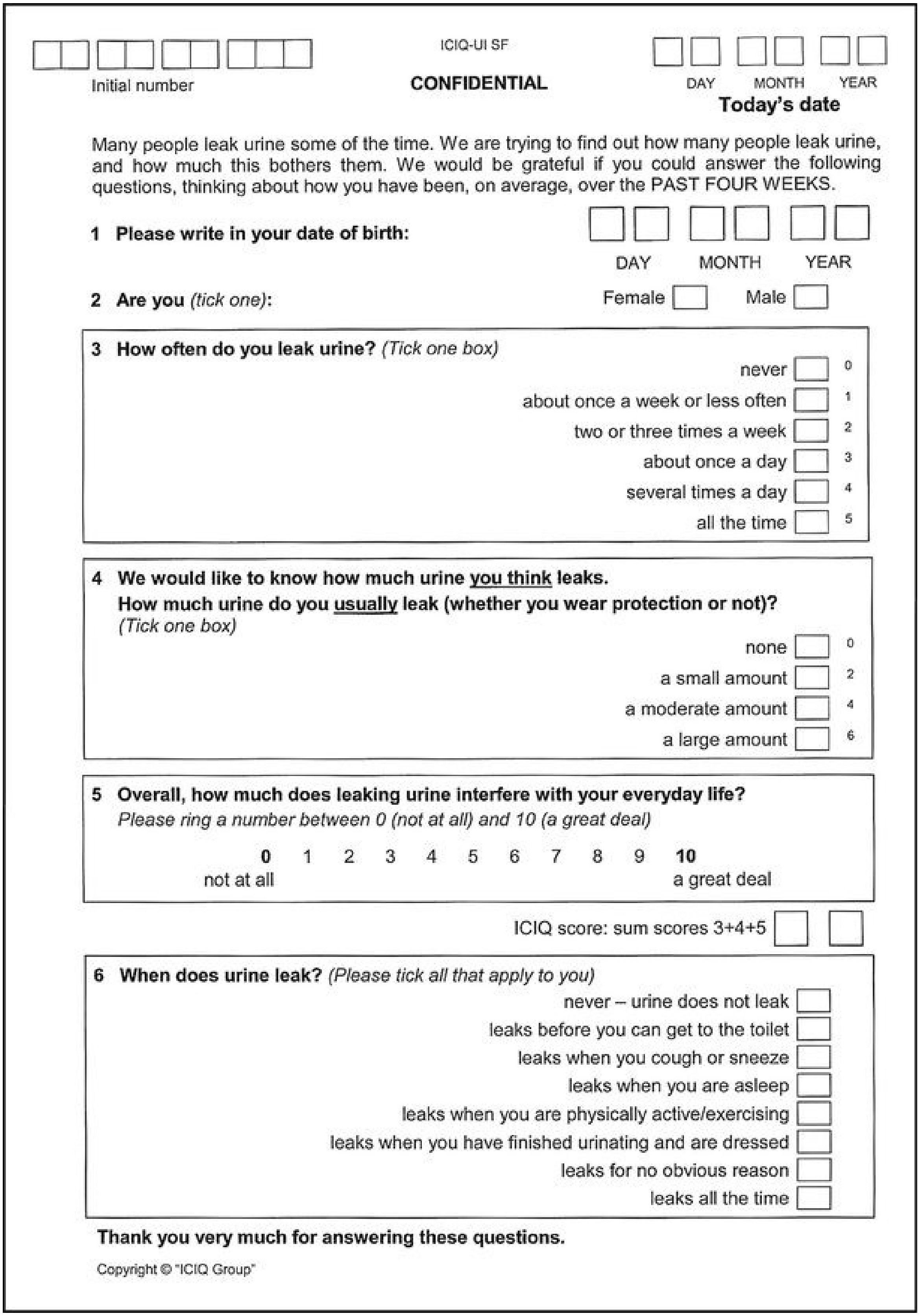

☐☐ ☐☐ ☐☐ ☐☐

Initial number

ICIQ-UI SF

CONFIDENTIAL

☐☐ ☐☐ ☐☐

DAY MONTH YEAR

Today's date

Many people leak urine some of the time. We are trying to find out how many people leak urine, and how much this bothers them. We would be grateful if you could answer the following questions, thinking about how you have been, on average, over the PAST FOUR WEEKS.

1 Please write in your date of birth: ☐☐ ☐☐ ☐☐

DAY MONTH YEAR

2 Are you *(tick one)*: Female ☐ Male ☐

3 How often do you leak urine? *(Tick one box)*

never	☐	0
about once a week or less often	☐	1
two or three times a week	☐	2
about once a day	☐	3
several times a day	☐	4
all the time	☐	5

4 We would like to know how much urine you think leaks.
How much urine do you usually leak (whether you wear protection or not)?
(Tick one box)

none	☐	0
a small amount	☐	2
a moderate amount	☐	4
a large amount	☐	6

5 Overall, how much does leaking urine interfere with your everyday life?
Please ring a number between 0 (not at all) and 10 (a great deal)

0 1 2 3 4 5 6 7 8 9 **10**

not at all a great deal

ICIQ score: sum scores 3+4+5 ☐ ☐

6 When does urine leak? *(Please tick all that apply to you)*

- never – urine does not leak ☐
- leaks before you can get to the toilet ☐
- leaks when you cough or sneeze ☐
- leaks when you are asleep ☐
- leaks when you are physically active/exercising ☐
- leaks when you have finished urinating and are dressed ☐
- leaks for no obvious reason ☐
- leaks all the time ☐

Thank you very much for answering these questions.

Copyright © "ICIQ Group"

FIG. 113.2 International Consultation on Incontinence Questionnaire

Urinary Incontinence Short Form (ICIQ-UI-SF).

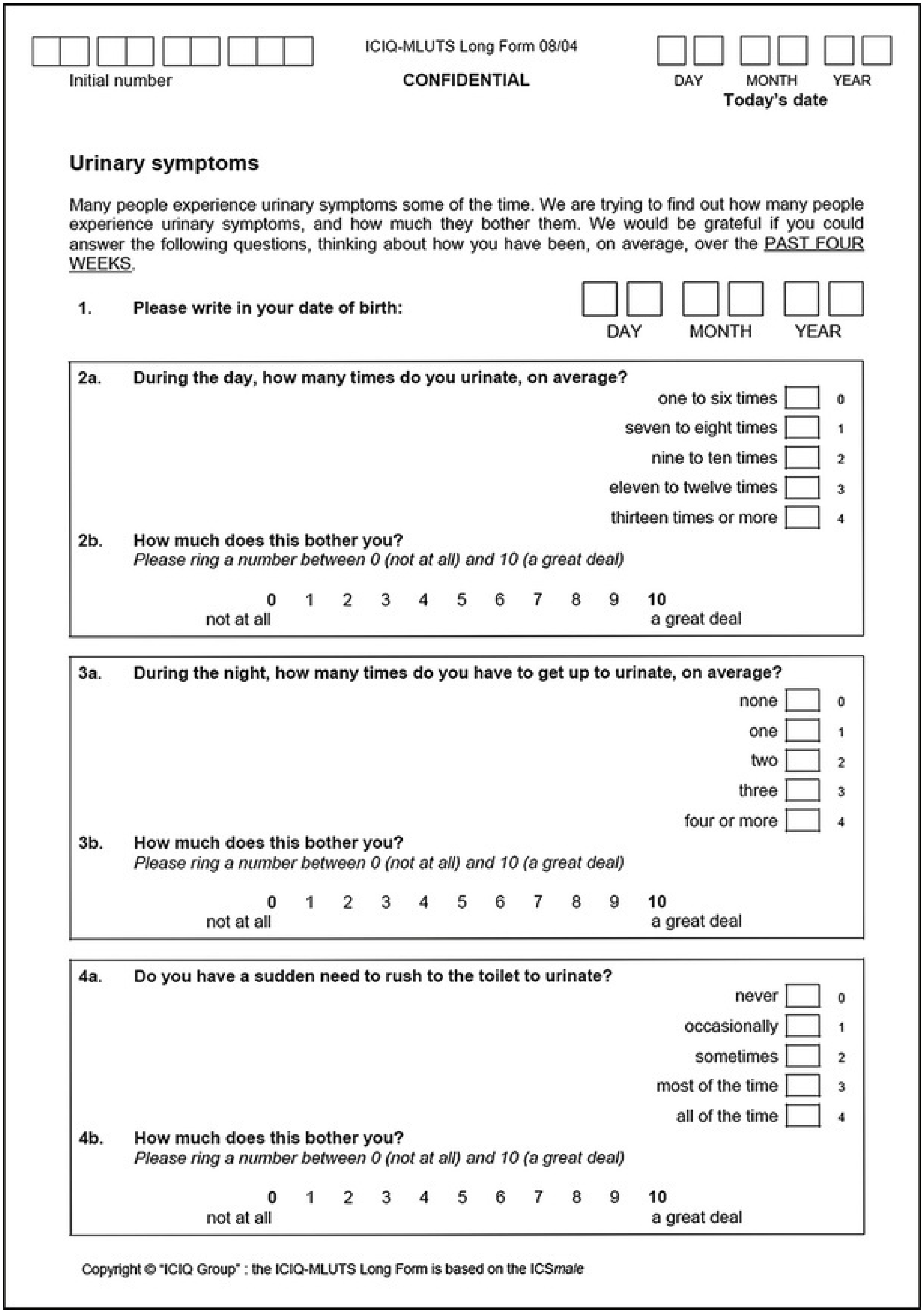

☐☐ ☐☐ ☐☐ ☐☐
Initial number

ICIQ-MLUTS Long Form 08/04

CONFIDENTIAL

☐☐ ☐☐ ☐☐
DAY MONTH YEAR
Today's date

Urinary symptoms

Many people experience urinary symptoms some of the time. We are trying to find out how many people experience urinary symptoms, and how much they bother them. We would be grateful if you could answer the following questions, thinking about how you have been, on average, over the PAST FOUR WEEKS.

1. Please write in your date of birth: ☐☐ ☐☐ ☐☐
DAY MONTH YEAR

2a. During the day, how many times do you urinate, on average?

one to six times ☐ 0
seven to eight times ☐ 1
nine to ten times ☐ 2
eleven to twelve times ☐ 3
thirteen times or more ☐ 4

2b. How much does this bother you?
Please ring a number between 0 (not at all) and 10 (a great deal)

0 1 2 3 4 5 6 7 8 9 **10**
not at all a great deal

3a. During the night, how many times do you have to get up to urinate, on average?

none ☐ 0
one ☐ 1
two ☐ 2
three ☐ 3
four or more ☐ 4

3b. How much does this bother you?
Please ring a number between 0 (not at all) and 10 (a great deal)

0 1 2 3 4 5 6 7 8 9 **10**
not at all a great deal

4a. Do you have a sudden need to rush to the toilet to urinate?

never ☐ 0
occasionally ☐ 1
sometimes ☐ 2
most of the time ☐ 3
all of the time ☐ 4

4b. How much does this bother you?
Please ring a number between 0 (not at all) and 10 (a great deal)

0 1 2 3 4 5 6 7 8 9 **10**
not at all a great deal

Copyright © "ICIQ Group" ; the ICIQ-MLUTS Long Form is based on the ICS*male*

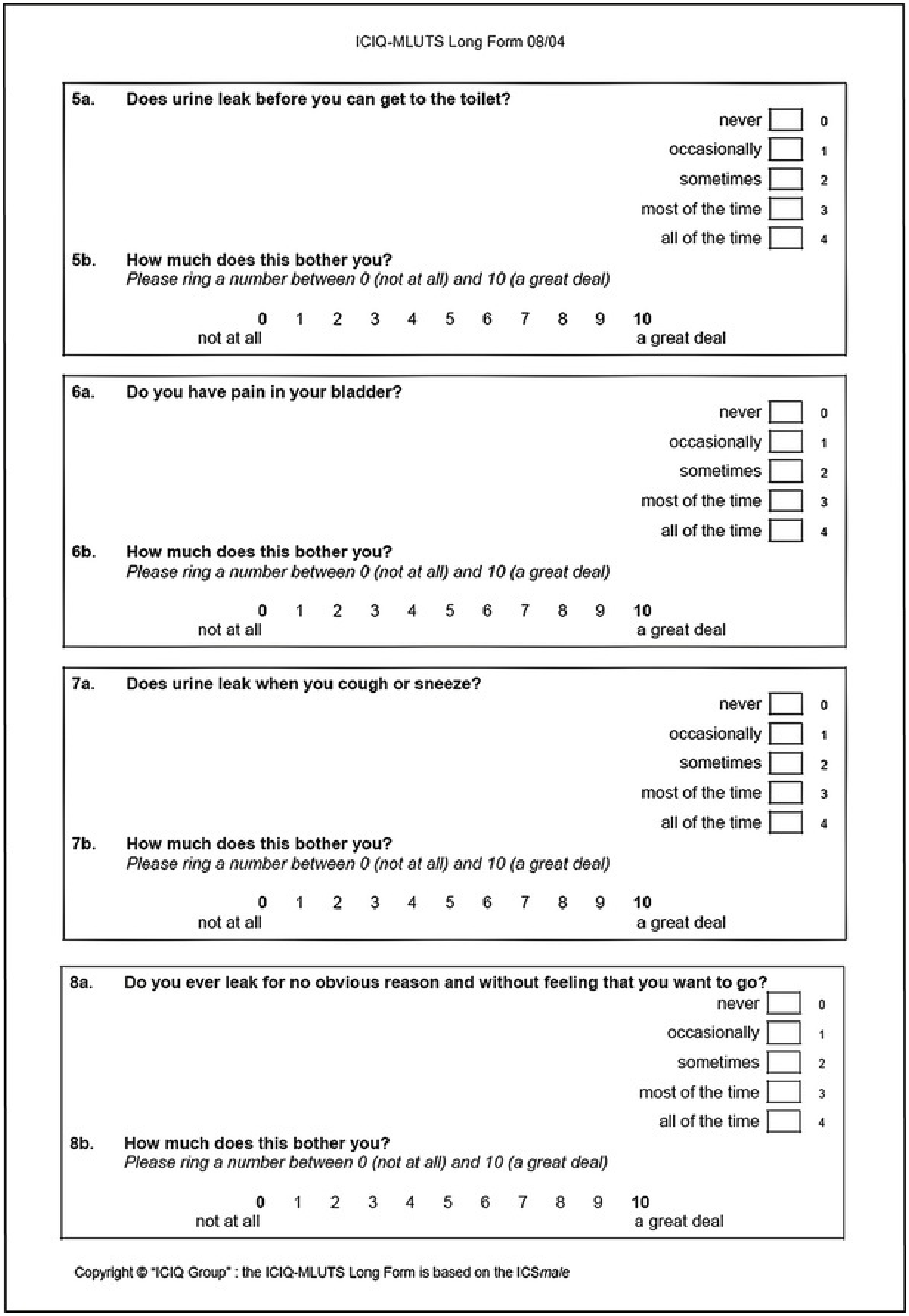

ICIQ-MLUTS Long Form 08/04

5a. **Does urine leak before you can get to the toilet?**

never ☐ 0
occasionally ☐ 1
sometimes ☐ 2
most of the time ☐ 3
all of the time ☐ 4

5b. **How much does this bother you?**
Please ring a number between 0 (not at all) and 10 (a great deal)

0 1 2 3 4 5 6 7 8 9 **10**
not at all ... a great deal

6a. **Do you have pain in your bladder?**

never ☐ 0
occasionally ☐ 1
sometimes ☐ 2
most of the time ☐ 3
all of the time ☐ 4

6b. **How much does this bother you?**
Please ring a number between 0 (not at all) and 10 (a great deal)

0 1 2 3 4 5 6 7 8 9 **10**
not at all ... a great deal

7a. **Does urine leak when you cough or sneeze?**

never ☐ 0
occasionally ☐ 1
sometimes ☐ 2
most of the time ☐ 3
all of the time ☐ 4

7b. **How much does this bother you?**
Please ring a number between 0 (not at all) and 10 (a great deal)

0 1 2 3 4 5 6 7 8 9 **10**
not at all ... a great deal

8a. **Do you ever leak for no obvious reason and without feeling that you want to go?**

never ☐ 0
occasionally ☐ 1
sometimes ☐ 2
most of the time ☐ 3
all of the time ☐ 4

8b. **How much does this bother you?**
Please ring a number between 0 (not at all) and 10 (a great deal)

0 1 2 3 4 5 6 7 8 9 **10**
not at all ... a great deal

Copyright © "ICIQ Group" : the ICIQ-MLUTS Long Form is based on the ICS*male*

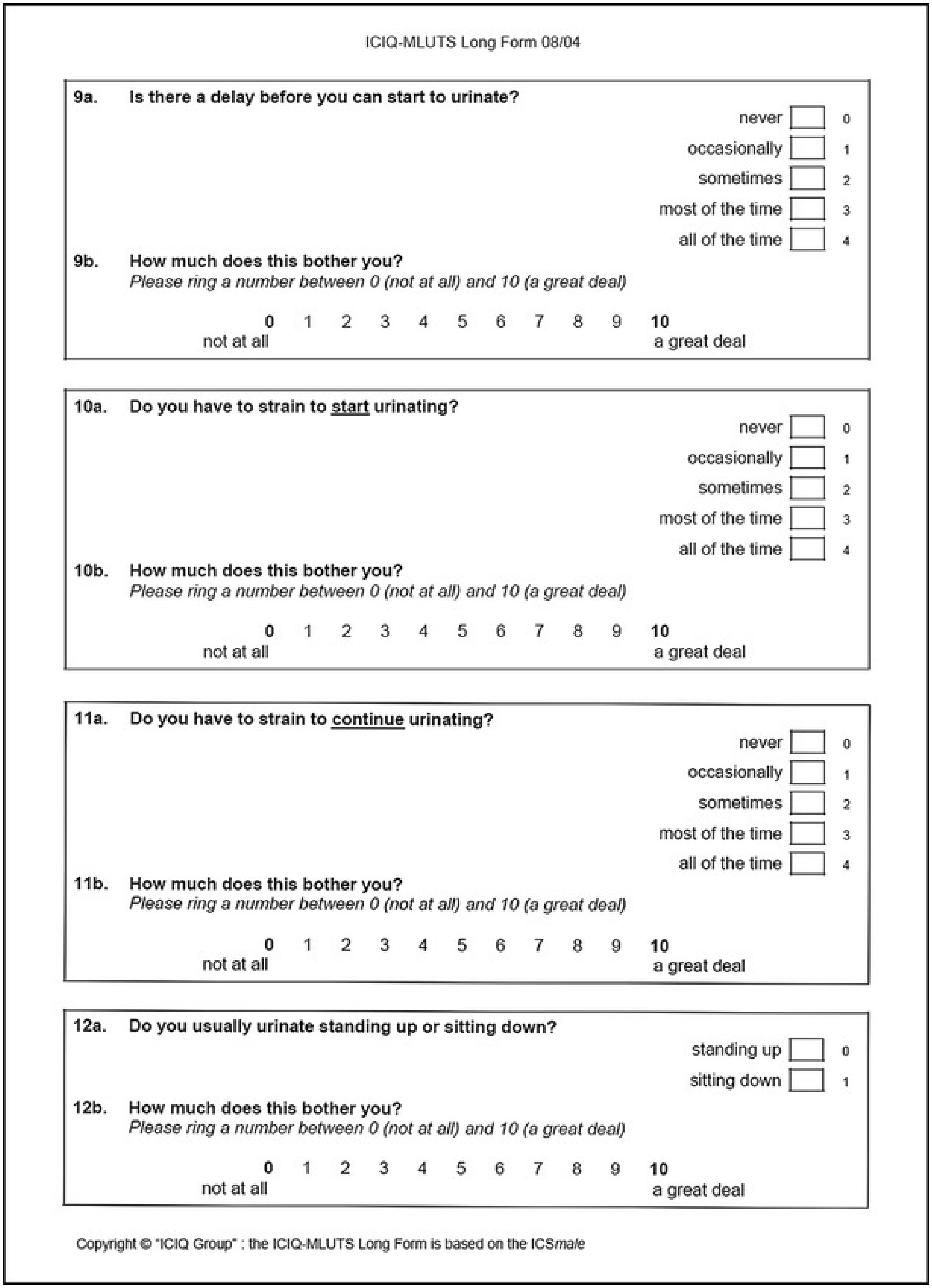

ICIQ-MLUTS Long Form 08/04

9a. Is there a delay before you can start to urinate?

never ☐ 0
occasionally ☐ 1
sometimes ☐ 2
most of the time ☐ 3
all of the time ☐ 4

9b. How much does this bother you?
Please ring a number between 0 (not at all) and 10 (a great deal)

0 1 2 3 4 5 6 7 8 9 **10**
not at all — a great deal

10a. Do you have to strain to start urinating?

never ☐ 0
occasionally ☐ 1
sometimes ☐ 2
most of the time ☐ 3
all of the time ☐ 4

10b. How much does this bother you?
Please ring a number between 0 (not at all) and 10 (a great deal)

0 1 2 3 4 5 6 7 8 9 **10**
not at all — a great deal

11a. Do you have to strain to continue urinating?

never ☐ 0
occasionally ☐ 1
sometimes ☐ 2
most of the time ☐ 3
all of the time ☐ 4

11b. How much does this bother you?
Please ring a number between 0 (not at all) and 10 (a great deal)

0 1 2 3 4 5 6 7 8 9 **10**
not at all — a great deal

12a. Do you usually urinate standing up or sitting down?

standing up ☐ 0
sitting down ☐ 1

12b. How much does this bother you?
Please ring a number between 0 (not at all) and 10 (a great deal)

0 1 2 3 4 5 6 7 8 9 **10**
not at all — a great deal

Copyright © "ICIQ Group" : the ICIQ-MLUTS Long Form is based on the ICS*male*

13a. Would you say that the strength of your urinary stream is...

normal ☐ 0
occasionally reduced ☐ 1
sometimes reduced ☐ 2
reduced most of the time ☐ 3
reduced all of the time ☐ 4

13b. How much does this bother you?
Please ring a number between 0 (not at all) and 10 (a great deal)

0 1 2 3 4 5 6 7 8 9 **10**
not at all a great deal

14. Do you think you have *always* had a weak stream?

no ☐ 0
yes ☐ 1

15. Would you say that the strength of your urinary stream is...
(please ring one number)

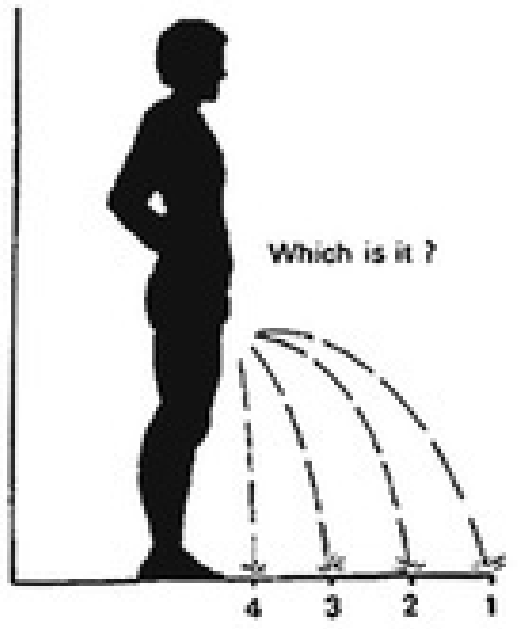

(from Peeling, 1989)

16a. Do you stop and start more than once while you urinate?

never ☐ 0
occasionally ☐ 1
sometimes ☐ 2
most of the time ☐ 3
all of the time ☐ 4

16b. How much does this bother you?
Please ring a number between 0 (not at all) and 10 (a great deal)

0 1 2 3 4 5 6 7 8 9 **10**
not at all a great deal

Copyright © "ICIQ Group" : the ICIQ-MLUTS Long Form is based on the ICS*male*

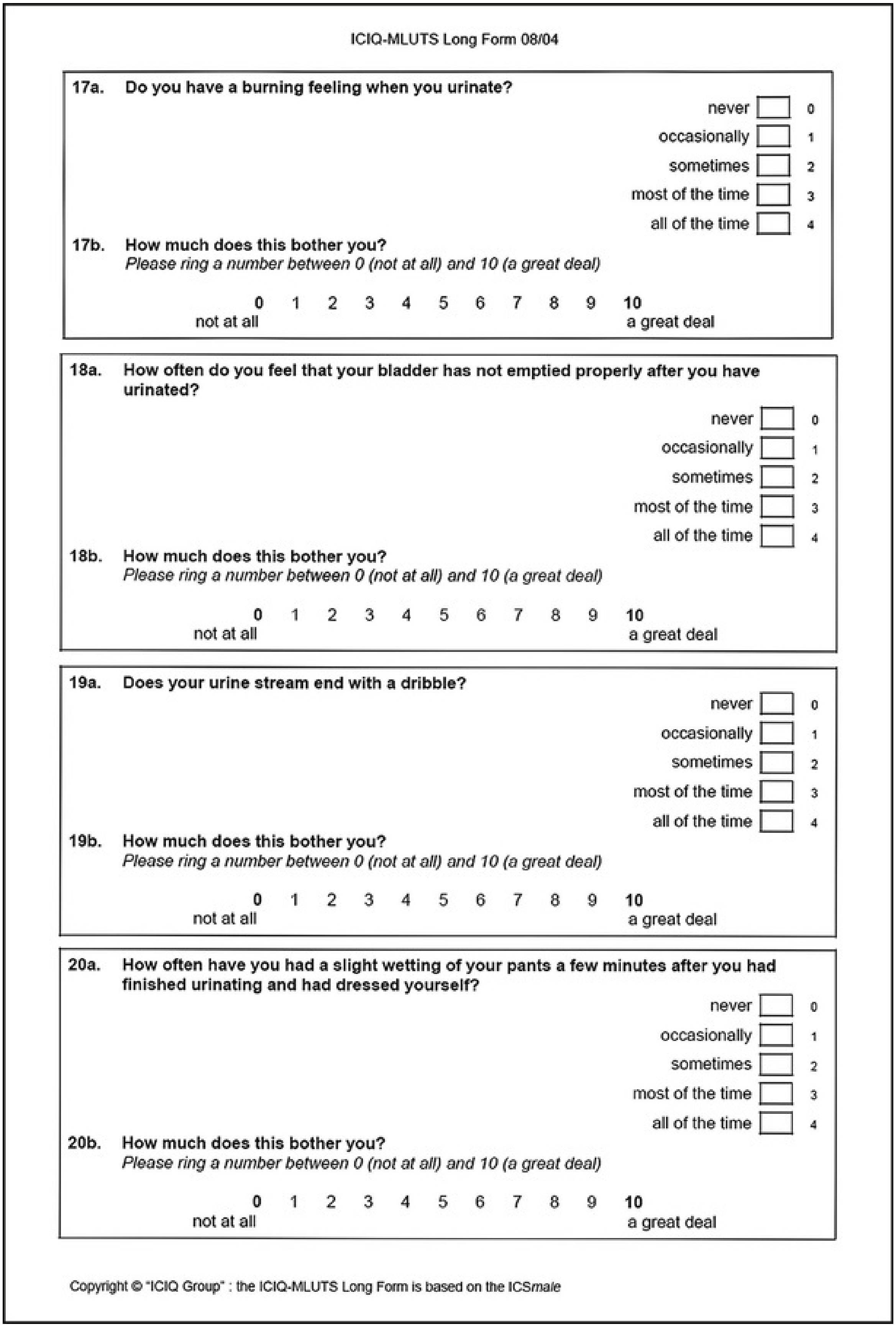

17a. **Do you have a burning feeling when you urinate?**

never ☐ 0
occasionally ☐ 1
sometimes ☐ 2
most of the time ☐ 3
all of the time ☐ 4

17b. **How much does this bother you?**
Please ring a number between 0 (not at all) and 10 (a great deal)

0 1 2 3 4 5 6 7 8 9 **10**
not at all … a great deal

18a. **How often do you feel that your bladder has not emptied properly after you have urinated?**

never ☐ 0
occasionally ☐ 1
sometimes ☐ 2
most of the time ☐ 3
all of the time ☐ 4

18b. **How much does this bother you?**
Please ring a number between 0 (not at all) and 10 (a great deal)

0 1 2 3 4 5 6 7 8 9 **10**
not at all … a great deal

19a. **Does your urine stream end with a dribble?**

never ☐ 0
occasionally ☐ 1
sometimes ☐ 2
most of the time ☐ 3
all of the time ☐ 4

19b. **How much does this bother you?**
Please ring a number between 0 (not at all) and 10 (a great deal)

0 1 2 3 4 5 6 7 8 9 **10**
not at all … a great deal

20a. **How often have you had a slight wetting of your pants a few minutes after you had finished urinating and had dressed yourself?**

never ☐ 0
occasionally ☐ 1
sometimes ☐ 2
most of the time ☐ 3
all of the time ☐ 4

20b. **How much does this bother you?**
Please ring a number between 0 (not at all) and 10 (a great deal)

0 1 2 3 4 5 6 7 8 9 **10**
not at all … a great deal

Copyright © "ICIQ Group" : the ICIQ-MLUTS Long Form is based on the ICS*male*

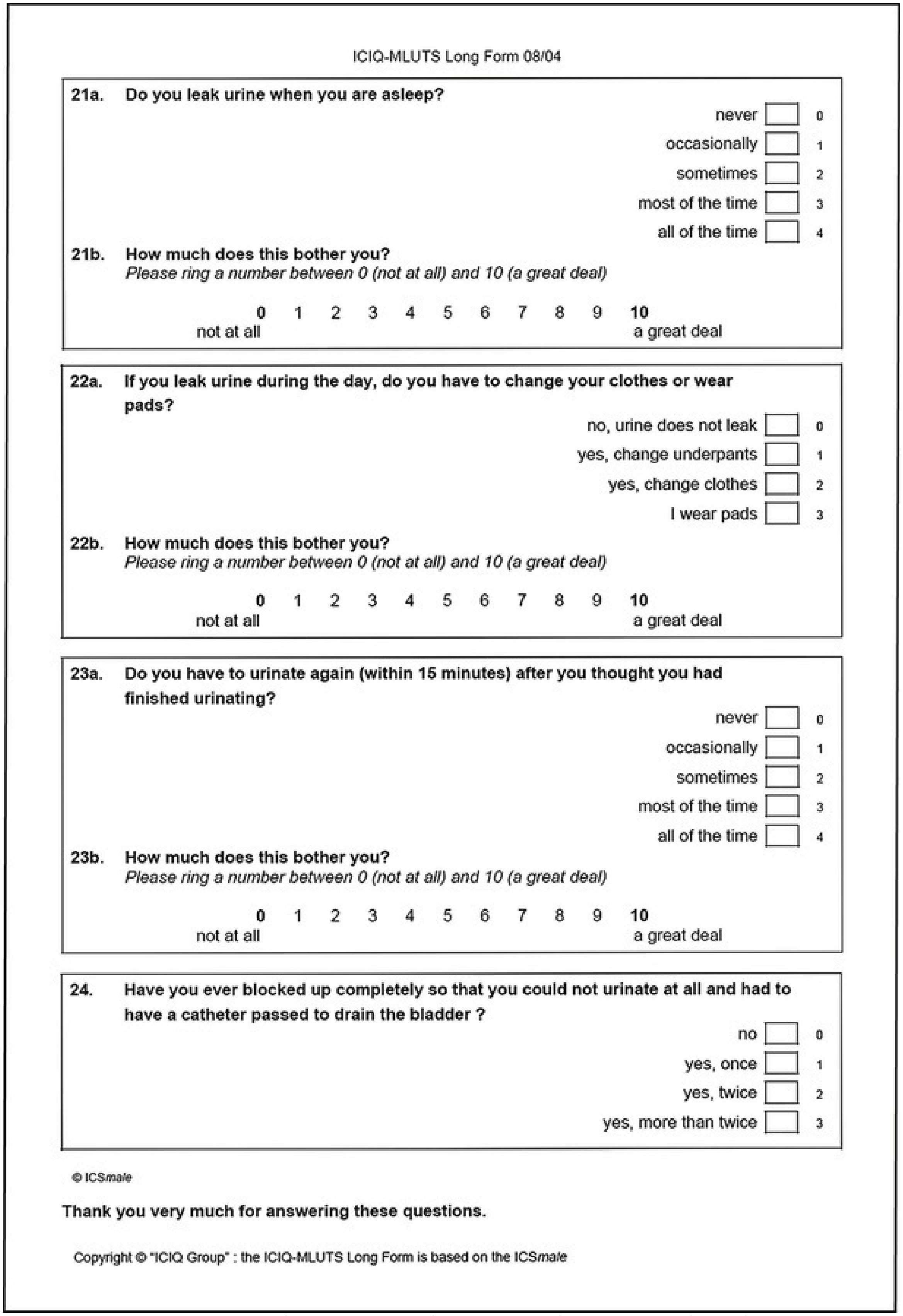

ICIQ-MLUTS Long Form 08/04

21a. **Do you leak urine when you are asleep?**

never ☐ 0
occasionally ☐ 1
sometimes ☐ 2
most of the time ☐ 3
all of the time ☐ 4

21b. **How much does this bother you?**
Please ring a number between 0 (not at all) and 10 (a great deal)

0 1 2 3 4 5 6 7 8 9 **10**
not at all — a great deal

22a. **If you leak urine during the day, do you have to change your clothes or wear pads?**

no, urine does not leak ☐ 0
yes, change underpants ☐ 1
yes, change clothes ☐ 2
I wear pads ☐ 3

22b. **How much does this bother you?**
Please ring a number between 0 (not at all) and 10 (a great deal)

0 1 2 3 4 5 6 7 8 9 **10**
not at all — a great deal

23a. **Do you have to urinate again (within 15 minutes) after you thought you had finished urinating?**

never ☐ 0
occasionally ☐ 1
sometimes ☐ 2
most of the time ☐ 3
all of the time ☐ 4

23b. **How much does this bother you?**
Please ring a number between 0 (not at all) and 10 (a great deal)

0 1 2 3 4 5 6 7 8 9 **10**
not at all — a great deal

24. **Have you ever blocked up completely so that you could not urinate at all and had to have a catheter passed to drain the bladder ?**

no ☐ 0
yes, once ☐ 1
yes, twice ☐ 2
yes, more than twice ☐ 3

© ICS*male*

Thank you very much for answering these questions.

Copyright © "ICIQ Group" : the ICIQ-MLUTS Long Form is based on the ICS*male*

EFIG. 113.3 International Consultation on Incontinence Questionnaire

Male Lower Urinary Tract Symptoms (ICIQ-MLUTS).

The bladder diary and QoL questionnaire help not only in the assessment of patients but also in looking at treatment effects if repeated after the patient has been treated.

Pad Testing

Pad testing is a diagnostic tool to detect and measure urine loss by weighing an absorbent pad before and after the test during specific period and standardized conditions. There is much controversy about the use of **pad testing** and the duration of time for which it should be performed. Should it be done for 1 hour or 24 hours? How many days should it be performed? Do pretreatment pad loss volumes predict outcomes? All these are questions that have not yet been answered by high-quality research. Also, pad testing does not help to differentiate between the different types of incontinence, especially UUI and SUI.

Most guidelines have not recommended the use of pad testing. However, pad testing can be useful in attempting to quantify the amount of leakage a patient experiences and perhaps in planning treatment accordingly. There is also disagreement in the literature as to what the definition of mild, moderate, and severe incontinence is, and whether the number of pads should be used to classify UI severity, or whether urine loss measured by pad weights should be used. Some would suggest that the use of one pad is considered mild, two to four pads is moderate, and more than four pads is severe, but patients sometimes change pads because of hygienic reasons rather than for necessity (Tsui et al., 2013). **Increased pad weight is therefore probably a better measure of the severity of UI, and usually less than 200 g/day is considered mild, 200 to 400 g/day is moderate, and more than 400 g/day is severe** (Kumar et al., 2009). However, it should be emphasized that these cut points have not been properly validated.

Urine Flow Rate and Postvoid Residual

Urine flow rates help in showing the pattern of the flow and the speed at which the patient is voiding, and ultrasound after voiding measures the postvoid residual (PVR). These measurements are inexpensive and easy to perform, and they are noninvasive. It is important, however, to learn how to interpret the measurements. A fast-rising flow rate may indicate an OAB resulting from urgency, and a slow-rising one with a long tail on the flow curve may indicate bladder outlet obstruction. If there is a high PVR, the obstruction may cause chronic retention, and if this is associated with high bladder-filling pressures, then night-time UI during sleep may occur.

It is recommended that at least two flows be performed to ensure that they are representative of the manner in which the patient normally voids (Garcia-Mora et al., 2013; Reynard et al., 1996). However, the latest ICS Good Urodynamic Practice document does suggest that one flow is sufficient if it is representative of the patient's normal voiding pattern (Rosier et al., 2017).

Measurement of Prostate-Specific Antigen

There is much controversy about prostate-specific antigen (PSA) testing, which will not be discussed here. However, if the testing is not going to change management, and if the digital rectal examination was normal, it should not be performed unless the patient requests it and is fully counseled about PSA testing.

Blood Tests

Blood tests should be tailored according to the patient history and examination. If the postvoid residual is high or a patient is diabetic, then renal function tests and glucose are indicated (Hill et al., 2013). In general, if it is an index case of UUI or SUI with no PVR, then blood tests are not indicated; however, the clinician may opt to perform blood tests because they are helpful in assessing renal function, and it would be difficult to select those patients with renal insufficiency (Madersbacher et al., 2004).

Advanced Investigations

Imaging.

Imaging with a plain x-ray radiograph or urinary tract ultrasound are not indicated in patients with UI, unless there is concern that the patient may be suffering with upper tract abnormalities, high postvoid residual (PVR), or if there is suspicion of stones (Abrams et al., 2008).

Endoscopy.

Urethrocystoscopy is indicated in patients suspected of having a urethral stricture, bladder outlet obstruction, or another pathology seen on

urinalysis, such as blood, or flow tests such as a high PVR (Sammer et al., 2015).

Urodynamic Studies.

Urodynamic studies (UDS), or urodynamics, include studies of the physics and physiology of the lower urinary tract (LUT). It is the gold standard to assess LUT function and dysfunction. Technically this includes flow rates. In everyday practice, however, the term *UDS* means invasive urodynamic testing and includes filling cystometry and voiding pressure/flow studies. It includes quality control, data analysis, and systemic documentation.

The general underlying principle when performing urodynamics is that it should not be performed unless it is going to change the management of the patient and unless it would provide the clinician with more information that would alter his or her management of the patient. Therefore, following baseline investigations, most major international guidelines including the International Consultation on Incontinence, the European Association of Urology, and the American Urological Association recommend that patients be treated with conservative therapy and medical therapy before performing urodynamics, and if these treatments fail to control the patient's symptoms and the patient would like to have, or needs, a surgical intervention, then that is when urodynamics is performed—that is, **before invasive therapy** (Winters et al., 2012).

Urodynamics should be considered in the following situations:

- To identify factors contributing to LUT dysfunction and to assess their relevance
- To predict the consequences of LUT dysfunction on the upper tracts
- To predict the consequences and outcomes of therapeutic intervention
- To confirm and/or understand the effects of interventional techniques
- To investigate the reasons for treatment failure
- Before undergoing any surgical intervention

Filling cystometry aims to define how the bladder and urethra behave during the storage phase. In other words, in an index non-neurologic patient, **the bladder can either be normal, or there is detrusor overactivity (DO), or there is poor compliance.** If the patient leaks during filling cystometry when a DO wave exists, that then is termed ***detrusor overactivity incontinence*** **(DOI)**. **It is important to mark on the urodynamics trace whether urgency was experienced at that time and whether there were any provocative maneuvers.**

The urethra, that is, the external urethral sphincter, can either be competent or incompetent during filling cystometry. If it is competent, then the patient will be continent and will not experience SUI. The patient is usually asked to perform Valsalva maneuvers or repeated coughs in the upright position when 200 mL of fluid have been instilled into the bladder. If the patient leaks, then the urethra is incompetent and the pressure at which leakage starts, the abdominal (Valsalva or cough) leak-point pressure, is recorded. Valsalva and coughs are also repeated at the end of the test at maximum capacity if the patient did not leak at 200 mL of bladder filling. **If the patient leaks on increasing intra-abdominal pressure, then he is said to have urodynamic stress incontinence (USI) instead of SUI; SUI is a symptomatic clinical diagnosis before urodynamics is performed.**

One important scenario that can occur during urodynamics is **cough-induced DOI, which happens when the patient coughs. This action initiates an involuntary detrusor contraction (DO), and the patient leaks because of the DO contraction rather than because of the raised intra-abdominal pressure generated by the cough.** Clinically it sounds as if the patient is leaking because of SUI, whereas the urodynamics shows that he has cough-induced DOI.

If during UDS it is difficult to be certain whether the man has USI or cough-induced DOI, then it may be helpful to fill the bladder with the man in a lying position, because then DO is less likely to occur. Then the patient is asked to cough to determine whether he leaks in the absence of DO, which would confirm the diagnosis of USI. If he does not leak with coughing, that is then good evidence that he only has DOI. If he leaks while lying down without DO, then the patient also has USI and therefore has DOI and USI, that is, mixed urodynamically proven UI.

After urodynamics is performed and the diagnosis is confirmed, invasive surgical treatment can be offered.

Key Points: Initial Evaluation of Patients With

Urinary Incontinence

Essential

- History and examination
- Measurement of height and weight to calculate BMI
- Dipstick urinalysis
- Bladder diary, for example, ICIQ-BD
- QoL questionnaire, for example, ICIQ-UI-SF
- Urine flow rate and measurement of PVR

Optional

- PSA
- Blood tests, for example urea and electrolytes
- Renal tract imaging
- Endoscopy
- UDS

Principal Methods of Treating Men With Urinary Incontinence

The aim of treatment is to control continence and improve QoL. Treatment (Fig. 113.4) of patients suffering with UI can be divided into the following:

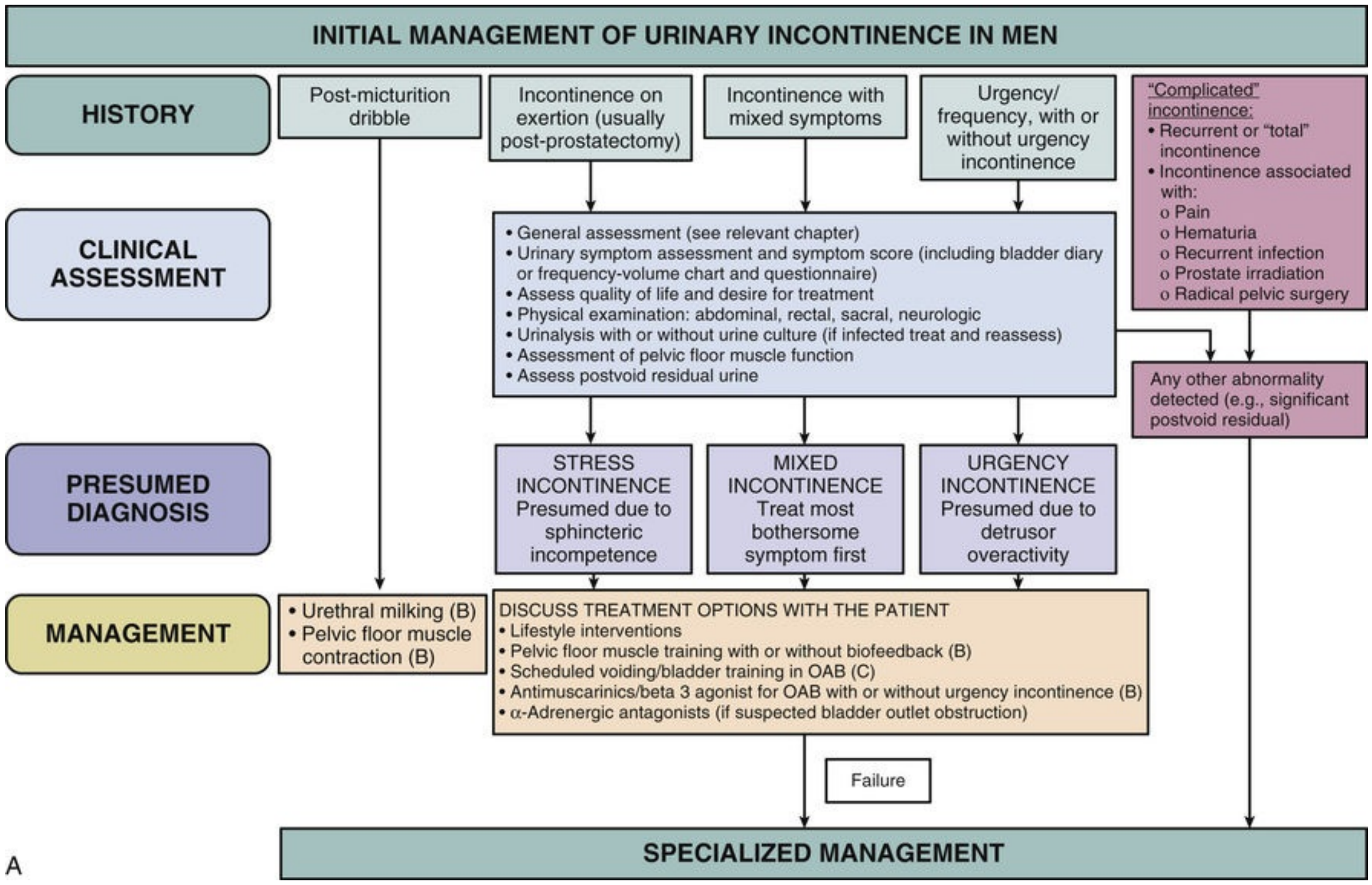
INITIAL MANAGEMENT OF URINARY INCONTINENCE IN MEN
HISTORY
Post-micturition dribble
Incontinence on exertion (usually post-prostatectomy)
Incontinence with mixed symptoms
Urgency/ frequency, with or without urgency incontinence
"Complicated" incontinence:
• Recurrent or "total" incontinence
• Incontinence associated with:
o Pain
o Hematuria
o Recurrent infection
o Prostate irradiation
o Radical pelvic surgery
CLINICAL ASSESSMENT
• General assessment (see relevant chapter)
• Urinary symptom assessment and symptom score (including bladder diary or frequency-volume chart and questionnaire)
• Assess quality of life and desire for treatment
• Physical examination: abdominal, rectal, sacral, neurologic
• Urinalysis with or without urine culture (if infected treat and reassess)
• Assessment of pelvic floor muscle function
• Assess postvoid residual urine
Any other abnormality detected (e.g., significant postvoid residual)
PRESUMED DIAGNOSIS
STRESS INCONTINENCE Presumed due to sphincteric incompetence
MIXED INCONTINENCE Treat most bothersome symptom first
URGENCY INCONTINENCE Presumed due to detrusor overactivity
MANAGEMENT
• Urethral milking (B)
• Pelvic floor muscle contraction (B)
DISCUSS TREATMENT OPTIONS WITH THE PATIENT
• Lifestyle interventions
• Pelvic floor muscle training with or without biofeedback (B)
• Scheduled voiding/bladder training in OAB (C)
• Antimuscarinics/beta 3 agonist for OAB with or without urgency incontinence (B)
• α-Adrenergic antagonists (if suspected bladder outlet obstruction)
Failure
SPECIALIZED MANAGEMENT
A

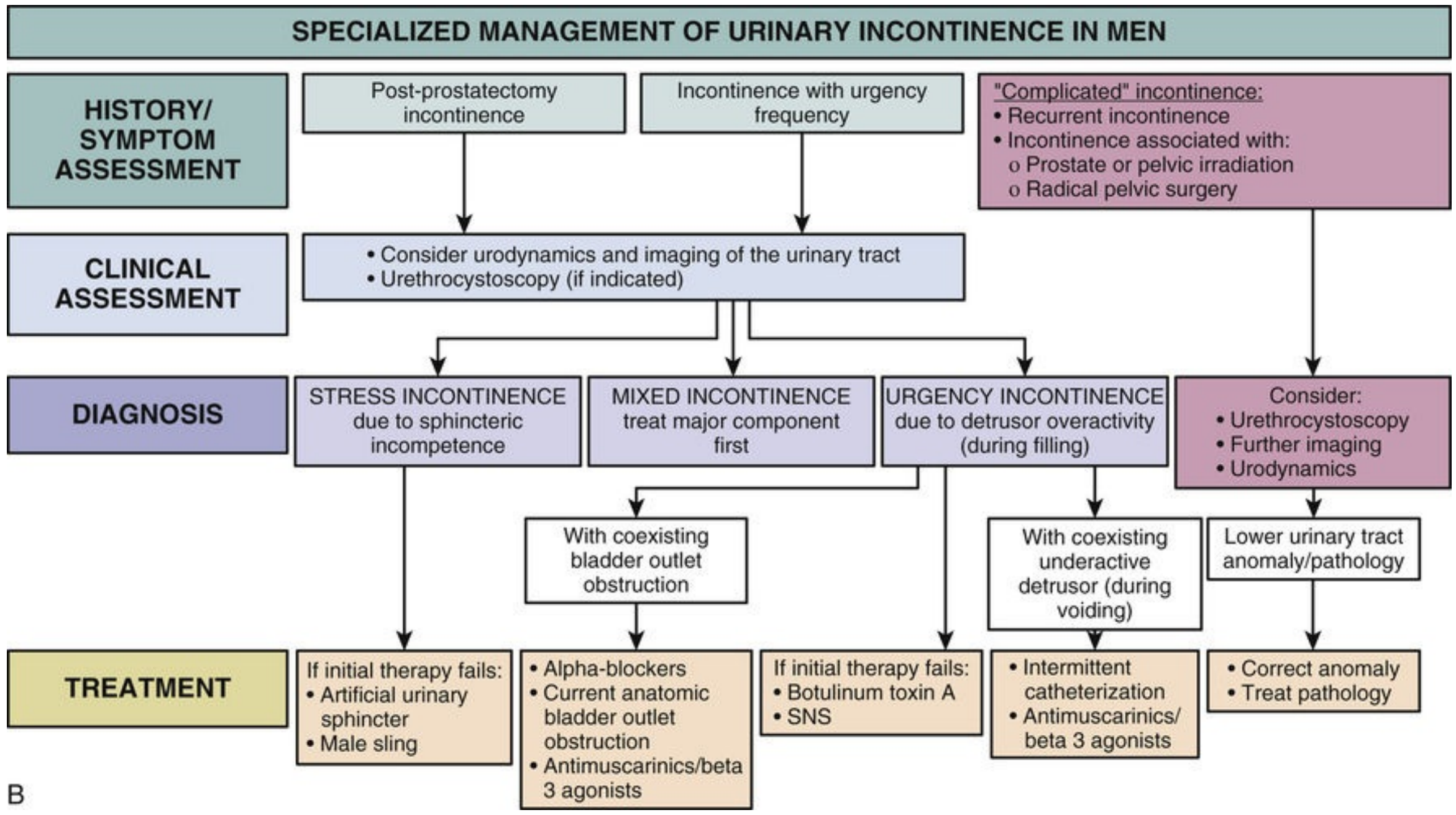
SPECIALIZED MANAGEMENT OF URINARY INCONTINENCE IN MEN
HISTORY/ SYMPTOM ASSESSMENT
Post-prostatectomy incontinence
Incontinence with urgency frequency
"Complicated" incontinence:
• Recurrent incontinence
• Incontinence associated with:
o Prostate or pelvic irradiation
o Radical pelvic surgery
CLINICAL ASSESSMENT
• Consider urodynamics and imaging of the urinary tract
• Urethrocystoscopy (if indicated)
DIAGNOSIS
STRESS INCONTINENCE due to sphincteric incompetence
MIXED INCONTINENCE treat major component first
URGENCY INCONTINENCE due to detrusor overactivity (during filling)
Consider:
• Urethrocystoscopy
• Further imaging
• Urodynamics
With coexisting bladder outlet obstruction
With coexisting underactive detrusor (during voiding)
Lower urinary tract anomaly/pathology
TREATMENT
If initial therapy fails:
• Artificial urinary sphincter
• Male sling
• Alpha-blockers
• Current anatomic bladder outlet obstruction
• Antimuscarinics/beta 3 agonists
If initial therapy fails:
• Botulinum toxin A
• SNS
• Intermittent catheterization
• Antimuscarinics/ beta 3 agonists
• Correct anomaly
• Treat pathology
B

FIG. 113.4 International Consultation on Incontinence algorithm on initial (A) and specialized (B) management of urinary incontinence in men. (From Abrams P, Cardozo L, Wagg A, et al.: Sixth International Consultation on Incontinence. *Incontinence* 2565–2567, 2017.)

Conservative

- Lifestyle changes: weight loss, stopping smoking, exercise, food and fluid manipulation

Lifestyle changes have been shown to have a positive impact on UI. Healthy eating, weight loss in overweight and obese patients (For SUI), smoking cessation, and reduced alcohol consumption are primary measures that may help to improve UI and related LUTS (Davis et al., 2013)

- Pelvic floor muscle training:

Effective first-line therapy mainly in men with postprostatectomy incontinence. Studies suggested better effect when exercises commence preoperatively (Dijkstra-Eshuis et al., 2015).

- Bladder training:

Scheduled voiding regimen and double voiding if necessary is a valid method to reduce UI and improve bladder capacity. Some studies suggested that bladder training was equivalent to pharmacologic therapy (Burgio et al., 2011).

Pharmacological (See details in Chapter 120 and Management of Different UI Types in Men.)

- Antimuscarinics/anticholinergics
- β3 agonist
- Serotonin norepinephrine reuptake inhibitors
- Others: alpha-blockers and PDE5 inhibitors

Minimally invasive (See details in Chapter 122 and Management of Different Urinary Incontinence Types in Men.)

- Botulinum toxin A
- Posterior tibial nerve stimulation
- Sacral neuromodulation
- Urethral bulking agents

Major surgery

- Augmentation cystoplasty
- Continent and incontinent urinary diversion
- Male slings
- Artificial urinary sphincter

Management of Different Urinary Incontinence Types in Men

Treatment of Urgency Urinary Incontinence

Initial conservative treatment of UUI includes behavioral modifications and lifestyle changes, such as reducing fluid input by 25% as long as the patient is drinking more than 1 L/day (Hashim and Abrams, 2008), stopping smoking, reducing weight, and avoiding caffeinated and fizzy drinks that may irritate the bladder (Hashim and Al Mousa, 2009). **The patient is also taught bladder training and pelvic floor muscle training** to supplement the fluid manipulation. These treatments must be attempted for at least 6 weeks to obtain benefit, and they should ideally be tried for 3 months.

If the previously outlined treatment fails, the patient can then be offered antimuscarinic therapy, if there are no contraindications. At least two antimuscarinics were recommended to be tried for at least 4 weeks each, starting at a low dose and building up to a maximum dose. Some studies, however, support the use of a single antimuscarinic then moving to other forms of management options (Chancellor et al., 2014). **There are seven antimuscarinics on the market** in the United Kingdom (oxybutynin, tolterodine, fesoterodine, solifenacin, darifenacin, propiverine, and trospium chloride). Most are oral tablets, but oxybutynin is also available in a topical gel formulation (in the United States) and as a skin patch. Each has advantages and disadvantages, and the choice of one in favor of the other depends on several factors, including licensing in the respective country, local guidelines, and clinician and patient preferences. All of the antimuscarinics have Level 1 evidence and Grade A recommendations for their use. Trial analysis (Madhuvrata et al., 2012) showed similar efficacy with all kinds of antimuscarinic with preferred choice of extended release formula over the immediate-release formula. Solifenacin may be preferred over tolterodine for better efficacy and less risk of dry mouth. Also, fesoterodine may have better efficacy over tolterodine but higher risk of withdrawal and discontinuation because of side effects (Madhuvrata et al., 2012). Trospium chloride, which is a nonselective quaternary amine antimuscarinic drug, which crosses the blood-brain barrier to a limited extent, only compared with other antimuscarinics.

Clinically, it seems to have good efficacy with no cognitive effect (Chancellor et al., 2012). The combination of two antimuscarinics or doubling the recommended dose of some antimuscarinics could be an option in selected patients to increase efficacy (Kosilov et al., 2014a) but is an off-license use.

If patients are unable to tolerate antimuscarinics or the antimuscarinics have failed to control symptoms, then patients can be prescribed **mirabegron, which is a β_3-agonist lipophilic medication that is metabolized in liver, and more than 50% is excreted in the urine. It has been licensed for the treatment of OAB in several countries, including the United States, the United Kingdom and other European countries, and Japan.** Mirabegron showed proven efficacy and superiority to tolterodine in terms of urinary incontinence episodes and frequency (Khullar et al., 2011).

Although some studies showed no difference in terms of efficacy between antimuscarinics and the β_3-agonist, the β_3-agonist does have advantages over antimuscarinics with respect to side effects such as less dry mouth and constipation (Chapple et al., 2014; Rossanese et al., 2015). However, it can cause palpitations and headaches resulting from hypertension.

Combination therapy of an antimuscarinic with a β_3-agonist has been shown to be an effective modality of treatment. In theory, because they work on different receptors they can be used in combination. A phase II trial has shown that the combination therapy of mirabegron and solifenacin is superior to monotherapy with a safe side effect profile (Abrams et al., 2015). A phase IIIB trial has shown that the combination of mirabegron 50 mg with solifenacin 5 mg is superior to dose escalation of solifenacin from 5 mg to 10 mg with better efficacy and less side effects (Drake et al., 2016).

Other forms of combination therapies have been recognized by the AUA (American Urological Association), EAU (European Association of Urology), and NICE (National Institute for Health and Care Excellence), such as a combination of alpha-blockers and antimuscarinics or alpha-blockers and β_3 agonists as a treatment option for patient with moderate to severe LUTS (Ichihara et al., 2015; Kaplan et al., 2013; Van Kerrebroeck et al., 2013) in patients with storage and voiding symptoms. PDE-5 inhibitors have been shown to improve LUTS and UI in men (Cellek et al., 2014). They relax the smooth muscles of the prostate, bladder, and urethra and improve bladder blood flow, which ultimately improves the patient's symptoms. **Tadalafil** is the only U.S. Food an Drug Association–approved PDE-5 inhibitor for the treatment of voiding LUTS in men (Cellek et al., 2014). More often than not, conservative and medical therapies are initiated at the same time to provide patients with a quicker and better relief of symptoms.

If conservative and medical therapies fail to control symptoms and the patient requests further treatment, invasive urodynamics is then performed to confirm DO and/or DOI, and minimally invasive surgery, where indicated and available, is offered. **This can either be in the form of cystoscopic intradetrusor injections of botulinum toxin-A, percutaneous sacral neuromodulation (SNM), or percutaneous posterior tibial nerve stimulation (PTNS).**

Botox, ona-botulinum toxin A, is the only licensed formulation of botulinum toxin A, for idiopathic UUI at 100 units, and for neurogenic DO at 200 units. Patients using Botox should be warned of the risk of urinary retention (approximately 10%), and they should be able and willing to perform intermittent catheterization. In addition, the injections must be repeated on average every 6 to 9 months.

SNM involves a test phase with a wire and external stimulator for 1 to 2 weeks, and a second stage with a tined lead and battery if the first one is successful, which is usually defined as more than a 50% improvement in symptoms. Recently, the test phase has been replaced by a permanent tined lead with a longer test phase for 2 to 4 weeks that is placed percutaneously under fluoroscopy in the S3 sacral foramen alongside the sacral nerve, then if the results were satisfactory, the battery will be implanted as a second stage. The mechanism of action of SNM is not clear; however, it is believed that it modulates the nerves supplying the bladder. The battery is changed every 5 to 7 years, on average, depending on the amount of use. The cure rate of UUI is 39%, and an improvement of greater than 50% is seen in 67% of patients. Long-term success has been evaluated with more than 10 years' follow-up with sustained results (Bettez et al., 2012).

PTNS, on the other hand, although licensed for OAB in some countries, does not seem to offer the same degree of benefit as Botox or SNM, and therefore PTNS is not widely used. The response rate is 54% to 81% (Bettez et al., 2012; Peters et al., 2013). PTNS involves inserting a needle into the ankle on the tibial nerve to electrically stimulate the sacral micturition center via the S2-S4 sacral nerve plexus. It is administered as 30-minute sessions, once per week for 12 weeks, and then it is maintained after that at once per month. Patients find it laborious, especially if it means traveling for long distances to receive treatment. In theory, this treatment can be self-administered if the patients are taught how to do it. The cost is higher than antimuscarinics therapy and there are no long-term outcome data available.

If these minimally invasive treatments fail and the patient continues to be bothered by symptoms, then the only treatments remaining are major surgical operations, unless the patient prefers to use containment products such as pads or a permanent suprapubic catheter. **Surgical options include augmentation cystoplasty, in its various forms, or an ileal conduit with or without a subtotal cystectomy.** In adults, autoaugmentation is no longer recommended for the treatment of DO because of the poor long-term success of this procedure resulting from complications (Leng et al., 1999: Ter Meulen et al., 1997).

Treatment of Stress Urinary Incontinence

SUI is treated initially with pelvic floor muscle training for at least 3 months. Ideally the training should be supervised, usually with a pelvic floor physiotherapist, to allow the best chance of success (Hay-Smith et al., 2012). If this treatment fails to control symptoms, then surgical options should be considered.

The most common cause for SUI in men occurs after prostatectomy. **After radical prostatectomy, it is recommended that no surgical treatment be considered until at least 6 to 12 months subsequently, because some patients will continue to improve** (Herschorn et al., 2010). While they are waiting to improve, patients can use a penile clamp such as *Dribble-Stop*, or, more frequently, containment products are used such as a condom catheter, urethral (not recommended long term because of risk of traumatic hypospadias) or suprapubic catheter, or incontinence pads.

Duloxetine, a combination of norepinephrine and serotonin reuptake inhibitor, can also be tried (Tsakiris et al., 2008). However, this is an off-license use of the medication that has only been licensed in several countries around the world to women who are experiencing moderate to severe incontinence. The efficacy data for men are limited.

If these treatments fail to control the incontinence and patients are still bothered, then surgical treatment is often offered, usually using an artificial urinary sphincter (AUS), which is the gold standard treatment with continence rates of about 80%. Alternative to the AUS, other surgical options that have shown variable efficacy in mild to moderate cases include urethral bulking agents, fixed male slings, adjustable male slings and, occasionally, the

ProACT (Table 113.2). It is important to rule out urethral or anastomotic strictures or bladder dysfunction before undergoing surgical treatment. Injection of bulking agents to enhance coaptation of the affected sphincter showed inferior results with no proven long-term efficacy regardless of the material used (Silva et al., 2014).

TABLE 113.2

Second- and Third-Line Therapy Recommendation for Men With Stress Urinary Incontinence

RECOMMENDATIONS	GR
Consider offering duloxetine to hasten recovery of continence after prostate surgery but inform the patient about the possible adverse events.	B
Only offer bulking agents to men with mild post-prostatectomy incontinence who desire temporary relief of incontinence symptoms.	C
Do not offer bulking agents to men with severe post-prostatectomy incontinence.	C
Offer fixed slings to men with mild to moderate post-prostatectomy incontinence.	B
Warn men that severe incontinence, prior pelvic radiotherapy, or urethral stricture surgery may worsen the outcome of fixed male sling surgery.	C
Offer artificial urinary sphincter (AUS) to men with moderate to severe post-prostatectomy incontinence.	B
Implantation of AUS or artificial compression device (ACT) for men should only be offered in expert centers.	C
Warn men receiving AUS or ACT that, even in expert centers, there is a high risk of complications or mechanical failure, or a need for explantation.	C
Do not offer non-circumferential compression device (ProACT) to men who have had pelvic radiotherapy.	C

Data from Burkhard FC, Bosch J, Cruz F, et al.: EAU Guidelines on Urinary Incontinence in Adults; 2017 (website): https://uroweb.org/wp-content/uploads/EAU-Guidelines-Urinary-Incontinence-2016.pdf.

Male slings have shown good efficacy with acceptable morbidity in mild to moderate SUI (Chapple et al., 2017). Male slings are inserted either by the transobturator or retropubic approach. The AdVance male sling is a commonly used fixed male sling that consists of polypropylene mesh that is placed via the transobturator approach under the membranous urethra with cure rates ranging between 9% and 63%. The success and cure rate variations are highly related to variation in definition of success and cure (Cornel et al., 2010). Similarly, adjustable male slings were introduced to improve basic continence with the theoretical advantage of adjusting the tension postoperatively for better continence rate. Three main adjustable slings are available in the market and have been studied with some variation in terms of efficacy. The Remeex system showed a success rate of 36% to 70% with multiple readjustment and 21% mechanical failure rate (Kim, 2011). The Argus system showed a subjective success of 58% and readjustment was reported to be up to 41% (Hubner et al., 2011). The adjustable transobturator male sling (the ATOMS) system is the most recent version of adjustable male slings. It consists of an inflatable soft silicon cushion compressing the urethra that can be adjusted through a titanium port access postoperatively either in the lower abdomen or in the scrotum. Objective cure rate was reported up to 60.5% with the need of multiple system adjustments and around 27.7% explantation rate (Hoda et al., 2013; Seweryn et al., 2012). More recent long-term data suggest that the third-generation ATOMS system with a pre-attached silicon-covered scrotal port showed good efficacy, durability, and fewer adjustments in the long-term follow-up mainly with primary implantation (Friedl et al., 2016; Strini et al., 2018). However, according to international guidelines, adjustable slings showed no additional benefits over standard slings with similar morbidity (Burkhard et al., 2017).

The ProACT device consists of a compressive balloon system that is placed in the bladder neck area, and volume can be readjusted via two scrotal ports with continence success rates of up to 68% and explantation rates of up to 55% (Hubner et al., 2007; Venturino et al., 2015).

Treatment of Mixed Urinary Incontinence

Treatment of MUI is more challenging. It should be aimed at treating the most bothersome symptom first. Diagnosis of the SUI component, even on urodynamics, is sometimes difficult if UUI is the predominant type of incontinence. Initial treatment usually involves treating DO with antimuscarinics and even with Botox or SNM and then repeating the urodynamics to determine if there is a SUI component.

Treatment of Other Types of Urinary Incontinence

The other types of UI (e.g., overflow incontinence) are treated based on the underlying cause (e.g., bladder outlet obstruction) which might need Transurethral resection of the prosatate (TURP).

Enuresis

Patients with high-pressure urinary retention causing nocturnal enuresis are treated by initial catheterization to relieve the pressure in the bladder, followed by appropriate assessment with a view to using endoscopic surgery to resect, to vaporize, or to enucleate the prostate, or open removal of the prostate.

Nocturnal enuresis, without residual urine, may be related to the OAB. This can be treated with antimuscarinics and potentially with desmopressin in the melt-formulation. It can also be related to relaxation of the pelvic floor during sleeping in patients with a neobladder after cystoprostatectomy. These patients sometimes only leak at night, and treatment is usually conservative.

Post-Micturition Dribble

Treatment of post-micturition dribble has not been well studied, and there are no medications available that have been approved for this indication. The main form of treatment is pelvic floor muscle training with a strong pelvic squeeze at the end of voiding and also urethral milking (Dorey et al., 2004; Paterson et al., 1997). The man is asked to wait for a few seconds after passing urine to ensure that the bladder is empty. Then he must place the fingertips of one of his hands three-fingerbreadths behind the scrotum and apply gentle pressure in the midline and gently move the fingertips toward the base of the penis under the scrotum. The aim is to push the urine forward into the middle part of the penis. From then on, the penis is milked, squeezed, and shaken to empty any remaining urine. The process is repeated twice to ensure that no urine remains in the urethra.

Key Points: Treatment of Urinary Incontinence

Urgency Urinary Incontinence

- Fluid manipulation and lifestyle changes
- Bladder training and pelvic floor muscle training
- Antimuscarinics and/or β_3 agonists
- Botox
- SNM
- Augmentation cystoplasty

- Urinary diversion, for example, ileal conduit

Stress Urinary Incontinence

- Weight loss and lifestyle changes
- Pelvic floor muscle training
- Duloxetine (off-license)
- Penile clamp
- AUS (gold standard)
- Male sub-urethral sling (fixed or adjustable)
- ProACT balloon

Algorithms for Management of Men With Urinary Incontinence

See Figs. 113.4 and 113.5.

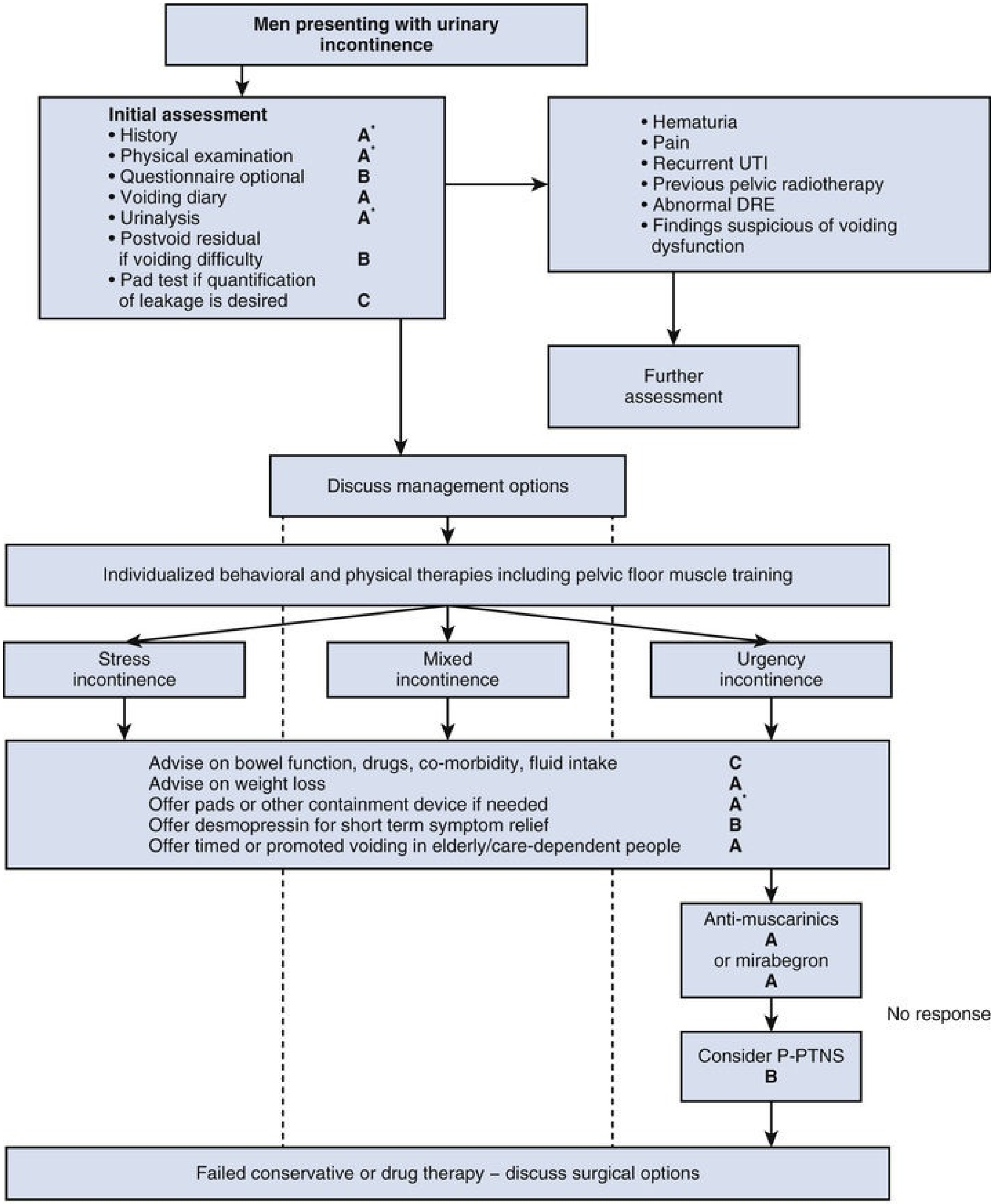
Men presenting with urinary incontinence
Initial assessment
• History A*
• Physical examination A*
• Questionnaire optional B
• Voiding diary A
• Urinalysis A*
• Postvoid residual if voiding difficulty B
• Pad test if quantification of leakage is desired C
• Hematuria
• Pain
• Recurrent UTI
• Previous pelvic radiotherapy
• Abnormal DRE
• Findings suspicious of voiding dysfunction
Further assessment
Discuss management options
Individualized behavioral and physical therapies including pelvic floor muscle training
Stress incontinence
Mixed incontinence
Urgency incontinence
Advise on bowel function, drugs, co-morbidity, fluid intake C
Advise on weight loss A
Offer pads or other containment device if needed A*
Offer desmopressin for short term symptom relief B
Offer timed or promoted voiding in elderly/care-dependent people A
Anti-muscarinics A or mirabegron A
No response
Consider P-PTNS B
Failed conservative or drug therapy – discuss surgical options

A

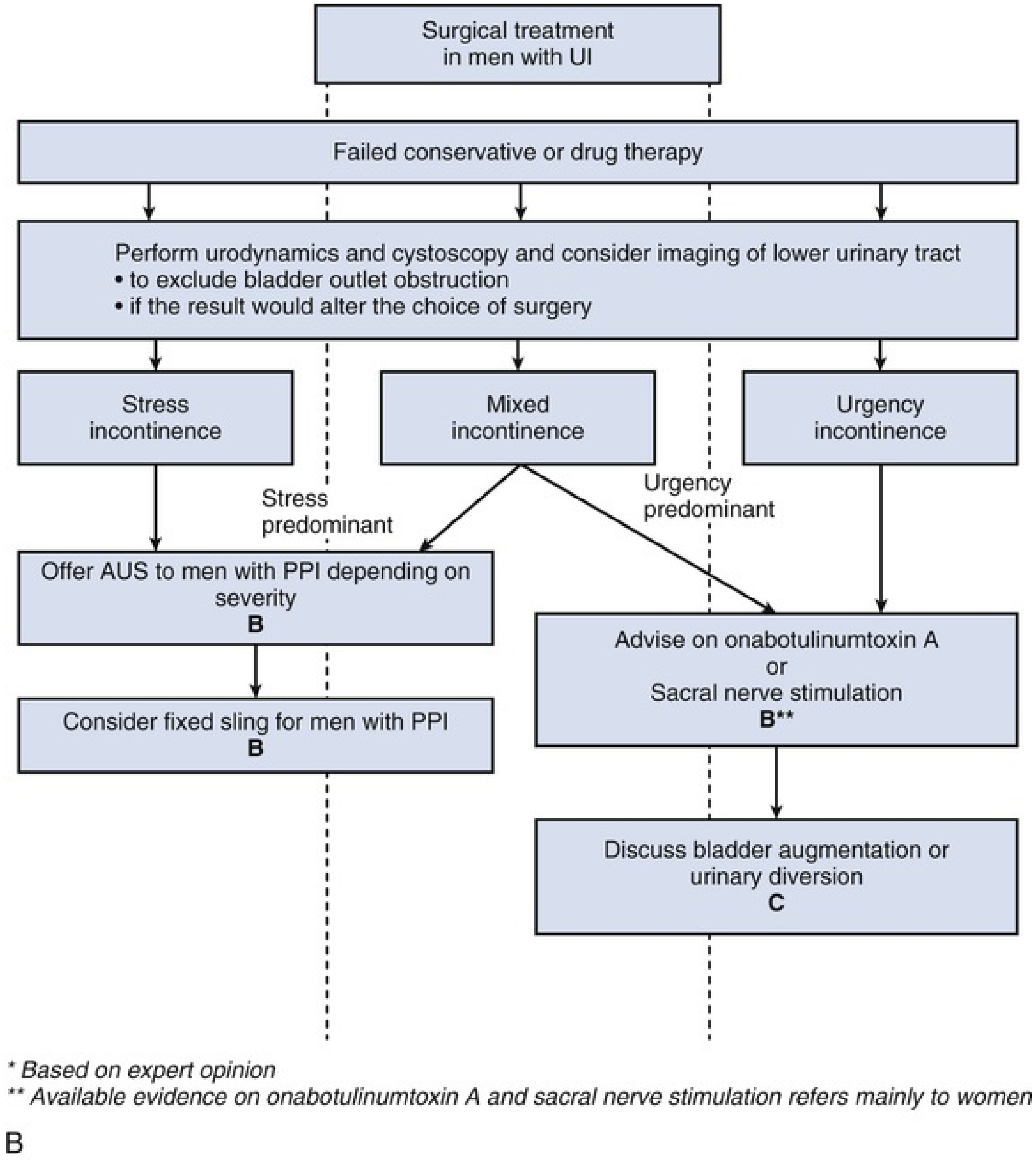
Surgical treatment in men with UI
Failed conservative or drug therapy
Perform urodynamics and cystoscopy and consider imaging of lower urinary tract
• to exclude bladder outlet obstruction
• if the result would alter the choice of surgery
Stress incontinence
Mixed incontinence
Urgency incontinence
Stress predominant
Urgency predominant
Offer AUS to men with PPI depending on severity
B
Consider fixed sling for men with PPI
B
Advise on onabotulinumtoxin A or Sacral nerve stimulation
B**
Discuss bladder augmentation or urinary diversion
C
* Based on expert opinion
** Available evidence on onabotulinumtoxin A and sacral nerve stimulation refers mainly to women
B

FIG. 113.5 European Association of Urology conservative (A) and surgical (B) treatment algorithm of men with urinary incontinence. *AUS,* Artificial urinary sphincter; *DRE,* digital rectal examination; *PPI,* post-prostatectomy incontinence; *P-PTNS,* percutaneous posterior tibial nerve stimulation; *UTI,* urinary tract infection. (From Burkhard FC, Bosch J, Cruz F, et al.: EAU Guidelines on Urinary Incontinence in Adults; 2017 [website]: https://uroweb.org/wp-content/uploads/EAU-Guidelines-Urinary-Incontinence-2016.pdf; pp 60–61.)

Conclusion

UI in men can be related to a number of conditions. It is important to assess these patients appropriately to formulate a management plan that will help improve the patient's QoL. Depending on the cause, initial treatment is usually conservative and medical, with surgical therapies reserved for those who fail initial treatment and in whom the UI is affecting their QoL.

Suggested Readings

Abrams P, Cardozo L, Wagg A, et al. *Incontinence*. ed 6. International Consultation on Incontinence: Tokyo; 2017.

Burkhard FC, Bosch J, Cruz F, et al. *EAU Guidelines on Urinary Incontinence in Adults*. [(website)] https://uroweb.org/wp-content/uploads/EAU-Guidelines-Urinary-Incontinence-2016.pdf; 2017.

Chapple C, Abrams P. *Male lower urinary tract symptoms (LUTS): an international consultation on male LUTS*. [Montreal, Canada] 2013 [Société Internationale d'Urologie].

References

Abrams P, Agarwal M, Drake M, et al. A proposed guideline for the urological management of patients with spinal cord injury. *BJU Int*. 2008;101:989–994.

Abrams P, Artibani W, Cardozo L, et al. Reviewing the ICS 2002 terminology report: the ongoing debate. *Neurourol Urodyn*. 2009;28(4):287.

Abrams P, Avery K, Gardener N, et al. The International Consultation on Incontinence modular questionnaire: www.iciq.net. *J Urol*. 2006;175(3 Pt 1):1063–1066 [discussion 1066].

Abrams P, Cardozo L, Fall M, et al. The standardisation of terminology of lower urinary tract function: report from the Standardisation Sub-Committee of the International Continence Society. *Neurourol Urodyn*. 2002;21(2):167–178.

Abrams P, Kelleher C, Staskin D, et al. Combination treatment with mirabegron and solifenacin in patients with overactive bladder: efficacy and safety results from a randomised, double-blind, dose-ranging, phase 2 study (Symphony). *Eur Urol*. 2015;67(3):577–588.

Avery K, Donovan J, Peters TJ, et al. ICIQ: a brief and robust measure for evaluating the symptoms and impact of urinary incontinence. *Neurourol Urodyn*. 2004;23(4):322–330.

Bettez M, Tu LM, Carlson K, et al. 2012 update: guidelines for adult urinary incontinence collaborative consensus document for the Canadian Urological Association. *Can Urol Assoc J*. 2012;6(5):354–363.

Bright E, Cotterill N, Drake M, et al. Developing and validating the International Consultation on Incontinence Questionnaire Bladder Diary. *Eur Urol*. 2014;66:294–300.

Burgio KL, Goode PS, Johnson TM, et al. Behavioral vs. drug treatment for overactive bladder in men: the motive trial. *J Am Geriatr Soc*. 2011;59(12):2209–2216.

Burkhard FC, Bosch J, Cruz F, et al. *EAU Guidelines on Urinary Incontinence in Adults*. [(website)] https://uroweb.org/wp-content/uploads/EAU-Guidelines-Urinary-Incontinence-2016.pdf; 2017.

Cellek S, Cameron NE, Cotter MA, et al. Microvascular dysfunction and efficacy of PDE5 inhibitors in BPH-LUTS. *Nat Rev Urol*. 2014;11(4):231–241.

Chancellor MB, Levanovich P, Rajaganapathy BR, et al. Optimum management of overactive bladder: medication vs Botox® vs InterStim® vs Urgent® PC. *Urology Practice*. 2014;1:7–12.

Chancellor MB, Staskin DR, Kay GG, et al. Bloodbrain barrier permeation and efflux exclusion of anticholinergics used in the treatment of overactive bladder. *Drugs Aging*. 2012;29(4):259–273.

Chapple CR, Cardozo L, Nitti VW, et al. Mirabegron in overactive bladder: a review of efficacy, safety, and tolerability. *Neurourol Urodyn*. 2014;33(1):17–30.

Chapple CR, Cruz F, Deffieux X, et al. Consensus statement of the European Urology Association and European Urogynecological Association on the use of Implanted Materials for treating pelvic organ prolapse and Stress Urinary Incontinence. *Eur Urol*. 2017;72:424–431.

Cornel EB, Elzevier HW, Putter H. Can advance transobturator sling suspension cure male urinary postoperative stress incontinence? *J Urol*. 2010;183:1459–1463.

Coyne KS, Kvasz M, Ireland AM, et al. Urinary incontinence and its relationship to mental health and health-related quality of life in men and women in Sweden, the United Kingdom, and the United States. *Eur Urol*. 2012;61(1):88–95.

Davis NJ, Vaughan CP, Johnson TM, et al. Caffeine intake and its association with urinary incontinence in United States men: results from national and nutrition examination surveys 2005-2006 and 2007-2008. *J Urol*. 2013;189(6):2170–2174.

Dijkstra-Eshuis J, Van den Bos TWL, Splinter R, et al. Effect of preoperative pelvic floor muscle therapy with biofeedback versus standard care on stress urinary incontinence and quality of life in men undergoing laparascopic radical prostatectomy: a randomized control trial. *Neurourol Urodynam*. 2015;34:144–150.

Dmochowski RR, Sanders SW, Appell RA, et al. Bladder-health diaries: an assessment of 3-day vs 7-day entries. *BJU Int*. 2005;96(7):1049–1054.

Dorey G, Speakman M, Feneley R, et al. Pelvic floor exercises for treating post-micturition dribble in men with erectile dysfunction: a randomized controlled trial. *Urol Nurs*. 2004;24(6):490–497 [512].

Drake MJ, Chapple C, Esen AA, et al. BESIDE study investigators, Efficacy and safety of mirabegron addon therapy to solifenacin in incontinent overactive bladder patients with an inadequate response to initial 4-week solifenacin monotherapy: a randomised double-blind multicentre phase 3B Study (BESIDE). *Eur Urol*. 2016;70(1):136–145.

DuBeau CE. The continuum of urinary incontinence in an aging population. *Geriatrics*. 2002;57(Suppl 1):S12–S17.

Friedl A, Mühlstädt S, Zachoval R, et al. Long-term efficacy and safety of the Adjustable Transobturator Male System (ATOMS): 6-year results of a European multi-institutional study. *Eur Urol Suppl*. 2016;15(3):e345.

Garcia-Mora A, Ismail M, Hashim H, et al. Should patients have one or two uroflows, that is the question? (Abstract 2274). *J Urol*. 2013;189(4):e932.

Hashim H, Abrams P. Is the bladder a reliable witness for predicting detrusor overactivity? *J Urol*. 2006;175(1):191–194 [discussion 194–195].

Hashim H, Abrams P. How should patients with an overactive bladder manipulate their fluid intake? *BJU Int*. 2008;102(1):62–66.

Hashim H, Blanker MH, Drake MJ, et al. An International Continence Society (ICS) report on the terminology for nocturia and nocturnal lower urinary tract function. *Neurourol Urodyn*. 2017 [Submitted in].

Hashim H, Al Mousa R. Management of fluid intake in patients with overactive bladder. *Curr Urol Rep*. 2009;10(6):428–433.

Haylen BT, de Ridder D, Freeman RM, et al. An International Urogynecological Association (IUGA)/International Continence Society (ICS) joint report on the terminology for female pelvic floor dysfunction. *Neurourol Urodyn*. 2010;29(1):4–20.

Hay-Smith J, Herderschee R, Dumoulin C, et al. Comparisons of approaches to pelvic floor muscle training for urinary incontinence in women: an abridged Cochrane systematic review. *Eur J Phys Rehabil Med*. 2012;48(4):689–705.

Herschorn S, Bruschini H, Comiter C, et al. Surgical treatment of stress incontinence in men. *Neurourol Urodyn*. 2010;29(1):179–190.

Hill TC, Baverstock R, Carlson KV, et al. Best practices for the treatment and prevention of urinary tract infection in the spinal cord injured population: the Alberta context. *Can Urol Assoc J*. 2013;7(3–4):122–130.

Hoda MR, Primus G, Fischereder K, et al. Early results of a European multicentre experience with a new self-anchoring adjustable transobturator system for treatment of stress urinary incontinence in men. *BJU Int*. 2013;111:296.

Hubner WA, Gallistl H, Rutkowski M, et al. Adjustable bulbourethral male sling: experience after 101 cases of moderate to severe male stress urinary incontinence. *BJU Int*. 2011;107:777.

Hubner WA, Schlarp OM. Adjustable continence therapy (ProACT): evolution of the surgical technique and comparison of the original 50 patients with the most recent 50 patients at a single centre. *Eur Urol*. 2007;52:680–686.

Ichihara K, Masumori N, Fukuta F, et al. A randomized controlled study of the efficacy of tamsulosin monotherapy and its combination with mirabegron for overactive bladder induced by benign prostatic obstruction. *J Urol*. 2015;193(3):921–926.

Kaplan SA, He W, Koltun WD, et al. Solifenacin plus tamsulosin combination treatment in men with lower urinary tract symptoms and bladder outlet obstruction: a randomized controlled trial. *Eur Urol*. 2013;63(1):158–165.

Khullar V, Cambronero J, Ströberg P, et al. *The efficacy and tolerability of mirabegron in patients with overactive bladder - results from a European-Australian Phase III trial*. [Presented at the 26th Annual Congress of the European Association of Urology, Vienna, Austria, 18-22 March] 2011.

Kim J. Long term follow-up of readjustable urethral sling procedure (Remeex System) for male stress urinary incontinence. *Neurourol Urodyn*. 2011;30:209.

Kosilov K, Loparev S, Iwanowskaya M, et al. Effectiveness of combined high-dosed trospium and solifenacin depending on severity of OAB symptoms in elderly men and women under cyclic therapy. *Cent European J Urol*. 2014;67(1):43–48.

Kumar A, Litt ER, Ballert KN, et al. Artificial urinary sphincter versus male sling for post-prostatectomy incontinence—what do patients choose? *J Urol*. 2009;181(3):1231–1235.

Leng W, et al. Enterocystoplasty or detrusor myectomy? Comparison of indications and outcomes for bladder augmentation. *J Urol*. 1999;161:758.

Madersbacher S, Alivizatos G, Nordling J, et al. EAU 2004 guidelines on assessment, therapy and follow-up of men with lower urinary tract symptoms suggestive of benign prostatic obstruction (BPH guidelines). *Eur Urol*. 2004;46(5):547–554.

Madhuvrata P, Cody JD, Ellis G, et al. Which anticholinergic drug for overactive bladder symptoms in adults. *Cochrane Database Syst Rev*. 2012;(1) [CD005429].

Markland AD, Goode PS, Redden DT, et al. Prevalence of urinary incontinence in men: results from the national health and nutrition examination survey. *J Urol*. 2010;184(3):1022–1027.

Peters KM, et al. Percutaneous tibial nerve stimulation for the long-term treatment of overactive bladder: 3-year results of the STEP study. *J Urol*. 2013;189:2194.

Paterson J, Pinnock CB, Marshall VR. Pelvic floor exercises as a treatment for post-micturition dribble. *Br J Urol*. 1997;79(6):892–897.

Reynard JM, Peters TJ, Lim C, et al. The value of multiple free-flow studies in men with lower urinary tract symptoms. *Br J Urol*. 1996;77(6):813–818.

Roehrborn CG, Bartsch G, Kirby R, et al. Guidelines for the diagnosis and treatment of benign prostatic hyperplasia: a comparative, international overview. *Urology*. 2001;58(5):642–650.

Rosier P, Schaefer W, Lose G, et al. International Continence Society Good Urodynamic Practices and Terms 2016: urodynamics, uroflowmetry, cystometry, and pressure-flow study. *Neurourol Urodyn*. 2017;36(5):1243–1260.

Rossanese M, Novara G, Challacombe B, et al. Critical analysis of phase II and III randomised control trials (RCTs) evaluating efficacy and tolerability of a β3-adrenoceptor agonist (mirabegron) for overactive bladder (OAB). *BJU Int*. 2015;115(1):32–40.

Sammer U, Walter M, Knüpfer SC, et al. Do we need surveillance urethro-cystoscopy in patients with neurogenic lower urinary tract dysfunction? *PLoS ONE*. 2015;10(10):e0140970.

Seweryn J, Bauer W, Ponholzer A, et al. Initial experience and results with a new adjustable transobturator male system for the treatment of stress urinary incontinence. *J Urol*. 2012;187:956.

Silva LA, Andriolo RB, Atallah ÁN, et al. Surgery for stress urinary incontinence due to presumed sphincter deficiency after prostate surgery. *Cochrane Database Syst Rev*. 2014;(9) [CD008306].

Strini KA, Ehrlich G, Holter M, et al. Does the adjustable transobturator male system maintain continence and satisfaction in long term? A single center experience. *Eur Urol Suppl*. 2018;17(2):e1665.

Ter Meulen PH, et al. A study on the feasibility of vesicomyotomy in patients with motor urge incontinence. *Eur Urol*. 1997;32:166.

Thom D. Variation in estimates of urinary incontinence prevalence in the community: effects of differences in definition, population characteristics, and study type. *J Am Geriatr Soc*. 1998;46(4):473–480.

Tikkinen KA, Agarwal A, Griebling TL. Epidemiology of male urinary incontinence. *Curr Opin Urol*. 2013;23(6):502–508.

Toozs-Hobson P, Freeman R, Barber M, et al. An International Urogynecological Association (IUGA)/International Continence Society (ICS) joint report on the terminology for reporting outcomes of surgical procedures for pelvic organ prolapse. *Neurourol Urodyn*. 2012;31(4):415–421.

Tsakiris P, de la Rosette JJ, Michel MC, et al. Pharmacologic treatment of male stress urinary incontinence: systematic review of the literature and levels of evidence. *Eur Urol*.

2008;53(1):53–59.

Tsui JF, Shah MB, Weinberger JM, et al. Pad count is a poor measure of the severity of urinary incontinence. *J Urol*. 2013;190(5):1787–1790.

Van Kerrebroeck P, Chapple C, Drogendijk T. NEPTUNE Study Group. Combination therapy with solifenacin and tamsulosin oral controlled absorption system in a single tablet for lower urinary tract symptoms in men: efficacy and safety results from the randomized controlled NEPTUNE trial. *Eur Urol*. 2013;64(6):1003–1012.

Vande Walle J, Rittig S, Bauer S, et al. Practical consensus guidelines for the management of enuresis. *Eur J Pediatr*. 2012;171(6):971–983.

Venturino L, Dalpiaz O, Pummer K, et al. Adjustable continence balloons in men: adjustments do not translate into long-term continence. *Urology*. 2015;85:1448–1452.

Wang Y, Hu H, Xu K, et al. Prevalence, risk factors and the bother of lower urinary tract symptoms in China: a population based survey. *Int Urogynecol J*. 2015;26(6):911–919.

Winters JC, Dmochowski RR, Goldman HB, et al. Urodynamic studies in adults: AUA/SUFU guideline. *J Urol*. 2012;188(6 Suppl):2464–2472.

Urodynamic and Video-Urodynamic Evaluation of the Lower Urinary Tract

---

Benjamin M. Brucker MD, Victor W. Nitti MD

Dysfunction of the lower urinary tract may result in a variety of lower urinary tract symptoms (LUTS) that can have a significant negative effect on quality of life. In addition, lower urinary tract dysfunction can be “silent” with no symptoms but can place a person at risk for upper tract deterioration. **Urodynamic studies (UDS) use a set of measurements to assess the function and dysfunction of the lower urinary tract** (Rosier et al., 2017a). UDS are often useful to diagnose suspected lower urinary tract dysfunction and also to assess the effects of known lower urinary tract dysfunction. The lower urinary tract has two essential functions: the storage of urine at low pressure and the voluntary evacuation of urine. Low-pressure storage is essential to protect kidneys and ensure continence, and voluntary evacuation allows for the elimination of urine in socially acceptable situations without fear of leakage or overdistension. It is clear that a number of conditions and diseases affect the lower urinary tract and disrupt the storage and/or evacuation of urine. This can lead to bothersome symptoms (e.g., urinary frequency, urgency and incontinence, slow or interrupted stream) or, in some cases, potentially harmful sequela (e.g., urinary tract infection, renal failure). In some cases, a precise assessment of storage and emptying is necessary to optimize patient treatment(s). UDS are composed of a number of dynamic tests that are individually or collectively used to gain information about the transport, storage, and evacuation of urine. UDS involve the assessment of the function and dysfunction of the urinary tract and includes the actual tests that are performed (UDS studies) and the observations during the testing (UDS observations) (Abrams et al., 2002).

The principles of urodynamics and the technical performance and interpretation of urodynamic studies have not changed much over the last several editions of this book.

Video 114.1 demonstrates some of the basics of urodynamics, in this case for women with pelvic floor dysfunction. What has changed is the widespread use of clinical guidelines. Some urodynamic-specific guidelines exist (Winters et al., 2012) that **“intended to assist the clinician in the appropriate selection of urodynamic tests, following evaluation and symptom characterization.”** However, there has also been a trend to include UDS in disease-specific guidelines, for example, neurogenic lower urinary tract dysfunction (NLUTD), urinary incontinence, stress incontinence, and overactive bladder (Kobashi et al., 2017; Lucas et al., 2013; Pannek et al., 2013). This chapter incorporates the current available literature and guidelines recommendation. It also places emphasis on the practical use and clinical utility of UDS and how they apply to specific conditions of the lower urinary tract. Some of the basics of urodynamics are illustrated in Video 114.1.

Urodynamic principles, equipment, and performance details apply to both adults and children. This chapter is limited to discussion of UDS in specific conditions to adults. Many of the conditions for which UDS is used in children involve anatomic and neurologic abnormalities in which lower urinary tract function is variable and unpredictable. UDS is used to establish as clearly as possible the baseline situation so that changes as a result of treatment and/or growth can be assessed and some guidance is obtained in the choice of treatment, even if the result of UDS testing is not necessarily the deciding factor (Hosker et al., 2009). In the pediatric population, the aim of UDS is not only to provide precise knowledge of lower urinary tract function, but also to provide an understanding of the current and future condition to the caregiver and patient (and his or her parents). Of course, it is still imperative that the testing should be relevant, reliable, and reproducible. The reader is referred to Chapter 28 for a more detailed discussion of specific conditions in children.

Role of Urodynamics in Clinical Practice

UDS have been used for decades, yet level 1 evidenced-based “indications” for its use are limited. There are myriad reasons for the evidence being sparse. It is difficult to conduct proper randomized controlled trials on UDS for conditions when lesser levels of evidence and expert opinion strongly suggest clinical utility and when “empiric treatment” is potentially harmful or even life-threatening (e.g., NLUTD). Additionally, symptoms can be caused by a number of different conditions, and it is difficult to study pure or homogeneous patient populations. High-level data looking at the role of UDS in counseling patients and the patient perception of the shared decision-making process before intervention is also not available. Further, data looking longitudinally at UDS findings to predict the most cost-effective evaluation methods and treatment options (e.g., who would benefit from early surgical intervention of bladder outlet obstruction [BOO] secondary to BPH) require complex modeling with accurate point estimates or expensive long-term studies (Bosch et al., 2011). However, two trials provide some level 1 evidence for the use of UDS before surgery in women with stress urinary incontinence (SUI) (Nager et al., 2012; van Leijsen et al., 2013). **Given the current state of evidence for UDS, what is most important is that the clinician has clear-cut clinical questions to answer by performing the study. This information obtained will be used to guide treatment and/or follow-up.**

In practical terms, UDS is most useful when history, physical examination, and simple tests are not sufficient to make an accurate diagnosis and/or institute treatment. This has clinical applicability in two general scenarios:

- To obtain information needed to make an accurate diagnosis for what condition(s) is causing symptoms (e.g., lower urinary tract symptoms or urinary incontinence).
- To determine the impact of a disease that has the potential to cause serious and irreversible damage to the upper and lower urinary tract (e.g., neurologic diseases such as spinal cord injury and multiple sclerosis, radiation cystitis). Sometimes profound abnormalities can be found in the relative absence of symptoms.

Rather than refer to a list of “indications for UDS” that often are all evidence-based, it is more useful for clinicians to think of how UDS should be used in a broader clinical perspective. In keeping with this theme, the role of UDS in clinical practice has been nicely summarized by Rosier et al. for the following situations (Rosier et al., 2017a):

- To identify or rule out factors contributing to lower urinary tract dysfunction (e.g., urinary incontinence) and assess their relative importance
- To obtain information about other aspects of lower urinary tract function or dysfunction whether or not expressed as a symptom or a recognizable sign
- To allow a prediction of the possible consequences of lower urinary tract dysfunction for the upper urinary tract (see Box 114.1 for UDS findings that are risk factors for upper tract decompensation)

Box 114.1

Urodynamic Risk Factors

The following UDS findings are potentially dangerous and usually require intervention to prevent upper and lower urinary tract decompensation:

1. Impaired compliance
2. Detrusor–external sphincter dyssynergia (DESD)
3. Detrusor–internal sphincter dyssynergia (DISD)
4. High-pressure detrusor overactivity present throughout filling
5. Elevated detrusor leak point pressure (>40 cm H_2O)
6. Poor emptying with high storage pressures

- To allow a prediction of the outcome, including undesirable side effects, of a contemplated treatment
- To confirm the effects of intervention or understand the mode of action of a particular type of treatment for lower urinary tract dysfunction, especially a new and/or experimental (not routine)

one
- To understand the reasons for failure of previous treatments for urinary incontinence or for lower urinary tract dysfunction in general (after unsatisfactory treatment)

It is important to remember that UDS is only one part of the comprehensive evaluation of symptoms and lower urinary tract function, and when it is done to investigate a patient's symptoms, the goal of the study is to reproduce the symptoms and determine the cause by urodynamic measurements or observations. To use UDS in a practical and effective way, it is important that the clinician has the proper expertise to know when and why to perform UDS. Despite many technical advances in the recording, processing, and printing of UDS, careful attention to technical details to assure accurate collection of data remains the cornerstone of a good study. Because not all patients undergo UDS for the same reasons, the clinician should “customize” UDS to the patient's symptoms and condition. This means deciding on the questions to be answered before starting each study and designing the study to obtain answers to those questions. It is important to remember that UDS are performed in an “unnatural setting” and therefore do not always duplicate real-life situations. A UDS that does not duplicate complaints or symptoms when an abnormality is recorded is not necessarily diagnostic. In addition, failure to record an abnormality does not always rule out its existence (e.g., failure to demonstrate detrusor overactivity in a patient with urgency incontinence). Finally, not all UDS observations are clinically significant. Therefore, it is important to interpret UDS in the context of the patient's history, including symptoms and concomitant diseases/conditions and other information like postvoid residual volumes and frequency volume charts (voiding and intake diaries) when clinically applicable.

Key Points

- Urodynamics is the dynamic study of the transport, storage, and evacuation of urine.
- UDS is composed of a number of tests that individually or collectively can be used to gain information about urine storage and evacuation.
- Guidelines are intended to *assist* the clinician to select appropriate

urodynamic tests after evaluation and symptom characterization.

Conducting a Urodynamic Study: Patient and Technical Factors

Functional Classification of Voiding Dysfunction

Perhaps the most important concept to understand when trying to set up, conduct, or interpret a UDS is the Functional Classification of Voiding Dysfunction, popularized by Wein (1981). This practical classification is a simple way of thinking about a complex subject of voiding dysfunction. It allows one to classify dysfunction of the lower urinary tract according to urodynamic findings. **Functionally, abnormalities of the lower urinary tract can be divided into the following:**

- Storage dysfunction (failure to properly store urine)
- Emptying dysfunction (failure to empty the bladder normally)
- Combined dysfunction (failure to store and empty)

In addition, functional abnormalities can be subclassified to the anatomic region of the lower urinary tract that is affected and how it is affected. Thus, storage and emptying abnormalities can be caused by the following:

- Bladder dysfunction: Overactive (causing failure to store) or underactive (causing failure to empty)
- Bladder outlet dysfunction: Overactive (causing failure to empty) or underactive (causing failure to store)
- Combined bladder and bladder outlet dysfunction

Keeping this system in mind allows the clinician to formulate a set of questions to be answered by the UDS and gives an understanding of the possible causes of symptoms or findings before starting the test. The other advantage of the functional classification system is that it helps organize the treatment options for a given patient. Thus, in practical terms, the UDS evaluation should help determine if there is bladder or bladder outlet dysfunction (or both) and whether there is a storage and/or emptying problem. Finally, when the study provides the answers, UDS can lead to a correct diagnosis and institution of appropriate treatment. Obviously, an understanding of the physiology of urine storage and voiding and the pathophysiology of voiding dysfunction (see Chapter 111) is required to formulate appropriate questions to be answered by a UDS. This simple classification can prevent a clinician from getting caught up in the intricate neurophysiologic aspects of voiding and storage dysfunction, failing to think in practical terms. One should always focus on the possible urodynamic findings in a given case and how each of the findings may ultimately affect the patient and his or her treatment. Symptoms and/or underlying conditions or diseases will determine these potential findings.

Preparing for Urodynamic Studies: Clinician, Patient, and Facility

Defining the Clinical Question

A list of problems or questions that should be solved or answered by UDS should be made before any invasive UDS is performed. All patients are not alike, and therefore each urodynamic evaluation may be different depending on the information needed to answer the questions relevant to a particular patient. **Three important rules before starting the UDS evaluation include the following** (Nitti and Combs, 1998):

- Decide on questions to be answered before starting a study.
- Design the study to answer these questions.
- Customize the study as necessary.

The simple fact that a patient has symptoms or a disorder that may affect the lower urinary tract is not sufficient to start the UDS evaluation. It is imperative to decide on what information needs to be obtained for a UDS before starting it. This will vary from patient to patient. It is also important to consider expert opinion (MacLachlan and Rovner, 2014), history, medication use, and physical examination before performing UDS. Many patients undergoing urodynamic testing will have been placed on medications that can affect bladder function (e.g., antimuscarinics). For such patients, the clinician should decide in advance what information is desired and whether or not the study should be done on or off medication. For example, if the goal of the study is to determine the therapeutic effect of a medication, obviously the UDS should be done with the patient on a regular dosing schedule for that medication. On the other hand, if medication was started empirically to treat symptoms and the goal of the urodynamic test is to uncover the etiology of those symptoms, then consideration can be given to discontinuing the medication before testing as this may give the highest yield. The medication used and status should also be documented.

Further, the International Continence Society (ICS) suggested that a validated symptom and bother score be obtained in addition to a 3-day frequency volume chart or bladder diary, and, finally, noninvasive measures such as a uroflowmetry and PVR. These tests inform the clinician of the most relevant clinical data before invasive testing is performed. An example of this would be the pre-UDS normal noninvasive flow rate and low PVR data allowing for the appropriate interpretation of an abnormal flow rate during invasive UDS as likely artefactual.

Patient Preparation

Patients should be properly prepared and told why the test is being done, how the results may affect treatment, and what to expect during the actual UDS. Studies have shown that UDS are generally well tolerated. Scarpero et al. (2005) used a questionnaire-based study to assess patient expectations of anxiety, pain, embarrassment, and apprehension before UDS and compared it with the patient's actual experience. They found that UDS was associated with minimal to moderate degrees of anxiety, discomfort, and embarrassment. After testing, most respondents (greater than 90% per question) thought that the test was the same or better than expected and it was associated with an expected or less than expected level of pain and embarrassment. This did not vary between the sexes, but a higher number of younger individuals found that the test experience was worse than expected, and a higher number of older individuals found that it was better than expected. Younger age has been found in other studies to portend higher pain and anxiety during UDS (Yeung et al., 2014; Yiou et al., 2013). Therefore, younger patients may require more reassurance and attention in preparation for the procedure. Similarly, Yokoyama et al. (2005) found UDS to be quite tolerable based on a questionnaire study. Patients experienced minimal degrees of pain, embarrassment, and physical burden from UDS. On a visual analog pain scale of 0 to 10 (*not at all* to *unbearable*) in 154 consecutive patients (56% men), the mean (SD) degrees of pain, embarrassment, and physical burden were 2.27 (2.53), 2.59 (2.69), and 1.76 (2.43), respectively, and 73.6% of men and 80.6% of women were willing to repeat the UDS. The most common complaint after UDS was micturition pain. Urinalysis showed that 4.6% of men and 7.5% of women had leukocyturia after the investigation. A prospective study recently evaluated the effect of dimmer lighting and audio distraction (instrumental music) in a mostly Hispanic female cohort undergoing UDS (Rezvan et al., 2017). Though not significant, the underpowered study trended strongly toward a clinically meaningful reduction in embarrassment and anxiety with inexpensive, readily available interventions.

Some populations of patients may not understand the role or purpose of UDS (Smith et al., 2011). Patient dissatisfaction with care may be affected if there is poor communication and understanding of diagnostic tests. However, prospective studies aimed at educating patients with an “explanatory pamphlet” have been largely disappointing (Hougardy et al., 2009; Bright et al., 2011). We therefore often rely on our staff. Well-trained, attentive, and supportive staff can be very helpful in ensuring that the patient has the best possible experience and is getting a good-quality study.

Best practice recommends that a urinalysis should be performed on all patients before invasive UDS (level 4 evidence) (Cameron et al., 2017). Further, in patients with a symptomatic UTI, urodynamics should be delayed until the patient completes treatment. The American Urological Association (AUA) Best Practice Policy (BPP) Statement on Urologic Surgery Antimicrobial Prophylaxis states that prophylactic antibiotics are not routinely indicated before UDS for patients without UTI risk factors (also called “index” patients) (Wolf et al., 2008). However, it is common for UDS to be performed on more complicated patients. Patients often have known or suspected abnormalities of the urinary tract. The Society of Urodynamics, Female Pelvic Medicine and Urogenital Reconstruction (SUFU) convened a Best Practice Policy Panel to formulate recommendations on the use of antimicrobial prophylaxis during UDS for the prevention of UTIs, with special attention aimed at patients who fall outside of the “index” patient. This paper suggests that patients who require antibiotic prophylaxis should receive a single dose within 1 hour before UDS. Oral trimethoprim/sulfamethozaxole is the first option, with acceptable alternatives including a first- or second-generation cephalosporin, amoxicillin/clavulanate, or intravenous aminoglycoside ± ampicillin and fluoroquinolones (level 3 evidence). Table 114.1 shows risk factors and recommendation of antibiotic use alone with level of evidence.

TABLE 114.1

Risk Factors and Recommendations for Antibiotics Before Invasive Urodynamic Studies

RISK FACTOR	RECOMMENDATION FOR ANTIBIOTICS	LEVEL OF EVIDENCE
Recommendations concerning pre-procedure urine testing Urinalysis should be performed on all patients before urodynamic study.	All patients need urinalysis, if positive and no urinary tract infection, need prophylaxis	4
Patients with current urinary tract infection In patients with a symptomatic urinary tract infection, urodynamic studies should be delayed until the patient completes treatment.	Cancel urodynamic studies until urinary tract infection treated	4
Patients with presumed normal genitourinary anatomy *Antibiotic prophylaxis is not recommended for urodynamic studies in patients with normal genitourinary anatomy and no risk factors*. The presence of an abnormality discovered during urodynamic studies that is a risk factor warrants antibiotic prophylaxis to be given immediately after the study.	No	1
Patients with neurogenic lower urinary tract dysfunction Antibiotic prophylaxis is recommended for urodynamic studies in patients with neurogenic lower urinary tract dysfunction.	Yes	4
Patients with bladder outlet obstruction and/or elevated postvoid residual Antibiotic prophylaxis is recommended for urodynamic studies in patients with clinically important elevated postvoid residual, regardless of the cause.	Yes	4
Advanced age (older than 70 years) Antibiotic prophylaxis is recommended for urodynamic studies in patients older than	Yes	2

70 years.		
Diabetes mellitus Antibiotic prophylaxis is not recommended for urodynamic studies in the presence of diabetes.	No	4
Recent prolonged hospitalization Antibiotic prophylaxis is not recommended for urodynamic studies in the presence of a recent prolonged hospitalization in the absence of other risk factors.	No	4
Diet and nutrition Antibiotic prophylaxis is not recommended for urodynamic studies in the presence of dietary or nutritional deficiencies including obesity.	No	4
Menopausal status Antibiotic prophylaxis is not recommended for urodynamic studies based on menopausal status.	No	2
Asymptomatic bacteriuria Antibiotic prophylaxis is recommended for urodynamic studies in patient with asymptomatic bacteriuria.	Yes	4
History of recurrent urinary tract infections Antibiotic prophylaxis is not recommended for urodynamic studies in patient with a history of recurrent urinary tract infections.	No	4
Gender Antibiotic prophylaxis is not recommended for urodynamic studies based on gender.	No	4
Immunosuppression, corticosteroids, and inherent immune deficiency Antibiotic prophylaxis is recommended for urodynamic studies in patients with immunosuppression from immunosupressants, chronic steroids, or innate immunosuppression, particularly those who have had renal transplant.	Yes	4
Patient with chronic catheters Antibiotic prophylaxis is recommended for urodynamic studies in patients with	Yes	4

indwelling urinary catheters (either urethral or suprapubic), external condom catheters, or those performing CIC.		
Prior urologic surgery Antibiotic prophylaxis is not recommended for urodynamic studies in the presence of a history of prior urologic surgery.	No	4
Cardiac valvular disease Antibiotic prophylaxis should not routinely be administered for urodynamic studies in the presence of cardiac valvular disease.	No	3
Orthopedic implant Antibiotic prophylaxis is recommended for patients undergoing urodynamic studies who have had total joint implant and who are at increased risk for developing joint infection from bacteremia or have an increased risk for actually developing bacteremia.	Yes	3

From Cameron AP, Campeau L, Brucker BM, et al. Best practice policy statement on urodynamic antibiotic prophylaxis in the non-index patient. *Neurourol Urodyn* 36:915–926, 2017.

Facility Setup

In addition to other technical aspects of UDS, the room setup is also important. Ideally, a room of suitable size should be dedicated to urodynamics (Nitti and Combs, 1998). This area does not have to be exclusively for urodynamics, but when a study is being performed, there should be no distractions from people walking into and out of the area for other reasons. A quite private area is the best. It is difficult enough to recreate a natural environment during testing without outside distractions. The room should be large enough to allow for the patient to lie down to have catheters placed and also to stand and sit on a commode as necessary. Many patients undergoing UDS may have concomitant neurologic conditions that limit or alter mobility, requiring assistance with positioning. The need for wheelchairs, walkers, scooters, and even lifts must be considered when determining the size of the room. Centers that perform videourodynamics will require a larger area to allow for fluoroscopic equipment. There may be local or institutional regulations regarding fluoroscopy that should be consulted as well.

Special equipment may be needed, and ensuring that it is available before starting the study can ensure that the test is done in the way most likely to yield data to answer the clinical question(s). Pessary kits, scopetts, and speculums may be needed if testing is done on women with pelvic organ prolapse. A simple stepstool can be helpful to obtain voiding images of the male urethra or to visualize the female urethra if the patient is standing for stress maneuvers and the c arm has a limited minimal high. Large catheters to drain the bladder may be useful if the pre-invasive UDS workup suggests very elevated PVR.

Additional Factors

By following these simple rules, one can maximize the chance of obtaining useful information from an invasive UDS. If a particular question is not answered, the study can be repeated in the same or a later session. Many authors utilize or advocate a second filling and/or voiding cycle, especially if questions remain unanswered (Bellucci et al., 2012; Broekhuis et al., 2010; Brucker et al., 2016). Even with multiple cycles and utilizing best practices (Rosier et al., 2017a), UDS do not always answer all of the important questions. But, by clearly defining the information needed before starting the study, unanswered questions can be kept to a minimum. We cannot emphasize enough that one of the most important parts of UDS is its proper performance with careful attention to technical details so that accurate interpretation is possible. It is beyond the scope of this chapter to describe the proper performance of UDS in detail; however, the reader is referred to Rosier et al. (2017b) for updated good urodynamic practices and terminology. Two other comprehensive works are frequently referenced in this update and round out the terminology and good practice details (Abrams et al., 2002; Schafer et al., 2002). The ICS defined the term *urodynamic observations* to denote those observations that occur during and are measured by the UDS test itself (Abrams et al., 2002). To be consistent, it is recommended that all clinicians performing and interpreting UDS use the current ICS terminology. Clinically, this terminology can help ensure that reporting is consistent and that the ensuing interpretation is understood by others. A list of common UDS terms is provided in Box 114.2.

Box 114.2

Terminology for Common Urodynamic Terms and Observations According to the International

Continence Society Standardization Sub-Committee

Included are common definitions that have not been changed from Abrams et al. (2002) and new definitions from Roiser et al. (2017) ICS, as indicated with an asterisk. To be consistent, it is recommended that all clinicians performing and interpreting UDS use the current ICS terminology.

Terminology for Common Urodynamic Terms and Observations According to the International Continence Society Standardization Subcommittee

In 2002, the ICS defined the term *urodynamic observations* to denote observations that occur during and are measured by urodynamics (UDS). They also attempted (and continue to attempt) to define terminology that all clinicians performing and interpreting UDS can use (Abrams et al., 2002). The most recent work (Rosier et al., 2017b) has continued to refine and newly define other terminology. This body of terminology is considered the “ICS standard.” It should be considered “Best practice, based on evidence, with the use of standard terms and standard techniques, evaluated and reported clinically or scientifically, in a complete and validated manner.” In certain cases, and/or in research studies, individuals may elect not to adhere to this standard, but should then specify any deviations. An asterisk represents a new definition.

Definitions of Study Types

Urodynamics: The general term to describe all measurements that assess the function and dysfunction of the LUT by any appropriate method. Urodynamics allow direct assessment of LUT function by the measurement of relevant physiologic parameters.

Invasive urodynamics: Any test that is invasive, as it involves insertion of one or more catheters or any other transducers into the bladder and/or other body cavities, or insertion of probes or needles, for example for EMG measurement.

Noninvasive urodynamics: All urodynamics done without the insertion of catheters: for example, uroflowmetry, PVR, penile compression-release test, penile cuff, urethral connector, condom catheter, or sonography.

Ambulatory urodynamics: A functional test of the lower urinary tract using natural filling and reproducing the subject's everyday activities (see van Waalwijk van Doorn et al., 2000).

ICS standard urodynamics protocol*: A patient undergoing collection of a clinical history (should include a valid symptom and bother score(s) and a medication list), relevant clinical examination, 3-day bladder diary, representative uroflowmetry with postvoid residual (PVR), and a complete ICS standard urodynamic test (see the following) is referred to as having had the "ICS standard urodynamics protocol (ICS-SUP)."

ICS standard urodynamic tests*: Uroflowmetry and PVR plus transurethral cystometry and pressure-flow study (see below): all tests are performed in the patient's preferred or most usual position: comfortably seated and/or standing, if physically possible. The patient(s) is reported as having had an ICS standard urodynamic test (ICS-SUT).

ICS supplementary urodynamic tests: ICS-SUT may be supplemented with EMG, with imaging, with continuous urethral pressure(s), and/or with urethral pressure profile measurement. Cystometry may be done via a suprapubic catheter (specify supplements).

Definitions of Common Values and Measures During or Interpreted After Invasive UDS

Intravesical pressure (p_{ves}): The pressure within the bladder.

Abdominal pressure (p_{abd}): The pressure surrounding the bladder; currently it is estimated from rectal, vaginal, or extraperitoneal pressure or a bowel stoma.

Detrusor pressure (p_{det}): The component of intravesical pressure created by forces on the bladder wall that are both passive and active. It is estimated by subtracting abdominal pressure from intravesical pressure.

Initial resting pressure*: p_{ves} and p_{abd} pressure at the beginning of the cystometry.

Physiologic filling rate: A filling rate less than the predicted maximum. Predicted maximum is the body weight in kilograms divided by 4 and expressed as milliliters per minute (typically in the range of 20 to 30 mL/min).

Nonphysiologic filling rate: A filling rate greater than the predicted maximum (commonly used).

Cough pressure peak*: A cough pressure peak is recognizable during posttest evaluation as a phasic positive pressure change observed in p_{ves} and in p_{abd}.

Position change*: A change in patient position, either active or passive (e.g., tilting), is visible on the cystometry trace by a lasting change of equal magnitude in both p_{ves} and p_{abd}.

Rectal contractions*: Rectal contractions are temporary phasic increases in p_{abd} without synchronous change in p_{ves} resulting in negative deflections of p_{det}.

Definitions of Bladder Sensations and Storage Observations

Normal bladder sensation: Judged by three points noted during filling cystometry and evaluated in relation to the bladder volume at that moment and in relation to the patient's symptomatic complaints. First sensation of bladder filling: the volume at which the patient first becomes aware of the bladder filling. First desire to void: the feeling during filling cystometry that would lead the patient to pass urine at the next convenient moment. Strong desire to void: a persistent desire to void without the fear of leakage. (Note: a visual analog scale is not suggested as a standard.*)

Increased bladder sensation: Early bladder sensation that occurs at low bladder volumes and persists.

Reduced bladder sensation: Diminished sensation throughout bladder filling.

Absent bladder sensation: No bladder sensation. Nonspecfic bladder sensation: the individual is aware of bladder filling because of other sensations such as abdominal fullness or vegetative symptoms.

Bladder pain: A self-explanatory term that is abnormal.

Urgency: A sudden compelling desire to void.

Cystometric capacity: The bladder volume at the end of the fillling cystogram when permission to void is given.

Maximum cystometric capacity: The volume at which the patient feels he or she can no longer delay micturition and has a strong desire to void.

Normal urethral closure mechanism: This maintains a positive urethral closure pressure during bladder filling, even in the presence of increased abdominal pressure.

Incompetent urethral closer mechanism: This is defined as one allowing leakage of urine in the absence of detrusor contraction.

Urethral relaxation incontinence: Leakage related to urethral relaxation in the absence of raised abdominal pressure or detrusor overactivity.

Urodynamic stress incontinence: The involuntary leakage of urine during increased abdominal pressure in the absence of a detrusor contraction.

Urodynamic stress test*: Any physical effort of the person tested, to elevate abdominal pressure during cystometry, with the aim of examining (urodynamic) SUI.

Leak point pressure*: The leak point pressure (LPP) is the pressure (spontaneous or provoked) that has caused fluid to be expelled from the bladder at the moment that it is visible outside the urethra (may also be used for extraurethral urine loss or stoma). This may refer to abdominal, cough or Valsalva, or detrusor LPP.

Definitions Related to Detrusor Function During Invasive UDS

Detrusor overactivity: Involuntary detrusor contractions during the filling phase, spontaneous or provoked. Phasic detrusor overactivity: a characteristic waveform that may or may not lead to urinary incontinence.

Terminal detrusor overactivity: A single involuntary detrusor contraction occurring at cystometric capacity that cannot be suppressed, resulting in incontinence with bladder emptying.

Detrusor overactivity incontinence: Incontinence related to involuntary detrusor contractions. This may be qualified according to cause.

Neurogenic detrusor overactivity: Overactivity accompanied by a neurologic condition.

Idiopathic detrusor overactivity: Detrusor overactivity without concurrent neurologic etiology.

Provocative maneuvers: Techniques used during urodynamic border to provoke detrusor overactivity.

Cough-associated detrusor overactivity*: When the onset of the detrusor overactivity (with or without leakage) occurs immediately after the cough pressure peak.

Bladder outflow obstruction (BOO) ("outflow" to recognize what is

measured)*: A (specified) cutoff of bladder outflow resistance based on the pressure-flow relation (ratio) that is considered clinically relevant.

Normal voiding function*: Flow rate (and pressure-rise) are within normal limits; begin more or less directly after permission to void, and end with an empty bladder.

Situational inability to void and situational inability to void as usual*: When, in the opinion of the person performing the test, in communication with the patient, the attempted voiding has not been representative.

Detrusor voiding contraction*: For any analysis of combined pressure and flow (± other variables) that qualifies or quantifies the actual observed voiding.

Detrusor contractility*: Any method that aims to quantify “intrinsic” detrusor muscle properties (e.g., potential-maximum-force or velocity) by any method

Normal detrusor function: Allows bladder filling with little or no change in pressure and no involuntary contractions despite provocative maneuvers.

Dropped p_{abd} at void*: A drop in p_{abd} during voiding is reported during the voiding time, p_{abd} decreases below the previous resting pressure (as a consequence of pelvic and abdominal muscle relaxation).

Straining*: Straining is observable as a temporary increase in both p_{ves} and p_{abd} pressure. Straining may be associated with (patient-active) position change (such as repositioning from leaning backward to upright).

After-contraction*: A continued or new detrusor pressure rise immediately after flow ended. It is important to note if this occurs with the complete emptying of the bladder.

Urethral Pressure Measurements

Urethral pressure: The fluid pressure needed to just open a closed urethra.

Urethral pressure profile: A graph indicating the intraluminal pressure along the length of the urethra.

Urethral closure pressure profile: The subtraction of intravesical pressure from urethral pressure.

Maximum urethral pressure: The maximum pressure of the measured profile.

Maximum urethral closure pressure (MUCP): The maximum difference between the urethral pressure and the intravesical pressure.

Functional profile length: The length of the urethra along which the urethral pressure exceeds intravesical pressure in women.

Pressure transmission ratio: The increment in urethral pressure on stress as a percentage of the simultaneously recorded increment in intravesical pressure.

Abdominal leak point pressure: The intravesical pressure at which urine leakage occurs because of increased abdominal pressure in the absence of a detrusor contraction.

Detrusor leak point pressure: The lowest detrusor pressure at which urine leakage occurs in the absence of either a detrusor contraction or increased abdominal pressure.

Pressure-flow studies: The method by which the relationship between pressure in the bladder and urine flow rate is measured during bladder emptying.

Premicturition pressure: The pressure recorded immediately before the initial isovolumetric contraction.

Opening pressure: The pressure recorded at the onset of urine flow.

Opening time: The elapsed time from original rise in detrusor pressure to onset of flow.

Maximum pressure: The maximum value of the measured pressure.

Pressure at maximum flow: The lowest pressure recorded at maximum measured flow rate.

Closing pressure: The pressure measured at the end of measured flow.

Minimum voiding pressure: The minimum pressure during measurable flow.

Flow delay: The time delay between a change in bladder pressure and the corresponding change in measured flow rate.

Definitions Related to Artifacts of Invasive Urodynamics

Dead signal*: A signal that is not showing small pressure fluctuations and is not adequately responding on straining, patient movement, or coughing.

Pressure drift*: Continuous slow fall or rise in pressure that is physiologically inexplicable.

Poor pressure transmission*: When the cough/effort pressure peak signals on p_{ves} and p_{abd} are not nearly equal.

Expelled catheter*: When a catheter is expelled, this is observed as a sudden drop in either p_{ves} or p_{abd}, usually below zero.

Catheter flush*: When one of the catheters is flushed during the test, a steep pressure rise is observed in that pressure line for one or two seconds followed by an immediate fall to resting pressure.

Tube knock*: Observable as high-frequency, short-duration spikes visible in p_{ves}, p_{abd}, or both and with spikes also usually visible in p_{det}.

Pump vibrations*: Pump vibrations are visible as stable frequency oscillations of small but constant amplitude if the filling tube touches the pressure connecting tube (when a two-catheter system is used) and the pump is switched on (switching of the pump can ascertain the situation).

Data from Abrams P, Cardozo L, Fall M, et al. The standardization of terminology of lower urinary tract function: report from the Standardization Subcommittee of the International Continence Society. *Neurourol Urodyn* 21:167–178, 2002; Schafer W, Abrams P, Liao L, et al. Good urodynamic practices: uroflowmetry, filling, cystometry, and pressure-flow studies. *Neurourol Urodyn* 21:261–274, 2002; Rosier PFWM, Schaefer W, Lose G., et al. International Continence Society Good Urodynamic Practices and Terms 2016: Urodynamics, uroflowmetry, cystometry, and pressure-flow study. *Neurourol Urodyn* 36(5):1243–1260, 2017.

The ICS has also published updated condition-specific terminology references for female pelvic floor dysfunction and adult neurogenic patients, which may include additional terminology (Gajewski et al., 2017; Haylen et al., 2010).

Components of the Urodynamic Study

Before discussing the details of the UDS, it is useful to be familiar with the different components of the test. These tests within the study can be used individually or in combination, depending on the information desired. For the purposes of this chapter, we will discuss each component as part of the entire multichannel UDS or video UDS (VUDS). Uroflow and postvoid residual (PVR) determination are two simple, noninvasive tests that can be used to evaluate voiding function and perhaps prompt further testing. In addition, both are part of a multichannel UDS.

Postvoid residual is an excellent assessment of bladder emptying. It can be performed by ultrasonography (bladder scan) or catheterization (method should be specified). Elevation of PVR indicates a problem with emptying but does not tell why. An elevated PVR may prompt further testing. In cases when PVR is elevated, it should be confirmed with a second measurement, especially for situations in which a patient did not have a true desire to void before PVR was measured.

Uroflowmetry is measurement of the rate of urine flow over time. It is also an assessment of bladder emptying. There are multiple data points that can be reported from noninvasive uroflowmetry. These include the following:

- Voided volume (VV; mL)
- Flow rate (Q; mL/sec)
- Maximum flow rate (Q_{max}; mL/sec)
- Average flow rate (Q_{ave}; mL/sec)
- Voiding time (total time during micturition; sec)
- Flow time (time during which flow occurred; sec)
- Time to maximum flow (onset of flow to Q_{max}; sec)

Voided percentage (void %) or voiding efficiency is a numerical description of the voiding efficacy or efficiency that is the proportion of bladder content emptied [(volume voided/volume voided + PVR) × 100].

In addition to these objective measurements, it is also important to observe the pattern or shape of the uroflow curve. A normal uroflow curve is bell-shaped (Fig. 114.1). Uroflow curve interpretation is somewhat subjective because of difficulty in qualitatively judging a pattern (Boone and Kim, 1998). When the flow rate is reduced or the pattern is altered, this could indicate dysfunction of the bladder (detrusor underactivity) or bladder outlet (anatomic or functional) (see Fig. 114.1). Although certain patterns are suggestive of certain voiding dynamics (e.g., an interrupted or straining pattern with detrusor underactivity and a flattened pattern with a fixed obstruction), one cannot definitively identify specific underlying abnormalities without detrusor pressure data (see invasive pressure-flow urodynamics later). When done as a standalone test, it may be easiest to optimize patient comfort and reduce anxiety by allowing the patient to perform the voiding in his or her preferred position (e.g., sitting or standing). The patient should also be queried if the urine flow was representative of what occurs during a voiding during nontesting conditions (daily living). Also, the urodynamic voided volume can be compared with frequency volume charts or bladder diary when available. Position of void should be recorded (Gleeson and Lattimer, 1962).

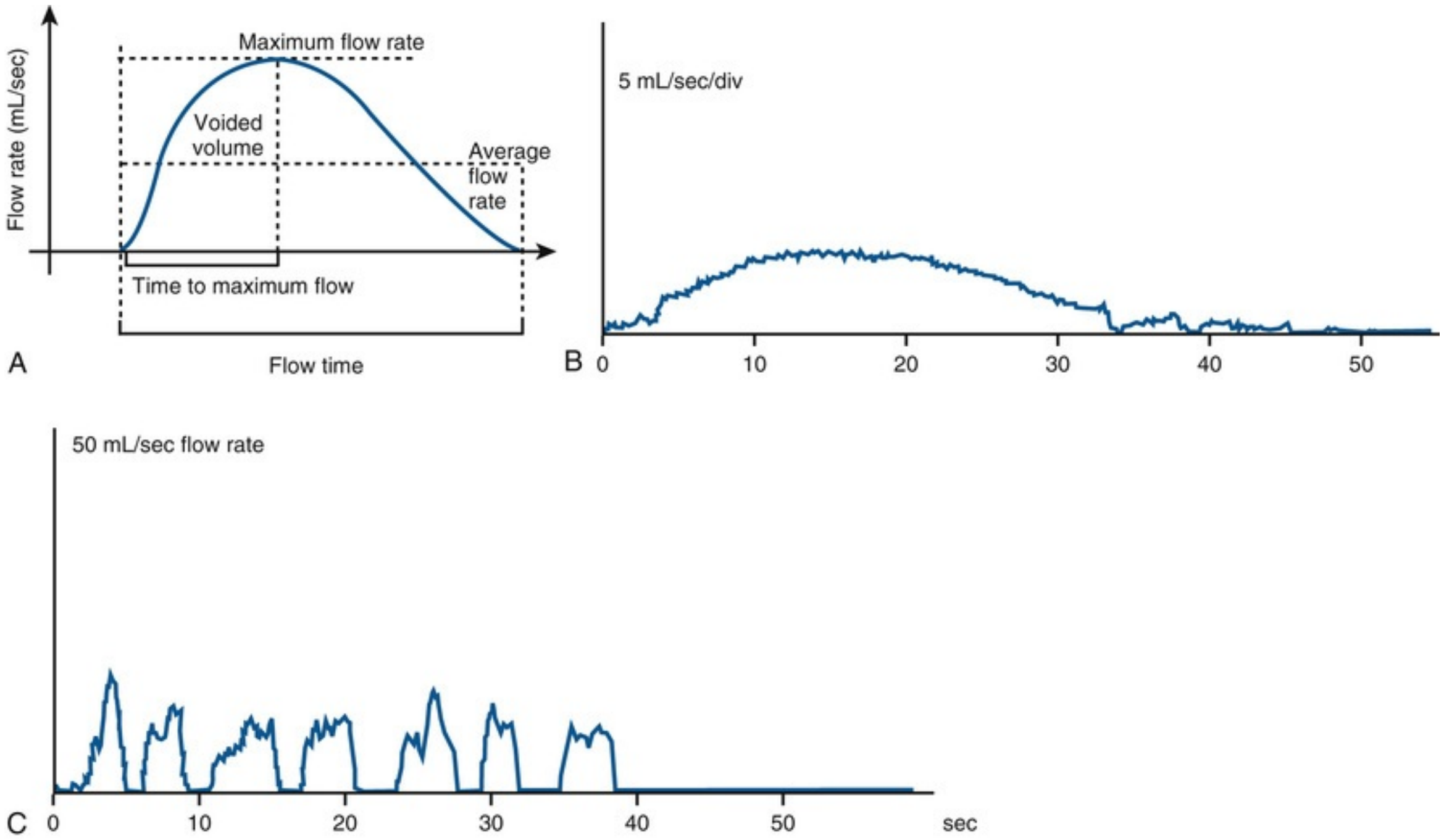

FIG. 114.1 Examples of uroflow curves. (A) normal bell-shaped flow curve of flow rate versus time. (B) flattened pattern usually indicative of obstruction. (C) An interrupted or straining pattern that can be seen with impaired bladder contractility, obstruction, or voiding with or by abdominal straining. (A, from Wein AJ, English WS, Whitemore KE. Office urodynamics. *Urol Clin North Am* 15:609, 1988; B and C, from Boone TB, Kim YH. Uroflowmetry. In Nitti VW, ed. *Practical urodynamics.* Philadelphia,

PA: WB Saunders; 1998:28–51.)

Cystometry or **cystometrogram (CMG)**, or, more appropriately, **filling cystometry** is the method by which the pressure/volume relationship of the bladder is measured during bladder filling. The filling phase starts when filling commences and ends when the patient and urodynamicist decide that "permission to void" has been given (maximum cystometric capacity). Cystometry can be performed by the single measurement of bladder pressure via a bladder catheter (urethral or suprapubic); however, changes in bladder pressure can represent a change in detrusor pressure (p_{det}) or a change in abdominal pressure (p_{abd}) (see later). Therefore, it is recommended that cystometry be performed by measuring both the total vesical pressure (p_{ves}) and p_{abd} (measured by a catheter placed in the rectum or vagina). To calculate detrusor pressure (p_{det}), the following equation is used (Fig. 114.2):

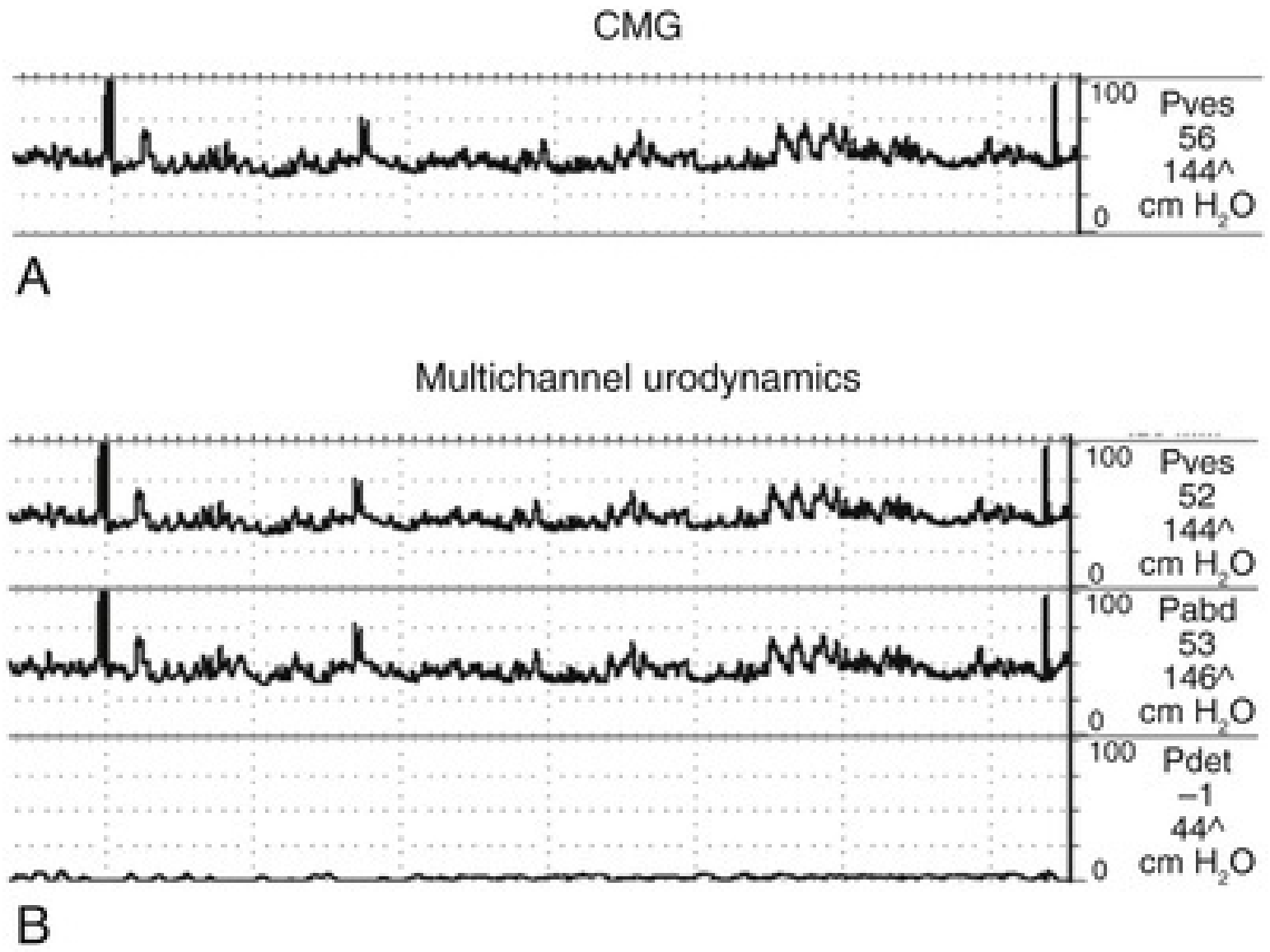

FIG. 114.2 Cystometrogram *(CMG)* measures the pressure in the bladder as the bladder fills over time. Standard fill rates in adults are 30 to 100 cm H_2O per minute. Adding intra-abdominal pressure monitoring gives a better representation of the true detrusor pressure. (A) Single-channel CMG in which only the total vesical pressure *(pves)* is measured. Note the multiple spikes and rises in pressure. Without having simultaneous monitoring of intra-abdominal pressure, it is impossible if these pressure spikes are caused by a rise in detrusor or abdominal pressure. (B) This same tracing with intra-abdominal pressure *(pabd)* monitoring added *(multichannel urodynamics).* This allows for the determination of (subtracted) detrusor pressure *(pdet).* Now it can be clearly seen that changes in pves were

caused by the changes in pabd (e.g., movement, coughing). The pdet curve it is noted to be flat and without any rises in pressure. (From Nitti VW. Cystometry and abdominal pressure monitoring. In Nitti VW, ed. *Practical urodynamics.* Philadelphia, PA: WB Saunders; 1998:38–51.)

$$p_{det} = p_{ves} - p_{abd}$$

Pelvic muscle electromyography (EMG) is the study of the electronic potentials produced by the depolarization of muscle membranes. In the case of UDS, EMG measurement of the striated sphincter muscles of the perineum is done to evaluate possible abnormalities of pelvic floor muscle function, which are often associated with lower urinary tract symptoms and dysfunction. EMG activity is measured during both filling and emptying. ICS standard is now specified as two skin surface electrodes on the perineal surface with an appropriate referent (Rosier et al., 2017b). EMG can also be obtained by vaginal probe (vaginal EMG), anal probe (anal EMG), or needle electrodes (needle EMG).

Urethral pressure profile (UPP) is a graph indicating the intraluminal pressure along the length of the urethra. Urethral pressure is defined as the fluid pressure needed to just open a closed urethra. UPP is obtained by the withdrawal of a pressure sensor (catheter) along the length of the urethra.

Pressure-flow studies (PFS) of voiding are the method by which the relationship between detrusor pressure and urine flow rate is measured during bladder emptying (voiding). Detrusor pressure is measured as noted earlier with the simultaneous measurement of flow rate by a uroflowmeter. The voiding phase starts when “permission to void” is given, or when uncontrollable voiding begins, and ends when the patient considers voiding has finished.

Urodynamic Equipment

Urodynamic Systems

There are a variety of urodynamic systems available today. They range in cost depending on their complexity and the features they contain. Current UDS systems are computer-based digital systems that allow for easy data storage and postprocessing of the study. In addition, they allow for hardware and software upgrades as necessary. It is beyond the scope of this chapter to describe in detail the options available for UDS systems. However, when choosing a system, one must consider the patient population and spectrum of diseases frequently encountered; available space; convenience of operation (if a factor); and the need for data storage and processing and possible electronic medical record integration. In addition, it is recommended that a multichannel system be used where channels are available to measure vesical pressure, abdominal pressure (and subtracted detrusor pressure), and flow rate. Some clinicians may also desire channels for electromyography and urethral pressure measurement. The UDS system and software market is constantly changing, so what is state-of-the-art today may seem “outdated” tomorrow. However, despite all the advances, the clinician performing the study remains the most important constant in data collection and interpretation. For the most realistic assessment, the infusant should be a liquid (e.g., normal saline or radiographic contrast) that most approximates urine. The use of gas, such as carbon dioxide, is not recommended. Many advanced urodynamic centers now perform VUDS. Adding this capability is costly but allows one to perform the most comprehensive study possible. There are certain clinical settings in which VUDS is preferred and may be the “test of choice” (e.g., in advanced NLUTD) (Groen et al., 2016). In addition to the necessary urodynamic hardware and software, a fluoroscopy unit and room of adequate size are required. Obviously, this is not practical or necessary in every setting. VUD studies also require a greater time commitment on the part of the clinician to assure accurate data collection. Thus, VUDS is ideally preformed in centers with a specific interest in complex storage and voiding dysfunction. For specific recommendations regarding UDS equipment performance, the reader is referred to the recently published ICS document on this subject (Gammie et al., 2014).

Signal Transmission and Transducers

Transducers are the hardware that allows pressure in the patient to be measured and transferred to the UDS system. External strain gauge transducers located “between” the patient and the urodynamic machine have been popular for years. Pressurized tubing (to avoid dampening or dissipation of the pressure) extends from the pressure transducer to the catheters placed in the patient. An electronic cable or “wireless transmission” brings the signal from the transducer to the urodynamic machine. Traditionally, a water-filled system was used in which the entire system from transducer to patient is filled with water. Because this system depends on the transmission of pressure through fluid (water), it is crucial that there are no air bubbles in the transducer or tubing. The pressurized tubing transmission lines should be lucent to allow for easy recognition of air in the line. The transducers are usually set at the level of the patient's bladder (symphysis pubis) at the start of the study. This is important because if the patient changes position during the test (e.g., standing to sitting), the height of the transducer can be adjusted so that it remains at the level of the bladder.

More recently **air-charged catheters** (T-Doc, Wenonah, NJ) have become popular for pressure measurement. Air-charged catheters use a miniature, air-filled balloon placed circumferentially around a polyethylene catheter. External forces on the balloon of the catheter are transmitted to the air-filled catheter lumen and communicated to an external semiconductor transducer. The technology of the balloon system allows circumferential measurement readings. The catheters are disposable and intended for single use. Air-charged catheters have several practical advantages over fluid-filled pressure lines because there is no fluid connection between the patient and the urodynamic equipment—just air. This means there is no hydrostatic pressure effect to account for, so there is no need to position anything at the level of the symphysis pubis, and there is no need to flush the system through to exclude air (essential when using a fluid-filled system). Also, there are no artefactual fluctuations in pressure produced when the patient moves. It must also be remembered that **many UDS nomograms and other “standards of measurement” were determined using fluid-filled systems. There is comparative evidence for the use of air-charged catheters to measure urethral pressure** and Valsalva leak point pressure. One study showed comparable performance between air-charged and microtip catheters (Pollak et al., 2004). Another study concluded that they cannot be used interchangeably as air-charged catheters showed systematically higher readings

(Zehnder et al., 2008).

In an experimental model, Cooper et al. showed that **air-charged and water-filled catheters respond to pressure changes in dramatically different ways** (Cooper et al., 2011). Water-filled catheters acted as an underdamped system, resonating at 10.13 ± 1.03 Hz and attenuating signals at frequencies higher than 19 Hz. They demonstrated significant motion and hydrostatic artifacts. Air-charged catheters acted as an overdamped system and attenuated signals at frequencies higher than 3.02 ± 0.13 Hz. They demonstrated significantly less motion and hydrostatic artifacts than water-filled catheters. The authors point out that most urodynamic signals occur below 3 Hz, and, as such, air-charged systems could be beneficial because most of the higher-frequency noise is dampened. However, urodynamic signals can have frequency components greater than 3 Hz, particularly when utilizing rapidly changing signals, such as coughs. The authors concluded that "knowledge of the characteristics of the pressure-measuring system is essential to finding the best match for a specific application."

Two additional studies compared simultaneous pressure values of water-filled systems and air-filled systems during UDS in women (Digesu et al., 2014; Gammie et al., 2016). The studies reported that the systems are not interchangeable because values obtained from each were significantly different. p_{det} values could vary between systems by up to 10 cm H_2O. Pattern analysis was not affected, however, when absolute (subtracted) pressures become relevant (as in pressure-flow analysis or urethral pressure profiles), the possibility of clinically relevant differences exists. Some experts suggest that further validation of measurement techniques with air-filled systems be done before clinical similarity can be established (Abrams et al., 2016).

The conclusions of the 6th International Consultation on Incontinence are that air-charged catheters may provide an acceptable alternative for measuring the closure pressure of the female urethra, however, reference values have not been established (Rosier et al., 2017b). They have not been tested in men, children, or patients with NLUTD. The different catheters record different values and are not interchangeable. Thus, it is recommended that investigators planning to use air-charged catheters for intravesical and intra-abdominal pressure monitoring check for themselves that they have an equivalent performance to their current system for measuring pressure (Rosier et al., 2017).

Finally, a microtip or fiberoptic system can be used to process pressure transmission. Here, the transducer is contained within the catheter. This in turn is connected directly into the urodynamic machine via a cable. These catheters are quite expensive; they are reusable and thus must be sterilized before each use.

Uroflowmeters

Urine flow rate or uroflow can be determined by a number of different types of devices or uroflowmeters. Modern uroflowmeters use weight, electrical capacitance, or a rotating disc to determine urinary flow rates. The two most common techniques used today are the weight transducer or load cell method and the rotating disk method. With the load cell, the voided “weight” is measured and is then differentiated with respect to time to determine the flow rate. In the rotating disc method, the urine stream is directed onto a rotating disc, and the power necessary to keep a disc rotating at a constant rate is measured. This power is proportional to the flow rate. The electronic dipstick flowmeter measures the electrical capacitance of a dipstick mounted in a collecting chamber. The output of the signal is proportional to the accumulated volume, and the volumetric flow rate is determined by differentiation. Each of these methods has advantages and disadvantages. The weight transducer method is simple, reliable, and accurate regardless of the site of stream impact, but it requires that the density of urine be set. The rotating disc method is also reliable and accurate, and it provides a direct measurement without the need for differentiation of volume with respect to time. Electronic flowmeters provide a range of electronically read flow parameters with graphical depiction of the uroflow and have sufficient precision for clinical use with error rates of 1% to 8% in voided volume and 4% to 15% in flow rate (Susset, 1983). Variations in specific gravity of the fluid voided (infusant when doing UDS) can affect the calculated flow rate. Most systems allow for calibrations for various fluids such as radiographic contrast.

Electromyography

Muscle depolarization must be detected by an electrode placed in or near the muscle. Several different methods are available to do this including surface electrodes, needle electrodes, anal or vaginal plug, or urethral catheter mounted electrodes (O'Donnell, 1998). Surface electrodes are self-adhesive skin patch electrodes that are applied over the skin of the anal sphincter (Barrett, 1980). Except in some neurologic diseases, external anal sphincter activity will match external urethral sphincter EMG. Surface electrodes have a significant advantage compared with the needle electrode regarding patient convenience and comfort. However, the surface electrodes provide an inferior signal source and must be precisely placed to provide an adequate signal source. Most clinicians feel that the concentric needle electrode is the superior technique for obtaining a signal source of EMG activity of the striated external sphincter muscles. Compared with the surface electrode, placement of the needle electrode has the disadvantage of being uncomfortable for the patient, especially if more than one attempt at placement of the electrode is required to obtain an adequate signal. Also, the needle electrode is easily dislodged and may require replacement during the study. Patients typically have a low tolerance for replacement of the needle electrode during UDS (Brucker et al., 2012). The performance of an EMG and the selection of the type of electrode to be used are dependent on the UDS question to be answered. EMG recording must also be interpreted in the context of the overall clinical picture of the patient being examined (Khullar et al., 2017).

Key Points

- The functional classification system can help clarify treatment options for a given patient, thus, in practical terms, the UDS evaluation should be performed to help determine if there is bladder or bladder outlet dysfunction (or both) and whether there is a storage and/or emptying problem.
- There should be a clearly defined reason to perform a UDS. The intention should be that the information obtained could be used to guide treatment of the patient.
- UDS is only one part of the comprehensive evaluation of symptoms and lower urinary tract function. The main goal of UDS is to reproduce the patient's symptoms, when present, and determine the cause of these symptoms by urodynamic measurements or observations.
- UDS are interpreted in the context of the patient's history, including symptoms and concomitant diseases/conditions, and other information such as postvoid residual volumes and frequency volume charts (voiding and intake diaries) when clinically applicable.

- Proper urodynamic practices and appropriate terminology should be used when possible.
- Well-trained, attentive, and supportive staff involved with the UDS cannot be overemphasized. Patients should be properly prepared and told why the test is being done, how the results may affect treatment, and what to expect during the actual UDS.

The Urodynamic Study: Analysis and Interpetation

When analyzing and interpreting UDS, it is useful to separate the UDS into filling/storage and voiding phases. This allows for ease of classification of lower urinary tract dysfunction according to the functional classification system mentioned earlier. The filling/storage phase consists primarily of cystometrogram (CMG) and provocative testing (e.g., measurement of abdominal leak point pressure) and urethral pressure measurement during storage. The voiding phase evaluates bladder contractility, bladder outlet resistance, and sphincter coordination by pressure-flow analysis EMG and, in some cases, fluoroscopy.

Filling and Storage Phase

The CMG assesses the bladder's response to filling. The CMG can measure filling pressure, sensation, involuntary contractions (or detrusor activity), compliance, and capacity. Sensation is the part of cystometry that is truly subjective and therefore requires an alert and attentive patient and clinician. The ICS recognizes several subjective parameters that can be recorded during filling (see Table 114.1). Categorizing lower urinary tract sensation during bladder filling (e.g., “urgency” or “early filling sensation”) is now thought to be more clinically important than previously thought. Some treatments are thought to have a specific influence on sensation (de Wachter et al., 2011; Herringa et al., 2011). The end of the CMG is marked by “permission to void” indicated on the urodynamic graph or by stopping the fill pump (however, this may be delayed). End filling should be at a strong but not uncomfortable need to void. A bladder diary or frequency volume chart, along with prior postvoid residual should be considered.

Normal Filling and Storage

Normally, the bladder should store urine at a low pressure and not contract involuntarily. Once capacity is reached or voluntary voiding is desired, intravesical pressure will increase (voluntary detrusor contraction). In actuality, this is preceded by relaxation of the external sphincter. A normalized adult CMG is shown in Fig. 114.3. **Normally detrusor pressure should remain near zero during the entire filling cycle until voluntary voiding is initiated. That means baseline pressure stays constant (and low), and there are no involuntary contractions.** In a terminology guideline for female pelvic floor dysfunction, Haylen et al. (2010) describe this as normal (previously “stable”) detrusor function.

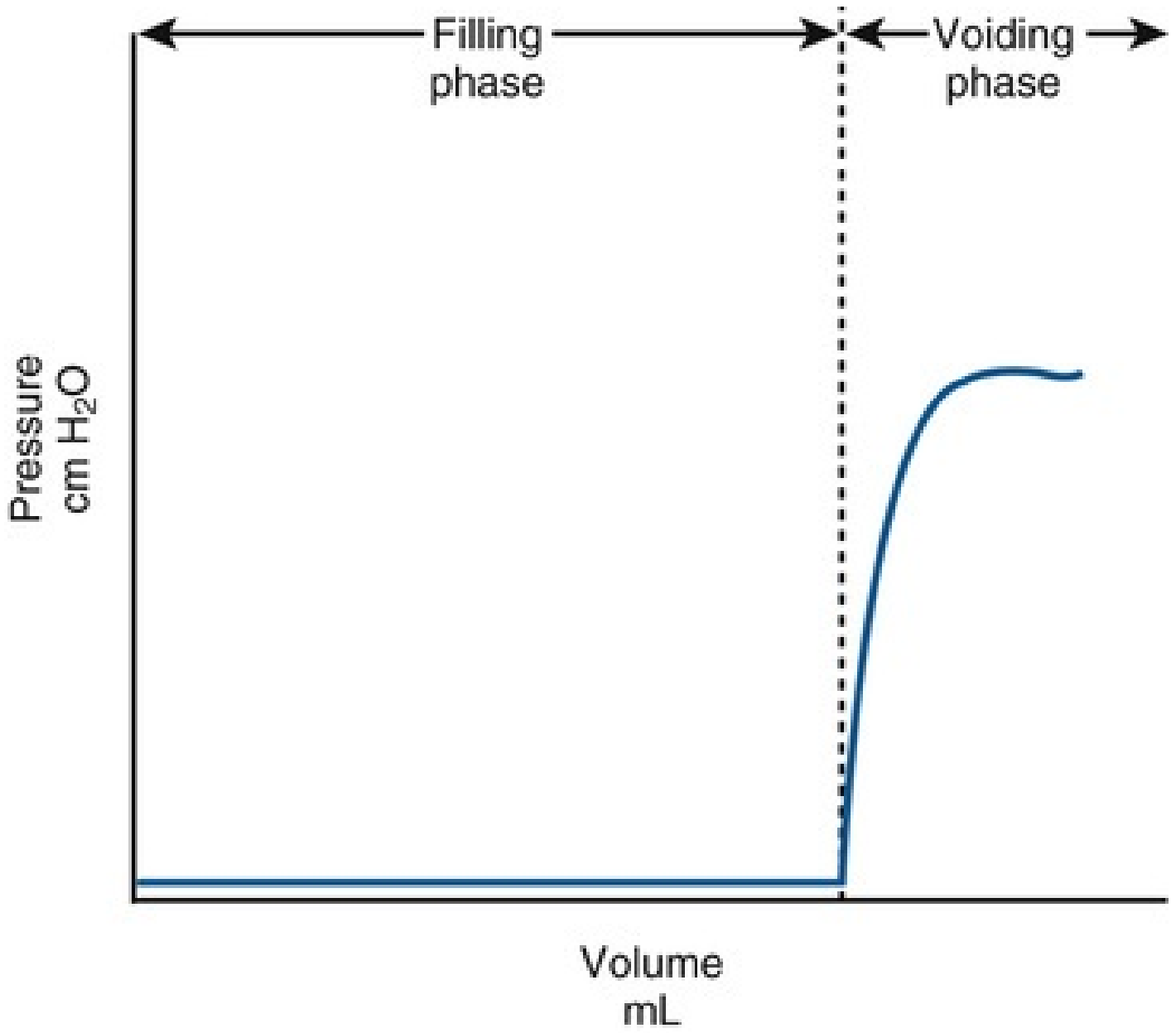

FIG. 114.3 Normal, idealized adult CMG with low-pressure storage until the patient is given the command to void and the voiding phase starts. Note that the baseline bladder pressure is near zero (compliant) and there are no involuntary contractions.

As mentioned earlier, the simultaneous measurement of p_{abd} is done by a rectal, vaginal, or stomal catheter, and p_{ves} during UDS provides a means of calculating the true p_{det}. Data are limited for vaginal and stomal catheter use, and thus a rectal catheter should be used when possible. **The ability to calculate subtracted p_{det} allows one to distinguish between a true rise in detrusor pressure (either via a contraction or loss of compliance) and the effect of increased abdominal pressure** (e.g., straining, Valsalva). This is especially important when rises in detrusor pressure are small or when they are accompanied by changes in abdominal pressure.

Abnormalities of Bladder Filling: Detrusor Overactivity and Impaired Compliance

During filling, involuntary detrusor contractions (IDCs) can occur. These are often associated with urgency and even urgency incontinence. **Detrusor overactivity (DO) is a *urodynamic observation* characterized by IDCs during the filling phase, which may be spontaneous or provoked (Fig. 114.4). DO may be further characterized as *neurogenic DO* when it is associated with a relevant neurologic condition (e.g., spinal cord injury, multiple sclerosis) or *idiopathic DO* when there is "no defined cause" (non-neurogenic)** (Abrams et al., 2002). The term *idiopathic DO* is a bit of a misnomer in that the cause of DO in a non-neurogenic patient may be inferred (e.g., BOO, inflammatory process) or may be truly "unknown." Thus, from a practical standpoint, the terms *neurogenic DO* and *non-neurogenic DO* make more sense but do not fit the ICS definitions. (It should be noted that the term *neurogenic DO (NDO)* replaced the term *detrusor hyperreflexia*, and the term *idiopathic DO* replaced the term *detrusor instability* from older ICS terminology). Neurogenic and idiopathic DO may look identical on CMG. These terms are strictly defined by the patient's neurologic status and not the CMG appearance of the IDCs.

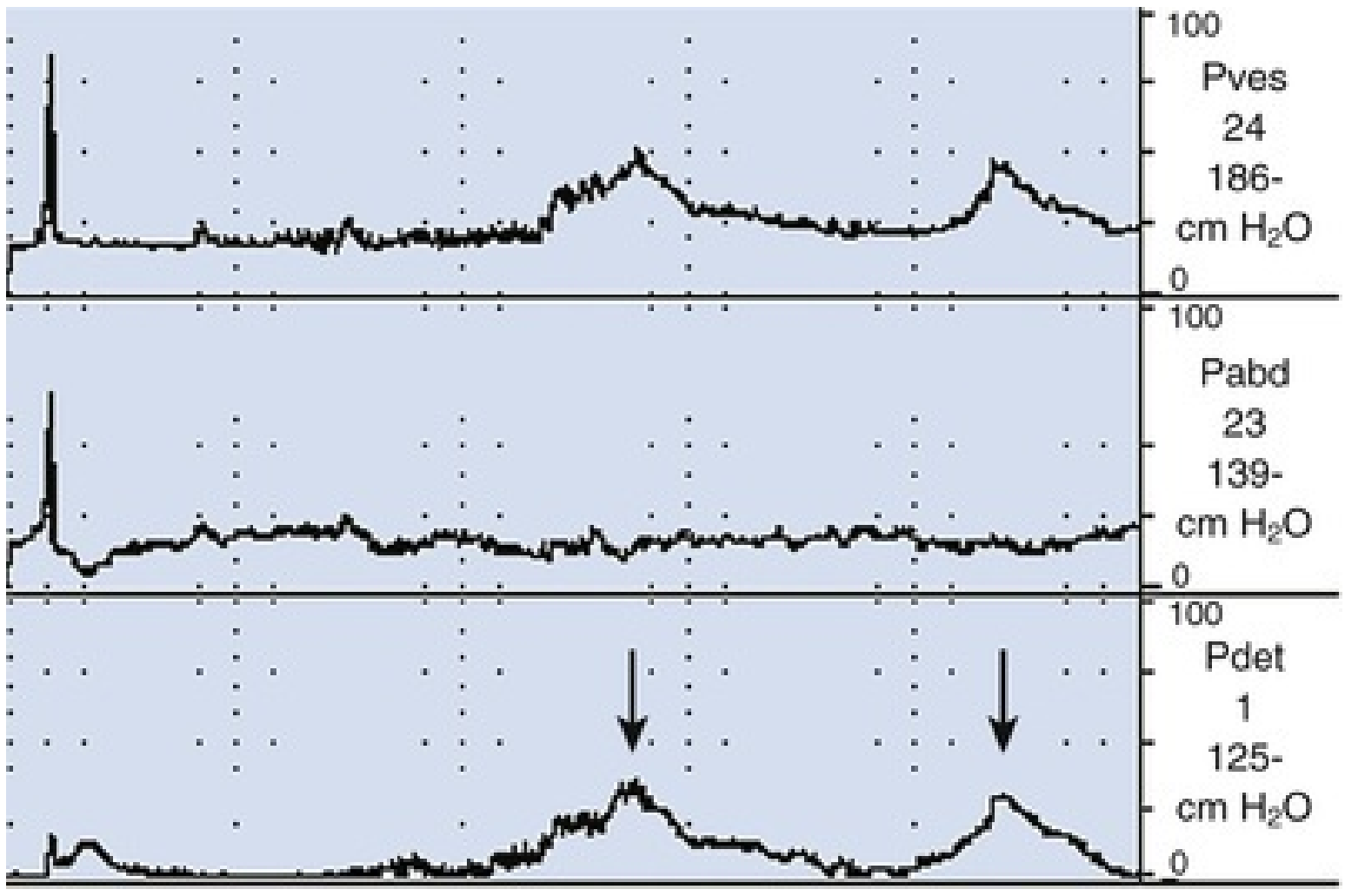

FIG. 114.4 Detrusor overactivity. In this tracing, there are two IDCs *(arrows).* There is a rise in Pves with no associated rise in Pabd, and therefore the subtracted Pdet looks identical to the Pves.

The presence of DO during UDS must be interpreted in the context of the patient's symptoms and condition. Ideally, a patient's symptoms should be reproduced during UDS, so we would expect DO to be accompanied by urgency or urgency incontinence, although it can occur and be significant without being symptomatic, particularly in neurogenic DO. However, **DO can also be “test induced” or clinically insignificant.** It has been reported in 14% to 18% of healthy asymptomatic volunteers undergoing UDS (Wyndaele and De Wachter, 2002; Robertson, 1999; van Waalwijk van Doorn et al., 1992). This is even more dramatic in ambulatory UDS in which the presence of DO has been found in as many as 69% of asymptomatic females (van Waalwijk van Doorn et al., 1996). Conversely, **failure to demonstrate DO on UDS does not rule out its existence.** It is well known that up to 50% of women with urgency incontinence do not demonstrate DO on UDS. **However, the ability to suppress DO during UDS may in and of itself be significant.** For example, Osman showed that patients with mixed incontinence and a normal CMG (no DO) not only had excellent cure rates for stress incontinence, but also had an 87% cure rate for urgency incontinence compared with only a 43% cure rate for urgency incontinence for women randomized to receive antimuscarinic medication instead of stress incontinence surgery (Osman, 2003).

It is important that the person performing the UDS be certain that the contraction is involuntary and not a voluntary attempt at voiding. Sometimes a patient may become confused during the study and actually void as soon as he or she feels the desire. The volume at which contractions occur and the pressure of the contractions should be recorded. It is often worthwhile to repeat the CMG at a slower filling rate if the patient experiences uncharacteristic symptoms associated with DO. If the patient experiences incontinence during an involuntary contraction (DO incontinence), this should be noted.

In addition to the presence of DO, its characteristics can be noted. DO can be observed as a single event or as multiple IDCs. It can be phasic (continuous), sporadic, or terminal (occurring at the end of filling near capacity). It can also be suppressed or nonabortable and may lead to leakage or precipitant micturition. Classifying DO in such a way can be valuable in certain circumstances. For example, overactive bladder symptoms associated with obstruction have been shown to have a higher likelihood of resolving with intervention (e.g., TURP) when DO occurs as a single terminal IDC rather than continuous or sporadic IDCs (Kageyama et al., 2000).

The detection of DO can be influenced by the patient's position. A review of studies on the influence of patient position found that 14 of 16 showed a higher incidence of DO in the vertical position (supine or standing) or onset of DO when changing to a vertical versus supine position (Al-Hayek et al., 2008). Thus, when the detection/documentation of DO is clinically important, it would seem appropriate to test the patient in the position in which he or she experiences specific symptoms.

Other parameters of the IDC have been suggested as factors that may contribute or predict upper urinary tract damage in cases of NDO (Musco et al., 2018). Maximal detrusor pressure is one of these values proposed to inversely relate to renal function; the higher the maximal detrusor pressure, the more impaired renal function (Shin et al., 2014; Cetinel et al., 2017). Further, the duration of the IDC has been reported as correlating with other signs of upper urinary tract deterioration (Musco et al., 2018). Here it is suggested the longer contraction in neurogenic patients, the more risk for upper urinary tract deterioration (Linsenmeyer et al., 1998; Elmelund et al., 2017).

In summary, DO is often a significant UDS observation and may explain a number of storage symptoms. In addition to its presence, the characteristics of DO should be noted. It is also important that clinicians recognize normal test-retest variation and that "usual lower urinary tract behavior" is not always replicated in the test setting.

The vesicoelastic properties of the bladder, based on its composition of smooth muscle, collagen, and elastin, normally produce a highly compliant structure. Therefore, as the bladder fills, there is little change in pressure (**see normalized CMG, Fig. 114.3**). **Compliance is the relationship between change in bladder volume and change in detrusor pressure** (Δ volume/Δ pressure) and is measured in mL/cm H_2O. The ICS recommends two standard points: the p_{det} at the start of bladder filling (usually zero) and the pdet at cystometric capacity or before the start of any detrusor contraction that results in significant leakage (Abrams et al., 2002). Both points are measured excluding any detrusor contractions**. It is difficult to definitively define what "normal compliance" is in terms of mL/cm H_2O.** Several authors have shown that mean values for compliance in healthy subjects range from 46 to 124 mL/cm H_2O (Hosker, 2004; Sorensen et al 1988; van Waalwijk van Doorn et al., 1992). However, there is great variation. For example, van Waalwijk van Doorn et al. showed a variation of compliance from 11 to 150 mL/cm H_2O (mean 46) in 17 healthy subjects (van Waalwijk van Doorn et al., 1992). Some of the variation in a "normal" bladder is likely because compliance per se is dependent on bladder capacity. Furthermore, various definitions of impaired compliance have been used (e.g., between 10 and 20 mL/cm H_2O), however, there is no consistent definition based on mL/cm H_2O. Stohrer et al. suggest that a value of less than 20 mL/cm H_2O is consistent with impaired compliance and implies a poorly accommodating bladder (Stohrer et al., 1999). However, examples can be cited (e.g., small cystometric capacity) in which this may not be the case. Therefore, **in practical terms, absolute pressure is probably more useful than a “compliance number” or value.** For example, it has been shown that storage greater than 40 cm H_2O are associated with harmful effects on the upper tracts (McGuire et al., 1981) (Fig. 114.5). Also, depending on the clinical scenario, a particular compliance in terms of mL/cm H_2O can mean very different things (Fig. 114.6). As a general rule, one might say that **prolonged storage at high pressures can lead to upper tract deterioration.** Elevated storage pressures and impaired compliance should be interpreted in the context of the clinical scenario. It has been shown that **conventional cystometry can provoke filling pressures higher than natural filling in some cases.** Robertson showed that for six patients with neuropathic bladder and severely impaired compliance on conventional cystometry, compliance was actually normal on ambulatory monitoring with natural filling (Robertson, 1999).

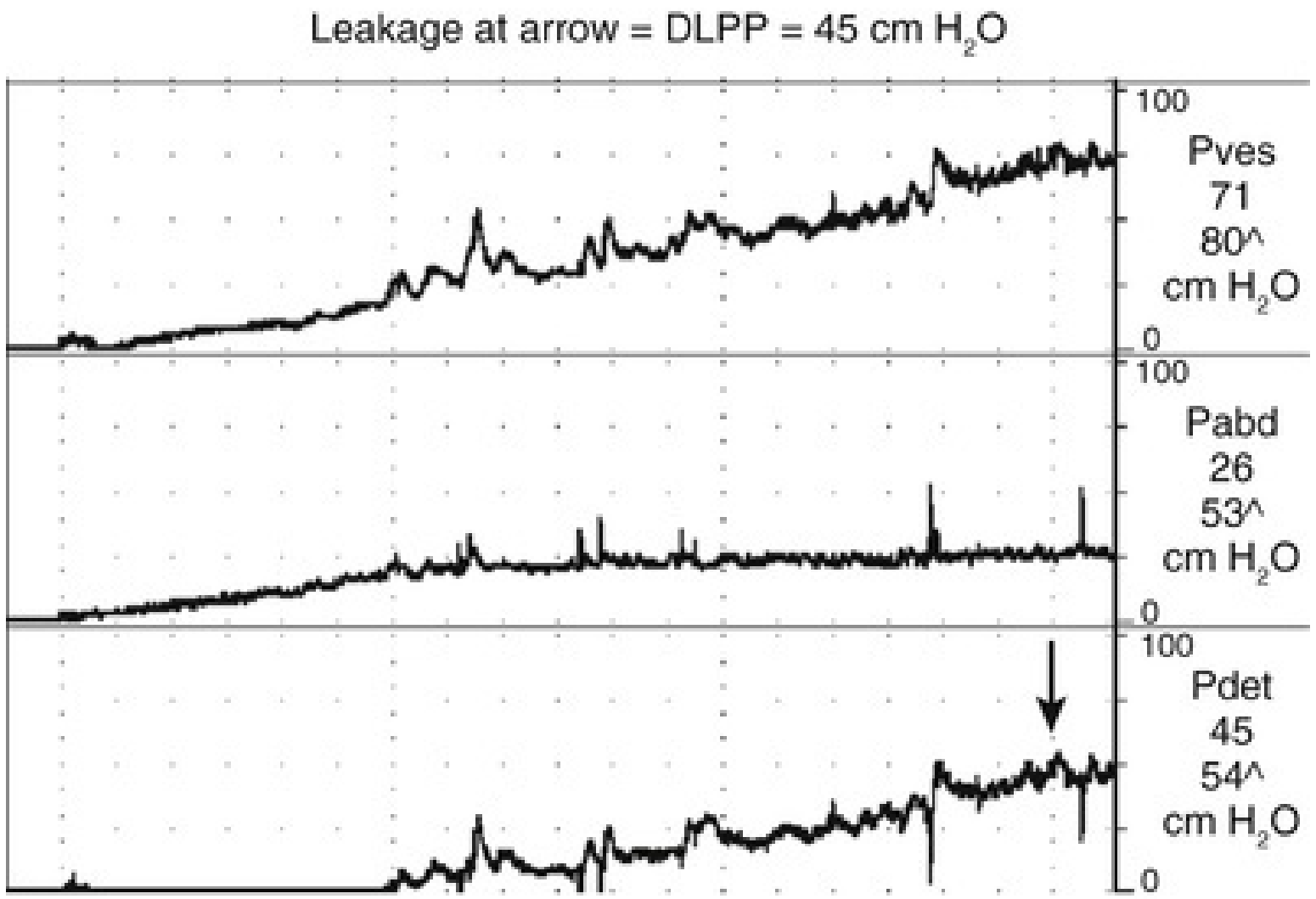

FIG. 114.5 Impaired compliance. Note the rise in pves (and pdet) with bladder filling. The pdet at the end of filling is approximately 45 cm H_2O, which is a potentially dangerous situation. In this case, the bladder was filled to a volume of 300 mL, so the compliance is 6.67 mL/cm H_2O. The *arrow* is the point at which incontinence was demonstrated, which is the

detrusor leak point pressure *(DLPP).*

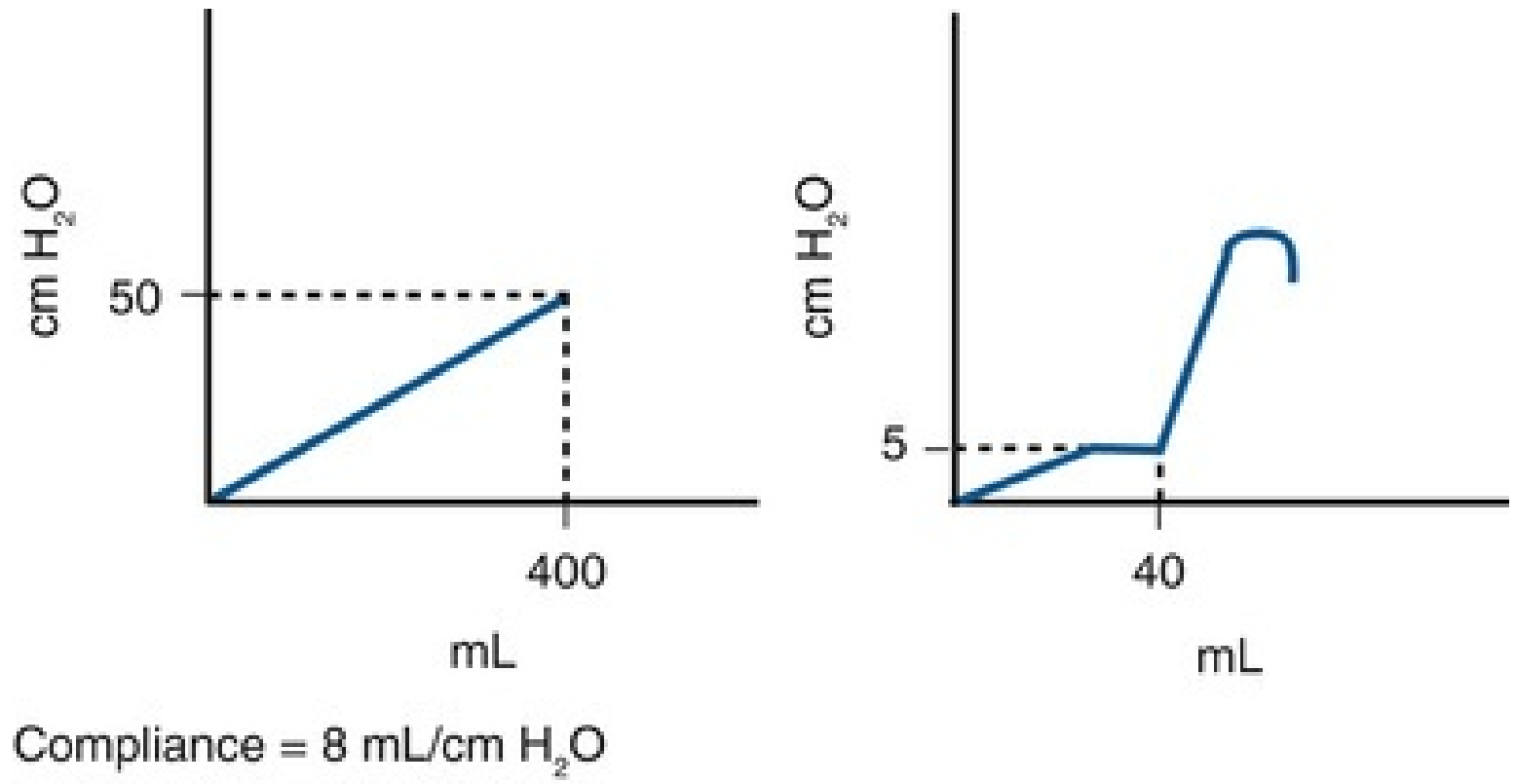

FIG. 114.6 A problem with measuring compliance. Two theoretical CMGs are shown. The one on the *left* demonstrates impaired compliance with a constant rise in pdet throughout filling. At 400 mL, the pdet is 50 cm H_2O (8 mL/cm H_2O), a dangerous situation. There is significant storage time when the det is >40 cm H_2O. The CMG on the *right* could represent a small-capacity bladder with DO and precipitant micturition. At a volume of only 40 mL, an IDC occurs. The pdet just before this was only 5 cm H_2O. The calculated compliance would be 6 mL/cm H_2O, the same as the one on the left. Yet the CMG on the right does not demonstrate a dangerous situation, just a highly symptomatic (incontinent) patient.

Impaired compliance is seen in a variety of neurologic conditions (spinal cord injury/lesion, spina bifida) and usually results from increased outlet resistance (e.g., detrusor–external sphincter dyssynergia [DESD]) or decentralization in the case of lower motor neuron lesions. It can also result from long-term BOO (e.g., benign prostatic obstruction) (Leng and McGuire, 2003) or structural changes such as radiation cystitis or tuberculosis. **Impaired compliance with prolonged elevated storage pressures is a urodynamic risk factor and usually needs to be treated to prevent renal damage (see Table 114.1).**

A number of factors can affect the measurement of compliance. Sometimes an increase in p_{det} during cystometry is seen as a result of rapid filling (filling during cystometry is almost always faster than physiologic filling). This is more of an accommodation problem rather than a true decrease in compliance. When p_{det} is seen to be rising, filling may need to be stopped or reduced to see if the effect is real. An IDC, particularly of a sustained and low amplitude, can be confused with impaired compliance. If filling is stopped and the pressure returns to baseline, then the compliance is not impaired. Finally, there are a number of "pop-off" mechanisms that can make compliance seem better than it actually is. Vesicoureteral reflux (VUR) and bladder diverticulum are two examples. With VUR, pressure is actually transferred to the refluxing renal unit and may be harmful. The volume that is refluxed into the upper tract can be a large volume (e.g., larger than bladder volume). Videourodynamics (see later) is very useful in these cases. Because a bladder diverticulum is actually part of the bladder, it may provide a protective effect for the upper tracts. Finally, an incompetent outlet may be a pop-off mechanism. This may only become apparent when outlet resistance is increased. This can be done during cystometry by occluding the outlet, but it may not be seen until the outlet resistance is surgically increased (e.g., with an artificial urinary sphincter or sling procedure).

Leak Point Pressures

The leak point pressure (LPP) is the pressure (spontaneous or provoked) that has caused fluid to be expelled from the bladder at the moment that it is visible outside the urethra (may also be used for extraurethral urine loss or stoma) (Rosier et al., 2017b). This term is inclusive of abdominal, cough or Valsalva, or detrusor LPP. When describing the LPP, provocation and the pressure recording site (e.g., the type of LPP) should be recorded.

From a practical standpoint, the LPP should be thought of as two distinct types: abdominal leak point pressure (ALPP) and detrusor leak point pressure (DLPP). The two are independent of each other and conceptually measure completely different things. Remember, they only occur in patients that have incontinence.

ALPP is a measure of sphincteric "strength" or, more practically, the ability of the sphincter to resist changes in abdominal pressure (McGuire et al., 1993)**. ALPP is defined as the intravesical pressure at which urine leakage occurs as a result of increased abdominal pressure in the absence of a detrusor contraction** (Abrams et al., 2002)**. This measure of intrinsic urethral function is applicable to patients with stress incontinence. An ALPP can only be demonstrated in a patient with SUI. Conceptually, the lower the ALPP, the "weaker" or less resistant the sphincter. There is no normal ALPP as patients without stress incontinence will not leak at any physiologic abdominal pressure. ALPP should be measured as the total abdominal pressure required to cause leakage, not the change in pressure**

(McGuire et al., 1993). Therefore, if ALPP is measured in the standing position, it should include the baseline p_{abd} (or p_{ves}), which is usually about 20 to 40 cm H_2O. Classically the reading is taken from the p_{ves} channel as long as there is no involuntary contraction (Fig. 114.7). In cases in which patients do not leak with a urethral catheter in place, the ALPP can be measured from the abdominal pressure channel either rectally or vaginally (Stohrer et al., 1999). The original description of ALPP was done at an arbitrary bladder volume of 150 mL; however, in some cases it is necessary to fill the bladder more. The volume at which ALPP is determined should be noted, as some investigators have found that it decreases at higher volumes (Faerber and Vashi, 1998). As a general rule, we start testing at 150 mL and then every 50 mL thereafter until SUI is demonstrated. If there is no SUI demonstrated at capacity, the urethral catheter is removed and ALPP is measured via the abdominal (usually rectal) catheter (provided there is no increase in p_{det} from DO or impaired compliance).

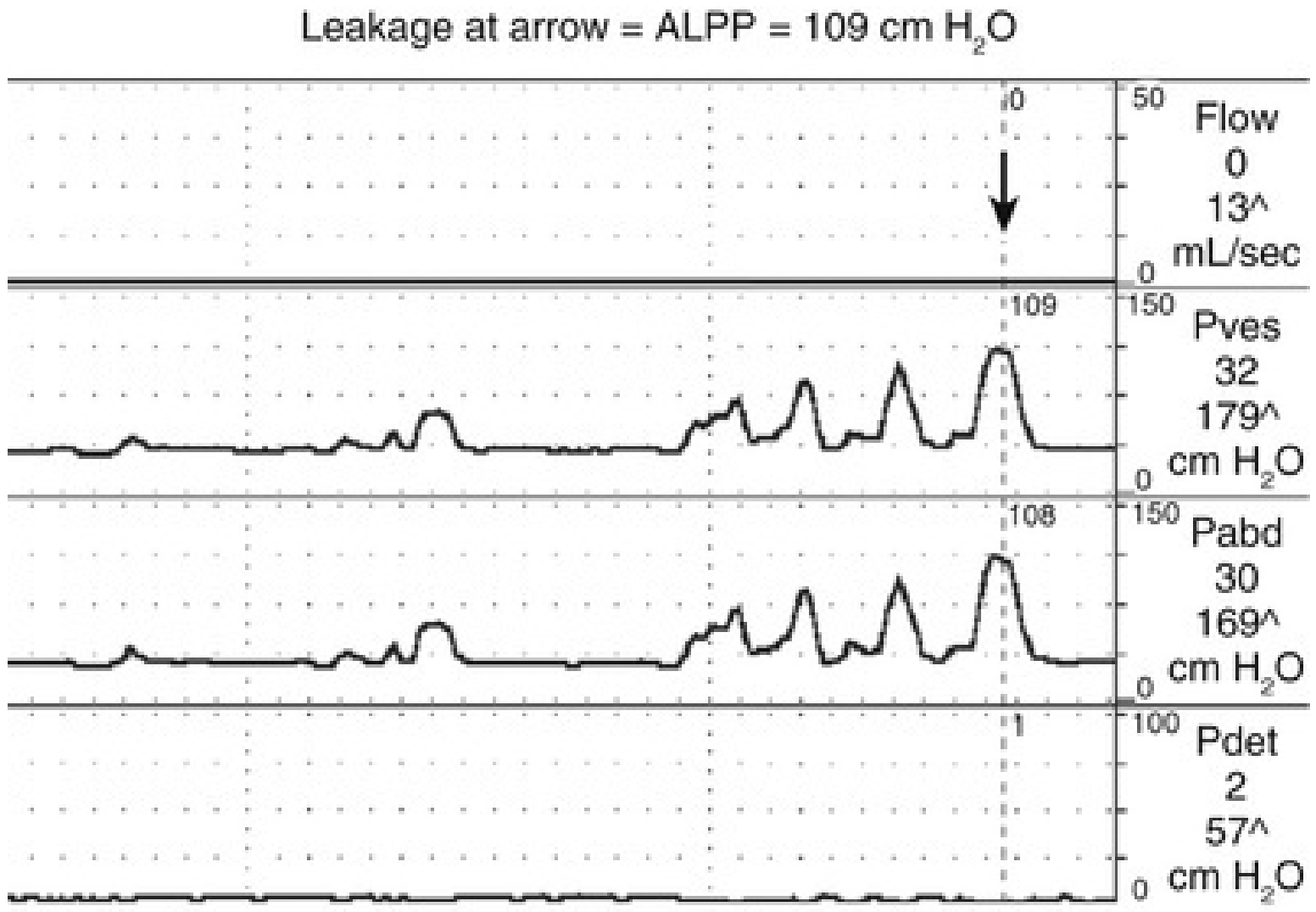

FIG. 114.7 Abdominal leak point pressure measurement. After progressive Valsalva maneuvers, leakage is demonstrated on the last one at 109 cm H_2O *(arrow).* There is no rise in Pdet.

Attempts have been made to quantify intrinsic sphincter deficiency (ISD) in women using ALPP. In 1993, McGuire et al. (1993) measured ALPP in 125 women with SUI. When the ALPP was less than 60 cm H_2O, all patients had high-grade incontinence, with 81% having continuous leakage and 75% having a fixed urethra (no urethral hypermobility). When ALPP was between 61 and 89 cm H_2O, 80% had pronounced urethral hypermobility and moderate to high-grade incontinence. When ALPP was 90 cm H_2O or greater, patients had lesser grades of incontinence and minimal to gross urethral hypermobility. The inference is that:

ALPP less than 60 cm H_2O signifies ISD.
ALPP between 60 and 90 cm H_2O is equivocal (there is a component of ISD).
ALPP greater than 90 cm H_2O indicates little or no ISD.

Current technology does not permit a method to distinguish between ISD in the face of urethral hypermobility (usually defined by placing a Q-tip in the urethra and assessing deflection from baseline to be greater than 30 degrees) in women. Therefore, although these ALPP values are often used as reference points, **they should be interpreted with caution.** For example, **if there is no urethral hypermobility, SUI must be caused by ISD, regardless of the ALPP.** Furthermore, Fleischmann et al. (2003) found that urethral hypermobility was equally common in women with lower versus higher ALPP. ISD and urethral hypermobility may coexist, and they do not define discrete classes of patients with SUI. Thus, an isolated measure of ALPP without considering other factors such as cystometry and urethral mobility is of limited utility in predicting success for commonly performed female SUI procedures (Hosker et al., 2009; Rosier et al., 2013). The use of ALPP in the diagnosis and treatment of female SUI is discussed further later in this chapter.

The term *ALPP* has been used interchangeably with *"Valsalva" leak point pressure (VLPP);* however, this is not entirely correct. ALPP can be measured during UDS by a voluntary Valsalva maneuver (VLPP) or by a cough leak point pressure (CLPP). In the same person, **VLPP tends to be significantly lower than CLPP.** Therefore, exact terminology and methods should be used when describing ALPP. ALPP can also be influenced by the presence or the size of a urethral catheter (Bump et al., 1995; Huckabay et al., 2005; Türker et al., 2010). It has been shown in women with SUI that the larger the catheter, the lower the ALPP. ALPP can also be measured without a urethral catheter by assessing the abdominal pressure via a rectal (vaginal or stomal) catheter. It has been shown that 15% of women with SUI (Türker et al., 2010) and 35% of men with postprostatectomy SUI will demonstrate ALPP only with the urethral catheter removed (Huckabay et al., 2005). Cough and Valsalva LPP are two ways to increase intraabdominal pressure, but we now have new terminology that is even more inclusive. ***Urodynamic stress test*** **is a new term that is defined as any physical effort used to elevate abdominal pressure during cystometry with the aim of examining SUI** (Rosier et al., 2017b).

The second type of leak point pressure is the detrusor leak point pressure (DLPP), which is a measure of detrusor pressure in a patient with decreased (poor) bladder compliance. It is defined as the lowest detrusor pressure at which urine leakage occurs in the absence of either a detrusor contraction or increased abdominal pressure (Abrams et al., 2002) **(see Fig. 114.5).** The higher the urethral resistance, the higher the DLPP will be. One can imagine that in a poorly compliant bladder, if outlet resistance is low, incontinence will occur at a relatively low or "safe" pressure. However, if outlet resistance is high, the pressure in the bladder will continue to increase as the bladder fills. There is potentially less incontinence, but eventually the pressure is transmitted to the upper tracts (Fig. 114.8).

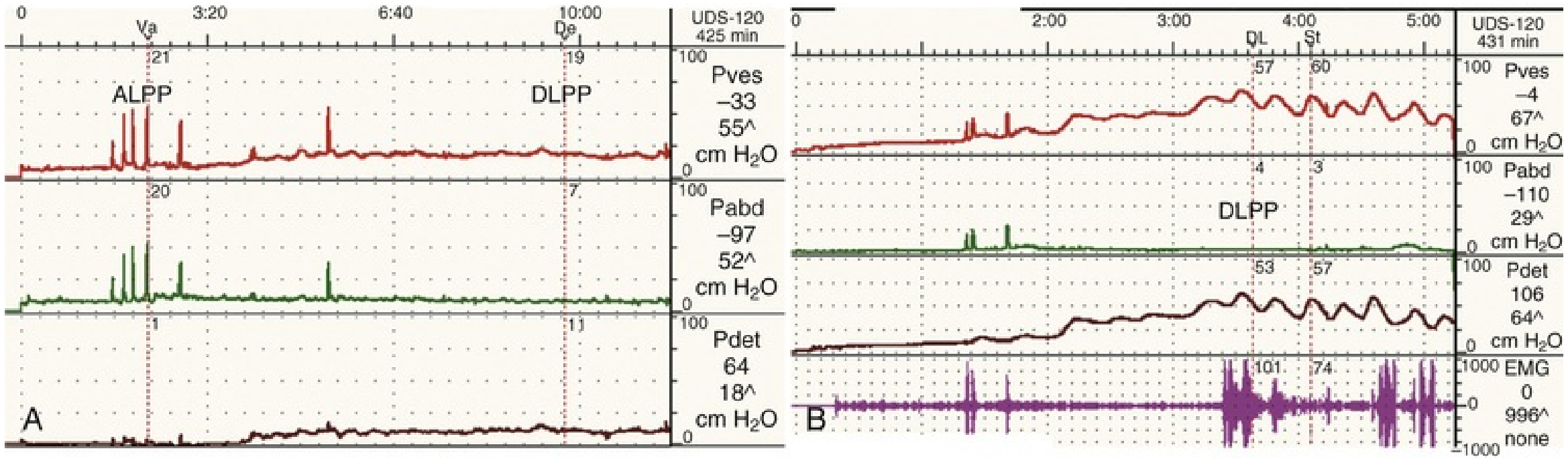

FIG. 114.8 Outlet resistance causes impaired compliance. UDS of two children with the same neurologic problem and symptoms but dramatically different findings. (A) UDS tracing of a young boy with spina bifida who is incontinent between catheterizations. The study shows a low-pressure system with poor outlet resistance and stress incontinence (ALPP demonstrated) and a low DLPP. His upper tracts are protected. (B) UDS tracing of a young girl with spina bifida who is incontinent between catheterizations. The study shows a high-pressure system with strong outlet resistance and a high DLPP. There was no stress incontinence. Her upper tracts are at risk. The difference in these two cases is the difference in storage pressures caused by the difference in outlet resistance.

From a clinical perspective, DLPP is important to assess in patients with upper motor neuron lesions with high storage pressures (usually secondary to DO and

DESD), patients with lower motor neuron disease causing “decentralization,” and in non-neurogenic patients with low bladder compliance (after multiple bladder surgeries, radiation, and tuberculous cystitis). The higher the DLPP, the more likely is upper tract damage as intravesical pressure is transferred to the kidneys. McGuire et al. (1981) documented the deleterious effects that a high detrusor leak point pressure has on the upper urinary tract; **a DLPP of greater than 40 cm H_2O resulted in hydronephrosis or vesicoureteral reflux in 85% of myelodysplastic patients. Although 40 cm H_2O clearly appears to be detrimental in the pediatric population that was studied, most experts would agree that there is limited evidence that an absolute cutoff of 40 cm H_20 should be used to determine a “safe” storage pressure. In reality, when treating impaired compliance, expert opinion leans toward the concept of aiming for as low a pressure that is “reasonably achievable”** (Rosier et al., 2013)**. This would be considerably below 40 cm H_2O in most cases.**

For example, more recent work in children with NLUTD (specifically myelodysplastic disease) suggests that a cut point for a DLPP of 20 cm H_2O had a higher sensitivity for upper urinary tract damage (91.5%) than the higher cut point of 40 cm H_2O (Tarcan et al., 2017). The original data regarding the high DLPP predicting upper tract deterioration were from retrospective cohort studies considered to be a low level of evidence. With more data and experience with this measure, the ICS published a teaching module in 2017 stating “that existing data confirm that patients with lower DLPP do better than patients with higher DLPP in terms of their upper urinary tract” (Tarcan et al., 2017). The idea of no reliable “safe/no safe” cutoff for DLPP is also echoed in a well-done systematic review of the value of urodynamic findings in predicting upper urinary tract damage in neurologic patients by concluding that a risk factor or upper tract deterioration is associated with simply “high detrusor leak point pressure” (not specifying a cutoff) (Musco et al., 2018). These papers acknowledged that there are urodynamic factors other than DLPP that influence upper urinary tract deterioration, such as compliance.

The significance of an elevated DLPP is that that bladder pressures are getting too high before the “pop-off” mechanism of urethral leakage occurs. In most cases, treatment is aimed at lowering bladder pressures so the DLPP is never reached. In some cases, DLPP can be lowered by decreasing outlet resistance, for example with a sphincterotomy in a patient with DESD. In these cases, follow-up UDS are useful to confirm the intended effect.

In summary, ALPP and DLPP—although both called “leak point pressure”—are completely different. The ALPP measures the sphincter response to increased abdominal pressure. The lower the ALPP, the “weaker” or less resistant the sphincter. The DLPP measures the injured bladder response to increased outlet resistance. The higher the resistance (e.g., DESD), the higher the DLPP, which is potentially dangerous to the upper tracts.

The ICS 2017 terminology for adult NLUTD also includes a new term for detrusor overactivity leak point pressure (Gajewski et al., 2017)**. As the name suggests, this is the lowest detrusor pressure rise with detrusor overactivity at which urine leakage first occurs. This is in the absence of voluntary detrusor contraction or increased abdominal pressure. The clinical significance of this will need to be further explored.**

Stress-Induced Detrusor Overactivity

Sometimes detrusor overactivity can be triggered by a rise in abdominal pressure (Fig. 114.9). Thus, the symptom may appear to be stress incontinence, but the condition causing the symptom is actually an involuntary contraction, not sphincteric weakness. In a patient with stress-induced detrusor overactivity (SIDO), it is important to note if there is also urodynamic SUI and/or DO independent of the SIDO. Similarly, the ICS (2017) has included in the term *cough-associated detrusor overactivity.* This describes DO (with or without leakage) occurring immediately after the cough pressure peak.

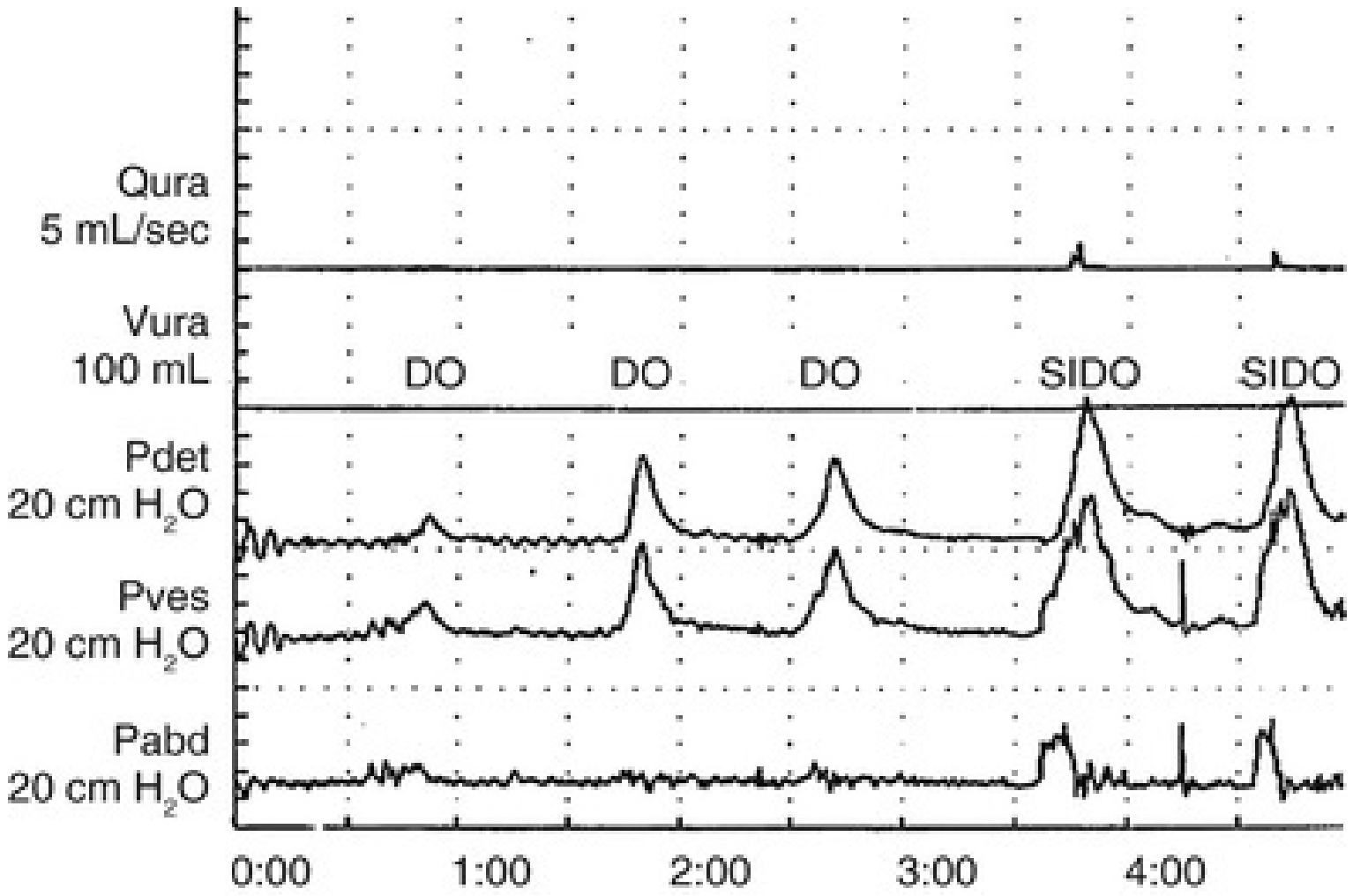

FIG. 114.9 Stress-induced detrusor overactivity. In this case, there are three episodes of detrusor overactivity *(DO)* preceding two episodes of

stress-induced detrusor overactivity *(SIDO).* In the case of SIDO, note that as Pabd increases so does Pves. Shortly after this, Pdet rises and continues long after Pabd returns to baseline. With both episodes of stress-induced overactivity, incontinence occurred as can be seen on the flow (Qura) curve. (From Nitti VW. Cystometry and abdominal pressure monitoring. In Nitti VW, ed. *Practical urodynamics*. Philadelphia, PA: WB Saunders; 1998:38–51.)

Occult Stress Incontinence

Stress incontinence on prolapse reduction, also referred to as *occult incontinence* or *latent stress incontinence*, is stress incontinence that is demonstrated in a clinically continent woman with pelvic prolapse only when the prolapse is reduced (Ballert et al., 2009; Haylen et al., 2010). Prolapse reduction can be done with a pessary, a packing, forceps, or manually. Technically, if this is demonstrated during urodynamic testing, it may be referred to as *urodynamic occult SUI.*

Urethral Pressure Profilometry

The method of urethral pressure profilometry (UPP) was popularized by Brown and Wickham in 1969 using small catheters with lateral apertures through which fluid is continuously infused (Brown and Wickham, 1969). Simultaneous bladder and urethral pressure is measured as the catheter is slowly withdrawn along the course of the urethra. The urethral pressure transducer measures the fluid pressure required to lift the urethral wall off the catheter side holes and thus elevates the circumferential and radial stresses induced by the presence of the catheter in the urethra and the slow urethral profusion. **Thus, urethral pressure is defined as the fluid pressure needed to just open a closed urethra** (Abrams et al., 2002). Accurate measurements are recorded only in those cases in which the urethra is distensible and therefore able to create a perfect seal.

Despite abundant literature on urethral profilometry, **its clinical relevance is controversial.** Many urologists do not routinely perform urethral profilometry. The urethral pressure profile (UPP) represents the intraluminal pressure along the length of the urethra in graphic form (Fig. 114.10). Several parameters can be obtained from the UPP:

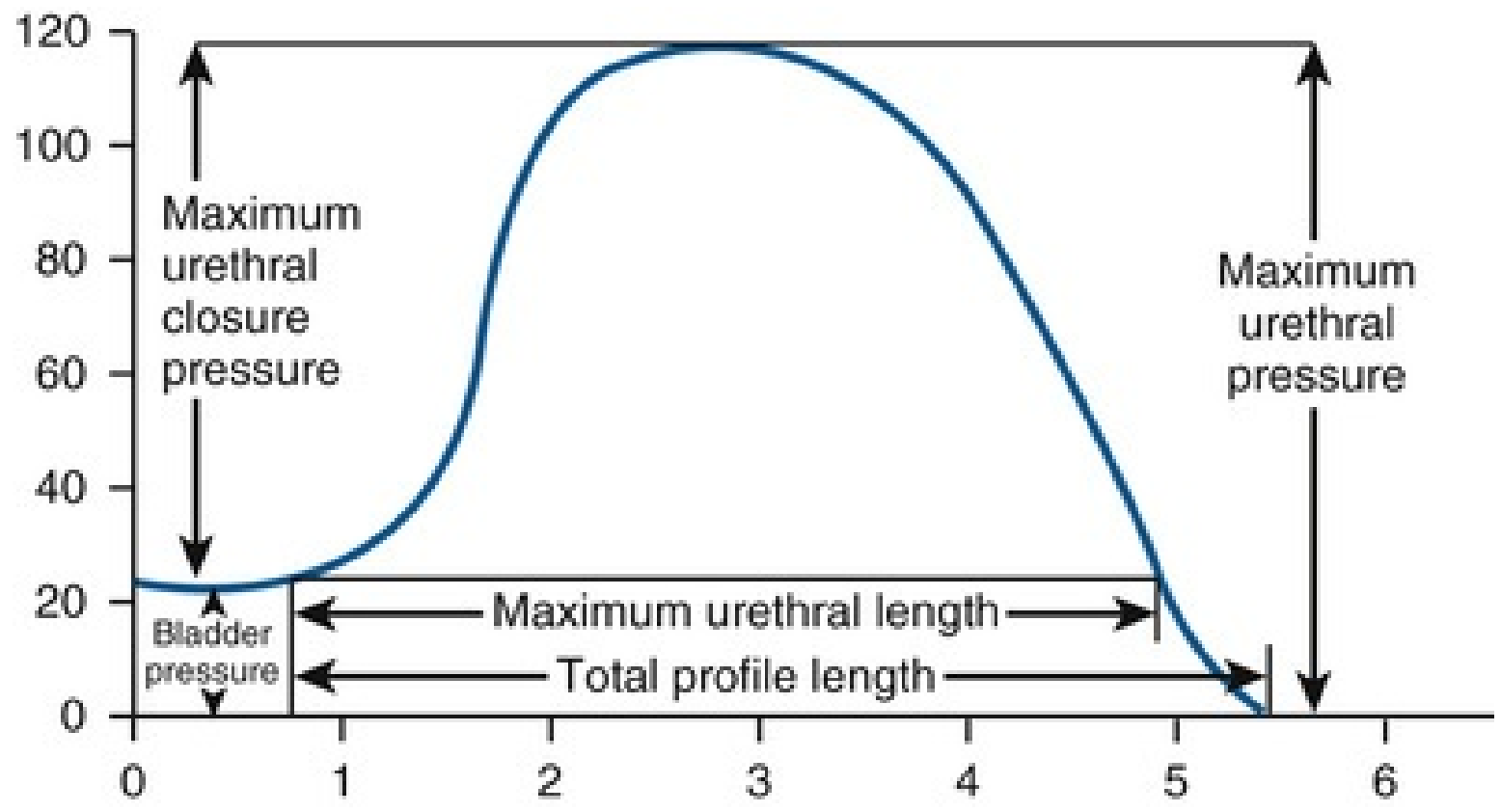

FIG. 114.10 Urethral pressure profile with appropriate parameters identified.

The urethral closure pressure (UCP) profile is obtained by subtracting intravesical pressure from urethral pressure.

Maximum urethral pressure (MUP) is the highest pressure measured along the UPP.

Maximum urethral closure pressure (MUCP) is the maximum difference between the urethral pressure and the intravesical pressure.

Functional profile length is the length of the urethra along which the urethral pressure exceeds intravesical pressure in women.

In most continent women, the functional urethral length is approximately 3 cm and the MUCP is 40 to 60 cm H_2O, but normal values vary widely. MUCP has also been used to define ISD. McGuire (1981) performed a retrospective evaluation of women who failed SUI surgery and found that a preoperative MUCP less than or equal to 20 cm H_2O resulted in higher surgical failure rates. These patients represented a specific subtype of SUI caused by a fixed, open urethra (type III SUI). In 1992, the term was redefined as ISD. **Many authors have used the definition of MUCP less than or equal to 20 cm H_2O to define ISD; however, this definition has many of the same problems as ISD definitions for ALPP.** Another caveat of UPP is that its measurement does not diagnose stress incontinence, and SUI is not required to measure it (contrary to ALPP). MUCP in incontinent women has been shown to be lower than in continent women, but there is certainly overlap (Schick et al., 2004). In addition, **MUCP is not always indicative of the severity of incontinence.** For example, there is a difference between the urethra of an incontinent patient whose MUCP

= 38 cm H_2O and that of a continent woman with the same MUCP.

In 2002, the ICS standardization subcommittee concluded that the clinical utility of urethral pressure measurement is unclear (Lose et al., 2002)**. Furthermore, there are no urethral pressure measurements that discriminate urethral incompetence from other disorders; provide a measure of the severity of the condition; or provide a reliable indicator to surgical success, and return to normal after surgical intervention** (Lose et al., 2002)**. In 2013, Rosier et al. reported that since the 2002 ICS report there is no new evidence, nor evidence regarding newer techniques, that intrinsic urethral pressure measuring quality has improved to a clinically relevant level with regard to sensitivity, specificity, and reliability. This recommendation was not altered in the 2017 edition (Rosier et al., 2017a).**

Voiding and Emptying Phase

Normal Voiding and Emptying

Evaluation of the voiding phase provides an assessment of both detrusor contractility and bladder outlet resistance. The bladder needs to contract and overcome the outlet resistance to allow for bladder emptying. In simple terms, abnormalities of bladder emptying are caused by “overactivity” of the bladder outlet (too much outlet resistance), “underactivity” of the detrusor (weak detrusor contraction force, short detrusor contraction duration, impaired contraction velocity), or a combination of both. The simultaneous measurement of detrusor pressure and urinary flow rate during voluntary voiding, known as a *pressure-flow study,* is the most accurate way to access these two critical parameters (Fig. 114.11).

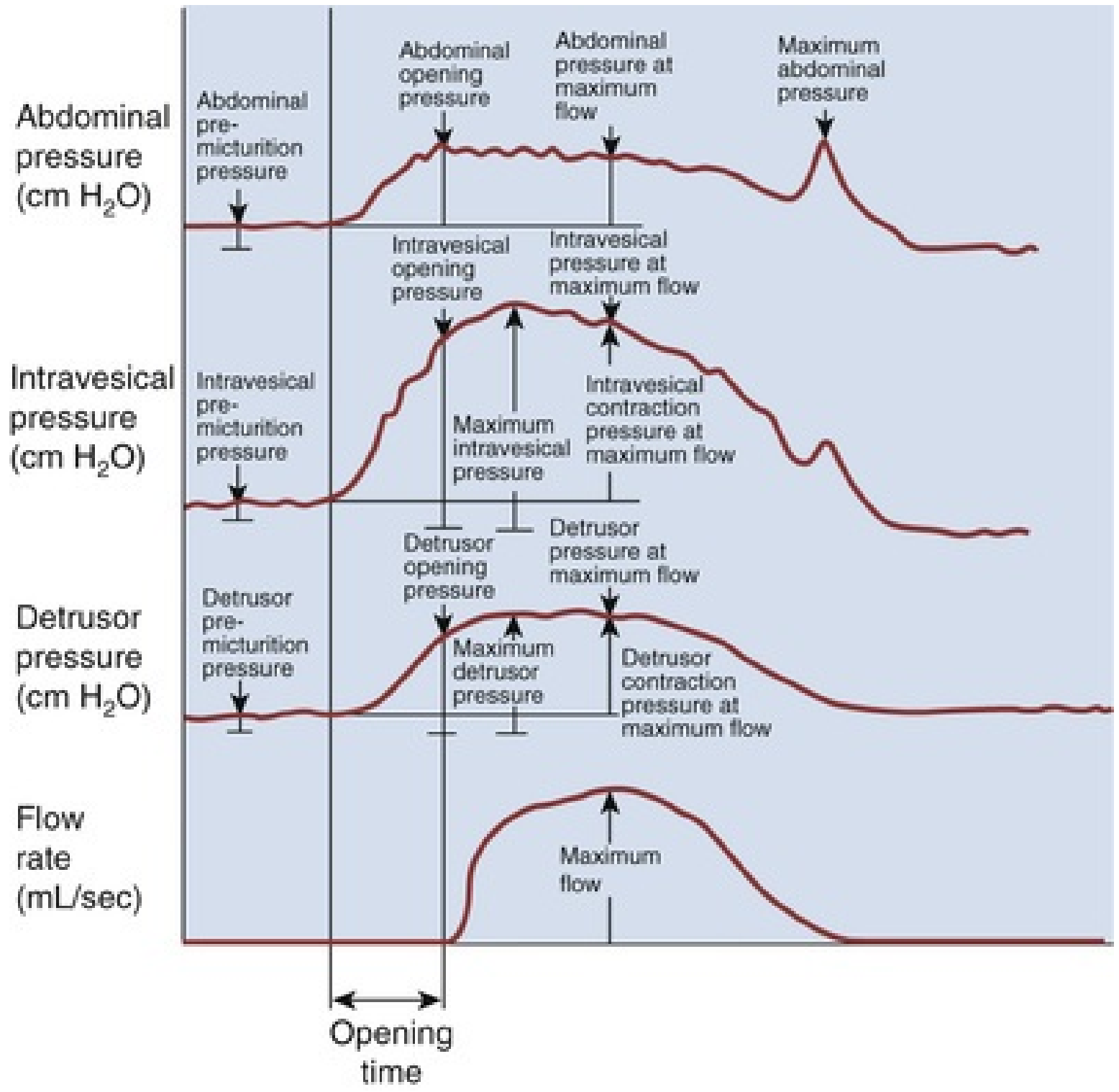
Abdominal pressure (cm H_2O)
Abdominal pre-micturition pressure
Abdominal opening pressure
Abdominal pressure at maximum flow
Maximum abdominal pressure
Intravesical pressure (cm H_2O)
Intravesical pre-micturition pressure
Intravesical opening pressure
Intravesical pressure at maximum flow
Maximum intravesical pressure
Intravesical contraction pressure at maximum flow
Detrusor pressure (cm H_2O)
Detrusor pre-micturition pressure
Detrusor opening pressure
Detrusor pressure at maximum flow
Maximum detrusor pressure
Detrusor contraction pressure at maximum flow
Flow rate (mL/sec)
Maximum flow
Opening time

FIG. 114.11 Schematic pressure-flow study labeled with recommended terminology.

When the void is "normal," the term *normal voiding function* can be used. This term indicates that flow rate and pressure-rise are within normal limits, begins more or less directly after permission to void, and ends with an empty bladder. When this does not occur during a urodynamic test, the term *bladder outflow obstruction* can be used; this is a cutoff of bladder outflow resistance based on the pressure-flow relation that is considered clinically relevant. It can be used in all patients regardless of age or gender (Rosier et al., 2017b).

To understand the relationship between bladder contractility and outlet resistance, one must start with an understanding of the normal micturition process. Normal voiding is accomplished by activation of the micturition reflex, which involves the following (Fig. 114.12):

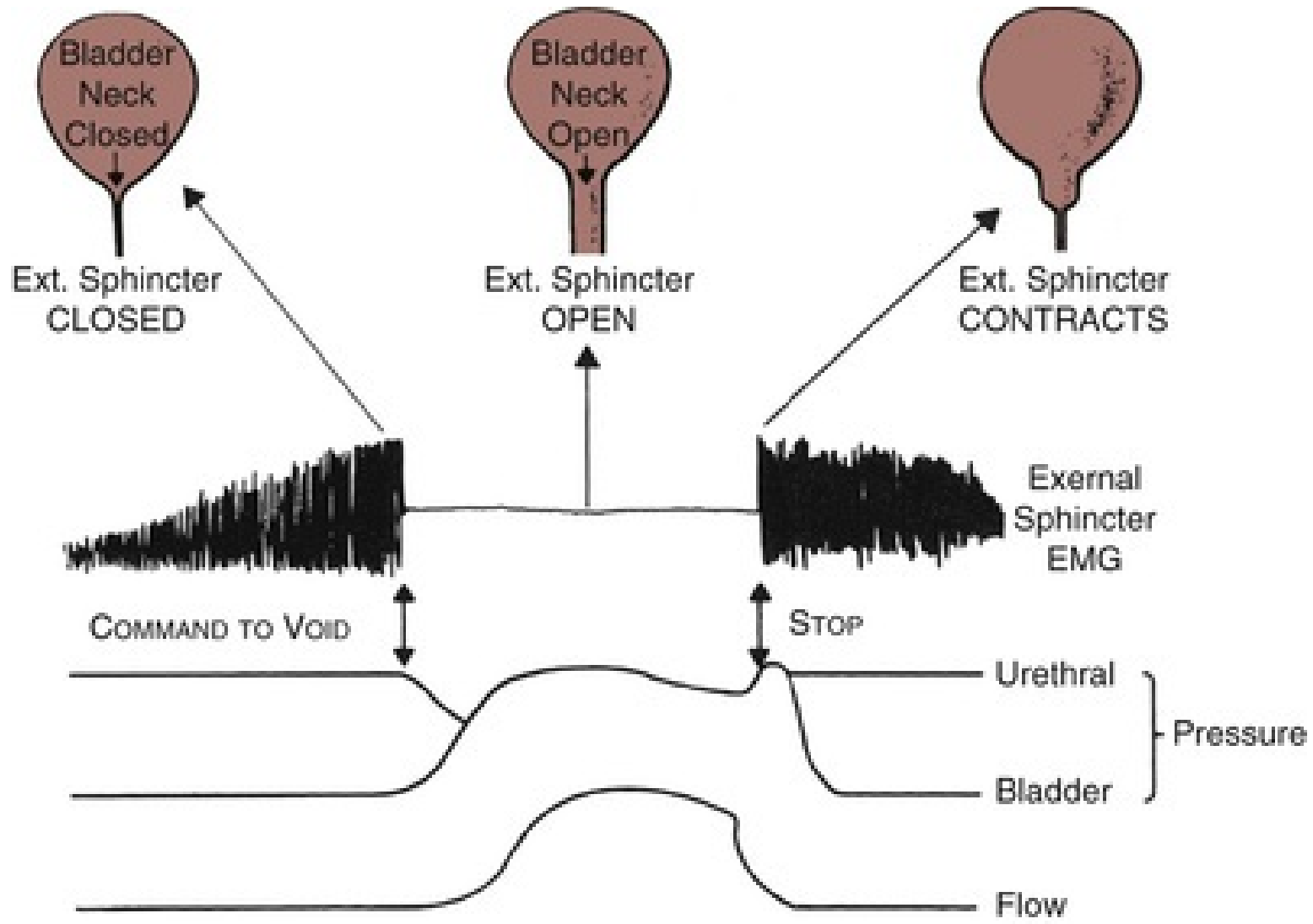
Bladder Neck Closed
Bladder Neck Open
Ext. Sphincter CLOSED
Ext. Sphincter OPEN
Ext. Sphincter CONTRACTS
Exernal Sphincter EMG
COMMAND TO VOID
STOP
Urethral
Bladder
Pressure
Flow

FIG. 114.12 Physiology of micturition. See text for details. (From Blaivas JG. Pathophysiology of lower urinary tract dysfunction. *Urol Clin North Am* 12(2):215–224, 1985.)

- Relaxation of striated urethral sphincter
- Contraction of detrusor muscle
- Opening of vesical neck and urethra
- Onset of urine flow

This occurs as a result of coordination between pontine and sacral micturition centers with suprapontine input that allows for voluntary control of the micturition reflex.

UDS can evaluate the critical parameters during the voiding phase, which include detrusor contractility, relaxation of the bladder outlet, and coordination of sphincters (Fig. 114.13).

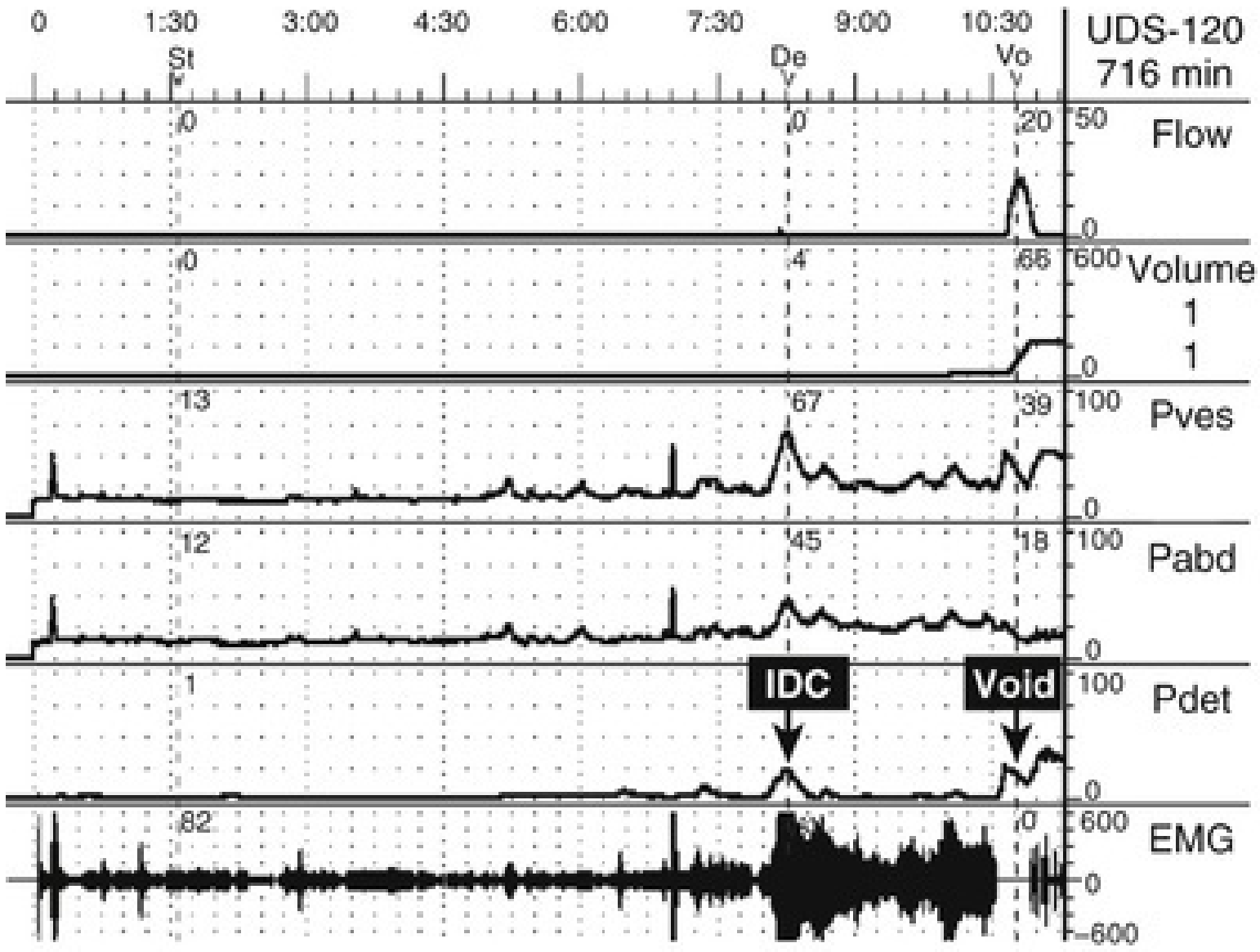

FIG. 114.13 Multichannel UDS showing filling and voiding phases with pressure and EMG readings. In this case, the patient experienced an IDC, which led to increased external sphincter contraction and an increase in EMG activity (guarding reflex). However, shortly after that, when the patient is given permission to void, there is quieting of the EMG (sphincter relaxation) followed by an increase in pdet and volitional voiding with a normal appearing uroflow curve.

According to the ICS, *normal detrusor function* is characterized by a voluntarily initiated continuous contraction that leads to complete bladder emptying within a normal time span and in the absence of obstruction. *Detrusor underactivity* occurs when there is a contraction of reduced strength and/or duration, resulting in prolonged bladder emptying and/or a failure to achieve complete bladder emptying within a normal time span. Finally, an *acontractile detrusor* occurs when there is no demonstrable contraction during UDS (Abrams et al., 2002). The term *areflexia* has been used in case of a neurologic cause of an *acontractile detrusor,* but it is now suggested that this term be replaced by ***neurogenic acontractile detrusor,* when appropriate** (Gajewski et al., 2017; Haylen et al., 2010).

The current definition of *detrusor underactivity* is hampered by the subjective interpretation of what constitutes reduced strength, reduced length of contraction, or prolonged emptying (Osman et al., 2014). Normal detrusor function and detrusor underactivity are somewhat “nebulously defined” in terms of absolute pressure because bladder pressure is influenced by outlet resistance. When evaluating detrusor function urodynamically, UDS must be correlated with clinical findings. For example, if a patient who normally voids is unable to void during a UDS, one cannot make a definitive diagnosis of “acontractile detrusor.” **If in the opinion of the person performing the test, in communication with the patient, the attempted voiding has not been representative, the term *situational inability to void as usual* can be used** (Rosier et al., 2017b). Specific measures of detrusor contractility are mentioned later in the text.

Urinary flow rate in combination with PVR is a useful clinical tool to assess emptying. When flow rate is reduced or PVR is elevated, it tells us that emptying is not complete, but it does not tell us why (e.g., obstruction vs. impaired contractility). Flow rate is also dependent on voided volume as there is a linear relationship between Q_{max} and voided volume, with a voided volume above and a hyperbolic relationship below a voided volume of 150 mL (Drach et al., 1979). Therefore, many authors have recommended a minimum voided volume of 150 mL to accurately assess uroflow. However, establishing a minimum voided volume puts major limitations on uroflowmetry as many patients with voiding dysfunction do not routinely void large enough volumes to be valuable. The corrected form of Q_{max} (Q_{max} divided by the square root of voided volume) may provide useful information in such patients (Boone and Kim, 1998). Over the years, several nomograms have been developed to define normal flow rates for a specified population and correct for voided volume. These include the Siroky nomogram for men (Siroky et al., 1979, 1980) and the Liverpool nomogram for men and women (Haylen et al., 1989).

The bethanechol supersensitivity test has been used to help distinguish the cause of detrusor underactivity as neurogenic or myogenic. It is based on Cannon's law of denervation, which states that denervated structures develop increased sensitivity to chemical stimulation. Lapides et al. applied this concept to the bladder (Lapides et al., 1962). The original bethanechol supersensitivity test described by these authors was performed by infusing liquid at a rate of 1 mL/sec to a volume of 100 mL, where the pressure is measured. This can be done up to three times and the pressure values averaged. The patient is then given 2.5 mg of bethanechol chloride (later revised to 0.035 mg/kg) subcutaneously, and the study is repeated at 10, 20, and 30 minutes. A normal bladder (or myogenically impaired bladder) should show an increase of less than 15 cm H_2O above the control value at 100 mL at 30 minutes. This is considered a negative study. A positive study, indicating a sensory or motor paralytic bladder, is a response of at least 15 cm H_2O above the control value. More recent studies have indicated that the bethanechol supersensitivity test is rather unreliable in predicting “neurogenic bladder.” Blaivas et al. (1980) reported only 76% sensitivity and 50% specificity. Even if the test were able to differentiate between neurogenic and myogenic dysfunction, treatment is often the same (e.g., clean intermittent catheterization). Bethanechol chloride, whether administered subcutaneously or orally, has not proven to be a consistently effective treatment for the underactive detrusor (Wein et al., 1978, 1980). In addition, a positive test does not predict improved voiding when it is used therapeutically**. Therefore, there is a very limited role for the use of the bethanechol supersensitivity test in clinical practice**.

Voiding Pressure-Flow Studies

Once the bladder is filled to cystometric capacity, the voiding portion of the pressure-flow study can begin. This examines the emptying phase of micturition. The same bladder and rectal (in some case vaginal or stomal) catheters are used while simultaneously collecting pressure data along with uroflowmetry. Ideally, such a study should assess a voluntary void. When there is flow of urine during an involuntary detrusor contraction, patients may contract the pelvic floor to prevent leakage. Such an event should be annotated on study. In addition, some subjects may have a difficult time voiding on demand in a public setting and with invasive monitoring in place. These stressors and the artificial environment of the testing need to be accounted for when interpreting the test.

As mentioned earlier, detrusor pressure during voiding is a function of outlet resistance. For a normal detrusor, the greater the outlet resistance is, the higher the detrusor pressure during voiding will be. This is accompanied by a reduced flow rate. A healthy bladder is able to overcome obstruction by contracting more forcefully, and, although flow may be slower, the bladder is able to empty itself. Over time, the detrusor may decompensate and may no longer be able to generate the necessary pressure to overcome obstruction. When this occurs, the result will be incomplete bladder emptying or retention of urine.

The voiding pressure-flow study helps assess two critical parameters related to the bladder and bladder outlet: detrusor activity (normal vs. impaired) and outlet resistance (obstructed vs. unobstructed). In general, the pressure-flow study can identify three fundamental conditions:

- Low (or normal) detrusor pressure and high (or normal) flow rate (normal, unobstructed voiding)

- High detrusor pressure and low (or normal) flow rate (obstruction)
- Low detrusor pressure with low flow rate (detrusor underactivity)

It is important to remember that these three categories are broad and general, and a final diagnosis should be made after considering UDS findings and the patient's clinical presentation (see later). It is also important to note that in cases of detrusor underactivity (i.e., low detrusor pressure and low flow), obstruction may coexist with detrusor underactivity, but making the “urodynamic diagnosis” of obstruction may not be possible if the detrusor is too decompensated.

The urodynamic manifestation BOO is high-pressure and low-flow voiding (or more practically speaking, increased pressure and reduced flow). Over time, if bladder decompensation results, detrusor underactivity or impaired contractility can result.

To use the common measures of obstruction and impaired contractility that are used today, it is important to understand basic bladder output and urethral resistance relations. Attempts to mathematically define urethral resistance date back to 1962 (Gleeson and Lattimer, 1962). Early equations calculating urethral resistance followed standard hydrodynamic formulae calculating outlet resistance. These concepts failed to consider that the urethra is not a rigid tube but rather has an active and distensible nature. They also failed to consider the importance of bladder volume. Rigid tube hydrodynamics were abandoned in favor of more dynamic ways to analyze micturition. In 1972, Griffiths introduced **bladder output relation (BOR),** which depicts the interrelations between bladder pressure and uroflow at a given volume and essentially measures the function of the bladder independent of the function of the urethra (Castro and Griffiths, 1972). Griffiths further defined a method to evaluate urethral resistance independent of bladder function, the **urethral resistance relation (URR).** According to this relation, as bladder pressure rises, the flow rate will be zero until the intrinsic bladder pressure equals the intrinsic urethral pressure. At this point, flow will start and the flow rate will rise rapidly with further increases in intrinsic bladder pressure. If pairs of simultaneously measured values of detrusor pressure and flow rate are plotted against each other throughout the course of a micturition event, a curve is obtained that shows the resistance to flow independent of detrusor function, representing the urethral resistance relation. If the urethra were relaxed or tightened during voiding, the

URR would move toward the left or right, respectively. Because the BOR represents the function of the bladder independent of the urethra and the URR depicts urethral function independent of bladder function, the actual detrusor pressure and flow rate are determined by the intersection of the bladder output relation and the urethral resistance relation, which is the point at which intrinsic bladder pressure equals urethral pressure (Fig. 114.14). A change in one of these relations during micturition would not affect the curve representing the other relation but would result in the point of intersection to moving along that curve.

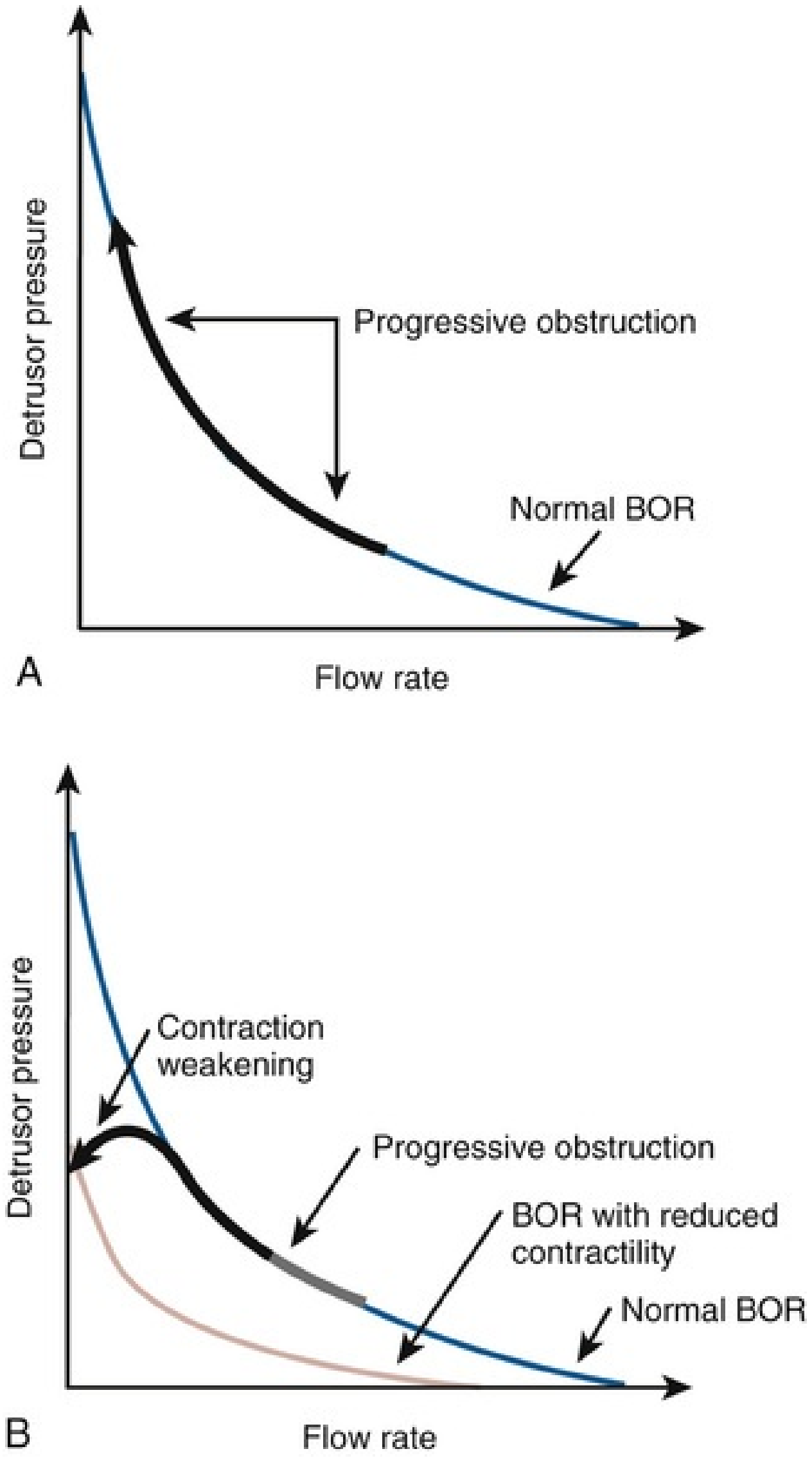

FIG. 114.14 (A and B) Relationship between detrusor pressure and flow in a given person—the bladder outlet relation. See text for details. (From Griffiths DJ. The mechanics of the urethra and of micturition. *Br J Urol*

45:497–507, 1973.)

In cases of suspected detrusor underactivity, a stop test can be performed. This is done by voluntary or mechanical interruption of urine flow during voiding (i.e., occluding the urethra). This allows for an estimation of isovolumetric detrusor pressure (P_{iso}) (Sullivan and Yalla, 2007). In a voluntary ‘ ‘stop test,’ ’ patients interrupt flow midstream by contracting the external urethral sphincter. In a mechanical “stop test,” interruption involves blocking the urethra by pulling a catheter balloon against the bladder neck during midstream or clamping or squeezing the urethra. In a continuous occlusion test, the outflow is occluded before the onset of detrusor contraction and the patient is asked to void against the occlusion. The three techniques show good correlation with each other in both men (Sullivan et al., 1995) and women (Tan et al., 2003). However, the voluntary stop test gives a lower P_{iso} than the other two (Sullivan et al., 1995).

Bladder Outlet Obstruction and Detrusor Underactivity in Men

The value of making a precise diagnosis of obstruction in men comes from the assumption that the outcomes of surgery to treat benign prostatic hyperplasia (BPH) and its consequent lower urinary tract symptoms (LUTS) are improved when obstruction can be documented. Because BPH and benign prostatic obstruction (BPO) are highly prevalent conditions, it was intuitive to use them as a model for defining obstruction. Most of the analytical work has focused on defining obstruction-based PFS. Three well known nomograms based on PFS have been described to diagnose men as obstructed, equivocal, or unobstructed. **These are the Abrams Griffiths nomogram** (Abrams and Griffiths, 1979)**; the Urethra Resistance Factor (URA)** (Griffiths et al., 1989)**; and the Linear Passive Urethral Resistance Relation or Schafer nomogram** (Schafer, 1990). The categories of obstruction described in these nomograms are based on observations of men who underwent surgery for LUTS (mainly transurethral resection of the prostate, TURP). After surgery, the detrusor pressure at maximum flow ($p_{det}Q_{max}$) was reduced in the obstructed group, reduced unpredictably in the equivocal group, and unchanged in the unobstructed group. Subsequently, Lim and Abrams (1995) showed that patients were similarly classified by all three methods. **They described a number, the AG number (now known as the bladder outlet obstruction index [BOOI]) derived from**

the equation for the slope of the line dividing obstructed from equivocal in the Abrams Griffiths nomogram, which is the same line dividing obstructed from slightly obstructed in the Schafer nomogram: BOOI = $p_{de}tQ_{max}$-2(Q_{max}). Subsequently Griffiths et al (1997) (**Fig. 114.15**) **described the ICS provisional nomogram which is now suggested for use for the diagnosis of obstruction in men with LUTS suggestive of BPH** (Abrams 1999)**. Men are considered obstructed if BOOI ≥40, unobstructed if BOO ≤20, and equivocal if BOOI is 20 to 40.**

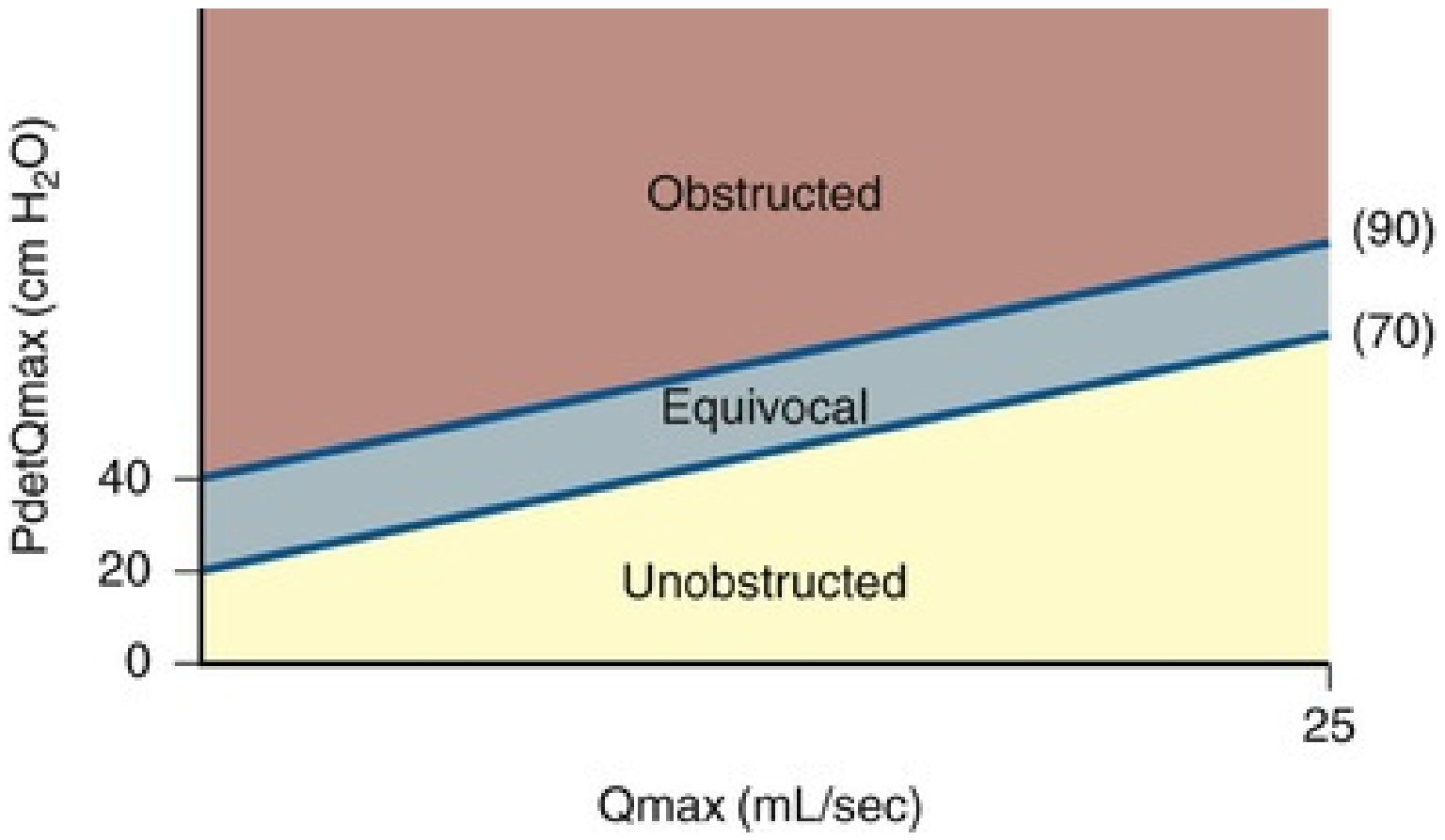

FIG. 114.15 The Provisional International Continence Society nomogram. See text for details.

Voiding pressure-flow studies show consistent reproducibility in the diagnosis of BOO in men. In a review of the topic Abrams et al. (2001) concluded that random variations of about 9 to 14 cm H_2O in pressure measurement and about 0.4 to 2 mL/s in maximum flow rate occur. In repeated studies during the same session, there was usually a systematic decrease of up to 4 cm H_2O in detrusor pressure and 0.4 mL/s in maximum flow rate. These variations have little clinical importance as they cause only 10% to 16% of patients to change classification on the ICS nomogram, and in all but about 1% the change is only by one class (e.g., from equivocal to unobstructed or from obstructed to equivocal).

Although much effort has focused on defining outlet resistance (i.e., obstruction), an index for bladder contractility can also be derived from the contractility groups Schafer (1995) described (strong, normal, weak, very weak). The **slope of Schafer's lines, now known as the bladder contractility index (BCI), is given by the formula: $p_{det}Q_{max}$ + 5(Q_{max})** (Abrams, 1999)**. Strong**

contractility is a BCI greater than 150; normal contractility is a BCI of 100 to 150; and weak contractility is a BCI less than 100 (Fig. 114.16). The BCI is the most common measure of bladder contractility used today because of its easy calculation and relationship to the BOOI and ICS nomogram.

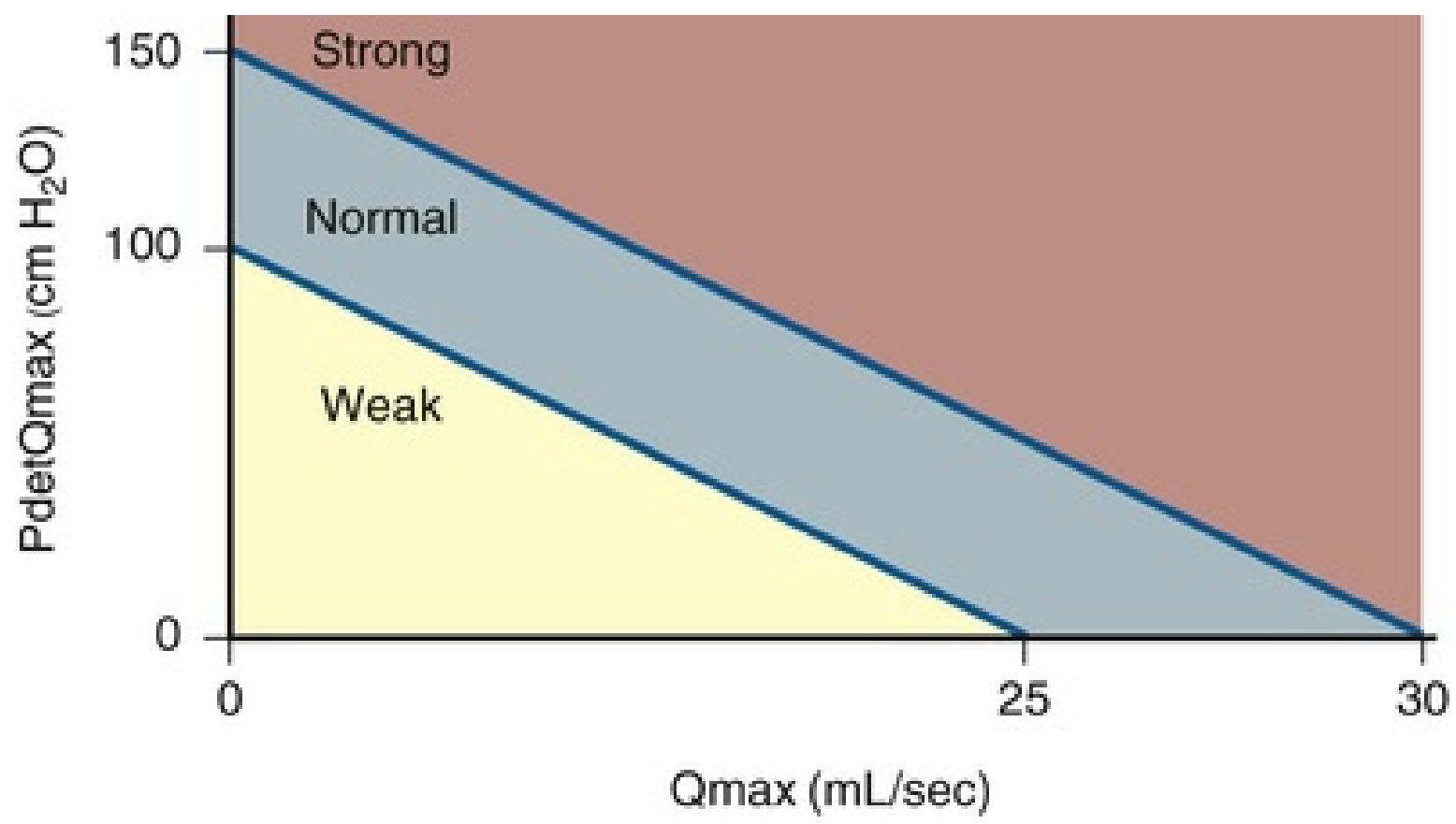

FIG. 114.16 The bladder contractility nomogram. See text for details.

Although contractility and obstruction can be independently measured, it is sometimes impossible to diagnosis obstruction in the face of detrusor underactivity using the ICS or other nomograms. For example, to make a diagnosis of unequivocal obstruction, BOOI must be at least 40 cm H_2O. That means that a p_{det} of at least 40 cm H_2O must be generated, and that assumes flow is zero. If the Q_{max} is 5 mL/s, then $p_{det}Q_{max}$ must be at least 50 cm H_2O. Thus, the ICS nomogram can exclude obstructed patients whose impaired contractility is the result of long-term obstruction. In such cases, clinical judgment becomes important.

Another measure of detrusor function is the Watts factor (WF), a quantification of detrusor power by a formula that estimates the power per unit area of bladder surface generated by the detrusor, corrected for the finite power required for either isometric contraction or for shortening against no load.

$$WF = [(P_{det} + a)(V_{det} + b) - ab]/2\pi$$

where V_{det} represents detrusor shortening velocity, and a and b are fixed constants (a = 25 cm H_2O; b = 6 mm/s), obtained from experimental and clinical studies (Griffiths, 1991).

Because detrusor pressure and velocity vary during the voiding phase, so too does the WF. Two points have been proposed as the most representative of detrusor contractility: the maximum WF (WF_{max}) (Griffiths et al., 1989) and the WF at maximum flow (W_{qmax}). An advantage of the WF calculation is that it depends minimally on bladder volume (Griffiths, 1991) and is not affected by the presence of BOO (Lecamwasam et al., 1998). However, it does not provide a measure of contraction sustainability and involves a complex calculation, limiting its use in clinical practice (Osman et al., 2014). In addition, threshold values for normal have not been validated; however, some have suggested using a W_{max} value of 7.0 W/m^2 (van Koeveringe et al., 2011).

BOO is associated with abnormalities of storage as well. This is presumably caused by changes in ultrastructure that occur with obstruction. Detrusor overactivity and impaired compliance occur in conjunction with obstruction. For example, about two-thirds of men with symptomatic BPO have DO that resolves 50% to 67% of the time with treatment of obstruction (Abrams et al., 1979). Reduced compliance is also associated with obstruction and has been shown to improve with treatment of obstruction (TURP) (Leng and McGuire, 2003).

An alternative to voiding pressure-flow studies as a way of measuring outlet resistance is the **micturitional urethral pressure profile (MUPP),** or voiding profilometry. This technique, popularized by Yalla, can both diagnose and localize obstruction (Yalla et al., 1980, 1981). The MUPP is performed with a triple-lumen catheter under fluoroscopic guidance similar to the static UPP described earlier. During voiding, the catheter is slowly withdrawn and the pressure is measured from the bladder neck through the anterior urethra (Steele et al., 1998). Normally during voiding, the pressure in the bladder is isobaric with the prostatic urethra and then pressure decreases across the membranous urethra and gradually decays along the rest of the anterior urethra. The membranous urethra is the narrowest segment of the bladder outlet during voiding, which accounts for the expected pressure drop of 20 to 30 cm H_2O. In patients with obstruction secondary to BPH, the MUPP is quite different. One will typically see a pressure disparity somewhere along the prostatic urethra. When this pressure disparity is greater than 5 cm H_2O, obstruction at the point of pressure drop is present. MUPP has been shown to be as effective in diagnosing BOO as standard PFS (DuBeau et al., 1995). An analysis of symptomatic BPH patients has shown that successful treatment outcomes have been achieved with treatment based on MUPP results (Lecamwasam et al., 1994).

In cases in which it is difficult to differentiate obstruction from detrusor underactivity by standard pressure-flow dynamics (e.g., in men with inefficient emptying in whom neither obstruction nor detrusor underactivity can be diagnosed by standard pressure-flow studies), P_{iso} can be measured by a stop test (see earlier). In men, a P_{iso} less than 50 cm H_2O is uncommon and has been considered to be diagnostic of detrusor underactivity (Comiter et al., 1996; Sullivan and Yalla, 1996).

Donkelaar et al. (2017) compared three methods to determine detrusor contraction strength in adult men including: LinPURR, BCI, and W_{max}. This retrospective comparison of more than 1200 UDS found all methods correlated well. The authors concluded that the LinPURR method was simple and intuitive. Further, this method had the advantage of combining detrusor contraction and bladder outflow obstruction simultaneously. WF_{max} calculation was suggested as a potentially used tool in studies aiming to improve detrusor contractility.

Currently urodynamic studies are “required” to diagnose detrusor underactivity, but there are no standardized criteria included in the ICS definitions for the “normal duration of detrusor contraction” and a “normal time span of micturition” (Abrams et al., 2002; Yang et al., 2018). This means there is no universal criteria to diagnose detrusor underactivity.

Bladder Outlet Obstruction in Women

BOO in women can present more of a diagnostic dilemma than in men. Because there is no highly prevalent condition (like BPH) that causes female obstruction, it is difficult to establish nomograms. Furthermore, nomograms derived for men cannot be applied to women as voiding dynamics differ. In addition, anatomic differences allow many women to empty their bladders by simply relaxing the pelvic floor, and some will augment voiding by abdominal straining. Minor elevations in detrusor pressure or decreases in flow rate, which might be considered insignificant in the male population, might signify BOO in women. Accordingly, clinicians must have a high index of suspicion based on the presence of lower urinary tract symptoms, incomplete emptying, persistent urinary tract infections, and a history of anti-incontinence surgery, prolapse, or other conditions.

In an effort to develop cutoff values for pressure and flow for the diagnosis of obstruction in women, Chassagne et al. studied a group of “clinically obstructed women” (after incontinence surgery; secondary to cystocele; or “other etiologies”) and compared them to a group of controls (women with stress incontinence) (Chassagne et al., 1998). Using receiver operator (ROC) curve analysis, they found the optimum sensitivity and specificity for predicting obstruction was obtained with a Q_{max} less than or equal to 15 mL/s and a $p_{det}Q_{max}$ of greater than or equal to 20 cm H_2O (74.3% sensitivity and 91.1% specificity). In 2000, with an expanded population, Lemack and Zimmern (2000) revised this to Q_{max} less than or equal to 11 mL/s and $p_{det}Q_{max}$ greater than or equal to 21 cm H_2O as optimal for the selection of patients with BOO. In the most recent publication, Defreitas et al. (2004) used normal asymptomatic women as the control group and found the highest sensitivity and specificity for predicting obstruction was obtained with Q_{max} less than or equal to 12 mL/s and $p_{det}Q_{max}$ greater than or equal to 25 cm H_2O. These cut-point studies have some limitations, namely obstruction was predefined clinically, and only patients with anatomic obstruction were included. Women with functional obstruction (e.g., from primary bladder neck obstruction or dysfunctional voiding) were not included in any of the cut-point analyses. This would be a difficult group of women to define “clinically” without any testing. Brucker et al. (2013) compared urodynamic findings of women with anatomic and functional outlet obstruction. Given the similarities in voiding pressure and large flow rate overlap, the authors suggest that future work attempting to characterize BOO in women need not exclude either group.

In 1999, Nitti et al. showed that the addition of fluoroscopic imaging to urodynamics was helpful in diagnosing female BOO (see Videourodynamics section later in this chapter). In this study, patients were classified as obstructed if there was radiographic evidence of obstruction between the bladder neck and distal urethra in the presence of a sustained detrusor contraction of any magnitude. In addition to diagnosing BOO, it also localizes the site of obstruction and allows for the diagnosis of obstruction in the face of impaired contractility if indeed the site can be localized. **With both the videourodynamic and cut-point criteria, there is a significant difference in mean Q_{max} and $p_{det}Q_{max}$ in the group of obstructed women versus the group of unobstructed women, but there is a large overlap of values between obstructed and unobstructed patients. This demonstrates that absolute pressure and flow values are imprecise and that another parameter (e.g., radiographic or clinical evidence of obstruction) is necessary for diagnosis.**

Blaivas and Groutz (2000) presented a nomogram for defining female BOO. Citing the fact that in their series there was a significantly higher flow rate in the same woman without a catheter, they choose to use a noninvasive flow rate in their nomogram. Also, because they found no statistical difference between $p_{det}Q_{max}$ and $pdet_{max}$ in obstructed or unobstructed patients, they choose $pdet_{max}$ as the pressure parameter. Using cluster analysis to classify patients with low- and moderate-grade obstruction, they formulated the nomogram. The nomogram places women into four zones: no, mild, moderate, and severe obstruction. An obvious criticism of the nomogram is that it is based on two separate voids (invasive and noninvasive), and one must assume that the pressure characteristics of the void are the same. Akikwala et al. (2006) compared the three methods of diagnosing BOO in women and found good concordance between the videourodynamic and cut-point criteria. They also noted that the Blaivas-Groutz nomogram overdiagnosed obstruction compared with the other two methods.

Obstruction in women cannot be defined by the ICS nomogram or the BOOI, as these will grossly underestimate female BOO. This is because normally women void at much lower pressures than men, and therefore the obstructed female bladder outlet may not respond as dramatically (or at least with the same pressures) as in the male. There is no condition in women that causes BOO as commonly as BPO in men, and therefore creating a consistent standard is difficult. Thus, concepts are the same (higher pressure and lower flow), but the values are different and less well defined. Those who are interested are referred to suggested readings (Akikwala et al., 2006; Blaivas and Groutz, 2000; Defreitas et al., 2004; Nitti et al., 1999).

More recently, the Solomon-Greenwell nomogram was described to diagnose BOO in women (Solomon et al., 2017). The authors used radiographic obstruction (VUDS criteria) as the referent. Here a cohort of 185 women were plotted $P_{det}Q_{max}$ against Q_{max}, and cluster analysis was performed to determine an axis that best divided the definitely obstructed and unobstructed (functional and anatomical obstruction). The yielded an axis of $P_{det}Q_{max} = 2 \times Q_{max}$. Using an additional 350 women added to the cohort, they calculate a nomogram representing the probability of obstruction. **Presented as a mathematical formula, if $P_{det}Q_{max} - 2.2 \times Q_{max}$ is less than 0, there is a less than 10% chance of obstruction; if it is greater than 5, there is likely obstruction (50%); and if it is greater than 18, obstruction is almost certain (>90%).**

Theoretically, one can consider measuring P_{iso} via a stop test in women to measure detrusor strength and to help differentiate between detrusor underactivity and obstruction. P_{iso} has not been used to accurately characterize women. However, it is known that P_{iso} values are significantly lower in older women than in men. Tan et al. (2003) showed that the mean P_{iso} in women at least 53 years of age with urgency incontinence was 31.2, 47.2, and 48.7 cm H_2O for the voluntary, mechanical, and continuous stop test, respectively.

Detrusor underactivity as its own condition has also gained more interest recently in women, but like in men, there is still no agreed universal criteria. Yang et al. (2018) studied a large cohort of women with VUDS and found that those with detrusor underactivity (defined as women who did not have a voiding detrusor contraction of more than 10 cm H_2O and needed to void by abdominal straining, or were unable to void) had decreased bladder sensation compared with the normal group and other voiding dysfunctional groups. Further, they describe a negative association between detrusor contractility and bladder sensation in linear regression.

Sphincter Coordination

The External Sphincter

Normal voiding requires external sphincter relaxation followed by contraction of the detrusor. The external sphincter (and internal sphincter) should remain relaxed until voiding is complete. In normal voluntary voiding, a rise in detrusor pressure is preceded by a fall in urethral pressure and relaxation of the external sphincter as measured by electromyography (EMG). The sphincter and urethral pressure remain low during voiding and then increase when voiding is completed **(Fig. 114.17). Failure of the sphincter to relax or stay completely relaxed during micturition is abnormal** (Abrams et al., 2002)**. Thus, normally EMG activity decreases before a voluntary bladder contraction; however, it is not abnormal for EMG activity to increase with an involuntary contraction as part of a guarding reflex to inhibit the IDC (see Fig. 114.13).**

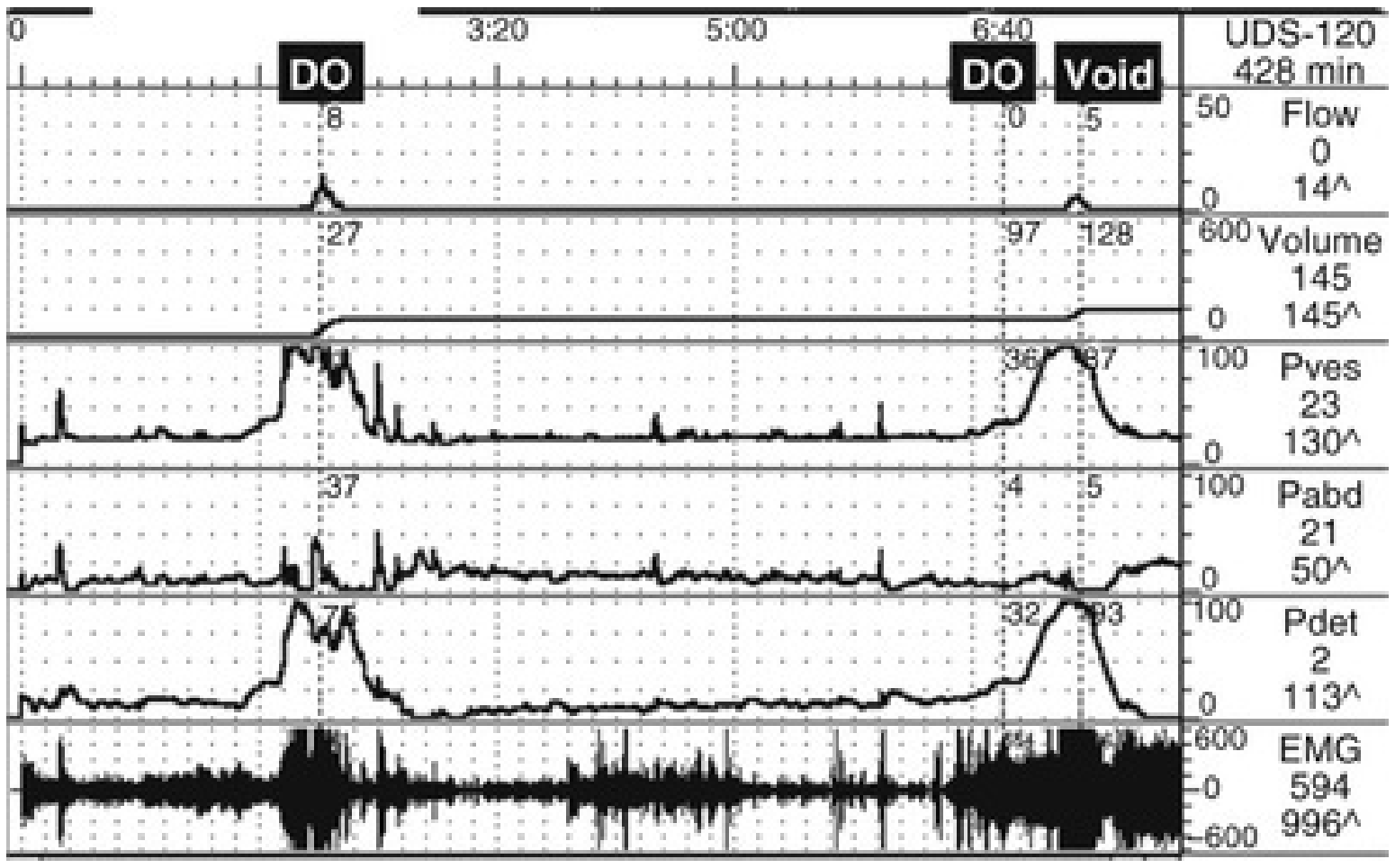

FIG. 114.17 UDS tracing of a patient with myelodysplasia and neurogenic DO and DESD. Note the initial IDC associated with DESD and incontinence (measured on the flow channel). With refilling, there is again DO with DESD. Then the patient is told to voluntarily void, and there is persistent increased EMG activity. As a result, there is high-pressure, low-flow voiding (obstruction from the dyssynergic sphincter).

There are several abnormalities related to external sphincter relaxation (or lack thereof). **DESD occurs when there is an involuntary increase in external sphincter activity associated with DO and also with voiding (see Fig. 114.18). It is caused by a neurologic lesion in the suprasacral spinal cord. DESD can produce profound changes as the detrusor involuntarily contracts against a relatively closed sphincter. This will result in high pressures and can even cause impaired bladder compliance over time. Because long periods of elevated detrusor pressure during bladder filling or (abnormally prolonged) voiding put the upper urinary tract at risk, DESD may be considered a urodynamic risk factor for upper tract deterioration (see Table 114.1)** (Kurzrock and Polse, 1998; McGuire et al., 1996; Tanaka et al., 1999)**. True DESD only occurs when there is a known neurologic lesion above the sacral micturition center. The higher the lesion, the more likely DESD will occur** (Blaivas, 1982)**. If there is no neurologic lesion, then the "dyssynergia" is considered to be a learned behavior and is known as *dysfunctional voiding*.** The term *dysfunctional* describes malfunction (failure to relax or involuntarily contraction of the external sphincter) during the voiding phase only and says nothing about the storage phase (Neveus et al., 2006). However, it is entirely possible and quite common for a patient to experience storage symptoms (and UDS abnormalities) associated with dysfunctional voiding. Although the condition has been extensively described in children, it has also been described in adult men (He et al., 2010; Kaplan et al., 1997; Nitti et al., 2001) and women (Carlson et al., 2001) and can be a major cause of LUTS. It is recommended that when dysfunctional voiding is diagnosed by UDS, the flow pattern (reduced and/or intermittent) is confirmed by noninvasive uroflowmetry to rule out a test-induced phenomenon (Barrett and Wein, 1981; Carlson et al., 2001). Other studies have suggested increase diagnostic accuracy of dysfunctional voiding using fluoroscopy at the same time as pressure-flow studies (Brucker et al., 2012). He et al. (2010) used the following diagnostic criteria in men: no abnormality detected in the history; no symptoms on examination for neurologic diseases; transient and intermittent closure of the external sphincter during voiding detected by EMG and fluoroscopic cystourethrography; and higher external sphincter EMG activity with no abdominal pressure increase in the voiding phase. Uroflowmetry was assessed individually to show any discontinuity in a diagram of urinary flow, in conditions with as little external interference as possible.

The urethral sphincter can also be described as “nonrelaxing,” resulting in reduced urine flow. The term *delayed relaxation of the urethral sphincter* is also used to described hindered relaxation during an attempt at voiding (resulting in delay of urine flow) during pressure-flow studies of adults with neurologic lower urinary tract dysfunction (Gajewski et al., 2017).

The Internal Sphincter

Just as there can be a lack of coordination of the detrusor and external sphincter, so too can there be dyscoordination of the internal sphincter or bladder neck. In the case of neurologic disease, if a suprasacral spinal cord lesion is above the level of the sympathetic ganglia (T10 to L1), detrusor–internal sphincter dyssynergia (DISD) may occur in conjunction with external sphincter dyssynergia (Pan et al., 2009). In non-neuropathic men, women, and children, the phenomenon of bladder neck dyssynergia or primary bladder neck obstruction is a well-known cause of LUTS, although its exact etiology is not known (Combs et al., 2005; Diokno et al., 1984; Norlen and Blaivas, 1986). Conditions of internal sphincter dysfunction require videourodynamics for an exact diagnosis and are described in the next section.

Key Points

- Normally detrusor pressure should remain near zero during the entire filling cycle until voluntary voiding is initiated.
- The ability to calculate subtracted p_{det} allows one to distinguish between a true rise in detrusor pressure (either via a contraction or loss of compliance) and the effect of increased abdominal pressure.
- It is important that the person performing the UDS be absolutely sure that a bladder contraction is indeed involuntary. Sometimes patients become confused during the study and actually void as soon as they feel the desire.
- “Usual lower urinary tract behavior” is not always replicated in the test setting.
- As a general rule, prolonged storage at high pressures can lead to upper tract deterioration.
- ALPP and DLPP, although both called “leak point pressure” are completely different. The ALPP measures the sphincter response to increased abdominal pressure. The lower the ALPP, the “weaker” the sphincter. The DLPP measures the injured bladder response to increased outlet resistance. The higher the resistance, the higher the DLPP, which is potentially dangerous to the upper tracts.
- According to the ICS, *normal detrusor function* is characterized by a voluntarily initiated continuous contraction that leads to complete bladder emptying within a normal time span and in the absence of obstruction.
- According to the ICS, *detrusor underactivity* is characterized by a contraction of reduced strength and/or duration resulting in prolonged bladder emptying and/or a failure to achieve complete bladder emptying within a normal time span.
- The urodynamic manifestation of BOO is high-pressure and low-flow voiding.
- Normally EMG activity decreases before a voluntary bladder contraction; however, it is not abnormal for EMG activity to increase with an involuntary contraction as part of a guarding reflex to inhibit the IDC.
- True DESD only occurs when there is a known neurologic lesion above the sacral micturition center.

Videourodynamics

Videourodynamics (VUDS) consists of the simultaneous measurement of UDS parameters and fluoroscopic imaging of the lower urinary tract. It provides the most precise evaluation of voiding function and dysfunction and is particularly useful when anatomic structure and function are important (Drake et al., 2016; Keane et al., 1993; McGuire et al., 1996). Examples of when VUDS are useful include the localization of obstruction, detecting incontinence not seen on physical examination, and evaluating vesicoureteral reflux during storage and/or voiding. It can be particularly useful in cases of NLUTD. VUDS is the only way to evaluate bladder neck function and/or dysfunction. The fluoroscopic images can also confirm sphincteric dysfunction when diagnosed by EMG or give a diagnosis if EMG is questionable (Brucker et al., 2012). Also, there are instances in which a known anatomic abnormality exists and simultaneous imaging can determine if that abnormality is playing a role in voiding dysfunction or urodynamic parameters (e.g., bladder or urethral diverticulum, vesicoureteral reflux).

VUDS can be performed using a variety of different methods. Most commonly fluoroscopy is employed using a C-arm. This gives the most flexibility in allowing patient positioning. However, a fixed unit with a fluoroscopy table that can move from 90 to 180 degrees may also be used. It is important that the patient be positioned properly to evaluate the desired function and anatomy. For example, SUI in men and women is best evaluated in the standing position. Voiding is best evaluated in the position that the patient characteristically voids (usually sitting for women and standing for men). It is always recommended that fluoroscopy time be limited and focus on situations of high yield such as during provocative maneuvers to demonstrate SUI, during rises in pressure associated with impaired compliance or involuntary contractions, and during voiding.

VUDS can be extremely useful for the diagnosis of BOO in women (Nitti et al., 1999; Blaivas and Groutz, 2000). In 1999, Nitti et al. described the VUDS criteria for the diagnosis of obstruction in which radiographic evidence of obstruction between the bladder neck and urethral meatus during voluntary voiding defines and localizes obstruction. **Primary bladder neck obstruction can only be diagnosed on VUDS.** Figs. 114.18 and 114.19 distinguish between the two most common causes of functional obstruction in women, primary bladder neck obstruction and dysfunctional voiding.

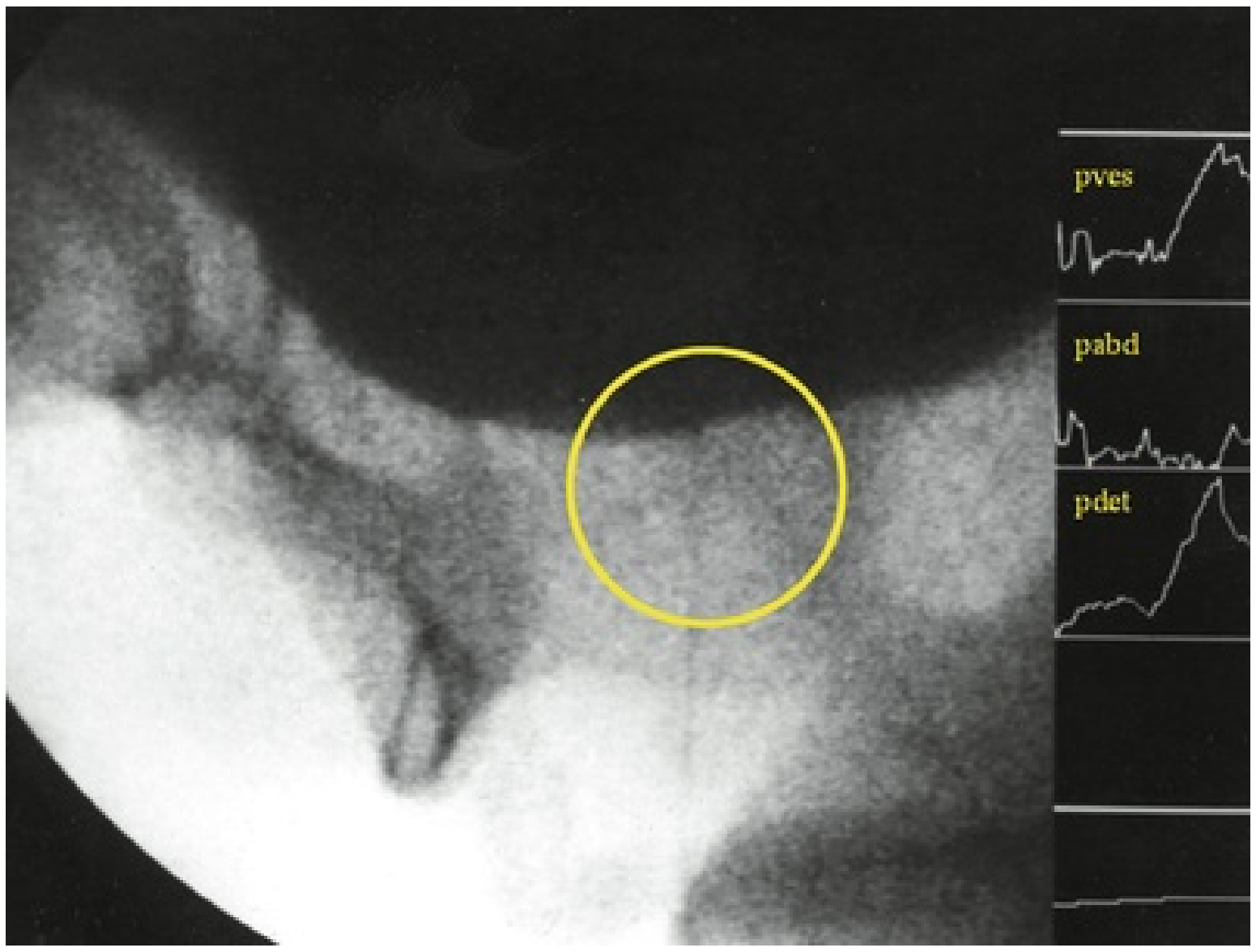

FIG. 114.18 Primary bladder neck obstruction in a 35-year-old woman with obstructive voiding symptoms and intermittent urinary retention. Note the failure of the bladder neck to open at all, despite a detrusor contraction of greater than 60 cm H_2O. (From Nitti VW. Primary bladder neck obstruction in men and women. *Rev Urol* 7[Suppl 8]:S12–S17, 2005.)

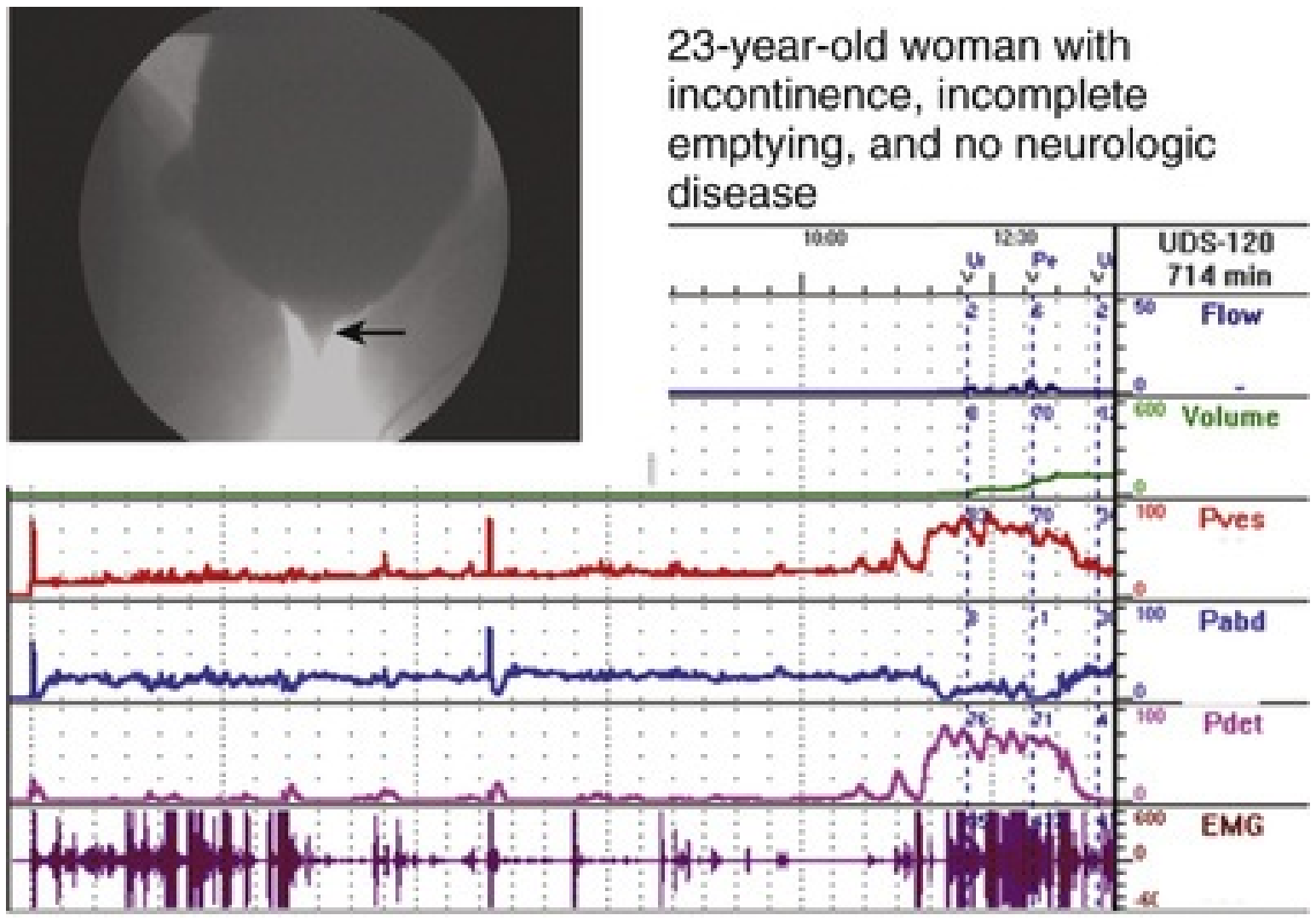
23-year-old woman with incontinence, incomplete emptying, and no neurologic disease

FIG. 114.19 Dysfunctional voiding. UDS of a 23-year-old woman with urgency incontinence, incomplete emptying, and no neurologic disease. Just before voiding, there is an IDC. With voiding, there is increased EMG activity. The fluoroscopic picture taken during voiding shows a

characteristic “spinning-top urethra” with the level of obstruction at the external sphincter. The high-pressure, low-flow voiding is also characteristic of obstruction.

Similarly, VUDS can be used to evaluate LUTS in young men and, in particular, make a diagnosis of primary bladder neck obstruction (Kaplan et al., 1996; Norlen and Blaivas, 1986). Although presence of obstruction can be diagnosed by pressure-flow studies alone, many surgeons do not feel comfortable performing surgical intervention on a young man without localizing the obstruction. In addition, sometimes bladder neck obstruction can present without classical findings of high pressure and low flow. Three distinct types have been described (Nitti et al., 2001): classic high-pressure–low-flow (type I); normal-pressure–low-flow with narrowing at the bladder neck (type II); and delayed opening of the bladder neck (type III). Fig. 114.20 shows types I and II male primary bladder neck obstruction. Fluoroscopy is critical to the diagnosis, especially in types II and III. In fact, simultaneous fluoroscopy during UDS can localize the anatomic site of obstruction in many conditions (e.g., BPO, bladder neck contracture, urethral stricture) once the “urodynamic diagnosis” of obstruction is confirmed.

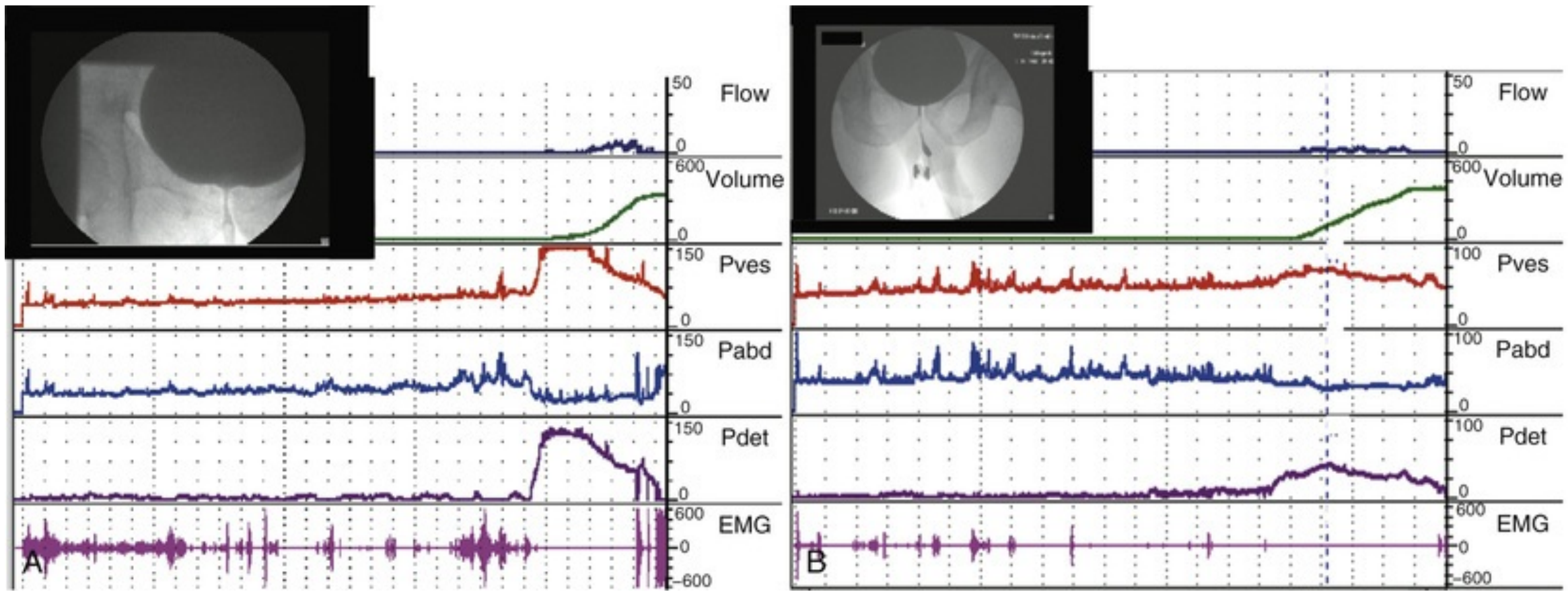

FIG. 114.20 Primary bladder neck obstruction (dysfunction). (A) Type 1—high-pressure, low-flow voiding in a 45-year-old male with severe LUTS including frequency, urgency, and decreased force of stream. Image is taken during voiding; note the incompletely opened bladder neck. (B) Type 2—normal-pressure low-flow voiding in a 35-year-old male with similar LUTS as in (A). There is also an incompletely open bladder neck during voiding. The much lower voiding pressures compared with (A) should still be enough to empty normally, though there may be a component of impaired contractility because the bladder was unable to compensate for the increased resistance at the bladder neck. (From Nitti VW. Primary

bladder neck obstruction in men and women. *Rev Urol* 7[Suppl 8]:S12–S17, 2005.)

VUDS has been shown to be very useful in diagnosing voiding phase dysfunction in women and can be more accurate than surface electrodes in determining EMG activity. We recently found that VUDS was more accurate than surface EMG in diagnosing dysfunctional voiding and differentiating it from primary bladder neck obstruction in women (Brucker et al., 2012). In this study, it was assumed that VUDS would be the most accurate method to diagnose voiding phase dysfunction in women. We found that that if the surface EMG findings alone were used, the incorrect diagnosis would have been made in 20.6% of the women with dysfunctional voiding diagnosed by VUDS. In contrast, increased EMG activity during voiding was seen in 14.3% of women with primary bladder neck obstruction by VUDS (e.g., a patient voiding with high pressure and low flow without any funneling or opening of the bladder neck and during voiding).

The AUA/SUFU Urodynamics Guideline supports the use of VUDS in young men and women without an obvious anatomic cause of obstruction as it can differentiate between functional causes of obstruction such as primary bladder neck obstruction and dysfunctional voiding (Winters et al., 2012). The guideline further states that VUDS is the only diagnostic tool that can document pressure-flow parameters and localize functional bladder neck obstruction. However, the panel recognized that studies have not been performed comparing treatment outcomes of men and women diagnosed with VUDS versus those who had treatment but no VUDS.

VUDS is an important aid in diagnosing NLUTD and other conditions that may cause elevated storage pressures. In cases in which vesicoureteral reflux occurs, the volume and pressure at which it starts should be documented. If possible, the side(s) and degree of reflux should also be noted. In cases of impaired compliance in which there is compensation by the “pop-off” mechanism of vesicoureteral reflux, the impaired compliance might not be identified unless the reflux is also recognized by fluoroscopy (Fig. 114.21). Without knowing there is reflux, the measured compliance may be underestimating the true bladder compliance, a potentially unsafe situation.

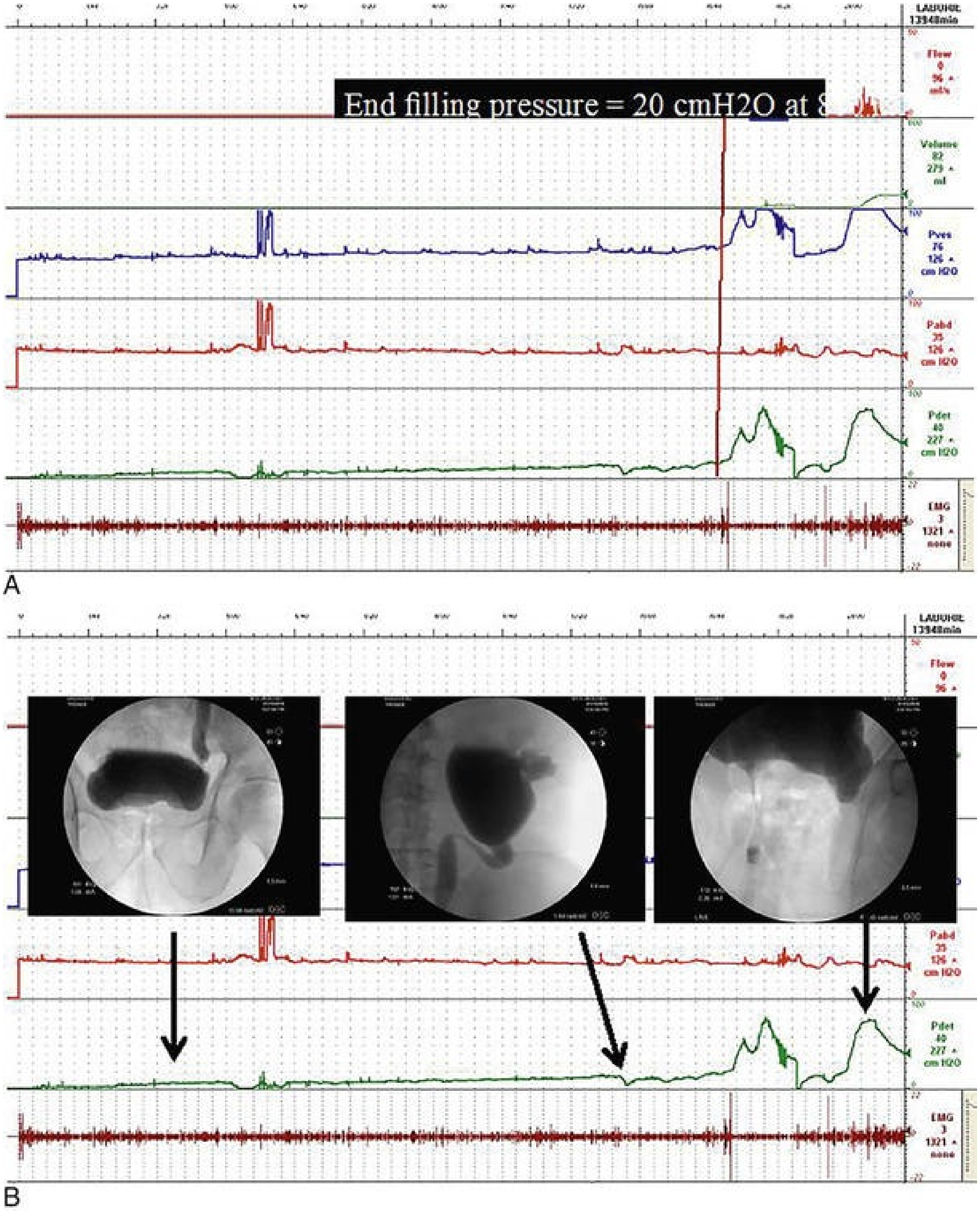
End filling pressure = 20 cmH2O at 8
LABORIE
13948min
Flow
0
96
ml/s
Volume
82
279
ml
Pves
76
126
cm H2O
Pabd
35
126
cm H2O
Pdet
40
227
cm H2O
EMG
3
1321
none
A
B

FIG. 114.21 (A) UDS of a 75-year-old male with elevated PVR and left hydronephrosis. The end filling pressure is 20 cm H_2O, indicating “safe” storage pressures. (B) VUDS shows early reflux at low bladder pressures and significant reflux as bladder filling continues. This represents a “pop-off” mechanism, and the true “functional” bladder compliance is actually significantly more impaired than would be determined by bladder pressure alone.

In addition, an accurate DLPP can be obtained in cases in which it would otherwise be impossible to position a patient to observe leakage (e.g., some tetraplegics). Furthermore, in cases of possible DISD (often found in conjunction with DESD), VUDS is the only way to make the diagnosis and can dramatically change treatment (Fig. 114.22). **The EAU guidelines state that VUDS is the gold standard for invasive UDS in patients with NLUTD** (Pannek et al., 2013)**. If VUDS is not available, then a filling CMG plus pressure-flow study should be done.** The AUA/SUFU Urodynamics Guidelines also recognize the value of VUDS in patients with neurogenic LUTD (Winters et al., 2012). The panel concluded that adding simultaneous fluoroscopy during CMG and pressure-flow study provided additional worthwhile diagnostic information beyond what either study alone could provide. However, they also warn that because radiation exposure is additive, studies should be done in a manner that provides the desired clinical information at the lowest possible radiation dose to the patient.

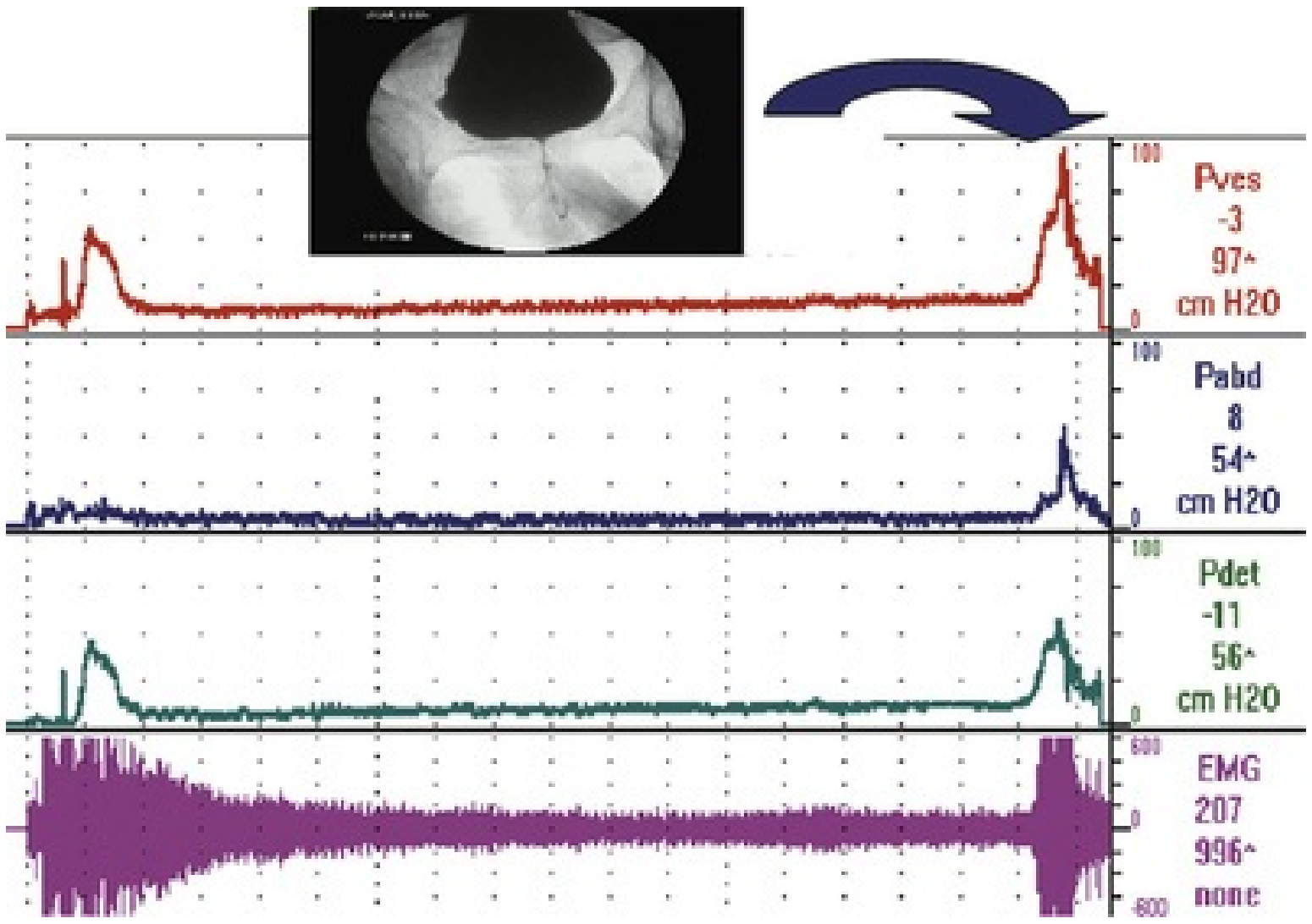

FIG. 114.22 Video-urodynamic evaluation of a cervical spine-injured man with neuropathic voiding dysfunction with incontinence and incomplete emptying. The UDS tracing clearly shows DO with DESD (increased EMG activity with involuntary contraction. However, it is only with the fluoroscopic view of the bladder outlet during an involuntary contraction that detrusor–internal sphincter dyssynergia is diagnosed (the bladder neck remains relatively closed).

VUDS may improve diagnostic acumen in some selected patient populations (Marks and Goldman, 2014), but it must be weighed against the added risk for radiation exposure (Brucker et al., 2016) and the potential increase in health care costs. VUDS may not be readily available to all heath care providers. **VUDS is the diagnostic tool of choice for documenting bladder neck dysfunction in men and women. In addition, patients at high risk for complicated voiding dysfunction, such as those with known or suspected NLUTD, unexplained urinary retention in women, prior radical pelvic surgery, urinary diversion, prerenal or postrenal transplant, or prior pelvic radiation, should be considered for referral to a center with VUDS capabilities if a complete and accurate diagnosis cannot otherwise be obtained** (Scarpero et al., 2009).

Key Point

- VUDS is usually considered the gold standard for invasive UDS in patients with NLUTD.

Ambulatory Urodynamics

Ambulatory urodynamic studies are defined as a functional test of the lower urinary tract, utilizing natural filling, and reproducing the subject's everyday activities (Abrams et al., 2002). The development of natural and slow-filling urodynamic studies was initially undertaken in the investigation of patients with NLUT by Comarr (1957) using diuresis-induced natural filling. Comar demonstrated an increase in bladder capacity and decreases in bladder pressures during natural filling when compared with retrograde filling CMG. Similar investigations of spinal cord injury (SCI) patients by Tsiju et al. (1960) demonstrated increased phasic detrusor overactivity associated with incontinence during natural filling. Today it is a well-established method for investigating lower urinary tract function under the conditions of normal daily activities. Ambulatory UDS has its greatest value in patients in whom conventional UDS is not suitable or for those who are unable to reproduce the symptoms in question.

In 2000, the ICS published guidelines for the performance of ambulatory UDS (van Waalwijk van Doorn et al., 2000). Before the investigation, patients receive detailed information describing the test and the necessary preparation. Patients were instructed on how to accurately record symptoms and how to identify catheter displacement and hardware failure. A sample diary was given to record all relevant events so that UDS findings could be correlated with symptoms. Most systems employ microtip transducer catheters, which allow the most mobility. These are placed transurethrally to record bladder pressure and transrectally to record abdominal pressure. These catheters are firmly secured to the patient and are connected to a portable recording device. Some systems contain a third channel that can be used for measuring urinary leakage objectively using an absorbent electronic (capacitance change) nappy pad (Robertson and Neil, 1998). This allows accurate data to be obtained on the relationship of urinary leakage to detrusor activity. Home uroflowmetry units are also available. Ambulatory UDS tracings are analyzed after completion of testing, and this can be a time-consuming process depending on the length of the study. This must be done with great care and frequent quality checks to make sure that the urethral and abdominal catheters are properly transducing pressure (e.g., using cough tests). In addition, the reader must be able to identify physiologic artifacts (after contractions and aberrant rectal pressures) and technical artifacts (movement or variation in pressure and lack of balance in transducer lines), which could impact the interpretation of the study. The ambulatory study should be designed to reproduce symptoms. For example, if the patient complains of stress incontinence, a standard protocol of exercises can be performed and recorded (e.g., jumping up and down, squatting, coughing).

Clinical Utility of Ambulatory Urodynamics

Ambulatory urodynamic monitoring (AUM) may be considered as a second-line tool to investigate lower urinary tract symptoms and dysfunction, when conventional laboratory UDS are inconclusive (Digesu et al., 2017). This clinical utility of ambulatory UDS is still debated, and its role in clinical practice continues to need further elucidation. Proponents of ambulatory monitoring believe that it will capture more realistic or physiologic observations, for example incontinence episodes (Hosker et al., 2009). It attempts to increase sensitivity by taking place over a longer time frame and providing a longer time for abnormalities (i.e., detrusor overactivity) to manifest. When deciding to perform AUM in clinical practice, consideration of how the results of the study will alter or direct treatment should be made. AUM has been most commonly used to diagnosis the cause of urinary incontinence, but has also been applied to the diagnosis of male BOO and NLUTD. However, AUM is not without limitations. Aside from obvious potential technical challenges, Rosier et al. (2013) noted that there are no published data on the reproducibility or test-retest differences of AUM studies or reports that evaluate the investigator dependence on the posttest analysis of recorded data. Further, a Cochrane review looking for randomized or quasi-randomized trials did not show adequate evidence that one technique of UDS was superior to the other (Glazener and Lapitan, 2012).

It has been shown that ambulatory monitoring detects more actual incontinence in symptomatically incontinent patients than retrograde filling CMG (Cassidenti and Ostergard, 1999). Dokmeci et al. (2010) prospectively classified incontinent women into three groups (urgency incontinence, stress incontinence, and mixed incontinence) using the UDI-6 questionnaire. Both conventional UDS and ambulatory UDS were prospectively performed. Overall, ambulatory UDS findings matched the classification in 77.3% of women, compared with 6.8% using conventional UDS ($P = 0.001$). The authors suggested that conventional UDS has a higher false-negative rate than conventional UDS. It is important to note that, during this study, the conventional UDS were only performed in the supine position (and then the seated position) but not in the standing position, which is often recommended. Another limitation was that the measure of incontinence during ambulatory UDS was only based on the patient-controlled event marker. This introduces a bias; thus the results must be interpreted cautiously.

Several studies have shown ambulatory UDS to be more sensitive than conventional CMG for the diagnosis of DO (Heslington and Hilton, 1996; Robertson et al., 1994). Radley et al. (2001) found that ambulatory monitoring revealed DO in 70 in 106 women with symptoms suggestive of DO (twice as many as conventional CMG with provocation by hand washing) and that it detected DO incontinence (DOI) in 40 of the 70 women. The observation of DOI was correlated with symptom severity, but it was not clear how many women complaining of urgency incontinence showed DO incontinence. Thus, the sensitivity is unknown. The finding of higher rates (and sensitivity) of DO found on ambulatory monitoring must be weighed against the fact that higher rates of DO were also found on ambulatory UDS in asymptomatic volunteers. The rates of DO found in asymptomatic females was noted as high as 69% versus 18% for conventional CMG (van Waalwijk van Doorn et al., 1996) and 38% versus 17% in asymptomatic men and women (Robertson et al., 1994). Thus, some degree of detrusor overactivity may be normal in the setting of a urethral catheter for a prolonged period, making some sort of standardization important.

In a review of 422 female ambulatory UDS over a 12-year period, Patravali (2007) argued for the value of the study. Patravali noted that 85% of patients complaining of urinary incontinence showed detectable leakage with a diagnosable mechanism on ambulatory study, and in 77% of 74 women with a normal CMG, ambulatory UDS diagnosed the cause of incontinence and provided “clear added value.” DO was a component in 42 of these 57 patients (76%). What is not known is exactly what is meant by “clear added value” and how treatment was affected. In a smaller study of 25 patients, Pannek and Pieper (2008) had similar findings but a more useful interpretation of those findings. They found that AUM was helpful (versus conventional UDS) in diagnosing lower urinary tract dysfunction in 72% of the evaluable examinations. However, 24% of the studies were not evaluable because of technical problems or catheter dislocation. Thus, ambulatory UDS was clinically useful in only 48% of the patients who underwent this examination. When a diagnosis was made on ambulatory UDS, successful treatment was established in 42% of the patients. However, when ambulatory UDS was not helpful and patients were treated based on clinical symptoms, 33.3% were treated successfully. Gorton and Stanton (2000) also looked at the effect of ambulatory UDS on clinical management. In a retrospective review of 71 women, there were technical difficulties in 42% of the studies with two being noninterpretable. DO was found in 45%, and nearly all patients were treated with medication. Among the remainder without DO, fewer received medication. However, fewer than one-half of those who received medication improved. The authors concluded that ambulatory UDS was not very helpful in deciding on management.

Ambulatory UDS has been used for the diagnosis of obstruction in men with LUTS and inconclusive (borderline or nondiagnostic) conventional PFS. Rosario et al. (1999) reclassified 24% of such patients as either obstructed or nonobstructed. However, Robertson et al. (1996) found no difference in the classification of patients with ambulatory versus conventional PFS.

It has been demonstrated that storage pressures in patients with NLUTD (and chronic obstruction) are lower on ambulatory, natural-fill UDS than on conventional CMG (Webb et al., 1989, 1991, 1992). Patients with poor compliance (high filling pressures) and hydronephrosis on conventional CMG were found to have normal compliance, but significant phasic neurogenic DO on ambulatory monitoring. It has been suggested that phasic neurogenic DO, not impaired compliance, may lead to upper tract deterioration in these patients. Although this may be true, it needs to be proven in a series of patients followed over time, and for now, based on available evidence, one must still conclude that significantly impaired compliance on conventional CMG is a risk factor for upper tract damage.

Martens et al. (2010) looked at 27 patients with SCI and symptoms suggestive of neurogenic DO. These patients underwent both conventional and ambulatory UDS (for 6 hours). It was reported that a greater percentage of patients were found to have neurogenic DO in the ambulatory study (92% vs. 69%, $P = 0.031$), but there was no difference in bladder pressure during the involuntary detrusor contraction. Comparing each method to the “clinical diagnosis of DO,” ambulatory UDS had a sensitivity to detect neurogenic DO of 85%, and conventional UDS had a sensitivity of 75%, but this was not significant ($P = 0.375$). The authors also found that the interindividual agreement to diagnosis neurogenic DO was higher for the conventional UDS compared with the ambulatory UDS. They did look at how the studies altered management recommendations and concluded that although ambulatory UDS did not need to be used as a standard tool for risk assessment in SCI patients, ambulatory UDS remain indicated if conventional UDS are not conclusive for treatment decisions.

VUDS are often considered the gold standard for the evaluation of patients with NLUTD (Pannek et al., 2013), but most studies in this population have compared ambulatory UDS to conventional UDS, but not VUDS. Vírseda-Chamorro et al. (2014) compared ambulatory UDS (with a single natural fill cycle) in 69 SCI patients. The patients were grouped by findings noted on fluoroscopy including having an open bladder neck at rest, DESD, and vesicoureteral reflux (in this population representing 25%, 64%, and 6% of patients, respectively). The authors found no association with ambulatory UDS findings. The only statistically significant finding was patients with an open bladder neck on VUD had a higher percentage of neurogenic DO (67%) on ambulatory UDS compared with those whose bladder neck was closed at rest (35%) ($P = 0.025$). This study also found lack of agreement in most other filling parameters when comparing other VUDS parameters to ambulatory UDS parameters. The cytometric capacity on ambulatory UDS (275 mL) aligned more closely with frequency volume chart bladder capacity (296 mL). VUD capacity was noted to be higher (416 mL). It is not clear that this information alters management or affects outcomes.

When considering the use of ambulatory UDS in the clinical evaluation of NLUTD, the possibility of autonomic dysreflexia (AD) deserves mention (Cameron, 2011). It was suggested that prolonged periods of catheterization and irritation from multiple catheters could be an issue, but the data about frequency of AD episodes and the ability to recognize and adequately manage AD has not been systematically evaluated.

Attempts have been made to modify the ambulatory urodynamic equipment needed and have shown some promising results in identifying neurogenic DO (Kim, 2010, 2012). Aside from technical advances and accuracy cost, convenience and patient experience must also be considered moving forward.

In conclusion, ambulatory UDS may be useful in a select group of patients in whom conventional UDS is nondiagnostic and the information provided would affect treatment, counseling, or follow-up. Ambulatory UDS and its interpretation are time-consuming and technically challenging. The data obtained for ambulatory UDS must be weighed against the fact that for many findings, standards, both normal and abnormal, have not been established. More data are needed on the reproducibility of ambulatory UDS. The impact that ambulatory UDS has on altering management and changing both patient-reported and objective outcomes should be

investigated across varied patient populations.

Key Point

- Ambulatory urodynamic monitoring may be useful in a select group of patients in whom conventional UDS is nondiagnostic and the information provided would affect treatment, counseling, or follow-up.

Clinical Applications of Urodynamic Studies: Evidence-Based Review and Guidelines Pertaining to Urodynamics

Thus far, we have described the technical aspects of UDS and general indications for use. In this section, we will provide an evidence-based review of UDS for different common clinical applications. In many situations, there is not enough evidence in the literature to conclude how useful UDS is for a particular case, and as such, its use should be based on a clinical impression. Nevertheless, there are some instances and indications in which the evidence is strong enough to provide guidance as to how useful UDS will be. Over the past many years, there has been a push to establish clinical guidelines.

Guidelines

In 2012, the AUA/SUFU produced a guideline for UDS (Winters et al., 2012). The AUA makes efforts to periodically review and confirm the validity of guidelines, but this guideline has not been reconfirmed at the time of this writing. The AUA/SUFU Guideline Panel believes that UDS guidelines do not necessarily establish the standard of care, but rather should encourage compliance by practitioners with current best practices related to the condition being treated. Individual health care providers must take into account individual patient situations including patient willingness to be treated, variations in resources, and patient tolerances, needs, and preferences. The AUA/SUFU guideline on UDS made a total of 19 statements about UDS on four disease states: SUI/pelvic organ prolapse, overactive bladder urgency urinary incontinence and mixed urinary incontinence, neurogenic bladder, and lower urinary tract symptoms. The AUA/SUFU guideline was “intended to review the literature regarding urodynamic testing in common lower urinary tract conditions and assist clinicians in the proper selection and application of urodynamic tests, following an appropriate evaluation and symptom characterization.” This format has an advantage when considering a specific set of diagnostic tests, but disease-specific guidelines may have some practical advantage for the clinician to understand when and how to use a test for a condition-specific question.

An example of a condition-specific guideline is the new AUA/SUFU guideline on **surgical treatment of SUI,** which contains two statements pertaining to UDS (Kobashi et al., 2017). The AUA/SUFU guideline on overactive bladder and bladder pain syndrome/interstitial cystitis are other disease-specific guideline from the AUA that comments on UDS and the role in each condition (Gormley et al., 2015; Hanno et al., 2015).

In fact, there are a multitude of other guidelines from other agencies that are redundant and ultimately based on the same available data. The European Association of Urology (EAU) Guidelines on Urinary Incontinence also summarizes level of evidence and makes six statements about performing UDS in neurologically intact adults with urinary incontinence (Lucas et al., 2013). This guideline had been recently updated, but the ensuing updates have not changed the recommendations regarding UDS (Burkhard et al., 2017). These guidelines will be explored later.

Overall, the development of most guidelines usually begins with a systematic review. This gives the committee a basis to come up with evidence when possible to support their recommendations. The work is often presented with a grading system. This give the reader an assessment of the strength of each recommendation and the strength of data used to make that determination. For example, the AUA guidelines on UDS utilize the Oxford system. This system gives a grade A recommendation usually if it depends on consistent level 1 evidence. This often means that the recommendation is effectively mandatory and placed within a clinical care pathway. A grade B recommendation usually depends on consistent level 2 or 3 evidence studies, or “majority evidence” from randomized controlled trials. A grade C recommendation usually depends on level 4 evidence studies or “majority evidence” from level 2 or 3 studies or from “expert opinion.”

Guidelines are based on best evidence available to experts; however, they do not necessarily result in differences or improvement in outcomes. They should not replace clinical expertise for individual patients. They are not meant to mandate care or be considered a legal standard.

We will specifically address four areas in which UDS is commonly used for evaluation and enough evidence exists to make valid conclusions or recommendations: women with SUI, men and women with LUTS, and NLUTD.

Evaluation of Women With Stress Incontinence

For the past decade, it has generally been felt that for women with pure SUI without urgency symptoms who empty normally and demonstrate SUI on physical examination, UDS will not provide much useful information. For example, in the SISTEr trial, a randomized trial comparing the efficacy of Burch procedure versus pubovaginal sling in 655 *selected* women with pure or predominate SUI and no obvious emptying problems, UDS, including ALPP and presence of DO, added little to help determine surgical outcomes with respect to efficacy (Nager et al., 2008) or postoperative voiding dysfunction (Lemack et al., 2008). In 2006, in the UK, the National Institute of Health and Clinical Excellence (NICE) issued guidelines that urodynamics was recommended before surgery for urinary incontinence only if there is a clinical suspicion of DO, or if there has been previous surgery for stress incontinence or anterior compartment prolapse, or if there are symptoms suggestive of voiding dysfunction. In the past several years, there have been two randomized controlled trials designed to answer the question of how useful UDS is in the evaluation of women with straightforward SUI.

The Value of Urodynamic Evaluation (ValUE) Trial was a multicenter, randomized, noninferiority trial involving women with uncomplicated, stress-predominant urinary incontinence who were planning to undergo surgery, to determine whether outcomes at 1 year among women who underwent only an office evaluation were inferior to those among women who also underwent preoperative urodynamic studies (Nager et al., 2012). The study included a select group of women with pure or stress-predominant SUI based on a validated questionnaire, a PVR of less than 150 mL, a negative urinalysis or urine culture, and urethral mobility with a positive provocative stress test. Women with previous surgery for incontinence, a history of pelvic irradiation, pelvic surgery within the previous 3 months, and significant anterior or apical pelvic-organ prolapse were excluded. A total of 630 women were equally randomized to office evaluation plus UDS versus office evaluation alone. The primary outcome was surgical treatment success measured as a reduction in the Urogenital Distress Inventory score from baseline to 12 months of 70% or more and a Patient Global Impression of Improvement response of “very much better” or “much better” at 12 months. The proportion in which treatment was successful was 76.9% in the urodynamic-testing group versus 77.2% in the evaluation-only group (difference, −0.3 percentage points; 95% confidence interval [CI] −7.5 to 6.9), which was consistent with noninferiority. The authors did note that based on UDS, 18 women had the type of surgery changed from transobturator to retropubic midurethral sling (12) or from retropubic to transobturator sling (6). It is not clear if these changes affected outcomes. The authors concluded that for women with uncomplicated, demonstrable SUI, preoperative office evaluation alone was not inferior to evaluation with urodynamic testing for outcomes at 1 year. In a follow-up study, the authors found that for patients who underwent UDS, physician confidence for the diagnosis of ISD, OAB-wet and dry (presumably detrusor overactivity), and voiding phase dysfunction, but not SUI, increased (Zimmern et al., 2014). However, this did not correlate with treatment success.

In another study to investigate the value of urodynamics before SUI surgery, van Leijsen et al. (2013) conducted a multicenter diagnostic cohort study with an embedded noninferiority randomized controlled trial in six academic and 24 nonacademic Dutch hospitals. All women in the trial had SUI or stress-predominant mixed incontinence and underwent UDS. Those who had UDS that were discordant with clinical assessment (SUI was not confirmed, detrusor overactivity, weak flow, elevated post void residual, small cystometric maximum capacity, or a reduced bladder sensation) were then randomly allocated to receive either immediate surgery or individually tailored therapy based on UDS. Possible treatment options included anticholinergics for detrusor overactivity, prolonged pelvic floor exercises or bladder training in cases of dysfunctional voiding, a pessary, expectant management, intravesical botulinum toxin injections, or pretibial nerve stimulation at the physician's discretion. Of the 578 included women, 268 women (46%) had urodynamic findings that were discordant with clinical history and physical examination. Consent for randomization was obtained from 126 patients. Of the patients randomized to individualized treatment, 57 of 62 received surgery as the initial treatment. The mean improvement on the Urogenital Distress Inventory UI subscale was 39 points (±25) in the group who received individually tailored treatment compared with 44 points (±24) in the group receiving immediate surgery. The difference in mean improvement was 5 points in favor of the group receiving immediate surgery, confirming noninferiority for either one of the strategies. Subjective cure as measured with the Urogenital Distress Inventory and objective cure as measured with the stress test and bladder diary were no different between the two arms. In the surgery group, subjective cure was 43 of 58 (74%) and in the individual treated group 42 of 56 (75%) (relative risk 0.99, 95% CI 0.80 to 1.23). Objectively cured were 37 of 38 women (97%) in the surgery group and 33 of 34 women (97%) in the individual treated group (relative risk 1.00, 95% CI 0.93 to

1.09). The authors concluded that in women with uncomplicated SUI, an immediate midurethral sling operation is not inferior to individually tailored treatment based on urodynamic findings.

These two well-done studies suggest that UDS is not essential before surgical treatment of stress-predominant urinary incontinence in women when SUI is seen clinically. However, many women with SUI who are considering surgical correction have mixed symptoms or emptying difficulties, and it is here that UDS probably has its most significant role for female SUI. In addition, previous studies have found significant variation of the predictive value of symptoms in identifying the three UDS observations of urodynamic SUI, DOI, and mixed urinary incontinence (Agur et al., 2009; Harvey and Versi, 2001; Homma, 2002). This variation is probably explained by nonhomogeneous patient populations and an inconsistency in the clinical and UDS diagnosis between the studies.

We believe that UDS does have a valuable and definitive role in the preoperative evaluation of some women with SUI and significant urgency symptoms. In fact, several studies have shown excellent cure rates for both stress and urgency symptoms in women with urodynamic SUI and a normal CMG (no DO) for pubovaginal sling (Chou et al., 2003; Osman, 2003), Burch procedure (Osman, 2003), and tension-free vaginal tape (Rezapour and Ulmsten, 2001). It should be noted that the trials that have shown no difference in success of treatment with or without DO were primarily done in patients with stress-predominant SUI. The presence or absence of DO in women with more significant urgency symptoms may play a more significant role in predicting outcomes.

Based on a thorough review of the literature, the AUA Urodynamics Guideline Panel has made the following statements (Winters et al., 2012):

- “Clinicians who are making the diagnosis of urodynamic stress incontinence **should** assess urethral function (Recommendation; Evidence Strength: Grade C).” The committee recommends that if UDS is performed, an assessment of urethral function (e.g., ALPP or MUCP) should be performed. This seems reasonable as an ALPP may for some surgeons affect the type of surgery performed, as inferior outcomes have been found for some procedures in patients with low ALPP and/or MUCP.

- “Surgeons considering invasive therapy in patients with SUI **should** assess PVR urine volume (Expert Opinion).” An elevated PVR may prompt a change in treatment for additional testing such as UDS.
- “Clinicians **may** perform multichannel UDS in patients with both symptoms and physical findings of SUI who are considering invasive, potentially morbid, or irreversible treatments. (Option; Evidence Strength: Grade C).” This statement allows the clinician to make a decision of the selective use of preoperative UDS based on the patient's symptoms, how the study will influence choice of surgery, and the degree of confidence that the surgeon has in his or her diagnosis.
- “Clinicians **should** perform repeat stress testing with the urethral catheter removed in patients suspected of having SUI who do not demonstrate this finding with the catheter in place during urodynamic testing (Recommendation; Evidence Strength: Grade C).” It is well established that some women will not demonstrate SUI with a catheter in place. This maneuver is especially important in women who do not demonstrate SUI on physical examination.
- “In women with high-grade POP but without the symptom of SUI, clinicians **should** perform stress testing with reduction of the prolapse. Multichannel UDS with prolapse reduction **may** be used to assess for occult stress incontinence and detrusor dysfunction in these women with associated LUTS (Option; Evidence Strength: Grade C).” Prolapse reduction is extremely important if the demonstration of occult SUI on UDS will influence the type of prolapse surgery performed (i.e., a simultaneous anti-incontinence with prolapse repair).

Women can develop SUI after prolapse surgery, and different options exist for managing the urethra at the time of prolapse surgery or trying to prevent incontinence. Two randomized controlled trials, with and without concomitant anti-incontinence surgeries, have suggested that there is more de novo SUI in women that have occult SUI preoperatively (Visco et al., 2008; Wei et al., 2012). Therefore, the surgeon may elect to “risk-stratify” women pre–prolapse surgery by looking for occult incontinence, and UDS with reduction is one way to assess these women; however, this is a commonly debated topic (Serati et al., 2015).

The ICS committee on pathophysiology of urinary incontinence (2016) in the 6th edition of *Incontinence* feels it is clear that UDS can add some information in women undergoing pelvic organ prolapse surgery and could facilitate patient counseling, but note that there is no compelling evidence that surgical outcomes are determined by the test.

Some studies have suggested that office evaluation with reduction may perform as well as UDS in determining the presence or absence of occult incontinence (Hwang et al., 2018). van der Ploeg et al. (2018) found that UDS were more likely to find SUI compared with office evaluation, but it did not have added value in predicting postoperative SUI. Though the office evaluation had a higher diagnostic odds ratio, the confidence intervals overlapped and the author sites lack of power (suggested on a post hoc calculation) and different baseline characteristics as limitations of the study.

The AUA guidelines on the surgical treatment of SUI also make statements about UDS (see Guidelines section earlier in this chapter) (Kobashi et al., 2017). They are as follows:

- Physicians may omit urodynamic testing for the index patient desiring treatment when SUI is clearly demonstrated (conditional recommendation; grade B recommendation)
- Physicians may perform urodynamic testing in nonindex patients (expert opinion). Urodynamic testing may be performed at the clinician's discretion in certain nonindex patients, including but not limited to patients with the following:
  - History of prior anti-incontinence surgery
  - History of prior POP surgery
  - Mismatch between subjective and objective measures
  - Significant voiding dysfunction
  - Significant urgency, UUI, OAB, MUI with significant urgency component

- Elevated PVR per clinician judgment
- Unconfirmed SUI
- NLUTD

The EAU Guidelines on Urinary Incontinence, though not specific to women with SUI, start by suggesting that when performing UDS there is adherence to *good urodynamic practice standards* as described by the ICS (Nambiar et al., 2018; Rosier et al., 2017b). They then make a number of practical recommendations about UDS, which are generally consistent with the AUA guidelines.

Clinicians carrying out UDS in neurologically intact patients with urinary incontinence should:

- Attempt to replicate the patient's symptoms (strength rating: strong)
- Check recoding for quality control (strength rating: strong)
- Interpret results in the context of the clinical problem (strength rating: strong)
- Remember there may be physiologic variability within the same individual (strength rating: strong)
- Not routinely carry out urodynamics when offering treatment for uncomplicated SUI (strength rating: strong)
- Perform urodynamics if the findings may change the choice of invasive treatment (strength rating: weak)
- Not routinely carry out urethral pressure profilometry or leak point pressure to grade severity of incontinence (strength rating: strong)

Both AUA and EAU guidelines give the clinician the discretion to perform UDS before surgery, based on the individual patient, clinical scenario, and whether UDS will ultimately affect the choice of treatment (the latter varies based on the individual clinician).

The National Institute for Health and Care Excellence (NICE) (National Collaborating Centre for Women's and Children's Health, UK, 2013) and the Canadian Urological Association (Bettez et al., 2012) also have guidelines on “urinary incontinence” (not necessarily SUI incontinence in women) that comment on or make statements pertaining to UDS. Syan and Brucker (2016) published “Guidelines of Guidelines” for urinary incontinence. A part of this review was analyzing the statement of these various publications and conclude the statements related to UDS agree that the invasive UDS are not needed before conservative treatments, but may be used if the data may alter treatment recommendation and management (e.g., before more invasive therapies). Overall there is agreement to recommend UDS if urinary incontinence is recurrent after invasive treatments have been unsuccessful. Also, the authors note there is considerable redundancy in available guidelines.

Evaluation of Men and Women With Lower Urinary Tract Symptoms

The cause of LUTS in men and women is multifactorial comprising at least four conditions 1) BOO, 2) detrusor underactivity, 3) detrusor overactivity, and 4) “sensory urgency” (Blaivas, 1988). Often storage symptoms of frequency and urgency accompany voiding symptoms of decreased force of stream and hesitancy. Urgency incontinence can also occur as a result of DO with or without BOO. LUTS are common among men of 50 years and older. It has been established that coexistence of BOO and DO in men increases with age and with the degree of BOO (Oelke et al., 2008; Vesely et al., 2003). In such cases, UDS can be helpful to establish the underlying bladder and or bladder outlet abnormality.

Noninvasive testing such as PVR and uroflowmetry can be helpful in the evaluation of men and women with LUTS and may also prompt further invasive UDS testing. The AUA Urodynamics Guideline (Winters et al., 2012) states that “Clinicians may perform PVR in patients with LUTS as a safety measure to rule out significant urinary retention both initially and during follow-up (Clinical Principle).” Although it is true that PVR cannot differentiate between obstruction and nonobstructive conditions (e.g., detrusor underactivity) and that there is no agreed upon definition of exactly what volume constitutes an elevated PVR, most urologists would agree with this statement. The guideline also states that uroflow may be used by clinicians in the initial and ongoing evaluation of male patients with LUTS that suggest an abnormality of voiding/emptying (Recommendation; Evidence Strength: grade C). Like PVR, an abnormal uroflow cannot differentiate between obstruction or detrusor underactivity, but it can be helpful in instituting or not instituting certain therapies or in prompting further testing.

The question of how much help UDS is in the evaluation and treatment of male LUTS has been debated for years. How necessary is a diagnosis of BOO before transurethral prostate resection, for example? The answer is dependent on how comfortable the clinician is making a diagnosis and treating with less invasive and less definitive testing. Few would argue that to institute an α-receptor blocker for the treatment of LUTS in a man with relatively normal bladder emptying, UDS is not required. However, as the scenario becomes more complex and the treatment more invasive and potentially morbid, a precise diagnosis will be helpful in many cases. Often it is ultimately up to the clinician to decide how much information is useful or necessary to make a treatment decision and properly counsel patients.

It is well documented that in men with BOO, surgery such as transurethral prostate resection (by any means) reduces obstruction and relieves symptoms. However, storage symptoms such as urgency frequency and urgency incontinence persist in about one-third of cases. It has been shown that when storage symptoms are associated with DO and BOO, UDS can help predict resolution of those symptoms. In such a scenario, storage symptoms have a higher likelihood of resolving with intervention (e.g. TURP) when DO occurs as a single terminal IDC rather than continuous or sporadic IDCs (Kageyama et al., 2000). Such information can be quite valuable when counseling patients. For example, given the same UDS presentation of BOO plus continuous IDCs, a patient primarily concerned with his inability to empty may opt for surgery, whereas a patient who is primarily concerned about OAB symptoms may not.

As for the utility of UDS before surgical treatment or no treatment of LUTS thought to be secondary to BPH, the literature is mixed with several studies supporting its necessity (Javle et al., 1998; Porru et al., 2002; Rodrigues et al., 2001; Thomas et al., 2004). Others have concluded that UDS are not necessary (Kanik et al., 2004; Pannek et al., 1998) or necessary only in inconclusive cases (Ignjatovic, 1997). Other reviews have suggested that UDS has some, but not strong predictive value for treatment outcomes (Abrams et al., 2001; Brucker and Jaffe, 2009; Clemens, 2003; Homma, 2001). Another review by Bhargava et al. (2004) concluded that conventional urodynamic studies are useful in providing preoperative information about detrusor function, and to exclude patients less likely to benefit from prostate surgery. Despite this, some regard the need for performing urodynamic evaluation routinely, before transurethral resection of the prostate, as still controversial. This led the experts at the 6th International Consultation on New Developments in Prostate Cancer and Diseases to conclude that although almost all evidence for the advantages of UDS before invasive therapy for benign prostatic obstruction (BPO) is level 3 (good-quality retrospective "case-control studies" or "case series"), the quantity of evidence allows a grade B recommendation (Abrams et al., 2006). In a similar statement, **the AUA/SUFU Urodynamics Guideline states that "Clinicians should perform pressure-flow studies in men when it is important to determine if urodynamic obstruction is present in men with LUTS, particularly when invasive, potentially morbid, or irreversible treatments are considered (Standard; Evidence Strength: grade B)** (Winters et al., 2012).

The EAU Guidelines on the Assessment of Non-neurogenic Male Lower Urinary Tract Symptoms Including Benign Prostatic Obstruction directly addresses when pressure-flow studies should be performed (Gratzke et al., 2015). The recommendations are as follows:

- Pressure-flow studies **should be performed only in individual patients for specific indications** before surgery or when evaluation of the underlying pathophysiology of LUTS is warranted (level 3, grade B recommendation).
- Pressure-flow studies **should be performed** in men who have had previous unsuccessful (invasive) treatment for LUTS (level 3, grade B recommendation).
- When considering surgery, pressure-flow studies **may be used** for patients who cannot void greater than 150 mL (level 3, grade C recommendation).
- When considering surgery in men with bothersome predominantly voiding LUTS, pressure-flow studies **may be performed** in men with PVR greater than 300 mL (level 3, grade C recommendation).
- When considering surgery in men with bothersome predominantly voiding LUTS, pressure-flow studies **may be performed** in men older than 80 years of age (level 3, grade C recommendation).
- When considering surgery in men with bothersome

> predominantly voiding LUTS, pressure-flow studies **should be performed** in men age younger than 50 years of age (level 3, grade B recommendation).

Chua et al. assessed available guidelines of non-neurogenic male LUTS and found pressure-flow urodynamics generally as an optional test (Chua et al., 2015). The recommendation for uroflow and PVR were also usually “optional,” but some guidelines consider these tests to be “recommended” and even mandatory in one case.

Most of the time when BOO is treated it is done so because of symptoms. However, “asymptomatic” BOO, if not relieved in time, may lead to progression of the disease and affect organ function. Historically most attention was paid the backpressure effects of obstruction on the kidneys (from high voiding pressures and/or impaired compliance). However, it is now known that that BOO affects bladder function, leading to structural changes. Because the changes may eventually become irreversible, some would argue that management should be directed toward early relief of significant obstruction (Brierly et al., 2003; Flanigan et al., 1998; Lu et al., 2000). More longitudinal studies are needed. **However, at this time, a critical level of obstruction (e.g., based on the BOOI) has not been defined. There are no evidence-based studies to suggest when surgical relief is indicated to prevent bladder decompensation. However, many papers have shown that if there is no evidence of obstruction on PFS, the results of surgical relief are not as favorable** (Porru et al., 2002; Thomas et al., 2004)**. Significantly impaired compliance remains the only “absolute urodynamic indication” for treating BOO.**

There are times when it may be important to diagnose DO or more importantly impaired compliance that is associated with LUTS. In addition to BOO, conditions such as radiation cystitis and certain inflammatory diseases (e.g., tuberculosis) can cause impaired compliance. Impaired compliance, however, can only be diagnosed by CMG. In such cases, the diagnosis of impaired compliance can result in the institution of therapy independent of symptoms. Thus, in cases in which impaired compliance is suspected, we recommend UDS testing. This is consistent with the following AUA/SUFU Urodynamics Guideline statements:

> - “Clinicians may perform multichannel filling cystometry when it is important to determine if altered compliance, DO or other

> urodynamic abnormalities are present (or not) in patients with urgency incontinence in whom invasive, potentially morbid, or irreversible treatments are considered. (Option; Evidence Strength: Grade C)"
> • "Clinicians may perform multi-channel filling cystometry when it is important to determine if DO or other abnormalities of bladder filling/urine storage are present in patients with LUTS, particularly when invasive, potentially morbid, or irreversible treatments are considered (Expert Opinion)."

The AUA/SUFU OAB guidelines also include UDS in a statement related to diagnostic testing (Gormley et al., 2015). **"UDS… are not recommended in the initial diagnostic workup of the uncomplicated OAB patient." Here latitude is given to the clinician when the OAB patient is complicated or refractory to multiple OAB treatments. In these cases, the use of UDS depend on patient history and presentation and clinician judgment.**

As in men, women with emptying problems (poor emptying and/or voiding symptoms) may benefit from UDS with voiding pressure-flow studies. This can help differentiate obstruction from impaired contractility. UDS is particularly helpful when the cause of obstruction is not obvious. Anatomic obstruction (high-grade prolapse, incomplete emptying after incontinence surgery, urethral mass) is usually obvious. However, functional obstruction like dysfunctional voiding or primary bladder neck obstruction is not obvious on physical examination or endoscopy and requires evaluation during voiding. We agree with the AUA/SUFU Urodynamics Guideline statement that "Clinicians may perform pressure-flow studies in women when it is important to determine if obstruction is present. (Recommendation; Evidence Quality: Grade C)" (Winters et al., 2012). We find VUDS to be particularly helpful as it can diagnose and localize obstruction (see Videourodynamics section earlier in this chapter).

Evaluation of Neurogenic Lower Urinary Tract Dysfunction

NLUTD usually presents clinically as incontinence and/or inability to empty the bladder. Incontinence may be of bladder origin (detrusor overactivity or impaired compliance) or sphincter origin. Poor emptying can also be of bladder origin (neurogenic detrusor underactivity or neurogenic acontractile detrusor) or sphincter origin (dyssynergia). In addition to symptomatic presentation, NLUTD can present as upper urinary tract decompensation with hydroureteronephrosis and renal insufficiency without bothersome symptoms. The goal of management in these patients is to prevent upper tract decompensation and relieve symptoms. A specific understanding of the pathophysiology of the condition in each individual is essential for the correct choice of therapy (Rivas and Chancellor, 1995; Stohrer, 1990; Stohrer et al., 1994). **UDS probably has its most important role in the evaluation and management of patients with neurogenic voiding dysfunction.**

The aims of therapy for NLUTD are to achieve physiologic filling (and if possible voiding) conditions and to control symptoms and create a management situation acceptable to the patient in daily life. Much of the evidence base for management of the lower urinary tract in the neurogenic patient consists of level 3 or lower evidence. This is primarily because of the potential negative consequences of untreated neurogenic dysfunction. As such, randomized controlled trials are thought by many to be dangerous and unethical. Because prolonged periods of elevated detrusor pressure during bladder filling or abnormally prolonged elevated pressures during voiding have been found to put the upper urinary tract at risk (Kurzrock and Polse, 1998; McGuire et al., 1996; Tanaka et al., 1999), the primary aim of therapy in patients with such problems is conversion to a low-pressure bladder during filling, even if this leads to incomplete emptying and the need to supplement emptying with catheterization. Adequate therapy depends on whether the detrusor is overactive or has reduced compliance, and only urodynamics can answer these questions unequivocally. In addition to the prevention and amelioration of upper and lower urinary tract abnormalities/decompensation, timely and adequate diagnosis of DO and impaired compliance is thought to be of paramount importance for the patient's quality of life (Bomalaski et al., 1995; Cardenas et al., 1995; Stohrer, 1990, Stohrer et al., 1994). UDS is also essential for assessing the response to treatment and following any sequelae of the disease and its management (Hosker et al., 2009).

Another test that has been described in neurogenic patients is the “ice water test” (IWT). This was first described in 1957, but there is still no generally agreed upon algorithm of how to perform this test in clinical practice (Bors and Blinn, 1957). It has been suggested that instillation of cold water will differentiate between an upper (positive test) and lower (negative test) motor neuron lesion (Kozomara et al., 2018). The ice water instilled into the bladder is thought to elicit a C-fiber–mediated reflex. Bladder temperature receptors can elicit a spinal reflex contraction of the detrusor, a reflex that is normally inhibited by supraspinal centers. If an upper motor neuron lesion interrupts this inhibitory pathway, the result is a reflex contraction, whereas if the lesion is a lower motor neuron, the contraction does not occur. Most studies show value to differentiation between reflexic and areflexic neurologic bladder (Apostolidis et al., 2017). The ICS considers it an option test that needs to be interpreted in the context of all other available data but that should not precede regular UDS.

Not all NLUTD requires UDS before observation or treatment. Conditions in which high storage pressures are not suspected (e.g., urgency incontinence in a poststroke patient or a woman with multiple sclerosis and a low PVR) can often be managed initially without UDS. But in cases in which the neurologic condition/lesion can cause potentially harmful storage situations (spinal cord injury, myelomeningocele), UDS is essential both before treatment and in ongoing follow-up of the condition and to monitor the response to treatment. In the middle are situations in which UDS can be helpful in guiding management (e.g., men with possible BPO and Parkinson's disease or multiple sclerosis). The AUA/SUFU Urodynamic Guidelines contain five very important and practical statements regarding UDS in NLUTD (Winters et al., 2012):

- Clinicians should perform PVR assessment, either as part of complete urodynamic study or separately, during the initial urologic evaluation of patients with relevant neurologic conditions (e.g., spinal cord injury, myelomeningocele) and as part of ongoing follow-up when appropriate (Standard; Evidence Strength: grade B).
- Clinicians should perform a complex CMG during initial urologic evaluation of patients with relevant neurologic conditions with or without symptoms and as part of ongoing follow-up when appropriate. In patients with other neurologic diseases, physicians may consider CMG as an option in the urologic evaluation of patients with LUTS (Recommendation; Evidence Strength: grade C).
- Clinicians should perform pressure-flow analysis in patients

with relevant neurologic disease with or without symptoms or in patients with other neurologic disease and elevated PVR or urinary symptoms (Recommendation; Evidence Strength: grade C).

- When available, clinicians may perform VUDS in patients with relevant neurologic disease at risk for NLUTD or in patients with other neurologic disease and elevated PVR or urinary symptoms (Recommendation; Evidence Strength: grade C).
- Clinicians should perform EMG in combination with CMG with or without pressure-flow studies in patients with relevant neurologic disease at risk for NLUTD or in patients with other neurologic disease and elevated PVR or urinary symptoms (Recommendation; Evidence Strength: grade C)

The EAU has also produced a specific guideline on NLUTD (Groen et al., 2016; Pannek et al., 2013). This comprehensive guideline has a section with recommendations about UDS in neurogenic patients. The EAU guideline suggests the following:

- Noninvasive testing is mandatory before invasive UDS is planned (grade A).
- UDS investigation is necessary to detect and specify LUTS dysfunction (grade A).
- Same-session repeat measurement can be helpful in clinical decision making (grade C).
- VUDS is the gold standard for invasive UDS in neurourologic patients (grade A).
- A physiologic filling rate with body-warm saline should be used (grade A).
- Specific uro-neurophysiologic tests (e.g., electromyography, nerve conduction studies of pudendal nerve) are elective procedures (grade C).

The EAU Guideline on Neurogenic Lower Urinary Tract Dysfunction compliments other available guidelines (Groen et al., 2016; Pannek et al., 2013). The suggestions here are similar to the AUA/SUFU guidelines on UDS. There is a suggestion to start with noninvasive testing before invasive UDS, utilizing VUDS in neurogenic patients. However, the EAU guidelines make a few technical suggestions dealing with the technical aspects of the test.

Key Points

- There is mounting evidence that UDS is not essential before surgical treatment of stress-predominant urinary incontinence in women when SUI is seen clinically.
- According to the AUA guidelines on UDS, perform pressure-flow studies in men when it is important to determine if urodynamic obstruction is present in men with LUTS, particularly when invasive, potentially morbid, or irreversible treatments are considered.
- As in men, women with emptying problems (poor emptying and/or voiding symptoms) may benefit from UDS with voiding pressure-flow studies. This can help differentiate obstruction from impaired contractility. UDS is particularly helpful when the cause of obstruction is not obvious.
- UDS probably has its most important role in the diagnosis and management of patients with neurogenic voiding dysfunction.

Future Directions

Invasive urodynamics have been a valuable research tool to gaining understanding of lower urinary tract function and dysfunction. The tools have allowed an understanding of how therapeutic interventions alter the lower urinary tract. We now understand how to diagnose lower urinary tract dysfunction and, in some cases, can predict outcomes with the information UDS give us. We also need to consider how UDS can alter our clinical decision making, impact our patients' understanding and choices, phenotype patients, and perhaps predict long-term management strategies.

New directions in urodynamics also include new methods and techniques, technology, and cut points. These tools are investigated to give us an understanding if they have a role in the UDS armamentarium. For example, many noninvasive tests have been used to assess the voiding phase of men. In a systematic review, Malde et al. (2017) looked at the ability of these noninvasive tests to diagnosis male BOO. These include detrusor wall thickness (median sensitivity 82%, specificity 92%); near-infrared spectroscopy (NIRS) (median sensitivity 85%, specificity 87%); the penile cuff test (median sensitivity 88%, specificity 75%); uroflowmetry with a maximum flow rate less than 10 mL/s (median sensitivity 68%, specificity 70%); and intravesical prostatic protrusion greater than 10 mm (median sensitivity 68%, specificity 75%). The extensive review of available literature, however, concluded that there are current limitations in the evidence base such as issues with heterogeneity of definitions and threshold values used, small sample sizes, and lack of stringent methodologic standards. Further, it is complicated because to really understand each tool, the clinician may need to consider the efficacy and value of combining tests together.

There is also some data about new methods of assessing bladder storage (Farag and Heesakkers, 2011). Ultrasound parameters (e.g., bladder wall thickness, detrusor wall thickness, bladder weight) have also been examined as some potential surrogates for DO in patients with OAB. The potential role of NIRS, an optical technology capable of measuring the changes in concentration of bladder wall chromophores (i.e., oxyhemoglobin and deoxyhemoglobin), is also assessed. Here it is used to look at the presence of DO. NIRS detects the hemodynamic changes caused by involuntary detrusor contractions in real time, but motion artifacts currently limit its clinical applicability. Finally, laboratory biomarkers (i.e., NGF) also show substantial correlation with DO/OAB, but currently lack specificity. In a review of methods for the storage phase, Farag and Heesakkers (2011) concluded that the methods “still have limitations and cannot be applied reliably in routine clinical practice.” Further, other than DO, the methods are unable to quantify other important parameters of bladder storage function. Thus, the conclusion was that filling cystometry remains the gold standard tool in the diagnosis of bladder storage disorders.

Another newer tool that has been used to help understand neuronal control of the micturition cycle is functional magnetic resonance imaging (fMRI). fMRI works by quantifying the paramagnetic properties of oxygenated and deoxygenated hemoglobin, which correlate with neuronal activity as it relates to changes in blood flow (Krhut et al., 2012). It is mentioned in this chapter as it can be paired with concurrent UDS during filling and micturition. This has been carried out in normal controls and patients with dysfunction (i.e., OAB) (Shy et al., 2014; Komesu et al., 2011). The technique can identify areas and the sequences of brain network activation as they relate to the micturition cycle. This pairing of UDS and fMRI is still developing as a research tool, but it may someday have more clinical implications.

References

Abrams P, Cardoza L, Fall M, et al. The standardization of terminology in lower urinary tract function: report from the standardization sub-committee of the International Continence Society. *Neurourol Urodyn*. 2002;21:167–178.

Abrams P, D'Ancona C, Griffiths D, et al. Lower tract symptom: etiology, patient assessment and predicting outcome from therapy. McConnell J, Abrams P, Denis L. *Male lower urinary tract dysfunction evaluation and management*. Health Publications Ltd.: Plymouth, UK; 2006:69–142.

Abrams P, Damaser MS, Niblett P, et al. Air filled, including “air-charged,” catheters in urodynamic studies: does the evidence justify their use? *Neurourol Urodyn*. 2016;36:1234–1242.

Abrams P, Griffiths D, et al. The urodynamic assessment of lower urinary tract symptoms. Chatelain C, Denis L, Foo K, et al. *Benign prostatic hyperplasia*. Health Publication Ltd.: Plymouth; 2001:227–281.

Abrams P, Griffiths DJ. The assessment of prostatic obstruction from urodynamic measurements and from residual urine. *Br J Urol*. 1979;51:129–134.

Abrams P. Bladder outlet obstruction index, bladder contractility index and bladder voiding efficiency: three simple indices to define bladder voiding function. *BJU Int*. 1999;84:14–15.

Abrams PH, Farrar DJ, Turner-Warwick RT, et al. The results of prostatectomy: a symptomatic and urodynamic analysis of 192 patients. *J Urol*. 1979;121:640.

Agur W, Housami F, Drake M, et al. Could the National Institute for Health and Clinical Excellence guidelines on urodynamics in urinary incontinence put some women at risk of a bad outcome from stress incontinence surgery? *BJU Int*. 2009;103:635–639.

Akikwala TV, Fleischman N, Nitti VW. Comparison of diagnostic criteria for female bladder outlet obstruction. *J Urol*. 2006;176:2093–2097.

Al-Hayek S, Belal M, Abrams P. Does the patient's position influence the detection of detrusor overactivity? *Neurourol Urodyn*. 2008;27:279–286.

Apostolidis A, Drake M, Emmanuel A, et al. Neurological urinary and faecal incontinence. Abrams P, Cardoza L, Wagg A, et al. *Incontinence 6th International Consultation on Incontinence*. Health Publications Ltd.: Plymouth, UK; 2017:1111.

Ballert KN, Biggs GY, Isenalumhe A, et al. Managing the urethra at transvaginal pelvic organ prolapse repair: a urodynamic approach. *J Urol*. 2009;181:679–684.

Barrett DM, Wein AJ. Flow evaluation and simultaneous external sphincter electromyography in clinical urodynamics. *J Urol*. 1981;125:538–541.

Barrett DM. Disposable (infant) surface electrocardiogram electrodes in urodynamics: a simultaneous comparative study of electrodes. *J Urol*. 1980;124:663–665.

Bellucci CH, Wöllner J, Gregorini F, et al. Neurogenic lower urinary tract dysfunction—do we need same session repeat urodynamic investigations? *J Urol*. 2012;187:1318–1323.

Bettez M, Tu L-M, Carlson K, et al. 2012 update: guidelines for adult urinary incontinence collaborative consensus document for the Canadian Urological Association. *Can Urol Assoc J*. 2012;6:354–363.

Bhargava S, Canda AE, Chapple CR. A rational approach to benign prostatic hyperplasia evaluation: recent advances. *Curr Opin Urol*. 2004;14:1–6.

Blaivas JG, Groutz A. Bladder outlet obstruction nomogram for women with lower urinary tract symptomatology. *Neurourol Urodyn*. 2000;19:553–564.

Blaivas JG, Labib KB, Michalik SJ, et al. Failure of bethanecol denervation supersensitivity as a diagnostic aid. *J Urol*. 1980;123:199–201.

Blaivas JG. The neurophysiology of micturition: a clinical study of 550 patients. *J Urol*. 1982;127:958–963.

Blaivas JG. Pathophysiology and differential diagnosis of benign prostatic hypertrophy. *Urology*. 1988;32(6 Suppl):5–11.

Bomalaski MD, Teague JL, Brooks B. The longterm impact of urological management on the quality of life of children with spina bifida. *J Urol*. 1995;154:778–781.

Boone TB, Kim YH. Uroflowmetry. Nitti VW. *Practical urodynamics*. WB Saunders: Philadelphia, PA; 1998:28–51.

Bors EH, Blinn KA. Spinal reflex activity from the vesical mucosa in paraplegic patients. *AMA Arch Neurol Psychiatry*. 1957;78:339.

Bosch JL, Cardozo L, Hashim H, et al. Constructing trials to show whether urodynamic studies are necessary in lower urinary tract dysfunction. *Neurourol Urodyn*. 2011;30:735–740.

Brierly RD, Hindley RG, McLarty E, et al. A prospective evaluation of detrusor intrastructural changes in bladder outlet obstruction. *BJU Int*. 2003;91:360–364.

Bright E, Parsons BA, Swithinbank L. Increased patient information does not reduce patient anxiety regarding urodynamic studies. *Urol Int*. 2011;87:314–318.

Broekhuis SR, Kluivers KB, Hendriks JC, et al. Reproducibility of same session repeated cystometry and pressure-flow studies in women with symptoms of urinary incontinence. *Neurourol Urodyn*. 2010;29:428–431.

Brown M, Wickham JEA. The urethral pressure profile. *Br J*

Urol. 1969;41:211–217.

Brucker BM, Campeau L, Fong E, et al. Radiation exposure during videourodynamics: establishing risk factors. *Low Urin Tract Symptoms*. 2016;8:447.

Brucker BM, Fong E, Shah S, et al. Urodynamic differences between dysfunctional voiding and primary bladder neck obstruction in women. *Urology*. 2012;80:55–60.

Brucker BM, Jaffe WI. Urodynamics to guide surgical therapy in LUTS/BPH. *Curr Bladder Dysfunct Rep*. 2009;4(1):53–60.

Brucker BM, Shah S, Mitchell S, et al. Comparison of urodynamic findings in women with anatomical versus functional bladder outlet obstruction. *Female Pelvic Med Reconstr Surg*. 2013;19:46–50.

Bump RC, Elser DM, Theofratous JP, et al. Valsalva leak point pressures in women with genuine stress incontinence: reproducibility, effect of catheter caliber, and correlations with other measures of urethral resistance. Continence Program for Women Research Group. *Am J Obstet Gynecol*. 1995;173:551–557.

Burkhard FC, Bosch JLHR, Cruz F, et al. *Guideline on urinary incontinence*. [European Association of Urology] 2017.

Cameron AP, Campeau L, Brucker BM, et al. Best practice policy statement on urodynamic antibiotic prophylaxis in the non-index patient. *Neurourol Urodyn*. 2017;36:915–926.

Cameron AP. Incontinence: the role of ambulatory urodynamics in spinal cord injury. *Nat Rev Urol*. 2011;8:298–299.

Cardenas DD, Mayo ME, Turner LR. Lower urinary changes over time in suprasacral spinal cord injury. *Paraplegia*. 1995;33:326–329.

Carlson KV, Rome S, Nitti VW. Dysfunctional voiding in women. *J Urol*. 2001;165:143–147.

Cassidenti AP, Ostergard DR. Multichannel urodynamics: ambulatory versus standard urodynamics. *Curr Opin Obstet*

Gynecol. 1999;11:485–487.

Castro JE, Griffiths HJ. Urinary dynamics in benign prostatic hypertrophy. *J Urol*. 1972;107(2):289–292.

Cetinel B, Onal B, Can G, et al. Risk factors predicting upper urinary tract deterioration in patients with spinal cord injury: a retrospective study. *Neurourol Urodyn*. 2017;36:653–658.

Chassagne S, Bernier PA, Haab F, et al. Proposed cutoff values to define bladder outlet obstruction in women. *Urology*. 1998;51:408–411.

Chou ECL, Flisser AJ, Panagopoulis G, et al. Effective treatment for mixed urinary incontinence with a pubovaginal sling. *J Urol*. 2003;170:494–497.

Chua ME, Mendoza J, See M 4th, et al. A critical review of recent clinical practice guidelines on the diagnosis and treatment of non-neurogenic male lower urinary tract symptoms. *Can Urol Assoc J*. 2015;9(7–8):E463–E470.

Clemens JQ. The role of urodynamics in the diagnosis and treatment of benign prostatic hyperplasia. *Curr Urol Rep*. 2003;4:269–275.

Comarr EA. Excretory cystometry: a more physiological method. *J Urol*. 1957;77:622–633.

Combs AJ, Grafstein N, Horowitz M, et al. Primary bladder neck dysfunction in children and adolescents I: pelvic floor electromyography lag time—a new noninvasive method to screen for and monitor therapeutic response. *J Urol*. 2005;173:207–210.

Comiter CV, Sullivan MP, Schacterle RS, et al. Prediction of prostatic obstruction with a combination of isometric detrusor contraction pressure and maximum urinary flow rate. *Urology*. 1996;48:723–729.

Cooper MA, Fletter PC, Zaszczurynski PJ, et al. Comparison of air-charged and water-filled urodynamic pressure measurement catheters. *Neurourol Urodyn*. 2011;30:329–334.

de Wachter SG, Herringa R, van Koeveringe GA, et al. On the nature of bladder sensation: the concept of sensory modulation. *Neurourol Urodyn*. 2011;30:1220–1226.

Defreitas GA, Zimmern PE, Lemack GE, et al. Refining diagnosis of anatomic female bladder outlet obstruction: comparison of pressure-flow study parameters in clinically obstructed women with those of normal controls. *Urology*. 2004;64:675–679.

Digesu GA, Derpapas A, Robshaw P, et al. Are the measurements of water-filled and air-charged catheters the same in urodynamics? *Int Urogynecol J*. 2014;25:123–130.

Digesu GA, Gargasole C, Hendricken C, et al. ICS teaching module: ambulatory urodynamic monitoring. *Neurourol Urodyn*. 2017;36:364–367.

Diokno AC, Hollander JB, Bennett CJ. Bladder neck obstruction in women: a real entity. *J Urol*. 1984;132:294–298.

Dokmeci F, Seval M, Gok H. Comparison of ambulatory versus conventional urodynamics in females with urinary incontinence. *Neurourol Urodyn*. 2010;29:518–521.

Donkelaar SCT, Rosier P, de Kort L. Comparison of three methods to analyze detrusor contraction during micturition in men over 50 years of age. *Neurourol Urodyn*. 2017;36:2153–2159.

Drach GW, Layton TN, Binard WJ. Male peak urinary flow rate: relationships to volume voided and age. *J Urol*. 1979;122:210–214.

Drake MJ, Apostolidis A, Cocci A, et al. Neurogenic lower urinary tract dysfunction: clinical management recommendations of the Neurologic Incontinence Committee of the Fifth International Consultation on Incontinence 2013. *Neurourol Urodyn*. 2016;35:657–665.

DuBeau CE, Sullivan MP, Cravalho EG, et al. Correlation between micturitional pressure profile and pressure-flow criteria in bladder outlet obstruction. *J Urol*. 1995;154:489–503.

Elmelund M, Klarskov N, Bagi P, et al. Renal deterioration after spinal cord injury is associated with length of detrusor contractions during cystometry—a study with a median of 41 years follow-up. *Neurourol Urodyn*. 2017;36(6):1607–1615.

Faerber GJ, Vashi AR. Variations in Valsalva leak point pressure with increasing vesical volume. *J Urol*. 1998;159:1909–1911.

Farag FF, Heesakkers JP. Non-invasive techniques in the diagnosis of bladder storage disorders. *Neurourol Urodyn*. 2011;30:1422–1428.

Flanigan RC, Reda DJ, Wasson JH, et al. 5-year outcome of surgical resection and watchful waiting for men with moderately symptomatic benign prostatic hyperplasia: a Department of Veterans study. *J Urol*. 1998;160:12–17.

Fleischmann N, Flisser AJ, Blaivas JG, et al. Sphincteric urinary incontinence: relationship of vesical leak point pressure, urethral mobility and severity of incontinence. *J Urol*. 2003;169:999–1002.

Gajewski JB, Schurch B, Hamid R, et al. An International Continence Society (ICS) report on the terminology for adult neurogenic lower urinary tract dysfunction (ANLUTD). *Neurourol Urodyn*. 2017;59:1438.

Gammie A, Abrams P, Bevan W, et al. Simultaneous in vivo comparison of water-filled and air-filled pressure measurement catheters: implications for good urodynamic practice. *Neurourol Urodyn*. 2016;35:926–933.

Gammie A, Clarkson B, Constantinou C, et al. International Continence Society guidelines on urodynamic equipment performance. *Neurourol Urodyn*. 2014;33:370–379.

Glazener CM, Lapitan MC. Urodynamic studies for management of urinary incontinence in children and adults.

Cochrane Database Syst Rev. 2012;(1) [CD003195].

Gleeson DM, Lattimer JK. The pressure-flow study: a method for measuring bladder neck resistance. *J Urol*. 1962;87:844–852.

Gormley EA, Lightner DJ, Faraday M, American Urological Association; Society of Urodynamics, Female Pelvic Medicine, et al. Diagnosis and treatment of overactive bladder (non-neurogenic) in adults: AUA/SUFU guideline amendment. *J Urol*. 2015;193:1572–1580.

Gorton E, Stanton S. Ambulatory urodynamics: do they help clinical management? *BJOG*. 2000;107:316–319.

Gratzke C, Bachmann A, Descazeaud A, et al. EAU guidelines on the assessment of non-neurogenic male lower urinary tract symptoms including benign prostatic obstruction. *Eur Urol*. 2015;67(6):1099–1109.

Griffiths D, Hofner K, van Mastrigt R, et al. ICS Report on the standardization of terminology of lower urinary tract function: pressure-flow studies of voiding, urethral resistance and urethral obstruction. *Neurourol Urodyn*. 1997;16:1–18.

Griffiths DJ, van Mastrigt R, Bosch R. Quantification of urethral resistance and bladder function during voiding, with special reference to the effects of prostate size reduction in urethral obstruction due to benign prostatic hyperplasia. *Neurourol Urodyn*. 1989;8:29–52.

Griffiths DJ. Assessment of detrusor contraction strength or contractility. *Neurourol Urodyn*. 1991;10:1–18.

Groen J, Pannek J, Castro Diaz D, et al. Summary of European Association of Urology (EAU) guidelines on neuro-urology. *Eur Urol*. 2016;69:324–333.

Hanno PM, Erickson D, Moldwin R, et al. Diagnosis and treatment of interstitial cystitis/bladder pain syndrome: AUA Guideline Amendment. *J Urol*. 2015;193:1545–1553.

Harvey MA, Versi E. Predictive value of clinical evaluation of stress urinary incontinence: a summary of the published literature. *Int Urogynecol J Pelvic Floor Dysfunct*. 2001;12:31–37.

Haylen BT, Ashby D, Sutherst JR, et al. Maximum and average urine flow rates in normal male and female populations—the Liverpool nomograms. *Brit J Urol*. 1989;64:30–38.

Haylen BT, de Ridder D, Freeman RM, et al. An International Urogynecological Association (IUGA)/International Continence Society (ICS) joint report on the terminology for female pelvic floor dysfunction. *Int Urogynecol J*. 2010;21(1):5–26.

He W, Chen M, Zu X, et al. Chronic prostatitis presenting with dysfunctional voiding and effects of pelvic floor biofeedback treatment. *BJU Int*. 2010;105(7):975–977.

Herringa R, de Wachter SG, van Keerrebroeck PE, et al. Normal bladder sensations in healthy volunteers: a focus group investigation. *Neurourol Urodynam*. 2011;30:1350–1355.

Heslington K, Hilton P. Ambulatory monitoring and conventional cystometry in asymptomatic female volunteers. *Br J Obstet Gynaecol*. 1996;103:434–441.

Homma Y. The clinical significance of the urodynamic investigation in incontinence. *BJU Int*. 2002;90:489–497.

Homma Y. Pressure-flow studies in benign prostatic hyperplasia: to do or not to do for the patient? *BJU Int*. 2001;87:19–23.

Hosker G, Rosier P, Gajewski J, et al. Dynamic testing. Abrams P, Cardoza L, Khoury S, et al. *Incontinence 4th International Consultation on Incontinence*. Health Publications Ltd.: Plymouth, UK; 2009:413–552.

Hosker G. Urodynamics. Hillard T, Purdie D. *The yearbook of obstetrics and gynaecology*. RCOG Press: London, UK; 2004:233–254.

Hougardy V, Vandeweerd J-M, Reda AA, et al. The impact of detailed explanatory leaflets on patient satisfaction with urodynamic consultation: a double-blind randomized controlled trial. *Neurourol Urodyn*. 2009;28:374–379.

Huckabay C, Twiss C, Berger A, et al. A urodynamics protocol to optimally assess men with post-prostatectomy incontinence. *Neurourol Urodyn*. 2005;24:622–626.

Hwang SM, de Toledo LGM, da Silva Carramão S, et al. Is urodynamics necessary to identify occult stress urinary incontinence? *World J Urol*. 2018;79 [539–535].

Ignjatovic I. Prediction of unfavorable symptomatic outcome of transurethral prostatectomy in patients with the relative indication for operation. *Int Urol Nephrol*. 1997;29:653–660.

Javle P, Jenkins SA, Machin DG, et al. Grading of benign prostatic obstruction can predict the outcome of transurethral prostatectomy. *J Urol*. 1998;160:1713–1717.

Kageyama S, Watanabe T, Kurita Y, et al. Can persisting detrusor hyperreflexia be predicted after transurethral prostatectomy for benign prostatic hypertrophy? *Neurourol Urodyn*. 2000;19:233–240.

Kanik EA, Erdem E, Abidinoglu D, et al. Can the outcome of transurethral resection of the prostate be predicted preoperatively? *Urology*. 2004;64:302–305.

Kaplan SA, Ikeguchi EF, Santarosa RP, et al. Etiology of voiding dysfunction in men less than 50 years of age. *Urology*. 1996;47:836–839.

Kaplan SA, Santarosa RP, D'Alisera PM, et al. Pseudodyssynergia (contraction of the external sphincter during voiding) misdiagnosed as chronic nonbacterial prostatitis and the role of biofeedback as a therapeutic option. *J Urol*. 1997;157:2234–2237.

Keane DP, Winder A, Lewis P, et al. A combined urodynamic and continence unit—a review of the first 19 years. *Br J Urol*. 1993;71(2):161–165.

Khullar V, Amarenco G, Doumouchtsis SK, et al. Imaging, neurophyisological testing and other tests. Abrams P, Cardozo L, Wagg A, et al. *Incontinence*. 2017:673–804 [ICUD-EAU].

Kim KS, Seo JH, Kang JU, et al. Implementation of a multi-functional ambulatory urodynamics monitoring system based on newly devised abdominal pressure measurement. *J Med Syst*. 2010;34:1011–1021.

Kim KS, Song CG. Availability of a newly devised ambulatory urodynamics monitoring system based on personal device assistance in patients with spinal cord injury. *Comput Methods Programs Biomed*. 2012;106:260–273.

Kobashi KC, Albo ME, Dmochowski RR, et al. Surgical treatment of female stress urinary incontinence: AUA/SUFU Guideline. *J Urol*. 2017;198:875–883.

Komesu YM, Ketai LH, Mayer AR, et al. Functional MRI of the brain in women with overactive bladder: brain activation during urinary urgency. *Female Pelvic Med Reconstr Surg*. 2011;17:50–54.

Kozomara M, Mehnert U, Seifert B, et al. Is detrusor contraction during rapid bladder filling caused by cold or warm water? A randomized, controlled, double-blind trial. *J Urol*. 2018;199:223–238.

Krhut J, Tintera J, Holý P, et al. A preliminary report on the use of functional magnetic resonance imaging with simultaneous urodynamics to record brain activity during micturition. *J Urol*. 2012;188:474–479.

Kurzrock EA, Polse S. Renal deterioration in myelodysplastic children: urodynamic evaluation and clinical correlates. *J Urol*. 1998;159:1657–1661.

Lapides J, Friend CR, Ajemian EP, et al. Denerveation supersensitivity as a test for neurogenic bladder. *Surg Gynecol Obstet*. 1962;114:241.

Lecamwasam HS, Yalla SV, Cravalho EG, et al. The maximum watts factor as a measure of detrusor contractility independent of outlet resistance. *Neurourol Urodyn*. 1998;17:621–635.

Lecamwasam HS, Sullivan MP, Desirreddi N, et al. Voiding profilometry as a diagnostic aid in patients with prostatism: assessment with post-therapeutic symptom evaluation. *Neurourol Urodyn*. 1994;13:391.

Lemack GE, Krauss S, Litman H, et al. Normal preoperative urodynamic testing does not predict voiding dysfunction after Burch colposuspension versus pubovaginal sling. *J Urol*. 2008;180:2076–2080.

Lemack GE, Zimmern PE. Pressure flow analysis may aid in identifying women with outflow obstruction. *J Urol*. 2000;163:1823–1828.

Leng WW, McGuire EJ. Obstructive uropathy induced bladder dysfunction can be reversible: bladder compliance measures before and after treatment. *J Urol*. 2003;169:563–566.

Lim CS, Abrams P. The Abrams-Griffiths nomogram. *World J Urol*. 1995;13:34–39.

Linsenmeyer TA, Bagaria SP, Gendron B. The impact of urodynamic parameters on the upper tracts of spinal cord injured men who void reflexly. *J Spinal Cord Med*. 1998;21:15–20.

Lose G, Griffiths D, Hosker G, et al. Standardization of urethral pressure measurement: report from the Standardization Sub-Committee of the International Continence Society. *Neurourol Urodyn*. 2002;21:258–260.

Lu SH, Wei YH, Chang LS, et al. Morphological and morphometric analysis of human detrusor mitochondria with urodynamic correlation after partial bladder outlet obstruction. *J Urol*. 2000;163:225–229.

Lucas MG, Bedretdinova D, Bosch JLHR. *Guidelines on*

Urinary Incontinence. [Arnhem, the Netherlands: European Association of Urology] 2013.

MacLachlan LS, Rovner ES. Good urodynamic practice: key to performing a quality UDS study. *Urol Clin North Am*. 2014;41:363–373.

Malde S, Nambiar AK, Umbach R, et al. Systematic review of the performance of noninvasive tests in diagnosing bladder outlet obstruction in men with lower urinary tract symptoms. *Eur Urol*. 2017;71:391–402.

Marks BK, Goldman HB. Videourodynamics: indications and technique. *Urol Clin North Am*. 2014;41:383–391 [vii–viii].

Martens FM, van Kuppevelt HJ, Beekman JA, et al. No primary role of ambulatory urodynamics for the management of spinal cord injury patients compared to conventional urodynamics. *Neurourol Urodyn*. 2010;29:1380–1386.

McGuire EJ, Cespedes RD, O'Connell HE. Leakpoint pressures. *Urol Clin North Am*. 1996;23:253–262.

McGuire EJ, Fitzpatrick CC, Wan J, et al. Clinical assessment of urethral sphincter function. *J Urol*. 1993;150:1452–1454.

McGuire EJ, Woodside JR, Borden TA, et al. Prognostic value of urodynamic testing in myeloplastic children. *J Urol*. 1981;126:205–209.

McGuire EJ. Urodynamic findings in patients after failure of stress incontinence operations. *Prog Clin Biol Res*. 1981;78:351–354.

Musco S, Padilla-Fernández B, Del Popolo G, et al. Value of urodynamic findings in predicting upper urinary tract damage in neuro-urological patients: a systematic review. *Neurourol Urodyn*. 2018;37(5):1522–1540.

Nager CW, Brubaker L, Litman HJ, et al. A randomized trial of urodynamics before stress incontinence surgery. *N Engl J Med*. 2012;366(21):1987–1997.

Nager CW, FitzGerald M, Kraus SR, et al. Urodynamic measures do not predict stress continence outcomes after surgery for stress urinary incontinence in selected women. *J Urol*. 2008;179:1470–1474.

Nambiar AK, Bosch R, Cruz F, et al. EAU guidelines on assessment and nonsurgical management of urinary incontinence. *Eur Urol*. 2018;73(4):596–609.

National Collaborating Centre for Women's and Children's Health (UK). *Urinary incontinence in women: the management of urinary incontinence in women. London: Royal College of Obstetricians and Gynaecologists (UK)*. National Institute for Health and Care Excellence: Clinical Guidelines. 2013 [Available at] https://www.ncbi.nlm.nih.gov/pubmed/25340217.

Neveus T, von Gontard A, Hoebeke P, et al. The standardization of terminology of lower urinary tract function in children and adolescents: report from the Standardization Committee of the International Children's Continence Society. *J Urol*. 2006;176:314–324.

Nitti VW, Combs AJ. Urodynamics when why and how. Nitt VW. *Practical urodynamics*. Saunders: Philadelphia; 1998:15–26.

Nitti VW, Lefkowitz G, Ficazzola M, et al. Lower urinary tract symptoms in young men: videourodynamic findings and correlation with noninvasive measures. *J Urol*. 2001;168:135–138.

Nitti VW, Tu LM, Gitlin J. Diagnosing bladder outlet obstruction in women. *J Urol*. 1999;161:1535–1540.

Norlen LJ, Blaivas JG. Unsuspected proximal urethral obstruction in young and middle-aged men. *J Urol*. 1986;135:972–976.

O'Donnell PD. Electromyography. Nitti VW. *Practical urodynamics*. WB Saunders: Philadelphia, PA; 1998:65–71.

Oelke M, Baard J, Wijkstra H, et al. Age and bladder outlet obstruction are independently associated with detrusor overactivity in patients with benign prostatic hyperplasia. *Eur Urol*. 2008;54:419–426.

Osman NI, Chapple CR, Abrams P, et al. Detrusor underactivity and the underactive bladder: a new clinical entity? A review of current terminology, definitions, epidemiology, aetiology, and diagnosis. *Eur Urol*. 2014;65:389–398.

Osman T. Stress incontinence surgery for patients presenting with mixed incontinence and a normal cystometrogram. *BJU Int*. 2003;92:964–968.

Pan D, Troy A, Rogerson A, et al. Long-term outcomes of external sphincterotomy in a spinal injured population. *J Urol*. 2009;181:705–709.

Pannek J, Berges RR, Haupt G, et al. Value of the Danish prostate symptom Score compared to the AUA symptom score and pressure/flow studies in the preoperative evaluation of men with symptomatic benign prostatic hyperplasia. *Neurourol Urodyn*. 1998;17:9–18.

Pannek J, Block B, Castro-Diaz D, et al. Guidelines on neurogenic lower urinary tract dysfunction. *European Association of Urology*. 2013.

Pannek J, Pieper P. Clinical usefulness of ambulatory urodynamics in the diagnosis and treatment of lower urinary tract dysfunction. *Scand J Urol Nephol*. 2008;42:428–432.

Patravali N. Ambulatory urodynamic monitoring: are we wasting our time? *J Obstet Gynaecol*. 2007;27:413–415.

Pollak JT, Neimark M, Connor JT, et al. Air-charged and microtransducer urodynamic catheters in the evaluation of urethral function. *Int Urogynecol J Pelvic Floor Dysfunct*. 2004;15:124–128.

Porru D, Jallous H, Cavalli V, et al. Prognostic value of a combination of IPSS, flow rate and residual urine volume compared to pressure-flow studies in the preoperative evaluation of symptomatic BPH. *Eur Urol*. 2002;41:246–249.

Radley SC, Rosario DJ, Chapple CR, et al. Conventional and ambulatory urodynamic findings in women with symptoms suggestive of bladder overactivity. *J Urol*. 2001;166:2253–2258.

Rezapour M, Ulmsten U. Tension-free vaginal tape (TVT) in women with recurrent stress urinary incontinence—a long-term follow up. *Int Urogynecol J Pelvic Floor Dysfunct*. 2001;12(Suppl 2):S9–S11.

Rezvan A, Amaya S, Betson L, et al. Randomized controlled trial of the effect of environment on patient embarrassment and anxiety with urodynamics. *Int Urogynecol J*. 2017;29:1–6.

Rivas DA, Chancellor MB. Neurogenic vesical dysfunction. *Urol Clin North Am*. 1995;22:579–591.

Robertson A, Neal DE. Ambulatory urodynamics. Nitti VW. *Practical urodynamics*. WB Saunders: Philadelphia, PA; 1998:273–286.

Robertson AS, Griffiths C, Neal DE. Conventional urodynamics and ambulatory monitoring in the definition and management of bladder outflow obstruction. *J Urol*. 1996;155:506–511.

Robertson AS, Griffiths CJ, Ramsden PD, et al. Bladder function in healthy volunteers: ambulatory monitoring and conventional urodynamic studies. *Br J Urol*. 1994;73:242–249.

Robertson AS. Behaviour of the human bladder during natural filling: the Newcastle experience of ambulatory monitoring and conventional artificial filling cystometry. *Scand J Urol Nephrol Suppl*. 1999;201:19–24.

Rodrigues P, Lucon AM, Freire GC, et al. Urodynamic pressure flow studies can predict the clinical outcome after transurethral prostatic resection. *J Urol*. 2001;165:499–502.

Rosario DJ, MacDiarmid SA, Radley SC, et al. A comparison of ambulatory and conventional urodynamic studies in men with borderline outlet obstruction. *BJU Int*. 1999;83:400–409.

Rosier PFWM, Kuo HC, De Gennaro M, et al. Urodynamic testing. Abrams P, Cardoza L, Khoury S, et al. *Incontinence 5th International Consultation on Incontinence*. Health Publications Ltd.: Plymouth, UK; 2013:429–506.

Rosier PFWM, Kuo HC, Agro EF, et al. Urodynamic testing. Abrams P, Cardoza L, Wagg A, et al. *Incontinence 6th International Consultation on Incontinence*. Health Publications Ltd.: Plymouth, UK; 2017:599–670.

Rosier PFWM, Schaefer W, Lose G, et al. International Continence Society Good Urodynamic Practices and Terms 2016: urodynamics, uroflowmetry, cystometry, and pressure-flow study. *Neurourol Urodyn*. 2017;36(5):1243–1260.

Scarpero HM, Kaufman MR, Koski M, et al. *Urodynamics Best Practices*. [American Urological Association Update Series, Lesson 9] 2009.

Scarpero HM, Padmanabhan P, Xue X, et al. Patient perception of videourodynamic testing: a questionnaire based study. *J Urol*. 2005;173:555–559.

Schafer W, Sterling AM, Liao L, et al. Good urodynamic practice: report from the standardization sub-committee of the International Continence Society. *Neurourol Urodyn*. 2002;21:261–274.

Schafer W. Analysis of bladder outlet function with the linearized passive urethral resistance relation, linPURR, and a disease-specific approach for grading obstruction from complex to simple. *World J Urol*. 1995;13:47–58.

Schafer W. Principles and clinical application of advanced urodynamic analysis of voiding function. *Urol Clin North Am*. 1990;17:553–566.

Schick E, Dupont C, Bertrand PE, et al. Predictive value of maximum urethral closure pressure, urethral hypermobility and urethral incompetence in the diagnosis of clinically significant female genuine stress incontinence. *J Urol*. 2004;171:1871–1875.

Serati M, Giarenis I, Meschia M, et al. Role of urodynamics before prolapse surgery. *Int Urogynecol J*. 2015;26:165–168.

Shin JC, Lee Y, Yang H, et al. Clinical significance of urodynamic study parameters in maintenance of renal function in spinal cord injury patients. *Ann Rehabil Med*. 2014;38:353–359.

Shy M, Fung S, Boone TB, et al. Functional magnetic resonance imaging during urodynamic testing identifies brain structures initiating micturition. *J Urol*. 2014;192:1149–1154.

Siroky MB, Olsson CA, Krane RJ. The flow rate nomogram: I. Development. *J Urol*. 1979;122:665–668.

Siroky MB, Olsson CA, Krane RJ. The flow rate nomogram: II. Clinical correlation. *J Urol*. 1980;123:208–210.

Smith AL, Nissim HA, Le TX, et al. Misconceptions and miscommunication among aging women with overactive bladder symptoms. *Urology*. 2011;77:55–59.

Solomon E, Yasmin H, Duffy M, et al. Developing and validating a new nomogram for diagnosing bladder outlet obstruction in women. *Neurourol Urodyn*. 2017;37:368–378.

Sorensen S, Gregersen H, Sorensen SM. Long term reproducibility of urodynamic investigations in healthy fertile females. *Scand J Urol Nephrol Suppl*. 1988;114:35–41.

Steele GS, Sullivam MP, Yalla SV. Urethral pressure profilometry: vesicourethral pressure measurements under resting and voiding conditions. Nitti VW. *Practical urodynamics*. WB Saunders: Philadelphia, PA; 1998:108–130.

Stohrer M, Goepel M, Kondo A, et al. The standardization of terminology in neurogenic lower urinary tract dysfunction with suggestions for diagnostic procedures. *Neurourol*

Urodyn. 1999;18:139–158.

Stohrer M. Alterations in the lower urinary tract after spinal cord injury—diagnosis, prevention and therapy of late sequelae. *World J Urol*. 1990;7:205.

Stohrer M, Kramer G, Lochner-Ernst D, et al. *Diagnosis and treatment of bladder dysfunction in spinal cord injury patients*. [European Urology Update series] 1994.

Sullivan MP, DuBeau CE, Resnick NM, et al. Continuous occlusion test to determine detrusor contractile performance. *J Urol*. 1995;154:1834–1840.

Sullivan MP, Yalla SV. Detrusor contractility and compliance characteristics in adult male patients with obstructive and nonobstructive voiding dysfunction. *J Urol*. 1996;155:1995–2000.

Sullivan MP, Yalla SV. Functional studies to assess bladder contractility. *J Urol Urogynakol*. 2007;14:7–10.

Susset JG. Development of nomograms for application of uroflowmetry. Hinman F, Boyarski S. *Benign prostatic hypertrophy*. Springer-Verlag: New York, NY; 1983:528–538.

Syan R, Brucker BM. Guideline of guidelines: urinary incontinence. *BJU Int*. 2016;117:20–33.

Tan TL, Bergmann MA, Griffiths D, et al. Which stop test is best? Measuring detrusor contractility in older females. *J Urol*. 2003;169:1023–1027.

Tanaka H, Kakizaki H, Kobayashi S, et al. The relevance of urethral resistance in children with myelodysplasia: its impact on upper urinary tract deterioration and the outcome of conservative management. *J Urol*. 1999;161:929–932.

Tarcan T, Demirkesen O, Plata M, et al. ICS teaching module: detrusor leak point pressures in patients with relevant neurological abnormalities. *Neurourol Urodyn*. 2017;36:259–262.

Tarcan T, Sekerci CA, Akbal C, et al. Is 40 cm H_2O detrusor leak point pressure cut-off reliable for upper urinary tract protection in children with myelodysplasia? *Neurourol Urodyn*. 2017;36:759–763.

Thomas AW, Cannon A, Bartlett E, et al. The natural history of lower urinary tract dysfunction in men: the influence of detrusor underactivity on the outcome after transurethral resection of the prostate with a minimum 10-year urodynamic follow-up. *BJU Int*. 2004;93:745–750.

Tsiju I, Kuroda K, Nakajima F. Excretory cystography in paraplegic patients. *J Urol*. 1960;83:839–844.

Türker P, Kilic G, Tarcan T. The presence of transurethral cystometry catheter and type of stress test affect the measurement of abdominal leak point pressure (ALPP) in women with stress urinary incontinence (SUI). *Neurourol Urodyn*. 2010;29(4):536–539.

van der Ploeg JM, Zwolsman SE, Posthuma S, et al. The predictive value of demonstrable stress incontinence during basic office evaluation and urodynamics in women without symptomatic urinary incontinence undergoing vaginal prolapse surgery. *Neurourol Urodyn*. 2018;37:1011–1018.

van Koeveringe GA, Vahabi B, Andersson KE, et al. Detrusor underactivity: a plea for new approaches to a common bladder dysfunction. *Neurourol Urodyn*. 2011;30:723–728.

van Leijsen SAL, Kluivers KB, Mol BWJ, et al. Value of urodynamics before stress incontinence surgery: a randomized controlled trial. *Obstet Gynecol*. 2013;121(5):999–1008.

van Waalwijk van Doorn E, Anders K, Khullar V, et al. Standardization of ambulatory urodynamic monitoring: report of the standardization sub-committee of the International Continence Society. *Neurourol Urodyn*. 2000;19:113–125.

van Waalwijk van Doorn ES, Meier AH, et al. Ambulatory urodynamics: extramural testing of the lower and upper urinary tract by Holter monitoring of cystometrogram, uroflowmetry, and renal pelvic pressures. *Urol Clin North Am*. 1996;23:345–371.

van Waalwijk van Doorn ES, Remmers A, Janknegt RA. Conventional and extramural ambulatory urodynamic testing of the lower urinary tract in female volunteers. *J Urol*. 1992;147:1319–1326.

Vesely S, Knutson T, Fall M, et al. Clinical diagnosis of bladder outlet obstruction in men with lower urinary tract symptoms: reliability of commonly measured parameters and the role of idiopathic detrusor overactivity. *Neurourol Urodyn*. 2003;22:301–305.

Vírseda-Chamorro M, Salinas-Casado J, la Marta-García de M, et al. Comparison of ambulatory versus video urodynamics in patients with spinal cord injury. *Spinal Cord*. 2014;52(7):551–555.

Visco AG, Brubaker L, Nygaard I, et al. The role of preoperative urodynamic testing in stress-continent women undergoing sacro-colpopexy: the colpopexy and urinary reduction efforts (CARE) randomized surgical trial. *Int Urogynecol J Pelvic Floor Dysfunct*. 2008;19:607–614.

Webb RJ, Griffiths CJ, Ramsden PD, et al. Ambulatory monitoring of bladder pressure in low compliance neurogenic bladder dysfunction. *J Urol*. 1992;148:1477–1481.

Webb RJ, Griffiths CJ, Zachariah KK, et al. Filling and voiding pressures measured by ambulatory monitoring and conventional studies during natural and artificial bladder filling. *J Urol*. 1991;146:815–818.

Webb RJ, Styles RA, Griffiths CJ, et al. Ambulatory monitoring of bladder pressures in patients with low compliance as a result of neurogenic bladder dysfunction. *Br J Urol*. 1989;64:150–154.

Wei JT, Nygaard I, Richter HE, et al. A midurethral sling to reduce incontinence after vaginal prolapse repair. *N Engl J Med*. 2012;366:2358–2367.

Wein AJ, Hanno PM, Dixon DO, et al. The effect of oral bethanecol chloride on the cystometrogram of the normal adult male. *J Urol*. 1978;120:330–331.

Wein AJ, Raezer DM, Malloy TR. Failure of the bethanecol supersensitivity test to predict voiding after subcutaneous bethanecol administration. *J Urol*. 1980;123:202–203.

Wein AJ. Classification of neurogenic voiding dysfunction. *J Urol*. 1981;125:605–609.

Winters JC, Dmochowski RR, Goldman HB, et al. Urodynamic studies in adults: AUA/SUFU guideline. *J Urol*. 2012;188:2464–2472.

Wolf JS, Bennett CJ, Dmochowski RR, et al. Best practice policy statement on urologic surgery antimicrobial prophylaxis. *J Urol*. 2008;179:1379–1390.

Wyndaele JJ, De Wachter S. Cystometrical sensory data from a normal population: comparison of two groups of young healthy volunteers examined with 5 years interval. *Eur Urol*. 2002;42:34–38.

Yalla SV, Blute R, Waters W, et al. Urodynamic evaluation of prostatic enlargements with vesicourethral static pressure profiles. *J Urol*. 1981;125:685–689.

Yalla SV, Sharma GV, Barsamian EM. Micturitional urethral pressure profile during voiding and the implications. *J Urol*. 1980;124:649–656.

Yang T-H, Chuang F-C, Kuo H-C. Urodynamic characteristics of detrusor underactivity in women with voiding dysfunction. *PLoS ONE*. 2018;13:e0198764.

Yeung JY, Eschenbacher MA, Pauls RN. Pain and embarrassment associated with urodynamic testing in women. *Int Urogynecol J*. 2014;25:645–650.

Yiou R, Audureau E, Loche CM, et al. Comprehensive evaluation of embarrassment and pain associated with invasive urodynamics. *Neurourol Urodyn*. 2013;34:156–160.

Yokoyama T, Nozaki K, Nose H, et al. Tolerability and morbidity of urodynamic testing: a questionnaire based study. *Urology*. 2005;66:74–76.

Zehnder P, Roth B, Burkhard FC, et al. Air charged and microtip catheters cannot be used interchangeably for urethral pressure measurement: a prospective, single-blind, randomized trial. *J Urol*. 2008;180:1013–1017.

Zimmern PE, Litman H, Nager C, et al. Pre-operative urodynamics in women with stress urinary incontinence increases physician confidence, but does not improve outcomes. *Neurourol Urodyn*. 2014;33:302–306.

115

Urinary Incontinence and Pelvic Prolapse

Epidemiology and Pathophysiology

Gary E. Lemack MD, Maude Carmel MD

Definition and Classification of Urinary Incontinence

Introduction and Overview of the Lower Urinary Tract

Urinary incontinence (UI) profoundly affects millions of women and men, their partners, and their family members and results in billions of dollars in direct and indirect health care expenses. Although the number of visits and procedures related to UI has steadily increased throughout the past several decades, the number of symptomatic yet undiagnosed women remains substantial, suggesting significant under-reporting (Miller et al., 2009). One study of a middle-aged managed care population of women noted that 53% of all women who were found to have no mention of UI on their clinical office visit in fact reported UI in the last year when directly questioned, and 37% reported UI within the last week. Moreover, more than half classified it as moderate to severe (Wallner et al., 2009). Therefore, although great advances have been made in medical and surgical treatments, there remains a great challenge for clinicians to identify women with UI, appropriately characterize it, and initiate a discussion of management strategies.

The lower urinary tract (LUT) is composed of the bladder and urethra, supported by a complex system of neural innervation and musculofascial support in the lower pelvis. Lower urinary tract symptoms (LUTS), including UI, can develop as a result of anatomic abnormalities in the lower urinary tract that may be at the macroscopic, microscopic, or ultrastructural level. Such abnormalities include functional alterations in the various components of the LUT (e.g., the urothelium, detrusor musculature, sphincteric unit) or abnormalities of the surrounding structures affecting the ability of the LUT to perform its normal functions. Those normal functions, which principally involve storing urine at low intravesical pressures and expelling urine at socially appropriate and convenient times, may indeed be inexorably influenced by a variety of coexisting urologic and nonurologic conditions, demographic/environmental risks, lifestyle choices, and genetic factors.

Signs, Symptoms, and Urodynamic Observations of Urinary Incontinence

Evaluating the LUT involves distinguishing among signs, symptoms, and (urodynamic) observations. These distinctions are necessary particularly because symptoms of LUT dysfunction are often nonspecific. That is to say, varying causes of LUT dysfunction can result in very similar LUTS. Urinary urgency, for example, can be present with overactive bladder (OAB), bladder outlet obstruction (BOO), pelvic organ prolapse (POP), and interstitial cystitis/painful bladder syndrome, as well as other conditions. The extent of the diagnostic evaluation necessary to clarify the cause varies by condition, invasiveness/risk of the proposed intervention, and, to a certain extent, comfort level of the clinician and patient. Therefore, although it is safe to assume that the more definitive the diagnosis, the more effective a particular treatment strategy is likely to be, it is clear that an extensive and expensive diagnostic evaluation is not necessary in all cases to offer appropriate treatment options.

A sign of LUT dysfunction is considered one that is observable by the clinician. For the purpose of LUT dysfunction, this may include, for example, the finding of UI during a supine stress test or the finding of pelvic organ prolapse (POP) in a woman who complains of pelvic pressure. Signs are reproducible and objective.

Symptoms are the subjective report, made directly by the patient or given by a caregiver/family member, describing a condition or a change in a condition from what had been previously experienced. By their nature, symptoms are descriptive/experiential, and they may reflect noticeable alterations in the patient's perception of their LUT function. Symptoms can be self-reported, or they can be determined through the use of a variety of validated questionnaires, many of which are developed for the sole purpose of attempting to make more objective what is, at its essence, a very subjective report. Symptoms, including incontinence, do not necessarily indicate bother, which is a critical distinction to make, because quality-of-life (QoL) impact is the most common reason to intervene for LUTS. In the absence of QoL change, treatment may not necessarily be indicated. A symptom that is very bothersome to one patient may be essentially unnoticed by another.

Observations may be urodynamic or nonurodynamic. Nonurodynamic observations include, for example, information gleaned from patient-completed voiding (bladder) diaries. Urodynamic observations are specific findings made during urodynamic studies that may help in delineating the underlying physiologic basis of LUTS. Specific guidelines have been developed regarding indications for (Winters et al., 2012), and implementation of, urodynamic studies (Rosier et al., 2013). Abnormalities of storage (obtained during the cystometrogram portion), voiding (obtained during the pressure flow portion), and postmicturition may be ascertained during the study. Although it is the goal of each urodynamic study to recreate the symptoms reported by the patient, it is clear that this is not always feasible. For example, patients with symptoms of pure stress incontinence often have divergent urodynamic findings; it then becomes the role of the clinician to determine if the urodynamic observations or the patient-reported symptoms are more appropriate to treat (Digesu et al., 2009).

Terminology of Lower Urinary Tract Symptoms and Incontinence

The terminology used to describe LUT dysfunction in women has been standardized through a joint effort of the International Continence Society (ICS) and The International Urogynecological Association (IUGA) (Table 115.1; Haylen et al., 2010). Although LUTS are the focus of the present chapter, this important document and its precedent manuscript (Abrams et al., 2002) also include standard terminology used for characterizing prolapse, as well as for performing and interpreting urodynamic investigations. LUTS terminology is typically broken down into symptoms associated with (1) incontinence, (2) bladder storage, (3) bladder sensation, (4) voiding, and (5) postmicturition disturbances.

TABLE 115.1

Lower Urinary Tract Symptom Definitions

SYMPTOM	DESCRIPTION
Stress urinary incontinence	Complaint of involuntary urinary loss with physical exertion, sneezing/coughing, or other activities raising intra-abdominal pressure
Urgency urinary incontinence	Complaint of involuntary urinary loss associated with sensation of urgency
Mixed urinary incontinence	Complaint of involuntary urinary loss associated with physical exertion/rise in intra-abdominal pressure *and* with urgency
Nocturnal enuresis	Complaint of involuntary urine loss during sleep
Continuous urinary incontinence	Complaint of continuous urine loss, day and night
Insensible urinary incontinence	Complaint of urine loss without knowledge of what precipitated the event or when it occurred
Urinary frequency	Complaint that micturition occurs more frequently than deemed normal
Urinary urgency	Complaint of sudden compelling desire to urinate that is difficult to defer
Overactive	Complaint of urinary urgency, with or without urgency incontinence,

bladder syndrome	typically with frequency and nocturia
Nocturia	Complaint of interruption of sleep resulting from the need to void, where the interruption is preceded and followed by sleep

Incontinence

UI is the symptomatic complaint of the involuntary loss of urine. For UI assessment, it is essential to establish the causative factors (i.e., urgency, particular activity or action), severity, impact on QoL, duration, and frequency with which the incontinence occurs. Validated questionnaires, bladder diaries, physical examination, and urodynamic testing may be helpful to evaluate UI symptoms and to distinguish the type of incontinence present. None of these tools alone is capable of answering all of these essential questions regarding UI, and their combined use is often helpful in developing treatment strategies.

Stress urinary incontinence (SUI) is the complaint of involuntary loss of urine with physical exertion (i.e., walking, straining, exercise) or other activities that cause a rise in intra-abdominal pressure (such as sneezing or coughing). It can be witnessed on exam as involuntary leakage per urethra synchronous with effort, straining (Valsalva maneuver), physical exertion, or coughing. This provocative testing is often performed during an office supine stress test. **Urodynamic stress incontinence refers to the finding of involuntary urine leakage during filling cystometry associated with an increase in intra-abdominal pressure in the absence of a detrusor contraction.**

Urgency urinary incontinence (UUI) is the complaint of involuntary urine loss associated with urgency. It can, occasionally, be noted on physical exam as the observation of involuntary leakage from the urethra synchronous with the sensation of a sudden, compelling desire to void that is difficult to defer. Whereas urgency incontinence may be diagnosed urodynamically (leakage associated with sudden urgency during bladder filling, not associated with increase in abdominal pressure measurement), it need not be present with any specific urodynamic finding such as detrusor overactivity (DO), bladder oversensitivity, or diminished maximum bladder capacity. **Detrusor overactivity incontinence, a urodynamic diagnosis, may be present in patients with UUI, although it need not be present to establish the diagnosis**

of UUI.

Mixed urinary incontinence (MUI) is the complaint of involuntary urine loss associated with urgency and also associated with effort, physical exertion, sneezing, or coughing, or other activity causing a rise in intra-abdominal pressure. Mixed symptoms may be urge predominant, stress predominant, or equal. **Postural UI is the complaint of involuntary urine loss associated with a change in position (typically from sitting/lying down to standing). Nocturnal enuresis is the complaint of involuntary urine loss occurring during sleep** and should be distinguished from urgency incontinence, which may occur during the night after being awakened to void but having insufficient time to get to the bathroom to void. **Continuous UI is the complaint of continuous urine loss, day and night,** typically seen with fistula of the lower urinary tract involving the vagina (i.e., vesicovaginal and ureterovaginal fistulae). Patients with continuous incontinence may have few or no volitional voids. **Insensible UI is the complaint of urine loss when the patient is unaware of how or precisely when the urine loss occurred.** Coital incontinence is the complaint of involuntary loss of urine with sexual intercourse. It may occur with initial penetration, intromission, and/or during orgasm.

Bladder Storage and Sensation

These symptoms are associated with abnormalities of bladder filling and include increased daytime **frequency,** which is the complaint that micturition occurs more frequently than previously deemed normal. In general, eight or more voids within a 24-hour period are considered more than normal, although this finding alone does not necessarily imply bladder dysfunction because polyuria will normally result in an increase in urinary frequency. **Nocturia is the complaint of interruption of sleep because of the need to void, where each interruption is preceded and followed by sleep**. **Urgency is the sudden compelling desire to urinate, which is difficult to defer.** Urge, by comparison, is a normal bladder sensation that occurs and signals the need to micturate. **OAB syndrome includes urinary urgency, with or without urgency incontinence, typically accompanied by frequency and nocturia.**

Increased bladder sensation implies that the patient experiences the desire to void earlier than previously deemed normal. This differs from urgency in that voiding can be postponed. Such patients may report a sensation of the need to void with less than 50 mL of bladder filling during urodynamics. **Reduced bladder sensation,** in contrast, implies that the desire to void comes later than that previously experienced by the patient, despite the fact that the patient is aware that the bladder is filling. **Absent bladder sensation** involves the complaint that the sensation of bladder filling and the desire to void are absent.

Epidemiology of Urinary Incontinence in Women

General Comments

Epidemiologic studies on the topic of UI must be closely scrutinized when determining their relevance. Several factors must be considered when evaluating these types of data. Among the most important of these factors is the definition of UI—indeed altering the definition will result in widely divergent estimates of disease prevalence. In a condition that often does not rely on a specific pathological diagnosis, and one in which the diagnosis may often be made, appropriately, by history alone, estimates clearly vary widely. The importance of clearly defining the patient population and surveying instrument has been highlighted in a recent study. This study suggested that studies that do not specifically focus on women with UI using validated questionnaires that permit adequate grading of symptom severity may give the most accurate prevalence information (Bedretdinova et al., 2016).

Questionnaires to assess incontinence differ greatly in specificity, length, and complexity, which often results in very different estimates of prevalence. **Questionnaires used to characterize incontinence attempt to differentiate the type of incontinence present, identify the frequency with which UI occurs, and assess the severity of the condition as determined by bother or impact on QoL.** The timeframe questioned in the survey instrument must be determined, which will affect the prevalence rates greatly. Thus, for example, asking a woman if she has leaked (at any time) in the past month will result in very different findings than if the timeframe is narrower**. In addition, a questionnaire that inquires about bother associated with leakage to define UI will yield varying findings from a questionnaire that merely assesses the presence of the condition**. In a nonmorbid condition such as UI, the impact of the condition on QoL (associated bother) would seem to be paramount. Similarly, studies that rely on the physical demonstration of UI, either on exam or during urodynamics, are likely to report very different findings regarding condition prevalence than those based on questionnaires alone. An assessment of UI prevalence must include careful analysis of the incontinence definition used.

Patient populations may also be different in assessment of epidemiologic aspects of UI. Examining a group of young, nulliparous women, for example, will yield different findings than examining octogenarians living in skilled nursing facilities. Studies examining incidence and remission rates of UI may be even more vulnerable to bias and misinterpretation given the high overall prevalence of this condition compared with the relatively low incidence rate. Time between inquiries regarding incontinence, age of the population studied, duration of time that the patient is queried regarding the last time she experienced leakage, and the nature of the questions asked will often differ considerably among studies. All of these issues must be considered when evaluating reported incidence rates.

For young women, pregnancy, which is further discussed in the risk factors section, may be the most common event associated with incident incontinence, and the risk increases with gestational age. Risk factors for the development of SUI during pregnancy have been analyzed (Sangsawang, 2014). Obesity, pre-existent SUI, gestational diabetes, age, and constipation have been noted to increase the risk of SUI during pregnancy. Also, compared with age-matched nulliparous women, primiparous women appear to have a threefold increased likelihood of UI during pregnancy that remains 2.5 times higher 1 year after delivery (Hansen et al., 2012). Furthermore, more than 50% of affected women reported a significant impact on QoL (Dolan et al., 2004). A recent analysis that followed women for 12 years after pregnancy evaluated incidence and remission rates of UI after delivery (MacArthur et al., 2016). Overall, 33% of women reported UI at 3 months after their delivery. Interestingly, only 13.5% of women who reported UI at 3 months after delivery had no UI at 6 and 12 years. Of those women reporting at all time points who had UI at 3 months, 64% reported it again at 6 and 12 years. **These data highlight that incident UI is relatively common after pregnancy (33%–40%) and that remission rates are surprisingly low, depending on the UI definition used.**

Several factors have been noted to decrease the risk of UI during and after pregnancy. Properly performed pelvic floor muscle training programs during and after delivery may reduce the risk of incident UI during pregnancy as well as post-delivery UI (Ahlund et al., 2013; Boyle et al., 2008; Stafne et al., 2012). In addition, weight-reduction programs after delivery have been shown to hasten the recovery from UI after delivery (Wesnes, 2010).

Hysterectomy may also be associated with incident incontinence, as well as resolution of pre-existing UI in some patients. A study of more than 25,000 women enrolled in the National Swedish Registry for Gynecologic Surgery noted that, of the 70% of women without UI before hysterectomy, 8.5% developed de novo UI (Bohlin et al., 2017). Obesity and prior vaginal delivery were associated with incident UI after hysterectomy. Interestingly, 13% of patients who had UI before hysterectomy did not report it 1 year after surgery. Larger uterine weight (>300 g), low body mass index (BMI) (<25 kg/m^2), and presence of POP were predictive of UI resolution.

Overall, in middle-aged women (40 to 60 years), annual UI incidence rates appear to range from 1% to 10%, approximately 3% for each category of UI each year (Komesu et al., 2016). One extended study following 40-year-old women for 10 years showed that 40% developed new-onset incontinence during this period (Jahanlu and Hunskaar, 2011). As one would expect, SUI is most commonly reported among younger cohorts reporting new symptoms (responsible for 50% of new cases). Interestingly, the incidence of SUI, but not UUI or severe UI, was noted to increase with the menopausal transition from ages 48 to 54 (Mishra et al., 2010). In general, older cohorts have been found to have higher annualized incidence rates—typically between 10% and 20% (Herzog and Fultz, 1990). Among middle-aged or older women, Caucasians, compared with African-Americans, appear more likely to develop UI when followed over 5 years (Thom et al., 2010). Caucasian women with higher BMI at baseline and those with weight gain during the survey period appeared to be at greatest risk.

Annualized resolution rates typically remain less than 10%, although UI remission is clearly and consistently noted in most longitudinal studies. Higher remission rates have been noted in several studies and may be more typical of studies following younger patients at baseline (Botlero et al., 2011) and those with less severe forms of UI (Espuna-Pons et al., 2017). Remission rates as high as 30% have been noted when studying patients for prolonged periods of time (biannual surveys), with MUI having the lowest likelihood of resolving (Komesu et al., 2016). Interestingly, remission rates may be highest among African-American women (Townsend et al., 2011), although other studies have noted remission rates for SUI highest among Hispanic women (Komesu et al., 2016). The fact that remission has been reported emphasizes the existence of transient causes of incontinence, the subjective nature of the condition, and the possibility of recall bias.

Key Points: Incidence and Remission of Urinary

Incontinence

- Pregnancy/delivery is associated with incident incontinence in up to 33% of patients, and remission may be as low as 13% for up to 12 years.
- Hysterectomy may be associated with incontinence resolution in 13% of patients and is more common when the uterine weight is more than 300 g.
- Annualized incidence rates for UI in women vary between 1% and 10% (approximately 3% for each subtype) and are heavily influenced by the population surveyed and the survey tool used.
- The remission rate for UI is variable depending on the definition used and population studied. Remission appears to be higher in younger women and is lower overall for MUI.
- Remission rates for men with UI are considerably higher than for women in most studies.

Risk Factors for Urinary Incontinence in Women

Aging

Aging has clearly and consistently been identified as an independent risk factor for the development of UI in women (Fig. 115.1). This risk extends beyond the menopausal years, when many epidemiologic studies demonstrate a sharp rise in incidence. In a study of more than 5000 Medicare beneficiaries (all more than 65 years of age), 37% reported UI (Hawkins et al., 2011). There was a clear association with aging noted, even among this older group. Another survey of nearly 800 community-dwelling women aged more than 65 years showed that 28% of women reported UUI occasionally or often, whereas 21% reported a similar degree of SUI (Sims et al., 2011). A systematic global review of urgency urinary incontinence noted a very clear association between age and UUI in men and women (Fig. 115.3; Milsom et al., 2014). **These findings highlight the change in incontinence type that tends to occur with aging, with a shift away from SUI toward MUI and UUI.** Interestingly, among older women (>75) UUI appears to be associated with impaired physical mobility, whereas SUI is not (Fritel et al., 2013). Among nonagenarians, UI has been independently linked to frailty and has been established as an independent risk factor for death, suggesting that treatment may be warranted even among the oldest of our patients (Berardelli et al., 2013).

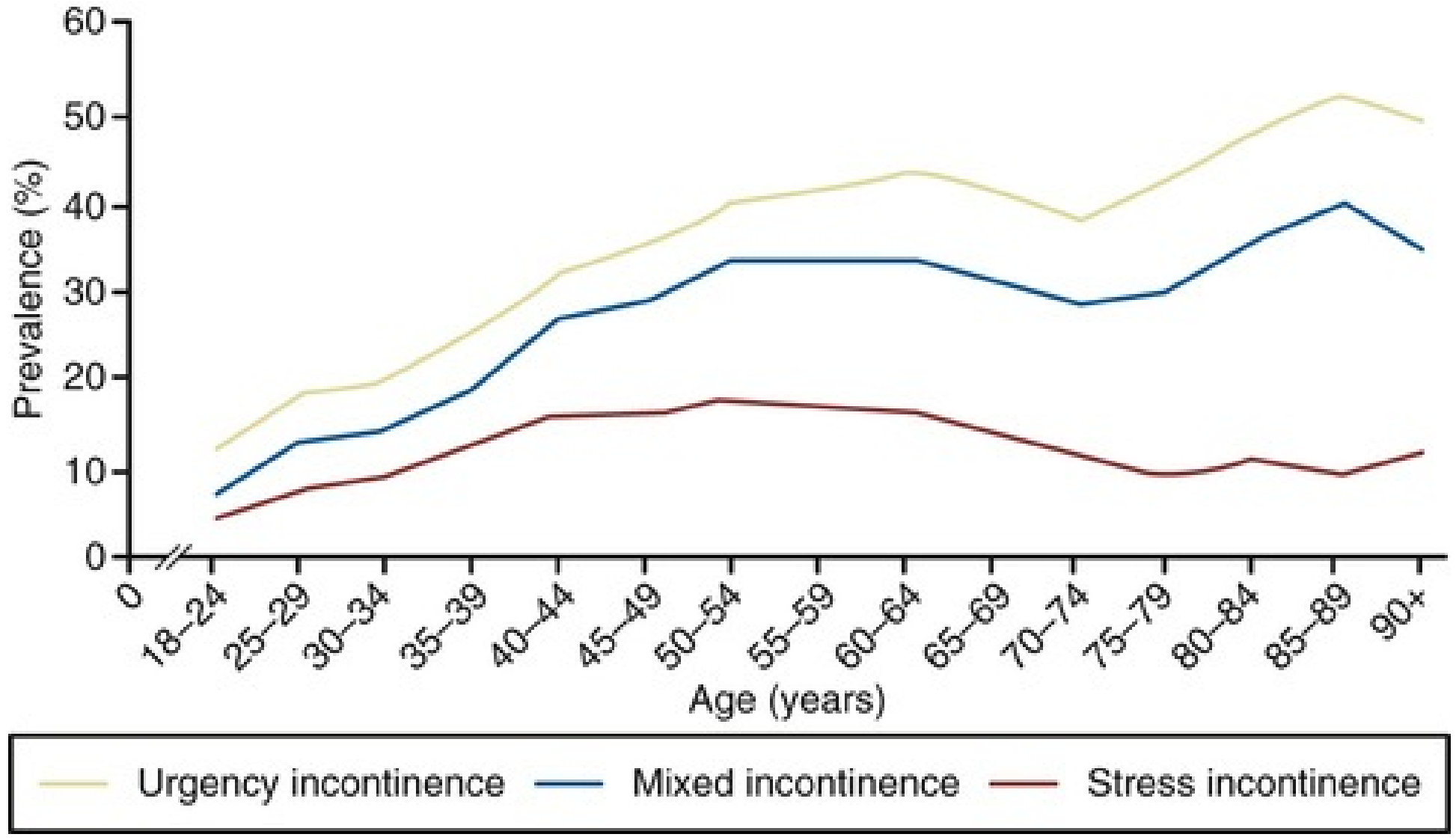

FIG. 115.1 Prevalence of urinary incontinence subtypes over time in women. (From Aoki Y, Brown HW, Brubaker L, et al.: Urinary incontinence in women. *Nat Rev Dis Primers* 3, 2017; article number 17042.)

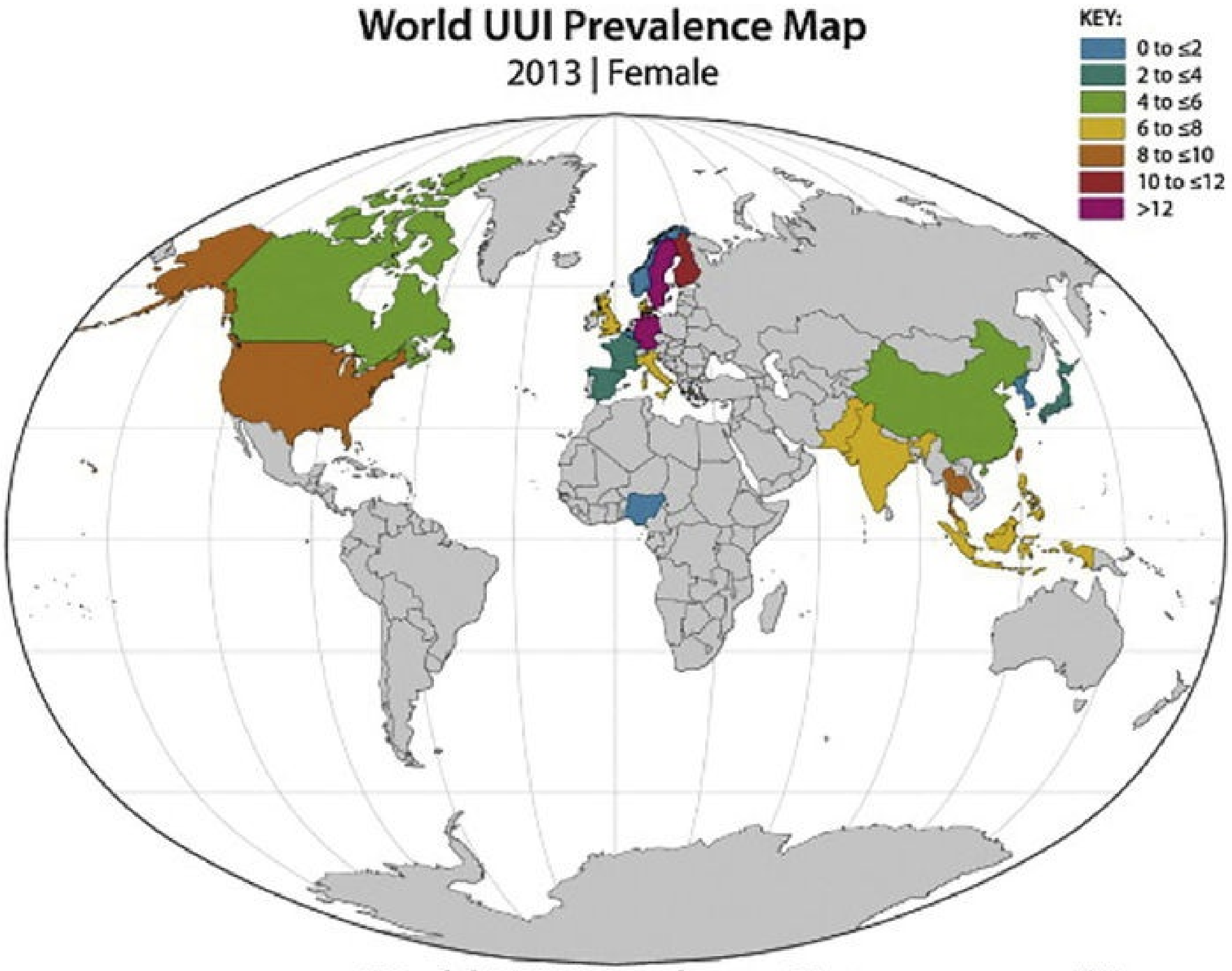
World UUI Prevalence Map
2013 | Female
KEY:
0 to ≤2
2 to ≤4
4 to ≤6
6 to ≤8
8 to ≤10
10 to ≤12
>12

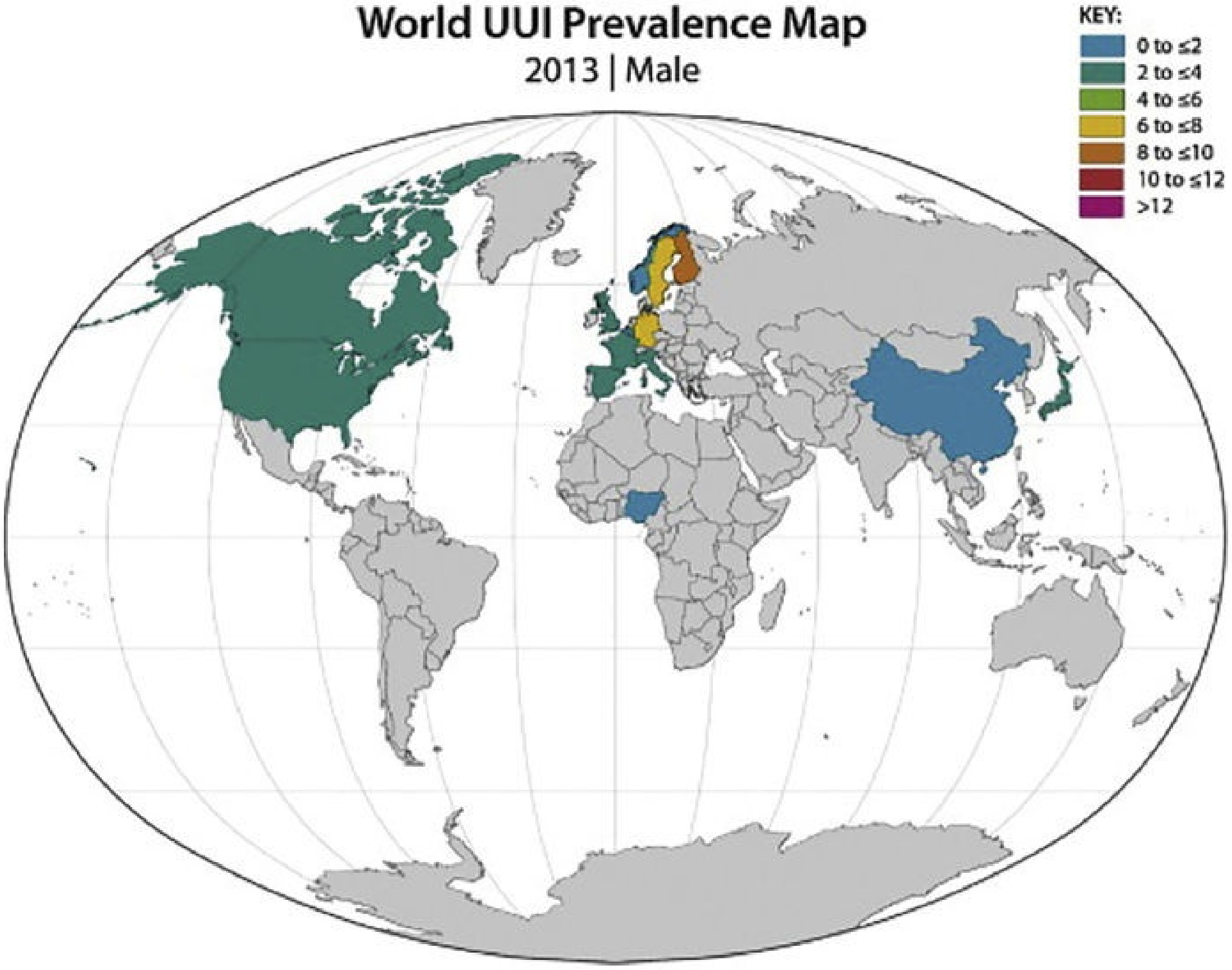
World UUI Prevalence Map
2013 | Male
KEY:
0 to ≤2
2 to ≤4
4 to ≤6
6 to ≤8
8 to ≤10
10 to ≤12
>12

FIG. 115.2 Worldwide prevalence of urgency urinary incontinence (UUI) in men and women. (From Milsom I, Coyne K, Nicholson, et al.: Global prevalence and economic burden of urgency urinary incontinence: a systematic review. *Eur Urol* 65:79–85, 2014.)

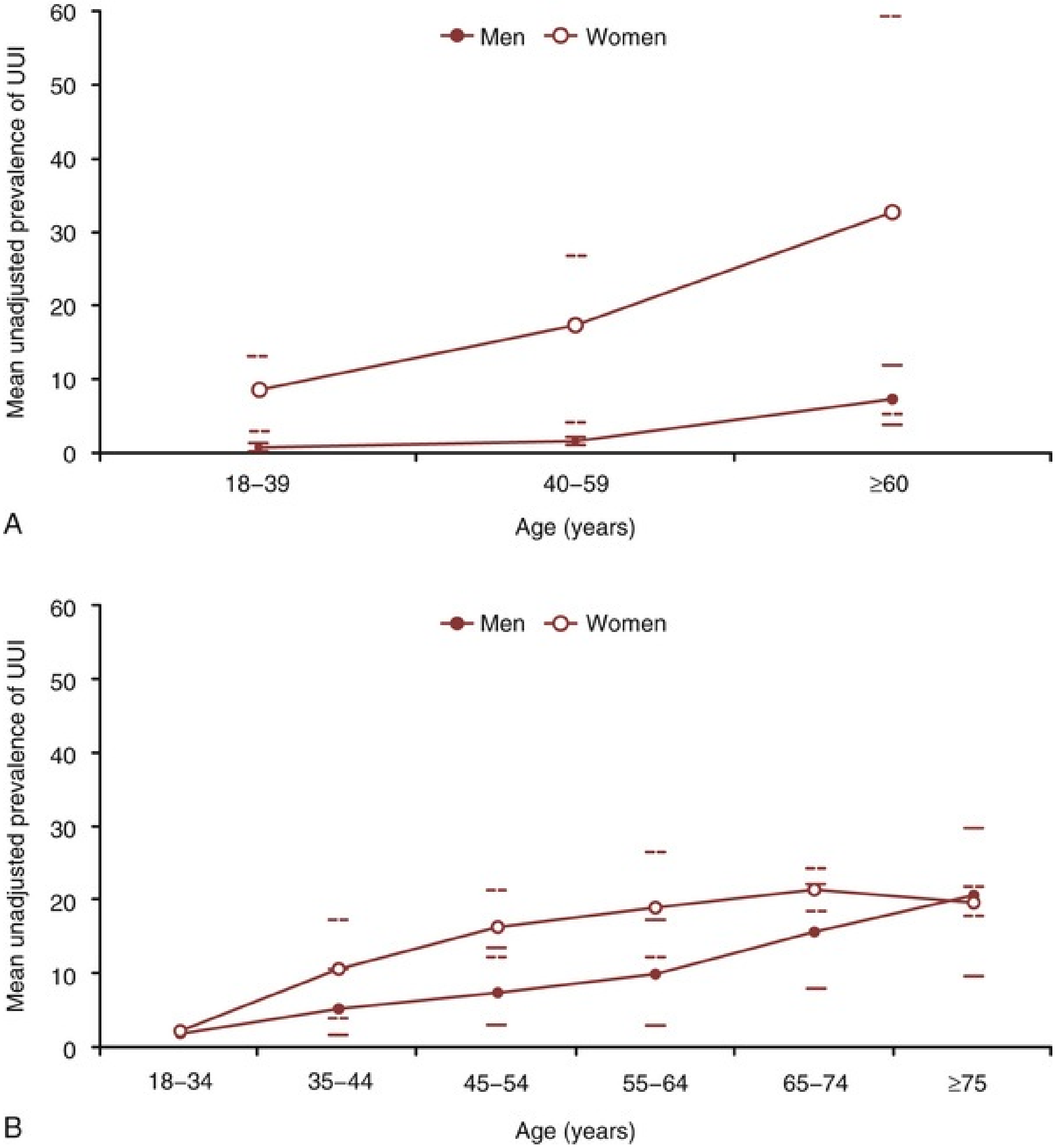

FIG. 115.3 Prevalence estimates of urgency urinary incontinence (UUI) (including UUI and mixed urinary incontinency [MUI]) in men compared with women, compared by age. Panel A uses a wider age interval (20 years). Panel B (based on different studies) summarizes data from studies

reporting a narrower age interval and demonstrates the increasing incidence of UUI in aging men, which in some series exceeds the prevalence seen in women. *Solid bars* (men) and *dashed bars* (women) indicate maximal and minimal values reported in the studies included. (From Milsom I, Coyne K, Nicholson, et al.: Global prevalence and economic burden of urgency urinary incontinence: a systematic review. *Eur Urol* 65:79–85, 2014.)

Women living in long-term care facilities (LTCFs) may be at the greatest risk for UI. Several studies have demonstrated the high prevalence of UI in women living in LTCFs (Hunskaar et al., 1998; Ouslander et al., 1982; Saxer et al., 2008; Sgadari et al., 1997). An analysis of nearly 5000 women living in residential care facilities found an incontinence prevalence of more than 40% at admission (De Gagne et al., 2013). Severe impairment in the activities of daily living had the strongest association with the presence of UI (odds ratio [OR] 21.59). Poor nutritional status, impaired mobility, and increased dementia symptoms have been correlated with the severity of UI. Group-based behavioral exercise programs have been shown to decrease incontinence in women in LTCFs (Tak et al., 2012).

Pregnancy

Pregnancy increases the risk of future incontinence. As noted previously, the risk of incident incontinence may be as high as 40%, and risk factors have been described. **It is also clear that the development of UI during pregnancy does increase the risk of future (and persistent) incontinence.** In the large Swedish Registry study, of those women reporting at all time points who had UI at 3 months, 64% reported it again at 6 and 12 years (MacArthur et al., 2016). Older age at time of pregnancy and obesity appear to be associated with persistent incontinence after pregnancy. Similarly, a systematic review of risk factors for UI noted that age over 30 at the time of first pregnancy increases the likelihood of UI later in life (OR 3.1) (Troko et al., 2016). Other studies have noted that alcohol consumption and depression were associated with persistent incontinence after pregnancy, whereas higher level of physical activity and black race were protective (Maserejian et al., 2014).

Aspects of Delivery

Not only does pregnancy confer an increased risk of UI but also mode, duration, and nature of the delivery also appear to influence the risk of UI later in life.

Cesarean delivery appears to confer an advantage over normal spontaneous vaginal delivery with regard to the development of UI and SUI (Findik et al., 2012). Five years after delivery, primiparous women who had undergone cesarean section were significantly less likely to report UI overall, although these women may be more bothered by UUI when it occurs than their counterparts (Liang et al., 2013). Similarly a study of women followed for 12 years after delivery noted that, although cesarean section did confer a decreased likelihood of UI, this was only the case if all deliveries were by this method—if other deliveries were vaginal, any protective effect was lost (MacArthur et al., 2011). **Further, it has been suggested that the number needed to treat to prevent one case of moderate to severe urinary incontinence is 13 cesarean sections** (Gyhagen et al., 2013a and 2013b). Other factors such as length of delivery, use of forceps, type of anesthesia, and use of episiotomy have been suggested as factors potentially associated with the development of either transient or long-standing UI after delivery, although no conclusive evidence supports modifying obstetric practice based on these findings. In contrast, **any history of vaginal birth of a large baby with increased birth weight has been consistently associated with an increased likelihood for developing UI** (Connolly et al., 2007; Thom et al., 2011). For example, among women who had at least one child with a birth weight of more than 4 kg, the OR of experiencing weekly UI later in life was 1.47 when compared with those without large babies.

Parity

A single pregnancy and delivery significantly increase a woman's risk for UI in later life, with an OR of approximately 1.5. Subsequent deliveries may increase this risk further, although a direct linear relationship is unlikely (Danforth et al., 2006; Grodstein et al., 2003; Juliato et al., 2017; Rortveit et al., 2001; Waetjen et al., 2007). Whether the number of deliveries is clearly associated with UI risk is unclear: a survey of more than 8000 women in Germany and Denmark demonstrated equivalent elevated risk (OR approximately 1.5 compared with nulliparous women) regardless of the number of deliveries (Pedersen et al., 2017). This risk appears to be accentuated by the timing of the first birth; women having their first child closer to the age of 20 seem to be at greatest risk in most studies, although controversy exists on this topic. The association between incontinence and parity appears to be strongest for SUI.

Race and Ethnicity

Most cross-sectional studies have indicated that Caucasian women have an increased prevalence of UI and an increased risk for developing incident UI/SUI when compared with African-American women and Asian women (Townsend et al., 2010). Although various explanations exist for this finding, at least one group has noted higher urethral closure pressures in African-American women (DeLancey et al., 2010). This difference in prevalence is less clear when compared with other populations, including Hispanic women. Differences in MUI and UUI based on race are less obvious in comparison and, in fact, are likely inconsequential overall. It appears that Caucasian and African-American women are equally likely to seek care for UI (Berger et al., 2011), although this difference is clearly affected by the degree of leakage (Lewicky-Gaupp et al., 2009). Cross-cultural differences in UI prevalence are less clear overall. However, after including only studies reporting similar definitions for UUI, a systematic review noted substantial differences in UUI prevalence in different countries ranging from as low as 0.51% in Nigeria to as high as 14.3% in Germany (Milsom et al., 2014) (Fig. 115.3).

Hormonal Therapy

Oral estrogen treatment with or without progestogens is associated with the development of UI in middle-aged and older women (Brown et al., 2009). When compared with placebo, the rate of incident incontinence nearly doubled during a 1-year period in a well-conducted large clinical trial of postmenopausal women treated with placebo, estrogen, or estrogen and progestin therapy (Hendrix et al., 2005). By comparison, topical (vaginal) estrogen use is not clearly linked to the development of SUI and has proven efficacy in treating women with vaginal atrophy and recurrent urinary tract infections (UTIs).

Obesity

The presence and severity of UI are strongly associated with obesity in women. Although the association appears to be strongest for SUI and MUI, all types of UI have been associated with the development of obesity in women. BMI in excess of 30 has been shown to more than double a woman's risk of UI (Danforth et al., 2006; Hannestad et al., 2003). Even women who do not meet the criteria for obesity but who are overweight (BMI >24) are at increased risk for UI, suggesting a progressive impact of weight gain on urinary continence mechanisms (Troko et al., 2016). Incontinence associated with weight gain may be reversible, however, because surgically induced weight loss and weight loss experienced as a result of a carefully executed weight-loss program have been associated with improvements in UI symptoms that are maintained as long as the weight is kept off (Bump et al., 1992; Richter et al., 2005). A meta-analysis of nonsurgical weight-loss programs (diet, exercise, medications) noted significant improvements in UI with a mean standardized reduction of −0.30 episodes per day (Vissers et al., 2014).

Smoking

Although data remain inconsistent, several compelling studies have demonstrated a link between urinary symptoms and smoking. A Finnish study of more than 2000 women noted a clear association between symptoms of urinary urgency and frequency and current smoking status. In fact, heavy smoking was associated with more severe urgency symptoms than light smoking (Tahtinen et al., 2011). In a cross-sectional study of more than 80,000 nurses, severe incontinence was associated with current smoking (OR 1.34) (Danforth et al., 2006). Last, among women scheduled for SUI surgery, incontinence severity was clearly correlated with current tobacco use. Overall, current smokers had 56% more incontinence episodes than nonsmokers (Richter et al., 2005). Various causes for this link have been suggested, and although some data question the relationship between smoking and incontinence, there appears to be a growing consensus that some relationship exists, particularly with storage urinary symptoms.

Diet

Certain foods have been purported to be associated with UI. Overall data are inconsistent, with the association between caffeine (coffee in particular) intake and symptoms of urgency incontinence, mixed incontinence, or OAB generating the most compelling data. This appears to be true in men and women (Davis et al., 2013). There is no consistent link between dietary intake and SUI in most studies. Carbonated beverages and artificial sweeteners have also been primarily associated with urgency symptoms, although confirmatory studies are lacking (Jura et al., 2011).

Medical Conditions

UI appears to be more prevalent among women with certain medical conditions, including diabetes mellitus (DM) and depression. The prevalence of UI among women with type 2 diabetes may be as high as two times greater than age-matched nondiabetic women, with emerging evidence suggesting the same finding in women with type 1 DM (Lifford et al., 2005; Phelan et al., 2009a). Among more than 9000 nurses with type 2 DM who were surveyed, 48% reported at least monthly UI, with 29% reporting at least weekly incontinence episodes. Obesity enhanced the risk of UI significantly in this cohort of women (Devore et al., 2012). Similar findings were noted in an interventional trial (weight loss) of obese women with type 2 DM, in whom 27% reported weekly incontinence (Phelan et al., 2009b). The National Health and Nutrition Examination Survey (NHANES) cross-sectional study of 1400 women with type 2 DM additionally identified macroalbuminuria and peripheral neuropathic pain as independent risk factors for UI in patients with type 2 diabetes (Brown et al., 2006). Data from women with type 1 DM are less robust, although a study of more than 500 women demonstrated weekly incontinence in 17% of them, which was a far greater rate in comparison with a nondiabetic cohort from the NHANES analysis (Sarma et al., 2009).

Depression has also been associated with UI in women. The link is likely multifactorial; certainly UI leads to a diminished perception of one's self-health, but a common pathophysiologic link between depression and UI has also been proposed. **Regardless of the direction of the association, it is clear that the presence of depression leads to an increased likelihood of the later development of UI in women** (Thom et al., 1997).

The presence of multiple comorbid conditions has also been associated with UI (Melville et al., 2005). In addition to depression and diabetes, the presence of hypertension and osteoarthritis has been independently associated with UI (Renata et al., 2016). Although the mechanism for these individual associations likely differs, the cumulative effect of multiple conditions may result in UI in vulnerable women.

Key Points: Risk Factors for Urinary Incontinence in Women

- **Age:** Aging is the strongest nonmodifiable risk factor for the development of UI in women. Advancing age is clearly linked with a greater likelihood of incontinence and a shift away from SUI to, more commonly, MUI or UUI in later years.
- **LTCFs/impairment in activities of daily living:** Distinct from aging, maintaining residence in an LTCF is an independent risk factor for UI. Similarly, severe impairment in activities of daily living has a particularly strong association with UI.
- **Pregnancy and postpartum:** Prevalence of SUI, in particular, increases during pregnancy and increases with gestational age during pregnancy. Prevalence decreases considerably within 3 months postpartum. Properly performed pelvic floor muscle training has been shown to decrease the likelihood of developing SUI.
- **Aspects of delivery:** Cesarean section, when compared with vaginal delivery, appears to confer an advantage with regard to the later development of UI. This advantage may be lost with even one vaginal delivery. Birth weight of the largest child also appears to be positively correlated with an increased risk of later UI. Other factors such as forceps use and length of delivery have been proposed as risk factors for UI, although overall the association is less clear.
- **Parity:** Whereas a single vaginal delivery increases the risk of UI (and SUI in particular), subsequent deliveries further increase this risk. Age at time of delivery also appears to augment this risk, and those women who are younger when they first experience pregnancy and delivery appear to be at greatest risk.
- **Race/ethnicity:** An increased prevalence of UI and SUI is noted in Caucasian women when compared with African-American and Asian women. Differences compared with Hispanic populations are less clear.
- **Hormonal therapy:** Oral estrogen use with or without progestogen is associated with the development of SUI in middle-aged and older women. Topical estrogen has not been clearly associated with this finding, and it can be used for the treatment of vaginal atrophy and, frequently, associated UTIs.
- **Obesity:** The presence and severity of UI is positively correlated with obesity and weight gain. SUI and MUI are most strongly linked to BMI. UI related to weight gain may be reversible, with either surgical treatment or

regimented weight-loss programs providing evidence of substantial improvements in UI.

- **Smoking:** Urinary urgency and frequency are associated with active smoking, although a link with UI is less clear. Heavy smokers may be at greatest risk. Data on the impact of smoking cessation are scant.
- **Diet:** Caffeine intake (coffee in particular) has been linked to OAB. No clear association exists with SUI. Carbonated beverages and artificial sweeteners have also been associated with storage urinary symptoms, although less clearly so.
- **Medical conditions:** Diabetes and depression are the two most common medical conditions associated with UI, though multi-morbidity in general is associated with UI. Depression in the early years or midlife increases the risk of developing UI later in life.

Epidemiology of Urinary Incontinence in Men

Prevalence, Incidence, Remission Rates

The overall prevalence of UI in men is considerably lower than that found in women. In particular, SUI is uncommon in men, with the exception of men who have previously undergone radical pelvic surgery (e.g., radical prostatectomy [RP] or abdominoperineal resection) or endoscopic or open surgery for benign prostatic enlargement or who have a neurologic condition that may predispose them to SUI. UUI and MUI are more common in men than SUI, and in many cases these conditions may be attributable to BOO from benign prostatic enlargement, other outlet disorders, OAB, or other inflammatory or infectious processes. **Prevalence estimates for UI in men have ranged from 11% to 34% in older men, with up to 11% reporting daily incontinence** (Buckley et al., 2010; Coyne et al., 2012; Markland et al., 2010).

The likelihood of developing UI in men is age dependent. Several studies have indicated an incidence rate of approximately 1% to 10% annually in men from 60 to 70 years of age followed for 5 to 10 years (Herzog and Fultz, 1990). The remission rate for UI tends to be higher in men than in women. This is largely because of the fact that leakage in men is more typically urgency related, which may have several reversible (infectious/inflammatory) causes. **Depending on the age studied, remission rates as high as 40% have been noted in men with UI** (McGrother et al., 2004).

Risk Factors for Urinary Incontinence in Men

Age appears to be the strongest independent risk factor for UI developing in men, an association that may be even stronger than that noted in women (Diokno et al., 2007). Men appear to be particularly vulnerable to UI with infectious processes such as acute cystitis and prostatitis, the prevalence of which are also clearly associated with aging. Similar to findings in women, altered cognition, diminished mobility, and the presence of other comorbidities are associated with an increased likelihood of UI. Certain neurologic conditions more commonly found in aging populations (Parkinson disease, cerebrovascular accident [CVA]) are also associated with incontinence in men, most commonly UUI. Recent data suggest an association between UI and chronic obstructive pulmonary disease (COPD) in men (Burge et al., 2017). One study noted an interesting association between American men younger than 55 and UI; these men were 3 times more likely to report UI (Vaughan et al., 2014).

RP and other radical pelvic surgeries have been associated with the development of UI in men. The likelihood of UI varies considerably, with overall estimates ranging from 8% to 60% at 1 year after RP depending largely on the definition of UI used (Ficarra et al., 2009). **The absence of preexisting LUTS/previous transurethral resection of the prostate (TURP), technique of surgery (bladder neck sparing and neurovascular bundle sparing), and younger age at the time of surgery have been shown to be associated with a lower risk of postoperative UI,** although conflicting data exist (Gupta et al., 2011). **The impact of robotic-assisted approaches to RP on UI rates has been modest, with the most recent studies noting incontinence rates comparable with the open approach** (Haglind et al., 2015). When compared with a laparoscopic approach, robot-assisted RP appears to result in earlier return to continence and overall improved continence (95% vs. 83% at 1 year) (Porpligia et al., 2013). In comparison, TURP, whether performed with electrosurgical cauterization or using the potassium titanyl phosphate (KTP) laser approach, is associated with a low (1%) likelihood of developing UI postoperatively.

Key Points: Epidemiologic Aspects of Urinary Incontinence in Men

- UI is considerably less prevalent in men than in women.
- UUI is the most common form of UI in men, followed by MUI and then SUI. In some studies of elderly men, UUI rates exceed that reported in women.
- SUI in men is associated with previous radical pelvic surgery (in particular RP) and certain neurologic diseases.
- SUI prevalence rates following RP range from 8% to 60%.
- Robotic prostatectomy may lead to an earlier return of continence compared with laparoscopic approaches, but there is no clear consensus that the robotic approach has led to a lower incidence of postoperative UI compared

with an open approach.

- Remission rates for UI are higher in men than in women. Remission rates as high as 40% have been reported.
- Age is even more closely associated with the development of UI in men than in women.

Definitions and Classification of Pelvic Organ Prolapse

Pelvic organ prolapse refers to the downward displacement of the pelvic organs, which results in protrusion of the uterus and/or the different vaginal compartments and their surrounding organs, such as the bladder, the rectum, or the bowel. It results from the loss of support of one or more compartments of the vagina. Prolapse should be described using segments of the lower reproductive tract. Older terms such as cystocele, rectocele, enterocele, or urethrovesical junction prolapse should be avoided because of the uncertainty of the anatomic structure on the other side of the vaginal bulge, especially in women who had previous prolapse surgeries. **Anterior compartment prolapse** corresponds to the descent of the anterior vaginal wall. Most commonly this represents the descent of the bladder (**cystocele**), but it can also represent an anterior enterocele, especially after prior reconstructive surgery. It is the most common segment of the vagina to prolapse (Hendrix et al., 2002). **Apical prolapse** corresponds to the descent of the uterus (uterine or cervical prolapse) or, in a post-hysterectomy patient, the vaginal cuff. It can include the small intestine **(enterocele).** An enterocele is present when a peritoneal sac containing part of the bowel and possibly the omentum comes down in the area of the rectovaginal space. It can be asymptomatic but can also be associated with significant defecatory dysfunction and pelvic pain or pressure (Takahashi et al., 2006). **Posterior compartment prolapse** is a weakness of the posterior vaginal wall and can involve the rectum **(rectocele)** but can also include the small bowel or colon even in the presence of an intact uterus. **Procidentia** refers to total vaginal eversion with complete uterine or vaginal cuff prolapse.

Symptoms of Pelvic Organ Prolapse

Prolapse can cause a multitude of symptoms and have a significant impact on a woman's quality of life**. A vaginal bulge that can be seen or felt by a patient is the most specific symptom for POP** (Tan et al., 2005). Other symptoms that can be attributed to POP include pelvic pressure or discomfort, discharge, splinting or digitation for urination or defecation, and low backache. Even though it is important to assess urinary symptoms such as frequency, nocturia, urinary and fecal incontinence, voiding and defecatory dysfunction, and sensation of incomplete emptying in patients with prolapse, **there is a poor correlation between these symptoms and the severity and site of prolapse** (Ellerkmann et al., 2001). In fact, many of those prolapse-related symptoms are not caused by the prolapsing vagina but by coexisting or associated bladder, anorectal, or pelvic floor dysfunction. This is especially true for many bowel symptoms such as constipation, fecal incontinence, feeling of incomplete emptying, straining, and defecatory dysfunction. In general, at the most, weak correlations have been noted between bowel symptoms and the presence and severity of pelvic organ prolapse (Ellerkmann et al., 2001). Clinically, this lack of correlation has significant relevance. For example, **the presence of constipation alone without the sensation of a vaginal bulge should rarely prompt surgical intervention for posterior compartment prolapse**. The exception to this would be if the patient feels that stool gets caught “in a pocket” during defecation and needs to splint to have a bowel movement. This particular symptom can be a sign of rectocele defect. However, there seems a much stronger correlation between the development of symptoms such as sensation of vaginal bulge or need to splint to urinate or defecate when the leading edge of the prolapse is beyond the vaginal hymen (Swift et al., 2003).

Other symptoms and signs should also be assessed in patients with POP. For example, the timing of the development of SUI is important to determine. In general, the severity and prevalence of SUI declines as the POP extends beyond the hymen, possibly from urethral obstruction secondary to urethral kinking, and treatment of POP with concomitant treatment for SUI may be indicated in certain cases (Ellerkmann et al., 2001; Wei et al., 2012). Sexual dysfunction should also be evaluated because POP is known to negatively affect body image and sexual function, and treatment can improve sexual function (Jelovsek and Barber, 2006; Özel et al., 2005). Sexually inactive patients should be asked about their desire to resume sexual activity after POP repair because this can influence treatment decisions. A history of abnormal or postmenopausal uterine bleeding should never be attributed to POP and warrants appropriate gynecologic evaluation before any intervention for POP. Although many patients complain of low back pain and pelvic pain secondary to their prolapse, there has been little evidence indicating that prolapse can cause pain. The complaint of pain with prolapse warrants investigation of other sources of pain before attributing it to prolapse. A trial of pessary can be very useful to determine if some of the patient's symptoms are a result of prolapse. If the symptoms improve with a pessary, it can be assumed that POP is likely the cause of these symptoms, and they are more likely to improve after surgical management.

Physical Examination of Pelvic Organ Prolapse

Multiple grading systems have been used to classify the degree of anatomic deformity. One of the most commonly used is the **Baden-Walker Halfway Scoring System.** This system uses the hymen as a fixed anatomic reference point. A score is assigned to each of the six specific midline sites (urethral, vesical, uterine, cul de sac, rectal, and perineal). A score is assigned to each of the six specific midline sites (urethral, vesical, uterine, cul de sac, rectal, and perineal). It consists of four grades. Grade 0 is considered normal, absence of prolapse. Grade 1 is a descent halfway to the hymen, grade 2 is a descent to the hymen, grade 3 is a descent halfway past the hymen, and grade 4 represents maximum prolapse. Although this system offers a good description of the prolapse, there is a lack of information about the exact location of specific structures, and the interobserver variability is high (Persu et al., 2011).

In an effort to design an objective and reproducible system of grading prolapse, the **Pelvic Organ Prolapse Quantification (POPQ) system** (▶Video 115.1) was developed in 1993 (Bump et al., 1996). This system was later updated in 2002 (Abrams et al., 2002). It is now the recommended staging system for prolapse (Haylen et al., 2016). The POPQ system relies on specific measurements of defined points in the midline of the vaginal wall. All these points are measured in relation to a fixed reference point, which is the hymenal ring. The use of this scoring system should be favored for research purposes, as well as routine clinical use, because the measurements are much more precise and the interobserver agreement and reliability are also improved (Swift et al., 2006).

The POPQ system provides a precise, objective description of a woman's pelvic support that defines POP relative to a fixed reference point, the hymen. There are three reference points located anteriorly **(Aa, Ba, C)** and three located posteriorly **(Ap, Bp, and D).** In addition, there are three other landmarks **(gh, pb, and tvl).** All points are measured in centimeters. Negative numbers refer to points located inside the introitus, and positive numbers reflect prolapse beyond the introitus, with the plane of the hymen being defined as zero (Fig. 115.4). The Aa point is located 3 cm proximal to the hymenal ring on the anterior vaginal wall and corresponds to the approximate location of the urethrovesical junction. By definition, the range of position of point Aa relative to the hymen is −3 and +3, −3 being in the absence of prolapse. The Ba is the most distal point of the prolapse between the Aa point and the vaginal apex. In the absence of prolapse, its position is −3. In woman with total uterine prolapse or posterior hysterectomy vaginal eversion, Ba would have a positive value equal to the position of the vaginal cuff (point C). The C point represents the most distal edge of the cervix or the leading edge of the vaginal cuff (if patient has had prior hysterectomy). The D point denotes the posterior fornix or pouch of Douglas in a woman who still has a cervix. It represents the level of uterosacral ligament attachment to the proximal posterior cervix. The D point is omitted in the absence of cervix. On the posterior vaginal wall, two other points are measured, Ap (point located 3 cm proximal to the hymen, which is meant to parallel the Aa point on the anterior vaginal wall) and Bp (lowest point of the prolapse between the Ap and the apex). In the same way as for point Ba, Bp has a value of −3 in the absence of prolapse and would have a positive value equal to the position of the vaginal cuff in woman with total uterine prolapse or posterior hysterectomy vaginal eversion. All of these measurements are taken during demonstration of maximal prolapse (with the patient either straining/performing Valsalva maneuver, either supine or standing). The last three measurements are taken at rest. The genital hiatus (gh) is the distance between the middle of the urethral meatus and the posterior hymenal ring. The perineal body (pb) is the distance between the posterior aspect of the genital hiatus to the midanal opening. Last, the total vaginal length (tvl) at rest is the length of the vagina (cm) from the posterior fornix to the hymen when point C or D is reduced to its full normal position. Measurements directly after the removal of a vaginal pessary are unreliable because it will tend to underestimate the degree of prolapse.

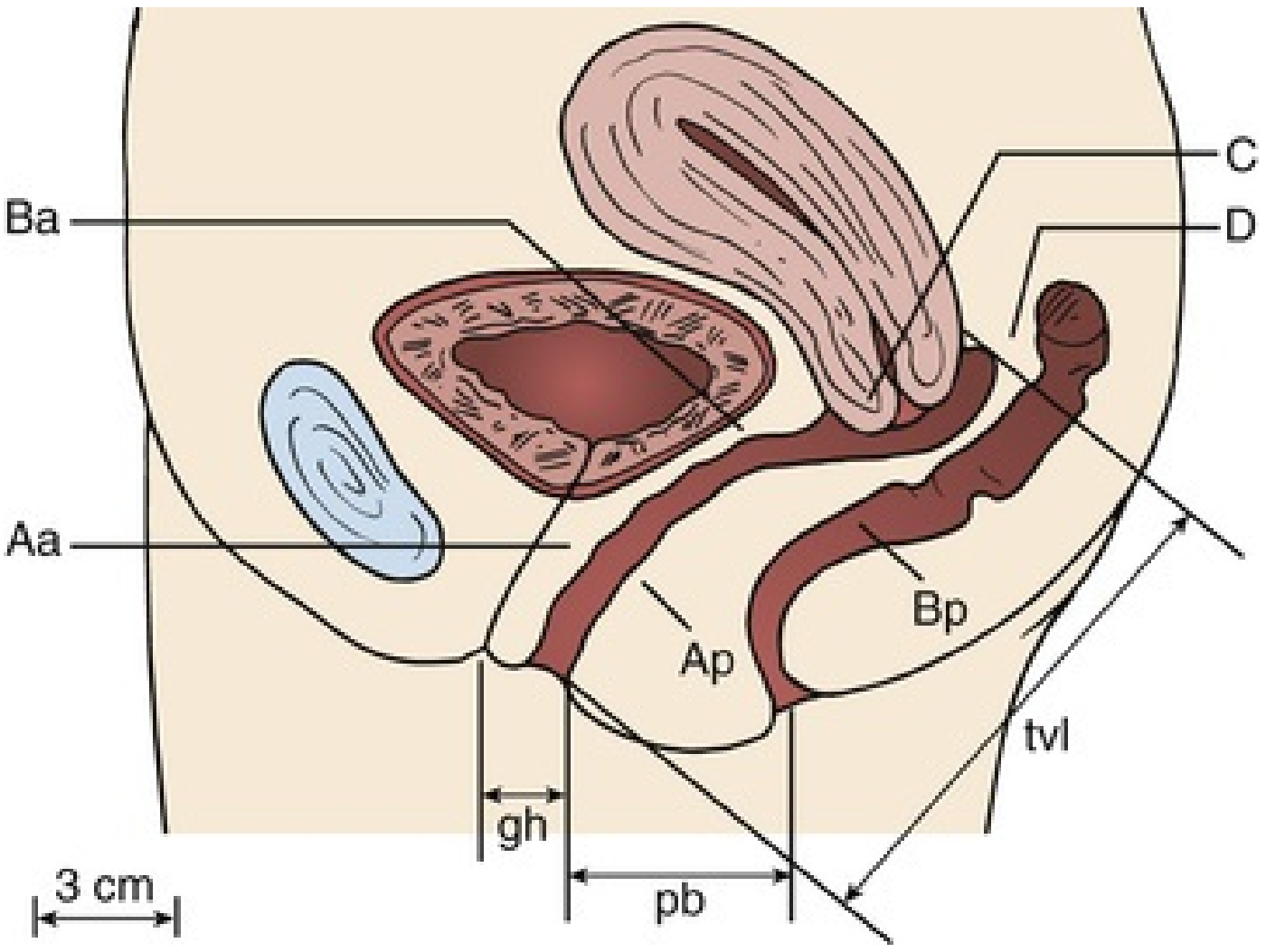

FIG. 115.4 Pelvic Organ Prolapse Quantification system and specific points measured. *gh,* Genital hiatus; *pb,* perineal body; *tvl,* total vaginal length.

The 9-point scoring system is placed on a three-by-three grid (Fig. 115.5; Bump et al., 1996). Once the measurements are taken, patients are assigned to the corresponding stage. Stages are assigned according to the most severe portion of the prolapse on maximal strain. **Stage 0** is the absence of prolapse (points Aa, Ba, Ap, Bp are −3, and point C and D are between −tvl and −[tvl −2]cm). **Stage 1** prolapse is when the most distal portion of the prolapse is more than 1 cm above the level of the hymen. In **stage 2**, the most distal portion of the prolapse is situated between 1 cm above the hymen and 1 cm below the hymen (between −1 and +1). In **stage 3**, the most distal portion of the prolapse is more than 1 cm beyond the hymen but everted at least 2 cm less than the total vaginal length (tvl−2), and not all the vagina has prolapsed (> +1 but < +[tvl−2]cm). **Stage 4** is the complete eversion or eversion at least within 2 cm of the total vaginal length (≥ +[tvl −2]cm). Fig. 115.6 demonstrates POPQ measurements in a woman with normal anatomy and a woman with stage 4 post-hysterectomy vaginal vault prolapse. A simplified POPQ can be used, which is based on the POPQ with similar ordinal staging, but only four points are measured instead of nine. It is performed in the dorsal lithotomy position with the patient performing Valsalva. The only points measured are the Ba, Bp, C, and D (in non-hysterectomized patients) (Haylen et al., 2016).

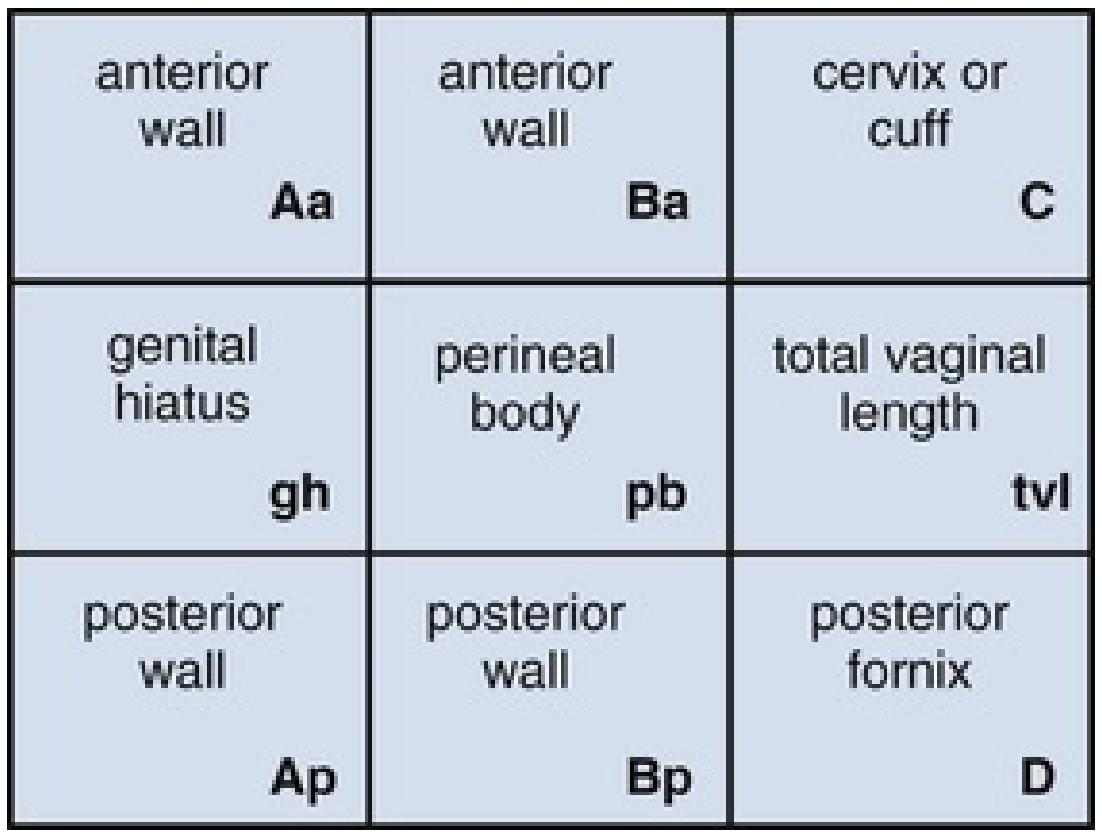

anterior wall **Aa**	anterior wall **Ba**	cervix or cuff **C**
genital hiatus **gh**	perineal body **pb**	total vaginal length **tvl**
posterior wall **Ap**	posterior wall **Bp**	posterior fornix **D**

FIG. 115.5 The 9-point Pelvic Organ Prolapse Quantification scoring system placed on a 3 × 3 grid. *gh,* Genital hiatus; *pb,* perineal body; *tvl,* total vaginal length.

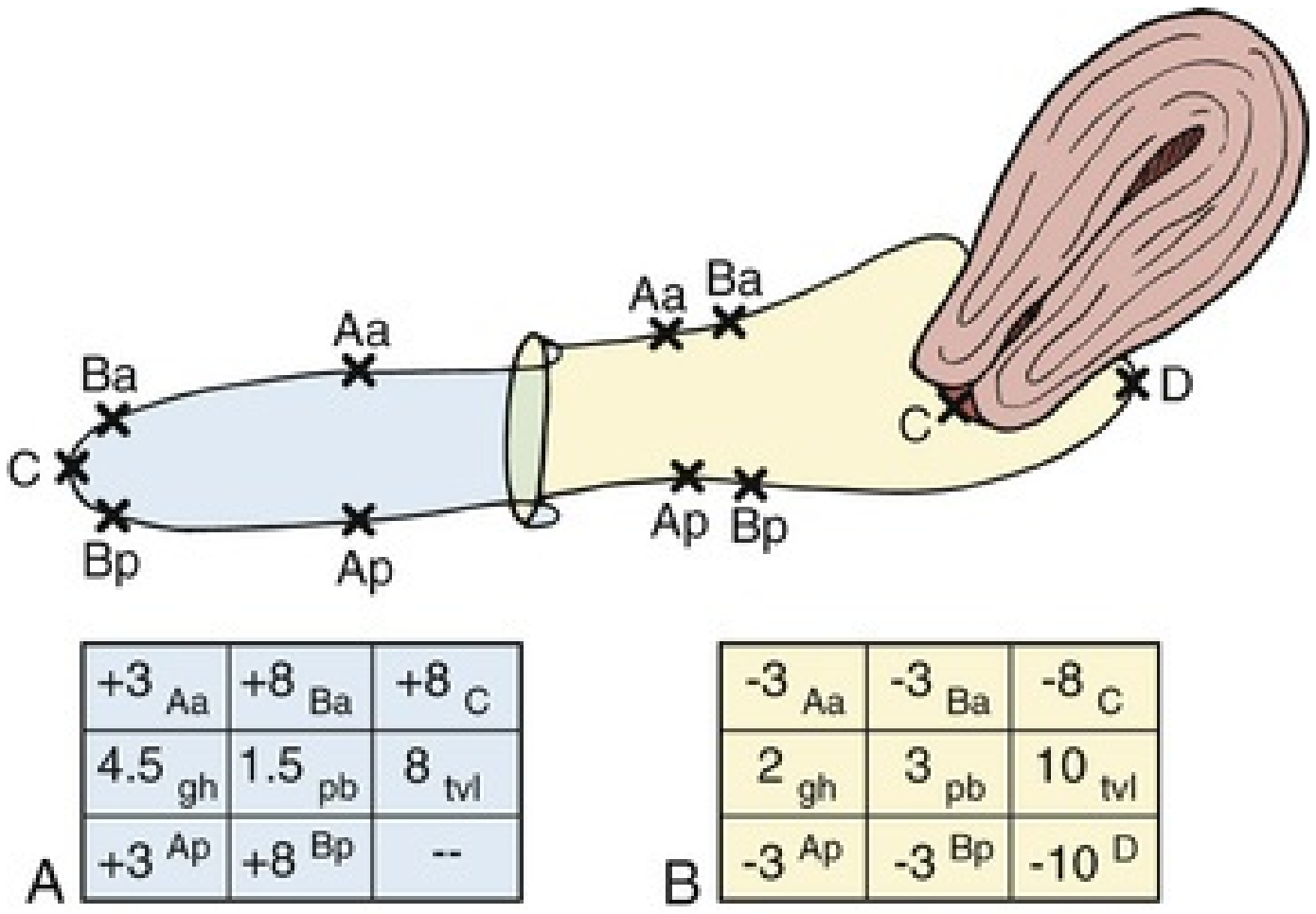

A

+3 Aa	+8 Ba	+8 C
4.5 gh	1.5 pb	8 tvl
+3 Ap	+8 Bp	--

B

-3 Aa	-3 Ba	-8 C
2 gh	3 pb	10 tvl
-3 Ap	-3 Bp	-10 D

FIG. 115.6 (A) Pelvic Organ Prolapse Quantification (POPQ) description of patient with total vault eversion posthysterectomy. (B) Woman with no prolapse (normal POPQ measurements). *gh,* Genital hiatus; *pb,* perineal body; *tvl,* total vaginal length.

A comprehensive history and physical examination with POPQ system are usually sufficient to properly assess the degree of prolapse. Most patients require little additional testing to specifically evaluate the prolapse. Radiology studies to establish the extent or to characterize a patient's prolapse are generally unnecessary. Pelvic ultrasound can be useful to identify pelvic organ abnormalities and identify possible mesh in the pelvis in patients with prior surgeries for prolapse or incontinence. The use of ultrasound to evaluate anatomic defect in POP is considered investigational by most (Barry and Dietz, 2005). For women with incomplete bowel emptying, significant defecatory dysfunction or when physical examination and prolapse severity does not correlate with symptoms, defecography, sometimes combined with dynamic magnetic resonance imaging (MRI) can be used (Rao, 2010). The resting and straining MRI can be particularly helpful in identifying the presence of enterocele (Fig. 115.7A and B). However, the benefit of routine use of MRI to describe the location of pelvic-support defects before attempting surgical repair has yet to be demonstrated to be necessary, cost effective, or result in superior outcomes and therefore still should be used at the discretion of the treating physician. **For the majority of patients, a careful POPQ physical examination and, if necessary, reassessment at the time of surgery remain the cornerstones of POP assessment.**

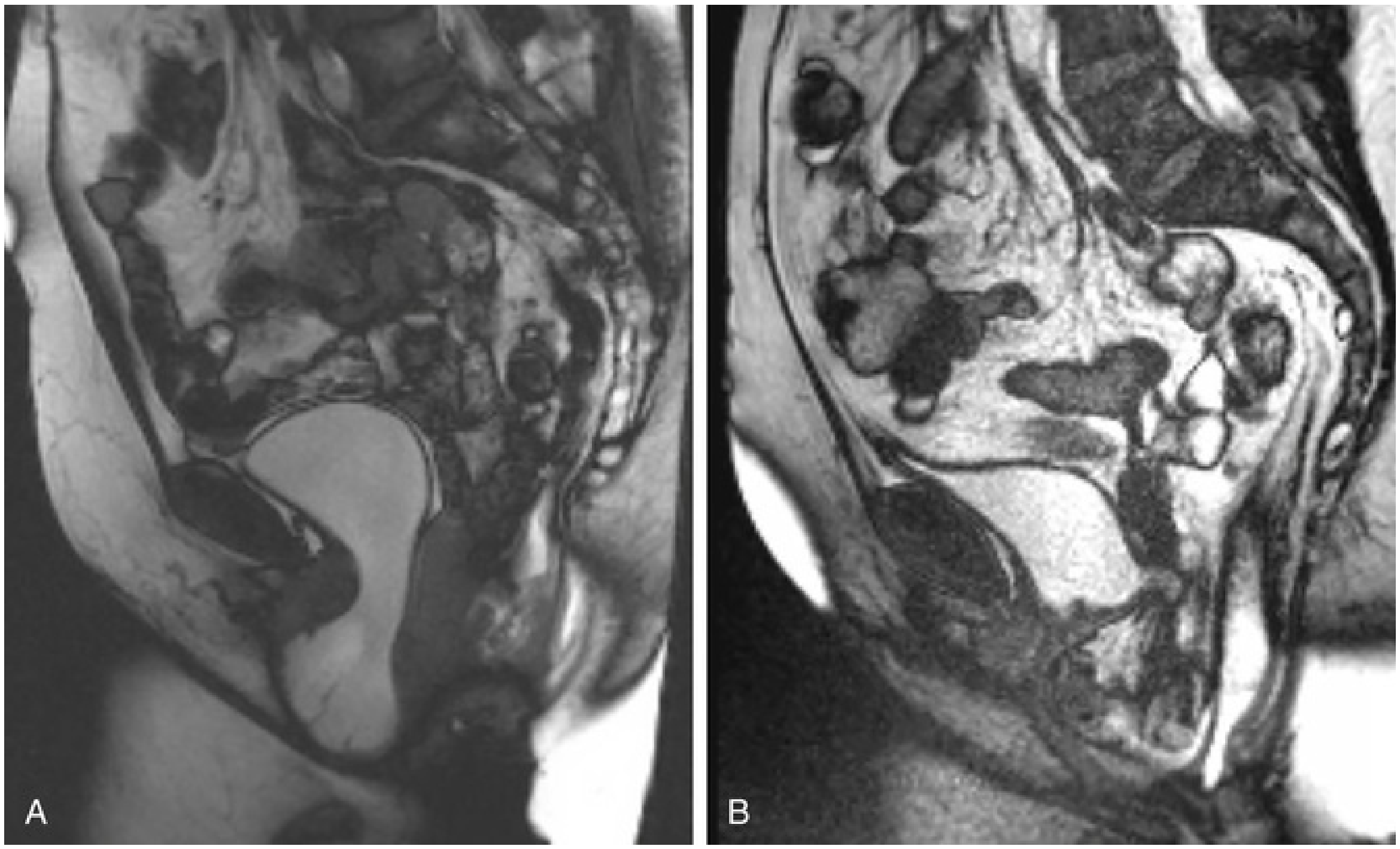

FIG. 115.7 (A) Magnetic resonance imaging (MRI) defecography of female with severe cystocele and uterine descent. (B) MRI defecography of female with defecatory dysfunction and severe enterocele.

Key Points: Definition and Classification of Pelvic Organ Prolapse

- POP should be described using anterior vaginal wall, uterine, apical, or posterior vaginal wall prolapse. Terms such as “cystocele, rectocele, enterocele, and urethrovesical junction prolapse” should be avoided.
- The POPQ system should be used to record the stage or prolapse.
- A careful POPQ physical examination remains the cornerstones of POP assessment for the majority of patients.

Epidemiology of Pelvic Organ Prolapse

Prevalence and incidence of POP+ are difficult to estimate because epidemiologic studies or the incidence and prevalence of this disorder are rare (Hunskaar et al., 2005). The prevalence of POP also varies depending on the definition used. This lack of a good definition stems in part from a poor understanding of what represents normal versus abnormal pelvic organ support in women. It is difficult to identify POP based on symptoms alone because symptoms experienced by patients with POP do not necessarily correlate with the location and the severity of the prolapse (Ellerkmann et al., 2001). Furthermore, prolapse often does not become symptomatic until it reaches the hymenal ring. Loss of vaginal or uterine support in women visit can be seen in up to 43% to 90% of patients (Durnea et al., 2014; Samuelsson et al., 1999; Swift et al., 2005). It is now clear that stage 1 prolapse of the anterior and posterior vaginal wall are so common that they are likely to be part of the normal spectrum. In a multicenter observational study of 1004 patients seeking routine gynecologic care, only 24% of patients had no prolapse. The prevalence of stage 1, 2, and 3 prolapse was 38%, 35%, and 2%, respectively (Swift et al., 2005). Thus some loss of uterovaginal support is present in the majority of adult women. Prolapse symptoms are typically not present until the prolapse reaches the hymen (Dietz and Mann, 2014; Swift et al., 2005). **Therefore asymptomatic stages 1 to 2 POP are considered normal in adult women and rarely require treatment.** Similarly, in the Women's Health Initiative, which measured prolapse in postmenopausal women with physical examination, the overall presence of any degree of prolapse was 41% for women with a uterus and 38% of women post-hysterectomy (Hendrix et al., 2002). Anterior vaginal wall prolapse was the most common single site of prolapse, seen in 34%. Posterior compartment prolapse was present in 19% of women and uterine prolapse in 14%. **Prolapse occurs most frequently in the anterior compartment, followed by the posterior compartment, and least commonly in the apex.** However, it is possible that apical prolapse has been underdiagnosed or underreported. It has become clear that apical prolapse is almost always present when there is significant anterior and posterior vaginal wall prolapse (Elliott et al., 2013; Rooney et al., 2006). This is particularly true for anterior vaginal wall prolapse. In a retrospective study, Elliott et al. confirmed that clinically significant apical vaginal prolapse incased significantly with increased anterior vaginal wall prolapse. Significant apical prolapse (C of −3 or greater) was reported in 42%, 85%, and 100% of patient with stage 2, 3, and 4 anterior vaginal wall prolapse respectively. **Surgeons planning cystocele repair should have a high degree of suspicion for vaginal apical prolapse and should consider concomitant vault suspension repair.**

The prevalence of prolapse based on sensation of a vaginal bulge, pressure, or protrusion or visible bulge from the vagina has been reported to be between 3% and 12% (Nygaard et al., 2008; Rortveit et al., 2007; Slieker-ten Hove et al., 2009; Wu et al., 2014). However, questionnaire-based estimates likely under-report the true prevalence of POP compared with incidence based on physical examination. This can be due to the fact that women often feel ashamed of their prolapse and are uncomfortable speaking about it with anyone, including physicians (Dunivan et al., 2014a). Furthermore, the degree of bother varies significantly among women. Whereas some women will be greatly symptomatic with a stage 2 prolapse, others will have no symptoms whatsoever. Some evidence suggests that symptoms severity and distress can vary according to the ethnic background. Dunivan et al. (2014b) reported that among women with stage 2 prolapse, Hispanic and Native American women experienced a higher degree of bother compared with non-Hispanic white women. However, the level of bother was not different between ethnic groups for prolapse stage 3 or greater.

A few studies have reported the natural history of POP. In a subgroup analysis of women enrolled in the Women's Health Initiative Estrogen Plus Progestin Trial and followed for 2 to 8 years, Handa et al. (2004) found that the annual incidences based on physical examination of new cystoceles, rectocele, and uterine prolapse were 9.3, 5.7, and 1.5 cases per 100 women-years. Their data also suggested that spontaneous regression was common, especially for grade 1 prolapse. In a group of symptomatic women who declined intervention and elected for observation, minimal change in prolapse staging was found during the observation period. After a median follow-up of 16 months (6–91), only 19% of patients demonstrated progression, 78% demonstrated no change, and 3% demonstrated regression (Gilchrist et al., 2013). **Generally, the natural history of pelvic organ prolapse is one of very slow progression, if at all, over time, even among symptomatic patients with advanced prolapse.**

Risk Factors for Pelvic Organ Prolapse

Many risk factors for pelvic organ prolapse have been suggested, and it seems most plausible that the cause is multifactorial. Vaginal childbirth, advancing age, and obesity are the most well-established risk factors for POP. Vaginal childbirth is the factor the most frequently associated with prolapse. The Oxford Family Planning Study was a prospective cohort study of more than 17,000 women. In this study, parity had the strongest association with the development of POP, with an adjusted relative risk of 8.4 for a woman who had delivered two children and 10.85 for someone who had delivered four or more children (95% confidence interval [CI] 4.65 to 33.81) (Mant et al., 1997). The Women's Health Initiative also demonstrated a strong association between parity and POP. A single childbirth was associated with raised odds of uterine prolapse (odds ratio [OR] 2.13; 95% CI 1.67–2.72), cystocele (OR 2.22; 95% CI 1.84–2.68), and rectocele (OR 1.91; 95% CI 1.67–2.19). Every additional delivery up to five births increases the risk of prolapse by 10% to 20% (Hendrix et al., 2002). In a case control study, women who had a vaginal delivery had an odds ratio of 2.9 of undergoing surgery for POP (95% CI 0.9–10.0), and women who had forceps delivery had an odds ratio of 5.4, suggesting certain aspects of vaginal delivery may affect the development of POP (Moalli et al., 2003). Another factor associated with the need of prolapse surgery in that study was age younger than 25 years at the time of first delivery. Interestingly, infant birth weight of greater than 4000 g was not associated with the need for prolapse surgery in this study. Substantial associations between delivery mode and symptoms and signs of prolapse were also demonstrated in a retrospective observational study by Trutnovsky et al. (2016). Nulliparous women showed the lowest prevalence of prolapse, followed by women who exclusively delivered by cesarean sections. The highest prevalence of prolapse was found in patients who delivered at least once by forceps and normal vaginal delivery. Compared with women who had delivered by cesarean sections only, the adjusted odds ratios for reporting symptoms of prolapse were 2.4 (95% CI 1.30–4.59) and 3.2 (95% CI 1.65–6.12) in the normal vaginal delivery with or without vacuum extraction and forceps groups, respectively.

Cesarean section seems to be protective against prolapse, but the degree to which cesarean delivery prevents the development of POP is unclear. In a cross-sectional study by Lukacz et al. (2006), there was no significant difference in the prevalence of prolapse between the cesarean delivery and nulliparous groups. In addition, there was an increased prevalence of prolapse in the labored cesarean group compared with unlabored cesarean group, which was similar to the rate of prolapse in the vaginal delivery group. This indicates that cesarean delivery after labor may not eliminate the risk of future symptomatic POP. Lukacz et al. calculated that the proportion of prolapse that could be prevented with a policy of routine elective cesarean section was 46% in this population.

The incidence and the prevalence of POP increase with advancing age (Hunskaar et al., 2005). In a cross-sectional study of 1004 US women aged between 18 and 83 years who saw their doctors for a yearly examination, the relative prevalence of prolapse rose by about 40% with every decade of life (Swift et al., 2005). In the Women's Health Initiative, women between the ages of 60 and 69 and 70 and 79 had a higher risk of prolapse than women aged between 50 and 59 years old (Hendrix et al., 2002). The risk of requiring surgery for POP and urinary incontinence also increase with age, peaking in the seventh decade (Olsen et al., 1997).

Obesity also has a role in the development of pelvic organ prolapse. In the same study by Hendrix et al., being overweight was associated with a significant increase in the occurrence of uterine prolapse by 31%, rectocele by 38%, and cystocele by 39%. Obesity was also associated with a significantly increased risk of uterine, posterior, and anterior prolapse 40%, 75%, and 57% increase, respectively. Waist circumference of at least 88 cm was similarly associated with an increased risk of rectocele and cystocele. Similar findings were also demonstrated by Swift et al., who noted that patients with a BMI between 25 and 30 kg/m^2 and more than 30 kg/m^2 had increased odds of developing POP (OR 2.51, 95% CI 1.18–5.35) and 2.56 (OR 2.56, 95% CI 1.23–5.35), respectively (Swift et al., 2005).

Hysterectomy is associated with an increased risk of developing POP. Interestingly, when the indication for hysterectomy is prolapse, a higher risk of subsequent POP surgery has been noted (Lykke et al., 2015). In the Oxford Family Planning Study (Mant et al., 1997), the cumulative risk of surgery for prolapse in women who had undergone a hysterectomy was 29 per 1000 women-years versus 16 per 1000 women-years for the entire cohort. The cumulative risk rose from 1% at 3 years after a hysterectomy to 5% 15 years after hysterectomy. The risk of prolapse was the highest, 5.5 times higher, for patient who had undergone previous hysterectomy for prolapse compared to other reasons. Hysterectomy performed for POP is a strong predictor of the need for repeat pelvic floor surgery, although this in part may be a result of failure to perform concomitant vaginal vault suspension at the time of hysterectomy.

Some evidence suggests that **race** plays a role in POP. Black women have the lowest prevalence of POP, and Hispanic women have the highest prevalence after controlling for possible confounding factors. Based on physical examination, Hendrix et al. (2002) found that Hispanic and Asian women had increased risks of developing cystocele (Hispanic, OR 1.20, 95% CI 1.05–1.36; Asian, OR 2.18, 95% CI 1.8–2.64) compared with white individuals. African-American women had a lower risk (OR 0.65, 95% CI 0.59–0.73). Based on symptoms, Rortveit et al. (2007) found ORs of 0.4 (95% CI 0.2–0.8) for African-American and 1.3 (95% CI 0.8–2.2) for Hispanic women, with white women as the reference group.

Other factors have also been studied in relation to POP risk. An association between **maximum birth weight** and the development of POP has also been found, although not consistently (Moalli et al., 2003; Samuelsson et al., 1999). **Menopause** has been cited often as a risk factor for prolapse. However, studies investigating the relationship between hormonal status and prolapse have failed to consistently find an association between estrogen status and POP (Mant et al., 1997; Nygaard et al., 2004). Some evidence suggests that **heritable or genetic factors** can play a part in the development of POP. One study reported a higher risk of prolapse in women with a mother or a sister of reporting prolapse (Chiaffarino et al., 1999). Others have shown a fivefold increased risk of prolapse among siblings of women with severe prolapse compared with the general population (Jack et al., 2006). **Chronic constipation** has been also associated with pelvic organ prolapse. In a population-based study by Rortveit et al. (2007), chronic constipation was found to be a factor independently and significantly associated with symptomatic prolapse, with a 2.5-fold increase risk. Other factors have been linked inconsistently with prolapse, such as smoking, heavy lifting, intense physical activity, and chronic pulmonary disease (Vergeldt et al., 2015).

Key Points: Epidemiology of Pelvic Organ Prolapse

- The prevalence of symptomatic prolapse ranges from 3% to 12%, although asymptomatic prolapse is present in the majority of adult women.
- Anterior compartment prolapse is the most frequent location of prolapse.
- The incidence and prevalence of POP increase with age, as do rates of surgery for POP.
- Parity is associated with an increased risk for POP later in life. The risk of

POP increases with every additional vaginal childbirth. Forceps delivery increases further the risk of developing POP.

- Elective cesarean section or unlabored cesarean section seems to be protective against prolapse.
- Obesity is a major risk factor for the development of POP.
- Hysterectomy, especially when performed for prolapse, increases the risk for POP and is a strong predictor of secondary pelvic floor surgery.
- POP is more common in Caucasian and Hispanic women when compared with African-American women.
- Other factors associated with the development of POP include maximum birth weight, menopause, genetic factors, and chronic constipation.

Relationship Between Urinary Incontinence and Pelvic Organ Prolapse

Etiologic risk factors for UUI and SUI overlap with the risk factors for POP. In fact, more than 40% to 55% of women with SUI will have a significant anterior vaginal prolapse, and almost 20% of patients with OAB symptoms will have an anterior vaginal wall prolapse (Cardozo and Stanton, 1980; Norton et al., 2014).

Community and hospital-based studies noted that the prevalence of OAB symptoms was higher in patients with prolapse than without prolapse (de Boer et al., 2010). However, no relationship was found between the compartment or the stage of the prolapse and the presence of OAB symptoms. Improvement in OAB symptoms can be expected after prolapse surgery. In fact, up to 69% of women experience an improvement in their OAB symptoms after prolapse surgery (de Boer et al., 2010). In fact, Fletcher et al. (2010) found that anterior compartment repair resulted in a reduction of frequency (by 33%), UUI (49%), and difficulty voiding (74%) at a median of 21 months’ follow-up. However, the results of the various studies that tried to identify predictors for the resolution of OAB symptoms after prolapse surgery were inconclusive (de Boer et al., 2011). **It is still impossible to reliably predict the presence or persistence of OAB symptoms after prolapse surgery.** The pathophysiology of OAB in women with pelvic organ prolapse is still unclear. BOO is likely the most important mechanism by which prolapse induces OAB symptoms. Chronic stretching of the bladder wall is likely also to occur with vaginal prolapse, which could be a factor in the development of detrusor overactivity. One theory suggests that a severe cystocele can put traction of the urethra, which opens the bladder neck. This may allow urine to enter the urethra and causes detrusor overactivity (Jung et al., 1999).

More than half of women with SUI will also have POP. In the Trial of Mid Urethral Slings (TOMUS), a multicenter National Institute of Diabetes and Digestive and Kidney Diseases (NIDDK)-sponsored study assessing the efficacy and safety of two types of mid-urethral sling for the treatment of stress urinary incontinence, stage 2 POP was present in 49% of patients and stage 3 prolapse was present in 6% of patients at baseline. Even though the majority of patients with stage 3 prolapse were symptomatic (78%), only 25% of patients with stage 2 prolapse reported symptoms (Norton et al., 2014). Of the asymptomatic women with stage 2 prolapse, 15% underwent a concomitant prolapse repair at the time of the sling surgery. **Failure to recognize POP at the time of UI treatment may greatly increase the need for subsequent surgery for POP** (Anger et al., 2007). Data from a 5% national random sample of 1999 to 2001 Medicare claims for patients undergoing UI surgery showed that urologists performed concomitant prolapse repairs at the time of sling in 29.1% of cases, whereas gynecologists performed prolapse repairs in 55.7% ($P < 0.0001$). In the 12 months after sling surgery, patients who underwent surgery by a urologist were more likely to undergo a repeat surgery for prolapse (26.0% vs. 12.2%, $P < 0.0001$). These findings emphasize the importance of identifying and managing symptomatic prolapse when evaluating patients with UI.

In addition, previously continent women can also develop de novo SUI after POP surgery. Up to a quarter of patients with advanced prolapse may have such **"occult" stress urinary incontinence** (Brubaker et al., 2006). Cystocele can create a kink at the level of the urethra, causing urethral obstruction. Treating the prolapse may resolve the obstruction, which can then lead to the "unmasking" of SUI. It is also not uncommon to notice an improvement of stress incontinence symptoms as the prolapse stage progresses in severity. Urodynamic study performed with prolapse reduction can help to identify occult stress incontinence and help guide treatment planning. Visco et al. (2008) selected a subgroup of patients from the Colpopexy and Urinary Reduction Efforts (CARE) trial and assessed stress-continent patients with stages 2 to 4 prolapse who underwent urodynamic study with prolapse reduction to estimate if urodynamic study with prolapse reduction can predict postoperative stress incontinence. Overall, of those found to have stress incontinence during prolapse reduction during urodynamics, 58% of patients who did not undergo a concomitant Burch colposuspension at the time of sacrocolpopexy developed postoperative stress incontinence, compared with 38% of those in whom a colposuspension was performed ($P = 0.04$). Preoperative SUI during urodynamic study with prolapse reduction is associated with a higher risk of postoperative stress incontinence after prolapse repair. Similar findings were also revealed in the Outcomes Following Vaginal Prolapse Repair and Midurethral Sling (OPUS) trial (Wei et al., 2012). This trial randomized women without symptoms of SUI to receive a concomitant mid-urethral sling (vs. sham) at the time of vaginal prolapse surgery. At 1 year after surgery, incontinence was present in 27.3% of women in the sling group compared with 43% in the sham group ($P = 0.002$). The number needed to treat with a sling to prevent one case of urinary incontinence at 12 months after prolapse surgery was 6.3. However, complications were increased among those who underwent a sling, including bladder perforation in 6.7% (vs. 0), UTI (31.0% vs. 18.3%), major bleeding complications (3.1% vs. 0), and incomplete bladder emptying 6 weeks after surgery (3.7% vs. 0, $P \leq .05$ for all comparisons). **These studies emphasize the relationship between anterior vaginal prolapse and SUI. Prophylactic sling placement at the time of POP surgery for women who do not report SUI reduces the risk of de novo stress incontinence after surgery but increases the likelihood of adverse events. Counseling of women who are planning to undergo prolapse surgery should include benefits and potential additional risks associated with prophylactic sling placement.**

Key Points: Conditions Associated With Pelvic Organ Prolapse

- More than 40% of women with SUI and 20% of women with OAB symptoms will have an anterior vaginal wall prolapse.
- Occult SUI is stress incontinence only observed after the reduction of coexistent prolapse. Failure to address occult SUI at the time of surgery for POP may lead to more severely symptomatic SUI postoperatively.

Consequences of Urinary Incontinence and Prolapse

Societal Costs of Urinary Incontinence

The costs of diagnosing and treating UI are significant, as are personal hygiene-related costs. Estimates of cost are difficult to make because they include many variables not easily quantified in health care cost analyses, including many out-of-pocket expenses that place the financial burden squarely on individuals rather than on government or third-party payers. Therefore, in addition to the costs of diagnostic studies, office visits, medications, surgeries, and other interventions, and treatment of related UTIs or care for skin breakdown, one must take into account personal expenses related to absorbent products, increased laundering related to leakage, missed work, and other personal costs. **A review of the financial burden associated with the management of female SUI alone reported annual costs in excess of $12 billion in the United States, with more than 70% considered out-of-pocket expenses** (Chong et al., 2011). A report from the Urinary Incontinence Treatment Network noted that women with severe incontinence had $900 of out-of-pocket expenses annually for incontinence routine care, and a mean reduction of $625 was noted after surgical intervention (Subak et al., 2006, 2014). **With regard to OAB, if one uses a prevalence estimate of 42 million Americans affected, a societal cost of $25 billion annually has been estimated** based on outpatient visits, medical treatments, work time lost, and other related expenses (Onukwugha et al., 2009).

Social Impact of Urinary Incontinence

Nearly every aspect of a patient's life is affected by UI (Coyne et al., 2012). Relationships are affected, and sexual activity may be curtailed by the threat of UI. Adults of all ages and their partners are affected by the impact of UI on sexual activity, and surgery to improve incontinence has a positive effect on sexual function (Brubaker et al., 2009; Mengerink et al., 2016; Nilsson et al., 2009). Patients often avoid travel, restrict what they eat and drink (and inappropriately dehydrate themselves), alter what they wear (wearing dark clothing to guard against obviating leakage), and avoid contact with strangers.

They may have decreased work productivity because they need to urinate often (or desire to urinate to try to avoid leakage episodes). Because sleep disturbances are more common in some forms of UI, daytime alertness and productivity may be affected as well.

UI appears to affect the QoL of patients at all ages. Young nulligravid women with incontinence report greatly diminished overall well-being compared with age-matched women without UI (O'Halloran et al., 2012). Elderly patients are affected as well, with the severity of UI rather than the type of UI primarily responsible for the impact on QoL (Aguilar-Navarro et al., 2012; Barentsen et al., 2012). **The impact of UI is seen in nearly all QoL domains, and the severity of impact may be greater than that seen with other common conditions associated with aging, including arthritis and diabetes** (Hawkins et al., 2011). As for the most bothersome LUTS, a population-based study of more than 3700 men and women confirmed that urgency and urgency incontinence are the most troublesome overall (Agarwal et al., 2014).

Key Points: Consequences of Urinary Incontinence

- Societal costs of UI are difficult to estimate, but at least tens of billions of dollars are spent on UI. Costs include incontinence/hygiene products, medical and surgical treatments, office visits, decreased work productivity, and others.
- Interpersonal relationships are affected by UI. Sexual activity may be curtailed because of concerns regarding incontinence.
- Almost all QoL domains are affected by UI. Travel, leisure, and recreational activities are often curtailed. Diet is often altered and fluids may be inappropriately restricted.
- Sleep disturbances are associated with certain types of UI.

Impact of Pelvic Organ Prolapse on Quality of Life

POP has a significant negative impact on QoL. Similar to UI, POP is often not discussed freely in public. Women may experience shame about the condition and are often uncomfortable discussing it, even with their own physician

(Dunivan et al., 2014a). Women seeking treatment for POP have decreased body image and overall QoL. Body image has been shown to be an important determinant of QoL in patients with prolapse (Jelovsek and Barber, 2006). Svihrova et al. (2014) evaluated the impact of pelvic organ prolapse on quality of life by estimating the disability-adjusted life-years (DALYs) lost as a result of symptomatic prolapse. It was estimated that prolapse caused the loss of 14.5 DALYs per woman in middle-aged women because of disability. Surgical intervention has been proven to improve loss of QoL associated with POP (Doace et al., 2014).

POP also negatively affects sexual function. It has been estimated that 38% of women with prolapse avoid intercourse as a result of their condition (Barber et al., 2002). Women with both POP and UI are more likely to report decreased libido, decreased sexual excitement, and difficulty achieving orgasm during intercourse when compared with women with UI alone (Özel et al., 2005).

Financial Impact of Pelvic Organ Prolapse

Olsen et al. (1997) reported an 11% lifetime risk of undergoing a single operation for POP and UI in American women. It was also found that reoperation for recurrent prolapse and incontinence was common (29%). Smith et al. (2010) reported a 19% lifetime risk of undergoing prolapse surgery in Western Australia. POP is the most common indication for hysterectomy among women over the age of 54 in the United States (Wilcox et al., 1994). In 1997 the direct costs of POP surgery were $1.012 billion, including $494 million (49%) for vaginal hysterectomy, $279 million (28%) for cystocele and rectocele repair, and $135 million (13%) for abdominal hysterectomy (Subak et al., 2001). Urinary incontinence procedures were performed in 21% of prolapse operations, accounting for $218 million. Given the aging of the population, POP will represent an even greater public health burden in the next few years, given that aging women appear to be the fastest-growing population (He et al., 2005). It has been estimated that the number of American women with at least one pelvic floor disorder will also increase from 28.1 million in 2010 to 43.8 million in 2050, and the number of women with POP will increase by 46% (Wu et al., 2009). Using the 2007 Nationwide Inpatient Sample and the 2006 National Survey of Ambulatory Surgery, Wu et al. (2011) calculated the rates for inpatient and outpatient SUI and POP surgery from 2010 through 2050. They estimated that the number of patients who will have surgery for prolapse will increase

48%, from 166,000 in 2010 to 245,970 in 2050. These data suggest that surgeons will be faced with a much higher demand for prolapse and incontinence procedures over the upcoming several decades.

Physiology of Urinary Continence

Overview of Normal Continence Mechanisms

Urinary continence is maintained via an interplay of complex neural, structural, and ultrastructural mechanisms involving the lower urinary tract and surrounding structures. Failure of any one of these contributing factors can lead to UI. Diseases and their treatments, as well as aging, may affect more than one of these mechanisms, leading to UI. For example, diabetes, particularly when poorly controlled, can lead to UI initially mitigated, in part, by hyperglycemic polyuria. Later, with microvascular changes and resultant oxidative stress, direct neurogenic and myogenic changes occur, which may result in UUI and SUI.

Neural Control of the Lower Urinary Tract

Bladder storage at its very essence is a neurologically mediated event. **Parasympathetic transmission (via the pelvic nerve) is suppressed and sympathetic transmission (via the hypogastric nerve) is active, and both are imperative to the creation of a low-pressure reservoir that is maintained during the entirety of the filling phase.** Spinal reflex mechanisms allow afferent signaling from the bladder (via A delta myelinated nerves) to promote sympathetic-mediated closure of the bladder neck, a closure mechanism that is decidedly stronger in men than in women. The pontine micturition center in the brainstem integrates afferent input and ultimately is responsible for parasympathetic-mediated bladder contraction (Drake et al., 2010). However, before a coordinated contraction, tonic inhibition of coordinated parasympathetic activity by suprapontine centers prevents bladder contraction. In addition, ongoing pudendal nerve activation (via Onuf nucleus in the sacral cord) of the external sphincter mechanism results in the continuous resistance required to maintain continence during bladder filling.

Bladder: an Organ Capable of Significant Expansion at Low Pressures

The position of the bladder also provides a unique ability to allow for

significant expansion while placing the vulnerable sphincteric unit in a more protected environment where external forces are less likely potentially to influence the ability of the outlet to maintain continence (particularly in men). The dome of the bladder can expand well into the peritoneal cavity with relatively no extravesical force opposing this expansion. In contrast, the bladder base and neck sit in a stable retropubic location. In men, this position is fixed and immobile, and unless neurologic/traumatic/operative events occur, only a direct impact on the sphincteric unit will result in leakage. In women, in whom pelvic floor laxity can affect bladder neck position and function, incontinence may result, at least in part, from changes in the position of the bladder outlet.

The structure of the bladder wall and characteristics of smooth muscle cells allow for passive filling without increases in pressure that would create undue forces on the bladder outlet. **Relatively poor coupling between detrusor smooth muscle cells appears to contribute to the ability of the bladder to avoid the propagation of unplanned spontaneous smooth muscle contractions into a coordinated bladder contraction during filling.** Although individual smooth muscle cells may be triggered to contract by stretching during bladder fill, in most situations a sustained bladder contraction requires coordinated parasympathetic stimulation. The multiple-layered mucosal lining of the bladder further enhances the ability of the bladder to store urine, as the urothelial cell layers ("umbrella cells") can flatten considerably with filling. Further, **the extracellular matrix composition of the bladder wall, and in particular the type of collagen (type I favored in normally compliant bladders), as well as the collagen-to-elastin ratio, are critical to the maintenance of a low-pressure state in the bladder during normal filling, with elastin in particular contributing to compliance** (Lemack et al., 1999).

Key Points: Factors Contributing to Low-Pressure Reservoir During Bladder Filling

- **Neural:** Parasympathetic suppression, sympathetic activation promotes detrusor relaxation.
- **Anatomic (gross):** Intraperitoneal position of bladder dome permits unimpeded expansion.
- **Anatomic (micro):**

- Multilayered mucosal layer of bladder promotes expansion with filling, collapse with emptying.
- Poor coupling between detrusor smooth muscle cells dissipates aberrant contractions.
- Extracellular matrix composition promotes minimal change in bladder pressure by enhancing bladder elasticity. Collagen type I is major collagen subtype. Elastin content is critical in maintenance of bladder compliance.

Bladder Outlet and Sphincteric Mechanisms

Maintenance of a low-pressure reservoir would be of no value in ensuring continence if not for the presence of sufficient outlet resistance (higher than storage pressures). **A competent bladder outlet results from specific urethral mucosa attributes, which are the so-called internal sphincter (intrinsic properties of the bladder neck/proximal urethra) and the distal (rhabdo) sphincter.** Urethral mucosal longitudinal folds allow for distensibility (for opening during voiding) and contribute to the creation of a mucosal “seal” that enhances urethral closure during bladder filling. The well-vascularized spongy submucosal layer contributes to the distensibility of the urethral lumen. In addition, there are important structural and functional differences characterizing the sphincteric units in men and women that help to explain further how incontinence can be maintained in each of the sexes.

Male Sphincteric Mechanisms

The internal sphincter is a contributory continence mechanism extending from the bladder neck to the distal verumontanum. In the absence of disease, injury, or prior surgery, urine does not descend beyond the bladder neck to the level of the external sphincter. Dryness created by the forces at the bladder neck is, in part, a result of α-adrenergic activation of smooth muscle at the bladder neck and within the prostatic urethra. This smooth muscle extends distally and then toward the rhabdosphincter, where the greatest intraurethral forces are generated (Koraitim, 2008). **Sympathetic activation of α receptors in this zone, when combined with β-adrenergic–stimulated relaxation of the bladder body, promotes dryness**. Other aspects of the internal sphincter continence unit include the prostate, which further enhances outlet resistance. Because of these factors, loss of external sphincter function, such as with traumatic pelvic injury, may not result in incontinence in men with an intact bladder neck. This is in contradistinction to the bladder neck in women, which is relatively weak, making women more vulnerable to incontinence with any deficiency of external sphincter function. An artist's rendering of the male sphincteric unit, with accompanying histologic dissections in shown in Fig. 115.8 (Schwalenberg et al., 2010).

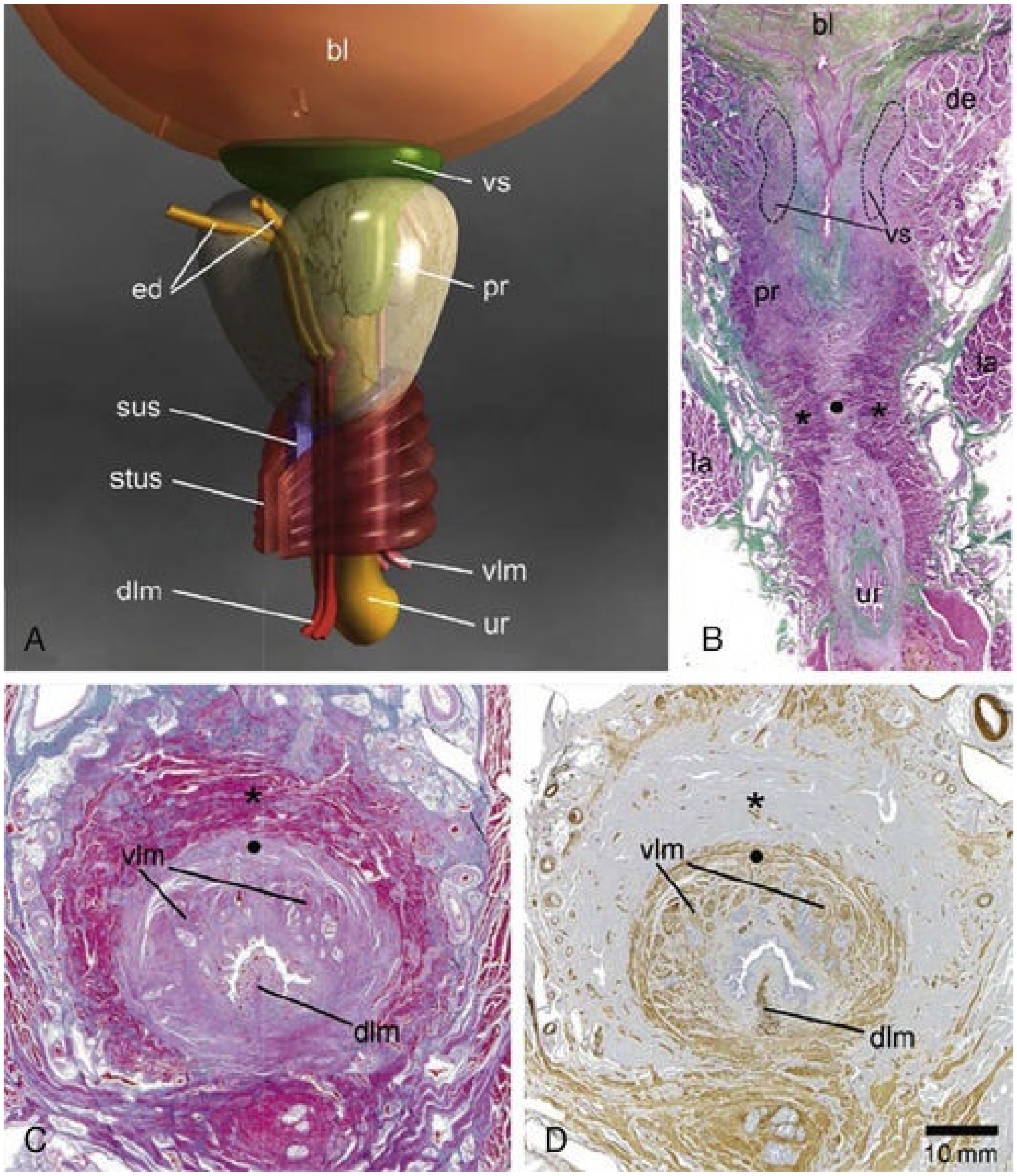

FIG. 115.8 Male urethral sphincter complex artist rendering (A) with accompanying histologic sections (B–D). Bladder *(bl),* bladder neck/internal sphincter *(vs),* ejaculatory ducts *(ed),* prostate *(pr),* rhabdosphincter *(stus),* smooth muscle component of urethral sphincter *(sus),* urethra *(ur),* ventral (inner) longitudinal muscle of urethra *(vlm),* and dorsal (inner) longitudinal muscle of urethra *(dlm)* shown. *Circle* and *asterisk* represent internal smooth muscle and external striated muscle components of the external

urethral sphincter complex, respectively.

The external sphincter is composed largely of skeletal muscle and, as such, has the ability to create intense compressive forces. Indeed, pressures at the rhabdosphincter are in excess of 40 cm H_2O continuously during bladder filling, and these pressures can rise considerably further with voluntary contraction. Pudendal nerve injury or denervation can result in the loss of external sphincter strength and subsequent UI (Gill et al., 2013; Sajadi et al., 2012). The strength of the external sphincter is highlighted in the presence of the failure of and/or the injury to the bladder neck (i.e., during TURP), in which case the presence of an intact rhabdosphincter nearly always results in the maintenance of continence. **The rhabdosphincter is a concentric muscle composed largely of type I (slow-twitch) skeletal muscle**, although smooth muscle fibers are noted to intermingle with the more prominent skeletal muscle bundles. **The presence of slow-twitch fibers is what is largely responsible for the tonic ability of the sphincter to maintain urethral closure essentially in a continuous fashion during bladder filling**. Fast-twitch fibers found in the surrounding levator musculature contribute then to the ability transiently to enhance voluntary closure during times of increased stress on the sphincteric unit. Further anatomic support of the rhabdosphincter is derived from the pubourethral ligaments, which anchor the sphincteric unit solidly in an anterior position. Ventral support of the sphincter comes from the condensation of musculofascial elements that ultimately fuse at the perineal body. This unique arrangement of the male sphincteric unit stabilizes and protects the sphincter from the impact of external forces.

Key Points: Continence Mechanisms of the Bladder Outlet and Urethra in Men

- Internal sphincter:
  - α-Adrenergic activation of bladder neck and prostatic smooth muscle
  - Prostatic restrictive forces on urethra
- External sphincter:
  - Rhabdosphincter (largely slow-twitch type I skeletal muscle) provides tonic compression.
  - Levator muscular elements (fast-twitch) assist during times of increased

stress on external sphincter.
- Anterior fixation by pubourethral ligaments
- Posterior support of musculofascial plate fusing at the perineal body

Female Sphincteric Mechanisms

Unlike the powerful continence zone created at the level of the bladder neck in men, continence in women is largely a result of forces created along the proximal urethra and/or mid-urethra, in addition to somewhat less forceful distal urethral muscular contributions. **Indeed it is fairly common for the bladder neck to be incompetent in women, although continence remains intact** (Chapple et al., 1989; Versi et al., 1990). As in men, longitudinal smooth muscle courses toward the external sphincter, although **the bulk of the muscle responsible for sphincteric control in women is circular striated muscle located in the proximal urethra and/or mid-urethra. Muscular forces (primarily striated muscle) create a nearly complete circumferential compression of the mid-urethra** (DeLancey, 1988) **under the influence of tonic pudendal simulation.** Experimental studies in rats have demonstrated transverse and longitudinal orientation of striated muscle inserting directly into the connective tissue of the urethral wall (Mondet et al., 2003) (indicating circular and longitudinal muscle orientation). Pudendal denervation and resultant sphincteric weakness, potentially occurring as a result of prolonged labor, is one mechanism by which incontinence may result from the effects of labor and delivery.

More distally, striated muscular fibers are not oriented circularly but are located ventrally. These muscular fibers contribute to the compressor urethra (which originates in the perineal membrane) and urethrovaginal sphincter (which originates in the vaginal wall). These further contribute to the sphincteric unit in women. Unlike the relative stability and immobility of the male external sphincter, the female sphincteric unit is most certainly vulnerable to common external forces.

A combination of attributes of the female urethra contribute to urinary continence. **Intrinsic properties of the urethral mucosa and urethral wall are an important part of maintaining continence in women. The spongy nature of estrogen-sensitive urethral submucosa enhances the apposition of urethral mucosa, which aids in the creation of an effective watertight seal.** In fact, it has been estimated that up to 30% of the forces responsible for continence are derived from this seal (Raz et al., 1972).

Surrounding musculofascial elements further support continence mechanisms in women. **A strong muscular backing (anterior vaginal wall) provides posterior support and additional compression of the mid-urethra.** Laxity in vaginal support can result in anterior vaginal prolapse and a shearing effect in the continence zone, particularly if anterior ligamentous support at the proximal urethra (pubourethral ligaments) is intact. **Indeed fixation of the urethra by ligamentous support (pubourethral ligaments) normally minimizes movement of the proximal urethra,** further contributing to continence by helping to prevent abdominal forces to be transmitted to the remainder of the urethra**. The urethropelvic ligaments further anchor the urethra to the tendineous arc bilaterally. It is the combined effect of these extraurethral forces, intrinsic urethral properties, and muscular elements that promotes continence, and loss of any one, or typically several, can result in UI in women.**

Key Points: Continence Mechanisms of the Outlet in Women

- **External sphincter mechanisms:**
    - Circular striated muscle of the external sphincter in the mid-urethra under pudendal innervation supplies the majority of active mid-urethral compression by the external sphincter.
    - More distally, longitudinal striated muscle arising from the vagina and perineal membrane contributes to sphincteric forces.
- **Urethral attributes:**
    - Mucosa of urethral wall tends to adhere to itself.
    - Spongy, vascular nature of urethral submucosal layer promotes apposition of the urethral wall.
- **Surrounding support structures:**
    - Anterior vaginal wall provides firm posterior support of the urethra allowing compression of the mid-urethra.
    - Fixation of the mid-urethra anteriorly by the pubourethral ligaments helps prevent transmission of intra-abdominal forces to the remainder of the urethra.
    - Further anchoring of the urethra anterolaterally to the arcus tendineus is

provided by the urethropelvic ligaments.

Pathophysiology of Urinary Incontinence: General Principles

Factors Affecting Bladder Storage

UI resulting from bladder dysfunction is induced by a variety of neurologic, iatrogenic, and common demographic risk factors. **Any neurologic process interrupting the normal suprapontine inhibition of the pontine micturition center may result in neurogenic detrusor overactivity (NDO) and cause UUI.** CVAs, multiple sclerosis, and Parkinson disease are among the more common neurologic processes that may result in UUI. DM, even early in diagnosis, has been associated with NDO and UUI. Obstruction resulting from anti-incontinence surgery in women can lead to de novo UUI secondary to induced detrusor overactivity (DO). In men, BOO induced by prostatic enlargement (or other obstructive process) can be associated with DO and resultant UUI.

Poor emptying from detrusor underactivity or detrusor areflexia (causing overflow incontinence) **can also cause UI**. This type of detrusor dysfunction is common with neurologic diseases affecting the lumbosacral cord or conus medullaris. Systemic diseases, which can result in peripheral neuropathies such as diabetes, tabes dorsalis, and alcoholism, can similarly cause overflow incontinence. Whereas early in the disease process DM can lead to UUI, later in the process sensation can be altered as can detrusor contractility, resulting in impaired bladder emptying, UTIs, and UI. Radical pelvic surgeries (i.e., radical hysterectomy, abdominoperineal resection) can also result in significant, sometime permanent, neurogenic detrusor dysfunction leading to urinary retention and overflow incontinence. Pelvic external beam radiation (commonly used in the treatment of prostate cancer and other pelvic malignancies) can alter bladder compliance, increase detrusor leak point pressure, and contribute to UI.

Factors Affecting Sphincteric Function

The most common causes of **intrinsic sphincteric deficiency (ISD)** are iatrogenic, although, less commonly, neurologic disease can directly affect sphincter function. Traumatic or vascular injury to the lumbosacral cord can impair sphincter function and can result in ISD (Gomelsky et al., 2003). Multiple systems atrophy typically results in loss of intrinsic sphincteric function in men and a high likelihood (≥20%) of UI after TURP in men who are considering this surgery. Other processes such as traumatic cervical or upper thoracic spinal cord injury can cause **detrusor sphincter dyssynergia,** creating impaired bladder emptying and UI, particularly when coupled with NDO. Medications used purposely to enhance voiding (alpha-blockers) can reduce outlet resistance sufficiently to cause leakage in vulnerable patients. Any medication with either α-antagonistic properties or skeletal muscle relaxant properties can also cause UI by inhibiting outlet resistance.

In women, urethral surgery or anti-incontinence surgery can lead to urethral scarring, periurethral fibrosis, and ISD. The likelihood of ISD appears to increase with an increased number of failed surgeries previously. Advanced prolapse surgery performed without concomitant treatment of the bladder outlet appears to result in an increased likelihood of postoperative UI. This appears to be true of abdominal sacrocolpopexy and vaginal surgery for significant anterior prolapse (Brubaker et al., 2008; Wei et al., 2012). Still, the risks of incontinence surgery, and the reality that some patients who never would have developed UI (and thus are overtreated) must be weighed against the risk of needing future surgery or the impairment of QoL associated with ongoing leakage.

Labor and delivery can also affect sphincter function in women. **Prolonged labor, third-degree lacerations, large birth weight, multiparity, and forceps deliveries are aspects of labor and delivery that have been associated with sphincteric dysfunction.** The mechanisms by which labor appears to result in UI include direct injury to ligamentous/fascial support, ischemic injury to the pelvic floor as a result of prolonged compression, pelvic or pudendal denervation induced by compression, and direct genitourinary injury. This finding is further corroborated by a study of women followed for decades after cesarean section compared with women who had a single vaginal delivery. Twenty years after delivery, women who underwent vaginal delivery are more likely to experience MUI, SUI, and UUI and are more likely to report severe forms of UI (Gyhagen et al., 2013a, b).

RP, the most common surgical cause of incontinence in men, generally causes leakage via a direct impairment of sphincter function. Among incontinent men studied urodynamically, ISD is the predominant finding in approximately 70%, whereas DO and altered compliance are less common causes, although they may contribute to the condition in more than 30% of cases (Dubbelman et al., 2012).

It is clear, however, that the finding of DO is common among men after RP (more than 50% of men 3 years after RP), regardless of the presence of UI (Song et al., 2010). After RP, decreases in functional urethral length (64%) and maximum urethral closure pressure (MUCP, 41%) have been noted. In this regard, higher baseline MUCP has been associated with earlier urinary control and lower likelihood of postprostatectomy incontinence (PPI) (Dubbelman et al., 2012). Although the approach of RP (open vs. robotic) does not appear to affect greatly the risk of ISD, preservation of the bladder neck and, in particular, nerve sparing for open and robotic approaches to RP seems to hasten the recovery of continence and to lower the overall likelihood of PPI (Campodonico and Manuputty, 2012; Srivastava et al., 2013).

Pathophysiology of Stress Urinary Incontinence in Women

Original theories explaining the pathophysiology of UI in women focused on the descent of the proximal urethra and bladder neck, and the implications of moving away from an intra-abdominal location with anterior pelvic prolapse. It was believed that as the urethra became hypermobile, intraperitoneal forces could no longer constrict the urethra and incontinence resulted (Enhorning, 1961). The pressure transmission theory was the basis of several effective operations (i.e., Marshall-Marchetti-Krantz and Burch colposuspension) designed to restore the urethra to its normal anatomic location.

Loss of Urethral Support

Gradually the understanding of the urethral support mechanisms and causative factors for SUI evolved. It became clear that urethral support emanated from the endopelvic fascia and was enhanced by anterior support (pubourethral ligament) and posterior support (vaginal wall), all of which normally prevent excessive urethral mobility. **Proponents of the current theory thought it best to explain incontinence resulting from urethral hypermobility as the "hammock hypothesis," based on the work of John DeLancey** (1994). **This theory suggests that posterior musculofascial fascial/ligamentous support of the urethra from the anterior vaginal wall and extending laterally from the vagina to the levator ani and arcus tendineus fascia pelvis contribute to the maintenance of continence seen at times of increases in intra-abdominal pressure** (Figs. 115.9 and 115.10). Compression of the urethra against this firm posterior backing (hammock) enables the urethra to prevent urinary loss with stress maneuvers. Loss of backing from this musculofascial support leads to incontinence because of an inability to compress the urethra, particularly if combined with intact anterior support (creating a shearing effect) and loss of compressive sphincteric forces (Mostwin et al., 1995). Therefore this theory suggests that repositioning the urethra, previously considered to be essential, is not necessarily essential to restoring continence in women who leak with SUI. The essential element to restoring continence, then, rests with restoring the layer of support to the posterior urethra and therefore allowing the urethra to be compressed adequately (DeLancey, 1997).

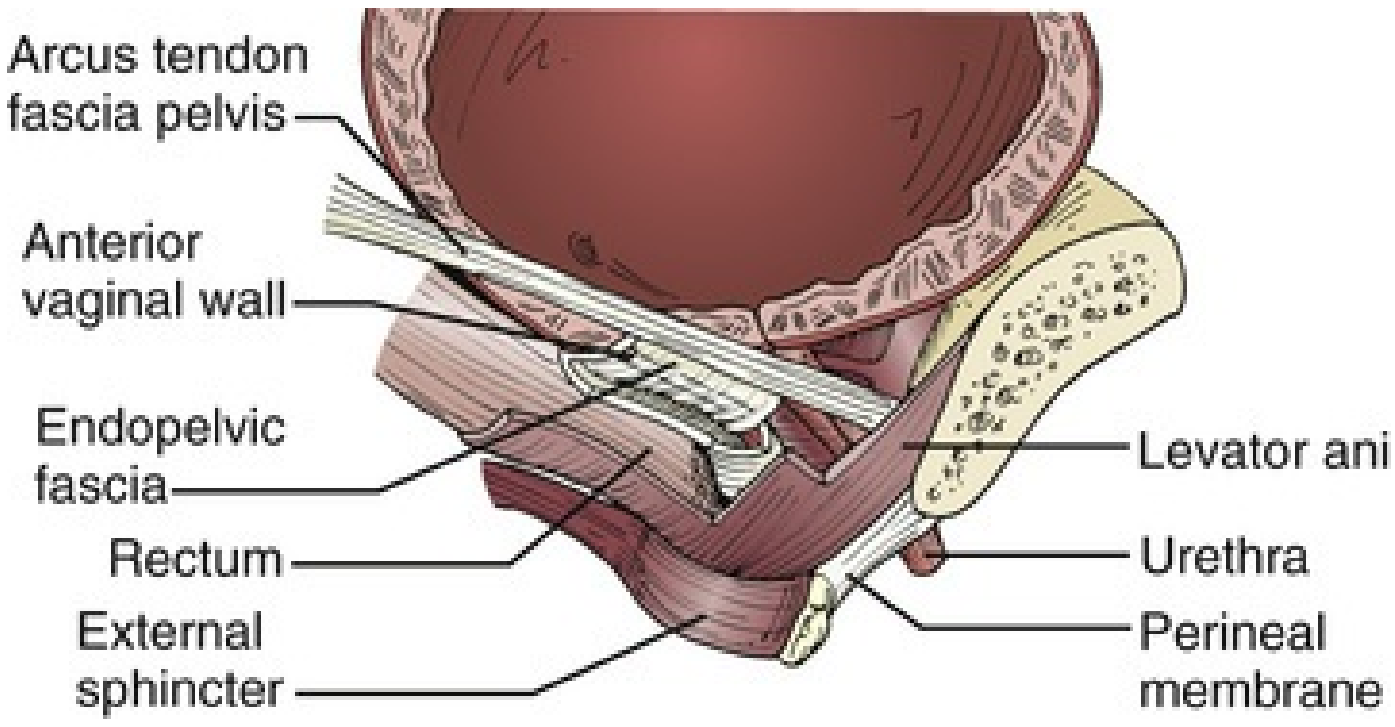
Arcus tendon fascia pelvis
Anterior vaginal wall
Endopelvic fascia
Rectum
External sphincter
Levator ani
Urethra
Perineal membrane

FIG. 115.9 Structures involved in urethral support drawn from dissection and three-dimensional reconstruction made from serial sections. Note the connection of the endopelvic fascia and the vaginal wall that lies under the urethra to the arcus tendineus fasciae pelvis and its connection to the levator ani muscle.

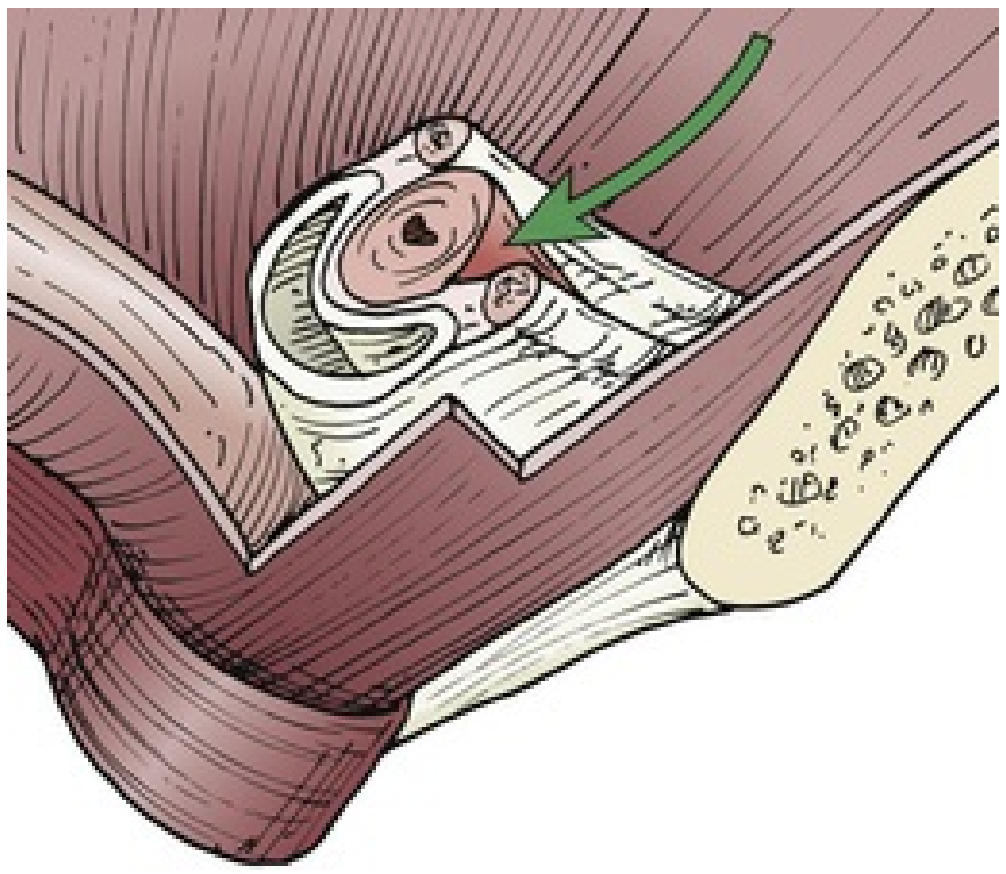

FIG. 115.10 Lateral view of the pelvic floor with urethra, vagina, and fascial tissues transected at the level of the vesical neck drawn from three-dimensional reconstruction, indicating compression of the urethra by downward force *(arrow)* against supportive tissues, indicating the influence of abdominal pressure on urethra.

Petros and Ulmsten (1990) proposed an additional explanation for SUI and UUI. **The "integral theory" pinpoints the site of the maximal continence zone in the mid-urethra at the pubourethral ligaments. During times of bladder storage, anterior forces from the pubococcygeus muscle pull the vagina up against the pubourethral ligament to close the urethra. In**

addition, backward forces stretch the vagina and bladder neck in a plane around the pubourethral ligament to allow proximal urethral closure (Petros and Skilling, 2001; Petros and Woodman, 2008). The authors contend that laxity of these forces secondary to connective tissue damage leads to the loss of urine with stress and, further, that muscular forces stretching the vaginal membrane against the ligaments activate stretch receptors, causing them to fire prematurely. This last event is thought to contribute to urinary urgency and UUI. The concept of mid-urethral tension-free sling procedures to treat symptomatic SUI was largely based on treating the anatomic deficiencies proposed by Petros and Ulmsten (1990) in their discussion of the integral theory.

Intrinsic Sphincteric Deficiency

Despite the breakthrough in understanding urethral anatomy, function, and support, it remained clear that even with extensive pelvic relaxation and urethral hypermobility, some women were completely continent. More importantly, some women with no hypermobility had fairly severe SUI, particularly those with scarred urethras or certain types of neurogenic disease. **The concept of intrinsic sphincteric deficiency (ISD) was introduced in the urologic literature by McGuire and Lytton (1978) in their initial description of the use of autologous fascial slings for patients with SUI resulting from absent or poor urethral function,** typically secondary to previous urethral surgeries. In this landmark article, the authors noted significant improvements in the majority of patients with severe urethral dysfunction (diagnosed urodynamically) treated by pubovaginal sling, without apparent obstruction in early assessment. Blaivas and Olsson (1988) further characterized ISD later as type III UI to distinguish it from forms of incontinence involving urethral mobility. ISD implies the sphincter activity is dysfunctional, whether because of a neural or a structural problem. Patients with ISD have classically been described as having a “pipestem” urethra, meaning a fixed urethra with little intrinsic closure function. This finding may result from previous surgery and is typically iatrogenic in some way. **Subtler forms of ISD, which typically coexist with the finding of urethral hypermobility, are more commonly found and are likely responsible for most forms of SUI.** ISD in this setting may be secondary to ischemic injury (birth or other trauma) or other forms of progressive pudendal nerve damage.

ISD was historically identified urodynamically using the concept of

Valsalva leak point pressure (VLPP) (McGuire et al., 1996). VLPP testing describes the abdominal pressure required to cause urethral incontinence. VLPP measurement cannot be made in the presence of a detrusor contraction or altered bladder compliance. Low VLPP (less than 60 cm H_2O) has been associated with ISD, and this has been used in the past to direct specific treatments for ISD, such as bulking agents or pubovaginal sling. Both of these treatments may address sphincteric abnormalities and thus were presumed to be more appropriate treatment selections for patients without hypermobility. Our current understanding is that most forms of SUI likely involve some degree of ISD, even if urethral hypermobility is present. This fact underlies the finding that even among patients with hypermobility, treatments such as pubovaginal sling, mid-urethral sling, and even bulking agents appear to have reasonable efficacy (Blaivas et al., 2011; ter Meulen et al., 2009). It is clear, however, that the converse is untrue: that treatments aimed specifically at the correction of hypermobility may be less helpful in the presence of severe ISD and limited mobility. It is for this reason that Burch colposuspension and various needle suspension procedures, for example, have limited usefulness in the treatment of ISD, particularly in the setting of a fixed urethra.

Key Points: Theories on the Pathophysiology of Stress Urinary Incontinence in Women

- **Pressure transmission theory** proposes that descent of the urethra from its protected intraperitoneal position increases the forces placed on more distal urethral continence mechanisms and promotes SUI. Supported by Enhorning (1961) and others, these theories contend that the proximal urethra functionally becomes contiguous with the bladder and, as such, transmission of intra-abdominal forces is placed directly on the urethra. More distal sphincteric mechanisms may not adequately protect against incontinence.
- **Hammock hypothesis**, proposed by **DeLancey** (1994), suggests that the urethra is not truly in an intraperitoneal position, rather that firm posterior and lateral support allows compression of the urethra at times of increased intra-abdominal pressure, when combined with active mid-urethral sphincteric mechanisms. Loss of this support permits the development of

SUI. This theory combines elements of previous theories on urethral hypermobility into a more cohesive, anatomically based explanation.

- **Integral theory,** proposed by Petros and Ulmsten (1990), suggests that UI and SUI are caused by laxity in the vaginal wall and/or surrounding structures (such as pubourethral ligaments). Stretch receptors in the bladder neck, activated at times of increased abdominal pressure with urine deposition in the proximal urethra/bladder neck, are proposed to contribute to urgency incontinence.

Pathophysiology of Insensible Incontinence

Although in most instances women will be able to discern when urine loss occurs, in other cases the timing of incontinence may be unclear. Particularly when incontinence cannot be demonstrated on examination, or cannot be discerned from a thorough history, urodynamic studies and other diagnostic tests may help to determine the cause of leakage. In most cases, the common types of incontinence will still be responsible even if urine loss is insensible, such as sphincteric deficiency or detrusor overactivity incontinence. Other less common causes, however, must be considered, particularly when standard nonoperative measures fail to improve the symptom. Other causes such as urethral diverticula (typically postvoid urine loss), ectopic ureter (typically continuous urine loss), and overflow incontinence (typically small-volume frequent urine loss, urinary frequency, and small volume voids) should be considered. Although urodynamics should identify overflow incontinence, it may miss the other sources, and it may be nondiagnostic in a relatively frequent number of cases (Brucker et al., 2013). Thus in unique circumstances, pelvic MRI (to identify suspected urethral diverticula) and upper tract studies (to identify ureteral ectopy) should be considered in the evaluation of women with insensible urine loss.

Pelvic Floor Support Mechanism

Anatomic support of the pelvic organs in women is provided by endopelvic fascia, the perineal membrane, the levator ani muscle complex, and their attachments to the bony pelvis. **The levator ani muscle complex consists of the pubococcygeus, puborectalis, and iliococcygeus muscles.** It provides the primary support to the pelvic organs, providing a stable base upon which the pelvic organs rest. The opening between the opening of the levator ani muscles through which the urethra, vagina, and rectum pass is the levator hiatus. The endopelvic fascial attachments, in particular the condensations of the endopelvic fascia referred to as the uterosacral and cardinal ligaments, stabilize the pelvic organs in the correct position so that the pelvic muscles can provide optimal support. POP can occur when there is disruption or dysfunction of one or some of these structures.

The normal support of the vagina has been separated into three levels based on cadaveric dissections by DeLancey (1992) (Fig. 115.11). Level I represents the cervix and the upper third of the vagina, level II is the midportion of the vagina, and level III is the most caudal region of the vagina.

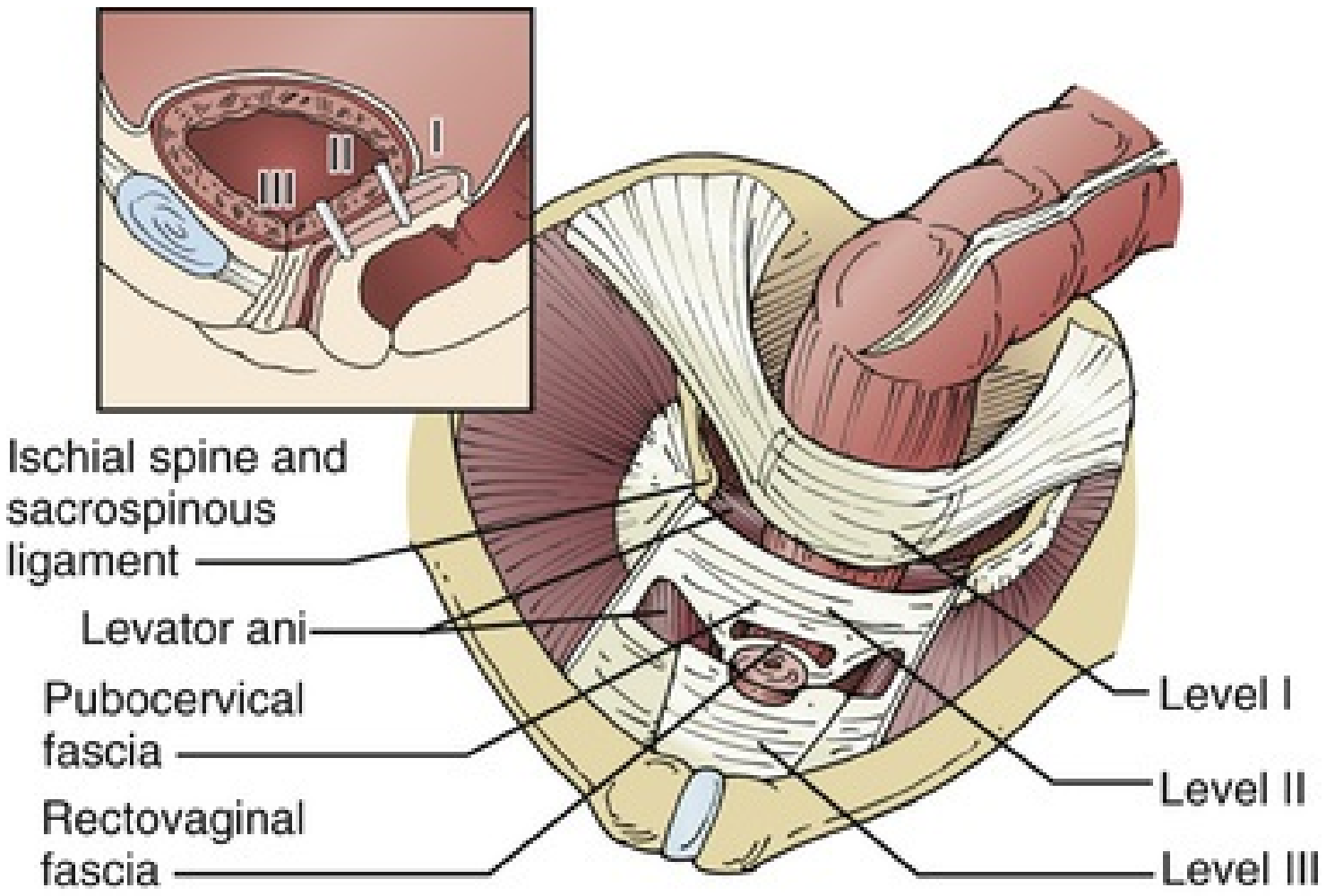

FIG. 115.11 Levels of support, as described by DeLancey (1992). In level I, the paracolpium suspends the vagina from the lateral pelvic walls. In level II, the vagina is attached to the arcus tendineus of the pelvic fascia and superior fascia of the levator ani muscles. The vagina's lower third fuses with the perineal membrane, levator ani muscles, and perineal body (level III).

Level I support suspends the uterus and upper vagina to the sacrum and lateral pelvic sidewall. Level I is composed of the parametrium and the paracolpium, which is the portion of the endopelvic fascia extending from the uterine arteries at its cephalic margin to the point wherever the vagina fuses with the levator ani muscles below. The portion of the endopelvic fascia that attaches the uterus to the pelvis side wall is the parametrium and the portion that attaches to the vagina is the paracolpium. The uterosacral ligament and cardinal ligament complex forms the parametrium and supports the upper third of the vagina and the uterus. The paracolpium is a long sheet of tissue that suspends the superior portion of the vagina by attaching it to the pelvic wall. The uterosacral ligaments are important components of this support. Loss of level I contributes to the prolapse of the uterus or vaginal apex. According to DeLancey, the paracolpium's vertical fibers in level I form the critical factor that differentiates vaginal eversion from posthysterectomy cystocele, rectocele, or enterocele in which the vaginal apex remains well suspended. **Level II** support includes the paravaginal attachments of the middle third of the vagina laterally to the superior fascia of the levator ani muscle and the arcus tendineus fascia pelvis (Fig. 115.12). At that level, the paracolpium changes configuration to form a more direct lateral attachment of the midportion of the vagina to the pelvic wall. The arcus tendineus fascia pelvis is a band of connective tissue attached at one end to the lower sixth of the pubic bone, 1 cm lateral to the midline, and at the other end, just above the ischial spine. Loss of level II support contributes to anterior vaginal wall prolapse. Anterior vaginal wall prolapse can occur either because of a lateral detachment of the paravaginal fascia, referred as **lateral defect**, or a weakness in the midline perivesical fascia, referred as **central defect**. The role of lateral detachment in the development of cystocele was first well established by Richardson et al. (1981). They observed that the most frequently encountered defect in patients undergoing surgery for cystocele was a detachment of the arcus tendineus fascia pelvis from the ischial spine, and rarely from the pubic bone. The posterior aspect of level II connects the midposterior vagina to the inside of the levator ani muscles by sheets of endopelvic fascia.

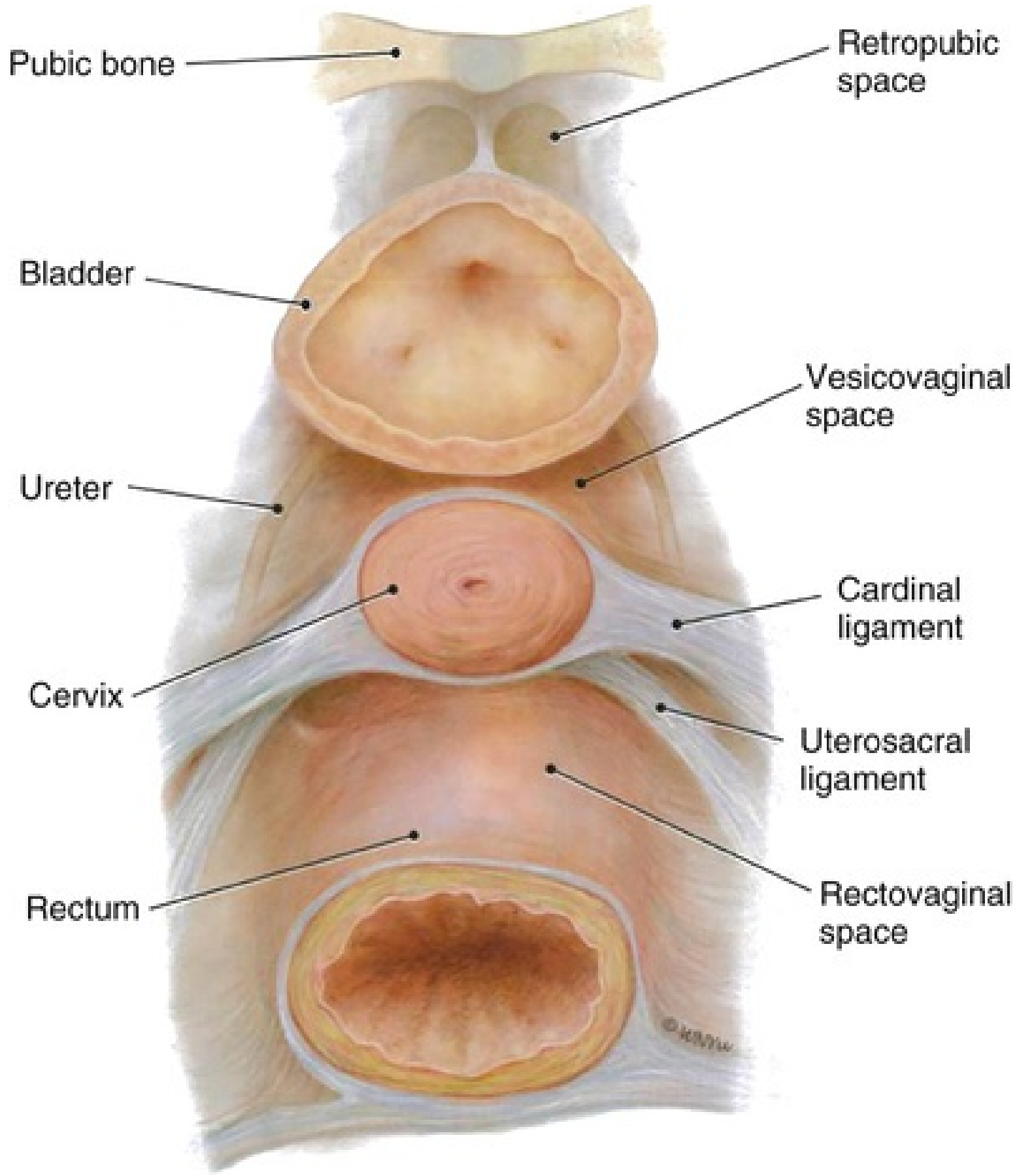
Pubic bone
Retropubic space
Bladder
Vesicovaginal space
Ureter
Cardinal ligament
Cervix
Uterosacral ligament
Rectum
Rectovaginal space
©KMW

FIG. 115.12 The cardinal and uterosacral ligaments provide support to the cervix and indirectly to the bladder base. The retropubic, vesicovaginal, and rectovaginal spaces are seen at the level of the cervix. (Modified from Raz S, Stothers L, Chopra A: Vaginal reconstructive surgery for incontinence and prolapse. In Walsh PC, Retik AB, Vaughan Jr ED, et al., editors: *Campbell's urology,* ed 7, Philadelphia, 1998, Saunders, pp 1059–1094.)

Level III is the distal vagina. At that level, the vagina's lower third fuses anteriorly with the urethra, posteriorly with the perineal body, and laterally with the levator ani muscle (superficial and deep perineal muscles). Below the levator ani muscles lies the perineal membrane, which is a layer of connective tissue that attaches the urethra, vagina, and perineal body to the ischiopubic rami. The fibers of the perineal membrane connect to the perineal body, providing a layer of support to prevent downward descent of the rectum. Loss of level III support anteriorly results in urethral hypermobility, whereas loss of posterior level III support results in a distal rectocele or perineal descent.

This classification may oversimplify the pathophysiology of prolapse. The loss of one level of support rarely occurs in isolation. It has become clear that isolated cystoceles or rectoceles are rare and a component of apical prolapse is almost always present (Elliott et al., 2013; Rooney et al., 2006). **The loss of apical support (level I) is highly correlated with the development of anterior prolapse and correlated moderately with the development of posterior prolapse. Therefore the identification of apical prolapse (loss of level I support) is crucial in optimizing the management of prolapse.**

Pathophysiology of Pelvic Organ Prolapse

The levator ani muscle complex is an important component of the pelvic organ support. The opening between the opening of the levator ani muscles through which the urethra, vagina, and rectum pass is referred as the levator hiatus. The portion of the levator hiatus that is situated ventral to the perineal body is the urogenital hiatus. It is through this last hiatus that prolapse of the vagina, uterus, bladder, and rectum occurs. The urogenital hiatus is kept closed by the tonic activity of the levator muscles, which compresses the urethra, vagina, and rectum against the pubic bone and therefore closes the lumen of the vagina.

In the event of direct muscle trauma or denervation, the levator ani muscle tone may decrease, which leads to enlargement of the urogenital hiatus and resultant prolapse (DeLancey, 2005; Singh et al., 2003). This widening of the urogenital hiatus also worsens as the prolapse progresses (Singh et al., 2003). Trauma to the levator ani muscles is most commonly a result of childbirth. On MR imaging, up to 20% of primiparous women have been noted to have visible defects in the levator ani muscle complex, defects that are not seen in nulliparous women. **This suggests that vaginal delivery contributes to POP through levator ani muscle injury** (DeLancey et al., 2003).

Pelvic organ support strongly depends on the interaction between the levator ani muscles and the endopelvic fascia. As long as the urogenital hiatus is kept closed by the levator muscles’ tone, the endopelvic fascia provide little support to the pelvic organ. However, once the organs are unsupported by the levator muscles, the entire support for the pelvic organs has to be provided by the ligaments of the endopelvic fascia. After a period of time, these ligaments tend to fail and prolapse ensues. Injury or stretching of these ligaments can occur during vaginal delivery, hysterectomy, chronic straining, or with normal aging (DeLancey, 2005). There seems to be consistent evidence that collagen metabolism is significantly altered in women with prolapse, which may underlie the failure of these ligamentous attachments. It is also possible that an alteration in the ratio of collagen type I and III could lead to pelvic floor dysfunction (Jackson et al., 1996; Moalli et al., 2005). Whether this alteration is the cause or effect of pelvic organ prolapse remains unclear. However, it is clear that connective tissue disorders have been linked to the development of POP;

patients with Ehlers-Danlos or Marfan syndrome are at enhanced risk of POP (Carley and Schaffer, 2000), supporting the etiologic role of connective tissue disorders as a factor in the pathogenesis of POP.

POP can also result from neuropathic injury. There are two main nerve supplies to the pelvic floor. The pudendal nerve supplies the urethral and anal sphincters and perineal muscles. The nerves to the levator muscles, which originate from S3 to S5 nerve roots, innervate the main musculature of the pelvic floor. Pelvic floor nerve injury probably occurs during vaginal delivery. Weidner et al. (2006) performed electromyography of the levator ani muscles of 58 primiparous women antepartum, at 6 weeks and 6 months after delivery. They found evidence of neuropathy in 24% of woman at 6 weeks and 29% at 6 months. Almost no injury was seen in patients who had undergone elective cesarean sections. Similar levator ani dysfunction was also found in women with cesarean section after labor.

Key Points: Pelvic Floor Support Mechanism and Pathophysiology of Pelvic Organ Prolapse

- The endopelvic fascia, the perineal member, the levator ani muscle complex, and their attachments to the bony pelvis provide the support of the pelvic organs.
- Level I support suspends the uterus and upper vagina to the sacrum and lateral pelvic sidewall. The loss of level I results in uterine and vaginal apical prolapse.
- Level II support provides the support of the middle third of the vagina. Loss of level II support contributes to anterior vaginal wall prolapse.
- Level III support represents the distal vagina. Loss of level III results in urethral hypermobility, distal rectocele, or perineal descent.
- The cause of POP is multifactorial and involves a combination of direct muscle trauma, muscle denervation, and injury or stretching of the endopelvic fascia.

Suggested Readings

Abrams P, Cardozo L, Fall M, et al. The standardization of terminology of lower urinary tract infection: report from the Standardisation Sub-committee of the International Continence Society. *Neurourol Urodyn*. 2002;21(2):167–178.

Bump RC, Mattiasson A, Bø K, et al. The standardization of terminology of female pelvic organ prolapse and pelvic floor dysfunction. *Am J Obstet Gynecol*. 1996;175(1):10–17.

DeLancey JO. Structural support of the urethra as it relates to stress urinary incontinence: the hammock hypothesis. *Am J Obstet Gynecol*. 1994;170:1713–1720.

Haylen BT, de Ridder D, Freeman RM, et al. An International Urogynecological Association (IUGA)/International Continence Society (ICS) joint report on the terminology for female pelvic floor dysfunction. *Neurourol Urodyn*. 2010;29:4.

Haylen BT, Maher CF, Barber MD, et al. An International Urogynecological Association (IUGA)/International Continence Society (ICS) joint report on the terminology for female pelvic organ prolapse (POP). *Int Urogynecol J*. 2016;27:165–194.

Markland AD, Goode PS, Redded DT, et al. Prevalence of urinary incontinence in men: results from the national health and nutrition examination survey. *J Urol*. 2010;184:1022–1027.

Milsom I, Coyne K, Nicholson S, et al. Global prevalence and economic burden of urgency urinary incontinence: a systematic review. *Eur Urol*. 2014;65:79–85.

Nygaard I, Barber MD, Burgio KL, et al. Prevalence of symptomatic pelvic floor disorders in US women. *J Am Med Assoc*. 2008;300:1311–1316.

Persu C, Chapple CR, Cauni V, et al. Pelvic Organ Prolapse Quantification System (POP-Q)—a new era in pelvic prolapse staging. *J Med Life*. 2011;4(1):75–81.

Petros PE, Ulmsten UI. An integral theory of female urinary incontinence: experimental and clinical considerations. *Acta Obstet Gynecol Scand Suppl*. 1990;153:7–31.

Swift S, Woodman P, O'Boyle A, et al. Pelvic Organ Support Study (POSST): the distribution, clinical definition, and epidemiologic condition of pelvic organ support defects. *Am J Obstet Gynecol*. 2005;192:795–806.

Wei JT, Nygaard I, Richter HE, et al. A midurethral sling to reduce incontinence after vaginal prolapse repair. *N Engl J Med*. 2012;366(25):2358–2367.

References

Abrams P, Cardozo L, Fall M, et al. Standardisation Sub-committee of the International Continence Society. The standardization of terminology of lower urinary tract dysfunction: report from the Standardisation Sub-committee of the International Continence Society. *Neurourol Urodyn*. 2002;21(2):167–178.

Agarwal A, Eryuzlu LN, Cartwright R, et al. What is the most bothersome lower urinary tract symptom? Individual- and population-level perspectives for both men and women. *Eur Urol*. 2014;65:1211–1217.

Aguilar-Navarro S, Navarrete-Reyes AP, Grados-Chavarria BH, et al. The severity of urinary incontinence decreases health related quality of life among community-dwelling elderly. *J Gerontol A Biol Sci Med Sci*. 2012;67:1266–1271.

Ahlund S, Nordgren B, Wilander EL, et al. Is home-based pelvic floor muscle training effective in treatment of urinary incontinence after birth in primiparous women? a randomized controlled trial. *Acta Obstet Gynecol Scand*. 2013;92:909–915.

Anger JT, Litwin MS, Wang Q, et al. Variations in stress incontinence and prolapse management by surgeon specialty. *J Urol*. 2007;178(4 Pt 1):1411–1417.

Barber MD, Visco AG, Wyman JF, et al. Sexual function in woman with urinary incontinence and pelvic organ prolapse. *Obstet Gynecol*. 2002;99(2):281–289.

Barentsen JA, Visser E, Hofstetter H, et al. Severity, not type, is the main predictor of decreased quality of life in elderly women with urinary incontinence: a population-based study as part of a randomized controlled trial in primary care. *Health Qual Life Outcomes*. 2012;10:153.

Barry C, Dietz HP. The use of ultrasound in the evaluation of pelvic organ prolapse. *Rev Gynaecol Pract*. 2005;5(3):182–195.

Bedretdinova D, Fritel X, Panjo H, et al. Prevalence of female incontinence in the female population according to different defintitions and study designs. *Eur Urol*. 2016;69:256–264.

Berardelli M, De Rango F, Morelli M, et al. Urinary incontinence in the elderly and in the oldest: correlation with frailty and mortality. *Rejuvenation Res*. 2013;16:206–211.

Berger MB, Patel DA, Miller JM, et al. Racial differences in self reported health care seeking and treatment for urinary incontinence in community dwelling women from the EPI study. *Neurourol Urodyn*. 2011;30:1442–1447.

Blaivas JG, Chaikin DC. Pubovaginal fascial sling for the treatment of all types of stress urinary incontinence: surgical technique and long-term outcome. *Urol Clin North Am*. 2011;38:7–15.

Blaivas JG, Olsson CA. Stress incontinence: classification and surgical approach. *J Urol*. 1988;139:429–435.

Bohlin KS, Ankardal M, Lindkvist H, et al. Factors influencing the incidence and remission of urinary incontinence after hysterectomy. *Am J Obstet Gynecol*. 2017;216:53 [e1–9].

Botlero R, Davis SR, Urquhart DM, et al. Incidence and resolution rates of different types of urinary incontinence in women: findings from a cohort study. *J Urol*. 2011;185:1331–1337.

Boyle R, Hay-Smith EJ, Cody JD, et al. Pelvic floor muscle training for prevention and treatment of urinary and faecal incontinence in antenatal and postnatal women. *Cochrane Database Syst Rev*. 2008;(10) [CD007471].

Brown JS, Grady D, Ouslander JG, et al. Prevalence of urinary incontinence and associated risk factors in postmenopausal women. Heart & Estrogen/Progestin Replacement Study

(HERS) Research Group. *Obstet Gynecol*. 2009;84:66–70.

Brown JS, Vittinghoff E, Line F, et al. Prevalence and risk factors for urinary incontinence in women with type 2 diabetes and impaired fasting glucose: findings from the National Health and Nutrition Examination Survey (NHANES) 2001–2002. *Diabetes Care*. 2006;29:1307–1312.

Brubaker L, Chiang S, Zyczynski H, et al. The impact of stress incontinence surgery on female sexual function. *Am J Obstet Gynecol*. 2009;200:562 [E1–E7].

Brubaker L, Cundiff GW, Fine P, et al. Abdominal sacrocolpopexy with Burch colposuspension to reduce urinary stress incontinence. *N Engl J Med*. 2006;354:1557–1566.

Brubaker L, Nygaard I, Richter HE, et al. Two year outcomes after sacrocolpopexy with and without Burch to prevent stress urinary incontinence. *Obstet Gynecol*. 2008;112:49–55.

Brucker BM, Fong E, Kaefer D, et al. Urodynamic findings in women with insensible incontinence. *Int J Urol*. 2013;20:429–433.

Buckley BS, Lapitan MC. Prevalence of urinary incontinence in men, women, and children—current evidence: findings of the fourth International Consultation on Incontinence. [the; Epidemiology Committee of the Fourth International Consultation on Incontinence, Paris 2008] *Urology*. 2010;76:265–279.

Bump RC, Sugerman HJ, Fantl JA, et al. Obesity and lower urinary tract function in women: effect of surgically induced weight loss. *Am J Obstet Gynecol*. 1992;167:397–399.

Bump RC, Mattiasson A, Bø K, et al. The standardization of terminology of female pelvic organ prolapse and pelvic floor dysfunction. *Am J Obstet Gynecol*. 1996;175(1):10–17.

Burge AT, Lee AL, Kein C, et al. Prevalence and impact of urinary incontinence in men with chronic obstructive pulmonary disease: a questionnaire survey. *Physiotherapy*. 2017;103(1):53–58.

Campodonico F, Manuputty EE. Nerve-sparing approach during radical prostatectomy is strongly associated with the rate of postoperative urinary continence recovery. *BJU Int*. 2012;110:E430.

Cardozo LD, Stanton SL. Genuine stress incontinence and detrusor instability—a review of 200 patients. *Br J Obstet Gynaecol*. 1980;87(3):184–190.

Carley ME, Schaffer J. Urinary incontinence and pelvic organ prolapse in women with Marfan or Ehlers-Danlos syndrome. *Am J Obstet Gynecol*. 2000;182(5):1021–1023.

Chapple CR, Helm CW, Blease S, et al. Asymptomatic bladder neck incompetence in nulliporous female. *Br J Urol*. 1989;64:357–359.

Chiaffarino F, Chatenoud L, Dindelli M, et al. Reproductive factors, family history, occupation and risk of urogenital prolapse. *Eur J Obstet Gynecol Reprod Biol*. 1999;82:63–67.

Chong EC, Khan AA, Anger JT. The financial burden of stress urinary incontinence among women in the United States. *Curr Urol Rep*. 2011;12:358–362.

Connolly TJ, Litman HJ, Tennstedt SL, et al. The effect of mode of delivery, parity and birth weight on risk of urinary incontinence. *Int Urogynecol J Pelvic Floor Dysfunct*. 2007;18:1033–1042.

Coyne KS, Kvasz M, Ireland AM, et al. Urinary incontinence and its relationship to mental health and health-related quality of life in men and women in Sweden, the United Kingdom, and the United States. *Eur Urol*. 2012;61:88–95.

Danforth KN, Townsend MK, Lifford K, et al. Risk factors for urinary incontinence among middle aged women. *Am J Obstet Gynecol*. 2006;194:339–345.

Davis NJ, Vaughan CP, Johnson TM, et al. Caffeine intake and its association with urinary incontinence in United States men: results from National Health and Nutrition Examination Surveys 2005–2006 and 2007–2008. *J Urol*. 2013;189:2170–2174.

de Boer TA, Salvatore S, Cardozo L, et al. Pelvic organ prolapse and overactive bladder. *Neurourol Urodyn*. 2010;29:30–39.

de Boer TA, Vierhout ME. Predictors for overactive bladder symptoms after pelvic organ prolapse surgery. *Curr Opin Obstet Gynecol*. 2011;23(5):366–370.

De Gagne JC, So A, Oh J, et al. Sociodemographic and health indicators of older women with urinary incontinence: 2010 national survey of residential care facilities. *J Am Geriatr Soc*. 2013;61:981–986.

DeLancey JO. Structural aspects of the extrinsic continence mechanisms. *Obstet Gynecol*. 1988;72:296–301.

DeLancey JO. Anatomic aspects of vaginal eversion after hysterectomy. *Am J Obstet Gynecol*. 1992;166(6 Pt 1):1717–1724 [discussion 1724–8].

DeLancey JO. Structural support of the urethra as it relates to stress urinary incontinence: the hammock hypothesis. *Am J Obstet Gynecol*. 1994;170:1713–1720.

DeLancey JO. The pathophysiology of stress urinary incontinence and its implications for surgical treatment. *World J Urol*. 1997;15:268–274.

DeLancey JO, Kearney R, Chou Q, et al. The appearance of levator ani muscle abnormalities in magnetic resonance images after vaginal delivery. *Obstet Gynecol*. 2003;101(1):46–53.

DeLancey JO. The hidden epidemic of pelvic floor dysfunction: achievable goals for improved prevention and treatment. *Am J Obstet Gynecol*. 2005;192:1488–1495.

DeLancey JO, Fenner DE, Guire K, et al. Differences in continence system between community-dwelling black and white women with and without urinary incontinence in the EPI study. *Am J Obstet Gynecol*. 2010;202:584 [e1–12].

Devore EE, Townsend MK, Resnick NM, et al. The epidemiology of urinary incontinence in women with type 2 diabetes. *J Urol*. 2012;188:1816–1821.

Dietz HP, Mann KP. What is clinically relevant prolapse? An attempt at defining cutoffs for the clinical assessment of pelvic organ descent. *Int Urogynecol J*. 2014;25:451–455.

Digesu GA, Hendricken C, Fernando R, et al. Do women with pure stress urinary incontinence need urodynamics. *Urology*. 2009;74:278.

Diokno AC, Estanol MV, Ibrahim IA, et al. Prevalence of urinary incontinence in community dwelling men: a cross sectional nationwide epidemiological survey. *Int Urol Nephrol*. 2007;39:129–136.

Doace M, Moradi-Lakeh M, Nourmohammadi A, et al. Management of pelvic organ prolapse and quality of life: a systematic review and meta-analysis. *Int Urogynecol J*. 2014;25:153–163.

Dolan LM, Walsh D, Hamilton S, et al. A study of quality of life in primigravidae with urinary incontinence. *Int Urogynecol J Pelvic Floor Dysfunct*. 2004;15:160–164.

Drake MJ, Fowler CJ, Griffiths D, et al. Neural control of the lower urinary and gastrointestinal tracts: supraspinal CNS mechanisms. *Neurourol Urodyn*. 2010;29:119–127.

Dubbelman Y, Groen J, Wildhagen M, et al. Quantification of changes in detrusor function and pressure-flow parameters after radical prostatectomy: relation to postoperative continence status and the impact of intensity of pelvic floor muscle exercises. *Neurourol Urodyn*. 2012;31:637–641.

Dunivan GC, Anger JT, Alas A, et al. Pelvic organ prolapse: a disease of silence and shame. *Female Pelvic Med Reconstr Surg*. 2014;20(6):322–327.

Dunivan GC, Cichowski SB, Komesu YM, et al. Ethnicity and variations of pelvic organ prolapse bother. *Int Urogynecol J*. 2014;25(1):53–59.

Durnea CM, Khashan AS, Kenny LC, et al. Prevalence, etiology and risk factors of pelvic organ prolapse in premenopausal primiparous women. *Int Urogynecol J*. 2014;25:1463–1470.

Ellerkmann RM, Cundiff GW, Melick CF, et al. Correlation of symptoms with location and severity of pelvic organ prolapse. *Am J Obstet Gynecol*. 2001;185(6):1332–1337 [discussion 1337–8].

Elliott CS, Yeh J, Comiter CV, et al. The predictive value of a cystocele for concomitant vaginal apical prolapse. *J Urol*. 2013;189:200–203.

Enhorning G. Simultaneous recording of the intravesical and intraurethral pressures: a study on urethral closure and stress incontinent women. *Acta Chir Scand*. 1961;276(Suppl):1–68.

Espuna-Pons M, Ros C, Ortega JA, et al. Prevalence, incidence, and remission rates of urinary incontinence in women attended in gynecological practice. [for the; Pelvic Floor Research Group] *Neurourol Urod*. 2017;36(4):1081–1085.

Ficarra V, Novara G, Artibani W, et al. Retropubic, laparoscopic, and robot-assisted radical prostatectomy: a systematic review and cumulative analysis of comparative studies. *Eur Urol*. 2009;55:1037–1063.

Findik RB, Unluer AN, Sahin E, et al. Urinary incontinence in women and its relation with pregnancy, mode of delivery, connective tissue disease and other factors. *Adv Clin Exp Med*. 2012;21:207–213.

Fletcher SG, Haverkorn RM, Yan J, et al. Demographic and urodynamic factors associated with persistent OAB after anterior compartment prolapse repair. *Neurourol Urodyn*. 2010;29(8):1414–1418.

Fritel X, Lachal L, Cassou B, et al. Mobility impairment is associated with urge but not stress urinary incontinence in community dwelling older women: results from the Ossebo study. *BJOG*. 2013;120(12):1566–1572.

Gilchrist AS, Campbell W, Steele H, et al. Outcomes of observation as therapy for pelvic organ prolapse: a study in the natural history of pelvic organ prolapse. *Neurourol Urodyn*. 2013;32:383–386.

Gill BC, Damaser MS, Vasavada SP, et al. Stress incontinence in the era of regenerative medicine: reviewing the importance of the pudendal nerve. *J Urol*. 2013;190:22–28.

Gomelsky A, Lemack GE, Weld KJ, et al. Urodynamic patterns following ischemic spinal cord events. *J Urol*. 2003;170:122–125.

Grodstein F, Fretts R, Lifford K, et al. Association of age, race, and obstetric history with urinary symptoms among women in the Nurses' Health Study. *Am J Obstet Gynecol*. 2003;189:428–434.

Gupta NP, Singh P, Nayyar R. Outcomes of robot-assisted radical prostatectomy in men with previous transurethral resection of the prostate. *BJU Int*. 2011;108:1501–1505.

Gyhagen M, Bullarbo M, Nielsen T, et al. Prevalence of urinary incontinence 20 years after childbirth in a national cohort study of singleton primiparae after vaginal or caesarean delivery. *BJOG*. 2013;120:152–160.

Gyhagen M, Bullarbo M, Nielsen TF, et al. A comparison of the long-term consequences of vaginal delivery versus caesarean section on the prevalence, severity and bothersomeness of urinary incontinence subtypes: a national cohort study in primiparous women. *BJOG*. 2013;120:1548–1555.

Haglind E, Carlsson S, Stranne J, et al. LAPPRO steering committee urinary incontinence and erectile dysfunction after robotic versus open radical prostatectomy: a prospective, controlled, nonrandomised trial. *Eur Urol*. 2015;68(2):216–225.

Handa VL, Garrett E, Hendrix S, et al. Progression and remission of pelvic organ prolapse: a longitudinal study of menopausal women. *Am J Obstet Gynecol*. 2004;190(1):27–32.

Hannestad YS, Rortveit G, Daltveit AK, et al. Are smoking and other lifestyle factors associated with female urinary incontinence? The Norwegian EPINCONT Study. *BJOG*. 2003;110:247–254.

Hansen BB, Svare J, Viktrup L, et al. Urinary incontinence during pregnancy and 1 year after delivery in primiparous women compared with a control group of nulliparous women. *Neurourol Urodyn*. 2012;31:475–480.

Hawkins K, Pernarelli J, Ozminkowski R, et al. The prevalence of urinary incontinence and its burden on the quality of life among older adults with medical supplement insurance. *Qual Life Res*. 2011;20:723–732.

Haylen BT, de Ridder D, Freeman RM, et al. An International Urogynecological Association (IUGA)/International Continence Society (ICS) joint report on the terminology for female pelvic floor dysfunction. *Neurourol Urodyn*. 2010;29:4.

Haylen BT, Maher CF, Barber MD, et al. An International Urogynecological Association (IUGA)/International Continence Society (ICS) joint report on the terminology for female pelvic organ prolapse (POP). *Int Urogynecol J*. 2016;27:165–194.

He W, Sengupta M, Velkoff Va, et al. *US Census Bureau, current population reports, P23-209, 65+ in the United States: 2005*. US Government Printing Office: Washington DC; 2005.

Hendrix SL, Clark A, Nygaard I, et al. Pelvic organ prolapse in the Women's Health Initiative: gravity and gravidity. *Am J Obstet Gynecol*. 2002;186(6):1160–1166.

Hendrix SL, Cochrane BB, Nygaard IE, et al. Effects of estrogen with and without progestin on urinary incontinence. *J Am Med Assoc*. 2005;293:935–948.

Herzog AR, Fultz NH. Epidemiology of urinary incontinence: prevalence, incidence and correlates in community populations. *Urol Suppl*. 1990;36.

Hunskaar S, Ostbye T, Borrie MJ. Prevalence of urinary incontinence in elderly Canadians with special emphasis on the association with dementia, ambulatory function, and institutionalization. *Norwegian J Epidem*. 1998;8:177.

Hunskaar S, Burgio K, Clark A. Epidemiology of urinary (UI) and faecal (FI) incontinence and pelvic organ prolapse (POP). Health Publications: Paris; 2005:255–313. Abrams P, Cardozo L, Khoury S, et al. *Incontinence—basics & evaluation*. vol 1.

Jack GS, Nikolova G, Vilain E, et al. Familial transmission of genitovaginal prolapse. *Int Urogynecol J*. 2006;17(5):498–501.

Jackson ST, Avery NC, Tarlton JF, et al. Changes in metabolism of collagen in genitourinary prolapse. *Lancet*. 1996;347:1658–1661.

Jahanlu D, Hunskaar S. Type and severity of new-onset urinary incontinence in middle-aged women: the Hordaland women's cohort. *Neurourol Urodyn*. 2011;30:87–92.

Jelovsek JE, Barber MD. Women seeking treatment for advanced pelvic organ prolapse have decreased body image and quality of life. *Am J Obstet Gynecol*. 2006;194(5):1455–1461.

Juliato CRT, Baccaro LF, Pedro AO, et al. Factors associated with urinary incontinence in middle-aged women: a population-based household survey. *Int Urogynecol J*.

2017;28:423–429.

Jung SY, Fraser MO, Ozawa H, et al. Urethral afferent nerve activity affects the micturition reflex; implication for the relationship between stress incontinence and detrusor instability. *J Urol*. 1999;162:204–212.

Jura YH, Townsend MK, Curhan GC, et al. Caffeine intake, and the risk of stress, urgency and mixed urinary incontinence. *J Urol*. 2011;185:1775–1780.

Komesu YM, Schrader RM, Ketai LH, et al. Epidemiology of mixed, stress, and urgency urinary incontinence in middle-aged/older women: the importance of incontinence history. *Int Urogynecol J*. 2016;27:763–772.

Koraitim MM. The male urethral sphincter complex revisited: an anatomical concept and its physiological correlate. *J Urol*. 2008;179:1683–1689.

Lemack GE, Szabo Z, Urban Z, et al. Altered bladder function in transgenic mice expressing rat elastin. *Neurourol Urodyn*. 1999;18:55–68.

Lewicky-Gaupp C, Brincat C, Trowbridge ER, et al. Racial differences in bother for women with urinary incontinence in the Establishing the Prevalence of Incontinence (EPI) study. *Am J Obstet Gynecol*. 2009;201:e1–e6.

Liang CC, Wu MP, Lin YJ, et al. Clinical impact of and contributing factors in women 5 years after first delivery. *Int Urogynecol J*. 2013;24:99–104.

Lifford KL, Curhan GC, Hu FB, et al. Type 2 diabetes mellitus and risk of developing urinary incontinence. *J Am Geriatr Soc*. 2005;53:1851–1857.

Lukacz ES, Lawrence JM, Contreras R, et al. Parity, mode of delivery, and pelvic floor disorders. *Obstet Gynecol*. 2006;107(6):1253–1260.

Lykke R, Blaakaer J, Ottesen B, et al. The indication for hysterectomy as a risk factor for subsequent pelvic organ prolapse repair. *Int Urogynecol J*. 2015;26:1661–1665.

MacArthur C, Glazener C, Lancashire R, et al. ProLong study group. Exclusive caesarean section delivery and subsequent urinary and faecal incontinence: a 12-year longitudinal study. *BJOG*. 2011;118:1001–1007.

MacArthur C, Wilson D, Herbison P, et al. Urinary incontinence persisting after childbirth: extent, delivery history, and effects in a 12–year longitudinal cohort study. [on behalf of the; Prolong study group] *BJOG*. 2016;123:1022–1029.

Mant J, Painter R, Vessey M. Epidemiology of genital prolapse: observations from the Oxford Family Planning Association Study. *Br J Obstet Gynaecol*. 1997;104(5):579–585.

Markland AD, Goode PS, Redded DT, et al. Prevalence of urinary incontinence in men: results from the national health and nutrition examination survey. *J Urol*. 2010;184:1022–1027.

Maserejian NN, Minassian VA, Chen S, et al. Treatment status and risk factors for incidence and persistence of urinary incontinence in women. *Int Urogynecol J*. 2014;25:775–782.

McGrother CW, Donaldson MM, Shaw C, et al. Storage symptoms of the bladder: prevalence, incidence and need for services in the UK. *BJU Int*. 2004;93:763–769.

McGuire EJ, Cespedes RD, O'Connell HE. Leak-point pressures. *Urol Clin North Am*. 1996;23:253–263.

McGuire EJ, Lytton B. Pubovaginal sling procedure for stress incontinence. *J Urol*. 1978;119:82–84.

Melville JL, Katon W, Delaney K, et al. Urinary incontinence in US women. *Arch Intern Med*. 2005;537–542.

Mengerink BB, Van Leijsen SA, Vierhout Me, et al. The impact of midurethral sling surgery on sexual activity and function in women with stress urinary incontinence. *J Sex Med*. 2016;13(10):1498–1507.

Miller DC, Saigal CS, Litwin MS. The demographic burden of urologic disease in America. *Urol Clin North Am*. 2009;36:11.

Milsom I, Coyne K, Nicholson S, et al. Global prevalence and economic burden of urgency urinary incontinence: a systematic review. *Eur Urol*. 2014;65:79–85.

Mishra GD, Cardozo L, Kuh D. Menopausal transition and the risk of urinary incontinence: results from a British prospective cohort. *BJU Int*. 2010;106:1170–1175.

Moalli PA, Jones Ivy S, Meyn LA, et al. Risk factors associated with pelvic floor disorders in women undergoing surgical repair. *Obstet Gynecol*. 2003;101(5 Pt 1):869–874.

Moalli PA, Shand SH, Zyczynski HM, et al. Remodeling of vaginal connective tissue in patients with prolapse. *Obstet Gynecol*. 2005;106:953–963.

Mondet F, Sebe P, Sebille A, et al. Organization and innervation of striated muscle fibers of the striated sphincter in the rat. *Prog Urol*. 2003;13:629–635.

Mostwin JL, Yang A, Sanders R, et al. Radiography, sonography and magnetic resonance imaging for stress incontinence: contributions, uses, and limitations. *Urol Clin North Am*. 1995;22:539–549.

Nilsson M, Lalos A, Lalos O. The impact of female urinary incontinence and urgency on quality of life and partner relationship. *Neurourol Urodyn*. 2009;28:976–981.

Norton P, Brubaker L, Nager CW, et al. Pelvic organ prolapse in a cohort of women treated for stress urinary incontinence. *Am J Obstet Gynecol*. 2014;211:550 [e1–5].

Nygaard I, Bradley C, Brandt D. Pelvic organ prolapse in older women: prevalence and risk factors. *Obstet Gynecol*. 2004;104(3):489–497.

Nygaard I, Barber MD, Burgio KL, et al. Prevalence of symptomatic pelvic floor disorders in US women. *J Am Med Assoc*. 2008;300:1311–1316.

O'Halloran T, Bell RJ, Robinson PJ, et al. Urinary incontinence in young nulligravid women: a cross-sectional analysis. *Ann Intern Med*. 2012;157:87–93.

Olsen AL, Smith VJ, Bergstrom JO, et al. Epidemiology of surgically managed pelvic organ prolapse and urinary incontinence. *Obstet Gynecol*. 1997;89(4):501–506.

Onukwugha E, Zuckerman IH, McNally D, et al. The total economic burden of overactive bladder in the United States: a disease-specific approach. *Am J Manag Care*. 2009;15(Suppl 4):S90–S97.

Ouslander JG, Kane RL, Abrass IB. Urinary incontinence in elderly nursing home patients. *J Am Med Assoc*. 1982;248:1194–1198.

Özel B, White T, Urwitz-Lane R, et al. The impact of pelvic organ prolapse on sexual function in women with urinary incontinence. *Int Urogynecol J*. 2005;17(1):14–17.

Pedersen SL, Lose G, Hoybe MT, et al. Prevalence of urinary incontinence among women and analysis of potential risk factors in Germany and Denmark. *Acta Obstet Gynecol Scand*. 2017;96:939–948.

Persu C, Chapple CR, Cauni V, et al. Pelvic Organ Prolapse Quantification System (POP-Q)—a new era in pelvic prolapse staging. *J Med Life*. 2011;4(1):75–81.

Petros PE, Skilling PM. Pelvic floor rehabilitation in the female according to the integral theory of female urinary incontinence: first report. *Eur J Obstet Gynecol Reprod Biol*. 2001;94:264–269.

Petros PE, Ulmsten UI. An integral theory of female urinary incontinence: experimental and clinical considerations. *Acta Obstet Gynecol Scand Suppl*. 1990;153:7–31.

Petros PE, Woodman PJ. The integral theory of continence. *Int Urogynecol J Pelvic Floor Dysfunct*. 2008;19:35–40.

Phelan S, Grodstein F, Brown JS. Clinical research in diabetes and urinary incontinence: what we know and need to know. *J Urol*. 2009;182(Suppl 6):S14–S17.

Phelan S, Kanaya AM, Subak LL, et al. Prevalence and risk factors for urinary incontinence in overweight and obese diabetic women: action for health in diabetes (look ahead) study. *Diabetes Care*. 2009;32:1391–1397.

Porpligia F, Morra I, Chiarissi ML, et al. Randomised controlled trial comparing laparoscopic and robot-assisted radical prostatectomy. *Eur Urol*. 2013;63:606–614.

Rao SS. Advances in diagnostic assessment of fecal incontinence and dyssynergic defecation. *Clin Gastroentoerol Hepatol*. 2010;8(11):910–919.

Raz S, Caine M, Zeigler M. The vascular component in the production of intraurethral pressure. *J Urol*. 1972;108:93–96.

Renata B, Reigota RB, Pedro AO, et al. Prevalence of urinary incontinence and its association with multimorbidity in women aged 50 years or older: a population-based study. *Neurourol Urod*. 2016;35:62–68.

Richardson AC, Edmonds PB, Williams NL. Treatment of stress urinary incontinence due to paravaginal fascial defect. *Obstet Gynecol*. 1981;57(3):357–362.

Richter HE, Burgio KL, Brubaker L, et al. Urinary incontinence treatment network. Factors associated with incontinence frequency in a surgical cohort of stress incontinent women. *Am J Obstet Gynecol*. 2005;193:2088–2093.

Rooney K, Kenton K, Mueller ER, et al. Advanced anterior vaginal wall prolapse is highly correlated with apical prolapse. *Am J Obstet Gynecol*. 2006;195(6):1837–1840.

Rortveit G, Hannestad YS, Daltveit AK, et al. Age and type-dependent effects of parity on urinary incontinence: the Norwegian EPINCONT study. *Obstet Gynecol*. 2001;98:1004–1010.

Rortveit G, Brown JS, Thom DH, et al. Symptomatic pelvic organ prolapse: prevalence and risk factors in a population-based, racially diverse cohort. *Obstet Gynecol*. 2007;109(6):1396–1403.

Rosier PFWM, Kuo H-C, Gennaro MD, et al. *Urodynamic testing in incontinence*. [In: International Consultation on Incontinence] 2013:2431–2506.

Sajadi KP, Lin DL, Steward JE, et al. Pudendal nerve stretch reduces external urethral sphincter activity in rats. *J Urol*. 2012;188:1389–1395.

Samuelsson EC, Victor FT, Tibblin G, et al. Signs of genital prolapse in a Swedish population of women 20 to 59 years of age and possible related factors. *Am J Obstet Gynecol*. 1999;180(2 Pt 1):299–305.

Sangsawang B. Risk factors for the development of stress urinary incontinence during pregnancy in primigravidae: a review of the literature. *Eur J Obstet Gynecol Reprod Biol*. 2014;178:27–34.

Sarma AV, Kanaya AM, Nyberg LM, et al. Diabetes control and complications trial/epidemiology of diabetes interventions and complications research group. *J Urol*. 2009;181:1224–1230.

Saxer S, Halfens RJ, De Bie RA, et al. Prevalence and incidence of urinary incontinence of Swiss nursing home residents at admission and after six, 12 and 24 months. *J Clin Nurs*. 2008;17:2490–2496.

Schwalenberg T, Neuhaus J, Dartsch M, et al. Funktionelle Anatomie des mannlichen Kontinenzmechanismus. *Urologe*. 2010;49:472–480.

Sgadari A, Topinkova E, Bjornson J, et al. Urinary incontinence in nursing home residents: a cross-national comparison. *Age Ageing*. 1997;26(Suppl 2):49–54.

Singh K, Jakab M, Reid W, et al. Three-dimensional magnetic resonance imaging assessment of levator ani morphologic features in different grades of prolapse. *Am J Obstet Gynecol*. 2003;188(4):910–915.

Sims J, Browning C, Lundgren-Lindquist B, et al. Urinary incontinence in a community sample of older adults: prevalence and impact on quality of life. *Disabil Rehabil*. 2011;33:1389–1398.

Slieker-ten Hove MC, Pool-Goudzwaard AL, Eijkemans MJ, et al. Symptomatic pelvic organ prolapse and possible risk factors in a general population. *Am J Obstet Gynecol*. 2009;200(2):184 [e1–7].

Smith FJ, Holman CD, Moorin RE, et al. Lifetime risk of undergoing surgery for pelvic organ prolapse. *Obstet Gynecol*. 2010;116:1096–1100.

Song C, Lee J, Hong JH, et al. Urodynamic interpretation of changing bladder function and voiding pattern after radical prostatectomy: a long-term follow-up. *BJU Int*. 2010;106:681–686.

Srivastava A, Chopra S, Pham A, et al. Effect of a risk-stratified grade of nerve-sparing technique on early return of continence after robot-assisted laparoscopic radical prostatectomy. *Eur Urol*. 2013;63:438–444.

Stafne SN, Salvesen KA, Romundstad PR, et al. Does regular exercise including pelvic floor muscle training prevent urinary and anal incontinence during pregnancy? a randomised controlled trial. *BJOG*. 2012;119:1270–1280.

Subak LL, Waetjen LE, van den Eeden S, et al. Cost of pelvic organ prolapse surgery in the United States. *Obstet Gynecol*. 2001;98(4):646–651.

Subak LL, Brown JS, Kraus SR, et al. Diagnostic Aspects of Incontinence Study Group. The “costs” of urinary incontinence for women. *Obstet Gynecol*. 2006;107:908–916.

Subak LL, Goode PS, Brubaker L, et al. Urinary incontinence management costs are reduced following Burch or sling surgery for stress incontinence. [for the; Urinary Incontinence Treatment Network] *Am J Obstet Gynecol*. 2014;211:171 [e1–e7].

Svihrova V, Svihra J, Luptak J, et al. Disability-adjusted life years (DALYs) in general population with pelvic organ prolapse: a study based on the prolapse quality-of-life questionnaire (P-QOL). *Eur J Obstet Gynecol Reprod Biol*. 2014;182:22–26.

Swift SE, Tate SB, Nicholas J, et al. Correlation of symptoms with degree of pelvic organ support in a general population of women: what is pelvic organ prolapse? *Am J Obstet Gynecol*. 2003;189(2):372–377.

Swift S, Woodman P, O'Boyle A, et al. Pelvic Organ Support Study (POSST): the distribution, clinical definition, and epidemiologic condition of pelvic organ support defects. *Am J Obstet Gynecol*. 2005;192:795–806.

Swift S, Morris S, McKinnie V, et al. Validation of a simplified technique for using the POPQ pelvic organ prolapse classification system. *Int Urogynecol J*. 2006;17:615–620.

Tahtinen RM, Auvinen A, Cartwright R, et al. Smoking and bladder symptoms in women. *Obstet Gynecol*. 2011;118:643–648.

Tak EC, van Hespen A, van Dommelen P, et al. Does improved functional performance help to reduce urinary incontinence in institutionalized older women? a multicenter randomized clinical trial. *BMC Geriatr*. 2012;12:51.

Takahashi T, Yamana T, Sahara R, et al. Enterocele: what is the clinical implication? *Dis Colon Rectum*. 2006;49(10 Suppl):S75–S81.

Tan JS, Lukacz ES, Menefee SA, et al. Predictive value of prolapse symptoms: a large database study. *Int Urogynecol J Pelvic Floor Dysfunct*. 2005;16(3):203–209 [discussion 209].

ter Meulen PH, Berghmans LC, Nieman FH, et al. Effects of

Macroplastique Implantation System for stress urinary incontinence and urethral hypermobility in women. *Int Urogynecol J*. 2009;20:177–183.

Thom DH, Brown JS, Schembri M, et al. Parturition events and risk of urinary incontinence in later life. *Neurourol Urodyn*. 2011;30:1456–1461.

Thom DH, Haan MN, Van Den Eeden SK. Medically recognized urinary incontinence and risks of hospitalization, nursing home admission and mortality. *Age Ageing*. 1997;26:367–374.

Thom DH, Brown JS, Schembri M, et al. Incidence of and risk factors for change in urinary incontinence status in a prospective cohort of middle-aged and older women: the reproductive risk of incontinence study in Kaiser. *J Urol*. 2010;184:1394–1401.

Townsend MK, Curhan GC, Resnick NM, et al. The incidence of urinary incontinence across Asian, black, and white women in the United States. *Am J Obstet Gynecol*. 2010;202(378):e1–e7.

Townsend MK, Curhan GC, Resnick NM, et al. Original research: rates of remission, improvement, and progression of urinary incontinence in Asian, black, and white women. *Am J Nurs*. 2011;111:26–33.

Troko J, Bach F, Toozs-Hobson P. Predicting urinary incontinence in women in later life: a systematic review. *Maturitas*. 2016;94:100–116.

Trutnovsky G, Kamisan Atan I, Martin A, et al. Delivery mode and pelvic organ prolapse: a retrospective observational study. *BJOG*. 2016;123:1551–1556.

Vaughan CP, Johnson TM 2nd, Goode PS, et al. Military exposure and urinary incontinence among American men. *J Urol*. 2014;191(1):125–129.

Vergeldt TF, Weemhoff M, IntHout J, et al. Risk factors for pelvic organ prolapse and its recurrence: a systematic review. *Int Urogynecol J*. 2015;26:1559–1573.

Versi E, Cardozo DL, Studd JW. Distal urethral compensatory mechanisms in women with an incompetent bladder neck who remain continent after the menopause. *Neurourol Urodyn*. 1990;9:579–590.

Visco AG, Brubaker L, Nygaard I, et al. The role of preoperative urodynamic testing in stress-continent women undergoing sacrocolpopexy: the Colpopexy and Urinary Reduction Efforts (CARE) randomized surgical trial. *Int Urogynecol J*. 2008;19:607–614.

Vissers D, Neels H, Vermandel A, et al. The effect of non surgical weight loss interventions on urinary incontinence in overweight women: a systematic review and meta-analysis. *Obes Rev*. 2014;15:610–617.

Waetjen LE, Lian S, Johnson WO, et al. Factors associated with prevalent and incident urinary incontinence in a cohort of midlife women: a longitudinal analysis of data: study of women's health across the nation. *Am J Epidemiol*. 2007;165:309–318.

Wallner LP, Porten S, Meenan R, et al. Prevalence and severity of undiagnosed urinary incontinence in women. *Am J Med*. 2009;122:1037–1042.

Wei JT, Nygaard I, Richter HE, et al. A midurethral sling to reduce incontinence after vaginal prolapse repair. *N Engl J Med*. 2012;366(25):2358–2367.

Weidner AC, Jamison MG, Branham V, et al. Neuropathic injury to the levator ani occurs in 1 in 4 primiparous women. *Am J Obstet Gynecol*. 2006;195(6):1851–1856.

Wesnes SL, Hunskaar S, Bo K, et al. Urinary incontinence and weight change during pregnancy and postpartum: a cohort study. *Am J Epidemiol*. 2010;172:1034–1044.

Wilcox LS, Koonin LM, Pokras R, et al. Hysterectomy in the

United States, 1988–1990. *Obstet Gynecol*. 1994;83(4):549–555.

Winters JC, Dmochowski RR, Goldman HB, et al. Urodynamic studies in adults: AUA/SUFU guideline. *J Urol*. 2012;188:2464–2472.

Wu JM, Hundley AF, Fulton RG, et al. Forecasting the prevalence of pelvic floor disorders in US women: 2010 to 2050. *Obstet Gynecol*. 2009;114:1278–1283.

Wu JM, Kawasaki A, Hundley AF, et al. Predicting the number of women who will undergo incontinence and prolapse surgery, 2010 to 2050. *Am J Obstet Gynecol*. 2011;205(3):230 [e1–5].

Wu JM, Vaughan CP, Goode PS, et al. Prevalence and trends of symptomatic pelvic floor disorders in U.S. women. *Obstet Gynecol*. 2014;123:141–148.

Neuromuscular Dysfunction of the Lower Urinary Tract

Casey G. Kowalik MD, Alan J. Wein MD, PhD (Hon), FACS, Roger R. Dmochowski MD, MMHC, FACS

Objectives

The first part of this chapter is a summary of the abnormalities of the micturition cycle produced by different types of neuromuscular disease, injury, or dysfunction. The background material for the central and peripheral factors involved in the pathophysiology and pharmacology of lower urinary tract (LUT) function are discussed in Chapter 111. An understanding of the physiology and pharmacology of normal urinary storage and emptying, as well as the patterns and location of neuropathic insults, will usually, but not always, enable clinicians to easily infer the associated lower tract dysfunction. The second part of the chapter summarizes secondary factors that can modify the type of observed LUT dysfunction. These secondary factors are important to consider because they cause persistence of storage and voiding abnormalities, even after the initial precipitating factors have resolved or have been corrected. The third part of the chapter describes in detail the specific types of LUT dysfunction that occur secondary to the most common categories of neuromuscular disease, injury, or dysfunction. Ideally, in any such discussion, the expected states of the following urodynamic parameters should be described (see Chapter 115 for specific definitions of terms) (Abrams et al., 2003):

- Sensation (normal, absent, impaired)
- Detrusor activity (normal, overactive, areflexic, impaired contractility)
- Detrusor compliance (normal, decreased, increased)
- Smooth sphincter activity (synergic, dyssynergic)
- Striated sphincter activity (synergic, dyssynergic, bradykinetic, impaired voluntary control, fixed tone)

Table 116.1 is a summary of many of these dysfunctions, grouped by the status of the aforementioned urodynamic parameters and the most common type of abnormal pattern resulting from a given disease or injury. This abbreviated classification is not meant to be all-inclusive but to simply indicate that, for the most part, an individual with a specific neurologic abnormality and subsequent LUT dysfunction will typically have the type of dysfunction listed.

TABLE 116.1

Most Common Patterns of Voiding Dysfunction Seen With Various Types of Neurologic Disease or Injury[a]

DISORDER	DETRUSOR ACTIVITY	COMPLIANCE	SMOOTH SPHINCTER	STRIATED SPHINCTER	OT
Cerebrovascular accident	Ov	N	S	S	Th de se lo tra
			±VC		
Brain tumor	Ov	N	S	S	Th de se lo tra
Cerebral palsy	Ov	N	S	S	
				D (25% of those with detrusor overactivity) ±VC	
Parkinson disease	Ov I	N	S	S Bradykinesia	
Multiple system atrophy	Ov I	N ↓	Op	S	St sp ex de
Multiple sclerosis	Ov	N	S	S D (30%–65%)	Dy fi pe th de ac
Spinal cord injury					
Suprasacral	Ov	N	S	D	Sm sp be if

					ab
Sacral	A	N ↓ (may develop)	CNR Op (may develop)	F	
Autonomic hyperreflexia	Ov	N	D	D	
Myelodysplasia	A	N O	Op ↓ (may develop)	F	Fir wi dif ser sp co sh evi de
Tabes, pernicious anemia	I A	N ↑	S	S	Pri pro of De be de se ov
Disk disease	A	N	CNR	S	Str sp sh of an
Radical pelvic surgery	I A	↓ N	Op	F	
Diabetes	I A Ov	N ↑	S	S	Se co but mo ne we

[a] See chapter content for percentages of patients with dysfunction.

Compliance: *N,* normal; ↓, decreased; ↑, increased.

Detrusor activity: *A,* areflexia; *I,* impaired; *Ov,* overactive.

Smooth sphincter: *CNR,* competent, nonrelaxing; *D,* dyssynergic; *Op,* open, incompetent at rest; *S,* synergic.

Striated sphincter: *D,* dyssynergic; *F,* fixed tone; *S,* synergic; ±*VC,* voluntary control may be impaired.

The chapter concludes with a general consideration of the principles that should guide the selection of therapeutic interventions for the types of neuromuscular dysfunctions considered. Other chapters cover in detail the individual therapies and their potential consequences, as well as the types of LUT dysfunction in the pediatric age group and their management.

Patterns of Neuropathic Voiding Dysfunction

In general, discrete neurologic lesions affect the filling and storage and the emptying and voiding phases of LUT function in a relatively consistent manner. This nature of the impact is dependent on (1) the area(s) of the nervous system affected; (2) the physiologic function(s) and the contents and location of the area(s) affected; and (3) whether the lesion or process is destructive, inflammatory, or irritative. The acute dysfunction produced may, for a variety of reasons, be different from the chronic one.

Neuroplasticity

As it relates to the nervous system and the structures it innervates, ***plasticity*** **is the inherent capacity to undergo structural and functional modification.** These induced changes can be reflected on a number of levels: structural, metabolic, and neurologic. In addition, the neurologic changes can then be reflected on a number of levels: morphologic, neurochemical, electrical, and organizational. Each of these changes can be studied at a variety of different levels, from investigation of the end product (e.g., the clinical manifestations) to exploration of the initial molecular correlates and the factors that induce or affect them. The chronic clinical manifestations that we associate with a particular voiding dysfunction may be the ultimate results of the phenomena that fall under the rubric “plasticity.” Up to a certain point the changes may be reversible, but after a certain point they may not be. Thus **plasticity may account for the persistence of clinical symptoms after the initial stimulus.**

Perhaps the most obvious changes that occur as a result of plasticity are (1) chronic changes in neural organization of the micturition reflex that occur after complete spinal cord transection above the cord level of S2 and (2) the changes in peripheral neural organization that occur after damage to or transection of the peripheral parasympathetic innervation of the LUT. Specific details are contained in the relevant sections of this chapter.

Perhaps the less obvious results of plasticity are many of the changes that occur subsequent to bladder outlet obstruction. The most obvious changes that occur are those related to muscle and collagen content. However, these are initiated by molecular events that ultimately cause increased contractile protein synthesis and hypertrophic bladder tissue growth (Levin et al., 1995). The initial stimulus may be stretch from overdistention (Cheng et al., 1999) or ischemia, likewise from distention (Chen et al., 1996). Compensation of the bladder smooth muscle cells to initially overcome the increased demand associated with obstruction is associated with alterations in the expression and function of many proteins involved in excitation-contraction coupling and active force generation of bladder smooth muscle (Chacko et al., 1999). Although urodynamic studies reflect obstruction, satisfactory emptying is usually preserved. Changes in the composition of the extracellular matrix occur as well, presumably also caused by an initial stretch stimulus. The ratio of type III collagen to type I collagen increases, and the localization of type III collagen changes as well (within some muscle bundles as well as around them) (Macarak and Howard, 1999). The increase in connective tissue could be related to an increase in certain growth factors emanating from the smooth muscle or to a decrease in the activity of certain metabolic pathways contributing to the breakdown of various forms of collagen (Borer et al., 1999). Ischemia, which can be caused by obstruction or by atherosclerosis, has also been hypothesized to contribute to remodeling of the extracellular matrix and fibrosis (Azadzoi et al., 1999; Mostwin et al., 2005).

Bladder outlet obstruction has a suggested association with partial denervation because of damage to the intrinsic innervation of the bladder smooth muscle from a combination of pressure and ischemia (Mostwin et al., 2005; Turner and Brading, 1997). With all of these potential adverse changes occurring, it seems almost miraculous that the bladder is able to maintain its function, but it does for variable periods of time under different circumstances. However, there does come a point at which the ability to fill and store and empty is adversely affected, but not necessarily to the same extent. Filling and storage changes seem related primarily to (1) changes in the extracellular matrix, leading to decreased compliance, and (2) the appearance of phasic bladder overactivity. This overactivity could be myogenic (caused by partial denervation [Turner and Brading, 1997]), or it could be neurogenic and related to another facet of plasticity. Afferent neuroplasticity mediated by nerve growth factors (NGFs) occurs experimentally in response to bladder outlet obstruction, a phenomenon that is inhibited by autoimmunization against NGF (Steers et al., 1996). The ability to empty can be adversely affected by factors related to neurogenic or myogenic mechanisms. The myogenic mechanisms could include a reversal of the compensatory changes that initially occur (see Chacko et al., 1999) or a breakdown of the structure and function of the proteins that enable the smooth muscle cells to take up, store, and release calcium, affecting the calcium activation of the contractile apparatus (Chacko et al., 1999; Zderic et al., 1998).

Furthermore, these neurogenic changes associated with outflow obstruction may alter the neurotransmitter milieu of the LUT. In a model of fetal sheep bladder outlet obstruction, ligation of the urachus at mid-gestation in fetal sheep for 1 month resulted in a shifting of muscarinic, purinergic, and nitrergic mechanisms normally present during fetal development and growth. With outflow obstruction, bladder hypocontractility was induced and contractile forces decreased during stimulated conditions, consistent with denervation and the possibility of atropine resistance. Normal urothelial exerted negative ionotropic effects (nitric oxide mediated) were also lost after obstruction. In addition, loss of compliance resulted in reduced elasticity in the obstructed bladders, consistent with denervation (Thiruchelvam et al., 2003). At this time, certain precipitating factors for the initiation of LUT dysfunction cannot be reversed, such as spinal cord transection and peripheral nerve injury. Therefore the fact that the changes that result from the neuroplasticity induced by these insults are permanent is not surprising. However, **there are instances in which the initiating "cause" of a particular voiding dysfunction can be removed and yet the symptoms do not entirely disappear. This may be another instance in which neuroplasticity is a major factor.** For instance, irritative lower urinary tract symptoms (LUTS) fail to disappear in a certain percentage of patients with outlet obstruction who undergo surgical correction. Chai et al. (1998) found an increased incidence of a positive ice-water test result in patients with bladder outlet obstruction, indicating the presence of a primitive reflex circuitry capable of mediating an abnormal micturition reflex. Because the ice-water test is mediated by C-afferent fibers, the findings support the hypothesis that bladder outlet obstruction is associated with afferent neuroplasticity, detectable in this case by ice-water cystometry. Furthermore, persistence of this afferent neural plasticity after relief of the obstruction could account for at least a proportion of the symptomatic treatment failures after urodynamically successful outlet reduction. A bladder outlet obstruction animal model demonstrated normalization of bladder function and gene expression profiles after de-obstruction in those animals who had detrusor overactivity before de-obstruction (Lee et al., 2017b). Specifically, de-obstructed rats with detrusor overactivity and bladder outlet obstruction had lower expression levels of cyclin-dependent kinase inhibitor 1A, zinc finger protein 162, and vascular endothelial growth factor A (more closely resembling a normal bladder) than those rats without detrusor overactivity and bladder outlet obstruction. These data suggest that detrusor overactivity in response to bladder outlet obstruction not only may be an adaptive process to ensure bladder emptying but also exhibits the plasticity of the bladder to diseased and treated states.

Vizzard (1999, 2000a, 2000b, 2000c, 2000d) and Qiao and Vizzard (2004) have written prolifically about various aspects of neuroplasticity, specifically on the occurrence and potential role of such changes in altered LUT dysfunction after spinal cord injury (SCI) and irritant-induced cystitis. Changes in spinal cord protein expression from bladder neurotrophic factors transported retrograde could play a role in the neurochemical, electrophysiologic, and organizational properties of the LUT seen in both of these conditions and could account, in the latter case, for persistence of symptomatic and/or urodynamic abnormalities after the irritating stimulus has been removed (e.g., in patients with interstitial cystitis).

Diseases at or Above the Brainstem

Cerebrovascular Disease

Cerebrovascular Accident (Stroke)

Cerebrovascular accident (CVA) is a common cause of death and one of the most common causes of disability in the world. CVA is the most devastating manifestation of cerebrovascular disease, with an **annual incidence in the United States that has been cited as more than 795,000** (https://www.cdc.gov/stroke) **and 15 million worldwide** (www.strokecenter.org). The prevalence of stroke in persons older than 65 years has been cited as approximately 60 in 1000, and in persons 75 years of age and older, 95 per 1000 (Khan et al., 1990; Public health and aging, 2003). Wyndaele et al. (2005, 2009) estimated that 1 in 200 individuals will sustain a CVA. Although CVA is the fifth leading cause of death in the United States (https://www.cdc.gov/stroke), approximately 75% of stroke victims survive (Addo et al., 2012), often with post-stroke sequelae, such as impaired mobility, changes in cognitive function, and urinary urgency, frequency, and incontinence.

Thrombosis, occlusion, and hemorrhage are the most common causes of stroke leading to ischemia and infarction of variably sized areas in the brain, usually around the internal capsule, but with the potential to affect areas responsible for coordinated voiding. Strokes most commonly affect the elderly; therefore the presentation and management of these patients are more complex because of preexistent LUT pathology and other comorbidities that may affect the LUT. Although the urinary symptoms may have been manageable before the CVA, they may become significantly worse afterward. Also, other deficits after CVA can affect general rehabilitation and control of the LUT dysfunction. These may include cognitive impairment, dysphasia, inappropriate and aggressive behavior, impaired mobility, and low motivation, complicating management of the urinary symptoms.

The exact acute and chronic incidence of any voiding dysfunction after CVA is difficult to determine, but **the cited prevalence of urinary incontinence ranges from 32% to 79% on hospital admission for CVA, 25% to 28% on discharge, and 12% to 19% several months** later (Brittain et al., 1998). Fowler (1999) cited studies showing that the presence of urinary incontinence within 7 days of a stroke is a more powerful prognostic indicator for poor survival and functional dependence than a depressed level of consciousness. Gariballa (2003) found that urinary incontinence at admission had a hazard ratio of 2.8 as a predictor of death from CVA at 3 months. Stroke patients who were incontinent had an increased risk of infectious complications and were malnourished, possible confounders of the increased death risk. Patel et al. (2001) reported that urinary incontinence was associated with age older than 75 years, dysphagia, visual field defect, and motor weakness.

Certain specific types of strokes also appear to be associated with unusual forms of incontinence. Lenticulocapsular strokes have been noted to be associated with incontinence. Fifty-two percent of patients with strokes in this area of the brain demonstrated post-stroke emotional incontinence, which was not related to other aspects of stroke or gender (Kim, 2002). The prevalence of urinary and fecal incontinence after hemispheric vascular accident has ranged from 21% to 56% in earlier studies. Urinary incontinence associated with fecal incontinence is the most prevalent condition on admission to rehabilitation units after a vascular event, being prevalent in approximately 33% of patients. Isolated urinary incontinence follows at a rate of 12% and finally isolated fecal incontinence with 8%. The most prevalent form of urinary incontinence is impaired awareness (insensate or delayed awareness of voiding events), occurring in 12% to 58% of individuals, as compared with pure urge, which occurs in 9% to 42%. This impaired awareness incontinence is a more significant negative prognostic indicator for resolution of symptoms as compared with patients who retain the sensation of urgency (Kovindha et al., 2010; McKenzie and Badlani, 2012).

After an acute CVA, urinary retention from detrusor areflexia often occurs because of “cerebral shock”; however, the neurophysiology of this “cerebral shock” is unclear. After a variable degree of recovery from the neurologic insult, a fixed deficit may become apparent over a few weeks or months. **The most common LUT dysfunction after CVA is phasic detrusor overactivity** (Fowler, 1999; Khan et al., 1990; Wein and Barrett, 1988; Wyndaele et al., 2005). Recall that detrusor overactivity is the urodynamic observation of an involuntary detrusor contraction during filling. **Sensation is variable but most typically intact, and thus the patient experiences urinary urgency and frequency with detrusor overactivity. In response to the detrusor overactivity, the patient may try to voluntarily and forcefully contract the striated sphincter to prevent leakage. If this can be accomplished, only urgency and frequency result; if not, then urge urinary**

incontinence occurs.

In addition, the LUT dysfunction may be significantly and adversely affected by treatment regimens that concentrate on detrusor overactivity alone (e.g., anticholinergic or antispasmodic therapy). Vigorous pharmacologic therapy of detrusor overactivity with agents that cross the blood-brain barrier and inhibit M_1 muscarinic receptors may worsen preexisting confusion, disorientation, and other problems of mentation in these patients.

In a nationwide Danish assessment of patients after an acute stroke, at 1 month after the stroke, patients were asked to assess the severity of their urinary symptoms as well as bother related to each symptom. A total of 482 eligible patients were assessed; 94% of patients had had at least one urinary symptom in the prior 2 weeks, with nocturia being the most frequent (76%), followed by urgency (70%) and urinary daytime frequency (59%). Urgency was the symptom associated with the most bother, followed by nocturia and finally frequency. If a patient had at least one symptom, bother was at least 78%. Bother caused by urinary symptoms was associated with severity of lower extremity paresis, as well as use of analgesics. The overall conclusion was that LUTS were highly prevalent and also had significant impact on overall bother in this population (Tibaek et al., 2008).

Previous descriptions of LUT dysfunction patterns after CVA have overwhelmingly cited detrusor overactivity with coordinated striated and smooth sphincter activity (Drake et al., 2013; Kolominsky-Rabas et al., 2003; Wyndaele et al., 2005). **It is difficult to reconcile this with the relatively high rates of urinary incontinence in these patients, despite the probability that a percentage of these patients already had an incontinence problem before the CVA.** Tsuchida et al. (1983) and Khan et al. (1990) made early significant contributions in this area by correlating the urodynamic and computed tomographic (CT) pictures after CVA. They concluded that patients with lesions in only the basal ganglia or thalamus have normal sphincter function. This indicates that these patients could voluntarily contract the striated sphincter and abort or minimize the effect of an abnormal micturition reflex when an impending involuntary contraction was sensed. Most patients with involvement of the cerebral cortex, internal capsule, or both were unable to forcefully contract the striated sphincter under these circumstances. Although the authors and others have called this problem “uninhibited relaxation of the sphincter” (Marinkovic and Badlani, 2001), this term is a misnomer. In actuality, the term implies that a profound abnormality exists in the cerebral to corticospinal circuitry that is necessary for voluntary control of the striated sphincter. In an assessment of 192 stroke patients, of whom 69 had undergone urodynamic evaluation, minor urodynamic differences were noted among patients with strokes in the dominant versus nondominant hemisphere versus bilateral hemispheric strokes. Of the dominant hemispheric stroke patients, 64.2% demonstrated detrusor overactivity; detrusor underactivity was present in 35% of the patients. In contradistinction, nondominant hemispheric stroke resulted in detrusor overactivity in 66% of patients and detrusor underactivity in 33%, whereas of bilateral stroke patients, 60% demonstrated detrusor overactivity and 40% detrusor underactivity. Therefore no significant difference was noted between location of stroke and urodynamic findings (Kim et al., 2010).

Thus there are two possible mechanisms for the incontinence associated with involuntary bladder contractions in patients who have sustained a CVA: (1) impaired striated sphincter control and (2) lack of appreciation of bladder filling and impending bladder contraction. In general, the smooth sphincter is unaffected after CVA and remains synergic. Some authors describe striated sphincter dyssynergia in 5% to 21% of patients who manifest brain disease and voiding dysfunction (Sakakibara et al., 1999); however, this appears to be incompatible with accepted neural circuitry. **True detrusor striated sphincter dyssynergia does not occur in this situation, although pseudodyssynergia has been found to occur** during urodynamic testing of these patients (Wein and Barrett, 1982). This finding refers to an electromyographic sphincter “flare” during filling cystometry that is secondary to attempted inhibition of an involuntary bladder contraction by voluntary contraction of the striated sphincter. The guarding reflex in these patients usually remains intact (Siroky and Krane, 1982).

Detrusor hypocontractility or areflexia may rarely persist after CVA. The exact incidence of areflexia as a cause of chronic voiding symptoms after CVA is uncertain, but some estimates place it as high as 20% (Arunable and Badlani, 1993). Patients with urinary retention after CVA generally have not only poor functional status in the rehabilitation period but also poorer recovery (Son et al., 2017). Linsenmeyer and Zorowitz (1992) found that 35% of men who were incontinent after a CVA had involuntary bladder contractions with urodynamic evidence of bladder outlet obstruction and 6% had detrusor areflexia. In comparison, 13% of women in this group had involuntary contraction with a large residual urine volume and 19% had areflexia. **Poor flow rates and high residual urine volumes in a man with LUTS before CVA usually indicate**

prostatic obstruction. However, a full urodynamic evaluation to exclude detrusor overactivity with impaired contractility as a cause of symptoms is advisable before committing such a patient to surgical reduction of bladder outlet obstruction.

The underlying basic mechanisms of bladder overactivity after CVA remain unclear. Experimental models of middle cerebral artery occlusion have been described, followed by reperfusion to simulate the clinical condition (Pehrson et al., 2003). Shimizu et al. (2003) described the development of a rat model involving an electrolytic lesion of the right basal forebrain. After middle cerebral artery occlusion, neural signaling changes seem to involve glutaminergic, dopaminergic, and γ-aminobutyric acid (GABA)-ergic mechanisms (Kanie et al., 2000; Yokoyama et al., 2002). In addition, Fu et al. (2004) have shown upregulation of proinflammatory cytokines and the neuronal nitric oxide synthase gene in the spinal cord and bladder after acute vascular injury. Such findings raise interesting theoretic possibilities for central pharmacologic management. Cerebrovascular injury manifesting with suprapontine injury also can result in an alteration of urinary urgency perception, producing symptomatic frequency and urge incontinence. The underlying pathophysiology of this effect may be elimination of cortical ambulatory control of the pontine micturition center (PMC), possibly combined with facilitation of excitatory control. These aberrant signaling pathways may arise from abnormalities in acetylcholine, dopamine, and glutamate regulatory changes with upregulation or downregulation of excitatory and inhibitory pathways resulting in the overactivity associated with diagnosis (Yokoyama et al., 2009).

Brainstem Stroke

The brainstem includes the midbrain, the pons, and the medulla oblongata. The PMC is involved in suprapsinal coordination of micturition and is located in the pons. In another study of 39 patients with acute brainstem stroke (Sakakibara et al., 1996d), the primary complaints were nocturnal frequency and voiding difficulty in 6, urinary retention in 8, and urinary incontinence in 3. Symptoms did not occur in those with strictly midbrain lesions but occurred in 18% of patients with medullary stroke and in 35% of patients with pontine lesions. Detrusor overactivity was found in 8 of the 11 symptomatic patients who underwent urodynamic evaluation, and low compliance was found in 1 patient.

Yum et al. (2013) reported on 30 patients who underwent urodynamic evaluation after a brainstem stroke. No patients had pre-stroke urinary symptoms. Fourteen (46%) were found to have a low bladder capacity, which was more common in those with a pontine infarction, and 7 (23%) had a bladder emptying disorder, which was more common in patients with a medullary infarction.

In a study of 20 patients with brainstem stroke (14 with pontine stroke and 4 with medullary stroke) by Lee et al. (2017a), urodynamic studies most commonly showed detrusor underactivity in 11 out of 14 with pontine stroke and 1 out of 4 with medullary stroke. These studies demonstrate that different patterns of voiding dysfunction can be associated with locations of brainstem stroke and that pontine lesions can disrupt pathways of coordinated voiding; however, stroke location cannot always predict findings, and complete evaluation with urodynamic studies is prudent.

Dementia

Dementia is a poorly understood disease complex involving atrophy and the loss of gray and white matter of the brain, especially in the frontal lobes, causing deficits with memory and the performance of tasks requiring intellectual mentation. Associated conditions include widespread vascular disease, Alzheimer disease, Pick disease, Creutzfeldt-Jakob disease, syphilis, traumatic brain injury, and encephalitis. Alzheimer disease is the principal cause of dementia in the elderly (Drake et al., 2013; Wyndaele et al., 2005). **Although urinary dysfunction does not consistently accompany dementia, when voiding dysfunction occurs the result is typically incontinence. It is difficult to ascertain whether the pathophysiology and considerations are similar to those in the stroke patient or whether the incontinence reflects a situation in which the individual has simply lost the awareness of the desirability of voluntary urinary control.** Even if the person has voluntary sphincter control, such individuals may void when and where they please, because impaired mentation fails to dictate why they should not. Such activity may be caused by detrusor overactivity or an otherwise normal, but inappropriately timed, micturition reflex. An accurate estimate of the prevalence of dementia-associated incontinence is confounded by the difficulty in distinguishing this from age-related changes in the bladder and from other concomitant diseases, as pointed out by Wyndaele et al. (2005) and Drake et al. (2013), who cite figures of 30% to 100%. Prevalence may be also difficult to establish because patients with dementia may not be aware of incontinence as highlighted in this study by Cohn et al. (2017), who found only moderate agreement between patient-reported incontinence and nurse-reported incontinence in geriatric inpatients. Treatment can be difficult and the outcomes frustrating without a desire for improvement. Medical therapy for incontinence generally involves the use of anticholinergic medications, which are associated with worsening cognitive impairment, delirium, and falls (Saraf et al., 2017). One theory on the cause of Alzheimer disease is cortical cholinergic loss, thus use of anticholinergics can further exacerbate symptoms.

Traumatic Brain Injury

Traumatic brain injury has been cited as the most common form of severe neurologic impairment resulting from trauma (Blaivas and Chancellor, 1995a). **As with many neurologic insults, there may be an initial period of detrusor areflexia when LUT dysfunction occurs. With lesions above the PMC, detrusor overactivity and coordinated sphincter function are the most frequent manifestations of chronic LUT dysfunction. In patients who have more isolated brainstem injuries with involvement below the PMC, additional findings may include detrusor striated sphincter dyssynergia.**

Chua et al. (2003) assessed 66 males and 18 females within 6 weeks of acute traumatic brain injury. Of these patients, 62% had urinary incontinence on admission, with urinary retention (defined as postvoid residual volume greater than 100 mL) noted in 9.5%. Sixty-two percent required either indwelling catheters or external collecting devices for urinary maintenance. Urinary incontinence was associated with poor functional status and bilateral lesions, whereas urinary retention was more commonly noted in patients with comorbid diabetes mellitus or fecal impaction. After rehabilitation, 36% remained incontinent. Patients with traumatic brain injury often have concomitant spinal injuries, contributing to the LUT dysfunction and complicating management.

Brain Tumor

Disturbances of bladder function have been associated with primary and metastatic brain tumors. When dysfunction results, it is related to the localized area involved rather than to the tumor type. **The areas most frequently involved with associated micturition dysfunction are the superior aspects of the frontal lobe** (Blaivas, 1985). **When LUT dysfunction occurs, it usually**

consists of detrusor overactivity and urinary incontinence. These individuals may have a markedly diminished awareness of all LUT events and, if so, may be totally unable to even attempt suppression of the micturition reflex. **In general, smooth and striated sphincters are synergic,** whereas pseudodyssynergia may occur during urodynamic testing. In a review of frontal lobe lesions and bladder control, Fowler (1999) cites instances of improvement of micturition symptoms for a period of time after tumor resection, raising the question of whether the phenomenon of tumor-associated bladder overactivity was a positive one (activating some system) rather than a negative one (releasing a system from control). **Urinary retention has also been described** in patients with space-occupying lesions of the frontal cortex, in the absence of other associated neurologic deficits (Lang et al., 1996). Posterior fossa tumors may be associated with voiding dysfunction (32% to 70%, based on references cited by Fowler, 1999). Retention or difficulty voiding is the rule, with incontinence being a rare finding.

Cerebellar Ataxia

Cerebellar ataxia is a group of diseases involving pathologic degeneration of the nervous system, usually involving the cerebellum but with possible extension to the brainstem, spinal cord, and dorsal nerve roots (Leach et al., 1982). Cerebellar involvement often results in poor coordination, depressed deep tendon reflexes (DTRs), dysarthria, dysmetria, and choreiform movements. **LUT dysfunction typically manifests with incontinence, usually associated with detrusor overactivity and sphincter synergy. Retention or high postvoid residual urine volume may occur as well. When present, impaired emptying is most commonly caused by detrusor areflexia, but it may also be associated with detrusor striated sphincter dyssynergia, presumably a result of spinal cord involvement.** Sakakibara et al. (1998b) reported micturition symptoms in 184 patients with spinocerebellar degeneration, of whom 29 (15.8%) had stress urinary incontinence. Although 20 of these 29 also had detrusor overactivity, low compliance, and/or elevated residual urine, the remaining 9 had none of these findings. The authors speculated that, in the absence of other findings, spinal lesions affecting the Onuf nucleus and consequently pudendal nerve function were responsible for the development of stress urinary incontinence.

Normal-Pressure Hydrocephalus

Normal-pressure hydrocephalus (NPH) is a neurologic condition characterized by progressive dementia, ataxia, and urinary incontinence occurring in patients with normal cerebrospinal fluid pressure and distended cerebral ventricles. NPH can be idiopathic or occur after neurologic insults, such as a CVA. The urinary incontinence is secondary to detrusor overactivity with synergic sphincters (Blaivas, 1985; Krzastek et al., 2017a). Cerebrospinal fluid shunting, primarily via a ventriculoperitoneal shunt, is the mainstay of treatment and can result in clinical improvement of urinary symptoms, specifically urinary urgency and urge incontinence (Krzastek et al., 2017b).

Cerebral Palsy

Cerebral palsy (CP) is a nonprogressive injury of the brain that typically occurs during the first year of life (but potentially up to 3 years of age) and produces neuromuscular disability and/or specific symptom complexes of cerebral dysfunction. In general, the cause is infection or a period of hypoxia. Affected children exhibit delayed gross motor development, abnormal motor performance, altered muscle tone, abnormal posture, and exaggerated reflexes. **Most children and adults with only CP have urinary control and what seems to be normal storage and emptying.** The actual incidence of LUT dysfunction in the CP population is unclear, because the few available series report findings predominantly in those with LUTS. Andrews (1994) estimates that a third or more of children with CP have urinary symptoms, whereas Roijen et al. (2001) surveyed children and adolescents from six rehabilitation centers and cited the prevalence of “primary urinary incontinence” as 23.5%. The most important factors influencing the occurrence of incontinence were spastic tetraplegia and low intellectual capacity. Wyndaele et al. (2005) and Drake et al. (2013) cite the occurrence of LUT dysfunction as 36%. Those children who do attain daytime and nighttime continence do so at a higher median age compared with normal controls (Wright et al., 2016a).

Reid and Borzyskowski (1993) described findings in 27 patients (ages 3 to 20 years) who were referred because of LUT dysfunction. Incontinence (74%), urinary frequency (56%), and urgency (37%) were the most common presenting symptoms, and detrusor overactivity was the most common urodynamic abnormality (87% of those undergoing urodynamics), with 25% of these exhibiting apparent striated sphincter dyssynergia. Mayo (1992) reported on 33 CP patients referred for evaluation of micturition dysfunction, of whom 10 were older than 20 years. Difficulty urinating was the predominant symptom in about half the patients, but half of these also had overactivity and urgency when the bladder was full. The cause of the difficulty in voluntarily initiating micturition was thought to be a problem with relaxing the pelvic floor and not true striated sphincter dyssynergia. Incontinence was the major presenting symptom in the other half, with associated detrusor overactivity in 14 of 16. All patients exhibited normal voiding otherwise. Decreased sensation was reported in 17 of 23 patients younger than 20 years of age and in 4 of 10 older than 20. The more serious manifestations, such as retention, were found only in the adults, prompting the authors to suggest that difficulty urinating may progress in adulthood. In another assessment of a children with CP, Richardson and Palmer (2009) evaluated 15 boys and 16 girls with urodynamics. Social continence was highly associated with larger capacity bladder with lower storage pressures (presumably improved compliance), lack of uninhibited contractions, and coordinated (lack of pseudodyssynergia) sphincter activity. Bladder sensation differed substantially in continent versus incontinent patients. The main difference between continent and incontinent groups appeared to be delayed bladder sensation in the incontinent group (Richardson and Palmer, 2009). Cotter et al. (2016) performed urodynamic studies in 49 adults with CP and voiding dysfunction with findings of detrusor overactivity in 30% and detrusor sphincter dyssynergia (DSD) in 12%. Importantly, poor compliance and elevated detrusor leak point pressure above 40 cm H_2O were seen in more than half of patients. **Adults with CP and urinary symptoms should undergo complete evaluation because the rate of bladder dysfunction is high** with risks of renal damage.

In individuals with CP who exhibit significant dysfunction, the type of damage that one would suspect from the most common urodynamic abnormalities seems to be localized anatomically above the brainstem. Therefore this is most commonly reflected by phasic detrusor overactivity and coordinated sphincters. However, spinal cord damage can occur, and perhaps this accounts for those individuals with CP who seem to have evidence of striated sphincter dyssynergia or of a more distal type of neural axis lesion. Reid and Borzyskowski (1993) noted that incontinence can be significantly improved in most CP patients and that, in their experience, intellectual delay is not a barrier to successful management. Goldfarb et al. (2016) found that conservative management, specifically education, incontinence padding, and perineal hygiene, was successful in 75%. In those patients requiring catheterization, initiation of intermittent catheterization was successful in 32%, whereas 39% ultimately underwent surgical reconstruction and the remainder returned to previous voiding patterns. The severe degree of mental delay encountered in some of these individuals makes their management very difficult; any evaluation or treatment that requires cooperation may be impossible.

Parkinson Disease

Parkinson disease (PD) is a neurodegenerative disorder of unknown cause that affects primarily the dopaminergic neurons of the substantia nigra and heterogeneous populations of neurons in other locations (Lang and Lozano, 1998). The most important site of pathology is the substantia nigra pars compacta, the origin of the dopaminergic nigrostriatal tract to the caudate nucleus and putamen. **Dopamine deficiency in the nigrostriatal pathway accounts for most of the classic clinical motor features of PD,** a symptom complex referred to as *parkinsonism*, the major signs of which are tremor, skeletal rigidity, and bradykinesia. Other pathways that may contribute to abnormal neural physiology in PD include the corpus striatum, thalamus, periaqueductal gray matter (PAG), and L and M regions of the PMC, as well as the ventral tegmental area (VTA) of the midbrain (Barbalat, 2010). The role of alterations in dopaminergic receptor subtypes has been assessed in animal models of PD. Treatment with dopamine D_2 agonists and D_1 antagonists appears to result in a reduction of bladder capacity in these models. Brusa et al. (2006) studied a group of 87 patients with mild PD who were evaluated by symptomatic change and urodynamics after administration of selective dopaminergic agents. Use of agents causing central acute D_2 stimulation resulted in a reduction in bladder capacity and worsened detrusor overactivity, as compared with peripheral dopaminergic antagonists (Brusa et al., 2006). Lang and Lozano (1998) compiled an excellent review of conditions causing parkinsonism other than PD and clinical features of these conditions distinguishing them from PD. These other causes of parkinsonism include (1) multiple system atrophy (MSA) (includes striatonigral degeneration, sporadic olivopontocerebellar atrophy, and Shy-Drager syndrome); (2) progressive supranuclear palsy (PSP); (3) cortical-basal ganglionic degeneration; (4) so-called vascular parkinsonism; and (5) Lewy body dementia. **The combination of asymmetry of symptoms and signs, the presence of a resting tremor, and a good response to levodopa best differentiates PD from parkinsonism produced by other causes, although none of these is individually specific for PD** (Fowler, 2007).

Wyndaele et al. (2005) and Drake et al. (2013) endorsed **additional criteria that favor MSA as a cause of LUTS rather than PD: (1) urinary symptoms that precede or occur with onset of parkinsonism; (2) presence of urinary incontinence; (3) significant postvoid residual volume; (4) initial erectile dysfunction; and (5) abnormal striated sphincter electromyographic findings.** In addition, 5% of patients initially diagnosed with PD are found to have Parkinson-plus syndromes, characterized by early dementia and/or falls, symmetrical symptoms, wide-based gait, normal eye movements, autonomic dysfunction, and marked disability. These variants tend to have a worse prognosis than idiopathic PD, and urinary function is not well described in this subgroup of patients (Nutt and Wooten, 2005).

The gold standard for the diagnosis of PD is neuropathological examination. In addition to the characteristic pattern of the loss of selected populations of neurons, there is the presence of degenerating ubiquitin-positive neuronal processes or neurites (Lewy neurites) found in all affected brainstem regions. The Lewy body is an intracytoplasmic eosinophilic hyaline inclusion consistently observed in selectively vulnerable neuronal populations. Lewy bodies are not specific to PD and may be found in small numbers in other neurodegenerative disorders. PD affects both sexes roughly equally, and the prevalence is cited as 0.3% of the general population and 3% of people older than 65 years (Lang and Lazano, 1998).

Depending on the definition, LUT dysfunction occurs in 35% to 70% of patients with PD (Berger et al., 1990; Blaivas et al., 1998a; Sotolongo, 1993; Wein and Rovner, 1999; Wyndaele et al., 2005). Preexisting detrusor dysfunction or bladder outlet abnormalities may be present, and the symptomatology may be affected by various types of treatment for the primary disease. LUTS is a frequent manifestation of PD. The time from onset of PD to initiation of LUTS in most studies averages 5 years. The most frequent symptoms include nocturia in 86% of patients, followed by frequency in 71% of patients and urgency in 68% of patients. It has been hypothesized that dopamine modulates the normal micturition reflex, and therefore neurogenic degeneration in the nigrostriatal pathway leads to the significant LUT dysfunction associated with PD (Campeau et al., 2011). One early manifestation of PD may be deficient perception of sensory information in visceral neuronal pathways resulting in delayed perception of bladder filling. Studies have demonstrated that the deep brain stimulation used for improvement of moving function in patients with PD may also benefit this sensory perception (Herzog et al., 2006).

When LUT dysfunction does occur, 50% to 75% of the time symptoms consist of urgency, frequency, nocturia, and urgency incontinence. The remainder of patients have obstructive symptoms or a combination of storage and voiding symptoms. **The most common urodynamic finding is detrusor overactivity.** The pathophysiology of detrusor overactivity most widely proposed (Fowler, 1999) is that the basal ganglia normally have an inhibitory effect on the micturition reflex, which is abolished by the cell loss in the substantia nigra. It is currently unclear whether the dopamine D_1 or D_2 receptor (or both) is primarily responsible. It has been suggested that loss of inhibitory D_1-like receptors causes detrusor overactivity, allowing D_2 receptors to facilitate micturition (Andersson, 2004). **The smooth sphincter is synergic.** Sporadic involuntary activity in the striated sphincter during involuntary bladder contraction has been reported in as many as 60% of patients; however, this does not cause obstruction and cannot be termed *true* detrusor sphincter dyssynergia (DSD), which in general does not occur.

Pseudodyssynergia may occur, as well as a delay in striated sphincter relaxation (bradykinesia) at the onset of voluntary micturition, both of which can be urodynamically misinterpreted as true dyssynergia. Impaired detrusor contractility may also occur, in the form of low amplitude or poorly sustained contractions or a combination of these. Detrusor areflexia is relatively uncommon in PD. PET revealed changes in nine patients in brain activation associated with detrusor overactivity, specifically in the periaqueductal gray, supplementary motor area, cerebellar vermis, insula, putamen, and thalamus. The most prominent degree of increased activation was noted in the cerebellum, with no change in pons during detrusor overactivity (Kitta et al., 2006).

However, many cases of “PD” in the older literature may actually have been MSA, and citations regarding symptoms and urodynamic findings may therefore not be accurate. A good and important example of this is the inference from the publication by Staskin et al. (1988) that transurethral resection of the prostate (TURP) in the patient with PD is associated with a high incidence of urinary incontinence because of poor striated sphincter control. Retrospective interpretation (Drake et al., 2013; Fowler, 1999, 2001; Wyndaele et al., 2005) has shown that these were patients with MSA and not PD and that **TURP should not be contraindicated in patients with PD, because striated sphincter acontractility is extremely rare** in such patients. However, irrespective of similar studies, one must be cautious with such patients, and a complete urodynamic or videourodynamic evaluation is advisable. Poorly sustained bladder contractions, sometimes with slow sphincter relaxation, should make one less optimistic regarding the results of outlet reduction in the male. In addition, the diagnosis of PD should be confirmed and MSA should be excluded before benign prostatic hypertrophy surgery because sphincter involvement in MSA could lead to florid incontinence after surgery.

LUT dysfunction secondary to PD defies routine classification within any system. It manifests mostly with storage failure secondary to bladder overactivity, but detailed urodynamic evaluation is mandatory before any definitive therapy is initiated. There may be limitations on the use of certain treatments in this population (e.g., limited mobility for rapid toilet access, hand control insufficient for clean intermittent catheterization [CIC]). The role of medications used to treat PD and exacerbation of LUTS in these patients has been postulated. Some studies have shown a relationship between the degree of neurologic impairment associated with PD and LUTS. Quality of life has been shown to be directly linked to the severity of LUTS; urinary frequency and nocturia have the most deleterious impact. Overall, in a study of 110 patients, 63 (57.3%) were symptomatic from the urinary tract standpoint. No impact on LUTS was associated with use of levodopa, anticholinergics, or dopamine receptor agonists. Similar symptomatic impact occurred in both genders (Sammour et al., 2009).

Bromocriptine may have a role in the exacerbation of urgency in PD patients. In a prospective trial of 8 patients with stable PD, bromocriptine was administered followed by urodynamic and systematic assessment. Urinary urgency was found to be symptomatically exacerbated after bromocriptine administration, and this was accompanied by increased detrusor overactivity. However, there was improvement in bladder emptying associated with enhanced detrusor contractility and decreased bladder outlet resistance (Uchiyama et al., 2009). Animal models of PD have been developed using injections of 1-methyl-4-phenyl-1,2,3,6-tetrahydropyridine or 6-hydroxydopamine into the nigrostriatal pathway (Andersson, 2004; Drake et al., 2013; Wyndaele et al., 2005; Yoshimura et al., 2003).

Subthalamic nucleus deep brain stimulation has been shown to be effective for motor symptoms and dyskinesias in patients with moderate to severe PD. Clinical studies have shown that this type of stimulation improves urinary function in these patients by ameliorating bladder sensation and also improving functional bladder capacity. Herzog et al. (2006) studied 11 patients undergoing deep brain stimulation with PET scans of regional cerebral blood flow. In addition, subjects were studied with urodynamics with stimulation on and stimulation off. At urodynamic capacity, significant increases in anterior cingulate regional blood flow were noted and were increased when deep brain stimulation was off. At bladder capacity, there was also an increase in lateral frontal cortical blood flow with stimulation off. These results were thought to be indicative of deep brain stimulation improvement of bladder function by the modulation of afferent bladder information to cortical and subcortical areas (Herzog et al., 2006). Further evidence of the effect of deep brain stimulation on PD was reported by Winge and Nielsen (2012). A cohort of patients received oral medications only and was compared with a group of individuals being treated either with deep brain stimulation or with apomorphine pump for control of symptoms. A total of 170 patients were available, and outcomes reported were symptom scores (International Prostate Symptom Score [IPSS] and Danish Prostate Symptom Score [DanPSS]). There was no significant difference between the treatment groups in terms of overall symptom scores. Bladder symptom score did correlate with the stage of disease progression except for those individuals treated with deep brain stimulation, in whom symptom severity correlated to deep brain stimulation duration. Deep brain stimulation significantly decreased the amount of nocturia patients experienced (Winge and Nielsen, 2012). Witte et al. (2018) recently published a post-hoc analysis of patients undergoing deep brain stimulation of either the subthalamic nucleus or globus pallidus pars interna and found improvements in urinary frequency and incontinence; however, no significant improvement in nocturia was noted.

Sakakibara et al. (2016) published guidelines for the treatment of LUT dysfunction in PD. Botulinum toxin has demonstrated benefit in patients with PD; varying the doses of different toxin serotypes has demonstrated improvements in urinary frequency and quality of life as well as incontinence episodes for up to 9 months (Giannantoni et al., 2009; Kulaksizoglu and Parman, 2010). In addition, peripheral intermittent neuromodulation (posterior tibial nerve stimulation) has demonstrated improvements in detrusor overactivity and improved mean cystometric capacity in five of seven patients undergoing intervention (Kabay et al., 2009). Another therapy that has demonstrated some benefit for LUT dysfunction in PD is repetitive transcranial magnetic stimulation. In eight patients with advanced PD, this therapy demonstrated temporary improvement in LUTS as well as improvement in bladder capacity and first sensation on cystometric filling. The beneficial effect of this therapy was noted to last for approximately 2 weeks, consistent with findings associated with other temporary forms of neuromodulation (Brusa et al., 2009).

Multiple System Atrophy

MSA results from glial α-synucleinopathy and is a progressive neurodegenerative disease of unknown cause. The symptoms encompass parkinsonism and cerebellar, autonomic (including urinary and erectile problems), and pyramidal cortical dysfunction in a multitude of combinations. The clinical features and the differentiation from PD are nicely described in a consensus statement by Gilman et al. (1999). These investigators advocate a designation of MSA-P if parkinsonian features predominate and one of MSA-C if cerebellar features predominate. Older names such as *striatonigral degeneration*, *sporadic olivopontocerebellar atrophy*, and *Shy-Drager syndrome* (Wein, 2002a, 2002b) should be discarded in favor of these terms.

The neurologic lesions of MSA consist of cell loss and gliosis in widespread areas and occur to a significantly greater degree than with PD. This more diffuse nature of cell loss probably explains why bladder symptoms may occur earlier and be more severe than in PD, and why erectile function may be affected as well (Beck et al., 1994; Chandiramani et al., 1997; Kirby et al., 1986). Affected areas have been identified in the cerebellum, substantia nigra, globus pallidus, caudate, putamen, inferior olives, intermediolateral columns of the spinal cord, and Onuf nucleus. Males and females are equally affected, with the onset in middle age. MSA is usually progressive and associated with a poor prognosis.

Shy-Drager syndrome has been described in the past as characterized clinically by orthostatic hypotension, anhidrosis, and varying degrees of cerebellar and parkinsonian dysfunction. Voiding and erectile dysfunction are common. Some consider this to be late-stage MSA (Chandiramani et al., 1997).

Chandiramani et al. (1997) **compared the clinical features of 52 patients with probable MSA and 41 patients with PD.** For 60% of patients with MSA, urinary symptoms precede or occur with their symptoms of parkinsonism; 94% of patients with PD had been diagnosed for several years before the onset of urinary symptoms. In patients with MSA, urinary incontinence was a significant complaint in 73%; 19% had only frequency and urgency without incontinence, and 66% had a significant postvoid residual volume (100 to 450 mL). In patients with PD, frequency and urgency were the predominant symptoms in 85%, incontinence was the primary complaint in 15%, and the postvoid residual volume was elevated in only 5 of the 32 patients in whom it was measured. Eleven men with MSA underwent TURP, and 9 of these had deterioration of their urinary incontinence afterward. All 3 women with MSA were incontinent after pelvic floor repair. Five men with PD underwent prostatectomy, and 3 reported a good result. Of 27 men with MSA questioned about erectile function, 93% reported erectile failure, and in 13 of these (48%) the erectile dysfunction preceded the diagnosis of MSA. Seven of the 21 men with PD had erectile failure, but in all of these men the diagnosis of erectile dysfunction followed the diagnosis of PD by 1 to 4 years. The urogenital criteria favoring a diagnosis of MSA over PD are outlined in Box 116.1 (Fowler, 2001). Others have reported the progressive nature of LUTS associated with MSA. With time, incontinence and significant postvoid residual volume become more problematic, with steady progression of the condition in all patients (Papatsoris et al., 2008).

Box 116.1

Urogenital Criteria Favoring Diagnosis of Multiple System Atrophy

- Urinary symptoms that precede or occur with parkinsonism
- Erectile dysfunction that precedes or occurs with parkinsonism
- Urinary incontinence
- High postvoid residual volume
- Open bladder neck
- Striated sphincter denervation on electromyogram
- Worsening lower urinary tract function after urologic surgery

The initial urinary symptoms of MSA are urgency, frequency, and urgency incontinence, occurring up to 4 years before the diagnosis is made. **As would be expected from the central nervous system (CNS) areas affected, detrusor overactivity is frequently found; however, decreased compliance may also occur, reflecting distal spinal involvement of the locations of the cell bodies of autonomic neurons innervating the LUT. As the disease progresses, difficulty in initiating and maintaining voiding may occur,**

probably from pontine and sacral cord lesions, and this usually is associated with a poor prognosis. Cystourethrography or videourodynamic studies may reveal an open bladder neck, and many patients exhibit evidence of striated sphincter denervation on motor unit electromyography. The smooth and striated sphincter abnormalities predispose women to sphincteric incontinence and make prostatectomy hazardous in men.

The treatment of significant LUT dysfunction caused by MSA is difficult and seldom satisfactory. Treatment of detrusor overactivity during filling may worsen problems initiating voluntary micturition or worsen impaired contractility during emptying. **Patients usually have sphincteric insufficiency**; therefore an **outlet-reducing procedure is rarely indicated**. Conversely, drug treatment for sphincteric incontinence may further worsen emptying problems. In general, the goal in these patients is to facilitate storage, and CIC would often be desirable. Unfortunately, patients with advanced disease often are not candidates for CIC. Some patients do respond well to desmopressin administration for predominant nocturia; however, the majority of the patients do not respond well to antimuscarinic or other types of therapy (Wenning and Stefanova, 2009).

Progressive Supranuclear Palsy

Like other parkinsonian disease, progressive supranuclear palsy (PSP) is a neurodegenerative disease. It addition to parkinsonism, it is characterized by vertical gaze palsy, loss of balance, and cognitive impairment. Patients with PSP can also experience LUT symptoms, most commonly urinary frequency, urgency, and incontinence. In a study (Kim et al., 2018) including 10 patients with PSP, 90% had impaired detrusor contraction and 70% had detrusor overactivity. Sphincter abnormalities may also be present. In addition to neuronal loss of the basal ganglia, in PSP there is also loss of neurons in Onuf nucleus, reflecting the sphincter involvement that can accompany this disease (Scaravilli et al., 2000).

Diseases Primarily Involving the Spinal Cord

Multiple Sclerosis

Multiple sclerosis (MS) is primarily a disease of adults aged 20 to 50 years with a twofold predilection for women. The Multiple Sclerosis International Federation in 2016 estimated that 2.3 million people worldwide had MS. Most commonly the age of onset is 30 to 38 years of age for relapsing, remitting, and progressive phases. Common symptoms include optic nerve dysfunction, pyramidal tract abnormalities (hyperreflexia), ataxia, bowel dysfunction, neurogenic bladder, and bowel and sexual dysfunction. Primary and secondary progressive MS are predominantly spinal diseases, and their activity affects LUT function. **MS is often a progressive disease, so frequent follow-up and reassessment are indicated**.

Although the cause is not clear, the disease is believed to be immune mediated and is characterized by neural demyelination in the brain and spinal cord; it is characterized, in general, by axonal sparing (Noseworthy et al., 2000). This demyelination causes impairment of saltatory conduction and conduction velocity in axonal pathways, resulting in various neurologic abnormalities that are subject to exacerbation and remission. Lesions, known as *plaques,* range from 1 mm to 4 cm and are scattered throughout the white matter of the nervous system (Chancellor and Blaivas, 1993; Clanet, 2008). **The demyelinating process most commonly involves the lateral corticospinal (pyramidal) and reticulospinal columns of the cervical spinal cord.** It is thus not surprising that LUT dysfunction and sphincter dysfunction are so common. Autopsy studies have revealed almost constant evidence of demyelination in the cervical spinal cord, but involvement of the lumbar and sacral cord occurs in approximately 40% and 18%, respectively (Blaivas and Kaplan, 1988). Lesions may also occur in the optic nerve and in the cerebral cortex and midbrain, the latter accounting for the intellectual deterioration and/or euphoria that may accompany physical findings (Kirby, 1994; Noseworthy et al., 2000) in as many as 43% to 65% of patients (Litwiller et al., 1999).

Supraspinal neural control of micturition in MS patients was studied in a group of women using functional magnetic resonance imaging (MRI). Results demonstrated activation of the bilateral middle and right inferior frontal gyrus and the brainstem of those with neurogenic detrusor overactivity (NDO) compared with those without NDO (Khavari et al., 2017). These areas of the brain are associated with executive functioning. The authors suggest that because NDO is typically associated with urinary incontinence, activation of these areas of the brain in women with NDO is explained as an inhibition signal. In addition, women with DSD had increased activation in areas of executive functioning, emotional processing, movement, and the brainstem.

Some patients with MS demonstrate intravesical changes in receptor density and type. In a study of 18 patients with LUTS associated with MS, patients underwent evaluation with urologic assessment and urodynamics. Two groups were identified: one with pronounced NDO and minimal outflow obstruction, and the second with some degree of NDO or detrusor hypocontractility during voiding and a high degree of bladder outflow obstruction. Cold-cup biopsies were performed on all patients, and the density of calcitonin gene–related peptide (CGRP) and substance P (SP)–positive nerve fibers was noted to be higher in the first group, suggesting that denser innervation is present in patients with milder degrees of outflow obstruction and retention of detrusor contractility as compared with individuals without these findings (Radziszewski et al., 2009).

The incidence of LUT dysfunction in MS is related to disability status. Of patients with MS, **50% to 90% report voiding symptoms at some time; the prevalence of incontinence is cited as 37% to 72%** (Drake et al., 2013; Wyndaele et al., 2005). In a comprehensive review of the literature, Litwiller et al. (1999) cited symptoms of frequency or urgency in 31% to 85% of patients, incontinence in 37% to 72%, and obstructive symptoms with urinary retention in 2% to 52%. LUT involvement may constitute the sole initial complaint or may be part of the presenting symptom complex in up to 15% of patients, typically with a presentation of acute urinary retention of unknown cause or as an acute onset of urgency and frequency (Wyndaele et al., 2005).

In terms of urodynamic findings, detrusor overactivity is the most common abnormality detected, occurring in 34% to 99% of patients in reported series (Blaivas and Kaplan, 1988; Chancellor and Blaivas, 1993; Litwiller et al., 1999; Sirls et al., 1994). **Striated sphincter dyssynergia coexists with overactivity in 30% to 65% of patients. The prevalence of coexistent impaired detrusor contractility or areflexia ranges from 12% to 38%** (Drake et al., 2013; Wyndaele et al., 2005), **a phenomenon that can considerably complicate treatment efforts.** More recent estimates suggest that

62% of patients with MS have NDO with bladder outlet obstruction, 25% have NDO with DSD, 20% have detrusor underactivity, and 10% have no initial abnormal urodynamic findings. The variability and potential multiplicity of lesions associated with MS may prohibit accurate diagnosis based on urodynamics alone (Ukkonen et al., 2004).

In general, **the smooth sphincter is synergic.** Chancellor and Blaivas (1993) reviewed urodynamic findings in multiple series of patients with MS and voiding dysfunction and cited the incidence of detrusor overactivity with striated sphincter synergia to be 26% to 50% (average, 38%), detrusor overactivity with striated sphincter dyssynergia to be 24% to 46% (average, 29%), and detrusor areflexia to be 19% to 40% (average, 26%). Litwiller et al. (1999) report approximately the same ranges in a review of 22 studies. It is also possible to see relative degrees of sphincteric flaccidity caused by MS. Although this finding is relatively rare and occurs in fewer than 15% of patients (Litwiller et al., 1999), it could contribute to and predispose patients to sphincteric incontinence. De Ridder et al. (1998) reported weakness of pelvic floor contraction in almost all of the 30 women with MS whom they studied. Spasticity of the pelvic floor was present in all patients with striated sphincter dyssynergia but in none with detrusor overactivity alone. Up to 80% of patients will have neurogenic vesicourethral dysfunction at some point during the course of their disease (Fletcher and Lemack, 2009).

Sensation is frequently intact in these patients, so clinicians must be careful to distinguish urodynamic pseudodyssynergia from true striated sphincter dyssynergia. Blaivas et al. (1981) subcategorized true striated sphincter dyssynergia in patients with MS and identified some varieties that are more worrisome than others. For example, a brief period of striated sphincter dyssynergia during detrusor contraction in a woman with MS may be relatively inconsequential, as long as it does not result in excessive intravesical pressure during voiding, substantial postvoid residual urine volume, or secondary detrusor hypertrophy. However, more sustained episodes of striated sphincter dyssynergia that result in high bladder pressures of long duration are most associated with urologic complications. Giannantoni et al. (1998) likewise concluded that there was a significant relationship between the maximum amplitude of the involuntary bladder contractions and upper urinary tract deterioration in their MS population of 116 patients. Chancellor and Blaivas (1993) emphasized what they believed were **the most important parameters predisposing patients with MS to significant urologic complications: (1)**

striated sphincter dyssynergia in men; (2) high detrusor filling pressure; and (3) an indwelling catheter. Wyndaele's committee (Drake et al., 2013; Wyndaele et al., 2005) **concluded that progressive neurologic disease in patients with MS rarely causes upper urinary tract damage, even when severe spasticity and disability exist.** The reason for this is unknown, but the committee proposed that the situation and concerns with respect to MS were unlike those for SCI. In contrast, a series of 141 patients with MS found that disability status was a risk factor for urodynamic abnormalities (poor compliance and vesicoureteral reflux [VUR]) that can cause upper tract damage (Ineichen et al., 2018). Patients with MS and LUTS should undergo evaluation with history, physical examination, and urodynamic testing given the high likelihood LUT dysfunction and the potential for upper tract damage.

Aggressive and anticipatory medical management can obviate most of the significant complications. Sirls et al. (1994) reported that less than 10% of their patients required surgical intervention resulting from failure of aggressive medical management and that none developed hydronephrosis on such therapy. The regimens used were (1) medications to decrease detrusor overactivity plus CIC (57%); (2) medications alone (13%); (3) CIC alone (15%); and (4) behavioral therapy. **Caution should be exercised in recommending irreversible therapeutic options, because a significant proportion of patients with MS with and without new symptoms will develop changes in their detrusor compliance and urodynamic pattern** (Ciancio et al., 2001). No factors appear to be predictive of upper tract changes in MS. In a 4-year follow-up of 113 MS patients, 66 underwent both urodynamic and renal ultrasound testing. Eleven of the 66 patients (17%) had abnormal ultrasound findings; the most significant finding was minor caliectasis of no clinical significance. Neither creatinine nor urodynamic findings were associated with the abnormal renal ultrasound findings (Lemack et al., 2005). **Others have noted the lack of predictability of urinary symptoms for disease status, making baseline testing with urodynamics critical to disease assessment and management** (Nakipoglu et al., 2009). Surgical intervention for MS appears to be diminishing with improved pharmacologic management and the realization of the alternating neurologic picture of lower urinary dysfunction associated with MS (Togami et al., 2013; Ukkonen et al., 2004).

Physiotherapeutic management has demonstrated success for this condition. In an Australian trial with 73 patients with MS, 40 patients were randomized to an individualized bladder rehabilitation program that included baseline assessment

(3-day voiding charts, fluid balance, intake restrictions, postvoid residual measurement, and urodynamics). Subsequently, bladder re-education, pelvic floor exercises, and instruction in techniques for improved bladder emptying and a bowel program were instituted. A nonintervention group served as control. Substantial improvements in all subjective quality-of-life indicators were noted in the intervention group, as compared with the nonintervention group, demonstrating the benefit of a bladder and bowel regimen in this population (Khan et al., 2009).

At present, there is no consensus on optimal bladder management for patients with MS, and management is most commonly predicated on symptomatic and urodynamic findings. On the basis of expert consensus, De Ridder et al. (2005) concluded that in early MS, anticholinergics and CIC were considered to be the cornerstones of therapy. For patients with advanced MS (with an Expanded Disability Status Scale [EDSS] score >7), specific guidelines are still lacking. In general, Credé voiding or Valsalva voiding is contraindicated, especially in the presence of DSD. The committee further recommended that indwelling catheters be reserved for patients for whom all other possible treatments have failed. In the approximately 30% of patients with MS using indwelling urinary catheters, the suprapubic route is the preferred route in men and women. This form of management is considered reasonable for that subpopulation, as long as vigilant long-term follow-up is maintained (De Ridder et al., 2005).

The role of onabotulinum toxin therapy for bladder overactivity related to MS has been reported. Detrusor overactivity suppressed with onabotulinum toxin injection can provide social continence and improved quality of life. Stability of response and safety have been reported over treatment periods as long as five cycles. Kennelly et al. (2013) reported long-term experience with 387 patients with NDO caused by either MS or SCI and found that 73% to 94% of patients reported incontinence episode reductions of at least 50% depending on treatment cycle assessed.

Sacral neuromodulation may have an emerging role in MS and has shown to be effective and safe in small series (Engeler et al., 2015). However, the limiting feature at this time is that current sacral neuromodulation systems are not compatible with MRI systems, a not infrequent imaging modality used during the management of MS. As understanding of the disease process of MS and its effects on micturition expands, the hope is for new treatment strategies in the future.

Spinal Cord Injury

Epidemiology, Morbidity, General Concepts

SCI may occur as a consequence of acts of violence, fracture, or dislocation of the spinal column secondary to motor vehicle collisions, diving accidents or falls, vascular injuries or surgical repairs, infection, disk prolapse, or sudden and/or severe hyperextension from other causes. Altered LUT and sexual function frequently occur secondary to SCI and have a significant impact on quality of life. SCI patients are at risk urologically for urinary tract infection (UTI), sepsis, upper urinary tract and LUT deterioration, upper urinary tract and LUT calculi, autonomic hyperreflexia (dysreflexia), skin complications, and depression (which can complicate urologic management). Failure to properly address the LUT dysfunction can lead to significant morbidity and mortality. There is great variation in urologic practice regarding initial evaluation, follow-up, and surveillance among spinal injury units (Bycroft et al., 2004), a problem that Boone (2004) properly attributes to a lack of evidence-based decision making.

Complete anatomic transection of the spinal cord is rare, and the degree of neurologic deficit varies with the level and severity of the injury. **Spinal column (bone) segments are numbered by the vertebral level, and these have a different relationship to the spinal cord segmental level at different locations. Discussions of SCI must include cord or column level. The sacral spinal cord begins at about spinal column level T12 to L1. The spinal cord terminates in the cauda equina at approximately the spinal column level of L2.** Multiple-level injuries may occur, and, even with a single isolated initial injury, cord damage may not remain confined to a single cord segment and may extend cephalad, caudad, or both.

The National SCI Database (2016) estimates that the annual rate of SCI is 54 cases per million persons in the United States or about 17,000 new SCI cases per year. The prevalence in the United States was approximately 282,000 persons living with SCI. The most common mechanisms of injury are motor vehicle accidents (38%), falls (30.5%), violence (13.5%), and sports-related injuries (9%). Males account for 80% of patients with SCI. From 1973 to 1979, the average age at injury was 28.7 years. However, as the median age of the general population of the United States has increased by approximately 9 years since the mid-1970s, the average age at injury has also steadily increased over time. In 2016 the average age at injury was 42 years. Children constitute 3% to 5% of all patients with SCI (Generao et al., 2004). The National SCI Database reported that neurologically incomplete quadriplegics constituted the largest group of SCI patients at the time of hospital admission (45%), followed by incomplete paraplegics (21.3%), complete paraplegics (20%), and complete quadriplegics (13.3%%). Less than 1% of persons experienced complete neurologic recovery by hospital discharge. The majority of SCIs occur at or above the T12 spinal column (vertebral) level, with injury to one of the eight cervical segments accounting for the patients with tetraplegia and with patients with paraplegia having injury in the thoracic, lumbar, or sacral regions of the spinal cord.

SCI is associated with long-term urologic functional compromise. In an assessment of 236 patients with mean follow-up of 24 years, 43% of patients continue to report incontinence at time of follow-up, with paraplegics reporting daily incontinence more frequently than tetraplegics (presumably because of catheter dependence of the latter group). Only 19% of patients used some form of medication for assistance in management of their incontinence. Surprisingly, CIC was associated with higher rates of incontinence than other types of bladder drainage techniques (Hansen et al., 2010).

Although earlier data (Hackler, 1977) **indicated that renal disease was the major cause of death, at least in the paraplegic patient, a retrospective study of more than 5000 patients who sustained SCI between 1973 and 1980 revealed that the leading causes of death at that time were pneumonia, septicemia, pulmonary emboli, heart disease, accidents, and suicide** (Soden et al., 2000; Stover and Fine, 1987). These figures seemingly indicate a distinct improvement in the urologic care of these patients. Impaired mobility is commonly noted in the SCI patient and may substantially affect urinary habits and continence (Biering-Sorensen et al., 2004). Urologic phenomena also figure prominently in chronic SCI; approximately 7% of patients will develop an initial kidney stone within 10 years after initial injury. The greatest risk occurs during the first 3 months after injury, and 98% of these stones will be apatite or struvite in composition. There appear to be two specific time frames for stone formation in this population, one being the acute phase associated with hypercalciuria from immobilization. A more chronic phase stone formation period that usually is associated with chronic catheter management occurs years after injury and predominately involves the LUT (Post and Noreau, 2005).

Controlled and coordinated LUT function depends on an intact neural axis. Bladder contractility and the occurrence of reflex contractions depend on an intact sacral spinal cord and its afferent and efferent connections.

Key Points: Spinal Cord Injury

- In general, complete SCI above the sacral spinal cord but below the area of the sympathetic outflow results in detrusor overactivity, absent sensation below the level of the lesion, smooth sphincter synergia, and striated sphincter dyssynergia.
- Lesions at or above the spinal cord level of T7 or T8 (the spinal column level of T6) may result in smooth sphincter dyssynergia as well.
- Neurologic examination is no substitute for urodynamic evaluation in these patients in determining risk factors and treatment.

Bladder dysfunction associated with acute SCI has been investigated in a variety of animal models. In rodent models using a moderate contusion injury at three different thoracic levels—T1, T4, or T9—versus complete crush injury at T1 and T9, differences in bladder function were noted. T4 and T9 contusions were associated with a relative increase in urinary retention, whereas T1 defects had less impact on retained volume. Lesions at T1 spared a critical descending modulating pathway for voiding in rats. Crush injuries were associated with much more defect emphasis (David and Steward, 2010). Receptor behavior has also been noted to change in SCI. Differential expression of channel receptors has been demonstrated in muscle strips from neurogenic patients. K_{ATP} calcium channels appear to regulate spontaneous hyperactivity in neurogenic patients as compared with normal individuals. However, BK_{Ca} channels are more involved in regulation of normal patients as compared with neurogenic patients (Oger and AlKhawajah, 2010).

These topics are not further specifically considered in detail here, nor are the ramifications of this information relative to potential improvement of SCI after stem cell implant or reinnervation. Reviews can be found by Olson (1997); Fawcett (1998); Kakulas (1999); Rabchevsky and Smith (2001) (this also includes a discussion of pathophysiology and experimental models); Cao et al. (2002) (stem cell repair); Fawcett (2002) (repair of SCI); Rossi and Cattaneo (2002) (stem cell therapy); Mitsui et al. (2003) (stem cell repair); Kakulas (2004) (neuropathology and natural history of the spinal cord changes); and Livshits et al. (2004) (reinnervation). A recent review of SCI and regeneration by Chhabra and Sarda (2017) discussed advances in cellular therapeutics promoting axonal regrowth.

Sexual and reproductive dysfunction in the patient with SCI is a topic that deserves much attention in the overall rehabilitation plan but is beyond the scope of this chapter. Pertinent general and specific concepts of sexual and reproductive dysfunction and their normalization in this special group of patients can be found in Chapters 26, 30, and 32. Other excellent reviews on the specifics of sexual function in SCI are those by Bennett et al. (1988), Smith and Bodner (1993), and Biering-Sorensen and Sonksen (2001), and on infertility by Linsenmeyer and Perkash (1991), Rajaskaran and Monga (1999), and Rutkowski et al. (1999).

Spinal Shock

A period of “spinal shock” may be expected after an SCI, defined as decreased excitability of spinal cord segments at and below the level of the lesion. There is **absent somatic reflex activity and flaccid muscle paralysis below this level.** Although classic teaching refers to generalized areflexia below the level of the lesion for days to months, Thomas and O'Flynn (1994) confirm that the most peripheral somatic reflexes of the sacral cord segments (the anal and bulbocavernosus reflexes) may never disappear or, if they do, may return within minutes or hours of the injury. However, functions proximal to the level of the injury may be depressed as well (Atkinson and Atkinson, 1996), which is felt to be a result of rearrangement of spinal cord pathways. Although the course of spinal shock is well known, the actual pathophysiology remains poorly understood. From animal models, with the first hours of initial injury signs of trauma appear in the gray matter followed by protein accumulation. Reperfusion injury may also play a role in cellular injury, but it is not clearly understood.

Spinal shock includes a suppression of autonomic activity as well as somatic activity, and the bladder is acontractile and areflexic. Radiologically, the bladder has a smooth contour with no evidence of trabeculation. The bladder neck is usually closed and competent, unless there has been prior surgery or the patient has sustained a potential thoracolumbar and presumably sympathetic injury (Sullivan and Yalla, 1992). **The smooth sphincter mechanism appears to be functional. Some electromyographic activity may be recorded from the striated sphincter, and the maximum urethral closure pressure is lower than normal but still maintained at the level of the external sphincter zone. However, the normal guarding reflex (striated sphincter response during filling) is absent, and**

there is no voluntary control (Fam and Yalla, 1988). Because sphincter tone exists, urinary incontinence usually does not result unless there is gross overdistention with overflow. In evolving lesions, every attempt should be made to preserve as low a bladder storage pressure as possible. **Urinary retention is the rule,** and catheterization is necessary to circumvent this problem. Although almost all would agree that CIC is an excellent and preferred method of management during this period, Lloyd et al. (1986) reported their own experience and that of others that indicate no differences in outcome when a small-bore indwelling urethral catheter or suprapubic tube is used at this stage.

If the distal spinal cord is intact but is simply isolated from higher centers, there is usually a return of reflex detrusor contractility. At first, such reflex activity is poorly sustained and produces only low-pressure changes, but the strength and duration of such involuntary contractions typically increase, producing involuntary voiding, usually with incomplete bladder emptying. This return of reflex bladder activity typically manifests with involuntary voiding between catheterizations and occurs along with the recovery of lower extremity deep tendon reflexes (DTRs). Spinal shock usually lasts 6 to 12 weeks in complete suprasacral spinal cord lesions but may last up to 1 or 2 years. It may last a shorter period of time in incomplete suprasacral lesions.

Suprasacral Spinal Cord Injury

There is no consensus agreement on the neurobiology of the development of reflex bladder contraction in response to bladder distention after suprasacral SCI. de Groat et al. (1997) have studied this phenomenon extensively in cats and listed four potential mechanisms for the recovery of such micturition and the development of C-fiber afferent evoked bladder reflexes: (1) elimination of bulbospinal inhibitory pathways; (2) strengthening of existing synapses, or formation of new synaptic connections from axonal sprouting in the spinal cord; (3) changes in synthesis, release, or actions of neurotransmitters; and (4) alterations in afferent input (afferent axonal sprouting) from peripheral organs. Reports of specific alterations in animal models are summarized by Morrison et al. (2005) as (1) increased sensitivity of C-fiber afferents, possibly involving NGF; (2) enlargement of dorsal root ganglion cells; (3) increased electrical excitability of afferents associated with a shift in expression of sodium channels from a high-threshold tetrodotoxin-resistant type to a low-threshold tetrodotoxin-sensitive type. Other findings possibly related to the development of LUT dysfunction after SCI have been reported as (1) increased concentrations of glutamate, glycine, and taurine (Smith et al., 2002); (2) disruption of bladder epithelium barrier function (Apodaca et al., 2003); (3) change from low affinity M_1 to high affinity M_3 receptors at pre-junctional cholinergic nerve endings (Somogyi et al., 2003); (4) increased release of adenosine triphosphate (ATP) from bladder urothelium (Khera et al., 2004); (5) increased spinal cord NGF (Seki et al., 2004); and (6) alterations in smooth muscle myosin heavy chain gene expression (Wilson et al., 2005). In murine models of acute SCI, nicotinic or purinergic receptor mechanisms have been shown to be the primary mechanism for ATP release because atropine has been shown to be only partially effective in stimulating ATP release (predominantly a muscarinic receptor phenomenon in the absence of injury). These findings further indicate a change in receptor-mediated bladder activity associated with SCI (Salas et al., 2007). Yet another mechanism of bladder dysfunction may arise from modulation of TRPA-1 receptors, which has been shown to attenuate bladder overactivity in SCI models, indicating the importance of these receptors in the spinal cord–injured bladder (Andrade et al., 2011).

The characteristic pattern in a patient with a complete lesion above the sacral spinal cord is detrusor overactivity, smooth sphincter synergia (with lesions below the sympathetic outflow), and striated sphincter dyssynergia (Chancellor and Blaivas, 1995a; Sullivan and Yalla, 1992; Thomas and O'Flynn, 1994). **Neurologic examination shows spasticity of skeletal muscle distal to the lesion, hyperreflexic DTRs, and abnormal plantar responses. There is impairment of superficial and deep sensation.** Figs. 116.1 to 116.3 typify the cystourethrographic and urodynamic patterns. The guarding reflex is absent or weak in most patients with a complete suprasacral SCI. In incomplete lesions the reflex is often preserved but variable (Morrison et al., 2005). The striated sphincter dyssynergia causes a functional obstruction with poor emptying and high detrusor pressure. In an effort to subclassify detrusor sphincter dyssynergia, Karsenty et al. (2005) retrospectively evaluated videourodynamic recordings of patients with complete SCI with untreated neurogenic overactive bladder and detrusor sphincter dyssynergia. They identified two time periods within the tracings, with Delay A being defined as that period between the onset of external urethral sphincter (EUS) pressure increase and the subsequent onset of bladder pressure increase. Delay B was defined as the period between the onset of urethral sphincter pressure increase and the moment at which bladder pressure increase reached a level of 10 cm H_2O or greater above the baseline value. The recordings of 20 patients were assessed, with the Delay A timeframe found to be significant in 16 of 20 patients, with a mean time for delay of 2.2 seconds. There was a positive association between this delay and the completeness of the SCI and the presence of continuous DSD on electromyogram. Delay B was positive in all patients with a mean delay time of 7.6 seconds. The authors concluded that EUS contraction starts before the onset of bladder contraction in most patients with coexistent SCI and detrusor sphincter dyssynergia.

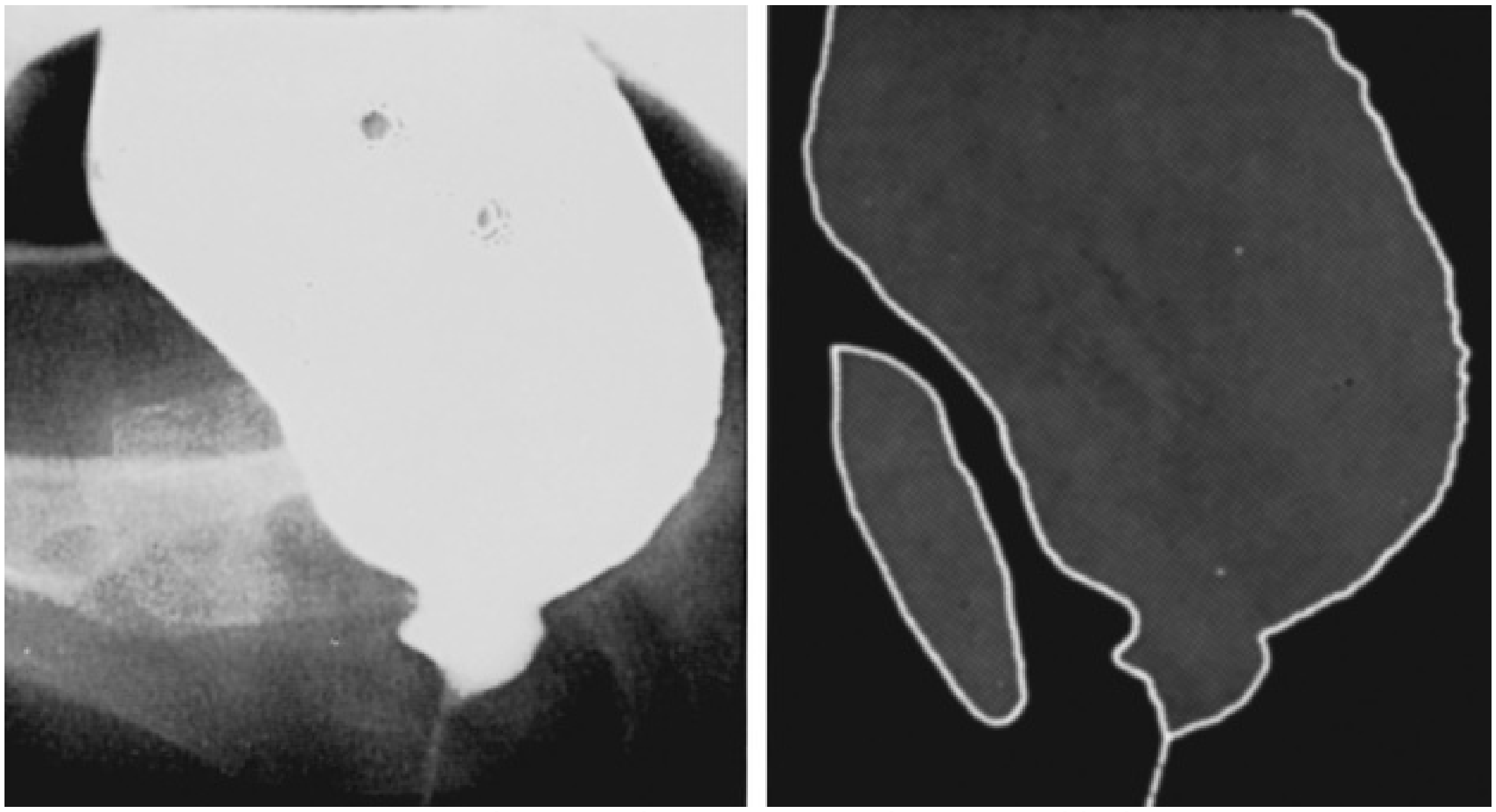

FIG. 116.1 Cystourethrogram in a 19-year-old woman with detrusor-striated sphincter dyssynergia secondary to a complete spinal cord injury at vertebral level T11. Image was taken during an involuntary bladder contraction with exaggerated bladder neck opening caused by the obstruction below. (From Nordling J, Olesen KP: Basic urographic and cystourethrographic patterns. In Pollack HM, editor: *Clinical urography*, Philadelphia, 1990, Saunders, p 1953.)

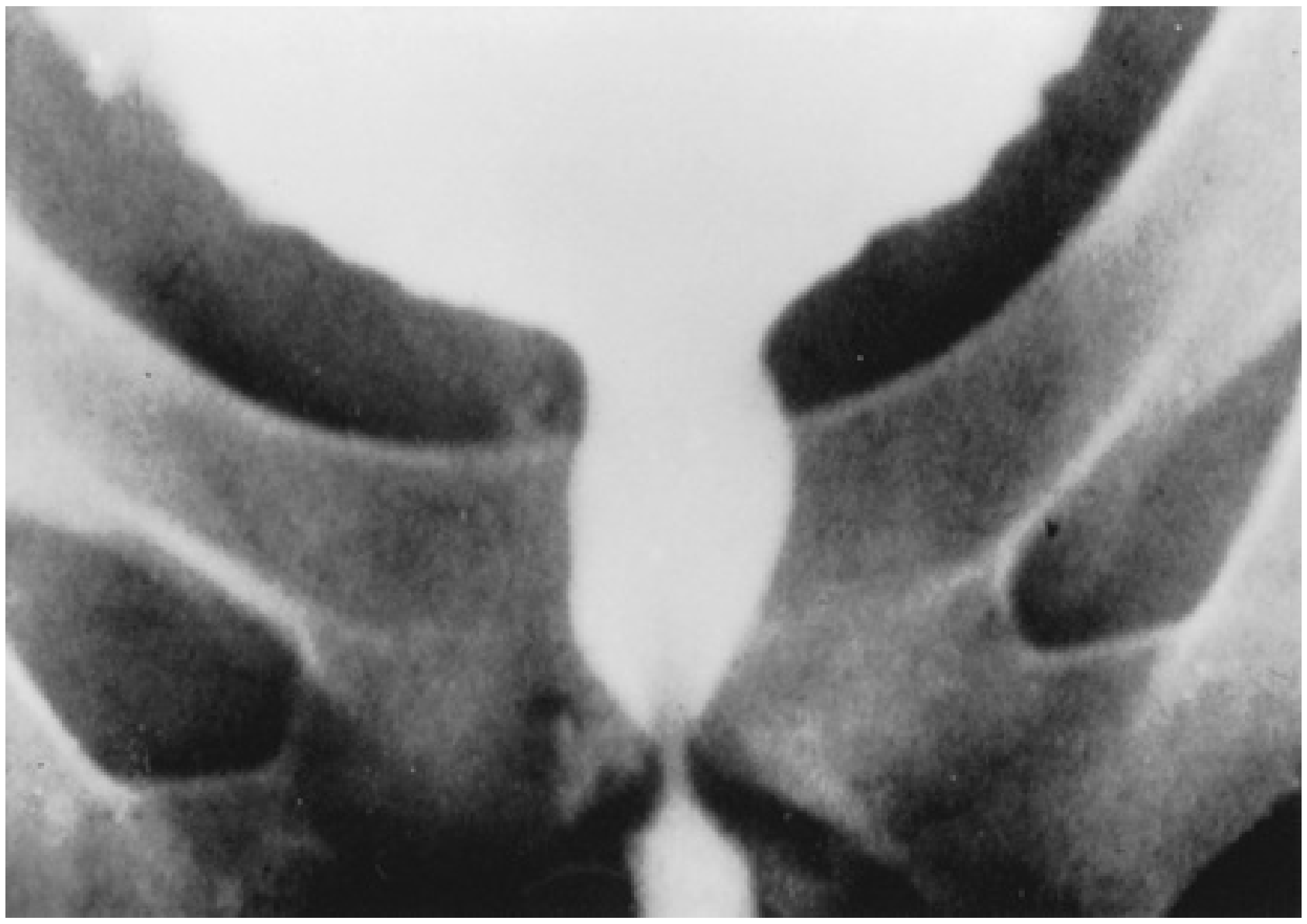

FIG. 116.2 Typical cystourethrographic configuration of a synergic smooth sphincter and a dyssynergic striated sphincter in a man during a bladder contraction. (From Nanninga JB: Radiological appearances following surgery for neuromuscular diseases affecting the urinary tract. In Pollack HM, editor: *Clinical urography,* Philadelphia, 1990, Saunders, p 2003.)

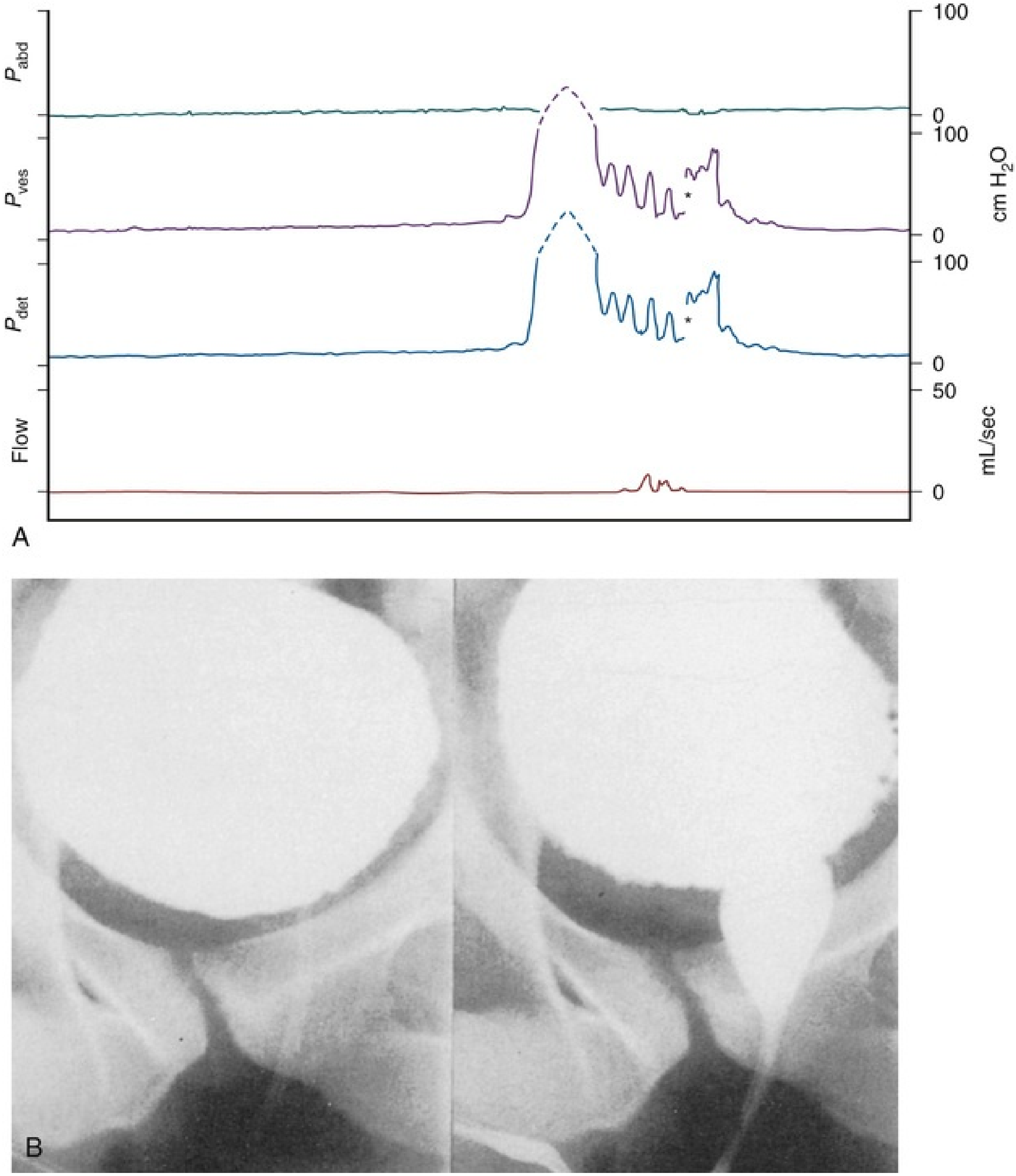

FIG. 116.3 Video images in B at corresponding points of the urodynamic tracings in A. Detrusor hyperreflexia (Pdet 150 cm H_2O), synergic bladder neck, dyssynergic striated sphincter. The *asterisk* represents a range change from a scale of 0 to 100 cm H_2O. (From Lawrence WT, Thomas DC: Urodynamic techniques in the neurologic patient. In O'Reilly PH, George NJR, Weiss RM, editors: *Diagnostic techniques in urology,* Philadelphia, 1990, Saunders, p 360.)

The presence of striated sphincter dyssynergia causes a functional

obstruction with poor emptying and high detrusor pressures. Occasionally, incomplete bladder emptying may result from what seems to be a poorly sustained or absent detrusor contraction. This seems to occur more commonly in lesions close to the conus medullaris than with more cephalad lesions. This may result from a second occult lesion or may be caused by locally functioning reflex arcs, which result in detrusor inhibition from strong striated pelvic floor muscle contraction, or by a loss of higher center–mediated detrusor facilitation, which normally occurs after the initial increase in pressure during a bladder contraction (Thomas and O'Flynn, 1994). Once reflex voiding is established, it can be initiated or reinforced by the stimulation of certain dermatomes, such as by tapping the suprapubic area. The urodynamic and upper tract consequences of the striated sphincter dyssynergia vary with severity (usually worse in complete lesions), duration (continuous contraction during detrusor activity is worse than intermittent contraction), and anatomy (male is worse than female) (Linsenmeyer et al., 1998).

The type of dyssynergia also appears to be associated with degree of injury and potential for progression of dysfunction. Schurch et al. (2005) evaluated 105 male patients with SCI and noted a correlation between the type of DSD and completeness of spinal cord lesion. Men with incomplete sensory and motor lesions more commonly had type 1 DSD (increase in detrusor pressure and electromyographic activity), whereas complete sensory and motor lesions were more commonly associated with either type 2 (sporadic contractions of the striated sphincter throughout detrusor contraction) or type 3 DSD (crescendo-decrescendo pattern of sphincter contraction). However, there was no correlation noted between the type of DSD and the lesion level. At long-term follow-up, DSD type was noted to evolve from type 2 or type 3 DSD in approximately a quarter of the studied patients, whereas 65% of patients remained stable with the same type of DSD at follow-up (Schurch et al., 2005).

From a functional standpoint, the voiding dysfunction most commonly seen in suprasacral SCI represents a filling or storage and an emptying or voiding failure. If bladder pressures are suitably low or if they can be sufficiently and safely lowered with nonsurgical or surgical management, the problem can be treated primarily as an emptying failure. CIC can then be continued as a safe and effective way of satisfying many of the goals of treatment. The role of additive antimuscarinic administration appears to be supported by the preponderance of evidence in this patient population (Madersbacher et al., 2012). Consensus opinion has stressed the conservative use of antibiotics in patients using long-term CIC. Wyndaele (2012) expressed the importance of demonstrating definitive evidence of UTI before initiating antimicrobial therapy. Alternatively, sphincterotomy or intrasphincteric injection of onabotulinumtoxinA can be used in males to lower the detrusor leak point to an acceptable level and render the patient incontinent, thus converting the dysfunction primarily to a storage failure (incontinence), which can be obviated either by timed stimulation or with an external collecting device. In the dexterous SCI patient, the former approach using CIC is becoming predominant. Electrical stimulation of the anterior sacral roots with some form of deafferentation is also now a distinct reality (Creasey et al., 2001; Seif et al., 2004). Ongoing investigations with ventral nerve surgery (Lam Van Ba et al., 2018) and use of stem cells may completely change the paradigm of suprasacral cord injury management in the future (Snyder and Teng, 2012).

Key Points: Management of Patients With Suprasacral Spinal Cord Injury

- The characteristic urodynamic pattern is detrusor overactivity, smooth sphincter synergia (with lesions below the sympathetic outflow), and striated sphincter dyssynergia.
- A careful initial evaluation and periodic, routine follow-up evaluation must be performed to identify and correct risk factors and potential complications: high-pressure storage, high detrusor leak point pressure, VUR, stone formation (lower and upper tracts), and complicating infection, especially in association with reflux.
- Avoid use of long-term antibiotics to prevent infection in patients performing CIC.
- Ongoing investigations with ventral nerve surgery and use of stem cells may completely change the paradigm of suprasacral cord injury management.

Sacral Spinal Cord Injury

After the patient has recovered from spinal shock, there is **typically a depression of DTRs below the level of a complete lesion with varying degrees of flaccid paralysis. Sensation is usually absent below the lesion level. Detrusor areflexia with high or normal compliance is the common**

initial result. However, decreased compliance may also develop, a finding in some distal SCI lesions that most likely represents a complex response to neurologic decentralization probably involving reorganization and plasticity of neural pathways (Blaivas et al., 1998b; de Groat et al., 1997; Fam and Yalla, 1988). There is surprisingly little consensus on the evolution of the appearance or function of the bladder neck or smooth sphincter area after sacral SCI. **The classic outlet findings are described as a competent but nonrelaxing smooth sphincter and a striated sphincter that retains some fixed tone but is not under voluntary control. Closure pressures are decreased in both areas** (Sullivan and Yalla, 1992; Thomas and O'Flynn, 1994). The late appearance of the bladder neck may be “open” (Kaplan et al., 1991). Attempted voiding by straining or Credé maneuver results in “obstruction” at the level of the potentially closed bladder neck or at the distal sphincter area if the sphincter tone is fixed (Fam and Yalla, 1988; Thomas and O'Flynn, 1994). Fig. 116.4 illustrates the typical cystourographic and urodynamic pictures of the late phases of such a complete lesion.

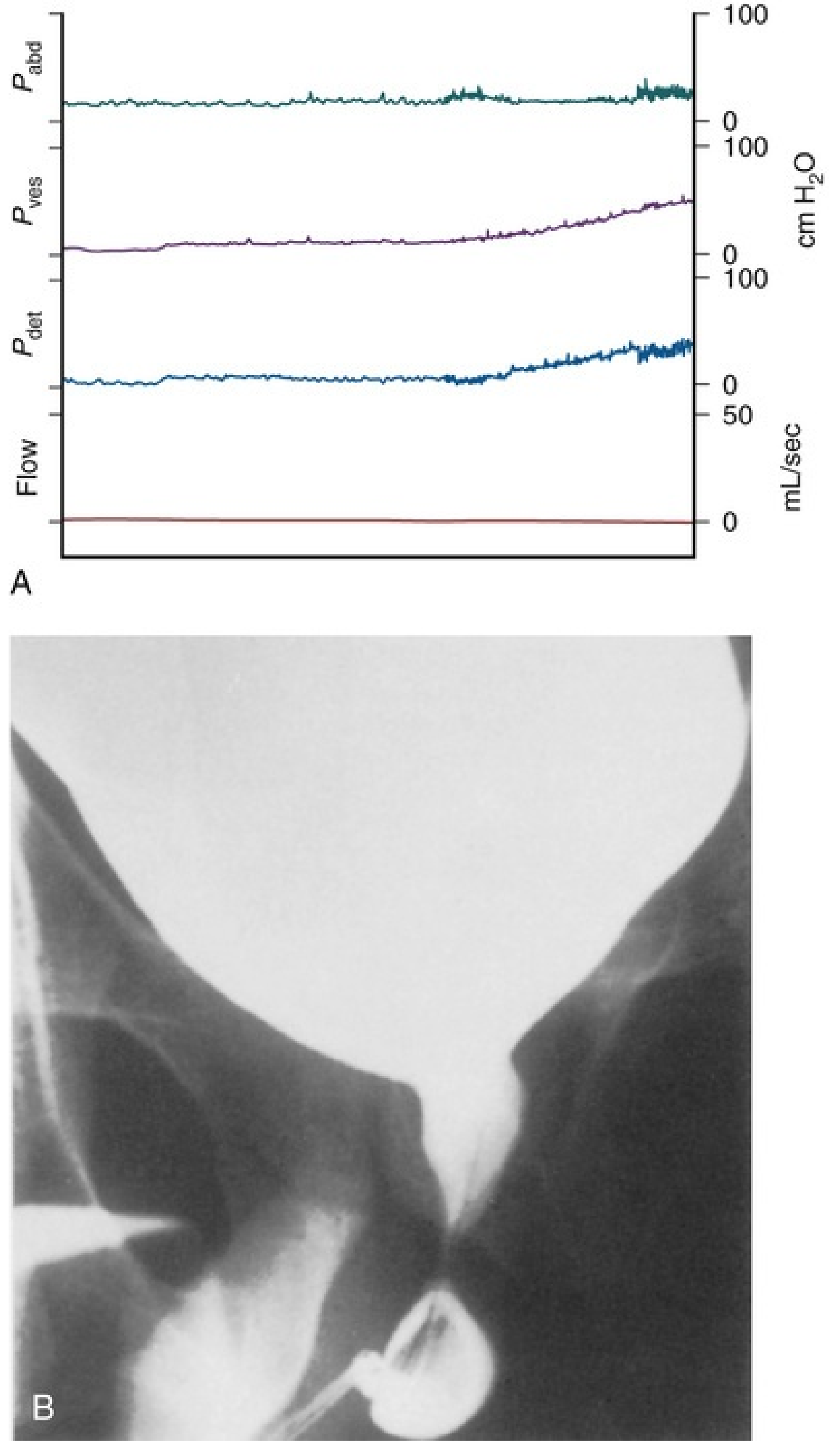

FIG. 116.4 Simultaneous video (B) and urodynamic study (A) from a 28-year-old man whose bladder has been filled with 420 mL of contrast material. There is low compliance; the bladder neck is incompetent; and with straining, the distal sphincter mechanism does not open—a pattern often seen in sacral spinal cord or efferent nerve root injury or disease. (From Lawrence WT, Thomas DC: Urodynamic techniques in the neurologic patient. In O'Reilly PH, George NJR, Weiss RM, editors: *Diagnostic techniques in urology,* Philadelphia, 1990, Saunders, p 362.)

Key Points: Management of Patients With Sacral Spinal Cord Injury

- Potential risk factors and complications are those previously described, with particular emphasis on storage pressure, which can result in silent upper tract decompensation and deterioration in the absence of VUR.
- Treatment is usually directed toward producing or maintaining low-pressure storage while circumventing emptying failure with CIC when possible. Pharmacologic and electrical stimulation may be useful in promoting emptying in certain circumstances.

Neurologic and Urodynamic Correlation

Although generally correct, the correlation between somatic neurologic findings and urodynamic findings in suprasacral and sacral SCI patients is not exact. A number of factors should be considered in this regard. First, whether a lesion is complete or incomplete is sometimes a matter of definition, and a complete lesion, somatically speaking, may not translate into a complete lesion autonomically and vice versa. In addition, multiple injuries may actually exist at different levels, even though what is seen somatically may reflect a single level of injury. Further demonstration of the unpredictability of LUT status in patients with incomplete lesions was reported by Patki et al. (2006), who assessed a group of 43 men and 21 women with incomplete SCI (American Spinal Injury Association [ASIA] grades D and E) during a 2-year period. Forty patients initially assessed as having a bladder not at risk for deterioration ultimately experienced deterioration requiring CIC. Conversely, 5 of 20 patients who initially required CIC no longer required this with time. In long-term follow-up, 68% of patients continued to have abnormal urodynamic findings, and 37% of patients required a change in urologic management in the absence of perceptible change in neurologic status, indicating the potential for continued bladder changes in the absence of other detectable neurologic disease (Patki et al., 2005).

In a classic article, Blaivas (1982) correlated clinical and urodynamic data from 550 patients with LUT dysfunction. In 155 patients with complete and incomplete suprasacral neurologic lesions, physiologically normal voiding was reported in 41%. DSD was demonstrated in 34%, and, surprisingly (and seemingly paradoxically), detrusor areflexia was noted in 25%. Other authors have noted detrusor areflexia with suprasacral SCI or disease with hypothesized causes of a coexistent distal spinal cord lesion or a disordered integration of afferent activity at the sacral root or cord level (Beric and Light, 1992; Light et al., 1985). DSD was reported in 45% of 119 patients with suprasacral spinal cord lesions, whereas none of 36 patients with supraspinal neurologic lesions had DSD. These data support prior conclusions that **(1) coordinated voiding is regulated by neurologic centers above the spinal cord and (2) a diagnosis of striated sphincter dyssynergia implies a neurologic lesion that interrupts the neural axis between the pontine-mesencephalic reticular formation and the sacral spinal cord.** All 27 patients with neurologic lesions above the pons who were able to void did so synergistically (i.e., with relaxation of the striated sphincter followed by detrusor contraction). Twenty of these patients had detrusor overactivity, but 12 of the 20 had voluntary control of the striated sphincter, supporting a thesis of separate neural pathways governing voluntary control of the bladder and of the periurethral striated musculature. Most of these patients with detrusor overactivity secondary to suprapontine lesions were able to voluntarily contract the striated sphincter, but without abolishing bladder contraction. This seems to indicate that the inhibition of bladder contraction by pudendal motor activity is not merely a simple sacral reflex, but rather a complex neurologic event. Twenty-two of these patients had evidence of either sacral or infrasacral neurologic impairment of bladder function with suprasacral control of striated sphincter function or vice versa. This provides a clinical correlate to the separate anatomic locations of the parasympathetic motor nucleus and the pudendal nucleus in the sacral spinal cord.

Wyndaele (1997) correlated the neurologic and urodynamic data in 92 patients with SCI and came to the same general conclusion: **Although there was a general correlation between the neurologic level of injury and the expected vesicourethral function, it was neither absolute nor specific, especially in the group of patients with paraplegia resulting from spinal cord lesions at column level T10 to L2.** With reference to this latter group, Pesce et al. (1997) reported on 46 patients with complete SCIs from vertebral lesions between T11 and L2: 50% of the patients had detrusor areflexia and 50% had detrusor overactivity. Of the patients with detrusor overactivity, 16 also had DSD. Of 22 patients with lesions above vertebral level L1, 8 showed areflexia and 14 showed detrusor overactivity, of whom 9 demonstrated DSD. Of 9 patients with a lesion between T12 and L1, 3 showed detrusor areflexia and 6 overactivity, of whom 4 showed DSD. Of 15 patients with a lesion at L1 or lower, 3% showed detrusor overactivity and DSD.

Based on their review of 243 post-traumatic SCI patients who underwent complete spinal computed tomography (CT) or MRI, Weld and Dmochowski (2000) agreed that the correlation between somatic neurologic findings or spinal imaging studies and urodynamic findings in SCI patients is not exact. The authors’ correlation between level of injury and urodynamic findings was better than those previously reported, most likely attributable to the precision of the radiologic imaging studies. Of 196 patients with suprasacral injuries, 94.9% demonstrated overactivity and/or DSD, 41.8% had low bladder compliance (defined as 12.5 mL/cm H_2O), and 40.3% had detrusor leak point pressures greater than 40 cm H_2O. Of the 14 patients with sacral injuries, 85.7% demonstrated detrusor areflexia; 78.6%, low compliance; and 85.7%, high leak point pressures. Of 33 patients with combined suprasacral and sacral injuries, 68% demonstrated detrusor overactivity and/or DSD, 27% had areflexia, 58% had low compliance, and 61% had high leak point pressures.

Other factors such as underlying histology may also contribute to upper tract deterioration. Ozkan et al. (2006) performed full-thickness bladder biopsies in a group of patients undergoing augmentation cystoplasty for NDO. A relationship between the degree and severity of detrusor fibrosis was noted to be a significant risk factor for upper tract deterioration. In addition, leak-point pressures of greater than 75 cm H_2O were also found to be consistent with upper tract deterioration (Ozkan et al., 2006). Recent data suggest that detrusor overactivity occurring greater than one-third the duration of bladder filling is associated with renal damage in SCI (Elmelund et al., 2017). **Aggressive treatment of NDO should be undertaken in SCI patients to prevent long-term upper tract damage.**

The International Continence Society published a paper on good urodynamic practices to improve urodynamic methods (Rosier et al., 2017). Data reviewed on urodynamic evaluation for neurogenic lower urinary tract dysfunction suggested wide variation in same-setting repeat urodynamic parameters such as cytometric capacity, storage pressures, and voiding data but good correlation in the detection of detrusor overactivity. This suggests that **a single urodynamic study may not provide an adequate picture of the patient's LUT function, and repeated evaluations may be necessary to make accurate clinical assessments.**

In summary, all of these data suggest that **management of the urinary tract**

in such patients must be based on urodynamic principles and findings rather than inferences from the neurologic history and evaluation. Conversely, clinicians should not draw neurologic conclusions solely on the basis of urodynamic findings, although the information regarding complete lesions is, for the most part, valid (Cameron et al., 2012; Lenherr and Clemens, 2013). **Regular urodynamic follow-up is recommended to evaluate changes over time, assess response to treatments, and prevent upper tract damage** (Schurch et al., 2018).

Autonomic Dysreflexia

First described by Guttmann and Whitteridge in 1947, autonomic hyperreflexia (autonomic dysreflexia) is a potentially fatal emergency unique to the SCI patient. Excellent source materials include the reviews by Trop and Bennett (1991), Vaidyanathan et al. (1998), and Karlsson (1999). **Autonomic hyperreflexia represents an acute massive disordered autonomic (primarily sympathetic) response to specific stimuli in patients with SCI above the cord level of T6 to T8 (the sympathetic outflow).** It is more common in cervical (60%) than thoracic (20%) SCI. Onset after injury is variable—usually soon after spinal shock, but it may occur up to years after injury, and distal spinal cord viability is a prerequisite.

Symptomatically, autonomic hyperreflexia is a **syndrome of exaggerated sympathetic activity in response to stimuli below the level of the lesion. The symptoms include pounding headache, hypertension, and flushing and sweating of the face and body above the level of the lesion. Bradycardia is a typical accompaniment, although tachycardia or arrhythmia may occur. Hypertension may vary in severity** from causing a mild headache before voiding to life-threatening cerebral hemorrhage or seizure.

The stimuli for this exaggerated response commonly arise from the bladder or rectum and typically involve distention. Precipitation may be the result of simple LUT instrumentation, tube change, catheter obstruction, or clot retention, and in such cases the symptoms resolve quickly if the stimulus is withdrawn. Additional causes or exacerbating factors may include other upper urinary tract or LUT pathology (e.g., calculi), gastrointestinal pathology, long bone fracture, sexual activity, electrocoagulation, and decubitus ulcers. Risk factors for autonomic dysreflexia during urodynamic evaluation include complete injury, cervical-level of injury, presence of detrusor sphincter dyssynergia, poor bladder compliance, and more than 2 years since injury (Liu et al., 2017). **In addition, with more SCI patients participating in athletic pursuits, the instigation of this condition related to sports activities is also being increasingly recognized** (Krassioukov, 2012).

DSD invariably occurs, and, at least in males, smooth sphincter dyssynergia is also usually a part of the syndrome. The pathophysiology is that of nociceptive stimulation via afferent impulses that ascend through the cord and elicit reflex motor outflow, causing arteriolar, pilomotor, and pelvic visceral spasm and sweating. Normally, the reflexes would be inhibited by secondary output from the medulla, but because of the SCI this does not occur below the lesion level. Vaidyanathan et al. (1998) emphasized that the SCI disrupts control of the sympathetic preganglionic neurons because bulbospinal input has been lost, and the remaining regulation is accomplished by spinal circuits consisting of dorsal root afferent and spinal interneurons. Karlsson (1999), however, points out that the underlying pathogenic mechanisms may not be as simple as they first appear. The amplitude of the blood pressure reaction indicates involvement of a large vascular bed, perhaps larger than that of the skin and skeletal muscle. It may be that the splanchnic vascular bed is involved as well, either from the standpoint of active vasoconstriction or simply from a lack of the ability to exhibit compensatory vasodilatation. Afferent and efferent plasticity in the sympathetic nervous system (SNS) may also be involved.

Urodynamic evaluation continues to be a critical component of the evaluation of the LUT in SCI; however, it can incite autonomic dysreflexia. A study of 120 patients with suprasacral SCI undergoing urodynamics assessed the incidence of autonomic dysreflexia (defined as systolic blood pressure increase of 20 mm Hg or more); 42.6% of patients with injuries at T6 or above met criteria for the diagnosis of autonomic dysreflexia. Overall, 36.7% of patients experienced this condition. Surprisingly, 15.4% of patients with lesions below T6 experienced blood pressure elevations. Significant blood pressure increases were more commonly associated with DSD occurring continuously during bladder filling or in individuals with severely impaired bladder compliance as compared with individuals without those two variables. Most patients in this trial (75%) did not experience significant pulse rate changes (10 beats per minute), and, surprisingly, only 22.7% of those with the diagnosis of autonomic dysreflexia actually experienced bradycardia. The finding of dysreflexia in patients with lesions below the classically defined T6 level serves as a signal for close surveillance of SCI patients receiving LUT evaluation (Huang et al., 2011).

Ideally, any endoscopic procedure in susceptible patients should be done using spinal anesthesia or carefully monitored general anesthesia. The hemodynamic effects of this syndrome may be managed with β-adrenergic and/or α-adrenergic blocking agents. Ganglionic blockers were once the mainstay of treatment (Wein, 2002a), but their usage has essentially been abandoned. Sublingual nifedipine is capable of alleviating this syndrome when given during cystoscopy (10 to 20 mg) and of preventing it when given orally 30 minutes before cystoscopy (10 mg) (Dykstra et al., 1987). The rationale for giving this medicine was that smooth muscle contraction would be prevented through its calcium antagonist properties, and the increase in peripheral vascular resistance normally seen with sympathetic stimulation would likewise be prevented. Before electroejaculation, Steinberger et al. (1990) recommended oral prophylaxis with 20 mg of nifedipine, finding this markedly lowered pressure rises during treatment. The use of sublingual nifedipine, however, has been prohibited in many medical centers. Other rapidly acting agents have been reported to be beneficial, and labetalol is recommended by many anesthesiologists (Bycroft et al., 2005). Captopril, hydralazine, and diazoxide are still occasionally recommended but may be less advantageous (Furlan, 2013). **The current recommendation for the acute pharmacologic treatment of autonomic dysreflexia is placement of 2% nitroglycerin paste above the level of the lesion for rapid blood pressure reduction secondary to vasodilation** (Eldahan and Rabchevsky, 2017). Nitrites induce smooth muscle relaxation via conversion to nitric oxide. In instances of persistent hypertension despite transdermal or sublingual nitroglycerin, intravenous nitroprusside may be used. **Pharmacologic treatment should be initiated only after removal of the stimulus (i.e., bladder distention).**

Medical prevention of autonomic dysreflexia has also been examined. Chancellor et al. (1994) reported on the use of terazosin (a selective α_1-adrenergic blocker) for long-term management (3-month study) and prophylaxis of autonomic hyperreflexia. A nightly dose of 5 mg reduced severity, whereas erectile function and blood pressure were unchanged. Vaidyanathan et al. (1998) confirmed the success of prophylactic terazosin. They treated 18 tetraplegic adults and 3 paraplegics with gradually increasing doses of the drug, ultimately varying from 1 to 10 mg daily. The authors reported complete resolution of dysreflexic symptoms in all patients; only 1 tetraplegic patient required drug discontinuation because of persistent dizziness. Such prophylaxis may be particularly important in view of the fact that significant elevations in blood pressure can occur without other symptoms of autonomic hyperreflexia (Linsenmeyer et al., 1996).

Similar salubrious results have been reported with prazosin as prophylaxis for this condition (Bycroft et al., 2005). Prophylaxis, however, does not eliminate the need for careful monitoring during provocative procedures. There are patients with severe dysreflexia that is intractable to oral prophylaxis and correction by urologic procedures. For these unfortunate individuals, a number of neurologic ablative procedures have been used: sympathectomy, sacral neurectomy, sacral rhizotomy, cordectomy, and dorsal root ganglionectomy (Trop and Bennett, 1991). Hohenfellner et al. (2001) advocate sacral bladder denervation by sacral rhizotomy as a moderately invasive, relatively low risk procedure that, along with intermittent catheterization, produces good results in refractory patients.

Vesicoureteral Reflux

The reported incidence of vesicoureteral reflux (VUR) in patients with SCI varies between 17% and 25% (Thomas and Lucas, 1990), **and the condition is more common in those with suprasacral SCI. Contributing factors include (1) elevated intravesical pressure during filling and emptying and (2) infection. Persistent reflux can lead to chronic renal damage and may be an important factor in the long-term survival of patients with SCI.** Hackler et al. (1965) reported that persistent reflux was present in 60% of patients with SCI dying of renal disease. In patients with only transient VUR over a 5- to 15-year period, urography was normal or minimally changed in 83%. High storage and voiding pressures irrespective of VUR can be responsible for renal damage (McGuire, 1984; Vega and Pascual, 2001). Ku et al. (2005) reported on 179 men with SCI at a mean follow-up after injury of 29 years. The incidence of VUR in this group was 15.1%, whereas 34% of patients were diagnosed with pyelonephritis at some point during their follow-up. Nearly 25% developed renal stones, and 32% experienced upper tract deterioration as manifested by hydronephrosis. Upper tract degeneration was more prevalent in those managed with urethral catheters (51%) than in those managed with either spontaneous voiding or CIC. Urethral catheter drainage was inferior to all other forms of bladder drainage in terms of protecting the upper tracts, underscoring the inadvisability of chronic urethral catheterization in this patient population (Ku et al., 2005).

The best initial treatment for VUR in a patient with voiding dysfunction

secondary to neurologic disease or injury is to normalize LUT urodynamics (i.e., decrease storage pressures and decrease outlet resistance). Depending on the clinical circumstances, this may be achieved by pharmacotherapy, urethral dilatation (in the myelomeningocele patient), neuromodulation, deafferentation, augmentation cystoplasty, or sphincterotomy (Flood et al., 1994; Perkash et al., 1998). If this fails, the question of whether to operate on such patients for correction of the reflux or to correct the reflux while performing another procedure (e.g., augmentation cystoplasty) is not an easy one, because correction of reflux in a frequently very thickened bladder may not be an easy task.

Transureteroureterostomy for unilateral reflux is feasible, but even experienced urologists have had difficulties with ureteral calculi trapping, recurrent VUR, and obstruction at the vesicoureteral junction after such procedures in this difficult group of patients (Van Arsdalen and Hackler, 1983). Submucosal trigonal injection of bulking substances has added a new dimension to the treatment of this difficult problem. Despite increased awareness of renal dysfunction related to high-pressure reflux in the SCI population, the prevalence of renal functional compromise in this population remains significant (Fischer et al., 2012).

Occasionally, bladder neck closure and permanent suprapubic drainage are indicated in the case of the severely dysfunctional or destroyed urethra arising from long-term indwelling catheterization (Colli and Lloyd, 2011). Urinary diversion continues to be a common method for management of LUT complications in this patient population (Peterson et al., 2012). However, in some cases, alternative diversion techniques using detubularized bowel segments may be successful (Khavari et al., 2012).

Finally, clinicians must remember the potential artifact that significant reflux can introduce into urodynamic studies. **Measured bladder capacity appears artifactually large, and measured pressures at given inflow volumes may appear lower than those after reflux correction.** The apparent significance of detrusor overactivity may thus be underestimated.

Urinary Tract Infection

UTI is relatively common in patients with SCI and occurred in 100% of patients with SCI in one study with 40- to 50-year follow-up (Gao et al., 2017). UTI or bacteriuria may occur in up to 57% of patients with SCI in the first year after initial hospitalization (Morton et al., 2002). Identified risk factors for UTI include male gender, cervical-level of injury, and condom catheter use (Gao et al., 2017). Recurrent infections may be a manifestation of upper or lower tract calculi, symptomatic or silent pyelonephritis, or LUT dysfunction causing persistently elevated residual urine. In conjunction with poor urodynamic function, UTI can lead to high morbidity, poor quality of life, and decreased life expectancy in patients with SCI (Sauerwein, 2002). The use of antibiotics in SCI patients remains a topic of controversy. **A consensus reached by the National Institute on Disability and Rehabilitation Research Group in 1992 stated that bacteriuria should be treated only when the patient has signs or symptoms of a UTI** (Penders et al., 2003). Although several years old, this comprehensive review by Biering-Sorensen et al. (2001) recommended the following, which remain true in the management of bacteriuria and UTIs:

1. Treat bacteriuria only if symptomatic.
2. Use antimicrobial agents, if possible, with little or no impact on normal flora.
3. Treat at least 5 days, and 7 to 14 days for those with reinfection or relapse.
4. Repair structural and functional risk factors.
5. Use prophylaxis only in those with recurrent UTI when no underlying cause can be found and especially in those patients with dilated upper tracts.
6. Do not use antibiotics to prevent UTI in patients with an indwelling catheter or intermittent catheterization.

The role of catheter type and infection risk has been assessed extensively, with evidence supporting the use of hydrophilic catheters (Bermingham et al., 2013; Li et al., 2013). There have been conflicting studies about the use of prophylactic antibiotics in patients with recurrent UTIs and/or the need for catheterization (Morton et al., 2002; Sauerwein 2002) and in truth, there are few evidence-based data in this area (Hooton et al., 2010). In a recent initiative, the American Board of Internal Medicine partnered with the American Urological Association to create recommendations for the **Choosing Wisely campaign, which recommends against the prescription of antibiotics for patients using indwelling or intermittent catheterization in the absence of signs and symptoms of a UTI (www.choosingwisely.org)**.

Spinal Cord Injury in Women

There are many aspects of management of the LUT affected by SCI that are specific to women (Yang and Cardenas, 2001). The body composition of women with SCI shows deficient protein and bone mass and excess fat, predisposing them to an increased risk of skin breakdown and incidence of fractures, a finding compounded by osteoporosis. The symptoms of menopause (e.g., hot flashes) may be difficult to distinguish from those of autonomic dysreflexia, and incontinence and UTIs worsen with age in women in the general population and particularly in those with SCI (Kalpakjian et al., 2010).

Suitable bladder reservoir function can usually be achieved either pharmacologically or surgically, and paraplegic women can usually master CIC. However, special difficulty is encountered in these patients because of the lack of an appropriate external collecting device. Although some tetraplegic women can be trained to perform CIC, there is no practical alternative to indwelling catheterization for most (Lindan et al., 1987). There are reports of long-term drainage with an indwelling urethral catheter being well tolerated; however, McGuire and Savastano (1986) point out the potential for significant incontinence around the catheter and the development of upper tract changes (Kalpakjian et al., 2010).

For those female patients with SCI who can perform CIC or who have around-the-clock medical or family care, creation of adequate bladder reservoir function is reasonable. For those not in this category, the alternatives are limited and challenging. Bennett et al. (1995) compared the incidence of major complications in a group of female patients with SCI who were managed long term by (1) CIC; (2) reflex voiding and incontinence padding; and (3) an indwelling catheter. There were 10 major complications in the 25 patients in group 2, 58 in the 22 patients in group 3, and only 4 major complications in group 1. Singh and Thomas (1997) looked at the results of treatment in a group of female tetraplegics. Twenty-three of 27 patients with complete lesions wound up using an indwelling catheter, 3 underwent diversion, and in 1 patient the caregiver performed CIC. In 20 patients with incomplete lesions, all with poor functional recovery, 14 had permanent indwelling catheters, 3 were able to perform CIC, and 3 used reflex voiding by triggering. Of 37 patients with incomplete lesions with good functional recovery, only 3 required indwelling catheterization, 4 used CIC, and most were able to use reflex voiding by triggering. The authors noted also that 55% of the women with permanent catheters had bladder calculi, 35% had leakage around the catheter, and 33% had recurrent symptomatic infection. Although upper tract changes were seen in only

5%, it is obvious that the authors consider that, for the most part, female patients with voiding dysfunction secondary to cervical SCI who exhibit poor functional recovery represent urologic failures of management. Surgical intervention for stress urinary incontinence in this population also may be beneficial in well-selected patients. Mid-urethral tapes have been reported to produce reasonable outcomes in selected women with SCI (Pannek, 2012). Other groups have reported durable and safe results using autologous tissue as the sling type (Athanasopoulos et al., 2012).

Spinal Cord Injury (Neurogenic Bladder) and Bladder Cancer

There is a strong association between the development of bladder cancer and long-term indwelling catheterization. Kaufman et al. (1977) initially reported squamous cell carcinoma of the bladder in 6 of 59 patients with SCI who had long-term indwelling catheters. Four of these patients had no obvious tumors visible at endoscopy, and the diagnosis was made by bladder biopsy. Five of these patients also had transitional cell elements in their tumor. Broecker et al. (1981) surveyed 81 consecutive SCI patients with an indwelling urinary catheter for more than 10 years, and, although the investigators did not find frank carcinoma in any patient, they found squamous metaplasia of the bladder in 11 and leukoplakia in 1. Locke et al. (1985) noted 2 cases of squamous cell carcinoma of the bladder in 25 consecutive SCI patients catheterized for a minimum of 10 years. Bickel et al. (1991) reported 8 cases of bladder cancer in men with SCI, although the denominator was uncertain. Four of the men had been managed by indwelling catheterization for 7, 10, 14, and 19 years, respectively. All of these 4 had transitional cell carcinoma, whereas in the other 4 men there were 2 cases of transitional and 2 of squamous cell carcinoma. In a series by Chao et al. (1993), 6 patients developed bladder cancer, 3 of whom had indwelling catheters (of a total of 32) and 3 of whom (of 41) did not. Stonehill et al. (1996) retrospectively reviewed all bladder tumors in their SCI patients for 7 years and compared these with matched controls. They found 17 malignant and 2 benign bladder tumors; indwelling catheter and a history of bladder calculi were statistically significant risk factors.

Hess et al. (2003) reported their own series and summarized one view of the literature regarding SCI and bladder cancer: (1) the relative risk in SCI patients is 16% to 28% greater than the general population; (2) the overall incidence is 2.3% to 10%; (3) there is a higher proportion of squamous cell than transitional cell carcinoma; (4) the prevalence peaks at an earlier age than in the general population; (5) diagnosis is often made at a more advanced stage; (6) risk factors include chronic indwelling catheterization, bladder stones, and chronic UTI; (7) neither cystoscopy nor cytology is an entirely reliable diagnostic tool; and (8) those with multiple risk factors should have a more aggressive evaluation.

There is not agreement of the utility of cystoscopy and cytology in the screening and diagnosis of bladder cancer in neurogenic bladder. Pannek et al. (2017) reported that cystoscopy and cytology in combination can improve bladder tumor detection. Conversely, Alimi et al. (2018) in a systematic literature search concluded there were insufficient data to definitively recommend using cytology and cystoscopy in the screening of bladder cancer. Despite the paucity of data, cystology and cystoscopy remain the principal tools in screening for bladder cancer in this population.

Tempering these views are reports by Pannek (2002), who reviewed the data from 43,561 patients with SCI in three countries and concluded that the incidence of bladder cancer is comparable with that of the general population. However, more than 60% of those affected had muscle invasive disease on initial presentation. Chronic indwelling catheters and persistent or recurrent UTI are suggested as risk factors rather than the SCI. Subramonian et al. (2004), in an assessment of spina bifida patients, reported similar conclusions regarding age-standardized incidence of bladder cancer relative to the general population. They reported a lifetime risk of 2.4% in their reported population. This compares with a lifetime risk estimation of 30.7 to 720 per 100,000. Seventy-five percent of the affected patients in the series had indwelling catheters for 18 to 32 years.

Whether the incidence of bladder cancer is increased or not in the SCI population, the natural history of bladder cancer is thought to be more highly aggressive in neurogenic patients and is responsible for 0.3% to 2.8% of known deaths in the SCI population. A recent meta-analysis by Ismail et al. (2017) demonstrated a 0.3% incidence of bladder cancer in patients with neurogenic bladder. The majority of the patients had SCI (99%), and 44.5% of patients had an indwelling catheter. Transitional cell carcinoma was the most common histology, but the tumors were more likely to be muscle invasive, which is a contributing factor to the higher mortality rate seen compared with the general population.

Follow-Up

With advances in medical and surgical care, mortality of SCI patients has decreased over time, resulting in a greater need for meticulous long-term urologic follow-up. In a cohort of SCI patients with 40 to 50 years follow-up (Gao et al., 2017), all patients experienced at least one UTI; however, on average, patients experienced 48.6 UTI episodes. Other than UTI, the most common complications were bladder stones in 49%, hydronephrosis in 47%, and VUR in 33%. Less common, but still problematic, complications included pyelonephritis, autonomic dysreflexia, urethral injury, and urosepsis. **The complexity of these patients, and the high likelihood of complications, highlights the necessity of lifelong urologic follow-up.**

Linsenmeyer and Culkin (1999) reported the American Paraplegia Society (APS) guidelines for urologic care of SCI. **Annual follow-up is recommended for the first 5 to 10 years after injury, and if the patient is doing well, then follow-up every other year is advised. Upper and lower tract evaluation should be done initially, yearly for 5 to 10 years, and then every other year.** Burns et al. (2001) recommended at least plain films and nuclear renal scans, with a decrease of more than 20% in renal plasma flow warranting further investigation. **Urodynamic evaluation was recommended by the APS at the same intervals as upper and lower tract screening. Cystoscopy was recommended annually in those with an indwelling catheter.**

In 2006 the Consortium for Spinal Cord Medicine detailed a set of guidelines for bladder management in adults with SCI and stated that, in general, a urologic evaluation should be done yearly, although no studies exist on the optimum frequency of such examinations or the tests that should be included (Consortium for Spinal Cord Medicine, 2006).

The European Association of Urology (EAU) guidelines for follow-up of all neurogenic LUT dysfunctions call for meticulous and regular re-evaluations at intervals of no more than 1 to 2 years, and more frequently for patients with MS and acute SCI and other unstable conditions. They include the following guidelines:

1. Supply the patient with urinary dipsticks to check the urine at least every 2 months and whenever a urinary infection is suspected.
2. Perform upper urinary tract and bladder morphology every 6 months (ultrasonography), along with residual urine determination.
3. Conduct physical examinations and blood chemistries yearly.
4. Obtain detailed specialist investigation every 1 to 2 years and on demand when risk factors emerge (Pannek et al., 2011).

Cervical Myelopathy

Cervical myelopathy is usually caused by compression, secondary to spondylosis, ossification of the posterior longitudinal ligament, or cervical disk herniation (Mochida et al., 1996; Sakakibara et al., 1995a). Sakakibara et al. (1995a) studied 128 affected patients, of whom 95 had voiding symptoms, 61 had storage symptoms, 71 had obstructive symptoms, and 25 had urinary incontinence. Urodynamic studies revealed detrusor overactivity in 61 patients and DSD in 22. On the other hand, Mochida et al. (1996) reported that 22 of 60 (37%) patients undergoing surgery for cervical myelopathy were found to have neuropathic bladder dysfunction on urodynamic evaluation. Of these, 9 (41%) were found to have detrusor overactivity, but 13 (59%) were characterized as having an underactive detrusor. These findings are at odds with what is expected with only cervical spinal cord pathology; therefore the need for urodynamic study to optimally guide therapy in patients with neurogenic bladder is reinforced.

Acute Transverse Myelitis

Acute transverse myelitis is a rapidly developing condition with motor, sensory, and sphincter abnormalities, usually with a well-defined upper sensory limit and no signs of spinal cord compression or other neurologic disease (Kalita et al., 2002). It may result from a variety of mechanisms—parainfectious, autoimmune, vascular, or demyelinating (Ganesan and Borzyskowski, 2001). The condition usually stabilizes within 2 to 4 weeks and is not progressive afterward; however, recovery may be variable and some residual neurologic deficits are possible. Although recovery is more variable, and the prognosis, in general, is more favorable, the development and nature of voiding dysfunction have been reported to be similar, level by level, to those of SCI (Sakakibara et al., 1995b). Kalita et al. (2002) reported on 18 patients with acute transverse myelitis whose 6-month outcome included persistent retention in 6 and storage symptoms in 10, of whom 5 had emptying problems as well. Only 2 patients had regained normal voiding. In the acute state, urodynamics showed an areflexic or contractile bladder in 10, detrusor overactivity with poor compliance in 2, and DSD in 3. Seventeen had urinary retention on presentation. More recently, Gupta et al. (2017) performed urodynamic studies in 43 patients after recovery from the spinal shock phase. The majority (86%) had detrusor overactivity, and 20 patients had dyssynergia. Five patients had detrusor underactivity, and 1 patient had a normal study. There was no identifiable pattern correlating severity of disease with urodynamic findings. As in SCI, urodynamic studies in patients with acute transverse myelitis are necessary to guide irreversible therapy because the activity of the bladder and outlet during storage and emptying does not always correspond to the expected pattern based on the level of pathology.

Neurospinal Dysraphism

Neurospinal dysraphism is the malformation of the vertebral arches and, commonly, malformation of the neural tube. The term includes spina bifida occulta, which involves only a bony (vertebral) arch defect; and spina bifida cystica (aperta), which involves a bony defect and a neural tube (spinal cord) defect. The two primary subclasses of spina bifida cystica are myelomeningocele (the nerve roots or portions of the spinal cord have evaginated beyond the vertebral bodies) and meningoceles (which contain only a herniated meningeal sac with no neural elements). If fatty tissue is present in the sac in either case, the prefix *lipo*- is added (Churchill et al., 2001). **Myelomeningocele accounts for more than 90% of spina bifida cystica and is the most devastating condition in terms of sequelae. Of myelomeningoceles, 2% are cervical, 5% thoracic, 26% lumbar, 47% lumbosacral, and 20% sacral. The level(s) of the lesion correlate(s) poorly with urodynamic findings** (Churchill et al., 2001). **Myelomeningocele occurs in approximately 1 per 1000 live births** (Drake et al., 2013; Wyndaele et al., 2005). **The incidence of LUT dysfunction is not absolutely documented, but most studies suggest an incidence of more than 90%** (Drake et al., 2013, Liu et al., 2018; Wyndaele et al., 2005). The incidence of spina bifida has decreased in recent years because of the recognition of the importance of folate ingestion in pregnant women and advanced prenatal diagnostic capabilities resulting in selective termination of pregnancies. However, up to 85% of patients with spina bifida do survive to adulthood; therefore this condition is becoming a more significant chronic care issue in the general population. Transitional care from childhood through adolescence to adulthood is becoming a focus of specialized clinics despite the fact that many barriers do exist (Summers et al., 2014).

McGuire and Denil (1991) and Woodhouse (2005) point out that, because of progress in the overall care of children with myelodysplasia, urologic dysfunction often becomes a problem of the adolescent or adult with this disease. In McGuire and Denil's (1991) experience, **the "typical" myelodysplastic patient shows an areflexic bladder with an open bladder neck. The bladder usually fills until the resting residual fixed external sphincter pressure is reached, and then leakage occurs. Stress incontinence may also occur** because of changes in intra-abdominal pressure. A small percentage (10% to 15%) of patients demonstrate DSD, but these individuals show normal bladder neck function that, if detrusor reflex activity is controlled, may be associated with urinary continence. After puberty, most authors report that the majority of myelodysplastic patients note an improvement in continence, but at that age and afterward they are less inclined than children to tolerate any degree of incontinence. In adult patients, the problems encountered in myelodysplastic children still exist but are often compounded by prior surgery, upper tract dysfunction, and one form of urinary diversion or another.

Perhaps the most important intervention for myelomeningocele is amelioration of the initial impact of the disease. **A prenatal intervention trial was discontinued before study completion when the primary outcome of fetal or neonatal death or the need for cerebrospinal fluid shunt by age of 12 months was substantially less in the treated group** (Adzick et al., 2011). An additional primary outcome of overall mental development and motor function at age 30 months showed that in individuals undergoing prenatal surgery, substantial improvement was encountered as compared with those receiving only postnatal interventions. In the prenatal surgery group, 40% of patients required cerebrospinal fluid shunts, whereas 82% of those in the postnatal group did. In addition, highly significant improvement in motor function and mental development was noted in the prenatal as compared with the postnatal group. A variety of secondary outcomes also were improved in this group, including the risk of hindbrain herniation at 12 months and ambulation by 30 months. However, there was an increased risk of preterm delivery and uterine dehiscence at delivery in the prenatal group as compared with the postnatal group. In terms of the lower urinary tract, there was no difference in intermittent catheterization rates between the prenatal and postnatal groups, but those patients undergoing prenatal surgery has less bladder trabeculation and less likely to have an open bladder neck (Brock et al., 2015). The significance of these findings on the lower urinary tract remains unclear; nonetheless, this randomized trial of prenatal versus postnatal repair showed significant benefits to prenatal repair, resulting in termination of this trial on elevation of this intervention to a primary consideration for the condition of prenatally diagnosed myelomeningocele

(Adzick et al., 2011).

Nowhere is the failure of a neurologic examination to predict urodynamic behavior more obvious than in patients with myelomeningocele. van Gool et al. (2001) categorized the urodynamic findings in 188 children with myelomeningocele into five groups: (1) normal detrusor and sphincter activity (7%); (2) detrusor overactivity and an inactive sphincter (11%); (3) detrusor overactivity and an overactive sphincter (45%); (4) inactive detrusor and inactive sphincter (23%); and (5) an inactive detrusor and an overactive sphincter (14%). In 16 adults with myelomeningocele, Sakakibara et al. (2003a) reported detrusor overactivity in 38%, low compliance in 81%, impaired bladder sensation in 25%, DSD in 50%, low maximum urethral pressure in 56%, and silent sphincter electromyographic findings in 25%. Webster et al. (1986) reported that 62% of their patients with myelomeningocele had detrusor overactivity, whereas 38% had detrusor areflexia. Thirty of 34 patients in the latter group had low compliance with high terminal filling pressures. Striated sphincter behavior was characterized as follows: true DSD in 15%, an apparently innervated but fixed nonrelaxing sphincter in 15%, and some evidence of striated sphincter denervation in 69%. **Regardless of the pattern of LUT dysfunction in the adult, the main goal of therapy is the avoidance of high storage pressures** (McGuire and Denil, 1991; Persun et al., 1999; Woodhouse, 2005).

LUT dysfunction secondary to occult spinal dysraphism may not manifest in childhood, and such patients may be referred as adults for symptoms as commonplace as urinary incontinence or recurrent UTIs. Delayed diagnosis of such voiding dysfunction has been reported by several authors (Jakobsen et al., 1985; Yip et al., 1985). **The treatment strategy in women is to increase urethral sphincter efficiency without causing an increase in urethral closing pressure significant enough to result in a change in bladder compliance** (McGuire and Denil, 1991). **Periurethral injection therapy may be a safer option than the pubovaginal sling and artificial urethral sphincter in this case. Stress incontinence in men with myelodysplasia may follow similar general rules as in women, and bulking agents may give good results in this group as well. When the urethra is very widely dilated and somewhat rigid, and neither procedure alone provides sufficient coaptation, it may be possible to combine a “prostatic sling” with periurethral bulking.** Ongoing trials using stem cells in the treatment of stress incontinence in women and treatment of post-prostatectomy incontinence in men may one day translate into treatment options for the neurogenic population. **Continent individuals will**

remain on CIC.

The urologic rehabilitation of patients with spinal dysraphism relies primarily on medical management and intravesical injection of onabotulinumtoxinA, with the selective use of augmentation enterocystoplasty or urinary diversion if failure occurs. However, surgery does not necessarily yield superior results. In a review of 421 patients managed for complications relating to spina bifida, 45% were treated medically, either with CIC, spontaneous voiding, or no specific method, and 55% were treated surgically. Overall incontinence episodes were higher in the surgical management group; however, these outcomes may have been reflective of the aggressiveness of management as well as the severity of disease (Lemelle et al., 2006). A recent evaluation of individuals being followed long term for myelomeningocele (20-year follow-up) found that 7 patients (13% of the original 52 followed) had unilateral renal dysfunction and 8 (15%) had bilateral overall renal dysfunction. Those with bilateral dysfunction had a significantly higher risk of detrusor overactivity during childhood urodynamic evaluation (63%) compared with those with normal function (24%). Overall, 48% of patients were continent at follow-up. Eight patients required surgical intervention sometime during the course of their condition. Nine used regular antimuscarinic ingestion, and 3 had had intravesical botulinum toxin injection. In addition, 27 required intermittent catheterization for management. Therefore urodynamic findings may be predictive of long-term consequences (Thorup et al., 2011). Surgery remains a salvage option for those not optimally managed by medical intervention. An assessment of national data practices using administrative data sets from a nationwide inpatient sample assessed patients undergoing bladder augmentation versus ileal conduit urinary diversion over a 7-year timeframe (1998 to 2005) for the primary diagnosis of spina bifida. Overall, 3403 patients underwent bladder augmentation, whereas 772 underwent ileal loop diversion. The bladder augmentation group tended to be younger patients (16 vs. 36 years) and more commonly male (52%). Urinary diversion was more commonly associated with the female patients as well as older patients. Overall, those undergoing urinary diversion had higher health care expenses and longer hospital stays. There was some difference in care choice based on insurance status (Wiener et al., 2011).

Neural rerouting has been proposed as a potential option for some of these individuals. Xiao et al. (2005) have performed microanastomosis of the fifth lumbar ventral root to the third sacral ventral root to bypass low-level spina bifida injury. Initial improvements in bladder compliance and urinary incontinence were noted in patients and paralleled similar findings in patients with SCI (Joseph, 2005). In a small randomized trial comparing spinal cord detethering alone with detethering plus the Xiao procedure (nerve transfer procedure) found greater improvements in bladder capacity and bladder overactivity, although no difference in continence rates, in the group undergoing detethering plus the Xiao procedure (Tuite et al., 2016).

Tethered cord syndrome (TCS) is defined as a stretch-induced functional disorder of the spinal cord with its caudal part anchored by inelastic structures and restricting vertical movement. The anchoring structures can include scar from prior surgery, fibrous or fibroadipose filum terminale, a bony septum, or tumor (Yamada et al., 2004a, 2004b). Adults with TCS can be divided into those with a prior history of spinal dysraphism with a previously stable neurologic status who experience subtle progression in adulthood and those without associated spinal dysraphism who present with new-onset subtle neurologic symptoms (Yamada et al., 2004a, 2004b). **Symptoms can include back pain, leg weakness, foot deformity, scoliosis, sensory loss, and bowel or LUT dysfunction** (Phuong et al., 2002). **TCS is reported to occur in 3% to 15% of patients with myelomeningocele. There is no typical dysfunction in TCS, and treatment must be based on urodynamic evaluation.** LUT dysfunction may not be present until the teenage years or later (Husmann, 1995; Kaplan and Blaivas, 1988). Giddens et al. (1999) point out that, whereas children often develop symptoms of tethered cord after growth spurts, in adults the presenting symptomatology often follows activities that stretch the spine, such as sports or motor vehicle accidents. In adults, urologic presentation can include storage or voiding symptoms, incontinence, or complete retention. In a group of adult patients, urgency (67%) and urgency incontinence (50%) were the most common findings at presentation. Pretreatment urodynamics in 18 patients revealed detrusor overactivity in 72%, DSD in 22%, decreased sensation in 22%, decreased compliance in 17%, and what was termed a “hypocontractile” detrusor in 11%. Postoperative urodynamic findings improved in only 29% and were unchanged in 71%. Steinbok et al. (2007) assessed 8 children undergoing section of the filum that induced the tethered cord and compared them with 7 children who had abnormal urodynamic findings and did not undergo filum release. Clinical improvement occurred in 7 of the 8 children at a mean follow-up of 3 years with improved urodynamics in 4 of 7 children tested after surgery. These improvements were also associated with nonurologic functional improvements (i.e., motor leg function). Two patients in the nonsurgical group had urologic improvement at a mean follow-up of 3 years; however, 3 patients required surgical intervention and 5 had persistence of nonurologic symptoms. Thus section of the cord appeared to improve function as compared with conservative, nonsurgical management.

Not all symptoms of tethered cord are remediated by surgery. In a retrospective assessment of 29 patients undergoing first-time tethered cord release, clinical symptoms were evaluated at 1 and 3 months after surgery as well as every 6 months thereafter. Garces-Ambrossi et al. (2009) addressed rates of improvement in motor and urinary dysfunction over time. The most common causes of tethered cord included lipomyelomeningocele (10%), tight filum (10%), lumbosacral lipoma (14%), intradural tumor (10%), and previous surgery (7%). In addition, 48% of patients had had previous repair of myelomeningocele defects. Symptoms before intervention occurred for a mean of 5 months. Symptomatic presentation included diffuse pain and paresthesias in both lower extremities (45%) or perineum (62%). Lower extremity weakness was noted in patients with gait disturbances (59%) and bladder dysfunction (48%). Multilevel laminectomy accompanied by duraplasty (30% of patients) was performed as the primary intervention. At 18 months postoperatively, 47% of the patients with urinary symptoms had improvement in those symptoms, 69% had improvement in the lower extremity weakness, and 79% had improved painful dysesthesias. Mean time for improvement was 1 month for pain and 2.3 months for motor symptoms. Urinary symptoms lagged at 4.3 months. The majority of patients demonstrated improvement within 6 months of surgery (96%). After 1 year, only 4% showed no improvement (Garces-Ambrossi et al., 2009).

Recent emphasis on transitional aspects of care from childhood to adulthood has centered on the need for meticulous follow-up and optimization of bladder and renal function in light of social stigma, patient concerns, independence, and also bowel-related dysfunction. Consensus agreement stresses the need for established algorithmic approaches for follow-up inclusive of annual surveillance for early identification of urinary tract deterioration. These assessments should include renal and bladder ultrasonography and urodynamics when indicated (by symptomatic change or clinical physical examination finding). In addition, serum creatinine and renal scintigraphy may be performed when upper tract changes are suspected. Goals of therapy include reduction in detrusor pressure and maintenance of bladder compliance and social continence (de Kort et al., 2012). Barriers to young adults transitioning from pediatric to adult care must be considered and addressed, and often a multidisciplinary approach is necessary (Grimsby et al., 2016). Lifelong urologic follow-up is mandatory.

Tabes Dorsalis, Pernicious Anemia

Although tabes dorsalis, also known as syphilitic myelopathy, is rapidly disappearing as a major neurologic problem, involvement of the spinal cord dorsal columns and posterior sacral roots can result in a loss of bladder sensation and large postvoid residual urine volumes and therefore can be a cause of "sensory neurogenic bladder." Although this represents the classic tabetic bladder (Wheeler et al., 1986), Hattori et al. (1990) reported on some patients with only tabes dorsalis as an obvious cause of their LUT dysfunction who had low compliance or detrusor overactivity. Another spinal cord cause of the classic "sensory bladder" is pernicious anemia, a disease caused by impaired uptake of vitamin B_{12} resulting from the lack of intrinsic factor in the gastric mucosa. Pernicious anemia is closely associated with subacute combined degeneration (SACD) of the dorsolateral columns of the spinal cord with common pathophysiology of vitamin B12 deficiency.

Subacute Combined Degeneration

SACD is demyelination of the posterior and lateral columns of the spinal cord resulting most commonly from vitamin B12 deficiency but can also be a result of copper deficiency. Vitamin B12 deficiency is associated with deficient dietary intake (vegetarianism and old age), gut malabsorption, gastrectomy, fish tapeworm infestation, and autoimmune disorders. In a study of eight patients with this condition, multiple nonurologic symptoms were associated with the condition, including ambulation problems in addition to joint spasticity. Urinary symptoms represented a mix of storage (five of eight patients), voiding (seven of eight patients), and combined dysfunctions (four of eight patients). Urodynamic evaluation revealed detrusor areflexia in two patients, NDO in three, and normal studies in the remainder. After treatment with vitamin B_{12} supplementation, detrusor areflexia improved in two patients, dysfunction improved in three patients completely, and four had partial recovery (Misra et al., 2008). Typical MRI findings include T2 hyperintensity in the posterior spinal column and subcortical white matter defects.

Poliomyelitis

Although not always present, when voiding dysfunction is seen in patients with polio, it is that of a typical “motor neurogenic bladder” with urinary retention, detrusor areflexia, and intact sensation. The reported incidence of LUT dysfunction in patients with polio was described as ranging from 4% to 42% by Bors and Comarr (1971). A study describing bladder symptoms among polio survivors found that urinary hesitancy, weak stream, incomplete emptying, nocturia, and urge incontinence occurred with higher frequency in polio survivors compared with the normal population (Kay and Bertelsen, 2013).

Disease Distal to the Spinal Cord

Disk Disease

Goldman and Appell (2000a, 2000b) nicely summarize the anatomic and neurologic considerations applicable to voiding dysfunction from lumbar disk disease. **In the adult, the sacral segments of the spinal cord are at the level of the L1 and L2 vertebral bodies.** In this distal end of the spinal cord **(conus medullaris),** the spinal cord segments are named for the vertebral body at which the nerve roots exit the spinal canal. Thus, although the sacral spinal cord segment is located at vertebral segment L1, its nerve roots run in the subarachnoid space posterior to the L2 to L5 vertebral bodies until reaching the S1 vertebral body, at which point they exit the canal. Therefore all of the sacral nerves that originate at the L1 and L2 spinal column levels run posterior to the lumbar vertebral bodies until they reach their appropriate site of exit from the spinal canal. This group of nerve roots running at the distal end of the spinal cord is commonly referred to as the ***cauda equina.***

Usually, disk prolapse is in a posterolateral direction, which does not affect the majority of the cauda equina. However, in 1% to 15% of the cases (Goldman and Appell, 2000b), central disk prolapse occurs and compression of the cauda equina may result. Thus disk prolapse anywhere in the lumbar spine could interfere with the parasympathetic and somatic innervation of the LUT, striated sphincter, and other pelvic floor musculature, and afferent activity from the bladder and affected somatic segments to the spinal cord. **Most disk protrusions compress the spinal roots in the L4 to L5 or L5 to S1 vertebral interspaces. When LUT dysfunction is present, it typically occurs with the usual clinical manifestations of low back pain radiating in a girdle-like fashion along the involved spinal root areas. The most characteristic findings on physical examination are sensory loss in the perineum or perianal area (S2 to S4 dermatomes), sensory loss on the lateral foot (S1 to S2 dermatomes), or both.**

A review of the literature on LUT dysfunction associated with lumbar disk disease found that the incidence ranged from 27% to 68%; however, the true incidence is unknown because many series describe findings only in patients with LUT dysfunction (Siracusa et al., 2013). Bartolin et al. (1998) found detrusor areflexia in 27% and normal detrusor activity in the remaining 73% of

114 patients with lumbar disk protrusion. **All 31 patients with detrusor areflexia reported difficulty voiding with straining, and patients with voiding dysfunction generally presented with these symptoms or in urinary retention. The most consistent urodynamic finding was that of a normally compliant areflexic bladder associated with normal innervation or findings of incomplete denervation of the perineal floor musculature.** In a later report, Bartolin et al. (2002) described findings in 122 patients with lumbar disk protrusion. Detrusor areflexia was found in 32 (26%) and normal bladder urodynamic findings in 90 (74%). All with areflexia complained of difficulty voiding; 8 could not void at all, 14 had an interrupted flow, and 10 had a continuous but low flow. Occasionally, patients may show detrusor overactivity attributed to irritation of the nerve roots (O'Flynn et al., 1992).

The detrusor areflexia associated with lumbar disk protrusion shows a lower incidence of concomitant decreased compliance than in the voiding dysfunction associated with myelomeningocele. Sandri et al. (1987) offered two possible explanations for this difference: (1) the effect of the disk represents a more incomplete lesion of the preganglionic parasympathetic fibers and (2) the lesion is more sensory than motor, implying that the decreased compliance seen with the type of neural lesion in myelomeningocele is caused primarily by injury of the preganglionic parasympathetic motor fibers to the bladder.

Laminectomy may not improve LUT function in many cases, and pre-laminectomy urodynamic evaluation is prudent because it may be difficult postoperatively to separate causation of voiding dysfunction resulting from the disk sequelae from changes secondary to the surgery. In a group of patients with lumbar disk protrusion who underwent corrective surgery, Bartolin et al. (1999) reported that detrusor activity returned to normal in only 6 of 27 patients with preoperative detrusor areflexia. Of the 71 patients with normal urodynamic findings preoperatively, 4 developed detrusor overactivity and 3 developed postoperative detrusor areflexia. Although there are several reasons to explain this finding, such as recurrence of nerve compression, worsening of the original disease process, or iatrogenic cause from surgery, it is clear that patients undergoing lumbosacral spinal surgery are at risk for postoperative urinary dysfunction, and the medicolegal implications of a presurgical and postsurgical urodynamic evaluation are obvious.

***Cauda equina syndrome* is a term applied to the clinical picture of perineal sensory loss with loss of voluntary control of anal and urethral sphincter and of sexual responsiveness.** The clinical picture in cauda equina syndrome can vary widely, from minimal to maximal sensory and motor involvement. This can occur secondary to not only disk disease (severe central posterior disk protrusion) but also other pathological processes affecting the spinal canal. Yamanishi et al. (2003) place the incidence of cauda equina syndrome at 1% to 5% of all prolapsed lumbar disks. All eight patients undergoing emergency corrective surgery had an acontractile detrusor with no bladder sensation, and four of seven had an inactive sphincter electromyogram. Follow-up urodynamics showed that all still had an acontractile detrusor and three had normal electromyographic activity. Three patients had electromyographic activity, but with denervation potentials in two and low activity in two. One hypothesis for the finding that electromyographic activity returned while detrusor function remained poor is that recovery of autonomic nerves affecting bladder function may be slower than that of somatic nerves controlling the sphincter.

In the case of cauda equina syndrome, urgent surgical decompression is recommended and can help improve the likelihood of bladder function recovery. In a meta-analysis of surgical outcomes of cauda equina syndrome secondary to lumbar disk herniation, patients undergoing surgery within 48 hours had significantly better resolution of their symptoms, including urinary and rectal incontinence, compared with those undergoing surgery 48 hours or more after the onset of symptoms (Ahn et al., 2000). Overall, of the 322 patients included in the meta-analysis, 73% had urinary continence after surgery. However, despite surgical management of patients with disk herniation, recovery of normal lower urinary tract function is variable.

Spinal Stenosis

Spinal stenosis is a term applied to any narrowing of the spinal canal, nerve root canals, or intervertebral foramina. It may be congenital, developmental, or acquired. Compression of the nerve roots or cord by such a problem may lead to neuronal damage, ischemia, or edema. **Spinal stenosis may occur without disk prolapse. Symptoms may range from those consequent to cervical spinal cord compression to a cauda equina syndrome with corresponding urodynamic findings** (Smith and Woodside, 1988). Back and lower extremity pain, cramping, and paresthesias related to exercise and relieved by rest are the classic symptoms of lumbar stenosis caused by lumbar spondylosis and are believed to result from a sacral nerve root ischemia. The urodynamic findings are dependent on the level and the amount of spinal cord or nerve root damage. Deen et al. (1994) reported subjective improvement in more than 50% of such patients with bladder dysfunction who were treated by decompressive laminectomy. In cervical spondylitic spinal stenosis, detrusor overactivity or underactivity may occur, depending on whether the primary pathological process affecting the micturition neural axis is compression of the inhibitory reticulospinal tracts or myelopathy in the posterior funiculus, which carries proprioceptive sensation (Tammela et al., 1992). Because there is no consistent pattern of dysfunction with any type of spinal stenosis, urodynamic studies again should serve as the cornerstone of therapy. In a study of 26 patients undergoing urodynamic assessment of spinal stenosis preoperatively and postoperatively, substantive improvements were noted in postvoid residual volume, maximal cystometric capacity, and flow rate postoperatively after successful surgical intervention in all patients. Urodynamic evaluation was important from a diagnostic standpoint to identify patients who were experiencing LUT compromise (Cong et al., 2010).

Radical Pelvic Surgery

The inferior hypogastric plexus (pelvic plexus), which innervates the viscera of the pelvic cavity, is a paired structure located on the side of the rectum in males and at the sides of the rectum and vagina in females. LUT dysfunction after pelvic plexus injury occurs most commonly after abdominoperineal resection (APR) and radical hysterectomy. The true incidence of neurogenic vesicourethral dysfunction after various types of pelvic surgery is unknown because there are few prospectively studied series of patients with preoperative and postoperative urodynamic evaluation. **The incidence has been estimated to range from 20% to 68% of patients after APR, 16% to 80% after radical hysterectomy, 20% to 25% after anterior resection, and 10% to 20% after proctocolectomy** (Blaivas and Chancellor, 1995b). These are estimates drawn from past literature, and the current incidence is most likely significantly lower because of the use of nerve-sparing techniques during these types of pelvic procedures. It has been estimated that **the LUT dysfunction remains permanent in 15% to 20% of affected individuals** (McGuire, 1984; Mundy, 1984). The injury may occur from denervation or neurologic decentralization, tethering of the nerves or encasement in scar, direct bladder or urethral trauma, or bladder devascularization. Adjuvant treatment, such as chemotherapy or irradiation, may compound the damage. The type of LUT dysfunction that occurs is dependent on the specific nerves involved, the degree of injury, and any pattern of reinnervation or altered innervation that occurs over time (see the previous section on neuroplasticity). Therapeutic and disease-related effects on pelvic nerves have substantive effects on long-term functional outcomes after treatment for anal-rectal carcinomas. Approximately one-third of patients have some element of urinary tract dysfunction (urinary frequency, urgency, and/or poor detrusor contraction resulting in retention and incomplete emptying). This can be related to surgical, radiotherapeutic, and chemotherapeutic effects. Abdominoperineal resection has the greatest impact on function, most likely because of autonomic nerve injury at time of resection. Other dysfunctions related to sexual activity, ejaculatory dysfunction in men, and vaginal dryness and dyspareunia in women are also commonly associated with the management of this malignancy (Lange and van de Velde, 2011). Parasympathetic decentralization has been reported to lead to a marked increase in adrenergic innervation of the bladder in some experimental models, with the resultant conversion of the usual β (relaxant) response of the bladder body in response to sympathetic stimulation to the α (contractile) effect (Sundin et al., 1977). Literature on the effects of parasympathetic decentralization on neuromorphology and neuropharmacology of the LUT in many animal models is abundant (Wein and Barrett, 1988). Hanno et al. (1988) confirmed that, in the cat model, parasympathetic decentralization does result in adrenergic hyperinnervation of the detrusor but that pelvic plexus neurectomy alone or parasympathetic decentralization plus hypogastric neurectomy yields no detectable increase in adrenergic innervation. In their experimental model, decentralization did result in synaptic reorganization in bladder wall ganglia with new cholinergic excitatory inputs from the hypogastric nerves. Koyanagi was the first to call attention to what he referred to as supersensitivity of the urethra to α-adrenergic stimulation in a similar group of patients with neurologic decentralization of the LUT, implying a similar change in adrenergic receptor function in the urethra after parasympathetic decentralization (Koyanagi et al., 1988). Nordling et al. (1981) described a similar change in women after radical hysterectomy and ascribed this change to damage to the sympathetic innervation of the LUT.

When permanent LUT dysfunction occurs after radical pelvic surgery, the pattern is usually one of impaired bladder contractility or a failure of the bladder to voluntarily contract. Urodynamically, obstruction may be

seen from likely residual fixed striated sphincter tone, which is not subject to voluntarily induced relaxation. Often, the smooth sphincter is open and nonfunctional. Whether this appearance of the bladder neck and proximal urethra is caused by parasympathetic damage or terminal sympathetic damage or whether it results from the hydrodynamic effects of obstruction at the level of the striated sphincter is debated and unknown. **Decreased compliance is common in these patients, and, with the "obstruction" caused by fixed residual striated sphincter tone, may result in storage and emptying failure. These patients often experience leakage across the distal sphincter area and are unable to empty the bladder, because, although intravesical pressure may be increased, they cannot mount a true bladder contraction. The patient often has urinary incontinence that is characteristically and most commonly initiated with increases in intra-abdominal pressure.** This is usually most obvious in women, because the prostatic bulk in men often masks an equivalent deficit in urethral closure function. Alternatively, patients may have variable degrees of urinary retention.

Urodynamic studies may show decreased compliance, poor proximal urethral closure function, loss of voluntary control of the striated sphincter, and a positive bethanechol supersensitivity test, findings similar to those in Fig. 116.4. **Upper tract risk factors are related to intravesical pressure and the detrusor leak point pressure, and the therapeutic goal is always low-pressure storage with periodic emptying. In men, the temptation to perform a prostatectomy should be avoided unless a clear bladder outlet obstruction is demonstrated at this level.** Otherwise, prostatectomy simply decreases urethral sphincter function and thereby may result in the occurrence or worsening of sphincteric urinary incontinence.

We strongly urge caution in the early postoperative period, because the temptation to "do something" other than perform CIC initially after surgery in these patients is often strong, especially in those patients with little or no preexistent voiding dysfunction because most of these dysfunctions will be transient. Frequently, 6 to 12 months may elapse before detrusor function returns to an acceptable level (Blaivas and Chancellor, 1995b). Many of the changes after radical pelvic surgery are similar to those seen in sacral cord injury or disease. In an excellent study on decreased bladder compliance after decentralization, Sislow and Mayo (1990) noted a higher prevalence of this finding in patients who had undergone radical pelvic surgery than in those who had sustained conus medullaris or cauda equina injury.

Simple and Radical Hysterectomy

Questions remain as to whether nonradical pelvic surgery such as simple hysterectomy can be ultimately responsible for storage or emptying abnormalities on the basis of neurologic damage. In a multicenter Danish trial (Gimbel et al., 2005), a total of 319 women with benign disease were randomized to undergo either total abdominal hysterectomy (158) or subtotal abdominal hysterectomy (161). At 1-year follow-up after intervention, urinary incontinence was less often noted in patients undergoing total abdominal hysterectomy. Both groups, however, did experience an increase in incomplete emptying requiring double voiding. Both groups experienced an overall decrease in urinary incontinence frequency as compared with baseline. At this time, there is no consensus opinion, and more series that include sophisticated preoperative and early and late postoperative urodynamic evaluation are necessary.

In a study of the effects of hysterectomy on LUT function, 430 women who underwent either vaginal or abdominal hysterectomy for benign conditions (without prolapse as an indication) were assessed. Patients completed validated questionnaires before surgery and up to 10 years after surgery. Significant differences were noted between the vaginal and abdominal approaches in terms of symptoms as measured by the Urogenital Distress Inventory and Defecation Distress Inventory questionnaires. Women who underwent hysterectomy by the vaginal approach were more likely to have micturition symptoms as compared with abdominal approach patients (18% vs. 8%). In addition, defecation symptoms also appeared to be more common after vaginal hysterectomy (58% vs. 46%) (Lakeman et al., 2011; Sultan and Thakar, 2006). As compared with simple hysterectomy, radical hysterectomy may have more debilitating effects on bladder and bowel function. In a study of 209 patients undergoing radical hysterectomy for malignant disease with a survey return rate of 32% (66 of 209) (Brooks et al., 2009), 42% of patients undergoing radical hysterectomy reported mild incontinence symptoms as compared with 50% of controls. Moderate symptoms were seen in 34% of subjects and 35% of controls. Moderate-to-severe symptoms were noted in 18% of subjects and 14% of controls. Fecal symptoms did not differ between subjects and controls. Radical hysterectomy in this group did not appear to be associated with more long-term bladder or anorectal dysfunction (Brooks et al., 2009). In addition, nerve-sparing radical hysterectomy has been shown to result in reduced long-term urinary symptoms, while maintaining oncologic principles, in a randomized controlled trial of 92 women with cervical cancer (Roh et al., 2015).

Childbirth

There have been no prospective trials documenting a long-term follow-up relationship between urinary dysfunction and method of delivery, and no prospective clinical trials have been done to determine if cesarean section is protective against the development of incontinence. The debate regarding cesarean section as an alternative to spontaneous vaginal delivery and impact of each on the LUT also continues. The Epidemiology of Incontinence in the County of Nord-Trøndelag (EPINCONT) study assessed 15,307 women for the development of voiding dysfunction during longitudinal follow-up. The risk of urinary incontinence of all types was noted to be higher in women who had had cesarean sections as compared with nulliparous women and those who had had vaginal deliveries. However, the risk of moderate to severe incontinence was actually less in patients who had undergone cesarean sections than in those who had delivered vaginally. Urgency incontinence was the only exception, being equal across all groups. The adjusted ratio for any incontinence in women after cesarean section was 1.5 versus 1.7 for women with vaginal deliveries. Stress incontinence appeared to be associated with mode of delivery (Rortveit et al., 2003a, 2003b). McKinnie et al. (2005) studied 1004 women over an 18-month period to determine the relationship between urinary and fecal incontinence and type of delivery. In this study, pregnancy increased the overall risk of urinary and fecal incontinence, and there was no apparent relationship to mode of delivery.

Herpesvirus Infections

Invasion of the sacral dorsal root ganglia and posterior nerve roots with herpes zoster virus may produce urinary retention and detrusor areflexia days to weeks after the other primary viral manifestations (Ryttov et al., 1985). In general, painful cutaneous eruptions secondary to the virus are also present, but initially the patient may have only fever, malaise, perineal and thigh paresthesias, and obstipation. **Urinary incontinence secondary to detrusor overactivity may also occur, but the pathophysiology is unclear.** It may be related to nerve root irritation, inflammation of the meninges or spinal cord, or “zoster cystitis” (Broseta et al., 1993). Cystoscopy may reveal vesicles in the bladder mucosa similar to those seen on the skin. **Spontaneous resolution**

usually occurs in 1 to 2 months. Out of 57 patients with herpes zoster infection, 15 (26%) showed urologic manifestations, but only 2 had frank urinary retention (Broseta et al., 1993). Three patients demonstrated urinary incontinence, and all 3 demonstrated detrusor overactivity on urodynamics. Ten patients demonstrated irritative storage symptoms with dysuria and frequency.

Out of 423 patients admitted with a diagnosis of herpes zoster LUT, 17 (4%) had voiding dysfunction (Chen et al., 2002). Excluding those with cranial rather than spinal nerve involvement, the incidence was 8.8%; however, when only patients with lumbosacral dermatome distribution were considered, the figure rose to 28.6%. The authors subdivided the bladder disorders into three types. Twelve of the 17 affected patients (71%) had voiding dysfunction caused by herpetic cystitis and had dysuria, frequency, retention, pyuria, or hematuria on presentation. Four of the 17 patients (24%) had neuritis-associated voiding dysfunction, presumably affecting the sacral motor neurons, and on presentation had urinary retention with a “flaccid bladder.” One patient had myelitis-associated voiding dysfunction with spinal cord involvement, with detrusor overactivity on presentation. All 17 patients regained a normal or “balanced bladder” within 8 weeks, and no major urologic sequelae were noted.

Urinary retention has also been reported to occur in association with anogenital herpes simplex virus infection. Caplan et al. (1977) reported 11 such patients with the typical clinical picture of herpes genitalis, all of whom developed urinary retention 2 to 7 days after the genital eruption. Three such patients showed pleocytosis of the cerebrospinal fluid, a finding that Hemrika et al. (1986) believed was indicative of CNS involvement. They termed the coexistence of bilateral involvement of the sacral nerve roots of rapid onset accompanied by sphincteric incontinence with cerebrospinal fluid pleocytosis the ***Elsberg syndrome*** and tabulated 47 such cases reported before their article. Haanpaa and Paavonen (2004) added 2 patients, both of whom had transient urinary retention but developed chronic neuropathic pain in the sacral area. As with herpes zoster, the LUT dysfunction was transient.

Diabetes Mellitus

Diabetes is the most common cause of peripheral neuropathy in Europe and North America. The exact prevalence of diabetes in the United States is between 1% and 6%, depending on whether one includes only diagnosed patients and on the fasting blood glucose criteria used for inclusion (the higher estimate of prevalence represents a reduction in blood glucose criteria to 126 mg/dL) (Chancellor and Blaivas, 1995a; Goldman and Appell, 2000a). The clinical spectrum of LUT dysfunction thought to be caused by diabetes has been extensively reviewed by a number of authors (Beck et al., 1994; Chancellor and Blaivas, 1995a; Goldman and Appell, 2000a; Kaplan and Blaivas, 1988; Kaplan et al., 1995; Wein and Rovner, 1999). The exact incidence of LUT dysfunction caused by diabetes is uncertain; **however, 5% to 59% of patients with diabetes report symptoms of LUT dysfunction.** In attempting to estimate the true incidence and types of LUT dysfunction specifically associated with diabetes, clinicians must carefully discriminate between articles that consider patients referred for voiding symptoms versus those that have evaluated unselected patients from a population known to have diabetes. In the Nurses' Health Study, urinary incontinence was found to be more prevalent in women with diabetes (8.7% vs. 5.3% of controls). The odds of developing urinary incontinence increased by 20% with diabetes. The predominant type of associated incontinence noted in this study was urge incontinence. No association between diabetes and stress incontinence was recognized (Danforth et al., 2009).

Current evidence points to a sensory and a motor neuropathy as being involved in the pathogenesis, with the motor aspect contributing to the impaired detrusor contractility. **The classic urodynamic findings include impaired bladder sensation, increased cystometric bladder capacity, decreased bladder contractility, impaired uroflow, and, later, increased residual urine volume.** At least in men, the main differential diagnosis is bladder outlet obstruction, because both conditions commonly produce a low urinary flow rate; however, pressure-flow urodynamic studies easily differentiate the two. **Smooth or striated sphincter dyssynergia usually is not seen in classic diabetic cystopathy,** but these diagnoses can easily be erroneously made on a poor or incomplete urodynamic study (e.g., voiding may involve abdominal straining, which will produce an interference electromyographic pattern [pseudodyssynergia], and abdominal straining alone will not open the bladder neck area).

Other authors have suggested that findings seen in classic diabetic cystopathy may not represent the predominant form of LUT dysfunction. Chancellor and Blaivas (1995a) detailed the urodynamic findings in 43 patients with diabetes, with 33% having involuntary bladder contractions with normal contractility, 23% having involuntary bladder contractions with impaired contractility but were able to void, 9% having impaired bladder contractility alone but were able to void, 23% having detrusor areflexia, and only 12% having a normal urodynamic study. Ueda et al. (1997) also found involuntary bladder contractions in a moderate percentage of patients with diabetes (25%) but noted that all these patients had a history of cerebrovascular disease and that no patient had involuntary bladder contractions who did not have such a history. Although it is obvious that some (or even many) of the patients with diabetes who exhibited involuntary bladder contractions may have had factors other than diabetes to account for their bladder overactivity, the importance of urodynamic study in patients with diabetes before the institution of therapy cannot be overemphasized.

Alloxan-induced diabetic rats demonstrate detrusor overactivity, whereas sucrose-fed rats demonstrate normal bladder contractions. In addition, streptozotocin-induced diabetic rats more commonly demonstrate pyuria, raising the question of an inflammatory component. Therefore the type of model used should be considered when attempting to interpret experimental findings (Yoshimura et al., 2003). Liu and Daneshgari (2005) concluded that the bladders of diabetic and diuretic rats weighed more than control animals and that diabetes and diuresis caused a significant increase in overall fluid intake, urine output, and bladder size. An increased response after field stimulation was noted in diabetic and diuretic conditions, and a reduced response to cholinergic activity was noted as compared with controls. The authors noted that this finding indicated the possibility of neurogenically mediated bladder contraction in the diabetic rat. Numerous authors have proposed potential pathophysiologic mechanisms that could account for the various types of voiding dysfunction seen in diabetic patients. Clark and Lee (1995) describe the basic mechanism of interference with physiologic mechanisms as increases in blood glucose increasing the intercellular accumulation of glucose and its subsequent metabolic products. Hyperglycemia is then proposed to lead to microvascular and neurologic complications, with the neurologic sequelae ultimately resulting in a loss of myelinated and unmyelinated fibers, wallerian degeneration, and blunted nerve fiber reproduction and function. The proposed mechanisms include increased accumulation of polyols (sorbitol) from glucose through the aldolase-reductase pathway, inhibiting glomerular and neural synthesis of myo-inositol. The decrease in myo-inositol synthesis depresses phosphoinositide metabolism, decreasing Na^+,K^+-ATPase activity. Hyperglycemia also leads to the formation of advanced glycosylation end products, inhibition of the formation of which in animals has been shown to improve response to functional and structural abnormalities of peripheral nerves. In a study of 47 patients with type 2 diabetes and LUTS, increased serum measurements of glycosylation end products correlated with impaired detrusor function (Gali et al., 2017).

NGFs and other nerve trophic factors also appear to play a role in regulation of the pathogenesis of diabetic voiding dysfunction. In addition, nitrergic and adrenergic mechanisms also contribute to the ultimate pathophysiologic cascade of this condition (Torimoto et al., 2009). In another report of streptozotocin-induced diabetic rats, the diabetic condition was associated with increased bladder weight. This was associated with a decreased blood vessel density that occurred on a time-dependent basis. In a comparator group of polyuric animals, similar changes were noted. These findings appeared to support not only direct change but also diuretic-induced changes as being an additional physiologic consequence of the diabetic condition (Liu et al., 2011).

Another aspect of diabetic bladder dysfunction may occur at the organelle level. In rodent models, morphologic changes in chronic diabetes have also included mitochondrial abnormalities, particularly in the urothelium. Increased collagen was noted to be deposited in capillary walls, with an interruption or extensive widening of the gap junctions between myocytes in the bladder muscularis. Reduced mitochondrial counts were noted in the urothelium and bladder muscle. Degenerated nerve fibers and myelin bodies were identified between myocytes, with increased collagen and mast cell inflammatory aggregates noted in the stroma of diabetic rats as compared with nondiabetic controls. The duration of diabetes appeared to amplify these changes, and the authors concluded that diabetic changes were a time-dependent phenomenon (Rizk et al., 2006).

In addition to this overall hypothesis, there are interesting data from various investigators that may or may not prove to be involved in the pathogenesis of diabetic voiding dysfunction. In streptozotocin-induced diabetic rats, Hashitani and Suzuki (1996) reported reduced spontaneous spike activity, failure of neuromuscular transmission, reduced potency of the smooth muscle sodium-potassium pump, and the development of a post-junctional, muscarinic supersensitivity, without alteration of the ATP receptor sensitivity. Mumtaz et al. (1999) reported an impairment of nitric oxide–mediated urethral smooth muscle relaxation in alloxan-induced diabetic rabbits along with a significant impairment of nonadrenergic, noncholinergic (NANC) nerve-mediated relaxation in this area. They hypothesized that nitric oxide may be functionally inactive and/or unavailable in this type of diabetes, and this lack may contribute to non–benign prostatic hyperplasia (BPH)–related outlet obstruction in patients with long-term diabetes and to detrusor overactivity, although it is a bit unclear how changes in only the outlet may influence overactivity. In addition to the inhibitory nitric oxide, the NANC pathway is mediated by purinergic receptors (e.g., P2X), which can induce bladder contractions. In streptozotocin-induced diabetic rats, muscarinic and purinergic receptors had increased expression, which was associated with increased bladder contractility compared with controls (Yoshizawa et al., 2018). Gupta et al. (1996) and Gupta and Wein (1999) suggested that diabetes diminishes sodium pump activity, thereby inhibiting agonist-induced contractions in bladder smooth muscle by an increase in intracellular sodium concentration, the latter acting to diminish calcium influx. Cardozo et al. (2002) reported enhancement of bladder contractions to substance P and des-Arg-bradykinin in a streptozotocin model. Sasaki et al. (2002) described decreased NGF in bladder tissue and L6 to S1 dorsal root ganglia. In alloxan-induced diabetic animals, Khan et al. (2002) noted decreased apoptosis of bladder urothelial cells. In this same model, Su et al. (2004) reported increased myosin light chain phosphorylation and decreased sensitivity to activator calcium. Changolkar et al. (2005) reported decreased smooth muscle force associated with increased lipid peroxides and sorbitol and an overexpression of aldolase reductase and polyol pathway activation. Another interesting pathophysiologic explanation is one that is attributed to autoimmune phenomena. Antibody-mediated bladder dysfunction in type 1 diabetes has been identified in a murine model, in which anti–voltage-gated calcium channel antibodies induce urodynamic findings such as phasic detrusor contractions and also loss of bladder wall compliance compatible with overactive bladder. The autoimmune dysfunction was reversed by the administration of agonists for voltage-gated calcium channels. The possible reversibility of this phenomenon remains intriguing for early stage treatment (Wan et al., 2007).

Hyperglycemia-induced oxidative stress in detrusor smooth muscle resulting in microvascular and macrovascular events has been postulated to contribute to urologic symptoms and complications associated with diabetes (Kirschner-Hermanns et al., 2012). In addition, further evidence of oxidative stress has been identified by comparative gene expression studies. When nondiabetic versus streptozotocin-induced–diabetic animals were assessed for oxidative stress via a variety of protein-based metabolic assays (glutathione and *S*-transferase activity, lipid peroxidation, and carbonylation and nitrosylation of proteins), global gene expression in the diabetic animals demonstrated a significant increase in markers for oxidative stress. This was subsequently further hypothesized to have a downstream effect on protein damage and apoptosis. This hypothesis was confirmed by demonstrating an increase in protein degradation products (Nedd-4 and LC3B) in diabetic bladders. The conclusion was that oxidative stress resulted in aberration and protein-based pathways resulting directly from oxidative stress (Kanika et al., 2011).

Tong et al. (1999) reported an upregulation of M_2 receptor protein in the bladder of streptozotocin-induced diabetic rats and an upregulation of M_2 receptor protein in bladder body tissue (Tong and Cheng, 2002). Presumably, this could be related to detrusor overactivity and conceivably account for a differential effect of various anticholinergic agents, depending on their receptor specificity. In a trial using rodent (mouse) exposure to streptozocin in an M_2 muscarinic receptor knockout model as compared with wild-type specimens, the M_2 receptor was found to modulate bladder overdistention associated with streptozocin-induced neuropathy and therefore preserve function. The difference between function in the wild-type versus the knockout model approximated a 70% difference in those animals with retained M_2 receptors (Pak et al., 2010a). With the same study construct (wild type versus M_2 muscarinic receptor knockout exposure to streptozotocin), rodents were exposed to oxotremorine-M (an M_2 muscarinic agonist). In the wild-type animals, contractile function was maintained by enhanced mediation by M_2 contractile activity despite loss of M_3 activity in these animals (Pak et al., 2010b).

Smooth-muscle ultrastructural and functional changes in detrusor smooth muscle associated with streptozotocin-induced bladder dysfunction in mice has been attributed to the contribution of the L-type voltage-operated channels (L-VOCCs). The presence of these receptors and an increased density of M_3 receptors were noted in streptozotocin-induced diabetic animals. The role of these L-VOCC channels continues to be explored (Leiria et al., 2011). Another channel, TRPV1, expressed in bladder afferent nerves has also been implicated in the bladder dysfunction associated with diabetes (Sharopov et al., 2018).

Therefore the pathophysiology of diabetic cystopathy can be attributed to five possible sources (Nanigian et al., 2007)**:**

1. **Alterations in muscarinic receptor densities specifically with overexpression of M_2 receptors may be one mode of dysfunction.**

2. **Direct neural damage caused by hyperglycemia resulting in glycosylated end products may accelerate microvascular disease as well as inducing endothelial dysfunction and causing a deleterious effect on nitric oxide release.**
3. **In addition, the production of sorbitol in a hyperglycemic environment may increase reactive oxygen species, resulting in oxidative stress at the muscle cell level.**
4. **Hyperglycemia may, as well, increase the production of diacylglycerol, resulting in the activation of protein kinase C, which affects transcription of a variety of connective tissue constituents including type IV collagen, contractile proteins, and fibronectin, as well as damaging local endothelial and neural cells.**
5. **Finally, there may be a decrease in NGF, which has been previously hypothesized to protect bladder activity.**

Early institution of timed voiding will avoid some of the impaired detrusor contractility from chronic distention and detrusor decompensation. Experimental studies are currently directed at inhibiting the proposed mechanisms by which hyperglycemia produces neuropathy (Clark and Lee, 1995). Ayan et al. (1999) cite references showing that intensive therapy for diabetes can slow its progression and slow the development of abnormal autonomic tests. On a short-term basis, the authors showed that insulin therapy in alloxan-induced diabetic rabbits prevented the urodynamic effects (e.g., increased bladder capacity and compliance) and histopathologic changes seen in a similar but non–insulin-treated group of animals. Insulin reversed most of the changes reported by Cardozo et al. (2002). Despite improvement in other organ systems with enhanced glycemic control, LUTS in patients with type 1 diabetes do not appear to respond well to otherwise well-documented glycemic control (Van Den Eeden et al., 2009).

A prospective evaluation of women with type 2 diabetes assessed urodynamic findings as compared with responses to Aδ and C fibers in the bladder using intravesical current responses to threshold frequencies at 250 and 5 Hz, respectively. Of the 86 women evaluated, 34.9% had detrusor underactivity, 14% (12) had detrusor overactivity, 12.8% (11) had bladder outlet obstruction by the criteria of the trial, and 38.4% (33) had normal detrusor function. With the normal detrusor function group used as a comparator, the underactivity group showed not only decreased emptying capabilities but also decreased sensation on cystometry and intravesical current perception threshold testing. The overactivity group demonstrated impaired storage and emptying function but had no significant changes in intravesical current reception. In this trial, an increase in current perception threshold values was associated with a decrease in bladder voiding efficiency at 5 and 250 Hz. These data underscored the evidence that impaired Aδ, as well as C-fiber function, had direct effect on bladder pathways for emptying in patients with diabetes mellitus (Lee et al., 2009). Pop-Busui et al. (2015) studied 635 men with type 1 diabetes and found an association between autonomic neuropathy and LUTS, suggesting a clinical association between diabetes and bladder dysfunction as a result of autonomic neuropathy. The **exact mechanism for diabetic cystopathy has not been precisely elucidated and is likely a result of multifactorial insults on the neurologic and cardiovascular systems and the bladder**.

Key Point: Diabetes

- Detrusor overactivity has been cited as the most frequent urodynamic finding in diabetic cystopathy. This could be a result of a difference in the time of diagnosis with reference to the natural history of the effects of diabetes on the LUT.

Guillain-Barré Syndrome

Guillain-Barré syndrome (GBS) is **a potentially life-threatening, inflammatory demyelinating disorder of the peripheral somatic and autonomic nervous system.** It is described as a recognizable clinical entity characterized by rapidly evolving symmetrical limb weakness, loss of tendon reflexes, absent or mild sensory signs, and variable autonomic dysfunctions (Hahn, 1998). It results from aberrant immune responses directed against peripheral nerve components (Hahn, 1998; Hartung et al., 1995) and is triggered by a preceding bacterial or viral infection, with the immune responses directed toward the infecting organisms cross-reacting with neural tissues. The immune reactions against Schwann cell surface membrane or myelin result in acute inflammatory demyelinating neuropathy (accounting for 85% of cases), whereas reactions against axonal membrane components cause acute motor-sensory axonal neuropathy, accounting for the remaining 15%. Two-thirds of patients report an antecedent acute infectious illness, most commonly respiratory tract infection or gastroenteritis that has resolved by the time the neurologic symptoms begin. Several anecdotal case reports have linked GBS to vaccination by temporal association alone. About 75% of cases reach their nadir within 2 weeks, and 94% within 4 weeks. After a brief plateau phase, paralysis gradually resolves over weeks to months. In general, the outcome is favorable, but Hahn (1998) quotes a mortality rate of 5% to 8% despite the most aggressive management. **Autonomic neuropathy is a common complication.** Cardiac arrhythmia, hypertension and hypotension, and bowel, bladder, and sexual dysfunction may occur. **The prevalence of LUT dysfunction ranges from 25% to more than 80%** (Wyndaele et al., 2005). Zochodne (1994) reviewed multiple series and reported a urinary retention rate of 11% to 30%. Of the 7 of 28 GBS patients with voiding dysfunction, 3 had transient urinary retention; 2 had urgency, nocturia, and urge incontinence; 1 had stress incontinence; and 1 had otherwise unexplained voiding difficulty (Sakakibara et al., 1997a, 2009). Although many of these patients may have an indwelling catheter in the acute setting, **their voiding dysfunction should be managed by reversible therapy** (e.g., CIC, anticholinergic therapy) pending resolution. The urinary symptoms associated with GBS are multifaceted. In other reports, approximately 27% of patients with GBS have demonstrated urinary symptoms, with urinary retention being present in 9.2% of patients. Defecatory dysfunction and urinary dysfunction are highly related to the motor grade of GBS symptomatology. Antibody titers have no relationship to symptomatic urinary dysfunction. The most common urinary findings include increased postvoid residual volume, followed by decreased bladder sensation, detrusor overactivity, diminished bladder compliance, and underactive detrusor contraction, as well as sphincteric dyssynergia. These findings underscore the difficulty in prediction of LUTS based on condition diagnosis only (Sakakibara et al., 2009). In another study of GBS patients, 38 patients were assessed using Hughes motor grading, overall disability sum score (ODSS), and Medical Research Council (MRC) sum score with urodynamics at baseline and at 2 months. Ten of 38 patients had urinary symptoms; 23 of the 38 had urodynamic abnormalities; the most significant was detrusor underactivity in 15 patients. DSD was found in 6 patients, bladder acontractility in 5, and detrusor overactivity in 3. There was a correlation between disability based on these scoring systems and urodynamic findings (Naphade et al., 2012).

Miscellaneous Neurologic Diseases Causing Lower Urinary Tract Dysfunction

Amyotrophic Lateral Sclerosis

Amyotrophic lateral sclerosis (ALS), also known as Lou Gehrig disease, is a fatal neurodegenerative disorder of upper and lower motor neurons. There is no known cure for ALS and treatment is supportive. Symptoms include muscle weakness, cramping, and, in later stages, dysphagia, dyspnea, and eventually respiratory failure. There have been few studies on the effect of ALS on the lower urinary tract, but in a recent descriptive study by Arlandis et al. (2017), of 55 patients with ALS, 24 (43.6%) had clinically significant LUTS based on questionnaires. Of those patients reporting LUTS, the majority had storage and voiding symptoms and 26% reported urge incontinence. Urodynamic evaluation was done on 10 of these patients of which 7 had detrusor overactivity with a nonrelaxing external sphincter (5 patients) or bladder neck (2 patients). Although LUTS are not commonly associated with ALS, there is a high prevalence in this population, and treatment may be indicated to maintain quality of life.

Lyme Disease

The associated neurologic symptoms of Lyme disease (neuroborreliosis) fall broadly into three syndromes: (1) encephalopathy, (2) polyneuropathy, and (3) leukoencephalitis. The Lyme spirochete can also (rarely) invade the bladder. Puri et al. (2013) compared LUT symptoms in 17 patients with Lyme disease with matched controls and found that 35% of patients with Lyme disease had symptoms of bladder dysfunction, whereas none of the controls reported symptoms. Chancellor et al. (1993) described seven patients who also had LUT dysfunction. Five had detrusor overactivity, none had dyssynergia, and two had detrusor areflexia. In two women, urinary retention was the presenting symptom of Lyme disease. Other subjective symptoms noted were urgency, frequency, nocturia, and urge incontinence. Follow-up at 6 months to 2 years after treatment revealed residual urgency and frequency in three patients.

Hereditary Spastic Paraplegia

Hereditary spastic paraplegia (HSP) is a genetically transmitted disorder, usually autosomal dominant, less commonly autosomal recessive, and rarely sex linked. There is a pattern of central demyelination with axon loss and progressive lower extremity spasticity with muscle weakness. Bushman et al. (1993) described three patients, two of whom had detrusor overactivity (one with striated sphincter dyssynergia), one who had significantly decreased compliance, and one who was urodynamically normal except for a high maximum urethral pressure of uncertain significance. Pure forms of this disease are associated with primary lower extremity spasticity at presentation, but variance exists.

Jensen et al. (1998) reported the voiding characteristics of 11 patients with autosomal dominant pure spastic paraplegia linked to chromosome 2p21-p24. These patients were culled from 6 of 8 families with the disorder; the authors commented that LUTS were present in 16 of 44 definitely affected family members. One patient had an indwelling catheter, and thus an accurate description of symptomatology was not possible. For the other patients, urinary urgency and frequency were the dominant complaints, with 6 of these 10 patients regularly experiencing urgency urinary incontinence. Urodynamically, 3 patients showed detrusor overactivity, 6 demonstrated normal detrusor activity, and 1 demonstrated “hyporeflexia” with delayed first sensation. Satisfactory sphincter electromyographic recordings were obtained from 7 patients, and all were normal. Postvoid residual urine volumes were elevated in 8 of 10 patients. The bulbocavernosus reflex was absent in 6 patients and was truly normal in only 1 patient. The authors commented that the frequency of urinary symptoms in their patients (36%) correlated well with other reports in the literature. They proposed that the LUTS (along with bowel and sexual dysfunction) in patients with this disorder are caused by a combination of somatic and autonomic nervous system involvement, supporting a multisystem involvement. LUT dysfunction is well recognized in this condition and is associated with high prevalence rates in those of Eastern European extraction (approaching 77%). In a study of 29 HSP patients, the primary urinary symptom was urgency in 72%, followed by frequency in 65%, incontinence in 55%, and hesitancy in 51%. Urodynamic findings included detrusor overactivity in 51% and sphincter dyssynergia in 66%, with increased postvoid residual volume in 41%. However, there was no significant risk of upper tract complications related to this condition (Fourtassi et al., 2012). In another study of patients with HSP, 49 patients were assessed and 38 (77.6%) had some urinary concern. LUT dysfunction occurred similarly in the pure and complex forms of the disease. The most common symptoms associated with this condition were urinary incontinence of any type (69.4%), urinary hesitancy (59.2%), increased frequency (55.1%), and associated urinary urgency (51.0%). Incomplete bladder emptying was the least common (36.7% of patients). Increased LUT dysfunction was more commonly associated with the female gender (Braschinsky et al., 2010).

Tropical Spastic Paraparesis

Tropical spastic paraparesis is primarily a spinal cord myelopathy caused by a retrovirus (human T-cell leukemia virus 1 [HTLV-1]) that is similar to human immunodeficiency virus (HIV). Progressive lower limb weakness and back pain are typically the primary complaints, but LUT dysfunction occurs in up to 60% of those affected (Walton and Kaplan, 1993). Troisgros et al. (2017) reviewed 60 patients with HTLV-1–associated myelopathy who underwent urodynamic evaluation. The most common urodynamic abnormalities were DSD in 78% and detrusor overactivity in 68.3%. Bladder compliance was decreased in 25%, and 21.7% had detrusor underactivity. Walton and Kaplan (1993) found that 4 of 5 consecutive patients had detrusor overactivity and DSD, whereas 1 had overactivity and synergia. The type of voiding dysfunction depends on whether the damage is primarily to the descending spinal tracts, to the sacral nuclei, or to the sacral outflow. The disease must be distinguished from other myelopathic conditions associated with LUT dysfunction, such as multiple sclerosis.

Acquired Immunodeficiency Syndrome

Infection with HIV can affect the central and the peripheral nervous systems, and so it is not unexpected that symptoms of LUT dysfunction occur. As with many other conditions, there is some disagreement as to the overall prevalence of such symptoms in this population. AIDS-related neurogenic voiding dysfunction is associated with a poor outcome, with a mortality rate of approximately 40% within 8 months of development of urologic symptoms (Heyns and Fisher, 2005). In a prospective study of 39 patients with HIV infection and voiding symptoms, clinical symptoms included frequency, urgency, and incontinence in 41% of patients, acute urinary retention in 28%, dysuria and frequency in 18%, and decreased flow in 13% (Hermieu et al., 1996). Seventeen of the patients had involuntary bladder contractions, and, of these, 8 had DSD or a lack of sphincter relaxation during micturition, 5 had detrusor areflexia, 4 had what was termed a “hypertonic urethra,” 3 had “hypersensitivity,” and 5 had a normal urodynamic evaluation. The authors characterized the voiding dysfunctions broadly as inability to void in 41% of the cases and frequency, urgency, or incontinence in 41%. Furthermore, the authors proposed that the appearance of neurogenic voiding disturbances heralded a poor prognosis. Eighteen HIV-positive patients, 13 with acquired immunodeficiency syndrome (AIDS), with voiding dysfunction were urodynamically characterized by Kane et al. (1996). Chief presenting complaints were daytime frequency in 8 patients, retention in 3, nocturia in 2, and having to strain to void, feeling incompletely empty, and having incontinence, a split stream, or groin pain in 1 each. Five patients (28%) showed detrusor overactivity, 5 showed DSD, and 1 (6%) showed detrusor areflexia. The authors remarked that there is a correlation among cytomegalovirus infection, polyradiculopathy, and detrusor areflexia, which is a phenomenon reported by others as well. Lima et al. (2002) evaluated a group of 26 men with HIV-induced bladder dysfunction. Eighty percent of those patients demonstrated detrusor overactivity, and 34% had detrusor-sphincter dyssynergia. These findings are indicative of the myopathy associated with HIV (Lima et al., 2002). Other common causes of LUT dysfunction exist as well: 5 patients had outlet obstruction, 4 secondary to BPO and 1 from urethral stricture. The fact that HIV can cause demyelination at any site in the nervous system complicates symptom-based management of the HIV-infected patient and mandates sufficient LUT evaluation as a guide for therapy (Delgado et al., 2014). Renal functional impairment may result from LUT dysfunction or from primary renal involvement by the disease (Tonolini et al., 2013). Gyrtrup et al. (1995) prospectively investigated voiding function in 77 men and 4 women with HIV infection or AIDS consecutively attending an outpatient clinic. Eight of these (10%) had moderate subjective voiding problems, whereas two (2%) had severe problems. The authors believed that in only 4% of patients did the nature of the disturbance warrant urodynamic examination and concluded that urinary voiding symptoms are only a modest problem overall in an HIV/AIDS population. They concluded that neuropathic bladder dysfunction is rare and occurs mostly in the late stages of the disease. However, as treatment for HIV/AIDS improves, the mean age of patients will increase and along with that the incidence of more common LUT conditions, such as BPH. Consideration must be given to evaluate for possible neurogenic voiding dysfunction given the poor prognosis in this population, but treatment of benign causes for LUTS should not be overlooked.

Acute Disseminated Encephalomyelitis

Acute disseminated encephalomyelitis (ADEM) is an acute inflammatory demyelinating disorder of the CNS of unknown cause. It is also sometimes known as *parainfectious* or *postinfectious encephalomyelitis.* The locations of lesions are multifocal and can include the cerebral white matter, cerebellum, brainstem, and spinal cord. Of 61 patients with ADEM, 33% ($n = 20$) had LUTS with retention being the most common in 16, followed by incontinence in 4, urgency in 3, and frequency in 2. On urodynamic evaluation, detrusor overactivity was present in 4 and detrusor underactivity in 4 (Panicker et al., 2009). Three months after treatment, 5 patients had persistent symptoms. In another study of 11 patients with ADEM, 9 had urinary retention; the other 2 had urgency, frequency, nocturia, and difficulty voiding (Sakakibara et al., 1996b). One patient in the latter group had enuresis and urgency incontinence as well. The urodynamic findings are difficult to correlate with the presenting symptoms, because in 4 of the patients the studies were done considerably after the onset of the disease. During the follow-up period, 7 of the 9 patients who originally had retention became able to urinate. Five had difficulty voiding, and four developed irritative symptoms. Six of the patients ultimately had a near-complete neurologic recovery, but voiding symptoms persisted in 3. The authors concluded that the supra-nuclear and nuclear types of pelvic and pudendal nerve dysfunction were primarily responsible for the micturitional disturbances in patients with this disease and that voiding dysfunction was very common in these patients.

Syringomyelia

Syringomyelia is a chronic disorder of the spinal cord characterized by dissociated sensory loss and brachial amyotrophy. It usually affects the cervical spinal cord but can extend caudally. LUT dysfunction has been reported in 9% to 25% of patients. Fourteen patients with syringomyelia were studied urologically by Sakakibara et al. (1996c). Eleven of these had urinary symptoms: difficulty voiding in 8, retention in 3, nocturnal and daytime frequency in 3, incontinence in 2, and urgency and enuresis in 1. The urinary symptoms appeared from 2 months to 13 years after the initial neurologic symptoms. Urodynamic studies revealed detrusor overactivity in 7, DSD in 4, detrusor areflexia in 4, and “uninhibited sphincter relaxation” in 2. Motor unit electromyographic recordings disclosed findings compatible with denervation of the striated sphincter in 5 of 6 patients. The authors concluded that supranuclear and nuclear types of peripheral autonomic and somatic nerve dysfunction are responsible for the LUT dysfunctions seen. The micturitional status gradually improved in 4 of 6 patients after syringosubarachnoid shunts.

Schistosomal Myelopathy

Schistosomiasis is a tropical, parasitic disease and may cause LUT dysfunction from bladder neck obstruction and impaired muscle contractility as a result of infiltration of the bladder smooth muscle. In addition, it can rarely cause spinal cord involvement, either as a granulomatous intrathecal mass or as an acute transverse myelitis (Razdan et al., 1997). Two such patients had urinary incontinence as their chief urologic complaint, and both had detrusor overactivity, one without dyssynergia and with minimal motor weakness and one with DSD and a T11 sensory level. It was believed that the findings in the former patient were characteristic of a partial spinal cord or cerebral lesion and that the second patient had a suprasacral transverse myelopathy. In the first patient, the urinary symptoms developed approximately 2 months after exposure and after the development of systemic symptoms, whereas in the second case, symptoms developed some 5 years after the initial diagnosis.

Gomes et al. (2002) reviewed the records of 14 patients with schistosomal myelopathy referred because of LUT dysfunction. Of 5 patients with acute disease, 3 had retention and 2 were incontinent. Urodynamics were performed in three of these. Two (1 in retention, 1 with hesitancy and incontinence) demonstrated detrusor areflexia, and one (with retention) showed detrusor overactivity and DSD. Of the 9 patients with chronic disease, 5 showed detrusor overactivity with DSD, 1 had decreased compliance, 2 had overactivity with synergic sphincters, and 1 had detrusor areflexia with decreased compliance. In another study of 26 patients with schistosomiasis, all patients had chronic neurologic and urologic symptoms secondary to this diagnosis. The most common urinary symptoms were difficulty in bladder emptying in 65% of the patients followed by incontinence in 54% and urgency and frequency in 50% of the patients, UTI in 30% of patients, and bilateral hydronephrosis in 19%. Detrusor overactivity associated with sphincter dyssynergia was present in 54% of the patients; detrusor areflexia was present in 23% of the patients. Patients with dyssynergia had a much higher incidence of upper tract decompensation.

These findings are consistent with classically defined involvement of spinal cord as a common complication of this disease (Gomes et al., 2005).

Systemic Lupus Erythematosus

Systemic lupus erythematosus (SLE) is a disease with a likely autoimmune origin in which there is widespread inflammatory change in the connective tissues and small vessels of the skin and systemic organs (Hahn cited by Sakakibara et al., 2003b). The prevalence of nervous system involvement ranges from 18% to 75%, and myelopathy occurs in 1% to 3% of SLE patients. Sakakibara et al. (2003b) reported on eight patients with SLE with LUT dysfunction, six with voiding difficulty (two of whom had retention), and four with urinary incontinence. Five exhibited decreased flow, three had increased residual urine, five had detrusor overactivity, five had impaired detrusor contractility, four had DSD, and two of four patients studied exhibited abnormal striated sphincter electromyographic potentials. Sensation was impaired in two. Although three patients had subacute encephalomyelopathy (one subacute myelopathy, four chronic myelopathy), the LUT dysfunction seemed to have been related mainly to the myelopathy.

In addition, there have been reports of lupus cystitis affecting about 2% of patients with SLE (Koh et al., 2015). Lupus cystitis is characterized by bladder wall thickening and diffuse inflammation of the bladder mucosa with associated erythema and hematuria. Patients may also have bilateral hydronephrosis and/or vesicoureteral reflux. Treatment of the underlying disease process with steroids and immunosuppressive agents improves bladder findings (Harris et al., 2015).

Reflex Sympathetic Dystrophy

Reflex sympathetic dystrophy (RSD) is a disabling syndrome characterized by severe pain with autonomic changes, such as vasomotor disturbances. The condition usually follows a traumatic injury, although the exact cause and pathogenesis are unclear. The prevalence of LUT dysfunction in patients with RSD is unknown, but it must be more than a rare occurrence because Chancellor et al. (1996) were able to collect 20 consecutive patients with neurologically verified RSD who were referred because of new-onset voiding symptoms. Seven of the patients had urinary retention, although some of these had undergone various types of surgery designed to treat the symptoms of the dystrophy. Five presented with urgency incontinence, 1 of whom also had stress incontinence. Six had urgency as a primary complaint, 1 had daytime frequency, and 1 had severe nocturia. Detrusor overactivity was demonstrated in 8 patients, DSD in 1, detrusor areflexia in 8, and hypersensitivity on filling in 3. Because the authors excluded patients who acutely developed voiding dysfunctions after back surgery and those with herniated disks, one must conclude that significant LUT dysfunction can develop as a direct result of, or in association with, RSD. However, the cause-and-effect relationship is so far unclear.

Tuberculosis

Spinal tuberculosis has been associated with significant evidence of micturition disturbances including high postvoid residual volume and urinary symptoms. In an assessment of patients undergoing clinical urodynamics and spinal MRI, 30 spinal tuberculosis patients were assessed; 15 had some form of micturition disturbance, including urinary incontinence or storage disorder. Four of the 15 also demonstrated retention, 2 had stress incontinence, 6 had urinary hesitancy, 11 reported urgency, and 9 had urge incontinence. These symptoms were associated with a significant incidence of either paraparesis or quadriparesis (13 patients). Detrusor overactivity with high-pressure voiding was present in 6. Detrusor areflexia was present in 4, with the remainder having increased postvoid residual volumes. After intervention, those patients with prior micturition disturbances had poor functional recovery as compared with patients without micturition disturbances. There was a strong relationship between bladder symptomatology and severity of paraplegia, horizontal sensory level, and signal abnormality in the cord; these variables were associated with poorer outcome than in those patients without them (Kalita et al., 2010).

In a prospective study of 51 patients with tuberculous meningitis, 17 (33%) had urinary symptoms related to storage or voiding dysfunction, but 36 had an abnormal urodynamic evaluation. Reduced bladder sensations were present in 11 (31%) and NDO in 10 (28%). Three patients (8%) had detrusor areflexia and 6 (17%) had DSD. At 6 months after treatment, of the 36 patients with an abnormal UDS, 18 had resolution of the abnormalities (Gupta et al., 2013). Bladder dysfunction is common in patients with spinal tuberculosis but resolves in a large number of patients after treatment.

Miscellaneous Conditions Definitely, Probably, or Possibly Related to Neuromuscular Dysfunction

Detrusor Sphincter Dyssynergia

Dyssynergia* is the kinesiologic disassociation of two groups of muscles that, in general, work in harmony.** ***Sphincter dyssynergia is an involuntary contraction, or lack of relaxation, of either the striated sphincter (the striated muscle surrounding the proximal urethra and the striated muscle that forms a part of the urethra for a variable distance from the "urogenital diaphragm" to the bladder neck) or the smooth sphincter (the smooth muscle of the bladder neck and proximal urethra). ***Detrusor sphincter dyssynergia,*** unless specified otherwise, is dyssynergia of the striated sphincter and is sometimes abbreviated DSD or DESD.

True DSD should exist only in patients who have an abnormality in pathways between the sacral spinal cord and the brainstem PMC and is usually caused by neurologic injury or disease (Blaivas, 1982; Chancellor and Rivas, 1995; Rudy, 1993; Wein and Rovner, 1999). The diagnosis of DSD should be suspected in any patient with a neurologic lesion in this area. Common causes include traumatic SCI, MS, and transverse myelitis. Conversely, **in patients without such a lesion, this diagnosis should always be viewed with skepticism,** and, without such apparent pathology, such a patient deserves exhaustive study to exclude a neural diagnosis. One exception to this precept is in infants and children with dysfunctional voiding or the Hinman syndrome (see later).

Blaivas et al. (1981) have described three categories of DSD. In type 1 there is a concomitant increase in detrusor pressure and electromyographic activity; at the peak of the detrusor contraction, the sphincter suddenly relaxes and unobstructed voiding occurs. In type 2 there are sporadic contractions of the striated sphincter throughout the detrusor contraction. In type 3 there is a crescendo-decrescendo pattern of sphincter contraction that results in outlet obstruction throughout the entire detrusor contraction. Schurch et al. (2005) have correlated neurologic status and DSD type after SCI and found that those with an incomplete sensory and motor lesion typically have type 1 DSD, whereas those patients with complete sensory and motor lesions have type 2 and type 3. Weld et al. (2000) prefer to classify DSD as intermittent or continuous; however, in their experience the clinical significance of DSD type is not crucial because both types require urodynamic surveillance and expedient treatment to minimize complications. No significant association between type and level of injury was found; however, continuous DSD was more associated with complete injuries.

Sphincter electromyographic activity that increases simultaneously with intravesical or detrusor pressure does not always indicate true DSD. These instances are referred to as *pseudodyssynergia* (Wein and Barrett, 1982), and such a misdiagnosis may be accompanied by adverse therapeutic consequences. **Common causes of pseudodyssynergia include (1) abdominal straining to either initiate or augment a bladder contraction or in response to discomfort and (2) attempted inhibition of a bladder contraction either because of its involuntary nature or because of discomfort.** Rudy (1993) reported that pseudodyssynergia can reliably be differentiated from true DSD urodynamically by analyzing the patterns of detrusor and electromyographic activity, but others have not consistently found this to be the case.

Without proper treatment, more than 50% of men with DSD will develop significant complications, such as VUR, upper tract deterioration, urolithiasis, urosepsis, and ureterovesical obstruction (Chancellor and Rivas, 1995). In women, these complications are much less common, most likely a result of the lower detrusor pressures generated. Using Blaivas's categorization, type 1 DSD is usually managed with observation alone unless there is persistent VUR, hydronephrosis, or autonomic hyperreflexia, whereas types 2 and 3, in general, require treatment. In assessing success or failure of treatment, Kim et al. (1998) used bladder leak point pressure greater than 40 cm H_2O as an indicator of the failure of sphincterotomy, because in their experience there was a significantly higher incidence of upper tract damage and persistent DSD in such patients. This most likely applies to other treatments as well.

Therapy for DSD is designed to either eliminate or significantly minimize the abnormal sphincter activity or to bypass the sphincter. Oral medical therapy directed toward the striated sphincter has not enjoyed wide success. The most common treatment approaches currently are (1) CIC (usually combined with therapy to control detrusor overactivity), (2) sphincterotomy, (3) injection of onabotulinumtoxinA into the sphincter, (4) continuous indwelling catheterization, and (5) urinary diversion. Urethral stent placement across the sphincter has fallen out of favor because of complications (Wilson et al., 2002), and the device is no longer commercially available.

Dysfunctional Voiding

Dysfunctional voiding, also described by various authors as non-neurogenic neurogenic bladder, occult voiding dysfunction, occult neuropathic bladder, learned voiding dysfunction, and Hinman syndrome, demonstrates what urodynamically appears to be involuntary obstruction at the striated sphincter level existing in the absence of demonstrable neurologic disease (Hinman, 1986). It is very difficult to prove urodynamically that an individual has this entity, and the diagnoses in many of the patients reported have been made on the basis of only history, isolated flowmetry, isolated measurements of total intra-vesical pressure, and pelvic floor electromyographic activity (Wein and Barrett, 1988). Unequivocal demonstration of this entity requires pressure-flow electromyographic evidence of bladder emptying occurring simultaneously with involuntary striated sphincter contraction in the absence of any element of abdominal straining, either in an attempt to augment bladder contraction or as a response to discomfort during urination. Such reports do exist and confirm the existence of this syndrome. The cause is uncertain and may represent a persistent transitional phase in the development of micturitional control or persistence of a reaction phase to the stimulus of LUT discomfort during voiding, long after the initial cause of the problem has disappeared (Jorgensen et al., 1982).

Stoffel et al. (2017) published a consensus paper on the management of non-neurogenic urinary retention, defined as a postvoid residual above 300 mL that has persisted for at least 6 months and documents on at least two occasions and is classified as high or low risk and symptomatic or asymptomatic. After a thorough history and physical examination, if a high-risk variable is present, such as hydronephrosis, hydroureter, chronic kidney disease, recurrent UTI, or urinary incontinence with skin sequalae, then treatment with bladder drainage, either intermittent catheterization or indwelling catheter, is recommended. If patient is experiencing symptoms, the underlying cause should be targeted for treatment. If long-term catheterization is required, it was the authors’ opinion that suprapubic catheter is preferable to urethral. Importantly patients with chronic urinary retention must be followed long term to assess for changes and mitigate any high-risk factors.

Bladder Neck Dysfunction

Bladder neck dysfunction is defined here as **an incomplete opening of the bladder neck during voluntary or involuntary voiding.** It has also been referred to as *smooth sphincter dyssynergia, proximal urethral obstruction, primary bladder neck obstruction,* and *dysfunctional bladder neck.* **The term *smooth sphincter dyssynergia* or *proximal sphincter dyssynergia* is usually used when referring to this urodynamic finding in an individual with autonomic hyperreflexia.** In male patients with autonomic hyperreflexia, the neurologic pathophysiology is clear. **The term *bladder neck dysfunction* more often refers to a poorly understood, non-neurogenic condition first described more than a century ago but first fully characterized by Turner-Warwick et al. in 1973. The dysfunction is found almost exclusively in young and middle-aged men, who characteristically report long-standing voiding and storage symptoms** (Norlen and Blaivas, 1986; Trockman et al., 1996; Webster et al., 1980; Wein and Barrett, 1988; Yamanishi et al., 1997). **These patients have often been seen by many urologists and have been diagnosed as having psychogenic voiding dysfunction because of a normal prostate on rectal examination, a negligible residual urine volume, and a normal endoscopic bladder appearance.** The differential diagnosis also includes anatomic bladder neck contracture, benign prostatic enlargement (BPE) or BPO, dysfunctional voiding, prostatitis, neurogenic micturition dysfunction, and low pressure and low flow. **Objective evidence of outlet obstruction in these patients is easily obtainable by urodynamic study. Once obstruction has been diagnosed, it can be localized to the level of the bladder neck by videourodynamic study, cystourethrography during a bladder contraction, or micturitional urethral profilometry.** The diagnosis may also be made indirectly by the urodynamic findings of outlet obstruction in the absence of urethral stricture, prostatic enlargement, and DSD. Noble et al. (1994) cited the incidence of concomitant involuntary bladder contractions or decreased compliance as 50%; Trockman et al. (1996) quoted it as 34%.

The exact cause of this problem is unknown. Some have proposed that there is an abnormal arrangement of musculature in the bladder neck region, such that coordinated detrusor contractions cause bladder neck narrowing instead of the normal funneling (Bates et al., 1975). The occurrence of this problem in young, anxious, and “high-strung” individuals, and its partial relief by α-adrenergic blocking agents, have prompted some to speculate that it may in some way be related to sympathetic hyperactivity.

When prostatic enlargement develops in individuals with this problem, a double obstruction results, and Turner-Warwick (1984) has coined the term *trapped prostate* to describe these patients. Because the lobes of the prostate cannot expand the bladder neck, they expand into the urethra. In general, a patient so affected has a lifelong history of voiding dysfunction that has gone relatively unnoticed because he has always accepted this as normal, and exacerbation of these symptoms may occur during a relatively short and early period of prostatic enlargement. Although α-adrenergic blocking agents provide improvement in some patients with bladder neck dysfunction, definitive relief in men is best achieved by a bladder neck incision. In patients with this and a trapped prostate, marked relief is typically effected by a small prostatic resection or ablation that includes the bladder neck, or a transurethral incision of the bladder neck and prostate. Such patients often note afterward that they have “never” voided as well as after their treatment.

Bladder Outlet Obstruction in Women

The female counterpart of male non-neurogenic bladder neck dysfunction is rare but does exist. **Bladder outlet obstruction in women in general is uncommon.** Diokno et al. (1984) were among the first to clearly define this entity in women on the basis of video-urodynamic studies. Nitti et al. (1999) evaluated the videourodynamic studies of 261 of 331 women who underwent multichannel studies for non-neurogenic voiding dysfunction. **They defined *bladder outlet obstruction* as radiographic evidence of obstruction between the bladder neck and the distal urethra in the presence of a sustained detrusor contraction of any magnitude, which is usually associated with reduced or delayed urinary flow rate. Obstruction at the level of the bladder neck was diagnosed when the bladder neck was closed or narrowed during voiding. Obstruction of the urethra was diagnosed as a discrete area of narrowing associated with proximal dilation.** Strict pressure-flow criteria were not used to classify cases as obstructed or not obstructed. Using these criteria, the authors found 76 (23%) of their cases to be obstructed and of those, only 12 (16%) were diagnosed as having primary bladder neck obstruction (the counterpart to non-neurogenic bladder neck dysfunction in the male). Thirty-three percent of the cases of obstruction were caused by dysfunctional voiding, 28% by cystocele, 14% by obstruction created by prior incontinence surgery, 4% by urethral stricture, 3% by uterine prolapse, and 1% each by urethral diverticulum and rectocele. Groutz et al. (2000) **defined obstruction as a persistent low, noninvasive maximum flow rate less than 12 mL/ sec on repeated study combined with a detrusor pressure at maximum measured flow rate of more than 20 cm H_2O in a pressure-flow study.** Of the 587 consecutive women referred for urodynamic evaluation of voiding symptoms, only 38 (6.5%) met these criteria of bladder outlet obstruction. Of those, only 3 women (8%) were characterized as having primary bladder neck obstruction. Ten women (26%) had obstruction on the basis of prior anti-incontinence surgery, 24% because of severe genital prolapse, 13% because of urethral stricture, 5% because of dysfunctional voiding, 5% because of true DSD, and 3% because of urethral diverticulum; in 16% there was no identifiable cause. A new nomogram for defining bladder outlet obstruction in women was introduced by Solomon et al. (2017) based on video urodynamic and clinical data of 185 women and then validated the nomogram on 350 women. This nomogram uses Qmax (maximum flow rate) and Pdet@Qmax (detrusor pressure at maximum flow) to determine the probability of obstruction and showed very good agreement with Nitti's nomogram, which relies on urodynamic parameters in addition to fluoroscopy findings to determine obstruction.

Most authors would agree that surgical treatment of this problem in women should be approached with caution because sphincteric incontinence is a significant risk. Smith and Appell (2006) commented on the importance of urodynamics in distinguishing dysfunctional voiding versus bladder neck dysfunction. They commented on the importance of evaluation inclusive of symptom assessment, uninstrumented uroflow patterns, simultaneous urodynamic and electromyographic assessment of voiding, as well as the addition of fluoroscopy to assess function of the bladder neck during voiding. They further stressed multidisciplinary therapy including pelvic floor therapy (biofeedback), behavioral modification, and the addition of pharmacotherapy.

Pelvic organ prolapse (POP), particularly if high grade, can anatomically result in bladder outlet obstruction from urethral kinking. Hoffman and Nitti (2016) reported that 58% of patients with high-grade POP can experience obstructive voiding. It is important to assess improvement in obstruction and associated symptoms with reduction of the prolapse before surgical correction. Up to 94% will have improvements in maximum flow rate with correction of POP.

Low-Pressure and Low-Flow Voiding in Younger Men: Paruresis (Bashful Bladder)

Low-pressure and low-flow voiding **can be the result of a number of causes, most notably a decompensating detrusor** (usually from bladder outlet obstruction) or as a part of the syndrome known as *detrusor hyperactivity with impaired contractility* (DHIC). **When this occurs in a young man, it is usually characterized by frequency, hesitancy, and a poor stream.** The entity is readily demonstrated on urodynamic assessment and with no coexisting endoscopic abnormality. **The patient usually notes marked hesitancy when attempting to initiate micturition in the presence of others, called paruresis,** although more often referred to as a “shy bladder” or a “bashful bladder.” The estimate of the incidence of this problem in younger male patients referred for urodynamic assessment varies from 2.8% (Hammelstein et al., 2005) to 19% (George and Slade, 1979).

Barnes et al. (1985) suggested that, psychologically, these men tend to be obsessional rather than anxious. They suggest that these individuals have a lifelong tendency to over-control the process of micturition and are thus vulnerable to LUTS under stress. The authors recommend that a behavioral modification program be considered. Rosario et al. (2000) performed ambulatory urodynamic studies on 40 consecutive symptomatic men with a mean IPSS of 19 who were unable to “perform” during conventional videourodynamic study. They concluded that a surgically correctable cause of the symptoms could be found in only 20% of men, and only in those 40 years of age and older. They concluded that the contribution of ambulatory urodynamic monitoring in such cases in men younger than 40 years was negligible. As with previous studies, these authors thought that a significant proportion of such nonobstructed cases would respond to drug therapy or behavioral intervention. Furthermore, Kuoch et al. (2017) performed a systematic review and found that many with paruresis suffer from comorbid psychological disorders, specifically 29% had anxiety disorder and 22% had major depressive episodes suggesting that treatment may also require psychological intervention.

Urinary Retention: Fowler Syndrome in Young Women

Although urinary retention is encountered fairly commonly in men with anatomic obstruction from BPE, urinary retention in women is unusual but not rare. As in men, **the potential causes are classically cited as neurologic, pharmacologic, anatomic, myopathic, functional, and psychogenic.** A comprehensive review and algorithm for evaluation and treatment of the various causes of urinary retention in women has been published by Smith et al. (1999).

Fowler syndrome (Fowler, 1999, 2003; Fowler et al., 1988; Noble et al, 1994; Swinn and Fowler, 2001) is **urinary retention in young women in the absence of overt neurologic disease. The typical history is that of a woman younger than 30 years who is unable to void for a day or more with no urinary urgency but increasing lower abdominal discomfort. A bladder capacity of more than 1 L with no sensation of urgency is necessary for the diagnosis. There are no neurologic or laboratory features to support a diagnosis of any neurologic disease.** MRI scans of the brain and the entire spinal cord have been reported to be normal. However, a MRI assessment of patients with Fowler syndrome has suggested exaggerated cortical procontinence behavior attributable to increased afferent activity emanating from the urethra inhibiting bladder afferents at the sacral level. This increased afferent activity is partially modulated by successful sacral neuromodulation resulting in decreased overall sphincteric activity (Griffiths and Fowler, 2010).

On concentric needle electrode examination of the striated muscle of the urethral sphincter, however, Fowler et al. (1988) described a unique electromyographic abnormality. This abnormal activity, localized to the urethral sphincter, consists of a type of activity that would be expected to cause inappropriate contraction of the muscle. Sphincter activity consists of two components: complex repetitive discharges and decelerating bursts. This abnormal activity impairs sphincter relaxation. These patients often have polycystic ovaries, raising the possibility that the activity is linked in some way to impaired muscle membrane stability. This, in turn, allows direct spread of electrical impulses throughout the muscle, possibly from a hormonal abnormality. Thus the disorder may possibly be the manifestation of a focal, hormonally dependent “channelopathy.” This would potentially explain why the condition is seen only in premenopausal women. Efforts to treat this condition by hormonal manipulation, pharmacologic therapy, or injections of onabotulinumtoxinA have been unsuccessful. This condition is highly responsive to neuromodulation, with a success rate approaching 70% even in women who have had urinary retention for many months or years.

The urodynamic finding is detrusor acontractility; however, the same electromyographic abnormality is found sometimes in women with obstructed voiding. This type of electromyographic activity is not uncommon; FitzGerald et al. (2000) cite an incidence of 8% in a series of women undergoing routine urodynamic and electromyographic studies, but its correlation with complete retention is relatively rare.

In one of the largest reports of Fowler syndrome, 247 women with a presumptive diagnosis of Fowler syndrome were assessed. Overall, the diagnosis was confirmed in 57.5% of patients. However, distressingly, in 32% of patients the authors were not able to determine an ultimate diagnosis. Of the study group, 4.8% had congenital intestinal pseudo-obstruction (associated in some patients with ingestion of high-dose opiates). Other cases of voiding dysfunction included detrusor failure (1.6%), pain or structural abnormality in the LUT (1.6%), recurrent obstruction after surgery for sphincteric incontinence (1.2%), and a neurologic abnormality other than Fowler syndrome (1.2%). The authors based their diagnosis on the classic Fowler syndrome (nonpainful urinary retention in women 20 to 35 years of age); patients frequently had polycystic ovaries and relatively mild LUT dysfunction. They further identified urodynamic findings including a very high urethral closure pressure (greater than 100 cm H_2O) and increased sphincter volume based on ultrasonographic assessment, perhaps suggesting a hormonal-based effect on channel receptors. The authors reported a success rate of 40% to 68% for peripheral nerve evaluation with neuromodulation, followed by a 60% complete success rate after formal implantation and an additional 14% partial success rate in their population. The possibility of autonomic dysfunction as being contributory to this condition was also raised (Kavia et al., 2006).

De Ridder et al. (2007) reported 62 women who underwent sacral nerve stimulation, 30 of whom had findings compatible with Fowler syndrome and 32 with idiopathic retention. Somatoform disorder was found in 26% of the Fowler syndrome patients and 43.8% of the idiopathic group. Depression was also higher in the Fowler syndrome group (30% vs. 18.8%). Neither of these findings, however, had correlation with outcome. Nine patients with Fowler syndrome (compared with 19 patients without Fowler syndrome) failed neuromodulation. The authors concluded that Fowler syndrome was actually a positive predictive factor for SNS response in patients with female urinary retention.

Postoperative Urinary Retention

Postoperative urinary retention is a well-recognized but poorly understood event. Its reported incidence is highly variable, between 5% to 70%, with many factors affecting rates (Baldini et al., 2009). It occurs more frequently after LUT and perineal, gynecologic, and anorectal surgery. In the placebo arms of four trials of adrenergic blocker prophylaxis after these types of surgery, the incidence of postoperative retention ranged from 18.8% to 57% (Velanovich, 1992). **Although not mutually exclusive, contributing factors include the following:**

1. Traumatic instrumentation
2. Bladder overdistention
3. Diminished awareness of bladder sensation
4. Decreased bladder contractility
5. Increased outlet resistance
6. Decreased micturition reflex activity
7. Nociceptive inhibitory reflex
8. Preexistent outlet pathology (e.g., BPH)

Anesthesia and analgesia can contribute to factors 2, 3, 4, and 6. The idea of a nociceptive inhibitory reflex initiated by pain or discomfort is an attractive one, because a sympathetic efferent limb could directly affect factors 4, 5, and 6.

Bladder decompression for 18 to 24 hours postoperatively decreased the incidence of retention in patients undergoing joint replacement surgery by 52% versus 27% (Michelson et al., 1988) and 65% versus 0 (Carpiniello et al., 1988), compared with CIC. The incidence of urinary infection with continuous catheterization was no different in the study by Michelson et al. (15% vs. 11%) and was less in the study by Carpiniello et al. (16% vs. 43%) in which CIC was carried out in the recovery room as well. The avoidance of acute bladder overdistention to prevent postoperative urinary retention is supported by the experimental observation of a reduced bladder response to sacral neural stimulation during overdistention (>80% reduction) and, as well, after overdistention (19% reduction) (Bross et al., 1999).

Historically, prophylactic adrenergic blockade with phenoxybenzamine has seemed effective in decreasing the incidence of postoperative retention. Velanovich (1992) performed a meta-analysis on the use of phenoxybenzamine and concluded that this agent reduced the occurrence by 29.1%. In a retrospective review of colorectal patients treated with and without phenoxybenzamine, Goldman et al. (1988) found a 54.7% incidence of retention in patients not given this agent versus a 19.2% incidence in those who were. The regimen for those not catheterized preoperatively was 10 mg orally the evening before and 1 hour before surgery, 2 hours after, and 10 mg twice daily for 3 days. For those who were catheterized before the procedure, the regimen was 10 mg twice daily, initiated the day before catheter removal. The mechanism of action is uncertain. If an inhibitory nociceptive reflex is initiated, and this is similar to the sympathetic reflex elicited by bladder filling (see Chapter 69), the mechanism is likely multifactorial. Alternatively, the drug may act only on the outlet to decrease resistance, which may be pathologically increased by anxiety, pain, and other factors related to surgery.

Whether other adrenergic blockers are as effective is uncertain (Cataldo and Senagore, 1991). A study of 95 men undergoing spinal surgery were randomized to alpha-blockage therapy 48 hours before surgery, specifically tamsulosin, or placebo, and there was no difference in postoperative urinary retention (Basheer et al., 2017). Although rare, urinary retention after spinal surgery must be distinguished from postoperative cauda equina syndrome resulting from epidural hematoma, which in addition to urinary retention is associated with saddle anesthesia and leg weakness.

Hyperthyroidism

Patients with thyrotoxicosis often have symptoms caused by sympathetic overactivity and autonomic nervous system imbalance. Hyperthyroidism has an association with LUTS, especially in women. Autonomic dysfunction may play a contributory role. In an assessment of 65 newly diagnosed untreated women with hyperthyroidism compared with 62 age-matched controls, the women with hyperthyroidism demonstrated significantly higher mean symptom scores for incomplete emptying, frequency, straining, and overall total symptoms. More than 80% demonstrated high total symptom scores and diminished peak flow rates. In follow-up, LUTS and flow times improved significantly after therapy.

There is no relationship between LUTS and serum thyroid levels, hormone levels, or other hyperthyroid symptoms (Ho et al., 2011). Goswami et al. (1997) reported that 12 of 30 patients (40%) experienced the onset of voiding symptoms 1 to 6 months after the onset of the symptoms of thyrotoxicosis. Four of these patients had enuresis. Of the 5 patients who underwent urodynamic studies, all had reduced flow rates, and 4 had a significant postvoid residual volume, 3 of whom had an enlarged bladder capacity and increased perineal electromyographic activity during voiding. The LUT dysfunction and urodynamic abnormalities resolved after resolution of the hyperthyroidism. The bladder symptoms were more common in females than in males. A higher incidence of bladder symptoms was noted in patients with thyrotoxicosis: a 7% incidence of urgency with or without hesitancy and a 1% incidence of enuresis.

Schizophrenia

Bonney et al. (1997) proposed that a significant subset of schizophrenic patients have involuntary bladder contractions secondary to brain pathology. In a previous study (Gupta et al., 1995), the same group demonstrated involuntary bladder contractions in 4 of 10 evaluable patients with schizophrenia who were referred because of voiding dysfunction or incontinence. All of these patients had a history of significant childhood incontinence, urge incontinence, bedwetting, and a diminished bladder capacity. In the later report (Bonney et al., 1997), the prevalence of urinary incontinence and related symptoms in a group of patients with chronic schizophrenia was compared with that of a group of comparable patients hospitalized with mood disorders. There was a significantly higher prevalence of urge incontinence (34% vs. 17%) and bedwetting (46% vs. 20%) in the group with schizophrenia, whereas there were no significant differences in urinary urgency, overall voiding dysfunction, fecal incontinence, or sexual dysfunction. The hypothesis of a neurobiologic correlation between schizophrenia and the occurrence of involuntary bladder contractions is an intriguing one. Another hypothesis is that treatment of schizophrenia with antipsychotics may cause urinary incontinence primarily via α-adrenergic blockade and a hypodopaminergic state. In a study of 8 patients on antipsychotic medications underwent urologic evaluation with urodynamic studies. The most common symptom was urinary urgency in 6 (75%) followed by nocturnal enuresis in 4 (50%) and five patients (62.5%) had detrusor overactivity on urodynamic evaluation (Sinha et al., 2016). It is possible that patients with psychotic disorders have bladder dysfunction related to the primary disease process and as a result of the medical treatment for their disorder.

Gastroparesis

Gastroparesis is a condition characterized by symptoms from impaired transit of intraluminal gastric contents into the duodenum in the absence of mechanical obstruction. It may be caused by diabetes, occur after gastric surgery, or be idiopathic. Goldman and Dmochowski (1997) characterized the voiding dysfunction of 17 patients with gastroparesis who were referred because of voiding symptoms, 10 of whom had idiopathic gastroparesis and in 7 of whom the condition was secondary to diabetes. Seven patients had abnormal detrusor contraction and delayed sensation, 5 had poor detrusor function and normal sensation, 3 had normal detrusor function and poor sensation, and 2 had normal detrusor contraction and sensation. There was no difference in the occurrence of the dysfunctions between the two groups. Predominant symptoms were urinary frequency in 7 and difficulty emptying in 10. Patients with idiopathic gastroparesis were more likely to note difficulty emptying (70%), whereas those with diabetic gastroparesis were more likely to have urinary frequency (71%). The authors postulated an association between idiopathic gastroparesis and bladder dysfunction and proposed that a common autonomic neuropathic syndrome may account for the bladder dysfunction in the idiopathic and the diabetic forms of this syndrome.

Myasthenia Gravis

Any neuromuscular disease that affects the tone of the smooth or striated muscle of the distal sphincter mechanism can predispose an individual to a greater chance of urinary incontinence after even a well-performed transurethral or open prostatectomy. Myasthenia gravis is an autoimmune disease caused by autoantibodies to acetylcholine nicotinic receptors. This leads to neuromuscular blockade and subsequent weakness in a variety of striated muscle groups. The incidence of incontinence after prostatectomy is indeed greatly increased in patients with this disease (Greene et al., 1974; Khan and Bhola, 1989). In addition, Sandler et al. (1998) reviewed three cases of de novo voiding dysfunction in patients with myasthenia gravis (one woman with intrinsic sphincter deficiency, poor pelvic muscle contractility, and detrusor overactivity; one man with detrusor hyporeflexia who reported urgency and incontinence; and one young woman with an acontractile bladder). The authors add a personal report of a fourth patient with urinary retention from detrusor areflexia. They hypothesize that such autonomic dysfunction in a patient with myasthenia may indicate a unique subset with a worse prognosis. There have been documented reports of successful treatment of OAB in patients with myasthenia gravis with intradetrusor onabotulinumtoxinA (Wright et al., 2016b) and percutaneous tibial nerve stimulation (Antoniou et al., 2016) without change in neurologic symptoms.

Isaacs Syndrome

Isaacs syndrome is a rare neurologic disorder characterized by continuous muscle contraction, fasciculations, myokymia, excessive sweating, and elevated creatinine kinase level. It is caused by antibodies possibly directed against potassium channels on peripheral nerves and is associated with peripheral neuropathy, autoimmune diseases, malignancies, and endocrine disorders. Tiguert et al. (1999) presented a case with urinary retention associated with a picture of acute demyelinating neuropathy. Their patient had painful urinary and fecal retention; the urinary retention was thought to be caused by spasm of the periurethral striated sphincter and was diagnosed by an inability to pass a catheter beyond this area. Rectal sphincter spasm was also diagnosed. The condition was treated with plasmapheresis and pharmacologic agents to relax the skeletal muscle. Suprapubic drainage was instituted. The condition subsided, and normal urinary function was ultimately restored.

Wernicke Encephalopathy

Wernicke encephalopathy is a rare but well-documented condition caused by a deficiency in thiamine (vitamin B_1) in alcoholic and nonalcoholic populations. Pathologic lesions are characteristically distributed periventricularly at the levels of the third and fourth ventricles, including the mammillary body, medial thalamic nucleus, hypothalamus, superior cerebellar vermis, PAG, and mid-brain tegmentum. The two major clinical manifestations of thiamine deficiency involve the cardiovascular and neurologic systems, with the latter manifesting in general as a peripheral neuropathy, also known as Wernicke encephalopathy. The initial symptoms of the polyneuropathy range from burning feet to muscle weakness. Sakakibara et al. (1997b) report a case of a pregnant woman with multiple neurologic manifestations of central and peripheral neuropathy and urgency incontinence, manifesting urodynamically with involuntary bladder contractions and a decreased bladder volume. **Resolution of the urinary symptoms occurred after thiamine replacement.** The authors hypothesized that lesions in the medial thalamic-hypothalamic area and PAG were primarily responsible for the micturitional disturbance. Tjandra and Janknegt (1997) reported a case of a man with chronic alcoholism with seemingly isolated erectile and voiding dysfunction. The emptying complaints correlated with a prolonged void with a peak flow rate of 6.4 mL/sec and an interrupted pattern during flowmetry, suggesting poor detrusor contractility. The erectile dysfunction was determined to be neurogenic, and both resolved with thiamine replacement.

Systemic Sclerosis (Scleroderma)

Scleroderma is a disease of the connective tissue characterized by thickening and fibrosis of the skin, abnormalities of the small arteries, and involvement of the gastrointestinal tract, heart, lung, and kidneys. The pathogenesis is unknown but thought to be caused by overexpression of the collagen gene DNA that contributes to excessive production of collagen in these patients. Lazzeri et al. (1995) reported the urodynamic assessment and histologic evaluation of 9 such women, of whom 5 had hesitancy, 4 had decreased stream, 2 had frequency and nocturia, and 2 had suprapubic pain. Four patients had detrusor areflexia, 1 of whom also had decreased compliance. Another patient with a decreased stream also had decreased compliance. Three of the patients with areflexia demonstrated collagen accumulation on histologic examination of bladder biopsies. The authors reviewed 5 literature reports of various aspects of LUT function and histology in patients with scleroderma but failed to find a consistent pattern. They hypothesized that the areflexia resulted from impaired neurologic modulation because of the histologic changes in the detrusor tissue.

Conversely, Minervini et al. (1998) evaluated 23 females with systemic sclerosis and found urodynamic alterations in only 3 of 9 patients who reported urinary symptoms. They were unable to correlate voiding symptoms, urodynamic changes, and the degree of bladder wall fibrosis or visceral involvement. Evidence of autonomic nervous system dysfunction was found outside the urinary tract in 13 of these patients. The authors speculate that when LUT dysfunction occurs, it could be caused by the fibrotic replacement of bladder smooth muscle. However, they did not exclude some degree of autonomic dysfunction, as well.

Ehlers-Danlos Syndrome

Ehlers-Danlos syndrome refers to a heterogeneous group of disorders characterized by inherited abnormalities of connective tissue. The main clinical manifestations are skin fragility, skin hyperextensibility, and joint mobility. More than 10 subtypes of the syndrome have been defined based on clinical, genetic, and biochemical criteria. Bladder diverticula and VUR have been associated with this disorder. Tokhmafshan et al. (2017) found at least 30 reports of bladder diverticula in the literature, and it has been suggested that operative repair is characterized by a higher recurrence rate than would ordinarily be expected. Deveaud et al. (1999) reported on one such patient with a large left-sided, non-emptying diverticulum, along with a greatly enlarged bladder capacity and high postvoid residual urine volume. Simultaneously, they reported a second patient without Ehlers-Danlos syndrome who had a UTI and left pyelonephritis. This patient also reported a decreased force of stream, and evaluation disclosed left VUR with a left (presumably congenital) periureteral diverticulum. The diverticulum enlarged with voiding, and the patient had a high postvoid residual volume. Both patients were successfully treated surgically. The authors thought the tissue from the non-periureteral diverticulum was more closely related to the pathophysiology of Ehlers-Danlos syndrome, noting the tissue from that diverticulum to be more compliant. They attributed this to changes in the extracellular matrix protein caused by the Ehlers-Danlos syndrome.

Myotonic Dystrophy

Myotonic dystrophy is an autosomal dominant hereditary multi-organ disease characterized by myotonia and distal muscle atrophy. In addition, this condition in later stages is characterized by cataracts, endocrine disturbances, mental retardation or dementia, testicular atrophy and infertility, progressive frontal alopecia, and disturbances in cardiac conduction. Although myotonic activity has not been found in the sphincter or pelvic floor, many patients have voiding complaints. Bernstein et al. (1992) reported on 10 patients, 8 of whom had urinary complaints by history (4 infrequent voiders, 1 with urgency and stress incontinence, 1 with urge and urgency incontinence, 1 with slight urgency without incontinence, and 1 with obstructive symptoms only in the morning). There were no characteristic urodynamic patterns observed, and urodynamic findings did not correlate particularly well with symptoms. Sakakibara et al. (1995b) also reported LUTS in such patients; however, there is **no characteristic pattern of dysfunction.** Thus such patients must be characterized urodynamically before any assumptions are made regarding therapy based on symptoms alone.

Corticobasal Degeneration

Corticobasal degeneration is a rare neurodegenerative disorder of the corticobasal tracts in the cerebral cortex and basal ganglia. The disorder tends to have a unilateral predominance and is most likely present in the supranuclear parasympathetic system. Cortical, extrapyramidal, long-tract, and urinary symptoms are commonly noted in this disease process. Sakakibara et al. (2004b) assessed 10 patients with this disorder and compared them with 11 age-matched controls. As compared with controls, the degeneration patients had more common urinary symptoms (80% of study group). Urinary symptoms usually appeared within 1 to 3 years after onset of the disease and became more common with longer disease duration. Nocturnal frequency tended to be the initial urinary symptom, followed by incontinence, urgency, and frequency. Urodynamic findings included decreased bladder capacity, detrusor overactivity (most common), detrusor hypocontractility, and low compliance in individual patients. DSD was not noted.

Sacrococcygeal Teratoma

Sacrococcygeal teratoma is the most common congenital neoplasm, can cause significant neurourologic dysfunction, and can be associated with upper tract deterioration as a result of high-grade reflux and abnormal bladder storage pressures. Partridge et al. (2014) retrospectively reviewed 45 patients who underwent resection for sacrococcygeal teratoma and found that urologic complications occurred in 33%, with neurogenic bladder in 12, urinary incontinence in 7, and vesicoureteral reflux in 5. The presence of hydronephrosis on prenatal imaging was significantly associated with urologic sequelae.

Williams-Beuren Syndrome

Williams-Beuren syndrome (WBS) is an autosomal disorder caused by a deletion in chromosome 7. It is associated with cardiovascular abnormalities, facial changes, cognitive dysfunction resulting in mental retardation, and developmental delay. LUTS is also highly prevalence in this population. In a study of 87 children (41 girls, 46 boys) with this syndrome, LUTS was assessed by questionnaire and all had a frequency-volume chart. Eighty percent of children had LUTS: urgency was the most common in 70%, followed by frequency in 69%, and urge incontinence in 61% (Sammour et al., 2017). In a smaller study of 28 children (16 boys, 12 girls) assessment included renal functional studies, voiding cystourethrography, and urodynamics. Fifty percent of patients had urinary tract abnormalities; bladder diverticula was the most common (43%). Urodynamic findings demonstrated detrusor overactivity in 60% of patients and sphincteric dyssynergia with detrusor overactivity in 14%. Decreased cystometric capacity was identified in 28% of patients (Sammour et al., 2006).

Amyloidosis

Subtypes of amyloidosis are associated with neurologic disorders. Type 1 Portuguese familial amyloid polyneuropathy is a rare, progressive, autosomal dominant disease characterized by autonomic and somatic dysfunction with early onset of gastrointestinal and genitourinary symptoms. In a study of 23 women gene carriers undergoing urodynamic evaluation, the presence of reduced bladder sensation and detrusor underactivity was higher in those with more advanced disease, although these symptoms were still present in 33% and 25%, respectively, of asymptomatic carriers. Bladder and anal sphincteric dysfunction also appears to occur early in the disease process. Stress incontinence often results, and the anal sphincter was found to have decreased tone (Andrade, 2009; Gomes et al., 2014). Impaired detrusor contractility is thought to be caused by amyloid infiltration of peripheral nerves.

Machado-Joseph Disease

A variant of spinocerebellar degeneration is spinocerebellar ataxia type 3, otherwise known as Machado-Joseph (MJ) disease. This is the most common hereditary spinocerebellar ataxia dominant disease. It is associated with a defined expansion of the *MJD1* gene from the 14q32.1 chromosome. Symptoms include pyramidal spasticity, extrapyramidal rigidity, athetosis, dystonia, visual movement disorder (ophthalmoplegia), eyelid retraction, amyotrophy, and impairment of global sensory function. In a study of 122 patients with this disorder, 17 (13.9%) experienced LUT dysfunction. The mean age of occurrence of the disease was the mid-fifth decade, with urgency being the predominant symptom in 15 and incontinence found in 9 patients. The most common urodynamic finding was detrusor overactivity in 8 patients, areflexia in 1, and normal contractility in 4. Bladder sensory disorder defined by delayed perceptions was identified in 6 patients. Postvoid residual volumes greater than 100 mL were noted in 9 (Musegante et al., 2011).

Radiation

Many pelvic neoplasms are treated with radiotherapy, and despite improved imaging and targeting techniques, nearby healthy tissue, such as the bladder, can be adversely affected. **An early radiation reaction, most prominent at 4 to 6 weeks,** is described by Vale et al. (1993). **Storage symptoms are common, and urodynamic studies have demonstrated reduced volume at first desire to void, reduced cystometric capacity, and reduced compliance. These parameters tend to return to pretreatment values by 6 months. Radiation effects on tissue evolve over time, and symptoms associated with later radiation effects are less common but may be progressive and intractable. Storage symptoms again predominate, and urodynamic studies, when positive, demonstrate reductions in first desire to void and maximum cystometric capacity, presence of involuntary bladder contractions in up to a third of patients, and an increase in maximum subtracted detrusor pressure during filling.** Historical explanations have concentrated on urothelial injury and ulceration with fibrosis. In an experimental rat model, the authors found a biphasic reduction in compliance, with the first reduction developing at 4 to 6 weeks after irradiation, followed by recovery. A second reduction phase in compliance started at 10 to 12 weeks and persisted. Only half of the irradiated bladders demonstrated fibrotic infiltration of muscle bundles, and there was no association between the presence of fibrosis and the magnitude of reduction and compliance. Mast cells were more abundant in irradiated bladders than in controls. Electron microscopic studies in the irradiated bladders showed the presence of areas displaying focal degeneration of smooth muscle cells, with these cells demonstrating disaggregation of filaments and, in some cases, cytoplasmic organelles free in the intracellular space. In scattered foci, selective degeneration of unmyelinated axon profiles was noted, ranging from marked to lesser degrees of axonal injury. Thus the authors were unable to confirm a fibrosis-based hypothesis of postirradiation bladder dysfunction in their experimental model but did reveal other changes that could contribute to such dysfunction (neural degeneration and changes in the detrusor muscle).

Choo et al. (2002) reported on videourodynamic parameters in 15 of 17 patients completing studies at baseline and at 3 and 18 months after external-beam irradiation for prostate cancer. Between baseline and 18 months there were no statistically significant changes in detrusor pressure, peak flow rate, voided volume, postvoid residual, compliance, occurrence of detrusor overactivity, or outlet obstruction. There was a mean reduction in bladder capacity of 100 mL in the supine position and 54 mL in the upright position. There was no change in self-assessed qualitative urologic function (IPSS, quality-of-life assessment index, and urinary frequency). There were, however, individual patients who developed decreased compliance (4 patients) and detrusor overactivity (2 patients), urgency (5 patients), and urgency incontinence (3 patients).

There has been a correlation shown between radiation dose received by the bladder from external beam radiotherapy for the treatment of prostate cancer and LUT symptoms, specifically incontinence and frequency (Yahya et al., 2017). Urinary tract effects secondary to radiation often require further management. In a study by Mayer et al. (2017) of 73 men receiving combined modality radiotherapy for prostate cancer, at a median time of 8 years from radiotherapy, 25% of men required reconstruction (ureteral n = 4, rectourethral fistula n = 2, and posterior urethroplasty n = 13) and 32% underwent urinary diversion, highlighting the significant long-term morbidity of radiotherapy.

Defunctionalized Bladder

The timing of bladder defunctionalization and the age of the individual at time of defunctionalization may be predictive of bladder functionality. In fetal sheep, urinary diversion results in loss of overall bladder weight with marked connective tissue infiltration and loss of smooth muscle organization. Also, a reduced response to carbachol stimulation and increased response to field stimulation were noted in tissue from animals undergoing early diversion (Matsumoto et al., 2003).

The previously normal defunctionalized bladder often demonstrates decreased capacity and involuntary bladder contractions and/or decreased compliance. Previously abnormal bladders will usually demonstrate their prior pathology, many times with these additional abnormalities. Rehabilitation of a defunctionalized bladder is certainly possible and should definitely be attempted by cycling with progressively increasing volumes. Serrano et al. (1996) considered this subject while evaluating the outcome of transplantation in five long-term defunctionalized bladders. Successful bladder rehabilitation was accomplished, and the transplantation was successful without bladder augmentation, although one patient required CIC. Normal compliance was inferred by the fact that there was no evidence of hydronephrosis after long-term allograft function up to 10 years. The authors proposed that transplantation can be accomplished into a previously defunctionalized bladder when a capacity greater than 100 mL and a voiding pressure less than 100 cm H_2O are demonstrated during bladder rehabilitation. The presence of a defunctionalized bladder may not prevent subsequent renal transplantation. In an assessment of 12 pediatric patients with markedly diminished-capacity (defunctionalized) bladders, transplantation was performed without pretransplant bladder augmentation. The overall transplant survival rates in this group were 100%. Minimal reflux was noted. In addition, all patients were able to void spontaneously without incontinence (Alexopoulos et al., 2011).

A study of bladder receptors at the gene expression level suggested no significant differences between pre-transplant patients with or without defunctionalized bladders, and voiding function was similar between the two groups at 1 year post-transplant, leading authors to question the usefulness of classifying bladders as defunctionalized pre-transplant (Neves Neto et al., 2018). These are interesting data; however, in appropriate patients an assessment of bladder function is prudent before renal transplant to ensure postoperative success given the high stakes.

Disorders of Sexual Differentiation

Disorders of sexual differentiation, such as congenital adrenal hyperplasia (CAH) or androgen insensitivity syndrome (AIS), may have effects on urinary symptoms as a result of feminizing surgery or a primary affect of the disorder. Davies et al. (2005) studied 19 women with CAH, of whom 16 had undergone childhood feminizing surgery. Compared with age-matched controls, the CAH population had a higher incidence of urgency incontinence (68%) and stress incontinence (47%). In a similar study, women with CAH or AIS found LUTS to be common in this population; however, they were not significantly increased compared with controls (Fagerholm et al., 2013). It remains uncertain the effects of disorders of sexual differentiation on urinary symptoms.

Aging

Structural changes of the autonomic pathways in normal aging may be at least partially responsible for bladder effects. Neurons in an aged animal model demonstrated terminal axonal dystrophy (Schmidt, 2002). In addition, decreases in muscarinic receptor expression within the detrusor may be a contributor to bladder dysfunction in normal aging (Mansfield et al., 2005). However, when the effects of aging on the LUT are considered, it is not possible to separate the effects of chronologic age itself from the various anatomic, neurophysiologic, neuropharmacologic, metabolic, and hormonal changes that coexist with aging, along with the effects of other coexistent disease processes.

In a study of 85 healthy females without a history of neurologic disease, pelvic surgery, or diabetes, there was an age-related decline in detrusor contractility, bladder sensation during filling, and maximum urethral closure pressure (Pfisterer et al., 2006). In addition, neurologic phenomena may masquerade as LUTS associated with bladder outlet obstruction. These phenomena may include multiple cerebral infarctions, cervical spondylosis, and lumbar spondylosis, all findings noted in the Olmsted County longitudinal study and indicative of the need for urodynamics in older men with complex urinary symptoms (Woderich and Fowler, 2006). There is an excellent review of this topic by the Committee on Pathophysiology of the Urinary Bladder and Obstruction and Aging for the 4th International Consultation on BPH (Nordling et al., 2001).

Benign Joint Hypermobility Syndrome

Benign joint hypermobility syndrome (BJHS) is an inherited connective tissue disease characterized by musculoskeletal pain and hypermobility of joints and has an apparent association with pelvic floor dysfunction. Manning et al. (2003) prospectively evaluated 1000 women referred for urodynamic evaluation and noted benign joint hypermobility to be associated with increasing bowel dysfunction and a higher degree of urinary tract symptomatology. Also noted was a significant childhood history for both of these phenomena. In a study of 38 women with joint hypermobility as compared with normal controls, symptom questionnaires were administered to both groups; 18 of 30 (60%) with benign joint hypermobility demonstrated urinary incontinence as compared with an incidence of 30% in the controls. In addition, 23% of the women with joint hypermobility also demonstrated anal incontinence as compared with none of the controls (Jha et al., 2007). In a pediatric population with BJHS, 60% had VUR; grade II was the most common, in 37.5% (Beiraghdar et al., 2013). These findings have been attributed to disorders of collagen metabolism; however, the absolute cause has not been clearly delineated.

Attention-Deficit/Hyperactivity Disorder

Attention-deficit/hyperactivity disorder (ADHD) occurs in 3% to 5% of children, and LUTS are common in this group. In a study of 62 children with ADHD and 124 controls, assessment of LUTS through a validated questionnaire indicated children with ADHD had significantly higher enuresis, urgency, holding maneuvers, and voiding and other symptoms (Burgu et al., 2011). Treatment of ADHD may result in improved LUTS, as a study of 40 children treated for ADHD and 43 matched controls showed that incontinence rates did not differ between the groups, although children with ADHD reached continence at an older age (Niemczyk et al., 2015).

Other Conditions

The effect of disordered function of other organs within the pelvis is also potentially contributory to LUT dysfunction. Some of this disordered function may arise as a result of altered afferent neurologic activity induced by other organ disorders. The potential for visceral “crosstalk” has been proposed as a cause of LUT dysfunction and includes syndromes such as interstitial cystitis and irritable bowel syndrome. Noronha et al. (2007) assessed the short- and long-term effects of acid-induced colitis on bladder function in a rodent model. Detrusor muscle contractility and histology were evaluated, acutely and subacutely after induction of chemical colitis. During the active phase (3 days postinjury), bladder muscle structure appeared histologically normal and inflammation was absent. However, some abnormalities in detrusor muscle contractility in response to electric field stimulation were noted. During the subacute period and after recovery of colitis (15 and 30 days), bladder muscle contractility returned to control levels with no discernible histologic change. These reversible changes were postulated to result from altered afferent input from the colon, resulting in “field” type changes affecting the bladder.

Any neurologic disease or injury can affect LUT function. Many have been mentioned in this chapter, but case reports and small series document many others. The dysfunction produced by some is logically deducible on the basis of similarity to other neurologic lesions. For others, the LUT dysfunctions are inconsistent and seemingly at odds with what would be predicted on the basis of neuroanatomic and neurophysiologic principles. For those who wish to further pursue this subject, the following referenced list may be helpful:

- Adrenoleukodystrophy, adrenomyeloneuropathy (Sakakibara et al., 1998a; Silveri et al., 2004)
- Adult polyglucosan body disease (Gray et al., 1988)
- Behçet disease (Saito and Miyagawa, 2000; Sakakibara et al., 2000; Theodorou et al., 1999)
- Brown-Séquard syndrome (Sakakibara et al., 2001)
- Central cord syndrome (Newey et al., 2000; Smith et al., 2000)
- Incontinence in cystic fibrosis (Dodd and Langman, 2005; Neemuchwala, 2017)
- Down syndrome (Handel et al., 2003)
- Duchenne muscular dystrophy (MacLeod et al., 2003)
- Familial dysautonomia (Saini et al., 2003)
- Intramedullary epidermoid cyst (Ferrara et al., 2003)
- Lambert-Eaton myasthenic syndrome (Satoh et al., 2001)
- Lateral meningocele syndrome (Lehman syndrome) (Ejaz et al., 2016)
- Neurofibromatosis (Brownlee et al., 1998)
- Pituitary adenomas and urinary symptoms (Yamamoto et al., 2005)
- Sjögren syndrome (Kovacs et al., 2003)
- Spinal cord tumors (Uchiyama et al., 2004)
- Spinal muscular atrophy (von Gontard et al., 2001)

Treatment of Neurogenic Lower Urinary Tract Dysfunction: Overview

In later chapters, the various therapies available for the treatment of LUT dysfunction are discussed. Only a discrete number of such therapies are available, and these are easily categorized on a functional basis according to whether they are used primarily to facilitate urine filling and storage or voiding and emptying and according to whether their primary effect is on the bladder or on the outlet.

The initial choice of a mode of management for a given problem is multifactorial, **and certain goals of management for LUT dysfunction are beyond debate** (Box 116.2). The fact that these goals have remained relatively unchanged over the past editions of this text attests to their general validity. As a corollary, absolute or relative indications for changing or augmenting a particular regimen exist, and, likewise, there is general agreement on these, although the relative importance of the indication for change may be disputed (Box 116.3). The term *inadequate*, when applied to storage and emptying, applies not only to volumes (capacity, voided volume, residual) but also to unacceptably high detrusor pressures during either or both of the two phases of the micturition cycle. In the planning of goals of therapy and reasons for change, the concept of a “hostility score,” such as that of Galloway (1989), is attractive. His hostility score includes five urodynamic characteristics—bladder compliance, overactivity, dyssynergia, outlet resistance, and VUR. Each is allocated a score of 0, 1, or 2. The best possible score is 0 and implies normal compliance, no inappropriate detrusor activity, a synergic sphincter, a low leak pressure, and no reflux.

Box 116.2

Voiding Dysfunction: Goals of Management

- Upper urinary tract preservation or improvement
- Absence or control of infection
- Adequate storage at low intravesical pressure

- Adequate emptying at low intravesical pressure
- Control over micturition
- No catheter or stoma
- Social acceptability and adaptability
- Vocational acceptability and adaptability

Box 116.3

Reasons to Change or Augment a Given Regimen

- Upper urinary tract deterioration
- Recurrent sepsis or fever of urinary tract origin
- Lower urinary tract deterioration
- Inadequate storage
- Inadequate emptying
- Inadequate control
- Unacceptable treatment side effects
- Skin changes secondary to incontinence or collecting device

The results of treatment of voiding dysfunction are rarely perfect, and they do not have to be. The goals are satisfaction and avoidance of adverse outcomes. A very flexible approach must be adopted in choosing therapy that takes into account the individual wishes of each patient and family and the practicality of each proposed solution for that particular patient (Box 116.4). The therapeutic decisions are thus made with the patient and with the family. In every case, within the limits of practicality, the following should be discussed: reversibility, side effects that occur with some regularity, ultimate best and worst possible scenario, frequency and extent of follow-up, and alternate methods of management. Treatment should always begin with the simplest, most reversible form(s) of therapy, proceeding gradually up the ladder of complexity, but with the knowledge that it is only the patient (and/or family) who is (are) empowered to say when “enough is enough.” Again, satisfaction and avoidance of adverse outcomes are the primary goals. A combination of therapeutic maneuvers can sometimes be used to achieve a particular end, especially if these modalities act through different mechanisms and their side effects are not synergistic or additive. There are circumstances and locales in which health care resources and hospital bed use must also be considered.

Box 116.4

Patient Factors to Consider When Choosing Therapy

- Prognosis of underlying disease, especially if progressive or malignant
- General health
- Limiting factors: inability to perform certain tasks (e.g., hand dexterity, ability to transfer, body habitus)
- Mental status
- Motivation, patient compliance with treatments
- Desire to remain catheter or appliance free
- Desire to avoid surgery
- Sexual activity status
- Reliability
- Educability
- Psychosocial environment, interest, reliability, and cooperation of family
- Economic resources

The importance of graded intervention for neurogenic disease with the ultimate goals of control of bladder pressures, preservation of renal function, control of UTI, and social continence has been underscored by two guidelines (Consortium for Spinal Cord Medicine, 2006; Pannek et al., 2011). Bladder management options include catheterization (intermittent or indwelling) and surgery. Consensus guidelines stress the importance of intermittent catheterization as the foundational strategy in the management of the willing and motivated patient or health care provider with the goal of keeping catheterization volumes below 500 mL. Credé or Valsalva is not a recommended technique for improving bladder emptying, given concerns regarding outlet resistance. When chronic catheterization is required, suprapubic management is preferable to indwelling urethral catheterization. However, CIC remains the gold standard (EAU guidelines). The basis of progressive therapy from medical ascending through surgical is a foundational concept (Wyndaele et al., 2010). An ongoing multi-institutional study by the Neurogenic Bladder Research Group (study protocol: Patel et al., 2017) comparing various bladder management strategies will shed light on patient outcomes, satisfaction, and quality of life; help guide physician-patient discussions; and improve informed decision making.

Urodynamics may provide a useful guide for directing intervention. Differences in bladder compliance may be predictive of intervention success. Type A (total) versus type C (end fill) compliance patterns respond differently to antimuscarinic management, with resultant impacts on bladder storage pressures and upper tract function (Park and Linsenmeyer, 2001).

Optimal management of the bladder in spinal cord injuries has, in general, focused on the use of CIC where available. In a study of 179 patients undergoing management either with suprapubic or urethral catheterization, both groups had complications related to management technique. Tube revision and incontinence through the suprapubic tract were common in the group so managed. In the urethral management group, urethral erosion and incontinence were also common. The rates of UTI, bladder calculi, and bladder cancer were similar between the two groups (Katsumi et al., 2010). A prospective randomized assessment of spinal cord–injured patients using CIC was performed to address the rate of UTI with this condition. The time to first UTI requiring antibiotic management was significantly lengthened in patients using hydrophilic-coated catheters as compared with uncoated catheters. A 33% daily risk for symptomatic infection in those using the hydrophilic catheters was identified. In institutional settings, the use of these catheters reduced infection rate by approximately 21% (Cardenas et al., 2011).

Medical therapy is first-line treatment for NDO; anticholinergic medications are the most studied. Mirabegron, a selective β3 agonist, has also demonstrated efficacy in NDO (Wollner and Pannek, 2016). In patients with NDO refractory to medications or patients intolerant to the medication side effects, treatment with intradetrusor onabotulinum toxinA injection has shown good therapeutic results with up to 60% of patients continuing with this treatment over the long term (Leitner et al., 2016).

The treatment of DSD is challenging. Although limited to select male patients, when sphincter ablation is necessary, sphincterotomy using laser treatment is considered the standard method (Linsenmeyer, 2007). However, there is an emerging role of onabotulinum toxin A intra-sphincteric injection, which has been shown to lower detrusor pressures and increase voided volumes and has low morbidity, although repeated injections are needed (Utomo et al., 2014).

New therapies continue to be proposed for patients with neurogenic LUT dysfunction refractory to medical therapies. The use of dorsal penile or clitoral nerve stimulation for controlled NDO has been described. Opisso et al. (2008) studied a group of 17 patients with neurologic disorders (4 women and 13 men) who underwent 3 filling cystometries. With stimulation of the dorsal nerve, 16 were noted to have suppression of detrusor contractions and 14 had an average increase in bladder capacity of 68 mL. Larger studies with longer follow-up are needed to assess long-term effectiveness and durability.

Pudendal nerve stimulation has been used for improving neurogenic voiding dysfunction. Spinelli et al. (2005) treated 15 patients with varied types of neurogenic voiding dysfunction. After pudendal stimulation, there was a significant decrease in incontinence episodes: 8 of 15 patients became continent during stimulation, and 2 demonstrated improvement approximating 90%. Twelve of 15 ultimately progressed to permanent implantation. In the chronically implanted patients, maximal cystometric capacity was noted to significantly increase, and maximum detrusor pressure was also noted to decrease substantially. Neurophysiologic guidance was considered critical for adequate implantation.

Another form of neuromodulatory therapy for which more experience is being reported in SCI is anterior root stimulation. One of the largest experiences with sacral deafferentation and anterior root stimulator implantation was reported by Kutzenberger et al. (2005). A total of 464 paraplegic patients received this intervention, with most patients receiving the intradural approach. At a mean of 6.6 years, 440 of these patients were available for long-term follow-up. Complete deafferentation was successful in 94% of patients; 420 patients used the sacral anterior root stimulator for voiding, and 401 used it for defecation. Overall, 364 (83%) patients were continent. Postoperatively, UTIs decreased from a mean of 6 to 1, and kidney function remained stable in this population. Complications included cerebrospinal fluid leaks in 6 patients and infected implants in 5. In addition, later complications included device failure or cable failure in 35 patients. Autonomic dysreflexia also disappeared or was resolved in most of these cases. The Dutch experience with the Brindley bladder stimulator compared with a matched control group was reported; 93 stimulator-implanted patients were compared with a control group of 70 new patients with SCI and NDO. The main outcomes in the study were quality of life as assessed by the Qualiveen metric. In those patients implanted, long-term stimulators were still used for voiding dysfunction in 63% of the patients (46 patients). Those patients with functional stimulator implants had substantially improved symptom scores and general quality-of-life ratings in addition to improved continence and fewer UTIs as compared with the control group. The associated rhizotomy appeared to benefit even patients who had deactivated their stimulator device. The follow-up for these individuals after implant ranged from 1 to 3 years (Martens et al., 2011).

Bladder reinnervation is an upcoming area of study. Unilateral lumbar to sacral ventral root rerouting surgery has demonstrated success in axonal regrowth and restoration of bladder function in a feline model with complete thoracic spinal cord injury (Lam Van Ba et al., 2018). The future of urinary tract dysfunction related to SCI may be dependent on advances in the use of stem cells for spinal cord repair. However, differences in study type, model used, type of stem cells, and techniques used for stem cell implantation and perpetuation have yet to be standardized for purposes of assessing the potentials of this therapy for impact on long-term urinary function (Snyder and Teng, 2012).

As a nonsurgical alternative to catheterization, women with detrusor areflexia can consider using the inFlow device, which is a magnetized valve-pump device inserted into the urethra. During voiding, an activator is held over the pubic bone and turned “on” to open the valve and allow urine flow. Once the bladder is empty, the “on” button is released and the valve closes, allowing urine storage. In a multicenter trial, those women who completed the study reported significant improvements in quality of life (Chen et al., 2005). However, there was a high drop-out rate because of patient discomfort and leakage. This device may have a role in those patients who are unable to catheterize.

As a treatment of last resort, urinary diversion may provide significant functional improvement in addition to improved quality of life in selected patients with neurologic dysfunction (e.g., those unable to catheterize). One method for management of incontinence or other refractory storage issues related to neurogenic bladder is bladder neck closure associated with chronic suprapubic catheter management. In a retrospective review of 35 patients undergoing this intervention for a variety of conditions (SCI, 71%; MS, 23%; CVA, 9%) the majority of patients had adequate response to therapy. Only 2 patients were incontinent at follow-up. Overall complications were experienced by 17% of patients (Colli and Lloyd, 2011). In another assessment of bladder neck closure and suprapubic tube placement, 29 patients were assessed for the efficacy of this intervention (MS, 48%; SCI, 28%; myelodysplasia, 17%). Bladder neck closure was performed via a retropubic approach in most patients at the time of suprapubic tube placement. Eight of 29 patients had persistent incontinence, 2 with peristomal leakage and 6 with urethral leakage. Catheter complications were associated with 7 of the 8 urinary leaks. Perineal bladder neck closure was associated with much higher fistula rates than retropubic approaches. In addition, poor catheter management also resulted in worse success rates (Ginger et al., 2010). Stein et al. (2005) reported on 24 patients undergoing Mainz pouch diversion. Urinary diversion was associated with stability of the upper tracts and daytime continence, but with some nocturnal incontinence per stoma. Comparing this group with a separate group of patients undergoing bladder augmentation with suburethral fascial sling, all patients in the augmentation group had stability of the upper tracts, and 8 of 10 were continent. Both alternatives were considered adequate for neurogenic voiding dysfunction. Ileovesicostomy also is an option for the management of the neurogenic bladder. In a report of 15 individuals undergoing ileovesicostomy (7 open and 8 robotic), surgical robotic operative times were substantially longer than with open cases; however, there were trends toward less blood loss and shorter hospital stays in the robotic group. With both procedures, there was an improvement in urinary continence from baseline and a trend toward decreased UTI. Overall costs were substantially greater with the robotic versus the open group despite differentials in length of stay. This further underscores the need for further larger studies to assess the possible role of advanced minimally invasive technology for this condition (Vanni and Stoffel, 2011).

Suggested Readings

Abrams P, Cardozo L, Fall M, et al. The standardization of terminology in LUT function: report from the Standardization Subcommittee of the International Continence Society. *Urology*. 2003;61:37–49.

Blaivas JG. The neurophysiology of micturition: a clinical study of 550 patients. *J Urol*. 1982;127:958–964.

Churchill BM, Abramson RP, Wahl EF. Dysfunction of the lower urinary and distal gastrointestinal tracts in pediatric patients with known spinal cord problem. *Pediatr Clin North Am*. 2001;57:230–245.

Drake M, Apostolidis A, Emmanuel A, et al. Neurologic urinary and fecal incontinence. Abrams P, Cardozo L, Khoury S, et al. *Incontinence*. EAU-ICUD; 2013:827–1000.

Fowler C. Neurological disorders of micturition and their treatment. *Brain*. 1999;122:1213–1231.

Rosier PFWM, Schaefer W, Lose G, et al. International Continence Society Good Urodynamic Practices and Terms 2016: urodynamics, uroflowmetry, cystometry, and pressure-flow study. *Neurourol Urodyn*. 2017;36(5):1243–1260.

Schurch B, Iacovelli V, Averbeck MA, et al. Urodynamics in patients with spinal cord injury: a clinical review and best practice paper by a working group of The International Continence Society Urodynamics Committee. *Neurourol Urodyn*. 2018;37(2):581–591.

Serf C, Junenann KP, Braun PM. Deafferentation of the urinary bladder and implantation of a sacral anterior root stimulator (SARS) for treatment of the neurogenic bladder in paraplegic patients. *Biomed Technik*. 2003;49:88–92.

Wein AJ, Barrett DM. *Voiding function and dysfunction—a logical and practical approach*. Year Book: Chicago; 1988.

Weld KJ, Dmochowski RR. Association of level of injury and bladder behavior in patients with post traumatic spinal cord injury. *Urology*. 2000;55:490–494.

Woodhouse CR. Myelomeningocele in young adults. *BJU Int*. 2005;95:223–230.

Wyndaele JJ, Castro D, Madersbacher H, et al. Neurogenic and faecal incontinence. Abrams P, Cardozo L, Khoury S, et al. *Incontinence*. Health Publications: Paris; 2005:1059–1162.

Wyndaele JJ, Kovindha A, Madersbacker H, et al. Neurologic urinary and faecal incontinence. Abrams P, Cardozo L, Khoury S, et al. *Incontinence*. Health Publications: Paris; 2009:793–960.

References

Abrams P, Cardozo L, Fall M, et al. The standardisation of terminology in lower urinary tract function: report from the standardisation sub-committee of the International Continence Society. *Urology*. 2003;61:37–49.

Addo J, Ayerbe L, Mohan KM, et al. Socioeconomic status and stroke: an updated review. *Stroke*. 2012;43(4):1186–1191.

Adzick NS, Thom EA, Spong CY, et al. A randomized trial of prenatal versus postnatal repair of myelomeningocele. *N Engl J Med*. 2011;364:993–1004.

Ahn UM, Ahn NU, Buchowski JM, et al. Cauda equina syndrome secondary to lumbar disc herniation. *Spine*. 2000;25:1515–1522.

Alexopoulos S, Lightner A, Concepcion W, et al. Pediatric kidney recipients with small capacity, defunctionalized urinary bladders receiving adult-sized kidney without prior bladder augmentation. *Transplantation*. 2011;91:452–456.

Alimi Q, Hascoet J, Manunta A, et al. Reliability of urinary cytology and cystoscopy for the screening and diagnosis of bladder cancer in patients with neurogenic bladder: a systematic review. *Neurourol Urodyn*. 2018;37(3):916–925.

Andersson KE. Mechanisms of disease: central nervous system involvement in overactive bladder syndrome. *Nat Clin Pract Urol*. 2004;1(2):103–108.

Andrade EL, Forner S, Bento AF, et al. TRPA1 receptor modulation attenuates bladder overactivity induced by spinal cord injury. *Am J Physiol Renal Physiol*. 2011;300:F1223–F1234.

Andrade MJ. Lower urinary tract dysfunction in familial amyloidotic polyneuropathy, Portuguese type. *Neurourol Urodyn*. 2009;28:26–32.

Andrews I. Bladder disorders in brain damage. Ruston D. *Handbook of neuro-urology*. Marcel Dekker: New York; 1994:253–279.

Antoniou A, Mendez Rodrigues J, Comi N. Successful treatment of urodynamic detrusor overactivity in a young patient with myasthenia gravis using pretibial nerve stimulation with follow-up to two years. *JRSM Open*. 2016;7(8).

Apodaca G, Kiss S, Ruiz W, et al. Disruption of bladder epithelium barrier function after spinal cord injury. *Am J Physiol Renal Physiol*. 2003;284(5):F966–F976.

Arlandis S, Vazquez-Costa JF, Martinez-Cuenca E, et al. Urodynamic findings in amyotrophic lateral sclerosis patients with lower urinary tract symptoms: results from a pilot study. *Neurourol Urodyn*. 2017;36(3):626–631.

Arunable MB, Badlani G. Urologic problems in cerebrovascular accidents. *Probl Urol*. 1993;7:41–53.

Athanasopoulos A, Gyftopoulos K, McGuire EJ. Treating stress urinary incontinence in female patients with neuropathic bladder: the value of the autologous fascia rectus sling. *Int Urol Nephrol*. 2012;44:1363–1367.

Atkinson PP, Atkinson JL. Spinal shock. *Mayo Clin Proc*. 1996;71(4):384–389.

Ayan S, Kaloglu C, Gokce G, et al. Effect of insulin therapy for diabetic cystopathy—urodynamic and histological findings in a rabbit model. *Scand J Urol Nephrol*. 1999;33(6):392–395.

Azadzoi KM, Tarcan T, Siroky MB, et al. Atherosclerosis-induced chronic ischemia causes bladder fibrosis and non-compliance in the rabbit. *J Urol*. 1999;161(5):1626–1635.

Baldini G, Bagry H, Aprikian A, et al. Postoperative urinary retention: anesthetic and perioperative considerations. *Anesthesiology*. 2009;110(5):1139–1157.

Barbalat Y. *Contemporary Evaluation and Management of*

Voiding Dysfunction in Parkinsonism. 2010.

Barnes JC, Harrison G, Murray K. Low pressure/low flow voiding in younger men: psychological aspects. *Br J Urol*. 1985;57(4):414–417.

Bartolin Z, Gilja I, Bedalov G, et al. Bladder function in patients with lumbar intervertebral disk protrusion. *J Urol*. 1998;159(3):969–971.

Bartolin Z, Savic I, Persec Z. Relationship between clinical data and urodynamic findings in patients with lumbar intervertebral disc protrusion. *Urol Res*. 2002;30:219–222.

Bartolin Z, Vilendecic M, Derezic D. Bladder function after surgery for lumbar intervertebral disk protrusion. *J Urol*. 1999;161(6):1885–1887.

Basheer A, Alsaidi M, Schultz L, et al. Preventative effect of tamulosin on postoperative urinary retention in neurosurgical patients. *Surg Neurol Int*. 2017;8:75.

Bates CP, Arnold EP, Griffiths DJ. The nature of the abnormality in bladder neck obstruction. *Br J Urol*. 1975;47:651–655.

Beck R, Fowler CJ, Mathias CJ. Genitourinary dysfunction in disorders of the autonomic nervous system. Ruston D. *Handbook of neuro-urology*. Marcel Dekker: New York; 1994:281–301.

Beiraghdar F, Rostami Z, Panahi Y, et al. Vesicoureteral reflux in pediatrics with hypermobility syndrome. *Nephrourol Mon*. 2013;5(4):924–927.

Bennett CJ, Seager SW, Vasher EA, et al. Sexual dysfunction and electroejaculation in men with spinal cord injury: review. *J Urol*. 1988;139(3):453–457.

Bennett CJ, Young MN, Adkins RH, et al. Comparison of bladder management complication outcomes in female spinal cord injury patients. *J Urol*. 1995;153(5):1458–1460.

Berger Y, Salinas JN, Blaivas JG. Urodynamic differentiation of

Parkinson disease and the Shy-Drager syndrome. *Neurourol Urodyn*. 1990;9:117–121.

Beric A, Light JK. Function of the conus medullaris and cauda equina in the early period following spinal cord injury and the relationship to recovery of detrusor function. *J Urol*. 1992;148:1845–1848.

Bermingham SL, Hodgkinson S, Wright S, et al. Intermittent self catheterisation with hydrophilic, gel reservoir, and non-coated catheters: a systematic review and cost effectiveness analysis. *BMJ*. 2013;346:e8639.

Bernstein IT, Andersen BB, Andersen JT, et al. Bladder function in patients with myotonic dystrophy. *Neurourol Urodyn*. 1992;11:218–223.

Bickel A, Culkin DJ, Wheeler JS Jr. Bladder cancer in spinal cord injury patients. *J Urol*. 1991;146(5):1240–1242.

Biering-Sorensen F, Bagi P, Hoiby N. Urinary tract infections in patients with spinal cord lesions: treatment and prevention. *Drugs*. 2001;61(9):1275–1287.

Biering-Sorensen F, Hansen RB, Biering-Sorensen J. Mobility aids and transport possibilities 10–45 years after spinal cord injury. *Spinal Cord*. 2004;42(12):699–706.

Biering-Sorensen F, Sonksen J. Sexual function in spinal cord lesioned men. *Spinal Cord*. 2001;39(9):455–470.

Blaivas JG. The neurophysiology of micturition: a clinical study of 550 patients. *J Urol*. 1982;127(5):958–963.

Blaivas JG. Non-traumatic neurogenic voiding dysfunction in the adult. *AUA Update Series*. 1985;4:1–15.

Blaivas JG, Chalkin DC, Chancellor MB, et al. Bladder dysfunction with neurologic disease. *Continuum (N Y)*. 1998;4:79–124.

Blaivas JG, Chalkin DC, Chancellor MB, et al. Pathophysiology of the neurogenic bladder. *Continuum (N Y)*. 1998;4:21–28.

Blaivas JG, Chancellor M. Cerebrovascular accidents and other intracranial lesions. Chancellor MB, Blaivas JG. *Practical neurourology*. Butterworth-Heinemann: Boston; 1995:119–126.

Blaivas JG, Chancellor MB. Cauda equina and pelvic plexus injury. Chancellor MB, Blaivas JG. *Practical neurourology*. Butterworth-Heinemann: Boston; 1995:155–164.

Blaivas JG, Kaplan SA. Urologic dysfunction in patients with multiple sclerosis. *Semin Neurol*. 1988;8(2):159–165.

Blaivas JG, Sinha HP, Zayed AA, et al. Detrusor–external sphincter dyssynergia. *J Urol*. 1981;125(4):542–544.

Bonney WW, Gupta S, Hunter DR, et al. Bladder dysfunction in schizophrenia. *Schizophr Res*. 1997;25(3):243–249.

Boone T. Editorial comment. *Neurourol Urodyn*. 2004;23:257.

Borer JG, Park JM, Atala A, et al. Heparin-binding EGF-like growth factor expression increases selectively in bladder smooth muscle in response to lower urinary tract obstruction. *Lab Invest*. 1999;79(11):1335–1345.

Bors E, Comarr A. *Neurological urology*. University Park Press: Baltimore; 1971.

Braschinsky M, Zopp I, Kals M, et al. Bladder dysfunction in hereditary spastic paraplegia: what to expect? *J Neurol Neurosurg Psychiatry*. 2010;81:263–266.

Brittain KR, Peet SM, Castleden CM. Stroke and incontinence. *Stroke*. 1998;29(2):524–528.

Brock JW 3rd, Carr MC, Adzick NS, et al. Bladder function after fetal surgery for myelomeningocele. *Pediatrics*. 2015;136(4):3906–3913.

Broecker BH, Klein FA, Hackler RH. Cancer of the bladder in spinal cord injury patients. *J Urol*. 1981;125(2):196–197.

Brooks RA, Wright JD, Powell MA, et al. Long-term assessment of bladder and bowel dysfunction after radical hysterectomy. *Gynecol Oncol*. 2009;114:75–79.

Broseta E, Osca JM, Morera J, et al. Urological manifestations of herpes zoster. *Eur Urol*. 1993;24(2):244–247.

Bross S, Schumacher S, Scheepe JR, et al. Effects of acute urinary bladder overdistension on bladder response during sacral neurostimulation. *Eur Urol*. 1999;36:354–359.

Brownlee RD, Clark AW, Sevick RJ, et al. Symptomatic hamartoma of the spinal cord associated with neurofibromatosis type 1. Case report. *J Neurosurg*. 1998;88(6):1099–1103.

Brusa L, Finazzi Agro E, Petta F, et al. Effects of inhibitory rTMS on bladder function in Parkinson's disease patients. *Mov Disord*. 2009;24:445–448.

Brusa L, Petta F, Pisani A, et al. Central acute D2 stimulation worsens bladder function in patients with mild Parkinson's disease. *J Urol*. 2006;175(1):202–206 [discussion 206–7].

Burgu B, Aydogdu O, Gurkan K, et al. Lower urinary tract conditions in children with attention deficit hyperactivity disorder: correlation of symptoms based on validated scoring systems. *J Urol*. 2011;185(2):663–668.

Burns AS, Rivas DA, Ditunno JF. The management of neurogenic bladder and sexual dysfunction after spinal cord injury. *Spine*. 2001;26(24 Suppl):S129–S136.

Bushman W, Steers WD, Meythaler JM. Voiding dysfunction in patients with spastic paraplegia: urodynamic evaluation and response to continuous intrathecal baclofen. *Neurourol Urodyn*. 1993;12(2):163–170.

Bycroft J, Hamid R, Bywater H, et al. Variation in urological practice amongst spinal injuries units in the UK and Eire. *Neurourol Urodyn*. 2004;23:252–256.

Bycroft J, Shergill IS, Chung EA, et al. Autonomic dysreflexia: a medical emergency. *Postgrad Med J*. 2005;81(954):232–235.

Cameron AP, Rodriguez GM, Schomer KG. Systematic review of urological followup after spinal cord injury. *J Urol*. 2012;187(2):391–397.

Campeau L, Soler R, Andersson KE. Bladder dysfunction and parkinsonism: current pathophysiological understanding and management strategies. *Curr Urol Rep*. 2011;12:396–403.

Cao Q, Benton RL, Whittemore SR. Stem cell repair of central nervous system injury. *J Neurosci Res*. 2002;68(5):501–510.

Caplan LR, Kleeman FJ, Berg S. Urinary retention probably secondary to herpes genitalis. *N Engl J Med*. 1977;297(17):920–921.

Cardenas DD, Moore KN, Dannels-McClure A, et al. Intermittent catheterization with a hydrophilic-coated catheter delays urinary tract infections in acute spinal cord injury: a prospective, randomized, multicenter trial. *PM R*.

2011;3:408–417.

Cardozo AH, Cabrini DA, Campos MM, et al. Diabetes induced changes in responsiveness of rat bladder and vas deferens to peptides in vitro: susceptibility to reversal by insulin. *Can J Physiol Pharmacol*. 2002;80:334–340.

Carpiniello VL, Cendron M, Altman HG, et al. Treatment of urinary complications after total joint replacement in elderly females. *Urology*. 1988;32(3):186–188.

Cataldo PA, Senagore A. Does alpha sympathetic blockade prevent urinary retention following surgery? *Dis Colon Rectum*. 1991;34:1113–1117.

Chacko S, DiSanto M, Menon C, et al. Contractile protein changes in urinary bladder smooth muscle following outlet obstruction. *Adv Exp Med Biol*. 1999;462:137–153.

Chai TC, Gray ML, Steers WD. The incidence of a positive ice water test in bladder outlet obstructed patients: evidence for bladder neural plasticity. *J Urol*. 1998;160(1):34–38.

Chancellor MB, Blaivas JG. Multiple sclerosis. *Probl Urol*. 1993;7:15–33.

Chancellor MB, Blaivas JG. Diabetic neurogenic bladder. Chancellor MB, Blaivas JG. *Practical neurourology*. Butterworth-Heinemann: Boston; 1995:99–118.

Chancellor MB, Erhard MJ, Hirsch IH, et al. Prospective evaluation of terazosin for the treatment of autonomic dysreflexia. *J Urol*. 1994;151:111–115.

Chancellor MB, McGinnis DE, Shenot PJ, et al. Urinary dysfunction in Lyme disease. *J Urol*. 1993;149(1):26–30.

Chancellor MB, Rivas DA. Current management of detrusor-sphincter dyssynergia. McGuire E. *Advances in urology*. Mosby: St. Louis; 1995:291–324.

Chancellor MB, Shenot PJ, Rivas DA, et al. Urological symptomatology in patients with reflex sympathetic dystrophy. *J Urol*. 1996;155:634–637.

Chandiramani VA, Palace J, Fowler CJ. How to recognize patients with parkinsonism who should not have urological surgery. *Br J Urol*. 1997;80:100–104.

Changolkar AK, Hypolite JA, Disanto M, et al. Diabetes induced decrease in detrusor smooth muscle force is associated with oxidative stress and overactivity of aldose reductase. *J Urol*. 2005;173(1):309–313.

Chao R, Clowers D, Mayo ME. Fate of upper urinary tracts in patients with indwelling catheters after spinal cord injury. *Urology*. 1993;42(3):259–262.

Chen MW, Buttyan R, Levin RM. Genetic and cellular response to unilateral ischemia of the rabbit urinary bladder. *J Urol*. 1996;155(2):732–737.

Chen PH, Hsueh HF, Hong CZ. Herpes zoster-associated voiding dysfunction: a retrospective study and literature review. *Arch Phys Med Rehabil*. 2002;83(11):1624–1628.

Chen TYH, Ponsot Y, Carmel M, et al. Multi-centre study of intraurethral valve-pump catheter in women with a hypocontractile or acontractile bladder. *Eur Urol*. 2005;48:628–633.

Chhabra HS, Sarda K. Clinical translation of stem cell based interventions for spinal cord injury- Are we there yet? *Adv Drug Deliv Rev*. 2017;120:41–49.

Cheng EY, Decker RS, Lee C. Role of angiotensin II in bladder smooth muscle growth and function. *Adv Exp Med Biol*. 1999;462:183–191.

Choo R, Do V, Herschorn S, et al. Urodynamic changes at 18 months post therapy in patients treated with external beam radiotherapy for prostate carcinoma. *Int J Radiat Oncol Biol Phys*. 2002;53:290–296.

Chua K, Chuo A, Kong KH. Urinary incontinence after traumatic brain injury: incidence, outcomes and correlates. *Brain Inj*. 2003;17(6):469–478.

Churchill BM, Abramson RP, Wahl EF. Dysfunction of the lower urinary and distal gastrointestinal tracts in pediatric patients with known spinal cord problems. *Pediatr Clin North Am*. 2001;48(6):1587–1630.

Ciancio SJ, Mutchnik SE, Rivera VM, et al. Urodynamic pattern changes in multiple sclerosis. *Urology*. 2001;57(2):239–245.

Clanet M. Jean-Martin Charcot. 1825 to 1893. *Int MS J*. 2008;15:59–61.

Clark CM Jr, Lee DA. Prevention and treatment of the complications of diabetes mellitus. *N Engl J Med*. 1995;332(18):1210–1217.

Cohn J, Shah AS, Goggins KM, et al. Health literacy, cognition, and urinary incontinence among geriatric inpatients discharged to skilled nursing facilities. *Neurourol Urodyn*. 2017;37(2):854–860.

Colli J, Lloyd LK. Bladder neck closure and suprapubic catheter placement as definitive management of neurogenic bladder. *J Spinal Cord Med*. 2011;34(3):273–277.

Cong ML, Gong WM, Zhang QG, et al. Urodynamic study of bladder function for patients with lumbar spinal stenosis treated by surgical decompression. *J Int Med Res*. 2010;38:1149–1155.

Consortium for Spinal Cord Medicine. Bladder management for adults with spinal cord injury: a clinical practice guideline for health-care providers. *J Spinal Cord Med*. 2006;29(5):527–573.

Cotter KJ, Levy ME, Goldfarb RA, et al. Urodynamic findings in adults with moderate to severe cerebral palsy. *Urology*. 2016;95:216–221.

Creasey GH, Grill JH, Korsten M, et al. An implantable neuroprosthesis for restoring bladder and bowel control to patients with spinal cord injuries: a multicenter trial. *Arch*

Phys Med Rehabil. 2001;82(11):1512–1519.

Danforth KN, Townsend MK, Curhan GC, et al. Type 2 diabetes mellitus and risk of stress, urge and mixed urinary incontinence. *J Urol*. 2009;181(1):193–197.

David BT, Steward O. Deficits in bladder function following spinal cord injury vary depending on the level of the injury. *Exp Neurol*. 2010;226:128–135.

Davies MC, Crouch NS, Woodhouse CR, et al. Congenital adrenal hyperplasia and lower urinary tract symptoms. *BJU Int*. 2005;95(9):1263–1266.

de Groat WC, Kruse MN, Vizzard MA, et al. Modification of urinary bladder function after spinal cord injury. *Adv Neurol*. 1997;72:347–364.

de Kort LM, Bower WF, Swithinbank LV, et al. The management of adolescents with neurogenic urinary tract and bowel dysfunction. *Neurourol Urodyn*. 2012;31:1170–1174.

De Ridder D, Ost D, Bruyninckx F. The presence of Fowler's syndrome predicts successful long-term outcome of sacral nerve stimulation in women with urinary retention. *Eur Urol*. 2007;51(1):229–233 [discussion 233–4].

De Ridder D, Ost D, Van der Aa F, et al. Conservative bladder management in advanced multiple sclerosis. *Mult Scler*. 2005;11(6):694–699.

De Ridder D, Vermeulen C, De Smet E, et al. Clinical assessment of pelvic floor dysfunction in multiple sclerosis: urodynamic and neurological correlates. *Neurourol Urodyn*. 1998;17:537–542.

Deen HG Jr, Zimmerman RS, Swanson SK, et al. Assessment of bladder function after lumbar decompressive laminectomy for spinal stenosis: a prospective study. *J Neurosurg*. 1994;80(6):971–974.

Delgado SR, Maldonado J, Rammohan KW. CNS demyelinating disorder with mixed features of neuromyelitis optica and multiple sclerosis in HIV-1 infection. Case report and literature review. *J Neurovirol*. 2014;20(5):531–537.

Deveaud CM, Kennedy WA 2nd, Zderic SA, et al. Biochemical and physiological characterization of the urinary bladder in Ehlers-Danlos syndrome. *Adv Exp Med Biol*. 1999;462:201–214 [discussion 225–33].

Diokno AC, Hollander JB, Bennett CJ. Bladder neck obstruction in women: a real entity. *J Urol*. 1984;132:294–302.

Dodd ME, Langman H. Urinary incontinence in cystic fibrosis. *J R Soc Med*. 2005;98(Suppl 45):28–36.

Drake M, Apostolidis A, Emmanuel A, et al. Neurologic urinary and fecal incontinence. Abrams P, Cardozo L, Khoury S. *Incontinence*. EAU-ICUD; 2013:827–1000.

Dykstra DD, Sidi AA, Anderson LC. The effects of nifedipine on cystoscopy induced autonomic hyperreflexia in patients with high spinal cord injuries. *J Urol*. 1987;138:1155–1160.

Ejaz R, Carter M, Gripp K. Lateral meningocele syndrome. Adam MP, Ardinger HH, Pagon RA, et al. *GeneReviews*. 2016.

Eldahan KC, Rabchevsky AG. Autonomic dysreflexia after spinal cord injury: systemic pathophysiology and methods of management. *Auton Neurosci*. 2017;209:59–70.

Elmelund M, Klarskov N, Bagi P, et al. Renal deterioration after spinal cord injury is associated with length of detrusor contractions during cystometry: a study with a median of 41 years follow up. *Neurourol Urodyn*. 2017;36(6):1607–1615.

Engeler DS, Meyer D, Abt D, et al. Sacral neuromodulation for the treatment of neurogenic lower urinary tract dysfunction caused by multiple sclerosis: a single-centre prospective series. *BMC Urol*. 2015;15:105.

Fagerholm R, Rintala R, Taskinen S. Lower urinary tract symptoms after feminizing genitoplasty. *J Pediatr Urol*.

2013;9(1):23–26.

Fam B, Yalla SV. Vesicourethral dysfunction in spinal cord injury and its management. *Semin Neurol*. 1988;8(2):150–155.

Fawcett J. Repair of spinal cord injuries: where are we, where are we going? *Spinal Cord*. 2002;40(12):615–623.

Fawcett JW. Spinal cord repair: from experimental models to human application. *Spinal Cord*. 1998;36(12):811–817.

Ferrara P, Costa S, Rigante D, et al. Intramedullary epidermoid cyst presenting with abnormal urological manifestations. *Spinal Cord*. 2003;41(11):645–648.

Fischer MJ, Krishnamoorthi VR, Smith BM, et al. Prevalence of chronic kidney disease in patients with spinal cord injuries/disorders. *Am J Nephrol*. 2012;36(6):542–548.

FitzGerald MP, Blazek B, Brubaker L. Complex repetitive discharges during urethral sphincter EMG: clinical correlates. *Neurourol Urodyn*. 2000;19(5):577–583.

Fletcher S, Lemack GE. Evaluation and management of neurogenic vesico-urethral dysfunction in multiple sclerosis. *Curr Bladder Dysfunct Rep*. 2009;4:71–78.

Flood HD, Ritchey ML, Bloom DA, et al. Outcome of reflux in children with myelodysplasia managed by bladder pressure monitoring. *J Urol*. 1994;152(5 Pt 1):1574–1577.

Fourtassi M, Jacquin-Courtois S, Scheiber-Nogueira MC, et al. Bladder dysfunction in hereditary spastic paraplegia: a clinical and urodynamic evaluation. *Spinal Cord*. 2012;50:558–562.

Fowler CJ. Neurological disorders of micturition and their treatment. *Brain*. 1999;122(Pt 7):1213–1231.

Fowler CJ. Urinary disorders in Parkinson's disease and multiple system atrophy. *Funct Neurol*. 2001;16(3):277–282.

Fowler CJ. Urinary retention in women. *BJU Int*. 2003;91(6):463–464.

Fowler CJ. Update on the neurology of Parkinson's disease. *Neurourol Urodyn*. 2007;26(1):103–109.

Fowler CJ, Christmas TJ, Chapple CR, et al. Abnormal electromyographic activity of the urethral sphincter, voiding dysfunction, and polycystic ovaries: a new syndrome? *BMJ*. 1988;297(6661):1436–1438.

Fu D, Ng YK, Gan P, et al. Permanent occlusion of the middle cerebral artery upregulates expression of cytokines and neuronal nitric oxide synthase in the spinal cord and urinary bladder in the adult rat. *Neuroscience*. 2004;125:819–831.

Furlan JC. Autonomic dysreflexia: a clinical emergency. *J Trauma Acute Care Surg*. 2013;75(3):496–500.

Gali A, Mucciardi G, Buttice S, et al. Correlation between advanced glycation end-products, lower urinary tract symptoms, and bladder dysfunctions in patients with type 2 diabetes mellitus. *Low Urin Tract Symptoms*. 2017;9(1):15–20.

Galloway NT. Classification and diagnosis of neurogenic bladder dysfunction. *Probl Urol*. 1989;3:1–8.

Ganesan V, Borzyskowski M. Characteristics and course of urinary tract dysfunction after acute transverse myelitis in childhood. *Dev Med Child Neurol*. 2001;43:473–475.

Gao Y, Danforth T, Ginsberg DA. Urologic management and complications in spinal cord injury patients: a 40- to 50-year follow-up study. *Urology*. 2017;104:52–58.

Garces-Ambrossi GL, McGirt MJ, Samuels R, et al. Neurological outcome after surgical management of adult tethered cord syndrome. *J Neurosurg Spine*. 2009;11:304–309.

Gariballa SE. Potentially treatable causes of poor outcome in acute stroke patients with urinary incontinence. *Acta Neurol Scand*. 2003;107:336–340.

Generao SE, Dall'era JP, Stone AR, et al. Spinal cord injury in children: long-term urodynamic and urological outcomes. *J Urol*. 2004;172(3):1092–1094 [discussion 1094].

George NJ, Slade N. Hesitancy and poor stream in younger men without outflow tract obstruction—the anxious bladder. *Br J Urol*. 1979;51(6):506–509.

Giannantoni A, Rossi A, Mearini E, et al. Botulinum toxin A for overactive bladder and detrusor muscle overactivity in patients with Parkinson's disease and multiple system atrophy. *J Urol*. 2009;182:1453–1457.

Giannantoni A, Scivoletto G, Di Stasi SM, et al. Urological dysfunctions and upper urinary tract involvement in multiple sclerosis patients. *Neurourol Urodyn*. 1998;17(2):89–98.

Giddens JL, Radomski SB, Hirshberg ED, et al. Urodynamic findings in adults with the tethered cord syndrome. *J Urol*. 1999;161(4):1249–1254.

Gilman S, Low P, Quinn N, et al. [Consensus on the diagnosis of multi-system atrophy]. *Neurologia*. 1999;14(9):425–428.

Gimbel H, Zobbe V, Andersen BJ, et al. Lower urinary tract symptoms after total and subtotal hysterectomy: results of a randomized controlled trial. *Int Urogynecol J Pelvic Floor Dysfunct*. 2005;16(4):257–262.

Ginger VA, Miller JL, Yang CC. Bladder neck closure and suprapubic tube placement in a debilitated patient population. *Neurourol Urodyn*. 2010;29:382–386.

Goldfarb RA, Pisansky A, Fleck J, et al. Neurogenic lower urinary tract dysfunction in adults with cerebral palsy: outcomes following a conservative management approach. *J Urol*. 2016;195(4 Pt 1):1009–1013.

Goldman G, Kahn PJ, Kashtan H, et al. Prevention and treatment of urinary retention and infection after surgical treatment of the colon and rectum with alpha adrenergic blockers. *Surg Gynecol Obstet*. 1988;166(5):447–450.

Goldman HB, Appell RA. Diabetic bladder dysfunction. Appell

RA. *Voiding dysfunction*. Humana: Totowa (NJ); 2000:139–147.

Goldman HB, Appell RA. Lumbar disc disease. Appell RA. *Voiding dysfunction*. Humana: Totowa (NJ); 2000.

Goldman HB, Dmochowski RR. Lower urinary tract dysfunction in patients with gastroparesis. *J Urol*. 1997;157(5):1823–1825.

Gomes CM, Hisano M, Machado LR, et al. Urological manifestations of chronic schistosomal myeloradiculopathy. *BJU Int*. 2005;96(6):853–856.

Gomes CM, Trigo-Rocha F, Arap MA, et al. Schistosomal myelopathy: urologic manifestations and urodynamic findings. *Urology*. 2002;59(2):195–200.

Gomes MJ, Silva AM, Casado JS, et al. Is lower urinary tract dysfunction an early marker of Portuguese type familial amyloidotic polyneuropathy in women? Preliminary results. *Arch Esp Urol*. 2014;67(6):557–564.

Goswami R, Seth A, Goswami AK, et al. Prevalence of enuresis and other bladder symptoms in patients with active Graves’ disease. *Br J Urol*. 1997;80(4):563–566.

Gray F, Gherardi R, Marshall A, et al. Adult polyglucosan body disease (APBD). *J Neuropathol Exp Neurol*. 1988;47(4):459–474 [164].

Greene LF, Ghosh MK, Howard FM Jr. Transurethral prostatic resection in patients with myasthenia gravis. *J Urol*. 1974;112(2):226–227.

Griffiths D, Fowler C. Brain imaging in Fowler's syndrome. *Curr Bladder Dysfunct Rep*. 2010;5:114–118.

Grimsby GM, Burgess R, Culver S, et al. Barriers to transition in young adults with neurogenic bladder. *J Pediatr Urol*. 2016;12(4):258.e1–258.e5.

Groutz A, Blaivas JG, Chaikin DC. Bladder outlet obstruction in women: definition and characteristics. *Neurourol Urodyn*.

2000;19(3):213–220.

Gupta A, Garg RK, Singh MK, et al. Bladder dysfunction and urodynamic study in tuberculous meningitis. *J Neurol Sci*. 2013;327(1–2):46–54.

Gupta A, Kumar SN, Taly AB. Urodynamic profile in acute transverse myelitis patients: its correlation with neurological outcome. *J Neurosci Rural Pract*. 2017;8(1):44–48.

Gupta S, Bonney WW, Sethi PS, et al. Preliminary report: detrusor hyper-reflexia in schizophrenia. *Neurourol Urodyn*. 1995;14(4):371–378.

Gupta S, Wein AJ. Role of Na(+)-K(+)-ATPase activity in regulation of detrusor contractility and diabetic bladder dysfunction. *Adv Exp Med Biol*. 1999;462:293–302.

Gupta S, Yang S, Cohen RA, et al. Altered contractility of urinary bladder in diabetic rabbits: relationship to reduced Na+ pump activity. *Am J Physiol*. 1996;271(6 Pt 1):C2045–C2052.

Guttmann L, Whitteridge D. Effects of bladder distension on autonomic mechanisms after spinal cord injuries. *Brain*. 1947;70(Pt 4):361–404.

Gyrtrup HJ, Kristiansen VB, Zachariae CO, et al. Voiding problems in patients with HIV infection and AIDS. *Scand J Urol Nephrol*. 1995;29(3):295–298.

Haanpaa M, Paavonen J. Transient urinary retention and chronic neuropathic pain associated with genital herpes simplex virus infection. *Acta Obstet Gynecol Scand*. 2004;83(10):946–949.

Hackler RH. A 25-year prospective mortality study in the spinal cord injured patient: comparison with the long-term living paraplegic. *J Urol*. 1977;117(4):486–488.

Hackler RH, Dalton JJ Jr, Bunts RC. Changing concepts in the preservation of renal function in the paraplegic. *J Urol*. 1965;94:107–111.

Hahn AF. Guillain-Barré syndrome. *Lancet*.

1998;352(9128):635–641.

Handel LN, Barqawi A, Checa G, et al. Males with Down's syndrome and nonneurogenic neurogenic bladder. *J Urol*. 2003;169(2):646–649.

Hammelstein P, Pietrowsky R, Merbach M, et al. Psychogenic urinary retention ('paruresis'): diagnosis and epidemiology in a representative male sample. *Psychother Psychosom*. 2005;74(5):308–314.

Hanno AG, Atta MA, Elbadawi A. Intrinsic neuromuscular defects in the neurogenic bladder: IX. Effects of combined parasympathetic decentralization and hypogastric neurectomy on neuromuscular ultrastructure of the feline bladder base. *Neurourol Urodyn*. 1988;7:93–98.

Hansen RB, Biering-Sørensen F, Kristensen JK. Urinary incontinence in spinal cord injured individuals 10-45 years after injury. *Spinal Cord*. 2010;48(1):27–33.

Harris CR, Alwaal A, Ziad UB, et al. Lupus cystitis presenting with urinary symptoms. *Urol Ann*. 2015;7(3):414–415.

Hartung HP, Pollard JD, Harvey GK, et al. Immunopathogenesis and treatment of the Guillain-Barré syndrome—Part I. *Muscle Nerve*. 1995;18(2):137–153.

Hashitani H, Suzuki H. Altered electrical properties of bladder smooth muscle in streptozotocin-induced diabetic rats. *Br J Urol*. 1996;77(6):798–804.

Hattori T, Yasuda K, Kita K, et al. Disorders of micturition in tabes dorsalis. *Br J Urol*. 1990;65(5):497–499.

Hemrika DJ, Schutte MF, Bleker OP. Elsberg syndrome: a neurologic basis for acute urinary retention in patients with genital herpes. *Obstet Gynecol*. 1986;68(3 Suppl):37S–39S.

Hermieu JF, Delmas V, Boccon-Gibod L. Micturition disturbances and human immunodeficiency virus infection. *J Urol*. 1996;156(1):157–159.

Herzog J, Weiss PH, Assmus A, et al. Subthalamic stimulation modulates cortical control of urinary bladder in Parkinson's disease. *Brain*. 2006;129(Pt 12):3366–3375.

Hess MJ, Zhan EH, Foo DK, et al. Bladder cancer in patients with spinal cord injury. *J Spinal Cord Med*. 2003;26(4):335–338.

Heyns CF, Fisher M. The urological management of the patient with acquired immunodeficiency syndrome. *BJU Int*. 2005;95(5):709–716.

Hinman F Jr. Nonneurogenic neurogenic bladder (the Hinman syndrome)—15 years later. *J Urol*. 1986;136(4):769–777.

Ho CH, Chang TC, Guo YJ, et al. Lower urinary tract symptoms and urinary flow rates in female patients with hyperthyroidism. *Urology*. 2011;77:50–54.

Hohenfellner M, Pannek J, Botel U, et al. Sacral bladder denervation for treatment of detrusor hyperreflexia and autonomic dysreflexia. *Urology*. 2001;58(1):28–32.

Hoffman DS, Nitti VW. Female bladder outlet obstruction. *Curr Urol Rep*. 2016;17(4):31.

Hooton TM, Bradley SF, Cardenas DD, et al. Diagnosis, prevention, and treatment of catheter-associated urinary tract infection in adults: 2009 International Clinical Practice Guidelines from the Infectious Diseases Society of America. *Clin Infect Dis*. 2010;50(5):625–663.

Huang YH, Bih LI, Chen GD, et al. Autonomic dysreflexia during urodynamic examinations in patients with suprasacral spinal cord injury. *Arch Phys Med Rehabil*. 2011;92:1450–1454.

Husmann DA. Occult spinal dysraphism (the tethered cord) and the urologist. *AUA Update Series*. 1995;XIV:78–83.

Ineichen BV, Schneider MP, Hlavica M, et al. High EDSS can predict risk for upper urinary tract damage in patients with multiple sclerosis. *Mult Scler*. 2018;24(4):529–534.

Ismail S, Karsenty G, Chartier-Kastler R, et al. Prevalence, management, and prognosis of bladder cancer in patients with neurogenic bladder: a systematic review. *Neurourol Urodyn*. 2017 [Ahead of print].

Jakobsen H, Holm-Bentzen M, Halt T. Neurogenic bladder dysfunction in sacral agenesis. *Neurourol Urodyn*. 1985;4:99–104.

Jensen LN, Gerstenberg T, Kallestrup EB, et al. Urodynamic evaluation of patients with autosomal dominant pure spastic paraplegia linked to chromosome 2p21-p24. *J Neurol Neurosurg Psychiatry*. 1998;65:693–696.

Jha S, Arunkalaivanan AS, Situnayake RD. Prevalence of incontinence in women with benign joint hypermobility syndrome. *Int Urogynecol J Pelvic Floor Dysfunct*. 2007;18(1):61–64.

Jorgensen TM, Djurhuus JC, Schroder HD. Idiopathic detrusor sphincter dyssynergia in neurologically normal patients with voiding abnormalities. *Eur Urol*. 1982;8(2):107–110.

Joseph DB. Bladder rehabilitation in children with spina bifida: state-of-the-“ART.”. *J Urol*. 2005;173(6):1850–1851.

Kabay SC, Kabay S, Yucel M, et al. Acute urodynamic effects of percutaneous posterior tibial nerve stimulation on neurogenic detrusor overactivity in patients with Parkinson's disease. *Neurourol Urodyn*. 2009;28:62–67.

Kakulas BA. The applied neuropathology of human spinal cord injury. *Spinal Cord*. 1999;37(2):79–88.

Kakulas BA. Neuropathology: the foundation for new treatments in spinal cord injury. *Spinal Cord*. 2004;42(10):549–563.

Kalita J, Misra UK, Kumar G, et al. Bladder dysfunction in spinal tuberculosis: clinical, urodynamic and MRI study. *Spinal Cord*. 2010;48:697–703.

Kalita J, Shah S, Kapoor R, et al. Bladder dysfunction in acute transverse myelitis: magnetic resonance imaging and neurophysiological and uro-dynamic correlations. *J Neurol Neurosurg Psychiatry*. 2002;73(2):154–159.

Kalpakjian CZ, Quint EH, Bushnik T, et al. Menopause characteristics and subjective symptoms in women with and without spinal cord injury. *Arch Phys Med Rehabil*. 2010;91(4):562–569.

Kane CJ, Bolton DM, Connolly JA, et al. Voiding dysfunction in human immunodeficiency virus infections. *J Urol*. 1996;155(2):523–526.

Kanie S, Yokoyama O, Komatsu K, et al. GABAergic contribution to rat bladder hyperactivity after middle cerebral artery occlusion. *Am J Physiol Regul Integr Comp Physiol*. 2000;279(4):R1230–R1238.

Kanika ND, Chang J, Tong Y, et al. Oxidative stress status accompanying diabetic bladder cystopathy results in the activation of protein degradation pathways. *BJU Int*. 2011;107:1676–1684.

Kaplan SA, Blaivas JG. Diabetic cystopathy. *J Diabetes Complications*. 1988;2(3):133–139.

Kaplan SA, Te AE, Blaivas JG. Urodynamic findings in patients with diabetic cystopathy. *J Urol*. 1995;153(2):342–344.

Kaplan SA, Chancellor MB, Blaivas JG. Bladder and sphincter behavior in patients with spinal cord lesions. *J Urol*. 1991;146(1):113–117.

Karlsson AK. Autonomic dysreflexia. *Spinal Cord*. 1999;37(6):383–391.

Karsenty G, Reitz A, Wefer B, et al. Understanding detrusor sphincter dyssynergia—significance of chronology. *Urology*. 2005;66(4):763–768.

Katsumi HK, Kalisvaart JF, Ronningen LD, et al. Urethral versus suprapubic catheter: choosing the best bladder management for male spinal cord injury patients with indwelling catheters. *Spinal Cord*. 2010;48:325–329.

Kaufman JM, Fam B, Jacobs SC, et al. Bladder cancer and squamous metaplasia in spinal cord injury patients. *J Urol*. 1977;118(6):967–971.

Kavia RB, Datta SN, Dasgupta R, et al. Urinary retention in women: its causes and management. *BJU Int*. 2006;97(2):281–287.

Kay L, Berelsen M. Bladder symptoms among polio survivors. *J Rehabil Med*. 2013;45(6):560–564.

Kennelly M, Dmochowski R, Ethans K, et al. Long-term efficacy and safety of onabotulinumtoxinA in patients with urinary incontinence due to neurogenic detrusor overactivity: an interim analysis. *Urology*. 2013;81(3):491–497.

Khan F, Pallant JF, Shea TL, et al. Multiple sclerosis: prevalence and factors impacting bladder and bowel function in an Australian community cohort. *Disabil Rehabil*. 2009;31(19):1567–1576.

Khan MA, Thompson CS, Calvert RC, et al. Decreased urinary bladder apoptosis in a rabbit model of diabetes mellitus. *Urol Res*. 2002;30(1):79–83.

Khan Z, Bhola A. Urinary incontinence after transurethral resection of prostate in myasthenia gravis patients. *Urology*. 1989;34(3):168–169.

Khan Z, Starer P, Yang WC, et al. Analysis of voiding disorders in patients with cerebrovascular accidents. *Urology*. 1990;35(3):265–270.

Khavari R, Fletcher SG, Liu J, et al. A modification to augmentation cystoplasty with catheterizable stoma for neurogenic patients: technique and long-term results. *Urology*. 2012;80(2):460–464.

Khavari K, Karmonik C, Shy M, et al. Functional magnetic resonance imaging with concurrent urodynamic testing identifies brain structures involved in micturition cycle in patients with multiple sclerosis. *J Urol*. 2017;197(2):438–

444.

Khera M, Somogyi GT, Kiss S, et al. Botulinum toxin A inhibits ATP release from bladder urothelium after chronic spinal cord injury. *Neurochem Int*. 2004;45(7):987–993.

Kim JS. Post-stroke emotional incontinence after small lenticulocapsular stroke: correlation with lesion location. *J Neurol*. 2002;249(7):805–810.

Kim KJ, Jeong SJ, Kim JM. Neurogenic bladder in progressive supranuclear palsy: a comparison with Parkinson's disease and multiple system atrophy. *Neurourol Urodyn*. 2018;37(5):1724–1730.

Kim TG, Yoo KH, Jeon SH, et al. Effect of dominant hemispheric stroke on detrusor function in patients with lower urinary tract symptoms. *Int J Urol*. 2010;17:656–660.

Kim YH, Kattan MW, Boone TB. Bladder leak point pressure: the measure for sphincterotomy success in spinal cord injured patients with external detrusor-sphincter dyssynergia. *J Urol*. 1998;159(2):493–496 [discussion 496–7].

Kirby R. Non-traumatic neurogenic bladder dysfunction. Mundy AR, Stephenson TP, Wein AJ. *Urodynamics: principles, practice, application*. Churchill Livingstone: London; 1994:365–373.

Kirby R, Fowler C, Gosling J, et al. Urethro-vesical dysfunction in progressive autonomic failure with multiple system atrophy. *J Neurol Neurosurg Psychiatry*. 1986;49:554–560.

Kirschner-Hermanns R, Daneshgari F, Vahabi B, et al. Does diabetes mellitus-induced bladder remodeling affect lower urinary tract function? ICI-RS 2011. *Neurourol Urodyn*. 2012;31:359–364.

Kitta T, Kakizaki H, Furuno T, et al. Brain activation during detrusor overactivity in patients with Parkinson's disease: a positron emission tomography study. *J Urol*. 2006;175(3 Pt 1):994–998.

Koh JH, Lee J, Jung SM, et al. Lupus cystitis in Korean patients with systemic lupus erythematosus: risk factors and clinical outcomes. *Lupus*. 2015;24(12):1300–1307.

Kolominsky-Rabas PL, Hilz MJ, Neundoerfer B, et al. Impact of urinary incontinence after stroke: results from a prospective population-based stroke register. *Neurourol Urodyn*. 2003;22(4):322–327.

Kovacs L, Papos M, Takacs R, et al. Autonomic nervous system dysfunction involving the gastrointestinal and the urinary tracts in primary Sjögren's syndrome. *Clin Exp Rheumatol*. 2003;21(6):697–703.

Kovindha A, Wyndaele JJ, Madersbacher H. Prevalence of incontinence during rehabilitation in patients following a stroke. *Curr Bladder Dysfunct Rep*. 2010;5:32–38.

Koyanagi T, Morita H, Taniguchi K, et al. Neurogenic urethra: clinical relevance of isolated neuropathic dysfunction of the urethra, and the denervation supersensitivity of the urethra revisited. *Eur Urol*. 1988;15(1–2):77–83.

Krassioukov A. Autonomic dysreflexia: current evidence related to unstable arterial blood pressure control among athletes with spinal cord injury. *Clin J Sport Med*. 2012;22:39–45.

Krzastek SC, Bruch WM, Robinson SP, et al. Characterization of lower urinary tract symptoms in patients with idiopathic normal pressure hydrocephalus. *Neurourol Urodyn*. 2017;36(4):1167–1173.

Krzastek SC, Robinson SP, Young HF, et al. Improvement in lower urinary tract symptoms across multiple domains following ventriculoperitoneal shunting for idiopathic normal pressure hydrocephalus. *Neurourol Urodyn*. 2017;36(4):1167–1173.

Ku JH, Choi WJ, Lee KY, et al. Complications of the upper urinary tract in patients with spinal cord injury: a long-term follow-up study. *Urol Res*. 2005;33(6):435–439.

Kulaksizoglu H, Parman Y. Use of botulinim toxin-A for the treatment of overactive bladder symptoms in patients with Parkinson's disease. *Parkinsonism Relat Disord*. 2010;16:531–534.

Kuoch KLJ, Meyer D, Austin DW, et al. A systematic review of paruresis: clinical implications and future directions. *J Psychosom Res*. 2017;98:122–129.

Kutzenberger J, Domurath B, Sauerwein D. Spastic bladder and spinal cord injury: seventeen years of experience with sacral deafferentation and implantation of an anterior root stimulator. *Artif Organs*. 2005;29(3):239–241.

Lakeman MM, van der Vaart CH, Roovers JP. A long-term prospective study to compare the effects of vaginal and abdominal hysterectomy on micturition and defecation. *BJOG*. 2011;118:1511–1517.

Lam Van Ba O, Barbe MF, Caremel R, et al. Lumbar to sacral root rerouting to restore bladder function in a feline spinal cord injury model: urodynamic and retrograde nerve tracing results from a pilot study. *Neurourol Urodyn*. 2018;37(1):153–162.

Lang AE, Lozano AM. Parkinson's disease. *N Engl J Med*. 1998;339:1044–1053.

Lang EW, Chesnut RM, Hennerici M. Urinary retention and space-occupying lesions of the frontal cortex. *Eur Neurol*. 1996;36(1):43–47.

Lange MM, van de Velde CJ. Urinary and sexual dysfunction after rectal cancer treatment. *Nat Rev Urol*. 2011;8:51–57.

Lazzeri M, Beneforti P, Benaim G, et al. Vesical dysfunction in systemic sclerosis (scleroderma). *J Urol*. 1995;153(4):1184–1187.

Leach GE, Farsaii A, Kark P, et al. Urodynamic manifestations of cerebellar ataxia. *J Urol*. 1982;128(2):348–350.

Lee HS, Choi JG, Shin JH. Urological disturbance and its neuroanatomical correlate in patients with chronic brainstem stroke. *Neurourol Urodyn*. 2017;36(1):136–141.

Lee T, Lim US, Kang DH, et al. Near-normalized gene expression profiles in bladder with detrusor overactivity in rats with bladder outlet obstruction after deobstruction. *Int Neurourol J*. 2017;21(4):247–258.

Lee WC, Wu HP, Tai TY, et al. Investigation of urodynamic characteristics and bladder sensory function in the early stages of diabetic bladder dysfunction in women with type 2 diabetes. *J Urol*. 2009;181(1):198–203.

Leiria LO, Monica FZ, Carvalho FD, et al. Functional, morphological and molecular characterization of bladder dysfunction in streptozotocin-induced diabetic mice: evidence of a role for L-type voltage-operated Ca2+ channels. *Br J Pharmacol*. 2011;163:1276–1288.

Leitner L, Guggenbuhl-Roy S, Knupfer SC, et al. More than 15 years of experience with intradetrusor onabotulinumtoxinA injections for treating refractory neurogenic detrusor overactivity: lessons to be learned. *Eur Urol*. 2016;70(3):522–528.

Lemack GE, Frohman E, Zimmern P, et al. Urodynamic distinctions between idiopathic detrusor overactivity and detrusor overactivity secondary to multiple sclerosis. *J Urol*. 2005;67(5):960–964.

Lemelle JL, Guillemin F, Aubert D, et al. A multicenter evaluation of urinary incontinence management and outcome in spina bifida. *J Urol*. 2006;175(1):208–212.

Lenherr SM, Clemens JQ. Urodynamics: with a focus on appropriate indications. *Urol Clin North Am*. 2013;40:545–557.

Levin RM, Monson FC, Haugaard N, et al. Genetic and cellular characteristics of bladder outlet obstruction. *Urol Clin North*

Am. 1995;22(2):263–283.

Li L, Ye W, Ruan H, et al. Impact of hydrophilic catheters on urinary tract infections in people with spinal cord injury: systematic review and meta-analysis of randomized controlled trials. *Arch Phys Med Rehabil*. 2013;94(4):782–787.

Light JK, Faganel J, Beric A. Detrusor areflexia in suprasacral spinal cord injuries. *J Urol*. 1985;134(2):295–297.

Lima CL, Rabolini G, Menna-Barreto M, et al. Urodynamic alterations in patients with HTLV-1 infection. *Int Braz J Urol*. 2002;28(5):452–456 [discussion 456–7].

Lindan R, Leffler EJ, Bodner D. Urological problems in the management of quadriplegic women. *Paraplegia*. 1987;25(5):381–385.

Linsenmeyer TA. Update on bladder evaluation recommendations and bladder management guideline in patients with spinal cord injury. *Curr Bladder Dysfunct Rep*. 2007;2:134–140.

Linsenmeyer TA, Bagaria SP, Gendron B. The impact of urodynamic parameters on the upper tracts of spinal cord injured men who void reflexly. *J Spinal Cord Med*. 1998;21(1):15–20.

Linsenmeyer TA, Campagnolo DI, Chou IH. Silent autonomic dysreflexia during voiding in men with spinal cord injuries. *J Urol*. 1996;155(2):519–522.

Linsenmeyer TA, Culkin D. APS recommendations for the urological evaluation of patients with spinal cord injury. *J Spinal Cord Med*. 1999;22(2):139–142.

Linsenmeyer TA, Perkash I. Infertility in men with spinal cord injury. *Arch Phys Med Rehabil*. 1991;72(10):747–754.

Linsenmeyer TA, Zorowitz RD. Urodynamic findings in patients with urinary incontinence after cerebrovascular accident. *Neurol Rehabil*. 1992;2:23–26.

Litwiller SE, Frohman EM, Zimmern PE. Multiple sclerosis and the urologist. *J Urol*. 1999;161(3):743–757.

Liu G, Daneshgari F. Alterations in neurogenically mediated contractile responses of urinary bladder in rats with diabetes. *Am J Physiol Renal Physiol*. 2005;288(6):F1220–F1226.

Liu G, Li M, Vasanji A, et al. Temporal diabetes and diuresis-induced alteration of nerves and vasculature of the urinary bladder in the rat. *BJU Int*. 2011;107:1988–1993.

Liu N, Zhou MW, Biering-Sorensen F, et al. Cardiovascular response during urodynamics in individuals with spinal cord injury. *Spinal Cord*. 2017;55(3):279–284.

Liu T, Ouyang L, Thibadeau J, et al. Longitudinal study of bladder continence in patients with spina bifida in the National Spina Bifida Patient Registry. *J Urol*. 2018;199(3):837–843.

Livshits A, Catz A, Folman Y, et al. Reinnervation of the neurogenic bladder in the late period of the spinal cord trauma. *Spinal Cord*. 2004;42(4):211–217.

Lloyd LK, Kuhlemeier KV, Fine PR, et al. Initial bladder management in spinal cord injury: does it make a difference? *J Urol*. 1986;135(3):523–527.

Locke JR, Hill DE, Walzer Y. Incidence of squamous cell carcinoma in patients with long-term catheter drainage. *J Urol*. 1985;133(6):1034–1035.

Macarak EJ, Howard PS. The role of collagen in bladder filling. *Adv Exp Med Biol*. 1999;462:215–223 [discussion 225–33].

MacLeod M, Kelly R, Robb SA, et al. Bladder dysfunction in Duchenne muscular dystrophy. *Arch Dis Child*. 2003;88(4):347–349.

Madersbacher H, Cardozo L, Chapple C, et al. What are the causes and consequences of bladder overdistension? ICI-RS 2011. *Neurourol Urodyn*. 2012;31:317–321.

Manning J, Korda A, Benness C, et al. The association of obstructive defecation, lower urinary tract dysfunction and the benign joint hypermobility syndrome: a case-control study. *Int Urogynecol J Pelvic Floor Dysfunct*. 2003;14(2):128–132.

Mansfield KJ, Liu L, Mitchelson FJ, et al. Muscarinic receptor subtypes in human bladder detrusor and mucosa, studied by radioligand binding and quantitative competitive RT-PCR: changes in ageing. *Br J Pharmacol*. 2005;144:1089–1099.

Marinkovic SP, Badlani G. Voiding and sexual dysfunction after cerebrovascular accidents. *J Urol*. 2001;165(2):359–370.

Martens FM, den Hollander PP, Snoek GJ, et al. Quality of life in complete spinal cord injury patients with a Brindley bladder stimulator compared to a matched control group. *Neurourol Urodyn*. 2011;30:551–555.

Matsumoto S, Kogan BA, Levin RM, et al. Response of the fetal sheep bladder to urinary diversion. *J Urol*. 2003;169(2):735–739.

Mayer EN, Tward JD, Bassett M. Management of radiation therapy oncology group grade 4 urinary adverse events after radiotherapy for prostate cancer. *BJU Int*. 2017;119(5):700–708.

Mayo ME. Lower urinary tract dysfunction in cerebral palsy. *J Urol*. 1992;147(2):419–420.

McGuire EJ. Clinical evaluation and treatment of neurogenic vesical dysfunction. Leslie JA. *International perspectives in urology*. Williams & Wilkins: Baltimore; 1984:43–56.

McGuire EJ, Denil J. Adult myelodysplasia. *AUA Update Series*. 1991;X:297–304.

McGuire EJ, Savastano J. Comparative urological outcome in women with spinal cord injury. *J Urol*. 1986;135(4):730–731.

McKenzie P, Badlani GH. The incidence and etiology of overactive bladder in patients after cerebrovascular accident. *Curr Urol Rep*. 2012;13:402–406.

McKinnie V, Swift SE, Wang W, et al. The effect of pregnancy and mode of delivery on the prevalence of urinary and fecal incontinence. *Am J Obstet Gynecol*. 2005;193(2):512–517 [discussion 517–8].

Michelson JD, Lotke PA, Steinberg ME. Urinary-bladder management after total joint-replacement surgery. *N Engl J Med*. 1988;319(6):321–326.

Minervini R, Morelli G, Minervini A, et al. Bladder involvement in systemic sclerosis: urodynamic and histological evaluation in 23 patients. *Eur Urol*. 1998;34(1):47–52.

Misra UK, Kalita J, Kumar G, et al. Bladder dysfunction in subacute combined degeneration: a clinical, MRI and urodynamic study. *J Neurol*. 2008;255(12):1881–1888.

Mitsui T, Kakizaki H, Tanaka H, et al. Immortalized neural stem cells transplanted into the injured spinal cord promote recovery of voiding function in the rat. *J Urol*. 2003;170(4 Pt 1):1421–1425.

Mochida K, Shinomiya K, Andou M. Urodynamics and electrophysiologic study of the urinary disturbances caused by cervical myelopathy. *J Spinal Disord*. 1996;2:141–145.

Morrison J, Birder L, Craggs M, et al. Neural control. Abrams P, Cardozo L, Khoury S, et al. *Incontinence*. Health Publications: Paris; 2005:363–422.

Morton SC, Shekelle PG, Adams JL, et al. Antimicrobial prophylaxis for urinary tract infection in persons with spinal cord dysfunction. *Arch Phys Med Rehabil*. 2002;83(1):129–138.

Mostwin J, Bourcier A, Haab F, et al. Pathophysiology of urinary incontinence, fecal incontinence, and pelvic organ prolapse. Abrams P, Cardozo L, Khoury S, et al. *Incontinence*. Health Publications: Paris; 2005:423–484.

Multiple Sclerosis International Federation. *Atlas of MS:*

multiple sclerosis around the world (website). http://www.msif.org/about-ms/publications-and-resources/; 2016.

Mumtaz FH, Sullivan ME, Thompson CS, et al. Alterations in the nitric oxide synthase binding sites and non-adrenergic, non-cholinergic mediated smooth muscle relaxation in the diabetic rabbit bladder outlet: possible relevance to the pathogenesis of diabetic cystopathy. *J Urol*. 1999;162(2):558–566.

Mundy AR. Pelvic plexus injury. Mundy AR, Stephenson T, Wein AJ. *Urodynamics: principles, practice and application*. Churchill Livingston: London; 1984:273–277.

Musegante AF, Almeida PN, Barboza AL, et al. Urinary symptoms and urodynamic findings in patients with Machado-Joseph disease. *J Neurol*. 2011;258:623–626.

Nakipoglu GF, Kaya AZ, Orhan G, et al. Urinary dysfunction in multiple sclerosis. *J Clin Neurosci*. 2009;16:1321–1324.

Nanigian D, Keegan K, Stone A. Diabetic cystopathy. *Curr Bladder Dysfunct Rep*. 2007;2:197–202.

Naphade PU, Verma R, Garg RK, et al. Prevalence of bladder dysfunction, urodynamic findings, and their correlation with outcome in Guillain-Barre syndrome. *Neurourol Urodyn*. 2012;31:1135–1140.

Neemuchwala F, Ahmed F, Nasr SZ. Prevalence of pelvic incontinence in patients with cystic fibrosis. *Glob Pediatr Health*. 2017 [eCollection].

Neves Neto JF, Palomino Z, Mizuno Watanabe IK, et al. Pretransplant defunctionalized bladder-overrated condition? *Neurourol Urodyn*. 2018;37(5):1559–1566.

Newey ML, Sen PK, Fraser RD. The long-term outcome after central cord syndrome: a study of the natural history. *J Bone Joint Surg Br*. 2000;82(6):851–855.

Niemczyk J, Equit M, Hoffmann L, et al. Incontinence in children with treated attention-deficit/hyperactivity disorder. *J Pediatr Urol*. 2015;11(3):141.e1–141.e6.

Nitti VW, Tu LM, Gitlin J. Diagnosing bladder outlet obstruction in women. *J Urol*. 1999;161(5):1535–1540.

Noble JG, Lemieux M, Fowler CJ. Nonurological obstruction voiding and retention. Rushton D. *Handbook of neuro-urology*. Churchill Livingstone: New York; 1994:273–277.

Nordling J, Artibani W, Hald T, et al. Pathophysiology of the urinary bladder in obstruction and aging. Chatelin C, Dennis L, Foo KT, et al. *Benign prostatic hyperplasia (5th International Consultation on Benign Prostatic Hyperplasia)*. Health Publications: Plymouth, UK; 2001:107–166.

Nordling J, Meyhoff HH, Hald T. Sympatholytic effect on striated urethral sphincter. A peripheral or central nervous system effect? *Scand J Urol Nephrol*. 1981;15(3):173–180.

Norlen LJ, Blaivas JG. Unsuspected proximal urethral obstruction in young and middle-aged men. *J Urol*. 1986;135(5):972–976.

Noronha R, Akbarali H, Malykhina A, et al. Changes in urinary bladder smooth muscle function in response to colonic inflammation. *Am J Physiol Renal Physiol*. 2007;293(5):F1461–F1467.

Noseworthy JH, Lucchinetti C, Rodriguez M, et al. Multiple sclerosis. *N Engl J Med*. 2000;343(13):938–952.

Nutt JG, Wooten GF. Clinical practice. Diagnosis and initial management of Parkinson's disease. *N Engl J Med*. 2005;353(10):1021–1027.

O'Flynn KJ, Murphy R, Thomas DG. Neurogenic bladder dysfunction in lumbar intervertebral disc prolapse. *Br J Urol*. 1992;69(1):38–40.

Oger J, AlKhawajah M. Where are we going with drugs to treat MS? Will cost continue to increase? *Can J Neurol Sci*. 2010;37:305–308.

Olson L. Regeneration in the adult central nervous system: experimental repair strategies. *Nat Med*. 1997;3(12):1329–1335.

Opisso E, Borau A, Rodriguez A, et al. Patient controlled versus automatic stimulation of pudendal nerve afferents to treat neurogenic detrusor overactivity. *J Urol*. 2008;180(4):1403–1408.

Ozkan KU, Bauer SB, Khoshbin S, et al. Neurogenic bladder dysfunction after sacrococcygeal teratoma resection. *J Urol*. 2006;175(1):292–296 [discussion 296].

Pak KJ, Ostrom RS, Matsui M, et al. Impaired M3 and enhanced M2 muscarinic receptor contractile function in a streptozotocin model of mouse diabetic urinary bladder. *Naunyn Schmiedebergs Arch Pharmacol*. 2010;381:441–454.

Pak KJ, Ostrom RS, Matsui M, et al. The M2-muscarinic receptor inhibits the development of streptozotocin-induced neuropathy in mouse urinary bladder. *J Pharmacol Exp Ther*. 2010;335:239–248.

Panicker JN, Nagaraja D, Kovoor JM, et al. Lower urinary tract dysfunction in acute disseminated encephalomyelitis. *Mult Scler*. 2009;15(9):1118–1122.

Pannek J. Transitional cell carcinoma in patients with spinal cord injury: a high risk malignancy? *Urology*. 2002;59(2):240–244.

Pannek J. Prophylaxis of urinary tract infections in subjects with spinal cord injury and bladder function disorders—current clinical practice. *Aktuelle Urol*. 2012;43:55–58.

Pannek J, Radeacher F, Wollner J. Clinical usefulness of urine cytology in the detection of bladder tumors in patients with neurogenic lower urinary tract dysfunction. *Res Rep Urol*. 2017;9:219–223.

Pannek J, Stöhrer M, Blork B, et al. *Guidelines on neurogenic lower tract dysfunction*. [Arnheim, Netherlands: European

Association of Urology] 2011:64.

Papatsoris AG, Papapetropoulos S, Singer C, et al. Urinary and erectile dysfunction in multiple system atrophy (MSA). *Neurourol Urodyn*. 2008;27(1):22–27.

Park YI, Linsenmeyer TA. A method to minimize indwelling catheter calcification and bladder stones in individuals with spinal cord injury. *J Spinal Cord Med*. 2001;24(2):105–108.

Partridge EA, Canning D, Long C, et al. Urologic and anorectal complications of sacrococcygeal teratomas; prenatal and postnatal predictors. *J Pediatr Surg*. 2014;49(1):139–142.

Patel DP, Lenherr SM, Stoffel JM, et al. Study protocol: patient reported outcomes for bladder management strategies in spinal cord injury. *BMC Urol*. 2017;17(1):95.

Patel M, Coshall C, Rudd AG, et al. Natural history and effects on 2-year outcomes of urinary incontinence after stroke. *Stroke*. 2001;32(1):122–127.

Patki P, Woodhouse J, Bycroft J, et al. Stress urinary incontinence: current understanding. *Hosp Med*. 2005;66:335–340.

Patki P, Woodhouse J, Hamid R, et al. Lower urinary tract dysfunction in ambulatory patients with incomplete spinal cord injury. *J Urol*. 2006;175(5):1784–1787 [discussion 1787].

Pehrson R, Stenman E, Andersson KE. Effects of tramadol on rat detrusor overactivity induced by experimental cerebral infarction. *Eur Urol*. 2003;44(4):495–499.

Penders J, Huylenbroeck AA, Everaert K, et al. Urinary infections in patients with spinal cord injury. *Spinal Cord*. 2003;41(10):549–552.

Perkash I, Linsenmeyer TA, Bodner DR, et al. Detrusor-sphincter dyssynergia and vesicourethral reflux: management. *Spinal Cord*. 1998;36(1):2–5.

Persun ML, Ginsberg PC, Harmon JD, et al. Role of urologic evaluation in the adult spina bifida patient. *Urol Int*. 1999;62(4):205–208.

Pesce F, Castellano V, Finazzi Agro E, et al. Voiding dysfunction in patients with spinal cord lesions at the thoracolumbar vertebral junction. *Spinal Cord*. 1997;35(1):37–39.

Peterson AC, Curtis LH, Shea AM, et al. Urinary diversion in patients with spinal cord injury in the United States. *Urology*. 2012;80(6):1247–1251.

Pfisterer MH, Griffiths DJ, Schaefer W, et al. The effect of age on lower urinary tract function: a study in women. *J Am Geriatr Soc*. 2006;54:405–412.

Phuong LK, Schoeberl KA, Raffel C. Natural history of tethered cord in patients with meningomyelocele. *Neurosurgery*. 2002;50(5):989–993 [discussion 993–5].

Pop-Busui R, Hotaling J, Braffett BH, et al. Cardiovascular autonomic neuropathy, erectile dysfunction and lower urinary tract symptoms in men with type 1 diabetes: findings from the DCCT/EDIC. *J Urol*. 2015;193:2045–2051.

Post M, Noreau L. Quality of life after spinal cord injury. *J Neurol Phys Ther*. 2005;29:139–146.

Public health and aging: hospitalizations for stroke among adults aged > 65 years—United States, 2000. *J Am Med Assoc*. 2003;290(8):1023–1024.

Puri BK, Shah M, Julu PO. Urinary bladder detrusor dysfunction symptoms in Lyme disease. *Int Neurourol J*. 2013;17(3):127–129.

Qiao LY, Vizzard MA. Upregulation of phosphorylated CREB but not c-Jun in bladder afferent neurons in dorsal root ganglia after cystitis. *J Comp Neurol*. 2004;469:262–274.

Rabchevsky AG, Smith GM. Therapeutic interventions following mammalian spinal cord injury. *Arch Neurol*. 2001;58(5):721–726.

Radziszewski P, Crayton R, Zaborski J, et al. Multiple sclerosis produces significant changes in urinary bladder innervation which are partially reflected in the lower urinary tract functional status-sensory nerve fibers role in detrusor overactivity. *Mult Scler*. 2009;15:860–868.

Rajaskaran M, Monga M. Cellular and molecular causes of male infertility in spinal cord injury. *J Androl*. 1999;20:326–330.

Razdan S, Vlachiotis JD, Edelstein RA, et al. Schistosomal myelopathy as a cause of neurogenic bladder dysfunction. *Urology*. 1997;49(5):777–780.

Reid CJ, Borzyskowski M. Lower urinary tract dysfunction in cerebral palsy. *Arch Dis Child*. 1993;68(6):739–742.

Richardson I, Palmer LS. Clinical and urodynamic spectrum of bladder function in cerebral palsy. *J Urol*. 2009;182(4 Suppl):1945–1948.

Rizk DE, Padmanabhan RK, Tariq S, et al. Ultra-structural morphological abnormalities of the urinary bladder in streptozotocin-induced diabetic female rats. *Int Urogynecol J Pelvic Floor Dysfunct*. 2006;17(2):143–154.

Roh JW, Lee DO, Suh DH, et al. Efficacy and oncologic safety of nerve-sparing radical hysterectomy for cervical cancer: a randomized controlled trial. *J Gynecol Oncol*. 2015;26(2):90–99.

Roijen LE, Postema K, Limbeek VJ, et al. Development of bladder control in children and adolescents with cerebral palsy. *Dev Med Child Neurol*. 2001;43(2):103–107.

Rortveit G, Daltveit AK, Hannestad YS, et al. Urinary incontinence after vaginal delivery or cesarean section. *N Engl J Med*. 2003;348(10):900–907.

Rortveit G, Daltveit AK, Hannestad YS, et al. Vaginal delivery parameters and urinary incontinence: the Norwegian EPINCONT study. *Am J Obstet Gynecol*. 2003;189(5):1268–

1274.

Rosario DJ, Chapple CR, Tophill PR, et al. Urodynamic assessment of the bashful bladder. *J Urol*. 2000;163(1):215–220.

Rosier PFWM, Schaefer W, Lose G, et al. International Continence Society Good Urodyanmic Practices and Terms 2016: urodynamics, uroflowmetry, cystometry, and pressure-flow study. *Neurourol Urodyn*. 2017;36(5):1243–1260.

Rossi F, Cattaneo E. Opinion: neural stem cell therapy for neurological diseases: dreams and reality. *Nat Rev Neurosci*. 2002;3(5):401–409.

Rudy DC. Detrusor–external sphincter dyssynergia. *Probl Urol*. 1993;7:8–93.

Rutkowski SB, Geraghty TJ, Hagen DL, et al. A comprehensive approach to the management of male infertility following spinal cord injury. *Spinal Cord*. 1999;37(7):508–514.

Ryttov N, Aagaard J, Hertz J. Retention of urine in genital herpetic infection. Survey and case report. *Urol Int*. 1985;40(1):22–24.

Saito M, Miyagawa I. Bladder dysfunction due to Behçet's disease. *Urol Int*. 2000;65(1):40–42.

Saini J, Axelrod FB, Maayan C, et al. Urinary incontinence in familial dysautonomia. *Int Urogynecol J Pelvic Floor Dysfunct*. 2003;14(3):209–213 [discussion 213].

Sakakibara R, Fowler CJ, Hattori T. Voiding and MRI analysis of the brain. *Int Urogynecol J Pelvic Floor Dysfunct*. 1999;10:192–199.

Sakakibara R, Hattori T, Boku K, et al. Micturitional disturbance in neuro-Behçet's syndrome. *Auton Neurosci*. 2000;83:86–89.

Sakakibara R, Hattori T, Fukutake M, et al. Micturitional disturbance in a patient with adrenomyeloneuropathy (AMN). *Neurourol Urodyn*. 1998;17:207–212.

Sakakibara R, Hattori T, Kica K, et al. Stress-induced urinary incontinence in patients with spino-cerebella degeneration. *J Neurol Neurosurg Psychiatry*. 1998;64:389–391.

Sakakibara R, Hattori T, Kuwabara S, et al. Micturitional disturbance in patients with Guillain-Barré syndrome. *J Neurol Neurosurg Psychiatry*. 1997;63:389–391.

Sakakibara R, Hattori T, Tojo M, et al. The location of the paths subserving micturition: studies in patients with cervical myelopathy. *J Auton Nerv Syst*. 1995;55:165–168.

Sakakibara R, Hattori T, Tojo M, et al. Micturitional disturbance in myotonic dystrophy. *J Auton Nerv Syst*. 1995;52:17–21.

Sakakibara R, Hattori T, Uchiyama T, et al. Urinary dysfunction in Brown-Sequard syndrome. *Neurourol Urodyn*. 2001;20:661–667.

Sakakibara R, Hattori T, Uchiyama T, et al. Uroneurological assessment of spina bifida cystica and occulta. *Neurourol Urodyn*. 2003;22:328–334.

Sakakibara R, Hattori T, Yasuda K, et al. Micturitional disturbance in acute disseminated encephalopathy. *J Auton Nerv Syst*. 1996;10:200–205.

Sakakibara R, Hattori T, Yasuda K, et al. Micturitional disturbance in syringomyelia. *J Neurol Sci*. 1996;143:100–106.

Sakakibara R, Hattori T, Yasuda K, et al. Micturitional disturbance in Wernicke's encephalopathy. *Neurourol Urodyn*. 1997;15:111–115.

Sakakibara R, Hattori T, Yasuda T, et al. Micturition disturbance in acute transverse myelitis. *Spinal Cord*. 1996;345:481–485.

Sakakibara R, Panicker J, Finazzi-Agro E, et al. A guideline for the management of bladder dysfunction in Parkinson's disease and other gait disorders. *Neurourol Urodyn*. 2016;35(5):551–563.

Sakakibara R, Uchiyama T, Kuwabara S, et al. Prevalence and mechanism of bladder dysfunction in Guillain-Barré syndrome. *Neurourol Urodyn*. 2009;28(5):432–437.

Sakakibara R, Uchiyama T, Yamanishi T, et al. Urinary function in patients with corticobasal degeneration: comparison with normal subjects. *Neurourol Urodyn*. 2004;23(2):154–158.

Sakakibara R, Uchiyama T, Yoshiyama M. Urinary dysfunction in patients with systemic lupus erythematosus. *Neurourol Urodyn*. 2003;22:593–596.

Salas NA, Somogyi GT, Gangitano DA, et al. Receptor activated bladder and spinal ATP release in neurally intact and chronic spinal cord injured rats. *Neurochem Int*. 2007;50(2):345–350.

Sammour ZM, de Bessa J Jr, Hisano M, et al. Lower urinary tract symptoms in children and adolescents with Williams-Beuren syndrome. *J Pediatr Urol*. 2017;13(2):203.e1–203.e6.

Sammour ZM, Gomes CM, Barbosa ER, et al. Voiding dysfunction in patients with Parkinson's disease: impact of neurological impairment and clinical parameters. *Neurourol Urodyn*. 2009;28:510–515.

Sammour ZM, Gomes CM, Duarte RJ, et al. Voiding dysfunction and the Williams-Beuren syndrome: a clinical and urodynamic investigation. *J Urol*. 2006;175:1472–1476.

Sandler PM, Avillo C, Kaplan SA. Detrusor areflexia in a patient with myasthenia gravis. *Int J Urol*. 1998;5(2):188–190.

Sandri S, Fanciullacci F, Politi P, et al. Urinary disorders in intervertebral disc prolapse. *Neurourol Urodyn*. 1987;6:11–15.

Sasaki K, Chancellor MB, Phelan MW, et al. Diabetic cystopathy correlates with a long-term decrease in nerve growth factor levels in the bladder and lumbosacral dorsal root Ganglia. *J Urol*. 2002;168(3):1259–1264.

Saraf AA, Peterson AW, Simmons SF, et al. Medications associated with geriatric syndromes and their prevalence in older hospitalized adults discharged to skilled nursing facilities. *J Hosp Med*. 2017;11(10):694–700.

Satoh K, Motomura M, Suzu H, et al. Neurogenic bladder in Lambert-Eaton myasthenic syndrome and its response to 3,4-diaminopyridine. *J Neurol Sci*. 2001;183(1):1–4.

Sauerwein D. Urinary tract infection in patients with neurogenic bladder dysfunction. *Int J Antimicrob Agents*. 2002;19(6):592–597.

Scaravilli T, Pramstaller PP, Salerno A, et al. Neuronal loss in Onuf's nucleus in three patients with progressive supranuclear palsy. *Ann Neurol*. 2000;48(1):97–101.

Schmidt RE. Age-related sympathetic ganglionic neuropathology: human pathology and animal models. *Auton Neurosci*. 2002;96:63–72.

Schurch B, Iacovelli V, Averbeck MA, et al. Urodynamics in patients with spinal cord injury: a clinical review and best practice paper by a working group of The International Continence Society Urodynamics Committee. *Neurourol Urodyn*. 2018;37(2):581–591.

Schurch B, Schmid DM, Karsenty G, et al. Can neurologic examination predict type of detrusor sphincter-dyssynergia in patients with spinal cord injury? *Urology*. 2005;65(2):243–246.

Seif C, Junemann KP, Braun PM. Deafferentation of the urinary bladder and implantation of a sacral anterior root stimulator (SARS) for treatment of the neurogenic bladder in paraplegic patients. *Biomed Tech (Berl)*. 2004;49(4):88–92.

Seki S, Sasaki K, Igawa Y, et al. Suppression of detrusor-sphincter dyssynergia by immunoneutralization of nerve growth factor in lumbosacral spinal cord in spinal cord injured rats. *J Urol*. 2004;171(1):478–482.

Serrano DP, Flechner SM, Modlin CS, et al. Transplantation into the long-term defunctionalized bladder. *J Urol*. 1996;156:885–888.

Sharopov BR, Gulak KL, Philyppov IB, et al. TRPV1 alterations in urinary bladder dysfunction in a rat model of STZ-induced diabetes. *Life Sci*. 2018;193:207–213.

Shimizu I, Kawashima K, Ishii D, et al. Urodynamics in a rat neurogenic bladder model with a unilateral electrolytic lesion of the basal forebrain. *BJU Int*. 2003;91(9):861–867.

Silveri M, De Gennaro M, Gatti C, et al. Voiding dysfunction in X-linked adrenoleukodystrophy: symptom score and urodynamic findings. *J Urol*. 2004;171(6 Pt 2):2651–2653.

Singh G, Thomas DG. The female tetraplegic: an admission of urological failure. *Br J Urol*. 1997;79(5):708–712.

Sinha P, Gupta A, Reddi VS, et al. An exploratory study for bladder dysfunction in atypical antipsychotic-emergent urinary incontinence. *Indian J Psychiatry*. 2016;58(4):438–442.

Siracusa G, Sparacino A, Lentini VL. Neurogenic bladder and disc disease: a brief review. *Curr Med Res Opin*. 2013;29:1025–1031.

Sirls LT, Zimmern PE, Leach GE. Role of limited evaluation and aggressive medical management in multiple sclerosis: a review of 113 patients. *J Urol*. 1994;151(4):946–950.

Siroky MB, Krane RJ. Neurologic aspects of detrusor-sphincter dyssynergia, with reference to the guarding reflex. *J Urol*. 1982;127(5):953–957.

Sislow JG, Mayo ME. Reduction in human bladder wall compliance following decentralization. *J Urol*. 1990;144(4):945–947.

Smith AY, Woodside JR. Urodynamic evaluation of patients with spinal stenosis. *Urology*. 1988;32(5):474–477.

Smith CP, Kraus S, Boone TR. Urinary retention in the young female. *AUA Update Series*. 1999;18:145–152.

Smith CP, Kraus SR, Nickell KG, et al. Video urodynamic findings in men with the central cord syndrome. *J Urol*. 2000;164:2014–2017.

Smith CP, Somogyi GT, Bird ET, et al. Neurogenic bladder model for spinal cord injury: spinal cord microdialysis and chronic urodynamics. *Brain Res Brain Res Protoc*. 2002;9(1):57–64.

Smith EM, Bodner DR. Sexual dysfunction after spinal cord injury. *Urol Clin North Am*. 1993;20(3):535–542.

Smith PP, Appell RA. Functional obstructed voiding in the neurologically normal patient. *Curr Urol Rep*. 2006;7(5):346–353.

Snyder EY, Teng YD. Stem cells and spinal cord repair. *N Engl J Med*. 2012;366:1940–1942.

Soden RJ, Walsh J, Middleton JW, et al. Causes of death after spinal cord injury. *Spinal Cord*. 2000;38(10):604–610.

Solomon E, Yasmin H, Duffy M, et al. Developing and validating a new nomogram for diagnosing bladder outlet obstruction in women. *Neurourol Urodyn*. 2017;37(1):368–378.

Somogyi GT, Zernova GV, Yoshiyama M, et al. Change in muscarinic modulation of transmitter release in the rat urinary bladder after spinal cord injury. *Neurochem Int*. 2003;43(1):73–77.

Son SB, Chung SY, Kang S, et al. Relation of urinary retention and functional recovery in stroke patients during rehabilitation program. *Ann Rehabil Med*. 2017;41(2):204–210.

Sotolongo JR Jr. Urologic aspects of prevention of end-stage renal disease in spinal cord injury. *Mt Sinai J Med*. 1993;60:299–301.

Spinelli M, Weil E, Ostardo E, et al. New tined lead electrode in sacral neuromodulation: experience from a multicentre

European study. *World J Urol*. 2005;23:225–229.

Staskin DR, Varde Y, Siroky MB. Postprostatectomy continence in the Parkinsonian patient: the significance of poor voluntary sphincter control. *J Urol*. 1988;140:117–122.

Steers WD, Creedon DJ, Tuttle JB. Immunity to nerve growth factor prevents afferent plasticity following urinary bladder hypertrophy. *J Urol*. 1996;155(1):379–385.

Stein R, Wiesner C, Beetz R, et al. Urinary diversion in children and adolescents with neurogenic bladder: the Mainz experience. Part I: bladder augmentation and bladder substitution—therapeutic algorisms. *Pediatr Nephrol*. 2005;20(7):920–925.

Steinberger RE, Ohl DA, Bennett CJ, et al. Nifedipine pretreatment for auto-nomic dysreflexia during electroejaculation. *Urology*. 1990;36(3):228–231.

Steinbok P, Kariyattil R, MacNeily AE. Comparison of section of filum terminale and non-neurosurgical management for urinary incontinence in patients with normal conus position and possible occult tethered cord syndrome. *Neurosurgery*. 2007;61(3):550–555 [discussion 555–6].

Stoffel J, Lightner D, Peterson A, et al. AUA White paper on non-neurogenic chronic urinary retention: consensus definition, management strategies, and future opportunities. *J Urol*. 2017;198:153–160.

Stonehill WH, Dmochowski RR, Patterson AL, et al. Risk factors for bladder tumors in spinal cord injury patients. *J Urol*. 1996;155(4):1248–1250.

Stover SL, Fine PR. The epidemiology and economics of spinal cord injury. *Paraplegia*. 1987;25(3):225–228.

Su X, Changolkar A, Chacko S, et al. Diabetes decreases rabbit bladder smooth muscle contraction while increasing levels of myosin light chain phosphorylation. *Am J Physiol Renal Physiol*. 2004;287(4):F690–F699.

Subramonian K, Cartwright RA, Harnden P, et al. Bladder cancer in patients with spinal cord injuries. *BJU Int*. 2004;93(6):739–743.

Sullivan M, Yalla S. Spinal cord injury and other forms of myeloneuropathies. *Probl Urol*. 1992;6:643–658.

Sultan AH, Thakar R. Hysterectomy and pelvic organ dysfunction. *J Urol*. 2006;176:2566–2575.

Summers SJ, Elliott S, McAdams S, et al. Urologic problems in spina bifida patients transitioning to adult care. *Urology*. 2014;84(2):440–444.

Sundin T, Dahlstrom A, Norlen L, et al. The sympathetic innervation and adrenoreceptor function of the human lower urinary tract in the normal state and after parasympathetic denervation. *Invest Urol*. 1977;14(4):322–328.

Swinn MJ, Fowler CJ. Isolated urinary retention in young women, or Fowler's syndrome. *Clin Auton Res*. 2001;11(5):309–311.

Tammela TL, Heiskari MJ, Lukkarinen OA. Voiding dysfunction and urodynamic findings in patients with cervical spondylotic spinal stenosis compared with severity of the disease. *Br J Urol*. 1992;70(2):144–148.

Theodorou C, Floratos D, Hatzinicolaou P, et al. Neurogenic bladder dysfunction due to Behçet's disease. *Int J Urol*. 1999;6(8):423–425.

Thiruchelvam N, Wu C, David A, et al. Neurotransmission and viscoelasticity in the ovine fetal bladder after in utero bladder outflow obstruction. *Am J Physiol Regul Integr Comp Physiol*. 2003;284(5):R1296–R1305.

Thomas DG, Lucas M. The urinary tract following spinal cord injury. Chisholm GD, Fair WR. *Scientific foundations of urology*. Year Book: Chicago; 1990:286–299.

Thomas DG, O'Flynn KJ. Spinal cord injury. Mundy AR, Stephenson T, Wein AJ. *Urodynamics: principles, practice* *and application*. Churchill Livingstone: London; 1994:345–358.

Thorup J, Biering-Sorensen F, Cortes D. Urological outcome after myelomeningocele: 20 years of follow-up. *BJU Int*. 2011;107:994–999.

Tibaek S, Gard G, Klarskov P, et al. Prevalence of lower urinary tract symptoms (LUTS) in stroke patients: a cross-sectional, clinical survey. *Neurourol Urodyn*. 2008;27:763–771.

Tiguert R, Lewis RA, Gheiler EL, et al. Case report: acute urinary retention secondary to Isaacs' syndrome. *Neurourol Urodyn*. 1999;18(2):113–114.

Tjandra BS, Janknegt RA. Neurogenic impotence and lower urinary tract symptoms due to vitamin B1 deficiency in chronic alcoholism. *J Urol*. 1997;157(3):954–955.

Togami W, Sei A, Okada T, et al. Effects of water-holding capability of the PVF sponge on the adhesion and differentiation of rat bone marrow stem cell culture. *J Biomed Mater Res A*. 2013.

Tokhmafshan F, Brophy PD, Gbadegesin RA, et al. Vesicoureteral reflux and the extracellular matrix connection. *Pediatr Nephrol*. 2017;32(4):565–575.

Tong YC, Cheng JT. Alternation of M3 subtype muscarinic receptors in the diabetic rat urinary bladder. *Pharmacology*. 2002;64:148–151.

Tong YC, Chin WT, Cheng JT. Alterations in urinary bladder M2-muscarinic receptor protein and mRNA in 2-week streptozotocin-induced diabetic rats. *Neurosci Lett*. 1999;277(3):173–176.

Tonolini M, Villa F, Villa C, et al. Renal and urologic disorders in antiretroviral-treated patients with HIV infection or AIDS: spectrum of cross-sectional imaging findings. *Curr Probl Diagn Radiol*. 2013;42(6):266–278.

Torimoto K, Sasaki K, Matsuyoshi H, et al. Lower urinary tract:

diabetes mellitus—focused on recent experimental results. *Low Urin Tract Symptoms*. 2009;1:587–589.

Trockman BA, Gerspach J, Dmochowski R, et al. Primary bladder neck obstruction: urodynamic findings and treatment results in 36 men. *J Urol*. 1996;156(4):1418–1420.

Troisgros O, Barnay J, Darbon-Naghibzadeh F, et al. Retrospective clinic and urodynamic study in the neurogenic bladder dysfunction caused by human T cell lymphotrophic virus type 1 associated myelopathy/tropical spastic paraparesis (HAM/TSP). *Neurourol Urodyn*. 2017;36(2):449–452.

Trop CS, Bennett CJ. Autonomic dysreflexia and its urological implications: a review. *J Urol*. 1991;146(6):1461–1469.

Tsuchida S, Noto H, Yamaguchi O, et al. Urodynamic studies on hemiplegic patients after cerebrovascular accident. *Urology*. 1983;21(3):315–318.

Tuite GF, Homsy Y, Polsky EG, et al. Urological outcome of the Xiao procedure in children with myelomeningocele and lipomeningocele undergoing spinal cord detethering. *J Urol*. 2016;196(6):1735–1740.

Turner WH, Brading AF. Smooth muscle of the bladder in the normal and the diseased state: pathophysiology, diagnosis and treatment. *Pharmacol Ther*. 1997;75(2):77–110.

Turner-Warwick R, Whiteside CG, Worth PH, et al. A urodynamic view of the clinical problems associated with bladder neck dysfunction and its treatment by endoscopic incision and trans-trigonal posterior prostatectomy. *Br J Urol*. 1973;45(1):44–59.

Turner-Warwick RT. Bladder outflow obstruction in the male. Mundy AR, Stephenson T, Wein AJ. *Urodynamics: principles, practice and application*. Churchill Livingstone: London; 1984:183–204.

Uchiyama T, Sakakibara R, Hattori T, et al. Lower urinary tract dysfunctions in patients with spinal cord tumors. *Neurourol Urodyn*. 2004;23(1):68–75.

Uchiyama T, Sakakibara R, Yamamoto T, et al. Comparing bromocriptine effects with levodopa effects on bladder function in Parkinson's disease. *Mov Disord*. 2009;24:2386–2390.

Ueda T, Yoshimura N, Yoshida O. Diabetic cystopathy: relationship to autonomic neuropathy detected by sympathetic skin response. *J Urol*. 1997;157(2):580–584.

Ukkonen M, Elovaara I, Dastidar P, et al. Urodynamic findings in primary progressive multiple sclerosis are associated with increased volumes of plaques and atrophy in the central nervous system. *Acta Neurol Scand*. 2004;109:100–105.

Utomo E, Groen J, Blok BF. Surgical management of functional bladder outlet obstruction in adults with neurogenic bladder dysfunction. *Cochrane Database Syst Rev*. 2014;(5) [CD004927].

Vaidyanathan S, Soni BM, Sett P, et al. Pathophysiology of autonomic dysreflexia: long-term treatment with terazosin in adult and paediatric spinal cord injury patients manifesting recurrent dysreflexic episodes. *Spinal Cord*. 1998;36(11):761–770.

Vale JA, Bowsher WG, Liu K, et al. Post-irradiation bladder dysfunction: development of a rat model. *Urol Res*. 1993;21(6):383–388.

Van Arsdalen KN, Hackler RH. Transureterostomy in spinal cord injury patients for persistent vesicoureteral reflux: 6 to 14 year follow up. *J Urol*. 1983;129:1117–1122.

Van Den Eeden SK, Sarma AV, Rutledge BN, et al. Effect of intensive glycemic control and diabetes complications on lower urinary tract symptoms in men with type 1 diabetes: Diabetes Control and Complications Trial/Epidemiology of Diabetes Interventions and Complications (DCCT/EDIC) study. *Diabetes Care*. 2009;32:664–670.

van Gool JD, Dik P, de Jong TP. Bladder sphincter dysfunction in myelomeningocele. *Eur J Pediatr*. 2001;160:414–420.

Vanni AJ, Stoffel JT. Ileovesicostomy for the neurogenic bladder patient: outcome and cost comparison of open and robotic assisted techniques. *Urology*. 2011;77:1375–1380.

Vega JM, Pascual L. High pressure bladder: an underlying factor mediating renal damage in the absence of reflux? *BJU Int*. 2001;87:581–584.

Velanovich V. Pharmacologic prevention and treatment of postoperative urinary retention. *Infect Urol*. 1992;3:87–91.

Vizzard MA. Alterations in growth-associated protein (GAP-43) expression in lower urinary tract pathways following chronic spinal cord injury. *Somatosens Mot Res*. 1999;16(4):369–381.

Vizzard MA. Alterations in spinal cord Fos protein expression induced by bladder stimulation following cystitis. *Am J Physiol Regul Integr Comp Physiol*. 2000;278(4):R1027–R1039.

Vizzard MA. Changes in urinary bladder neurotrophic factor mRNA and NGF protein following urinary bladder dysfunction. *Exp Neurol*. 2000;161(1):273–284.

Vizzard MA. Increased expression of spinal cord Fos protein induced by bladder stimulation after spinal cord injury. *Am J Physiol Regul Integr Comp Physiol*. 2000;279(1):R295–R305.

Vizzard MA. Upregulation of pituitary adenylate cyclase activating polypeptide in urinary bladder pathways after chronic cystitis. *J Comp Neurol*. 2000;420:335–348.

von Gontard A, Laufersweiler-Plass C, Backes M, et al. Enuresis and urinary incontinence in children and adolescents with spinal muscular atrophy. *BJU Int*. 2001;88:409–413.

Walton GW, Kaplan SA. Urinary dysfunction in tropical spastic paraparesis: preliminary urodynamic survey. *J Urol*.

1993;150(3):930–932.

Wan EC, Gordon TP, Jackson MW. Autoantibody-mediated bladder dysfunction in type 1 diabetes. *Scand J Immunol*. 2007;65(1):70–75.

Webster GD, el-Mahrouky A, Stone AR, et al. The urological evaluation and management of patients with myelodysplasia. *Br J Urol*. 1986;58(3):261–265.

Webster GD, Lockhart JL, Older RA. The evaluation of bladder neck dysfunction. *J Urol*. 1980;123(2):196–198.

Wein AJ. Neuromuscular dysfunction of the lower urinary tract and its management. Walsh PC, Retik AB, Vaughan D Jr, et al. *Campbell's urology*. ed 8. Elsevier: Philadelphia; 2002:931–1026.

Wein AJ. Pathophysiology and categorization of voiding dysfunction. Walsh PC, Retik AB, Vaughan D Jr, et al. *Campbell's urology*. ed 8. Elsevier: Philadelphia; 2002:887–899.

Wein AJ, Barrett DM. Etiologic possibilities for increased pelvic floor electromyography activity during cystometry. *J Urol*. 1982;127(5):949–952.

Wein AJ, Barrett DM. *Voiding function and dysfunction—a logical and practical approach*. Year Book: Chicago; 1988.

Wein AJ, Rovner E. Adult voiding dysfunction secondary to neurologic disease or injury. *AUA Update Series*. 1999;18:42–47.

Weld KJ, Dmochowski RR. Association of level of injury and bladder behavior in patients with post-traumatic spinal cord injury. *Urology*. 2000;55(4):490–494.

Weld KJ, Graney MJ, Dmochowski RR. Clinical significance of detrusor sphincter dyssynergia type in patients with post-traumatic spinal cord injury. *Urology*. 2000;56(4):565–568.

Wenning GK, Stefanova N. Recent developments in multiple system atrophy. *J Neurol*. 2009;256:1791–1808.

Wheeler JS Jr, Culkin DJ, O'Hara RJ, et al. Bladder dysfunction and neuro-syphilis. *J Urol*. 1986;136(4):903–905.

Wiener JS, Antonelli J, Shea AM, et al. Bladder augmentation versus urinary diversion in patients with spina bifida in the United States. *J Urol*. 2011;186:161–165.

Wilson TS, Aziz KA, Vazques D, et al. Changes in detrusor smooth muscle myosin heavy chain mRNA expression following spinal cord injury in the mouse. *Neurourol Urodyn*. 2005;24(1):89–95.

Wilson TS, Lemack GE, Dmochowski RD. UroLume stents: lessons learned. *J Urol*. 2002;167(6):2477–2480.

Winge K, Nielsen KK. Bladder dysfunction in advanced Parkinson's disease. *Neurourol Urodyn*. 2012;31:1279–1283.

Witte LP, Odekerken VJJJ, Boel JA, et al. Does deep brain stimulation improve lower urinary tract symptoms in Parkinson's disease? *Neurourol Urodyn*. 2018;37(1):354–359.

Woderich R, Fowler CJ. Management of lower urinary tract symptoms in men with progressive neurological disease. *Curr Opin Urol*. 2006;16(1):30–36.

Wollner J, Pannek J. Initial experience with the treatment of neurogenic detrusor overactivity with a new beta-3 agonist (mirabegron) in patients with spinal cord injury. *Spinal Cord*. 2016;54(1):78–82.

Woodhouse CR. Myelomeningocele in young adults. *BJU Int*. 2005;95(2):223–230.

Wright AJ, Fletcher O, Sutton D, et al. Bladder and bowel continence in bilateral cerebral palsy: a population study. *J Pediatr Urol*. 2016;12(6):383–e8.

Wright I, Civitarese A, Baverstock R. The use of intra-detrusor onabotulinumtoxinA in patients with myasthenia gravis. *Can Urol Assoc J*. 2016;10(5–6):E184–E185.

Wyndaele JJ. Correlation between clinical neurological data and urodynamic function in spinal cord injured patients. *Spinal*

Cord. 1997;35:213–216.

Wyndaele JJ. Autologous incubated macrophage treatment failed to show a difference in the neurological outcome in patients with acute, complete spinal cord injury. *Spinal Cord*. 2012;50:645.

Wyndaele JJ, Castro D, Madersbacher H, et al. Neurologic urinary and faecal incontinence. Abrams P, Cardozo L, Khoury S, et al. *Incontinence*. Health Publications: Paris; 2005:1059–1162.

Wyndaele JJ, Kovindha A, Madersbacher H, et al. Neurologic urinary and faecal incontinence. Abrams P, Cardozo L, Khoury S, et al. *Continence*. Health Publications: Paris; 2009:793–960.

Wyndaele JJ, Kovindha A, Madersbacher H, et al. Neurologic urinary incontinence. *Neurourol Urodyn*. 2010;29:159–164.

Xiao CG, Du MX, Li B, et al. An artificial somatic-autonomic reflex pathway procedure for bladder control in children with spinal bifida. *J Urol*. 2005;173(6):2112–2116.

Yahya N, Ebert MA, House MJ, et al. Modeling urinary dysfunction after external beam radiation therapy of the prostate using bladder dose-surface maps: evidence of spatially variable response of the bladder surface. *Int J Radiat Oncol Biol Phys*. 2017;97(2):420–426.

Yamada S, Won DJ, Siddiqi J, et al. Tethered cord syndrome: overview of diagnosis and treatment. *Neurol Res*. 2004;26(7):719–721.

Yamada S, Won DJ, Yamada SM. Pathophysiology of tethered cord syndrome: correlation with symptomatology. *Neurosurg Focus*. 2004;16(2):E6.

Yamamoto T, Sakakibara R, Uchiyama T, et al. Lower urinary tract function in patients with pituitary adenoma compressing hypothalamus. *J Neurol Neurosurg Psychiatry*. 2005;76(3):390–394.

Yamanishi T, Yasuda K, Sakakibara R, et al. The nature of detrusor bladder neck dyssynergia in non-neurogenic bladder dysfunction. *J Auton Nerv Syst*. 1997;66:163–168.

Yamanishi T, Yasuda K, Yuki T, et al. Urodynamic evaluation of surgical outcome in patients with urinary retention due to central lumbar disc prolapse. *Neurourol Urodyn*. 2003;22:670–675.

Yang CC, Cardenas DD. Bladder management in women with neurologic disabilities. *Phys Med Rehabil Clin N Am*. 2001;12(1):91–110.

Yip CM, Leach GE, Rosenfeld DS, et al. Delayed diagnosis of voiding dysfunction: occult spinal dysraphism. *J Urol*. 1985;134(4):694–697.

Yokoyama O, Ishiura Y, Nakamura Y. Animal model with detrusor overactivity caused by cerebral infarction as a useful tool for pharmacological therapeutic approaches. *Low Urin Tract Symptoms*. 2009;1:S98–S100.

Yokoyama O, Yoshiyama M, Namiki M, et al. Changes in dopaminergic and glutamatergic excitatory mechanisms of micturition reflex after middle cerebral artery occlusion in conscious rats. *Exp Neurol*. 2002;173(1):129–135.

Yoshimura N, Kuno S, Chancellor MB, et al. Dopaminergic mechanisms underlying bladder hyperactivity in rats with a unilateral 6-hydroxydopamine (6-OHDA) lesion of the nigrostriatal pathway. *Br J Pharmacol*. 2003;139(8):1425–1432.

Yoshizawa T, Hayashi Y, Yoshida A, et al. Concomitant alteration in number and affinity of P2X and muscarinic receptors are associated with bladder dysfunction in early stage diabetic rats. *Int Urol Nephrol*. 2018;50(3):451–458.

Yum KS, Na S-J, Lee K-Y, et al. Pattern of voiding dysfunction after acute brainstem infarction. *Eur Neurol*. 2013;70(5–6):291–296.

Zderic SA, Wein A, Rohrman D, et al. Mechanisms of bladder smooth-muscle hypertrophy and decompensation: lessons from normal development and the response to outlet obstruction. *World J Urol*. 1998;16(5):350–358.

Zochodne DW. Autonomic involvement in Guillain-Barré syndrome: a review. *Muscle Nerve*. 1994;17(10):1145–1155.

117

Overactive Bladder

W. Stuart Reynolds MD, MPH, Joshua A. Cohn MD

Terminology and Definitions

The International Continence Society (ICS) defined overactive bladder (OAB) syndrome as “**urinary urgency, usually accompanied by frequency and nocturia, with or without urgency urinary incontinence (UUI), in the absence of urinary tract infection (UTI) or other obvious pathology**” (Abrams et al., 2002; Haylen et al., 2010). Therefore OAB syndrome is a syndrome composed of one or more component symptoms of dysfunctional bladder storage associated with a too-frequent or exceptionally strong desire to urinate.

Specifically, the bladder storage symptoms that make up OAB syndrome consist of “increased daytime urinary frequency,” “nocturia,” “urgency,” and “urgency (urinary) incontinence” (Haylen et al., 2010; Table 117.1). The term “urge (urinary) incontinence” was revised to “urgency (urinary) incontinence” for consistency across terms and to better align the language with an undesirable sensation (Abrams et al., 2009).

TABLE 117.1

Standardized Terminology and Definitions to Describe Lower Urinary Tract Dysfunction Related to Overactive Bladder

TERMINOLOGY	DEFINITION	REFERENCE
Overactive bladder syndrome	Urinary urgency, usually accompanied by frequency and nocturia, with or without urgency urinary incontinence, in the absence of urinary tract infection (UTI) or other obvious pathology	Haylen et al., 2010
Increased daytime urinary frequency	Complaint by the patient who considers that he/she voids too often by day[a] (seven voids upper limit of normal[b])	Abrams et al., 2002; Haylen et al., 2010
Nocturia	Complaint of interruption of sleep one or more times because of the need to micturate. Each void is preceded and followed by sleep.	Haylen et al., 2010
Urgency	Complaint of a sudden, compelling desire to void that is difficult to defer	Haylen et al., 2010
Urgency (urinary) incontinence	Complaint of involuntary loss of urine associated with urgency	Haylen et al., 2010

[a] Abrams et al., 2002.

[b] Haylen et al., 2010.

All component symptoms of OAB have been associated with diminished health-related quality of life, with the strongest negative association found for urgency and UUI (Milsom et al., 2012). Bother from daytime urinary frequency is greater in individuals voiding every 2 hours or more frequently, which more or less corresponds to eight or more daytime voids (Lukacz et al., 2009). However, subjective bother for a given number of daytime voids can be variable and significant, even when the number of daytime voids is fewer than eight (FitzGerald et al., 2002). Bother from nocturia is correlated with waking two or more times to void, with more significant bother associated with three or more episodes (Tikkinen et al., 2010). **Nocturia in the absence of other bladder storage symptoms may be related to medical conditions resulting in increased nocturnal urine output or conditions resulting in poor sleep quality rather than lower urinary tract (LUT) dysfunction** (Cornu et al., 2012; Weiss et al., 2011).

The introduction of standardized definitions by the International Continence Society addressed a confusing situation that for many years hampered research and management. The English-speaking world had adopted Patrick Bates's term *unstable bladder* to describe involuntary detrusor contractions seen during urodynamic studies as the bladder was filled, whereas the Scandinavians used the term *detrusor hyperreflexia*. To resolve the discrepancy, the International Continence Society designated the term *unstable bladder* to be applied where there was no obvious cause for the contractions and *detrusor hyperreflexia* for patients whose involuntary contractions were caused neurologically (Bates et al., 1980a,b). Nonetheless, the use of different terms in neurogenic and non-neurogenic patient groups became increasingly difficult. “Overactive Bladder” was the title of a consensus conference, and a formal definition was proposed in 1999 (Abrams and Wein, 1999), culminating in the unified ICS definition that is still used (Abrams et al., 2002). For women, another terminology document, jointly drafted by the International Urogynecology Association and the ICS, was published more recently, with definitions that largely mirror the 2002 ICS document (Haylen et al., 2010).

The syndrome of OAB is based on symptoms; in contrast, detrusor overactivity (DO) is a urodynamic observation, characterized by involuntary detrusor contractions during the filling phase, which may be spontaneous or provoked (Abrams et al., 2002). OAB and DO are thus not interchangeable terms, signified by the recognition that OAB patients undergoing urodynamic testing may not have DO (Al-Ghazo et al., 2011). Conversely DO observed during urodynamics may not be associated with any sensation or may be a consequence of instrumentation rather than reflective of physiology outside of invasive testing.

Mixed Symptoms Incorporating Urinary Urgency

OAB can coexist with stress urinary incontinence (SUI). **Mixed urinary incontinence (MUI) is the "complaint of involuntary loss of urine associated with urgency and also with effort or physical exertion or on sneezing or coughing"** (Haylen et al., 2010). Thus in MUI, SUI and UUI ("OAB wet") are present in the same person. A person with SUI and "OAB dry" does not have MUI; no suitable phrase has yet been standardized for this situation, so such a patient's mixed symptoms should be categorized descriptively. For example, it may be necessary to state that the patient experiences SUI and urgency but does not have UUI.

The coexistence of urinary and anal incontinence can be referred to as "mixed incontinence," and it should not be confused with MUI. Fig. 117.1 describes the relationships among SUI, MUI, and OAB. In general, MUI is associated with more severe levels of leakage, although the relative contributions of the two types of incontinence can be difficult for the patient to quantify, particularly if there is also an element of **insensible urinary incontinence (UI; defined as "complaint of urinary incontinence where the [patient] has been unaware of how it occurred"**) (Haylen et al., 2010).

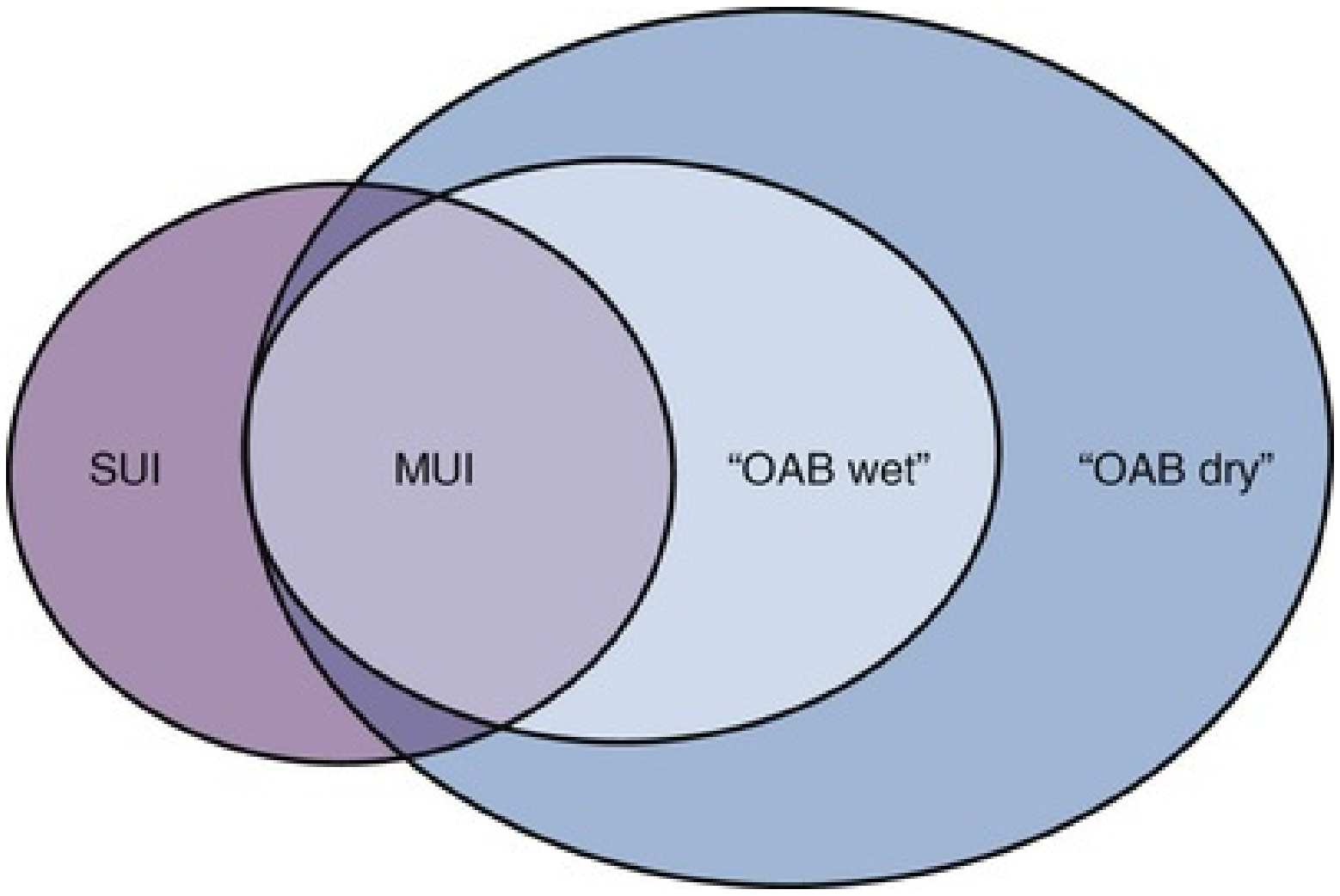

FIG. 117.1 Incontinence may be stress urinary incontinence (SUI), mixed urinary incontinence (MUI), or urgency urinary incontinence ("overactive bladder [OAB] wet"), especially in women. SUI can coexist with "OAB dry," giving rise to mixed symptoms of stress incontinence and urgency.

Distinguishing Overactive Bladder From Bladder Pain Syndrome

Older standardizations defined urgency as a strong desire to void accompanied by the fear of leakage or the fear of pain (Abrams et al., 1988). **However, pain is not typically a component of OAB syndrome but is a required component of bladder pain syndrome (BPS), defined as "the complaint of suprapubic pain related to bladder filling, accompanied by other symptoms such as increased daytime and night-time frequency in the absence of proven urinary infection or other obvious pathology"** (Abrams et al., 2002). Therefore it has been argued that the two conditions are separate entities with symptomatic overlap from urgency and day and nighttime frequency. The entities are distinguished by primary fear of incontinence in OAB and primary fear of pain in bladder pain syndrome (Abrams et al., 2005; Hanno et al., 2008; Fig. 117.2).

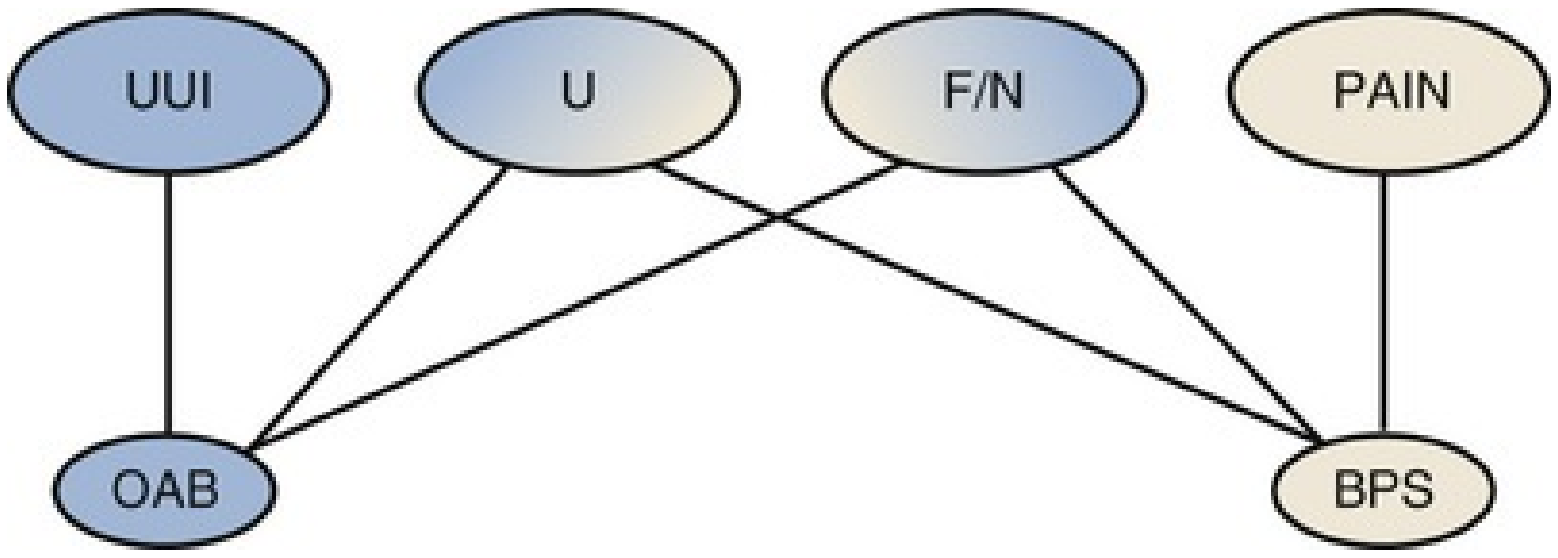

FIG. 117.2 Overactive bladder (OAB) and bladder pain syndrome (BPS) give rise to urgency (U), frequency (F), and nocturia (N); pain, but not urgency urinary incontinence (UUI), is seen in BPS.

The relationship between urgency and filling sensation may be different in OAB and BPS (Fig. 117.3). **Differences that help to distinguish BPS include the painful nature of symptoms, the steady increase in pain with filling, the more consistent voided volumes compared with OAB, and the ability to defer voiding** (albeit at the cost of greater pain). In BPS, suprapubic pain is typical and additional perineal (urethral/vaginal/penile) discomfort and/or pain can also occur (FitzGerald et al., 2005); in OAB, urgency is typically felt in the perineum/base of penis or vagina/urethra.

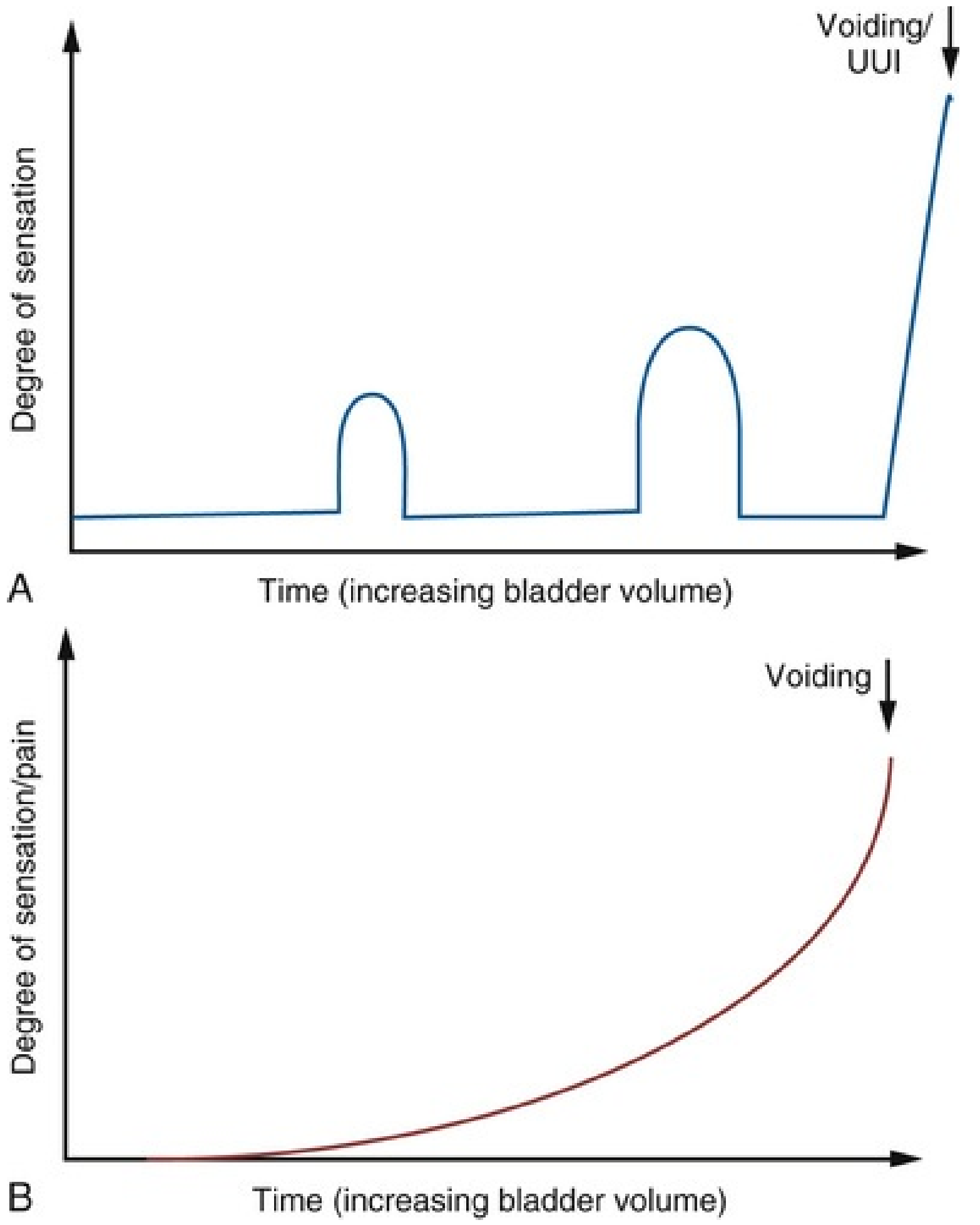

FIG. 117.3 The differences in the development of bladder sensation in overactive bladder (OAB) and bladder pain syndrome (BPS). (A) In OAB, phasic increases in urgency arise and recede as filling progresses, until severe urgency compels the patient to void or an urgency urinary incontinence (UUI) episode sets in. (B) In BPS, pain increases throughout filling, accelerating as filling progresses.

However, it is likely that, in many patients, OAB and bladder pain syndrome are variable presentations of overlapping pathophysiology, possibly rooted in common alterations in afferent nerve sensitivity and/or central sensitization and somatization (Kowalik et al., 2018; Lai et al., 2015, 2016; Reynolds et al., 2017a,b).

Key Points: Overactive Bladder Terminology

- The current definition of OAB is urinary urgency usually accompanied by frequency and nocturia, with or without UUI, in the absence of UTI or other obvious pathology.
- OAB is a symptomatic diagnosis and is distinct from DO, which is a urodynamic observation.
- Urgency is an abnormal sensation defined as the complaint of a sudden compelling desire to void that is difficult to defer.
- Mixed urinary incontinence is the complaint of involuntary leakage associated with urgency and with exertion, effort, sneezing, or coughing.
- “Fear of leakage” and “fear of pain” may distinguish urgency in OAB from BPS; however, the cause of both conditions may be related to different symptomatic manifestations of central sensitization.

Epidemiology and Economics

Prevalence of Overactive Bladder and Related Lower Urinary Tract Symptoms

Several epidemiologic studies provide data on the prevalence of OAB, primarily in the United States (Table 117.2). As is the case with many epidemiologic studies, variations in case definitions and sample populations limit direct comparisons. The overall prevalence of OAB in men and women is variably reported as between 11.8% and 28.7% and UUI 1.5% to as high as 17.3% (Coyne et al., 2009, 2013a; Dooley et al., 2008; Irwin et al., 2006; Kupelian et al., 2006; Stewart et al., 2003), underscoring the tremendous burden of OAB symptoms across ethnically and socioeconomically diverse populations in the United States and Europe.

TABLE 117.2

Studies Examining Prevalence Data for Overactive Bladder

STUDY NAME	POPULATION	METHOD(S), TIMING	DEFINITION OF OAB	PREVALENCE(S)
NOBLE (Stewart et al., 2003)	US population[a], age ≥18 years (n = 5204)	CATI	≥4 episodes of urgency in preceding 4 weeks and ≥8 voids per day or use of bladder coping mechanisms	OAB, 16.5% with UUI, 6.1%
EpiLUTS (Coyne et al., 2009)	Multinational participants, age ≥40 years (n = 30,000)	Internet survey	Urgency at least “sometimes” and/or UUI	OAB, 28.7% with UUI, 17.3%
OAB-POLL (Coyne et al., 2013a)	US participants[a], age 18–70 years (n = 10,000)	Internet survey	Urgency at least “sometimes” and/or UUI	OAB, 23.3% with UUI, 12.6%
NHANES (Dooley et al.,	US population, women[a], age ≥21 years (n = 4229)	Interview	Any incontinence in past 12 months	UUI, 7.9% with MUI, 17%

2008)				
BACH (Kupelian et al., 2006)	Boston, MA[a], age 30–79 years (n = 5506)	Interview	American Urological Association symptom index ≥8	LUTS, 18.7%
EPIC (Irwin et al., 2006)	Multinational, age ≥18 years (n = 19,165)	CATI	ICS definitions	OAB, 11.8% with UUI, 1.5%
Milsom (Milsom et al., 2001)	Multinational, age ≥40 years (n = 16,776)	Interview	Any symptom of OAB	Any OAB symptoms, 16.6%

[a] Selective sampling applied to allow generalization to the US population

BACH, Boston Area Community Health Survey; *CATI,* computer-assisted telephone interviewing; *EpiLUTS,* epidemiology of lower urinary tract symptoms; *ICS,* International Continence Society; *LUTS,* lower urinary tract symptoms; *MUI,* mixed urinary incontinence; *NHANES,* National Health and Nutrition Examination Survey; *NOBLE,* National Overactive Bladder Evaluation; *OAB,* overactive bladder; *OAB-POLL,* impact of overactive bladder on physical and occupational limitations; *UUI,* urgency urinary incontinence.

OAB is common in men and women but tends to disparately affect women. **Most epidemiologic studies report a prevalence of OAB in women of approximately 1.5 to 2 times that of men and rates of UUI of 2 to 3 times those in men.** Although in the National Overactive Bladder Evaluation Study (NOBLE), the incidence of OAB was similar at 16.9% in women and 16.0% in men; 7.6% of women reported UUI versus just 2.6% of men (Stewart et al., 2003). The multinational Epidemiology of Lower Urinary Tract Symptoms (EpiLUTS) reported a prevalence of urgency “at least sometimes” among women with or without associated incontinence of 35.7% versus 22.4% in men and rates UUI of 24.4% in women versus 9.3% in men (Coyne et al., 2009). These findings were echoed in the Overactive Bladder on Physical and Occupational Limitations (OAB-POLL) US-based study, which reported OAB prevalence in women to be approximately double that in men (30.0% vs. 16.4%) (Coyne et al., 2013a).

The prevalence of symptoms of OAB increases with aging, appearing to increase in women in their 40s and men in their 50s and 60s. In the five-country EPIC study, the prevalence of storage of lower urinary tract symptoms (LUTS) was 17.9% and 26.0%, 25.0% and 32.0%, and 43.6% and 46.5% among men and women aged 39 years or younger, 40 to 59 years, and 60 years or older, respectively (Irwin et al., 2006). In NOBLE, aging was associated with a steady increase in OAB in women, whereas OAB in men increased from 8.5% before age 45 years to 21.8% in men more than 55 years of age (Stewart et al., 2003). The prevalence of UUI increased from 2.0% to 19% in women, rising predominantly after age 44 years and from 0.3% to 9% in men with the most dramatic increases observed beyond age 64 years. To this end, beyond age 75 years, 41.9% of men and 31.3% of women in six European countries reported one or more symptoms of OAB versus approximately 10% or less for both sexes before age 55 years (Milsom et al., 2001).

The prevalence of OAB also varies by race/ethnicity for men and women across several studies. The EpiLUTS study reported a prevalence of OAB of 33.3% in African-American men, 28.0% in Hispanic men, 27.0% in Asian men, and 26.3% in white men, and 45.9% of African-American, 43.4% of white, 42.0% of Hispanic, and 26.6% of Asian women (Coyne et al., 2012). The results of OAB-POLL differed slightly despite similar methods but similarly reported slightly higher rates of OAB in African-American men and women than in other ethnic groups (Coyne et al., 2013a). Accordingly, the National Health and Nutrition Examination Survey reported the highest prevalence of UUI in African-American women (11.0%) relative to white and Mexican-American women (7.5% and 7.5%, respectively) (Dooley et al., 2008).

Incidence and Progression of Overactive Bladder

OAB seems to be a dynamic condition, with symptoms waxing and waning over time. Longitudinal study data on the natural history of OAB are limited, but incident new OAB appears to be around 3% to 8% per year in women (Heidler et al., 2011; Irwin et al., 2010; Wennberg et al., 2009). Symptom progression, in terms of developing UUI with a prior history of OAB without UI, is approximately 1% per year, whereas remission of OAB is approximately 6% per year (Heidler et al., 2011).

Health Burden of Overactive Bladder

It is well recognized that OAB causes significant impairment to overall quality of life because it interferes with daily activities as well as contributes to disturbed sleep, decreased self-esteem, decreased sexuality, and feelings of overall declining health. The presence of UUI appears to add an additional degree of burden beyond OAB without UI. For men and women, individuals with OAB are significantly less likely to report moderate and vigorous physical activity in their leisure time (Coyne et al., 2013b).

Almost uniformly men and women with OAB report significantly increased impairment in all aspects of occupation compared with those without OAB, including factors such as work time missed and impairment while working resulting from urinary symptoms. Unemployment is higher for those with OAB than without (men: 43.6% vs. 24.2%, $P < 0.0001$; women: 54.1% vs. 41.4%, $P < 0.0001$) (Coyne et al., 2013b). In addition, individuals with OAB have 2.2 more missed workdays because of medically related absenteeism (RR 1.2, $P < 0.01$) and 3.4 more because of disability (RR 1.7, $P < 0.01$) than those without OAB (Wu et al., 2005).

Despite its commonness, relatively few individuals who have OAB seek care, and even fewer receive care. In fact, individuals with symptoms of OAB often delay seeking treatment or even discussing their symptoms with health care providers (Dmochowski and Newman, 2007). For those who had never discussed OAB symptoms, 84% did not think the problem was important enough, 71% were not asked about OAB by a health care provider, and 69% thought OAB symptoms were just something with which to cope. Even among those who had discussed their symptoms with a provider, 64% thought OAB was something they had to live with and 32% were not aware that anything could be done about it. Overall, only 44% of women surveyed reported being asked about OAB symptoms by their provider.

Fewer than 6% of the population with symptoms of OAB report taking a medication for their symptoms (Hall et al., 2009), the reasons for which are multifactorial. Although individual clinical trials support pharmacotherapy as generally efficacious, in aggregate, the mainstay of pharmacotherapy (i.e., anticholinergic medications) are only modestly superior to placebo (Reynolds et al., 2015; Shamliyan et al., 2012). As such, persistence or compliance with pharmacotherapy is limited. Medical claims and prescription data suggest that 92% of patients with OAB fail initial treatment with anticholinergic medication within 2 years. Most discontinue therapy within the first 6 months after initial prescription, and half do not even refill their initial prescription (Chancellor et al., 2013; Sexton et al., 2011). Primary reasons for discontinuing OAB medications include unmet treatment expectations (46%), side effects (21%), and cost (17%) (Benner et al., 2010).

The costs of OAB therapy extend well beyond those associated with pharmacotherapy. Information on US health care resource use for OAB is relatively scarce. However, it is estimated that, in 2009, US women made 8.1 million ambulatory visits (i.e., 1.6% of all ambulatory visits) associated with anticholinergic OAB medications, representing an annual rate of 68 visits per 1000 women (Ju et al., 2014). From a patient's perspective, the brunt of costs associated with OAB tends to be for routine care, such as incontinence pads, diapers, and laundry, generally reflecting the burden of UI (Subak et al., 2007). However, from a societal perspective, estimates suggest the total costs of OAB in the United States, including direct costs (i.e., medical and nonmedical) and indirect costs (i.e., lost productivity), approached $65.9 billion in 2007, with projected increases to $76.2 billion and $82.6 billion in 2015 and 2020, respectively (Ganz et al., 2010). Estimates of per capita costs are similar between men and women, although direct nonmedical costs were generally higher for women than men, likely reflecting greater UI.

Pathophysiology and Etiology

The pathophysiology of OAB appears multi-factorial and multi-layered across all levels of neural control. Historically, detrusor overactivity (the urodynamic finding of uninhibited detrusor contraction during filling cystometry, DO) (Abrams et al., 2002) was considered the *sine qua non* of OAB. However, DO is no longer considered the defining functional aspect of OAB; less emphasis is placed on this urodynamic finding, in part because of the lack of clinical utility, but also because of more broad acceptance of the definition of OAB based on the symptom of urinary urgency. Indeed, only about half of all patients with DO experience urgency (Wyndaele et al., 2004), whereas among patients with urgency 44% to 69% exhibit DO during cystometric studies (Hashim and Abrams, 2006).

Because the basis of the condition relies on a subjective symptom of urgency, basic science research into OAB has to use indirect or surrogate markers. Thus there is no animal model of OAB, because reporting of subjective symptoms in animals is not possible (Parsons and Drake, 2011). Accordingly, research focus has particularly concentrated on three key aspects: sensory activity, motor control, and reflexes of the LUT.

- Understanding abnormalities of **sensory nerve (afferent) signaling** is appropriate because it is presumed that urgency sensation largely derives from afferent input. The processes involved are signal transduction, afferent traffic, gating, sensitization, and conscious perception. The role of urothelium and the suburothelial layers of the bladder are now considered substantial contributors to the signal transduction and the afferent traffic through the release of mediators (Birder and Andersson, 2013), cellular interactions (Birder et al., 2010), and release of cytokines and growth factors (Andersson and McCloskey, 2014). Sensitization of bladder nerves by inflammation in the gut innervation has been demonstrated experimentally (Malykhina et al., 2012). Conscious perception is not well understood, but functional brain imaging has highlighted centers in the central nervous system (CNS) that could yield valuable information in the future (Arya et al., 2017; Komesu et al., 2011).

- **Contractile (motor) function** comprises the motility of the detrusor muscle and relevant drivers—for example efferent nerves, interstitial cells, and locally released mediators. Increasingly the focus has been to evaluate how these aspects summate in the contractility of the whole bladder, which is what determines the urodynamic observations. The whole organ can manifest areas of localized micromotions adjacent to quiescent areas in a constantly changing play of activity (Fig. 117.4). Thus full understanding of intravesical pressure will not be achieved until properties of the overall motile and nonmotile areas can be explained.

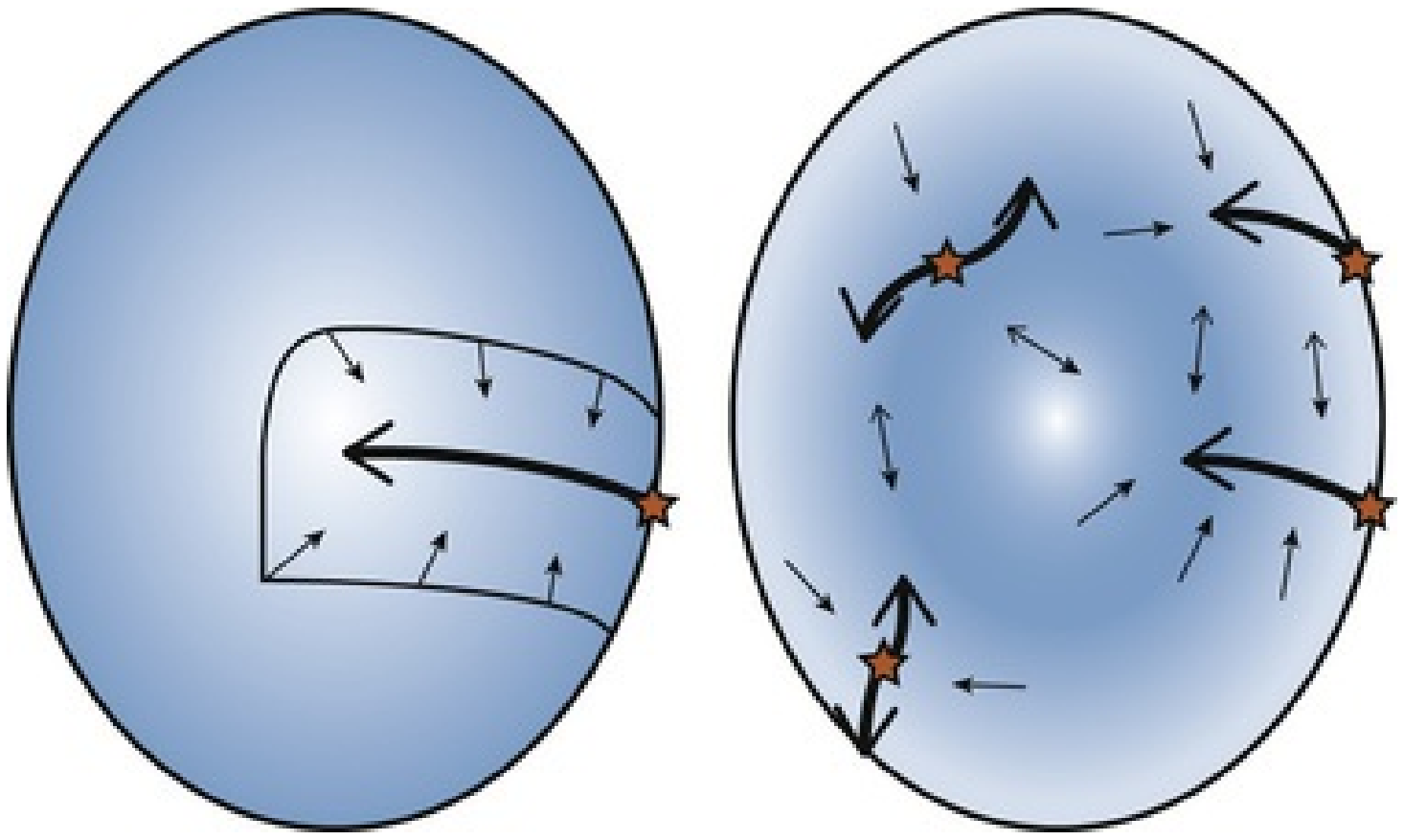

FIG. 117.4 *Left,* Schematic representation of a whole bladder during urinary storage illustrating a localized “micromotion” contraction, starting from an initiation point *(star)*, and spreading to a limited part of the bladder wall. Such activity is characteristic of the normal isolated bladder in all species tested (including human), and it is associated with only small fluctuations in bladder pressure (Drake et al., 2003a, 2003b), presumably because the noncontracting part of the bladder stays relaxed. In the overactive bladder *(right)*, multifocal trigger points lead to continuous activity; this enhances the effect on bladder pressure (as the bulk of the bladder is active) and stimulates afferents by the extensive distorting movements.

- **The sensory information ascending in afferents is integrated at several levels in the CNS** (Drake et al., 2010), where it converges with information from other relevant structures (Fig. 117.5). The integration of this information underpins the coordinated motor behavior of LUT reflexes. In the sacral spinal cord, there is some integration enabling reflex voiding, which is relevant in neonates and in neurologic disease. **The main regulatory region is at the level of the midbrain and brainstem,** where the periaqueductal gray and pontine micturition center integrate the key elements of vegetative function, including the voiding reflex. **At the higher levels of the CNS, more sophisticated aspects are integrated, for example consciousness (LUT sensations, as opposed to subconscious sensory information), awareness of environmental suitability, and voluntary initiation.** There is likely some basic integration in the periphery as well, where interactions may occur between urothelium, interstitial cells, and detrusor muscle (Drake, 2007).

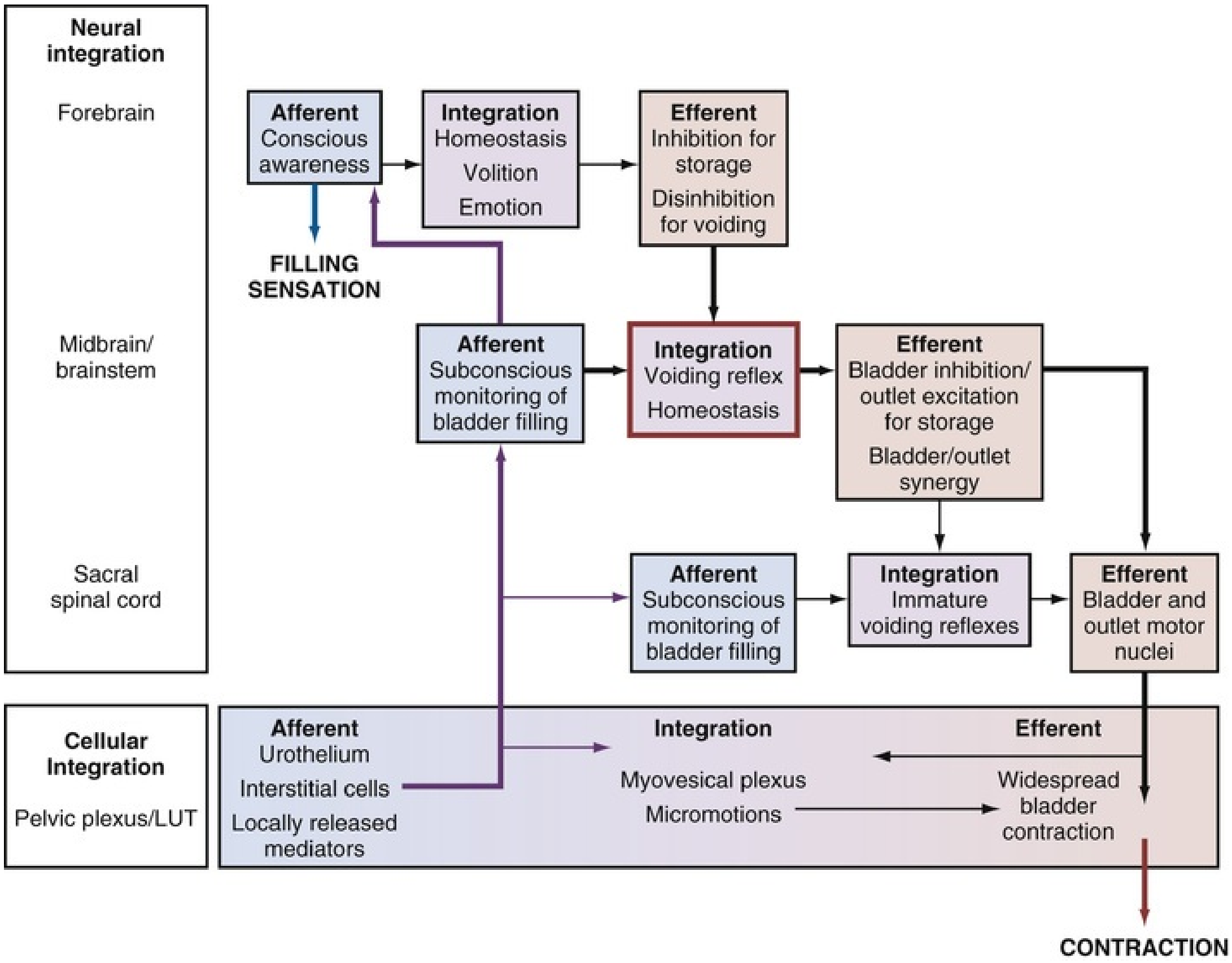
Neural integration
Forebrain
Midbrain/ brainstem
Sacral spinal cord
Cellular Integration
Pelvic plexus/LUT
Afferent
Conscious awareness
Integration
Homeostasis
Volition
Emotion
Efferent
Inhibition for storage
Disinhibition for voiding
FILLING SENSATION
Afferent
Subconscious monitoring of bladder filling
Integration
Voiding reflex
Homeostasis
Efferent
Bladder inhibition/ outlet excitation for storage
Bladder/outlet synergy
Afferent
Subconscious monitoring of bladder filling
Integration
Immature voiding reflexes
Efferent
Bladder and outlet motor nuclei
Afferent
Urothelium
Interstitial cells
Locally released mediators
Integration
Myovesical plexus
Micromotions
Efferent
Widespread bladder contraction
CONTRACTION

FIG. 117.5 Central nervous system circuitry controls the lower urinary tract (LUT) at multiple levels. Sensory information in afferent is affected by peripheral factors, such as mediators and urothelium. It is carried centrally with some input to the sacral cord, which is important for voiding in infants, and it ascends to the midbrain where it inputs to the pontine micturition center (PMC). At this level there is widespread integration of information from vegetative organs, which is crucial for homeostasis. Sensory information is relayed on to the forebrain, where conscious awareness (sensation) is mediated. The forebrain also mediates voluntary control, including the active decision not to pass urine (storage) or to initiate voiding in the right circumstances. Descending forebrain inputs to the PMC allow the switching from storage to voiding phase, with the synergic regulation of the sacral nuclei responsible for bladder contraction and outlet relaxation. There is also possible integration of sensory information in the periphery, contributing to the generation of bladder motility.

The development of functional brain imaging technology allows estimation of gross activity in specific brain areas and has been used to study bladder filling in normal and symptomatic individuals (Griffiths, 2011). Intriguing insights into contributions from various parts of the cerebral cortex, such as the insula and the prefrontal cortex, have resulted. Alterations in the regional brain activity of symptomatic individuals with OAB have been reported (Arya et al., 2017; Griffiths et al., 2007; Komesu et al., 2011). Early research demonstrating alterations in brain activity in response to sacral nerve stimulation lend further insight into the neural mechanisms of OAB and response to therapy (Gill et al., 2017; Weissbart et al., 2018).

Afferent Mechanisms in Overactive Bladder

In theory, **increased sensory activity may give rise to increased sensation, and hence OAB.** Thus the properties of the bladder afferents and factors that influence them are highly relevant in OAB. **The afferent nerve endings are widely distributed in the bladder wall and are particularly dense in the connective tissue beneath the urothelium.** Afferent nerves innervating the bladder are predominantly small-caliber, myelinated Aδ fibers and are primarily responsible for sensing bladder volume and the contractile state of the detrusor (Birder et al., 2010). These mechanosensitive nerves consist of a combination of low-threshold and high-threshold fibers that are responsive to changes in intravesical pressure and bladder volumes, respectively. With their cell bodies located in the dorsal root ganglia at the S2-S4 and T11-L2 spinal segments, these Aδ fibers are important for normal physiologic filling as they continually gauge the degree of bladder wall distention and convey sensations of bladder fullness to the spinal cord (Kanai, 2011; Kanai and Andersson, 2010). Projections from Aδ fibers synapse with spinal neurons that project to the higher brain centers.

Large-caliber, unmyelinated C fibers are also present and usually respond only to high-intensity activation (such as extreme distention, cold, heat, or chemical irritation) and are thus termed “silent,” as they do not participate in normal physiologic bladder function (Birder et al., 2010; Chapple, 2014). However, in animal models of pathological bladder states such as OAB, these “silent” C fibers can become spontaneously active and hypersensitive to low-intensity input (Häbler et al., 1990; Yoshimura and de Groat, 1999), and these changes are mediated by second-order neurons in the spinal cord (Mazières et al., 1998; Xiao et al., 2014).

Afferent nerves travel through the hypogastric and pelvic nerves along with sympathetic and parasympathetic efferent nerves, respectively. Efferent nerve activity during bladder storage includes direct and indirect stimulation by the sympathetic and parasympathetic systems, which are pathways that have been targeted with common OAB medications (i.e., anticholinergic antimuscarinics and β_3 agonists).

Although several potential mechanisms may contribute, the pathophysiology of OAB can be broadly categorized into mechanisms resulting in abnormally increased afferent signals from the bladder or decreased capacity to modulate afferent signals in the CNS (Chapple, 2014).

Mechanisms of Increased Afferent Activity

There are two predominant hypotheses of increased afferent activity, which may give rise to characteristic symptoms of OAB and to the phenomenon of uninhibited detrusor contractions and DO: the urothelium-based hypothesis and the myogenic hypothesis. However, additional mechanisms may play a role.

In the urothelium-based hypothesis, the urothelium actively responds to local mechanical, osmotic, inflammatory, and chemical stimuli with alterations in expression and/or sensitivity of cell membrane receptors and channels and with release of chemical mediators that act on adjacent afferent neurons, effectively transducing stimulating signals to afferent nerves (Birder et al., 2010; Keay et al., 2014). Urothelial cells exhibit receptor activity for a variety of neurotransmitters, including bradykinin, neurotrophins, purines (P2X and P2Y), norepinephrine (NE) (α and β), acetylcholine (ACh) (nicotinic and muscarinic), epithelial Na^+ channels (ENaC), and a number of transient receptor potential (TRP) channels. These cells can also release signaling molecules that have excitatory and/or inhibitory actions on afferent nerves, including ATP, prostaglandins (PG), nerve growth factor (NGF), ACh, and nitric oxide (NO). It is postulated that in OAB, intrinsic aberrations in homeostatic processes at the level of the urothelium/suburothelium, perhaps in response to unidentified local stimuli, trigger afferent nerve signaling generally in excess of normal levels. This increased afferent activity then augments the afferent stimulation produced by bladder fullness to produce urinary urgency and activate the micturition reflex.

The myogenic hypothesis suggests that overactive detrusor contractions result from a combination of an increased likelihood of spontaneous excitation within the smooth muscle of the bladder and enhanced propagation of this activity to affect an excessive proportion of the bladder wall (Brading, 1997; Brading and Turner, 1994). Patchy denervation is a common observation in DO, regardless of cause (Charlton et al., 1999; Drake et al., 2000; German et al., 1995; Mills et al., 2000). A smooth muscle cell deprived of its innervation shows an upregulation of surface membrane receptors and may have altered membrane potential, which increases the likelihood of spontaneous contraction in that cell. DO is also associated with structural changes (Elbadawi et al., 1993; Haferkamp et al., 2003a,b), which could facilitate the excessive spread of spontaneous contractions throughout a wider proportion of the bladder than normal. Although the observations in different models of DO and from clinical specimens do not uniformly describe these features, understanding of altered smooth muscle behavior remains a relevant factor for understanding DO.

Furthermore, the myogenic hypothesis suggests that a range of triggers can generate localized detrusor contractions, which can spread in the bladder wall through various routes of propagation. Coolsaet et al. (1993) described localized contractions **(“micromotions”)** in pigs, and these contractions were postulated as a basis for urinary urgency. They have been widely reported in normal animals and humans. Importantly, such micromotions are exaggerated in models of DO and in human OAB (Drake et al., 2003a,b, 2005; Van Os-Bossagh et al., 2001). **Normal small distortions caused by micromotions may be detected by afferents, therefore generating the sensation of bladder filling without change in detrusor pressure (see Fig. 117.4). In OAB, the distortions may be excessive as a result of exaggerated**

micromotions. They will be associated with urgency and possibly urodynamic DO if the movements become coordinated across a substantial proportion of the bladder (Drake et al., 2001).

Other Mechanisms of Increased Afferent Signaling.

In addition to the above mechanisms for increased afferent signaling arising from the bladder (i.e., the urothelium and myogenic hypotheses), additional mechanisms may result in increased bladder afferent signaling that may arise independent of the bladder. **Specifically, bladder overactivity may result from stimulating signals that arise separately from the bladder but act on the bladder through common afferent pathways** (Chapple, 2014; Kanai, 2011; Ustinova et al., 2010). Overlapping neural pathways that converge in the CNS at the level of the dorsal root ganglia, the spinal cord, or the brain underscore pelvic organ cross-talk (Arendt-Nielsen and Yarnitsky, 2009; Malykhina, 2007; Ustinova et al., 2010). Visceral organ cross-talk involving the bladder is best understood relative to the bowel, which shares sensory innervation in regions of the thoracic and sacral spinal cord with the bladder (Giamberardino et al., 2010). Convergent neural mechanisms of the bladder and the bowel explain the reproducible interactions demonstrated in experimental models (Brumovsky and Gebhart, 2010; Malykhina et al., 2012; Ustinova et al., 2010). For instance, in animal studies, rectal stimulation either through distention (Minagawa et al., 2013; Wyndaele et al., 2013) or inflammation (Malykhina et al., 2006) precipitates detrusor inhibition and/or overactivity that is mediated by activation of convergent bladder and bowel C-fiber afferent nerves in the spinal cord (Minagawa et al., 2013). Similarly, in animal models of pelvic pain or cystitis, colonic stimulation increases pain responses attributed to bladder inflammation (Rudick et al., 2007). Clinical studies that document overlap between bladder and bowel function (Guo et al., 2010; Monga et al., 1997; Wyndaele et al., 2011, 2015) support these experimental findings from animal models. For example, rectal distention results in changes in bladder capacity, bladder sensation, and detrusor overactivity (Burgers et al., 2013; De Wachter and Wyndaele, 2003), while straining to defecate and constipation can impair bladder emptying and increase the severity of voiding and storage symptoms (Alling Møller et al., 2000; Cardozo and Robinson, 2002; Carter and Beer-Gabel, 2012; Coyne et al., 2011; Klingele et al., 2010; Wyndaele et al., 2011, 2015).

Abnormal Handling of Afferent Signals.

In addition to increased afferent activity from the bladder and other sources, an abnormal handling of afferent signals also may play a role in the pathophysiology of OAB. **Even in a nonpathological state, continuous bladder afferent activity during the micturition cycle delivers a myriad of signals conveying pain, mechanosensation, chemical sensitivity, and motor and/or sensory function to the CNS for processing** (Gillespie et al., 2009). Termed “afferent noise,” only a fraction of these signals generate sensations, although most components contribute to reflexes coordinating bladder filling, sphincter function, and voiding. **The CNS is responsible for modulating these signals to suppress unnecessary and/or unconscious bladder sensations and to facilitate afferent signals necessary for homeostasis. If the CNS is unable to modulate these signals appropriately because of disease or dysfunction, then these normally unconscious bladder sensations may be perceived as urgency.**

Neurologic disease is associated with a high prevalence of LUT dysfunction, including OAB, and this is to be anticipated from the fundamental regulatory influence of the innervation on the bladder and its outlet. **Given that most of the time the bladder is storing urine (rather than emptying), it is likely that the CNS exerts continuous inhibitory influence on bladder contractility**, whether through sympathetic inhibition of the detrusor muscle directly through β_3 adrenoceptors, or indirectly by inhibiting parasympathetic ganglia. Thus neurologic disease may affect the continuous inhibition, leading to emergence of OAB symptoms.

Other Pathophysiologic Mechanisms

Additional potential factors appear to contribute to the development of OAB, likely at the level of the bladder, by promoting urothelial and myogenic dysfunction and leading to alterations in nerve mechanisms, including increased afferent activity. Ischemia and reperfusion injury are proposed to cause OAB via hypoxia and oxidative stress pathways, as may be seen in the setting atherosclerosis or arterial obstruction, resulting in damage to epithelial cells, smooth muscle cells, microvasculature, and nerve fibers (Zhao et al., 2016). Evidence of chronic inflammation as measured by increases in cytokines, chemokines, and growth factors isolated from bladder tissue samples, urine, and blood point to upregulation of pro-inflammatory processes in the development of OAB (Kashyap et al., 2018; Kupelian et al., 2012; Tyagi et al., 2014). Recent investigations into urine microbiota demonstrating differences in patients with UUI and OAB suggest that changes in urine microbial composition may contribute to OAB; however, the relation to signaling systems in the bladder-brain axis remains unknown (Pearce et al., 2014, 2015; Thomas-White et al., 2016).

Etiology and Attributable Risk Factors

For most cases of OAB, the cause is unknown and likely multifactorial. Attributable risk factors associated with OAB may affect pathophysiologic mechanisms to initiate or exacerbate the OAB disease process. **Aging is clearly associated with increased LUTS, including OAB;** the wide range of changes in cellular function and the CNS means that increasing OAB with aging is probably multifactorial. As noted, OAB occurs in men and women, although most studies report higher prevalence in women, especially younger women, and higher rates of UUI in women (Coyne et al., 2009). Partial bladder outlet obstruction (BOO) has long been considered an etiologic factor in the generation of DO and OAB, and BOO is a widely used means of generating enhanced nonmicturition contractions as an animal model of DO. However, the relationship between BOO and DO or OAB in humans is not clear cut. Prevalence of OAB in women, in whom BOO is rare, is broadly similar to that in men, in whom BOO is common because of prostate enlargement. Furthermore, DO rarely resolves with prostate surgery. Overall, BOO is probably a relevant factor, but **the influence of BOO may be indirect, perhaps by accelerating some of the changes brought on by aging.** Epidemiologic data on racial/ethnic differences in OAB suggest there may be associated factors, but the underlying details remain unknown.

There are psychological overtones involved in the experience of OAB, and interest in psychological and psychosocial factors associated with OAB is increasing. Many authors have described the associations between psychological conditions and OAB, which further compound the health burden OAB experienced by affected individuals. The most widely studied associations are depression and anxiety (Kinsey et al., 2016); however, OAB also significantly affects self-esteem, sexuality, and relationships. Personal embarrassment and shame are common themes as well. Overall, individuals with concomitant incontinence (OAB and urge-UI) report more psychological burden than those without UI (Vrijens et al., 2015). **Although the strong association between**

psychology and OAB suggests a possible causative effect, the nature of this relationship requires further study (Cortes et al., 2012)**, because it may involve serotonergic mechanisms on the CNS and/or dysregulation of the pituitary-hypothalamic-adrenal axis** (Vrijens et al., 2015). Indeed, stress appears to affect OAB via this route (Smith et al., 2016).

The overlap with other functional syndromes and other health influences indicates the need to recognize wider contributory factors to mechanisms underlying the emergence of OAB and its clinical assessment, particularly in relation to bowel function (Daly and Chapple, 2013; Kaplan et al., 2013), metabolic syndrome (Bunn et al., 2015; Lai et al., 2018), and hormonal status (Robinson et al., 2014).

Key Points: Pathophysiology and Etiology

- Sensory information ascending along afferent pathways are integrated at multiple levels of the CNS, with the main regulatory regions located at the level of the midbrain and brainstem.
- Failure of integration of afferent inputs and sensory inputs at the highest levels of the CNS resulting from disease or dysfunction may lead to perception of normally unconscious symptoms as urgency.
- The urothelium-based and myogenic hypotheses are the two primary bladder-centric theories behind the mechanisms of OAB.
- In the urothelium-based hypothesis, the urothelium actively responds to local mechanical, osmotic, inflammatory, and chemical stimuli, resulting in increased stimulation of afferent nerves.
- The myogenic hypothesis posits that overactive detrusor contractions result from spontaneous excitation within the smooth muscle of the bladder and enhanced propagation of this activity to affect an excessive proportion of the bladder wall.
- The relationship between BOO and OAB is not likely to be a direct causal relationship but rather separate consequences of changes associated with aging.

Clinical Assessment

Initial Evaluation

OAB is a syndrome diagnosed by the presence of characteristic LUTS (Abrams et al., 2002). Empiric treatment can be delivered based upon clinical history and noninvasive testing aimed at characterizing symptoms and ruling out an acute causative process. The American Urological Association/Society of Urodynamics, Female Pelvic Medicine & Urogenital Reconstruction (AUA/SUFU) Guideline for the Diagnosis and Treatment of Overactive Bladder (Non-neurogenic) in Adults maintains **a careful history, physical examination, and urinalysis as the appropriate initial components of evaluation** (Gormley et al., 2012, 2015). The European Association of Urology's Guidelines on the Management of Non-Neurogenic Male Lower Urinary Tract Symptoms (LUTS), including Benign Prostatic Obstruction (BPO) (Gratzke et al., 2015) and Guidelines on Urinary Incontinence (Lucas et al., 2012) concur with these recommendations and strongly encourage the use of validated symptom questionnaires when feasible.

History

The clinical history should establish the diagnosis and assess bother. The following elements should be covered:

- **Presence of and bother from each of the storage LUTS that make up the OAB syndrome (i.e., urgency, urgency incontinence, daytime frequency, and nocturia), other storage disorders (e.g., SUI), and voiding LUTS (e.g., straining, hesitancy, sensation of incomplete emptying) whose presence may indicate BOO. Post-micturition LUTS, dysuria, hematuria, and hematuria should also be assessed.** Symptom assessment questionnaires may facilitate this process but may be of limited utility in many patients because of poor health literacy or a language barrier (Table 117.3; Anger et al., 2012; Moses et al., 2017; Senekjian et al., 2011; Wang et al., 2013).

TABLE 117.3

Description and Readability of Common Lower Urinary Tract Symptoms Assessment Questionnaires

QUESTIONNAIRE	DESCRIPTION	READING GRADE LEVEL (RANGE)	REFERENCE
American Urological Association Symptom Index (AUASI)	7-items, 0–5 scale, assessing voiding and storage components (0–35 total score) and a 0–6 quality of life score	6[a]	Barry et al., 1992
Urogenital Distress Inventory (UDI)	19-item, 4-point bother scale, 3 subscales (storage symptoms, voiding symptoms, stress urinary incontinence) 0–100 summed for 0–300 score	10.5 (7.7–12.0)[b]	Shumaker et al., 1994
Urogenital Distress Inventory-6 (UDI-6)	Reduced 6-item questionnaire from parent survey, scaled to 0–100 score	8.4 (4.8–12.0)[b]	Uebersax et al., 1995
Incontinence Impact Questionnaire (IIQ)	30-item assessment of impact of UDI symptoms	11 (8.5–12.0)[b]	Shumaker et al., 1994
Incontinence Impact Questionnaire-7 (IIQ-7)	Reduced 7-item questionnaire from parent survey, scaled to 0–100 score	11 (9.5–12.0)[b]	Uebersax et al., 1995
Bristol Female Lower Urinary Tract Symptoms (BFLUTS)	33-item assessment of storage and voiding symptoms (12), incontinence (8), quality of life (9), sexual function (4)	7.1 (2.2–12.0)[b]	Jackson et al., 1996
Bristol Female Lower Urinary Tract Symptoms-Short Form (BFLUTS-SF)	12-item reduced questionnaire from parent-form	6.3 (3.2–12.0)[b]	Brookes et al., 2004
Overactive Bladder Questionnaire (OAB-q)	8-item bother scale and 25 quality of life items, 0–6 scale, summed and adjusted to 0–100 score	Not assessed	Coyne et al., 2002
Overactive Bladder Questionnaire Short Form (OAB-q SF)	6-items from OAB-q bother scale and 13 from HRQL scale	Not assessed	Coyne et al., 2015

[a] MacDiarmid SA, Goodson TC, Holmes TM, et al.: An assessment of the comprehension of the American Urological Association Symptom Index. *J Urol* 159:873–874, 1998.

[b] Alas AN, Bergman J, Dunivan GC, et al.: Readability of common health-related quality-of-life instruments in female pelvic medicine. *Female Pelvic Med Reconstr Surg* 19:293–297, 2013.

- **Nature and volume of fluid intake**, recognizing that stimulants (e.g., caffeine) and polydipsia affect LUTS and that patients may adapt their intake to reduce the impact of symptoms.
- **Whether occult neurologic disease could be present**; for example, recent onset of OAB with symptoms of erectile dysfunction or tremor or history of spine surgery or disk disease with or without sensory and/or musculoskeletal symptoms.
- **Obstetric and gynecologic history, previous surgery and/or radiotherapy, bowel symptoms (i.e., constipation, diarrhea, fecal incontinence), and medication history**. The prevalence of fecal incontinence is 7% to 15% in the general population but may be closer to 50% in women with OAB (Bharucha et al., 2015; Lim et al., 2018)**.**
- **Other medical conditions that may directly contribute to LUTS** (e.g., polyuria resulting from poorly controlled diabetes), may be relative contraindications to therapy with antimuscarinics (e.g., poorly controlled closed-angle glaucoma, cognitive impairment, history of urinary retention, and impaired gastric emptying) or β_3 agonists (e.g., poorly controlled hypertension, cardiac arrhythmia), or may be associated with behaviors or medications associated with increased urine output (e.g., obstructive sleep apnea, psychogenic primary polydipsia, lithium-induced diabetes insipidus).

A frequency-volume chart (FVC) (Abrams and Klevmark, 1996) can be informative in all cases but particularly when history suggests that polyuria is responsible for urinary frequency and/or nocturia in isolation or in combination with bladder dysfunction (Cornu et al., 2012). **In OAB the pattern of voided volumes is characteristically erratic. On the FVC, frequency is defined as**

the number of voids recorded during waking hours, including the last void before sleep and the first void after waking and rising in the morning (Abrams et al., 2002)**.** The maximum voided volume on an FVC can be used as a measure of OAB severity, and it has also been used to estimate severity of DO (Miller et al., 2002). In addition, the bladder diary collects objective information on fluid intake and incontinence episodes. A symptom scale has been evaluated for use in conjunction with a bladder diary validated by the International Consultation on Incontinence Questionnaire (ICIQ) group in nonselected populations (Bright et al., 2012, 2014; Table 117.4).

TABLE 117.4

Bladder Sensation Scale Used in the International Consultation on Incontinence Questionnaire Bladder Diary

SCALE	DESCRIPTION
0	If you had no sensation of needing to pass urine, but passed urine for “social reasons,” for example, just before going out or because you are unsure where the next toilet is
1	If you had a normal desire to pass urine and no urgency. Urgency is different from normal bladder feelings and is the sudden compelling desire to pass urine that is difficult to defer, or a sudden feeling that you need to pass urine and if you don't you will have an accident
2	If you had urgency but it passed before you had to visit the toilet
3	If you had urgency and managed to get to the toilet, still with urgency, but did not leak urine

From Bright E, Cotterill N, Drake M, et al.: Developing a validated urinary diary: phase 1. *Neurourol Urodyn* 31(5):625–633, 2012.

The Patient Perception of Intensity of Urgency Scale (PPIUS) is a five-point scale designed to rate the level of urinary urgency for each void during completion of a micturition diary (Cartwright et al., 2011).

1. No urgency: I felt no need to empty my bladder but did so for other reasons.
2. Mild urgency: I could postpone voiding for as long as necessary without fear of wetting myself.
3. Moderate urgency: I could postpone voiding for a short while without fear of wetting myself.
4. Severe urgency: I could not postpone voiding but had to rush to the toilet

to avoid wetting myself.
5. Urgency incontinence: I leaked before arriving at the toilet.

Increased frequency may be a behavioral response to urgency, as patients attempt to reduce the incidence of severe urgency or incontinence, and this can be assessed with additional interpretations of the measures mentioned previously. The total urgency and frequency score (TUFS) (Chapple et al., 2014) is calculated by adding the PPIUS scores of every void by a patient in the patient's voiding diary and dividing this number by the number of days recorded in the diary. The OAB Symptom Composite Score (OAB-SCS) (Zinner et al., 2005) is a similarly derived by summation of Indevus Urgency Severity Scale scores but has not been validated.

Compliance with the fairly cumbersome task of completing an FVC may limit its utility in clinical practice. Use of an electronic diary and smartphone applications can facilitate data collection and analysis (Abrams et al., 2016).

Physical Examination

Focused physical examination should include the abdomen and pelvis, extremities (e.g., edema, tremor), a basic neurologic examination, and general assessment of cognition and frailty (Wagg et al., 2015). Assessment of bladder emptying is necessary. This can be performed by palpation of the lower abdomen in a slim patient but in the urology clinic is more commonly performed with a bladder scanner. The decision to obtain a postvoid residual (PVR) is at the discretion of the clinician but has become routine; with a bladder scanner it can provide important information at little cost or discomfort for the patient (Gormley et al., 2012, 2015; Gratzke et al., 2015).

Laboratory Examination

Urinalysis is mandatory in all patients to exclude urinary tract infection, hematuria, and pyuria. Urine culture should be obtained if infection is suspected based upon the clinical presentation and urinalysis. Assessment of renal function with serum creatinine and urea nitrogen is not routinely indicated but should be reviewed if available.

Advanced Evaluation

Urodynamics, cystoscopy, and diagnostic renal and bladder ultrasound should not be used in the initial workup of the uncomplicated patient (Gormley et al., 2012, 2015). The decision to pursue cystourethroscopy and imaging is based upon the presence of symptoms or urinalysis findings requiring these studies. Although controversy exists over the definition and public health implications of widespread workup of asymptomatic microscopic hematuria (Asymptomatic microscopic hematuria in women, 2017; Davis et al., 2012; Subak and Grady, 2017), the clinician should be bear in mind that patients with OAB and microscopic hematuria are not asymptomatic. To this end, the association between LUTS and LUT pathology such as cancer or stricture should be borne in mind and potentially lower the threshold for cystoscopic evaluation (Hampson et al., 2016; Zhou et al., 2015).

Consensus guidelines recommend urodynamics testing when the presence or absence of altered compliance, DO, or other urodynamic abnormalities will affect the decision to pursue or avoid an invasive, irreversible, or potentially morbid treatment (Abrams et al., 2013; Nambiar et al., 2017; Winters et al., 2012). Treatment based upon urodynamics testing may improve treatment satisfaction (Verghese et al., 2018); however, urodynamics have not been clearly shown to improve outcomes for the index OAB patient (i.e., a woman with low PVR, no significant prolapse, no neurologic disease, and minimal stress urinary incontinence) (Goldman et al., 2018). Urodynamics may be beneficial in patients in whom the presence of BOO is suspected, such as those who have persistent or new-onset OAB symptoms after an outlet procedure.

The primary aim of urodynamic studies is to reproduce the patient's symptoms and to identify additional factors likely to influence management decisions, the likelihood of which is increased by adhering to ICS Good Urodynamic Practices (Schäfer et al., 2002). **The two main urodynamic diagnoses associated with OAB are DO (Fig. 117.6) and early and/or exaggerated filling sensation.** Whether to discontinue antimuscarinic drugs before urodynamic testing can be argued either way; stopping the drugs provides the best chance of observing DO if present, whereas continuing them allows evaluation of the mechanism underlying residual refractory symptoms.

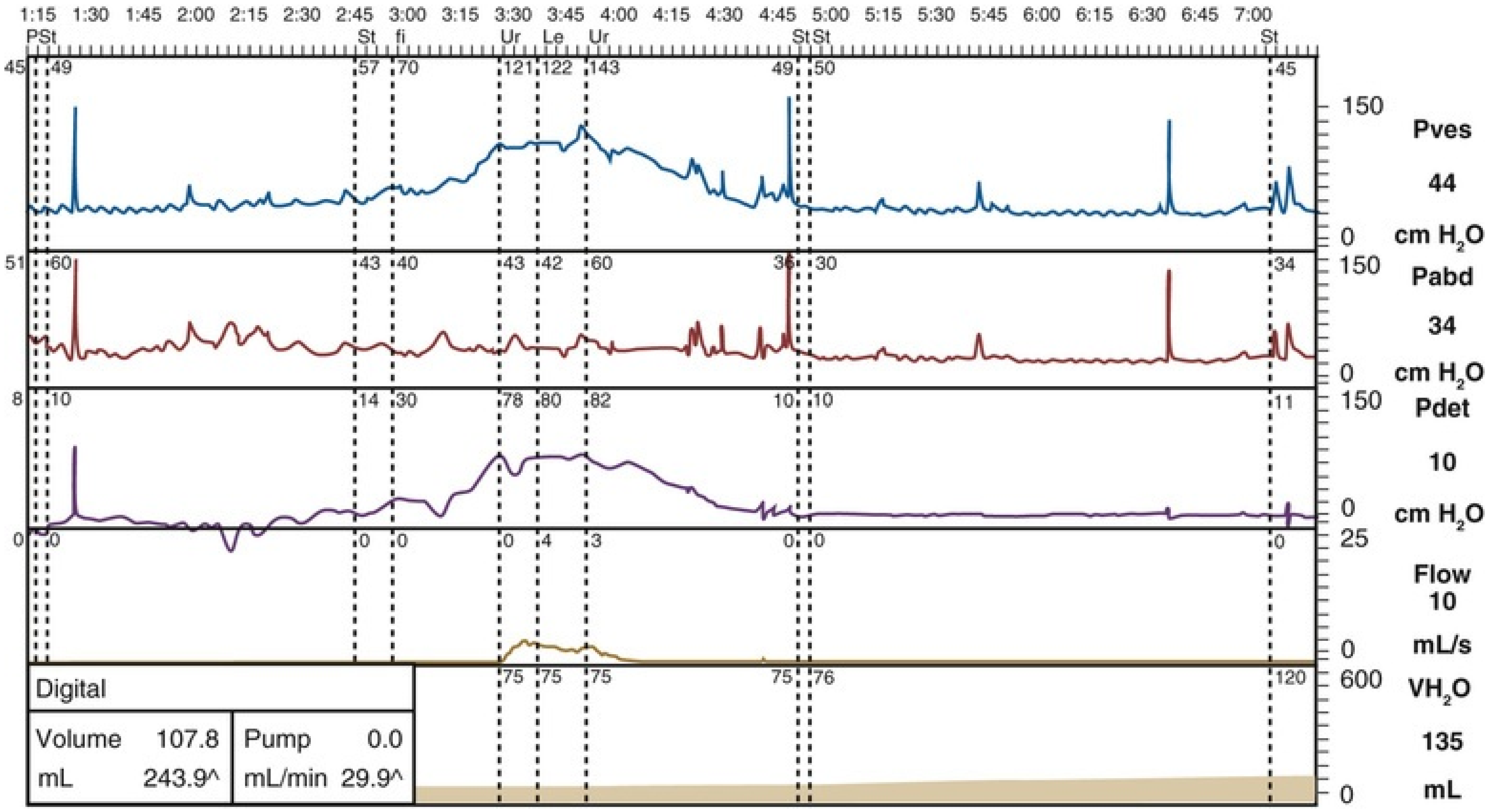

FIG. 117.6 Filling cystometry urodynamic trace showing detrusor overactivity incontinence. *Blue,* Bladder pressure (Pves; *top*). *Red,* Rectal pressure (Pabd). *Purple,* Detrusor pressure (Pdet). *Light brown,* Flow. *Orange*, Filling (VH_2O; *bottom*). The bladder pressure and detrusor pressure rise substantially from baseline, and between 3 minutes 30 seconds and 4 minutes *(top axis)*, there is incontinence seen in the flow trace that is associated with urgency (Ur).

The ICS report describes two types of DO (Abrams et al., 2002):

1. **Phasic DO** is the characteristic pattern seen in most idiopathic DO. It exhibits a characteristic waveform and may or may not lead to incontinence (see Fig. 117.6). It tends to be characterized by contractions of increasing amplitude as the bladder volume increases.
2. **Terminal DO** is a single involuntary detrusor contraction occurring at cystometric capacity, which causes incontinence, often resulting in complete bladder emptying. It is most characteristically seen in the elderly person with “precipitant voiding,” such as in elderly patients who have suffered a cerebrovascular accident. Such patients appear to lose awareness of impending micturition and the ability to inhibit what turns out to be a voiding contraction.

Nonphasic changes in detrusor pressure before micturition should be regarded as changes in bladder compliance rather than as DO. Note that some patients with DO are asymptomatic (i.e., they do not experience OAB). **Any phasic**

detrusor contraction during filling constitutes DO, regardless of amplitude (Abrams et al., 2002). **DO may be absent in many patients with OAB, but its presence is correlated with increased severity of urgency and the presence of incontinence** (Al-Zahrani and Gajewski, 2012, 2016; Chung et al., 2011; Hashim and Abrams, 2006). Accordingly, approximately 60% to 70% of men and 40% to 50% of women with urinary urgency without incontinence ("OAB-dry") will have DO on cystometrogram, whereas nearly all men (>90%) with UI ("OAB-wet") will demonstrate DO. Because of the "misinterpretation" of SUI as urgency leakage, incontinence in women is a less reliable predictor of DO, which may be absent in 30% to 40% of women with reported urgency incontinence (Al-Ghazo et al., 2011; Hashim and Abrams, 2006). Contact of urine with urethral receptors caused by urodynamic stress incontinence (USI) may stimulate urethral receptors, causing an urgency sensation and perhaps a secondary bladder contraction. In some individuals, DO can be elicited by asking the patient to cough; this stress-provoked DO (in which cough results in DO, which causes leakage) must not be confused with USI (in which the cough causes an immediate leak and no DO is seen).

Fig. 117.7 illustrates the relationship between the symptom-based diagnosis of OAB and the urodynamic-based diagnosis of DO. **Where DO is absent the patient will usually report increased bladder sensation, defined as "an early and persistent desire to void"** (Abrams et al., 2002). If DO is not seen during filling, the investigator should attempt to use any provocations that the patient says lead to OAB symptoms, such as the sound of running water or having the patient stand up if possible. Filling rate must be considered carefully; a high filling rate can be used to induce DO. However, a high filling rate may also result in repeated DO that prevents assessment of other urodynamic parameters relevant to the patient's presenting symptoms such as flow rate and detrusor pressure during a volitional void. Fast filling can also mask DO and cause low compliance, particularly in neurogenic DO.

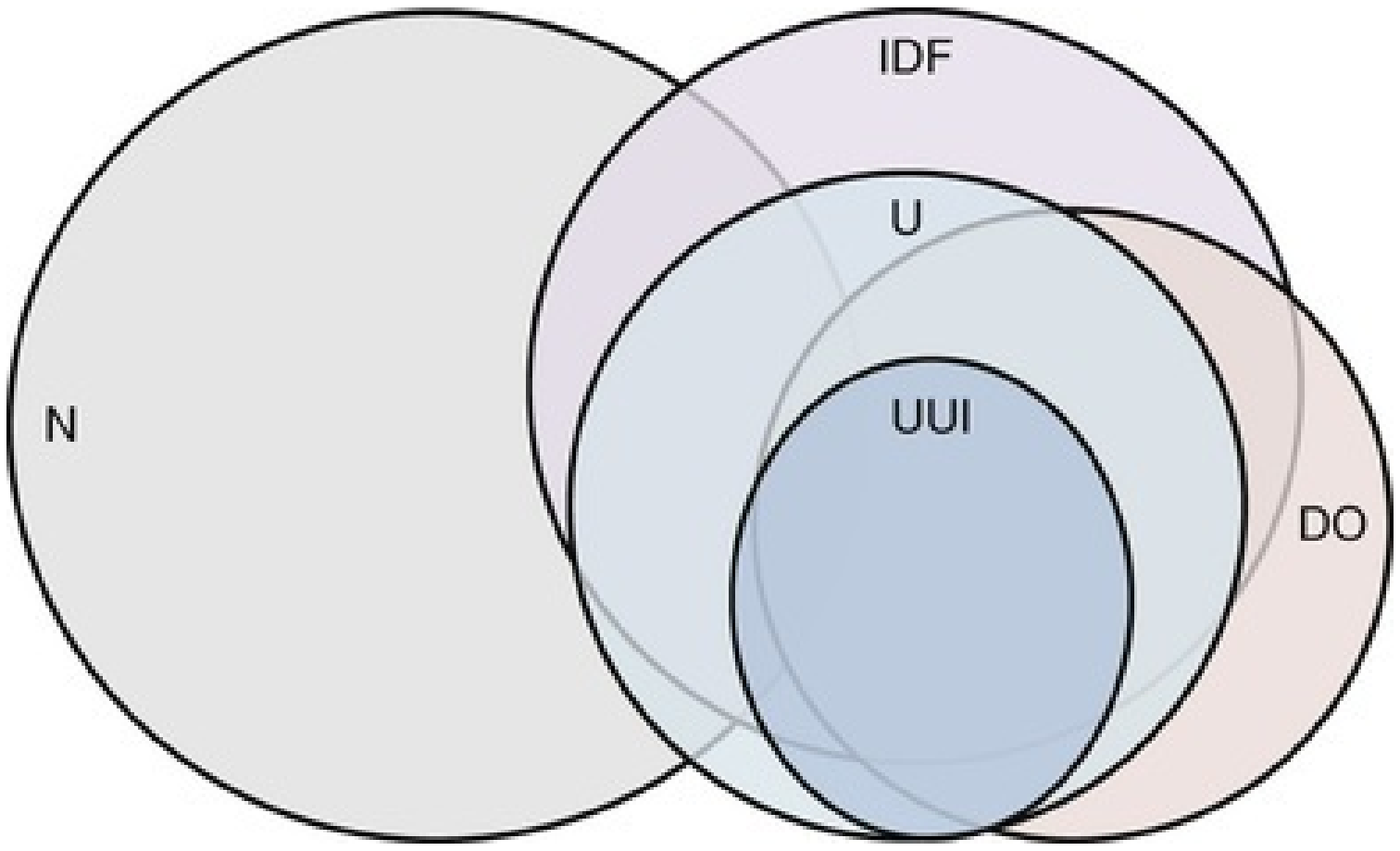

FIG. 117.7 Correlation between the symptom-based diagnosis of overactive bladder (increased daytime frequency [IDF], urgency [U], nocturia [N], and urgency urinary incontinence [UUI]) and the urodynamic diagnosis of detrusor overactivity (DO). The correlation is best for UUI and worst for N.

It is critical to assess for the presence of BOO or inefficient bladder emptying for two reasons. First, **OAB treatment measures that aim to improve bladder reservoir function may impair voiding, perhaps necessitating intermittent self-catheterization.** For example, each 10-mL increase in PVR has been associated with a 27% increased risk of need for catheterization after botulinum toxin injection (Osborn et al., 2015). Second, **increasing severity of BOO is associated with DO** (Oelke et al., 2008; Oh et al., 2011), **suggesting that OAB symptoms may be unlikely to improve if BOO is left untreated. However, treatment of BOO does not necessarily result in improvement in OAB symptoms.** The prevalence of DO may be as high as 60% in men who have undergone prior transurethral resection of the prostate (TURP) (Thomas et al., 2005), despite the fact that they remain unobstructed. **The urodynamic finding that has been most consistently associated with decreased likelihood of resolution of DO or OAB symptoms is terminal DO at diminished capacity** (Antunes et al., 2015; Zhao et al., 2014). Although symptomatic improvement is seen in many men with BOO and DO, it is probably less likely than in men without DO.

Ideally the patient should be seated or standing for filling cystometry, because OAB symptoms are usually experienced when upright. However, where there is severe DO at low volumes, it may be difficult to ascertain if USI is also present. In these patients, a second filling cycle in the supine position generally reduces DO (Al-Hayek et al., 2008), making it easier to detect USI if present.

The urodynamic report should clearly state whether the patients' symptoms were reproduced completely, reproduced in part, or not reproduced to ensure that due caution is exercised in major treatment decisions where there is diagnostic uncertainty. Technical artifacts should be recognized and handled immediately (Hogan et al., 2012; Schäfer et al., 2002). **Ambulatory urodynamics may be considered when conventional cystometry fails to reproduce symptoms. However, DO may be difficult to interpret because it has been found in more than 60% of asymptomatic women undergoing ambulatory urodynamics** (Heslington and Hilton, 1996).

Key Points: Overactive Bladder Clinical Assessment

- The minimum requirements to document symptoms and signs of OAB and to exclude other potential causative disorders are a careful history, physical exam, and urinalysis.
- Clinicians must consider the possibility of malignancy, neurologic disease, systemic disease, and/or an elevated postvoid residual.
- The frequency volume chart is the principal method for objective evaluation of day and nighttime frequency and polyuria.
- Urodynamics, cystoscopy, and diagnostic renal and bladder ultrasound should not be used in the initial workup of the uncomplicated patient.
- Urodynamics testing is indicated when the presence or absence of altered compliance, DO, or other urodynamic abnormalities will affect the decision to pursue or avoid an invasive, irreversible, or potentially morbid treatment.
- Increasing severity of BOO is associated with the presence of DO; however, treatment of obstruction does not ensure OAB symptom resolution.

Management

In general, OAB is a chronic symptom complex that affects quality of life but is not life threatening. Patients should be informed as such and management recommendations made within this context. Patients may elect not to proceed with any intervention whose benefits do not outweigh the financial, physical, or opportunity costs associated with treatment.

First-Line Therapy

First-line therapy for OAB includes behavioral therapies such as bladder training, bladder control strategies, pelvic floor physical therapy, weight loss, and fluid management (Gormley et al., 2012, 2015; Nambiar et al., 2018). Patients in clinical trials receiving placebo therapy experience significant benefits across multiple OAB symptom parameters, including daily incontinence and micturition episodes and mean voided volume (Mangera et al., 2011). The “placebo effect” consistently observed across OAB trials underscores the benefit of non-pharmacologic intervention, often in the form of education, on symptoms.

Fluid reduction can improve OAB symptom scores (Imamura et al., 2015), **albeit at the cost of thirst and other adverse effects of underhydration.** Furthermore, many patients have already implemented fluid avoidance strategies before seeking care, limiting its efficacy as an intervention (Smith et al., 2011). Nevertheless, a decrease in fluid intake by 25% can be expected to meaningfully reduce OAB symptoms and should be encouraged when feasible (Hashim and Abrams, 2008).

Caffeine reduction has not been consistently demonstrated to reduce urinary incontinence but does improve other OAB symptoms such as urgency and frequency (Arya et al., 2000; Bryant et al., 2002; Swithinbank et al., 2005; Tomlinson et al., 1999). Patients should be educated about the impact of caffeine on symptoms and encouraged to assess whether any perceived improvement in symptoms is “worth” the trade-off of giving up or reducing intake of the caffeinated beverages they enjoy.

Weight loss reduces stress urinary incontinence but may significantly reduce episodes of UUI as well. To this end, mean weight loss of 7.8 kg among obese women with incontinence randomized to an intensive weight-loss program was associated with a significantly greater likelihood of meaningful decrease in UUI episodes relative to controls (who experienced mean weight loss of 1.5 kg) (Subak et al., 2009). Patients with severe obesity may benefit from a caring and honest discussion regarding the potential benefits of bariatric surgery, which has been associated with an approximately 7% to 8% reduced risk of urinary incontinence per each 5% reduction in weight (Subak et al., 2015).

Behavioral therapies such as pelvic floor muscle training and bladder training can significantly improve urinary urgency and urgency incontinence episodes among patients committed to treatment at little or no risk of adverse effects. Improvement in the frequency of incontinence episodes is typically 50% to 80%, and as such behavioral treatments are endorsed as first-line treatment by multiple societies (Corcos et al., 2017; Gormley et al., 2012, 2015; Nambiar et al., 2018). Behavioral therapy may be offered concomitantly with medical therapy according to patient preferences and symptoms.

Second-Line Therapy

Options for pharmacologic management of OAB predominantly include antimuscarinic agents as well as β_3 agonists. Pharmacologic management of OAB is covered in detail in another chapter. If recommending antimuscarinic medication, prescribers should educate the patient about potential side effects, including dry mouth, constipation, cognitive effects, visual impairment, and others (Leone Roberti Maggiore et al., 2012). A range of agents and doses are available, and patients should be advised that the idiosyncratic nature of responses means that it may take some adjustment to find an optimum regimen. In general, antimuscarinic agents have been found to increase likelihood of cure over placebo by 20% to 70% but are associated with a high rate of withdrawal because of inefficacy or adverse events (Nambiar et al., 2018). **Extended-release formulations should preferentially be prescribed in favor of short-acting formulations** because of lower rates of dry mouth (Gormley et al., 2012, 2015; Nambiar et al., 2018), and if a patient experiences inadequate symptom control and/or unacceptable adverse drug events with one antimuscarinic medication, then a dose modification or a different antimuscarinic medication may be tried. **The β_3-adrenergic agonist mirabegron has become an established treatment of OAB with decreased risk of dry mouth but otherwise similar rates of adverse events and efficacy relative to antimuscarinic therapy** (Nitti et al., 2013b). In men with voiding LUTS, α_1-

adrenergic antagonists represent first-line drug therapy; however, in men with LUTS suggestive of OAB, inclusion of an antimuscarinic in may be appropriate (Gratzke et al., 2015; Nambiar et al., 2018). The use of **an antimuscarinic in the treatment of a man with BOO and concomitant OAB can ameliorate symptoms and provide a modest improvement in quality of life** (Athanasopoulos et al., 2011). However, the incidence of **acute urinary retention in men receiving antimuscarinics with or without an α_1-adrenergic blocker is up to 3%** (Kaplan et al., 2011). Therefore caution is advised in initiating OAB therapy when PVR is elevated, particularly at volumes exceeding 250 mL (McVary et al., 2011).

In evaluation of response to pharmacologic therapy, **repeat use of the symptom assessment questionnaire is valuable because subjective perceptions and recollections of LUTS can be unreliable.** In patients failing initial pharmacologic treatment, **altered drug dose, a different agent, or combination therapy may achieve sufficient improvement to obviate the need to consider more invasive investigation and treatment.**

Third-Line Therapy

Third-line interventions for OAB primarily include tibial nerve stimulation, sacral nerve stimulation, and intravesical botulinum toxin injection. Each of these treatments, which are reviewed in detail later in this text, may be offered for OAB symptoms refractory to first- and second-line therapy because of either inefficacy or intolerance. Treatment selection, including the decision not to proceed with further therapy, depends on patient preferences, which should be guided by an informative discussion of benefits and drawbacks of each.

Tibial nerve stimulation may result in clinical response in approximately 60% to 80% of patients with medication-refractory OAB with limited risk of adverse events (Gormley et al., 2015; Gupta et al., 2015). The burden associated with weekly treatments during the 12-week induction phase and delayed response until weeks 8 to 10 can limit real-world compliance with treatment (Sirls et al., 2017).

Injection of botulinum toxin for OAB reduced urinary frequency by 29%, urgency by 38%, and daily incontinence episodes by 59% on pooled analysis of placebo-controlled trials (Mangera et al., 2014). Approximately one-quarter of patients may experience complete resolution of urinary incontinence (Chapple et al., 2013; Nitti et al., 2013a; Visco et al., 2012). The primary risks of botulinum toxin injection include symptomatic UTI in approximately 20% and the need to initiate intermittent catheterization in 0 to 12% in clinical trials (Mangera et al., 2014) but as many as 25% to 30% or more in “real-world” studies (Osborn et al., 2015; Siegel, 2017).

Sacral neuromodulation has been associated with a 5-year therapeutic success rate of approximately 70% to 80%, with mean reduction in daily urgency incontinence episodes of 2.0 +/−2.2 and voids of 5.4 +/−4.3 among participants completing 5-year follow-up (Siegel et al., 2018). Certain drawbacks of sacral neuromodulation include a revision rate exceeding 30% at 5 years resulting from adverse events such as undesirable change in stimulation, pain, or inefficacy. Furthermore, all patients wishing to maintain efficacy eventually require revision for battery replacement even if efficacy of the lead is maintained (Goldman et al., 2018).

Fourth-Line Therapy

In rare circumstances, symptoms of OAB are severe enough to warrant consideration of augmentation cystoplasty or urinary diversion. The impact of OAB on quality of life must be weighed against the short- and long-term risks associated with major surgery and those of alternative options including containment (i.e., pads/diapers) or indwelling catheters.

Key Points: Clinical Management

- First-line therapy comprises caffeine and fluid avoidance, weight loss, and behavioral therapy such as bladder training and pelvic floor muscle therapy.
- Second-line therapy consists of pharmacologic treatment with antimuscarinics (oral or transdermal) or β_3 agonists.
- Third-line therapy consists of tibial neuromodulation, botulinum toxin injection, and sacral neuromodulation. Shared decision making should guide treatment decisions.
- Fourth-line therapy comprises major surgery such as augmentation cystoplasty or urinary diversion. The risks of major surgery must be weighed against alternative options such as containment or indwelling catheterization.

Approach

The fifth ICI (Abrams et al., 2013) has produced a comprehensive review of the spectrum of incontinence management, weighted according to levels of evidence, and providing grades of recommendation (Abrams and Khoury, 2010). The ICI care pathways for the management of urinary incontinence in women, men, and the frail elderly are illustrated in Fig. 117.8. The AUA/SUFU Guideline on Non-Neurogenic Overactive Bladder in Adults also presents a Diagnosis and Treatment Algorithm for providers (https://www.auanet.org/Documents/education/clinical-guidance/Overactive-Bladder-Algorithm.pdf), as does the SUFU Overactive Bladder Clinical Care Pathway (https://sufuorg.com/docs/oab/sufu-oab-flyer.aspx). Themes common across diagnostic and treatment algorithms include the following:

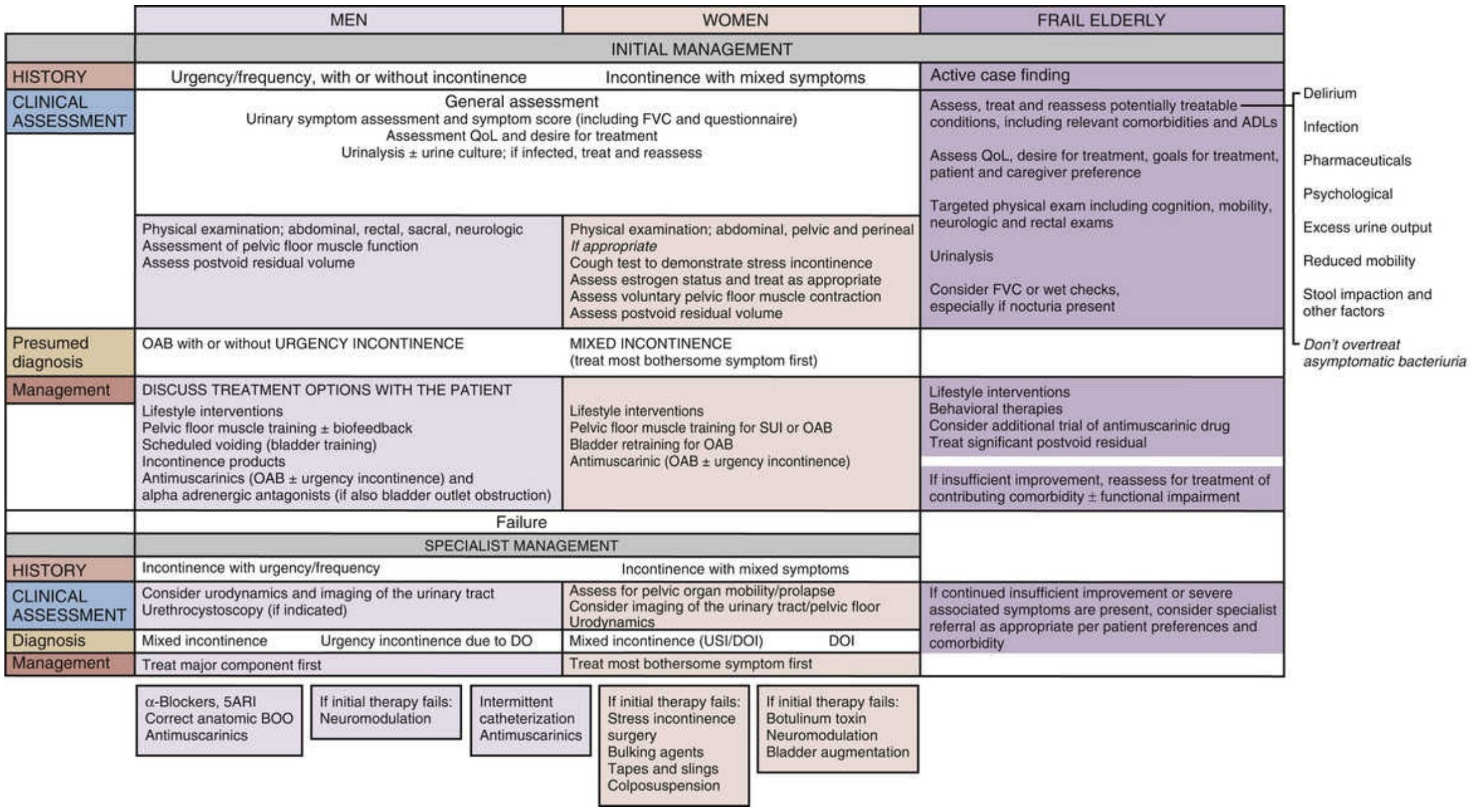

	MEN	WOMEN	FRAIL ELDERLY
	INITIAL MANAGEMENT		
HISTORY	Urgency/frequency, with or without incontinence	Incontinence with mixed symptoms	Active case finding
CLINICAL ASSESSMENT	General assessment Urinary symptom assessment and symptom score (including FVC and questionnaire) Assessment QoL and desire for treatment Urinalysis ± urine culture; if infected, treat and reassess		Assess, treat and reassess potentially treatable conditions, including relevant comorbidities and ADLs Assess QoL, desire for treatment, goals for treatment, patient and caregiver preference Targeted physical exam including cognition, mobility, neurologic and rectal exams Urinalysis Consider FVC or wet checks, especially if nocturia present
	Physical examination; abdominal, rectal, sacral, neurologic Assessment of pelvic floor muscle function Assess postvoid residual volume	Physical examination; abdominal, pelvic and perineal *If appropriate* Cough test to demonstrate stress incontinence Assess estrogen status and treat as appropriate Assess voluntary pelvic floor muscle contraction Assess postvoid residual volume	
Presumed diagnosis	OAB with or without URGENCY INCONTINENCE	MIXED INCONTINENCE (treat most bothersome symptom first)	
Management	DISCUSS TREATMENT OPTIONS WITH THE PATIENT Lifestyle interventions Pelvic floor muscle training ± biofeedback Scheduled voiding (bladder training) Incontinence products Antimuscarinics (OAB ± urgency incontinence) and alpha adrenergic antagonists (if also bladder outlet obstruction)	Lifestyle interventions Pelvic floor muscle training for SUI or OAB Bladder retraining for OAB Antimuscarinic (OAB ± urgency incontinence)	Lifestyle interventions Behavioral therapies Consider additional trial of antimuscarinic drug Treat significant postvoid residual If insufficient improvement, reassess for treatment of contributing comorbidity ± functional impairment
	Failure		
	SPECIALIST MANAGEMENT		
HISTORY	Incontinence with urgency/frequency	Incontinence with mixed symptoms	
CLINICAL ASSESSMENT	Consider urodynamics and imaging of the urinary tract Urethrocystoscopy (if indicated)	Assess for pelvic organ mobility/prolapse Consider imaging of the urinary tract/pelvic floor Urodynamics	If continued insufficient improvement or severe associated symptoms are present, consider specialist referral as appropriate per patient preferences and comorbidity
Diagnosis	Mixed incontinence Urgency incontinence due to DO	Mixed incontinence (USI/DOI) DOI	
Management	Treat major component first	Treat most bothersome symptom first	

α-Blockers, 5ARI
Correct anatomic BOO
Antimuscarinics

If initial therapy fails:
Neuromodulation

Intermittent catheterization
Antimuscarinics

If initial therapy fails:
Stress incontinence surgery
Bulking agents
Tapes and slings
Colposuspension

If initial therapy fails:
Botulinum toxin
Neuromodulation
Bladder augmentation

Delirium
Infection
Pharmaceuticals
Psychological
Excess urine output
Reduced mobility
Stool impaction and other factors
Don't overtreat asymptomatic bacteriuria

FIG. 117.8 Overactive bladder in men, women, and the frail elderly; assessment and management derived from the respective algorithms of the fifth International Consultation on Incontinence (Abrams et al., 2013). *ADLs,* Activities of daily living; *5ARI,* 5α-reductase inhibitor; *BOO,* bladder outlet obstruction; *DO,* detrusor overactivity; *DOI,* detrusor overactivity incontinence; *FVC,* frequency volume chart; *OAB,* overactive bladder; *QoL,* quality of life; *SUI,* stress urinary incontinence; *USI,* urodynamic stress incontinence.

1. A careful clinical assessment to confirm the diagnosis of OAB and rule

out alternative diagnoses
2. Patient education regarding the diagnosis and treatment plan
3. Initial (first-line) treatment, consisting of lifestyle and behavioral modifications and behavioral therapy and/or pelvic floor muscle training
4. Second-line treatment, consisting of pharmacotherapy
5. Third-line or advanced therapies, consisting of tibial nerve stimulation, sacral neuromodulation, or chemodenervation

At each step in the pathway, symptoms, side effects, and patient preferences for continuation or alteration in treatment must be assessed. The minimum duration required to assess efficacy of behavioral therapies is variably reported at 4 to 12 weeks and pharmacologic therapies 4 to 12 weeks (Syan and Brucker, 2016). Progression to third-line treatments generally follows failure of conservative and pharmacologic management, although symptom severity and patient comorbidities may make extended pharmacologic treatment unfeasible. In such cases, earlier progression to third-line therapy may be appropriate.

Suggested Readings

Abrams P, Cardozo L, Fall M, et al. The standardisation of terminology of lower urinary tract function: report from the standardisation sub-committee of the International Continence Society. *Neurourol Urodyn*. 2002;21:167–178.

Drake MJ, Fowler CJ, Griffiths D, et al. Neural control of the lower urinary and gastrointestinal tracts: supraspinal CNS mechanisms. *Neurourol Urodyn*. 2010;29:119–127.

Gormley EA, Lightner DJ, Burgio KL, et al. Diagnosis and treatment of overactive bladder (non-neurogenic) in adults: AUA/SUFU guideline. *J Urol*. 2012;188:2455–2463 https://www.auanet.org/guidelines/incontinence-non-neurogenic-overactive-bladder-(2012-amended-2014).

Gratzke C, Bachmann A, Descazeaud A, et al. EAU guidelines on the assessment of non-neurogenic male lower urinary tract symptoms including benign prostatic obstruction. *Eur Urol*. 2015;67:1099–1109 https://uroweb.org/wp-content/uploads/Gratzke-C-et-al.-Eur-Urol-2015-6761099.-EAU-Guidelines-on-the-assessment-of-non-neurogenic-male-LUTS-including-BPO.pdf.

Haylen BT, de Ridder D, Freeman RM, et al. An International Urogynecological Association (IUGA)/International Continence Society (ICS) joint report on the terminology for female pelvic floor dysfunction. *Neurourol Urodyn*. 2010;29:4–20.

Nambiar AK, Bosch R, Cruz F, et al. EAU guidelines on assessment and nonsurgical management of urinary incontinence. *Eur Urol*. 2018;73:596–609 http://eu-acme.org/europeanurology/upload_articles/Incontinence%20C

Nambiar AK, Lemack GE, Chapple CR, et al. The role of urodynamics in the evaluation of urinary incontinence: the

European Association of Urology Recommendations in 2016. *Eur Urol*. 2017;71:501–503 https://uroweb.org/wp-content/uploads/Nambiar-et-al.-Eur-Urol-2017-71-501-503.-The-Role-of-Urodynamics-in-the-Evaluation-of-UI-The-EAU-Recommendations-in-2016.pdf.

References

Abrams P, Artibani W, Cardozo L, et al. Reviewing the ICS 2002 terminology report: the ongoing debate. *Neurourol Urodyn*. 2009;28:287.

Abrams P, Blaivas JG, Stanton SL, et al. The standardisation of terminology of lower urinary tract function. The International Continence Society Committee on Standardisation of Terminology. *Scand J Urol Nephrol Suppl*. 1988;114:5–19.

Abrams P, Cardozo L, Fall M, et al. The standardisation of terminology of lower urinary tract function: report from the standardisation sub-committee of the International Continence Society. *Neurourol Urodyn*. 2002;21:167–178.

Abrams P, Cardozo L, Khoury S, et al. *Incontinence: 5th International Consultation on Incontinence*. ICUD-EAU: Paris; 2013.

Abrams P, Hanno P, Wein A. Overactive bladder and painful bladder syndrome: there need not be confusion. *Neurourol Urodyn*. 2005;24:149–150.

Abrams P, Khoury S. International consultation on urological diseases: evidence-based medicine overview of the main steps for developing and grading guideline recommendations. *Neurourol Urodyn*. 2010;29:116–118.

Abrams P, Klevmark B. Frequency volume charts: an indispensable part of lower urinary tract assessment. *Scand J Urol Nephrol Suppl*. 1996;179:47–53.

Abrams P, Paty J, Martina R, et al. Electronic bladder diaries of differing duration versus a paper diary for data collection in overactive bladder. *Neurourol Urodyn*. 2016;35:743–749.

Abrams P, Wein AJ. The overactive bladder and incontinence: definitions and a plea for discussion. *Neurourol Urodyn*. 1999;18:413–416.

Al-Ghazo MA, Ghalayini IF, Al-Azab R, et al. Urodynamic detrusor overactivity in patients with overactive bladder symptoms. *Int Neurourol J*. 2011;15:48–54.

Al-Hayek S, Belal M, Abrams P. Does the patient's position influence the detection of detrusor overactivity? *Neurourol Urodyn*. 2008;27:279–286.

Alling Møller L, Lose G, Jørgensen T. Risk factors for lower urinary tract symptoms in women 40 to 60 years of age. *Obstet Gynecol*. 2000;96:446–451.

Al-Zahrani AA, Gajewski J. Urodynamic findings in women with refractory overactive bladder symptoms. *Int J Urol*. 2016;23:75–79.

Al-Zahrani AA, Gajewski JB. Association of symptoms with urodynamic findings in men with overactive bladder syndrome. *BJU Int*. 2012;110:E891–E895.

Andersson K-E, McCloskey KD. Lamina propria: the functional center of the bladder? *Neurourol Urodyn*. 2014;33:9–16.

Anger JT, Lee UJ, Mittal BM, et al. Health literacy and disease understanding among aging women with pelvic floor disorders. *Female Pelvic Med Reconstr Surg*. 2012;18:340–343.

Antunes AA, Iscaife A, Reis ST, et al. Can we predict which patients will experience resolution of detrusor overactivity after transurethral resection of the prostate? *J Urol*. 2015;193:2028–2032.

Arendt-Nielsen L, Yarnitsky D. Experimental and clinical applications of quantitative sensory testing applied to skin, muscles and viscera. *J Pain*. 2009;10:556–572.

Arya LA, Myers DL, Jackson ND. Dietary caffeine intake and the risk for detrusor instability: a case-control study. *Obstet Gynecol*. 2000;96:85–89.

Arya NG, Weissbart SJ, Xu S, et al. Quantitative changes in cerebral perfusion during urinary urgency in women with overactive bladder. *Biomed Res Int*. 2017;2017:2759035.

Asymptomatic microscopic hematuria in women. *Female Pelvic Med Reconstr Surg*. 2017;23:228–231.

Athanasopoulos A, Chapple C, Fowler C, et al. The role of antimuscarinics in the management of men with symptoms of overactive bladder associated with concomitant bladder outlet obstruction: an update. *Eur Urol*. 2011;60:94–105.

Barry MJ, Fowler FJ Jr, O'Leary MP, et al. The American Urological Association symptom index for benign prostatic hyperplasia. *J Urol*. 1992;148:1549–1557.

Bates P, Bradley WE, Glen E, et al. Function of the lower urinary tract. 3. Report on terminology standardization: studies on urination analysis, pressure-flow functions and residual urine. *Z Urol Nephrol*. 1980;73:768–772.

Bates P, Bradley WE, Glen E, et al. Function of the lower urinary tract. 3rd Report on standardization of terminology (author's transl). *Urologe A*. 1980;19:315–317.

Benner JS, Nichol MB, Rovner ES, et al. Patient-reported reasons for discontinuing overactive bladder medication. *BJU Int*. 2010;105:1276–1282.

Bharucha AE, Dunivan G, Goode PS, et al. Epidemiology, pathophysiology, and classification of fecal incontinence: state of the science summary for the National Institute of Diabetes and Digestive and Kidney Diseases (NIDDK) workshop. *Am J Gastroenterol*. 2015;110:127–136.

Birder L, Andersson K-E. Urothelial signaling. *Physiol Rev*. 2013;93:653–680.

Birder L, de Groat W, Mills I, et al. Neural control of the lower urinary tract: peripheral and spinal mechanisms. *Neurourol Urodyn*. 2010;29:128–139.

Brading AF, Turner WH. The unstable bladder: towards a common mechanism. *Br J Urol*. 1994;73:3–8.

Brading AF. A myogenic basis for the overactive bladder.

Urology. 1997;50:57–67 [discussion 68–73].

Bright E, Cotterill N, Drake M, et al. Developing a validated urinary diary: phase 1. *Neurourol Urodyn*. 2012;31:625–633.

Bright E, Cotterill N, Drake M, et al. Developing and validating the International Consultation on Incontinence Questionnaire bladder diary. *Eur Urol*. 2014;66:294–300.

Brookes ST, Donovan JL, Wright M, et al. A scored form of the Bristol Female Lower Urinary Tract Symptoms questionnaire: data from a randomized controlled trial of surgery for women with stress incontinence. *Am J Obstet Gynecol*. 2004;191:73–82.

Brumovsky PR, Gebhart GF. Visceral organ cross-sensitization—an integrated perspective. *Auton Neurosci*. 2010;153:106–115.

Bryant CM, Dowell CJ, Fairbrother G. Caffeine reduction education to improve urinary symptoms. *Br J Nurs*. 2002;11:560–565.

Bunn F, Kirby M, Pinkney E, et al. Is there a link between overactive bladder and the metabolic syndrome in women? A systematic review of observational studies. *Int J Clin Pract*. 2015;69:199–217.

Burgers R, de Jong TPVM, Visser M, et al. Functional defecation disorders in children with lower urinary tract symptoms. *J Urol*. 2013;189:1886–1891.

Cardozo L, Robinson D. Special considerations in premenopausal and postmenopausal women with symptoms of overactive bladder. *Urology*. 2002;60:64–71 [discussion 71].

Carter D, Beer-Gabel M. Lower urinary tract symptoms in chronically constipated women. *Int Urogynecol J*. 2012;23:1785–1789.

Cartwright R, Srikrishna S, Cardozo L, et al. Validity and reliability of the patient's perception of intensity of urgency scale in overactive bladder. *BJU Int*. 2011;107:1612–1617.

Chancellor MB, Migliaccio-Walle K, Bramley TJ, et al. Long-term patterns of use and treatment failure with anticholinergic agents for overactive bladder. *Clin Ther*. 2013;35:1744–1751.

Chapple C, Sievert K-D, MacDiarmid S, et al. OnabotulinumtoxinA 100 U significantly improves all idiopathic overactive bladder symptoms and quality of life in patients with overactive bladder and urinary incontinence: a randomised, double-blind, placebo-controlled trial. *Eur Urol*. 2013;64:249–256.

Chapple C. Chapter 2: pathophysiology of neurogenic detrusor overactivity and the symptom complex of 'overactive bladder.'. *Neurourol Urodyn*. 2014;33(Suppl 3):S6–S13.

Chapple CR, Drake MJ, Van Kerrebroeck P, et al. Total urgency and frequency score as a measure of urgency and frequency in overactive bladder and storage lower urinary tract symptoms. *BJU Int*. 2014;113:696–703.

Charlton RG, Morley AR, Chambers P, et al. Focal changes in nerve, muscle and connective tissue in normal and unstable human bladder. *BJU Int*. 1999;84:953–960.

Chung S-D, Liao C-H, Chen Y-C, et al. Urgency severity scale could predict urodynamic detrusor overactivity in patients with overactive bladder syndrome. *Neurourol Urodyn*. 2011;30:1300–1304.

Coolsaet BL, Van Duyl WA, Van Os-Bossagh P, et al. New concepts in relation to urge and detrusor activity. *Neurourol Urodyn*. 1993;12:463–471.

Corcos J, Przydacz M, Campeau L, et al. CUA guideline on adult overactive bladder. *Can Urol Assoc J*. 2017;11:E142–E173.

Cornu J-N, Abrams P, Chapple CR, et al. A contemporary assessment of nocturia: definition, epidemiology, pathophysiology, and management—a systematic review and meta-analysis. *Eur Urol*. 2012;62:877–890.

Cortes E, Sahai A, Pontari M, et al. The psychology of LUTS: ICI-RS 2011. *Neurourol Urodyn*. 2012;31:340–343.

Coyne K, Revicki D, Hunt T, et al. Psychometric validation of an overactive bladder symptom and health-related quality of life questionnaire: the OAB-q. *Qual Life Res*. 2002;11:563–574.

Coyne KS, Cash B, Kopp Z, et al. The prevalence of chronic constipation and faecal incontinence among men and women with symptoms of overactive bladder. *BJU Int*. 2011;107:254–261.

Coyne KS, Margolis MK, Kopp ZS, et al. Racial differences in the prevalence of overactive bladder in the United States from the epidemiology of LUTS (EpiLUTS) study. *Urology*. 2012;79:95–101.

Coyne KS, Sexton CC, Bell JA, et al. The prevalence of lower urinary tract symptoms (LUTS) and overactive bladder (OAB) by racial/ethnic group and age: results from OAB-POLL. *Neurourol Urodyn*. 2013;32:230–237.

Coyne KS, Sexton CC, Clemens JQ, et al. The impact of OAB on physical activity in the United States: results from OAB-POLL. *Urology*. 2013;82:799–806.

Coyne KS, Sexton CC, Thompson CL, et al. The prevalence of lower urinary tract symptoms (LUTS) in the USA, the UK and Sweden: results from the Epidemiology of LUTS (EpiLUTS) study. *BJU Int*. 2009;104:352–360.

Coyne KS, Thompson CL, Lai J-S, et al. An overactive bladder symptom and health-related quality of life short-form: validation of the OAB-q SF. *Neurourol Urodyn*. 2015;34:255–263.

Daly D, Chapple C. Relationship between overactive bladder (OAB) and irritable bowel syndrome (IBS): concurrent disorders with a common pathophysiology? *BJU Int*.

2013;111:530–531.

Davis R, Jones JS, Barocas DA, et al. Diagnosis, evaluation and follow-up of asymptomatic microhematuria (AMH) in Adults: AUA Guideline. *J Urol*. 2012 http://dx.doi.org/10.1016/j.juro.2012.09.078.

De Wachter S, Wyndaele J-J. Impact of rectal distention on the results of evaluations of lower urinary tract sensation. *J Urol*. 2003;169:1392–1394.

Dmochowski RR, Newman DK. Impact of overactive bladder on women in the United States: results of a national survey. *Curr Med Res Opin*. 2007;23:65–76.

Dooley Y, Kenton K, Cao G, et al. Urinary incontinence prevalence: results from the National Health and Nutrition Examination Survey. *J Urol*. 2008;179:656–661.

Drake MJ, Fowler CJ, Griffiths D, et al. Neural control of the lower urinary and gastrointestinal tracts: supraspinal CNS mechanisms. *Neurourol Urodyn*. 2010;29:119–127.

Drake MJ, Harvey IJ, Gillespie JI, et al. Localized contractions in the normal human bladder and in urinary urgency. *BJU Int*. 2005;95:1002–1005.

Drake MJ, Harvey IJ, Gillespie JI. Autonomous activity in the isolated guinea pig bladder. *Exp Physiol*. 2003;88:19–30.

Drake MJ, Hedlund P, Harvey IJ, et al. Partial outlet obstruction enhances modular autonomous activity in the isolated rat bladder. *J Urol*. 2003;170:276–279.

Drake MJ, Hedlund P, Mills IW, et al. Structural and functional denervation of human detrusor after spinal cord injury. *Lab Invest*. 2000;80:1491–1499.

Drake MJ, Mills IW, Gillespie JI. Model of peripheral autonomous modules and a myovesical plexus in normal and overactive bladder function. *Lancet*. 2001;358:401–403.

Drake MJ. The integrative physiology of the bladder. *Ann R Coll Surg Engl*. 2007;89:580–585.

Elbadawi A, Yalla SV, Resnick NM. Structural basis of geriatric voiding dysfunction. III. Detrusor overactivity. *J Urol*. 1993;150:1668–1680.

FitzGerald MP, Butler N, Shott S, et al. Bother arising from urinary frequency in women. *Neurourol Urodyn*. 2002;21:36–40 [discussion 41].

FitzGerald MP, Kenton KS, Brubaker L. Localization of the urge to void in patients with painful bladder syndrome. *Neurourol Urodyn*. 2005;24:633–637.

Ganz ML, Smalarz AM, Krupski TL, et al. Economic costs of overactive bladder in the United States. *Urology*. 2010;75:526–532 [532.e1–18].

German K, Bedwani J, Davies J, et al. Physiological and morphometric studies into the pathophysiology of detrusor hyperreflexia in neuropathic patients. *J Urol*. 1995;153:1678–1683.

Giamberardino MA, Costantini R, Affaitati G, et al. Viscero-visceral hyperalgesia: characterization in different clinical models. *Pain*. 2010;151:307–322.

Gill BC, Pizarro-Berdichevsky J, Bhattacharyya PK, et al. Real-time changes in brain activity during sacral neuromodulation for overactive bladder. *J Urol*. 2017;198:1379–1385.

Gillespie JI, van Koeveringe GA, de Wachter SG, et al. On the origins of the sensory output from the bladder: the concept of afferent noise. *BJU Int*. 2009;103:1324–1333.

Goldman HB, Lloyd JC, Noblett KL, et al. International Continence Society best practice statement for use of sacral neuromodulation [Internet]. *Neurourol Urodyn*. 2018 http://dx.doi.org/10.1002/nau.23596.

Gormley EA, Lightner DJ, Burgio KL, et al. Diagnosis and treatment of overactive bladder (non-neurogenic) in adults: AUA/SUFU guideline. *J Urol*. 2012;188:2455–2463.

Gormley EA, Lightner DJ, Faraday M, American Urological

Association, Society of Urodynamics, Female Pelvic Medicine, et al. Diagnosis and treatment of overactive bladder (non-neurogenic) in adults: AUA/SUFU guideline amendment. *J Urol*. 2015;193:1572–1580.

Gratzke C, Bachmann A, Descazeaud A, et al. EAU Guidelines on the assessment of non-neurogenic male lower urinary tract symptoms including benign prostatic obstruction. *Eur Urol*. 2015;67:1099–1109.

Griffiths D, Tadic SD, Schaefer W, et al. Cerebral control of the bladder in normal and urge-incontinent women. *Neuroimage*. 2007;37:1–7.

Griffiths DJ. Use of functional imaging to monitor central control of voiding in humans. *Handb Exp Pharmacol*. 2011;81–97.

Guo Y-J, Ho C-H, Chen S-C, et al. Lower urinary tract symptoms in women with irritable bowel syndrome. *Int J Urol*. 2010;17:175–181.

Gupta P, Ehlert MJ, Sirls LT, et al. Percutaneous tibial nerve stimulation and sacral neuromodulation: an update. *Curr Urol Rep*. 2015;16:4.

Häbler HJ, Jänig W, Koltzenburg M. Activation of unmyelinated afferent fibres by mechanical stimuli and inflammation of the urinary bladder in the cat. *J Physiol*. 1990;425:545–562.

Haferkamp A, Dörsam J, Elbadawi A. Ultrastructural diagnosis of neuropathic detrusor overactivity: validation of a common myogenic mechanism. *Adv Exp Med Biol*. 2003;539:281–291.

Haferkamp A, Dörsam J, Resnick NM, et al. Structural basis of neurogenic bladder dysfunction. III. Intrinsic detrusor innervation. *J Urol*. 2003;169:555–562.

Hall SA, Link CL, Hu JC, et al. Drug treatment of urological symptoms: estimating the magnitude of unmet need in a community-based sample. *BJU Int*. 2009;104:1680–1688.

Hampson LA, Elliott SP, Erickson BA, et al. Multicenter analysis of urinary urgency and urge incontinence in patients with anterior urethral stricture disease before and after urethroplasty. *J Urol*. 2016;196:1700–1705.

Hanno P, Nordling J, van Ophoven A. What is new in bladder pain syndrome/interstitial cystitis? *Curr Opin Urol*. 2008;18:353–358.

Hashim H, Abrams P. How should patients with an overactive bladder manipulate their fluid intake? *BJU Int*. 2008;102:62–66.

Hashim H, Abrams P. Is the bladder a reliable witness for predicting detrusor overactivity? *J Urol*. 2006;175:191–194 [discussion 194–195].

Haylen BT, de Ridder D, Freeman RM, et al. An International Urogynecological Association (IUGA)/International Continence Society (ICS) joint report on the terminology for female pelvic floor dysfunction. *Neurourol Urodyn*. 2010;29:4–20.

Heidler S, Mert C, Temml C, et al. The natural history of the overactive bladder syndrome in females: a long-term analysis of a health screening project. *Neurourol Urodyn*. 2011;30:1437–1441.

Heslington K, Hilton P. Ambulatory monitoring and conventional cystometry in asymptomatic female volunteers. *Br J Obstet Gynaecol*. 1996;103:434–441.

Hogan S, Gammie A, Abrams P. Urodynamic features and artefacts. *Neurourol Urodyn*. 2012;31:1104–1117.

Imamura M, Williams K, Wells M, et al. Lifestyle interventions for the treatment of urinary incontinence in adults. *Cochrane Database Syst Rev*. 2015;(12) [CD003505].

Irwin DE, Milsom I, Chancellor MB, et al. Dynamic progression of overactive bladder and urinary incontinence symptoms: a systematic review. *Eur Urol*. 2010;58:532–543.

Irwin DE, Milsom I, Hunskaar S, et al. Population-based survey of urinary incontinence, overactive bladder, and other lower urinary tract symptoms in five countries: results of the EPIC study. *Eur Urol*. 2006;50:1306–1314 [discussion 1314–1315].

Jackson S, Donovan J, Brookes S, et al. The Bristol Female Lower Urinary Tract Symptoms questionnaire: development and psychometric testing. *Br J Urol*. 1996;77:805–812.

Ju R, Garrett J, Wu JM. Anticholinergic medication use for female overactive bladder in the ambulatory setting in the United States. *Int Urogynecol J*. 2014;25:479–484.

Kanai A, Andersson K-E. Bladder afferent signaling: recent findings. *J Urol*. 2010;183:1288–1295.

Kanai AJ. Afferent mechanism in the urinary tract. *Handb Exp Pharmacol*. 2011;171–205.

Kaplan SA, Dmochowski R, Cash BD, et al. Systematic review of the relationship between bladder and bowel function: implications for patient management. *Int J Clin Pract*. 2013;67:205–216.

Kaplan SA, Roehrborn CG, Abrams P, et al. Antimuscarinics for treatment of storage lower urinary tract symptoms in men: a systematic review. *Int J Clin Pract*. 2011;65:487–507.

Kashyap MP, Pore SK, de Groat WC, et al. BDNF overexpression in the bladder induces neuronal changes to mediate bladder overactivity. *Am J Physiol Renal Physiol*. 2018;315:F45–F56.

Keay SK, Birder LA, Chai TC. Evidence for bladder urothelial pathophysiology in functional bladder disorders. *Biomed Res Int*. 2014;2014:865463.

Kinsey D, Pretorius S, Glover L, et al. The psychological impact of overactive bladder: a systematic review. *J Health Psychol*. 2016;21:69–81.

Klingele CJ, Lightner DJ, Fletcher JG, et al. Dysfunctional urinary voiding in women with functional defecatory disorders. *Neurogastroenterol Motil*. 2010;22:1094–e284.

Komesu YM, Ketai LH, Mayer AR, et al. Functional MRI of the brain in women with overactive bladder: brain activation during urinary urgency. *Female Pelvic Med Reconstr Surg*. 2011;17:50–54.

Kowalik CG, Cohn JA, Delpe S, et al. Painful bladder symptoms related to somatic syndromes in a convenience sample of community women with overactive bladder symptoms. *J Urol*. 2018 http://dx.doi.org/10.1016/j.juro.2018.06.070.

Kupelian V, Rosen RC, Roehrborn CG, et al. Association of overactive bladder and C-reactive protein levels. Results from the Boston Area Community Health (BACH) Survey. *BJU Int*. 2012;110:401–407.

Kupelian V, Wei JT, O'Leary MP, et al. Prevalence of lower urinary tract symptoms and effect on quality of life in a racially and ethnically diverse random sample: the Boston Area Community Health (BACH) Survey. *Arch Intern Med*. 2006;166:2381–2387.

Lai HH, Helmuth ME, Smith AR, et al. Relationship between central obesity, general obesity, overactive bladder syndrome and urinary incontinence among male and female patients seeking care for their lower urinary tract symptoms. *Urology*. 2018 http://dx.doi.org/10.1016/j.urology.2018.09.012.

Lai HH, Krieger JN, Pontari MA, et al. Painful bladder filling and painful urgency are distinct characteristics in men and women with urological chronic pelvic pain syndromes: a MAPP Research Network Study. *J Urol*. 2015;194:1634–1641.

Lai HH, Shen B, Rawal A, et al. The relationship between depression and overactive bladder/urinary incontinence symptoms in the clinical OAB population. *BMC Urol*.

2016;16:60.

Leone Roberti Maggiore U, Salvatore S, Alessandri F, et al. Pharmacokinetics and toxicity of antimuscarinic drugs for overactive bladder treatment in females. *Expert Opin Drug Metab Toxicol*. 2012;8:1387–1408.

Lim C, Cohn J, Kowalik C, et al. MP27-06 risk factors associated with fecal incontinence in patients with overactive bladder. *J Urol*. 2018;199:e348.

Lucas MG, Bosch RJL, Burkhard FC, et al. EAU guidelines on assessment and nonsurgical management of urinary incontinence. *Eur Urol*. 2012;62:1130–1142.

Lukacz ES, Whitcomb EL, Lawrence JM, et al. Urinary frequency in community-dwelling women: what is normal? *Am J Obstet Gynecol*. 2009;200:552.e1–552.e7.

Malykhina AP, Qin C, Greenwood-van Meerveld B, et al. Hyperexcitability of convergent colon and bladder dorsal root ganglion neurons after colonic inflammation: mechanism for pelvic organ cross-talk. *Neurogastroenterol Motil*. 2006;18:936–948.

Malykhina AP, Wyndaele J-J, Andersson K-E, et al. Do the urinary bladder and large bowel interact, in sickness or in health? ICI-RS 2011. *Neurourol Urodyn*. 2012;31:352–358.

Malykhina AP. Neural mechanisms of pelvic organ cross-sensitization. *Neuroscience*. 2007;149:660–672.

Mangera A, Apostolidis A, Andersson KE, et al. An updated systematic review and statistical comparison of standardised mean outcomes for the use of botulinum toxin in the management of lower urinary tract disorders. *Eur Urol*. 2014;65:981–990.

Mangera A, Chapple CR, Kopp ZS, et al. The placebo effect in overactive bladder syndrome. *Nat Rev Urol*. 2011;8:495–503.

Mazières L, Jiang C, Lindström S. The C fibre reflex of the cat urinary bladder. *J Physiol*. 1998;513(Pt 2):531–541.

McVary KT, Roehrborn CG, Avins AL, et al. Update on AUA Guideline on the management of benign prostatic hyperplasia. *J Urol*. 2011;185:1793–1803.

Miller KL, DuBeau CE, Bergmann M, et al. Quest for a detrusor overactivity index. *J Urol*. 2002;167:578–584 [discussion 584–585].

Mills IW, Greenland JE, McMurray G, et al. Studies of the pathophysiology of idiopathic detrusor instability: the physiological properties of the detrusor smooth muscle and its pattern of innervation. *J Urol*. 2000;163:646–651.

Milsom I, Abrams P, Cardozo L, et al. How widespread are the symptoms of an overactive bladder and how are they managed? A population-based prevalence study. *BJU Int*. 2001;87:760–766.

Milsom I, Kaplan SA, Coyne KS, et al. Effect of bothersome overactive bladder symptoms on health-related quality of life, anxiety, depression, and treatment seeking in the United States: results from EpiLUTS. *Urology*. 2012;80:90–96.

Minagawa T, Wyndaele M, Aizawa N, et al. Mechanisms of pelvic organ cross-talk: 2. Impact of colorectal distention on afferent nerve activity of the rat bladder. *J Urol*. 2013;190:1123–1130.

Monga AK, Marrero JM, Stanton SL, et al. Is there an irritable bladder in the irritable bowel syndrome? *BJOG*. 1997;104:1409–1412.

Moses KA, Heslop D, Griffith DM, et al. Development and initial testing of the FLOW Instrument, a novel assessment of lower urinary tract symptoms in men. *J Urol*. 2017 http://www.sciencedirect.com/science/article/pii/S00225

Nambiar AK, Bosch R, Cruz F, et al. EAU guidelines on assessment and nonsurgical management of urinary incontinence. *Eur Urol*. 2018;73:596–609.

Nambiar AK, Lemack GE, Chapple CR, European Association of Urology, et al. The role of urodynamics in the evaluation of urinary incontinence: the European Association of Urology Recommendations in 2016. *Eur Urol*. 2017;71:501–503.

Nitti VW, Dmochowski R, Herschorn S, et al. OnabotulinumtoxinA for the treatment of patients with overactive bladder and urinary incontinence: results of a phase 3, randomized, placebo controlled trial. *J Urol*. 2013;189:2186–2193.

Nitti VW, Khullar V, van Kerrebroeck P, et al. Mirabegron for the treatment of overactive bladder: a prespecified pooled efficacy analysis and pooled safety analysis of three randomised, double-blind, placebo-controlled, phase III studies. *Int J Clin Pract*. 2013;67:619–632.

Oelke M, Baard J, Wijkstra H, et al. Age and bladder outlet obstruction are independently associated with detrusor overactivity in patients with benign prostatic hyperplasia. *Eur Urol*. 2008;54:419–426.

Oh MM, Choi H, Park MG, et al. Is there a correlation between the presence of idiopathic detrusor overactivity and the degree of bladder outlet obstruction? *Urology*. 2011;77:167–170.

Osborn DJ, Kaufman MR, Mock S, et al. Urinary retention rates after intravesical onabotulinumtoxinA injection for idiopathic overactive bladder in clinical practice and predictors of this outcome. *Neurourol Urodyn*. 2015;34:675–678.

Parsons BA, Drake MJ. Animal models in overactive bladder research. *Handb Exp Pharmacol*. 2011;15–43.

Pearce MM, Hilt EE, Rosenfeld AB, et al. The female urinary microbiome: a comparison of women with and without urgency urinary incontinence. *MBio*. 2014;5 [e01283–14].

Pearce MM, Zilliox MJ, Rosenfeld AB, et al. The female urinary microbiome in urgency urinary incontinence. *Am J Obstet Gynecol*. 2015;213:347.e1–347.e11.

Reynolds WS, Brown ET, Danford J, et al. Temporal summation to thermal stimuli is elevated in women with overactive bladder syndrome. *Neurourol Urodyn*. 2017;36:1108–1112.

Reynolds WS, McPheeters M, Blume J, et al. Comparative effectiveness of anticholinergic therapy for overactive bladder in women: a systematic review and meta-analysis. *Obstet Gynecol*. 2015;125:1423–1432.

Reynolds WS, Mock S, Zhang X, et al. Somatic syndromes and chronic pain in women with overactive bladder. *Neurourol Urodyn*. 2017;36:1113–1118.

Robinson D, Cardozo L, Milsom I, et al. Oestrogens and overactive bladder. *Neurourol Urodyn*. 2014;33:1086–1091.

Rudick CN, Chen MC, Mongiu AK, et al. Organ cross talk modulates pelvic pain. *Am J Physiol Regul Integr Comp Physiol*. 2007;293:R1191–R1198.

Schäfer W, Abrams P, Liao L, et al. Good urodynamic practices: uroflowmetry, filling cystometry, and pressure-flow studies. *Neurourol Urodyn*. 2002;21:261–274.

Senekjian L, Heintz K, Egger MJ, et al. Do women understand urogynecologic terminology? *Female Pelvic Med Reconstr Surg*. 2011;17:215–217.

Sexton CC, Notte SM, Maroulis C, et al. Persistence and adherence in the treatment of overactive bladder syndrome with anticholinergic therapy: a systematic review of the literature. *Int J Clin Pract*. 2011;65:567–585.

Shamliyan T, Wyman J, Kane RL. *Nonsurgical treatments for urinary incontinence in adult women: diagnosis and comparative effectiveness*. Agency for Healthcare Research and Quality (US): Rockville (MD); 2012.

Shumaker SA, Wyman JF, Uebersax JS, et al. Health-related quality of life measures for women with urinary incontinence: the Incontinence Impact Questionnaire and the Urogenital Distress Inventory. Continence Program in Women (CPW)

Research Group. *Qual Life Res*. 1994;3:291–306.

Siegel S, Noblett K, Mangel J, et al. Five-year followup results of a prospective, multicenter study of patients with overactive bladder treated with sacral neuromodulation. *J Urol*. 2018;199:229–236.

Siegel S. OnabotulinumtoxinA is preferred over sacral neuromodulation for refractory overactive bladder. *J Urol*. 2017;197:11–13.

Sirls ER, Killinger KA, Boura JA, et al. Percutaneous tibial nerve stimulation in the office setting: real-world experience of over 100 patients. *Urology*. 2017 http://dx.doi.org/10.1016/j.urology.2017.11.026.

Smith AL, Hantsoo L, Malykhina AP, et al. Basal and stress-activated hypothalamic pituitary adrenal axis function in postmenopausal women with overactive bladder. *Int Urogynecol J*. 2016;27:1383–1391.

Smith AL, Nissim HA, Le TX, et al. Misconceptions and miscommunication among aging women with overactive bladder symptoms. *Urology*. 2011;77:55–59.

Stewart WF, Van Rooyen JB, Cundiff GW, et al. Prevalence and burden of overactive bladder in the United States. *World J Urol*. 2003;20:327–336.

Subak L, Van Den Eeden S, Thom D, et al. Urinary incontinence in women: direct costs of routine care. *Am J Obstet Gynecol*. 2007;197:596.e1–596.e9.

Subak LL, Grady D. Asymptomatic microscopic hematuria—rethinking the diagnostic algorithm. *JAMA Intern Med*. 2017;177:808–809.

Subak LL, King WC, Belle SH, et al. Urinary incontinence before and after bariatric surgery. *JAMA Intern Med*. 2015;175:1378–1387.

Subak LL, Wing R, West DS, et al. Weight loss to treat urinary incontinence in overweight and obese women. *N Engl J Med*.

2009;360:481–490.

Swithinbank L, Hashim H, Abrams P. The effect of fluid intake on urinary symptoms in women. *J Urol*. 2005;174:187–189.

Syan R, Brucker BM. Guideline of guidelines: urinary incontinence. *BJU Int*. 2016;117:20–33.

Thomas AW, Cannon A, Bartlett E, et al. The natural history of lower urinary tract dysfunction in men: minimum 10-year urodynamic followup of transurethral resection of prostate for bladder outlet obstruction. *J Urol*. 2005;174:1887–1891.

Thomas-White KJ, Hilt EE, Fok C, et al. Incontinence medication response relates to the female urinary microbiota. *Int Urogynecol J*. 2016;27:723–733.

Tikkinen KAO, Johnson TM II, Tammela TLJ, et al. Nocturia frequency, bother, and quality of life: how often is too often? A Population-Based Study in Finland. *Eur Urol*. 2010;57:488–498.

Tomlinson BU, Dougherty MC, Pendergast JF, et al. Dietary caffeine, fluid intake and urinary incontinence in older rural women. *Int Urogynecol J Pelvic Floor Dysfunct*. 1999;10:22–28.

Tyagi P, Tyagi V, Qu X, et al. Association of inflammaging (inflammation + aging) with higher prevalence of OAB in elderly population. *Int Urol Nephrol*. 2014;46:871–877.

Uebersax JS, Wyman JF, Shumaker SA, et al. Short forms to assess life quality and symptom distress for urinary incontinence in women: the Incontinence Impact Questionnaire and the Urogenital Distress Inventory. Continence Program for Women Research Group. *Neurourol Urodyn*. 1995;14:131–139.

Ustinova EE, Fraser MO, Pezzone MA. Cross-talk and sensitization of bladder afferent nerves. *Neurourol Urodyn*. 2010;29:77–81.

Van Os-Bossagh P, Kosterman LM, Hop WC, et al.

Micromotions of bladder wall in chronic pelvic pain (CPP): a pilot study. *Int Urogynecol J Pelvic Floor Dysfunct*. 2001;12:89–96.

Verghese TS, Middleton LJ, Daniels JP, et al. The impact of urodynamics on treatment and outcomes in women with an overactive bladder: a longitudinal prospective follow-up study. *Int Urogynecol J*. 2018;29:513–519.

Visco AG, Brubaker L, Richter HE, et al. Anticholinergic therapy vs. onabotulinumtoxina for urgency urinary incontinence. *N Engl J Med*. 2012;367:1803–1813.

Vrijens D, Drossaerts J, van Koeveringe G, et al. Affective symptoms and the overactive bladder—a systematic review. *J Psychosom Res*. 2015;78:95–108.

Wagg A, Gibson W, Ostaszkiewicz J, et al. Urinary incontinence in frail elderly persons: report from the 5th International Consultation on Incontinence. *Neurourol Urodyn*. 2015;34:398–406.

Wang DS, Jani AB, Tai CG, et al. Severe lack of comprehension of common prostate health terms among low-income inner-city men. *Cancer*. 2013;119:3204–3211.

Weiss JP, Blaivas JG, Bliwise DL, et al. The evaluation and treatment of nocturia: a consensus statement. *BJU Int*. 2011;108:6–21.

Weissbart SJ, Bhavsar R, Rao H, et al. Specific changes in brain activity during urgency in women with overactive bladder after successful sacral neuromodulation: a functional magnetic resonance imaging study. *J Urol*. 2018;200:382–388.

Wennberg A-L, Molander U, Fall M, et al. A longitudinal population-based survey of urinary incontinence, overactive bladder, and other lower urinary tract symptoms in women. *Eur Urol*. 2009;55:783–791.

Winters JC, Dmochowski RR, Goldman HB, et al. Urodynamic studies in adults: AUA/SUFU guideline. *J Urol*. 2012;188:2464–2472.

Wu EQ, Birnbaum H, Marynchenko M, et al. Employees with overactive bladder: work loss burden. *J Occup Environ Med*. 2005;47:439–446.

Wyndaele J-J, Van Meel TD, De Wachter S. Detrusor overactivity. Does it represent a difference if patients feel the involuntary contractions? *J Urol*. 2004;172:1915–1918.

Wyndaele M, De Wachter S, De Man J, et al. Mechanisms of pelvic organ crosstalk: 1. Peripheral modulation of bladder inhibition by colorectal distention in rats. *J Urol*. 2013;190:765–771.

Wyndaele M, De Winter BY, Pelckmans P, et al. Lower bowel function in urinary incontinent women, urinary continent women and in controls. *Neurourol Urodyn*. 2011;30:138–143.

Wyndaele M, De Winter BY, Pelckmans PA, et al. Exploring associations between lower urinary tract symptoms (LUTS) and gastrointestinal (GI) problems in women: a study in women with urological and GI problems vs a control population. *BJU Int*. 2015;115:958–967.

Xiao Z, Rogers MJ, Shen B, et al. Somatic modulation of spinal reflex bladder activity mediated by nociceptive bladder afferent nerve fibers in cats. *Am J Physiol Renal Physiol*. 2014;307:F673–F679.

Yoshimura N, de Groat WC. Increased excitability of afferent neurons innervating rat urinary bladder after chronic bladder inflammation. *J Neurosci*. 1999;19:4644–4653.

Zhao Y-R, Liu W-Z, Guralnick M, et al. Predictors of short-term overactive bladder symptom improvement after transurethral resection of prostate in men with benign prostatic obstruction. *Int J Urol*. 2014;21:1035–1040.

Zhao Z, Azad R, Yang J-H, et al. Progressive changes in detrusor function and micturition patterns with chronic bladder ischemia. *Investig Clin Urol*. 2016;57:249–259.

Zhou J, Kelsey KT, Smith S, et al. Lower urinary tract symptoms and risk of bladder cancer in men: results from the health professionals follow-up study. *Urology*. 2015;85:1312–1318.

Zinner N, Harnett M, Sabounjian L, et al. The overactive bladder-symptom composite score: a composite symptom score of toilet voids, urgency severity and urge urinary incontinence in patients with overactive bladder. *J Urol*. 2005;173:1639–1643.

The Underactive Detrusor

Christopher R. Chapple MD, FRCS (Urol), Nadir I. Osman MBChB (Hons), MRCS

An impaired ability to empty the bladder is common in both men and women with aging. It may be attributable to increased resistance of the bladder outlet and/or a reduction in the ability to generate an efficient bladder contraction, referred to as *detrusor underactivity (DUA)* by the International Continence Society (ICS), although the symptomatic condition could be labeled the *underactive bladder.* Increased bladder outlet resistance, far more common in men because of the effect of benign prostatic hyperplasia (BPH) with aging, has been the target of most therapeutic interventions for lower urinary tract symptoms (LUTS) in men. By contrast, DUA mostly lacks any effective treatment other than catheterization (preferably by intermittent self-catheterization [ISC]), when the postvoid residual (PVR) is raised. Despite its common prevalence, which increases with age, in patients with LUTS referred to urologists, the underlying cause and pathophysiologic mechanisms are poorly understood. Recently there has been a resurgence of interest in this poorly understood condition (Miyazato et al., 2013; Osman et al., 2014; van Koeveringe et al., 2011). In this chapter, we summarize and discuss the contemporary evidence relating to symptomatology, epidemiology, cause, diagnosis, and management of the underactive bladder.

Terminology, Definitions, and Symptoms

A confusing multitude of terms are used to describe impaired bladder voiding function, including *impaired detrusor contractility*, *detrusor areflexia*, and *detrusor failure.* **The ICS standardization document in 2002 termed the problem *DUA* defined on the basis of a urodynamic study (UDS) as “a contraction of reduced strength and/or duration, resulting in prolonged bladder emptying and/or failure to achieve complete bladder emptying within a normal time span”** (Abrams et al., 2002) **(Fig. 118.1A). What constitutes reduced strength, reduced length of contraction, or prolonged emptying is not specified. If no contraction occurs, the term *acontractile detrusor* is used (see Fig. 118.1B).** In clinical practice, it is important to distinguish this from an isolated inability to void during a UDS (or “bashful bladder”), which is common and often can be correlated with a history of being unable to void in public restrooms.

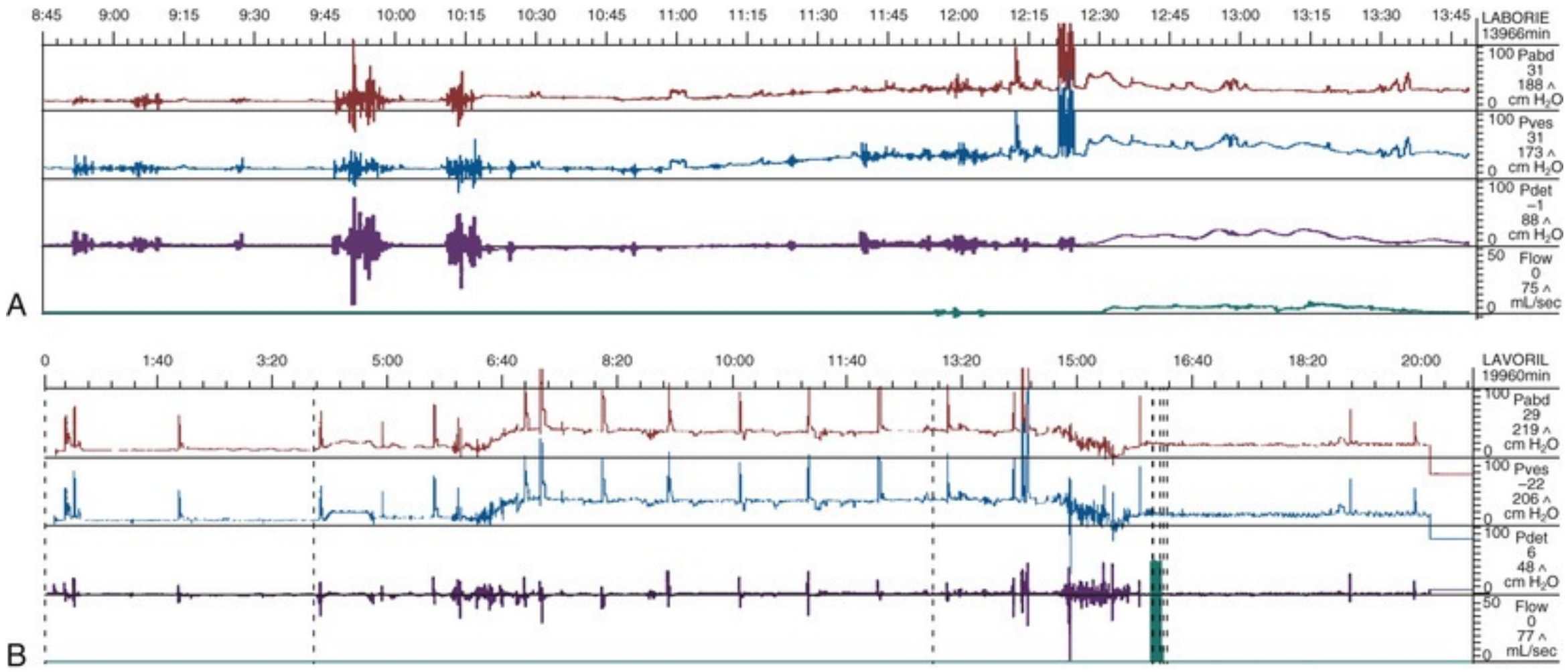

FIG. 118.1 Urodynamic traces. (A) A 67-year-old male patient with benign prostatic enlargement and predominant voiding lower urinary tract symptoms. The voiding phase demonstrates low detrusor pressure, prolonged detrusor contraction, and prolonged voiding time. The postvoid residual was 100 mL, and the diagnosis is detrusor underactivity. (B) A 29-year-old female patient with a history of lower back injury and urinary retention managed with intermittent self-catheterization. The diagnosis is acontractile detrusor. *Pabd,* Abdominal pressure; *Pdet,* detrusor pressure; *Pves,* intravesical pressure.

- Defining DUA in purely urodynamic terms is problematic, because this currently necessitates an invasive test that is neither available nor appropriate in all health care settings. These were some of the reasons why the overactive bladder (OAB) symptom complex was introduced as an adjunct to the urodynamic concepts. Nevertheless, the two situations are not entirely analogous, because OAB can be defined by the presence of urinary urgency (albeit variably correlated to detrusor overactivity [DOA]). **A symptom syndrome of underactive bladder is difficult to define because of the absence of individual symptoms that can be considered pathognomonic of the underlying detrusor abnormality. In particular, the symptoms of DUA are diverse and overlap significantly with those seen in OAB and are associated with bladder outlet obstruction (BOO)**. **During the voiding phase, patients may experience weak stream, intermittency, hesitancy, and straining. After voiding, some report a feeling of incomplete bladder emptying. In the storage phase, some experience urinary frequency and nocturia, whereas others may have a loss of the normal urge to void (the opposite of urinary urgency) and report infrequent voiding. In the presence of a very large PVR, patients may experience incontinence (especially during sleep).** One could speculate that the reason for these very different clinical pictures is related to the degree of residual bladder sensation, with patients with very poor sensation typically being infrequent voiders and those with intact sensation voiding frequently in the presence of a raised PVR (Fig. 118.2). A further problem at present relates to the lack of consensus over what represents a clinically significant residual volume in the bladder, with the suggestion being that the threshold is more than 40% of the functional capacity (volume voided + residual).

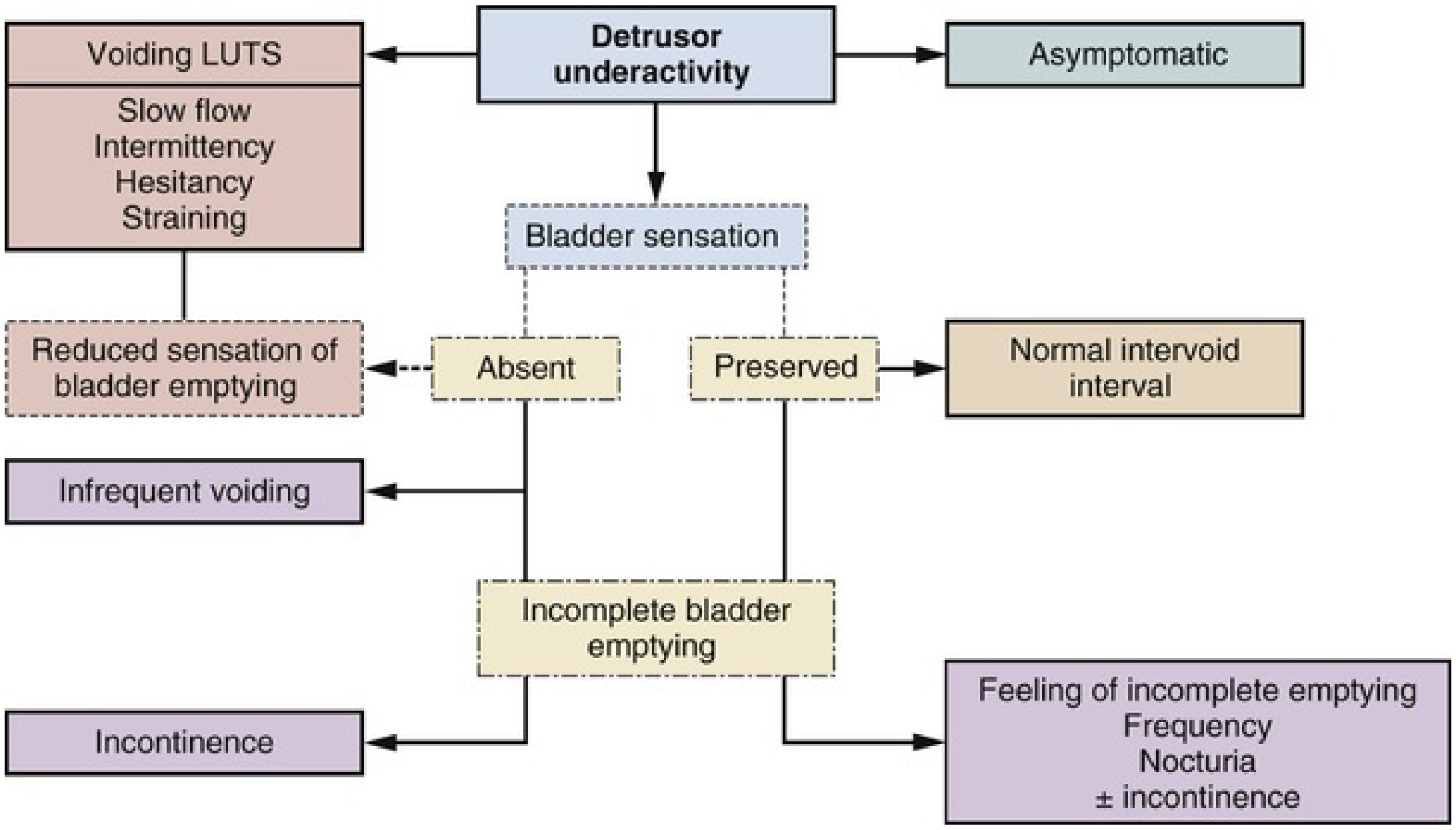
Voiding LUTS
Slow flow
Intermittency
Hesitancy
Straining
Detrusor underactivity
Asymptomatic
Bladder sensation
Reduced sensation of bladder emptying
Absent
Preserved
Normal intervoid interval
Infrequent voiding
Incomplete bladder emptying
Incontinence
Feeling of incomplete emptying
Frequency
Nocturia
± incontinence

FIG. 118.2 Lower urinary tract symptoms (LUTS) in detrusor underactivity (DUA). DUA may manifest with a spectrum of voiding, storage, and postmicturition LUTS or cause no symptoms. Patients with significantly impaired bladder sensation void infrequently and, if bladder emptying is reduced, may have incontinence, typically more pronounced during nighttime (urethral relaxation during sleep). Patients who have preserved bladder sensation can have a normal intervoid interval provided bladder emptying is normal. If bladder emptying is poor, these patients typically experience a sensation of incomplete emptying after voiding, urinary frequency, and nocturia ± incontinence. This wide variation in symptomatology and its overlap with LUTS/benign prostatic hyperplasia and overactive bladder hampers the development of a reliable symptom-based definition.

- Notwithstanding the above limitations, several attempts have been made at defining UAB. The most recent was proposed by Chapple et al. (2018) and has been accepted by the standardization committee of the international continence society (ICS).
- **Underactive bladder** is characterized by a slow urinary stream, hesitancy, and straining to void, with or without a feeling of incomplete bladder emptying, sometimes with storage symptoms. (Note: Underactive bladder occurs in association with diverse pathophysiologies and, based on current knowledge, there is no single distinguishing symptom. Storage symptoms are varied and

may be highly prevalent, including nocturia, increased daytime frequency, reduced sensation of filling, and incontinence. Underlying mechanisms of storage symptoms are diverse and are often related to a significant PVR urine volume.) Two recent studies (one quantitative, one qualitative) have suggested this definition is in keeping with the symptoms patients with urodynamic DUA are most likely to experience (Gammie et al., 2016; Uren et al., 2017).

Epidemiology

Epidemiologic studies have demonstrated that LUTS have a high prevalence in the population, increasing significantly with age. However, the extent to which DUA is a contributing factor is unknown. The Epidemiology of LUTS (EpiLUTS) study, conducted in the United Kingdom, United States, and Sweden, included 30,000 participants older than 40 years of age and showed that storage LUTS (occurring at least sometimes) are present in 45.7% of men and 66.8% of women. Voiding LUTS (occurring at least sometimes) were documented in 57.1% of men and 48% of women (Sexton et al., 2009). Postmicturition symptoms occur with a similar prevalence in both men and women. A more recent survey of 633 community dwelling individuals (mean age 74.3 years) reported a total of 23% had difficulty emptying their bladder (Valente et al., 2014). **Although it is clearly likely that multiple factors contribute to this clinical picture, it is difficult to establish on a population basis to what extent DUA is a cause of these symptoms because of the lack of a simple noninvasive marker.**

In men, voiding LUTS, raised PVR, or reduced urinary flow rate, individually or collectively, cannot be used as proxy measures for DUA, because they could be attributed to BOO. Similarly, in women, voiding LUTS such as straining often can occur in the context of frequency and low voided volumes associated with OAB. However, if voiding LUTS occur in association with more objective evidence such as reduced flow rate and raised PVR, underlying DUA becomes more likely as a result of the extremely low incidence of BOO in women (2.7% to 8% of those referred for UDS) (Carr and Webster, 1996).

In the absence of reliable epidemiologic data, clinical studies indicate that DUA is very common in patients with LUTS referred for urodynamic assessment, particularly in the older age groups (Table 118.1). **DUA is diagnosed in 9% to 28% of males younger than 50 years of age and 48% in those older than 70 years of age. In females, DUA is present in 12% to 45%, being more common in elderly nursing home residents who often have concomitant DOA, an entity described as detrusor hyperactivity impaired contractility (DHIC)** (Resnick et al., 1989). It must be borne in mind that these data cannot be extrapolated to the general population and are limited by the inconsistency in definitions used in these studies, the populations studied, and the post-hoc data interpretation.

TABLE 118.1

Prevalence of Detrusor Underactivity in Clinical Studies

STUDY	POPULATION	SIZE	AGE RANGE OR MEAN AGE (YEARS)	DIAGNOSTIC CRITERIA	PREVALENCE OF DUA + (% OF ACONTRACTILE DETRUSORS)
Fusco et al., 2001	Male	541	26–89	Pdet@Qmax ≤30 cm H_2O and Qmax ≤12 mL/sec	10
Kuo, 2007b	Male	1407	46–96	Relaxed sphincter EMG with open membranous urethra during voiding and low flow rate	10.6
Nitti et al., 2002	Male	85	18–45	Bladder outlet obstruction index <20 cm H_2O and uroflow <12 mL/sec	9
Wang et al., 2003	Male	90	18–50	Pdet@Qmax <30 cm H_2O and Qmax <15 mL/sec	10
Kaplan et al., 1996	Male	137	18–50	Pdet@Qmax <45 cm H_2O and Qmax <12 mL/sec	23 (5)
Karami et al., 2011	Male	456	18–40	ICS definition	12.9 (10.5)
Abarbanel and Marcus, 2007	Male	82	>70	Pdet@Qmax <30 cm H_2O and Qmax <10 mL/sec	48
	Female	99	>70		12
Jeong et al., 2012	Male	632	>65	Bladder contractility index <100 (men)	40.2

	Female	547	>65	Qmax ≤12 mL/sec and Pdet@Qmax ≤10 cm H_2O (women)	13.3
Resnick et al., 1989	Male	17	87	In the absence of obstruction, underactive detrusor: “Failure to empty in the absence of an increase in abdominal pressure”	41.2
	Female (institutionalized)	77		DHIC: “Involuntary detrusor contraction that emptied less than half of volume instilled”	37.7
Resnick et al., 1996	Female (institutionalized)	97	87.6	“Reproducible failure of the involuntary contraction to empty at least half of bladder contents in the absence of straining, urethral obstruction, and detrusor-sphincter dyssynergia”	45
Groutz et al., 1999	Female	206	62.6 ± 15.8	ICS definition	19
Valentini et al., 2011	Female	442	>55	“Impaired detrusor contraction leading to prolonged voiding time and high residual volume”	13.8

DHIC, Detrusor hyperactivity impaired contractility; *DUA,* detrusor underactivity; *EMG,* electromyography; *ICS,* International Continence Society; *Pdet,* detrusor pressure; *Qmax,* maximal urinary flow rate.

From Osman NI, Chapple CR, Abrams P, et al. Detrusor underactivity and the underactive bladder: a new clinical entity? A review of current terminology, definitions, epidemiology, aetiology, and diagnosis. *Eur Urol* 65:389–398, 2014.

One of the largest clinical urodynamic series demonstrated that DUA often coexists with other lower urinary tract dysfunctions (LUTDs) in the elderly (Jeong et al., 2012). In their study of 1179 patients older than 65 years of age, 46.5% of males with DUA also had DOA or BOO, and 72.6% of the females with DUA also had DOA or urodynamic stress urinary incontinence (Fig. 118.3). In our opinion, this is further support for the case for urodynamic assessment before surgical intervention for LUTS in this group.

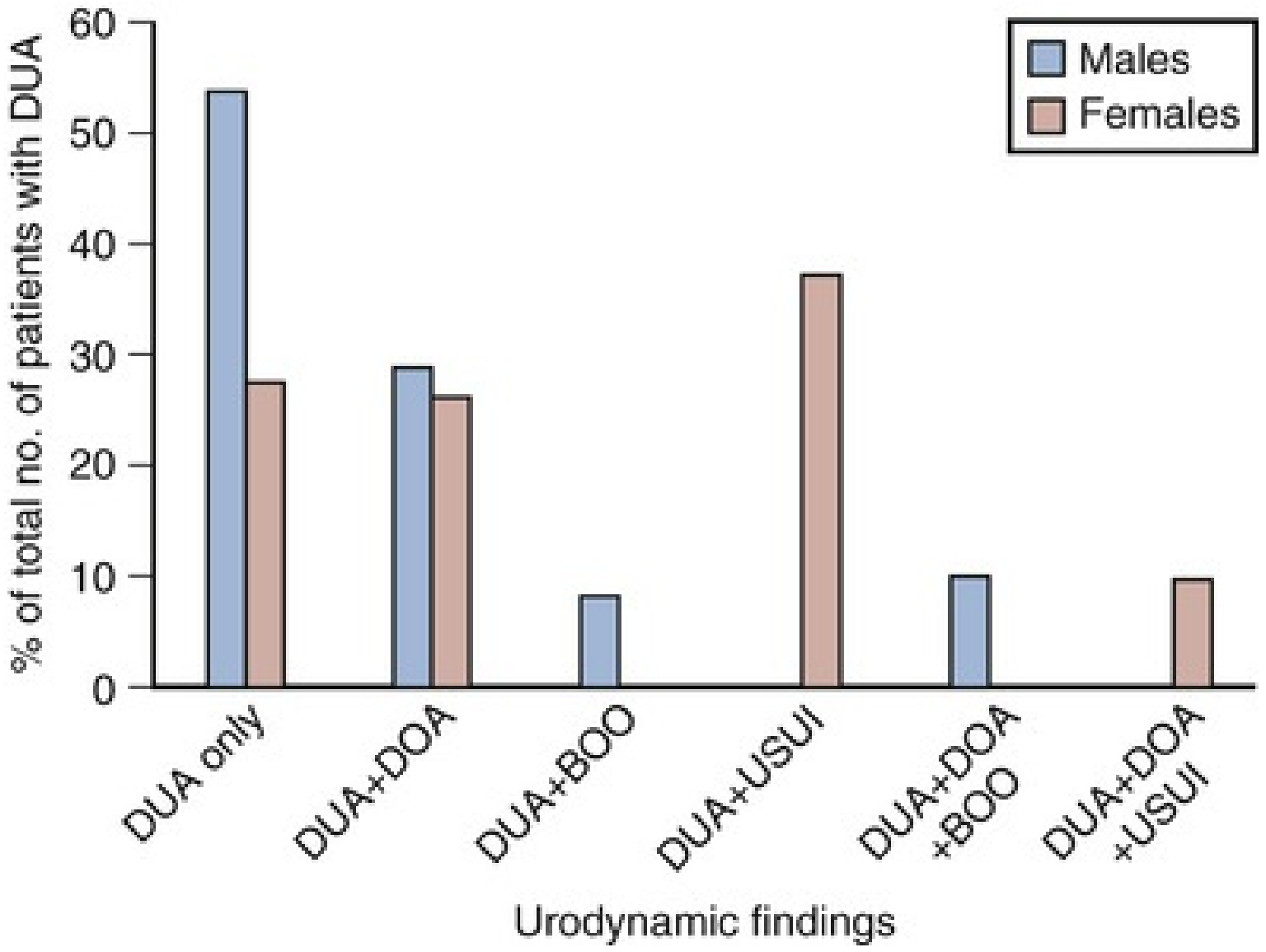

FIG. 118.3 The overlap between detrusor underactivity (DUA), detrusor overactivity (DOA), and bladder outlet obstruction (BOO) in 1179 patients (632 men and 547 women) older than 65 years of age in a Korean clinical series of urodynamic studies. DUA was defined as a bladder contractility index less than 100 in men and Qmax 12 mL/sec or less and Pdet@Qmax 10 cm H_2O or less in women. In total, 40.2% of men and 13.3% of women were classified as having DUA. The data suggest a significant overlap between DUA and other urodynamic diagnoses. *USUI,* Urodynamic stress urinary incontinence. (Raw data provided by Dr. Sang Eun Lee. From Jeong SJ, Kim HJ, Lee YJ, et al. Prevalence and clinical features of detrusor underactivity among elderly with lower urinary tract symptoms: a comparison between men and women. *Korean J Urol* 53:342–348, 2012.)

Very little is known of the natural history of DUA. In a 10-year study of 69 men with non-neurogenic DUA (with a maximal urinary flow rate [Qmax] of <15 mL/sec and detrusor pressure [Pdet] at Qmax [Pdet@Qmax] of <40 cm H_2O) managed conservatively, there was minimal symptomatic or urodynamic progression (Thomas et al., 2005b). In this cohort, 11 patients underwent transurethral resection of the prostate (TURP), 3 for acute urinary retention and 8 for worsening LUTS (all of whom showed no change in Qmax preoperatively compared with baseline values).

Key Points: Terminology, Definitions, Symptoms, and Epidemiology

- DUA is a common clinical problem associated with a range of storage, voiding, and postmicturition LUTS.
- The population prevalence of DUA is not known because of the lack of a noninvasive marker.
- DUA affects 9% to 28% of men younger than 50 years of age and 48% of those older than 70 years of age undergoing UDS and is more prevalent among the institutionalized elderly.
- In women, DUA is found in 12% to 45% undergoing UDS and is more prevalent among the institutionalized elderly.
- DUA commonly coexists with other LUTDs.

Etiopathogenesis

DUA occurs in both sexes and diverse clinical groups. Several distinct etiologic factors are recognized, such as diabetes mellitus and cauda equina compression. **In clinical practice, many patients do not have any obvious cause for DUA, neurologic or otherwise, suggesting that DUA may occur secondary to common age-related changes. In particular, an age-related decline in detrusor function with normal aging is likely, although it has not been conclusively demonstrated.**

Direct measurement of the contractility of bladder muscle strips from rodents, comparing younger to older animals, has yielded contradictory results that are difficult to extrapolate to humans because of differences in functional innervation. The few studies that used human bladder muscle strips often have failed to demonstrate a decline in contractile responses to electrical stimulation and a variety of agonists (Fry et al., 2011; Mark et al., 1992; Yoshida et al., 2001). Some clinical urodynamic data suggest an age-related reduction in Pdet and flow rate accompanied with an increase in PVR (Pfisterer et al., 2006; Smith et al., 2009; Valentini et al., 2011). Most studies have included symptomatic individuals with probable underlying pathophysiologic abnormalities that could be expected to progress with time. **It is to be expected that there would be a more pronounced decline in detrusor contractility in men because of bladder wall changes (increased connective tissue and reduced smooth muscle) occurring as a result of BOO; however, these changes are also seen in women, suggesting that they may be partly attributable to normal aging** (Holm et al., 1995; Lepor et al., 1992) **(Fig. 118.4A–C).**

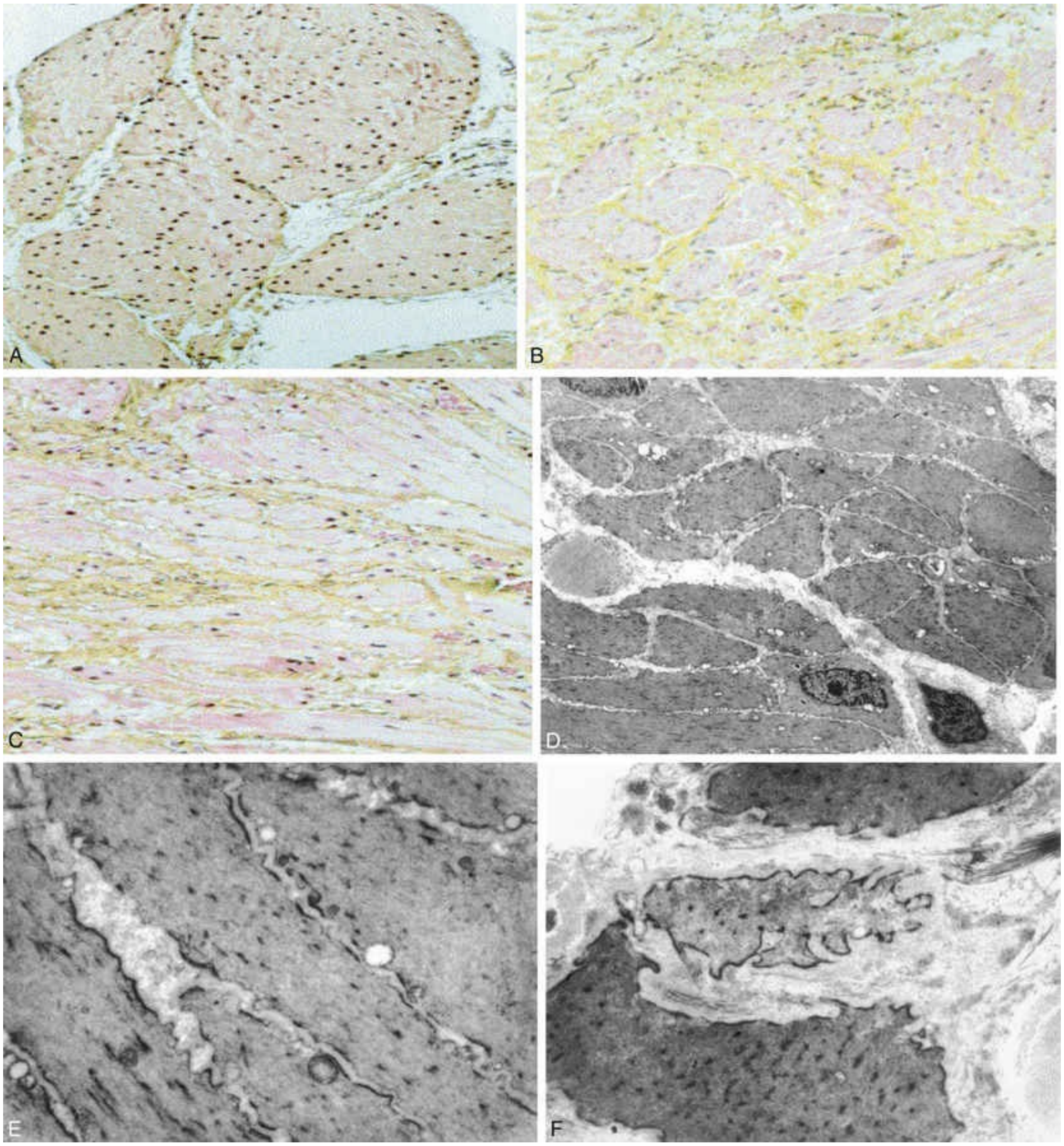

FIG. 118.4 Morphologic detrusor changes in aging and disease. (A–C) Light microscopy. (A) Normal detrusor. (B) Male patient with bladder outlet obstruction showing an increase in muscle mass and increase in fibrous tissue deposition inside and between muscle bundles. (C) Elderly female patient without lower urinary tract symptoms showing similar deposition of fibrous tissue, suggesting extracellular matrix changes also occur with aging. (D–F) Electron microscopy. (D) Normal detrusor muscle showing two muscle bundles. A wide collagen-rich septum dividing the bundles is seen. Within the bundles are individual fascicles separated by a thin microseptum (magnification ×6000). (E) Normal muscle cells at higher power magnification; smooth intact sarcolemma with a thin interstitium between adjacent cells. (F) Degeneration pattern. A disruptive cell, with a shriveled appearance and sarcolemma breakdown, with debris and

collagen deposition in the interstitium. (A to C from Nordling J. The aging bladder: a significant but underestimated role in the development of lower urinary tract symptoms. *Exp Gerontol* 37:991–999, 2002; D to F from Brierly RD, Hindley RG, McLarty E, et al. A prospective controlled study of ultrastructural changes in the underactive detrusor. *J Urol* 169:1374–1378, 2003.)

The mechanisms by which different causes result in DUA can be classified as (1) myogenic, affecting the cellular functions of detrusor myocytes or the surrounding extracellular matrix or (2) neurogenic, affecting the afferent pathways, efferent pathways, or brain circuits involved in the micturition reflex. (These mechanisms and the probable major etiologic factors are summarized in Fig. 118.5.)

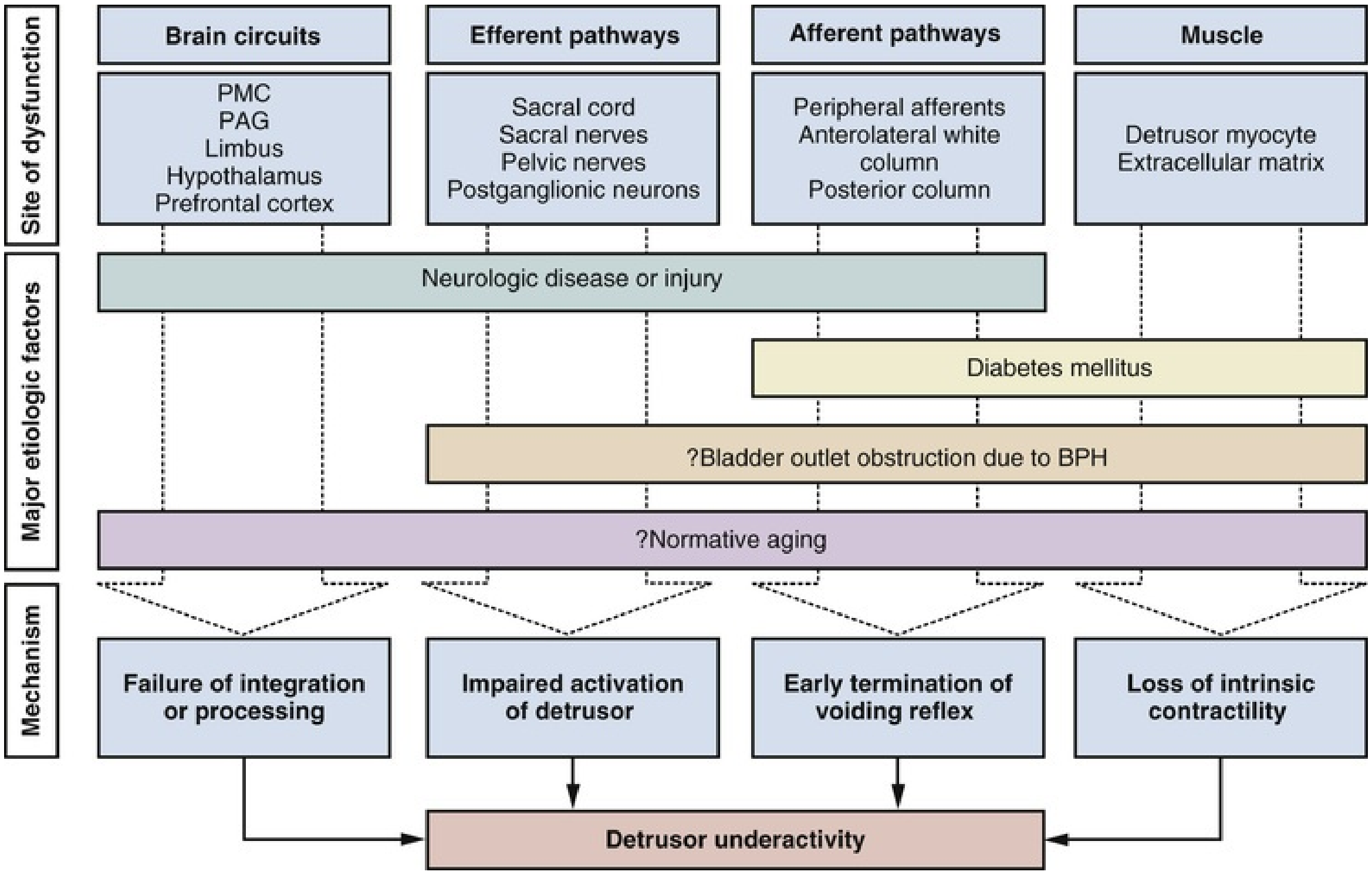

Site of dysfunction
Brain circuits
PMC
PAG
Limbus
Hypothalamus
Prefrontal cortex
Efferent pathways
Sacral cord
Sacral nerves
Pelvic nerves
Postganglionic neurons
Afferent pathways
Peripheral afferents
Anterolateral white column
Posterior column
Muscle
Detrusor myocyte
Extracellular matrix
Major etiologic factors
Neurologic disease or injury
Diabetes mellitus
?Bladder outlet obstruction due to BPH
?Normative aging
Mechanism
Failure of integration or processing
Impaired activation of detrusor
Early termination of voiding reflex
Loss of intrinsic contractility
Detrusor underactivity

FIG. 118.5 Etiopathogenesis of detrusor underactivity (DUA). The mechanisms by which the likely major etiologic factors lead to DUA. Bladder outlet obstruction and normative aging are probable rather than definite factors. *BPH,* Benign prostatic hyperplasia; *PAG,* periaqueductal gray; *PMC,* pontine micturition center.

Myogenic Factors

Processes that alter the normal structure and function of the detrusor muscle extracellular matrix may result in diminution of transmitted contractile force. The intrinsic ability of detrusor muscle cells to generate contractile activity may be compromised by dysfunction of cellular mechanisms (e.g., ion storage/exchange, excitation-contraction coupling, calcium storage, energy generation) such that even in the presence of normal extrinsic neuronal activity, a reduced contraction may occur (Brierly et al., 2003).

Morphologic changes have been reported to occur in the detrusor with normal aging and disease. Elbadawi et al. proposed that distinct ultrastructural patterns observed by electron microscopy characterized the normally contractile aging detrusor and different bladder dysfunctions, including DUA (Elbadawi et al., 1993a, 1993b, 1993c). Although the applicability of this classification system is disputed, other groups have noted similar findings (Brierly et al., 2003; Hindley et al., 2002). This degeneration pattern, which consists of widespread disrupted detrusor myocytes and axonal degeneration, has been associated with DUA (Elbadawi et al., 1993a). Whether detrusor myocyte disruption is the cause of DUA or a consequence of a pathologic insult is not clear (see Fig. 118.4D–E).

Neurogenic Factors

Brain Circuits

The central neural control mechanism governing micturition involves key processes including perception and integration of storage and voiding that, if disturbed, may result in DUA (Suskind and Smith, 2009). The micturition reflex is facilitated by the spino-bulbo-spinal pathway passing through the sacral parasympathetic nucleus and the pontine micturition center (PMC). The PMC receives input from higher centers in the cerebral cortex and in particular the limbic system. Many insights have been gained from functional neuroimaging studies in animals (de Groat et al., 1998; Sugaya et al., 2003, 2005). Certain populations of PMC neurons (“direct neurons”) appear to become activated immediately before and during reflex bladder contractions, whereas outside these periods they are completely inactive. A large number of these neurons pass to the lumbosacral spinal cord, suggesting a role in the micturition reflex. Human functional neuroimaging suggests similar areas of the brainstem and cortex are implicated—the insula, hypothalamus, periaqueductal gray, and PMC (Blok et al., 1997). Any lesion affecting these regions could in theory result in DUA, albeit a clinical correlation between the site of a neurologic lesion and the urodynamic finding is not always apparent in all diseases (Kim et al., 1998).

Bladder Efferent Pathways

Interruption or impairment of efferent signaling in the sacral cord, sacral roots, and pelvic nerves may manifest as absent or reduced detrusor contraction. There is evidence to suggest that a reduction in autonomic innervation occurs in the human bladder as a consequence of normal aging (Gilpin et al., 1986). A range of diseases and injuries can result in disturbance of efferent signaling (discussed later in this section).

Bladder and Urethral Afferent Pathways

Intact bladder sensation is critical to the functioning of the efferent limb of the micturition reflex. Bladder afferents monitor both volumes during bladder filling in the storage phase of the micturition cycle and the magnitude of detrusor contractions during the voiding phase. Urethral afferents have an important role in the perception of both flow through the urethra and detrusor contraction (Bump, 2000; Feber et al., 1998)**. An impairment in afferent function (from bladder or urethra) is likely to reduce or prematurely end the micturition reflex, leading to impairment or loss of voiding efficiency** (Suskind and Smith, 2009). There is evidence that normal aging is associated with a decline in sensory function in the lower urinary tract. In support of this, an age-related increase in the thresholds for reaching bladder capacity was observed in women (Pfisterer et al., 2006, 2007) and functional magnetic resonance imaging in asymptomatic older people has shown a reduced response to bladder filling in the insula (the region that maps visceral sensation).

Given that both tissue changes and a decline in sensory function appear to occur with aging, it is likely that both factors contribute to DUA in the elderly. An interesting hypothesis that integrates both aspects has been proposed (Smith, 2010). It is based on the concept that afferent outflow is a function of bladder wall stress and suggests that increased connective tissue deposition and smooth muscle disruption results in a loss of bladder elasticity that leads to changes in the normal passive compliance curve. There would also be impairment of normal sensory innervations resulting from connective tissue infiltration into the bladder wall. Conceptually the bladder progressively loses the property of receptive relaxation and becomes more akin to a stiff balloon. Such a stiff-walled bladder will exhibit a precipitous rise in wall stress with physiologic filling. Clinically this would be manifested by delayed bladder sensation, and soon after this, the sensation of urgency as the functional bladder capacity is reached. After a small volume of urine is passed, wall stress is dramatically reduced, with a reduction in afferent stimulation resulting in premature termination of the detrusor contraction before the bladder is emptied and an increased PVR. A small clinical study in which DUA was characterized by a strong desire to void at higher volume, similar contractility (as assessed by the Watts factor), but smaller voided volumes and elevated PVRs as compared with other LUTDs, suggest the above hypothesis may represent the situation in a substantial proportion of patients with DUA (Smith et al., 2015).

The important role of the urothelium in both normal and abnormal bladder functioning is increasingly recognized. Several recent studies looking at bladder biopsies in patients with DUA suggest that impaired urothelial signaling and sensory transduction pathways may have a role in the pathophysiology (Cho et al., 2017; Jiang and Kuo, 2017a). It is, however, difficult to establish whether these changes are causative or an effect of other processes (e.g., BOO). Ultimately, it will be difficult to establish causality or effect in the context of human studies, and animal models are necessarily limited by differences in functional innervation between animals and humans.

Specific Etiologic Factors

See Box 118.1.

Box 118.1

Etiologic Factors

Idiopathic

Normal aging
Unknown factor in younger people

Neurogenic Injury and Disease

Vascular

    - Stroke (early phase)
- Degenerative
    - Parkinson disease
    - Multisystem atrophy
- Demyelinating neuropathies
    - Multiple sclerosis
- Peripheral neuropathies
    - Guillain-Barré syndrome
    - Neurosyphilis (tabes dorsalis)
    - Herpes-zoster and herpes simplex
    - Diabetes mellitus
    - Acquired immunodeficiency syndrome
- Spinal cord and cauda equina
    - Intravertebral disk prolapse
    - Cauda equina lesions
    - Spinal cord tumors
    - Spinal canal stenosis
    - Spinal cord injury
    - Sacral fracture
- Pelvic fracture
- Pudendal nerve injury (bilateral)

Myogenic

- Bladder outlet obstruction
- Diabetes
- Pelvic arterial ischemia

Iatrogenic

- Radical pelvic surgery
- Radical prostatectomy
- Radical hysterectomy
- Anterior resection, abdominoperineal resection
- Detrusor myomectomy
- Intravesical phenol injections
- Radiation therapy

Functional

- Fowler syndrome
- Dysfunctional voiding

Pharmacotherapy

- Drugs with anticholinergic effects
  - Antimuscarinics
  - Antihistamines
  - Antipsychotics
  - Anti-Parkinson medications
  - Antispasmodics
  - Tricyclic antidepressants
  - Opioids

Bladder Outlet Obstruction

DUA also may occur as consequence of a series of changes in the detrusor induced by the increased work requirements to overcome BOO. In rodent models of partial BOO, the sequence of events leading to DUA is well described and has been separated into three stages. Initially a surgically created BOO (e.g., ring or ligature) increases bladder outlet resistance and results in bladder distention. The detrusor muscle then undergoes compensatory hypertrophy and hyperplasia, with bladder weight increasing sharply over the next few weeks before stabilizing. During this time, tissue blood supply also increases. The contractile function at this point is almost normal, and the bladder is said to have entered the compensated stage in which mass and function remain relatively stable. After a period of variable length, detrusor contractile function declines and bladder emptying is impaired, marking the decompensation phase (Levin et al., 1992; Saito et al., 1997). This is characterized by reduced response to electrical stimulation and agonists and replacement of bladder muscle with connective tissue (fibrosis). Typically, if the obstruction is not relieved before the stage of decompensation and connective tissue deposition, permanent contractile dysfunction ensues. In such an obstructed bladder, laser Doppler estimation of blood flow has demonstrated this to be decreased, further contributing to the bladder wall dysfunction by a direct effect on both neural and muscular dysfunction (Greenland and Brading, 1996). Other work has demonstrated that there is denervation of the bladder as a consequence of BOO in both humans and in an animal model (Harrison et al., 1987; Sibley, 1987).

Clearly the hypothesis to explain the sequential changes observed in animals centers on ischemic/reperfusion injury and pathologic connective tissue infiltration consequent on increased intravesical pressure being necessary to overcome outlet resistance. This results in increased bladder wall tension during contraction (the law of Laplace). This leads to compression of bladder wall vessels, tissue ischemia, and hypoxia. Cycles of ischemia and reperfusion during the micturition cycle (as the bladder empties and then fills) lead to generation of reactive oxygen species (Erdem et al., 2005) and release of free intracellular calcium. These factors cause activation of proteases, phospholipases, and membrane lipid peroxidation, which damages cellular and subcellular membranes, including nerve cells, synaptic membranes, mitochondria, and sarcoplasmic reticulum. The outcome of these processes is impaired cellular function and denervation, leading to decompensation of detrusor function (Schroder et al., 2001).

Relating the insights from this work to humans is problematic, because the animals studied are usually immature and often female; the obstruction is acute and certainly not representative of the clinical scenario. Indeed, the sequential changes that have been described, with consistency, do not correlate with the diverse outcomes men with BOO experience clinically. In addition, this sequence of events is not seen in patients presenting with a urethral stricture and does not explain the genesis of the similar bladder dysfunction seen clinically in female patients.

A longitudinal study has demonstrated that prolonged BOO commonly does not necessarily result in clinical decompensation. In a cohort of 170 men with BOO followed for a mean of 13.9 years, no significant deterioration was found in urodynamic parameters (no change in pdet@Qmax (detrusor pressure at maximum flow) and a reduction in Qmax (maximum flow rate) of only 1 mL/sec), and only 17% required any form of intervention (Thomas et al., 2005a). Of men who decompensate their bladders acutely (i.e., develop acute urinary retention), most have preserved detrusor function. Even among men with chronic retention, there are some who have preserved contractility and typically poor compliance and upper renal tract changes (high-pressure chronic retention) (Djavan et al., 1997; George et al., 1983). The pathophysiologic explanation for these divergent clinical outcomes remains unknown.

Some aspects of the pathophysiology relating to BOO remain unclear.

Animal models do not predict or explain what is seen in the clinical setting. It is likely that the clinical picture in any individual patient is multifactorial and thus unlikely to be explained by any single hypothesis.

Diabetes Mellitus

Diabetes mellitus may impair detrusor function through a combination of myogenic and neurogenic mechanisms. Diabetes-induced bladder dysfunction (DBD), classically termed *diabetic cystopathy,* results in a reduction in emptying efficiency in a time-dependent fashion during the course of the disease (Lee et al., 2004; Lifford et al., 2005). This is traditionally attributed to an autonomic neuropathy occurring as a result of axonal degeneration and segmental demyelination resulting in diminished bladder sensation (Hill et al., 2008). The mechanisms underlying this process are thought to occur as consequences of hyperglycemia. These include activation of the polyol pathway, increases in the generation of free radicals, activation of protein kinase C, and formation of advanced glycated end products (Daneshgari et al., 2009; Miyazato et al., 2013). It has been suggested that a reduction in nerve growth factor (essential for maintaining normal sympathetic and sensory nerve function) is also implicated in DBD. In support of this, studies in streptozotocin-induced diabetes mellitus in rats have shown reduced levels of nerve growth factor in the dorsal root ganglia associated with increased PVR and bladder capacity (Hellweg et al., 1994; Sasaki et al., 2002).

DBD also may result from detrusor myocyte dysfunction occurring as a result of alterations in intercellular connections and excitability, intracellular signaling, receptor density, and distribution. These mechanisms are poorly understood; most insights are derived from animal studies, which have demonstrated both increases and reductions in bladder contractility. Daneshgari et al. (2009) suggested this may be explained by time-dependent changes occurring in the bladder wall, the DBD temporal theory. This theory postulates that initially osmotic diuresis induced by hyperglycemia causes bladder wall stretching, which with increased intravesical pressure results in compensatory bladder hypertrophy. This stage would correspond clinically to storage symptoms early in the disease time course. It is suggested that as the disease progresses, accumulation of toxic products of oxidative stress results in bladder decompensation, clinically manifested as poor bladder sensation and impaired voiding function with associated LUTS.

Neurologic Disease or Injury

A range of neurologic diseases or injuries affecting the brain, spinal cord, or peripheral nerves can lead to DUA (see Box 118.1). Although neurogenic DOA is the most common chronic urologic sequela of cerebrovascular accident, in the acute phase approximately one-half of patients develop urinary retention (attributed to "cerebral shock"); 75% of these have acontractile detrusors (Burney et al., 1996). Similarly, in Parkinson disease DUA is far less common than DOA, occurring in less than 20% of cases (Araki et al., 2000).

Anticholinergic parkinsonian medication may be an important contributor; in a study in which these were withdrawn before urodynamic assessment, DUA was not demonstrated in any patient (Stocchi et al., 1997). Multisystem atrophy, otherwise known as Shy-Drager syndrome, is a condition often confused with Parkinson disease, in which 52% to 95% of patients demonstrate DUA on UDS (Bloch et al., 2010; Yamamoto et al., 2014) as a result of atrophy of efferent parasympathetic nerves, and clinically the majority of these patients develop urinary retention. DUA occurs in 20% of patients with multiple sclerosis (Litwiller et al., 1999), particularly when plaques affect the lumbosacral cord.

Injury at the level of lumbosacral spinal cord, the cauda equina, and sacral and pelvic nerves can occur as a result of trauma or a prolapsed intervertebral disk and also commonly results in DUA related to cauda equina syndrome. In particular, radical pelvic surgery can lead to injury to the pelvic plexus (located near the anterolateral wall of the lower rectum) or postganglionic fibers that traverse the lateral wall of the upper vagina.

A systematic review found that the overall incidence of LUTD after radical hysterectomy was 72% (Plotti et al, 2011). Although high incidences were reported in older series of patients undergoing rectal cancer surgery, more recently lower rates have been reported (<5%), which can be attributed to the adoption of nerve-sparing techniques (Maurer et al., 2001). The true incidence of DUA in this context is difficult to define because of the lack of studies correlating preoperative and postoperative urodynamic findings. Nevertheless, many patients appear to recover bladder function by 1 year after surgery. In support of this, a study of feline pelvic plexus extirpation suggests this may be caused by restitution of intrinsic cholinergic nerves and muscle cell regeneration after an initial injury-related degeneration (Elbadawi et al., 1988).

In neurologic disorders associated with infective causes, DUA can be either entirely reversible, such as in Guillain-Barré syndrome and herpes zoster (shingles), or permanent, as seen with progressive problems such as acquired immunodeficiency syndrome or neurosyphilis (tabes dorsalis), as was common in the preantibiotic era.

Pelvic Arterial Ischemia

Aging and environmental factors such as smoking and diet are associated with an increased prevalence of atherosclerosis, metabolic syndrome, hypertension, hyperlipidemia, and diabetes mellitus. The association of LUTS with advancing age has led to the hypothesis that vascular risk factors for atherosclerosis, resulting in chronic bladder ischemia, may play a role in the development of LUTS and other disorders such as erectile dysfunction. Several animal studies have shown that induced pelvic arterial insufficiency leads to bladder wall ischemia and decreased oxygenation (Azadzoi et al., 1999a, 1999b). This results in oxidative stress causing ultrastructural damage and denervation (Azadzoi et al., 2010, Nomiya et al., 2014) leading to features of DUA in some animal studies (Nomiya et al., 2012, Zhao et al., 2016).

Key Points: Eitopathogenesis

- The etiopathogenesis of DUA is incompletely understood; a diverse range of factors and pathophysiologic mechanisms are likely to be implicated.
- Confirmed etiologic factors include neurologic injury/disease and diabetes mellitus; BOO, aging, and artherosclerosis are probable rather than definite contributory factors.
- These factors may cause DUA by impairing or disrupting processes that are essential for the generation of an efficient voiding contraction.
- The pathophysiologic mechanisms can be classified as follows:
  - Myogenic: Affecting detrusor myocytes or their surrounding extracellular matrix
  - Neurogenic: Affecting the central neural control mechanisms governing the voiding reflex by an action on either afferent or efferent nerves

Diagnosis

The only accepted modality for clinically estimating detrusor voiding function is an invasive UDS; however, there are currently no universally agreed criteria for diagnosing DUA. Current methods of estimating detrusor voiding function almost exclusively focus on detrusor contraction strength (Table 118.2), neglecting other potentially important aspects such as the speed and sustainability of a detrusor contraction.

TABLE 118.2

Summary of Diagnostic Methods and Criteria

TYPE	METHOD	ADVANTAGES	LIMITATIONS
Mathematical calculations	Watts factor	Measure of bladder power Minimally dependent on volume of urine Not affected by presence of BOO	Lengthy and complex calculation No validated thresholds Does not measure sustainability of contraction
	Detrusor shortening velocity	May identify early-stage DUA	
Indices	Detrusor contraction coefficient (DECO)	Simple to use Measurement easy to obtain Estimation of isovolumetric contraction	Does not measure sustainability of contraction May not be applicable to other groups
	Bladder contractility index (BCI)		
Occlusion testing	Voluntary stop test	Real-time indication of isovolumetric contraction strength No calculations	Uncomfortable or painful for patients Impractical No information on sustainability of contraction (in continuous occlusion) May underestimate isovolumetric pressure
	Mechanical stop test		
	Continuous occlusion		

			(stop test) Unusable in some patient groups
Ranges of urodynamic measurements	Pdet@Qmax (e.g., <40) Qmax (e.g., <15)	Simple to use	No widely accepted “normal” ranges Underestimate contraction strength Does not conceptually consider coexistence of BOO and DUA

BOO, Bladder outlet obstruction; *DUA,* detrusor underactivity; *Pdet,* detrusor pressure; *Qmax,* maximal urinary flow rate.

From Osman NI, Chapple CR, Abrams P, et al. Detrusor underactivity and the underactive bladder: a new clinical entity? A review of current terminology, definitions, epidemiology, aetiology, and diagnosis. *Eur Urol* 65:389–398, 2014.

Detrusor Contraction Strength

A detrusor contraction generates both pressure and flow (Griffiths, 2003); thus many authors have used two parameters to diagnose DUA: Qmax and Pdet@Qmax. Reductions in both are considered to be below the lower limits of the normal ranges for the particular patient group. For men, these ranges were derived from series of patients undergoing bladder outlet surgery (Abrams and Griffiths, 1979; Schäfer et al., 1989). In healthy men and women, these ranges are less well characterized (Pfisterer et al., 2006; Rosario et al., 2008; Schmidt et al., 2002).

There are two limitations with this approach. First, it is likely to underestimate the contraction strength because of bladder outlet relation (BOR), the normal inverse relationship between Pdet and urine flow (Griffiths, 1973). The BOR is an adaptation of the Hill equation for actively contracting muscle and can be summarized as during voiding when flow is low the pressure is high and vice versa. On this basis, the Pdet@Qmax actually represents the point of least pressure. Second, the variability in bladder outlet resistance that also can affect flow rate is not considered. The clinical implications of this are that when Pdet is low, a low Qmax also can be attributed to increased outlet resistance (e.g., BOO caused by BPH), or alternatively a normal Qmax can result from reduced outlet resistance (e.g., postprostatectomy incontinence).

To more accurately assess contraction strength, methods that estimate isovolumetric pressure were developed. These are based either on post-hoc

mathematical calculations or volitional or mechanical interruption to the flow of urine during UDS (Griffiths, 2004)**. Many of these are complicated, time-consuming, or impractical, limiting their use in clinical practice.**

The Watts factor (WF) is an estimate of the power per unit area of bladder surface that is generated by the detrusor, corrected for the finite power required for either isometric contraction or for shortening against no load. It is calculated by the following formula:

$$\mathrm{WF} = [(\mathrm{Pdet} + a)(\mathrm{Vdet} + b) - ab]/2\pi$$

where Vdet is detrusor shortening velocity, and *a* and *b* are fixed constants (*a* = 25 cm H_2O, *b* = 6 mm/sec), derived from experimental and clinical data (Griffiths, 1991). Throughout micturition, the WF varies because of the variation in Pdet and Vdet; the points proposed to best represent detrusor contraction strength is the point at which the WF peaks, the maximal WF (WFmax). The major advantages of the WF are that it minimally depends on volume (Griffiths, 1991) and that it is not affected by increased outlet resistance (Lecamwasam et al., 1998). However, as of yet there are no validated cutoffs for the normal range, but based on expert opinion a WFmax of 7 W/m^2 was deemed to represent the threshold for reduced contractility (van Koeveringe et al., 2011), although some authors use a value of 10 W/m^2 (Mitsui et al., 2012). Ultimately, the WF found little use in everyday clinical practice because of the complexity of the calculation, and, as with all current measures, it does not consider the sustainability of a contraction.

Schäfer (1995) proposed an alternative method of estimating isometric contraction strength that is based on superimposing the BOR on his pressure-flow nomogram. The BOR is simplified to a straight line and “projected” back to the *y*-axis (Pdet) from the point representing Pdet@Qmax to obtain the isovolumetric pressure (Fig. 118.6). This projected isovolumetric pressure (PIP) can be calculated by the following formula:

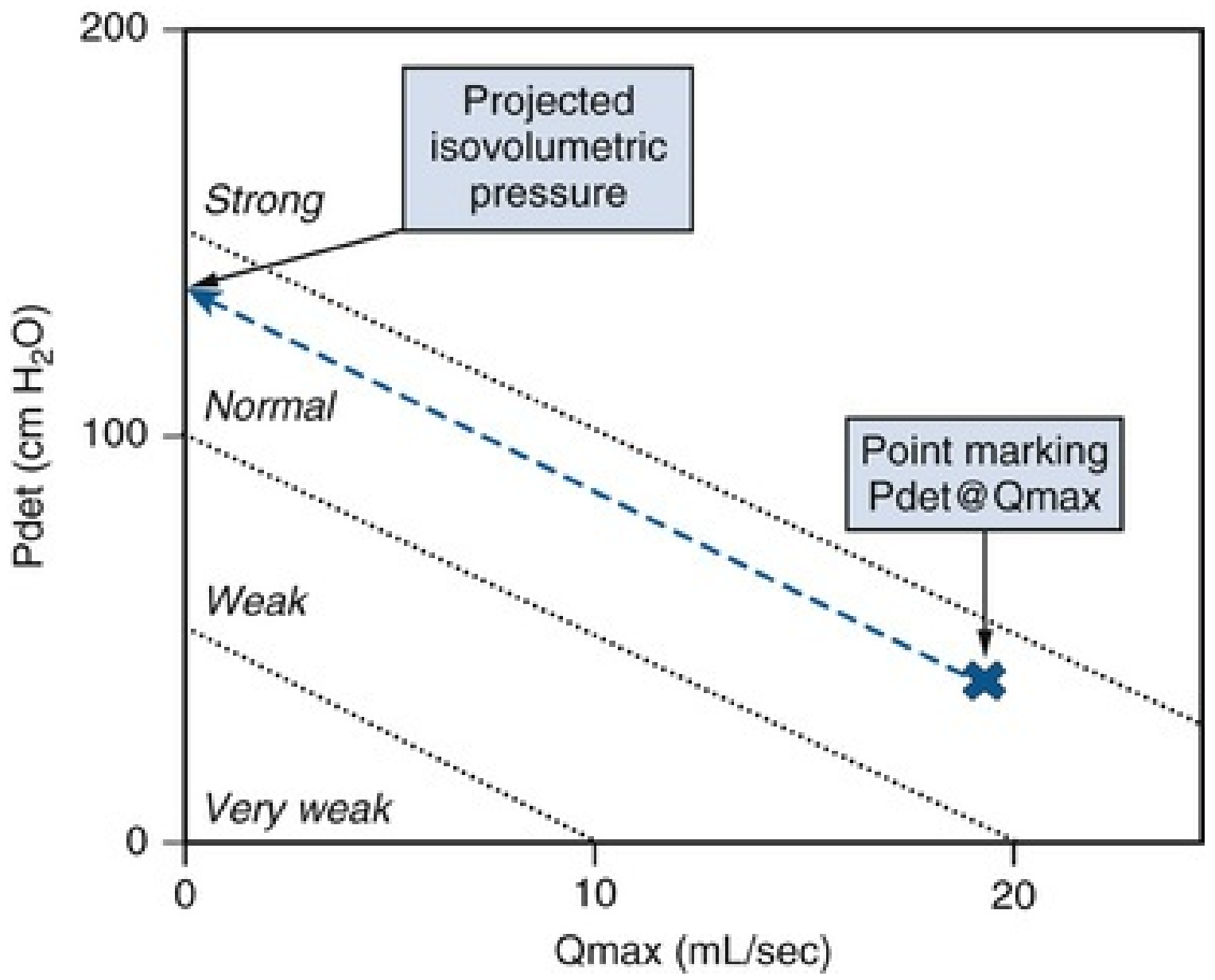

FIG. 118.6 Method of determining the projected isovolumetric pressure. The point marking the detrusor pressure (Pdet) @Qmax is plotted on Shäfer's contractility nomogram and is projected back to the *y*-axis. In this case, the pressure is 130 cm H_2O, which is in the normal contractility range.

$$\mathrm{PIP} = \mathrm{Pdet}\ @\ \mathrm{Qmax} + \mathrm{KQmax}$$

where K is a fixed constant representing the slope of the BOR (Schäfer, 1995). The value of K depends on the specific population studied. In men with BPH, it is taken as 5 cm H_2O/mL/sec, whereas in older women 1 cm H_2O/mL/sec was found to be more accurate (Griffiths, 2004).

Based on this, the suggested formula for use in men in clinical practice is as follows:

$$\mathrm{PIP} = \mathrm{Pdet}\ @\ \mathrm{Qmax} + 5\ \mathrm{Qmax}$$

A PIP greater than 150 represents strong contractility, 100 to 150 normal contractility, 50 to 100 weak contractility, and less than 50 very weak contractility. The corresponding BORs at these cutoffs were plotted on the Schäfer pressure-flow nomogram to give subdivisions for contractility (see Fig. 118.6).

Although there are two other reported variations of PIP, all three are essentially the same. **The detrusor coefficient is the PIP divided by 100, where a value less than 1 signifies weak contraction.**

$$\mathrm{PIP} = \mathrm{Pdet} @ \mathrm{Qmax} + 5\ \mathrm{Qmax}/100$$

The bladder contractility index, described by Abrams, is calculated using the same formula as PIP and includes three groupings (strong >150, normal 100 to 150, and weak <100) (Abrams, 1999). Evidently all these methods are fairly easy and quick to calculate but tend to overestimate PIP, because such adjustments need to be made for use in different populations. Although test-retest reliability is thought to be acceptable, it is less consistent than measures that directly record isovolumetric pressure (Tan et al., 2003).

Isovolumetric pressure can be measured directly by mechanically obstructing the flow of urine (Sullivan and Yalla, 2007)**. This can be achieved through either (1) a stop test, interruption of urine flow after it has begun, or (2) a continuous occlusion test, in which the urine outflow is blocked before and during the course of the voiding contraction.**

There are two types of stop test: a voluntary stop test, in which the patient voluntary contracts the urethral sphincter, and a mechanical stop test, in which the bladder outflow is occluded by the investigator (e.g., by tugging a catheter balloon against the bladder neck). These techniques correlate well with each other in both sexes (Tan et al., 2003), but the voluntary stop test tends to produce a lower value for isovolumetric pressure by approximately 20 cm H_2O. This is probably explained by the reflex detrusor inhibition induced by urethral sphincter contraction (Sullivan et al. 1995). The voluntary stop test is difficult and sometimes impossible to conduct in patients with urethral sphincter weakness. The continuous occlusion testing has greater test-retest reliability and allows assessment of sustainability of contraction, although the consequence is that a representative flow measurement during that particular contraction is not obtained. Although it correlates well with the ability of the bladder to empty (Sullivan and Yalla, 1996), continuous occlusion is potentially painful and has found little applicability outside of a research setting.

Overall, the different criteria for assessing contraction strength are not in concordance when applied to patients with DUA with a reported variation in the diagnosis of DUA between 5% and 55% when applied to patients with non-neurogenic LUTS (Jeong et al., 2017). Thus it is imperative in the future to develop a standardized methodology and criteria, and this is currently the subject of ongoing work.

Detrusor Contraction Speed

A bladder that contracts more slowly could in theory result in clinical symptoms, although this is not part of the ICS definition. A reduction in detrusor shortening velocity, calculated by the following formula:

$$\mathrm{Vdet} = Q/2[3/(V + Vt)/4\pi]0.66$$

(where Q represents the flow rate [mL/sec], V represents bladder volume [mL], and Vt represents the volume of noncontracting bladder wall tissue) was found to precede reduction in WF in a series of longitudinal studies in both males and females (Cucchi et al., 2007, 2008, 2010).

Detrusor Contraction Duration

A detrusor contraction of reduced duration is suggested by the ICS as part of the definition of DUA (Abrams et al., 2002); however, the limits of a normal voiding detrusor contraction are not defined. There are only a few studies that assess contraction duration as a urodynamic parameter. In a study of men with BPH, unobstructed patients with poor contractility actually had significantly longer contraction durations than those with no obstruction and normal contractility (Ameda et al., 1998). It is likely that the contraction duration reflects the underlying pathophysiologic mechanisms—for example, an early termination of the micturition reflex could presumably lead to a shorter duration. **A standardized method for measuring duration of the detrusor contraction is needed before any conclusions can be reached.**

Bladder Sensation

An assessment of bladder sensation is clearly relevant to the evaluation of DUA because the afferent nerves play such a central role in the initiation and maintenance of a detrusor contraction. An analysis of urodynamic traces of 1329 men highlighted that patients with DUA had decreased bladder sensation compared with groups with LUTDs (Jiang and Kuo, 2017b). **Assessment of**

bladder sensation is most commonly undertaken using the patient's perceptions of bladder filling (first sensation, first desire, strong desire, and capacity).

Thresholds in normal individuals are available (Wyndaele, 1998), although this method can be criticized because patients may report bladder sensation even when the bladder is not being filled (De Wachter et al., 2008; Erdem et al., 2004); as with any subjective measure, there is substantial individual variation because of the circumstances of a UDS and the anxiety level of the study subject. Testing sensory responses to the passage of electrical current through the bladder wall (current perception threshold testing) may provide a more objective measure but is clearly a rather invasive approach and is as yet an unvalidated research technique.

Ambulatory Urodynamics

Patients often fail to void during UDS because of anxiety or a bashful bladder. It is thought this arises as a result of poor pelvic floor relaxation and reflex detrusor inhibition. Alternatively the patient may have true DUA or acontractile detrusor. A careful history is usually sufficient to differentiate the two situations. Where doubt exists, ambulatory UDS may be useful (Rosario et al., 2000). van Koeveringe et al. (2010) demonstrated that 84% of patients who failed to generate a detrusor contraction during standard UDS had evidence of demonstrable contraction during an ambulatory study. It must, however, be borne in mind that there is no accepted standardization of ambulatory urodynamic criteria, as they often differ significantly from what is seen on a standard urodynamic test when carried out sequentially in the same patient. Nevertheless, in a recent study of 239 patients (71 male and 168 female), the largest subgroup of patients (79; 33%) who underwent ambulatory urodynamic monitoring did so based on clinical suspicion of an acontractile bladder (Rademakers et al., 2017). It was evident that 66 of these patients (83.5%) still showed contractions on ambulatory urodynamics.

Key Points: Diagnosis

- There is no published consensus on the diagnostic criteria for DUA.
- Most available criteria focus on the strength of contraction as determined by

the Pdet during UDS.

- Several indices and formulas to estimate isometric detrusor strength are available, most of which are unvalidated and are not applicable to all patient groups.
- Urodynamic stop and occlusion tests are more reliable but may be painful and impractical.
- The significance of other aspects of detrusor contraction such as speed and duration is unclear.

Management

The goals of managing the patient with DUA are to improve symptoms and quality of life and reduce the risk for complications of impaired bladder emptying. These include urinary tract infections (UTIs), bladder stones, ureteric reflux leading to back-pressure on the upper urinary tract, and skin damage from urinary overflow incontinence associated with chronic retention. There is a profound lack of effective treatments to improve detrusor function and thereby facilitate bladder emptying. Thus management commonly entails bladder drainage techniques (e.g., catheterization) or therapies aimed at reducing bladder outlet resistance, for example, by relaxing the external urethral sphincter mechanism. The clinical approach and therapies that are available in contemporary clinical practice and potential experimental approaches are reviewed in the next sections (Fig. 118.7).

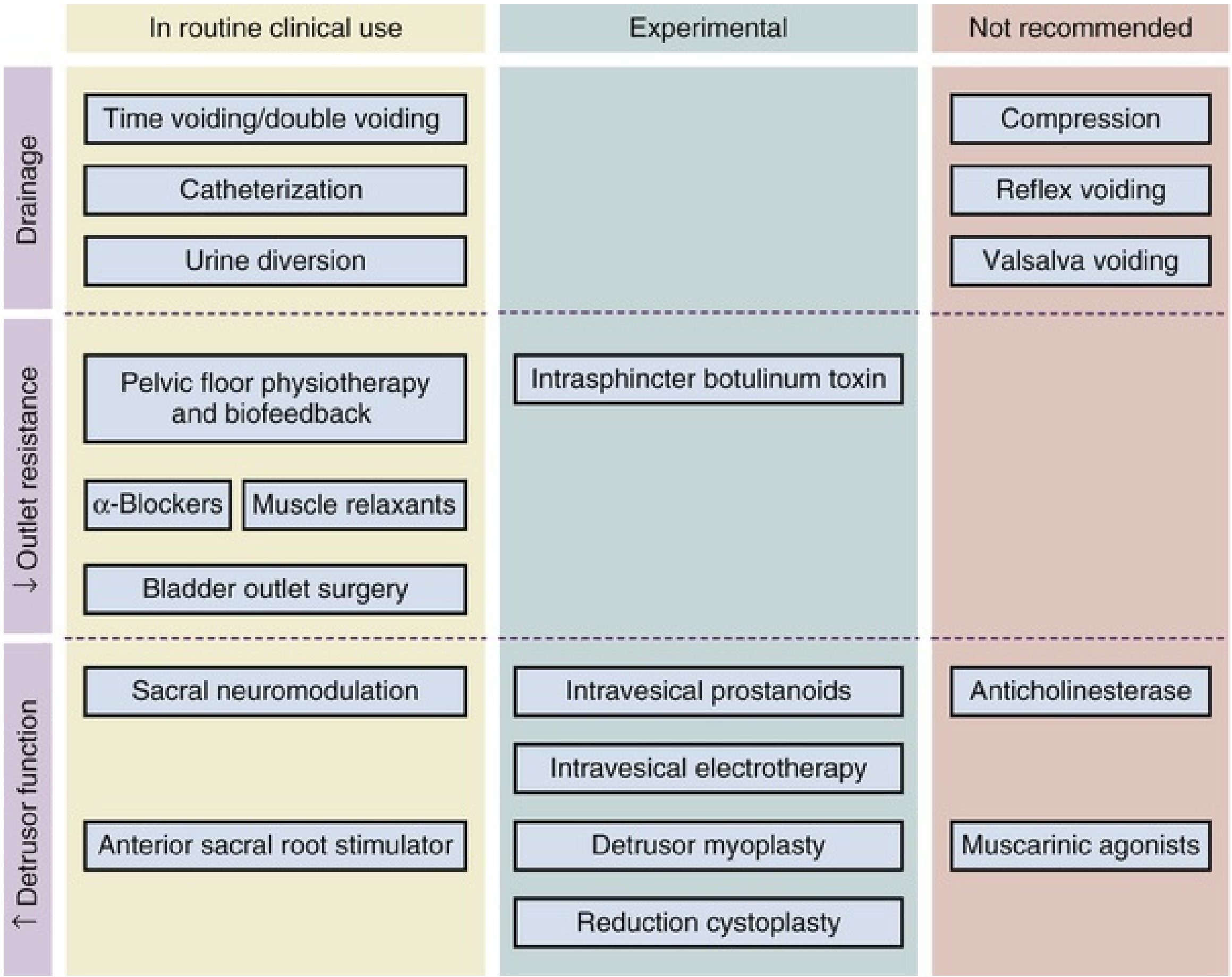

	In routine clinical use	Experimental	Not recommended
Drainage	Time voiding/double voiding Catheterization Urine diversion		Compression Reflex voiding Valsalva voiding
↓ Outlet resistance	Pelvic floor physiotherapy and biofeedback α-Blockers Muscle relaxants Bladder outlet surgery	Intrasphincter botulinum toxin	
↑ Detrusor function	Sacral neuromodulation Anterior sacral root stimulator	Intravesical prostanoids Intravesical electrotherapy Detrusor myoplasty Reduction cystoplasty	Anticholinesterase Muscarinic agonists

FIG. 118.7 Management options in detrusor underactivity.

Initial Assessment

The assessment of patients with symptoms suggestive of DUA entails routine urologic evaluation (bladder diary, digital rectal examination, urinalysis, uroflowmetry, PVR estimation using ultrasonography) and neurologic assessment (sacral dermatomes, anal tone, the bulbocavernosal reflex, lower limb reflexes). Neurologic deficits require further specialist evaluation; magnetic resonance imaging of the spine is commonly performed in particular to assess the lumbar spinal cord and cauda equina. A careful drug history should be taken to identify medications that impair bladder contractility (agents with anticholinergic or opioid effects) (see Box 118.1) or that increase outlet resistance (e.g., α-adrenoreceptor agonists). Fecal impaction/constipation may contribute to poor bladder emptying by a direct obstructive effect, and, if identified, its treatment may facilitate improved

bladder emptying (Charach et al., 2001).

Conservative Management

Behavioral interventions in patients with DUA aim to reduce the symptoms and complications of incomplete bladder emptying. Scheduled voiding can be instituted to increase the frequency of voids in patients with sensory impairment. Double voiding to improve bladder emptying may help reduce bothersome frequency, and patients often use this strategy before seeking treatment. Bladder expression techniques such as Valsalva voiding or the Credé maneuver are used in only very specific neurogenic situations (i.e., DUA with incompetent sphincter) and are otherwise not recommended because of the risk for generating high vesical pressure, causing vesicoureter reflux or causing reflux into the prostate and seminal vesicles.

Pelvic floor physiotherapy and biofeedback have been used to successfully treat children and adults with dysfunctional voiding (de Jong et al., 2007; Minardi et al., 2010)**. In this group, poor relaxation of the pelvic floor muscles and the external urethral sphincter mechanism may obstruct urine flow and cause reflex inhibition of detrusor contraction.** In a study by van Koeveringe et al. (2010), 24% of patients with acontractile detrusor on conventional UDS who subsequently demonstrated contractility on ambulatory studies were successfully treated with physiotherapy.

ISC is the preferred method of establishing bladder drainage in patients with problematic high PVR. Provided cognition and dexterity are adequate, this method is safe and effective, with lower infection rates than with indwelling catheters. Specific problems include urethral bleeding (one-third of patients) (Webb et al., 1990) and production of false passages. Additionally, the technique may be time-consuming and socially restricting; some patients may be unable to overcome the psychological barriers such as a fear of inflicting harm or infection (Mangnall, 2012). An indwelling urethral catheter is best avoided in the long term, and in this context a suprapubic catheter is the best long-term option in patients unwilling or unable to perform ISC.

Pharmacotherapies

Parasympathomimetics for Underactive Bladder

Acetylcholine is the principal neurotransmitter mediating bladder contraction, acting on muscarinic (M_3) receptors. **Parasympathomimetic agents, including direct muscarinic receptor agonists or anticholinesterases, have been used with the aim of increasing bladder contractility. Bethanechol and carbachol, the most common compounds studied, are quaternary amines that are selective for the muscarinic receptor but not receptor subtype selective.** In mechanistic terms, these compounds are more likely to be effective if the problem is reduced or absent contractile stimulus (e.g., reduced efferent input, impaired acetylcholine release from parasympathetic nerves, increased acetylcholine breakdown). Anticholinesterases (e.g., distigmine) would require the presence of at least some endogenous acetylcholine, to amplify its effect. Conversely, if the underlying cause is reduced tissue responsiveness to stimulation (e.g., detrusor muscle cell dysfunction, bladder wall fibrosis), parasympathomimetics are less likely to benefit. Similarly, if the problem is loss of the detrusor muscle, no pharmacotherapy is likely to be effective.

The efficacy of parasympathomimetics has been assessed in a small group of heterogeneous studies, mainly for the prevention and treatment of postoperative urinary retention. A systematic review of this literature (Barendrecht et al., 2007) found that only 4 of 10 randomized clinical trials included (two of the four in patients with DUA) showed a significant benefit over placebo. However, all of these studies could be considered to be underpowered. Bethanechol was used in all four (dose of 10 to 50 mg up to four times daily). A further three studies failed to show any advantage with use of this agent. One study found that distigmine (5 mg) actually increased PVR compared with placebo. It was concluded that there is little, if any, benefit in using parasympathomimetics.

When bethanechol is given to neurologically normal individuals, it causes a rise in bladder wall stiffness and sensory perception (De Wachter and Wyndaele, 2001). De Wachter and Wyndaele (2003) also noted that women with DUA responding to bethanechol demonstrated significant reductions in bladder sensory thresholds. Hence, intact sensory pathways may be a prerequisite for improvement in voiding with muscarinic agonists, which may explain their lack of efficacy in unselected groups. Alternatively, it could be that the doses used are simply too low because of the concern with side effects. **Parasympathomimetics are associated with significant dose-dependent systemic side effects, including nausea, bronchospasm, abdominal cramping, diarrhea, increased salivation, flushing, and visual disturbances. A rare but potentially lethal side effect is severe cardiac depression resulting in cardiac arrest. In contemporary practice, parasympathomimetic agents**

are generally avoided because of their questionable efficacy and potentially serious side effects.

α-Adrenoreceptor Antagonists

α-Adrenoreceptor antagonists have been used to reduce bladder outlet resistance in children and adults with both neurogenic bladder and dysfunctional voiding. Chang et al. (2008) studied the use of tamsulosin (0.2 mg) in 52 women with DUA (Pdet@Qmax <10 cm H_2O). The authors found that 38.5% had a greater than 50% improvement in voiding LUTS, 53.8% had a greater than 30% improvement in Qmax, and 32.7% were judged to have had a good therapeutic response. **Combination therapy with an α-adrenoreceptor antagonist and a parasympathomimetic has long been considered a therapeutic possibility** (Khanna and Gonick, 1975). In a prospective single-blind randomized study of 119 patients with DUA, urapidil alone did not result in a reduction in Qmax in either sex and led to a reduction in PVR in women only (Yamanishi et al., 2004). By contrast, a combined regimen of urapidil (60 mg) with either bethanechol (60 mg) or distigmine (15 mg) led to significantly improved flow rates (by 2.66 mL/sec in women, $P < .01$, and 4.33 mL/sec in men, $P < .05$) and significantly reduced PVR in women (by 54.1 mL/sec, $P < .01$) (Yamanishi et al., 2004).

Prostanoids

Prostanoids are a subclass of signaling molecules that may be implicated in the micturition reflex. The efficacy of prostanoids in treating DUA is not clear. Most clinical studies have evaluated the effect of intravesical prostaglandin (PG) instillation in the prevention of postoperative urinary retention.

There are five principal endogenous prostanoids (PGE_2, $PGF_{2\alpha}$, PGI_2, PGD_2, and thromboxane A) that are all synthesized in the bladder wall and released into the general circulation when the bladder is stretched (Maggi, 1992; Rahnama'i et al., 2012). Detrusor contraction in response to acetylcholine and adenosine triphosphate stimulation is enhanced by prostanoid production. Conversely, nonsteroidal anti-inflammatory agents (inhibitors of prostanoid synthesis) cause a loss of tone in the isolated bladder that is reversed with the administration of prostanoids. $PGF_{2\alpha}$, PGE_1, and PGE_2 all enhance detrusor contraction; PGE_1 and PGE_2 cause urethral relaxation, and $PGF_{2\alpha}$ results in urethral contraction (Rahnama'i et al., 2012).

The clinical studies conducted to date have demonstrated mixed outcomes (Bergman et al., 1992, 1993; Koonings et al., 1990; Tammela et al., 1987; Wagner et al., 1985); however, a recent pooled analysis of the results of two randomized trials assessing PGE_2 and a third assessing $PGF_{2\alpha}$ demonstrated a statistically significant association between instillation and successful voiding (risk ratio 3.07) (Buckley and Lapitan, 2010). Both PGE and PGF series also stimulate contraction of the uterus, a potential side effect of treatment (O'Brien, 1995).

Future Prospects in Pharmacotherapy

In the absence of any effective compound, there are several avenues aimed at increasing bladder contractility that can be explored, as follows:

- Parasympathomimetics could yet be an option; however, their side-effect profile is concerning. Development of a bladder-specific agent could avoid these effects permitting dose escalation. However, this is unlikely based on contemporary knowledge.
- Novel muscarinic receptor manipulation such as postsynaptic allosteric receptor enhancement or the presynaptic M_2-receptor antagonist could be promising.
- Exogenous prostanoids require further investigation; agents with selectivity for the urinary tract over the uterus and gastrointestinal tract are under development; however, whether they will be effective if taken orally is an important question.
- Agonists of transient receptor potential (TRP) channels, such as TRPV4 agonist GSK1016790A, can increase contractility and are worthy of further investigation.
- Treatments of analogous conditions affecting other organ systems, such as cardiac inotropes in cardiac failure or prokinetics for intestinal dysmotility, could provide alternative options to increase contractility.
- Improving bladder sensation using sensory sensitizers could hypothetically help patients with impaired afferent signaling.

To develop effective drug therapies, there is a need to better understand the pharmacologic principles that underpin normal detrusor contraction and the mechanisms of detrusor dysfunction underlying DUA. This is the subject of ongoing work at present with no new candidate drugs available in clinical trials at present.

Electrical Stimulation

A variety of electrical stimulation techniques have been applied in DUA of different causes. Brindley et al. (1982, 1986) developed the sacral root stimulator for patients with complete spinal cord injury to activate the anterior sacral roots and achieve volitional bladder emptying. For the procedure to be successful, there is a need for intact peripheral efferents and the absence of myogenic dysfunction. This is confirmed by the presence of reflex detrusor contractions on bladder filling preoperatively. The anterior sacral roots are stimulated through an implantable receiver, stimulation wires, and external transmitter. Stimulation also activates urethral somatic efferents; this is overcome by using intermittent stimulation patterns that exploit the longer relaxation time of smooth muscle compared with skeletal muscle to generate a sustained detrusor contraction with short intermittent periods of sphincter contraction. Clinically, this results in an interrupted void pattern. Sauerwein (1990) subsequently modified the technique by combining it with total sacral root rhizotomy, thereby abolishing all reflex activity.

Katona and Berenyi (1975) popularized the technique of applying electrical current to the bladder wall through a transurethral electrode in 1958, termed *intravesical electrotherapy* (IVE). The bladder is filled with saline, and current is passed through an electrode (cathode) at the tip of the catheter; the circuit is completed by a neutral electrode applied to the skin in an area of normal sensation. Daily sessions of stimulation are undertaken, usually of 1 hour or more, with 10 to 15 sessions considered a trial period.

Animal experiments have shown that IVE activates mechanosensitive bladder afferents (myelinated Aδ fibers) and, as a consequence, central reflex activation of the detrusor (Ebner et al., 1992)**. It is postulated that repeat activation of this pathway upregulates its performance during bladder filling and volitional voiding, resulting in improved sensation and emptying. On this basis, where the underlying cause is complete denervation or bladder wall fibrosis, IVE is considered unlikely to be**

successful.

IVE has been studied primarily in the pediatric age group with some encouraging results, but is still considered a controversial therapy. There is considerable heterogeneity in inclusion criteria and technical aspects, and most studies include only small numbers, limiting definitive conclusions as to efficacy. In children with both neurogenic and idiopathic DUA, voiding was normalized after treatment in as many as 85% of cases (Gladh et al., 2002). In adults with predominately neurogenic DUA, 39% of those without a detrusor contraction and 75% without bladder sensation before treatment experienced a restoration of these parameters (Primus et al., 1996). Several studies have failed to show benefit, including the only sham controlled randomized prospective study (Boone et al., 1992). Moreover, IVE often is undertaken alongside an intensive bladder training/biofeedback regimen, which may partially explain the favorable outcomes (Madersbacher, 1990). **Although not associated with significant complications (except a small risk for UTI), its principal limitations are the significant time and resource requirements. An average of 47 sessions was required for a durable effect in a cohort of children followed for 10 years after treatment** (Kaplan, 2000).

Sacral neuromodulation (SNM) was first introduced over 30 years ago by Tanagho and Schmidt (1982)**. It has been used with good efficacy in a group of patients with nonobstructive urinary retention and DUA** (Everaert et al., 1997; Swinn et al., 2000). It is postulated that abnormal afferent signals generated from the urethral sphincter (because of pelvic floor/sphincter disorders) have an inhibitory effect on bladder afferents at the level of the sacral spinal cord, preventing their transmission in the periaqueductal gray and higher brain centers. **SNM is thought to inhibit urethral afferent signals and allow restoration of normal afferent flow to the brain and the resumption of normal bladder sensation and detrusor contractions.** A direct effect on bladder efferents is possible but less likely (DasGupta and Fowler, 2004). SNM has also shown potential in treatment of patients with DHIC, who pose a particular treatment challenge due to the co-existence of DOA and DUA, with the treatment of one aspect often negatively affecting the other. It is evident that sacral neuromodulation can have some effect if there is underlying detrusor function. The crucial aspect that requires clarification is in patients with a combination of detrusor underactivity and BOO. Recent work has aimed at providing a diagnostic approach to help with this differentiation (Rademakers et al., 2017).

An alternative form of electrical stimulation, transcutaneous electrotherapy (using skin electrodes) was recently studied in a small randomized controlled trial in children alongside urotherapy (Kajbafzadeh et al., 2016). Though significant improvements in voiding time, bladder capacity, and flow rate were noted in the active treatment group, the lack of sham treatment group is a significant limitation.

Botulinum Toxin

Botulinum neurotoxin A (BoNT-A) injected into the urethral sphincter has been used to reduce outlet resistance and improve bladder emptying in patients with detrusor-sphincter dyssynergia (Dykstra et al., 1988; Phelan et al., 2001; Schurch et al., 1996)**. The potential rationale for its use in DUA is to relax the urethral sphincter mechanism, thereby overcoming reflex inhibition of detrusor function** (Park et al., 1997)**, or to facilitate Valsalva-induced voiding.**

Kuo (2003) reported the results of urethral BoNT-A (50 U in 4 mL of normal saline) in 20 patients with DUA of mixed causes. The toxin was injected cystoscopically in men and periurethrally in women. Seven patients who previously required indwelling catheters could void with low PVRs (≤150 mL). In the 7 patients performing ISC at baseline, it could be stopped or reduced in frequency after injection. The same author also reported the effects of urethral BoNT-A (50 U or 100 U in 4 mL and 8 mL of normal saline, respectively) in 27 patients (5 men and 22 women) with idiopathic DUA (low or no Pdet and Qmax of <10 mL/sec and PVR >150 mL) (Kuo, 2007a). An increase in Pdet and Qmax with a decrease in PVR occurred in 13 patients (48%), all of whom could void without abdominal straining. Analysis of baseline characteristics identified the responders as having significantly better bladder sensation. Patients with evidence of poor sphincter relaxation before treatment were more likely to improve (87%) compared with patients who had DUA only (33%) or DHIC (30%).

The evidence available suggests that the action of BoNT-A, when injected into the urethral sphincter mechanism, is short-lived, and to date no adequate clinical studies have been conducted to evaluate the appropriate dose. In this context, it is not licensed for use and cannot be used outside of a clinical trial setting.

Surgery

Bladder Outlet Surgery

The role of bladder outlet surgery in the management of men with non-neurogenic DUA is a controversial topic in which there is a lack of high-level evidence to guide clinical decision making. A recent meta-analysis assessing a total of 10 comparative studies assessing transurethral surgery found that those with DUA had significantly poorer improvement in I-PSS (International Prostate Symptom Score) and maximal flow rate in comparison with patients who had preserved contractility (Kim et al., 2018). Both groups showed similar changes in quality-of-life score, and PVR volumes were equivalent.

Although the findings of such meta-analysis confirms the experience of most urologists that overall such patients do less favorably, it is important to differentiate between two common clinical scenarios from a practical point of view: the patient with DUA with a low or minimal PVR whose primary complaint is symptoms, and the patient with DUA who is catheter-dependent (i.e., chronic retention). In the former, although BOO cannot be definitively excluded, because of the limitations of urodynamic analysis discussed earlier, it is generally less likely to be significant as the patient is able to empty the bladder with a low Pdet. In this situation, outlet surgery is generally considered to be unlikely to significantly improve voiding LUTS. This supposition is supported by a study that followed 22 men with DUA treated with TURP for a mean of 11.3 years (Thomas et al., 2004). The majority of patients underwent TURP on the basis of symptoms (3 of 22 after acute retention). There was no significant improvement in any symptoms. A small reduction of questionable clinical significance in the BOO index (BOOI = Pdet@Qmax − 2 Qmax) did occur but was not associated with an improvement in flow rate or voiding efficiency. **It can be concluded that when compared with patients who have DUA undergoing conservative treatment, outlet surgery confers no significant improvement in symptoms or urodynamic parameters.** Other studies with shorter follow-up support these findings (Javle et al., 1998; Rollema and Van Mastrigt, 1992).

In the situation in which the patient with DUA is catheter-dependent and has arguably reached a later stage of detrusor decompensation, even less evidence is available as to the benefit of outlet surgery. Surgery is performed with the aim of reducing outlet resistance enough to permit bladder emptying, albeit the flow rate and PVR rarely return to normal in this scenario. Predictors of poor outcome include low voiding pressures (<45 cm H_2O) (Ghalayini et al., 2005), older age (>80 years), and high residual volume (>1500 mL) (Djavan et al., 1997). **Although the limited evidence suggests men with DUA and chronic retention do less favorably after bladder outlet surgery** (Ghalayini et al., 2005)**, a significant proportion resume spontaneous voiding** (Monoski et al., 2006)**. In the absence of any other effective treatments, some advocate surgery in the younger, medically fit patient who wishes to become catheter free**.

The use of urethral dilation for women with DUA and significant residuals has been advocated but lacks an adequate evidence base to permit clear conclusions to be drawn (Basu and Duckett, 2010)**. Resection or incision of the bladder neck in women with DUA is not recommended, because this may lead to significant problems with either incontinence or bladder neck stenosis.**

Urinary Diversion

Because of the general acceptability and safety of both ISC and indwelling catheterization techniques, urinary diversion is rarely performed for DUA outside of the neurogenic population. When urethral clean intermittent catheterization is not possible and the patient wishes to avoid a suprapubic catheter, as is often the case in young women with idiopathic urinary retention refractory to SNM, a continent catheterizable stoma can be created. An incontinent diversion (e.g., ileal conduit) is occasionally performed when there are signs of renal deterioration resulting from obstruction to the intramural ureters secondary to a thick-walled bladder.

Reconstructive Surgery

Few reports of reconstructive surgical procedures for DUA are available. Stenzl et al. (1998) reported the first series of latissimus dorsi detrusor myoplasty (LDDM) in patients with DUA in 1998. The muscle is harvested, and its pedicle is anastomosed to the inferior epigastric vessels, with the nerve coapted to the intercostal branch. The muscle is wrapped in a spiral configuration around the bladder, covering over three-fourths of its surface. It is then anchored to the pelvic floor fascia and ligaments. The long-term outcomes of this technique in 24 catheter-dependent patients with acontractile detrusor have been reported (Gakis et al., 2011). Seventeen patients recovered the ability to void (mean PVR

= 25 mL). The mean bladder contractility index increased from 20.1 ± 7.6 to 176.2 ± 25.4 ($P < .001$). Complications occurred in one-third of patients, including thromboembolism, pelvic abscess, and wound infection, though there were no long-term problems. Rectus abdominis detrusor myoplasty was also reported as a potentially less morbid and complex intervention than LDDM. In five patients with spinal cord injury and DUA or acontractile bladder, complete spontaneous voiding was possible, with no major complications at over 1-year follow-up (Agarwal et al., 2018). Reconstructive surgery for DUA remains investigational at present.

Partial cystectomy (or reduction cystoplasty) has been reported in a few series as an alternative approach (Klarskov et al., 1988; Weinberg et al, 1974). However, there are no recent reported studies, and it is no longer considered in contemporary practice.

Regenerative Medicine

Although tissue engineering of whole bladders has been investigated for over a decade and resulted in a small clinical study with some success (Atala et al., 2006), such bladders can only fulfill a storage function because of the difficulty of recreating the complex neural innervation to enable volitional emptying. An alternative approach is to inject stem cells at various sites to restore bladder function. Several studies investigating different cell types to treat bladder dysfunction in animals are available. These studies follow the scheme of using a model of underactive bladder, injecting stem cells in the bladder or at the site of damage to the neural innervation, and then performing urodynamic assessment of bladder contractility. Some of these studies have shown an improvement in contractility (Chen et al., 2012; Nishijima et al., 2007). Recently, a study in which autologous muscle-derived stem cells were injected in the bladder wall of a 79-year-old male with DUA reported some improvement in voiding parameters at 1 year follow-up, however the patient still needed to perform ISC (Levanovich et al., 2015). To conclude, the major barriers to overcome include our incomplete understanding of the structure and function of the lower urinary tract and the inevitable concern regarding whether muscle cells injected into the bladder wall will in fact be able to acquire a functional innervation and hence contribute to wall function in a meaningful fashion.

Key Points: Management

- There are no effective pharmacotherapies for the treatment of DUA.
- Parasympathomimetic agents have questionable efficacy, are associated with potentially fatal systemic effects, and are not used in routine practice.
- Intravesical electrotherapy has shown promising results in restoring detrusor contraction; however, it is time- and resource-consuming.
- SNM is effective in restoring voiding in patients with DUA associated with urethral sphincter/pelvic floor disorders.
- Bladder outlet surgery has a high risk for failure in men with DUA not reliant on catheters. Men with DUA and chronic retention dependent on catheter drainage experience poorer outcomes than those with normal

detrusor function; however, they still may benefit from surgery.

Conclusions

DUA is a common problem that can pose a difficult challenge for both patients and physicians because of the lack of simple and effective treatments. This problem has received little attention in clinical and basic science research in comparison to other common LUTDs such as OAB and DOA. Defining the problem in symptom-based terms is difficult because there is a wide spectrum of manifesting symptoms, underlying clinical conditions, and absence of accurate noninvasive markers. Clinical studies suggest that the problem is highly prevalent in both men and women with LUTS presenting to urologists. A variety of causes are implicated, affecting all aspects of the micturition reflex. There is a lack of any simple and effective treatments. Preserved bladder sensation appears to predict better responses to treatment. There is a need for a greater understanding of the mechanisms governing normal detrusor contraction and how these are affected by disease. Until this is achieved, it will be difficult to develop compounds that enhance detrusor strength and duration of contractility or enhance bladder sensation. In the future, developments in regenerative medicine, stem cell therapy, and gene therapy may provide interesting avenues for further research, but a prerequisite for this will be to develop a better understanding of both normal structure and function of the lower urinary tract and the way in which this is altered in cases of DUA.

Suggested Readings

Elbadawi A, Yalla SV, Resnick NM. Structural basis of geriatric voiding dysfunction. II. Aging detrusor: normal versus impaired contractility. *J Urol*. 1993;150(5 Pt 2):1657–1667.

Jeong SJ, Kim HJ, Lee YJ, et al. Prevalence and clinical features of detrusor underactivity among elderly with lower urinary tract symptoms: a comparison between men and women. *Korean J Urol*. 2012;53:342–348.

Resnick NM, Yalla SV, Laurino E. The pathophysiology of urinary incontinence among institutionalized elderly persons. *N Engl J Med*. 1989;320:1–7.

Thomas AW, Cannon A, Bartlett E, et al. The natural history of lower urinary tract dysfunction in men: minimum 10-year urodynamic follow-up of untreated detrusor underactivity. *BJU Int*. 2005;96:1295–1300.

References

Abarbanel J, Marcus EL. Impaired detrusor contractility in community-dwelling elderly presenting with lower urinary tract symptoms. *Urology*. 2007;69:436–440.

Abrams P, Cardozo L, Fall M, et al. The standardisation of terminology of lower urinary tract function: report from the Standardisation Sub-committee of the International Continence Society. *Neurourol Urodyn*. 2002;21:167–178.

Abrams P. Bladder outlet obstruction index, bladder contractility index and bladder voiding efficiency: three simple indices to define bladder voiding function. *BJU Int*. 1999;84:14–15.

Abrams PH, Griffiths DJ. The assessment of prostatic obstruction from urodynamic measurements and from residual urine. *Br J Urol*. 1979;51:129–134.

Agarwal P, Husain S, Wankhede S, et al. Rectus abdominis detrusor myoplasty (RADM) for acontractile/hypocontractile bladder in spinal cord injury patients: preliminary report. *J Plast Reconstr Aesthet Surg*. 2018;71(5):736–742.

Ameda K, Steele GS, Sullivan MP, et al. Detrusor contraction duration as a urodynamic parameter of bladder outlet obstruction for evaluating men with lower urinary tract symptoms. *J Urol*. 1998;160:482–486.

Araki I, Kitahara M, Oida T, et al. Voiding dysfunction and Parkinson's disease: urodynamic abnormalities and urinary symptoms. *J Urol*. 2000;164:1640–1643.

Atala A, Bauer SB, Soker S, et al. Tissue-engineered autologous bladders for patients needing cystoplasty. *Lancet*. 2006;367:1241–1246.

Azadzoi KM, Radisavljevic ZM, Golabek T, et al. Oxidative modification of mitochondrial integrity and nerve fiber density in the ischemic overactive bladder. *J Urol*. 2010;183:362–369.

Azadzoi KM, Tarcan T, Kozlowski R, et al. Overactivity and structural changes in the chronically ischemic bladder. *J Urol*. 1999;162:1768–1778.

Azadzoi KM, Tarcan T, Siroky MB, et al. Atherosclerosis-induced chronic ischemia causes bladder fibrosis and non-compliance in the rabbit. *J Urol*. 1999;161:1626–1635.

Barendrecht MM, Oelke M, Laguna MP, et al. Is the use of parasympathomimetics for treating an underactive urinary bladder evidence-based? *BJU Int*. 2007;99:749–752.

Basu M, Duckett JRA. Effect of urethral dilatation on women with voiding dysfunction. *Curr Bladder Dysfunct Rep*. 2010;5:23–26.

Bergman A, Mushkat Y, Gordon D, et al. Prostaglandin for enhancing bladder function after vaginal surgery: does it work? *J Reprod Med*. 1992;37:320–322.

Bergman A, Mushket Y, Gordon D, et al. Prostaglandin prophylaxis and bladder function after vaginal hysterectomy: a prospective randomised study. *Br J Obstet Gynaecol*. 1993;100:69–72.

Bloch F, Pichon B, Bonnet AM, et al. Urodynamic analysis in multiple system atrophy: characterisation of detrusor-sphincter dyssynergia. *J Neurol*. 2010;257:1986–1991.

Blok BF, Willemsen AT, Holstege G. A PET study on brain control of micturition in humans. *Brain*. 1997;120(Pt 1):111–121.

Boone TB, Roehrborn CG, Hurt G. Transurethral intravesical electrotherapy for neurogenic bladder dysfunction in children with myelodysplasia: a prospective, randomized clinical trial. *J Urol*. 1992;148:550–554.

Brierly RD, Hindley RG, McLarty E, et al. A prospective controlled quantitative study of ultrastructural changes in the underactive detrusor. *J Urol*. 2003;169:1374–1378.

Brindley GS, Polkey CE, Rushton DN, et al. Sacral anterior root stimulators for bladder control in paraplegia: the first 50 cases. *J Neurol Neurosurg Psychiatry*. 1986;49:1104–1114.

Brindley GS, Polkey CE, Rushton DN. Sacral anterior root stimulators for bladder control in paraplegia. *Paraplegia*. 1982;20:365–381.

Buckley BS, Lapitan MC. Drugs for treatment of urinary retention after surgery in adults. *Cochrane Database Syst Rev*. 2010;(10) [CD008023].

Bump RC. The urethrodetrusor facilitative reflex in women: results of urethral perfusion studies. *Am J Obstet Gynecol*. 2000;182:794–802 [discussion 802–804].

Burney TL, Senapati M, Desai S, et al. Acute cerebrovascular accident and lower urinary tract dysfunction: a prospective correlation of the site of brain injury with urodynamic findings. *J Urol*. 1996;156:1748–1750.

Carr LK, Webster GD. Bladder outlet obstruction in women. *Urol Clin North Am*. 1996;23:385–391.

Chang SJ, Chiang IN, Yu HJ. The effectiveness of tamsulosin in treating women with voiding difficulty. *Int J Urol*. 2008;15:981–985.

Chapple CR, Osman NI, Birder L, et al. Terminology report from the International Continence Society (ICS) Working Group on Underactive Bladder (UAB). *Neurourol Urodyn*. 2018;37(8):2928–2931.

Charach G, Greenstein A, Rabinovich P, et al. Alleviating constipation in the elderly improves lower urinary tract symptoms. *Gerontology*. 2001;47:72–76.

Chen S, Zhang HY, Zhang N, et al. Treatment for chronic ischaemia-induced bladder detrusor dysfunction using bone marrow mesenchymal stem cells: an experimental study. *Int J Mol Med*. 2012;29:416–422.

Cho KJ, Koh JS, Choi J, et al. Changes in adenosine triphosphate and nitric oxide in the urothelium of patients with benign prostatic hyperplasia and detrusor underactivity. *J Urol*. 2017;198:1392–1396.

Cucchi A, Quaglini S, Guarnaschelli C, et al. Urodynamic findings suggesting two-stage development of idiopathic detrusor underactivity in adult men. *Urology*. 2007;70:75–79.

Cucchi A, Quaglini S, Rovereto B. Development of idiopathic detrusor underactivity in women: from isolated decrease in contraction velocity to obvious impairment of voiding function. *Urology*. 2008;71:844–888.

Cucchi A, Quaglini S, Rovereto B. Different evolution of voiding function in underactive bladders with and without detrusor overactivity. *J Urol*. 2010;183:229–233.

Daneshgari F, Liu G, Birder L, et al. Diabetic bladder dysfunction: current translational knowledge. *J Urol*. 2009;182:S18–S26.

DasGupta R, Fowler CJ. Urodynamic study of women in urinary retention treated with sacral neuromodulation. *J Urol*. 2004;171:1161–1164.

de Groat WC, Araki I, Vizzard MA, et al. Developmental and injury induced plasticity in the micturition reflex pathway. *Behav Brain Res*. 1998;92:127–140.

de Jong TP, Klijn AJ, Vijverberg MA, et al. Effect of biofeedback training on paradoxical pelvic floor movement in children with dysfunctional voiding. *Urology*. 2007;70:790–793.

De Wachter S, Van Meel TD, Wyndaele JJ. Can a faked cystometry deceive patients in their perception of filling sensations? A study on the reliability of spontaneously reported cystometric filling sensations in patients with non-neurogenic lower urinary tract dysfunction. *Neurourol Urodyn*. 2008;27:395–398.

De Wachter S, Van Meel TD, Wyndaele JJ. Study of the afferent nervous system and its evaluation in women with impaired detrusor contractility treated with bethanechol. *Urology*. 2003;62:54–58.

De Wachter S, Wyndaele JJ. Does bladder tone influence sensation of filling and electro-sensation in the bladder? A blind controlled study in young healthy volunteers using bethanechol. *J Urol*. 2001;165:802–804.

Djavan B, Madersbacher S, Klingler C, et al. Urodynamic assessment of patients with acute urinary retention: is treatment failure after prostatectomy predictable? *J Urol*. 1997;158:1829–1833.

Dykstra DD, Sidi AA, Scott AB, et al. Effects of botulinum A toxin on detrusor-sphincter dyssynergia in spinal cord injury patients. *J Urol*. 1988;139:919–922.

Ebner A, Jiang C, Lindstrom S. Intravesical electrical stimulation: an experimental analysis of the mechanism of action. *J Urol*. 1992;148:920–924.

Elbadawi A, Atta M, Hanno A. Intrinsic neuromuscular defects in the neurogenic bladder. VIII. Effects of unilateral pelvic and pelvic plexus neurectomy on ultrastructure of the feline bladder base. *Neurourol Urodyn*. 1988;7:77.

Elbadawi A, Yalla SV, Resnick NM. Structural basis of geriatric voiding dysfunction. II. Aging detrusor: normal versus impaired contractility. *J Urol*. 1993;150:1657–1667.

Elbadawi A, Yalla SV, Resnick NM. Structural basis of geriatric voiding dysfunction. III. Detrusor overactivity. *J Urol*. 1993;150:1668–1680.

Elbadawi A, Yalla SV, Resnick NM. Structural basis of geriatric voiding dysfunction. IV. Bladder outlet obstruction. *J Urol*. 1993;150:1681–1695.

Erdem E, Akbay E, Doruk E, et al. How reliable are bladder perceptions during cystometry? *Neurourol Urodyn*.

2004;23:306–309 [discussion 310].

Erdem E, Leggett R, Dicks B, et al. Effect of bladder ischaemia/reperfusion on superoxide dismutase activity and contraction. *BJU Int*. 2005;96:169–174.

Everaert K, Plancke H, Lefevere F, et al. The urodynamic evaluation of neuromodulation in patients with voiding dysfunction. *Br J Urol*. 1997;79:702–707.

Feber JL, Van Asselt E, Van Mastrigt R. Neurophysiological modeling of voiding in rats: urethral nerve response to urethral pressure and flow. *Am J Physiol*. 1998;274:R1473–R1481.

Fry CH, Bayliss M, Young JS, et al. Influence of age and bladder dysfunction on the contractile properties of isolated human detrusor smooth muscle. *BJU Int*. 2011;108:E91–E96.

Fusco F, Groutz A, Blaivas JG, et al. Videourodynamic studies in men with lower urinary tract symptoms: a comparison of community based versus referral urological practices. *J Urol*. 2001;166:910–913.

Gakis G, Ninkovic M, van Koeveringe GA, et al. Functional detrusor myoplasty for bladder acontractility: long-term results. *J Urol*. 2011;185:593–599.

Gammie A, Kaper M, Dorrepaal C, et al. Signs and symptoms of detrusor underactivity: an analysis of clinical presentation and urodynamic tests from a large group of patients undergoing pressure flow studies. *Eur Urol*. 2016;69:361–369.

George NJ, O'Reilly PH, Barnard RJ, et al. High pressure chronic retention. *Br Med J (Clin Res Ed)*. 1983;286:1780–1783.

Ghalayini IF, Al-Ghazo MA, Pickard RS. A prospective randomized trial comparing transurethral prostatic resection and clean intermittent self-catheterization in men with chronic urinary retention. *BJU Int*. 2005;96:93–97.

Gilpin SA, Gilpin CJ, Dixon JS, et al. The effect of age on the autonomic innervation of the urinary bladder. *Br J Urol*. 1986;58:378–381.

Gladh G, Mattsson S, Lindstrom S. *Intravesical electrical stimulation in the treatment of micturition dysfunction in children*. Linköping University: Linköping, Sweden; 2002.

Greenland JE, Brading AF. Urinary bladder blood flow changes during the micturition cycle in a conscious pig model. *J Urol*. 1996;156:1858–1861.

Griffiths D. Detrusor contractility: order out of chaos. *Scand J Urol Nephrol Suppl*. 2004;215:93–100.

Griffiths DJ. Assessment of detrusor contraction strength or contractility. *Neurourol Urodyn*. 1991;10:1–18.

Griffiths DJ. Bladder failure: a condition to reckon with [editorial]. *J Urol*. 2003;169:1011–1012.

Griffiths DJ. The mechanics of the urethra and of micturition. *Br J Urol*. 1973;45:497–507.

Groutz A, Gordon D, Lessing JB, et al. Prevalence and characteristics of voiding difficulties in women: are subjective symptoms substantiated by objective urodynamic data? *Urology*. 1999;54:268–272.

Harrison SC, Hunnam GR, Farman P, et al. Bladder instability and denervation in patients with bladder outflow obstruction. *Br J Urol*. 1987;60:519–522.

Hellweg R, Raivich G, Hartung HD, et al. Axonal transport of endogenous nerve growth factor (NGF) and NGF receptor in experimental diabetic neuropathy. *Exp Neurol*. 1994;130:24–30.

Hill SR, Fayyad AM, Jones GR. Diabetes mellitus and female lower urinary tract symptoms: a review. *Neurourol Urodyn*. 2008;27:362–367.

Hindley RG, Brierly RD, McLarty E, et al. A qualitative ultrastructural study of the hypocontractile detrusor. *J Urol*.

2002;168:126–131.

Holm NR, Horn T, Hald T. Detrusor in ageing and obstruction. *Scand J Urol Nephrol*. 1995;29:45–49.

Javle P, Jenkins SA, Machin DG, et al. Grading of benign prostatic obstruction can predict the outcome of transurethral prostatectomy. *J Urol*. 1998;160:1713–1717.

Jeong SJ, Kim HJ, Lee YJ, et al. Prevalence and clinical features of detrusor underactivity among elderly with lower urinary tract symptoms: a comparison between men and women. *Korean J Urol*. 2012;53:342–348.

Jeong SJ, Lee JK, Kim KM, et al. How do we diagnose detrusor underactivity? Comparison of diagnostic criteria based on an urodynamic measure. *Investig Clin Urol*. 2017;58:247–254.

Jiang YH, Kuo HC. Urothelial barrier deficits, suburothelial inflammation and altered sensory protein expression in detrusor underactivity. *J Urol*. 2017;197:197–203.

Jiang YH, Kuo HC. Video-urodynamic characteristics of non-neurogenic, idiopathic underactive bladder in men—A comparison of men with normal tracing and bladder outlet obstruction. *PLoS ONE*. 2017;12:e0174593.

Kajbafzadeh AM, Sharifi-Rad L, Ladi-Seyedian SS, et al. Transcutaneous interferential electrical stimulation for the management of non-neuropathic underactive bladder in children: a randomised clinical trial. *BJU Int*. 2016;117:793–800.

Kaplan SA, Ikeguchi EF, Santarosa RP, et al. Etiology of voiding dysfunction in men less than 50 years of age. *Urology*. 1996;47:836–839.

Kaplan WE. Intravesical electrical stimulation of the bladder: pro. *Urology*. 2000;56:2–4.

Karami H, Valipour R, Lotfi B, et al. Urodynamic findings in young men with chronic lower urinary tract symptoms. *Neurourol Urodyn*. 2011;30:1580–1585.

Katona F, Berenyi M. Intravesical transurethral electrotherapy of bladder paralysis. *Orv Hetil*. 1975;116:854–856.

Khanna OP, Gonick P. Effects of phenoxybenzamine hydrochloride on canine lower urinary tract: clinical implications. *Urology*. 1975;6:323–330.

Kim YH, Goodman C, Omessi E, et al. The correlation of urodynamic findings with cranial magnetic resonance imaging findings in multiple sclerosis. *J Urol*. 1998;159:972–976.

Kim M, Jeong CW, Oh SJ. Effect of preoperative urodynamic detrusor underactivity on transurethral surgery for benign prostatic hyperplasia: a systematic review and meta-analysis. *J Urol*. 2018;199:237–244.

Klarskov P, Holm-Bentzen M, Larsen S, et al. Partial cystectomy for the myogenic decompensated bladder with excessive residual urine: urodynamics, histology and 2-13 years' follow-up. *Scand J Urol Nephrol*. 1988;22:251–256.

Koonings PP, Bergman A, Ballard CA. Prostaglandins for enhancing detrusor function after surgery for stress incontinence in women. *J Reprod Med*. 1990;35:1–5.

Kuo HC. Effect of botulinum A toxin in the treatment of voiding dysfunction due to detrusor underactivity. *Urology*. 2003;61:550–554.

Kuo HC. Recovery of detrusor function after urethral botulinum A toxin injection in patients with idiopathic low detrusor contractility and voiding dysfunction. *Urology*. 2007;69:57–61 [discussion 61–62].

Kuo HC. Videourodynamic analysis of pathophysiology of men with both storage and voiding lower urinary tract symptoms. *Urology*. 2007;70:272–276.

Lecamwasam HS, Yalla SV, Cravalho EG, et al. The maximum Watts factor as a measure of detrusor contractility independent of outlet resistance. *Neurourol Urodyn*.

1998;17:621–635.

Lee WC, Wu HP, Tai TY, et al. Effects of diabetes on female voiding behavior. *J Urol*. 2004;172:989–992.

Lepor H, Sunaryadi I, Hartanto V, et al. Quantitative morphometry of the adult human bladder. *J Urol*. 1992;148:414–417.

Levanovich PE, Diokno A, Hasenau DL, et al. Intradetrusor injection of adult muscle-derived cells for the treatment of underactive bladder: pilot study. *Int Urol Nephrol*. 2015;47:465–467.

Levin RM, Longhurst PA, Barasha B, et al. Studies on experimental bladder outlet obstruction in the cat: long-term functional effects. *J Urol*. 1992;148:939–943.

Lifford KL, Curhan GC, Hu FB, et al. Type 2 diabetes mellitus and risk of developing urinary incontinence. *J Am Geriatr Soc*. 2005;53:1851–1857.

Litwiller SE, Frohman EM, Zimmern PE. Multiple sclerosis and the urologist. *J Urol*. 1999;161:743–757.

Madersbacher H. Intravesical electrical stimulation for the rehabilitation of the neuropathic bladder. *Paraplegia*. 1990;28:349–352.

Maggi CA. Prostanoids as local modulators of reflex micturition. *Pharmacol Res*. 1992;25:13–20.

Mangnall J. Key considerations of intermittent catheterisation. *Br J Nurs*. 2012;21:392–394 [396–398].

Mark S, Gilling P, Van Mastrigt R, et al. Detrusor contractility: age related correlation with urinary flow rate in asymptomatic males. *Neurourol Urodyn*. 1992;11:315–317.

Maurer CA, Z'Graggen K, Renzulli P, et al. Total mesorectal excision preserves male genital function compared with conventional rectal cancer surgery. *Br J Surg*. 2001;88:1501–1505.

Minardi D, D'Anzeo G, Parri G, et al. The role of uroflowmetry biofeedback and biofeedback training of the pelvic floor muscles in the treatment of recurrent urinary tract infections in women with dysfunctional voiding: a randomized controlled prospective study. *Urology*. 2010;75:1299–1304.

Mitsui T, Tanaka H, Harabayashi T, et al. Changes in urodynamics and lower urinary tract symptoms after radical prostatectomy: implications of preoperative detrusor contractility. *Low Urin Tract Symptoms*. 2012;4:82–86.

Miyazato M, Yoshimura N, Chancellor MB. The other bladder syndrome: underactive bladder. *Rev Urol*. 2013;15:11–22.

Monoski MA, Gonzalez RR, Sandhu JS, et al. Urodynamic predictors of outcomes with photoselective laser vaporization prostatectomy in patients with benign prostatic hyperplasia and preoperative retention. *Urology*. 2006;68:312–317.

Nishijima S, Sugaya K, Miyazato M, et al. Restoration of bladder contraction by bone marrow transplantation in rats with underactive bladder. *Biomed Res*. 2007;28:275–280.

Nitti VW, Lefkowitz G, Ficazzola M, et al. Lower urinary tract symptoms in young men: videourodynamic findings and correlation with noninvasive measures. *J Urol*. 2002;168:135–138.

Nomiya M, Yamaguchi O, Akaihata H, et al. Progressive vascular damage may lead to bladder underactivity in rats. *J Urol*. 2014;191:1462–1469.

Nomiya M, Yamaguchi O, Andersson KE, et al. The effect of atherosclerosis-induced chronic bladder ischemia on bladder function in the rat. *Neurourol Urodyn*. 2012;31:195–200.

O'Brien WF. The role of prostaglandins in labor and delivery. *Clin Perinatol*. 1995;22:973–984.

Osman NI, Chapple CR, Abrams P, et al. Detrusor underactivity and the underactive bladder: a new clinical entity? A review of current terminology, definitions, epidemiology, aetiology, and diagnosis. *Eur Urol*. 2014;65:389–398.

Park JM, Bloom DA, McGuire EJ. The guarding reflex revisited. *Br J Urol*. 1997;80:940–945.

Pfisterer MH, Griffiths DJ, Rosenberg L, et al. Parameters of bladder function in pre-, peri-, and postmenopausal continent women without detrusor overactivity. *Neurourol Urodyn*. 2007;26:356–361.

Pfisterer MH, Griffiths DJ, Schaefer W, et al. The effect of age on lower urinary tract function: a study in women. *J Am Geriatr Soc*. 2006;54:405–412.

Phelan MW, Franks M, Somogyi GT, et al. Botulinum toxin urethral sphincter injection to restore bladder emptying in men and women with voiding dysfunction. *J Urol*. 2001;165:1107–1110.

Plotti F, Angioli R, Zullo MA, et al. Update on urodynamic bladder dysfunctions after radical hysterectomy for cervical cancer. *Crit Rev Oncol Hematol*. 2011;80:323–329.

Primus G, Kramer G, Pummer K. Restoration of micturition in patients with acontractile and hypocontractile detrusor by transurethral electrical bladder stimulation. *Neurourol Urodyn*. 1996;15:489–497.

Rademakers KL, Drossaerts JM, van Kerrebroeck PE, et al. Prediction of sacral neuromodulation treatment success in men with impaired bladder emptying—time for a new diagnostic approach. *Neurourol Urodyn*. 2017;36:808–810.

Rahnama'i MS, Van Kerrebroeck PE, De Wachter SG, et al. The role of prostanoids in urinary bladder physiology. *Nat Rev Urol*. 2012;9:283–290.

Resnick NM, Brandeis GH, Baumann MM, et al. Misdiagnosis of urinary incontinence in nursing home women: prevalence and a proposed solution. *Neurourol Urodyn*. 1996;15:599–613 [discussion 613–618].

Resnick NM, Yalla SV, Laurino E. The pathophysiology of urinary incontinence among institutionalized elderly persons.

N Engl J Med. 1989;320:1–7.

Rollema HJ, Van Mastrigt R. Improved indication and followup in transurethral resection of the prostate using the computer program CLIM: a prospective study. *J Urol*. 1992;148:111–115 [discussion 115–116].

Rosario DJ, Chapple CR, Tophill PR, et al. Urodynamic assessment of the bashful bladder. *J Urol*. 2000;163:215–220.

Rosario DJ, Woo HH, Chapple CR. Definition of normality of pressure-flow parameters based on observations in asymptomatic men. *Neurourol Urodyn*. 2008;27:388–394.

Saito M, Yokoi K, Ohmura M, et al. Effects of partial outflow obstruction on bladder contractility and blood flow to the detrusor: comparison between mild and severe obstruction. *Urol Int*. 1997;59:226–230.

Sasaki K, Chancellor MB, Phelan MW, et al. Diabetic cystopathy correlates with a long-term decrease in nerve growth factor levels in the bladder and lumbosacral dorsal root ganglia. *J Urol*. 2002;168:1259–1264.

Sauerwein D. Surgical treatment of spastic bladder paralysis in paraplegic patients: sacral deafferentiation with implantation of a sacral anterior root stimulator. *Urologe A*. 1990;29:196–203.

Schäfer W, Watervär F, Langen P-H, et al. A simplified graphic procedure for detailed analysis of detrusor and outlet function during voiding. *Neurourol Urodyn*. 1989;8:405–407.

Schäfer W. Analysis of bladder-outlet function with the linearized passive urethral resistance relation, linPURR, and a disease-specific approach for grading obstruction: from complex to simple. *World J Urol*. 1995;13:47–58.

Schmidt F, Shin P, Jorgensen TM, et al. Urodynamic patterns of normal male micturition: influence of water consumption on urine production and detrusor function. *J Urol*. 2002;168:1458–1463.

Schroder A, Chichester P, Kogan BA, et al. Effect of chronic bladder outlet obstruction on blood flow of the rabbit bladder. *J Urol*. 2001;165:640–646.

Schurch B, Hauri D, Rodic B, et al. Botulinum-A toxin as a treatment of detrusor-sphincter dyssynergia: a prospective study in 24 spinal cord injury patients. *J Urol*. 1996;155:1023–1029.

Sexton CC, Coyne KS, Kopp ZS, et al. The overlap of storage, voiding and postmicturition symptoms and implications for treatment seeking in the USA, UK and Sweden: EpiLUTS. *BJU Int*. 2009;103(Suppl 3):12–23.

Sibley GN. The physiological response of the detrusor muscle to experimental bladder outflow obstruction in the pig. *Br J Urol*. 1987;60:332–336.

Smith AL, Kim JH, Rodríguez LV, et al: Urodynamic trends in the female aging population: detrusor hyperactivity with impaired contractility, two conditions or one? Presented at: 39th Annual Meeting of the International Continence Society; 2009; Sept 29–Oct 3; San Francisco, CA.

Smith PP. Aging and the underactive detrusor: a failure of activity or activation. *Neurourol Urodyn*. 2010;29:408–412.

Smith PP, Chalmers DJ, Feinn RS. Does defective volume sensation contribute to detrusor underactivity. *Neurourol Urodyn*. 2015;34:752–756.

Stenzl A, Ninkovic M, Kolle D, et al. Restoration of voluntary emptying of the bladder by transplantation of innervated free skeletal muscle. *Lancet*. 1998;351:1483–1485.

Stocchi F, Carbone A, Inghilleri M, et al. Urodynamic and neurophysiological evaluation in Parkinson's disease and multiple system atrophy. *J Neurol Neurosurg Psychiatry*. 1997;62:507–511.

Sugaya K, Nishijima S, Miyazato M, et al. Central nervous control of micturition and urine storage. *J Smooth Muscle*

Res. 2005;41:117–132.

Sugaya K, Ogawa Y, Hatano T, et al. Ascending and descending brainstem neuronal activity during cystometry in decerebrate cats. *Neurourol Urodyn*. 2003;22:343–350.

Sullivan M, Yalla S. Functional studies to assess bladder contractility. *J Urol Urogynakol*. 2007;14:7–10.

Sullivan MP, Dubeau CE, Resnick NM, et al. Continuous occlusion test to determine detrusor contractile performance. *J Urol*. 1995;154:1834–1840.

Sullivan MP, Yalla SV. Detrusor contractility and compliance characteristics in adult male patients with obstructive and nonobstructive voiding dysfunction. *J Urol*. 1996;155:1995–2000.

Suskind AM, Smith PP. A new look at detrusor underactivity: impaired contractility versus afferent dysfunction. *Curr Urol Rep*. 2009;10:347–351.

Swinn MJ, Kitchen ND, Goodwin RJ, et al. Sacral neuromodulation for women with Fowler's syndrome. *Eur Urol*. 2000;38:439–443.

Tammela T, Kontturi M, Kaar K, et al. Intravesical prostaglandin F2 for promoting bladder emptying after surgery for female stress incontinence. *Br J Urol*. 1987;60:43–46.

Tan TL, Bergmann MA, Griffiths D, et al. Which stop test is best? Measuring detrusor contractility in older females. *J Urol*. 2003;169:1023–1027.

Tanagho EA, Schmidt RA. Bladder pacemaker: scientific basis and clinical future. *Urology*. 1982;20:614–619.

Thomas AW, Cannon A, Bartlett E, et al. The natural history of lower urinary tract dysfunction in men: the influence of detrusor underactivity on the outcome after transurethral resection of the prostate with a minimum 10-year urodynamic follow-up. *BJU Int*. 2004;93:745–750.

Thomas AW, Cannon A, Bartlett E, et al. The natural history of lower urinary tract dysfunction in men: minimum 10-year urodynamic follow-up of untreated bladder outlet obstruction. *BJU Int*. 2005;96:1301–1306.

Thomas AW, Cannon A, Bartlett E, et al. The natural history of lower urinary tract dysfunction in men: minimum 10-year urodynamic follow-up of untreated detrusor underactivity. *BJU Int*. 2005;96:1295–1300.

Uren AD, Cotterill N, Harding C, et al. Qualitative exploration of the patient experience of underactive bladder. *Eur Urol*. 2017;72:402–407.

Valente S, Dubeau C, Chancellor D, et al. Epidemiology and demographics of the underactive bladder: a cross-sectional survey. *Int Urol Nephrol*. 2014;46(Suppl 1):S7–S10.

Valentini FA, Robain G, Marti BG. Urodynamics in women from menopause to oldest age: what motive? What diagnosis? *Int Braz J Urol*. 2011;37:100–107.

van Koeveringe GA, Rahnama'i MS, Berghmans BC. The additional value of ambulatory urodynamic measurements compared with conventional urodynamic measurements. *BJU Int*. 2010;105:508–513.

van Koeveringe GA, Vahabi B, Andersson KE, et al. Detrusor underactivity: a plea for new approaches to a common bladder dysfunction. *Neurourol Urodyn*. 2011;30:723–728.

Wagner G, Husslein P, Enzelsberger H. Is prostaglandin E2 really of therapeutic value for postoperative urinary retention? Results of a prospectively randomized double-blind study. *Am J Obstet Gynecol*. 1985;151:375–379.

Wang CC, Yang SS, Chen YT, et al. Videourodynamics identifies the causes of young men with lower urinary tract symptoms and low uroflow. *Eur Urol*. 2003;43:386–390.

Webb RJ, Lawson AL, Neal DE. Clean intermittent self-catheterisation in 172 adults. *Br J Urol*. 1990;65:20–23.

Weinberg SR, Tanenbaum B, Bertoni G. Hypotonic bladder. Treatment by partial cystectomy. *Urology*. 1974;3:43–47.

Wyndaele JJ. The normal pattern of perception of bladder filling during cystometry studied in 38 young healthy volunteers. *J Urol*. 1998;160:479–481.

Yamamoto T, Sakakibara R, Uchiyama T, et al. Time-dependent changes and gender differences in urinary dysfunction in patients with multiple system atrophy. *Neurourol Urodyn*. 2014;33:516–523.

Yamanishi T, Yasuda K, Kamai T, et al. Combination of a cholinergic drug and an alpha-blocker is more effective than monotherapy for the treatment of voiding difficulty in patients with underactive detrusor. *Int J Urol*. 2004;11:88–96.

Yoshida M, Homma Y, Inadome A, et al. Age-related changes in cholinergic and purinergic neurotransmission in human isolated bladder smooth muscles. *Exp Gerontol*. 2001;36:99–109.

Zhao Z, Azad R, Yang JH, et al. Progressive changes in detrusor function and micturition patterns with chronic bladder ischemia. *Investig Clin Urol*. 2016;57:249–259.

119

Nocturia

Stephen D. Marshall MD, Jeffrey P. Weiss MD, FACS

Nocturia, defined as waking because of the desire to void during intended sleep, can be the result of an abnormality in the genitourinary tract or a symptom of an underlying medical condition. Because of its multifactorial nature, uncovering the etiology of a patient's nocturia and treating it appropriately can be a diagnostic and therapeutic challenge for the urologist. A systematic approach, including a thorough history and physical examination, is essential to determine conditions contributing to nocturia. Therapeutic options are numerous and include conservative/behavioral management, pharmacotherapy, phytotherapy, and invasive procedures. Tailoring appropriate therapy to accurate diagnosis should lead to effective treatment and patient satisfaction.

Rationale for Evaluation and Management

Nocturia Is Bothersome

The International Continence Society (ICS) defines **nocturia as voiding that occurs during the hours of sleep (i.e., voiding that is preceded and not necessarily followed by sleep)** (Hashim et al., 2017; van Kerrebroeck et al., 2002). Key terms are listed in Table 119.1. Some clinicians do not consider one void during the night to be clinically significant. This may be because several studies have shown that less than two voids per night does not generate bother and that two or more voids per night can impair quality of life (Häkkinen et al., 2006; Hernández et al., 2008; Tikkinen et al., 2009b). **The definition of nocturia does not take into account the patient's degree of bother.** For example, one patient who voids once per night may report being very bothered versus another patient who voids two or three times per night who may report little bother. **Degree of bother influences quality of life.** According to the Boston Area Community Health (BACH) Survey, a population-based study of 5502 men and women 30 to 79 years of age, nocturia is associated with a decreased quality of life and an increased prevalence of depressive symptoms in both men and women (Kupelian et al., 2012). Compared with those with low bother, patients reporting high levels of nocturia-specific bother were found to be significantly more likely to have difficulty initiating sleep (47.7 minutes ± 34.4 vs. 23.5 minutes ± 13.6, *P* = .05), difficulty returning to sleep (28.9 minutes ± 16.1 vs. 15.4 minutes ± 9.6, *P* = .03), and greater morning fatigue (3.3 ± 0.7 vs. 2.5 ± 1.0, *P* = .04). The subjective morning fatigue and sleep ratings scale ranges from 1 to 7; higher scores equate to worse fatigue or sleep characteristics (Vaughan et al., 2012). In a prospective study of various sleep parameters and nocturia in a cohort of community-dwelling men and women, nocturia, common among older individuals with insomnia, was associated with both increased subjective nocturnal and decreased daytime wakefulness (Zeitzer et al., 2013).

TABLE 119.1

Key Terms and Definitions

TERM	DEFINITION
Night	The period between going to bed with the intention of sleeping and waking with the intention of arising
Nocturia	Waking one or more times to void during the hours of sleep; each void is preceded and followed by sleep
Total urine volume (TUV)	Total volume of urine produced during a 24-hour period
First-morning void	The first void after waking with the intention of rising
Nocturnal urine volume (NUV)	Total volume of urine passed during the night, including the first-morning void
Maximum voided volume (MVV)	The largest single voided volume in a 24-hr period
Nighttime frequency or actual number of nightly voids (ANV)	The number of voids recorded from the time the individual goes to bed with the intention of sleeping, to the time the individual wakes with the intention of rising
Nocturia index (Ni)	Ni = NUV/MVV; when Ni > 1 NUV exceeds maximum storage capacity and nocturia or enuresis occurs
Nocturnal polyuria	Nocturnal volume >20%-33% of total 24-hr volume (age dependent), other definitions include: NUV >6.4 mL/kg NUV >0.9 mL/min (54 mL/h) NUV >1.5 mL/min (>90 mL/h)
Nocturnal polyuria index (NPi)	NPi = NUV/TUV; if NPi > 0.20-0.33 (age dependent); patient has nocturnal polyuria
Predicted number of nightly voids (PNV)	PNV = Ni − 1, used for calculation of NBCi
Nocturnal bladder capacity index (NBCi)	NBCi = ANV − PNV; NBCi > 0 indicates that nocturia will occur at voided volumes < MVV. NBCi >2 associated with severe nocturia
Global polyuria	24-hour voided volume of >2.8 L in a 70-kg adult (>40 mL/kg)
Nocturnal enuresis	Voiding occurring during sleep

Modified from van Kerrebroeck P. Standardization of terminology in nocturia: commentary on the ICS report. *BJU Int* 90(Suppl 3):16–17, 2002.

Nocturia Is Common

Nocturia affects people of different ages, races, and genders all over the world. The BACH Survey, composed of 5502 men and women between 30 and 79 years of age, found that the overall **prevalence of nocturia (more than one void per night) was 28.4%, 25.2% among men and 31.3% among women** (Fitzgerald et al., 2007). A review of 43 pertinent articles revealed that prevalence rates of nocturia in younger men (20 to 40 years of age) were one or more voids in 11% to 35% and two or more voids in 2% to 17%. In older men (>70 years), rates were one or more voids in 69% to 93% and two or more voids in 29% to 59%. Prevalence rates in younger women were one or more voids in 20% to 44% and two or more voids in 4% to 18%. In older women, rates were one or more voids in 74% to 77% and two or more voids in 28% to 62%. It is noteworthy that **one in every five or six people 20 to 40 years of age wakes two or more times per night and that up to nearly three in every five people older than 70 years of age wake to void two or more times nightly** (Bosch and Weiss, 2010). The Fujiwara-Kyo study included 4427 men and women older than 65 years of age. Nocturia was defined as awakening to void two or more times per night. In this population, the prevalence was reported to be 47% at baseline and 50% 1 year later. The incidence was found to be 20%, and the remission rate was 15%. The authors showed that women and younger patients were more likely to spontaneously remit (Hirayama et al., 2013).

The prevalence of nocturia in both men and women increases with age (Bosch and Weiss, 2010). In a survey of 1424 elderly individuals (55 to 84 years of age), 53% of the sample listed nocturia as a self-perceived cause of nocturnal sleep disturbance every night or almost every night (Bliwise et al., 2009). Data acquisition methodology regarding nocturia may influence calculated prevalence. In the Krimpen study, a Dutch cohort of community-dwelling men 50 to 78 years of age, the International Prostate Symptom Score (IPSS) nocturia question overestimated the percentage, with nocturia three times or more compared with recordings on frequency-volume charts, in younger men (<60 years). In contrast, older men (>60 years) underestimated their nighttime frequency when scoring the IPSS nocturia question. In the Krimpen study, nocturia was three times more prevalent in men with low functional bladder capacity (<300 mL) than in men with greater capacity (Bosch and van Doorn, 2012).

Association of Nocturia With Early Mortality

Nocturia affects both quality and quantity of life. Several studies have implicated nocturia in overall survival. In the Third National Health and Nutrition Examination Survey (NHANES III), a US population-based sample of 7455 men and 8533 women, two or more voids per night were associated with poorer survival compared with zero to one voids per night. This was particularly true in subjects younger than 65 years of age (Kupelian et al., 2011). In a community sample of 784 Japanese individuals 70 years of age and older, subjects with nocturia were at greater risk for skeletal fracture and death than those without nocturia during the 5-year observation period, even when adjusting for covariates including diabetes; smoking status; history of coronary disease, renal disease, and stroke; and use of tranquilizers, hypnotics, and diuretics (Nakagawa et al., 2010). In contrast, the Krimpen study, which analyzed 1114 men 50 to 78 years of age based on frequency-volume chart data, determined that the association between nocturia and mortality was explained by confounding factors including age, chronic obstructive pulmonary disease, smoking, and hypertension (age being the most profound). Specifically, nocturia was associated with increased mortality in the univariate analysis but was not associated with mortality in the multivariate analysis (van Doorn et al., 2012).

Nocturia affects sleep efficiency and sleep latency. Sleep efficiency is defined as actual time asleep (minutes) divided by total time of intended sleep (minutes); normal is considered greater than 85%. Sleep latency is defined as the time it takes to go from being completely awake to being completely asleep. Dew et al. (2003) showed that older adults with certain electroencephalography (EEG) sleep characteristics have an increased risk for dying independent of age, gender, and medical comorbidities. Individuals with sleep latency times of greater than 30 minutes were found to have greater than twice the risk for death, and those with sleep efficiency less than 80% were found to have nearly twice the risk for death when controlling for age, gender, and medical burden. Vaughan et al. (2013) prospectively analyzed 63 patients with Parkinson's disease using the IPSS and polysomnography. Of the 60 who completed the IPSS, 37 (61%) reported two or more episodes of nocturia. These patients demonstrated lower polysomnography-defined sleep efficiency and whole-night total sleep time than patients with zero to one episode of nocturia per night. Also, patients who reported two or three episodes of nocturia with *high* bother on the IPSS demonstrated lower whole-night total sleep time (281 ± 116 minutes vs. 373 ± 59 minutes, $P = .03$) and poorer sleep efficiency (59% ± 23% vs. 76% ± 11%, $P = .04$) compared with participants who reported two or three episodes of nocturia with *low* bother. These results show that individuals with higher bother on the IPSS experience poorer sleep as defined by polysomnography and that patients with Parkinson's disease and nocturia have poor sleep in general. Bliwise et al. (2015) demonstrated that a shorter first uninterrupted sleep period (FUSP) is associated with lower sleep quality, shorter sleep duration, poorer sleep efficiency, and greater daytime dysfunction. In a subsequent study, the authors concluded that simple interventions to increase FUSP results in better sleep quality (Tyagi et al., 2017). Increases in FUSP have been shown to improve the PSQI (Pittsburgh Sleep Quality Index) or overall sleep quality as suggested by Bliwise et al. (2014). Better sleep quality, measured by increases in FUSP, may also help reduce blood glucose levels and improve overall cardiometabolic health (Juul et al., 2016).

It is not surprising that nocturia is associated with an increased risk for mortality, because **nocturia can be a symptom of serious systemic illnesses including hypertension, diabetes, heart disease, and kidney disease** (Ancoli-Israel et al., 2012). Bliwise et al. (2017) showed that both men and women in a racially diverse population have elevated glucose levels in individuals habitually obtaining less than 7 hours of sleep. Sleep loss can negatively affect health by decreasing immune function, increasing the risk for cardiovascular disease, and increasing the risk for developing obesity and type 2 diabetes (Asplund, 2005; Spiegel et al., 2004). This can be better understood by defining the various states and stages of sleep. **Sleep is divided into two states: rapid eye movement (REM) and non–rapid eye movement (NREM).** NREM accounts for approximately 75% of total sleep time and is divided into four stages. Stage 1 accounts for the transition from wakefulness to sleep; stage 2 accounts for light sleep; and stages 3 and 4 consist of deep, restorative sleep or slow-wave sleep (SWS) (Keenan, 1999). The normal sleep cycle alternates between stages 1 and 4 of NREM and REM sleep (Roehrs, 2000). Each night consists of roughly four to six sleep cycles. In the beginning of the night, SWS predominates, whereas in the later hours of the night REM sleep predominates. Awakening during REM sleep is more natural and may still leave one feeling rested compared with awakening during SWS, which leaves one to experience daytime fatigue and discomfort irrespective of the total length of sleep time (Lentz et al., 1999). Because the first nocturia episode often occurs within the first 2 to 3 hours of sleep on average, SWS may be interrupted by nocturia, which may explain why nocturics often experience decreased quality of life (van Kerrebroeck et al., 2007).

SWS plays a role in glucose homeostasis. Tasali et al. (2008) demonstrated that suppression of SWS for three nights impairs glucose tolerance and insulin sensitivity. This explains why aging individuals with impaired SWS are at higher risk for developing type 2 diabetes. The body's regulation of SWS is a homeostatic process as well. This was illustrated by a study that monitored the EEG activity of both control subjects and subjects receiving acoustic stimulation during the first 3 hours of sleep to decrease the amount of SWS. Individuals who had decreased SWS early in the night because of acoustic stimulation were noted to have inadequately compensated amounts of SWS later in the night (Dijk, 2009). In a related study, when the first void occurred during the first two sleep cycles, patients had (on average) 37 minutes of SWS compared with those in whom the first void occurred after the first two sleep cycles, tallying (on average) 56 minutes of SWS (P = .023). The actual number of nightly voids (ANV) also affected SWS. Patients who experienced zero to one void per night had an average of 62 minutes of SWS compared with those who experienced two or more voids per night, who had an average of 40 minutes of SWS (P = .014) (Torimoto et al., 2013). In the Sleep Heart Health Study, 2813 men and 3097 women between 40 and 100 years of age were enrolled in a community-based prospective study that examined the cardiovascular consequences of sleep-disordered breathing. Usual sleep durations were obtained by questionnaire, and hypertension was defined as systolic blood pressure (BP) greater than 104 mm Hg, diastolic BP greater than 90 mm Hg, or the use of medication to treat hypertension. Usual sleep duration above or below the median of 7 to 8 hours per night was associated with an increased risk for hypertension, particularly in individuals who sleep less than 6 hours per night (Gottlieb et al., 2006). **Sleep duration less than 6 hours or greater than 8 hours may be a factor predisposing to metabolic syndrome. Compared with those sleeping 7 to 8 hours per night, those sleeping for longer or shorter durations were at least 45% more likely to have metabolic syndrome** (Hall et al., 2008). A recent analysis of the BACH survey revealed that among baseline lower urinary tract symptoms (LUTS), only nocturia was associated with incident sleep problems at 5-year follow-up (odds ratio [OR] 1.98 with or without body mass index adjustment, $P < .001$) (Araujo et al., 2014). In a US cohort of 2447 men (40 to 79 years of age) who were followed for a median of 17 years, nocturia was found to be a marker for coronary heart disease in men younger than 60 years of age (adjusted OR 1.36) and a marker for death in men 60 years of age and older (OR 1.48) (Lightner et al., 2012). A systematic review and meta-analysis found consistent evidence of increased mortality for men or women with nocturia equivalent to a 28% excess risk per year (Pesonen et al., 2014). **In summation, present evidence points to nocturia as a risk factor for future development of both metabolic syndrome and early mortality as a result of its proxy**

effect on sleep impairment.

Nocturia is among the LUTS most strongly associated with falls (Parsons et al., 2009) and is a risk factor for hip fractures (regardless of age). In an Austrian study, 1820 men 40 to 80 years of age completed the IPSS. Although the IPSS was not correlated with the occurrence of hip fractures, nocturia (two or more voids per night) was an age-independent risk factor for hip fracture (OR 1.36; 95% confidence interval [CI] 1.03, 1.80; *P* = .03) (Temml et al., 2009). Hip fracture has been associated with an in-hospital mortality rate of 5.3%, hence providing explanation for early mortality related to nocturia (Alvarez-Nebreda et al., 2008). What is not clear is whether successful therapy for nocturia could diminish falls, fractures, metabolic syndrome, or early mortality.

Costs to Society

Assuming that 28 million people 25 years of age or older in the United States experience nocturia (more than two voids per night) and this results in a productivity loss of 127 hours per individual, then based on the average US wage of $17.38 per hour (based on small-size, private industry salaries), the economic value of productivity lost in 2008 was $61 billion (Holm-Larsen et al., 2010). In a Swedish study, productivity, vitality, and quality of life were assessed in more than 200 professionally active adults with one or more voids per night. Compared with controls, patients with nocturia had significantly increased work impairment (assessed using a work productivity and activity impairment questionnaire) and increased impairment in nonwork activities (*P* < .001). Patients with nocturia also had significantly reduced vitality (based on responses to Short Form-36 Health Survey) and reduced overall quality of life (based on responses to the EQ-5D) compared with controls (*P* < .001). EQ-5D is a standardized instrument for assessing health status. It also was found that work impairment increased and vitality decreased in proportion to nocturia severity (*P* < .05, < .01, respectively) (Kobelt et al., 2003). Nocturnal awakenings were found to be associated with sleepiness, naps, and sick leave in the general adult population in a study in which 76% of respondents reported needing to void as the reason for awakening (i.e., true nocturia) (Ohayon, 2008).

Key Points: Rationale for Evaluation and Management

- Nocturia is waking during intended sleep because of the desire to void.
- Two or more voids per night appears to be clinically significant.
- The prevalence of nocturia increases with age.
- Nocturia is costly to society because it can lead to decreased productivity, increased time away from work, and increased falls and fractures.
- Nocturia impairs sleep efficiency, sleep latency, and SWS, and is associated with increased mortality.
- Nocturia can be a symptom of serious systemic illness, including hypertension, diabetes, heart disease, and kidney disease, leading to metabolic syndrome.

Evaluation

The cause of nocturia can be multifactorial and complex; therefore, the evaluation of nocturia should be focused and systematic, beginning with a complete history and physical examination. By way of example, a history of medication use, such as lithium, should alert the clinician to the possibility of global polyuria as a result of drug-induced nephrogenic diabetes insipidus. Physical findings pertinent to an evaluation of nocturia might include peripheral edema resulting from cardiac disease, nephrotic syndrome, or venous insufficiency and be associated with nocturnal polyuria. Physical findings such as obesity and short neck might be suggestive of obstructive sleep apnea (OSA); the latter also is associated with nocturnal polyuria. In the population-based Finnish National Nocturia and Overactive Bladder (FINNO) study, numerous risk factors for nocturia were identified, such as urinary urgency, benign prostatic hyperplasia (BPH), snoring, obesity, antidepressant usage, restless legs syndrome, and prostate cancer in men, and obesity, urinary urgency, snoring, diabetes, restless legs syndrome, and coronary artery disease in women. However, none of the identified risk factors were associated with nocturia in more than 50% of the affected subjects of both sexes, highlighting the multifactorial cause of nocturia (Tikkinen et al., 2009a). Hence, it is essential that clinicians consider factors beyond the LUT when treating bothersome nocturia.

Some of the questions to consider when evaluating nocturia are: How is nighttime defined? Is the patient awakened by the need to void, or does the patient void because he or she is already awake? A recent study by Weinberger et al. (2013) showed that 92% of men and 90% of women are awakened by the urge to void, leaving the remainder as incidental nocturnal convenience voids. **Nighttime is defined as the period between going to bed with the intention of sleeping and awakening with the intention of arising** (van Kerrebroeck et al., 2002). This definition becomes relevant when explaining to the patient how to complete a 24-hour voiding diary or **frequency-volume chart,** the most valuable objective instrument in evaluating nocturia. When completing a frequency-volume chart, the patient must be aware that nocturnal voids are preceded and followed by the intention of sleep regardless of time of day. Because at least 16% of the US population consists of shift workers who occasionally sleep during the day, it is important to remember that nocturia may occur during the day (Beers, 2000). Changing time zones (jet lag) also complicates the definition of nighttime. Before having a patient complete a frequency-volume chart, it is best to allow sufficient recovery time to eliminate the effect of jet lag.

Although the first-morning void after a night's sleep is counted toward daytime (diurnal) frequency rather than the ANV, the volume of the first-morning void is included in the tally of nocturnal voided volume. Hence, **nocturnal urine volume (NUV)** is the sum of all nocturnally voided volumes plus that of the first-morning void, because the urine in the latter void is produced during the hours of sleep. An untested assumption is that most patients void before bedtime. Hence the first nocturia-related void is also assumed to have been excreted during the hours of sleep. **Maximum voided volume (MVV)** is the largest voided volume of urine during a 24-hour period. The nocturia index (Ni) is calculated by dividing NUV by MVV (Weiss et al., 1999). When NUV is greater than MVV, the Ni is greater than 1, in which case nocturia must occur if the patient awakens, and, if not, enuresis will occur. Epstein et al. showed that improvements in nocturia were associated with a decrease in 24-hour urine volume and NUV, but not MVV, suggesting that improved patients consumed less fluid (Epstein et al., 2018). Improved patients also had an increase in FUSP, suggesting that therapy for nocturia can improve sleep architecture.

Nocturnal polyuria is increased production of urine at night that is offset by lowered daytime urine production, such that 24-hour urine volume remains within normal limits (Asplund, 1995). Because urine is normally produced in an age-dependent circadian pattern, it is worthwhile to determine the nocturnal polyuria index (NPi), which is the percentage of urine produced during nighttime (calculated as NUV/total 24-hour urine volume). In healthy adults 21 to 35 years of age, the mean NPi = 0.14 versus those 65 years of age and older, whose mean NPi = 0.34 (Rembratt et al., 2002). The NPi for middle-aged adults lies between 0.14 and 0.34. Accordingly, to simplify the definition, the ICS has defined NP as NPi greater than 20% (0.20) in young adults and greater than 33% (0.33) in patients older than 65 years of age when 24-hour urine production is within normal limits (van Kerrebroeck et al., 2002). Other definitions of nocturnal polyuria include NUV greater than 6.4 mL/kg and NUV greater than 0.9 mL/min (54 mL/h) (Matthiesen et al., 1996). Blanker et al. (2002) defined nocturnal polyuria as greater than 1.5 mL/min (>90 mL/h), which was 2 standard deviations above the mean of 60 mL/h in their study of men 50 to 78 years of age. van Doorn et al. (2013) found that prevalence, incidence, and resolution rates of nocturnal polyuria vary greatly depending on which definition is used. When analyzing the cohort of 1688 men 50 to 78 years of age in the Krimpen study, men who had nocturnal polyuria, defined as nocturnal urine production greater than 90 mL/h (NUP90), had a baseline prevalence of 15.0% that increased to 21.7% after 6.5 years. When nocturnal polyuria was defined as NUV greater than 33% of 24-hour voided volume (NUV33), baseline prevalence was 77.8% and increased to 80.5% after 6.5 years. At baseline, NUV33 was prevalent in 91.9% of men with nocturia and 70.1% of men without nocturia, and NUP90 was prevalent in 27.7% of men with nocturia and 8.0% of those without nocturia (van Doorn et al., 2013). A universally accepted definition of nocturnal polyuria has yet to be defined.

Everaert et al. (2018) recently studied the relationship between diuresis rate and urge perception score. Their goal was to see if diuresis rate has an effect on daytime and nighttime urinary urgency and frequency by analyzing 202 diaries from 126 unique patients (110 men, 16 women, mean age = 65). They found that nocturnal diuresis rate did correlate with nocturia severity (ANV), but there was no correlation between diuresis rate and urge perception score. This supports that nocturnal urgency is multifactorial and complex.

Another cause of nocturia is **decreased bladder capacity.** This can result from either a global decrease in bladder capacity as expressed by a low MVV or simply a decrease in nocturnal bladder capacity. In both instances, NUV exceeds nocturnal bladder capacity, and the patient arises because of the need to void. The **nocturnal bladder capacity index (NBCi)** is a useful means to examine the relationship between the patient's own bladder capacity and nocturnal voided volumes during a 24-hour period. NBCi is calculated by subtracting the predicted number of nightly voids (PNV) from the ANV. The PNV is calculated by subtracting 1 from Ni (NUV/MVV). Therefore NBCi = (ANV − PNV), where PNV = (Ni − 1). If NBCi is greater than 0, then nocturia occurs at volumes less than MVV (Weiss, 2012). As an example, a patient who voids eight times per night (ANV = 8), voids a total of 800 mL during the intended hours of sleep (NUV = 800 mL), and has an MVV of 200 mL would have an Ni of 4 (Ni = NUV/MVV = 800 mL/200 mL = 4). This patient's PNV = Ni − 1 = 4 − 1 = 3. Therefore, this patient's NBCi = ANV − PNV = 8 − 3 = 5. An NBCi of 5 indicates a substantially diminished nocturnal bladder capacity. Although there is a significant association between patients with severe nocturia and NBCi greater than 2 (Weiss et al, 1999), an analysis of a sample of normal volunteers suggested that nocturia is related to diminished nocturnal bladder capacity when

NBCi is greater than 1.3 (Burton et al, 2011).

Global polyuria also can cause an individual to awaken to void during the hours of sleep. Global polyuria is defined as 24-hour urine output greater than 40 mL/kg causing both daytime urinary frequency and nocturia (Oelke and van Kerrebroeck, 2012). For example, a 75-kg patient would be considered to have global polyuria if the 24-hour urine output exceeded 3000 mL (75 kg × 40 mL/kg = 3000 mL). It is worthwhile to note that nocturia can have a mixed cause, as well; that is, a patient may awaken to void during the hours of sleep because of diminished nocturnal bladder capacity combined with either or both nocturnal polyuria or global polyuria. In an effort to increase patient compliance, a nocturnal FVC combined with 24-hour urine volume (omitting capture of detailed daytime voided volumes) may substitute for a standard FVC (Denys et al., 2016).

Key Points: Evaluation

- Evaluation of nocturia should include a relevant history and physical examination.
- A frequency-volume chart or a voiding diary is the single most useful tool in evaluating and classifying the cause of nocturia.
- When NUV is greater than MVV, the Ni is greater than 1, and nocturia will occur if the patient awakens. If the patient does not awaken, enuresis will occur.
- Nocturnal polyuria is increased production of urine at night and has several definitions.
- Global polyuria is defined as 24-hour urine output in excess of 40 mL/kg, causing both daytime urinary frequency and nocturia.

Cause and Management

Classification of nocturia using a frequency-volume chart, along with a focused history and physical examination, unlocks up to 17 different underlying medical conditions that may potentially contribute to its genesis (Table 119.2). Diary-based classification of nocturia also can help the urologist follow a treatment algorithm (Fig. 119.1). Although unproved, it is assumed that more accurate classification leads to better treatment outcomes.

TABLE 119.2

Diary-Based Classification of Nocturia and Respective Underlying Medical Conditions

NOCTURIA CATEGORY	UNDERLYING MEDICAL CONDITIONS
Nocturnal polyuria	Excessive nighttime fluid intake Peripheral edema Obstructive sleep apnea Diabetes mellitus Congestive heart failure
Diminished global or low nocturnal bladder capacity	Ureteral calculi Bladder calculi Pharmacologic agents Anxiety disorders Learned voiding dysfunction Cancer of bladder, prostate, or urethra Neurogenic bladder Nocturnal detrusor overactivity Prostatic obstruction
Global (24-hour) polyuria	Primary polydipsia Diabetes insipidus Diabetes mellitus

Modified from Weiss JP. Assessment of nocturia and nocturnal polyuria. In: Oelke M, van Kerrebroeck P, eds. *Current aspects on diagnosis and treatment of nocturia*. London, 2012, UNI MED Verlag AG, p 72.

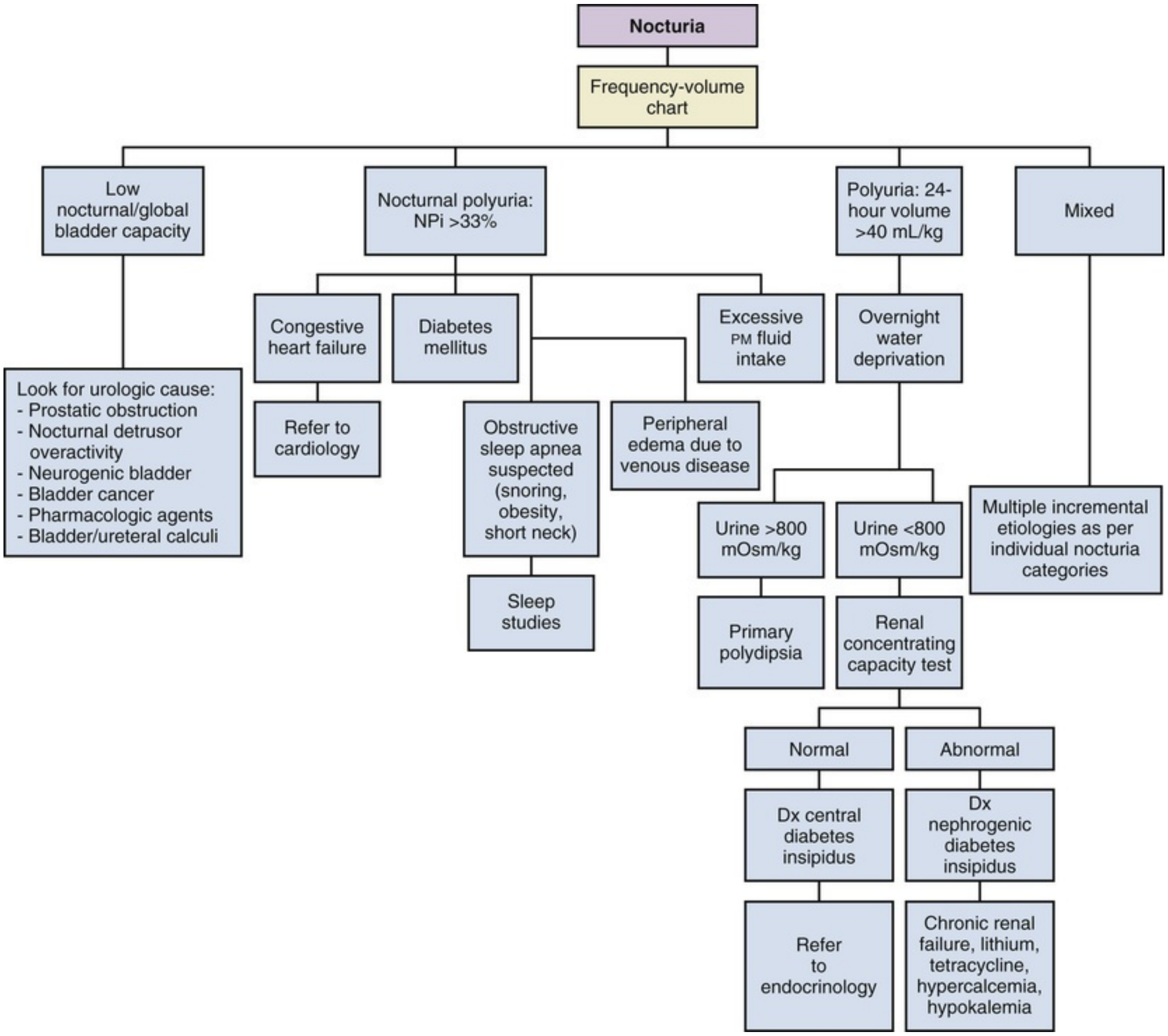
Nocturia
Frequency-volume chart
Low nocturnal/global bladder capacity
Nocturnal polyuria: NPi >33%
Polyuria: 24-hour volume >40 mL/kg
Mixed
Look for urologic cause:
- Prostatic obstruction
- Nocturnal detrusor overactivity
- Neurogenic bladder
- Bladder cancer
- Pharmacologic agents
- Bladder/ureteral calculi
Congestive heart failure
Diabetes mellitus
Excessive PM fluid intake
Overnight water deprivation
Refer to cardiology
Obstructive sleep apnea suspected (snoring, obesity, short neck)
Peripheral edema due to venous disease
Sleep studies
Urine >800 mOsm/kg
Urine <800 mOsm/kg
Multiple incremental etiologies as per individual nocturia categories
Primary polydipsia
Renal concentrating capacity test
Normal
Abnormal
Dx central diabetes insipidus
Dx nephrogenic diabetes insipidus
Refer to endocrinology
Chronic renal failure, lithium, tetracycline, hypercalcemia, hypokalemia

FIG. 119.1 Flowchart depicting comprehensive evaluation of nocturia and algorithm for treatment. *Dx,* Diagnosis; *NPi,* nocturnal polyuria index. (Modified from Weiss JP. Assessment of nocturia and nocturnal polyuria. In: Oelke M, van Kerrebroeck P, eds. *Current aspects on diagnosis and treatment of nocturia.* London, 2012, UNI MED Verlag AG, p 73.)

Nocturnal Polyuria

Epidemiology and Causes

The definition of nocturnal polyuria has a major impact on its perceived prevalence. Among patients with nocturia, nocturnal polyuria seems to be quite common. In a population recruited for a pharmacologic study of nocturia, 819 (88%) of 934 subjects with nocturia (more than two voids per night) who completed a voiding diary had nocturnal polyuria (NUV >33% of 24-hour volume) (Weiss, 2009). On the other hand, in analyzing the Krimpen database, Blanker et al. (2000) found that nocturnal polyuria prevalence for men 50 to 54 and 65 to 69 years of age was 44% and 54%, respectively, at baseline and increased to 51% and 65%, respectively, after 6.5 years of follow-up when nocturnal polyuria was defined as NUV/24-hour urine volume greater than 33%. When the nocturnal polyuria definition was changed to NUV >90 mL/h, the prevalence for men 50 to 54 and 65 to 69 years of age was 14% and 23%, respectively, and increased to 19% and 26%, respectively, after 6.5 years of follow-up. In an effort to prevent the overestimation of nocturnal polyuria prevalence, van Haarst and Bosch proposed that nocturnal polyuria exists when the NPi exceeds 53% (van Haarst and Bosch, 2012).

The physiology of renal water handling is relevant to an understanding of the pathophysiology of nocturnal polyuria and its treatment. Normal circadian urine production is age dependent. In those younger than 25 years of age, NUV/total = 14%, and in those older than 65 years of age, NUV/total = 34% (Rembratt et al., 2002). Water is the largest component of the human body; the major determinant of body water is arginine vasopressin (AVP)-regulated water excretion by the kidneys. AVP is stimulated by high serum osmolality, hypovolemia, and angiotensin II, and is inhibited by natriuretic peptides and negative feedback via baroreceptors. AVP causes vasoconstriction via V_{1a} receptors and causes renal reabsorption of water through its action on V_2 receptors as follows: AVP stimulation of V_2 receptors, located in the basolateral membrane of the renal collecting tubular cell, activates a Gs subtype of guanine nucleotide-binding protein (guanosine triphosphate [GTP]), which in turn activates adenylate cyclase. The result is increased concentration of cyclic 3′-5′-adenosine monophosphate (cAMP) and activation of protein kinase A (PKA). PKA triggers vesicles containing aquaporin 2 (AQP2) to fuse with the luminal plasma membrane of the collecting tubule, thereby allowing water to enter the cell. Passive resorption of water through the basolateral membrane (aquaporins 3 and 4) along osmotic gradients by way of other water channels into the vasa recta ultimately leads to water retention (Fig. 119.2). Other factors that inhibit ADH and cause diuresis (inhibit water reabsorption) include prostaglandin E_2 (PGE_2), atrial natriuretic peptide (ANP), hypercalcemia, hypokalemia, lithium, and tetracyclines (Nielsen et al., 1999). Reversal of water diuresis, accordingly, may occur through stimulation of V_2 receptors, either by endogenous AVP or a congener thereof, such as desmopressin. Therefore, low antidiuretic hormone (ADH) levels cause a larger volume of dilute urine to be produced. During sleep hours, this translates into a greater likelihood for nocturia.

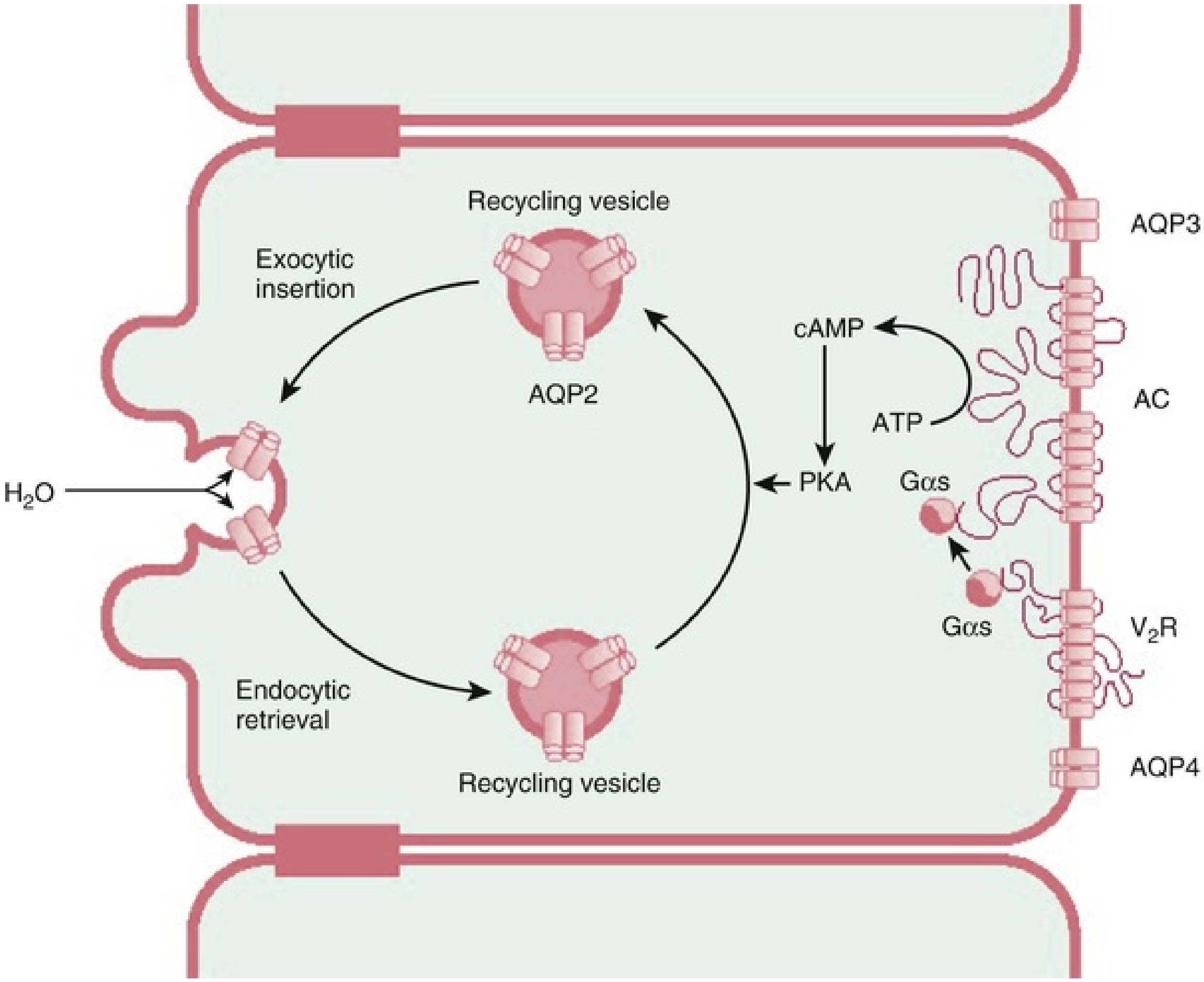
Recycling vesicle
Exocytic insertion
AQP3
AQP2
cAMP
ATP
AC
H_2O
PKA
Gαs
Gαs
V_2R
Endocytic retrieval
Recycling vesicle
AQP4

FIG. 119.2 Schematic diagram depicting arginine vasopressin regulation of water reabsorption from renal tubular cells. Schematic representation of aquaporin 2 trafficking within a cell. *AC,* adenyl cyclase; *AQP,* aquaporin; *ATP,* adenosine triphosphate; *cAMP,* cyclic 3′5′-adenosine monophosphate; *Gαs,* G-protein subunit (guanosine triphosphatase); *PKA,* protein kinase A; *V_2R,* V_2 receptor. (From Nielsen S. Renal aquaporins: an overview. *BJU Int* 90[Suppl 3]:1–6, 2002.)

OSA is a common cause of nocturnal polyuria. OSA is defined as the sudden cessation of respiration during sleep because of airway obstruction. Older adults with severe sleep-disordered breathing have a greater number of nocturia episodes (Endeshaw et al., 2004; Yalkut et al., 1996). The mechanism behind this is as follows: Increased airway pressure leads to hypoxia, which in turn causes pulmonary vasoconstriction, the latter leading to increased right atrial transmural pressure with a resulting increase in atrial natriuretic peptide

(ANP) production and ultimately increased renal sodium and water excretion. OSA is more likely as nocturia worsens in severity; the sleep apnea incidence in men with no, one, two, and three or more episodes of nocturia is 10%, 13%, 17%, and 20%, respectively. The sleep apnea incidence in women with no, one, two, and three or more episodes of nocturia is 7%, 9%, 12%, and 19%, respectively (Hashim et al., 2011). Men and women with three or more voids per night are more likely to have severe OSA (Kaynak et al., 2004).

Management

Treating nocturnal polyuria should begin with a conservative approach. Directly address the nocturnal polyuria itself by recommending cessation of fluid intake 4 hours before bedtime, the use of compressive lower extremity stockings, and/or administration of diuretics in the mid-afternoon for edema states. Individuals who have insomnia and nocturia may benefit from behavioral therapy directed at improving the insomnia. Tyagi et al. (2014) showed that individuals with insomnia and nocturia saw a greater improvement in number of nocturnal voids when treated with behavioral therapy versus receiving printed materials (information control). The behavioral therapy group saw a decrease in total number of nocturnal voids by 6.5 ± 4.8 over a 14-day period, whereas the information control group saw an increase of nocturnal voids by 1.3 ± 1.7 ($P = .05$). In addition, treating sleep disturbances, hypertension, and obesity in patients with nocturia also may decrease the number of nightly voids and improve quality of life (Sağlam et al., 2013).

A large roster of pharmaceutical agents may contribute to nocturia (Box 119.1). Further, timing of certain medications can influence nocturnal urine output. Diuretics work by preventing water accumulation and forcing water out of the system; they are indicated in patients with lower limb venous insufficiency and congestive heart failure. Timing of diuretic administration should be during the mid-afternoon, to allow for elimination of lower extremity excess body fluid during normal waking hours. In a small randomized double-blind, placebo-controlled trial, 49 men (>50 years of age) with nocturnal polyuria were randomized to receive 40 mg of furosemide 6 hours before sleep versus placebo. Among the 43 men who completed the study, the reduction in nocturic episodes was 0.5 versus 0.0 (furosemide vs. placebo, $P = .014$). There was also a significant reduction in percentage of nighttime voided volume: −18% versus 0% (furosemide vs. placebo, $P < .001$). Therefore men with nocturnal polyuria may benefit from diuretic therapy 6 hours before sleep (Reynard et al., 1998).

Box 119.1

Drug Effects Causing Nocturia

Increased Urine Output

- Diuretics
- SSRIs (block ADH secretion)[a,b]
- Calcium channel blockers (increase ANP, block sodium reabsorption in PCT)[c]
- Tetracycline (attenuates ADH via decreases in cAMP accumulation and action)[d]
- Lithium (decreases AQP2)[e]

Insomnia and CNS Effects

- CNS stimulants
  - Dextroamphetamine
  - Methylphenidate
- Antihypertensives
  - α-Blockers
  - β-Blockers
  - Methyldopa
- Respiratory
  - Albuterol
  - Theophylline
- Decongestants
  - Phenylephrine
  - Pseudoephedrine
- Hormones (corticosteroids, thyroid)
- Psychotropics
  - MAOIs
  - SSRIs
  - Atypical antidepressants

    Dopaminergic agonists (carbidopa)
    Antiepileptics (phenytoin)

Direct Lower Urinary Tract Effects

- Ketamine
    - Direct bladder toxin
- Tiaprofenic acid (Surgam)
    - Toxic cystitis
- Cyclophosphamide

ADH, Antidiuretic hormone; *ANP,* atrial natriuretic peptide; *AQP,* aquaporin; *cAMP,* cyclic 3′5′-adenosine monophosphate; *CNS,* central nervous system; *MAOI,* monoamine oxidase inhibitor; *PCT,* proximal convoluted tubule; *SSRI,* selective serotonin reuptake inhibitor.

---

[a] Rottmann CN. SSRIs and the syndrome of inappropriate antidiuretic hormone secretion. *Am J Nurs* 107:51–58; quiz 58–59, 2007.

[b] Asplund R, Johansson S, Henriksson S, et al. Nocturia, depression and antidepressant medication. *BJU Int* 95:820–823, 2005.

[c] Otsuka K, Tanaka H, Horinouchi T, et al. Functional contribution of voltage-dependent and Ca^{2+} activated K^+ (BK[Ca]) channels to the relaxation of guinea-pig aorta in response to natriuretic peptides. *J Smooth Muscle Res* 38:117–29, 2002.

[d] Guzzo J, Cox M, Kelley AB, et al. Tetracycline-induced inhibition of Na^+ transport in the toad urinary bladder. *Am J Physiol* 235:F359–F366, 1978.

[e] Marples D, Christensen S, Christensen EI, et al. Lithium-induced downregulation of aquaporin-2 water channel expression in rat kidney medulla. *J Clin Invest* 95:1838–1845, 1995.

Imipramine is a tricyclic antidepressant with a complex pharmacologic profile, including nonsubtype-selective antimuscarinic effects, also shown to have varied effects in modulating AVP release and potentiating renal proximal tubular sodium and water reabsorption in children. (Tomasi et al., 2001).

Imipramine should be used with caution because it has been shown to prolong the PR, QRS, and QTc intervals; increase heart rate; and lower T-wave amplitude during a 4-week treatment course (Giardina et al., 1979). There have been rare reports of torsades de pointes and sudden death resulting from imipramine administration (Swanson et al., 1997).

The influence of nocturnal polyuria on nocturia therapy with antimuscarinics has been addressed in four pooled 3-month phase III randomized controlled trials, in which 2534 of 3032 patients reported nocturia at baseline (62% of these patients were classified as having nocturnal polyuria). These patients were randomized to receive solifenacin 5 mg, 10 mg, or placebo. In patients without nocturnal polyuria, there was a statistically significant reduction in nocturia: −0.18 episode reduction advantage for 5 mg versus placebo and −0.18 episode reduction advantage for 10 mg versus placebo. Nocturia episode reduction in patients with nocturnal polyuria was not significant. However, failure to achieve statistically significant decreased nocturia between drug and placebo in the nocturnal polyuria group appeared to be caused by unexpectedly high performance of placebo in the latter arm (Brubaker and Fitzgerald, 2007).

Weiss et al. (2012) defined a clinically significant improvement in nocturia as one that improves the Nocturia Quality of Life (N-QoL) score. The N-QoL questionnaire consists of 13 statements in two domains (sleep/energy and bother/concern). Patients ranked each statement from 1 (lowest QoL) to 4 (highest QoL). One fewer nocturnal void was associated with a 4.68 increase in total N-QoL score, and a 1-hour increase in the first period of undisturbed sleep was associated with a 3.68 increase in total N-QoL score. This study is interpreted as indicating that reducing nocturia improves quality of life.

Bal et al. (2012) found that nocturia mainly occurs during superficial/REM sleep and that OSA severity is directly related to both nocturia severity and daytime sleepiness, and inversely related to sleep efficiency and total sleep time. **Treatment of OSA with continuous positive airway pressure (CPAP) can improve nocturia.** In a study of 88 men with OSA, the average number of nightly voids before treatment was 3.8 ± 0.4 voids per night and after treatment with CPAP decreased to 0.7 ± 0.3 voids per night (Guilleminault et al., 2004). A significant improvement in nocturia by treating OSA with CPAP also has been observed in women (Fitzgerald et al., 2006).

Because ADH is essential in controlling urinary concentration, it is not surprising that synthetic antidiuretics have been used to treat nocturia in addition to being standard replacement therapy for polyuric conditions such as central diabetes insipidus and primary nocturnal enuresis (PNE). Desmopressin (DDAVP) is a selective V_2-receptor agonist that retains the antidiuretic properties of vasopressin but lacks its unwanted pressor activity (Vilhardt, 1990). **When bound to V_2 receptors in the renal collecting tubules, desmopressin increases water permeability, enhances water reabsorption, dilutes extracellular fluid, and concentrates urine** (Hammer and Vilhardt, 1985). There have been multiple clinical trials of nocturia patients treated with desmopressin (Table 119.3). Desmopressin currently has the following recommendations for the treatment of nocturia:

TABLE 119.3

Clinical Trials Involving Desmopressin Treatment in Patients With Nocturia

STUDY	TARGET POPULATION	MEAN AGE (RANGE)	EFFECTIVE DOSES	ROUTE OF DELIVERY	CLINICAL RESPONDERS IN TREATMENT ARM (%)
Mattiasson et al., 2002	Men	65.1 (24.2–87.6)	0.1, 0.2, 0.4 mg (dose titration)	Oral	34
Lose et al., 2003	Women	57.1 (20.6–88.7)	0.1, 0.2, 0.4 mg (dose titration)	Oral	44
Lose et al., 2004	Men and women	60.5 (21–88)	0.1, 0.2, 0.4 mg (dose titration)	Oral	67
van Kerrebroeck et al., 2007	Men and women	63.4 (19.8–94.0)	0.1, 0.2, 0.4 mg (dose titration)	Oral	33
Weiss et al., 2012	Men and women	62.0 (N/A)	100 µg (25 µg in women)	Sublingual	71
Rembratt et al., 2003	Men and women	75.5[b] (66–90)	0.2 mg	Oral	82
Kuo, 2002	Men and women	75.4 (65–84)	0.1 mg	Oral	66.7
Wang et al., 2011	Men	74.0 (65–88)	0.1 mg	Oral	61.4

Weiss et al., 2013a	Men	60.4 (N/A)	50 µg or 75 µg	Sublingual	2.04[c]

[a] For 100-µg dose only.

[b] Median age.

[c] Odds ratio for achieving >33% decrease in number of nocturnal voids at 75 µg.

From Friedman FM, Weiss JP. Desmopressin in the treatment of nocturia: clinical evidence and experience. *Ther Adv Urol* 5:310–317, 2013.

- **ICI:** Grade A (level 1 evidence) (Andersson et al., 2013)
- **European Association of Urology (EAU):** Grade A (level 1b evidence) (Gravas et al., 2016)

For maximum concentration of urine, large amounts of urea must be deposited in the interstitium of the inner renal medulla. V_2 receptor activation (e.g., by DDAVP) increases urea permeability by 400% in the terminal portions of the inner medullary collecting duct by activating an AVP-regulated urea transporter, most likely by means of PKA-induced phosphorylation (Sands, 2003). **Desmopressin tablet studies have shown long-term reduction in nocturnal voids compared with baseline in both men (48% to 58%) and women (55% to 59%)** (Lose et al., 2004) **while increasing the initial sleep period by 2 hours in both** (Lose et al., 2003; Mattiasson et al., 2002)**. Hyponatremia is a well-known undesired effect of desmopressin.** In high-dose desmopressin tablet studies, 4.9% of all patients developed hyponatremia (defined as serum sodium <130 mmol/L). Patients with hyponatremia were older, smaller, and moderately more polyuric and had slightly lower basal serum sodium level and moderately lower creatinine clearance rate than those without hyponatremia. Nearly all patients who developed hyponatremia in the tablet studies were older than 65 years of age (Rembratt et al., 2006). More recently, studies have been completed with the intraorally dispersable preparation of desmopressin (“melt”). Melt was found to decrease overall nocturia severity and to increase the 33% responder rate. In a 4-week randomized, double-blind study, 757 patients who reported three or more voids per night (90% of whom had nocturnal polyuria) received 10, 25, 50, or 100 µg of melt or placebo. Those who received placebo, 10, 25, 50, or 100 µg of melt had the following reduction in number of nocturnal voids from baseline respectively: −0.86, −0.83, −1.00, −1.18*, and −1.43* and had the following percent increase in 33% responder rate: 47%, 47%, 50%, 53%, 71%* (Weiss et al., 2012). In both men at 50 µg and women at 25 µg desmopressin melt, the odds of increasing the first uninterrupted sleep period to 4 hours or longer was significantly greater than placebo at 1 week and after months 1, 2, and 3 ($P < .0001$) (Sand et al., 2013; Weiss et al, 2013b). In a follow-up study designed to investigate the lowest possible therapeutically effective dose of desmopressin, the efficacy and safety of desmopressin orally disintegrating tablets (ODT) 50 µg and 75 µg in men with nocturia (two or more nocturnal voids) was investigated. In men treated with 50 µg of desmopressin, there was a −0.37 difference in reduction of nightly voids versus placebo ($P = .0003$). In men treated with 75 µg of desmopressin, there was a −0.41 difference in reduction of nightly voids versus placebo ($P < .0001$). In those treated with 50 µg, 0% had serum sodium from 126 mmol/L to 129 mmol/L, and 2% had serum sodium less than 125 mmol/L. In those treated with 75 µg, 4% had serum sodium from 126 mmol/L to 129 mmol/L, and 3% had serum sodium less than 125 mmol/L (Weiss et al., 2013b). From these data, it could be concluded that 50 µg of desmopressin melt may be the lowest therapeutically beneficial dose for men. In a related study, 261 women (19 to 87 years of age) with an average of three voids per night were given 25 µg of desmopressin ODT. Desmopressin ODT reduced nocturia by −1.46 (treatment difference vs. placebo: −0.22; $P = .028$) and increased odds of a 33% or greater response (from baseline nocturia severity) versus placebo by 85% (OR 1.85; $P = .006$) at month 3. This low dose of desmopressin melt increased mean time to first nocturnal void by 155 minutes (treatment difference vs. placebo: 49 min; $P = .003$) and reduced NUV by 235 mL (treatment difference vs. placebo: 83 mL; $P = .003$) at month 3. There were no serum sodium drops less than 125 mmol/L or treatment withdrawals as a result of hyponatremia (Sand et al., 2013).

Most recently, Noctiva nasal spray underwent FDA testing. Noctiva is desmopressin with cyclopentadecanolide (CPD), a cyclic fatty acid that works as a permeation enhancer. Three doses were tested: 0.75 µg, 1.0 µg, and 1.5 µg. Nadir serum sodium levels were studied to see what percentage of each cohort experienced hyponatremia (a serum sodium of 126 to 129 mmol/L with symptoms or a serum sodium of ≤125 mmol/L with or without symptoms). It was found that 0.4% of patients receiving placebo, 1% of patients receiving 0.75 µg, 2.7% of patients receiving 1.0 µg, and 4.3% of patients receiving 1.5 µg developed hyponatremia. Gender was not a risk factor for hyponatremia. The FDA approved Noctiva for adults with nocturnal polyuria who wake at least 2 times per night to void. The recommended dose for patients younger than 65 years of age is 1.5 µg. For patients 65 years of age and older, it is recommended that they start at 0.75 µg and have their dosage titrated up as needed, provided that their serum sodium remains normal (Noctiva, 2015).

Women appear to be more sensitive (by a factor of at least 2) to desmopressin than men in terms of effects on nocturnal urine production (Juul et al., 2011) **and duration of action** (Yamaguchi et al, 2013). This may be because the gene for the V_2 receptor is located on the X chromosome. It is hypothesized that the duplicated gene for V_2 in women results in less inactivation and thus a greater response to desmopressin. The phenomenon of gender differential sensitivity to desmopressin may explain why women seem to fare as well with a lower dose of the melt preparation than men (25 µg vs. 50 µg minimum effective dosages, respectively, based on the most recent studies as described herein).

Bae et al. demonstrated that desmopressin is a useful treatment in men with nocturia refractory to treatment with α-blockers (Bae et al., 2013). There were 216 patients enrolled in this study (76% with nocturnal polyuria, 7.2% with decreased nocturnal bladder capacity, and 16.8% with mixed cause). The number of nocturnal voids decreased from a mean of 7.0 to 5.7 episodes for 3 days at the 24-week visit.

In summary, when considering the use of desmopressin to treat nocturia, voiding diary analysis should immediately follow a urologic history and physical examination. Patients found to have global polyuria should be excluded for further evaluation. Patients with low volumes per void and no nocturnal polyuria may need “urologic” nonantidiuretic treatment approaches. **Current thinking is that desmopressin would be the most appropriate therapy for patients with nocturia related to nocturnal polyuria.** There is a gender sensitivity differential between genders (men appear to require a higher dose than women). Even though the risk for hyponatremia is less than 1% in those younger than 65 years of age and 8% in those older than 65 years of age, it is always wise to obtain a baseline serum sodium before commencing therapy. Desmopressin should not be given to elderly patients (>65 years of age) with baseline hyponatremia. It is advisable to monitor the serum sodium within 7 days and then 28 days after initial or incremental dosing, then continuing to check sodium levels every 6 months or more often as indicated. Table 119.4 presents a complete summary of medications used to treat nocturnal polyuria.

TABLE 119.4

Summary of Pharmacotherapeutic Agents Used to Treat Nocturnal Polyuria

DRUG NAME	DOSE	SIDE EFFECT(S)	CONTRAINDICATION(S)
Furosemide[a]	40 mg PO 6 h before sleep (Dose range 20–80 mg PO in adults. The study mentioned in this text used only 40 mg in the context of nocturia.)	Anorexia Nausea/vomiting Constipation Cramping Diarrhea Blurred vision Hearing loss Tinnitus Headache Orthostatic hypotension Hypokalemia Dehydration Metabolic alkalosis Muscle cramps SLE exacerbation	Hypersensitivity Anuria Hepatic coma Hypovolemia Severe hypokalemia
Imipramine[a]	10 mg, 25 mg, 50 mg (Dose range: 10–75 mg PO qhs)	Prolongs PR interval Prolongs QRS interval Prolongs QTc interval Increases heart rate Lowers T-wave amplitude Torsades de pointes Sudden death	Hypersensitivity Usage of MAOI within 14 days Acute recovery period after MI
Desmopressin[a]	Intranasal: 10 µg/spray; max 40 µg/day (central DI indication only) Noctiva[b]	Water intoxication Hyponatremia Flushing Diarrhea	Hypersensitivity CrCl <50 mL/min Hyponatremia History of hyponatremia Von Willebrand disease, type

	Starting dose: 1.5 µg for patients <65 years. For patients ≥65 or <65 years at increased risk for hyponatremia, starting dose: 0.75 µg Oral: 0.1-mg tablets; max 0.6 mg/day for PNE Melt: 60-, 120-, 240-µg melt tabs Melt “low dose”: 25 µg (women) and 50–100 µg (men)	Mild abdominal cramps Nausea Increased SGOT Thrombosis Cough Dyspnea Drowsiness Dizziness Headache Abnormal thinking Seizures	IIB Polydipsia Uncontrolled HTN Concomitant use of loop diuretics Concomitant use of systemic or inhaled glucocorticoids Known or suspected SIADH secretion

[a] RxDrugs Drug Index. Accessed January 2018.

[b] Noctiva prescribing information. Available at: https://www.accessdata.fda.gov/drugsatfda_docs/label/2017/201656lbl.pdf.

CrCl, Creatine clearance; *DI,* diabetes insipidus; *h,* hour; *MAOI,* monoamine oxidase inhibitor; *MI,* myocardial infarction; *PO,* by mouth; *PNE,* primary nocturnal enuresis; *SGOT,* serum glutamic oxaloacetic transaminase; *SLE,* systemic lupus erythematosus; *qhs,* at bedtime.

Diminished Global and Nocturnal Bladder Capacity

Causes

Diminished bladder capacity has many “urologic” causes, including infravesical obstruction, idiopathic nocturnal detrusor overactivity (NDO), neurogenic bladder, cystitis (bacterial, interstitial, tuberculous, radiation), and cancer of the bladder, prostate, or urethra. NDO occurs in association with nocturia in most patients with detrusor overactivity plus overactive bladder (OAB). NDO is not a normal concomitant of sleep, is not caused by sleep disturbance, and is not linked to nocturnal polyuria (Krystal et al., 2010). Additional causes of low global or nocturnal bladder capacity include learned voiding dysfunction, anxiety disorders, bladder calculi, ureteral calculi, and drugs such as xanthines (caffeine, theophylline) and β-blockers (Weiss, 2012). Low bladder compliance is also a risk factor for nocturia severity (Tsui et al., 2013).

Management

Treating bladder outlet obstruction (BOO) is thought to improve nocturia by lowering postvoid residual (PVR) volume, increasing functional bladder capacity, and reducing global urinary frequency. Reducing BOO also diminishes input from afferents in the bladder neck and the prostatic urethra (Cumming and Chisholm, 1992; Housami and Abrams, 2008; Margel et al., 2007). Tamsulosin therapy and transurethral resection of prostate (TURP) significantly reduced the number of episodes of nocturia in 17.9% and 32.2% of patients, respectively (Yoshimura et al., 2003), and by an average of 1.3 episodes per night in patients treated with TURP (Antunes et al., 2009). Outlet reduction also may act by increasing hours of uninterrupted sleep, with commensurate benefit to nocturia-specific quality of life. In patients who underwent **simple prostatectomy,** nocturia episodes decreased from a baseline of 3.4 to 2.6, 2 to 3 months postoperatively ($P < .001$) and hours of uninterrupted sleep increased from 1.83 at baseline to 2.74, 2 to 3 months postoperatively ($P < .001$) (Margel et al., 2007). In a retrospective analysis of 1258 men, improvement in nocturia-related quality of life was studied after various forms of treatment for BPH, including watchful waiting, α-blockers, TURP, and transurethral microwave treatment (TUMT). After 6 to 12 months, watchful waiting, α-blockers, TURP, and TUMT yielded reduction in nocturia episodes by 7%, 17%, 75%, and 32%, respectively. Improvements in nocturia-related quality of life were most strongly associated with treatment-associated declines in nocturia severity (van Dijk et al., 2010). Greenlight photoselective vaporization of the prostate has shown similar success to that of TURP in reducing BOO and improving nocturia (Cho et al., 2012). Other reports point out that nocturia still persists despite bladder outlet–reducing surgery. The third national health and nutrition examination survey (NHANES III) in the United States showed that among those who undergo TURP, nocturia (≥ two voids per night) persists for 41% of men 60 to 69 years of age and 50% of men older than 70 years of age (Platz et al., 2002).

TURP appears to be superior to tamsulosin for treatment of BPH-related nocturia. In a single-center study, 66 men with LUTS (mean age = 68.9 years) were randomized to receive **TURP or tamsulosin 0.4 mg orally at bedtime** for management of nocturia. Nocturia severity was assessed at baseline, 3 months, and 1 year. TURP was associated with a significant improvement compared with tamsulosin in the number of nocturnal awakenings, IPSS, International Consultation on Incontinence Questionnaire Nocturia (ICIQ-N) scores, and ICIQ-N Quality of Life (N-QoL) scores. Hours of uninterrupted sleep increased in both groups but were not statistically different (Simaioforidis et al., 2011). Newer-generation treatments for LUTS secondary to BPH such as Rezum aquablation, mechanical stenting (UroLift), and prostate artery embolization are all alternatives to traditional pharmacotherapy and less invasive alternatives to TURP (Pham and Sharma, 2018). However, none of these modalities have been proven more efficacious than TURP at improving LUTS, specifically nocturia.

A secondary analysis of the Department of Veterans Affairs Cooperative Study Trial studied the changes in nocturia in a cohort of 1078 men with BPH who were randomly assigned to receive **terazosin, finasteride, combination, or placebo.** Overall, episodes of nocturia decreased from a baseline mean of 2.5 to 1.8, 2.1, 2.0, and 2.1 episodes in the terazosin, finasteride, combination, and placebo groups, respectively. Mean reduction of nocturia episodes from treatment with terazosin alone was significantly different from that with treatment with combination therapy ($P = .03$), finasteride ($P = .0001$), and placebo ($P = .0001$). Terazosin and combination therapy reduced the number of nocturia episodes in men with BPH, although the advantage of terazosin over placebo was only a net reduction of 0.3 episode (Johnson et al., 2003).

In a 12-week randomized, controlled study, 850 patients were given 4 mg **tolterodine extended release** (Tolt ER) or placebo once daily 4 hours before going to bed. All subjects had eight or more micturitions per 24 hours with or without urge incontinence and nocturia (mean of 2.5 episodes per night). Tolt ER did not significantly reduce the total number of nocturnal micturitions; however, it did significantly reduce OAB-related and severe OAB-related nocturnal micturitions versus placebo. Tolt ER did not affect non-OAB nocturnal micturitions (Rackley et al., 2006). The suggestion here was that antimuscarinic therapy would benefit nocturic voids that are characterized by severe urgency.

In a randomized, controlled trial of 658 patients at 52 sites, patients were given either placebo or **trospium chloride** 20 mg twice daily. This was a 12-week, multicenter, parallel, double-blind, placebo-controlled study. After 12 weeks, a significant decrease was found in the mean number of nocturic episodes per night: 0.29 episode for placebo versus 0.57 episode for drug (baseline was two episodes per night) (Rudy et al., 2006).

Fesoterodine significantly improved all diary end points compared with placebo except for nocturnal voids and nocturnal urgency episodes (Dmochowski et al., 2010; Herschorn et al., 2010; Nitti et al., 2007). However, in a study powered to determine the effect of fesoterodine on nocturnal urgency as a primary end point, **fesoterodine** did decrease the number of nocturnal urgency episodes and the number of nocturnal voids when compared with placebo. This particular study looked at change from baseline to week 12 in the number of nocturnal urgency episodes per 24 hours. Urgency was defined as an intense and/or sudden need to urinate. The subject rated the feeling of urgency associated with each micturition episode using the 5-point Urinary Sensation Scale (USS) (Coyne et al., 2011), in which 1 = no feeling of urgency and 5 = unable to hold and leaked urine. Nocturnal urgency episodes were defined as those with a USS rating of 3 or greater. The mean reduction from baseline to week 12 in nocturnal urgency episodes per 24 hours was statistically significantly greater with fesoterodine than placebo (−1.29 vs. −1.06, $P = .0030$). Mean reduction from baseline to week 12 in nocturnal micturitions per 24 hours was significantly greater with fesoterodine than placebo (−1.02 vs. −0.84, $P = .0112$) (Weiss et al., 2013a).

A prospective randomized trial was conducted with 2583 men with one or more episodes of nocturia at baseline who were treated with doxazosin, finasteride, combination therapy (doxazosin + finasteride), or placebo. Treatment effectiveness was measured by a self-reported number of nocturia episodes at 1 and 4 years after treatment. After 1 year, mean nocturia was reduced by 0.35, 0.40, 0.54, and 0.58 in the placebo, finasteride, doxazosin, and combination groups, respectively; reductions with combination therapy and with doxazosin were statistically greater than with placebo ($P < .05$). After 4 years, the number of nocturia episodes was also significantly reduced in patients treated with doxazosin and combination therapy versus placebo ($P < .05$). In a subgroup of men older than 70 years of age ($n = 495$), all of the drugs significantly reduced nocturia at 1 year (finasteride 0.29, doxazosin 0.46, and combination 0.42) compared with placebo (0.11, $P < .05$). This study confirmed that α-blockers alone are as effective as α-blockers in combination with 5α-reductase inhibitors (5-ARIs) for treatment of nocturia (Johnson et al., 2007).

A randomized, double-blind, placebo-controlled study was carried out in which patients were assigned to one of four groups for 12 weeks: placebo ($n = 222$), 4 mg tolterodine extended release (Tolt ER, $n = 217$), 0.4 mg tamsulosin ($n = 215$), and combination 4 mg Tolt ER + 0.4 mg tamsulosin ($n = 225$). The combination of Tolt ER + tamsulosin significantly reduced the number of micturitions per night versus placebo (−0.59 vs. −0.39, $P = .02$) (Kaplan et al., 2006).

In conclusion, α-blockers, 5-ARIs, antimuscarinics, and antimuscarinics plus α-blockers have been found to have a statistically significant reduction

in nocturia episodes, but clinical significance appears to be minimal. When 5-ARIs and α-blockers are used in combination, they have the same degree of success as α-blockers alone. The optimal patients to treat with medications that target the bladder and the prostate appear to be those who have a large number of nocturia episodes (mostly resulting from severe urgency).

There have also been various alternative treatments for nocturia, including cyclooxygenase-2 inhibitors combined with α-blockers (Gorgel et al., 2013), sedatives (Song and Ku, 2007; Sugaya et al., 2007), melatonin (Drake et al., 2004; Sugaya et al., 2007), and phytotherapy. A systematic review of 1562 men from 18 randomized controlled trials examined the effect of *Pygeum africanum* on various BPH symptoms, including nocturia. There was no comparison of *P. africanum* to other pharmacologic treatments for BPH, including α-blockers and 5-ARIs. Compared with men taking placebo, those taking *P. africanum* reported a 19% reduction in nocturia (weighted mean difference [WMD] of −0.9 times per evening, $P > .05$) (Wilt et al., 1998).

Another phytotherapeutic, Cernilton, is prepared from the rye-grass pollen *Secale cereale*. A systematic review was conducted to assess the efficacy of Cernilton on urinary symptoms in men with BPH. Cernilton reduced nocturia compared with placebo and another neutraceutical, Paraprost. Versus placebo, the weighted risk ratio for improvement of nocturia was 2.05 (95% CI = 1.41 to 3.00); thus those taking Cernilton were approximately two times more likely to have their nocturia improve over those taking placebo. Versus Paraprost, the WMD was −0.40 nocturic episodes per evening (95% CI = −0.73 to −0.07). Data were collected from a self-rated urinary symptom survey. The limitations of these trials were short duration, limited number of enrollees, gaps in reported outcomes, quality control of preparations, and lack of a proved active control (Wilt et al., 2011).

Mirabegron, a β_3-adrenergic agonist approved by the US Food and Drug Administration to treat OAB, showed an improvement in nocturia measured by the OAB symptom score at 3 and 6 months after beginning treatment in women older than 70 years of age who did not respond to anticholinergics (Nakanishi, 2013). For a complete list of medications used to treat diminished global or nocturnal bladder capacity, see Table 119.5.

TABLE 119.5

Pharmacotherapeutic Agents Used to Treat Diminished Global and Nocturnal Bladder Capacity

DRUG NAME	DOSE	SIDE EFFECT	CONTRAINDICATION(S)
Tamsulosin[a]	0.4 mg, 0.8 mg PO qhs	Orthostatic hypotension Syncope Dizziness Asthenia Somnolence Headache Insomnia Diarrhea Abnormal ejaculation Intraoperative floppy iris syndrome Rhinitis Pharyngitis Sinusitis Cough Priapism Back pain Chest pain	Hypersensitivity
Terazosin[a]	1–5 mg PO qhs Max dose: 20 mg/day	Headache Dizziness Somnolence Vertigo Asthenia Nervousness Depression Paresthesias Hypotension Palpitations Syncope Supraventricular tachycardia Atrial fibrillation Postural hypotension Weight gain Peripheral edema Thrombocytopenia Dyspnea Nasal congestion	Hypersensitivity

		Rhinitis Sinusitis Nausea Blurred vision Amblyopia Intraoperative floppy iris syndrome Impotence UTI Decreased libido Priapism	
Finasteride[a]	5 mg/day PO	Orthostatic/postural hypotension Peripheral edema Asthenia Headache Dizziness Somnolence Decreased libido Impotence Rhinitis Dyspnea Decreased ejaculate volume Gynecomastia Breast cancer	Hypersensitivity Women and children Pregnancy
Solifenacin[a]	5–10 mg/day PO	Dizziness Depression Dry mouth Constipation Nausea Colonic obstruction Severe fecal impaction Intestinal obstruction Dyspepsia Upper abdominal pain Vomiting Hypertension QT prolongation Torsades de pointes	Hypersensitivity Urinary retention Gastric retention Uncontrolled narrow-angle glaucoma Severe hepatic impairment

		Cough Blurred vision Dry eyes Urinary retention UTI Fatigue	
Tolterodine[a]	1–2 mg PO bid LA formulation: 2–4 mg/day PO	Dizziness Headache Somnolence Chest pain Dry mouth Constipation Dyspepsia Abnormal vision Xerophthalmia Urinary retention Dysuria Dry skin Arthralgia Sinusitis Weight gain Flulike symptoms Fatigue	Hypersensitivity Urinary retention Gastric retention Uncontrolled narrow-angle glaucoma Potassium salts
Trospium chloride[a]	Adults <75 years: 20 mg PO bid Adults >75 years: 20 mg PO qhs (based on tolerability)	Dry mouth Constipation Flatulence Abdominal pain Abdominal distention Dyspepsia Headache Fatigue Rash Stevens-Johnson syndrome Nasopharyngitis Dry eyes Nasal dryness Abnormal vision Urinary retention Rhabdomyolysis Fever	Hypersensitivity Urinary retention Gastric retention Uncontrolled narrow-angle glaucoma Severe renal impairment

		Heat stroke Influenza Anaphylaxis	
Fesoterodine[a]	4–8 mg/day PO If on potent CYP3A4 inhibitors: 4 mg/day PO	Dry mouth Constipation Nausea Abdominal pain Dyspepsia Gastroenteritis Cough Dry throat Upper respiratory tract infection Tachycardia Angina Chest pain QT prolongation Dysuria Urinary retention UTI Rash Dry eyes Back pain Edema Heat stroke	Hypersensitivity Urinary retention Gastric retention Uncontrolled narrow-angle glaucoma Severe hepatic impairment
Doxazosin[a]	Immediate release: 1–8 mg/day PO Extended release: 4–8 mg/day PO	Dizziness Headache Drowsiness Weakness Mental depression Syncope Vertigo Orthostatic hypotension Hypotension Arrhythmias Palpitations Edema Dyspnea Syncope Blurred vision Reddened sclera	Hypersensitivity

		Epistaxis Dry mouth Nasal congestion Rash Vomiting Diarrhea Nausea Abdominal cramps	
Mirabegron[b]	25–50 mg/day PO	Hypertension Urinary retention	Hypersensitivity

[a] RxDrugs Drug Index. Accessed January 2018.

[b] Astellas Pharma US package insert.

bid, Twice a day; *LA,* long-acting; *PO,* by mouth; *qhs,* at bedtime; *UTI,* urinary tract infection.

Several other treatments can also help reduce the number of nighttime voids. Onabotulinum toxin A (100 units) has been shown to significantly reduce nocturia episodes when compared with placebo in patients with OAB (Chapple et al., 2013; Nitti et al., 2013). Posterior tibial nerve stimulation (PTNS) can also significantly reduce nocturia in the OAB population (van Balken et al., 2001; van der Pal et al., 2006; Yoong et al., 2010).

Mixed Nocturnal Polyuria and Diminished Global and Nocturnal Bladder Capacity

In a review of 194 consecutive patients with nocturia, 13 (7%) had nocturnal polyuria (NPi >0.35), 111 (57%) had decreased nocturnal bladder capacity, and 70 (36%) had a “mixed” cause. Forty-five (23%) also had polyuria (defined as 24-hour urine output >2500 mL). Nocturnal polyuria was a significant component of nocturia in 43% of the patients. Thus the cause of nocturia was found to be multifactorial and often unrelated to an underlying urologic condition (Weiss et al., 1998). In a US veteran population of men 50 years of age and older, Vaughan et al. demonstrated a significant improvement in ANV ($P < .001$), bother ($P < .001$), time to initiating sleep ($P = .003$), time to return to sleep ($P = .03$), and quality of sleep ($P < .001$) after single or combined pharmacotherapy and/or behavioral modification to address the mixed etiologic category of nocturia (Vaughan et al., 2009). Behavior modification included reduced caffeine and alcohol intake, limited nighttime fluid intake, and improved sleep hygiene through moderate exercise and attention to room temperature, noise, and lighting. Additional interventions included early evening leg elevation and compression stockings if patients had bilateral lower extremity edema. Also, if patients had BPH-related symptoms (American Urological Association symptom score ≥8, maximum uroflow [Qmax] 4 to 15 mL/sec), terazosin was titrated as tolerated/needed to 10 mg daily. If patients reported eight or more voids in 24 hours, Tolt ER 2 to 4 mg daily was initiated. If return to sleep required 30 minutes or more after an awakening, zaleplon 5 mg nightly after the first nocturia episode between 11:00 PM and 3:00 AM was recommended. This proved to be a structured, multimodal approach with little risk (one trip to an emergency room for hypotension after taking terazosin) (Vaughan et al., 2009). Multicomponent treatment was further found to be an effective strategy to treat nocturia in a study by Johnson et al. (2013) in which men on α-blockers received individually titrated drug therapy (extended-release oxybutynin) or multicomponent behavioral treatment (pelvic floor muscle training, delayed voiding, and urge-suppression techniques). Participants with two or more episodes of nocturia at baseline showed larger changes with behavioral treatment compared with antimuscarinic therapy (mean reduction = 1.26 vs. 0.61, respectively; P = .008).

Polyuria

Etiology

Polyuria is defined as 24-hour urine output greater than 40 mL/kg. Once a steady state is reached, polyuria is associated with excessive oral intake of fluids (polydipsia). This results in urinary frequency both day and night because of the global overproduction of urine in excess of bladder capacity. Nocturia is often the manifesting symptom of patients with polyuria of any cause. Hence, it behooves the urologist to understand both its cause and diagnostic measures to sort out its various causes. Common underpinnings of polyuria include uncontrolled diabetes mellitus, diabetes insipidus, and primary polydipsia (dipsogenic, caused by an abnormality of the thirst mechanism, and psychogenic).

Diabetes insipidus is a disorder of water balance in which inappropriate excretion of water leads to polydipsia in an effort to prevent circulatory collapse. Diabetes insipidus can be central or nephrogenic. Central diabetes insipidus occurs when there is a deficiency in the synthesis or secretion of endogenous ADH. This can be caused by loss of neurosecretory neurons in the hypothalamus or the posterior pituitary gland as a result of trauma, primary pituitary tumors (e.g., craniopharyngioma), metastatic disease (e.g., breast, lung), infiltrative disease (e.g., sarcoid), infarction (e.g., Sheehan syndrome postpartum), or infection (e.g., tuberculosis, meningitis), or it can be idiopathic (Shapiro and Weiss, 2012). Nephrogenic diabetes insipidus is diuresis in the setting of normal ADH secretion, but the kidneys do not respond appropriately to the hormone, as in some patients with chronic kidney disease. Some extrarenal causes of diabetes insipidus include PGE_2, ANP, hypercalcemia, hypokalemia, lithium, and certain tetracyclines. This mechanism may explain how nonsteroidal anti-inflammatory drugs can improve nocturia, because of the effect of these drugs in blocking PGE_2-mediated diuresis (Araki et al., 2004).

The diagnostic algorithm for polyuria begins with an overnight water-deprivation test (OWDT). To perform an OWDT, the patient is told not to drink anything during the night. It is normal if the first-morning urine osmolality is greater than 800 mOsm/kg H_2O. Normal implies that there is an appropriate secretion of ADH and an appropriate renal response. If the OWDT is normal, polyuria is a result of primary polydipsia (neurogenic or dipsogenic). If the OWDT is abnormal, the patient has diabetes insipidus. To distinguish central from nephrogenic diabetes insipidus, a renal concentrating capacity test (RCCT) may be performed. The RCCT is performed by giving 40 µg of desmopressin intranasally or 0.4 mg orally. The patient's bladder is emptied, and urine osmolality is tested 3 to 5 hours later. Water is restricted for the first 12 hours after the drug is administered. The RCCT is normal if the urine osmolality rises to at least 800 mOsm/kg H_2O (Weiss, 2012). If the RCCT is normal, the patient has central diabetes insipidus and can be treated with desmopressin replacement therapy. If the RCCT is abnormal, the patient has nephrogenic diabetes insipidus, which has no specific treatment unless external causative factors such as lithium can be stopped.

Management

Patients who have a 24-hour urine production greater than 30 mL/kg may benefit from water restriction during the day and night. Tani et al. (2014) showed that adjusting water and food intake so that 24-hour urine production is less than 30 mL/kg reduced NUV and nocturnal urinary frequency with no adverse events. This illustrates that guidance on water intake may be a safe and effective conservative lifestyle management strategy. Because primary thirst disorders are distinctly rare, a safety mechanism in recommending fluid intake restriction is to have patients drink only just enough to satisfy their thirst.

A patient with **primary (dipsogenic or psychogenic) polydipsia** will have normal urine osmolality on water deprivation tests. **Dipsogenic polydipsia** is associated with a history of a central neurologic abnormality such as a history of brain trauma or radiation. Psychogenic polydipsia is a long-term behavioral or psychiatric disorder. It is important to identify the cause of a patient's polyuria to treat it effectively. For example, if a patient with polyuria has diabetes mellitus, controlling glycosuria may improve the polyuria. Central diabetes insipidus may be treated with synthetic vasopressin analogues. Patients without diabetes insipidus who are found to have polydipsia and are compulsive water drinkers may benefit from psychotherapy (Weiss, 2012). Nocturia as a manifesting complaint is expected to benefit from appropriate therapy for polyuria.

Key Points: Evaluation and Management of Nocturia

- Classification of nocturia using a frequency-volume chart yields up to 17 different underlying medical conditions that may potentially contribute to its genesis.
- OSA is a common cause of nocturnal polyuria.
- The normal circadian pattern of nocturnal urine production is age-dependent.
- Treating nocturnal polyuria should focus on underlying contributing medical comorbidities.
- There are many causes of diminished bladder capacity, including infravesical obstruction, idiopathic nocturnal detrusor overactivity, neurogenic bladder, cystitis (bacterial, interstitial, tuberculous, radiation), and cancer of the bladder, prostate, or urethra.
- Treating BOO is thought to improve nocturia by lowering PVR volume, increasing functional bladder capacity, and reducing overall urinary frequency.
- α-Blockers, 5-ARIs, antimuscarinics, and antimuscarinics plus α-blockers have been found to result in statistically but questionably clinically significant reductions in nocturia episodes.
- When 5-ARIs and α-blockers are used in combination, they have the same

degree of success as α-blockers alone.

- The optimal group to treat with medications that target the bladder and the prostate appear to be those who have a large number of nocturia episodes (mostly as a response to severe urgency) unrelated to nocturnal polyuria.
- Polyuria is defined as 24-hour urine output greater than 40 mL/kg and thus must be diagnosed through use of frequency-volume charts. Treatment of conditions underlying polyuria should benefit nocturia.
- Patients with nocturnal polyuria unrelated to specific causes such as peripheral edema, cardiopulmonary disease, or sleep apnea may benefit from empiric treatment with desmopressin.
- Desmopressin is associated with increased risk for clinically significant hyponatremia in elderly patients (>65 years) and those with borderline pretreatment hyponatremia, impaired renal function, and small body habitus.

Suggested Readings

Fitzgerald MP, Litman HJ, Link CL, et al. The association of nocturia with cardiac disease, diabetes, body mass index, age and diuretic use: results from the BACH survey. *J Urol*. 2007;177:1385–1389.

Oelke M, van Kerrebroeck P. *Current aspects on diagnosis and treatment of nocturia*. UNI-MED: London; 2012.

Weiss JP, Blaivas JG, Van Kerrebroeck PEV, et al. *Nocturia: causes, consequences, and clinical approaches*. Springer: London; 2012.

References

Alvarez-Nebreda ML, Jiménez AB, Rodríguez P, et al. Epidemiology of hip fracture in the elderly in Spain. *Bone*. 2008;42:278–285.

Ancoli-Israel S, Bliwise D, Noorgaard JP. Nocturia and sleep disorders. Weiss JP, Blaivas JG, Van Kerrebroeck PEV, et al. *Nocturia: causes, consequences, and clinical approaches*. Springer-Verlag: New York, NY; 2012:37.

Andersson K-E, Chapple CR, Cardozo L, et al. Pharmacologic treatment of urinary incontinence. Abrams P, Cardozo L, Khoury S, et al. *Incontinence. 5th International Consultation on Incontinence*. EAU-ICUD: Paris; 2013:633.

Antunes AA, Srougi M, Coelho RF, et al. Transurethral resection of the prostate for the treatment of lower urinary tract symptoms related to benign prostatic hyperplasia: how much should be resected? *Int Braz J Urol*. 2009;35:683–689 [689–691].

Araki T, Yokoyama T, Kumon H. Effectiveness of a nonsteroidal anti-inflammatory drug for nocturia on patients with benign prostatic hyperplasia: a prospective non-randomized study of loxoprofen sodium 60 mg once daily before sleeping. *Acta Med Okayama*. 2004;58:45–49.

Araujo AB, Yaggi HK, Yang M, et al. Sleep related problems and urological symptoms: testing the hypothesis of bidirectionality in a longitudinal, population based study. *J Urol*. 2014;191:100–106.

Asplund R. Nocturia: consequences for sleep and daytime activities and associated risks. *Eur Urol Suppl*. 2005;3:24–32.

Asplund R. The nocturia polyuria syndrome (NPS). *Gen Pharmacol*. 1995;26:1203–1209.

Bae WJ, Bae JH, Kim SW, et al. Desmopressin add-on therapy for refractory nocturia in men receiving α-blockers for lower urinary tract symptoms. *J Urol*. 2013;190:180–186.

Bal K, Ayik S, Issi Y, et al. Sleep analysis of patients with nocturia and benign prostatic obstruction. *Urology*. 2012;80:383–388.

Beers T. Flexible schedules and shift work: replacing the “9 to 5” workday? *Mon Labor Rev*. 2000;23:33–40.

Blanker MH, Bernsen RM, Ruud Bosch JL, et al. Normal values and determinants of circadian urine production in older men: a population based study. *J Urol*. 2002;168(4 Pt 1):1453–1457.

Blanker MH, Bohnen AM, Groeneveld FP, et al. Normal voiding patterns and determinants of increased diurnal and nocturnal voiding frequency in elderly men. *J Urol*. 2000;164:1201–1205.

Bliwise DL, Foley DJ, Vitiello MV, et al. Nocturia and disturbed sleep in the elderly. *Sleep Med*. 2009;10:540–548.

Bliwise DL, Holm-Larsen T, Goble S. Increases in duration of first uninterrupted sleep period are associated with improvements in PSQI-measured sleep quality. *Sleep Med*. 2014;15(10):1276–1278.

Bliwise DL, Holm-Larsen T, Goble S, et al. Short time to first void is associated with lower whole night sleep quality in nocturia patients. *J Clin Sleep Med*. 2015;11(1):53–55.

Bliwise DL, Greer SA, Scullin MK, et al. Habitual and recent sleep durations: graded and interactive risk for impaired glycemic control in a biracial population. *Am J Med*. 2017;130(5):564–571.

Bosch JL, Weiss JP. The prevalence and causes of nocturia. *J Urol*. 2010;184:440–446.

Bosch JLHR, van Doorn B. Diary-based population analysis of nocturia in older men: findings of the Krimpen study. Weiss JP, Blaivas JG, van Kerrebroeck P. *Nocturia: causes,* *consequences and clinical approaches*. Springer: New York, NY; 2012:59–75.

Brubaker L, Fitzgerald MP. Nocturnal polyuria and nocturia relief in patients treated with solifenacin for overactive bladder symptoms. *Int Urogynecol J Pelvic Floor Dysfunct*. 2007;18:737–741.

Burton C, Weiss JP, Parsons M, et al. Reference values for the Nocturnal Bladder Capacity Index. *Neurourol Urodyn*. 2011;30:52–57.

Chapple C, Sievert KD, MacDiarmid S. OnabotulinumtoxinA 100 U significantly improves all idiopathic overactive bladder symptoms and quality of life in patients with overactive bladder and urinary incontinence: a randomised, double-blind, placebo-controlled trial. *Eur Urol*. 2013;64(2):249–256.

Cho SY, Park S, Jeong MY, et al. 120W GreenLight High Performance System laser for benign prostate hyperplasia: 68 patients with 3-year follow-up and analysis of predictors of response. *Urology*. 2012;80(2):396–401.

Coyne KS, Margolis MK, Hsieh R, et al. Validation of the urinary sensation scale (USS). *Neurourol Urodyn*. 2011;30:360–365.

Cumming JA, Chisholm GD. Changes in detrusor innervation with relief of outflow tract obstruction. *Br J Urol*. 1992;69:7–11.

Denys MA, Cherian J, Rahnama'I MS, et al. ICI-RS 2015—Is a better understanding of sleep the key to managing nocturia? *Neurourol Urodyn*. 2016;37(7):2048–2052.

Dew MA, Hoch CC, Buysse DJ, et al. Healthy older adults' sleep predicts all-cause mortality at 4 to 19 years of follow-up. *Psychosom Med*. 2003;65:63–73.

Dijk DJ. Regulation and functional correlates of slow wave sleep. *J Clin Sleep Med*. 2009;5(Suppl 2):S6–S15.

Dmochowski RR, Peters KM, Morrow JD, et al. Randomized, double-blind, placebo-controlled trial of flexible-dose fesoterodine in subjects with overactive bladder. *Urology*. 2010;75:62–68.

Drake MJ, Mills IW, Noble JG. Melatonin pharmacotherapy for nocturia in men with benign prostatic enlargement. *J Urol*. 2004;171:1199–1202.

Endeshaw YW, Johnson TM, Kutner MH, et al. Sleep-disordered breathing and nocturia in older adults. *J Am Geriatr Soc*. 2004;52:957–960.

Epstein M, Blaivas J, Wein AJ, et al. Nocturia treatment outcomes: analysis of contributory frequency volume chart parameters. *Neurourol Urodyn*. 2018;37(1):186–191.

Everaert K, Herve F, Bower W, et al. How can we develop a more clinically useful and robust algorithm for diagnosing and treating nocturia? ICI-RS 2017. *Neurourol Urodyn*. 2018;37:S46–S59.

Fitzgerald MP, Litman HJ, Link CL, et al. The association of nocturia with cardiac disease, diabetes, body mass index, age and diuretic use: results from the BACH survey. *J Urol*. 2007;177:1385–1389.

Fitzgerald MP, Mulligan M, Parthasarathy S. Nocturic frequency is related to severity of obstructive sleep apnea, improves with continuous positive airways treatment. *Am J Obstet Gynecol*. 2006;194:1399–1403.

Giardina EG, Bigger JT Jr, Glassman AH, et al. The electrocardiographic and antiarrhythmic effects of imipramine hydrochloride at therapeutic plasma concentrations. *Circulation*. 1979;60:1045–1052.

Gorgel SN, Sefik E, Kose O, et al. The effect of combined therapy with tamsulosin hydrochloride and meloxicam in patients with benign prostatic hyperplasia symptoms and impact on nocturia and sleep quality. *Int Braz J Urol*.

2013;39:657–662.

Gottlieb DJ, Redline S, Nieto FJ, et al. Association of usual sleep duration with hypertension: the Sleep Heart Health Study. *Sleep*. 2006;29(8):1009–1014.

Gravas S, Bach T, Bachmann A, European Association of Urology, et al. Guidelines on the management of non-neurogenic male lower urinary tract symptoms (LUTS), incl. benign prostatic obstruction (BPO). *European Association of Urology*. 2016 [Available at] https://uroweb.org/wp-content/uploads/EAU-Guidelines-Management-of-non-neurogenic-male-LUTS-2016.pdf.

Guilleminault C, Lin CM, Goncalves MA, et al. A prospective study of nocturia and the quality of life of elderly patients with obstructive sleep apnea or sleep onset insomnia. *J Psychosom Res*. 2004;56:511–515.

Häkkinen JT, Hakama M, Shiri R, et al. Incidence of nocturia in 50 to 80-year-old Finnish men. *J Urol*. 2006;176:2541–2545.

Hall MH, Muldoon MF, Jennings JR, et al. Self-reported sleep duration is associated with the metabolic syndrome in midlife adults. *Sleep*. 2008;31:635–643.

Hammer M, Vilhardt H. Peroral treatment of diabetes insipidus with a polypeptide hormone analog, desmopressin. *J Pharmacol Exp Ther*. 1985;234:754–760.

Hashim H, Blanker M, Djurhuss JC, et al: The ICS Standardisation of Terminology in Nocturia 2017; in press.

Hashim H, Coyne K, Chapple C, et al. Nocturia: risk factors and associated comorbid conditions—findings from an international cross-sectional study. EPILUTS. *Eur Urol Suppl*. 2011;10:278.

Hernández C, Estivill E, Prieto M, et al. Nocturia in Spanish patients with lower urinary tract symptoms suggestive of benign prostatic hyperplasia (LUTS/BPH). *Curr Med Res Opin*. 2008;24:1033–1038.

Herschorn S, Swift S, Guan Z, et al. Comparison of fesoterodine and tolterodine extended release for the treatment of overactive bladder: a head-to-head placebo-controlled trial. *BJU Int*. 2010;105:58–66.

Hirayama A, Torimoto K, Mastusita C, et al. Evaluation of factors influencing the natural history of nocturia in elderly subjects: results of the Fujiwara-kyo Study. *J Urol*. 2013;189:980–986.

Holm-Larsen T, Weiss JP, Langkilde K. Economic burdern of nocturia in the US adult population. *J Urol*. 2010;183:e1.

Housami F, Abrams P. Persistent detrusor overactivity after transurethral resection of the prostate. *Curr Urol Rep*. 2008;9:284–290.

Johnson TM 2nd, Jones K, Williford WO, et al. Changes in nocturia from medical treatment of benign prostatic hyperplasia: secondary analysis of the Department of Veterans Affairs Cooperative Study Trial. *J Urol*. 2003;170:145–148.

Johnson TM 2nd, Burrows PK, Kusek JW, et al. The effect of doxazosin, finasteride and combination therapy on nocturia in men with benign prostatic hyperplasia. *J Urol*. 2007;178:2045–2050 [discussion 2050–2051].

Johnson TM 2nd, Markland AD, Goode PS, et al. Efficacy of adding behavioural treatment or antimuscarinic drug therapy to α-blocker therapy in men with nocturia. *BJU Int*. 2013;112:100–108.

Juul KV, Klein BM, Sandström R, et al. Gender difference in antidiuretic response to desmopressin. *Am J Physiol Renal Physiol*. 2011;300:F1116–F1122.

Juul KV, Jessen N, Bliwise DL, et al. Delaying time to first nocturnal void may have beneficial effects on reducing blood glucose levels. *Endocrine*. 2016;53(3):722–729.

Kaplan SA, Roehrborn CG, Rovner ES, et al. Tolterodine and tamsulosin for treatment of men with lower urinary tract symptoms and overactive bladder: a randomized controlled trial. *JAMA*. 2006;296:2319–2328.

Kaynak H, Kaynak D, Oztura I. Does frequency of nocturnal urination reflect the severity of sleep-disordered breathing? *J Sleep Res*. 2004;13:173–176.

Keenan S. Normal human sleep. *Respir Care Clin North Am*. 1999;5:319–331.

Kobelt G, Borgström F, Mattiasson A. Productivity, vitality and utility in a group of healthy professionally active individuals with nocturia. *BJU Int*. 2003;91:190–195.

Krystal AD, Preud'homme XA, Amundsen CL, et al. Detrusor overactivity persisting at night and preceding nocturia in patients with overactive bladder syndrome: a nocturnal cystometrogram and polysomnogram study. *J Urol*. 2010;184:623–628.

Kuo H. Efficacy of desmopressin in treatment of refractory nocturia in patients older than 65 years. *Urology*. 2002;59:485–489.

Kupelian V, Fitzgerald MP, Kaplan SA, et al. Association of nocturia and mortality: results from the Third National Health and Nutrition Examination Survey. *J Urol*. 2011;185:571–577.

Kupelian V, Wei JT, O'Leary MP, et al. Nocturia and quality of life: results from the Boston area community health survey. *Eur Urol*. 2012;61:78–84.

Lentz ML, Landis CA, Rothermel J, et al. Effects of slow wave sleep disruption on musculoskeletal pain and fatigue in middle aged women. *J Rheumatol*. 1999;26:1586–1592.

Lightner DJ, Krambeck AE, Jacobson DJ, et al. Nocturia is associated with an increased risk of coronary heart disease and death. *BJU Int*. 2012;110:848–853.

Lose G, Lalos O, Freeman RM, et al. Efficacy of desmopressin

(Minirin) in the treatment of nocturia: a double-blind placebo-controlled study in women. *Am J Obstet Gynecol*. 2003;189:1106–1113.

Lose G, Mattiasson A, Walter S, et al. Clinical experiences with desmopressin for long-term treatment of nocturia. *J Urol*. 2004;172:1021–1025.

Margel D, Lifshitz D, Brown N, et al. Predictors of nocturia quality of life before and shortly after prostatectomy. *Urology*. 2007;70:493–497.

Matthiesen TB, Rittig S, Nørgaard JP, et al. Nocturnal polyuria and natriuresis in male patients with nocturia and lower urinary tract symptoms. *J Urol*. 1996;156:1292–1299.

Mattiasson A, Abrams P, Van Kerrebroeck P, et al. Efficacy of desmopressin in the treatment of nocturia: a double-blind placebo-controlled study in men. *BJU Int*. 2002;89:855–862.

Nakagawa H, Niu K, Hozawa A, et al. Impact of nocturia on bone fracture and mortality in older individuals: a Japanese longitudinal cohort study. *J Urol*. 2010;184:1413–1418.

Nakanishi S. Efficacy of mirabegron, a β_3-adrenergic agonist, switched from an anticholinergic agent for female patients aged over 70 years. *Hinyokika Kiyo*. 2013;59:561–564.

Nielsen S, Kwon TH, Christensen BM, et al. Physiology and pathophysiology of renal aquaporins. *J Am Soc Nephrol*. 1999;10:647–663.

Nitti VW, Dmochowski R, Sand PK, et al. Efficacy, safety and tolerability of fesoterodine for overactive bladder syndrome. *J Urol*. 2007;178:2488–2494.

Nitti VW, Dmochowski R, Herschorn S, et al. OnabotulinumtoxinA for the treatment of patients with overactive bladder and urinary incontinence: results of a phase 3, randomized, placebo controlled trial. *J Urol*. 2013;189(6):2186–2193.

Noctiva (SER 120) – Reduction in Mean Nocturic Episodes by

Gender, Age and Nocturia Etiology ISE DB3/DB4 Studies, ITT Population (Serenity Pharmaceuticals Integrated Safety Summary, 2015).

Oelke M, van Kerrebroeck PEV. *Current aspects on diagnosis and treatment of nocturia*. Uni-Med: London; 2012:15.

Ohayon MM. Nocturnal awakenings and comorbid disorders in the American general population. *J Psychiatr Res*. 2008;4:48–54.

Parsons JK, Mougey J, Lambert L, et al. Lower urinary tract symptoms increase the risk of falls in older men. *BJU Int*. 2009;104:63–68.

Pesonen JS, Cartwright R, Santti H, et al. The impact of nocturia on mortality: a systemic review and metaanalysis. *NAU*. 2014;33(6):783–784.

Pham H, Sharma P. Emerging, newly-approved treatments for lower urinary tract symptoms secondary to benign prostatic hypertrophy. *Can J Urol*. 2018;25(2):9228–9237.

Platz EA, Smit E, Curhan GC, et al. Prevalence of and racial/ethnic variation in lower urinary tract symptoms and noncancer prostate surgery in U.S. men. *Urology*. 2002;59:877–883.

Rackley R, Weiss JP, Rovner ES, et al. Nighttime dosing with tolterodine reduces overactive bladder-related nocturnal micturitions in patients with overactive bladder and nocturia. *Urology*. 2006;67:731–736.

Rembratt A, Nørgaard J, Andersson K. What is nocturnal polyuria? *BJU Int*. 2002;90(Suppl 3):18–20.

Rembratt A, Nørgaard J, Andersson K. Desmopressin in elderly patients with nocturia: short-term safety and effects on urine output, sleep and voiding patterns. *BJU Int*. 2003;91:642–646.

Rembratt A, Riis A, Nørgaard JP. Desmopressin treatment in nocturia: an analysis of risk factors for hyponatremia.

Neurourol Urodyn. 2006;25:105–109.

Reynard JM, Cannon A, Yang Q, et al. A novel therapy for nocturnal polyuria: a double-blind randomized trial of furosemide against placebo. *Br J Urol*. 1998;81:215–218.

Roehrs T. Sleep physiology and pathophysiology. *Clin Cornerstone*. 2000;2:1–15.

Rudy D, Cline K, Harris R, et al. Multicenter phase III trial studying trospium chloride in patients with overactive bladder. *Urology*. 2006;67:275–280.

Sağlam HS, Gökkaya CS, Salar R, et al. The effects of age, metabolic syndrome, nocturnal polyuria and sleep disorders on nocturia. *Adv Clin Exp Med*. 2013;22:489–494.

Sand PK, Dmochowski RR, Reddy J, et al. Efficacy and safety of low dose desmopressin orally disintegrating tablet in women with nocturia: results of a multicenter, randomized, double-blind, placebo controlled, parallel group study. *J Urol*. 2013;190:958–964.

Sands JM. Molecular mechanisms of urea transport. *J Membr Biol*. 2003;191:149–163.

Shapiro M, Weiss JP. Diabetes insipidus: a review. *J Diabetes Metab*. 2012 [S8:001].

Simaioforidis V, Papatsoris AG, Chrisofos M, et al. Tamsulosin versus transurethral resection of the prostate: effect on nocturia as a result of benign prostatic hyperplasia. *Int J Urol*. 2011;18:243–248.

Song YS, Ku JH. Zolpidem pharmacotherapy combined with alpha-blocker therapy for nocturia unresponsive to alpha-blocker monotherapy in men with lower urinary tract symptoms: a preliminary study. *Int Urol Nephrol*. 2007;39:1147–1152.

Spiegel K, Tasali E, Penev P, et al. Brief communication: sleep curtailment in healthy young men is associated with decreased leptin levels, elevated ghrelin levels and increased hunger and appetite. *Ann Intern Med*. 2004;141:846–850.

Sugaya K, Nishijima S, Miyazato M, et al. Effects of melatonin and rilmazafone on nocturia in the elderly. *J Int Med Res*. 2007;35:685–691.

Swanson JR, Jones GR, Krasselt W, et al. Death of two subjects due to imipramine and desipramine metabolite accumulation during chronic therapy: a review of the literature and possible mechanisms. *J Forensic Sci*. 1997;42:335–339.

Tani M, Hirayama A, Torimoto K, et al. Guidance on water intake effectively improves urinary frequency in patients with nocturia. *Int J Urol*. 2014;21:595–600.

Tasali E, Leproult R, Ehrmann DA, et al. Slow-wave sleep and the risk of type 2 diabetes in humans. *Proc Natl Acad Sci USA*. 2008;105:1044–1049.

Temml C, Ponholzer A, Gutjahr G, et al. Nocturia is an age-independent risk factor for hip-fractures in men. *Neurourol Urodyn*. 2009;28:949–952.

Tikkinen KA, Auvinen A, Johnson TM 2nd, et al. A systemic evaluation of factors associated with nocturia: the population-based FINNO study. *Am J Epidemiol*. 2009;170:361–368.

Tikkinen KA, Johnson TM 2nd, Tammela TL, et al. Nocturia frequency, bother, and quality of life: how often is too often? A population-based study in Finland. *Eur Urol*. 2009;57:488–496.

Tomasi PA, Siracusano S, Monni AM, et al. Decreased nocturnal urinary antidiuretic hormone excretion in enuresis is increased by imipramine. *BJU Int*. 2001;88:932–937.

Torimoto K, Hirayama A, Matsushita C, et al. Evaluation of sleep quantity and quality in older adults with nocturia using portable electroencephalogram acquisition device. *J Urol*. 2013;189:e557–e558.

Tsui JF, Marshall SD, Weiss JP, et al. Low bladder compliance is a risk factor in nocturia severity. *J Urol*. 2013;189:e930.

Tyagi S, Resnick NM, Perera S, et al. Behavioral treatment of insomnia: also effective for nocturia. *J Am Geriatr Soc*. 2014;62:54–60.

Tyagi S, Perera S, Clarkson BD, et al. Nocturnal polyuria in older women with urge urinary incontinence: role of sleep quality, time in bed and medications used. *J Urol*. 2017;197:753–758.

van Balken MR, Vandoninck V, Gisolf KW, et al. Posterior tibial nerve stimulation as neuromodulative treatment of lower urinary tract dysfunction. *J Urol*. 2001;166(3):914–918.

van der Pal F, van Balken MR, Heesakkers JP, et al. Correlation between quality of life and voiding variables in patients treated with percutaneous tibial nerve stimulation. *BJU Int*. 2006;97(1):113–116.

van Dijk MM, Wijkstra H, Debruyne FM, et al. The role of nocturia in the quality of life of men with lower urinary tract symptoms. *BJU Int*. 2010;105:1141–1146.

van Doorn B, Blanker MH, Kok ET, et al. Prevalence, incidence, and resolution of nocturnal polyuria in a longitudinal community-based study in older men: the Krimpen study. *Eur Urol*. 2013;63:542–547.

van Doorn B, Kok ET, Blanker MH, et al. Mortality in older men with nocturia: a 15-year followup of the Krimpen study. *J Urol*. 2012;187:1727–1731.

van Haarst EP, Bosch JL. A cutoff value based on analysis of a reference population decreases overestimation of the prevalence of nocturnal polyuria. *J Urol*. 2012;188:869–873.

van Kerrebroeck P, Abrams P, Chaikin D, et al. The standardisation of terminology in nocturia: report from the Standardisation Sub-committee of the International Continence Society. *Neurourol Urodyn*. 2002;21:179–183.

van Kerrebroeck P, Rezapour M, Cortesse A, et al.

Desmopressin in the treatment of nocturia: a double-blind, placebo-controlled study. *Eur Urol*. 2007;52:221–229.

Vaughan CP, Endeshaw Y, Nagamia Z, et al. A multicomponent behavioural and drug intervention for nocturia in elderly men: rationale and pilot results. *BJU Int*. 2009;104:69–74.

Vaughan CP, Eisenstein R, Bliwise DL, et al. Self-rated sleep characteristics and bother from nocturia. *Int J Clin Pract*. 2012;66:369–373.

Vaughan CP, Juncos JL, Trotti LM, et al. Nocturia and overnight polysomnography in Parkinson disease. *Neurourol Urodyn*. 2013;32:1080–1085.

Vilhardt H. Basic pharmacology of desmopressin. *Drug Invest*. 1990;2(Suppl 5):2–8.

Wang C, Lin Y, Huang S, et al. Low dose oral desmopressin for nocturnal polyuria in patients with benign prostatic hyperplasia: a double-blind, placebo controlled, randomized study. *J Urol*. 2011;185:219–223.

Weinberger JM, Weiss JP, Kashan M, et al. Nocturia: why do people void at night? *J Urol*. 2013;189(4S Suppl):e800–e801.

Weiss JP. Prevalence of nocturnal polyuria in nocturia. *J Urol*. 2009;181:538.

Weiss JP. *Introduction to nocturia: causes, consequences and clinical approaches*. Springer: New York, NY; 2012:1–10.

Weiss JP, Blaivas JG, Stember DS, et al. Nocturia in adults: etiology and classification. *Neurourol Urodyn*. 1998;17:467–472.

Weiss JP, Blaivas JG, Stember DS, et al. Evaluation of the etiology of nocturia in men: the nocturia and nocturnal bladder capacity indices. *Neurourol Urodyn*. 1999;18:559–565.

Weiss JP, Zinner NR, Klein BM, et al. Desmopressin orally disintegrating tablet effectively reduces nocturia: results of a randomized, double-blind, placebo-controlled trial. *Neurourol*

Urodyn. 2012;31:441–447.

Weiss JP, Herschorn S, Albei CD, et al. Efficacy and safety of low dose desmopressin orally disintegrating tablet in men with nocturia: results of a multicenter, randomized, double-blind, placebo controlled, parallel group study. *J Urol*. 2013;190:965–972.

Weiss JP, Jumadilova Z, Johnson TM 2nd, et al. Efficacy and safety of flexible dose fesoterodine in men and women with overactive bladder symptoms including nocturnal urinary urgency. *J Urol*. 2013;189:1396–1401.

Wilt TJ, Ishani A, Mac Donald R, et al. Pygeum africanum for benign prostatic hyperplasia. *Cochrane Database Syst Rev*. 1998;(2) [CD001044].

Wilt TJ, Macdonald R, Ishani A, et al. Cernilton for benign prostatic hyperplasia. *Cochrane Database Syst Rev*. 2011;(5) [CD001042].

Yalkut D, Lee LY, Grider J, et al. Mechanism of atrial natriuretic peptide release with increased inspiratory resistance. *J Lab Clin Med*. 1996;128:322–328.

Yamaguchi O, Nishizawa O, Juul KV, et al. Gender difference in efficacy and dose response in Japanese patients with nocturia treated with four different doses of desmopressin orally disintegrating tablet in a randomized, placebo-controlled trial. *BJU Int*. 2013;111:474–484.

Yoong W, Ridout AE, Damodaram M, et al. Neuromodulative treatment with percutaneous tibial nerve stimulation for intractable detrusor instability: outcomes following a shortened 6-week protocol. *BJU Int*. 2010;106(11):1673–1676.

Yoshimura K, Ohara H, Ichioka K, et al. Nocturia and benign prostatic hyperplasia. *Urology*. 2003;61:786–790.

Zeitzer JM, Bliwise DL, Hernández B, et al. Nocturia compounds nocturnal wakefulness in older individuals with

insomnia. *J Clin Sleep Med*. 2013;9:259–262.

---

[*] $P < .05$.

Pharmacologic Management of Lower Urinary Tract Storage and Emptying Failure

Karl-Erik Andersson MD, PhD

Introduction

The function of the lower urinary tract (LUT) is to effect efficient and low-pressure bladder filling, low-pressure urine storage with normal sensation and perfect continence, and periodic complete voluntary emptying, again at low pressure. The structures involved include the smooth musculature of the bladder and the bladder outlet, and striated muscle, both intrinsic (to the bladder outlet) and extrinsic (the striated musculature surrounding the bladder outlet and the striated musculature of the pelvic floor). These component structures are controlled by a complex interplay among the central and peripheral nervous systems and local regulatory factors. **Pharmacologic alteration of LUT function can occur at any point along the afferent or efferent limb of this complex neuromuscular cascade by receptor activation or stimulation or blockade, by affecting the concentration of neurotransmitter at an activation site, or by stimulating or inhibiting signal transduction mechanisms** (Andersson and Wein, 2004; Andersson et al., 2009, 2013a, 2017; Birder et al., 2009; Fry et al., 2009; see also Chapter 69).

This chapter considers the pharmacologic management of bladder filling and storage and bladder emptying and voiding dysfunction. The conceptual basis of the organization is that of the expanded functional classification shown in Boxes 70.1 and 70.2 in Chapter 70 and the division of therapies in the relatively simple manner of those that facilitate urine storage and bladder filling and those that facilitate bladder emptying and voiding (see Boxes 70.3 and 70.4 in Chapter 70). Although the principles expressed are generally applicable to patients of all ages, specifics concerning usage in the pediatric age groups and in the elderly are considered in detail in Chapters 141 and 142. Specific information regarding the pharmacologic management of LUT dysfunction secondary to obstruction by benign prostatic enlargement (BPE) is considered in detail in Chapter 103, whereas drug therapy for the treatment of bladder and pelvic pain disorders is considered in detail in Chapters 13 and 14.

As an apology in explanation to significant contributors to the field whose works have not been specifically referenced by name as frequently as they could have been, please note that the citations have been chosen primarily because of their comprehensive review or specific informational content and not because of originality or initial publication on a particular subject, except where noted.

Pharmacologic Therapy to Facilitate Bladder Filling and Urine Storage

Inhibiting Bladder Contractility, Decreasing Sensory Input, Increasing Bladder Capacity

Bladder Contraction

The major portion of the neurohumoral stimulus for physiologic bladder contraction is acetylcholine (ACh)-induced stimulation of postganglionic parasympathetic muscarinic cholinergic receptor sites in the bladder (detrusor smooth muscle and possibly other sites) (see Chapter 69). **Atropine and atropine-like agents will depress normal bladder contractions and involuntary bladder contractions (detrusor overactivity [DO]) of any cause** (Andersson, 1988, 1993; Andersson and Wein, 2004)**. In patients with involuntary contractions, the volume to the first DO will usually be increased, the amplitude of the contraction decreased, and the total bladder capacity increased** (Jensen, 1981).

It has been stated that bladder compliance in normal individuals and in those with neurogenic detrusor overactivity (NDO) (Abrams et al., 2002), in whom the initial slope of the filling curve on cystometry is normal before the involuntary contraction, does not seem to be significantly altered by antimuscarinic agents and that the effect of pure antimuscarinics in patients who exhibit only decreased compliance had not been well studied. Regarding the subject of bladder tone during filling, Andersson (1999a, 1999b, 2004, 2011b) and Andersson and Yoshida (2003) have pointed out that although it is widely accepted that there is normally no sacral parasympathetic outflow to the bladder during filling, antimuscarinic drugs increase, and anticholinesterase inhibitors decrease, bladder capacity. **Because antimuscarinic drugs do seem to affect the sensation of urgency during filling, this suggests an ongoing ACh-mediated stimulation of detrusor tone (see later). If this is correct, agents that inhibit ACh release or activity would be expected to contribute to bladder relaxation or the maintenance of low bladder tone during filling with a consequent decrease in filling and storage symptomatology unrelated to the occurrence of DO. Outlet resistance, at least as reflected by urethral pressure measurements, does not seem to be clinically affected.**

Although the antimuscarinic agents usually produce significant clinical improvement in patients with DO and associated symptoms, they typically produce only partial inhibition. In many animal models, atropine only partially antagonizes the response of the whole bladder to pelvic nerve stimulation and of bladder strips to field stimulation, although it does completely inhibit the response of bladder smooth muscle to exogenous cholinergic stimulation. This phenomenon, which is called *atropine resistance,* is secondary to release of a transmitter other than ACh (Andersson, 1993; Andersson and Wein, 2004; Andersson et al., 1999; see Chapter 69). Atropine resistance is the most common hypothesis invoked to explain the clinical difficulty in eradicating DO with antimuscarinic agents alone, and it is also invoked to support the rationale of combined treatment of DO with agents that have different mechanisms of action (Andersson, 2006).

Andersson and Wein (2004) cite references stating that atropine resistance seems to be of little importance in normal human bladder muscle, but point out that atropine-resistant (nonadrenergic, noncholinergic [NANC]) contractions have been reported in human detrusor smooth muscle and in morphologically and/or functionally changed bladders in individuals with various types of voiding dysfunction. Thus, **the importance or unimportance of an atropine-resistant component to detrusor contraction in the treatment of DO in humans remains to be established.**

Muscarinic Receptors

In the human bladder, where the mRNAs for all the five pharmacologically defined muscarinic receptors, M_1 to M_5, have been demonstrated (Abrams et al., 2006a; Andersson, 2011a; Giglio and Tobin, 2009; Sigala et al., 2002)**, there is a predominance of mRNAs encoding M_2 and M_3 receptors** (Abrams et al., 2006a; Andersson, 2011a; Giglio and Tobin, 2009; Sigala et al., 2002; Yamaguchi et al., 1996). This seems to be the case also in the animal species investigated (Andersson and Arner, 2004; Chess-Williams, 2002; Hegde and Eglen, 1999). **Both M_2 and M_3 receptors can be found on detrusor muscle cells, where M_2 receptors predominate at least 3 : 1 over M_3 receptors, but also in other bladder structures, which may be of importance for detrusor activation. Thus, muscarinic receptors can be found on urothelial cells, on suburothelial nerves, and on other suburothelial structures, such as interstitial cells** (Andersson, 2011a; Bschleipfer et al., 2007; Chess-Williams, 2002; Giglio and Tobin, 2009; Gillespie, 2004; Gillespie et al., 2003; Mansfield et al., 2005).

In human and animal detrusor, the M_3 receptors are believed to be the most important for contraction (Abrams et al., 2006a; Andersson, 1993, 2011a; Chess-Williams, 2002; Giglio and Tobin, 2009). No differences between genders could be demonstrated in rat and human bladders (Kories et al., 2003). **The functional role for the M_2 receptors has not been clarified,** and even in M_3 receptor knockout (KO) mice they seem responsible for less than 5% of the carbachol-mediated detrusor contraction (Matsui et al., 2000). Stimulation of M_2 receptors has been shown to oppose sympathetically (β-adrenoceptor [β-AR]) mediated smooth muscle relaxation (Hegde et al., 1997). However, based on animal experiments, M_2 receptors have been suggested to directly contribute to contraction of the bladder in certain disease states (denervation, outflow obstruction). Experiments on human detrusor muscle by Stevens et al. (2007) could not confirm this, however. Pontari et al. (2004) analyzed bladder muscle specimens from patients with neurogenic bladder dysfunction to determine whether the muscarinic receptor subtype mediating contraction shifts from the M_3 to M_2 receptor subtype, as found in the denervated, hypertrophied rat bladder. They concluded that normal detrusor contraction is mediated by the M_3 receptor subtype, whereas contractions can be mediated by the M_2 receptors in patients with neurogenic bladder dysfunction.

Muscarinic receptors are coupled to G proteins, but the signal transduction systems may vary. **In general, M_1, M_3, and M_5 receptors are considered to couple preferentially to $G_{q/11}$, activating phosphoinositide hydrolysis, in turn leading to mobilization of intracellular calcium. M_2 and M_4 receptors couple to pertussis toxin–sensitive $G_{i/o}$, resulting in inhibition of adenylyl cyclase activity.** In the human detrusor, Schneider et al. (2004a), confirming that the muscarinic receptor subtype mediating carbachol-induced contraction is the M_3 receptor, also demonstrated that the phospholipase C inhibitor, U-73122, did not significantly affect carbachol-stimulated bladder contraction, despite blocking inositol trisphosphate (IP_3) generation. They concluded that carbachol-induced contraction of human urinary bladder is mediated via M_3 receptors and largely depends on Ca^{2+} entry through nifedipine-sensitive channels and activation of the Rho-kinase pathway. **Thus, it may be that the main pathways**

for muscarinic-receptor activation of the detrusor via M_3 receptors are calcium influx via L-type calcium channels, and increased sensitivity to calcium of the contractile machinery via inhibition of myosin light chain phosphatase through activation of Rho-kinase.

The **signaling mechanisms for the M_2 receptors are less clear than those for M_3 receptors.** As mentioned earlier, **M_2 receptor stimulation may oppose sympathetically induced smooth muscle relaxation, mediated by β-ARs via inhibition of adenylyl cyclase** (Hegde et al., 1997). In agreement with this, Matsui et al. (2003) suggested, based on results obtained in M_2 receptor KO mice, that a component of the contractile response to muscarinic agonists in smooth muscle involves an M_2 receptor–mediated inhibition of the relaxant effects of agents that increase cyclic adenosine monophosphate (cAMP) levels. M_2-receptor stimulation can also activate nonspecific cation channels and inhibit K_{ATP} channels through activation of protein kinase C (Bonev and Nelson, 1993; Kotlikoff et al., 1999).

Muscarinic receptors may also be located on the presynaptic nerve terminals and participate in the regulation of transmitter release. The inhibitory prejunctional muscarinic receptors have been classified as muscarinic M_2 in the rabbit (Tobin and Sjögren, 1995) and rat (Somogyi and de Groat, 1992) and M_4 in the guinea pig (Alberts, 1995) and in the human bladder (D'Agostino et al., 2000). Prejunctional facilitatory muscarinic receptors appear to be of the M_1 subtype in the bladders of rat, rabbit (Somogyi and de Groat, 1992; Tobin and Sjögren, 1995), and humans (Andersson, 2011b; Giglio and Tobin, 2009; Somogyi and de Groat, 1999). The muscarinic facilitatory mechanism seems to be upregulated in overactive bladders (OABs) from chronic spinal cord–transected rats. The facilitation in these preparations is primarily mediated by M_3 muscarinic receptors (Somogyi and de Groat, 1999).

The relative roles of the different presynaptic and postsynaptic receptor subtypes in normal and abnormal bladder function still require clarification, and thus speculation regarding optimal drug therapy based only on in vitro receptor selectivity profiles represents, at the very least, a gross oversimplification of assumptions regarding the muscarinic regulation of bladder function. The muscarinic receptor functions may be changed in different urologic disorders, such as outflow obstruction, neurogenic bladders, DO without overt neurogenic cause, and diabetes (Andersson, 2000a, 2011b). **However, it is not always clear what the changes mean in terms of changes in detrusor function.**

In general, all drug therapy for LUT dysfunction is hindered by a concept that can be expressed in one word: *uroselectivity* (Andersson, 1998)**. The clinical usefulness of available antimuscarinic agents is limited by their lack of selectivity, responsible for the classic peripheral antimuscarinic side effects of dry mouth, constipation, blurred vision, and increase in heart rate (HR) and for the effects on cognitive functions (Table 120.1).** Although M_3-receptor selective agents have the potential to eliminate some of these side effects, it would appear that the M_3 receptors in tissues of the LUT are identical to those elsewhere in the body (Caulfield and Birdsall, 1998). It may be speculated, however, that there is some heterogeneity among M_3 receptors, and this has prompted many pharmaceutical companies to continue to search for the "ideal" antimuscarinic agent to treat DO, one that would be relatively selective for muscarinic receptors involved in the regulation of bladder contraction. Receptor selectivity, however, is not the only basis on which a drug may be uroselective. From a clinical standpoint, it would seem particularly important to be able to describe in relative terms the ratio between a drug dose required for a desired therapeutic action and the dose that produces side effects. A differential effect could be based not only on receptor selectivity but also on other known and as yet undefined physiologic, pharmacologic, or metabolic characteristics. Organ selectivity would thus seem to be the "holy grail" of such therapy. The same problematic set of concepts applies to virtually all drugs used for the treatment of LUT dysfunction.

TABLE 120.1

Muscarinic Receptors: Distribution and Function

REGION	SUBTYPE OF MUSCARINIC RECEPTOR	FUNCTION
Bladder	$M_2 > M_3$ (3 : 1)	M_3: mediates human detrusor contraction
Salivary glands, parotid gland	M_1, M_3	M_1: high-viscosity lubrication M_3: salivation
Gastrointestinal tract	$M_2 > M_3$ (4 : 1)	M_3: stimulation of gastrointestinal motility

Brain	M_1 to M_5 (M_3 sparse)	Involved in higher cognitive processes such as learning and memory (mostly M_1)
Eye	M_1 to M_5 (M_3 predominates)	Controls iris sphincter contraction
Heart	M_2	Modulates pacemaker activity, atrioventricular conduction, and the force of contraction

Data from Abrams P, Andersson KE, Buccafusco JJ, et al. Muscarinic receptors: their distribution and function in body systems, and the implications for treating overactive bladder. *Br J Pharmacol* 148:565–578, 2006.

Prevalence of Lower Urinary Tract Symptoms

The prevalence of lower urinary tract symptoms (LUTS), including OAB syndrome, varies with the criteria for diagnosis. According to Irwin et al. (2006), using the 2002 International Continence Society (ICS) definition, the overall prevalence of OAB was 11.8% (the EPIC study). The rates were similar in men and women and increased with age. A similar study by Herschorn et al. (2008) found the OAB prevalence to be 13% in Canadian men and 14% in women. Irwin et al. (2011) estimated and predicted the worldwide and regional prevalence of LUTS, OAB, urinary incontinence (UI), and LUTS suggestive of bladder outlet obstruction (LUTS/BOO) in 2008, 2013, and 2018 based on current ICS symptom definitions in adults older than 20 years of age. An estimated 45.2%, 10.7%, 8.2%, and 21.5% of the 2008 worldwide population (4.3 billion) were affected by at least one LUTS, OAB, UI, and LUTS/BOO, respectively. By 2018, an estimated 2.3 billion individuals will be affected by at least one LUTS (18.4% increase), 546 million by OAB (20.1%), 423 million by UI (21.6%), and 1.1 billion by LUTS/BOO (18.5%).

LUTS may be the result of several different mechanisms, both myogenic and neurologic (Banakhar et al., 2012; Birder et al., 2009; Koelbl et al., 2009; Morrison et al., 2002), and abundant drugs have been used for treatment. The 6th International Consultation on Incontinence assessed drugs used for treatment of incontinence (Andersson et al., 2017). The assessment criteria (Table 120.2) were based on the Oxford guidelines, and the drugs included are listed in Tables 120.3 and 120.4.

TABLE 120.2

International Consultation on Incontinence: Oxford Guidelines

(Modified)

LEVELS OF EVIDENCE	
Level	**Description**
Level 1	Systematic reviews, meta-analyses, good-quality RCTs
Level 2	RCTs, good-quality prospective cohort studies
Level 3	Case-control studies, case series
Level 4	Expert opinion
GRADES OF RECOMMENDATION	
Grade	**Description**
Grade A	Based on level 1 evidence (highly recommended)
Grade B	Consistent level 2 or 3 evidence (recommended)
Grade C	Level 4 studies or "majority evidence" (optional)
Grade D	Evidence inconsistent or inconclusive (no recommendation possible), or evidence indicates that the drug should not be recommended

RCTs, Randomized controlled trials.

From Andersson K-E, Cardozo L, Cruz F, et al. Pharmacological treatment of urinary incontinence. In: Abrams P, Cardozo L, Wagg A, Wein AJ, eds. Incontinence. 6th International Consultation on Incontinence. Paris: ICUD-EAU; 2017:805–957.

TABLE 120.3

Drugs Used in the Treatment of Lower Urinary Tract Symptoms (LUTS), Overactive Bladder (OAB), and Detrusor Overactivity (DO): Assessments According to the Oxford System (Modified)

	LEVEL OF EVIDENCE	GRADE OF RECOMMENDATION
ANTIMUSCARINIC DRUGS		
Atropine, hyoscyamine	3	C
Darifenacin	1	A
Fesoterodine	1	A
Imidafenacin	1	A

Propantheline	2	B
Solifenacin	1	A
Tolterodine	1	A
Trospium	1	A
DRUGS WITH MIXED ACTIONS		
Oxybutynin	1	A
Propiverine	1	A
Flavoxate	2	D
DRUGS ACTING ON MEMBRANE CHANNELS		
Calcium antagonists	2	D
Potassium channel openers	2	D
ANTIDEPRESSANTS		
Imipramine	3	C
Duloxetine	2	C
α-ADRENERGIC RECEPTOR ANTAGONISTS		
Alfuzosin	3	C
Doxazosin	3	C
Prazosin	3	C
Terazosin	3	C
Tamsulosin	3	C
Silodosin	3	C
Naftopidil	3	C
β-ADRENOCEPTOR AGONISTS		
Terbutaline (β_2)	3	C
Salbutamol (β_2)	3	C
Mirabegron (β_3)	1	B
PHOSPHODIESTERASE TYPE 5 (PDE$_5$) INHIBITORS[a]		
Sildenafil, tadalafil, vardenafil	1	B
CYCLOOXYGENASE (COX) INHIBITORS		
Indomethacin	2	C
Flurbiprofen	2	C
Toxins		
Botulinum toxin (neurogenic)[b]	1	A
Botulinum toxin (idiopathic)[b]	1	B
Capsaicin (neurogenic)[c]	2	C
Resiniferatoxin (neurogenic)[c]	2	C

OTHER DRUGS		
Baclofen[d]	3	C
Hormones		
Estrogen	2	C
Desmopressin[e]	1	A

[a] Male LUTS/OAB.

[b] Bladder wall.

[c] Intravesical.

[d] Intrathecal.

[e] Nocturia (nocturnal polyuria), caution hyponatremia, especially in the elderly.

From Andersson K-E, Cardozo L, Cruz F, et al. Pharmacological treatment of urinary incontinence. In: Abrams P, Cardozo L, Wagg A, Wein AJ, eds. Incontinence. 6th International Consultation on Incontinence. Paris: ICUD-EAU; 2017:805–957.

TABLE 120.4

Drugs Used in the Treatment of Stress Urinary Incontinence: Assessments According to the Oxford System (Modified)

DRUG	LEVEL OF EVIDENCE	GRADE OF RECOMMENDATION
Clenbuterol	3	C
Duloxetine	1	B
Ephedrine	3	D
Estrogen	2	D
Imipramine	3	D
Methoxamine	2	D
Midodrine	2	C
Norephedrine (phenylpropanolamine)	3	D

From Andersson K-E, Cardozo L, Cruz F, et al. Pharmacological treatment of urinary incontinence. In: Abrams P, Cardozo L, Wagg A, Wein AJ, eds. Incontinence. 6th International Consultation on Incontinence. Paris: ICUD-EAU; 2017:805–957.

Antimuscarinic (Anticholinergic) Agents

Mechanism of Action.

For many years, antimuscarinic drugs have been the gold standard for

treatment of OAB. Still, the ways by which they exert their beneficial effect have not yet been established.

ACh stimulates both muscarinic and nicotinic receptors (Abrams and Andersson, 2007). Antimuscarinics block selectively muscarinic receptors. They are currently the mainstay of treatment of OAB symptoms, even if new therapeutic options have been introduced (Andersson et al., 2017). The **traditional view** is that in OAB and DO, the drugs act by blocking the muscarinic receptors on the detrusor muscle, which are stimulated by ACh, released from activated cholinergic (parasympathetic) nerves. Thereby, they decrease the ability of the bladder to contract. **However, antimuscarinic drugs act mainly during the storage phase, decreasing urgency and increasing bladder capacity, and during this phase, there is normally no parasympathetic input to the LUT** (Andersson, 2004; Morrison et al., 2002). Furthermore, antimuscarinics are usually competitive antagonists. This implies that when there is a massive release of ACh, as during micturition, the effects of the drugs should be decreased; otherwise the reduced ability of the detrusor to contract would eventually lead to urinary retention. Undeniably, high doses of antimuscarinics can produce urinary retention in humans, **but in the dose range used for beneficial effects in OAB and DO, there is little evidence for a significant reduction of the voiding contraction** (Finney et al., 2006) **(Fig. 120.1).** There is indirect clinical evidence for release of ACh during bladder filling in certain abnormal conditions. Smith et al. (1974) found that in patients with recent spinal cord injury (SCI), inhibition of ACh breakdown by use of cholinesterase inhibitors could increase resting tone and induce rhythmic contractions in the bladder. Yossepowitch et al. (2001) inhibited ACh breakdown with edrophonium in a series of patients with disturbed voiding or UI. They found a significant change in sensation and decreased bladder capacity, induction or amplification of involuntary detrusor contractions, or significantly decreased detrusor compliance in 78% of the patients with the symptom pattern of OAB, but in no patients without specific complaints suggesting DO. Thus, **during the storage phase, ACh may be released from both neuronal and non-neuronal sources** (e.g., the urothelium and suburothelium) **and directly or indirectly (by increasing detrusor smooth muscle tone) excite afferent nerves in the suburothelium and within the detrusor. There is also good experimental evidence that antimuscarinics act during the storage phase by decreasing the activity in afferent nerves (both C and Aδ fibers) from the bladder** (De Laet et al., 2006; Iijima et al., 2007).

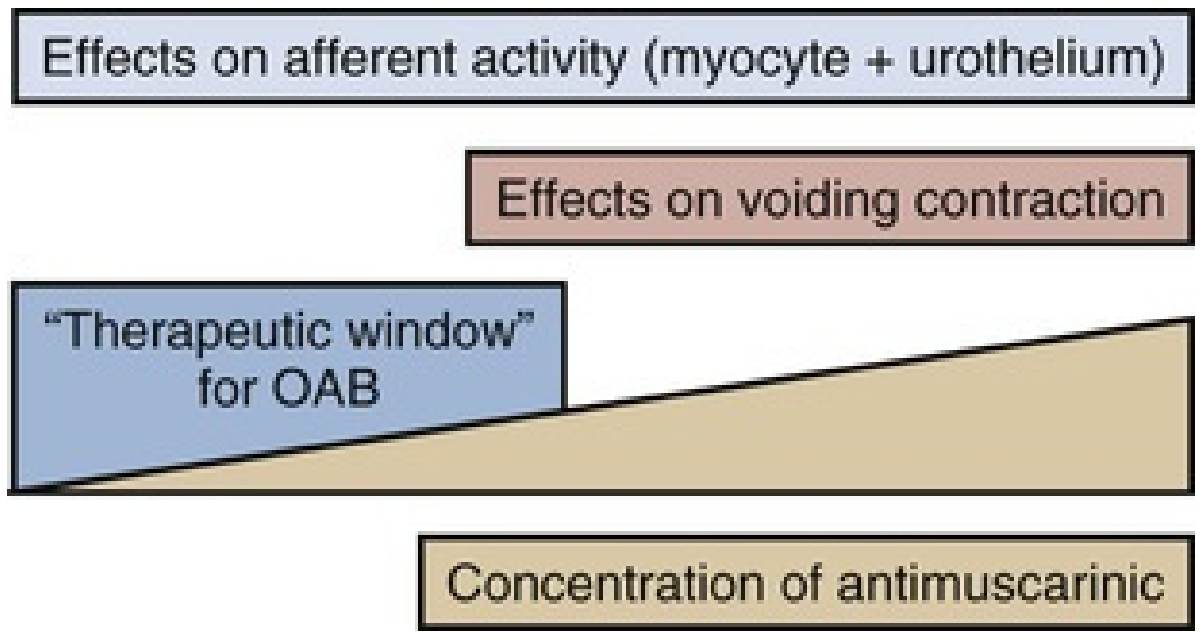
Effects on afferent activity (myocyte + urothelium)
Effects on voiding contraction
"Therapeutic window" for OAB
Concentration of antimuscarinic

FIG. 120.1 Rationale for use of antimuscarinic agents in overactive bladder (OAB).

Muscarinic receptors are found on bladder urothelial cells, where their density can be even higher than in detrusor muscle. The role of the urothelium in bladder activation has attracted much interest (Andersson, 2002a, 2011b; Birder and Andersson, 2013; Birder and de Groat, 2007; Birder et al., 2009; de Groat, 2004; Giglio and Tobin, 2009), but whether the muscarinic receptors on urothelial cells can influence micturition has not yet been established. Yoshida et al. (2004, 2006, 2008) found that there is basal ACh release in human bladder. This release was resistant to tetrodotoxin and much diminished when the urothelium was removed; thus, the released ACh was probably of non-neuronal origin and at least partly generated by the urothelium. Thus, during the storage phase, ACh and adenosine triphosphate (ATP) may be released from both neuronal and non-neuronal sources (e.g., the urothelium) and directly or indirectly (by increasing detrusor smooth muscle tone) excite afferent nerves in the suburothelium and within the detrusor. These mechanisms may be important in the pathophysiology of OAB and represent possible targets for antimuscarinic drugs.

Pharmacologic Properties.

In general, antimuscarinics can be divided into tertiary and quaternary amines (Abrams and Andersson, 2007; Guay, 2003). They differ with regard to lipophilicity, molecular charge, and even molecular size, tertiary compounds typically having higher lipophilicity and lower or neutral charge than quaternary amines. **Atropine, darifenacin, fesoterodine (and its active metabolite 5-hydroxymethyl tolterodine [5-HMT]), imidafenacin, oxybutynin, propiverine, solifenacin, and tolterodine are tertiary amines. They are generally well absorbed from the gastrointestinal tract and should theoretically be able to pass into the central nervous system (CNS),** dependent on their individual physicochemical properties. **High lipophilicity, small molecular size, and less charge will increase the possibilities to pass**

the blood-brain barrier, but for some of the drugs, this is counteracted by active transport out of the CNS by P-glycoprotein. Quaternary ammonium compounds, such as propantheline and trospium, are not well absorbed, pass into the CNS to a limited extent, and have a low incidence of CNS side effects (Guay, 2003). They still produce well-known peripheral antimuscarinic side effects, such as accommodation paralysis, constipation, increase in HR, and dry mouth.

Many antimuscarinics are metabolized by the P450 enzyme system to active and/or inactive metabolites (Guay, 2003)**. The most commonly involved P450 enzymes are CYP2D6 and CYP3A4. The metabolic conversion creates a risk for drug-drug interactions, resulting in either reduced (enzyme induction) or increased (enzyme inhibition, substrate competition) plasma concentration or effect of the antimuscarinic and /or interacting drug.** Antimuscarinics secreted by the renal tubules (e.g., trospium) may theoretically be able to interfere with the elimination of other drugs using this mechanism.

Antimuscarinics are still the most widely used treatment for urgency and urgency incontinence (Andersson, 2004; Andersson et al., 2009, 2013a, 2017). However, currently used drugs lack selectivity for the bladder, and effects on other organ systems may result in side effects that limit their usefulness. For example, all antimuscarinic drugs are contraindicated in untreated narrow-angle glaucoma.

One way of avoiding many of the antimuscarinic side effects is to administer the drugs intravesically. However, this is practical in only a limited number of patients.

Clinical Use.

The clinical relevance of efficacy of antimuscarinic drugs relative to placebo has been questioned (Herbison et al., 2003). However, large meta-analyses of studies performed with the currently most widely used drugs clearly show that antimuscarinics are of significant clinical benefit (Chapple et al., 2005a, 2008a; Novara et al., 2008). It was recommended that because the pharmacologic profiles of each drug (see later) and dosages differ, these factors should be considered in making treatment choices.

The durability of the effects of antimuscarinics is not known, and the relapse rate of symptoms after discontinuation of treatment has not been systematically studied. In 173 women with OAB symptoms for longer than 6 months, Lee et al.

(2011) studied in a prospective, randomized, open-label trial what happened 3 months after the patients had been successfully treated for 1, 3, or 6 months. The relapse rate was 62%, and the request for retreatment was 65%, indirectly suggesting an efficacy of treatment.

None of the antimuscarinic drugs in common clinical use (darifenacin, fesoterodine, imidafenacin, oxybutynin, propiverine, solifenacin, tolterodine, or trospium) is ideal as a first-line treatment for *all* OAB or DO patients. Optimal treatment should be individualized, implying that the patient's comorbidities and concomitant medications, and the pharmacologic profiles of the different drugs, should be taken into consideration (Chapple et al., 2008a).

To compare the effects of different antimuscarinic drugs for OAB symptoms, Madhuvrata et al. (2012) analyzed 86 trials, 70 with parallel and 16 with crossover designs (31,249 adults), drawing attention to the significance of the adverse effect of dry mouth. They concluded that when the prescribing choice is between oral immediate-release (IR) oxybutynin or tolterodine, tolterodine might be preferred because of the reduced risk for dry mouth. Also, extended-release (ER) preparations of oxybutynin or tolterodine might be preferred to IR preparations because there is less risk for dry mouth. Comparing solifenacin and IR tolterodine, solifenacin might be preferred for better efficacy and less risk for dry mouth. Fesoterodine might be preferred over ER tolterodine for superior efficacy but has a higher risk for withdrawal because of adverse events in general, but in particular a higher risk for dry mouth.

Several studies have documented that **the persistence with prescribed antimuscarinic therapy for OAB is low** (Andersson, 2017a; Basra et al., 2008; Chapple et al., 2017; Kelleher et al., 2005; Sears et al., 2010; Wagg et al., 2012)**. The most common causes seem to be lack of efficacy and adverse effects.** In a two-phase survey, Benner et al. (2010) examined the reasons for discontinuing OAB pharmacotherapy. Expectations about treatment efficacy (46.2%) and side effects (21.1%) were the most important considerations. However, there is some evidence suggesting that the tolerability of the different antimuscarinics may differ. Wagg et al. (2012) analyzed prescription data for patients receiving antimuscarinics for treatment of OAB syndrome over a 12-month period (Wagg et al., 2012). At 12 months, they found that the proportions of patients still on their original treatment were as follows: solifenacin, 35%; tolterodine ER, 28%; propiverine, 27%; oxybutynin ER, 26%; trospium, 26%; tolterodine IR, 24%; oxybutynin IR, 22%; darifenacin, 17%; and flavoxate, 14%. The longest mean persistence was reported for solifenacin (187 days vs. 77 to 157 days for the other treatments). Gomes et al. (2012) compared the persistence of oxybutynin or tolterodine therapy among older patients who were newly prescribed one of these drugs. This was a retrospective cohort study of Ontarians 66 years of age and older. Persistence with treatment was defined on the basis of refills for the drug within a grace period equal to 50% of the prescription duration. The authors identified 31,996 patients who were newly treated with oxybutynin and 24,855 who were newly treated with tolterodine. After 2 years of follow-up, persistence on oxybutynin (9.4%) was significantly lower than that on tolterodine (13.6%, $P < .0001$). The median times to discontinuation of oxybutynin and tolterodine were 68 and 128 days, respectively. Kessler et al. (2011) analyzed 69 trials enrolling 26,229 patients with OAB. The aim was to compare adverse events of antimuscarinics using a network meta-analytic approach that overcomes shortcomings of conventional analyses. They found similar overall adverse event profiles for darifenacin, fesoterodine, transdermal oxybutynin, propiverine, solifenacin, tolterodine, and trospium chloride, but not for oxybutynin orally administered when currently used starting dosages were compared. They concluded that most currently used antimuscarinics seem to be equivalent first-choice drugs to start the treatment of OAB, except for oral oxybutynin doses of 10 mg/day or more, which may have more unfavorable adverse event profiles.

In a retrospective, longitudinal, observational study using anonymized data from the UK Clinical Practice Research Datalink GOLD database, Chapple et al. (2017) compared the persistence and adherence with the β_3-AR agonist, mirabegron, versus tolterodine ER and other antimuscarinics in routine clinical practice over a 12-month period. The study population included 21,996 patients, and the antimuscarinics studied, besides tolterodine ER, were darifenacin, fesoterodine, flavoxate, oxybutynin ER or IR, propiverine, solifenacin, tolterodine IR, and trospium chloride. The primary end point was persistence (time to discontinuation), and secondary end points included 12-month persistence rates and adherence, assessed using the medication possession ratio (MPR). The median time-to-discontinuation was significantly longer for mirabegron (169 days) compared with tolterodine ER (56 days) and other antimuscarinics (range, 30 to 78 days). The 12-month persistence rates, 38% and 20%, respectively, and MPR were also significantly greater with mirabegron than with all the antimuscarinics investigated.

Adverse Effects.

Even if the use of antimuscarinics is associated with many adverse effects, they are generally considered to be “safe” drugs. However, among the more serious concerns related to their use is the risk for cardiac adverse effects, particularly QT prolongation and induction of polymorphic ventricular tachycardia (torsades de pointes), and increases in HR (Andersson, 2011c; Andersson and Olshansky, 2007; Rosa et al., 2013). QT prolongation and its consequences are not related to blockade of muscarinic receptors, but rather linked to inhibition of the hERG potassium channel in the heart (Roden, 2004). Thus, QT prolongation is not a class effect of antimuscarinics. However, the experiences with terodiline, an antimuscarinic drug that caused torsades de pointes in patients (Connolly et al., 1991; Stewart et al., 1992), have placed the whole drug class under scrutiny.

The parasympathetic actions on the heart oppose the excitatory actions of the sympathetic nervous system and slow the HR. An elevated resting HR has been linked to overall increased morbidity and mortality, particularly in patients with cardiovascular disease. The prevalence of cardiovascular comorbidities was found to be significantly higher in patients with OAB compared with those without OAB (Andersson et al., 2010b). Because mean changes in HR reported in population studies might not be applicable to an individual patient, and particularly in patients at risk for cardiac disease, even moderate increases in HR might be harmful. The potential of the different antimuscarinic agents to increase HR and/or prolong the QT time has not been extensively explored for all agents in clinical use. Differences among drugs cannot be excluded, but risk assessments based on available evidence are not possible.

Another concern is that antimuscarinic drugs commonly used to treat OAB can be associated with CNS side effects including cognitive dysfunction, memory impairment, dizziness, fatigue, and headache. A growing body of literature has emerged to address these concerns. Antimuscarinic agents used to treat symptoms of overactive bladder may cross the blood-brain barrier and provoke subtle or not so subtle cognitive impairment (Callegari et al., 2011; Gray et al., 2015; Jacobsen et al., 2011; Pagoria et al., 2011; Wagg et al., 2010). Higher cumulative anticholinergic use was reported to be associated with an increased risk for dementia (Gray et al., 2015). Oxybutynin in particular, because of its small molecular size and increased propensity to cross the blood-brain barrier, has consistently shown potential to elicit cognitive impairment in new users after a single high dose of this agent or at steady state, and should be avoided in elderly patients (Donnellan et al., 1997; Katz et al., 1998; Kay et al., 2008, Wesnes et al., 2009). However, with the exception of oxybutynin IR, CNS-related side effects are not commonly found when investigated. The potential to cause CNS-related adverse effects may differ among drugs, but in the absence of comparative trials, relative risk assessments are not possible.

Taken together, increasing evidence suggests that with the exception of oxybutynin, use of the other antimuscarinic agents poses little or no cognitive risk to otherwise healthy older adults with symptoms of overactive bladder (Esin et al., 2015). However, the integrity of the blood-brain barrier may be compromised in many older adults with cerebrovascular disease, diabetes, or certain forms of dementia, with the results of studies in healthy older adults not generalizable to frailer individuals (Kay et al., 2005). In addition, long-term use of anticholinergic agents over months or years may yield more detrimental cognitive effects than single-dose or short-term use.

Antimuscarinics With “Pure” Action

Here, data on the different antimuscarinics are presented. These drugs are assumed to block only muscarinic receptors (motivating the term *pure*). The amount of information for the individual drugs varies, and so does the degree of detail from the different studies presented. However, the information has been chosen to give a reasonable efficacy and adverse-effect profile of each individual drug.

Atropine Sulfate.

Atropine (*dl*-hyoscyamine) is rarely used for treatment of OAB or DO because of its systemic side effects, which preclude its use as an oral treatment. However, in patients with NDO, intravesical atropine may be effective for increasing bladder capacity without causing systemic adverse effects, as shown in open pilot trials (Deaney et al., 1998; Enskat et al., 2001; Ekström et al., 1992; Fader et al., 2007; Glickman et al., 1995). It appears that intravesical atropine may be as effective as intravesical oxybutynin in patients with NDO (Fader et al., 2007).

The pharmacologically active antimuscarinic component of atropine is L-hyoscyamine. Although still used, few clinical studies are available to evaluate the antimuscarinic activity of L-hyoscyamine sulfate (Muskat et al., 1996). For assessment, see Table 120.3.

Darifenacin Hydrobromide.

Darifenacin is a tertiary amine with moderate lipophilicity, well absorbed

from the gastrointestinal tract after oral administration, and extensively metabolized in the liver by the cytochrome P450 isoforms CYP3A4 and CYP2D6, the latter saturating within the therapeutic range (Skerjanec, 2006). UK-148993, UK-73689, and UK-88862 are the three main circulating darifenacin metabolites, of which only UK-148993 is said to have significant antimuscarinic activity. However, available information suggests that various metabolites of darifenacin contribute little to its clinical effects (Michel and Hegde, 2006). The metabolism of darifenacin by CYP3A4 suggests that coadministration of a potent inhibitor of this enzyme (e.g., ketoconazole) may lead to an increase in the circulating concentration of darifenacin (Kerbusch et al., 2003).

Darifenacin is a relatively selective muscarinic M_3-receptor antagonist. In vitro, it is selective for human cloned muscarinic M_3 receptors relative to M_1, M_2, M_4, or M_5 receptors. Theoretically, drugs with selectivity for the M_3 receptor can be expected to have clinical efficacy in OAB and DO with reduction of the adverse events related to the blockade of other muscarinic receptor subtypes (Andersson, 2002b). However, the clinical efficacy and adverse effects of a drug are dependent not only on its profile of receptor affinity, but also on its pharmacokinetics, and on the importance of muscarinic receptors for a given organ function.

Darifenacin has been developed as a controlled-release formulation, which allows once-daily administration. Recommended doses are 7.5 and 15 mg/day. The clinical effectiveness of the drug has been documented in several randomized controlled trials (RCTs) (Abrams et al., 2008; Cardozo and Dixon, 2005; Chancellor et al., 2008b; Chapple et al., 2005b, 2007a; Dwyer et al., 2008; Foote et al., 2005; Haab et al., 2004, 2006; Hill et al., 2006; Steers et al., 2005; Zinner et al., 2006; for reviews, see Chapple et al., 2008a; Guay, 2005; Novara et al., 2008; Zinner, 2007). Haab et al. (2004) reported a multicenter, double-blind, placebo-controlled, parallel-group study that enrolled 561 patients (19 to 88 years; 85% female) with OAB symptoms for more than 6 months, and included some patients with prior exposure to antimuscarinic agents. After washout and a 2-week placebo run-in, patients were randomized (1 : 4 : 2 : 3) to once-daily oral darifenacin controlled-release tablets, 3.75 mg (*n* = 53), 7.5 mg (*n* = 229), or 15 mg (*n* = 115), or matching placebo (*n* = 164) for 12 weeks. Using an electronic diary during weeks 2, 6, and 12 (directly preceding clinic visits), patients recorded daily incontinence episodes, micturition frequency, bladder capacity (mean voided volume [MVV]), frequency of urgency, severity of urgency, incontinence episodes resulting in change of clothing or pads, and nocturnal awakenings caused by OAB. Tolerability data were evaluated from adverse event reports. Darifenacin 7.5 mg and 15 mg had a rapid onset of effect, with significant improvement compared with placebo being seen for most parameters at the first clinic visit (week 2). Darifenacin 7.5 mg and 15 mg were significantly superior to placebo for (median) improvements in micturition frequency (7.5 mg, −1.6; 15 mg, −1.7; placebo, −0.8), frequency of urgency per day (−2.0; −2.0; −0.9), and number of incontinence episodes leading to a change in clothing or pads (−4.0; −4.7; −2.0). There was no significant reduction in nocturnal awakenings caused by OAB. The most common adverse events were mild-to-moderate dry mouth and constipation, with a CNS and cardiac safety profile comparable to placebo. No patients withdrew from the study as a result of dry mouth, and discontinuation related to constipation was rare (0.6% for placebo vs. 0.9% for darifenacin).

In a dose titration study on 395 OAB patients, darifenacin, allowing individualized dosage (7.5 or 15 mg), was found to be effective and well-tolerated (Steers et al., 2005). A 2-year open-label extension study of these investigations (Haab et al., 2004; Steers et al., 2005) confirmed a favorable efficacy, tolerability, and safety profile (Haab et al., 2006).

Chapple et al. (2005b) reported a review of the pooled darifenacin data from the three phase III, multicenter, double-blind clinical trials in patients with OAB. After a 4-week washout and run-in period, 1059 adults (85% female) with symptoms of OAB (urgency incontinence, urgency, and frequency) for at least 6 months were randomized to once-daily oral treatment with darifenacin 7.5 mg (n = 337) or 15 mg (*n* = 334) or matching placebo (*n* = 388) for 12 weeks. Efficacy was evaluated using electronic patient diaries that recorded incontinence episodes (including those resulting in a change of clothing or pads), frequency and severity of urgency, micturition frequency, and bladder capacity (volume voided). Safety was evaluated by analysis of treatment-related adverse events, withdrawal rates, and laboratory tests. Relative to baseline, 12 weeks of treatment with darifenacin resulted in a dose-related significant reduction in median number of incontinence episodes per week (7.5 mg, −8.8 [−68.4%; placebo −54%, *P* < .004]; 15 mg, −10.6 [−76.8%; placebo 58%, *P* < .001]. Significant decreases in the frequency and severity of urgency, micturition frequency, and number of incontinence episodes resulting in a change of clothing or pads were also apparent, along with an increase in bladder capacity. Darifenacin was well tolerated. The most common treatment-related adverse events were dry mouth and constipation, although together these resulted in few discontinuations (darifenacin 7.5 mg, 0.6% of patients; darifenacin 15 mg, 2.1%; placebo, 0.3%). The incidence of CNS and cardiovascular adverse events were comparable to placebo. The results were confirmed in other RCTs, including also a pooled analysis of three phase III studies in older patients (≥65 years), showing that darifenacin (7.5 and 15 mg) had an excellent efficacy, tolerability, and safety profile (Foote et al., 2005; Hill et al., 2006; Zinner et al., 2005).

The time to effect with darifenacin was analyzed in a pooled analysis of efficacy and safety data from 1059 patients participating in three double-blind 12-week studies (Khullar et al., 2011). Darifenacin significantly improved all OAB symptoms as early as 6 to 8 days.

One of the most noticeable clinical effects of antimuscarinics is their ability to reduce urgency and allow patients to postpone micturition. A study was conducted to assess the effect of darifenacin on the warning time associated with urinary urgency. Warning time was defined as the time from the first sensation of urgency to the time of voluntary micturition or incontinence. This was a multicenter, randomized, double-blind, placebo-controlled study consisting of a 2-week washout, a 2-week medication-free run-in, and a 2-week treatment phase (Cardozo and Dixon, 2005). Warning time was defined as the time from the first sensation of urgency to voluntary micturition or incontinence and was recorded via an electronic event recorder at baseline (visit three) and study end (visit four) during a 6-hour clinic-based monitoring period, with the subject instructed to delay micturition for as long as possible. During each monitoring period, up to three urgency-void cycles were recorded. Of the 72 subjects who entered the study, 67 had warning time data recorded at both baseline and study end and were included in the primary efficacy analysis (32 on darifenacin, 35 on placebo). Darifenacin treatment resulted in a significant ($P <$ .004) increase in mean warning time, with a median increase of 4.3 minutes compared with placebo (darifenacin group from 4.4 to 1.8 minutes; placebo from 7.0 to −1.0 minutes). Overall, 47% of darifenacin-treated subjects compared with 20% receiving placebo achieved a 30% or greater increase in mean warning time. There were methodologic problems associated with this study; it used a dose of 30 mg (higher than the dose recommended for clinical use), the treatment period was short, it was conducted in a clinical-centered environment, the methodology carried with it a significant potential training effect, and the placebo group had higher baseline values than the treatment group. In another warning time study (Zinner et al., 2006) on 445 OAB patients, darifenacin treatment (15 mg) resulted in numeric increases in warning time; however, these were not significant compared with placebo.

Further studies have demonstrated that darifenacin treatment is associated with clinically relevant improvements in health-related quality of life (QoL) in patients with OAB (Abrams et al., 2008), and such improvements were sustained as shown in a 2-year extension study (Dwyer et al., 2008). It was shown that neither the positive effects on micturition variables nor those on health-related QoL produced by darifenacin (7.5 and 15 mg) were further enhanced by a behavior modification program including timed voiding, dietary modifications, and Kegel exercises (Chancellor et al., 2008b).

Because darifenacin is a substrate for the P-glycoprotein drug efflux transporter (Chancellor et al., 2012; Miller et al., 2011), which is present in both the blood-brain and the blood-ocular barriers, several clinical studies have been devoted to investigate possible effects of darifenacin on cognition. Compared with placebo, no effect of darifenacin (3.75 to 15 mg daily) could be demonstrated in healthy volunteers 19 to 44 years of age, healthy patients 60 years of age or older, or volunteers 65 years of age or older (Chancellor et al., 2012; Kay and Ebinger 2008; Kay and Wesnes, 2005; Kay et al., 2006; Lipton et al., 2005).

To study whether darifenacin had any effect on QT and QTc intervals, Serra et al. (2005) performed a 7-day, randomized, parallel-group study (n = 188) in healthy volunteers receiving once-daily darifenacin at steady-state therapeutic (15 mg) and supratherapeutic (75 mg) doses alongside controls receiving placebo or moxifloxacin (positive control, 400 mg) once daily. No significant increase in Fridericia's corrected QT interval (QTcF) could be demonstrated compared with placebo. Mean changes from baseline at pharmacokinetic Tmax versus placebo were −0.4 and −2.2 msec in the darifenacin 15-mg and 75-mg groups, respectively, compared with +11.6 msec in the moxifloxacin group ($P < .01$). The conclusion was that darifenacin does not prolong the QT or QTc interval.

Darifenacin 15 mg/day given to healthy volunteers did not significantly change HR compared with placebo (Olshansky et al., 2008). The impact of darifenacin on constipation has been assessed in an analysis of the phase III, IIIb, and IV darifenacin published trials (Tack et al., 2012). The pooled phase III data suggested 14.8% (50/337) of patients on darifenacin 7.5 mg/day and 21.3% (71/334) on 15 mg/day experienced constipation. Only 0.6% and 1.2% of patients taking darifenacin 7.5 mg/day and 15 mg/day, respectively, stopped treatment as a result of constipation. Furthermore, 3.3% [11/337] and 6.6% [22/334] in the darifenacin 7.5 mg/day and 15 mg/day groups required concomitant laxative medications. At the end of a long-term study (2 years), the incidence of constipation was 20.9% (150/716), and 5.6% (40/716) of patients initiated use of fiber supplements, stool softeners, or laxatives (Tack et al. 2012).

Assessment.

Darifenacin has a well-documented beneficial effect in OAB and DO (see Table 120.3), and tolerability and safety seem acceptable.

Fesoterodine Fumarate.

Fesoterodine functions as an orally active prodrug that is converted to the active metabolite 5-HMT by nonspecific esterases (Malhotra et al., 2009b; Michel, 2008). This compound, which is chemically identical to the 5-hydroxy metabolite of tolterodine, is a **non–subtype selective muscarinic-receptor antagonist** (Ney et al., 2008)**. All of the effects of fesoterodine in humans are thought to be mediated via 5-HMT,** because the parent compound remains undetectable after oral administration. 5-HMT is metabolized in the liver, but a significant part of 5-HMT is excreted renally without additional metabolism. Because the renal clearance of 5-HMT is about 250 mL/min, with more than 15% of the administered fesoterodine dose excreted as unchanged 5-HMT, this raises the possibility that 5-HMT also could work from the luminal side of the bladder (Michel, 2008). The bioavailability of fesoterodine, averaging 52%, was independent of food intake, and the drug may be taken with or without a meal (Malhotra et al., 2009c). Peak plasma concentration of 5-HMT is reached at 5 hours after oral administration, and the agent has a half-life of 7 to 9 hours (Malhotra et al., 2008). The suggested starting dose, 4 mg/day, can be used in patients with moderately impaired renal or hepatic function because of the combination of renal excretion and hepatic metabolism of 5-HMT (de Mey et al., 2011; Malhotra et al., 2009a).

The clinical efficacy and tolerability of fesoterodine have been documented in several RCTs (Chapple et al., 2007b; Dell'Utri et al., 2012; Dmochowski et al., 2010c; Herschorn et al., 2010; Kaplan et al., 2011; Nitti et al., 2007, 2010). In a multicenter, double-blind, double-dummy RCT with tolterodine ER, 1132 patients were enrolled and received treatment (Chapple et al., 2007b). The trial showed that both the 4- and 8-mg doses of fesoterodine were effective in improving symptoms of OAB, with the 8-mg dose having a greater effect at the expense of a higher rate of dry mouth. There appeared to be little difference between fesoterodine 4 mg and tolterodine ER. Only one patient from the fesoterodine 8-mg group and one patient from the tolterodine ER group withdrew from the study because of dry mouth. The dose-response relationship was confirmed in another study that pooled data from two phase III RCTs (Khullar et al., 2008). Fesoterodine 8 mg performed better than the 4-mg dose in improving urgency and urge UI as recorded by 3-day bladder diary, offering the possibility of dose titration.

A head-to-head placebo-controlled trial compared fesoterodine 8 mg with tolterodine ER 4 mg and placebo (Herschorn et al., 2010). The study randomized 1590 patients to assess the primary outcome of reduced urgency incontinence episodes at 12 weeks. Fesoterodine produced statistically significant improvements in urgency incontinence episodes, complete dry rates (64.0% vs. 57.2%, $P = .015$), and MVV per void (+32.9 mL vs. +23.5 mL, $P = .005$) and in patients' assessments of bladder-related problems as measured by the OAB questionnaire (except sleep domain), Patient Perception of Bladder Condition (PPBC; 40% vs. 33% with >2-point improvement, $P < .001$), and Urgency Perception Scale (46% vs. 40% with improvement, $P = .014$) compared with tolterodine. The clinical significance of these statistically significant findings is questionable because there was no difference between agents with respect to number of micturitions, urgency episodes, and frequency-urgency sum per 24 hours. The improved efficacy of fesoterodine came at the cost of greater dry mouth (27.8% vs. 16.4%), headache (5.6% vs. 3.4%), constipation (5.4% vs. 4.1%), and withdrawal rates (6% vs. 4%). Nonetheless, this first head-to-head trial comparing two drugs in class supports the use of fesoterodine 8 mg for additional benefit over tolterodine ER 4 mg.

Wyndaele et al. (2009) reported the first flexible-dose open-label fesoterodine trial, which was conducted at 80 different centers worldwide and included 516 participants (men and women) older than 18 years of age who self-reported OAB symptoms for at least 3 months before screening and had been treated with either tolterodine or tolterodine ER within 2 years without symptom improvement. Approximately 50% opted for dose escalation to 8 mg at week 4. Significant improvements from baseline to week 12 were observed in micturitions, urgency urinary incontinence (UUI) episodes, micturition-related urgency episodes, and severe micturition-related urgency episodes per 24 hours. Significant improvements from baseline were observed in QoL parameters. Dry mouth (23%) and constipation (5%) were the most common adverse events; no safety issues were identified.

Kaplan et al. (2011) performed the largest double-blind, double-dummy, flexible-dose fesoterodine RCT, which was conducted at 210 different centers with 2417 patients enrolled. All patients were healthy, older than 18 years of age, and self-reported OAB symptoms for at least 3 months. The 960 patients who received fesoterodine 8 mg showed significantly greater mean improvements at week 12 in most efficacy parameters (diary variables)—UUI and urgency episodes, micturition frequency, and MVV—than those receiving either tolterodine ER 4 mg or placebo. No statistically significant changes were shown in reduction of nocturnal micturitions compared with the tolterodine group, whereas when comparing the mean changes in nighttime micturition with the placebo group a significant difference was found. This phase III study confirmed the superiority of fesoterodine 8 mg over tolterodine ER 4 mg for improving UUI and urgency episodes and 24-hour micturitions but not for MVV and nocturia. In another RCT of flexible-dose fesoterodine, Dmochowski et al. (2010c) reported statistically significant improvements at week 12 in the mean number of micturitions per 24 hours and in both UUI and urgency episodes. Between groups, the difference in nocturnal micturition was not statistically significant.

A subsequent pooled analysis of two phase III trials confirmed superiority of fesoterodine 8 mg to tolterodine ER 4 mg (Ginsberg et al., 2013). In women, fesoterodine 8 mg was superior to tolterodine 4 mg at 12 weeks in UUI, urgency, micturition episodes, diary dry rates, Patient Perception of Bladder Condition (PPBC), Urge Perception Score (UPS), and Overactive Bladder Questionnaire (OAB-q) scores. In men, superiority with fesoterodine 8 mg was only demonstrated for severe urgency and the symptom bother domain of the OAB-q. In women, dry mouth rates were 29%, 15%, and 6%; constipation rates were 5%, 4%, and 2%; and urinary retention rates were <1%, <1%, and 0% for fesoterodine 8 mg, tolterodine ER 4 mg, and placebo, respectively. In men, dry mouth rates were 21%, 13%, and 5%; constipation rates were 5%, 3%, and 1%; and urinary retention rates were 2%, <1%, and 2% for fesoterodine 8 mg, tolterodine ER 4 mg and placebo, respectively (Ginsberg et al., 2013).

Kaplan et al. (2014) assessed fesoterodine 8 mg and placebo in patients who had not responded to tolterodine ER 4 mg (<50% reduction in UUI). At week 12, UUI and urgency episodes were significantly better in the fesoterodine group, but micturition episodes and diary dry rates were statistically no different compared with placebo. Patients with greater than 50% and greater than 70%

UUI episodes showed improvement in the fesoterodine 8 mg group at 8 weeks. Furthermore, at 12 weeks, improvements in favor of fesoterodine compared with placebo were seen in PPBC, UPS, and OAB-q scores. Dry mouth and constipation were seen in 16.6% and 3.9% in the fesoterodine group and 4% and 1.3% in the placebo group, respectively (Kaplan et al., 2014).

Little is known on the impact of antimuscarinics on nocturnal urgency. Weiss et al. (2013) explored this is a multicenter randomized, double-blind, placebo-controlled 12-week flexible dosing trial in the United States. In the fesoterodine group, 61% were escalated at the clinicians' discretion to the 8-mg dose. Nocturnal urgency episodes (–1.28 vs. –1.07), nocturnal micturition episodes, and nocturnal frequency-urgency sum (urgency sensations were rated on a 1 to 5 scale), were significantly better in the fesoterodine group. Interestingly, UUI per 24 hours was not statistically different between fesoterodine and placebo in this trial, and the authors acknowledge there is no minimally important difference in nocturnal urgency episodes to ascertain clinical significance definitively. However, in an Asian post-hoc analysis of a double-blind placebo-controlled trial of fesoterodine 4 mg and 8 mg involving 555 patients, fesoterodine was not statistically better than placebo in reducing nocturnal micturition episodes at 12 weeks (Yokoyama et al., 2014). If patients with a nocturnal polyuris index of >33% were excluded, fesoterodine 8 mg was statistically better than placebo in reducing nocturnal micturition episodes. Undisturbed sleep increased in both fesoterodine arms (4 mg, 80 minutes; 8 mg, 74 minutes) but was only statistically significant in the 4-mg dose compared with placebo (54 minutes). Significant improvements in the sleep/energy domain of the King's Health Questionnaire (KHQ) was seen in both fesoterodine groups compared with placebo.

Nitti et al. (2010) determined whether the presence of DO in patients with OAB and UUI was a predictor of the response to treatment with fesoterodine in a phase II randomized, multicenter, placebo-controlled trial. They concluded that regardless of the presence of DO, the response to fesoterodine treatment was dose-proportional and associated with significant improvements in OAB symptoms, indicating that **the response to OAB pharmacotherapy in patients with UUI was independent of the urodynamic diagnosis of DO.**

Kelleher et al. (2008) evaluated the effect of fesoterodine on health-related QoL in patients with OAB syndrome. Pooled data from two randomized placebo-controlled phase III studies were analyzed (Chapple et al., 2007b; Nitti et al., 2007). Eligible patients were randomized to placebo or fesoterodine 4 or 8 mg for 12 weeks; one trial also included tolterodine ER 4 mg. By the end of treatment, all active-treatment groups had significantly improved health-related QoL compared with those on placebo. In a post-hoc analysis of data pooled from these studies, significant improvements in all King's Health Questionnaire (KHQ) domains, International Consultation on Incontinence Questionnaire Urinary Incontinence Short Form (ICIQ-UI-SF) scores, and bladder-related problems were observed at 12 and 24 months compared with open-label baseline (Kelleher et al., 2012). The authors concluded that treatment satisfaction was high throughout the open-label treatment regardless of gender and age.

A large postmarketing study from Korea has confirmed the efficacy of fesoterodine in OAB (Kim et al., 2016). The mean duration of symptoms was 165 days, but, interestingly, 63% had symptom duration of less than 1 week. Of the patients included, 92.7% (2879/3107), 76.8% (2387/3107), and 37.5% (1164/3107) reported having symptoms of urinary frequency, urgency, and UUI, respectively, and mean fesoterodine treatment duration was 83.2 ± 75.3 days. Frequency, urgency, and UUI per 24 hours declined from 12.1 to 8.0, 3.7 to 1.3, and 1.1 to 0.3, respectively (all $P < 0.001$). Utilizing the PPBC questionnaire, their bladder condition caused some very minor problems (43.0%, 1265/2939) or no problems at all (22.2%, 651/2939). Adverse events were reported in 8.2%, with dry mouth in 5.4% and constipation in 1.5% (Kim et al. 2016).

Malhotra et al. (2010) performed a thorough QT study to investigate the effects of fesoterodine on cardiac repolarization in a parallel-group study. Subjects were randomly assigned to receive double-blind fesoterodine 4 mg, fesoterodine 8 mg, or placebo or open-label moxifloxacin 400 mg (positive control) for 3 days. Electrocardiograms (ECGs) were obtained on days 1 (baseline) and 3. The primary analysis was of the time-averaged changes from baseline for QTcF on day 3. Among 261 subjects randomized to fesoterodine 4 mg ($n = 64$), fesoterodine 28 mg ($n = 68$), placebo ($n = 65$), or moxifloxacin 400 mg ($n = 64$), 256 completed the trial. The results indicated that fesoterodine is not associated with QTc prolongation or other ECG abnormalities at either therapeutic or supratherapeutic doses.

Assessment.

Fesoterodine has a well-documented beneficial effect in OAB (see Table 120.3), and the adverse event profile seems acceptable.

Imidafenacin.

Imidafenacin (KRP-197/ONO-8025, 4-[2-methyl-1H-imidazol-1-yl]-2,2-diphenylbutanamide) is **an antagonist for the muscarinic ACh receptor with higher affinities for M_3 and M_1 receptors than for the M_2 receptor.** Metabolites of imidafenacin (M-2, M-4, and M-9) had low affinities for muscarinic ACh receptor subtypes (Kobayashi et al., 2007). The drug blocks prejunctional and postjunctional muscarinic receptors and was shown to block both detrusor contractions and ACh release (Murakami et al., 2003). The receptor-binding affinity of imidafenacin in vitro was found to be significantly lower in the bladder than in the submaxillary gland or colon (Yamada et al., 2011), and in rats orally administered imidafenacin distributes predominantly to the bladder and exerts more selective and longer-lasting effect there than on other tissues. Whether this can be translated to the human situation has to be established before claims of clinical bladder selectivity can be made.

Imidafenacin is well absorbed from the gastrointestinal tract, and its absolute bioavailability in humans is 57.8% (Ohmori et al., 2007; Ohno et al., 2008). It is rapidly absorbed, with maximum plasma concentration occurring 1 to 3 hours after oral administration (Ohno et al., 2008). Metabolites in the plasma are produced mainly by first-pass effects. The major enzymes responsible for the metabolism of the drug are CYP3A4 and UGT1A4. The oxidative metabolism is reduced by concomitant administration of CYP3A4 inhibitors. In contrast, imidafenacin and its metabolites have no inhibitory effect on the CYP-mediated metabolism of concomitant drugs (Kanayama et al., 2007).

Kitagawa et al. (2011) reported that the subjective efficacy of imidafenacin was observed from 3 days after the commencement of administration and that the mean total Overactive Bladder Symptom Score (OABSS) decreased gradually during 2 weeks after administration.

A randomized, double-blind, placebo-controlled phase II dose-finding study in Japanese OAB patients was performed to evaluate the efficacy, safety and tolerability, and dose-response relationship of imidafenacin (Homma et al., 2008). Overall, 401 patients were enrolled and randomized for treatment with 0.1 mg of imidafenacin per day (99 patients), 0.2 mg of imidafenacin per day (100), 0.5 mg of imidafenacin per day (101), or placebo (101). After 12 weeks of treatment, the number of incontinence episodes was reduced in a dose-dependent manner, and a significant difference between the imidafenacin treatment and the placebo groups was observed ($P < .0001$). Compared with placebo, imidafenacin caused significant reductions in urgency incontinence, voiding frequency, and urinary urgency and a significant increase in the urine volume voided per micturition. Imidafenacin was also well tolerated. The incidence of dry mouth in the imidafenacin groups increased in a dose-dependent manner. Even though the percentage of patients receiving 0.5 mg/day who discontinued treatment because of dry mouth was high (8.9%), the percentages in the 0.1 mg/day and 0.2 mg/day groups (1.0% and 0.0%, respectively) were comparable with that in the placebo group (0.0%).

Homma et al. (2009) conducted a randomized, double-blind, placebo- and propiverine-controlled trial of 781 Japanese patients with OAB symptoms. Patients were randomized to imidafenacin (324), propiverine (310), or a placebo (147). After 12 weeks of treatment, a significantly larger reduction in the mean number of incontinence episodes was observed in the imidafenacin group than in the placebo group ($P < .0001$). The noninferiority of imidafenacin compared with propiverine was confirmed for the reduction in UI episodes ($P = .0014$; noninferiority margin, 14.5%). Imidafenacin was well tolerated. The incidence of adverse events with imidafenacin was significantly lower than with propiverine ($P = .0101$). Dry mouth, the most common adverse event, was significantly more common in the propiverine group than in the imidafenacin group. There were no significant increases in either the imidafenacin or the placebo group in the mean QTc interval, whereas there was a significant increase in the mean QTc interval in the propiverine group ($P < .0001$). However, clinical arrhythmia and clinical arrhythmic events were not seen in any of the treatment groups.

The long-term safety, tolerability, and efficacy of imidafenacin were studied in Japanese OAB patients (Homma et al., 2008), of whom 478 received treatment and 376 completed a 52-week program. Imidafenacin was well tolerated, the most common adverse event being dry mouth (40.2% of the patients). Long-term treatment did not produce an increase in the frequency of adverse events compared with short-term treatment. A significant efficacy of the drug was observed from week 4 to week 52. After 52 weeks, imidafenacin had produced mean changes from baseline in the number of incontinence episodes (−83.51%), urgency incontinence episodes (−84.21%), voiding frequency (−2.35 micturitions per day), urgency episodes (−70.53%), and volume voided per micturition (28.99 mL). There were also significant reductions from baseline in all domains of the KHQ. Imidafenacin had no significant effects on the corrected QT interval, vital signs, results from laboratory tests, or postvoid residual (PVR) volume.

Zaitsu et al. (2011) conducted a 52-week prospective, open, randomized, comparative study to evaluate the efficacy and tolerability of imidafenacin (0.2 mg/day) and solifenacin (5 mg/day) in a total of 41 Japanese patients with untreated OAB. They were randomly assigned to imidafenacin and solifenacin groups. There were no differences in OAB and KHQ scores between the two groups, but the severity and incidence of adverse events caused by the drugs showed increased differences between the groups with time. The severity of dry mouth and the incidence of constipation were significantly lower in the imidafenacin group ($P = .0092$ and $P = .0013$, respectively). An important limitation of this study is the low number of patients. Only 25 patients (17 male, 8 female) were available for long-term analysis.

Yokoyama et al. (2013) reported similar results in their comparative long-term study with equivalent efficacy and better tolerability for imidafenacin compared with solifenacin, but high discontinuation rates in both arms at study end.

Two small open-label studies and a post-hoc analysis of a large multicenter RCT of imidafenacin have suggested benefits on noctura and/or nocturnal polyuria (Kadekawa et al.,. 2012; Wada et al., 2012; Yokoyama et al., 2013). Wada et al. (2012) reported improvements in OAB symptoms, Pittsburgh Sleep Quality Index scores, nocturia episodes, and nocturnal polyuria in patients older than 75 years of age with imidafenacin 0.1 mg twice daily. Patients whose main complaint was nocturia were treated with 0.1 mg daily and after 4 weeks were allowed a dose escalation to 0.2 mg daily if required. This group showed significant improvements with regard to nocturia and other OAB parameters, OABSS, and International Prostate Symptom Score (IPSS)-QoL Index score (Kadekawa et al., 2012). A stratified analysis of a large RCT showed that in 46 patients with nocturia and nocturnal polyuria (>33% urine production at night), imidafenacin 0.1 mg twice daily after 12 weeks of treatment significantly reduced nighttime micturition and nocturnal percentage of 24-hour production, and the interval to the first nighttime void was significantly longer compared with placebo (Yokoyama et al., 2013).

A multicenter noninferiority phase IV trial of imidafenacin 0.1 mg twice daily versus fesoterdine 4 mg was conducted in Korea (Lee et al., 2013). No significant differences were observed between the two treatments for OAB symptoms of KHQ scores. Dry mouth rates were 39.4% and 37.3% in the imidafenacin and fesoterodine groups, respectively, and no statistical differences were shown for adverse events, blood pressure, pulse, or residual volume between the groups. In another postmarketing surveillance study, imidafenacin was shown to be safe, with dry rates of 8.5% and no significant deterioration in

MMSE at 48 weeks, with an acceptable mild cognitive impairment conversion to dementia rate (3.6%) (Sakakibara et al., 2014).

Assessment.

Imidafenacin seems to be effective and to have an acceptable tolerability (see Table 120.3).

Propantheline Bromide.

Propantheline is a quaternary ammonium compound, nonselective for muscarinic receptor subtypes, that has a low (5% to 10%) and individually varying biologic availability. It is metabolized (metabolites inactive) and has a short half-life (less than 2 hours) (Beermann et al., 1972). It is usually given in a dose of 15 to 30 mg four times daily, but to obtain an optimal effect, individual titration of the dose is necessary, and often higher doses are required. Using this approach in 26 patients with DO contractions, Blaivas et al. (1980) in an open study obtained a complete clinical response in all patients but one, who did not tolerate more than propantheline 15 mg four times daily. The range of doses varied from 7.5 to 60 mg four times daily. In contrast, Thüroff et al. (1991), comparing the effects of oxybutynin 5 mg three times daily, propantheline 15 mg three times daily, and placebo in a randomized, double-blind, multicenter trial on the treatment of frequency, urgency, and incontinence related to DO (154 patients) found no differences between the placebo and propantheline groups. In another randomized comparative trial with crossover design (23 women with idiopathic detrusor overactivity [IDO]) and with dose titration, Holmes et al. (1989) found no differences in efficacy between oxybutynin and propantheline. Six controlled randomized trials reviewed by Thüroff et al. (1998) confirmed a positive but varying response to the drug.

Assessment.

Although the effect of propantheline on OAB and DO has not been well documented in controlled trials satisfying the standards of today, it can be considered effective and may be clinically useful in individually titrated doses (see Table 120.3). No new studies on the use of this drug for treatment of OAB and DO seem to have been performed during the past decade.

Solifenacin Succinate.

Solifenacin succinate (YM905) is a tertiary amine that is well absorbed from

the gastrointestinal tract (absolute bioavailability 90%). The mean terminal half-life is 45 to 68 hours (Kuipers et al., 2002; Smulders et al., 2002, 2004). **It undergoes significant hepatic metabolism** involving the cytochrome P450 enzyme system (CYP3A4). In patients who received a single oral dose of 10 mg solifenacin on day 7 of a 20-day regimen of ketoconazole administration (200 mg), Cmax and AUC0-inf were increased by only approximately 40% and 56%, respectively (Swart et al., 2006). **Solifenacin has a modest selectivity for M_3 over M_2 (and M_1) receptors** (Abrams and Andersson, 2007). Supporting an effect of solifenacin on sensory function, 15 women with DO receiving 10 mg of the drug per day showed an increase in the area under the bladder-volume sensation curve (Lowenstein et al., 2012). Solifenacin also increased maximum bladder capacity, a finding in agreement with other studies (Hsiao et al., 2011; Tanaka et al., 2010).

Two large-scale phase II trials with parallel designs, including men and women, were performed (Chapple et al., 2004a; Smith et al., 2002). The first dose-ranging study evaluated solifenacin 2.5 mg, 5 mg, 10 mg, and 20 mg and tolterodine (2 mg twice daily) in a multinational placebo-controlled study of 225 patients with urodynamically confirmed DO (Chapple et al., 2004a). Patients received treatment for 4 weeks followed by 2 weeks of follow-up. Inclusion criteria for this and subsequent phase III studies of patients with OAB included at least eight micturitions per 24 hours and either one episode of incontinence or one episode of urgency daily as recorded in 3-day micturition diaries. Micturition frequency, the primary efficacy variable, was statistically significantly reduced in patients taking solifenacin 5 mg (−2.21), 10 mg (−2.47), and 20 mg (−2.75), but not in patients receiving placebo (−1.03) or tolterodine (−1.79). This effect was rapid, with most of the effect observed at the earliest assessment visit, 2 weeks after treatment initiation. In addition, there were numerically greater reductions in episodes of urgency and incontinence when compared with placebo. Study discontinuations caused by adverse events were similar across treatment groups, albeit highest in the 20-mg solifenacin group. Because the 5-mg and 10-mg doses caused lower rates of dry mouth than tolterodine and had superior efficacy outcomes relative to placebo, these dosage strengths were selected for further evaluation in large-scale phase III studies.

The second dose-ranging study of solifenacin 2.5 mg to 20 mg was carried out in the United States (Smith et al., 2002). This trial included 261 evaluable men and women receiving solifenacin or placebo for 4 weeks followed by a 2-week follow-up period. Micturition frequency was statistically significantly reduced relative to placebo in patients receiving 10 mg and 20 mg of solifenacin. The number of micturitions per 24 hours showed reductions by day 7 and continued to decrease through day 28; day 7 was the earliest time point tested in solifenacin trials, and these findings demonstrated efficacy as early as 1 week. The 5-mg, 10-mg, and 20-mg dosage groups experienced statistically significant increases in volume voided; the 10-mg solifenacin dose was associated with statistically significant reductions in episodes of incontinence.

In one of the early RCTs, 1077 patients were randomized to 5-mg solifenacin, 10-mg solifenacin, tolterodine (2 mg twice daily), or placebo (Chapple et al., 2004b). It should be noted that this study was powered only to compare active treatments with placebo. Compared with placebo (−8%), mean micturitions per 24 hours were significantly reduced with solifenacin 10 mg (−20%), solifenacin 5 mg (−17%), and tolterodine 2 mg twice daily (−15%). Solifenacin was well tolerated, with few patients discontinuing treatment. Incidences of dry mouth were 4.9% with placebo, 14.0% with solifenacin 5 mg, 21.3% with solifenacin 10 mg, and 18.6% with tolterodine 2 mg twice daily.

Cardozo et al. (2004b) randomized 911 patients to 12-week once-daily treatment with solifenacin 5 mg, solifenacin 10 mg, or placebo. The primary efficacy variable was change from baseline to study end point in mean number of micturitions per 24 hours. Secondary efficacy variables included changes from baseline in mean number of urgency, nocturia, and incontinence episodes per 24 hours, and MVV per micturition. Compared with changes obtained with placebo (−1.6), the number of micturitions per 24 hours was statistically significantly decreased with solifenacin 5 mg (−2.37) and 10 mg (−2.81). A statistically significant decrease was observed in the number of all incontinence episodes with both solifenacin doses (5 mg, −1.63, 61%; 10 mg, −1.57, 52%), but not with placebo (−1.25, 28%). Of patients reporting incontinence at baseline, 50% achieved continence after treatment with solifenacin (based on a 3-day micturition diary, placebo responses not given). Episodes of nocturia were statistically significantly decreased in patients treated with solifenacin 10 mg versus placebo. Episodes of urgency and MVV per micturition were statistically significantly reduced with solifenacin 5 mg and 10 mg. Treatment with solifenacin was well tolerated. Dry mouth, mostly mild in severity, was reported in 7.7% of patients receiving solifenacin 5 mg and 23% receiving solifenacin 10 mg (vs. 2.3% with placebo). A 40-week follow-up of these studies demonstrated that the favorable profile, both in terms of efficacy and tolerability, was maintained over the study period (Cardozo et al., 2004b; Chapple et al., 2004b;

Haab et al., 2005).

The STAR trial (Chapple et al., 2005c, 2007c) was a prospective, double-blind, double-dummy, two-arm, parallel-group, 12-week study conducted to compare the efficacy and safety of solifenacin 5 or 10 mg and tolterodine extended release (TOLT-ER) 4 mg once daily in OAB patients. The primary effect variable was micturition frequency. After 4 weeks of treatment, patients had the option to request a dose increase, but were dummied throughout because approved product labeling allowed an increase only for those on solifenacin. The results showed that solifenacin, with a flexible dosing regimen, was noninferior to tolterodine with regard to the primary effect variable, micturition frequency. However, solifenacin showed significant greater efficacy to tolterodine in decreasing urgency episodes (−2.85 vs. −2.42), incontinence (−1.60 vs. −.83), urgency incontinence (−1.42 vs. −0.83), and pad use (−1.72 vs. −1.19). More solifenacin-treated patients became continent by study end point (59% vs. 49%) and reported improvements in perception of bladder condition (−1.51 vs. −1.33) assessments. However, this was accompanied by an adverse event incidence that was greater with solifenacin than with tolterodine. Dry mouth and constipation (mild, moderate, or severe) were the most common (solifenacin, 30 [6.4%]; tolterodine, 23 [2.5%]). The majority of side effects were mild to moderate in nature, and discontinuations were comparable and low (5.9% and 7.3%) in both groups.

Luo et al. (2012) performed a systematic review and meta-analysis of solifenacin RCTs and provided a comprehensive assessment regarding the efficacy and safety of the drug. Their results, which largely confirmed what could be deduced from previously published information, indicated that solifenacin significantly decreased the number of urgency episodes per 24 hours, micturitions per 24 hours, incontinence episodes per 24 hours, nighttime micturitions per 24 hours, and UUI episodes per 24 hours and improved volume voided per micturition compared with placebo or the tolterodine treatment.

A number of studies and reviews have further documented the effects of solifenacin (Cardozo et al., 2006; Chapple et al., 2006a, 2007c; Maniscalco et al., 2006; see also Chapple et al., 2008b; Luo et al., 2012; Novara et al., 2008; Serels et al., 2010; Toglia et al., 2009; Vardy et al., 2009), including in men with OAB without BOO (Kaplan et al., 2010). In a pooled analysis of four RCTs, Abrams and Swift demonstrated positive effects on urgency, frequency, and nocturia symptoms in OAB dry patients (Abrams and Swift, 2005). In an analysis of four phase III clinical trials, Brubaker and FitzGerald confirmed a significant effect of solifenacin 5 and 10 mg on nocturia in patients with OAB (reductions of nocturia episodes with 5 mg, −0.6, $P < .025$; with 10 mg, −0.6, $P < .001$; vs. placebo, −0,4) but without nocturnal polyuria (NP) (Brubaker and FitzGerald, 2007). Other studies have reported a positive impact on nocturia and sleep quality in patients with OAB treated with solifenacin (Takao et al., 2011; Yokoyama et al., 2011). Kelleher et al. (2006) and Staskin and Te (2006) presented data showing efficacy in patients with mixed incontinence.

A pooled analysis of four studies confirmed the efficacy and tolerability of solifenacin 5 mg and 10 mg in elderly (65 years or older) patients and also showed a high level of persistence in a 40-week extension trial (Wagg et al., 2006). Post hoc analysis of two 12-week, open-label, flexible-dosage studies on 2645 patients older than 65 years of age with OAB revealed that solifenacin was associated with improvements in measures assessing patients' perception of their bladder problems, symptom bothersomeness, and aspects of health-related QoL (Capo' et al., 2011). Solifenacin was equally well tolerated in younger (<65 years) and older (>65 years) patients (Herschorn et al., 2011b). An exploratory pilot study with single doses of solifenacin 10 mg administered to 12 elderly volunteers suggested no clear propensity to impair cognitive functions (Wesnes et al., 2009).

Several studies have documented improvement of QoL with solifenacin treatment (Garely et al., 2006; Kelleher et al., 2005). In 30 patients with multiple sclerosis, van Rey and Heesakkers (2011) improved OAB symptoms and neurogenic disease-specific QoL measures.

Information on solifenacin treatment in children is scarce. A chart review of 138 children with therapy-resistant OAB, treated with solifenacin, showed increased mean voided volume and improved continence (Hoebeke et al., 2009). An open-label study utilizing solifenacin doses 1.25 mg to 10 mg in children with refractory incontinence was reported (Nadeau et al., 2014). In total, 112 girls and 132 boys were included (191 had IDO, and 53 had NDO), with mean age of 9.2 years at the start of treatment. Significant improvements were seen in urodynamic parameters, PPBC, and UI episodes, with the dry rate being 36%. Treatment outcomes were more successful for IDO than NDO. The majority of patients reported no side effects ($n = 175$).

The SONIC trial assessed efficacy and tolerability of solifenacin in patients with multiple sclerosis (MS) and SCI in a prospective randomized phase IIIb/IV parallel group study (Amarenco et al., 2017). Approximately one-fourth of the patients were taking muscle relaxants to help with spasticity. Patients were randomized to solifenacin 5 mg, solifenacin 10 mg, oxybutynin 5 mg three times daily, or placebo for 4 weeks after a placebo run-in. The primary analysis was solifenacin 10 mg vs placebo. The majority of MS patients were female, and the majority of SCI patients were male. The primary end point of maximum cystometric capacity was significantly increased with solifenacin 10 mg (134 mL) compared with placebo (5 mL). Furthermore, significant improvements were also observed with regard to bladder volume at first contraction and at first leak and detrusor pressure at first leak. PPBC and I-QoL subscales significantly improved in favor of solifeancin 10 mg compared with placebo. Significant improvements were also seen for oxybutynin compared with placebo, but the trial was not designed to compare outcomes of the different active treatments (Amarenco et al. 2017). The overall incidence of adverse events were low, and dry mouth rates were 2.3%, 4.2%, 7.8%, and 17% for placebo, solifenacin 5 mg, solifenacin 10 mg and oxybutynin 5 mg three times daily, respectively.

A noninterventional observational study in men alone ($n = 799$) was conducted in multiple centers in Germany in a real-life practice setting (Burger et al. 2014). In this 12-week study, the majority were taking solifenacin 5 mg at study end (71%), and only 1.9% discontinued the treatment. Significant improvement in OAB symptoms were observed. In a subgroup of men with mild to moderate dementia, Mini Mental State Examination (MMSE) scores did not change significantly over the 12 weeks. Unusually dry mouth was only reported in 1.1%, and mean PVR did not change. In 80% PVR did not change, and in only 2.2% was the change greater than or equal to 50 mL. No retention of urine was observed (Burger et al., 2014).

Serati et al. assessed the use of solifenacin 5 mg in patients with de novo OAB symptoms after an obturator midurethral synthetic sling and compared this to a group who was stress-incontinence treatment naïve (Serati et al., 2014). Women with a pre-existing diagnosis of DO or who had OAB symptoms were excluded as were patients with significant voiding dysfunction or persistent stress incontinence. At 3-month follow-up, interestingly, the reduction in all OAB symptoms, Patient Global Impression of Improvement (PGI-I), and OAB-q SF scores were significantly better in the stress-incontinent treatment naïve group compared with the de novo OAB group.

Jiang et al. (2016) studied the efficacy and safety of solifenacin succinate versus solifenacin succinate with local estrogen for the treatment of overactive bladder in 104 postmenopausal women randomized to receive either solifenacin 5 mg daily plus promestriene vaginal capsules or solifenacin alone. The primary outcome measure was change from baseline to end of treatment in the mean number of voids per 24 hours. QoL was assessed using IPSS and OAB symptoms score questionnaires. The median decreases in number of voids in 24 hours in the two groups were 5.4 and 4.3, respectively, which was not statistically different. The median decrease in urgency episodes was 2.0 and 2.5, respectively. In addition, the QoL scores significantly changed in both groups (both <0.05). The authors concluded that solifenacin with or without local estrogen was effective and safe for overactive bladder treatment in postmenopausal women. The addition of local estrogen improved subjective feelings and QoL (Jiang et al., 2016).

Michel et al. (2008) studied cardiovascular safety and overall tolerability of solifenacin in routine clinical use in a 12-week, open-label, postmarketing surveillance study. They concluded that "in real-life conditions, i.e., with inclusion of large numbers of patients with cardiovascular co-morbidities and taking comedications, therapeutically effective doses of solifenacin did not increase heart rate or blood pressure."

In female volunteers 19 to 79 years of age, the effect of 10 mg and 30 mg of solifenacin on QT interval was evaluated at the time of peak solifenacin plasma concentration in a multidose, randomized, double-blind, placebo- and positive-controlled (moxifloxacin 400 mg) trial (Product monograph, Vesicare). The QT interval prolonging effect appeared greater for the 30 mg (8 msec, 4, 13: 90% CI) compared with the 10 mg (2 msec, –3, 6) dose of solifenacin. Although the effect of the highest solifenacin dose (three times the maximum therapeutic dose) studied did not appear as large as that of the positive control moxifloxacin at its therapeutic dose, the confidence intervals overlapped. This study was not designed to draw direct statistical conclusions between the drugs or the dose levels.

Assessment.

Solifenacin has a well-documented beneficial effect in OAB and DO (see Table 120.3), and the adverse-event profile seems acceptable.

Tolterodine Tartrate.

Tolterodine is a tertiary amine that is rapidly absorbed and extensively metabolized by the cytochrome P450 system (CYP2D6). The major active 5-hydroxymethyl metabolite (5-HMT) has a similar pharmacologic profile as the mother compound (Nilvebrant et al., 1997b) **and significantly contributes**

to the therapeutic effect of tolterodine (Brynne et al., 1997, 1998). Both tolterodine and 5-HMT have a plasma half-life of 2 to 3 hours, but the effects on the bladder seem to be longer lasting than could be expected from the pharmacokinetic data. Urinary excretion of tolterodine accounted for less than 1% to 2.4% of the dose; 5% to 14% of 5-HMT is eliminated in the urine (Brynne et al., 1997). Whether or not the total antimuscarinic activity of unchanged tolterodine and 5-HMT excreted in urine is sufficient to exert any effect on the mucosal signaling mechanisms has not been established. However, the preliminary studies by Kim et al. (2006) and Chuang et al. (2008) do not support such an effect.

The relatively low lipophilicity of tolterodine and even lesser one of 5-HMT imply limited propensity to penetrate into the CNS, which may explain a low incidence of cognitive side effects (Clemett and Jarvis, 2001; Hills et al., 1998; Salvatore et al., 2008). However, tolterodine may disturb sleep in subjects who are unable to form the even less lipophilic 5-HMT because of a low activity of CYP2D6 (Diefenbach et al., 2008).

Tolterodine has no selectivity for muscarinic receptor subtypes but is claimed to have functional selectivity for the bladder over the salivary glands (Nilvebrant et al., 1997a; Stahl et al., 1995). In healthy volunteers, oral tolterodine at a high dose (6.4 mg) had a powerful inhibitory effect on micturition and also reduced stimulated salivation 1 hour after administration of the drug (Stahl et al., 1995). However, 5 hours after administration, the effects on the urinary bladder were maintained, whereas no significant effects on salivation could be demonstrated.

Animal experiments have suggested that antimuscarinics may affect signaling from the bladder (Andersson et al., 2011b). Vijaya et al. (2012) found confirming data in humans. In a randomized, placebo-controlled study, they evaluated the effect of tolterodine on urethral and bladder afferent nerves in women with DO compared with placebo, by studying the changes in the current perception threshold (CPT). They found a significantly increased CPT value at 5 Hz (described as urgency) and 250 Hz on both urethral and bladder stimulation after 1 week of treatment. When compared with placebo, women taking tolterodine had significantly increased bladder CPT values at 5 Hz ($P < .05$).

Tolterodine is available in IR (TOLT-IR; 1 or 2 mg; twice-daily administration) and ER (TOLT-ER) forms (2 or 4 mg; once-daily administration). The ER form seems to have advantages over the IR form in terms of both efficacy and tolerability (Van Kerrebroeck et al., 2001).

Several randomized, double-blind, placebo-controlled studies on patients with OAB and DO (both IDO and NDO) have documented a significant reduction in micturition frequency and number of incontinence episodes (Clemett and Jarvis, 2001; Hills et al., 1998; Salvatore et al., 2008). Comparative RCTs such as the OBJECT (Overactive Bladder: Judging Effective Control and Treatment) and OPERA (Overactive Bladder: Performance of Extended Release Agents) studies have further supported its effectiveness.

The OBJECT trial compared oxybutynin ER (OXY-ER) 10 mg once daily with TOLT-IR 2 mg twice daily (Appell et al., 2001) in a 12-week randomized, double-blind, parallel-group study including 378 patients with OAB. Participants had 7 to 50 episodes of urgency incontinence per week and 10 or more voids in 24 hours. The outcome measures were the number of episodes of urgency incontinence, total incontinence, and micturition frequency at 12 weeks adjusted for baseline. At the end of the study, OXY-ER was found to be significantly more effective than TOLT-IR in each of the main outcome measures adjusted for baseline (see the discussion of oxybutynin chloride later in this chapter). Dry mouth, the most common adverse event, was reported by 33% and 28% of participants taking OXY-ER and TOLT-IR, respectively. Rates of CNS and other adverse events were low and similar in both groups. The authors concluded that OXY-ER was more effective than TOLT-IR and that the rates of dry mouth and other adverse events were similar in both treatment groups.

In the OPERA study (Diokno et al., 2003), OXY-ER at 10 mg/day or TOLT-ER at 4 mg/day were given for 12 weeks to women with 21 to 60 urgency incontinence episodes per week and an average of 10 or more voids per 24 hours. Episodes of incontinence (primary end point), total incontinence (urgency and nonurgency), and micturition were recorded in seven 24-hour urinary diaries at baseline and at weeks 2, 4, 8, and 12 and compared. Adverse events were also evaluated. Improvements in weekly urgency incontinence episodes were similar for the 790 women who received OXY-ER (391) or TOLT-ER (399). OXY-ER was significantly more effective than TOLT-ER in reducing micturition frequency, and 23.0% of women taking OXY-ER reported no episodes of UI compared with 16.8% of women taking TOLT-ER. Dry mouth, usually mild, was more common with OXY-ER. In general, adverse events were mild and occurred at low rates, with both groups having similar discontinuation of treatment because of adverse events. The conclusions were that reductions in weekly urgency incontinence and total incontinence episodes were similar with the two drugs. Dry mouth was more common with OXY-ER, but tolerability was otherwise comparable, including adverse events involving the CNS.

In the Antimuscarinic Clinical Effectiveness Trial (ACET) (Sussman and Garely, 2002), which consisted of two trials, patients with OAB were randomized to 8 weeks of open-label treatment with either 2 mg or 4 mg of once-daily TOLT-ER (study one) and to 5 mg or 10 mg of OXY-ER (study two). In total, 1289 patients were included. Fewer patients prematurely withdrew from the trial in the TOLT-ER 4-mg group (12%) than either the OXY-ER 5-mg (19%) or OXY-ER 10-mg group (21%). More patients in the OXY-ER 10-mg group than in the TOLT-ER 4-mg group withdrew because of poor tolerability (13% vs. 6%). After 8 weeks, 70% of patients in the TOLT-ER 4-mg group perceived an improved bladder condition, compared with 60% in the TOLT-ER 2-mg group, 59% in the OXY-ER 5-mg group, and 60% in the OXY-ER 10-mg group. Dry mouth was dose-dependent with both agents, although differences between doses reached statistical significance only in the oxybutynin trial (OXY-ER 5 mg vs. OXY-ER 10 mg; $P = .05$). Patients treated with TOLT-ER 4 mg reported a significantly lower severity of dry mouth compared with OXY-ER 10 mg. The conclusion that the findings suggest improved clinical efficacy of TOLT-ER (4 mg) than of OXY-ER (10 mg) is weakened by the open-label design of the study.

Zinner et al. (2002) evaluated the efficacy, safety, and tolerability of TOLT-ER in older (≥65) and younger (<65) OAB patients, in a 12-week RCT including 1015 patients with urgency incontinence and urinary frequency. Patients were randomized to treatment with TOLT-ER 4 mg once daily (507) or placebo (508) for 12 weeks. Efficacy, measured with micturition charts (incontinence episodes, micturitions, volume voided per micturition) and subjective patient assessments; safety; and tolerability end points were evaluated relative to placebo. Compared with placebo, significant improvements in micturition chart variables with TOLT-ER showed no age-related differences. Dry mouth (of any severity) was the most common adverse event in both the TOLT-ER and placebo treatment arms, irrespective of age (<65: ER 22.7%, placebo 8.1%; ≥65: ER 24.3%, placebo 7.2%). A few patients (<2%) experienced severe dry mouth. No CNS (cognitive functions were not specifically studied), visual, cardiac (per ECG), or laboratory safety concerns were noted in this study. Withdrawal rates caused by adverse events on TOLT-ER 4 mg qd were comparable in the two age cohorts (<65: 5.5%; ≥65: 5.1%).

The central symptom in the OAB syndrome is urgency. Freeman et al. (2003) presented a secondary analysis of a double-blind, placebo-controlled study evaluating the effect of once-daily TOLT-ER on urinary urgency in patients with

OAB. Patients with urinary frequency (eight or more micturitions per 24 hours) and urgency incontinence (five or more episodes per week) were randomized to oral treatment with TOLT-ER 4 mg once daily ($n = 398$) or placebo ($n = 374$) for 12 weeks. Efficacy was assessed by use of patient perception evaluations. Of patients treated with TOLT-ER, 44% reported improved urgency symptoms (compared with 32% for placebo), and 62% reported improved bladder symptoms (placebo, 48%). The proportion of patients unable to hold urine on experiencing urgency was decreased by 58% with TOLT-ER, compared with 32% with placebo ($P < .001$).

In the Improvement in Patients: Assessing Symptomatic Control with Tolterodine ER (IMPACT) study, the efficacy of TOLT-ER for patients' most bothersome OAB symptom was investigated in an open-label primary care setting (Elinoff et al., 2006). Patients with OAB symptoms for 3 months or longer received TOLT-ER (4 mg once daily) for 12 weeks. By week 12, there were significant reductions in patients' most bothersome symptom: incontinence, urgency episodes, or nocturnal and daytime frequency. The most common adverse events were dry mouth (10%) and constipation (4%), and it was concluded that in primary care practice, bothersome OAB symptoms can be effectively and safely treated with TOLT-ER, even in patients with comorbid conditions.

Various aspects of the efficacy and tolerability of tolterodine have been further documented in a number of RCTs (Bharucha et al., 2008; Choo et al., 2008; Coyne et al., 2008; Dmochowski et al., 2007a, 2007b; Rogers et al., 2008; Rovner et al., 2008b; see also Chapple et al., 2008b; Novara et al., 2008). It is important to note that the QTc effects of tolterodine were determined in a crossover-designed QT study of recommended (2 mg twice daily) and supratherapeutic (4 mg twice daily) doses of tolterodine, moxifloxacin (400 mg once daily), and placebo. No subject receiving tolterodine exceeded the clinically relevant thresholds of 500-msec absolute QTc or 60-msec change from baseline, and it was concluded that tolterodine does not have a clinically significant effect on QT interval (Malhotra et al., 2007).

Olshansky et al. (2008) compared the effects on HR of TOLT-ER 4 mg/day with those of darifenacin 15 mg/day in healthy volunteers. They found that tolterodine, but not darifenacin, significantly increased mean HR per 24 hours. The proportion of subjects with an increase of more than 5 beats/min was significantly greater in those receiving TOLT-ER (25%) than with darifenacin (8.9%).

Hsiao et al. (2011) compared the urodynamic effects, therapeutic efficacy, and safety of solifenacin (5 mg) versus tolterodine ER (4 mg) treatment in women with the OAB syndrome. Both solifenacin and tolterodine had similar urodynamic effects, therapeutic efficacy, and adverse events; however, tolterodine had a greater effect in increasing HR than solifenacin.

In a prospective, open study, Song et al. (2006) compared the effects of bladder training (BT) and/or tolterodine as first-line treatment in female patients with OAB. One hundred and thirty-nine female patients with OAB were randomized to treatment with BT, tolterodine (2 mg twice daily), or both for 12 weeks. All treatments were effective; however, combination therapy was the most effective. Mattiasson et al. (2003) compared the efficacy of tolterodine 2 mg twice daily plus simplified BT with tolterodine alone in patients with OAB in a multicenter single-blind study. At the end of the study, the median percentage reduction in voiding frequency was greater with tolterodine plus BT than with tolterodine alone (33% vs. 25%; $P < .001$), whereas the median percentage increase in volume per void was 31% with tolterodine plus BT and 20% with tolterodine alone ($P < .001$). There was a median of 81% fewer incontinence episodes than at baseline with tolterodine alone, which was not significantly different from that with tolterodine plus BT (−87%). It was concluded that the effectiveness of tolterodine 2 mg twice daily can be augmented by a simplified BT regimen. However, Millard and the Asia Pacific Tolterodine Study Group (2004) investigated whether the combination of tolterodine plus a simple pelvic floor muscle exercise program would provide improved treatment benefits compared with tolterodine alone in 480 patients with OAB. Tolterodine therapy for 24 weeks resulted in significant improvement in urgency, frequency, and incontinence; however, no additional benefit was demonstrated for a simple pelvic floor muscle exercise program. In a 16-week, multicenter, open-label study, tolterodine ER plus behavioral intervention resulted in high treatment satisfaction and improved bladder diary variables in patients who had previously been treated and were dissatisfied with tolterodine or other antimuscarinics (Klutke et al., 2009).

More recently, the combination of intravaginal estradiol and tolterodine has been assessed to ascertain its impact on OAB (Ellington et al., 2016). After 12 weeks of monotherapy with either tolterodine ER 4 mg or estradiol, no significant differences in OABSS or bladder diary was seen between the groups, although within-group changes were observed. In the extension study, the addition of tolterodine ER to intravaginal estradiol significantly improved OAB symptom bother score when compared with estradiol alone (Ellington et al., 2016).

Abrams et al. (2006c) studied the safety and tolerability of tolterodine for the treatment of OAB symptoms in men with BOO. They found that tolterodine did not adversely affect urinary function in these men. Urinary flow rate was unaltered, and there was no evidence of clinically meaningful changes in voiding pressure and PVR or urinary retention. It was suggested that antimuscarinics can be safely administered in men with BOO. Lee et al. (2008a) reviewed the safety and efficacy of antimuscarinic agents in treating men with BOO and OAB and emphasized their safety and efficacy. They also concluded that combination therapy with antimuscarinics and α_1-adrenoceptor (α_1-AR) antagonists improves the symptoms effectively without increasing the incidence of acute urinary retention (AUR).

The beneficial effect of TOLT-ER in men with BPE and LUTS, including OAB, has been well documented. Both as monotherapy, but particularly in combination with α_1-AR antagonists, TOLT-ER was found effective (Höfner et al., 2007; Kaplan et al., 2006, 2008a, 2008b; Roehrborn et al., 2008a; Rovner et al., 2008a). This effect was obtained irrespective of prostate size and was not associated with increased incidence of AUR (Roehrborn et al., 2008a). A large, 26-week, multicenter, randomized, double-blind, placebo-controlled, three-period crossover study enrolled women 18 years of age and older who were diagnosed with OAB and reported eight or more micturitions per 24 hours and four or more urgency episodes per week in a 5-day bladder diary at baseline (Marencak et al., 2011). Patients were randomized to 1 of 10 treatment sequences and received three of five treatments, each for 4 weeks with 4-week washout periods: standard-dose pregabalin/tolterodine ER (150 mg bid/4 mg qd; $n = 102$); pregabalin alone (150 mg bid; $n = 105$); tolterodine ER alone (4 mg qd; $n = 104$); low-dose pregabalin/tolterodine ER (75 mg bid/2 mg qd; $n = 105$); and placebo ($n = 103$). Patients completed 5-day diaries at the end of treatment and washout periods. The primary end point was change from baseline to week 4 in MVV per micturition. Baseline-adjusted changes in MVV were significantly greater after treatment with standard-dose pregabalin/tolterodine ER (39.5 mL) versus tolterodine ER alone (15.5 mL; $P < .0001$) and with pregabalin alone (27.4 mL) versus tolterodine ER alone ($P = .005$) and placebo (11.9 mL; $P = .0006$). Treatments were generally well tolerated; discontinuation rates because of adverse events were 4%, 2%, 5%, 0%, and 1% with standard- and low-dose pregabalin/tolterodine ER, pregabalin, tolterodine ER, and placebo, respectively.

For more information, see the discussion of combination therapies in the New Developments section later in this chapter.

Dmochowski et al. (2014) assessed a new formulation of IR tolterodine 2 mg with sustained-release (SR) pilocarpine 9 mg twice daily. In this double-blind crossover trial with open-label extension, a combination of tolterodine and pilocarpine and tolterodine alone were better than placebo at improving daily incontinence and micturition episodes, however, they were no different when compared with each other. Dry mouth as assessed by visual analog scale (VAS; 0–100) were 20.9, 28.7, and 40.4 for placebo, tolterodine/pilocarpine, and tolterodine alone, respectively. Other parameters such as general discomfort around the mouth and difficulty swallowing/chewing showed similar trends. The incidence of dry mouth with tolterodine/pilocarpine was similar to placebo (3.9% vs. 5.3%). In the extension study, patients were randomized to tolturodine 3 mg and pilocarpine 13.5 mg twice daily or tolterodine ER 4 mg once daily. Incidence of dry mouth were similar in the two groups despite the tolterodine/pilocarpine combination having 50% more tolterodine (Dmochowski et al., 2014).

Assessment.

Both the IR and ER forms of tolterodine have a well-documented effect in OAB and DO (see Table 120.3) and are well tolerated.

Trospium Chloride.

Trospium is a quaternary ammonium compound with a biologic availability of less than 10% (Doroshyenko et al., 2005; Fusgen and Hauri, 2000). The drug has a plasma half-life of approximately 20 hours and is **mainly (60% of the dose absorbed) eliminated unchanged in urine.** The concentration obtained in urine seems to be enough to affect the mucosal signaling system in a rat model (Kim et al., 2006). Whether or not it contributes to the clinical efficacy of the drug remains to be established.

Trospium is not metabolized by the cytochrome P450 enzyme system (Beckmann-Knopp et al., 1999; Doroshyenko et al., 2005)**. It is expected to cross the blood-brain barrier to a limited extent** because it is a substrate for the drug-efflux transporter P-glycoprotein, which restricts its entry into the brain (Davis et al., 2014). This was demonstrated by Staskin et al. (2010), who showed that trospium chloride levels in cerebrospinal fluid (CSF) samples were undetectable on day 10 at steady-state peak plasma concentration concurrent with measureable peak plasma values. Clinically, trospium seems to have no negative cognitive effects (Chancellor et al., 2012; Fusgen and Hauri, 2000; Staskin et al., 2010; Todorova et al., 2001; Wiedemann et al., 2002).

Trospium has no selectivity for muscarinic receptor subtypes. In isolated detrusor muscle, it was more potent than oxybutynin and tolterodine to antagonize carbachol-induced contractions (Uckert et al., 2000).

Several RCTs have documented positive effects of trospium both in NDO (Madersbacher et al., 1995; Menarini et al., 2006; Stöhrer et al., 1991) and non-neurogenic DO (Alloussi et al., 1998; Cardozo et al., 2000; Dmochowski et al., 2008; Halaska et al., 2003; Jünemann and Al-Shukri, 2000; Rudy et al., 2006; Staskin et al., 2007; Zinner et al., 2004). In a placebo-controlled, double-blind study on patients with NDO, the drug was given twice daily at a dose of 20 mg over a 3-week period (Stöhrer et al., 1991). It increased maximum cystometric capacity, decreased maximal detrusor pressure, and increased compliance in the treatment group, whereas no effects were noted in the placebo group. Side effects were few and comparable in both groups. In another RCT including patients with spinal cord injuries and NDO, trospium and oxybutynin were equieffective; however, trospium seemed to have fewer side effects (Madersbacher et al., 1995).

The effect of trospium in urgency incontinence has been documented in several RCTs. Alloussi et al. (1998) compared the effects of the drug with those of placebo in 309 patients in a urodynamic study of 3 weeks’ duration. Trospium 20 mg was given twice daily. Significant increases were noted in volume at first involuntary contraction and in maximum bladder capacity. Cardozo et al. (2000) investigated 208 patients with DO who were treated with trospium 20 mg twice daily for 2 weeks. Also in this study, significant increases were found in mean volume at first unstable contraction (from 233 to 299 mL; placebo, 254 to 255 mL) and in maximum bladder capacity (from 329 to 356 mL; placebo, 345 to 335 mL) in the trospium-treated group. Trospium was well tolerated with similar frequency of adverse effects as in the placebo group. Jünemann and Al-Shukri (2000) compared trospium 20 mg twice daily with tolterodine 2 mg twice daily in a placebo-controlled, double-blind study on 232 patients with urodynamically proven DO, urgency incontinence without demonstrable DO, or mixed incontinence. Trospium reduced the frequency of micturition, which was the primary end point, more than tolterodine and placebo, and also reduced the number of incontinence episodes more than the comparators. Dry mouth was comparable in the trospium and tolterodine groups (7% and 9%, respectively).

Halaska et al. (2003) studied the tolerability and efficacy of trospium chloride in doses of 20 mg twice daily for long-term therapy in patients with urgency syndrome. The trial included a total of 358 patients with urgency syndrome or urgency incontinence. After randomization in the ratio of 3 : 1, participants were treated continuously for 52 weeks with either trospium chloride (20 mg twice daily) or oxybutynin (5 mg twice daily). Urodynamic measurements were performed at the beginning and at 26 and 52 weeks to determine the maximal cystometric bladder capacity. Analysis of the micturition diary clearly indicated a reduction in the micturition frequency, incontinence frequency, and the number of urgency episodes in both treatment groups. Mean maximum cystometric bladder capacity increased during treatment with trospium chloride by 92 mL after 26 weeks and 115 mL after 52 weeks ($P = .001$). Further comparison with oxybutynin did not reveal any statistically significant differences in urodynamic variables between the drugs. Adverse events occurred in 65% of the patients treated with trospium and 77% of those treated with oxybutynin. The main symptom encountered in both treatment groups was dry mouth. An overall assessment for each of the drugs revealed a comparable efficacy level and a better benefit-risk ratio for trospium than for oxybutynin resulting from better tolerability.

Zinner et al. (2004) treated 523 patients with symptoms associated with OAB and urgency incontinence with 20 mg trospium twice daily or placebo in a 12-week, multicenter, parallel, double-blind, placebo-controlled trial. Dual primary end points were change in average number of toilet voids and change in urgency incontinence episodes per 24 hours. Secondary efficacy variables were change in average volume per void, voiding urgency severity, urinations during day and night, time to onset of action, and change in Incontinence Impact Questionnaire score. By week 12, trospium significantly decreased average frequency of toilet voids per 24 hours (−2.37) and urgency incontinence episodes 59% compared with placebo (−1.29; 44%). It significantly increased average volume per void (32 mL; placebo, 7.7 mL) and decreased average urgency severity and daytime frequency. All effects occurred by week 1, and all were sustained throughout the study. Nocturnal frequency decreased significantly by week 4 (−0.43; placebo, −0.17), and Incontinence Impact Questionnaire scores improved at week 12. Trospium was well tolerated. The most common side effects were dry mouth (21.8%; placebo 6.5%), constipation (9.5%; placebo 3.8%), and headache (6.5%; placebo 4.6%). In a large US multicenter trial with the same design and including 658 patients with OAB, Rudy et al. (2006) confirmed the data by

Zinner et al. (2004), with respect to both efficacy and adverse effects.

Dose escalation seems to improve therapeutic efficacy. In a 12-week, randomized, double-blind, phase IIIb study including 1658 patients with urinary frequency plus urgency incontinence, patients received trospium chloride 15 mg tid ($n = 828$) or 2.5 mg oxybutynin hydrochloride tid ($n = 830$). After 4 weeks, daily doses were doubled and not readjusted in 29.2% (242 of 828) of patients in the trospium group and in 23.3% (193 of 830) in the oxybutynin group, until the end of treatment. At study end, there were no relevant differences between the "dose adjustment" subgroups and the respective "no dose adjustment" subgroups (trospium, $P = .249$; oxybutynin, $P = .349$). After dose escalation, worsening of dry mouth was higher in both dose-adjusted subgroups compared with the respective "no dose adjustment" subgroups ($P < .001$). Worsening of dry mouth was lower in the trospium groups than in the oxybutynin groups (Bödeker et al., 2010).

An ER formulation of trospium allowing once-daily administration has been introduced (Silver et al., 2010), and its effects have been tested in controlled trials (Chancellor et al., 2010; Dmochowski et al., 2008; MacDiarmid et al., 2011; Sand et al., 2011a, 2011b; Staskin et al., 2007; Zinner et al., 2011). These studies demonstrated similar efficacy as found with previous formulations, but include experiences in, for example, elderly patients (>75 years), obese patients, and patients who use multiple concomitant medications. The most frequent side effects were dry mouth (12.9%; placebo, 4.6%) and constipation (7.5%; placebo, 1.8%) (Dmochowski et al., 2008).

Intravesical application of trospium may be an interesting alternative. Fröhlich et al. performed a randomized, single-blind, placebo-controlled, monocenter clinical trial in 84 patients with urgency or urgency incontinence (Fröhlich et al., 1998). Compared with placebo, intravesical trospium produced a significant increase in maximum bladder capacity and a decrease in detrusor pressure accompanied by an increase in residual urine. There was an improvement in uninhibited bladder contractions. No adverse events were reported. It is interesting to note that intravesical trospium does not seem to be absorbed (Walter et al., 1999), thus offering an opportunity for treatment with minimal systemic antimuscarinic effects.

Assessment.

Trospium has a well-documented effect in OAB and DO, and tolerability and safety seem acceptable (see Table 120.3).

Antimuscarinics With “Mixed” Action

Some drugs used for treatment of OAB and DO have been shown to have more than one mechanism of action. They all have a more-or-less pronounced antimuscarinic effect and an often poorly defined “direct” action on bladder muscle. For several of these drugs, the antimuscarinic effects can be demonstrated at much lower drug concentrations than the direct action, which may involve blockade of voltage-gated Ca^{2+} channels. Most likely the clinical effects of these drugs can be explained mainly by an antimuscarinic action. Among the drugs with mixed actions was terodiline, which was withdrawn from the market because it was suspected to cause polymorphic ventricular tachycardia (torsades de pointes) in some patients (Connolly et al., 1991; Stewart et al., 1992).

Oxybutynin Chloride.

Oxybutynin is a tertiary amine that is well absorbed and undergoes extensive upper gastrointestinal and first-pass hepatic metabolism via the cytochrome P450 system (CYP3A4) into multiple metabolites. The primary metabolite, *N*-desethyloxybutynin, has pharmacologic properties similar to those of the parent compound (Waldeck et al., 1997) **but occurs in much higher concentrations after oral administration** (Hughes et al., 1992)**. It has been implicated as the major cause of the troublesome side effect of dry mouth associated with the administration of oxybutynin.** It seems reasonable to assume that the effect of oral oxybutynin to a large extent is exerted by the metabolite. The occurrence of an active metabolite may also explain the lack of correlation between plasma concentration of oxybutynin itself and side effects in geriatric patients reported by Ouslander et al. (1988). The plasma half-life of the oxybutynin is approximately 2 hours, but with wide interindividual variation (Douchamps et al., 1988; Hughes et al., 1992).

Oxybutynin has several pharmacologic effects in vitro, some of which seem difficult to relate to its effectiveness in the treatment of DO. **It has both an antimuscarinic and a direct muscle relaxant effect and, in addition, local anesthetic action. The latter may be of importance when the drug is administered intravesically, but probably play no role when it is given orally. In vitro, oxybutynin was 500 times weaker as a smooth muscle relaxant than as an antimuscarinic agent** (Kachur et al., 1988)**. Most likely, when given systemically, oxybutynin acts mainly as an antimuscarinic drug.** Oxybutynin has a high affinity for muscarinic receptors in human bladder tissue and effectively blocks carbachol-induced contractions (Nilvebrant and Sparf, 1988; Waldeck et al., 1997). **The drug was shown to have slightly higher affinity for muscarinic M_1 and M_3 receptors than for M_2 receptors** (Nilvebrant and Sparf, 1986; Norhona-Blob and Kachur, 1991), but the clinical significance of this is unclear.

The IR form of oxybutynin (OXY-IR) is recognized for its efficacy, and most of the newer antimuscarinic agents have been compared with it once efficacy over placebo has been determined. In general, the new formulations of oxybutynin and other antimuscarinic agents offer patients efficacy roughly equivalent to that of OXY-IR, and the advantage of the newer formulations lies in improved dosage schedules and side-effect profiles (Appell et al., 2001; Diokno et al., 2003; Dmochowski et al., 2002). An OXY-ER once-daily oral formulation and an oxybutynin transdermal delivery system (OXY-TDS) are available. OXY-TDS offers a twice-weekly dosage regimen and the potential for improved patient compliance and tolerability. McCrery and Appell overviewed (2006) some of the available formulations of oxybutynin.

Immediate-Release Oxybutynin.

Several controlled studies have shown that OXY-IR is effective in controlling DO, including NDO (Andersson and Chapple, 2001; Yarker et al., 1995). The recommended oral dose of the IR form is 5 mg three times daily or four times daily, even if lower doses have been used. Thüroff et al. (1998) summarized 15 RCTs on a total of 476 patients treated with oxybutynin. The mean decrease in incontinence was recorded as 52%, and the mean reduction in frequency per 24 hours was 33% (data on placebo not presented). The overall “subjective improvement” rate was reported as 74% (range 61% to 100%). The mean percent of patients reporting an adverse effect was 70% (range 17% to 93%). Oxybutynin 7.5 to 15 mg/day significantly improved QoL of patients with OAB in a large open multicenter trial. In this study, patient compliance was 97%, and side effects, mainly dry mouth, were reported by only 8% of the patients (Amarenco et al., 1998). In 75 nursing home residents, Ouslander et al. (1995) found that oxybutynin did not add to the clinical effectiveness of prompted voiding in a placebo-controlled, double-blind, crossover trial. On the other hand, in another controlled trial in 57 elderly subjects, oxybutynin with BT was found to be superior to BT alone (Szonyi et al., 1995).

Several open studies in patients with spinal cord injuries suggested that oxybutynin, given orally or intravesically, can be of therapeutic benefit (Kim et al., 1996; Szollar and Lee, 1996).

The therapeutic effect of OXY-IR on DO is associated with a high incidence of side effects (up to 80% with oral administration). These are typically antimuscarinic in nature (dry mouth, constipation, drowsiness, blurred vision) and are often dose limiting (Baigrie et al., 1988; Jonville et al., 1992). The effects of oxybutynin on ECG were studied in elderly patients with UI (Hussain et al., 1996); no changes were found. It cannot be excluded that the commonly recommended dose of 5 mg × 3 is unnecessarily high in some patients, and that a starting dose of 2.5 mg × 2 with subsequent dose titration would reduce the number of adverse effects (Amarenco et al., 1998).

Extended-Release Oxybutynin.

The OXY-ER formulation was developed to decrease liver metabolite formation of desethyloxybutynin (DEO) with the presumption that it would result in decreased side effects, especially dry mouth, and improve patient compliance with remaining on oxybutynin therapy (Arisco et al., 2009). The formulation uses an osmotic system to release the drug at a controlled rate over 24 hours distally primarily into the large intestine where absorption is not subject to first-pass metabolism in the liver. This reduction in metabolism is meant to improve the rate of dry mouth complaints when compared with OXY-IR. DEO is still formed through the hepatic cytochrome P450 enzymes, but clinical trials have indeed demonstrated improved dry mouth rates compared with OXY-IR (Appell et al., 2003). Salivary output studies have also been interesting. Two hours after administration of OXY-IR or TOLT-IR, salivary production decreased markedly and then gradually returned to normal. With OXY-ER, however, salivary output was maintained at predose levels throughout the day (Chancellor et al., 2001).

The effects of OXY-ER have been well documented (Siddiqui et al., 2004). In the OBJECT study, the efficacy and tolerability of 10-mg OXY-ER was compared with a twice-daily 2-mg dose of TOLT-IR (Appell et al., 2001). OXY-ER was statistically more effective than TOLT-IR in weekly urgency incontinence episodes (OXY-ER from 25.6% to 6.1%; TOLT-IR 24.1% to 7.8%), total incontinence (OXY-ER from 28.6% to 7.1%; TOLT-IR 27.0% to 9.3%), and frequency (OXY-ER 91.8% to 67.1%; TOLT-IR 91.6% to 71.5%), and both medications were equally well tolerated. The basic study was repeated as the OPERA study, with the difference that this study was a direct comparison of the two ER forms, OXY-ER (10 mg) and TOLT-ER (4 mg), and the results were quite different (Diokno et al, 2003). In this study, there was no significant difference in efficacy for the primary end point of urgency incontinence; however, TOLT-ER had a statistically lower incidence of dry mouth. OXY-ER 10 mg was statistically better than TOLT-ER 4 mg in only reduction of the rate of urinary frequency. These studies made it clear that in comparative studies, IR entities of one drug should no longer be compared with ER entities of the other.

Greater reductions in urgency and total incontinence have been reported in patients treated in dose-escalation studies with OXY-ER. In two randomized studies, the efficacy and tolerability of OXY-ER were compared with those of OXY-IR. In the 1999 study, 105 patients with urgency or mixed incontinence were randomized to receive 5 to 30 mg of OXY-ER once daily or 5 mg of OXY-IR one to four times a day (Anderson et al., 1999). Dose titrations began at 5 mg, and the dose was increased every 4 to 7 days until one of three end points was achieved. These were (1) the patient reported no urgency incontinence during the final 2 days of the dosage period; (2) the maximum tolerable dose was reached; or (3) the maximum allowable dose (30 mg for OXY-ER or 20 mg for OXY-IR) was reached. The mean percent reduction in weekly urgency and total incontinence episodes was statistically similar between OXY-ER and OXY-IR, but dry mouth was reported statistically more often with OXY-IR. In the 2000 study, 226 patients were randomized between OXY-ER and OXY-IR with weekly increments of 5 mg daily up to 20 mg daily (Versi et al., 2000). As in the 1999 study, OXY-ER again achieved a greater than 80% reduction in urgency and total incontinence episodes, and a significant percentage of patients became dry. A negative aspect of these studies is that there were no naïve patients included; all patients were known responders to oxybutynin. Similar efficacy results have been achieved, however, with OXY-ER in a treatment-naïve population (Gleason et al., 1999).

In an RCT comparing different daily doses of oxybutynin (5, 10, and 15 mg), Corcos et al. found a significant dose-response relationship for both urgency incontinence episodes and dry mouth (Corcos et al., 2006). The greatest satisfaction was with 15 mg of oxybutynin per day.

In a multicenter, prospective, observational, flexible-dosing Korean study, Yoo et al. (2012) investigated the prescription pattern and dose distribution of OXY-ER in patients with OAB syndrome in actual clinical practice. The dose for each patient was adjusted after discussions of efficacy and tolerability between doctor and patient, over a 12-week treatment period. Efficacy was measured by administering the Primary OAB Symptom Questionnaire (POSQ) before and after treatment. Patients were also administered a patient perception of treatment benefit (PPTB) questionnaire at the end of the study. Of the 809 patients enrolled, 590 (73.2%) continued to take study medication for 12 weeks. Most patients were prescribed 5 to 10 mg of oxybutynin ER per day as both starting and maintenance doses, with a dose escalation rate of only 14.9%. All OAB symptoms evaluated by the POSQ were improved; 94.1% of patients reported benefits from treatment, and 89.3% were satisfied.

Transdermal Oxybutynin.

Transdermal delivery also alters oxybutynin metabolism, reducing DEO production to an even greater extent than OXY-ER. A study comparing OXY-TDS with OXY-IR demonstrated a statistically equivalent reduction in daily incontinence episodes (from 7.3 to 2.3 [66%] for OXY-TDS; and 7.4 to 2.6 [72%] for OXY-IR), but much less dry mouth (38% for OXY-TDS and 94% for OXY-IR) (Davila et al., 2001). In another study, the 3.9-mg daily-dose patch significantly (vs. placebo) reduced the mean number of daily incontinence episodes (from 4.7 to 1.9; placebo 5.0 to 2.9) while reducing average daily urinary frequency, confirmed by an increased average voided volume (from 165 to 198 mL; placebo 175 to 182 mL) (Dmochowski et al., 2002). Furthermore, dry mouth rate was similar to placebo (7% vs. 8.3%). In a third study, OXY-TDS was compared not only with placebo but with TOLT-ER (Dmochowski et al., 2003b). Both drugs equivalently and significantly reduced daily incontinence episodes and increased the average voided volume, but TOLT-ER was associated with a significantly higher rate of antimuscarinic adverse events. **The primary adverse event for OXY-TDS was application site reaction pruritus in 14% and erythema in 8.3%, with nearly 9% feeling that the reactions were severe enough to withdraw from the study** despite the lack of systemic problems.

The pharmacokinetics and adverse effect dynamics of OXY-TDS (3.9 mg/day) and OXY-ER (10 mg/day) were compared in healthy subjects in a randomized, two-way crossover study (Appell et al., 2003). Multiple blood and saliva samples were collected and pharmacokinetic parameters and total salivary output were assessed. OXY-TDS administration resulted in greater systemic availability and minimal metabolism to DEO compared with OXY-ER, which resulted in greater salivary output in OXY-TDS patients and less dry mouth symptomatology than when taking OXY-ER.

Dmochowski et al. (2005) analyzed the combined results of two RCTs and concluded that transdermal oxybutynin was shown to be efficacious and well tolerated. The most common systemic side effect was dry mouth (7.0% vs. placebo 5.3%). Application site erythema occurred in 7% and pruritus in 16.1%. Also, Cartwright and Cardozo (2007)reviewed published and presented data and concluded that transdermal oxybutynin has a good balance between efficacy and tolerability with a rate of systemic antimuscarinic side effects that is lower than with oral antimuscarinics; however, this benefit was offset by the rate of local skin reaction (Cartwright and Cardozo, 2007). The reviews by Sahai et al. and Staskin and Salvatore largely confirmed these conclusions, which also have been supported by further studies (Sahai et al., 2008; Staskin and Salvatore, 2010; Cartwright et al., 2011).

In a Japanese OAB population, an alternative daily 73.5-mg transdermal oxybutynin patch was assessed against propiverine 20 mg daily and placebo (Yamaguchi et al., 2014). Approximately 570 patients were in the active arms and 380 in placebo. At 12 weeks, the oxybutynin patch was significantly superior than placebo and noninferior to propiverine for daily micturition episodes. Urgency and voided volume was better compared with placebo for transdermal oxybutynin, however, urgency incontinence episodes and nocturia were no different. Furthermore 8 of 9 domains assessed utilizing the KHQ were better for transdermal oxybutynin compared with placebo, suggesting better QoL in this group. Dry mouth and constipation were seen in 6.5% and 0.7%, 13.2% and 5%, and 1.8% and 1% in the transdermal oxybutynin, propiverine and placebo groups, respectively. In the transdermal oxybutynin group, application site dermatitis was seen in 31.8%, with site erythema in 5.6%.

The transdermal patch (3.9 mg/day) has been shown to be subjectively effective in a small pediatric population but with 35% skin site irritation and 20% discontinuation rate (Gleason et al., 2014).

Oxybutynin Topical Gel.

Given the efficacy and tolerability of the transdermal application, limited only by skin site reactions, a gel formulation was developed. Oxybutynin topical gel (OTG) was approved by the U.S. Food and Drug Administration (FDA) in January 2009. OTG is applied once daily to the abdomen, thigh, shoulder, or upper arm area (Staskin et al., 2009). The 1-g application dose delivers approximately 4 mg of drug to the circulation, with stable plasma concentrations and a “favorable” *N*-desethyloxybutynin metabolite–oxybutynin ratio, believed to minimize the antimuscarinic side effects (Staskin and Robinson, 2009). In a multicenter RCT, 789 patients (89% women) with urgency-predominant incontinence were assigned to OTG or placebo once daily for 12 weeks (Staskin et al., 2009). The mean number of urgency episodes, as recorded by a 3-day voiding diary, was reduced by 3.0 episodes per day versus 2.5 in the placebo arm ($P < .0001$). Urinary frequency decreased by 2.7 episodes per day, and voided volume increased by 21 mL (vs. 2.0 episodes [$P = .0017$] and 3.8 mL [$P = .0018$], respectively, in the placebo group). Dry mouth was reported in 6.9% of the treatment group versus 2.8% of the placebo group. Skin reaction at the application site was reported in 5.4% of the treatment group versus 1.0% in the placebo arm. It was felt that improved skin tolerability of the gel over the OXY transdermal patch delivery system was secondary to lack of adhesive and skin occlusion. The gel dries rapidly on application and leaves no residue; person-to-person transference via skin contact is largely eliminated if clothing is worn over the application site (Dmochowski et al., 2011). The evolution of the transdermal gel allows greater patient tolerability and improved compliance. This was confirmed by Sand et al. (2012a), who showed that in 704 women with OAB, OTG significantly reduced the number (mean ± standard deviation [SD]) of daily incontinence episodes (OTG, −3.0 ± 2.8 episodes; placebo, −2.5 ± 3.0 episodes), reduced urinary frequency, increased voided volume, and improved select health-related QoL domains versus placebo. Dry mouth was the only drug-related adverse event significantly more common with OTG (7.4%) than with placebo (2.8%).

A newer 3% topical oxybutynin gel has been assessed in a phase III randomized placebo-controlled trial (randomized $n = 626$) (Goldfischer et al., 2015). This product is administered via a metered-dose pump dispenser and was hypothesized to have less adverse events. Furthermore, it is made with propylene glycol to help with skin permeation. Two doses of 84 mg/day and 56 mg/day of the 3% topical oxybutynin were assessed against placebo gel in this population of patients with urgency and/or urge-predominant mixed incontinence. The 84 mg/day dose was statistically better than placebo after 12 weeks in improving weekly UI episodes (primary end point) and also daily urinary frequency and urine voided volumes. The lower dose of 56 mg/day was not statistically better than placebo. Dry mouth and application site erythema was seen in 12.1% and 3.3% in the 84 mg/day group compared with 5% and 0.5% in the placebo arm.

Other Administration Forms.

Rectal administration was reported to have fewer adverse effects than the conventional tablets (Collas and Malone-Lee, 1997).

Administered intravesically, oxybutynin has in several studies been demonstrated to increase bladder capacity and produce clinical improvement with few side effects, both in neurogenic and in other types of DO, and in both children and adults (Fader et al., 2007; George et al., 2007; Guerra et al., 2008; Lose and Norgaard, 2001), although adverse effects may occur (Kasabian et al., 1994; Palmer et al., 1997). More recently a phase II exploratory randomized placebo-controlled trial (*n* = 323) of intravaginal oxybutynin ring was conducted based on the premise that there is a shared lymphovascular network between the vagina and bladder (Gittelman et al. 2014). Approximately one-fourth of the patients had an accidental fallout of the ring. Both formulations of 4 and 6 mg were better than placebo at reducing weekly UI episodes when compared with placebo. Dry rates, frequency, and UUI episodes were also statistically better in the 6-mg intravaginal oxybutynin group compared with placebo. UTI, dry mouth, and vaginal discharge were the most common adverse events. UTI and dry mouth rates were 11.6% and 10.2% in the 6-mg oxybutynin group, 9.1% and 4.9% in the 4-mg oxybutynin group and 4.5% and 2.6% in the placebo groups.

Effects on Cognition.

Several studies have documented the possibility that oxybutynin may have negative effects on cognitive functions, particularly in the elderly population but also in children (Kay and Ebinger, 2008; Kay et al., 2006; Klausner and Steers, 2007). This factor should be taken into consideration when prescribing the drug.

Assessment.

Oxybutynin has well-documented efficacy in the treatment of OAB and DO (see Table 120.3). Despite the adverse-effect profile, it is still an established therapeutic option.

Propiverine Hydrochloride.

Madersbacher and Murz reviewed several aspects of the preclinical, pharmacokinetic, and clinical effects of propiverine (Madersbacher and Murz, 2001). The drug is rapidly absorbed (Tmax 2 hours) but has a high first-pass metabolism, and its biologic availability is about 50%. Propiverine is an inducer of hepatic cytochrome P450 enzymes in rats in doses about 100 times above therapeutic doses in humans (Walter et al., 2003). Several active metabolites that quantitatively and qualitatively differ from the mother compound are formed

(Haustein et al., 1988; Müller et al., 1993; Sugiyama et al., 2008; Wuest et al., 2006; Zhu et al., 2008). Most likely these metabolites contribute to the clinical effects of the drug, but their individual contributions have not been clarified (Michel and Hegde, 2006). The half-life of propiverine itself is about 11 to 14 hours. An ER preparation was shown to be effective (Jünemann et al., 2006; May et al., 2008). Oral absorption of propiverine is site dependent and influenced by dosage form and circadian time–dependent elimination processes (May et al., 2008).

Propiverine has combined antimuscarinic and calcium antagonistic actions (Haruno, 1992; Tokuno et al., 1993)**. The importance of the calcium antagonistic component for the drug's clinical effects has not been established. Propiverine has no selectivity for muscarinic receptor subtypes.** Christ et al. (2008) investigated the effects of propiverine on cardiac ion channels and action potentials. In a concentration-dependent manner, propiverine blocked ihERG channels expressed in HEK293 cells, and native I(Kr) current in ventricular myocytes of guinea pig. However, action potential duration was not prolonged in guinea pig and human ventricular tissue, and the investigators concluded that their results did not provide evidence for an enhanced cardiovascular safety risk with the drug.

Propiverine has been shown to have beneficial effects in patients with DO in several investigations. Thüroff et al. (1998) analyzed nine randomized studies on a total of 230 patients and found a 17% reduction in micturitions per 24 hours, a 64-mL increase in bladder capacity, and a 77% (range 33% to 80%) subjective improvement. Side effects were found in 14% (range 8% to 42%). In patients with NDO, controlled clinical trials have demonstrated propiverine's superiority over placebo (Stöhrer et al., 1999). Propiverine also increased bladder capacity and decreased maximum detrusor contractions. Controlled trials comparing propiverine, flavoxate, and placebo (Wehnert et al., 1989) and propiverine, oxybutynin, and placebo (Madersbacher et al., 1999; Wehnert et al., 1992) have confirmed the efficacy of propiverine, and suggested that the drug may have equal efficacy and fewer side effects than oxybutynin. In a comparative RCT including 131 patients with NDO, propiverine and oxybutynin were compared (Stöhrer et al., 2007). The drugs were found to be equally effective in increasing bladder capacity and lowering bladder pressure. Propiverine caused a significantly lower frequency of dry mouth than oxybutynin.

Also in children and adolescents with NDO, propiverine was found to be effective (Grigoleit et al., 2006; Schulte-Baukloh et al., 2006), with a low incidence rate of adverse events (<1.5%) (Grigoleit et al., 2006). Marschall-Kehrel et al. (2009) performed a randomized, double-blind, placebo-controlled trial with parallel-group design in children 5 to 10 years of age. Of 171 randomized children, 87 were treated with propiverine and 84 with placebo. Decrease in voiding frequency per day was the primary efficacy parameter; secondary end points included voided volume and incontinence episodes. There was a significant decrease in voiding frequency episodes for propiverine versus placebo. Superiority could also be demonstrated for voided volume and incontinence episodes per day. Propiverine was well tolerated; 23% of patients reported side effects for propiverine and 20% for placebo.

In a randomized, double-blind, multicenter clinical trial, patients with IDO were treated with 15 mg of propiverine twice daily or 2 mg of TOLT-IR twice daily over a period of 28 days (Jünemann et al., 2005). The maximum cystometric capacity was determined at baseline and after 4 weeks of therapy. The difference of both values was used as the primary end point. Secondary end points were voided volume per micturition, evaluation of efficacy (by the investigator), tolerability, PVR volume, and QoL. It was found that the mean maximum cystometric capacity increased significantly ($P < .01$) in both groups. The volume at first urgency and the frequency and volume chart parameters also showed relevant improvements during treatment. The most common adverse event, dry mouth, occurred in 20 patients in the propiverine group and in 19 patients in the tolterodine group. The scores for QoL improved comparably in both groups.

Madersbacher et al. (1999) compared the tolerability and efficacy of propiverine (15 mg three times daily), oxybutynin (5 mg twice daily), and placebo in 366 patients with urgency and urgency incontinence in a randomized, double-blind, placebo-controlled clinical trial. Urodynamic efficacy of propiverine was judged similar to that of oxybutynin, but the incidence of dry mouth and the severity of dry mouth were judged to be less with propiverine than with oxybutynin. Dorschner et al. (2000) investigated in a double-blind, multicenter, placebo-controlled, randomized study the efficacy and cardiac safety of propiverine in 98 elderly patients (mean age 68 years) with urgency, urgency incontinence, or mixed urgency-stress incontinence. After a 2-week placebo run-in period, the patients received propiverine (15 mg three times daily) or placebo (three times daily) for 4 weeks. Propiverine caused a significant reduction of the micturition frequency (from 8.7 to 6.5) and a significant decrease in episodes of incontinence (from 0.9 to 0.3 per day). The incidence of adverse events was very low (2% dry mouth under propiverine—2 of 49 patients). Resting and ambulatory ECGs indicated no significant changes. Donath et al. (2011) further studied the cardiac safety of propiverine in two comprehensively designed monocentric ECG studies (including 24 healthy women, followed by a second study on 24 male patients with coronary heart disease (CHD) and a pathologic Pardee Q wave on the ECG). Both studies were placebo controlled and compared the effects of single-dose (30 mg sid) and multiple-dose (15 mg tid) administration of propiverine hydrochloride in a crossover design over 6 and 13 days, respectively. They were performed to investigate the influence of propiverine hydrochloride and its main metabolite, propiverine *N*-oxide, on cardiac function with regard to QTc prolongation, QTc dispersion, and T-wave shape. No negative effects on cardiac safety could be demonstrated.

Abrams et al. (2006b) compared the effects of propiverine and oxybutynin on ambulatory urodynamic monitoring (AUM) parameters, safety, and tolerability in OAB patients. Seventy-seven patients received two of the following treatments during two 2-week periods: propiverine 20 mg once daily, propiverine 15 mg three times daily, oxybutynin 5 mg three times daily, and placebo. The researchers found that oxybutynin 15 mg was more effective than propiverine 20 mg in reducing symptomatic and asymptomatic involuntary detrusor contractions in ambulatory patients. Oxybutynin had a higher rate of dry mouth, and propiverine had a more pronounced effect on gastrointestinal, cardiovascular, and visual function.

Yamaguchi et al. (2007) performed a multicenter, 12-week, double-blind phase III trial in Japanese men and women with OAB (1593 patients were randomized, and 1584 were treated), comparing solifenacin 5 or 10 mg, propiverine 20 mg, and placebo. Changes at end point in number of voids per 24 hours, urgency, incontinence, urgency incontinence, and nocturia episodes, volume per void, restoration of continence, and QoL were examined. It was found that at end point there were greater reductions in mean (SD) voids per 24 hours with all drug regimens than with placebo. All active treatments improved the volume voided and QoL versus placebo; solifenacin 10 mg reduced nocturia episodes and significantly improved urgency episodes and volume voided versus propiverine 20 mg, and solifenacin 5 mg caused less dry mouth. Solifenacin 10 mg caused more dry mouth and constipation than propiverine 20 mg. Wada et al. (2011) performed a prospective nonrandomized crossover study of female OAB patients, assigned alternately to treatment with propiverine (20 mg) for 8 weeks and then solifenacin (5 mg) for 8 weeks, or solifenacin for 8 weeks and then propiverine for 8 weeks. At baseline, 8th week, and 16th week, symptoms were assessed using the OABSS. Of the 121 patients enrolled, 83 were analyzed. Both drugs were effective. Urgency was further improved after switching from propiverine to solifenacin, but not after switching from solifenacin to propiverine. Solifenacin was better tolerated than propiverine.

In another multicenter, prospective, parallel, double-blind, placebo-controlled trial, Lee et al. (2010) studied the effects of 30 mg of propiverine per day in 264 OAB patients (mean age 52.2 years), 221 of whom had efficacy data available from baseline and at least one on-treatment visit with greater than 75% compliance. The study was focused on improving urgency. Overall, among patients treated with propiverine, 39% rated their treatment as providing "much benefit," compared with 15% in the placebo group. Adverse events reported by 32 (22.5%) and 10 (12.7%) patients in the propiverine and placebo group were all tolerable. The ER formulation of propiverine was compared with the ER formulation of tolterodine in a noninferiority trial with approximately 150 patients in each study arm (Leng et al., 2017). Statistically more significant reductions were seen for propiverine ER compared with tolterodine ER. Discontinuation rates because of adverse events were more in the tolterodine ER group compared with propiverine ER (7.4% vs 3.1%). Based on the way the study was designed and powered, the authors concluded that ER propiverine was noninferior to ER tolterodine (Leng et al., 2017).

Masumori et al. (2011) examined prospectively the efficacy and safety of propiverine in patients with OAB who responded poorly to previous treatment with solifenacin, tolterodine, or imidafenacin. Of 73 patients enrolled (29 men and 44 women, median age 71 years), 52 completed the protocol treatment. The OABSS was significantly improved by propiverine treatment. The scores of OAB symptoms (nighttime frequency, urgency, and urgency incontinence) except daytime frequency also improved significantly. No increase in PVR was observed. The most frequent adverse event was dry mouth (13.7%), followed by constipation (6.8%).

In a noncontrolled study in patients with wet OAB, the efficacy of propiverine on symptoms and QoL was confirmed (Komatsu et al., 2009).

Assessment.

Propiverine has a documented beneficial effect in the treatment of OAB and DO (see Table 120.3) and seems to have an acceptable side-effect profile. It

is not approved for use in the United States.

Flavoxate Hydrochloride.

Flavoxate is often discussed as a drug with mixed actions; however, its main mechanism of action may not be antimuscarinic. Flavoxate is well absorbed, and oral bioavailability appeared to be close to 100% (Guay, 2003). The drug is extensively metabolized, and plasma half-life was found to be 3.5 hours (Sheu et al., 2001). Its main metabolite (3-methylflavone-8-carboxylic acid [MFCA]) has been shown to have low pharmacologic activity (Caine et al., 1991; Cazzulani et al., 1988). **The main mechanism of flavoxate's effect on smooth muscle has not been established.** The drug has been found to possess a moderate calcium antagonistic activity, to have the ability to inhibit phosphodiesterase (PDE), and to have local anesthetic properties; no antimuscarinic effect was found (Guarneri et al., 1994).). On the other hand, Uckert et al. (2000) found that in strips of human bladder, the potency of flavoxate to reverse contraction induced by muscarinic receptor stimulation and by electrical field stimulation was comparable. It has been suggested that pertussis toxin–sensitive G proteins in the brain are involved in the flavoxate-induced suppression of the micturition reflex, because intracerebroventricularly or intrathecally administered flavoxate abolished isovolumetric rhythmic bladder contractions in anesthetized rats (Oka et al., 1996).

The clinical effects of flavoxate in patients with DO and frequency, urgency, and incontinence have been studied in both open and controlled investigations, but with varying rates of success (Ruffmann, 1988). Stanton (1973) compared emepronium bromide and flavoxate in a double-blind crossover study of patients with DO and reported improvement rates of 83% and 66% after flavoxate or emepronium bromide, respectively, both administered at 200 mg three times daily. In another double-blind crossover study comparing flavoxate 1200 mg/day with oxybutynin 15 mg/day in 41 women with idiopathic motor or sensory urgency, and using both clinical and urodynamic criteria, Milani et al. (1993) found both drugs effective. No difference in efficacy was found between them, but flavoxate had fewer and milder side effects. Other investigators comparing the effects of flavoxate with those of placebo have not been able to show any beneficial effect of flavoxate at doses up to 400 mg three times daily (Briggs et al., 1980; Chapple et al., 1990; Dahm et al., 1995). In general, few side effects have been reported during treatment with flavoxate. On the other hand, its efficacy compared with other therapeutic alternatives is not well documented in

RCTs (see Table 120.3). However, a recent meta-analysis of 43 published studies claimed to demonstrate that flavoxate had better clinical efficacy than placebo, had almost no side effects, and was worthy of consideration for the treatment of OAB (Sweeney et al., 2016). This was also a conclusion drawn by Zor et al. (2015), who suggested that flavoxate deserves more clinical studies to assess its efficacy because more studies and novel drug formulations may reveal or improve its efficacy in daily practice. Further RCTs seem to be needed to establish the place of flavoxate in the therapeutic arsenal.

Assessment.

No RCTs seem to have been performed with flavoxate during the past decade. The scarcity of evidence regarding documented clinical efficacy should be considered before use of the drug (see Table 120.3).

Key Points: Antimuscarinic Therapy

- Drugs can alter LUT function by acting at any point along the afferent or efferent limb of innervation by reception activation or blockade, by affecting the concentration of the neural transmitter at an activation site, or by stimulating or inhibiting signal transduction mechanisms. Functionally, these actions can be divided into those that facilitate bladder filling or urine storage versus those that facilitate bladder emptying or voiding. Furthermore, these actions can be subdivided into those that primarily affect the bladder or outlet. Some drugs will have an effect on both. Atropine and atropine-like agents that inhibit muscarinic receptors are the most commonly used agents to inhibit involuntary contractions. They also act to maintain low bladder tone during filling with a consequent decrease in filling and storage symptoms that are unrelated to the occurrence of an involuntary contraction. They do so primarily by the inhibition of muscarinic receptors located on detrusor muscle cells, urothelial cells, suburothelial nerves, and interstitial cells. There are five pharmacologically defined muscarinic receptors; the M_2 receptor is the most common in the human bladder, but the M_3 receptor is the most important for contraction. As opposed to the traditional view that antimuscarinics in the usual administered clinical doses act by blocking the muscarinic receptors on the detrusor muscle, they appear to act mainly during the storage phase, decreasing urgency and increasing bladder capacity. In the dosage range used for treatment of the symptoms of OAB or DO, there is little evidence for a significant reduction of the voiding contraction. Higher doses can and will produce a reduction of the voiding contraction.

- In general, drug therapy for LUT dysfunction is hindered by lack of *uroselectivity.*
- Antimuscarinics are of significant clinical benefit in the treatment of OAB and related symptoms. There are numerous such agents available, and the pharmacologic profiles of each drug and their individual characteristics differ. None, however, is ideal as a first-line treatment for all patients with OAB or DO.
- Persistence with current antimuscarinic agents for such treatment is low as a result of a combination of relative lack of efficacy and adverse effects.
- Some drugs are labeled as primarily antimuscarinic but with a mixed action, meaning there is often a poorly defined direction of action on bladder smooth muscle; however, most likely the clinical effects of such drugs can be explained primarily by the antimuscarinic action.

Drugs Acting on Membrane Channels

Calcium Antagonists.

Activation of detrusor muscle, through both muscarinic-receptor and NANC pathways, seems to require influx of extracellular Ca^{2+} through Ca^{2+} channels and via mobilization of intracellular Ca^{2+} (Andersson, 1993; Andersson and Arner, 2004)**. The influx of extracellular calcium can be blocked by calcium antagonists, blocking L-type Ca^{2+} channels, and theoretically this would be an attractive way of inhibiting DO and regulating detrusor smooth muscle tone** (Berridge, 2008)**. Two major groups of calcium channels include the voltage-gated** (Catterall et al., 2003) **and the store-operated channels** (Leung et al., 2008)**. Although both can contribute to the maintenance of smooth muscle tone in general, store-operated calcium channels apparently contribute only to a limited, if any, extent to the regulation of bladder smooth muscle tone** (Schneider et al., 2004a, 2004b). On the other hand, various types of voltage-gated calcium channels have been implicated in the regulation of bladder smooth muscle including Q-type

(Frew and Lundy, 1995) and L-type channels (Wuest et al., 2007). The latter appear to be of particular importance because inhibitors of L-type channels have repeatedly been shown to inhibit bladder contraction in vitro with tissue from multiple mammalian species, including humans (Frazier et al., 2008). However, the relative importance of L-type channels may be somewhat less in humans than in other mammalian species (Wuest et al., 2007). In confirmation of the role of L-type calcium channels, it has been shown that KO mice lacking a crucial subunit of this channel exhibit a markedly impaired bladder contractility (Wegener et al., 2004).

Although these in vitro data suggest a possible role for calcium channel inhibitors, particularly those of L-type channels, in the treatment of DO and incontinence, only limited clinical studies are available in this regard. One urodynamic study compared the effects of intravesical instillation of the calcium channel inhibitor verapamil, the muscarinic-receptor antagonists oxybutynin and trospium, and placebo in patients with urgency or urgency incontinence. Whereas the two muscarinic-receptor antagonists significantly increased bladder capacity, verapamil treatment was not associated with relevant changes in bladder function (Fröhlich et al., 1998). In a clinical study of limited size, the calcium channel inhibitor nimodipine (30 mg/day) did not significantly improve the number of incontinence episodes as compared with placebo (Naglie et al., 2002). It should be noted that despite long-standing and widespread use of calcium channel inhibitors in the treatment of cardiovascular disease, there are no major reports on impaired bladder contractility as a side effect of such treatment. The reasons for the discrepancy between the promising in vitro data and the lack of clinical data are not fully clear, but they may relate to pharmacokinetic properties of the currently used drugs, which may insufficiently either reach or penetrate bladder tissue in therapeutically administered doses. **At present, there is no clinical evidence to support a possible use of calcium channel inhibitors in the treatment of bladder dysfunction** (see Table 120.3).

Potassium Channel Openers.

Potassium channels contribute to the membrane potential of smooth muscle cells and hence to the regulation of smooth muscle tone. Numerous types of potassium channels exist in the bladder (Gutman et al., 2003; Petkov, 2011; 2014). With regard to bladder function, ATP-dependent (K_{ATP}) and big calcium-activated (BK_{Ca}) channels have been studied most intensively. The BK_{Ca} channels also appear to be important physiologically because their activation can cause hyperpolarization of bladder smooth muscle cells, and by this mechanism they can contribute to the relaxation of bladder smooth muscle by, for example, β-AR agonists (Frazier et al., 2008). Openers of both K_{ATP} (Howe et al., 1995; Hu and Kim, 1997; Martin et al., 1997) and BK_{Ca} channels (Hu and Kim, 1997; Sheldon et al., 1997) have been shown to induce bladder smooth muscle relaxation in various mammalian species, but the density of some types of potassium channels may differ markedly among species. Some potassium channel openers have also been shown to suppress nonvoiding detrusor contractions in vivo in animal models of DO (Howe et al., 1995; Martin et al., 1997; Tanaka et al., 2003), and this also includes activators of the KCNQ type of potassium channels (Streng et al., 2004). Although potassium channel openers are believed to mainly act directly on smooth muscle cells (Gopalakrishnan and Shieh, 2004; Petkov, 2011; 2014), they may also at least in part affect bladder function by modulating the activity of afferent neurons (Tanaka et al., 2003).

Although the aforementioned data demonstrate the potential of potassium channel openers to inhibit nonvoiding detrusor contractions, these channels are expressed not only in bladder, but also in, for example, vascular smooth muscle. Therefore, potassium channel openers may also affect cardiovascular function, and in effective doses may considerably lower blood pressure (Howe et al., 1995; Shieh et al., 2007). Whereas some compounds of this class have a certain degree of selectivity for the bladder as compared with the cardiovascular system, it remains unclear whether the degree of selectivity offers a sufficiently large therapeutic window for clinical use. This consideration has led to a considerable hesitancy to study potassium channel openers in OAB patients. Nevertheless, one randomized, placebo-controlled clinical study on the K_{ATP} opener ZD0947 has been reported (Chapple et al., 2006). ZD0947 at the chosen dose did not lower blood pressure or cause adverse events typical for a vasodilating drug, but it also failed to achieve superiority relative to placebo for the treatment of OAB symptoms. Therefore, **despite promising preclinical efficacy data, potassium channel openers at present are not a therapeutic option and may never become one because of a lack of selectivity for bladder over cardiovascular tissues (see Table 120.3).**

Christ et al. (2001) **suggested another way to use potassium channels to normalize bladder function was by in a rat model of detrusor hyperactivity. They injected “naked” hSlo/pcDNA3 (maxiK channel) into the bladder and found a significant amelioration of the hyperactivity. Whether this principle can be therapeutically useful in humans is currently under investigation.**

At present, there is no clinical evidence to support the possible use of potassium channel openers in the treatment of bladder dysfunction (see Table 120.3).

α-Adrenoceptor Antagonists

It is well documented that α_1-AR antagonists can ameliorate LUTS in men (Andersson, 2002b; Ishizuka et al., 2013; Lepor et al., 2012; McVary et al., 2011; Michel, 2010; Oelke et al., 2013; Yuan et al., 2013). **Currently used α_1-AR antagonists are considered effective for treatment of both storage and voiding symptoms in men with LUTS associated with or suggestive of benign prostatic hyperplasia (BPH)** (Lepor et al., 2012; Soler et al., 2013)**. However, in a study in which tamsulosin was given alone or together with tolterodine to patients with male LUTS and OAB symptoms, monotherapy with the drug was not effective** (Kaplan et al., 2006)**. Doxazosin monotherapy resulted in only minimal effects in International Prostate Symptom Score (IPSS) storage subscore and urgency episodes and no improvement in PPBC** (Lee et al., 2011).

A pivotal question is whether better efficacy and/or tolerability can be achieved by highly subtype-selective drugs than with the commonly used alternatives. **α_1-ARs include three receptor subtypes, α_{1A}, α_{1B}, and α_{1D}, that are structurally and pharmacologically distinct and have different tissue distributions** (Andersson and Gratzke, 2007; Nishimune et al., 2012; Yamada and Ito, 2011)**. α_{1A}-ARs are the predominant subtype in the human prostate,** where they mediate smooth muscle contraction. A fourth subtype, α_{1L}, also found in human prostate, is derived from the same gene as the α_{1A} subtype, but α_{1L} and α_{1A} receptors have different pharmacologic properties and bind some α-AR antagonists with different affinities. The precise structural relationship between the two subtypes remains to be elucidated. Selectivity for α_{1B}-AR has been considered disadvantageous from a cardiovascular point of view (Schwinn and Roehrborn, 2008; Schwinn et al., 2004). Kojima et al. (2008) studied the expression of α_1-AR in the transitional zone of prostates from 55 patients with BPH, comparing patients treated with tamsulosin, presumed to block α_{1A}-ARs, and naftopidil, presumed to block α_{1D}-ARs. However, the selectivity of naftopidil for α_{1D}-ARs versus α_{1A}-ARs is modest (Take et al., 1998), and its use as a tool to differentiate among α_1-AR subtypes is questionable. Nevertheless, the tamsulosin and naftopidil groups were classified as α_{1A}-AR dominant (22 and 12 patients) and α_{1D}-AR dominant (11 and 16, respectively). The efficacy of tamsulosin and naftopidil differed depending on the dominant expression of the α_1-AR subtype in the prostate. Tamsulosin was more effective in patients with dominant expression of the α_{1A}-AR subtype, whereas naftopidil was more effective in those with dominant expression of the α_{1D}-AR subtype. In another study, the same group assessed whether there was a direct correlation between the prostatic expression of α_1-AR subtype mRNA and severity of LUTS or BOO (Kojima et al., 2011). They found no direct correlation between the expression of α_1-AR subtype mRNA in the prostate and severity of LUTS or BOO, although there was a significant regression of this expression with patient age. Kojima et al. (2011) concluded that the expression level of α_1-AR subtype mRNA in the prostate could be a predictor of the efficacy of subtype-selective α_1-AR antagonists in patients with BPH and suggested that genetic differences were responsible for the diverse responses to the drugs.

Silodosin (KD-3213), which has a high selectivity for α_{1A}-ARs (Lepor and Hill, 2010; Tatemichi et al., 2006a, 2006b; Yoshida et al., 2011), had clinically good effects on both voiding and storage symptoms in men with BPH (Chapple et al., 2011; Kawabe et al., 2006; Marks et al., 2009a, 2009b; Montorsi et al., 2016; Morganroth et al., 2010; Novara et al 2013; Yoshida et al., 2007, 2011). Chapple et al. (2011) conducted a multicenter double-blind, placebo- and active-controlled parallel group study comparing silodosin, tamsulosin, and placebo. A total of 1228 men 50 years of age and older, with an IPSS of 13 or higher and a urine maximum flow rate (Qmax) greater than 4 and less than or equal to 15 mL/sec, were selected at 72 sites in 11 European countries. The patients were entered into a 2-week washout and a 4-week placebo run-in period. A total of 955 patients were randomized (2 : 2 : 1) to silodosin 8 mg ($n = 381$), tamsulosin 0.4 mg ($n = 384$), or placebo ($n = 190$) once daily for 12 weeks. Its overall efficacy was not inferior to tamsulosin. Only silodosin showed a significant effect on nocturia over placebo. There was no significant difference among the two α_1-AR antagonists and the placebo in terms of Qmax. There was also no difference between the two α-AR antagonists for the QoL parameter, although both were better than the placebo. Active treatments were well tolerated, and discontinuation rates resulting from adverse events were low in all groups (2.1%, 1.0%, and 1.6% with silodosin, tamsulosin, and placebo, respectively). The most frequent adverse event with silodosin was a reduced or absent ejaculation during orgasm (14%), a reversible effect as a consequence of the potent and selective α_{1A}-AR antagonism of the drug. The incidence was higher than that observed with tamsulosin (2%); however, only 1.3% of silodosin-treated patients discontinued treatment because of this adverse event. Silodosin treatment improved DO and obstruction grade by decreasing detrusor opening pressure, detrusor pressure at Qmax, BOO Index score, and Schafer obstruction class significantly (Yamanishi et al., 2009). In a different open, nonblinded prospective study, silodosin 8 mg led to a significant increase in bladder capacity at first desire to void with no significant change in maximum cystometric capacity. In the voiding phase, mean detrusor pressure at maximum flow significantly decreased, mean BOO Index score decreased significantly, and obstruction grade as assessed by the Schaefer nomogram improved significantly (Matsukawa et al., 2009).

It thus seems that **selective blockade of α_{1A}-ARs is a clinically effective approach,** and silodosin is an effective and well-tolerated treatment for the relief of both voiding and storage symptoms in male patients with LUTS, even if treatment is associated with a high incidence of ejaculatory dysfunction.

Interest has also been focused on the α_1-ARs (α_{1D}), specifically in the bladder (Schwinn and Roehrborn, 2008; Schwinn et al., 2004), on the assumption that these receptors were responsible for storage symptoms. However, **the interrelationship between the α_{1D}-ARs in the human detrusor smooth muscle and the pathophysiology of LUTS is unclear.** Naftopidil was shown to significantly improve the OABSS (Sakai et al., 2011) and urgency episodes (Yokoyama et al., 2009). Ikemoto et al. (2003) gave tamsulosin and naftopidil to 96 patients with BPH for 8 weeks in a crossover study. Whereas naftopidil monotherapy decreased the IPSS for storage symptoms, tamsulosin monotherapy decreased the IPSS for voiding symptoms. However, this difference (which was suggested to depend on differences in affinity for α_1-AR subtypes between the drugs) could not be reproduced in a randomized head-to-head comparison between the drugs (Gotoh et al., 2005). Based on available evidence, it therefore cannot be concluded that the α_{1D}-ARs on the detrusor smooth muscle are the main therapeutic target. However, α_{1D}-ARs may have effects on different locations in the bladder aside from the detrusor smooth muscle: the detrusor vasculature, the urothelium, and the afferent and efferent nerve terminals and intramural ganglia (Andersson and Gratzke, 2007; Moro et al., 2013; Yamada and Ito, 2011). The importance and functional role of this observation remain to be established.

In women, treatment of OAB symptoms with α_1-AR antagonists seems to be ineffective. In an RCT including 364 women with OAB, no effect of tamsulosin versus placebo could be demonstrated (Robinson et al., 2007). On the other hand, voiding symptoms in women with functional outflow obstruction or LUTS were treated (with modest success) with an α_1-AR antagonist (Kessler et al., 2006; Low et al., 2008). **It should be remembered that in women, these drugs may produce stress incontinence** (Dwyer and Teele, 1992).

In patients with NDO, treatment with α_1-AR antagonists was moderately successful (Abrams et al., 2003).

β-Adrenoceptor Agonists

Background.

The three cloned subtypes of β-ARs (β_1, β_2, and β_3) have been identified in the detrusor of most species, including humans (Andersson and Arner, 2004; Michel and Vrydag, 2006). In addition, the human urothelium contains all three receptor subtypes (Otsuka et al., 2008). Studies using real-time reverse transcription polymerase chain reaction (RT-PCR) have revealed a predominant expression of β3-AR mRNA in human detrusor muscle (Igawa et al., 2010; Michel and Vrydag, 2006; Nomiya and Yamaguchi, 2003), and the functional evidence for an important role in both normal and neurogenic bladders is convincing (Biers et al., 2006; Fujimura et al., 1999; Igawa et al., 1999, 2001, 2010; Leon et al., 2008; Michel and Vrydag, 2006; Morita et al., 2000; Takeda et al., 1999;). The human detrusor also contains β_2-ARs, and most likely both receptors are involved in the physiologic effects (relaxation) of noradrenaline (NA) in this structure (Andersson and Arner, 2004; Igawa et al., 2010; Michel and Vrydag, 2006).

The generally accepted mechanism by which β-ARs induce detrusor relaxation in most species is activation of adenylyl cyclase with the subsequent formation of cAMP. However, there is evidence suggesting that in the bladder, K^+ channels, particularly BK_{Ca} channels, may be more important in β-AR–mediated relaxation than cAMP (Frazier et al., 2005, 2008; Hudman et al., 2000; Uchida et al., 2005). However, other mechanisms of action cannot be excluded (Andersson, 2017). Stimulation of β_3-AR inhibits spontaneous contractile activity in the detrusor (in vitro: microcontractions; in vivo: nonvoiding contractions) and reduces bladder afferent activity (Aizawa et al., 2012; Biers et al., 2006; Gillespie et al., 2012; Hatanaka et al., 2013; Igawa and Michel, 2013; Takasu et al., 2007). Spontaneous contractile detrusor activity may be a source of increased afferent activity. Aizawa et al. (2012) showed that the β_3-AR agonist mirabegron could inhibit filling-induced activity in both mechanosensitive Aδ- and C-fiber primary bladder afferents of the rat bladder. Gillespie et al. suggested that effects on neither spontaneous microcontractions nor on nonvoiding contractions (e.g., in obstructed rats) can fully explain the effects of mirabegron (Eastham and Gillespie, 2013; Gillespie et al., 2015a,b; Granato et al., 2015). Assuming that spontaneous release of ACh from cholinergic terminals during bladder filling stimulates spontaneous contractile activity, the finding that activation of prejunctional β_3-ARs may downregulate ACh release may be of importance (Andersson, 2017; D'Agostino et al., 2015; Rouget et al., 2014).

Because β-ARs are present in the urothelium, their possible role in bladder relaxation has been investigated (Murakami et al., 2007; Otsuka et al., 2008). However, to what extent a urothelial signaling pathway contributes in vitro and in vivo to the relaxant effects of β-AR agonists in general, and β_3-AR agonists specifically, remains to be elucidated.

The in vivo effects of β_3-AR agonists on bladder function have been studied in several animal models. It has been shown that compared with other agents (including antimuscarinics**)**, **β_3-AR agonists increase bladder capacity with no change in micturition pressure and the residual volume** (Fujimura et al., 1999; Igawa et al., 2010; Kaidoh et al., 2002; Takeda et al., 2002; Woods et al., 2001). For example, Hicks et al. (2007) studied the effects of the selective β_3-AR agonist GW427353 in the anesthetized dog and found that the drug evoked an increase in bladder capacity under conditions of acid-evoked bladder hyperactivity, without affecting voiding.

There have been some reports that β_3-AR agonists (e.g., mirabegron) may have effects that are off-target (Dehvari et al., 2018) or not related to β_3-AR stimulation (e.g., relaxing effects on urethral α-ARs) (Alexandre et al., 2016) or non–β_3-AR–mediated cardiac effects (Mo et al., 2017). However, it seems unlikely that these pharmacologic effects demonstrated in vitro have any clinical relevance (Andersson 2016; 2017).

Clinical Use.

The selective β_3-AR agonist mirabegron has been approved for treatment of OAB in Japan (Betanis), the United States (Myrbetriq), and Europe (Betmiga), and its properties and clinical effects have been extensively reviewed (Andersson et al., 2013b; Bridgeman et al., 2013; Chapple et al., 2014b; Sacco and Bientinesi, 2012; Sebastianelli et al., 2018). There are proof-of-concept studies for other β_3-AR selective agonists such as solabegron and ritobegron (Igawa and Michel, 2013, see later). However, the development of ritobegron has been ceased because it failed to reach the primary efficacy end point in phase III studies.

Mirabegron

Pharmacokinetics.

Mirabegron is **rapidly absorbed** after oral administration. It circulates in the plasma as the unchanged form, its glucuronic acid conjugates and other metabolites, **the metabolites being inactive** (Takusagawa et al., 2012b). Of the administered dose, **55% is excreted in urine, mainly as the unchanged form, and 34% is recovered in feces,** almost entirely as the unchanged form. **Mirabegron is highly lipophilic and is metabolized in the liver via multiple pathways,** mainly by cytochrome P450 3A4 and 2D6 (CYP3A4, CYP2D6) (Takusagawa et al., 2012a,c). It may therefore be subject to clinically relevant drug-drug interactions and should be used with caution in patients who are taking ketoconazole or other potent CYP3A4 inhibitors.

Tmax in both extensive and poor metabolizers was about 2 hours, and the terminal elimination half-life was approximately 23 to 25 hours (Eltink et al., 2012; Krauwinkel et al., 2012).

Efficacy.

Several phase II RCTs have shown that in OAB patients mirabegron consistently improved mean number of micturitions in 24 hours and number of continence episodes in 24 hours (Chapple et al., 2013a, 2013b, 2013c). Mirabegron was further evaluated in three pivotal phase III, 12-week RCTs in patients with OAB symptoms of UUI, urgency, and urinary frequency (Herschorn et al., 2013; Khullar et al., 2013; Nitti et al., 2013a). These trials had basically similar design. Entry criteria required that patients had symptoms of OAB for at least 3 months' duration, at least eight micturitions per day, and at least three episodes of urgency with or without incontinence over a 3-day period. The majority of patients were Caucasian (94%) and female (72%), with a mean age of 59 years (range 18 to 95 years).

In the study by Nitti et al. (2013a), 1329 patients were randomized to receive placebo or mirabegron 50 or 100 mg once daily for 12 weeks. **Coprimary end points were change from baseline to final visit (study end) in the mean number of incontinence episodes per 24 hours and micturitions per 24 hours.** At the final visit, mirabegron 50 and 100 mg showed **statistically significant improvements in the coprimary efficacy end points and MVV per micturition compared with placebo.**

Khullar et al. (2013) performed a similarly designed study enrolling 1978 patients. The study included a fourth arm in which tolterodine SR 4 mg was used as a comparator. As in the study by Nitti et al. (2013a), it was found that mirabegron caused a statistically significant improvement from baseline compared with placebo in the number of urgency incontinence episodes and number of micturitions per 24 hours. Mirabegron 50 and 100 mg were statistically superior to placebo, whereas tolterodine was not, in these two key OAB symptoms, but the study was not powered for head-to-head evaluation.

In a third phase III study in which Herschorn et al. (2013) evaluated the effects of 25 and 50 mg of mirabegron, both doses were associated with significant improvements in efficacy measures of incontinence episodes and micturition frequency.

Nitti et al. (2013c) reported on the effects of mirabegron on maximum urinary flow rate and detrusor pressure at maximum flow rate in a urodynamic safety study on male patients with BOO and LUTS. Two hundred men with OAB symptoms and a BOO Index score above 20 were randomized to receive placebo, mirabegron 50 mg, or mirabegron 100 mg once daily for 12 weeks. Mirabegron did not adversely affect flow rate, detrusor pressure at maximum flow rate, or bladder contractile index and was well tolerated.

Otsuki et al. (2013) reported on the efficacy and safety of mirabegron in a predominantly male population of OAB patients. In this prospective, nonrandomized, controlled study, patients with at least one episode of urgency per week and scoring at least 2 for urinary urgency in the OABSS were enrolled. Fifty-two patients (36 men) with newly diagnosed OAB received mirabegron 50 mg once daily; 45 patients (36 men) with OAB refractory to antimuscarinics switched to mirabegron; and another 27 patients (18 men) with newly diagnosed

OAB received antimuscarinics and served as controls. Patients on a stable α_1-AR blocker dose for treatment of LUTS were allowed in the study, but those with a PVR greater than 100 mL were excluded. Mirabegron achieved significant improvements in all efficacy outcomes (OABSS and IPSS). In patients with newly diagnosed OAB, improvements were not significantly different to those achieved by antimuscarinics. Mirabegron was well tolerated and did not significantly change PVRs. However, these encouraging results for mirabegron in treating male OAB should be interpreted with caution in view of the limitations of the study, which included small patient numbers, lack of randomization, and a suboptimal treatment period for the indication.

In a study by Chapple et al. (2013c) assessing the 12-month safety and efficacy of mirabegron, tolterodine was used as an active control. There were no significant differences in efficacy between drugs. However, whether mirabegron has similar efficacy to antimuscarinics awaits direct comparison studies. Mirabegron seems to have definite advantages over the antimuscarinics with respect to adverse events. Dry mouth and constipation are essentially nonexistent in comparison to placebo (Chapple et al., 2013a, 2013b, 2013c, 2014; Cui et al., 2014; Rossanese et al., 2015).

Mirabegron 50 mg and solifenacin 5 mg were recently compared in OAB patients who were dissatisfied with previous antimuscarinic treatment. The BEYOND study (Batista et al., 2015) was a randomized, double-blind, phase IIIb, noninferiority study that enrolled male and female patients 18 years of age and older, with symptoms of OAB for 3 months or longer, who were dissatisfied with their previous antimuscarinic drug because of lack of efficacy.

Tolerability and Adverse Effects.

In a proof-of-concept study of mirabegron 100 and 150 mg bid (Chapple et al., 2013a)**, adverse events were experienced by 45.2% of the patients—the incidence was similar among those treated with placebo (43.2%) and mirabegron (43.8% to 47.9%). The most commonly reported adverse events considered to be treatment related were gastrointestinal disorders,** including constipation, dry mouth, dyspepsia, and nausea. There was **no patient-reported acute retention.** No significant difference in ECG parameters between the groups was demonstrated. However**, a small but significant increase in mean pulse rate was observed after mirabegron 100 mg and 150 mg (1.6 and 4.1 beats/min, respectively), although this was not associated with an increase in cardiovascular adverse events in this study.** The overall discontinuation rate resulting from adverse events was 3.2% (placebo 3.0% vs. mirabegron 2.4% to 5.3%).

In the study by Khullar et al. (2013), the incidence of adverse effects was similar across the placebo and mirabegron 50- and 100-mg groups (50.1%, 51.6%, and 46.9%, respectively). The most common (≥3%) adverse effects in any treatment group were hypertension (6.6%, 6.1%, and 4.9%, respectively), urinary tract infection (1.8%, 2.7%, and 3.7%), headache (2.0%, 3.2%, and 3.0%), and nasopharyngitis (2.9%, 3.4%, and 2.5%). The incidence of dry mouth was similar in the placebo and mirabegron groups (2.6% vs. 2.8%) and lower than observed in patients receiving tolterodine SR (10.1%). The incidence of constipation was similar in all treatment groups (placebo, 1.4%; mirabegron, 1.6%), including tolterodine (2.0%).

In the **12-month safety and efficacy study** of mirabegron referred to previously, the incidence and severity of treatment-emergent and serious adverse effects (primary outcome parameters) were similar across the mirabegron 50-mg (59.7%), mirabegron 100-mg (61.3%), and tolterodine SR 4-mg (62.6%) groups (Chapple et al., 2013c). **The most frequent treatment-emergent adverse events (TEAEs) were hypertension, constipation, and headache,** which occurred at a similar incidence across all treatment groups; the incidence of dry mouth was more than threefold lower compared with the tolterodine SR 4-mg group (Chapple et al., 2013c).

One concern with the use of β_3-AR agonists has been the possibility of negative cardiovascular effects. In healthy subjects, mirabegron (50 to 300 mg/day for 10 days) increased **blood pressure** in a dose-dependent manner (Mirabegron prescribing information, 2012). However, in the studies on OAB patients, the mean increase (compared with placebo) in systolic and diastolic blood pressure after therapeutic doses of mirabegron once daily was approximately 0.5 to 1 mm Hg and was reversible on discontinuation of treatment.

In a study of healthy volunteers, mirabegron increased HR and systolic blood pressure and reduced stroke volume, whereas cardiac output and diastolic blood pressure were unaffected (van Gelderen et al., 2017). The data indicated that mirabegron has a positive chronotropic effect at supratherapeutic concentrations, which is at least partly mediated by stimulation of β_1-AR.

Mirabegron increased HR in a dose-dependent manner. Maximum mean increases in HR from baseline for the 50-mg, 100-mg, and 200-mg dose groups compared with placebo were 6.7 beats/min, 11 beats/min, and 17 beats/min, respectively (van Gelderen et al., 2017). However, in the clinical efficacy and safety studies, the change from baseline in mean pulse rate for mirabegron 50 mg was approximately 1 beat/min and reversible on discontinuation of treatment.

The cardiac safety of mirabegron was evaluated in a thorough QT/QTc (HR-corrected QT interval) study, including supratherapeutic dose. This was a randomized, placebo- and active- controlled (moxifloxacin 400 mg), four–treatment-arm, parallel crossover study (Malik et al., 2012), and the design followed the recommendations of the International Conference on Harmonisation (ICH). Equal numbers of men and women were enrolled in each treatment group, and the pharmacokinetic and pharmacodynamic analyses included 333 and 317 subjects, respectively. The effect of multiple doses of mirabegron 50 mg, 100 mg, and 200 mg once daily on QTc interval was studied, and according to ICH E14 criteria, mirabegron **did not cause QTcI prolongation at the 50-mg therapeutic and 100-mg supratherapeutic doses in patients of either sex**. Mirabegron prolonged QTcI interval at the 200-mg supratherapeutic dose (upper one-sided 95% CI >10 msec) in women, but not in men.

Even if the cardiovascular effects of mirabegron observed in clinical studies have been minimal and clinically not relevant, effects on HR and blood pressure need to be monitored when the drug is prescribed and patients with cardiovascular morbidities are treated.

New Developments

Thiagamoorthy et al. (2015) reviewed “novel and putative” β_3-AR agonists for management of OAB, including CL-316243, TRK-380, AJ-9677, and BRL37344. Another agent, vibegron, was claimed to have an overall superior preclinical profile compared with MK-0634, which was discontinued because of unacceptable structure-based toxicity in preclinical species (Edmonson et al., 2016). Vibegron is a potent, selective full β_3-AR agonist across species, and it dose-dependently increased bladder capacity, decreased micturition pressure, and increased bladder compliance in rhesus monkeys (Di Salvo et al., 2017). The relaxation effect of vibegron was enhanced when combined with muscarinic antagonists, but differentially influenced by muscarinic receptor subtype selectivity. The effect was greater when vibegron was coadministered with tolterodine, a nonselective antagonist, compared with coadministration with darifenacin, a selective M_3-receptor antagonist. Furthermore, a synergistic effect for bladder strip relaxation was observed with the combination of a β_3-AR agonist and tolterodine in contrast with simple additivity with darifenacin. The authors speculated that a combination of β_3-AR agonists with M_2/M_3 antimuscarinics has the potential to redefine the standard of care for the pharmacologic treatment of overactive bladder. Even if these agents have been reported as being in development, no clinical data have been published, and it may be questioned whether any of them can be regarded as “novel and putative.” Phase II and III randomized, double blind, placebo-controlled studies of ritobegron in patients with OAB have been initiated and completed, but the results have not been published, and it seems that that the primary efficacy end point of the studies was not met. No new clinical trials with ritobegron seem to have been initiated.

Efficacy and safety of solabegron (GW427353) have been reported in a phase II multicenter, randomized, proof-of-concept trial in 258 women with wet OAB. The drug produced a statistically significant difference in percent change from baseline to week 8 in incontinence episodes over 24 h (primary outcome) when compared with placebo ($P = 0.025$) and was well tolerated (Ohlstein et al., 2012).

There seems to be a number of β_3-AR agonists in the pipeline, some of which are under development. However, it is uncertain which, if any, will come to market and be available for the management of OAB.

Phosphodiesterase Inhibitors

Drugs stimulating the generation of cAMP are known to relax smooth muscles, including the detrusor (Andersson and Wein, 2004; Andersson et al., 1999)**. It is also well established that drugs acting through the nitric oxide (NO)/cyclic guanosine monophosphate (cGMP) system can relax the smooth muscle of the bladder outflow region** (Andersson and Arner, 2004)**. Use of PDE inhibitors to enhance the presumed cAMP- and cGMP-mediated relaxation of LUT smooth muscles (detrusor, prostate, urethra) should then be a logical approach** (Andersson, 2011c; Andersson et al., 2007; Ückert et al., 2013). There are presently 11 families of PDEs, some of which preferentially hydrolyze either cAMP or cGMP (Rahnama'i et al., 2013; Uckert et al., 2006).

As a basis for PDE inhibitor treatment of LUTS, Uckert et al. (2006) investigated human bladder tissue, revealing mRNA for PDE types 1A, 1B, 2A, 4A, 4B, 5A, 7A, 8A, and 9A; most of these PDE types preferably inhibit the breakdown of cAMP. In vitro, human detrusor muscle responded poorly to sodium nitroprusside and to agents acting via the cGMP system (Truss et al., 2000). However, significant relaxation of human detrusor muscle, paralleled by increases in cyclic nucleotide levels, was induced by papaverine, vinpocetine (a low-affinity inhibitor of PDE type 1 [PDE1]), and forskolin (stimulating the generation of cAMP), suggesting that the cAMP pathway and PDE1 may be important in regulation of detrusor smooth muscle tone (Truss et al., 2001). Significant dose-dependent relaxations were also induced by human cAMP analogues (Truss et al., 2001). With these studies as a background, Truss et al. (2000) presented preliminary clinical data for vinpocetine in patients with urgency and urgency incontinence or low-compliance bladders who were not responding to standard antimuscarinic therapy. This initial open pilot study suggested a possible role for vinpocetine in the treatment of OAB. However, the results of a larger RCT in patients with DO showed that vinpocetine only showed statistically significant results for one parameter (Truss et al., 2001). Studies with PDE1 inhibitors other than vinpocetine (which may not be an optimal drug for elucidation of the principle) do not seem to have been performed.

PDE4 (which also preferably hydrolyzes cAMP) has been implicated in the control of bladder smooth muscle tone. PDE4 inhibitors reduced the in vitro contractile response of guinea pig (Longhurst et al., 1997) and rat (Kaiho et al.,

2008) bladder strips and also suppressed rhythmic bladder contractions of the isolated guinea pig and rat bladder (Gillespie and Drake, 2004; Nishiguchi et al., 2007). Previous experiences with selective PDE4 inhibitors showed emesis to be a dose-limiting effect (Giembycz, 2005). If this side action can be avoided, PDE4 inhibition seems to be a promising approach.

Oger et al. showed that the PDE5 inhibitor sildenafil–induced relaxation of human detrusor smooth muscle involved cGMP-, cAMP- and K^+ channel–dependent signaling pathways, with a minor contribution from NO (Oger et al., 2010). In combination with the α_1-AR antagonist doxazosin, sildenafil reduced adrenergic tone of prostatic and cavernosal smooth muscle, and their combination provided a significant benefit when targeting relaxation of both tissues (Oger et al., 2008).

In vivo, several studies have indicated a role for PDE5 inhibitors in the regulation of micturition function. Systemic vardenafil reduced both nonvoiding contractions and bladder afferent nerve firing in unanesthetized, decerebrate, spinal cord–injured rats, indicating potential mechanisms by which PDE5 inhibitors improve storage symptoms in SCI patients (Behr-Roussel et al., 2010). The effect of vardenafil on OAB symptoms could be related to a cGMP-dependent RhoA/ROCK signaling inhibition, as shown in spontaneously hypertensive rats (Morelli et al., 2009a, 2009b). Using the same animal model, bladder hypoxia was significantly reduced by acute vardenafil treatment (Morelli et al., 2009b). Thus, in addition to relaxing muscular wall, PDE5 inhibition may positively affect urinary bladder blood perfusion. In the same respect, tadalafil was shown to increase prostate tissue oxygenation in spontaneously hypertensive rats, and human vesicular-deferential artery is characterized by a high expression and activity of PDE5, which was inhibited by tadalafil in vitro; these results suggest another possible mechanism through which PDE5 inhibitors exert beneficial effects on LUTS (Morelli et al., 2011).

NO has been demonstrated to be an important inhibitory neurotransmitter in the smooth muscle of the urethra, and its relaxant effect is associated with increased levels of cGMP (Andersson and Arner, 2004). However, few investigations have addressed the cAMP- and cGMP-mediated signal transduction pathways and the key enzymes of the cGMP system in the mammalian urethra. Morita et al. (1994) examined the effects of isoproterenol, prostaglandin E_1 (PGE_1), and PGE_2, and sodium nitroprusside on the contractile force and tissue content of cAMP and cGMP in the rabbit urethra. They concluded that both cyclic nucleotides can produce relaxation of the urethra.

Werkström et al. (2006) characterized the distribution of PDE5, cGMP, and protein kinase PKG1 in female pig and human urethra and evaluated the effect of pharmacologic inhibition of PDE5 in isolated smooth muscle preparations. After stimulation with the NO donor, DETA NONOate, the cGMP immunoreactivity in urethral and vascular smooth muscles increased. There was a wide distribution of cGMP- and vimentin-positive interstitial cells between pig urethral smooth muscle bundles. PDE5 immunoreactivity could be demonstrated within the urethral and vascular smooth muscle cells, but also in vascular endothelial cells that expressed cGMP immunoreactivity. Nerve-induced relaxations of urethral preparations were enhanced at low concentrations of sildenafil, vardenafil, and tadalafil, whereas there were direct smooth muscle relaxant actions of the PDE5 inhibitors at high concentrations. Fibbi et al. (2009) confirmed that the highest expression and biologic activity of PDE5 was found in the bladder. However, consistent PDE5 expression and activity were also found in prostatic urethra. In contrast, the prostate gland showed the lowest PDE5 abundance, and cultures derived from this tissue were less sensitive to vardenafil. Using a different animal model associated with C-fiber afferent activation, it was shown that the NO/cGMP signaling pathway is involved in the regulation of the micturition reflex, with an action that seems more predominant on the sensory rather than on the motor component of the micturition reflex (Caremel et al., 2010).

The observation that patients treated for erectile dysfunction (ED) with PDE5 inhibitors had an improvement of their LUTS has sparked a new interest in using these drugs also for treatment of LUTS and OAB. After the report in an open study that treatment with sildenafil appeared to improve urinary symptom scores in men with ED and LUTS (Sairam et al., 2002), this observation has been confirmed in several well-designed and well-conducted RCTs.

To date, several RCTs have been published comparing the effect of PDE5 inhibitors alone with placebo, and the combination of α_1-AR antagonists and PDE5 inhibitors versus α_1-AR antagonists alone (Andersson et al., 2017; Bechara et al., 2008; Gacci et al., 2012, 2016; Kaplan et al., 2007; Liguori et al., 2009; McVary et al., 2007a, 2007b; Porst et al., 2009, 2011; Roehrborn et al., 2008b; Stief et al., 2008; Tamimi et al., 2010; Tuncel et al., 2010). In these studies, different PDE5 inhibitors and different doses were administered.

PDE5 inhibitors significantly improve IPSS and International Index of Erectile Function (IIEF) scores, but not Qmax, when compared with placebo. According to a recent meta-analysis by Gacci et al. (2012), differences in IPSS score were significantly lower in older and obese patients. The combination of PDE5 inhibitors and α-blockers led to significant improvements in IPSS and IIEF scores and in Qmax when compared with the use of α-blockers alone. Dmochowski showed that tadalafil once daily for LUTS had no significant effect on bladder function as measured by detrusor pressure at maximum urinary flow rate or maximum detrusor pressure and BOO Index score while improving IPSS (Dmochowski et al., 2010b). PDE5 inhibitors were shown to be generally safe and well tolerated.

The mechanism behind the beneficial effect of the PDE inhibitors on LUTS and OAB and their site(s) of action largely remain to be elucidated (Andersson et al., 2011b; Giuliano et al., 2013). If the site of action were the smooth muscles of the outflow region (and the effect relaxation), an increase in flow rate should be expected. No such effect was found in urodynamic studies (Dmochowski et al., 2010b, 2013). However, there are several other structures in the LUT that may be involved, including those in the urothelial signaling pathway (urothelium, interstitial cells, and suburothelial afferent nerves). In general, it is believed that major mechanisms contributing to LUTS include reduced NO/cGMP signaling pathway, increased RhoA-kinase pathway activity, autonomic overactivity, increased bladder afferent activity, and pelvic ischemia (Andersson et al., 2011b). Nomiya et al. (2013) found in a rat model of chronic bladder ischemia that tadalafil had a marked protective effect, preventing both functional and morphologic bladder changes induced by progressive ischemia. This is in line with the proposal by Cellek et al. (2013) linking the effectiveness of PDE5 inhibitors on BPH and LUTS (and ED) to microvascular dysfunction within the pelvic organs. They suggested that a combination of endothelial and neural dysfunction may lead to a vicious cycle of hypoxia, vasoconstriction, altered smooth muscle contractility, and degeneration of autonomic neurons and ganglia.

It has to be mentioned that **as of the time of this writing, only tadalafil has been approved for the treatment of LUTS caused by benign prostatic obstruction (BPO);** long-term experience with PDE5 inhibitors in patients with LUTS is still lacking (Oelke et al., 2014). In addition, insufficient information is available on the combination of PDE5 inhibitors with other LUTS medications such as 5α-reductase inhibitors.

Antidepressants

Some clinicians believe that tricyclic antidepressants, particularly

imipramine (Tofranil, others), are useful agents for facilitating urine storage, both by decreasing bladder contractility and increasing outlet resistance (Wein, 1995a, 1995b). These agents have been the subject of a voluminous amount of highly sophisticated pharmacologic investigation to determine the mechanisms of action responsible for their varied effects (Baldessarini, 2006; Maggi et al., 1989a; Richelson, 1994). Most data have been accumulated as a result of trying to explain the antidepressant properties of these agents and are thus primarily from CNS tissue. The results, conclusions, and speculations inferred from the data are extremely interesting, but it should be emphasized that it is essentially unknown whether they apply to or have relevance for the LUT.

Tricyclic antidepressants possess varying degrees of at least three major pharmacologic actions: (1) They have central and peripheral antimuscarinic effects at some, but not all, sites; (2) they block the active transport system in the presynaptic nerve ending that is responsible for the reuptake of the released amine neurotransmitters norepinephrine and serotonin; and (3) they are sedatives, an action that occurs presumably on a central basis but is perhaps related to antihistaminic properties (at H_1 receptors, although they also antagonize H_2 receptors to some extent). There is also evidence that they desensitize at least some α_2- and some β-ARs. Paradoxically, they also have been shown to block some α-ARs and 5-HT_1 receptors.

Several antidepressants have been reported to have beneficial effects in patients with DO (Lose et al., 1989; Martin and Schiff, 1984). **However, the use of antidepressants was shown to be an independent risk factor for LUTS suggestive of BPH in a community-based population of healthy aging men** (Kok et al., 2009). In a prospective trial, and in total, 205 consecutive female patients (113 patients taking antidepressants for various disorders and 92 healthy controls), Albayrak et al. (2015) found that the prevalence of OAB was significantly higher in antidepressant users (64%) than in the control group (33%) ($P = 0.003$). They suggested that because each SSRI and SNRI has a unique pharmacologic profile, this could explain the opposing reports in the literature.

Imipramine.

Imipramine is the only drug that has been widely used clinically to treat storage symptoms. Imipramine has complex pharmacologic effects, including marked systemic antimuscarinic actions (Baldessarini, 2006) and blockade of the reuptake of serotonin and noradrenaline (Maggi et al., 1989b), but its mode of action in DO has not been established (Hunsballe and Djurhuus, 2001). **Even if it is considered that imipramine is a useful drug in the treatment of DO, no good-quality RCTs that can document this have been retrieved.** It has been known for a long time that imipramine can have favorable effects in the treatment of nocturnal enuresis in children, with a success rate of 10% to 70% in controlled trials (Glazener et al., 2003; Hunsballe and Djurhuus, 2001). It is well established that therapeutic doses of tricyclic antidepressants, including imipramine, may cause serious toxic effects on the cardiovascular system (orthostatic hypotension, ventricular arrhythmias). Imipramine prolongs QTc intervals and has an antiarrhythmic (and proarrhythmic) effect similar to that of quinidine (Bigger et al., 1977; Giardina et al., 1979). Children seem particularly sensitive to the cardiotoxic action of tricyclic antidepressants (Baldessarini, 2006). The risks and benefits of imipramine in the treatment of voiding disorders do not seem to have been assessed. Very few studies have been performed during the past decade (Hunsballe and Djurhuus, 2001; Natalin et al., 2009). No good-quality RCTs have documented that the drug is effective in the treatment of DO. However, a beneficial effect has been documented in the treatment of nocturnal enuresis.

A prospective (no controls) study of the impact of the “three-drug therapy” (antimuscarinic, α-blocker, and tricyclic antidepressants) on refractory DO showed a significant increase in bladder capacity and decreases in urgency, urgency incontinence, and frequency. Objective urodynamic data and symptom score improved significantly with triple therapy (Natalin et al., 2009).

In a retrospective study, Hillelsohn et al. (2014) evaluated 43 patients who were treated with desipramine for OAB refractory to antimuscarinic therapy. Twelve patients (28%) discontinued desipramine, 9 because of perceived lack of efficacy. Still, the authors concluded that desipramine is a potential useful treatment for patients with OAB symptoms (e.g., those with pain). To confirm any useful effect of desipramine, RCTs are needed.

Doxepin.

Doxepin is another tricyclic antidepressant that was found to be more potent, using in vitro rabbit bladder strips, than other tricyclic compounds with respect to antimuscarinic and musculotropic relaxant activity (Levin and Wein, 1984). In a randomized, double-blind crossover study of women with involuntary bladder contractions and frequency, urgency, or urgency incontinence, Lose et al. (1989) found that this agent caused a significant decrease in urine loss (pad-weighing test) and in the cystometric parameters of first sensation and maximal bladder capacity. The dose of doxepin used was either a single 50-mg bedtime dose or this dose plus an additional 25 mg in the morning. The number of daytime incontinence episodes decreased in both doxepin and placebo groups, and the difference was not statistically significant. Doxepin treatment was preferred by 14 patients, whereas 2 preferred placebo. Three patients had no preference. Of the 14 patients who stated a preference for doxepin, 12 claimed that they became continent during treatment, whereas 2 claimed improvement; the 2 patients who preferred placebo claimed improvement. The Agency for Health Care Policy and Research (AHCPR) guidelines combine results for imipramine and doxepin, citing only three RCTs, with an unknown percent of female patients. Percent cures (all figures refer to percent drug effect minus percent effect on placebo) are listed as 31%, percent reduction in urgency incontinence as 20% to 77%, and percent side effects as 0% to 70% (AHCPR, 1992).

Milnacipran Hydrochloride and Paroxetine Hydrochloride.

Milnacipran hydrochloride, a serotonin-norepinephrine reuptake inhibitor (SNRI), and *paroxetine hydrochloride,* a selective serotonin reuptake inhibitor (SSRI), were analyzed in a prospective open trial in neurogenic OAB patients (Sakakibara et al., 2008). Milnacipran reduced daytime urinary frequency, improved the QoL index score, and increased bladder capacity as shown in urodynamic studies. No such changes were noted in the other categories of the LUTS questionnaire or urodynamic studies, or in the paroxetine group.

Duloxetine.

Duloxetine is a noradrenaline-serotonin reuptake inhibitor that has been shown to significantly increase sphincteric muscle activity during the filling and storage phase of micturition in the cat acetic acid model of irritated bladder function (Katofiasc et al., 2002; Thor and Katofiasc, 1995). **Bladder capacity was also increased in this model,** with both effects mediated centrally through both motor efferent and sensory afferent modulation (Fraser et al., 2003). The effects of duloxetine were studied in a placebo-controlled trial of 306 women (21 to 84 years of age) with OAB who were randomly treated with placebo (153) or duloxetine (80 mg/day for 4 weeks, which was increased to 120 mg/day for 8 weeks) (Steers et al., 2007). The primary efficacy analysis compared the treatment effects on mean change from baseline to end point in the mean number of voiding episodes per 24 hours. **Patients randomized to duloxetine had significant improvements over those randomized to placebo for decreases in voiding and incontinence episodes (−1.81 vs. −0.62), for increases in daytime voiding intervals (29 vs. 7 minutes), and for improvements in Incontinence Quality of Life (I-QoL) scores at both doses of duloxetine.** Urodynamic studies showed no significant increases in maximum cystometric capacity or in the volume threshold for DO. The most common TEAEs with duloxetine (nausea 31% [placebo 4.6%], dry mouth 16% [placebo 1.3%], dizziness 14% [placebo 0.7%], constipation 14% [placebo 3.3%], insomnia 13% [placebo 1.3%], and fatigue 11% [placebo 2.0%]) were the same as those reported by women with stress urinary incontinence (SUI) (see later) and were significantly more common with duloxetine than placebo. Also, in women with mixed incontinence, improvement of the OAB component has been demonstrated (Bent et al., 2008; Schagen van Leeuwen et al., 2008). For assessment, see Table 120.3.

Side Effects and Cardiovascular Risks.

With the typically larger doses used for antidepressant effects, **the most frequent side effects of the tricyclic antidepressants are those attributable to their systemic antimuscarinic activity** (Baldessarini, 2006; Richelson, 1994). Allergic phenomena, including rash, hepatic dysfunction, obstructive jaundice, and agranulocytosis may also occur, but rarely. CNS side effects may include weakness, fatigue, Parkinsonian effect, a fine tremor noted mostly in the upper extremities, a manic or schizophrenic picture, and sedation, probably from an antihistaminic effect. Postural hypotension may also be seen, presumably on the basis of selective blockade (a paradoxic effect) of α_1-ARs in some vascular smooth muscle. Tricyclic antidepressants can also cause excess sweating of obscure cause and a delay of orgasm or orgasmic impotence, the cause of which is likewise unclear. They can also produce arrhythmias and interact in deleterious ways with other drugs, so caution must be observed in their use in patients with cardiac disease (Baldessarini, 2006). Whether cardiotoxicity will prove to be a legitimate concern in patients receiving the smaller doses (than for treatment of depression) for LUT dysfunction remains to be seen but is a potential matter of concern. Consultation with a patient's internist or cardiologist is always helpful before instituting such therapy in questionable situations. It is well established that **therapeutic doses of tricyclic antidepressants, including**

imipramine, may cause serious toxic effects on the cardiovascular system (orthostatic hypotension, ventricular arrhythmias). Imipramine prolongs QTc intervals and has an antiarrhythmic (and proarrhythmic) effect similar to that of quinidine (Bigger et al., 1977; Giardina et al., 1979). Children seem particularly sensitive to the cardiotoxic action of tricyclic antidepressants (Baldessarini, 2006).

With respect to the potential cardiovascular risks of antidepressant medication, two additional points need to be made. First of all, it may be depression itself that is associated with an increased risk for myocardial infarction, cardiovascular disease, and all-cause mortality (see references in Cohen et al., 2000). Although treatments for depression, including antidepressive medications, are certainly a potential factor underlying this association, the separation from disease association and treatment association is difficult at best. The second point relates to whether there is a difference in this regard between the use of tricyclic antidepressants and SSRIs. Data presented by Cohen et al. suggest that with respect to long-term adverse cardiovascular outcome, there is an association between the use of tricyclic antidepressants but not SSRIs, a conclusion that differs from earlier data, indicating no significant differences in the safety or efficacy of these two groups of agents (AHCPR report, cited by Cohen et al., 2000). As a closing statement on this subject, it should be noted that data in the literature refer to therapeutic doses of these medications for depression and not the smaller (in comparison) doses of imipramine used for the treatment of voiding dysfunction.

The use of imipramine is contraindicated in patients receiving monoamine oxidase inhibitors, because severe CNS toxicity can be precipitated, including hyperpyrexia, seizures, and coma. Some potential side effects of the antidepressants may be especially significant for the elderly, specifically weakness, fatigue, and postural hypotension. Psychotropic drugs in general have been shown to increase the risk for falls and hip fractures in the elderly (Liu et al., 1998). If imipramine or any of the tricyclic antidepressants is to be prescribed for the treatment of voiding dysfunction, the patient should be thoroughly informed of the fact that this is not the usual indication for this drug and that potential side effects exist. Reports of significant side effects (severe abdominal distress, nausea, vomiting, headache, lethargy, and irritability) after abrupt cessation of high doses of imipramine in children would suggest that the drug should be discontinued gradually, especially in patients receiving high doses.

Cyclooxygenase Inhibitors

Human bladder mucosa has the ability to synthesize eicosanoids (Jeremy et al., 1987), and these agents can be liberated from bladder muscle and mucosa in response to different types of trauma (Downie and Karmazyn, 1984; Leslie et al., 1984). Even if prostaglandins cause contraction of human detrusor (Andersson, 1993), **it is still unclear whether prostaglandins contribute to the pathogenesis of DO. More important than direct effects on the bladder muscle may be sensitization of sensory afferent nerves, increasing the afferent input produced by a given degree of bladder filling.** Involuntary bladder contractions can then be triggered at a small bladder volume. If this is an important mechanism, treatment with prostaglandin synthesis inhibitors could be expected to be effective. However, **clinical evidence for this is scarce.**

Cardozo et al. (1980) performed a double-blind, controlled study of 30 women with DO using the prostaglandin synthesis inhibitor flurbiprofen at a dose of 50 mg three times daily. The drug was shown to have favorable effects, although it did not completely abolish DO. There was a high incidence of side effects (43%) including nausea, vomiting, headache, and gastrointestinal symptoms. Palmer (1983) studied the effects of flurbiprofen 50 mg × 4 versus placebo in a double-blind crossover trial in 37 patients with IDO (27% of the patients did not complete the trial). Active treatment significantly increased maximum contractile pressure, decreased the number of voids, and decreased the number of urgent voids compared with baseline. Indomethacin 50 to 100 mg daily was reported to give symptomatic relief in patients with DO compared with bromocriptine in a randomized, single-blind crossover study (Cardozo and Stanton, 1980). The incidence of side effects was high, occurring in 19 of 32 patients. However, no patient had to stop treatment because of side effects.

The few controlled clinical trials on the effects of prostaglandin synthesis inhibitors in the treatment of DO, and the limited number of drugs tested, makes it difficult to evaluate their therapeutic value. No new RCTs on the effects of cyclooxygenase (COX) inhibitors in OAB and DO patients seem to have been published during the past decade.

Although these early clinical studies with nonselective COX inhibitors showed some promise in the treatment of these disorders, the drugs were not further developed for this indication, mainly because of side effects. The interest in the use of selective COX-2 inhibitors was hampered by concerns about long-term cardiovascular toxicity with these drugs.

Key Points: Drugs for Overactive Bladder

- Theoretically, calcium antagonists and potassium channel openers would be attractive methods to inhibit DO and regulate detrusor smooth muscle tone. However, there is no current clinical evidence to support the use of either class of drug in the treatment of bladder dysfunction. The use of α-AR antagonists to treat storage symptoms in men, as distinct from their effect on voiding symptoms, is somewhat unclear. Some studies suggest no effect of commonly used agents, whereas other studies suggest that selective blockade of α_{1A}-ARs is clinically effective, albeit associated with a high incidence of ejaculatory dysfunction. In women, treatment of OAB filling and storage symptoms with α_{1A}-AR antagonists seems ineffective.
- The most recent drug approved for the treatment of OAB is a β_3-AR agonist, mirabegron, which acts both to relax and maintain low detrusor tone during filling and also to inhibit activity in sensory afferents in an animal model. In such a model, these drugs increase bladder capacity but do not change voiding pressure or voiding volume. Clinically, mirabegron, the only such agent currently available, improves OAB symptoms without affecting emptying parameters. The side-effect profile is quite different from that of the antimuscarinic agents, and some concern exists regarding negative cardiovascular effects (blood pressure and HR); in clinical studies, these have been minimal and clinically not relevant, but it has been recommended that these be monitored during treatment.
- There are logical theoretic mechanisms whereby PDE inhibitors should enhance the relaxation of LUT smooth muscle. PDE5 inhibitors have been shown to have beneficial effects on LUTS, including those of OAB, although their site(s) and mechanism(s) remains to be established.
- Although there are theoretic mechanisms by which tricyclic antidepressants, particularly imipramine, should facilitate storage both by decreasing bladder contractility and increasing outlet resistance, there are no good-quality RCTs to adequately test this hypothesis. Duloxetine, primarily a noradrenalin-serotonin reuptake inhibitor, has been shown to increase some significant storage symptoms, but trials directed specifically toward this effect are lacking. Although there are theoretic mechanisms by which prostaglandin synthesis inhibitors could affect filling and storage

symptoms, clinical evidence for this is scarce.

Other Drugs

Dimethyl Sulfoxide.

Dimethyl sulfoxide (DMSO) is a relatively simple, naturally occurring organic compound that has been used as an industrial solvent for many years. It has multiple pharmacologic actions (membrane penetrant, anti-inflammatory, local analgesic, bacteriostatic, diuretic, cholinesterase inhibitor, collagen solvent, vasodilator) and has been used for the treatment of arthritis and other musculoskeletal disorders, usually in a 70% solution. The formulation for human intravesical use is a 50% solution. Sant (1987) has summarized the pharmacology and clinical use of DMSO and has tabulated “good to excellent” results in 50% to 90% of collected series of patients treated with intravesical instillation for interstitial cystitis (Sant, 1987). **However, DMSO has not been shown to be useful in the treatment of NDO or IDO or in any patients with urgency or frequency but without interstitial cystitis.** The subject of interstitial cystitis and its treatment is considered in Chapter 14.

Baclofen.

γ-Aminobutyric acid (GABA) is a ubiquitous inhibitory neurotransmitter in the CNS that can inhibit the micturition reflex at several points along its central pathway (de Groat, 1997; Pehrson and Andersson, 2002). Experimental data suggest the GABAergic system as an interesting target for bladder dysfunction therapy. Baclofen intrathecally attenuated oxyhemoglobin-induced DO, suggesting that the **inhibitory actions of GABA-B–receptor agonists in the spinal cord may be useful for controlling micturition disorders caused by C-fiber activation in the urothelium and/or suburothelium** (Pehrson and Andersson, 2002). In spinal-intact rats, intrathecal application of bicuculline induced detrusor-sphincter dyssynergia (DSD)–like changes, whereas intrathecal application of baclofen induced urethral relaxation during isovolumetric bladder contractions (Miyazato et al., 2008). Miyazato et al. (2008) found signs of hypofunction of the GABAergic system after SCI (glutamate decarboxylase 67 mRNA levels in the spinal cord and dorsal root ganglia were decreased) and showed that activation of GABA-A and GABA-B receptors in the spinal cord inhibited DO, as evidenced by a reduction in nonvoiding contractions. GABA-B–receptor activation preferentially reduced DO before inhibiting voiding contractions, whereas GABA-A–receptor activation inhibited DO and voiding contractions at the same concentration.

As a GABA agonist on GABA-B receptors, baclofen was used orally in IDO patients. However, its efficacy was poor, eventually dictated by the fact that baclofen does not cross the blood-brain barrier (Taylor and Bates, 1979). Baclofen is one of the most effective drugs for the treatment of spasticity after SCI, traumatic or hypoxic brain injury, and cerebral palsy (Ochs, 1993), and *intrathecal* baclofen was shown to be useful in some patients with spasticity and bladder dysfunction (Bushman et al., 1993). Baldo et al. (2000) found a rapid (24 hours) and persistent increment in the volume to first detrusor contraction and of the maximal cystometric capacity, whereas maximal detrusor pressure decreased. At 10 days, the volume to first detrusor contraction had increased from 143 mL to 486 mL. In selected patients with spasticity and bladder dysfunction, intrathecal baclofen seems to be an effective therapy.

Combinations

α_{1A}-AR Antagonists With Antimuscarinics.

Traditionally, male LUTS were thought to result from BPO secondary to BPE. However, **male LUTS may arise from prostatic pathology, bladder dysfunction, or both.** Thus, diagnosis and appropriate treatment of men with OAB symptoms are complex and difficult. α_1-AR antagonists remain the most widely used pharmacologic agents for relief of bladder outflow resistance, as they relax prostatic and urethral smooth muscle tone, the dynamic component of BPO (Andersson and Gratzke, 2007; Lepor et al., 2012). In contrast, antimuscarinics, which function by competitively blocking the muscarinic receptors, are the first-line pharmacologic treatment for OAB (Andersson et al., 2009). Given the prevalence of combined voiding and OAB symptoms and the finding that the QoL of these patients is affected primarily by the symptoms of OAB, it might be logical for this category of patients to be given antimuscarinic drugs (Ruggieri et al., 2005).

A variety of such combinations have been evaluated. **Several randomized, controlled trials demonstrated that the combination treatment of antimuscarinic drugs and α_1-AR antagonists was more effective at reducing male LUTS than α_1-AR antagonists alone in men with OAB and coexisting BPO** (Athanasopoulos et al., 2003; Lee et al., 2004, 2005; Kaplan et al., 2006, 2007, 2013; Saito et al., 1999; van Kerrebroeck et al., 2013a, 2013b). Saito et al. (1999) reported therapeutic benefit of combining an antimuscarinic agent (propiverine) with an α_1-AR antagonist (tamsulosin), as compared with an α_1-AR antagonist alone. The rates of improvement in daytime frequency, incontinence, and urgency were greater in the combination group than the α_1-AR antagonist–alone group. **The PVR was unchanged** in both groups, and there was only one case (1.5%) of AUR with the combined treatment.

Subsequently, Lee et al. (2005) compared the efficacy and safety of combination therapy with propiverine and doxazosin in 211 men with urodynamically confirmed BOO and OAB symptoms for 8 weeks. Compared with the doxazosin arm, the patients in the combination therapy group showed greater improvement in urinary frequency, average micturition volume, and storage and urgency scores of IPSS. Patient satisfaction was significantly higher in the combination group. There was also a significant increase in PVR (+20.7 mL) in the combination group, but no case of urinary retention was reported.

A large-scale, multicenter, randomized, double-blind, placebo-controlled trial **(the TIMES study)** demonstrated the efficacy and safety of tolterodine ER alone, tamsulosin alone, and the combination of both in 879 men with OAB and BPO (Kaplan et al., 2006). In the primary efficacy analysis, 172 men (80%) receiving tolterodine ER plus tamsulosin reported treatment benefits by week 12 ($P < .001$ vs. placebo; $P = .001$ vs. tolterodine ER; $P = .03$ vs. tamsulosin). In the secondary efficacy analysis, patients receiving tolterodine ER plus tamsulosin compared with placebo experienced small but significant reductions in urgency incontinence, urgency episodes, daytime frequency, and nocturia. However, there were no significant differences between tamsulosin monotherapy and placebo for any diary variables at week 12. Patients receiving tolterodine ER plus tamsulosin demonstrated significant improvements in total IPSS (−8.02 vs. placebo −6.19, $P = .003$) and QoL (−1.61 vs. −1.17, $P = .003$). Although there were significant improvements in the total IPSS among patients who received tamsulosin alone, the differences in total IPSS among patients who received tolterodine ER versus placebo were not significant. **The combination of antimuscarinics and α_1-AR antagonists may be the most effective therapy in men with OAB symptoms in the presence of BPO.**

A subanalysis of data from the TIMES study focused on the urgency perception scale and concluded that the group of 217 men who received tolterodine plus tamsulosin showed significantly improved urgency variables and patient-reported outcomes (Rovner et al., 2008a). Moreover, this group of patients reported increased satisfaction with the treatment and willingness to continue the treatment. Another subanalysis of data from the TIMES study examined the effects of the drugs on urinary symptoms as assessed by the IPSS (Kaplan et al., 2008a). Based on this subanalysis, the authors concluded that tolterodine ER plus tamsulosin was significantly more effective than placebo in treating storage LUTS, including OAB symptoms. However, these results should be considered with caution because they were derived from post hoc analysis of the TIMES data.

Maruyama et al. (2006) **reported different results** in their prospective, randomized controlled study in which naftopidil (25 to 75 mg/day), an α_{1D}-AR antagonist, alone or in combination with propiverine hydrochloride (10 to 20 mg/day) or oxybutynin hydrochloride (2 to 6 mg/day), was administered for 12 weeks to 101 BPH patients. In the study, the IPSS and QoL index score improved significantly in both groups, with no marked differences between groups. Qmax and PVR tended to improve in both groups, again with no differences between groups. However, median post-therapeutic PVR was significantly larger in the combination group (45.0 mL) than in the monotherapy group (13.5 mL, $P = .021$). There were significantly more patients with increased residual urine volume relative to unchanged residuals in the combination therapy group (22.9%) versus the monotherapy group (5.0%, $P = .038$). **The authors of this study concluded that combination therapy with a low-dose antimuscarinic agent was not more effective than monotherapy.** Moreover, although they did not encounter any cases of urinary retention, the percentage of patients with increased residual urine volume was significantly greater in the combination therapy group than in the monotherapy group.

Kang et al. (2009) published the results of another study using low-dose antimuscarinic therapy. They evaluated the efficacy and safety of combined treatment with tamsulosin 0.2 mg and propiverine hydrochloride 10 mg compared with tamsulosin monotherapy. After 3 months, both groups showed significant improvements in IPSS, QoL, voided volume, Qmax, and PVR, but only the QoL index was significantly different between groups in favor of the combination group. No cases of AUR were recorded in this low-dose study.

The efficacy and safety of solifenacin in combination with tamsulosin were assessed in several large-scale RCTs, including the VICTOR trial (Kaplan et al., 2013) and the SATURN trial (Van Kerrebroeck et al., 2013a). The VICTOR trial was a randomized, placebo-controlled study assessing solifenacin 5 mg as an add-on therapy to α_1-AR antagonists treatment in men with residual OAB symptoms (Kaplan et al., 2013). Significant reductions in daytime frequency, the primary outcome of the study, were achieved in both solifenacin (and tamsulosin) and placebo (and tamsulosin) trials compared with baseline, but the difference between the two drug groups was not significant. Solifenacin add-on significantly reduced daily urgency episodes compared with placebo, but this was the only significant efficacy difference between solifenacin and placebo. Seven patients (3%) in the solifenacin group developed retention problems, with three requiring catheterization, versus none in the placebo group. The SATURN study was a randomized, placebo-controlled trial evaluating the combination of different doses of solifenacin (3, 6, and 9 mg/day) with tamsulosin versus tamsulosin alone in men with voiding and storage LUTS (Van Kerrebroeck et al., 2013a). Decreases in micturition frequency and total urgency and frequency scores and increases in void volume per micturition were significantly greater with increasing solifenacin dosage in the combination groups versus with tamsulosin monotherapy. In a post-hoc analysis, patients with at least two urgency episodes and at least eight micturitions per 24 hours at baseline showed clear improvements in storage and QoL parameters with combination treatment over tamsulosin alone. The subgroup of patients with fewer storage symptoms experienced little or no additional benefit from combination therapy compared with tamsulosin monotherapy. Combination therapy was well tolerated, and adverse events were consistent with the safety profiles of each individual compound. Mean PVR volume increased with increasing solifenacin dose, but the changes were not clinically relevant and were not accompanied by an increase in the incidence of retention.

A meta-analysis compared the efficacy and safety of treatment with α-blockers and anticholinergics to α-blocker monotherapy among men with storage urinary symptoms related to benign prostatic hyperplasia (BPH) (Filson et al., 2013). Combination therapy produced a significantly greater reduction in IPSS storage subscore (Δ –0.73, 95% CI –1.09 to –0.37) and voiding frequency (Δ –0.69 voids, 95% CI –0.97 to –0.41) than monotherapy. There was also a greater reduction in Qmax (Δ –0.59 mL/sec, 95% CI –1.04 to –0.14) and an increase in PVR (Δ 11.60 mL, 95% CI 8.50 to 14.70) with combination therapy. The number of patients needed to be treated with combination therapy to cause one acute urinary retention episode was 101.

The efficacy and safety of a fixed-dose combination (FDC) tablet containing solifenacin 6 mg plus an oral controlled absorption system (OCAS) formulation of tamsulosin (TOCAS) 0.4 mg has been studied in a phase III trial

(NEPTUNE). NEPTUNE, which included 1334 men with LUTS/BPH who had moderate-to-severe storage symptoms and voiding symptoms, showed that an FDC of solifenacin 6 mg plus TOCAS improved storage symptoms and QoL compared with TOCAS alone (van Kerrebroeck et al., 2013b). FDC treatment was also well tolerated and exhibited an adverse-event profile similar to those reported for the individual monotherapies. Consequently, a once-daily FDC tablet of solifenacin 6 mg plus TOCAS 0.4 mg aimed at treating both storage and voiding symptoms in men with LUTS/BPH is licensed and available in several countries, including the United Kingdom. NEPTUNE and NEPTUNE II open-label extension studies further evaluated the long-term (up to 52 weeks) safety and efficacy of flexible dosing of two FDCs of solifenacin plus TOCAS (solifenacin 6 mg plus TOCAS 0.4 mg or solifenacin 9 mg plus TOCAS 0.4 mg) in men with moderate-to-severe storage and voiding symptoms (Drake et al., 2015). Reductions in total IPSS and total urgency and frequency score (TUFS) during NEPTUNE were maintained for up to 52 weeks of FDC treatment, with mean reductions of 9.0 (standard deviation [SD]: 5.7) and 10.1 (SD: 9.2), respectively, from baseline to end of treatment. Urinary retention occurred in 13 of 1208 (1.1%) patients receiving one or more FDCs in NEPTUNE and/or NEPTUNE II; 8 (0.7%) required catheterization. Responder and health-related QoL (HRQoL) analyses of the NEPTUNE study reported that men treated with an FDC of solifenacin 6 mg plus TOCAS consistently had significantly improved outcomes compared with both the placebo and TOCAS (Drake et al., 2016). There was a significant correlation between the reduction in total urgency frequency score and the improvement in HRQoL defined by the IPSS-QoL score, the OAB-q symptom bother score, the overall patient global impression bladder symptoms, and the general health of the patient. Drake et al. expected that the positive HRQoL data for FDC of solifenacin 6 mg plus TOCAS are likely to translate into improved persistence of treatment and possibly increased confidence to prescribe combined therapy as the initial treatment for moderate-to-severe LUTS/BPH (Drake et al., 2016).

Medical therapy to reduce DO in a neurogenic bladder has focused on antimuscarinic therapy, which increases bladder capacity, decreases bladder filling pressure, and improves compliance (Goessl et al., 1998; Stöhrer et al., 2009). Although use of antimuscarinics combined with clean intermittent catheterization (CIC) is the most commonly recommended medical therapy for neurogenic bladder, the results are sometimes unsatisfactory, and many patients continue to have poor bladder compliance and remain incontinent (Razdan et al., 2003). McGuire and Savastano (1985) reported that α-AR antagonists decreased bladder pressure with filling and increased capacity, and that the addition of an antimuscarinic enhanced these effects, indicating that α-AR antagonists and the antimuscarinic had a synergistic effect on detrusor tone in the decentralized bladder. This finding led to the widespread use of α_1-AR antagonists in the treatment of neurogenic bladder (Abrams et al., 2003; Chancellor et al., 1994; Swierzewski et al., 1994). Swierzewski et al. (1994) treated 12 patients with SCI who had poor bladder compliance, despite therapy with CIC and an antimuscarinic, with 5 mg of terazosin for bladder management. After 4 weeks, compliance increased by 73%, bladder pressure decreased by 36 cm H_2O, and capacity increased by 157 mL. **These results support the assumption that α_1-AR antagonists and antimuscarinics may have an additional synergistic effect on the bladder in the neurogenic population.**

In a retrospective chart review, combination therapy with an antimuscarinic agent, an α_1-AR antagonist, and imipramine produced superior results to those obtained using a single agent in patients with neurogenic bladder dysfunction (Cameron et al., 2009). These patients showed significant improvement in clinical parameters and compliance and decreased bladder pressures at capacity. It has been shown that in the decentralized human detrusor, there may be an increase in α-AR sites and a switch to α-AR–mediated contractile function from the typical β-AR–mediated relaxation function during bladder filling (Sundin et al., 1977). Imipramine is a systemic muscarinic-receptor antagonist and a direct smooth muscle inhibitor that also blocks the reuptake of serotonin and noradrenaline. This suggests that targeting multiple receptors may maximize the effectiveness of pharmacologic treatment of neurogenic bladder and should be considered in patients in whom treatment with antimuscarinics alone fails.

β_3-AR Agonist With Antimuscarinics.

β_3-AR agonists are believed to exert their therapeutic effects through stimulation of adenylyl cyclase and activation of potassium K^+ channels, but also through other mechanisms. The former leads to an increase in cAMP and the latter to hyperpolarization, both of which result in relaxation. The beneficial effects of modulation of these pathways are inhibition of spontaneous activity, increased bladder compliance (decreased bladder tone during filling), greater distention needed to activate the micturition reflex (increased bladder capacity), and decreased afferent activity, with no effect on voiding contraction (no risk for urinary retention).

These mechanisms are distinct from those of antimuscarinic therapies used to treat OAB. Accordingly, the combination of these two types of medications is being investigated to determine whether concomitant use can result in increased efficacy with an acceptable profile of safety and tolerability. Based on results with an animal model, it was concluded that the “combination of antimuscarinics and β_3-AR agonists can result in increased efficacy and potency and supports the hypothesis that combining these compound classes in the clinic could have beneficial effects in treating urinary bladder dysfunction” (Rekik et al., 2013).

Abrams et al. reported results of a phase II trial (Symphony) of combination treatment with mirabegron and solifenacin in patients with OAB (Abrams et al., 2015). A total of 1306 patients were randomly assigned to 12 groups: placebo, 6 combination groups (solifenacin 2.5, 5, or 10 mg plus mirabegron 25 or 50 mg), and 5 monotherapy groups (solifenacin 2.5, 5, or 10 mg, or mirabegron 25 or 50 mg) for a 12-week treatment period. The primary end point was change from baseline to end of treatment in mean volume voided per micturition (MVV). All combinations with solifenacin 5 or 10 mg improved MVV significantly comparing to solifenacin 5 mg monotherapy, and a decreasing trend in the mean number of micturitions per 24 hours was observed with increasing solifenacin and mirabegron doses. The three drug combinations (solifenacin 5 mg plus mirabegron 50 mg, solifenacin 10 mg plus mirabegron 25 mg, and solifenacin 10 mg plus mirabegron 50 mg) demonstrated significant improvements compared with both solifenacin 5 mg and placebo. No severe adverse events were reported, and treatment was generally well tolerated. In Japan, Yamaguchi et al. conducted a multicenter, open-label, phase IV study (MILAI study) to assess the safety and efficacy of mirabegron in combination with solifenacin in OAB patients who were being treated with solifenacin 2.5 mg or 5 mg once daily for at least 4 weeks (Yamaguchi et al., 2015). A total of 223 patients were randomly assigned to one of four groups: solifenacin 2.5 mg plus mirabegron 25 mg ($n = 35$), solifenacin 2.5 mg plus mirabegron 50 mg ($n = 37$), solifenacin 5 mg plus mirabegron 25 mg ($n = 58$), or solifenacin 5 mg plus mirabegron 50 mg ($n = 93$) for a 16-week treatment period. The overall incidence of drug-related TEAEs was 23.3%, and all TEAEs were mild or moderate. All treatments showed significant improvements in OABSS total score, overactive bladder questionnaire short form (OAB-q SF) score (symptom bother and total HRQoL score), mean number of micturitions in 24 hours, mean number of urgency episodes in 24 hours, mean number of UI episodes in 24 hours, mean number of urgency UI episodes in 24 hours, mean volume voided per micturition, and mean number of nocturia episodes per night. Recently, a phase IIIB trial (BESIDE) in incontinent OAB patients was carried out in Europe (Drake et al., 2016). Patients with OAB ($n = 2174$), who remained incontinent despite solifenacin 5 mg once daily during a 4-week single-blind run-in, were randomized 1 : 1 : 1 to a double-blind daily combination ($n = 727$), solifenacin 5 mg ($n = 728$), or 10 mg ($n = 719$) for 12 weeks. The primary efficacy end point was change in mean number of incontinence episodes per 24 hours. Key secondary efficacy end points were change in mean number of micturitions per 24 hours and the number of incontinence episodes noted in the 3-day voiding diary. All combinations significantly improved daily incontinence episodes ($P = 0.001$), daily micturitions ($P < 0.001$), and incontinence noted in a 3-day voiding diary ($P = 0.014$) compared with solifenacin 5 mg monotherapy. The combination of drugs was not inferior to solifenacin 10 mg for key secondary end points and was superior to solifenacin 10 mg for improving daily micturitions. All treatments were well tolerated. These results suggest that combination therapy of mirabegron 50 mg with solifenacin 5 mg may be an alternative to dose escalation of solifenacin in patients with insufficient response to solifenacin 5 mg monotherapy.

β_3-AR Agonist With α_{1A}-AR Antagonists.

Ichihara et al. (2015) evaluated the efficacy and safety of add-on treatment with mirabegron for overactive bladder symptoms remaining after α_1-AR antagonist (tamsulosin) treatment in men with benign prostatic obstruction. The change in PVR urine volume was significantly greater in the combination group. Six patients (out of 76) experienced adverse events in the combination group, and urinary retention was observed in 1 patient. Nevertheless, the authors concluded that the combination was effective and safe in these patients.

Combined Antimuscarinics.

Although antimuscarinic agents are the first choice of treatment for patients with OAB symptoms, these drugs do not always lead to the desired effect of detrusor stability and continence, especially for patients with SCI or neurologic diseases such as multiple sclerosis or meningomyelocele. In these patients, the goal of urologic therapy is to maintain continence and to reduce intravesical pressure. When antimuscarinic treatment fails, however, invasive procedures such as the injection of botulinum neurotoxin type A (BoNTA), intravesical application of drugs, or surgery are necessary.

Amend et al. (2008) evaluated a combined antimuscarinic regimen as a noninvasive alternative for patients who had neurogenic bladder dysfunction with incontinence, reduced bladder capacity, and increased intravesical pressure. They added secondary antimuscarinics to the existing double-dose antimuscarinics for patients who previously demonstrated unsatisfactory outcomes with double-dose antimuscarinic monotherapy. The study drugs were tolterodine, oxybutynin, and trospium. After a 4-week combined regimen, incontinence episodes decreased, and reflex volume, maximal bladder capacity, and detrusor compliance increased. Side effects were comparable to those seen with normal-dose antimuscarinics. Those positive findings were speculated to be the result of (1) additive or synergistic activation of different muscarinic receptors or interactions of receptors on different parts of the bladder wall, (2) undiscovered faster metabolism of antimuscarinics requiring an increased dose of different antimuscarinic drugs, and/or (3) downregulation of subdivisions of antimuscarinic receptors under monotherapy that may lead to better susceptibility of other subdivisions when treated by the second drug.

Kosilov et al. evaluated the effectiveness of cyclic therapy of combined high-dose trospium and solifenacin depending on severity of OAB symptoms in elderly men and women (Kosilov et al., 2014a,b, 2016). They found that cyclic therapy of high-dose solifenacin and trospium in elderly patients with moderate-to-severe symptoms of OAB enabled patients to maintain a longer therapeutic effect with an acceptable level of side effects (Kosilov et al., 2014a). They conducted another study to evaluate the efficiency of treatment for severe symptoms of OAB with cyclic therapy of combined antimuscarinic drugs in elderly men and women and determined that cyclic therapy with combined antimuscarinics appeared to be effective for controlling severe OAB in elderly patients, increasing the compliance level (76% to 84%). However, continuous therapy with standard doses of trospium and solifenacin results in low adherence and high rates of treatment withdrawal (≥66%) despite satisfactory clinical and urodynamic results.

The effectiveness of combination therapy with two different antimuscarinics was also evaluated in patients with severe symptoms of OAB and BPH (Kosilov et al., 2015b, 2016). Patients in the experimental group for 2 months received treatment with a daily combination of solifenacin 5 mg and trospium 5 mg simultaneous with tamsulosin 0.4 mg. Patients in the control group were treated only with tamsulosin. In the experimental group, the number of episodes of incontinence reduced from a moderate level of 3.4 (0.8) per day to 0.9 (0.7) per day, and most urodynamic indices normalized significantly. In the control group, changes in urodynamic indices were not significant. The quantity of side effects did not exceed the level that is commonly found in patients receiving antimuscarinic monotherapy. The authors concluded that a combination of trospium and solifenacin in standard doses is an efficient and safe method for managing severe symptoms of OAB over the course of treatment with tamsulosin in patients with OAB/BPH (Kosilov et al., 2016). However, in patients with OAB/BPH, the efficacy and side effects of combination therapy using different antimuscarinics should be further evaluated.

The combined regimen needs further investigation to verify its efficacy as a noninvasive alternative for patients in whom antimuscarinic monotherapy fails.

Antimuscarinics and 5α-Reductase Inhibitors.

The standard first-line medical therapy for men with moderate-to-severe LUTS is an α_1-AR antagonist, a 5α-reductase inhibitor, or combination therapy with both. Both α_1-AR antagonists and 5α-reductase inhibitors alleviate LUTS in men by reducing bladder outlet resistance. **α_1-AR antagonists decrease smooth muscle tone in the prostate and bladder neck, whereas 5α-reductase inhibitors reduce prostate volume. As mentioned, several trials have demonstrated the efficacy and safety of combination therapy with antimuscarinics and α_1-AR antagonists for patients with OAB and coexisting BPO. However, post hoc analyses of the TIMES study** (Kaplan et al., 2006) **suggested that men with smaller prostates benefit more from antimuscarinic therapy than those with larger prostates** (Roehrborn et al., 2008a, 2009). Chung et al. (2010) conducted an open-label, fixed-dose study to assess the efficacy and safety of tolterodine ER in combination with dutasteride in men with a large prostate (≥30 g) and persistent OAB symptoms after α_1-AR antagonist therapy who had been unsuccessfully treated with dutasteride alone. At the start of the study, all patients had been on dutasteride 0.5 mg daily for at least 6 months, and α_1-AR antagonist therapy had failed. All patients were given 4 mg of tolterodine ER daily for 12 weeks and had discontinued α_1-AR antagonist therapy before the start of the study. At 12 weeks, the frequency (−3.2/24 hour, $P < .02$), urgency (19.2%, $P < .03$), number of severe OAB episodes (71.4%, $P < .05$), and incidence of nighttime voiding (−0.9, $P < .003$) were found to have decreased significantly from baseline. The IPSS decreased with dutasteride treatment (from 19.3 to 14.3) and further decreased with the addition of tolterodine to 7.1 ($P < .001$). Storage symptoms decreased from 9.8 to 4.5 ($P < .001$). Dry mouth occurred in four (7.5%) patients, constipation in one (2%), and decreased sexual function in two (3.9%). PVR increased by 4.2 mL, Qmax decreased by 0.2 mL/sec, and no patients developed retention. The authors concluded that the combination of tolterodine and dutasteride was effective, safe, and well tolerated in men with large prostates with persistent OAB symptoms and LUTS secondary to BPO.

Dutasteride was evaluated in terms of OAB symptoms and bladder ischemia in men with BPE (Wada et al., 2015). Twenty-four weeks after dutasteride treatment, bladder vascular resistive index (RI) significantly decreased, and urgency score of IPSS was significantly improved from 2.3 ± 1.9 to 1.4 ± 1.4 ($P < 0.01$). In 20 patients with persistent urgency after dutasteride, RI was less improved than in an additional 10 patients without urgency. Posttreatment bladder outlet obstruction index (BOOI) and PdetQmax in patients with persistent urgency were significantly higher than in those without urgency after dutasteride. The authors suggested that reduction of obstruction and improvement of bladder ischemia might play important roles in the beneficial impact of dutasteride on OAB symptoms.

The results of this study indicate that antimuscarinics are safe and effective in selected patients with OAB and BPO when used in combination with 5α-reductase inhibitors. Further studies are required to verify the efficacy of antimuscarinics combined with 5α-reductase inhibitors in these patients.

α_1-AR Antagonists With 5α-Reductase Inhibitors.

It has been **well established that the combinations of α_1-AR antagonists with 5α reductase inhibitors** (doxazosin finasteride in the Medical Therapy of Prostatic Symptoms **[MTOPS]** trial; dutasteride plus tamsulosin in the Combination of Avodart and Tamsulosin **[CombAT]** study) **can improve clinical outcomes and reduce the incidence of BPH and LUTS progression** measured as symptom worsening, retention, or progression to surgery (McConnell et al., 2003; Roehrborn et al., 2010). A combination of α_1-AR antagonist with a 5α-reductase inhibitor is recommended by the American

Urological Association (AUA) and European Association of Urology (EAU) for men with bothersome moderate-to-severe LUTS, high risk for disease progression-enlarged prostate (prostate volume >40 mL), and higher prostate specific antigen (PSA) (McVary et al., 2011; Oelke et al., 2013). The possible disadvantage of combinations of α_1-AR antagonists with 5α-reductase inhibitors is the increased incidence of adverse events, because there are concomitant effects of both classes of drugs (Fullhase et al., 2013; La Torre et al., 2016). Potential side effects (e.g., ejaculation dysfunction with α_1-AR antagonists or loss of libido with 5α-reductase inhibitors) might be additive and may negatively affect patient QoL and, especially, sexual function.

Key Points: Drugs for Male Lower Urinary Tract Symptoms

- Because male LUTS may arise from prostatic obstruction, bladder dysfunction, or both, a logical step is to combine an α_1-AR antagonist with antimuscarinics to treat such patients. There are several trials demonstrating that this combination is more effective at reducing male LUTS than just α_1-AR antagonists alone in men with OAB and BPO. In these trials, the PVR was unchanged. However, there is no universal agreement because other trials do not show effects. Such usage has been recorded in patients with NDO with successful results.
- Because β_3-AR agonists and antimuscarinics have different mechanisms of action, it is attractive to speculate that a combination would be more effective than either drug used alone, especially because the adverse-effect profiles are different. Such trials are ongoing.
- Also under investigation is the combination of different antimuscarinic agents in patients in whom antimuscarinic monotherapy fails.
- Antimuscarinic therapy in patients with OAB symptoms and prostatic pathology is more effective in men with smaller prostates.
- It is well established that the combination of an α-AR antagonist and a 5α-reductase inhibitor will improve clinical outcomes and reduce the incidence of symptomatic progression in patients with LUTS and BPH or BPO.

Toxins

Intravesical pharmacologic therapy for LUTS stems from the fact that circumventing systemic administration of active compounds offers two potential advantages. First, high concentrations of pharmacologic agents can be given to the bladder tissue, producing enhanced local effects. Second, drugs inappropriate for systemic administration because of off-target effects can be safely used. Attractive as it may be, intravesical pharmacologic therapy should still be considered as a second-line treatment in patients who are refractory to oral therapy or who do not tolerate its systemic side effects. However, this statement is based on the assumption that intervention therapy should follow oral medication. Research aiming at defining if patient subgroups will benefit from intravesical therapy as first-line treatment is clearly necessary.

Botulinum Toxin

Mechanism of Action.

Botulinum toxin (BoNT) is a **neurotoxin** produced by *Clostridium botulinum*. **Of the seven subtypes of BoNT, subtype A (BoNTA) has the longest duration of action, making it the most relevant clinically.** BoNTA is available in four different commercial forms, with the proprietary names of Botox, Dysport, Xeomin, and Prosigne. Although the toxin is the same, it is wrapped by different proteins that modify the relative potency of each brand. This was the basis for the introduction of the nonproprietary names onabotulinumtoxinA (onabotA), abobotulinumtoxinA (abobotA), and incobotulinumtoxinA (incobotA) for Botox, Dysport, and Xeomin, respectively. Prosigne is the proprietary name of a BoNTA produced in China, which currently does not have a known nonproprietary name. Although the potency of each one is usually expressed in units (U), the doses are not interchangeable. **Clinical dose conversion studies for the LUT do not exist.** Available information indicates that onabotA is roughly three times more potent than abobotA and equivalent to incobotA. Nevertheless, these equivalences should be approached with caution.

Most of the information available about intravesical application of BoNTA derives from the use of onabotA (Botox). However, in addition to subtype A, some studies have investigated the effect of detrusor injection subtype B, rimabotulinumtoxinB (proprietary names being Miobloc or Neurobloc according to countries).

BoNT consists of a heavy and a light chain linked by a disulfide bond. In the synaptic cleft, the toxin binds to synaptic vesicle protein 2 (SV2) by the heavy chain before being internalized by the nerve terminal along with the recycling process of synaptic vesicles (Dong et al., 2006). The two chains are then cleaved, and the light chain passes into the cytosol, where it cleaves the attachment proteins involved with the mechanism of fusion of synaptic vesicles to the cytoplasmic membrane necessary for neurotransmitter release. Attachment proteins (SNARE [soluble *N*-ethylmaleimide sensitive factor attachment protein receptor]) include synaptosome-associated protein 25 kD (SNAP-25), synaptobrevin (vesicle-associated membrane protein [VAMP]), and syntaxin. **BoNTA cleaves SNAP-25, rendering the SNARE complex inactive** (Chancellor et al., 2008a; Humeau et al., 2000). Subtype B acts preferentially through the inactivation of VAMP (Humeau et al., 2000).

BoNTA application was extensively evaluated in striated muscle. In this tissue, paralysis occurs by prevention of ACh release from cholinergic motor nerve endings (Humeau et al., 2000). Accumulation of neurotransmitter-containing synaptic vesicles is followed by terminal axonal degeneration. Striated muscle paralysis recovers within 2 to 4 months. During this time, axons develop lateral sprouts and eventually regenerate completely (de Paiva et al., 1999).

In the human bladder, SV2 and SNAP-25 expression has been demonstrated in parasympathetic, sympathetic, and sensory fibers (Coelho et al., 2010, 2012a, 2012b). Almost all parasympathetic nerves express the two proteins (Coelho et al., 2010, 2012a). Because these nerves play a fundamental role in detrusor contraction during voiding, **the blockade of ACh release is believed to play an essential role in detrusor hypocontractility or acontractility that follows BoNTA injection in the bladder.** In accordance with this view, it was shown that in normal or spinal cord–injured animals, BoNTA treatment decreased the bladder contractions evoked by electrical stimulation of spinal nerves without altering intrinsic contractions (Ikeda et al., 2012). However, cholinergic axon sprouting concomitant with clinical remission could not be documented in the detrusor (Haferkamp et al., 2004).

Bladder sensory impairment is also expected to play an important role in the final effect of BoNTA bladder injection. BoNTA inhibits the spinal cord release of glutamate, substance P (SP), and calcitonin gene–related peptide (CGRP) from sensory nerves (Aoki, 2005; Meng et al., 2007; Purkiss et al., 2000) **and the release of neuropeptides at the peripheral extremities** (Lucioni et al., 2008; Rapp et al., 2006)**. BoNTA has also been shown to reduce the**

suburothelium immunoreactivity for transient receptor potential (TRP) channel TRPV1 or $P2X_3$ (Apostolidis et al., 2005b)**. Morenilla-Palao et al.** (2004) **have shown that BoNTA impedes TRPV1 trafficking from intracellular vesicles to the neuronal membrane, a process that is also dependent on SNARE proteins. All of these mechanisms may contribute to the recent observation that BoNTA reduces afferent firing from bladder afferents and antidromic release of neuropeptides** (Ikeda et al., 2012). Although SV2 and SNAP-25 immunoreactivity has not been detected in urothelial cells (Coelho et al., 2010), urothelial function also seems compromised after BoNTA administration. BoNTA has been shown to inhibit ATP release from urothelium in animal models of SCI (Khera et al., 2004; Smith et al., 2008). Therefore, it is not surprising that administration of BoNTA to inflamed rat bladders reduces spinal c-Fos counts at the L6 and S1 spinal cord segments (Vemulakonda et al., 2005).

Cleaved, inactive SNAP-25 appears rapidly after BoNTA injection. In the guinea pig, a robust expression of cleaved SNAP-25 could be detected already at 12 hours, and maximum intensity could be detected at 24 hours with little changes afterward. In guinea pigs, cleaved SNAP-25 expression was restricted to nerve fibers. Almost all parasympathetic fibers, either preganglionic or postganglionic, were affected, whereas less than one-half of the sensory fibers expressed the cleaved protein (Coelho et al., 2012a, 2012b). In the human urinary bladder, cleaved SNAP-25 could be detected in NDO patients up to 11 months after BoNTA injection (Schulte-Baukloh et al., 2007). The longer duration of cleaved SNAP-25 in the detrusor smooth muscle, longer than in striated muscles, has no firm explanation at the present time. However, the longer persistence of the inactive form of SNAP-25 plus the involvement of preganglionic and postganglionic parasympathetic neurons may contribute to persistence of the BoNTA effect in the bladder.

Myofibroblasts form a syncytium through extensive coupling via the gap-junction protein connexin 43 and have close contacts with sensory nerves. These facts led to the hypothesis that myofibroblasts act as modulators of bladder behavior (Apostolidis et al., 2006; Wiseman et al., 2003). However, the expression of connexin 43 is not altered by BoNTA (Roosen et al., 2009). Hence, at the present time, firm evidence for the action of BoNTA on myofibroblasts is scant.

BoNTA may decrease the levels of neurotrophic agents in the bladder tissue. Levels of nerve growth factor (NGF) (Giannantoni et al., 2006, 2013; Liu et al.,

2009) and brain-derived neurotrophic factor (BDNF) (Pinto et al., 2010) have been shown to decrease in the bladder and/or urine after BoNTA injection. Because both neurotrophins have paramount roles in growth, maintenance, and plasticity of peptidergic sensory nerves, these findings may point toward another mechanism whereby BoNTA acts on the bladder.

Clinical Use.

Comprehensive reviews of the clinical use of BoNTA have been produced during the past few years, covering different aspects of this treatment (Andersson et al., 2013a, 2017; Apostolidis et al., 2009; Chapple and Patel, 2006; Cruz et al., 2011; Denys et al., 2012; Dowson et al., 2011, 2012; Duthie et al., 2011; Fowler et al., 2012; Herschorn et al., 2011a; Karsenty et al., 2008; Kuo, 2005a, 2005b, 2007; Mangera et al., 2011; Nitti, 2006; Patel et al., 2006; Sahai et al., 2009; Tincello et al., 2014).

Efficacy.

RCTs have documented the clinical effects of onabotulinumtoxinA both in NDO and IDO, wherein the drug decreases incontinence episodes, frequency, and urgency and improves QoL (Andersson et al., 2017; Dmochowski et al., 2010a; Mangera et al., 2011; Sahai et al., 2007; Tincello et al., 2012). **The drug was also shown to be effective in patients with OAB** (Andersson et al., 2017; Nitti et al., 2013b). **Successful OAB treatment with BoNTA does not appear to be related to the existence of DO.** No differences in outcomes were found between those with and those without baseline DO (Kanagarajah et al., 2012; Rovner et al., 2011). Nitti et al. (2013b) reported results of the first large (N = 557) phase III placebo-controlled trial of onabotulinumtoxinA in OAB patients. To be included, patients had three or more UUI episodes in 3 days and eight or more micturitions per day. They were randomized 1 : 1 to receive an intradetrusor injection of onabotulinumtoxinA 100 units or placebo (saline). Coprimary end points were change from baseline in UI episodes per day and proportion of patients with a positive response on the treatment benefit scale (TBS) at week 12 after treatment. Secondary end points included other OAB symptoms and health-related QoL. OnabotulinumtoxinA significantly reduced the daily frequency of UI episodes versus placebo (−2.65 vs. −0.87; $P < .001$), and 22.9% versus 6.5% of patients became completely continent. A larger proportion of onabotulinumtoxinA-treated patients than those receiving placebo reported a positive response on the TBS (60.8% vs. 29.2%; $P < .001$). All other

OAB symptoms improved versus placebo ($P \leq .05$). OnabotulinumtoxinA improved patients' health-related QoL across multiple measures ($P < .001$).

The finding that onabotulinumtoxinA 100 units was consistently effective with a twofold to fourfold improvement over placebo in all symptoms of OAB is important; an effect of this magnitude versus placebo does not seem to have been reported previously with antimuscarinics or β_3-AR agonists.

Adverse Effects.

The most frequent side effects reported after intradetrusor BoNTA injection are bladder pain and urinary infection (Del Popolo et al., 2008; Karsenty et al., 2008; Kuo et al., 2010)**. Hematuria may also occur, most of the times mild in nature. The most dangerous side effect, paralysis of the striated musculature caused by circulatory leakage of the toxin, has never been reported. Transient muscle weakness was, nevertheless, reported with abobotA application in several studies** (Akbar et al., 2007; Del Popolo et al., 2008; Wyndaele and Van Dromme, 2002). Of 199 NDO patients followed for 8 years, 5 developed hyposthenia when injected with abotbotA 1000 units (Del Popolo et al., 2008). In another study with 44 patients, 3 adults also treated with 1000 units developed muscular weakness, which subsided after 5 to 7 weeks (Akbar et al., 2007). No such cases were reported with onabotA (Karsenty et al., 2008). The reason for the lack of transient muscle weakness in BoNTA-treated patients is unclear but might be related to the larger size of its molecule, which limits diffusion into the bloodstream. Caution should be used in selecting high-risk patients for treatment, including children, patients with low pulmonary reserve, and patients with myasthenia gravis. Aminoglycosides should be avoided during BoNTA treatment because they might block motor plates and therefore enhance BoNTA effect.

The most feared complication of BoNTA application in patients with voluntary voiding is urinary retention and a transient necessity to perform CIC. It is therefore strongly recommended that in patients with spontaneous voiding, BoNTA administration be preceded by a complete discussion of information regarding this risk. Caregivers should ideally teach CIC to each patient before toxin injection. In the study by Nitti et al. (2013a), the majority of adverse effects occurred in the first 12 weeks (15.5% with onabotA vs. 5.9% with placebo). The most frequently reported adverse effect was uncomplicated urinary tract infection with no upper urinary tract involvement. Other adverse effects were dysuria (12.2%), bacteriuria (5.0%), and urinary retention (5.4%).

PVR urine volume significantly increased with onabotA versus placebo, with the highest volume at week 2 after treatment, and 8.7% of patients had an increase from baseline of 200 mL or more in PVR urine volume at any time after the initial toxin treatment (none with placebo). The proportion of patients who initiated CIC at any time during treatment cycle 1 was 6.1% versus none in the placebo group; for over one-half of the patients who initiated CIC (10 of 17), the duration of CIC was 6 weeks or less. This value is lower than those reported in previous studies on IDO. In the study by Nitti et al. (2013b), discontinuation rates because of adverse effects were low in both the onabotulinumtoxinA (1.8%) and in the placebo (1.4%) groups.

Visco et al. (2012) performed a double-blind, double placebo-controlled, randomized trial (the ABC trial) in women with idiopathic UUI. The participants were randomly assigned for a 6-month period to daily oral antimuscarinic medication (solifenacin, 5 mg initially, with possible escalation to 10 mg and, if necessary, subsequent switch to trospium ER, 60 mg) plus one intradetrusor injection of saline or one intradetrusor injection of 100 units of onabotulinumtoxinA plus daily oral placebo. The authors concluded that oral antimuscarinic therapy and onabotulinumtoxinA by injection were associated with similar reductions in the frequency of daily episodes of UUI. The group receiving onabotulinumtoxinA was less likely to have dry mouth and more likely to have complete resolution of UUI but had higher rates of transient urinary retention and urinary tract infections.

Capsaicin and Resiniferatoxin (Vanilloids).

There is a rationale for the use of intravesical vanilloids (capsaicin and resiniferatoxin [RTX]) to suppress DO and urgency without DO. Results have not been consistent, and practical application has been a hurdle.

Rationale for Intravesical Vanilloids.

The rationale for intravesical vanilloid application in patients with DO is the demonstration that capsaicin, following bladder C-fiber desensitization, suppresses involuntary detrusor contractions dependent on a sacral micturition reflex (de Groat, 1997). The C-fiber micturition reflex is usually inactive, but it was shown that it is enhanced in patients with chronic spinal cord lesions above sacral segments (de Groat, 1997) in those with chronic BOO (Chai et al., 1998) and in those with IDO (Silva et al., 2002). In the bladders of NDO patients, the enhancement of the micturition reflex is accompanied by an increase in the number of suburothelial C-fibers expressing TRPV1 (Brady et al., 2004a). It is curious that NDO patients who responded better to intravesical RTX exhibited a significant decrease in the density of TRPV1 immunoreactive fibers, whereas nonresponders experienced a nonsignificant variation (Brady et al., 2004a). A decrease in TRPV1 expression in urothelial cells of NDO patients was also demonstrated after intravesical application of RTX (Apostolidis et al., 2005a, 2005b, 2006).

Changes in suburothelial C-fiber innervation expressing neuropeptides (Smet et al., 1997) or TRPV1 (Liu and Kuo, 2007) were also reported in patients with sensory urgency. In IDO patients, responders to intravesical RTX are closely associated with the overexpression of the receptor in the bladder mucosa (Liu and Kuo, 2007). In women with sensory urgency, TRPV1 mRNA expressed in trigonal mucosa was not only increased but also inversely correlated with the bladder volume at first sensation of filling during cystometry, further indicating that TRPV1 may play a role in premature bladder sensation (Liu et al., 2007).

Intravesical Capsaicin.

Intravesical capsaicin for NDO was studied in six noncontrolled (Cruz et al., 1997; Das et al., 1996; De Ridder et al., 1997; Fowler et al., 1992b, 1994; Geirsson et al., 1995) and one controlled (de Sèze et al., 1998) clinical trial. Capsaicin was dissolved in 30% alcohol, and 100 to 125 mL (or half of the bladder capacity if lower than that volume) of 1- to 2-mM solutions were instilled into the bladder and left in contact with the mucosa for 30 minutes. The Best clinical results were found in patients with incomplete spinal cord lesions, in whom clinical improvement could be observed in up to 70% to 90% (Cruz et al., 1997; De Ridder et al., 1997; Fowler et al., 1994). In patients with complete spinal cord lesions, the success rate was much lower (Geirsson et al., 1995).

Only one small RCT compared capsaicin against 30% ethanol, the vehicle solution. Ten patients received capsaicin; a significant regression of the incontinence and urge sensation was found. In contrast, only 1 of the 10 patients who received ethanol had clinical improvement (de Sèze et al., 1998).

The pungency of alcoholic capsaicin solutions has prevented the widespread use of this compound. In particular, the possibility of triggering autonomic dysreflexia with capsaicin, especially in patients with higher spinal cord lesions, has progressively restrained its use. The relevance of capsaicin might, however, be back, with a recent report by de Sèze et al. (2006), who used a new capsaicin formulation. They conducted a double-blind placebo-controlled study with a glucidic solution of capsaicin in 33 NDO patients. The glucidic capsaicin–treated group showed improvement both in symptoms and in urodynamic parameters above the comparator arm. The global tolerance of this new capsaicin formulation was excellent (de Sèze et al., 2006).

Resiniferatoxin in Neurogenic Detrusor Overactivity.

RTX has the **advantage over capsaicin in being much less pungent** (Cruz et al., 1997). Intravesical RTX application in NDO patients was evaluated in five small open-label studies (Cruz et al., 1997; Kuo, 2003; Lazzeri et al., 1997, 1998; Silva et al., 2000). Different RTX concentrations, 10 nM, 50 nM, 100 nM, and 10 µM, were tested. RTX brought a rapid improvement or disappearance of UI in up to 80% of the selected patients and a 30% decrease in their daily urinary frequency. Furthermore, RTX also increased the volume to FDC and maximal cystometric capacity. In general, in patients receiving 50- or 100-nM RTX, the effect was long-lasting, with a duration of more than 6 months being reported. In patients treated with 10-µM doses, transient urinary retention sometimes occurred (Lazzeri et al., 1998).

In a placebo-controlled study, the urodynamic effects of RTX in NDO patients were specifically evaluated. Only in the RTX arm, a significant increase in FDC and maximal cystometric capacity was found (Silva et al., 2005). RTX also caused a significant improvement in urinary frequency and incontinence (Silva et al., 2005).

RTX 600 nM was compared against BoNTA (Botox, 300 units) in a study involving 25 patients with NDO from chronic SCI. Both neurotoxins were capable of significantly reducing the number of daily incontinence episodes and improving maximum bladder capacity, although BoNTA turned out to be more effective.

Resiniferatoxin in Idiopathic Detrusor Overactivity.

The first study with intravesical RTX in IDO patients was designed as a proof-of-concept study and involved 13 patients. Intravesical RTX 50 nmol/L was associated with an improvement in volume to FDC from 170 ± 109 mL to 440 ± 153 mL at 30 days, and to 391 ± 165 mL at 90 days. An increase in mean MCC from 291 ± 160 mL to 472 ± 139 mL at 30 days and to 413 ± 153 mL at 90 days was also observed. These improvements were accompanied by a decrease in episodes of urgency incontinence and of daily frequency (Silva et al., 2002). Subsequent small open-label studies confirmed these observations using either a single high dose (50 to 100 nM) or multiple low doses (10 nM) (Dinis et al., 2004; Kuo, 2003, 2005b).

The effect of RTX on refractory IDO was evaluated in two randomized clinical trials (Kuo et al., 2006; Rios et al., 2007). Kuo et al. (2006) randomized 54 patients to receive four weekly instillations of a low-concentration RTX solution (10 nmol/L) or the vehicle solution, 10% ethanol in saline (Kuo et al., 2006). Three months after completing the four intravesical treatments, the RTX-treated group had 42.3% and 19.2% of patients feeling much better or improved, respectively. This was significantly more than in the placebo group—14.2% and 7.1%, respectively. At 6 months, treatment remained effective in 50% of patients in the RTX group but only in 11% in the placebo group (Kuo et al., 2006). Such clinical and urodynamic findings could not be reproduced in another study in which patients were randomly assigned to receive a single intravesical dose of 100 mL of either RTX 50 nM or placebo. Patients were followed for only 4 weeks. During this period a single 50-nM intravesical dose of RTX was not better than placebo for the treatment of women with IDO and urgency incontinence (Rios et al., 2007).

Resiniferatoxin and Urgency.

The involvement of bladder C fibers in IDO has led some investigators to explore the role of these sensory afferents in the genesis of urgency. In a noncontrolled study involving 12 male patients with LUTS associated with BPH, mean IPSS halved after intravesical administration of RTX (50 nmol/L). The decrease in IPSS was largely the result of improvements in scores related to urgency, in addition to improvement in nocturia and frequency (Dinis et al., 2005). In another open-label study, 15 patients with intractable urgency and frequency, with or without urgency incontinence or bladder pain or discomfort, and without urodynamic evidence of DO received one single administration of 50-nM RTX solution. A trend toward an improvement of urgency was noticed (Apostolidis et al., 2006).

In a quasi-randomized study, 23 OAB patients with refractory urgency entered a 30 day run-in period in which medications influencing the bladder function were interrupted. At the end of this period, patients filled out a 7-day bladder diary. Then patients underwent instillation of 100 mL of 10% ethanol in saline (vehicle solution), and 30 days later a second 7-day diary was collected. Finally, patients underwent instillation of 100 mL of 50-nM RTX in 10% ethanol in saline, and additional bladder diaries were collected at 1 and 3 months. After vehicle instillation, the mean number of episodes of urgency per week was 56 ± 11. At 1 and 3 months after RTX instillation, the number of episodes of urgency decreased to 39 ± 9 ($P = .002$) and 37 ± 6 ($P = .02$), respectively (Silva et al., 2007).

Key Points: Toxins for Overactive Bladder

- Intradetrusor injections of onabotulinumtoxinA have been shown to be effective in the treatment of NDO and IDO and OAB symptoms without DO. The mechanism of action seems to be through both efferent and afferent decreases in the release of transmitter(s) substance(s). The doses used are different for neurogenic and idiopathic conditions. A potential complication in patients with voluntary voiding is urinary retention, and all such patients should be informed of this risk.
- There is a definite rationale for the use of intravesical capsaicin and RTX (vanilloids) for the treatment of patients with DO. Alcoholic capsaicin solution is extremely irritating, and RTX is much less pungent. There have been positive clinical trials with RTX, although some negative results occur as well. At the present time, this is not commonly used.

Estrogens for Urgency Urinary Incontinence and Overactive Bladder Symptoms

Estrogen has been used to treat postmenopausal urgency and urgency incontinence for many years, but there have been few controlled trials to confirm that it is of benefit (Hextall, 2000). A double-blind multicenter study of 64 postmenopausal women with “urge syndrome” failed to show efficacy (Cardozo et al., 1998). All women underwent pretreatment urodynamic investigation to ensure that they had either “sensory” urgency or DO. They were randomized to treatment with oral estriol 3 mg daily or placebo for 3 months. Compliance with therapy was confirmed by a significant improvement in the maturation index of vaginal epithelial cells in the active but not the placebo group. Estriol produced subjective and objective improvements in urinary symptoms but was not significantly better than placebo.

Another RCT from the same group using 25-mg estradiol implants confirmed the previous findings (Rufford et al., 2003) and furthermore found a high complication rate in the estradiol-treated patients (vaginal bleeding).

Symptoms of OAB increase in prevalence with increasing age, and LUTS and recurrent urinary tract infections are commonly associated with urogenital atrophy. Although the evidence supporting the use of estrogens in LUT dysfunction remains controversial, there are considerable data to support their use in urogenital atrophy, and the vaginal route of administration correlates with better symptom relief by improvement in vaginal dryness, pruritus, and dyspareunia, greater improvement in cytologic findings, and higher serum estradiol levels (Cardozo et al., 1998). Overall, vaginal estradiol has been found to be the most effective in reducing patient symptoms, although conjugated estrogens produced the most extensive cytologic change and the greatest increase in serum estradiol and estrone. Suckling et al. (2003) reported the most recent meta-analysis of intravaginal estrogen treatment in the management of urogenital atrophy. Overall, 16 trials including 2129 women were analyzed, and intravaginal estrogen was found to be superior to placebo in terms of efficacy, although there were no differences among types of formulation. Fourteen trials compared safety among the different vaginal preparations and found a higher risk for endometrial stimulation with conjugated equine estrogens (CEEs) as compared with estradiol.

Thus, theoretically there could be a role for combination treatment with an antimuscarinic agent and vaginal estrogen in postmenopausal women. However, the two clinical trials that have been reported to date differ in their outcomes. Tseng et al. (2009) showed superior efficacy in terms of symptom improvement for OAB when tolterodine was used with vaginal estrogen cream as opposed to tolterodine alone. However, Serati et al. (2009) found no difference between tolterodine with or without topical estrogen in women with symptomatic DO.

Evidence Regarding Estrogens and Incontinence From Large Clinical Trials.

The Heart and Estrogen/Progestin Replacement Study (HERS) included 763 postmenopausal women younger than 80 years of age with CHD and intact uteri (Grady et al., 2001). **It was designed to evaluate the use of estrogen in secondary prevention of cardiac events. In a secondary analysis, 1525 participants who reported at least one episode of incontinence per week at baseline were included.** Participants were randomly assigned to 0.625 mg of conjugated estrogens plus 2.5 mg of medroxyprogesterone acetate (MPA) in one tablet (*n* = 768) or placebo (*n* = 757) and were followed for a mean of 4.1 years.

Severity of incontinence was classified as improved, unchanged, or worsened. The results showed that incontinence improved in 26% of the women assigned to placebo compared with 21% assigned to hormones, whereas 27% of the placebo group worsened compared with 39% of the hormone group (*P* = .001). This difference was evident by 4 months of treatment, for both UUI and SUI. The number of incontinence episodes per week increased an average of 0.7 in the hormone group and decreased by 0.1 in the placebo group (*P* < .001). The authors concluded that **daily oral estrogen plus progestogen therapy was associated with worsening UI in older postmenopausal women with weekly incontinence and did not recommend this therapy for treatment of incontinence.** However, it is possible that the progestogen component may have had an influence on the results of this study.

The **Women's Health Initiative (WHI)** was a multicenter double-blind placebo-controlled randomized clinical trial of **menopausal hormone therapy in 27,347 postmenopausal women 50 to 79 years of age who were enrolled from 1992 to 1998; UI symptoms were known in 23,296 participants at baseline and 1 year** (Hendrix et al., 2005). The women were randomized based on hysterectomy status to active treatment or placebo. Those with a uterus were given 0.625 mg of conjugated equine estrogen (CEE) per day plus 2.5 mg of MPA per day (CEE + MPA), whereas those who had undergone hysterectomy received estrogen alone (CEE). At 1 year, hormone therapy was shown to increase the incidence of all types of UI in women who were continent at baseline. The risk was highest for SUI, followed by mixed UI. The combination of CEE and MPA had no significant effect on development of urge UI, but CEE alone increased the risk. For those women experiencing UI at baseline, frequency of micturition worsened in both active groups. Quantity of UI worsened at 1 year in both active groups. Those women receiving hormone therapy were more likely to report that UI limited their daily activities at 1 year. Thus, based on this secondary analysis of data from a huge study, **CEE alone or in combination with MPA after 1 year of therapy was shown to increase the risk for UI in continent menopausal women and worsen UI in those incontinent at baseline.**

The **Nurses' Health Study** was a biennial postal questionnaire that started in 1976 (Grodstein et al., 2004). In the study, 39,436 postmenopausal women 50 to 75 years of age who reported no urinary leakage at the start of the study were followed up for 4 years to identify incident cases of UI; 5060 women with occasional incontinence and 2495 with frequent incontinence were identified.

The **risk for developing UI was increased in postmenopausal women taking hormones compared with women who had never taken hormones.** After cessation of hormone therapy, there was a decreased risk for incontinence such that 10 years after stopping hormones the risk was identical in women who had and who never had taken hormone therapy.

Cody et al. (2009) performed the most recent meta-analysis of the effect of estrogen therapy on the LUT. This study is notable because the conclusions are starkly different from those drawn from the previous review (Moehrer et al., 2003). Overall, 33 trials were identified, including 19,313 incontinent women (1262 involved in trials of local administration), of whom 9417 received estrogen therapy. **Systemic administration (of unopposed oral estrogens—synthetic equine estrogens and CEEs) resulted in worse incontinence than placebo,** although this was heavily influenced by the size of the WHI study (Hendrix et al., 2005). **With regard to combination therapy, there was a similar worsening effect on incontinence when compared with placebo. There was some evidence suggesting that the use of local estrogen therapy may improve incontinence, and overall there were one to two fewer voids in 24 hours and less frequency and urgency.**

The authors concluded that local estrogen therapy for incontinence may be beneficial, although there was little evidence of long-term effect. The evidence would suggest that systemic hormone replacement using CEEs may make incontinence worse. In addition, they reported that there are too few data to comment reliably on the dose type of estrogen and route of administration.

Estrogen has an important physiologic effect on the female LUT, and its deficiency is an etiologic factor in the pathogenesis of a number of conditions. However, the use of estrogen either alone or in combination with progestogen has yielded poor results. **The current level 1 evidence against the use of estrogen for the treatment of UI comes from studies powered to assess their benefit in the prevention of cardiovascular events,** and therefore the secondary analyses have been based only on self-reported symptoms of urinary leakage without any objective data. Despite this, all of these large RCTs show a worsening of preexisting UI, both SUI and UUI, and an increased new incidence of UI with both estrogen and estrogen plus progestogen. However, the majority of subjects in all of these studies were taking combined equine estrogen, and this may not be representative of all estrogens taken by all routes of administration.

In a systematic review of the effects of estrogens for symptoms suggestive of OAB, the conclusion was that estrogen therapy may be effective in

alleviating OAB symptoms, and that local administration may be the most beneficial route of administration (Cardozo et al., 2004c)**. It is quite possible that the reason for this is that the symptoms of urinary urgency, frequency, and urgency incontinence may be a manifestation of urogenital atrophy in older postmenopausal women rather than a direct effect on the LUT** (Robinson and Cardozo, 2003)**. Although there is good evidence that the symptoms and cytologic changes of urogenital atrophy may be reversed by low-dose (local) vaginal estrogen therapy, there is currently no evidence that estrogens with or without progestogens should be used in the treatment of UI.**

Key Points: Hormones and Urinary Incontinence

- Conclusions reached in a number of studies have been that (1) daily oral estrogen plus progestogen therapy is associated with worsening UI in older postmenopausal women with weekly incontinence and (2) CEE alone or in combination with MPA increases the risk for UI in continent menopausal women and worsens UI in those incontinent at baseline.
- There is some evidence suggesting that local (vaginal) therapy with estrogen may improve OAB symptoms in postmenopausal women, perhaps by its reversal of urogenital atrophy.

Other Hormones and Desmopressin

Progesterone and progestogens are thought to increase the risk for UI. LUTS, especially SUI, have been reported to increase in the progestogenic phase of the menstrual cycle (Hextall et al., 2001). In similar studies, progesterone has been shown to increase β-AR activity, leading to a decrease in the urethral closure pressure in female dogs (Raz et al., 1973). However, in the WHI there appeared to be no difference whether or not progestin was given in addition to estrogen (Hendrix et al., 2005).

Selective estrogen receptor modulators (SERMs) have been reported to have varying effects. Each of the SERMs has receptor ligand conformations that are unique and have both estrogenic and antiestrogenic effects. In the clinical trials of levormeloxifene, there was a fourfold increase in the incidence of incontinence, leading to cessation of the clinical trial (Hendrix et al., 2001).

However, raloxifene has not been shown to have any effect on UI (Waetjen et al., 2004). There are no reported clinical trials evaluating the effect of androgens and, in particular, testosterone, on UI in women.

Desmopressin.

The endogenous hormone vasopressin (also known as *antidiuretic hormone*) has two main functions: It causes contraction of vascular smooth muscle, and it stimulates water reabsorption in the renal medulla. These functions are mediated by two specific vasopressin receptors, of which there are two major subtypes, namely **the V_1 and V_2 receptors. The V_2 subtype is particularly important for the antidiuretic effects of vasopressin.** A genetic or acquired defect in making and secreting vasopressin leads to central diabetes insipidus, and genetic defects in the gene encoding the V_2 receptor can cause nephrogenic diabetes insipidus (Insel et al., 2007). Accordingly, **decreased vasopressin levels are believed to be important in the pathophysiology of some forms of polyuria, specifically NP,** which can lead to symptoms such as nocturia (Matthiesen et al., 1996; Weiss et al., 2011a). Nocturia is currently defined by the ICS as the complaint that an individual has to wake at night one or more times to void. It is, however, “an underreported, understudied, and infrequently recognized problem in adults” (Weiss et al., 2011b). Nocturia leads to decreased QoL (Kupelian et al., 2011) and has been associated with both increased morbidity and mortality (Kupelian et al., 2012; Nakagawa et al., 2010). Although it remains largely unknown which fraction of patients with nocturia can indeed be explained by too little vasopressin, the presence of NP in the absence of behavioral factors explaining it (such as excessive fluid intake) is usually considered as an indication that a (relative) lack of vasopressin may exist (Bosch and Weiss, 2010; Weiss et al., 2011b).

Based on these considerations, vasopressin-receptor agonists have been used to treat nocturia, both in children and in adults. Desmopressin is the most common vasopressin analogue used to treat nocturia. Desmopressin shows selectivity for antidiuretic over vasopressor effects. It has a more powerful and longer-lasting antidiuretic action than vasopressin. It is available in formulations for oral, parenteral, and nasal administration. It has a fast onset of action, with urine production decreasing within 30 minutes of oral administration (Rittig et al., 1998). Because symptomatic hyponatremia with water intoxication, which is the only serious adverse event reported in children, occurred after intranasal or intravenous administration of desmopressin (Robson et al., 2007; Thumfart et al., 2005; Van de Walle et al., 2010), the FDA and the European Medicines Agency (EMA) removed the indication for the treatment of primary nocturnal enuresis from all intranasal preparations of desmopressin. An oral lyophilisate formulation (MELT) requiring no concomitant fluid intake is currently available. In a recent open-label, randomized, crossover study, desmopressin MELT was shown to have similar levels of efficacy and safety at lower doses than the tablet formulation of desmopressin in children. A recent study confirmed the superior pharmacodynamic characteristics of desmopressin MELT to desmopressin tablets (De Guchtenaere et al., 2011).

Glazener and Evans (2002) comprehensively reviewed the use of desmopressin in children with nocturnal enuresis. These authors evaluated 47 RCTs involving 3448 children, of whom 2210 received desmopressin. According to the analysis, desmopressin was effective relative to placebo in reducing bedwetting; a dose of 20 µg resulted in a reduction of 1.34 wets per night (95% CI 1.11 to 1.57), and children were more likely to become dry with desmopressin (98%) than with placebo (81%). However, there was no difference between desmopressin and placebo after discontinuation of treatment, indicating that **desmopressin suppresses the symptom of enuresis but does not cure the underlying cause.** In addition, not all children responded sufficiently to desmopressin monotherapy. The combination of desmopressin and an enuresis alarm resulted in a greatly improved short-term success rate and decreased relapse rates (Alloussi et al., 2011). The combination of desmopressin and antimuscarinics resulted in better short- and long-term success rates and a lower relapse rate than desmopressin alone (Alloussi et al., 2009; Austin et al., 2008). For nonresponders to desmopressin, replacement of desmopressin with other medications such as tricyclic antidepressants or loop diuretics could be of benefit, whereas muscarinic-receptor antagonists may be ineffective in such children (De Guchtenaere et al., 2007; Neveus and Tullus, 2008).

Other studies have explored a possible treatment role for desmopressin in the treatment of nocturia in adults. A search for these studies in Medline using the terms *desmopressin* and *nocturia* was performed and limited to clinical studies of de novo nocturia, that is, those that excluded subjects in whom childhood enuresis persisted into adulthood. Several previous studies investigated the use of desmopressin for the treatment of nocturia in the context of multiple sclerosis (Eckford et al., 1994, 1995). One study with single-dose administration reported a reduction in NP, but by design did not assess nocturia (Eckford et al., 1995). Three placebo-controlled, double-blind studies with small patient numbers (16 to

33 patients total per study) reported a significant reduction in nocturia (Eckford et al., 1994; Hilton et al., 1983; Valiquette et al., 1996). Other controlled studies of similar size, most with a crossover design, used micturition frequency within the first 6 hours after desmopressin administration rather than nocturia as their primary end point. These studies consistently reported that desmopressin treatment for up to 2 weeks was efficacious (Fredrikson, 1996; Hoverd and Fowler, 1998; Kinn and Larsson, 1990). Although desmopressin treatment was generally well tolerated, 4 of 17 patients in one study discontinued treatment because of asymptomatic or minimally symptomatic hyponatremia (Valiquette et al., 1996). Accordingly, **desmopressin is now registered for the treatment of nocturia in multiple sclerosis patients** (Cvetkovic and Plosker, 2005). In a small open-label study, desmopressin was also reported to reduce NP in SCI patients (Zahariou et al., 2007).

Further studies have explored the use of desmopressin in adults with nocturia in the apparent absence of neurologic damage. The recruited patient populations were based on different criteria, including having at least two nocturia episodes per night or having NP. Earlier studies mostly used a desmopressin dose of 20 µg given either orally (Asplund et al., 1999) or intranasally (Cannon et al., 1999; Hilton and Stanton, 1982), and tended to be very small (25 or fewer patients). Later studies, as part of the NOCTUPUS program, were considerably larger, involving a total of 1003 screened patients, and higher oral doses (0.1 to 0.4 mg) were administered for a period of 3 weeks of double-blind treatment in adults (Lose et al., 2004; Mattiasson et al., 2002; van Kerrebroeck et al., 2007). A total of 632 patients entered the dose-titration phase, and 422 patients entered the double-blind phase of the three NOCTUPUS trials. To counter the argument that the study was performed in desmopressin responders after the dose-titration phase, all patients in the NOCTUPUS trials were washed out after the dose-titration phase, and to be randomized the patients were required to be returned to baseline nocturnal diuresis before inclusion in the double-blind phase. The trials showed that oral desmopressin (0.1, 0.2, or 0.4 mg) is effective in both men and women 18 years of age or older with nocturia. The number of nocturnal voids decreased from 3 to 1.7 in the desmopressin group compared with 3.2 to 2.7 in the placebo group. In women, the number of nocturnal voids in the desmopressin group decreased from 2.92 to 1.61, whereas that in the placebo group decreased from 2.91 to 2.36. When clinical response was defined as 50% or greater reduction in nocturnal voids from baseline, 34% of men experienced clinical response with desmopressin, compared with 3% of men who received placebo.

In women, 46% of desmopressin-treated patients experienced a clinical response, compared with 7% of patients on placebo.

The efficacy of desmopressin for the treatment of nocturia was confirmed in a long-term (10 to 12 months) open-label study involving 249 patients, which was an extension of the randomized studies in known desmopressin responders. However, a rebound effect was seen when treatment was withdrawn, confirming the association between continued treatment and response (Lose et al., 2004). An open-label pilot study in a nursing home setting also reported that desmopressin had beneficial effects (Johnson et al., 2006).

Around 75% of community-dwelling men and women with nocturia (two or more voids per night) have NP (Rembratt et al., 2003; Swithinbank et al., 2004). The key urologic factors most relevant to nocturia are NP and OAB in women (Irwin et al., 2008) and NP and BPH in men. About 74% of women with OAB have nocturia, and 62% of patients with OAB and nocturia have NP. Among men with nocturia, 83% have NP, 20% have NP alone, and 63% have NP in combination with another factor such as a small nocturnal bladder capacity or BOO (Chang et al., 2006). Therefore, desmopressin combination therapy with α_1-AR antagonists and/or antimuscarinics should be considered for patients with treatment-resistant nocturia. Seventy-three percent of α_1-AR antagonist–resistant BPH patients experienced a 50% or greater reduction in nocturnal voids with oral desmopressin (Yoong et al., 2005). A randomized, double-blind, placebo-controlled study evaluating the long-term (1, 3, 6, and 12 months) efficacy and safety of low-dose (0.1 mg) oral desmopressin in elderly patients (≥65 years of age) reported that low-dose oral desmopressin led to a significant reduction in the number of nocturnal voids and nocturnal urine volume in patients with BPH (Wang et al., 2011).

Because nocturia can be caused by different factors, several studies have investigated whether desmopressin may be beneficial in patients with other symptoms in addition to nocturia. In a small, nonrandomized pilot study of men believed to have BPH, desmopressin was reported not only to improve nocturia, but also to reduce the overall IPSS (Chancellor et al., 1999). An exploratory, placebo-controlled, double-blind study in women with daytime UI reported that intranasal administration of 40 µg of desmopressin increased the number of leakage-free episodes 4 hours after drug administration (Robinson et al., 2004). One double-blind, placebo-controlled pilot study in patients with OAB treated with 0.2 mg of oral desmopressin reported a reduction in voids along with an improvement in QoL (Hashim et al., 2009). Although these data indicate that desmopressin may be effective in treating LUT dysfunction not limited to nocturia, they are too sparse to allow treatment recommendations.

Desmopressin was well tolerated in all the studies and resulted in significant improvements compared with placebo in reducing nocturnal voids and increasing the hours of undisturbed sleep. There was also an improvement in QoL. However, one of the main clinically important side effects of desmopressin use is hyponatremia. Hyponatremia can lead to a variety of adverse events ranging from mild headache, anorexia, nausea, and vomiting to loss of consciousness, seizures, and death. Hyponatremia usually occurs soon after treatment is initiated. **The risk for hyponatremia appears to increase with age, cardiac disease, and increasing 24-hour urine volume** (Rembratt et al., 2006). Based on a meta-analysis, the incidence is around 7.6% (Weatherall, 2004). **Increased age and female gender are well-known risk factors** for the development of desmopressin-induced hyponatremia. Bae et al. (2007) assessed the effects of long-term oral desmopressin on serum sodium and baseline antidiuretic hormone secretion in 15 elderly male patients with severe nocturia (more than three voids nightly) who did not show hyponatremia within 7 days of administration of 0.2 mg desmopressin. Desmopressin (0.2 mg) was administered orally nightly for 1 year. Before and 1 month after the 1-year medication, 24-hour circadian studies were performed to monitor changes in antidiuretic hormone. Every 3 months during the 1-year medication period, serum changes and timed urine chemistry were monitored. The results showed that long-term desmopressin administration gradually decreased serum sodium and induced statistically, but not clinically significant, hyponatremia after 6 months of treatment. Administration of desmopressin for 1 year did not affect baseline antidiuretic hormone secretion. The authors recommended that for long-term desmopressin administration, serum sodium should be assessed regularly, at least every 6 months.

A recent focus has been on exploring gender differences in the antidiuretic response to desmopressin. Juul et al. (2011) found an increasing incidence of hyponatremia with increasing dose, and **at the highest dose level of 100 µg, decreases in serum sodium were approximately twofold greater in women older than 50 years of age than in men.** The gender difference could not be explained by pharmacokinetic differences. They calculated an ED_{50} ratio for men/women to be 2.7 (1.3 to 8.1). A new dose recommendation stratified by gender was suggested in the treatment of nocturia: For men, 50 to 100 µg MELT was suggested to be an efficacious and safe dose, and for women a dose of 25 µg

MELT was recommended as efficacious with no observed incidences of hyponatremia. Weiss et al. investigated the efficacy and safety of 50 and 75 mcg of desmopressin orally disintegrating tablets in 385 men with nocturia. They showed that both doses increased the time to first void from baseline by approximately 40 minutes compared with placebo. The response to desmopressin was seen within 1 week of treatment and was sustained producing significant increases in health-related QoL and sleep quality compared with placebo. Only two subjects 74 and 79 years of age developed hyponatremia (Weiss et al., 2013). A similar study carried out in women explored the efficacy and safety of 25 mcg of desmopressin orally disintegrating tablets compared with placebo. In this study, 261 women with nocturia were randomized to either 25 mcg of desmopressin or placebo. Desmopressin significantly reduced the mean number of nocturnal voids compared with placebo and increased the mean time to first nocturnal void by 49 minutes compared with placebo. Once again, response was seen within the first week of treatment and sustained throughout the 3-month trial. Desmopressin was well tolerated with only three transient decreases in serum sodium level (Sand et al., 2013).

Initiation of desmopressin is currently not indicated for patients 65 years of age and older. The mechanisms behind desmopressin-induced hyponatremia are well understood, and **serum sodium monitoring at baseline and early during treatment of older patients for whom treatment with desmopressin is indicated can greatly reduce their risk for developing the condition.** Other advice regarding treatment administration, such as restriction of evening fluid intake and adherence to the recommended administration regimen, should be followed to minimize the risk for hyponatremia (Vande Walle et al., 2007).

Desmopressin is **useful for patients with nocturia and for children with nocturnal enuresis.** The drug has been proven to be well tolerated and effective in several randomized, placebo-controlled trials and is **recommended as a first-line treatment (either as monotherapy or in combination with other agents)** with proper precaution for patients who have been appropriately evaluated and whose nocturia is related to NP, whether or not this is accompanied by BPH or OAB. For assessment, see Table 120.3. A rapid-acting, quickly metabolized preparation with minimal risk for hyponatremia would obviously be useful for the treatment of nocturia in adults and could have application for “spot usage” for a limited period in patients with OAB.

Key Points: Desmopressin in Nocturnal Polyuria

- Desmopressin is an analogue of vasopressin that shows selectivity for antidiuretic effects (water reabsorption in the renal medulla) over vasopressor effects. It suppresses the symptom of nocturnal enuresis in children without curing the underlying cause. It has been used in a number of studies in patients with and without neurogenic disease for the treatment of nocturia. Results in general have been statistically significant improvements in nocturnal voids and hours of undisturbed sleep.
- The most important adverse event is hyponatremia, an increased risk for which is seen with age, female gender, cardiac disease, and increased 24-hour urine volume. Some regimen of serum sodium monitoring is indicated along with other advice designed to minimize the risk for hyponatremia.

Drug Treatment of Overactivity in Augmented or Intestinal Neobladders

With regard to the subject of overactivity in augmented bowel or intestinal neobladders, Andersson et al. (1992) reviewed this subject and its pharmacologic treatment. They noted a few instances of positive results with drugs given systematically, but locally applied agents were believed to offer more promise. Pure antimuscarinic agents had produced few good results, either locally or systemically. Oxybutynin had shown some good results with local therapy but poor results with systemic therapy. The α- and β-AR agonists had shown little or no effects. Other possibilities mentioned included opioid agonists (diphenoxylate and loperamide), calcium antagonists, potassium channel openers, and NO donors. Apostolidis et al. (2007) reported a case of successful treatment with botulinum toxin A after failed augmentation ileocystoplasty.

Future Possibilities

Peripherally Acting Drugs

Vitamin D_3-Receptor Analogues.

It is well known that vitamin D affects skeletal muscle strength and functional efficiency, and vitamin D insufficiency has been associated with notable muscle weakness. The levator ani and coccygeus skeletal muscles are critical components of the pelvic floor and may be affected by vitamin D nutritional status. Weakened pelvic floor musculature is thought to be associated with the development of UI and fecal incontinence symptoms. Aging women are at increased risk for both pelvic floor dysfunction and vitamin D insufficiency; to date, only small case reports and observational studies have shown an association between insufficient vitamin D and pelvic floor dysfunction symptom severity (Parker-Autry et al., 2012). Rat and human bladders were shown to express receptors for vitamin D (Crescioli et al., 2005), which makes it conceivable that the bladder may also be a target for vitamin D. Analogues of vitamin D_3 have also been shown to inhibit BPH cell proliferation and to counteract the mitogenic activity of potent growth factors for BPH cells (Crescioli et al., 2002, 2003, 2004). Experiments in rats with bladder outflow obstruction (Schröder et al., 2006) showed that one of the analogues, BXL-628, at nonhypercalcemic doses did not prevent bladder hypertrophy, but reduced the decrease in contractility of the bladder smooth muscle that occurred with increasing bladder weight (Schröder et al., 2006). The mechanism of action for the effects has not been clarified. However, elocalcitol was shown to have an inhibitory effect on the RhoA/Rho-kinase pathway (Morelli et al., 2007). Upregulation of his pathway has been associated with bladder changes associated with diabetes, outflow obstruction, and DO (Peters et al., 2006; Christ and Andersson, 2007). In rats with outflow obstruction, previous elocalcitol treatment improved the effects of tolterodine on bladder compliance (Streng et al., 2012). It was suggested that in rats, elocalcitol exerted additional beneficial actions on outflow obstruction–induced functional changes during the filling phase of micturition. If this finding is valid in humans, combined therapy with the drug would be of value.

The effect of elocalcitol on prostate volume was evaluated in patients with BPH, and it was found that elocalcitol was able to arrest prostate growth within 12 weeks in men 50 years of age and older with prostatic volume of 40 mL or greater (Colli et al., 2006). In an RCT enrolling 120 female patients with OAB in which the primary end point was an increase in MVV, a significant increase versus placebo (22% vs. 11%) was demonstrated (Colli et al., 2007). **The determination of whether or not vitamin D–receptor agonism (monotherapy or in combination) will be a useful alternative for the treatment of LUTS and OAB requires further RCTs. However, currently the development of the drug seems to be stopped** (Tiwari, 2009).

Transient Receptor Potential Channel Antagonists.

The **TRP channel superfamily has been shown to be involved in nociception and mechanosensory transduction in various organ systems,** and studies of the LUT have indicated that several TRP channels, including TRPV1, TRPV2, TRPV4, TRPM8, and TRPA1, are expressed in the bladder and may act as sensors of stretch and/or chemical irritation (Andersson et al., 2010a; Araki et al., 2008, 2011; Avelino et al., 2013; Deruyver et al., 2015; Everaerts et al., 2008; Franken et al., 2014). **TRPV1 and TRPV4 channels have been found to be expressed in the urinary bladder** (Birder et al., 2001; Gevaert et al., 2007; Tominaga et al., 1998). TRPV1 is present and active both in the urothelium and in the nerve fibers of several species including humans (Charrua et al., 2009b; Ji et al., 2002). TRPV4 was initially described in the urothelium of rodents and humans (Janssen et al., 2011). Coexpression of the two receptors was observed in 20% of rat urothelial cells (Kullmann et al., 2009). Recent observations indicate, however, that TRPV4 may also be expressed in bladder afferents. In fact, about 30% of L6 dorsal root ganglia neurons that project to the urinary bladder coexpress TRPV1 and TRPV4 (Cao et al., 2009). The physiologic meaning of this observation is unclear.

TRPV1 KO mice have a normal or quasi-normal phenotype. In awake animals, the only change detected in TRPV1 KO mice was a smaller volume per void when compared with wild-type (WT) controls (Birder et al., 2001). In cystometries performed under anesthesia, the TRPV1 KO mice phenotype seems also very benign. Some studies reported that these animals have totally normal cystometric traces (Charrua et al., 2007). However, other studies showed that TRPV1 KO mice develop a few nonvoiding contractions preceding the voiding contraction (Birder et al., 2001; Frias et al., 2012). Accordingly, TRPV1 antagonists (GRC-6211) did not show any relevant effect on bladder activity of intact rodents (Charrua et al., 2009a). In contrast with TRPV1 KO mice, the micturition phenotype of TRPV4 KO animals is clearly abnormal. TRPV4 KO mice are incontinent, most likely because of incomplete bladder emptying (Gevaert et al., 2007). Cystometric studies carried out under physiologic conditions revealed that TRPV4 KO mice have a marked increase in the intercontraction interval when compared with WT littermates (Birder et al., 2002; Gevaert et al., 2007). Likewise, TRPV4 antagonists (HC-067047) decreased the frequency of bladder contractions and increased the intercontraction interval (Everaerts et al., 2010). These observations indicated that TRPV4 has a role in the control of the normal micturition reflex.

Indisputably, TRPV1 and TRPV4 have a role in the increase of micturition frequency associated with cystitis (Charrua et al., 2007; Everaerts et al., 2010). Whereas inflamed WT mice exhibit bladder hyperactivity and intense spinal Fos expression after different forms of bladder inflammation, including acetic acid or bacterial extracts, TRPV1 KO mice have normal cystometries and normal spinal c-Fos expression (Charrua et al., 2007). The same holds true for TRPV4. In fact, TRPV4 KO mice exhibit significantly lower voiding frequencies and larger voided volumes than WT after inflammation with cyclophosphamide (Everaerts et al., 2010).

The blockade of TRPV1 and TRPV4 with specific antagonist confirms the observations carried out in KO animals. As a matter of fact, the TRPV1 antagonist GRC-6211 and the TRPV4 antagonist HC-067047 both abolish the increase of micturition frequency associated with chemical cystitis (Charrua et al., 2009a; Everaerts et al., 2010). Systemic coadministration of TRPV1 and TRPV4 antagonist was more effective in treating the cystitis-induced increase of micturition frequency than the individual application of each antagonist (Avelino et al., 2013). In particular, the effect could be observed at very low doses of the TRPV1 and TRPV4 antagonists, which had no effect when given isolated. This observed effect might be the answer to overcome the eventual adverse events related to the application of some of these antagonists (Planells-Cases et al., 2011). Just to mention a few, TRPV1 antagonists are associated with hyperthermia and increased risk for cardiac ischemia (Avelino et al., 2013), and TRPV4 antagonists may eventually precipitate urinary retention and overflow incontinence (Gevaert et al., 2007).

It has long been known that TRPV1 is involved in the emergence of NDO after spinal cord transection (Avelino and Cruz, 2006). A TRPV1 antagonist, GRC-6211, has been shown to decrease reflex DO in rats after chronic spinal cord transection. With increasing doses, it was possible to obtain a total suppression of bladder activity (Santos-Silva et al., 2012).

Interestingly, Uvin et al. (2015) found evidence for involvement of TRPM8 in rat and mouse models of acute cold-induced urinary urgency.

There seem to be several links between activation of different members of the TRP superfamily and LUTS, DO, and OAB, and further exploration of the involvement of these channels in LUT function, normally and in dysfunction, may be rewarding. However, proof-of-concept studies in humans are still lacking.

Prostanoid-Receptor Agonists and Antagonists.

Developments in the field of prostanoid receptors may open new possibilities for use of selective prostanoid-receptor antagonists for OAB and DO treatment (Aoki et al., 2009; Jones et al., 2009). There is evidence suggesting that PGE_2 contributes to the pathophysiology of OAB and DO: PGE_2 infused into the bladder induces DO in humans and animals and increases PGE_2 production in DO models, and there are high concentrations of PGE_2 in the urine of patients with OAB (McCafferty et al., 2008). PGE_2 is an agonist at EP receptors 1 to 4, all G protein–coupled, which mediate its physiologic effects. Based on studies using KO mice and EP_1-receptor antagonists, it was suggested that the effects of PGE_2 on bladder function were mediated through EP_1 receptors (Schröder et al., 2004). EP receptors can be found on urothelium/suburothelium, in detrusor smooth muscle, and in intramural ganglia (Rahnama'i et al., 2010, 2011; Wang et al., 2008). Functionally, it has been proposed that modulation of bladder activity exerted via EP_1 receptors occurs via an afferent mechanism. Schröder et al. (2004) found no difference in urodynamic parameters between unobstructed EP_1 receptor KO and WT mice. However, EP_1 receptor KO mice did not respond to intravesical PGE_2 instillation, whereas WT mice developed DO. The lack of EP_1 receptor did not prevent bladder hypertrophy caused by partial bladder outflow obstruction, but after obstruction WT mice had pronounced DO, whereas this was negligible in EP_1 receptor KO mice.

Lee et al. (2008b) found that in normal rats a selective EP-receptor antagonist significantly increased bladder capacity, micturition volume, and micturition intervals. The antagonist significantly decreased the stimulatory effects of PGE_2 and decreased the frequency and amplitude of nonvoiding contractions in animals with BOO. It has also been shown that EP_3 receptor KO mice have a diminished response to bladder infusion of PGE_2 and demonstrate an enhanced bladder capacity under basal conditions (Jones et al., 2009). These findings suggest an important contribution for EP_3 receptors in the modulation of bladder function under physiologic conditions and under conditions of enhanced PGE_2 production evoking DO. Thus, EP_1 and EP_3 receptors may have a role in PGE_2-mediated DO.

It is interesting to note that activation of EP_3 receptors evoked diuresis and that EP_3-receptor antagonism was found to induce an antidiuretic effect (Jugus et al., 2009). Thus, to modulate bladder activity, it appears that the EP_3 receptor has a role in regulating urine production. Both effects may be useful for treatment of OAB and DO. It cannot be denied that EP_1 and EP_3 receptors constitute interesting and promising targets for drugs aimed at OAB and DO treatment. However, a randomized, double-blind, placebo-controlled phase II study to investigate the efficacy and safety of the EP_1-receptor antagonist ONO-8539 in patients with OAB syndrome suggests that the role of EP_1-receptor antagonism in the management of the OAB syndrome is minimal (Chapple et al., 2014a).

Intraprostatically Injected Drugs

NX-1207.

NX-1207 is a **new drug under investigation for the treatment of LUTS associated with BPH.** It is a new therapeutic protein of proprietary composition with selective proapoptotic properties (Shore, 2010). The drug is injected directly into the transitional zone of the prostate as a single administration to induce focal cell loss in prostate tissue through apoptosis, leading to nonregressive prostate shrinkage and both short- and long-term symptomatic improvement. Information about the drug is scarce and mostly published in abstract form and not yet in the peer-reviewed literature. Two US phase II trials have been performed (Shore, 2010). One of them was a multicenter, randomized, noninferiority study involving 32 clinical sites with 85 patients and two dose ranges (2.5 and 0.125 mg) and an active open-label comparator (finasteride). Patients and investigators on NX-1207 were double-blind as to dose. The primary end point was change in American Urological Association (AUA) Symptom Index score at 90 and 180 days for a single injection of NX-1207 as compared with finasteride on a noninferiority basis. Inclusion criteria included an AUA symptom score of 15 or higher, diminished peak urine flow (<15 mL/sec), and a prostate size of 30 to 70 mg. The mean AUA symptom score improvement after 90 days in the intent-to-treat group was 9.71 points for 2.5-mg NX-1207 ($n = 48$) versus 4.13 points for finasteride ($n = 24$) ($P = .001$) and 4.29 for 0.125-mg NX-1207 ($n = 7$) ($P = .034$). The 180-day results also were positive (NX-1207 2.5 mg noninferior to open-label finasteride).

No significant changes in serum testosterone or serum prostate-specific antigen (PSA) levels were noted in the NX-1207 cohorts. There were no reported adverse effects on sexual function. Two US multicenter, double-blind, placebo-controlled phase III studies are currently underway. The results of such studies are needed to assess whether or not this therapeutic principle is a useful addition to the current treatment alternatives.

PRX302.

PRX302 is a modified form of proaerolysin, a highly toxic bacterial pore-forming protoxin that requires proteolytic processing by PSA (Singh et al., 2007). The safety and efficacy of PRX302 was evaluated in men with moderate-to-severe BPH (Denmeade et al., 2011). The patients were refractory, intolerant, or unwilling to undergo medical therapies for BPH and had an IPSS higher than 12, a QoL score higher than 3, and prostate volumes of 30 to 80 g. Fifteen patients were enrolled in phase I studies, and 18 patients entered phase II studies. Patients received intraprostatic injection of PRX302 into the right and left transition zone via a transperineal approach in an office-based setting. Phase I subjects received increasing concentrations of PRX302 at a fixed volume; phase II subjects received increasing volumes per deposit at a fixed concentration. IPSS, QoL, prostate volume, Qmax, IIEF score, serum PSA levels, pharmacokinetics, and adverse events were recorded at 30, 60, 90, 180, 270, and 360 days after treatment. Sixty percent of men in the phase I study and 64% of men in the phase II study treated with PRX302 had greater than 30% improvement compared with baseline in IPSS out to day 360. Patients also experienced improvement in QoL and reduction in prostate volume out to day 360. Patients receiving more than 1 mL of PRX302 per deposit had the best response overall. There were no deleterious effects on erectile function. Adverse events were mild to moderate and transient in nature. The major study limitation was the small sample size.

Elhilali et al. (2013) conducted a phase IIb double-blind safety and efficacy evaluation of intraprostatic injection of PRX302 in 92 patients with IPSS of 15 or greater, peak urine flow of 12 mL/sec or less, and prostate volume of 30 to 100 mL. The patients were randomized 2 : 1 to a single ultrasound-guided intraprostatic injection of PRX302 versus vehicle (placebo). It was concluded that PRX302 produced clinically meaningful and statistically significant improvement in patient subjective (IPSS) and quantitative objective (peak urine flow) measures sustained for 12 months.

Cannabinoids.

There is increasing evidence that cannabinoids can influence micturition in animals and in humans, both normally and in bladder dysfunction (Ruggieri, 2011). The effects of the cannabinoids are exerted via two types of well-defined receptors, CB_1 and CB_2, distributed widely in the body. However, additional receptor subtypes cannot be excluded (Pertwee et al., 2010; Ruggieri, 2011). Both in the CNS and in peripheral tissues, CB_1 and CB_2 receptors have been identified; centrally CB_1 and peripherally CB_2 receptors seem to be predominant (Pertwee et al., 2010; Ruggieri, 2011). CB_1 and CB_2 receptors have been identified in all layers of the human bladder (Gratzke et al., 2009; Merriam et al., 2008; Tyagi et al., 2009; Walczak et al., 2009); their expression in the urothelium was found to be significantly higher than in the detrusor, and the expression of CB_1 was higher than that of CB_2 (Tyagi et al., 2009). Gratzke et al. (2009) found higher expression of CB_2 receptors, but not CB_1 receptors, in the mucosa than in the detrusor. Compared with the detrusor, larger amounts of CB_2 receptor–containing nerves that also expressed TRPV1 or CGRP were observed in the suburothelium. Nerve fibers containing CB_2 receptors and VAChT (cholinergic neurons) were located in the detrusor. In general, activation of CB_1 peripherally has been associated with vasodilation and motility changes via suppression of release of neurotransmitters, whereas activation of CB_2 appears to induce anti-inflammatory, antinociceptive, and immunosuppressive actions (Pertwee et al., 2010; Ruggieri, 2011). Several animal studies have suggested a modulatory role of CB_2 receptors in both afferent signaling and cholinergic nerve activity (Gratzke et al., 2009, 2010, 2011). Thus, in vivo, the selective CB_2-receptor agonist, cannabinor, increased micturition intervals and volumes and increased threshold and flow pressures, suggesting that peripheral CB_2 receptors may be involved in sensory functions. In rats with partial urethral obstruction treated daily for 14 days with cannabinor, bladder weight was lower, the ability to empty the bladder was preserved, and nonvoiding contraction frequency was low compared with those in controls.

The key enzyme for the degradation of anandamide and other endogenous cannabinoids is fatty acid amide hydrolase (FAAH). FAAH was found to be expressed in rat and human urothelium and was coexpressed with CB_2 receptors. In rats, an FAAH inhibitor altered urodynamic parameters that reflect sensory functions, suggesting a role for the endocannabinoid system in bladder mechanoafferent functions (Strittmatter et al., 2012).

It has not been established whether the effects of the cannabinoids are exerted in the CNS (brain, spinal cord) or peripherally. In a preliminary report, Blyweert et al. (2003) demonstrated an effect of combined CB_1/CB_2-receptor activation on DO in rats with spinal cord transection, which seemed to exclude the brain as a main site of action.

Clinical experiences with cannabinoid treatment of micturition disturbances including LUTS are limited (Ruggieri, 2011), but both open-label and placebo-controlled studies have demonstrated that orally administered cannabinoid modulators may alleviate neurogenic OAB symptoms refractory to first-line treatment (Brady et al., 2004b; Freeman et al., 2006; Kavia et al., 2010). Brady et al. (2004b) evaluated the efficacy of two whole-plant extracts (Δ^9-tetrahydrocannabinol and cannabidiol) of *Cannabis sativa* in patients with advanced MS and refractory LUTS. Urinary urgency, the number and volume of incontinence episodes, frequency, and nocturia decreased significantly after treatment. Freeman et al. (2006) tested in a subanalysis of a multicenter trial (the Cannabinoids in Multiple Sclerosis [CAMS] study) whether cannabinoids could decrease urgency incontinence episodes without affecting voiding in patients with MS. The CAMS study randomized 630 patients to receive oral administration of the cannabis extract Δ^9-tetrahydrocannabinol or matched placebo. Based on incontinence diaries, a significant decrease in incontinence episodes was demonstrated.

Kavia et al. (2010) assessed the efficacy, tolerability, and safety of Sativex (nabiximols) as an add-on therapy in alleviating bladder symptoms in patients with MS. They performed a 10-week, double-blind, randomized, placebo-controlled, parallel-group trial on 135 randomized subjects with MS and OAB. The primary end point, reduction in daily number of UI episodes from baseline to end of treatment (8 weeks), showed little difference between Sativex and placebo. However, four of seven secondary end points were significantly in favor of Sativex, including number of episodes of nocturia, number of voids per day, and number of daytime voids. The improvement in I-QoL was in favor of Sativex but did not reach statistical significance.

Systemic cannabinoids have effects on the LUT that may have therapeutic potential; local delivery (intravesical, spinal) may be possible, but more information is needed. The mechanisms of cannabinoid receptors in control of the human LUT are incompletely known, and **further research is necessary for the development of novel cannabinoid drugs for treatment of LUT disorders.**

Centrally Acting Drugs.

Many parts of the brain seem to be activated during storage and voiding (Fowler et al., 2008; Griffiths, 2007, 2011; Griffiths and Tadic, 2008), and there is increasing interest in drugs modulating the micturition reflex by a central action (Andersson and Pehrson, 2003). Several drugs used for pain treatment also affect micturition, morphine and some antiepileptic drugs being a few examples. However, **central nervous mechanisms have so far not been preferred targets for drugs aimed to treat OAB, because selective actions may be difficult to achieve.** Holstege (2005), reviewed some of the central mechanisms involved in micturition, including the periaqueductal gray (PAG) and the pontine micturition center (PMC). In this review, Holstege suggested that “the problem in OAB or urgency-incontinence is at the level of the PAG or PMC and their connections, and possible treatments for this condition should target the micturition pathways at that level.”

Gonadotropin-Releasing Hormone Antagonists.

The beneficial effects of the 5α-reductase inhibitors finasteride and dutasteride in the treatment of male LUTS are well documented. The efficacy of other hormonal treatments—for example, antiandrogens or gonadotropin-releasing hormone (GnRH; also known as *luteinizing hormone-releasing hormone* [LHRH]) agonists—is either poor or occurs at the expense of unacceptable side effects such as medical castration associated with hot flushes, decrease of potency and libido, and negative effects on bone density after long-term androgen ablation (Eri and Tveter, 1993; Bosch et al., 1989; Peters and Walsh, 1987; Schroeder et al., 1986). With GnRH antagonists, submaximal noncastrating blockade of the androgen testosterone and consequently of dihydrotestosterone can be achieved, thus avoiding medical castration. Several GnRH antagonists, such as cetrorelix, ozarelix, and teverelix, have been tested in phase IIA/IIB clinical trials for their ability to improve LUTS in patients with BPH (Colli and Tankó, 2010).

In a phase II RCT, Debruyne et al. (2008) demonstrated that the LHRH antagonist cetrorelix, given subcutaneously weekly for 20 weeks to 140 men with LUTS (IPSS ≥13, peak urinary flow rates 5 to 13 mL/sec), rapidly caused a significant improvement in the mean IPSS. The peak decrease was −5.4 to −5.9 versus −2.8 for placebo. All dosage regimens tested were well tolerated, and the authors concluded that the drug offered a safe and effective treatment for male LUTS.

Because of these results, two phase III studies were conducted in the United States and Europe (Æterna Zentaris); in the US study, 637 men were randomized to receive either two doses of placebo or cetrorelix on weeks 2 and 26. The drug showed no statistically significant benefit in improving IPSS. In addition, cetrorelix did not have a significant effect on peak flow rate or prostate volume versus placebo. It is difficult to reconcile this lack of efficacy, given favorable prior results. A subsequent multicenter European trial also failed to show any treatment-related efficacy of cetrorelix. The experience with cetrorelix highlights the importance of randomized, placebo-controlled trials that are appropriately powered to show clinical benefit and safety.

Gabapentin.

Gabapentin is one of the new first-generation antiepileptic drugs that expanded its use into a broad range of neurologic and psychiatric disorders (Striano and Striano, 2008). It was originally designed as an anticonvulsant GABA mimetic capable of crossing the blood-brain barrier (Maneuf et al., 2003). The effects of gabapentin, however, do not appear to be mediated through interaction with GABA receptors, and its **mechanism of action remains controversial** (Maneuf et al., 2003). It has been suggested that it acts by binding to a subunit of the $\alpha_2\delta$ unit of voltage-dependent calcium channels (Gee et al., 1996; Striano and Striano, 2008). Gabapentin is also **widely used not only for seizures and neuropathic pain, but for many other indications, such as anxiety and sleep disorders, because of its apparent lack of toxicity.**

Carbone et al. (2006) reported on the effect of gabapentin on NDO. They found a positive effect on symptoms and significant improvement in urodynamic parameters and suggested that the effects of the drug should be explored in further controlled studies in both NDO and non-neurogenic DO. Kim et al. (2004) studied the effects of gabapentin in patients with OAB and nocturia who were not responding to antimuscarinics. They found that 14 of 31 patients improved with oral gabapentin. The drug was generally well tolerated, and the authors suggested that it can be considered in selective patients when conventional modalities have failed. **It is possible that gabapentin and other $\alpha_2\delta$ ligands (e.g., pregabalin and analogues) will offer new therapeutic alternatives, but convincing RCTs are still lacking.**

Tramadol.

Tramadol is a well-known analgesic drug (Grond and Sablotzki, 2004). By itself,

it is a weak μ-receptor agonist, but it is metabolized to several different compounds, some of them almost as effective as morphine at the μ receptor. However, the drug (metabolites) also inhibits serotonin (5-HT) and noradrenaline reuptake (Grond and Sablotzki, 2004). This profile is of particular interest, because both μ-receptor agonism and amine reuptake inhibition may be useful principles for treatment of LUTS, OAB, and DO, as shown in a placebo-controlled study with duloxetine (Steers et al., 2007).

In rats, tramadol abolished experimentally induced DO caused by cerebral infarction (Pehrson and Andersson, 2003). Tramadol also inhibited DO induced by apomorphine in rats (Pehrson and Andersson, 2003)—a crude model of bladder dysfunction in Parkinson disease. Singh et al. (2008) gave tramadol epidurally and found the drug to increase bladder capacity and compliance and to delay filling sensations without adverse effects on voiding. Safarinejad and Hosseini (2006) evaluated in a double-blind, placebo-controlled, randomized study the efficacy and safety of tramadol in patients with IDO. A total of 76 patients 18 years or older were given 100 mg of tramadol SR every 12 hours for 12 weeks. Clinical evaluation was performed at baseline and every 2 weeks during treatment. Tramadol significantly ($P < .01$) reduced the number of incontinence periods per 24 hours from 3.2 ± 3.3 to 1.6 ± 2.8) and induced improvements in urodynamic parameters. The main adverse event was nausea. It was concluded that in patients with non-neurogenic DO, tramadol provided beneficial clinical and urodynamic effects. **However, the study was later retracted because of unacceptable statistical errors** (Safarinejad and Hosseini, 2006; retracted 2014).

Even if tramadol may not be the most suitable drug for treatment of LUTS and OAB, the **study suggests efficacy for modulation of micturition via the μ receptor.**

NK_1-Receptor Antagonists.

The main endogenous tachykinins—SP, neurokinin A (NKA), and neurokinin B (NKB)—and their preferred receptors—NK_1, NK_2, and NK_3, respectively—have been demonstrated in various CNS regions, including those involved in micturition control (Covenas et al., 2003; Lecci and Maggi, 2001; Saffroy et al., 2003). NK_1 receptor–expressing neurons in the dorsal horn of the spinal cord may play an important role in DO, and tachykinin involvement via NK_1 receptors in the micturition reflex induced by bladder filling has been demonstrated (Ishizuka et al., 1994) in normal rats and, more clearly, rats with bladder hypertrophy secondary to BOO. Capsaicin-induced DO was reduced by blocking NK_1 receptor–expressing neurons in the spinal cord, using intrathecally administered SP-saponin conjugate (Seki et al., 2005). Furthermore, blockade of the spinal NK_1 receptor could suppress detrusor activity induced by dopamine receptor (L-dopa) stimulation (Ishizuka et al., 1995).

In conscious rats undergoing continuous cystometry, antagonists of both NK_1 and NK_2 receptors inhibited micturition, decreasing micturition pressure and increasing bladder capacity at low doses and inducing dribbling incontinence at high doses. This was most conspicuous in animals with outflow obstruction (Gu et al., 2004). Intracerebroventricular administration of NK_1- and NK_2-receptor antagonists to awake rats suppressed detrusor activity induced by dopamine receptor (L-dopa) stimulation (Ishizuka et al., 2000). Taken together, available information suggests that spinal and supraspinal NK_1 and NK_2 receptors may be involved in micturition control.

Aprepitant, an NK_1-receptor antagonist used for treatment of chemotherapy-induced nausea and vomiting (Massaro and Lenz, 2005), significantly improved symptoms of OAB in postmenopausal women with a history of urgency incontinence or mixed incontinence (with predominantly UUI), as shown in a well-designed pilot RCT (Green et al., 2006). The primary end point was percent change from baseline in average daily micturitions assessed by a voiding diary. Secondary end points included average daily total UI and urgency incontinence episodes and urgency episodes. Aprepitant significantly ($P < .003$) decreased the average daily number of micturitions (−1.3 ± 1.9) compared with placebo (−0.4 ± 1.7) at 8 weeks. The average daily number of urgency episodes was also significantly ($P < .047$) reduced (−23.2 ± 32%) compared with placebo (−9.3 ± 40%), and so were the average daily number of urgency incontinence and total UI episodes, although the difference was not statistically significant. In general, aprepitant was well tolerated and the incidence of side effects, including dry mouth, was low.

Since this initial proof-of-concept study suggested that NK_1-receptor antagonism holds promise as a potential treatment approach for OAB symptoms, a randomized, double-blind, multicenter trial enrolled 557 adults with OAB (eight or more average daily micturitions and one or more daily urgency incontinence episodes) (Frenkl et al., 2010). After a 1-week placebo run-in, the patients were randomized to treatment with 8 weeks of daily 0.25-, 1-, or 4-mg serlopitant; 4-mg tolterodine ER; or placebo. Patients kept 7-day voiding diaries. The primary end point was change from baseline in micturitions per day. Secondary end points included urgency, total incontinence, urgency incontinence episodes, and incidence of dry mouth. Of the 557 patients randomized, 476 completed the trial and had valid efficacy data for analysis. Mean change from baseline in daily micturitions was significantly greater for 0.25-mg (−1.1) and 4-mg (−1.1) serlopitant and for tolterodine (−1.5) than for placebo (−0.5), but not for 1-mg serlopitant (−0.8). No serlopitant dose response was demonstrated. Tolterodine was numerically superior to all doses of serlopitant in mean micturitions per day and secondary end points. The incidence of dry mouth on serlopitant (3.3%) was comparable to that on placebo (4.6%) and lower than tolterodine (8.8%). Serlopitant was generally well tolerated.

Haab et al. (2014) performed a phase II, multicenter, double-blind study in which adults with OAB symptoms for longer than 6 months were randomized to receive one of three doses of netupitant (50, 100, or 200 mg) or placebo once daily for 8 weeks. The primary efficacy end point was percentage change from baseline in average number of daily micturitions at week 8. UI, UUI, and urgency episodes were also assessed. They found that the primary efficacy end point was similar in the treatment groups (–13.85 for placebo to –16.17 in the netupitant 200-mg group), with no statistically significant differences between netupitant and placebo.

NK_1-receptor antagonists may have a role in the treatment of OAB, but at least the compounds tested so far do not offer advantages in efficacy compared with tolterodine.

A different approach, modulation of neuropeptide release rather than NK-receptor blockade, was tested in a pilot study with cizolirtine, which is an SP and CGRP release modulator at the spinal cord level. The modulation of SP and CGRP is probably related to the increase in extracellular levels of NA and serotonin. Cizolirtine 200 and 400 mg were compared with placebo in 79 OAB patients. Although the decrease in key OAB symptoms was significantly higher in the active arms, adverse events were reported in 68% and 81% of the patients on cizolirtine 200 and 400 mg, respectively. More commonly reported side effects were gastrointestinal in nature, including dry mouth and dizziness (Martínez-García et al., 2009).

Key Points: Overactive Bladder Mechanisms and

Targets

- There are a number of possibilities, mostly based on theoretic mechanisms of action and studies in experimental animals, for drugs to favorably affect the symptoms of OAB and NDO or IDO.
- These mechanisms, at both the central and the peripheral levels, are intriguing, but with the possible exception of drugs directed at prostate bulk or internal organization, none have achieved consistent clinical success.

Increasing Outlet Resistance

Many factors seem to be involved in the pathogenesis of SUI: urethral support, vesical neck function, and function of the nerves and musculature of the bladder, urethra, and pelvic floor (Chapple and Milsom, 2012; DeLancey, 1997; Koelbl et al., 2009; Mostwin et al., 2005). **Anatomic factors cannot be treated pharmacologically. However, women with SUI have lower resting urethral pressures than age-matched continent women** (Henriksson et al., 1979; Hilton et al., 1983)**, and because it seems likely that there is a reduced urethral closure pressure in most women with SUI, it seems logical to increase urethral pressure to improve the condition.**

Factors that may contribute to urethral closure include tone of urethral smooth and striated muscle and the passive properties of the urethral lamina propria, in particular its vasculature. The relative contribution to intraurethral pressure of these factors is still subject to debate. However, there is ample pharmacologic evidence that a substantial part of urethral tone is mediated through stimulation of α-ARs in the urethral smooth muscle by released NA (Andersson, 1993; Andersson and Wein, 2004). A contributing factor to SUI, mainly in elderly women with lack of estrogen, may be lack of mucosal function. **The pharmacologic treatment of SUI aims at increasing intraurethral closure forces by increasing the tone in the urethral smooth and striated muscles. Several drugs may contribute to such an increase** (Andersson, 1988; Zinner et al., 2004), but relative lack of efficacy and/or side effects have limited their clinical use. For assessments, see Table 120.4.

Drugs Used for Treatment of Stress Incontinence in Women

Estrogens

Estrogens and the Continence Mechanism.

The estrogen-sensitive tissues of the bladder, urethra, and pelvic floor all play an important role in the continence mechanism. For women to remain continent, the urethral pressure must exceed the intravesical pressure at all times except during micturition. **The urethra has four estrogen-sensitive functional layers, all of which have a role in the maintenance of a positive urethral pressure: (1) epithelium, (2) vasculature, (3) connective tissue, and (4) muscle.**

Two types of estrogen receptors (α and β) have been identified in the trigone of the bladder, urethra, and vagina, and in the levator ani muscles and fascia and ligaments within the pelvic floor (Copas et al., 2001; Gebhardt et al., 2001; Smith et al., 1990). After menopause, estrogen receptor α has been shown to vary depending on exogenous estrogen therapy (Fu et al., 2003). In addition, exogenous estrogens affect the remodeling of collagen in the urogenital tissues, resulting in a reduction of the total collagen concentration with a decrease in the cross-linking of collagen in both continent and incontinent women (Falconer et al., 1998; Keane et al., 1997). Studies in both animals and humans have shown that estrogens also increase vascularity in the periurethral plexus, which can be measured as vascular pulsations on urethral pressure profilometry (Endo et al., 2000; Robinson et al., 1996; Versi and Cardozo, 1986).

Estrogens for Stress Urinary Incontinence.

The role of estrogen in the treatment of SUI has been controversial despite a number of reported clinical trials (Hextall, 2000). Some have given promising results, but this may have been because they were small observational studies and not randomized, blinded, or controlled. The situation is further complicated by the fact that a number of different types of estrogen have been used with varying doses, routes of administration, and durations of treatment.

Fantl et al. (1996) treated 83 hypoestrogenic women with urodynamic stress incontinence and/or DO with CEEs 0.625 mg and medroxyprogesterone 10 mg cyclically for 3 months. Controls received placebo tablets. At the end of the study period, the clinical and QoL variables had not changed significantly in either group. Jackson et al. (1996) treated 57 postmenopausal women with urodynamic stress or mixed incontinence with estradiol 2 mg or placebo daily for 6 months. There was no significant change in objective outcome measures, although both the active and placebo groups reported subjective benefit.

Two meta-analyses of early data have been performed. In the first, a report by the Hormones and Urogenital Therapy (HUT) Committee, the use of estrogens to treat all causes of incontinence in postmenopausal women was examined (Fantl et al., 1994). Of 166 articles identified, which were published in English from 1969 to 1992, only 6 were controlled trials and 17 were uncontrolled series. **The results showed that there was a significant subjective improvement for all patients and those with urodynamic stress incontinence. However, assessment of the objective parameters revealed that there was no change in the volume of urine lost;** maximum urethral closure pressure increased significantly, but this result was influenced by only one study showing a large effect.

In the **second meta-analysis,** Sultana and Walters (1990) reviewed 8 controlled and 14 uncontrolled prospective trials and included all types of estrogen treatment. They also found that **estrogen therapy was not an efficacious treatment for SUI** but may be useful for the often associated symptoms of urgency and frequency. **Estrogen when given alone therefore does not appear to be an effective treatment for SUI.**

Several studies have shown that estrogen may have a role in combination with other therapies—for example, α-adrenoceptor agonists. However, phenylpropanolamine (the most widely used α-adrenoceptor agonist in clinical practice) has now been restricted or banned by the FDA.

In a randomized trial, Ishiko et al. (2001) compared the effects of the combination of pelvic floor exercise (PFE) and estriol (1 mg/day) in 66 patients with postmenopausal SUI. Efficacy was evaluated every 3 months based on stress scores obtained from a questionnaire. They found a significant decrease in stress score in mild and moderate stress-incontinent patients in both groups 3 months after the start of therapy and concluded that combination therapy with estriol plus PFE was effective and could be used as first-line treatment for mild SUI. Unfortunately, this has not been reproduced in other clinical trials.

Thus, even before the more recently reported secondary analyses of HERS (Grady et al., 2001) **and WHI** (Hendrix et al., 2005)**, it was already recognized that estrogen therapy had little effect in the management of urodynamic stress incontinence** (Al-Badr et al., 2003; Robinson and Cardozo, 2003).

α-AR Agonists.

Several drugs with agonistic effects on peripheral α-ARs have been used in the treatment of SUI. Relatively recently, a central role of NA has been discovered in increasing the excitability of urethral rhabdosphincter motor neurons in the rat analog of the Onuf nucleus, an effect caused at least in part by α_1-AR–dependent depolarization. This could contribute to the mechanism by which NA reuptake inhibitors improve SUI (Yashiro et al., 2010). **Ephedrine and norephedrine (phenylpropanolamine [PPA]) seem to have been the most widely used** (Andersson and Wein, 2012). The original AHCPR guidelines reported eight RCTs with PPA, 50 mg twice daily for SUI in women (AHCPR, 1992). Percent cures (all figures refer to percent effect in patients on drug minus percent effect in patients on placebo) were listed as 0% to 14%; percent reduction in continence as 19% to 60%; and percent side effects and percent dropouts as 5% to 33% and 0% to 4.3%, respectively. **The most recent Cochrane review on the subject** (Alhasso et al., 2005, reprinted virtually unchanged in 2008) **assessed randomized or quasi- RCTs in adults with SUI** that included an adrenergic agonist drug in at least one arm of the trial. There were no controlled studies reported on the use of such drugs in men. Twenty-two eligible trials were identified, 11 of which were crossover trials, which included 1099 women, 673 of whom received an adrenergic drug (PPA in 11, midrodrine in 2, norepinephrine in 3, clenbuterol in 3, terbutaline in 1, eskornade in 1, and RO 115-1240 in 1). The authors concluded that “there was **weak evidence to suggest that use of an adrenergic agonist was better than placebo in reducing the number of pad changes and incontinence episodes, and improving subjective symptoms.”** There was not enough evidence to evaluate the merits of an adrenergic agonist compared with estrogen, whether used alone or in combination. Regarding adverse events, the review reported similar numbers with adrenergic, placebo, or alternative drug treatment. Over 25% of subjects reported such effects, but when these consisted of effects resulting from adrenergic stimulation, they caused discontinuation in only 4% of the total.

Ephedrine and PPA lack selectivity for urethral α-ARs and can increase blood pressure and cause sleep disturbances, headache, tremor, and palpitations (Andersson and Wein, 2012). Kernan et al. (2000) reported the risk for hemorrhagic stroke to be 16 times higher in women younger than 50 years of age who had been taking PPA as an appetite suppressant (statistically significant) and 3 times higher in women who had been taking the drug for less than 24 hours as a cold remedy (not statistically significant). There was no increased risk in men. PPA has been removed from the market in the United States. It is still allowed as a treatment for SUI in a few countries. Numerous case reports of adverse reactions caused by ephedra alkaloids exist, and some suggested that sale of these compounds as a dietary supplement be restricted or banned (Bent et al., 2003). In December 2003, the FDA decreed such a ban, a move which has survived legal appeal.

Midodrine and methoxamine stimulate α_1-ARs with some degree of selectivity. According to the RCTs available, the effectiveness of these drugs is moderate at best, and the clinical usefulness seems to be limited by adverse effects (Alhasso et al., 2003; Radley et al., 2001; Weil et al., 1998).

Attempts to develop agonists with relative selectivity for the human urethra continue. Musselman et al. (2004) reported on a phase II randomized crossover study with Ro 115-1240, a peripherally active selective $\alpha_{1A/1L}$-AR partial agonist (Blue et al., 2004), in 37 women with mild-to-moderate SUI (Musselman et al., 2004). A moderate, positive effect was demonstrated, but side effects have apparently curtailed further development of the drug. PF-3774076, a CNS-penetrating partial α_{1A}-AR agonist, increased peak urethral pressure in dogs and was selective with respect to α_{1B} and α_{1D} receptors, but HR and blood pressure changes caused significant concern (Conlon et al., 2009). Furuta et al. (2009) reported that the α_2-AR can inhibit the release of glutamate presynaptically in the spinal cord and proposed that α_2-AR antagonists would be useful as a treatment for SUI. This hypothesis awaits testing.

β-AR Agonists

Clenbuterol.

β-AR stimulation is generally conceded to decrease urethral pressure (Andersson, 1993), but β_2-AR agonists have been reported to increase the contractility of some fast-contracting striated muscle fibers and suppress that of slow-contracting fibers of others (Fellenius et al., 1980). Some β-AR agonists also stimulate skeletal muscle hypertrophy—in fast-twitch more than slow-twitch fibers (Kim and Sainz, 1992). Clenbuterol has been reported to potentiate the field stimulation–induced contraction in rabbit isolated periurethral muscle preparations, an action that is suppressed by propranolol and greater than that produced by isoproterenol (Kishimoto et al., 1991). These authors were first to report an increase in urethral pressure with clinical use of clenbuterol and to speculate on its potential for the treatment of SUI. Yamanishi et al. (1994) reported an inotropic effect of clenbuterol and terbutaline on the fatigued striated urethral sphincter of dogs, abolished by β-AR blockade.

Yasuda et al. (1993) described the results of a double-blind placebo-controlled trial with this agent in 165 women with SUI. Positive statistical significance was achieved for subjective evaluation of incontinence frequency, pad use per day, and overall global assessment. Pad weight decreased from 11.7 ± 17.9 g to 6.0 ± 12.3 g for drug and from 18.3 ± 29.0 g to 12.6 ± 24.7 g for placebo, raising questions about the comparability of the two groups. The “significant” increase in maximal urethral closure pressure (MUCP) was from 46.0 ± 18.2 cm H_2O to 49.3 ± 19.1 cm H_2O, versus a change of −1.5 cm H_2O in the placebo group. Fifty-six of 77 patients in the clenbuterol group reported some degree of improvement versus 48 of 88 in the placebo group. The positive effects were suggested to be a result of an action on urethral striated muscle and/or the pelvic floor muscles. Ishiko et al. (2000) investigated the effects of clenbuterol on 61 female patients with stress incontinence in a 12-week randomized study, comparing drug therapy and PFEs. The frequency and volume of stress incontinence and the patient's own impression were used as the basis for the assessment of efficacy. The improvement in incontinence was 76.9%, 52.6%, and 89.5% in the respective groups. In an open study, Noguchi et al. (1997) reported positive results with clenbuterol (20 mg bid for 1 month) in 9 of 14 patients with mild-to-moderate stress incontinence after radical prostatectomy (RP). **Further well-designed RCTs investigating the effects of clenbuterol are needed to adequately assess its potential as a treatment for stress incontinence.**

β-AR Antagonists.

The theoretic basis for the use of β-AR antagonists in the treatment of stress incontinence is that blockade of urethral β-ARs may enhance the effects of NA on urethral α-ARs. Propranolol has been reported to have beneficial effects in the treatment of stress incontinence (Gleason et al., 1974; Kaisary, 1984), but there are no RCTs supporting such an action. In the study by Gleason et al., the beneficial effects manifest only after 4 to 10 weeks of treatment, a phenomenon that is difficult to explain (Gleason et al., 1974). Donker and Van der Sluis (1976) reported that β-blockade did not change the urethral pressure profile in normal women. Although suggested as an alternative to α-AR agonists in patients with SUI and hypertension, these agents may have major potential cardiac and pulmonary side effects of their own, related to their therapeutic β-AR blockade.

Serotonin-Noradrenaline Uptake Inhibitors

Imipramine.

Imipramine, among several other pharmacologic effects, has classically been reported to inhibit the reuptake of NA and serotonin in adrenergic nerve endings. In the urethra, this could theoretically be expected to enhance the contractile effects of NA on urethral smooth muscle by both a peripheral and a central action. Gilja et al. (1984) reported in an open study on 30 women with stress incontinence that imipramine, 75 mg daily, produced subjective continence in 21 patients and increased mean MUCP from 34 to 48 mm Hg. A 35% cure rate was reported by pad test and, in an additional 25%, a 50% or more improvement. Lin et al. (1999) assessed the efficacy of imipramine (25 mg of imipramine three times a day for 3 months) as a treatment for genuine stress incontinence in 40 women with genuine stress incontinence. A 20-minute pad test, uroflowmetry, filling and voiding cystometry, and stress urethral pressure profile were performed before and after treatment. The efficacy of "successful treatment" was 60% (95% CI 11.8 to 75.2). **There are no RCTs on the effects of imipramine on SUI.** No subsequent published reports have appeared.

It is interesting to note that Gillman (2007) reported that clomipramine had far greater 5-HT reuptake inhibition than imipramine and roughly similar NA reuptake inhibition. Desipramine and reboxetine had greater NA reuptake inhibition (desipramine superior), with lesser effect than imipramine on 5-HT uptake (desipramine superior).

Duloxetine.

Duloxetine hydrochloride is a combined norepinephrine and serotonin reuptake inhibitor that has been shown to significantly increase sphincteric muscle activity during the filling and storage phase of micturition in the cat acetic acid model of irritated bladder function (Katofiasc et al., 2002; Thor and Katofiasc, 1995). Bladder capacity was also increased in this model, with both effects mediated centrally through both motor efferent and sensory afferent modulation (Fraser et al., 2003). The sphincteric effects were reversed by α_1-adrenergic antagonism (prazosin) and 5-HT_2 serotonergic antagonism (LY-53857), whereas the bladder effects were mediated by temporal prolongation of the actions of serotonin and norepinephrine in the synaptic cleft (Fraser et al., 2003). Duloxetine is lipophilic, well absorbed, and extensively metabolized (CYP2D6). Its plasma half-life is approximately 12 hours (Sharma et al., 2000).

Thor et al. (2007) described the mechanisms of action and the physiologic effects of duloxetine. 5-HT (serotonin) and NA terminals are dense in spinal areas associated with LUT functioning, especially around the pudendal nerve neurons in the Onuf nucleus. These are projections from separate areas in the brainstem. Glutamate is the primary excitatory neurotransmitter in the spinal cord, activating the pudendal neurons in the Onuf nucleus, causing contraction of the urethral rhabdosphincter. The rhabdosphincter innervation is proposed as distinct from that of the levator ani (Thor and de Groat, 2010). The responsiveness of the rhabdosphincter motor neurons to glutamate is modulated (facilitated) by 5-HT (through 5-HT_2 receptors) and NA (through α_1-ARs). 5-HT and NA, however, only modulate, and, when micturition occurs, glutamate excitation and rhabdosphincter contraction cease. Excitatory effects on urethral sphincter activity are shared to a lesser extent by receptors for 5-HT_{1A} (indirect through a supraspinal stimulation), thyrotropin-releasing hormone vasopressin, *N*-methyl-ᴅ-aspartate (NMDA), and AMPA; inhibitory effects are similarly mediated by κ_2 opioid receptors, α_1-ARs, and GABA-A, GABA-B, and glycine receptors (Thor and de Groat, 2010). Some CNS-penetrant selective 5-HT_{2C} agonists have been found to increase urethral muscle tone and inhibit micturition reflexes in animal models, and these are additional candidates for clinical development for the treatment of SUI (Andrews et al., 2011; Brennan et al., 2009).

Several RCTs have documented the effect of duloxetine in SUI (Dmochowski et al., 2003a; Millard and the Asia Pacific Tolterodine Study Group, 2004; Norton et al., 2002; Van Kerrebroeck et al., 2004). **A Cochrane review of the effects of duloxetine for SUI in women is available;** the last substantive amendment is listed as May 25, 2005 (Mariappan et al., 2005). Fifteen reports were deemed eligible for analysis, 9 primary studies and 6 additional reports related to one or two of the primary references. An additional analysis “performed under the auspices of the Cochrane Incontinence Group” was performed on just the nine primary trials comparing duloxetine and placebo, and published separately (Mariappan et al., 2005). The results can be summarized as follows. **Subjective “cure” in the duloxetine 80 mg daily (40 mg bid) group was higher than in the placebo group (10.8% vs. 7.7%,** overall relative risk [RR] 1.42, 95% CI 1.02 to 1.98, $P = .04$). The estimated absolute size of effect was about 3 more patients cured for every 100 treated. **Objective cure data, available from only one trial, showed no clear difference between the drug**

and placebo. Duloxetine showed greater improvement in I-QoL (weighted mean difference for 80 mg 4.5, 95% CI 2.83 to 6.18, $P < .00001$). Adverse effects in six trials were analyzed. These were reported by 71% of drug subjects and 59% of those allocated to placebo. Nausea was the most common adverse event, with an incidence that ranged from 23% to 25%, and was the main reason for discontinuation. Other side effects reported were vomiting, constipation, dry mouth, fatigue, dizziness, and insomnia—overall RR was 1.30 (95% CI 1.23 to 1.37). Across these six trials, 17% in the drug group withdrew, as did 4% in the placebo arm. In the 2007 article, the authors conclude by saying that **further research is needed regarding whether management policies incorporating duloxetine are clinically effective and cost-effective compared with other current minimally invasive and more invasive approaches** in patients with varying severity of SUI, and that "longer term experience is now a priority to determine whether there is sustained efficacy during and after duloxetine use and to rule out complications."

Hurley et al. (2006) characterized the safety of duloxetine for treatment of SUI in women, using an integrated database generated from four published placebo-controlled clinical trials. The database included 1913 women randomized to duloxetine (958) or placebo (955), examining adverse events, serious adverse events, vital signs, ECGs, and laboratory analytes. Adverse events occurring initially or worsening during the double-blind treatment period were considered treatment emergent. Differences between duloxetine-treated and placebo-treated groups were compared statistically. Common TEAEs included nausea (23.2%), dry mouth (13.4%), fatigue (12.7%), insomnia (12.6%), constipation (11.0%), headache (9.7%), dizziness (9.5%), somnolence (6.8%), and diarrhea (5.1%). Most TEAEs that emerged early were mild to moderate, rarely worsened, and resolved quickly. Overall, adverse event discontinuation rates were 20.5% for duloxetine and 3.9% for placebo ($P < .001$). Most discontinuations (83%) occurred within the first month of treatment. Serious adverse events were uncommon and did not differ between treatments. Statistically significant but clinically unimportant mean increases in HR (2.4 beats/min) and systolic and diastolic blood pressure (≤2 mm Hg) occurred. No arrhythmogenic potential was observed, and any rare, transient, asymptomatic increases in hepatocellular enzymes were normalized. The authors concluded that duloxetine was safe and tolerable, although transient adverse events were not uncommon. Hashim and Abrams (2006) suggested that to reduce the risk for nausea, treatment should begin with a dose of 20 mg twice daily for 2 weeks, which should then be increased to the recommended 40-mg bid dose.

Ghoneim et al. (2005) randomized women with SUI to one of four treatment combinations: duloxetine alone (40 mg bid), pelvic floor muscle training (PFMT), combination, and placebo. Overall, drug with or without PFMT was superior to PFMT alone or placebo, whereas pad results and QoL data favored combination therapy over single treatment. Cardozo et al. (2004a) reported that 20% of women awaiting continence surgery changed their minds while taking duloxetine. Duckett et al. (2006) offered a 4-week course to women awaiting a tension-free vaginal tape operation. Thirty-seven percent (of 73) declined. Excluding women for whom concomitant prolapse surgery was planned, 8 of 33 (24%) scheduled for incontinence surgery alone came off the list. Sixteen (48%) discontinued duloxetine because of adverse events, and 9 (27%) found the drug ineffective.

Bent et al. (2008) reported on the effects of 12 weeks of duloxetine (40 mg bid) versus placebo in a large group of women with mixed urinary incontinence (MUI). For SUI episodes, the mean incontinence episode frequency (IEF) per week decreased 58.9% with drug (7.69 to 3.93) versus 43.3% for placebo (8.93 to 6.05). It is interesting to note that corresponding decreases for UUI episodes were 57.7% versus 39.6%. Both sets of values are statistically significant, but the baselines are different and the absolute change for SUI amounted to −3.76 episodes per week for drug and −2.87 for placebo. Nausea was reported by 18% of patients on drug and 4.5% on placebo. Corresponding percents for other adverse events included dry mouth (12 vs. 2.8), dizziness (9.7 vs. 2.4), constipation (8.3 vs. 4.2), and fatigue (6.7 vs. 2.8). Nausea and dizziness were less common in a subgroup taking concurrent antidepressants. In a study by Schagen van Leeuwen et al. (2008), women 65 years of age and older with SUI or stress-predominant MUI (S-MUI) were given duloxetine (40 mg bid after a 2-week start on 20 mg bid) or placebo for 12 weeks. Their report concludes that “this study supports the use of duloxetine in elderly women with SUI or S-MUI.” The data show an absolute change in SUI plus S-MUI episodes of −11.7 and −6.9 incontinence per week (drug and placebo) and median percent changes of −52.5% versus −36.7% from 24-hour diaries, both significant at $P < .001$. However, the changes for SUI alone were −53% versus −42% (nonsignificant), whereas for S-MUI alone they were −51.6% versus −32.7% ($P < .001$). Nausea was less than in other trials (7.5% vs. 3.1%), perhaps because of the lower starting dose. Other adverse events included fatigue (14.2% vs. 5.4%), constipation (10.4% vs. 0.8%), dizziness (9.0% vs. 4.6%), and excess sweating

(5.2% vs. 0%).

Vella et al. (2008) studied persistence on duloxetine and found that only 31% of an original cohort of 228 were still taking the drug beyond 4 weeks, 12% at 4 months, 10% at 6 months, and 9% at 1 year. Fifty-six percent of the discontinuations were attributed to side effects, and 33% were attributed to lack of efficacy. Bump et al. (2008), however, reported that the positive effects of duloxetine were maintained in patients who continued treatment for up to 30 months, but admitted that this subgroup was likely to include predominantly patients who had favorable responses. The number decreased from 1424 in this cohort at 3 months to 368 at 30 months.

Shaban et al. (2010) concluded that duloxetine is an "optional second line for women not willing or unfit for surgery after warning against side effects as recommended by NICE [National Institute for Health and Care Excellence] guidelines in the UK" Robinson and Cardozo (2010) also expressed similar sentiments.

Duloxetine is licensed at 40 mg twice daily for the treatment of SUI in the European Union in women with moderate-to-severe incontinence (defined as 15 or more episodes per week). It was withdrawn from the FDA consideration process in the United States for the treatment of SUI but is approved for the treatment of major depressive disorder (20 to 30 mg bid initially, 60 mg once daily for maintenance), diabetic peripheral neuropathic pain (60 mg once daily), generalized anxiety disorder (60 mg once daily), **fibromyalgia** (30 mg once daily initially, 60 mg once daily for maintenance), and **chronic musculoskeletal pain** (30 mg once daily initially, 60 mg once daily for maintenance. **The product information contains a black box warning** of "increased risk of suicidal thinking and behavior in children, adolescents and young adults taking antidepressants for major depressive disorder and other psychiatric disorders," noting also that "depression and certain other psychiatric disorders are themselves associated with increases in the risk of suicide" (Cymbalta prescribing information, revised 2019). Other warnings and precautions in the prescribing information for psychiatric indications, not SUI, include hepatotoxicity (not to be used in patients with substantial alcohol use or chronic liver disease); orthostatic hypotension; serotonin syndrome (general statement regarding SSRIs and SNRIs); abrupt discontinuation (may result in dizziness, paresthesias, irritability, and headache); inhibitors of CYP1A2 (such as ciprofloxacin) and thioridazine (do not administer concomitantly); and potent inhibitors of CYP2D6 (may increase concentration). Adverse events for 6801 drug- and 4487 placebo-treated patients reported in the prescribing information for Cymbalta (treatment for the indications mentioned) are nausea (24% vs. 8%), dry mouth (13% vs. 5%), fatigue (10% vs. 5%), somnolence (10% vs. 3%), insomnia (10% vs. 6%), constipation (10% vs. 4%), and dizziness (10% vs. 5%).

Drugs Used for Treatment of Stress Urinary Incontinence in Men

Although a problem of significant magnitude, especially after RP for cancer, **the pharmacologic treatment of male SUI is an area that has received relatively little attention.**

Intrinsic sphincter function is the most important outlet factor maintaining continence in men. Urethral support is less important, and there is no entity similar to the hypermobility phenomenon in women. The proximal urethral sphincter extends from the bladder neck through the prostatic urethra. Its function is removed by RP. The distal urethral sphincter includes the rhabdosphincter, urethral smooth muscle, and extrinsic paraurethral skeletal muscle, extending from the prostatic urethra below the verumontanum through the membranous urethra (Koelbl et al., 2009). Tsakiris et al. (2008) searched for articles on drug treatment of male SUI published from 1966 to 2007 and did a generalized database search in addition. Nine trials were identified as using α-adrenergic agonists, β_2 antagonists, or SNRIs. Only one of these included a comparison arm (Filocamo et al., 2007), 40-mg bid duloxetine plus PFE versus PFE with placebo. The results suggested a positive effect of drug but were a bit confusing. Of patients completing the 4-month trial (92 of 112), 78% of the drug-treated patients versus 52% of those in the placebo group were “dry.” However, 1 month after the end of the study, the corresponding figures were 46% versus 73%, a shift still observed 2 months later. The authors of the review article recommended further larger and well-designed studies on duloxetine for this potential use.

Cornu et al. (2011) reported a series of post-RP men with SUI or S-MUI randomized to duloxetine (15) and placebo (16) after a 2-week placebo run-in. The dosage was 20 mg bid for 7 days, 40 mg bid for 67 days, and 20 mg bid for 14 days. Subjects were at least 1 year postsurgery. Outcome measures included percent decrease in IEF, 1-hour pad test, and various QoL measures. Statistical significance for IEF percent decrease occurred only at weeks 8 and 12 ([−]52.2% ± 38.6% vs. [+]19% ± 43.5%), but there was clearly a trend at 4 weeks. There was no statistical difference in 1-hour pad test weights, but there was in various QoL scores. A 50% to 100% decrease in IEF was seen at 12 weeks in over one-half of the patients. Adverse events for drug and placebo included fatigue (50% vs. 13%), insomnia (25% vs. 7%), libido loss (19% vs. 7%), constipation (13% vs. 7%), nausea (13% vs. 7%), diarrhea (13% vs. 7%), dry mouth (6% vs. 0%), anorexia (6% vs. 0%), and sweating (25% vs. 20%). Drawbacks and concerns are the small number (the original proposed sample size was 90) and the lack of any placebo effect on IEF and QoL. There were four men with MUI in the drug group and five in the placebo group. Results for SUI and UUI were not separated.

One would logically not expect improvement to continue after drug withdrawal unless a permanent change occurred in behavior, anatomy, or neuromuscular function. In another uncontrolled use study on men with post-RP SUI, Collado Serra et al. (2011) reported on 68 men whose median interval from surgery was 28.8 months. The reported results are somewhat confusing, but the overall impression is that some success was achieved. Treatment was intended to last for 9 months and restarted at 3 months if UI had worsened after cessation. The follow-up examinations were performed every 3 months, evaluating the symptoms, adverse effects, number of pads used daily, and International Consultation on Incontinence Questionnaire Urinary Incontinence Short Form (ICIQ-IU-SF) results. At the end of the first follow-up period, 39 (57%) of 68 patients had reduced the number of pads used daily. The pads per day nadir was achieved at the second follow-up visit in 29 (43%) of 68 patients, in 3 (8%) of 37 at the third visit, and in 2 (12%) of 17 at the fourth visit. Once the nadir of success with treatment had been reached, the efficiency of duloxetine was maintained in 84% of patients and worsened in 16% despite continuing treatment. In this study, 25% of patients withdrew because of adverse events and 33% because of lack of effect.

Usage of duloxetine for SUI in men is universally off-label. A drug for this indication would be welcome. **Larger, controlled, and better-designed studies are necessary to provide conclusive positive or negative data on this subject.**

Key Points: Drugs for Stress Urinary Incontinence

- Pharmacologic efforts to increase outlet resistance in men and women have focused on increasing urethral tone or contractile ability at a peripheral or central level.

- The role of estrogen in the treatment of SUI has been somewhat controversial; however, the majority opinion seems to be that estrogen when given alone does not appear to be an effective treatment for SUI in the woman.
- The use of peripheral α_1-AR agonists has largely been abandoned because of the adverse effects associated with these agents and the weak evidence of efficacy compared with placebo.
- Paradoxically, there are theoretic rationales for using both β-AR agonists and antagonists for treatment of SUI, but there are few data suggesting significant efficacy over control, and further well-designed randomized clinical trials are necessary.
- Duloxetine is a combined norepinephrine and serotonin reuptake inhibitor that increased sphincteric activity in an animal experimental model during the filling and storage phase of micturition. This compound has been widely tried in a variety of situations and using a variety of parameters. Some trials suggest statistical efficacy, more so in subjective data than objective data, and further research is needed regarding whether management policies incorporating this compound are clinically effective and cost-effective compared with other current approaches in women with varying degrees of SUI. Currently, duloxetine is licensed in the European Union for women with moderate-to-severe stress incontinence. It is approved in the United States for treatment of a variety of disorders, but was withdrawn from the approval process for the treatment of SUI.
- Effective pharmacologic management of SUI in men would be a welcome addition to the armamentarium, but this has received relatively little attention. There are a few clinical trials with interesting experimental designs and results, and it is obvious that larger, controlled, and better-designed studies are necessary to provide conclusive positive or negative data. The use of duloxetine for SUI in men is universally off-label.

Pharmacologic Therapy to Facilitate Bladder Emptying

Increasing Intravesical Pressure and Bladder Contractility

Parasympathomimetic Agents

Because a major portion of the final common pathway in physiologic bladder contraction is stimulation of parasympathetic postganglionic muscarinic cholinergic receptor sites, agents that imitate the actions of ACh might be expected to be effective in treating patients who cannot empty the bladder because of inadequate bladder contractility. ACh, **which is a quaternary amine,** cannot be used for therapeutic purposes because of its action at both muscarinic and nicotinic receptors; it is rapidly hydrolyzed by acetylcholinesterase and by butyrylcholinesterase (Brown and Taylor, 2006). Many ACh-like drugs exist, but only bethanechol chloride exhibits a relatively selective in vitro action on the urinary bladder and gut with little or no nicotinic action (Brown and Taylor, 2006). **Bethanechol is cholinesterase resistant and causes an in vitro contraction of smooth muscle from all areas of the bladder** (see Chapter 69).

Bethanechol, or agents similar to it, has historically been recommended for the treatment of postoperative or postpartum urinary retention, but only if the patient is awake and alert and if there is no outlet obstruction. The recommended dose has been 5 to 10 mg subcutaneously. For over 50 years, bethanechol has been recommended for the treatment of the atonic or hypotonic bladder and has been reported as effective in achieving "rehabilitation" of the chronically atonic or hypotonic detrusor (Sonda et al., 1979). Bethanechol has also been reported to stimulate or facilitate the development of reflex bladder contractions in patients in spinal shock secondary to suprasacral SCI (Perkash, 1975).

Although bethanechol has been reported to increase gastrointestinal motility and has been used in the treatment of gastroesophageal reflux, and although anecdotal success in specific patients with voiding dysfunction seems to occur, **there was little or no evidence to support its success in facilitating bladder emptying in a series of patients in whom the drug was the only variable** (Barendrecht et al., 2007; Finkbeiner, 1985). In one set of trials, a pharmacologically active subcutaneous dose (5 mg) did not demonstrate significant changes in flow parameters or residual urine volume in (1) a group of women with a residual urine volume greater than or equal to 20% of bladder capacity but no evidence of neurologic disease or outlet obstruction; (2) a group of 27 “normal” women of approximately the same age; or (3) a group of patients with a positive bethanechol supersensitivity test (Wein et al., 1980a, 1980b). This dose did increase cystometric filling pressure and also decreased bladder capacity threshold, findings previously described by others (Sonda et al., 1979). Short-term studies in which the drug was the only variable have usually failed to demonstrate significant efficacy in terms of flow and residual urine volume data (Barrett, 1981). Farrell et al. conducted a double-blind randomized trial that looked at the effects of two catheter-management protocols and the effect of bethanechol on postoperative retention after gynecologic incontinence surgery (Farrell et al., 1990). They concluded that bethanechol was not helpful at all in this setting. Although bethanechol is capable of eliciting an increase in bladder smooth muscle tension, as would be expected from in vitro studies, its ability to stimulate or facilitate a coordinated and sustained physiologic-like bladder contraction in patients with voiding dysfunction has been unimpressive (Andersson, 1988; Finkbeiner, 1985).

It is difficult to find reproducible urodynamic data that support recommendations for the use of bethanechol in any specific category of patients. Most, if not all, “long-term” reports in such patients are neither prospective nor double-blind and do not exclude the effects of other simultaneous regimens (such as treatment of urinary infection, bladder decompression, timed emptying, or other types of treatment affecting the bladder or outlet), an important observation to consider when reporting such drug studies. Whether repeated doses of bethanechol or any cholinergic agonist can achieve a clinical effect that a single dose cannot is speculative, as are suggestions that bethanechol has a different mode of action or effect on atonic or decompensated bladder muscle than on normal tissue.

Bethanechol administered subcutaneously does cause an increased awareness of a distended bladder and presumably the desire to void (Downie, 1984). This could facilitate more frequent emptying at lower volumes and thereby help to avoid overdistention, but, it would seem, only in a bladder that is capable of a contraction. O'Donnell and Hawkins (1993) administered 5 mg of bethanechol subcutaneously to 10 neurologically intact men and made the following cystometric observations: Bladder volume at first desire to void decreased (220 mL to 85 mL), maximal bladder capacity decreased (380 mL to 160 mL), first desire to void occurred at a higher pressure (5 cm H_2O vs. 28 cm H_2O), and compliance was reduced. They concluded that bethanechol affects the ability of the bladder to accommodate volume. Patients were comfortable at a resting bladder pressure of 20 cm H_2O (uncommon in their population), and the pressures at maximal bladder capacity were considerably higher than commonly seen under normal conditions. This suggested to them that either bladder pressure alone is not a significant factor in the perception of a sensation of first desire to void or that bethanechol somehow alters the threshold at which perception of desire to void occurs (because these patients showed a tolerance for increased intravesical pressure before first desire to void and at maximal bladder capacity). De Wachter and Wyndaele (2001) determined the bladder electrical threshold in healthy volunteers receiving 5 mg of bethanechol subcutaneously. They found a marked decrease in the volume at which various filling sensations occurred and that the electrical threshold decreased after drug administration. De Wachter et al. (2003) treated 18 women with impaired detrusor contraction with subcutaneous bethanechol (5 mg four times daily) for 10 days. At the end of treatment, 61% of the patients voided without a PVR volume. They also found that in these women the sensation of filling and the electrical sensitivity were significantly increased compared with before treatment. The authors suggested that patients likely to respond to bethanechol can be identified by determination of the bladder electrical perception threshold.

Riedl et al. (2000) performed a clinical study in 45 patients with detrusor areflexia. The patients were tested with electromotive administration of intravesical bethanechol. Bethanechol 25 mg given orally once daily was then prescribed for 15 patients, and voiding control was assessed after 6 weeks of therapy. A mean pressure increase of 34 cm H_2O during the electromotive administration of bethanechol was found in 24 of 26 patients with areflexia and neurologic disease compared with only 3 cm H_2O in 3 of 11 with a history of chronic bladder dilation. Oral bethanechol restored spontaneous voiding in 9 of 11 patients who had had a positive response to the electromotive administration of bethanechol, whereas all 4 without a pressure increase during the electromotive administration of bethanechol did not void spontaneously. The researchers concluded that electromotive administration of intravesical bethanechol can identify patients with an atonic bladder and adequate residual detrusor muscle function who are candidates for restorative measures, such as oral bethanechol and intravesical electrostimulation. Those who do not respond to the electromotive administration of bethanechol do not benefit from oral bethanechol and are candidates for catheterization.

No agreement exists as to whether cholinergic stimulation produces an increase in urethral resistance (Wein et al., 1980a, 1980b). It would appear that pharmacologically active doses, in fact, do increase urethral closure pressure, at least in patients with NDO (Sporer et al., 1978). This would of course tend to inhibit bladder emptying. As to whether cholinergic agonists can be combined with agents to decrease outlet resistance to facilitate emptying and achieve an additive or synergistic effect, our own experience with such therapy, using even 200 mg (50 mg qid) of oral bethanechol daily, has been disappointing. Certainly, most clinicians would agree that a total divided daily dose of 50 to 100 mg rarely affects any urodynamic parameter at all. In a prospective, single-blind, randomized study consisting of 119 patients with underactive detrusor, Yamanishi et al. (2004) studied the effect of a combination of a cholinergic drug (bethanechol 60 mg daily or distigmine 15 mg daily) and an α-AR antagonist (urapidil 60 mg daily). The effectiveness of each therapy was assessed 4 weeks after initialization of the therapy using IPSS. IPSS remained unchanged after the cholinergic therapy, but was significantly lower after the α-AR antagonist treatment and the combination therapy. With regard to the total IPSS, there were significant differences between the cholinergic and the α-AR antagonist groups, and also between the cholinergic and combination groups, in favor of the latter. The average and maximum flow rates did not increase significantly after monotherapy with either the cholinergic drug or the α-AR antagonist, but they significantly increased after combination therapy compared with baseline values. PVR volume did not decrease significantly after the cholinergic drug therapy but decreased significantly after the α-AR antagonist and the combination therapies. The authors concluded that combination therapy with a cholinergic drug and an α-AR antagonist appeared to be more useful than monotherapy for the treatment of underactive detrusor.

The question of whether bethanechol may be efficacious in a particular patient can be answered by a brief urodynamically controlled trial in which institution of therapy is the only variable. In the laboratory, a functioning micturition reflex is an absolute requirement for the production of a sustained bladder contraction by a subcutaneous injection of the drug (Downie, 1984). **Patients with incomplete lower motor neuron lesions constitute the most reasonable group for a trial of bethanechol** (Awad, 1985), although subcutaneous administration may be required. **It is generally agreed that, at least in a “denervated” bladder, an oral dose of 200 mg is required to produce the same urodynamic effects as a subcutaneous dose of 5 mg** (Diokno and Lapides, 1977).

The **potential side effects of cholinomimetic drugs** include flushing, nausea, vomiting, diarrhea, gastrointestinal cramps, bronchospasm, headache, salivation, sweating, and difficulty with visual accommodation (Brown and Taylor, 2006). Intramuscular and intravenous use can precipitate acute and severe side effects, resulting in acute circulatory failure and cardiac arrest, and are therefore prohibited. Contraindications to the use of this general category of drug include bronchial asthma, peptic ulcer, bowel obstruction, enteritis, recent gastrointestinal surgery, cardiac arrhythmia, hyperthyroidism, and any type of BOO.

One potential avenue of increasing bladder contractility is cholinergic enhancement or augmentation. Such an action might be useful alone or in combination with a parasympathomimetic agent. **Metoclopramide** is a dopamine-receptor antagonist with cholinergic properties (Pasricha et al., 2006). It has a central antiemetic effect in the chemoreceptor trigger zone and peripherally increases the tone of the lower esophageal sphincter, promoting gastric emptying. Its effects seem to be related to its ability to antagonize the inhibitory action of dopamine, to augment ACh release, and to sensitize the muscarinic receptors of gastrointestinal smooth muscle. Some data from dogs suggest that this agent can increase detrusor contractility (Mitchell and Venable, 1985), but there are no controlled studies documenting a useful clinical effect in the treatment of detrusor underactivity.

Cisapride is a substituted piperidinyl benzamide with a number of different pharmacologic activities, including a possible direct stimulation of smooth muscle (Pasricha, 2006). Until recently, it was commonly used as a prokinetic agent, particularly for gastroesophageal reflux and gastroparesis. It was also suggested that it could improve bladder contractility (Binnie et al., 1988; Carone et al., 1993; Steele et al., 2001). However, there was never any particularly convincing data that the drug improved voiding function, and it is no longer available in the United States because of its potential to induce serious and occasional cardiac arrhythmias (Pasricha, 2006). The concept, however, of cholinergic enhancement or augmentation remains attractive but awaits the development of a bladder-selective compound.

Prostaglandins

The reported use of prostaglandins to facilitate emptying is based on hypotheses that these substances contribute to the maintenance of bladder tone and bladder contractile activity (see Chapter 69; Andersson, 1993, 1999a, 1999b, 1999c; Andersson and Wein, 2004; Zderic et al., 1995). **Prostaglandins and thromboxane A_2 (TXA_2) have been shown to be present in human bladder in the following quantitative order: $PGE_2 > PGE_1 > PGF_{2\alpha} > TXA_2$; isolated detrusor muscle is contracted by $PGF_{2\alpha}$, PGE_1, PGE_2, and TXA_2** (see references in Andersson and Wein, 2004). **Prostanoids are synthesized locally in both bladder muscle and mucosa, with synthesis being initiated by various physiologic stimuli such as detrusor muscle stretch, mucosal injury, neural stimulation; by ATP; and by mediators of inflammation** (Andersson and Wein, 2004). Prostanoids may affect bladder activity directly by effects on the smooth muscle or indirectly through effects on neurotransmission. **Possible roles mentioned by Andersson include (1) neuromodulators of efferent and afferent neurotransmission; (2) sensitization or perhaps activation of certain sensory nerves; and (3) potentiation of ACh release from cholinergic nerve terminals through prejunctional prostanoid receptors** (Andersson, 2000b)**. PGE_2 seems to cause a net decrease in urethral smooth muscle tone; $PGF_{2\alpha}$ causes an increase.**

Bultitude et al. (1976) first reported that instillation of 0.5 mg of PGE_2 into the bladders of female patients with varying degrees of urinary retention resulted in acute emptying and in improvement of longer-term emptying (several months) in two-thirds of the patients studied ($N = 22$). Desmond et al. (1980) reported results with intravesical use of 1.5 mg of this agent (diluted with 20 mL of 0.2% neomycin solution) in patients whose bladders exhibited no contractile activity or in whom bladder contractility was relatively impaired. Twenty of 36 patients showed a strongly positive immediate response, and 6 showed a weakly positive one. Fourteen patients were reported to show prolonged beneficial effects, all but 1 of whom had shown a strongly positive immediate response. Stratification of the data revealed that an intact sacral reflex arc was a prerequisite for any type of positive response. Tammela et al. (1987) reported that one intravesical administration of 10 mg of $PGF_{2\alpha}$ facilitated voiding in women who were in retention 3 days after surgery for SUI. The drug was administered in 50 mL of saline solution as a single dose and retained for 2 hours. However, in these “successfully” treated patients, the average maximum flow rate was 10.6 mL/sec with a mean residual urine volume of 107 mL, and the authors stated that “bladder emptying deteriorated in most patients on the day after treatment.” Koonings et al. (1990) reported that daily intravesical $PGF_{2\alpha}$ and intravaginal PGE_2 reduced the number of days required for catheterization after stress incontinence surgery when compared with a control group receiving intravesical saline solution.

Others, however, have reported negative results. Grignaffini and Bazzani (1998) reported on instillation of 1.5 mg of PGE_2 in 50 mL of saline solution into the bladder of 50 patients on their fourth day after vaginal hysterectomy and cystourethropexy, with a control group of 60 patients. The results are presented in an interesting fashion. After catheter removal, after the PGE_2 or control treatment, 58% of the PGE_2-treated group voided spontaneously as compared with 48.3% of the control group. This difference was not significant. Thus 42% of the treated group and 51.7% of the control group were in retention. Of those who were in retention, the number who were in retention for less than 3 days was greater in the PGE_2 group (32%) versus the control group (25%), and this was statistically significant. Likewise, the number who remained in urinary retention for 3 days or longer after the initial treatment was 10% in the PGE_2-treated group versus 26.7% in the control group. Stanton et al. and Delaere et al. reported on success using intravesical PGE_2 in doses similar to those reported earlier (Delaere et al., 1981; Stanton et al., 1979). Delaere et al. (1981) similarly reported no success using $PGF_{2\alpha}$ in a group of women with emptying difficulties of various causes. Wagner et al. (1985) used PGE_2 in doses of 0.75 to 2.25 mg and reported no effect on urinary retention in a group of patients after anterior colporrhaphy.

In a prospective randomized, double-blind study, Hindley et al. (2004) tested the hypothesis that the combination of intravesical PGE_2 and oral bethanechol is additive or synergistic in improving bladder emptying. Nineteen patients with detrusor underactivity (17 men and 2 women) were eligible and randomized to one of two treatments. One group (9 patients) received once-weekly intravesical PGE_2 (1.5 mg in 20 mL of 0.9% saline) plus bethanechol 50 mg four times daily, for a total of 6 weeks. A second group of 10 patients received a once-weekly instillation of saline together with placebo tablets, again for 6 weeks. Although there was evidence of a pharmacologic effect, bethanechol and PGE_2 had a limited therapeutic effect compared with placebo. The authors did not recommend this treatment as routine but suggested that it may be considered for the occasional treatment of a patient with detrusor underactivity.

There has been little recent activity in this area, a fact that usually means that clinicians have lost interest or that the initial optimistic results have not been confirmed. **Prostaglandins have a relatively short half-life, and it is difficult to understand how any effects after a single application can last up to several months. If such does occur, it must be the result of a "triggering effect" on some unknown physiologic or metabolic mechanism. Because of the number of conflicting positive and negative reports with various intravesical preparations, double-blind, placebo-controlled studies would obviously be helpful to see whether there are circumstances in which prostaglandin use can reproducibly facilitate emptying or treat postoperative retention.** Potential systemic side effects of prostaglandin use include vomiting, diarrhea, pyrexia, hypertension, and hypotension (Campbell and Halushka, 1996).

Blockers of Inhibition

de Groat et al. have demonstrated a sympathetic reflex during bladder filling that, at least in the cat, promotes urine storage partly by exerting an α-AR–mediated inhibitory effect on pelvic parasympathetic ganglionic transmission (see Chapter 69; de Groat, 1997; de Groat et al., 1993, 1999; Zderic et al., 1995). Some have suggested that α-AR blockade, in addition to decreasing outlet resistance, may in fact facilitate transmission through these ganglia and thereby enhance bladder contractility. On this basis, Raz and Smith (1976) were first to advocate a trial of an α-AR–blocking agent for the treatment of nonobstructive urinary retention. A complete discussion of postoperative retention, including the use of α-AR antagonists for its treatment, is presented in Chapter 65.

Opioid-Receptor Antagonists

Endogenous opioids have been hypothesized to exert a tonic inhibitory effect on the micturition reflex at various levels (see Chapter 69; Zderic et al., 1995), and agents such as opioid-receptor antagonists therefore may offer possibilities for stimulating reflex bladder activity.

Thor et al. (1983) were able to stimulate a micturition contraction with naloxone, an opioid-receptor antagonist, in unanesthetized cats with chronic SCI.

The effects, however, were transient, and tachyphylaxis developed. Vaidyanathan et al. (1981) reported that an intravenous injection of 0.4 mg of naloxone enhanced detrusor reflex activity in 5 of 7 patients with neuropathic bladder dysfunction caused by incomplete suprasacral spinal cord lesions. The maximum effect occurred within 1 to 2 minutes after intravenous injection and was gone by 5 minutes. Murray and Feneley (1982) reported that the same dose of naloxone caused, in a group of patients with IDO, an increase in detrusor pressure at zero volume and at first desire to void, a decrease in the maximum cystometric capacity, and a worsening of the degree of instability. Galeano et al. (1986) reported that although naloxone increased bladder contractility in cats with chronic spinal injury, it also aggravated DSD and spasticity—a potential problem in the treatment of emptying failure. Wheeler et al. (1987) noted no significant cystometric changes in a group of 15 SCI patients after intravenous naloxone, whereas 11 showed decreased perineal EMG activity. **Although an intriguing area, the concept of reversing an inhibitory opioid influence to stimulate reflex bladder activity is of little practical use at present.**

Key Points: Treatment of Detrusor Underactivity

- A pharmacologic agent that is effective for the treatment of detrusor underactivity or underactive bladder would be welcome. It is difficult to find reproducible urodynamic data that support a recommendation for the use of oral bethanechol chloride in any specific category of patients, despite its pharmacologic characteristics as a cholinergic agonist. It is possible that bethanechol, by increasing static intravesical pressure, may cause afferent stimulation at a lower bladder volume than usual, prompting detrusor contraction at a more favorable bladder volume. Such an action would be expected to occur only in bladders that were not truly acontractile.
- Prostaglandins could theoretically facilitate bladder activity either directly by effects on the smooth muscle or indirectly through effects on neurotransmission or increased sensitization to filling stimuli. Initial reports of the use of intravesical prostanoids producing lasting favorable clinical effects have not been confirmed. Work continues on oral agents.

Decreasing Outlet Resistance

At a Site of Anatomic Obstruction

This topic includes the treatment of BOO secondary to BPE. A full discussion is appropriately included in Chapter 104.

At the Level of the Smooth Sphincter

α-Adrenoceptor Antagonists.

Whether or not one believes that there is significant innervation of the bladder and proximal urethral smooth musculature by postganglionic fibers of the sympathetic nervous system, one must acknowledge the existence of α- and β-AR sites. **The smooth muscle of the bladder base and proximal urethra contains predominantly α-ARs, although β-ARs are present. The bladder body contains both varieties of ARs, with β-ARs (β_3) being more common (see Chapter 69;** Andersson, 2000b; Zderic et al., 1995**). The human LUT contains more α_2- than α_1-ARs, but adrenergically induced prostatic smooth muscle contraction and human LUT smooth muscle contraction are mediated largely, if not exclusively, by α_1-ARs.** There are at least three subtypes of α_1-ARs, designated α_{1A}, α_{1B}, and α_{1D}. **Adrenergically induced smooth muscle contraction in the human LUT is mediated largely by the α_{1A}** (and in the detrusor α_{1D}) subtype (Andersson and Gratzke, 2007; Andersson and Wein, 2004; Docherty, 1998; Harada and Fujimura, 2000; Michel and Vrydag, 2006; Yamada and Ito, 2011). In addition to the three cloned α_1-ARs, there is a possible fourth, α_{1L}, although the α_{1L}-AR is probably a variant of the α_{1A} type. There is a tremendous amount of information and controversy in the literature regarding the selectivity of certain α-AR–blocking agents for these respective receptor subtypes. Conclusions are drawn regarding the "best" α_1-AR antagonist for the treatment of at least BPH on the basis of in vitro and in vivo pharmacologic selectivity, but many authors note that this does not necessarily translate into functional selectivity in a given patient (Andersson, 2002c; Djavan et al., 2004). The various α-AR antagonists are discussed in more detail in Chapter 104.

Krane and Olsson (1973) **were among the first to promote the concept of a physiologic internal sphincter partially controlled by tonic sympathetic stimulation of contraction-mediating α-ARs in the smooth musculature of the bladder neck and proximal urethra. Furthermore, they hypothesized**

that some obstructions at this level during bladder contraction are a result of inadequate opening of the bladder neck and/or of an inadequate decrease in resistance in the area of the proximal urethra. They also theorized and presented evidence that α-AR blockade could be useful in promoting bladder emptying in such a patient with an adequate detrusor contraction but without anatomic obstruction or DSD. They and many others (see Wein and Barrett, 1988) have confirmed the usefulness of α-AR blockade in the treatment of what is now usually referred to as *smooth sphincter* or *bladder neck dyssynergia* or *dysfunction.* Successful results, usually defined as an increase in flow rate, a decrease in residual urine, and an improvement in upper tract appearance (where pathologic), could often be correlated with an objective decrease in urethral profile closure pressure.

One would expect success with such therapy to be most evident in patients without DSD, as reported by Hachen (1980). Mobley (1976), however, reported a startling 86% subjective success rate in 21 patients with a reflex neurogenic bladder, with a corresponding success rate of 66% in what was called “flaccid” and 57% of what was called “autonomous” neurogenic bladder dysfunction, with success being defined as PVR urine volume consistently less than 100 mL. On the other hand, Scott and Morrow (1978) noted excellent results with phenoxybenzamine therapy in 9 of 10 patients with a flaccid bladder and a flaccid external sphincter and in a single patient with an upper motor neuron bladder with intact sympathetic innervation, but in only 8 of 21 patients with hyperreflexia and autonomic dysreflexia, and in none of 6 patients with an upper motor neuron bladder and sympathetic denervation (lesion between T10 and L2).

Although most would agree that α-AR–blocking agents exert their favorable effects on voiding dysfunction by affecting the smooth muscle of the bladder neck and proximal urethra, **information in the literature suggests that they may decrease striated sphincter tone as well,** and other information suggests that they may exert some of their effects on at least the filling and storage symptoms of voiding dysfunction by decreasing bladder contractility (see earlier discussion). Much of the confusion relative to whether α-AR–blocking agents have a direct (as opposed to indirect) inhibitory effect on the striated sphincter relates to the interpretation of clinical observations and experimental data referable to their effect on urethral pressure in the region of the urogenital diaphragm and on electromyographic activity in the periurethral striated muscle of this area. One cannot tell by pressure tracings alone whether decreased resistance in this area of the urethra is secondary to a decrease in smooth or striated muscle activity. Nanninga et al. (1977) found that the electromyographic activity of the external sphincter decreased after phentolamine administration in three paraplegic patients and attributed this effect to a direct inhibition of sympathetic action on the striated sphincter. Nordling et al. (1981) demonstrated that clonidine and phenoxybenzamine (both of which pass the blood-brain barrier) also decreased urethral pressure in this area and yet had no effect on EMG activity. They concluded that (1) the effect of phentolamine was from smooth muscle relaxation alone; (2) the effect of clonidine, and possibly phenoxybenzamine, was elicited mostly through centrally induced changes in striated urethral sphincter tonus; and (3) these agents also had an effect on the smooth muscle component of urethral pressure. None of the three drugs, however, affected the reflex rise in either urethral pressure or electromyographic activity seen during bladder filling, and none decreased the urethral pressure or electromyographic activity response to voluntary contraction of the pelvic floor striated musculature. Gajewski et al. (1984) concluded that α-AR blockers do not influence the pudendal nerve–dependent urethral response in the cat through a peripheral action but that at least prazosin can significantly inhibit this response at a central level. Thind et al. (1992) reported on the effects of prazosin on static urethral sphincter function in 10 healthy women. They found a reduction—predominantly in the midurethral area—and hypothesized that the response was caused by a decrease in both smooth and striated sphincter activity, the latter as a result of reduced somatomotor output from the CNS. Clinically, Chancellor et al. (1994) reported that terazosin, a selective α_1-AR antagonist, had little or no effect on striated sphincter function in SCI patients and had no effect on functional obstruction caused by DSD in these patients.

α-AR blocking agents have also been used to treat both bladder and outlet abnormalities in patients with so-called “autonomous” bladders, such as those with myelodysplasia, sacral spinal cord or infrasacral neural injury, and voiding dysfunction after radical pelvic surgery (Wein and Barrett, 1988). Decreased bladder compliance is a common clinical problem in such patients, and this, along with a fixed urethral sphincter tone, results in the paradoxic occurrence of both storage and emptying failure.

Phenoxybenzamine.

Phenoxybenzamine was the α-AR antagonist originally used for the treatment of voiding dysfunction (Te, 2002). Phenoxybenzamine has **blocking properties at both α_1- and α_2-AR sites.** The initial adult dose of this agent is 10 mg/day, and the usual daily dose for voiding dysfunction is 10 to 20 mg. **After discontinuation, the effects of administration may persist for days, because the drug irreversibly inactivates α-ARs** and the duration of effect depends on the rate of receptor synthesis (Hoffman and Lefkowitz, 1996). Approximately 30% of patients experience side effects (Kirby, 1999). These include orthostatic hypotension, reflex tachycardia, nasal congestion, diarrhea, miosis, sedation, nausea, and vomiting (secondary to local irritation). It has mutagenic activity in the Ames test, and repeated administration to animals can cause peritoneal sarcomas and lung tumors (Westfall and Westfall, 2006). Although this agent has been in clinical use for some 35 years without clinically apparent oncologic associations, one must now consider the potential medicolegal ramifications of long-term therapy, especially in younger persons. Te reassessed the use of phenoxybenzamine for treatment of urinary tract disorders (Te, 2002). It is seldom used at present.

Prazosin.

Prazosin was the first potent selective α_1-AR antagonist (Westfall and Westfall, 2006) used to lower outlet resistance (Andersson et al., 1981). The duration of action is 4 to 6 hours; therapy is usually begun in daily divided doses of 2 to 3 mg. The dose may be very gradually increased to a maximum of 20 mg daily, although seldom has anyone used more than 9 to 10 mg daily for voiding dysfunction. The potential side effects of prazosin are consequent to its α_1-AR blockade. Occasionally, there occurs a “first-dose phenomenon,” a symptom complex of faintness, dizziness, palpitation, and, infrequently, syncope, thought to be caused by acute postural hypotension. The incidence of this can be minimized by restricting the initial dose of the drug to 1 mg and administering this at bedtime. Other side effects associated with chronic prazosin therapy are usually mild and rarely necessitate withdrawal of the drug.

Terazosin and Doxazosin.

Terazosin and doxazosin are two highly selective postsynaptic α_1-AR antagonists. They are readily absorbed with high bioavailability and a long plasma half-life, enabling their activity to be maintained over 24 hours after a single oral dose. Both agents have been evaluated with respect to their efficacy in patients with LUTS and decreased flow rates presumed secondary to BPH. Their efficacy in decreasing symptoms and raising flow rates has been shown to be superior to placebo and similar to that of prazosin (Kirby, 1999; Lepor et al., 2012). Their safety profiles have been well documented as a result of their widespread use over several years for the treatment of hypertension. Side effects are related to peripheral vasodilation (postural hypotension), and both drugs have to be started at a low dose and titrated to obtain an optimum balance between efficacy and tolerability. Dizziness and weakness are sometimes observed, and these are presumed secondary to CNS actions. These drugs are marketed for the treatment of hypertension and LUTS presumed secondary to BPH.

Alfuzosin and Tamsulosin.

Alfuzosin and tamsulosin, both highly selective α_1-AR antagonists, have appeared and are marketed solely for the treatment of BPH because of some reports suggesting preferential action on prostatic rather than vascular smooth muscle (Djavan et al., 2004; Kirby, 1999; Lepor et al., 2012)**. Marketing claims aside, whether there is any difference in the efficacy or side-effect profiles of these individual agents remains a topic of controversy.** Both can be administered once daily and without titration. **Available data suggest that retrograde ejaculation and rhinitis are more common with tamsulosin and silodosin, whereas dizziness and asthenia are more common with terazosin and doxazosin** (Djavan et al., 2004; Kirby et al., 2000; Lepor et al., 2012).

Silodosin.

Silodosin is a novel, highly selective α_{1A}-AR antagonist (Yoshida et al., 2007). Clinical data demonstrated that silodosin showed significant improvement in LUTS associated with BPH, and in QoL (Chapple et al., 2011; Kawabe et al., 2006; Novara et al., 2013). The improvements were observed in both voiding and storage symptoms. Long-term study revealed that the efficacy and safety were sustained for 1 year. The most common adverse event in the silodosin group was abnormal ejaculation, which occurred in 22% of patients (Kawabe et al., 2006). Adverse events associated with lowering of blood pressure were low.

Thus, agents with α-AR–blocking properties at various levels of neural organization have been used in patients with very varied types of voiding dysfunction—functional outlet obstruction, urinary retention, decreased compliance, and DO. Our own experience would suggest that a trial of such an agent is certainly worthwhile, because the effect or lack of effect will become obvious in a matter of days, and any pharmacologic side effects are, of course, reversible. However, our results with such therapy for non–BPH-related voiding dysfunction have been somewhat less spectacular than those of at least some other investigators.

Nitric Oxide.

In the future, there may be other pharmacologic mechanisms that are explored to produce relaxation in the smooth muscle of the bladder neck, urethra, or prostatic stroma. **Nitric oxide** is a **neurotransmitter capable of producing smooth muscle relaxation, at least in the female rabbit urethra, pig urethra, and human bladder neck** (Andersson and Persson, 1993; Andersson and Wein, 2004). A selective nitrergic action on bladder neck and urethral smooth muscle is an interesting theoretic possibility. Mumtaz et al. (2000) suggested that a topical intraurethral NO donor could induce urethral smooth muscle relaxation without affecting bladder smooth muscle function and that this is a possible clinical avenue of exploration. Mamas et al. (2001, 2003) hypothesized that augmentation of external sphincter NO could be an effective pharmacologic treatment for DSD. In a functional urodynamic study, Reitz et al. (2004a) assessed the effect of the NO donor isosorbide dinitrate on the external urethral sphincter. Magnetic stimulation of the sacral roots was performed in eight healthy men to evoke reproducible contractions of the external urethral sphincter. Sublingual administration of isosorbide dinitrate (10 mg) could significantly reduce the resting pressure of the external urethral sphincter for at least 1 hour. The maximal contractile strength measured as the MUCP during single-pulse and continuous magnetic stimulation of the sacral roots also decreased significantly. NO did not induce a significantly faster fatigue of the external urethral sphincter during continuous magnetic stimulation of the sacral roots. The authors suggested that NO donors could offer a new pharmacologic approach to treat urinary retention caused by an overactive or nonrelaxing external urethral sphincter. In a later study on 12 male SCI patients with NDO and DSD, Reitz et al. (2004b) found that NO significantly reduced external urethral sphincter pressures at rest ($P < .05$) and during dyssynergic contraction ($P < .05$), whereas bladder pressures at rest and during contraction and the reflex volume remained unchanged. In patients who used suprapubic tapping for bladder emptying, the mean post-triggering residual volume was significantly reduced ($P < .05$). The researchers concluded based on their findings that NO donors could offer a potential pharmacologic option to treat DSD in SCI

patients.

At the Level of the Striated Sphincter

There is no class of pharmacologic agents that will selectively relax the striated musculature of the pelvic floor. Three different types of drugs have been used to treat voiding dysfunction secondary to outlet obstruction at the level of the striated sphincter: the benzodiazepines, dantrolene, and baclofen.

The benzodiazepines are classified both as antianxiety agents (Baldessarini, 2006) and as sedative-hypnotics, muscle relaxants, and anticonvulsants (Charney et al., 2006). Dantrolene and baclofen are characterized as antispasticity agents (Standaert and Young, 2006; Taylor, 2006). Baclofen and diazepam exert their actions predominantly within the CNS, whereas dantrolene acts directly on skeletal muscle. Unfortunately, **there is no completely satisfactory form of therapy for alleviation of skeletal muscle spasticity.** Although these drugs are capable of providing variable relief in given circumstances, their efficacy is far from complete; and troublesome muscle weakness, adverse effects on gait, and a variety of other side effects minimize their overall usefulness as treatments for spasticity (Standaert and Young, 2006; Taylor, 2006).

GABA and glycine have been identified as major inhibitory transmitters in the CNS (Andersson and Wein, 2004; Bloom, 2006). GABA is the most widely distributed inhibitory neurotransmitter in the mammalian CNS. GABA receptors have been divided into three types. The GABA-A receptor directly gates a chloride ionophore and has modulatory binding sites for benzodiazepines, barbiturates, neurosteroids, and ethanol (Bloom, 2006). The GABA-B or metabotropic receptor couples to calcium and potassium channels by means of G proteins and second-messenger systems. It inhibits adenylyl cyclase, activates potassium channels, and reduces calcium conductance. The GABA-B receptor is activated by baclofen and is resistant to drugs that modulate GABA-A receptors. There is a third class of GABA receptors, the GABA-C receptor, which is less widely distributed than the A and B subtypes (Bloom, 2006). GABA appears to mediate the inhibitory actions of local interneurons in the brain and presynaptic inhibition within the spinal cord (Bloom, 2006). Glycine receptors are prominent in the brainstem and spinal cord and have many features analogous to the GABA-A receptor.

Benzodiazepines.

Benzodiazepines potentiate the action of GABA by promoting GABA

binding to the GABA-A receptor (Baldessarini, 2006; Charney et al., 2006). Benzodiazepines are extensively used for the treatment of anxiety and related disorders (Baldessarini, 2006), although pharmacologically they can also be classified as centrally acting muscle relaxants. The generalized anxiety disorder that is responsive to pharmacotherapy with these agents is characterized by unrealistic and/or excessive anxiety and worry about life circumstances (Shader and Greenblatt, 1993). Specific symptoms can be related to motor tension, autonomic hyperactivity (frequent urination can be a manifestation of this, and nausea, vomiting, diarrhea, and abdominal distress), and excessive vigilance. Other common uses have included treatment of insomnia, stress-related disorders, muscle spasm, and epilepsy and as preoperative sedation (Lader, 1987). Side effects include nonspecific CNS depression manifesting as sedation, lethargy, drowsiness, a feeling of slowing of thought processes, ataxia, and decreased ability to acquire or store information (Baldessarini, 2006; Shader and Greenblatt, 1993). Some believe that any muscle relaxation effect in clinically used doses is caused by the CNS depressant effects and cite a lack of clinical studies showing any advantages of these agents over placebo or aspirin in this regard (Baldessarini, 2006; Charney et al., 2006). Effective total daily doses of diazepam, the most widely used agent of this group, range from 4 to 40 mg. Other benzodiazepine anxiolytic agents include chlordiazepoxide, clorazepate, prazepam, halazepam, clonazepam, lorazepam, oxazepam, and alprazolam.

Few references are available that provide evaluable data on the use of any of the benzodiazepines in the treatment of functional obstruction at the level of the striated sphincter. Opinions, however, are commonly expressed, at least with regard to diazepam. We have not found the recommended oral doses of diazepam to be effective in controlling the classic type of DSD secondary to neurologic disease. If the cause of incomplete emptying in a neurologically normal patient is obscure and the patient has what appears to be inadequate relaxation of the pelvic floor striated musculature urodynamically (e.g., dysfunctional voiding, occult neuropathic bladder, Hinman syndrome), a trial of such an agent may be worthwhile. The rationale for use is either that of relaxation of the pelvic floor striated musculature during bladder contraction or that such relaxation removes an inhibitory stimulus to reflex bladder activity. Improvement under such circumstances may simply be caused, however, by the antianxiety effect of the drug, or by the intensive explanation, encouragement, and modified biofeedback therapy that usually accompanies such treatment in these patients.

Baclofen.

Baclofen depresses monosynaptic and polysynaptic excitation of motor neurons and interneurons in the spinal cord by activating GABA-B receptors (Standaert and Young, 2006). Baclofen's primary site of action is in the spinal cord, but it is also reported to have activity at more rostral sites in the CNS. Baclofen has been found useful in the treatment of skeletal spasticity from a variety of causes, especially amyotrophic lateral sclerosis (Standaert and Young, 2006). Determination of the optimal dose in an individual patient requires careful titration. Treatment is started at an initial dose of 5 mg twice daily, and the dose is increased every 3 days up to a maximum daily dose of 20 mg four times a day. With reference to voiding dysfunction, Hachen and Krucker (1977) found a daily oral dose of 75 mg ineffective in patients with DSD from traumatic paraplegia, whereas they found a daily intravenous dose of 20 mg highly effective. Florante et al. (1980) reported that 73% of their patients with voiding dysfunction secondary to acute and chronic SCI showed lower striated sphincter responses and decreased residual urine volumes after baclofen treatment, but only with an average daily oral dose of 120 mg. Potential side effects of baclofen include drowsiness, insomnia, rash, pruritus, dizziness, and weakness. It may impair ability to walk or stand and is not recommended for the management of spasticity caused by cerebral lesions or disease. Sudden withdrawal has been shown to provoke hallucinations, anxiety, and tachycardia; hallucinations during treatment, which have been responsive to reductions in dosage, have also been reported (Roy and Wakefield, 1986).

Drug delivery often frustrates adequate pharmacologic treatment, and baclofen is a good example of this. GABA's hydrophilic properties prevent its crossing the blood-brain barrier in sufficient amounts to make it therapeutically useful. For oral use, the more lipophilic analogue, baclofen, was developed. However, its passage through the barrier is likewise limited, and it has proved to be a generally insufficient drug when given orally to treat severe somatic spasticity and micturition disorders secondary to neurogenic dysfunction (Kums and Delhaas, 1991).

Intrathecal infusion bypasses the blood-brain barrier; CSF levels 10 times higher than those reached with oral administration are achieved with infusion amounts 100 times less than those taken orally (Penn et al., 1989). Direct administration into the subarachnoid space by an implanted infusion pump showed initially promising results for not only skeletal spasticity but also striated sphincter dyssynergia and DO.

Nanninga et al. (1989) reported on such administration to seven patients with intractable spasticity. All patients experienced a general decrease in spasticity, and the amount of striated sphincter activity during bladder contraction decreased; six showed an increase in bladder capacity. Four previously incontinent patients were able to stay dry with CIC. The action on DO is not unexpected, given its spinal cord mechanism of action, and this inhibition of bladder contractility when the drug is administered intrathecally may in fact prove to be its most important benefit. Laubser et al. (1991) studied nine SCI patients with refractory spasticity, using an external pump to initially test response. Eight showed objective improvement in functional abilities; three of seven studied urodynamically showed an increase in bladder capacity. Kums and Delhaas (1991) reported on nine paraplegic or quadriplegic men (secondary to trauma or MS) with intractable muscle spasticity treated with intrathecal baclofen. After a successful test period through an external catheter, a drug delivery system was implanted and connected to a spinal catheter. Doses per 24 hours ranged from 74 to 840 µg. Patients were studied before and 4 to 6 weeks after initiation of therapy. Mean residual urine volume decreased from 224 to 110 mL ($P = .01$), mean urodynamic bladder capacity increased from 162 to 263 mL ($P = .005$), and pelvic floor spasm decreased at both baseline and at maximum bladder capacity ($P = .005$ and $P = .025$, respectively). Three subjects became continent. In addition, CIC was no longer complicated by adductor spasm. Bushman et al. (1993) reported an increase in bladder storage in three individuals with hereditary spastic paraplegia treated with intrathecal baclofen. Tolerance to intrathecal baclofen with a requirement for increasing doses may prove to be a problem with long-term chronic use, and studies are underway to investigate this. Vaidyanathan et al. (2004) reported a case with insidious development of autonomic dysreflexia and hydronephrosis resulting from dyssynergic voiding after discontinuation of intrathecal baclofen therapy. They recommended that in SCI patients in whom intrathecal baclofen therapy is terminated, close monitoring of the urologic status is needed.

Dantrolene.

Dantrolene exerts its effects by a direct peripheral action on skeletal muscle (Standaert and Young, 2006; Taylor, 2006)**. It is thought to inhibit the excitation-induced release of calcium ions from the sarcoplasmic reticulum of striated muscle fibers, thereby inhibiting excitation-contraction coupling and diminishing the mechanical force of contraction.** The blockade of calcium release is not complete, however, and contraction is not completely abolished. It reduces reflex more than voluntary contraction, probably because of a preferential action on fast-type, as compared with slow-type, skeletal muscle fibers. It has been shown to have therapeutic benefits for chronic spasticity associated with CNS disorders.

The drug has been reported to improve voiding function in some patients with classic DSD and was initially reported as being very successful in doing so (Murdock et al., 1976). Therapy in adults is recommended to begin at a dose of 25 mg daily, and this is gradually increased by increments of 25 mg every 4 to 7 days to a maximal oral dose of 400 mg given in four divided doses. Hackler et al. (1980) achieved improvement in voiding function in approximately one-half of their patients treated with dantrolene but found that such improvement required oral doses of 600 mg daily. Although no inhibitory effect on bladder smooth muscle seems to occur (Harris and Benson, 1980), the generalized weakness that dantrolene can induce is often significant enough to compromise its therapeutic effects. Other potential side effects include euphoria, dizziness, diarrhea, and hepatotoxicity. Fatal hepatitis has been reported in 0.1% to 0.2% of patients treated with the drug for 60 days or longer, and symptomatic hepatitis may occur in 0.5% of patients on treatment for more than 60 days, whereas chemical abnormalities of liver function are noted in up to 1%. The risk for hepatic injury is twofold greater in female patients (Ward et al., 1986).

One agreed-on use of dantrolene is to acutely manage malignant hyperthermia, a rare hereditary syndrome characterized by vigorous contraction of skeletal muscle precipitated by excess release of calcium from the sarcoplasmic reticulum, usually in response to neuromuscular-blocking agents or inhalational anesthetics. Almost all hospital pharmacies stock parenteral dantrolene for this purpose. **Virtually no one currently uses dantrolene for the treatment of voiding dysfunction.**

Botulinum Toxin.

As mentioned earlier, botulinum toxin is an inhibitor of the release of ACh and other transmitters at the neuromuscular junction of somatic nerves in striated muscle, and of autonomic nerves in smooth muscle (Simpson, 2004). It is interesting that it produces enough weakness of the muscle to prevent or considerably ameliorate spasm or involuntary contraction but not to completely block voluntary control, a phenomenon hypothesized to occur because more active neuromuscular junctions are more likely than less active junctions to be blocked by the effect of the drug (Hallett, 1999). **Dykstra et al. first reported its urologic use for the treatment of DSD** (Dykstra and Sidi, 1990; Dykstra et al., 1998, 2003). Injections were carried out weekly for 3 weeks, achieving a duration of effect averaging 2 months. The only side effects reported in the Dykstra articles were transitory limb paresis and transitory exacerbation of autonomic hyperreflexia.

Fowler et al. (1992a) injected botulinum toxin to six women with difficult voiding and urinary retention secondary to what is now called *Fowler syndrome* (manifesting with abnormal myotonus-like electromyographic activity in the striated urethral sphincter). Although voiding characteristics improved in no patient (a fact attributed to the type of repetitive discharge activity), three women did develop transient stress incontinence, a positive effect of sorts, indicating that the sphincter muscle had indeed been weakened. Petit et al. (1998) reported on the endoscopic injection of botulinum toxin A (Botox), 150 IU, into the striated urethral sphincter, using a four-point injection technique (medication was diluted to 4 mL with saline solution). Seventeen patients with SCI or spinal cord disease were treated, and evaluation 1 month after treatment disclosed the following positive results: (1) a decrease in PVR by an average of 176 mL; (2) a decrease in bladder pressure during an emptying contraction by an average of 19 cm H_2O; and (3) a decrease in urethral pressure during an emptying bladder contraction by an average of 24 cm H_2O. The authors judged voiding to be improved in 10 patients. Side effects included the new appearance of stress incontinence in two patients and exacerbation of preexisting incontinence in three. The duration of the effect was variable, but no less than 2 to 3 months. There were no adverse effects on striated muscle elsewhere. The authors concluded that Botox was a promising treatment for DSD in certain patients who are refractory to CIC or surgery. Gallien et al. (1998) injected Botox transperineally in five men with traumatic quadriplegia and DSD. Using a total initial dose of 100 units, divided into four injections of 25 U each, the authors noted what they called improved bladder function in all patients, with a significant decrease in residual urine volume (however, on examination of the figures, the mean reduction was only 14 mL, with one patient requiring a second set of injections). The maximum urethral pressure on average did not change, the maximum detrusor pressure during an emptying episode decreased 5 cm H_2O, and the functional detrusor capacity increased by an average of 89 mL. Urinary catheterization was able to be stopped in two patients, and autonomic hyperreflexia dramatically decreased in intensity in four patients. The time to improvement was 10 to 21 days, and the duration was 3 to 5 months. No patient had significant side effects. Wheeler et al. (1998) reported on three men with SCI, all of whom had emptying problems related to DSD. The sphincter was injected transperineally with botulinum toxin, using electromyographic control for localization. Two of the patients reported excellent results. Schurch et al. (1996) used both transurethral and transperineal injections in 24 male SCI patients with voiding dysfunction secondary to DSD. They judged that in 21 of these patients, DSD was significantly improved, with a concomitant decrease in PVR urine volume in “most cases.” Nine of 24 patients had a decreased PVR volume from 450 to 50 mL; in 7 patients, the residual urine volumes were less than 50 mL to begin with and remained unchanged; and in 8 patients, the PVR urine volumes were high and remained unchanged. The authors commented that transurethral injections appeared to be more effective, at least in reduction in maximum urethral pressure, than did transperineal injections. They noted no side effects. de Sèze et al. (2002) performed a double-blind lidocaine-controlled study in 13 patients with spinal cord disease and DSD and demonstrated the superiority of botulinum toxin compared with lidocaine in improving clinical symptoms and increased urethral pressure.

A potential side effect is the spread to nearby muscles, particularly when high volumes of the toxin are injected. Distant effects can also occur, but distant weakness or generalized weakness, caused by the toxins spreading in the blood, is very rare. Botulinum toxin should be used only under close supervision in patients with already disturbed neuromuscular transmission or during treatment with aminoglycosides.

Theoretically, any agent that promotes striated sphincter relaxation in a uroselective manner could be used to decrease outlet resistance and facilitate voiding dysfunction. Yoshiyama et al. (2000) described the laboratory use of intravenous α-bungarotoxin as improving voiding in SCI rats. The drug is a toxin extracted from the venom of a Formosan snake; it selectively blocks nicotinic receptors without influencing transmission in autonomic ganglia. Although a long way from clinical use, nicotinic receptors in the striated sphincter have been shown to be a potential target for drug therapy for DSD.

Key Points: Decreasing Outlet Resistance

- α-AR–blocking agents are capable of reducing smooth muscle tone in the bladder outlet in both men and women and in the prostatic muscle. Such agents can be used with success in patients with bladder neck dysfunction and in men with BOO secondary to prostatic enlargement. Blockade of the α_{1A}-AR would theoretically exert the greatest effect, and whether there is any difference in the efficacy of the individual agents available remains a topic of controversy.

- There is no class of pharmacologic agents that will selectively relax the striated musculature of the pelvic floor. There are few references that provide any information regarding efficacy of benzodiazepines for this purpose. Baclofen seems to be most useful when administered intrathecally; dantrolene is seldom if ever used for this purpose. Injection of botulinum toxin into the striated sphincter has been used with some clinical success, especially in patients with neurologic DSD. The potential for spread to nearby structures is greater than with intravesical therapy, and distant effects can also occur, but these are rare.

Suggested Readings

Alhasso A, Glazener CMA, Pickard R, et al. Adrenergic drugs for urinary incontinence in adults. *Cochrane Database Syst Rev*. 2005;(3) [CD001842; Reprinted in The Cochrane Library 2008, Issue 2].

Andersson KE. Alpha-adrenoceptors and benign prostatic hyperplasia: basic principles for treatment with alpha-adrenoceptor antagonists. *World J Urol*. 2002;19(6):390.

Andersson KE. Antimuscarinic mechanisms and the overactive detrusor: an update. *Eur Urol*. 2011;59(3):377–386.

Andersson KE. Muscarinic acetylcholine receptors in the urinary tract. *Handb Exp Pharmacol*. 2011;202:319–344.

Andersson KE, Arner A. Urinary bladder contraction and relaxation: physiology and pathophysiology. *Physiol Rev*. 2004;84(3):935–986.

Andersson KE, Chapple CR, Cardozo L, et al. Pharmacological treatment of urinary incontinence. Abrams P, Cardozo L, Khoury S, et al. *Incontinence, 5th International Consultation on Incontinence*. ICUD-EAU: Paris; 2013:623–728.

Andersson KE, Martin N, Nitti V. Selective beta$_3$-adrenoceptor agonists in the treatment of overactive bladder. *J Urol*. 2013;190(4):1173–1180.

Andersson KE, Wein AJ. Pharmacology of the lower urinary tract—basis for current and future treatments of urinary incontinence. *Pharmacol Rev*. 2004;56(4):581.

Athanasopoulos A, Cruz F. The medical treatment of overactive bladder, including current and future treatments. *Expert Opin Pharmacother*. 2011;12(7):1041–1055.

Bridgeman MB, Friia NJ, Taft C, et al. Mirabegron: beta$_3$-adrenergic receptor agonist for the treatment of overactive bladder. *Ann Pharmacother*. 2013;47(7–8):1029–1038.

Chapple CR, Cardozo L, Nitti VW, et al. Mirabegron in overactive bladder: a review of efficacy, safety, and tolerability. *Neurourol Urodyn*. 2014;33(1):17–30.

Cody JD, Richardson K, Moehrer B, et al. Oestrogen therapy for urinary incontinence in post-menopausal women. *Cochrane Database Syst Rev*. 2009;(4) [CD001405].

Dmochowski R, Chapple C, Nitti VW, et al. Efficacy and safety of onabotulinumtoxinA for idiopathic overactive bladder: a double-blind, placebo controlled, randomized, dose ranging trial. *J Urol*. 2010;184(6):2416–2422.

Hendrix SL, Cochrane BB, Nygaard IE, et al. Effects of estrogen with and without progestin on urinary incontinence. *JAMA*. 2005;293(8):935.

Herschorn S, Gajewski J, Ethans K, et al. Efficacy of botulinum toxin A injection for neurogenic detrusor overactivity and urinary incontinence: a randomized, double-blind trial. *J Urol*. 2011;185(6):2229–2235.

Ikeda Y, Zabbarova IV, Birder LA, et al. Botulinum neurotoxin serotype A suppresses neurotransmitter release from afferent as well as efferent nerves in the urinary bladder. *Eur Urol*. 2012;62(6):1157–1164.

Kaplan SA, Roehrborn CG, Rovner ES, et al. Tolterodine and tamsulosin for treatment of men with lower urinary tract symptoms and overactive bladder: a randomized controlled trial. *JAMA*. 2006;296(19):2319.

Madhuvrata P, Cody JD, Ellis G, et al. Which anticholinergic drug for overactive bladder symptoms in adults. *Cochrane Database Syst Rev*. 2012;(1) [CD005429].

Michel MC. The forefront for novel therapeutic agents based on the pathophysiology of lower urinary tract dysfunction: alpha-blockers in the treatment of male voiding dysfunction —how do they work and why do they differ in tolerability? *J Pharmacol Sci*. 2010;112(2):151–157.

Schurch B, Hauri D, Rodic B, et al. Botulinum-A toxin as treatment of detrusor sphincter dyssynergia: a prospective study in 24 spinal cord injury patients. *J Urol*. 1996;155:1023–1029.

Thor K, Katofiasc MA. Effects of duloxetine, a combined serotonin and norepinephrine reuptake inhibitor, on central neural control of lower urinary tract function in the chloralose-anesthetized female cat. *J Pharmacol Exp Ther*. 1995;274(2):1014.

Wagg A, Compion G, Fahey A, et al. Persistence with prescribed antimuscarinic therapy for overactive bladder: a UK experience. *BJU Int*. 2012;110:1767–1774.

References

Abrams P, Cardozo L, Fall M, et al. The standardisation of terminology of lower urinary tract function: report from the Standardisation Sub-committee of the International Continence Society. *Neurourol Urodyn*. 2002;21(2):167.

Abrams P, Amarenco G, Bakke A, et al. Tamsulosin: efficacy and safety in patients with neurogenic lower urinary tract dysfunction due to suprasacral spinal cord injury. *J Urol*. 2003;170(4 Pt 1):1242.

Abrams P, Swift S. Solifenacin is effective for the treatment of OAB dry patients: a pooled analysis. *Eur Urol*. 2005;48(3):483.

Abrams P, Andersson KE, Buccafusco JJ, et al. Muscarinic receptors: their distribution and function in body systems, and the implications for treating overactive bladder. *Br J Pharmacol*. 2006;148(5):565–578.

Abrams P, Cardozo L, Chapple C, et al. Comparison of the efficacy, safety, and tolerability of propiverine and oxybutynin for the treatment of overactive bladder syndrome. *Int J Urol*. 2006;13(6):692.

Abrams P, Kaplan S, De Koning Gans HJ, et al. Safety and tolerability of tolterodine for the treatment of overactive bladder in men with bladder outlet obstruction. *J Urol*. 2006;175(3 Pt 1):999–1004.

Abrams P, Andersson KE. Muscarinic receptor antagonists for overactive bladder. *BJU Int*. 2007;100(5):987.

Abrams P, Kelleher C, Huels J, et al. Clinical relevance of health-related quality of life outcomes with darifenacin. *BJU Int*. 2008;102(2):208.

Abrams P, Kelleher C, Staskin D, et al. Combination treatment with mirabegron and solifenacin in patients with overactive bladder: efficacy and safety results from a randomised, double-blind, dose-ranging, phase 2 study (Symphony). *Eur Urol*. 2015;67(3):577–588.

Agency for Health Care Policy and Research (AHCPR). *Urinary Incontinence Guideline Panel. Urinary incontinence in adults: clinical practice guideline (AHCPR publication #92-0038)*. US DePt of Health and Human Services: Rockville, MD; 1992.

Aizawa N, Homma Y, Igawa Y. Effects of mirabegron, a novel beta3-adrenoceptor agonist, on primary bladder afferent activity and bladder microcontractions in rats compared with the effects of oxybutynin. *Eur Urol*. 2012;62(6):1165–1173.

Akbar M, Abel R, Seyler TM, et al. Repeated botulinum-A toxin injections in the treatment of myelodysplastic children and patients with spinal cord injuries with neurogenic bladder dysfunction. *BJU Int*. 2007;100(3):639.

Al-Badr A, Ross S, Soroka D, et al. What is the available evidence for hormone replacement therapy in women with stress urinary incontinence? *J Obstet Gynaecol Can*. 2003;25(7):567.

Albayrak S, Solmaz V, Gencden Y, et al. Assessment of overactive bladder in women antidepressant users. *Int Urol Nephrol*. 2015;47(9):1479–1484.

Alberts P. Classification of the presynaptic muscarinic receptor subtype that regulates 3H-acetylcholine secretion in the guinea pig urinary bladder in vitro. *J Pharmacol Exp Ther*. 1995;274(1):458–468.

Alexandre EC, Kiguti LR, Calmasini FB, et al. Mirabegron relaxes urethral smooth muscle by a dual mechanism involving β_3-adrenoceptor activation and α_1-adrenoceptor blockade. *Br J Pharmacol*. 2016;173(3):415–428.

Alhasso A, Glazener CM, Pickard R, et al. Adrenergic drugs for urinary incontinence in adults. *Cochrane Database Syst Rev*.

2003;(2) [CD001842].

Alhasso A, Glazener CM, Pickard R, et al. Adrenergic drugs for urinary incontinence in adults (Review). *Cochrane Database Syst Rev*. 2005;(3) [CD001842; Reprinted in The Cochrane Library 2008, Issue 2].

Alloussi S, Laval KU, Eckert R. Trospium chloride (Spasmolyt) in patients with motor urge syndrome (detrusor instability): a double-blind, randomised, nulticentre, placebo-controlled study. *J Clin Res*. 1998;1:439.

Alloussi SH, Mürtz G, Gitzhofer S, et al. Failure of monotherapy in primary monosymptomatic enuresis: a combined desmopressin and propiverine treatment regimen improves efficacy outcomes. *BJU Int*. 2009;103(12):1706–1712.

Alloussi SH, Mürtz G, Lang C, et al. Desmopressin treatment regimens in monosymptomatic and nonmonosymptomatic enuresis: a review from a clinical perspective. *J Pediatr Urol*. 2011;7(1):10–20.

Amarenco G, Marquis P, McCarthy C, et al. Qualité de vie des femmes souffrant d'impériosité mictionelle avec ou sans fuites: étude prospective aprés traitement par oxybutinine (1701 cas). *Presse Med*. 1998;27:5.

Amarenco G, Sutory M, Zachoval R, et al. Solifenacin is effective and well tolerated in patients with neurogenic detrusor overactivity: results from the double-blind, randomized, active- and placebo-controlled SONIC urodynamic study. *Neurourol Urodyn*. 2017;36(2):414–421.

Amend B, Hennenlotter J, Schäfer T, et al. Effective treatment of neurogenic detrusor dysfunction by combined high-dosed antimuscarinics without increased side-effects. *Eur Urol*. 2008;53(5):1021–1028.

Anderson RU, Mobley D, Blank B, et al. Once-daily controlled versus immediate-release oxybutynin chloride for urge urinary incontinence. OROS Oxybutynin Study Group. *J Urol*. 1999;161:1809.

Andersson KE, Ek A, Hedlund H, et al. Effects of prazosin on isolated human urethra and in patients with lower motor neurons lesions. *Invest Urol*. 1981;19(1):39–42.

Andersson KE. Current concepts in the treatment of disorders of micturition. *Drugs*. 1988;35:477–486.

Andersson KE, Hedlund H, Månsson W. Pharmacologic treatment of bladder hyperactivity after augmentation and substitution enterocystoplasty. *Scand J Urol Nephrol Suppl*. 1992;142:42–46.

Andersson KE. Pharmacology of lower urinary tract smooth muscles and penile erectile tissues. *Pharmacol Rev*. 1993;45:253.

Andersson KE, Persson K. The l-arginine/nitric oxide pathway and non-adrenergic, non-cholinergic relaxation of the lower urinary tract. *Gen Pharmacol*. 1993;24:833–839.

Andersson KE. The concept of uroselectivity. *Eur Urol*. 1998;33(Suppl 2):7–11.

Andersson KE. Changes in bladder tone during filling: pharmacological aspects. *Scand J Urol Nephrol*. 1999;201:67–72.

Andersson KE. Pathways for relaxation of detrusor smooth muscle. Baskin L, Hayward S. *Advances in bladder research*. Plenum: New York, NY; 1999:241–252.

Andersson KE. Advances in the pharmacological control of the bladder. *Exp Physiol*. 1999;84:195–213.

Andersson KE, Appell R, Cardozo LD, et al. The pharmacological treatment of urinary incontinence. *BJU Int*. 1999;84(9):923.

Andersson KE. New roles for muscarinic receptors in the pathophysiology of lower urinary tract symptoms. *BJU Int*. 2000;86:36–43.

Andersson KE. Treatment of overactive bladder: other drug mechanisms. *Urology*. 2000;55(5A):51–57.

Andersson KE, Chapple CR. Oxybutynin and the overactive bladder. *World J Urol*. 2001;19(5):319.

Andersson KE. Bladder activation: afferent mechanisms. *Urology*. 2002;59(5 Suppl 1):43.

Andersson KE. Potential benefits of muscarinic M3 receptor selectivity. *Eur Urol Suppl*. 2002;1(4):23.

Andersson KE. Alpha-adrenoceptors and benign prostatic hyperplasia: basic principles for treatment with alpha-adrenoceptor antagonists. *World J Urol*. 2002;19(6):390.

Andersson KE, Pehrson R. CNS involvement in overactive bladder: pathophysiology and opportunities for pharmacological intervention. *Drugs*. 2003;63(23):2595.

Andersson KE, Yoshida M. Antimuscarinics and the overactive detrusor—which is the main mechanism of action? *Eur Urol*. 2003;43(1):1–5.

Andersson KE. Antimuscarinics for treatment of overactive bladder. *Lancet Neurol*. 2004;3(1):46.

Andersson KE, Arner A. Urinary bladder contraction and relaxation: physiology and pathophysiology. *Physiol Rev*. 2004;84(3):935–986.

Andersson KE, Wein AJ. Pharmacology of the lower urinary tract—basis for current and future treatments of urinary incontinence. *Pharmacol Rev*. 2004;56(4):581.

Andersson KE. Treatment-resistant detrusor overactivity—underlying pharmacology and potential mechanisms. *Int J Clin Pract Suppl*. 2006;151:8–16.

Andersson KE, Gratzke C. Pharmacology of alpha1-adrenoceptor antagonists in the lower urinary tract and central nervous system. *Nat Clin Pract Urol*. 2007;4(7):368–378.

Andersson KE, Olshansky B. Treating patients with overactive bladder syndrome with antimuscarinics: heart rate considerations. *BJU Int*. 2007;100:1007.

Andersson KE, Uckert S, Stief C, et al. Phosphodiesterases (PDEs) and PDE inhibitors for treatment of LUTS. *Neurourol Urodyn*. 2007;26(6 Suppl):928.

Andersson KE, Chapple CR, Cardozo L, et al. Pharmacological treatment of urinary incontinence. Abrams P, Cardozo L, Khoury S, et al. *Incontinence. 4th International Consultation on Incontinence*. Plymbridge Distributors: Plymouth (UK); 2009:633.

Andersson KE, Gratzke C, Hedlund P. The role of the transient receptor potential (TRP) superfamily of cation-selective channels in the management of the overactive bladder. *BJU Int*. 2010;106(8):1114–1127.

Andersson KE, Sarawate C, Kahler KH, et al. Cardiovascular morbidity, heart rates and use of antimuscarinics in patients with overactive bladder. *BJU Int*. 2010;106(2):268–274.

Andersson KE. Muscarinic acetylcholine receptors in the urinary tract. *Handb Exp Pharmacol*. 2011;202:319–344.

Andersson KE. Antimuscarinic mechanisms and the overactive detrusor: an update. *Eur Urol*. 2011;59(3):377–386.

Andersson KE. Drugs and future candidates. *Can Urol Assoc J*. 2011;5(5 Suppl 2):S131–S133.

Andersson KE, de Groat WC, McVary KT, et al. Tadalafil for the treatment of lower urinary tract symptoms secondary to benign prostatic hyperplasia: pathophysiology and mechanism(s) of action. *Neurourol Urodyn*. 2011;30(3):292–301.

Andersson KE, Wein AJ. Pharmacologic management of lower urinary tract storage and emptying failure. Wein A, Kavoussi L, Novick A, et al. *Campbell-Walsh urology*. Saunders: Philadelphia, PA; 2012:1967–2002.

Andersson KE, Chapple CR, Cardozo L, et al. Pharmacological treatment of urinary incontinence. Abrams P, Cardozo L, Khoury S, et al. *Incontinence. 5th International Consultation on Incontinence*. ICUD-EAU: Paris; 2013:623–728.

Andersson KE, Martin N, Nitti V. Selective beta3-adrenoceptor agonists in the treatment of overactive bladder. *J Urol*. 2013;190(4):1173–1180.

Andersson KE. Pharmacology: on the mode of action of mirabegron. *Nat Rev Urol*. 2016;13(3):131–132.

Andersson KE. Drugs for the overactive bladder: are there differences in persistence and compliance? *Transl Androl Urol*. 2017;6(3):597–601.

Andersson KE. On the site and mechanism of action of β_3-adrenoceptor agonists in the bladder. *Int Neurourol J*. 2017;21(1):6–11.

Andersson KE. Pharmacology: cardiovascular effects of mirabegron. *Nat Rev Urol*. 2017;14(10):587–588.

Andersson K-E, Cardozo L, Cruz F, et al. Pharmacological treatment of urinary incontinence. Abrams P, Cardozo L, Wagg A, et al. *Incontinence. 6th International Consultation on Incontinence*. ICUD-EAU: Paris; 2017:805–957.

Andrews MD, Fish P, Blagg J, et al. Pyrimido [4,5-d] azepines as potent and selective 5-HT2C receptor agonists: design, synthesis and evaluation of PF-3246799 as a treatment for urinary incontinence. *Bioorg Med Chem Lett*. 2011;21(9):2715–2720.

Aoki K, Hirayama A, Tanaka N, et al. A higher level of prostaglandin E_2 in the urinary bladder in young boys and boys with lower urinary tract obstruction. *Biomed Res*. 2009;30(6):343–347.

Aoki K. Review of a proposed mechanism for the antinociceptive action of botulinum toxin type A. *Neurotoxicology*. 2005;26(5):785.

Apostolidis A, Brady CM, Yiangou Y, et al. Capsaicin receptor TRPV1 in urothelium of neurogenic human bladders and effect of intravesical resiniferatoxin. *Urology*. 2005;65(2):400–405.

Apostolidis A, Popat R, Yiangou Y, et al. Decreased sensory receptors P2X3 and TRPV1 in suburothelial nerve fibers following intradetrusor injections of botulinum toxin for human detrusor overactivity. *J Urol*. 2005;174(3):977.

Apostolidis A, Gonzales GE, Fowler CJ. Effect of intravesical Resiniferatoxin (RTX) on lower urinary tract symptoms, urodynamic parameters, and quality of life of patients with urodynamic increased bladder sensation. *Eur Urol*. 2006;50(6):1299.

Apostolidis A, Popat R, Harper M, et al. Successful treatment with botulinum toxin A after failed augmentation ileocystoplasty. *Nat Clin Pract Urol*. 2007;4(5):280–284.

Apostolidis A, Kirana PS, Chiu G, et al. Gender and age differences in the perception of bother and health care seeking for lower urinary tract symptoms: results from the hospitalised and outpatients’ profile and expectations study. *Eur Urol*. 2009;56(6):937–947.

Appell RA, Chancellor MB, Zobrist RH, et al. Pharmacokinetics, metabolism, and saliva output during transdermal and extended-release oral oxybutynin administration in healthy subjects. *Mayo Clin Proc*. 2003;78(6):696.

Appell RA, Sand P, Dmochowski R, et al. Overactive bladder: judging effective control and treatment study group. Prospective randomized controlled trial of extended-release oxybutynin chloride and tolterodine tartrate in the treatment of overactive bladder: results of the OBJECT Study. *Mayo Clin Proc*. 2001;76(4):358.

Araki I, Du S, Kobayashi H, et al. Roles of mechanosensitive ion channels in bladder sensory transduction and overactive bladder. *Int J Urol*. 2008;15(8):681–687.

Araki I. TRP channels in urinary bladder mechanosensation. *Adv Exp Med Biol*. 2011;704:861–879.

Arisco AM, Brantly EK, Kraus SR. Oxybutynin extended release for the management of overactive bladder: a clinical review. *Drug Des Devel Ther*. 2009;3:151–161.

Asplund R, Sundberg B, Bengtsson P. Oral desmopressin for nocturnal polyuria in elderly subjects: a double-blind, placebo-controlled randomized exploratory study. *BJU Int*. 1999;83:591.

Athanasopoulos A, Gyftopoulos K, Giannitsas K, et al. Combination treatment with an alpha-blocker plus an anticholinergic for bladder outlet obstruction: a prospective, randomized, controlled study. *J Urol*. 2003;169:2253.

Austin PF, Ferguson G, Yan Y, et al. Combination therapy with desmopressin and an anticholinergic medication for nonresponders to desmopressin for monosymptomatic nocturnal enuresis: a randomized, double-blind, placebo-controlled trial. *Pediatrics*. 2008;122(5):1027–1032.

Avelino A, Charrua A, Frias B, et al. TRP channels in bladder function. *Acta Physiol (Oxf)*. 2013;207(1):110–122.

Avelino A, Cruz F. TRPV1 (vanilloid receptor) in the urinary tract: expression, function and clinical applications. *Naunyn Schmiedebergs Arch Pharmacol*. 2006;373(4):287–299.

Awad SA. Clinical use of bethanechol. *J Urol*. 1985;134:523–526.

Bae JH, Oh MM, Shim KS, et al. The effects of long-term administration of oral desmopressin on the baseline secretion of antidiuretic hormone and serum sodium concentration for the treatment of nocturia: a circadian study. *J Urol*. 2007;178(1):200.

Baigrie RJ, Kelleher JP, Fawcett DP, et al. Oxybutynin: is it safe? *Br J Urol*. 1988;62:319.

Baldessarini R. Drug therapy of depression and anxiety disorders. Brunton LL, Lazo JS, Parker KL. *Goodman and Gilman's the pharmacological basis of therapeutics*. McGraw-Hill: New York and Chicago; 2006:429–460.

Baldo A, Berger TH, Kofler M, et al. The influence of intrathecal baclofen on detrusor function. A urodynamic study. *Neurourol Urodyn*. 2000;19:444 [(Abstract 53)].

Banakhar MA, Al-Shaiji TF, Hassouna MM. Pathophysiology of overactive bladder. *Int Urogynecol J*. 2012;23(8):975–982.

Barendrecht MM, Oelke M, Laguna MP, et al. Is the use of parasympathomimetics for treating an underactive urinary bladder evidence-based? *BJU Int*. 2007;99:749.

Barrett DM. The effects of oral bethanechol chloride on voiding in female patients with excessive residual urine: a randomized double-blind study. *J Urol*. 1981;126:640–645.

Basra RK, Wagg A, Chapple C, et al. A review of adherence to drug therapy in patients with overactive bladder. *BJU Int*. 2008;102:774–779.

Batista JE, Kölbl H, Herschorn S, BEYOND study group, et al. The efficacy and safety of mirabegron compared with solifenacin in overactive bladder patients dissatisfied with previous antimuscarinic treatment due to lack of efficacy: results of a noninferiority, randomized, phase IIIb trial. *Ther Adv Urol*. 2015;7(4):167–179.

Bechara A, Romano S, Casabe A, et al. Comparative efficacy assessment of tamsulosin vs. tamsulosin plus tadalafil in the treatment of LUTS/BPH. Pilot study. *J Sex Med*. 2008;5:2170–2178.

Beckmann-Knopp S, Rietbrock S, Weyhenmeyer R, et al. Inhibitory effects of trospium chloride on cytochrome P450 enzymes in human liver microsomes. *Pharmacol Toxicol*. 1999;6:299.

Beermann B, Hellstrom K, Rosen A. On the metabolism of propantheline in man. *Clin Pharmacol Ther*. 1972;13(2):212.

Behr-Roussel D, Oger S, Caisey S, et al. Vardenafil decreases bladder afferent nerve activity in unanesthetized, decerebrate, spinal cord-injured rats. *Eur Urol*. 2010;59:272–279.

Benner JS, Nichol MB, Rovner ES, et al. Patient-reported reasons for discontinuing overactive bladder medication. *BJU Int*. 2010;105:1276–1282.

Bent A, Gousse A, Hendrix S. Duloxetine compared with placebo for the treatment of women with urinary incontinence. *Neurourol Urodyn*. 2008;27(3):212–221.

Bent S, Tiedt TN, Odden MC, et al. The relative safety of ephedra compared with other herbal products. *Ann Intern Med*. 2003;138(6):468.

Berridge MJ. Smooth muscle cell calcium activation mechanisms. *J Physiol*. 2008;586(Pt 21):5047–5061.

Bharucha AE, Seide B, Guan Z, et al. Effect of tolterodine on gastrointestinal transit and bowel habits in healthy subjects. *Neurogastroenterol Motil*. 2008;20(6):643.

Biers SM, Reynard JM, Brading AF. The effects of a new selective beta3-adrenoceptor agonist (GW427353) on spontaneous activity and detrusor relaxation in human bladder. *BJU Int*. 2006;98(6):1310.

Bigger JT, Giardina EG, Perel JM, et al. Cardiac antiarrhythmic effect of imipramine hydrochloride. *N Engl J Med*. 1977;296:206.

Binnie N, Creasey G, Edmond P, et al. The action of cisapride on the chronic constipation of paraplegia. *Paraplegia*. 1988;26:151–155.

Birder LA, de Groat WC. Mechanisms of disease: involvement of the urothelium in bladder dysfunction. *Nat Clin Pract Urol*. 2007;4(1):46–54.

Birder LA, Kanai AJ, de Groat WC, et al. Vanilloid receptor expression suggests a sensory role for urinary bladder epithelial cells. *Proc Natl Acad Sci USA*. 2001;98(23):13396–

13401.

Birder LA, Nakamura Y, Kiss S, et al. Altered urinary bladder function in mice lacking the vanilloid receptor TRPV1. *Nat Neurosci*. 2002;5(9):856–860.

Birder L, Drake M, deGroat W, et al. Neural control. Abrams P, Cardozo L, Khoury S, et al. *Incontinence*. ed 21 (Distributor). Health Publications: Paris; 2009:167–254.

Birder L, Andersson KE. Urothelial signaling. *Physiol Rev*. 2013;93(2):653–680.

Blaivas JG, Labib KB, Michalik J, et al. Cystometric response to propantheline in detrusor hyperreflexia: therapeutic implications. *J Urol*. 1980;124:259.

Bloom FE. Neurotransmission and the central nervous system. Brunton LL, Lazo JS, Parker KL. *Goodman and Gilman's the pharmacological basis of therapeutics*. McGraw-Hill: New York and Chicago; 2006:317–340.

Blue DR, Daniels DV, Gever JR, et al. Pharmacological characteristics of Ro 115-1240, a selective alpha1A/1L-adrenoceptor partial agonist: a potential therapy for stress urinary incontinence. *BJU Int*. 2004;93(1):162.

Blyweert W, Van Der Aa F, De Ridder D. Cannabinoid therapy in detrusor overactivity: local versus systemic effect in a spinalised rat model. *Neurourol Urodyn*. 2003;22:379–380.

Bonev AD, Nelson MT. Muscarinic inhibition of ATP-sensitive K^+ channels by protein kinase C in urinary bladder smooth muscle. *Am J Physiol*. 1993;265:C1723–C1728.

Bosch JL, Weiss JP. The prevalence and causes of nocturia. *J Urol*. 2010;184(2):440–446.

Bosch RJ, Griffiths DJ, Blom JHM, et al. Treatment of benign prostatic hyperplasia by androgen deprivation: effects on prostate size and urodynamic parameters. *J Urol*. 1989;141:68.

Brady CM, Apostolidis AN, Harper M, et al. Parallel changes in bladder suburothelial vanilloid receptor TRPV1 and pan-neuronal marker PGP9.5 immunoreactivity in patients with neurogenic detrusor overactivity after intravesical resiniferatoxin treatment. *BJU Int*. 2004;93(6):770.

Brady CM, DasGupta R, Dalton C, et al. An open-label pilot study of cannabis-based extracts for bladder dysfunction in advanced multiple sclerosis. *Mult Scler*. 2004;10:425–433.

Brennan PE, Whitlock GA, Ho DK, et al. Discovery of a novel azepine series of potent and selective 5-HT2C agonists as potential treatments for urinary incontinence. *Bioorg Med Chem Lett*. 2009;19:4999–5003.

Bridgeman MB, Friia NJ, Taft C, et al. Mirabegron: beta$_3$-adrenergic receptor agonist for the treatment of overactive bladder. *Ann Pharmacother*. 2013;47(7–8):1029–1038.

Briggs KS, Castleden CM, Asher MJ. The effect of flavoxate on uninhibited detrusor contractions and urinary incontinence in the elderly. *J Urol*. 1980;123:665.

Brown JH, Taylor P. Muscarinic agonists and antagonists. Brunton LL, Lazo JS, Parker KL. *Goodman and Gilman's the pharmacological basis of therapeutics*. McGraw-Hill: New York, NY; 2006:183–200.

Brubaker L, FitzGerald MP. Nocturnal polyuria and nocturia relief in patients treated with solifenacin for overactive bladder symptoms. *Int Urogynecol J Pelvic Floor Dysfunct*. 2007;18(7):737.

Brynne N, Dalen P, Alvan G, et al. Influence of CYP2D6 polymorphism on the pharmacokinetics and pharmacodynamics of tolterodine. *Clin Pharmacol Ther*. 1998;63:529.

Brynne N, Stahl MMS, Hallén B, et al. J. Pharmacokinetics and pharmacodynamics of tolterodine in man: a new drug for the treatment of urinary bladder overactivity. *Int J Clin Pharmacol Ther*. 1997;35:287.

Bschleipfer T, Schukowski K, Weidner W, et al. Expression and distribution of cholinergic receptors in the human urothelium. *Life Sci*. 2007;80(24–25):2303–2307.

Bultitude M, Hills N, Shuttleworth K, et al. Clinical and experimental studies on the action of prostaglandins and their synthesis inhibitors on detrusor muscle in vitro and in vivo. *Br J Urol*. 1976;48:631–637.

Bump RC, Voss S, Beardsworth A, et al. Long-term efficacy of duloxetine in women with stress urinary incontinence. *BJU Int*. 2008;102:214.

Burger M, Betz D, Hampel C, et al. Efficacy and tolerability of solifenacin in men with overactive bladder: results of an observational study. *World J Urol*. 2014;32(4):1041–1047.

Bushman W, Steers WD, Meythaler JM. Voiding dysfunction in patients with spastic paraplegia: urodynamic evaluation and response to continuous intrathecal baclofen. *Neurourol Urodyn*. 1993;12(2):163.

Bödeker RH, Madersbacher H, Neumeister C, et al. Dose escalation improves therapeutic outcome: post hoc analysis of data from a 12-week, multicentre, double-blind, parallel-group trial of trospium chloride in patients with urinary urge incontinence. *BMC Urol*. 2010;10:15.

Caine M, Gin S, Pietra C, et al. Antispasmodic effects of flavoxate, MFCA, and REC 15/2053 on smooth muscle of human prostate and urinary bladder. *Urology*. 1991;37(4):390.

Callegari E, Malhotra B, Bungay PJ, et al. A comprehensive non-clinical evaluation of the CNS penetration potential of antimuscarinic agents for the treatment of overactive bladder. *Br J Clin Pharmacol*. 2011;72:235–246.

Cameron AP, Clemens JQ, Latini JM, et al. Combination drug therapy improves compliance of the neurogenic bladder. *J Urol*. 2009;182(3):1062–1067.

Campbell WB, Halushka PV. Lipid derived autoacids; eicosanoids and platelet activity factor. Hardman JG, Limbird LE, Molinoff PB, et al. *Goodman and Gilman's the pharmacological basis of therapeutics*. ed 9. McGraw-Hill: New York, NY; 1996:601–616.

Cannon A, Carter PG, McConnell AA, et al. Desmopressin in the treatment of nocturnal polyuria in the male. *BJU Int*. 1999;84:20.

Cao DS, Yu SQ, Premkumar LS. Modulation of transient receptor potential vanilloid 4–mediated membrane currents and synaptic transmission by protein kinase C. *Mol Pain*. 2009;5:5.

Capo JP, Lucente V, Forero-Schwanhaeuser S, et al. Efficacy and tolerability of solifenacin in patients aged ≥ 65 years with overactive bladder: post-hoc analysis of 2 open-label studies. *Postgrad Med*. 2011;123(1):94–104.

Carbone A, Palleschi G, Conte A, et al. Gabapentin treatment of neurogenic overactive bladder. *Clin Neuropharmacol*. 2006;29(4):206.

Cardozo L, Castro-Diaz D, Gittelman M, et al. Reductions in overactive bladder-related incontinence from pooled analysis of phase III trials evaluating treatment with solifenacin. *Int Urogynecol J Pelvic Floor Dysfunct*. 2006;17(5):512.

Cardozo L, Chapple CR, Toozs-Hobson P, et al. Efficacy of trospium chloride in patients with detrusor instability: a placebo-controlled, randomized, double-blind, multicentre clinical trial. *BJU Int*. 2000;85(6):659.

Cardozo L, Dixon A. Increased warning time with darifenacin: a new concept in the management of urinary urgency. *J Urol*. 2005;173(4):1214.

Cardozo L, Drutz HP, Baygari SK, et al. Pharmacological treatment of women awaiting surgery for stress urinary incontinence. *Obstet Gynecol*. 2004;104(3):511–519.

Cardozo L, Lisec M, Millard R, et al. Randomized, double-blind placebo controlled trial of the once daily antimuscarinic agent solifenacin succinate in patients with overactive bladder. *J Urol*. 2004;172(5 Pt 1):1919.

Cardozo L, Lose G, McClish D, et al. A systematic review of the effects of estrogens for symptoms suggestive of overactive bladder. *Acta Obstet Gynecol Scand*. 2004;83:892.

Cardozo LD, Bachmann G, McClish D, et al. Meta-analysis of oestrogen therapy in the management of urogenital atrophy in postmenopausal women: second report of the Hormones and Urogenital Therapy Committee. *Obstet Gynecol*. 1998;92:722–727.

Cardozo LD, Stanton SL, Robinson H, et al. Evaluation on flurbiprofen in detrusor instability. *Br Med J*. 1980;280:281.

Cardozo LD, Stanton SL. A comparison between bromocriptine and indomethacin in the treatment of detrusor instability. *J Urol*. 1980;123:39.

Caremel R, Oger-Roussel S, Behr-Roussel D, et al. Nitric oxide/cyclic guanosine monophosphate signalling mediates an inhibitory action on sensory pathways of the micturition reflex in the rat. *Eur Urol*. 2010;58:616–625.

Carone R, Vercella D, Bertapelli P. Effects of cisapride on anorectal and vesicourethral function in spinal cord–injured patients. *Paraplegia*. 1993;31:125–130.

Cartwright R, Cardozo L. Transdermal oxybutynin: sticking to the facts. *Eur Urol*. 2007;51(4):907.

Cartwright R, Srikrishna S, Cardozo L, et al. Patient-selected goals in overactive bladder: a placebo controlled randomized double-blind trial of transdermal oxybutynin for the treatment of urgency and urge incontinence. *BJU Int*. 2011;107(1):70–76.

Catterall WA, Striessnig J, Snutch TP, et al. International Union of Pharmacology. XL. Compendium of voltage-gated ion channels: calcium channels. *Pharmacol Rev*. 2003;55:579.

Caulfield MP, Birdsall N. International Union of Pharmacology: XVI. Classification of muscarinic acetylcholine receptors. *Pharmacol Rev*. 1998;50:279–290.

Cazzulani P, Pietra C, Abbiati GA, et al. Pharmacological activities of the main metabolite of flavoxate 3-methylflavone-8-carboxylic acid. *Arzneimittelforschung*. 1988;38(3):379.

Cellek S, Cameron NE, Cotter MA, et al. Pathophysiology of diabetic erectile dysfunction: potential contribution of vasa nervorum and advanced glycation endproducts. *Int J Impot Res*. 2013;25(1):1–6.

Chai TC, Gray ML, Steers WD. The incidence of a positive ice water test in bladder outlet obstructed patients: evidence for bladder neural plasticity. *J Urol*. 1998;160(1):34.

Chancellor MB, Appell RA, Sathyan G, et al. A comparison of the effects on saliva output of oxybutynin chloride and tolterodine tartrate. *Clin Ther*. 2001;23(5):753.

Chancellor MB, Atan A, Rivas DA, et al. Beneficial effect of intranasal desmopressin for men with benign prostatic hyperplasia and nocturia: preliminary results. *Tech Urol*. 1999;5:191.

Chancellor MB, Erhard MJ, Rivas DA. Clinical effect of alpha-1 antagonism by terazosin on external and internal urinary sphincter function. *J Am Paraplegia Soc*. 1994;16:207–210.

Chancellor MB, Fowler CJ, Apostolidis A, et al. Drug insight: biological effects of botulinum toxin A in the lower urinary tract. *Nat Clin Pract Urol*. 2008;5(6):319.

Chancellor MB, Kianifard F, Beamer E, et al. A comparison of the efficacy of darifenacin alone vs. darifenacin plus a behavioural modification programme upon the symptoms of overactive bladder. *Int J Clin Pract*. 2008;62(4):606.

Chancellor MB, Oefelein MG, Vasavada S. Obesity is associated with a more severe overactive bladder disease state that is effectively treated with once-daily administration of trospium chloride extended release. *Neurourol Urodyn*. 2010;29(4):551–554.

Chancellor MB, Staskin DR, Kay GG, et al. Blood-brain barrier permeation and efflux exclusion of anticholinergics used in the treatment of overactive bladder. *Drugs Aging*. 2012;29(4):259–273.

Chang SC, Lin AT, Chen KK, et al. Multifactorial nature of male nocturia. *Urology*. 2006;67(3):541–544.

Chapple CR, Parkhouse H, Gardener C, et al. Double-blind, placebo-controlled, cross-over study of flavoxate in the treatment of idiopathic detrusor instability. *Br J Urol*. 1990;66:491.

Chapple CR, Arano P, Bosch JL, et al. Solifenacin appears effective and well tolerated in patients with symptomatic idiopathic detrusor overactivity in a placebo- and tolterodine-controlled phase 2 dosefinding study. *BJU Int*. 2004;93(1):71.

Chapple CR, Rechberger T, Al-Shukri S, et al. Randomized, double-blind placebo- and tolterodine-controlled trial of the once-daily antimuscarinic agent solifenacin in patients with symptomatic overactive bladder. *BJU Int*. 2004;93(3):303.

Chapple C, Khullar V, Gabriel Z, et al. The effects of antimuscarinic treatments in overactive bladder: a systematic review and meta-analysis. *Eur Urol*. 2005;48:5.

Chapple C, Steers W, Norton P, et al. A pooled analysis of three phase III studies to investigate the efficacy, tolerability and safety of darifenacin, a muscarinic M3 selective receptor antagonist, in the treatment of overactive bladder. *BJU Int*. 2005;95(7):993.

Chapple CR, Martinez-Garcia R, Selvaggi L, et al. A comparison of the efficacy and tolerability of solifenacin succinate and extended release tolterodine at treating overactive bladder syndrome: results of the STAR trial. *Eur Urol*. 2005;48(3):464.

Chapple C, Patel A. Botulinum toxin—new mechanisms, new therapeutic directions? *Eur Urol*. 2006;49(4):606–608.

Chapple CR, Cardozo L, Steers WD, et al. Solifenacin significantly improves all symptoms of overactive bladder syndrome. *Int J Clin Pract*. 2006;60(8):959.

Chapple CR, Patroneva A, Raines SR. Effect of an ATP-sensitive potassium channel opener in subjects with overactive bladder: a randomized, double-blind, placebo-controlled study (ZD0947IL/0004). *Eur Urol*. 2006;49:879.

Chapple C, DuBeau C, Ebinger U, et al. Long-term darifenacin treatment for overactive bladder in patients aged 65 years and older: analysis of results from a 2-year, open-label extension study. *Curr Med Res Opin*. 2007;23(11):2697.

Chapple C, Van Kerrebroeck P, Tubaro A, et al. Clinical efficacy, safety, and tolerability of once-daily fesoterodine in subjects with overactive bladder. *Eur Urol*. 2007;52(4):1204.

Chapple CR, Fianu-Jonsson A, Indig M, et al. Treatment outcomes in the STAR study: a subanalysis of solifenacin 5 mg and tolterodine ER 4 mg. *Eur Urol*. 2007;52(4):1195.

Chapple CR, Khullar V, Gabriel Z, et al. The effects of antimuscarinic treatments in overactive bladder: an update of a systematic review and meta-analysis. *Eur Urol*. 2008;54(3):543.

Chapple CR, Van Kerrebroeck PE, Jünemann KP, et al. Comparison of fesoterodine and tolterodine in patients with overactive bladder. *BJU Int*. 2008;102(9):1128–1132.

Chapple CR, Montorsi F, Tammela TL, et al. Silodosin therapy for lower urinary tract symptoms in men with suspected benign prostatic hyperplasia: results of an international, randomized, double-blind, placebo- and active-controlled clinical trial performed in Europe. *Eur Urol*. 2011;59(3):342–352.

Chapple C, Milsom I. Urinary incontinence and pelvic prolapse: epidemiology and pathophysiology. Wein A, Kavoussi L, Novick A, et al. *Campbell-Walsh urology*. Saunders: Philadelphia, PA; 2012:1871–1908.

Chapple CR, Amarenco G, López Aramburu MA, et al. A proof-of-concept study: mirabegron, a new therapy for overactive bladder. *Neurourol Urodyn*. 2013;32(8):1116–1122.

Chapple CR, Dvorak V, Radziszewski P, et al. A phase II dose-ranging study of mirabegron in patients with overactive bladder. *Int Urogynecol J*. 2013;24:1447–1458.

Chapple CR, Kaplan SA, Mitcheson D, et al. Randomized double-blind, active-controlled phase 3 study to assess 12-

month safety and efficacy of mirabegron, a beta(3)-adrenoceptor agonist, in overactive bladder. *Eur Urol*. 2013;63(2):296–305.

Chapple CR, Abrams P, Andersson KE, et al. Randomised, double-blind, placebo-controlled phase Ii study to investigate the efficacy and safety of the EP-1 receptor antagonist, ONO-8539, in idiopathic overactive bladder. *J Urol*. 2014;191(1):253–260.

Chapple CR, Cardozo L, Nitti VW, et al. Mirabegron in overactive bladder: a review of efficacy, safety, and tolerability. *Neurourol Urodyn*. 2014;33(1):17–30.

Chapple CR, Cardozo L, Nitti VW, et al. Mirabegron in overactive bladder: a review of efficacy, safety, and tolerability. *Neurourol Urodyn*. 2014;33(1):17–30.

Chapple CR, Nazir J, Hakimi Z, et al. Persistence and adherence with mirabegron versus antimuscarinic agents in patients with overactive bladder: a retrospective observational study in UK clinical practice. *Eur Urol*. 2017;72(3):389–399.

Charney DS, Mihic SJ, Harris RA. Hypnotics and sedatives. Brunton LL, Lazo JS, Parker KL. *Goodman and Gilman's the pharmacological basis of therapeutics*. McGraw-Hill: New York, NY; 2006:401–428.

Charrua A, Cruz CD, Cruz F, et al. Transient receptor potential vanilloid subfamily 1 is essential for the generation of noxious bladder input and bladder overactivity in cystitis. *J Urol*. 2007;177(4):1537–1541.

Charrua A, Cruz CD, Narayanan S, et al. GRC-6211, a new oral specific TRPV1 antagonist, decreases bladder overactivity and noxious bladder input in cystitis animal models. *J Urol*. 2009;181(1):379–386.

Charrua A, Reguenga C, Cordeiro JM, et al. Functional transient receptor potential vanilloid 1 is expressed in human urothelial cells. *J Urol*. 2009;182(6):2944–2950.

Chess-Williams R. Muscarinic receptors of the urinary bladder: detrusor, urothelial and prejunctional. *Auton Autacoid Pharmacol*. 2002;22:133–145.

Choo MS, Doo CK, Lee KS. Satisfaction with tolterodine: assessing symptom-specific patient-reported goal achievement in the treatment of overactive bladder in female patients (STARGATE study). *Int J Clin Pract*. 2008;62(2):191.

Christ GJ, Andersson KE. Rho-kinase and effects of Rho-kinase inhibition on the lower urinary tract. *Neurourol Urodyn*. 2007;26(6 Suppl):948–954.

Christ GJ, Day NS, Day M, et al. Bladder injection of “naked” hSlo/pcDNA3 ameliorates detrusor hyperactivity in obstructed rats in vivo. *Am J Physiol Regul Integr Comp Physiol*. 2001;281(5):R1699–R1709.

Christ T, Wettwer E, Wuest M, et al. Electrophysiological profile of propiverine—relationship to cardiac risk. *Naunyn Schmiedebergs Arch Pharmacol*. 2008;376(6):431–440.

Chuang YC, Thomas CA, Tyagi S, et al. Human urine with solifenacin intake but not tolterodine or darifenacin intake blocks detrusor overactivity. *Int Urogynecol J Pelvic Floor Dysfunct*. 2008;19(10):1353.

Chung DE, Te AE, Staskin DR, et al. Efficacy and safety of tolterodine extended release and dutasteride in male overactive bladder patients with prostates >30 grams. *Urology*. 2010;75(5):1144–1148.

Clemett D, Jarvis B. Tolterodine: a review of its use in the treatment of overactive bladder. *Drugs Aging*. 2001;18(4):277.

Cody JD, Richardson K, Moehrer B, et al. Oestrogen therapy for urinary incontinence in post-menopausal women. *Cochrane Database Syst Rev*. 2009;(4) [CD001405].

Coelho A, Cruz F, Cruz CD, et al. Effect of onabotulinumtoxinA on intramural parasympathetic ganglia: an experimental study in the guinea pig bladder. *J Urol*. 2012;187(3):1121–1126.

Coelho A, Cruz F, Cruz CD, et al. Spread of onabotulinumtoxinA after bladder injection. Experimental study using the distribution of cleaved SNAP-25 as the marker of the toxin action. *Eur Urol*. 2012;61(6):1178–1184.

Coelho A, Dinis P, Pinto R, et al. Distribution of the high-affinity binding site and intracellular target of botulinum toxin type A in the human bladder. *Eur Urol*. 2010;57(5):884–890.

Cohen HW, Gibson G, Alderman MH. Excess risk of myocardial infarction in patients treated with antidepressant medications: association with use of tricyclic agents. *Am J Med*. 2000;108:2–8.

Collado Serra A, Rubio-Briones J, Puvol Payás M, et al. Postprostatectomy established stress urinary incontinence treated with duloxetine. *Urology*. 2011;78(2):261–266.

Collas D, Malone-Lee JG. The pharmacokinetic properties of rectal oxybutynin—a possible alternative to intravesical administration. *Neurourol Urodyn*. 1997;16:346.

Colli E, Digesu GA, Olivieri L. Overactive bladder treatments in early phase clinical trials. *Expert Opin Investig Drugs*. 2007;16(7):999–1007.

Colli E, Rigatti P, Montorsi F, et al. BXL628, a novel vitamin D_3 analog arrests prostate growth in patients with benign prostatic hyperplasia: a randomized clinical trial. *Eur Urol*. 2006;49(1):82.

Colli E, Tankó LB. Gonadotropin-releasing hormone antagonists: from basic science to the clinic in patients with benign prostatic hyperplasia and lower urinary tract symptoms. *UroToday Int J*. 2010;3(5).

Conlon K, Christy C, Westbrook S, et al. Pharmacological properties of 2-((R-5-chloro-4-methoxymethylindan-1-yl)-1H-imidazole (PF-3774076), a novel and selective alpha1A-adrenergic partial agonist, in in vitro and in vivo models of urethral function. *J Pharmacol Exp Ther*. 2009;330(3):892–901.

Connolly MJ, Astridge PS, White EG, et al. Torsades de pointes ventricular tachycardia and terodiline. *Lancet*. 1991;338(8763):344.

Copas PM, Bukovsky A, Asubyr B, et al. Estrogen, progesterone and androgen receptor expression in levator ani muscle and fascia. *J Womens Health Gend Based Med*. 2001;10(8):785.

Corcos J, Casey R, Patrick A, et al. A double-blind randomized dose-response study comparing daily doses of 5, 10 and 15 mg controlled-release oxybutynin: balancing efficacy with severity of dry mouth. *BJU Int*. 2006;97(3):520.

Cornu JN, Merlet B, Ciofu C, et al. Duloxetine for mild to moderate postprostatectomy incontinence: preliminary results of a randomized, placebo-controlled trial. *Eur Urol*. 2011;59(1):148–154.

Covenas R, Martin F, Belda M, et al. Mapping of neurokinin-like immunoreactivity in the human brainstem. *BMC Neurosci*. 2003;4(1):3.

Coyne KS, Elinoff V, Gordon DA, et al. Relationships between improvements in symptoms and patient assessments of bladder condition, symptom bother and health-related quality of life in patients with overactive bladder treated with tolterodine. *Int J Clin Pract*. 2008;62(6):925.

Crescioli C, Ferruzzi P, Caporali A, et al. Inhibition of prostate cell growth by BXL-628, a calcitriol analogue selected for a phase II clinical trial in patients with benign prostate hyperplasia. *Eur J Endocrinol*. 2004;150(4):591.

Crescioli C, Ferruzzi P, Caporali A, et al. Inhibition of spontaneous and androgen-induced prostate growth by a nonhypercalcemic calcitriol analog. *Endocrinology*. 2003;144(7):3046.

Crescioli C, Morelli A, Adorini L, et al. Human bladder as a novel target for vitamin D receptor ligands. *J Clin Endocrinol Metab*. 2005;90(2):962–972.

Crescioli C, Villari D, Forti G, et al. Des (1-3) IGF-I-stimulated growth of human stromal BPH cells is inhibited by a vitamin D3 analogue. *Mol Cell Endocrinol*. 2002;198(1–2):69–75.

Cruz F, Guimaräes M, Silva C, et al. Suppression of bladder hyperreflexia by intravesical resiniferatoxin. *Lancet*. 1997;350(9078):640.

Cruz F, Herschorn S, Aliotta P, et al. Efficacy and safety of onabotulinumtoxinA in patients with urinary incontinence due to neurogenic detrusor overactivity: a randomised, double-blind, placebo-controlled trial. *Eur Urol*. 2011;60(4):742–750.

Cui Y, Zong H, Yang C, et al. The efficacy and safety of mirabegron in treating OAB: a systematic review and meta-analysis of phase III trials. *Int Urol Nephrol*. 2014;46(1):275–284.

Cvetkovic RS, Plosker GL. Desmopressin in adults with nocturia. *Drugs*. 2005;65:99.

D'Agostino G, Bolognesi ML, Lucchelli A, et al. Prejunctional muscarinic inhibitory control of acetylcholine release in the human isolated detrusor: involvement of the M4 receptor subtype. *Br J Pharmacol*. 2000;129:493–500.

D'Agostino G, Maria Condino A, Calvi P. Involvement of β_3-adrenoceptors in the inhibitory control of cholinergic activity in human bladder: direct evidence by [(3)H]-acetylcholine release experiments in the isolated detrusor. *Eur J Pharmacol*. 2015;758:115–122.

Dahm TL, Ostri P, Kristensen JK, et al. Flavoxate treatment of micturition disorders accompanying benign prostatic hypertrophy: a double-blind placebo-controlled multicenter investigation. *Urol Int*. 1995;55:205.

Das A, Chancellor MB, Watanabe T, et al. Intravesical capsaicin in neurologic impaired patients with detrusor hyperreflexia. *J Spinal Cord Med*. 1996;19(3):190.

Davila GW, Daugherty CA, Sanders SW. A short-term, multicenter, randomized double-blind dose titration study of the efficacy and anticholinergic side effects of transdermal compared to immediate release oral oxybutynin treatment of patients with urge urinary incontinence. *J Urol*. 2001;166(1):140.

Davis TP, Sanchez-Covarubias L, Tome ME. P-glycoprotein trafficking as a therapeutic target to optimize CNS drug delivery. *Adv Pharmacol*. 2014;71:25–44.

de Groat W. The urothelium in overactive bladder: passive bystander or active participant? *Urology*. 2004;64(6 Suppl 1):7–11.

de Groat WC, Booth AM, Yoshimura N. Neurophysiology of micturition and its modification in animal models of human disease. Maggi CA. *The autonomic nervous system*. Harwood Academic: London; 1993:227–290.

de Groat WC, Downie JW, Levin RM, et al. Basic neurophysiology and neuropharmacology. Abrams P, Khoury S, Wein A. *Incontinence, 1st International Consultation on Incontinence*. Plymbridge Distributors Ltd: Plymouth (UK); 1999:105–154.

de Groat WC. A neurologic basis for the overactive bladder. *Urology*. 1997;50(6A Suppl):36–52.

De Guchtenaere A, Van Herzeele C, Raes A, et al. Oral lyophylizate formulation of desmopressin: superior pharmacodynamics compared to tablet due to low food interaction. *J Urol*. 2011;185(6):2308–2313.

De Guchtenaere A, Vande Walle C, Van Sintjan P, et al. Desmopressin resistant nocturnal polyuria may benefit from furosemide therapy administered in the morning. *J Urol*. 2007;178:2635.

De Laet K, De Wachter S, Wyndaele JJ. Systemic oxybutynin decreases afferent activity of the pelvic nerve of the rat: new insights into the working mechanism of antimuscarinics. *Neurourol Urodyn*. 2006;25(2):156.

de Mey C, Mateva L, Krastev Z, et al. Effects of hepatic dysfunction on the single-dose pharmacokinetics of fesoterodine. *J Clin Pharmacol*. 2011;51(3):397–405.

de Paiva A, Meunier FA, Molgó J, et al. Functional repair of motor endplates after botulinum neurotoxin type A poisoning: biphasic switch of synaptic activity between nerve sprouts and their parent terminals. *Proc Natl Acad Sci USA*. 1999;96(6):3200–3205.

De Ridder D, Chandiramani V, Dasgupta P, et al. Intravesical capsaicin as a treatment for refractory detrusor hyperreflexia: a dual center study with long-term followup. *J Urol*. 1997;158(6):2087.

de Sèze M, Gallien P, Denys P, et al. Intravesical glucidic capsaicin versus glucidic solvent in neurogenic detrusor overactivity: a double blind controlled randomized study. *Neurourol Urodyn*. 2006;25(7):752–757.

de Sèze M, Petit H, Gallien P, et al. Botulinum a toxin and detrusor sphincter dyssynergia: a double-blind lidocaine-controlled study in 13 patients with spinal cord disease. *Eur Urol*. 2002;42(1):56–62.

de Sèze M, Wiart L, Joseph PA, et al. Capsaicin and neurogenic detrusor hyperreflexia: a double-blind placebo-controlled study in 20 patients with spinal cord lesions. *Neurourol Urodyn*. 1998;17(5):513.

De Wachter S, Van Meel TD, Wyndaele JJ. Study of the afferent nervous system and its evaluation in women with impaired detrusor contractility treated with bethanechol. *Urology*. 2003;62(1):54–58.

De Wachter S, Wyndaele JJ. Does bladder tone influence sensation of filling and electro-sensation in the bladder? A blind controlled study in young healthy volunteers using bethanechol. *J Urol*. 2001;165(3):802–804.

Deaney C, Glickman S, Gluck T, et al. Intravesical atropine suppression of detrusor hyperreflexia in multiple sclerosis. *J Neurol Neurosurg Psychiatry*. 1998;65:957.

Debruyne F, Gres AA, Arustamov DL. Placebo-controlled dose-ranging phase 2 study of subcutaneously administered LHRH antagonist cetrorelix in patients with symptomatic benign prostatic hyperplasia. *Eur Urol*. 2008;54(1):170.

Dehvari N, da Silva Junior ED, Bengtsson T, et al. Mirabegron: potential off target effects and uses beyond the bladder. *Br J Pharmacol*. 2018;175(21):4072–4082.

Del Popolo G, Filocamo MT, Li Marzi V, et al. Neurogenic detrusor overactivity treated with English botulinum toxin a: 8-year experience of one single centre. *Eur Urol*. 2008;53(5):1013.

Delaere KP, Thomas CM, Moonen WA, et al. The value of intravesical prostaglandin F_2alpha and E_2 in women with abnormalities of bladder emptying. *Br J Urol*. 1981;53:306–311.

DeLancey JO. The pathophysiology of stress urinary incontinence in women and its implications for surgical treatment. *World J Urol*. 1997;15:268.

Dell'Utri C, Digesu GA, Bhide A, et al. Fesoterodine in randomised clinical trials: an updated systematic clinical review of efficacy and safety. *Int Urogynecol J*. 2012;23(10):1337–1344.

Denmeade SR, Egerdie B, Steinhoff G, et al. Phase 1 and 2 studies demonstrate the safety and efficacy of intraprostatic injection of PRX302 for the targeted treatment of lower urinary tract symptoms secondary to benign prostatic hyperplasia. *Eur Urol*. 2011;59(5):747–754.

Denys P, Le Normand L, Ghout I, et al. Efficacy and safety of low doses of onabotulinumtoxinA for the treatment of refractory idiopathic overactive bladder: a multicentre, double-blind, randomised, placebo-controlled dose-ranging study. *Eur Urol*. 2012;61(3):520–529.

Deruyver Y, Voets T, De Ridder D, et al. Transient receptor potential channel modulators as pharmacological treatments for lower urinary tract symptoms (LUTS): myth or reality? *BJU Int*. 2015;115(5):686–697.

Desmond A, Bultitude M, Hills N, et al. Clinical experience with intravesical prostaglandin E_2: a prospective study of 36 patients. *Br J Urol*. 1980;53:357–362.

Di Salvo J, Nagabukuro H, Wickham LA, et al. Pharmacological characterization of a novel beta 3 adrenergic agonist, vibegron: evaluation of antimuscarinic receptor selectivity for combination therapy for overactive bladder. *J Pharmacol Exp Ther*. 2017;360(2):346–355.

Diefenbach K, Jaeger K, Wollny A, et al. Effect of tolterodine on sleep structure modulated by CYP2D6 genotype. *Sleep Med*. 2008;9(5):579.

Dinis P, Charrua A, Avelino A, et al. Intravesical resiniferatoxin decreases spinal c-fos expression and increases bladder volume to reflex micturition in rats with chronic inflamed urinary bladders. *BJU Int*. 2004;94(1):153–157.

Dinis P, Charrua A, Avelino A, et al. The distribution of sensory fibers immunoreactive for the TRPV1 (capsaicin) receptor in the human prostate. *Eur Urol*. 2005;48(1):162–167.

Diokno AC, Appell RA, Sand PK, et al. Prospective, randomized, double-blind study of the efficacy and tolerability of the extended-release formulations of oxybutynin and tolterodine for overactive bladder: results of the OPERA trial. *Mayo Clin Proc*. 2003;78(6):687.

Diokno AC, Lapides J. Action of oral and parenteral bethanechol on decompensated bladder. *Urology*. 1977;10:23–29.

Djavan B, Chapple C, Milani S, et al. State of the art on the efficacy and tolerability of alpha1-adrenoceptor antagonists in patients with lower urinary tract symptoms suggestive of benign prostatic hyperplasia. *Urology*. 2004;64(6):1081–1088.

Dmochowski RR, Davila GW, Zinner NR, et al. Efficacy and safety of transdermal oxybutynin in patients with urge and mixed urinary incontinence. *J Urol*. 2002;168(2):580.

Dmochowski RR, Miklos JR, Norton PA, et al. Duloxetine vs. placebo in the treatment of North American women with stress urinary incontinence. *J Urol*. 2003;170:1259.

Dmochowski RR, Sand PK, Zinner NR, et al. Comparative efficacy and safety of transdermal oxybutynin and oral tolterodine versus placebo in previously treated patients with urge and mixed urinary incontinence. *Urology*. 2003;62(2):237.

Dmochowski RR, Nitti V, Staskin D, et al. Transdermal oxybutynin in the treatment of adults with overactive bladder: combined results of two randomized clinical trials. *World J Urol*. 2005;23(4):263.

Dmochowski R, Abrams P, Marschall-Kehrel D, et al. Efficacy and tolerability of tolterodine extended release in male and female patients with overactive bladder. *Eur Urol*. 2007;51(4):1054.

Dmochowski R, Kreder K, MacDiarmid S, et al. The clinical efficacy of tolterodine extended-release is maintained for 24 h in patients with overactive bladder. *BJU Int*.

2007;100(1):107.

Dmochowski RR, Sand PK, Zinner NR, et al. Trospium 60 mg once daily (QD) for overactive bladder syndrome: results from a placebo-controlled interventional study. *Urology*. 2008;71(3):449.

Dmochowski R, Chapple C, Nitti VW, et al. Efficacy and safety of onabotulinumtoxinA for idiopathic overactive bladder: a double-blind, placebo controlled, randomized, dose ranging trial. *J Urol*. 2010;184(6):2416–2422.

Dmochowski R, Roehrborn C, Klise S, et al. Urodynamic effects of once daily tadalafil in men with lower urinary tract symptoms secondary to clinical benign prostatic hyperplasia: a randomized, placebo controlled 12-week clinical trial. *J Urol*. 2010;183:1092–1097.

Dmochowski RR, Peters KM, Morrow JD, et al. Randomized, double-blind, placebo-controlled trial of flexible-dose fesoterodine in subjects with overactive bladder. *Urology*. 2010;75(1):62–68.

Dmochowski RR, Newman DK, Sand PK, et al. Pharmacokinetics of oxybutynin chloride topical gel: effects of application site, baths, sunscreen and person-to-person transference. *Clin Drug Investig*. 2011;31(8):559–571.

Dmochowski R, Roehrborn C, Klise S, et al. Urodynamic effects of once daily tadalafil in men with lower urinary tract symptoms secondary to clinical benign prostatic hyperplasia: a randomized, placebo controlled 12-week clinical trial. *J Urol*. 2013;189(1 Suppl):S135–S140.

Dmochowski RR, Staskin DR, Duchin K, et al. Clinical safety, tolerability and efficacy of combination tolterodine/pilocarpine in patients with overactive bladder. *Int J Clin Pract*. 2014;68(8):986–994.

Docherty JR. Subtypes of functional alpha-1 and alpha-2 adrenoceptors. *Eur J Pharmacol*. 1998;361:1–15.

Donath F, Braeter M, Feustel C. The influence of propiverine hydrochloride on cardiac repolarization in healthy women and cardiac male patients. *Int J Clin Pharmacol Ther*. 2011;49(6):353–365.

Dong M, Yeh F, Tepp WH, et al. SV2 is the protein receptor for botulinum neurotoxin A. *Science*. 2006;312(5773):592.

Donker P, Van der Sluis C. Action of beta adrenergic blocking agents on the urethral pressure profile. *Urol Int*. 1976;31:6.

Donnellan CA, Fook L, McDonald P, et al. Oxybutynin and cognitive dysfunction. *BMJ*. 1997;315:1363.

Doroshyenko O, Jetter A, Odenthal KP, et al. Clinical pharmacokinetics of trospium chloride. *Clin Pharmacokinet*. 2005;44(7):701.

Dorschner W, Stolzenburg JU, Griebenow R, et al. Efficacy and cardiac safety of propiverine in elderly patients—a double-blind, placebo-controlled clinical study. *Eur Urol*. 2000;37:702.

Douchamps J, Derenne F, Stockis A, et al. The pharmacokinetics of oxybutynin in man. *Eur J Clin Pharmacol*. 1988;35:515.

Downie J. Bethanechol chloride in urology—a discussion of issues. *Neurourol Urodyn*. 1984;3:211–218.

Downie JW, Karmazyn M. Mechanical trauma to bladder epithelium liberates prostanoids which modulate neurotransmission in rabbit detrusor muscle. *J Pharmacol Exp Ther*. 1984;230:445.

Dowson C, Sahai A, Watkins J, et al. The safety and efficacy of botulinum toxin-A in the management of bladder oversensitivity: a randomised double-blind placebo-controlled trial. *Int J Clin Pract*. 2011;65(6):698–704.

Dowson C, Watkins J, Khan MS, et al. Repeated botulinum toxin type a injections for refractory overactive bladder: medium-term outcomes, safety profile, and discontinuation rates. *Eur Urol*. 2012;61(4):834–839.

Drake MJ, Chapple C, Sokol R, NEPTUNE Study Group, et al. Long-term safety and efficacy of single-tablet combinations of solifenacin and tamsulosin oral controlled absorption system in men with storage and voiding lower urinary tract symptoms: results from the NEPTUNE Study and NEPTUNE II open-label extension. *Eur Urol*. 2015;67(2):262–270.

Drake MJ, Sokol R, Coyne K, NEPTUNE Study Group, et al. Responder and health-related quality of life analyses in men with lower urinary tract symptoms treated with a fixed-dose combination of solifenacin and tamsulosin oral-controlled absorption system: results from the NEPTUNE study. *BJU Int*. 2016;117(1):165–172.

Duckett J, Aggarwal I, Patil A. Duloxetine treatment for women awaiting continence surgery. *Int Urogynecol J Pelvic Floor Dysfunct*. 2006;17(6):563–565.

Duthie JB, Vincent M, Herbison GP, et al. Botulinum toxin injections for adults with overactive bladder syndrome. *Cochrane Database Syst Rev*. 2011;(12) [CD005493].

Dwyer P, Kelleher C, Young J, et al. Long-term benefits of darifenacin treatment for patient quality of life: results from a 2-year extension study. *Neurourol Urodyn*. 2008;27(6):540.

Dwyer PL, Teele JS. Prazosin: a neglected cause of genuine stress incontinence. *Obstet Gynecol*. 1992;79:117.

Dykstra DD, Pryor J, Goldish G. Use of botulinum toxin type B for the treatment of detrusor hyperreflexia in a patient with multiple sclerosis: a case report. *Arch Phys Med Rehabil*. 2003;84(9):1399–1400.

Dykstra DD, Sidi AA, Scott AB, et al. Effects of botulinum A toxin on detrusor-sphincter dyssynergia in spinal cord injury patients. *J Urol*. 1998;139:919–922.

Dykstra DD, Sidi AA. Treatment of detrusor-striated sphincter dyssynergia with botulinum A toxin. *J Urol*. 1990;138:1155–

1160.

Eastham JE, Gillespie JI. The concept of peripheral modulation of bladder sensation. *Organogenesis*. 2013;9(3):224–233.

Eckford SD, Carter PG, Jackson SR, et al. An open, in-patient incremental safety and efficacy study of desmopressin in women with multiple sclerosis and nocturia. *Br J Urol*. 1995;76:459.

Eckford SD, Swami KS, Jackson SR, et al. Desmopressin in the treatment of nocturia and enuresis in patients with multiple sclerosis. *Br J Urol*. 1994;74:733.

Edmonson SD, Zhu C, Kar NF, et al. Discovery of vibegron: a potent and selective β_3 adrenergic receptor agonist for the treatment of overactive bladder. *J Med Chem*. 2016;59(2):609–623.

Ekström B, Andersson KE, Mattiasson A. Urodynamic effects of intravesical instillation of atropine and phentolamine in patients with detrusor hyperactivity. *J Urol*. 1992;149:155.

Elhilali MM, Pommerville P, Yocum RC, et al. Prospective, randomized, double-blind, vehicle controlled, multicenter phase IIb clinical trial of the pore forming protein PRX302 for targeted treatment of symptomatic benign prostatic hyperplasia. *J Urol*. 2013;189(4):1421–1426.

Elinoff V, Bavendam T, Glasser DB, et al. Symptom-specific efficacy of tolterodine extended release in patients with overactive bladder: the IMPACT trial. *Int J Clin Pract*. 2006;60(6):745.

Ellington DR, Szychowski JM, Malek JM, et al. Combined tolterodine and vaginal estradiol cream for overactive bladder symptoms after randomized single-therapy treatment. *Female Pelvic Med Reconstr Surg*. 2016;22(4):254–260.

Eltink C, Lee J, Schaddelee M, et al. Single dose pharmacokinetics and absolute bioavailability of mirabegron, a beta$_3$-adrenoceptor agonist for treatment of overactive bladder. *Int J Clin Pharmacol Ther*. 2012;50(11):838–850.

Endo RM, Girao MJ, Sartori MG, et al. Effect of estrogen-progestogen hormonal replacement therapy on periurethral and bladder vessels. *Int Urogynecol J Pelvic Floor Dysfunct*. 2000;11(2):120.

Enskat R, Deaney CN, Glickman S. Systemic effects of intravesical atropine sulphate. *BJU Int*. 2001;87:613.

Eri LM, Tveter KJ. A prospective, placebo-controlled study of the luteinizing hormone–releasing hormone agonist leuprolide as treatment for patients with benign prostatic hyperplasia. *J Urol*. 1993;150:359.

Esin E, Ergen A, Cankurtaran M, et al. Influence of antimuscarinic therapy on cognitive functions and quality of life in geriatric patients treated for overactive bladder. *Aging Ment Health*. 2015;19(3):217–223.

Everaerts W, Gevaert T, Nilius B, et al. On the origin of bladder sensing: Tr(i)ps in urology. *Neurourol Urodyn*. 2008;27(4):264–273.

Everaerts W, Zhen X, Ghosh D, et al. Inhibition of the cation channel TRPV4 improves bladder function in mice and rats with cyclophosphamide-induced cystitis. *Proc Natl Acad Sci USA*. 2010;107(44):19084–19089.

Fader M, Glickman S, Haggar V, et al. Intravesical atropine compared to oral oxybutynin for neurogenic detrusor overactivity: a double-blind, randomized crossover trial. *J Urol*. 2007;177(1):208.

Falconer C, Ekman-Ordeberg G, Blomgren B, et al. Paraurethral connective tissue in stress incontinent women after menopause. *Acta Obstet Gynecol Scand*. 1998;77(1):95.

Fantl JA, Bump RC, Robinson D, et al. Efficacy of estrogen supplementation in the treatment of urinary incontinence. *Obstet Gynecol*. 1996;88:745.

Fantl JA, Cardozo L, McClish DK. Estrogen therapy in the management of urinary incontinence in postmenopausal women: a meta-analysis. Frist report of the Hormones and Urogenital Therapy Committee. *Obstet Gynecol*. 1994;83:12.

Farrell SA, Webster RD, Higgins LM, et al. Duration of postoperative catheterization: a randomized double-blind trial comparing two catheter management protocols and the effect of bethanechol chloride. *Int Urogynecol J*. 1990;1:132–137.

Fellenius E, Hedberg R, Holmberg E, et al. Functional and metabolic effects of terbutaline and propranolol in fast and slow contracting skeletal muscle in vitro. *Acta Physiol Scand*. 1980;109:89.

Fibbi B, Morelli A, Vignozzi L, et al. Characterization of phosphodiesterase type 5 expression and functional activity in the human male lower urinary tract. *J Sex Med*. 2009;7:59–69.

Filocamo MT, LiMarzi V, Del Popoilo G, et al. Pharmacologic treatment in postprostatectomy stress urinary incontinence. *Eur Urol*. 2007;51:1559.

Filson CP, Hollingsworth JM, Clemens JQ, et al. The efficacy and safety of combined therapy with α-blockers and anticholinergics for men with benign prostatic hyperplasia: a meta-analysis. *J Urol*. 2013;190(6):2153–2160.

Finkbeiner AE. Is bethanechol chloride clinically effective in promoting bladder emptying? A literature review. *J Urol*. 1985;134:443–448.

Finney SM, Andersson KE, Gillespie JI, et al. Antimuscarinic drugs in detrusor overactivity and the overactive bladder syndrome: motor or sensory actions? *BJU Int*. 2006;98(3):503.

Florante J, Leyson J, Martin B, et al. Baclofen in the treatment of detrusor sphincter dyssynergy in spinal cord injury patients. *J Urol*. 1980;124:82–87.

Foote J, Glavind K, Kralidis G, et al. Treatment of overactive bladder in the older patient: pooled analysis of three phase III studies of darifenacin, an M_3 selective receptor antagonist. *Eur Urol*. 2005;48(3):471.

Fowler CJ, Auerbach S, Ginsberg D, et al. OnabotulinumtoxinA improves health-related quality of life in patients with urinary incontinence due to idiopathic overactive bladder: a 36-week, double-blind, placebo-controlled, randomized, dose-ranging trial. *Eur Urol*. 2012;62(1):148–157.

Fowler CJ, Beck RO, Gerrard S, et al. Intravesical capsaicin for the treatment of detrusor hyperreflexia. *J Neurol Neurosurg Psychiatry*. 1994;57:169.

Fowler CJ, Betts C, Christmas T, et al. Botulinum toxin in the treatment of chronic urinary retention in women. *Br J Urol*. 1992;70:387–393.

Fowler CJ, Griffiths D, de Groat WC. The neural control of micturition. *Nat Rev Neurosci*. 2008;9(6):453–466.

Fowler CJ, Jewkes D, McDonald WI, et al. Intravesical capsaicin for neurogenic bladder dysfunction. *Lancet*. 1992;339(8803):1239.

Franken J, Uvin P, De Ridder D, et al. TRP channels in lower urinary tract dysfunction. *Br J Pharmacol*. 2014;171(10):2537–2551.

Fraser MO, Chancellor MB. Neural control of the urethra and development of pharmacotherapy for stress urinary incontinence. *BJU Int*. 2003;91(8):743.

Frazier EP, Mathy MJ, Peters SL, et al. Does cyclic AMP mediate rat urinary bladder relaxation by isoproterenol? *J Pharmacol Exp Ther*. 2005;313(1):260.

Frazier EP, Peters SL, Braverman AS, et al. Signal transduction underlying control of urinary bladder smooth muscle tone by muscarinic receptors and beta-adrenoceptors. *Naunyn Schmiedebergs Arch Pharmacol*. 2008;377:449.

Fredrikson S. Nasal spray desmopressin in treatment of bladder dysfunction in patients with multiple sclerosis. *Acta Neurol Scand*. 1996;94:31.

Freeman R, Hill S, Millard R, et al. Reduced perception of urgency in treatment of overactive bladder with extended-release tolterodine. *Obstet Gynecol*. 2003;102(3):605.

Freeman RM, Adekanmi O, Waterfield MR, et al. The effect of cannabis on urge incontinence in patients with multiple sclerosis: a multicentre, randomised placebo controlled trial (CAMS-LUTS). *Int Urogynecol J Pelvic Floor Dysfunct*. 2006;17:636–641.

Frenkl TL, Zhu H, Reiss T, et al. A multicenter, double-blind, randomized, placebo controlled trial of a neurokinin-1 receptor antagonist for overactive bladder. *J Urol*. 2010;184(2):616–622.

Frew R, Lundy PM. A role for Q type $Ca2^+$ channels in neurotransmission in the rat urinary bladder. *Br J Pharmacol*. 1995;116:1595.

Frias B, Charrua A, Avelino A, et al. Transient receptor potential vanilloid 1 mediates nerve growth factor-induced bladder hyperactivity and noxious input. *BJU Int*. 2012;110(8 Pt B):E422–E428.

Fry CH, Kanai AJ, Roosen A, et al. Cell biology. Abrams P, Cardozo L, Khoury S, et al. *Incontinence*. ed 21 (Distributor). Health Publications: Paris; 2009:113–166.

Fröhlich G, Burmeister S, Wiedemann A, et al. Intravesical instillation of trospium chloride, oxybutynin and verapamil for relaxation of the bladder detrusor muscle. A placebo controlled, randomized clinical test. *Arzneimittelforschung*. 1998;48(5):486.

Fu X, Rezapour M, Wu X, et al. Expression of estrogen receptor alpha and beta in anterior vaginal walls of genuine stress incontinent women. *Int Urogynecol J Pelvic Floor Dysfunct*. 2003;14(4):276.

Fujimura T, Tamura K, Tsutsumi T, et al. Expression and possible functional role of the beta$_3$-adrenoceptor in human and rat detrusor muscle. *J Urol*. 1999;161(2):680.

Furuta A, Naruoka T, Suzuki Y, et al. alpha$_2$-Adrenoceptor as a new target for stress urinary incontinence. *Low Urin Tract Symptoms*. 2009;1:526–529.

Fusgen I, Hauri D. Trospium chloride: an effective option for medical treatment of bladder overactivity. *Int J Clin Pharmacol Ther*. 2000;38(5):223.

Füllhase C, Chapple C, Cornu JN, et al. Systematic review of combination drug therapy for non-neurogenic male lower urinary tract symptoms. *Eur Urol*. 2013;64(2):228–243.

Gacci M, Andersson KE, Chapple C, et al. Latest evidence on the use of phosphodiesterase type 5 inhibitors for the treatment of lower urinary tract symptoms secondary to benign prostatic hyperplasia. *Eur Urol*. 2016;70(1):124–133.

Gacci M, Vittori G, Tosi N, et al. A randomised, placebo-controlled study to assess safety and efficacy of vardenafil 10 mg and tamsulosin 0.4 mg versus tamsulosin 0.4 mg alone in the treatment of lower urinary tract symptoms secondary to benign prostatic hyperplasia. *J Sex Med*. 2012;9(6):1624–1633.

Gajewski J, Downie J, Awad S. Experimental evidence for a central nervous system site of action in the effect of alpha adrenergic blockers on the external urethral sphincter. *J Urol*. 1984;133:403.

Galeano C, Jubelin B, Biron L, et al. Effect of naloxone on detrusor-sphincter dyssynergia in chronic spinal cat. *Neurourol Urodyn*. 1986;5:203–210.

Gallien P, Robineau S, Verin M, et al. Treatment of detrusor sphincter dyssynergia by transperineal injection of botulinum toxin. *Arch Phys Med Rehabil*. 1998;79:715–717.

Garely AD, Kaufman JM, Sand PK, et al. Symptom bother and health-related quality of life outcomes following solifenacin treatment for overactive bladder: the VESIcare Open-Label Trial (VOLT). *Clin Ther*. 2006;28(11):1935.

Gebhardt J, Richard D, Barrett T. Expression of estrogen receptor isoforms alpha and beta messenger RNA in vaginal tissue of premenopausal and postmenopausal women. *Am J Obstet Gynecol*. 2001;185:1325.

Gee NS, Brown JP, Dissanayake VU, et al. The novel anticonvulsant drug, gabapentin (Neurontin), binds to the alpha$_2$delta subunit of a calcium channel. *J Biol Chem*. 1996;271(10):5768.

Geirsson G, Fall M, Sullivan L. Clinical and urodynamic effects of intravesical capsaicin treatment in patients with chronic traumatic spinal detrusor hyperreflexia. *J Urol*. 1995;154(5):1825.

George J, Tharion G, Richar J, et al. The effectiveness of intravesical oxybutynin, propantheline, and capsaicin in the management of neuropathic bladder following spinal cord injury. *ScientificWorldJournal*. 2007;7:1683.

Gevaert T, Vriens J, Segal A, et al. Deletion of the transient receptor potential cation channel TRPV4 impairs murine bladder voiding. *J Clin Invest*. 2007;117(11):3453–3462.

Ghoneim GM, Van Leeuwen JS, Elser DM, et al. A randomized controlled trial of duloxetine alone, pelvic floor muscle training alone, combined treatment, and no treatment in women with stress urinary incontinence. *J Urol*. 2005;173:1647.

Giannantoni A, Conte A, Farfariello V, et al. Onabotulinumtoxin-A intradetrusorial injections modulate bladder expression of NGF, TrkA, p75 and TRPV1 in patients with detrusor overactivity. *Pharmacol Res*. 2013;68(1):118–124.

Giannantoni A, Di Stasi SM, Nardicchi V, et al. Botulinum-A toxin injections into the detrusor muscle decrease nerve growth factor bladder tissue levels in patients with neurogenic detrusor overactivity. *J Urol*. 2006;175(6):2341.

Giardina EG, Bigger JT Jr, Glassman AH, et al. The electrocardiographic and antiarrhythmic effects of imipramine hydrochloride at therapeutic plasma concentrations. *Circulation*. 1979;60:1045.

Giembycz MA. Life after PDE4: overcoming adverse events with dual-specificity phosphodiesterase inhibitors. *Curr Opin Pharmacol*. 2005;5(3):238.

Giglio D, Tobin G. Muscarinic receptor subtypes in the lower urinary tract. *Pharmacology*. 2009;83(5):259–269.

Gilja I, Radej M, Kovacic M, et al. Conservative treatment of female stress incontinence with imipramine. *J Urol*. 1984;132:909.

Gillespie JI, Harvey IJ, Drake MJ. Agonist and nerve induced phasic activity in the isolated whole bladder of the guinea pig: evidence for two types of bladder activity. *Exp Physiol*. 2003;88:343–357.

Gillespie JI, Drake MJ. The actions of sodium nitroprusside and the phosphodiesterase inhibitor dipyridamole on phasic activity in the isolated guinea-pig bladder. *BJU Int*. 2004;93:851–858.

Gillespie JI. Phosphodiesterase-linked inhibition of nonmicturition activity in the isolated bladder. *BJU Int*. 2004;93(9):1325.

Gillespie JI, Palea S, Guilloteau V, et al. Modulation of non-voiding activity by the muscarinergic antagonist tolterodine and the β(3)-adrenoceptor agonist mirabegron in conscious rats with partial outflow obstruction. *BJU Int*. 2012;110(2 Pt 2):E132–E142.

Gillespie JI, Rouget C, Palea S, et al. Beta adrenergic modulation of spontaneous microcontractions and electrical field-stimulated contractions in isolated strips of rat urinary bladder from normal animals and animals with partial bladder outflow obstruction. *Naunyn Schmiedebergs Arch Pharmacol*. 2015;388(7):719–726.

Gillespie JI, Rouget C, Palea S, et al. The characteristics of intrinsic complex micro-contractile activity in isolated strips of the rat bladder. *Naunyn Schmiedebergs Arch Pharmacol*. 2015;388(7):709–718.

Gillman P. Tricyclic antidepressant pharmacology and therapeutic drug interactions updated. *Br J Pharmacol*. 2007;151(6):737–748.

Ginsberg D, Schneider T, Kelleher C, et al. Efficacy of fesoterodine compared with extended-release tolterodine in men and women with overactive bladder. *BJU Int*. 2013;112(3):373–385.

Gittelman M, Weiss H, Seidman L. A phase 2, randomized, double-blind, efficacy and safety study of oxybutynin vaginal ring for alleviation of overactive bladder symptoms in women. *J Urol*. 2014;191(4):1014–1021.

Giuliano F, Ückert S, Maggi M, et al. The mechanism of action of phosphodiesterase type 5 inhibitors in the treatment of lower urinary tract symptoms related to benign prostatic hyperplasia. *Eur Urol*. 2013;63(3):506–516.

Glazener CM, Evans JH, Peto RE. Tricyclic and related drugs for nocturnal enuresis in children. *Cochrane Database Syst Rev*. 2003;(3) [CD002117].

Glazener CM, Evans JH. Desmopressin for nocturnal enuresis in children. *Cochrane Database Syst Rev*. 2002;(3) [CD002112].

Gleason DM, Reilly SA, Bottacini MR, et al. The urethral continence zone and its relation to stress incontinence. *J Urol*. 1974;112:81.

Gleason DM, Susset J, White C, et al. Evaluation of a new once-daily formulation of oxybutynin in the treatment of urinary urge incontinence. The Ditropan XL Study Group. *Urology*. 1999;54:420.

Gleason JM, Daniels C, Williams K, et al. Single center experience with oxybutynin transdermal system (patch) for management of symptoms related to non-neuropathic overactive bladder in children: an attractive, well tolerated alternative form of administration. *J Pediatr Urol*. 2014;10(4):753–757.

Glickman S, Tsokkos N, Shah PJ. Intravesical atropine and suppression of detrusor hypercontractility in the neuropathic bladder. A preliminary study. *Paraplegia*. 1995;33:36.

Goessl C, Knispel HH, Fiedler U, et al. Urodynamic effects of oral oxybutynin chloride in children with myelomeningocele and detrusor hyperreflexia. *Urology*. 1998;51(1):94–98.

Goldfischer ER, Sand PK, Thomas H, et al. Efficacy and safety of oxybutynin topical gel 3% in patients with urgency and/or mixed urinary incontinence: a randomized, double-blind, placebo-controlled study. *Neurourol Urodyn*. 2015;34(1):37–43.

Gomes T, Juurlink DN, Mamdani MM. Comparative adherence to oxybutynin or tolterodine among older patients. *Eur J Clin Pharmacol*. 2012;68(1):97–99.

Gopalakrishnan M, Shieh CC. Potassium channel subtypes as molecular targets for overactive bladder and other urological disorders. *Expert Opin Ther Targets*. 2004;8:437.

Gotoh M, Kamihira O, Kinikawa T, et al. Comparison of alpha1A-selective adrenoceptor antagonist, tamsulosin, and alpha1D-selective adrenoceptor antagonist, naftopidil, for efficacy and safety in the treatment of benign prostatic hyperplasia: a randomized controlled trial. *BJU Int*. 2005;96(4):581–586.

Grady D, Brown JS, Vittinghoff E, et al. Postmenopausal hormones and incontinence: the Heart and Estrogen/Progestin Replacement Study. *Obstet Gynecol*. 2001;97:116.

Granato C, Korstanje C, Guilloteau V, et al. Prostaglandin E_2 excitatory effects on rat urinary bladder: a comparison between the β-adrenoceptor modulation of non-voiding activity in vivo and micro-contractile activity in vitro. *Naunyn Schmiedebergs Arch Pharmacol*. 2015;388(7):727–735.

Gratzke C, Streng T, Park A, et al. Distribution and function of cannabinoid receptors 1 and 2 in the rat, monkey and human bladder. *J Urol*. 2009;181:1939–1948.

Gratzke C, Streng T, Stief CG, et al. Cannabinor, a selective cannabinoid-2 receptor agonist, improves bladder emptying in rats with partial urethral obstruction. *J Urol*. 2011;185:731–736.

Gratzke C, Streng T, Stief CG, et al. Effects of cannabinor, a novel selective cannabinoid 2 receptor agonist, on bladder function in normal rats. *Eur Urol*. 2010;57(6):1093–1100.

Gray SL, Anderson ML, Dublin S, et al. Cumulative use of strong anticholinergics and incident dementia: a prospective cohort study. *JAMA Intern Med*. 2015;175(3):401–407.

Green SA, Alon A, Ianus J, et al. Efficacy and safety of a neurokinin-1 receptor antagonist in postmenopausal women with overactive bladder with urge urinary incontinence. *J Urol*. 2006;176(6 Pt 1):2535.

Griffiths D, Tadic SD. Bladder control, urgency, and urge incontinence: evidence from functional brain imaging. *Neurourol Urodyn*. 2008;27(6):466.

Griffiths D. Imaging bladder sensations. *Neurourol Urodyn*. 2007;26(6 Suppl):899.

Griffiths DJ. Use of functional imaging to monitor central control of voiding in humans. *Handb Exp Pharmacol*. 2011;202:81–97.

Grignaffini A, Bazzani F. Intravesicular prostaglandin E_2 for the prophylaxis of urinary retention after colpohysterectomy. *J Int Med Res*. 1998;26:87–92.

Grigoleit U, Mürtz G, Laschke S, et al. Efficacy, tolerability and safety of propiverine hydrochloride in children and adolescents with congenital or traumatic neurogenic detrusor overactivity—a retrospective study. *Eur Urol*. 2006;49(6):1114.

Grodstein F, Lifford K, Resnick NM, et al. Postmenopausal hormone therapy and risk of developing urinary incontinence. *Obstet Gynecol*. 2004;103(2):254.

Grond S, Sablotzki A. Clinical pharmacology of tramadol. *Clin Pharmacokinet*. 2004;43(13):879.

Gu B, Fraser MO, Thor KB, et al. Induction of bladder sphincter dyssynergia by κ-2 opioid receptor agonists in the female rat. *J Urol*. 2004;171:472.

Guarneri L, Robinson E, Testa R. A review of flavoxate: pharmacology and mechanism of action. *Drugs Today*. 1994;30:91.

Guay DR. Clinical pharmacokinetics of drugs used to treat urge incontinence. *Clin Pharmacokinet*. 2003;42(14):1243.

Guay DR. Darifenacin: another antimuscarinic for overactive bladder. *Consult Pharm*. 2005;20(5):424–431.

Guerra LA, Moher D, Sampson M, et al. Intravesical oxybutynin for children with poorly compliant neurogenic bladder: a systematic review. *J Urol*. 2008;180(3):1091.

Gutman GA, Chandy KG, Adelman JP, et al. International Union of Pharmacology. XLI. Compendium of voltage-gated ion channels: potassium channels. *Pharmacol Rev*. 2003;55:583.

Hachen H, Krucker V. Clinical and laboratory assessment of the efficacy of baclofen on urethral sphincter spasticity in patients with traumatic paraplegia. *Paraplegia*. 1977;18:229–

235.

Hachen H. Clinical and urodynamic assessment of alpha adrenolytic therapy in patients with neurogenic bladder function. *Paraplegia*. 1980;18:229–233.

Hackler R, Broecker B, Klein F, et al. A clinical experience with dantrolene sodium for external urinary sphincter hypertonicity in spinal cord injured patients. *J Urol*. 1980;124:78–83.

Haferkamp A, Schurch B, Reitz A, et al. Lack of ultrastructural detrusor changes following endoscopic injection of botulinum toxin type A in overactive neurogenic bladder. *Eur Urol*. 2004;46(6):784.

Halaska M, Ralph G, Wiedemann A, et al. Controlled, double-blind, multicentre clinical trial to investigate long-term tolerability and efficacy of trospium chloride in patients with detrusor instability. *World J Urol*. 2003;20(6):392.

Hallett M. One man's poison—clinical applications of botulinum toxin. *N Engl J Med*. 1999;341:118–120.

Harada K, Fujimura A. Clinical pharmacology of alpha-1A selective and non-selective alpha-1 blockers. *BJU Int*. 2000;86(Suppl 2):31–35.

Harris JD, Benson GF. Effect of dantrolene on canine bladder contractility. *Urology*. 1980;16:229–234.

Haruno A. Inhibitory effects of propiverine hydrochloride on the agonist-induced or spontaneous contractions of various isolated muscle preparations. *Arzneimittelforschung*. 1992;42:815.

Hashim H, Abrams P. Pharmacologic management of women with mixed urinary incontinence. *Drugs*. 2006;66(5):591.

Hashim H, Malmberg L, Graugaard-Jensen C, et al. Desmopressin, as a “designer-drug,” in the treatment of overactive bladder syndrome. *Neurourol Urodyn*. 2009;28(1):40–46.

Hatanaka T, Ukai M, Watanabe M, et al. In vitro and in vivo pharmacological profile of the selective β_3-adrenoceptor agonist mirabegron in rats. *Naunyn Schmiedebergs Arch Pharmacol*. 2013;386(3):247–253.

Haustein KO, Huller G. On the pharmacokinetics and metabolism of propiverine in man. *Eur J Drug Metab Pharmacokinet*. 1988;13(2):81.

Hegde SS, Choppin A, Bonhaus D, et al. Functional role of M2 and M3 muscarinic receptors in the urinary bladder of rats in vitro and in vivo. *Br J Pharmacol*. 1997;120:1409–1418.

Hegde SS, Eglen RM. Muscarinic receptor subtypes modulating smooth muscle contractility in the urinary bladder. *Life Sci*. 1999;64:419–428.

Hendrix SL, Cochrane BB, Nygaard IE, et al. Effects of estrogen with and without progestin on urinary incontinence. *JAMA*. 2005;293(8):935.

Hendrix SL, McNeeley SG. Effect of selective estrogen receptor modulators on reproductive tissues other than endometrium. *Ann N Y Acad Sci*. 2001;949:243.

Henriksson L, Andersson KE, Ulmsten U. The urethral pressure profiles in continent and stress incontinent women. *Scand J Urol Nephrol*. 1979;13:5.

Herbison P, Hay-Smith J, Ellis G, et al. Effectiveness of anticholinergic drugs compared with placebo in the treatment of overactive bladder: systematic review. *Br Med J*. 2003;326:841.

Herschorn S, Barkin J, Castro-Diaz D, et al. A phase III, randomized, double-blind, parallel-group, placebo-controlled, multicentre study to assess the efficacy and safety of the β_3 adrenoceptor agonist, mirabegron, in patients with symptoms of overactive bladder. *Urology*. 2013;82(2):313–320.

Herschorn S, Gajewski J, Schulz J, et al. A population-based study of urinary symptoms and incontinence: the Canadian

Urinary Bladder Survey. *BJU Int*. 2008;101(1):52.

Herschorn S, Swift S, Guan Z, et al. Comparison of fesoterodine and tolterodine extended release for the treatment of overactive bladder: a head-to-head placebo-controlled trial. *BJU Int*. 2010;105(1):58–66.

Herschorn S, Gajewski J, Ethans K, et al. Efficacy of botulinum toxin A injection for neurogenic detrusor overactivity and urinary incontinence: a randomized, double-blind trial. *J Urol*. 2011;185(6):2229–2235.

Herschorn S, Pommerville P, Stothers L, et al. Tolerability of solifenacin and oxybutynin immediate release in older (>65 years) and younger (≤65 years) patients with overactive bladder: sub-analysis from a Canadian, randomized, double-blind study. *Curr Med Res Opin*. 2011;27(2):375–382.

Hextall A, Bidmead J, Cardozo L, et al. The impact of the menstrual cycle on urinary symptoms and the results of urodynamic investigation. *BJOG*. 2001;108(11):1193.

Hextall A. Oestrogens and lower urinary tract function. *Maturitas*. 2000;36:83.

Hicks A, McCafferty GP, Riedel E, et al. GW427353 (solabegron), a novel, selective beta$_3$-adrenergic receptor agonist, evokes bladder relaxation and increases micturition reflex threshold in the dog. *J Pharmacol Exp Ther*. 2007;323(1):202.

Hill S, Khullar V, Wyndaele JJ, et al. Dose response with darifenacin, a novel once-daily M3 selective receptor antagonist for the treatment of overactive bladder: results of a fixed dose study. *Int Urogynecol J Pelvic Floor Dysfunct*. 2006;17(3):239.

Hillelsohn JH, Rais-Bahrami S, Bagadiya N, et al. Use of desipramine for the treatment of overactive bladder refractory to antimuscarinic therapy. *Urol J*. 2014;10(4):1114–1118.

Hills CJ, Winter SA, Balfour JA. Tolterodine. *Drugs*.

1998;55:813.

Hilton P, Hertogs K, Stanton SL. The use of desmopressin (DDAVP) for nocturia in women with multiple sclerosis. *J Neurol Neurosurg Psychiatry*. 1983;46:854.

Hilton P, Stanton SL. The use of desmopressin (DDAVP) in nocturnal urinary frequency in the female. *Br J Urol*. 1982;54:252.

Hindley RG, Brierly RD, Thomas PJ. Prostaglandin E_2 and bethanechol in combination for treating detrusor underactivity. *BJU Int*. 2004;93(1):89–92.

Hoebeke P, De Pooter J, De Caestecker K, et al. Solifenacin for therapy resistant overactive bladder. *J Urol*. 2009;182(4 Suppl):2040–2044.

Hoffman BB, Lefkowitz RJ. Catecholamines, sympathomimetic drugs and adrenergic receptor antagonists. Hardman JG, Limbird LE, Molinoff PB, et al. *Goodman and Gilman's the pharmacological basis of therapeutics*. ed 9. McGraw-Hill: New York, NY; 1996:199–248.

Holmes DM, Montz FJ, Stanton SL. Oxybutinin versus propantheline in the management of detrusor instability. A patient regulated variable dose trial. *Br J Obstet Gynaecol*. 1989;96:607.

Holstege G. Micturition and the soul. *J Comp Neurol*. 2005;493(1):15–20.

Homma Y, Yamaguchi O, Imidafenacin Study Group. A randomized, double-blind, placebo- and propiverine-controlled trial of the novel antimuscarinic agent imidafenacin in Japanese patients with overactive bladder. *Int J Urol*. 2009;16(5):499–506.

Homma Y, Yamaguchi T, Yamaguchi O. A randomized, double-blind, placebo-controlled phase II dose-finding study of the novel anti-muscarinic agent imidafenacin in Japanese patients with overactive bladder. *Int J Urol*. 2008;15(9):809–815.

Hoverd PA, Fowler CJ. Desmopressin in the treatment of daytime urinary frequency in patients with multiple sclerosis. *J Neurol Neurosurg Psychiatry*. 1998;65:778.

Howe BB, Halterman TJ, Yochim CL, et al. Zeneca ZD6169: a novel KATP channel opener with in vivo selectivity for urinary bladder. *J Pharmacol Exp Ther*. 1995;274:884.

Hsiao SM, Chang TC, Wu WY, et al. Comparisons of urodynamic effects, therapeutic efficacy and safety of solifenacin versus tolterodine for female overactive bladder syndrome. *J Obstet Gynaecol Res*. 2011;37(8):1084–1091.

Hu S, Kim HS. Modulation of ATP sensitive and large-conductance Ca^{2+}-activated K^+ channels by Zeneca ZD6169 in guinea pig bladder smooth muscle cells. *J Pharmacol Exp Ther*. 1997;280:38.

Hudman D, Elliott RA, Norman RI. K(ATP) channels mediate the beta(2)-adrenoceptor agonist-induced relaxation of rat detrusor muscle. *Eur J Pharmacol*. 2000;397(1):169.

Hughes KM, Lang JC, Lazare R, et al. Measurement of oxybutynin and its N-desethyl metabolite in plasma, and its application to pharmacokinetic studies in young, elderly and frail elderly volunteers. *Xenobiotica*. 1992;22:859.

Humeau Y, Doussau F, Grant NJ, et al. How botulinum and tetanus neurotoxins block neurotransmitter release. *Biochimie*. 2000;82(5):427.

Hunsballe JM, Djurhuus JC. Clinical options for imipramine in the management of urinary incontinence. *Urol Res*. 2001;29:118.

Hurley DJ, Turner CL, Yalcin I, et al. Duloxetine for the treatment of stress urinary incontinence: an integrated analysis of safety. *Eur J Obstet Gynecol Reprod Biol*. 2006;125:120.

Hussain RM, Hartigan-Go K, Thomas SHL, et al. Effect of oxybutynin on the QTc interval in elderly patients with urinary incontinence. *Br J Clin Pharmacol*. 1996;41(1):73–75.

Höfner K, Burkart M, Jacob G, et al. Safety and efficacy of tolterodine extended release in men with overactive bladder symptoms and presumed non-obstructive benign prostatic hyperplasia. *World J Urol*. 2007;25(6):627.

Haab F, Braticevici B, Krivoborodov G, et al. Efficacy and safety of repeated dosing of netupitant, a neurokinin-1 receptor antagonist, in treating overactive bladder. *Neurourol Urodyn*. 2014;33(3):335–340.

Haab F, Cardozo L, Chapple C, et al. Long-term open-label solifenacin treatment associated with persistence with therapy in patients with overactive bladder syndrome. *Eur Urol*. 2005;47(3):376.

Haab F, Corcos J, Siami P, et al. Long-term treatment with darifenacin for overactive bladder: results of a 2-year, open-label extension study. *BJU Int*. 2006;98(5):1025.

Haab F, Stewart L, Dwyer P. Darifenacin, an M_3 selective receptor antagonist, is an effective and well-tolerated once daily treatment for overactive bladder. *Eur Urol*. 2004;45(4):420.

Ichihara K, Masumori N, Fukuta F, et al. A randomized controlled study of the efficacy of tamsulosin monotherapy and its combination with mirabegron for overactive bladder induced by benign prostatic obstruction. *J Urol*. 2015;193(3):921–926.

Igawa Y, Aizawa N, Homma Y. Beta_3-adrenoceptor agonists: possible role in the treatment of overactive bladder. *Korean J Urol*. 2010;51(12):811–818.

Igawa Y, Michel MC. Pharmacological profile of beta_3-adrenoceptor agonists in clinical development for the treatment of overactive bladder syndrome. *Naunyn Schmiedebergs Arch Pharmacol*. 2013;386(3):177–183.

Igawa Y, Yamazaki Y, Takeda H, et al. Functional and molecular biological evidence for a possible beta$_3$-adrenoceptor in the human detrusor muscle. *Br J Pharmacol*. 1999;126(3):819.

Igawa Y, Yamazaki Y, Takeda H, et al. Relaxant effects of isoproterenol and selective beta$_3$-adrenoceptor agonists on normal, low compliant and hyperreflexic human bladders. *J Urol*. 2001;165(1):240.

Iijima K, De Wachter S, Wyndaele JJ. Effects of the M$_3$ receptor selective muscarinic antagonist darifenacin on bladder afferent activity of the rat pelvic nerve. *Eur Urol*. 2007;52(3):842.

Ikeda Y, Zabbarova IV, Birder LA, et al. Botulinum neurotoxin serotype A suppresses neurotransmitter release from afferent as well as efferent nerves in the urinary bladder. *Eur Urol*. 2012;62(6):1157–1164.

Ikemoto I, Kiyota H, Ohishi Y, et al. Usefulness of tamsulosin hydrochloride and naftopidil in patients with urinary disturbances caused by benign prostatic hyperplasia: a comparative, randomized, two-drug crossover study. *Int J Urol*. 2003;10(11):587–594.

Insel PA, Tang CM, Hahntow I, et al. Impact of GPCRs in clinical medicine: genetic variants and drug targets. *Biochim Biophys Acta*. 2007;1768:994.

Irwin DE, Abrams P, Milsom I, et al. Understanding the elements of overactive bladder: questions raised by the EPIC study. *BJU Int*. 2008;101(11):1381–1387.

Irwin DE, Kopp ZS, Agatep B, et al. Worldwide prevalence estimates of lower urinary tract symptoms, overactive bladder, urinary incontinence and bladder outlet obstruction. *BJU Int*. 2011;108(7):1132–1138.

Irwin DE, Milsom I, Hunskaar S, et al. Population-based survey of urinary incontinence, overactive bladder, and other lower urinary tract symptoms in five countries: results of the EPIC study. *Eur Urol*. 2006;50(6):1306.

Ishiko O, Hirai K, Sumi T, et al. Hormone replacement therapy plus pelvic floor muscle exercise for postmenopausal stress incontinence. A randomized controlled trial. *J Reprod Med*. 2001;46:213.

Ishiko O, Ushiroyama T, Saji F, et al. Beta(2)-Adrenergic agonists and pelvic floor exercises for female stress incontinence. *Int J Gynaecol Obstet*. 2000;71:39.

Ishizuka O, Igawa Y, Lecci A, et al. Role of intrathecal tachykinins for micturition in unanaesthetized rats with and without bladder outlet obstruction. *Br J Pharmacol*. 1994;113(1):111.

Ishizuka O, Igawa Y, Nishizawa O, et al. Role of supraspinal tachykinins for volume- and l-dopa-induced bladder activity in normal conscious rats. *Neurourol Urodyn*. 2000;19(1):101.

Ishizuka O, Imamura T, Kurizaki Y, et al. Male lower urinary tract symptoms and alpha1D-adrenoceptors. *Int J Urol*. 2013;20(1):73–78.

Ishizuka O, Mattiasson A, Andersson KE. Effects of neurokinin receptor antagonists on l-dopa induced bladder hyperactivity in normal conscious rats. *J Urol*. 1995;154(4):1548.

Jackson S, Shepherd A, Abrams P. The effect of oestradiol on objective urinary leakage in postmenopausal stress incontinence: a double blind placebo controlled trial. *Neurourol Urodyn*. 1996;15:322.

Jacobsen SM, Kerstein H, Molden E. Evaluation of brain anticholinergic activities of urinary spasmolytic drugs using a high-throughput radio receptor bioassay. *J Am Geriatr Soc*. 2011;59:501–505.

Janssen DA, Hoenderop JG, Jansen KC, et al. The mechanoreceptor TRPV4 is localized in adherence junctions of the human bladder urothelium: a morphological study. *J*

Urol. 2011;186(3):1121–1127.
Jensen D Jr. Pharmacological studies of the uninhibited neurogenic bladder. *Acta Neurol Scand*. 1981;64:175–180.
Jeremy JY, Tsang V, Mikhailidis DP, et al. Eicosanoid synthesis by human urinary bladder mucosa: pathological implications. *Br J Urol*. 1987;59:36.
Ji RR, Samad TA, Jin SX, et al. p38 MAPK activation by NGF in primary sensory neurons after inflammation increases TRPV1 levels and maintains heat hyperalgesia. *Neuron*. 2002;36(1):57–68.
Jiang F, Zhu L, Xu T, et al. Efficacy and safety of solifenacin succinate tablets versus solifenacin succinate tablets with local oestrogen for the treatment of overactive bladder in postmenopausal women—a multicenter, randomised, open-label, controlled comparison study. *Menopause*. 2016;23(4):451–457.
Johnson TM 2nd, Miller M, Tang T, et al. Oral ddAVP for nighttime urinary incontinence in characterized nursing home residents: a pilot study. *J Am Med Dir Assoc*. 2006;7:6.
Jones RL, Giembycz MA, Woodward DF. Prostanoid receptor antagonists: development strategies and therapeutic applications. *Br J Pharmacol*. 2009;158:104–145.
Jonville AP, Dutertre JP, Autret E, et al. Adverse effects of oxybutynin chloride (Ditropan). Evaluation of the official survey of Regional Pharmacovigilance Centers. *Therapie*. 1992;47(5):389–392.
Jugus MJ, Jaworski JP, Patra PB, et al. Dual modulation of urinary bladder activity and urine flow by prostanoid EP_3 receptors in the conscious rat. *Br J Pharmacol*. 2009;158:372–381.
Juul KV, Klein BM, Sandstrom R, et al. Gender difference in antidiuretic response to desmopressin. *Am J Physiol Renal Physiol*. 2011;300:F1116–F1122.

Jünemann KP, Al-Shukri S. Efficacy and tolerability of trospium chloride and tolterodine in 234 patients with urge-syndrome: a double-blind, placebo-controlled multicentre clinical trial. *Neurourol Urodyn*. 2000;19:488.

Jünemann KP, Halaska M, Rittstein T, et al. Propiverine versus tolterodine: efficacy and tolerability in patients with overactive bladder. *Eur Urol*. 2005;48(3):478.

Jünemann KP, Hessdörfer E, Unamba-Oparah I, et al. Propiverine hydrochloride immediate and extended release: comparison of efficacy and tolerability in patients with overactive bladder. *Urol Int*. 2006;77(4):334.

Kachur JF, Peterson JS, Carter JP, et al. R and S enantiomers of oxybutynin: pharmacological effects in guinea pig bladder and intestine. *J Pharmacol Exp Ther*. 1988;247:867.

Kadekawa K, Onaga T, Shimabukuro S, et al. Effect of imidafenacin before sleeping on nocturia. *Low Urin Tract Symptoms*. 2012;4(3):130–135.

Kaidoh K, Igawa Y, Takeda H, et al. Effects of selective beta$_2$ and beta$_3$-adrenoceptor agonists on detrusor hyperreflexia in conscious cerebral infarcted rats. *J Urol*. 2002;168(3):1247.

Kaiho Y, Nishiguchi J, Kwon DD, et al. The effects of a type 4 phosphodiesterase inhibitor and the muscarinic cholinergic antagonist tolterodine tartrate on detrusor overactivity in female rats with bladder outlet obstruction. *BJU Int*. 2008;101(5):615.

Kaisary AV. Beta adrenoceptor blockade in the treatment of female stress urinary incontinence. *J Urol (Paris)*. 1984;90:351.

Kanagarajah P, Ayyathurai R, Caruso DJ, et al. Role of botulinum toxin-A in refractory idiopathic overactive bladder patients without detrusor overactivity. *Int Urol Nephrol*. 2012;44(1):91–97.

Kanayama N, Kanari C, Masuda Y, et al. Drug-drug interactions in the metabolism of imidafenacin: role of the human cytochrome P450 enzymes and UDP-glucuronic acid transferases, and potential of imidafenacin to inhibit human cytochrome P450 enzymes. *Xenobiotica*. 2007;37(2):139–154.

Kang IS, Sung ZH, Jong BL. The efficacy and safety of combination therapy with alpha-blocker and low-dose propiverine hydrochloride for benign prostatic hyperplasia accompanied by overactive bladder symptoms. *Korean J Urol*. 2009;50:1078–1082.

Kaplan SA, Cardozo L, Herschorn S, et al. Assessment of Fesoterodine after Tolterodine ER (AFTER) Study Group. Efficacy and safety of fesoterodine 8 mg in subjects with overactive bladder after a suboptimal response to tolterodine ER. *Int J Clin Pract*. 2014;68(9):1065–1073.

Kaplan SA, Goldfischer ER, Steers WD, et al. Solifenacin treatment in men with overactive bladder: effects on symptoms and patient-reported outcomes. *Aging Male*. 2010;13(2):100–107.

Kaplan SA, Gonzalez RR, Te AE. Combination of alfuzosin and sildenafil is superior to monotherapy in treating lower urinary tract symptoms and erectile dysfunction. *Eur Urol*. 2007;51:1717–1723.

Kaplan SA, He W, Koltun WD, et al. Solifenacin plus tamsulosin combination treatment in men with lower urinary tract symptoms and bladder outlet obstruction: a randomized controlled trial. *Eur Urol*. 2013;63(1):158–165.

Kaplan SA, Roehrborn CG, Rovner ES, et al. Tolterodine and tamsulosin for treatment of men with lower urinary tract symptoms and overactive bladder: a randomized controlled trial. *JAMA*. 2006;296(19):2319.

Kaplan SA, Roehrborn CG, Chancellor M, et al. Extended-release tolterodine with or without tamsulosin in men with lower urinary tract symptoms and overactive bladder: effects on urinary symptoms assessed by the International Prostate Symptom Score. *BJU Int*. 2008;102(9):1133–1139.

Kaplan SA, Walmsley K, Te AE. Tolterodine extended release attenuates lower urinary tract symptoms in men with benign prostatic hyperplasia. *J Urol*. 2008;179(5 Suppl):S82.

Kaplan SA, Schneider T, Foote JE, et al. Superior efficacy of fesoterodine over tolterodine extended release with rapid onset: a prospective, head-to-head, placebo-controlled trial. *BJU Int*. 2011;107(9):1432–1440.

Karsenty G, Denys P, Amarenco G, et al. Botulinum toxin A (Botox) intradetrusor injections in adults with neurogenic detrusor overactivity/neurogenic overactive bladder: a systematic literature review. *Eur Urol*. 2008;53(2):275.

Kasabian NG, Vlachiotis JD, Lais A, et al. The use of intravesical oxybutynin chloride in patients with detrusor hypertonicity and detrusor hyperreflexia. *J Urol*. 1994;151:944.

Katofiasc MA, Nissen J, Audia JE, et al. Comparison of the effects of serotonin selective norepinephrine selective, and dual serotonin and norepinephrine reuptake inhibitors on lower urinary tract function in cats. *Life Sci*. 2002;71(11):1227.

Katz IR, Prouty Sands L, Bilker W, et al. Identification of medications that cause cognitive impairment in older people: the case of oxybutynin chloride. *J Am Geriatr Soc*. 1998;46:8.

Kavia R, De Ridder D, Constantinescu S, et al. Randomised controlled trial of Sativex to treat detrusor overactivity in multiple sclerosis. *Mult Scler*. 2010;16:1349–1359.

Kawabe K, Yoshida M, Homma Y, et al. Silodosin, a new alpha1A-adrenoceptor-selective antagonist for treating benign prostatic hyperplasia: results of a phase III randomized, placebo-controlled, double-blind study in Japanese men. *BJU Int*. 2006;98(5):1019–1024.

Kay G, Crook T, Rekeda L, et al. Differential effects of the antimuscarinic agents darifenacin and oxybutynin ER on memory in older subjects. *Eur Urol*. 2006;50(2):317.

Kay GG, Ebinger U. Preserving cognitive function for patients with overactive bladder: evidence for a differential effect with darifenacin. *Int J Clin Pract*. 2008;62:1792–1800.

Kay GG, Wesnes KA. Pharmacodynamic effects of darifenacin, a muscarinic M selective receptor antagonist for the treatment of overactive bladder, in healthy volunteers. *BJU Int*. 2005;96(7):1055.

Keane DP, Sims TJ, Abrams P, et al. Analysis of collagen status in premenopausal nulliparous women with genuine stress incontinence. *Br J Obstet Gynaecol*. 1997;104(9):994.

Kelleher C, Cardozo L, Kobashi K, et al. Solifenacin: as effective in mixed urinary incontinence as in urge urinary incontinence. *Int Urogynecol J Pelvic Floor Dysfunct*. 2006;17(4):382.

Kelleher CJ, Cardozo L, Chapple CR, et al. Improved quality of life in patients with overactive bladder symptoms treated with solifenacin. *BJU Int*. 2005;95:81–85.

Kelleher CJ, Dmochowski RR, Berriman S, et al. Sustained improvement in patient-reported outcomes during long-term fesoterodine treatment for overactive bladder symptoms: pooled analysis of two open-label extension studies. *BJU Int*. 2012;110(3):392–400.

Kelleher CJ, Tubaro A, Wang JT, et al. Impact of fesoterodine on quality of life: pooled data from two randomized trials. *BJU Int*. 2008;102(1):56.

Kerbusch T, Wahlby U, Milligan PA, et al. Population pharmacokinetic modelling of darifenacin and its hydroxylated metabolite using pooled data, incorporating saturable first-pass metabolism, CYP2D6 genotype and formulation-dependent bioavailability. *Br J Clin Pharmacol*. 2003;56(6):639.

Kernan WN, Viscoli CM, Brass LM, et al. Phenylpropanolamine and the risk of hemorrhagic stroke. *N Engl J Med*. 2000;343(25):1826.

Kessler TM, Bachmann LM, Minder C, et al. Adverse event assessment of antimuscarinics for treating overactive bladder: a network meta-analytic approach. *PLoS ONE*. 2011;6(2):e16718.

Kessler TM, Studer UE, Burkhard FC. The effect of terazosin on functional bladder outlet obstruction in women: a pilot study. *J Urol*. 2006;176(4 Pt 1):1487.

Khera M, Somogyi GT, Kiss S, et al. Botulinum toxin A inhibits ATP release from bladder urothelium after chronic spinal cord injury. *Neurochem Int*. 2004;45(7):987.

Khullar V, Amarenco G, Angulo JC, et al. Efficacy and tolerability of mirabegron, a beta(3)-adrenoceptor agonist, in patients with overactive bladder: results from a randomised European-Australian phase 3 trial. *Eur Urol*. 2013;63(2):283–295.

Khullar V, Foote J, Seifu Y, et al. Time-to-effect with darifenacin in overactive bladder: a pooled analysis. *Int Urogynecol J*. 2011;22(12):1573–1580.

Khullar V, Rovner ES, Dmochowski R, et al. Fesoterodine dose response in subjects with overactive bladder syndrome. *Urology*. 2008;71(5):839.

Kim TH, Lee SE, Lee HE, et al. Safety and efficacy of fesoterodine fumarate in patients with overactive bladder: results of a post-marketing surveillance study in Korea. *Curr Med Res Opin*. 2016;32(8):1361–1366.

Kim Y, Yoshimura N, Masuda H, et al. Intravesical instillation of human urine after oral administration of trospium, tolterodine and oxybutynin in a rat model of detrusor overactivity. *BJU Int*. 2006;97:400.

Kim YH, Bird ET, Priebe M, et al. The role of oxybutynin in spinal cord injured patients with indwelling catheters. *J Urol*. 1996;158:2083.

Kim YS, Sainz RD. Beta adrenergic agonists and hypertrophy of skeletal muscles. *Life Sci*. 1992;50:397.

Kim YT, Kwon DD, Kim J, et al. Gabapentin for overactive bladder and nocturia after anticholinergic failure. *Int Braz J Urol*. 2004;30(4):275.

Kinn AC, Larsson PO. Desmopressin: a new principle for symptomatic treatment of urgency and incontinence in patients with multiple sclerosis. *Scand J Urol Nephrol*. 1990;24:109.

Kirby R, Andersson KE, Lepor H, et al. α1-Adrenoceptor selectivity and the treatment of benign prostatic hyperplasia and lower urinary tract symptoms. *Prostate Cancer Prostatic Dis*. 2000;3(2):76–83.

Kirby R. Clinical pharmacology of alpha-1 adrenoceptor antagonists. *Eur Urol*. 1999;36(Suppl 1):48–53.

Kishimoto T, Morita T, Okamiya Y, et al. Effect of clenbuterol on contractile response in periurethral striated muscle of rabbits. *Tohoku J Exp Med*. 1991;165(3):243.

Kitagawa Y, Kuribayashi M, Narimoto K, et al. Immediate effect on overactive bladder symptoms following administration of imidafenacin. *Urol Int*. 2011;86(3):330–333.

Klausner AP, Steers WD. Antimuscarinics for the treatment of overactive bladder: a review of central nervous system effects. *Curr Urol Rep*. 2007;8(6):441.

Klutke CG, Burgio KL, Wyman JF, et al. Combined effects of behavioral intervention and tolterodine in patients dissatisfied with overactive bladder medication. *J Urol*.

2009;181(6):2599–2607.

Kobayashi F, Yageta Y, Yamazaki T, et al. Pharmacological effects of imidafenacin (KRP-197/ONO-8025), a new bladder selective anti-cholinergic agent, in rats. Comparison of effects on urinary bladder capacity and contraction, salivary secretion and performance in the Morris water maze task. *Arzneimittelforschung*. 2007;57(3):147–154.

Koelbl H, Nitti V, Baessler K, et al. Pathophysiology of urinary incontinence, faecal incontinence and pelvic organ prolapse. Abrams P, Cardozo L, Khoury S, et al. *Incontinence*. ed 21. Health Publication, Limited: Paris; 2009:255–330.

Kojima Y, Sasaki S, Imura M, et al. Correlation between expression of alpha-adrenoceptor subtype mRNA and severity of lower urinary tract symptoms or bladder outlet obstruction in benign prostatic hyperplasia patients. *BJU Int*. 2011;107(3):438–442.

Kojima Y, Sasaki S, Kubota Y, et al. Expression of alpha1-adrenoceptor subtype mRNA as a predictor of the efficacy of subtype selective alpha1-adrenoceptor antagonists in the management of benign prostatic hyperplasia. *J Urol*. 2008;179(3):1040–1046.

Kok ET, Schouten BW, Bohnen AM, et al. Risk factors for lower urinary tract symptoms suggestive of benign prostatic hyperplasia in a community based population of healthy aging men: the Krimpen Study. *J Urol*. 2009;181:710–716.

Komatsu T, Gotoh M, Funahashi Y, et al. Efficacy of propiverine in improving symptoms and quality of life in female patients with wet overactive bladder. *Low Urin Tract Symptoms*. 2009;1:22–24.

Koonings P, Bergman A, Ballard CA. Prostaglandins for enhancing detrusor function after surgery for stress incontinence in women. *J Reprod Med*. 1990;35:1–6.

Kories C, Czyborra C, Fetscher C, et al. Gender comparison of muscarinic receptor expression and function in rat and human urinary bladder: differential regulation of M2 and M3 receptors? *Naunyn Schmiedebergs Arch Pharmacol*. 2003;367(5):524–531.

Kosilov K, Loparev S, Ivanowskaya M, et al. Effectiveness of combined high-dosed trospium and solifenacin depending on severity of OAB symptoms in elderly men and women under cyclic therapy. *Cent European J Urol*. 2014;67(1):43–48.

Kosilov KV, Loparev SA, Ivanovskaya MA, et al. Randomized controlled trial of cyclic and continuous therapy with trospium and solifenacin combination for severe overactive bladder in elderly patients with regard to patient compliance. *Ther Adv Urol*. 2014;6(6):215–223.

Kosilov K, Loparev S, Ivanovskaya M, et al. Additional correction of OAB symptoms by two anti-muscarinics for men over 50 years old with residual symptoms of moderate prostatic obstruction after treatment with Tamsulosin. *Aging Male*. 2015;18(1):44–48.

Kosilov KV, Loparev SA, Ivanovskaya MA, et al. Effectiveness of solifenacin and trospium for managing of severe symptoms of overactive bladder in patients with benign prostatic hyperplasia. *Am J Mens Health*. 2016;10(2):157–163.

Kotlikoff MI, Dhulipala P, Wang YX. M2 signaling in smooth muscle cells. *Life Sci*. 1999;64:437–442.

Krane R, Olsson C. Phenoxybenzamine in neurogenic bladder dysfunction: I. A theory of micturition. *J Urol*. 1973;110:650–654.

Krauwinkel W, van Dijk J, Schaddelee M, et al. Pharmacokinetic properties of mirabegron, a beta3-adrenoceptor agonist: results from two phase I, randomized, multiple-dose studies in healthy young and elderly men and women. *Clin Ther*. 2012;34(10):2144–2160.

Kuipers M, Tran D, Krauwinkel W, et al. *Absolute* *bioavailability of YM905 in healthy male volunteers. A single-dose randomized, two-period crossover study*. [Presented at; the 32nd International Continence Society Annual Meeting. Heidelberg, Germany] 2002.

Kullmann FA, Shah MA, Birder LA, et al. Functional TRP and ASIC-like channels in cultured urothelial cells from the rat. *Am J Physiol Renal Physiol*. 2009;296(4):F892–F901.

Kums JJ, Delhaas EM. Intrathecal baclofen infusion in patients with spasticity and neurogenic bladder disease. *World J Urol*. 1991;9:99–103.

Kuo HC. Effectiveness of intravesical resiniferatoxin in treating detrusor hyper-reflexia and external sphincter dyssynergia in patients with chronic spinal cord lesions. *BJU Int*. 2003;92(6):597.

Kuo HC. Clinical effects of suburothelial injection of botulinum A toxin on patients with nonneurogenic detrusor overactivity refractory to anticholinergics. *Urology*. 2005;66(1):94.

Kuo HC. Multiple intravesical instillation of low-dose resiniferatoxin is effective in the treatment of detrusor overactivity refractory to anticholinergics. *BJU Int*. 2005;95(7):1023.

Kuo HC, Liu HT, Yang WC. Therapeutic effect of multiple resiniferatoxin intravesical instillations in patients with refractory detrusor overactivity: a randomized, double-blind, placebo controlled study. *J Urol*. 2006;176(2):641.

Kuo HC. Comparison of effectiveness of detrusor, suburothelial and bladder base injections of botulinum toxin a for idiopathic detrusor overactivity. *J Urol*. 2007;178(4 Pt 1):1359.

Kuo HC, Liao CH, Chung SD. Adverse events of intravesical botulinum toxin a injections for idiopathic detrusor overactivity: risk factors and influence on treatment outcome. *Eur Urol*. 2010;58(6):919–926.

Kupelian V, Fitzgerald MP, Kaplan SA, et al. Association of nocturia and mortality. Results from the Third National Health and Nutrition Examination Survey. *J Urol*. 2011;185(2):571–577.

Kupelian V, Wei J, O'Leary M, et al. Nocturia and quality of life: results from the Boston Area Community Health Survey. *Eur Urol*. 2012;61(1):78–84.

La Torre A, Giupponi G, Duffy D, et al. Sexual dysfunction related to drugs: a critical review. Part V: α-blocker and 5-ARI drugs. *Pharmacopsychiatry*. 2016;49(1):3–13.

Lader M. Clinical pharmacology of benzodiazepines. *Annu Rev Med*. 1987;38:19–24.

Laubser PG, Narayan RK, Sadin KJ. Continuous infusion of intrathecal baclofen: long-term effects on spasticity in spinal cord injury. *Paraplegia*. 1991;29:48–54.

Lazzeri M, Beneforti P, Turini D, et al. Urodynamic effects of intravesical resiniferatoxin in humans: preliminary results in stable and unstable detrusor. *J Urol*. 1997;158(6):2093.

Lazzeri M, Spinelli M, Beneforti P, et al. Intravesical resiniferatoxin for the treatment of detrusor hyperreflexia refractory to capsaicin in patients with chronic spinal cord diseases. *Scand J Urol Nephrol*. 1998;32(5):331.

Lecci A, Maggi CA. Tachykinins as modulators of the micturition reflex in the central and peripheral nervous system. *Regul Pept*. 2001;101(1–3):1–18.

Lee JY, Kim HW, Lee SJ, et al. Comparison of doxazosin with or without tolterodine in men with symptomatic bladder outlet obstruction and an overactive bladder. *BJU Int*. 2004;94(6):817.

Lee KS, Choo MS, Kim DY, et al. Combination treatment with propiverine hydrochloride plus doxazosin controlled release gastrointestinal therapeutic system formulation for overactive bladder and coexisting benign prostatic obstruction: a prospective, randomized, controlled multicenter study. *J Urol*. 2005;174(4 Pt 1):1334.

Lee KS, Lee HW, Han DH. Does anticholinergic medication have a role in treating men with overactive bladder and benign prostatic hyperplasia? *Naunyn Schmiedebergs Arch Pharmacol*. 2008;377(4–6):491.

Lee T, Andersson KE, Streng T, et al. Simultaneous registration of intraabdominal and intravesical pressures during cystometry in conscious rats—effects of bladder outlet obstruction and intravesical PGE2. *Neurourol Urodyn*. 2008;27:88–95.

Lee KS, Lee HW, Choo MS, et al. Urinary urgency outcomes after propiverine treatment for an overactive bladder: the “Propiverine study on overactive bladder including urgency data”. *BJU Int*. 2010;105(11):1565–1570.

Lee SH, Chung BH, Kim SJ, et al. Initial combined treatment with anticholinergics and alpha-blockers for men with lower urinary tract symptoms related to BPH and overactive bladder: a prospective, randomized, multi-center, double-blind, placebo-controlled study. *Prostate Cancer Prostatic Dis*. 2011;14(4):320–325.

Lee KS, Park B, Kim JH, et al. A randomised, double-blind, parallel design, multi-institutional, non-inferiority phase IV trial of imidafenacin versus fesoterodine for overactive bladder. *Int J Clin Pract*. 2013;67(12):1317–1326.

Leng J, Liao L, Wan B, et al. Results of a randomized, double-blind, active-controlled clinical trial with propiverine extended release 30 mg in patients with overactive bladder. *BJU Int*. 2017;119(1):148–157.

Leon LA, Hoffman BE, Gardner SD, et al. Effects of the beta 3-adrenergic receptor agonist disodium 5-[(2R)-2-[[(2R)-2-(3-chlorophenyl)-2-hydroxyethyl]amino]propyl]-1,3-benzodioxole-2,2-dicarboxylate (CL-316243) on bladder micturition reflex in spontaneously hypertensive rats. *J Pharmacol Exp Ther*. 2008;326(1):178.

Lepor H, Hill LA. Silodosin for the treatment of benign prostatic hyperplasia: pharmacology and cardiovascular tolerability. *Pharmacotherapy*. 2010;30(12):1303–1312.

Lepor H, Kazzazi A, Djavan B. Alpha-blockers for benign prostatic hyperplasia: the new era. *Curr Opin Urol*. 2012;22(1):7–15.

Leslie CA, Pavlakis AJ, Wheeler JS Jr, et al. Release of arachidonate cascade products by the rabbit bladder: neurophysiological significance? *J Urol*. 1984;132:376.

Leung FP, Yung LM, Yao X, et al. Store-operated calcium entry in vascular smooth muscle. *Br J Pharmacol*. 2008;153(5):846–857.

Levin RM, Wein AJ. Comparative effects of five tricyclic compounds on the rabbit urinary bladder. *Neurourol Urodyn*. 1984;3:127–135.

Liguori G, Trombetta C, De Giorgi G, et al. Efficacy and safety of combined oral therapy with tadalafil and alfuzosin: an integrated approach to the management of patients with lower urinary tract symptoms and erectile dysfunction. Preliminary report. *J Sex Med*. 2009;6:544–552.

Lin HH, Sheu BC, Lo MC, et al. Comparison of treatment outcomes for imipramine for female genuine stress incontinence. *Br J Obstet Gynaecol*. 1999;106:1089.

Lipton RB, Kolodner K, Wesnes K. Assessment of cognitive function of the elderly population: effects of darifenacin. *J Urol*. 2005;173(2):493.

Liu B, Anderson G, Mittman N, et al. Use of selective serotonin reuptake inhibitors or tricyclic antidepressants and risk of hip fracture in elderly people. *Lancet*. 1998;351(9112):1303–1307.

Liu HT, Chancellor MB, Kuo HC. Urinary nerve growth factor levels are elevated in patients with detrusor overactivity and decreased in responders to detrusor botulinum toxin-A injection. *Eur Urol*. 2009;56(4):700–706.

Liu HT, Kuo HC. Increased expression of transient receptor potential vanilloid subfamily 1 in the bladder predicts the response to intravesical instillations of resiniferatoxin in patients with refractory idiopathic detrusor overactivity. *BJU Int*. 2007;100(5):1086.

Liu L, Mansfield KJ, Kristiana I, et al. The molecular basis of urgency: regional difference of vanilloid receptor expression in the human urinary bladder. *Neurourol Urodyn*. 2007;26(3):433–438.

Longhurst PA, Briscoe JA, Rosenberg DJ, et al. The role of cyclic nucleotides in guinea-pig bladder contractility. *Br J Pharmacol*. 1997;121(8):1665.

Lose G, Jorgensen L, Thunedborg P. Doxepin in the treatment of female detrusor overactivity: a randomized double-blind crossover study. *J Urol*. 1989;142:1024.

Lose G, Mattiasson A, Walter S, et al. Clinical experience with desmopressin for long-term treatment of nocturia. *J Urol*. 2004;172:1021.

Lose G, Norgaard JP. Intravesical oxybutynin for treating incontinence resulting from an overactive detrusor. *BJU Int*. 2001;87:767.

Low BY, Liong ML, Yuen KH, et al. Terazosin therapy for patients with female lower urinary tract symptoms: a randomized, double-blind, placebo controlled trial. *J Urol*. 2008;179(4):1461.

Lowenstein L, Kenton K, Mueller ER, et al. Solifenacin objectively decreases urinary sensation in women with overactive bladder syndrome. *Int Urol Nephrol*. 2012;44(2):425–429.

Lucioni A, Bales GT, Lotan TL, et al. Botulinum toxin type A inhibits sensory neuropeptide release in rat bladder models of acute injury and chronic inflammation. *BJU Int*. 2008;101(3):366.

Luo D, Liu L, Han P, et al. Solifenacin for overactive bladder: a systematic review and meta-analysis. *Int Urogynecol J*. 2012;23(8):983–991.

MacDiarmid SA, Ellsworth PI, Ginsberg DA, et al. Safety and efficacy of once-daily trospium chloride extended-release in male patients with overactive bladder. *Urology*. 2011;77(1):24–29.

Madersbacher H, Halaska M, Voigt R, et al. A placebo-controlled, multicentre study comparing the tolerability and efficacy of propiverine and oxybutynin in patients with urgency and urge incontinence. *BJU Int*. 1999;84:646.

Madersbacher H, Mürz G. Efficacy, tolerability and safety profile of propiverine in the treatment of the overactive bladder (non-neurogenic and neurogenic). *World J Urol*. 2001;19:324.

Madersbacher H, Stohrer M, Richter R, et al. Trospium chloride versus oxybutynin: a randomized, double-blind, multicentre trial in the treatment of detrusor hyper-reflexia. *Br J Urol*. 1995;75(4):452.

Madhuvrata P, Cody JD, Ellis G, et al. Which anticholinergic drug for overactive bladder symptoms in adults. *Cochrane Database Syst Rev*. 2012;(1) [CD005429].

Maggi CA, Barbanti G, Santicioli P, et al. Cystometric evidence that capsaicin-sensitive nerves modulate the afferent branch of micturition reflex in humans. *J Urol*. 1989;142:150–154.

Maggi CA, Borsini F, Lecci A, et al. The effect of acute and chronic administration of imipramine on spinal and supraspinal micturition reflexes in rats. *J Pharmacol Exp Ther*. 1989;248:278.

Malhotra BK, Glue P, Sweeney K, et al. Thorough QT study with recommended and supratherapeutic doses of tolterodine. *Clin Pharmacol Ther*. 2007;81(3):377.

Malhotra B, Gandelman K, Sachse R, et al. Assessment of the effects of renal impairment on the pharmacokinetic profile of fesoterodine. *J Clin Pharmacol*. 2009;49(4):477–482.

Malhotra B, Gandelman K, Sachse R, et al. The design and development of fesoterodine as a prodrug of 5-hydroxymethyl tolterodine (5-HMT), the active metabolite of tolterodine. *Curr Med Chem*. 2009;16(33):4481–4489.

Malhotra B, Guan Z, Wood N, et al. Pharmacokinetic profile of fesoterodine. *Int J Clin Pharmacol Ther*. 2008;46(11):556–563.

Malhotra B, Sachse R, Wood N. Influence of food on the pharmacokinetic profile of fesoterodine. *Int J Clin Pharmacol Ther*. 2009;47(6):384–390.

Malhotra B, Wood N, Sachse R, et al. Thorough QT study of the effect of fesoterodine on cardiac repolarization. *Int J Clin Pharmacol Ther*. 2010;48(5):309–318.

Malik M, van Gelderen EM, Lee JH, et al. Proarrhythmic safety of repeat doses of mirabegron in healthy subjects: a randomized, double-blind, placebo-, and active-controlled thorough QT study. *Clin Pharmacol Ther*. 2012;92(6):696.

Mamas MA, Reynard JM, Brading AF. Augmentation of nitric oxide to treat detrusor-external sphincter dyssynergia in spinal cord injury. *Lancet*. 2001;357(9272):1964–1967.

Mamas MA, Reynard JM, Brading AF. Nitric oxide and the lower urinary tract: current concepts, future prospects. *Urology*. 2003;61(6):1079–1085.

Maneuf YP, Gonzalez MI, Sutton KS, et al. Cellular and molecular action of the putative GABA-mimetic, gabapentin. *Cell Mol Life Sci*. 2003;60(4):742.

Mangera A, Andersson KE, Apostolidis A, et al. Contemporary management of lower urinary tract disease with botulinum toxin A: a systematic review of Botox (onabotulinumtoxinA) and Dysport (abobotulinumtoxinA). *Eur Urol*. 2011;60(4):784–795.

Maniscalco M, Singh-Franco D, Wolowich WR, et al. Solifenacin succinate for the treatment of symptoms of overactive bladder. *Clin Ther*. 2006;28(9):1247.

Mansfield KJ, Liu L, Mitchelson FJ, et al. Muscarinic receptor subtypes in human bladder detrusor and mucosa, studied by radioligand binding and quantitative competitive RT-PCR: changes in ageing. *Br J Pharmacol*. 2005;144(8):1089–1099.

Marencak J, Cossons NH, Darekar A, et al. Investigation of the clinical efficacy and safety of pregabalin alone or combined with tolterodine in female subjects with idiopathic overactive bladder. *Neurourol Urodyn*. 2011;30(1):75–82.

Mariappan P, Ballantyne Z, N'Dow JMO, et al. Serotonin and noradrenaline reuptake inhibitors (SNRI) for stress urinary incontinence in adults (review). *Cochrane Database Syst Rev*. 2005;(3) [CD004742].

Marks LS, Gittelman MC, Hill LA, et al. Rapid efficacy of the highly selective a1A-adrenoceptor antagonist silodosin in men with signs and symptoms of benign prostatic hyperplasia: pooled results of 2 phase 3 studies. *J Urol*. 2009;181:2634–2640.

Marks LS, Gittelman MC, Hill LA, et al. Silodosin in the treatment of the signs and symptoms of benign prostatic hyperplasia: a 9-month, open-label extension study. *Urology*. 2009;6:1318–1322.

Marschall-Kehrel D, Feustel C, Persson de Geeter C, et al. Treatment with propiverine in children suffering from nonneurogenic overactive bladder and urinary incontinence: results of a randomized placebo-controlled phase 3 clinical trial. *Eur Urol*. 2009;55(3):729–736.

Martin MR, Schiff AA. Fluphenazine/nortriptyline in the irritative bladder syndrome: a double-blind placebo-controlled study. *Br J Urol*. 1984;56:178.

Martin SW, Radley SC, Chess-Williams R, et al. Relaxant effects of potassium-channel openers on normal and hyper-reflexic detrusor muscle. *Br J Urol*. 1997;80:405.

Martínez-García R, Abadías M, Arañó P, et al. Cizolirtine citrate, an effective treatment for symptomatic patients with urinary incontinence secondary to overactive bladder: a pilot dose-finding study. *Eur Urol*. 2009;56(1):184–190.

Maruyama O, Kawachi Y, Hanazawa K, et al. Naftopidil monotherapy vs. naftopidil and an anticholinergic agent combined therapy for storage symptoms associated with benign prostatic hyperplasia: a prospective randomized controlled study. *Int J Urol*. 2006;13(10):1280–1285.

Massaro AM, Lenz KL. Aprepitant: a novel antiemetic for chemotherapy-induced nausea and vomiting. *Ann Pharmacother*. 2005;39(1):77.

Masumori N, Miyamoto S, Tsukamoto T, et al. The efficacy and safety of propiverine hydrochloride in patients with overactive bladder symptoms who poorly responded to previous anticholinergic agents. *Adv Urol*. 2011;2011:714978.

Matsui M, Griffin MT, Shehnaz D, et al. Increased relaxant action of forskolin and isoproterenol against muscarinic agonist-induced contractions in smooth muscle from M2 receptor knockout mice. *J Pharmacol Exp Ther*. 2003;305(1):106–113.

Matsui M, Motomura D, Karasawa H, et al. Multiple functional defects in peripheral autonomic organs in mice lacking muscarinic acetylcholine receptor gene for the M3 subtype. *Proc Natl Acad Sci USA*. 2000;97:9579–9584.

Matsukawa Y, Gotoh M, Komatsu T, et al. Efficacy of silodosin for relieving benign prostatic obstruction: prospective pressure flow study. *J Urol*. 2009;182:2831–2835.

Matthiesen TB, Rittig S, Norgaard JP, et al. Nocturnal polyuria and natriuresis in male patients with nocturia and lower urinary tract symptoms. *J Urol*. 1996;156:1292.

Mattiasson A, Abrams P, van Kerrebroeck P, et al. Efficacy of desmopressin in the treatment of nocturia: a double-blind placebo-controlled study in men. *BJU Int*. 2002;89:855.

Mattiasson A, Blaakaer J, Hoye K, et al. Simplified bladder training augments the effectiveness of tolterodine in patients with an overactive bladder. *BJU Int*. 2003;91(1):54.

May K, Westphal K, Giessmann T, et al. Disposition and antimuscarinic effects of the urinary bladder spasmolytics propiverine: influence of dosage forms and circadian-time rhythms. *J Clin Pharmacol*. 2008;48(5):570.

McCafferty GP, Misajet BA, Laping NJ, et al. Enhanced bladder capacity and reduced prostaglandin E_2-mediated bladder hyperactivity in EP_3 receptor knockout mice. *Am J Physiol Renal Physiol*. 2008;295:F507–F514.

McConnell JD, Roehrborn CG, Bautista OM, et al. The long-term effect of doxazosin, finasteride, and combination therapy on the clinical progression of benign prostatic hyperplasia. *N Engl J Med*. 2003;349(25):2387.

McCrery RJ, Appell RA. Oxybutynin: an overview of the available formulations. *Ther Clin Risk Manag*. 2006;2(1):19.

McGuire EJ, Savastano JA. Urodynamics and management of the neuropathic bladder in spinal cord injury patients. *J Am Paraplegia Soc*. 1985;8(2):28–32.

McVary KT, Monnig W, Camps JL Jr, et al. Sildenafil citrate improves erectile function and urinary symptoms in men with erectile dysfunction and lower urinary tract symptoms associated with benign prostatic hyperplasia: a randomized, double-blind trial. *J Urol*. 2007;177(3):1071.

McVary KT, Roehrborn CG, Kaminetsky JC, et al. Tadalafil relieves lower urinary tract symptoms secondary to benign prostatic hyperplasia. *J Urol*. 2007;177(4):1401.

McVary KT, Roehrborn CG, Avins AL, et al. Update on AUA guideline on the management of benign prostatic hyperplasia. *J Urol*. 2011;185:1793–1803.

Menarini M, Del Popolo G, Di Benedetto P, et al. Trospium chloride in patients with neurogenic detrusor overactivity: is dose titration of benefit to the patients? *Int J Clin Pharmacol Ther*. 2006;44(12):623.

Meng J, Wang J, Lawrence G, et al. Synaptobrevin I mediates exocytosis of CGRP from sensory neurons and inhibition by botulinum toxins reflects their anti-nociceptive potential. *J Cell Sci*. 2007;120(Pt 16):2864.

Merriam FV, Wang ZY, Guerios SD, et al. Cannabinoid receptor2 is increased in acutely and chronically inflamed bladder of rats. *Neurosci Lett*. 2008;445:130–134.

Michel MC, Hegde SS. Treatment of the overactive bladder syndrome with muscarinic receptor antagonists: a matter of metabolites? *Naunyn Schmiedebergs Arch Pharmacol*. 2006;374(2):79.

Michel MC, Vrydag W. Alpha1-, alpha2- and beta-adrenoceptors in the urinary bladder, urethra and prostate. *Br J Pharmacol*. 2006;147(Suppl 2):S88.

Michel MC, Wetterauer U, Vogel M, et al. Cardiovascular safety and overall tolerability of solifenacin in routine clinical use: a 12-week, open-label, post-marketing surveillance study. *Drug Saf*. 2008;31(6):505.

Michel MC. Fesoterodine: a novel muscarinic receptor antagonist for the treatment of overactive bladder syndrome. *Expert Opin Pharmacother*. 2008;9(10):1787.

Michel MC. The forefront for novel therapeutic agents based on the pathophysiology of lower urinary tract dysfunction: alpha-blockers in the treatment of male voiding dysfunction

—how do they work and why do they differ in tolerability? *J Pharmacol Sci*. 2010;112(2):151–157.

Milani R, Scalambrino S, Milia R, et al. Double-blind crossover comparison of flavoxate and oxybutynin in women affected by urinary urge syndrome. *Int Urogynecol J*. 1993;4:3.

Millard RJ, Asia Pacific Tolterodine Study Group. Clinical efficacy of tolterodine with or without a simplified pelvic floor exercise regimen. *Neurourol Urodyn*. 2004;23(1):48.

Miller DW, Hinton M, Chen F. Evaluation of drug efflux transporter liabilities of darifenacin in cell culture models of the blood-brain and blood-ocular barriers. *Neurourol Urodyn*. 2011;30(8):1633–1638.

Mitchell WC, Venable DD. Effects of metoclopramide on detrusor function. *J Urol*. 1985;134:791–795.

Miyazato M, Sasatomi K, Hiragata S, et al. GABA receptor activation in the lumbosacral spinal cord decreases detrusor overactivity in spinal cord injured rats. *J Urol*. 2008;179(3):1178–1183.

Mo W, Michel MC, Lee XW, et al. The β_3-adrenoceptor agonist mirabegron increases human atrial force through β_1-adrenoceptors: an indirect mechanism? *Br J Pharmacol*. 2017;174(16):2706–2715.

Mobley D. Phenoxybenzamine in the management of neurogenic vesical dysfunction. *J Urol*. 1976;116:737–741.

Moehrer B, Hextall A, Jackson S. Oestrogens for urinary incontinence in women. *Cochrane Database Syst Rev*. 2003;(2) [CD001405; Update in Cochrane Database Syst Rev 2009;(4):CD001405].

Montorsi F, Gandaglia G, Chapple C, et al. Effectiveness and safety of silodosin in the treatment of lower urinary tract symptoms in patients with benign prostatic hyperplasia: a European phase IV clinical study (SiRE study). *Int J Urol*. 2016;23(7):572–579.

Morelli A, Filippi S, Comeglio P, et al. Acute vardenafil administration improves bladder oxygenation in spontaneously hypertensive rats. *J Sex Med*. 2009;7:107–120.

Morelli A, Filippi S, Sandner P, et al. Vardenafil modulates bladder contractility through cGMP-mediated inhibition of RhoA/Rho kinase signaling pathway in spontaneously hypertensive rats. *J Sex Med*. 2009;6:1594–1608.

Morelli A, Sarchielli E, Comeglio P, et al. Phosphodiesterase type 5 expression in human and rat lower urinary tract tissues and the effect of tadalafil on prostate gland oxygenation in spontaneously hypertensive rats. *J Sex Med*. 2011;8:2746–2760.

Morelli A, Vignozzi L, Filippi S, et al. BXL-628, a vitamin D receptor agonist effective in benign prostatic hyperplasia treatment, prevents RhoA activation and inhibits RhoA/Rho kinase signaling in rat and human bladder. *Prostate*. 2007;67(3):234.

Morenilla-Palao C, Planells-Cases R, García-Sanz N, et al. Regulated exocytosis contributes to protein kinase C potentiation of vanilloid receptor activity. *Biol Chem*. 2004;279(24):25665.

Morganroth J, Lepor H, Hill LA, et al. Effects of the selective a1A-adrenoceptor antagonist silodosin on ECGs of healthy men in a randomized, double blind, placebo-moxifloxacin-controlled study. *Clin Pharmacol Ther*. 2010;87:609–613.

Morita T, Ando M, Kihara K, et al. Effects of prostaglandins E_1, E_2 and F_2alpha on contractility and cAMP and cGMP contents in lower urinary tract smooth muscle. *Urol Int*. 1994;52:200.

Morita T, Iizuka H, Iwata T, et al. Function and distribution of beta$_3$-adrenoceptors in rat, rabbit and human urinary bladder and external urethral sphincter. *J Smooth Muscle Res*. 2000;36(1):21.

Moro C, Tajouri L, Chess-Williams R. Adrenoceptor function and expression in bladder urothelium and lamina propria. *Urology*. 2013;81(1):211.e1–211.e7.

Morrison J, Steers WD, Brading A, et al. Neurophysiology and neuropharmacology. Abrams P, Khoury S, Wein A. *Incontinence: 2nd International Consultation on Incontinence*. Plymbridge Distributors: Plymouth (UK); 2002:85–161.

Mostwin J, Bourcier A, Haab F, et al. Pathophysiology of urinary incontinence, fecal incontinence and pelvic organ prolapse. Abrams P, Cardozo L, Khoury S, et al. *Incontinence*. Health Publications: Plymouth (UK); 2005:423.

Mumtaz FH, Khan MA, Thompson CS, et al. Nitric oxide in the lower urinary tract: physiological and pathological implications. *BJU Int*. 2000;85:567–578.

Murakami S, Chapple CR, Akino H, et al. The role of the urothelium in mediating bladder responses to isoprenaline. *BJU Int*. 2007;99(3):669.

Murakami S, Yoshida M, Iwashita H, et al. Pharmacological effects of KRP-197 on the human isolated urinary bladder. *Urol Int*. 2003;71(3):290–298.

Murdock M, Sax D, Krane R. Use of dantrolene sodium in external sphincter spasm. *Urology*. 1976;8:133–138.

Murray KH, Feneley RC. Endorphins—a role in lower urinary tract function? The effect of opioid blockade on the detrusor and urethral sphincter mechanisms. *Br J Urol*. 1982;54(6):638–640.

Muskat Y, Bukovsky I, Schneider D, et al. The use of scopolamine in the treatment of detrusor instability. *J Urol*. 1996;156:1989.

Musselman DM, Ford AP, Gennevois DJ, et al. A randomized crossover study to evaluate Ro 115-1240, a selective alpha_1

A/1L-adrenoceptor partial agonist in women with stress urinary incontinence. *BJU Int*. 2004;93(1):78.

Müller C, Siegmund W, Huupponen R, et al. Kinetics of propiverine as assessed by radioreceptor assay in poor and extensive metabolizers of debrisoquine. *Eur J Drug Metab Pharmacokinet*. 1993;18(3):265.

Nadeau G, Schröder A, Moore K, et al. Long-term use of solifenacin in pediatric patients with overactive bladder: extension of a prospective open-label study. *Can Urol Assoc J*. 2014;8(3–4):118–123.

Naglie G, Radomski SB, Brymer C, et al. A randomized, double-blind, placebo controlled crossover trial of nimodipine in older persons with detrusor instability and urge incontinence. *J Urol*. 2002;167:586.

Nakagawa H, Niu K, Hozawa A, et al. Impact of nocturia on bone fractures and mortality in older people: a Japanese longitudinal cohort study. *J Urol*. 2010;184:1413–1418.

Nanninga J, Frost M, Penn R. Effect of intrathecal baclofen on bladder and sphincter function. *J Urol*. 1989;142:101–106.

Nanninga J, Kaplan P, Lal S. Effect of phentolamine on peripheral muscle EMG activity in paraplegia. *Br J Urol*. 1977;49:537–541.

Natalin R, Reis LO, Alpendre C, et al. Triple therapy in refractory detrusor overactivity: a preliminary study. *World J Urol*. 2009;28:79–85.

Neveus T, Tullus K. Tolterodine and imipramine in refractory enuresis: a placebo-controlled crossover study. *Pediatr Nephrol*. 2008;23:263.

Ney P, Pandita RK, Newgreen DT, et al. Pharmacological characterization of a novel investigational antimuscarinic drug, fesoterodine, in vitro and in vivo. *BJU Int*. 2008;101(8):1036.

Nilvebrant L, Sparf B. Dicyclomine, benzhexol and oxybutynin distinguish between subclasses of muscarinic binding sites. *Eur J Pharmacol*. 1986;123:133.

Nilvebrant L, Sparf B. Receptor binding profiles of some selective muscarinic antagonists. *Eur J Pharmacol*. 1988;151(1):83–96.

Nilvebrant L, Andersson KE, Gillberg PG. Tolterodine—a new bladder-selective antimuscarinic agent. *Eur J Pharmacol*. 1997;327(2–3):195.

Nilvebrant L, Gillberg PG, Sparf B. Antimuscarinic potency and bladder selectivity of PNU-200577, a major metabolite of tolterodine. *Pharmacol Toxicol*. 1997;81(4):16.

Nishiguchi J, Kwon DD, Kaiho Y, et al. Suppression of detrusor overactivity in rats with bladder outlet obstruction by a type 4 phosphodiesterase inhibitor. *BJU Int*. 2007;99(3):680.

Nishimune A, Yoshiki H, Uwada J, et al. Phenotype pharmacology of lower urinary tract alpha(1)-adrenoceptors. *Br J Pharmacol*. 2012;165(5):1226–1234.

Nitti VW. Botulinum toxin for the treatment of idiopathic and neurogenic overactive bladder: state of the art. *Rev Urol*. 2006;8(4):198.

Nitti VW, Dmochowski R, Sand PK, et al. Efficacy, safety and tolerability of fesoterodine for overactive bladder syndrome. *J Urol*. 2007;178(6):2488–2494.

Nitti VW, Rovner ES, Bavendam T. Response to fesoterodine in patients with an overactive bladder and urgency urinary incontinence is independent of the urodynamic finding of detrusor overactivity. *BJU Int*. 2010;105(9):1268–1275.

Nitti VW, Auerbach S, Martin N, et al. Results of a randomized phase III trial of mirabegron in patients with overactive bladder. *J Urol*. 2013;189(4):1388–1395.

Nitti VW, Dmochowski R, Herschorn S, EMBARK Study Group, et al. OnabotulinumtoxinA for the treatment of patients with overactive bladder and urinary incontinence:

results of a phase 3, randomized, placebo controlled trial. *J Urol*. 2013;189(6):2186–2193.

Nitti VW, Rosenberg S, Mitcheson DH, et al. Urodynamics and safety of the beta 3-adrenoceptor agonist, mirabegron, in males with lower urinary tract symptoms and bladder outlet obstruction. *J Urol*. 2013;190(4):1320–1327.

Noguchi M, Eguchi Y, Ichiki J, et al. Therapeutic efficacy of clenbuterol for urinary incontinence after radical prostatectomy. *Int J Urol*. 1997;4:480.

Nomiya M, Burmeister DM, Sawada N, et al. Prophylactic effect of tadalafil on bladder function in a rat model of chronic bladder ischemia. *J Urol*. 2013;189(2):754–761.

Nomiya M, Yamaguchi O. A quantitative analysis of mRNA expression of alpha1 and beta-adrenoceptor subtypes and their functional roles in human normal and obstructed bladders. *J Urol*. 2003;170(2 Pt 1):649.

Nordling J, Meyhoff H, Hald T. Sympatholytic effect on striated urethral sphincter. *Scand J Urol Nephrol*. 1981;15:173–178.

Norhona-Blob L, Kachur JF. Enantiomers of oxybutynin: in vitro pharmacological characterization at M1, M2 and M3 muscarinic receptors and in vivo effects on urinary bladder contraction, mydriasis and salivary secretion in guinea pigs. *J Pharmacol Exp Ther*. 1991;256:562.

Norton PA, Zinner NR, Yalcin I, et al. Duloxetine versus placebo in the treatment of stress urinary incontinence. *Am J Obstet Gynecol*. 2002;187:40.

Novara G, Galfano A, Secco S, et al. Systematic review and meta-analysis of randomized controlled trials with antimuscarinic drugs for overactive bladder. *Eur Urol*. 2008;54(4):740–763.

Novara G, Tubaro A, Sanseverino R, et al. Systematic review and meta-analysis of randomized controlled trials evaluating silodosin in the treatment of non-neurogenic male lower urinary tract symptoms suggestive of benign prostatic enlargement. *World J Urol*. 2013;31(4):997–1008.

Ochs GA. Intrathecal baclofen. *Baillieres Clin Neurol*. 1993;2(1):73–86.

O'Donnell P, Hawkins WH. Effects of subcutaneous bethanechol on bladder sensation during cystometry. *Urology*. 1993;41:452–456.

Oelke M, Bachmann A, Descazeaud A, et al. EAU Guidelines on the treatment and follow-up of non-neurogenic male lower urinary tract symptoms including benign prostatic obstruction. *Eur Urol*. 2013;64(1):118–140.

Oelke M, Weiss JP, Mamoulakis C, et al. Effects of tadalafil on nighttime voiding (nocturia) in men with lower urinary tract symptoms suggestive of benign prostatic hyperplasia: a post hoc analysis of pooled data from four randomized, placebo-controlled clinical studies. *World J Urol*. 2014;32:1127–1132.

Oger S, Behr-Roussel D, Gorny D, et al. Combination of alfuzosin and tadalafil exerts in vitro an additive relaxant effect on human corpus cavernosum. *J Sex Med*. 2008;5:935–945.

Oger S, Behr-Roussel D, Gorny D, et al. Signalling pathways involved in sildenafil-induced relaxation of human bladder dome smooth muscle. *Br J Pharmacol*. 2010;160:1135–1143.

Ohlstein EH, von Keitz A, Michel MC. A multicenter, double-blind, randomized, placebo-controlled trial of the β_3-adrenoceptor agonist solabegron for overactive bladder. *Eur Urol*. 2012;62(5):834–840.

Ohmori S, Miura M, Toriumi C, et al. Absorption, metabolism, and excretion of [14C]imidafenacin, a new compound for treatment of overactive bladder, after oral administration to healthy male subjects. *Drug Metab Dispos*. 2007;35(9):1624–1633.

Ohno T, Nakade S, Nakayama K, et al. Absolute bioavailability of imidafenacin after oral administration to healthy subjects. *Br J Clin Pharmacol*. 2008;65(2):197–202.

Oka M, Kimura Y, Itoh Y, et al. Brain pertussis toxin-sensitive G proteins are involved in the flavoxate hydrochloride-induced suppression of the micturition reflex in rats. *Brain Res*. 1996;727(1–2):91.

Olshansky B, Ebinger U, Brum J, et al. Differential pharmacological effects of antimuscarinic drugs on heart rate: a randomized, placebo-controlled, double-blind, crossover study with tolterodine and darifenacin in healthy participants > or = 50 years. *J Cardiovasc Pharmacol Ther*. 2008;13(4):241–251.

Otsuka A, Shinbo H, Matsumoto R, et al. Expression and functional role of beta-adrenoceptors in the human urinary bladder urothelium. *Naunyn Schmiedebergs Arch Pharmacol*. 2008;377(4–6):473.

Otsuki H, Kosaka T, Nakamura K, et al. β3-Adrenoceptor agonist mirabegron is effective for overactive bladder that is unresponsive to antimuscarinic treatment or is related to benign prostatic hyperplasia in men. *Int Urol Nephrol*. 2013;45(1):53–60.

Ouslander JG, Blaustein J, Connor A, et al. Pharmacokinetics and clinical effects of oxybutynin in geriatric patients. *J Urol*. 1988;140:47.

Ouslander JG, Schnelle JF, Uman G, et al. Does oxybutynin add to the effectiveness of prompted voiding for urinary incontinence among nursing home residents? A placebo-controlled trial. *J Am Geriatr Soc*. 1995;43:610.

Pagoria D, O'Connor RC, Guralnick ML. Antimuscarinic drugs: review of the cognitive impact when used to treat overactive bladder in elderly patients. *Curr Urol Rep*. 2011;12:351–357.

Palmer J. Report of a double-blind crossover study of flurbiprofen and placebo in detrusor instability. *J Int Med*

Res. 1983;11(Suppl 2):11.

Palmer LS, Zebold K, Firlit CF, et al. Complications of intravesical oxybutynin chloride therapy in the pediatric myelomeningocele population. *J Urol*. 1997;157:638.

Parker-Autry CY, Burgio KL, Richter HE. Vitamin D status: a review with implications for the pelvic floor. *Int Urogynecol J*. 2012;23:1517–1526.

Pasricha PJ, Pehlivanov N, Sugumar A, et al. Drug insight: from disturbed motility to disordered movement—a review of the clinical benefits and medicolegal risks of metoclopramide. *Nat Clin Pract Gastroenterol Hepatol*. 2006;3(3):138–148.

Pasricha PJ. Treatment disorders of bowel motility and water flux; antiemetics; agents used in biliary and pancreatic disease. Brunton LL, Lazo JS, Parker KL. *Goodman and Gilman's the pharmacological basis of therapeutics*. McGraw-Hill: New York and Chicago; 2006:983–1008.

Patel AK, Patterson JM, Chapple CR. Botulinum toxin injections for neurogenic and idiopathic detrusor overactivity: a critical analysis of results. *Eur Urol*. 2006;50(4):684.

Pehrson R, Andersson KE. Effects of tiagabine, a gamma-aminobutyric acid re-uptake inhibitor, on normal rat bladder function. *J Urol*. 2002;167(5):2241.

Pehrson R, Andersson KE. Tramadol inhibits rat detrusor overactivity caused by dopamine receptor stimulation. *J Urol*. 2003;170(1):272.

Penn RD, Savoy SM, Corcos D. Intrathecal baclofen for severe spinal spasticity. *JAMA*. 1989;320:1517–1521.

Perkash I. Intermittent catheterization and bladder rehabilitation in spinal cord injury patients. *J Urol*. 1975;114(2):230–233.

Pertwee RG, Howlett AC, Abood ME, et al. International Union of Basic and Clinical Pharmacology. LXXIX. Cannabinoid receptors and their ligands: beyond CB1 and CB2.

Pharmacol Rev. 2010;62:588–631.

Peters CA, Walsh PC. The effect of nafarelin acetate, a luteinizing-hormone-releasing hormone agonist, on benign prostatic hyperplasia. *N Engl J Med*. 1987;317:599.

Peters SL, Schmidt M, Michel MC. Rho kinase: a target for treating urinary bladder dysfunction? *Trends Pharmacol Sci*. 2006;27(9):492.

Petit H, Wiart L, Gaujard E, et al. Botulinum A toxin treatment for detrusor sphincter dyssynergia in spinal cord disease. *Spinal Cord*. 1998;36:91–94.

Petkov GV. Central role of the BK channel in urinary bladder smooth muscle physiology and pathophysiology. *Am J Physiol Regul Integr Comp Physiol*. 2014;307(6):R571–R584.

Petkov GV. Role of potassium ion channels in detrusor smooth muscle function and dysfunction. *Nat Rev Urol*. 2011;9(1):30–40.

Pinto R, Lopes T, Frias B, et al. Trigonal injection of botulinum toxin A in patients with refractory bladder pain syndrome/interstitial cystitis. *Eur Urol*. 2010;58(3):360–365.

Planells-Cases R, Valente P, Ferrer-Montiel A, et al. Complex regulation of TRPV1 and related thermo-TRPs: implications for therapeutic intervention. *Adv Exp Med Biol*. 2011;704:491–515.

Pontari MA, Braverman AS, Ruggieri MR Sr. The M2 muscarinic receptor mediates in vitro bladder contractions from patients with neurogenic bladder dysfunction. *Am J Physiol Regul Integr Comp Physiol*. 2004;286(5):R874–R880.

Porst H, Kim ED, Casabe AR, et al. Efficacy and safety of tadalafil once daily in the treatment of men with lower urinary tract symptoms suggestive of benign prostatic hyperplasia: results of an international randomized, double-blind, placebo-controlled trial. *Eur Urol*. 2011;60:1105–1113.

Porst H, McVary KT, Montorsi F, et al. Effects of once-daily tadalafil on erectile function in men with erectile dysfunction and signs and symptoms of benign prostatic hyperplasia. *Eur Urol*. 2009;56:727–735.

Purkiss J, Welch M, Doward S, et al. Capsaicin-stimulated release of substance P from cultured dorsal root ganglion neurons: involvement of two distinct mechanisms. *Biochem Pharmacol*. 2000;59(11):1403.

Radley SC, Chapple CR, Bryan NP, et al. Effect of methoxamine on maximum urethral pressure in women with genuine stress incontinence: a placebo-controlled, double-blind crossover study. *Neurourol Urodyn*. 2001;20(1):43.

Rahnama'i MS, van Koeveringe GA, Essers PB, et al. Prostaglandin receptor EP1 and EP2 site in guinea pig bladder urothelium and lamina propria. *J Urol*. 2010;183(3):1241–1247.

Rahnama'i MS, de Wachter SG, van Koeveringe GA, et al. The relationship between prostaglandin E receptor 1 and cyclooxygenase I expression in guinea pig bladder interstitial cells: proposition of a signal propagation system. *J Urol*. 2011;185(1):315–322.

Rahnama'i MS, Ückert S, Hohnen R, et al. The role of phosphodiesterases in bladder pathophysiology. *Nat Rev Urol*. 2013;10(7):414–424.

Rapp DE, Turk KW, Bales GT, et al. Botulinum toxin type a inhibits calcitonin gene–related peptide release from isolated rat bladder. *J Urol*. 2006;175(3 Pt 1):1138.

Raz S, Smith RB. External sphincter spasticity syndrome in female patients. *J Urol*. 1976;115:443–448.

Raz S, Zeigler M, Caine M. The effect of progesterone on the adrenergic receptors of the urethra. *Br J Urol*. 1973;45(2):131.

Razdan S, Leboeuf L, Meinbach DS, et al. Current practice patterns in the urologic surveillance and management of patients with spinal cord injury. *Urology*. 2003;61(5):893–896.

Reitz A, Bretscher S, Knapp PA, et al. The effect of nitric oxide on the resting tone and the contractile behaviour of the external urethral sphincter: a functional urodynamic study in healthy humans. *Eur Urol*. 2004;45(3):367–373.

Reitz A, Knapp PA, Muntener M, et al. Oral nitric oxide donors: a new pharmacological approach to detrusor-sphincter dyssynergia in spinal cord injured patients? *Eur Urol*. 2004;45(4):516–520.

Rekik M, Rouget C, Palea S, et al. Effects of combining antimuscarinics and beta$_3$-adrenoceptor agonists on contractions induced by electrical field stimulation of rat isolated urinary bladder strips [AUA abstract]. *J Urol*. 2013;189(4 Suppl):e115–e116.

Rembratt A, Norgaard JP, Andersson KE. Desmopressin in elderly patients with nocturia: short-term safety and effects on urine output, sleep and voiding patterns. *BJU Int*. 2003;91(7):642–646.

Rembratt A, Riis A, Norgaard JP. Desmopressin treatment in nocturia; an analysis of risk factors for hyponatremia. *Neurourol Urodyn*. 2006;25(2):105.

Richelson E. Pharmacology of antidepressants—characteristics of the ideal drug. *Mayo Clin Proc*. 1994;69:1069–1073.

Riedl CR, Stephen RL, Daha LK, et al. Electromotive administration of intravesical bethanechol and the clinical impact on acontractile detrusor management: introduction of a new test. *J Urol*. 2000;164(6):2108–2111.

Rios LA, Panhoca R, Mattos D Jr, et al. Intravesical resiniferatoxin for the treatment of women with idiopathic detrusor overactivity and urgency incontinence: a single dose, 4 weeks, double-blind, randomized, placebo controlled trial. *Neurourol Urodyn*. 2007;26(6):773.

Rittig S, Jensen AR, Jensen KT, et al. Effect of food intake on the pharmacokinetics and antidiuretic activity of oral desmopressin (DDAVP) in hydrated normal subjects. *Clin Endocrinol (Oxf)*. 1998;48(2):235–241.

Robinson D, Cardozo L, Akeson M, et al. Antidiuresis: a new concept in managing female daytime urinary incontinence. *BJU Int*. 2004;93:996.

Robinson D, Cardozo L, Terpstra G, et al. A randomized double-blind placebo-controlled multicentre study to explore the efficacy and safety of tamsulosin and tolterodine in women with overactive bladder syndrome. *BJU Int*. 2007;100(4):840.

Robinson D, Cardozo L. New drug treatments for urinary incontinence. *Maturitas*. 2010;65(4):340–347.

Robinson D, Cardozo L. The role of estrogens in female lower urinary tract dysfunction. *Urology*. 2003;62(4 Suppl 1):45.

Robinson D, Rainer RO, Washburn SA, et al. Effects of estrogen and progestin replacement on the urogenital tract of the ovariectomized cynomolgus monkey. *Neurourol Urodyn*. 1996;15(3):215.

Robson WL, Leung AK, Norgaard JP. The comparative safety of oral versus intranasal desmopressin for the treatment of children with nocturnal enuresis. *J Urol*. 2007;178(1):24–30.

Roden DM. Drug-induced prolongation of the QT interval. *N Engl J Med*. 2004;350(10):1013–1022.

Roehrborn CG, Kaplan SA, Kraus SR, et al. Effects of serum PSA on efficacy of tolterodine extended release with or without tamsulosin in men with LUTS, including OAB. *Urology*. 2008;72(5):1061–1067.

Roehrborn CG, McVary KT, Elion-Mboussa A, et al. Tadalafil administered once daily for lower urinary tract symptoms secondary to benign prostatic hyperplasia: a dose finding study. *J Urol*. 2008;180:1228–1234.

Roehrborn CG, Kaplan SA, Jones JS, et al. Tolterodine extended release with or without tamsulosin in men with lower urinary tract symptoms including overactive bladder symptoms: effects of prostate size. *Eur Urol*. 2009;55(2):472–479.

Roehrborn CG, Siami P, Barkin J, CombAT Study Group, et al. The effects of combination therapy with dutasteride and tamsulosin on clinical outcomes in men with symptomatic benign prostatic hyperplasia: 4-year results from the CombAT study. *Eur Urol*. 2010;57(1):123–131.

Rogers R, Bachmann G, Jumadilova Z, et al. Efficacy of tolterodine on overactive bladder symptoms and sexual and emotional quality of life in sexually active women. *Int Urogynecol J Pelvic Floor Dysfunct*. 2008;19(11):1551.

Roosen A, Datta SN, Chowdhury RA, et al. Suburothelial myofibroblasts in the human overactive bladder and the effect of botulinum neurotoxin type A treatment. *Eur Urol*. 2009;55(6):1440–1448.

Rosa GM, Bauckneht M, Scala C, et al. Cardiovascular effects of antimuscarinic agents in overactive bladder. *Expert Opin Drug Saf*. 2013;12:815–827.

Rossanese M, Novara G, Challacombe B, et al. Critical analysis of phase II and III randomised control trials (RCTs) evaluating efficacy and tolerability of a β_3-adrenoceptor agonist (Mirabegron) for overactive bladder (OAB). *BJU Int*. 2015;115(1):32–40.

Rouget C, Rekik M, Camparo P, et al. Modulation of nerve-evoked contractions by β_3-adrenoceptor agonism in human and rat isolated urinary bladder. *Pharmacol Res*. 2014;80:14–20.

Rovner E, Kennelly M, Schulte-Baukloh H, et al. Urodynamic results and clinical outcomes with intradetrusor injections of onabotulinumtoxinA in a randomized, placebo-controlled dose-finding study in idiopathic overactive bladder. *Neurourol Urodyn*. 2011;30(4):556–562.

Rovner ES, Kreder K, Sussman DO, et al. Effect of tolterodine extended release with or without tamsulosin on measures of urgency and patient reported outcomes in men with lower urinary tract symptoms. *J Urol*. 2008;180(3):1034.

Rovner ES, Rackley R, Nitti VW, et al. Tolterodine extended release is efficacious in continent and incontinent subjects with overactive bladder. *Urology*. 2008;72(3):488.

Roy CW, Wakefield IR. Baclofen pseudopsychosis: case report. *Paraplegia*. 1986;24:318–323.

Rudy D, Cline K, Harris R, et al. Multicenter phase III trial studying trospium chloride in patients with overactive bladder. *Urology*. 2006;67(2):275.

Ruffmann R. A review of flavoxate hydrochloride in the treatment of urge incontinence. *J Int Med Res*. 1988;16:317.

Rufford J, Hextall A, Cardozo L, et al. A double blind placebo controlled trial on the effects of 25 mg estradiol implants on the urge syndrome in postmenopausal women. *Int Urogynecol J Pelvic Floor Dysfunct*. 2003;14(2):78.

Ruggieri MR Sr, Braverman AS, Pontari MA. Combined use of alpha-adrenergic and muscarinic antagonists for the treatment of voiding dysfunction. *J Urol*. 2005;174(5):1743.

Ruggieri MR Sr. Cannabinoids: potential targets for bladder dysfunction. *Handb Exp Pharmacol*. 2011;202:425–451.

Sacco E, Bientinesi R. Mirabegron: a review of recent data and its prospects in the management of overactive bladder. *Ther Adv Urol*. 2012;4(6):315–324.

Safarinejad MR, Hosseini SY. Safety and efficacy of tramadol in the treatment of idiopathic detrusor overactivity: a double-blind, placebo-controlled, randomized study. *Br J Clin*

Pharmacol. 2006;61(4):456–463 [Retraction in: Br J Clin Pharmacol 2014;77(1):216].

Saffroy M, Torrens Y, Glowinski J, et al. Autoradiographic distribution of tachykinin NK2 binding sites in the rat brain: comparison with NK1 and NK3 binding sites. *Neuroscience*. 2003;116(3):761.

Sahai A, Dowson C, Khan MS, et al. Improvement in quality of life after botulinum toxin-A injections for idiopathic detrusor overactivity: results from a randomized double-blind placebo-controlled trial. *BJU Int*. 2009;103(11):1509–1515.

Sahai A, Khan MS, Dasgupta P. Efficacy of botulinum toxin-A for treating idiopathic detrusor overactivity: results from a single center, randomized, double-blind, placebo controlled trial. *J Urol*. 2007;177(6):2231.

Sahai A, Mallina R, Dowson C, et al. Evolution of transdermal oxybutynin in the treatment of overactive bladder. *Int J Clin Pract*. 2008;62(1):167.

Sairam K, Kulinskaya E, McNicholas TA, et al. Sildenafil influences lower urinary tract symptoms. *BJU Int*. 2002;90(9):836.

Saito H, Yamada T, Oshima H. A comparative study of the efficacy and safety of tamsulosin hydrochloride alone and combination of propiverine hydrochloride and tamsulosin hydrochloride in the benign prostatic hypertrophy with pollakisuria and/or urinary incontinence. *Jpn J Urol Surg*. 1999;12:525–536.

Sakai H, Igawa T, Onita T, et al. Efficacy of naftopidil in patients with overactive bladder associated with benign prostatic hyperplasia: prospective randomized controlled study to compare differences in efficacy between morning and evening medication. *Hinyokika Kiyo*. 2011;57(1):7–13.

Sakakibara R, Hamano H, Yagi H. Cognitive safety and overall tolerability of imidafenacin in clinical use: a long-term, open-label, post-marketing surveillance study. *Low Urin Tract Symptoms*. 2014;6(3):138–144.

Sakakibara R, Ito T, Uchiyama T, et al. Effects of milnacipran and paroxetine on overactive bladder due to neurologic diseases: a urodynamic assessment. *Urol Int*. 2008;81:335–339.

Salvatore S, Serati M, Bolis P. Tolterodine for the treatment of overactive bladder. *Expert Opin Pharmacother*. 2008;9(7):1249.

Sand PK, Johnson Ii TM, Rovner ES, et al. Trospium chloride once-daily extended release is efficacious and tolerated in elderly subjects (aged ≥75 years) with overactive bladder syndrome. *BJU Int*. 2011;107:612–620.

Sand PK, Rovner ES, Watanabe JH, et al. Once-daily trospium chloride 60 mg extended release in subjects with overactive bladder syndrome who use multiple concomitant medications: post hoc analysis of pooled data from two randomized, placebo-controlled trials. *Drugs Aging*. 2011;28(2):151–160.

Sand PK, Davila GW, Lucente VR, et al. Efficacy and safety of oxybutynin chloride topical gel for women with overactive bladder syndrome. *Am J Obstet Gynecol*. 2012;206(2):168.e1–168.e6.

Sand PK, Dmochowski RR, Reddy J, et al. Efficacy and safety of low dose desmopressin orally disintegrating tablet in women with nocturia: results of a multicenter, randomized, double-blind, placebo controlled, parallel group study. *J Urol*. 2013;190(3):958–964.

Sant GR. Intravesical 50% dimethyl sulfoxide (RIMSO-50) in treatment of interstitial cystitis. *Urology*. 1987;29(Suppl 4):17–21.

Santos-Silva A, Charrua A, Cruz CD, et al. Rat detrusor overactivity induced by chronic spinalization can be abolished by a transient receptor potential vanilloid 1 (TRPV1) antagonist. *Auton Neurosci*. 2012;166(1–2):35–38.

Schagen van Leeuwen JH, Lange RR, Jonasson AF, et al. Efficacy and safety of duloxetine in elderly women with stress urinary incontinence or stress-predominant mixed urinary incontinence. *Maturitas*. 2008;60(2):138.

Schneider T, Fetscher C, Krege S, et al. Signal transduction underlying carbachol-induced contraction of human urinary bladder. *J Pharmacol Exp Ther*. 2004;309(3):1148–1153.

Schneider T, Hein P, Michel MC. Signal transduction underlying carbachol-induced contraction of rat urinary bladder. I. Phospholipases and Ca^{2+} sources. *J Pharmacol Exp Ther*. 2004;308(1):47–53.

Schroeder FH, Westerhof M, Bosch RJ, et al. Benign prostatic hyperplasia treated by castration or the LH-RH analogue buserelin: a report on 6 cases. *Eur Urol*. 1986;12:318.

Schröder A, Newgreen D, Andersson KE. Detrusor responses to prostaglandin E_2 and bladder outlet obstruction in wild-type and Ep1 receptor knockout mice. *J Urol*. 2004;172:1166–1170.

Schröder A, Colli E, Maggi M, et al. Effects of a vitamin D_3 analogue in a rat model of bladder outflow obstruction. *BJU Int*. 2006;98:637.

Schulte-Baukloh H, Mürtz G, Henne T, et al. Urodynamic effects of propiverine hydrochloride in children with neurogenic detrusor overactivity: a prospective analysis. *BJU Int*. 2006;97(2):355.

Schulte-Baukloh H, Zurawski TH, Knispel HH, et al. Persistence of the synaptosomal-associated protein-25 cleavage product after intradetrusor botulinum toxin A injections in patients with myelomeningocele showing an inadequate response to treatment. *BJU Int*. 2007;100(5):1075.

Schurch B, Hauri D, Rodic B, et al. Botulinum-A toxin as treatment of detrusor sphincter dyssynergia: a prospective study in 24 spinal cord injury patients. *J Urol*. 1996;155:1023–1029.

Schwinn DA, Price DT, Narayan P. Alpha$_1$-adrenoceptor subtype selectivity and lower urinary tract symptoms. *Mayo Clin Proc*. 2004;79(11):1423–1434.

Schwinn DA, Roehrborn CG. Alpha$_1$-adrenoceptor subtypes and lower urinary tract symptoms. *Int J Urol*. 2008;15(3):193–199.

Scott M, Morrow J. Phenoxybenzamine in neurogenic bladder dysfunction after spinal cord injury: I. Voiding dysfunction. *J Urol*. 1978;112:75–82.

Sears CL, Lewis C, Noel K, et al. Overactive bladder medication adherence when medication is free to patients. *J Urol*. 2010;183:1077–1081.

Sebastianelli A, Russo GI, Kaplan SA, et al. Systematic review and meta-analysis on the efficacy and tolerability of mirabegron for the treatment of storage lower urinary tract symptoms/overactive bladder: comparison with placebo and tolterodine. *Int J Urol*. 2018;25(3):196–205.

Seki S, Erickson KA, Seki M, et al. Elimination of rat spinal neurons expressing neurokinin 1 receptors reduces bladder overactivity and spinal c-fos expression induced by bladder irritation. *Am J Physiol Renal Physiol*. 2005;288(3):F466.

Serati M, Salvatore S, Uccella S, et al. Is there a synergistic effect of topical oestrogens when administered with antimuscarinics in the treatment of symptomatic detrusor overactivity? *Eur Urol*. 2009;55(3):713–719.

Serati M, Braga A, Sorice P, et al. Solifenacin in women with de novo overactive bladder after tension-free obturator vaginal tape—is it effective? *J Urol*. 2014;191(5):1322–1326.

Serels SR, Toglia MR, Forero-Schwanhaeuser S, et al. Impact of solifenacin on diary-recorded and patient-reported urgency in patients with severe overactive bladder (OAB) symptoms. *Curr Med Res Opin*. 2010;26(10):2277–2285.

Serra DB, Affrime MB, Bedigian MP, et al. QT and QTc interval with standard and supratherapeutic doses of darifenacin, a muscarinic M3 selective receptor antagonist for the treatment of overactive bladder. *J Clin Pharmacol*. 2005;45(9):1038.

Shaban A, Drake M, Hashim H. The medical management of urinary incontinence. *Auton Neurosci*. 2010;152(1–2):4–10.

Shader RI, Greenblatt DJ. Use of benzodiazepines in anxiety disorders. *N Engl J Med*. 1993;328:1398–1405.

Sharma A, Goldberg MJ, Cerimele BJ. Pharmacokinetics and safety of duloxetine, a dual- serotonin and norepinephrine reuptake inhibitor. *J Clin Pharmacol*. 2000;40(2):161.

Sheldon JH, Norton NW, Argentieri TM. Inhibition of guinea pig detrusor contraction by NS-1619 is associated with activation of BKCa and inhibition of calcium currents. *J Pharmacol Exp Ther*. 1997;283:1193.

Sheu MT, Yeh GC, Ke WT, et al. Development of a high-performance liquid chromatographic method for bioequivalence study of flavoxate tablets. *J Chromatogr B Biomed Sci Appl*. 2001;751(1):79.

Shieh CC, Brune ME, Buckner SA, et al. Characterization of a novel ATP-sensitive K^+ channel opener, A-251179, on urinary bladder relaxation and cystometric parameters. *Br J Pharmacol*. 2007;151:467.

Shore N. NX-1207: a novel investigational drug for the treatment of benign prostatic hyperplasia. *Expert Opin Investig Drugs*. 2010;19(2):305–310.

Siddiqui MA, Perry CM, Scott LJ. Oxybutynin extended release: a review of its use in the management of overactive bladder. *Drugs*. 2004;64(8):885.

Sigala S, Mirabella G, Peroni A, et al. Differential gene expression of cholinergic muscarinic receptor subtypes in male and female normal human urinary bladder. *Urology*. 2002;60:719–725.

Silva C, Ribeiro MJ, Cruz F. The effect of intravesical resiniferatoxin in patients with idiopathic detrusor instability suggests that involuntary detrusor contractions are triggered by C-fiber input. *J Urol*. 2002;168(2):575.

Silva C, Rio ME, Cruz F. Desensitization of bladder sensory fibers by intravesical resiniferatoxin, a capsaicin analog: long-term results for the treatment of detrusor hyperreflexia. *Eur Urol*. 2000;38(4):444.

Silva C, Silva J, Castro H, et al. Bladder sensory desensitization decreases urinary urgency. *BMC Urol*. 2007;11(7):9.

Silva C, Silva J, Ribeiro MJ, et al. Urodynamic effect of intravesical resiniferatoxin in patients with neurogenic detrusor overactivity of spinal origin: results of a double-blind randomized placebo-controlled trial. *Eur Urol*. 2005;48(4):650.

Silver N, Sandage B, Sabounjian L, et al. Pharmacokinetics of once-daily trospium chloride 60 mg extended release and twice-daily trospium chloride 20 mg in healthy adults. *J Clin Pharmacol*. 2010;50(2):143–150.

Simpson LL. Identification of the major steps in botulinum toxin action. *Annu Rev Pharmacol Toxicol*. 2004;44:167–193.

Singh R, Browning JL, Abi-Habib R, et al. Recombinant prostate-specific antigen proaerolysin shows selective protease sensitivity and cell cytotoxicity. *Anticancer Drugs*. 2007;18(7):809–816.

Singh SK, Agarwal MM, Batra YK, et al. Effect of lumbar-epidural administration of tramadol on lower urinary tract function. *Neurourol Urodyn*. 2008;27(1):65.

Skerjanec A. The clinical pharmacokinetics of darifenacin. *Clin Pharmacokinet*. 2006;45(4):325.

Smet PJ, Moore KH, Jonavicius J. Distribution and colocalization of calcitonin gene-related peptide, tachykinins, and vasoactive intestinal peptide in normal and idiopathic unstable human urinary bladder. *Lab Invest*. 1997;77(1):37.

Smith CP, Gangitano DA, Munoz A, et al. Botulinum toxin type A normalizes alterations in urothelial ATP and NO release induced by chronic spinal cord injury. *Neurochem Int*. 2008;52(6):1068.

Smith N, Grimes I, Ridge S, et al. *YM905 is effective and safe as treatment of overactive bladder in women and men: results from phase II study*. ICS Proceedings: Heidelberg, Germany; 2002:138 [(Abstract 222)].

Smith P, Heimer G, Norgren A, et al. Steroid hormone receptors in pelvic muscles and ligaments in women. *Gynecol Obstet Invest*. 1990;30(1):27.

Smith PH, Cook JB, Prasad EW. The effect of ubretid on bladder function after recent complete spinal cord injury. *Br J Urol*. 1974;46(2):187.

Smulders R, Tan H, Krauwinkel W, et al: A placebo-controlled, dose-rising study in healthy male volunteers to evaluate safety, tolerability, pharmacokinetics and pharmacodynamics of single oral doses of YM905. Presented at the 32nd International Continence Society Annual Meeting; 2002; Heidelberg, Germany.

Smulders RA, Krauwinkel WJ, Swart PJ, et al. Pharmacokinetics and safety of solifenacin succinate in healthy young men. *J Clin Pharmacol*. 2004;44(9):1023.

Soler R, Andersson KE, Chancellor MB, et al. Future direction in pharmacotherapy for non-neurogenic male lower urinary tract symptoms. *Eur Urol*. 2013;64(4):610–621.

Somogyi GT, de Groat WC. Evidence for inhibitory nicotinic and facilitatory muscarinic receptors in cholinergic nerve terminals of the rat urinary bladder. *J Auton Nerv Syst*.

1992;37:89–97.

Somogyi GT, de Groat WC. Function, signal transduction mechanisms and plasticity of presynaptic muscarinic receptors in the urinary bladder. *Life Sci*. 1999;64(6–7):411–418.

Sonda L, Gershon C, Diokno A. Further observations on the cystometric and uroflowmetric effects of bethanechol chloride on the human bladder. *J Urol*. 1979;122:775–783.

Song C, Park JT, Heo KO, et al. Effects of bladder training and/or tolterodine in female patients with overactive bladder syndrome: a prospective, randomized study. *J Korean Med Sci*. 2006;21(6):1060.

Sporer A, Leyson J, Martin B. Effects of bethanechol chloride on the external urethral sphincter in spinal cord injury patients. *J Urol*. 1978;120:62–67.

Stahl MM, Ekstrom B, Sparf B, et al. Urodynamic and other effects of tolterodine: a novel antimuscarinic drug for the treatment of detrusor overactivity. *Neurourol Urodyn*. 1995;14(6):647.

Standaert DG, Young AB. Treatment of central nervous system degenerative disorders. Brunton LL, Lazo JS, Parker KL. *Goodman and Gilman's the pharmacological basis of therapeutics*. McGraw-Hill: New York, NY; 2006:527–546.

Stanton SL, Cardozo LD, Ken-Wilson R. Treatment of delayed onset of spontaneous voiding after surgery for incontinence. *Urology*. 1979;13:494–500.

Stanton SL. A comparison of emepronium bromide and flavoxate hydrochloride in the treatment of urinary incontinence. *J Urol*. 1973;110:529–532.

Staskin DR, Te AE. Short- and long-term efficacy of solifenacin treatment in patients with symptoms of mixed urinary incontinence. *BJU Int*. 2006;97(6):1256.

Staskin D, Sand P, Zinner N, et al. Once daily trospium chloride is effective and well tolerated for the treatment of overactive bladder: results from a multicenter phase III trial. *J Urol*. 2007;178(3 Pt 1):978.

Staskin DR, Dmochowski RR, Sand PK, et al. Efficacy and safety of oxybutynin chloride topical gel for overactive bladder: a randomized, double-blind, placebo controlled, multicenter study. *J Urol*. 2009;181(4):1764–1772.

Staskin DR, Robinson D. Oxybutynin chloride topical gel: a new formulation of an established antimuscarinic therapy for overactive bladder. *Expert Opin Pharmacother*. 2009;10(18):3103–3111.

Staskin D, Kay G, Tannenbaum C, et al. Trospium chloride has no effect on memory testing and is assay undetectable in the central nervous system of older patients with overactive bladder. *Int J Clin Pract*. 2010;64(9):1294–1300.

Staskin DR, Salvatore S. Oxybutynin topical and transdermal formulations: an update. *Drugs Today (Barc)*. 2010;46(6):417–425.

Steele AC, Walsh P, Bentley M, et al. A randomized, double-blind placebo-controlled trial of the effects of the 5-hydroxytriptamine(4) agonist cisapride on the female urinary bladder. *Am J Obstet Gynecol*. 2001;185(1):62–64.

Steers W, Corcos J, Foote J, et al. An investigation of dose titration with darifenacin, an M3-selective receptor antagonist. *BJU Int*. 2005;95(4):580.

Steers WD, Herschorn S, Kreder KJ, et al. Duloxetine compared with placebo for treating women with symptoms of overactive bladder. *BJU Int*. 2007;100(2):337–345.

Stevens LA, Chapple CR, Chess-Williams R. Human idiopathic and neurogenic overactive bladders and the role of M2 muscarinic receptors in contraction. *Eur Urol*. 2007;52(2):531–538.

Stewart DA, Taylor J, Ghosh S, et al. Terodiline causes polymorphic ventricular tachycardia due to reduced heart rate and prolongation of QT interval. *Eur J Clin Pharmacol*. 1992;42(6):577.

Stief CG, Porst H, Neuser D, et al. A randomised, placebo-controlled study to assess the efficacy of twice-daily vardenafil in the treatment of lower urinary tract symptoms secondary to benign prostatic hyperplasia. *Eur Urol*. 2008;53(6):1236.

Streng T, Christoph T, Andersson KE. Urodynamic effects of the K^+ channel (KCNQ) opener retigabine in freely moving, conscious rats. *J Urol*. 2004;172:2054.

Streng T, Andersson KE, Hedlund P, et al. Effects on bladder function of combining elocalcitol and tolterodine in rats with outflow obstruction. *BJU Int*. 2012;110(2 Pt 2):E125–E131.

Striano P, Striano S. Gabapentin: a Ca^{2+} channel alpha 2-delta ligand far beyond epilepsy therapy. *Drugs Today (Barc)*. 2008;44(5):353.

Strittmatter F, Gandaglia G, Benigni F, et al. Expression of fatty acid amide hydrolase (FAAH) in human, mouse, and rat urinary bladder and effects by FAAH inhibition on bladder function in awake rats. *Eur Urol*. 2012;61:98–106.

Stöhrer M, Bauer P, Giannetti BM, et al. Effect of trospium chloride on urodynamic parameters in patients with detrusor hyperreflexia due to spinal cord injuries: a multicentre placebo controlled double-blind trial. *Urol Int*. 1991;47:138.

Stöhrer M, Blok B, Castro-Diaz D, et al. EAU guidelines on neurogenic lower urinary tract dysfunction. *Eur Urol*. 2009;56(1):81–88.

Stöhrer M, Madersbacher H, Richter R, et al. Efficacy and safety of propiverine in SCI-patients suffering from detrusor hyperreflexia—a double-blind, placebo-controlled clinical trial. *Spinal Cord*. 1999;37:196.

Stöhrer M, Mürtz G, Kramer G, et al. Propiverine compared to oxybutynin in neurogenic detrusor overactivity—results of a randomized, double-blind, multicenter clinical study. *Eur Urol*. 2007;51(1):235.

Suckling J, Lethaby AN, Kennedy R. Local oestrogen for vaginal atrophy in postmenopausal women. *Cochrane Database Syst Rev*. 2003;(4) [CD001500].

Sugiyama Y, Yoshida M, Masunaga K, et al. Pharmacological effects of propiverine and its active metabolite, M-1, on isolated human urinary bladder smooth muscle, and on bladder contraction in rats. *Int J Urol*. 2008;15(1):76.

Sultana CJ, Walters MD. Estrogen and urinary incontinence in women. *Maturitas*. 1990;20:129.

Sundin T, Dahlström A, Norlén L, et al. The sympathetic innervation and adrenoreceptor function of the human lower urinary tract in the normal state and after parasympathetic denervation. *Invest Urol*. 1977;14(4):322–328.

Sussman D, Garely A. Treatment of overactive bladder with once-daily extended-release tolterodine or oxybutynin: the antimuscarinic clinical effectiveness trial (ACET). *Curr Med Res Opin*. 2002;18(4):177.

Swart PJ, Krauwinkel WJ, Smulders RA, et al. Pharmacokinetic effect of ketoconazole on solifenacin in healthy volunteers. *Basic Clin Pharmacol Toxicol*. 2006;99(1):33.

Sweeney P, Mutambirwa S, Van An N, et al. Flavoxate in the symptomatic treatment of overactive bladder: a meta-analysis. *Eur Rev Med Pharmacol Sci*. 2016;20(17):3703–3712.

Swierzewski SJ 3rd, Gormley EA, Belville WD, et al. The effect of terazosin on bladder function in the spinal cord injured patient. *J Urol*. 1994;151(4):951–954.

Swithinbank LV, Vestey S, Abrams P. Nocturnal polyuria in community-dwelling women. *BJU Int*. 2004;93(4):523–527.

Szollar SM, Lee SM. Intravesical oxybutynin for spinal cord injury patients. *Spinal Cord*. 1996;34:284.

Szonyi G, Collas DM, Ding YY, et al. Oxybutynin with bladder retraining for detrusor instability in elderly people: a randomized controlled trial. *Age Ageing*. 1995;24:287.

Tack J, Wyndaele JJ, Ligozio G, et al. A review and additional post-hoc analyses of the incidence and impact of constipation observed in darifenacin clinical trials. *Drug Healthc Patient Saf*. 2012;4:127–139.

Takao T, Tsujimura A, Yamamoto K, et al. Solifenacin may improve sleep quality in patients with overactive bladder and sleep disturbance. *Urology*. 2011;78(3):648–652.

Takasu T, Ukai M, Sato S, et al. Effect of (R)-2-(2-aminothiazol-4-yl)-4’-{2-[(2-hydroxy-2-phenylethyl)amino]ethyl} acetanilide (YM178), a novel selective beta$_3$-adrenoceptor agonist, on bladder function. *J Pharmacol Exp Ther*. 2007;321(2):642–647.

Take H, Shibata K, Awaji T, et al. Vascular alpha$_1$-adrenoceptor subtype selectivity and alpha$_1$-blocker-induced orthostatic hypotension. *Jpn J Pharmacol*. 1998;77(1):61–70.

Takeda M, Obara K, Mizusawa T, et al. Evidence for beta3-adrenoceptor subtypes in relaxation of the human urinary bladder detrusor: analysis by molecular biological and pharmacological methods. *J Pharmacol Exp Ther*. 1999;288(3):1367.

Takeda H, Yamazaki Y, Igawa Y, et al. Effects of beta(3)-adrenoceptor stimulation on prostaglandin E(2)-induced bladder hyperactivity and on the cardiovascular system in conscious rats. *Neurourol Urodyn*. 2002;21(6):558.

Takusagawa S, Miyashita A, Iwatsubo T, et al. In vitro inhibition and induction of human cytochrome P450 enzymes by mirabegron, a potent and selective beta3-adrenoceptor agonist. *Xenobiotica*. 2012;42(12):1187–1196.

Takusagawa S, van Lier JJ, Suzuki K, et al. Absorption, metabolism and excretion of [14C]mirabegron (YM178), a potent and selective beta$_3$-adrenoceptor agonist, after oral administration to healthy male volunteers. *Drug Metab Dispos*. 2012;40(4):815–824.

Takusagawa S, Yajima K, Miyashita A, et al. Identification of human cytochrome P450 isoforms and esterases involved in the metabolism ofmirabegron, a potent and selective beta$_3$-adrenoceptor agonist. *Xenobiotica*. 2012;42(10):957–967.

Tamimi NA, Mincik I, Haughie S, et al. A placebo-controlled study investigating the efficacy and safety of the phosphodiesterase type 5 inhibitor UK-369,003 for the treatment of men with lower urinary tract symptoms associated with clinical benign prostatic hyperplasia. *BJU Int*. 2010;106:674–680.

Tammela T, Kontturi M, Kaar K, et al. Intravesical prostaglandin F_2 for promoting bladder emptying after surgery for female stress incontinence. *Br J Urol*. 1987;60:43–49.

Tanaka M, Sasaki Y, Kimura Y, et al. A novel pyrrole derivative, NS-8, suppresses the rat micturition reflex by inhibiting afferent pelvic nerve activity. *BJU Int*. 2003;92:1031.

Tanaka Y, Masumori N, Tsukamoto T. Urodynamic effects of solifenacin in untreated female patients with symptomatic overactive bladder. *Int J Urol*. 2010;17(9):796–800.

Tatemichi S, Akiyama K, Kobayashi M, et al. A selective alpha1A-adrenoceptor antagonist inhibits detrusor overactivity in a rat model of benign prostatic hyperplasia. *J Urol*. 2006;176(3):1236–1241.

Tatemichi S, Tomiyama Y, Maruyama I, et al. Uroselectivity in male dogs of silodosin (KMD-3213), a novel drug for the obstructive component of benign prostatic hyperplasia. *Neurourol Urodyn*. 2006;25(7):792–799.

Taylor MC, Bates CP. A double-blind crossover trial of baclofen—a new treatment for the unstable bladder syndrome. *Br J Urol*. 1979;51(6):504.

Taylor P. Drugs acting at the neuromuscular junction and autonomic ganglia. Brunton LL, Lazo JS, Parker KL. *Goodman and Gilman's the pharmacological basis of therapeutics*. McGraw-Hill: New York, NY; 2006:217–236.

Te AE. A modern rationale for the use of phenoxybenzamine in urinary tract disorders and other conditions. *Clin Ther*. 2002;24(6):851–861.

Thiagamoorthy G, Giarenis I, Cardozo L. Early investigational β_3 adreno-receptor agonists for the management of the overactive bladder syndrome. *Expert Opin Investig Drugs*. 2015;24(10):1299–1306.

Thind P, Lose G, Colstrup H, et al. The effect of alpha adrenoceptor stimulation and blockade on the static urethral sphincter function in healthy females. *Scand J Urol Nephrol*. 1992;26:219–224.

Thor K, Katofiasc MA. Effects of duloxetine, a combined serotonin and norepinephrine reuptake inhibitor, on central neural control of lower urinary tract function in the chloralose-anesthetized female cat. *J Pharmacol Exp Ther*. 1995;274(2):1014.

Thor K, Kirby M, Viktrup L. Serotonin and noradrenaline involvement in urinary incontinence, depression and pain: scientific basis for overlapping clinical efficacy from a single drug. *Int J Clin Pract*. 2007;61(8):1349–1355.

Thor KB, de Groat WC. Neural control of the female urethral and rhabdosphincteris and pelvic floor muscles. *Am J Physiol Regul Integr Comp Physiol*. 2010;299(2):R416–R438.

Thor KB, Roppolo JR, de Groat WC. Naloxone induced micturition in unanesthetized paraplegic cats. *J Urol*. 1983;129:202–207.

Thumfart J, Roehr CC, Kapelari K, et al. Desmopressin associated symptomatic hyponatremic hypervolemia in children. Are there predictive factors? *J Urol*. 2005;174(1):294–298.

Thüroff JW, Bunke B, Ebner A, et al. Randomized, double-blind, multicenter trial on treatment of frequency, urgency and incontinence related to detrusor hyperactivity: oxybutynin versus propantheline versus placebo. *J Urol*. 1991;145:813.

Thüroff JW, Chartier-Kastler E, Corcus J, et al. Medical treatment and medical side effects in urinary incontinence in the elderly. *World J Urol*. 1998;16(Suppl 1):S48–S61.

Tincello DG, Kenyon S, Abrams KR, et al. Botulinum toxin A versus placebo for refractory detrusor overactivity in women: a randomised blinded placebo-controlled trial of 240 women (the RELAX study). *Eur Urol*. 2012;62(3):507–514.

Tincello DG, Rashid T, Revicky V. Emerging treatments for overactive bladder: clinical potential of botulinum toxins. *Res Rep Urol*. 2014;6:51–57.

Tiwari A. Elocalcitol, a vitamin D_3 analog for the potential treatment of benign prostatic hyperplasia, overactive bladder and male infertility. *IDrugs*. 2009;12(6):381–393.

Tobin G, Sjögren C. In vivo and in vitro effects of muscarinic receptor antagonists on contractions and release of [3H]acetylcholine in the rabbit urinary bladder. *Eur J Pharmacol*. 1995;281:1–8.

Todorova A, Vonderheid-Guth B, Dimpfel W. Effects of tolterodine, trospium chloride, and oxybutynin on the central nervous system. *J Clin Pharmacol*. 2001;41(6):636.

Toglia MR, Serels SR, Laramée C, et al. Solifenacin for overactive bladder: patient-reported outcomes from a large placebo-controlled trial. *Postgrad Med*. 2009;121(5):151–158.

Tokuno H, Chowdhury JU, Tomita T. Inhibitory effects of propiverine on rat and guinea-pig urinary bladder muscle. *Naunyn Schmiedebergs Arch Pharmacol*. 1993;348:659.

Tominaga M, Caterina MJ, Malmberg AB, et al. The cloned capsaicin receptor integrates multiple pain-producing stimuli. *Neuron*. 1998;21(3):531–543.

Truss MC, Stief CG, Uckert S, et al. Initial clinical experience with the selective phosphodiesterase-I isoenzyme inhibitor vinpocetine in the treatment of urge incontinence and low compliance bladder. *World J Urol*. 2000;18:439.

Truss MC, Stief CG, Uckert S, et al. Phosphodiesterase 1 inhibition in the treatment of lower urinary tract dysfunction: from bench to bedside. *World J Urol*. 2001;19:344.

Tsakiris P, de la Rosette JJ, Michel M, et al. Pharmacologic treatment of male stress urinary incontinence: systemic review of the literature and levels of evidence. *Eur Urol*. 2008;53:53–59.

Tseng LH, Wang AC, Chang YL, et al. Randomised comparison of tolterodine with vaginal oestrogen cream versus tolterodine alone for the treatment of postmenopausal women with overactive bladder syndrome. *Neurourol Urodyn*. 2009;1:47–51.

Tuncel A, Nalcacioglu V, Ener K, et al. Sildenafil citrate and tamsulosin combination is not superior to monotherapy in treating lower urinary tract symptoms and erectile dysfunction. *World J Urol*. 2010;28:17–22.

Tyagi V, Philips BJ, Su R, et al. Differential expression of functional cannabinoid receptors in human bladder detrusor and urothelium. *J Urol*. 2009;181:1932–1938.

Uchida H, Shishido K, Nomiya M, et al. Involvement of cyclic AMP-dependent and -independent mechanisms in the relaxation of rat detrusor muscle via beta-adrenoceptors. *Eur J Pharmacol*. 2005;518(2–3):195.

Uckert S, Stief CG, Odenthal KP, et al. Responses of isolated normal human detrusor muscle to various spasmolytic drugs commonly used in the treatment of the overactive bladder. *Arzneimittelforschung*. 2000;50(5):456.

Uckert S, Hedlund P, Andersson KE, et al. Update on phosphodiesterase (PDE) isoenzymes as pharmacologic targets in urology: present and future. *Eur Urol*. 2006;50(6):1194–1207.

Ückert S, Kuczyk MA, Oelke M. Phosphodiesterase inhibitors in clinical urology. *Expert Rev Clin Pharmacol*. 2013;6(3):323–332.

Uvin P, Franken J, Pinto S, et al. Essential role of transient receptor potential M8 (TRPM8) in a model of acute cold-induced urinary urgency. *Eur Urol*. 2015;68(4):655–661.

Vaidyanathan S, Rao M, Chary KS. Enhancement of detrusor reflex activity by naloxone in patients with chronic neurogenic bladder dysfunction. *J Urol*. 1981;126:500–506.

Vaidyanathan S, Soni BM, Oo T, et al. Delayed complications of discontinuation of intrathecal baclofen therapy: resurgence of dyssynergic voiding, which triggered off autonomic dysreflexia and hydronephrosis. *Spinal Cord*. 2004;42(10):598–602.

Valiquette G, Herbert J, Maede-D'Alisera P. Desmopressin in the management of nocturia in patients with multiple sclerosis. A double-blind, crossover trial. *Arch Neurol*. 1996;53:1270.

Van de Walle J, Van Herzeele C, Raes A. Is there still a role for desmopressin in children with primary monosymptomatic nocturnal enuresis? A focus on safety issues. *Drug Saf*. 2010;33(4):261–271.

van Gelderen M, Stölzel M, Meijer J, et al. An exploratory study in healthy male subjects of the mechanism of mirabegron-induced cardiovascular effects. *J Clin*

Pharmacol. 2017;57(12):1534–1544.

Van Kerrebroeck P, Kreder K, Jonas U, et al. Tolterodine once-daily: superior efficacy and tolerability in the treatment of the overactive bladder. *Urology*. 2001;57(3):414.

Van Kerrebroeck P, Abrams P, Lange R, et al. Duloxetine vs. placebo in the treatment of European and Canadian women with stress urinary incontinence. *Br J Obstet Gynaecol*. 2004;111:249.

van Kerrebroeck P, Rezapour M, Cortesse A, et al. Desmopressin in the treatment of nocturia: a double-blind, placebo-controlled study. *Eur Urol*. 2007;52:221.

Van Kerrebroeck P, Chapple C, Drogendijk T, NEPTUNE Study Group. Combination therapy with solifenacin and tamsulosin oral controlled absorption system in a single tablet for lower urinary tract symptoms in men: efficacy and safety results from the randomised controlled NEPTUNE trial. *Eur Urol*. 2013;64(6):1003–1012.

Van Kerrebroeck P, Haab F, Angulo JC. Efficacy and safety of solifenacin plus tamsulosin OCAS in men with voiding and storage lower urinary tract symptoms: results from a phase 2, dose-finding study (SATURN). *Eur Urol*. 2013;64(3):398–407.

van Rey F, Heesakkers J. Solifenacin in multiple sclerosis patients with overactive bladder: a prospective study. *Adv Urol*. 2011;834753:2011.

Vande Walle J, Stockner M, Raes A, et al. Desmopressin 30 years in clinical use: a safety review. *Curr Drug Saf*. 2007;2(3):232–238.

Vardy MD, Mitcheson HD, Samuels TA, et al. Effects of solifenacin on overactive bladder symptoms, symptom bother and other patient-reported outcomes: results from VIBRANT—a double-blind, placebo-controlled trial. *Int J Clin Pract*. 2009;63(12):1702–1714.

Vella M, Duckett J, Basu M. Duloxetine 1 year on: the long term outcome of a cohort of women prescribed duloxetine. *Int Urogynecol J Pelvic Floor Dysfunct*. 2008;19(7):961–964.

Vemulakonda VM, Somogyi GT, Kiss S, et al. Inhibitory effect of intravesically applied botulinum toxin A in chronic bladder inflammation. *J Urol*. 2005;173(2):621–624.

Versi E, Appell R, Mobley D, et al. Dry mouth with conventional and controlled-release oxybutynin in urinary incontinence. The Ditropan XL Study Group. *Obstet Gynecol*. 2000;95(5):718–721.

Versi E, Cardozo LD. Urethral instability: diagnosis based on variations in the maximum urethral pressure in normal climacteric women. *Neurourol Urodyn*. 1986;5(6):535.

Vijaya G, Digesu GA, Derpapas A, et al. Antimuscarinic effects on current perception threshold: a prospective placebo control study. *Neurourol Urodyn*. 2012;31(1):75–79.

Visco AG, Brubaker L, Richter HE, et al. Anticholinergic versus botulinum toxin A comparison trial for the treatment of bothersome urge urinary incontinence: ABC trial. *Contemp Clin Trials*. 2012;33(1):184–196.

Wada N, Matsumoto S, Kita M, et al. Improvement of overactive bladder symptoms and bladder ischemia with dutasteride in patients with benign prostatic enlargement. *Low Urin Tract Symptoms*. 2015;7(1):37–41.

Wada N, Watanabe M, Kita M, et al. Effect of imidafenacin on nocturia and sleep disorder in patients with overactive bladder. *Urol Int*. 2012;89(2):215–221.

Wada N, Watanabe M, Kita M, et al. Efficacy and safety of propiverine and solifenacin for the treatment of female patients with overactive bladder: a crossover study. *Low Urin Tract Symptoms*. 2011;3:36–42.

Waetjen LE, Brown JS, Modelska K, et al. Effect of raloxifene on urinary incontinence: a randomized controlled trial. *Obstet*

Gynecol. 2004;103(2):261.

Wagg A, Compion G, Fahey A, et al. Persistence with prescribed antimuscarinic therapy for overactive bladder: a UK experience. *BJU Int*. 2012;110:1767–1774.

Wagg A, Verdejo C, Molander U. Review of cognitive impairment with antimuscarinic agents in elderly patients with overactive bladder. *Int J Clin Pract*. 2010;64:1279–1286.

Wagg A, Wyndaele JJ, Sieber P. Efficacy and tolerability of solifenacin in elderly subjects with overactive bladder syndrome: a pooled analysis. *Am J Geriatr Pharmacother*. 2006;4(1):14–24.

Wagner G, Husstein P, Enzelsberger H. Is prostaglandin E_2 really of therapeutic value for postoperative urinary retention? Results of a prospectively randomized double blind study. *Am J Obstet Gynecol*. 1985;151:375–381.

Walczak JS, Price TJ, Cervero F. Cannabinoid CB1 receptors are expressed in the mouse urinary bladder and their activation modulates afferent bladder activity. *Neuroscience*. 2009;159(3):1154–1163.

Waldeck K, Larsson B, Andersson KE. Comparison of oxybutynin and its active metabolite, N-desethyl-oxybutynin, in the human detrusor and parotid gland. *J Urol*. 1997;157:1093.

Walter P, Grosse J, Bihr AM, et al. Bioavailability of trospium chloride after intravesical instillation in patients with neurogenic lower urinary tract dysfunction: a pilot study. *Neurourol Urodyn*. 1999;18(5):447–453.

Walter R, Ullmann C, Thummler D, et al. Influence of propiverine on hepatic microsomal cytochrome p450 enzymes in male rats. *Drug Metab Dispos*. 2003;31(6):714.

Wang CJ, Lin YN, Huang SW, et al. Low dose oral desmopressin for nocturnal polyuria in patients with benign prostatic hyperplasia: a double-blind, placebo controlled, randomized study. *J Urol*. 2011;185(1):219–223.

Wang X, Momota Y, Yanase H, et al. Urothelium EP1 receptor facilitates the micturition reflex in mice. *Biomed Res*. 2008;29:105–111.

Ward A, Chaffman MO, Sorkin EM. Dantrolene: a review of its pharmacodynamic and pharmacokinetic properties and therapeutic use in malignant hyperthermia, the neuroleptic syndrome and an update of its use in muscle spasticity. *Drugs*. 1986;32:130–134.

Weatherall M. The risk of hyponatremia in older adults using desmopressin for nocturia: a systematic review and meta-analysis. *Neurourol Urodyn*. 2004;23(4):302.

Wegener JW, Schulla V, Lee TS, et al. An essential role of CaV1.2 L-type calcium channel for urinary bladder function. *FASEB J*. 2004;18:1159.

Wehnert J, Sage S. Comparative investigations to the action of Mictonorm (propiverin hydrochloride) and Spasuret (flavoxat hydrochloride) on detrusor vesicae. *Z Urol Nephrol*. 1989;82:259.

Wehnert J, Sage S. Therapie der Blaseninstabilität und Urge-Inkontinenz mit Propiverin hydrochlorid (Mictonorm) und Oxybutynin chlorid (Dridase)—eine randomisierte Crossover- Vergleichsstudie. *Actuel Urol*. 1992;23:7.

Weil EH, Eerdmans PH, Dijkman GA, et al. Randomized double-blind placebo controlled multicenter evaluation of efficacy and dose finding of midodrine hydrochloride in women with mild to moderate stress urinary incontinence: a phase II study. *Int Urogynecol J Pelvic Floor Dysfunct*. 1998;9(3):145.

Wein A, Malloy T, Shofer F, et al. The effects of bethanechol chloride on urodynamic parameters in normal women and in women with significant residual urine volumes. *J Urol*.

1980;124:397–405.

Wein A, Raezer D, Malloy T. Failure of the bethanechol supersensitivity test to predict improved voiding after subcutaneous bethanechol administration. *J Urol*. 1980;123:202–206.

Wein AJ, Barrett DM. *Voiding function and dysfunction–a logical and practical approach*. Year Book: Chicago; 1988.

Wein AJ. Pharmacology of incontinence. *Urol Clin North Am*. 1995;22:557–577.

Wein AJ. Principles of pharmacologic therapy: practical drug treatment of voiding dysfunction in the female. Raz S. *Female urology*. ed 2. Saunders: Philadelphia, PA; 1995:283–316.

Weiss JP, Blaivas J, Bliwise D, et al. The evaluation and treatment of nocturia: a consensus statement. *BJU Int*. 2011;108(1):6–21.

Weiss JP, van Kerrebroeck PE, Klein BM, et al. Excessive nocturnal urine production is a major contributing factor to the etiology of nocturia. *J Urol*. 2011;186(4):1358–1363.

Weiss JP, Herschorn S, Albei CD, et al. Efficacy and safety of low dose desmopressin orally disintegrating tablet in men with nocturia: results of a multicenter, randomized, double-blind, placebo controlled, parallel group study. *J Urol*. 2013;190(3):965–972.

Werkström V, Svensson A, Andersson KE, et al. Phosphodiesterase 5 in the female pig and human urethra: morphological and functional aspects. *BJU Int*. 2006;98(2):414.

Wesnes KA, Edgar C, Tretter RN, et al. Exploratory pilot study assessing the risk of cognitive impairment or sedation in the elderly following single doses of solifenacin 10 mg. *Expert Opin Drug Saf*. 2009;8(6):615–626.

Westfall TC, Westfall DP. Adrenergic agonists and antagonists.

Brunton LL, Lazo JS, Parker KL. *Goodman and Gilman's the pharmacological basis of therapeutics*. McGraw-Hill: New York and Chicago; 2006:237–296.

Wheeler JS Jr, Robinson CJ, Culkin DJ, et al. Naloxone efficacy in bladder rehabilitation of spinal cord injury patients. *J Urol*. 1987;137:1201–1206.

Wheeler JS Jr, Walter JS, Chintam RS, et al. Botulinum toxin injections for voiding dysfunction following SCI. *J Spinal Cord Med*. 1998;21:227–229.

Wiedemann A, Füsgen I, Hauri D. New aspects of therapy with trospium chloride for urge incontinence. *Eur J Geriatr*. 2002;3:41.

Wiseman OJ, Fowler CJ, Landon DN. The role of the human bladder lamina propria myofibroblast. *BJU Int*. 2003;91(1):89–93.

Woods M, Carson N, Norton NW, et al. Efficacy of the beta3-adrenergic receptor agonist CL-316243 on experimental bladder hyperreflexia and detrusor instability in the rat. *J Urol*. 2001;166(3):1142.

Wuest M, Hiller N, Braeter M, et al. Contribution of Ca^{2+} influx to carbachol-induced detrusor contraction is different in human urinary bladder compared to pig and mouse. *Eur J Pharmacol*. 2007;565:180.

Wuest M, Weiss A, Waelbroeck M, et al. Propiverine and metabolites: differences in binding to muscarinic receptors and in functional models of detrusor contraction. *Naunyn Schmiedebergs Arch Pharmacol*. 2006;374(2):87.

Wyndaele JJ, Goldfischer ER, Morrow JD, et al. Effects of flexible-dose fesoterodine on overactive bladder symptoms and treatment satisfaction: an open-label study. *Int J Clin Pract*. 2009;63(4):560–567.

Wyndaele JJ, Van Dromme SA. Muscular weakness as side effect of botulinum toxin injection for neurogenic detrusor overactivity. *Spinal Cord*. 2002;40(11):599.

Yamada S, Ito Y. Alpha(1)-adrenoceptors in the urinary tract. *Handb Exp Pharmacol*. 2011;202:283–306.

Yamada S, Seki M, Ogoda M, et al. Selective binding of bladder muscarinic receptors in relation to the pharmacokinetics of a novel antimuscarinic agent, imidafenacin, to treat overactive bladder. *J Pharmacol Exp Ther*. 2011;336(2):365–371.

Yamaguchi O, Shisda K, Tamura K, et al. Evaluation of mRNAs encoding muscarinic receptor subtypes in human detrusor muscle. *J Urol*. 1996;156:1208–1213.

Yamaguchi O, Marui E, Kakizaki H, et al. Randomized, double blind, placebo- and propiverine-controlled trial of the once-daily antimuscarinic agent solifenacin in Japanese patients with overactive bladder. *BJU Int*. 2007;100(3):579.

Yamaguchi O, Uchida E, Higo N, Oxybutynin Patch Study Group, et al. Efficacy and safety of once-daily oxybutynin patch versus placebo and propiverine in Japanese patients with overactive bladder: a randomized double-blind trial. *Int J Urol*. 2014;21(6):586–593.

Yamaguchi O, Kakizaki H, Homma Y, et al. Safety and efficacy of mirabegron as “add-on” therapy in patients with overactive bladder treated with solifenacin: a post-marketing, open-label study in Japan (MILAI study). *BJU Int*. 2015;116(4):612–622.

Yamanishi T, Mizuno T, Tatsumiya K, et al. Urodynamic effects of silodosin, a new alpha 1A-adrenoceptor selective antagonist, for the treatment of benign prostatic hyperplasia. *Neurourol Urodyn*. 2009;29:558–562.

Yamanishi T, Yasuda K, Kamai T, et al. Combination of a cholinergic drug and an alpha-blocker is more effective than monotherapy for the treatment of voiding difficulty in patients with underactive detrusor. *Int J Urol*. 2004;11(2):88–96.

Yamanishi T, Yasuda K, Tojo M, et al. Effects of beta-2 stimulants on contractility and fatigue of canine urethral sphincter. *J Urol*. 1994;151:1073.

Yarker YE, Goa KL, Fitton A. Oxybutynin—a review of its pharmacodynamic and pharmacokinetic properties, and its therapeutic use in detrusor instability. *Drugs Aging*. 1995;6:243.

Yashiro K, Thor K, Burgard E. Properties of urethral rhabdosphincter motoneurons and their regulation by noradrenaline. *J Physiol*. 2010;588(Pt 24):4951–4967.

Yasuda K, Kawabe K, Takimoto Y, et al. A double blind clinical trial of a beta-2 adrenergic agonist in stress incontinence. *Int Urogynecol J*. 1993;4:146.

Yokoyama T, Uematsu K, Watanabe T, et al. Naftopidil and propiverine hydrochloride for treatment of male lower urinary tract symptoms suggestive of benign prostatic hyperplasia and concomitant overactive bladder: a prospective randomized controlled study. *Scand J Urol Nephrol*. 2009;43:307–314.

Yokoyama O, Yamaguchi O, Kakizaki H, et al. Efficacy of solifenacin on nocturia in Japanese patients with overactive bladder: impact on sleep evaluated by bladder diary. *J Urol*. 2011;186(1):170–174.

Yokoyama O, Homma Y, Yamaguchi O. Imidafenacin, an antimuscarinic agent, improves nocturia and reduces nocturnal urine volume. *Urology*. 2013;82(3):515–520.

Yokoyama O, Hiro S, Hotta S, et al. Efficacy of fesoterodine on nocturia and quality of sleep in Asian patients with overactive bladder. *Urology*. 2014;83(4):750–755.

Yoo DS, Han JY, Lee KS, et al. Prescription pattern of oxybutynin ER in patients with overactive bladder in real life practice: a multicentre, open-label, prospective observational study. *Int J Clin Pract*. 2012;66(2):132–138.

Yoong HF, Sundaram MB, Aida Z. Prevalence of nocturnal polyuria in patients with benign prostatic hyperplasia. *Med J Malaysia*. 2005;60(3):294–296.

Yoshida M, Miyamae K, Iwashita H, et al. Management of detrusor dysfunction in the elderly: changes in acetylcholine and adenosine triphosphate release during aging. *Urology*. 2004;63(3 Suppl 1):17.

Yoshida M, Inadome A, Maeda Y, et al. Non-neuronal cholinergic system in human bladder urothelium. *Urology*. 2006;67(2):425.

Yoshida M, Homma Y, Kawabe K. Silodosin, a novel selective alpha1A-adrenoceptor selective antagonist for the treatment of benign prostatic hyperplasia. *Expert Opin Investig Drugs*. 2007;16(12):1955–1965.

Yoshida M, Masunaga K, Satoji Y, et al. Basic and clinical aspects of non-neuronal acetylcholine: expression of non-neuronal acetylcholine in urothelium and its clinical significance. *J Pharmacol Sci*. 2008;106(2):193.

Yoshida M, Kudoh J, Homma Y, et al. Safety and efficacy of silodosin for the treatment of benign prostatic hyperplasia. *Clin Interv Aging*. 2011;6:161–172.

Yoshiyama M, deGroat WC, Fraser MO. Influences of external urethral sphincter relaxation induced by alpha-bungarotoxin, a neuromuscular junction blocking agent, on voiding dysfunction in the rat with spinal cord injury. *Urology*. 2000;55(6):956–960.

Yossepowitch O, Gillon G, Baniel J, et al. The effect of cholinergic enhancement during filling cystometry: can edrophonium chloride be used as a provocative test for overactive bladder? *J Urol*. 2001;165(5):1441.

Yuan J, Liu Y, Yang Z, et al. The efficacy and safety of alpha-1 blockers for benign prostatic hyperplasia: an overview of 15 systematic reviews. *Curr Med Res Opin*. 2013;29(3):279–

287.

Zahariou A, Karagiannis G, Papaionnou P, et al. The use of desmopressin in the management of nocturnal enuresis in patients with spinal cord injury. *Eura Medicophys*. 2007;43:333.

Zaitsu M, Mikami K, Ishida N, et al. Comparative evaluation of the safety and efficacy of long-term use of imidafenacin and solifenacin in patients with overactive bladder: a prospective, open, randomized, parallel-group trial (the LIST Study). *Adv Urol*. 2011;2011:854697.

Zderic SA, Levin RM, Wein AJ. Voiding function: relevant anatomy, physiology, pharmacology and molecular aspects. Gillenwater JY, Howards SS, Grayhack JT, et al. *Adult and pediatric urology*. ed 3. Mosby–Year Book: Chicago, IL; 1995:1159–1219.

Zhu HL, Brain KL, Aishima M, et al. Actions of two main metabolites of propiverine (M-1 and M-2) on voltage-dependent L-type Ca^{2+} currents and Ca^{2+} transients in murine urinary bladder myocytes. *J Pharmacol Exp Ther*. 2008;324(1):118.

Zinner N, Gittelman M, Harris R, et al. Trospium chloride improves overactive bladder symptoms: a multicenter phase III trial. *J Urol*. 2004;171(6 Pt 1):2311.

Zinner N, Susset J, Gittelman M, et al. Efficacy, tolerability and safety of darifenacin, an M(3) selective receptor antagonist: an investigation of warning time in patients with OAB. *Int J Clin Pract*. 2006;60(1):119.

Zinner N. Darifenacin: a muscarinic M3-selective receptor antagonist for the treatment of overactive bladder. *Expert Opin Pharmacother*. 2007;8(4):511–523.

Zinner NR, Dmochowski RR, Staskin DR, et al. Once-daily trospium chloride 60 mg extended-release provides effective, long-term relief of overactive bladder syndrome symptoms.

Neurourol Urodyn. 2011;30(7):1214–1219.

Zinner NR, Mattiasson A, Stanton SL. Efficacy, safety, and tolerability of extended-release once-daily tolterodine treatment for overactive bladder in older versus younger patients. *J Am Geriatr Soc*. 2002;50(5):799.

Zinner NR, Tuttle J, Marks L. Efficacy and tolerability of darifenacin, a muscarinic M3 selective receptor antagonist (M3 SRA), compared with oxybutynin in the treatment of patients with overactive bladder. *World J Urol*. 2005;23:248–252.

Zor M, Aydur E, Dmochowski RR. Flavoxate in urogynecology: an old drug revisited. *Int Urogynecol J*. 2015;26(7):959–966.

121

Conservative Management of Urinary Incontinence

Behavioral and Pelvic Floor Therapy, Urethral and Pelvic Devices

Diane K. Newman DNP, ANP-BC, FAAN, Kathryn L. Burgio PhD

Conservative behavioral treatments for urinary incontinence (UI) and associated lower urinary tract symptoms (LUTS) include any therapy not involving surgical treatment (Moore et al., 2013). Because behavioral treatments are effective and essentially risk free, they are the mainstay of conservative treatment and are recommended as first-line therapy by several guidelines and consensus panels (Dumoulin et al., 2017; Gormley et al., 2015; Hartmann et al., 2009; Shamliyan et al., 2008). **Behavioral treatments are a group of interventions that improve UI and LUTS by changing patients' behavior or environment or by teaching new skills.**

Behavioral treatment programs usually comprise multiple components; the best programs are individualized according to the patient's condition, needs, and environment. **Components of a behavioral program may include patient education and any of the following: self-monitoring (bladder diary), pelvic floor muscle training (PFMT) and pelvic floor muscle exercise (PFME), active use of pelvic floor muscles (PFMs) for urethral occlusion ("stress strategies," the "knack"), urge prevention and suppression techniques (urge strategies), bladder training (BT) with urge control techniques (distraction, self-assertions), biofeedback (BF), electrical stimulation (E-stim), fixed or incremental voiding schedules, delayed voiding, fluid management, caffeine reduction, dietary changes, weight loss, teaching normal voiding techniques, and/or other lifestyle changes.** The most common behavioral interventions are depicted in Fig. 121.1, and a list of LUTS to which they are potentially applicable is presented in eTable 121.1. In most urologic settings, conservative treatment programs are designed and administered by advanced practice providers (APPs) (Newman, 2014; Newman and Wein, 2013) after a simple, noninvasive assessment.

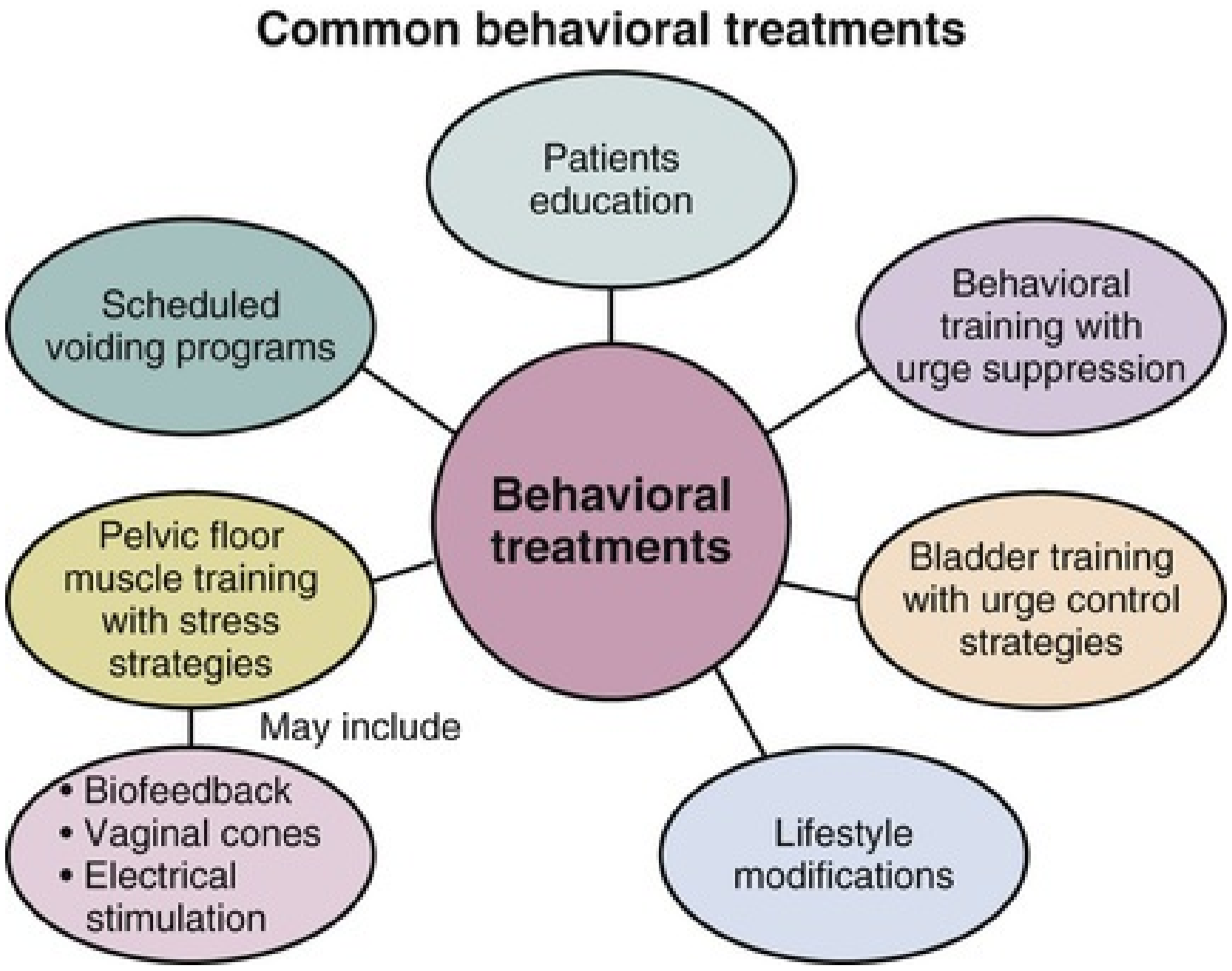
Common behavioral treatments
Patients education
Scheduled voiding programs
Behavioral training with urge suppression
Behavioral treatments
Pelvic floor muscle training with stress strategies
Bladder training with urge control strategies
May include
• Biofeedback
• Vaginal cones
• Electrical stimulation
Lifestyle modifications

FIG. 121.1 Common behavioral treatments.

eTABLE 121.1

Conditions for Which Behavioral Treatments Have Shown Benefit

Stress urinary incontinence
Overactive bladder (urgency, frequency)
Urgency urinary incontinence
Neurogenic detrusor overactivity
Mixed urinary incontinence
Nocturia
Pelvic floor muscle spasm (dysfunction, high tone muscle)
Nonrelaxing striated sphincter

Modified from Newman DK, Wein AJ: *Managing and treating urinary incontinence*, ed 2, Baltimore, 2009, Health Professions Press, pp 245–306; Newman DK, Wein AJ: Office-based behavioral therapy for management of incontinence and other pelvic disorders. *Urol Clin North Am* 40(4):613–635, 2013.

The most established behavioral treatment programs are PFMT, behavioral training with urge suppression, and BT. These therapies encompass **two fundamental approaches** to treating LUTS. One approach focuses on the **bladder *outlet***, teaching skills for improving pelvic floor muscle (PFM) strength and control and techniques for suppressing bladder urgency. The other approach focuses on **controlling bladder *function* by changing voiding habits,** such as with BT and delayed voiding, also supported with urge control techniques. These therapies are grounded in the concept that patients with LUTS can be educated about their condition and develop skills and strategies to reduce or eliminate symptoms.

Behavioral treatments can also be categorized as **"patient dependent"** or **"caregiver dependent"** (Newman et al., 2014, 2018). BT, PFMT, and behavioral training are examples of "patient-dependent" interventions because they rely on active patient participation. These therapies require adequate function, learning capability, and motivation of the individual. **Caregiver-dependent interventions, such as prompted voiding (PV), are useful in people with functional disabilities.** The success of these interventions is largely dependent on caregiver knowledge and motivation, rather than on the patient's physical function and mental status.

In addition to these established primary treatment approaches that focus on improving the patient's direct control over bladder and PFM function, **a number of lifestyle modifications may improve LUTS indirectly by changing the patient's behavior or avoiding factors that exacerbate symptoms or make the bladder more difficult to control.** These interventions include fluid management, caffeine reduction, reduction of bladder irritants, management of constipation, smoking cessation, and weight loss.

Behavioral (conservative) treatments are supported by a large body of research (Dumoulin et al., 2017) and have been recommended as treatment for UI and non-neurogenic overactive bladder (OAB) by multiple organizations (Gormley et al., 2015; Qaseem et al., 2014; Shamliyan et al., 2008) and international guidelines (Dumoulin et al., 2017). The International Consultation on Incontinence (ICI) Committee on Adult Conservative Management (Dumoulin et al., 2017) details evidence and recommendations for all conservative behavioral treatments for women, men, and frail older adults (eBoxes 121.1, 121.2, and 121.3) using the Oxford grading system (eBox 121.4). In this chapter, we also describe a number of devices that can prevent urine loss mechanically.

eBox 121.1

Lifestyle Modifications: International Consultation on Incontinence Recommendations

Obesity (Weight Loss)

Weight loss of 5% of initial body weight has an impact on the reduction of UI symptoms, and the odds of developing UI at 1 year can be reduced by 3% for every kilogram lost by overweight and obese women. Weight loss as a nonsurgical intervention should be considered a first-line treatment to reduce UI in obese and overweight women.

Grade of Recommendation: A

Weight loss through lifestyle changes should be recommended to obese and overweight men with UI, particularly those with type 2 diabetes.

Grade of Recommendation: B

Physical Activity

Moderate exercise may help in decreasing the incidence of UI; this effect may be mediated by weight control.

Grade of Recommendation: C

Constipation-Chronic Straining

There is some evidence to suggest that chronic straining during defecation may be a risk factor for the development of UI.

Dietary Modification

Indications from epidemiologic data suggest diet may play a role in UI. Minor decrease of fluid intake by 25% may be recommended provided baseline consumption is not less than 30 mL/kg a day.

Caffeine reduction may help in improving incontinence and related symptoms.

Grade of Recommendation: B

A reduction in caffeine intake is recommended for those with incontinence symptoms; evidence suggests the equivalent of 2 cups of coffee a day (250 mg) is associated with UI in men and women.

Grade of Recommendation: C

Smoking

Data suggest that smoking increases the risk of more severe UI and that urinary frequency may be improved by smoking abstinence. There remains a need for further prospective studies of smoking cessation for urinary symptoms.

Grade of Recommendation: B

Smoking abstinence should be recommended for men with UI.

Grade of Recommendation: C

Modified from Dumoulin C, Adewuyi T, Booth J, et al.: Adult conservative management. In Abrams P, Cardozo L, Wagg A, Wein A, editors: *Incontinence, 6th International Consultation on Incontinence*, International Continence Society, Bristol, UK, 2017, pp 1443–1628.

eBox 121.2

International Consultation on Incontinence Levels of Evidence for Frail Older Adults

RECOMMENDATIONS FOR PRACTICE	LEVEL OF EVIDENCE

Late afternoon administration of a diuretic may reduce nocturia in persons with lower extremity venous insufficiency or congestive heart failure unresponsive to other interventions.	2
Prompted voiding is effective in the short-term treatment of daytime UI in nursing home residents and home-care clients when caregivers comply with the protocol.	1
Prompted voiding is ineffective and should not be used for people who need the assistance of more than one person to transfer, cannot follow a one-step command, have less than a 20% reduction in wet checks or less than a 66% appropriate toileting rate after a 3-day trial; these people should be managed with “check and change.”	1
Interventions combining toileting and functional training decrease urine loss and improve endurance in nursing home residents.	1
It is uncertain whether habit retraining or timed voiding reduces UI in frail older persons.	4
It is uncertain whether bladder training reduces UI in frail older persons.	4
Biofeedback-assisted PFMT in combination with bladder training reduces UI in homebound older adults.	2
Functional training in combination with PFMT reduces UI and improves walking time in frail older women.	2
There are no proven interventions to reduce the incidence of UI in hospitalized frail older persons.	4

PFMT, Pelvic floor muscle training; *UI,* urinary incontinence.

Modified from Wagg A, Chen LK, Johnson T, et al.: Incontinence in frail older persons. In Abrams P, Cardozo L, Wein A, et al., editors: *Incontinence. Proceedings from the 6th International Consultation on Incontinence,* Bristol, UK, 2017, International Continence Society, pp 1309–1442.

eBox 121.3

International Consultation on Incontinence Recommendations for Conservative Behavioral Treatments

GROUP	RECOMMENDATION	GRADE
PELVIC FLOOR MUSCLE TRAINING		
General	Clinicians should provide the most intensive health professional-led PFMT program possible	A

	within service constraints because programs that are taught and supervised by health professionals are better than those with little or no supervision.	
	Although studies are limited, there does not appear to be clear benefit for adding other modalities (i.e., motor learning, abdominal- or hip-muscle training, intravaginal resistance device) to PFMT.	B
	There is no clear benefit from adding clinic or home-based BF to a PFMT program. The use of clinic or home-based BF should remain a therapist/individual decision based on individual's needs and service constraints.	B (clinic/office based) B (home based)
	There is evidence of benefit that PFMT is effective in reducing pelvic floor symptoms.	A
Women with UI	Supervised PFMT should be offered as first-line conservative therapy to women with UI.	A
Older women	There is preliminary evidence that PFMT may help prevent UI.	C
Prevention of UI in childbearing women	Continent, pregnant women should be offered a supervised (including regular health professional contact) and intensive strengthening antepartum PFMT program to prevent antepartum and postpartum UI.	A
Treatment of UI in childbearing women	PFMT should be offered as first-line conservative therapy to women with persistent UI symptoms 3 months after delivery.	**A**
	An “intensive” PFMT program (in terms of supervision and exercise content) is likely to increase the treatment effect.	B
Prevention/treatment of UI in childbearing women	Health providers should carefully consider the cost/benefit of population based approaches to health professional taught antepartum or postpartum PFMT, that is, health professional instruction to all pregnant or postpartum women regardless of their current or prior continence status.	A (antepartum) B (Postpartum)
	Where a population approach is used, the “best” evidence suggests the following: (a) an intervention comprising a daily home PFMT and weekly physiotherapist-led exercise classes	C

	for 12 weeks, starting at 16–24 weeks' gestation for pregnant women, and (b) an individually taught strengthening PFMT program that incorporates adherence strategies for postpartum women who have had a forceps delivery or a vaginal delivery of a large baby (4000 g or more).	
Women with stress UI	PFMT and VC are both effective as conservative therapy, although PFMT is superior.	B
	PFMT is better than E-stim as first-line conservative therapy.	B
	PFMT is better than BT as first-line conservative therapy.	B
	PFMT and drug therapy are effective as first-line treatment; PFMT avoids the adverse effects experienced with drug therapy.	B
	Surgery is more effective than PFMT, but potential benefit should be weighed against potential adverse events. PFMT should be offered as first-line conservative therapy.	B
	PFMT and continence pessary are both effective as first-line conservative therapy.	
	In treatment of women with stress UI and vaginal atrophy, combining PFMT and intravaginal estrogen may be better than estrogen alone.	C
Women with stress UI or mixed UI	VC does not appear to be better than PFMT in the treatment of UI. PFMT should be recommended as first-line conservative therapy.	B
	VCs with supervised training sessions by a trained health professional can be offered to women who can and are prepared to use them. VC may be inappropriate for some women because of inability to insert or retain the cone or because of side effects and discomfort.	B
Women with urgency UI	PFMT and BT should be offered as effective first-line conservative therapy.	B
	For treatment of urgency UI (tolterodine) but not for stress UI (duloxetine), consider adding PFMT to drug therapy.	B

Women with urgency UI or mixed UI	PFMT and BT should be offered as effective first-line conservative therapies.	B
	PFMT is better than oxybutynin as first-line therapy.	B
Women with stress UI, urgency UI or mixed UI	Consider a combination of PFMT and BT rather than BT alone.	C
Women with POP	PFMT does not influence the development of prolapse postnatally.	B
	PFMT intervention delivered 12 years+ after childbirth can reduce symptoms of prolapse, which develop in the longer term.	B
	There is some evidence of benefit showing that PFMT is effective in alleviating specific prolapse symptoms (e.g., vaginal bulge).	C
	There is no evidence that PFMT is effective in reducing severity of prolapse based on POP-Q stage.	B
	Perioperative PFMT does not improve prolapse symptoms in women undergoing surgery for vault prolapse.	B
	Combined pessary and PFMT and PFMT alone can be equally effective in reducing symptoms and increasing muscle strength and should be considered for treatment.	B
Men post-prostatectomy	Some preoperative or immediate postoperative instruction in PFMT for men undergoing radical prostatectomy may be helpful in earlier recovery of continence.	B
	The use of BF to assist PFMT is currently a therapist/patient decision based on economics and preference. The use of BF in clinic/office setting, over and above home PFMT, should remain a therapist/individual decision based on economics and preference.	B
	It is not clear whether PFMT taught by digital rectal examination (DRE) offers any benefit over and above verbal or written instruction in PFMT.	B

	There does not appear to be any benefit of adding E-stim to a PFMT program for men with persistent post-prostatectomy UI.	B
Men with symptoms of postmicturition dribbling	Offer men with PMD instruction to do a strong PFM contraction immediately after voiding or urethral massage to empty the urethra.	C
VAGINAL CONES		
General	VCs may be inappropriate in some cases because of inability to insert or retain the cone or because of side effects and discomfort. Trained health professional assessment is recommended.	D
Women with stress UI	VC with supervised training sessions by a trained health professional may be offered as a first-line conservative therapy to those who can and are prepared to use them.	B
Women with stress UI or mixed UI	VCs do not appear to be better than PFMT in the treatment of UI.	B
PELVIC FLOOR ELECTRICAL STIMULATION (E-STIM)		
General	Based on current limited evidence, E-stim could be considered as an alternative to medical treatment.	B
	The addition of E-stim to PFMT or BF-assisted PFMT program does not appear to add benefit.	B
Women with stress UI	E-stim may be better than no treatment to improve symptoms and QoL.	B
	Maximal clinic-based E-stim may be better than daily low-intensity home-based E-stim in improving symptoms.	B
Urgency UI	May be considered for treatment to improve symptoms	B
BLADDER TRAINING		
General	Clinicians should provide the most intensive BT supervision possible within service constraints.	D
	Clinicians and researchers are advised to refer to the operant conditioning and educational literature to provide a rationale for their choice of training parameters or approach.	D
	Timed voiding with a 2-hour voiding interval may be considered as a sole intervention for women with mild UI or	C

	infrequent voiding patterns. Timed voiding may also be considered as an adjunct to other treatment. A 2-hour timed voiding interval may be beneficial in treating women with mild UI or infrequent voiding patterns.	
	Routine addition of a “simplified” BT to drug therapy does not provide additional improvement in urgency but should be considered in treatment of voiding frequency in women with UI and OAB.	B
	BT should be offered as treatment for urinary frequency and nocturia, but in choosing between BT and an anticholinergic drug for women with frequency, either may be effective.	B
Women with UI	BT should be recommended as first-line conservative therapy.	A
Women with UI and/or OAB	Insufficient evidence exists to support the use of BT to treat urgency in women with UI and/or OAB or to guide the choice of BT vs. drug treatment as initial treatment aimed at urinary urgency.	D
In combination with drug therapy	When considering BT and anticholinergic drug in women with DO or UUI, either may be effective.	B
	BT may be preferred by women and clinicians because it is not associated with the drug-related side effects.	D
	Limited evidence suggests the addition of written information on BT for women with OAB and on an antimuscarinic drug does not further improve UI.	B
	Routine addition of a “simplified” BT to drug therapy does not provide additional improvement in urgency but should be considered in treatment of voiding frequency in women with UI and OAB.	B
In combination with PFMT	The available evidence (single trial) supports the use of BT as a supplement to PFMT in improving short-term outcomes but not longer-term results.	C

BF, Biofeedback; *BT,* bladder training; *DO,* detrusor overactivity; *E-stim,* electrical stimulation; *OAB,* overactive bladder; *PFMT,* pelvic floor muscle training; *POP-Q,* pelvic organ prolapse-quantification; *QoL,* quality of life; *UI,* urinary incontinence; *UUI,* urgency urinary incontinence; *VC,* vaginal cone.

eBox 121.4

Oxford Levels of Evidence and Grades of Recommendation

LEVEL	EVIDENCE
1	Usually involves meta-analysis of randomized controlled trials (RCTs) or a good quality RCT, or "all-or-none" studies in which no treatment is not an option, for example, in vesicovaginal fistula.
2	Includes "low"-quality RCT (e.g., <80% follow-up) or meta-analysis (with homogeneity) of good-quality prospective "cohort studies." These may include a single group when individuals who develop the condition are compared with others from within the original cohort group. There can be parallel cohorts in which those with the condition in the first group are compared with those in the second group.
3	Includes: • Good-quality retrospective "case-control studies" in which a group of patients who have a condition are matched appropriately (e.g., for age, sex) with control individuals who do not have the condition. • Good-quality "case series" in which complete group of patients, all with the same condition/disease/therapeutic intervention, are described, without a comparison control group.
4	Includes expert opinion in which the opinion is based not on evidence, but on "first principles" (e.g., physiologic or anatomic) or bench research. The Delphi process can be used to give "expert opinion" greater authority. In the Delphi process a series of questions are posed to a panel; the answers are collected into a series of "options"; the options are serially ranked; if a 75% agreement is reached, then a Delphi consensus statement can be made.

Uses four grades from the Oxford system. As with the levels of evidence, the grades of evidence may apply either positively (do the procedure) or negatively (do not do the procedure).

GRADE	RECOMMENDATION
A	Usually depends on consistent level 1 evidence and often means that the recommendation is effectively mandatory and placed within a clinical care

	pathway. However, there will be occasions where excellent evidence (level 1) does not lead to a grade A recommendation, for example, if therapy is prohibitively expensive, dangerous, or unethical. Grade A recommendation can follow from level 2 evidence. However, a grade A recommendation requires a greater body of evidence if based on anything except level 1 evidence.
B	Usually depends on consistent level 2 and/or 3 studies or "majority evidence" from RCTs.
C	Usually depends on level 4 studies or "majority evidence" from level 2 and/or 3 studies or Delphi processed expert opinion.
D	"No recommendation possible" would be used when the evidence is inadequate or conflicting and when expert opinion is delivered without a formal analytical process, such as by Delphi.

Any level of evidence may be positive (the therapy works) or negative (the therapy doesn't work). A level of evidence is given to each individual study.

Modified from Abrams P, Khoury S, Grant A: Evidence based medicine—overview of the main steps for developing and grading guideline recommendation. In Abrams P, Cardozo L, Khoury S, et al., editors: *Incontinence*, EAU/ICUD, 2013, pp 8–9, (website): https://www.ics.org/Publications/ICI_5/INCONTINENCE.pdf.

Indications

Behavioral interventions are conservative treatments that are well established for treating stress, urgency, and mixed UI and OAB. Behavioral interventions are also appropriate for voiding dysfunction, although less evidence exists for this condition. Although most patients experience some degree of improvement, there is wide variation in outcomes and little is known of the characteristics of patients who respond best to behavioral treatment. **Therefore, because they are virtually risk free, behavioral treatments should be offered as first-line therapy to any man or woman who is willing and able to participate**. Even patients with dementia can benefit from the appropriate, caregiver-guided behavioral treatment program.

Assessment Before Behavioral Treatments

Perhaps the most important step in evaluating the patient with LUTS is gathering a **focused** and **detailed history,** including onset of symptoms, duration, progression, characteristics, and situational antecedents or “triggers” (Newman, 2005; Newman and Wein, 2013). Understanding these factors will determine the design of a behavioral treatment program and guide its implementation.

To supplement the history, it is very useful for the patient to complete a 3- to 7-day bladder diary or frequency volume chart (Locher et al., 2001; Tincello et al., 2007; Fig. 121.2). **The diary is a valuable tool for the patient as well as for the provider.** In the assessment phase, the diary provides information on the type and amount of fluid intake, type and frequency of symptoms, such as incontinence episodes, frequency (and amount) of urination, the urgency associated with each, and the circumstances or reasons for incontinence episodes, which helps the provider plan appropriate components of behavioral intervention (Sampselle, 2003). Many providers are interested also in having the patient note the type and quantity of absorbent incontinence pads used and to quantify amount of urine leakage.

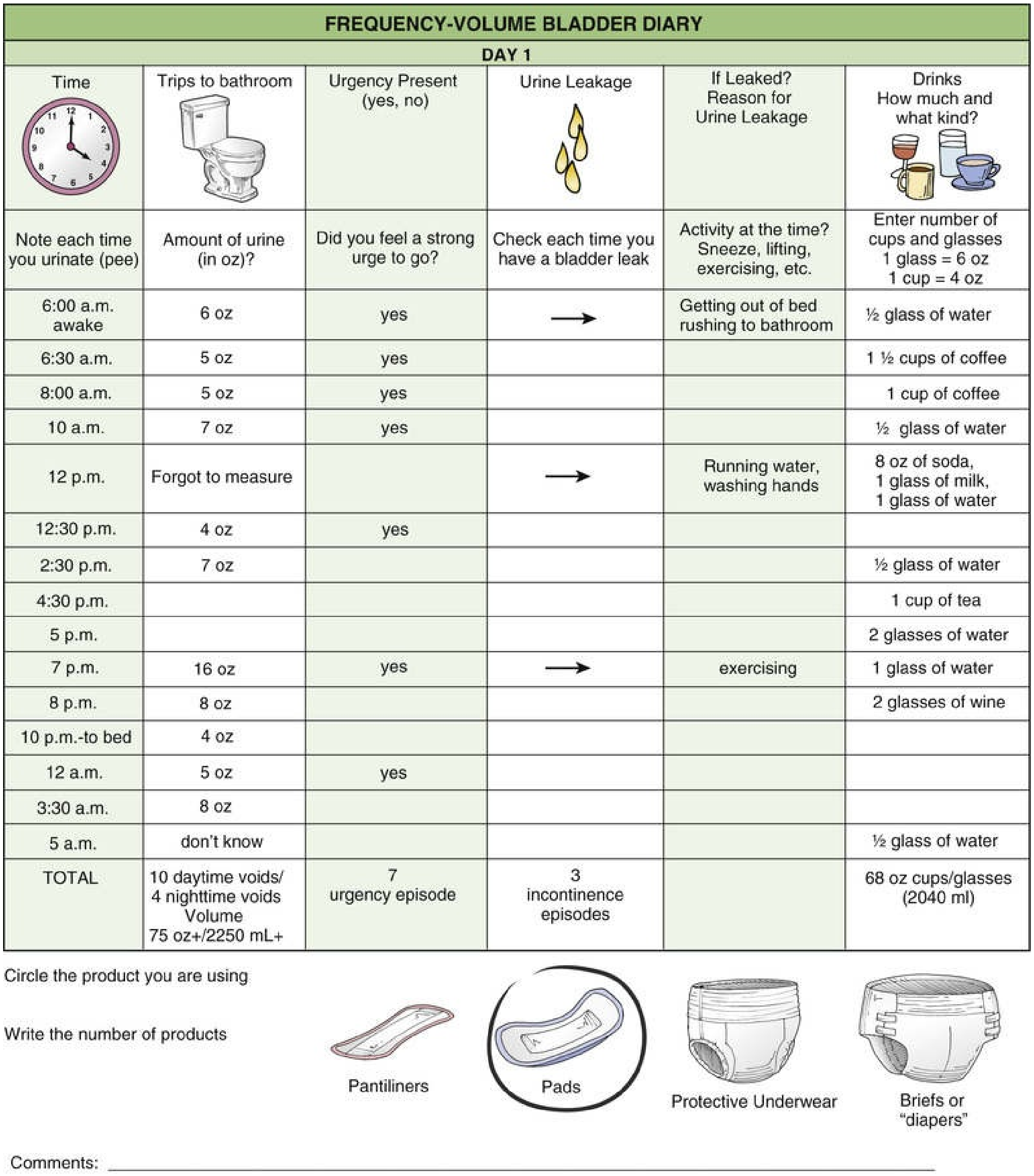

FREQUENCY-VOLUME BLADDER DIARY

DAY 1

Time	Trips to bathroom	Urgency Present (yes, no)	Urine Leakage	If Leaked? Reason for Urine Leakage	Drinks How much and what kind?
Note each time you urinate (pee)	Amount of urine (in oz)?	Did you feel a strong urge to go?	Check each time you have a bladder leak	Activity at the time? Sneeze, lifting, exercising, etc.	Enter number of cups and glasses 1 glass = 6 oz 1 cup = 4 oz
6:00 a.m. awake	6 oz	yes	→	Getting out of bed rushing to bathroom	½ glass of water
6:30 a.m.	5 oz	yes			1 ½ cups of coffee
8:00 a.m.	5 oz	yes			1 cup of coffee
10 a.m.	7 oz	yes			½ glass of water
12 p.m.	Forgot to measure		→	Running water, washing hands	8 oz of soda, 1 glass of milk, 1 glass of water
12:30 p.m.	4 oz	yes			
2:30 p.m.	7 oz				½ glass of water
4:30 p.m.					1 cup of tea
5 p.m.					2 glasses of water
7 p.m.	16 oz	yes	→	exercising	1 glass of water
8 p.m.	8 oz				2 glasses of wine
10 p.m.-to bed	4 oz				
12 a.m.	5 oz	yes			
3:30 a.m.	8 oz				
5 a.m.	don't know				½ glass of water
TOTAL	10 daytime voids/ 4 nighttime voids Volume 75 oz+/2250 mL+	7 urgency episode	3 incontinence episodes		68 oz cups/glasses (2040 ml)

Circle the product you are using

Write the number of products

Pantiliners [✓ Pads] Protective Underwear Briefs or "diapers"

Comments: ____________________

FIG. 121.2 Example of a completed frequency-volume bladder diary.

A bladder diary is also the best noninvasive tool available to objectively monitor the patient's voiding habits and the effect of treatment on symptoms, guiding the use of various treatment components. Voided volumes, included in a frequency-volume record, may be more burdensome for patients to document, but they provide a practical estimate of the patient's functional bladder capacity in daily life.

In addition to guiding behavioral treatment from the provider's perspective, **the self-monitoring effect of completing a diary can enhance patients' awareness of drinking and voiding habits and helps them recognize how their LUTS, especially incontinent episodes, may be related to their activities.** This increased awareness is thought to empower patients to help them retrain more effectively (Vella et al., 2012). A review of a diary can assist patients in identifying the times when they are at increased risk of a UI episode and activities that precipitate UI episodes, which helps them be prepared to implement behavioral skills.

Another approach to collecting information on bladder habits is the validated Questionnaire-Based Voiding Diary (QVD) for self-assessment of the type and volume of fluid intake and the type of UI which can be completed in an initial office visit in 5 to 7 minutes (Arya et al., 2008, 2011; eFig. 121.3).

QUESTIONNAIRE-BASED VOIDING DIARY (QVD)

Instructions: We would like to find out about your fluid intake, urinary output and urinary symptoms. Please answer each question, thinking about your fluid consumption and the symptoms you have experienced in **the last month.**

A. Please fill in the bubble for the number of drinks **AND** the amount for each beverage. If you do not drink a certain type of beverage **daily**, please fill in the bubble corresponding to 0.

Beverage	**Number of drinks per day** *(If 1 or more drinks per day, please indicate drink size→)*												**Size of each drink**
A1. Water	○ 0	○ 1	○ 2	○ 3	○ 4	○ 5	○ 6	○ 7	○ 8	○ 9	○ 10	○ 10+	○Less than 8 oz ○8-16 oz ○17-24 oz ○More than 24 oz
A2. Caffeinated Coffee	○ 0	○ 1	○ 2	○ 3	○ 4	○ 5	○ 6	○ 7	○ 8	○ 9	○ 10	○ 10+	○Less than 8 oz ○8-16 oz ○17-24 oz ○More than 24 oz
A3. Decaffeinated Coffee	○ 0	○ 1	○ 2	○ 3	○ 4	○ 5	○ 6	○ 7	○ 8	○ 9	○ 10	○ 10+	○Less than 8 oz ○8-16 oz ○17-24 oz ○More than 24 oz
A4. Caffeinated Tea	○ 0	○ 1	○ 2	○ 3	○ 4	○ 5	○ 6	○ 7	○ 8	○ 9	○ 10	○ 10+	○Less than 8 oz ○8-16 oz ○17-24 oz ○More than 24 oz
A5. Decaffeinated Tea	○ 0	○ 1	○ 2	○ 3	○ 4	○ 5	○ 6	○ 7	○ 8	○ 9	○ 10	○ 10+	○Less than 8 oz ○8-16 oz ○17-24 oz ○More than 24 oz
A6. Caffeinated Soda	○ 0	○ 1	○ 2	○ 3	○ 4	○ 5	○ 6	○ 7	○ 8	○ 9	○ 10	○ 10+	○Less than 8 oz ○8-16 oz ○17-24 oz ○More than 24 oz
A7. Decaffeinated Soda	○ 0	○ 1	○ 2	○ 3	○ 4	○ 5	○ 6	○ 7	○ 8	○ 9	○ 10	○ 10+	○Less than 8 oz ○8-16 oz ○17-24 oz ○More than 24 oz
A8. Milk	○ 0	○ 1	○ 2	○ 3	○ 4	○ 5	○ 6	○ 7	○ 8	○ 9	○ 10	○ 10+	○Less than 8 oz ○8-16 oz ○17-24 oz ○More than 24 oz
A9. Fruit juice/drinks (Hi-C, Kool Aid, cranberry cocktail)	○ 0	○ 1	○ 2	○ 3	○ 4	○ 5	○ 6	○ 7	○ 8	○ 9	○ 10	○ 10+	○Less than 8 oz ○8-16 oz ○17-24 oz ○More than 24 oz
A10. Alcoholic Drinks	○ 0	○ 1	○ 2	○ 3	○ 4	○ 5	○ 6	○ 7	○ 8	○ 9	○ 10	○ 10+	○Less than 8 oz ○8-16 oz ○17-24 oz ○More than 24 oz

B. Fluid Intake Behavior	**Never**	**Occasionally**	**Sometimes**	**Most of the time**	**All of the time**
B1. Do you drink large amounts of caffeinated tea or coffee?	○	○	○	○	○
B2. Do you drink large amounts of carbonated drinks?	○	○	○	○	○
B3. Do you drink extra fluids to lose or maintain your weight?	○	○	○	○	○
B4. Do you 'make yourself' drink fluid even if you are not thirsty?	○	○	○	○	○
B5. Do you restrict or cut down on your fluid intake to control your urinary symptoms?	○	○	○	○	○

QUESTIONNAIRE-BASED VOIDING DIARY (QVD)

C. Urinary output	**Never**	**Occasionally**	**Sometimes**	**Most of the time**	**All of the time**
C1. Do you urinate large amounts of urine when you first wake up in the morning?	○	○	○	○	○
C2. Do you urinate large amounts of urine in the afternoon (12 noon to 5 pm)?	○	○	○	○	○
C3. Do you urinate large amounts of urine in the evening (5 pm to bedtime)?	○	○	○	○	○
C4. Do you urinate large amounts of urine in the night after you have fallen asleep?	○	○	○	○	○

D. Urinary symptoms

D1. How often do you urinate in the daytime?
○ 1-5
○ 6-10
○ 11-15
○ 16-20
○ more than 20 times

D2. How often do you have to get up in the night to urinate after you have fallen asleep?
○ Never
○ 1
○ 2
○ 3
○ 4 or more

D3. Do you have to rush to the toilet to urinate?
○ Never
○ Occasionally
○ Sometimes
○ Most of the time
○ All of the time

D4. Do you leak urine (even small drops) as you are rushing to the toilet?
○ Never
○ Occasionally
○ Sometimes
○ Most of the time
○ All of the time

D5. Do you leak urine when you cough or sneeze or are physically active?
○ Never
○ Occasionally
○ Sometimes
○ Most of the time
○ All of the time

D6a. How often do you experience urinary leakage?
○ Less than once a month
○ A few times a month
○ A few times a week
○ Every day and/or night

D6b. How much urine do you lose each time?
○ Drops
○ Small splashes
○ More

Severity Index. This will be completed by your doctor or nurse.
☐ Slight, ☐ Moderate, ☐ Severe, ☐ Very Severe

Arya LA, Banks C, Gopal M, et al. Development and testing of a new instrument to measure fluid intake, output, and urinary symptoms: the questionnaire-based voiding diary. Am J Obstet Gynecol 2008;198:559.e1-559.e7.

EFIG. 121.3 Questionnaire-based voiding diary (QVD).

Patient Education

Because behavioral treatments are based on principles of learning, an important first step in any behavioral program is to provide basic education so that patients can understand their condition, the treatment process, and the therapeutic goals. Patient education includes an explanation of the anatomy of the bladder, urethra, vagina/prostate, PFMs, and rectum; how they function and are interrelated; and the causes and mechanisms of their particular condition. **It is essential for patients to understand that a behavioral program is based on changing habits and learning new skills, and that improvement is often gradual** (Lukacz et al., 2011). Further, understanding that their results will depend on active participation and daily practice facilitates adherence and realistic expectations about therapeutic outcomes.

Pelvic Floor Muscle Training

PFMT and exercise, also known as pelvic floor rehabilitation (Payne, 2012) **is a cornerstone of behavioral treatment for UI and urinary urgency and frequency.** First described by Margaret Morris in 1936, it was originally designed to teach patients how to control and exercise peri-vaginal muscles with the goal of strengthening the muscles and reducing stress UI. PFMT and PFME were first popularized by Arnold Kegel, a gynecologist who proposed that stress UI was due to a lack of awareness of function and coordination of PFMs (Kegel, 1948). Kegel also demonstrated that women could reduce their stress UI through repetitive muscle contractions to increase strength (Kegel, 1948, 1956). Over time, this intervention has evolved as a nurse-directed behavior treatment and as a physical therapy, combining principles from both fields into a widely accepted conservative treatment for incontinence and other LUTS (Newman et al., 2018).

In women, it is postulated that a PFM contraction may raise the urethra and press it toward the symphysis pubis, prevent urethral descent, and improve structural support of the pelvic organs (Berghmans et al., 1998). **PFMT may result in hypertrophy of the striated muscles, thus increasing the external mechanical pressure on the urethra. Intensive PFMT is also hypothesized to reinforce structural support of the bladder neck in women, limiting its downward movement during increases in abdominal pressure** (Bø, 1995, 2004).

PFMT involves the patient learning how to contract and relax the PFM, performing a regular exercise regimen to improve strength and control, and actively using a PFM contraction to occlude the urethra during physical activities that increase abdominal pressure and precipitate urine leakage (Miller et al., 1998). Details of training regimens vary, and few are well described in the current evidence-based literature (Dumoulin et al., 2017; Newman et al., 2018).

Assessment of Pelvic Floor Muscle Function

Before initiation of PFMT, an assessment of the PFM can provide useful baseline information about strength, coordination, and control. **PFM function can be assessed by several methods, including visual observation, digital palpation, electromyography (EMG), manometry, or ultrasound.** In women, visual observation can be used to assess a correct PFM contraction, which is seen by perineal elevation (inward [ventrocephalad] movement of the vulva, perineum, and anus) or an incorrect contraction exhibited by perineal descent (excessive dorsocaudal movement of the vulva, perineum, and anus) (Bø et al., 2017). Digital assessment is the most commonly used technique in clinical practice (Newman and Wein, 2009, 2013; Newman et al., 2018). The most widely used digital palpation methods are the Brink score and the Laycock PERFECT (Power, Endurance, Repetitions, Fast, Every, Contraction, Timed) assessment scheme (Newman and Laycock, 2008). The Brink score employs a 4-point scale to assess the contraction pressure, vertical displacement, and endurance of squeeze (Brink et al., 1989). The Laycock PERFECT assessment scheme uses a 6-point scale to score strength and endurance and the number of repetitions and fast contractions (Laycock and Jerwood, 2001).

PFM strength can be determined in women by inserting one or two fingers into the vagina to the level of the first knuckle, then palpating the muscular attachments along the pubic arch and the insertion of the levator ani and coccygeus muscles (Newman, 2014, Newman and Laycock, 2008). The levator ani can be palpated just superior to the hymeneal ring, at the 4 and 8 o'clock positions, to determine strength, and whether palpation reproduces any discomfort or tenderness. The patient is asked to contract the PFMs around the examiner's finger with as much force and for as long as she is able and in short, fast contractions called “flicks.” Tactile feedback in the form of tapping or a slight, quick muscle stretch can be used to assist the patient in identifying the PFMs. Tactile feedback may enhance verbal feedback and help a patient who may not know what muscle to contract, does not understand how to contract the PFMs, and/or has very weak PFMs. **It is important to realize that, when asked to contract the PFM, women may use the wrong muscles,** straining down or performing a Valsalva maneuver**, or fail to activate all layers of the pelvic musculature.** The examiner notes through observation whether accessory muscles (such as gluteal, abdominal muscles) also contract.

When assessing PFM strength, clinicians should use three criteria (Brink et al., 1989) and note the results:

- Pressure: The amount of pressure or strength of the muscle contraction, which can range from imperceptible to a firm squeeze
- Duration: The number of seconds that the examiner feels the

muscle contraction
- Alteration in position: In a well-supported pelvic floor, the muscle contraction can lift the base of the examiner's finger. Use of accessory muscles should be noted (abdominal movement, gluteal lifting). If the patient has an “overactive PFM” (voluntary PFM relaxation is absent or partial), the degree should be noted. Overactive PFM (also referred to as high tone muscle) is defined as one that does not relax or may even contract when relaxation is functionally needed (e.g., during micturition) (Messelink et al., 2005).

Assessment of the PFM in men and women can also be performed by evaluating anal sphincter contraction and tone. This is done by having the patient relax and bear down. As the sphincter relaxes, the examiner gently inserts an index finger into the anal canal in a direction pointing toward the umbilicus. Normally, the muscles of the anal sphincter close snugly around the entire circumference of the examiner's finger. The puborectalis portion of the levator ani muscle can be palpated about 2.5 to 4 cm from the anal verge. To assess the strength of the sphincter muscle, the patient is asked to tighten the rectum. The examiner should feel a griping or “pulling in” around the entire finger circumference. Resting sphincter tone can be noted as weak, moderate, or strong.

Teaching Pelvic Floor Muscle Control

The first step in PFMT is to teach the patient how to identify the PFMs and to contract and relax them reliably. This can be done using verbal feedback based on vaginal or anal palpation during a digital assessment. It can also be done using visual or auditory BF or E-stim (Newman, 2014; Newman and Wein, 2009, 2013). Instructions to patients can include the following:

- “Contract your muscles around my finger(s). Try to pull up and in.”
- “Without tensing the muscles of your legs, buttocks, or stomach, imagine trying to prevent the passing of gas or pinching off a stool by tightening the ring of muscles around the anus. A closing

and lifting sensation should be felt."

- For men: "Imagine moving the penis up and down without moving any other part of the body."
- For women: "You should feel your vagina and rectum pull up and in."

One problem commonly encountered in teaching PFM control is muscle isolation; more than one-third of women report not feeling confident about their ability to do a PFM contraction correctly (Chiarelli et al., 2003). Patients tend to recruit other muscles (referred to as co-contractions), such as the rectus abdominis muscles or gluteal muscles, instead of or in addition to the PFMs (Newman et al., 2018). Women substitute a straining-down Valsalva maneuver, which threatens to worsen the very condition the contractions are intended to prevent or treat (Sampselle and DeLancey, 1992). Contracting certain abdominal muscles can be counterproductive when it increases pressure on the bladder or pelvic floor. **Thus it is important to observe for the use of other muscles and to help patients to contract PFMs selectively while relaxing ancillary muscles.** Instructing patients not to hold their breath or to count out loud can be helpful to avoid bearing down. Coordinated training of transversus abdominis muscles has also been recommended by some clinicians because it is believed that these muscles facilitate PFM contraction. However, in a review of the literature, Bø et al. (2009) noted an absence of evidence for this type of training, and it remains controversial.

It is important to verify that patients have identified and can contract the PFMs properly before initiating an exercise regimen. Not being able to identify the PFMs or to exercise them correctly may be the most common reason for poor outcomes with this treatment modality. PFM control is a skill that may take time to master, but with repeated training, most patients are successful.

In the past, most patients were given a pamphlet or brief verbal instructions on how to do PFMEs and were told to "lift the pelvic floor" or to interrupt the urinary stream. Although these simple approaches may be adequate for some patients, they do not ensure that patients understand which muscles to use when they begin a structured exercise program at home.

Pelvic Floor Muscle Exercise Regimens

Once patients demonstrate the ability to properly contract and relax the PFMs, they are given instructions for daily practice and exercise. **The purpose of daily exercise is twofold: to increase muscle strength and to enhance motor skills through practice.** Specific exercise regimens vary considerably in frequency and intensity, and the ideal exercise regimen has not yet been determined (Dumoulin et al., 2017; Newman et al., 2018). However, good results have been achieved in several trials using 45 to 60 paired contractions and relaxations per day.

We use an “exercise prescription” to prescribe the daily exercise program (eTable 121.2) (Newman, 2014; Newman and Wein, 2013). One approach is to recommend a series of “quick flicks” or 1- to 2-second contractions, followed by sustained contractions (endurance contractions) of 5 seconds building to 10 seconds. The patient is encouraged to aim for a high level of concentrated effort with each PFM contraction because greater contraction intensity is associated with improvement in PFM strength.

eTABLE 121.2

Sample Pelvic Floor Muscle Exercise Prescription

Please complete the following exercises every day:

1. Short, quick exercise
   Contract the muscle quickly for 1–2 seconds and immediately relax.
2. Long, sustained exercise
   Contract the muscle, and hold the contraction for a count of 5 building to 10 seconds then immediately relax for the same amount of time.
   After each muscle contraction, be sure to rest your muscle for the same amount of seconds.
   When you have completed both types of exercises in all 3 positions, you will have completed one session.

EXERCISE SESSION

Lying Down

Do 5 exercises and squeeze for 1–2 seconds.
Do 5 exercises and squeeze for 5 (building to 10) seconds.

Sitting

Do 5 exercises and squeeze for 1–2 seconds.
Do 5 exercises and squeeze for 5 (building to 10) seconds.

Standing

Do 5 exercises and squeeze for 1–2 seconds.
Do 5 exercises holding for 5 (building to 10) seconds.

- Do 2 exercise sessions each day, one in the morning and one in the evening, for a total of 60 exercises.

SPECIAL TIPS

- Always empty your bladder before starting your exercise session.
- Count out loud when doing the sustained or long exercises so that you make sure you are not holding your breath.
- Keep your stomach, leg, and buttock muscles relaxed. Rest your hand on your stomach. It should not move or tense. Breathing as you contract and relax your muscles will keep your stomach muscle relaxed.
- If it helps, take a deep breath between each exercise to help you keep other muscles relaxed.

Modified from Newman DK, Wein AJ: Office-based behavioral therapy for management of incontinence and other pelvic disorders. *Urol Clin North Am* 40(4):613–635, 2013; Newman DK, Wein AJ: *Managing and treating urinary incontinence,* ed 2, Baltimore, 2009, Health Professions Press, pp 245–306.

It is equally important to relax the PFM completely between each contraction. Each exercise consists of a muscle contraction followed by a period of relaxation using a 1 : 1 or 1 : 2 ratios. This allows the muscles to recover between contractions and facilitates optimal strength building.

It is usually recommended that patients space the exercises throughout the day, typically in 2 to 5 sessions per day to avoid muscle fatigue. Exercising while in the prone position is often recommended at first, because it is the least challenging. However, it is important for patients to progress to sitting or standing positions with time so that they become comfortable and skilled using their muscles to avoid incontinence in any position (Newman et al., 2018).

Use of Pelvic Floor Muscle Contraction to Prevent Stress Incontinence

The goal of behavioral treatment for stress UI is to teach patients how to prevent urine loss in daily life by occluding the urethra using active contraction of PFMs (Miller et al., 1998). **Although exercise alone can improve urethral pressure and structural support and reduce incontinence, this motor skill enables patients to consciously occlude the urethra at specific times when urine loss is imminent.** A careful history or examination of a bladder diary can alert the provider and patient of the circumstances during which each individual patient commonly experiences urine loss. Patients then learn to anticipate these activities and prevent leakage by a volitional contraction of the PFM to occlude the urethra before and during coughing, sneezing, lifting, or any other physical activities that has precipitated urine leakage.

This additional PFM technique uses an anticipatory muscle contraction to preempt a bladder problem at the time of occurrence. This skill has been referred to as the “stress strategy” (Burgio, et al., 1989) and “the Knack” maneuver (Miller et al.1996, 1998, 2008). Miller et al. (1998, 2008) demonstrated immediate reduction in the volume of urine leakage with a cough when an anticipatory PFM contraction was used. Although using this technique requires initial vigilance on the part of the patient and a conscious effort to develop the habit of using muscles to increase urethral closure, it eventually becomes automatic. A handout with instructions for the patient is presented in eTable 121.3.

eTABLE 121.3

Handout for Teaching Stress Strategies and the “Knack”

Urine leakage occurs when the pressure pushing urine out is higher than the pressure holding it in your bladder. Any activity or movement that increases pressure in your abdomen (stomach) may cause you to lose urine. So you may find that you leak urine when you cough, sneeze, stand up, exercise, bend, or lift. If you contract or squeeze your pelvic muscle at the right time, you can prevent a bladder accident or leakage. This is a clever trick or skill you learn, the “knack” for making your pelvic muscle tighten at the right time. You need to anticipate the event or activity that causes leakage and squeeze your pelvic floor muscles before and hold that squeeze through that event. Keeping that muscle tight is what prevents urine from leaking. A bladder diary will help you identify activities that cause leakage.

1. Quickly squeeze your pelvic floor muscles (like trying to hold back gas) just *before and during* the event or activity that normally causes you to leak (cough, sneeze, bending, lifting, getting up from a chair).
2. If you forget to squeeze your muscles and urine leaks out, go ahead and squeeze your muscles right then. It won't prevent that leakage but will help link squeezing the muscles with that activity and help you remember in the future, help you get the “knack” for doing it the next time.
3. This trick takes careful timing and practice. It may take some time for you to get the “knack” of doing it. Don't get discouraged. Eventually, it will become automatic.
4. Remember: “Squeeze before you sneeze.”

Modified from Burgio KL, Pearce KL, Lucco AJ: *Staying dry: a practical guide to bladder control,* Baltimore, 1989, Johns Hopkins Press, pp 67–100; Newman DK, Wein AJ: *Managing and treating urinary incontinence,* ed 2, Baltimore, 2009, Health Professions Press, pp 245–306.

Evidence for Pelvic Floor Muscle Training

PFMT is an established treatment supported by a very large body of evidence (Dumoulin et al., 2017, 2018). A Cochrane review of PFMT-based treatments concluded that these treatments were effective for stress UI and mixed UI (Dumoulin et al., 2014, 2018) and can reduce urgency, but women with pure stress UI may have better outcomes (Bø and Herbert, 2013). PFMT is better than no treatment, a placebo drug, or an inactive control treatment for women with stress, urgency, and mixed UI (Ayeleke et al., 2013; Dumoulin et al., 2017, 2018). Women treated with PFMT show benefit on a number of outcomes, including cure, better quality of life (QoL), reduction in daily leakage episodes, and less urine leakage on a pad or paper towel test immediately after treatment and long term. Cure rates for PFMT range from 16% to 27% and improvement rates from 48% to 80.7%. Evidence is lacking regarding the best approach to PFMT, but **there is consensus that supervised PFMT is more effective than unsupervised programs** (Dumoulin et al., 2017; Hay-Smith et al., 2011, 2012), although the degree and type of supervision needed are uncertain. Moreover, the treatment effect appears to be enhanced when PFMT is based on sound muscle training principles, such as specificity, overload progression, correct contraction confirmed before training, and active use of the PFM to occlude the urethra (referred to as stress strategy or the “knack” contraction).

The effect of PFMT in women with stress UI does not seem to decrease with age; in trials of older women, primary and secondary outcome measures were comparable with those in trials focused on younger women. Thus age should not be a deterrent to PFMT (Betschart et al., 2013). **Based on this evidence, supervised PFMT should be offered as a first-line conservative therapy for women of all ages with stress, urgency, or mixed UI**.

Antenatal Urinary Incontinence

According to a recent Cochrane review, targeting continent antenatal women early in pregnancy and offering a structured PFMT program may prevent the onset of UI in late pregnancy and postpartum (Woodley et al., 2017).

Postpartum Urinary Incontinence

PFMT is recommended during pregnancy and after childbirth for

prevention and treatment of incontinence (Hilde et al., 2013; Mørkved and Bø, 2013; Neilson, 2009; Wesnes and Lose, 2013). Cochrane reviews of randomized or quasi-randomized controlled trials in pregnant or postnatal women included 22 trials involving 8485 women (Boyle et al., 2012, 2014). Postpartum women with UI who were randomized to PFMT taught and supervised by a health care professional were less likely to be incontinent 6 to 12 months after delivery, compared with no treatment or usual care. The ICI committee (Dumoulin et al., 2017) recommends that **PFMT should be offered as first-line therapy to postpartum women with UI persisting 3 months after delivery.** Evidence for the value of perinatal PFMT for the prevention of postpartum UI can be found in eBox 121.3.

Post-Prostatectomy Urinary Incontinence

Stress UI is a complication of radical prostatectomy (RP), regardless of the technique used (Resnick et al., 2013). **PFMT is the primary conservative treatment for UI secondary to prostatectomy.** It may be taught using digital rectal exam with verbal feedback or with BF or E-stim (Mariotti et al., 2009).

Trials of PFMT for established postprostatectomy UI have yielded mixed results but generally show that **PFMT reduces UI in the first 3 months after surgery** (Campbell et al., 2012; Dumoulin et al., 2017). Less research has focused on UI that persists long term. One randomized controlled trial (RCT) compared behavioral training (PFMT + bladder control strategies) versus no treatment in men with UI persisting 1 to 17 years after radical prostatectomy (Goode et al., 2011). After 8 weeks of treatment, men in the behavioral training group showed 55% reduction in UI episodes, significantly greater than the 24% reduction in the control group, and improvements were sustained to 12 months.

According to Dumoulin et al. (2017), it is not clear whether PFMT should be delivered in the form of “hands-on” therapy or verbal instruction. **Current evidence suggests that the addition of PFM E-stim or BF does not appear to improve continence outcomes over PFMT alone. However, BF is an effective approach, and providers may prefer it over digital rectal exam**.

Many studies of postprostatectomy UI involve perioperative PFMT for prevention of post-prostatectomy before UI is established. These studies are covered in eBox 121.3.

Vaginal Cones for Pelvic Floor Muscle Training

Weighted vaginal cones were developed as a method for testing pelvic floor muscle (PFM) function and are sometimes used to **help women identify and control their PFMs** and to support adherence to PFMT (Dumoulin et al., 2017; Herbison and Dean, 2013; eFig. 121.4 for an example of a set of graded weighted vaginal cones). These weighted cones provide progressive muscular overload during strengthening PFM exercises (Peattie et al., 1988). **When a cone is placed in the vagina while standing, the sensation of "losing the cone" provides a strong sensory feedback that prompts the PFM to contract to prevent it from slipping out (**Dumoulin et al., 2017). Women are instructed to insert the heaviest cone they can retain while standing, at first, and then while walking around. When successful with this first cone, they should incrementally increase cone weight and amount of time retaining the cone. The goal is for women to be able to retain the cone using a PFM contraction while walking around for two sessions of 20 minutes per day. The gradual increase in cone weight maintains muscle overload over the course of the exercise program. Some women find the cones helpful and motivating. Others find them uncomfortable, difficult to insert (because of a narrowed vaginal opening), or impossible to retain (because of pelvic organ prolapse [POP] or enlarged vaginal opening). Effectiveness of the cones as a PFMT aid is questionable because orientation of the vagina is not completely vertical; some women can retain the cone without actually contracting the PFMs.

EFIG. 121.4 Example of weighted vaginal cones.

A 2013 Cochrane review (Herbison and Dean, 2013) analyzed 23 trials involving 1806 women, of whom 717 received cones. All of the trials were small, and in many, the quality was difficult to judge. They **concluded that there was some evidence that weighted vaginal cones are better than no active treatment in women with stress UI** and may be of similar effectiveness to PFMT and pelvic floor E-stim. However, more definitive trials are needed to understand the role of weighted vaginal cones in the treatment of UI.

Other Pelvic Floor Muscle Training Devices

The Colpexin sphere is another type of weighted device that women with POP and UI can use for PFMT. It consists of a smooth medical-grade polycarbonate sphere with an attached braided string (eFig. 121.5). It is self-inserted with an applicator or by hand into the vaginal vault and placed within the vaginal canal above the levator musculature (Fig. 121.6). By elevating the prolapse defect, it facilitates the performance of a proper PFM contraction (Deng, 2018). The Colpexin sphere is fitted for each woman based on size (32, 36, 39, 42, and 44 mm) and degree of prolapse and the underlying PFM tone. Similar to vaginal cones, PFM exercises are performed at least twice a day while wearing the sphere. As the PFMs become stronger, the patient can challenge herself by gently tugging on the string while tightening the muscles. In Manonai's et al. (2012) study on the use of the Colpexin sphere in women with stage I or II prolapse in a single-blind RCT, 85 subjects randomized to one of two groups: PFME alone ($n = 45$ control) or Colpexin + PFME ($n = 46$ study group). All women were instructed to perform three sets of exercises daily. Those in the Colpexin group exercised with the device in situ. The intervention duration was 16 weeks. PFM strength was measured using the Colpexin pull test (Jean-Michel et al., 2010) and digitally using the Brink scale, at baseline, 4, 8, 12, and 16 weeks after treatment. There were no significant differences between the two groups in improvement in PFM strength between the two groups at 16 weeks; 85 women (93%, equal in both groups) completed the 16-week assessment with 80% compliance to daily exercise. However, the trial was low risk for selection bias, performance and detection bias, attrition bias, reporting bias, and other bias (Dumoulin et al., 2017). Vaginal symptom score decreased in both groups, while the stages of prolapse did not change (Manonai et al., 2012). Adverse events included vaginal discomfort (85%), vaginal discharge, and abdominal discomfort.

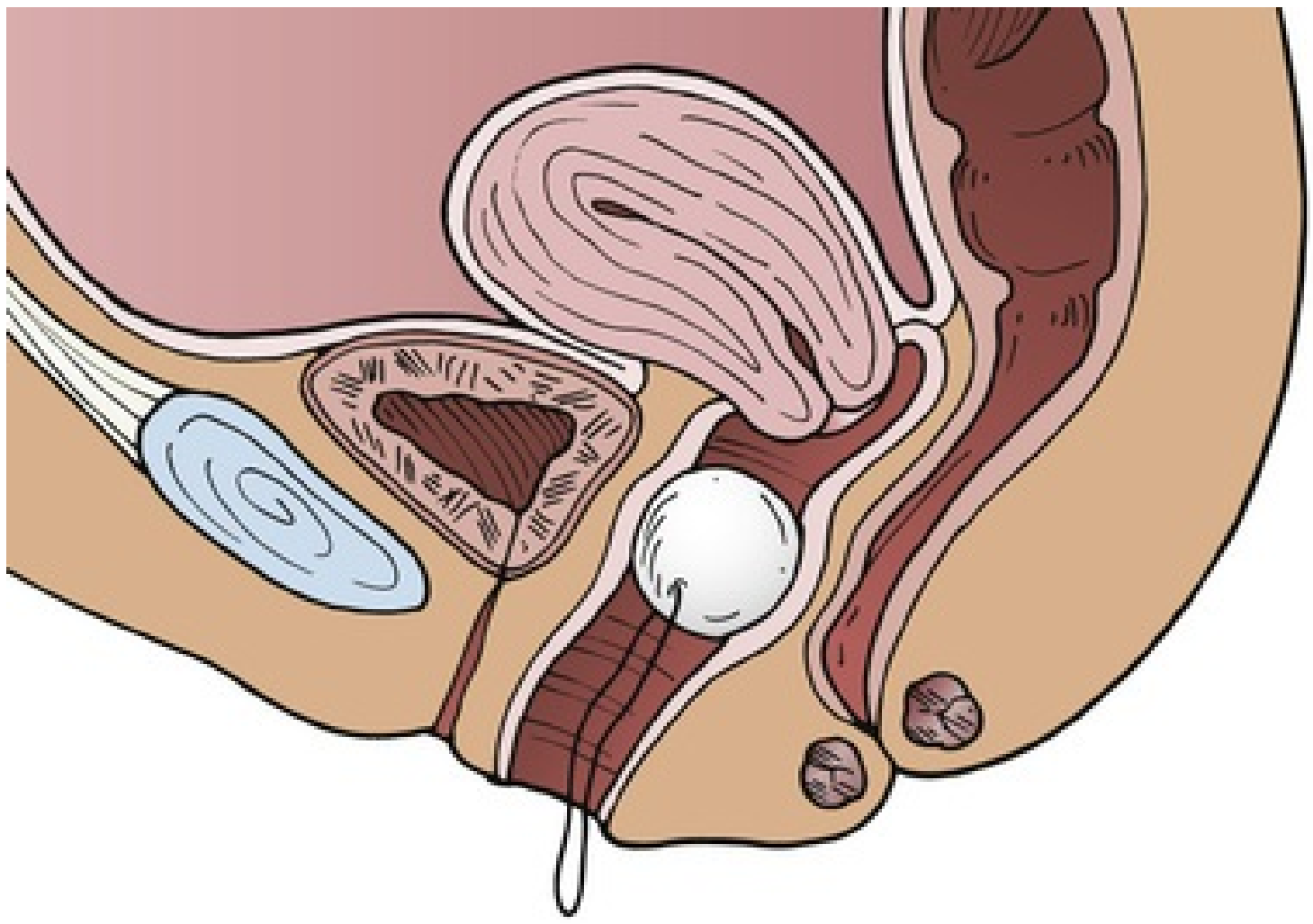

FIG. 121.6 Colpexin sphere vaginal device in place in the vagina.



EFIG. 121.5 Colpexin sphere vaginal device.

A critical factor in the outcome of a successful PFMT program is the patient's willingness to perform the exercises correctly and consistently. Theories of motivation emphasize the positive role that perceived competence in a physical activity can intrinsically motivate a person to continue that activity. Research shows that mastering a goal is most strongly related to positive outcomes, such as increased self-perception, autonomous motivation, enjoyment, and behavioral persistence (Keshtidar and Behzadnia, 2017). A successful strategy, used by health care professionals to educate women on their proficiency with PFM exercises, is the use of BF as part of a training device (Newman, 2014). Delgado et al. (2013) noted that the use of a PFMT device (pelvic floor trainer) appeared to help women gain confidence that they were doing the exercises properly plus motivated them to continue.

Technologic advancements, including smart phone applications, have resulted in the availability of numerous home-based PFMT devices for women (Araujo et al., 2019; Starr et al., 2016). Many purport to aid women in performing PFMEs properly. A systematic review of available mApps for PFMT by Latorre et al. (2019) concluded that this technology has potential to improve adherence. Dr. Kegel described a vaginal pressure device (a perineometer) for PFMT that was connected to a manometer, “devised specifically for the exercise of birth canal muscles, with measurement of each muscular contraction visible to the patient” (Kegel, 1948; eFig. 121.7). Ong et al. (2015) conducted a pilot prospective study to compare the effectiveness of doing PFMEs with and without a pelvic trainer device (Fig. 121.8). Forty women (≥age 18) with stress UI were enrolled in a control group (PFME alone, $n = 19$) or to the pelvic trainer group (PFME with the device, $n = 21$). Both groups underwent 16 weeks of training, and PFM strength testing at weeks 0, 4, and 16. In the control group three women (15.8%) withdrew during week 16. The women in the device group had significant improvement in stress UI scores ($P = 0.35$) at week 4 but no significant differences between the two groups at week 16. PFM strength was better in the pelvic trainer device at week 4 ($P = 0.025$) and week 16 ($P = 0.001$).

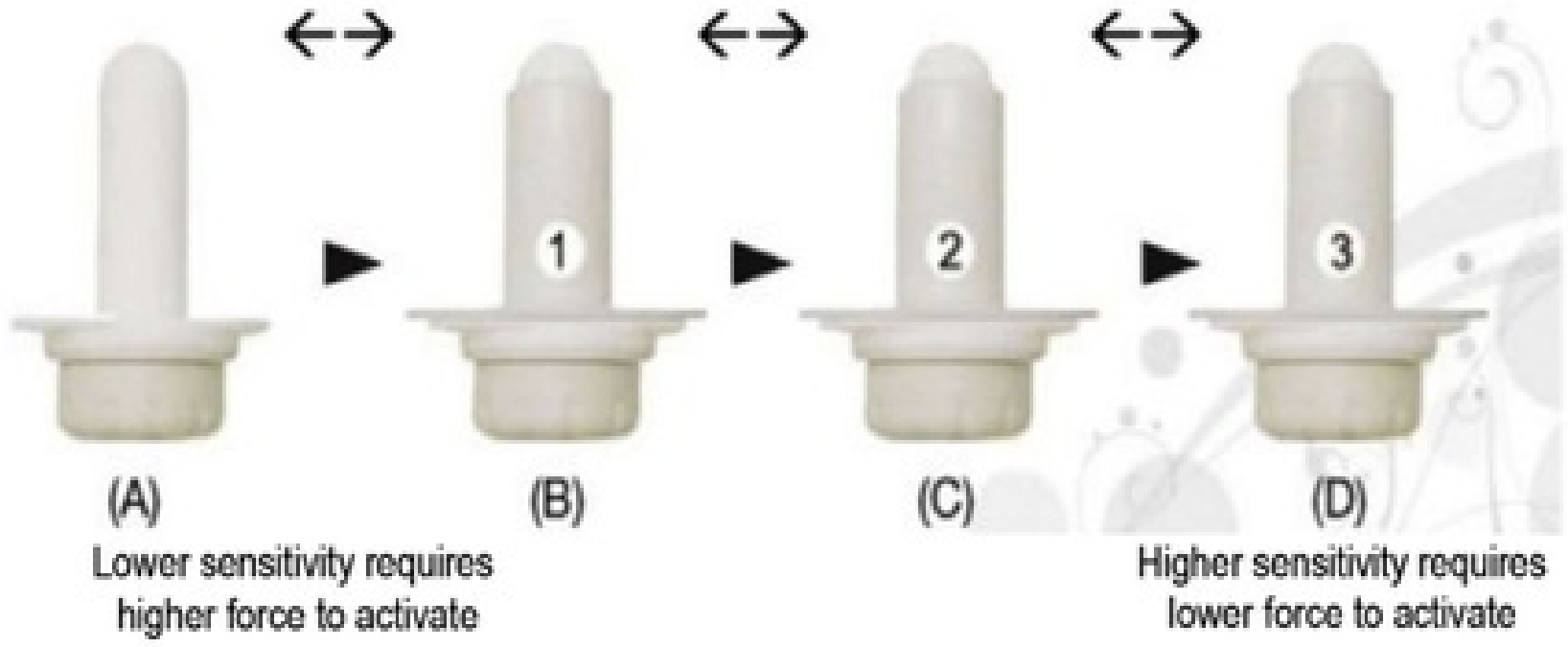
1
2
3
(A)
(B)
(C)
(D)
Lower sensitivity requires higher force to activate
Higher sensitivity requires lower force to activate

FIG. 121.8 Pelvic muscle training device (Vibrance) with progressive resistance training sleeves.

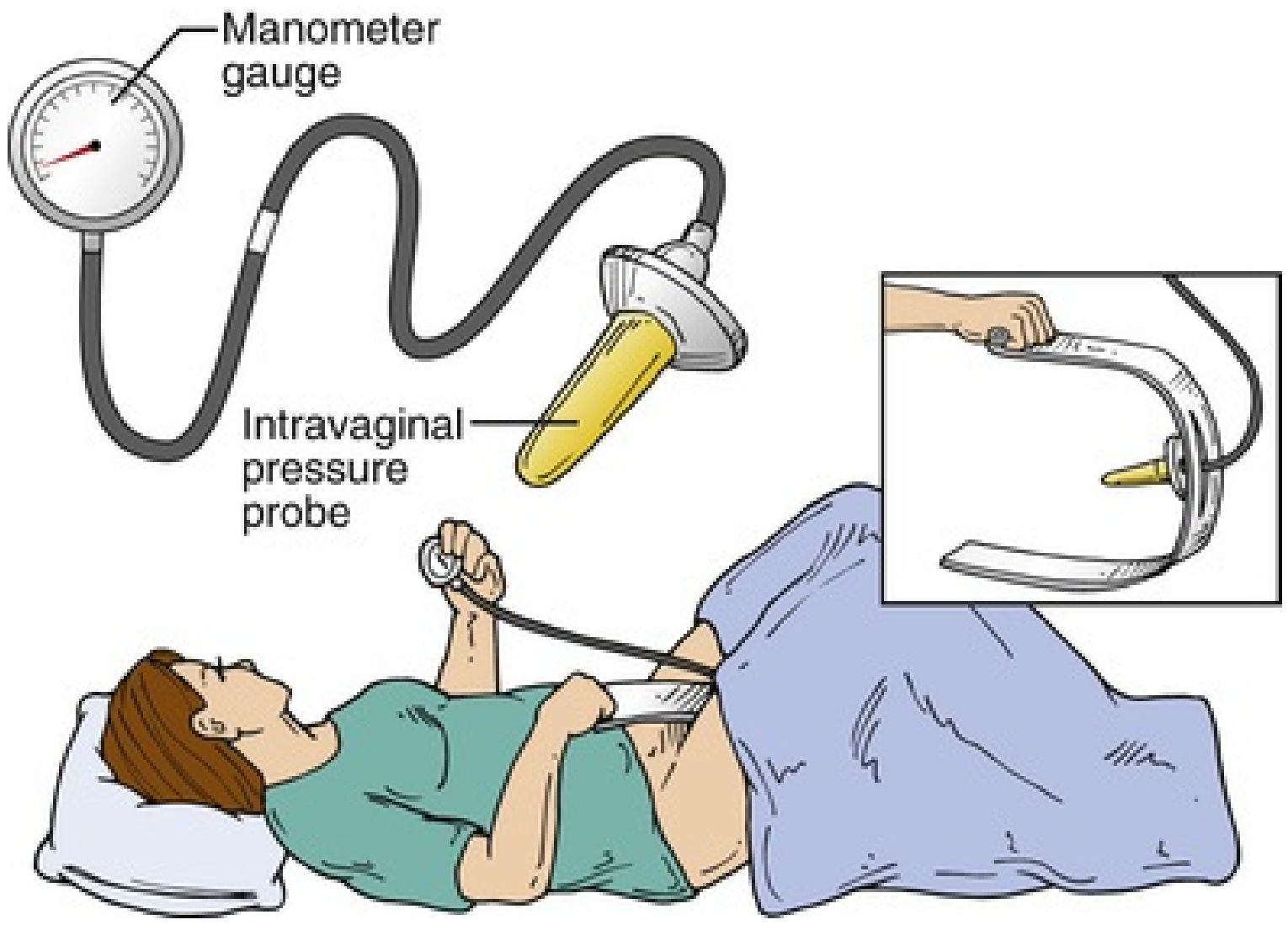
Manometer gauge
Intravaginal pressure probe

EFIG. 121.7 Dr. Kegel's perineometer.

Many of these devices fall short in offering progressive resistance and accurate feedback with standardized instruction. The need exists for a practical and safe PFMT device with these features to better instruct and motivate women with UI and LUTS in performing in-home PFMEs correctly and consistently.

Behavioral Training With Urge Suppression

Behavioral training is a stand-alone treatment that teaches patients how to use their PFMs to inhibit a detrusor contraction and how to use this skill as a part of a larger urge-suppression strategy that constitutes a new way of responding to urge for patients with urgency, frequency, and/or urgency UI. Behavioral training evolved out of BF-assisted behavioral training in which bladder and anal sphincter BF were used together to teach patients to inhibit a detrusor contraction during retrograde bladder filling. Originally, the focus of training was on bladder pressure feedback and learning cortical inhibition of detrusor contraction. During these BF sessions, it was observed that spontaneous anal sphincter activity appeared to affect detrusor pressures, and it was subsequently demonstrated that **a well-timed, volitional contraction of the anal sphincter (reflecting PFM), guided by visual BF, could abort fully developed detrusor contractions, deter developing contractions, and suppress the sensation of urgency** (Burgio et al., 1986, 1998).

Later, it was shown that this skill could be taught without BF, using verbal feedback based on vaginal palpation instead. In a randomized trial of behavioral training with and without BF, older women with urgency UI, taught using verbal feedback based on vaginal palpation, achieved outcomes as good as those achieved using bladder-sphincter BF when this skill was integrated into a larger strategy (Burgio et al., 2002).

Based on these findings, **although PFMT and PFME were originally designed for the treatment of stress UI, they are now used as central elements in the treatment of urgency UI and OAB.** In behavioral training, patients are taught PFM control and exercise in the same way as for stress UI. What differs is how they use their muscles to manage urgency and prevent urine loss. In addition to using the PFM to occlude the urethra, patients learn to use PFM contractions as one part of a broader strategy to respond to the sensation of urge. Urge-suppression strategies with emphasis on incremental increases in voiding intervals are an integral part of BT, which is discussed later in this chapter.

Patients with urgency and urgency UI often feel compelled to rush to the nearest bathroom when they feel the urge to void, believing that they are about to lose control. **With behavioral training, they learn how this natural “gotta go” response is actually counterproductive** because it increases physical pressure on the bladder, increases the feeling of fullness, exacerbates urgency, and triggers detrusor contraction. Further, as the patient approaches the toilet, visual cues can trigger urgency and incontinence. To avoid this conditioned response, **patients are taught not to rush to the bathroom when they feel the urge to void. Instead, they are advised to stay away from the bathroom so as to avoid exposure to cues that trigger urgency** (Burgio et al., 1989). They are encouraged to pause, sit down if possible, relax the entire body, and contract PFMs repeatedly, without relaxing in between contractions, to diminish urgency, inhibit detrusor contraction, and prevent urine loss. They focus on inhibiting the urge sensation, giving it time to pass. Once the sensation subsides, they walk at a normal pace to the toilet. (A handout for teaching the urge-suppression strategy and BT is in Fig. 121.9.)

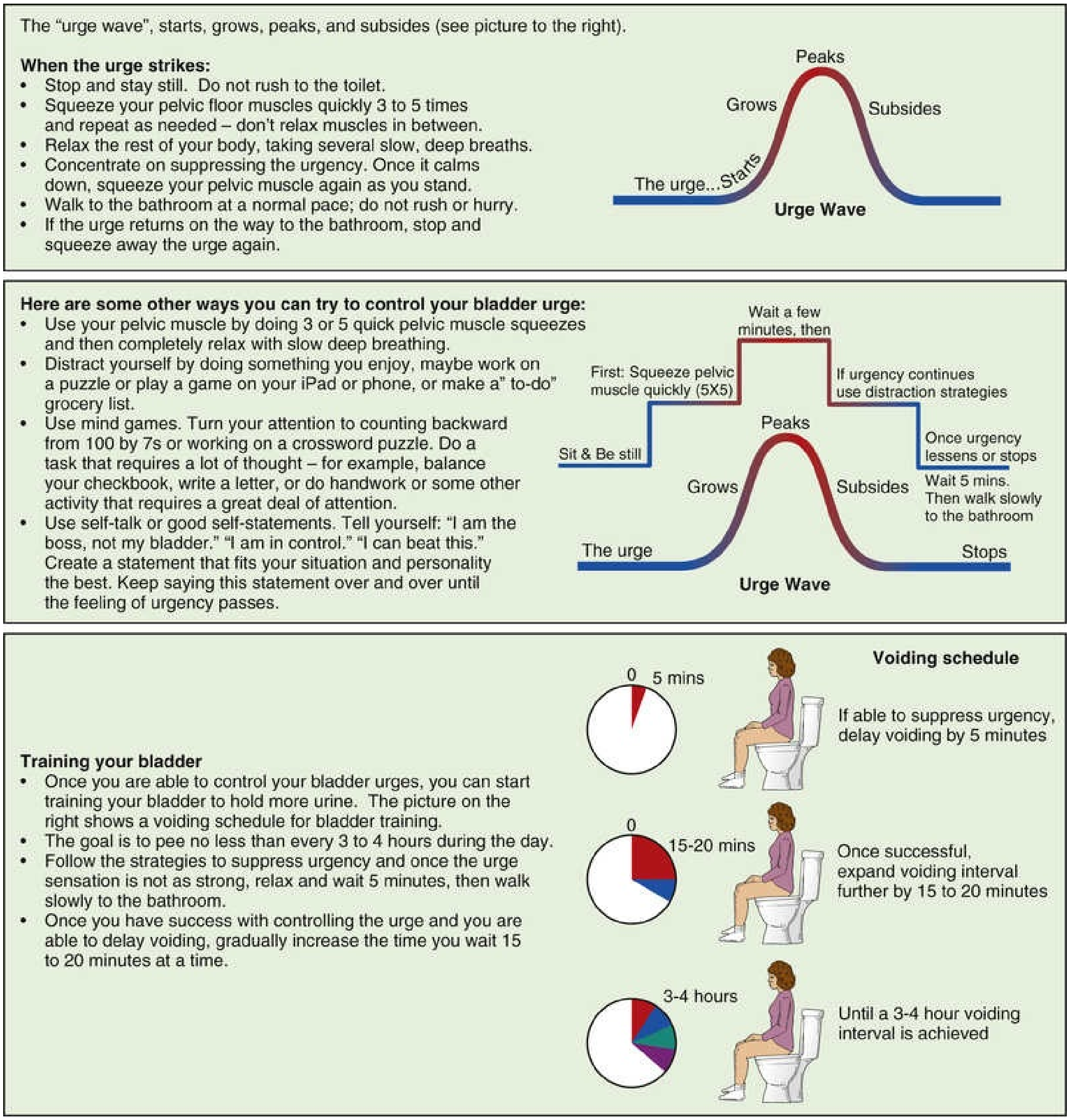

The “urge wave”, starts, grows, peaks, and subsides (see picture to the right).

When the urge strikes:

- Stop and stay still. Do not rush to the toilet.
- Squeeze your pelvic floor muscles quickly 3 to 5 times and repeat as needed – don’t relax muscles in between.
- Relax the rest of your body, taking several slow, deep breaths.
- Concentrate on suppressing the urgency. Once it calms down, squeeze your pelvic muscle again as you stand.
- Walk to the bathroom at a normal pace; do not rush or hurry.
- If the urge returns on the way to the bathroom, stop and squeeze away the urge again.

Peaks
Grows
Subsides
The urge...Starts
Urge Wave

Here are some other ways you can try to control your bladder urge:

- Use your pelvic muscle by doing 3 or 5 quick pelvic muscle squeezes and then completely relax with slow deep breathing.
- Distract yourself by doing something you enjoy, maybe work on a puzzle or play a game on your iPad or phone, or make a” to-do” grocery list.
- Use mind games. Turn your attention to counting backward from 100 by 7s or working on a crossword puzzle. Do a task that requires a lot of thought – for example, balance your checkbook, write a letter, or do handwork or some other activity that requires a great deal of attention.
- Use self-talk or good self-statements. Tell yourself: “I am the boss, not my bladder.” “I am in control.” “I can beat this.” Create a statement that fits your situation and personality the best. Keep saying this statement over and over until the feeling of urgency passes.

Wait a few minutes, then
First: Squeeze pelvic muscle quickly (5X5)
If urgency continues use distraction strategies
Sit & Be still
Peaks
Once urgency lessens or stops
Grows
Subsides
Wait 5 mins. Then walk slowly to the bathroom
The urge
Stops
Urge Wave

Training your bladder

- Once you are able to control your bladder urges, you can start training your bladder to hold more urine. The picture on the right shows a voiding schedule for bladder training.
- The goal is to pee no less than every 3 to 4 hours during the day.
- Follow the strategies to suppress urgency and once the urge sensation is not as strong, relax and wait 5 minutes, then walk slowly to the bathroom.
- Once you have success with controlling the urge and you are able to delay voiding, gradually increase the time you wait 15 to 20 minutes at a time.

Voiding schedule

If able to suppress urgency, delay voiding by 5 minutes

Once successful, expand voiding interval further by 15 to 20 minutes

Until a 3-4 hour voiding interval is achieved

0
5 mins
0
15-20 mins
3-4 hours

FIG. 121.9 Patient handout with instructions for the urge-suppression strategies and bladder training. (Adapted from Newman, Borello-France & Sung, 2018; Burgio et al, 1989; Wyman & Fantl, 1991; Newman and Wein, 2009, 2013.)

Once patients master the urge-suppression strategy, they are encouraged to delay voiding for 5 minutes to consolidate their skill. If they are voiding too frequently, this delayed voiding interval can be increased gradually until they achieve a normal voiding frequency.

The effectiveness of behavioral training with urge suppression as a stand-alone therapy for urgency UI has been established in several clinical series studies and in RCTs using intention-to-treat models, in which mean reductions of incontinence range from 60% to 80% (Burgio et al., 1998, 2002). In one RCT, behavioral training reduced incontinence episodes significantly more than individually titrated drug treatment, and patient perceptions of improvement and satisfaction with their progress were higher (Burgio et al., 1998).

This therapy has also been shown to reduce urgency, frequency, and nocturia in men and women. As an example, the Male Overactive Bladder in Veterans (MOTIVE) study compared behavioral training with urge suppression to antimuscarinic therapy (extended-release oxybutynin) in men with OAB in the absence of bladder outlet obstruction (Burgio et al., 2011). Mean 24-hour voids decreased significantly in both groups, and these reductions were statistically equivalent. In another trial, 24-voiding frequency was lower after treatment when compared with combination drug therapy (anti-muscarinic + an alpha blocker) (Burgio et al., 2018).

Behavioral training with urgency suppression has also been shown to reduce nocturia in men and women (Burgio et al., 2011; Johnson et al., 2005, 2013, 2016). Patients are instructed to use urge-suppression techniques when they wake up at night with bladder fullness or an urge to void. If the fullness/urge subsides, they are encouraged to go back to sleep. If after a minute or two the urge to void has not subsided, they are advised to get up and void, so as not to interfere unnecessarily with their sleep. Johnson et al. (2005) showed that behavioral training and drug therapy reduced nocturia more than placebo in women, and behavioral training was significantly more effective than drug therapy. In a study in men with OAB (Johnson et al., 2013), behavioral treatment (PFMT, delayed voiding, and urge-suppression techniques) and drug (antimuscarinic) therapy reduced nocturia in men when added to alpha-blocker therapy, but the addition of behavioral treatment was statistically better than the addition of antimuscarinic therapy for nocturia. In a trial with men with nocturia, behavioral training, alone or combined with alpha-blocker therapy, showed large and statistically significant nocturia reductions (Johnson et al., 2016).

There is also evidence that combining behavioral training with drug therapy can improve outcomes of drug therapy for urgency UI. In a multi-site trial conducted by the National Institute of Diabetes and Digestive and Kidney Diseases (NIDDK) Urinary Incontinence Treatment Network, women with urge-predominant incontinence were randomized to receive extended-release tolterodine with or without behavioral training. Women who underwent behavioral training in addition to drug therapy reported greater improvements on patient perception of improvement, patient satisfaction, and validated measures of symptom distress and bother while on active therapy, as well as 6 months after drug therapy was discontinued (Burgio et al., 2008). In an RCT of combined behavioral and drug therapy in men with voiding frequency, mean voiding frequencies after treatment were significantly lower in the combined therapy group compared with the drug alone but not significantly lower than the behavioral-alone group. Further, combined therapy yielded the best results on secondary outcomes, including patient perception of improvement and satisfaction (Burgio et al., 2018).

In addition to be a central element of behavioral training, the urge-suppression strategy has also been adopted as one of several techniques to help patients postpone voiding in BT or delayed voiding programs.

Role of Biofeedback

BF is not a treatment but a technique for teaching patients control over physical responses. Commonly known for its role in treatment of headaches, muscle spasm, and hypertension, it is also a very effective method for teaching bladder and PFM control in the treatment of LUTS. **BF helps patients learn by giving them precise, instantaneous feedback of their physiologic responses, such as PFM contraction.** The “perineometer” (see eFig. 121.7) developed by Dr. Kegel was a BF instrument that assisted women to learn PFM control by giving women immediate feedback of efforts to contract PFMs. BF may be especially helpful in patients who are having difficulty identifying and isolating the correct muscles, to track PFM strength during treatment or who need encouragement to continue with prescribed treatment.

Most BF instruments are now computerized and display feedback visually on a monitor (Fig. 121.10). **PFM activity can be measured by manometry or surface electrode electromyography (sEMG),** using vaginal or anal probes or surface skin electrodes. Signals are enhanced through the computer, and feedback is provided on a monitor for visual feedback (eFig. 121.11) or via speakers for auditory feedback. When patients observe the results of their attempts to control PFM muscle activity (Fig. 121.12 and eFig. 121.13), learning occurs by means of operant conditioning (trial and error learning).

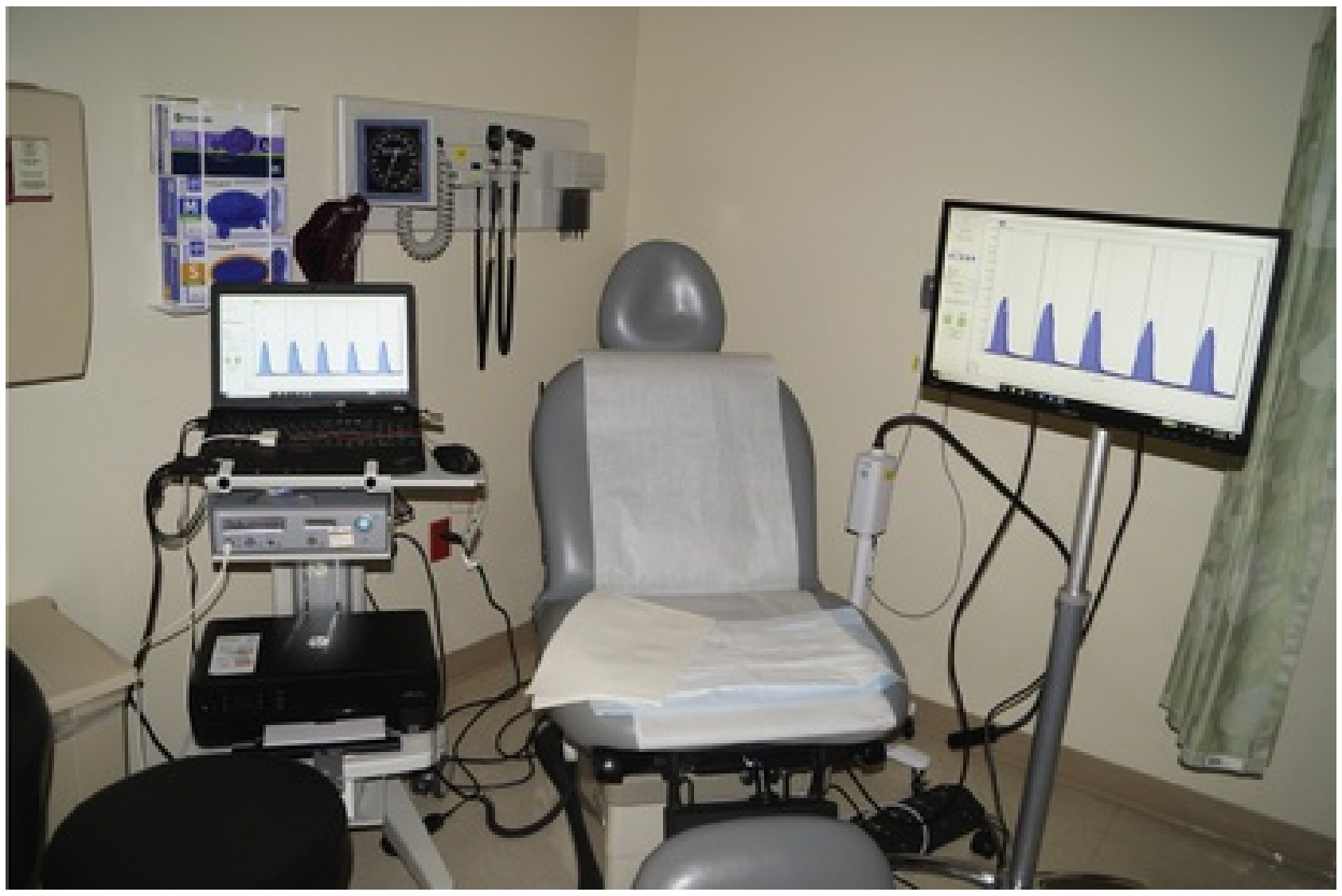

FIG. 121.10 Prometheus biofeedback equipment with monitors for visual

feedback.

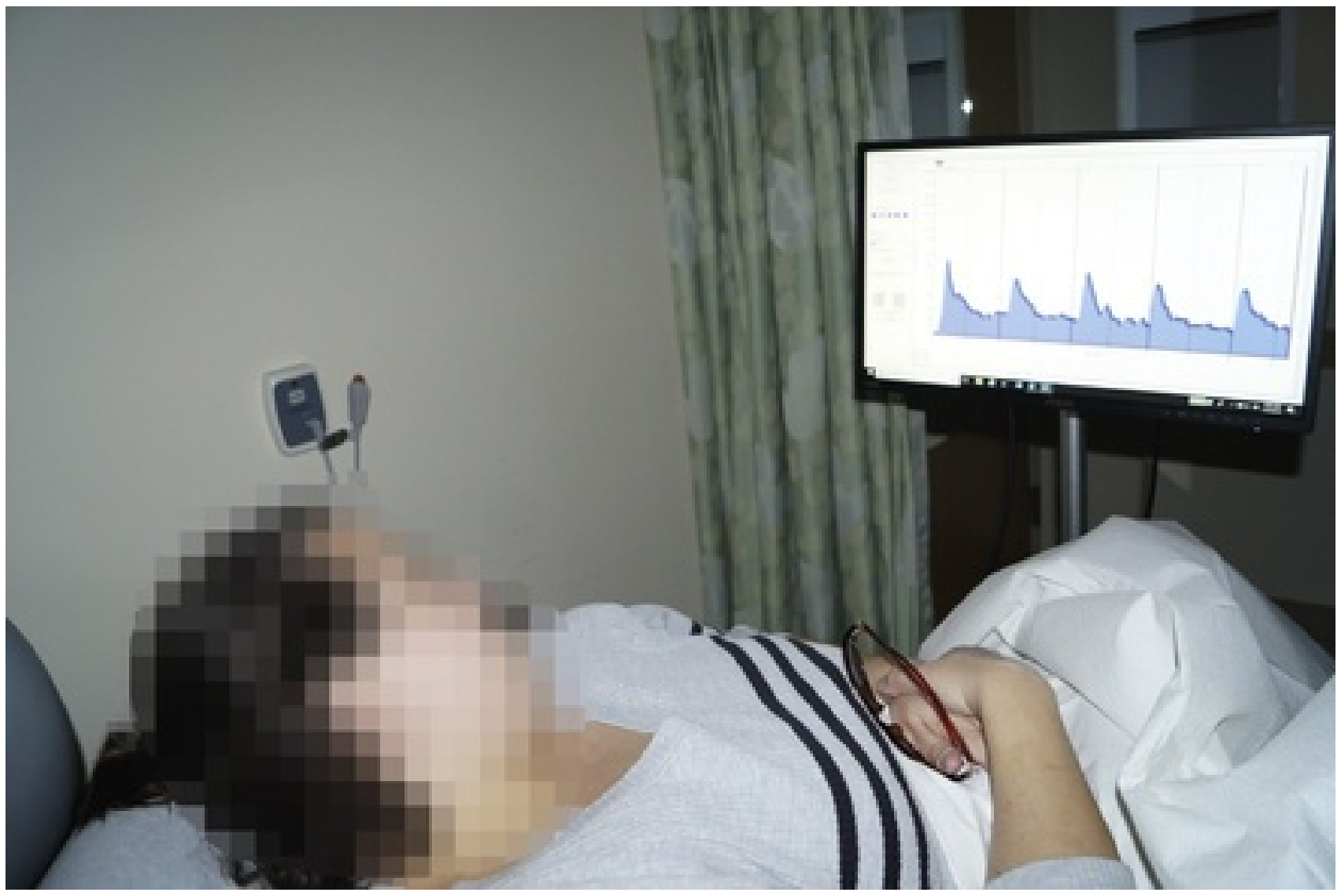

FIG. 121.12 Female patient reclining to view biofeedback monitor while contracting pelvic floor muscles.

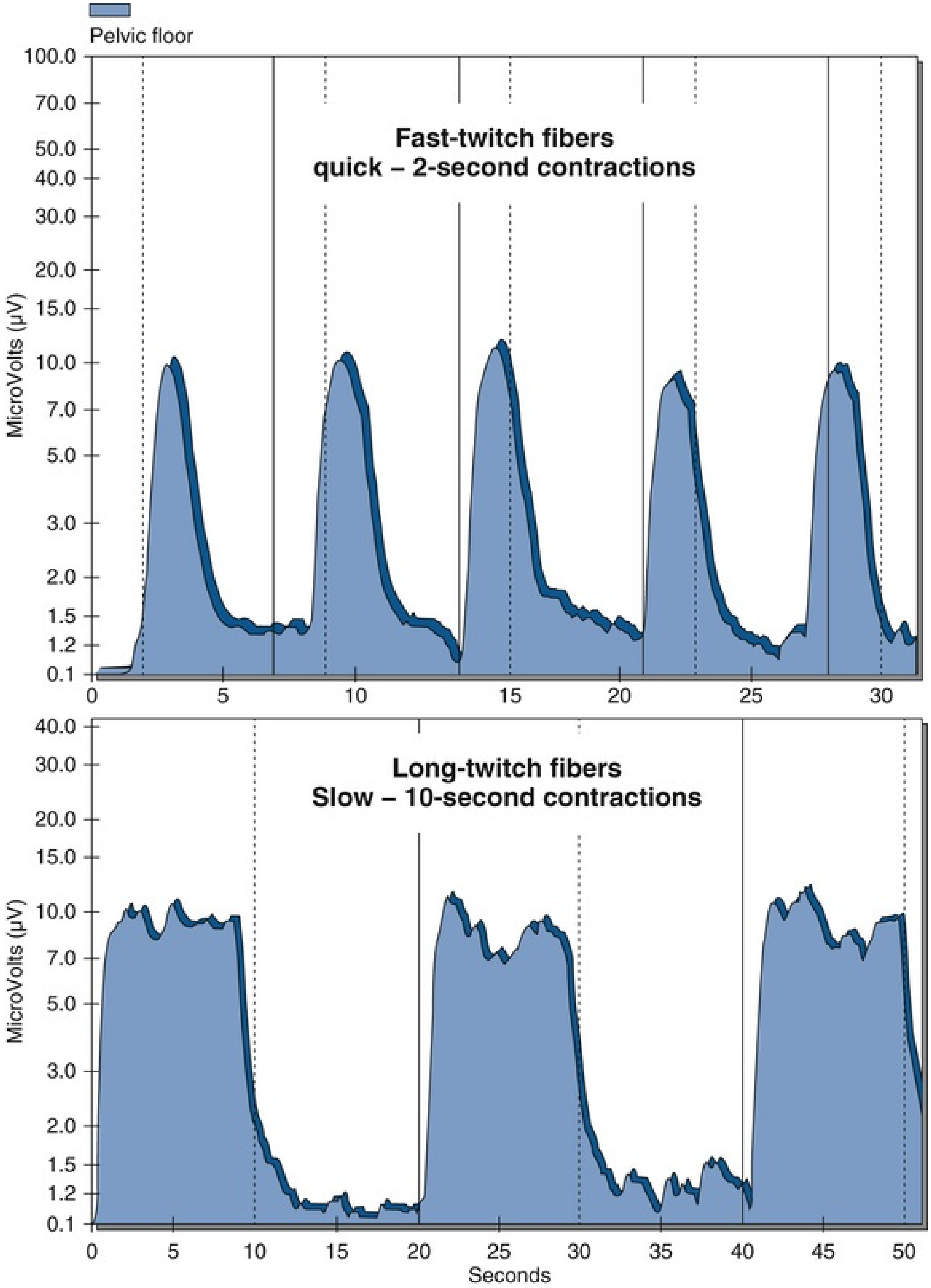

EFIG. 121.11 Biofeedback graph showing quick and long contractions.

EFIG. 121.13 Male patient sitting to view biofeedback monitor while contracting pelvic floor.

An advantage of EMG over manometric pressure is that, provided the machinery is of sufficient sophistication with adequate filtering, EMG apparatus can use the newer types of electrodes that are lightweight and designed to stay in place, therefore allowing more functional positions during assessment and treatment. Like other methods, EMG can be multi-channel, which allows the simultaneous display of PFM contraction and inhibition of counterproductive accessory muscle contractions (e.g., abdominal, gluteal muscle).

BF-assisted PFMT in conjunction with other conservative treatment components has been tested in several studies, producing mean reductions of UI ranging from 60% to 85% (Dumoulin et al., 2017). BF technology is an excellent method to help patients identify and exercise PFMs, but it is not the only effective method. **The literature is inconsistent on the issue of whether BF enhances outcomes of PFMT.** A 2011 Cochrane review (Herderschee et al., 2011, 2013) included 24 trials involving 1583 women and concluded that women who received PFMT with BF were significantly more likely to report cure or improvement compared with those who received PFMT alone. However, these studies should be interpreted cautiously because the treatment groups differed on parameters other than BF, such as preparation of the clinician providing the therapy, and women in the BF groups usually had more extensive contact with providers. Urology and urogynecology practices who offer conservative behavioral treatments and physical therapists who specialize in PFM rehabilitation commonly use BF as part of PFMT (Newman, 2014;

Newman and Wein, 2013; Schmitt et al., 2017; Starr et al., 2013, 2016).

Pelvic Floor Muscle Electrical Stimulation

PFM E-stim with a non-implanted device involves the application of a low grade of E-stim to the PFMs to stimulate a contraction in patients with different types of UI or symptoms of urgency, frequency, and nocturia (Newman and Wein, 2009). **E-stim has a twofold action: contraction of PFMs and inhibition of unwanted detrusor contractions** (Schreiner et al., 2013). E-stim is provided by office-based machines or portable battery-powered stimulators that are used in the medical office or by the patient at home. These units have different combinations of current types, waveforms, frequencies, intensities, electrode types, and placements.

Pelvic floor muscle E-stim is usually a component of conservative treatment in PFM rehabilitation practices; clinicians use it to assist in PFM identification (Starr et al., 2013). Patients with LUTS secondary to neurologic disease (e.g., multiple sclerosis) may also benefit from this treatment because E-stim can build muscle strength. Many clinicians institute this treatment in patients who have failed other behavioral and medical treatments and prescribe home units for long-term treatment. **There are two main types of E-stim:**

1. Long-term or chronic E-stim delivered below the sensory threshold aiming at detrusor inhibition by afferent pudendal nerve stimulation. According to Fall and Lindstrom (1994), the electrically evoked activity results in reflex activation of hypogastric efferents and central inhibition of pelvic efferent mechanisms sensitive to low-frequency stimulation. The device is used for 6 to 12 hours per day for several months.
2. Maximal E-stim, using a high-intensity stimulus (just below the pain threshold), aims to improve urethral closure by direct and reflexogenic contraction of striated peri-urethral musculature (Fall et al., 1991). Detrusor inhibition by afferent pudendal nerve stimulation has also been suggested as a mechanism (Berghmans et al., 2002). This type of E-stim is applied for short durations (15 to 30 minutes) several times a week (or one to two times daily using portable devices at home).

In the context of conservative therapy, E-stim is delivered transcutaneously via suprapubic, sacral, or external anal skin surface electrodes or intravaginal or intrarectal sensors. Parameters for E-stim include current source, pulse width and duration, current intensity (range), stimulus frequency, pulse shape, length of session, total number of sessions, and rest-to-work ratio, which are varied according to type of UI and type of electrical stimulation. Berghmans et al. (2002) reported that frequencies of 5 to 20 Hz are usually used for urgency UI, 20 to 50 Hz for stress UI (including post-prostatectomy), and for mixed UI around 20 Hz or high and low frequency alternately. Pulse durations range from 200 to 1000 µsec. The pulse shape is generally rectangular, and biphasic pulses are preferred.

The literature indicates that E-stim is effective for improving stress UI in women (Stewart et al., 2017) **and for urgency and mixed UI compared with sham or no treatment (**Dumoulin et al., 2017)**. However, it does not appear to enhance outcomes over those obtained through PFMT alone or PFMT with BF.** Less work has been done examining E-stim in men (Berghmans et al., 2013; Goode et al., 2011), and there is **little evidence to suggest that E-stim improves outcomes of PFMT, with or without BF, but it may hasten the recovery of continence after prostatectomy.**

Bladder Training and Scheduled Voiding Regimens

Scheduled voiding regimens, also known as toileting programs, have for decades been a mainstay of treatment for urgency UI and OAB. Scheduled voiding regimens include BT, timed voiding (TV), habit training (HT), and PV (eTable 121.4). Although these regimens share the common feature of being based on a toileting schedule, they differ on the role of the patient (active vs. passive), how adjustments are made to the voiding schedule, the nature of patient education, the use of reinforcement techniques, and the nature of the patient-provider interaction (Dumoulin et al., 2017). BT is self-administered and requires the patient to resist urgency and delay voiding. TV, HT, and PV most often rely on caregiver involvement.

eTABLE 121.4

Understanding Toileting Programs

TYPE	DEFINITION	KEY COMPONENTS
Timed voiding (or scheduled toileting)	Fixed, predetermined time intervals between toileting	The following is an example of a toileting program that can be used by institutions or caregivers that includes 8 times in a 24-hour period, or every 3 hours: • Day: Upon awakening, after breakfast, mid-morning, before lunch, and after an afternoon nap (mid-afternoon) • Evening: Before dinner and at bedtime • Night: Determine if person wants to be awakened at night to void and identify times.
Habit training	Fixed voiding schedule based on identified patterns of incontinence to pre-empt incontinence	Using a bladder diary, incontinence and voiding patterns are identified and an individualized toileting schedule is developed. In institutions such as nursing homes, a typical toileting schedule may be determined around daily events.
Prompted	Involves prompting and	The major elements of prompted

voiding	assisting patients to toilet and positive reinforcement for requesting toileting assistance either spontaneously or following verbal prompts from a caregiver	voiding are the following: • Monitoring: The caregiver checks on a regular basis (use toileting schedule described in scheduled toileting) and person is asked to report verbally if wet or dry. • Prompting: The person is asked if they need to void and assisted with voiding. • Praise and encouragement: The caregiver provides these if the person is continent. Most successful in individuals who can ask for assistance or void when prompted.
Functional incidental training	Combines prompted voiding with functionally oriented, low-intensity endurance and strength-training exercises	Combines mobility and transfer training with prompted voiding
Bladder training	Training involves establishing a voiding schedule and incrementally increasing the voiding interval	Promotes restoration of normal bladder function through incremental voiding schedules and education regarding urge inhibition techniques. Requires person to be able and willing to participate actively. Four primary components: 1. Education program that usually combines written, visual, and verbal instruction addressing the physiology and pathophysiology of the lower urinary tract 2. Scheduled voiding with systematic delay of voiding that requires the ability to resist or inhibit the sensation of urgency to postpone voiding and to urinate according to a timetable rather than according to the urinary urge 3. Use of techniques to suppress urgency (quick PFM contractions, deep breathing with relaxation, distraction techniques) 4. Gradual increases in voiding interval 5. Reinforcement through consistent encouragement and positive feedback

Modified from Flanagan L, Roe B, Jack B, et al.: Systematic review of care intervention studies for the management of incontinence and promotion of continence in older people in care homes with urinary incontinence as the primary focus (1966-2010). *Geriatr Gerontol Int* 12(4):600–611, 2012; Newman DK, Burgio KL, Markland A D, Goode PS: Urinary incontinence: nonsurgical treatments. In Griebling TL, editor: *Geriatric urology,* London, 2014, Springer-Verlag, Ltd, p 142; Newman DK, Wein AJ: *Managing and treating urinary incontinence,* ed 2, Baltimore, 2009, Health Professions Press, pp 245–263.

Bladder Training

BT is a behavioral intervention developed originally for the treatment of urgency UI. Many patients who experience urgency UI or urgency without leakage tend to void frequently. This response provides immediate relief from the sensation of urgency, but it sets the stage for more and more frequent urination. Once frequent voiding becomes a habit, it can be difficult to change and may lead to reduced functional bladder capacity, detrusor overactivity, and in some cases, urge UI. Detrusor overactivity produces urgency, completing a cycle of urgency and frequency that is then perpetuated. **This cycle can be broken using BT or a program of progressive delayed voiding.**

The goal of BT is to restore normal bladder function and capacity using consistent, incremental voiding schedules. First known as bladder drill, it was an intensive intervention that was often conducted in an inpatient setting. Now the program is implemented more gradually in an outpatient setting. **Bladder training is a multi-component intervention that involves patient education regarding lower urinary tract function, setting incremental voiding schedules, and teaching urge control techniques to help patients postpone voiding and adhere to the schedule** (Fantl et al., 1991; Wallace et al., 2009; Wyman and Fantl, 1991).

Usually BT begins with the patient completing a bladder diary to document voiding patterns and frequency. Based on the diary, an initial voiding interval is established (Dumoulin et al., 2017). Often, this is a 1-hour interval during waking hours, although a shorter interval (e.g., 30 minutes or less) may be necessary at first. Another method is for the clinician to select a voiding interval based on the longest time interval between voids that is comfortable for the patient. The patient is to void upon waking in the morning, every time the interval has passed, and just before bedtime. The schedule is increased by 15 to 30 minutes per week depending on the patient's tolerance of the schedule (i.e., fewer incontinent episodes than the previous week, minimal interruptions to the schedule, and the individual's control over urgency) (see Fig. 121.9).

In BT the patient is asked to postpone urination, which for most patients involves coping with the sensation of urgency while they wait. **The approach used in clinical practice to manage urgency has been to suggest various techniques for relaxation or distraction to another activity** (Fantl et al., 1991, Wyman, 2007; Wyman and Fantl, 1991). Patients are encouraged to get their mind off the bladder by engaging in an activity that requires mental but not physical effort (see Fig. 121.9).

Common activities include playing a game on a mobile device such as an iPad or phone, reading, or making a to-do list. Distracting attention from the bladder in this way can reduce anxiety and allows time for the urge to subside. Also used are affirming self-statements such as “I am in control of my bladder,” or “I can wait.”

Another method for postponing urination is performing a few quick PFM contractions. Shafik and Shafik (2003) demonstrated detrusor relaxation in response to a PFM contraction in men and women with OAB ($n = 28$) and without ($n = 17$). They hypothesized the quick muscle contraction created a mechanical compression of the urethra for a few seconds causing inhibition of a detrusor contraction leading to reduced desire to void. **So repeated rapid contractions of the PFM (termed “quick flicks”) with the individual remaining posturally still and waiting for the sensation to pass (urge suppression) has proven to be a useful adjunct to BT regimen for OAB** (Dumoulin et al., 2017; Newman et al., 2018; Newman and Wein, 2009).

Ideally, the clinician should monitor a patient's progress on a weekly basis during the training period, make individualized adjustments to the voiding interval, and provide positive reinforcement during the training period. **Patient self-monitoring using voiding diaries is a useful tool to help the patient and clinician evaluate adherence to the schedule, evaluate progress, and determine whether the voiding schedule should be changed.**

The underlying mechanisms of how BT works are unknown. However, one of the most important features of BT is that it dissociates voiding from urgency, and it may be that voiding by the clock, rather than in response to urgency, weakens the urge-void response. Other hypotheses include improved cortical control of bladder activity and urethral closure, improved central modulation of afferent stimuli, altered behavior because of better awareness of lower urinary tract function, and increased bladder capacity.

Evidence for Bladder Training

Several systematic reviews have been published that provide synthesis and grading of evidence for BT in the treatment of UI or urgency UI (Berghmans et al., 2002; Dumoulin et al., 2017; Fantl et al., 1996; Moore et al., 2013; Roe et al., 2007, Wallace et al., 2009). The ICI included RCTs with participants who had UI (urgency, stress, and mixed), as well as participants who had OAB without UI. Based on 17 trials involving 2462 women and five trials with 142 men, the ICI noted and described remarkable variability in BT protocols and concluded that there was no evidence to suggest the most effective method or specific parameters of BT. However, they **recommend that clinicians provide the most intensive BT supervision possible within service constraints** (Dumoulin et al., 2017).

From the few trials available of BT **in women with urgency UI, stress UI, and mixed UI, the ICI concluded that BT is more effective than no treatment, but there was insufficient evidence to draw conclusions on its effect in men. They also found insufficient evidence to draw conclusions on the comparative effectiveness of BT and current drug therapy, or for their combined effectiveness for women with detrusor overactivity or urgency UI.**

In a comparative effectiveness review of nonsurgical treatments for UI in women, the Agency for Healthcare Research and Quality (AHRQ) (Shamliyan et al., 2008) found that UI outcomes did not differ between BT and PFMT, nor were there differences between BT alone and BT combined with PFMT.

Other Scheduled Voiding Regimens

Toileting programs are the cornerstone of continence care for cognitively impaired patients. Other than BT, toileting programs are usually “caregiver dependent,” defined as the need for a professional or family caregiver to assist with toileting (Newman and Wein, 2009). **Scheduled voiding can be beneficial for toileting-dependent residents in nursing homes or individuals living at home who have an available and willing caregiver.** Individuals who have difficulty or require human or mechanical assistance with toileting are referred to as having “toileting disability” (Talley et al., 2014). These individuals may have mobility or cognitive impairment, may need some assistance from at least one person, but are able to cooperate with toileting. The choice of timed voiding, habit training, or a prompted voiding program is determined by the cognitive and functional status of the individual, the variability of the voiding pattern, and the need for reinforcement for adherence to the regimen.

Timed Voiding

Timed voiding (TV) has also been called scheduled toileting, routine toileting, and fixed toileting. **The goal of TV is to prevent incontinence by providing regular opportunities for bladder emptying before the bladder reaches capacity.** Keeping the bladder volume below capacity may decrease leakage associated with a detrusor contraction that occurs with a full bladder, as well as decrease leakage that may occur with stress UI. No other physiologic mechanism has been determined. TV has been recommended for patients who cannot toilet independently. It has been **used primarily in institutional settings as a passive toileting assistance program, in which a caregiver takes the patient to void every 2 to 4 hours except at night, and for patients with neurogenic bladders associated with spinal cord injuries** (Ostaszkiewicz et al., 2004a, 2005a,b). Ideally, the schedule for toileting is based on some objective measure, such as a bladder diary, on data collected using a bladder volume recording instrument (Newman et al., 2005; Suzuki et al., 2019), or from an electronic device used to monitor and record incontinence episodes (Colling et al., 2003).

TV is a “passive” type of toileting program, because it takes place whether or not the patient has a sensation to void, but the schedule is usually only followed during waking hours (Ostaszkiewicz et al., 2005a,b). The goal is to keep the person dry, and no effort is made to motivate the person to resist the urge to urinate. **Although fewer than 20% of frail elders become completely dry with TV, between 30% and 50% of incontinent elders may improve,** reducing the number and volume of incontinence episodes. This is probably also true in people being cared for in their homes.

TV can also be useful for cognitively intact elders who have developed bladder sensory impairment because of neurologic conditions. Voiding by the clock, instead of waiting for urgency, and before spontaneous bladder emptying occurs, can prevent or reduce incontinence. A brief, 2- to 3-day trial of timed voiding can determine if it will be successful for an individual. TV is also intended to normalize frequency in a patient with infrequent voiding and/or diminished sensation (Payne, 2012).

Habit Training

Habit training (HT) is a variant of TV, with the difference being that the **toileting**

schedule is matched to the patient's voiding pattern, rather than being fixed as it is in TV. Using the patient's bladder diary, a toileting schedule is assigned to fit a time interval that is shorter than the patient's normal voiding pattern and to precede the time period when incontinent episodes are expected. Thus the voiding interval may be lengthened or shortened throughout the day depending on the patient's voiding pattern with the goal to preempt incontinence. In the traditional applications of HT, **it is a caregiver-dependent toileting assistance program that is initiated and maintained by the active involvement of a professional or family caregiver** (Ostaszkiewicz et al., 2004b).

HT has primarily been used in institutional settings with cognitively and physically impaired adults; but it also has been tested with the homebound elderly population (Colling et al., 2003). The interval may be set permanently or gradually increased.

Colling et al. (2003) developed an HT program called pattern urge-response toileting (PURT) and tested it with 78 caregiver-dependent (relatives, primarily spouses) homebound frail elders. Three weeks of voiding patterns were obtained from electronic data logs; individualized toileting schedules were identified based on each person's voiding pattern; and caregivers were taught when and how to toilet the care recipient. The PURT program reduced the number of incontinent episodes over 24 hours by 18%, decreased the mean number of daily episodes from 4.9 to 4.0, and reduced the volume of UI over 24 hours by 39%.

Prompted Voiding

Prompted voiding (PV) is a toileting program that combines scheduled voiding with "prompting" from a caregiver with contingent social approval (Wagg et al., 2017). **It is used to teach people with or without cognitive impairment to initiate their own toileting through requests for help and positive reinforcement from caregivers when they do so.** It has been used primarily in nursing home settings with cognitively and physically impaired older adults (Burgio et al., 1994; Eustice et al., 2000; Schnelle et al., 1989) as well as in home care settings (Engberg et al., 2002).

Prompted voiding has **three components:** (1) regular monitoring with encouragement to report continence status, (2) prompting of the individual to toilet on a scheduled basis, and (3) praise with positive feedback when the individual is continent and tries to toilet (Lekan-Rutledge, 2000; Lyons and Specht, 2000). PV is appropriate for older adults with urgency, mixed, or functional UI and includes cognitively intact and impaired individuals

(Newmanet al., 2018). The main requirement of PV is the *consistent* availability of a caregiver to provide the voiding prompts to incontinent individuals. For PV to be effective, individuals must be able to delay voiding and cooperate with toileting or have awareness of when they need to void.

A systematic review (Flanagan et al., 2012) of four RCTs from 1996 to 2010 of **the management of incontinence in care homes using PV showed a decrease in incontinent episodes.** PV has been shown to be effective in the short-term treatment of daytime UI in nursing home residents and home care clients when caregivers comply with the protocol (Wagg et al., 2017). The majority of the research has shown that between 25% and 40% of incontinent nursing home residents respond well to toileting assistance, whereas approximately 38% cannot successfully toilet, even when provided help by research assistants (Ouslander et al., 1995a). In one study of 191 incontinent residents in seven nursing facilities, 25% to 40% responded well to PV during the day, with incontinence episodes decreasing from three or four during the day to one or none.

Ouslander et al. (2005) combined PV with other activities of daily living, as part of a multi-component intervention known as functional incidental training (FIT). FIT used a “designated” versus “integrated” nursing assistant role to combine restorative care including a walking program, exercise therapy, and continence care. This intervention has repeatedly been shown to improve physical function, as well as UI in nursing facility residents (Ouslander et al., 2005; Schnelle et al., 1995). A 3-day trial of PV can demonstrate whether or not it is likely to be effective (Ouslander et al., 1995a).

Lai and Wan (2017) conducted an RCT to examine the effectiveness of the use of PV by nursing home staff in managing UI among residents in five nursing homes in Hong Kong over a 6-month period. There were significant differences between the two groups in wet episodes per day, incontinence rate per day, and total continent toileting per day at 6 months’ post-intervention. A decrease of 9.1% was observed in the incontinence rate of the intervention group. The PV program delivered by staff was sustainable for a 6-month period.

Another method to individualize PV is through the use of bladder volume instruments to scan the bladder to determine amount of urine in the bladder. Suzuki et al. (2019) conducted an RCT in 13 nursing homes in Japan and compared the efficacy and feasibility between ultrasound-assisted prompted voiding (USAPV) and conventional prompted voiding (CPV) in decreasing daytime urine loss in residents with UI. Residents were randomized to either a

CPV (*n* = 7) or USAPV group (*n* = 6). Over an 8-week period, staff conducted PV every 2 to 3 hours on the CPV group, but in the USAPV group, staff monitored bladder volume using an ultrasound device and prompted the resident to void when the volume reached optimal bladder capacity. Measurement of urine loss was recorded using a frequency-volume bladder chart at baseline and after the 8 weeks. The change in daytime urine loss was greater in the USAPV (median, −80 g) than in the CPV group (median, −9.0 g; $P = 0.18$). At the end of the 8 weeks, daytime urine loss less than 25% was seen in 51% of the USAPV group and only in 26% of the CPV group ($P = 0.010$). However, QoL measures were unchanged in either group. Caregiver burden scale score worsened in the CPV group.

Challenges of Caregiver-Administered Voiding Schedules.

The impact of a toileting regimen on caregivers can be significant (Roe et al., 2011). **UI management has been rated as the third most troublesome caregiving task,** behind a lack of time for their own needs and managing the care recipient's emotional and behavioral problems (Colling et al., 2003). Engberg et al. (2002) reported areas of caregiver strain in relation to incontinence, including odor (56%), toileting (55%), changing pads and clothing (53%), UI-related costs for pads or briefs (53%), wet clothing (50%), and changing bed linens (44%). Drennan et al. (2012) conducted a qualitative study of managing incontinence for people with dementia living at home and found that toilet prompting or reminding can lead to irritation and arguments because patients perceive this as being treated like a child.

Delayed Voiding

Delayed voiding is another approach to helping patients to expand the interval between voids. It differs from BT in that patients are not placed on a predetermined voiding schedule. When first experiencing an urge to void, patients are instructed to use their urge-suppression techniques until the urge subsides. However, instead of going to the bathroom immediately after suppressing the urge, they postpone urination by waiting 5 minutes before voiding. This technique can be used in combination with other behavioral components (BT, PFMT, urge suppression) to reduce excessive voiding frequency (Burgio et al., 2011).

In patients who have experienced urgency UI, even a mild urge to void triggers a trip to bathroom as soon as possible because of the fear of leakage otherwise. However, most patients can be convinced to try a 5-minute delay, particularly in safe circumstances such as being at home alone. Often, they are surprised to find that after a brief wait, the urge subsides or disappears altogether. This enhances their sense of control and helps restore confidence so that they can gradually increase the delay time to achieve a normal frequency.

Behavioral Treatment for Voiding and Pelvic Floor Dysfunction

Pelvic floor muscle dysfunction, especially PFM overactivity (high-tone PFM dysfunction), is characterized by elevated resting tone (hypertonicity) and decreased relaxation capacity. It manifests in such symptoms as pelvic floor tenderness/pain, bladder pain syndrome, and/or voiding symptoms, including hesitancy, straining to void, and incomplete bladder emptying. Assessment includes digital palpation of the PFMs to detect tenderness and pain, resting tone, contraction strength, and ability to relax. Some women have an “overactive pelvic floor” characterized by generally high resting tone. Others may have increased muscle tension only when attempting to void.

When muscle tension or spasm is detected, behavioral treatment focuses on teaching conscious relaxation of PFM, especially in the context of voiding. The first step is to educate the patient about bladder and pelvic floor anatomy and function. Normal voiding is a coordinated process, in which pelvic floor relaxation precedes and can initiate detrusor contraction and urethral relaxation. Some women habitually void by Valsalva, believing that they need to bear down to push urine out and empty the bladder. This can result in a reflex contraction of the PFMs, impeding urine flow. Patients with dysfunctional voiding need to understand that pushing is not necessary and may be counterproductive. Instead, they can facilitate voiding through volitional PFM relaxation, which will allow the bladder to empty naturally.

PFMT focuses on developing an awareness of muscle tension as distinct from muscle relaxation. Actively contracting the muscles demonstrates the sensations associated with muscle tension and assists patients to discriminate and contrast it with the sensations of relaxation. An active contraction also leads to a more complete subsequent relaxation. BF can also be used to bring muscle tension to a conscious level.

Using PFMT to enhance muscle relaxation in patients with high-tone PFM is referred to as “down training.” Teaching a muscle to relax is often more difficult than teaching it how to contract (up training). Pain patients will often benefit from BF-assisted PFMT, which enables them to coordinate PFM movement with the BF visual signal. Once they are able to feel the muscle release and relax, the patient can begin coordination of muscle relaxation following a contraction.

As with PFME for incontinence, daily exercise involves not only contracting but also relaxing muscles fully between contractions. This is particularly important for patients with voiding dysfunction. To emphasize relaxation, these patients are taught to focus more on the relaxation phase, which is extended with a 1 : 4 ratio or longer as indicated.

Once the patient has learned the sensation of adequate PFM relaxation during exercise sessions, it is important to address voiding habits so that the relaxation skills can be generalized. For many women, voiding is an activity that is rushed because of a busy lifestyle, and they do not take the time needed to allow normal voiding. **With behavioral treatment, patients are encouraged to create a relaxing environment and plan adequate time for voiding.** They are instructed in good voiding technique. Specifically, they are to slow down, take a deep breath, relax their body, relax their PFMs, and wait for the urine to flow. Anecdotally, some women benefit from double voiding, or lingering until another detrusor contraction occurs, leading to more complete emptying. A second void can be facilitated by rising up from the toilet seat slightly, sitting back down, and relaxing the PFMs once more.

Lifestyle Modifications

In addition to the behavioral interventions that improve symptoms through teaching new skills or strategies, there are a number of lifestyle modifications that change a person's habits and/or lifestyle choices to mitigate factors that may contribute to LUTS. Lifestyle modification involves a conscious choice by the individual to change a practice that is under their control and may contribute to LUTS. Lifestyle modifications are sometimes referred to as “self-care practices.” They can be used as a primary intervention in some cases, but usually they are adjunctive. Lifestyle changes include **fluid management, reduction of caffeine and other dietary irritants, addressing constipation, smoking cessation, and weight loss. Although there is much less evidence for lifestyle modifications** (Imamura et al., 2015), **these changes can have a significant impact on overall bladder health and have become integral to conservative management** (Burgio et al., 2013).

Fluid Management

Fluid intake plays a role in the prevention of several urinary system diseases, and adverse effects on the urinary system can result from insufficient hydration.

Modifying the type or volume of fluids, either as a primary or as an adjunctive strategy, is often recommended to optimize outcomes as part of conservative intervention for LUTS. Fluid intake modifications depend on the patients' pattern of intake, which can be assessed by having them complete a 24- to 48-hour diary of intake and output, including voided volumes when possible. Reviewing such a diary can reveal excessive fluid intake, inadequate fluid intake, and diurnal patterns of intake that may be contributing to LUTS.

Excessive Fluid Intake.

Excessive fluid intake **can be a problem when large-volume intake triggers symptoms of urgency, frequency, or incontinence** (Segal et al., 2011). Fluid intake averaging more than 3700 mL/day has been associated with higher voiding frequency and incidence of UI compared with an intake of approximately 2400 mL/day (Miller et al., 2011). In a study of healthy young men, those with excessive fluid intake had not only significantly increased urine volume and frequency but also significantly elevated bladder pressure on ambulatory urodynamics (Schmidt et al., 2004). Some people increase their fluid intake deliberately in an effort to "flush" their kidneys or lose weight. In others it is simply a habit. In in-depth interviews conducted with participants in the Boston Area Community Health (BACH) study (Elstad et al., 2011), women reported the need to increase fluid intake attributing it to popular health messages recommending daily fluid intake and that water was "good for you." Men, on the other hand, tended to describe the function of water in the body was to ward off infection, "flush out the kidneys," or "keep your system cool." **When patients consume an abnormally high volume of fluid (e.g., >2100 mL of output per 24 hours), reducing excess fluids is often an appropriate measure and can be helpful for reducing urgency, frequency, and urgency incontinence**.

Inadequate Fluid Intake.

In practice, it is more common to see inadequate fluid intake, because people with bladder problems often restrict their intake in an effort to control symptoms. In the BACH study interviews (Elstad et al., 2011), men and women across all three racial/ethnic groups reported decreasing fluid intake to manage or cope with urinary symptoms. Studies of community-residing elders with LUTS also report self-care practices including self-imposed restrictions of fluids to prevent urinary urgency, frequency, and incontinence (Brink et al., 1987; Diokno et al., 2004a, 2006; Johnson et al., 2000; Miller et al., 2003; Wyman and Fantl, 1991; Wyman et al., 2009). Working women also report limiting fluid intake as strategies to avoid urinary symptoms (Fitzgerald et al., 2000, 2002; Nygaard et al., 1997).

In some cases, particularly in older adult women, the resulting fluid intake may be inadequate and places them at risk of dehydration. Underhydration may play a role in the development of urinary tract infections and constipation and decrease the functional capacity of the bladder. In a study of 791 female teachers, those who drank less than the volume they desired had more than twice the risk of UTI (Nygaard et al., 1997).

Fluid intake should be regulated to 6 to 8 8-ounce glasses or 30 cc/kg body weight per day with a 1500 mL/day minimum at designated times unless contraindicated by a medical condition. The Institute of Medicine issued a report (2005) **with guidelines for total water intake for healthy people**. **That recommendation for women was 2.7 L per day but was intended to include water consumed through beverages and food.** This food versus fluid component has been a source of confusion for the public and professionals, with a misperception of fluid source as only deriving from beverage intake. In an older adult, who may be limiting fluid intake because of the fear of LUTS and is at risk for dehydration, an oral fluid record should be considered (Palmer et al., 2014).

A useful strategy to encourage increased fluid intake when appropriate is to point out that concentrated urine has a stronger odor than more dilute urine. Patients with incontinence are often sensitive about urinary odor and welcome a suggestion to decrease odor.

Timing of Fluid Intake.

Although overall fluid restriction is not a good strategy, **it can be very helpful to restrict fluids at particular times when toilet access will be limited,** such as before a social outing. Patients using temporary fluid restriction should be encouraged to keep their total daily fluid intake optimized, by making up the missed fluids earlier or later.

Avoiding excessive fluid intake in the evening hours can also be helpful for reducing nocturia (e.g., 3 to 4 hours before bedtime)**. In patients who retain fluid during the day and have nocturia resulting from mobilization of fluid during sleep, behavioral interventions focus on managing daytime accumulation of fluid. Patients are advised to wear support stockings to**

prevent accumulation of edema fluids or to elevate the lower extremities in the late afternoon to mobilize the fluid well before bedtime.

In some patients, a mid- to late afternoon loop diuretic is useful to complete diuresis before bedtime. For patients who are already taking a loop diuretic, nocturia can often be improved by altering the timing of the diuretic (so that most of the effect has occurred before bedtime). Loop diuretics are also known to aggravate incontinence by increasing the rate of bladder filling and producing sudden urges. Such effects can sometimes be avoided by discontinuing the diuretic, changing to a non-loop diuretic, or altering the timing of administration. An example is taking the loop diuretic in the later afternoon or *after* coming home from work so that diuresis can be accomplished during the evening, but before bedtime.

Evidence for Fluid Management.

Although fluid management is widely used in clinical practice, **there is little scientific evidence on fluid intake related to bladder health.** Two small randomized trials suggest a negative effect for increased fluid intake. In one study ($n = 24$), adults with OAB were randomized to either decrease or increase fluids (Hashim and Abrams, 2008). When patients decreased their fluid input by 25%, there was a significant reduction in daytime frequency (23%), urgency (34%), and nocturia (7%). Increasing fluid input by 25% and 50% resulted in a worsening of daytime frequency but had no effect on urgency, nocturia, or urgency incontinence. In a study of women with urodynamically confirmed idiopathic detrusor overactivity ($n = 30$), decreasing fluid intake significantly decreased voiding frequency and urgency incontinent episodes (Swithinbank, Hashim, and Abrams, 2005). However, the Nurses’ Health Study prospectively investigated the association between total fluid intake and incident UI over 4 years in 65,167 women and found no association between fluid intake and UI (including stress, urgency, and mixed UI) (Townsend et al., 2011).

Caffeine Reduction

Caffeine plays a role in symptoms of urgency, frequency, and urgency incontinence partly because it is a diuretic and partly because it is a bladder irritant for many people. The consumption of caffeinated beverages, foods, and medications is easily underestimated. Caffeine is found in many foods and drinks that people consume daily, particularly coffee and tea. Caffeine is consumed regularly by more than 85% of adults in the United States (Mitchell et al., 2014). Approximately 73% of children consume caffeine on a given day, and coffee and energy drinks represent a greater proportion of caffeine intake than soda intake, which has declined (Branum et al., 2014).

Urodynamic studies have shown that caffeine increases detrusor pressure (Creighton and Stanton, 1990) and is a risk factor for detrusor overactivity (Arya et al., 2000; Holroyd-Leduc et al., 2004). Caffeine promotes LUTS via decreased threshold of sensation in the filling phase and increased flow rate and voided volume (Jura et al., 2011; Lohsiriwat et al., 2011). Lohsiriwat et al. (2011) found that caffeine, at a dose of 4.5 mg/kg, caused diuresis and decreased the threshold for bladder sensation in the filling phase, with an increase in flow rate and voided volume. Similarly, daily administration of oral caffeine (150 mg/kg) resulted in detrusor overactivity and increased bladder sensory signaling in the mouse (Kershen et al., 2012).

Caffeine intake has also been associated with LUTS in epidemiologic studies in men (Davis et al., 2013) and women (Gleason et al., 2013; Jura et al., 2011; Townsend et al., 2012). Data from the Nurses' Health Study II reported that 25% of these participants experienced frequent (at least once a week) UI with high caffeine intake (Townsend et al., 2012). The BACH study reported on beverage intake and LUTS in a large cohort (n = 4144) (Maserejian et al., 2013). Women who had increased coffee intake by at least 2 servings/day had 64% higher odds of progression of urgency. Women who had recently increased soda intake, particularly caffeinated diet soda, had higher symptom scores, urgency, and LUTS progression.

In men, greater coffee intake (>2 cups/day vs. none) or total caffeine intake at baseline increased the odds of storage symptom progression (Maserejian et al., 2013). Davis et al. (2013) also found that caffeine consumption (equivalent to approximately 2 cups of coffee daily; 250 mg) was significantly associated with moderate to severe UI in US men.

There is also evidence that reducing caffeine intake can help to reduce episodes of stress and urgency incontinence (Bryant et al., 2002; Gray, 2001; Tomlinson et al., 1999). **Based on the literature, the ICI recommends a reduction in caffeine intake to improve incontinence and related symptoms** (Dumoulin et al., 2017). However, the amount of caffeine reduction necessary to prevent associated LUTS is not known.

Many patients are reluctant, initially, to forgo their caffeinated beverages, but they may be convinced to try it for a short period of time, such as 3 to 5 days, to determine if they are sensitive to caffeine's effects. If they experience relief from their symptoms, they are often more willing to reduce or eliminate caffeine from their diet. To avoid symptoms of caffeine withdrawal, most notably headaches and irritability, it is recommended that caffeine reduction be approached gradually and include mixing caffeinated and decaffeinated beverages incrementally over several weeks.

Other Dietary Irritants

Although data are scarce, there are a number of other substances that are thought to irritate the bladder, including sugar substitutes (aspartame), citrus fruits, highly spiced foods, and tomato products. There are innumerable clinical cases in which these substances appear to be aggravating urgency and incontinence, and reducing them has provided clinical improvement. However, this should not be interpreted to mean that all patients with LUTS should eliminate these foods from their diets. **A diary of food and beverage intake is useful for identifying which substances are in fact irritants for individual patients;** and a trial period of eliminating these substances one at a time can be used to confirm the relationship.

It has also been **suggested that alcohol intake can contribute to urgency, frequency, and incontinence by means of a diuretic effect. However, there is little in the literature to support this hypothesis.** In a study of alcohol consumption and UI among community-dwelling Japanese women (Hirayama and Lee, 2012), increases in risk of UI with alcohol drinking and mean ethanol intake did not reach statistical significance.

A study in men concluded that among other factors, alcohol consumption was an avoidable risk factor for the development of LUTS (Haidinger et al., 2000). Another study in men aged at least 20 years demonstrated that high alcohol consumption was a factor positively associated with an increased risk of moderate and severe LUTS (Seim et al., 2005). Research is needed on the effect of caffeinated alcoholic beverage on LUTS because consumption is widespread among adults in the United States (MacKillop et al., 2012). Acidic liquids and fruit intake are also thought to contribute to UI, but Townsend et al. (2013) found no relation between acidic fruit intake and UI in a large prospective study of women enrolled in the Nurses’ Health Studies.

Bowel Function

Bowel disorders, including chronic constipation (fewer than 3 stools per

week) and straining during defecation, have been linked to LUTS (Cardozo and Robinson, 2002; Carter et al., 2012), and the ICI committee concluded there is "some evidence" to suggest that chronic straining during defecation may be a risk factor for the development of UI (Dumoulin et al., 2017). The proximity of the bladder and urethra to the rectum and their similar nerve innervations make it likely that there are reciprocal effects between them. As early as 1988, Lubowski reported that denervation of the external anal sphincter and PFMs may occur in association with a history of excessive straining on defecation (Lubowski et al., 1988). Many believe that if straining is a lifetime habit, it may have a cumulative effect on pelvic floor and bladder function as well. Further, animal studies and clinical data support bladder-bowel cross-sensitization, or crosstalk between the bowel and bladder (Kaplan et al., 2013).

The Epidemiology of Lower Urinary Tract Symptoms (**EpiLUTS) II** (Coyne et al., 2011) survey (n = 2160) **indicated that OAB is more likely to be reported by men and women with chronic constipation.** In a case-control study of women with LUTS (n = 820) and matched controls (n = 148), constipation and straining during defecation were significantly more common among the women with LUTS, including detrusor overactivity and urgency, than among the controls (Manning et al., 2003). In a prospective observational cohort study of more than 500 women seeking care for LUTS (Cameron et al., 2018), when compared with those without UI, women with UI had higher PROMIS (Patient-Reported Outcomes Measurement Information System) constipation (51.9 vs. 48.4, $P = 0.003$), and diarrhea scores (49.5 vs. 46.2, $P = 0.008$), indicating worse bowel function. The presence of UI was associated with constipation and more severe UI symptoms, regardless of UI subtype, were associated with worse bowel function (fecal incontinence, diarrhea, constipation).

Fecal impaction and constipation have been cited as factors contributing to UI in women, particularly in nursing home populations (Ouslander and Schnelle, 1995b). Fecal impaction can be an irritating factor in OAB or obstruct normal voiding, causing incomplete bladder emptying and overflow incontinence.

Self-care practices that promote bowel regularity are an integral part of any behavioral treatment plan. Initial assessment should include questions about bowel history and bowel habits. When constipation is reported, recommendations include ensuring adequate dietary fiber and fluids to ensure normal stool consistency. Sufficient fluid intake is necessary for fiber supplementation to be effective. Also helpful are regular exercise, external stimulation, and establishment of a regular time for bowel evacuation, preferably after a meal to capitalize on postprandial bowel motility.

Obesity and Weight Reduction

Obesity is the most clearly established risk factor for UI. There is a large amount of epidemiologic and interventional data, including several systematic reviews, demonstrating an association between body mass index (BMI) and UI, as well as for other LUTS, including urgency and frequency (Dallosso et al., 2003; Khullar et al., 2014; Milsom et al., 2017; Subak, et al., 2009; Vaughan et al., 2012). Across a wide range of studies, obese women have approximately double the risk of UI. Further, **reductions in UI have been observed in morbidly obese women who have had dramatic weight loss after bariatric surgery** (Bump et al., 1992; Burgio et al., 2007; Knoepp et al., 2013) **and in women who achieved moderate weight loss through supervised behavioral weight-loss programs** (Bump et al., 1992; Subak et al., 2005, 2009; Wing et al., 2010a,b). Obesity increases intra-abdominal pressure, predisposing to stress UI, whereas metabolic syndrome associated with obesity predisposes to urgency UI.

Knoepp et al. (2013) reported on the resolution and incidence of UI in women undergoing bariatric surgery by examining national claims data for 3765 cases with 3 years of follow-up claims data. After surgery, 62.4% of patients (83/133) diagnosed with UI before their surgery no longer had a coding diagnosis of UI. In contrast, only 42.1% (56/133) of those in a non-bariatric surgery cohort lost their coding diagnosis of UI (P = 0.0009). Incidence of new UI did not differ significantly between the groups, however.

Even moderate weight loss has been shown to improve bladder symptoms in overweight women. In fact, loss of 5% to 10% of body weight, sustained over a 12-month period, can decrease incontinence episodes as much as 70% (Bump et al., 1992; Subak et al., 2005; Wing et al., 2010a,b). The most definitive of the studies is a randomized trial comparing the effects of an intensive 6-month, group-administered, weight-loss program (including diet, exercise, and behavior modification) to a structured education control program (Subak et al., 2009). Both groups also received a booklet describing a step-by-step self-administered behavioral program to reduce incontinence. After a mean weight loss of 8.0%, the weight loss group reported a significantly greater reduction in incontinence episodes compared with the control group with a mean weight loss of 1.6% (mean = 47% vs. 28%). Thus weight loss can be a useful component of a behavioral program for incontinence in overweight women.

Based on this evidence, **more clinicians should recommend weight loss as a component of lifestyle interventions for UI in overweight women** (Vissers et al., 2014). Given that BMI is a modifiable risk factor, it is plausible that UI may be prevented if women maintain their weight within suggested guidelines.

Adherence to Conservative Treatment

It is widely accepted that the effectiveness of conservative behavioral treatments relies on the active participation of an involved and motivated patient (Dumoulin et al., 2015a). In fact, most behavioral interventions can be conceptualized as self-management. Therefore the greatest challenge for the clinician becomes how to motivate patients to be actively involved in their care, to follow their daily program consistently, and to persist for long enough to experience meaningful change in their symptoms. Progress in behavioral programs is typically gradual, which makes compliance even more difficult for patients who expect immediate results. **Clinicians can support patient adherence by communicating realistic expectations, making it clear that it may take weeks to months for symptom improvement, and it may be irregular, with "good" days and "bad" days.** Clinicians can provide support by scheduling follow-up appointments to maintain accountability, track and reinforce progress, identify and address barriers, adjust the daily regimen, encourage persistence, and let patients know that they are not alone.

Measurement of adherence to behavioral protocols has often been overlooked in research (Dumoulin et al., 2015b). **Few studies provide information about how adherent patients were with PFME, behavioral strategies, voiding schedules, or other components of behavioral treatment** (Bø and Talseth, 1996; Borello-France et al., 2010; Dumoulin et al., 2015b; Fine et al., 2007; Mørkved et al., 2013), **and the literature is sparse on methods to identify barriers and improve adherence** (Alewijnse et al., 2003; Bø et al., 2005; Borello-France et al., 2010, 2013; Dumoulin et al., 2015b).

Borello-France et al. (2013) reported on adherence to PFME and bladder control strategies as a secondary analysis of a multi-site RCT comparing three interventions for stress-predominant UI: intravaginal continence pessary versus multi-component behavioral therapy (including PFMT and bladder control strategies) versus pessary and behavioral therapy combined (Richter et al., 2007). The authors concluded that adherence to PFME and bladder control strategies, when implemented by trained interventionists, can be high and sustained over time.

The most common barriers to adherence were trouble remembering to exercise and difficulty finding time. To help patients overcome these particular barriers, clinicians can use various forms of reminders (e.g., timers), provide exercise aids, link daily exercises to environmental cues, and integrate exercises into the patient's everyday activities.

Other reported determinants of adherence to PFMT include positive intentions to adhere, self-efficacy expectations, attitudes about the exercises and its benefits, perceptions of social pressure and enthusiasm of the therapist (Alewijnse et al., 2003; Dumoulin et al., 2015b). Patients and clinicians agree that patient-related factors are the most important adherence barriers (Frawley et al., 2015). A review of qualitative studies (*n* = 13) identified six “modifiers” of adherence: knowledge; physical skill; feelings about PFMT; cognitive analysis, planning, and attention; prioritization; and services provision. Women described difficulties in each of these areas when adopting and maintaining a program of PFME (McClurg et al., 2015). Given the multi-faceted nature of adherence and differences among patients’ personal circumstances, it is recommended that clinicians assess adherence, during and at the end of therapy, and employ patient-focused strategies to enable adherence and optimize the benefits of intervention (Dumoulin et al., 2015a).

Although most clinicians agree that adherence to a maintenance protocol is necessary for long-term effectiveness, **there is little work on long-term adherence or the durability of the effects of behavioral treatments.** Long-term studies have shown that women following a PFMT program tend to decrease their adherence over time (Fine et al., 2007). Bø and Hilde (2013) reported that long-term adherence to PFMT varied between 10% and 70%. Work on determinants of long-term adherence has identified positive adherence intentions and self-efficacy expectations (Alewijnse et al., 2003). The few studies of long-term outcomes are inconsistent, but promising, in that many patients are able to sustain improvements in bladder control over time (Bø and Talseth, 1996; Cammu and Van Nylen, 1995; Weinberger et al., 1999). There is clearly a need for more studies of long-term outcomes to understand the reasons for regression and to learn how the effects of treatment can be maintained over a lifetime.

Prevention of Urinary Incontinence

The noninvasive nature of conservative interventions allows for their use as preventive strategies. Primary prevention of UI using behavioral interventions, including PFMT, behavioral training, or lifestyle changes (weight loss, fluid moderation, diet modification), has been investigated in three at-risk populations: older women, childbearing women, and men undergoing prostatectomy (Dumoulin et al., 2017; Newman et al., 2017; Sievert et al., 2012).

Older Women

Age is perhaps the most established risk factor for UI in men and women; however, little work has been done to study approaches to preventing UI in this population. The **first prevention study** was an RCT comparing a group behavior modification program to no intervention in continent, postmenopausal women, 55 years and older, to determine whether the behavioral intervention could prevent UI, increase PFM strength, and decrease voiding frequency (Diokno et al., 2004a,b). **At 12 months, the treatment group had statistically significantly better outcomes than the control group** in continence status, PFM strength (pressure score and displacement score), improved voiding frequency, and intervoid interval.

Later, a smaller study was conducted in 43 women, 65 years and older, residing in an independent-living facility to determine the feasibility of a 6-week pelvic fitness and educational program to control UI and OAB (Dugan et al., 2013). Statistically significant improvements in bladder symptoms were found after 6 weeks in the treatment group, based on visual analog scale scores for symptom bothersomeness, symptoms distress (Urogenital Distress Inventory, short form), and impact on QoL (Incontinence Impact Questionnaire, short form).

Two methods for delivering bladder health information including behavioral skills, a 2-hour bladder health class and a 20-minute video, were compared in a randomized trial with 647 older women (55 years or older) who were essentially continent (no UI or only minimal leakage) (Sampselle et al., 2017). Neither group showed significant increases in incontinence or urgency after 12 and 24 months, indicating lack of symptom progression. Further, outcomes did not differ significantly between groups, indicating that the interventions were comparable.

Childbearing Women

Pregnancy and childbirth are established risk factors for UI in women. For this reason, most prenatal classes include teaching about the role of the pelvic floor and PFM exercises. There is also a **growing body of evidence for the preventive value of formal PFMT.** Research with primiparous women has shown that intensive antenatal PFMT, including one-on-one instruction to ensure proper muscle control and continued supervision of training, can prevent the development of UI during pregnancy (35 to 36 weeks' gestation) and short-term postpartum (6 weeks to 6 months) (Boyle et al., 2012, 2014; Dumoulin et al., 2017; Mørkved and Bø, 2013; Pelaez et al., 2014). A recent Cochrane review examined the evidence for PFMT based on 38 trials involving 9892 women from 20 countries. Similarly, the authors concluded that in continent pregnant women, performing antenatal PFMT may decrease the risk of UI in late pregnancy and in the mid-postnatal period (>3 to 6 months postpartum) (Woodley et al., 2017).

Less clear is the impact of PFMT on preventing UI long term and in multiparous women. Based on research, the ICI committee (Dumoulin et al., 2017) recommends (a) an intervention comprising a daily home PFMT and weekly health professional-led exercise classes for 12 weeks, starting at 16 to 24 weeks' gestation for pregnant women, and (b) an individually taught strengthening PFMT program that incorporates adherence strategies for postpartum women who have had a forceps delivery or a vaginal delivery of a large baby (4000 g or more). **The ICI also recommended education to older women to prevent UI should be provided** (Newman et al., 2017).

Men Undergoing Prostatectomy

Postoperative UI is almost universal immediately after prostatectomy. Although continence status usually improves in the ensuing weeks and months, the literature is mixed with regard to the effects of various approaches to behavioral treatment of post-prostatectomy UI (Anderson et al., 2015). **There is some evidence that it is possible to speed the recovery of continence using behavioral interventions such as PFMT. One approach is to teach men how to control their PFM before surgery,** so they will have the opportunity to practice using their muscles in advance of needing to use them more actively after surgery. In one trial, a single session of BF-assisted behavioral training reduced the duration of UI, as well as severity of symptoms in the 6 months after radical prostatectomy (Burgio et al., 2006).

Another approach is to initiate PFMT immediately after catheter removal or early in the recovery period. Results of this approach are inconsistent but generally show benefit for the training at least in the first 3 months (Filocamo et al., 2005). **Trials that have combined preoperative and early postoperative training also indicate that severity of post-prostatectomy UI can be reduced with PFMT, in the short term (3 months)** and in some studies up to 12 months (Hirschhorn et al., 2014). According to Dumoulin et al. (2017), whether PFMT should be delivered in the form of hands-on therapy or verbal instruction and support remains unclear.

Urology practices have begun to include various levels of PFMT for men undergoing RP; however, translation from research to practice has not been optimum: most men undergoing RP do not receive instruction on PFMT. Some clinicians take the approach of watchful waiting and reserve treatment for men with persistent UI. However, even transient UI can be distressing for men recovery from RP, and hastening the return of bladder control may be important to their activity level, social life, or general well-being.

Future of Lower Urinary Tract Symptom Prevention and Bladder Health Promotion Research

Research on prevention of UI and other LUTS has been an area of growing emphasis. For many years, the ICI has examined various approaches to education-based interventions to increase public awareness and promote bladder health on a population level (Newman et al., 2017). In addition, they have examined a number of delivery models for using more behavioral skill-based approaches to prevention of UI in at-risk populations, such as older adults, childbearing women, and men undergoing prostatectomy.

In 2010 a multidisciplinary panel of experts convened to discuss the importance of a healthy bladder on overall health. They published a consensus statement to raise awareness and encourage stakeholders to pursue primary prevention strategies aimed at providing public education to promote optimal bladder health and reduce the personal, societal, and economic impact of bladder conditions (Lukacz et al., 2011). In addition, they proposed clinical directives based on research to improve and maintain bladder health.

In 2015 the National Institute of Diabetes and Digestive and Kidney Diseases (NIDDK) formed the Prevention of Lower Urinary Tract Symptoms (PLUS) Research Consortium, a 7-site research network devoted to developing the concept of bladder health and other foundational work to inform future policy and initiatives related to promoting bladder health and preventing LUTS in women and girls across the life course (Bavendam et al., 2016; Harlow et al., 2018).

Vaginal and Urethral Mechanical Devices for Incontinence

Mechanical devices are of two main types, those that are placed in the vagina to support the bladder neck and urethra, and those that are placed in the urethra or at its opening to block the passage of urine. Mechanical devices are most commonly used for stress UI, but they have also been used for urgency and mixed incontinence. There is no device that is used externally over the meatus or inserted in the urethra currently available in the United States. **A 2011 Cochrane review** (Lipp et al., 2011) **noted there was not enough evidence to recommend any specific type of device or to determine whether mechanical devices are better than other forms of treatment.** The ideal mechanical device is one that can adequately control urine leakage, is easy to apply or insert, has few adverse effects, and is of low cost. The following is a short review of devices currently in use.

Intravaginal Devices

Women who leak urine during physical activities may benefit from a mechanical device that provides pelvic support. When pelvic support tissues are weak, the urethra may drop to a position where increased abdominal pressure cannot be transmitted to the urethra assisting with urethral closure. Intravaginal devices aim to restore the position of the upper urethra to above the level of the pelvic floor where intra-abdominal pressure can improve its closure. This can be accomplished using an (in)continence pessary.

A vaginal pessary is one of the oldest medical devices and has been used for centuries as a conservative treatment of POP (Deng, 2018; Shah et al., 2006) and, more recently, for SUI (Nygaard, 1995). The guidelines of the Dutch College of General Practitioners recommend offering women with stress UI a choice between PFMT and a pessary as initial treatment (Daman-Van Beek et al., 2016).

Continence pessaries are placed transvaginally and are designed to prevent urine loss by stabilizing and supporting the urethra and bladder neck, increase urethra length, and provide gentle compression of the urethra against the pubic bone during increases in intra-abdominal pressure. This structural arrangement can reduce and often prevent stress-related incontinence. As seen in Fig. 121.14, the knob of an (in)continence ring pessary is placed against the urethrovesical junction. From this position, the pessary supports the urethrovesical junction in the same way a vaginal sling implanted surgically would (Komesu et al., 2008). In addition to its use in women with stress UI, some women who have urinary urgency and frequency because of pressure from POP may also benefit from the support of a continence pessary.

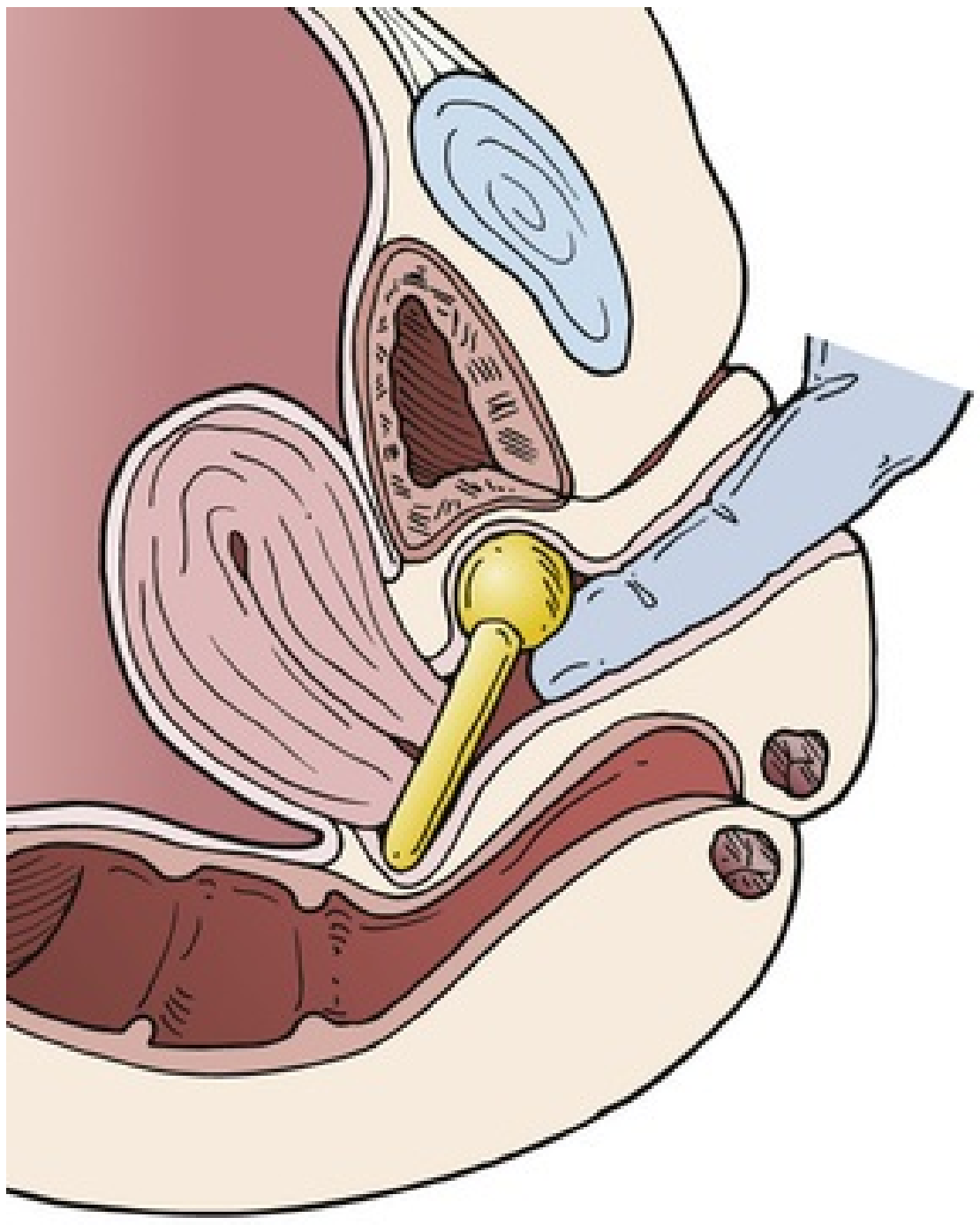

FIG. 121.14 Incontinence ring with support and knob resting against the urethrovesical junction.

Pessaries are made of an inert plastic or silicone material to prevent odors and absorption of vaginal secretions. Some have been designed to specifically treat stress UI (eFigs. 121.15 to 121.17). There are very few contraindications to pessary use, but a pessary should not be placed in patients with evidence of an active pelvic or vaginal infection, severe ulceration, or allergy to silicone or latex, or in patients who are likely to be noncompliant with maintenance care and follow-up appointments (Deng, 2018). Difficulty with self-removal and insertion may limit more widespread use of currently available pessaries.

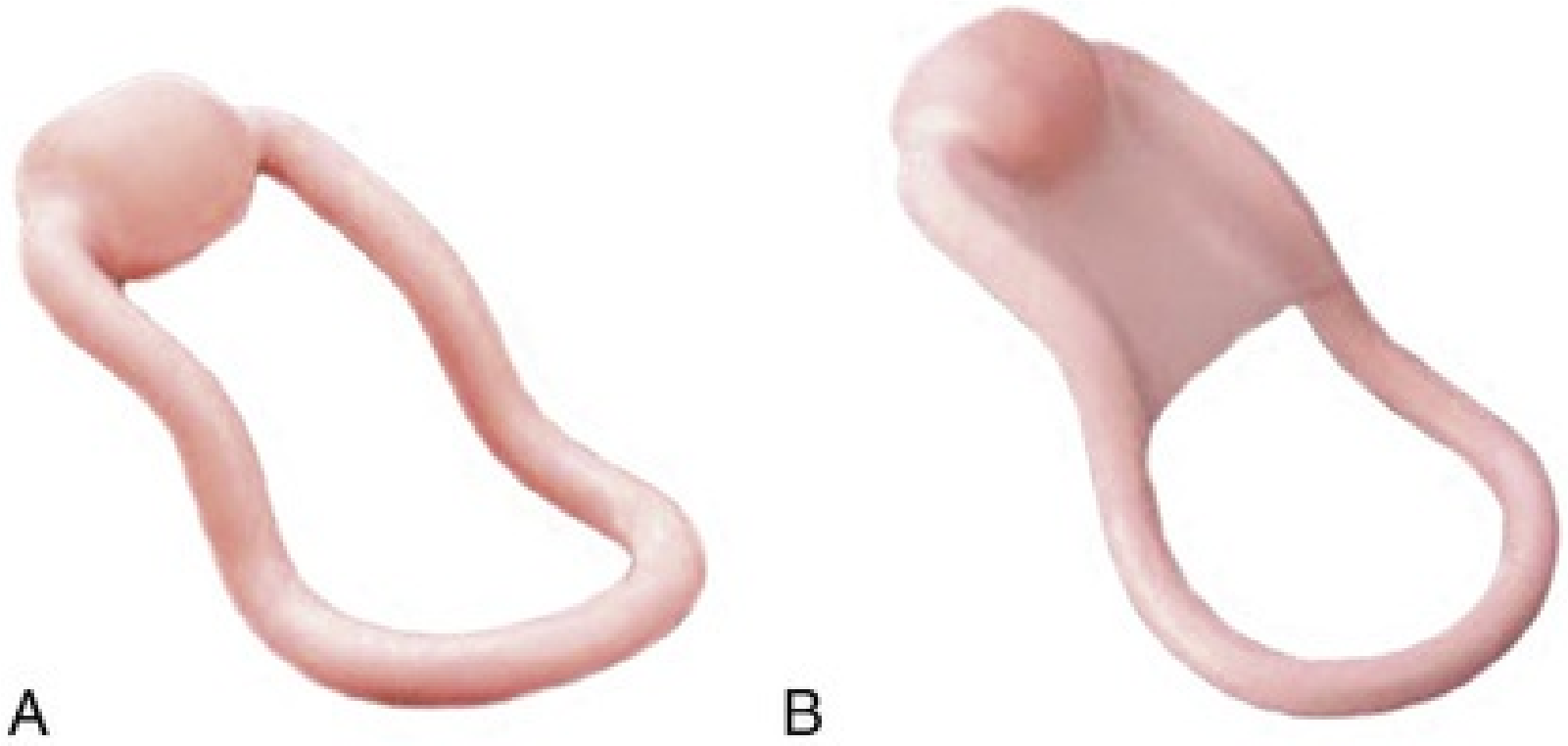

EFIG. 121.15 Incontinence hodge pessary (A) without and (B) with support.

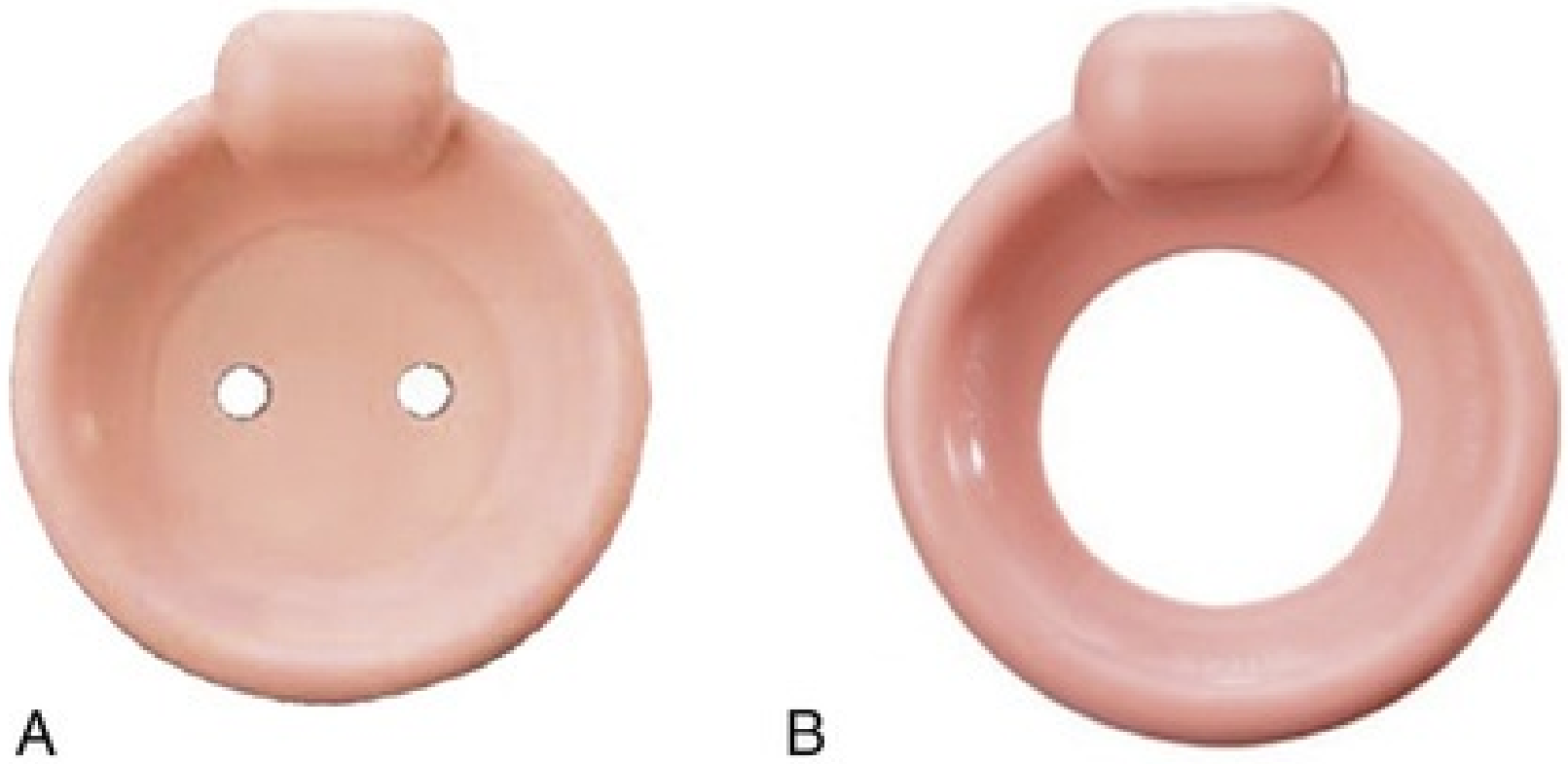

EFIG. 121.16 Incontinence dish pessary (A) without and (B) with support.

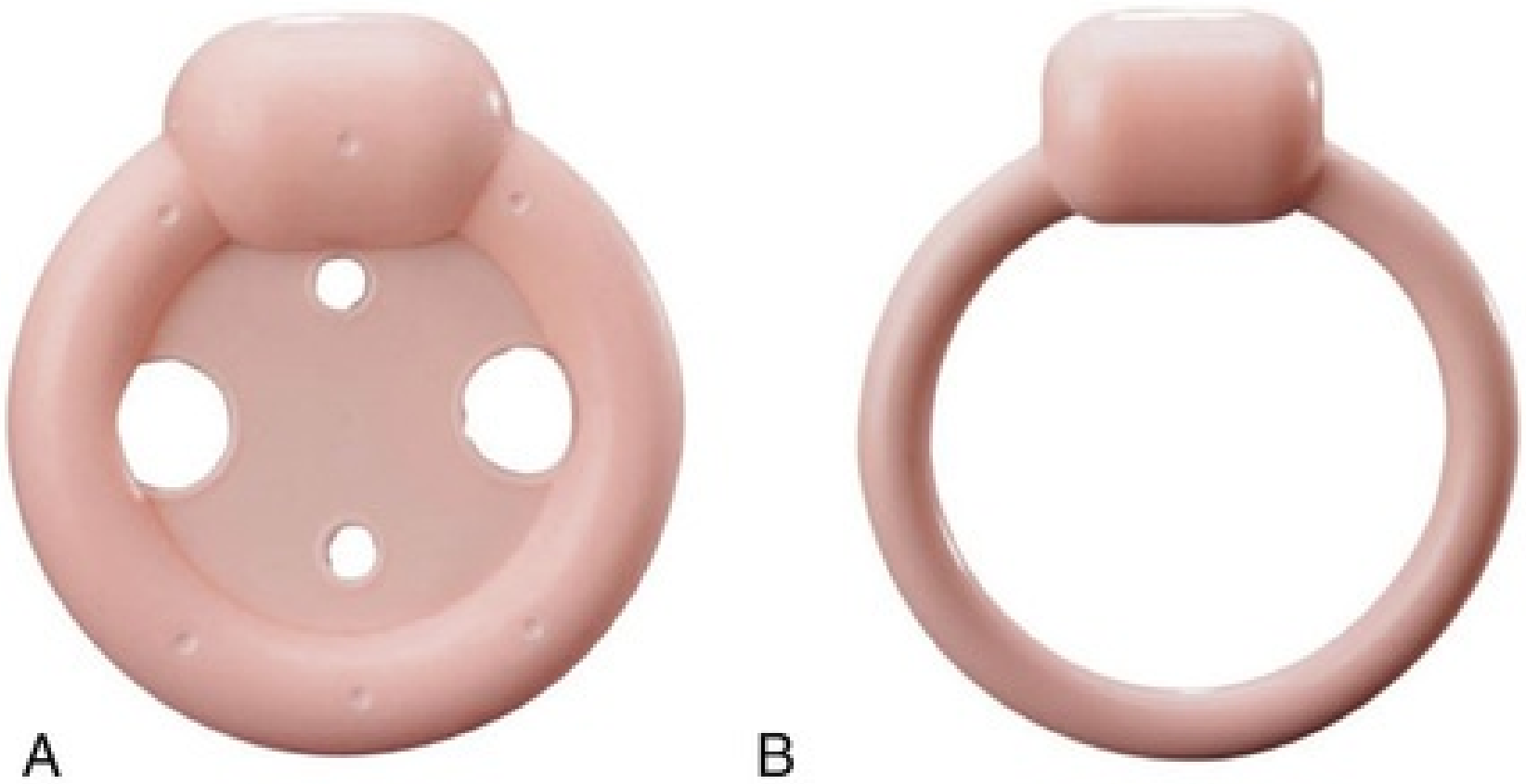

EFIG. 121.17 Incontinence ring pessary (A) without and (B) with support.

Common side effects include vaginal discharge and odor. Serious complications from pessaries are rare; however, vesicovaginal fistula, rectovaginal fistula, erosion, and subsequent impaction have been reported (Arias et al., 2008; Penrose et al., 2014). The more severe complications were reported after long-term (6–10 years) use of pessaries in patients with prolapse. They included bleeding, severe vaginal discharge, pain, and constipation; 23% of women had more than one type of complication and most had more than one episode (Sarma et al., 2009). A continence pessary can be worn continuously or intermittently during exercise or physical activity.

Research on pessary use for incontinence is limited. Stress and mixed UI improved with a pessary in approximately 50% of women in two trials (Donnelly et al., 2004; Richter et al., 2010). A multi-site randomized trial of a continence pessary compared with behavioral therapy was conducted by the NICHD Pelvic Floor Disorders Network (Richter et al., 2010). The Ambulatory Treatments for Leakage Associated with Stress Incontinence (ATLAS) trial randomized 446 women with stress predominant incontinence to intravaginal pessary, behavioral therapy, or combined treatment. At 3 months, 40% of the pessary group and 49% of the behavioral group rated themselves as “much better” or “very much better,” but these outcomes were not statistically different. Significantly ($P = 0.006$), more women in the behavioral group than in the pessary group reported having no bothersome incontinence symptoms (49% vs. 33%) and treatment satisfaction (75% vs. 63%). The combined group had a 44% success rate, which was significantly better than the pessary group but not the behavioral group. At 12 months, patient satisfaction remained above 50% for all treatment groups, but group differences were not sustained on any measure.

Sze and Hobbs (2014) performed a comparative retrospective parallel cohort study of women whose OAB was treated with ring pessary or multicomponent behavioral therapy (BT while using PFME to suppress urinary urgency as needed) over a 42-month period. Ring pessary and behavioral therapy had similar cure rates (29 out of 150 [19%] vs. 46 out of 231 [20%], respectively).

There are other intravaginal devices available to control incontinence, with different mechanism of action, materials, and designs than a pessary (Deng, 2018); these include the Uresta and the Impressa.

The Uresta is a bell-shaped pessary (eFig. 121.18) with a handle at its base for easy insertion and removal. Its narrow tip allows for easy insertion into the vagina, like a tampon, and it positions itself so that the wide base provides support to the urethra (see Fig. 121.19). A complete Uresta set includes three sizes (size 3, 4, and 5) that can be fitted by a health care provider or by the patient. Farrell et al. (2007) tested this intravaginal device in 32 women. Incontinence episodes decreased by 4 per week (based on 7-day diary) (P = 0.028) and pad weights by 11 g (P = 0.006). No complications were reported. At 2 weeks, 66% of women were satisfied with the pessary. After 12 months, 50% of subjects continued pessary use with statistically significant differences in number of leakage episodes, pad weight, symptom severity, and impact on QoL.

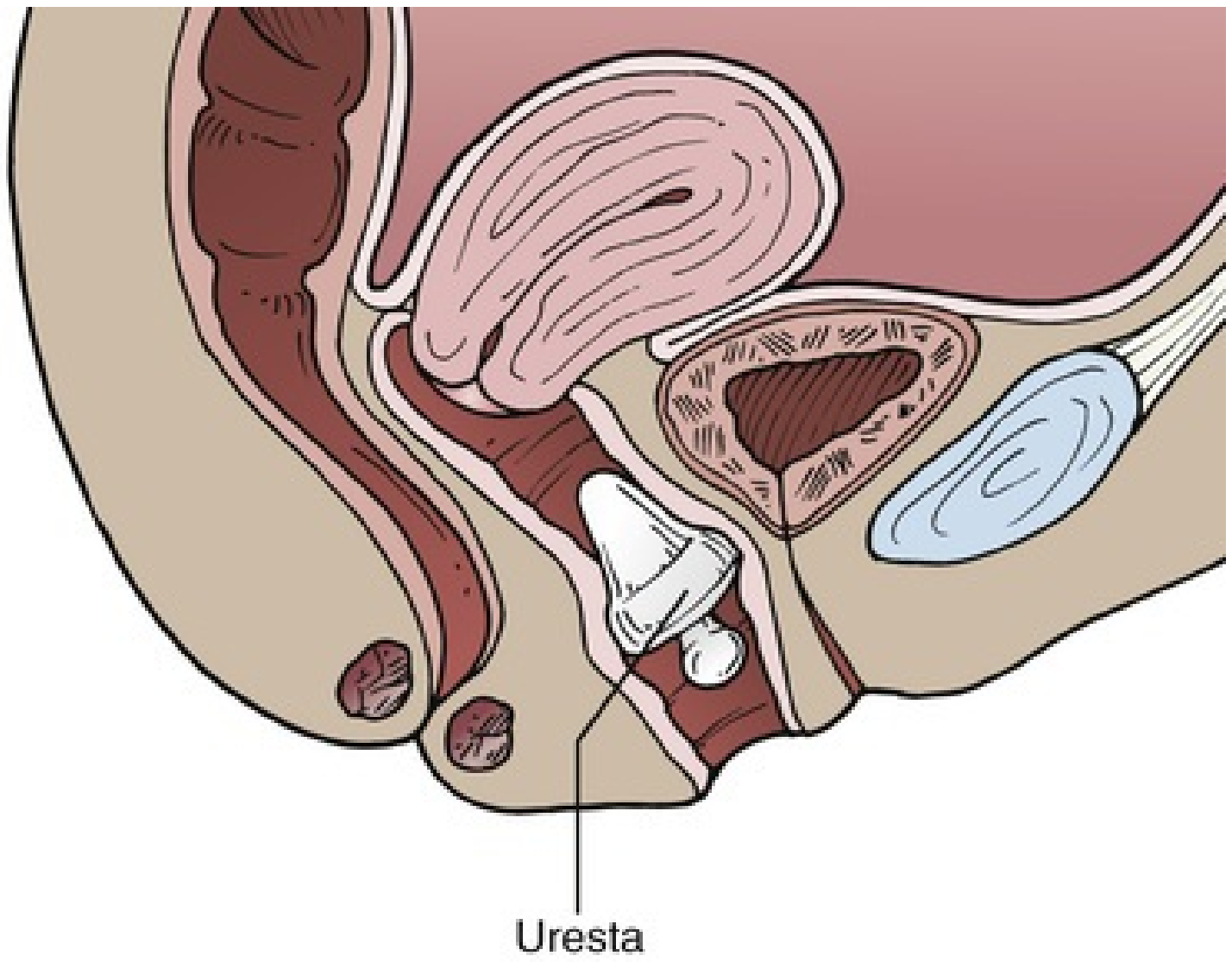

FIG. 121.19 Uresta in place.

EFIG. 121.18 Uresta kit.

Impressa is a disposable single-use tampon-like device that has a core, cover, and applicator (see Fig. 121.20). The core is made of medical-grade silicone, composed of flexible anchor and support poles made of resin. The Impressa is designed to prevent the device from moving within the vagina and to produce sub-urethral tension-free support whenever pressure is transferred from the abdominal cavity to the pelvic floor (eFig. 121.21). The cover around the core is made of soft, biocompatible, nylon mesh that stretches between the arms of the support poles to act as a tension-free sling without obstructing urinary flow or vaginal secretions. The core and cover are preassembled within a smooth, small-diameter plastic applicator similar to those used for tampons, allowing for insertion directly into the vagina and a string for removal. It is nonabsorbent, and it is not necessary to remove it before urination or defecation but should be removed during menstruation and sexual intercourse. In an open-label, controlled, two-center study, 60 women were recruited to test the device for 28 days. The primary end point was the percentage of women who achieved a more than 70% reduction in pad weight gain from the control period to the last 14 days of Impressa device usage. All women had severe stress UI based on pre-study urodynamic study. Eighty-five percent of participants achieved a more than 70% reduction in pad weight gain. Mean pad weight in grams decreased from 17 g/8 hours to 2 g/8 hours. This is a mean percent reduction of 86%. All women reported feeling urine leakage during the control period, whereas only

8% felt UI at study end. Urinary flow rates and postvoid residual volumes were not significantly changed. Postvoid residual volumes were 14.5 mL pre-study compared with 17 mL during device usage. A high degree of satisfaction was reported. Ninety-two percent of the women reported a QoL improvement of 10%, 88% reported a QoL improvement of 50%, and 70% of the participants reported 90% improvement (Ziv et al., 2008, 2009). There were 27 cases of vaginal discomfort, 15 cases of vaginal pain, 14 cases of vaginal spotting (mild), and 1 case of candidiasis. There were no vaginal excoriations, sores, ulcers, scratches, or any signs of inflammation on vaginal exam (Ziv et al., 2008).

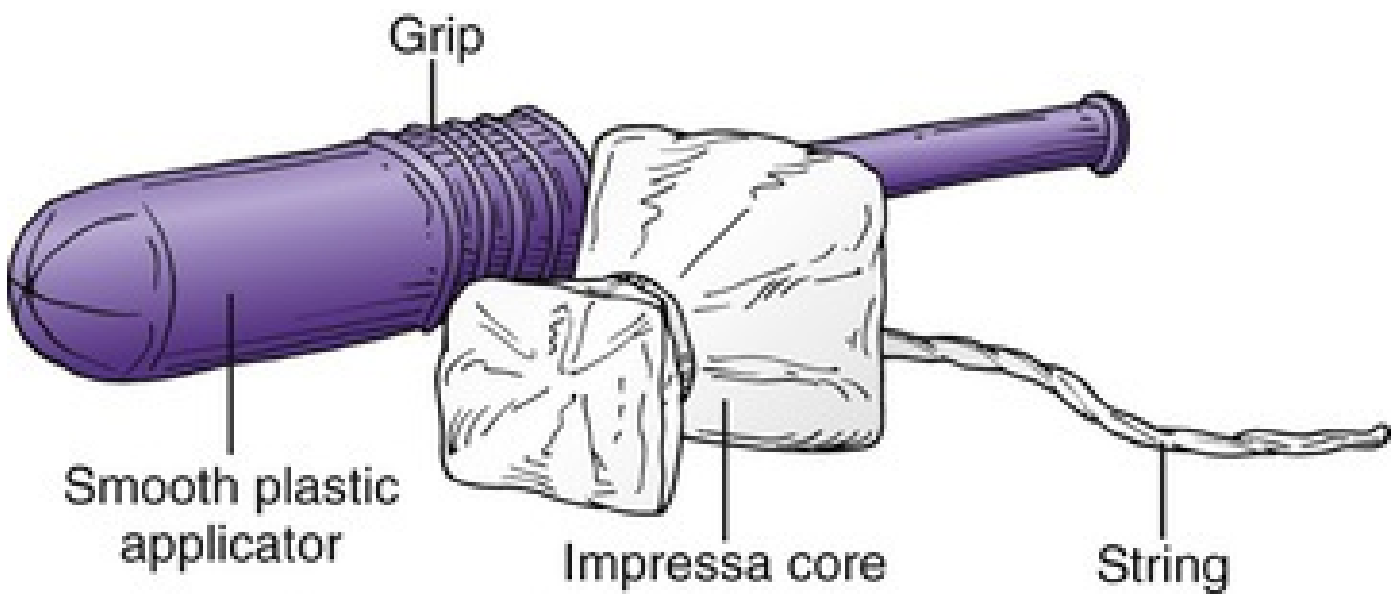

FIG. 121.20 Impressa vaginal support applicator with all parts.

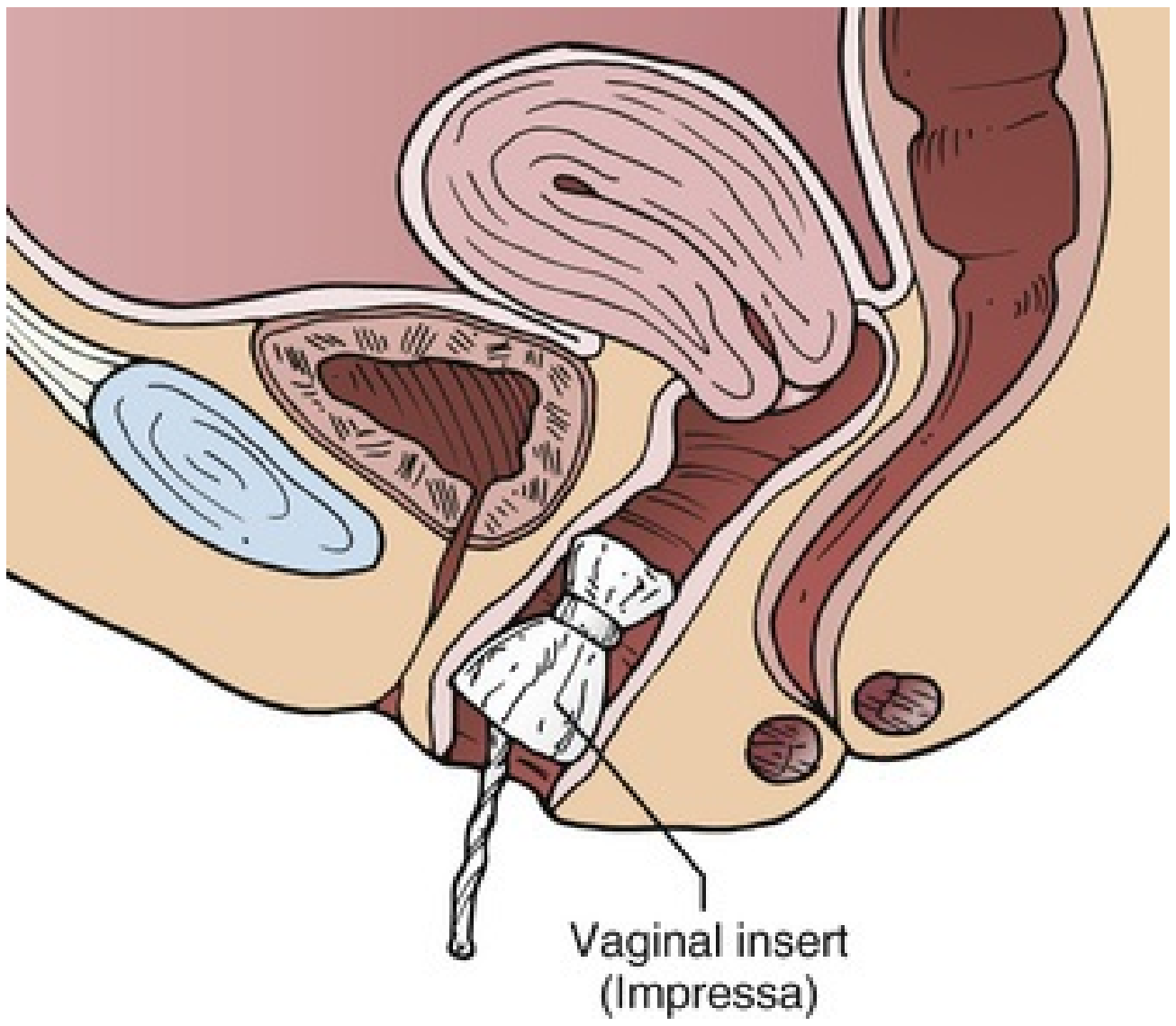

EFIG. 121.21 Impressa vaginal support in the vagina.

Models of Delivery

Despite the evidence for the effectiveness of behavioral treatments for UI and other LUTS, and guidelines recommending them as first-line therapies, these conservative interventions are not well integrated into clinical practice or widely accessible in many areas. One limitation has been the availability of qualified providers.

One successful model that has emerged in urologic practice is the integration of advanced practice providers (APPs), including continence nurse practitioners and physician assistants. Historically, APPs have embraced behavioral treatments as a specialty practice for nonsurgical treatment of a wide range of lower urinary tract conditions. An algorithm for a behavioral treatment pathway can be found in eFig. 121.22. Urology lends itself to a multidisciplinary model of a continence and pelvic health service that provides comprehensive surgical and medical care. These centers usually offer the combined knowledge of a multidisciplinary group of experts in the field of UI, voiding, and pelvic floor dysfunction. Changes in reimbursement for nonsurgical treatments such as BF-assisted PFMT, E-stim, and posterior tibial nerve stimulation have allowed urologists to consider the expansion of current treatments (pharmacologic and surgical) to alternative multi-faceted behavioral treatment programs.

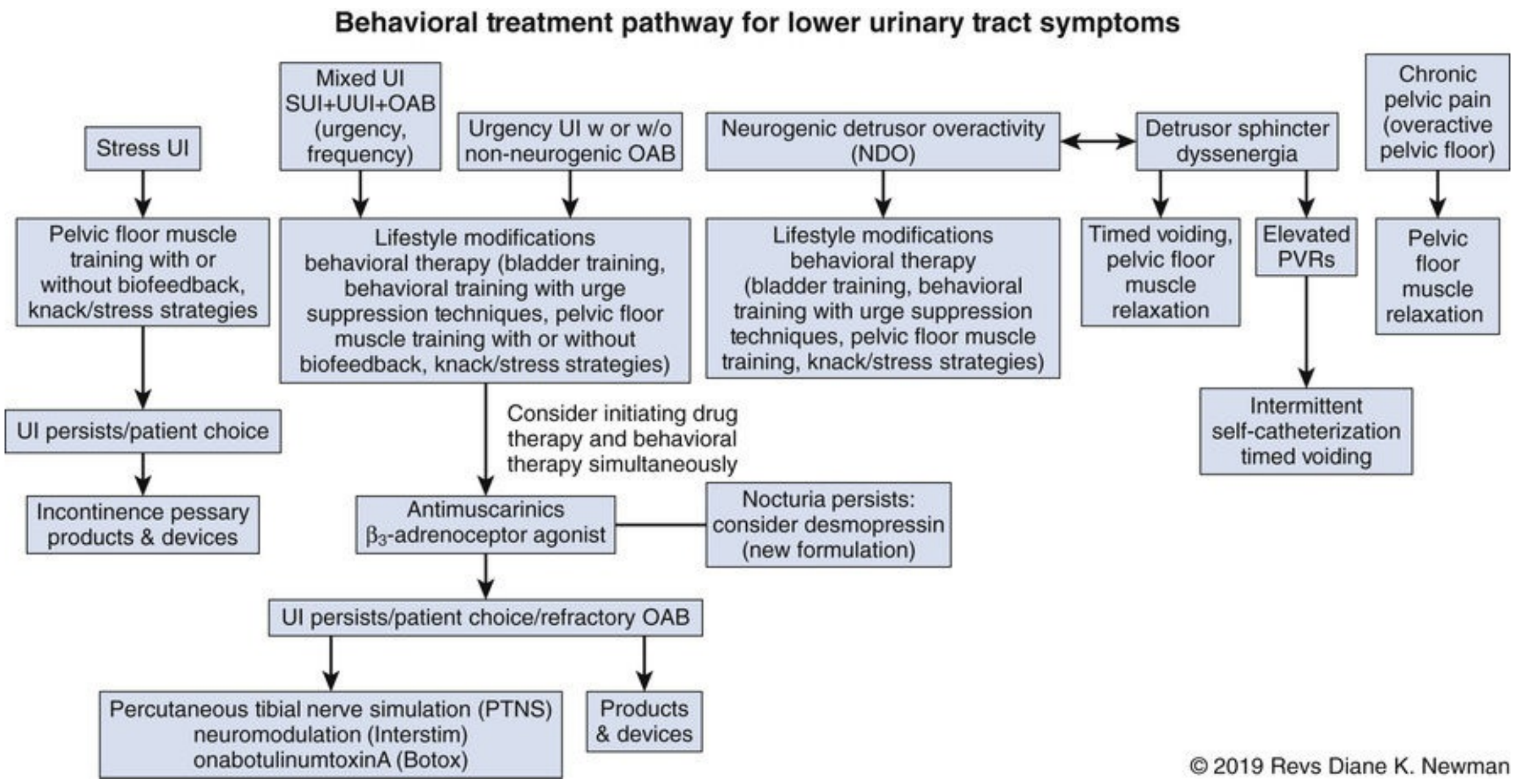
Behavioral treatment pathway for lower urinary tract symptoms
Stress UI
Mixed UI SUI+UUI+OAB (urgency, frequency)
Urgency UI w or w/o non-neurogenic OAB
Neurogenic detrusor overactivity (NDO)
Detrusor sphincter dyssenergia
Chronic pelvic pain (overactive pelvic floor)
Pelvic floor muscle training with or without biofeedback, knack/stress strategies
Lifestyle modifications behavioral therapy (bladder training, behavioral training with urge suppression techniques, pelvic floor muscle training with or without biofeedback, knack/stress strategies)
Lifestyle modifications behavioral therapy (bladder training, behavioral training with urge suppression techniques, pelvic floor muscle training, knack/stress strategies)
Timed voiding, pelvic floor muscle relaxation
Elevated PVRs
Pelvic floor muscle relaxation
Intermittent self-catheterization timed voiding
UI persists/patient choice
Consider initiating drug therapy and behavioral therapy simultaneously
Incontinence pessary products & devices
Antimuscarinics β_3-adrenoceptor agonist
Nocturia persists: consider desmopressin (new formulation)
UI persists/patient choice/refractory OAB
Percutaneous tibial nerve simulation (PTNS) neuromodulation (Interstim) onabotulinumtoxinA (Botox)
Products & devices

© 2019 Revs Diane K. Newman

EFIG. 121.22 Behavioral treatment pathway for the treatment of lower urinary tract symptoms. *OAB,* Overactive bladder; *PVRs,* postvoid residuals; *SUI,* stress urinary incontinence; *UI,* urinary incontinence; *UUI,* urgency urinary incontinence. (Courtesy Diane K. Newman.)

Another approach to improving access to behavioral intervention is use of group delivery models (Newman et al., 2017). PFMT has long been included as a component of prenatal education classes and fitness classes to promote pelvic health during pregnancy and the postpartum period (Bø et al., 2011; Hilde et al., 2014; Pelaez et al., 2014). PFMT has also been integrated into general fitness programs, as well as specific pelvic health classes (Alves et al., 2015; Bø et al., 1990; de Oliveira et al., 2009; Dugan et al., 2013; Felicissimo et al., 2010; Hill et al., 2007; Janssen et al., 2001; Kim et al., 2011; Lamb et al., 2009; Pereira et al., 2011) to treat symptomatic women. These programs generally focus on strengthening PFMs and therefore require multiple sessions across several weeks. Other group programs are delivered in a classroom or community setting and use more of a health class format (Diokno et al., 2004a,b, 2018; Sampselle et al., 2017; Tak et al., 2012; Tannenbaum et al., 2013). These classes take a broader behavioral approach with multiple components, including education about bladder anatomy and function, voiding habits, toileting techniques, and/or behavioral strategies for bladder control. Such bladder health classes have been shown to be effective for preventing symptoms in older populations (Diokno et al., 2004a,b; Sampselle et al., 2017), and as well as for reducing existing symptoms (Diokno et al., 2010, 2018; McFall et al., 2000; Tannenbaum et al., 2013).

Diokno et al. (2018) conducted a multisite RCT of community-dwelling adult women (mean [SD] age, 64 [7] years) with UI who were randomized to either a one-time group-administered behavioral treatment (GBT) that included a 2-hour bladder health class supported by a PFME audio CD (n = 232) or a control no-treatment group who received no treatment (n = 231). Both groups were followed for 12 months. Primary outcome was a change in International Consultation on Incontinence Questionnaire-Short Form (ICIQ-SF) score. In the intent-to-treat analysis, the ICIQ-SF score for the GBT was consistently lower than control across all time points (3, 6, 9, 12 months) but did not achieve the projected 3-point difference. The authors note that a one-time GBT is modestly effective and cost effective for reducing UI frequency, severity, and bother and improving QoL in older adult women.

These less-intensive programs may not be as effective as more individually supervised therapies recommended by guidelines. However, they are essentially risk free, can be cost effective, and can be implemented by health care professionals in a variety of medical or nonmedical settings. Thus they have the potential to reach a broader population of men and women, including those with mild or preclinical symptoms, conveying basic information about their bladder health and techniques that can treat, prevent, or delay onset of symptoms, as well as the availability of other more traditional treatment approaches should they wish to access the health care system.

Key Points

- Conservative behavioral treatments are a group of interventions that improve urinary incontinence and other LUTS by changing patients' behavior or environment or by teaching new skills.
- There is strong evidence that conservative interventions are effective first-line treatments for patients with UI and other LUTS.
- The effectiveness of conservative treatments relies on the active participation of an involved and motivated patient.
- Intensive behavioral interventions that involve an experienced clinician have been shown to be more effective.

Suggested Readings

Bø K. Pelvic floor muscle training is effective in treatment of female stress urinary incontinence, but how does it work? *Int Urogynecol J Pelvic Floor Dysfunct*. 2004;15(2):76–84.

Boyle R, Hay-Smith EJ, Cody JD, et al. Pelvic floor muscle training for prevention and treatment of urinary and faecal incontinence in antenatal and postnatal women. *Cochrane Database Syst Rev*. 2012;(10) [CD007471].

Burgio KL, Goode PS, Johnson TM, et al. Behavioral versus drug treatment for overactive bladder in men: the Male Overactive Bladder Treatment in Veterans (MOTIVE) Trial. *J Am Geriatr Soc*. 2011;59(12):2209–2216.

Burgio KL, Locher JL, Goode PS, et al. Behavioral versus drug treatment for urge incontinence in older women: a randomized clinical trial. *J Am Med Assoc*. 1998;23:1995–2000.

Campbell SE, Glazener CM, Hunter KF, et al. Conservative management for postprostatectomy urinary incontinence. *Cochrane Database Syst Rev*. 2012;(1) [CD001843].

Diokno AC, Newman DK, Low LK, et al. Effect of group-administered behavioral treatment on urinary incontinence in older women: a randomized clinical trial. *JAMA Intern Med*. 2018;178(10):1333–1341.

Dumoulin C, Adewuyi T, Booth J, et al. Adult conservative management. Abrams P, Cardozo L, Wagg A, et al. *Incontinence, 6th international consultation on incontinence*. International Continence Society: Bristol, UK; 2017:1443–1628.

Dumoulin C, Hay-Smith EJ, Mac Habée-Séguin G. Pelvic floor muscle training versus no treatment, or inactive control treatments, for urinary incontinence in women. *Cochrane*

Database Syst Rev. 2014;(5) [CD005654].

Fantl JA, Wyman JF, McClish DK, et al. Efficacy of bladder training in older women with urinary incontinence. *J Am Med Assoc*. 1991;265:609–613.

Filocamo MT, Li Marzi V, Del Popolo G, et al. Effectiveness of early pelvic floor rehabilitation treatment for post-prostatectomy incontinence. *Eur Urol*. 2005;48:734–738.

Goode PS, Burgio KL, Johnson TM 2nd, et al. Behavioral therapy with or without biofeedback and pelvic floor electrical stimulation for persistent post-prostatectomy incontinence. *J Am Med Assoc*. 2011;305:151–159.

Miller JM, Ashton-Miller JA, DeLancey JOL. A pelvic muscle precontraction can reduce cough-related urine loss in selected women with mild SUI. *J Am Geriatr Soc*. 1998;46:870–874.

Wallace SA, Roe B, Palmer WK. Bladder training for urinary incontinence in adults. *Cochrane Database Syst Rev*. 2009;(1) [CD001308].

References

Alewijnse D, Mesters I, Metsemakers J, et al. Predictors of long-term adherence to pelvic floor muscle exercise therapy among women with urinary incontinence. *Health Educ Res*. 2003;18:511–524.

Alves FK, Riccetto C, Adami DB, et al. A pelvic floor muscle training program in postmenopausal women: a randomized controlled trial. *Maturitas*. 2015;81:300–305.

Anderson CA, Omar MI, Campbell SE, et al. Conservative management for postprostatectomy urinary incontinence. *Cochrane Database Syst Rev*. 2015;(1) [Art. No.: CD001843].

Araujo CC, Marques AA, Juliato CRT. The adherence of home pelvic floor muscles training using a mobile device application for women with urinary incontinence: a randomized controlled trial. *Female Pelvic Med Reconstr Surg*. 2019 [Epub ahead of print].

Arias BE, Ridgeway B, Barber MD. Complications of neglected vaginal pessaries: case presentation and literature review. *Int Urogynecol J Pelvic Floor Dysfunction*. 2008;19(8):1173–1178.

Arya LA, Banks C, Gopal M, et al. Development and testing of a new instrument to measure fluid intake, output, and urinary symptoms: the questionnaire-based voiding diary. *Am J Obstet Gynecol*. 2008;198:559 [e1–7].

Arya LA, Heidi H, Cory L, et al. Construct validity of a questionnaire to measure the type of fluid intake and type of urinary incontinence. *Neurourol Urodyn*. 2011;30(8):1597–1602.

Arya LA, Myers DL, Jackson ND. Dietary caffeine intake and the risk for detrusor instability: a case-control study. *Obstet*

Gynecol. 2000;96:85–89.

Ayeleke RO, Hay-Smith EJ, Omar MI. Pelvic floor muscle training added to another active treatment versus the same active treatment alone for urinary incontinence in women. *Cochrane Database Syst Rev*. 2013;(11) [CD010551].

Bavendam TG, Star RA, Rodgers GP. Research to improve urological health for women and girls: focus on prevention. *J Womens Health (Larchmt)*. 2016;25(11):1081–1082.

Berghmans B, Hendriks E, Bernards A, et al. Electrical stimulation with non-implanted electrodes for urinary incontinence in men. *Cochrane Database Syst Rev*. 2013;(6) [CD001202].

Berghmans LCM, Van Waalwijk van Doorn ESC, Nieman FHM, et al. Efficacy of physical therapeutic modalities in women with proven bladder overactivity. *Eur Urol*. 2002;41:581–588.

Berghmans LC, Hendriks HJ, Bø K, et al. Conservative treatment of stress urinary incontinence in women: a systematic review of randomized clinical trials. *Br J Urol*. 1998;82:181–191.

Betschart C, Mol SE, Lütolf-Keller B, et al. Pelvic floor muscle training for urinary incontinence: a comparison of outcomes in premenopausal versus postmenopausal women. *Female Pelvic Med Reconstr Surg*. 2013;19(4):219–224.

Bø K, Frawley HC, Hayden BT, et al. An International Urogynecological Association (IUGA)/International Continence Society (ICS) joint report on the terminology for the conservative and nonpharmacological management of female pelvic floor dysfunction. *Int Urogynecol J*. 2017;28:191–213.

Bø K, Herbert RD. There is not yet strong evidence that exercise regimens other than pelvic floor muscle training can reduce stress urinary incontinence in women: a systematic review. *J Physiother*. 2013;59(3):159–168.

Bø K, Hilde G. Does it work in the long term? A systematic review on pelvic floor muscle training for female stress urinary incontinence. *Neurourol Urodyn*. 2013;32(3):215–223.

Bø K, Morkved S, Frawley H, et al. Evidence for benefit of transversus abdominus training alone or in combination with pelvic floor muscle training to treat female urinary incontinence: a systematic review. *Neurourol Urodyn*. 2009;28:368–373.

Bø K, Kvarstein B, Nygaard I. Lower urinary tract symptoms and pelvic floor muscle exercise adherence after 15 years. *Obstet Gynecol*. 2005;105(5 Pt 1):999–1005.

Bø K. Pelvic floor muscle training is effective in treatment of female stress urinary incontinence, but how does it work? *Int Urogynecol J Pelvic Floor Dysfunct*. 2004;15(2):76–84.

Bø K, Talseth T. Long-term effect of pelvic floor muscle exercise 5 years after cessation of organized training. *Obstet Gynecol*. 1996;87:261–265.

Bø K. Pelvic floor muscle exercise for the treatment of stress urinary incontinence: an exercise physiology perspective. *Int Urogynecol J*. 1995;6:282–291.

Bø K, Haakstad LA. Is pelvic floor muscle training effective when taught in a general fitness class in pregnancy? A randomised controlled trial. *Physiotherapy*. 2011;97:190–195.

Bø K, Hagen RH, Kvarstein B, et al. Pelvic floor muscle exercise for the treatment of female stress urinary incontinence: III. Effects of two different degrees of pelvic floor muscle exercises. *Neurourol Urodyn*. 1990;9:489–502.

Borello-France D, Burgio KL, Goode PS, et al. Pelvic Floor Disorders Network: adherence to behavioral interventions for stress incontinence: rates, barriers, and predictors. *Phys Ther*.

2013;93(6):757–773.

Borello-France D, Burgio KL, Goode PS, et al. Adherence to behavioral interventions for urge incontinence when combined with drug therapy: adherence rates, barriers, and predictors. [for the; Urinary Incontinence Treatment Network] *Phys Ther*. 2010;90(10):1493–1505.

Boyle R, Hay-Smith EJ, Cody JD, et al. Pelvic floor muscle training for prevention and treatment of urinary and fecal incontinence in antenatal and postnatal women: a short version Cochrane review. *Neurourol Urodyn*. 2014;33(3):269–276.

Boyle R, Hay-Smith EJ, Cody JD, et al. Pelvic floor muscle training for prevention and treatment of urinary and faecal incontinence in antenatal and postnatal women. *Cochrane Database Syst Rev*. 2012;(10) [CD007471].

Branum AM, Rossen LM, Schoendorf KC. Trends in caffeine intake among U.S. children and adolescents. *Pediatrics*. 2014;133(3):386–393.

Brink CA, Wells TJ, Diokno AC. Urinary incontinence in women. *Public Health Nurs*. 1987;4:114–119.

Brink CA, Sampselle CM, Wells TJ, et al. A digital test for pelvic muscle strength in older women with urinary incontinence. *Nurs Res*. 1989;38(4):196–199.

Bryant CM, Dowell CJ, Fairbrother G. Caffeine reduction education to improve urinary symptoms. *Br J Nurs*. 2002;11:560–565.

Bump RC, Sugerman HJ, Fantl JA, et al. Obesity and lower urinary tract function in women: effect of surgically induced weight loss. *Am J Obstet Gynecol*. 1992;167:392–397.

Burgio K, Kraus S, Johnson IIT, et al: Combined behavioral and drug treatment of lower urinary tract symptoms in men: the COBALT Randomized Trial. *(Abstract) presented at Annual Scientific Meeting of the International Continence Society,* *Philadelphia, PA, August 31, 2018*.

Burgio KL, Newman DK, Rosenberg MT, et al. Impact of behaviour and lifestyle on bladder health. *Int J Clin Pract*. 2013;67(6):495–504.

Burgio KL, Goode PS, Johnson TM, et al. Behavioral versus drug treatment for overactive bladder in men: the Male Overactive Bladder Treatment in Veterans (MOTIVE) Trial. *J Am Geriatr Soc*. 2011;59(12):2209–2216.

Burgio KL, Kraus SR, Menefee S, et al. Behavioral therapy to enable drug discontinuation in the treatment of urge incontinence: a randomized controlled trial. [for the; Urinary Incontinence Treatment Network] *Ann Intern Med*. 2008;149:161–169.

Burgio KL, Richter HE, Clements RH, et al. Changes in urinary and fecal incontinence symptoms with weight loss surgery in morbidly obese women. *Obstet Gynecol*. 2007;110(5):1034–1040.

Burgio KL, Goode PS, Urban DA, et al. Preoperative biofeedback assisted behavioral training to decrease post-prostatectomy incontinence: a randomized, controlled trial. *J Urol*. 2006;175:196–201.

Burgio KL, Goode PS, Locher JL, et al. Behavioral training with and without biofeedback in the treatment of urge incontinence in older women: a randomized controlled trial. *J Am Med Assoc*. 2002;288:2293–2299.

Burgio KL, Locher JL, Goode PS, et al. Behavioral versus drug treatment for urge incontinence in older women: a randomized clinical trial. *J Am Med Assoc*. 1998;23:1995–2000.

Burgio LD, McCormick KA, Scheve AS, et al. The effects of changing prompted voiding schedules in the treatment of incontinence in nursing home residents. *J Am Geriatr Soc*. 1994;42(3):315–320.

Burgio KL, Pearce KL, Lucco AJ. *Staying Dry: a practical guide to bladder control*. Johns Hopkins Press: Baltimore, MD; 1989:67–100.

Burgio KL, Robinson JC, Engel BT. The role of biofeedback in Kegel exercise training for stress urinary incontinence. *Am J Obstet Gynecol*. 1986;157:58–64.

Cameron AP, Smith AR, Lai HH, et al. LURN Study Group. Bowel function, sexual function, and symptoms of pelvic organ prolapse in women with and without urinary incontinence. *Neurourol Urodyn*. 2018;37(8):2586–2596.

Campbell SE, Glazener CM, Hunter KF, et al. Conservative management for postprostatectomy urinary incontinence. *Cochrane Database Syst Rev*. 2012;(1) [CD001843].

Cammu H, Van Nylen M. Pelvic floor muscle exercises: 5 years later. *Urology*. 1995;45:113–118.

Carter D, Beer-Gabel M. Lower urinary tract symptoms in chronically constipated women. *Int Urogynecol J*. 2012;23:1785–1789.

Cardozo L, Robinson D. Special considerations in premenopausal and postmenopausal women with symptoms of overactive bladder. *Urology*. 2002;60:64–71.

Chiarelli P, Murphy B, Cockburn J. Women's knowledge, practices, and intentions regarding correct pelvic floor exercises. *Neurourol Urodyn*. 2003;22:246–249.

Colling J, Owen TR, McCreedy M, et al. The effects of a continence program on frail community dwelling elderly persons. *Urol Nurs*. 2003;23(2):117–122 [127–31].

Coyne KS, Cash B, Kopp Z, et al. The prevalence of chronic constipation and faecal incontinence among men and women with symptoms of overactive bladder. *BJU Int*. 2011;107:254–261.

Creighton SM, Stanton SL. Caffeine: does it affect your bladder? *Br J Urol*. 1990;66:613–614.

Daman-Van Beek Z, Teunissen D, Dekker JH, et al. Practice guidelines ‘urinary incontinence in women’ from the Dutch College of General Practitioners. *Ned Tijdschr Geneeskd*. 2016;160:D674.

Dallosso HMMC, Matthews RJ, Donaldson MM, Leicestershire MRC Incontinence Study Group. The association of diet and other lifestyle factors with overactive bladder and stress incontinence: a longitudinal study in woEfficacy of physical therapeutic modalities in women with proven bladder overactivity. *BJU Int*. 2003;92(1):69–77.

Davis NJ, Vaughan CP, Johnson TM 2nd, et al. Caffeine intake and its association with urinary incontinence in United States men: results from National Health and Nutrition Examination Surveys 2005-2006 and 2007-2008. *J Urol*. 2013;189(6):2170–2174.

Delgado D, White P, Trochez R, et al. A pilot randomized controlled trial of the pelvic toner device in female stress urinary incontinence. *Int Urogynecol J*. 2013;24(10):1739.

Deng DY. Urologic devices. Newman DK, Rovner ES, Wein AJ. *Clinical application of urologic catheters and products*. Springer International Publishing: Switzerland; 2018:173–220.

de Oliveira Camargo F, Rodrigues AM, Arruda RM, et al. Pelvic floor muscle training in female stress urinary incontinence: comparison between group training and individual treatment using PERFECT assessment scheme. *Int Urogynecol J Pelvic Floor Dysfunct*. 2009;20:1455–1462.

Diokno AC, Sand PK, Macdiarmid S, et al. Perceptions and behaviours of women with bladder control problems. *Fam Pract*. 2006;23(5):568–577.

Diokno AC, Burgio K, Fultz NH, et al. Medical and self-care practices reported by women with urinary incontinence. *Am J Manag Care*. 2004;10:69–78.

Diokno AC, Sampselle CM, Herzog AG, et al. Prevention of urinary incontinence by behavioral modification program: a randomized controlled trial among older women in the community. *J Urol*. 2004;171(3):1165–1171.

Diokno AC, Ocampo MS Jr, Ibrahim IA, et al. Group session teaching of behavioral modification program (BMP) for urinary incontinence: a randomized controlled trial among incontinent women. *Int Urol Nephrol*. 2010;42:375–381.

Diokno AC, Newman DK, Low LK, et al. Effect of group-administered behavioral treatment on urinary incontinence in older women: a randomized clinical trial. *JAMA Intern Med*. 2018;178(10):1333–1341.

Donnelly MJ, Powell-Morgan S, Olsen AL, et al. Vaginal pessaries for the management of stress and mixed urinary incontinence. *Int Urogynecol J*. 2004;15:302–307.

Drennan VM, Greenwood N, Cole L, et al. Conservative interventions for incontinence in people with dementia or cognitive impairment, living at home: a systematic review. *BMC Geriatr*. 2012;28(12):77.

Dugan SA, Lavender MD, Hebert-Beirne J, et al. A pelvic floor fitness program for older women with urinary symptoms: a feasibility study. *PM R*. 2013;5(8):672–676.

Dumoulin C, Hay-Smith EJ, Mac Habée-Séguin G. Pelvic floor muscle training versus no treatment, or inactive control treatments, for urinary incontinence in women. *Cochrane Database Syst Rev*. 2014;(5) [CD005654].

Dumoulin C, Alewijnse D, Bø K, et al. Pelvic-floor-muscle training adherence: tools, measurements and strategies-2011 ICS State-of-the-Science Seminar Research Paper II of IV. *Neurourol Urodyn*. 2015;34(7):615–621.

Dumoulin C, Hay-Smith J, Fraw-ley H, et al. 2014 consensus statement on improving pelvic floor muscle training adherence: international Continence Society 2011 State-of-the-Science Seminar. *Neurourol Urodyn*. 2015;34(7):600–605.

Dumoulin C, Adewuyi T, Booth J, et al. Adult conservative management. Abrams P, Cardozo L, Wagg A, et al. *Incontinence, 6th international consultation on incontinence*. International Continence Society: Bristol, UK; 2017:1443–1628.

Dumoulin C, Cacciari LP, Hay-Smith EJC. Pelvic floor muscle training versus no treatment, or inactive control treatments, for urinary incontinence in women. *Cochrane Database Syst Rev*. 2018;(10) [CD005654].

Elstad EA, Maserejian NN, McKinlay JB, et al. Fluid manipulation among individuals with lower urinary tract symptoms: a mixed methods study. *J Clin Nurs*. 2011;20(1–2):156–165.

Engberg SJ, Sereika SM, McDowell BJ, et al. Effectiveness of prompted voiding in treating urinary incontinence in cognitively impaired homebound older adults. *J Wound Ostomy Continence Nurs*. 2002;29:252–265.

Eustice S, Roe B, Paterson J. Prompted voiding for the management of urinary incontinence in adults. *Cochrane Database Syst Rev*. 2000;(2) [CD002113].

Fall M, Lindstrom S. Functional electrical stimulation: physiological basis and clinical principles. *Int Urogynecol J Pelvic Floor Dysfunct*. 1994;5:296–304.

Fall M, Lindstrom S. Electrical stimulation; a physiologic approach to the treatment of urinary incontinence. *Urol Clin North Am*. 1991;18(2):393–407.

Fantl JA, Wyman JF, McClish DK, et al. Efficacy of bladder training in older women with urinary incontinence. *J Am Med Assoc*. 1991;265:609–613.

Fantl JA, Newman DK, Colling JC, et al. Urinary incontinence in adults: acute and chronic management. *Clinical Practice*

Guideline: Update. 1996;2.

Farrell SA, Baydock S, Amir B, et al. Effectiveness of new self-positioning pessary for the management of urinary incontinence in women. *Am J Obstet Gynecol*. 2007;196:474 [e1–e8].

Felicissimo MF, Carneiro MM, Saleme CS, et al. Intensive supervised versus unsupervised pelvic floor muscle training for the treatment of stress urinary incontinence: a randomized comparative trial. *Int Urogynecol J*. 2010;21:835–840.

Filocamo MT, Li Marzi V, Del Popolo G, et al. Effectiveness of early pelvic floor rehabilitation treatment for post-prostatectomy incontinence. *Eur Urol*. 2005;48:734–738.

Fine P, Burgio K, Borello-France D, et al. Pelvic Floor Disorders Network:. Teaching and practicing of pelvic floor muscle exercises in primiparous women during pregnancy and the postpartum period. *Am J Obstet Gynecol*. 2007;197:107 [e1–e5].

Fitzgerald S, Palmer MH, Berry SJ, et al. Urinary incontinence: impact on working women. *AAOHN J*. 2000;48(3):112–118.

Fitzgerald ST, Palmer MH, Kirkland VL, et al. The impact of urinary incontinence in working women: a study in a production facility. *Women Health*. 2002;35(1):1–16.

Flanagan L, Roe B, Jack B, et al. Systematic review of care intervention studies for the management of incontinence and promotion of continence in older people in care homes with urinary incontinence as the primary focus (1966-2010). *Geriatr Gerontol Int*. 2012;12(4):600–611.

Frawley HC, McClurg D, Mahfooza A, et al. Health professionals' and patients' perspectives on pelvic floor muscle training adherence-2011 ICS State-of-the-Science Seminar research paper IV of IV. *Neurourol Urodyn*. 2015;34(7):632–639.

Gleason JLRH, Redden DT, Goode PS, et al. Caffeine and urinary incontinence in US women. *Int Urogynecol J*. 2013;24(2):295–302.

Goode PS, Burgio KL, Johnson TM 2nd, et al. Behavioral therapy with or without biofeedback and pelvic floor electrical stimulation for persistent post-prostatectomy incontinence. *J Am Med Assoc*. 2011;305:151–159.

Gormley EA, Lightner DJ, Faraday M, et al. Society of Urodynamics FPM. Diagnosis and treatment of overactive bladder (non-neurogenic) in adults: AUA/SUFU guideline amendment. *J Urol*. 2015;193:1572–1580.

Gray M. Caffeine and urinary continence. *J Wound Ostomy Continence Nurs*. 2001;28:66–69.

Haidinger G, Temml C, Schatzl G, et al. Risk factors for lower urinary tract symptoms in elderly men. For the Prostate Study Group of the Austrian Society of Urology. *Eur Urol*. 2000;37:413–420.

Harlow BL, Bavendam TG, Palmer MH, et al. The Prevention of Lower Urinary Tract Symptoms (PLUS) Research Consortium: a transdisciplinary approach toward promoting bladder health and preventing lower urinary tract symptoms in women across the life course. *J Womens Health (Larchmt)*. 2018;27(3):283–289.

Hartmann KE, McPheeters ML, Biller DH, et al. Treatment of overactive bladder in women. *Evid Rep Technol Assess (Full Rep)*. 2009;1–120.

Hashim H, Abrams P. How should patients with an overactive bladder manipulate their fluid intake? *BJU Int*. 2008;102:62–66.

Hay-Smith JHR, Dumoulin C, Herbison P. Comparisons of approaches to pelvic floor muscle training for urinary incontinence in women: an abridged Cochrane systematic review. *Eur J Phys Rehabil Med*. 2012;48(4):689–705.

Hay-Smith EJ, Herderschee R, Dumoulin C, et al. Comparisons of approaches to pelvic floor muscle training for urinary incontinence in women. *Cochrane Database Syst Rev*. 2011;(12) [CD009508].

Herbison GP, Dean N. Weighted vaginal cones for urinary incontinence. *Cochrane Database Syst Rev*. 2013;(7) [CD002114].

Herderschee R, Hay-Smith EC, Herbison GP, et al. Feedback or biofeedback to augment pelvic floor muscle training for urinary incontinence in women: shortened version of a Cochrane systematic review. *Neurourol Urodyn*. 2013;32(4):325–329.

Herderschee R, Hay-Smith EJ, Herbison GP, et al. Feedback or biofeedback to augment pelvic floor muscle training for urinary incontinence in women. *Cochrane Database Syst Rev*. 2011;(7) [CD009252].

Hilde G, Staer-Jensen J, Siafarikas F, et al. Postpartum pelvic floor muscle training and urinary incontinence: a randomized controlled trial [Erratum appears in: obstet Gynecol. 2014 Sep;124(3):639]. *Obstet Gynecol*. 2013;122:1231–1238.

Hill L, Fereday-Smith J, Credgington C, et al. Bladders behaving badly, a randomized controlled trial of group versus individual interventions in the management of female urinary incontinence. *J Assoc Chart Physio Women's Health*. 2007;101:30–36.

Hirayama F, Lee AH. Is caffeine intake associated with urinary incontinence in Japanese adults? *J Prev Med Public Health*. 2012;45(3):204–208.

Hirschhorn AD, Kolt GS, Brooks AJ. A multicomponent theory-based intervention improves uptake of pelvic floor muscle training before radical prostatectomy: a “before and after” cohort study. *BJU Int*. 2014;113(3):383–392.

Holroyd-Leduc JM, Straus SE. Management of urinary incontinence in women: scientific review. *J Am Med Assoc*.

2004;291:986–995.

Imamura M, Williams K, Wells M, et al. Lifestyle interventions for the treatment of urinary incontinence in adults (Review). *Cochrane Database Syst Rev*. 2015;(12) [Art. No.: CD003505].

Institute of Medicine. *Dietary reference intakes for water, potassium, sodium, chloride, and sulfate*. The National Academies Press: Washington, DC; 2005.

Janssen CC, Lagro-Janssen AL, Felling AJ. The effects of physiotherapy for female urinary incontinence: individual compared with group treatment. *BJU Int*. 2001;87:201–206.

Jean-Michel M, Biller DH, Bena JF, et al. Measurement of pelvic floor muscular strength with the Colpexin pull test: a comparative study. *Int Urogynecol J*. 2010;21(8):1011–1017.

Johnson TM 2nd, Markland AD, Goode PS, et al. Efficacy of adding behavioural treatment or antimuscarinic drug therapy to α-blocker therapy in men with nocturia. *BJU Int*. 2013;112(1):100–108.

Johnson TM 2nd, Burgio KL, Redden DT, et al. Effects of behavioral and drug therapy on nocturia in older incontinent women. *J Am Geriatr Soc*. 2005;53:846–850.

Johnson TM 2nd, Kincade JE, Bernard SL, et al. Self-care practices used by older men and women to manage urinary incontinence: results from the national follow-up survey on self-care and aging. *J Am Geriatr Soc*. 2000;48:894–902.

Johnson TM 2nd, Vaughan CP, Goode PS, et al. Pilot results from a randomized trial in men comparing alpha-adrenergic antagonist versus behavior and exercise for nocturia and sleep. *Clin Ther*. 2016 [S0149-2918(16)30742-1].

Jura YHTM, Curhan GC, Resnick NM, et al. Caffeine intake, and the risk of stress, urgency and mixed urinary incontinence. *J Urol*. 2011;185(5):1775–1780.

Kaplan SA, Dmochowski R, Cash BD, et al. Systematic review of the relationship between bladder and bowel function: implications for patient management. *Int J Clin Pract*. 2013;67(3):205–216.

Kegel AH. Progressive resistance exercise in the functional restoration of the perineal muscles. *Am J Obstet Gynecol*. 1948;56:238–248.

Kegel AH. Stress incontinence of urine in women: physiologic treatment. *J Int Coll Surg*. 1956;25:487–499.

Kershen R, Mann-Gow T, Yared J, et al. Caffeine ingestion causes detrusor overactivity and afferent nerve excitation in mice. *J Urol*. 2012;188(5):1986–1992.

Keshtidar M, Behzadnia B. Prediction of intention to continue sport in athlete students: a self-determination theory approach. *PLoS ONE*. 2017;12(2):e0171673.

Khullar V, Sexton CC, Thompson CL, et al. The relationship between BMI and urinary incontinence subgroups: results from EpiLUTS. *Neurourol Urodyn*. 2014;33(4):392–399.

Kim H, Yoshida H, Suzuki T. The effects of multidimensional exercise treatment on community-dwelling elderly Japanese women with stress, urge, and mixed urinary incontinence: a randomized controlled trial. *Int J Nurs Stud*. 2011;48:1165–1172.

Knoepp LR, Semins MJ, Wright EJ, et al. Does bariatric surgery affect urinary incontinence? *Urology*. 2013;82(3):547–551.

Komesu YM, Ketai LH, Rogers RG, et al. Restoration of continence by pessaries: magnetic resonance imaging assessment of mechanism of action. *Am J Obstet Gynecol*. 2008;198:563–566.

Lai CKY, Wan X. Using prompted voiding to manage urinary incontinence in nursing homes: can it be sustained? *J Am Med Dir Assoc*. 2017;18(6):509–514.

Lamb SE, Pepper J, Lall R, et al. Group treatments for sensitive health care problems: a randomised controlled trial of group versus individual physiotherapy sessions for female urinary incontinence. *BMC Womens Health*. 2009;14(9):26.

Latorre GFS, de Fraga R, Seleme MR, et al. An ideal e-health system for pelvic floor muscle training adherence: systematic review. *Neurourol Urodyn*. 2019;38(1):63–80.

Laycock J, Jerwood D. Pelvic floor assessment; the PERFECT scheme. *Physiotherapy*. 2001;87(12):631–642.

Lekan-Rutledge D. Diffusion of innovation. A model for implementation of prompted voiding in long-term care settings. *J Gerontol Nurs*. 2000;26(4):25–33.

Lipp A, Shaw C, Glavind K. Mechanical devices for urinary incontinence in women. *Cochrane Database Syst Rev*. 2011;(7) [CD001756].

Locher JL, Roth DL, Goode PS, et al. Reliability assessment of the bladder diary for urinary incontinence in older women. *J Gerontol A Biol Sci Med Sci*. 2001;56A:M32–M35.

Lohsiriwat S, Hirunsai M, Chaiyaprasithi B. Effect of caffeine on bladder function in patients with overactive bladder symptoms. *Urol Ann*. 2011;3(1):14–18.

Lubowski DZ, Swash M, Nicholls RJ, et al. Increase in pudendal nerve terminal motor latency with defaecation straining. *Br J Surg*. 1988;75:1095–1097.

Lukacz ES, Sampselle C, Gray M, et al. A healthy bladder: a consensus statement. *Int J Clin Pract*. 2011;65(10):1026–1036.

Lyons SS, Specht JK. Prompted voiding protocol for individuals with urinary incontinence. *J Gerontol Nurs*. 2000;26(6):5–13.

MacKillop J, Howland J, Rohsenow DJ, et al. Initial development of a measure of expectancies for combinations of alcohol and caffeine: the Caffeine + Alcohol Combined Effects Questionnaire (CACEQ). *Exp Clin Psychopharmacol*. 2012;20(6):466–472.

Manning J, Korda A, Benness C, et al. The association of obstructive defecation, lower urinary tract dysfunction and the benign joint hypermobility syndrome: a case-control study. *Int Urogynecol J Pelvic Floor Dysfunct*. 2003;14:128–132.

Manonai J, Harnsomboon T, Sarit-Apirak S, et al. Effect of Colpexin sphere on pelvic floor muscle strength and quality of life in women with pelvic organ prolapse stage I/II: a randomized controlled trial. *Int Urogynecol J*. 2012;23:307–312.

Mariotti G, Sciarra A, Gentilucci A, et al. Early recovery of urinary continence after radical prostatectomy using early pelvic floor electrical stimulation and biofeedback associated treatment. *J Urol*. 2009;181:1788–1793.

Maserejian NN, Wager CG, Giovannucci EL, et al. Intake of caffeinated, carbonated, or citrus beverage types and development of lower urinary tract symptoms in men and women. *Am J Epidemiol*. 2013;177(12):1399–1410.

McClurg D, Frawley H, Hay-Smith J, et al. Scoping review of adherence promotion theories in pelvic floor muscle training - 2011 ICS state-of-the-science seminar research paper i of iv. *Neurourol Urodyn*. 2015;34(7):606–614.

McFall SL, Yerkes AM, Cowan LD. Outcomes of a small group educational intervention for urinary incontinence: episodes of incontinence and other urinary symptoms. *J Aging Health*. 2000;12(2):250–267.

Messelink B, Benson T, Berghmans B, et al. Standardization of terminology of pelvic floor muscle function and dysfunction: report from the pelvic floor clinical assessment group of the International Continence Society. [clinical assessment group of the; International Continence Society] *Neurourol Urodyn*. 2005;24:374–380.

Miller JM, Guo Y, Rodseth SB. Cluster analysis of intake, output, and voiding habits collected from diary data. *Nurs*

Res. 2011;60(2):115–123.

Miller JM, Sampselle C, Ashton-Miller J, et al. Clarification and confirmation of the Knack maneuver: the effect of volitional pelvic floor muscle contraction to preempt expected stress incontinence. *Int Urogynecol J Pelvic Floor Dysfunct*. 2008;19(6):773–782.

Miller JM, Ashton-Miller JA, DeLancey JOL. A pelvic muscle precontraction can reduce cough-related urine loss in selected women with mild SUI. *J Am Geriatr Soc*. 1998;46:870–874.

Miller J, Aston-Miller J, DeLancey J. The knack: use of precisely-timed pelvic muscle contraction can reduce leakage in SUI. *Neurourol Urodyn*. 1996;15:302–393.

Miller YD, Brown WJ, Smith N, et al. Managing urinary incontinence across the lifespan. *Int J Behav Med*. 2003;10:143–161.

Milsom I, Altman D, Cartwright R, et al. Epidemiology of urinary incontinence (UI) and other lower urinary tract symptoms (LUTS), pelvic organ prolapse (POP) and anal incontinence (AI). Abrams P, Cardozo L, Wagg A, et al. *Incontinence: 6th international consultation on incontinence*. International Continence Society: Bristol, UK; 2017:4–141.

Mitchell DC, Knight CA, Hockenberry J, et al. Beverage caffeine intakes in the U.S. *Food Chem Toxicol*. 2014;63:136–142.

Moore K, Bradley C, Burgio B, et al. Adult conservative management. Abrams P, Cardozo L, Khoury S, et al. *Incontinence: proceedings from the 5th International Consultation on Incontinence*. Health Publications: Plymouth UK; 2013:1101–1228.

Mørkved S, Bø K. Effect of pelvic floor muscle training during pregnancy and after childbirth on prevention and treatment of urinary incontinence: a systematic review. *Br J Sports Med*. 2013;48(4):299–310.

Morris M. *Maternity and post-operative exercises*. William Heinemann: London; 1936.

Neilson JP. Pelvic floor muscle training for prevention and treatment of urinary and faecal incontinence in antenatal and postnatal women. *Obstet Gynecol*. 2009;113(3):733–735.

Newman D, Specht J, Eason S. Prompted voiding for persons with urinary incontinence. Butcher HK. *Series on evidence-based practice guidelines*. The University of Iowa College of Nursing Barbara & Richard Csomay Center for Gerontological Excellence: Iowa City, IA; 2018.

Newman DK, Borello-France D, Sung VW. Structured behavioral treatment research protocol for women with mixed urinary incontinence and overactive bladder symptoms. *Neurourol Urodyn*. 2018;37(1):14–20.

Newman DK, Cockerell R, Griebling T, et al. Primary prevention, continence promotion, models of care, and education. Abrams P, Cardozo L, Wagg A, et al. *Incontinence, 6th international consultation on incontinence*. International Continence Society: Bristol, UK; 2017:1443–1628.

Newman DK. Pelvic floor muscle rehabilitation using biofeedback. *Urol Nurs*. 2014;34(4):193–202.

Newman DK, Burgio KL, Markland AD, et al. Urinary incontinence: nonsurgical treatments. Griebling TL. *Geriatric urology*. Springer-Verlag, Ltd: London; 2014:141–168.

Newman DK, Wein AJ. Office-based behavioral therapy for management of incontinence and other pelvic disorders. *Urol Clin North Am*. 2013;40(4):613–635.

Newman DK, Wein AJ. *Managing and treating urinary incontinence*. 2nd ed. Health Professions Press: Baltimore, MD; 2009:245–306.

Newman DK, Laycock J. Clinical evaluation of the pelvic floor muscles. Baessler K, Schussler B, Burgio KL, et al. *Pelvic* *floor re-education: principles and practice*. ed 2. Springer-Verlag: London; 2008:91–104.

Newman DK, Gaines T, Snare E. Innovation in bladder assessment: use of technology in extended care. *J Gerontol Nurs*. 2005;31(12):33–41.

Newman DK. Assessment of the patient with an overactive bladder. *J WCON*. 2005;32(3S):S5–S10.

Nygaard I. Prevention of exercise incontinence with mechanical devices. *J Reprod Med*. 1995;40:89–94.

Nygaard I, Linder M. Thirst at work–an occupational hazard? *Int Urogynecol J Pelvic Floor Dysfunct*. 1997;8:340–343.

Ong TA, Khong SY, Ng KL, et al. Using the Vibrance Kegel Device with pelvic floor muscle exercise for stress urinary incontinence: a randomized controlled pilot study. *Urology*. 2015;86(3):487–491.

Ostaszkiewicz J, Roe B, Johnston L. Effects of timed voiding for the management of urinary incontinence in adults: systematic review. *J Adv Nurs*. 2005;52:420–431.

Ostaszkiewicz J, Johnston L, Roe B. Timed voiding for the management of urinary incontinence in adults. *J Urol*. 2005;173(4):1262–1263.

Ostaszkiewicz J, Johnston L, Roe B. Timed voiding for the management of urinary incontinence in adults. *Cochrane Database Syst Rev*. 2004;(1) [CD002802].

Ostaszkiewicz J, Johnston L, Roe B. Habit retraining for the management of urinary incontinence in adults. *Cochrane Database Syst Rev*. 2004;(2) [CD002801].

Ouslander JG, Griffiths PC, McConnell E, et al. Functional incidental training: a randomized, controlled, crossover trial in veterans affairs nursing homes. *J Am Geriatr Soc*. 2005;53:1091–1100.

Ouslander JG, Schnelle JF, Uman G, et al. Predictors of successful prompted voiding among incontinent nursing home residents. *J Am Med Assoc*. 1995;273(17):1366–1370.

Ouslander JG, Schnelle JF. Incontinence in the nursing home. *Ann Intern Med*. 1995;122(6):438–449.

Palmer MH, Marquez CS, Kline KV, et al. Hydrate for Health: listening to older adults’ need for information. *J Gerontol Nurs*. 2014;40(10):24–30.

Payne CA. Conservative management of urinary incontinence: behavioral and pelvic floor therapy, urethral and pelvic devices. Wein AJ, Kavoussi LR, Novick AC, et al. *Campbell-Walsh urology*. 9th ed. Saunders Elsevier: Philadelphia; 2012:2003–2025.

Peattie AB, Plevnik S, Stanton SL. Vaginal cones: a conservative method of treating genuine stress incontinence. *Br J Obstet Gynaecol*. 1988;95(10):1049–1053.

Pelaez M, Gonzalez-Cerron S, Montejo R, et al. Pelvic floor muscle training included in a pregnancy exercise program is effective in primary prevention of urinary incontinence: a randomized controlled trial. *Neurourol Urodyn*. 2014;33(1):67–71.

Penrose KJ, Yin J, Tsokos N. Delayed vesicovaginal fistula after ring pessary usage. *Int Urogynecol J*. 2014;25:291–293.

Pereira VS, Correia GN. Driusso P: individual and group pelvic floor muscle training versus no treatment in female stress urinary incontinence: a randomized controlled pilot study. *Eur J Obstet Gynecol Reprod Biol*. 2011;159:465–471.

Qaseem A, Dallas P, Forciea MA, et al. Nonsurgical management of urinary incontinence in women: a clinical practice guideline from the American College of Physicians. *Ann Intern Med*. 2014;161(6):429–440.

Resnick MJ, Koyama T, Fan K-H, et al. Long-term functional outcomes after treatment for localized prostate cancer. *N Engl J Med*. 2013;368:436–445.

Richter HE, Burgio KL, Brubaker L, et al. Continence pessary compared with behavioral therapy or combined therapy for stress incontinence. [Pelvic Floor Disorders Network] *Obstet Gynecol*. 2010;115(3):609–617.

Richter HE, Burgio KL, Goode PS, et al. Pelvic floor disorders: non-surgical management of stress urinary incontinence: Ambulatory Treatments for Leakage Associated with Stress (ATLAS) trial. *Clin Trials*. 2007;4:92–101.

Roe B, Ostaszkiewicz J, Milne J, et al. Systematic reviews of bladder training and voiding programmes in adults: a synopsis of findings from data analysis and outcomes using meta study techniques. *J Adv Nurs*. 2007;57(1):15–31.

Roe B, Flanagan L, Jack B, et al. Systematic review of the management of incontinence and promotion of continence in older people in care homes: descriptive studies with urinary incontinence as primary focus. *J Adv Nurs*. 2011;67(2):228–250.

Sampselle CM, Newman DK, Miller JM, et al. A randomized controlled trial to compare 2 scalable interventions for lower urinary tract symptom prevention: main outcomes of the TULIP Study. *J Urol*. 2017;197:1480–1486.

Sampselle CM. Teaching women to use a voiding diary. *Am J Nurs*. 2003;103(11):62–64.

Sampselle CM, DeLancey J. The urine stream interruption test and pelvic muscle function. *Nurs Res*. 1992;41:73–77.

Sarma S, Ying T, Moore KH. Long term vaginal ring pessary use: discontinuation rates and adverse events. *BJOG*. 2009;116:1715–1721.

Schmidt F, Jørgensen TM, Djurhuus JC. Twenty-four-hour ambulatory urodynamics in healthy young men. *Scand J Urol Nephrol Suppl*. 2004;215:75–83.

Schnelle JF, MacRae PG, Ouslander JG, et al. Functional Incidental Training, mobility performance, and incontinence care with nursing home residents. *J Am Geriatr Soc*.

1995;43(12):1356–1362.

Schnelle JF, Traughber B, Sowell VA, et al. Prompted voiding treatment of urinary incontinence in nursing home patients: a behavior management approach for nursing home staff. *J Am Geriatr Soc*. 1989;37(11):1051–1057.

Schreiner L, Santos TG, Souza AB, et al. Electrical stimulation for urinary incontinence in women: a systematic review. *Int Braz J Urol*. 2013;39(4):454–464.

Seim A, Hoyo C, Ostbye T, et al. The prevalence and correlates of urinary tract symptoms in Norwegian men: the HUNT study. *BJU Int*. 2005;96:88–92.

Segal S, Saks EK, Arya LA. Self-assessment of fluid intake behavior in women with urinary incontinence. *J Womens Health (Larchmt)*. 2011;20(12):1917–1921.

Schmitt JJ, Singh R, Weaver AL, et al. Prospective outcomes of a pelvic floor rehabilitation program including vaginal electrogalvanic stimulation for urinary, defecatory, and pelvic pain symptoms. *Female Pelvic Med Reconstr Surg*. 2017;23(2):108–113.

Shah SM, Sultan AH, Thakar R. The history and evolutions of pessaries for pelvic organ prolapse. *Int Urogynecol J Pelvic Floor Dysfunc*. 2006;17:170–175 [31].

Shafik A, Shafik IA. Overactive bladder inhibition in response to pelvic floor muscle exercises. *World J Urol*. 2003;20(6):374–377.

Shamliyan TA, Kane RL, Wyman J, et al. Systematic review: randomized, controlled trials of nonsurgical treatments for urinary incontinence in women. *Ann Intern Med*. 2008;148:459–473.

Sievert KD, Amend B, Toomey PA, et al. Can we prevent incontinence? ICI-RS 2011. *Neurourol Urodyn*. 2012;31(3):390–399.

Starr JA, Drobnis EZ, Cornelius C. Pelvic floor biofeedback via a smart phone app for treatment of stress urinary incontinence. *Urol Nurs*. 2016;36(2):88–91 [97].

Starr JA, Drobnis EZ, Lenger S, et al. Outcomes of a comprehensive nonsurgical approach to pelvic floor rehabilitation for urinary symptoms, defecatory dysfunction, and pelvic pain. *Female Pelvic Med Reconstr Surg*. 2013;19(5):260–265.

Stewart F, Berghmans B, Bø K, et al. Electrical stimulation with non-implantable devices for stress urinary incontinence in woman. (Review). *Cochrane Database Syst Rev*. 2017;(12) [Art. No.: CD012390].

Subak LL, Richter HE, Hunskaar S. Obesity and urinary incontinence: epidemiology and clinical research update. *J Urol*. 2009;182:S2–S7.

Subak LL, Wing R, West DS, et al. Weight loss to treat urinary incontinence in overweight and obese women. *N Engl J Med*. 2009;360:481–490.

Subak LL, Whitcomb E, Shen H, et al. Weight loss: a novel and effective treatment for urinary incontinence. *J Urol*. 2005;174:190–195.

Suzuki M, Miyazaki H, Kamei J, et al. Ultrasound-assisted prompted voiding care for managing urinary incontinence in nursing homes: a randomized clinical trial. *Neurourol Urodyn*. 2019;38(2):757–763.

Swithinbank L, Hashim H, Abrams P. The effect of fluid intake on urinary symptoms in women. *J Urol*. 2005;174:187–189.

Sze EH, Hobbs G. A retrospective comparison of ring pessary and multicomponent behavioral therapy in managing overactive bladder. *Int Urogynecol J*. 2014;25:1583–1588.

Tak ECPM, van Hespen A, van Dommelen P, et al. Does improved functional performance help to reduce urinary incontinence in institutionalized older women? A multicenter randomized clinical trial. *BMC Geriatr*. 2012;12:51.

Talley KM, Wyman JF, Bronas UG, et al. Factors associated with toileting disability in older adults without dementia living in residential care facilities. *Nurs Res*. 2014;63(2):94–104.

Tannenbaum C, Agnew R, Benedetti A, et al. Effectiveness of continence promotion for older women via community organisations: a cluster randomised trial. *BMJ Open*. 2013;3:e004135.

Tincello DG, Williams KS, Joshi M, et al. Urinary diaries: a comparison of data collected for three days versus seven days. *Obstet Gynecol*. 2007;109:277–280.

Tomlinson BU, Dougherty MC, Pendergast JF, et al. Dietary caffeine, fluid intake and urinary incontinence in older rural women. *Int Urogynecol J Pelvic Floor Dysfunct*. 1999;10:22–28.

Townsend MK, Devore EE, Resnick NM, et al. Acidic fruit intake in relation to incidence and progression of urinary incontinence. *Int Urogynecol J*. 2013;24(4):605–612.

Townsend MK, Jura YH, Curhan GC, et al. Fluid intake and risk of stress, urgency, and mixed urinary incontinence. *Am J Obstet Gynecol*. 2011;205(1):73 [e1–6].

Townsend MKRN, Grodstein F. Caffeine intake and risk of urinary incontinence progression among women. *Obstet Gynecol*. 2012;119(5):950–957.

Vaughan CPAA, Cartwright R, Johnson TM 2nd, et al. Impact of obesity on urinary storage symptoms: results from the FINNO study. *J Urol*. 2012;189(4):1377–1382.

Vella M, Robinson D, Cardozo L, et al. The bladder diary: do women perceive it as a useful investigation? *Eur J Obstet Gynecol Reprod Biol*. 2012;162(2):221–223.

Vissers D, Neels H, Vermandel A, et al. The effect of non-surgical weight loss interventions on urinary incontinence in overweight women: a systematic review and meta-analysis.

Obes Rev. 2014;15(7):610–617.

Wagg A, Chen LK, Johnson T, et al. Incontinence in frail older persons. Abrams P, Cardozo L, Wein A, et al. *Incontinence: proceedings from the 6th International Consultation on Incontinence*. International Continence Society: Bristol, UK; 2017:1309–1442.

Wallace SA, Roe B, Williams K, et al. Bladder training for urinary incontinence in adults. *Cochrane Database Syst Rev*. 2009;(1) [CD001308].

Weinberger MW, Goodman BM, Carnes M. Long-term efficacy of nonsurgical urinary incontinence treatment in elderly women. *J Gerontol*. 1999;54:M117–M121.

Wesnes SL, Lose G. Preventing urinary incontinence during pregnancy and postpartum: a review. *Int Urogynecol J*. 2013;24(6):889–899.

Wing RR, Creasman JM, West DS, et al. Program to reduce incontinence by diet and exercise: improving urinary incontinence in overweight and obese women through modest weight loss. *Obstet Gynecol*. 2010;116:284–292.

Wing RR, West DS, Grady D, et al. Program to reduce incontinence by diet and exercise group: effect of weight loss on urinary incontinence in overweight and obese women: results at 12 and 18 months. *J Urol*. 2010;184:1005–1010.

Woodley SJ, Boyle R, Cody JD, et al. Pelvic floor muscle training for prevention and treatment of urinary and faecal incontinence in antenatal and postnatal women. *Cochrane Database Syst Rev*. 2017;(12) [CD007471].

Wyman JF, Burgio KL, Newman DK. Practical aspects of lifestyle modifications and behavioural interventions in the treatment of overactive bladder and urgency urinary incontinence. *Int J Clin Pract*. 2009;63(8):1177–1191.

Wyman JF. Bladder training for OAB. Bø K, Berghmans B, Morkved S, et al. *Evidence-based physical therapy for the* *pelvic floor*. Churchill Livingstone, Elsevier: London; 2007:208–218.

Wyman JF, Fantl JA. Bladder training in ambulatory care management of urinary incontinence. *Urol Nurs*. 1991;11(3):11–17.

Ziv E, Stanton SL, Abarbanel J. Efficacy and safety of a novel disposable intravaginal device for treating stress urinary incontinence. *Am J Obstet Gynecol*. 2008;198:594 [e1–e7].

Ziv E, Stanton SL, Abarbanel J. Significant improvement in the quality of life in women treated with a novel disposable intravaginal device for stress urinary incontinence. *Int Urogynecol J*. 2009;20:651–658.

Electrical Stimulation and Neuromodulation in Storage and Emptying Failure

John P.F.A. Heesakkers MD, PhD, Bertil Blok MD, PhD

History of Electrical Stimulation

Influencing the behavior of the lower urinary tract through electrical stimulation of the innervation system can be regarded as successful and multi-potent. However, the idea of achieving a specific response in human organs by electrical stimulation of the nervous system is conceptually logical, of long standing, and by no means confined to urology.

As early as the year 46, Scribonius Largus already described how the torpedo fish, the ray, and the eel could be used for the treatment of headaches and gout in his *Compositiones medicae.* As quoted by Martellucci (2015), Scribonius Largus stated that by direct application of electrical torpedo fish to the human body or by placing painful extremities into a pool of water containing torpedo fish, the resulting electrical shocks stunned the nervous system, allowing an immediate and residual numbness in the extremity (*De compositione medicamentorum liber*. Cratandrus, Basileae 1529; digital edition by the University and State Library Düsseldorf):

> *For any sort of podagra (foot gout), when the pain comes on, it is good to put a living black torpedo-fish under his feet standing on a beach, not dry but one on which the sea washes, until he feels that his whole foot and shank are numb up to the knees. This will both relieve the current pain and alleviate future recurrences.*

Because this method was almost certainly a difficult one to apply, it was not until the invention of the battery in the 18th century that additional medical applications for the use of electricity were developed. Further advances in the field of transistors in the 1950s made it possible to use pacemaker implants in humans for the first time. After it had been proven in the field of cardiology that these implants could successfully stimulate the heart, the use of the technique quickly spread to urology.

In initial experience, these attempts at stimulation were largely muscle based. The most logical idea was to use electric current to stimulate the contraction of the bladder or the sphincter as a treatment for, respectively, bladder contractility and stress incontinence. Caldwell et al. described in 1965 the first use of a sphincter stimulator in an attempt to contract the urethral sphincter. A year earlier, Bradley had tried to produce contraction of the detrusor via direct bladder stimulation. A decade later, Nashold et al. sought in 1972 to induce urination through the electrical stimulation of the sacral cores in the conus medullaris of the spinal cord. This was followed by Jonas et al. (1976), who likewise attempted to trigger micturition with different kinds of surface, deep, and cuff electrodes. However, this proved difficult to achieve during experiments with dogs, because the bladder and the urethral sphincter were activated simultaneously. It was only after this pioneering work on animals that tests were later carried out on neurologic patients. This patient population was chosen because their innervation system was hampered and because the efficient direct stimulation of an organ by electricity was painful in people with a properly functioning innervation system. This was not the case in patients with paraplegia or spina bifida. Unfortunately, these early human tests were not a huge success. Not only was the direct application of the electric stimulation to an organ painful, but also it was relatively ineffective. The stimulation only had an effect in the immediate vicinity of its application. It was eventually discovered that better results could be achieved by indirect stimulation of the end organ via its afferent nerves. This required the use of less current and enabled the entirety of the end organ to be treated. This was the start of the era of practical clinical neurostimulation.

One of the most spectacular applications of neurostimulation in urology was introduced by the neuroscientist Giles Brindley (Brindley and Craggs, 1978). Brindley's sacral anterior root stimulator (SARS) provided stimulation, as the name implies, to the anterior sacral roots responsible for the contraction of the bladder and therefore voiding, defecation, and penile erection. Because anterior stimulation is not able to reduce detrusor overactivity (DO), the SARS was later combined with a sacral dorsal rhizotomy of the same roots. During the last 25 years this combination of rhizotomy and electrical stimulation has resulted in a significant improvement in the quality of life (QoL) for many paraplegic patients by enhancing the functioning of their organs. In addition to Brindley, Sauerwein et al. (1990) in Germany and Sarrias et al. in Spain have also made major contributions to the development and use of this technique.

Around 1985 the emergence of the sacral neuromodulation (SNM), or sacral nerve stimulation (SNS), occurred. The literature is unclear regarding who should claim credit for this discovery, but it gradually became apparent that electric stimulation of the sacral roots could be used to lead not to an increase but to a decrease in bladder activity. This represented a significant breakthrough for the treatment of an overactive bladder (OAB). Up to this point in time, there had been no really effective method for combating this debilitating disorder. Emil Tanagho and Rick Schmidt were the pioneers of SNM, which was successfully introduced into urologic practice worldwide (Bazeed et al., 1982; Hohenfellner et al., 1992; Lue et al., 1985; Thüroff et al., 1982).

It was only with the advent of functional magnetic resonance imaging (fMRI) studies that it became clear that the value of this technique was based on an indirect approach. The sacral roots contain efferent and afferent nerve fibers. The application of an electrical current stimulates the afferent fibers that can influence the relevant areas in the central nervous system (CNS). The stimulus is then conducted by the efferent nerve fibers to the relevant pelvic organs. Because this process does not involve the direct stimulation of the organ but indirectly influences the entire micturition and urine storage system, the procedure is known as neuromodulation. American as well as European pioneers of nerve stimulation and nerve modulation learned the basic techniques of SNM from Emil Tanagho, and theory was successfully put in practice (Van Kerrebroeck et al., 2007).

Around the turn of the 21st century, another new technique made its appearance: percutaneous tibial nerve stimulation (PTNS). For thousands of years Chinese acupuncturists have been activating the acupuncture stimulation point SP6 in the ankle as a treatment for bladder disorders, including OAB. In 1983 McGuire was the first physician who tried to influence the bladder through neuromodulation via the tibialis posterior nerve, situated at the same location as SP6. After this anecdotal use, PTNS spread widely in the years after 2000. This new type of neuromodulation was technically simpler and cheaper than sacral neuromodulation. Because there was no need for an implant and because the stimulation was discontinuous, it was possible to demonstrate the net effect of PTNS in a convincing manner (Peters et al., 2010). New clinical attempts and developments now focus on other sites to stimulate or modulate the lower urinary tract. Examples of these are dorsal genital nerve (DGN) stimulation, pudendal nerve stimulation, intravaginal stimulation, and transcutaneous tibial nerve stimulation (TTNS) by means of a patch. Also, technical developments such as small, chargeable devices are being developed and put into clinical practice. The future will tell which of these developments can stand the test of time.

Neurophysiology Relevant to Electrical Stimulation for Storage and Voiding Disorders

Electrical stimulation for treatment of functional urinary bladder disorders works presumably via modulation of nerves and central neural pathways. It is not known exactly how this electrical therapy works successfully in bladder disorders. Most theories on the working mechanism are focused on the modulation of the central components of the micturition pathways and do not discuss the potential involvement of other brain areas. Some basic knowledge of the main central pathways involved will be summarized.

Failure to urine storage results from either bladder or bladder outlet abnormalities or a combination of both. Such bladder abnormalities include involuntary detrusor contractions, low bladder wall compliance, and altered bladder sensation. Outlet abnormalities include decreased outlet resistance, which may be continuous or intermittent.

Failure to empty the bladder can also occur because of either bladder or outlet abnormalities or a combination of both. Relevant bladder abnormalities include a hypocontractile and/or hyposensitive bladder; outlet abnormalities causing ineffective bladder emptying include anatomic obstruction, such as prostate enlargement and urethral stricture, and urethral sphincter dysfunction or dyssynergia. Electrical stimulation does not restore detrusor or sphincter muscle volume and cannot correct an anatomic abnormality such as urethral stricture or low compliance resulting from fibrosis.

The control of normal urinary continence and urine storage depends on a synergic action between the urinary bladder and the outlet of the bladder of which the external urethral sphincter (EUS) is the most relevant structure. The bladder is relaxed and the EUS continuously contracted involuntarily during the storage or filling phase. When micturition is necessary and socially acceptable, the EUS relaxes first, which is followed 1 to 2 seconds later by a contraction of the detrusor muscle. This antagonistic action between the bladder and its sphincter is controlled by separated descending pathways from the caudal brainstem. Normal voiding is not possible without adequate relaxation of the EUS.

An understanding of the role of the brain and its control of the urinary bladder and urethral sphincter can be facilitated by identifying nuclei and axonal tracts in the caudal brainstem and spinal cord, which are part of the micturition and the continence reflex, and nuclei and axonal pathways, located in the forebrain and mesencephalon, which modulate these micturition and continence reflex areas and their tracts.

The central afferent components of the micturition reflex consist of sacral spinal interneurons and their ascending sensory pathway to the periaqueductal gray (PAG) and the pontine micturition center (PMC) in the caudal brainstem, and the PMC and its descending motor pathway to the preganglionic parasympathetic motoneurons in the sacral cord (Fig. 122.1). The afferent thin, myelinated Aδ nerves from the urothelium, suburothelium, and detrusor muscle in the bladder wall convey bladder filling information via the pelvic and hypogastric nerves to the lumbosacral spinal cord. The afferent information from the bladder neck and urethra is conveyed via the pudendal and hypogastric nerves to the lumbosacral spinal cord (Blok, 2002; De Groat et al., 2015). These lower urinary tract afferents terminate on interneurons in the lateral aspect of the dorsal horn and in the intermediate zone of the lumbosacral cord. Most of the interneurons make intraspinal connections for proprioception, but other spinal interneurons send ascending fiber tracts to specific areas in the pons and midbrain. Some of these interneurons are involved in conveying information related to bladder filling. Other lumbosacral interneurons relay information to forebrain structures, including the thalamus and the hypothalamus (Giesler et al., 1981; Katter et al., 1991). The spinothalamic and spinohypothalamic tracts are thought not to play a specific role in the basic micturition reflex but are involved in sensory processes such as sensation of urogenital pain, temperature, touch, and conscious awareness of bladder filling and voiding. The sensory cortex is constantly informed about the fullness of the urinary bladder via the spinothalamic tract (Chandler et al., 1992). In patients with OAB there is an overawareness of bladder filling, which can be suppressed by conservative or invasive therapy, such as pelvic floor physiotherapy, medication, or electrical stimulation. In patients with complete spinal cord injury (SCI) it is possible that the brain receives bladder fullness information via the vagal nerve (Krhut et al., 2017).

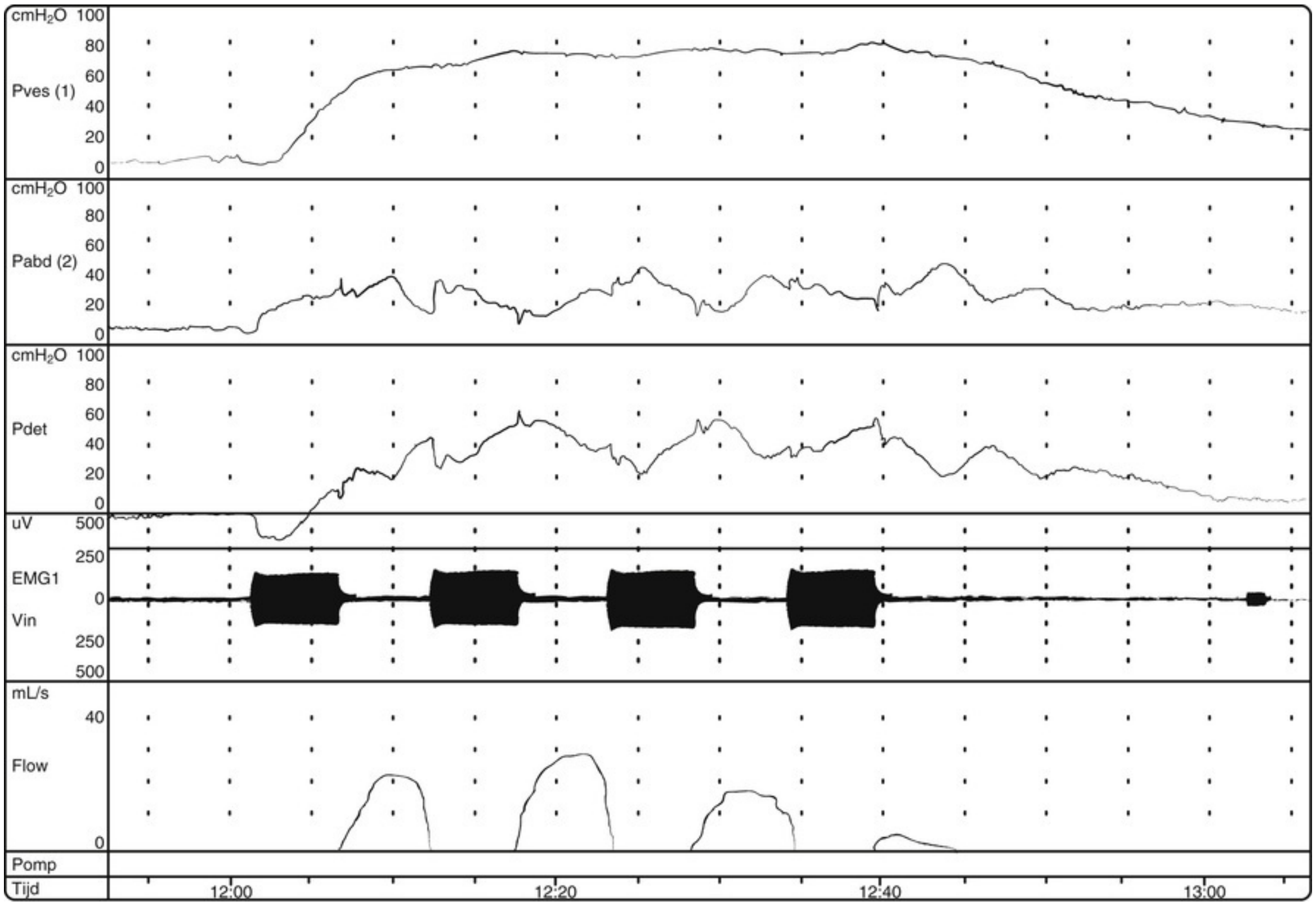

FIG. 122.1 Technique of post-stimulus voiding with the Finetech-Brindley stimulator. The three upper traces show the intravesical (Pves), intra-abdominal (Pabd), and detrusor pressure (Pdet) during stimulation. The increase in EMG signal reflects the activation of the stimulus during 5 seconds. Stimulation is activated every 12 seconds. The intermittent stimulation pattern allows the urethral sphincter to relax while the detrusor continues contracting and detrusor pressure remains elevated. This results in an intermittent flow pattern.

The motor components of the micturition reflex are composed of the PMC and its descending pathway to the sacral cord (see Fig. 122.1). The PMC is located in the dorsolateral pons, and its long descending axons make direct contact via their excitatory terminal boutons with the parasympathetic preganglionic motoneurons in the intermediolateral cell column in the sacral cord (Blok et al., 1997a,b,c). These excitatory terminals contain the neurotransmitter glutamate (Matsumoto et al., 1995). The cholinergic parasympathetic preganglionic motoneurons send their axons to the parasympathetic postganglionic neurons in the bladder wall (De Groat et al., 2015). The descending pathway from the PMC makes direct excitatory glutaminergic contact with inhibitory interneurons in the sacral intermediomedial cell column via collaterals (Blok et al., 1997a,b,c). These inhibitory interneurons contain GABA and glycine (Blok et al., 1997a,b,c; Sie et al., 2001) and send their axons to the motoneurons of the EUS (Konishi et al., 1985). Stimulation of the sacral intermediomedial cell column of the cat results in a strong relaxation of the EUS, mimicking the relaxation of the sphincter during micturition (Blok et al., 1998a,b). In mammals, activation of the PMC results in urethral sphincter relaxation via the indirect pathway to the inhibitory sacral interneurons, followed by a bladder contraction via the direct pathway to the bladder motoneurons. This bimodal activation is simultaneous at the level of the sacral spinal cord and has an immediate relaxing effect in the striated EUS and a delayed contracting effect in the smooth detrusor muscle. The PMC is the final common pathway or micturition switch for the relaxation phase, involving the EUS, and the contraction phase, involving the smooth muscle of the urinary bladder. The thoracolumbar segments T10 to L2 contain sympathetic preganglionic motoneurons, which are involved in the relaxation of the bladder wall. Efferent nerves travel within the hypogastric nerve via the thoracolumbar sympathetic ganglionic chain to the bladder wall. The sympathetic tone keeps the intravesical pressure low during end of the storage phase. The sympathetic nerves to the bladder only start to fire at about 60% of bladder capacity (Vaughan et al., 1992). Furthermore, resection of the sympatholytic drugs or resection of the sympathetic chain have little effect on bladder storage (Fowler et al., 2008). The sympathetic system is therefore supposed not the provider of continence during most of the time in healthy subjects.

The PMC receives input from the mesencephalic PAG, which is thought to be a crucial component of the micturition reflex in higher mammals. The PAG is a midbrain area initially appreciated for its role in pain modulation (Basbaum and Fields, 1984). In recent years it has become clear that this dense neuronal matter, which abuts the aqueduct of Sylvius, is essential for many vital basic functions, including respiration, aggression, mating, defecation, and micturition (Dampney, 2015; Holstege, 2014). In the cat, anterogradely labeled fibers from the lumbosacral spinal cord form a dense terminal field particularly in the lateral PAG (Blok et al., 1995). Furthermore, bladder and pelvic nerve stimulation evokes activation of the PAG (Noto et al., 1991). The importance of the PAG in the cat is exemplified by the observation that electrical stimulation of the lateral PAG results in micturition in cats, which includes an initial relaxation of the EUS followed by a bladder contraction (Blok and Holstege 1997; Taniguchi et al., 2002). Disconnection of the PAG from the PMC results in an extreme form of urgency urinary incontinence (UUI), in which the bladder empties completely after minimal filling (Ruch and Tang, 1956). The forebrain controls the PAG and the PMC like a switch, which means that when this PMC switch is not turned on, the relaxation of the EUS—the first stage of voiding—does not happen. Lesions rostral to the mesencephalic PAG result in the loss of control of the timing of micturition, but the micturition reflex remains intact. A pivotal role for the PAG and PMC in bladder control has been described in humans using positron emission tomography and fMRI (Blok et al., 1997a,b,c, 1998a,b; Griffiths et al., 2005; Michels et al., 2015). Afferent information from the bladder and urethra is relayed via the thalamus to the cingulate and insular cortices. These areas help to decide whether it is safe to start voluntary voiding via the prefrontal cortex (Blok et al., 1997a,b,c). Urinary continence is controlled by the pontine continence center or L-region (Blok, 2002; De Groat et al., 2015). The pontine continence center continuously excites the EUS during continence (see Fig. 122.1). This tonic contraction is interrupted six to seven times per day by the relaxation of the sphincter by the PMC during micturition. Furthermore, this continuous and involuntary EUS contraction cannot be stopped by the verbal command or instruction to relax the pelvic musculature. Pelvic floor rehabilitation by physiotherapy or Kegel exercises works by voluntary contraction by the primary motor cortex on top of the involuntary tonic contraction (Blok et al., 1997a,b,c). When this voluntary pelvic floor contraction stops, the contraction state returns to the baseline involuntary contraction. This explains why physiotherapy is usually ineffective in urinary retention.

Sacral Anterior Root Stimulation and Sacral Dorsal Rhizotomy

In 1969 Giles Brindley invented and introduced sacral anterior root stimulation (SARS) (Brindley and Craggs, 1978). Brindley's SARS stimulated the anterior sacral roots responsible for the contraction bladder and rectum to induce voiding and defecation. Moreover it was possible to achieve penile erection by electrical anterior root stimulation. Because anterior stimulation is not able to overcome DO and therefore could not abolish incontinence because of DO, SARS was later combined with a sacral dorsal rhizotomy of the same roots. During the last 25 years this combination of rhizotomy and electrical stimulation of the sacral roots has resulted in a significant improvement in the QoL of many paraplegic and tetraplegic patients by enhancing the functioning of their pelvic organs. The device is known as the Finetech-Brindley System (Finetech Medical Ltd., Welwyn Garden City, UK).

Stimulator

The Brindley system is composed of an external and implanted part. The implanted part can be positioned intradurally or extradurally. The implant consists of electrodes, connecting cables, and a receiver block. Patients have to put the external stimulator on the skin over the implanted receiver to evoke stimuli. The receiver is activated by the chargeable external stimulator and does not have an energy source. Electrical stimuli are evoked by radiofrequency waves. With the possibility of separate stimulation with various stimulation settings of individual sacral anterior roots (S2, S3, or S4; sometimes S5), it is possible to apply various stimulation programs to optimize micturition, defecation, and penile erections.

For intradural application, a tripolar electrode cuff is used for stimulation of the sacral anterior roots. A three-channel implant is composed of two electrode groupings. The upper grouping contains three parallel slots for right S3 root (one slot lateral right) and right and left S2 roots (two roots in one middle slot) and the left S3 root (one slot lateral left). The lower grouping contains one slot for both S4 roots. Each slot contains three metal strips acting as cathode or anode. There is one cathode in the center and an anode at each of the two ends. With this setup one can avoid to leak electrical currents at nerves outside the slot. The two-channel implant allows stimulation of two root levels or sets of root levels. The four-channel implant has the same configuration as the three-channel implant but allows independent stimulation of four sets of roots. The choice of the number of channels depends on the number of different rootlet combinations that have to be able to be stimulated. Each channel is connected to the subcutaneous receiver block by a silicone-coated cable (Fig. 122.2).

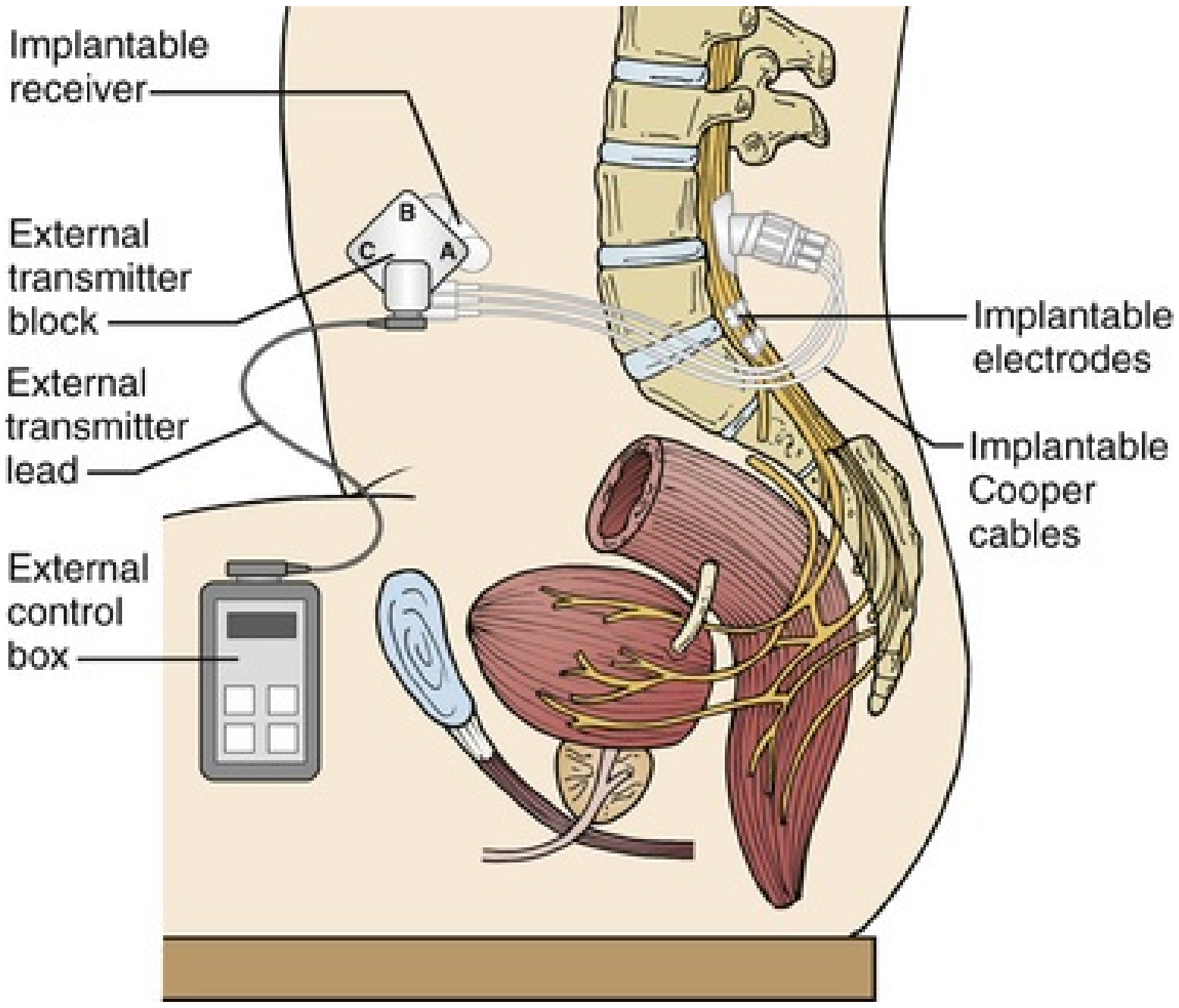
Implantable receiver
B
C
A
External transmitter block
External transmitter lead
External control box
Implantable electrodes
Implantable Cooper cables

FIG. 122.2 The implanted Finetech-Brindley sacral anterior root stimulator and the external stimulator. The user selects one of the stimulation programs (for voiding, defecations, or erections) on the external control box. The external control box then sends power and control signals to the external transmitter block via the external transmitter lead. The user holds the external transmitter block over the site of the implanted receiver. The receiver converts the signals from the external transmitter block into electrical impulses. The impulses travel via implantable cables to the implantable electrodes. The electrodes transfer the impulses to the nerves.

Extradural electrodes are used in patients in whom intradural electrodes could not be placed because of conditions such as arachnoiditis or a previous intradural electrode implantation that failed with consequent dural fibrosis. Some centers prefer to use primarily extradural electrodes for nearly all patients. The extradural implant has three helical electrodes at its end, which are also configured with a cathode between two anodes.

An essential step of the surgical procedure is the isolation of the posterior sensory roots and anterior motor roots of spinal cord segments S2, S3, and S4. The intradural procedure requires a sacral laminectomy to accomplish this. After this, the spinal cord roots are stimulated individually with electrical currents to investigate their function.

Technique of Post-Stimulus Voiding

Most of the small-diameter parasympathetic efferent nerve fibers for bladder innervation are located in the sacral anterior roots (S2-S4/5). Small-diameter nerve fibers need a higher amplitude stimulus for excitation than large-diameter fibers. Consequently, electrical stimulation of the sacral anterior roots for detrusor contractions also causes contraction of the urethral sphincter resulting from stimulation of somatic large diameter nerve fibers at the same time. This prevents emptying of the bladder. To overcome this problem post-stimulus voiding is used. The duration of striated muscle relaxation of the urethral sphincter is shorter than the relaxation time of smooth muscles of the detrusor. When intermittent stimulation pulse trains are applied, the difference in muscle relaxation time can be used for voiding. When the stimulation stops, the striated sphincter muscle relaxes immediately, whereas the smooth muscle fibers of the detrusor continue to contract and relax slowly, which allows the patient to void (see Fig. 122.1). The intervals between two stimulation pulse trains allow a decrease of the urethral sphincter pressure, while a high intravesical pressure remains. This results in post-stimulus voiding with an intermittent pattern of the micturition flow. A comparable mechanism can used for defecation.

Goal and Effect of Dorsal Rhizotomy of the Sacral Nerves

Sauerwein (1990) structurally expanded SARS with a posterior or dorsal rhizotomy of the sacral roots S2, S3, S4, and S5, the so-called deafferentiation. A dorsal rhizotomy is important because it suppresses neurogenic DO and detrusor-external sphincter dyssynergia. This results in a low-pressure bladder without reflex contractions of the detrusor and subsequently continence. Moreover, it reduces autonomic dysreflexia (Hohenfellner et al., 2001; Van Kerrebroeck et al., 1996). Dorsal sensory roots form a reflex arch with the anterior motor roots, and this influences motor control over the bladder. Leaving the dorsal roots intact therefore leads to persistent DO. Therefore a rhizotomy is done to surgically dissect the dorsal (sensory) roots. Despite the benefits of preventing bladder reflex activity and in this way preventing incontinence, patients are sometimes reluctant to undergo this necessary surgical procedure because they feel that this surgical step is irreversible and takes away hope for future developments that may reverse the SCI and return to normal. Moreover sphincter weakness may occur after deafferentiation (Chinier et al., 2016). Patient education for these aspects is therefore paramount.

Patient Selection

A Brindley procedure is suitable for a selected group of skeletally mature patients with complete SCI and with DO. Patients with severe autonomic dysreflexia or detrusor-external sphincter dyssynergia may benefit especially from the dorsal rhizotomy. Patients with incomplete injury will lose their sensory function because of the dorsal rhizotomy and have the risk to experience pain sensation during stimulation because of an incomplete rhizotomy. Patients need to have intact efferent nerve pathways to the bladder and a contracting bladder.

Contractions of at least 50 cm H_2O in males or 30 cm H_2O in females must be present during filling cystometry (Brindley et al., 1986). If no sufficient spontaneous contraction occurs during urodynamic investigation, patients can be tested to find out whether they are fit for the procedure by rectal stimulation similar to electro-ejaculation procedures or direct needle stimulation of the sacral roots to provoke bladder contractions. Preoperative magnetic resonance imaging

(MRI) is performed to exclude fibrosis of the cauda equina, which precludes the intradural approach.

Surgical Implantation Technique

Laminectomy from L3-L4 to S1-S2 is performed for an intradural rhizotomy and intradural implantation of the electrode book. The dura and arachnoid membrane are opened in the midline to expose the sacral nerve roots. The anterior and dorsal components of the roots, especially relevant anterior roots for micturition, can be identified intradurally by electrical stimulation of these roots. If the roots innervate the bladder, increase in detrusor pressure can be observed during intraoperative urodynamic monitoring. At the same time blood pressure and somatomotor response monitoring is performed to identify any systemic or cardiovascular effects. After the anterior roots are separated from the posterior roots, posterior rhizotomy of the identified posterior sacral roots is done. The anterior sacral roots are positioned into the corresponding slot of the electrode cuff. After the electrode group is closed, the dura will be closed with a watertight closure to prevent dura leaks. The connecting cables of the electrode book are subcutaneously tunneled to a subcutaneous pocket for the receiver. Implantation of extradural electrodes requires a laminectomy from L5-S1 to S3-S4. The dorsal rhizotomy is done at the level of the ganglia of S2-S5. Electrical stimulation tests are used to identify the anterior and dorsal component of the sacral roots. The extradural electrode is implanted and fixated to the nerve using a strip of silicone rubber sheet, which is sutured to itself and surrounds the nerve. The connecting cables and receiver are implanted the same way as for the intradural procedure (Fig. 122.3). Fig. 122.4 shows the intradural situation after implantation of the anterior right and left S2, S3, and S4 roots in the electrode book.

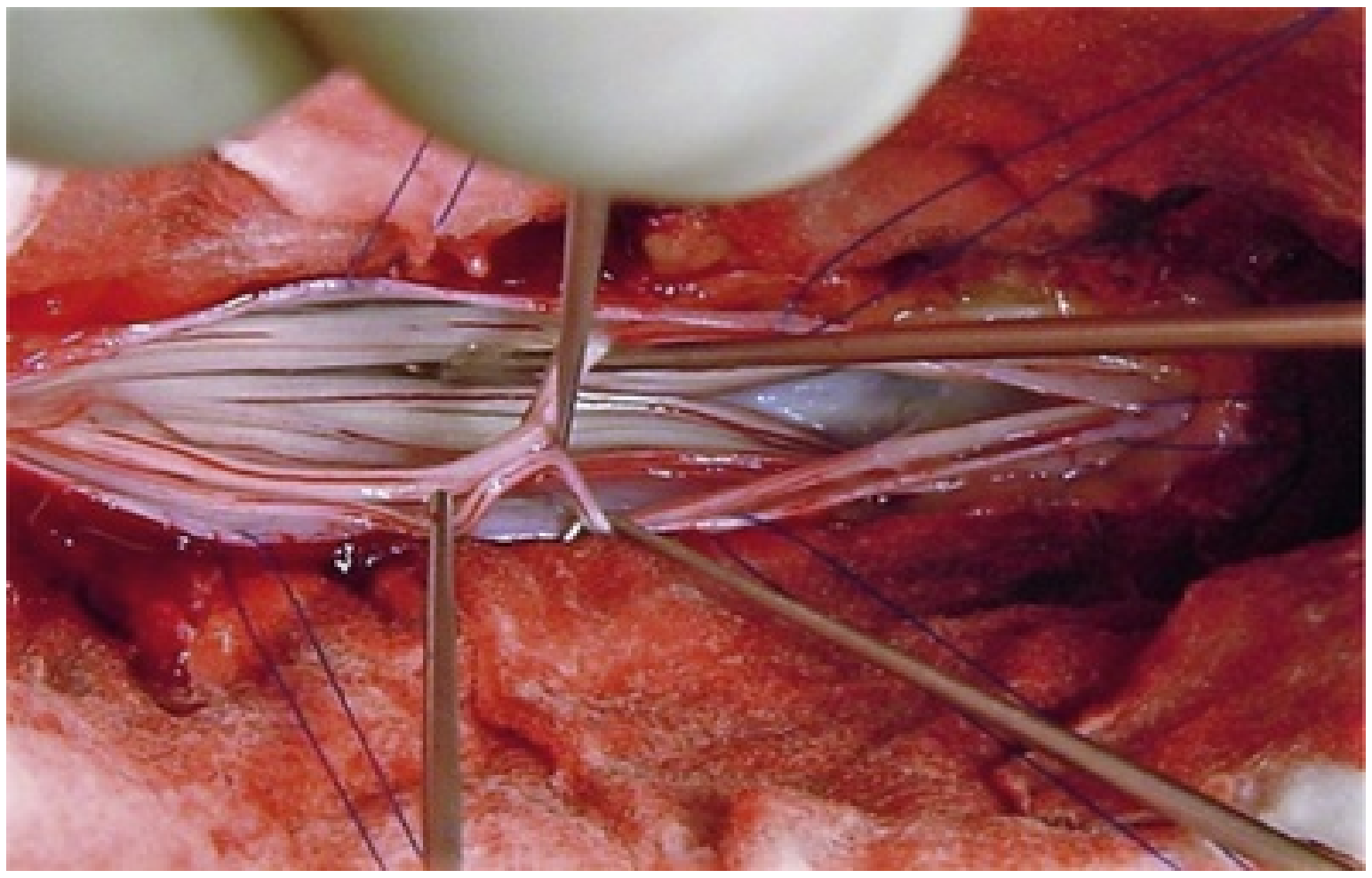

FIG. 122.3 Intraoperative photograph of the intradural anatomy after opening the dura mater at cauda equina level via a laminectomy. Stay sutures are used to expose the sacral nerves. The nerve roots of the left and right S2, S3, and S4 can be seen. The anterior roots and the posterior roots run together intradurally and have to be separated. The photo shows how the anterior root is separated from the posterior root. The anterior roots usually are small and have to be preserved; the posterior roots are thicker and have to be rhizotomized. The separation is done by so-called nerve hooks as can be seen on the photo.

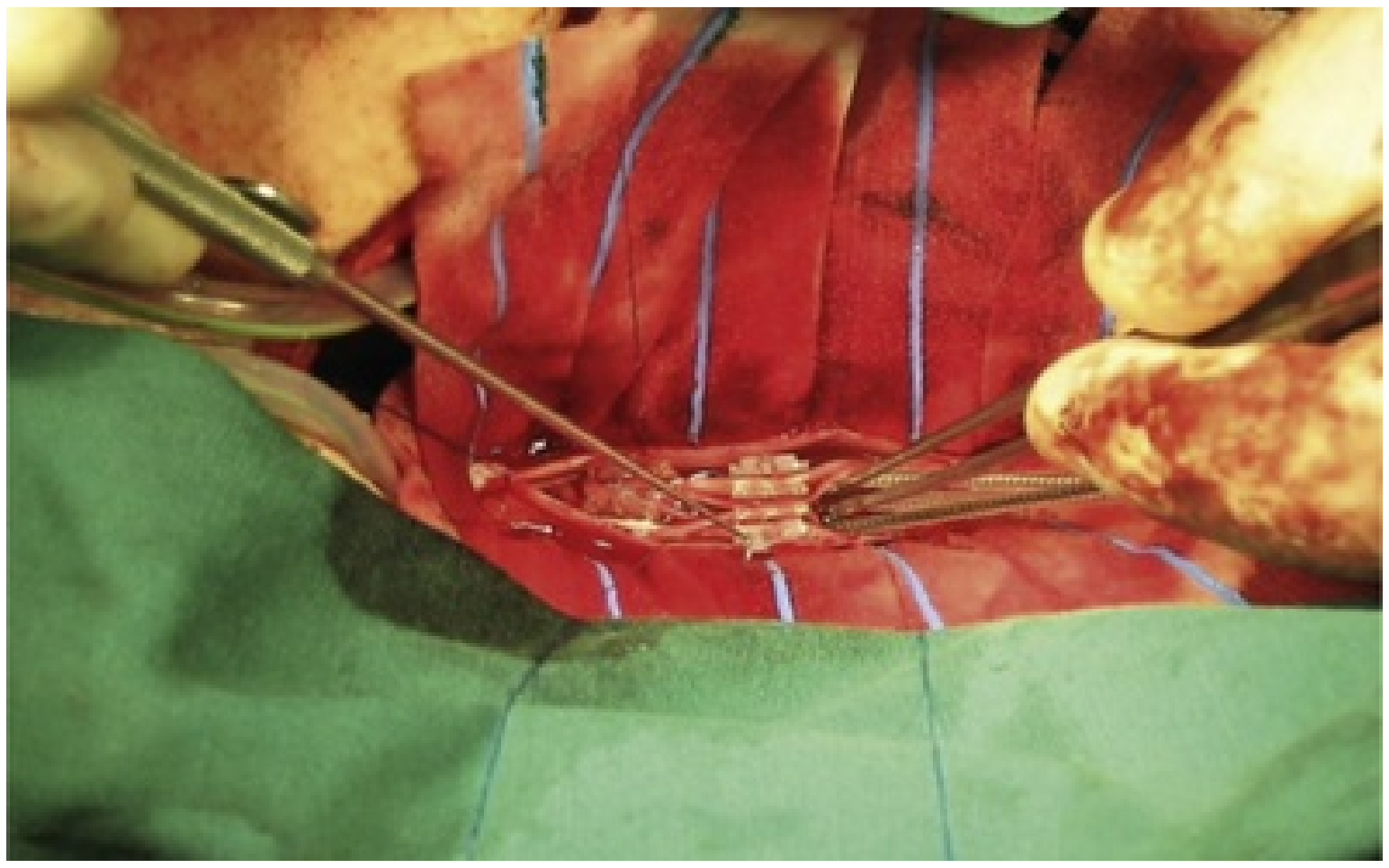

FIG. 122.4 Photo of the intradural situation after implantation of the electrodes combined in the electrode book. After separation of the sacral nerves the sensory posterior roots are rhizotomized or cut. The motoric anterior roots are placed in the electrode book. What can be seen is that the right and left S3 anterior roots are placed separately in the two outer slots of the proximal electrode book. The anterior right and left S2 roots are placed together in the middle slot of the proximal electrode book. The anterior right and left S4 root are placed in the distal single slot of the

electrode book.

Clinical Results

Table 122.1 shows an overview of publications on the clinical results of the Brindley procedure (Martens and Heesakkers, 2018). These results include those obtained by anterior stimulation by the Finetech-Brindley stimulator, which enables micturition, defecation, and erections, as well as the dorsal rhizotomy to achieve continence.

TABLE 122.1

Publications on Clinical Results of the Brindley Procedure

AUTHOR AND PUBLICATION YEAR[a]	PATIENTS IN FOLLOW-UP	RHIZOTOMY (INTRADURAL/EXTRADURAL)	IMPLANTATION (INTRADURAL/
Brindley et al., 1986	38 ♂ 12 ♀	17/0 (S2 and/or S3)	50/0
Madersbacher et al., 1988	1 ♂ 6 ♀	7/0	7/0
Robinson et al., 1988	20 ♂ 2 ♀	-	-
MacDonagh et al., 1990	9 ♂ 3 ♀	9/0	12/0
Sauerwein, 1990	5 ♂ 6 ♀	0/12	0/12
Van Kerrebroeck et al., 1993	90 ♂ 94 ♀[b]	-	166/18
Madersbacher and Fischer, 1993	8 ♂ 22 ♀	-	27/4

Sarrias et al., 1993	1 ♂ 6 ♀	7/0	0/7
Brindley, 1994	271 ♂ 229 ♀[b]	-	≤477/≥23
Van Kerrebroeck et al., 1996	29 ♂ 18 ♀	47/0	47/0
Schurch et al., 1997	3 ♂ 7 ♀	10/0	10/0
Egon et al., 1998	68 ♂ 28 ♀	0/0	90/9
Van der Aa et al., 1999	33 ♂ 4 ♀	37/0	37/0
Bauchet et al., 2001	6 ♂ 14 ♀	20/0	20/1
Creasey et al., 2001	16 ♂ 7 ♀	23/0	0/23
Vastenholt et al., 2003	32 ♂ 5 ♀	37/0	37/0
Hamel et al., 2004	4 ♂	4/0	0/4
Kutzenberger et al., 2005	440 ♂+♀	Almost all intradural	Almost all intradu
Krasmik et al., 2014	81 ♂ 56 ♀	137/0	137/0
Castaño-Botero et al., 2016	95 ♂ 9 ♀	0/104	0/104

[a] Full references can be found in the reference list.

This overview includes several multicenter studies ([b]), which include overlapping results with the reports of various single-center studies. Therefore no accumulation of results is possible. (-), Unreported data or incomplete data for calculation; *UTI,* urinary tract infection.

The stimulator can instigate micturition in 73% to 100% of patients during follow-up. However, stimulation is not always completely successful, and the results include patients who use additional methods to empty their bladder. The number of patients who have residual urine of 50 mL or less is lower than the number of patients who use the stimulator for micturition. Additional methods for bladder emptying comprise intermittent catheterization, abdominal straining (Valsalva maneuver), abdominal compression (Credé maneuver), or suprapubic tapping to evoke reflex contractions.

Continence is achieved in 57% to 100% of patients, and bladder capacity increases substantially and may be more than doubled. Results on continence also included additional treatments, such as anticholinergics and stress incontinence surgery.

Overall, patients have less urinary tract infections compared with the situation preoperatively.

The Finetech-Brindley stimulator is used for defecation in 29% to 100% of patients, but success is achieved in different degrees. Not all patients achieve complete evacuation of defecation using only stimulation. Some patients need laxatives in addition to prevent constipation or enable defecation. Many patients only use the stimulator to move the stool into the rectum, whereafter they use digitation for emptying.

Erections can be evoked in a substantial number of patients, but rigidity varies considerably. This explains the relatively low number of patients who actually use the stimulator for sexual intercourse (0–32%). Rigidity can be inadequate for sexual intercourse or deteriorates over time.

Autonomic dysreflexia is mostly modulated after the Brindley procedure as a result of the dorsal rhizotomy, although there are some case reports of stimulation-induced autonomic dysreflexia.

Current and Future Perspectives for Neurostimulation

The ultimate treatment of neurourologic disorders of the lower urinary tract would be to remedy the neurogenic disorder that causes the LUTD. As long as the reversible restorative treatment is not available, symptomatic treatment options are required. Intradetrusor botulinum toxin A injections are now commonly used, often in combination with (intermittent) catheterization. However, the Brindley procedure has several advantages for suitable patients compared with botulinum toxin A, especially if other than urologic organ systems are taken into account. SCI comprises a variety of linked, physical problems. Therefore management of multiple organ dysfunctions should be advocated. The Brindley procedure not only enables continence and micturition but also completes defecation or improvement of defecation pattern, penile erections, and reduction of autonomic dysreflexia and spasms. Patients do not need assistance for intermittent catheterization and can empty their bladder at will. When the treatment options are discussed with a patient, this more extensive application of the Brindley procedure should be mentioned.

The Brindley procedure generally shows good clinical results for restoration of function in SCI patients with multiple organ dysfunction, including bladder, bowel, and erectile dysfunction. Moreover, the Brindley procedure improves QoL (Martens et al., 2011). Recent publications show that it is also cost effective.

The procedure is also relatively easy to perform. However, not every patient is suited for the procedure, and the success depends on selection of appropriate patients. Prerequisites are a complete spinal cord lesion (because neurostimulation can cause pain in incomplete spinal cord lesions), an intact sacral motor neuron pathway enabling stimulation of the bladder, and a detrusor muscle that is capable to contract on stimulation. Second, a dorsal rhizotomy and implantation of a Brindley stimulator is complex and not a routine procedure for urologists and should be reserved for specialized centres. Third, the technique is also prone to failures.

A main issue for patients who consider a Brindley procedure is the irreversibility of the rhizotomy and the possibility that future treatment options are not within reach anymore. Although SARS can restore penile erections after a rhizotomy, qualitative useful stimulation of erections is not possible in a substantial number of patients. New techniques to avoid dorsal rhizotomy are sought. Continuous or conditional neuromodulation, selective anodal block, and high-frequency block could be of help for this in the future, but so far the clinical applications of these innovations are very limited (Boger et al., 2008; Brindley and Craggs, 1980; Hansen et al., 2005; Kirkham et al., 2001; Rijkhoff et al., 1997; Seif et al., 2002). The Brindley implant is not approved by the US Food and Drug Administration (FDA).

Working Mechanism of Electrical Stimulation in Non-Neurogenic Storage and Voiding Disorders

It can be expected that electrical therapies aimed at functional bladder disorders not only target the lower urinary tract or the spinal cord but also influence higher brain centers, which, in turn, may modulate the micturition reflex components.

Several theories have been proposed on how electrical stimulation can restore normal function in bladder disorders, but none of these have been confirmed or substantiated. The suggested theories are usually focused on the working mechanism of SNM. Other relevant forms of electrical stimulation are not taken into account. However, it can be assumed that there are strong similarities among all neuromodulatory options, such as PTNS, transcutaneous electrical nerve stimulation (TENS), dorsal genital nerve stimulation, intravaginal stimulation, and intravesical stimulation (IVES). The main difference with those alternative therapies is that the SNM recruits at least 1000 times more axons by stimulating the sacral root and not a small nerve or some superficial nerve fibers. Moreover, SNM provides continuous stimulation as opposed to the other treatment options, which use a stimulation protocol of 30 minutes every 1 to 2 weeks. The implanted neuromodulator offers more flexibility in the stimulation parameters.

Another important aspect is the possible common mode of central involvement in electrical stimulation of the lower urinary tract and that used in other diseases, such as fecal incontinence and chronic pain, or even with deep brain stimulation for neurologic and psychiatric diseases.

Bladder overactivity with or without urinary incontinence is believed to be caused by a loss of voluntary inhibitory control, which emerges during the postnatal maturation of the voiding reflex. SNM may help to restore this voluntary inhibitory control (Fig. 122.5).

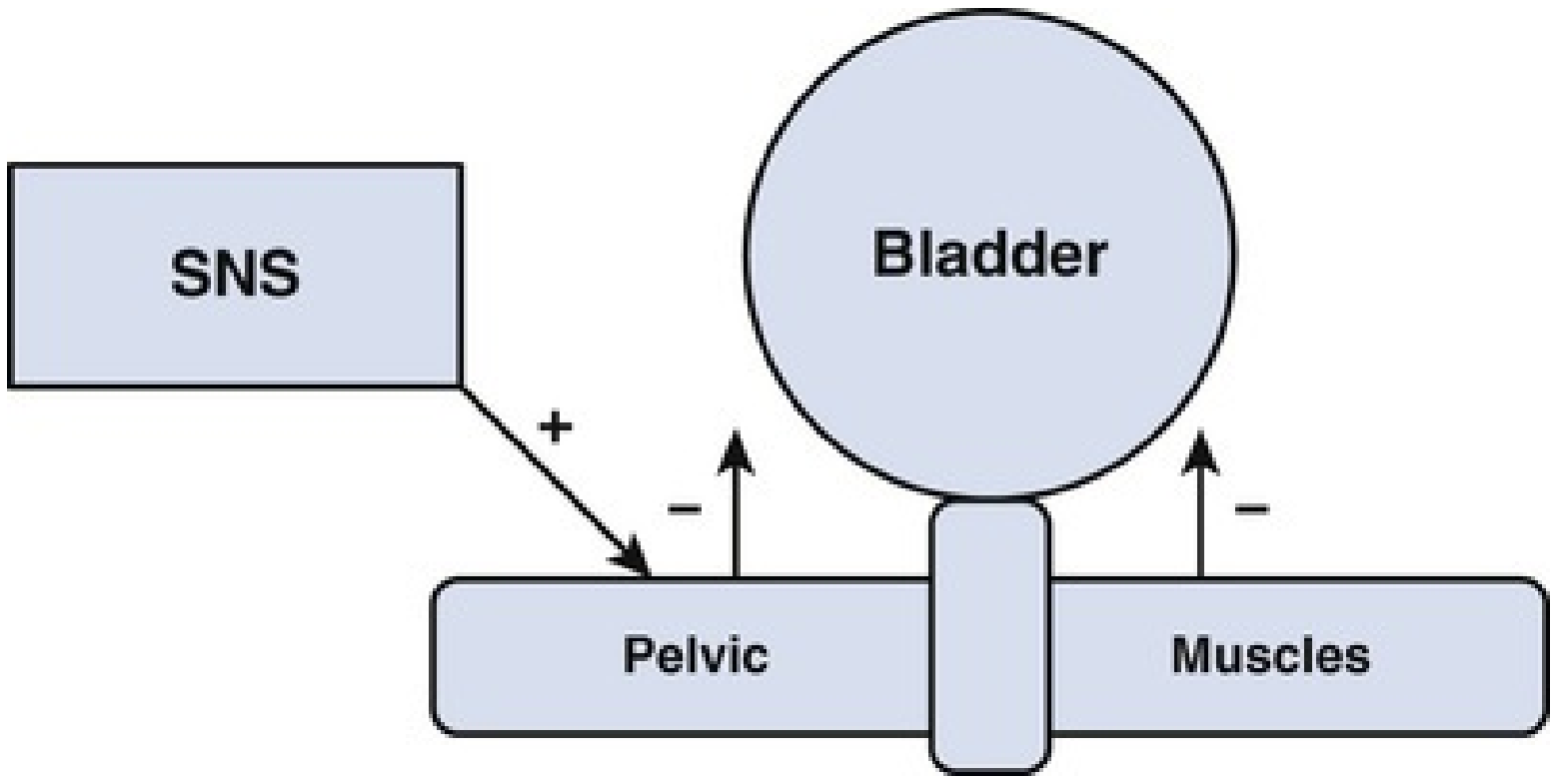

FIG. 122.5 Early theory on working mechanism of electrical stimulation in idiopathic bladder dysfunction. *SNS,* Sacral nerve stimulation.

The early theories of the mechanism of electrical stimulation in voiding dysfunction assumed that stimulation of motor nerves resulted in pelvic muscle contraction (see Fig. 122.1). This pelvic muscle contraction, in turn, would relax the bladder muscle via intramural postganglion cells (Tanagho and Schmidt, 1988). This early theory is now less plausible, because a pelvic floor contraction elicited by SNM is not necessary for a beneficial effect. Furthermore, activation of exclusive sensory nerves such as the dorsal clitoral and dorsal penile nerves results in similar effects on the bladder as SNM (Goldman et al., 2008; Groen and Blok, 2015). A similar theory was put forward for underactive bladder (Leng and Chancellor, 2005), in which SNM would inhibit the excitatory outflow via the efferent axons in the pudendal nerve. This sphincter suppression would facilitate bladder emptying (Fig. 122.6).

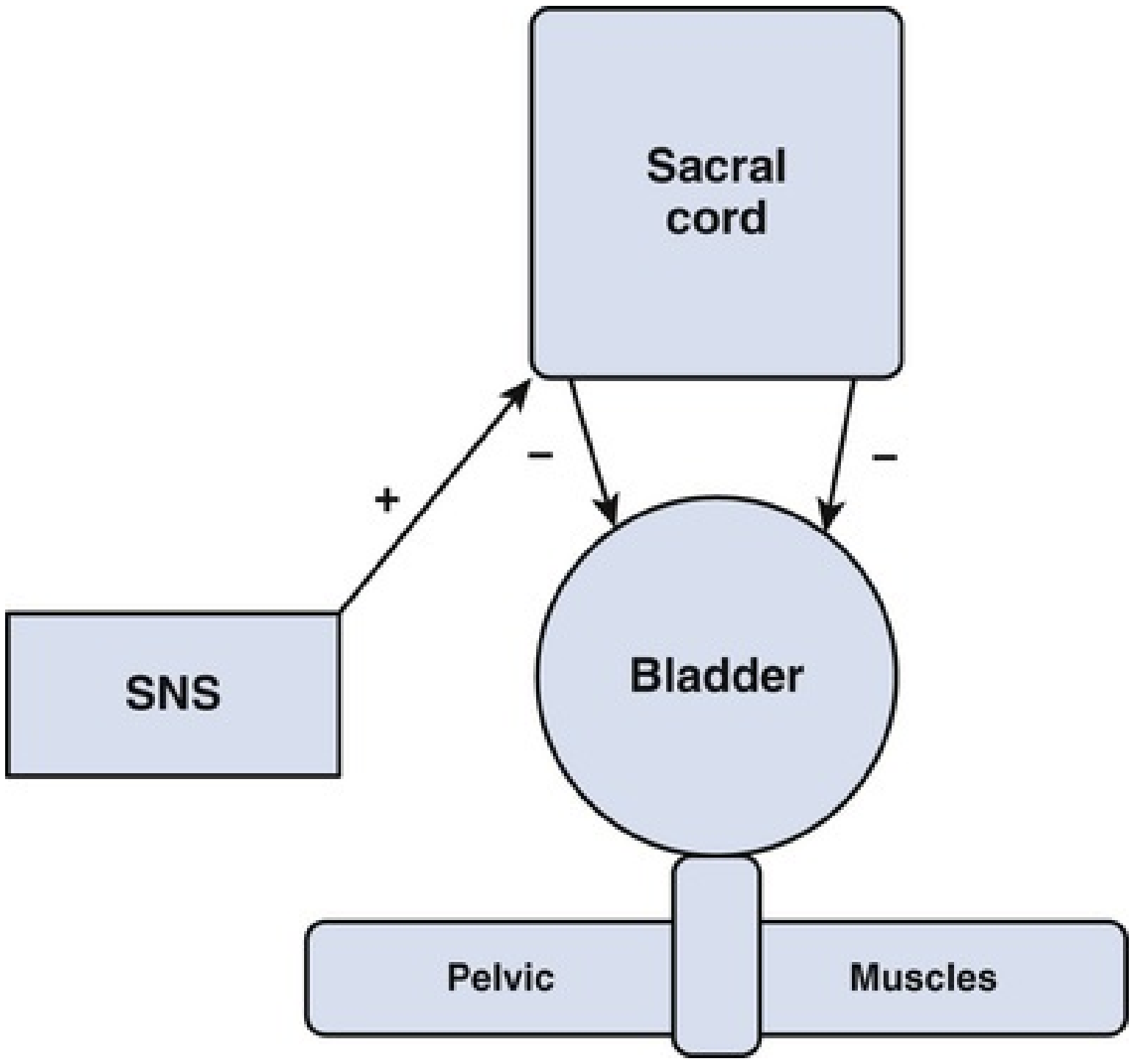

FIG. 122.6 Spinal cord theory on working mechanism of electrical stimulation in idiopathic bladder dysfunction. *SNS,* Sacral nerve stimulation.

In 2005 (see Fig. 122.2) it was suggested that the sacral cord may have a prominent target of SNM (Leng and Chancellor, 2005). The afferent pathways projecting to the sacral cord may inhibit OAB contractions by inhibiting local sacral interneurons and direct inhibition of the preganglionic parasympathetic bladder motoneurons. The same authors discussed the alternative theory that SNM would inhibit the PMC activation and, in turn, would decrease OAB contractions (Fig. 122.7).

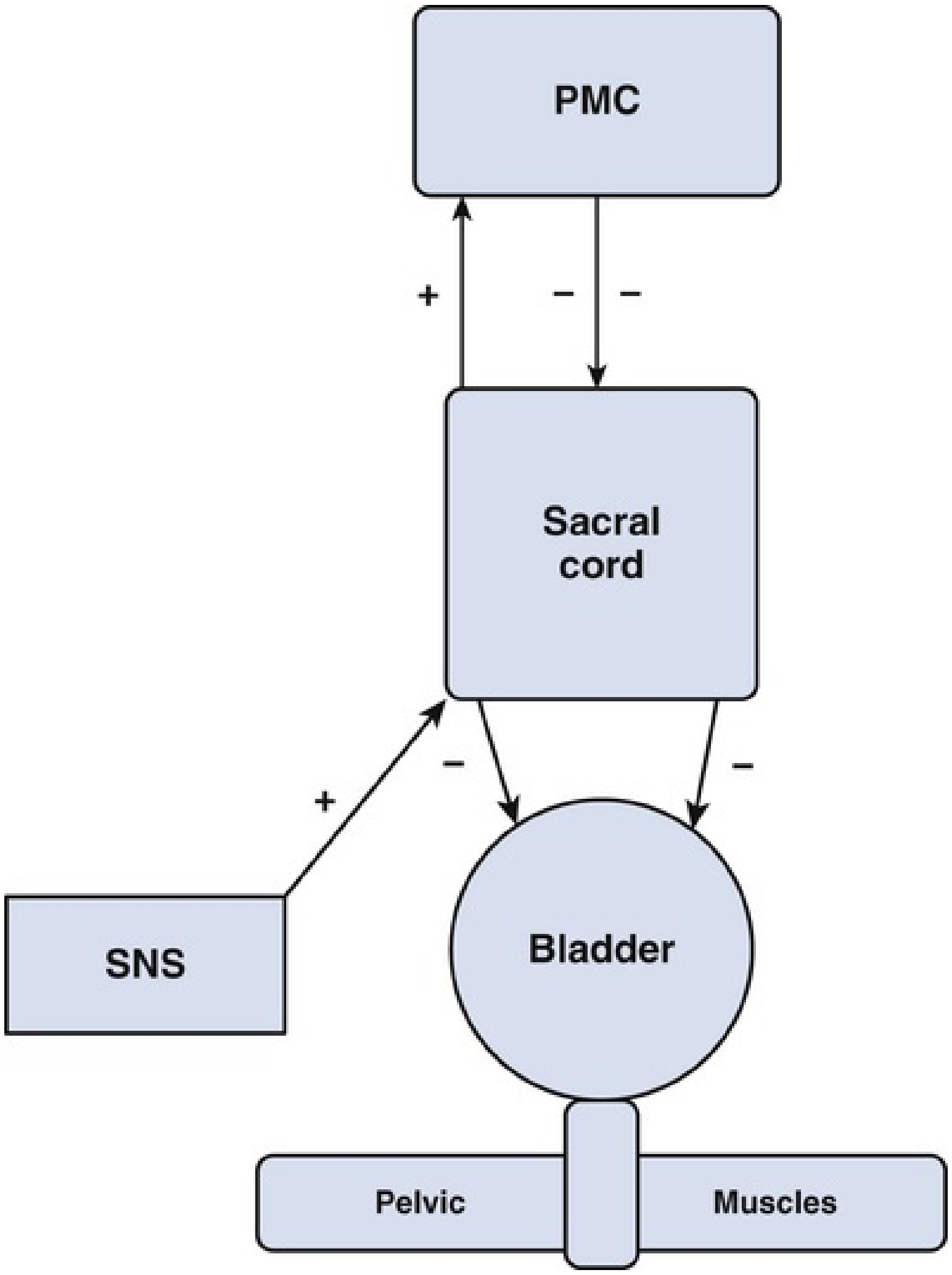

FIG. 122.7 Spinal cord-pontine micturition center theory on working mechanism of electrical stimulation in idiopathic bladder dysfunction. *PMC,* Pontine micturition center; *SNS,* sacral nerve stimulation.

Later, higher brain areas were also incorporated into relevant theories. Cortical sensory areas of the brain may be altered by SNM. Positron emission tomography showed differences in regional cerebral blood flow during acute and chronic SNM (Blok et al., 2006). The primary and associative sensory cortices were not the only areas modulated during SNM; modulation was also seen in areas important for attention and alertness. The results also suggested that chronic SNM induces neuroplasticity (Blok et al., 2006) (Fig. 122.8).

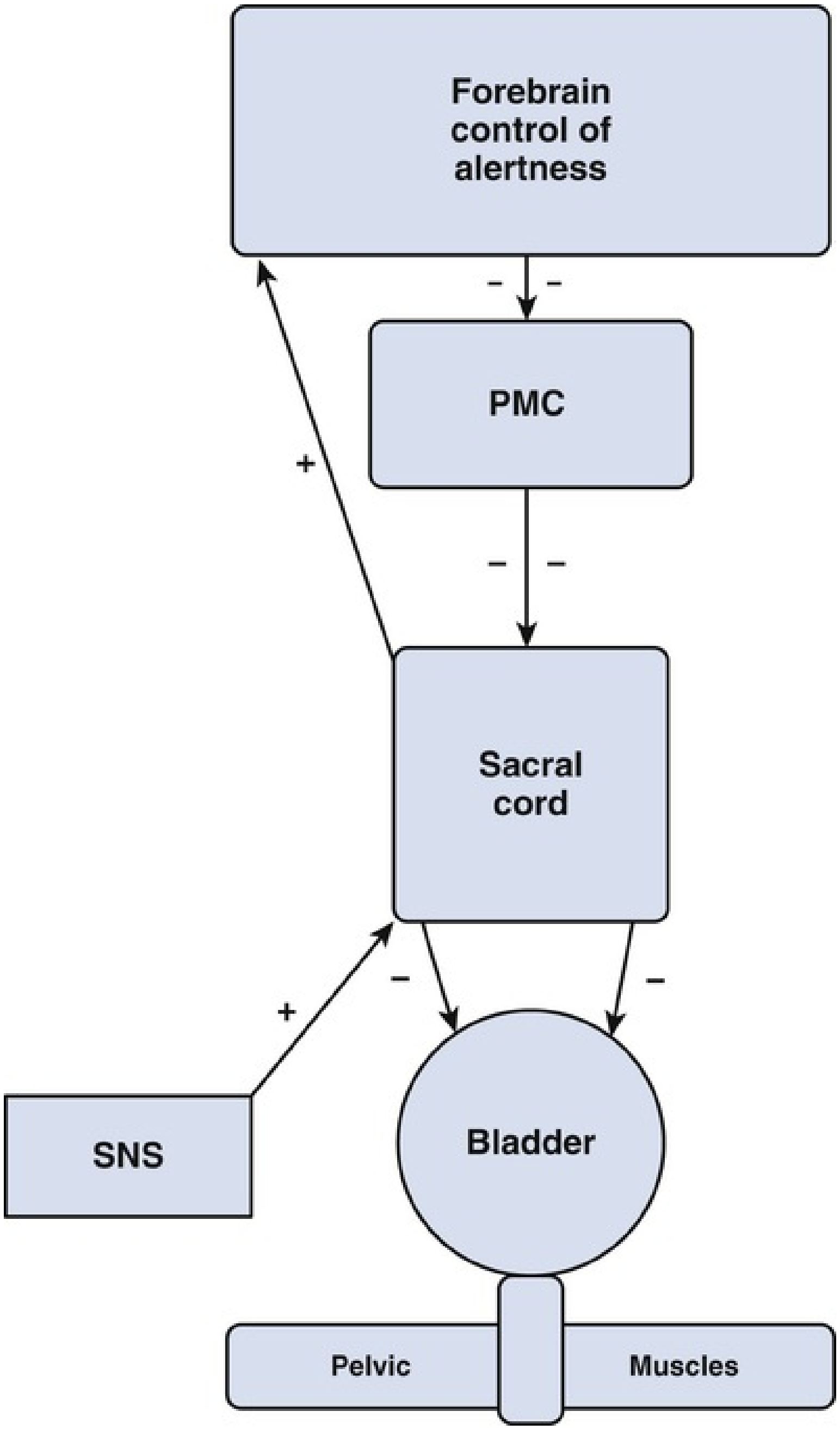
Forebrain control of alertness
–
–
PMC
+
–
–
Sacral cord
–
–
+
SNS
Bladder
Pelvic
Muscles

FIG. 122.8 Forebrain theory on working mechanism of electrical stimulation in idiopathic bladder dysfunction. *PMC,* Pontine micturition center; *SNS,* sacral nerve stimulation.

At present (see Fig. 122.6), it is thought that SNM activates afferent pathways that modulate forebrain structures involved in awareness and alertness. This modulation in patients with OAB results in less firing of the PMC, thereby restoring normal urinary continence. Patients with an underactive bladder lack an effective sensation of bladder filling, which does not lead to activation of the

PMC switch. SNM results in an increased awareness of bladder filling and pelvic floor contraction state. This awareness makes it possible for the patient to turn on the micturition switch and effectively relax the EUS via the PMC. In our view, SNM exerts its beneficial effect in underactive bladder mainly via relaxing the striated sphincter mediated by the descending pathways from the PMC and much less primarily via contracting the smooth muscle of the bladder.

Techniques of Electrostimulation of the Lower Urinary Tract

Intravesical Stimulation

Intravesical stimulation (IVES) first was attempted by Saxtorph to treat detrusor underactivity and urinary retention by inserting an active electrocatheter into the bladder with a neutral electrode placed in the skin (Madersbacher, 1990).

The main mechanism underlying IVES is thought to occur from direct field stimulation of Aδ afferents from low-threshold bladder mechanoreceptors, which make up the sensory system responsible for initiating and maintaining the micturition reflex (Jiang, 1998). Intact pelvic nerve afferents are necessary to provide adequate afferent feedback to generate effective bladder contractions to empty the bladder. Effects of IVES remain controversial: some studies have shown successful outcome, but other studies did not achieve dramatic effectiveness (Gladh et al., 2003; Hagerty et al., 2007; Kaplan, 2000; Madersbacher et al., 1982).

The technique of IVES is performed by inserting a sterile catheter with a connected active electrode via the urethra into the bladder. The bladder is filled with a solution that can conduct electrical currents like saline. A ground or neutral electrode is mostly attached to the abdominal skin above the pubic bone. The active electrode and the ground electrode are connected to the stimulator. Various stimulation parameters can be used: monopolar square pulses or biphasic pulse waves; amplitudes ranging from 1 up to 100 mA, pulse frequencies from up to 50 Hz, and the pulse widths ranging from 200 to 800 ms. Then a number of treatment sessions start in an outpatient session or at home.

There are few clinical studies that describe the results of this intervention. Gladh et al. (2003) applied IVES in 44 children with detrusor underactivity of various origin. Long-term normalization of the voiding after a mean of 2.5 years follow-up was obtained for 20 out of 24 children with idiopathic problems (83%) and 8 out of 20 with neurogenic problems (40%). Another 4 had much improved bladder function. The neurogenic group required more stimulation sessions than the idiopathic group. Of 15 patients on intermittent catheterization who completed IVES, 11 could discontinue the catheterization. They concluded that IVES is a promising method to treat the underactive detrusor in children.

Recently, Deng et al. (2017) published their 8-year results of IVES on detrusor underactivity in 105 patients. Of the 105 patients with different causes for detrusor underactivity (incomplete SCI 23, complete SCI 9, conus medullaris and cauda equina syndrome 36, lumbar disc surgery 15, hemorrhoid surgery 4, other causes 18) the information of residual urine volume and voiding volume was obtained in 89 patients, and pre- and post-IVES bladder sensation information was available. The patients were treated with a mean of 27 (5–181) sessions of IVES. Of the 89 patients, 47% were responders and had more than 50% reduction in the postvoid residual (PVR). Voiding efficiency of more than 50% defined as:

$$\text{Volume voided}/(\text{Volume voided}+\text{PVR})\times 100\%$$

was seen in 30% of the patients. Their analyses showed that patients with incomplete neurogenic lesions and post-hemorrhoidal surgery demonstrated the best significant improvements. They speculate that a full or partially complete central pathway reflex may be the premise condition. Also the results suggest that patients without central nerve damage may achieve increased success, which is consistent with the mechanism underlying IVES. They also concluded that the results were promising.

These data illustrate that IVES is possible and is applied especially in detrusor underactivity. However, the published series are small and much variation exists between devices and applied techniques. Future developments should aim at standardization with improved study methodology.

Transcutaneous Electrostimulation

Transcutaneous Tibial Nerve Stimulation

Since its clinical introduction in 1999 PTNS has been routinely available for a number of years. The technique received FDA approval in 2000 for office-based treatment of OAB and approval from the National Institute for Health and Clinical Excellence in 2006. Most treatment schedules consist of 12 outpatient consecutive treatment sessions lasting 30 minutes each, given 1 to 3 times per week. This schedule implies considerable effort for patients and clinic given 12 weekly outpatient clinic visits. Moreover after a successful 12-week treatment scheme, some maintenance program has to be undertaken to preserve the positive effects of PTNS.

Because of these limitations transcutaneous tibial nerve stimulation (TTNS) has been developed. This noninvasive treatment is safe because it uses only surface electrodes. It can be self-administered by the person at home, thus supporting self-management. Moreover it is convenient because the scheme of stimulation is decided entirely by the patient and can therefore reflect personal choices and lifestyle. However, there is a drawback: percutaneous stimulation is more effective than transcutaneous stimulation (George et al., 2013). Transcutaneous electrical currents require a higher amplitude because the skin acts as a capacitor, which is often painful. As a consequence the lower amplitude stimulation is used, which results in suboptimal stimulation parameters and effects.

The pros and cons of transcutaneous stimulation have been assessed in the systematic review by Booth et al. (2017). They assessed 10 randomized controlled trials (RCTs) and 3 prospective cohort studies involving 629 participants (437 women [70%] and 176 men [28%], with 16 [2%] participants not reported). TTNS was compared with sham, antimuscarinics, exercises as extra to first-line with behavioral therapy alone and with different stimulation sites. Idiopathic OAB was the focus of 7 of 10 RCTs. The other studies were about neurogenic OAB caused by multiple sclerosis (MS), Parkinson disease, cerebrovascular accident (CVA), and SCI. The studies were very heterogeneous in various ways, had not many participants, and often were underpowered. The stimulation intervention was not standardized across the studies, and a range of dosages were delivered. The duration of treatment program ranged from 4 to 12 weeks, and the total number of included sessions from 5 to 90 (mean 21.6, standard deviation [SD] 23). The length of individual stimulation sessions was 20 to 30. The number of weekly sessions varied from daily stimulation to twice weekly and once weekly.

With all associated limitations, results showed that 48% to 93% of participants achieved significant symptom improvement with TTNS. Meta-analysis of data from two included studies found a clinically and statistically significant reduction of 3.88 points on the International Consultation of Incontinence Questionnaire Urinary Incontinence-Short Form, which shows that TTNS is effective for OAB in older adults. Moreover the absence of any adverse events indicates safety and tolerability of TTNS for idiopathic and neurogenic OAB. Direct comparisons with PTNS do not exist yet and are sought. An important clinical issue is the place of TTNS in the OAB treatment algorithm. The review from Booth et al. suggests the potential effectiveness of TTNS for use in idiopathic OAB and its safety for treating neurogenic OAB. These findings, together with the utility of TTNS in a supported self-management regimen and the low cost of the intervention, make TTNS an attractive alternative to other regular first-line treatments.

Transcutaneous Sacral Dermatome Stimulation

Transcutaneous electrical stimulation is a recognized neurostimulatory technique that has been successfully employed in pain management. It has been suggested that the applied current is propagated from skin receptors to posterior root ganglion cells and then to spinal centers via Aβ, C, or Aδ fibers (Thompson, 1995).

Transcutaneous electrical stimulation has been applied in some studies to suppress DO resulting in OAB. Walsh et al. applied transcutaneous neurostimulation in a randomized fashion (Coba 208 neurostimulator unit, Tenscare Ltd., Surrey, UK) with bilaterally positioned skin electrodes overlying the S3 dermatomes (Walsh et al., 2001).

One hundred eleven female patients and 35 male patients with urgency incontinence were recruited for the study. The patients had neurogenic ($n = 35$) and non-neurogenic diseases. Patients were randomized into age- and gender-matched control and study groups. The mean patient age was 47 years (range, 17–79). All patients had remained refractory to an average of three previous treatments. The study group ($n = 74$) comprised 28 patients with DO and 18 with neurogenic DO. Of the 72 control patients, 27 had DO and 17 neurogenic DO. One of the observations was an increase in cystometric capacity of 50 cm H_2O. A majority of patients experienced the first involuntary detrusor contraction to be significantly increased during bladder filling with approximately 120 seconds in the non-neurogenic group and 58 seconds in the neurogenic group. The latter was not significant. The mean amplitude of neurogenic detrusor contraction went down from 36 cm H_2O to 23 cm H_2O, which was statistically significant. These results show that it is possible to increase bladder capacity and diminish DO.

Fjorback et al. evaluated the possibility for electrical stimulation of the sacral dermatomes to suppress detrusor contractions in MS patients with neurogenic DO, hereby providing an alternative to dorsal genital nerve stimulation (Fjorback et al., 2007). A total of 14 patients with MS (8 males and 6 females) with a bladder capacity of less than 300 mL and a recent urodynamic study showing DO-induced incontinence participated in the study. Three successive slow-fill cystometries (16 mL/min) were carried out in each patient. The first filling served as control filling in which no stimulation was applied. In the second and third fillings, electrical stimulation of either the DPN or sacral dermatomes was applied automatically whenever the detrusor pressure exceeded 10 cm H_2O. The control filling showed DO in 12 of the 14 patients. In contrast to dorsal genital nerve stimulation, electrical stimulation of the sacral dermatomes failed to suppress detrusor contractions in all patients. They concluded that although therapeutic effects may be present from stimulation of the sacral dermatomes, acute suppression of DO with sacral dermatome stimulation is not possible.

These two studies show that it is possible to have some beneficial urodynamic effects of sacral dermatome stimulation. Sacral dermatome stimulation can increase bladder capacity and perhaps reduce maximal detrusor pressures, which may be important to preserve kidney function. However, for conditional stimulation it is perhaps not useful. With conditional stimulation an attempt is made to stimulate at the occurrence of an involuntary detrusor contraction to be able to suppress it. This is appealing because it does not need continuous stimulation. However, the published investigations are scarce and the studies are not performed in many patients, so the results should be scrutinized carefully.

Percutaneous Tibial Nerve Stimulation

Neuromodulation of the lower urinary tract is extensively applied in patients with OAB complaints. The best known and best documented technique is SNS. Percutaneous tibial nerve stimulation (PTNS) also is extensively documented as an alternative way of nerve stimulation. Because PTNS is less expensive as compared with SNS, it is often named the poor man's fashion of neuromodulation. Because costs are less for PTNS, it is accessible to more patients and therefore has gained much popularity in many countries.

The innervation of the lower urinary tract originates from the lumbar, sacral, and coccygeal segmental nerves located at L2-S4 (Fig. 122.9).

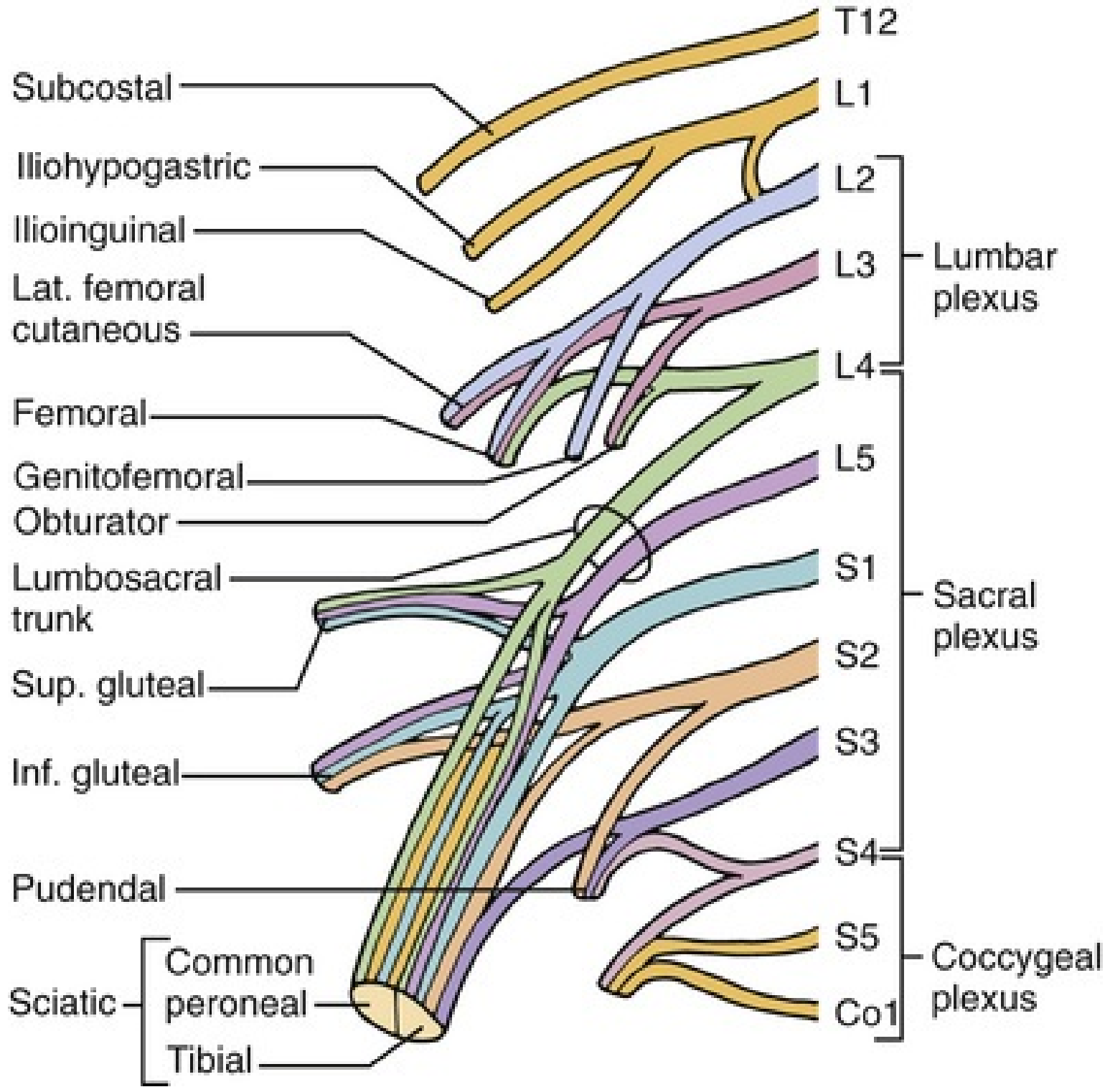
T12
L1
L2
L3
L4
L5
S1
S2
S3
S4
S5
Co1
Lumbar plexus
Sacral plexus
Coccygeal plexus
Subcostal
Iliohypogastric
Ilioinguinal
Lat. femoral cutaneous
Femoral
Genitofemoral
Obturator
Lumbosacral trunk
Sup. gluteal
Inf. gluteal
Pudendal
Sciatic
Common peroneal
Tibial

FIG. 122.9 Structure of the lower lumbar, sacral, and coccygeal nerve plexus, the merger of the various roots and the most important nerves that branches from the merged nerve plexus. The tibial nerve has its offspring in the sacral roots of mainly S2 and S3.

A network of afferent and efferent fibers is formed after exiting the spinal cord. The sciatic nerve is composed of fibers from L4 to S3 and descends toward the lower extremities (De Groat and Yoshimura, 2015). One of its distal branches is the posterior tibial nerve. Neuromodulation is postulated to be the effect of cross-signaling between sympathetic and parasympathetic postganglionic nerve terminals and synapses, causing alteration of efferent nerve signals from the spinal cord to the bladder. De Groat et al. (2015) described the different neural circuits involved in controlling the lower urinary tract. Stimulation of peripheral nerves and subsequent “cross-talk” at the level of the postganglionic neuroeffector junctions can modulate efficiency of transmission. The pudendal nerve, the dorsal genital nerve, and the posterior tibial nerve are examples of such peripheral nerves. This implies that stimulating one area of the innervations system may influence nerve behavior of other systems, which, for example, may change bladder behavior.

Some animal studies have been developed that try to elucidate the working mechanisms of PTNS in OAB. Different effects of PTNS were shown on normal reflex bladder activity triggered by intravesical saline installation versus intravesical instillation by diluted acetic acid, the latter representing a model for OAB. Opioid receptors are likely to be involved in reflex contractions seen in OAB (Ferroni et al., 2015). In the same study of cats with an intact CNS, intravenous injection with the opioid receptor antagonist naloxone blocked the acute inhibition of DO induced by PTNS in the OAB model but was unable to alter the inhibition of the normal reflex bladder activity induced by PTNS. This confirms that bladder activity in OAB is mediated via nociceptive afferent C fibers, whereas normal reflex bladder activity is mediated through Aδ afferent fibers. In one of the few studies that explored the effect of PTNS on the central nervous system, Finazzi-Agro et al. (2009) also studied information processing in the brain by recording somatosensory evoked potentials (SEP) after stimulation of the peripheral somatosensory system. Short-latency somatosensory evoked potentials (SL-SEP) and long-latency somatosensory evoked potentials (LL-SEP) were recorded before and after PTNS and sham stimulation. LL-SEP changes imply that durable changes in SEP occur. They found that the amplitude of LL-SEP changes of P80 and P100 waves in the active PTNS group was significantly higher as compared with the placebo group, suggesting long-term modifications in synaptic efficiency of the somatosensory pathway induced by PTNS. Long-term potentiation or long-term depression of excitatory synaptic transmission can contribute to experience-dependent modifications of brain function, including learning and memory. This suggests that the chronic mechanism of neuromodulation may be due to reorganization of the cortical network.

History of Percutaneous Tibial Nerve Stimulation

Peripheral neurostimulation is derived from techniques used in traditional Chinese medicine, better known as acupuncture. By puncturing specific points the Chinese attempt to restore “the energetic harmony” of the body. In 1683 a Dutch physician Wilhelmus Ten Rhyne discovered and described this Eastern traditional way of medicine in a book, *Dissertatio de Arthritide: Mantissa Schematica: De Acupunctura*. In his book he described the technique of “acupunctura” in which needles were used to treat diseases. One of the most commonly used acupuncture points used is the SanYin Jiao point, or Spleen 6 (SP-6). It is located on the medial side of the lower leg, about 6 to 8 cm cephalad to the prominence of the medial malleolus. It lies close to the medial crest of the tibia. The location of the SP-6 acupuncture point and the organs affected by its stimulation has remarkable similarities with PTNS. When electrical current is applied to the acupuncture needle, the technique is called electrical acupuncture. Especially when electroacupuncture is performed with similar stimulation parameters (2–15 Hz, 10–20 mA), it resembles PTNS (Minni et al., 1990). The main difference lies in the actual anatomic substrate used in PTNS instead of “energetic pathways” stimulated in acupuncture. McGuire et al. were the first to describe tibial nerve stimulation in 1983. He applied TTNS in 22 patients with neurogenic OAB, of whom 87% showed complete or partial improvement of their symptoms (McGuire et al., 1983). After that Stoller further developed PTNS as a treatment for OAB in pig-tailed monkeys and later human subjects with promising results (Stoller et al., 1987).

Technique of Percutaneous Tibial Nerve Stimulation

PTNS is applied in supine position with the medial malleolus pointing upward. A 34-gauge stainless steel needle is inserted approximately 3 to 4 cm, or 3 fingerbreadths, cephalad to the medial malleolus, between the posterior margin of the tibia and soleus muscle with an angulation of 60 degrees to 90 degrees. The tip of the needle has to be juxtaposed with the tibial nerve without actually touching it. Optimal depth and angulation may be varied and changed depending on patient's response. A grounding pad is placed on the same leg. The needle and grounding pad are connected to a low-voltage (9 volts) stimulator with an adjustable pulse intensity of 0 to 10 mA, a fixed pulse width of 200 microseconds, and a frequency of 20 Hz.

PTNS leads to effects in efferent and afferent nerve fibers. **Flexion of the great toe, or fanning, is a result of an efferent effect. The sensory efferent effect is a radiation tickling sensation of the foot sole. Once optimal position is ensured, stimulation is applied at an tolerable intensity level.** Based on studies most treatment schedules consist of 12 outpatient consecutive treatment sessions lasting 30 minutes given once to three times per week (Peters et al., 2010; Van Balken et al., 2001). A schematic figure is depicted in Fig. 122.10.

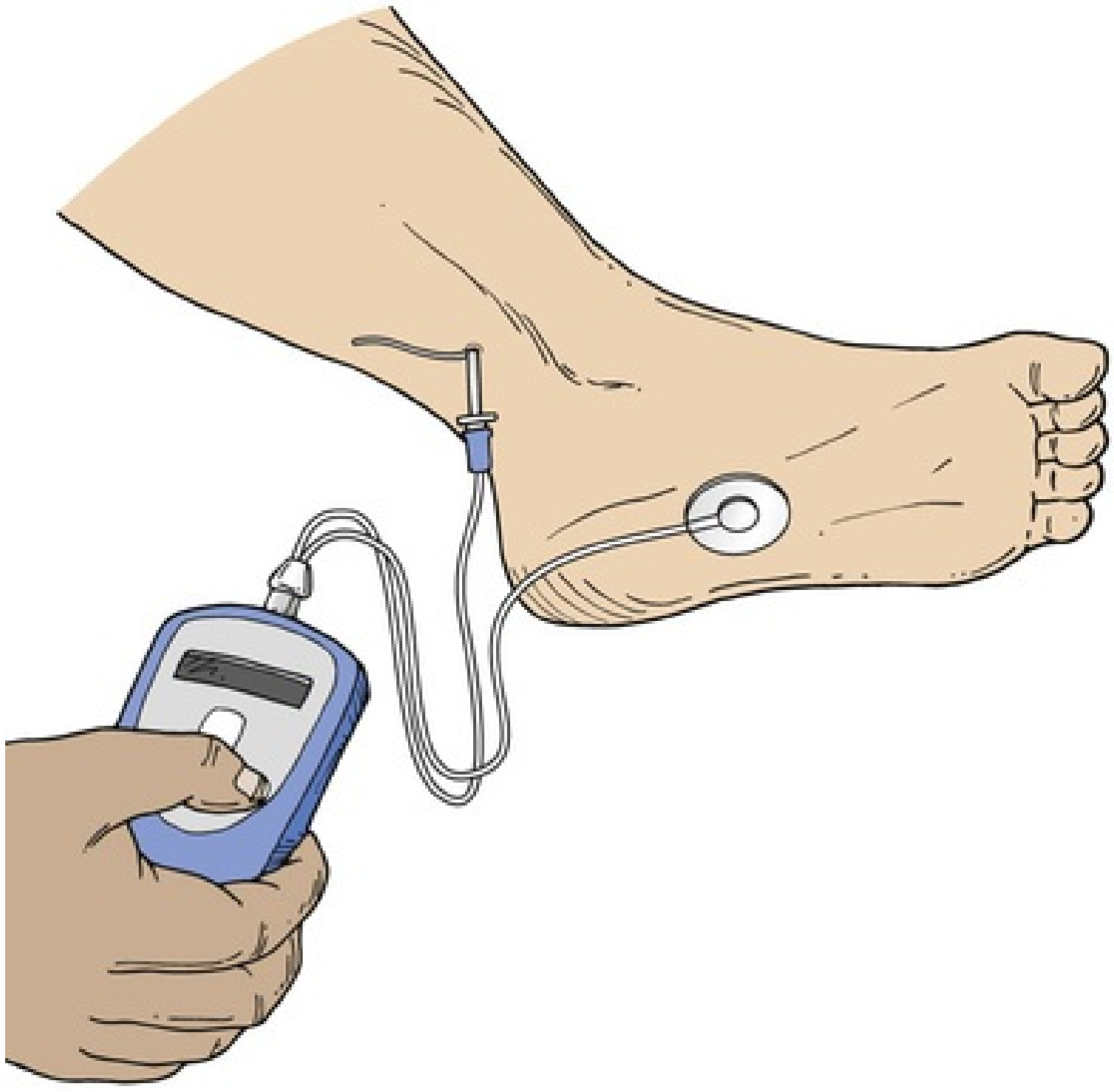

FIG. 122.10 Technique of percutaneous tibial nerve stimulation with needle at the tibial nerve, the ground pad electrode, and the stimulator.

Clinical Results of Percutaneous Tibial Nerve Stimulation

Many clinical trials have been on patients with mainly OAB symptoms. Objective outcome parameters in these studies are mainly based on frequency voiding charts (FVC), whereas subjective outcome is mostly measured by QoL questionnaires. Overall subjective success, defined as improved QoL or willingness to continue treatment, was found in 56% to 64%. Overall objective success with 50% or more decrease in urge or urgency urinary incontinence (UUI) and 25% reduction in daytime and/or nighttime frequency was found in 33% to 71% (Van Balken et al., 2001; Van der Pal et al., 2006; Vandoninck et al., 2003).

Urodynamic studies done to provide more objective data show conflicting results. PTNS performed in eight neurologic patients as soon as DO was observed during cystometry failed to suppress detrusor contractions (Fjorback et al., 2007a). Vandoninck et al. (2003) found complete suppression of DO only in a few cases, whereas others report elimination of DO in 76.9% (Kabay et al., 2008). Nevertheless, in both studies cystometric capacity increased significantly.

Peters et al. (2010) performed one of the most important studies on PTNS. In a multicenter, double-blind RCT (SUmiT trial), 12 weeks of PTNS was compared with sham stimulation. This was the first study including a validated sham arm to provide more information on the placebo effect. In total, 220 patients were included. Outcome parameters were improvement in global response assessment (GRA), FVC data including urgency, urge-incontinence, and QoL questionnaires. The GRA is a self-reported 7-point scale measuring the individual perceptive of change during treatment. Success was defined as moderate or marked improvement in the GRA. Subjects receiving PTNS showed 55% moderate or marked improvement compared with 21% in the sham group. FVC parameters after 12 weeks showed significant improvements in frequency, nighttime voids, voids with moderate to severe urgency, and UUI episodes in the PTNS group compared with the sham group. Finazzi-Agro et al. (2010) performed another sham-controlled RCT with similar results.

Thus far, no standard treatment regimen exists. Different protocols are described with the most objective data to be in favor of the 12-weeks regimen based on the previously mentioned two RCTs. Although most objective data published favor a 12-week protocol, shortened regimes may be effective as well but may be less sustainable. Until further data are published, treatment protocols remain mainly dependent on individual patient-doctor preferences.

Relapse of symptoms after successful treatment is likely to occur after PTNS. Therefore a maintenance or tapering protocol should be applied so that the brain continues to “remember” that brain control on the lower urinary tract should be sustained. Yoong et al. (2013) published the 2-year follow-up of 23 patients without deterioration of initially achieved results when a maintenance schedule was applied. The satisfaction score after 2 years of maintenance PTNS therapy was comparable with that recorded at 6 weeks (7.25/10 vs. 9.6/10, $P = 0.25$). Peters et al. (2013) followed 50 participants from the SUmiT Trial who met the primary effectiveness end point after 12 weekly PTNS. These patients were prescribed a fixed-schedule 14-week tapering protocol followed by a personal treatment. Of this group 29 patients completed the 36-month protocol receiving a median of 1.1 treatments per month. At 3 years 77% remained relapse free with 8.7 median voids per day (baseline 12.0) and 0.3 UUI episodes per day (baseline 3.3). QoL remained markedly improved from baseline through 3 years.

OAB is also a common problem in children. If standard treatment options such as behavioral therapy or urotherapy, pelvic floor therapy, and antimuscarinics fail, PTNS may be a good option. One study observed that PTNS with the percutaneous needle technique was well tolerated in 23 children with refractory lower urinary tract symptoms. In 71% of patients, symptoms improved and low scores on the visual analog scale for pain were noted, which even decreased further during the treatment period (De Gennaro et al., 2004).

Percutaneous Tibial Nerve Stimulation Compared With Other Treatments

Several studies aimed to establish the role of PTNS compared with other treatment options. Two RCTs (Peters et al., 2009; Preyer et al., 2015) compared PTNS versus tolterodine in patients with non-neurogenic OAB. Incontinence episodes decreased significantly after 3 months in both groups and QoL increased, but no significant treatment difference was seen between PTNS and tolterodine regarding QoL, urgency, and UUI, although fewer side effects were seen in the PTNS group.

Comparisons of muscarinics other than tolterodine with PTNS resulted in similar outcomes. A large Cochrane review compared seven trials with various types of peripheral neuromodulation (intravaginal electrical stimulation, PTNS, stoller afferent nerve stimulation, transcutaneous electrical nerve stimulation) to antimuscarinics. Subjective improvement rates were observed in favor of electrical stimulation. In 54% no improvement was seen with antimuscarinics versus 33% with electrical stimulation (risk ratio [RR] 0.64, 95% confidence interval [CI] 1.15–2.34). However, this was statistically significant only for PTNS (RR 2.21, 95% CI 1.13–4.33) and was not supported by significant differences in improvement of micturition frequency, nocturia, UUI, and QoL. The conclusion was that, although antimuscarinic therapy is a well-established therapy for OAB, the limited evidence from small trials may suggest that electrical stimulation is a better option in patients refractory to antimuscarinics (Rai et al., 2012).

Prognostic Factors for Percutaneous Tibial Nerve Stimulation

Few data exist concerning the prognostic factors for PTNS. Urodynamic studies in patients with OAB receiving PTNS suggest better treatment outcome in those patients without DO (Vandoninck et al., 2003).

Van Balken evaluated many clinical parameters in 132 patients, but most lacked any prognostic value. Only patients with a low SF-36 Mental Component Summary were especially prone to fail. These patients also scored worse on disease-specific QoL questionnaires, although there was no difference in disease severity compared with patients with good mental health (Van Balken et al., 2006). Mental health questionnaires therefore can be of help as a tool to select optimal candidates.

Implantable Percutaneous Tibial Nerve Stimulation

Because chronic stimulation seems necessary to sustain therapeutic effect, soon after its clinical introduction it was realized that the repeated visits to the clinic, once weekly or once bi- or triweekly, would finally lead to a logistic problem. Transcutaneous stimulation with surface electrodes was attempted, but results indicate that it may be less effective because of the impendence of the skin (Andrews and Reynard, 2003).

A new promising development came with the introduction of an implantable stimulator near the ankle. Van der Pal et al. (2006) were the first to study the subcutaneous implant-Urgent-SQ in 8 patients with refractory OAB. The Urgent-SQ (Fig. 122.11) was surgically implanted approximately 5 cm above the medial malleolus near the tibial nerve without exactly exposing it. During the procedure the implant was activated to confirm the correct position. Motor and sensory responses were evaluated postoperatively at day 10 and after 3 to 6 to 12 months. The primary objective was at least a 50% reduction in the number of incontinence episodes and/or voids on bladder diary. At 3, 6, and 12 months, respectively, 5, 6, and 4 patients met the primary objective. At 3- and 6-month follow-up, voiding and QoL parameters had significantly improved in these patients. At 12 months it remained stable compared with 6 months. Urinary tract infection, temporary walking difficulties, and spontaneous radiating sensations were reported as adverse events, and there was no local infection, erosion, or dislocation. As in studies concerning sacral stimulation not all patients who respond well on PTNS have similar results with the implantable device. In one patient the implant was removed because of technical failure.



FIG. 122.11 The Urgent SQ, the first percutaneous tibial nerve stimulation implant. (Courtesy J. Heesakkers.)

Janssen et al. (2013) published the long-term efficacy and safety of these patients in an open-label study. The 7 patients with the implant still in situ were contacted after 9 years and evaluated with an interview, physical examination, ankle x-ray, voiding diaries, and completed questionnaires about adverse events, performance, efficacy, safety, and QoL questionnaires. Results showed that 6 of the 7 patients still had sensory and locomotor responses on stimulation at 9-year follow-up. Three patients, who had a successful treatment response at 1 year, still used the device. The implants were intact without migration and/or displacement. Two patients experienced minor discomfort. The conclusion was that after 9 years the Urgent-SQ implant was a safe device and well tolerated.

Recently some results of a new tibial implanted device (BlueWind Medical, Herzliya, Israel) were published (Heesakkers et al., 2017). The installation procedure was similar to that of the Urgent-SQ. In the 36 patients in whom the device was implanted, significant improvement in daytime frequency and UUI was seen. At 6 months’ follow-up 71% experienced clinical success. Leaks per day, leak severity, and pad changes per day decreased significantly over time with 28% of urgency incontinence subjects that became “dry.” Voids per day, degree of urgency, volume per void, and number of used pads also improved significantly. QoL improved as well as symptom severity scores measured by the OAB questionnaire. The listed adverse events were implant site pain in 14%, suspected infection in 22%, and procedural wound complications in 8%. A significant change was seen in 24-hour micturition frequency from a mean 12 to

8 per day. The number of severe urinary incontinence episodes decreased from 2.8 (SD 5.2) to 0.3 (SD 0.4) episodes per day. In one patient the device was explanted because of pain and swelling suspicious for infection, although tissue cultures did not reveal a bacterial infection. Implantable devices are well tolerated and safe without long-term complications. Pilot studies show promising results, but further research is necessary to establish its therapeutic value compared with conventional treatments. The Bluewind device is depicted in Fig. 122.12.

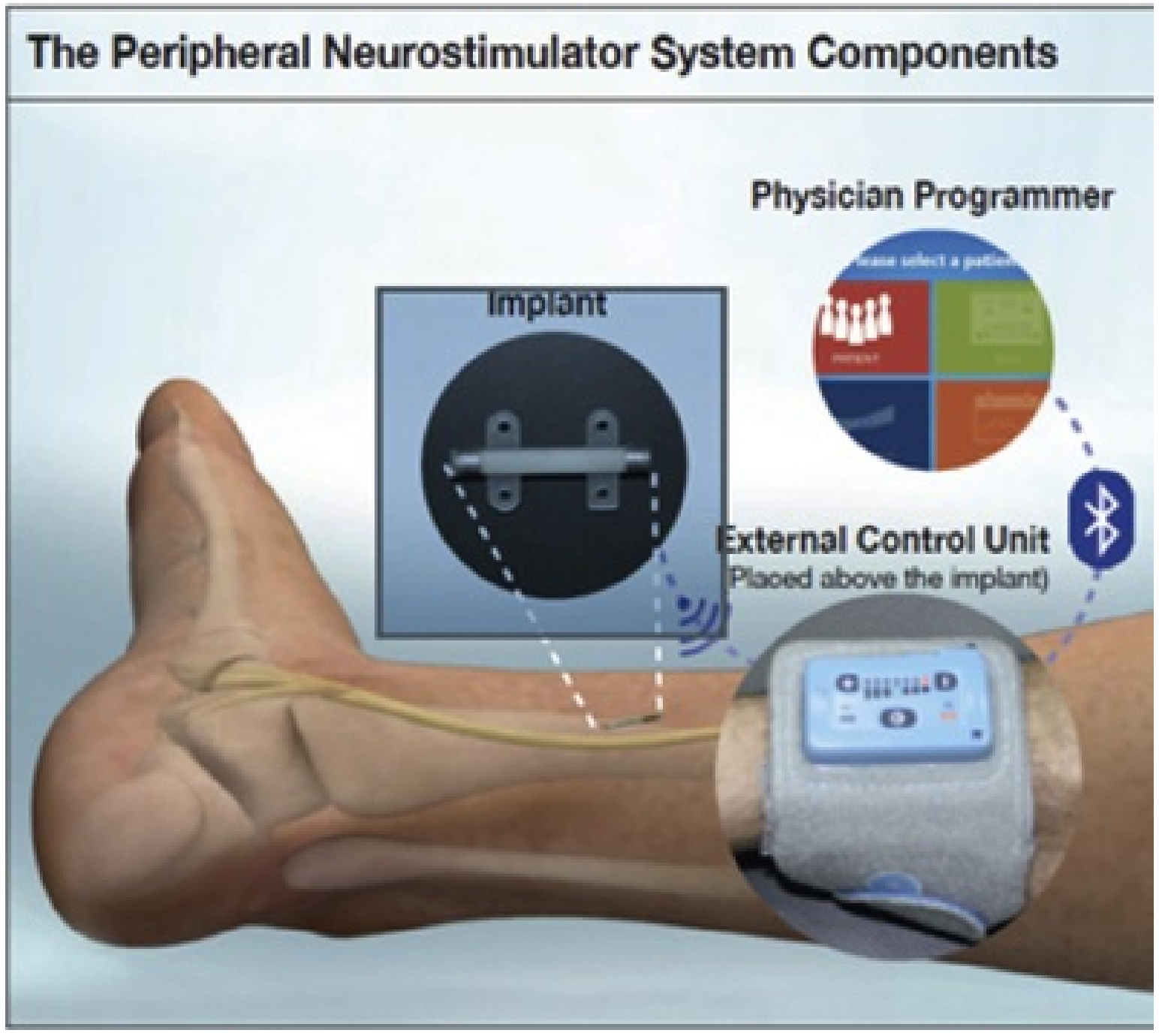
The Peripheral Neurostimulator System Components
Physician Programmer
Implant
External Control Unit
(Placed above the implant)

FIG. 122.12 Schematic foot with the Bluewind implant external control unit. The device weighs 0.6 g and measures 25 mm by 3.4 mm.

Another tibial nerve implant is the Bioness Stimrouter neuromodulation system (Bioness Inc., Valencia, CA). It can be implanted under local anesthesia. It consists of a lead and an integrated receiver, which are implanted. The lead captures can be activated via a wireless external pulse transmitter and electrode patch. In July 2018 a prospective, multicenter, randomized, double-blind trial was done to look at safety and efficacy in OAB (ClinicalTrials.gov, Identifier: NCT02873312).

There are more developments with a tibial nerve implant to correct for LUTD; however, not all of them have reached the clinical stage yet nor have they been introduced into clinical practice. The Gecko 1.0 system (Nuviant Medical Inc., Dallas, TX) has only been tested in animals so far (Moazzam et al., 2017).

A new location of stimulation is the saphenous nerve, a purely sensory branch of the femoral nerve. It can be stimulated below and anterior to the medial tibial condyle. First results are promising, but there still is a long way to go (MacDiarmid et al., 2018).

Conclusions

PTNS can modulate the voiding and storage function of the bladder leading to an overall subjective improvement of symptoms in about 60% of the patients and 47% to 56% improvement of FVC parameters. Placebo effect is about 21% and even higher in children. After 2 to 3 years 53% to 77% of the patients still report improvement of symptoms if maintenance treatment is given. PTNS is minimally invasive and not very expensive, but it is time consuming. Therefore new techniques with implants are being explored, showing promising results.

Pudendal Nerve Stimulation

The pudendal nerve originates from the S2 to S4 sacral nerves and travels over the ischial spina and enters the pudendal (Alcock) canal. Proximal in the pudendal canal, it gives rise to the inferior rectal nerve, and distally it branches into the perineal dorsal genital nerve.

Low-frequency stimulation of the afferent fibers of the pudendal nerve stimulation has been shown to be an effective target to inhibit the OAB. More specifically, stimulation of the dorsal genital nerve in patients with a complete thoracic or cervical spinal cord lesion resulted in a strong inhibitory effect on the micturition reflex (Vodusek et al., 1986).

The pudendal nerve can be stimulated percutaneously via through the pudendal canal (Spinelli et al., 2005). At present this is off label with the use of a tined quadripolar lead, which is placed via a posterior approach. The perineal approach is more prone to lead infection. This approach can be used for treatment of idiopathic and neurogenic OAB and chronic pelvic pain (Heinze et al., 2015; Peters et al., 2005). Patients with voiding dysfunction who did not respond to sacral neuromodulation were selected to receive pudendal nerve stimulation. When pelvic pain is the predominant presenting complaint, it has been suggested that only bilateral pudendal leads will lead to a successful test (Heinze et al., 2015). However, the FDA has not approved chronic pudendal nerve stimulation for voiding dysfunction or pelvic pain. Furthermore, the

Conformité Européenne Mark of pudendal nerve stimulation for OAB has now expired.

Dorsal Genital Nerve Stimulation

Dorsal genital nerve (DGN) stimulation is done by means of the dorsal clitoral nerve in women and dorsal penile nerve in men.

DGN stimulation with needle electrodes is an experimental neuromodulation technique to treat neurogenic and OAB disease; however, it is not yet applied in daily clinical practice. The DGN is a branch of the pudendal nerve. Stimulating the DGN may have several advantages compared with other frequently stimulated nerves such as the sacral roots or the posterior tibial nerve. The DGN is like the posterior tibial nerve, easy accessible for needle electrodes. The nerve is also a direct branch of the pudendal nerve and has therefore quicker access and more focused access to the sacral nerves that control lower urinary tract function. Moreover, theoretically the DGN is better suited for neuromodulation of the lower urinary tract. Similar to the mechanism of neuromodulation, the first route of the neuromodulative stimulus is afferent to the brain. This implies that pure sensory nerves such as the DGN theoretically are more effective in transporting the stimulus afferently to the brain (Martens et al., 2011). Successful stimulation of the DGN can be detected by monitoring the presence of the genitoanal reflex. Martens et al. experimented with percutaneous DGN stimulation in 6 patients with SCI with proven DO. DO could be suppressed with DGN stimulation. The clinical results that have been published should be regarded with caution. Studies are mostly acute experiments and with a small number of patients. The longest-lasting study is from Goldman et al. (2008). He examined DGN stimulation in 21 female OAB-wet patients with a percutaneous wire electrode. Patients received 7 days of continuous stimulation, and all but 2 completed the study (*n* = 9). In 47% of the patients, there was a reduction in incontinence episodes/day of more than 50%, and 81% of patients had a reduction of severe urgency episodes/day of more than 50%. The results of a pilot study by Van Breda et al. (2016) was also promising but had limited follow-up.

This study investigated on-demand DGN stimulation through a percutaneously placed wire electrode in six patients with non-neurogenic OAB. The idea is that with on-demand stimulation, when patients experience urgency, activation of a stimulating device that suppresses urgency is more effective because it is not influenced by habituation and is more efficient because it uses less energy. Overall, 73% reported improvement in symptoms, including urgency and incontinence severity. Although DGN stimulation is promising and has shown some good results, larger study cohorts are needed to determine the applicability of this type of neuromodulation. The drawback so far is that it is not easy to fix the stimulating electrodes in such a way that they keep in close contact with the small DGN branches. Moreover the area of stimulation, the dorsal base of the penis or the clitoral area, may be problematic for patients.

Sacral Nerve Stimulation

Sacral neurostimulation (SNM) is an effective third-line therapy in patients with OAB. The working mechanism of electrical therapy in bladder dysfunction including SNM has been discussed in the previous paragraph. The clinical use and outcomes of SNM are described for several forms of bladder dysfunction.

Current Indications and Outcomes for Sacral Neuromodulation

The American Urological Association and European Association of Urology recommend SNM as a third-line treatment option when first-line treatments (e.g., lifestyle intervention and pelvic floor exercises) and second-line treatments (e.g., medication) have failed in patients with idiopathic OAB symptoms. The first approved sacral neuromodulator, Interstim (Medtronic, Minneapolis, MN), received a CE Mark in Europe in 1994 for the treatment of functional disorders of the pelvis and lower urinary or intestinal tract. In 1997 Interstim was approved by the FDA for the treatment of UUI, and in 1999 for urinary urgency-frequency and urinary retention. The updated neuromodulator Interstim II received a CE Mark in 2006. The Interstim therapy uses a non-rechargeable voltage driven battery. It was in 2004 the rechargeable battery became available for spinal cord stimulation in chronic pain patients. At this time, there is no rechargeable battery available for urologic patients in the US market.

Overactive Bladder With or Without Urinary Incontinence

The International Continence Society definition of OAB with urinary incontinence is any involuntary urinary leakage which is preceded or accompanied by urgency, a sudden compelling desire to pass urine that is difficult to defer (Abrams et al., 2002). It is generally accepted that seven times per 24 h is the upper limit of the normal voiding frequency. OAB without urinary incontinence (i.e., “urinary urgency and frequency”) is then defined as eight times voiding or more per 24 h with urgency for voiding that is difficult to defer. However, this definition does not exclude urinary frequency resulting from excessive fluid intake. It is obvious that the voiding frequency very much depends on the fluid intake. Therefore it is important to assess frequency of voiding with a urinary diary before starting any treatment for OAB. Other causes, such as urinary tract infection, underactive bladder with significant postvoid residual bladder stones, and bladder cancer, have to be ruled out. Urodynamic investigation in patients with OAB may or may not demonstrate detrusor overactive contractions during the filling phase of the micturition cycle. Several studies demonstrated no association between DO and successful treatment with chronic SNM (Groenendijk et al., 2008; South et al., 2007).

Multiple studies have shown the efficacy of SNM in the short and long term, but the definition of success varies considerably among the studies. A recent prospective randomized trial (INSITE) in 147 OAB patients with mild to moderate symptoms compared SNM with standard medical treatment (Siegel et al., 2015). Intention-to-treat analysis demonstrated a 61% success rate for neuromodulation and 42% success for standard medical treatment at 6 months of treatment. In another prospective randomized study over 6 months, 34 implanted patients were observed and 42 patients, who received standard medical therapy, made up the control group (Schmidt et al., 1999). Voiding and incontinence parameters were significantly better in the SNM group compared with the control group with 76% success, including 47% completely without incontinence.

Another recent prospective randomized trial (ROSETTA) compared onabotulinumtoxinA (BTX) to SNM in 381 women (Amundsen et al., 2016). The mean number of incontinence episodes decreased more in the BTX group than in the SNM group (−3.9 vs. −3.3 episodes per day) at 6 months. However, in this study the amount of 200 U of BTX was twice the recommended starting dose for idiopathic OAB and not the standard of care for this third-line therapy. This alternative dose of 200 U was used off label before the compound was registered for idiopathic OAB, but this is not clinical practice at present because of a higher chance of adverse events such as urinary retention and urinary tract infection (Dmochowski et al., 2010). The registered dose BTX for idiopathic OAB is 100 U, which was significantly more effective than placebo at 4 months

(Nitti et al., 2013).

The long-term follow-up results of the ROSETTA trial were recently published (Amundsen et al., 2018). It was concluded that BTX and SNM offer sustained and equal reductions in the primary outcome urgency urinary incontinence episodes after 2 years. Higher satisfaction and treatment endorsement were maintained in the BTX group through the 24 months. Recurrent urinary tract infections were higher after BTX injections (24% vs. 10%; $P < 0.01$), and 6% required intermittent catheterization after the second injection. SNM revision was needed in 3% and removal in 9% of cases. Interestingly, the intermittent catheterization frequency was lower in the BTX group than previously reported, as were the SNM revision and removal rates, possibly because of standardized lead placement with strict treatment response criteria.

Two additional prospective cohort studies on OAB and SNM had a follow-up of at least 5 years. The study groups comprised 96 male and female patients and 60 female patients, respectively (Groen et al., 2011; Van Kerrebroeck et al., 2007). Significantly fewer incontinence episodes were found in 58% and 50% of the patients, respectively, and in 61% and 53% (significantly) less use of pads.

Nonobstructive Chronic Underactive Bladder (Voiding Dysfunction)

Nonobstructive chronic underactive bladder is defined as a nonpainful bladder with a chronic high postvoid residual, which necessitates regular drainage of the bladder. The amount of clinically accepted urinary residual volume after voiding is debatable but has often been defined as 100 mL. An underactive bladder is, as a rule, also hyposensitive with larger-than-normal maximum capacity of more than 500 mL. Clinically, it is critical to assess the actual residual volume because this is the only objective parameter to measure success or failure of treatment. In 1999 the FDA approved SNM for the treatment of chronic urinary retention without obstruction.

In a prospective randomized study, 68 out of 177 patients with urinary retention qualified for full SNM implantation after a test of 3 to 7 days. Of these 68 patients, 37 patients received SNM implantation and were compared with 31 patients who continued self-catherization (Jonas et al., 2001). After 6 months, 69% of the SNM patients no longer catheterized compared with none in the control group. Another retrospective study in 21 men with chronic urinary retention demonstrated a similar success rate of 67% with the notation that men younger than 43 years of age were more likely to respond.

Other Indications

SNM is not FDA approved for chronic bladder pain and neurogenic bladder dysfunction. In selected patients SNM may be offered, especially when there are also symptoms of OAB. Because measurement of change in pain perception is very subjective and strongly influenced by pain medication, the recording of OAB symptoms makes it possible to determine an objective improvement during the test phase. Most of the studies on SNM in bladder pain syndrome and chronic pelvic pain used a retrospective approach in a small number of selected patients. In a prospective study, 17 patients were treated with SNM for a mean of 14 months (Comiter, 2003). Mean voided volume increased from 111 to 264 mL, and pain decreased from 5.8 to 1.6 on a 0 to 10 visual analog pain scale. Another study with a follow-up of a mean of 86 months reported a 64% reduction of pain in 30 patients who underwent SNM (Marinkovic et al., 2011). SNM may be effective for treating neurogenic bladder patients, but, as in bladder pain syndrome, the level of evidence is low (Groen et al., 2016). A systematic review identified 224 patients in 22 studies who underwent SNM (Kessler et al., 2010). Patients with MS and SCI were most prevalent and had mainly a mix of symptoms of OAB and urinary retention. The pooled success rate was 92% after a mean follow-up of 26 months. It was concluded that the effectiveness of SNM in non-neurogenic patients and neurogenic patients is comparable (Kessler et al., 2010; Figs. 122.13 and 122.14).

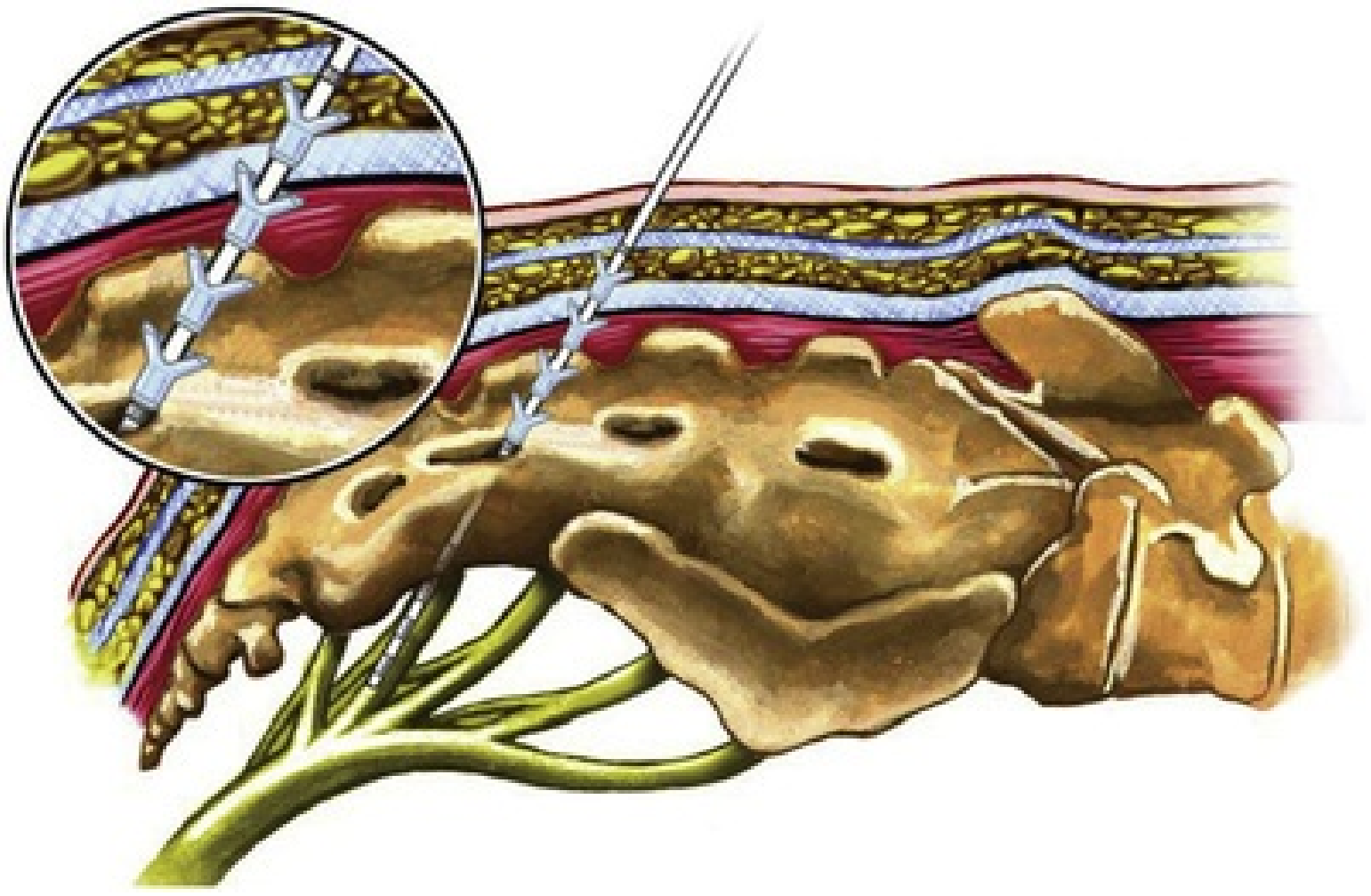

FIG. 122.13 The tined lead is introduced typically into the S3 nerve

foramen. The tines allow the lead to be fixed into the fascial layers above the sacrum. This lead has a quadripolar configuration (four contact points). (Courtesy Medtronic, Minneapolis, MN.)

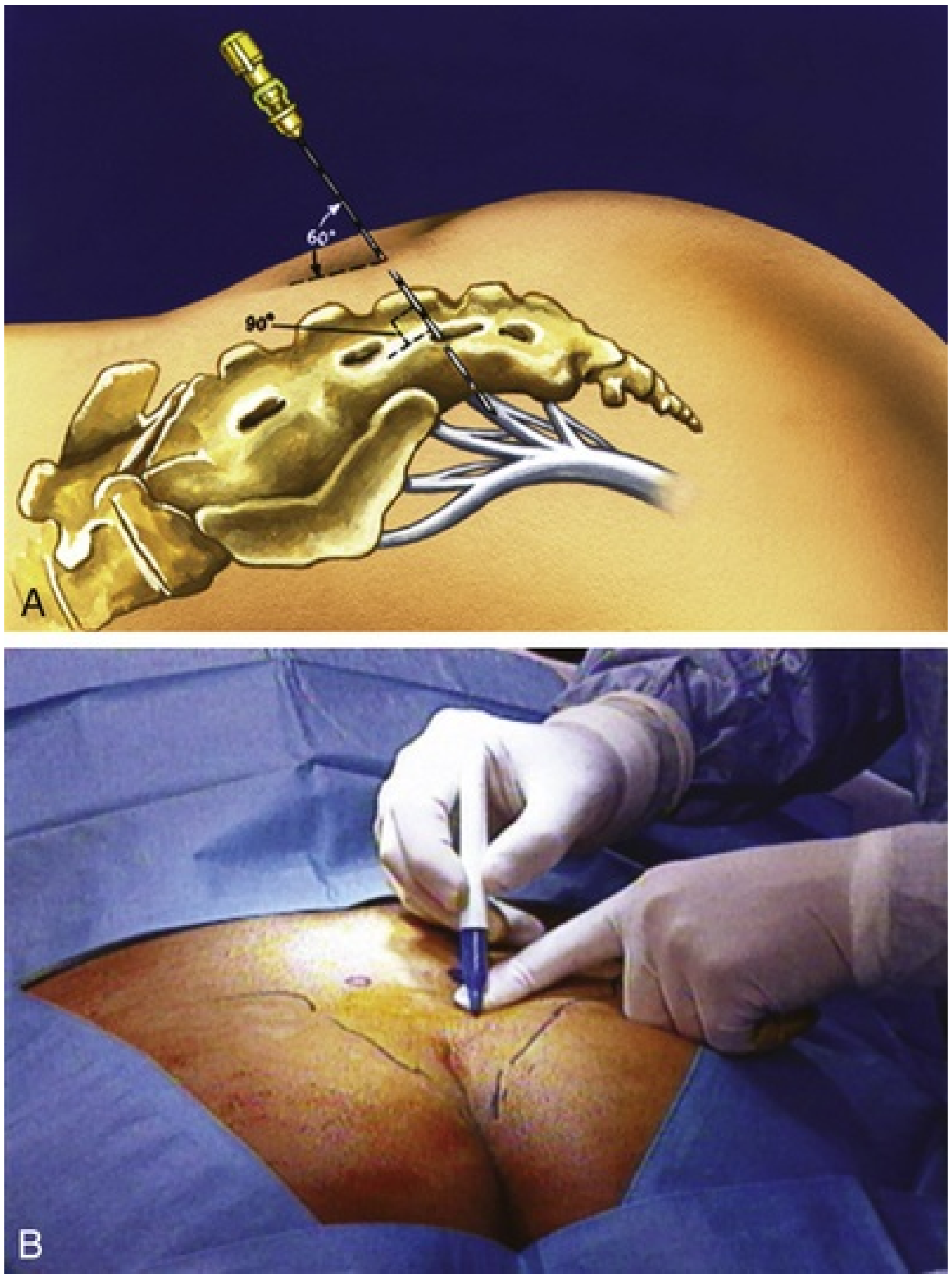

FIG. 122.14 (A) The percutaneous test stimulation is performed in an outpatient setting. A small lead wire is placed into S3 and connected to an external stimulator for 1 week to administer stimulation to the nerve roots. (B) Measurement of the S3 nerve foramen is typically 9 cm to the coccyx and 11 cm to the anal verge. To find the rough site of the S3 nerve foramen, 1 to 2 cm lateral to this mark is measured. The “cross hair” technique can be used to find the midline fluoroscopically and the lower aspect of the sacroiliac joints laterally to find the S3 nerve foramen, as well. (Courtesy Medtronic, Minneapolis, MN.)

Sacral Neuromodulation Patient Selection and Implantation

Procedure

The SNM implants are products of Medtronic and contain a lead with four electrodes and a neurostimulator, named Interstim II. The success of an implanted SNM depends to a large extent on a correct selection of the patient. Theoretically, test stimulation is not necessary and selected OAB patients receive immediate implantation of the complete SNM with a chance of success of at least 90%. However, clinical practice dictates that all candidate patients receive a stimulation test trial. The test may be done in an ambulatory environment, known as peripheral or percutaneous nerve evaluation (PNE), or can be performed with a two-stage implant in the operation room. The patient may get a complete implantation of SNM when there is 50% improvement or more in one or more of the voiding parameters: frequency of voiding, voided volume, and incontinence episodes. Comparing the baseline bladder diary filled out by the patient for 3 to 5 days before the test trial with a second bladder diary filled out during the test period constitutes the assessment.

Percutaneous Nerve Evaluation Test.

During a PNE, an insulated needle is introduced into the third or fourth sacral foramen under local anesthesia on the basis of bony landmarks, such as coccygeal bone, the iliac crest, and the lumbosacral joint. Fluoroscopy may be used during or after placement, but with respect to SNM, the anatomic location is not fully correlated with the functional outcome. Correct placement during electrical stimulation by an external neurostimulator is confirmed by induction of perineal sensations. Usually, these sensory responses precede possible motor responses, such as contraction of the external anal sphincter and flexion of the great toe. Subsequently, a temporary flexible test lead with an electrode at the tip is introduced via the needle, which is removed when the lead is in place. The lead is adhered to the skin and connected to a receiver in a belt. The receiver is wirelessly controlled by an external neurostimulator. When the patient is not distracted and is focused on the perineal area, he or she will feel a small perineal sensation, which is not painful or annoying. The test phase lasts usually 5 to 7 days, during which a bladder diary is recorded. The PNE is assumed positive when one or more bladder diary parameters shows more than 50% improvement. In our clinic the PNE test is positive in 60% of the OAB patients. We do not use the PNE test for urinary retention because of the high failure rate. When patients pass the test, they may receive the complete SNM, which consists of the quadripolar lead and a neuromodulator. The advantage of PNE is that it is an incision-free procedure performed in the outpatient clinic under local anesthesia. The main disadvantage of the temporary PNE lead is that it is prone to dislocation, which may lead to test failure.

Staged Implant Procedure.

Patients who failed or could not tolerate PNE may be offered the two-staged procedure. In response to patients who had a positive PNE but a less favorable result with complete SNM, the two-stage implant procedure was introduced (Janknegt et al., 1997). The first stage involves implantation of the permanent electrode (Fig. 122.15). Originally, the lead was placed in the S3 foramen during an open procedure via a 10-cm vertical incision over the sacral bone and after placement in the foramen fixed on the periosteum of the bone. Since 2003 such an invasive procedure is not necessary, and the lead can be placed percutaneously in the relatively short time of about 30 min (Spinelli et al., 2003). In our hospital the patients receive preoperatively the first-generation cephalosporin cefalozin and metronidazole intravenously (IV) to protect against perineal anaerobic organisms. A retrospective study on surgical site infections in patients undergoing SNM suggested adding prophylactic treatment for methicillin-resistant *Staphylococcus aureus* (Brueseke et al., 2015). The permanent lead is coupled to a temporary extension wire, which is placed subcutaneously toward the flank and connected in the same way as described for the PNE. The tunneling reduces the risk of infection, the lead is more precisely placed than the PNE lead, and the evaluation can be prolonged by up to 4 weeks while the neurostimulator program is optimized. Implantation of the neuromodulator at the buttock and removal of the extension wire follow in the second stage after 2 to 4 weeks in case of 50% or more improvement in one or more of the voiding parameters. In the case of test failure, the lead and extension wires are removed and alternative treatment options can be offered. A recent narrative review from the International Continence Society SNS consensus panel presented their recommendations on best practices for neuromodulation (Goldman et al., 2018). They concluded that the preferred target for SNM is the S3 nerve, but in some cases also S4 may be appropriate. The surgeon should strive to achieve appropriate motor and/or sensory responses on all 4 contacts at low stimulus amplitudes, but fewer than 4 contacts and/or higher voltage can be successful.

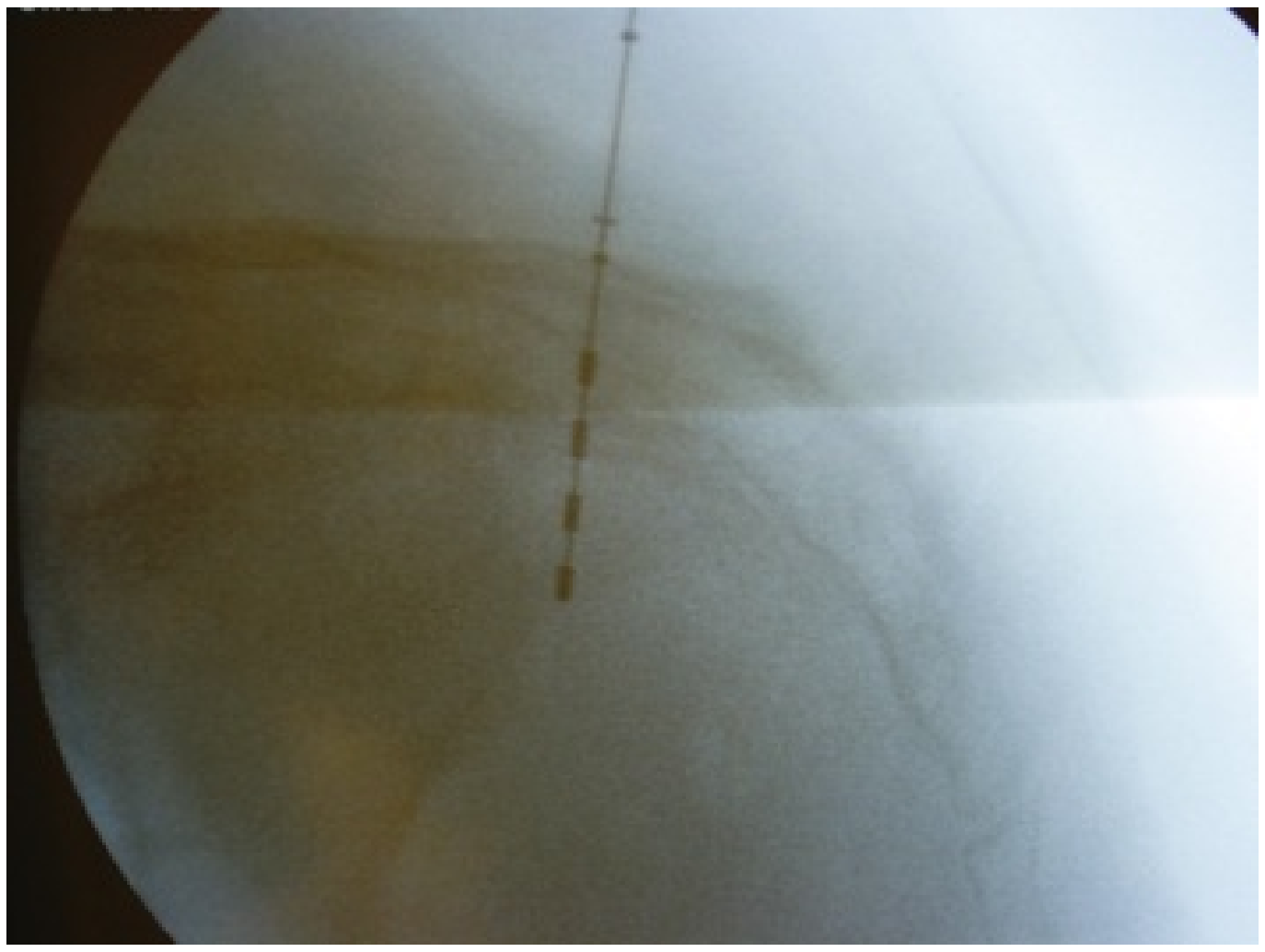

FIG. 122.15 Fluoroscopy is used to confirm lead placement, typically with the lead configurations to obtain optimal muscle (bellows response and ipsilateral toe contractions) and sensory (vaginal, penile, or scrotal "pulsating" feeling) responses. The lead then may be deployed.

The minimal invasive staged implant can be done under local anesthesia, sedation, or general anesthesia. The staged procedure results in an increased rate of implants compared with the PNE test. In a retrospective study, 69 patients with OAB and 31 with urinary retention received a PNE test followed by a staged implantation (Leong et al., 2011). Success was observed in 47% after PNE and in 69% after staged implantation.

The Interstim II neuromodulator was introduced in 2006. It has a lithium battery (1.3 A-h at 3.2 V), which is covered by a titanium box (51 × 44 × 7.7 mm). The neuromodulator weighs 22 g, and its volume is 14 cc. The voltage driven battery provides continuous or intermittent pulses from 2.1 to 130 Hz (in 49 steps) with a pulse width of 60 to 450 µs (per 30 µs). The upper limit of voltage is 8.5 V. The much larger Interstim was the precursor of the Interstim II and has not been available since July 2017. For bladder dysfunction, pulse width is set at 210 µs and rate at 10 to 16 Hz. The amplitude is set around the threshold of urogenital or anal sensation. Programming of neuromodulator ensures the optimal stimulation with the best tolerable sensation at the lowest amplitude. Stimulation can be carried out in either unipolar or bipolar fashion. After implantation and the initial programming, the neuromodulator has to be adjusted on average three times during the first year and 0.8 per year in the following years in patients with OAB (Groen et al., 2011). The durability of Interstim was around 7 years, whereas that of the smaller Interstim II is on average 4.4 years (Groen et al., 2011). A smaller neuromodulator will improve the comfort of the patient, but this comes at the high replacement rate and increased risk infection with the device and its lead around the time of operation. At Erasmus Medical Center, more than 50% of our SNM budget for 70 full implants is allocated to replacement of the Interstim II, leaving fewer resources for new patients.

Future Perspectives of Sacral Neuromodulation

No clear predictors of success have been identified, and a positive response does not lead to a successful outcome in all patients in the long term (Scheepens et al., 2002). Because SNM treatment is usually for life, other modes of battery use have been investigated.

Constant Versus Intermittent Stimulation

SNM uses a continuous stimulation protocol. Other forms of electrical neuromodulation for OAB, such as PTNS, use stimulation for 30 minutes per 1 or 2 weeks. The effectiveness of this PTNS protocol suggests that intermittent SNM stimulation may have a beneficial effect on OAB symptoms. Indeed, a prospective randomized crossover trial showed no difference of the effects between continuous and cyclic stimulation with 16 seconds on and 8 seconds off (Price et al., 2015). Another prospective cohort study in 19 patients demonstrated no difference between SNM for 8 hours on and 16 hours off and continuous SNM (T Hoen et al., 2017). Closed-loop neurostimulation is also a future possibility for SNM in idiopathic OAB. In such a stimulation protocol the electrical stimulation is only necessary just before the OAB symptoms are present. The start of the stimulation could be set on the basis of a certain bladder volume at which the first sensation is perceived by the patient or at the point that the bladder pressure increases. Both parameters, bladder volume and increased bladder pressure, could be measured directly by a microchip on the bladder or indirectly by measurement of afferent pelvic nerve activity.

Rechargeable Neurostimulator

The need for different stimulation protocols such as intermittent and closed loop stimulation to save battery life becomes less obvious with the recent introduction of a rechargeable current driven neurostimulator by Axonics. Clinical results after 3 months for the treatment of OAB in 51 patients demonstrated success in 73% after implantation of the complete device without prior test stimulation (Blok, 2017; Blok et al., 2018a,b). These results are comparable with the Interstim therapy in patients with OAB. It is claimed that this rechargeable neurostimulator can last for more than 15 years. The use of a current driven stimulation protocol results in fewer adjustments of the stimulation parameters than a voltage-driven stimulation protocol as with the Interstim II neurostimulator. An additional advantage of the rechargeable device is that it can be switched to the Medtronic lead via an extension cable when the Interstim II battery is empty. In Europe, the new rechargeable neuromodulator from Axonics received the CE Mark in 2016. It is expected that the Axonics device will receive FDA approval in 2019.

Other Issues

Some publications suggested bilateral neuromodulation in the case of failing unilateral stimulation (Marcelissen et al., 2011). This is not clinical practice because of the lack of definitive evidence of superiority compared with unilateral stimulation and the potential of increased economic burden for the health care system.

The Interstim II neurostimulator has conditional FDA labeling for 1.5 Tesla MRI head scans, but 1.5 Tesla MRI is contraindicated for the lower body, including the lower back and pelvic region. The use of 3 or 7 Tesla MRI scans or MRI scans of any part of the body is contraindicated for this device. The rechargeable Axonics neurostimulator has conditional labeling approval in Europe to safely undergo head and neck MRI scans in 1.5 and 3 Tesla environments.

Key Points: Electrical Stimulation and Neuromodulation for Lutd

- Electrical stimulation is a young but fast-growing treatment entity for LUTD.
- Nearly every nerve involved in the innervation of the lower urinary tract could theoretically be used to influence the lower urinary tract.
- SARS is very effective and improves QoL dramatically but is also very invasive and irreversible.
- The future innovation of the Brindley technique should avoid dorsal rhizotomy.
- Of the peripheral types of neuromodulation, PTNS is the best tested and developed and it has FDA approval.
- New initiatives to have more patient- and doctor-friendly techniques are in development.
- SNM is an established third-treatment option for idiopathic bladder dysfunction. SNM does have FDA approval for idiopathic OAB and nonobstructive underactive bladder but not for bladder or pelvic pain

syndrome and neurogenic bladder.

Suggested Readings

Amundsen CL, Komesu YM, Chermansky C, et al. Two-year outcomes of sacral neuromodulation versus onbotulinumA for refractory urgency urinary incontinence: a randomized trial. *Eur Urol*. 2018;74:66–73.

Amundsen CL, Richter HE, Menefee SA, et al. OnabotulinumtoxinA vs sacral neuromodulation on refractory urgency urinary incontinence in women: a randomized clinical trial. *J Am Med Assoc*. 2016;316(13):1366–1374.

De Groat WC, Griffiths D, Yoshimura N. Neural control of the lower urinary tract. *Compr Physiol*. 2015;5:327–396.

Gormley EA, Lightner DJ, Faraday M, et al. Diagnosis and treatment (non-neurogenic) in adults: AUA/SUFU guideline amendment. *J Urol*. 2015;193:1572–1580.

Groen J, Pannek J, Castro Diaz D, et al. Summary of European Association of Urology (EAU) guidelines on neuro-urology. *Eur Urol*. 2016;69(2):324–333.

References

Abrams P, Cardozo L, Fall M, et al. The standardisation of terminology of lower urinary tract function: report from the Standardisation Sub-committee of the International Continence Society. *Neurourol Urodyn*. 2002;21(2):167–178.

Amundsen CL, Komesu YM, Chermansky C, et al. Two-year outcomes of sacral neuromodulation versus onbotulinumA for refractory urgency urinary incontinence: a randomized trial. *Eur Urol*. 2018;74:66–73.

Amundsen CL, Richter HE, Menefee SA, et al. OnabotulinumtoxinA vs sacral neuromodulation on refractory urgency urinary incontinence in women: a randomized clinical trial. *J Am Med Assoc*. 2016;316(13):1366–1374.

Andrews BJ, Reynard JM. Transcutaneous posterior tibial nerve stimulation for treatment of detrusor hyperreflexia in spinal cord injury. *J Urol*. 2003;170(3):926.

Basbaum AI, Fields HL. Endogenous pain control systems: brainstem spinal pathways and endorphin circuitry. *Annu Rev Neurosci*. 1984;7:309–338.

Bauchet L, Segnarbieux F, Martinazzo G, et al. Neurosurgical treatment of hyperactive bladder in spinal cord injury patients. *Neurochirurgie*. 2001;47:13–24.

Bazeed MA, Thüroff JW, Schmidt RA, et al. Effect of chronic electrostimulation of the sacral roots on the striated urethral sphincter. *J Urol*. 1982;128:1357–1362.

Blok BF. Central pathways controlling micturition and urinary continence. *Urology*. 2002;59:13–17.

Blok BF. OnabotulinumtoxinA vs sacral neuromodulation for urgency incontinence. *J Am Med Assoc*. 2017;317(5):534–535.

Blok BF, De Weerd H, Holstege G. Ultrastructural evidence for a paucity of projections from the lumbosacral cord to the pontine micturition center or M-region in the cat: a new concept for the organization of the micturition reflex with the periaqueductal gray as central relay. *J Comp Neurol*. 1995;359:300–309.

Blok BF, de Weerd H, Holstege G. The pontine micturition center projects to sacral cord GABA immunoreactive neurons in the cat. *Neurosci Lett*. 1997;233:109–112.

Blok BF, Groen J, Bosch JL, et al. Different brain effects during chronic and acute sacral neuromodulation in urge incontinent patients with implanted neurostimulators. *BJU Int*. 2006;98(6):1238–1243.

Blok BF, Holstege G. Ultrastructural evidence for a direct pathway from the pontine micturition center to the parasympathetic preganglionic motoneurons of the bladder of the cat. *Neurosci Lett*. 1997;222:195–198.

Blok BF, Sturms LM, Holstege G. Brain activation during micturition in women. *Brain*. 1998;121:2033–2042.

Blok BF, Sturms LM, Holstege G. A PET study on cortical and subcortical control of pelvic floor musculature in women. *J Comp Neurol*. 1997;389:535–544.

Blok B, van Kerrebroeck P, de Wachter S, et al. Three month clinical results with a rechargeable sacral neuromodulation system for the treatment of overactive bladder. *Neurourol Urodyn*. 2018;37(S2):S9–S16.

Blok B, van Kerrebroeck P, de Wachter S, et al. Programming settings and recharge interval in a prospective study of a rechargeable sacral neuromodulation system for the treatment of overactive bladder. *Neurourol Urodyn*. 2018;37:S17–S22.

Blok BF, van Maarseveen JT, Holstege G. Electrical stimulation of the sacral dorsal gray commissure evokes relaxation of the external urethral sphincter in the cat. *Neurosci Lett*. 1998;249:68–70.

Blok BF, Willemsen AT, Holstege G. A PET study on brain control of micturition in humans. *Brain*. 1997;120:11–21.

Boger A, Bhadra N, Gustafson KJ. Bladder voiding by combined high frequency electrical pudendal nerve block and sacral root stimulation. *Neurourol Urodyn*. 2008;27:435–439.

Booth J, Connelly L, Dickson S, et al. The effectiveness of transcutaneous tibial nerve stimulation (TTNS) for adults with overactive bladder syndrome: a systematic review. *Neurourol Urodynam*. 2017;1–14.

Brindley GS. The first 500 patients with sacral anterior root stimulator implants: general description. *Paraplegia*. 1994;32:795–805.

Brindley GS, Craggs MD. A technique for anodally blocking large nerve fibres through chronically implanted electrodes. *J Neurol Neurosurg Psych*. 1980;43:1083–1090.

Brindley GS, Craggs MD. One-way stimulation of the large fibres of spinal roots through chronically implanted electrodes. *J Physiol*. 1978;281:12P.

Brindley GS, Polkey CE, Rushton DN, et al. Sacral anterior root stimulators for bladder control in paraplegia: the first 50 cases. *J Neurol Neurosurg Psychiatry*. 1986;49:1104–1114.

Brueseke T, Livingston B, Warda H, et al. Risk factors for surgical site infection in patients undergoing sacral nerve modulation therapy. *Female Pelvic Med Reconstr Surg*. 2015;21:198–204.

Caldwell KP, Flack FC, Broad AF. Urinary incontinence following spinal injury treated by electronic implant. *Lancet*. 1965;1:846–847.

Castaño-Botero JC, Ospina-Galeano IA, Gómez-Illanes R, et al. Extradural implantation of sacral anterior root stimulator in spinal cord injury patients. *Neurourol Urodyn*. 2016;35:970–974.

Chandler MJ, Hobbs SF, Fu QG, et al. Responses of neurons in ventroposterolateral nucleus of primate thalamus to urinary bladder distension. *Brain Res*. 1992;571:26–34.

Chinier E, Egon G, Hamel O, et al. Predictive factors of stress incontinence after posterior sacral rhizotomy. *Neurourol Urodyn*. 2016;35:206–211.

Comiter CV. Sacral neuromodulation for the symptomatic treatment of refractory interstitial cystitis: a prospective study. *J Urol*. 2003;169(4):1369–1373.

Creasey GH, Grill JH, Korsten M, et al. An implantable neuroprosthesis for restoring bladder and bowel control to patients with spinal cord injuries: a multicenter trial. *Arch Phys Med Rehabil*. 2001;82:1512–1519.

Dampney RA. Central mechanisms regulating coordinated cardiovascular and respiratory function during stress and arousal. *Am J Physiol Regul Integr Comp Physiol*. 2015;309:R429–R443.

De Gennaro M, Capitanucci ML, Mastracci P, et al. Percutaneous tibial nerve neuromodulation is well tolerated in children and effective for treating refractory vesical dysfunction. *J Urol*. 2004;171(5):1911–1913.

De Groat WC, Griffiths D, Yoshimura N. Neural control of the lower urinary tract. *Compr Physiol*. 2015;5:327–396.

De Groat WC, Yoshimura N. Anatomy and physiology of the lower urinary tract. *Handbook Clin Neurol*. 2015;130:61–108.

Deng H, Liao L, Wu J, et al. Clinical efficacy of intravesical electrical stimulation on detrusor underactivity: 8 years of experience from a single center. *Medicine (Baltimore)*. 2017;96(38).

Dmochowski R, Chapple C, Nitti VW, et al. Efficacy and safety of onabotulinumtoxinA for idiopathic overactive bladder: a double-blind, placebo controlled, randomized, dose ranging trial. *J Urol*. 2010;184(6):2416–2422.

Egon G, Barat M, Colombel P, et al. Implantation of anterior sacral root stimulators combined with posterior sacral rhizotomy in spinal injury patients. *World J Urol*. 1998;16:342–349.

Ferroni MC, Slater RC, Shen B, et al. Role of the brain stem in tibial inhibition of the micturition reflex in cats. *Am J Physiol Renal Physiol*. 2015;309(3):F242–F250.

Finazzi-Agro E, Petta F, Sciobica F, et al. Percutaneous tibial nerve stimulation effects on detrusor overactivity incontinence are not due to a placebo effect: a randomized, double-blind, placebo controlled trial. *J Urol*. 2010;184(5):2001–2006.

Finazzi-Agro E, Rocchi C, Pachatz C, et al. Percutaneous tibial nerve stimulation produces effects on brain activity: study on the modifications of the long latency somatosensory evoked potentials. *Neurourol Urodynam*. 2009;28(4):320–324.

Fjorback MV, van Rey FS, Rijkhoff NJM, et al. Electrical stimulation of sacral dermatomes in multiple sclerosis patients with neurogenic detrusor overactivity. *Neurourol Urodyn*. 2007;26(4):525–553.

Fjorback MV, van Rey FS, van der Pal F, et al. Acute urodynamic effects of posterior tibial nerve stimulation on neurogenic detrusor overactivity in patients with MS. *Eur Urol*. 2007;51:464–470.

Fowler CJ, Griffiths D, de Groat WC. The neural control of micturition. *Nat Rev Neurosci*. 2008;9:453–466.

George AT, Kalmar K, Sala S, et al. Randomized controlled trial of percutaneous versus transcutaneous posterior tibial nerve stimulation in faecal incontinence. *Brit J Surg.*2013;100:330–338.

Giesler GJ Jr, Spiel HR, Willis WD. Organization of spinothalamic tract axons within the rat spinal cord. *J Comp Neurol*. 1981;195:243–252.

Gladh G, Mattsson S, Lindström S. Intravesical electrical stimulation in the treatment of micturition dysfunction in children. *Neurourol Urodyn*. 2003;22:233–242.

Goldman HB, Amundsen CL, Mangel J, et al. Dorsal genital nerve stimulation for the treatment of overactive bladder symptoms. *Neurourol Urodyn*. 2008;27:499–503.

Goldman HB, Lloyd JC, Noblett KL, et al. International Continence Society best practice statement for the use of sacral neuromodulation. *Neurourol Urodyn*. 2018;37(5):1823–1848.

Groen J, Blok BF. Neuromodulation for continence. Kilgore K. *Implantable neuroprostheses for restoring function*. Elsevier: Boston, MA; 2015.

Groen J, Blok BF, Bosch JL. Sacral neuromodulation as treatment for refractory idiopathic urge urinary incontinence: 5-year results of a longitudinal study in 60 women. *J Urol*. 2011;186:954–959.

Groen J, Pannek J, Castro Diaz D, et al. Summary of European Association of Urology (EAU) guidelines on neuro-urology. *Eur Urol*. 2016;69(2):324–333.

Groenendijk PM, Lycklama a Nyeholt AA, Heesakkers JP, et al. Urodynamic evaluation of sacral neuromodulation for urge urinary incontinence. *BJU Int*. 2008;101(3):325–329.

Griffiths D, Derbyshire S, Stenger A, et al. Brain control of normal and overactive bladder. *J Urol*. 2005;174:1862–1867.

Hagerty JA, Richards I, Kaplan WE. Intravesical electrotherapy for neurogenic bladder dysfunction: a 22-year experience. *J Urol*. 2007;178:1680–1683.

Hamel O, Perrouin-Verbe B, Robert R. Brindley technique with intradural deafferentation and extradural implantation by a single sacral laminectomy. *Neurochirurgie*. 2004;50:661–666.

Hansen J, Media S, Nøhr M, et al. Treatment of neurogenic detrusor overactivity in spinal cord injured patients by conditional electrical stimulation. *J Urol*. 2005;173:2035–2039.

Heesakkers JPFA, Digesu GA, van Breda J, et al. A novel leadless, miniature implantable Tibial Nerve Neuromodulation System for the management of overactive bladder complaints. *Neurourol Urodyn*. 2018; 10.1002/nau.23401 [2017 Sep 11].

Heinze K, Hoermann R, Fritsch H, et al. Comparative pilot study of implantation techniques for pudendal neuromodulation: technical and clinical outcome in first 20 patients with chronic pelvic pain. *World J Urol*. 2015;33:289–294.

Hohenfellner M, Paick JS, Trigo-Rocha F, et al. Site of deafferentation and electrode placement for bladder stimulation: clinical implications. *J Urol*. 1992;147:1665–1670.

Hohenfellner M, Pannek J, Botel U, et al. Sacral bladder denervation for treatment of detrusor hyperreflexia and autonomic dysreflexia. *Urology*. 2001;58(1):28–32.

Holstege G. The periaqueductal gray controls brainstem emotional motor systems including respiration. *Prog Brain Res*. 2014;209:379–405.

Janknegt RA, Weil EH, Eerdmans PH. Improving neuromodulation technique for refractory voiding dysfunctions: two-stage implant. *Urology*. 1997;49(3):358–362.

Janssen DA, Farag F, Heesakkers JP. Urgent-SQ implant in treatment of overactive bladder syndrome: 9-year follow-up study. *Neurourol Urodyn*. 2013;32(5):472–475.

Jiang CH. Modulation of the micturition reflex pathway by intravesical electrical stimulation: an experimental study in the rat. *Neurourol Urodyn*. 1998;17:543–553.

Jonas U, Fowler CJ, Chancellor MB, et al. Efficacy of sacral nerve stimulation for urinary retention: results 18 months after implantation. *J Urol*. 2001;165(1):15–19.

Jonas U, Jones LW, Tanagho EA. Controlled electrical bladder evacuation via stimulation of the sacral micturition center or direct detrusor stimulation. *Urol Int*. 1976;31:108–110.

Kabay SC, Yucel M, Kabay S. Acute effect of posterior tibial nerve stimulation on neurogenic detrusor overactivity in patients with multiple sclerosis: urodynamic study. *Urology*. 2008;71(4):641–645.

Kaplan WE. Intravesical electrical stimulation of the bladder: pro. *Urology*. 2000;56:2–4.

Katter JT, Burstein R, Giesler GJ Jr. The cells of origin of the spinohypothalamic tract in cats. *J Comp Neurol*. 1991;303:101–112.

Kessler TM, La Framboise T, Trelle S, et al. Sacral neuromodulation for neurogenic lower urinary tract dysfunction: systematic review and meta-analysis. *Eur Urol*. 2010;58(6):865–874.

Kirkham AP, Shah NC, Knight SL, et al. The acute effects of continuous and conditional neuromodulation on the bladder in spinal cord injury. *Spinal Cord*. 2001;39:420–428.

Konishi A, Itoh K, Sugimoto T, et al. Leucine-enkephalin-like immunoreactive afferent fibers to pudendal motoneurons in the cat. *Neurosci Lett*. 1985;61:109–113.

Krasmik D, Krebs J, van Ophoven A, et al. Urodynamic results, clinical efficacy, and complication rates of sacral intradural deafferentation and sacral anterior root stimulation in patients with neurogenic lower urinary tract dysfunction resulting from complete spinal cord injury. *Neurourol Urodyn*. 2014;33:1202–1206.

Krhut J, Tintera J, Bilkova K, et al. Brain activity on fMRI associated with urinary bladder filling in patients with a complete spinal cord injury. *Neurourol Urodyn*. 2017;36:155–

159.

Kutzenberger J, Domurath B, Sauerwein D. Spastic bladder and spinal cord injury: seventeen years of experience with sacral deafferentation and implantation of an anterior root stimulator. *Artif Organs*. 2005;29:239–241.

Leng WW, Chancellor MB. How sacral nerve stimulation neuromodulation works. *Urol Clin North Am*. 2005;32:11–18.

Leong RK, De Wachter SG, Nieman FH, et al. PNE versus 1st stage tined lead procedure: a direct comparison to select the most sensitive test method to identify patients suitable for sacral neuromodulation therapy. *Neurourol Urodyn*. 2011;30(7):1249–1252.

Lue TF, Schmidt RA, Tanagho EA. Electrostimulation and penile erection. *Urol Int*. 1985;40:60–64.

MacDiarmid SA, John MS, Yoo PB. A pilot feasibility study of treating overactive bladder patients with percutaneous saphenous nerve stimulation. *Neurourol Urodyn*. 2018; 10.1002/nau.23531 [2018 Feb 21; Epub ahead of print; PubMed PMID] 29464764.

MacDonagh RP, Sun WM, Smallwood R, et al. Control of defecation in patients with spinal injuries by stimulation of sacral anterior nerve roots. *BMJ*. 1990;300(6738):1494–1497.

Madersbacher H. Intravesical electrical stimulation for the rehabilitation of the neuropathic bladder. *Paraplegia*. 1990;28:349–352.

Madersbacher H, Fischer J. Sacral anterior root stimulation: prerequisites and indications. *Neurourol Urodyn*. 1993;12:489–494.

Madersbacher H, Fischer J, Ebner A. Anterior sacral root stimulator (Brindley): experiences especially in women with neurogenic urinary incontinence. *Neurourol Urodyn*. 1988;7:593–601.

Madersbacher H, Pauer W, Reiner E, et al. Rehabilitation of micturition in patients with incomplete spinal cord lesions by transurethral electrostimulation of the bladder. *Eur Urol*. 1982;8:111–116.

Marcelissen TA, Leong RK, Serroyen J, et al. The use of bilateral sacral nerve stimulation in patients with loss of unilateral treatment efficacy. *J Urol*. 2011;185(3):976–980.

Marinkovic SP, Gillen LM, Marinkovic CM. Minimum 6-year outcomes for interstitial cystitis treated with sacral neuromodulation. *Int. Urogynecol. J*.2011;22(4):407–412.

Martellucci J. Electrical stimulation for pelvic floor disorders: historical background. Martellucci J. *Electrical stimulation for pelvic floor disorders*. Springer: Heidelberg; 2015:2–19.

Martens FMJ, Heesakkers JPFA. Sacral dorsal rhizotomy and sacral anterior root stimulation in neurogenic patients: the Brindley procedure. Dmochowski R, Heesakkers J. *Neurourology*. Springer: New York; 2018.

Martens FM, Heesakkers JP, Rijkhoff NJ. Surgical access for electrical stimulation of the pudendal and dorsal genital nerves in the overactive bladder: a review. *J Urol*. 2011;186:798–804.

Matsumoto G, Hisamitsu T, de Groat WC. Role of glutamate and NMDA receptors in the descending limb of the spinobulbospinal micturition reflex pathway of the rat. *Neurosci Lett*. 1995;183:58–61.

McGuire EJ, Zhang SC, Horwinski ER, et al. Treatment of motor and sensory detrusor instability by electrical stimulation. *J Urol*. 1983;129(1):78–79.

Michels L, Blok BF, Gregorini F, et al. Supraspinal control of urine storage and micturition in men – an fMRI study. *Cereb Cortex*. 2015;25:3369–3380.

Minni B, Capozza N, Creti G, et al. Bladder instability and enuresis treated by acupuncture and electro-therapeutics: early urodynamic observations. *Acupunct Electrother Res*.

1990;15(1):19–25.

Moazzam Z, Paquette J, Duke AR, et al. Feasibility of long-term tibial nerve stimulation using a multi-contact and wirelessly powered neurostimulation system implanted in rats. *Urology*. 2017;102:61–67.

Nashold BS, Friedman H, Glenn J, et al. Electromicturition in paraplegia. *Arch Surg*. 1972;104:195–202.

Nitti VW, Dmochowski R, Herschorn S, et al. OnabotulinumtoxinA for the treatment of patients with overactive bladder and urinary incontinence: results of a phase 3, randomized, placebo controlled trial. *J Urol*. 2013;189(6):2186–2193.

Noto H, Roppolo JR, Steers WD, et al. Electrophysiological analysis of the ascending and descending components of the micturition reflex pathway in the rat. *Brain Res*. 1991;549:95–105.

Peters KM, Carrico DJ, Perez-Marrero RA, et al. Randomized trial of percutaneous tibial nerve stimulation versus sham efficacy in the treatment of overactive bladder syndrome: results from the SUmiT trial. *J Urol*. 2010;183:1438–1443.

Peters KM, Carrico DJ, Wooldridge LS, et al. Percutaneous tibial nerve stimulation for the long-term treatment of overactive bladder: 3-year results of the STEP study. *J Urol*. 2013;189:2194–2201.

Peters KM, Feber KM, Bennett RC. Sacral versus pudendal nerve stimulation for voiding dysfunction: a prospective, single-blinded, randomized, crossover trial. *Neurourol Urodyn*. 2005;32:11–18.

Peters KM, Macdiarmid SA, Wooldridge LS, et al. Randomized trial of percutaneous tibial nerve stimulation versus extended-release tolterodine: results from the overactive bladder innovative therapy trial. *J Urol*. 2009;182(3):1055–1061.

Preyer O, Umek W, Laml T, et al. Percutaneous tibial nerve stimulation versus tolterodine for overactive bladder in women: a randomised controlled trial. *Eur J Obstet Gynecol Reprod Biol*. 2015;191:51–56.

Price DM, Noblett K. Prospective randomized crossover trial comparing continuous and cyclic stimulation in interstim therapy. *Female Pelvic Med Reconstr Surg*. 2015;21:355–358.

Rai BP, Cody JD, Alhasso A, et al. Anticholinergic drugs versus non-drug active therapies for non-neurogenic overactive bladder syndrome in adults. *Cochrane Database Syst Rev*. 2012;(12) [CD003193].

Rijkhoff NJ, Wijkstra H, Van Kerrebroeck PE, et al. Selective detrusor activation by electrical sacral nerve root stimulation in spinal cord injury. *J Urol*. 1997;157:1504–1508.

Robinson LQ, Grant A, Weston P, et al. Experience with the Brindley anterior sacral root stimulator. *Br J Urol*. 1988;62(6):553–557.

Ruch TC, Tang PC. Localization of brain stem and diencephalic areas controlling the micturition reflex. *J Comp Neurol*. 1956;106:213–245.

Sarrias M, Sarrias F, Borau A. The ‘Barcelona’ technique. *Neurourol Urodyn*. 1993;12:495–496.

Sauerwein D. Surgical treatment of spastic bladder paralysis in paraplegic patients. Sacral deafferentation with implantation of a sacral anterior root stimulator. *Urologe A*. 1990;29:196–203.

Sauerwein D, Ingunza W, Fischer J, et al. Extradural implantation of sacral anterior root stimulators. *J Neurol Neurosurg Psychiatry*. 1990;53(8):681–684.

Scheepens WA, Jongen MM, Nieman FH, et al. Predictive factors for sacral neuromodulation in chronic lower urinary tract dysfunction. *Urology*. 2002;60:598–602.

Schmidt RA, Jonas U, Oleson KA, et al. Sacral nerve stimulation for treatment of refractory urinary urge incontinence. *Sacral Nerve Stimulation Study Group J. Urol*. 1999;162(2):352–357.

Schurch B, Rodic B, Jeanmonod D. Posterior sacral rhizotomy and intradural anterior sacral root stimulation for treatment of the spastic bladder in spinal cord injured patients. *J Urol*. 1997;157:610–614.

Seif C, Braun PM, Bross S, et al. Selective block of urethral sphincter contraction using a modified Brindley electrode in sacral anterior root stimulation of the dog. *Neurourol Urodyn*. 2002;21:502–510.

Sie JA, Blok BF, de Weerd H, et al. Ultrastructural evidence for direct projections from the pontine micturition center to glycine-immunoreactive neurons in the sacral dorsal gray commissure in the cat. *J Comp Neurol*. 2001;429:631–637.

Siegel S, Noblett K, Mangel J, et al. Results of a prospective, randomized, multicenter study evaluating sacral neuromodulation with InterStim therapy compared to standard medical therapy at 6-months in subjects with mild symptoms of overactive bladder. *Neurourol Urodyn*. 2015;34(3):224–230.

South MM, Romero AA, Jamison MG, et al. Detrusor overactivity does not predict outcome of sacral neuromodulation test stimulation. *Int Urogynecol J Pelvic Floor Dysfunct*. 2007;18(12):1395–1398.

Spinelli M, Giardiello G, Arduini A, et al. New percutaneous technique of sacral nerve stimulation has high initial success rate: preliminary results. *Eur Urol*. 2003;43(1):70–74.

Spinelli M, Malaguti S, Giardiello G, et al. A new minimally invasive procedure for pudendal nerve stimulation to treat neurogenic bladder: description of the method and preliminary data. *Neurourol Urodyn*. 2005;24:305–309.

Stoller ML, Copeland S, Millard RJ, et al. The efficacy of acupuncture in reversing the unstable bladder in pig-tailed monkeys. *J Urol*. 1987;137(4):A104.

Tanagho EA, Schmidt RA. Electrical stimulation in the clinical management of the neurogenic bladder. *J Urol*. 1988;140:1331–1339.

Taniguchi N, Miyata M, Yachiku S, et al. A study of micturition inducing sites in the periaqueductal gray of the mesencephalon. *J Urol*. 2002;168:1626–1631.

Thompson JW. Transcutaneous electrical nerve stimulation for the relief of pain. *Acupuncture Med*. 1995;13:35–40.

Thüroff JW, Bazeed MA, Schmidt RA, et al. Functional pattern of sacral root stimulation in dogs. I. Micturition. *J Urol*. 1982;127:1031–1033.

T Hoen LA, Groen J, Scheepe JR, et al. Intermittent sacral neuromodulation for idiopathic urgency urinary incontinence in women. *Neurourol Urodyn*. 2017;36:385–389.

Van Balken MR, Vandoninck V, Gisolf KW, et al. Posterior tibial nerve stimulation as neuromodulative treatment of lower urinary tract dysfunction. *J Urol*. 2001;166(3):914–918.

Van Balken MR, Vergunst H, Bemelmans BL. Prognostic factors for successful percutaneous tibial nerve stimulation. *Eur Urol*. 2006;49(2):360–365.

Van Breda HM, Farag FF, Martens FM, et al. Subject-controlled, on-demand, dorsal genital nerve stimulation to treat urgency urinary incontinence; a pilot. *Front Neurosci*. 2016;10:24.

Van der Aa HE, Alleman E, Nene A, et al. Sacral anterior root stimulation for bladder control: clinical results. *Arch Physiol Biochem*. 1999;107:248–256.

Vandoninck V, Van Balken MR, Finazzi Agro E, et al. Posterior tibial nerve stimulation in the treatment of urge incontinence. *Neurourol Urodyn*. 2003;22(1):17–23.

Vandoninck V, van Balken MR, Finazzi Agro E, et al. Percutaneous tibial nerve stimulation in the treatment of overactive bladder: urodynamic data. *Neurourol Urodyn*. 2003;22(3):227–232.

Van der Pal F, van Balken MR, Heesakkers JP, et al. Correlation between quality of life and voiding variables in patients treated with percutaneous tibial nerve stimulation. *BJU Int*. 2006;97(1):113–116.

Van der Pal F, van Balken MR, Heesakkers JP, et al. Implant-driven tibial nerve stimulation in the treatment of refractory overactive bladder syndrome: 12-month follow-up. *Neuromodulation.*2006;9(2):163–171.

Van Kerrebroeck PE, Koldewijn EL, Rosier PF, et al. Results of the treatment of neurogenic bladder dysfunction in spinal cord injury by sacral posterior root rhizotomy and anterior sacral root stimulation. *J Urol*. 1996;155:1378–1381.

Van Kerrebroeck PE, Koldewijn EL, Debruyne FM. Worldwide experience with the Finetech-Brindley sacral anterior root stimulator. *Neurourol Urodyn*. 1993;12:497–503.

Van Kerrebroeck PE, van Voskuilen AC, Heesakkers JP, et al. Results of sacral neuromodulation therapy for urinary voiding dysfunction: outcomes of a prospective, worldwide clinical study. *J Urol*. 2007;178:2029–2034.

Vastenholt JM, Snoek GJ, Buschman HP, et al. A 7-year follow-up of sacral anterior root stimulation for bladder control in patients with a spinal cord injury: quality of life and users' experiences. *Spinal Cord*. 2003;41:397–402.

Vaughan CW, Satchell PM. Role of sympathetic innervation in the feline continence process under natural filling conditions. *J Neurophysiol*. 1992;68:1842–1849.

Vodusek DB, Light JK, Libby JM. Detrusor inhibition by stimulation of pudendal nerve afferents. *Neurourol Urodyn*. 1986;5:381–389.

Walsh IK, Thompson T, Loughridge WG, et al. Non-invasive antidromic neurostimulation: a simple effective method for improving bladder storage. *Neurourol Urodyn*. 2001;20(1):73–84.

Yoong W, Shah P, Dadswell R, et al. Sustained effectiveness of percutaneous tibial nerve stimulation for overactive bladder syndrome: 2-year follow-up of positive responders. *Int Urogynecol J*. 2013;24(5):795–799.

123

Retropubic Suspension Surgery for Incontinence in Women

Siobhan M. Hartigan MD, Christopher R. Chapple MD, FRCS (Urol), Roger R. Dmochowski MD, MMHC, FACS

Continence in women results from a complex interplay of anatomic and physiologic properties of the lower urinary tract (bladder, urethra and sphincter, and pelvic floor) acting under the coordinating control of an intact central and peripheral nervous system. The role of the pelvic floor is to provide support to the bladder and the urethra and to facilitate normal abdominal pressure transmission to the proximal urethra, thereby maintaining continence.

Stress incontinence is a symptom, a sign, and a clinical diagnosis; the clinical symptom is that of involuntary loss of urine on effort or physical exertion (e.g., sporting activities) or with increased intra-abdominal pressure, such as occurs during coughing and sneezing (Haylen et al., 2010). The International Continence Society defines urodynamic stress incontinence as the involuntary leakage of urine during filling cystometry, associated with increased intra-abdominal pressure, in the absence of detrusor (bladder wall muscle) contraction (Haylen et al., 2010). Thus urodynamic evaluation is a prerequisite for the diagnosis of urodynamic stress incontinence. Therefore, in discussing stress incontinence, this chapter refers to women with stress urinary incontinence (SUI) diagnosed on the basis of symptoms alone or as proven by urodynamics, so-called urodynamic stress incontinence.

Treatment options for SUI include conservative techniques and pharmacologic and surgical interventions. In general, surgical procedures to treat SUI aim to improve the support to the urethrovesical junction and to correct deficient urethral closure. There is a contemporary lack of consensus, however, regarding the precise mechanism by which continence is achieved in the "normal asymptomatic woman" and therefore not surprisingly in how "normality" is restored by surgical manipulation. Anti-incontinence surgery is usually used to address the failure of normal anatomic support of the bladder neck and proximal urethra, and intrinsic sphincter deficiency. **Anti-incontinence surgery does not necessarily work by restoring the same mechanism of continence that was present before the onset of incontinence. Rather, it works by a compensatory approach, creating a new mechanism of continence** (Jarvis, 1994a).

Therapeutic Options

The surgeon's preference, coexisting problems, and anatomic features of the patient and her general health condition influence the choice of procedure. Numerous surgical methods have been described, but they essentially fall into seven categories (Box 123.1).

Box 123.1

Surgical Methods

Open retropubic colposuspension
Laparoscopic retropubic colposuspension
Suburethral sling procedure
Needle suspension
Periurethral injection
Artificial sphincter
Vaginal anterior repair (anterior colporrhaphy)

This wide variety of treatment options for stress incontinence indicates the lack of a clear consensus as to which procedure is the most effective. Several groups have reviewed the literature, often using systematic and methodical analyses of well-designed randomized controlled trials (RCTs) (Black and Downs, 1996; Fantl et al., 1996; Fusco et al., 2017; Jarvis, 1994b; Lapitan et al., 2003; Leach et al., 1997; Moehrer et al., 2000, 2003). **Most of these reviews, however, are hampered by the quality of the existing evidence base, and these reviews are based on studies of mixed quality with little standardization of the points in Box 123.2.**

Box 123.2

Standardization Needed for Studies

The patients under study (with regard to age, history of prior surgery, body mass)

The nature of the surgical technique, taking into account the surgeon's experience
Outcome measures and follow-up

A review of existing literature on confounding variables affecting outcome of therapy (Rovner et al., 2017) concluded the following:

1. **Age may not be a contraindication to colposuspension:** Success in the elderly was equivalent to success in younger patients at long-term follow-up in some studies (Gillon and Stanton, 1984; Tamussino et al., 1999), although others have reported less success with increasing age (Chilaka et al., 2002; Langer et al., 2001). Smith et al. (2009), from their review of the literature, concluded that the effect of age on outcomes is poorly defined. The Stress Incontinence Surgical Treatment Efficacy study investigated the effect of age on perioperative and postoperative outcomes of pubovaginal slings and colposuspension (Richter et al., 2008). Overall, compared with younger women (mean age 49.4 years), older women (mean age 69.7 years) took longer to return to normal activities (50 vs. 42 days; $P = 0.05$), but there was no difference in return to normal voiding. The older group were more likely to have a positive stress test at follow-up (odds ratio [OR] 3.7; 95% confidence interval [CI] 1.70–7.97; $P = 0.001$), less subjective improvement in stress and urgency symptoms, and more likely to require repeat surgery (OR 3.9; 95% CI 1.30–11.48). The effect of aging on the lower urinary tract includes a higher rate of detrusor overactivity as well as urgency incontinence and intrinsic sphincteric deficiency (ISD). In addition, older patients are more likely to have had prior interventions and may therefore have a higher rate of periurethral fibrosis and/or other abnormalities in the tissues surrounding the lower urinary tract. The presence of multiple comorbidities may also affect overall surgical outcome, including creating the possibility for increased complications and a prolonged postoperative course.
2. The influence of the level of postoperative activity has been inadequately studied, so no recommendations can be made (Smith et al., 2009).
3. There is level 4 evidence that medical comorbidity may have an impact on surgical outcomes, depending on the outcomes selected. There is level 3 evidence that psychological factors have an impact on subjective

and objective outcomes in different ways (Smith et al., 2005).

4. Obesity as a confounding variable is the subject of conflicting evidence in the literature and has not been studied in a prospective fashion. Obesity has been studied only retrospectively in case series as a risk factor for success or morbidity in stress incontinence surgery (level 4 evidence). **There are no prospective, randomized trials that suggest superiority of one surgical technique over another in the obese population.** Some studies have suggested increased failure rates in obese patients undergoing retropubic colposuspension (Alcalay et al., 1995; Brieger and Korda, 1992). Conversely, in a retrospective study of 198 women undergoing anti-incontinence surgery, cure rates were markedly better in those undergoing Burch colposuspension (Zivkovic et al., 1999).
5. **Surgery for recurrent stress incontinence has a lower success rate.** One study has reported that Burch colposuspension has an 81% success rate after one previous surgical procedure has failed, but this drops to 25% after two previous repairs and to 0 after three previous operations (Petrou and Frank, 2001). Other series report excellent results for colposuspension carried out after prior failed surgery. Maher et al. (1999) and Cardozo et al. (1999) have shown good objective (72% and 79%) and subjective (89% and 80%) success rates with repeated colposuspension at a mean follow-up of 9 months. In two small retrospective studies of women who underwent open and laparoscopic Burch colposuspension after failed suburethral tape procedures, the objective cure rates were 77% and 54% at a median follow-up 1 year and 24½ months, respectively (De Cuyper et al., 2008; Giarenis et al., 2012;). Nitahara et al. (1999) reported a 69% subjective success at a mean follow-up of 6.9 years.
6. Berglund et al. (1996) reported that the duration of symptoms is a predictor of outcome, with a better response in those with a shorter history, which as a finding was independent of type of approach (e.g., vaginal vs. retropubic). Ward and Hilton (2002), in a randomized comparison of colposuspension and tension-free vaginal tape (TVT), found no significant impact of symptom severity on outcomes for either procedure. Tamussino et al. (1999), in a review of 327 women assessed a minimum of 5 years postoperatively, noted that women with moderate or severe incontinence fared worse than those with milder symptoms. In

their series, only Burch colposuspension was unaffected by the severity of preoperative symptoms.

7. It has been reported that as many as 23% of women undergoing urodynamics have mixed urodynamic stress incontinence and detrusor overactivity (Clarke, 1997). In a retrospective cohort study, Colombo et al. (1996b) compared 44 women with mixed incontinence with a matched group with urodynamic stress incontinence. The cure rate was 95% in the latter group compared with 75% in the former. Other studies report a less favorable outcome of 24% to 43% in those with detrusor overactivity combined with stress incontinence (Lose et al., 1988; Milani et al., 1985; Stanton et al., 1978).
   Smith et al. (2009) concluded that **surgery for urodynamic stress incontinence should not be considered contraindicated in women with mixed symptoms of SUI and overactive bladder syndrome or mixed urodynamic findings of urodynamic stress incontinence and detrusor overactivity (grade B recommendation).** All patients undergoing surgery for SUI should be appropriately counseled to have realistic expectations of outcome; this is particularly important in those with mixed symptoms or mixed urodynamic stress incontinence (grade B recommendation).
8. The International Consultation on Incontinence (ICI), although allowing the fact that there is no consensus on the definition of intrinsic sphincter deficiency, concluded that **there are limited evidence-based data to support that intrinsic sphincter deficiency influences either the outcomes of surgery or the type of surgical treatment** (Smith et al., 2009). It would appear that a low leak point pressure is less predictive of outcome when compared with the presence or absence of urethral hypermobility (Smith et al., 2009).

Choice of Surgical Technique

Two types of stress incontinence have been suggested: one associated with a **hypermobile but otherwise healthy urethra,** a manifestation of weakened support of the proximal urethra, and one arising from a **deficiency of the urethral sphincter mechanism,** thereby compromising the ability of the urethra to act as a watertight outlet. **Hypermobility of the bladder neck and proximal urethra results from a weakening or loss of their supporting elements (ligaments, fascia, and muscles), which in turn may be a consequence of aging, hormonal changes, childbirth, and prior surgery. It seems likely that the majority of women with SUI will also have an element of intrinsic sphincteric weakness with a variable degree of loss of the normal anatomic support of the bladder neck and proximal urethra, resulting in hypermobility. An individual with normal bladder function will not have leakage regardless of how much she strains.**

Differentiating Relative Contributions of Hypermobility and Intrinsic Sphincter Deficiency

The influence of urethral function defined by leak point pressure or maximum urethral closure pressure (MUCP) is difficult to define because of the large variation in outcome measures used. Furthermore, other variables such as urethral mobility are often not controlled for. **ISD** is usually defined as a leak point pressure below 60 or MUCP below 20. A standardized test is not available to differentiate the relative contributions of ISD and hypermobility, and therefore few studies have been able to accurately separate their individual contributions to the development of incontinence (Chapple et al., 2005). **Retropubic procedures restore the bladder neck and proximal urethra to a fixed, retropubic position and are used when hypermobility is thought to be an important factor in the development of that woman's stress incontinence. This may facilitate the function of a marginally compromised intrinsic urethral sphincter mechanism, but if significant ISD is present, it is likely that SUI will persist despite efficient surgical repositioning of the bladder neck and proximal urethra;** at present this hypothesis remains unproven. In such circumstances a sling procedure (particularly a snug fascial sling) or an artificial sphincter is most likely to be the therapy of choice.

In the healthy, continent woman, the bladder neck and proximal urethra are supported in a retropubic position and the bladder base is dependent. Increases in intra-abdominal pressure are transmitted to the bladder and the proximal urethra such that the pressure difference between the two is unchanged, promoting continence (Einhorning, 1961). A valvular effect at the bladder neck created by the transmission of abdominal pressure to the dependent bladder base may also be operative here (Penson and Raz, 1996). Furthermore, with proper bladder neck support, reflex contraction of the pelvic floor muscles during Valsalva maneuvers and coughing acts as a backboard for urethral compression (Staskin et al., 1985).

Surgical Procedures

This chapter deals with retropubic surgical procedures, usually chosen as surgical therapy for patients with stress incontinence in which there is a significant component of hypermobility.

Open retropubic colposuspension is the surgical approach of lifting the tissues near the bladder neck and proximal urethra into the area of the pelvis behind the anterior pubic bones. When it is an open procedure, the approach is through an incision over the lower abdomen. There are four variations of open retropubic colposuspension: Marshall-Marchetti-Krantz (MMK), Burch, vagino-obturator shelf (VOS), and paravaginal procedures.

The term *colposuspension* was originally used to denote suspension of the urethra by the vaginal wall; however, by common usage, it now generally includes the paraurethral fascia and sometimes only this without the vagina. Retropubic colposuspension urethral repositioning can be achieved by three distinctly different procedures; these are all based on a similar underlying principle, but in a spectrum in relation to the degree of the support or elevation they achieve, and their outcomes differ somewhat in the longer term.

The **Burch colposuspension** (Fig. 123.1A) is the elevation of the anterior vaginal wall and paravesical tissues toward the iliopectineal line of the pelvic sidewall with use of two to four sutures on either side (Burch, 1961). The **VOS repair** (see Fig. 123.1B) aims to anchor the vagina to the internal obturator fascia and is a modification of a combination of the Burch and paravaginal defect repair, with placement of the sutures laterally, anchored to the internal obturator fascia rather than hitching the vagina up to the iliopectineal line

(Turner-Warwick, 1986), although a more recent modification does, where appropriate, insert stitches into the internal obturator and iliopectineal line (see Fig. 123.1C). The **paravaginal defect repair** (see Fig. 123.1D) aims to close a presumed fascial weakness laterally at the site of attachment of the pelvic fascia to the internal obturator fascia (Richardson et al., 1976). The **MMK procedure** (see Fig. 123.1E) is the suspension of the vesicourethral junction (bladder neck) toward the periosteum of the symphysis pubis (Marshall et al., 1949) and was thought to buttress the paraurethral area and bringing the vesicourethral junction into a more elevated “intra-abdominal” position.

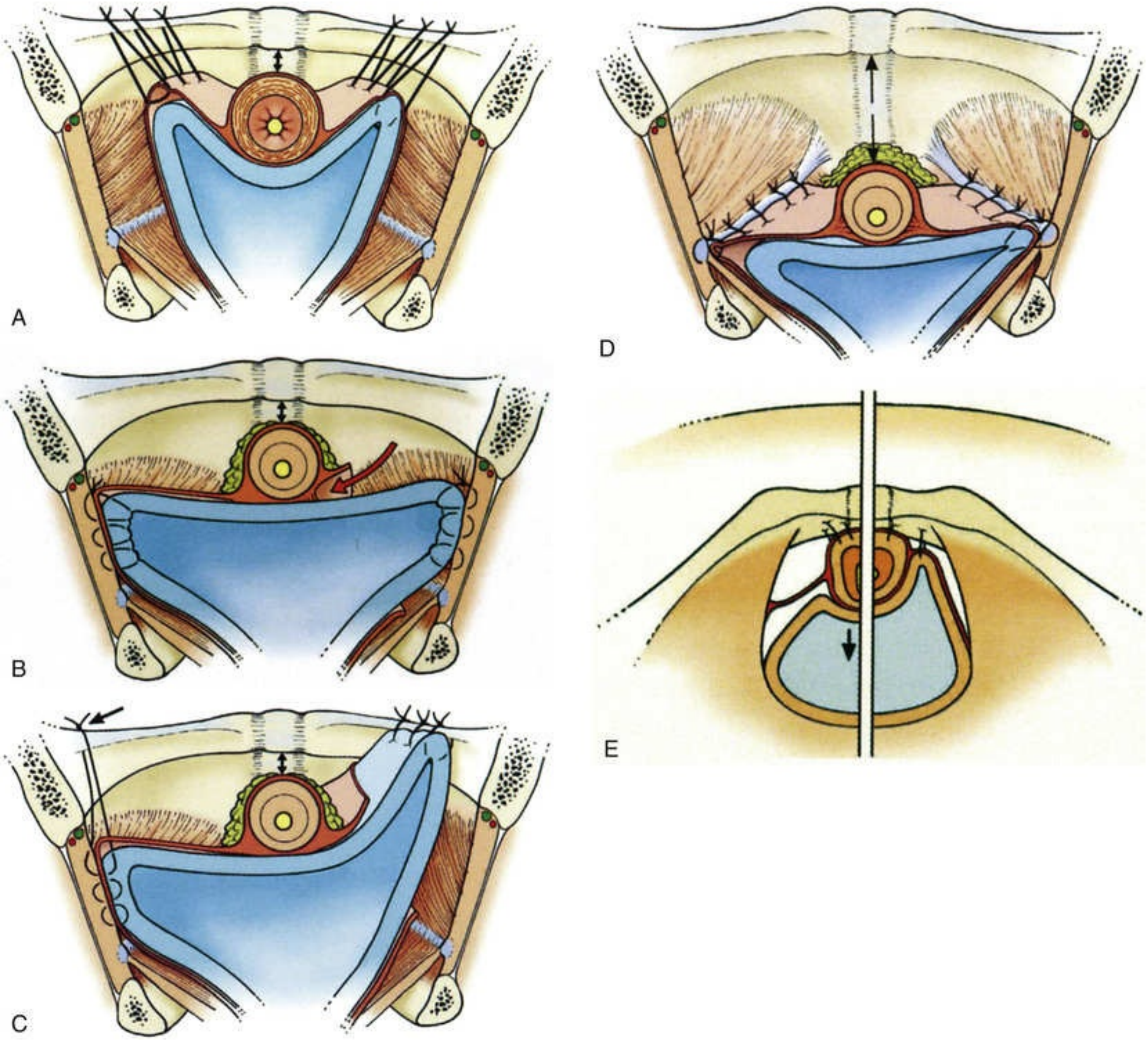

FIG. 123.1 (A) Coronal view, diagrammatic representation of a Burch colposuspension. (B) Coronal view, diagrammatic representation of a vagino-obturator shelf procedure. (C) Coronal view, diagrammatic representation of a vagino-obturator shelf procedure on the left, augmented

by stitching to the iliopectineal line, and a Burch procedure on the right. (D) Coronal view, diagrammatic representation of a paravaginal repair. (E) Diagram demonstrating the sutures in a Marshall-Marchetti-Krantz procedure and their proximity to the urethra. (From Turner-Warwick R, Chapple CR: *Functional reconstruction of the urinary tract and gynaeco-urology: an exposition of functional principles and surgical procedures,* Oxford, 2002, Blackwell Science.)

Degree of Urethral Elevation

The extent of the urethral elevation achieved by the Burch (see Fig. 123.1A) and the VOS suspensions (see Fig. 123.1B and C) is higher than the arcus tendineus anchorage of the paravaginal defect repair (see Fig. 123.1D).

Configuration of the Suspensions

A particular advantage of the horizontal urethral elevation achieved by the VOS and the paravaginal repair suspensions is the significantly lower susceptibility to tension on the urethra and to obstructive problems than with the V-shaped configuration of the Burch suspension (see Fig. 123.1A).

Tissue Approximation

The VOS and the paravaginal repair suspensions are anchored by tissue-approximating sutures; thus, unlike the Burch procedure, neither the VOS nor the paravaginal repair suspension is suture dependent in the longer term once the initial healing is complete because there is direct tissue adhesion. The VOS anchorage and suspension are significantly more robust than those of the paravaginal defect repair; the elevation this procedure achieves can be further augmented by additionally including the iliopectineal ligament in the upper sutures (see Fig. 123.1C).

Laparoscopic colposuspension is the most popular of the laparoscopic incontinence procedures that were first introduced in the early 1990s (Vancaillie and Schuessler, 1991) with the premise that, as minimally invasive procedures, they would benefit patients by avoiding the major incision of conventional open surgery and shorten the time for a return to normal activity. As in open colposuspension, sutures are inserted into the paravaginal tissues on either side of the bladder neck and then attached to the iliopectineal ligaments on the same side. However, there are technical variations in surgery with respect to the laparoscopic approach (transperitoneal into the abdominal cavity or extraperitoneal) and in the number and types of sutures, the site of anchor, and the use of mesh and staples (Jarvis et al., 1999).

Assessing Outcomes of Therapy

Before the best procedure is determined, several issues regarding outcome reporting must be addressed.

Duration of Follow-Up

Prolonged follow-up is required to assess the true benefit of an incontinence procedure. **Short-term follow-up should be considered to have begun in all studies after participants have reached 1 year of follow-up** (Abrams et al., 2002). In the short term (2 years), most procedures are successful, and success rates among procedures are similar (Leach et al., 1997). However, with longer follow-up (>5 years), failures manifest and the true benefit of the better procedures is realized. Most studies report outcomes after short-term follow-up, thus results must be interpreted with caution.

Issue of Intrinsic Sphincter Deficiency

There is no consistency in the existing literature data to support the likelihood that intrinsic sphincter deficiency can influence either the outcomes or the type of surgical treatment. The main problem is that there is no uniform consensus on the meaning of *intrinsic sphincter deficiency* and how to diagnose it (Smith et al., 2005, 2009). Nevertheless, although unsubstantiated by any unequivocal evidence, it is likely that although mild degrees of intrinsic sphincter deficiency coexist with hypermobility in most cases, in a situation in which intrinsic sphincter deficiency is the predominant problem, a repositioning procedure such as a colposuspension is less likely to be successful than a tight fascial sling or artificial sphincter.

Definition of Cure

The definition of cure varies among studies. Some authors report cure of SUI only, whereas others define cure as complete continence postoperatively, implying the absence of urgency incontinence as well. The assessment of cure may vary. Some authors report subjective cure based on patient history, questionnaire, bladder diary, or medical chart review; others use more objective measures, such as pad tests, stress tests, and urodynamics.

Finally, is the goal of complete continence reasonable, given that the condition of SUI is usually a degenerative one and corrective surgery does not replace the defective components? As well, **even in normal, healthy women, urinary continence is a spectrum of dryness; approximately 40% of nulliparous 30- to 49-year-olds experience some degree of incontinence with exercise** (Nygaard et al., 1990). It seems unreasonable to expect surgery for a degenerative condition to achieve results that are better than the nondegenerative state.

Patient's Versus the Physician's Perspective

A patient's satisfaction with treatment is often based on the difference between her expectations and her experiences (Sofaer and Firminger, 2005). Thus fulfillment of positive expectations is a key element of a patient's satisfaction (Sitzia and Wood, 1997). Because expectations vary widely, satisfaction is not a standard concept. Consequently, treatment plans must be tailored to meet a nonstandard goal. An integral step in achieving this goal is the development of a patient-physician partnership that promotes the negotiation of realistic expectations.

Logically, agreement of patient and physician with respect to treatment plan and goals should improve outcomes. When a diagnosis has been made, asking patients what they already know about the condition may give clues to expectations for treatment. The “ask-tell-ask” method may be used to mend the gaps between the physician's and the patient's expectations. The physician explains the proposed treatment plan and expectations for the outcome, then encourages the patient to ask questions. The physician provides the information requested and invites questions again, continuing the process until a mutual understanding of treatments and expectations is reached (Barrier et al., 2003). This approach may prevent “surprises,” such as unexpected pain of treatment, adverse events of medication, and prolonged recovery time. Elkadry et al. (2003) emphasized this point by demonstrating a significant association between feeling unprepared for surgery and the patient's dissatisfaction after pelvic reconstruction. The same investigators also reported that achievement of patient-defined goals was more predictive of a patient's satisfaction than were objective measures of surgical success.

Clearly, one or more high-quality validated symptom and quality-of-life instruments should be chosen at the outset of a clinical trial, representing the patient's viewpoint, accurately defining baseline symptoms as well as any other areas in which treatment may be beneficial, and assessing the objective severity and subjective impact of both. **Whereas many urologists think that urodynamic studies are helpful in defining the underlying pathophysiologic process in patients with incontinence, they have not been proven to have adequate sensitivity, specificity, or predictive value** (Chapple et al., 2005)**. The ICI meeting scientific committee concluded that although urodynamic studies, such as frequency-volume charts and pad tests, are useful, there is inadequate evidence to justify pressure-flow studies for routine testing, as either entry criteria or outcome measures in clinical trials. They recommended that most large-scale clinical trials enroll subjects by carefully defined symptom-driven criteria when the treatment will be given on an empirical basis** (Abrams et al., 2002). **The committee recommended against the use of urethral function measurements of leak point pressures and urethral closure pressures as a single factor to grade the severity of urinary incontinence and therefore did not recommend the use of contemporary urethral function tests to predict the outcome of any surgical treatment for SUI** (Rovner et al., 2017)**.**

Indications for Retropubic Repair

The treatment of SUI in women must be tailored to the individual patient. Once evaluation has identified contributing factors, a trial of conservative therapy should be pursued and surgery considered for patients who do not respond to this. Careful assessment of the patient is essential in making an accurate diagnosis (Fig. 123.2).

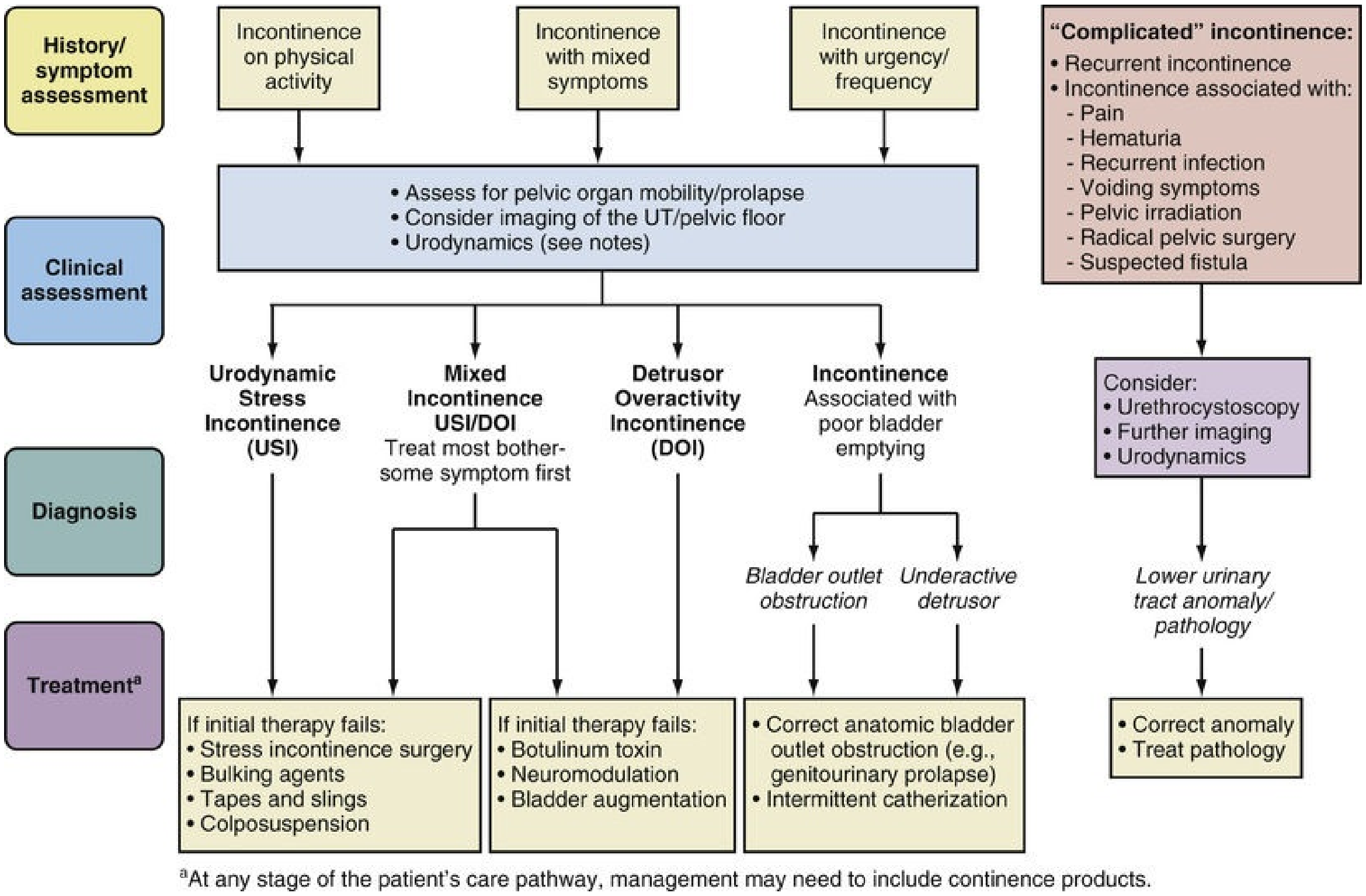
History/ symptom assessment
Clinical assessment
Diagnosis
Treatment^a
Incontinence on physical activity
Incontinence with mixed symptoms
Incontinence with urgency/ frequency
"Complicated" incontinence:
• Recurrent incontinence
• Incontinence associated with:
- Pain
- Hematuria
- Recurrent infection
- Voiding symptoms
- Pelvic irradiation
- Radical pelvic surgery
- Suspected fistula
• Assess for pelvic organ mobility/prolapse
• Consider imaging of the UT/pelvic floor
• Urodynamics (see notes)
Urodynamic Stress Incontinence (USI)
Mixed Incontinence USI/DOI Treat most bothersome symptom first
Detrusor Overactivity Incontinence (DOI)
Incontinence Associated with poor bladder emptying
Consider:
• Urethrocystoscopy
• Further imaging
• Urodynamics
Bladder outlet obstruction
Underactive detrusor
Lower urinary tract anomaly/ pathology
If initial therapy fails:
• Stress incontinence surgery
• Bulking agents
• Tapes and slings
• Colposuspension
If initial therapy fails:
• Botulinum toxin
• Neuromodulation
• Bladder augmentation
• Correct anatomic bladder outlet obstruction (e.g., genitourinary prolapse)
• Intermittent catherization
• Correct anomaly
• Treat pathology

^{a}At any stage of the patient's care pathway, management may need to include continence products.

FIG. 123.2 Algorithm for the specialized management of stress urinary incontinence in women (after the Third International Consultation on Incontinence, Monaco, 2004). *UT,* Urinary tract.

The selection of technique is largely based on the surgeon's preference and prior experience; bladder base and urethral hypermobility may be surgically corrected by either a vaginal or a retropubic approach. Co-existing pelvic floor problems, the anatomic features of the patient, and her general health condition may also influence the choice of procedure (Lapitan et al., 2017). Although it has been suggested that a retropubic colposuspension should be considered in patients who frequently generate high intra-abdominal pressure (e.g., those with chronic cough from obstructive pulmonary disease and women in strenuous occupations) (Appell, 1993), it could also be argued that these patients may be better served by a pubovaginal sling as well.

Although SUI is now more commonly managed surgically with minimally invasive procedures, particularly with the use of mid-urethral slings, these resources and procedures are not readily available in many countries. Limitation in experience plays a role but, more importantly, this is due to the difficulty in acquiring the slings, either because of their unavailability or their prohibitive cost (Lapitan et al., 2017).

Specific Indications

A retropubic approach for the correction of anatomic SUI is indicated (1) for a patient undergoing a laparotomy for concomitant abdominal surgery that cannot be performed vaginally and (2) where there is limited vaginal access.

Potential Contraindications

If there is a history of prior failed incontinence procedures, the existence of significant sphincteric deficiency must be suspected, even if hypermobility exists, and consideration given to performing a pubovaginal sling, although retropubic colposuspension may be successful in this scenario as well (Cardozo et al., 1999; Maher et al., 1999; Nitahara et al., 1999).

When SUI exists solely because of intrinsic sphincter deficiency (i.e., a fixed, nonfunctional proximal urethra with intrinsic urethral sphincter dysfunction), a retropubic suspension procedure is less likely to be successful because there is no hypermobility to correct and the patient is better served by a pubovaginal sling, collagen injections, or artificial sphincter (Bergman et al., 1989b). Although data are limited, the ICI committee statement on urethral occlusive forces discusses two studies that showed improved outcomes among women with higher degrees of urethral hypermobility who underwent transobturator midurethral sling procedures (Rovner et al., 2017).

In cases with a pan–pelvic floor weakness, a colposuspension should not be used in isolation but should be part of a comprehensive approach to the pelvic floor and combined as appropriate with other alternative pelvic floor repair procedures. A retropubic colposuspension does not always adequately correct the associated vaginal prolapse that frequently coexists with bladder neck hypermobility. Although lateral defect cystocele and enterocele lend themselves to retropubic repair, a central defect cystocele, rectocele, and introital deficiency do not.

A retropubic colposuspension is contraindicated **when there is an inadequate vaginal length or mobility of the vaginal tissues, for example, after prior vaginal surgery, radiotherapy, or a prior vaginal incontinence procedure** (Appell, 1993). The lysis of retropubic adhesions can be performed adequately and safely by a vaginal approach in conjunction with a needle suspension procedure or pubovaginal sling.

Vaginal Versus Retropubic Surgery

From a review of the literature, there is clearly a difference in the success rate of vaginal versus retropubic surgery alone with respect to correction of stress incontinence. An **anterior colporrhaphy** can certainly be efficacious for the correction of prolapse, with reported efficacy rates in randomized controlled studies of 42% and 57% in the management of cystoceles (Sand et al., 2001; Weber et al., 2001). For the treatment of a cystocele and stress incontinence, an anterior colporrhaphy should be combined with a sling procedure. Goldberg et al. (2001), in a case-control series, demonstrated that in women with a cystocele and SUI, the addition of a pubovaginal sling to an anterior colporrhaphy significantly decreased the recurrence rate from 42% in the control group to 19% in the anterior colporrhaphy group.

A recent Cochrane review by Lapitan, Cody, and Masheyekhi (2017) reviewed the literature on randomized or quasi-randomized trials that compared open retropubic colposuspension with anterior colporrhaphy for the treatment of urinary incontinence. Evidence from seven trials evaluating a total of 695 women showed that anterior vaginal repair was less effective than open abdominal retropubic suspension on the basis of subjective cure rates with the benefit maintained over time. For anterior colporrhaphy versus open abdominal retropubic colposuspension, respectively, they found incontinence rates of 9% versus 19% (relative risk [RR] 0.46, 95% CI 0.30–0.72) before the first year of follow-up, 14% versus 36% (RR 0.37, 95% CI 0.27–0.51) at 1 to 5 years, and 28% versus 53% (RR 0.49, 95% CI 0.32–0.75) in periods beyond 5 years (Lapitan et al., 2017). Open retropubic colposuspension was also found to have more effective objective cure rates with similar results at short-term follow-up and maintained over time. Overall, the risk of failing to cure urinary incontinence through open retropubic colposuspension was only half that of anterior repair, with an estimated absolute risk reduction (ARR) of 21% (ARR 0.21, 95% CI 0.15–0.27). In addition, fewer women in the colposuspension group had repeat anti-incontinence surgery, 6.3% versus 23.4% (RR 0.11, 95% CI 0.04–0.30).

Based on data from five trials (Bergman et al., 1989a; Colombo et al., 2000, Holmes et al., 1985; Liapis et al., 1996; Quadri et al., 1999) reviewed with long-term follow-up of at least 1 year, the risk of recurrent or new prolapse was found to be more common in women who underwent open colposuspension versus anterior colporrhaphy (16% vs. 5%); however, there was significant heterogeneity across these studies, and this did not reach statistical significant when a random-effects model was used (RR 2.51, 85% CI 0.62–10.10) (Lapitan et al., 2017). Lapitan et al. (2017) concluded that **open retropubic colposuspension provides a better cure rate compared with anterior colporrhaphy alone.**

Based on the existing evidence, transvaginal sling procedures and open retropubic suspension procedures have similar success rates in the treatment of stress incontinence. However, with longer follow-up (and with the exception of the pubovaginal sling and loose mid-urethral tapes [see later in this chapter]), patients who have retropubic procedures fare better than those undergoing vaginal repairs.

Key Points: Recommendation From the International Consultation on Incontinence Committee

- Open Burch colposuspension can be recommended as an effective treatment for primary and recurrent SUI, which has longevity (Grade A recommendation) (Rovner et al., 2017).
- Anterior colporrhaphy should not be used in the management of SUI alone (Grade A recommendation) (Smith et al., 2009).

General Technical Issues

Retropubic Dissection

In open retropubic suspension procedures, good access to the retropubic space is crucial. This is best performed with the patient in the supine position with the legs abducted, in either a low or a modified dorsal lithotomy position with use of stirrups, allowing access to the vagina during the procedure and a perineal-abdominal progression. A urethral Foley catheter is inserted; the catheter balloon is used for subsequent identification of the urethra and bladder neck, and indeed, it is invaluable in allowing palpation of the edges of the bladder by appropriate manipulation. A Pfannenstiel or lower midline abdominal incision is made, separating the rectus muscles in the midline and sweeping the anterior peritoneal reflection off the bladder. It is essential to optimize the access to the retropubic space, and if a Pfannenstiel skin incision is made, it is advisable to use the suprapubic V modification described by Turner-Warwick et al. (1974). Likewise, whatever incision is made, extra valuable access to the retropubic space is obtained by extending the division of the rectus muscles down to the pubic bone and elevating the aponeurotic insertion of the rectus muscle off the upper border of the pubic bone.

The retropubic space is then developed by teasing away the retropubic fat and underlying retropubic veins from the back of the pubic bone. The bladder neck, anterior vaginal wall, and urethra are then easy to identify, often facilitated by the presence of the Foley balloon. In patients who have had previous retropubic surgery, the dissection is performed sharply, and it is important to take down all old retropubic adhesions, particularly in the case of a prior failed repair. If difficulty is encountered in the identification of the bladder neck, the bladder may be partially filled or even opened to identify its limits, and an examining finger in the vagina is invaluable in aiding the dissection (Gleason et al., 1976; Symmonds, 1972).

It is important to identify the lateral limits of the bladder as it reflects off the vaginal wall because only in this manner can the surgeon avoid inadvertent suturing of the bladder. Dissection over the bladder neck and urethra in the midline is to be avoided so as not to damage the intrinsic musculature. The lateral bladder wall may be “rolled off” medially and cephalad from the vaginal wall with a mounted swab and by use of countertraction with a finger in the vagina. It is often necessary to incise the endopelvic fascia. Occasional venous bleeding from the large vaginal veins can be controlled by suture ligation, although it often resolves with tying of elevating sutures. To aid in the identification of the lateral margin of the bladder, it is helpful to displace the balloon of the Foley catheter into the lateral recess, where it can easily be palpated through the bladder wall.

Suture Material

Absorbable sutures were used in the original descriptions of the MMK procedure (chromic catgut), Burch procedure (chromic catgut), and VOS procedure (polyglycolic acid or polydioxanone), whereas the original paravaginal repair used nonabsorbable sutures (silicon-coated Dacron). Fibrosis during subsequent healing is likely to be the most important factor in providing continued fixation of the perivaginal fascia to the suspension sites (Tanagho, 1996); nevertheless, some surgeons believe that a nonabsorbable suture material is better because of the risk of suture dissolution before the development of adequate fibrosis (Penson and Raz, 1996). Clearly, the type of suspension suture material is a personal choice, but erosion of nonabsorbent sutures into the lumen of the bladder is a not-uncommon complication and a not-uncommon source of medical litigation (Woo et al., 1995).

Bladder Drainage

Some degree of immediate postoperative voiding difficulty can be expected after retropubic suspensions (Colombo et al., 1996a; Lose et al., 1987). Immediately postoperatively, bladder drainage may take the form of a urethral or a suprapubic catheter, in general based on the surgeon's preference. A voiding trial is usually performed around the fifth day postoperatively. However, there is some evidence that a suprapubic catheter may be advantageous with respect to a lower incidence of asymptomatic and febrile urinary tract infection and earlier resumption of normal bladder function (Andersen et al., 1985; Bergman et al., 1987). In addition, the use of a suprapubic tube is usually more comfortable, allows the patient to participate in catheter management, and avoids the need for clean intermittent self-catheterization. Catheterization can be discontinued when efficient voiding has resumed, which is usually indicated by a postvoid residual (PVR) volume either less than 100 mL or less than 30% of the functional bladder volume, although no definitive evidence exists for a precise quantification of acceptable PVR.

Drains

A tube drain may be placed in the retropubic space when there is concern about ongoing bleeding from perivaginal veins that may prove difficult to control with suture and electrocautery. Often, tying the suspension sutures is sufficient to stop this bleeding, but when it persists, drainage of the retropubic space is indicated. The drain is usually removed on the first to third day, when minimal output is noted.

Marshall-Marchetti-Krantz Procedure

Technique

Marshall, Marchetti, and Krantz in 1949 described a retropubic approach for the elevation and fixation of the anterolateral aspect of the urethra to the posterior aspect of the pubic symphysis and the adjacent periosteum. Technically, the original description of the MMK procedure reported a double suture bite of the paraurethral tissue included with the vaginal wall; this may be generically entitled a cystourethropexy procedure. In 1949 Marshall et al. described their retropubic vesicourethral suspension in 50 patients; 38 of the patients had symptoms of SUI, and in 25 of those, prior gynecologic operations for urinary incontinence had failed. A simple suprapubic procedure was described by which the vesical outlet was suspended to the pubis (Marshall et al., 1949). In the original description, three pairs of sutures (taking double bites of tissue) were placed on each side of the urethra, incorporating full-thickness vaginal wall (excluding mucosa) and lateral urethral wall (excluding mucosa) (Marshall et al., 1949). Marchetti (1949) then modified the procedure to omit the tissue bite through the urethral wall because of concern about urethral injury. Apart from modifications in suture number and material over the years, the procedure remains the same today.

Cystourethropexy was often used as a secondary procedure for the resolution of persistent leaking after an anterior colporrhaphy. **A cystourethropexy procedure does not support the posterior wall of the urethra unless the sutures include the paraurethral vaginal wall, nor does it positively reduce an anterior vaginal wall prolapse in the way that the true retropubic colposuspension procedures do.** After cystourethropexy, if there is a significant urinary residual volume postcolporrhaphy with associated laxity of the anterior vaginal wall, then with the descent, this applies traction to the posterior aspect of the bladder neck and tends to “tent” it open because the anterior aspect is tethered by sutures to the back of the pubis (see Fig. 123.1E). Sutures are placed on either side of the urethra (avoiding the urethral wall), taking bites through the paraurethral fascia and anterior vaginal wall (excluding mucosa). The most proximal sutures are placed at the level of the bladder neck. Each suture is then passed into an appropriate site in the cartilaginous portion of the symphysis (Fig. 123.3). However, the main technical problem relating to the MMK procedure is the difficulty of obtaining an adequately robust anchorage of the anterior wall of the urethra and the paraurethral fascia to the symphysis and the periosteum of the pubis, where the suture bites are relatively insecure. As shown in Fig. 123.3, these sutures can potentially either distort the bladder neck and impair sphincter function (see Fig. 123.3A) or obstruct the bladder neck (see Fig. 123.3B). All sutures are inserted, and while an assistant elevates the anterior vaginal wall, each suture is individually tied, starting with the more distal pair. The proximal, or bladder neck, suture frequently must be passed through the insertion of the rectus abdominis muscle. Additional sutures may or may not be placed between the anterior bladder wall and the rectus muscles to pull the bladder farther anteriorly.

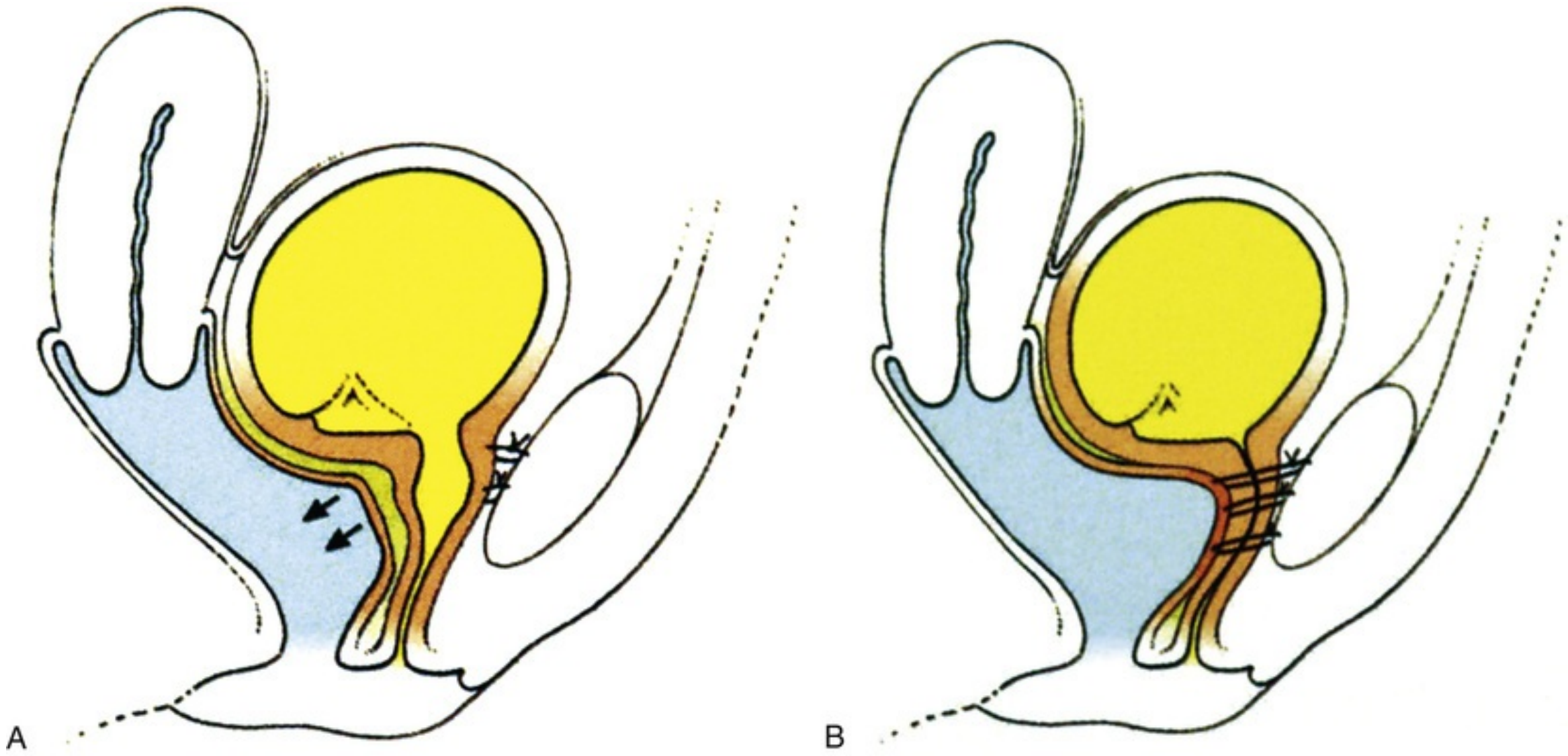

FIG. 123.3 (A) Potential risk of tethering the urethra with the Marshall-Marchetti-Krantz (MMK) procedure, influencing the function of the urethral sphincter mechanism. (B) Potential risk of obstruction of the urethra with the paraurethral sutures of the MMK procedure. (From Turner-Warwick R, Chapple CR: *Functional reconstruction of the urinary tract and gynaeco-urology: an exposition of functional principles and surgical procedures,* Oxford, 2002, Blackwell Science.)

Results

Krantz described a personal series of 3861 cases with a follow-up of up to 31 years and a 96% subjective cure rate (Smith et al., 2005). Short- and medium-term results with the MMK procedure have been good. Mainprize and Drutz

(1988) reviewed 58 articles (predominantly retrospective) published from 1951 to 1988 for treatment outcomes in 3238 cases. The cure rate, mostly based on subjective criteria, was 88%, with an improvement rate of 91%. Jarvis's meta-analysis of studies in the literature (1994b) noted subjective continence in 88.2% (range 72% to 100%) of 2460 patients with 1- to 72-month follow-up and objective continence in 89.6% (range 71% to 100%) of 384 patients with 3- to 12-month follow-up. Whether the procedure was being done primarily or secondarily affected the outcome: subjective continence in 92% if it was done primarily versus 84.5% if it was done secondarily. Longer-term data are limited in amount. McDuffie et al. (1981) reported 75% success at 15 years. More recently, Clemens et al. (1998) noted subjective cure or improvement (SUI and urgency urinary incontinence) in only 41% of patients with a mean follow-up of 17 years, and Czaplicki et al. (1998) noted decreasing continence rates from 77% at 1 year to 57% at 5 years to 28% at 10 years, with a mean duration of continence of 78½ months. There are significant limitations to the data because most series are retrospective, with preoperative assessment based mainly on history and physical examination and few studies using objective data as outcome measures.

Complications occur in up to 21% of cases (Mainprize and Drutz, 1988), and the placement of sutures through the pubic symphysis incurs the risk of osteitis pubis, a potentially devastating complication of the MMK procedure that has been reported in 0.9% to 3.2% of patients (Lee et al., 1979; Mainprize and Drutz, 1988; Zorzos and Paterson, 1996). Patients usually are seen 1 to 8 weeks postoperatively with acute pubic pain radiating to the inner thighs, aggravated by moving. Physical examination reveals tenderness over the pubic symphysis, and radiography demonstrates haziness to the borders of the pubic symphysis and possibly lytic changes. Treatment is with bed rest, analgesics, and possibly corticosteroids (Lee et al., 1979). Other specific complications of the MMK procedure have included the occasional erosion of nonabsorbable cystourethropexy sutures into the bladder lumen with stone formation. Also, the positioning of sutures in the endopelvic fascia close to the bladder neck can result in a significant outlet obstruction.

Although the MMK procedure produces a cure rate similar to that of colposuspension, the complication of osteitis pubis means that there is little to support its use as an alternative to other colposuspension procedures. Indeed, the ICI committee (Smith et al., 2009) **concluded that, although short-term results indicate comparable cure rates to colposuspension, there**

is limited evidence that the longer term outcome is poorer after MMK (evidence level 1) and declines further over time (evidence level 3). Although no new randomized controlled trials involving the MMK procedure are available, there is no evidence to support the continued use of MMK over colposuspension (Rovner et al., 2017).

Key Point: Recommendation From the International Consultation on Incontinence Committee

- The MMK procedure is not recommended for the treatment of SUI (grade A recommendation).

Data from Rovner E, Anathasiou S, Choo YM, et al.: Surgery for urinary incontinence in women. In Abrams P, Cardozo L, Wagg A, et al., editors: *Incontinence*, ed 6, Tokyo, Japan, 2017, pp 1741–1854.

Burch Colposuspension

Technique

Burch's original description of colposuspension in 1961 followed his original procedure, which was essentially a paravaginal repair attaching the paravaginal fascia to the white line of the pelvis, the arcus tendineus. The Burch colposuspension was a novel approach to restore the urethrovesical junction to a retropubic location by approximating the periurethral fascia to the tough bands of fibrous tissue running along the superior aspect of the pubic bone (Cooper [iliopectineal] ligament) with three pairs of sutures. The original Burch retropubic colposuspension is appropriate only if the patient has adequate vaginal mobility and capacity to allow the lateral vaginal fornixes to be elevated toward and approximated to the Cooper ligament on either side. This technique has been modified. Tanagho's modification (1978) approximated the vaginal wall to the lateral pelvic wall, with the sutures holding the anterior vaginal wall to the Cooper ligament being tied loosely so that two fingers could be placed between the symphysis and urethra. This achieved broad support for the urethra and bladder neck and potentially minimized the risk of postoperative voiding dysfunction. A more recent modification (Shull and Baden, 1989; Turner-Warwick and Chapple, 2002) involves a hybrid approach in which the vaginal tissues are approximated to the internal obturator fascia with an anchoring bite to the iliopectineal ligament (see the section on VOS repair later in this chapter).

Suture placement is facilitated by the elevation of the dissected anterolateral vaginal wall into the field by the surgeon's left vaginal-examining fingers (Fig. 123.4). The bladder is retracted to the opposite side with a mounted swab. Two to four sutures are placed on each side, each suture taking a good bite of fascia and vaginal wall, with care taken not to pass through the vaginal mucosa. Some recommend taking double bites of tissue to lessen the risk of suture pull-through (Jarvis, 1994a). The most distal suture is at the level of the bladder neck and placed no closer than 2 cm lateral to it, although some place distal sutures at the mid-urethral level (Tanagho, 1978). The suspension suture bites of the paraurethral fascia should not be positioned too close to the bladder neck and the urethra, as they are in the cystourethropexy procedures (MMK), because the unwanted effect of lateral traction-tension created by their anchorage to the iliopectineal ligaments may increase the sphincteric occlusive effect on the urethra or create a degree of obstructed voiding. Subsequent sutures are placed proximal to the level of the bladder neck, at about 1-cm intervals. The sutures are then placed into corresponding sites in the Cooper ligament, the emphasis being on a mediolateral direction for the sutures. The exact mechanism of continence of the Burch procedure is still unknown. Burch (1968) thought it to be secondary to elevation and stabilization of the bladder neck and urethra. In support of the suggestion regarding suture placement, Digesu et al. (2004) reviewed magnetic resonance imaging (MRI) findings before and 1 year after open Burch colposuspension (OBC) in 28 women to see if this would explain the mechanism. In the 86% who were cured, the distance between the levator ani muscle and bladder neck was significantly shorter than in those in whom treatment failed. Digesu's suggestion is that insertion of sutures in a medial-lateral direction as opposed to an anterior-posterior direction may better appose the levator ani muscle and bladder neck. The highly vascular vaginal wall may bleed profusely during suture placement, and large vaginal veins often must be oversewn, but most bleeding ceases once the sutures are tied and the vagina is suspended. To facilitate tying of the sutures, the assistant elevates the appropriate portion of the vaginal wall as each suture is tied, commencing with the more distant pair.

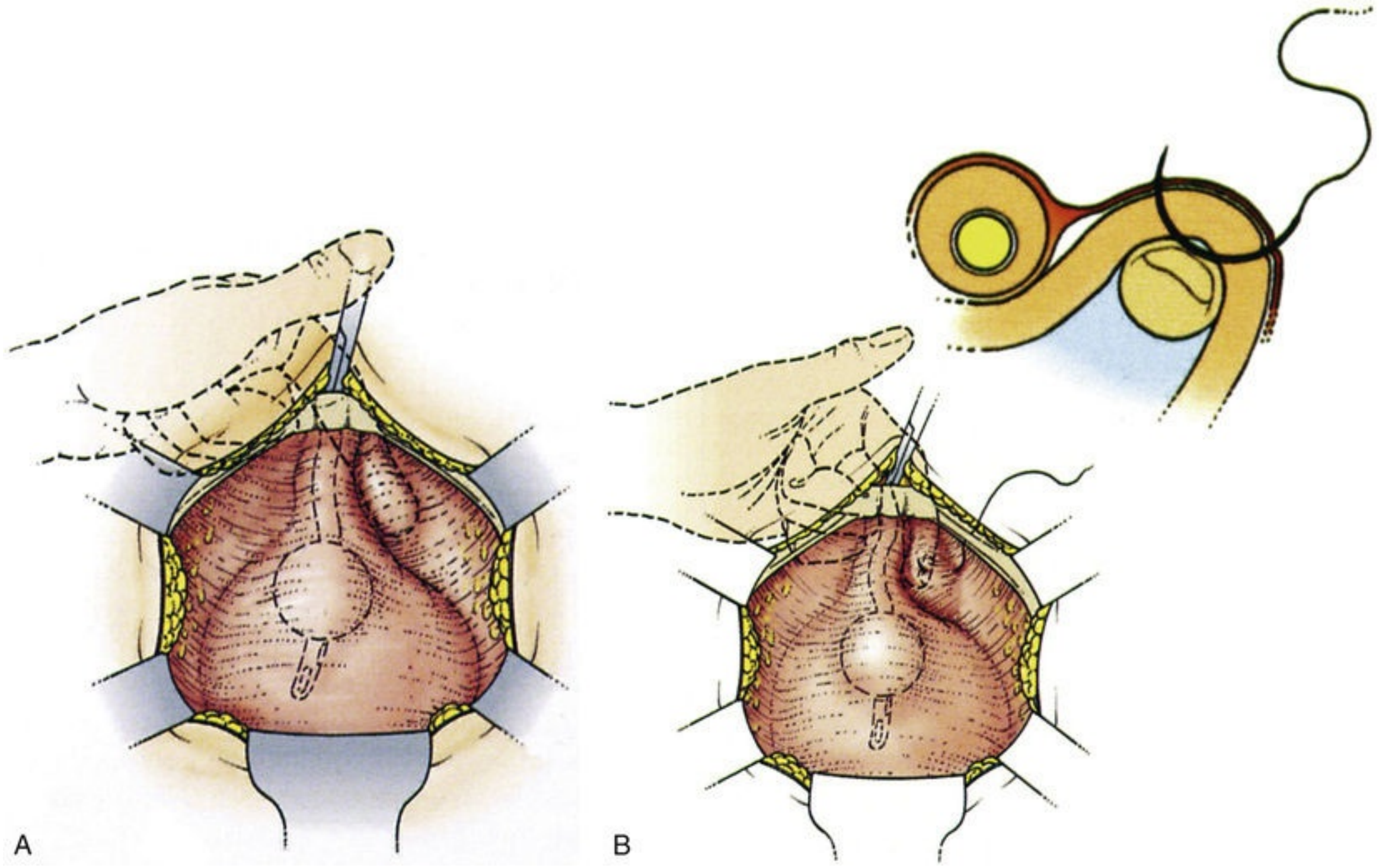

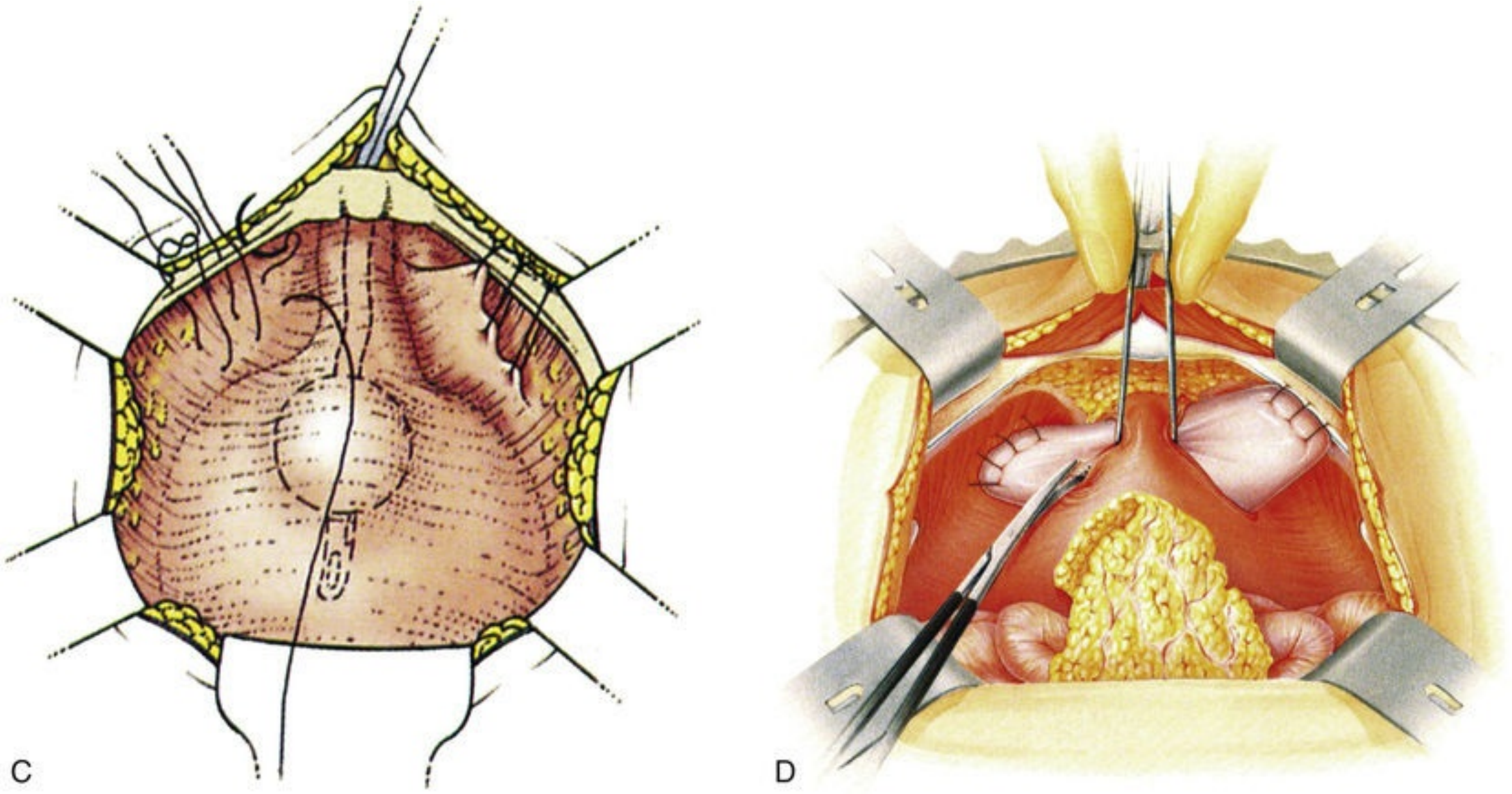

FIG. 123.4 (A) The use of a finger in the vagina when the pelvic tissues are dissected superomedially off the vagina. (B) Medial suture placement; note the role of the finger in steering the suture *(inset)*. (C) Note the mediolateral orientation of the sutures. (D) Completion of a retropubic colposuspension with a vagino-obturator hitch on the left and a Burch procedure on the right. (From Turner-Warwick R, Chapple CR: *Functional reconstruction of the urinary tract and gynaeco-urology: an exposition of functional principles and surgical procedures,* Oxford, 2002, Blackwell Science.)

No attempt should be made to tie the sutures tightly. Often the vaginal wall does not approximate to the Cooper ligaments, and free suture material is seen between the vagina and the ligaments. The principle is to approximate the vaginal wall to the lateral pelvic wall, where it will heal and promote adhesion formation (Shull and Baden, 1989; Tanagho, 1978; Turner-Warwick and Chapple, 2002)**, thereby creating a broad support for the urethra and bladder neck.**

Results

As in the MMK procedure, short- and medium-term outcomes with the Burch procedure have been good. In Jarvis's meta-analysis (1994b), subjective continence was achieved in 91% (range 63% to 97%) of more than 1300 patients with 3 to 72 months of follow-up and objective continence in 84% of more than 1700 patients with 1 to 60 months of follow-up. Lapitan et al. (2003) reviewed 33 trials involving a total of 2403 women who underwent open colposuspension and found an overall cure rate of 68.9% to 88.0%, with a 1-year cure rate of approximately 85% to 90%. This decreased to 70% at 5 years. Although there may be a decline in the cure rate of only 15% to 20% beyond 5 years, Alcalay et al. (1995) noted a subjective and objective SUI cure rate of 69% with a mean follow-up of 13.8 years. Baessler and Stanton (2004) examined the impact of surgery on coital incontinence. Of the 30 women available for postoperative evaluation, 73% preoperatively had incontinence with penetration, 10% with orgasm only, and 17% with both. Postoperatively, 70% were cured of their coital incontinence. Moreover, in those who were subjectively cured of their stress incontinence, 87% were also cured of their coital incontinence.

Lapitan, Cody, and Mashayekhi (2017) updated the Cochrane Collaboration review on open retropubic colposuspension for urinary incontinence in women. They reviewed 55 trials, including a total of 5417 women, and noted that the overall cure rate was 68.9% to 88.0% for open retropubic colposuspension. Two small studies suggested lower continence rates compared with conservative treatment; one trial suggested lower continence rates after open retropubic colposuspension compared with anticholinergic treatment. The evidence accrued from 6 trials showed a lower incontinence rate after open retropubic colposuspension than after anterior colporrhaphy, with these benefits being maintained over time. Evidence was obtained from 22 trials in comparison of open retropubic colposuspension with suburethral slings (traditional slings or trans-vaginal tape or transobturator tape) and found no significant differences in incontinence rates in all time periods assessed. However, subgroup analysis of studies comparing traditional slings and open colposuspension showed better effectiveness with traditional slings in the medium and long term. In comparison with needle suspension, there was a lower incontinence rate after colposuspension in the first year after surgery (RR 0.66, 95% CI 0.42–1.03), after the first year (RR 0.56, 95% CI 0.39–0.81), and beyond 5 years (RR 0.32, 95% CI 15–0.71). The patient-reported continence rates at short-, medium-, and long-term follow-up showed no significant difference between open and laparoscopic retropubic colposuspension, but with wide confidence intervals. In two trials, incontinence was less common after Burch colposuspension than after the MMK procedure at 1- to 5-year follow-up. There were few data at any other follow-up time. The general finding was that the evidence did not show a higher morbidity or complication rate with open retropubic colposuspension compared with the other open surgical techniques, although pelvic organ prolapse (POP) was more common than after anterior colporrhaphy and sling procedures. The authors concluded that **open retropubic colposuspension is an effective treatment modality for SUI, especially in the long term.** Within the first year of treatment the overall continence rate is approximately 85% to 90%. After 5 years approximately 70% of patients can expect to be dry. Laparoscopic colposuspension should allow speedier recovery, but its relative safety and long-term efficacy remain to be established (Lapitan et al., 2017).

Unlike with the MMK procedure, the good results with the Burch procedure appear to be durable with longer follow-up. Lapitan et al. (2003) **reached the conclusion from a review of two trials comparing the Burch colposuspension and the MMK procedure that the Burch technique results in higher cure rates. Thus it should be regarded as the *standard* open retropubic colposuspension procedure.**

Open colposuspension is as effective as any other procedure in primary or secondary surgery at curing SUI with proven long-term success (level 1 evidence, grade A recommendation) (Smith et al., 2005).

Prophylactic Colposuspension

In 2006 the Colpopexy and Urinary Reduction Efforts (CARE) trial demonstrated that the **postoperative risk of stress incontinence in stress continent women undergoing open abdominal sacrocolpopexy could be substantially reduced by the addition of a Burch colposuspension** (Brubaker et al., 2006). Initial results at 3 months postprocedure demonstrated reduction of de novo stress incontinence from 44% in the untreated group to 24% in the Burch group, without increased rates of voiding dysfunction or urgency symptoms. Subsequent 1- and 2-year outcomes from the CARE trial showed continued benefit in patients who received the concomitant Burch procedure (Brubaker et al., 2008; Burgio et al., 2007).

Costantini et al. (2012) reported on POP repair with and without concomitant Burch colposuspension in incontinent women in an RCT with at least 5 years' follow-up. This study was an update of a previously published trial on the impact of Burch colposuspension as an anti-incontinence procedure in patients with urinary incontinence and POP. Forty-seven women were randomly assigned to abdominal POP surgery and concomitant Burch colposuspension (24 patients) or POP surgery alone without any anti-incontinence surgery (23 patients). The median follow-up was 82 months (range 60 to 107). From 47 patients, 30 reached 6-year follow-up and 2 patients were lost to follow-up. In the first group, undergoing both POP and Burch colposuspension, 2 patients showed a stage 1 rectocele. In the second group, 2 patients had a stage 1 rectocele and 1 a stage 2 rectocele. In the first group, 13 out of 23 were still incontinent after surgery (56.5%) compared with 9 out of 22 (40.9%) of those who underwent only prolapse surgery. There was no significant change over time from the original assessment of this group. The authors concluded that Burch colposuspension did not improve outcomes significantly in incontinent patients when they were undergoing POP repair.

Reoperative Surgery

Poorer results are likely to occur when the procedure is performed secondarily. Scarring and fibrosis from previous surgery can prevent adequate suspension in some cases, and suture cut-through is more likely. Furthermore, after failed surgery, patients may have coexisting sphincteric weakness that places them at greater risk of recurrence after colposuspension (Bowen et al., 1989; Koonings et al., 1990).

Nevertheless, Maher et al. (1999) and Cardozo et al. (1999) have shown good objective (72% and 79%) and subjective (89% and 80%) success with repeated colposuspension at a mean follow-up of 9 months. Nitahara et al. (1999) reported 69% subjective success at a mean follow-up of 6.9 years. Urgency incontinence and sphincteric weakness are the main causes of failure and dissatisfaction. Urgency incontinence accounted for 63% (12 of 19) of failures; the remaining 7 with persistent stress incontinence in Nitahara's series demonstrated sphincteric deficiency with mean Valsalva leak point pressures of 65 cm H_2O. The low-pressure urethra has often been quoted to be an adverse risk factor for colposuspension (Bowen et al., 1989; Haab et al., 1996; Koonings et al., 1990), but this topic also remains controversial. Several authors have studied the urethral pressure profilometry changes after colposuspension and have noted a statistically significant increase in the postoperative pressure transmission ratio but minimal changes in the postoperative MUCP, functional urethral length, and continence area (Faysal et al., 1981; Feyersiel et al., 1994; Weil et al., 1984). Although a low-pressure urethra (MUCP <20 cm H_2O) is considered a contraindication to the Burch procedure, a modification of the standard Burch operation has had some success in managing SUI associated with the low-pressure urethra. Bergman et al. (1989c) combined a standard Burch procedure with the Ball procedure (Ball, 1963), wherein before the Cooper ligament suspension is performed, two or three sutures are used to plicate the anterior urethral wall at the level of the proximal and middle urethra. These researchers retrospectively noted greater success with this technique than with a standard Burch procedure for the low-pressure urethra, and this was comparable to the success obtained with a standard Burch procedure in patients with a normal-pressure urethra (MUCP >20 cm H_2O). With longer follow-up, the Ball-Burch procedure continued to yield better results than the standard Burch procedure in patients with a low-pressure urethra, with a documented 5-year cure rate of SUI of 84% (Bergman et al., 1991; Elia and Bergman, 1995). However, there are no randomized studies addressing the issue, and whether these results can be extrapolated for the use of this technique in patients with intrinsic sphincter deficiency is debatable.

Giarenis et al. (2012) pose the question of what to do when a mid-urethral tape fails, emphasizing the potential role of open colposuspension as a salvage continence procedure. This was a retrospective study of 13 women who had undergone open colposuspension after a failed mid-urethral sling. The average time between insertion of the mid-urethral tape and the colposuspension was 22.6 (range 8 to 72) months. The mean operating time was 77 (range 43 to 123) minutes, including the time for the concomitant surgery. The mid-urethral tape was identified and partially excised. The authors reported a median follow-up of 12 months. Subjective and objective cure rates were 85% and 77%, respectively. Only 1 woman had severe SUI postoperatively, requiring further surgery. Three of the 8 women with preexisting urinary urgency reported postoperative improvement. Two patients reported de novo urinary urgency and urgency incontinence. Three of 10 women developed de novo detrusor overactivity that responded to anticholinergic medication. Long-term voiding difficulty was observed in only 1 patient, who performed clean intermittent catheterization for 3 months. No patients developed recurrent urinary incontinence. Three women (23%) developed symptomatic prolapse postoperatively. These patients were at stage II on the Pelvic Organ Prolapse-Quantification (POP-Q) System scale involving the posterior vaginal compartment and underwent posterior repair within 22 months of colposuspension. Bearing in mind that this is a small series, nevertheless it raises the point that, allowing for the fact that there is morbidity associated with a colposuspension in this context, it is still a potential therapeutic option in these patients.

A recent Cochrane meta-analysis has looked at the evidence for the treatment of recurrent SUI after failed minimally invasive synthetic suburethral tape surgery in women (Bakali et al., 2013). Twelve studies were identified, but all were excluded because they did not meet the eligibility criteria. Six were RCTs but were not eligible because the previous incontinence surgery had not been a suburethral tape. A subset of one RCT may have been eligible for inclusion because one of the women was having repeat surgery, but the authors were unable to obtain the data according to primary surgery for this cohort from the authors of the original study. The question of how to best deal with recurrent stress incontinence after a tape procedure will depend on whether the primary problem is that of intrinsic sphincter deficiency or problems with repositioning the urethra, and the question as to whether colposuspension may have a role in this context still remains open on the basis of this review of the literature because there is no clear evidence-based conclusion available.

Conversely, Shao et al. (2011) reported on TVT retropubic sling for recurrent SUI after Burch colposuspension failure. In this small series of 24 women undergoing TVT procedures for recurrent stress incontinence after a previous failed Burch colposuspension, the median follow-up was 57 months (range 12 to 96 months). Preoperative and postoperative urethral mobility and urodynamics were evaluated. It was noted that preoperatively in all women there was intrinsic sphincter deficiency, and 14 had urethral hypermobility. Postoperatively, 15 patients were completely dry, and 2 had a leakage of urine less than 5 g/h. The overall success rate was 70.8%, and there was a significant postoperative increase of MUCP and a decrease of average flow rates and average hypermobility. The authors concluded that recurrent SUI after a Burch colposuspension can be successfully treated with a TVT procedure. This, however, must be considered cautiously as a conclusion, because in the context of intrinsic sphincter deficiency, many authors in contemporary practice would express concern about putting in such a sling under any degree of tension to correct intrinsic sphincter deficiency because of the long-term potential complications with sling exposure that may occur. In this context, the potential use of an autologous sling should be carefully considered.

As with any major abdominal or pelvic surgical procedure, intraoperative and perioperative complications that may occur after a retropubic suspension include bleeding, injury to genitourinary organs (bladder, urethra, ureter), pulmonary atelectasis and infection, wound infection or dehiscence, abscess formation, and venous thrombosis or embolism. Other complications more specific to retropubic suspension procedures include postoperative voiding difficulty, detrusor overactivity, and vaginal prolapse. These are discussed in more detail along with other reported complications in a later section in this chapter.

Key Points: Recommendations From the International Consultation on Incontinence Committee

- Open Burch retropubic colposuspension can be recommended as an effective treatment for primary and recurrent SUI, which has longevity (grade A recommendation).
- Although open colposuspension has, to a large extent, been superseded by the less invasive mid-urethral tapes, it should still be considered for those women in whom an open abdominal procedure is required concurrently with surgery for SUI (grade D recommendation).

Data from Rovner E, Anathasiou S, Choo YM, et al.: Surgery for urinary incontinence in women. In Abrams P, Cardozo L, Wagg A, et al., editors: *Incontinence*, ed 6, Tokyo, Japan, 2017, pp 1741–1854.

Paravaginal Repair

Technique

The origins of the paravaginal repair date to White (1912, 1997), who described the importance of the “white line” of the pelvis (arcus tendineus) as an integral structure supporting the proximal urethra and bladder base to the pelvic wall and the development of paravaginal fascial tears predisposing to cystocele formation. He performed the paravaginal repair by a vaginal approach but envisioned that it would be easier if performed abdominally (White, 1912). Later, in his original description, Burch attached the vaginal wall to the arcus tendineus in seven patients, only to realize that the attachment may not be secure, prompting him to use the Cooper ligament as an attachment site (Burch, 1961). In the 1970s, Richardson et al. (1976) reintroduced the concept of a lateral defect cystourethrocele as a causative factor in the genesis of SUI and popularized the paravaginal repair as a technique for management.

The patient is placed in a low lithotomy position, just as for the MMK procedure and Burch colposuspension. If there are retropubic adhesions resulting from prior surgery, they are sharply incised; the dissection is facilitated by placement of two fingers of the surgeon's left hand in the vagina. The bladder and urethra are not mobilized from the vaginal attachments. Richardson et al. (1981) describe an extensive reattachment of the lateral vaginal sulcus with its overlying fascia to the arcus tendineus fasciae pelvis from the back of the lower edge of the symphysis pubis to the ischial spine, using six to eight sutures placed at 1-cm intervals. The vaginal wall in the region of the bladder neck is identified, and these interrupted sutures are placed at approximately 1-cm intervals through the paravaginal fascia and vaginal wall (excluding vaginal mucosa) beginning at the urethrovesical junction. The sutures are then passed through the adjacent obturator fascia and underlying muscle at the site of the arcus tendineus fascia (Fig. 123.5). If the arcus is not visible, the obturator foramen may be used as a landmark. It is situated 1.5 to 2 cm above the white line.

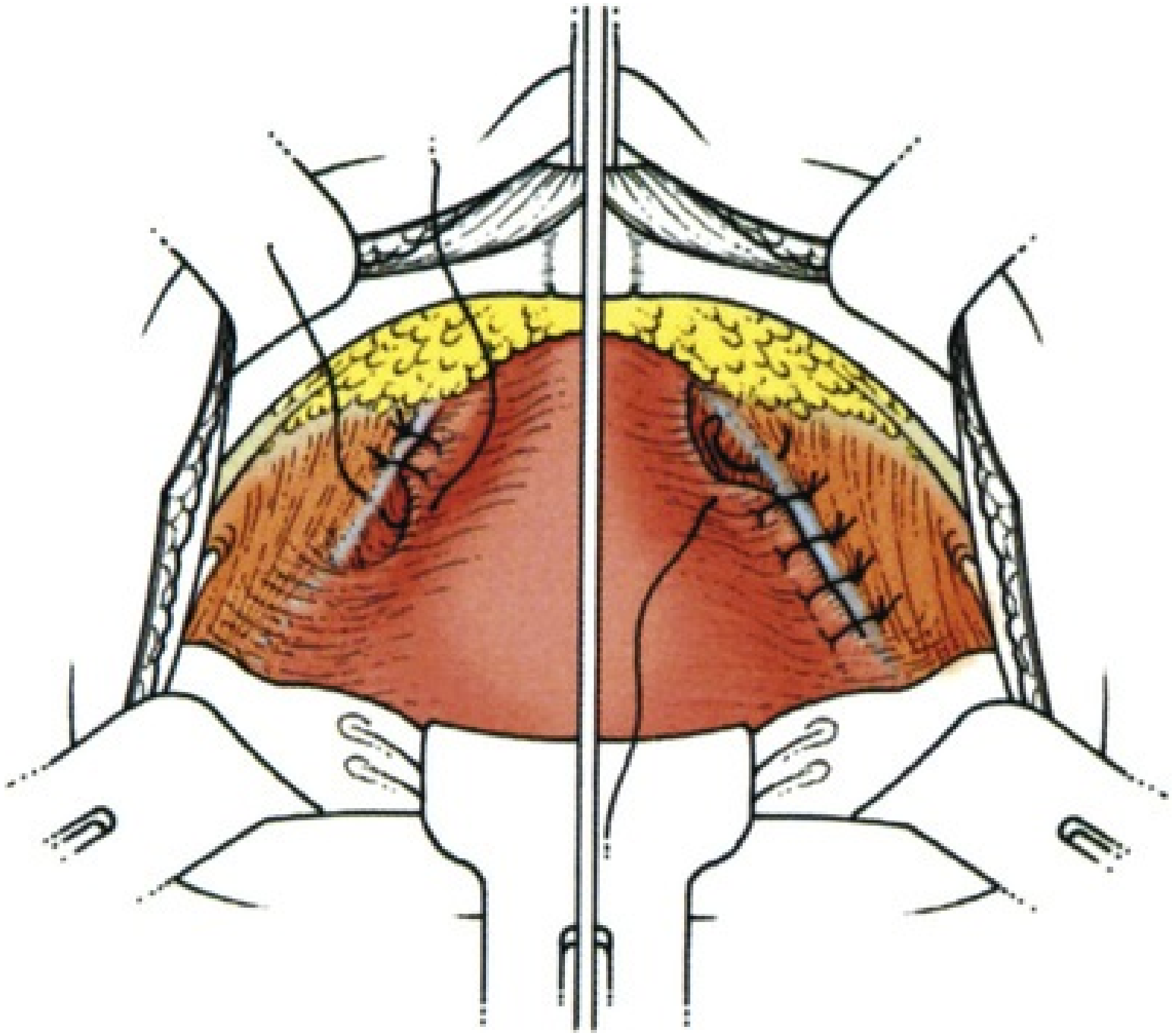

FIG. 123.5 A paravaginal repair procedure.

The end point that should be achieved is the reestablishment of the urethral axis in an anatomic position, easily allowing three fingerbreadths between the pubic symphysis and the proximal urethra but providing secure fixation and preventing rotational descent. Consequently, it has been reported that postoperative voiding difficulties are uncommon (Richardson et al., 1981).

Results

Few reports on the use of this technique have been published. With variable follow-up, cure rates greater than 90% have been reported for the paravaginal repair (Richardson et al., 1981; Shull and Baden, 1989). There is only a single randomized comparison of colposuspension with paravaginal repair including 36 patients who were randomly allocated to treatment by either colposuspension or paravaginal repair with nonabsorbable suture material. At 6 months of follow-up, there was an objective cure rate of 100% for those undergoing colposuspension and 72% for those undergoing paravaginal repair (Colombo et al., 1996a).

Small series have reported on vaginal approach to paravaginal repairs (Mallipeddi et al., 2001; Scotti et al., 1998). In particular, Mallipeddi et al. followed 45 patients (21 with SUI) after this approach for a mean of 1.6 years, and 57% had persistent stress incontinence; the conclusion of these researchers was that this technique had limited applicability for SUI. **It can be concluded that there is level 1 or 2 evidence that abdominal paravaginal repair is less effective than colposuspension. There are limited data (level 3 or 4) on laparoscopic and vaginal paravaginal repairs, but interpretation of these data is hampered by the small numbers of patients, the short follow-up, and a combination of this procedure with other types of incontinence procedures** (Smith et al., 2005).

There is limited evidence that abdominal paravaginal defect repair is less effective than open colposuspension (evidence level 2) (Smith et al., 2009).

Key Point: Recommendation From the International Consultation on Incontinence Committee

- Paravaginal defect repair is not recommended for the treatment of SUI alone (grade A recommendation).

Data from Smith AR, Chang D, Dmochowski R, et al.: Committee 14. Surgery for urinary incontinence in women. In Abrams P, Cardozo L, Khoury S, et al., editors: *Incontinence*, Plymouth, UK, 2009, Health Publications, pp 1191–1272.

Vagino-Obturator Shelf Repair

Technique

Turner-Warwick (1986; Turner-Warwick and Chapple, 2002) reported his variant of the paravaginal repair, which he called the *vagino-obturator shelf repair.* The premise for this is that there should be no restriction to the intrinsic sphincteric function of the urethra by fixation or paraurethral tethering, and there should be no urethral compression (Turner-Warwick and Kirby, 1993).

Just as for other retropubic suspension procedures (Fig. 123.6), the anterior wall of the lower segment of the bladder wall is exposed and the position of the bladder neck is identified by gentle traction on a balloon catheter in the urethra. The surgeon's forefinger in the vagina elevates its anterior wall and the overlying endopelvic fascia on either side of the urethra. Lateral displacement of the catheter balloon with the finger in the vagina facilitates the identification of the inferolateral margin of the bladder, lateral to the bladder neck, and its separation from the paraurethral endopelvic fascia is achieved by simple blunt dissection with a sponge or scissor-tip retraction. This naturally exposes the surface of the obturator muscle and the arcus tendineus origin of the levator muscles deep in the sulcus below this, the site of suture placement in the paravaginal repair (which is well below the vaginal anchorage point in the VOS procedure). The obturator nerves lie superolaterally; their canals run high up in a groove under the superior pubic ramus so that once they have been identified, injury to them can be avoided. The full thickness of the vagina and its overlying layer of endopelvic fascia are elevated by the surgeon's finger in the vagina and are approximated to the internal obturator muscle and anchored to the bulk of this with absorbable 0 or No. 1 sutures mounted on robust 35- to 40-mm half-circle needles. Slight flexion of the fingertip tents the vaginal wall and facilitates the full-thickness insertion of these suture bites through it, thus avoiding inclusion of the surgical glove. Three or four successive sutures are inserted. For knot security, these are best tied continuously, head to tail, as they are inserted, rather than separating them individually. Each tied suture bite facilitates the insertion of the next (unlike in the Burch procedure, in which the sutures are not tied until they have all been inserted). A similar obturator suspension of the elevated protrusion of the vagina and its overlying endopelvic fascia is achieved on the opposite side. Some additional elevation of the lateral anchorage of the VOS by the inclusion of a bite of the iliopectineal ligament within the suture bite approximating the vagina to the obturator muscle (as in a Burch procedure) may be used to reinforce the repair (Shull and Baden, 1989). This modification represents a hybrid with the Burch procedure, facilitating reattachment of the pubocervical fascia to the arcus tendineus fasciae pelvis, tissue apposition to the lateral pelvic wall, and nonobstructive elevation of the urethra and urethrovesical junction. In addition, obliteration of the pouch of Douglas (culdoplasty) may be needed to prevent enterocele (Shull and Baden, 1989; Turner-Warwick and Kirby, 1993).

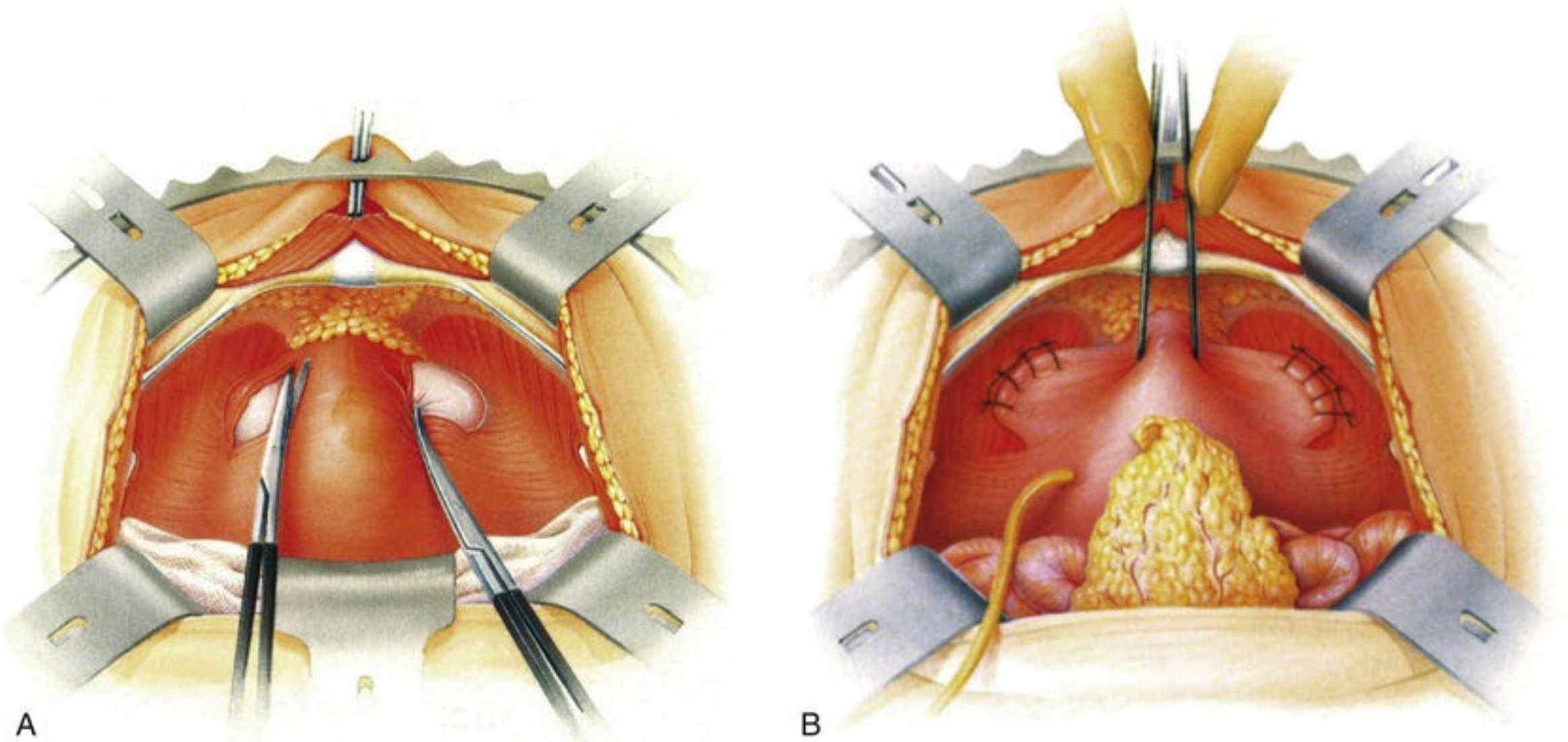

FIG. 123.6 (A) Mobilizing the tissues. The tissues should be stripped by blunt dissection with a mounted swab or the edge of a pair of scissors; only occasionally is sharp dissection necessary, provided the stripping action starts far laterally adjacent to the pubic bone. (B) Completed vagino-obturator shelf procedure. (From Turner-Warwick R, Chapple CR: *Functional reconstruction of the urinary tract and gynaeco-urology: an exposition of functional principles and surgical procedures,* Oxford, 2002, Blackwell Science.)

Results

There are limited data available for the VOS repair, which has had reported cure rates of 60% to 86%, depending on whether the procedure was performed primarily or secondarily (German et al., 1994; Turner-Warwick, 1986). German et al. (1994) reported that the VOS procedure is less likely to be successful in patients who have undergone previous surgery.

Ultimately, as with all such reconstructive surgery, the surgeon should select the correct procedure for the individual patient. Although the VOS, which is a synthesis of the principles of the paravaginal repair and the Burch colposuspension, is of interest, further clinical results are necessary before definitive conclusions can be drawn.

Laparoscopic Retropubic Suspension

Laparoscopic techniques for retropubic suspension were introduced by Vancaillie and Schuessler in 1991. They essentially performed an MMK urethropexy laparoscopically, and since that time, laparoscopic techniques have been applied to the Burch procedure and the paravaginal repair. Subsequent modifications to the suspension suturing techniques have been introduced, including the use of mesh (Ou et al., 1993), staples (Lyons, 1994), and fibrin sealant (Kiilholma et al., 1995), but all adhere to the same principles of their open counterparts. Proposed advantages of the laparoscopic approach include improved intraoperative visualization, less postoperative pain, shorter hospitalization, and quicker recovery times (Liu, 1993). Disadvantages include greater technical difficulty with resultant longer operating times and higher operating costs (Paraiso et al., 1999).

The procedure may be performed extraperitoneally or transperitoneally, and each approach has its proponents. Although the extraperitoneal technique may be associated with shorter operating times, easier dissection, and fewer bladder injuries (Frankel and Kantipong, 1993; Raboy et al., 1995), the transperitoneal approach provides a larger operating space and the ability to perform concomitant intraperitoneal procedures and apical prolapse repair (Paraiso et al., 1999). The specifics of the different procedures are beyond the scope of this chapter.

Short- and medium-term outcomes with the laparoscopic retropubic suspensions have become available. In their review of 13 studies of laparoscopic retropubic suspensions, Paraiso et al. (1999) found cure rates to range from 69% to 100% with follow-up of 1 to 36 months. This is comparable to outcomes of the open procedures as already noted. Retrospective (Polascik et al., 1995) and randomized, prospective comparisons (Summitt et al, 2000) between open and laparoscopic techniques have demonstrated similar short-term success. However, with longer follow-up, laparoscopic retropubic suspensions appear to fail more frequently. McDougall's group (1999) retrospectively noted only 30% cure of SUI and 50% cure or improvement after a laparoscopic Burch procedure with 45 months of follow-up, and this was no different from the results with a Raz procedure.

A recent Cochrane review updated by Dean et al. (2017) identified 22 eligible studies, 10 of which compared laparoscopic with open colposuspension, to determine the effects of laparoscopic colposuspension for urinary incontinence in women. All of these trials had varying lengths of follow-up ranging from 6 months to 5 years. In addition, the number or type of mesh or sutures used was not consistent across the studies. Burton (1997) used absorbable Dexon sutures, whereas six trials used nonabsorbable sutures, mainly Ethibond (Ankardal et al., 2004; Ankardal et al., 2005; Cheon et al., 2003; Kitchener et al., 2006; Su et al., 1997; Summitt et al., 2000) or polypropylene sutures (Fatthy et al., 2001). All of the studies except for two (Ankardal et al., 2004; Su et al., 1997) used the same number and type of suspension material for the laparoscopic and open procedures. Ankardal et al. (2004) used a polypropylene mesh and Titan staples for the laparoscopic colposuspensions and sutures for the open colposuspensions. According to unpublished data, Su et al. (1997) revealed methodologic problems with corrupted randomization and confounding factors of performance of additional surgery in some patients and the use of a different number of sutures on paravaginal fascia for laparoscopic (one suture) and open (three sutures) colposuspension. In three of the studies (Burton, 1997; Cheon et al., 2003; Fatthy et al., 2001), surgeons had performed fewer than 20 laparoscopic colposuspensions before starting the trial. Other studies either reported surgeons as being senior gynecologists with extensive experience in both procedures (Ankardal et al., 2004, 2005; Carey et al., 2000; Kitchener et al., 2006; Su et al., 1997) or did not report the experience of the surgeons (Morris et al., 2001; Summitt et al., 2000). The ability to synthesize data was also limited by the variable tests and definitions used to measure subjective and objective outcomes across the trials and failure to report standard definitions (Dean et al., 2017).

In their review, Dean et al. (2017), found subjective cure rates ranged from 58% to 96% in the open colposuspension and 62% to 100% in the laparoscopic colposuspension group within 18 months of follow-up (RR 0.95, 95% CI 0.90–1.00). The authors also re-ran an analysis after excluding the study by Su et al. (1997) because of concerns noted earlier and found that this did not change the results. The results from Burton (1997) were not included in these analyses because of the way they had presented their data. In this trial, based on visual analog scales of “cure,” the open group had better results and increasingly so at 3 and 5 years. This finding should be interpreted cautiously, however, because there are concerns that the surgeon's laparoscopic performance may have been suboptimal because he had performed few laparoscopic colposuspensions when the trial started. Kitchener et al. (2006) reported subjective cure rates at 2 years, and there were no differences between the laparoscopic and open groups (RR 1.00, 95% CI 0.81–1.25). Morris et al. (2001) reported data from 5 to 7 years of follow-up showing that the laparoscopic colposuspension group had a significantly higher subjective cure rate than the open colposuspension group (RR 1.53, 95% CI 1.00–2.35), which is contrary to the findings by Burton (1997).

Dean et al. (2017) identified two studies that used urinary diaries and pad tests to quantify symptoms on follow-up (Burton, 1997; Fatthy et al., 2001). Both groups in the Burton study (1997) improved significantly after surgery. However, this was less so in the laparoscopic group and there was a marked deterioration over time such that by 5 years' follow-up the mean number of incontinent episodes in the laparoscopic group was approaching the preoperative level. On the contrary, Fatthy et al. (2001) found no apparent difference between the groups in incontinent episodes at 18 months.

All 10 studies identified by Dean et al. (2017) assessed leakage on a clinical stress test and reported data as objective cure rates. Objective cure was defined by negative urodynamic testing in 6 studies and by negative pad test in 4 studies. Overall, the objective cure rate within 18 months showed a statistically significant reduction of risk ratio in laparoscopic colposuspension, thus favoring open colposuspension (RR 0.91, 95% CI 0.86 –0.96). There was no significant difference between laparoscopic and open colposuspension groups in objective cure rates between 18 months and 5 years (RR 1.01, 95% CI 0.88–1.16). In addition, there was no statistically significant differences in de novo detrusor overactivity within 18 months (RR 1.29, 95% CI 0.72–2.30) or at longer-term follow-up between 18 months and 5 years (RR 1.00, 95% CI 0.07–15.12) and after 5 years (RR 1.22, 95% CI 0.40–3.75). Similarly, there were no statistically significant differences in voiding dysfunction (RR 0.82, 95% CI 0.50–1.35).

Overall, there were significantly fewer perioperative complications in the laparoscopic colposuspension group (RR 0.74, 95% CI 0.58–0.96) (Dean et al., 2017). However, intraoperative complications were higher in the laparoscopic group with 21 bladder injuries reported among 521 laparoscopic colposuspensions compared with 10 among 507 open colposuspensions (RR 1.88, 95% CI 0.93–3.83). In addition, injury to the obturator vein was also reported during laparoscopic colposuspension in 2 studies (Carey et al., 2000; Summitt et al., 2000). Women who underwent laparoscopic colposuspension had significantly less pain and needed less postoperative analgesia compared with those undergoing open colposuspension (Dean et al., 2017). All studies, with the exception of Morris et al. (2001), reported the length of hospital stay to be longer for open colposuspension. Similarly, where reported, the time to return to normal activities was longer for open colposuspension. Laparoscopic surgery had significantly longer operative times than open colposuspension in the majority of studies (mean difference 14.06 minutes, 95% CI 11.39–16.73), whereas estimated blood loss was higher in the open groups in all studies that reported these data (Dean et al., 2017).

There were five studies included in the recent Cochrane review (Dean et al., 2017) that looked at different methods of laparoscopic colposuspension. One compared one double-bite suture with two single-bite sutures each side of the urethra (Persson et al., 2000), three compared mesh and staples with sutures (Ankardal et al., 2005; Ross, 1996; Zullo et al., 2002), and the final study compared two different methods of laparoscopic approach (Wallwiener et al., 1995). When comparing subjective cure rates between the one- versus two-suture groups, there was a significantly higher number of women who felt cured (89%) in the two-suture group compared with the one-suture group (65%) (RR 1.37, 95% CI 1.14–1.64). Similar results were found in objective cure with the number of cured women significantly higher in the two-suture group (83%) compared with one-suture (58%) (RR 1.42, 95% CI 1.14–1.77). In comparison of sutures versus mesh and staples in laparoscopic colposuspension, there were better subjective cure rates with sutures within 18 months (RR 1.28, 95% CI 1.11–1.47). Objective cure rates also showed a significantly better outcome in the suture group within 18 months (RR 1.20, 95% CI 1.07–1.35) and continued to favor the suture group at 3 years' follow-up, but this was not statistically significant (RR 1.50, 95% CI 0.83–2.70). Dean et al. (2017) concluded that the number of sutures used appears to have a significant influence on the cure rate, with more sutures resulting in a significantly higher success rate.

Overall, Dean et al. (2017) concluded in their recent Cochrane review that laparoscopic colposuspension appears to have short-term benefits over open surgery, such as less pain, quicker recovery, and fewer perioperative complications, but it appears to take longer to perform compared with open colposuspension. A single trial raises concerns about the long-term performance, but this may reflect a surgical learning effect and is not an independently reliable result. **Recent data on medium-term results from a large, multicenter trial show the effectiveness of laparoscopic colposuspension and are encouraging. If laparoscopic surgery is performed, the use of two paravaginal sutures appears to be the most effective method.**

Barr et al. (2009) looked at the long-term outcome of laparoscopic colposuspension in a report from a 10-year cohort study. A consecutive series of 139 patients who had undergone laparoscopic colposuspension was reviewed and compared with 52 women who had undergone an open colposuspension in the same unit. Subjects were contacted by telephone at least 10 years postoperatively. In total, 96 patients in the laparoscopic group and 31 in the open colposuspension group were available for follow-up. The authors reached the conclusion that laparoscopic colposuspension appeared to be as effective as open colposuspension at long-term follow-up when used as treatment for stress incontinence and could be considered as an alternative surgical approach. Although there is an increase in long-term follow-up results available compared with prior Cochrane reviews, **the place of laparoscopic colposuspension in clinical practice should become clearer when there are longer-term data available.**

In their recent committee paper, Rovner et al. (2017) discussed laparoscopic colposuspension in comparison with minimally invasive mid-urethral slings. Using the evidence from 8 trials, the authors found no statistically significant difference in subjective cure rates within 18 months (RR 0.91; 95% CI 0.80–1.02). Although the definition of objective cure had a large degree of variation between studies, overall the objective cure rate was higher for minimally invasive mid-urethral slings than laparoscopic colposuspension (RR 0.92; 95% CI 0.85–0.99). Compared with laparoscopic colposuspension, the mid-urethral sling procedures had significantly shorter operating time, hospital stay, and time for resuming normal activity.

Key Points: Recommendations From the International Consultation on Incontinence Committee

- Laparoscopic colposuspension can only be recommended for the surgical treatment of SUI in women by surgeons with appropriate training and expertise (grade C recommendation).
- Women should be advised about the limited evidence available about the long-term durability of laparoscopic colposuspension (grade C recommendation).

Data from Rovner E, Anathasiou S, Choo YM, et al.: Surgery for urinary

incontinence in women. In Abrams P, Cardozo L, Wagg A, et al., editors: *Incontinence*, ed 6, Tokyo, Japan, 2017, pp 1741–1854.

Complications of Retropubic Repairs

As with any major abdominal or pelvic surgical procedure, intraoperative and perioperative complications that may occur after a retropubic suspension include bleeding, injury to genitourinary organs (bladder, urethra, ureter), pulmonary atelectasis and infection, wound infection or dehiscence, abscess formation, and venous thrombosis or embolism. Other common complications more specific to retropubic suspension procedures include postoperative voiding difficulty, detrusor overactivity, and vaginal prolapse. Potentially, it is overcorrection of the urethrovesical angle that may be a major contributory factor in the development of the long-term complications of de novo urgency, voiding dysfunction, and enterocele formation.

Nevertheless, the reported incidence of these problems is relatively low. In their meta-analysis, Leach et al. (1997) noted a 3% to 8% transfusion rate for retropubic suspensions and no significant difference in the overall medical and surgical complication rates among retropubic suspensions, needle suspensions, anterior colporrhaphy, and pubovaginal slings. Mainprize and Drutz (1988), in their review of the MMK procedure literature (2712 patients), noted an overall complication rate of 21%, with wound complications and urinary infections making up the majority (5.5% and 3.9%, respectively). Direct surgical injury to the urinary tract occurred in only 1.6%, and genitourinary tract fistulas occurred in 0.3%. Ureteral obstruction has been reported rarely after Burch colposuspension, and it usually results from ureteral kinking after elevation of the vagina and bladder base, although direct suture ligation of the ureter can occur (Applegate et al., 1987). If it is identified intraoperatively, it is best remedied by removal of the offending ligature and temporary placement of a ureteral stent. The so-called post-colposuspension syndrome, which has been described as pain in one or both groins at the site of suspension, has been noted in up to 12% of patients after a Burch procedure (Galloway et al., 1987). More recently, Demirci et al. (2001) reported the occurrence of groin or suprapubic pain in 15 of 220 women (6.8%) after Burch colposuspension with a follow-up of 4½ years.

Postoperative Voiding Difficulty

Postoperative voiding difficulty after any type of retropubic suspension is not uncommon, and undoubtedly its occurrence is more likely if there is preexisting detrusor dysfunction or denervation resulting from extensive perivesical dissection. In most cases, however, it is the result of overcorrection of the urethral axis from inappropriately placed or excessively tightened sutures. If the sutures are placed too medially, they may also transfix the urethra or distort it.

Preoperatively, at-risk patients may be identified by their history of prior voiding dysfunction or episodes of urinary retention. These women should be carefully counseled preoperatively about the potential for postoperative voiding difficulty and the possible need for self-catheterization intermittently. Their incontinence should be of sufficient magnitude that its correction offsets the risk of the need for self-catheterization.

Women with postcystourethropexy voiding problems who have obstruction often do not exhibit the classic urodynamic features of obstruction. However, the history of postoperative voiding symptoms and associated new-onset bladder storage symptoms and a finding of a retropubically angulated and fixed urethra typically indicate that obstruction does exist (Carr and Webster, 1997). In such cases, revision of the retropubic suspension by releasing the urethra into a more anatomic position resolves voiding symptoms in up to 90% of patients (Carr and Webster, 1997; Nitti and Raz, 1994; Webster and Kreder, 1990).

The meta-analysis by Leach et al. (1997) **noted that the risk of temporary urinary retention lasting more than 4 weeks postoperatively is 5% for all retropubic suspensions, and the risk for permanent retention is estimated to be less than 5%. These risks are not significantly different from those for needle suspensions or pubovaginal slings.** Mainprize and Drutz's review of the literature (1988) yielded a 3.6% incidence of postoperative voiding problems after an MMK procedure, whereas the Burch procedure literature reports an incidence of postoperative voiding disorders ranging from 3% to 32% (Alcalay et al., 1995; Colombo et al., 1996a; Eriksen et al., 1990; Galloway et al., 1987; Hilton and Stanton, 1983). In more recent literature, voiding dysfunction may be persistent, as noted in 3.5% of a series of 310 women with a mean follow-up of 36 months (Viereck et al., 2004). Nonpersistent voiding dysfunction has been reported in 12.5% (6% to 37.2%) after primary surgery (Smith et al., 2005). After colposuspension conducted as a secondary procedure, Bidmead et al. (2001) reported voiding difficulties requiring intermittent self-catheterization in 6% of cases.

Because the paravaginal repair aims to restore normal anatomy, there is theoretically little chance of overcorrection of the urethral axis, which should translate into a lower risk of postoperative obstruction. In a study by Richardson et al. (1981), 80% of patients were able to void immediately after paravaginal repair, and “all patients had satisfactory bladder function at the time of discharge.” However, temporary voiding difficulty has been noted in up to 17% of patients after a VOS procedure (German et al., 1994), and chronic (>2 years) voiding difficulty has been noted in up to 11% of patients after the paravaginal repair (Colombo et al., 1996a).

All patients should be counseled before surgery about the potential need for intermittent self-catheterization.

Bladder Overactivity

Bladder overactivity commonly accompanies anatomic SUI, and its incidence preoperatively has been reported to be as high as 30% in patients undergoing either first correction or repeated operations (McGuire, 1981)**. Provided it is considered as a diagnosis, urodynamic evaluation has been performed to show whether detrusor overactivity is present, an attempt at treatment of the related overactive bladder symptoms has been made (with or without success), and the patient has been advised that the presence of detrusor overactivity will increase the risk of continuing storage symptoms postoperatively, then preoperative bladder overactivity does not contraindicate a retropubic suspension procedure, provided that anatomic SUI has also been demonstrated.** In the majority of patients, the bladder overactivity symptoms resolve after surgical repair (McGuire, 1988). A meta-analysis by Leach et al. (1997) found the risk of urgency after a retropubic suspension to be 66% if urgency and detrusor overactivity were present preoperatively, 36% if there was urgency but no documented overactivity preoperatively, and only 11% if there was neither urgency nor overactivity preoperatively. There was no significant difference in the incidence of postoperative urgency among retropubic suspensions, needle suspensions, and pubovaginal slings. Postoperative urgency was noted in only 0.9% of MMK procedures in Mainprize and Drutz's meta-analysis of 15 series (1988), although Parnell et al. (1982) reported that 28.5% of their patients developed postoperative storage symptoms. Jarvis's meta-analysis (1994b) of Burch procedures found the incidence of de novo bladder overactivity to be 3.4% to 18%. More recently, Smith et al. (2005) quoted a figure for postoperative detrusor overactivity of 6.6% for colposuspension (range 1.0% to 16.6%), whereas the incidence of postoperative urgency or urgency incontinence after the paravaginal or VOS repair has been reported to be 0 to 6% (Colombo et al., 1996a; German et al., 1994; Shull and Baden, 1989).

For patients in whom postoperative storage symptoms persist, proven to be associated with detrusor overactivity and intractable to management with anticholinergic therapy and behavioral modification, surgical techniques including intravesical botulinum toxin therapy, neuromodulation, augmentation cystoplasty, or detrusor myectomy may be indicated.

Bladder storage symptoms arising de novo after retropubic suspension may be associated with bladder outlet obstruction. This premise is supported by the frequent coexistence of these symptoms with impaired voiding after suspension procedures and confirmed by the finding that urethrolysis, by freeing the urethra from an obstructed position, often resolves storage and voiding symptoms (Raz, 1981; Webster and Kreder, 1990).

Vaginal Prolapse

Retropubic suspensions alter vaginal and bladder base anatomy, thus postoperative vaginal prolapse is a potential complication. Genitourinary prolapse has been reported as a sequel to Burch colposuspension in 22.1% of women (range 9.5% to 38.2%) by Smith et al. (2005) in their review of the literature. **The Burch procedure, because of lateral vaginal elevation, may aggravate posterior vaginal wall weakness, predisposing to enterocele.** The incidence varies from 3% to 17% (Burch, 1961, 1968; Galloway et al., 1987; Wiskind et al., 1992); **because of this, prophylactic obliteration of the cul-de-sac of Douglas is sometimes considered in performing retropubic suspensions** (Shull and Baden, 1989; Turner-Warwick and Kirby, 1993). However, simultaneous hysterectomy is not recommended prophylactically because it does not enhance the outcome of a retropubic suspension and should be performed only if there is concomitant uterine disease (Langer et al., 1988; Milani et al., 1985). Although the Burch procedure and paravaginal or VOS repair correct lateral defect cystourethroceles, recurrent cystourethroceles have been noted in 11% and 39% of Burch procedures and paravaginal repairs, respectively (Colombo et al., 1996a). In Mainprize and Drutz's review (1988), postoperative cystocele was noted in only 0.4% of patients after an MMK procedure.

Wiskind et al. (1992) noted that 27% of patients who had undergone a Burch colposuspension developed prolapse requiring surgery: rectocele in 22%, enterocele in 11%, uterine prolapse in 13%, and cystocele in 2%. More recently, it has been suggested that most women are asymptomatic, and less than 5% have been reported to request further surgery (Smith et al., 2005). Ward and Hilton (2004) reported that 4.8% of women needed a posterior repair, whereas Kwon et al. (2003) reported that 4.7% required subsequent pelvic reconstruction.

Auwad et al. (2006) reported the findings of the first prospective study to determine the prevalence of POP after colposuspension and to investigate possible preoperative and operative risk factors. Seventy-seven women who underwent colposuspension from 1996 to 1997 were investigated. POP was assessed before colposuspension using the POP-Q. Women were reassessed at 1 and 7 to 8 years (or when referred with symptomatic POP). By 7 to 8 years, of the 77 women, 29 (38%) had developed symptomatic prolapse, 29 (38%) had asymptomatic prolapse, 7 (9%) had no symptoms and no prolapse, and 12 (16%) could not be assessed. POP at 1 year was significantly associated with the presence of posterior vaginal descent before colposuspension (OR 3.07, 95% CI 1.10 to 8.60, $P = 0.03$). No potentially predisposing variable reached statistical significance by 8 years postcolposuspension. The results add support to the view that there is an association between colposuspension and the development of symptomatic POP (requiring surgery).

Key Point: Complications of Retropubic Repairs

- Because retropubic suspensions are unable to correct central defect cystoceles, patients must be carefully examined preoperatively to exclude their presence and must be counseled if undergoing a colposuspension because of the high risk of needing further surgery in the long term. Particularly, those in whom a weakness of the posterior compartment is identified preoperatively and those with a past history of hysterectomy may be at increased risk.

Comparisons of Incontinence Procedures

Retropubic Repair Versus Needle Suspension and Anterior Repair

Three articles that reviewed the literature on incontinence procedures found retropubic suspensions to be more effective than either needle suspensions or anterior colporrhaphies (Black and Downs, 1996; Jarvis, 1994b; Leach et al., 1997). Cure rates were approximately 85% for the retropubic suspensions compared with 50% to 70% for the needle suspensions and anterior colporrhaphies. Results were more durable for the retropubic suspensions and better if the procedure was primary. A recent Cochrane review by Lapitan et al. (2017) found that fewer women were incontinent after colposuspension, 11%, compared with needle suspension, 15%, in the first year after surgery (RR 0.66%; 95% CI 0.42–1.03). Although incontinence rates increased over time after both procedures, there were a lower percentage of women who were incontinent more than 5 years after surgery in the colposuspension group, 18%, compared with the needle suspension group, 57% (RR 0.32; 95% CI 0.15–0.71). Overall, there is now high-level evidence to indicate that open colposuspension has better outcomes than anterior colporrhaphy, bladder neck needle suspension, and MMK procedure (evidence level 1) (Rovner et al., 2017).

Key Point: Recommendation From the International Consultation on Incontinence Committee

- Endoscopic and nonendoscopic bladder neck needle suspension procedures, with and without bone anchors, are not recommended for the treatment of SUI (grade A recommendation).

Data from Smith AR, Chang D, Dmochowski R, et al.: Committee 14. Surgery for urinary incontinence in women. In Abrams P, Cardozo L, Khoury S, et al., editors: *Incontinence*, Plymouth, UK, 2009, Health Publications, pp 1191–1272.

Retropubic Repair Versus Pubovaginal Sling

Most studies in the historical literature have not demonstrated a significant difference in cure rates between retropubic suspensions (usually a Burch procedure) and pubovaginal slings (Black and Downs, 1996; Jarvis, 1994b; Leach et al., 1997). However, often, selection bias exists in that the pubovaginal sling is usually reserved for patients with multiple prior failed incontinence procedures, with less prolapse, and the presence of presumed intrinsic sphincter deficiency (a fixed urethra with periurethral fibrosis) is often used in clinical practice as a contraindication to a retropubic suspension. In an interesting randomized study in patients with a prior failed incontinence procedure (anterior repair) but without a low-pressure urethra (i.e., MUCP <20 cm H_2O), Enzelsberger's group (1996) found no significant difference in cure (subjective or objective) at 32 to 48 months between the Burch procedure and the Lyodura sling. However, they noted significantly more postoperative voiding difficulty with the pubovaginal sling (13% vs. 3%) and more vaginal prolapse (enterocele or rectocele) with the Burch procedure (13% vs. 3%).

A high-quality multicenter randomized clinical trial in women with stress incontinence compared the Burch colposuspension with a pubovaginal sling, using autologous rectus fascia (Aldo et al., 2007). Women were eligible for the study if they had predominant symptoms associated with the condition, a positive stress test result, and urethral hypermobility. The primary outcomes were success in terms of overall urinary-incontinence measures, which required a negative pad test result, no urinary incontinence (as recorded in a 3-day diary), a negative cough and Valsalva stress test result, no self-reported symptoms, and no retreatment for the condition, and success in terms of specific measures of stress incontinence as well as an assessment of postoperative urgency incontinence, voiding dysfunction, and adverse events. A noteworthy aspect of the study was the careful approach to standardization (using the recommendations from the standardization committees of the International Continence Society) with regard to clinical terms, urodynamic nomenclature, and methods of evaluation of patients across all sites. Key elements of the two surgical procedures were standardized among all participating surgeons and included the use of preoperative antibiotics, skin-incision length, number and type of Burch sutures, fascial-sling length and width, and cystoscopic evaluation of the bladder. A criticism that can be leveled at the study is the choice of technique for the Burch colposuspension with very medial paraurethral sutures.

The techniques utilized are demonstrated in Fig. 123.7.

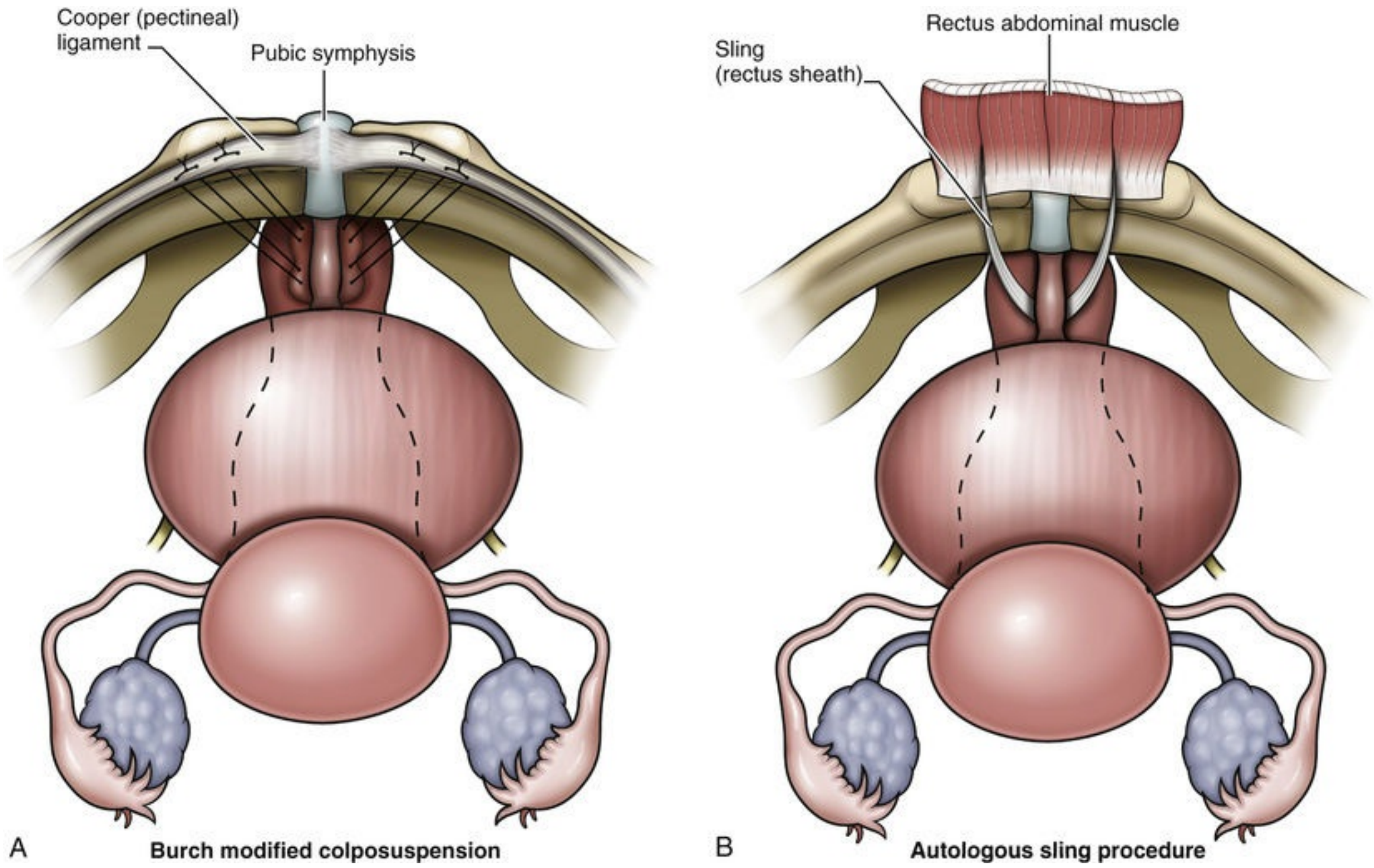
Cooper (pectineal) ligament
Pubic symphysis
A
Burch modified colposuspension
Sling (rectus sheath)
Rectus abdominal muscle
B
Autologous sling procedure

FIG. 123.7 In the Burch colposuspension (A), sutures are placed in the anterior vaginal wall at the level of the bladder neck and proximal urethra and sutured to the iliopectineal ligament. In the autologous sling procedure (B), a strip of rectus fascia is harvested and permanent sutures placed at both ends. The sling is positioned beneath the urethra via a vaginal incision. The two ends of the sling are then secured to the anterior abdominal wall, either together or to the rectus fascia. (Modified from Aldo ME, Richter HE, Brubaker L, et al.: Burch colposuspension versus fascial sling to reduce urinary stress incontinence. *N Engl J Med* 356:2143–2155, 2007.)

Because these procedures are frequently performed in conjunction with surgery for pelvic prolapse, abdominal and vaginal approaches for pelvic prolapse repair and hysterectomy were permitted; however, surgeons were required to declare before randomization which concomitant procedures would be performed.

A total of 655 women were randomly assigned to study groups: 326 to undergo the sling procedure and 329 to undergo the Burch procedure; 520 women (79%) completed the outcome assessment. At 24 months, success rates were higher for women who underwent the sling procedure than for those who underwent the Burch procedure, for the overall category of success (47% vs.

38%, $P = 0.01$) and the category specific to stress incontinence (66% vs. 49%, $P < 0.001$). There was no significant difference between the sling and Burch groups in the percentage of patients who had serious adverse events (13% and 10%, respectively; $P = 0.20$). However, more women who underwent the sling procedure had adverse events than in the Burch group, with 415 events among 206 women in the sling group as compared with 305 events among 156 women in the Burch group. This difference was primarily the result of urinary tract infections; 157 women in the sling group (48%) had 305 events and 105 women in the Burch group (32%) had 203 events. When urinary tract infections were excluded, the rates of adverse events were similar between the two groups.

The distribution of time to return to normal voiding differed significantly between the two groups ($P < 0.001$). Voiding dysfunction was more common in the sling group than in the Burch group (14% vs. 2%, $P < 0.001$). Consequently, surgical procedures to reduce voiding symptoms or improve urinary retention were performed exclusively in the sling group, in which 19 patients underwent 20 such procedures. (63% vs. 47%, $P < 0.001$). Treatment-satisfaction rates for the 480 patients who answered the satisfaction question at 24 months were significantly higher in the sling group than in the Burch group (86% vs. 78%, $P = 0.02$).

A further analysis of this study focused on sexual activity as assessed by the Pelvic Organ Prolapse/Urinary Incontinence Sexual Questionnaire (PISQ)-12 among those sexually active at baseline and 2 years after surgery (Brubaker et al., 2009). This report demonstrated that sexual function improves after successful surgery and does not differ between Burch and sling procedures.

Chai et al. (2009) reviewed complications in women undergoing Burch colposuspension versus autologous rectus fascial sling for SUI. These authors reviewed serious adverse events in the Stress Incontinence Surgical Treatment Efficacy Trial (SISTEr). The conclusion reached was that concomitant surgery and continence procedures increased the risk of complications. Sling surgery was associated with a higher risk of cystitis within the first 6 weeks postoperatively, and intermittent self-catheterization increased the risk of cystitis in this group. Complications were associated with surgical factors and not with patient-related factors. The authors concluded that blood loss and operative time were significantly associated with adverse events. Intermittent self-catheterization increased the cystitis rate by 17% and 23% in the Burch and sling groups, respectively.

Kraus et al. (2011) reported on changes in urodynamic measures 2 years after

Burch colposuspension or autologous sling surgery in a report from this large study (SISTEr). They noted that 655 women underwent standard urodynamic studies before and 2 years after Burch or sling surgery. The conclusion reached was that the Burch colposuspension and autologous fascial sling procedure were associated with similar decreases in noninstrumental flow rates and that slings were associated with great increase in the detrusor pressure at maximum flow and bladder outlet obstruction index. They concluded that these changes suggested that both procedures were effective in part because of increasing outlet resistance; it was suggested that sling procedures may be more obstructive based on the urodynamic parameters measured.

Richter et al. (2012) reviewed patient-related factors associated with long-term urinary continence after Burch colposuspension and pubovaginal fascial sling surgery in a long-term follow-up of SISTEr. The follow-up of patients in this study was up to 7 years after surgery. The authors concluded that urinary continence rates decreased during a period of 2 to 7 years postoperatively from 43% to 13% in the Burch group and from 53% to 27% in the sling group. The baseline factors included in the first multivariate model were age, prior SUI surgery, menopausal state, urge index, assigned surgery, and recruiting site. All of these were independently associated with increased risk of incontinence. In the final multivariate model, included baseline and postoperative factors were Burch surgery, baseline variables of prior urinary incontinence surgery, menopausal state, and postoperative urge index. All of these were significantly associated with a greater risk of recurrent urinary incontinence. The authors concluded that preoperative and postoperative urgency incontinence symptoms, Burch urethropexy, prior SUI surgery, and menopausal status were negatively associated with long-term continence rates. More effective treatment of urgency urinary incontinence in patients who undergo SUI surgery may improve long-term overall continence rates. They concluded that in women followed for a minimum of 5 years after Burch colposuspension or pubovaginal fascial sling, prior SUI surgery, being menopausal without hormone replacement therapy, having undergone a Burch procedure, and increased postoperative urgency incontinence symptoms were significantly associated with long-term incontinence. The final conclusion was that knowledge of risk factors for surgical failure can be used to better inform patients of the likelihood of long-term continence or decreased continence rates to be experienced as a result of the surgery. The suggestion put forward is that overall continence status may be improved by proactive preoperative and postoperative assessment and effective treatment of urgency incontinence.

According to a recent Cochrane review by Lapitan et al. (2017), **autologous fascia pubovaginal sling is modestly more effective than colposuspension at mid-term to long-term follow-up, albeit with a higher rate of early postoperative voiding dysfunction.** Based on the limited data available, it is suggested that the overall rates of late surgical complications are similar after pubovaginal sling and colposuspension. Rovner et al. (2017) concluded that there is an insufficient database on which to recommend or differentiate these procedures on the basis of adverse events or complications alone. It can be reliably concluded that in specialist centers working in a standardized fashion**, the autologous fascial sling results in a higher rate of successful treatment of stress incontinence but also greater morbidity than the Burch colposuspension.**

Key Point: Recommendations From the International Consultation on Incontinence Committee

- Autologous fascia pubovaginal sling is recommended as an effective treatment for female SUI, which has longevity for primary and revision surgery (grade A recommendation).

Data from Rovner E, Anathasiou S, Choo YM, et al.: Surgery for urinary incontinence in women. In Abrams P, Cardozo L, Wagg A, et al., editors: *Incontinence*, ed 6, Tokyo, Japan, 2017, pp 1741–1854.

Burch Colposuspension Versus Marshall-Marchetti-Krantz Procedure Versus Paravaginal Repair

In general, comparisons between the MMK and the Burch procedures have yielded similar results. Jarvis, in his meta-analysis of the literature (1994b), noted that overall continence rates were 89.6% and 83.9% for the MMK and the Burch procedures, respectively. When he looked at the effect of prior incontinence surgery, the continence rates were 92.1% and 94% when there was no prior surgery and 84.5% and 84% when there was a history of prior incontinence surgery for the MMK and Burch procedures, respectively. Similarly, Black and Downs (1996), in reviewing five studies (one randomized) that directly compared the MMK procedure with the Burch procedure, found that there was no significant difference in cure rates between the two procedures, although the Burch procedure yielded better results in general. However, they pointed out that overall the studies were of poor quality with small sample sizes.

Two randomized studies that assessed urethral sphincteric function by urethral pressure profilometry had conflicting results. Quadri's group (1999) compared the MMK procedure with the Burch procedure in women with a hypermobile, low-pressure urethra (MUCP <20 cm H_2O) and noted significantly higher subjective and objective 1-year cure rates with the MMK procedure. They used urethroscopy to facilitate MMK suture placement. On the other hand, Colombo's group (1994) excluded women with a low-pressure urethra (MUCP <30 cm H_2O) and performed a cystotomy to facilitate MMK suture placement. With 2- to 7-year follow-up (mean, 3 years), they noted higher subjective and objective cure rates with the Burch procedure, although these were not statistically significant. In addition, significantly more MMK patients had persistent postoperative voiding difficulties (28% vs. 8%).

The literature on the paravaginal repair is sparse. The only randomized study that compared the Burch procedure with a paravaginal repair found significantly greater subjective and objective cure with the Burch procedure (Colombo et al., 1996a). Until large, randomized studies with prolonged follow-up are available, the issue of which is the best procedure will remain unresolved.

Tension-Free Vaginal Tape Procedure Versus Colposuspension

Since its introduction in 1996 by Ulmsten, the TVT procedure has gained widespread acceptance for treatment of SUI, given its low morbidity, its short-term success rates, and the fact it can be performed as an outpatient procedure with use of a local or regional anesthetic (Ulmsten et al., 1996). The 7-year objective and subjective success rate for TVT is 81% (Nilsson et al., 2004). In a more recent review of this series by Nilsson et al. (2013) at 17 years' follow-up, 74 of the initial cohort of 90 women (82%) were potentially available for follow-up and of these, 78% could be contacted and capable of cooperating by clinic visit (46 women) or telephone interview (12 women). The objective cure rate, assessed by negative stress test, was found to be 91% and did not show a decline between 5 and 17 years' follow-up. The authors found a corresponding subjective perception of either cure or improvement of 87%, with a slight decline during the last 6 years. There was one woman who was found to have a small, asymptomatic mesh erosion, which had not been previously present on vaginal exam at 7 years' follow-up (Nilsson et al., 2013).

There have been a number of well-designed, prospective, randomized trials comparing the Burch colposuspension with TVT. Liapis et al. (2002) reported a prospective randomized comparative study of Burch colposuspension ($n = 35$) and TVT ($n = 36$). They concluded that at 2-year follow-up, the TVT and Burch procedures were equally effective with an objective pad test cure rate of 84% and 86%, respectively. TVT had a shorter operative time and entailed less postoperative pain with a faster return to normal activity.

Ward and Hilton (2004) published a 2-year follow-up of their landmark prospective randomized trial comparing TVT and open Burch colposuspension. At 2 years, 74% of the initial TVT and 69% of the open colposuspension patients completed the evaluation. The objective cure rates for the TVT (81%) and colposuspension (80%) were not significantly different. However, if the missing patients were evaluated by the last observation carried forward analysis, the cure rates would favor TVT (78% vs. 68%). The subjective cure rates differ from the objective rates dramatically, with only 43% and 37% reporting subjective cure of stress incontinence after TVT and colposuspension, respectively. At 2 years, the colposuspension group still had significantly lower scores on mental and emotional health. The incidences of enterocele and vault prolapse were higher in the colposuspension group, requiring significantly more prolapse surgery. Likewise, the number of patients still requiring intermittent catheterization was higher in the colposuspension group. The intraoperative complications were higher in the TVT group, whereas the postoperative complications were higher in the colposuspension group. The authors' conclusion at 2 years, because of patients lost to follow-up, was unchanged from their conclusion at 6 months, namely, that TVT may be better than, worse than, or the same as colposuspension.

In a further report from the Ward and Hilton study, 98 of those who had TVT and 79 of those who had colposuspension returned for 5-year follow-up; 72 in the TVT group and 49 in the colposuspension group had full subjective and objective data (Ward et al., 2008). The primary outcome in this analysis was a negative 1-hour pad test result, and this was not significantly different between the two groups: 58 of 72 (81%) women in the TVT group and 44 of 49 (90%) in the colposuspension group (*P* = 0.021, Fisher's exact test) at 5 years. Significantly, more women in the colposuspension group (11 [7.5%]) underwent surgery for prolapse during the follow-up period than those in the TVT group (3 [1.8%]). Tape-related complications were seen in 6 women. In the first year, 1 tape was divided for obstructed voiding; there was 1 suprapubic extrusion and 1 vaginal erosion. Two further vaginal erosions were detected at 5-year follow-up, and in addition, 1 woman was found to have tape within the bladder at cystoscopy after complaining of overactive bladder symptoms. There were no reported suture-related complications in the colposuspension group. The effect of both procedures on cure of incontinence and improvement in quality of life appears from this follow-up of a portion of the originally treated patients to be maintained in the long term out to 5 years (Ward et al., 2008). Eight-one percent of the women who had undergone TVT and 90% who had undergone colposuspension regarded themselves as satisfied or very satisfied with the results of their surgery at 5 years.

A Cochrane review of open colposuspension examined a total of 12 trials comparing open retropubic colposuspension and TVT (Lapitan et al., 2017). In the short term within 1 year of treatment, medium term 1 to 5 years', and long term more than 5 years' follow-up, there was no statistically significant difference between the two treatment groups in the risk for incontinence as assessed subjectively. In the objective assessment of incontinence, the results were similar with no statistically significant differences within any time periods between the retropubic colposuspension and TVT groups.

Key Points: Long-Term Efficacy of Tension-Free Vaginal Tape and Colposuspension

- The Cochrane review concluded that TVT trials have shown noninferiority in terms of cure rates when compared with open colposuspension.
- Clinicians should inform women of the differences in adverse events between the two procedures. Open colposuspension has been shown to be associated with POP, particularly in the long term, whereas sling operatives put women at a higher risk for postoperative voiding dysfunction. Late tape erosion may occur several years after surgery.

Data from Lapitan MCM, Cody JD, Mashayekhi A: Open retropubic colposuspension for urinary incontinence in women. *Cochrane Database Syst Rev* 7:CD002912, 2017.

Persson et al. (2002) were one of the first groups to compare TVT and laparoscopic Burch colposuspension. At 1-year follow-up, there was no difference between objective and subjective cure rates. Valpas et al. (2004) conducted a prospective randomized trial comparing TVT and laparoscopic mesh colposuspension at 1-year follow-up. The objective cure rate (negative stress test result, 86% vs. 57%), satisfaction, and quality of life were statistically better for the TVT group.

Paraiso et al. (2004) prospectively randomized 72 patients into laparoscopic Burch colposuspension and TVT at a mean follow-up of 20 months, but only 17 and 16 patients were available in the laparoscopic and TVT groups, respectively. Whereas objective and subjective cure rates were significantly higher in the TVT group, satisfaction of patients was equal in each group, and no difference was reported in voiding dysfunction, urgency, or symptomatic pelvic prolapse. All these laparoscopic studies require longer follow-up with greater power to demonstrate a persistent difference between TVT and Burch colposuspension.

A recent Cochrane review by Dean et al. (2017) reviewed eight trials comparing laparoscopic colposuspension with “self-fixing” slings, or tension-free vaginal tape. Overall, the authors found that subjective cure rates are equally good for both of these minimally invasive techniques, in the short and long term. The objective cure rate within 18 months appeared to favor the vaginal sling technique when compared with laparoscopy using mesh or sutures. There were no significant differences between the two procedures in terms of postoperative voiding dysfunction, de novo detrusor overactivity, and perioperative complications; however, laparoscopic colposuspension had a longer operative time, longer hospital stay, and slower return to normal activities. Based on these results, the authors concluded that **“self-fixing” slings are as, if not more, clinically effective than laparoscopic colposuspension;** however, more longer-term data are needed to better assess long-term outcomes (Dean et al., 2017). As the skill needed to perform laparoscopic colposuspension is greater than that needed for TVT sling placement, many surgeons training in the stress urinary incontinence surgeries are more likely to become efficient in the sling procedures.

The shift in practice pattern away from Burch colposuspension for the treatment of SUI to mid-urethral slings as the primary treatment of SUI shows one of the difficulties in conducting surgical RCTs, especially when the field has changed as quickly as it has in recent years in the treatment of urinary incontinence. A recent survey of urogynecology fellows found that the average third-year fellow had performed 257 mid-urethral sling procedures and only 13 Burch procedures (LeBrun et al., 2008). It would be interesting to determine if surgeon's experience with Burch colposuspension is correlated with outcomes. Indeed, the outcomes reported in the existing literature base are likely to be very different from those seen in many clinicians' clinical practices, where this has become a rare operation and where many have had very limited experience of carrying out the procedure during their training over the last decade.

A 10-year follow-up study reached the conclusion that TVT is more cost effective than Burch colposuspension in the treatment of female SUI (Laudano et al., 2013). The conclusion reached was that the cost and the effectiveness of TVT affected the cost-effectiveness analysis. The major criticism of any such study is that it does not take account of potential complications, which are never adequately considered in any such study, bearing in mind the potential publication bias in the literature toward best practice from specialized centers and the concern that the complications seen in real-life practice may not be reflected in the published literature. Nevertheless, this is a well-conducted study and does provide clear evidence that TVT is a cost-effective alternative.

At this time, TVT appears to be an equivalent operation to the open or laparoscopic Burch colposuspension. TVT or transobturator tape (TOT) procedures have now largely supplanted colposuspension in contemporary practice. An open colposuspension should still be considered as a surgical option in patients undergoing open surgery and still has a role when there is associated prolapse. Laparoscopic colposuspension has been shown in the short term to have some advantages over open colposuspension in experienced hands, but as a procedure has largely been supplanted by TVT or TOT in contemporary practice.

World Without Mesh

The use of synthetic mesh in female pelvic medicine and reconstructive surgery has been the subject of a large degree of controversy and litigation in recent years. In July 2011 the US Food and Drug Administration (FDA) re-classified transvaginal mesh used specifically for POP as "high risk" while maintaining tapes used for SUI as "low risk." They state on their website that the safety and efficacy of multi-incision slings (tapes) have been well established in clinical trials that followed patients for up to 1 year. A position statement released by the Society of Urodynamics, Female Pelvic Medicine and Urogenital Reconstruction (SUFU) and the American Urogynecologic Society (AUGS), supported by other professional bodies and the American Urological Association (AUA), strongly supported the FDA decision in regard to tapes for SUI.

After the FDA warning about the use of transvaginal mesh for POP repair in 2011, many products were withdrawn from the market under pressure generated by numerous lawsuits after severe complications with this technique (Sedrakyan et al., 2016). Despite the consistent differentiation between tapes/slings for stress incontinence and transvaginal mesh for prolapse by the FDA and other international scientific associations (FDA, 2018; Haylen et al., 2011), litigation and plaintiff lawyers as well as the general public, do not make a distinction between these two scientifically different products, placed in a different anatomic location to treat different pelvic floor problems. As a consequence of these misconceptions and increased media attention, mid-urethral slings have also come under scrutiny, leading to some government jurisdictions taking steps toward severe restrictions or even banning synthetic slings (Haylen et al., 2018). In fact, these products are the subject of ongoing lawsuits filed by the states of Washington, California, Kentucky, and Mississippi, which claim that Johnson & Johnson did not fully disclose the potential risks and side effects of surgical mesh.

As the use of synthetic tapes for midurethral slings come under increased restriction, it may boost the resurgence of open or laparoscopic Burch colposuspension as a first-line surgical treatment for stress urinary incontinence (Veit-Rubin et al., 2019). However, the experience of many clinicians with any of these alternate options may be little or none, leaving an enormous number of incontinence sufferers and their surgeons without a first-line minimally invasive surgical option (Haylen et al., 2018). It is therefore imperative that training in open and laparoscopic Burch colposuspension be provided in residency and fellowship training programs worldwide to afford the next generation of surgeons the ability to offer these procedures to their patients. **It is essential to counsel patients on the different types and qualities of synthetic mesh implants, their uses, and alternatives. As synthetic mesh use becomes more restricted, there may be a change in practice toward autologous sling material and colposuspension in the future.**

Key Points: Retropubic Suspension Surgery for Incontinence

- Anti-incontinence surgery does not necessarily work by restoring the same mechanism of continence that was present before the onset of incontinence. It works by a compensatory approach.
- The surgeon's preference, coexisting problems, and anatomic features of the patient and her general health condition influence the choice of procedure.
- There is lack of a clear consensus regarding which surgical procedure for stress incontinence is most effective, but contemporary practice is shifting to the urethral sling being the most widely used and having largely replaced the colposuspension.
- A number of variables may influence surgical outcome: age, postoperative activity, medical comorbidity, obesity, duration of symptoms, coexistence of detrusor overactivity, prior surgery, and intrinsic sphincter deficiency.
- There is no consensus on how to differentiate the relative contributions of hypermobility and sphincteric weakness.
- There remains no consensus on how to assess the outcomes of surgery, but this requires careful assessment with adequate follow-up and use of simple objective measures as well as taking particular account of patient-perceived outcomes.
- During short-term follow-up, vaginal and open retropubic suspension procedures have similar success rates. With longer follow-up (and with the exception of the pubovaginal sling), patients who have retropubic procedures fare better.
- With the MMK procedure, placement of sutures through the pubic symphysis incurs the risk of osteitis pubis in 0.9% to 3.2% of patients.

- Burch colposuspension is as effective as any other procedure in primary or secondary surgery at curing SUI, with proven long-term success. Thus it should be regarded as the *standard* open retropubic procedure for incontinence.
- Abdominal paravaginal repair is less effective than other forms of colposuspension.
- As with any major abdominal or pelvic surgical procedure, intraoperative and perioperative complications that may occur after a retropubic suspension include bleeding, injury to genitourinary organs (bladder, urethra, ureter), pulmonary atelectasis and infection, wound infection or dehiscence, abscess formation, and venous thrombosis or embolism. Other common complications more specific to retropubic suspension procedures include postoperative voiding difficulty, detrusor overactivity, and vaginal prolapse.
- The risk of temporary urinary retention lasting more than 4 weeks postoperatively is 5% for all retropubic suspensions. The risk of permanent retention is estimated to be less than 5%. These risks are not significantly different from those of needle suspensions or pubovaginal slings.
- All patients should be counseled before surgery about the potential need for intermittent self-catheterization.
- Because retropubic suspensions are unable to correct central defect cystoceles, patients must be carefully examined preoperatively to exclude their presence. The Burch procedure, because of lateral vaginal elevation, may aggravate posterior vaginal wall weakness, predisposing to enterocele.
- Retropubic suspensions are more effective than either needle suspensions or anterior colporrhaphies.
- Laparoscopic colposuspension is not recommended as a routine surgical procedure and, when performed, should be carried out only by a surgeon skilled in laparoscopic surgery.
- Most studies in the literature have not demonstrated a significant difference in cure rates between retropubic suspensions (usually a Burch procedure) and pubovaginal slings.
- Comparisons between the MMK procedure and the Burch procedure have yielded similar results in general.
- The literature on the paravaginal repair is sparse. The only randomized

study that compared the Burch procedure with a paravaginal repair found significantly greater subjective and objective cure rates with the Burch procedure.

- At this time, the TVT procedure appears to be at least equivalent to the Burch colposuspension, and in general is probably better.
- As synthetic mesh use becomes more restricted and controversial, there may be a change in practice toward autologous sling material and colposuspension in the future.

Suggested Readings

Abrams P, Cardozo L, Khoury S, et al. *Incontinence*. Health Publications: Plymouth (UK); 2009. *4th International Consultation on Incontinence*. .

DeLancey JO. Structural support of the urethra as it relates to stress urinary incontinence: the hammock hypothesis. *Am J Obstet Gynecol*. 1994;170:1713–1720.

DeLancey JO. The pathophysiology of stress urinary incontinence in women and its implications for surgical treatment. *World J Urol*. 1997;15:268–274.

Haylen BT, de Ridder D, Freeman RM, et al. An International Urogynecological Association (IUGA)/International Continence Society (ICS) joint report on the terminology for female pelvic floor dysfunction. *Neurourol Urodyn*. 2010;29(1):4–20.

International Continence Society. [website] https://www.ics.org; 2019.

Petros PP, Ulmsten U. An integral theory of female urinary incontinence. Experimental and clinical considerations. *Acta Obstet Gynecol Scand Suppl*. 1990;153:7–31.

Rovner E, Athanasiou S, Choo YM, et al. Surgery for urinary incontinence in women. Abrams P, Cardozo L, Wagg A, et al. *Incontinence*. ed 6. 2017:1741–1854 [Tokyo, Japan].

References

Abrams P, Cardozo L, Fall M, et al. The standardization of terminology of lower urinary tract function: report from the standardisation sub-committee of the International Continence Society. *Neurourol Urodyn*. 2002;21:167–178.

Alcalay M, Monga A, Stanton SL. Burch colposuspension: a 10-20 year follow up. *Br J Obstet Gynaecol*. 1995;102:740–745.

Aldo ME, Richter HE, Brubaker L, et al. Burch colposuspension versus fascial sling to reduce urinary stress incontinence. *N Engl J Med*. 2007;356:2143–2155.

Andersen JT, Heisterberg L, Hebjorn S, et al. Suprapubic versus transurethral bladder drainage after colposuspension/vaginal repair. *Acta Obstet Gynecol Scand*. 1985;64:139–143.

Ankardal M, Ekerydh A, Crafoord K, et al. A randomized trial comparing open Burch colposuspension using sutures with laparoscopic colposuspension using mesh and staples in women with stress urinary incontinence. *BJOG*. 2004;111:974–981.

Ankardal M, Milsom I, Stjerndahl JH, et al. A three-armed randomized trial comparing open Burch colposuspension using sutures with laparoscopic colposuspension using sutures and laparoscopic colposuspension using mesh and staples in women with stress urinary incontinence. *Acta Obstet Gynecol Scand*. 2005;84(8):773–779.

Appell RA. Retropubic procedures for female stress incontinence. Webster GD, Kirby R, King L, et al. *Reconstructive urology*. Blackwell Scientific: Oxford (UK); 1993:887–894.

Applegate GB, Bass KM, Kubik CJ. Ureteral obstruction as a complication of the Burch colposuspension procedure: case report. *Am J Obstet Gynecol*. 1987;156:445.

Auwad W, Bombieri L, Adekanmi O, et al. The development of pelvic organ prolapse after colposuspension: a prospective, long-term follow-up study on the prevalence and predisposing factors. *Int Urogynecol J*. 2006;17:389–394.

Baessler K, Stanton SL. Does Burch colposuspension cure coital incontinence? *Am J Obstet Gynecol*. 2004;190:1030–1033.

Bakali E, Buckley BS, Hilton P, et al. Treatment of recurrent stress urinary incontinence after failed minimally invasive synthetic suburethral tape surgery in women. *Cochrane Database Syst Rev*. 2013;(2) [CD009407].

Ball TL. *Gynecologic surgery and urology*. ed 2. Mosby: St. Louis; 1963:165–209.

Barr S, Reid FM, North CE, et al. The long-term outcome of laparoscopic colposuspension: a 10-year cohort study. *Int Urogynecol J Pelvic Floor Dysfunct*. 2009;20(4):443–445.

Barrier PA, Li JT, Jensen NM. Two words to improve physician-patient communication: what else? *Mayo Clin Proc*. 2003;78:211–214.

Bergman A, Ballard CA, Koonings PP. Comparison of three different surgical procedures for genuine stress incontinence: prospective randomized study. *Am J Obstet Gynecol*. 1989;160(5 Pt 1):1102–1106.

Bergman A, Koonings PP, Ballard CA. Negative Q-tip test as risk factor for failed incontinence surgery in women. *J Reprod Med*. 1989;34:193.

Bergman A, Koonings PP, Ballard CA. Proposed management of low urethral pressure type of genuine stress incontinence. *Gynecol Obstet Invest*. 1989;27:155–159.

Bergman A, Koonings PP, Ballard CA. The Ball-Burch procedure for stress incontinence with low urethral pressure. *J Reprod Med*. 1991;36:137–140.

Bergman A, Matthews L, Ballard CA, et al. Suprapubic versus transurethral bladder drainage after surgery for stress urinary incontinence. *Obstet Gynecol*. 1987;69:546–549.

Bidmead J, Cardozo L, McLellan A, et al. A comparison of the objective and subjective outcomes of colposuspension for stress incontinence in women. *BJOG*. 2001;108:408–413.

Black NA, Downs SH. The effectiveness of surgery for stress incontinence in women: a systematic review. *Br J Urol*. 1996;78(4):497–510.

Bowen LW, Sand PK, Ostergard DR, et al. Unsuccessful Burch retropubic urethropexy: a case controlled urodynamic study. *Am J Obstet Gynecol*. 1989;160:452–458.

Brieger G, Korda A. The effect of obesity on the outcome of successful surgery for genuine stress incontinence. *Aust N Z J Obstet Gynaecol*. 1992;32(1):71–72.

Brubaker L, Chiang S, Zyczynski H, et al. The impact of stress incontinence surgery on female sexual function. *Am J Obstet Gynecol*. 2009;200:562.e1–562.e7.

Brubaker L, Cundiff GW, Fine P, et al. Abdominal sacrocolpopexy with Burch colposuspension to reduce urinary stress incontinence. *N Engl J Med*. 2006;354:1557–1566.

Brubaker L, Nygaard I, Richter HE, et al. Two-year outcomes after sacrocolpopexy with and without Burch to prevent stress urinary incontinence. *Obstet Gynecol*. 2008;112:49–55.

Burch JC. Urethrovaginal fixation to Cooper's ligament for correction of stress incontinence, cystocoele and prolapse. *Am J Obstet Gynecol*. 1961;81(2):281–290.

Burch JC. Cooper's ligament urethrovesical suspension for stress incontinence. *Am J Obstet Gynecol*. 1968;100:764–774.

Burgio KL, Nygaard IE, Richter HE, et al. Bladder symptoms one year after abdominal sacrocolpopexy with and without

Burch colposuspension in women without preoperative stress incontinence symptoms. *Am J Obstet Gynecol*. 2007;197:647.e1–647.e6.

Burton G. A three-year prospective randomized urodynamic study comparing open and laparoscopic colposuspension. *Neurourol Urodyn*. 1997;16(5):353–354.

Cardozo L, Hextall A, Bailey J, et al. Colposuspension after previous failed incontinence surgery: a prospective observational study. *Br J Obstet Gynaecol*. 1999;106:340–344.

Carey M, Rosamilia A, Dwyer P, et al. Laparoscopic versus open colposuspension: a prospective multicenter randomized single-blind comparison. *Neurourol Urodyn*. 2000;19(4):389–391.

Carr LK, Webster GD. Voiding dysfunction following incontinence surgery: diagnosis and treatment with retropubic or vaginal urethrolysis. *J Urol*. 1997;157:821–823.

Chai TC, Albo ME, Richter HE, et al. Complications in women undergoing Burch colposuspension versus autologous rectus fascial sling for stress urinary incontinence. *J Urol*. 2009;181(5):2192–2197.

Chapple CR, Wein AJ, Artibani W, et al. A critical review of diagnostic criteria for evaluating patients with symptomatic stress urinary incontinence. *BJU Int*. 2005;95(3):327–334.

Cheon WC, Mak JH, Liu JY. Prospective randomised controlled trial comparing laparoscopic and open colposuspension. *Hong Kong Med J*. 2003;9(1):10–14.

Chilaka VN, Amu O, Mayne CJ. Factors affecting outcome of colposuspension. *J Obstet Gynaecol*. 2002;22(1):72–74.

Clarke B. The role of urodynamic assessment in the diagnosis of lower urinary tract disorders. *Int Urogynecol J Pelvic Floor Dysfunct*. 1997;8(4):196–199.

Clemens JQ, Stern JA, Bushman WA, et al. Long-term results of the Stamey bladder neck suspension: direct comparison with the Marshall-Marchetti-Krantz procedure. *J Urol*. 1998;160:372–376.

Colombo M, Milani R, Vitobello D, et al. A randomized comparison of Burch colposuspension and abdominal paravaginal defect repair for female stress urinary incontinence. *Am J Obstet Gynecol*. 1996;175:78–84.

Colombo M, Scalambrino S, Maggioni A, et al. Burch colposuspension versus modified Marshall-Marchetti-Krantz urethropexy for primary genuine stress incontinence: a prospective, randomized clinical trial. *Am J Obstet Gynecol*. 1994;171:1573–1579.

Colombo M, Vitobello D, Proietti F, et al. Randomised comparison of Burch colposuspension versus anterior colporrhaphy in women with stress urinary incontinence and anterior vaginal wall prolapse. *Br J Obstet Gynaecol*. 2000;107(4):544–551.

Colombo M, Zanetta G, Vitobello D, et al. The Burch colposuspension for women with and without detrusor overactivity. *Br J Obstet Gynaecol*. 1996;103:255–260.

Costantini E, Lazzeri M, Bini V, et al. Pelvic organ prolapse repair with and without concomitant Burch colposuspension in incontinent women: a randomised controlled trial with at least 5-year followup. *Obstet Gynecol Int*. 2012;2012:967923.

Czaplicki M, Dobronski P, Torz C, et al. Long-term subjective results of Marshall-Marchetti-Krantz procedure. *Eur Urol*. 1998;34:118–123.

De Cuyper EM, Ismail R, Maher CF. Laparoscopic Burch colposuspension after failed sub-urethral tape procedures: a retrospective audit. *Int Urogynecol J Pelvic Floor Dysfunct*. 2008;19(5):681–685.

Dean N, Ellis G, Herbison GP, et al. Laparoscopic colposuspension for urinary incontinence in women. *Cochrane Database Syst Rev*. 2017;(7) [CD002239].

Demirci F, Yucel O, Eren S, et al. Long-term results of Burch colposuspension. *Gynecol Obstet Invest*. 2001;51(4):243–247.

Digesu GA, Bombieri L, Hutchings A, et al. Effects of Burch colposuspension on the relative positions of the bladder neck to the levator ani muscle: an observational study that used magnetic resonance imaging. *Am J Obstet Gynecol*. 2004;190:614–619.

Einhorning G. Simultaneous recording of intravesical and intraurethral pressure. *Acta Chir Scand*. 1961;276:1–6.

Elia G, Bergman A. Genuine stress urinary incontinence with low pressure urethra: five-year follow-up after the Ball-Burch procedure. *J Reprod Med*. 1995;40:503–506.

Elkadry EA, Kenton KS, FitzGerald MP, et al. Patient-selected goals: a new perspective on surgical outcome. *Am J Obstet Gynecol*. 2003;189:1551–1557 [discussion 1557–1558].

Enzelsberger H, Helmer H, Schatten C. Comparison of Burch and Lyodura sling procedures for repair of unsuccessful incontinence surgery. *Obstet Gynecol*. 1996;88:251–256.

Eriksen BC, Hagen B, Eik-Nes SH, et al. Long-term effectiveness of the Burch colposuspension in female urinary stress incontinence. *Acta Obstet Gynecol Scand*. 1990;69:45–50.

Fantl JA, Newman DK, Colling J, et al. *Urinary incontinence in adults: acute and chronic management*. [Clinical practice guideline. No. 2, 1996 update. Rockville (MD): U.S. Department of Health and Human Services. Public Health Service, Agency for Health Care Policy and Research] 1996 [AHCPR Publication No.: 96-0682].

Fatthy H, El Hao M, Samaha I, et al. Modified Burch colposuspension: laparoscopy versus laparotomy. *J Am Assoc*

Gynecol Laparosc. 2001;8(1):99–106.

Faysal M, Constantinou CE, Rother L, et al. The impact of bladder neck suspension on the resting and stress urethral profile: a prospective study comparing controls with incontinent patients preoperatively and postoperatively. *J Urol*. 1981;125:55.

Feyersiel JF, Dreher E, Haenggi W, et al. Long term results after Burch colposuspension. *Am J Obstet Gynecol*. 1994;171:647–652.

Frankel G, Kantipong M. Sixteen-month experience with video-assisted extraperitoneal laparoscopic bladder neck suspension. *J Endourol*. 1993;9:259–264.

Fusco F, Abdel-Fattah M, Chapple CR, et al. Updated systematic review and meta-analysis of the comparative data on colposuspensions, pubovaginal slings, and midurethral tapes in the surgical treatment of female stress urinary incontinence. *Eur Urol*. 2017;72(4):567–591.

Galloway NT, Davies N, Stephenson TP. The complications of colposuspension. *Br J Urol*. 1987;60:122–124.

German KA, Kynaston H, Weight S, et al. A prospective randomized trial comparing a modified needle suspension procedure with the vagina/obturator shelf procedure for genuine stress incontinence. *Br J Urol*. 1994;74:188–190.

Giarenis I, Mastoroudes H, Cardozo L, et al. What do we do when a midurethral tape fails? Rediscovery of open colposuspension as a salvage continence operation. *Int Urogynecol J*. 2012;23(8):1117–1122.

Gillon G, Stanton SL. Long-term follow-up of surgery for urinary incontinence in elderly women. *Br J Urol*. 1984;56:478–481.

Gleason DM, Reilly RJ, Pierce JA. Vesical neck suspension under vision with cystotomy enhances treatment of female incontinence. *J Urol*. 1976;115:555–557.

Goldberg RP, Koduri S, Lobel RW, et al. Protective effect of suburethral slings on postoperative cystocele recurrence after reconstructive pelvic operation. *Am J Obstet Gynecol*. 2001;185(6):1307–1312 [discussion 1312–1313].

Haab F, Zimmern PE, Leach GE. Female stress urinary incontinence due to intrinsic sphincteric deficiency: recognition and management. *J Urol*. 1996;156:3–17.

Haylen BT, de Ridder D, Freeman RM, et al. An International Urogynecological Association (IUGA)/International Continence Society (ICS) joint report on the terminology for female pelvic floor dysfunction. *Neurourol Urodyn*. 2010;29(1):4–20.

Haylen BT, Freeman RM, Swift SE, et al. An International Urogynecological Association (IUGA)/International Continence Society (ICS) joint terminology and classification of the complications related directly to the insertion of prostheses (meshes, implants, tapes) and grafts in female pelvic floor surgery. *Neurourol Urodyn*. 2011;30(1):2–12.

Haylen BT, Lee JKS, Sivagnanam V, et al. What if there were no tapes? *Neurourol Urodyn*. 2018;37(6):2026–2034.

Hilton P, Stanton SL. A clinical and urodynamic assessment of the Burch colposuspension for genuine stress incontinence. *Br J Obstet Gynaecol*. 1983;90:934–939.

Holmes D, Stanton S, Chamberlain GVP. *Randomised trial to compare the colposuspension with the anterior repair in the management of genuine stress incontinence*. Personal communication. 1985.

Jarvis GJ. Stress incontinence. Mundy AR, Stephenson TP, Wein AJ. *Urodynamics: principles, practice and application*. ed 2. Churchill Livingstone: New York; 1994:299–326.

Jarvis GJ. Surgery for genuine stress incontinence. *Br J Obstet Gynaecol*. 1994;101(5):371–374.

Jarvis GJ, Bent A, Cortesse A, et al. Surgical treatment for incontinence in adult women surgery of female lower genitourinary fistulae. Abrams P, Khoury S, Wein A. *Incontinence: 1st International Consultation on Incontinence*. Health Publications: Plymouth (UK); 1999:637–668. *Recommendations of the International Scientific Committee: the evaluation and treatment of urinary incontinence*. vol 15.

Kiilholma P, Haarala M, Polvi H, et al. Sutureless colposuspension with fibrin sealant. *Tech Urol*. 1995;2:441–444.

Kitchener HC, Dunn G, Lawton V, et al. Laparoscopic versus open colposuspension—results of a prospective randomised controlled trial. *BJOG*. 2006;113:1007–1013.

Koonings PP, Bergman A, Ballard CA. Low urethral pressure and stress urinary incontinence in women: risk factor for failed retropubic surgical procedure. *Urology*. 1990;35:245–248.

Kraus SR, Lemack GE, Richter HE, et al. Changes in urodynamic measures two years after Burch colposuspension or autologous sling surgery. *Urology*. 2011;78(6):1263–1268.

Kwon CH, Culligan PJ, Koduri S, et al. The development of pelvic organ prolapse following isolated Burch retropubic urethropexy. *Int Urogynecol J Pelvic Floor Dysfunct*. 2003;14:321–325 [discussion 325].

Langer R, Lipshitz Y, Halperin R, et al. Long-term (10-15 years) follow-up after Burch colposuspension for urinary stress incontinence. *Int Urogynecol J Pelvic Floor Dysfunct*. 2001;12:323–326 [discussion 326–327].

Langer R, Ron-El R, Neuman M, et al. The value of simultaneous hysterectomy during Burch colposuspension for stress urinary incontinence. *Obstet Gynecol*. 1988;72:866–869.

Lapitan MCM, Cody JD, Mashayekhi A. Open retropubic colposuspension for urinary incontinence in women.

Cochrane Database Syst Rev. 2017;(7) [CD002912].

Lapitan MC, Cody DJ, Grant AM. Open retropubic colposuspension for urinary incontinence in women. *Cochrane Database Syst Rev*. 2003;(1) [CD002912].

Laudano MA, Seklehner S, Chughtai B, et al. Cost-effectiveness analysis of tension-free vaginal tape vs. Burch colposuspension for female stress urinary incontinence in the USA. *BJU Int*. 2013;112(2):E151–E158.

Leach GE, Dmochowski RR, Appell RA, et al. Female Stress Urinary Incontinence Clinical Guidelines Panel summary report on surgical management of female stress urinary incontinence. The American Urological Association. *J Urol*. 1997;158(3 Pt 1):875–880.

LeBrun EE, Sears CL, Young SB. An anonymous survey of urogynecology fellowship surgical experience: a pilot study. *J Pelvic Med Surg*. 2008;14:115.

Lee RA, Symmonds RE, Goldstein RA. Surgical complications and results of modified Marshall-Marchetti-Krantz procedure for urinary incontinence. *Obstet Gynecol*. 1979;53:447–450.

Liapis A, Bakas P, Creatsas G. Burch colposuspension and tension-free vaginal tape in the management of stress urinary incontinence in women. *Eur Urol*. 2002;41(4):469–473.

Liapis AE, Asimiadis V, Loghis CD, et al. A randomized prospective study of three operative methods for genuine stress incontinence. *J Gynecol Surg*. 1996;12(1):7–14.

Liu CY. Laparoscopic retropubic colposuspension (Burch procedure)—a review of 58 cases. *J Reprod Med*. 1993;38:526–530.

Lose G, Jørgensen L, Johnsen A. Predictive value of detrusor instability index in surgery for female urinary incontinence. *Neurourol Urodyn*. 1988;7:141–148.

Lose G, Jørgensen L, Mortensen SO, et al. Voiding difficulties after colposuspension. *Obstet Gynecol*. 1987;69:33–37.

Lyons TL. Minimally invasive retropubic urethropexy: the Nolan-Lyons modification to the Burch procedure. *Gynecol Endosc*. 1994;3:40–42.

Maher C, Dwyer P, Carey M, et al. The Burch colposuspension for recurrent urinary stress incontinence following retropubic continence surgery. *Br J Obstet Gynaecol*. 1999;106:719–724.

Mainprize TC, Drutz HP. The Marshall-Marchetti-Krantz procedure: a critical review. *Obstet Gynecol Surv*. 1988;43:724–729.

Mallipeddi PK, Steele AC, Kohli N, et al. Anatomic and functional outcome of vaginal paravaginal repair in the correction of anterior vaginal wall prolapse. *Int Urogynecol J Pelvic Floor Dysfunct*. 2001;12(2):83–88.

Marchetti AA. The female bladder after correction for stress incontinence. *Am J Obstet Gynecol*. 1949;58:1145.

Marshall FV, Marchetti AA, Krantz KE. The correction of stress incontinence by simple vesicourethral suspension. *Surg Gynecol Obstet*. 1949;88:509–518.

McDougall EM, Heidorn CA, Portis AJ, et al. Laparoscopic bladder neck suspension fails the test of time. *J Urol*. 1999;162:2078–2081.

McDuffie RW Jr, Litin RB, Blundon KE. Urethrovesical suspension (Marshall-Marchetti-Krantz). Experience with 204 cases. *Am J Surg*. 1981;141(2):297–298.

McGuire EJ. Urodynamic findings in patients after failure of stress incontinence operations. *Prog Clin Biol Res*. 1981;78:351–360.

McGuire EJ. Bladder instability in stress urinary incontinence. *Neurourol Urodyn*. 1988;7:563.

Milani R, Scalambrino S, Quadri G, et al. Marshall-Marchetti-Krantz procedure and Burch colposuspension in the surgical treatment of female urinary incontinence. *Br J Obstet*

Gynaecol. 1985;92:1050–1053.

Moehrer B, Carey M, Wilson D. Laparoscopic colposuspension: a systematic review. *BJOG*. 2003;110:230–235.

Moehrer B, Ellis G, Carey M, et al. Laparoscopic colposuspension for urinary incontinence in women. *Cochrane Database Syst Rev*. 2000;(3) [CD002239].

Morris AR, Reilly ETC, Hassan A, et al. 5-7 year follow-up of a randomised trial comparing laparoscopic colposuspension (LC) and open colposuspension (OC) in the treatment of genuine stress incontinence (Abstract). *Int Urogynecol J Pelvic Floor Dysfunct*. 2001;12.

Nilsson CG, Falconer C, Rezapour M. Seven-year follow-up of tension-free vaginal tape procedure for treatment of urinary incontinence. *Obstet Gynecol*. 2004;104:1259–1262.

Nilsson CG, Palva K, Aarnio R, et al. Seventeen years' follow-up of the tension-free vaginal tape procedure for female stress urinary incontinence. *Int Urogynecol J*. 2013;24(8):1265–1269.

Nitahara KS, Aboseif S, Tanagho EA. Long-term results of colpocystourethropexy for persistent or recurrent stress urinary incontinence. *J Urol*. 1999;162:138–141.

Nitti VW, Raz S. Obstruction following anti-incontinence procedures: diagnosis and treatment with transvaginal urethrolysis. *J Urol*. 1994;152:93–98.

Nygaard I, DeLancey JO, Arnsdorf L, et al. Exercise and incontinence. *Obstet Gynecol*. 1990;75:848–851.

Ou SC, Presthus J, Beadle E. Laparoscopic bladder neck suspension using hernia mesh and surgical staples. *J Laparoendosc Surg*. 1993;3:563–566.

Paraiso MF, Falcone T, Walters MD. Laparoscopic surgery for genuine stress incontinence. *Int Urogynecol J*. 1999;10:237–247.

Paraiso MF, Walters MD, Karram MM, et al. Laparoscopic

Burch colposuspension versus tension-free vaginal tape: a randomized trial. *Obstet Gynecol*. 2004;104:1249–1258.

Parnell JP, Marshall VF, Vaughn ED. Primary management of urinary stress incontinence by the Marshall-Marchetti-Krantz vesicourethropexy. *J Urol*. 1982;127:679–682.

Penson DF, Raz S. Why anti-incontinence surgery succeeds or fails. Raz S. *Female urology*. ed 2. Saunders: Philadelphia; 1996:435–442.

Persson J, Teleman P, Eten-Berquist C, et al. Cost analyses based on a prospective randomized study comparing laparoscopic colposuspension with a tension-free vaginal tape procedure. *Acta Obstet Gynecol Scand*. 2002;81:1066–1073.

Persson J, Wølner-Hanssen P. Laparoscopic Burch colposuspension for stress urinary incontinence: a randomized comparison of one or two sutures on each side of the urethra. *Obstet Gynecol*. 2000;95(1):151–155.

Petrou SP, Frank I. Complications and initial continence rates after a repeat pubovaginal sling procedure for recurrent stress urinary incontinence. *J Urol*. 2001;165(6 Pt 1):1979–1981.

Polascik TJ, Moore RG, Rosenberg MT, et al. Comparison of laparoscopic and open retropubic urethropexy for treatment of stress urinary incontinence. *Urology*. 1995;45:647–652.

Quadri G, Magatti F, Belloni C, et al. Marshall-Marchetti-Krantz urethropexy and Burch colposuspension for stress urinary incontinence in women with low pressure and hypermobility of the urethra: early results of a prospective randomized clinical trial. *Am J Obstet Gynecol*. 1999;181:12–18.

Raboy A, Hakim LS, Ferzli G, et al. Extraperitoneal endoscopic vesicourethral suspension. *J Laparoendosc Surg*. 1995;3:505–508.

Raz S. Modified bladder neck suspension for female stress incontinence. *Urology*. 1981;17:82–85.

Richardson AC, Edmonds PB, Williams NL. Treatment of stress urinary incontinence due to paravaginal fascial defect. *Obstet Gynecol*. 1981;57:357–362.

Richardson AC, Lyon FB, Williams NL. A new look at pelvic relaxation. *Am J Obstet Gynecol*. 1976;126:568–573.

Richter HE, Goode PS, Brubaker L, et al. Two-year outcomes after surgery for stress urinary incontinence in older compared with younger women. *Obstet Gynecol*. 2008;112(3):621–629.

Richter HE, Brubaker L, Stoddard AM, et al. Patient related factors associated with long-term urinary continence after Burch colposuspension and pubovaginal fascial sling surgeries. *J Urol*. 2012;188(2):485–489.

Ross J. Two techniques of laparoscopic Burch repair for stress incontinence: a prospective, randomized study. *J Am Assoc Gynecol Laparosc*. 1996;3(3):351–357.

Rovner E, Athanasiou S, Choo YM, et al. Surgery for urinary incontinence in women. Abrams P, Cardozo L, Wagg A, et al. *Incontinence*. ed 6. 2017:1741–1854 [Tokyo, Japan].

Sand PK, Koduri S, Lobel RW, et al. Prospective randomized trial of polyglactin 910 mesh to prevent recurrence of cystoceles and rectoceles. *Am J Obstet Gynecol*. 2001;184(7):1357–1362 [discussion 1362–1364].

Scotti RJ, Garely AD, Greston WM, et al. Paravaginal repair of lateral vaginal wall defects by fixation to the ischial periosteum and obturator membrane. *Am J Obstet Gynecol*. 1998;179(6 Pt 1):1436–1445.

Sedrakyan A, Chughtai B, Mao J. Regulatory warnings and use of surgical mesh in pelvic organ prolapse. *JAMA Intern Med*. 2016;176(2):275–277.

Shao Y, He HC, Shen ZJ, et al. Tension-free vaginal tape retropubic sling for recurrent stress urinary incontinence after Burch colposuspension failure. *Int J Urol*. 2011;18(6):452–

457.
Shull BL, Baden WF. A six year experience with paravaginal defect repair for stress urinary incontinence. *Am J Obstet Gynecol*. 1989;160:1432–1440.
Sitzia J, Wood N. Patient satisfaction: a review of issues and concepts. *Soc Sci Med*. 1997;45(12):1829–1843.
Smith AR, Chang D, Dmochowski R, et al. Committee 14. Surgery for urinary incontinence in women. Abrams P, Cardozo L, Khoury S, et al. *Incontinence*. Health Publications: Plymouth (UK); 2009:1191–1272.
Smith AR, Daneshgari F, Dmochowski R, et al. Committee 16. Surgery for urinary incontinence in women. Abrams P, Cardozo L, Khoury S, et al. *Incontinence*. Health Publications: Plymouth (UK); 2005:1297–1370. *Management*. vol 2.
Sofaer S, Firminger K. Patient perceptions of the quality of health services. *Annu Rev Public Health*. 2005;26:513–559.
Stanton SL, Cardozo L, Williams JE, et al. Clinical and urodynamic features of failed incontinence surgery in the female. *Obstet Gynecol*. 1978;51(5):515–520.
Staskin DR, Zimmern PE, Hadley HR, et al. The pathophysiology of stress incontinence. *Urol Clin North Am*. 1985;12:271–278.
Su TH, Wang KG, Hsu CY, et al. Prospective comparison of laparoscopic and traditional colposuspensions in the treatment of genuine stress incontinence. *Acta Obstet Gynecol Scand*. 1997;6(76):576–582.
Summitt RL, Lucente V, Karram MM, et al. Randomized comparison of laparoscopic and transabdominal Burch urethropexy for the treatment of genuine stress incontinence. *Obstet Gynecol*. 2000;95(4 Suppl 1):S2.
Symmonds RE. The suprapubic approach to anterior vaginal relaxation and urinary stress incontinence. *Clin Obstet*

Gynecol. 1972;15:1107–1121.

Tamussino KF, Zivkovic F, Pieber D, et al. Five-year results after anti-incontinence operations. *Am J Obstet Gynecol*. 1999;181(6):1347–1352.

Tanagho EA. Colpocystourethropexy: the way we do it. *J Urol*. 1978;116:751–753.

Tanagho EA. Colpocystourethropexy. Raz S. *Female urology*. ed 2. Saunders: Philadelphia; 1996:319–324.

Turner-Warwick R. The Turner-Warwick vagino-obturator shelf urethral-repositioning procedure. Debruyne FM, Van Kerrebroeck PE. *Practical aspects of urinary incontinence*. Martinus Nijhoff: Dordrecht, The Netherlands; 1986:100–104.

Turner-Warwick R, Chapple CR. *Functional reconstruction of the urinary tract and gyneco-urology. An exposition of functional principles and surgical procedures*. Wiley-Blackwell: Hoboken, NJ; 2002.

Turner-Warwick R, Kirby RS. Principles of sphincteroplasty. Webster GD, Kirby R, King L, et al. *Reconstructive urology*. Blackwell Scientific: Oxford (UK); 1993:657–686.

Turner-Warwick R, Worth P, Milroy E, et al. The suprapubic V incision. *Br J Urol*. 1974;46:39–45.

Ulmsten U, Henrikson L, Johnson P, et al. An ambulatory surgical procedure under local anesthesia for treatment of female urinary incontinence. *Int Urogynecol J Pelvic Floor Dysfunct*. 1996;7:81–86.

US FDA. *Considerations about surgical mesh for SUI.* [website] https://www.fda.gov/MedicalDevices/ProductsandMedicalPr 2018.

Valpas A, Kivela A, Penttinen J, et al. Tension-free vaginal tape and laparoscopic mesh colposuspension for stress urinary incontinence. *Obstet Gynecol*. 2004;104:42–49.

Vancaillie TG, Schuessler W. Laparoscopic bladderneck suspension. *J Laparoendosc Surg*. 1991;1(3):169–173.

Veit-Rubin N, Dubuisson J, Ford A, et al. Burch colposuspension. *Neurourol Urodyn*. 2019;38(2):553–562.

Viereck V, Pauer HU, Bader W, et al. Introital ultrasound of the lower genital tract before and after colposuspension: a 4-year objective follow-up. *Ultrasound Obstet Gynecol*. 2004;23:277–283.

Wallwiener D, Grischke EM, Rimbach S, et al. Endoscopic retropubic colposuspension: “Retziusscopy” versus laparoscopy–a reasonable enlargement of the operative spectrum in the management of recurrent stress incontinence? *Endosc Surg Allied Technol*. 1995;3(2–3):115–118.

Ward K, Hilton P. Prospective multicentre randomised trial of tension-free vaginal tape and colposuspension as primary treatment for stress incontinence. *BMJ*. 2002;325:67.

Ward KL, Hilton P. A prospective multicenter randomized trial of tension-free vaginal tape and colposuspension for primary urodynamic stress incontinence: two-year follow-up. *Am J Obstet Gynecol*. 2004;190:324–331.

Ward KL, Hilton P, UK and Ireland TVT Trial Group. Tension-free vaginal tape versus colposuspension for primary urodynamic stress incontinence: 5-year follow up. *BJOG*. 2008;115:226–233.

Weber AM, Walters MD, Piedmonte MR, et al. Anterior colporrhaphy: a randomized trial of three surgical techniques. *Am J Obstet Gynecol*. 2001;185(6):1299–1304 [discussion 1304–1306].

Webster GD, Kreder KJ. Voiding dysfunction following cystourethropexy: its evaluation and management. *J Urol*. 1990;144:670–673.

Weil A, Reyes H, Bischoff P, et al. Modifications of the urethral rest and stress profiles after different types of surgery for stress incontinence. *Br J Obstet Gynaecol*. 1984;91:46.

White GR. An anatomic operation for the cure of cystocele. *Am J Obstet Dis Women Child*. 1912;65:286.

White GR. Cystocele—a radical cure by suturing lateral sulci of the vagina to the white line of pelvic fascia. 1909. *Int Urogynecol J Pelvic Floor Dysfunct*. 1997;8:288–292.

Wiskind AK, Creighton SM, Stanton SL. The incidence of genital prolapse after the Burch colposuspension. *Am J Obstet Gynecol*. 1992;167:399–405.

Woo HH, Rosario DJ, Chapple CR. Stone formation on permanent suture material used previously in colposuspension. *Br J Urol*. 1995;76:139–140.

Zivkovic F, Tamussino K, Pieber D, et al. Body mass index and outcome of incontinence surgery. *Obstet Gynecol*. 1999;93(5 Pt 1):753–756.

Zorzos I, Paterson PJ. Quality of life after a Marshall-Marchetti-Krantz procedure for stress urinary incontinence. *J Urol*. 1996;155:259–262.

Zullo F, Morelli M, Russo T, et al. Two techniques of laparoscopic retropubic urethropexy. *J Am Assoc Gynecol Laparosc*. 2002;9(2):178–181.

Vaginal and Abdominal Reconstructive Surgery for Pelvic Organ Prolapse

---

Jack Christian Winters MD, FACS, Ryan M. Krlin MD, Barry Hallner MD

Preparing the Patient for Prolapse Surgery

Because pelvic organ prolapse (POP) is, for the most part, a quality-of-life (QoL) issue, consideration must be given to the stage of prolapse, patient's symptoms, and the degree to which the patient's QoL is impaired (Novara and Artibani, 2005). In selecting surgical procedure(s), urologists must individualize management based on the unique clinical presentation of each patient, taking into account physiologic age, comorbidities, previous surgeries, and level of physical and sexual activity, as well as overall bother from POP symptoms (Flynn and Webster, 2002). Once the decision has been made to proceed with surgery, it is imperative to recall that the best chance at restoring normal support and function is most likely associated with the first surgery (Rogers, 2003). After the first procedure, the normal anatomic planes will no longer be present, which may add to the difficulty and complexity of subsequent surgeries. It has been demonstrated that recurrence rates increase with each attempt to surgically correct the defect(s) (Birch, 2005; Maher and Baessler, 2006a,b). A preoperative discussion is warranted to inform patients of the anticipated risks and benefits of each surgical option so that they can choose the type of operation (if any) is best for them. Some may feel that their level of bother may not warrant the risks of prolapse surgery, and that is a reasonable informed decision.

Prolapse repairs can be defined as restorative, compensatory, and obliterative (Van Rooyen, 2005). In patients whose comorbidities preclude prolonged surgery, obliterative procedures may offer symptom relief with minimal morbidity. These procedures are contraindicated in patients who wish to remain sexually active; however, for the right candidate these procedures can greatly reduce symptoms with lower risk. For those patients who have discrete defects in the fibromuscular layer of the endopelvic fascia, restorative repairs are an appropriate option. These repairs correct the defined defects in the native tissues by using endogenous support structures. For patients whose native tissues are particularly weak or in those who have had failed surgeries, compensatory procedures, which may include insertion of a graft, may be used. Grafts are made of synthetic materials, biologic, and autologous tissues.

Pelvic floor reconstruction may be performed through a vaginal, open abdominal, laparoscopic, or robotic approach or any combination of these techniques. Because POP is often mixed, surgery commonly involves a combination of repairs addressing all affected compartments. In addition, an anti-incontinence procedure may be performed at the same time. In regard to vaginal and abdominal approaches to prolapse surgery, both approaches offer high degrees of patient satisfaction and low rates of recurrent surgery for prolapse. Abdominal techniques are readily performed by laparoscopic/robotic approaches, with some evidence suggesting these repairs are more durable compared with vaginal techniques (Benson et al., 1996). It is important that all of these factors be considered when selecting the proper technique for each patient.

Preoperative Counseling of Patient for Vaginal Pelvic Organ Prolapse Surgery

It is clear that success after prolapse surgery is not just objective resolution of the anatomic defects. The absence of patient symptoms, whether resolution of vaginal bulging and/or minimizing de novo postoperative symptoms, has the strongest correlation with the patient's assessment of overall improvement and treatment success (Barber et al., 2009). Thus t**he concept (and definition) of success must include patient satisfaction and symptom improvement in addition to objective measures.** This process begins before the operation, as patients' expectations and readiness to undergo surgery for POP has been shown to affect their satisfaction and how they perceive their improvement (Kenton et al., 2007). Elkadry et al. (2003) found that patient satisfaction after surgery for POP correlated highly with achievement of self-described goals. Thus it is very useful to inquire of patients, "What are you expecting after surgery? What changes do you desire?" Furthermore, patients perceived the experience of routine postoperative events such as pain, hospital discharge with a catheter, constipation, urgency incontinence, and minor effects of anesthesia as surgical complications. These perceived complications were also associated with dissatisfaction, which existed despite high cure rates. A feeling of being unprepared for surgery was highly associated with a negative perception of outcome. **Thus negative patient perception equates with postoperative dissatisfaction even in the presence of high objective cure rates. It is vital to recognize that the absence of symptoms influences patient satisfaction greater than the elimination of anatomic prolapse.**

Kenton et al. (2007) evaluated patients with standardized counseling, which involved a 3-page handout on what to expect after surgery. Women who perceived they were fully prepared for surgery were more likely to be improved on the Patient Global Impression of Improvement (PGI-I) (Yalcin and Bump, 2003) and had lower postoperative Pelvic Organ Prolapse Distress Inventory (POPDI) (Barber et al., 2001) and Urinary Distress Inventory (UDI) (Shumaker et al., 1994) scores. Also, they found that objective measures of cure did not differ by preparedness. In conclusion, **the preoperative surgeon-patient interaction is vital and may facilitate improved postoperative patient satisfaction. Therefore it is recommended to complete a thorough consent about the surgery, alternatives to surgery, the purpose of planned surgery (what it can and cannot accomplish), the benefits of surgery (what symptoms can be improved), the risks, and complications. In addition, it is useful to review what to expect while the patient is in the hospital, what to expect at home, and strategies on coping with a catheter in the hospital and at home if needed** (Kenton et al., 2007).

Key Points: Preoperative Counseling for Pelvic Organ Prolapse Surgery

- The **absence** of recurrent prolapse **symptoms** influences patient satisfaction greater than the elimination of anatomic prolapse.
- It is vital to understand the patients’ goals and expectations of surgery and carefully review the risks and benefits of each surgical approach.
- Postoperative “events,” such as catheterization or urinary tract infection, are significant to the patient and negatively influence perception of outcomes.
- The preoperative informed consent is a good time to review the patient's goals and expectations as well as discuss the risks and benefits of each surgical option.
- It is important for the patient to be educated on what to expect throughout the perioperative course, because patients may perceive perioperative events as “complications,” having a negative impact on the overall perception of the procedure.

Use of Mesh in Vaginal Surgery: Current Controversy

The high failure rates of POP and stress urinary incontinence (SUI) surgery have long been recognized (Olsen et al., 1997). Because of inherent connective tissue defects that contribute to SUI and POP, surgeons have long sought after materials that may augment repairs and result in more durable outcomes. Biologic materials have been used but unfortunately have had inconsistent results because of variability of graft function. With the use of mesh as a graft in prolapse surgery, there are differences in volume of mesh, sites of mesh implantation, amounts of vaginal dissection, and surgical expertise required to perform these procedures competently when compared with mesh for SUI. Based on the enormous success of the mid-urethral sling (MUS), the US Food and Drug Administration (FDA) granted more than 100 510K exemptions for mesh “kits” to be used in the surgical management of POP (FDA, 2013). With use of the initial technique of transobturator access, the trocars and mesh grafts were modified to facilitate multi-compartment POP repair. This resulted in larger grafts being inserted or tunneled to the sacrospinous ligament (SSL), iliococcygeus fascia, arcus tendineus, obturator internus, the levator ani, and the perineal body. To accomplish this, considerably more vaginal dissection through wider incisions is required. Wider vaginal flaps can be more prone to “breakdown,” resulting in mesh exposure. Fluid accumulation or bleeding from deep dissection and tension or buckling of the mesh sheets may adversely affect graft incorporation leading to an exposure, erosion, or pain. Tacking or tunneling of larger volumes of mesh into the deep pelvic musculature may lead to neuromuscular dysfunction of the levator ani complex and subsequent pelvic floor dysfunction. Last, some surgeons who were not performing transvaginal tissue-based prolapse repairs may have started performing these procedures as an “extension” of the transobturator technique. It is very clear that much more advanced dissection skills and techniques are required to perform a mesh-based prolapse repair versus an MUS. There is no doubt that a number of high-volume, accomplished vaginal surgeons are performing mesh-based prolapse repairs safely on their patients (Murphy et al., 2012). However, it is not all just about experience of the surgeon. The volume, techniques of dissection, and location of the mesh for POP repairs are associated with a risk profile much greater than the

MUS, and these procedures are vastly different, even with the same type of mesh.

Outcomes data comparisons also reveal disparity between these two procedures. With the first-generation MUS, the efficacy and safety has been demonstrated worldwide through multiple studies with little dispute (Togami et al., 2012). Thus these procedures are a clear (and often preferred) option in the surgical treatment of SUI. The same cannot be said for POP repairs. Most would agree that anatomic outcomes appear better in the anterior compartment (Maher et al., 2013). However, the data are less compelling in the posterior compartment and apex. When subjective outcomes and reoperation rates are included, the data regarding mesh for prolapse are less clear, distinctly opposite from the first-generation MUS (Togami et al., 2012). Thus the precise indications for transvaginal mesh for prolapse are much less clear.

A public health notification is an important message from the FDA Center for Devices and Radiological Health to the health care community (Schultz, 2008). This message describes a risk associated with the use of a medical device and provides recommendations to avoid or reduce the risk. In October of 2008, the FDA released a public health statement: “Serious Complications Are Associated with Transvaginal Placement of Surgical Mesh in Repair of Pelvic Organ Prolapse and Stress Urinary Incontinence.” This report was designed to alert health care practitioners of complications associated with transvaginal placement of surgical mesh to treat POP and SUI. This report cited that over 3 years, the FDA received more than 1000 reports from nine surgical mesh manufacturers of complications that were associated with surgical mesh devices used to repair POP and SUI. As a result, a number of recommendations were made to physicians, which included obtaining specialized training for each mesh placement technique and informing patients that implantation of surgical mesh is permanent. It was also recommended to inform patients about the potential for serious complications and adverse effect on their QoL. As part of this notification, the FDA embarked on additional investigations into MUS and POP procedures using mesh, which resulted in an update of the public health notification in 2011 (Togami et al., 2012). This update was to inform the public once again regarding serious complications related to the use of transvaginal mesh in pelvic organ prolapse. **The 2011 notification was regarding POP only and did not include SUI** (Togami et al., 2012). In 2013 the FDA released additional findings regarding the use of mesh for SUI and POP (Togami et al., 2012). On the subject of mesh for SUI, the FDA concluded that “the safety and effectiveness of multi-incision slings is well-established in clinical trials that followed patients for up to one-year. Longer follow-up data is available in the literature, but there are fewer of these long-term studies compared to studies with one-year follow-up." They also concluded that "mesh sling surgeries for SUI have been reported to be successful in approximately 70 to 80 percent of women at one year, based on women's reports and physical exams…and the vaginal exposure of mesh occurred in 2% of cases" (Togami et al., 2008).

This is clearly different than the conclusions regarding the use of transvaginal mesh for POP, in which the FDA concluded that the complications are not rare and are of serious concern, and that there is no clear benefit to using mesh in the transvaginal correction of POP. These conclusions led the FDA to recommend changing the classification of transvaginal mesh to Class III devices, require extensive premarket testing on any new mesh kits for prolapse, and require 522 post-market surveillance studies compared with tissue-based repairs to demonstrate safety and efficacy of transvaginal mesh for prolapse. During this period, any prolapse kits using mesh currently available can still be used by surgeons. In contrast, the FDA did not reclassify transvaginal mesh for the sling in the treatment of SUI. No premarket data or post-market 522 data will be required for the first-generation MUS procedures (retropubic and obturator) (Togami et al., 2012). **Based on these observations, it is clear that the FDA concluded that the benefit-risk ratio of the first-generation MUS was clearly favorable and did not recommend any alteration of its use.** To be clear, the FDA did require post-market 522 studies of the second generation mini-slings because of concerns that these procedures have inferior efficacy compared with retropubic or transobturator slings (Togami et al., 2012). In 2016 the FDA reclassified the trocars used in mesh procedures to a Class II device. These are the instruments used to place the mesh only, and this reclassification did not change the previous recommendations for vaginal mesh in any way.

Subsequently, a plethora of legal actions have occurred based on the FDA activity regarding vaginal mesh. Multiple class action lawsuits have been organized against the manufacturers of mesh used for the treatment of SUI *and* POP. Millions of dollars have already been awarded, and this figure will likely rise exponentially. Several large companies have decided to withdraw their mesh products for POP from the marketplace. There is an infiltration of the media regarding class action lawsuits against mesh manufacturers, which has resulted in a global negative bias regarding mesh for the treatment of SUI and POP. Some of these advertisements contend that the mesh is "defective" and has been “recalled.” These claims are not congruent with the FDA findings and have also created concern in many women who have been successfully implanted with vaginal mesh, seeking removal of the “defective mesh.”

There has been no recall or clinical evidence of defective mesh. In fact, the FDA actions of allowing continued use of these products while undergoing post-market surveillance demonstrates that the FDA did not conclude that these products are defective. Also, the continued inclusion of the MUS in these advertisements is in direct opposition to the FDA findings and level I evidence through NIH-sponsored clinical trials, which demonstrate that MUS procedures are safe and effective.

So where does this leave clinicians of today? We are in an environment of having to deal with the realities of POP and SUI QoL disturbances and recurrences after native tissue repair in our patients who are now anxious and likely have a very negative bias against mesh. These realities exist with almost nonexistent high-quality, comparative evidence in the area of POP. What can we do to appropriately counsel and guide our patients through surgical procedures best for them? It is pretty clear that these answers do not exist, and comparative trials as well as registries are desperately needed to guide us through this process.

In an effort to aide surgeons, the following recommendations are offered with the goal of safe, judicious POP surgery:

- **Patients should be counseled extensively regarding the mesh procedure(s) recommended, including MUS procedures.** They should be informed that they are getting mesh (and why it is best for them), that there are non-mesh alternatives, and that there are complications that do occur that are unique to mesh. They should be informed that these complications may be permanent and may require more than one operation, which may or may not correct the problem. Patients should also be informed that the most common complication unique to mesh is mesh exposure, which may be asymptomatic or require a surgical revision, which may usually address the problem.
- **Clinicians should refer patients to the manufacturer's website regarding the specific procedure for them.** They

should be encouraged to learn more about their procedure in advance of the surgery. **Clinicians should refer patients to the FDA website regarding the FDA Vaginal Mesh Communication** and to the websites of the subspecialty societies *(American Urologic Association and the Society for Urodynamics, Female Pelvic Medicine and Urogenital Reconstruction),* which contain consensus statements and other links regarding vaginal mesh.

- **Clinicians should maintain the strong distinction between MUS procedures (retropubic and obturator) and transvaginal mesh procedures for POP**. Patients should be informed of the FDA actions that were vastly different between the two procedures and that there is prospective NIH research demonstrating the safety and efficacy of the MUS. Although the litigation involves all procedures, patients should be informed that the currently available evidence demonstrates the safety and efficacy of the MUS, making it the standard surgical treatment for SUI.
- **Widespread, routine use of transvaginal mesh, particularly on primary procedures, should be discouraged in patients with POP. In the current environment, the majority of POP mesh prolapse kits have been removed from the US market. In addition, several countries (UK, New Zealand, and Australia) have essentially removed transvaginal mesh for prolapse as an option for nearly all patients** (Polypropylene vaginal mesh implants for vaginal prolapse, 2007)**. In the current environment it is not recommended for surgeons with lesser degrees of experience in prolapse surgery to embark on these procedures.**
- Because the current evidence of transvaginal mesh for POP is much more limited and the indications far less clear, the American Urogynecologic Society (AUGS) position statement advocates for only experienced, credentialed surgeons to implant

mash vaginally for prolapse, and that in very special circumstance, mesh may be considered in highly select patients (AUGS, 2018).

- **Surgeons should be vigilant in assessing patient complaints.** Patients must be reassured that any postoperative concern is not "dismissed." Surgeons should directly address these concerns and offer assistance in second-opinion referrals in the absence of an explanation. With the current uncertainty and negative perceptions of mesh patients need reassurance that their concerns are adequately addressed and reasonable attempts are being made to address them.
- **Surgeons should endorse and participate in prospective, comparative clinical trials as well as registries to advance the knowledge of and identify best practices of transvaginal mesh usage.**

A summary of FDA activity regarding vaginal mesh is presented in Table 124.1.

TABLE 124.1

Summary of FDA Activity Regarding Vaginal Mesh

2002: FDA clearance of surgical mesh for POP • Approval via FDA 510(k) Clearance Process–POP RX considered substantially equivalent to mesh for SUI and hernia repairs
2008 Public Health Notification regarding safety of transvaginal mesh for POP and SUI
2011: FDA Update on Serious Complications Associated With Transvaginal Placement of Surgical Mesh for Pelvic Organ Prolapse (slings not mentioned) • Complications with POP kits "not rare" • Full-incision sling at 1 year appear "effective"
2014: 513(e) FDA order to reclassify POP vaginal mesh to class III
2016: Reclassify instrumentation from class I to class II

Surgical Management of Pelvic Organ Prolapse

See Table 124.2.

TABLE 124.2

Surgical Approach to Pelvic Organ Prolapse

POP-Q SITE	VAGINAL	ABDOMINAL
Aa Urethra	Anterior repair Bladder neck suspension Sling	Retropubic urethropexy
Ba Bladder	Anterior repair Paravaginal repair Colpocleisis	Wedge colpectomy Paravaginal repair ASC
C Cervix/cuff	Uterosacral ligament suspension Iliococcygeus suspension Sacrospinous fixation Manchester operation Hysteropexy Vaginal hysterectomy Colpocleisis	Abdominal hysterectomy Uterosacral ligament suspension ASC Uterine suspension
D Cul-de-sac	McCall culdoplasty	Halban culdoplasty Moschcowitz culdoplasty
Ap	Rectovaginal plication (posterior repair) Site-specific repairs	Colpoperineopexy

ASC, Abdominal sacrocopolpexy; *POP-Q,* pelvic organ prolapse-quantification.

Anterior Compartment

Anterior Colporrhaphy

Kelly (1913) first described his method of cystocele repair as a treatment for urinary incontinence. He emphasized the importance of repairing the pubocervical fascia with plication sutures to repair the central defect in the anterior vaginal wall. This procedure, now known as the anterior colporrhaphy or native tissue cystocele repair, remains a treatment of anterior prolapse. The use of this procedure for the treatment of incontinence diminished after the American Urological Association Female Stress Urinary Incontinence Clinical Guidelines Panel meta-analysis, which published a failure rate of nearly 40% (Leach et al., 1997).

Anterior compartment defects are commonly combined central and lateral defects (Fig. 124.1). Thus an anterior colporrhaphy, which corrects only central compartment defects, usually must be combined with a paravaginal repair or lateral anchoring for the treatment of anterior wall prolapse. Isolated central defects are rare, and in these instances a colporrhaphy alone may suffice. The early series on anterior colporrhaphy for the treatment of anterior vaginal wall prolapse reported objective success rates of 80% to 100% (Macer, 1978; Porges and Smilen, 1994; Stanton et al., 1982; Walter et al., 1982). Weber et al. (2001) in a randomized trial of three surgical techniques reported a 70% failure rate of native tissue anterior repairs. Recent re-analysis of this data set, using a more contemporary and agreed-upon definition of failure (prolapse beyond the hymen), reports a significantly better anatomic outcome with only 10% of patients experiencing prolapse beyond the hymen and only 5% of patients reporting prolapse symptoms (Chmielewski et al., 2011). The extreme differences in failure rates for anterior colporrhaphy seen in the literature can be explained primarily by the variability in definition of failure and the fact that in early series these procedures were performed in patients with multiple defects.

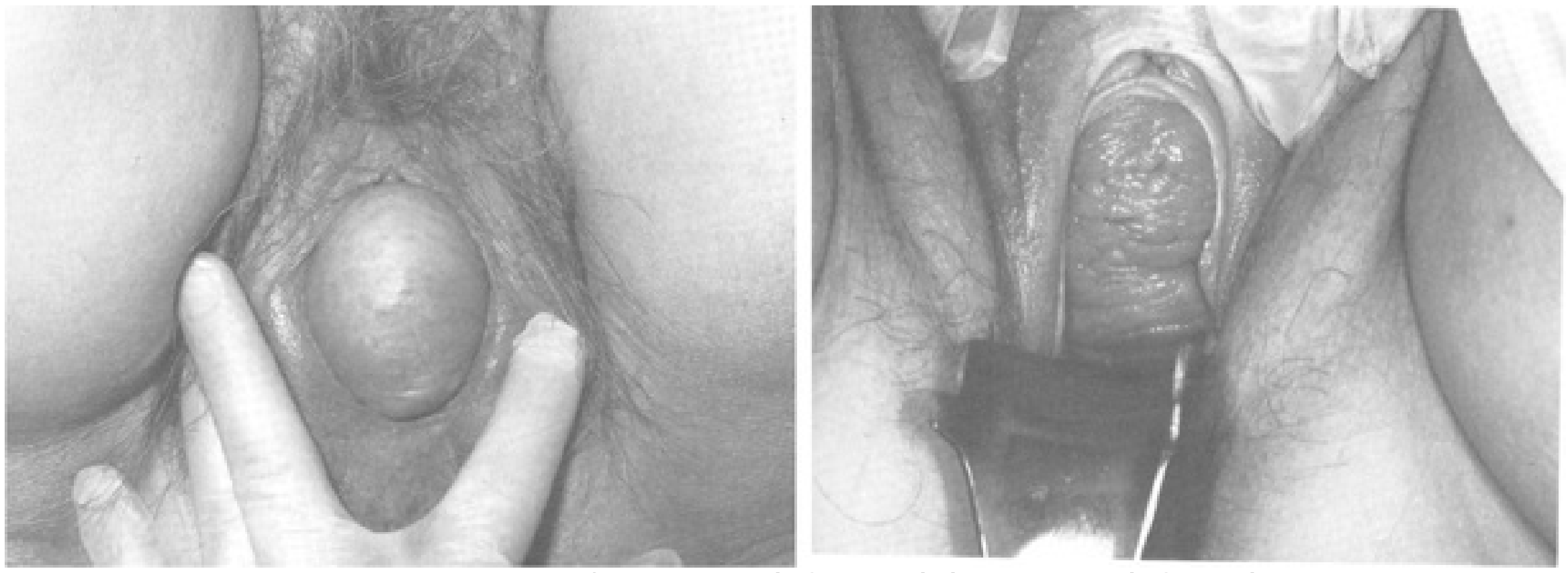

FIG. 124.1 Cystoceles. *Left,* Central defect. *Right,* lateral defect. (From Baggish M, Karram M: *Atlas of pelvic anatomy and gynecologic surgery,* ed 3, Philadelphia, 2010, Elsevier, p 645, Fig 53-3, 53-4.)

Anterior Colporrhaphy Technique (Fig. 124.2).

The patient is placed in the dorsal lithotomy position with all pressure points padded and the hip and knee joints flexed approximately 90 degrees. Fixed or handheld retraction can be helpful and generally depends on patient body habitus as well as availability of surgical staff for assistance. An indwelling urethral catheter is placed and the bladder is drained continuously throughout the procedure. Hydrodissection may be used to facilitate the dissection. A midline incision is made in the anterior vaginal wall, extending from the vaginal apex to the bladder neck. The incision should not extend to the urethra when a simultaneous MUS is anticipated. Optimally, the sling should be placed through a separate, mid-urethral incision. However, in performance of a pubovaginal sling, it is desirable to create one incision that extends from the vaginal apex to the mid-urethra to facilitate more precise sling positioning over the bladder neck. The vaginal wall is dissected off the pubocervical fascia starting in the midline and advancing laterally beyond the pubic rami. This dissection should allow sufficient visualization to delineate central and lateral defects. Allis clamps or a self-retaining ring retractor may be used to provide optimal exposure. The bladder is then reduced with a finger or instrument to facilitate lateral exposure and reapproximation of the lateral pubocervical tissues in the midline. Interrupted 2-0 or 3-0 delayed absorbable plication sutures are placed from the bladder neck to the apex in a sequential fashion. The plication sutures are then tied as the assistant reduces the prolapsed tissue. Care must be taken to avoid excessively deep suture placement that may penetrate the bladder or ureteral lumens or kink the distal ureters or intramural tunnels. Augmented repairs use allograft or mesh to reinforce the plication sutures (see the later discussion of augmented repairs). Excess anterior vaginal wall may be judiciously trimmed, and the anterior vaginal wall is closed with absorbable suture in a running fashion. After completion of the repair, indigo carmine or methylene blue is administered and cystoscopy is performed to inspect the bladder for iatrogenic injury and to visualize ureteral patency. Vaginal packing may be used to cover the surgical area and assist with hemostasis.

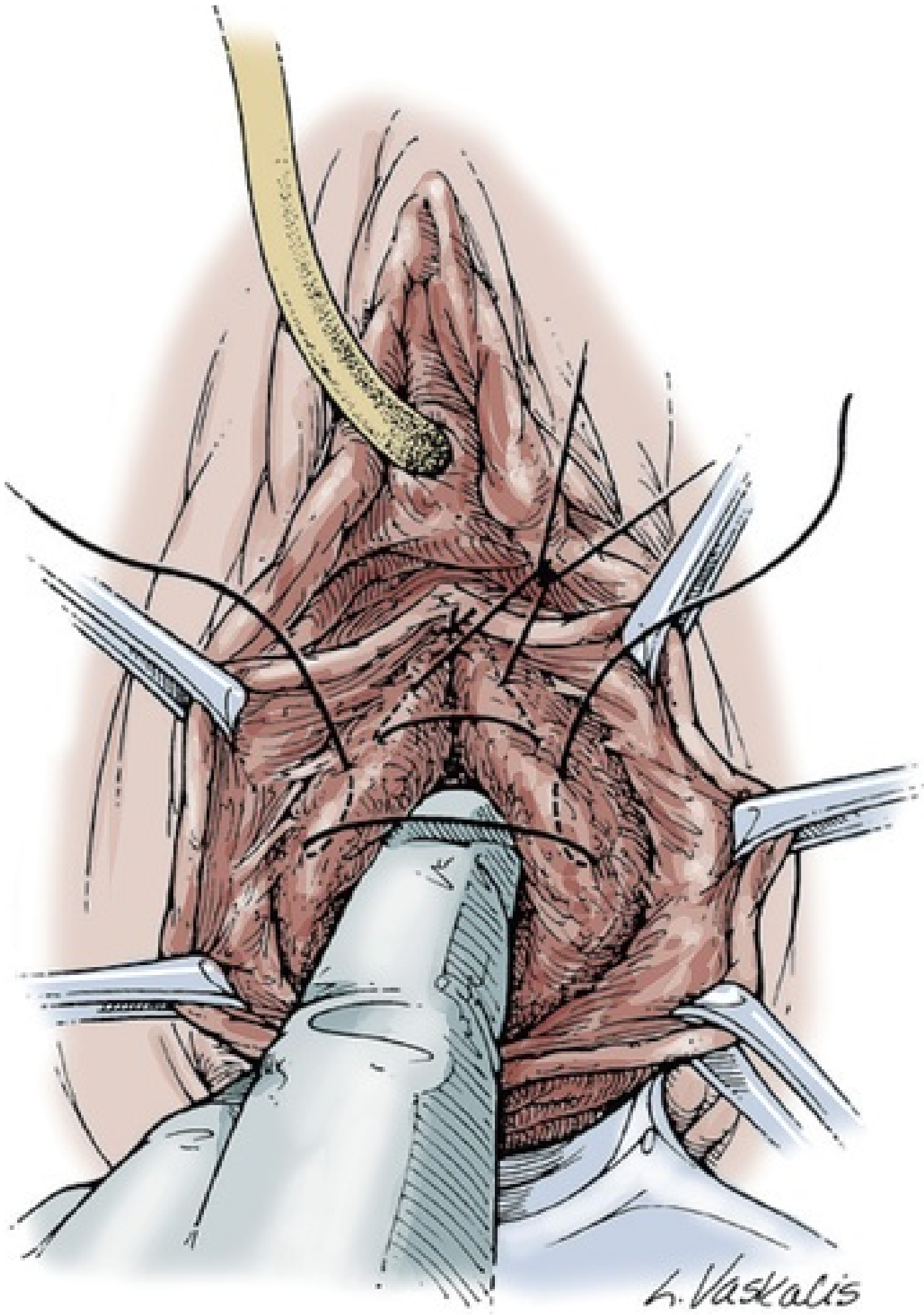

FIG. 124.2 Anterior colporrhaphy. The anterior fibromuscularis layer is imbricated with 2-0 delayed absorbable continuous or interrupted suture. (From Nicholas DH: Cystocele. In Nichols DH, editor: *Gynecologic and obstetric surgery,* St Louis, 1993, Mosby, pp 334–362.)

Anterior Colporrhaphy Repairs Results.

In earlier studies, the reported cure rate of anterior colporrhaphy was high (Table 124.3). In a large retrospective study looking at 299 patients with anterior vaginal wall prolapse, Porges and Smilen (1994) reported a recurrence rate of only 3%, with a mean follow-up of 31 months. In a prospective, randomized trial between Burch colposuspension and anterior colporrhaphy, Colombo et al. (2000) reported a recurrence rate again of only 3% in the 33 patients who underwent anterior colporrhaphy with a mean follow-up of 5 years. In contrast a retrospective secondary analysis study comparing anterior colporrhaphy alone to anterior colporrhaphy plus sling, anterior prolapse was noted in 42% of those who underwent anterior colporrhaphy alone versus 19% of those who had concomitant sling (Goldberg et al., 2001). In **series comparing anterior colporrhaphy with augmented repairs, reported recurrence rates for standard anterior colporrhaphy approach 40%, significantly higher than the earlier recurrence rates** (Table 124.4). Sand et al. (2001) reported on 161 women randomized to anterior colporrhaphy with polyglactin 910 (Vicryl) suture alone or anterior colporrhaphy with a free Vicryl mesh inlay placed under the trigone after plicating the pubocervical fascia. At 1 year, the women with Vicryl mesh inlay had a failure rate of 25% compared with 43% in women who underwent plication with suture alone (*P* = 0.02).

TABLE 124.3

Results of Anterior Compartment Repair Without Graft

AUTHOR	**YEAR**	***N***	**FOLLOW-UP**	**SUCCESS RATE**
ANTERIOR COLPORRHAPHY				
Stanton	1982	54	Up to 2 yr	85%
Macer	1978	109	5–20 yr	80%
Walter	1982	76	1.2 yr	100%
Porges	1994	388	2.6 yr	97%
Colombo	2000	33 AC 35 Colposuspension	8–17 yr 8–17 yr	97% 66%
Sand	2001	70 AC 73 AC+ Vicryl mesh	1 yr 1 yr	57% 75% No mesh complications
Weber	2001	57 AC	23 mo	37%
		26 AC+ Vicryl mesh	23 mo	42% No mesh complications
Iyer	2017	33 AC	7–10 yr	56%
		19 AC + Dermal graft		68%
VAGINAL PARAVAGINAL REPAIR				
White	1912	19	Up to 3 yr	100%
Shull	1994	62	0.6 yr	67%
Grody	1995	72	0.5–3 yr	99%
Elkins	2000	25	0.5–3 yr	92%
Mallipeddi	2001	45	0.6 yr	97%
Young	2001	100	11 mo	78%

Morse	2007	27 AC + VPVR	13	54%
		86 AC	24	45%
ABDOMINAL PARAVAGINAL REPAIR				
Richardson	1976	60	1.7 yr	97%
Richardson	1981	213	0.5–6 yr	95%
Shull	1989	149	0.5–4 yr	95%
Bruce	1999	27 APR and sling	17 mo	93%
		25 APR	17 mo	76%
Scotti	1998	40	39 mo	97%
Reid	2011	52 APR	10 yr	89%
		59 VPR		70%
Hosni	2013	20 APR	12 mo	
		20 VPR		
		5 LPR		
Minassain	2014	35 APR	2 yr	65%
		35 AC + Mesh		67%
ANTERIOR COLPORRHAPHY WITH SLING				
Goldberg	2001	53 AC and sling	1 yr	81%
		90 AC	1 yr	58%

AC, Anterior colporrhaphy; *APR*, abdominal paravaginal repair; *LPR*, laparoscopic paravaginal repair; *VPR*, vaginal paravaginal repair.

TABLE 124.4

Outcomes of Anterior Compartment Repair With Synthetic and Biologic Graft

GRAFT TYPE	STUDY (FIRST AUTHOR, YEAR)	N	MEAN F/U MONTHS	SUCCESS RATE (%)	POSTOPERA EVALUATIO
Mixed fiber mesh	Migliari, 1999	15	23.4	Mesh 93.3%	Baden-Walker
Polyglactin mesh	Weber, 2001	33 24 26	23.3	AC alone 30% Ultralat AC 46% AC + Mesh 42%	POP-Q
	Sand, 2001	70 73	12	AC alone 57%	Baden-Walker

				AC + Mesh 75%	
Polypropylene mesh	Nicita, 1998	44	13.9	Mesh 100%	SEAPI QMM Sca
	Migliari, 2000	12	20.5	Mesh 75%	Baden-Walker
	de Tayrac, 2002	48	18	Mesh 97.9%	POP-Q
	Dwyer, 2004	81	29	Mesh 92.6%	Baden-Walker
	Rodriguez, 2005	98	NR	AC + Mesh 84%	POP-Q
	de Tayrac, 2005	87	24	Mesh 91.6%	POP-Q
	de Tayrac, 2006	55	37	Mesh 89%	POP-Q
	Jo, 2007	35	18	AC + Mesh 94.3%	POP-Q
	Amrute, 2007	76	30.7	AC + Mesh 94.8%	Questionnaire
	de Tayrac, 2007	132	13	Mesh-Soft 93.2%	POP-Q
	Deffieux, 2007	89 49	32.1 7.1	Mesh 97% Mesh-Soft 92%	Baden-Walker
	Hiltunen, 2007	97 104	12	AC alone 61.5% AC + Mesh-Soft 93.3%	POP-Q
	Altman, 2008	78	2	Mesh 87%	POP-Q
	Sivaslioglu, 2008	42 43	12	AC alone 72% AC + Mesh-Light 91%	POP-Q
	Carey, 2009	61 63	12	AC alone 65.6% AC + Mesh 81%	POP-Q
	Nieminen, 2010	97 104	36	AC alone 59% AC + Mesh-	POP-Q

				Light 87%	
	Groutz, 2001	21	20.1	Fascia 100%	Baden-Walker
	Kobashi, 2002	132	12.4	Fascia 88.6%	Baden-Walker
	Chung, 2002	19	28	Fascia 89.5%	Baden-Walker
Cadaveric fascia	Clemons, 2003	33	18	AC + Fascia 59%	POP-Q
	Powell, 2004	19 39	22.8 28	Autolog Fascia 84.2% Fascia 79.5%	POP-Q
	Gandhi, 2005	78 76	13	AC alone 71% AC + Fascia 79%	POP-Q, Baden-W
	Frederick, 2005	251	60	Fascia 92.8%	Baden-Walker
	Ward, 2007	24	52	AC + Fascia 41.7%	POP-Q
	Gomelsky, 2004	70	24	Graft 87.1%	Baden-Walker
	Leboeuf, 2004	19 24	15	FDR + Graft 84.2% FDR 100%	SEAPI Test
	Salomon, 2004	27	14	Graft 85.2%	POP-Q
Porcine dermis	Wheeler, 2006	28	18.3	AC + Graft 50%	POP-Q
	Simsiman, 2006	89	24	Graft 78%	POP-Q
	Meschia, 2007	103 98	12	AC alone 81% AC + Graft 93%	POP-Q
	Handel, 2007	18 56 25	13.5	AC alone 94% AC + Graft 64% AC + Mesh 96%	Baden-Walker
Porcine	Natale,	94	24	Graft 56.4%	POP-Q

dermis—cont’d	2009	96		Mesh 71.8%	
	Hviid, 2010	26 28	12	AC alone 84.6% Graft 92.9%	POP-Q
	Menefee, 2011	24 26 28	24	AC 42% Porcine 54% Polypropylene 82%	POP-Q
	Guerette, 2009	27 17	24	AC alone 63% AC + Graft 76.5	POP-Q
	Feldner, 2010	27 29	12	AC 59.3% Porcine SIS 86.2%	POP-Q
Bovine pericardium					
Porcine SIS					

AC, Anterior colporrhaphy; *FDR,* four defect repair; *F/U,* follow up; *POP-Q,* pelvic organ prolapse-quantification; *SEAPI,* stress, emptying, anatomy, protection, and instability; *SIS,* small intestine submucosa.

Weber et al. (2001) compared anterior colporrhaphy reinforced with Vicryl mesh to traditional plication without tension using polydioxanone suture and “ultra-lateral” plication using polydioxanone suture and tension. In this study, 114 women with symptomatic cystoceles (mostly stages 2 and 3 on the pelvic organ prolapse-quantification [POP-Q]) were randomized among the three groups. With a mean follow-up of 23 months, there was no significant difference in failure rate (defined as stage 2 or greater on the POP-Q) among the three groups. The failure rate was 30% in those who underwent traditional plication, 46% in those who underwent ultra-lateral plication, and 42% in those who underwent traditional plication augmented with Vicryl mesh. Unfortunately, the study did not recruit enough women to achieve statistical power to detect differences among the groups. The results of this study still suggest, however, that there does not seem to be an advantage of one suturing technique over another for anterior colporrhaphy in terms of anatomic or symptomatic relief. As noted earlier, recent re-evaluation of the Weber dataset from 2001 revealed significantly better outcomes when applying failure as recurrent prolapse beyond the hymen (Chmielewski et al., 2011). Failure rates at 1 year were 11% in the traditional plication group, 23% in the ultra-lateral group, and 9% in the mesh augmented group, adding up to a combined objective recurrence rate of 12% with no statistically significant difference among groups. **Before the re-evaluation of this data, concern over high recurrence rates and lack of durability with anterior colporrhaphy led investigators to explore augmented repairs using biologic and non-biologic sources. A 2017 long-term follow-up study of 114 patients randomized to anterior colporrhaphy or ultra-lateral colporrhaphy with dermal graft found that after 7 to 10 years there was no statistical difference in success rates** (Iyer et al., 2018)**. However, a 2016 Cochrane review led by Maher looking at 33 trials composed of 3332 women concluded that biologic graft repair or absorbable mesh provides minimal advantage when compared with native tissue repair** (Maher et al., 2016b)**. They also found that native tissue repair was associated with increased awareness of prolapse and increased risk of repeat surgery for prolapse, as well as recurrence of anterior compartment prolapse, when compared with polypropylene mesh.**

Anterior Colporrhaphy Complications.

Reported complications from anterior colporrhaphy include de novo or occult SUI, de novo overactive bladder symptoms, postoperative urinary retention, incomplete bladder emptying, significant bleeding exceeding 350 mL, wound infection, bladder or ureteral injuries, vesicovaginal fistula, vaginal shortening, epithelial inclusion cyst, and dyspareunia. **De novo detrusor overactivity** can also occur in 5% to 7% of patients after standard colporrhaphy (Raz et al., 1991). Yet, **preexisting detrusor overactivity has also been reported to resolve in up to 63% of patients after surgical repair of POP** (Nguyen and Bhatia, 2001). In a secondary analysis of the Colpopexy and Urinary Reduction Efforts (CARE) trial, Davenport et al. (2017) found the incidence of de novo SUI after prolapse repair directly correlates to the degree of cystocele on preoperative examination. The incidence of de novo SUI based on the POP Quantification stage of anterior prolapse was 41.3%, 52.5%, and 66.1%, for stage 2, early stage 3, and advanced stage 3 or stage 4, respectively. Furthermore, point Ba was found to be significantly associated with de novo SUI on univariate (odds ratio [OR] = 1.17, $P = 0.015$) and multivariate analysis (OR = 1.16, $P = 0.04$). Urinary retention usually occurs in cases during which a concomitant anti-incontinence procedure was performed; however, retention or incomplete emptying may occur in the absence of anti-incontinence surgery and may be the result of neurologic trauma and impaired bladder contractility from the plication procedure. In most instances, the retention resolves after a brief period of clean intermittent catheterization (CIC). If the retention persists and the patient had a concomitant anti-incontinence procedure, a sling incision or urethrolysis may be required. When impaired bladder emptying is due to preexisting hypocontractility, the patient may require chronic CIC, neuromodulation, or, as a last resort, suprapubic tube drainage.

Bleeding during anterior colporrhaphy is usually due to the high vascularity of the vagina and to the venous complex beneath the inferior pubic bone. **During anterior colporrhaphy, problematic bleeding can occur if the dissection is carried out in the wrong plane. The vaginal wall should be dissected from the pubocervical fascia directly on its white, shiny surface.** In patients undergoing repeat anterior colporrhaphy, scarring often obscures the correct dissection plane. As such, these patients are at higher risk for bleeding.

Bladder or ureteral injuries are rare during standard anterior colporrhaphy. **Bladder injuries can occur when perforating into the retropubic space or during dissection of the vaginal flaps, especially in women with atrophic tissue. Ensuring proper bladder drainage before perforating the endopelvic fascia may reduce this.** Should an inadvertent bladder injury occur, a two-layer closure should be performed with absorbable suture. If the patient has a history of pelvic irradiation or if the repair quality seems tenuous, a labial fat pad interposition should be considered to prevent vesicovaginal fistula formation (Kreder, 1993). **Cystoscopy after the administration of indigo carmine should be routinely performed with every anterior colporrhaphy. If blue-stained urine is not seen effluxing from both ureteral orifices, ureteral catheterization, retrograde pyelography, or release of the plication sutures should be performed.** In some cases the ureter is patent, and an alternative reason, including inadequate fluid resuscitation or ureteral kinking, will explain the lack of efflux. Appropriate steps must be taken to ensure ureteral patency if the ureter cannot be catheterized.

Procedures for Lateral and Combined Defects

Vaginal Paravaginal Repair.

In his first description of a vaginal paravaginal repair, George White described a cystocele repair that involved suturing the lateral sulci of the vagina to the white line of the pelvic fascia in 1909 (White, 1997). White believed that the cause of a cystocele was weakness of the lateral vaginal attachments to the arcus tendineus fascia pelvis (ATFP). As Kelly's anterior colporrhaphy became the primary technique of cystocele repair for the next 70 years, White's concept fell into disfavor. In 1976 Richardson et al. reintroduced the paravaginal defect repair (PVdR), but he described the technique using an abdominal approach. Regardless of the approach, **the goal of a paravaginal repair is to repair a lateral compartment defect by reattaching the pubocervical fascia to the ATFP**. **A vaginal paravaginal repair may be combined with anterior colporrhaphy in patients with combined lateral and central defects.**

Technique (Fig. 124.3).

A midline vertical incision is made through the anterior vaginal wall from the bladder neck to the vaginal apex. After the vaginal wall is sharply dissected off the attenuated pubocervical fascia and bladder, the dissection is carried laterally to the pelvic sidewall. Blunt dissection can be used to facilitate this. Access to the pelvic sidewall is achieved by continued lateral dissection and perforation of the endopelvic fascia. Upon entry into the retropubic space, palpation is used to identify the ATFP as it courses from the ischial spine to the inferior aspect of the pubic ramus. Deep, lighted retractors may be useful to facilitate exposure. With the bladder retracted medially, multiple interrupted nonabsorbable sutures are placed at 1-cm intervals through the ATFP. A Capio Suture Capturing Device (Boston Scientific, Marlborough, MA) needle driver device may expedite placement of these sutures. We prefer the Capio Slim (Boston Scientific, Marlborough, MA). These sutures are then passed through the lateral edge of the detached pubocervical fascia. No sutures should be tied until all are placed on either one side or both sides (if bilateral defects). At this point, if indicated, central defect plication sutures may be placed to complete a combined repair. As with anterior colporrhaphy, cystoscopy must be performed to confirm ureteral patency and the absence of intravesical sutures. The vaginal wall is trimmed judiciously, if needed, and closed with a 2-0 absorbable suture. Vaginal packing is placed at the end of the case.

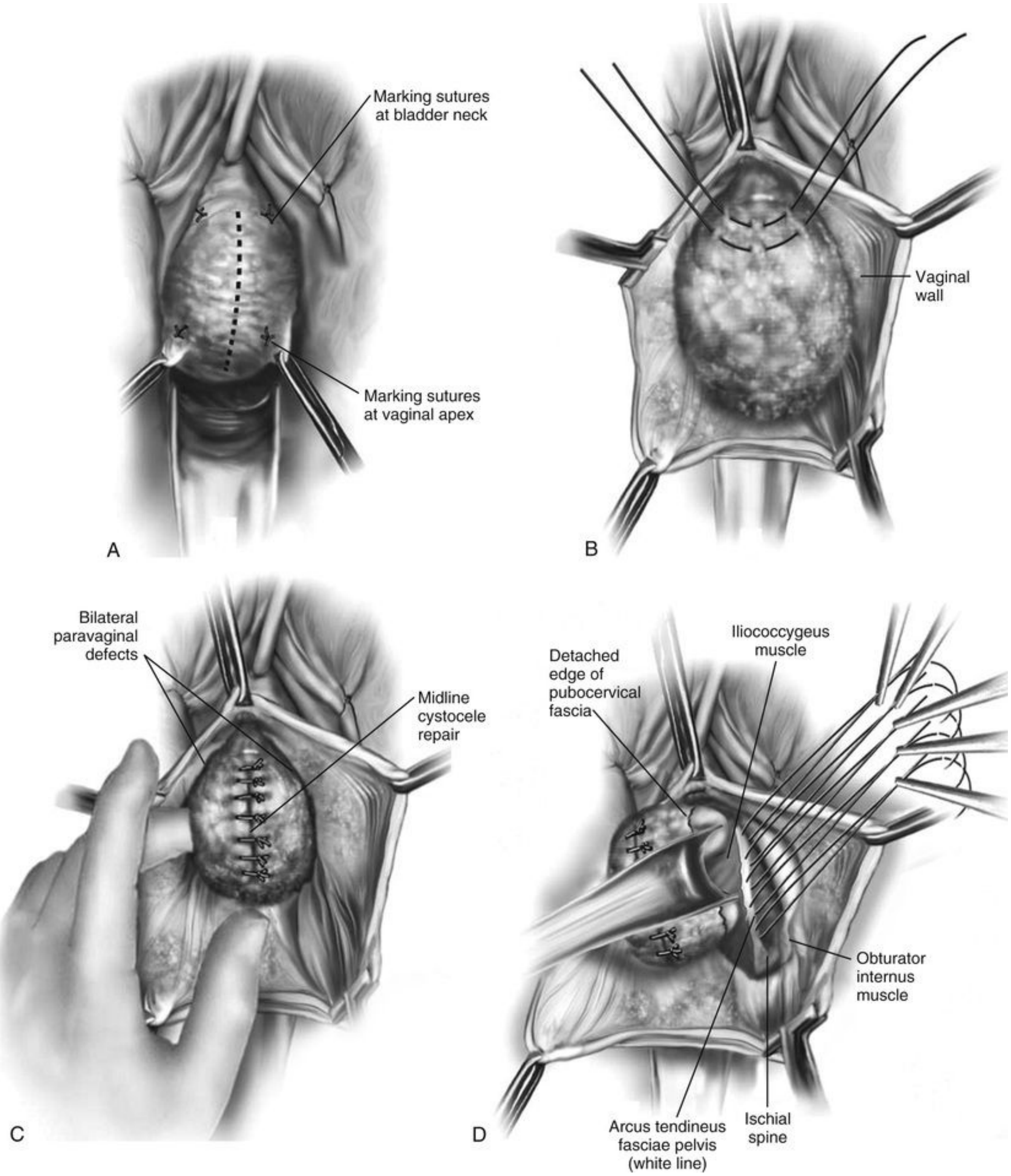
Marking sutures at bladder neck
Marking sutures at vaginal apex
A
Vaginal wall
B
Bilateral paravaginal defects
Midline cystocele repair
C
Detached edge of pubocervical fascia
Iliococcygeus muscle
Obturator internus muscle
Arcus tendineus fasciae pelvis (white line)
Ischial spine
D

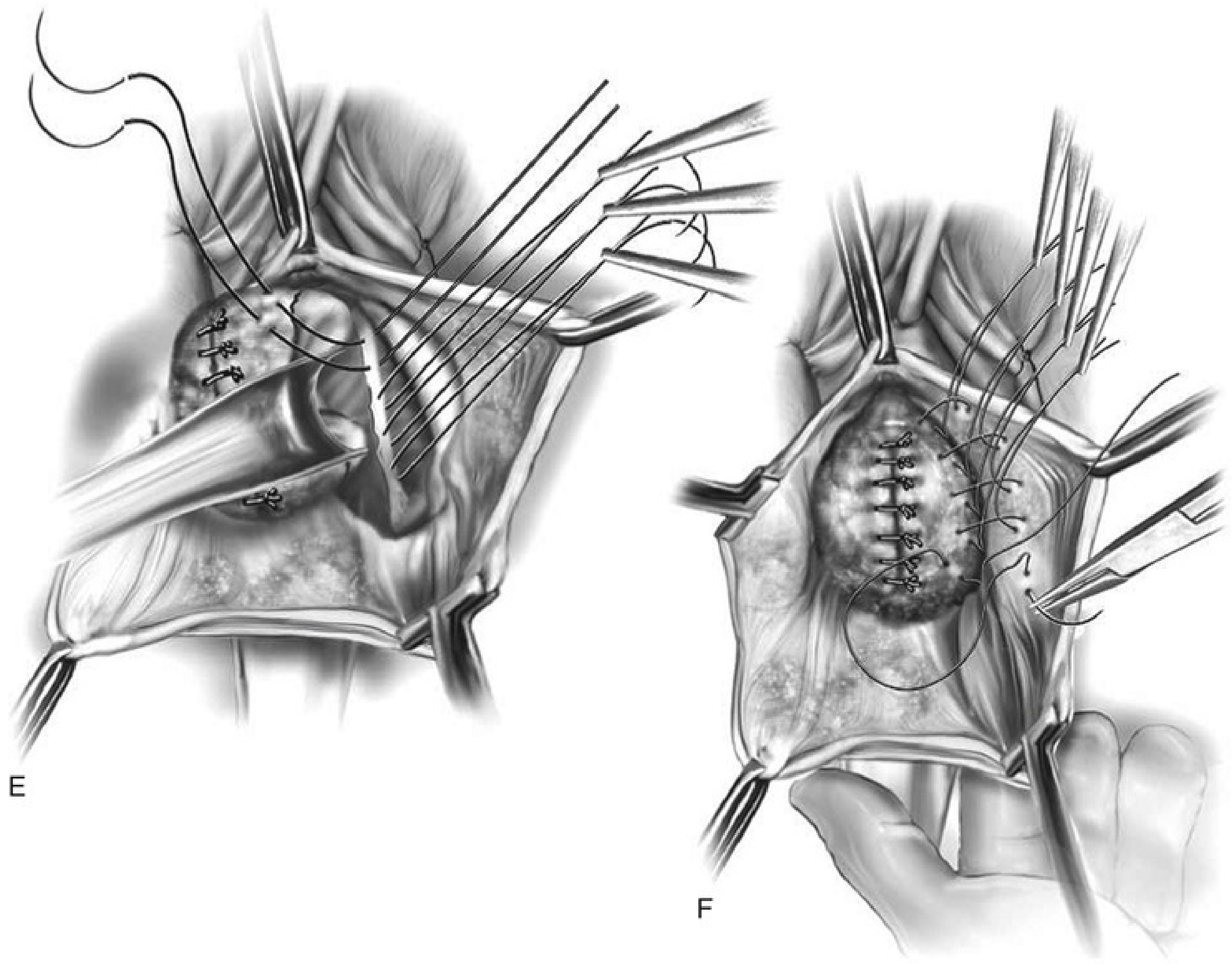

FIG. 124.3 Vaginal paravaginal repair. (A) Unopened anterior vaginal wall with marking sutures placed at anatomic level of bladder neck and vaginal apex. (B) Anterior vaginal wall opened via a midline incision. Sutures placed for midline cystocele repair. (C) Midline cystocele repair completed. Bilateral paravaginal defects identified. (D) Bladder retracted medially to expose lateral pelvic side wall. Permanent sutures have been passed through the white line. (E) Top two sutures have been passed through the detached edge of pubocervical fascia. (F) Three-point closure is completed with all sutures passed through the pubocervical fascia and inside wall of the vagina. (From Baggish M, Karram M: *Atlas of pelvic anatomy and gynecologic surgery,* ed 3, Philadelphia, 2010, Saunders.)

Vaginal Paravaginal Repair Results (See Table 124.3).

Shull et al. (1994) reported successful repair without any evidence of prolapse 73% of 41 patients after a mean follow-up of 1.6 years. Of the 15 recurrences, only 4 developed prolapse to or through the hymen, and in these 4 the prolapse was less than what was noted preoperatively. Grody et al. (1995) reported a 99% success rate in 72 patients 0.5 to 3 years after vaginal paravaginal repair. Elkins et al. (2000) reported an 8% lateral cystocele recurrence rate and a 22% central cystocele recurrence rate 0.5 to 3 years after vaginal paravaginal repair in 25 patients with grade 3 or greater anterior wall vaginal prolapse. Midline central defects were common, leading surgeons to perform joint repairs with an anterior colporrhaphy. Young et al. (2001) retrospectively evaluated 100 patients with symptomatic grades 2 to 4 combined central and lateral cystoceles. All 100 patients underwent vaginal paravaginal repair and concomitant anterior colporrhaphy. With a mean follow-up of 11 months, the lateral cystocele recurrence rate was only 2%, and the central cystocele recurrence rate was 22%. Mallipeddi et al. (2001) reported a 3% central cystocele recurrence 20 months after vaginal paravaginal repair in 35 patients with grades 2 to 4 anterior vaginal wall prolapse. Of the 21 patients with concomitant SUI, 12 (57%) had persistent SUI after the paravaginal repair. **The paravaginal repair, like standard anterior colporrhaphy, is ineffective in the treatment of SUI.**

A retrospective analysis of patients undergoing anterior colporrhaphy alone versus anterior colporrhaphy plus paravaginal defect repair reports no statistically significant differences between the groups in either subjective or objective outcome measures (Morse et al., 2007).

Although complications after vaginal paravaginal repair are infrequent, they are significant. Young et al. (2001) reported 21 major complications, including 3 major intraoperative hemorrhagic complications. Two patients developed lower extremity neuropathy; one was in the lithotomy position for a prolonged period of time. Elkins et al. (2000) reported a transfusion rate of 12%. Mallipeddi et al. (2001) reported 2 patients with vaginal abscesses that required drainage, 1 patient with retropubic hematoma who required re-exploration, and 1 patient with bilateral ureteric obstruction, which resolved after takedown of the repair and suture replacement.

The vaginal paravaginal repair as described is technically more challenging than the standard anterior colporrhaphy. Complication rates are higher and usually more serious. In addition, the conventional vaginal paravaginal repair relies on suture placement through weakened pubocervical fascia. To compensate for these factors, most surgeons describe transvaginal correction of lateral defects using placement of grafts, which are attached to the pelvic sidewalls bilaterally.

Anterior Compartment Repairs Using Grafts Technique

The incision and dissection into the retropubic space are carried out in a similar manner as in the vaginal paravaginal repair. Once access to the pelvic sidewall is achieved, the bladder is retracted medially, and 2 or more sutures (permanent or delayed absorbable) are placed into the arcus tendineus fascia pelvis and/or obturator internus fascia, which will serve as adequate lateral fixation for the graft. The graft material may also be anchored distally to the bladder neck and apically to the cervix, bladder, or vaginal wall. A Capio Suture Capturing Device (Boston Scientific, Marlborough, MA) may expedite placement of these sutures (Fig. 124.4). Before the graft is fashioned, it is useful to estimate the distance between the proximal and distal ipsilateral sutures and the distance between the sutures on each side. These measurements determine the dimensions of the graft material, which is trimmed to size. At this point, central plication sutures may be performed. The previously placed pelvic sidewall sutures are then brought out to the corresponding locations on the graft. The sutures are then tied, securing the graft to the pelvic sidewall. It is useful to leave the sutures long until after cystoscopy confirms patency of the ureters. The vaginal wall is judiciously trimmed, if needed, and closed with a 2-0 absorbable suture. Vaginal packing is placed at the end of the case.

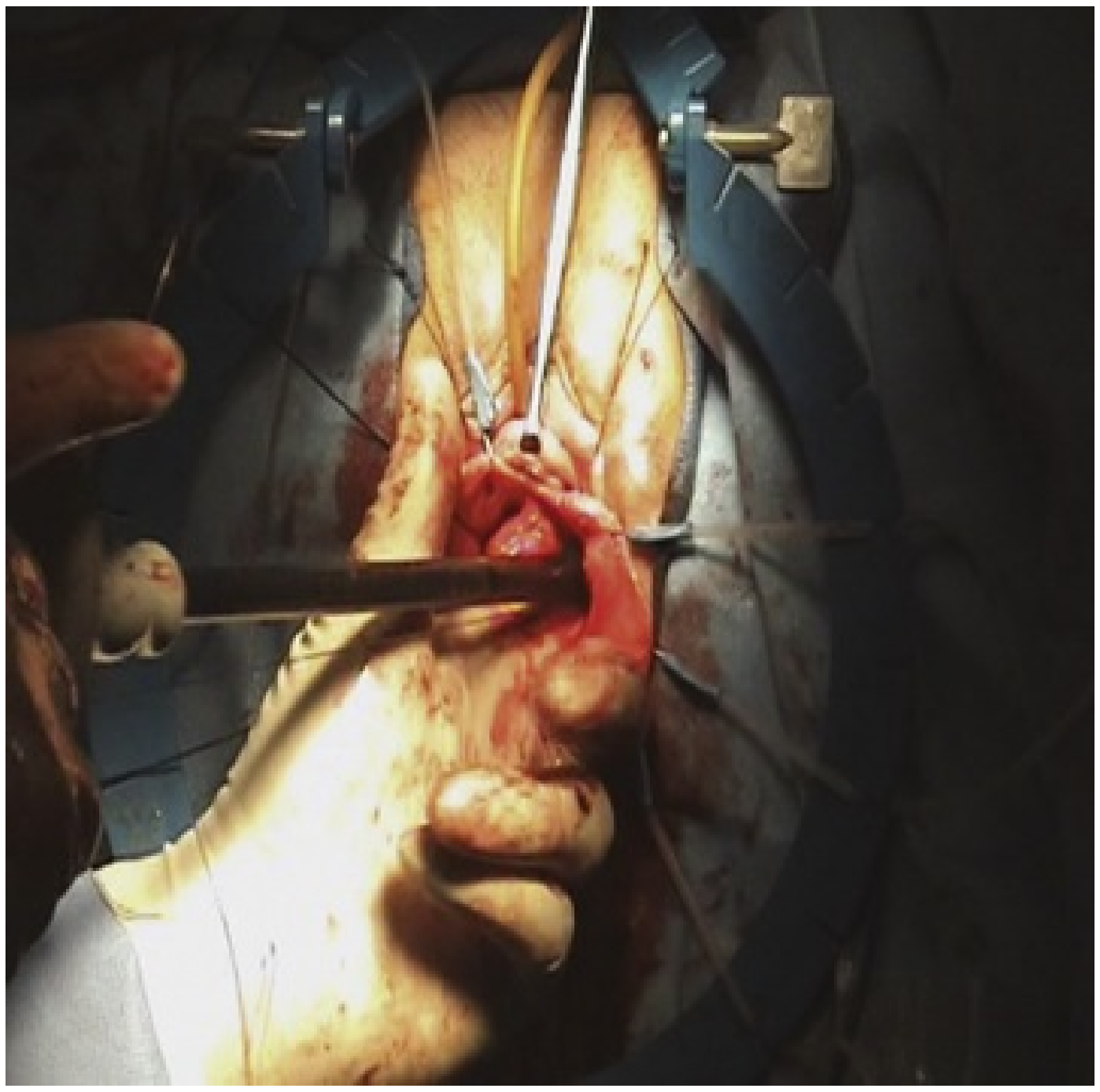

FIG. 124.4 Capio needle driver used to facilitate suture placement in the arcus tendineus fascia pelvis. (Courtesy Victor Nitti.)

Anterior Polypropylene Mesh Results

Nicita (1998) described the use of polypropylene mesh for the treatment of anterior vaginal wall prolapse (see Table 124.4). He sutured the mesh to the anterior aspect of the arcus tendineus fascia pelvis on each side using 3-0 Prolene sutures. With 2 years of follow-up, only 3 of the 44 patients (7%) had prolapse recurrence. The only patient that developed dyspareunia had vaginal mesh extrusion (exposure), and this was managed with mesh trimming and vaginal closure. Several subsequent studies using polypropylene mesh reported variable success ranging from 76% to 98% (de Tayrac et al., 2002, 2005, 2006; Salvatore et al., 2002; Sivaslioglu et al., 2008). de Tayrac et al. in 2002 described placement of polypropylene mesh (Gynemesh, Ethicon) into the retropubic space in a tension-free fashion without suture fixation. The lateral extensions of the mesh were placed in contact with the arcus tendineus fascia pelvis and anchored with a transobturator approach. A total of 48 women with grade 3 and 4 cystoceles underwent this procedure. After a mean follow-up of 18 months, the authors reported an anatomic success rate of 97.9%. Vaginal mesh extrusion was noted in 8.3%. In a subsequent series with 87 women and with 24 months of follow-up, de Tayrac again used Gynemesh and found that 77 women (88.5%) were cured of their symptomatic anterior vaginal wall prolapse, defined as POP-Q stage 0 or 1 (de Tayrac et al., 2005). Of the 7 patients with recurrent cystoceles, 5 were asymptomatic. Vaginal mesh extrusion was again noted in 8.3%, and the de-novo dyspareunia rate was 16.7%.

In a prospective study of 98 patients with stage 3 or 4 cystoceles, Rodríguez et al. (2005) attached a 5- × 5-cm piece of polypropylene mesh to the obturator internus fascia using 2-0 polyglactin suture after repair of the central defect with horizontal mattress sutures of 3-0 polyglactin sutures **(Fig. 124.5)**. All patients underwent a distal urethral polypropylene sling regardless of any SUI symptoms. The researchers reported an 85% anatomic success rate, defined as stage 0 or 1. Three patients who did not report SUI before the procedure developed mild de novo SUI after the procedure. Overall QoL associated with genitourinary symptoms improved from 4.7 (unhappy) to 1 (pleased) ($P < 0.005$).

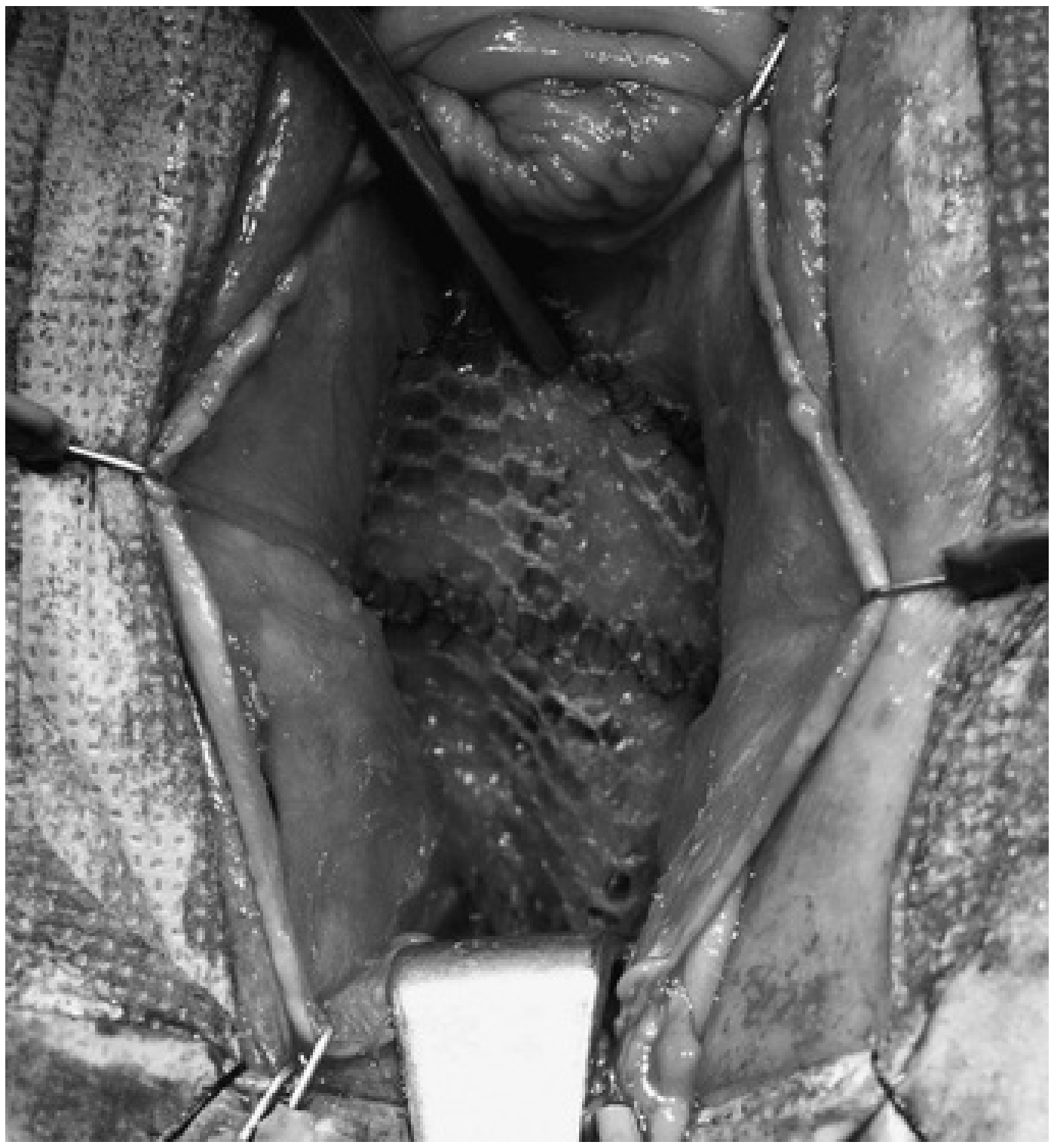

FIG. 124.5 Anterior compartment repair with polypropylene mesh graft. Polypropylene mesh is anchored to the sacrouterine ligament at the bladder base, laterally to the obturator fascia, and distal to the bladder neck using 2-0 polyglactin suture. (From Rodriguez LR, Bukkapatnam R, Shah SM, et al.: Transvaginal paravaginal repair of high-grade cystocele central and lateral defects with concomitant suburethral sling: report of early results, outcomes, and patient satisfaction with a new technique. *Urology* 66[Suppl 5A]:57–65, 2005).

Carey et al. (2009) reported on 139 women randomized to mesh augmented anterior and posterior repair versus anterior and posterior colporrhaphy. No statistical difference in outcomes was noted with either objective or subjective measures. De novo dyspareunia rates were equal in the groups. Vaginal mesh exposure occurred in 5.6%.

In a randomized controlled trial (RCT) of 202 women with anterior vaginal wall prolapse, Nieminen et al. (2010) compared anterior colporrhaphy (*n* = 97) to the same procedure reinforced with low-weight polypropylene mesh (*n* = 105) (Hiltunen et al., 2007). After 3 years of follow-up, the addition of the polypropylene mesh to the anterior repair did statistically decrease the risk of recurrent stage 2 or greater anterior prolapse. **Recurrence was noted in 14 of 105 women in the mesh group versus 40 of 97 women in the group with no graft ($P < 0.0001$). However, there was no statistically significant difference in symptomatic outcomes (pelvic pressure, vaginal bulge, or difficulty with**

bladder emptying) between the groups. Importantly, 18 patients in the mesh group (17.3%) had vaginal extrusion (exposure) of the mesh.

The 2013 Cochrane review reported that standard anterior repairs were associated with more postoperative anterior wall prolapse than polypropylene mesh repairs (relative risk [RR] 3.15; 95% confidence interval [CI] 2.50–3.96) and a higher rate of subjective failure (28% vs. 18%, RR 1.62, 95% CI 1.22–2.14) (Maher et al., 2013)**. Additional prolapse surgery was not more common in the anterior colporrhaphy group, and no differences in QoL data or de novo dyspareunia were identified. De novo SUI was greater in the mesh repair group (RR 1.8, 95% CI 1.0–3.1). The cumulative mesh erosion rate was 11.4%, and the reoperation rate to correct the erosion was 6.8%. Little has changed with this data in the 2016 Cochrane review other than concluding that the rate of de novo SUI was essentially equal between the two groups with few or no differences** (RR 0.67, 95% CI 0.44–1.01) (Maher et al., 2016b).These finding as well as an increased awareness of the severity of complications of using vaginal mesh for prolapse has led to the near abolition of the use of transvaginal mesh patch interposition or mesh kits.

Alteration of the vaginal axis with compensatory prolapse in an untreated compartment has been well reported. Development of apical and or posterior prolapse (stage 2 or greater) after an anterior repair with mesh was seen in 46% of 150 women (Withagen et al., 2010). Pooled analysis of two studies that reported de novo prolapse after anterior repair (Nieminen et al., 2010; Vollebregt et al., 2011) showed a lower rate after anterior colporrhaphy versus anterior mesh repair (9.5 vs. 17.7%, RR 0.49, 95% CI 0.24–0.97).

Anterior Repair With Cadaveric Fascia Results

Cadaveric fascia lata with or without pubovaginal sling has shown efficacy rates of 81% to 100% for the treatment of anterior vaginal wall prolapse (Frederick and Leach, 2005; Groutz et al., 2001; Kobashi et al., 2000; Powell et al., 2004; see Table 124.4). Kobashi et al. (2000) first described the cadaveric prolapse repair and sling procedure (CaPS) as combined treatment of symptomatic cystocele and SUI. The procedure was performed transvaginally using a 6- × 8-cm piece of cadaveric fascia lata and bone anchors. Groutz et al. (2001) treated 21 women with cadaveric fascia lata anchored to the ATFP bilaterally and the cardinal and uterosacral ligaments apically (Fig. 124.6). In a larger study (*n* = 251) with a mean follow-up of 2 years after CaPS, Frederick and Leach (2005) noted a symptomatic cystocele recurrence rate of only 7%. The cured or dry rate for SUI was only 56%, with most of the failures occurring beyond 1 year; the authors questioned the long-term efficacy of the sling portion of the procedure.

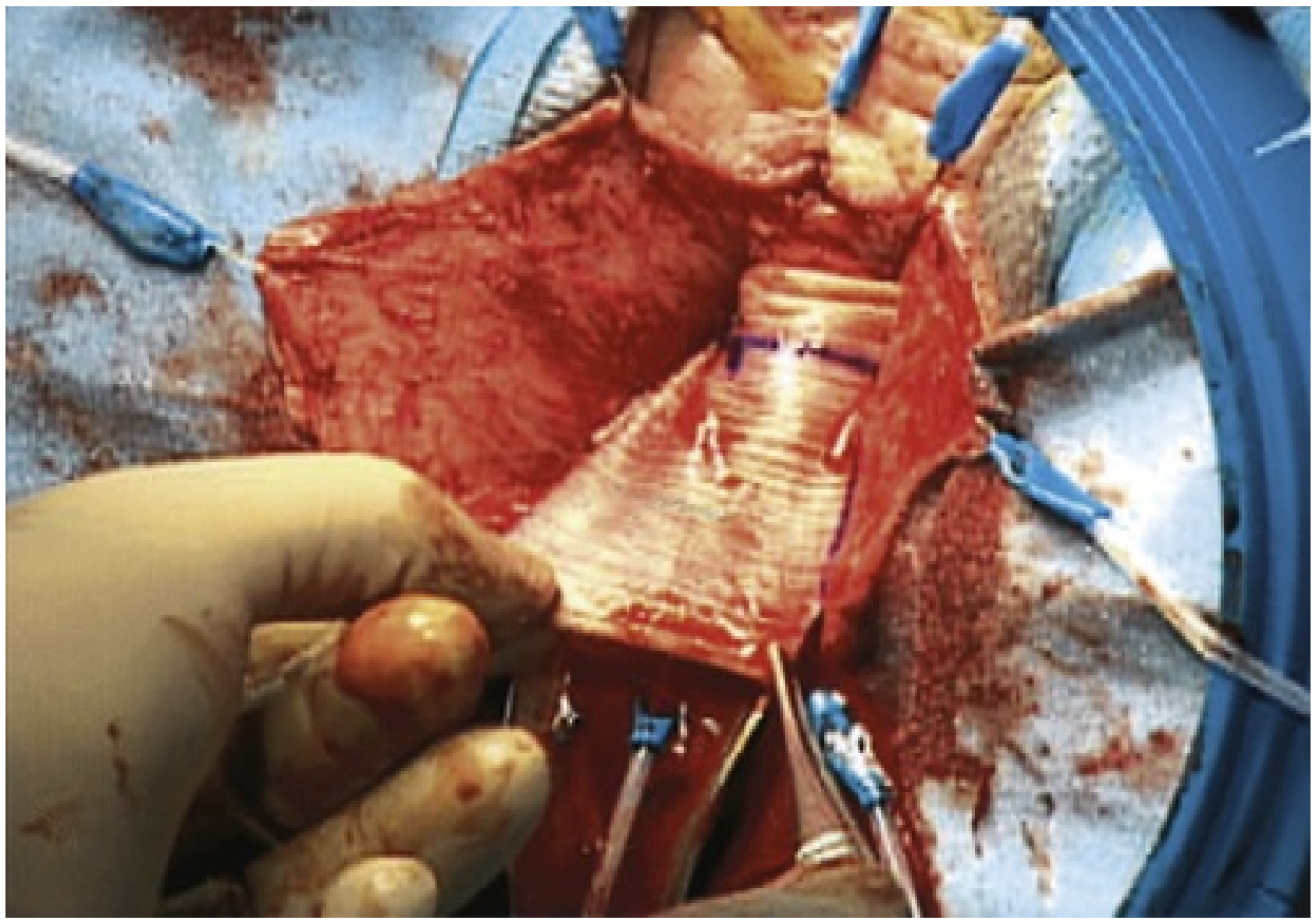

FIG. 124.6 Anterior compartment repair with cadaveric fascia graft. Cadaveric fascia patch was tailored appropriately. Typically a 5- × 7-cm patch is more than adequate. (From Groutz A, Chaikin DC, Theusen E, et al.: Use of cadaveric solvent-dehydrated fascia lata for cystocele repair—preliminary results. *Urology* 58:179–183, 2001.)

Gandhi et al. (2005) published a prospective RCT ($n = 162$) comparing ultralateral anterior colporrhaphy with 0 polyglactin suture to the same colporrhaphy reinforced with cadaveric fascia lata in women with grade 2 or greater anterior vaginal wall prolapse. The addition of the fascia lata patch to the anterior repair did not statistically decrease the risk of recurrent prolapse ($P = 0.23$). Of the 39 patients with recurrent prolapse, 26 (67%) were asymptomatic. Concomitant transvaginal Cooper ligament sling was associated with a significant decrease in recurrent prolapse (odds ratio [OR] 0.015, $P < 0.0001$).

Cadaveric dermis has been used in the treatment of anterior compartment prolapse with efficacy of 42% to 84% at 2 years of follow-up (Behnia-Willison et al., 2007; Chung et al., 2002; Clemons et al., 2003; Ward et al., 2007). Chung et al. (2002) described anchoring the proximal portion of the 3- × 7-cm graft to the uterosacral-cardinal ligament complex and the using the distal portion as the sling. Patients with lateral and paravaginal defects were excluded. Clemons et al. (2003) described a vaginal paravaginal repair using cadaveric dermis in 33 women with recurrent stage 2 or with primary or recurrent POP-Q stage 3 or 4 cystoceles. The 3- × 7-cm graft was positioned over the bladder base and secured to the ATFP with four sutures of 2-0 braided permanent polyester sutures bilaterally. **An updated 2016 Cochrane review concluded that biologic grafts provided no difference in awareness of prolapse** (RR 0.98, 95% CI 0.52–1.82) **or need for repeat surgery for prolapse when compared with traditional anterior repair** (RR 1.02, 95% CI 0.53–1.97). **Interestingly, they found that biologic grafts probably increased the risk of recurrent anterior compartment prolapse** (RR 1.32, 95% CI 1.06–1.65) (Maher et al., 2016b).

Anterior Repair With Porcine Dermis Results

The majority of clinical experience in the use of xenografts for POP has been with porcine dermis (see Table 124.4). Pelvicol (C.R. Bard) is acellular cross-linked porcine dermis (Chen et al., 2007). Gomelsky et al. (2004) reported favorable, durable outcomes using a 6- × 8-cm piece of porcine dermis sutured laterally to the ATFP to correct high-grade cystoceles (Fig. 124.7). In a retrospective review of 70 patients, 61 (87%) had no cystocele recurrence after a mean follow-up of 24 months. Of the 9 patients (13%) with recurrent cystoceles, none were symptomatic. One patient had superficial vaginal wound separation, which was treated with conservative measures.

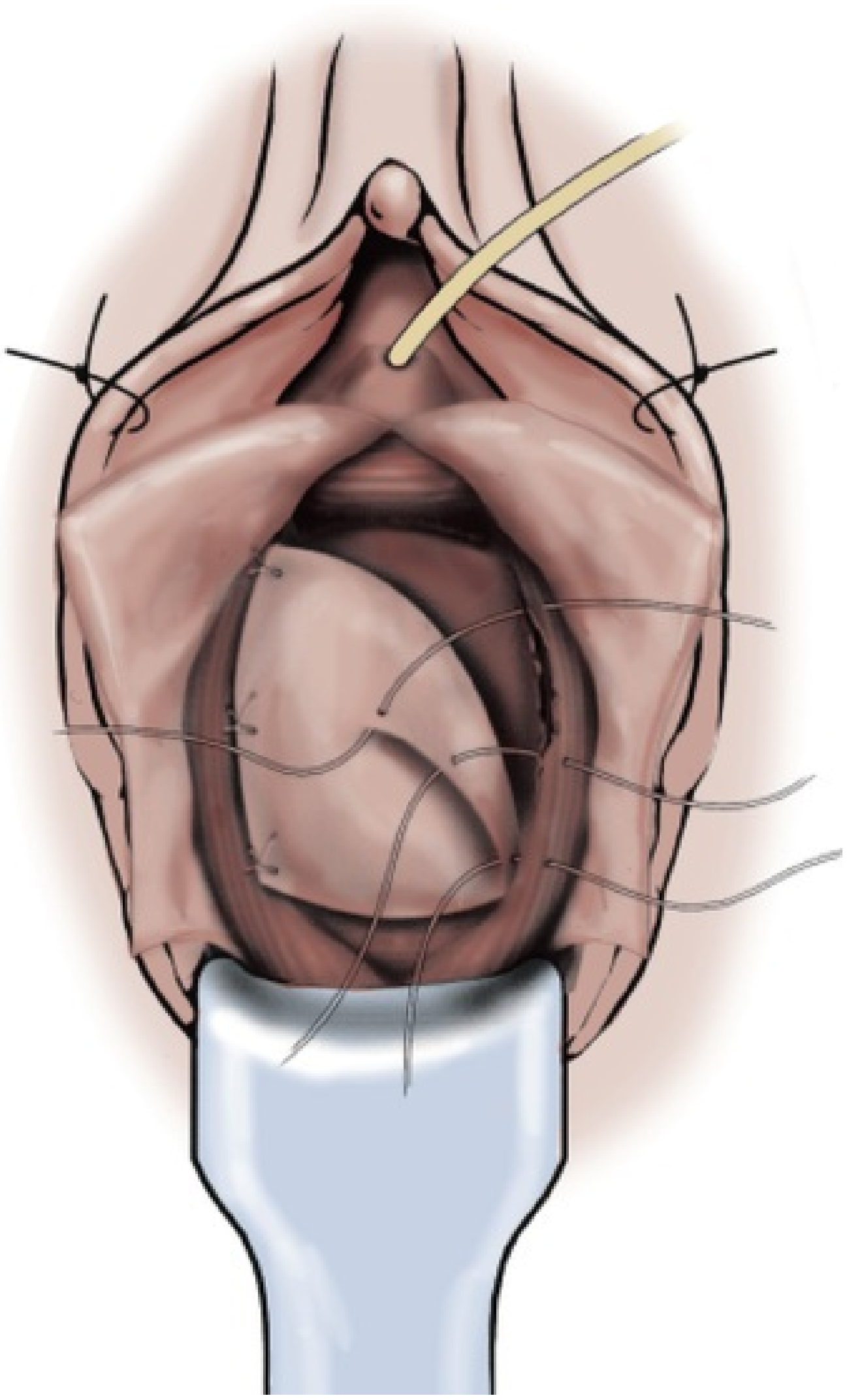

FIG. 124.7 Anterior compartment repair with porcine dermis graft. Three pairs of delayed absorbable sutures are inserted into the arcus tendineus fasciae pelvis and into the porcine dermis patch. (From Gomelsky A, Rudy DC, Dmochowski RR: Porcine dermis interposition graft for repair of high grade anterior compartment defects with or without concomitant pelvic organ procedures. *J Urol* 171:1581–1584, 2004.)

Meschia et al. (2007) published a prospective RCT comparing anterior colporrhaphy with 0 polyglactin suture (*n* = 103) versus the same colporrhaphy reinforced with a 4- × 7-cm piece of Pelvicol (*n* = 98) in women with stage 2 or greater anterior vaginal wall prolapse as defined by POP-Q. After 1 year of follow-up, the women randomized to receive the Pelvicol graft failed 7% of the time compared with the 19% failure rate in those women who underwent the anterior colporrhaphy alone (*P* = 0.019). One patient who received the Pelvicol graft had vaginal extrusion of the material 1 month after surgery. There were no differences between the 2 groups in the incidence of postoperative dyspareunia.

Handel compared two different grafts (polypropylene mesh [*n* = 25] and porcine dermis [*n* = 56]) versus traditional anterior colporrhaphy with suture alone (*n* = 18) (Handel et al., 2007). For patients undergoing repair with a graft, it was anchored to the levator fascia bilaterally and to the uterosacral-cardinal ligament complex apically. With a mean follow-up of 13.5 months, there was no significant difference in failure rate (defined as grade 2 or greater) among the 3 groups. There was a 21% rate of vaginal extrusion of the porcine dermis.

SIS has also been compared with colporrhaphy alone in an RCT (*N* = 57) (Feldner et al., 2010). The SIS group had 86.2% anatomic cure versus 59.3% in the colporrhaphy groups (*P* = 0.03). Both operations significantly improved QoL without differences noted between the groups. No infections or erosion were discovered.

Biologics Versus Mesh Results

Natale et al. (2009) performed a prospective randomized trial (*N* = 190) comparing polypropylene mesh (Gynecare) to porcine dermis (Pelvicol) in women with recurrent anterior wall prolapse. Objective cure was 71.9% in the mesh group and 56.4% in the porcine dermis group (*P* = 0.06). No difference in subjective cure was noted; however, a better impact of surgery on sexual function was reported in the porcine group. Mesh erosion occurred in 6.3% of the mesh group, and no erosion was seen with porcine dermis (*P* = 0.03).

Menefee et al. (2011) performed a randomized clinical trial comparing anterior colporrhaphy, vaginal paravaginal repair using porcine dermis, and vaginal paravaginal repair with self-styled polypropylene mesh. Two-year follow-up was completed on 78 of 99 (79%) enrolled subjects. Mesh repairs had the lowest anatomic failure rate (18%), followed by porcine (46%, *P* = 0.015), then colporrhaphy (58%, *P* = 0.002). Subjective improvement in prolapse and voiding scores were similar, and composite failure was no different among groups (4% mesh, 12% porcine, 13% colporrhaphy). Mesh erosion was reported in 14% and porcine erosion in 4% (*P* = 0.413).

A 2013 Cochrane review concluded that objective failure rates were higher with colporrhaphy alone than with the use of biologic graft (RR 2.08, 95% CI 1.08–4.01) (Maher et al., 2013). **Subjective cure rates were not different between groups. When the data was re-examined for the 2016 Cochrane review, it was seen again that objective failure rates were higher with colporrhaphy alone than with the use of polypropylene mesh** (RR 3.01, 95% CI 2.52–3.60) **or a biologic graft** (RR 1.32, 95% CI 1.06–1.65) (Maher et al., 2016b).

Mesh-Related Complications

Vaginal exposure (extrusion) has been reported in anterior compartment prolapse repair with most materials. In 21 trials on mesh-augmented repairs summarized in a Cochrane review, the mean mesh extrusion rate was 11.4% (64 of 563) with 6.8% (32 of 470) undergoing surgical intervention for the extrusion (Maher et al., 2013). **Reoperation rates for prolapse, QoL measures, and de novo dyspareunia were no different in women undergoing native tissue repair versus mesh repair** (Maher et al., 2013). **Dyspareunia has also been reported in 3.1% to 19% of patients with anterior colporrhaphy** (Dwyer and O'Reilly 2004; Milani et al. 2005; Yan et al., 2004). **Blood loss (mean difference [MD] 64 mL, 95% CI 48–81), operating time (MD 19 min, 95% CI 16–21), recurrences in apical or posterior compartment (RR 1.9, 95% CI 1.0–3.4), and de novo stress urinary incontinence (RR 1.8, 95% CI 1.0–3.1) were significantly higher with mesh repair than with native tissue repair.**

Other Procedures to Correct Anterior Compartment Defects

Abdominal Paravaginal Repair Technique (Fig. 124.8).

The patient is positioned and prepped to allow abdominal and vaginal access. The bladder is drained. The retropubic space is entered through either a low midline or transverse incision. In addition, the approach may be accomplished laparoscopically or robotically. The bladder neck, symphysis pubis, endopelvic fascia, ATFP, and obturator fascia should be clearly identified. The site of normal vaginal attachment on the pelvic sidewall from the interior aspect of the superior pubic ramus to the ischial spine is then identified. The surgeon's nondominant hand is placed into the vagina and used to elevate the lateral superior vaginal sulcus to its site of normal attachment along the course of the ATFP. With the bladder retracted medially, multiple interrupted nonabsorbable sutures are placed at 1-cm intervals through the ATFP, extending from the ischial spine to the pubic bone. These sutures are then placed in the appropriate location in the lateral wall of the vagina. Care is taken to avoid paravaginal veins, which commonly course through this area. Elevating the vagina to its normal anatomic position to localize suture placement site may facilitate vaginal suture placement. After the sutures are tied, cystoscopy must be performed to confirm ureteral patency and the absence of intravesical sutures. The incision is closed, and the catheter is left indwelling.

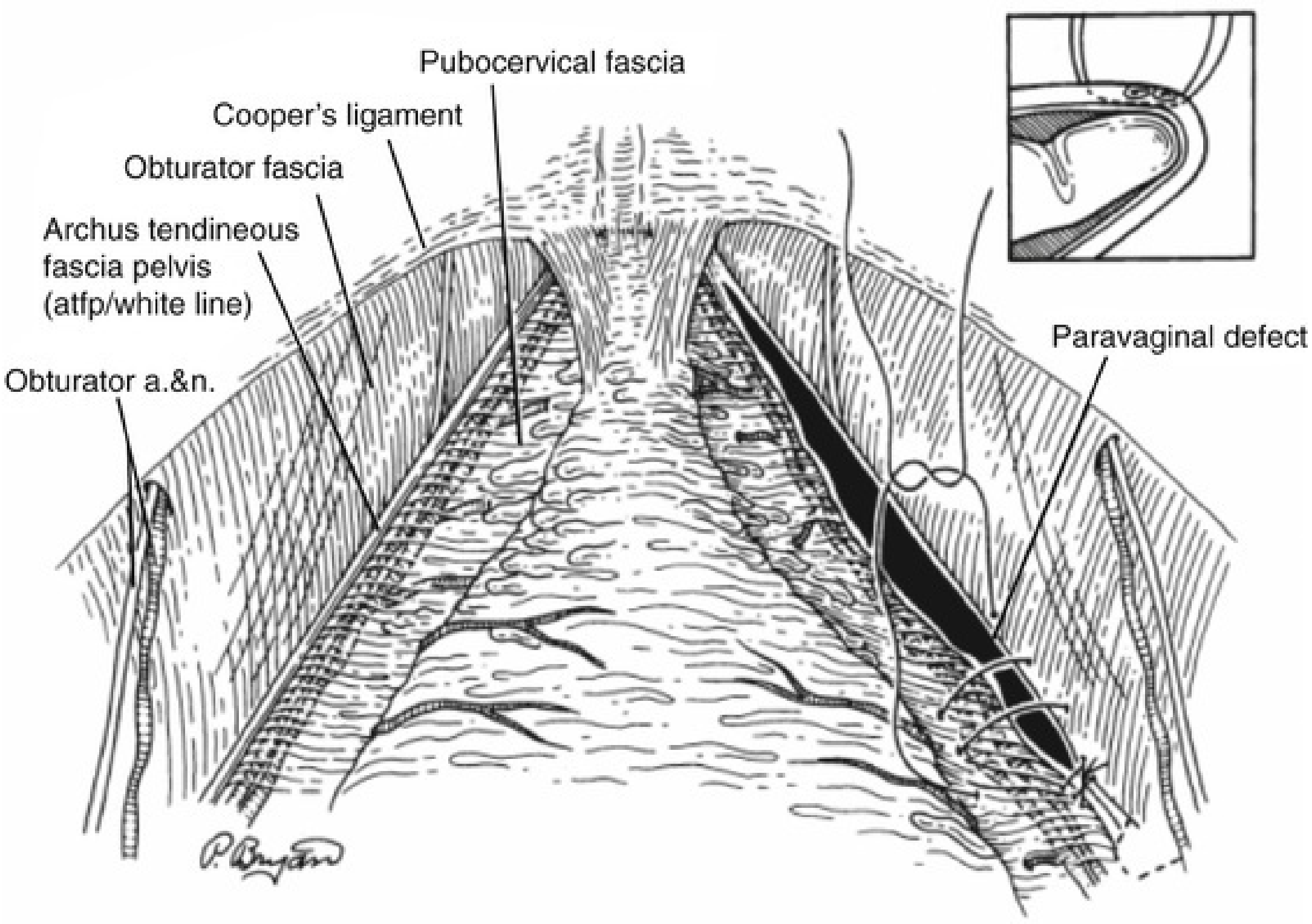

FIG. 124.8 Abdominal paravaginal repair. Paravaginal defect repair as viewed from the retropubic space: approximation of the pubocervical fascia medially to the arcus tendineus fascia pelvis laterally with 2-0 braided nonabsorbable suture. Note the vertical orientation of the vaginal vessels in relation to the transverse orientation of the bladder vessels. *Inset* shows suture being passed beneath the vaginal vessels to ensure generous purchase of pubocervical fascia and control of hemostasis. (From Bruce RG, El-Galley R, Galloway NT: Paravaginal defect repair in the treatment of female stress urinary incontinence and cystocele. *Urology* 54:647–651, 1999.)

Abdominal Paravaginal Results (See Table 124.4).

Richardson et al. (1976) popularized the abdominal paravaginal defect repair. In a retrospective study of 233 patients with follow-up spanning 2 to 8 years, Richardson et al. (1981) reported an anatomic cure rate of 95%. Of these patients, 53 (23%) had previously undergone 1 or more anterior vaginal wall prolapse repairs. No patient required transfusion. Eighty-eight percent of the women with preoperative SUI were cured after abdominal paravaginal repair.

Other authors published the results of case series that demonstrated similar encouraging anatomic results and SUI cure rates of 85% to 97% after abdominal paravaginal repair (Baden and Walker, 1987). **However, recent evidence over the last 15 years suggests that abdominal PVdR is not as effective as either the Burch colposuspension or suburethral sling for the treatment of SUI.** In 2000 Colombo et al. published the results of a randomized trial comparing PVdR with Burch colposuspension for the treatment of SUI in 18 patients. With a mean follow-up of 2.2 years, the objective (urodynamic) cure rates were 100% for Burch colposuspension and 61% for abdominal PVdR. Colombo found that Burch colposuspension increased the functional urethral length and pressure-transmission ratio in the proximal urethra, whereas the abdominal paravaginal repair did not. Bruce et al. (1999) examined the abdominal PVdR in the treatment of women with both lateral cystocele and symptomatic SUI. In this retrospective cohort of 52 patients, half underwent abdominal PVdR and half underwent abdominal PVdR with pubovaginal sling using rectus fascia. All the patients who underwent concomitant sling procedures had intrinsic sphincter deficiency (ISD). With a mean follow-up of 17 months, 4 patients (8%) had recurrent cystocele, 3 patients developed vault prolapse, and 1 patient developed an enterocele. Thus the overall prolapse cure rate was 85%. Finally, the overall cure rate for SUI was 72% in the group that underwent PVdR alone and 85% in the group that underwent PVdR and pubovaginal sling procedures. Comparing their results with abdominal and vaginal PVdR, Reid et al. (2011) found the 10-year durability was better with their abdominal approach ($N = 52$) than their vaginal approach ($N = 59$) with patients having a greater chance of remaining prolapse free in the long term (46 out of 52 [88.5%] vs. 41 out of 59 [69.5%]) (95% CI 1.029–2.708, $P = 0.038$). Interestingly no anatomic failure occurred after 38 months, inferring that site-specific repair by either route has curative potential. Symptom resolution was equivalent for all. Hosni et al. in a 2013 prospective study looked at the effectiveness of the abdominal, vaginal, and laparoscopic approaches for a PVdR. The results from 45 women found no statistical difference between the abdominal ($N = 20$) and vaginal ($N = 20$) approaches, but they had to abandon the laparoscopic ($N = 5$) approach because of the lack of improvement in prolapse stage (Hosni et al., 2013). In a 2014 RCT comparing anterior repair with vaginal mesh ($N = 35$) versus abdominal PVdR

(*N* = 35), Minassian et al. (2014) found at 2 years that success rates for both groups (<stage 2 POP) were similar, with most objective failures being asymptomatic.

Anterior Compartment Repair With Sling.

In patients with high-stage anterior compartment prolapse, the descent may create urethral kinking and urethral compression (Gallentine and Cespedes, 2001) (Fig. 124.9). This compression may prevent leakage of urine despite poor urethral function, thereby unmasking SUI after prolapse correction. Documenting the presence of SUI in patients with the prolapse reduced is helpful in the preoperative planning of women with high-stage anterior compartment prolapse. **SUI occurring in presumably continent women after prolapse correction is known as stress incontinence on prolapse reduction, formerly known as occult SUI. It is essential for women with high-stage prolapse to undergo an evaluation with the prolapse reduced to identify those are at risk for SUI.** In four prospective studies POP repair in clinically continent women was shown to result in postoperative SUI in 8.3% to 66.1% (Ballert et al., 2009; Borstad and Rud 1989; Davenport et al., 2017; Stanton et al., 1982).

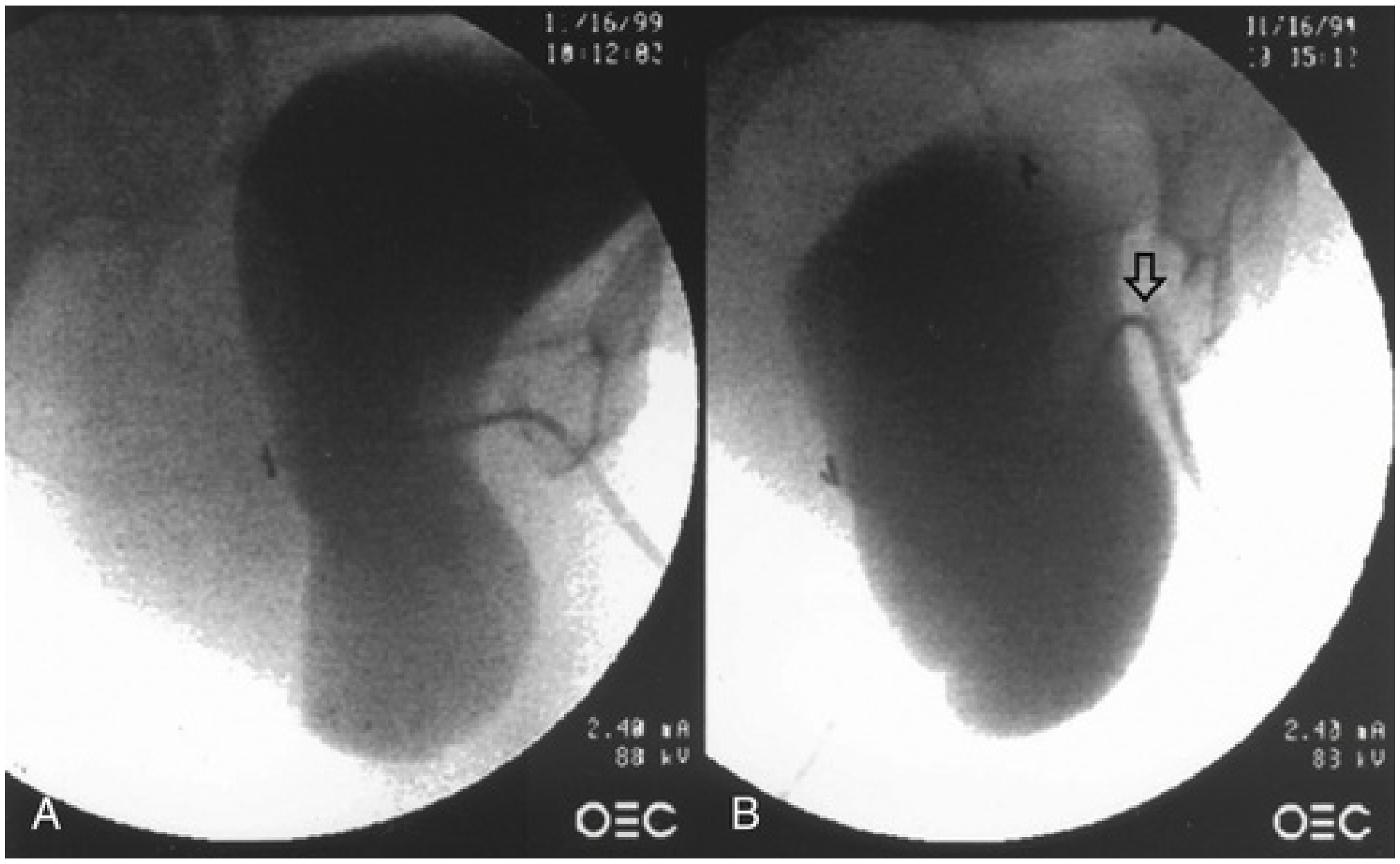

FIG. 124.9 Urethral kinking caused by large (grade IV) cystocele. Fluoroscopic imaging of the bladder demonstrating a large cystocele before (A) and after (B) Valsalva maneuver was performed. The urethra *(at arrow)* can clearly be seen to “kink” with the Valsalva. The patient did demonstrate

severe SUI after prolapse reduction. (From Gallentine ML, Cespedes RD: Occult stress urinary incontinence and the effect of vaginal vault prolapsed on abdominal leak point pressures. *Urology* 57:40–44, 2001.)

To diagnose SUI on prolapse reduction, the prolapse may be reduced with vaginal packing, rectal swabs, a speculum blade, or pessary. Ghoniem et al. (1994) used a vaginal pack (formed from two rolled 4 × 4 gauze pads) to reduce large cystoceles and found occult SUI in 69% of the women. They found that the vaginal pack provided superior visualization of the vesicourethral angle during fluoroscopic urodynamics. Gallentine used gauze packing and a speculum blade to reduce high-stage POP and found occult SUI in at least 50% of the women with high-stage anterior compartment prolapse (Gallentine and Cespedes, 2001). Using a fitted vaginal pessary, Chaikin et al. (2000) detected occult SUI in 58% of the women. They also noted that none of the women had urethral obstruction after pessary placement. There are multiple techniques used to reduce prolapse, and these methods are not standardized. This has led to variance in the reported incidence of “occult SUI” (Haessler et al., 2005). Veronikis et al. (1997) compared prolapse reduction with rectal swabs, Gellhorn pessary, and a Grave speculum blade. Because prolapse reduction with rectal swabs revealed a significantly lower mid-urethral closure pressure, these authors concluded that the rectal swabs were superior. **Sensitivity and specificity data are lacking with all of the methods used to reduce POP. Accordingly, no method for prolapse reduction has been proven to be superior.**

Performing a concomitant sling at the time of anterior vaginal wall prolapse repair in women without symptoms of SUI or SUI on prolapse reduction remains controversial. Twiss et al. (2007) recommended a simultaneous anti-incontinence procedure at the time of high-stage POP repair because they contend there is no correlation between the preoperative position of the urethra using any method of cystocele reduction and the ultimate position of the urethra after surgery. Thus they contend that the diagnosis of SUI on prolapse reduction is inconsistent and not reproducible. Consequently, SUI on prolapse reduction could be missed. Other authors argue that potential complications from the placement of a concomitant sling equal the risk of SUI on prolapse reduction, and therefore it should offered as a second-stage procedure in those whose incontinence cannot be demonstrated preoperatively (Ballert et al., 2009). Ballert et al. (2009) evaluated a protocol to assess the concomitant placement of MUS at the time of vaginal prolapse surgery. They performed urodynamic testing on 140 women with POP; if SUI was seen, they recommended concomitant sling with prolapse surgery. If no SUI was seen, they repeated the testing with prolapse reduction using a pessary. Again, if occult SUI was demonstrated, they recommended a sling with prolapse surgery. Using this protocol, they found an equal risk of intervention as a result of obstruction from an MUS (8.5%) and intervention for postoperative SUI in a patient without clinical, urodynamic, or occult SUI who did not undergo concomitant sling (8.3%). Therefore the risk of intervention resulting from sling obstruction was equal to the risk of intervention resulting from SUI when no clinical, urodynamic, or occult SUI was present preoperatively and no MUS was placed. Because the need to intervene for complications resulting from MUS equaled the risk of having to perform a secondary sling procedure, the necessity for a secondary surgery in women without SUI after repair of anterior vaginal wall prolapse is not decreased. The risk of intervention in those with clinical symptoms of SUI, but no urodynamic or SUI on prolapse reduction, was 30%.

It has also been reported that a concomitant suburethral sling may contribute to the long-term success of anterior compartment repairs. Goldberg et al. (2001) demonstrated a 55% reduction in postoperative cystocele recurrence in patients who underwent suburethral sling at the time of prolapse repair. Also, Cross et al. (1997) reported that the support created by the simultaneous placement of a pubovaginal sling in grades 3 and 4 cystoceles was improved.

The Colpopexy And Urinary Reduction Efforts (CARE) trial was the first large, randomized, controlled trial evaluating a simultaneous anti-incontinence procedure with POP repair (Brubaker et al., 2006). The investigators evaluated 322 patients with stage 2 to 4 POP who underwent abdominal sacrocolpopexy (ASC), of whom 157 were randomized to concomitant Burch colposuspension and 165 were randomized to ASC alone. The addition of a Burch colposuspension to ASC decreased postoperative SUI from 44.1% to 23.6% at 3 months postoperatively. In a subsequent study examining 2-year outcomes in the same group of patients, the authors found that 32% of patients who underwent concomitant Burch colposuspension were incontinent versus 45% of patients who underwent abdominal sacrocolpopexy alone (Brubaker et al., 2008). Approximately one-third of the women after Burch still had SUI. The Extended CARE (E-CARE) trial enrolled 213 of the original 322 participants with 181 completing 5 years of follow-up and 121 completing 7 years (Nygaard et al., 2013a,b). By year 7, the estimated probability of SUI in the urethropexy group was 62% and 77% in the non-urethropexy group. The time to treatment failure for SUI was longer in the urethropexy group.

Wei and colleagues for the Pelvic Floor Disorders Network (2012) reported on 337 women enrolled in the Outcomes Following Vaginal Prolapse Repair and Mid-Urethral Sling (OPUS) trial. Women with stage 2 or higher POP without symptoms of SUI underwent randomization for a concomitant MUS or sham at the time of vaginal prolapse surgery. At 12 months, urinary incontinence was present in 27% of sling patients and 43% of sham ($P = 0.002$). Higher rates of adverse events were seen in the sling group (bladder perforation, urinary tract infection, bleeding, incomplete bladder emptying; $P \leq 0.05$ for all). There was no difference noted between groups in patient-reported pelvic floor symptoms (Wei et al., 2012).

In summary, there is no standardization of testing for occult SUI. **However, it is clear that all women with advanced-stage anterior compartment prolapse should be screened for the presence of SUI with the prolapse reduced, and consideration should be given to a concomitant anti-incontinence procedure. All women with preoperative symptoms of SUI, occult SUI, or urodynamically proven SUI are at elevated risk of postoperative SUI and should consider a simultaneous anti-incontinence procedure. The risks and benefits of a prophylactic anti-incontinence procedure on continent women should be reviewed with each patient. It is our view that current literature supports selective use of an anti-incontinence procedure at the time of POP repair.**

Key Points: Anterior Compartment Repair

- Anterior compartment defects can be central, lateral, or combined. A central defect results from midline separation or attenuation of the pubocervical (perivesical) fascia. A lateral defect results when the pubocervical fascia detaches from the ATFP.
- Most anterior compartment defects have concomitant lateral and/or apical defects; isolated anterior colporrhaphy is not recommended when additional defects are present.
- Anterior compartment prolapse repair does not suspend the vaginal apex. Patients with anterior compartment and apical prolapse need concomitant repairs that address each defect.
- Anatomic results after anterior repair are improved by the addition of

biologic and synthetic grafts. However, graft complications may occur. Subjective results appear unchanged with the addition of biologic grafts but are improved with the addition of synthetic grafts. QoL measures, reoperation for prolapse, and dyspareunia rates are unchanged by the addition of synthetic mesh. The risk-benefit ratio of graft use must be thoroughly discussed with the patient.

- Anterior colporrhaphy and paravaginal repairs are ineffective alone in the treatment of SUI.
- All women with advanced-stage anterior compartment prolapse should be screened for occult SUI with prolapse reduction, and the risks and benefits of a concomitant anti-incontinence procedure should be discussed with the patient.

Apical Compartment

Middle compartment defects commonly involve the vaginal apex. The organs involved in defects of the middle compartment include the uterus, bowel, or omentum, and depending on the size, bladder and rectum. **The apex remains the cornerstone of vaginal support, and failure to ensure apical support at the time of prolapse correction will undoubtedly increase the risk of recurrence exponentially. Surgical correction can be approached vaginally, abdominally, and minimally invasively with and without uterine preservation.**

Apical Vaginal Vault Prolapse Repairs via Uterosacral Ligament Suspension

The uterosacral vault suspension preserves the orientation of the vaginal axis in its natural position, thus potentially preventing recurrence of prolapse in other segments (Silva et al., 2006). Several authors have reported that the uterosacral ligaments break at specific points rather than an attenuation of the uterosacral cardinal ligament complex, thus allowing for a more site-specific repair (Barber et al., 2000; Jenkins, 1997; Shull et al., 2000). These findings are in contrast to a histologic assessment of the uterosacral ligaments, which calls into question the integrity of this structure for long-term apical support (Cole et al., 2006).

Surgical Anatomy of the Uterosacral Ligaments.

The ligament is attached broadly to S1-S3, variably to S4 (Buller et al., 2001; see Figs. 124.9 and 124.10**)**. It proceeds in a fanlike manner anterolaterally to the cervical os and also onto the proximal portion of the posterior vagina. The ligament can be divided into three portions: the sacral, intermediate, and cervical portions. Beneath the sacral portion of the ligament runs the superior gluteal vein. Although there is great variability in the location of the ureter relative to the ischial spine (Karram et al., 2001), the ureter has been reported to be near the anterior margin of the uterosacral ligament near the cervix. As the ureter courses distally, the distance between the uterosacral ligament and ureter decreases from 4 cm near the sacrum to 0.9 cm near the cervix (Buller et al., 2001). Because of the fibrous tissues of the ureteral sheath, the ureter is subject to kinking from traction caused by sutures placed in the adjacent tissue (Dwyer and Fatton, 2008). If sutures are placed close to the sacrum, there is a risk of entrapping fibers of the sacral plexus trunk of S1-S4 (Siddique et al., 2006; Wieslander et al., 2007). This can result in buttock pain, which radiates to the posterior thigh and popliteal fossa. In a cadaveric study of uterosacral anatomy, Maldonado et al. (2017) concluded that the ischial spine is the most useful pelvic landmark and that increased S3 nerve injury may result from suture placement beyond the mean distance of 4.6 cm from the ischial spine in the direction of the path of the uterosacral ligament cephalad toward the sacrum. **Placing sutures in the intermediate portion of the uterosacral ligament appears to be the optimal site because there are fewer structures to be potentially affected and it provides a stable point of fixation. There is decreased chance of traction affecting the ureter at this point, because it is further away from the ureter and its sheath. Placing the sutures from lateral to medial will also minimize accidentally catching either the ureter or its attachments in the stitch** (Shull et al., 2000). The intermediate segment can be located 1 cm posterior along the palpable uterosacral ligament at the level of the ischial spine with the uterosacral ligament placed on tension (Buller et al., 2001). An advantage of suspension to the uterosacral ligament is that it minimizes injury to the pudendal and gluteal vessels relative to SSL fixation (Barber et al., 2000).

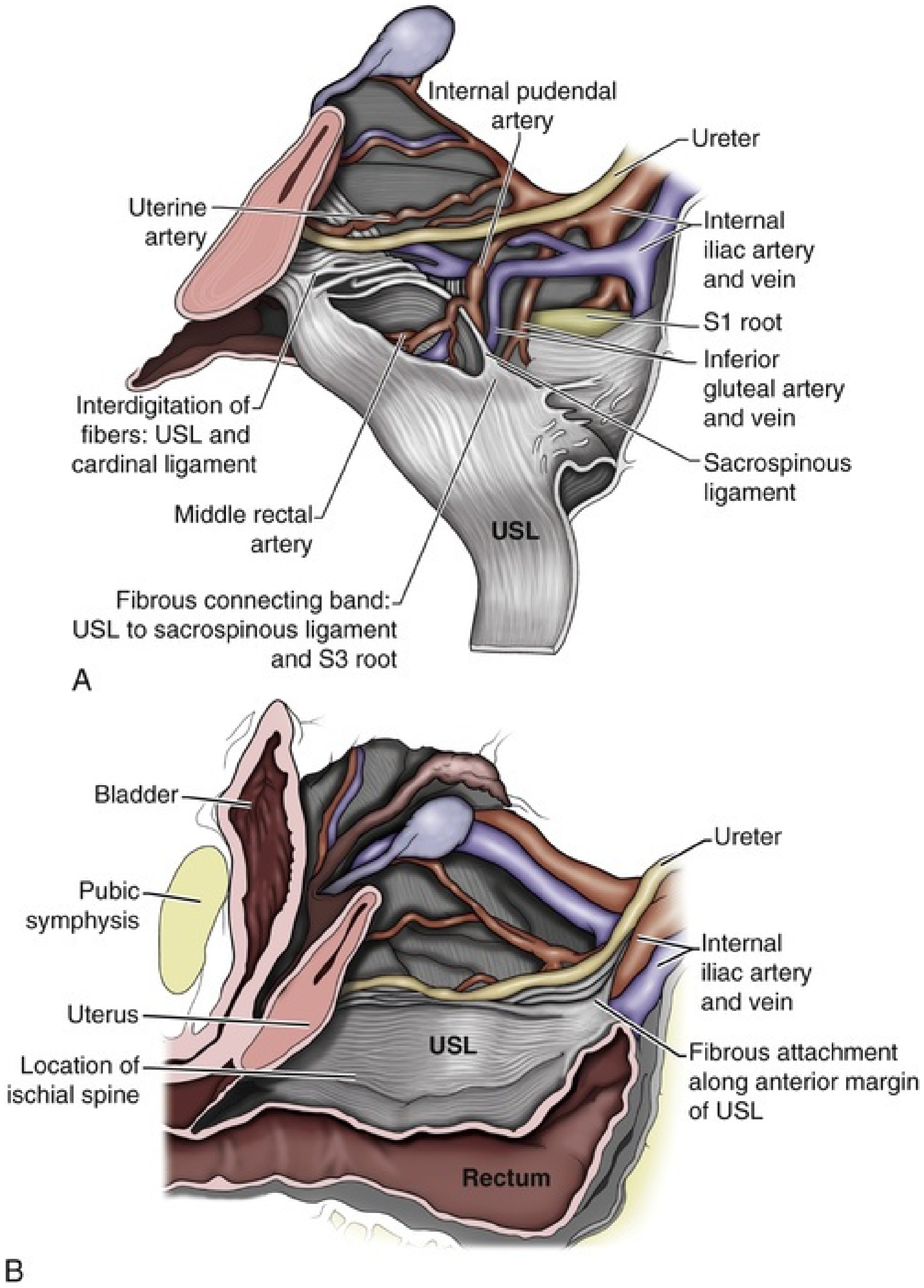
Internal pudendal artery
Ureter
Uterine artery
Internal iliac artery and vein
S1 root
Inferior gluteal artery and vein
Interdigitation of fibers: USL and cardinal ligament
Sacrospinous ligament
Middle rectal artery
USL
Fibrous connecting band: USL to sacrospinous ligament and S3 root
A
Bladder
Ureter
Pubic symphysis
Internal iliac artery and vein
Uterus
USL
Location of ischial spine
Fibrous attachment along anterior margin of USL
Rectum
B

FIG. 124.10 (A) Cross-section of the pelvic floor. Note the relationship of the uterosacral ligament *(USL)* to surrounding structures. (B) Right hemipelvis sagittal view. The peritoneum has been removed and the uterosacral ligament was left intact to show the proximity of the ureter in this specimen. (From Buller JL, Thompson JR, Cunfiff GW, et al.: Uterosacral ligament: description of anatomic relationships to optimize surgical safety. *Obstet Gynecol* 97:873–879, 2001.)

High Uterosacral Vaginal Vault Suspension Technique.

This procedure starts intraperitoneally (Karram et al., 2001). After hysterectomy, the apex is identified on the vaginal cuff at the 3 and 9 o'clock positions, which represent the attachments of the cardinal and uterosacral ligaments (Shull et al., 1993). It is useful to place stay sutures at these dimples before incision. The vaginal epithelium is dissected away from the peritoneum of the hernia sac. Once the dissection has mobilized the hernia sac from the epithelium to the neck of the sac, it is entered, and the sac excised (Fig. 124.11). Laparotomy pads are placed to pack the bowel away. Ischial spines can then be palpated transperitoneally. The uterosacral ligaments will be located posteriorly and medially to the ischial spines. By placement of traction to the stay sutures or by placement of an Allis clamp at the 5 o'clock and 7 o'clock positions of the apex, the uterosacral ligament will tent, and two to four nonabsorbable sutures can be placed through the uterosacral cardinal ligament complex (Fig. 124.12). The ureters should be located lateral to the uterosacral ligaments; however, depending on the degree of the prolapse, there can be significant variability in their location relative to the edge of the uterosacral ligament (Silva et al., 2006). If there is any question regarding their location, temporary catheters may be placed to facilitate their palpation. In placing the needles through the uterosacral ligaments, surgeons must pass them lateral to medial exiting away from the ureter to avoid inadvertent inclusion (Shull et al., 2000). To ensure the proper depth, the suture should be passed at the level of the ischial spines. Subsequent sutures are placed proximal to the last. If an anterior colporrhaphy or sling is planned, it may be done at this point. Suspensory sutures in the uterosacral ligaments are then placed in the most apical portions of the pubocervical and rectovaginal fascia. The highest sutures are then sewn to the most medial portions of the pubocervical and rectovaginal fascia. The more distal sutures are placed most laterally in the pubocervical and rectovaginal fascia and passed out of the vaginal epithelium on each side (Fig. 124.13). Cystoscopy is an essential step after this procedure to confirm ureteral patency and should be performed before trimming the suture because this will facilitate identification of the sutures if they must be removed because of obstruction. If no efflux of urine is seen, the sutures should be removed starting with the most lateral suture of the ipsilateral side. In addition, it is important to perform the cystoscopy after the suture is under tension or tied, not just placed (Yazdany and Bhatia, 2008). As the surgeon ties these suspending sutures, the rectovaginal fascia and pubocervical fascia are brought together at the uterosacral ligament complex, thus resuspending the apex of the vagina and closing the cul-de-sac (Fig.

124.14).

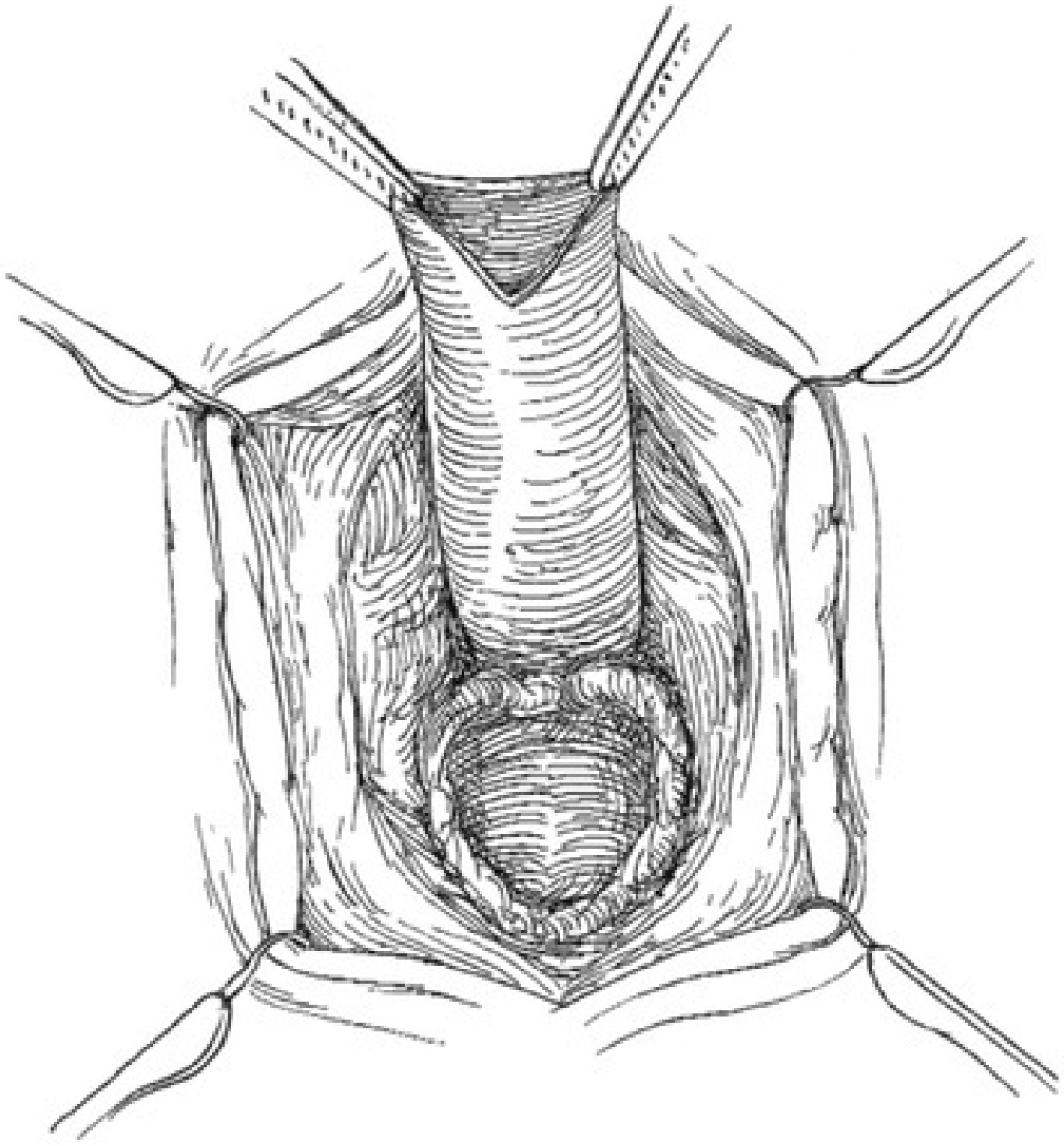

FIG. 124.11 Vaginal enterocele repair. Enterocele sac is identified and opened to reduce its contents. It is then tied in a purse-string suture and the excess is excised. Before the enterocele sac is closed, the peritoneal cavity is entered to access the uterosacral ligament.

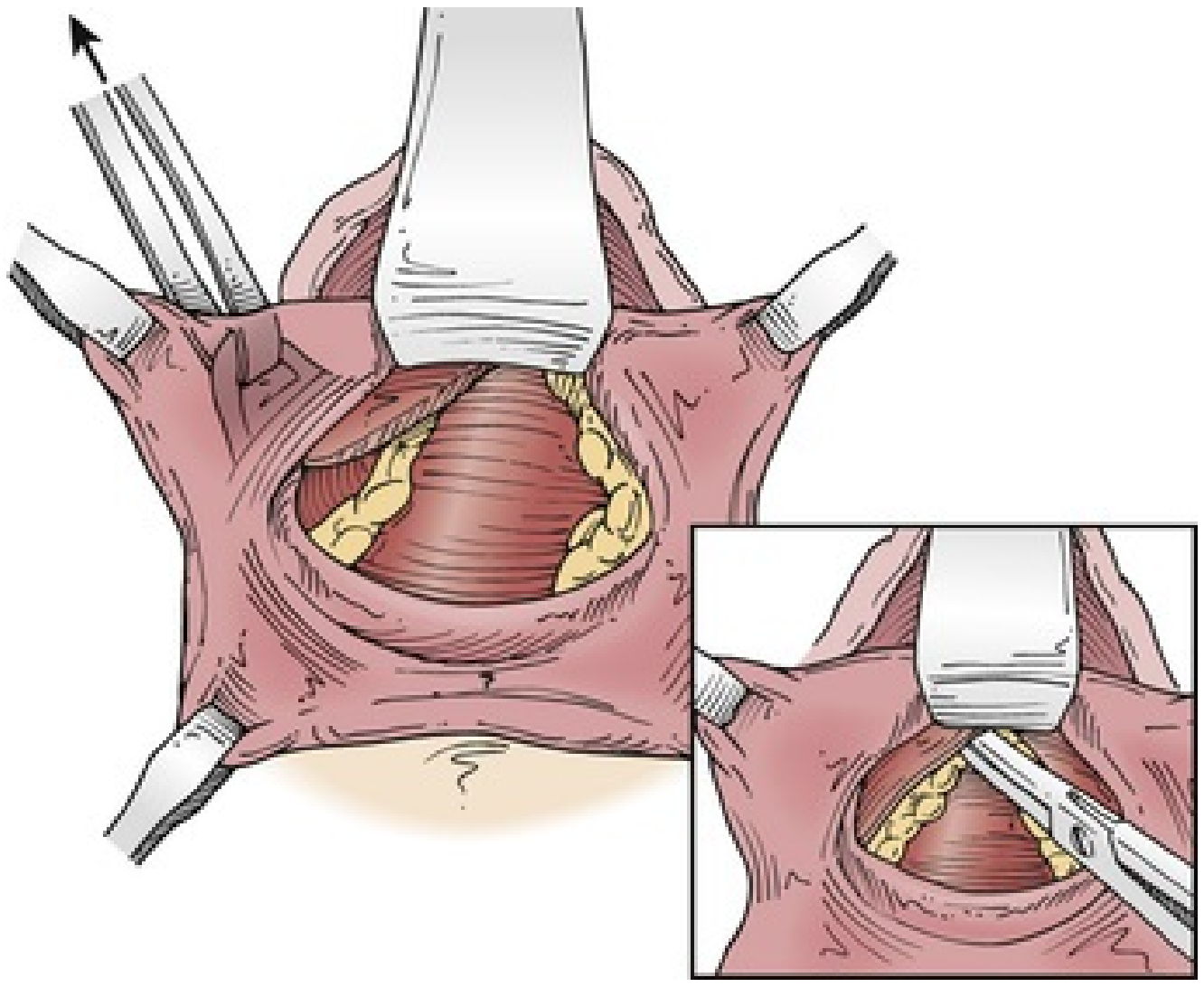

FIG. 124.12 To identify the uterosacral ligament, an Allis clamp is placed on the vaginal epithelium at the right apex and pulled straight upward. With the right uterosacral ligament on tension, the uterosacral ligament is visible in the pelvis. *Inset,* A long Allis clamp is used to grasp the right uterosacral ligament. (Modified from Walters MD, Muir TW: Surgical treatment of vaginal apex prolapse: transvaginal approaches. In Vasavada S, Appell R, Sans P, Raz S, editors: *Female urology, urogynecology and voiding dysfunction*, New York, 2005, Marcel Dekker, pp 663–676.)

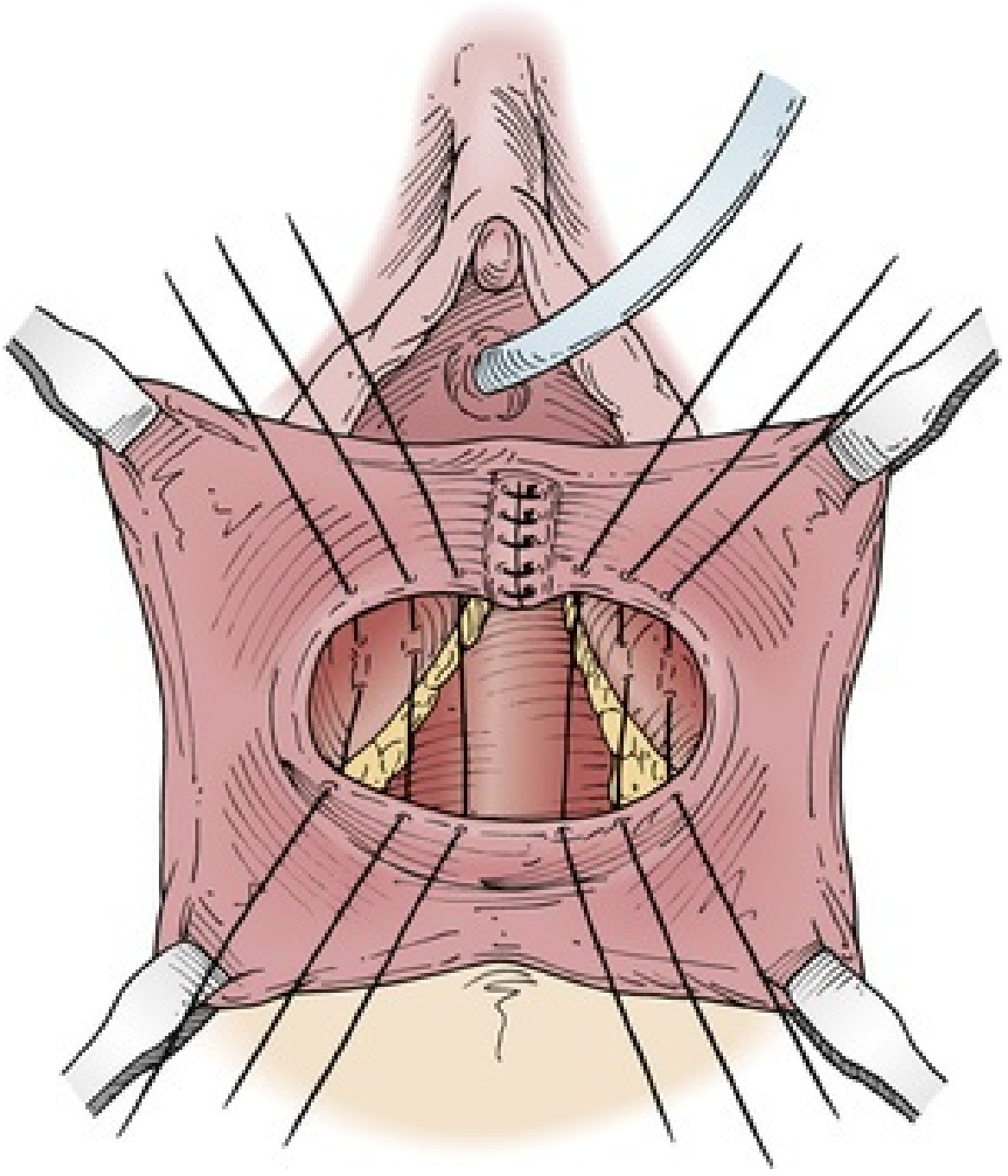

FIG. 124.13 High uterosacral ligament vaginal vault suspension. Three sutures are placed from lateral to medial in each uterosacral ligament. The sutures are brought through the vaginal muscularis anteriorly (pubocervical fascia) and posteriorly (rectovaginal fascia).

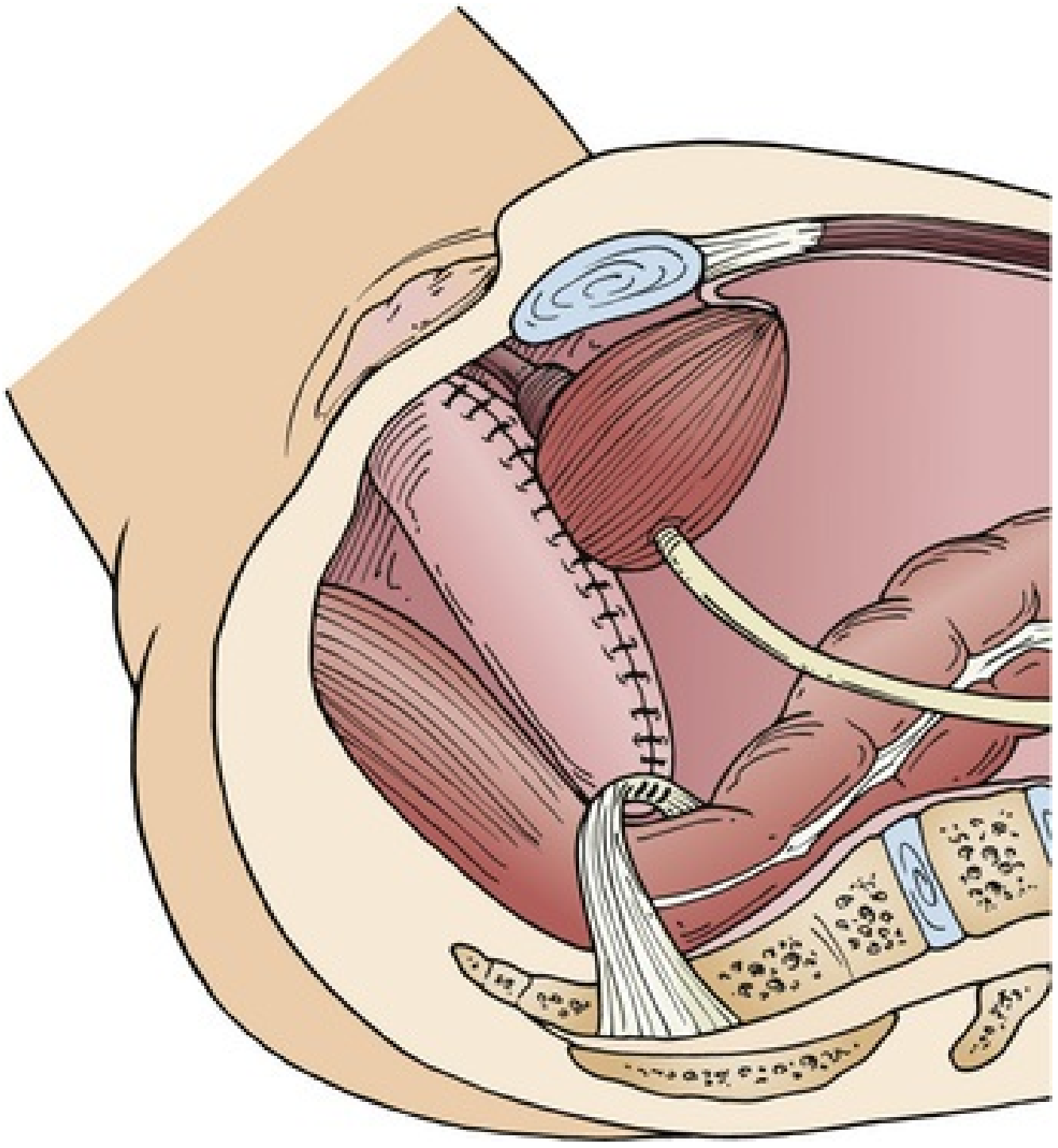

FIG. 124.14 Completed uterosacral vaginal vault suspension with anterior colporrhaphy. (Modified from Walters MD, Muir TW: Surgical treatment of vaginal apex prolapse: transvaginal approaches. In Vasavada S, Appell R, Sans P, Raz S, editors: *Female urology, urogynecology and voiding dysfunction*, New York, 2005, Marcel Dekker, pp 663–676.)

An extraperitoneal approach has also been described (Dwyer and Fatton, 2008). A midline incision is made, depending on concomitant prolapse. The vaginal epithelium is then dissected away from the endopelvic fascia, and the enterocele sac is identified and dissected free of the vault. Dissection is continued laterally until the uterosacral cardinal ligament complex is identified posterior and medial to the ischial spine. Palpation to tent the uterosacral cardinal ligament complex is facilitated by placing tension on the vagina. Use of the Briesky-Navratil retractor to retract the bladder and ureters anteriorly has prevented ureteral obstruction through traction or injury (Fatton et al., 2009). Once the ligaments are identified, the sutures are placed in a similar fashion to the intraperitoneal approach. Cystoscopy and vaginal closure are performed as described previously.

Abdominal Approach to the Uterosacral Ligaments.

The uterosacral ligaments may be accessed transabdominally (Lowenstein et al., 2009). This technique begins by elevating the uterus at the time of abdominal hysterectomy. Three permanent sutures are placed in each of the uterosacral ligaments proximal and medial to the ischial spine. They are numbered in the manner described by Shull et al. (2000) (Fig. 124.15). Once the hysterectomy has been performed and the cuff has been closed, the sutures are placed sequentially through the anterior and posterior leaves of the endopelvic fascia. By reapproximating the anterior and posterior muscularis of the vagina, any potential enterocele defects are closed and the cuff is elevated toward the sacrum recreating the normal vaginal axis. Cystoscopy is performed after tying the sutures, which are left uncut until efflux of urine is demonstrated. If no urine is seen, the most lateral ipsilateral suture is removed, and subsequent sutures are taken down in sequence.

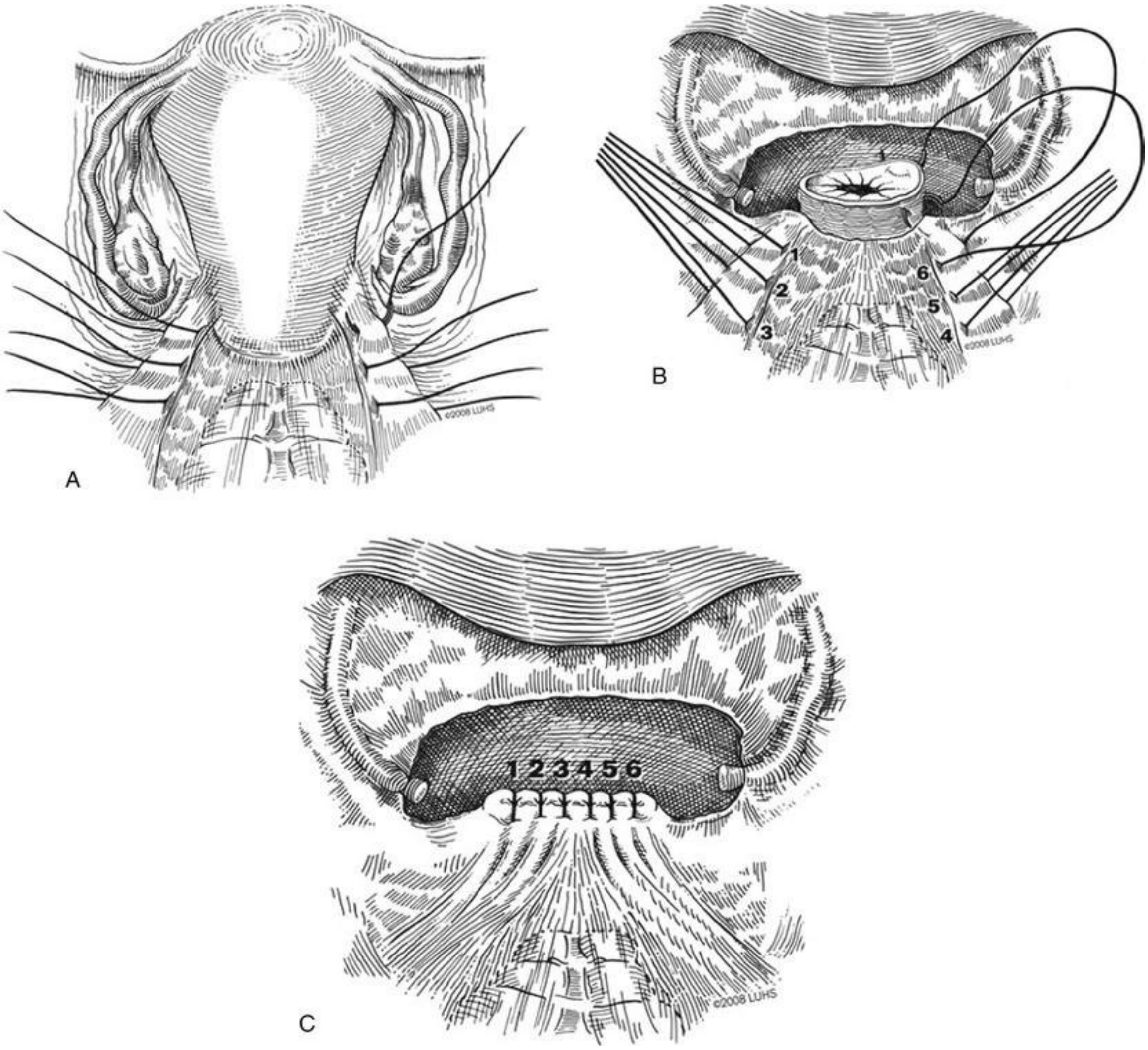

FIG. 124.15 (A) Three permanent sutures are placed in each of the uterosacral ligaments medial to the ischial spine. (B) One end of each of the 6 sutures is placed serially across vaginal apex through the anterior

endopelvic fascia and the other end through the posterior endopelvic fascia. (C) All sutures are tied to reapproximate the anterior and posterior vaginal muscularis, to close any potential enterocele defect, and to elevate the vaginal apex toward the sacrum. (Copyright 2008 Loyola University Health System. Used with permission from Mary Pat Fitzgerald, MD.)

Uterosacral Ligaments Results.

Transvaginal uterosacral ligament suspension has been evaluated primarily through uncontrolled retrospective case series. Table 124.5 summarizes the available literature with a mean objective success of 85% and a range of 48% to 96%. Mean reoperation rate for prolapse from the data in Table 124.5 is 5.8%. In 2010 Margulies et al. performed a meta-analysis and documented success based on POP-Q stage in the anterior (81.2%), apical (98.3%), and posterior (87.4%) compartments. Less than half the studies in the pooled analysis reported postoperative prolapse symptoms. In those that did, 82% to 100% of patients reported relief. Ureteral kinking or injury was reported in 1% to 11% of cases. Shull et al. (2000) have the largest reported series of patients who underwent uterosacral ligament suspension. Of 289 patients who followed up, a majority (87%) had no recurrence of support defect at any site on any postoperative examination. Only 5% of the patients had grade 2 prolapse or greater. The most common site was the anterior compartment in which 10 patients had grade 2 or 3 defects. One patient required ureteroneocystostomy. Two patients required removal of suspensory sutures. Karram et al. (2001) reported on 168 patients who underwent uterosacral vaginal vault suspension. Eighty-nine percent reported satisfaction with the results of the procedure. Ten women (5.5%) underwent subsequent surgery for recurrent prolapse. Seven women experienced a major intraoperative complication, 5 (2.4%) ureteral injuries, 1 small bowel injury, and 1 pelvic abscess requiring diverting colostomy (Karram et al., 2001). Silva et al. (2006) evaluated long-term (5.1 years) anatomic and functional outcomes of high uterosacral vaginal vault suspension. Surgical failure in one or more compartments occurred in 11 patients (15.3%); apical recurrence occurred in 2 of 78 patients. Seven patients had de novo postoperative dyspareunia. Patient-reported outcomes indicated improvement in irritative voiding, obstructive voiding, stress incontinence, and overall urinary symptoms compared with preoperative scores.

TABLE 124.5

Outcomes of Transvaginal Uterosacral Ligament Repairs

STUDY (FIRST AUTHOR, YEAR)	N (COMPLETED FOLLOW-UP)	MEAN FOLLOW-UP MONTHS (RANGE)	SUCCESS RATE % ALL COMPARTMENTS	METHOD OF EVALUATION
Jenkins, 1997	50 (47)	33 (6–48)	96%	Physical exam
Comiter, 1999	104 (100)	17.3 (6.5–35)	96%	Baden-Walker
Barber, 2000	46 (39)	15.5 (3.5–40.8)	60.6% Anatomic 90% Symptoms	POP-Q Symptom assessment
Shull, 2000	302 (289)	(2–38)	87%	Baden-Walker
Karram, 2001	202 (168)	21.6 (6–36)	92.8% Anatomic 89% Symptoms	Baden-Walker Symptom assessment
Amundsen, 2003	33	28 (6–43)	82%	POP-Q
Silva, 2006	72	61.2 (42–90)	84.7%	POP-Q
Antovska, 2006	32	24.5 (9–42)	87.50%	POP-Q
Wheeler, 2007	35	24.3 (9–46)	100% Anatomic 88.9% Symptoms	POP-Q Symptom assessment
De Boer, 2009	156 (98)	12	50%	POP-Q

Fatton, 2009 (Extraperitoneal)	123 (110)	48 (6–60)	85.5%	POP-Q
Doumouchtsis, 2011	42 (39)	59.4 (40–79)	66.7%	Baden-Walker POP-Q

A randomized control trial sponsored by the Pelvic Floor Disorders Network, the OPTIMAL trial, compared uterosacral ligament suspension to sacrospinous ligament fixation in 354 patients (Barber et al., 2014). After 2 years the surgical success rate was 64.5%, and perioperative pelvic floor muscle training was not associated with an improved outcome. In contrast, in a single institution study Lavelle et al. (2018) reported a failure rate of 25.7% in patients after uterosacral suspension in patients with stage 3 POP, which was higher than a cohort of patients undergoing ASC (7.8%).

Fatton et al. (2009) examined their results performing an extraperitoneal bilateral uterosacral vaginal vault suspension (n = 110) with a mean follow-up of 2 years. Concurrent procedures included anterior colporrhaphy (20%), anterior mesh reinforcement (49%), posteriorly colporrhaphy (56%), and sling (29%). Recurrence at the apex was noted in 4.6% of patients. Global anatomic success was reported in 85.5%. Mesh exposure occurred in 19.3%, was diagnosed within 6 months in the majority of the patients, and required conservative or minor interventions. The authors conclude that this procedure is effective at restoring apical support while avoiding the morbidity of an intraperitoneal operation.

Sacrospinous Ligament Fixation

The sacrospinous ligament fixation was first described by Richter in 1942 but was not widely used until Nichols (1982) reported on the technique. The sacrospinous ligament fixation has been shown to be an effective method to correct apical prolapse (Cruikshank and Muniz, 2003). This technique is appealing because of its extraperitoneal approach and consistency as a strong structure on which to anchor the apex. Access to the spine was originally achieved from the posterior approach, although dissection from the anterior approach may also be performed via the paravaginal space (Cespedes, 2000;

Winkler et al., 2000). The advantages of sacrospinous ligament suspension are the ability to repair concomitant pelvic floor defects, absence of a laparotomy (Morley and DeLancey 1988), shorter hospital stay (Brown et al., 1989), preservation of vaginal length and function (Brown et al., 1989; Morley and DeLancey, 1988), and cost effectiveness (Brown et al., 1989). The structures at risk with this technique include the pudendal or inferior gluteal vessels and the sciatic or pudendal nerves. Pudendal nerve entrapment results in posterior buttocks pain, which may radiate down the back of the thigh. **A disadvantage of this approach is the alteration in vaginal axis, which results in apical displacement posteriorly and to the right side when unilateral fixation is used. This posterior displacement can result in anterior compartment recurrence, even when an anterior repair is performed** (Morley and DeLancey, 1988; Sauer and Klutke, 1995; Shull et al., 1992). **In younger, more active women, contemporary data suggest favoring abdominal repairs.**

Sacrospinous fixation may be performed unilaterally or bilaterally (Pohl and Frattarelli, 1997). With the unilateral suspension, right-sided placement is generally preferred. Technically, it is easier to place the sutures on the right ligament for a right-handed surgeon (Sauer and Klutke, 1995). Cespedes reported success using the bilateral anterior support and noted the advantage of more midline location of the vaginal apex (Cespedes, 2000). Although bilateral placement has been advocated (Nichols, 1982), there is little to support the advantage of bilateral fixation over unilateral fixation when examining outcomes (Morley and DeLancey, 1988).

Surgical Anatomy of the Sacrospinous Ligament Fixation.

The sacrospinous ligament is approximately 7 to 8 cm in length (Morley and DeLancey, 1988) and extends from the ischial spine laterally, coursing medially under the coccygeus muscle and inserts into the sacrum. The pudendal nerves and vessels are close to the ligament, just proximal to their course around the ischial spine (Fig. 124.16). In addition, the hypogastric plexus of veins are located superiorly, and the hemorrhoidal vessels are located medially to the sacrospinous ligament (Morley and DeLancey, 1988), thus retraction should be carried out carefully in these respective areas. To avoid the gluteal vessels, the suture should be placed into the ligament and not behind it (Kettel and Hebertson, 1989). Pudendal nerve entrapment may result in pain, which localizes to the buttocks or perineum. This may be avoided by placing sutures medial to the ischial spine, about 1.5 cm (Alevizon and Finan, 1996; Sauer and

Klutke, 1995). Branches from the S3 and S4 nerve roots are more likely to cause postoperative gluteal pain. Precise suture placement on the ligament, limiting the depth of needle penetration into the ligament, and avoiding needle entry or exit above the upper extent of the sacrospinous ligament may avoid nerve entrapment and postoperative gluteal pain (Florian-Rodriguez et al., 2016).

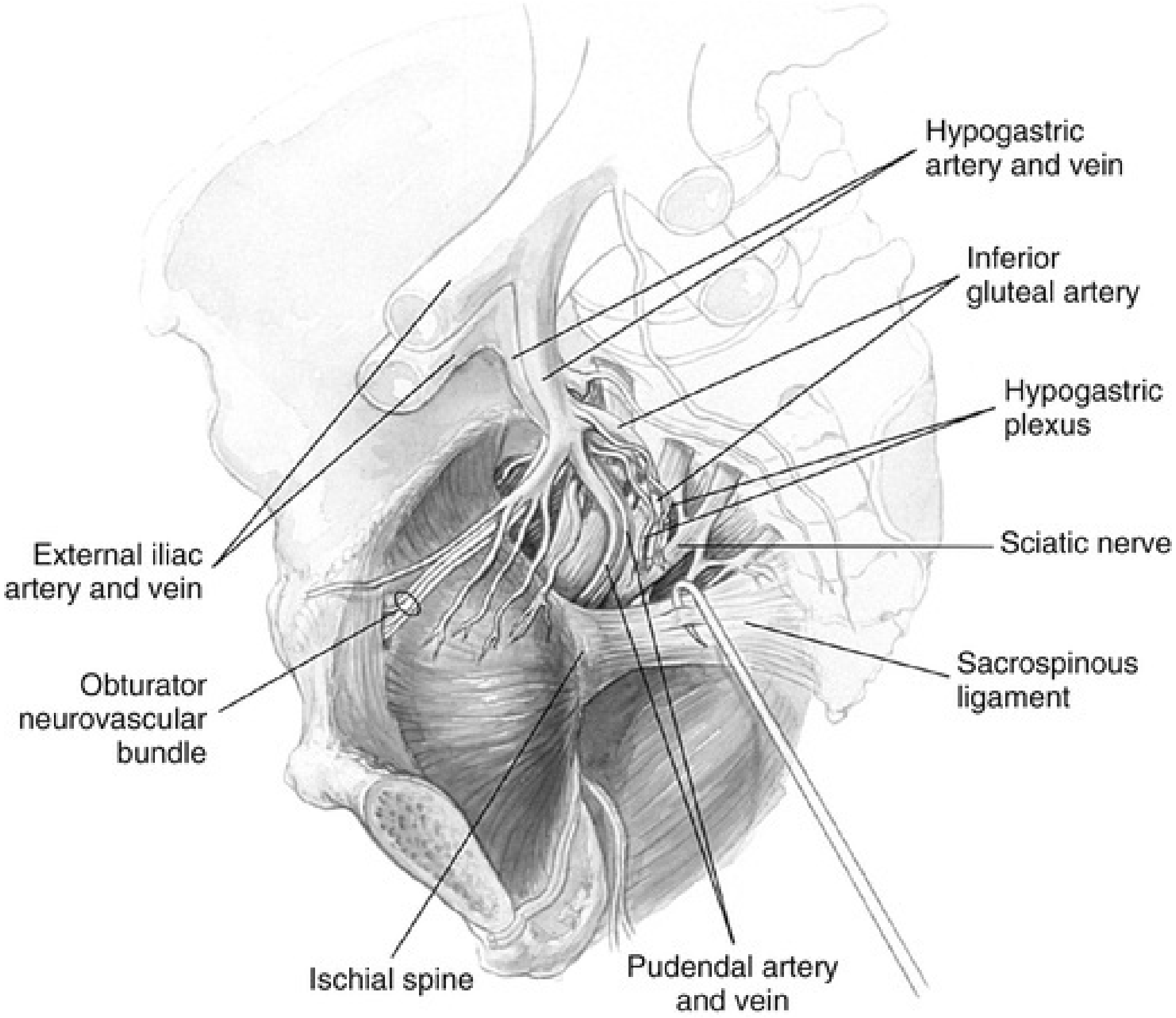
Hypogastric artery and vein
Inferior gluteal artery
Hypogastric plexus
Sciatic nerve
Sacrospinous ligament
External iliac artery and vein
Obturator neurovascular bundle
Ischial spine
Pudendal artery and vein

FIG. 124.16 Anatomy of the sacrospinous ligament and surrounding structures. Note the close proximity of the pudendal vessels, hypogastric plexus, inferior gluteal vessels, and sciatic nerve. (From Walters M, Karram M: *Urogynecology and reconstructive pelvic surgery,* ed 3, Philadelphia, 2006, Mosby.)

Katrikh et al. (2017) also found that the middle segment of the sacrospinous ligament has the lowest incidence of nerves and arteries associated with it and that the nerves supplying the pelvic floor muscles are at a higher risk of entrapment than the pudendal nerve. **Thus the optimal position of the suture placement is 1.5 to 3.0 cm medial to the ischial spine, directly into the SSL.** Placing it too far medially may risk failure of the repair as the sacrospinous ligament fans and thins as it inserts into the sacrum (Sauer and Klutke, 1995). In addition, there is a higher concentration of sacral nerves in this medial location. Barksdale performed a cadaveric study to assess the histology of the sacrospinous ligament, taking segments near the ischial spine, middle and sacral portions of the ligament (Barksdale et al., 1997). The highest concentration of nerves was found in the sacral portion of the SSL and the lowest near the ischial spine. Although it was postulated that the nerves embedded in the SSL were a potential source of neuropathic pain, no clinical correlation could be made in this cadaveric study. Lantzsch et al. (2001) concluded that localization and depth of the suture can also influence the occurrence and intensity of sciatic neuralgia.

Sacrospinous Ligament Fixation Technique.

The procedure starts by marking the apex of the vagina. The vaginal apex is then reduced to the sacrospinous ligament(s) intended to be used. This site of attachment is then tagged (or marked) for later fixation. Depending upon concomitant compartmental defects, the SSL can be approached either anteriorly or posteriorly. A standard midline vaginal incision is made in the vaginal epithelium, which is separated from the rectovaginal septum posteriorly or pubocervical fascia anteriorly. If an anterior compartment repair will be performed, the SSL may be approached anteriorly, exposing the paravesical space. The tissue attachments overlying the spine and ligament are swept medially. Alternatively, if the posterior approach is used, the surgeon must enter the perirectal space by bluntly mobilizing the rectum medially. Upon entering the perirectal space, the ischial spine is identified. With further dorsal and medial blunt dissection, the SSL is palpated. Blunt dissection is continued to ensure that the rectum is retracted medially and the ligament is adequately exposed. At this point Heaney or Breisky-Navratil retractors are very useful to visualize the ligament and facilitate suture placement. In addition, lighted retractors can provide added visualization. The sacrospinous ligament is then palpated. The suture is placed approximately one to two fingerbreadths medial from the spine to avoid damage to the structures in Alcock canal.

Several different methods have been used to fix the suture to the sacral spinous ligament. The Capio Suture Capturing Device or the Capio Slim Suturing Device (Boston Scientific, Marlborough, MA) enables the suture to be placed by palpation. Alternatively, the Miya Hook (CooperSurgical, Trumbull, CT) (Miyazaki, 1987), the Autosuture Endo Stitch Suturing Device (Covidien, Norwalk, CT) (Schlesinger, 1997), Deschamps Ligature Carrier, or freehand needle driver passage may be used to place the sutures under direct vision. Two sutures are most commonly placed. In cases of bilateral SSL fixation, one suture may be placed on each ligament. In the case of unilateral SSL fixation, the placement of the sutures on the ligament 2 cm apart will prevent constriction of the vaginal apex. Additional repairs may be performed at this point. After this, the previously placed SSL sutures are brought out of the vagina to the previously marked vaginal apex (Fig. 124.17). If a permanent suture is used for sacrospinous ligament fixation (SSLF), a pulley stitch is used, which ensures that the knot of the suture will remain internal, if needed. To create a pulley stitch, tying a knot onto the fibromuscular portion on the visceral side of the vagina creates a fixed point. The free end of the suture is then pulled, thus suspending the apex to the SSL, and this is then secured by tying a secure knot. Importantly, this resultant knot remains internal and is not within the vaginal canal. Closure of the vaginal wall halfway, before tying down the sutures, is useful, because the suspended apex may be difficult to reach. The sutures should be tied so that the vaginal apex is firmly attached to the coccygeal sacrospinous ligament complex with no intervening suture material bridging a gap (Morley and DeLancey, 1988; Sze and Karram, 1997). Palpation of the suture behind the vaginal cuff will ensure that the suture is tied securely. It is useful to leave the secured suture untrimmed until the cystoscopy is performed in case the suture must be removed. Once efflux is visualized bilaterally, the anchoring suture is trimmed, and the remainder of the vaginal incision is closed.

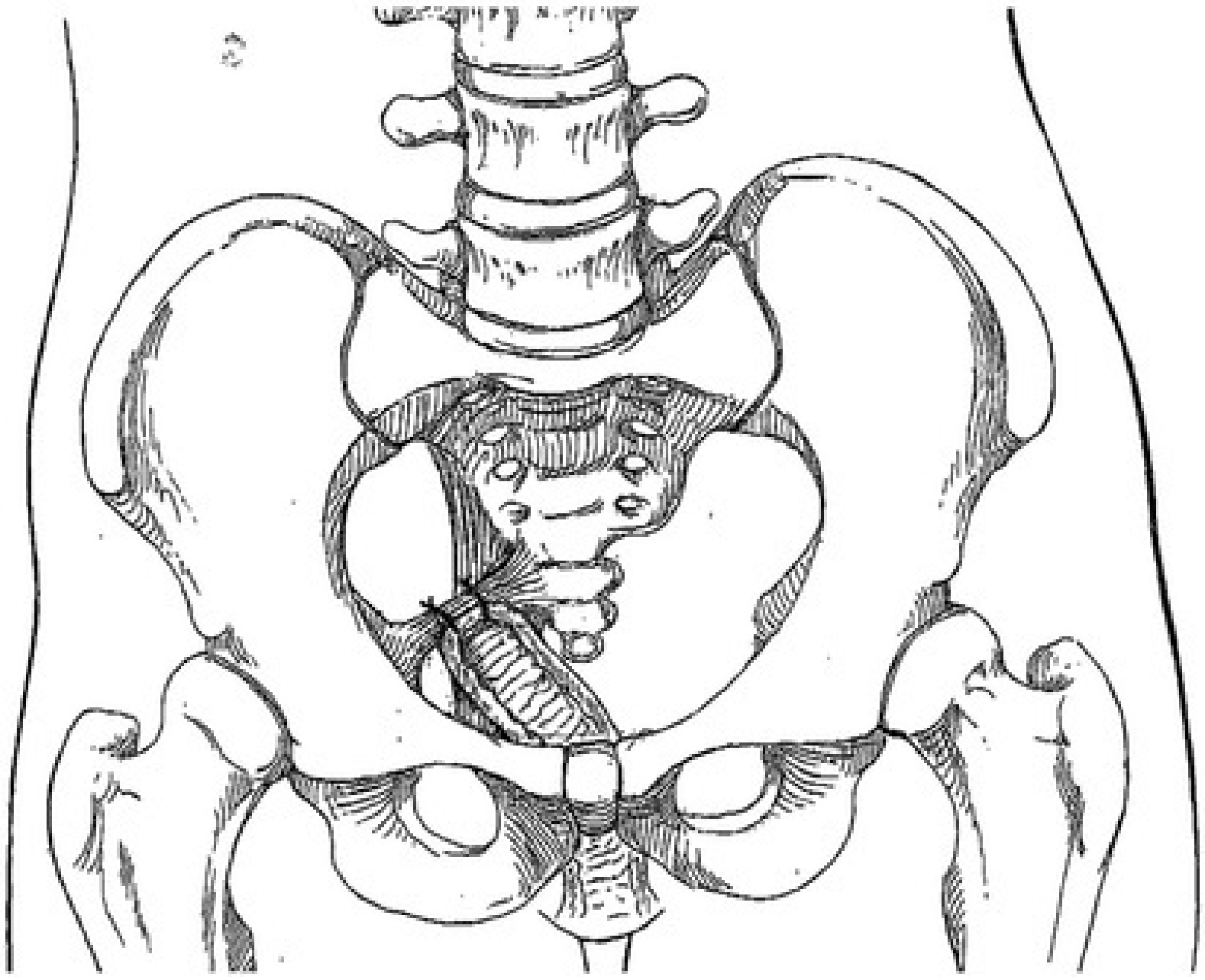

FIG. 124.17 Sacrospinous ligament fixation. With a unilateral suspension, the vagina is deflected to the right side and caudally. (From Richter K, Albright W: Long-term results following fixation of the vagina on the sacrospinous ligament by the vaginal route. *Am J Obstet Gynecol* 141:811–816, 1981.)

Sacrospinous Ligament Fixation Results (Table 124.6).

Early data reported the feasibility and success associated with this approach to apical correction. Nichols reported outcomes of SSLF in 163 patients, some with "massive" vaginal eversion and procidentia. There were no reported recurrences of vaginal vault prolapse; however, nine patients reported that the vagina was "too narrow" postoperatively (Nichols, 1982). This outcome was also observed in a study by Richter and Albrich (1981), who reported excellent patient satisfaction, although 8 patients were reluctant to resume sexual relations because of a perception of vaginal narrowing. Morley and DeLancey (1988) reported on 100 patients who underwent SSL fixation, 33 of whom underwent isolated apical treatment, while 67 had concomitant prolapse repairs. Apical success was noted in 95.7%, 90.1% globally; 4 patients had prolapse in the anterior compartment. They noted that the long-term results were acceptable with minimal adverse effects.

TABLE 124.6

Results of Sacrospinous Ligament Fixation

FIRST AUTHOR (YEAR)	STUDY DESIGN	N	MEAN FOLLOW-UP MO. (RANGE)	DEFINITION OF ANATOMIC SUCCESS[a]	ANATOMIC SUCCESS–ALL SEGMENTS	ANATOMI FAILURE BY SEGMEN
Morley (1988)	Retrospective	92	51.6 (1–132)	Not defined	90%	Apex 4 Anterio 6%
Imparato (1992)	Retrospective	155	Not stated	Not defined	90.3%	Not reporte
Shull (1992)	Retrospective	81	24–60	Grade 0–1	82%	Apex 4 Anterio 12% Posteri 1%
Pasley (1995)	Retrospective	144	35 (6–83)	Asymptomatic and above hymen	85.4%	Apex 5.6% Anterio 7.6% Posteri 1.4%
Benson (1996)	RCT SSLF vs. ASC	42	30 (12–66)	Vaginal walls above hymen or apical descent less than	67%	Apex 12% Anterio 28.5% Posteri 2.3%
Paraiso (1996)	Retrospective	243	76 (1–190)	Grade 0 or asymptomatic grade 1	79.7% at 5 years	Apex 4.9% Anterio 15.9% Posteri 4.9%
Penalver (1998)	Retrospective	160	40 (18–78)	Any symptomatic descent	85%	Apex 6 Anterio 6% Posteri 2.5%
Colombo (1998)	Retrospective	62	83 (48–108)	Grade 0–1	74%	Apex 8 Anterio 14% Posteri

						3%
Meschia (1999)	Retrospective	91	43 (12–86)	Grade 0–1	85%	Apex 4 Anterio 13% Posterio 9%
Sze (1997)	Retrospective	75	24 (3–72)	Above hymen	71%	Anterio 21% Other 8%
Lantzsch (2001)	Retrospective	123	58 (6–108)	Not defined	87%	Apex 3.5% Anterio 8% Posterio 1.6%
Lovatsis (2002)	Retrospective	293	(12–30)	At or beyond the introitus	97%	Apex 3 Anterio NR Posterio NR
Cruikshank and Muniz (2003)	Prospective cohort	695	43 (6–60)	Reoperation for recurrence	89.4%	Apex 5.1%
Nieminen (2003)	Retrospective	138	24	POP-Q stage 2 or greater	78.7%	Apex 4.9% Anterio 11.5% Posterio NR
Maher (2004b)	RCT SSLS vs. ASC	48	22 (6–58)	Grade 0–1	69%	Apex 19% Anterio 14% Posterio 7%
Hefni (2006)	Prospective	305	57 (24–84)	Vaginal vault at least 6 cm distal to hymen	96%	Apex 4 Anterio 13% Posterio 0

Toglia (2008)	Retrospective	64	26.5 (1–72)	Apex above introitus and no reoperation	78%	Apex 9 Anterio 17% Posteri 0
Aigmueller (2008)	Prospective	55	84 (24–180)	Above the hymen	64%	Apex 7 Anterio 29% Posteri 5%
Chou (2010)	Retrospective	76	36 (12–60)	Grade 0	91%	Apex 5.3% Anterio 3.7% Posteri NR

[a]Prospective and retrospective cohorts with n >50 published since 1985 and SSLS arms of 3 RCTs comparing SSLS with abdominal sacrocolpopexy (ASC).

Bilateral SSL suspension was compared with abdominal sacrocolpopexy in a prospective randomized study (Benson et al., 1996). Time to failure was shorter in the SSL group compared with the abdominal group (11 vs. 22 months); the vaginal group had 12 cystoceles requiring reoperation versus 4 cystoceles in the abdominal group. Sauer and Klutke (1995) reported on 24 patients with a mean follow-up of 13.8 months. Blood loss was minimal, and no transfusions were needed, but mild postoperative buttock pain was noted that resolved by 3 months. In 21 of 24 patients there was no recurrence of prolapse at the apex, but one patient underwent repeat operation for a significant cystocele. Meschia et al. (1999) reported on 103 patients who underwent SSL fixation and found excellent results for the posterior and apical compartments but disappointing results for the anterior compartment: 16% had grade II or greater prolapse. In a systemic review of published papers from 1995 to 2011, 24 studies reported an overall cure rate of 84.6% after SSLF. The apical recurrence rate was 5.3%, and the anterior recurrence rate was 18.3% (Tseng et al., 2013).

The anterior compartment has been reported as a particularly vulnerable site for developing a defect after sacrospinous vaginal vault suspension. Recurrent cystoceles have been reported in 7.6% to 92% of patients postoperatively (Morley and DeLancey, 1988; Pasley, 1995; Richter and Albrich, 1981). This has been attributed to vaginal retroversion (posterior displacement). This is noted not only postoperatively but also intraoperatively, although many who develop anterior defects remain asymptomatic and do not undergo subsequent surgery to correct the anterior compartment defect (Paraiso et al., 1996). The Pelvic Floor Network Dyfunction Network evaluated anatomic anterior compartment prolapse recurrence and the effect of concomitant repair after vaginal apical procedures. Patients with higher stages of POP (Ba > +1) undergoing SSLF and concomitant anterior compartment repair did have improved overall success rate. In patients with lower stage POP, undergoing uterosacral ligament suspension, a concomitant anterior repair did not improve postoperative anatomic success rates (Nager et al., 2019).

Several authors have demonstrated the feasibility and efficacy of an anterior approach to the SSL vaginal vault suspension (Cespedes, 2000; Winkler et al., 2000). Winkler et al. (2000) reported that the anterior compartment recurrence rate after an anterior SSL fixation and anterior repair was 9%, in contrast to a 24% after SSL fixation with posterior repair. Cespedes reported on the bilateral anterior approach and noted no recurrences. Some of the theoretic advantages of the anterior approach include improved ability of the vagina to withstand increased intraabdominal pressures (Pohl and Frattarelli, 1997), and less likelihood of rectal injury (Sauer and Klutke, 1995). Again, a low incidence of anterior compartment recurrence was noted at 7% (Cespedes, 2000).

Successful healing in the short term may predict long-term success of the SSL suspension. Shull et al. (1992) reported on 81 women undergoing sacrospinous ligament suspension; 72% had previous pelvic surgery. Those who showed absence of any compartment defect at the 6-week follow-up had only a 3% likelihood of requiring additional reconstructive surgery within 2 to 5 years.

Sacrospinous Ligament Fixation Complications.

Cruikshank and Muniz (2003) reported 15% of patients experiencing gluteal pain after SSL fixation on the ipsilateral side. Generally, this pain has shown spontaneous resolution within 2 to 3 months when delayed absorbable sutures were used (Maher et al., 2001). Postoperative mild to moderate neuropathic pain can be managed with observation, and patients should be counseled that duration may be as long as 3 months (Sauer and Klutke, 1995). Injection of the nerve with local anesthetic has been used for treatment (Lantzsch et al., 2001). In patients with severe or persistent radicular neuropathic type pain, suture removal may be considered. Rectal perforation has also been reported with this procedure. When a perforation was recognized at the time of surgery and repaired primarily, no sequelae were observed (Richter and Albrich, 1981; Sauer and Klutke, 1995). In addition, injury to the pudendal nerve and internal pudendal vessels may occur with sutures placed too near the ischial spine.

Iliococcygeus Suspension

The iliococcygeus suspension has the advantage of maintaining the vagina in a more normal axis and is useful in cases in which the uterosacral ligaments are insufficient for attachment or cannot be identified. With this technique, the vaginal vault is attached to the fascia of the iliococcygeus muscle as the anchoring site in contrast to the uterosacral or sacrospinous ligaments.

Iliococcygeus Suspension Technique and Results.

The approach is similar to the uterosacral and SSLF and is usually approached extraperitoneally. The fascia of the iliococcygeus muscle is identified lateral to the rectum and distal the ischial spine (Shull et al., 1993). The point of suture fixation is placed 1 cm distal to the ischial spine, near the insertion of the ATFP. This suture is then passed through the condensation of connective tissue at the apex of the vagina anteriorly through the pubocervical fascia and posteriorly through the rectovaginal fascia (Fig. 124.18). Another suture is placed on the contralateral side in a similar manner. It is recommended that bilateral suture fixation be performed to achieve optimal results. Once the sutures are tied securely, the vagina will be suspended bilaterally. As in SSLF, the sutures may be placed through an anterior or posterior approach. Special needle drivers and lighted retraction are useful to facilitate suture placement. In cases using permanent suture a pulley-stitch technique is applied, tying the knot internally.

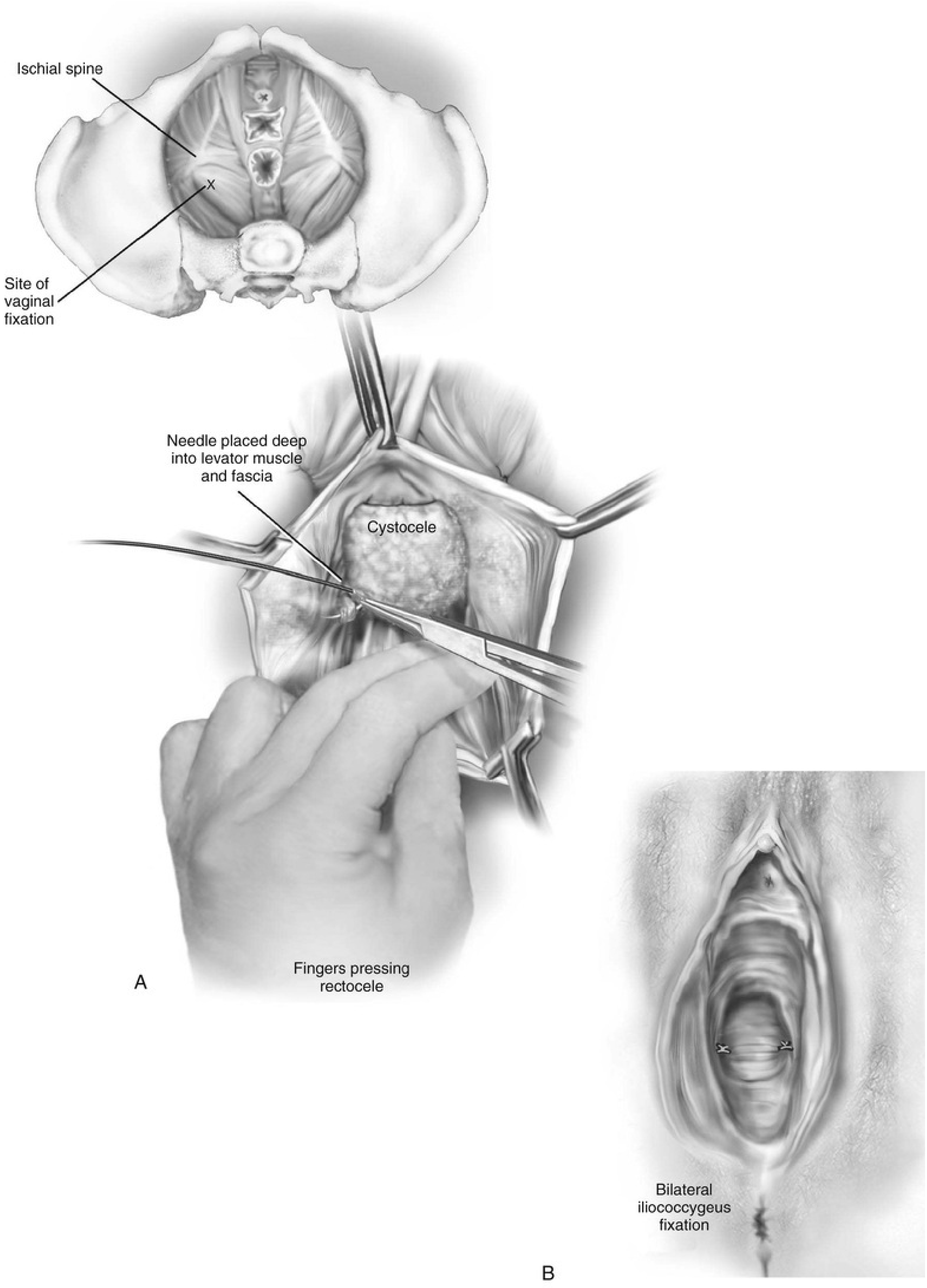
Ischial spine
Site of vaginal fixation
Needle placed deep into levator muscle and fascia
Cystocele
A
Fingers pressing rectocele
Bilateral iliococcygeus fixation
B

FIG. 124.18 Iliococcygeus fascia suspension. (A) With the surgeons

finger deflecting the rectum downward, the right iliococcygeus fascia sutures is placed. *Inset*, View of the dissected vagina. (B) Abdominal view of the endopelvic fascia. Approximate location of the sutures are delineated by the + sign. (From Walters M, Karram M: *Urogynecology and reconstructive pelvic surgery,* ed 3, Philadelphia, 2006, Mosby.)

Shull et al. (1993) reported on bilateral attachment of the vaginal cuff to the iliococcygeus fascia in 42 patients. Eight patients experienced pelvic support loss postoperatively, 3 in the middle (apical) compartment, 2 in the posterior compartment, and 4 in the anterior compartment. Six patients required additional surgery. Meeks et al. (1994) reported an anatomic cure of 96% in 110 patients. Intraoperative complications included rectal and bladder laceration and hemorrhage requiring transfusion. Postoperative complications included vaginal cuff abscess, fever, and transient femoral neuropathy. Maher et al. (2001) reported a 53% cure rate in 50 patients, and 19% of the patients experienced buttock pain. After a median follow-up of 66.8 months, Serati et al. (2015) reported overall cure rates of 84.1% in a single-institution study of 44 patients. Only preoperative stage 4 POP independently predicted prolapse recurrence (Serati et al., 2015).

Abdominal Sacrocolpopexy

Abdominal sacrocolpopexy should be considered a treatment option in the following clinical scenarios: failed previous vaginal repair, isolated uterine prolapse and/or enterocele, younger women, women with a highly active lifestyle, women who are sexually active, and women who desire one of the consistently most durable repairs at the expense of a potentially more invasive approach. In these patients, **ASC is an excellent choice because it maximizes functional vaginal length without significant distortion of the anatomic vaginal axis.** As discussed earlier, other pelvic floor defects and stress urinary incontinence can be addressed at the same time. In addition to open surgery, robotic-assisted laparoscopic and pure laparoscopic approaches have been described and are commonly used today (Daneshgari et al., 2006; Elliott et al., 2006; Rozet et al., 2005; Sundaram et al., 2004). The principles of the operation remain the same regardless of the approach.

Open Abdominal Sacrocolpopexy Technique.

The critical elements of the operation include the use of permanent mesh (polypropylene) or autologous fascia as graft material and secure fixation of the graft to the sacral promontory and vaginal cuff.

The patient is positioned in the low lithotomy position, providing transvaginal and transabdominal access. A Pfannenstiel or low midline abdominal incision may be used. Upon surgical entry into the peritoneal cavity, it is important to achieve exposure of true pelvis by careful packing of the small intestine and sigmoid colon. This is accomplished by releasing all adhesions in the pelvis and packing the bowel above the level of the sacral promontory and displacing the sigmoid to the left, exposing the sacral promontory and posterior peritoneum. An incision is made in the posterior peritoneum over the sacral promontory, extending inferiorly along the right lateral aspect of the rectum towards the cul-de-sac. Electrocautery is used when dividing the fatty tissue over the promontory to minimize bleeding and improve visualization. Careful dissection in this area is essential to avoid shearing of presacral veins because severe bleeding may occur. The middle sacral vessel traverses over the promontory and should be avoided. As the fatty tissue is dissected free, the anterior surface of the sacral promontory is visualized, usually by identification of the anterior longitudinal ligament. Two to three interrupted, nonabsorbable monofilament sutures are placed in the anterior longitudinal ligament with care to avoid perforation of the midline sacral vessels. Generally, sutures are placed under the vessels and tied down over the top of the vessels. Alternatively, if vessels overlie the ligament, bipolar energy can be used on the vessels to prevent bleeding before placing the sutures. These sutures are safely tagged for later placement into the mesh graft (Fig. 124.19). Alternatively, commercially available tacking devices may be used for securing the graft to the sacral promontory, although minimal data exist to confirm comparable efficacy.

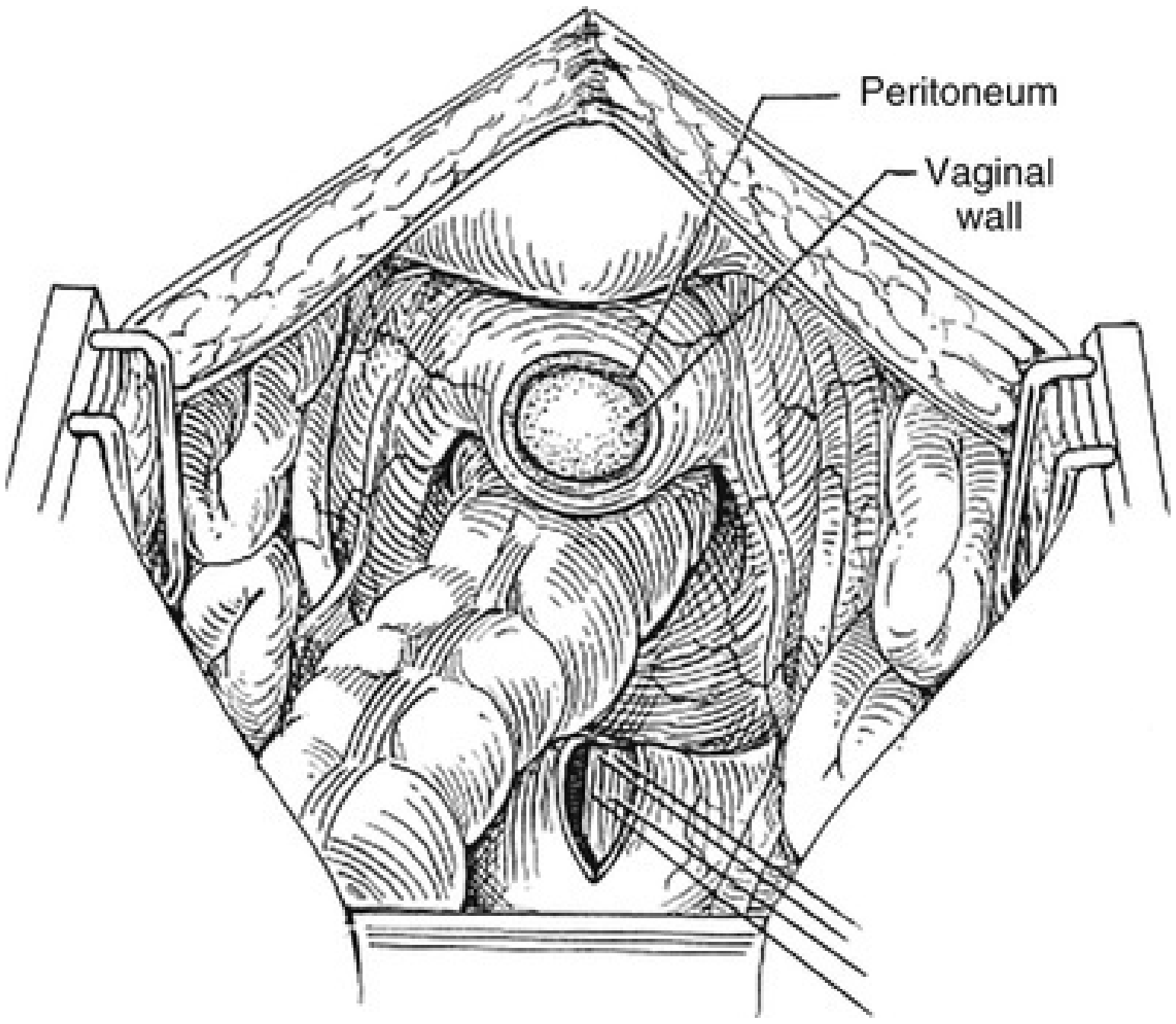

FIG. 124.19 Abdominal sacrocolpopexy. (A) Incision in the peritoneal cuff overlying the vagina, exposing the vaginal cuff. (B) Two permanent sutures are placed in the sacral promontory to secure the graft material. (C) Long incision in the posterior peritoneum, which will be used to cover the graft material. (From Winters JC, Cespedes RD, Vanlangendonck R: Abdominal sacral colpopexy and abdominal enterocele repair on the management of vaginal vault prolapse. *Urology* 56[6 Suppl 1]:55–63, 2000.)

After placing an end-to-end anastomosis sizer or commercially available vaginal stent in the vagina, the surgeon identifies the enterocele sac, if present, and secures it with an Allis clamp. If the enterocele is large, a Halban culdoplasty can be performed by placing linear permanent or delayed absorbable sutures through the posterior peritoneum and on the outer surface of rectum up to the vaginal cuff (Geomini et al., 2001). Upward retraction of the sizer assists in exposing the cul-de-sac. Usually 4 to 6 sutures are used to complete adequate cul-de-sac closure. This technique of (Fig. 124.20) closure is in contrast to the Moschowitz procedure, which involves purse-string closure and may predispose to ureteral angulation and obstruction. Alternatively, if an aggressive posterior vaginal dissection to the perineum is to be performed (see later) for placement of an extended piece of posterior mesh with subsequent retroperitonealization of the mesh, the culdoplasty is usually not needed.

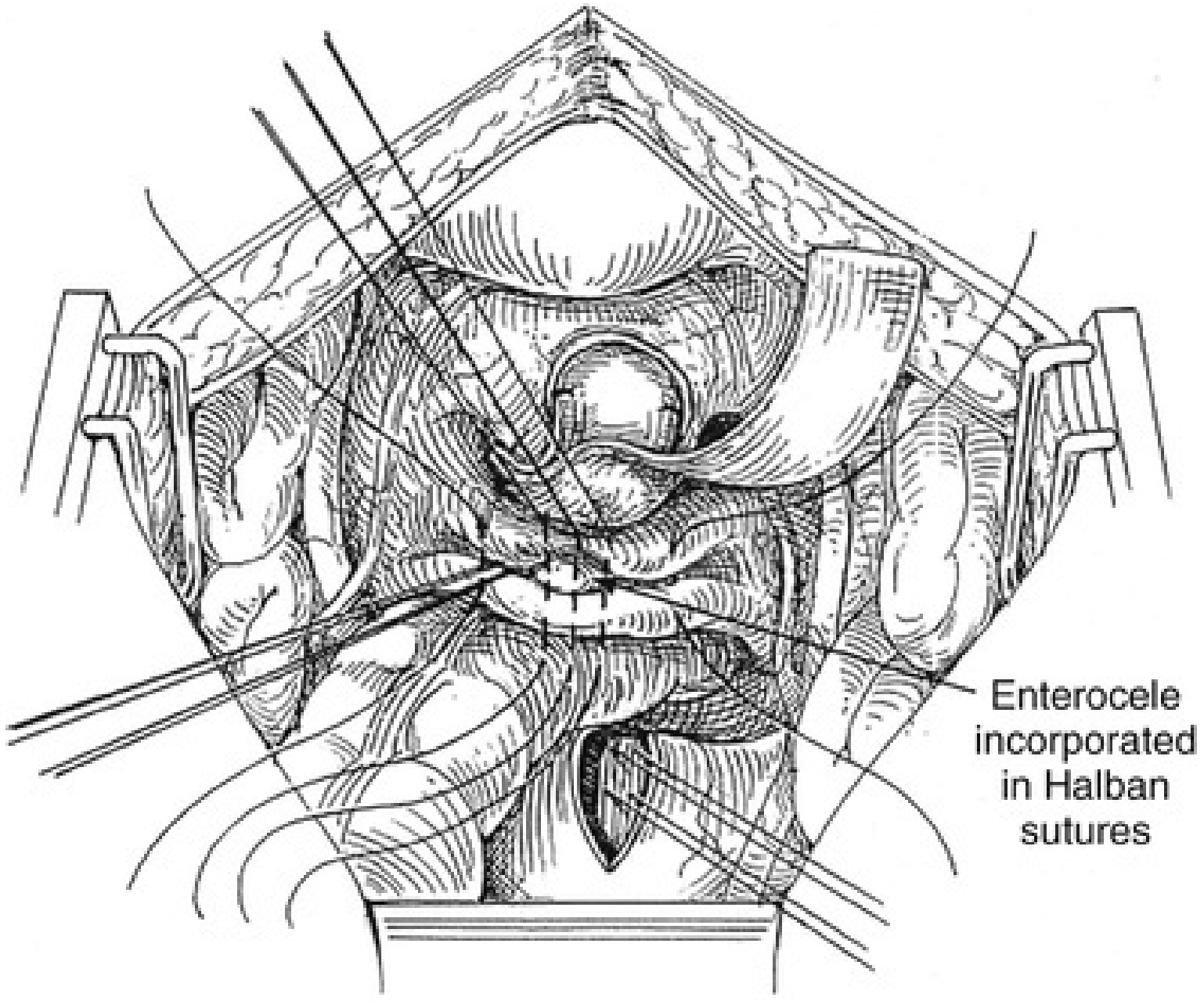

FIG. 124.20 Abdominal sacrocolpopexy Synthetic graft material is sutured securely to vaginal cuff using multiple interrupted permanent sutures. The peritoneal cul-de-sac is closed using linearly placed sutures to obliterate this potential space. (From Winters J, Cespedes R, Vanlangendonck R: Abdominal sacrocolpopexy and abdominal enterocele repair in the treatment of vaginal vault prolapse. *Urology* 56[6 Suppl 1]:55–63, 2000.)

The peritoneum over the vaginal cuff is incised, and the peritoneum is dissected off the anterior vaginal wall (see Fig. 124.20). There is significant variability in the amount of vaginal dissection reported. Some pelvic surgeons perform minimal dissection of the peritoneum and bladder off the vagina, enough to fix the mesh for 4 to 5 cm on each side, whereas other techniques describe a more extensive dissection that involves lifting the posterior bladder wall and trigone off the underlying vagina, as well as dissecting all the way to the perineal body. With the advent of robotic techniques, it seems that more extensive dissections are being carried out with longer mesh segments attached to the bladder, although there are no controlled studies to identify the optimal technique of graft placement to the vagina. Several mesh options exist for ASC, including prefabricated Y-shaped soft polypropylene mesh and sheets of soft polypropylene mesh that can be cut and fashioned to the surgeon's preference. A polypropylene, macroporous, monofilament, nonabsorbable mesh is recommended. A roughly 4.0-cm wide by roughly 6.0-cm long anterior segment of mesh is sutured to the exposed anterior vaginal wall using 6 to 8 permanent sutures, although some surgeons are now using delayed absorbable sutures to avoid suture complications (Fig. 124.21). Care is taken to identify the border of the bladder to avoid suturing the graft to the bladder and to secure the lateralmost portions of the mesh to prevent folding. An obturator in the vagina is useful to facilitate suture placement and secure the mesh to the vagina. The graft is secured to the vagina by folding over the cuff of the vagina and allowing the long end of the graft to exit posteriorly and extend to the sacrum. (Alternatively, a T-shaped configuration of the graft may be created. The short arm of the T is placed on the top of the vagina, and the long arm of the T is secured to the lower end of the vagina.) The posterior peritoneum is dissected off the posterior wall of the vagina entering the space between the rectum and vagina. The posterior segment of the mesh is then attached to the posterior vaginal wall with 6 to 8 interrupted monofilament delayed absorbable or nonabsorbable sutures. At this step, the central sutures from the culdoplasty are placed through the long arm of the mesh if desired.

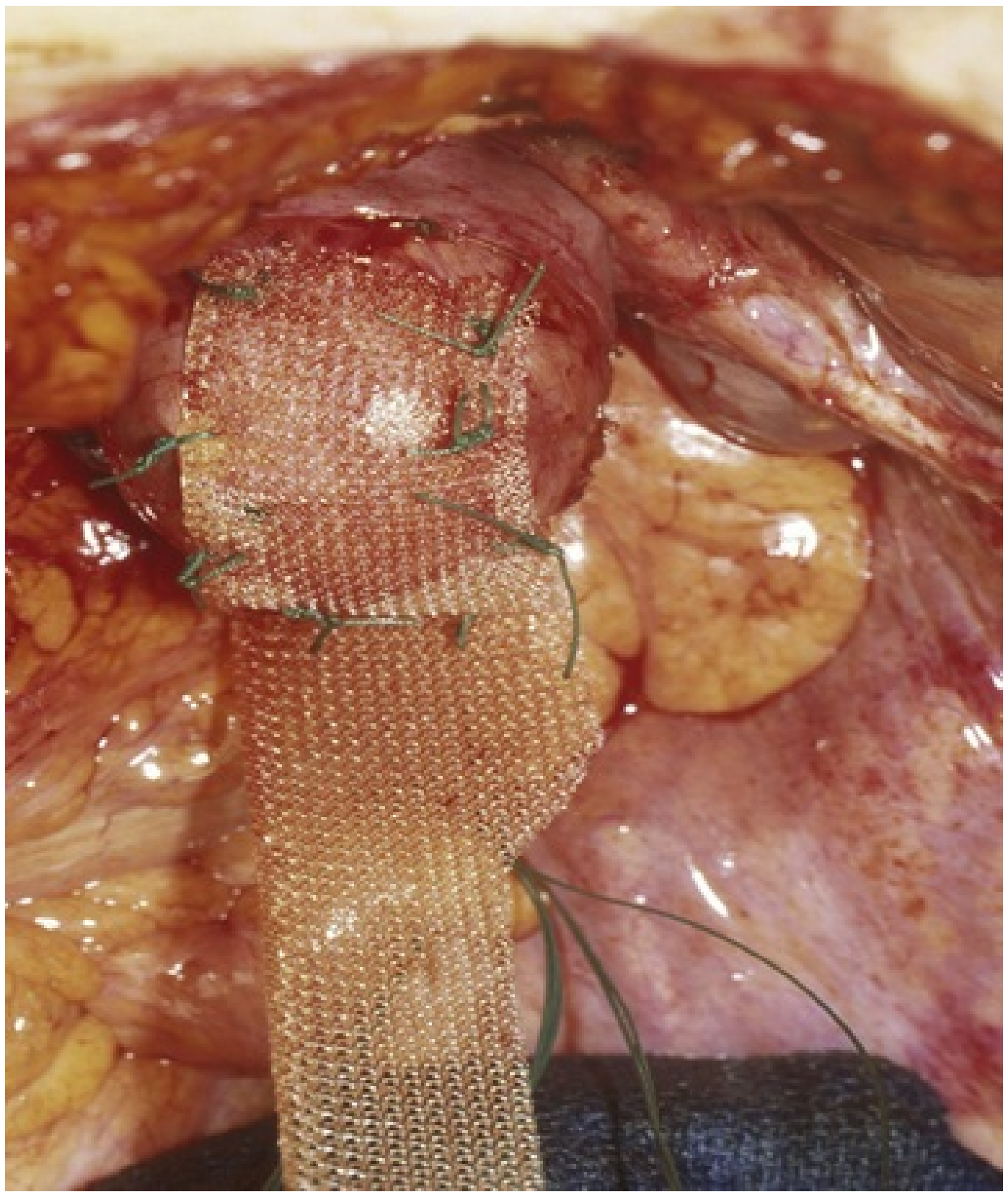

FIG. 124.21 Abdominal sacrocolpopexy: intraoperative view. Permanent mesh material sutured to vaginal cuff. Note: end-to-end anastomotic sizer used to provide exposure of vaginal cuff. (From Scarpero H, Cespedes R, Winters J: Abdominal approach to the repair of vaginal vault prolapse. *Tech Urol* 7:139–145, 2001.)

The graft is then secured to the sacral promontory. Care must be taken to avoid excessive tension. Placing the obturator all the way into the vagina but not pushing the vagina upward establishes the proper length for the graft. The graft is placed along the right lateral aspect of the rectum in the space previously developed by extending the opening of the peritoneum from the sacrum. A space of 2 fingers' width between the graft and the rectum prevents compression of the rectum over the graft (Fig. 124.22). Tensioning in this fashion is not feasible with a robotic or laparoscopic approach. It requires a visual cue of the mesh attachment while extending the vagina cephalad with an end-to-end anastomotic sizer to its maximal length without actively stretching it. The promontory sutures are then brought through the mesh and tied down securely. Any excess mesh is trimmed after fixation to the sacrum. Last, the graft is positioned in the retroperitoneal space by closing the posterior peritoneum over the graft and covering the graft on the vagina with the superior edge of the anterior peritoneum and bladder flap. Stress incontinence procedures (if indicated) are then performed. Cystoscopy is performed to ensure patency of the ureters. The patient is then examined to determine if any ancillary transvaginal prolapse repairs are needed.

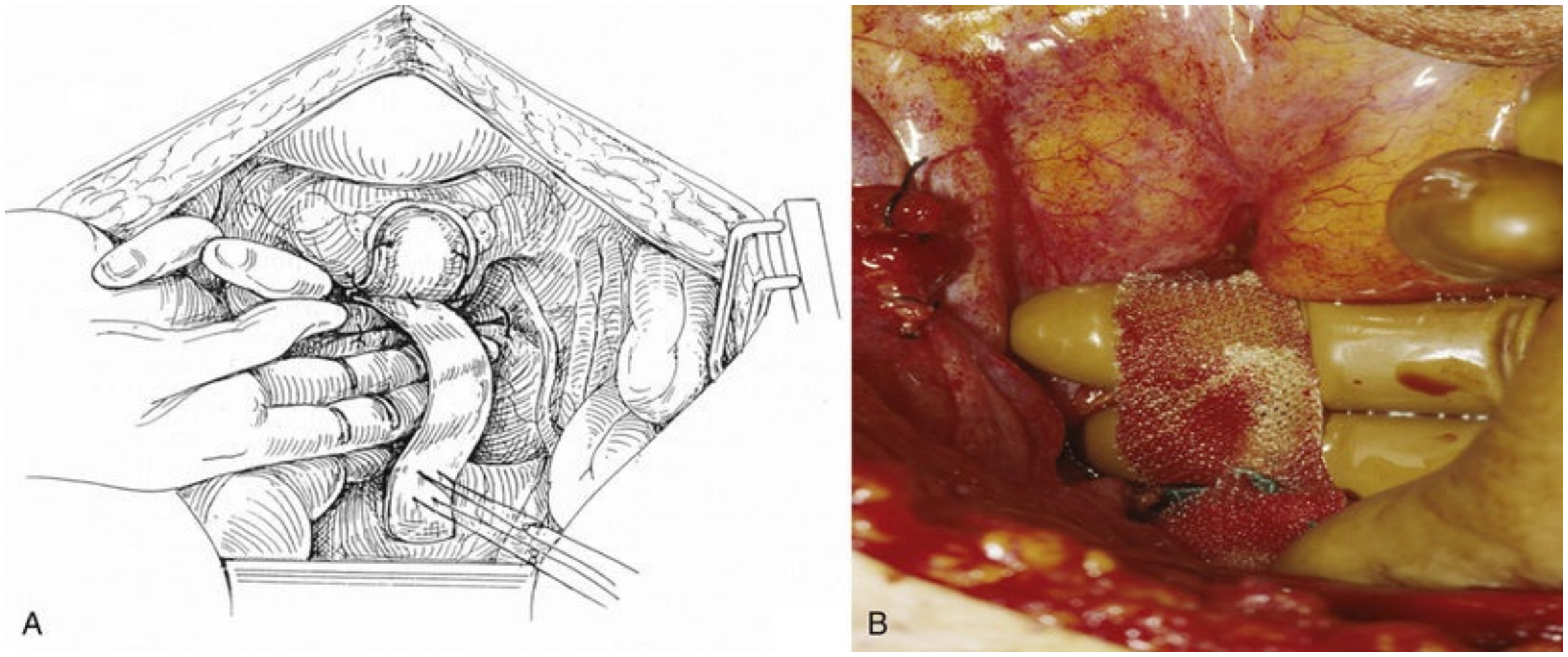

FIG. 124.22 Abdominal sacrocolpopexy. (A) Graft is secured without tension to sacral promontory. (B) Intraoperative view. (A, From Winters J, Cespedes R, Vanlangendonck R: Abdominal sacrocolpopexy and abdominal enterocele repair in the treatment of vaginal vault prolapse. *Urology* 56[6 Suppl 1]:55–63, 2000. B, From Scarpero H, Cespedes R, Winters J: Abdominal approach to the repair of vaginal vault prolapse. *Tech Urol* 7:139–145, 2001.)

Robotic-Assisted Laparoscopic Sacrocolpopexy Technique.

Sacrocolpopexy may be performed with a minimally invasive technique using laparoscopy or robotic surgery. The basic steps of the procedure are the same whether performed abdominally, robotically, or laparoscopically and differ mainly by the method of abdominal entry, trocar placement, docking the robotic patient cart, and method of suture fixation. The da Vinci surgical system (Intuitive Surgical, Sunnyvale, CA) is currently the only widely used robotic surgical system in the United States. The patient can be placed on a Pink Pad (Xodus Medical, New Kensington, PA) or another device to prevent slippage. After administration of general anesthesia, the patient is properly positioned in Allen stirrups in a low lithotomy position, the arms are properly tucked to the side, and all bony prominences are padded.

A pelvic exam is performed, the abdomen and vagina are surgically prepared, a Foley catheter is inserted into the bladder, and nasal/oral gastric tube is placed. Trocar placement begins with entry into the abdominal cavity via the technique with which the surgeon is most experienced. Laparoscopic entry can be performed with an open or closed technique; although the umbilicus is the most frequent site of entry, other sites include the left upper quadrant or subxiphoid and less commonly, transuterine and transvaginal. Closed-entry techniques offer quick access with low risk of injury (Bonjer et al., 1997; Catarci et al., 2001). However, meta-analyses have not shown that any of the techniques are superior to the others (Ahmad et al., 2008; Vilos et al., 2007).

Typically starting at the umbilicus, the surgeon makes an incision at the base of the umbilicus and an 8.5-mm robotic camera trocar is placed, the abdomen is inflated with CO_2 gas, and a diagnostic survey of the abdomen is performed. Two to three additional 8.5-mm robotic trocars are placed at least 9 cm apart in either a semi-lunar or W configuration. An additional 8.5- to 11-mm laparoscopic trocar is placed on the right side of the patient to allow for the surgical assistant access (Fig. 124.23). The bed is moved into the Trendelenburg position, and side or parallel docking is preferred to allow access to the vagina, bladder, and rectum intraoperatively. The typical robotic instruments used are the robotic monopolar scissors, robotic Maryland bipolar instrument, and a robotic bowel grasper.

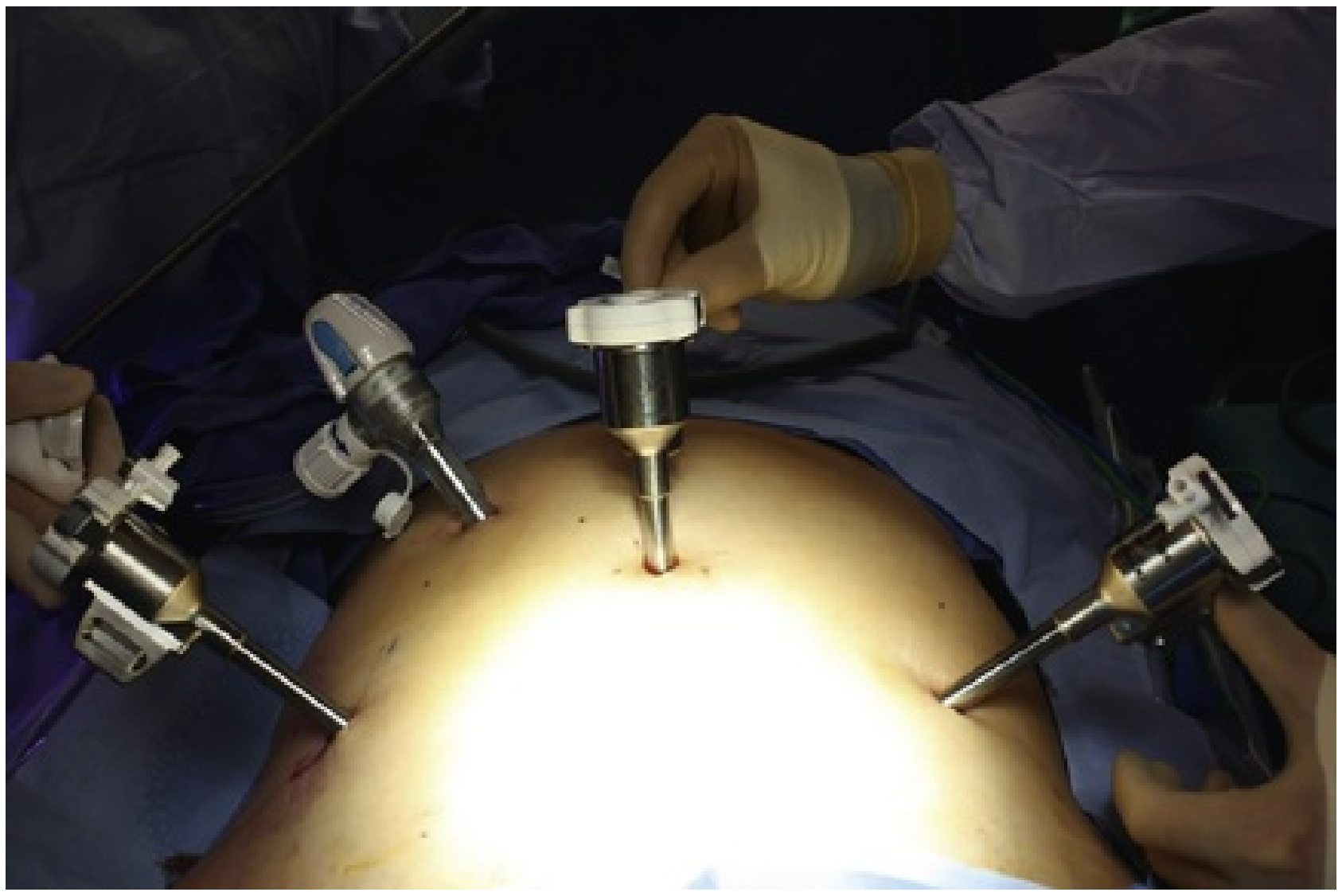

FIG. 124.23 Robotic trocar placement in a W fashion. (Courtesy Barry Hallner, LSU Department OB/GYN 2017.)

After any necessary adhesiolysis, the bowel is gently swept out of the pelvis and above the pelvic brim. The aortic bifurcation and iliac vessels are identified, and the sacral promontory is visualized and delineated at the midline (Fig. 124.24). Next the ureters are identified along the pelvic side walls, especially the right ureter, which is close to the area of dissection. An incision is made in the peritoneum over the sacral promontory, extending inferiorly along the right lateral aspect of the rectum toward the cul-de-sac, creating peritoneal leaves that will be used to retroperitonealize the graft (Fig. 124.25). Electrocautery is used when dividing the fatty tissue over the promontory to minimize bleeding and improve visualization. Careful dissection in this area is essential to avoid shearing of presacral veins because severe bleeding may occur. It is equally important to avoid the left common iliac vein, which is not infrequently located more medial than the artery and can be injured during exposure of the promontory (Good et al., 2013). The middle sacral vessel traverses over the promontory and should also be avoided. As the fatty tissue is dissected free, the anterior surface of the sacral promontory is visualized, usually by identification of the anterior longitudinal ligament (Fig. 124.26).

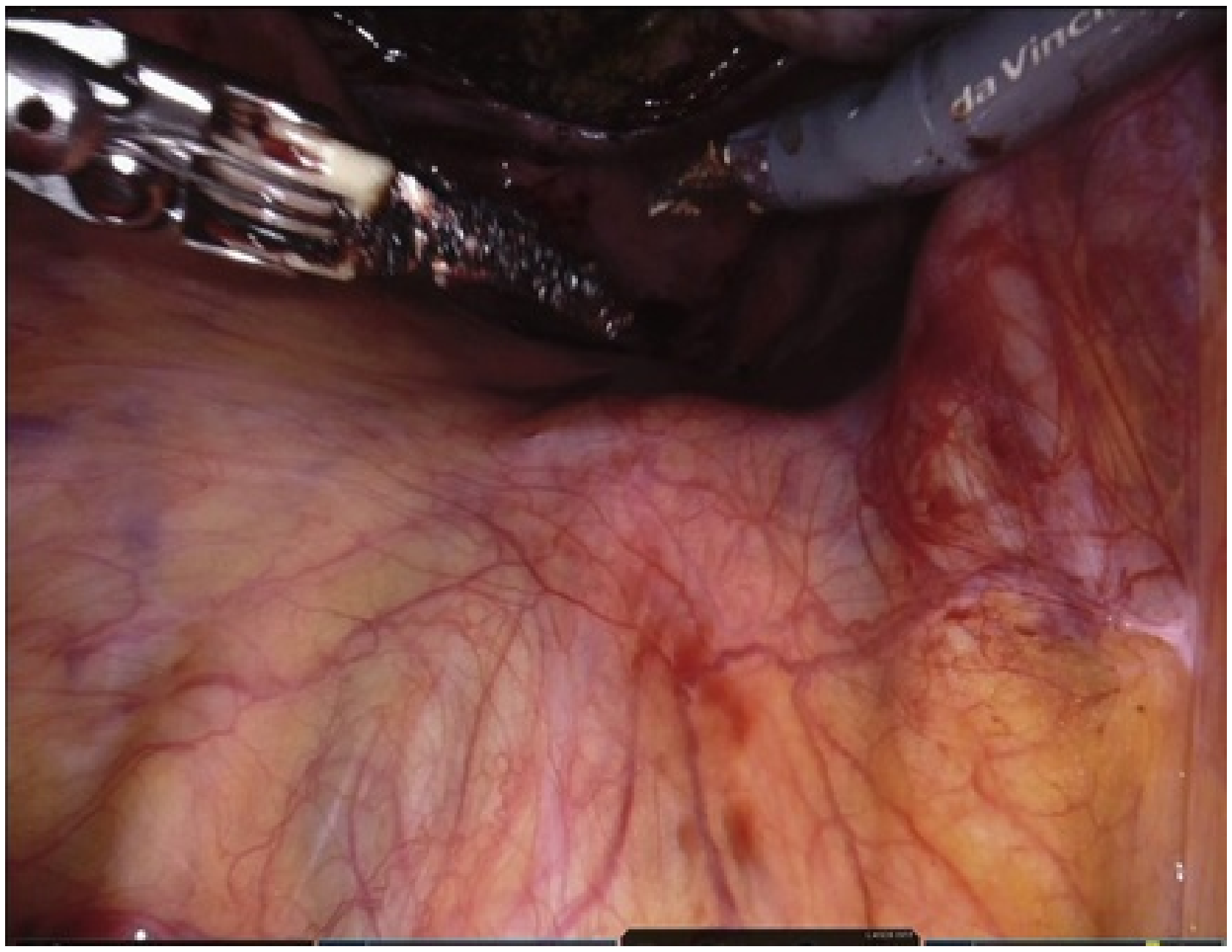

FIG. 124.24 Promontory and important anatomy identified. (Courtesy Barry Hallner, LSU Department OB/GYN 2017.)

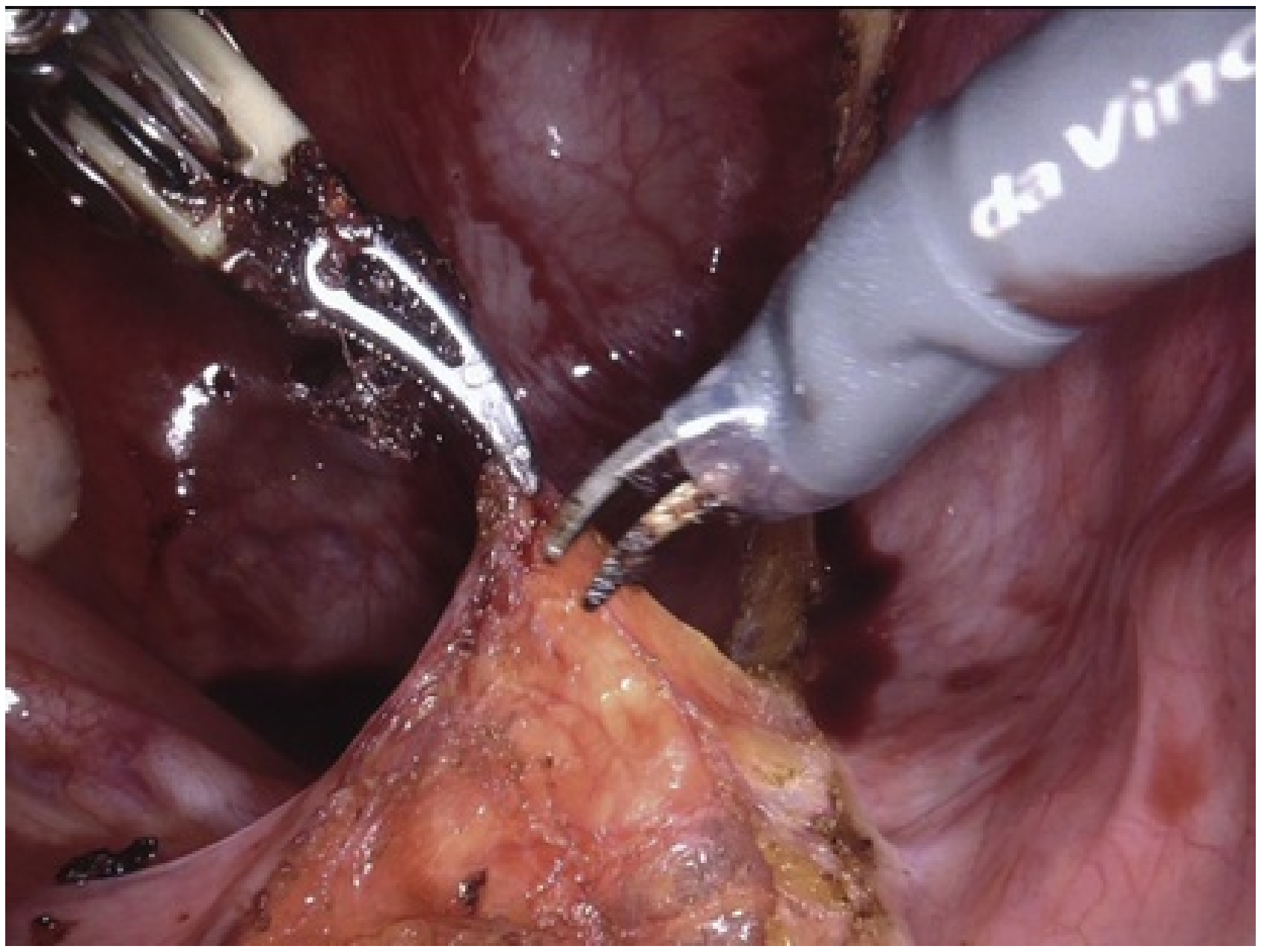

FIG. 124.25 Creation of peritoneal leaves. (Courtesy Barry Hallner, LSU Department OB/GYN 2017.)

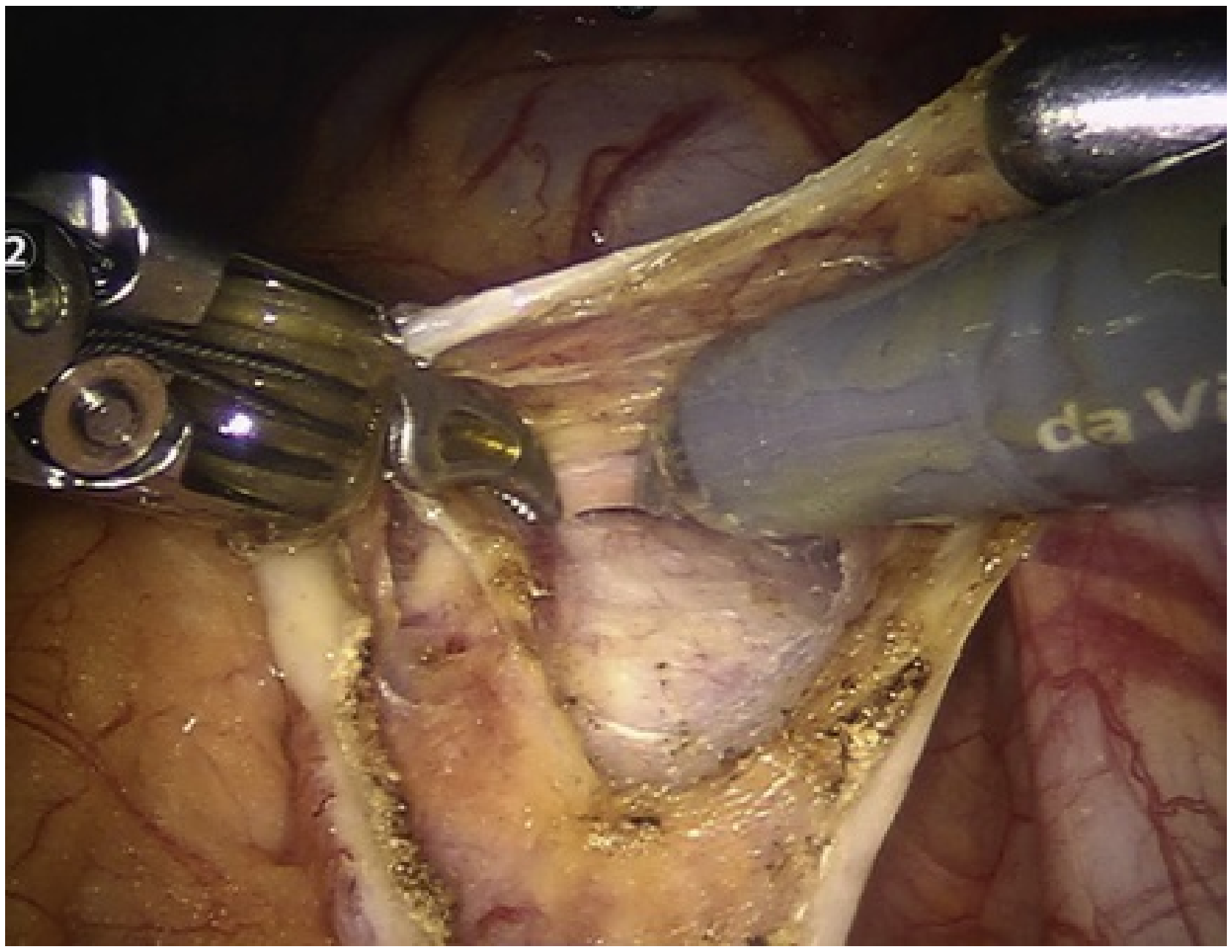

FIG. 124.26 Anterior longitudinal ligament. (Courtesy Barry Hallner, LSU Department OB/GYN 2017.)

The peritoneum incision is extended along the right pelvic side wall into the Douglas cu-de-sac. The upper vagina and vaginal apex must be elevated and distended with a vaginal stent. This permits adequate dissection and visualization of the fibromuscular layers of the vaginal wall and aids in graft placement. The vaginal stent may be a large end-to-end anastomosis sizer, a Lucite Stent (Marina Medical, Sunrise, FL), or the Colpassist Vaginal Positioning Device (Boston Scientific, Marlborough, MA). The vagina is elevated via the vaginal stent, and the peritoneum covering the vagina is incised transversely. Sharp and blunt dissection is used to separate the peritoneum and bladder from the anterior vaginal wall. This anterior dissection extends approximately 6 to 8 cm caudally to create an adequate site for graft fixation (Fig. 124.27).

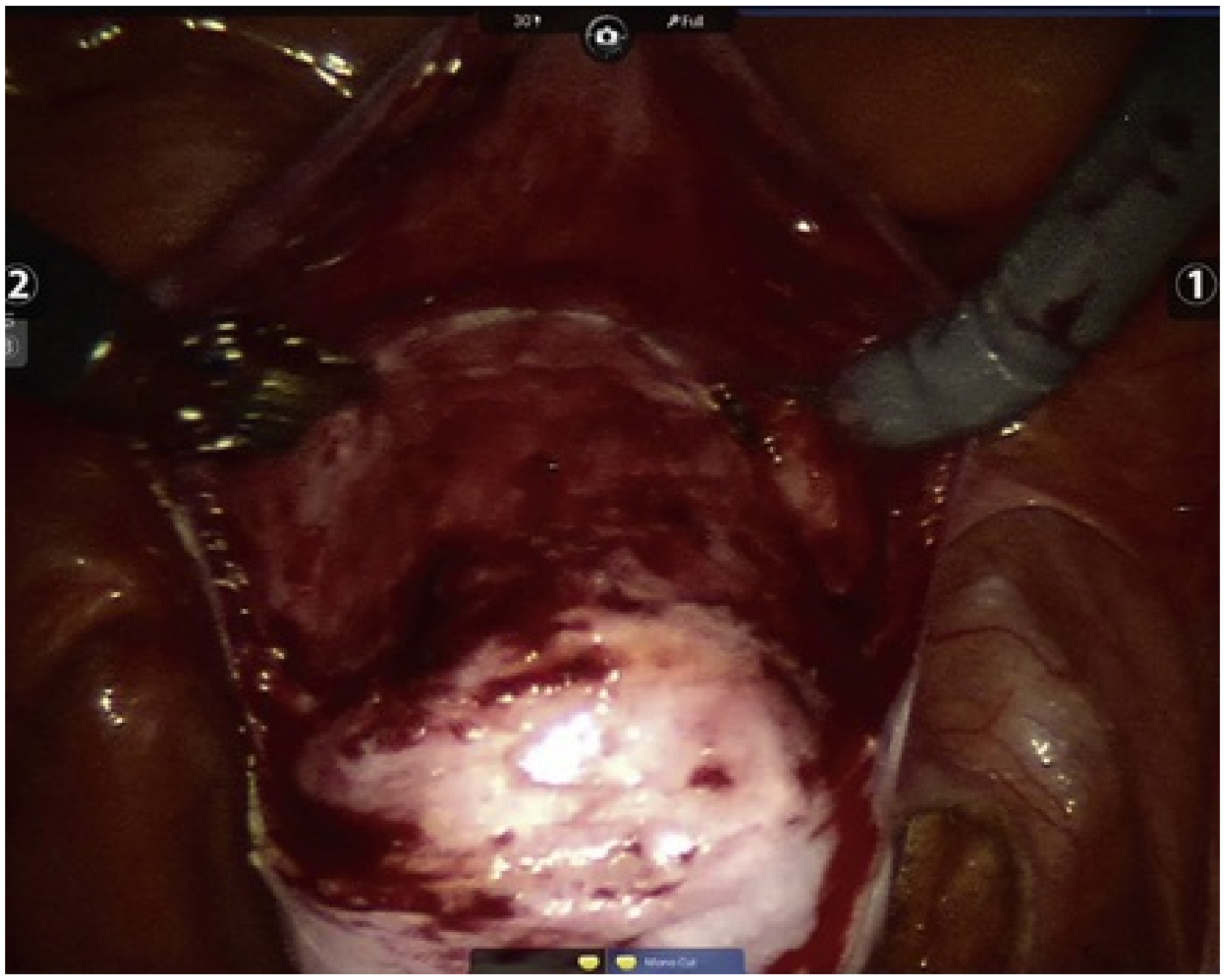

FIG. 124.27 Dissection of anterior vesicovaginal space. (Courtesy Barry Hallner, LSU Department OB/GYN 2017.)

Dissection should progress just above the fibromuscular layer in the loose areolar tissue of the vaginal wall. Dissecting in the appropriate plane decreases the risk of accidental entry into the vagina. Unintentional entry into the vaginal lumen increases the risk of future graft exposure especially when using synthetic mesh. If the vaginal wall is opened, it should be irrigated copiously followed by a two-layer closure with 2-0 or 3-0 delayed absorbable suture. Vaginal apex is redirected anteriorly, and the peritoneum covering the posterior wall is open. The rectovaginal spaces identified, and blunt dissection further opens this space to the level of the rectal reflection for distance of about 9 cm (Fig. 124.28).

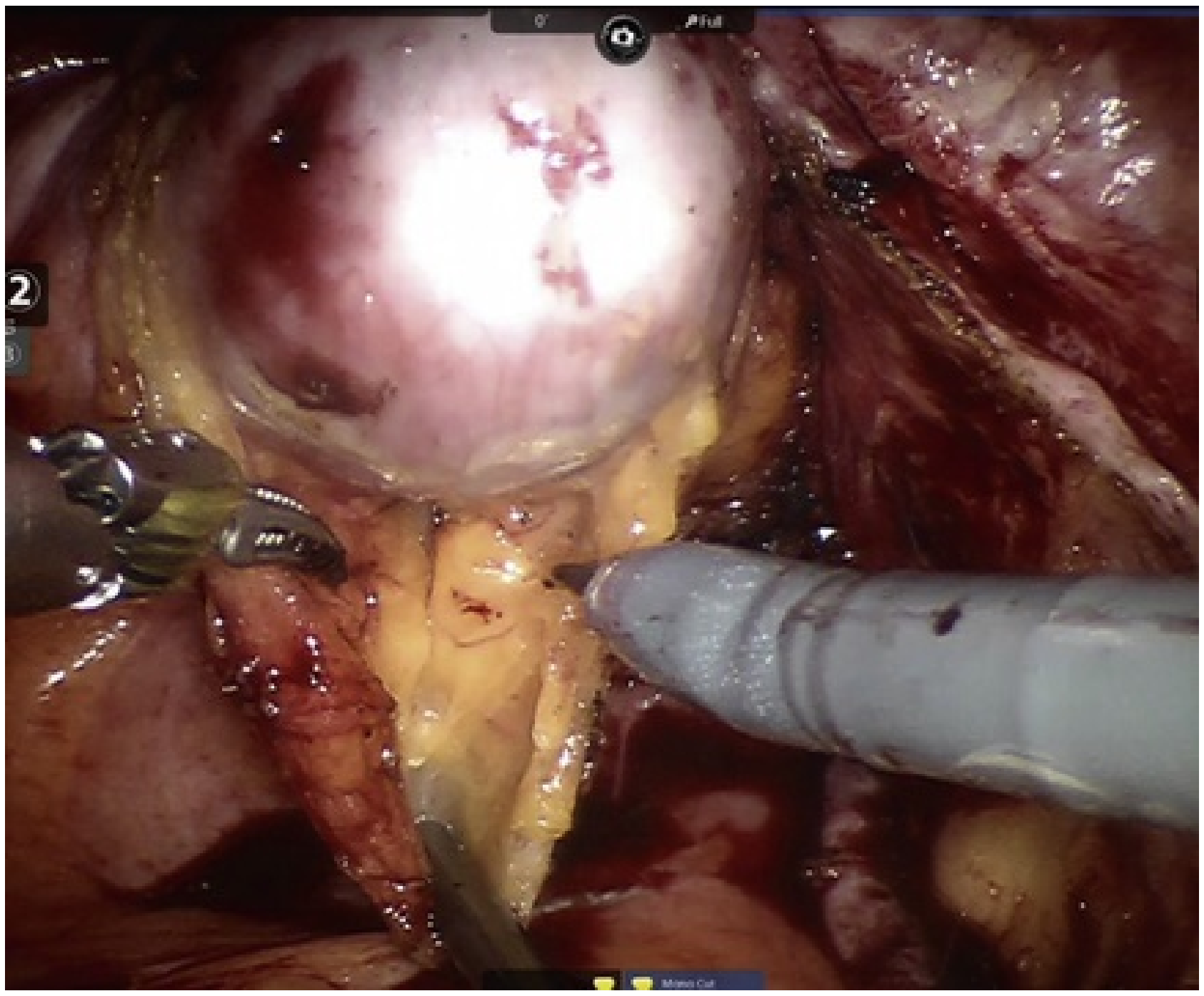

FIG. 124.28 Dissection of the posterior rectovaginal space. (Courtesy Barry Hallner, LSU Department OB/GYN 2017.)

If a sacrocolpoperineopexy is planned, dissection continues beyond the rectal reflection to the level of the perineal body (Reddy et al., 2011). The selection of the sacrocolpopexy graft is a preference of the surgeon, in general if using synthetic mesh it should be lightweight, flexible, and porous (Brown et al., 2015). Most often a prefabricated Y-shaped mesh is employed. The Y-shaped mesh is tapered and cut to the surgeon's preference. Once the initial dissection has been performed, the robotic instruments are switched to robotic needle drivers with the addition of a bowel-safe grasper. The mesh is passed into the peritoneal cavity via the assistant's trocar and guided into place. The graft may be secured to the anterior and posterior vaginal walls with delayed absorbable or permanent monofilament suture or a combination of both (Fig. 124.29). The suture is placed in full-thickness fashion without entering the vaginal lumen. Studies have shown equivalent long-term outcomes with the use of absorbable suture compared with permanent suture for sacrocolpopexy mesh fixation (Shepherd et al., 2010).

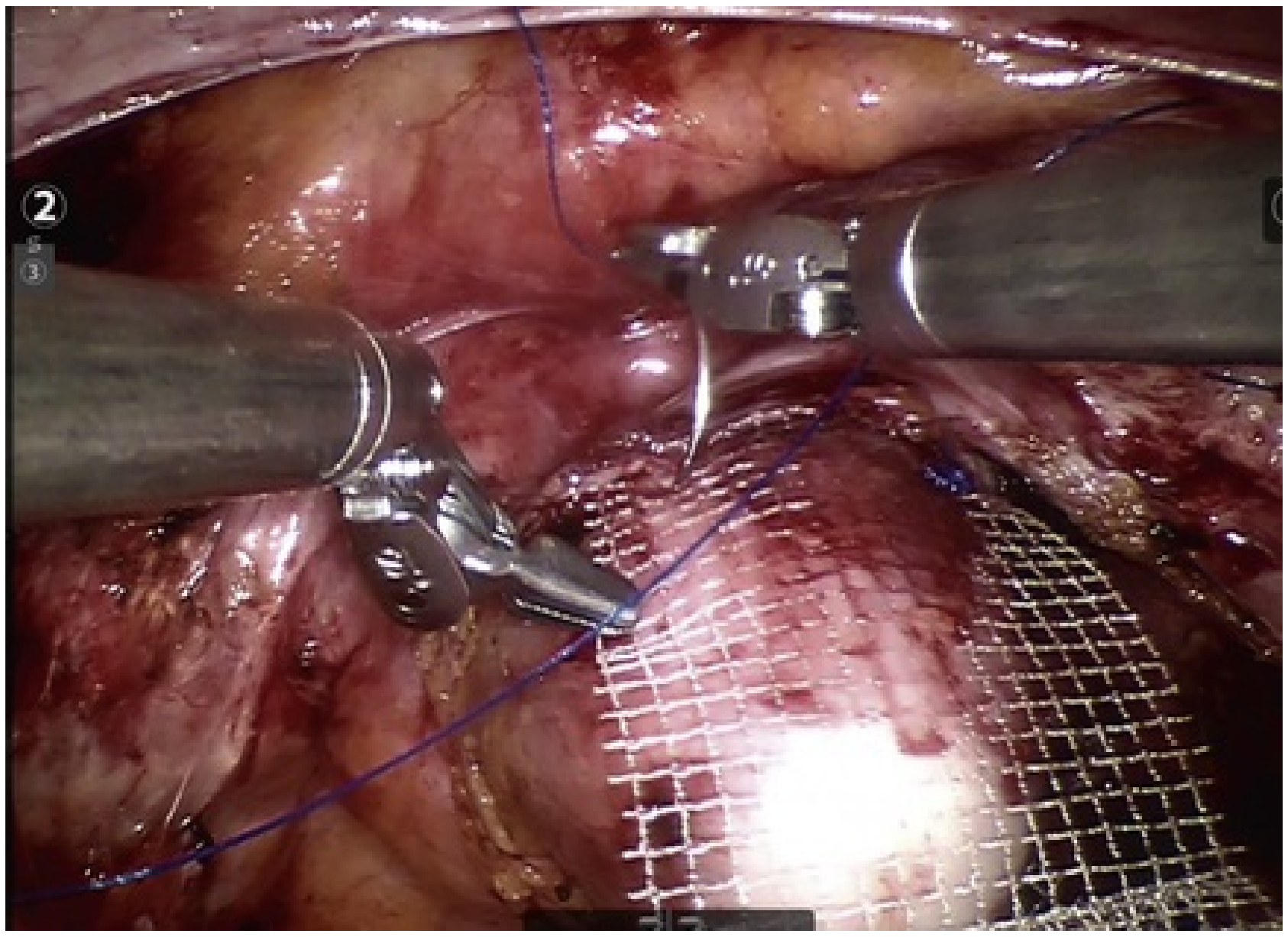

FIG. 124.29 Graft fixated to anterior and posterior vaginal wall. (Courtesy Barry Hallner, LSU Department OB/GYN 2017.)

The vaginal stent is then directed posteriorly toward the promontory and maximally extended cephalad. Tension on the stent is then released, allowing the apex to lie in a normal apical position with the prolapse reduced. Excessive tension should be avoided because it can result in pain or de novo stress urinary incontinence (Nygaard et al., 2013a,b). Tension can be performed through visual or direct vaginal examination techniques depending on surgeon preference and experience. The apical suspension should reduce the prolapse of the apex as well as the segments of the anterior and posterior vaginal walls. The tail of the graft is sutured to the anterior longitudinal ligament at the level selected by the surgeon. Traditionally sutures are placed at the S1 vertebral body or at the level of the sacral promontory (Nygaard et al., 2004a,b). Suture placement at S3 or S4 vertebral body increases the risk of injury to the presacral venous plexus, whereas placement sutures at the upper portion of the sacral promontory risks laceration of the middle sacral vessel or the left common iliac vein (Wieslander et al., 2006). However, at the level of S1 the middle sacral vessels are readily visible and can be easily isolated and avoided; two to three monofilament permanent sutures are used to fixate the graft to the anterior longitudinal ligament. The peritoneum is closed over the vaginal apex with delayed absorbable suture and continued to the level of the promontory (Fig. 124.30). The graft is now completely retroperitonealized. Cystoscopy is performed to rule out injury to the bladder, intravesical suture, or mesh perforation and to confirm ureteral patency. The robot is undocked, the patient is taken out of Trendelenburg position, the CO_2 gas is removed from the abdomen, the trocars are removed under direct vision, and trocar sites are closed according to surgeon preference.

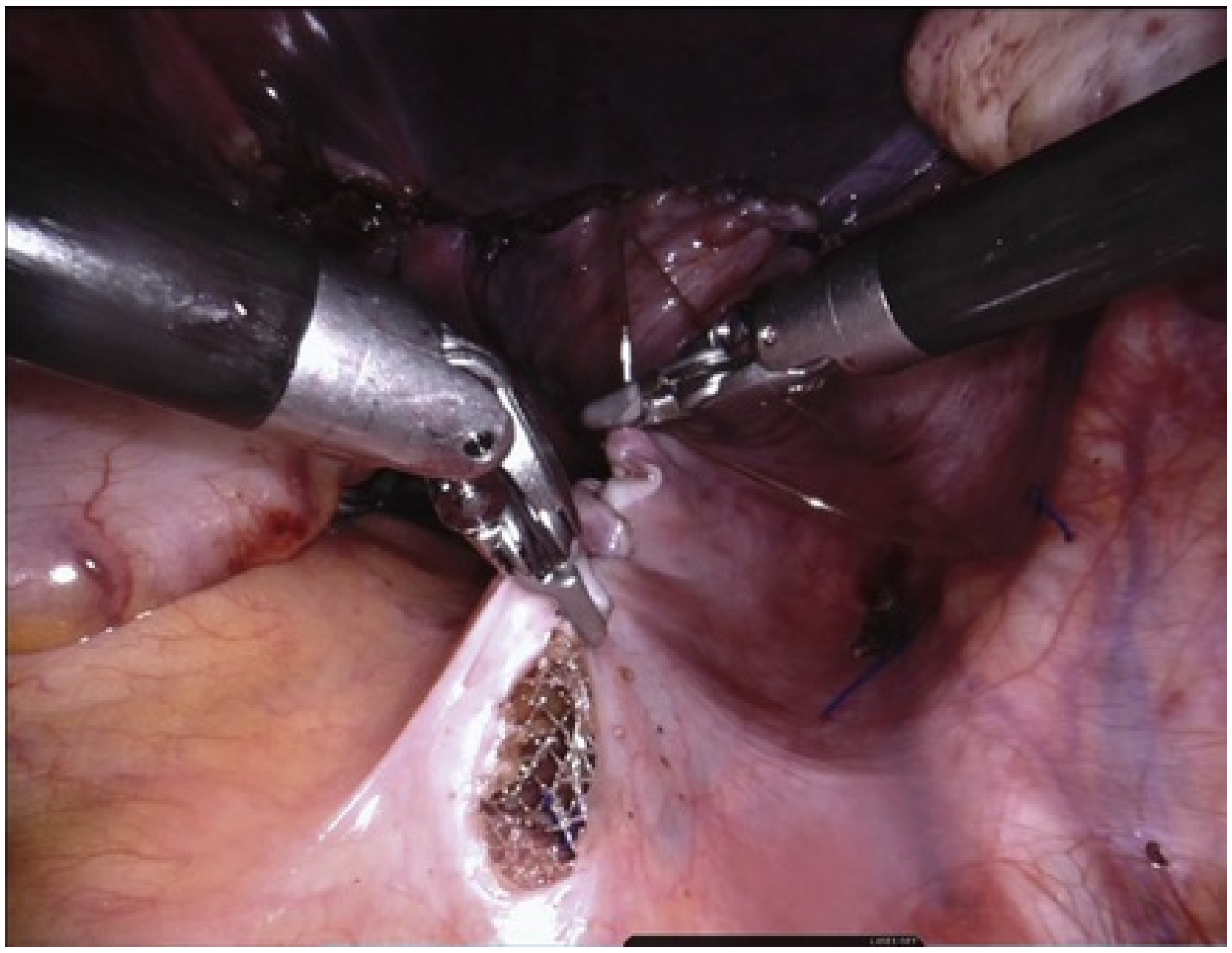

FIG. 124.30 Peritoneum is closed to the level of the promontory. (Courtesy Barry Hallner, LSU Department OB/GYN 2017.)

Laparoscopic Sacrocolpopexy Technique.

As stated earlier, sacrocolpopexy may be performed with a minimally invasive technique using laparoscopy or robotic surgery. After administration of general anesthesia, the patient is properly positioned in Allen stirrups in low lithotomy position, the arms are properly tucked to the side, and all bony prominences are padded, a pelvic exam is performed, the abdomen and vagina are surgically prepared, and a Foley catheter is inserted into the bladder. Trocar placement begins with entry into the abdominal cavity via the technique with which the surgeon is most experienced. The abdomen is inflated with CO_2 gas once entry into the abdomen is confirmed. A 0-degree laparoscope is inserted through the umbilical trocar and careful inspection of the peritoneal cavity is performed, delineating all the pertinent anatomy to performing the sacrocolpopexy. Depending on the anatomy and whether adhesiolysis is necessary, trocar placement can be performed.

There are many variations of trocar placement described, but in general trocar placement involves two additional trocars placed under direct visualization in the right and left lower quadrants, lateral to the inferior epigastric vessels, and one or two additional 5-mm ports are placed at the level of the umbilicus, lateral to the rectus muscle. Additional 5-mm trocar ports can be placed on the principal surgeon's side so that he or she can operate with two hands. Port placement is similar to robotic trocar placement and is shown in Fig. 124.23. Commonly used instruments are a unipolar scissors, bipolar cautery graspers, and laparoscopic blunt-tipped dissectors.

The patient is placed in Trendelenburg position, and the bowel is gently swept out of the pelvis. In a similar fashion as described in the robotic sacrocolpopexy section, the vagina is elevated via the vaginal stent, and the peritoneum covering the vagina is incised transversely. Sharp and blunt dissection is used to separate the peritoneum and bladder from the anterior vaginal wall. This anterior dissection extends approximately 6 to 8 cm caudally to create an adequate surface for graft fixation (see Fig. 124.27). Dissection should progress to the depth just above the fibromuscular layer of the vaginal wall. Dissecting in the appropriate plane will decrease the risk of accidental entry into the vagina. As stated earlier, if the vaginal wall is opened, it should be irrigated copiously followed by a two-layer closure with 2-0 or 3-0 delayed absorbable suture. The vaginal apex is redirected anteriorly, and the peritoneum covering the posterior wall is open. The rectovaginal spaces are identified, and blunt dissection further opens this space to the level of the rectal reflection for distance of about 7 to 9 cm. To avoid injury to the rectum, care is taken not to detach the perirectal fat tissue from the rectum.

Once the anterior and posterior dissections have been performed, the presacral dissection can begin. The sigmoid is retracted to the left. The peritoneum overlying the sacral promontory is elevated and opened on the right side of midline in a longitudinal fashion with laparoscopic scissors and extended to the cul-de-sac. The peritoneum is excised superficially and parallel to the sigmoid to create the retroperitoneal leaves that will be used later to cover the mesh. The loose fatty adipose tissue is dissected until the anterior longitudinal ligament is exposed. Care is taken to avoid the presacral vessel and the middle sacral vessels. Bleeding during the dissection is encountered; coagulation or clips can be used to achieve hemostasis. A lightweight, macroporous, polypropylene, prefabricated Y mesh can be used and is cut to surgeon preference. Alternatively, some surgeons may prefer to use individual stripes of mesh. For suturing, the surgeon determines the needle holder preference. Extracorporeally knot tying with either an open-ended or closed-ended knot pusher depends on surgeon preference. Some surgeons have chosen to avoid that tying altogether by securing the mesh for the barbed suture (V-Loc, Covidien/Medtronic, Minneapolis, MN, and Quill, Angiotech, Vancouver, BC). The mesh is passed into the peritoneal cavity via the assistant's trocar and guided into place. The graft may be secured to the anterior and posterior vaginal wall with delayed absorbable or permanent suture or a combination of both (see Fig. 124.29). The suture should incorporate the full thickness of the vaginal wall without entering the vaginal lumen. The sutures are tied extracorporeally or intracorporeally. As noted earlier, studies have shown equivalent long-term outcomes with the use of absorbable suture compared with permanent suture for sacrocolpopexy mesh fixation (Shepherd et al., 2010).

The vaginal stent is then directed posteriorly toward the promontory and maximumly extended cephalad. Tension on the stent is then released, allowing the apex to lie in a normal apical position with the prolapse reduced. Excessive tension can result in pain or de novo SUI (Nygaard et al., 2013a,b). Tension can be achieved through visual or direct vaginal examination techniques, depending on surgeon preference and experience. The apical suspension should reduce prolapse of the apex as well as the apical segments of the anterior posterior vaginal wall. The apical tail of the graft is sutured to the anterior longitudinal ligament at the level of S1 with two or three permanent monofilament sutures; alternatively titanium tacks can also be used to attach the mesh to the anterior longitudinal ligament sacrum. Currently, tacking devices are not commonly used in sacrocolpopexy as lumbosacral osteomyelitis and spondylodiscitis have been reported and are a rare but devastating complication. These rare cases have been reported in the literature, and most are related to suture or tack placement in the presacral space (Collins et al., 2011; Grimes et al., 2012; Muffly et al., 2010; Nosseir et al., 2010; Roth and Reight, 2012).

The peritoneum is closed over the vaginal apex with delayed absorbable suture and continued to the level of the promontory (see Fig. 124.30). Once the graft has been retroperitonealized, cystoscopy is performed to rule out injury to the bladder, intravesical suture, or mesh perforation and to confirm ureteral patency. The patient is taken out of Trendelenburg position, the CO_2 gas is removed from the abdomen, the trocars are removed under direct vision, and trocar sites are closed according to surgeon preference.

Sacrocolpopexy Complications.

In a comprehensive review by Nygaard et al. (2004a,b), intraoperative complications of sacrocolpopexy included hemorrhage or transfusion 4.4%, cystotomy 3.1%, enterotomy 1.6%, and ureteral injury 1.0%. Postoperative complications included urinary tract infection 10.9%, wound infection 4.6%, ileus 3.6%, deep venous thrombosis or pulmonary embolism 3.3%, and small bowel obstruction 1.1%. Significant hemorrhage may occur from disruption of the presacral vessels, and the occurrence of this complication may be reduced when fixation of the graft is performed higher on the sacral promontory. Dealing with these vessels preemptively with bipolar energy, especially with a minimally invasive approach, may preclude this complication. The CARE trial data reveal that the rate of reoperation for gastrointestinal complications with this procedure is 1.2% (Whitehead et al., 2007). Vaginal exposure of mesh is another complication and is heralded by persistent pain, discharge, or infections, and clinicians must be vigilant in follow-up (Karlovsky et al., 2005).

In meta-analysis, mesh exposure into the vagina has been reported at a rate of 3.4% to 5.4% and may vary depending on the type of mesh used (Brizzolara and Pillai-Allen, 2003; Nygaard et al., 2004a,b). Symptoms develop on average 14 months after surgery and classically consist of vaginal bleeding and discharge (Kohli et al., 1998). Exposures occur more often with Teflon or Gore-Tex–type materials and are less frequent with macroporous, monofilament meshes. Surgeons performing these procedures should be aware of the recently reported 9.9% mesh exposure rate from the extended follow-up of the multicenter CARE trial (Nygaard et al., 2013a,b). Several authors have suggested that hysterectomy at the time of colpopexy increases the rate of mesh extrusion, although these findings are not uniform (Marinkovic, 2008; Nygaard et al., 2004a,b), and no randomized trials address this issue (Nygaard et al., 2004a,b). In 60 patients undergoing concomitant hysterectomy using a two-layer closure of the vaginal cuff followed by ASC with synthetic nonabsorbable monofilament mesh, the exposure rate was 0.8% compared with 0 in the 64 patients with a prior hysterectomy (Wu et al., 2006). In patients undergoing a combined operation, supracervical hysterectomy or a meticulous two-layer closure of the cuff should be performed to decrease the incidence of mesh exposure.

Surgeons must be aware that the incidence of mesh exposure after ASC is higher after a total hysterectomy. **In patients needing hysterectomy, the feasibility of a supracervical hysterectomy should be strongly examined. In this scenario, a supracervical hysterectomy in conjunction with the ASC is**

preferred. These patients should also be informed that for uterine prolapse, a vaginal hysterectomy with vaginal vault suspension is an effective option as well. Options for the management of exposed mesh after colpopexy may include transvaginal mesh excision with or without partial colpocleisis (Quiroz et al., 2008) and abdominal mesh excision.

Results of Sacrocolpopexy.

ASC maintains a functional vagina and restores maximal vaginal length and support. In a comparative study, vaginal length was longer after ASC compared with sacrospinous fixation (Given et al., 1993). A nonabsorbable monofilament synthetic mesh should be used during ASC. In a study by Culligan et al. (2005), patients undergoing ASC were randomized to either absorbable cadaveric fascia lata graft (Tutoplast) or nonabsorbable monofilament polypropylene. The objective failure rate for recurrence at any other vaginal site was 14 out of 44 in the fascial group and 4 out of 45 in the mesh group (Culligan et al., 2005).

Numerous reports by multiple authors confirm the success of ASC using mesh, and multiple authors have reported success rates greater than 90% (Addison and Timmons, 1993; Addison et al., 1985; Cundiff et al., 1998; Nygaard et al., 2013a,b; Snyder and Krantz, 1991; Webb et al., 1998). In addition, there are several randomized, prospective trials comparing SSLF with abdominal sacrocolpopexy. In a comparative study between ASC versus vaginal repair, Benson et al. (1996) reported a lower success rate with vaginal repair and an equivalent hospital stay between the two groups. Lo and Wang (1998) reported on their results of ASC versus SSLF at a duration of 2.1 years: 94.2% success in ASC compared with 80% SSLF. Maher et al. (2004a) reported on a comparative study between ASC and SSLF. At 2 years' follow-up, symptoms and anatomic success were equivalent, but asymptomatic failures to the introitus and recurrent cystoceles were less after ASC.

Overall, vaginal (SSLF) procedures have a higher rate of recurrent anterior defects even when performed in the setting of a concomitant anterior colporrhaphy (Holley et al., 1995). After an isolated abdominal repair of vaginal vault prolapse without addressing concomitant pelvic floor defects, recurrent distal defects such as cystocele and rectocele may occur up to one-third of the time. This may predispose to decreased patient satisfaction and the possibility of secondary vaginal repair (Blanchard et al., 2006). Although most remain asymptomatic, secondary repair of these defects may be required (Blanchard et al., 2006). It is important to counsel patients preoperatively about the possibility of distal anterior or posterior defects after ASC, and the need for secondary vaginal repair, which can occur up to 20% of the time (Blanchard et al., 2006). In 2013 the extended CARE trial showed that at 7 years after ASC the recurrence rate of POP progressively increases. The anatomic treatment failure (C > tvl-2 or Ba/Bp > +1) rates for ASC with and without Burch urethropexy were 0.27 and 0.22, respectively. Interestingly, half of these were asymptomatic. The symptomatic failures were between 29% and 24%, anatomic failure rates were between 27% and 22%, and composite rates of failure were 48% and 34% for their 2 groups. However, half of these patients were not retreated (Nygaard et al., 2013a,b).

Rozet et al. (2005) reported on 363 patients who underwent laparoscopic sacrocolpopexy (LSC) between 1996 and 2002. Their mean age was 63 (range 35–78), average follow-up was 14.6 months, and the mean operating time was 97 minutes. Follow-up was a postal questionnaire and physical examination at 6 months and then yearly; 96% were satisfied with the results of their operation, and no patients complained of sexual dysfunction. There was a 4% recurrence rate of prolapse, 3 vaginal erosions, 2 urinary retentions that required TVT resection, 1 bowel incarceration, 1 spondylitis, and 2 mesh infections (Rozet et al., 2005; Tables 124.7 and 124.8).

TABLE 124.7

Clinic Outcomes of Laparoscopic Sacrocolpopexy Patient Series

STUDY	# OF PATIENTS	STUDY TYPE	DURATION OF FOLLOW-UP, MO	OPERATIVE TIME, MIN	ESTIMATED BLOOD LOSS, mL	C R
Rozet et al., 2005	363	Retrospective	14.6	97	10– 100 (> 100 in 3 patients)	8%
Claerhout et al., 2009	132	Prospective	12.5	181	185	5%

Granese et al., 2009	165	Prospective	60	55	100–250	N/
Sarlos et al., 2008	101	Prospective	12	141	95	2%

TABLE 124.8

Complications of Laparoscopic Sacrocolpopexy Patient Series

STUDY	# OF PATIENTS	MESH EROSION (%)	BLADDER INJURY (%)	BOWEL INJURY (%)	DE NOVO SUI (%)	LUTS (%)	DYSPARE (%)
Rozet et al., 2005	363	1	0	0	0	6	0
Claerhout et al., 2009	132	4	0	0	0	0	0
Granese et al., 2009	165	0.7	3	2	9	9	3
Sarlos et al., 2008	101	1	4	3	24	27	0

Claerhout et al. (2009) reported a prospective series of 132 women that underwent LSC between 2001 and 2006. The mean follow-up was 12.5 months with a mean operative time of 180.5 minutes. The objective cure rate was 98%, and a 18% failure rate was seen mainly in the posterior compartment, although no patient underwent reoperation. De novo SUI was noted in 7.4% of patients postoperatively. Mesh erosion was seen in 4.5% of patients, all within 1 year; 2.7% of patients experienced mesh-related pain (Claerhout et al., 2009) (see Tables 124.7 and 124.8).

In a 2014 review of robotic and LSC, Lee at al. (2014) reported results from 11 patient series encompassing 1221 patients with a mean follow-up of 26 months. Mean operative time was 124 minutes (range 55–185) with a 3% (range 0–11%) conversion rate. Objective cure was achieved in 91% of patients and similar satisfaction rates of 92% (Lee et al., 2014). Only a few well-designed comparative studies exist, and many have varying objective and subjective outcomes. A total of five studies compared the outcomes of LSC with ASC. Most are short term, with a mean follow-up of 12 months or less.

Abdominal Sacrocolpopexy Versus Laparoscopic Sacrocolpopexy (Table 124.9).

Recently Coolen et al. (2017) randomized 73 women with a history of hysterectomy who had symptomatic vaginal vault prolapse, with or without concomitant cystocele and rectocele, to either ASC or LSC. The mean follow-up was 12 months. The primary outcome of the study was functional outcome, which was evaluated using the UDI. The questionnaires also contain versions of the Defecatory Distress Inventory (DDI), the Incontinence Impact Questionnaire (IIQ), the PGI-I, and questions about sexuality, which were secondary outcomes. Secondary outcomes included procedure time, amount of estimated blood loss, hospital stay, perioperative complications, reinterventions, composite outcome of success (defined as no prolapse beyond the hymen), no bothersome bulge symptoms, and no repeat surgery or pessary use for recurrent prolapse within 12 months and long-term complications. The composite outcome of success was 83.8% (31 out of 37) for the laparoscopy group and 89.2% (33 out of 37) in the open abdominal group. In both groups, there were no recurrences of stage 2 or higher of the apical compartment. Two patients in the laparoscopy group had bothersome bulge symptoms compared with 4 in abdominal group. Five participants of the laparoscopy group had additional surgery for POP, versus 1 in the abdominal group. In both groups more participants became sexually active, there was less dyspareunia, and the coital frequency was increased at 12 months postoperatively. There are no significant differences between the groups.

TABLE 124.9

Clinical Outcomes of Laparoscopic Versus Open Abdominal Sacrocolpopexy

STUDY	STUDY TYPE	# OF PATIENTS (LSC VS. ASC)	DURATION OF FOLLOW-UP, MO	OBJECTIVE SUCCESS RATE WITH DEFINITION (%)	SUBJECTIVE SUCCESS RATE (%)	C T
Coolen et al., 2017	Randomized	37 vs. 37	12	84% vs. 89% Composite outcome of success. Primary outcome was quality of life.	71% vs. 74% PGI-I score much better	1
Costantini et al., 2016	Randomized	61 vs. 60	41.7 mean	100% for both stage ≤ 1, POP-Q point C/D −5 or less, TVL at least 7 cm	NS	N
Freeman et al., 2013	Randomized	23 vs. 24	12	NA	64% vs. 70%	1
Klauschie et al., 2009	Retrospective	43 vs. 41	7.4 vs. 10.6	100% vs. 88%, POP-Q point C higher than	91% vs. 95%	1

				half total vaginal length and no need for reoperation or pessary use for symptomatic apical failure		
Hsiao et al., 2007	Retrospective	25 vs. 22	6 vs. 11	100% vs 85% Baden-Walker stage ≥ 0	NA	2
Paraiso et al., 2005	Retrospective	56 vs. 61	13.5 vs. 15.7	NS	No significant difference in total reoperations for recurrent prolapse between groups	2

ASC, Abdominal sacrocolpopexy; *LSC,* laparoscopic sacrocolpopexy; *PGI-I,* Patient Global Impression of Improvement; *POP-Q,* pelvic organ prolapse-quantification.

Freeman et al. (2013) compared abdominal sacrocolpopexy with laparoscopic sacrocolpopexy in a multicenter randomized equivalence trial for treatment of post-hysterectomy vaginal vault prolapse. Patients were included if they had at least a stage 2 vaginal vault prolapse and did not need additional prolapse procedures. The primary outcomes were location of POP-Q point C and PGI-I scores at 1 year of follow-up (see Table 124.9). Secondary outcomes were intraoperative blood loss, mean drop in hemoglobin, length of postoperative hospitalization, operating time, postoperative pain assessment, return to daily activities, QoL, new onset of urinary incontinence, and reoperation rates. At 1 year, point C met equivalence criteria for the abdominal and laparoscopic groups (6.63 ± 1.4 cm and 6.65 ± 1.2 cm, respectively; $P > 0.050$). In addition, 90% of patients in the abdominal group and 80% of those in the laparoscopic group responded that they were either “very much better” or “much better” on the PGI-I at 1 year postsurgery. There was a lower blood loss (56.2 ± 34 vs. 240.4 ± 232 mL; $P < 0.01$), and a shorter length of hospital stay (3.2 ± 1.1 vs. 4.1 ± 1.6 days; $P = 0.02$) in the laparoscopic group. Interestingly, operative times did not differ between the abdominal and laparoscopic groups (131 ± 44 vs. 144 ± 28 min, respectively; $P = 0.24$). Although there was higher postoperative morphine use in the abdominal group, physical function scores at 1 week postoperatively on question 3 of the SF-36 did not differ between surgery groups (Freeman et al., 2013).

Geller et al. (2008) reported results of a retrospective cohort of 178 patients (73 robotic and 105 abdominal sacrocolpopexy). The primary outcome was vaginal vault support on postoperative POP-Q system examination. Secondary outcomes included blood loss, operative time, length of stay, blood transfusion, pulmonary embolus, gastrointestinal or genitourinary tract injury, ileus, bowel obstruction, postoperative fever, pneumonia, wound infection, and urinary retention. Robotic-assisted sacrocolpopexy (RSC) showed slight improvement on POP-Q “C” point (−9 compared with −8, $P = 0.008$) when compared with ASC and was associated with less blood loss (103+/−96 mL compared with 255+/-155 mL, $P < 0.001$). RSC had a longer total operative time (328+/−55 minutes compared with 225+/−61 minutes, $P < 0.001$), shorter length of stay (1.3+/−0.8 days compared with 2.7+/−1.4 days, P < 0.001), and a higher incidence of postoperative fever (4.1% compared with 0.0, $P = 0.04$). There were no gastrointestinal tract injuries, and there was one cystotomy in each surgery group ($P = 1.0$) (Geller et al., 2008).

Laparoscopic Sacrocolpopexy Versus Robotic-Assisted Sacrocolpopexy Versus Abdominal Sacrocolpopexy (Table 124.10).

Nosti et al. (2009) presented a multicenter retrospective cohort trial comparing perioperative and postoperative surgical outcomes between open and minimally invasive sacrocolpopexy in 831 women who underwent surgery between 1999 and 2009. Anatomic failure was defined as POP-Q stage of at least stage 2. Four hundred patients in the cohort underwent open sacrocolpopexy, 231 underwent laparoscopic, and 218 had RSC. Laparoscopic and robotic cases were analyzed as minimally invasive sacrocolpopexy. Anatomic failures were higher in the open group compared with the minimally invasive group (24.1% vs. 14.3%; $P < 0.01$), which was predominantly because of posterior support. Compared with women who underwent minimally invasive sacrocolpopexy, women undergoing open sacrocolpopexy had a higher operative blood loss (188 vs. 122 mL; $P < 0.01$), longer hospital stay (2.8 vs. 1.2 days; $P < 0.01$), and longer operative times (234 vs. 206 min; $P < 0.01$), despite fewer concomitant procedures in the open group (1.5 vs. 2.0; $P < 0.01$). **In a comparison of traditional and robotic sacrocolpopexy, robotic cases had fewer anatomic failures (5.9% vs. 18.9%; $P < 0.01$), despite more advanced preoperative prolapse in the robotic**

group.

TABLE 124.10

Clinical Outcomes Comparing Robotic-Assisted vs. Laparoscopic Sacrocolpopexy and/or Abdominal Sacrocolpopexy

STUDY	STUDY TYPE	# OF PATIENTS (RSC VS. LSC VS. ASC)	DURATION OF FOLLOW-UP, MO	OBJECTIVE SUCCESS RATE WITH DEFINITION (%)	SUBJECTIVE SUCCESS RATE (%)	O TI
Antosh et al., 2012	Retrospective	65 vs. 23 vs. NA	10.8 vs. 3	87.1 vs. 91.3 vs. NA	NA	23
Seror et al., 2012	Prospective	20 vs. 47 vs. NA	15 vs. 18 vs. NA	99% vs. 99%	NA	21 vs.
Paraiso et al., 2011	Randomized	40 vs. 38 vs. NA	12	88% vs. 91% vs. NA Pre- vs. postoperative POP-Q scores	NA	34 vs.
Geller et al., 2008	Retrospective	73 vs. NA vs. 105	6 wk	100% vs. NA vs. 100% Pre- vs. postoperative POP-Q scores	NA	32 vs.
Geller et al., 2012	Retrospective	23 vs. NA vs. 28	44.2	100% vs. NA vs. 100% ≤ 1 apical prolapse, C ≤ −5, total vaginal length ≥ 7	NA	Po PC im sin bas bo rob ab gr vs. (− −2 (− (al

						ba of
Siddiqui et al., 2012	Retrospective	125 vs. NA vs. 322	15 mo vs. NA vs. 11.7	94% vs. NA vs. 94% POP-Q point C less than ⅔ total vaginal length or Aa, Ba, Ap, or Bp ≤ 0	92% vs. NA vs. 96%	N
Nosti et al., 2014	Retrospective	218 vs. 213 vs. 400	7.6	94% vs. 81% vs. 91% POP-Q ≤ stage 2	NS	20

ASC, Abdominal sacrocolpopexy; *LSC*, laparoscopic sacrocolpopexy; *NA*, not available; *PFDI*, Pelvic Floor Distress Inventory; *PISQ*, Pelvic Organ Prolapse/Urinary Incontinence Sexual Questionnaire; *PFIQ*, Pelvic Floor Impact Questionnaire; *POP-Q*, pelvic organ prolapse-quantification; *RSC*, robotic-assisted sacrocolpopexy.

Laparoscopic Sacrocolpopexy Versus Robotic-Assisted Colpopexy.

Paraiso et al. (2011) randomized women with stage 2 to 4 post-hysterectomy vaginal apex prolapse to either LSC or RSC. The primary outcome was total operative time from incision to closure, but secondary outcomes included postoperative pain, functional activity, bowel and bladder symptoms, QoL, anatomic vaginal support, and cost from a health care perspective. Total operative time was significantly longer in the robotic group (227 +/−47 versus 162 +/−47 min; $P < 0.001$), with docking only accounting for an average of 14 additional minutes. Robotic suturing tying was longer (98 +/−22 vs. 68 +/−16 min; $P < 0.001$). Although pain scores were not significantly different on postoperative day 1, the robotic group reported more pain at rest and with normal activities at several points during the 6-week postoperative period. The authors thought the increase in pain was due to manipulation and fascial closure of the right paracolic gutter accessory port; they have since changed the port size to an 8-mm port. At 6- and 12-month follow-up, anatomic and QoL outcomes did not differ between the two groups (see Table 124.10).

Antosh et al. (2012) reported intraoperative and postoperative complications in their retrospective cohort comparison of RSC ($N = 65$) and LSC ($N = 23$). Median preoperative prolapse was stage 3 for both groups. There was no statistically significant difference in the median operative time between the RSC and LSC groups, although this did not include robot setup time and did include concurrent procedures that differed significantly between groups (334 vs. 325 minutes, *P* = 0.30). Estimated blood loss was lower in the robotic group (50 vs. 100 mL, *P* = 0.003). There were no differences in overall objective cure rates between RSC and LSC groups at 3 months of follow-up (87.1% vs. 91.3%, *P* = 0.72). Perioperative complications, including visceral injury and mesh erosion, did not differ significantly between these groups (Antosh et al., 2012) (see Table 124.10).

Long-term success and complication data from well-designed studies for sacrocolpopexy are limited. In 2013 the E-CARE trial reported that 7 years after open ASC, symptomatic failure was between 29% and 24%; anatomic failure rates were between 27% and 22%; and composite rates of failure were 48% and 34% for their 2 groups. Unger et al. (2017) reported results of a retrospective study of 1381 women undergoing uterosacral colpopexy, LSC, and RSC for treatment of POP between 2006 and 2012: 983 patients (71.1%) underwent USC, 256 (18.5%) patients underwent LSC, and 142 (11.2%) patients underwent RSC. Follow-up ranged from 1 to 28 months with median (interquartile range) follow-up time for each group: uterosacral colpopexy, 6.2 (1.5–27.6) months; laparoscopic sacrocolpopexy, 5.8 (1.9–13.5) months; robotic sacrocolpopexy, 5.8 (2.8–13.8) months. The interesting aspect of this study, however, was that the authors were able to extrapolate long-term outcomes. Median (range) months to failure were 17.1 (7.6–41) months for uterosacral colpopexy, 10.1 (4.7–25.1) months for LSC, and 9.7 (1.6–17.2) months for RSC. Rates of retreatment for POP were 14%, 8%, and 23% for uterosacral colpopexy, LSC, and RSC, respectively. In the RSC cohort, 86% of retreatment for POP was for symptomatic rectocele, and 14% were for symptomatic cystocele. In the LSC group, 67% were for symptomatic rectocele, and 33% were for symptomatic cystocele.

There were no retreatments for apical prolapse in the RSC or LSC groups. Authors suggest by year 6, using strict composite definitions, the estimated recurrence rates for the uterosacral colpopexy, RSC, and LSC may be as high as 40% to 60% (Unger et al., 2017). The majority of patients receiving uterosacral colpopexy were primary prolapse repairs, whereas up to 40% of the laparoscopic and robotic cases had undergone previous POP surgery. When baseline risk factors (such as previous POP surgery and concomitant rectocele repair) for recurrent POP were controlled for, uterosacral colpopexy appeared to have a higher risk of anatomic recurrent POP but a lower risk of symptomatic bulge and need for retreatment for POP when compared with RSC and LSC (Unger et al., 2017). In a meta-analysis of outcomes after robotic sacrocolpopexy, Hudson et al. (2014) found that the most common reason for reoperation after RSC was recurrent prolapse with a combined estimated rate of 3.3% (95% CI 1.4–5.2) with the majority being posterior repairs for non-apical prolapse.

Learning Curve.

Mustafa et al. (2012) described the LSC learning curve with a retrospective review of 47 consecutive women undergoing LSC at a single tertiary care medical center. Mean operative time significantly decreased from 196 to 162 min when comparing the first 15 versus the last 30 cases. Blood loss and complication rates were unchanged. The authors asserted that approximately 30 to 40 cases were necessary to master LSC. This experience was echoed by Claerhout et al. (2009), who noted an inflection point in the duration of surgery after 18 to 24 cases. A learning curve for RSC also exists. Germain et al. (2013) reported on 52 patients undergoing RSC over a 7-year period (Tables 124.11 and 124.12). Mean operative time decreased from 222 min during the first 10 cases to 183 for the next 10 cases. Lenihan et al. (2008) also reported that the learning curve for RSC comprised about 50 cases. A summary of clinical outcomes of RSC case series may be found in Tables 124.11 and 124.12.

TABLE 124.11

Clinical Outcomes of Robotic-Assisted Sacrocolpopexy Patient Series

STUDY	STUDY TYPE	# OF PATIENTS	DURATION OF FOLLOW-UP, MO	OPERATIVE TIME, MIN	ESTIMATED BLOOD LOSS, mL	CO RA
Moreno Sierra et al., 2011	Prospective	31	25	186	NA	3
Germain et al., 2013	Retrospective	52	42	190	NA	4
Salamon et al.,	Prospective	120	12	161	49	0

2013						

NA, Not available; *PFDI*, Pelvic Floor Distress Inventory; *PISQ*, Pelvic Organ Prolapse/Urinary Incontinence Sexual Questionnaire; *PFIQ*, Pelvic Floor Impact Questionnaire; *POP-Q*, pelvic organ prolapse-quantification.

TABLE 124.12

Complications of Robotic-Assisted Sacrocolpopexy Patient Series

STUDY	NO. OF PATIENTS	MESH EROSION (%)	BLADDER INJURY (%)	BOWEL INJURY (%)	DE NOVO SUI (%)	LUTS (%)	DYSPAREU (%)
Moreno Sierra et al., 2011	31	0	7	0	0	0	0
Germain et al., 2013	52	0	2	2	0	0	0
Salamon et al., 2013	120	0	0	0	4	2	2

LUTS, Lower urinary tract symptoms; *SUI,* stress urinary incontinence; *UTI,* urinary tract infection.

Cost.

The cost of minimally invasive prolapse surgery has been compared with open, vaginal, laparoscopic, and robotic procedures. Surgical costs can be calculated in several different ways; consequently, comparison of cost data can be difficult (Tarr and Paraiso, 2015). Judd et al., in a 2010 cost-minimization analysis comparing RSC, LSC, and ASC, noted that RSC was the most expensive, $8508 per procedure when compared with LSC at $7353 and ASC at $5792. RSC and LSC became cost-equivalent only when robotic operative time was reduced to

149 minutes. In the Paraiso et al., 2011 study, it was reported that RSC cost more than laparoscopic sacrocolpopexy ($16,278 ± $3326 vs. $14,342 ± $2941, respectively), with a mean difference of +$1936 (95% CI $417–$3454; *P* = 0.008). The cost discrepancy was mainly driven by the difference in operating room costs (MD +$1667; 95% CI $448–$2885; *P* = 0.008). The cost analysis did not account for the initial robot purchase or yearly maintenance (Paraiso et al., 2011). In a 2012 cost-minimization analysis performed in a retrospective cohort of patients who had undergone either RSC or open sacrocolpopexy at Stanford, it was determined that base case analysis revealed an overall 10% cost savings for RSC versus open sacrocolpopexy ($10,178 vs. $11,307). Elliot's Tornado analysis suggested that the number of institutional robotic cases done annually, length of stay, and cost per hospitalization day in the postoperative period were the largest drivers of cost (Elliott et al., 2012).

Comparison of Apical Procedures

In a 2016 Cochrane review of surgery for apical vaginal prolapse, vaginal procedures versus sacrocolpopexy were more likely to experience awareness of prolapse (RR 2.11, 95% CI 1.06–4.21), repeat surgery for prolapse (RR 2.28, 95% CI 1.20–4.32), recurrent prolapse (RR 1.89, 95% CI 1.33–2.70), stress incontinence (RR 1.86, 95% CI 1.17–2.94), and dyspareunia (RR 2.53, 95% CI 1.17–5.50) (Maher et al., 2016a). Vaginal procedures do have high success rates with low operation rates and may be the procedure of choice for many older women. The 2016 Cochrane review concluded that there was no evidence of any difference for any of the primary outcomes between different types of apical vaginal native tissue repairs. Likewise Siff and Barber (2016) in a comparative effectiveness trial found that SSLF and uterosacral ligament suspension were effective and provided similar outcomes in anatomy and function with few adverse events. In addition, they noted that regarding uterine preservation, sacrospinous hysteropexy was not inferior to vaginal hysterectomy with uterosacral suspension for the treatment of apical uterovaginal prolapse.

Colpocleisis

Colpocleisis is an obliterative procedure used in the treatment of post-hysterectomy vaginal vault prolapse or significant uterovaginal prolapse. In properly counseled, older patients who do not desire a functional vagina for sexual activity, colpocleisis may be an appropriate, noninvasive procedure. The total colpocleisis is performed in patients who have undergone hysterectomy and refers to removal of the vaginal epithelium to approximately 2 to 3 cm from the urethral meatus with complete closure. A partial colpocleisis is used in cases of uterovaginal prolapse. This procedure involves creating lateral channels to allow potential uterine drainage. Advantages of the colpocleisis procedures are shorter operative time, ability to use regional anesthesia or local anesthesia with sedation, minimal complications, minimal recurrence, and decreased recuperative time (Cespedes et al., 2001; FitzGerald et al., 2008). In those whose uterus is to be left in situ, preoperative evaluation should include a Papanicolaou smear, pelvic sonogram, and endometrial biopsy if indicated. Performance of hysterectomy at the time of colpocleisis eliminates the risk of developing cervical or endometrial cancer and eliminates the risk of developing pyometra, which is a serious complication of partial colpocleisis when the channels become obstructed (Shayya et al., 2009). However, most patients selected for colpocleisis are older with significant comorbidities that make a concomitant hysterectomy undesirable.

Partial Colpocleisis—Technique.

The patient is placed in standard lithotomy position. A Foley catheter is placed into the bladder. If an anti-incontinence procedure is needed, it may be performed first. The cervix is grasped with a tenaculum, and a rectangular segment of vaginal epithelium is marked anteriorly and posteriorly. The excision of the vaginal epithelium will extend 3 cm from the urethral meatus to 3 cm from the cervix (Cespedes et al., 2001). It is important to leave sufficient vaginal epithelium laterally to allow creation of the lateral channels to facilitate drainage. The epithelium is then excised. It is optional to place a 14-Fr Red Robinson catheter or a vessel loop along the vaginal sidewalls to assist in forming the channels. Then, starting at the leading edge of the prolapse, the surgeon places successive layers of 2-0 delayed absorbable sutures, which plicate and reduce the prolapse until the prolapsed tissues are above the levator plate (Fig. 124.31A). The sutures are placed in transverse rows consisting of linear sutures through the pubocervical fascia anteriorly and rectovaginal fascia posteriorly. As these sutures are tied, the apical prolapse is reduced proximally (Fig. 124.31B). Successive rows of sutures are placed until the apical prolapse is completely reduced. A high perineorrhaphy is performed by removing a triangular segment of the vaginal epithelium. The fibromuscular tissues of the perineal body are approximated in the midline with absorbable sutures to narrow the introitus. Fig. 124.32 shows the completed procedures. Indigo carmine is administered, and a cystoscopy is carried out to confirm ureteral patency.

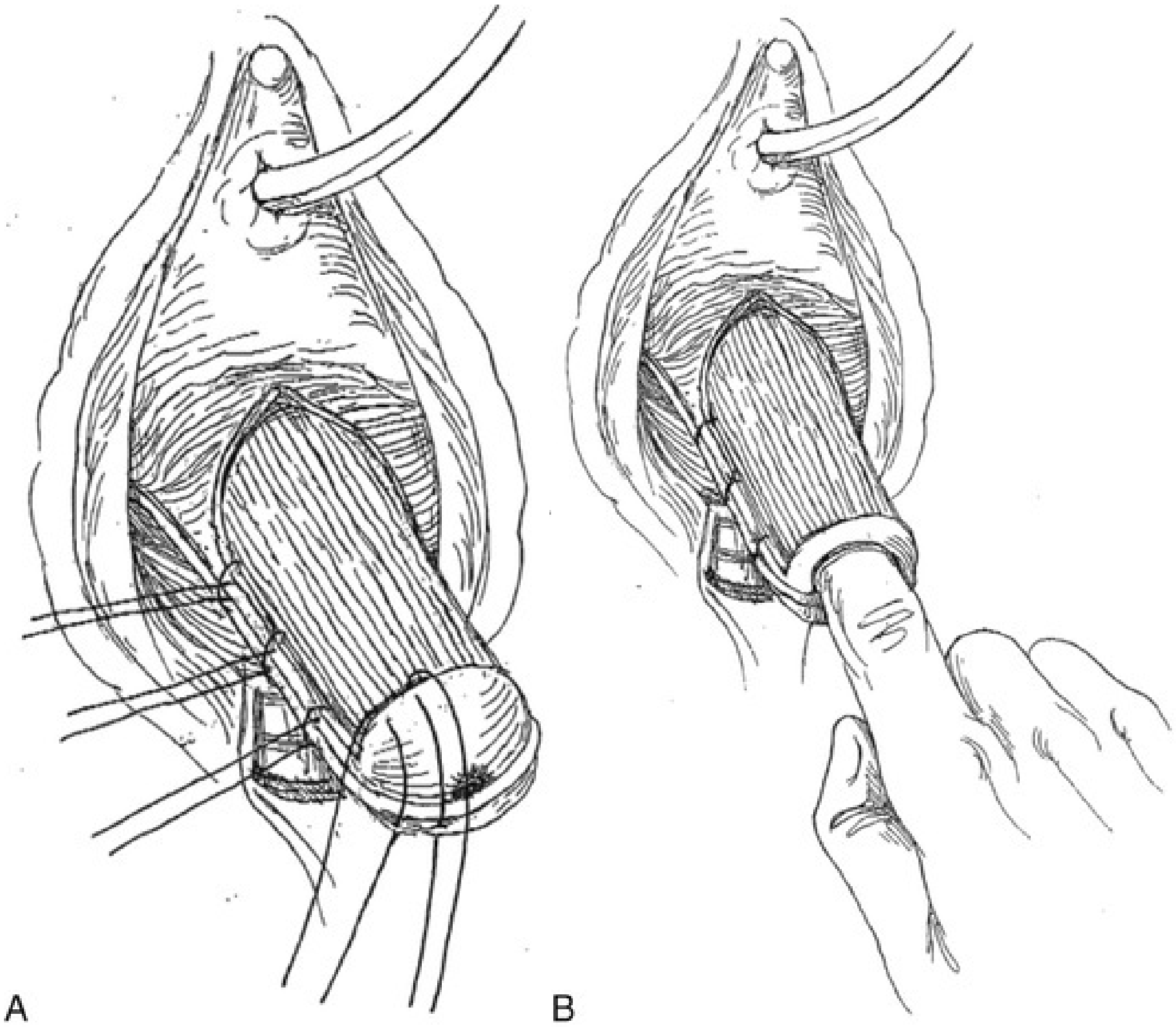

FIG. 124.31 (A) Partial colpocleisis is started by excising rectangular portions of the vaginal epithelium, leaving lateral channels. The cervix is then inverted over a Red Robinson catheter. (B) The cervix is inverted as the prolapse is reduced. (A, From Baggish M, Karram M: *Atlas of pelvic anatomy and gynecologic surgery,* ed 3, Philadelphia, 2010, Saunders, Fig 56-1, pp 724–726.)

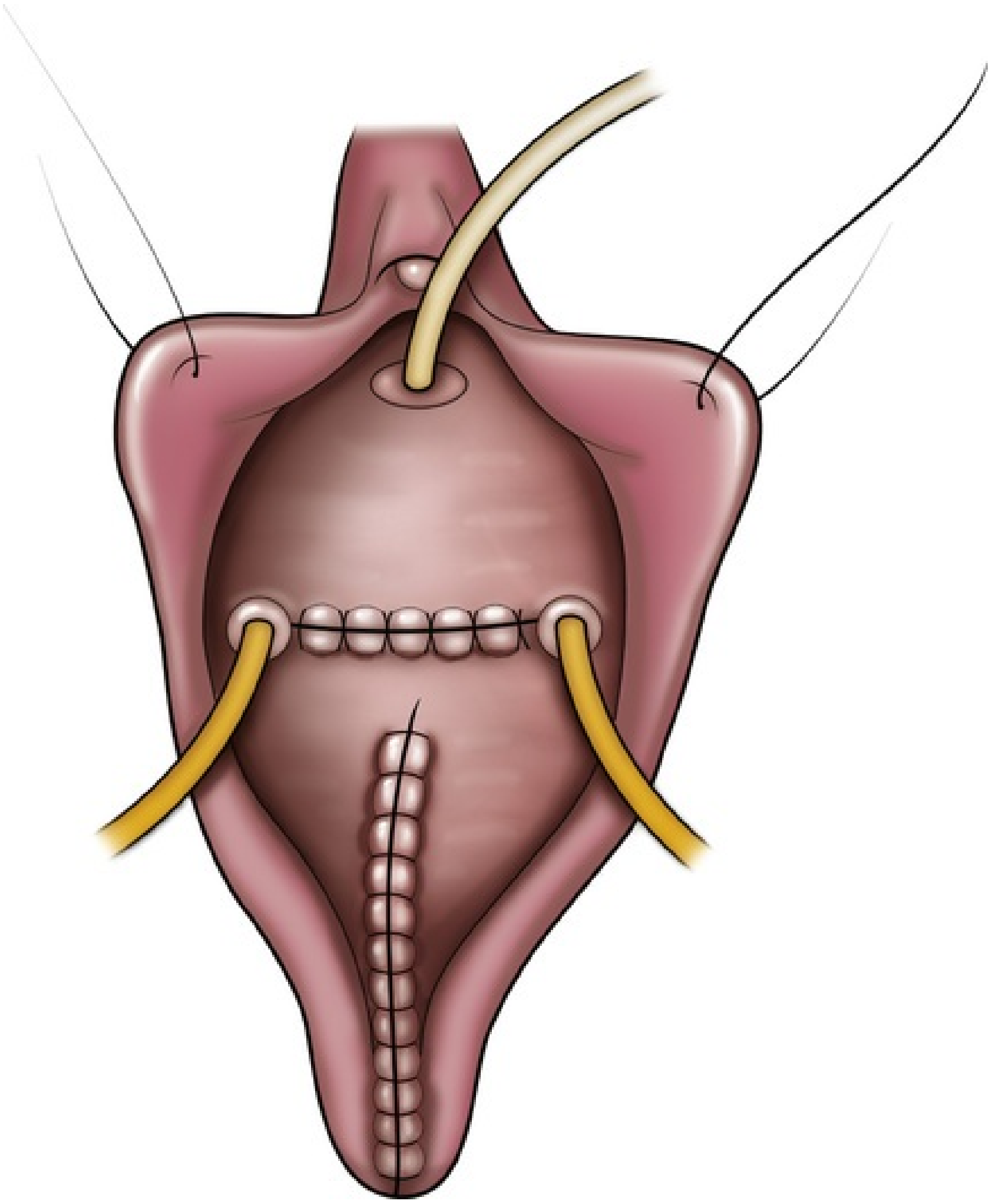

FIG. 124.32 The partial colpocleisis is completed along with perineorrhaphy. (From Cespedes RD, Winters CW: Colpocleisis for the treatment of severe vaginal vault prolapse. In Vasavada SP, Appell RA, Sand PK, et al., editors: *Female urology, urogynecology, and voiding dysfunction*. Boca Raton, FL, 2005, Taylor & Francis.)

Total Colpocleisis: Technique (Fig. 124.33).

The technique differs from partial colpocleisis in that the lateral channels are not left in place, but rather, the entire prolapsed vagina is denuded of its epithelium from the apex to 4 cm proximal to the urethral meatus (see Fig. 124.33C). The dissection is carried laterally and continued to the posterior lateral sulcus. The prolapse sac is dissected away from the vaginal epithelium. Usually the enterocele reduces easily, and no further treatment is necessary (Cespedes et al., 2001). At this point, the colpocleisis is carried out starting at the leading edge of the prolapse. Purse-string sutures of 2-0 absorbable sutures are placed circumferentially around the prolapse including pubocervical and prerectal (rectovaginal) fascia (see Fig. 124.33D). As each progressive suture is tied, the prolapse is reduced proximally (see Fig. 124.33D). These progressive purse-string sutures are carried out until the prolapse is adequately reduced. Alternatively, the prolapse may be reduced as described for the partial colpocleisis by placing transverse rows of interrupted sutures. As these rows are tied, the prolapse is reduced proximally. Successive rows of sutures are placed until the prolapse is fully reduced. The remainder of the procedure is carried out as described for the partial colpocleisis. After the prolapse is reduced, the posterior vaginal wall and perineum are repaired (see Fig. 124.33 E and F). A high perineorrhaphy (levator myorrhaphy) is important to narrow the introitus and prevent recurrence. Cystoscopy to ensure patency of the ureters is recommended. For both techniques, success depends on the amount of vaginal tissue sutured together. This creates a septum of support, which is enhanced by bringing the levator muscles together along with the perineorrhaphy.

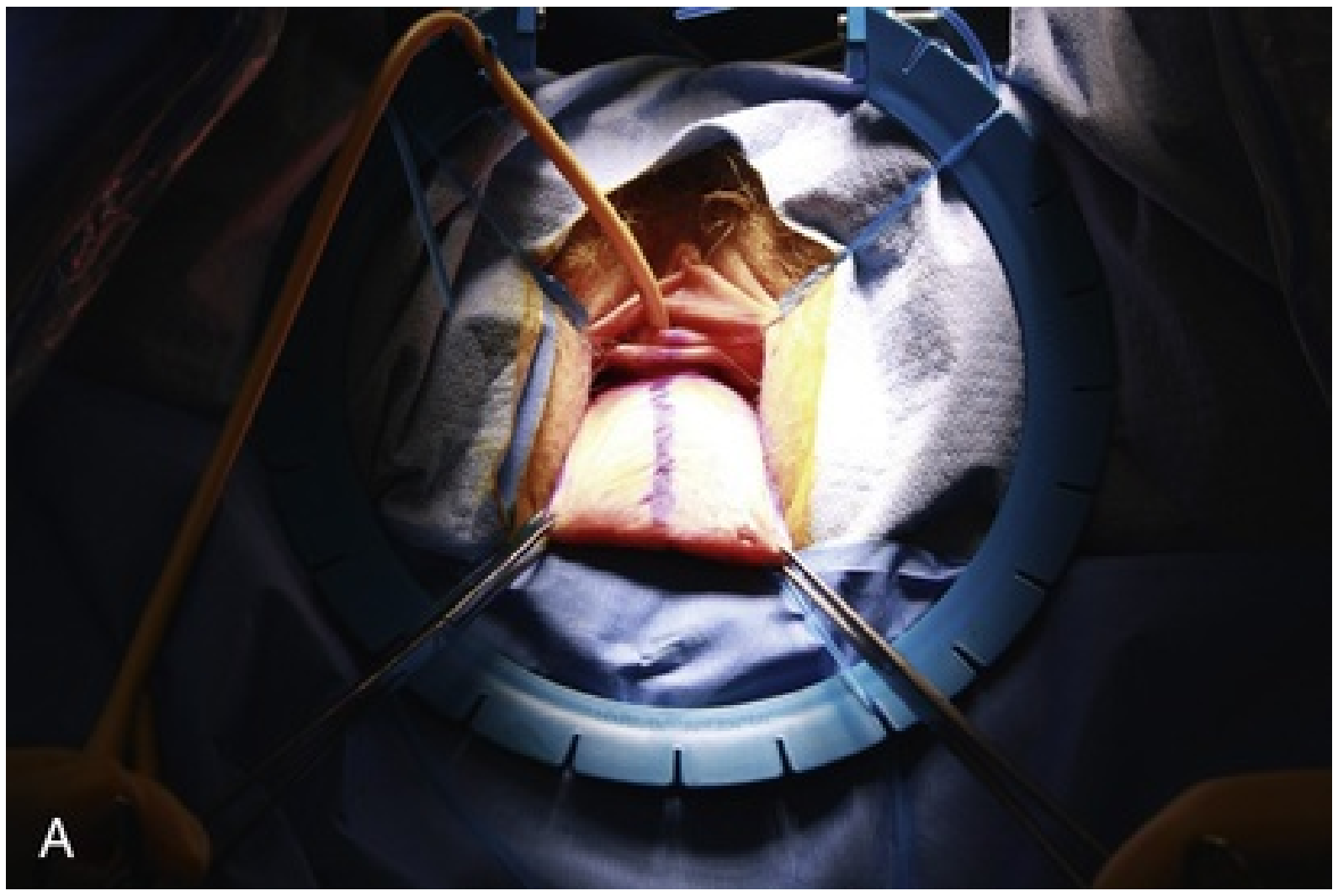

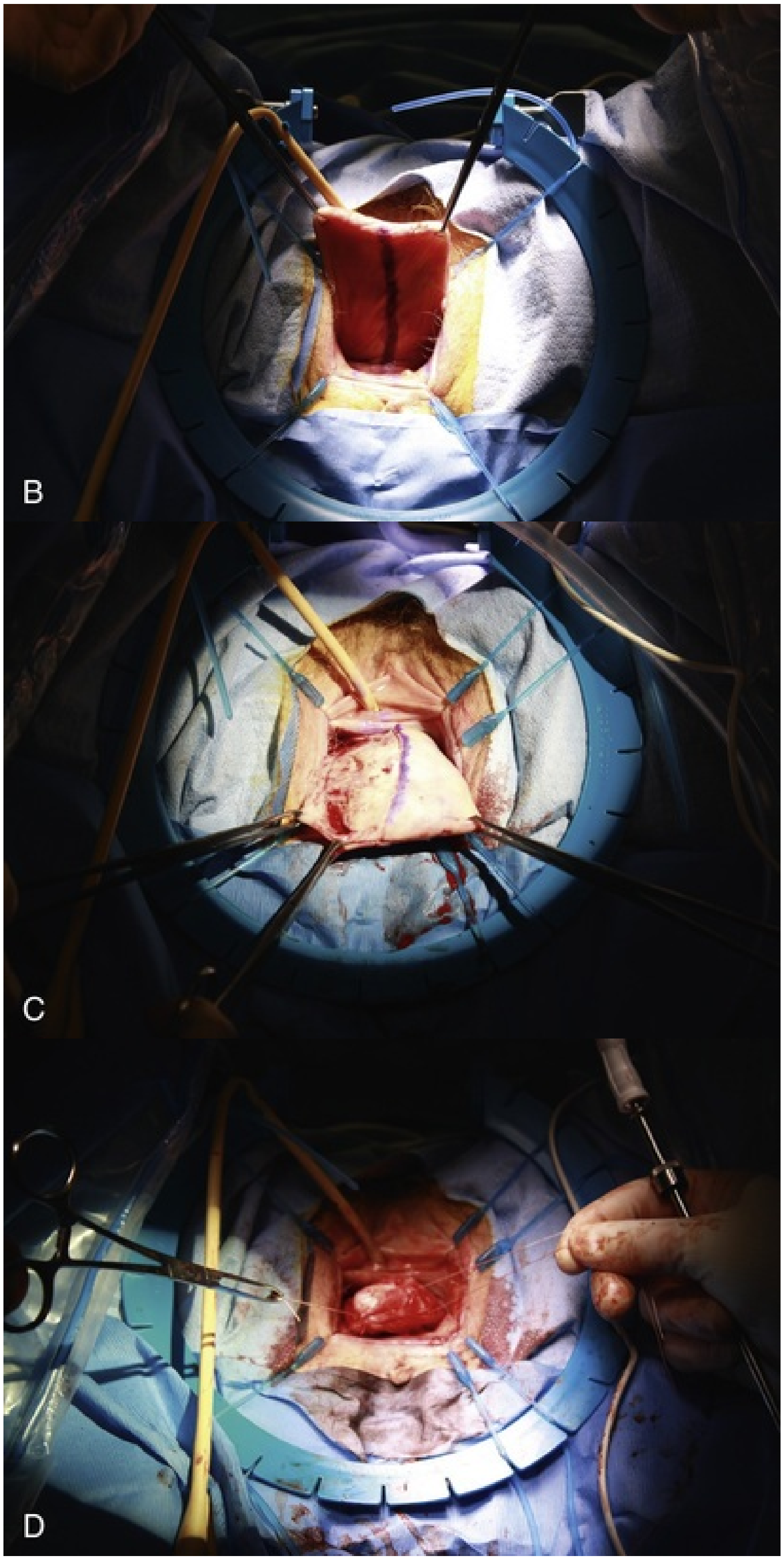
B
C
D

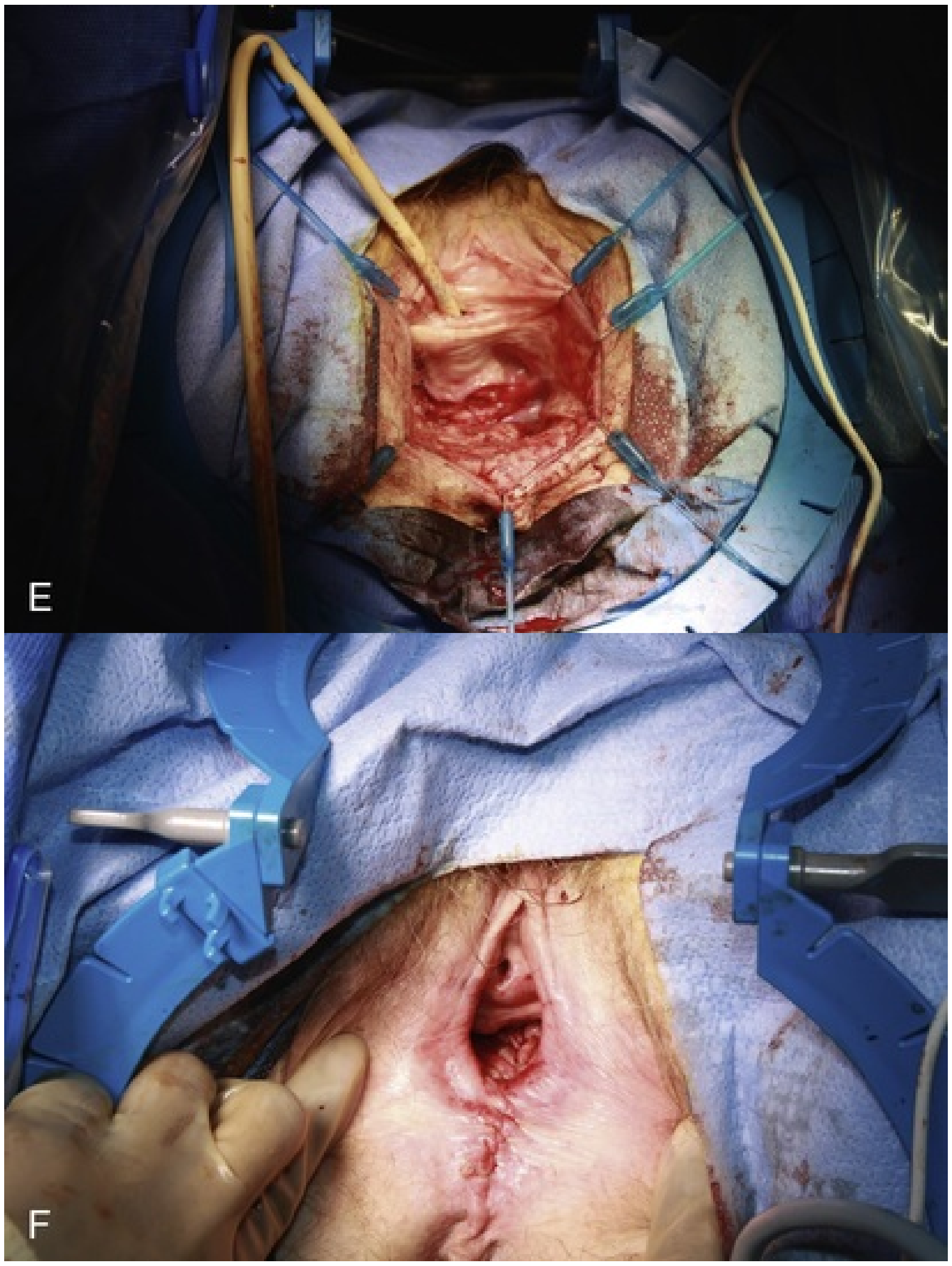

FIG. 124.33 (A) Total colpocleisis. Apex placed on tension. Anterior and lateral vaginal epithelium marked in quadrants to help maintain orientation. (B) Total colpocleisis. Posterior vaginal epithelium marked in quadrants to help maintain orientation. (C) The vaginal epithelium is removed in sections. Only the vaginal epithelium is removed, leaving as much fibromuscularis as possible behind. (D) Once the vaginal epithelium has been removed, a series of purse-string sutures are placed and the prolapse is reduced. (E) The posterior vaginal epithelium is excised to the lateral fornix, and an aggressive levatorplasty is performed. (F) Levatorplasty and perineorrhaphy are performed. The vaginal length is approximately 3 cm. (Courtesy Barry Hallner MD., LSU Department of OB/GYN/Urology 2017.)

Several authors have reported that it is unnecessary to open the enterocele sac if one is present, because the repair will close the potential space in which the bowel may protrude (DeLancey and Morley, 1997; Karin Glavind and Kempf, 2005). If the enterocele sac cannot be reduced, then purse-string absorbable sutures incorporating the sac and the uterosacral remnants can be used to reduce the sac (Cespedes, 2001).

Colpocleisis Results.

DeLancey and Morley (1997) reported on 33 women who underwent colpocleisis over a 20-year period. In this study, opening of the enterocele sac was avoided. One vaginal eversion recurrence was noted. She was treated with repeat colpocleisis and had a good response 1 year after the second colpocleisis. All but one patient expressly denied regret over the decision to have an operation that precludes the ability to have intercourse; however, one “accepted” her sexual inactivity. Many indicated relief of the discomfort associated with the prolapse and were positive about the outcome of the operation. Cespedes et al. (2001) reported on 38 patients who underwent a mean of 24 months’ follow-up. There was no recurrent prolapse. Three patients had postoperative incontinence. All were satisfied with the procedure, and no complications were noted. von Pechmann et al. (2003) reported on a large study (92 patients) who underwent colpocleisis. Patients were followed by examination and phone survey, which appraised satisfaction and regret. Regret over the loss of coital ability was expressed in 12.9% or 8 patients. In a multicenter, prospective study designed to study the effect of colpocleisis on pelvic support, symptoms, QoL, morbidity, and postoperative satisfaction, FitzGerald et al. (2006) reported on 152 patients with 1 year follow-up: 84% stated they were either very satisfied or satisfied about the decision for vaginal closure. One patient was dissatisfied, and one was very dissatisfied. One patient underwent repeat colpocleisis for recurrence. Most patients did not experience worsening of their body image. Koski et al. (2012) reported on 53 patients undergoing colpocleisis: 74% had a total colpocleisis, 91% described the procedure as successful on the PGI-I scale, and examinations correlated with these findings. Urinary frequency and urgency were the most bothersome symptoms reported in 33% of patients.

Partial Colpocleisis Results.

Goldman et al. (1981) reported on 118 patients who underwent Le Fort colpocleisis. Good anatomic results were noted in 107 patients with 101 reporting a relief of symptoms. There were 3 recurrences, but none underwent further operative therapy. Immediate postoperative complications included one pulmonary embolus, fever, and UTI. Langmade and Oliver (1986) reported on 102 patients. There were no recurrences and no de novo stress incontinence. Sixteen patients had transient postoperative urinary retention. There was no reported regret regarding the ability to engage in sexual intercourse. In a retrospective series of more than 300 women, the anatomic success rate was 98.1% with a patient satisfaction rate of 92.9%. These authors concluded that colpocleisis is an effective and low-risk procedure for the appropriate elderly patient with advanced POP (Zebede et al., 2013). In a multi-institution database search, Mueller et al. (2015) confirmed these findings. Of 4776 colpocleisis procedures, 43% done on women older than 80 years, the mean length of stay was 2.3 days and the mortality rate was 1.5%. The overall complication rate was 6.8% with a readmission rate of 4.2% (Mueller et al., 2015).

Crisp et al. (2013) reported on body image, regret, and satisfaction after LeFort and total colpocleisis. This multicenter trial confirmed the results of earlier studies, which demonstrated improved body image, improved pelvic floor symptoms, low levels of regret, and high levels of satisfaction (Crisp et al., 2013). Findings by Wang et al. (2017) were similar in their retrospective study of 287 women, yielding the same positive end results. Urinary incontinence after colpocleisis may occur and has been attributed to several mechanisms. Occult stress incontinence may be unmasked with reduction of the urethrovesical angle as described above. An alternative mechanism, secondary to traction on the urethra when it is approximated with the posterior vaginal muscularis, has been proposed (FitzGerald et al., 2006). Thus it is recommended to avoid colpectomy of at least 1.5 cm of the distal anterior vaginal wall adjacent to the urethral meatus (FitzGerald et al., 2006). As with other prolapse cases, the recommendation of a concomitant anti-incontinence procedure in an asymptomatic patient is controversial and remains to be substantiated by prospective studies. **However, it is clear that these women may develop SUI postoperatively. Thus all women before undergoing colpocleisis should be screened for the presence of occult SUI, and anti-incontinence procedures should be offered concomitantly in women with symptoms of SUI or occult SUI.** In addition, in the frail, elderly patients there is concern for urinary retention, frequently the result of impaired contractility (which may be appreciated preoperatively) and other perioperative factors. This may be more difficult to manage because these patients are more likely to be unable to perform intermittent catheterization. Thus these possibilities must be discussed with the patients in advance of surgery. Patients considered at significant risk for retention may be offered a suprapubic tube to assist in bladder management postoperatively.

Uterine Prolapse

POP is a common indication for routine hysterectomy. Although the majority of hysterectomies are performed transabdominally, the vaginal approach offers the advantages of less invasive surgery and the ability to repair concomitant pelvic floor defects (Doucette et al., 2001; Eilber and Raz, 2004).

The uterus is suspended in the pelvis by the cardinal uterosacral complex. The body of the uterus is enveloped between the two leaves of the broad ligament, which also surrounds the fallopian tube, round ligament, and ovarian ligament along with the uterine and ovarian vessels. The broad ligament does not provide significant support (Eilber and Raz, 2004). Therefore the defect prompting uterine prolapse is in the form of attenuated ligaments or specific breaks in the continuity of the cardinal uterosacral complex. Contraindications for the vaginal approach are endometriosis of unknown extent, obliteration of the cul-de-sac, large fibroids (size disproportion to the introitus), pelvic tumor, adnexal tumor, and malignancy of the uterus or ovaries (Eilber et al., 2005). If a patient has uterine prolapse, vaginal hysterectomy alone is not adequate treatment. Vaginal apex suspension should be performed at the time of hysterectomy for uterine prolapse to reduce the risk of recurrent POP; at a minimum the addition of a McCall culdoplasty should be considered. McCall (1957) highlighted this importance when he described his technique of posterior culdoplasty. This technique closed the peritoneal cul-de-sac posteriorly, thereby preventing enterocele formation and emphasized the importance of apical fixation. In this landmark paper, he described the following technique: “The posterior culdeplasty is a simple procedure which obliterates the redundant cul-de-sac of Douglas by a series of continuous sutures so as to suspend it by the uterosacral ligaments which then are brought together in the midline.”

Vaginal Hysterectomy With McCall Culdoplasty Technique

The patient is placed in dorsal lithotomy position. The type of stirrups used for the lithotomy position are at the sole discretion of the surgeon. Regardless of which type is used, careful attention is required to protect vulnerable bony, vascular, and neurologic points in the lower extremities. The patient is prepped and draped in the usual sterile fashion. A Foley catheter is placed to drain the bladder, although some surgeons may prefer not to catheterize the bladder before the anterior colpotomy to easily identify an unintentional cystotomy. Retraction of the labia and vaginal introitus with a ring retractor such as a Lone Star self-retaining retractor (CooperSurgical, Trumbull, CT) is useful. A Lahey-thyroid clamp is used to grasp the anterior and posterior lips of the cervix. Care must be taken to place the clamp on the most distal portion of the cervix, as the bladder may descend low on the anterior vaginal wall. Some surgeons find it useful to inject 1 : 200,000 epinephrine or lidocaine with epinephrine diluted in injectable saline into the vaginal wall to control small bleeding and for hydrodissection.

The cervix is placed on traction, and the initial anterior vaginal incision should be made through the full thickness of the vaginal epithelium at the border of the vaginal rugae and the smooth epithelium overline the cervix from the 10 to 2 o'clock position. The cervix is elevated outward and upward, and the posterior incision is made from the 8 to 4 o'clock position. If adequate dissent of the cervix is possible, the initial incision can be extended circumferentially around the cervix. An incision at the appropriate location allows the surgeon to avoid excessive dissection of the connective tissues between the vagina and the peritoneum and facilitates identification of the peritoneum entry. After the posterior incision has been completed, the posterior cul-de-sac and peritoneum can be readily identified with Allis clamp or tissue forceps placed on the outer edge of the incision. The Allis clamp or tissue forceps is pulled downward to create tension across the exposed posterior peritoneum. The peritoneum is cut with curved Mayo scissors and the cul-de-sac is entered. The posterior peritoneum is then affixed centrally to the posterior vaginal wall incision with the single stitch of delayed absorbable suture. Examination of the cul-de-sac can reveal further pathology, and palpation of the uterosacral ligaments can be performed. A long-bladed Steiner Auvard weighted speculum or long right-angle retractor can be introduced into the posterior peritoneal cavity. The cervix is then placed on outward and upward traction, and the uterosacral ligaments are identified by palpation, the ligament is clamped with the curved Heaney clamp, transected, and ligated with 0-gauge delayed absorbable suture using a transfection stitch. The opposite uterosacral ligament is then ligated in similar fashion.

The uterosacral cardinal ligaments may be isolated, clamped, and ligated individually or in combination depending on the size of each. Once the pedicles are secured, the free suture ends are not cut but rather held by hemostats. Clamping and tagging the uterosacral ligaments separately allow for their identification, later use in cuff repair, and, if desired, a McCall's culdoplasty at the end of the procedure. The cervix is then placed on outward and downward traction and the anterior vaginal tissue is elevated in the midline. Once the vesicouterine plane is fully developed, a lightweight right-angle retractor can be placed into the space to elevate the bladder and expose the anterior peritoneal fold. The anterior peritoneum is grasped and gently elevated and an anterior colpotomy performed with Metzenbaum scissors. Entry into the peritoneal cavity can be confirmed by seeing intraperitoneal fat. The incision opening is further stretched by spreading the scissors into the space to allow insertion of the right-angle retractor into the anterior cul-de-sac. This retractor should remain in position for the remainder of the hysterectomy to safely elevate the bladder out of the operative field. If a cystotomy occurs, the vaginal hysterectomy is usually completed before repair of the bladder.

The cervix is placed on outward and lateral traction, and the uterine artery is identified on one side and clamped with the curved Heaney clamp and cut. A suture of 0-gauge delayed absorbable sutures placed behind the clamp at the tip and is secured as the clamp is removed. The cervix is deflected to the opposite side and the opposite uterine artery is similarly ligated. The remainder of the broad ligament may be dissected with continued clamping and cutting on each side of the uterus. If the uterus a small and dissent is adequate, two curved Heaney clamps may be placed in tandem across the utero-ovarian ligaments, round ligament, and fallopian tubes. Each pedicle is double ligated. A simple suture on a passer is placed proximally and then with the transfixing stitch placed distally. Alternatively, if the uterus is large and dissent is poor, it may be brought closer to the surgeon and the vaginal introitus by using an alternate technique of intra-myometrial coring (Kovac, 1986). In this technique the myometrium can be circumferentially incised with the scalpel placed parallel to the long axis of the uterus and the serosal covering of the uterus with continuous traction on the cervix and direct visualization all times. This removes the core inside the uterus without violating the integrity of the endometrial cavity or uterine serosal. Plication of the uterine artery is necessary before coring. The coring incision reduces the size of the uterus by decreasing its width, by increasing its length. As the procedure continues, the uterus will begin to descend through the vagina, allowing the surgeon to visualize, clamp, and suture ligate the utero-ovarian ligament, round ligament, and fallopian tubes. An alternative technique is to bivalve the uterus with morcellation. A Lahey thyroid clamp may be placed on either side of the cervix, and with downward traction, the cervix may be incised with the scalpel vertically until the fundus of the uterus is reached. Once the fundus is reached, wedges of the myometrium are removed until the uterine size is significantly reduced to allow removal.

Once the pedicles are clamped and cut, the suture may be tagged and used to provide gentle traction on the pedicle and expose the ovary for evaluation or removal. Once the uterus has been removed, it is important to evaluate each pedicle to confirm hemostasis. At this point, either a salpingectomy and or oophorectomy may be performed if indicated. A uterosacral ligament suspension or McCall culdoplasty can be performed at this time also. The traditional McCall culdoplasty incorporates sutures in each uterosacral ligament accessed intraperitoneally and sutured to the posterior cuff (McCall, 1957). The McCall procedure begins by placing a moist pack into the posterior cul-de-sac; this helps prevent dissent of bowel or omentum into the operative field. The uterosacral ligaments, which were previously tagged during the vaginal hysterectomy, are placed on lateral tension to define the course of the ligament to the sacrum. The first suture row is placed caudad using 2-0 nonabsorbable monofilament suture. The first internal permanent suture is passed through the uterosacral ligament in a lateral-to-medial direction to avoid ureteral injury; subsequent series bites are placed 1 cm across the rectosigmoid serosa to reach and ligate the opposite uterosacral ligament. The sutures are left untied. Additional cephalad rows of sutures are similarly added with 1 cm between the rows being appropriate spacing. After completion of the 2 to 3 internal suture rows, one external suture is placed using 2-0 delayed absorbable monofilament suture that incorporates the posterior vaginal wall. The suture is initially placed through the full-thickness posterior vaginal wall and into the uterosacral ligament. Progressive bites are then taken serially through the rectosigmoid serosa to reach the opposite uterosacral ligament (Fig. 124.34A and B). Finally, the suture passed through the opposite uterosacral ligament and exits through the full thickness of the posterior vaginal wall to reenter the vagina. The sutures are then tied beginning with the most proximal suture and progressing caudad. Because of the proximity of the ureter to the uterosacral ligaments and placement of the sutures, cystoscopy should be performed to confirm ureteral patency. The vaginal cuff is then closed in either a vertical or transverse fashion with 2-0 delayed absorbable suture.

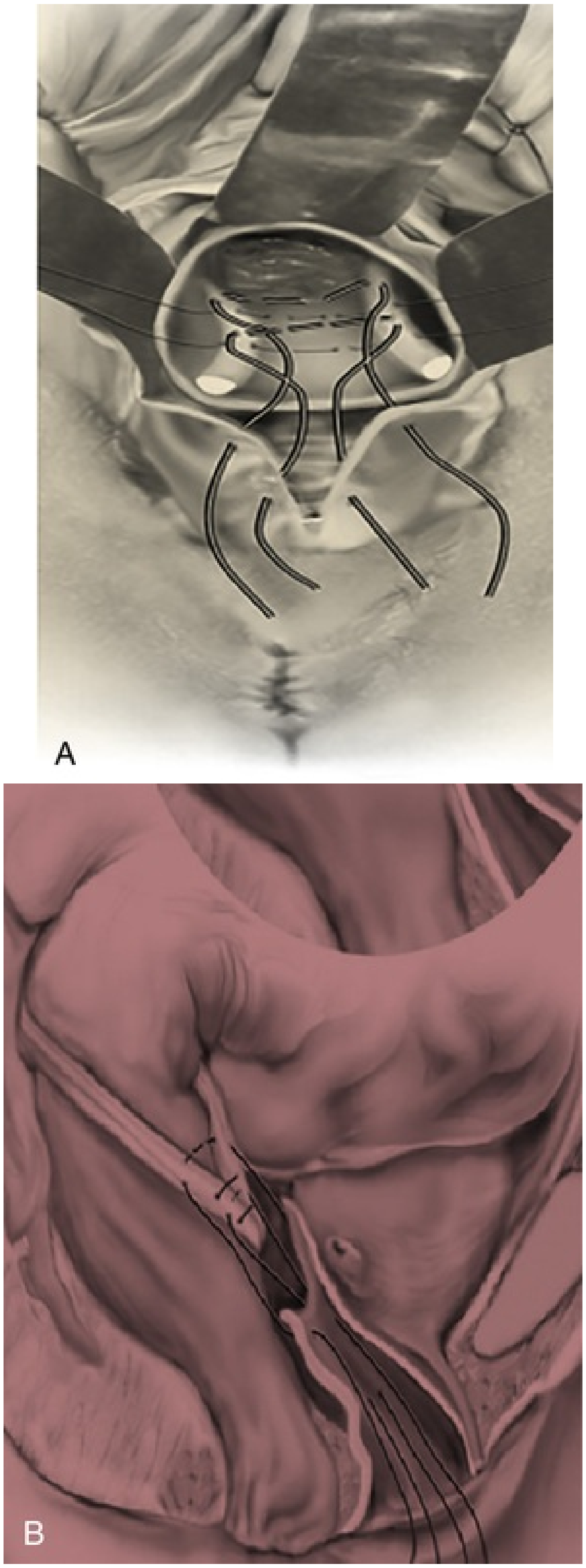

FIG. 124.34 (A and B) Internal and external McCall stitches are placed in a traditional fashion. Tying these sutures obliterates the cul-de-sac, supports the vaginal cuff, and increases posterior vaginal wall length. (From Walters M, Karram M: *Urogynecology and reconstructive pelvic surgery,* ed 4, Philadelphia, 2015, Saunders, p 366.)

Vaginal Hysterectomy Complications.

Intraoperative complications include visceral injury, intraoperative hemorrhage, and conversion of approach. Reported rates of hemorrhage range from 1.4% to 2.6% in vaginal hysterectomy (Harris, 1995; Weber and Lee, 1996). The incidence of urinary tract injury associated with hysterectomy for benign disease was 4.3%. The rate of bladder injury was 2.9%, and the rate of ureteral injury was 1.8% (Ibeanu et al., 2009). The rate of bowel injury was 0.4% (Dicker et al., 1982). A 0.4% conversion rate from vaginal to abdominal approach has been reported in a retrospective review of 220 patients (Kafy et al., 2006). In the Collaborative Review of Sterilization study of 1851 women undergoing elective hysterectomy for benign disease, 7.2% of patients experienced unexplained fevers with vaginal hysterectomy compared with 16.8% with abdominal hysterectomy. Urinary tract infections occurred in 3.4% of cases (Dicker et al., 1982). Other postoperative complications occured in less than 1% of patients and include vesicovaginal fistula, ileus, and fallopian tube prolapse (Harris, 1995). The incidence of vaginal vault prolapse after hysterectomy ranges from 0.2% to 43% (Barrington and Edwards, 2000; Cruikshank and Kovac, 1996; Toozs-Hobson et al., 1998).

A case-control study showed incidence of vaginal vault prolapse of 0.5% after hysterectomy (Dällenbach et al., 2008). Studies of hysterectomy outcomes indicated that symptom levels in women undergoing hysterectomy are generally high and have a substantial impact on quality of life. Their symptoms before surgery are noted to be significantly improved after the procedure (Kulkarni and Rogers, 2010). Significant improvement in mood states such as depression, anxiety, and irritability have been consistently reported (Carlson et al., 1994; Sculpher et al., 1996). Disruption of local nerve and supportive structures along with the changes in anatomic relationship the pelvic organs may result in altered sexual function. Few studies have attributed the decline in sexual function to hysterectomy (Kilkku, 1983). Studies have concluded that sexual function either improved or remained unchanged for the majority of women after hysterectomy, with or without cervical preservation. This study of 187 women examining the effects of different types of hysterectomy on sexual function prospectively noted that the percentages of patients reporting symptom improvement for the vaginal hysterectomy group were as follows: coital frequency 44.3%, deep dyspareunia 19.7%, libido 19.7%, achievement of orgasm 32.8%, and overall satisfaction

28.3% (El-Toukhy et al., 2004). The positive impact of surgery on sexual function was observed for total abdominal hysterectomy as well as laparoscopic hysterectomy and same study (El-Toukhy et al., 2004).

Uterine Sparing and Hysteropexy

Traditionally, surgical repairs to restore pelvic floor support in the setting of uterine prolapse included hysterectomy. Recently, however, there has been great interest in preservation of the uterus in prolapse surgery, to maintain future fertility, decrease surgical risk associated with the hysterectomy, and to satisfy women who feel a sense of identity with maintaining their uterus and who feel concerned about sexual function with the loss of their uterus (Maher et al., 2013).

Hysteropexy may be performed either by vaginal or abdominal approaches, although most abdominal approaches are being performed either laparoscopic or robotically. Frick et al. (2013) found that 60% of women surveyed indicated they would decline hysterectomy if presented with an equally efficacious alternative to a hysterectomy-based prolapse repair. In another study, Korbly et al. (2013) found that 36% of women preferred uterine preservation when presented with equally efficacious surgical options; 21% of women in this study continued to prefer uterine preservation, even when the uterine-sparing prolapse procedure was associated with worse efficacy. It is generally accepted that the uterus plays a passive role in the development of prolapse (DeLancey, 1992). The need for hysterectomy at the time of prolapse repair has never been proven. **Therefore hysterectomy may not be necessary to correct the underlying defect in the apical vaginal support structures of the uterosacral/cardinal ligament complex** (Bradley et al., 2018). **Uterine preservation is considered safe in select groups of women but is contraindicated in those with abnormal uterine or cervical pathology and certain medical histories** (Table 124.13; Ridgeway, 2015). Uterine-sparing procedures have been shown to decrease operative time and estimated blood loss (Ridgeway, 2015). There are no published RCTs comparing efficacy and/or safety between hysteropexy procedures to recommend one approach over another. There is, however, high-quality evidence comparing similar types of prolapse repairs with and without hysterectomy (Bradley et al., 2018). See Table 124.14 for perceived and studied advantages and disadvantages of uterine-preservation at the time of prolapse surgery

TABLE 124.13

Contraindications for Uterine Preservation

Postmenopausal bleeding
Current or recent cervical dysplasia
Familial cancer syndrome, *BRCA1* and *BRCA2*
Hereditary nonpolyposis colonic cancer syndrome
Tamoxifen therapy
Uterine abnormalities
Fibroids, adenomyosis, abnormal endometrial sampling
Abnormal uterine bleeding
Inability to comply with routine gynecologic surveillance
Cervical elongation (relative contraindication)

Modified from Ridgeway: Uterine conservation for pelvic organ prolapse. *Am J Obstet Gynecol* 2015.

TABLE 124.14

Perceived and Studied Advantages and Disadvantages of Uterine Preservation at the Time of Prolapse Surgery

ADVANTAGES	DISADVANTAGES
Reduction in surgical time and blood loss Maintenance of fertility Natural menopausal timing Avoidance of an unnecessary procedure Perceived role of the uterus and cervix in pelvic stability and sexual satisfaction Less invasive Association with quicker recovery Decreased risk of mesh exposure Similar short-term outcomes Patient preference	Fewer surgical outcome data available Maintenance of fertility Small, ongoing risk for cervical or endometrial cancer Subsequent hysterectomy may be difficult Continuation of menses Ongoing surveillance of cervix and endometrium Colpopexy may be easier for surgeon after hysterectomy

Modified from Ridgeway BM, Frick AC: Uterine conservation for the surgical treatment of uterovaginal prolapse. In Karram M, Walters M, editors: *Urogynecology and reconstructive pelvic surgery*, 4th ed, Philadelphia, 2015, Elsevier Saunders, pp. 383–399.

Transvaginal Uterine-Sparing Techniques.

Transvaginal approaches to uterine-sparing procedures may be performed with and without mesh. There are four techniques described for uterine-sparing transvaginal surgeries: the Manchester operation, uterosacral ligament fixation, sacrospinous ligament fixation, and LeFort colpocleisis (see section on colpocleisis for details).

Manchester Procedure.

The Manchester procedure was first described in 1888 by Archibald Donald of Manchester, England, for the treatment of cervical elongation. Procedure involves amputation of the cervix, cardinal and uterosacral ligament plication, and anterior and posterior colporrhaphy (Tola et al., 2015). Fothergill modified the technique, giving the anterior colporrhaphy incision a triangular shape with its base near the cervix and plicating the parametrium anterior to the cervix (Pearce, 2004). The operation has been known as the Manchester Donald Fothergill operation.

Once anesthesia is adequate, the patient is prepped and draped in the usual sterile fashion and placed in dorsal lithotomy position in stirrups. A Foley catheter is inserted into the bladder. A Lone Star self-retaining retractor can be used to facilitate exposure. A Lahey-thyroid clamp is placed on the anterior and posterior lip of the cervix, and the cervix is placed on traction in an outward direction. A circumferential incision is made around the cervix, dissecting the vaginal epithelium similar to the first steps of a vaginal hysterectomy, and clamping and transecting the uterosacral/cardinal ligaments bilaterally. The elongated cervix is amputated, the remaining cervix is retracted downward, and the uterosacral/cardinal ligament pedicles are sutured to the anterior aspect of the remaining cervix. This fixation may be performed with either delayed absorbable or permanent suture. A 5-mm Hegar dilator can be inserted into the cervical canal to help identify it. The cervical stump is then covered with the vaginal epithelium, leaving the uterine canal open. Additional surgical procedures, such as anterior or posterior repair or anti-incontinence procedures, can then be performed if indicated. Cystoscopy is performed to confirm ureteral patency.

Manchester Procedure Complications.

Complications related to the Manchester procedure must be taken in context of when the procedures were performed. In the series describing 960 patients, the procedures were performed from 1936 to 1955 and reported the following complications: cystotomy and proctotomy less than 0.5%, blood transfusion

20%, febrile morbidity 63%, urinary retention 15.2%, and mortality 0.7% (Ridgeway and Frick, 2015). The Ayhan et al. (2006) study reported the following complication rate in 232 patients undergoing the Manchester procedure from 1985 to 2004: early postoperative complications; 13.23% had febrile morbidity; retroperitoneal hematoma occurred in 0.49%; urinary retention occurred in 22.05%, and cervical stenosis 11.27%. At 1 year, 1 patient had undergone abdominal hysterectomy because of unsuccessful cervical dilation. At a mean of 3.6 years after the operation, 3.9% had undergone the tension-free vaginal tape procedure plus a vaginal hysterectomy for recurrent SUI and uterine prolapse. Tipton and Atkin (1970) examined 82 premenopausal women 6 to 12 years after they underwent the Manchester operation and found that uterine carcinoma had developed in 2.4%. Hopkins et al. (1997) also reported on 2 patients in whom adenocarcinoma of the endometrium developed in the retained uterus after they underwent the Manchester operation. This procedure is also associated with obstetric complications such as subfertility, infertility, prolonged labor, and pregnancy loss (Tola et al., 2015).

Manchester Procedure Results.

See Table 124.15 for a summary of studies. A retrospective study by Thomas et al. (1995) reported an anatomic cure rate of 94% in 88 patients. The authors concluded that the Manchester operation is quick, efficacious, and associated with less blood loss than vaginal hysterectomy. In the study by Tipton and Atkin (1970), the reoperation rate among 82 women treated with the Manchester operation for uterine prolapse 6 to 12 years after initial surgery was 21% because of recurrence, bleeding, or cancer. Comparisons of the Manchester operation with vaginal hysterectomy have often overlooked the fact that there are more vault prolapses after vaginal hysterectomy, whereas cystoceles recur more often after Manchester operations (Pearce, 2004; Thomas et al., 1995). Conger and Keettel in 1958 and Thomas et al. in 1995 reported the rates of recurrent prolapse to be approximately 4.3% and 6.0%, respectively. Ayhan et al. (2006) echoed a similar rate with recurrent prolapse rate of 3.9% for uterine prolapse and 1.47% for cystocele or rectocele in 204 patients.

TABLE 124.15

Vaginal Approach to Hysteropexy

	DURATION	OBJECTIVE

STUDY	PROCEDURE	# OF PATIENTS	OF FOLLOW-UP, MO	SUCCESS RATE WITH DEFINITION (%)	SU SU R
Tipton et al., 1970	Manchester	82	6 to 12 years	Not defined	N
Conger et al., 1958	Manchester	960	NA	NA	96
Thomas et al., 1995	Manchester	88	Mean 2.5 years	94%	N
Williams et al., 1966	Transvaginal uterosacral ligament suspension/plication	20	NA	85% success not defined	N
Romanzi et al., 2012	Transvaginal uterosacral ligament suspension	100	1.5 years, range 2.4 months to 10 years	Apex 96%, anterior wall 87%, posterior wall 97.8%. Success defined as ≤2 prolapse on Baden-Walker	N
Richardson et al., 1989	Sacrospinous hysteropexy (unilateral)	5	6 to 24 months	100%	N
Kovac et al	Sacrospinous	19	Mean 3.1	88% Success	N

Kovac et al., 1993	Sacrospinous hysteropexy (unilateral and bilateral)	19	Mean 3.1 years	88% Success not defined	N
Maher et al., 2001	Sacrospinous hysteropexy (unilateral)	34	Mean 26 months	72% No prolapse beyond mid-vagina	78
van Brummen et al., 2003	Sacrospinous hysteropexy (unilateral)	54	Mean 19.4 months	89.6%	N
Lin et al., 2005	Sacrospinous hysteropexy (unilateral)	60	5 to 10 years	85% Success not defined	N
Jeng et al., 2005	Sacrospinous hysteropexy (unilateral)	80	6 months	NA	N
Dietz et al., 2007	Sacrospinous hysteropexy (unilateral)	133	Mean 22.5 months	62% Success < II on POP-Q Comparison made to TVH and vault suspension	91
Dietz et al., 2010	Sacrospinous hysteropexy (unilateral)	35 Hysteropexy 31 TVH + USLS	1 year	79% Hysteropexy; 97% TVH and repair	N be gr

Detollenaere et al., 2015	Sacrospinous hysteropexy (unilateral) Compared to TVH + USLS	103 Hysteropexy 105 TVH + USLS	12 months	The original primary outcome variable of overall anatomic failure occurred in 50% of the women after sacrospinous hysteropexy compared with 44% after vaginal hysterectomy (95% confidence interval for difference −7.4% to 20.1%)	Q fu ou po re se fu no be gr

EBL, Estimated blood loss; *POP-Q,* pelvic organ prolapse-quantification; *QoL,* quality of life; *TVH,* total vaginal hysterectomy; *USLS,* uterosacral ligament suspension; *UTI,* urinary tract infection.

Modified from Ridgeway BM, Frick AC: Uterine conservation for the surgical treatment of uterovaginal prolapse. In Karram M, Walters M, editors: *Urogynecology and reconstructive pelvic surgery*, 4th ed, Philadelphia, 2015, Elsevier Saunders, pp. 383–399.

Transvaginal Uterosacral Ligament Hysteropexy Technique.

Once anesthesia is adequate, the patient is prepped and draped in the usual sterile fashion and placed in dorsal lithotomy position in stirrups. A Foley catheter is inserted into the bladder. A Lone Star self-retaining retractor can be used to facilitate exposure. A Lahey-thyroid clamp is placed on the posterior lip of the cervix, and the cervix is placed on traction in an outward and upward direction. A posterior colpotomy is performed to gain entry into the posterior peritoneal space. The bowel is packed out of the operative field with a moist laparotomy sponge to allow identification of uterosacral ligaments on each side. Gentle traction with an Allis clamp is exerted on the caudal part of the ligament, and two to three transfixion sutures of monofilament 0-gauge delayed absorbable or permanent suture are placed through the ligament bilaterally. The lowest suture is placed at the level of the ischial spine, and the two following are placed 1 cm above each. In total, four to six sutures are positioned.

To minimize ureteral injury risk, sutures are passed in a lateral to medial direction. After suture placement, the vaginal pack is removed. Each anterior needle is passed posteriorly through the peritoneum and full thickness of the vaginal epithelium. Each posterior needle is passed anteriorly through the peritoneum, pericervical ring, and vaginal epithelium. If permanent suture is used, it is important that the suture not pass through the vaginal epithelium, and the sutures should be tied within the abdominal cavity and not in the vaginal lumen. The most distal uterosacral ligament sutures were passed laterally, the proximal ones medially, and the intermediate ones between the previous sutures. Digital splinting of the prolapsed uterus into normal position at the vaginal apex is followed by counter-traction on the uterosacral suspension sutures, removing all slack to the maximum resuspension. All sutures were tied to close the cul-de-sac and the posterior vaginal colpotomy incision. Additional surgical procedures, such as anterior or posterior repair or anti-incontinence procedures, can then be performed if indicated. Cystoscopy is then done to confirm ureteral patency.

Transvaginal Uterosacral Ligament Hysteropexy Complications.

Williams (1966) reported a complication rate of 20%. Complications of the uterosacral ligament suspension included genital urinary tract infections, cellulitis, and atonic bladder symptoms. In a Romanzis 2012 study, the complication rate was 6% (Rideway and Frick, 2014). Operative data showed a 15% complication rate, with none directly related to uterine preservation. Recurrences were noted in 25% of patients, but 40% of them were due to cervical elongation. Cervical elongation can occur after hysteropexy in up to 62% of patients (Hyakutake et al., 2014; Kapoor et al., 2017; Rosen et al., 2008). In the Williams transvaginal uterosacral plication method, ureteral injury and neurologic morbidity are high in this type because the uterosacral ligaments are divided then plicated in the midline, and ureteral dissection cannot be adequately performed (Price et al., 2010). Another disadvantage of this method is that the plication portion is low because the uterosacral ligaments are transected close to the uterus (Tola et al., 2015).

Transvaginal Uterosacral Ligament Hysteropexy Results.

See Table 124.15 for a summary of studies. There are no RCTs that compare uterosacral hysteropexy to any other type of prolapse repair (uterine-sparing or hysterectomy based) nor is there any study comparing different approaches to uterosacral hysteropexy (transvaginal vs. minimally invasive) (Ridgeway and Cadish, 2017). In the 1966 case series by Williams it was reported that women who had uterovaginal prolapse at least to the introitus had a failure rate of 15%. In a large retrospective 2012 study comparing 100 women who underwent total vaginal hysterectomy with uterosacral ligament suspension with 100 women who underwent transvaginal uterine sparing uterosacral ligament suspension, there was no difference in outcomes at 24 months (Romanzi and Tyagi, 2012). In this same series the hysteropexy group apical success was noted to be 96%, anterior wall success was noted to be 86.8%, and posterior wall success was noted to be 97.8%, all of which were statistically similar to the hysterectomy group. There are conflicting data and a lack of RCTs comparing success rates of hysteropexy versus hysterectomy with uterosacral ligament suspension. Studies use different approaches to uterosacral ligament suspension, which may also account for these differences (Bradley et al., 2018).

Sacrospinous Hysteropexy Technique.

The patient is placed in lithotomy position, and an indwelling catheter is inserted. Adequate exposure is used to inspect the posterior vaginal wall and mark the proximal extent of the incision to prevent compromise of the apical tissue that will be used for vaginal vault fixation. A posterior vaginal wall incision is made deep to the rectovaginal fascia. If the patient has significant posterior compartment prolapse and a posterior repair is planned, then the incision should be made superficial to the rectovaginal fascia. The right-sided pararectal space is entered bluntly, the ischial spine is palpated, and tissue overlying the sacrospinous ligament is swept lateral to medial until the sacrospinous ligament is exposed. Two permanent or delayed absorbable sutures are placed through the sacrospinous ligament, either under direct vision by free suturing, with the aid of reusable ligature carriers such as the Miyazaki hook or the Deschamps needle ligature carrier or the Capio Suture Capturing Device (Boston Scientific, Marlborough, MA), taking care to avoid placement too close to the ischial spine. The posterior cervix is exposed, and a free needle is used to pass the two sutures through the posterior cervix, after which the posterior fornix is examined to ensure that the sutures are not protruding through the vaginal wall. The posterior vaginal incision is then closed. The surgeon ties down the two sacrospinous sutures to ensure tissue apposition, being sure to bury the knots under the vaginal mucosa if permanent suture is used. If indicated, anterior and/or anti-incontinence procedure can be performed. Cystoscopy is performed to confirm ureteral patency.

Sacrospinous Hysteropexy Complications.

Complications related to sacrospinous hysteropexy include rates of excessive blood loss ranging from 1.4% to 8%, rectal injury at 0.8%, urinary tract infection rates between 10% and 30%, urinary retention in 27%, and buttock pain in 10% to 15% (Dietz et al., 2008; van Brummen et al., 2003). Buttock pain typically resolves within 6 weeks; however, if a patient has specific neurologic symptoms and severe buttock pain, this likely represents sacral plexus or pudendal nerve entrapment and requires suture removal. Dietz et al. (2008) in a prospective study supported these findings and reported the following complications: reoperation for hemorrhage 1.4%, vaginal hematoma 2.8%, vaginal adhesion 4.2%, urinary tract infection 9.7%, buttock pain 18.1%, and urinary retention 27.8%. Additional studies report an ureteric obstruction rate of 2.9% (Beer and Kuhn, 2005; Sylvester et al., 2012). This complication profile seems acceptable compared with other treatment options for uterovaginal prolapse (Ridgeway and Frick, 2015).

Sacrospinous Hysteropexy Results.

See Table 124.15 for a summary of studies. **The sacrospinous hysteropexy is the best-studied uterine-sparing procedure** (Tola et al., 2015). **The literature contains numerous data points, as well as functional, reproductive, and sexual outcomes. Results of this procedure were first presented in 1998 in a case series. Five patients ranging in age from 24 to 31 were followed for 6 to 24 months.** No recurrences of prolapse nor pregnancy was reported. However, the data lack description of perioperative prolapse and definitions of success (Richardson et al., 1989). A larger study by Dietz et al. (2007) describes 133 women who underwent unilateral sacrospinous hysteropexy and anterior/posterior colporrhaphy as indicated. In this study 99 women responded to email questionnaires and 60 followed up for detailed POP-Q examination. At a mean follow-up of 22.8 months, 6% of the 133 women were diagnosed with recurrent uterovaginal prolapse to at least 1 cm above the hymen, 30% had stage 2 anterior vaginal wall prolapse, and 8% had stage 3 anterior vaginal wall prolapse. Of all patients, only three (2.8%) women required surgical treatment for recurrent prolapse. The majority of patients were very satisfied with the results of the surgery, and 91% would recommend the procedure to other women. In a large randomized trial Detollenaere et al. (2015) found sacrospinous hysteropexy to be not inferior to vaginal hysterectomy with uterosacral ligament suspension.

The primary outcome for the study was symptomatic recurrent apical prolapse at 12 months. There was no significant difference between the groups. A high rate of anatomic failure in both groups was noted in the anterior compartment (47% vs. 33%, RD 12.5; 95% CI 0.5–26.4). There was no statistically significant difference in overall anatomic and functional outcomes, complications, hospital stay, and sexual function (Detollenaere et al., 2015). Five-year follow-up is planned and should provide valuable insight to long-term outcomes (Kapoor et al., 2017). In another randomized trial, Dietz et al. (2010) compared sacrospinous hysteropexy with transvaginal hysterectomy and uterosacral ligament suspension in 71 women with the primary outcome of return to activities at home and work. At 1 year, 27% of women who underwent hysteropexy had recurrent prolapse (stage 2 or greater) compared with 11% after hysterectomy and uterosacral ligament suspension. Reoperation rates were similar. There was no difference in validated questionnaires for prolapse symptoms, incontinence symptoms, and QoL (Dietz et al., 2010).

Maher et al. (2001) reported on 77 women with uterovaginal prolapse to at least the introitus that self-selected to hysterectomy with sacrospinous ligament fixation or sacrospinous hysteropexy. Although not randomized, the groups were similar in all categories. The operative time and intraoperative blood loss were significantly less for the hysteropexy group. Fifty-six patients were available for follow-up; all were evaluated by a nonsurgical member who was blinded to the treatment with a mean follow-up of 33 months for the hysterectomy group and 26 months for the hysteropexy group. The subjective success rate was 86% in the hysterectomy group and 78% in the hysteropexy group. The objective cure rate (no prolapse beyond the mid-vagina) was similar between groups, 72% and 74%, respectively. Only two patients became pregnant in this cohort, delivering by cesarean section, with one requiring additional surgery for prolapse postdelivery (Maher et al., 2001).

van Brummen et al. (2003) mailed 103 questionnaires to women who underwent either vaginal hysterectomy or sacrospinous hysteropexy and possible anterior and posterior colporrhaphy for prolapse greater than or equal to grade II on the Baden-Walker system. The recurrence rate of grade 2 or higher vaginal prolapse was 11.4% for the sacrospinous hysteropexy group and 6.7% for the vaginal hysterectomy groups, which was not statistically significant (van Brummen et al., 2003).

Sacrospinous hysteropexy is usually done unilaterally. This deviates the axis of the vagina to the right; as a result dyspareunia and sexual function are concerns. A study by Lin et al. (2005) with a follow-up of at least 5 years noted that cervical elongation ($P = 0.007$) and grade 3 uterine prolapse are significant risk factors for failure after sacrospinous hysteropexy. The authors modified their technique based on these findings and reported that concomitant partial trachelectomy for patients with cervical elongation significantly reduced the failure rate from 75% to 0 ($P = 0.024$). Jeng et al. (2005) evaluated 150 women, all were younger than 50 years old and sexually active within the last 6 months before surgical intervention. Sexual functioning before and 6 months after surgery was examined via a face-to-face questionnaire. Sexual interest, sexual satisfaction, frequency of sexual intercourse, and frequency of orgasm were measured using an analog scale. Frequency of orgasm was the only parameter that changed significantly after surgery in the 2 groups. The sexual functioning scores were not different before or after surgical intervention in either group (Jeng et al., 2005).

Minimally Invasive Uterosacral Hysteropexy Technique.

Uterosacral ligament suspension can be performed in a minimally invasive technique using laparoscopy or with the da Vinci Surgical System (Intuitive Surgical, Sunnyvale, CA). Although there are minute variations between the two different approaches of minimally invasive uterosacral uterine suspension, each procedure attaches the uterus to a more proximal portion of the uterosacral ligament. The patient can be placed on a Pink Pad (Xodus Medical, New Kensington, PA) or another device to prevent slippage. After administration of general anesthesia, the patient is properly positioned in Allen stirrups in a low lithotomy position, the arms are properly tucked to the side and all bony prominences are padded, a pelvic exam is performed, the abdomen and vagina are surgically prepared, and a Foley catheter is inserted into the bladder. A uterine manipulator such as the Rumi II Koh System/Advincula Arch Koh System (CooperSurgical, Trumbull, CT), Vcare Plus (ComMed, Utica, NY), or another can be inserted.

Trocar placement begins with entry into the abdominal cavity via the technique with which the surgeon is most experienced. The abdomen is inflated with CO_2 gas once entry into the abdomen is confirmed. A 0-degree laparoscope is inserted through the umbilical trocar and careful inspection of the peritoneal cavity is performed, delineating all the pertinent anatomy to performing the uterosacral ligament suspension. Depending on the anatomy and whether adhesiolysis is necessary, additional trocar placement can be performed. There are many variations of trocar placement described, but in general, trocar placement involves two additional trocars placed under direct visualization in the right and left lower quadrants, lateral to the inferior epigastric vessels. One or two additional 5-mm ports are placed at the level of the umbilicus, lateral to the rectus muscle. Additional 5-mm trocar ports can be placed on the principal surgeon's side so that he or she can operate with two hands. With use of the da Vinci Surgical System, a 8.5-mm robotic camera trocar is placed at the umbilicus, and two to three additional 8.5-mm robotic trocars are placed at least 9 cm apart in either a semi-lunar or W configuration. An additional 8.5- to 11-mm laparoscopic trocar is placed on the right side of the patient to allow for the surgical assistant access. The bed is moved into the Trendelenburg position, and side or parallel docking is preferred to allow access to the vagina, bladder, and rectum intraoperatively. The pelvis is inspected, the bowel is swept out of the pelvis, and both uterosacral ligaments and ureters are identified. The proximal sacral portion of each ligament is grasped and put on tension. If the ureter is in close proximity to the uterosacral ligament, a peritoneal release incision can be performed to reduce ureteral kinking. A 0-gauge nonabsorbable or monofilament delayed absorbable suture is passed through the sacral and midportion of the ligament in 2 bites, securing it to the insertion portion of the ligament at the cervix. Additional sutures may be placed at the surgeon's discretion. The steps are repeat on the contralateral side. The uterine manipulator is directed toward the sacrum and the sutures are tied. Cystoscopy is performed to confirm ureteral patency. Any additional indicated procedures are then performed.

Minimally Invasive Uterosacral Hysteropexy Complications.

The existing literature indicates that laparoscopic uterosacral ligament uterine suspension is safe. When compared with vaginal hysterectomy with vault suspension, laparoscopic uterosacral ligament suspension resulted in less blood loss ($P < 0.0001$) and a shorter hospital stay ($P < 0.002$) (Diwan et al., 2006). In this retrospective cohort the mean reported operating time was less than an hour. Complications reported were few and included a uterine artery laceration resulting in a broad ligament hematoma that required laparotomy and transfusion and two cases involving ureteral linking remedied by a peritoneal ureteral-releasing incision.

Minimally Invasive Uterosacral Hysteropexy Results.

See Table 124.16 for a summary of studies. There are no RCTs comparing laparoscopic to robotic uterosacral uterine suspension, and most of the available data on outcomes come from studies retrospective studies comparing laparoscopic uterosacral uterine suspension to vaginal hysterectomy with uterosacral suspension. The current data available suggest that laparoscopic ligament hysteropexy is relatively safe and effective. A prospective study by Maher et al. (2001) reported outcomes on 43 nonobese patients with predominate anterior or uterine prolapse to or beyond the vaginal introitus undergoing laparoscopic uterosacral ligament uterine suspension and concomitant repairs deemed necessary. At a mean follow-up of 12 months, 81% of patients had no prolapse symptoms and 79% had no evidence of uterine prolapse recurrence; 16% (7/43) of patients had repeat surgery for recurrent prolapse (Maher et al., 2001). Recently, a retrospective cohort by Haj Yahya et al. (2017) echoed similar results in a series in which 48 women underwent laparoscopic uterosacral ligament uterine suspension with an anatomic cure rate of 85.4% (no prolapse at or below 1 cm above the hymen). The mean follow-up was 17.5 months and a clinical cure rate of 95.8%. One patient needed a repeat surgery for recurrent uterine prolapse 3 years postoperatively. They also reported no intraoperative complications such as blood loss requiring transfusion, bowel injury, or ureteral kinking. In this same series 95.5% of subjects reported their condition as very much better (PGI-I-A) or much better (PGI-I-B) (Haj Yahya et al., 2017).

TABLE 124.16

Uterosacral Hysteropexy

STUDY	STUDY TYPE	# OF PATIENTS	TYPE OF HYSTEROPEXY	COMPARATOR GROUP (N)	DURA OF FOLL UP, M
Nair et al.,	Systematic review	770	Laparoscopic suture	None	NA

2017	17 studies		hysteropexy Laparoscopic sacrohysteropexy		
Maher et al., 2001	Prospective	43	Laparoscopic uterosacral hysteropexy	None	Mean month
Haj Yahya et al., 2017	Retrospective	48	Laparoscopic uterosacral hysteropexy	None	17.5 m
Turner et al., 2016	Retrospective	54 vs. 119	Laparoscopic uterosacral hysteropexy (54)	Vaginal uterosacral hysteropexy (119)	Mean weeks
Diwan et al., 2006	Retrospective	25 vs. 25	Laparoscopic uterosacral hysteropexy (25)	TVH with uterosacral colpopexy (25)	Mean weeks

TVH, Total vaginal hysterectomy.

Diwan et al. (2006) were the first to compare laparoscopic uterosacral ligament uterine hysteropexy to vaginal hysterectomy with vaginal vault suspension in a retrospective cohort of 50 patients. The authors concluded that the uterine suspension procedure is a safe, effective treatment in selected patients with uterovaginal prolapse (Diwan et al., 2006). In another retrospective study, Turner et al. (2016) compared 54 patients who underwent uterosacral uterine suspension with 119 patients who underwent vaginal uterosacral ligament suspension. In the uterosacral uterine suspension group, a 13.2% recurrence rate was noted with no statistically significant difference when compared with the vaginal uterosacral ligament suspension group (Turner et al., 2016). Nair et al. (2017) recently published a systematic review on the anatomic and functional outcomes in women undergoing laparoscopic hysteropexy. A total of 770 patients in 17 studies were included in the review. Laparoscopic suture hysteropexy pooled success rate was 70.5%. The authors concluded that laparoscopic hysteropexy was associated with good anatomic cure rates of greater than 90% in most of the studies. There was an improvement in symptoms, and subjective cure rates were good in 73% to 100% of the patients. Reoperation rates were low, ranging from around 0 to 28%, and complication rates were generally low (Nair et al., 2017).

Open Abdominal Sacrohysteropexy Technique.

After administration of general anesthesia, the patient is properly positioned in Allen stirrups in a low lithotomy position, the arms are properly tucked to the side, and all bony prominences are padded, a pelvic exam is performed, the abdomen and vagina are surgically prepared, and a Foley catheter is inserted into the bladder. A uterine manipulator may be inserted into the uterus such as the Hulka-Kenwick Uterine elevating and manipulating forceps (Novo Surgical, Oak Brook, IL). Using a uterine manipulator such as this allows for additional instruments to be inserted into the vagina to delineate the vagina and posterior fornix. Alternatively, a RUMI uterine manipulator with a KOH colpotomizer system (CooperSurgical, Trumbull, CT) can be used. The use of a uterine manipulator allows the assistant to push up the vaginal wall, and the posterior fornix and dissection of the vesicovaginal and rectovaginal space can be done without difficulty. A Pfannenstiel or low midline abdominal incision may be used.

Upon surgical entry into the peritoneal cavity, it is important to achieve exposure of the true pelvis by careful packing of the small intestine and sigmoid colon. This is accomplished by releasing all adhesions in the pelvis and packing the bowel above the level of the sacral promontory and displacing the sigmoid to the left, exposing the sacral promontory and posterior peritoneum. To begin, the bladder is mobilized from the cervix to expose 3 to 4 cm of the underlying pubocervical fascia and proximal vagina. Bilateral windows are then made in the broad ligament at the level of the cervicouterine junction lateral to the uterine artery in an avascular area. Posteriorly, the rectovaginal space is entered at the level of the uterosacral ligaments and developed using blunt dissection to expose the rectovaginal fascia. The peritoneum overlying the sacral promontory is elevated and incised until the anterior longitudinal ligament is identified. Careful dissection is used to avoid the injury to middle sacral vessels. The peritoneum from the promontory is then incised along the right pelvic side wall to the posterior apex of the vagina. The course of the right ureter should be noted before creation of the peritoneal leaflets. A self-styled Y-shaped, T-shaped or oval-shaped-with-arms piece of monofilament polypropylene large-pore mesh can be used for the anterior vagina and cervix. The left and right mesh arms are passed through the left and right broad ligament and attached to the cervix and upper vagina with 2-0 polydioxanone sutures or monofilament, nonabsorbable polypropylene suture. If a Y-shaped mesh is not used, a rectangular second piece of monofilament polypropylene large-pore mesh is fixated to the posterior vagina and cervix with 2-0 polydioxanone sutures or monofilament, nonabsorbable polypropylene suture. The assistant then elevates the vagina and uterus toward the sacral promontory. The anterior long arms of the mesh and the posterior graft are fixed to the sacral promontory using 2 to 3 nonabsorbable monofilament sutures. Finally, the peritoneum is reapproximated. Cystoscopy is performed to confirm ureteral patency. Any additional indicated procedures are then performed.

Minimally Invasive Sacrohysteropexy Technique.

Sacrohysteropexy can be performed in a minimally invasive technique using laparoscopy or with the da Vinci Surgical System (Intuitive Surgical, Sunnyvale, CA). However, there are few variations with the two different approaches of minimally invasive sacrohysteropexy. The patient can be placed on a Pink Pad (Xodus Medical, New Kensington, PA) or another device to prevent slippage. After administration of general anesthesia, the patient is properly positioned in Allen stirrups in a low lithotomy position, the arms are properly tucked to the side, and all bony prominences are padded, a pelvic exam is performed, the abdomen and vagina are surgically prepared, and a Foley catheter is inserted into the bladder. A uterine manipulator may be inserted into the uterus such as the Hulka-Kenwick uterine elevating and manipulating forceps (Novo Surgical, Oak Brook, IL). Using a uterine manipulator such as this allows for additional instruments to be inserted into the vagina to delineate the vagina and posterior fornix. Alternatively, a RUMI uterine manipulator with a KOH colpotomizer system (CooperSurgical, Trumbull, CT) can be used. The use of a uterine manipulator allows the assistant to push up the vaginal wall and the posterior fornix, and dissection of the vesicovaginal and rectovaginal space can be done without difficulty.

Trocar placement begins with entry into the abdominal cavity via the technique with which the surgeon is most experienced. The abdomen is inflated with CO_2 gas once entry into the abdomen is confirmed. A 0-degree laparoscope is inserted through the umbilical trocar, and careful inspection of the peritoneal cavity is performed, delineating all the pertinent anatomy to perform the sacrohysteropexy. Depending on the anatomy and whether adhesiolysis is necessary, additional trocar placement can be performed. There are many variations of trocar placement described when performing robotic and laparoscopic approaches, but, in general, trocar placement involves two additional trocars placed under direct visualization in the right and left lower quadrants, lateral to the inferior epigastric vessels. One or two additional 5-mm ports are placed at the level of the umbilicus, lateral to the rectus muscle. Additional 5-mm trocar ports can be placed on the principal surgeon's side so that he or she can operate with two hands.

With use of the da Vinci Surgical System, a 8.5-mm robotic camera trocar is placed at the umbilicus, and two to three additional 8.5-mm robotic trocars are placed at least 9 cm apart in either a semi-lunar or W configuration. An additional 8.5- to 11-mm laparoscopic trocar is placed on the right side of the patient to allow for the surgical assistant access. The bed is moved into the Trendelenburg position, and side or parallel docking is preferred to allow access to the vagina, bladder, and rectum intraoperatively. If performed laparoscopically, a 30-degree laparoscope is used. To begin, the bladder is mobilized from the cervix to expose 3 to 4 cm of the underlying pubocervical fascia and proximal vagina. Bilateral windows were then made in the broad ligament at the level of the cervicouterine junction lateral to the uterine artery in a vascular area. Posteriorly, the rectovaginal space was entered at the level of the uterosacral ligaments and developed using blunt dissection to expose the rectovaginal fascia, this dissection can be continued to the perineal body if indicated. The peritoneum overlying the sacral promontory is elevated and incised until the anterior longitudinal ligament is identified. Careful dissection is used to avoid the injury to middle sacral vessels. The peritoneum from the promontory is then incised along the right pelvic side wall to the posterior apex of the vagina.

The course of the right ureter should be noted before creation of the peritoneal leaflets that will be used to cover the graft. A self-styled Y-shaped, T-shaped, or oval-shaped-with-arms piece of monofilament polypropylene large-pore mesh can be used for the anterior vagina and cervix. The left and right mesh arms are passed through the left and right broad ligament and attached to the cervix and upper vagina with 2-0 polydioxanone sutures or monofilament, nonabsorbable polypropylene suture. If a Y-shaped mesh is not used, a rectangular second piece of monofilament polypropylene large-pore mesh is fixated to the posterior vagina and cervix with 2-0 polydioxanone sutures or monofilament, nonabsorbable polypropylene suture. The posterior mesh should be fixated along the entire area of the rectovaginal dissection. A 30-degree angled camera scope improves visualization at this portion of the procedure. Care is taken to avoid the uterine vessels when placing the needle into the posterior aspect of the cervix and to avoid the ureters (especially the right ureter) during the procedure. The assistant then elevates the vagina and uterus towards the sacral promontory. The anterior long arms of the mesh and the posterior graft are fixed to the sacral promontory using 2 to 3 nonabsorbable polypropylene sutures (Ethicon Endo-surgery sutures). Finally, the peritoneum is reapproximated with poliglecaprone 25 or Vicryl suture. Cystoscopy is performed to confirm ureteral patency. Any additional indicated procedures are then performed.

Minimally Invasive Sacrohysteropexy Complications.

Although minimally invasive sacrohysteropexy may result in less blood loss, shorter hospital stays, decreased operative time, and avoidance of hysterectomy-specific complications, it can complicate future hysterectomy should it become necessary. It appears that complications of sacrohysteropexy are similar to those of sacrocolpopexy. Reported complications include wound infection, small bowel obstruction, hernia, mesh exposure, de novo incontinence, urinary urgency, dyspareunia, and persistent pain (Ridgeway, 2015). Mesh erosion is estimated at 4.2% within the first 12 months of surgery (Grimminck et al., 2016; Siddiqui et al., 2015). New-onset dyspareunia has been reported in 7% to 15% of subjects (Ridgeway, 2015). In one study with a 4-year follow-up, the mesh exposure rate was 3% (Barranger et al., 2003).

Sacrohysteropexy Results.

See Table 124.17 for a summary of studies. **The evidence supporting sacrohysteropexy is more robust compared with other open abdominal uterine conservation procedures** (Ridgeway, 2015). Most studies are limited by small sample size and lack of comparison groups. In a prospective study by Moiety et al. (2010), 33 women with a mean age of 45 (29–65) underwent open abdominal sacrohysteropexy. Preoperative POP-Q stage 2 was noted in 27 patients and stage 3 in 6 patients. At a relative short follow-up of 6 months, only 2 cases showed recurrence, and the objective and subjective success rates were 93.93% and 81.8%, respectively (Moiety et al., 2010). A retrospective cohort of 30 patients by Barranger et al. (2003) reported high objective and subjective success rates. The mean age of the women was 35.7 years (range, 29–43 years). All women were parous, 13 women had grade 2 uterovaginal prolapse, and 17 women had grade 3 prolapse. In addition to sacrohysteropexy all women underwent the Burch procedure and posterior colporrhaphy. Intraoperative and postoperative complications occurred in 2 patients (6.6%) and 4 patients (13.3%), respectively. The mean objective and subjective follow-up periods were 44.5 months (range, 2–156 months) and 94.6 months (range, 8–160 months), respectively; 93% of patients had no prolapse beyond the hymen at a mean follow-up of 44.5 months. Subjective rates were high as well; only 1 patient experienced recurrent prolapse symptoms at a mean follow-up of 95 months (Barranger et al., 2003).

TABLE 124.17

Sacrohysteropexy

STUDY	STUDY TYPE	# OF PATIENTS	TYPE OF HYSTEROPEXY	COMPARATOR GROUP (N)	DURAT OF FOLLO UP, MO
Costantini et al., 2005	Prospective	34 vs. 38	Abdominal sacrohysteropexy (34)	Abdominal hysterectomy and sacrocolpopexy (*n* = 38)	51 mont
Krause et al., 2006	Prospective	81	Laparoscopic suture hysteropexy	None	20.3 mo
Rosenblatt et al., 2008	Retrospective	40	Laparoscopic sacrocervicopexy	None	>6 mont
Price et al., 2010	Prospective	51	Laparoscopic sacrohysteropexy	None	10 week

Moiety et al., 2010	Prospective	33	Abdominal sacrohysteropexy	None	6 month
Barranger et al., 2003	Retrospective	30	Abdominal sacrohysteropexy	None	Mean 44 months
Mourik et al., 2012	Prospective	50	Robotic-assisted sacrohysteropexy	None	29 mont
Lee et al., 2013	Retrospective	15	Robotic-assisted sacrohysteropexy	None	6 month
Grimminck et al., 2016	Prospective	100	Robotic-assisted sacrohysteropexy	None	12 and 7 months

Limited data exist on the outcomes and complications of minimally invasive sacrohysteropexy. Published studies on the outcomes of laparoscopic sacrohysteropexy and robotic-assisted laparoscopic sacrohysteropexy are similar and seen as an effective alternative to the open approach (Paek et al., 2016). Lack of data on midterm and long-term follow-up have so far prevented the standard treatment for POP. There is no consensus on which technique would be most preferable; furthermore that is the question of whether uterine preservation is favorable (Grimminck et al., 2016). No RCTs have been published comparing sacrohysteropexy with hysterectomy with sacrocolpopexy. Costantini et al. (2005) reported a 91% success rate with abdominal sacrohysteropexy (*n* = 34) versus 92% with abdominal hysterectomy and sacrocolpopexy (*n* = 38) at 51 months. In 2013 Constantini et al. followed 32 sacrohysteropexy patients for 12 months with 100% objective success in both groups (apex <−6). Krause et al. (2006) followed 81 women prospectively after laparoscopic sacral suture hysteropexy (attaches the posterior cervix to the sacral promontory via the right uterosacral ligament). At a mean follow-up of 20.3 months, 88% had no symptoms of POP, whereas 95% had no objective evidence of prolapse (Krause et al., 2006). Data by Rosenblatt et al. (2008) on 23 women undergoing laparoscopic hysteropexy was also encouraging; all subjects were free of symptomatic prolapse at 12 months. A prospective cohort study by Price et al. (2010) of 51 women undergoing laparoscopic hysteropexy with anterior and posterior arms reported one failure at 10-week follow-up. Pan et al. (2016) in a retrospective cohort study reported outcomes at a mean follow-up of 33 months ($n = 65$ hysteropexy and $n = 34$ hysterectomy). No mesh erosions were noted in either group. Success was higher in the hysterectomy group, although it did not reach statistical significance (88% vs. 72%, $P = 0.07$). Subjective satisfaction rate was higher in the hysterectomy with sacrocolpopexy (92% vs. 100%, $P < 0.001$). Ten women required retreatment with either pessary ($n = 9$) or reoperation ($n = 1$) in the hysteropexy groups compared with no retreatment in the hysterectomy groups (Pan et al., 2016).

Robotic-assisted laparoscopic sacrohysteropexy allows three-dimensional (3D) viewing, suturing, and dissection capacity; has increased maneuvering capability; and is minimally invasive (Tola et al., 2015). It provides good hemostasis, shorter hospitalization times, less morbidity and postoperative pain, but it is an expensive method (Geller et al., 2008). Seror et al. (2012) reported that better long-term results could be achieved with improved suturing and dissection. The long-term effects of robotic-assisted laparoscopic sacrohysteropexy have been found to be comparable with abdominal operations. Robotic-assisted laparoscopic sacrohysteropexy has been described in a study by Mourik et al. (2012). In this cohort that included 50 women and a follow-up to 29 months, women undergoing robotic-assisted laparoscopic sacrohysteropexy had significant improvement in QoL. Subjective cure rates were 95% (Mourik et al., 2012). In a small retrospective cohort of 15 women undergoing robotic-assisted laparoscopic sacrocolpopexy, Lee et al. (2013) noted an objective success of 93% (14/15) and subjective success of 80% (12/15). The mean age of women was 51.8 years (28–64 years). No intraoperative complications were noted. The mean operating time was 159.4 minutes (130–201 minutes), and mean estimated blood loss was 35 mL (0–100 mL). The mean length of stay was 1.6 days (1–4 days), and mean length of follow-up was 10.8 months. Uterine prolapse improved in all 15 patients (Lee et al., 2013). In a prospective series Grimminck et al. reported that 81% (30/37) showed no recurrence of uterine prolapse at a follow-up of 5 years. In this same series they reported the overall success rate of POP was 89.2% (Grimminck et al., 2016).

Pregnancy data after uterine-sparing POP are limited. Women who have prolapse surgery should be counseled that the effects of pregnancy on uterine sparing procedures are not clear. Twenty-four (9.4%) of 257 women who underwent POP surgery became pregnant, of these, 6 had cesarean births, and 10 had vaginal births, 8 of which resulted in abortions (Maher et al., 2010). **There**

are not enough data to make a standard recommendation regarding the type of hysteropexy in women who desire future pregnancy, and there is not a recommended mode of delivery (Ridgeway, 2015).

Posterior Compartment Repair

Symptoms attributable to posterior compartment prolapse can be divided conceptually as herniation symptoms, defecatory dysfunction, and sexual dysfunction (Cundiff and Fenner, 2004). Herniation symptoms include vaginal bulging or even bleeding of the epithelium from excoriation. Symptoms of defecatory dysfunction include stool trapping requiring vaginal splinting or manual digitation, defecatory urgency, and constipation. Defecatory dysfunction does not include fecal incontinence. Some authors point out that it is important to differentiate among the causes of defecatory dysfunction as those attributable to outlet obstruction (specifically when caused by defects in the support of the posterior compartment, perineum and rectum, as well as anismus) and those attributable to motility disorders (Cundiff and Fenner, 2004). Outlet obstruction attributable to pelvic floor defects may be alleviated with surgical restoration of anatomy. However, motility disorders, which usually involve impaired transit of stool through the rectum and anus, are treated with dietary modifications and medication. Anismus, defined as the failure of the puborectalis to relax during defecation, often responds to biofeedback and pelvic floor physical therapy. In combined disorders, it is recommended that nonsurgical treatment for anismus or slow-transit constipation (most common disorder of motility) be treated before embarking on surgical intervention.

Sexual dysfunction, if present, is thought to be secondary to dyspareunia, although decreased desire and anorgasmia may also be contributing factors (Handa et al., 2004). Several authors have sought to identify patient factors that would predict who may benefit most from rectocele repair (Murthy et al., 1996; Watson et al., 1996). These include sensation of vaginal mass or bulge, need for digitalization (splinting) to complete rectal evacuation, non-emptying or partial emptying on defecography, and presence of a large rectocele. Sensation of incomplete emptying and constipation are not specific to rectoceles and may be associated with other disorders, including irritable rectum and slow transit constipation. **Patients should be counseled that surgical repair of the posterior compartment may likely reduce vaginal protrusion symptoms and decrease or eliminate the need for vaginal splinting. However, some patients**

may have persistence of constipation, because motility disorders and anismus can independently coexist with prolapse and persist after a seemingly successful repair.

Rectoceles can be approached transanally or transvaginally. Nieminen et al. (2004) randomized 30 patients to rectovaginal fascia plication or transanal repair. Both approaches resulted in a high rate of symptom resolution (93% for the vaginal approach vs. 73% for the transanal approach). However, the vaginal approach had better objective findings and a lower rate of prolapse recurrence (7% vs. 66%). The traditional posterior colporrhaphy was devised in the 19th century to treat perineal tears, which occurred during vaginal delivery. The original description involved plicating the pubococcygeus muscles and the posterior vaginal wall with reconstruction of the perineal body, which was termed posterior colpoperineorrhaphy (Cundiff and Fenner, 2004). This resulted in a rigid inferior shelf, reduced the herniation of the posterior wall, and aided in preventing descensus of the vaginal vault or uterus. In 1961 Francis and Jeffcoate reported a high incidence of dyspareunia after colporrhaphy with levator plication. In their series of 243 women, 50% developed postoperative dyspareunia. In addition, there is evidence to suggest that traditional posterior colporrhaphy with levator plication may worsen defecatory symptoms. Kahn and Stanton (1997) reported increased symptoms of fecal incontinence, constipation, incomplete evacuation, and dyspareunia postoperatively. **Because of the increase in dyspareunia postoperatively, plication of the levator ani muscles has largely been abandoned. Site-specific repairs and midline fascial plication without levator ani plication have emerged as the predominant surgical treatments of a rectocele.** Level 1 and Level 2 evidence support the superior objective outcomes of midline posterior plication without levatorplasty compared with site-specific repairs.

Posterior Colporrhaphy Technique

For the posterior colporrhaphy technique (Fig. 124.35), the patient is placed into dorsal lithotomy position. However, if a patient requires an anterior or middle compartment repair, it should be performed first (Rovner and Ginsberg, 2001). The anterior wall can be retracted with a Heaney or Lone Star retractor with hooks to improve visualization. Hydrodissection may be accomplished by injecting saline or a local anesthetic with or without epinephrine. A midline incision is made through the posterior vaginal epithelium. For a high rectocele the incision may be as high as the vaginal apex (cuff); for smaller rectoceles the incision is started at the most caudal position. The rectovaginal fascia (muscularis) is separated from the vaginal epithelium with Metzenbaum scissors. The tips of the scissors should be pointed toward the vaginal epithelium to avoid rectal injury. The dissection proceeds laterally until the pararectal attachments to the pelvic sidewall are visualized. In cases of large posterior defects, a purse-string suture of 2-0 or 3-0 absorbable suture may be placed at the base of the rectal herniation to reduce it; however, care should be taken to avoid foreshortening the posterior wall cephalad to caudad. In addition, this acts to bring the attenuated rectovaginal fascia together to aid in its re-approximation. The rectovaginal fascia is then plicated in the midline with either interrupted or continuous 2-0 absorbable sutures. Care should be taken to avoid excessive lateral placement or wide spacing of these sutures; this may result in overtightening or painful ridges along the posterior vaginal wall. Suture placement is continued distally and incorporated into the perineal body re-approximation. The excess vaginal epithelium is judiciously trimmed and closed with a running absorbable 2-0 suture. A perineorrhaphy may also be performed before the vaginal epithelium is closed if the introital laxity dictates and care is taken to avoid overtightening.

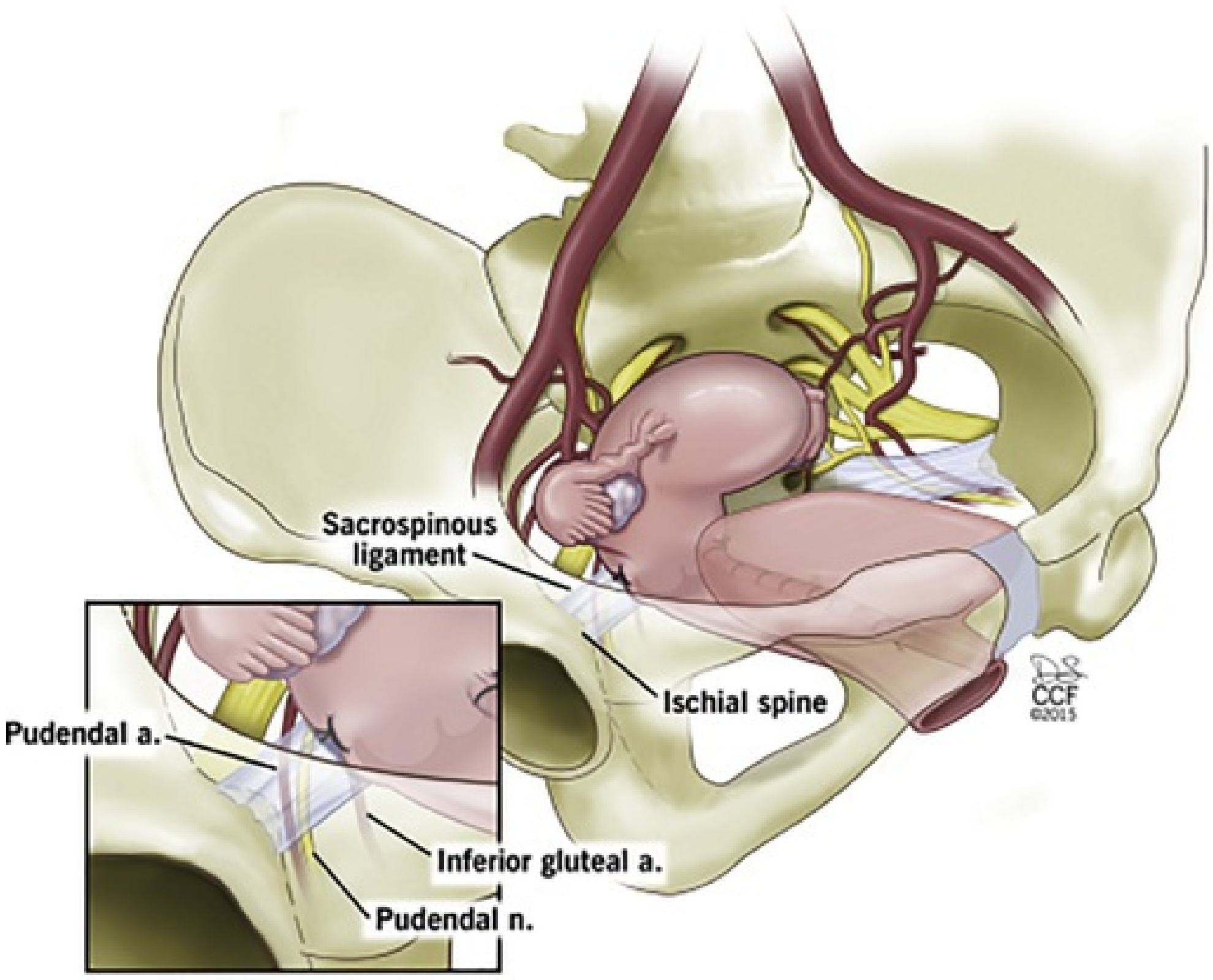

FIG. 124.35 Native tissue sacrospinous hysteropexy with the posterior cervix attached to the right sacrospinous ligament and anterior colporrhaphy. (From Ridgeway, BM: Does prolapse equal hysterectomy? The role of uterine conservation in women with uterovaginal prolapse. *Am J Obstetr Gynecol* 213[6]:802–809, 2015.)

Site Specific Repair: Technique.

To minimize complications associated with posterior colporrhaphy, a site-specific defect repair was described. Richardson (1993) described discrete defects in the rectovaginal fascia found in patients undergoing posterior colporrhaphy and cadaveric dissections. He found that the most common defect was the transverse configuration, separating the vaginal septum from the perineal body (Figs. 124.36 through 124.38). This essentially results in a separation of the rectovaginal fascia from the perineal body. The goal of the site-specific repair is to restore the anatomy by closing these discrete defects.

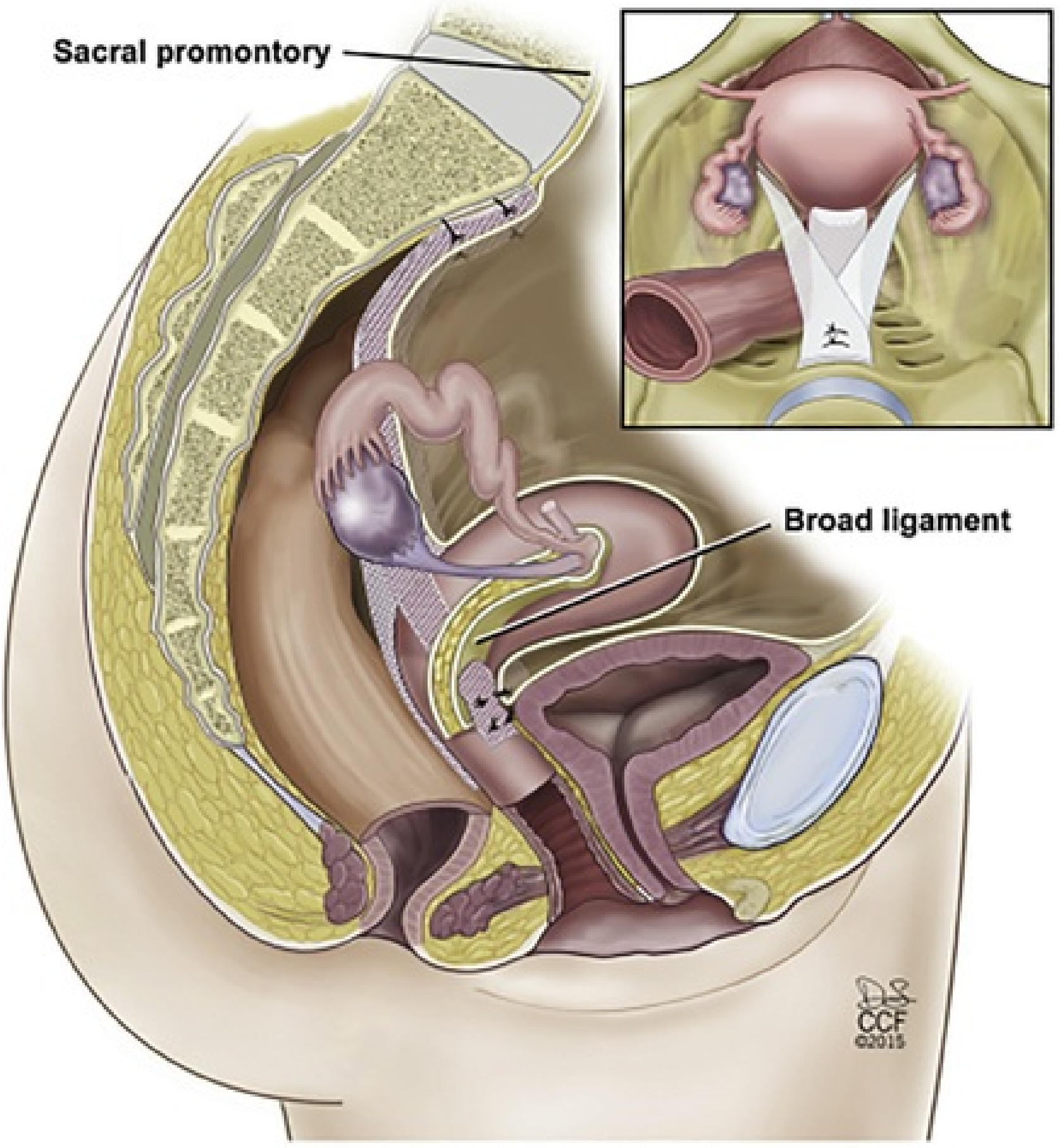
Sacral promontory
Broad ligament
CCF
©2015

FIG. 124.36 Sacrohysteropexy using anterior and posterior mesh. The two arms of the anterior mesh exit the broad ligament. They are secured with the posterior mesh to the anterior longitudinal ligament of the sacrum. (From Ridgeway BM: Does prolapse equal hysterectomy? The role of uterine conservation in women with uterovaginal prolapse*. Am J Obstetr Gynecol* 213[6]:802–809, 2015.)

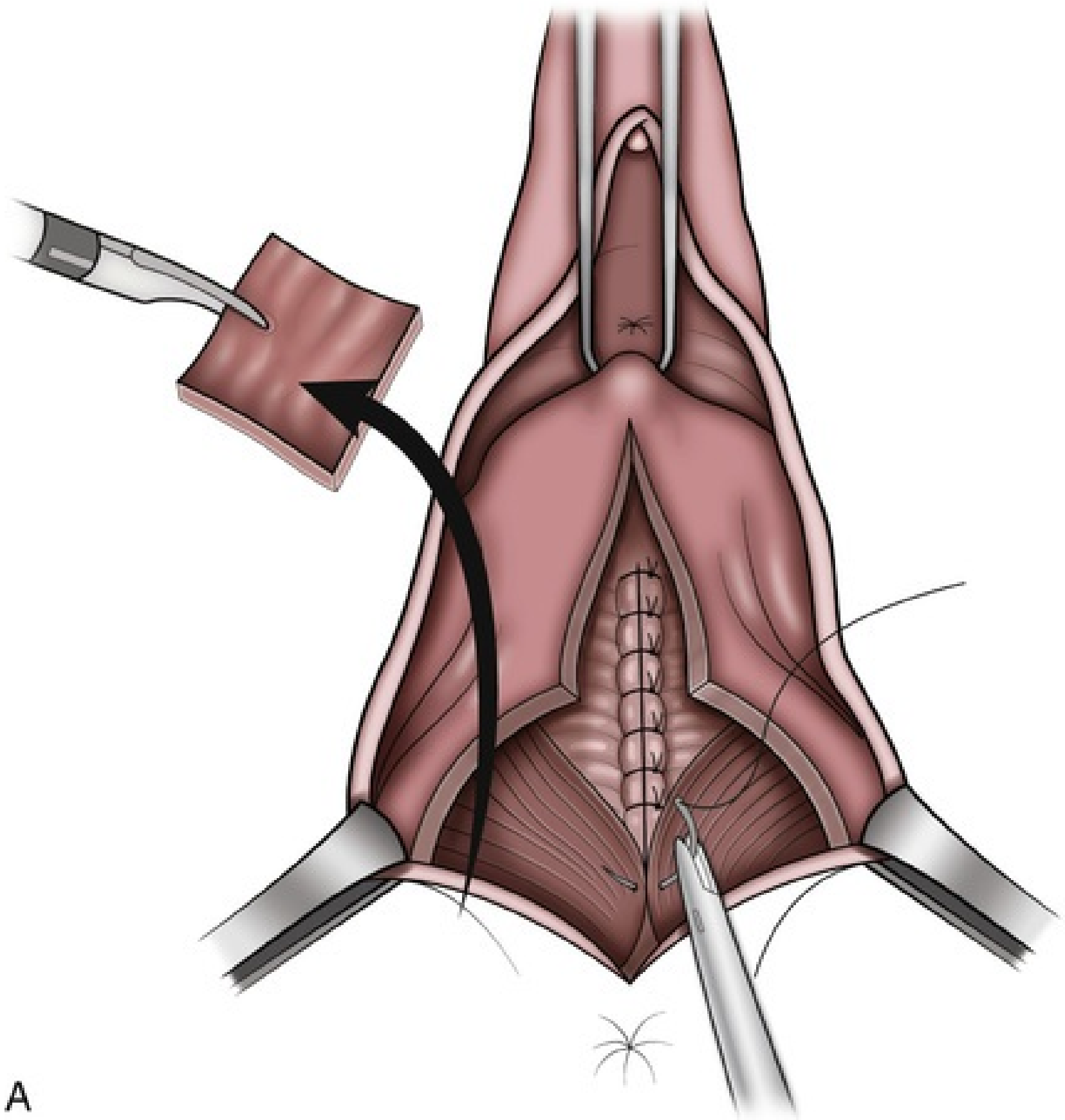
A

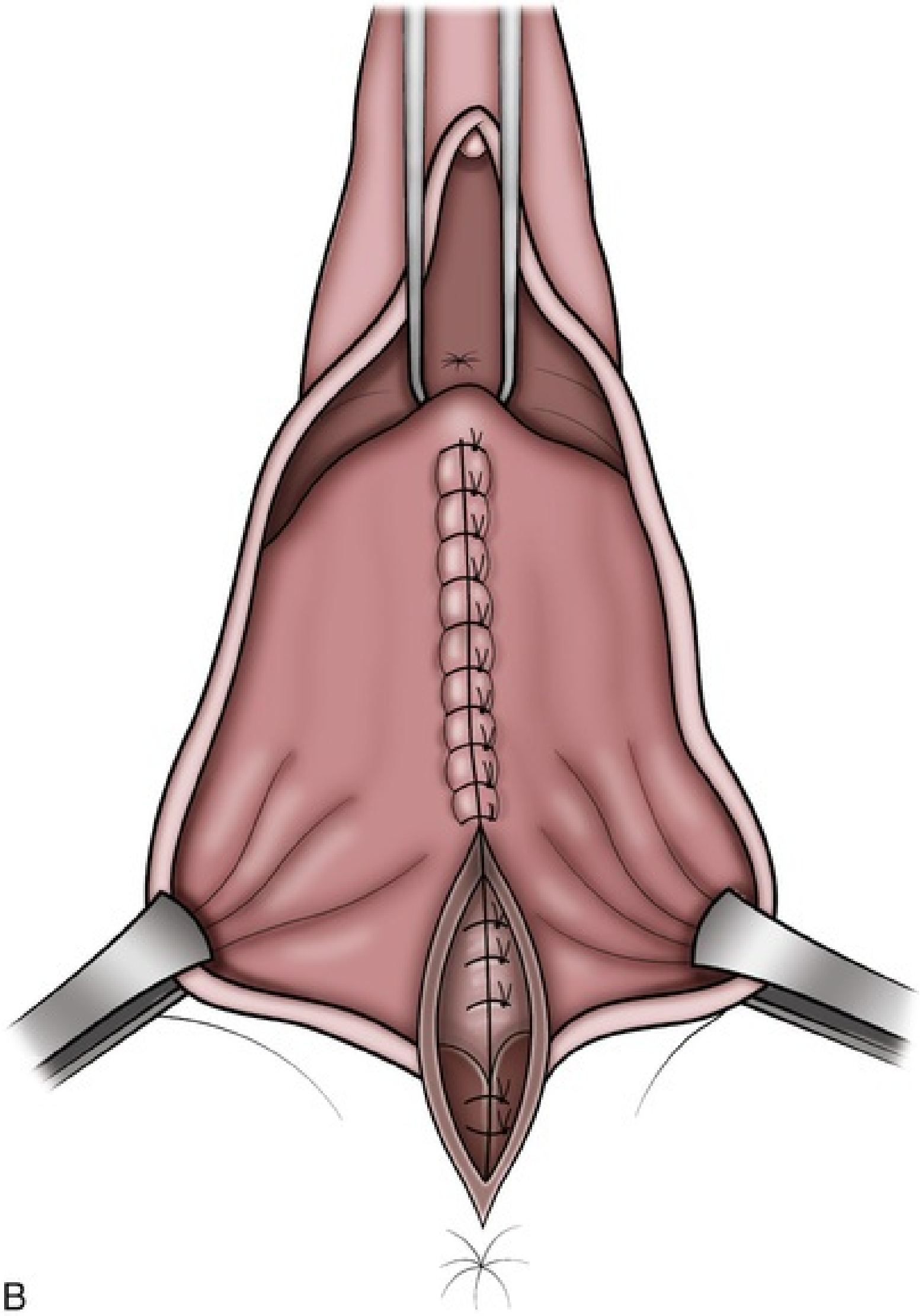

FIG. 124.37 (A and B) Technique of posterior colporrhaphy with rectovaginal tissue plication. (From Ginsberg D: Treatment of vaginal wall prolapse. In Goldman H, Vasabada S, editors: *Female urology: a practical clinical guide*, Totowa, NJ, 2007, Humana Press, pp 281–296.)

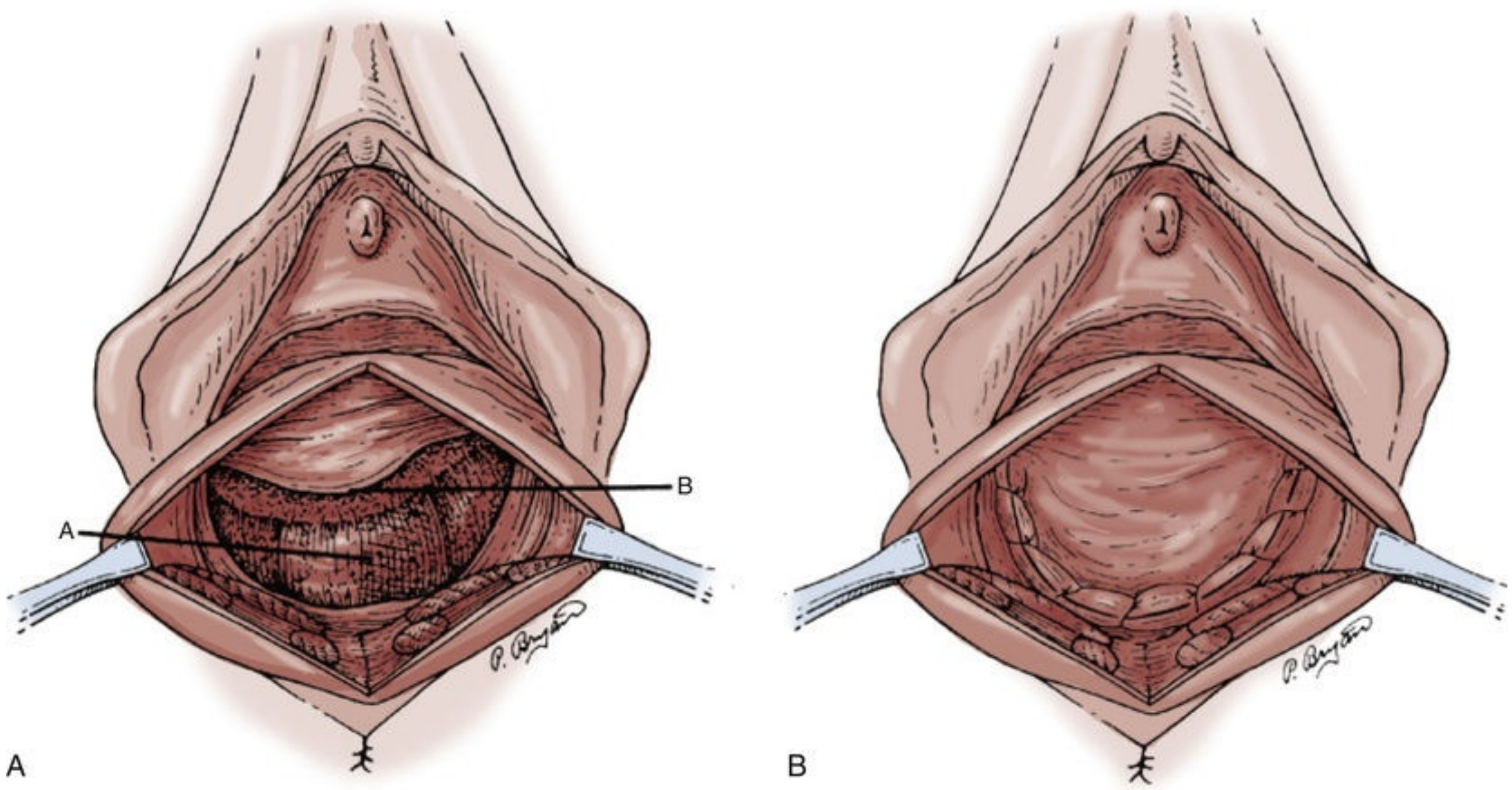

FIG. 124.38 Site-specific rectocele repair. A low transverse defect is identified and repaired primarily. (From Richardson AC: The rectovaginal septum revisited: its relationship to rectocele and its importance in rectocele repair. *Clin Obstet Gynecol* 36:976–983, 1993.)

A midline incision is made on the posterior vaginal epithelium. For a high rectocele the incision may be as high as the vaginal apex; for smaller rectoceles the incision is started at the most caudal position. The rectovaginal fascia (muscularis) is separated through a virtually bloodless plane from the vaginal epithelium. The index finger of the nondominant hand is then inserted into the rectum to facilitate identification of the fascial defect. The defect is closed with absorbable interrupted sutures. The excess vaginal epithelium is judicially trimmed, and the vaginal epithelium is closed with a running absorbable suture.

Perineorrhaphy: Technique.

A triangular incision at the mucocutaneous junction is removed (Rovner and Ginsberg, 2001). The triangular island of posterior vaginal wall is sharply removed from the pre-rectal levator fascia. Horizontal mattress sutures are used to approximate the attenuated perineal body fibromuscular tissue. Once these are brought together, the muscles of the urogenital diaphragm are reconstituted, and support is restored to the central tendon. It is important that a smooth contour be created along the suture line, because ridges may cause dyspareunia. A vaginal packing moistened with saline, antibiotic solution, cream, or gel may then then placed if warranted.

Posterior Colporrhaphy Results (Table 124.18).

Kahn and Stanton (1997) reported on the anatomic and functional results of posterior repair using levator plication. Both reported anatomic success; however, many patients complained of bowel symptoms and dyspareunia postoperatively (Kahn and Stanton, 1997). Because of the adverse events associated with levator plication, the technique has been abandoned by many surgeons.

TABLE 124.18

Results of Posterior Compartment Repair

TECHNIQUE	STUDY (FIRST AUTHOR [YEAR])	NUMBER	REVIEW (MOS)	ANATOMIC CURE (%)	VAGINA BULGE (%)
Midline fascial plication	Paraiso (2006) Preop Postop	37 28	24	24/28 (86)	
	Abramov (2005) Preop Postop	183 183	>12	150/183 (82)	100 4
	Maher (2004b) Preop Postop	38 38	12	33/38 (87)	100 5/38 (13)
	Singh (2003) Preop Postop	42 26	18	24/26 (92)	78 2/26 (8)
Site-specific repair					
	Sung (2012) Preop Postop	80 70	12	63/70 (90)	4/58 (7)
	Paraiso (2006) Preop	37 27	17.5	21/23 (78)	

	Postop				
	Abramov (2005) Preop Postop	124 124 124	>12	69/124 (56)	100 14/124 (11)
	Glavind (2000) Preop Postop	67 67	3	67/67 (100)	
	Porter (1999) Preop Postop	125 72	6	73/89 (82)	27/72 (38 10/72 (14
	Kenton (1999) Preop Postop	66 46	12	41/46 (90)	86 4/46 (9)
	Cundiff (1998) Preop Postop	69 61	12	50/61 (86)	100 11/61 (18
Augmented repairs					
SIS	Paraiso (2006) Preop Postop	31 26	17.5	14/26 (54)	
Cadaveric fascia lata	Kobashi (2005) Preop Postop	73 62	13.7		6/50 (6)
Cadaveric dermis	Kohli (2003) Preop Postop	43 30	12.9	28/30 (93)	

Paraiso et al. (2006) randomized patients prospectively to posterior colporrhaphy (rectovaginal fascial plication), site-specific repair, or site-specific repair with porcine SIS graft. They found that posterior colporrhaphy and site-specific rectocele repair had similar functional and anatomic outcomes. The addition of the porcine-derived graft did not improve anatomic outcomes. Rates of dyspareunia did not differ when comparing all three groups. In a follow-up study of these same patients specifically looking at bowel symptoms, Gustilo-Ashby et al. (2007) found that anatomic cure was associated with a reduced risk of postoperative straining and sensation of incomplete bowel evacuation, but not with other bowel symptoms. They found that bowel symptoms, including feeling of incomplete emptying, straining to defecate, splinting to defecate, and fecal incontinence improved significantly after rectocele repair. Abramov et al. (2005) retrospectively studied patients with advanced posterior vaginal prolapse and compared patients who underwent traditional posterior colporrhaphy with those who underwent site-specific repair. They found that the recurrence of posterior defects was higher in the site-specific group compared with the midline plication of the rectovaginal fascia: 33% versus 14% for second degree and 11% versus 4% for third degree. In addition, recurrence of symptomatic rectocele was greater in the site-specific group (11% vs. 4%). Rates of de novo dyspareunia and postoperative bowel symptoms were the same in both groups. Maher et al. (2004b) prospectively studied the efficacy of posterior repair with plication of the rectovaginal fascia. They found that improved anatomic outcome correlated with improved functional outcomes. Eighty-seven percent no longer experienced obstructive defecation postoperatively. Significant improvements were seen in awareness of prolapse, obstructive defecation, straining to defecate, hard stools, dyspareunia, and digitations. Dyspareunia decreased from 37% to 5%. Singh et al. (2003) reported on a prospective study of 42 women evaluated for bowel, sexual, urinary, and prolapse symptoms as well as anatomic outcomes after fascial plication technique. At 6-week follow-up, 87% noted an improvement of bowel symptoms. At 18 months, they estimated the relief of vaginal symptoms to be between 73% and 92%. Sixty-five percent had improvement of the defecatory symptoms, and 38% had improvement of sexual discomfort. None of the patients reported de novo dyspareunia or bowel symptoms.

In contrast to the generalized repair of midline plication of the rectovaginal fascia, several authors have reported their experience with site-specific repair. Glavind and Madsen (2000) prospectively studied 67 patients who underwent a discrete repair. Of the 67 patients 64 were found to have a discrete defect, which was repaired, and in 3 there was an attenuation of the tissue. At 3-month follow-up, 85% of those who reported bowel symptoms preoperatively reported resolution of symptoms. Two patients (3%) had de novo dyspareunia. Porter et al. (1999) examined anatomic, functional, and QoL aspects of posterior colporrhaphy in a retrospective study. Improvement or cure was noted for pain or pressure, vaginal mass, splinting, and difficulty with defecation. Constipation did not significantly change. Preoperative dyspareunia improved in 73% of patients, worsened in 19%, and occurred de novo in 3 patients. Emotional health also improved, specifically thoughts of embarrassment and frustration. Kenton et al. (2007) reported on 66 patients who underwent site-specific repair; all patients had reattachment of the rectovaginal septum to the perineal body. Statistically significant symptom relief was noted in the realms of protrusion, manual evacuation, difficult defecation, and dyspareunia. Constipation was unchanged. Three patients developed de novo dyspareunia and 1 had de novo constipation. At 1 year, 7 of 11 patients who used manual evacuation preoperatively returned to doing so. The authors commented that this may be due to a functional decompensation of the rectum, which is not corrected surgically. Finally, Cundiff et al. (1998) reported on the anatomic and functional aspects of discrete fascial defect repair of the posterior compartment. At 12-month follow-up, 86% were noted to have a stage 1 or less prolapse. Splinting was eliminated in 63% of patients who reported this symptom preoperatively. The mean satisfaction score was 8.6 (10 highest). **The mean improvement did not correlate to the anatomic correction but did correlate with alleviation of defecatory symptoms, stressing the importance of symptom relief being of priority to the patient over anatomic correction.** The Fifth International Collaboration on Incontinence offered a grade B recommendation that Level 1 and 2 evidence suggest that midline plication posterior repair without levatorplasty may have superior objective outcomes compared with site-specific posterior repair, concluding that midline fascial plication without levatorplasty is the procedure of choice for posterior compartment prolapse (Karram and Maher, 2013). However, a 2018 Cochrane review concluded that because of the paucity of data and lack of good trials, the evidence was insufficient to draw conclusions about the relative effectiveness of these two procedures for posterior compartment prolapse (Mowat et al., 2018).

Interposition Graft Repairs of the Posterior Compartment

Synthetic mesh and biologic grafts have been used in posterior repairs, although data are lacking regarding routine use. Also, several authors caution against the use of synthetic materials in the posterior compartment because of the potential for dyspareunia and visceral erosion, favoring the use of biologic grafts (Chen et al., 2007). Kohli and Miklos (2003) reported anatomic outcomes on 43 patients who underwent a site-specific repair with cadaveric dermis; 30 were available for evaluation at an average of 12.9 months. The graft was fixed proximally to the vaginal apex, laterally to the levator ani muscles and distally to the perineal body. They reported a 93% success rate using the POP-Q grading system. Kobashi et al. (2005) reported using cadaveric fascia lata in 73 patients. With a mean follow-up of 13.7 months, there was an 83% to 89% improvement in symptoms. Ninety percent of those examined had a grade 0 rectocele by the Baden-Walker classification. Dell and O'Kelley (2005) used Pelvisoft, a fenestrated, porcine dermal acellular matrix, and reported no wound complications. Despite these encouraging results, Altman et al. (2005) reported on 29 patients using collagen mesh for symptomatic rectoceles. Twenty-three were available at 3-year follow-up; 41% had recurrence of stage 2 or greater, and 12 of 23 patients reported incomplete rectal evacuation. They advocated further study before recommending the routine use of graft augmented tissue repair. A 2018 Cochrane review found that between traditional repair and biologic graft groups the evidence is insufficient to show whether there were any differences in rates of awareness of prolapse (RR 1.09, 95% CI 0.45–2.62) or repeat surgery for any prolapse (RR 0.60, 95% CI 0.18–1.97). In addition, they point out that the existing trials demonstrate no conclusive evidence of a difference in rates of recurrent posterior vaginal wall prolapse between groups (RR 0.55, 95% CI 0.30–1.01). Postoperative complications were more common with biologic repair (RR 1.82, 95% CI 1.22–2.72 (Mowat et al., 2018).

A number of authors have used permanent mesh materials via a posterior approach. Although not advocated by the authors of this chapter, we will review some of the salient, albeit limited, results. The use of mesh in the posterior compartment was reviewed by the Fifth International Collaboration on Incontinence after a thorough literature search of all English-language literature through January 2012. Their conclusion with a grade B recommendation (mostly level 2 and 3 evidence) was that **no studies have shown any benefit of mesh overlay or augmentation over a suture repair for posterior vaginal wall prolapse** (Karram and Maher, 2013). Using permanent materials, multi-compartmental repairs are more commonly performed, extending from the sacrospinous ligament to the perineal body. de Tayrac et al. (2006) reported on 26 patients with a 2-year follow-up. Objective and subjective cure rates of 92.3% and 88%, respectively, were observed. Dwyer used a technique in which atrium mesh was attached to the sacrospinous ligament bilaterally and to the perineal body (Dwyer and O'Reilly, 2004). Fifty patients underwent posterior repair, 17 of which had anterior and posterior repair. No rectocele recurrence was seen at 13 months. Lim et al. (2005) reported using a composite Vicryl-Prolene mesh

(Vypro II, Ethicon) for correction of isolated rectoceles. In this descriptive study, 90 patients underwent loose placement of an interposition graft in the posterior compartment with no primary repair. Success was noted in 27 of 31 patients (87%) at minimum 6-month follow-up. Five patients with recurrence of the rectocele did not have prolapse in other compartments (Lim et al., 2005). Mercer-Jones et al. (2004) reported on 22 patients who underwent transperineal placement of either Vypro II or Prolene mesh; 77% reported moderate, good, or excellent results after mesh repair.

When deciding on treatment options for the posterior compartment, the surgeon and the patient should be aware that graft extrusion rates of 1.3% to 12% have been reported (de Tayrac et al. 2006, 2007; Kobashi et al., 2005; Lim et al., 2005), as well as dyspareunia rates as high as 60% (Milani et al., 2005).

Key Points: Posterior Compartment Repair

- Because motility disorders often coexist with posterior compartment prolapse, patients should be counseled that constipation may persist despite successful anatomic correction.
- Levator ani muscle plication should not be performed during rectocele repair because of the high risk of dyspareunia postoperatively.
- Despite the high cure rates seen with the use of mesh in the posterior compartment, dyspareunia and vaginal extrusion may be significant.
- Repair of the perineal body is often performed at the time of rectocele repair to recreate approximation of the rectovaginal connective tissues to the central tendon of the perineum.

References

Abramov Yoram, Gandhi Sanjay, Goldberg Roger P, et al. Site-specific rectocele repair compared with standard posterior colporrhaphy. *Obstet Gynecol*. 2005;105(2):314–318 https://doi.org/10.1097/01.AOG.0000151990.08019.30 [(online journal)].

Addison WA, Livengood CH, Sutton GP, et al. Abdominal sacral colpopexy with mersilene mesh in the retroperitoneal position in the management of posthysterectomy vaginal vault prolapse and enterocele. *Am J Obstet Gynecol*. 1985;153(2):140–146 http://www.ncbi.nlm.nih.gov/pubmed/2931025 [(online journal)].

Addison WA, Timmons MC. Abdominal approach to vaginal eversion. *Clin Obstet Gynecol*. 1993;36(4):995–1004 http://www.ncbi.nlm.nih.gov/pubmed/8293600 [(online journal)].

Ahmad Gaity, Duffy James MN, Phillips Kevin, et al. Laparoscopic entry techniques. *Cochrane Database Syst Rev*. 2008;(2) [CD006583] https://doi.org/10.1002/14651858.CD006583.pub2 [(online journal)].

Aigmueller TH, Riss P, Dungl A, et al. Long-term follow-up after vaginal sacrospinous fixation: patient satisfaction, anatomical results and quality of life. *Int Urogynecol J Pelvic Floor Dysfunct*. 2008;19(7):965–969 https://doi.org/10.1007/s00192-008-0563-5.

Alevizon SJ, Finan MA. Sacrospinous colpopexy: management of postoperative pudendal nerve entrapment. *Obstet Gynecol*. 1996;88(4 Pt 2):713–715 http://www.ncbi.nlm.nih.gov/pubmed/8841264 [(online

journal)].

Altman Daniel, Väyrynen Tapio, Engh Marie Ellström, et al. Short-term outcome after transvaginal mesh repair of pelvic organ prolapse. *Int Urogynecol J*. 2008;19(6):787–793 https://doi.org/10.1007/s00192-007-0526-2.

Altman Daniel, Zetterström Jan, López Annika, et al. Functional and anatomic outcome after transvaginal rectocele repair using collagen mesh: a prospective study. *Dis Colon Rectum*. 2005;48(6):1233–1241 [discussion 1241-2] https://doi.org/10.1007/s10350-005-0023-y [author reply 1242 (online journal)].

American Urogynecologic Society (AUGS). *Update on vaginal mesh for prolapse and incontinence*. [(online journal); Available from:] https://www.augs.org/update-on-vaginal-mesh-for-prolapse-and-incontinence/; 2018.

Amrute KV, Eisenberg ER, Rastinehad AR, et al. Analysis of outcomes of single polypropylene mesh in total pelvic floor reconstruction. *Neurourol Urodyn*. 2007;26(1):53–58 https://doi.org/10.1002/nau.20362.

Amundsen CL, Flynn BJ, Webster GD. Anatomical correction of vaginal vault prolapse by uterosacral ligament fixation in women who also require a pubovaginal sling. *J Urol*. 2003;169(5):1770–1774 https://doi.org/10.1097/01.ju.0000061472.94183.26.

Antosh Danielle D, Grotzke Stephanie A, McDonald Marcela A, et al. Short-term outcomes of robotic versus conventional laparoscopic sacral colpopexy. *Female Pelvic Med Reconstr Surg*. 2012;18(3):158–161 https://doi.org/10.1097/SPV.0b013e31824b218d [(online journal)].

Antovska SV, Dimitrov DG. Vaginosacral Colpopexy (VSC)—a new modification of the mc call operation using vaginosacral ligaments as autologous sliding grafts in posthysterectomy vault prolapse. *Bratisl Lek Listy*. 2006;107(3):62–72 http://www.ncbi.nlm.nih.gov/pubmed/16796126.

Ayhan A, Esin S, Guven S, et al. The Manchester operation for uterine prolapse. *Int J Gynaecol Obstet*. 2006;92(3):228–233 https://doi.org/10.1016/j.ijgo.2005.12.002 [(online journal)].

Baden WF, Walker T. Urinary stress incontinence: evolution of paravaginal repair. *Female Patient*. 1987;12:89–105.

Ballert Katie N, Biggs Grace Y, Isenalumhe Anthony, et al. Managing the urethra at transvaginal pelvic organ prolapse repair: a urodynamic approach. *J Urol*. 2009;181(2):679–684 https://doi.org/10.1016/j.juro.2008.10.009 [(online journal)].

Barber MD, Kuchibhatla MN, Pieper CF, et al. Psychometric evaluation of 2 comprehensive condition-specific quality of life instruments for women with pelvic floor disorders. *Am J Obstet Gynecol*. 2001;185(6):1388–1395 https://doi.org/10.1067/mob.2001.118659 [(online journal)].

Barber MD, Visco AG, Weidner AC, et al. Bilateral uterosacral ligament vaginal vault suspension with site-specific endopelvic fascia defect repair for treatment of pelvic organ prolapse. *Am J Obstet Gynecol*. 2000;183(6):1402–1410 [discussion 1410-1] https://doi.org/10.1067/mob.2000.111298 [(online journal)].

Barber Matthew D, Brubaker Linda, Burgio Kathryn L, et al. “Comparison of 2.” transvaginal surgical approaches and perioperative behavioral therapy for apical vaginal prolapse. *J Am Med Assoc*. 2014;311(10):1023 https://doi.org/10.1001/jama.2014.1719 [(online journal)].

Barber Matthew D, Brubaker Linda, Menefee Shawn, et al. Operations and pelvic muscle training in the management of apical support loss (OPTIMAL) trial: design and methods. *Contemp Clin Trials*. 2009;30(2):178–189 https://doi.org/10.1016/j.cct.2008.12.001 [(online journal)].

Barksdale PA, Gasser RF, Gauthier CM, et al. Intraligamentous nerves as a potential source of pain after sacrospinous ligament fixation of the vaginal apex. *Int Urogynecol J Pelvic Floor Dysfunct*. 1997;8(3):121–125 http://www.ncbi.nlm.nih.gov/pubmed/9449581 [(online journal)].

Barranger Emmanuel, Fritel Xavier, Pigne Alain. Abdominal sacrohysteropexy in young women with uterovaginal prolapse: long-term follow-up. *Am J Obstet Gynecol*. 2003;189(5):1245–1250 http://www.ncbi.nlm.nih.gov/pubmed/14634548 [(online journal)].

Barrington JW, Edwards G. Posthysterectomy vault prolapse. *Int Urogynecol J Pelvic Floor Dysfunct*. 2000;11(4):241–245 http://www.ncbi.nlm.nih.gov/pubmed/11005477 [(online journal)].

Beer M, Kuhn A. Surgical techniques for vault prolapse: a review of the literature. *Eur J Obstet Gynecol Reprod Biol*. 2005;119(2):144–155 https://doi.org/10.1016/j.ejogrb.2004.06.042 [(online journal)].

Behnia-Willison Fariba, Seman Elvis I, Cook Jennifer R, et al. Laparoscopic paravaginal repair of anterior compartment prolapse. *J Minim Invasive Gynecol*. 2007;14(4):475–480 https://doi.org/10.1016/j.jmig.2006.12.002 [(online journal)].

Benson JT, Lucente V, McClellan E. Vaginal versus abdominal reconstructive surgery for the treatment of pelvic support defects: a prospective randomized study with long-term outcome evaluation. *Am J Obstet Gynecol*. 1996;175(6):1418–1421 [discussion 1421-2] http://www.ncbi.nlm.nih.gov/pubmed/8987919 [(online journal)].

Birch Colin. The use of prosthetics in pelvic reconstructive surgery. *Best Pract Res Clin Obstet Gynaecol*. 2005;19(6):979–991 https://doi.org/10.1016/j.bpobgyn.2005.08.013 [(online journal)].

Blanchard Kristie A, Vanlangendonck Richard, Winters J Christian. Recurrent pelvic floor defects after abdominal sacral colpopexy. *J Urol*. 2006;175(3):1010–1013 https://doi.org/10.1016/S0022-5347(05)00328-9 [(online journal)].

Bonjer HJ, Hazebroek EJ, Kazemier G, et al. Open versus closed establishment of pneumoperitoneum in laparoscopic surgery. *Br J Surg*. 1997;84(5):599–602 http://www.ncbi.nlm.nih.gov/pubmed/9171741 [(online journal)].

Borstad E, Rud T. The risk of developing urinary stress-incontinence after vaginal repair in continent women. a clinical and urodynamic follow-up study. *Acta Obstet Gynecol Scand*. 1989;68(6):545–549 http://www.ncbi.nlm.nih.gov/pubmed/2520812 [(online journal)].

Bradley Sarah, Gutman Robert E, Richter Lee A. Hysteropexy: an option for the repair of pelvic organ prolapse. *Curr Urol Rep*. 2018;19(2):15–2018 https://doi.org/10.1007/s11934-018-0765-4 [(online journal)].

Brizzolara Shawna, Pillai-Allen Anita. Risk of mesh erosion with sacral colpopexy and concurrent hysterectomy. *Obstet Gynecol*. 2003;102(2):306–310 http://www.ncbi.nlm.nih.gov/pubmed/12907104 [(online

journal)].

Brown Bryan N, Mani Deepa, Nolfi Alexis L, et al. Characterization of the host inflammatory response following implantation of prolapse mesh in Rhesus Macaque. *Am J Obstet Gynecol*. 2015;213(5):668.e1–668.e10 https://doi.org/10.1016/j.ajog.2015.08.002 [(online journal)].

Brown WE, Hoffman MS, Bouis PJ, et al. Management of vaginal vault prolapse: retrospective comparison of abdominal versus vaginal approach. *J Fla Med Assoc*. 1989;76(2):249–252 http://www.ncbi.nlm.nih.gov/pubmed/2926373 [(online journal)].

Brubaker Linda, Cundiff Geoffrey W, Fine Paul, et al. Abdominal sacrocolpopexy with burch colposuspension to reduce urinary stress incontinence. [the; Pelvic Floor Disorders Network] *N Engl J Med*. 2006;354(15):1557–1566 https://doi.org/10.1056/NEJMoa054208 [(online journal)].

Brubaker Linda, Nygaard Ingrid, Richter HE, et al. Two-year outcomes after sacrocolpopexy with and without burch to prevent stress urinary incontinence. *Obstet Gynecol*. 2008;112(1):49–55 https://doi.org/10.1097/AOG.0b013e3181778d2a.

Bruce RG, El-Galley RE, Galloway NT. Paravaginal defect repair in the treatment of female stress urinary incontinence and cystocele. *Urology*. 1999;54(4):647–651 http://www.ncbi.nlm.nih.gov/pubmed/10510922 [(online journal)].

Buller JL, Thompson JR, Cundiff GW, et al. Uterosacral ligament: description of anatomic relationships to optimize surgical safety. *Obstet Gynecol*. 2001;97(6):873–879 http://www.ncbi.nlm.nih.gov/pubmed/11384688 [(online

journal)].

Carey M, Higgs P, Goh J, et al. Vaginal repair with mesh versus colporrhaphy for prolapse: a randomised controlled trial. *BJOG*. 2009;116(10):1380–1386 https://doi.org/10.1111/j.1471-0528.2009.02254.x [(online journal)].

Carlson KJ, Miller BA, Fowler FJ. The Maine Women's Health Study: II. outcomes of nonsurgical management of leiomyomas, abnormal bleeding, and chronic pelvic pain. *Obstet Gynecol*. 1994;83(4):566–572 http://www.ncbi.nlm.nih.gov/pubmed/8134067 [(online journal)].

Catarci M, Carlini M, Gentileschi P, et al. Major and minor injuries during the creation of pneumoperitoneum. *Surg Endosc*. 2001;15(6):566–569 https://doi.org/10.1007/s004640000381 [(online journal)].

Cespedes RD. Anterior approach bilateral sacrospinous ligament fixation for vaginal vault prolapse. *Urology*. 2000;56(6 Suppl 1):70–75 http://www.ncbi.nlm.nih.gov/pubmed/11114566 [(online journal)].

Cespedes RD, Winters JC, Ferguson KH. Colpocleisis for the treatment of vaginal vault prolapse. *Tech Urol*. 2001;7(2):152–160 http://www.ncbi.nlm.nih.gov/pubmed/11383994 [(online journal)].

Chaikin DC, Groutz A, Blaivas JG. Predicting the need for anti-incontinence surgery in continent women undergoing repair of severe urogenital prolapse. *J Urol*. 2000;163(2):531–534 http://www.ncbi.nlm.nih.gov/pubmed/10647672 [(online journal)].

Chen Chi Chiung Grace, Ridgeway Beri, Paraiso Marie Fidela

R. Biologic grafts and synthetic meshes in pelvic reconstructive surgery. *Clin Obstet Gynecol*. 2007;50(2):383–411 https://doi.org/10.1097/GRF.0b013e31804b184c [(online journal)].

Chmielewski Lauren, Walters Mark D, Weber Anne M, et al. Reanalysis of a randomized trial of 3 techniques of anterior colporrhaphy using clinically relevant definitions of success. *Am J Obstet Gynecol*. 2011;205(1):69.e1–69.e8 https://doi.org/10.1016/j.ajog.2011.03.027.

Chou Li-Yun, Chang Daw-Yuan, Sheu Bor-Ching, et al. Clinical outcome of transvaginal sacrospinous fixation with the veronikis ligature carrier in genital prolapse. *Eur J Obstet Gynecol Reprod Biol*. 2010;152(1):108–110 https://doi.org/10.1016/j.ejogrb.2010.05.020.

Chung Steve Y, Franks Michael, Smith Christopher P, et al. Technique of combined pubovaginal sling and cystocele repair using a single piece of cadaveric dermal graft. *Urology*. 2002;59(4):538–541 http://www.ncbi.nlm.nih.gov/pubmed/11927309 [(online journal)].

Claerhout Filip, De Ridder Dirk, Roovers Jan Paul, et al. Medium-term anatomic and functional results of laparoscopic sacrocolpopexy beyond the learning curve. *Eur Urol*. 2009;55(6):1459–1468 https://doi.org/10.1016/j.eururo.2008.12.008 [(online journal)].

Clemons Jeffrey L, Myers Deborah L, Aguilar Vivian C, et al. Vaginal paravaginal repair with an AlloDerm graft. *Am J Obstet Gynecol*. 2003;189(6):1612–1618 [discussion 1618-9] http://www.ncbi.nlm.nih.gov/pubmed/14710083 [(online journal)].

Cole EE, Leu PB, Gomelsky Alex, et al. Histopathological evaluation of the uterosacral ligament: is this a dependable structure for pelvic reconstruction? *BJU Int*. 2006;97(2):345–348 https://doi.org/10.1111/j.1464-410X.2005.05903.x.

Collins Sarah A, Tulikangas Paul K, LaSala Christine A, et al. Complex sacral abscess 8 years after abdominal sacral colpopexy. *Obstet Gynecol*. 2011;118(2 Pt 2):451–454 https://doi.org/10.1097/AOG.0b013e3182234e7c [(online journal)].

Colombo Mario, Milani Rodolfo. Sacrospinous ligament fixation and modified McCall culdoplasty during vaginal hysterectomy for advanced uterovaginal prolapse. *Am J Obstet Gynecol*. 1998;179(1):13–20 https://doi.org/10.1016/S0002-9378(98)70245-5.

Colombo M, Vitobello D, Proietti F, et al. Randomised comparison of Burch colposuspension versus anterior colporrhaphy in women with stress urinary incontinence and anterior vaginal wall prolapse. *BJOG*. 2000;107(4):544–551 http://www.ncbi.nlm.nih.gov/pubmed/10759276 [(online journal)].

Comiter CV, Vasavada SP, Raz S. Transvaginal culdosuspension: technique and results. *Urology*. 1999;54(5):819–822 http://www.ncbi.nlm.nih.gov/pubmed/10565740.

Conger GT, Keettel WC. The Manchester-Fothergill operation, its place in gynecology; a review of 960 cases at university hospitals, Iowa City, Iowa. *Am J Obstet Gynecol*. 1958;76(3):634–640 http://www.ncbi.nlm.nih.gov/pubmed/13571326 [(online journal)].

Coolen Anne-Lotte WM, van Oudheusden Anique MJ, Mol Ben Willem J, et al. Laparoscopic sacrocolpopexy compared with open abdominal sacrocolpopexy for vault prolapse repair: a randomised controlled trial. *Int Urogynecol J*. 2017;28(10):1469–1479 https://doi.org/10.1007/s00192-017-

3296-5.

Costantini Elisabetta, Mearini Luigi, Lazzeri Massimo, et al. Laparoscopic versus abdominal sacrocolpopexy: a randomized, controlled trial. *J Urol*. 2016;196(1):159–165 https://doi.org/10.1016/J.JURO.2015.12.089.

Costantini Elisabetta, Mearini Luigi, Bini Vittorio, et al. Uterus preservation in surgical correction of urogenital prolapse. *Eur Urol*. 2005;48(4):642–649 https://doi.org/10.1016/j.eururo.2005.04.022 [(online journal)].

Costantini Elisabetta, Porena Massimo, Lazzeri Massimo, et al. Changes in female sexual function after pelvic organ prolapse repair: role of hysterectomy. *Int Urogynecol J*. 2013;24(9):1481–1487 https://doi.org/10.1007/s00192-012-2041-3 [(online journal)].

Crisp Catrina C, Book Nicole M, Smith Aimee L, et al. Body image, regret, and satisfaction following colpocleisis. *Am J Obstet Gynecol*. 2013;209(5):473.e1–473.e7 https://doi.org/10.1016/j.ajog.2013.05.019 [(online journal)].

Cross CA, Cespedes RD, McGuire EJ. Treatment results using pubovaginal slings in patients with large cystoceles and stress incontinence. *J Urol*. 1997;158(2):431–434 http://www.ncbi.nlm.nih.gov/pubmed/9224317 [(online journal)].

Cruikshank SH, Kovac SR. Anterior vaginal wall culdeplasty at vaginal hysterectomy to prevent posthysterectomy anterior vaginal wall prolapse. *Am J Obstet Gynecol*. 1996;174(6):1863–1872 http://www.ncbi.nlm.nih.gov/pubmed/8678152 [(online journal)].

Cruikshank Stephen H, Muniz Margo. Outcomes study: a comparison of cure rates in 695 patients undergoing sacrospinous ligament fixation alone and with other site-specific procedures—a 16-year study. *Am J Obstet Gynecol*. 2003;188(6):1509–1512 http://www.ncbi.nlm.nih.gov/pubmed/12824986 [(online journal)].

Culligan Patrick J, Blackwell Linda, Goldsmith Linda J, et al. A randomized controlled trial comparing fascia lata and synthetic mesh for sacral colpopexy. *Obstet Gynecol*. 2005;106(1):29–37 https://doi.org/10.1097/01.AOG.0000165824.62167.c1 [(online journal)].

Cundiff GW, Weidner AC, Visco AG, et al. An anatomic and functional assessment of the discrete defect rectocele repair. *Am J Obstet Gynecol*. 1998;179(6 Pt 1):1451–1456 http://www.ncbi.nlm.nih.gov/pubmed/9855580 [(online journal)].

Cundiff Geoffrey W, Fenner Dee. Evaluation and treatment of women with rectocele: focus on associated defecatory and sexual dysfunction. *Obstet Gynecol*. 2004;104(6):1403–1421 https://doi.org/10.1097/01.AOG.0000147598.50638.15 [(online journal)].

Dällenbach Patrick, Kaelin-Gambirasio Isabelle, Jacob Sandrine, et al. Incidence rate and risk factors for vaginal vault prolapse repair after hysterectomy. *Int Urogynecol J*. 2008;19(12):1623–1629 https://doi.org/10.1007/s00192-008-0718-4 [(online journal)].

Daneshgari Firouz, Paraiso Maria F, Kaouk Jihad, et al. Robotic and laparoscopic female pelvic floor reconstruction. *BJU Int*. 2006;98(s1):62–68 https://doi.org/10.1111/j.1464-410X.2006.06362.x [(online journal)].

Davenport Michael T, Sokol Eric R, Comiter Craig V, et al. Does the degree of cystocele predict de novo stress urinary incontinence after prolapse repair? Further analysis of the colpopexy and urinary reduction efforts trial. *Female Pelvic Med Reconstr Surg*. 2017 https://doi.org/10.1097/SPV.0000000000000487 [(online journal)].

De Boer TA, Milani AL, Kluivers KB, et al. The effectiveness of surgical correction of uterine prolapse: cervical amputation with uterosacral ligament plication (modified Manchester) versus vaginal hysterectomy with high uterosacral ligament plication. *Int Urogynecol J Pelvic Floor Dysfunct*. 2009;20(11):1313–1319 https://doi.org/10.1007/s00192-009-0945-3.

Deffieux X, de Tayrac R, Huel C, et al. Vaginal mesh erosion after transvaginal repair of cystocele using gynemesh or gynemesh-soft in 138 women: a comparative study. *Int Urogynecol J*. 2007;18(1):73–79 https://doi.org/10.1007/s0192-005-0041-2.

de Tayrac R, Gervaise A, Fernandez H. [Cystocele repair by the vaginal route with a tension-free sub-bladder prosthesis]. *J Gynecol Obstet Biol Reprod (Paris)*. 2002;31(6):597–599 http://www.ncbi.nlm.nih.gov/pubmed/12407332 [(online journal)].

de Tayrac Renaud, Deffieux Xavier, Gervaise Amélie, et al. Long-term anatomical and functional assessment of trans-vaginal cystocele repair using a tension-free polypropylene mesh. *Int Urogynecol J Pelvic Floor Dysfunct*. 2006;17(5):483–488 https://doi.org/10.1007/s00192-005-0046-x [(online journal)].

de Tayrac Renaud, Devoldere Guy, Renaudie Joël, et al. Prolapse repair by vaginal route using a new protected low-weight polypropylene mesh: 1-year functional and anatomical outcome in a prospective multicentre study. [the; French Ugytex Study Group] *Int Urogynecol J Pelvic Floor Dysfunct*. 2007;18(3):251–

256 https://doi.org/10.1007/s00192-006-0135-5 [(online journal)].

de Tayrac Renaud, Gervaise Amélie, Chauveaud Aurélia, et al. Tension-free polypropylene mesh for vaginal repair of anterior vaginal wall prolapse. *J Reprod Med*. 2005;50(2):75–80 http://www.ncbi.nlm.nih.gov/pubmed/15755042 [(online journal)].

de Tayrac Renaud, Picone Olivier, Chauveaud-Lambling Aurélia, et al. A 2-year anatomical and functional assessment of transvaginal rectocele repair using a polypropylene mesh. *Int Urogynecol J Pelvic Floor Dysfunct*. 2006;17(2):100–105 https://doi.org/10.1007/s00192-005-1317-2 [(online journal)].

DeLancey JO. Anatomic aspects of vaginal eversion after hysterectomy. *Am J Obstet Gynecol*. 1992;166(6 Pt 1):1717–1724 http://www.ncbi.nlm.nih.gov/pubmed/1615980 [(online journal)].

DeLancey JO, Morley GW. Total colpocleisis for vaginal eversion. *Am J Obstet Gynecol*. 1997;176(6):1228–1232 http://www.ncbi.nlm.nih.gov/pubmed/9215178 [(online journal)].

Dell Jeffrey R, O'Kelley Kenneth R. PelviSoft BioMesh augmentation of rectocele repair: the initial clinical experience in 35 patients. *Int Urogynecol J Pelvic Floor Dysfunct*. 2005;16(1):44–47 [discussion 47] https://doi.org/10.1007/s00192-004-1217-x [(online journal)].

Detollenaere RJ, den Boon Jan, Stekelenburg J, et al. Sacrospinous hysteropexy versus vaginal hysterectomy with suspension of the uterosacral ligaments in women with uterine prolapse stage 2 or higher: multicentre randomised non-inferiority trial. *BMJ (Clinical Research Ed.)*. 2015;351(July):h3717 http://www.ncbi.nlm.nih.gov/pubmed/2

Dicker RC, Greenspan JR, Strauss LT, et al. Complications of abdominal and vaginal hysterectomy among women of reproductive age in the United States. The Collaborative Review of Sterilization. *Am J Obstet Gynecol*. 1982;144(7):841–848 http://www.ncbi.nlm.nih.gov/pubmed/7148906 [(online journal)].

Dietz Viviane, Huisman Marieke, de Jong Joyce M, et al. Functional outcome after sacrospinous hysteropexy for uterine descensus. *Int Urogynecol J*. 2008;19(6):747–752 https://doi.org/10.1007/s00192-007-0520-8 [(online journal)].

Dietz Viviane, de Jong Joyce, Huisman Marieke, et al. The effectiveness of the sacrospinous hysteropexy for the primary treatment of uterovaginal prolapse. *Int Urogynecol J*. 2007;18(11):1271–1276 https://doi.org/10.1007/s00192-007-0336-6 [(online journal)].

Dietz Viviane, van der Vaart Carl H, van der Graaf Yolanda, et al. One-year follow-up after sacrospinous hysteropexy and vaginal hysterectomy for uterine descent: a randomized study. *Int Urogynecol J*. 2010;21(2):209–216 https://doi.org/10.1007/s00192-009-1014-7 [(online journal)].

Diwan Aparna, Rardin Charles R, Strohsnitter William C, et al. Laparoscopic uterosacral ligament uterine suspension compared with vaginal hysterectomy with vaginal vault suspension for uterovaginal prolapse. *Int Urogynecol J*. 2006;17(1):79–83 https://doi.org/10.1007/s00192-005-1346-x [(online journal)].

Doucette RC, Sharp HT, Alder SC. Challenging generally accepted contraindications to vaginal hysterectomy. *Am J Obstet Gynecol*. 2001;184(7):1386–1389 [discussion 1390-1] http://www.ncbi.nlm.nih.gov/pubmed/11408857.

Doumouchtsis SK, Khunda A, Jeffery ST, et al. Long-term outcomes of modified high uterosacral ligament vault suspension (HUSLS) at vaginal hysterectomy. *Int Urogynecol J*. 2011;22(5):577–584 https://doi.org/10.1007/s00192-010-1325-8.

Dwyer Peter L, Fatton Brigitte. Bilateral extraperitoneal uterosacral suspension: a new approach to correct posthysterectomy vaginal vault prolapse. *Int Urogynecol J Pelvic Floor Dysfunct*. 2008;19(2):283–292 https://doi.org/10.1007/s00192-007-0435-4.

Dwyer Peter L, O'Reilly Barry A. Transvaginal repair of anterior and posterior compartment prolapse with atrium polypropylene mesh. *BJOG*. 2004;111(8):831–836 https://doi.org/10.1111/j.1471-0528.2004.00194.x [(online journal)].

Eilber Karyn Schlunt, Raz Shlomo. Vaginal hysterectomy. Graham SJ. *Glenn's urologic surgery*. Lippincott Williams & Wilkins: Philadelphia; 2004:363–368.

Eilber Karyn Schlunt, Nirit Rosenblum, Raz Shlomo, et al. Surgical therapy for uterine prolapse. Vasavada SP, Appell R, Sand PK. *Female urology, urogynecology, and voiding dysfunction*. Taylor & Francis Group: Boca Raton (FL); 2005.

El-Toukhy TA, Hefni Mohamed A, Davies Angharad E, et al. The effect of different types of hysterectomy on urinary and sexual functions: a prospective study. *J Obstet Gynaecol*. 2004;24(4):420–425 https://doi.org/10.1080/01443610410001685574 [(online journal)].

Elkadry Eman A, Kenton Kimberly S, FitzGerald Mary P, et al. Patient-selected goals: a new perspective on surgical outcome. *Am J Obstet Gynecol*. 2003;189(6):1551–1557 http://www.ncbi.nlm.nih.gov/pubmed/14710061 [(online journal)].

Elkins Thomas E, Chesson Ralph R, Videla Felipe, et al. Transvaginal paravaginal repair: a useful adjunctive procedure in pelvic relaxation surgery. *Female Pelvic Med Reconstr Surg*. 2000 https://journals.lww.com/jpelvicsurgery/Abstract/2000/0 [January-February 2000].

Elliott Christopher S, Hsieh Michael H, Sokol Eric R, et al. Robot-assisted versus open sacrocolpopexy: a cost-minimization analysis. *J Urol*. 2012;187(2):638–643 https://doi.org/10.1016/j.juro.2011.09.160 [(online journal)].

Elliott Daniel S, Krambeck Amy E, Chow George K. Long-term results of robotic assisted laparoscopic sacrocolpopexy for the treatment of high grade vaginal vault prolapse. *J Urol*. 2006;176(2):655–659 https://doi.org/10.1016/j.juro.2006.03.040 [(online journal)].

Fatton Brigitte, Dwyer Peter L, Achtari Chahin, et al. Bilateral extraperitoneal uterosacral vaginal vault suspension: a 2-year follow-up longitudinal case series of 123 patients. *Int Urogynecol J Pelvic Floor Dysfunct*. 2009;20(4):427–434 https://doi.org/10.1007/s00192-008-0791-8 [(online journal)].

Feldner Paulo Cezar, Castro Rodrigo Aquino, Cipolotti Luiz Antonio, et al. Anterior vaginal wall prolapse: a randomized controlled trial of SIS graft versus traditional colporrhaphy. *Int Urogynecol J*. 2010;21(9):1057–1063 https://doi.org/10.1007/s00192-010-1163-8.

FitzGerald MP, Richter HE, Bradley CS, et al. Pelvic support, pelvic symptoms, and patient satisfaction after colpocleisis. [the; Pelvic Floor Disorders Network] *Int Urogynecol J*. 2008;19(12):1603–1609 https://doi.org/10.1007/s00192-008-0696-6 [(online journal)].

FitzGerald Mary P, Richter Holly E, Siddique Sohail, et al. Colpocleisis: a review. *Int Urogynecol J*. 2006;17(3):261–271 https://doi.org/10.1007/s00192-005-1339-9 [(online journal)].

Florian-Rodriguez Maria E, Hare Adam, Chin Kathryn, et al. Inferior gluteal and other nerves associated with sacrospinous ligament: a cadaver study. *Am J Obstet Gynecol*. 2016;215(5):646.e1–646.e6 https://doi.org/10.1016/j.ajog.2016.06.025 [(online journal)].

Flynn Brian J, Webster George D. Surgical management of the apical vaginal defect. *Curr Opin Urol*. 2002;12(4):353–358 http://www.ncbi.nlm.nih.gov/pubmed/12072658 [(online journal)].

Food and Drug Administration (FDA). *Reclassification of urogynecologic surgical mesh instrumentation*. [(website); Available from:] https://www.fda.gov/downloads/AdvisoryCommittees/CommUrologyDevicesPanel/UCM487224.pdf; 2016.

Francis WJ, Jeffcoate TN. Dyspareunia following vaginal operations. *J Obstet Gynaecol Br Commonw*. 1961;68(February):1–10 http://www.ncbi.nlm.nih.gov/pubmed/13701244 [(online journal)].

Frederick R, Leach G. Cadaveric prolapse repair with sling: intermediate outcomes with 6 months to 5 years of followup. *J Urol*. 2005;173(4):1229–1233 https://doi.org/10.1097/01.ju.0000155168.98462.81 [(online journal)].

Freeman RM, Pantazis K, Thomson A, et al. A randomised controlled trial of abdominal versus laparoscopic sacrocolpopexy for the treatment of post-hysterectomy vaginal vault prolapse: LAS study. *Int Urogynecol J*.

2013;24(3):377–384 https://doi.org/10.1007/s00192-012-1885-x [(online journal)].

Frick Anna C, Barber Matthew D, Paraiso Marie Fidela R, et al. Attitudes toward hysterectomy in women undergoing evaluation for uterovaginal prolapse. *Female Pelvic Med Reconstr Surg*. 2013;19(2):103–109 https://doi.org/10.1097/SPV.0b013e31827d8667 [(online journal)].

Gallentine ML, Cespedes RD. Occult stress urinary incontinence and the effect of vaginal vault prolapse on abdominal leak point pressures. *Urology*. 2001;57(1):40–44 http://www.ncbi.nlm.nih.gov/pubmed/11164140 [(online journal)].

Gandhi Sanjay, Goldberg Roger P, Kwon Christina, et al. A prospective randomized trial using solvent dehydrated fascia lata for the prevention of recurrent anterior vaginal wall prolapse. *Am J Obstet Gynecol*. 2005;192(5):1649–1654 https://doi.org/10.1016/j.ajog.2005.02.061 [(online journal)].

Geller Elizabeth J, Siddiqui Nazema Y, Wu Jennifer M, et al. Short-term outcomes of robotic sacrocolpopexy compared with abdominal sacrocolpopexy. *Obstet Gynecol*. 2008;112(6):1201–1206 https://doi.org/10.1097/AOG.0b013e31818ce394 [(online journal)].

Geller EJ, Parnell BA, Dunivan GC. Robotic vs abdominal sacrocolpopexy: 44-month pelvic floor outcomes. *Urology*. 2012;79(3):532–536 https://doi.org/10.1016/j.urology.2011.11.025.

Geomini PM, Brölmann HA, van Binsbergen NJ, et al. Vaginal vault suspension by abdominal sacral colpopexy for prolapse: a follow up study of 40 patients. *Eur J Obstet Gynecol Reprod Biol*. 2001;94(2):234–

238 http://www.ncbi.nlm.nih.gov/pubmed/11165731 [(online journal)].

Germain A, Thibault F, Galifet M, et al. Long-term outcomes after totally robotic sacrocolpopexy for treatment of pelvic organ prolapse. *Surg Endosc*. 2013;27(2):525–529 https://doi.org/10.1007/s00464-012-2472-4 [(online journal)].

Ghoniem GM, Walters F, Lewis V. The value of the vaginal pack test in large cystoceles. *J Urol*. 1994;152(3):931–934 http://www.ncbi.nlm.nih.gov/pubmed/8051758 [(online journal)].

Given FT, Muhlendorf IK, Browning GM. Vaginal length and sexual function after colpopexy for complete uterovaginal eversion. *Am J Obstet Gynecol*. 1993;169(2 Pt 1):284–288 http://www.ncbi.nlm.nih.gov/pubmed/8362937 [(online journal)].

Glavind K, Madsen H. A prospective study of the discrete fascial defect rectocele repair. *Acta Obstet Gynecol Scand*. 2000;79(2):145–147 http://www.ncbi.nlm.nih.gov/pubmed/10696964 [(online journal)].

Glavind Karin, Kempf Lillan. Colpectomy or Le Fort colpocleisis? A good option in selected elderly patients. *Int Urogynecol J*. 2005;16(1):48–51 https://doi.org/10.1007/s00192-004-1218-9 [(online journal)].

Goldberg RP, Koduri S, Lobel RW, et al. Protective effect of suburethral slings on postoperative cystocele recurrence after reconstructive pelvic operation. *Am J Obstet Gynecol*. 2001;185(6):1307–1313 https://doi.org/10.1067/mob.2001.119080 [(online journal)].

Goldman J, Ovadia J, Feldberg D. The Neugebauer-Le Fort operation: a review of 118 partial colpocleises. *Eur J Obstet Gynecol Reprod Biol*. 1981;12(1):31–35 http://www.ncbi.nlm.nih.gov/pubmed/7195840 [(online journal)].

Gomelsky Alex, Rudy Delbert C, Dmochowski Roger R. Porcine dermis interposition graft for repair of high grade anterior compartment defects with or without concomitant pelvic organ prolapse procedures. *J Urol*. 2004;171(4):1581–1584 https://doi.org/10.1097/01.ju.0000115956.25769.0a [(online journal)].

Good Meadow M, Abele Travis A, Balgobin Sunil, et al. Vascular and ureteral anatomy relative to the midsacral promontory. *Am J Obstet Gynecol*. 2013;208(6):486.e1–486.e7 https://doi.org/10.1016/j.ajog.2013.02.039 [(online journal)].

Granese R, Candiani M, Perino A, et al. Laparoscopic sacrocolpopexy in the treatment of vaginal vault prolapse: 8 years experience. *Eur J Obstet Gynecol Reprod Biol*. 2009;146(2):227–231 https://doi.org/10.1016/j.ejogrb.2009.06.013.

Grimes Cara L, Tan-Kim Jasmine, Garfin Steven R, et al. Sacral colpopexy followed by refractory candida albicans osteomyelitis and discitis requiring extensive spinal surgery. *Obstet Gynecol*. 2012;120(Pt 2):464–468 https://doi.org/10.1097/AOG.0b013e318256989e [(online journal)].

Grimminck K, Mourik SLL, Tjin-Asjoe F, et al. Long-term follow-up and quality of life after robot assisted sacrohysteropexy. *Eur J Obstet Gynecol Reprod Biol*. 2016;206(November):27–31 https://doi.org/10.1016/j.ejogrb.2016.06.027 [(online journal)].

Grody MHT, Nyirjesy P, Kelley LM, et al. Paraurethral fascial sling urethropexy and vaginal paravaginal defects cystopexy in the correction of urethrovesical prolapse. *Int Urogynecol J*. 1995;6(2):80–85 https://doi.org/10.1007/BF01962576 [Springer-Verlag].

Groutz A, Chaikin DC, Theusen E, et al. Use of cadaveric solvent-dehydrated fascia lata for cystocele repair–preliminary results. *Urology*. 2001;58(2):179–183 http://www.ncbi.nlm.nih.gov/pubmed/11489693.

Guerette NL, Peterson TV, Aguirre OA, et al. Anterior repair with or without collagen matrix reinforcement. *Obstet Gynecol*. 2009;114(1):59–65 https://doi.org/10.1097/AOG.0b013e3181a81b41.

Gustilo-Ashby A Marcus, Paraiso Marie Fidela R, Jelovsek John Eric, et al. Bowel symptoms 1 year after surgery for prolapse: further analysis of a randomized trial of rectocele repair. *Am J Obstet Gynecol*. 2007;197(1):76.e1–76.e5 https://doi.org/10.1016/j.ajog.2007.02.045 [(online journal)].

Haessler Alexandra L, Lin Lawrence L, Ho Mat H, et al. Reevaluating occult incontinence. *Curr Opin Obstet Gynecol*. 2005;17(5):535–540 http://www.ncbi.nlm.nih.gov/pubmed/16141769 [(online journal)].

Haj Yahya Rani, Chill Henry H, Herzberg Shmuel, et al. Anatomical outcome and patient satisfaction after laparoscopic uterosacral ligament hysteropexy for anterior and apical prolapse. *Female Pelvic Med Reconstr Surg*. 2017 https://doi.org/10.1097/SPV.0000000000000446 [June 1, 2017 (online journal)].

Handa Victoria L, Harvey Lynn, Cundiff Geoffrey W, et al. Sexual function among women with urinary incontinence and pelvic organ prolapse. *Am J Obstet Gynecol*. 2004;191(3):751–

756 https://doi.org/10.1016/j.ajog.2003.11.017 [(online journal)].

Handel LN, Frenkl TL, Kim YH. Results of cystocele repair: a comparison of traditional anterior colporrhaphy, polypropylene mesh and porcine dermis. *J Urol*. 2007;178(1):153–156.

Harris WJ. Early complications of abdominal and vaginal hysterectomy. *Obstet Gynecol Surv*. 1995;50(11):795–805 http://www.ncbi.nlm.nih.gov/pubmed/8545085 [(online journal)].

Hefni MA, El-Toukhy TA. Long-term outcome of vaginal sacrospinous colpopexy for marked uterovaginal and vault prolapse. *Eur J Obstet Gynecol Reprod Biol*. 2006;127(2):257–263 https://doi.org/10.1016/j.ejogrb.2005.11.028.

Hiltunen Reijo, Nieminen Kari, Takala Teuvo, et al. Low-weight polypropylene mesh for anterior vaginal wall prolapse. *Obstet Gynecol*. 2007;110(Suppl):455–462 https://doi.org/10.1097/01.AOG.0000261899.87638.0a [(online journal)].

Holley RL, Varner RE, Gleason BP, et al. Recurrent pelvic support defects after sacrospinous ligament fixation for vaginal vault prolapse. *J Am Coll Surg*. 1995;180(4):444–448 http://www.ncbi.nlm.nih.gov/pubmed/7719548 [(online journal)].

Hopkins MP, Devine JB, DeLancey JO. Uterine problems discovered after presumed hysterectomy: the manchester operation revisited. *Obstet Gynecol*. 1997;89(5 Pt 2):846–848 http://www.ncbi.nlm.nih.gov/pubmed/9166346 [(online journal)].

Hosni Mohamed M, El-Feky Alaa E H, Agur Wael I, et al. Evaluation of three different surgical approaches in repairing paravaginal support defects: a comparative trial. *Arch*

Gynecol Obstet. 2013;288(6):1341–1348 https://doi.org/10.1007/s00404-013-2927-4 [(online journal)].

Hsiao KC, Kalyan L, Govier FE, et al. Comparison of Laparoscopic and Abdominal Sacrocolpopexy for the Treatment of Vaginal Vault Prolapse. *J Endourol*. 2007;21(8):926–930 https://doi.org/10.1089/end.2006.0381.

Hudson Catherine O, Northington Gina M, Lyles Robert H, et al. Outcomes of robotic sacrocolpopexy. *Female Pelvic Med Reconstr Surg*. 2014;20(5):252–260 https://doi.org/10.1097/SPV.0000000000000070 [(online journal)].

Hviid Ulla, Hviid Thomas Vauvert F, Rudnicki Martin. Porcine skin collagen implants for anterior vaginal wall prolapse: a randomised prospective controlled study. *Int Urogynecol J*. 2010;21(5):529–534 https://doi.org/10.1007/s00192-009-1018-3.

Hyakutake Momoe Tina, Cundiff Geoffrey William, Geoffrion Roxana. Cervical elongation following sacrospinous hysteropexy: a case series. *Int Urogynecol J*. 2014;25(6):851–854 https://doi.org/10.1007/s00192-013-2258-9 [(online journal)].

Ibeanu Okechukwu A, Chesson Ralph R, Echols Karolynn T, et al. Urinary tract injury during hysterectomy based on universal cystoscopy. *Obstet Gynecol*. 2009;113(1):6–10 https://doi.org/10.1097/AOG.0b013e31818f6219 [(online journal)].

Imparato E, Aspesi G, Rovetta E, et al. Surgical management and prevention of vaginal vault prolapse. *Surg Gynecol Obstet*. 1992;175(3):233–237 http://www.ncbi.nlm.nih.gov/pubmed/1514157.

Iyer Shilpa, Seitz Miriam, Tran Alexis, et al. Anterior colporrhaphy with and without dermal allograft: a randomized control trial with long-term follow-up. *Female Pelvic Med Reconstr Surg*. 2018 https://doi.org/10.1097/SPV.0000000000000524 [(online journal)].

Jeng CJ, Yang YC, Tzeng CR, et al. Sexual functioning after vaginal hysterectomy or transvaginal sacrospinous uterine suspension for uterine prolapse: a comparison. *J Reprod Med*. 2005;50(9):669–674 http://www.ncbi.nlm.nih.gov/pubmed/16363755.

Jenkins VR. Uterosacral ligament fixation for vaginal vault suspension in uterine and vaginal vault prolapse. *Am J Obstet Gynecol*. 1997;177(6):1337–1344 http://www.ncbi.nlm.nih.gov/pubmed/9423733 [(online journal)].

Jo Hoenil, Kim JW, Park NH, et al. Efficacy and outcome of anterior vaginal wall repair using polypropylene mesh (Gynemesh). *J Obstet Gynaecol Res*. 2007;33(5):700–704 https://doi.org/10.1111/j.1447-0756.2007.00635.x.

Judd John P, Siddiqui Nazema Y, Barnett Jason C, et al. Cost-minimization analysis of robotic-assisted, laparoscopic, and abdominal sacrocolpopexy. *J Minim Invasive Gynecol*. 2010;17(4):493–499 https://doi.org/10.1016/j.jmig.2010.03.011.

Kafy Souzan, Huang Jack Y J, Al-Sunaidi Mohammed, et al. Audit of morbidity and mortality rates of 1792 hysterectomies. *J Minim Invasive Gynecol*. 2006;13(1):55–59 https://doi.org/10.1016/j.jmig.2005.10.003 [(online journal)].

Kahn MA, Stanton SL. Posterior colporrhaphy: its effects on bowel and sexual function. *Br J Obstet Gynaecol*. 1997;104(1):82–86 http://www.ncbi.nlm.nih.gov/pubmed/8988702 [(online journal)].

Kapoor Shveta, Sivanesan Kanapathippillai, Robertson Jessica Amy, et al. Sacrospinous hysteropexy: review and meta-analysis of outcomes. *Int Urogynecol J*. 2017;28(9):1285–1294 https://doi.org/10.1007/s00192-017-3291-x [(online journal)].

Karlovsky Matthew E, Thakre Atul A, Rastinehad Ardeshir, et al. Biomaterials for pelvic floor reconstruction. *Urology*. 2005;66(3):469–475 https://doi.org/10.1016/j.urology.2005.03.006 [(online journal)].

Karram M, Goldwasser S, Kleeman S, et al. High uterosacral vaginal vault suspension with fascial reconstruction for vaginal repair of enterocele and vaginal vault prolapse. *Am J Obstet Gynecol*. 2001;185(6):1339–1343 https://doi.org/10.1067/mob.2001.119077 [(online journal)].

Karram Mickey, Maher Christopher. Surgery for posterior vaginal wall prolapse. *Int Urogynecol J*. 2013;24(11):1835–1841 https://doi.org/10.1007/s00192-013-2174-z [(online journal)].

Katrikh Aaron Z, Ettarh Rajuno, Kahn Margie A. Cadaveric nerve and artery proximity to sacrospinous ligament fixation sutures placed by a suture-capturing device. *Obstet Gynecol*. 2017;130(5):1033–1038 https://doi.org/10.1097/AOG.0000000000002324 [(online journal)].

Kelly HA. Incontinence of urine in women. *Urol Cutaneous*. 1913;17:291–293.

Kenton K, Shott S, Brubaker L. Outcome after rectovaginal fascia reattachment for rectocele repair. *Am J Obstet Gynecol*. 1999;181(6):1360–1363 [discussion 1363–1364] https://doi.org/10.1016/s0002-9378(99)70406-0.

Kenton Kimberly, Pham Thythy, Mueller Elizabeth, et al.

Patient preparedness: an important predictor of surgical outcome. *Am J Obstet Gynecol*. 2007;197(6):654.e1–654.e6 https://doi.org/10.1016/j.ajog.2007.08.059 [(online journal)].

Kettel LM, Hebertson RM. An anatomic evaluation of the sacrospinous ligament colpopexy. *Surg Gynecol Obstet*. 1989;168(4):318–322 http://www.ncbi.nlm.nih.gov/pubmed/2928906 [(online journal)].

Kilkku P. Supravaginal uterine amputation vs. hysterectomy. effects on coital frequency and dyspareunia. *Acta Obstet Gynecol Scand*. 1983;62(2):141–145 http://www.ncbi.nlm.nih.gov/pubmed/6868962 [(online journal)].

Klauschie JL, Suozzi BA, O’Brien MM, et al. A comparison of laparoscopic and abdominal sacral colpopexy: objective outcome and perioperative differences. *Int Urogynecol J Pelvic Floor Dysfunct*. 2009;20(3):273–279 https://doi.org/10.1007/s00192-008-0768-7.

Kobashi KC, Leach GE, Chon J, et al. Continued multicenter followup of cadaveric prolapse repair with sling. *J Urol*. 2002;168(5):2063–2068 https://doi.org/10.1097/01.ju.0000033470.88298.35.

Kobashi KC, Mee SL, Leach GE. A new technique for cystocele repair and transvaginal sling: the cadaveric prolapse repair and sling (CAPS). *Urology*. 2000;56(6 Suppl 1):9–14 http://www.ncbi.nlm.nih.gov/pubmed/11114557 [(online journal)].

Kobashi Kathleen C, Leach Gary E, Frederick Robert, et al. Initial experience with rectocele repair using nonfrozen cadaveric fascia lata interposition. *Urology*. 2005;66(6):1203–1278 https://doi.org/10.1016/j.urology.2005.06.130 [(online

journal)].

Kohli N, Miklos JR. Dermal graft-augmented rectocele repair. *Int Urogynecol J Pelvic Floor Dysfunct*. 2003;14(2):146–149 https://doi.org/10.1007/s00192-002-1013-4 [(online journal)].

Kohli N, Walsh PM, Roat TW, et al. Mesh erosion after abdominal sacrocolpopexy. *Obstet Gynecol*. 1998;92(6):999–1004 http://www.ncbi.nlm.nih.gov/pubmed/9840566 [(online journal)].

Korbly Nicole B, Kassis Nadine C, Good Meadow M, et al. Patient preferences for uterine preservation and hysterectomy in women with pelvic organ prolapse. *Am J Obstet Gynecol*. 2013;209(5):470.e1–470.e6 https://doi.org/10.1016/j.ajog.2013.08.003 [(online journal)].

Koski Michelle E, Chow Denise, Bedestani Ahmet, et al. Colpocleisis for advanced pelvic organ prolapse. *Urology*. 2012;80(3):542–546 https://doi.org/10.1016/j.urology.2012.06.009 [(online journal)].

Kovac SR. Intramyometrial coring as an adjunct to vaginal hysterectomy. *Obstet Gynecol*. 1986;67(1):131–136 http://www.ncbi.nlm.nih.gov/pubmed/3940327.

Kovac SR, Cruikshank SH. Successful pregnancies and vaginal deliveries after sacrospinous uterosacral fixation in five of nineteen patients. *Am J Obstet Gynecol*. 1993;168(6 Pt 1):1778–1783 [discussion 1783–1786] http://www.ncbi.nlm.nih.gov/pubmed/8317520.

Krause Hannah G, Goh Judith T W, Sloane Kate, et al. Laparoscopic sacral suture hysteropexy for uterine prolapse. *Int Urogynecol J*. 2006;17(4):378–381 https://doi.org/10.1007/s00192-005-0019-0 [(online journal)].

Kreder KJ. Female urethral diverticulum and urethral fistulae. Goldwasser BKR, Webster GD. *Reconstructive urology*. Blackwell: Oxford; 1993.

Kulkarni Mamta Muralidhar, Rogers Rebecca Glenn. Vaginal hysterectomy for benign disease without prolapse. *Clin Obstet Gynecol*. 2010;53(1):5–16 https://doi.org/10.1097/GRF.0b013e3181cd3f0d [(online journal)].

Langmade CF, Oliver JA. Partial colpocleisis. *Am J Obstet Gynecol*. 1986;154(6):1200–1205 http://www.ncbi.nlm.nih.gov/pubmed/3717230 [(online journal)].

Lantzsch T, Goepel C, Wolters M, et al. Sacrospinous ligament fixation for vaginal vault prolapse. *Arch Gynecol Obstet*. 2001;265(1):21–25 http://www.ncbi.nlm.nih.gov/pubmed/11327088 [(online journal)].

Lavelle Erin Seifert, Giugale Lauren E, Winger Daniel G, et al. Prolapse recurrence following sacrocolpopexy vs uterosacral ligament suspension: a comparison stratified by pelvic organ prolapse quantification stage. *Am J Obstet Gynecol*. 2018;218(1):116.e1–116.e5 https://doi.org/10.1016/j.ajog.2017.09.015 [(online journal)].

Leach GE, Dmochowski RR, Appell RA, et al. Female stress urinary incontinence clinical guidelines panel summary report on surgical management of female stress urinary incontinence. The American Urological Association. *J Urol*. 1997;158(3 Pt 1):875–880 http://www.ncbi.nlm.nih.gov/pubmed/9258103 [(online journal)].

Leboeuf L, Miles RA, Kim SS, et al. Grade 4 cystocele repair using four-defect repair and porcine xenograft acellular matrix (Pelvicol): outcome measures using SEAPI. *Urology*. 2004;64(2):282–286 https://doi.org/10.1016/j.urology.2004.03.044.

Lee Ted, Rosenblum Nirit, Nitti Victor, et al. Uterine sparing robotic-assisted laparoscopic sacrohysteropexy for pelvic organ prolapse: safety and feasibility. *J Endourol*. 2013;27(9):1131–1136 https://doi.org/10.1089/end.2013.0171 [(online journal)].

Lee RK, Mottrie A, Payne CK, et al. A review of the current status of laparoscopic and robot-assisted sacrocolpopexy for pelvic organ prolapse. *Eur Urol*. 2014;65(6):1128–1137 https://doi.org/10.1016/j.eururo.2013.12.064.

Lenihan John P, Kovanda Carol, Seshadri-Kreaden Usha. What is the learning curve for robotic assisted gynecologic surgery? *J Minim Invasive Gynecol*. 2008;15(5):589–594 https://doi.org/10.1016/j.jmig.2008.06.015 [(online journal)].

Lim YN, Rane Ajay, Muller R. An ambispective observational study in the safety and efficacy of posterior colporrhaphy with composite vicryl-prolene mesh. *Int Urogynecol J Pelvic Floor Dysfunct*. 2005;16(2):126–131 [discussion 131] https://doi.org/10.1007/s00192-004-1236-7 [(online journal)].

Lin TY, Su TH, Wang YL, et al. Risk factors for failure of transvaginal sacrospinous uterine suspension in the treatment of uterovaginal prolapse. *J Formos Med Assoc*. 2005;104(4):249–253 http://www.ncbi.nlm.nih.gov/pubmed/15909062.

Lo TS, Wang AC. Abdominal colposacropexy and sacrospinous ligament suspension for severe uterovaginal prolapse: a comparison. *J Gynecol Surg*. 1998;14(2):59–64 [17553] [Google Scholar].

Lovatsis D, Drutz HP. Safety and efficacy of sacrospinous vault suspension. *Int Urogynecol J*. 2002;13(5):308–313 https://doi.org/10.1007/s001920200067.

Lowenstein Lior, Fitz Amelia, Kenton Kimberly, et al. Transabdominal uterosacral suspension: outcomes and complications. *Am J Obstet Gynecol*. 2009;200(6):656.e1–656.e5 https://doi.org/10.1016/j.ajog.2009.01.029 [(online journal)].

Macer GA. Transabdominal repair of cystocele, a 20 year experience, compared with the traditional vaginal approach. *Am J Obstet Gynecol*. 1978;131(2):203–207 http://www.ncbi.nlm.nih.gov/pubmed/645801 [(online journal)].

Maher CF, Qatawneh AM, Dwyer PL, et al. Abdominal sacral colpopexy or vaginal sacrospinous colpopexy for vaginal vault prolapse: a prospective randomized study. *Am J Obstet Gynecol*. 2004;190(1):20–26 https://doi.org/10.1016/j.ajog.2003.08.031.

Maher C, Baessler K, Barber M, et al. *Incontinence*. [ed 5, Paris, 2013, International Consultation on Incontinence (website); Available from:] http://www.icud.info/PDFs/INCONTINENCE 2013.pdf; 2013.

Maher CF, Carey MP, Murray CJ. Laparoscopic suture hysteropexy for uterine prolapse. *Obstet Gynecol*. 2001;97(6):1010–1014 http://www.ncbi.nlm.nih.gov/pubmed/11393196.

Maher CF, Cary MP, Slack MC, et al. Uterine preservation or hysterectomy at sacrospinous colpopexy for uterovaginal prolapse? *Int Urogynecol J Pelvic Floor Dysfunct*. 2001;12(6):381–385 http://www.ncbi.nlm.nih.gov/pubmed/11795641 [(online journal)].

Maher CF, Murray CJ, Carey MP, et al. Iliococcygeus or sacrospinous fixation for vaginal vault prolapse. *Obstet Gynecol*. 2001;98(1):40–44 http://www.ncbi.nlm.nih.gov/pubmed/11430954 [(online journal)].

Maher Christopher, Baessler Kaven. Surgical management of posterior vaginal wall prolapse: an evidence-based literature review. *Int Urogynecol J*. 2006;17(1):84–88 https://doi.org/10.1007/s00192-005-1295-4 [(online journal)].

Maher C, Baessler K. Surgical management of anterior vaginal wall prolapse: an evidence-based literature review. *Int Urogynecol J*. 2006;17(2):195–201 https://doi.org/10.1007/s00192-005-1296-3 [(online journal)].

Maher Christopher F, Qatawneh Aymen M, Baessler Kaven, et al. Midline rectovaginal fascial plication for repair of rectocele and obstructed defecation. *Obstet Gynecol*. 2004;104(4):685–689 https://doi.org/10.1097/01.AOG.0000139833.48063.03 [(online journal)].

Maher Christopher, Feiner Benjamin, Baessler Kaven, et al. Surgery for women with apical vaginal prolapse. *Cochrane Database Syst Rev*. 2016;(10) [CD012376] https://doi.org/10.1002/14651858.CD012376.

Maher C, Feiner B, Baessler K, et al. Surgery for women with anterior compartment prolapse. *Cochrane Database Syst Rev*. 2016;(11) [CD004014] https://doi.org/10.1002/14651858.CD004014.pub6 [(online journal)].

Maher Christopher, Feiner Benjamin, Baessler Kaven, et al. Surgical management of pelvic organ prolapse in women. *Cochrane Database Syst Rev*. 2010;(4) [CD004014] https://doi.org/10.1002/14651858.CD004014.pub4 [(online

journal)].

Maher Christopher, Feiner Benjamin, Baessler Kaven, et al. Surgical management of pelvic organ prolapse in women. *Cochrane Database Syst Rev*. 2013;(4) [CD004014] https://doi.org/10.1002/14651858.CD004014.pub5 [(online journal)].

Maldonado Pedro A, Stuparich Mallory A, McIntire Donald D, et al. Proximity of uterosacral ligament suspension sutures and S3 sacral nerve to pelvic landmarks. *Int Urogynecol J*. 2017;28(1):77–84 https://doi.org/10.1007/s00192-016-3039-z [(online journal)].

Mallipeddi PK, Steele AC, Kohli N, et al. Anatomic and functional outcome of vaginal paravaginal repair in the correction of anterior vaginal wall prolapse. *Int Urogynecol J Pelvic Floor Dysfunct*. 2001;12(2):83–88 http://www.ncbi.nlm.nih.gov/pubmed/11374518 [(online journal)].

Margulies Rebecca U, Rogers Mary A M, Morgan Daniel M. Outcomes of transvaginal uterosacral ligament suspension: systematic review and metaanalysis. *Am J Obstet Gynecol*. 2010;202(2):124–134 https://doi.org/10.1016/j.ajog.2009.07.052 [(online journal)].

Marinkovic Serge P. Will hysterectomy at the time of sacrocolpopexy increase the rate of polypropylene mesh erosion? *Int Urogynecol J Pelvic Floor Dysfunct*. 2008;19(2):199–203 https://doi.org/10.1007/s00192-007-0422-9 [(online journal)].

McCall ML. Posterior culdeplasty; surgical correction of enterocele during vaginal hysterectomy; a preliminary report. *Obstet Gynecol*. 1957;10(6):595–602 http://www.ncbi.nlm.nih.gov/pubmed/13484166 [(online journal)].

Meeks GR, Washburne JF, McGehee RP, et al. Repair of vaginal vault prolapse by suspension of the vagina to iliococcygeus (prespinous) fascia. *Am J Obstet Gynecol*. 1994;171(6):1444–1454 http://www.ncbi.nlm.nih.gov/pubmed/7802052 [(online journal)].

Menefee Shawn A, Dyer Keisha Y, Lukacz Emily S, et al. Colporrhaphy compared with mesh or graft-reinforced vaginal paravaginal repair for anterior vaginal wall prolapse. *Obstet Gynecol*. 2011;118(6):1337–1344 https://doi.org/10.1097/AOG.0b013e318237edc4 [(online journal)].

Mercer-Jones MA, Sprowson A, Varma JS. Outcome after transperineal mesh repair of rectocele: a case series. *Dis Colon Rectum*. 2004;47(6):864–868 https://doi.org/10.1007/s10350-004-0526-y [(online journal)].

Meschia M, Bruschi F, Amicarelli F, et al. The sacrospinous vaginal vault suspension: critical analysis of outcomes. *Int Urogynecol J Pelvic Floor Dysfunct*. 1999;10(3):155–159 http://www.ncbi.nlm.nih.gov/pubmed/10430007 [(online journal)].

Meschia Michele, Pifarotti Paola, Bernasconi Francesco, et al. Porcine skin collagen implants to prevent anterior vaginal wall prolapse recurrence: a multicenter, randomized study. *J Urol*. 2007;177(1):192–195 https://doi.org/10.1016/j.juro.2006.08.100 [(online journal)].

Migliari Roberto, De Angelis Michele, Madeddu Giuliana, et al. Tension-free vaginal mesh repair for anterior vaginal wall prolapse. *Eur Urol*. 2000;38(2):151–155 https://doi.org/10.1159/000020272.

Migliari R, Usai E. Treatment results using a mixed fiber mesh in patients with grade IV cystocele. *J Urol*.

1999;161(4):1255–1258 http://www.ncbi.nlm.nih.gov/pubmed/10081880.

Milani Rodolfo, Salvatore Stefano, Soligo Marco, et al. Functional and anatomical outcome of anterior and posterior vaginal prolapse repair with prolene mesh. *BJOG*. 2005;112(1):107–111 https://doi.org/10.1111/j.1471-0528.2004.00332.x [(online journal)].

Minassian Vatche A, Parekh Mitesh, Poplawsky Deborah, et al. Randomized controlled trial comparing two procedures for anterior vaginal wall prolapse. *Neurourol Urodyn*. 2014;33(1):72–77 https://doi.org/10.1002/nau.22396 [(online journal)].

Miyazaki FS. Miya hook ligature carrier for sacrospinous ligament suspension. *Obstet Gynecol*. 1987;70(2):286–288 http://www.ncbi.nlm.nih.gov/pubmed/3601293.

Moiety Fady M Shawky, Hegab Hassan Mansour, Ghanem Ibrahim Abdel Latif, et al. Abdominal sacrohysteropexy for uterovaginal prolapse: a prospective study on 33 cases. *Arch Gynecol Obstet*. 2010;281(4):631–636 https://doi.org/10.1007/s00404-009-1146-5 [(online journal)].

Moreno Sierra Jesús, Oshiro Elena Ortiz, Pérez Cristina Fernandez, et al. Long-term outcomes after robotic sacrocolpopexy in pelvic organ prolapse: prospective analysis. *Urol Int*. 2011;86(4):414–418 https://doi.org/10.1159/000323862.

Morley GW, DeLancey JO. Sacrospinous ligament fixation for eversion of the vagina. *Am J Obstet Gynecol*. 1988;158(4):872–881 http://www.ncbi.nlm.nih.gov/pubmed/3364499 [(online journal)].

Morse Abraham N, O'dell Katharine K, Howard Allison E, et al. Midline anterior repair alone vs anterior repair plus vaginal paravaginal repair: a comparison of anatomic and quality of life outcomes. *Int Urogynecol J Pelvic Floor Dysfunct*. 2007;18(3):245–249 https://doi.org/10.1007/s00192-006-0133-7 [(online journal)].

Mourik Sarah L, Martens Jolise E, Aktas Mustafa. Uterine preservation in pelvic organ prolapse using robot assisted laparoscopic sacrohysteropexy: quality of life and technique. *Eur J Obstet Gynecol Reprod Biol*. 2012;165(1):122–127 https://doi.org/10.1016/j.ejogrb.2012.07.025 [(online journal)].

Mowat Alex, Maher Declan, Baessler Kaven, et al. Surgery for women with posterior compartment prolapse. *Cochrane Database Syst Rev*. 2018;(3) [CD012975] https://doi.org/10.1002/14651858.CD012975 [(online journal)].

Mueller Margaret G, Ellimootil Chandy, Abernethy Melinda G, et al. Colpocleisis. *Female Pelvic Med Reconstr Surg*. 2015;21(1):30–33 https://doi.org/10.1097/SPV.0000000000000114 [(online journal)].

Muffly Tyler M, Diwadkar Gouri B, Paraiso Marie Fidela R. Lumbosacral osteomyelitis after robot-assisted total laparoscopic hysterectomy and sacral colpopexy. *Int Urogynecol J*. 2010;21(12):1569–1571 https://doi.org/10.1007/s00192-010-1187-0 [(online journal)].

Murphy Miles, Holzberg Adam, van Raalte Heather, et al. Time to rethink: an evidence-based response from pelvic surgeons to the FDA Safety Communication: “UPDATE on serious complications associated with transvaginal placement of surgical mesh for pelvic organ prolapse.”. [the; Pelvic Surgeons Network] *Int Urogynecol J*. 2012;23(1):5–9 https://doi.org/10.1007/s00192-011-1581-2 [(online

journal)].

Murthy VK, Orkin BA, Smith LE, et al. Excellent outcome using selective criteria for rectocele repair. *Dis Colon Rectum*. 1996;39(4):374–378 http://www.ncbi.nlm.nih.gov/pubmed/8878494 [(online journal)].

Mustafa Susana, Amit Amnon, Filmar Shlomo, et al. Implementation of laparoscopic sacrocolpopexy: establishment of a learning curve and short-term outcomes. *Arch Gynecol Obstet*. 2012;286(4):983–988 https://doi.org/10.1007/s00404-012-2391-6 [(online journal)].

Nager Charles W, Grimes Cara L, Nolen Tracy L, et al. Concomitant anterior repair, preoperative prolapse severity, and anatomic prolapse outcomes after vaginal apical procedures. *Female Pelvic Med Reconstr Surg*. 2019;25(1):22–28 https://doi.org/10.1097/SPV.0000000000000526 [(online journal)].

Nair R, Nikolopoulos KI, Claydon LS. Clinical outcomes in women undergoing laparoscopic hysteropexy: a systematic review. *Eur J Obstet Gynecol Reprod Biol*. 2017;208(January):71–80 https://doi.org/10.1016/j.ejogrb.2016.11.019.

Natale F, La Penna C, Padoa A, et al. A prospective, randomized, controlled study comparing gynemesh, a synthetic mesh, and pelvicol, a biologic graft, in the surgical treatment of recurrent cystocele. *Int Urogynecol J Pelvic Floor Dysfunct*. 2009;20(1):75–81 https://doi.org/10.1007/s00192-008-0732-6 [(online journal)].

Nguyen JK, Bhatia NN. Resolution of motor urge incontinence after surgical repair of pelvic organ prolapse. *J Urol*.

2001;166(6):2263–2266 http://www.ncbi.nlm.nih.gov/pubmed/11696748 [(online journal)].

Nichols DH. Sacrospinous fixation for massive eversion of the vagina. *Am J Obstet Gynecol*. 1982;142(7):901–904 http://www.ncbi.nlm.nih.gov/pubmed/7039324 [(online journal)].

Nicita G. A new operation for genitourinary prolapse. *J Urol*. 1998;160(3 Pt 1):741–745 http://www.ncbi.nlm.nih.gov/pubmed/9720536 [(online journal)].

Nieminen Kari, Hiltunen Kari-Matti, Laitinen Jukka, et al. Transanal or vaginal approach to rectocele repair: a prospective, randomized pilot study. *Dis Colon Rectum*. 2004;47(10):1636–1642 http://www.ncbi.nlm.nih.gov/pubmed/15540292 [(online journal)].

Nieminen Kari, Huhtala Heini, Heinonen PK. Anatomic and functional assessment and risk factors of recurrent prolapse after vaginal sacrospinous fixation. *Acta Obstet Gynecol Scand*. 2003;82(5):471–478 http://www.ncbi.nlm.nih.gov/pubmed/12752079.

Nieminen Kari, Hiltunen Reijo, Takala Teuvo, et al. Outcomes after anterior vaginal wall repair with mesh: a randomized, controlled trial with a 3 year follow-up. *Am J Obstet Gynecol*. 2010;203(3):235.e1–235.e235 https://doi.org/10.1016/j.ajog.2010.03.030 [(online journal)].

Nosseir Sandy B, Kim Yong H, Lind Lawrence R, et al. Sacral osteomyelitis after robotically assisted laparoscopic sacral colpopexy. *Obstet Gynecol*. 2010;116(Suppl):513–515 https://doi.org/10.1097/AOG.0b013e3181e10ea6 [(online journal)].

Nosti PA, Andy UU, Kane S, et al. Outcomes of abdominal and minimally invasive sacrocolpopexy. *Female Pelvic Med Reconstr Surg*. 2014;20(1):33–37 https://doi.org/10.1097/SPV.0000000000000036.

Nosti Patrick A, Lowman Joye K, Zollinger Terrell W, et al. Risk of mesh erosion after abdominal sacral colpoperineopexy with concomitant hysterectomy. *Am J Obstet Gynecol*. 2009;201(5):541.e1–541.e4 https://doi.org/10.1016/j.ajog.2009.07.053 [(online journal)].

Novara Giacomo, Artibani Walter. Surgery for pelvic organ prolapse: current status and future perspectives. *Curr Opin Urol*. 2005;15(4):256–262 http://www.ncbi.nlm.nih.gov/pubmed/15928515 [(online journal)].

Nygaard Ingrid, Brubaker Linda, Zyczynski Halina M, et al. Long-term outcomes following abdominal sacrocolpopexy for pelvic organ prolapse. *J Am Med Assoc*. 2013;309(19):2016 https://doi.org/10.1001/jama.2013.4919 [(online journal)].

Nygaard I, Brubaker L, Zyczynski HM, et al. Long-term outcomes following abdominal sacrocolpopexy for pelvic organ prolapse. *J Am Med Assoc*. 2013;309(19):2016 https://doi.org/10.1001/jama.2013.4919 [(online journal)].

Nygaard Ingrid E, McCreery Rebecca, Brubaker Linda, et al. Abdominal sacrocolpopexy: a comprehensive review. [the; Pelvic Floor Disorders Network] *Obstet Gynecol*. 2004;104(4):805–823 https://doi.org/10.1097/01.AOG.0000139514.90897.07 [(online journal)].

Nygaard Ingrid E, McCreery Rebecca, et al. Abdominal sacrocolpopexy: a comprehensive review. *Obstet Gynecol*.

2004;104(4):805–823 https://doi.org/10.1097/01.AOG.0000139514.90897.07 [(online journal)].

Olsen A, Smith V, Bergstrom J, et al. Epidemiology of surgically managed pelvic organ prolapse and urinary incontinence. *Obstet Gynecol*. 1997;89(4):501–506 https://doi.org/10.1016/S0029-7844(97)00058-6 [(online journal)].

Paek Jiheum, Lee Maria, Kim Bo Wook, et al. Robotic or laparoscopic sacrohysteropexy versus open sacrohysteropexy for uterus preservation in pelvic organ prolapse. *Int Urogynecol J*. 2016;27(4):593–599 https://doi.org/10.1007/s00192-015-2869-4 [(online journal)].

Pan Ke, Cao Lili, Ryan Nicholas A, et al. Laparoscopic sacral hysteropexy versus laparoscopic sacrocolpopexy with hysterectomy for pelvic organ prolapse. *Int Urogynecol J*. 2016;27(1):93–101 https://doi.org/10.1007/s00192-015-2775-9 [(online journal)].

Paraiso MF, Ballard LA, Walters MD, et al. Pelvic support defects and visceral and sexual function in women treated with sacrospinous ligament suspension and pelvic reconstruction. *Am J Obstet Gynecol*. 1996;175(6):1423–1431 http://www.ncbi.nlm.nih.gov/pubmed/8987920 [(online journal)].

Paraiso Marie Fidela R, Jelovsek J Eric, Frick Anna, et al. Laparoscopic compared with robotic sacrocolpopexy for vaginal prolapse. *Obstet Gynecol*. 2011;118(5):1005–1013 https://doi.org/10.1097/AOG.0b013e318231537c [(online journal)].

Paraiso Marie Fidela R, Barber Matthew D, Muir Tristi W, et al. Rectocele repair: a randomized trial of three surgical techniques including graft augmentation. *Am J Obstet*

Gynecol. 2006;195(6):1762–1771 https://doi.org/10.1016/j.ajog.2006.07.026 [(online journal)].

Paraiso Marie Fidela R, Walters MD, Rackley RR, et al. Laparoscopic and abdominal sacral colpopexies: a comparative Cohort Study. *Am J Obstet Gynecol*. 2005;192(5):1752–1758 https://doi.org/10.1016/j.ajog.2004.11.051.

Pasley WW. Sacrospinous suspension: a local practitioner's experience. *Am J Obstet Gynecol*. 1995;173(2):440–448 http://www.ncbi.nlm.nih.gov/pubmed/7645619 [(online journal)].

Pearce Eugene W. The Manchester procedure. *Mo Med*. 2004;101(1):46–50 http://www.ncbi.nlm.nih.gov/pubmed/15017753 [(online journal)].

Penalver Manuel, Mekki Yasir, Lafferty Heather, et al. Should sacrospinous ligament fixation for the management of pelvic support defects be part of a residency program procedure. *Am J Obstet Gynecol*. 1998;178(2):326–329 https://doi.org/10.1016/S0002-9378(98)80020-3.

Pohl JF, Frattarelli JL. Bilateral transvaginal sacrospinous colpopexy: preliminary experience. *Am J Obstet Gynecol*. 1997;177(6):1356–1362 http://www.ncbi.nlm.nih.gov/pubmed/9423735 [(online journal)].

Polypropylene vaginal mesh implants for vaginal prolapse. [(website); Available from:] https://www.ranzcog.edu.au/getattachment/Statements-Guidelines/Gynaecology/Polypropylene-Vaginal-Mesh-Implants-for-Vaginal-Pr/Polypropylene-vaginal-mesh-implants-for-vaginal-prolapse-(C-Gyn-20)-Jan18.pdf?lang=en-AU&ext=.pdf; 2007.

Porges RF, Smilen SW. Long-term analysis of the surgical management of pelvic support defects. *Am J Obstet Gynecol*. 1994;171(6):1518–1528 http://www.ncbi.nlm.nih.gov/pubmed/7802061 [(online journal)].

Porter WE, Steele A, Walsh P, et al. The anatomic and functional outcomes of defect-specific rectocele repairs. *Am J Obstet Gynecol*. 1999;181(6):1353–1359 http://www.ncbi.nlm.nih.gov/pubmed/10601912 [(online journal)].

Powell Curt R, Simsiman Amanda J, Menefee Shawn A. Anterior vaginal wall hammock with fascia lata for the correction of stage 2 or greater anterior vaginal compartment relaxation. *J Urol*. 2004;171(1):264–267 https://doi.org/10.1097/01.ju.0000100260.36697.91 [(online journal)].

Price N, Slack A, Jackson SR. Laparoscopic hysteropexy: the initial results of a uterine suspension procedure for uterovaginal prolapse. *BJOG*. 2010;117(1):62–68 https://doi.org/10.1111/j.1471-0528.2009.02396.x [(online journal)].

Quiroz Lieschen H, Gutman Robert E, Fagan Matthew J, et al. Partial colpocleisis for the treatment of sacrocolpopexy mesh erosions. *Int Urogynecol J Pelvic Floor Dysfunct*. 2008;19(2):261–266 https://doi.org/10.1007/s00192-007-0416-7 [(online journal)].

Raz S, Little NA, Juma S, et al. Repair of severe anterior vaginal wall prolapse (grade IV cystourethrocele). *J Urol*. 1991;146(4):988–992 http://www.ncbi.nlm.nih.gov/pubmed/1895456 [(online journal)].

Reddy Jhansi, Ridgeway Beri, Gurland Brooke, et al. Robotic sacrocolpoperineopexy with ventral rectopexy for the combined treatment of rectal and pelvic organ prolapse: initial report and technique. *J Robot Surg*. 2011;5(3):167–173 https://doi.org/10.1007/s11701-011-0257-8 [(online journal)].

Reid Richard I, You Hui, Luo Kehui. Site-specific prolapse surgery. I. Reliability and durability of native tissue paravaginal repair. *Int Urogynecol J*. 2011;22(5):591–599 https://doi.org/10.1007/s00192-010-1347-2 [(online journal)].

Richardson AC. The rectovaginal septum revisited: its relationship to rectocele and its importance in rectocele repair. *Clin Obstet Gynecol*. 1993;36(4):976–983 http://www.ncbi.nlm.nih.gov/pubmed/8293598 [(online journal)].

Richardson AC, Edmonds PB, Williams NL. Treatment of stress urinary incontinence due to paravaginal fascial defect. *Obstet Gynecol*. 1981;57(3):357–362 http://www.ncbi.nlm.nih.gov/pubmed/7465150 [(online journal)].

Richardson AC, Lyon JB, Williams NL. A new look at pelvic relaxation. *Am J Obstet Gynecol*. 1976;126(5):568–573 http://www.ncbi.nlm.nih.gov/pubmed/984127 [(online journal)].

Richardson DA, Scotti RJ, Ostergard DR. Surgical management of uterine prolapse in young women. *J Reprod Med*. 1989;34(6):388–392 http://www.ncbi.nlm.nih.gov/pubmed/2661812 [(online journal)].

Richter K, Albrich W. Long-term results following fixation of the vagina on the sacrospinal ligament by the vaginal route (vaginaefixatio sacrospinalis vaginalis). *Am J Obstet Gynecol*. 1981;141(7):811–816 http://www.ncbi.nlm.nih.gov/pubmed/7315907 [(online

journal)].

Ridgeway Beri M. Does prolapse equal hysterectomy? The role of uterine conservation in women with uterovaginal prolapse. *Am J Obstet Gynecol*. 2015;213(6):802–809 https://doi.org/10.1016/j.ajog.2015.07.035 [(online journal)].

Ridgeway Beri M, Cadish Lauren. Hysteropexy. *Clin Obstet Gynecol*. 2017;60(2):312–323 https://doi.org/10.1097/GRF.0000000000000281 [(online journal)].

Ridgeway BM, Frick AC. Uterine conservation for the surgical treatment of uterovaginal prolapse. Karram M, Walters M. *Urogynecology and reconstructive pelvic surgery*. ed 4. Elsevier Saunders: Philadelphia; 2015:383–399.

Rodríguez Larissa V, Bukkapatnam Raviender, Shah Sovrin M, et al. Transvaginal paravaginal repair of high-grade cystocele central and lateral defects with concomitant suburethral sling: report of early results, outcomes, and patient satisfaction with a new technique. *Urology*. 2005;66(Suppl 5):57–65 https://doi.org/10.1016/j.urology.2005.06.126 [(online journal)].

Rogers RJ. Swift Steven E, Bent Alfred E, Cundiff Geoffrey W. *Ostergard's urogynecology and pelvic floor dysfunction*. ed 5. Lippincott Williams & Wilkins: Philadelphia; 2003.

Romanzi Lauri J, Tyagi Renuka. Hysteropexy compared to hysterectomy for uterine prolapse surgery: does durability differ? *Int Urogynecol J*. 2012;23(5):625–631 https://doi.org/10.1007/s00192-011-1635-5 [(online journal)].

Rosen David MB, Shukla Anshumala, Cario Gregory M, et al. Is hysterectomy necessary for laparoscopic pelvic floor repair? A prospective study. *J Minim Invasive Gynecol*. 2008;15(6):729–

734 https://doi.org/10.1016/j.jmig.2008.08.010 [(online journal)].

Rosenblatt Peter L, Chelmow David, Ferzandi Tanaz R. Laparoscopic sacrocervicopexy for the treatment of uterine prolapse: a retrospective case series report. *J Minim Invasive Gynecol*. 2008;15(3):268–272 https://doi.org/10.1016/j.jmig.2008.01.001 [(online journal)].

Roth Ted M, Reight Ian. Laparoscopic mesh explantation and drainage of sacral abscess remote from transvaginal excision of exposed sacral colpopexy mesh. *Int Urogynecol J*. 2012;23(7):953–955 https://doi.org/10.1007/s00192-011-1630-x [(online journal)].

Rovner ES, Ginsberg DA. Posterior vaginal wall prolapse: transvaginal repair of pelvic floor relaxation, rectocele, and perineal laxity. *Tech Urol*. 2001;7(2):161–168 http://www.ncbi.nlm.nih.gov/pubmed/11383995 [(online journal)].

Rozet Francois, Mandron Eric, Arroyo Carlos, et al. Laparoscopic sacral colpopexy approach for genito-urinary prolapse: experience with 363 cases. *Eur Urol*. 2005;47(2):230–236 https://doi.org/10.1016/j.eururo.2004.08.014 [(online journal)].

Salamon CG, Lewis C, Priestley J, et al. Prospective study of an ultra-lightweight polypropylene Y mesh for robotic sacrocolpopexy. *Int Urogynecol J*. 2013;24(8):1371–1375 https://doi.org/10.1007/s00192-012-2021-7.

Salomon LJ, Detchev R, Barranger E, et al. Treatment of anterior vaginal wall prolapse with porcine skin collagen implant by the transobturator route: preliminary results. *Eur Urol*. 2004;45(2):219–225 http://www.ncbi.nlm.nih.gov/pubmed/14734010.

Salvatore S, Soligo M, Meschia M, et al. *Prosthetic surgery for genital prolapse: functional outcome*. [(website); Available from:] https://www.ics.org/Abstracts/Publish/40/000010.pdf; 2002.

Sand PK, Koduri S, Lobel RW, et al. Prospective randomized trial of polyglactin 910 mesh to prevent recurrence of cystoceles and rectoceles. *Am J Obstet Gynecol*. 2001;184(7):1357–1364 http://www.ncbi.nlm.nih.gov/pubmed/11408853 [(online journal)].

Sarlos Dimitri, Brandner Sonja, Kots LaVonne, et al. Laparoscopic sacrocolpopexy for uterine and Post-Hysterectomy prolapse: anatomical results, quality of life and perioperative outcome—a prospective study with 101 cases. *Int Urogynecol J*. 2008;19(10):1415–1422 https://doi.org/10.1007/s00192-008-0657-0.

Sauer HA, Klutke CG. Transvaginal sacrospinous ligament fixation for treatment of vaginal prolapse. *J Urol*. 1995;154(3):1008–1012 http://www.ncbi.nlm.nih.gov/pubmed/7637043 [(online journal)].

Schlesinger RE. Vaginal sacrospinous ligament fixation with the autosuture endostitch device. *Am J Obstet Gynecol*. 1997;176(6):1358–1362 https://doi.org/10.1016/S0002-9378(97)70358-2.

Schultz DC. *Update on serious complications associated with transvaginal placement of surgical mesh in repair of pelvic organ prolapse and stress urinary incontinence*. [(website); Available from:] https://wayback.archive-it.org/7993/20170406003155/https://www.fda.gov/MedicalDe surgicalmesh.html; 2008.

Sculpher MJ, Dwyer N, Byford S, et al. Randomised trial comparing hysterectomy and transcervical endometrial resection: effect on health related quality of life and costs two years after surgery. *Br J Obstet Gynaecol*. 1996;103(2):142–149 http://www.ncbi.nlm.nih.gov/pubmed/8616131 [(online journal)].

Serati Maurizio, Braga Andrea, Bogani Giorgio, et al. Iliococcygeus fixation for the treatment of apical vaginal prolapse: efficacy and safety at 5 years of follow-up. *Int Urogynecol J*. 2015;26(7):1007–1012 https://doi.org/10.1007/s00192-015-2629-5 [(online journal)].

Seror Julien, Yates David R, Seringe Elise, et al. Prospective comparison of short-term functional outcomes obtained after pure laparoscopic and robot-assisted laparoscopic sacrocolpopexy. *World J Urol*. 2012;30(3):393–398 https://doi.org/10.1007/s00345-011-0748-2 [(online journal)].

Shayya Rana F, Weinstein Milena M, Lukacz Emily S. Pyometra after Le Fort colpocleisis resolved with interventional radiology drainage. *Obstet Gynecol*. 2009;113(2 Pt 2):566–568 https://doi.org/10.1097/AOG.0b013e3181952366 [(online journal)].

Shepherd Jonathan P, Higdon Homer Lee, Stanford Edward J, et al. Effect of suture selection on the rate of suture or mesh erosion and surgery failure in abdominal sacrocolpopexy. *Female Pelvic Med Reconstr Surg*. 2010;16(4):229–233 https://doi.org/10.1097/SPV.0b013e3181d683a3 [(online journal)].

Shull BL, Bachofen C, Coates KW, et al. A transvaginal approach to repair of apical and other associated sites of pelvic organ prolapse with uterosacral ligaments. *Am J Obstet Gynecol*. 2000;183(6):1365–1374 https://doi.org/10.1067/mob.2000.110910 [(online

journal)].

Shull BL, Benn SJ, Kuehl TJ. Surgical management of prolapse of the anterior vaginal segment: an analysis of support defects, operative morbidity, and anatomic outcome. *Am J Obstet Gynecol*. 1994;171(6):1429–1439 http://www.ncbi.nlm.nih.gov/pubmed/7802050 [(online journal)].

Shull BL, Capen CV, Riggs MW, et al. Preoperative and postoperative analysis of site-specific pelvic support defects in 81 women treated with sacrospinous ligament suspension and pelvic reconstruction. *Am J Obstet Gynecol*. 1992;166(6 Pt 1):1764–1771 http://www.ncbi.nlm.nih.gov/pubmed/1615985 [(online journal)].

Shull BL, Capen CV, Riggs MW, et al. Bilateral attachment of the vaginal cuff to iliococcygeus fascia: an effective method of cuff suspension. *Am J Obstet Gynecol*. 1993;168(6 Pt 1):1669–1677 http://www.ncbi.nlm.nih.gov/pubmed/8317507 [(online journal)].

Shumaker SA, Wyman JF, Uebersax JS, et al. Health-related quality of life measures for women with urinary incontinence: the incontinence impact questionnaire and the urogenital distress inventory. continence program in women (CPW) research group. *Qual Life Res*. 1994;3(5):291–306 http://www.ncbi.nlm.nih.gov/pubmed/7841963 [(online journal)].

Siddiqui NY, Geller EJ, Visco AG. Symptomatic and anatomic 1-year outcomes after robotic and abdominal sacrocolpopexy. *Am J Obstet Gynecol*. 2012;206(5):435.e1–435.e5 https://doi.org/10.1016/j.ajog.2012.01.035.

Siddique Sohail A, Gutman Robert E, Schön Ybarra Miguel A, et al. Relationship of the uterosacral ligament to the sacral plexus and to the pudendal nerve. *Int Urogynecol J Pelvic*

Floor Dysfunct. 2006;17(6):642–645 https://doi.org/10.1007/s00192-006-0088-8 [(online journal)].

Siddiqui Nazema Y, Grimes Cara L, Casiano Elizabeth R, et al. Mesh sacrocolpopexy compared with native tissue vaginal repair. *Obstet Gynecol*. 2015;125(1):44–55 https://doi.org/10.1097/AOG.0000000000000570 [(online journal)].

Siff Lauren N, Barber Matthew D. Native tissue prolapse repairs. *Obstet Gynecol Clin North Am*. 2016;43(1):69–81 https://doi.org/10.1016/j.ogc.2015.10.003 [(online journal)].

Silva W Andre, Pauls Rachel N, Segal Jeffrey L, et al. Uterosacral ligament vault suspension: five-year outcomes. *Obstet Gynecol*. 2006;108(2):255–263 https://doi.org/10.1097/01.AOG.0000224610.83158.23 [(online journal)].

Simsiman AJ, Luber KM, Menefee SA. Vaginal paravaginal repair with porcine dermal reinforcement: correction of advanced anterior vaginal prolapse. *Am J Obstet Gynecol*. 2006;195(6):1832–1836 https://doi.org/10.1016/j.ajog.2006.07.005.

Singh K, Cortes E, Reid WMN. Evaluation of the fascial technique for surgical repair of isolated posterior vaginal wall prolapse. *Obstet Gynecol*. 2003;101(2):320–324 http://www.ncbi.nlm.nih.gov/pubmed/12576256 [(online journal)].

Sivaslioglu AA, Unlubilgin E, Dolen I. A randomized comparison of polypropylene mesh surgery with site-specific surgery in the treatment of cystocoele. *Int Urogynecol J Pelvic Floor Dysfunct*. 2008;19(4):467–471 https://doi.org/10.1007/s00192-007-0465-y [(online journal)].

Snyder TE, Krantz KE. Abdominal-retroperitoneal sacral colpopexy for the correction of vaginal prolapse. *Obstet Gynecol*. 1991;77(6):944–949 http://www.ncbi.nlm.nih.gov/pubmed/2030875 [(online journal)].

Stanton SL, Hilton P, Norton C, et al. Clinical and urodynamic effects of anterior colporrhaphy and vaginal hysterectomy for prolapse with and without incontinence. *Br J Obstet Gynaecol*. 1982;89(6):459–463 http://www.ncbi.nlm.nih.gov/pubmed/7082603.

Sundaram Chandru P, Venkatesh Ramakrishna, Landman Jaime, et al. Laparoscopic sacrocolpopexy for the correction of vaginal vault prolapse. *J Endourol*. 2004;18(7):620–624 https://doi.org/10.1089/end.2004.18.620 [(online journal)].

Sung VW, Rardin CR, Raker CA, et al. Porcine subintestinal submucosal graft augmentation for rectocele repair. *Obstet Gynecol*. 2012;119(1):125–133 https://doi.org/10.1097/AOG.0b013e31823d407e.

Sylvester Toni, Bond Virginia, Johnson Harry W, et al. Radiologic images of retrograde ureterography before and after release of bilateral sacrospinous ligament fixation sutures. *Female Pelvic Med Reconstr Surg*. 2012;18(3):168–169 https://doi.org/10.1097/SPV.0b013e318254f0b0 [(online journal)].

Sze E, Karram M. Transvaginal repair of vault prolapse: a review. *Obstet Gynecol*. 1997;89(3):466–475 https://doi.org/10.1016/S0029-7844(96)00337-7 [(online journal)].

Sze EH, Miklos JR, Partoll L, et al. Sacrospinous ligament fixation with transvaginal needle suspension for advanced pelvic organ prolapse and stress incontinence. *Obstet Gynecol*. 1997;89(1):94–

96 http://www.ncbi.nlm.nih.gov/pubmed/8990446.

Tarr Megan E, Paraiso Marie Fidela R. Laparoscopic and robotic surgery for pelvic organ prolapse and stress urinary incontinence. Karram M, Walters Mark. *Urogynecology and reconstructive pelvic surgery*. ed 4. Elsevier Saunders.: Philadelphia; 2015:295–317.

Thomas AG, Brodman ML, Dottino PR, et al. Manchester procedure vs. vaginal hysterectomy for uterine prolapse. a comparison. *J Reprod Med*. 1995;40(4):299–304 http://www.ncbi.nlm.nih.gov/pubmed/7623360 [(online journal)].

Tipton RH, Atkin PF. Uterine disease after the manchester repair operation. *J Obstet Gynaecol Br Commonw*. 1970;77(9):852–853 http://www.ncbi.nlm.nih.gov/pubmed/5458778 [(online journal)].

Togami J, Krlin R, Winters J. Graft materials in prolapse surgery. *AUA Update Series*. 2008;27(31):294–303.

Togami Joanna M, Brown Elizabeth, Winters J Christian. Vaginal mesh—the controversy. *F1000 Med Rep*. 2012;4(November):21 https://doi.org/10.3410/M4-21 [(online journal)].

Toglia MR, Fagan MJ. Suture erosion rates and Long-Term surgical outcomes in patients undergoing sacrospinous ligament suspension with braided polyester suture. *Am J Obstet Gynecol*. 2008;198(5):600.e1–600.e4 https://doi.org/10.1016/j.ajog.2008.02.049.

Tola Esra Nur, Erdemoğlu Evrim Ebru, Erdemoğlu Evrim Ebru. Uterine sparing surgical methods in pelvic organ prolapse. *Turk J Obstet Gynecol*. 2015;12(3):168–172 https://doi.org/10.4274/tjod.43179 [(online journal)].

Toozs-Hobson P, Boos K, Cardozo L. Management of vaginal vault prolapse. *Br J Obstet Gynaecol*. 1998;105(1):13–

17 http://www.ncbi.nlm.nih.gov/pubmed/9442155 [(online journal)].

Tseng Ling-Hong, Chen Ilene, Chang Shuenn-Dyh, et al. Modern role of sacrospinous ligament fixation for pelvic organ prolapse surgery—a systemic review. *Taiwan J Obstet Gynecol*. 2013;52(3):311–317 https://doi.org/10.1016/j.tjog.2012.11.002 [(online journal)].

Turner LC, Lavelle ES, Shepherd JP. Comparison of complications and prolapse recurrence between laparoscopic and vaginal uterosacral ligament suspension for the treatment of vaginal prolapse. *Int Urogynecol J*. 2016;27(5):797–803 https://doi.org/10.1007/s00192-015-2897-0.

Twiss Christian, Triaca Veronica, Raz Shlomo. Re: reevaluating occult stress incontinence. *Eur Urol*. 2007;51(3):850–851 http://www.ncbi.nlm.nih.gov/pubmed/17421062 [(online journal)].

Unger Cecile A, Barber Matthew D, Walters Mark D, et al. Long-term effectiveness of uterosacral colpopexy and minimally invasive sacral colpopexy for treatment of pelvic organ prolapse. *Female Pelvic Med Reconstr Surg*. 2017;23(3):188–194 https://doi.org/10.1097/SPV.0000000000000313 [(online journal)].

van Brummen HJ, van de Pol G, Aalders CIM, et al. Sacrospinous hysteropexy compared to vaginal hysterectomy as primary surgical treatment for a descensus uteri: effects on urinary symptoms. *Int Urogynecol J*. 2003;14(5):350–355 https://doi.org/10.1007/s00192-003-1084-x [(online journal)].

Van Rooyen JB. Swift SE, Cundiff G, Bent AE, et al. *Ostergard's Urogynecology and pelvic floor dysfunction*. Lippincott Williams & Wilkins: Philadelphia; 2005.

von Pechmann Walter S, Mutone Martina, Fyffe Joanne, et al. Total colpocleisis with high levator plication for the treatment of advanced pelvic organ prolapse. *Am J Obstet Gynecol*. 2003;189(1):121–126 http://www.ncbi.nlm.nih.gov/pubmed/12861149 [(online journal)].

Veronikis DK, Nichols DH, Wakamatsu MM. The incidence of low-pressure urethra as a function of prolapse-reducing technique in patients with massive pelvic organ prolapse (maximum descent at all vaginal sites). *Am J Obstet Gynecol*. 1997;177(6):1305–1314 http://www.ncbi.nlm.nih.gov/pubmed/9423729 [(online journal)].

Vilos George A, Ternamian Artin, Dempster Jeffrey, et al. Laparoscopic entry: a review of techniques, technologies, and complications. [the; CLINICAL PRACTICE GYNAECOLOGY COMMITTEE] *J Obstet Gynaecol Can*. 2007;29(5):433–447 https://doi.org/10.1016/S1701-2163(16)35496-2 [(online journal)].

Vollebregt A, Fischer K, Gietelink D, et al. Primary surgical repair of anterior vaginal prolapse: a randomised trial comparing anatomical and functional outcome between anterior colporrhaphy and trocar-guided transobturator anterior mesh. *BJOG*. 2011;118(12):1518–1527 https://doi.org/10.1111/j.1471-0528.2011.03082.x [(online journal)].

Walter S, Olesen KP, Hald T, et al. Urodynamic evaluation after vaginal repair and colposuspension. *Br J Urol*. 1982;54(4):377–380 http://www.ncbi.nlm.nih.gov/pubmed/7116104 [(online journal)].

Wang Xiaojuan, Chen Yisong, Hua Keqin. Pelvic symptoms, body image, and regret after lefort colpocleisis: a long-term follow-up. *J Minim Invasive Gynecol*. 2017;24(3):415–419 https://doi.org/10.1016/j.jmig.2016.12.015 [(online journal)].

Ward Renée M, Sung Vivian W, Clemons Jeffrey L, et al. Vaginal paravaginal repair with an alloderm graft: long-term outcomes. *Am J Obstet Gynecol*. 2007;197(6):670.e1–670.e5 https://doi.org/10.1016/j.ajog.2007.08.067 [(online journal)].

Watson SJ, Loder PB, Halligan S, et al. Transperineal repair of symptomatic rectocele with marlex mesh: a clinical, physiological and radiologic assessment of treatment. *J Am Coll Surg*. 1996;183(3):257–261 http://www.ncbi.nlm.nih.gov/pubmed/8784320 [(online journal)].

Webb MJ, Aronson MP, Ferguson LK, et al. Posthysterectomy vaginal vault prolapse: primary repair in 693 patients. *Obstet Gynecol*. 1998;92(2):281–285 http://www.ncbi.nlm.nih.gov/pubmed/9699767 [(online journal)].

Weber Anne M, Lee Jar-Chi. Use of alternative techniques of hysterectomy in Ohio, 1988–1994. *N Engl J Med*. 1996;335(7):483–489 https://doi.org/10.1056/NEJM199608153350706 [(online journal)].

Weber AM, Walters MD, Piedmonte MR, et al. Anterior colporrhaphy: a randomized trial of three surgical techniques. *Am J Obstet Gynecol*. 2001;185(6):1299–1306 https://doi.org/10.1067/mob.2001.119081 [(online journal)].

Wei John T, Nygaard Ingrid, Richter Holly E, et al. A midurethral sling to reduce incontinence after vaginal prolapse repair. *N Engl J Med*. 2012;366(25):2358–2367 https://doi.org/10.1056/NEJMoa1111967 [(online

journal)].

Wheeler TL, Gerten KA, Richter HE, et al. Outcomes of vaginal vault prolapse repair with a high uterosacral suspension procedure utilizing bilateral single sutures. *Int Urogynecol J Pelvic Floor Dysfunct*. 2007;18(10):1207–1213 https://doi.org/10.1007/s00192-007-0305-0.

Wheeler TL, Richter HE, Duke AG, et al. Outcomes with porcine graft placement in the anterior vaginal compartment in patients who undergo high vaginal uterosacral suspension and cystocele repair. *Am J Obstet Gynecol*. 2006;194(5):1486–1491 https://doi.org/10.1016/j.ajog.2006.01.075.

White GR. Cystocele–a radical cure by suturing lateral sulci of the vagina to the white line of pelvic fascia. 1909. *Int Urogynecol J Pelvic Floor Dysfunct*. 1997;8(5):288–292 http://www.ncbi.nlm.nih.gov/pubmed/9557993 [(online journal)].

Whitehead William E, Bradley Catherine S, Brown Morton B, et al. Gastrointestinal complications following abdominal sacrocolpopexy for advanced pelvic organ prolapse. [the; Pelvic Floor Network] *Am J Obstet Gynecol*. 2007;197(1):78.e1–78.e7 https://doi.org/10.1016/j.ajog.2007.02.046 [(online journal)].

Wieslander Cecilia K, Roshanravan Shayzreen M, Wai Clifford Y, et al. Uterosacral ligament suspension sutures: anatomic relationships in unembalmed female cadavers. *Am J Obstet Gynecol*. 2007;197(6):672.e1–672.e6 https://doi.org/10.1016/j.ajog.2007.08.065 [(online journal)].

Wieslander Cecilia K, Rahn David D, McIntire Donald D, et al. Vascular anatomy of the presacral space in unembalmed female cadavers. *Am J Obstet Gynecol*. 2006;195(6):1736–

1741 https://doi.org/10.1016/j.ajog.2006.07.045 [(online journal)].

Williams BF. Surgical treatment for uterine prolapse in young women. *Am J Obstet Gynecol*. 1966;95(7):967–971 http://www.ncbi.nlm.nih.gov/pubmed/5914131 [(online journal)].

Winkler HA, Tomeszko JE, Sand PK. Anterior sacrospinous vaginal vault suspension for prolapse. *Obstet Gynecol*. 2000;95(4):612–615 http://www.ncbi.nlm.nih.gov/pubmed/10787347 [(online journal)].

Withagen Mariëlla I J, Vierhout Mark E, Milani Alfredo L. Does trocar-guided tension-free vaginal mesh (prolift) repair provoke prolapse of the unaffected compartments? *Int Urogynecol J*. 2010;21(3):271–278 https://doi.org/10.1007/s00192-009-1028-1 [(online journal)].

Wu Jennifer M, Wells Ellen C, Hundley Andrew F, et al. Mesh erosion in abdominal sacral colpopexy with and without concomitant hysterectomy. *Am J Obstet Gynecol*. 2006;194(5):1418–1422 https://doi.org/10.1016/j.ajog.2006.01.051 [(online journal)].

Yalcin Ilker, Bump Richard C. Validation of two global impression questionnaires for incontinence. *Am J Obstet Gynecol*. 2003;189(1):98–101 http://www.ncbi.nlm.nih.gov/pubmed/12861145 [(online journal)].

Yan Ansquer, Anne Marcollet, Karine Alves, et al. Cystocele repair by a synthetic vaginal mesh secured anteriorly through the obturator foramen. *Eur J Obstet Gynecol Reprod Biol*. 2004;115(1):90–94 https://doi.org/10.1016/j.ejogrb.2003.05.007 [(online

journal)].

Yazdany Taji, Bhatia Narender. Uterosacral ligament vaginal vault suspension: anatomy, outcome and surgical considerations. *Curr Opin Obstet Gynecol*. 2008;20(5):484–488 https://doi.org/10.1097/GCO.0b013e32830eb8c6 [(online journal)].

Young SB, Daman JJ, Bony LG. Vaginal paravaginal repair: one-year outcomes. *Am J Obstet Gynecol*. 2001;185(6):1360–1367 https://doi.org/10.1067/mob.2001.119073 [(online journal)].

Zebede Salomon, Smith Aimee L, Plowright Leon N, et al. Obliterative LeFort colpocleisis in a large group of elderly women. *Obstet Gynecol*. 2013;121(2 Pt 1):279–284 https://doi.org/10.1097/AOG.0b013e31827d8fdb [(online journal)].

125

Slings

Autologous, Biologic, Synthetic, and Mid-urethral

Alex Gomelsky MD, Roger R. Dmochowski MD, MMHC, FACS

The Evolution of Slings

Suburethral slings are currently considered the procedure of choice for the surgical correction of female stress urinary incontinence (SUI). Over the past century, a variety of autologous, allograft, xenograft, and synthetic materials and techniques have been employed for sling construction. The concept of slings for urethral support was first cited in 1907 by Von Giordano (1907) as a transplanted gracilis muscle graft wrapped around the urethra. Soon thereafter, additional sling procedures performed via the abdominal approach were described. Goebel (1910) tunneled pyramidalis muscle flaps through the retropubic space and sutured them together as a bolster under the bladder neck. Squier (1911) interposed the levator ani muscle between the urethra and the vagina, and Frangenheim (1914) incorporated the overlying rectus fascia in the pyramidalis muscle flap. Stoeckel (1917) further modified the above technique by adding plication of the bladder neck to the procedure. What was later called the Goebell-Frangenheim-Stoeckel technique was the first procedure to use a combined abdominovaginal approach. While additional modifications of autologous slings soon followed (Deming, 1926; Martius, 1929; Miller, 1932; Thompson, 1923), significant complications led to tepid enthusiasm for this surgical procedure. At the time, it was theorized that the transplanted muscle would retain its contractility and, in effect, act as a neo-sphincter to prevent SUI. Unfortunately, these procedures compressed the urethra and created a partial obstruction, commonly resulting in complications such as recurrent cystitis, urethral sloughing, fistula formation, and outlet obstruction.

A seminal modification of the autologous sling was published by Aldridge (1942), who first theorized that the abdominal muscles’ response to increased intra-abdominal pressure could be used anatomically to compress the urethra. Via an abdominovaginal approach, Aldridge detached strips of rectus fascia and external oblique aponeurosis laterally while leaving them attached medially. The 1.5-cm × 6-cm fascial strips were then tunneled through retropubic space and transferred into the vaginal incision. Ultimately, the strips of fascia were sutured together under the urethra after a bladder neck plication. Aldridge's “fundamental principle” was the decision to leave the sling attached to the rectus fascia in the midline, and was inspired by Price (1933), who used a fascia lata sling passed around the urethra and attached to the rectus muscle to cure incontinence in a woman with congenital absence of the sacrum and coccyx. In this article, Price stated that by attaching the sling to the rectus muscle, he was able to take full advantage of changes in the woman's posture and position to tighten or relax the sling at times when incontinence is most likely to occur. Although the technique for dynamic compression described by Price was very similar to the modern autologous pubovaginal sling (PVS), we now know that, with time and expected incorporation into the body, the sling becomes fixed and immobile in the retropubic space. Hence, eventual continence is no longer related to the sling's attachment over the rectus abdominis fascia. This is anecdotally supported by the fact that cutting these securing sutures in a woman with an obstructive sling months after surgery will have no impact on the sling's tension.

Aldridge's operation was notable for several advancements. First, he theorized that mobilization of any of the previously used muscles inevitably left the muscles denervated and devascularized. Thus, if the woman was continent, it was caused by obstruction from a urethral stricture. Second, he identified an “almost bloodless plane” on either side of the urethra, permitting atraumatic entry into the space of Retzius. Finally, he cautioned surgeons who were inexperienced in the anatomy of the anterior vaginal wall and bladder wall to avoid undertaking the procedure. Despite his warnings, the simplicity of the Aldridge sling led it to become a popular technique for many years, with reported short-term cure rates ranging from 78% to 93% (Jeffcoate, 1956; McIndoe et al., 1987; McLaren, 1957). McLaren (1968) reported an initial cure rate of 87% in 48 women and a 71% long-term cure rate in women followed up to 16 years.

Conversely, Aldridge's operation was associated with several drawbacks. Mobility of the fascial strips was frequently limited by their medial attachments, and no technique existed to prevent excessive tension under the bladder neck and proximal urethra. Also, it was not always possible to achieve sufficient length to pass the sling under the urethra. To address this deficiency, Studdiford (1944) bridged the gap left by the shortened fascia by attaching sutures to each strip of fascia and tying the sutures together under the bladder neck. Variations on the Aldridge sling over the next few decades involved attempts to minimize morbidity and obtain suitable sling material from women with multiple previous abdominal procedures. In the 1950s, Barnes (1950) and Hodgkinson and Kelly (1957) used round ligament, and Kasdon (1951) used uterine ligament. Narik and Palmrich (1962) described a variation on the Aldridge technique in which strips of external oblique aponeurosis were left attached to the pubic tubercle and tied together under the bladder neck. Of 51 women, 90% were cured of SUI in follow-up periods ranging from 6 to 24 months. Despite the improved length and support capabilities of the autologous sling modifications, complications were common, and overall interest in slings waned during the next 15 years. The interest in less-invasive bladder neck suspensions peaked during this period.

A renewed interest in slings emerged the late 1970s and early 1980s as long-term efficacy of the needle suspensions began to be questioned. Improving on Aldridge's technique, McGuire and Lytton (1978) left a strip of rectus fascia attached laterally on one side and tunneled the free end of the strip through the body of the rectus muscle to a suburethral location. The strip was then reattached to the other side of the rectus fascia. The authors reported an 80% to 95% overall success rate in patients with type III SUI (McGuire and Lytton, 1978; McGuire et al., 1987). McGuire et al. (1986) also first described using a 1-cm × 3-cm free rectus strip under the urethra in a series of female myelomeningocele patients. Blaivas and Olsson (1988) further modified McGuire's technique in their description of the modern bladder neck PVS in an effort to correct urethral hypermobility and modify the pressure transmission invoked by intra-abdominal pressure changes. The authors completely detached the rectus fascial strip at both ends and perforated the endopelvic fascia on either side of the urethra to gain access to the space of Retzius.

From 1991 to 1998, the PVS had surpassed needle suspensions and anterior urethropexies to become the predominant invasive surgical method for the treatment of SUI in the United States (Anger et al., 2009). Then in 1998, the U.S. Food and Drug Administration (FDA) approved the first mid-urethral sling (MUS) for use in women with SUI, and the rate of sling surgery increased by more than threefold (78.3 to 237.4 per 100,000 person-years) (Jonsson Funk et al., 2012). Likewise, in a 5% national random sample of Medicare claims from 2000 to 2011, there was a 29.7% increase in the number of sling procedures and a 59.5% decrease in bulking procedures (Chughtai et al., 2016). Unfortunately, as with most national databases, Medicare data are limited by the fact that the Common Procedural Terminology codes do not reveal the exact type of sling that is placed. However, many authors have inferred that the dramatic acceleration in sling surgeries is most likely a result of the increased popularity of the MUS (Oliphant et al., 2009; Wu et al., 2011).

Pathophysiology of Stress Urinary Incontinence and Sling Mechanism of Action

Several theories exist regarding the pathophysiology of SUI and the mechanism of action of sling procedures. A normal pelvic adaptation to an increase in intra-abdominal pressure involves a reflex contraction of the levator muscle and urogenital diaphragm, which elevates and compresses the proximal urethra by increasing the tension on the urethropelvic ligaments. Mid-urethral pressure and urethral closure pressure should rise concurrently with abdominal pressure, and, in the setting of intact urethral support, the increased intra-abdominal pressure is transmitted equally to the bladder and urethra. The net effect of these changes is increased outlet resistance during stress maneuvers resulting in continence. Conversely, when normal transmission of abdominal pressure to the urethra is lost, incontinence results.

Enhorning (1961) originally theorized that this pressure transmission occurs because the female urethra is intra-abdominal, much like in males where the proximal urethra lies cephalad to the urogenital diaphragm. In this model, women with poor anatomic support and urethral hypermobility develop SUI from proximal urethral descent during stress and less-efficient pressure transmission to the urethra. One problem with this theory was that the female urethra does not pass through a solid tissue layer, and only the proximal one-third of the female urethra is intra-abdominal, thus subject to transmitted pressure changes.

DeLancey (1994) published a revised model that made a significant contribution to the current understanding of the continence mechanism. **DeLancey's proposal was that healthy women have a “suburethral hammock” attached laterally that supports the urethra. However, in women with SUI, there is a deficiency of this supporting layer that is evidenced by hypermobility of the bladder neck and urethra.** It was theorized that descent of these structures inferiorly allowed for unequal pressure transmission and subsequent SUI. **Therefore a PVS placed at the bladder neck can eliminate SUI by providing a strong layer of tissue that provides dynamic compression of the urethra during times of increased intra-abdominal**

pressure. This and other similar theories emphasize that urethral support is derived from attachments to the arcus tendineus fasciae pelvis (ATFP) and levator ani muscles.

A second seminal theory focuses on the mid-urethra as the linchpin for continence. Placement of the MUS in this location is partially based on the theories initially put forth by Ingelman-Sundberg (1953), who noted that the pubococcygeus muscles insert at the level of the mid-urethra just outside the vaginal epithelial wall and play a vital role in the mid-urethral continence mechanism. It was further postulated that this anatomic finding is important when considering methods to correct SUI. Decades later, Westby et al. (1982) and Asmussen and Ulmsten (1983) demonstrated that **maximum urethral closure pressure (MUCP) occurs at the mid-urethra in continent women,** and this phenomenon is most likely caused by the combined contribution of anatomic structures in this location.

Based on the aforementioned theories and other published experiments, **Petros and Ulmsten** (1990) **proposed a unifying concept called the *integral theory,*** which posited that adequate function of the pubourethral ligaments, suburethral vaginal hammock, and pubococcygeus muscles was the most important factor for preservation of continence in women. They postulated that injury to any of these three components from surgery, parturition, aging, or hormonal deprivation could lead to impaired mid-urethral function and subsequent urinary incontinence. In one of the studies used as the basis for the integral theory, Ulmsten et al. (1987) performed a biopsy of the skin and round ligament of eight continent women and seven incontinent women. The researchers found that the tissues of incontinent women contained 40% less collagen and concluded that weakness of the connective tissue supporting the urethra secondary to the loss of collagen may contribute to incontinence.

The Age of the Mid-Urethral Sling

Ulmsten and Petros (1995) applied the integral theory to the development of the first retropubic synthetic MUS, which they termed an *intravaginal slingplasty.* In this initial report, 78% of 50 women undergoing a synthetic polymer sling achieved complete cure of SUI, and no complications were reported. **Ulmsten et al.** (1998) **changed the name of the procedure to the *tension-free vaginal tape* (TVT)** and reported this surgical technique's safety and efficacy prospectively. In this multicenter study, 91% of 131 women were cured of their incontinence, and two women developed transient urinary retention that resolved. One woman required “a small adjustment” of the MUS via a vaginal incision, and other complications included hematomas (2), mesh perforation of the bladder recognized at the time of surgery (1), and, although vaginal mesh exposure cannot be corroborated, one woman developed a wound infection requiring a minor surgical procedure and vaginal estrogen. It was this first multicenter MUS trial that was also among the first to report two of the unique and troublesome complications of MUS surgery: mesh perforation of the urinary tract and mesh exposure.

In an effort to minimize the potential for perforation of the urinary tract, bowel, or neurovascular structures, Delorme (2001) introduced the transobturator MUS approach. In his initial report, 97.5% of 40 women were cured of their incontinence, and only one woman experienced a complication. Initially, many proponents of the transobturator sling believed that there was no need to perform a cystoscopy after trocar passage; however, the American Urological Association (AUA) SUI guideline states that “intraoperative cystoscopy should be performed with mid-urethral slings or fascial pubovaginal slings to confirm the integrity of the lower urinary tract and the absence of a foreign body within the bladder or urethra” (Kobashi et al., 2017). Ten years after the introduction of the MUS, **Richter et al.** (2010) **published a study demonstrating that retropubic and transobturator MUS procedures were similarly efficacious and generally safe.** More recently, the AUA/SUFU Guideline made a Moderate Recommendation based on Grade A evidence that either the retropubic or transobturator MUS may be offered to index patients electing surgery for SUI (Kobashi et al., 2017).

The most recent step in the evolution of the sling came in 2006 when the FDA approved the first single-incision MUS (SIMS), a procedure that is performed completely through a vaginal approach without the need for skin entry (Abdel-Fattah et al., 2011). Although the risk for bladder or urethral perforation is low, intraoperative cystoscopy is still recommended to rule out injury. Since the last version of this chapter, significant outcome data have emerged for the SIMS leading to a Conditional Recommendation based on Grade B evidence in the AUA/SUFU guideline (Kobashi et al., 2017). While physicians may offer the SIMS to index patients undergoing MUS surgery, some of the data were deemed immature and inconsistent. This procedure will be presented later in this chapter.

Over the past decade, numerous studies have consistently demonstrated the efficacy and safety of various types of sling procedures for the treatment of female SUI. During the same time frame, several regulatory and professional organizations have raised concerns regarding synthetic mesh exposure and perforation complications unique to synthetic mesh materials, biologic grafts, and the specialized tools used in their placement (Novara et al., 2008). The FDA has responded by releasing two warnings in 2008 and 2011, and, although most of these concerns are related to graft materials used in transvaginal pelvic organ prolapse (POP) surgery, suburethral slings have been implicated by technical similarities. Ultimately, these concerns have led to the reclassification of transvaginal meshes used for POP repair as Class III devices requiring more extensive testing, regulatory oversight, and postmarket surveillance. This topic is of great importance to pelvic surgeons and their patients and will be discussed in further detail later in this chapter.

In the spirit of consistency, we will use the terminology developed by the International Urogynecological Association (IUGA) and the International Continence Society (ICS) for complications stemming from insertion of synthetic and biologic materials during female pelvic surgery (Haylen et al., 2011). According to this report, synthetic mesh is termed a *prosthesis*, and a biologic implant is termed a *graft*. Mesh located in the lower urinary tract is termed a *perforation*, and extrusion of mesh through the skin or vagina is termed *exposure*.

Key Points: Evolution of Slings

- Early theories regarding the cause of stress incontinence were focused on the unequal transmission of pressure to the bladder and urethra, urethral hypermobility, and the excessively inferior location of the urethra.

- Later theories emphasized the importance of the pubourethral ligaments, the suburethral vaginal hammock, and the pubococcygeus muscle as vital support structures for the proximal and mid-urethra.
- Based on these theories, pubovaginal slings are placed under mild tension at the bladder neck to reestablish the suburethral hammock, and mid-urethral slings are placed loosely at the mid-urethra to prevent movement of the posterior urethral wall.

Preoperative Assessment

The goal of a diagnostic evaluation in an incontinent woman is to characterize the type of incontinence, assess the contribution of comorbid medical conditions, elucidate the differential diagnoses, and discover prognostic information that will aid in the selection of treatment. The AUA guideline on the surgical treatment of female SUI stated that the following are the components of an initial evaluation of a woman with SUI who is desiring surgical intervention (Clinical Principle): focused history, including assessment of bother (e.g., via validated questionnaire), focused physical examination (including pelvic examination), objective demonstration of SUI with a comfortably full bladder (e.g., cough or Valsalva stress test), assessment of postvoid residual (PVR) urine volume (any method), and urinalysis (Kobashi et al., 2017). For completeness, it is important to mention that the European Association of Urology (EAU) guidelines on both assessment, nonsurgical treatment (Nambiar et al., 2018), and surgical treatment (Lucas et al., 2013) of urinary incontinence have also been published.

The evaluation of urinary incontinence begins with a thorough history focused on the onset, frequency, character, and severity of the incontinence, as well as other storage and voiding symptoms. Elucidating factors that worsen the woman's incontinence, such as sexual intercourse or exercise, is also important. **It is likewise critical to accurately assess the degree of a woman's baseline urinary urgency, as this specific symptom correlates with poorer outcomes after sling surgery** (Richter et al., 2008). The remainder of the history should focus on the evaluation of other factors that can impact bladder and urethral function, such as neurologic diseases, medications, prior surgeries, and pelvic radiation. Also, it is important to query the woman about problems related to fecal incontinence or defecation.

A focused neurourologic examination and pelvic examination should be performed on any woman with complaints of urinary incontinence. Uncovering physical findings of a neurologic or musculoskeletal disorder may aid in the treatment of a woman's incontinence symptoms. The pelvic examination may uncover correctable anatomic abnormalities that can contribute to incontinence, such as a vesicovaginal fistula and any abnormalities that are the result of urinary incontinence such as vaginal epithelial irritation. The examination should evaluate the following components, both at rest and with provocative maneuvers (i.e., Valsalva and coughing): vaginal anatomy, including the urethral meatus and vaginal support (i.e., POP); quality of vaginal tissues, including the presence of tissue atrophy and irritation; the degree of urethrovesical hypermobility; and any other associated findings, such as the presence of fistulae, foreign materials, or other anatomic abnormalities. During the examination, the patient should be asked to perform Valsalva maneuvers to reveal or emphasize POP, urethral hypermobility, and SUI. Although the usefulness of this test is controversial, a woman is considered to have urethral hypermobility if a Q-tip inserted into the urethra moves more than 30 degrees from baseline during abdominal straining (Bergman and Bhatia, 1987). Lastly, if a supine stress test with a full bladder does not demonstrate urinary incontinence, then a standing stress test should be performed.

Based on the AUA SUI guideline, **a urinalysis and measurement of PVR volume should be performed in all women, but more extensive imaging is not a part of the initial evaluation of a woman with a complaint of SUI.** It was the panel's expert opinion that physicians should perform additional evaluations in some women with abnormal findings in the history, physical examination, or urinalysis (Kobashi et al., 2017). These situations include: an inability to make a definitive diagnosis based on symptoms and initial evaluation; inability to objectively demonstrate SUI; known or suspected neurogenic lower urinary tract dysfunction (e.g., multiple sclerosis); abnormal urinalysis (e.g. unexplained hematuria or pyuria); urgency-predominant mixed urinary incontinence (MUI); elevated PVR per clinician judgement; high-grade POP (POP-Q stage ≥3) if SUI is not demonstrated by POP reduction; and evidence of significant voiding dysfunction. The panel concluded that additional evaluation may be performed in women with concomitant overactive bladder (OAB) symptoms, those with failure of previous anti-incontinence surgery, and those with previous surgery for POP.

Additional testing may include radiographic evaluation, cystoscopy, and urodynamic studies (UDS). Radiography of the upper urinary tract may be useful in women with concomitant hematuria or suspected neurogenic dysfunction. Likewise, magnetic resonance imaging (MRI) of the head, spine, and pelvis may be useful to detect spinal cord or brain lesions. The panel concluded that cystoscopy should not be performed in the evaluation of SUI unless there is a concern for urinary tract abnormalities, such as neoplasia or foreign body.

The necessity and benefit of preoperative urodynamic evaluation, including filling cystometrogram, measurement of leak point pressures, electromyography, and pressure-flow studies, is an area of controversy. The AUA SUI guideline panel concluded that **urodynamics may be omitted in the index patient when SUI is clearly demonstrated (Conditional Recommendation; Grade B level of evidence).** This statement is predominantly based on the findings of the ValUE trial that randomized women with SUI or stress-predominant MUI to urodynamics or clinical evaluation only before anti-incontinence surgery (Nager et al., 2012). In this multicenter, randomized, noninferiority trial of 630 women, the authors concluded that preoperative office evaluation alone was not inferior to evaluation with urodynamic testing for 1-year outcomes after SUI surgery in women with uncomplicated, demonstrable SUI. Other factors cited as evidence against routine UDS are the somewhat invasive nature of the studies and the considerable costs incurred. In a secondary analysis of the ValUE trial, Norton et al. (2016) found that the average cost of urodynamic evaluation per woman exceeded $300, which extrapolated to a US expenditure of $13 to $33 million annually.

On the other hand, proponents of preoperative urodynamics cite this evaluation as the only way of definitively diagnosing intrinsic sphincter deficiency (ISD) before surgery. While no study has found that urodynamic evaluation definitively predicts postoperative outcomes for uncomplicated SUI, at least two studies have suggested that women in the lower quartile of Valsalva leak point pressure (VLPP) or MUCP measurement have poorer outcomes after transobturator MUS (Nager et al., 2011; Schierlitz et al., 2012). Likewise, poor urethral function diagnosed on urodynamics predicted a twofold increase in surgical failure at 1 year after retropubic and transobturator MUS in the TOMUS (Trial of Mid-Urethral Slings) trial (Richter et al., 2010). Additionally, the study design of the ValUE trial has been called into question. As the study only sought to include women with uncomplicated SUI, the finding that 85% of the 4000 women screened were ineligible for study inclusion may indicate that the overwhelming majority of women do not have uncomplicated SUI. Furthermore, 97% of the treating physicians were fellowship-trained, indicating potentially less need for rigorous urodynamic testing.

It was the expert opinion of the panel that urodynamics may be performed in the nonindex patient, specifically those with: history of prior anti-incontinence or POP surgery; mismatch between subjective and objective measures; significant voiding dysfunction, urge-predominant MUI, urgency, urgency urinary incontinence (UUI), or OAB; elevated PVR; unconfirmed SUI; and neurogenic lower urinary tract dysfunction. It goes without saying that this step of the evaluation is dependent on the willingness of the patient to undergo the studies and the possibility that additional evaluation may alter or better define treatment options. In those women with significant POP, **urodynamic testing should be performed with and without POP reduction (e.g., with sponge stick or pessary).**

One of the goals of urodynamics is to evaluate urethral function. In women with SUI, low MUCP and abdominal leak point pressure (ALPP) are often used as indicators of urethral dysfunction. McGuire looked at the urodynamic properties of women in whom anti-incontinence surgeries had failed and determined that an **MUCP less than 20 cm H_2O was indicative of type III SUI (now known as ISD)** (McGuire, 1981). Several years later, Sand et al. (1987) performed urodynamic studies on 86 women undergoing modified Burch colposuspensions and determined that women with MUCP less than or equal to 20 cm H_2O had a significantly higher failure rate (54% vs. 18%) than women with MUCP greater than 20 cm H_2O. Other authors have also used an MUCP less than or equal to 20 cm H_2O to characterize a patient with severe urethral dysfunction (Clemons and La Sala, 2007; Fritel et al., 2008).

In addition to MUCP, **ALPP** can also give the clinician an objective measure of urethral dysfunction (McGuire et al., 1993). The authors performed urodynamic studies on 125 women with SUI and determined that an **ALPP less than 60 cm H_2O signified ISD, and an ALPP greater than 90 cm H_2O signified very little or no ISD. Since then, the definition of ISD has evolved from one based on strict urodynamic criteria to a clinical diagnosis. In understanding surgical treatment, it is essential to appreciate that all women with stress incontinence have some component of ISD.**

In addition to the outlet evaluation during urodynamic studies, **assessment of bladder pressure during filling and emptying yields valuable prognostic information about bladder function.** Most importantly, **the discovery of detrusor overactivity (DO) during bladder filling may have an impact on the decision to pursue a particular treatment option.** It has been theorized that both the stress leakage of urine into the proximal urethra (Kuru, 1965) and the traction on pelvic nerves that occurs when increased abdominal pressure is applied to weakened pelvic supportive tissue (Serels et al., 2000) can induce DO. Thus, there is the potential to improve the DO with anti-incontinence surgery in these women with “stress-induced DO.” However, there is the potential for existing DO and urinary urgency to worsen in women after otherwise uncomplicated anti-incontinence surgery. Thus, alternative or complementary treatment options should at the least be considered before proceeding with sling surgery in women with DO. A low cystometric bladder capacity and decreased compliance may also negatively affect the outcomes of sling surgery, and these factors should also be considered. Finally, as previously mentioned, the overall value of urodynamics in predicting outcomes after sling surgery is debatable (Nager et al., 2008, 2011).

Key Points: Preoperative Assessment

- At minimum, a woman being evaluated for urinary incontinence should undergo a focused history, physical examination, and objective confirmation of SUI. In addition, basic clinical tests such as urinalysis and PVR volume measurement should be performed.
- While cystoscopy should not be performed in women with uncomplicated SUI, this diagnostic modality and other radiographic imaging may be performed in those women with hematuria and when urinary tract abnormalities are suspected.
- Urodynamic studies may be omitted in women with uncomplicated SUI and stress-predominant MUI who desire surgical intervention. However, these studies may prove useful if the diagnosis of SUI is unclear or when there are concomitant complicating factors, such as significant urinary storage and voiding symptoms, history of prior lower urinary tract surgery, suspected neurogenic bladder dysfunction, or significant POP.
- Although slings are an effective treatment for both SUI and stress-predominant MUI, a thorough understanding and characterization of a woman's preoperative symptoms and bother will help guide counseling and treatment decisions.

Alternative Treatment Options

As urinary incontinence rarely impacts *quantity* of life, nonsurgical treatment options should be discussed with each woman. It was the expert opinion of the AUA SUI guideline panel that treatment options should be tailored to the individual patient, and patient bother should be taken into account in the decision for therapy (Kobashi et al., 2017). Initial nonsurgical (conservative) therapy includes patient education, behavioral and dietary modification, judicious fluid restriction, weight loss, and pelvic floor muscle training (PFMT) (Dallosso et al., 2003). There is significant evidence in the literature to support the efficacy of these treatment methods (Osborn et al., 2013). Subak et al. (2009) randomized 338 obese women to one of two different weight-loss programs, and, after 6 months, the two programs showed an average 8- and 1.6-kg weight loss with a corresponding significant 58% and 33% reduction in SUI (Subak et al., 2009). A recent review concluded that weight loss may have a salubrious impact on both SUI and OAB symptoms (Fuselier et al., 2018).

Kegel exercises and formal PFMT are other nonsurgical treatment options and are theorized to help with pelvic floor muscle strength and coordination. A Cochrane Database systematic review of 21 randomized and quasi-randomized trials of PFMT in women with SUI concluded that PFMT should be recommended to most women before surgical treatment (Dumoulin et al., 2015b). Compared with no treatment, women undergoing PFMT were more likely to experience cure of SUI (risk ratio [RR] 8.38; 95% confidence interval [CI] 3.68 to 19.07) and cure or improvement (RR 17.33; 95% CI 4.31 to 69.64). PFMT was also associated with cure of any type of incontinence (RR 5.5; 95% CI 2.87 to 10.52) or cure and improvement (RR 2.39; 95% CI 1.64–3.47). However, as with any exercise regimen, vigilance in continuing PFMT remains the key to its success. An expert-panel consensus of the State-of-the-Science Seminar on PFMT held before the 41st International Continence Society scientific meeting concluded that adherence to PFMT is central to short- and longer term symptom improvement (Dumoulin et al., 2015a). Additionally, pessaries and other vaginal and urethral devices have been shown to help with SUI in select individuals (Robert and Mainprize, 2002; Staskin et al., 1998).

The **submucosal injection of periurethral bulking agents** using a cystoscope is a minimally invasive treatment for SUI, albeit one with variable success rates and frequent need for retreatment. The discontinuation of bovine-derived cross-linked collagen in 2011 by its manufacturer has led to the increased use of several newer synthetic, permanent agents. However, a recent Cochrane systematic review concluded that there was limited evidence for the benefit of these agents (Kirchin et al., 2017). Nevertheless, because of the low risk for side effects, periurethral bulking remains a potential treatment option for many women who are not ready to undergo a more invasive surgical procedure.

Pubovaginal Sling (PVS)

As compared with a MUS, a PVS is placed at the bladder neck. It is a highly versatile surgical procedure for both uncomplicated and complicated SUI associated with a deficiency in a portion of the mid-urethral complex, urethral hypermobility, ISD, MUI, concomitant cystocele (Cross et al., 1997; Serels et al., 1999), urethral diverticula, and neurologic conditions (Austin et al., 2001). In women with neurogenic SUI, such as those with myelodysplasia, a PVS is effective for the SUI that may occur between clean intermittent catheterizations (CIC) once a thorough urodynamic evaluation has confirmed sufficient bladder capacity and compliance. A PVS may also aid in the reconstruction of the urethra after damage secondary to trauma, synthetic mesh (or graft) perforation, and iatrogenic hypospadias, or it can be used for interposition during urethral repairs of urethrovaginal fistulae or urethral diverticula (Blaivas and Heritz, 1996; Gormley et al., 1994; Leng and McGuire, 1998; McGuire and O'Connell, 1995). Likewise, a PVS is effective in treating recurrent SUI after failed retropubic suspensions or MUS placement (Beck et al., 1988; Petrou and Frank, 2001). Although many different sling materials and techniques have been described, the PVS using autologous fascia remains the gold standard for management of ALL forms of SUI.

Anatomy and Mechanics of a Pubovaginal Sling

Female SUI is caused by a combination of damage to the mid-urethral complex and ISD. Urethral hypermobility is a physical indication that the mid-urethral complex may not be functioning optimally. The female urethra is positioned under the pubic symphysis, and the pubourethral ligaments suspend the anterior urethral wall to the pubic arch. In cases of urethral hypermobility, Valsalva or other increases in intra-abdominal pressure cause the posterior wall of the urethra to slide away from the anterior urethral wall and, in turn, open the bladder neck and proximal urethra. Uneven pressure transmission combined with the opening of the bladder neck (funneling) cause a loss of urine with stress maneuvers. **ISD** arises from defects within the urethra proper, so that the urethral sphincter is unable to coapt and generate enough resting urethral closing pressure to maintain continence.

The female urethra is composed of four separate tissue layers that assist in keeping it closed. Compression from the middle muscular layer helps maintain the resting urethral closure mechanism, and the outer seromuscular layer augments this closing pressure. In normal circumstances, the resting urethral closing pressure of the internal sphincter exceeds the resting or Valsalva pressure exerted by the bladder. In addition, fast-twitch fibers of the external sphincter are responsible for a sudden voluntary contraction, and slow-twitch fibers provide continuous passive control by the involuntary guarding reflex during bladder filling. In addition to these structures, the integrity of the pelvic diaphragm is also dependent on the levator ani for continence control. Lastly, the urethropelvic ligament and pubocervical fascia provide support to the bladder neck and undersurface of the bladder, respectively, to prevent SUI (Vasavada and Rackley, 2009).

The PVS is positioned at the bladder neck to provide dynamic urethral compression without obstruction during times of increased intra-abdominal pressure. The ultimate goal is to provide adequate urethral coaptation and increase urethral responsiveness to abdominal pressure. This must be balanced against the risks for ischemia, retention, and erosion from unnecessary tension. **Blaivas and Olsson** (1988) **described the current version of the PVS and modified McGuire's technique by using a shorter free graft of rectus fascia whose tension could be adjusted.** It is the incorporation of the sling into the endopelvic fascia and subsequent fixation and fibrosis, rather than entry into the retropubic space, that prevents the sling from giving way after increases in intra-abdominal pressure. The approximately 2-cm width of the PVS ensures that there is sufficient support to provide the needed urethral compression and a cross-sectional area adequate to avoid the formation of a narrow constricting band.

Pubovaginal Sling Materials

Throughout the past century, multiple autologous, allograft, xenograft, and synthetic materials have been used for the construction of a PVS. The ideal material provides long-lasting suburethral support with minimal adverse effects. While an ideal implanted material should incorporate itself into the host with minimal tissue reaction, in reality, most materials promote organized fibrosis and reinforce the sphincteric mechanism through improved suburethral support. Theoretically, a greater degree of fibrosis leads to better clinical results (Bidmead and Cardozo, 2000; Woodruff et al., 2008); however, inflammatory infiltration can lead to rapid sling material degradation and possible tissue destruction with erosion (Bidmead and Cardozo, 2000). **Although the autologous sling is completely biocompatible and has rarely been associated with urethral perforation, biologic grafts and synthetic prosthetics had gained popularity because of decreased operative time, morbidity, pain, and length of hospital stay after surgery with these materials** (Niknejad et al., 2002).

Autologous Pubovaginal Slings

The most commonly used autologous materials are **rectus abdominis fascia** harvested from the abdominal wall and **fascia lata** harvested from the lateral thigh. Fitzgerald et al. (2000) reported that after sling placement, rectus fascial grafts undergo extensive remodeling and have abundant fibroblasts and connective tissue on biopsy specimens. Other authors have published similar findings. Woodruff et al. (2008) performed a histologic comparison of PVS materials (10 synthetic, 5 autologous, 5 allografts, and 4 xenografts) and noted that autologous materials were associated with the greatest degree of host fibroblast infiltration and neovascularization, but minimal inflammatory or foreign-body reaction. Analysis of explanted specimens up to 65 months after placement revealed that the autologous fascial grafts were consistently intact and displayed minimal gross degradation. **In addition to the inherent benefit of minimal inflammation, autologous tissue also carries a negligible risk for urethral erosion** (Webster and Gerridzen, 2003)**. Disadvantages of harvesting autologous fascia include an increase in operative time, hospital stay, postoperative pain, and harvest site complications**.

It is important to note that even if the rectus fascia harvest site is scarred and thickened from prior operations, the quality of rectus graft may not be ultimately compromised. Nevertheless, there are some instances, such as a prior ventral hernia repair, in which **fascia lata** is the preferred autologous material for PVS. This fascia is harvested from the thigh and has similar properties to rectus fascia (Beck et al., 1988; Latini et al., 2004). Like rectus fascia, fascia lata is completely biocompatible and is associated with minimal tissue reaction. Unlike rectus fascia, the **recovery time is reportedly less, and there is minimal risk for abdominal harvest site complications. However, harvesting fascia lata does require repositioning of the woman, additional operative time, and operating in an area unfamiliar to most pelvic surgeons** (Govier et al., 1997). Furthermore, thigh pain may be a short-term sequela. Wheatcroft et al. (1997)

reported that 67% of women had pain on walking for 1 week after fascia lata harvest, although Latini et al. (2004) reported that only 7% of women complained of pain at the incision site 1 week after harvest using a Crawford fascial stripper. Thigh muscle herniation has also been reported in the literature, but this appears to only occur when large strips of fascia are removed (Dubiel and Wigren, 1974; Wheatcroft et al., 1997). In these studies, the rate of thigh herniation was 51% (20 of 39) with a 10- to 20-cm fascial graft and 0% (0 of 24) with a 1.5-cm by 12- to 15-cm fascial graft.

Vaginal epithelium has also been used as an autologous source for sling construction. Raz et al. (1989) described use of in situ vaginal wall; however, this tissue may lack sufficient tensile strength, and there is a risk for epithelial inclusion cyst formation and vaginal shortening. Also, a lack of retropubic space dissection may mitigate the overall efficacy of this procedure (Appell, 2000; Ghoniem and Hassouna, 1998; Loughlin, 1998).

Pubovaginal Sling Allograft Materials

Cadaveric allografts used in many nonurologic surgical arenas (e.g., orthopedics, neurosurgery) were eventually adopted for SUI surgery. **Allograft slings are currently derived from either cadaveric fascia lata (CFL) or acellular human dermis.** After harvest, the allografts are processed by solvent dehydration or by lyophilization (freeze-drying) to remove genetic material and to prevent the transmission of infectious agents. Secondary sterilization may also be achieved by gamma radiation (Gomelsky et al., 2003). Unlike autologous materials, histologic analysis reveals that cadaveric dermis (CD) has minimal host fibroblast infiltration and neovascularity, particularly in the central aspects of the graft (Woodruff et al., 2008). In addition, gross examination may reveal disruption of the sling scaffold and significant graft thinning and degradation.

In general, **allografts are pliable, easy to use, and available in a variety of sizes. No specific allograft has been associated with a clinical advantage;** however, acellular dermis rehydrates in 0.9% saline more quickly than does cadaveric fascia lata (5 minutes vs. 15 to 30 minutes) (Gomelsky et al., 2003). In addition, biomechanical studies have shown that solvent-dehydrated cadaveric fascia lata and acellular dermis have a higher maximal load to failure than freeze-dried cadaveric fascia lata (Hinton et al., 1992; Lemer et al., 1999). More specifically, Lemer et al. (1999) theorized that ice crystal formation produced by tissue freezing disrupts the collagen matrices and causes decreased tissue integrity and durability.

Since allografts are harvested from cadavers, their use may be associated with a theoretical concern of transmitting illnesses such as the human immunodeficiency virus (HIV), hepatitis, and Creutzfeldt-Jakob disease (CJD). Since the onset of tissue screening in 1985, there has been one documented case of HIV transmission from a nonurologic tissue transplant. The estimated risk for acquiring tissue from a properly screened donor infected with HIV is 1 per 1,667,600 (Gallantine and Cespedes, 2002). A few cases of CJD have been reported after transplantation of cadaveric dura or corneas; however, skin obtained from animals infected with these prions has demonstrated no detectable infectious particles. Currently, the theoretical risk for developing CJD from a non-neural allograft is 1 in 3.5 million, and no cases of hepatitis or CJD have ever been attributed to the use of processed cadaveric fascia or dermis (Amundsen et al., 2000b; Gallantine and Cespedes, 2002). The theoretical risk for developing hepatitis from allograft material is unknown; however, two cases of hepatitis transmission have been reported in the musculoskeletal tissue transplantation literature, both occurring before the implementation of extensive donor screening for viruses and bacteria and the availability of serologic tests (Shutkin, 1954). Despite the low risk for disease transmission, human DNA has been detected in various allograft materials (Choe and Bell, 2001; Hathaway and Choe, 2002); however, the clinical significance of this finding is unknown.

Pubovaginal Sling Xenograft Materials

Xenograft use was common in the 1980s (Descurtins and Buchmann, 1982; Iosif, 1987) because of the materials’ immediate accessibility and minimal associated morbidity; however, xenografts for sling construction have met with decreasing popularity in recent years. Available xenografts are either **porcine (dermis, small intestinal submucosa (SIS), or bladder acellular matrix graft) or bovine (dermis or pericardium) in origin.** Modern processing techniques using diisocyanate to remove genetic material have made porcine grafts both safer and more pliable; however, in a rabbit model, there was significant loss of tensile strength after implantation (Dora et al., 2004). It is interesting to note that histopathologic analysis has shown porcine small intestinal submucosa (SIS) to contain growth factors that may reduce host-graft immunologic reaction and lessen tissue scarring (Wiedemann and Otto, 2004). Although most data support SIS as nonimmunogenic, animal studies by Thiel et al. (2005b) suggested that an intense inflammatory reaction occurs 30 to 90 days after subcutaneous implantation. In a report by Kalota (2004), 33% of 18 women experienced postoperative inflammation after an SIS PVS procedure. Konig et al. (2004) reported a single case of postoperative inflammation with abscess formation with SIS use, although Ho et al. (2004) reported a similar reaction in 6 of 10 women. In a series by John et al. (2008), all of the women had pain and erythema at the abdominal incision, and 2 developed abscesses. Of note, five of the six women with inflammatory responses were continent. Five women were treated conservatively, and one required abscess drainage. The exact cause of these complications is unknown but is likely related to a foreign-body reaction from the multilayered (8-ply) SIS material, a reactive manufacturing ingredient, or the tendency for suprapubic fat to produce an inflammatory reaction.

In 2001, Kubricht et al. (2001) showed that porcine SIS has less tensile strength than cadaveric fascia lata. Bovine pericardium has been available in a preparation cross-linked with glutaraldehyde or as a non–cross-linked acellular matrix (Gomelsky et al., 2003). Histopathologic comparison of sling materials by Woodruff et al. revealed porcine dermis to have no host fibroblast infiltration, no inflammatory reaction, and no foreign-body reaction (Woodruff et al., 2008). This study also showed that xenograft had the highest propensity to encapsulate, with the capsule around the porcine dermis isolating the graft from the periurethral tissue. The grafts were described as appearing similar to their original appearance at time of implantation.

Pubovaginal Sling Synthetic Prosthetic Materials

Kraats introduced the first synthetic sling (nylon) (Kraatz, 1953), and in the decades since, other synthetic materials have been used for sling construction. The advantages of synthetic material for PVS surgery are consistent quality, elimination of harvest site complications, decreased operative time, and an extensive supply of artificial graft material in multiple sizes and shapes. **Compared with biologic grafts, synthetic materials are more uniform, consistent, and durable. In addition, synthetic prosthetic materials are sterile, biocompatible, and noncarcinogenic** (Niknejad et al., 2002)**. On histopathologic comparison, synthetic materials demonstrate the least amount of degradation or disruption and the greatest amount of fibroblast and tissue ingrowth into the specimen** (Woodruff et al., 2008). Microscopically, synthetic materials are associated with a foreign-body reaction characterized by giant cells and occasional microcalcifications. This foreign-body reaction is not visible grossly, and no graft disruption or adverse effects to the host have occurred.

Artificial graft materials do have potential drawbacks, including graft infection, urinary tract perforation, and vaginal exposure. Along with patient characteristics, the chemical and physical properties of each artificial material determine how the sling will ultimately incorporate into the surrounding host tissue. The susceptibility to infection and poor integration in multifilament synthetic prostheses is proportional to the pore size of the materials (Amid, 1997; Niknejad et al., 2002). Tightly woven, microporous meshes typically admit small bacteria but exclude macrophages and polymorphonuclear leukocytes. Conversely, loosely woven, macroporous meshes allow tissue ingrowth and neovascularization without limiting cellular access. Tissue bonding to the mesh strengthens and supports the repair. Increased mesh stiffness or decreased pliability may also contribute to mesh exposure.

The classification by Amid (1997) used for synthetic materials in hernia surgery may be practically applied to urology as well (Table 125.1). The most frequently used materials are grouped into four types. Type I are totally macroporous prostheses containing pores greater than 75 µm, which is the pore size for admission of macrophages, fibroblasts, blood vessels, and collagen fibers (Bobyn et al., 1982; White, 1988; White et al., 1981). Type II materials are completely microporous prostheses commonly made from expanded polytetrafluoroethylene (ePTFE) and contain pores less than 10 µm in at least one dimension. Type III includes macroporous prostheses with multifilamentous or microporous components, and type IV includes biomaterials with submicronic pore size (Amid et al., 1992) (see Table 125.1). Amid (1997) proposed that the risk for infection and seroma formation was decreased by the use of type I mesh.

TABLE 125.1

Classification of Synthetic Materials

TYPE	DESCRIPTION	REPRESENTATIVE MATERIAL	BRANDS	NOTES
I	Pores >75 µm; macroporous	Polypropylene	Trelex Natural Mesh, Marlex, Prolene	Monofilament with open weave pattern
II	Pores <10 µm; microporous	ePTFE	Gore-Tex, Surgical Membrane,	Very flexible

			Dualmesh	
III	Macroporous with multifilamentous or microporous components	PTFE	Teflon	Multifilament
		PE	Mersilene (braided Dacron[a] mesh)	Multifilament fibers, very porous, becomes firmly embedded in native tissues
		PE impregnated with collagen matrix	ProteGen	Removed from market in 1999 secondary to high rate of vaginal exposure
		Braided polypropylene	Surgipro	
		Perforated ePTFE patch	Gore-Tex MycroMesh	
IV	Submicronic pore size	Silicone plus woven PE	Silastic[b]	Minimal tissue reaction, which facilitates removal or revision if necessary
		PE/Silastic laminated sheeting	Celgard[c]	

[a] Dacron is polyethylene terephthalate (polyester) and is manufactured by DuPont USA.

[b] Silastic is a silicone polymer manufactured by Dow Corning Corporation in Midland, MI.

[c] Celgard is manufactured by Celgard LLC in Charlotte, NC.

ePTFE, Expanded polytetrafluoroethylene; *PE,* polyethylene terephthalate; *PTFE,* polytetrafluoroethylene.

Modified from Amid PK. Classification of biomaterials and their related complications in abdominal wall hernia surgery. *Hernia* 1:15–21, 1997; Niknejad K, Plzak LS, Staskin DR, et al. Autologous and synthetic urethral slings for female incontinence. *Urol Clin North Am* 29:597–611, 2002.

The most commonly used synthetic material for all slings is polypropylene mesh (type I). It is composed of loosely woven strands of polypropylene and has a pore size greater than 80 µm, permitting passage of macrophages and excellent host tissue ingrowth (Kobashi et al., 2002). Because of the propensity of many synthetic materials to become exposed or to perforate during PVS placement at the bladder neck, their mention in this chapter is predominantly of historical value. At present, synthetic materials are employed for loose sling placement at the mid-urethra (Niknejad et al., 2002).

Key Points: Pubovaginal Sling Materials

- The ideal material for the construction of a PVS is sterile, biocompatible, noncarcinogenic, and consistent in quality.
- The implanted material should be incorporated into the host with minimal tissue reaction and provide long-lasting suburethral support with minimal complications.
- Autologous materials remain the gold standard for PVS and are associated with no tissue reaction and negligible chance of urethral perforation. Other biomaterials have been used in an attempt to shorten operative time, hospital stay, and postoperative recovery.
- Tissue-processing techniques for allografts vary and may disrupt the microstructure thereby affecting ultimate graft strength.
- Xenografts have less tensile strength than allografts in situ and have the highest propensity to encapsulate. Like allografts, processing of these materials may vary significantly.
- Synthetic materials, as a whole, are characterized by significant inflammatory and foreign-body reactions and are associated with higher rates of graft infection and perforation. These prostheses are suboptimal for placement at the bladder neck.

Pubovaginal Sling Operative Procedure

Counseling

The risks associated with surgery in general should be discussed during the informed consent process. If a synthetic prosthesis or xenograft is being used, surgeons should thoroughly counsel their patients about the permanent nature of these products and the unique and sometimes serious complications related to their use. In our opinion, this step is paramount because many patients and their families have increased awareness of the **potential dangers of synthetic mesh.** Women should also be counseled about the risk for **transient and permanent voiding dysfunction after surgery.** This should include a discussion of postoperative difficulty emptying the bladder and de novo urgency and frequency. Preoperative instruction in performing CIC in select patients may minimize the need for an indwelling urethral catheter postoperatively.

Anesthesia, Patient Positioning, and Preparation

PVS placement may be performed under spinal or general anesthesia, and is ultimately based on patient, surgeon, and anesthesia provider consensus. Sling surgery is classified as a clean-contaminated case. An AUA Best Practice Policy Statement recommends the preoperative administration of a single dose of a first- or second-generation cephalosporin or an aminoglycoside plus metronidazole or clindamycin (Wolf et al., 2008). While fluoroquinolones have been previously listed as alternative options for preoperative antibiotic prophylaxis, recent changes have emerged in product labeling. On July 26, 2016, the FDA revised the black box warning, the FDA's strongest warning, to address serious safety issues that may result from the use of fluoroquinolones. The FDA specified that fluoroquinolones have serious side effects that outweigh the benefits in the use of conditions, such as uncomplicated UTIs, in patients for which other treatment options may be effective. The FDA did not comment on the use of fluoroquinolone antibiotics before outpatient procedures or the routine use perioperatively; however, because of the side-effect warning, physicians should consider switching to a different antibiotic in surgery or before a procedure on case-by-case basis.

We routinely place bilateral lower extremity intermittent pneumatic compression (IPC) devices before administration of anesthesia. The AUA Best Practice Policy Statement for the Prevention of Deep Venous Thrombosis in Patients Undergoing Urologic Surgery states that, for incontinence surgery, the use of IPC devices, low-dose unfractionated heparin, or low-molecular-weight heparin should be based on individual patient and procedural risk factors (Forrest et al., 2009).

The patient is placed in the dorsal lithotomy position, and care is taken to minimize the potential for lower extremity neural injury. Although the overall incidence is low (1.8%), Bohrer et al. observed 14 peripheral nerve injuries in 11 patients, with lateral femoral cutaneous (5), femoral (5), common fibular (1), ilioinguinal/iliohypogastric (1), saphenous (1), and genitofemoral (1) nerves affected (Bohrer et al., 2009). Fortunately, complete resolution of neuropathic symptoms occurred in all but one woman at a median time to symptom resolution of 31.5 days (range, 1 day to 6 months). The abdomen (from the umbilicus down) and vagina are prepared and draped in sterile fashion. In the United States, povidone-iodine is the most commonly used antiseptic for vaginal preparation; however, in other countries this is may not be the case (American College of Obstetricians and Gynecologists [ACOG], 2013). In September 2013, ACOG released a committee opinion that chlorhexidine gluconate solutions containing 4% alcohol or less were both safe and effective for vaginal preparation (off-label use).

A weighted speculum is placed in the vagina, and an 18-Fr Foley catheter is inserted into the urethra. The patient should be placed in a moderate Trendelenburg position; for optimal visualization during vaginal dissection, the surgeon may benefit from a headlight. A vaginal ring retractor may be used to retract the labia majora and, later in the case, to retract the incision, further improving visualization and ease of dissection.

In the case of fascia lata harvest, the IPC device is placed below the woman's patella on the harvest side. The knee is elevated and supported with a 1-L bag of intravenous fluid or an appropriate cushion or pad. The involved extremity is internally rotated at the hip and secured to the table using 3-inch tape, below the operative site. The thigh is prepared and draped to expose its anterolateral aspect from the greater trochanter to the patella distally. The greater trochanter and lateral femoral condyle of the femur are identified and marked. These landmarks denote the proximal and distal attachments of the fascia lata (Dwyer and Kreder, 2008).

Graft Harvest for Autologous Pubovaginal Sling

A 6- to 7-cm Pfannenstiel incision is made approximately 2 cm above the pubic symphysis and carried down to the rectus fascia. A 2-cm × 8-cm graft is then marked out on the rectus fascia in a transverse or longitudinal direction. The premarked graft is harvested using a scalpel or electrocautery (Fig. 125.1A). If a transverse fascial incision is used, maintaining a 2-cm or greater distance away from the pubic symphysis will help ensure a tension-free fascial closure. Freeing the edges of the fascia away from the underlying rectus muscle with a scalpel or electrocautery may also aid in a tension-free closure but could theoretically weaken the fascia. The fascia is closed with a running No. 1 polydioxanone suture (PDS). Alternatively, figure-of-eight 0-0 polyglactin 910 (Vicryl) may be used in women with minimal subcutaneous fat. On the rare occasion the fascia cannot be closed adequately, it may be necessary to place an interposing segment of synthetic mesh or biologic graft.

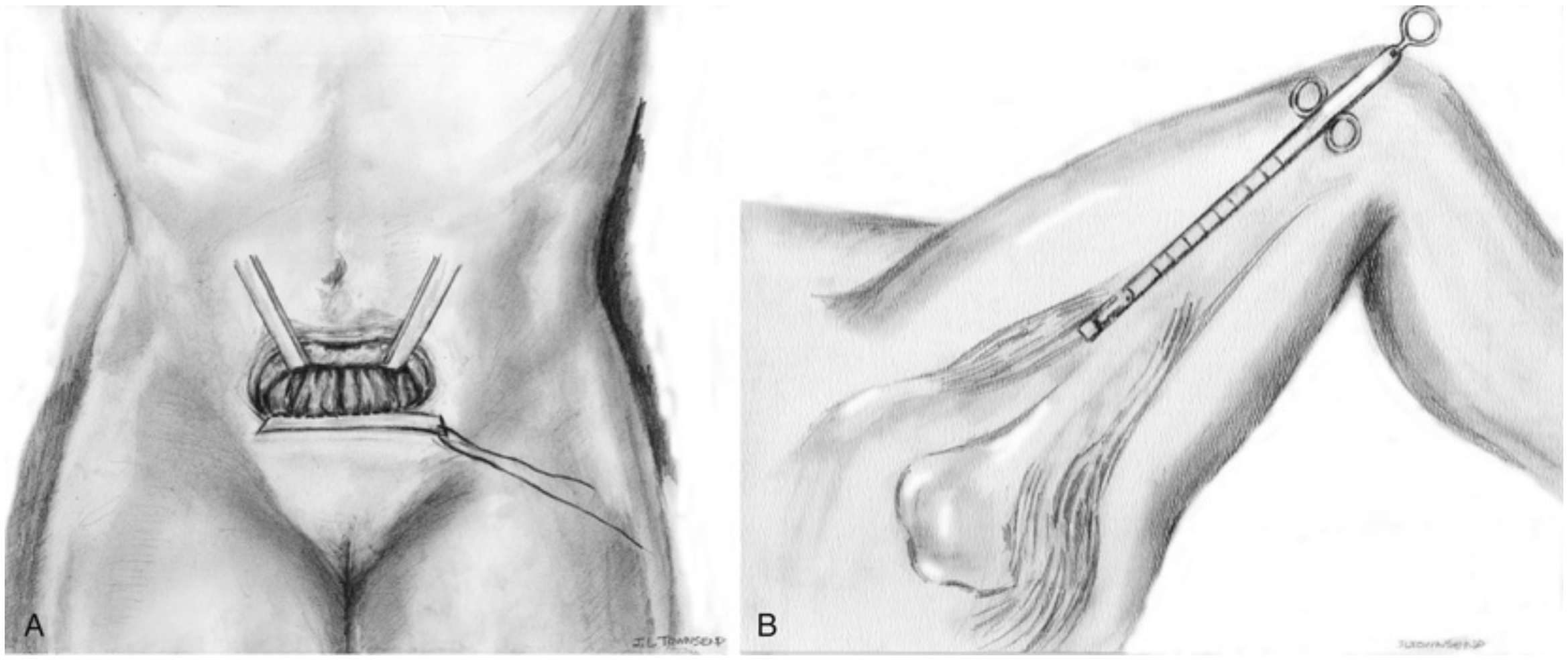

FIG. 125.1 (A) Rectus fascial graft harvest. (B) Autologous fascia lata harvest.

After harvest, the autologous graft is placed in a 0.9% normal saline solution with or without antibiotic. On a sterile side table, the overlying fat and perifascial tissue are cleaned off the graft and a separate No. 1 PDS or 1-0 polypropylene suture is secured to each end of the graft. Each suture should be placed perpendicular to the sling fibers (transverse harvest only), run across each end of the graft, and tied down. Sutures are left long, and the graft is again placed in the saline solution until needed.

For fascia lata harvest, a 3-cm longitudinal incision is marked beginning just above the patella over the iliotibial band (see Fig. 125.1B). Dissection is carried down to the level of the fascia lata, where two parallel, longitudinal, incisions are made 2 cm apart. The graft is bluntly lifted off the underlying muscle and clamped as far distally as possible with a right-angle clamp (3 cm to 4 cm) and transected, allowing one free end. The free end is secured with a No. 1 PDS, and the proximal fascia lata is lifted off the muscle belly with a thin, malleable retractor. The fascia lata is separated from both the adipose tissue and muscle fibers by passing the retractor superficially and deep to the fascia lata. With the free distal end under tension, a Crawford fascial stripper is used to extend the fascial incision proximally and divide it before removal. Classically, a full-length fascial strip (20 cm × 2 cm) was harvested; however, shorter lengths (8 cm) are now commonly used (Karram and Bhatia, 1990). A second No. 1 PDS is secured to the other free end of the graft and the sling is placed in saline until needed. Immediate compression is applied to the thigh to constrict any perforating vessels and the area is carefully evaluated for arterial bleeding before closure. The wound is irrigated and closed in three layers without closing the fascia lata. Once the thigh closure is complete, a compressive wrap is applied to the thigh and the IPC device is replaced. The compressive bandage should remain in place for 8 hours postoperatively and early ambulation should be encouraged (Dwyer and Kreder, 2008).

Pubovaginal Sling Vaginal Dissection

We begin by injecting 0.9% sterile normal saline into the vaginal epithelium corresponding to the mid-urethra and bladder neck to provide hydrodistention and aid in tissue dissection. We prefer an inverted U-shaped incision because it provides excellent exposure of the urethra to the level of the bladder neck and direct access to the endopelvic fascia and subsequently retropubic space (Fig. 125.2). The top of the incision is made approximately 2 cm below the urethral meatus (an Allis clamp placed immediately below the meatus improves visualization and exposure), and the arms of the inverted U-incision should extend to the level of the bladder neck (determined by palpation of the Foley balloon). A 15-blade knife is used to carry this incision down through the vaginal epithelium, with care to stay above the periurethral and pubocervical fascia (to avoid bleeding and injury to the urethra and bladder). Alternatively, a midline vaginal incision extending from the bladder base proximally to the mid-urethra distally can be used. With an Allis clamp and Metzenbaum scissors, thick vaginal epithelial flaps are created. The flaps are retracted with the help of the vaginal ring retractor. It is important to keep the arms of the inverted U-incision wide to avoid devascularizing the flap.

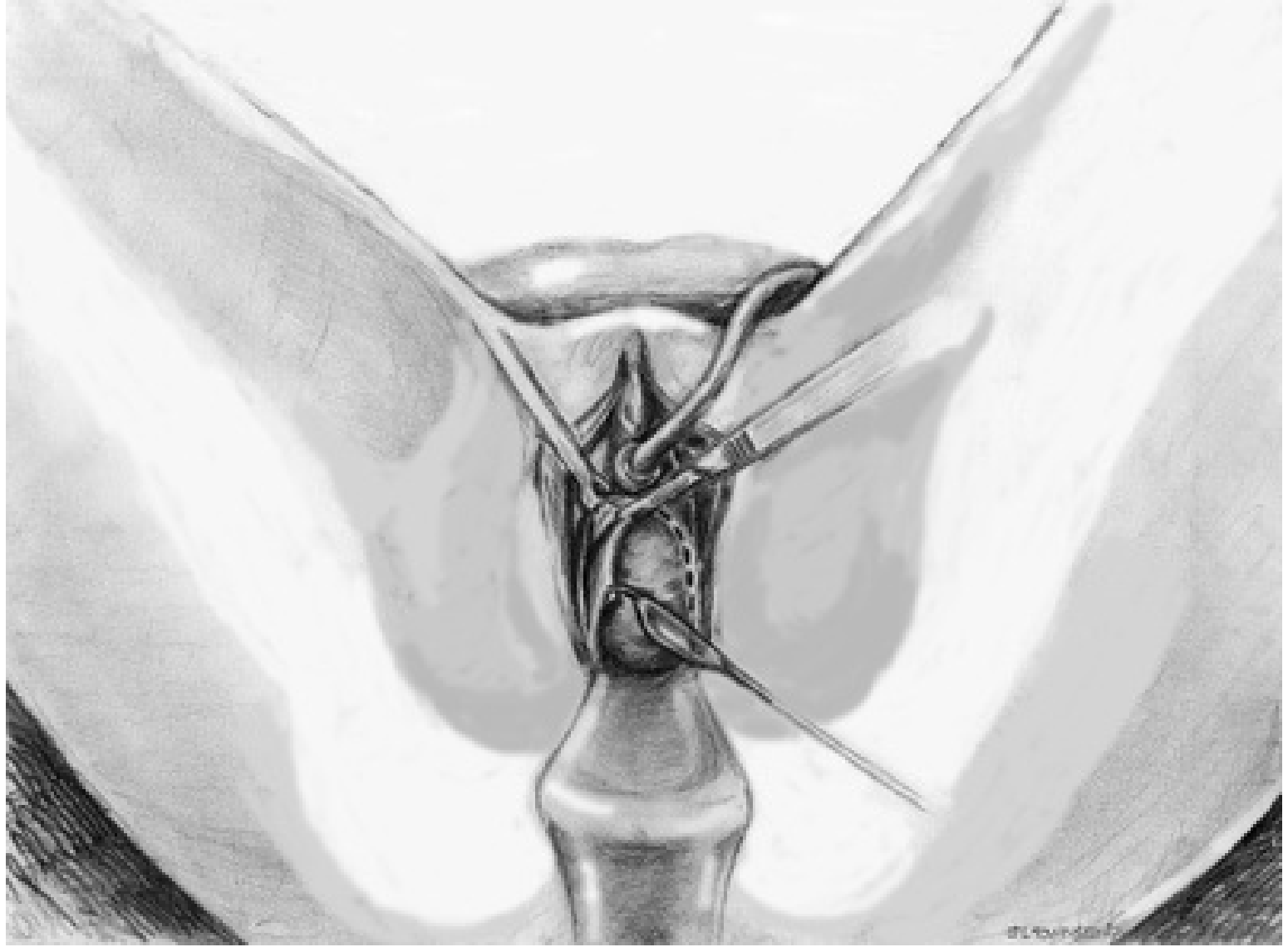

FIG. 125.2 Inverted-U incision.

Once adequate lateral flaps have been created, the endopelvic fascia should now be perforated under the easily palpable ischiopubic rami. To minimize the chance of inadvertent bladder perforation, it is imperative that the bladder be adequately drained before this maneuver and again before the passage of Stamey needles or larger clamps. With the Metzenbaum scissors angled toward the ipsilateral shoulder and the tips pointed upward, the endopelvic fascia is perforated by remaining directly medial and immediately under the ischiopubic ramus at the superior margin of dissection (Fig. 125.3). Perforation occurs in a superolateral direction, and the Metzenbaum scissors are spread widely to aid in the next step of dissection. Using blunt finger dissection, the retropubic space is dissected on either side of the urethra (Fig. 125.4). With this dissection, the infrapubic and retropubic dissection planes are now connected. During this step, it is important to ensure that the retropubic space is fully opened. The posterior surface of the pubic symphysis should be easily palpable with very little intervening tissue. Intraoperatively, this allows for free movement of the sling and easy tensioning.

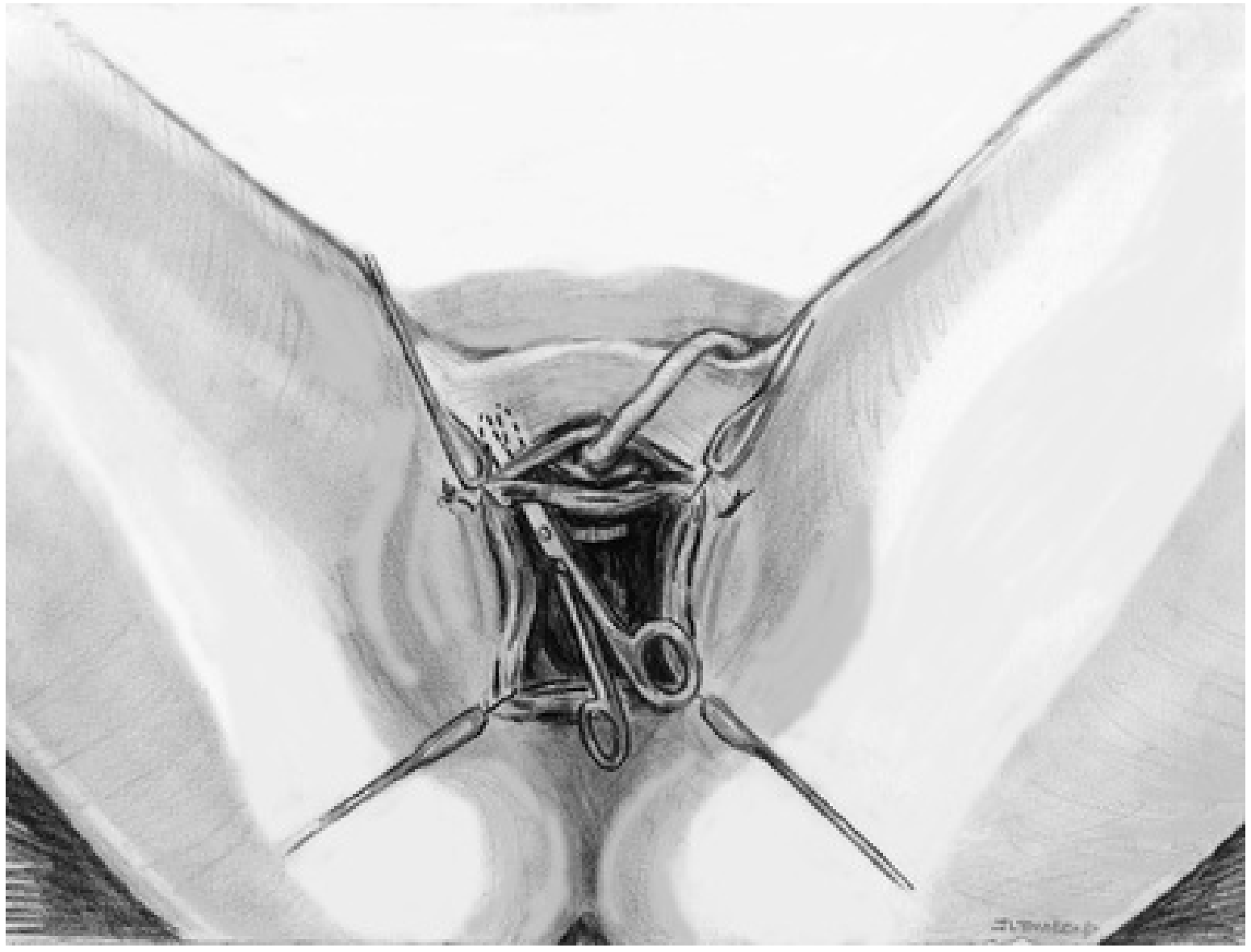

FIG. 125.3 Perforation of endopelvic fascia.

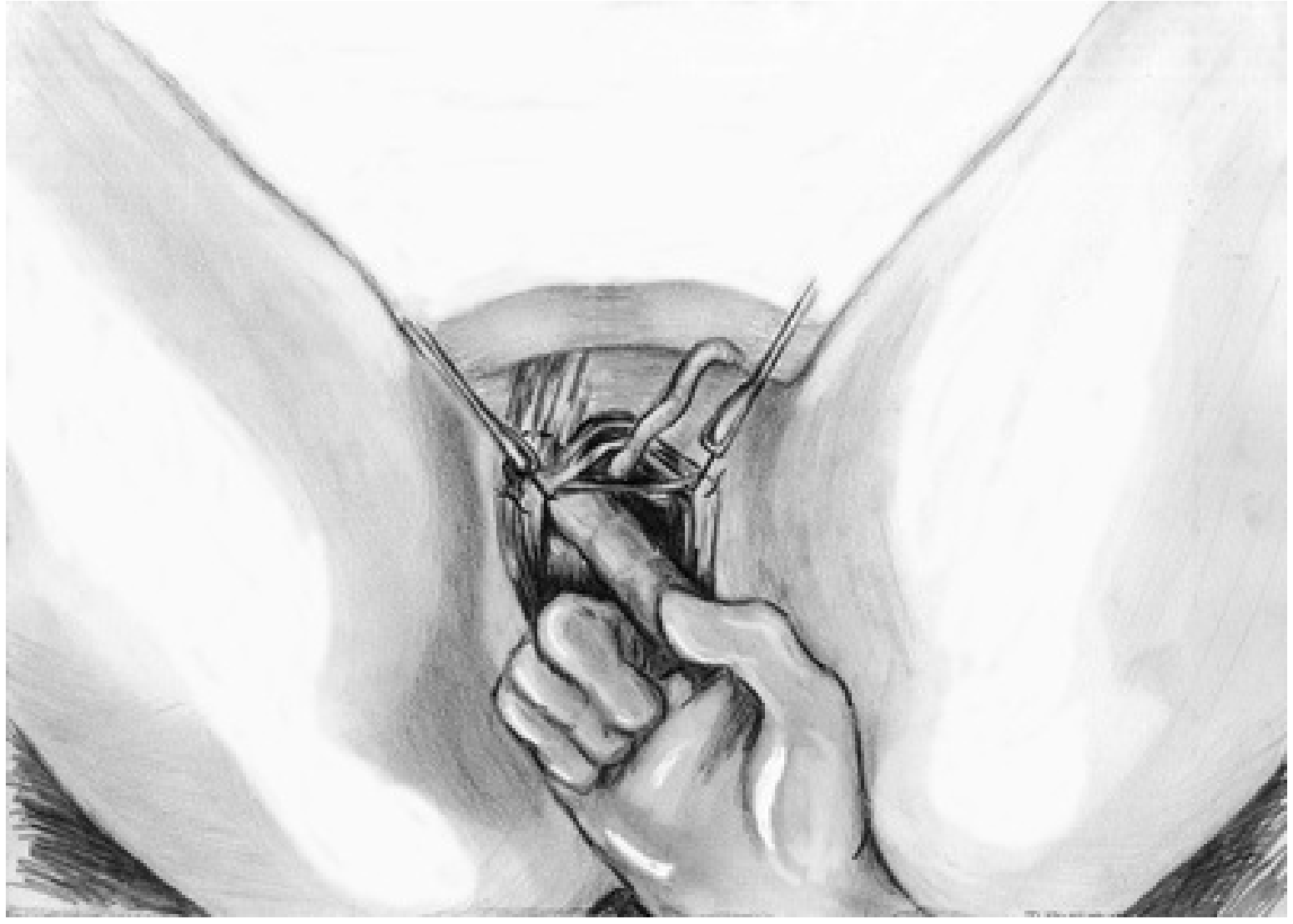

FIG. 125.4 Blunt dissection of retropubic space.

Even though the abdominal fascia is closed, simultaneous finger palpation through the abdominal and vaginal incisions should now be possible, while gently palpating the bladder medially. Aggressive medial mobilization should not be attempted because it may result in bladder injury. Hemostasis should be achieved with bipolar cautery. In the case of women who have undergone prior urethral suspension or sling procedures, more aggressive sharp dissection may be required. In difficult cases, the safest dissection plane into the retropubic space should be immediately adjacent to the periosteum of the pubis, and dissection should be performed sharply as much as possible to minimize the risk for injury to the pelvic viscera.

Pubovaginal Sling Placement and Fixation

Stamey or Cobb-Ragde needles are passed from above, through the abdominal incision by careful guidance behind the pubis. The needles are in contact with the pubis until they are brought out lateral to the bladder into the vaginal incision (Fig. 125.5). Alternatively, larger surgical instruments such as tonsil clamps may also be used for suture advancement (Blaivas and Olsson, 1988; McGuire and Lytton, 1978). **Again, it is important to emphasize that the bladder must be completely drained before passage of any suture passer to avoid inadvertent bladder injury.** Cystoscopy should be performed with a 70-degree lens after passage of needles to confirm integrity of the bladder by following the course of needles while an assistant moves the needles downward and medially toward the bladder. It is our belief that cystoscopy is an essential step that eliminates the serious complication of sling perforation of the bladder. In the case of a small bladder injury or inadvertent passage of Stamey needles through the bladder, the needles are removed and passed again and the procedure is completed. Cystoscopy should be performed after any subsequent needle passage to rule out puncture. After extravesical passage is confirmed, the ureteral orifices are monitored for brisk efflux on each side confirming ureteral patency. Likewise, intravenous methylene blue or sodium fluorescein and ureteral catheters may be used to confirm patency. The Foley catheter is replaced for completion of the case.

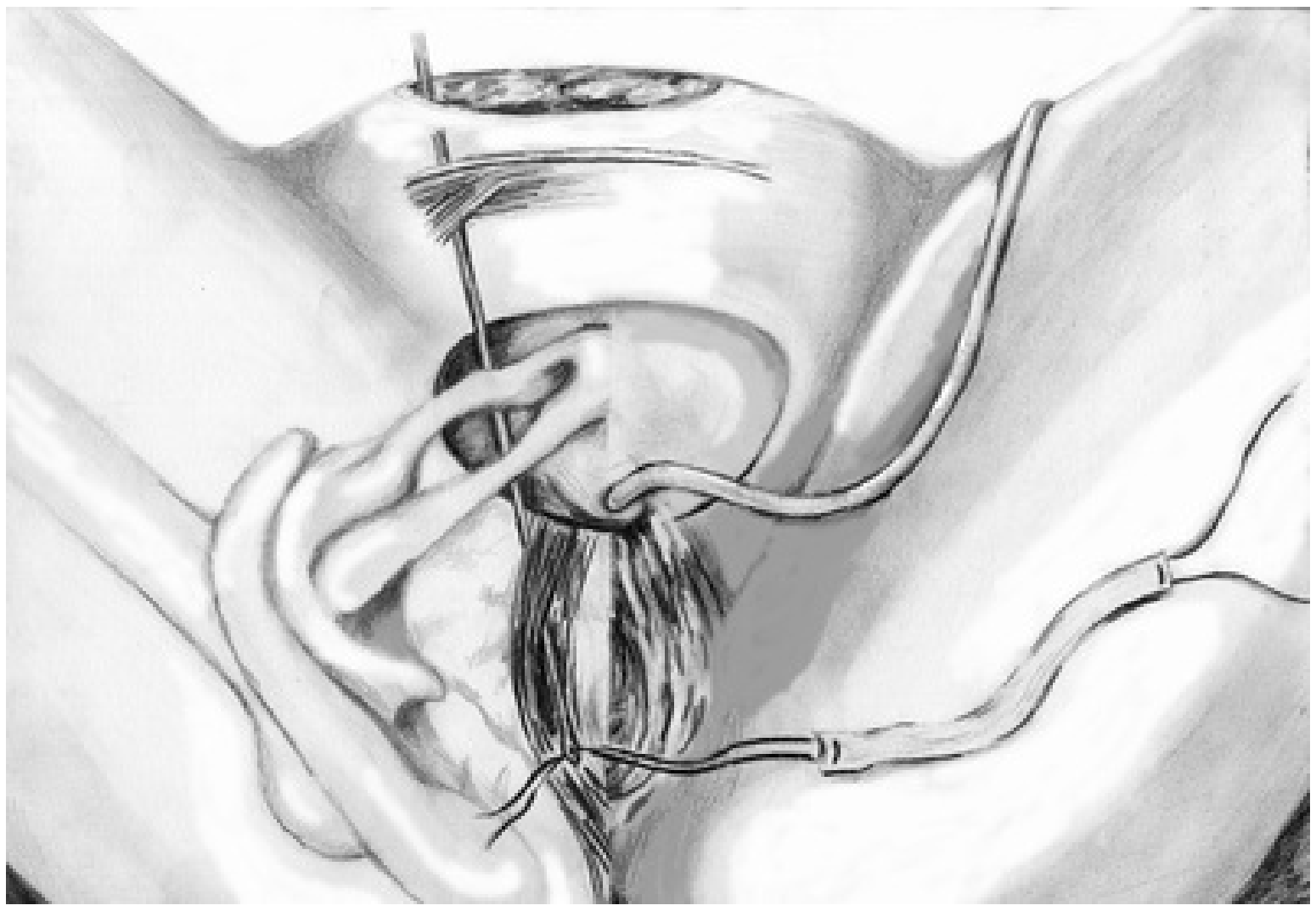

FIG. 125.5 Passage of Stamey needles behind pubis.

The ends of graft suture are passed through the Stamey needle eyelets. After marking the center of the graft with a clamp, the Stamey needles are removed, and the ends of the suture are brought out through the abdominal incision and tagged with hemostat clamps (Fig. 125.6). The distal aspect of the graft is sutured to the periurethral tissue with two simple 4-0 Vicryl sutures. After adequate hemostasis is achieved, the vaginal incision is closed with a watertight, running 2-0 Vicryl suture. **Before final tensioning of the sling, the vagina should be closed and weighted speculum removed to eliminate distortion that can affect the final tension. In addition, any additional procedures, such as transvaginal POP repair, should be completed before sling tensioning.** The PDSs are tied down above the rectus fascia (Fig. 125.7) leaving a two-fingerbreadth width distance between the rectus fascia and the PDS knot. The amount of tension may vary because of the mobility of the urethra or the desire to create permanent retention in a woman who will ultimately perform permanent CIC. The abdominal incision is closed with a subcuticular 4-0 polyglactin 910 suture. The Foley catheter is left to straight drainage, and a vaginal packing may be used. Conjugated estrogen cream may be added to the vaginal packing in postmenopausal women.

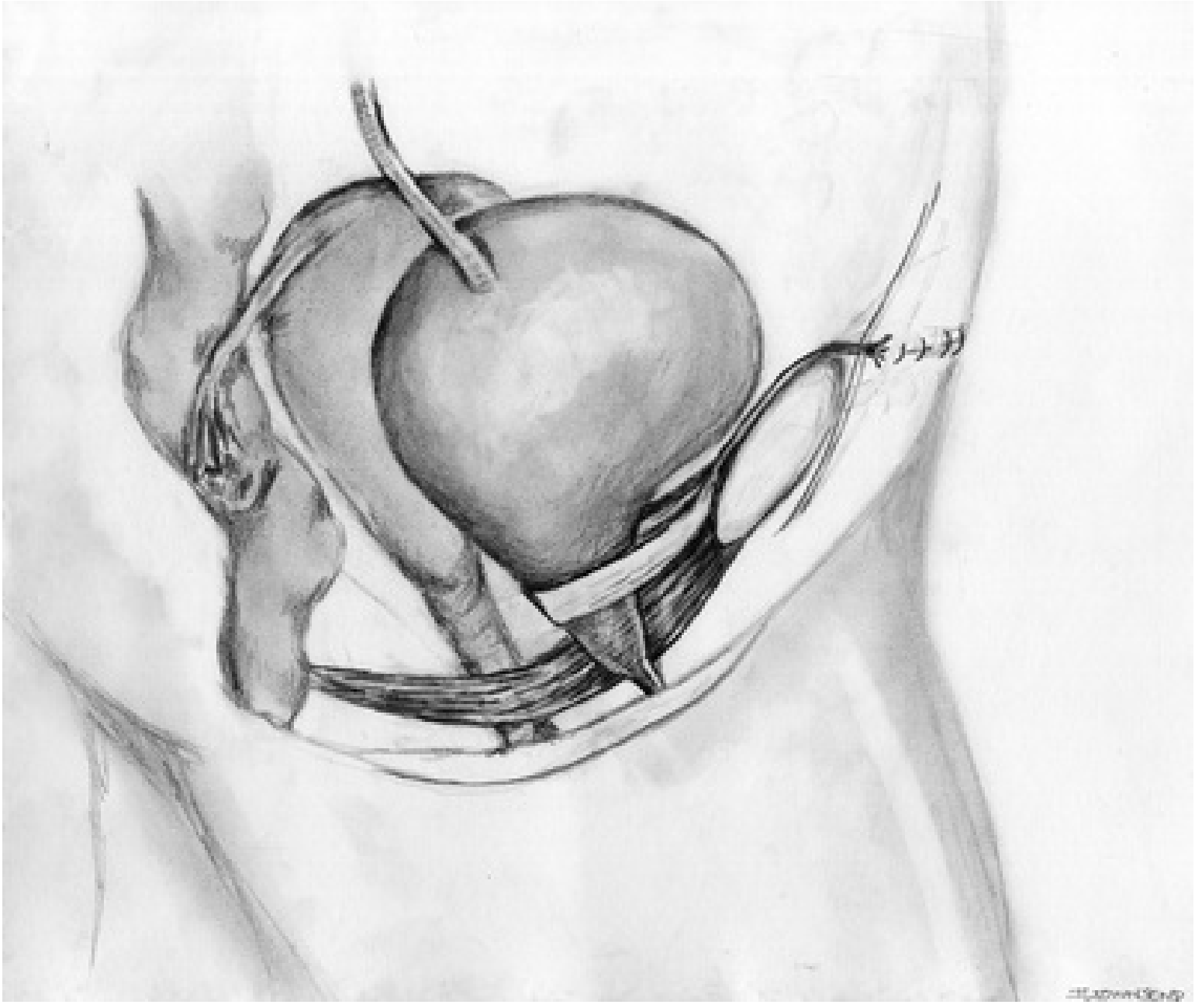

FIG. 125.6 Sagittal view of pubovaginal sling position at bladder neck in retropubic position.

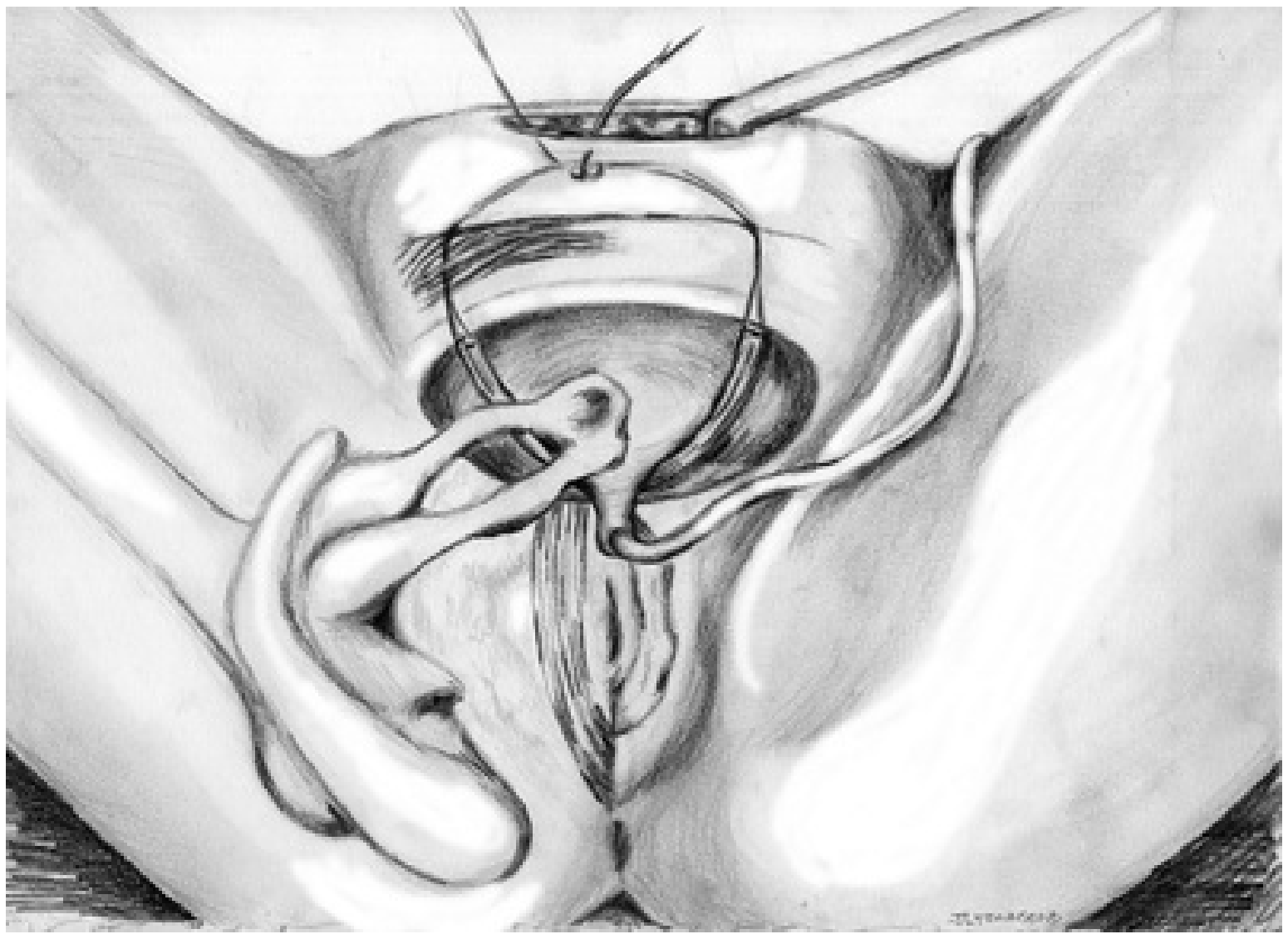

FIG. 125.7 Passage of and tying of sling through abdominal incision.

Pubovaginal Sling Postoperative Care

The patient is allowed liberal fluids and diet the night of surgery and the vaginal packing and urethral catheter are both removed on the morning of the first postoperative day. If the patient voids adequately with low PVR volumes, she is discharged home. If she is unable to urinate or has an elevated PVR volume, she is discharged home with an indwelling Foley catheter and will typically return within 5 days for a repeat trial of voiding. Patients are instructed to avoid lifting in excess of 10 pounds and sexual intercourse for at least 6 weeks after surgery. Sexual intercourse should be resumed only after a physical examination and confirmation of vaginal healing by the surgeon.

Key Points: Pubovaginal Sling Operative Procedure

- On occasion, closure of the rectus fascia without tension may be problematic. To prevent this, it is important to maintain a distance of 2 cm or more from the pubic symphysis.
- If undermining the fascial edges does not adequately mobilize the fascia, interposition of a segment of synthetic mesh or xenograft may be necessary to bridge the gap.
- It is important to ensure that the bladder is empty before perforation of the endopelvic fascia, dissection in the retropubic space, or passage of needles.
- Cystoscopy is recommended after initial trocar passage, and any subsequent passes, to ensure integrity of the bladder and urethra.
- Sling tensioning should be intentionally loose to minimize the chance of obstruction.

Outcomes of Pubovaginal Slings for Predominantly Stress Urinary Incontinence

Autologous Pubovaginal Slings

Since reintroduction in the late 1970s (McGuire and Lytton, 1978), the autologous PVS has remained reproducible and effective in treating SUI in long-term follow-up (Table 125.2). The earliest series included a diverse and complex patient population, including women with pelvic radiation, diabetes, spinal cord injury, and pelvic trauma (Blaivas and Jacobs, 1991; McGuire et al., 1987). Impressively, even the 34% of women with “proximal urethral function loss,” characterized by a MUCP less than 4 cm H_2O, had an 82% cure rate (McGuire et al., 1987). In addition, the majority of the women who required CIC postoperatively had a neurogenic bladder and were counseled to expect urinary retention. Several notable modifications have been described over the years that confirm the versatility of this technique. In a study of 63 women with ISD, Mason and Roach (1996) documented the success of a shorter (4 × 2 cm) modified rectus fascial sling at a mean follow-up of 12 months. Postoperatively, 19% of their population had urgency, and 16% had frank UUI. However, by 6 months, these symptoms had resolved in all but three women (5%), who remained on anticholinergic medication.

TABLE 125.2

Long-Term[a] Outcomes of Autologous Pubovaginal Slings

STUDY	N	TYPE	AGE (MEAN OR MEDIAN YEARS)	GSI	FOLLOW-UP (MEAN OR MEDIAN MONTHS)	CURED, IMPROVED, OR FAILED	ASSESSMENT OF OUTCOME	D U C
Haab et al., 1997	40	R	65.7	33%	48.2	73% cured 17% improved	VQ	1

						10% failed		
Morgan et al., 2000	247	R	54.5	56%	51	85% cured	CR	7
Latini et al., 2004	100	FL	NR	NR	52.8	85% cured or improved	VQ	N
Howden et al., 2006	153	R	62.7	NR	85.2	72% cured 28% failed	VQ; stress test	N
Brubaker et al., 2012	243	R	52.3	NR	60	31% cured 83% satisfied	Pad test; VD; no retreatment	1
Khan et al., 2015	61	R	59.4	NR	120	75.4% improved 50.8% dry	Subjective; VQ	0
Lee et al., 2015	84	R or FL	61	44%	89	63% cured or improved	VQ	1
Petrou et al., 2016[b]	21	R	75	38%	74	52% cured or improved	VQ	N

[a] ≥48 months.

[b] Failed prior MUS, with concomitant or previous MUS or mesh removal.

CR, Chart review; *FL,* fascia lata; *GSI,* genuine stress urinary incontinence; *NR,* not recorded; *R,* rectus fascia; *UUI,* urgency urinary incontinence; *VD,* voiding diary; *VQ,* validated questionnaire.

Cross et al. (1997) found that a concomitant anterior colporrhaphy and PVS yielded excellent results in women with grade 3 to 4 cystoceles and SUI. In their study, 92% of the 36 cystoceles were considered cured at a median of 20 months after surgery. Thirty-two women (89%) were cured of their SUI based on questionnaire results. While there was a 19% rate of postoperative de novo urgency and UUI, only 3% had persistent UUI requiring treatment. Lastly, 2.8% underwent further urethrolysis to resolve voiding difficulties related to obstruction. In 1998, two groups reported over 90% success rates in greater than 400 women after PVS as measured by questionnaires, telephone interviews, and physician assessment (Chaikin et al., 1998; Cross et al., 1998b).

The modified PVS (MPVS) involves the fixation of a 7- × 2.5-cm graft to the pubocervical and periurethral ligaments in a four-quadrant manner (Ghoniem, 1991). The initial success rate was 95% and, with longer-term follow-up, 89% of 112 women were cured of their SUI (Hassouna and Ghoniem 1999). The latter study assessed outcomes using a quality-of-life (QoL) questionnaire and found the success rate to be lower (81%). All 15 of the women with documented failure had UUI or severe urinary storage symptoms. The additional QoL assessment highlights the impact that UUI, frequency, nocturia, and pain can have on postoperative satisfaction.

A 2001 study by Groutz et al. (2001) involving 67 women is noteworthy because it stratified outcomes based on whether the PVS was for primary (57%) or recurrent SUI (43%). The latter group had undergone one to three prior unsuccessful anti-incontinence procedures, with the rates of transvaginal needle suspension, retropubic suspension, and PVS being 31%, 28%, and 10%, respectively. The cure rate was significantly higher in women with primary SUI (74% vs. 59%, $P = 0.006$); however, all of the women in both groups were either cured or improved based on a combination of 24-hour voiding diary variables, 24-hour pad test, and patient satisfaction.

Providing further evidence that the **PVS is an effective treatment for recurrent SUI,** Richter et al. (2001) assessed long-term QoL in a telephone interview of 57 women who had undergone a PVS. As in the 2001 study by Groutz et al., a significant number of women in this study had recurrent SUI after a failed retropubic (46%) or transvaginal needle suspension (24%). Telephone interviews revealed that 88% of women felt the sling improved their QoL, and 82% stated that they would undergo the surgery again. Remarkably, 87% of women failed their initial postoperative voiding trial, and 12% required long-term CIC. The telephone interviews revealed that 6% of the women had to use adaptive positions to facilitate voiding; however, all of these women were satisfied because of freedom from SUI and did not elect urethrolysis. This satisfaction may be related to an emphasis during preoperative counseling in conveying the possibility of long-term voiding dysfunction after a PVS. Petrou and Frank (2001) also looked at recurrent SUI, but focused on the safety and efficacy of a repeat PVS procedure after failed suburethral slings in 14 women (5 cadaveric bone-anchored slings, 3 autologous PVS, 3 cadaveric bone-anchored PVS, and 3 vaginal patch slings). Overall, 86% considered themselves cured or improved after surgery. Postoperative complications included a pelvic abscess related to a prior cadaveric sling, pubic osteomyelitis related to a prior bone-anchored sling, and one case of long-term urinary retention.

A 2006 study by Howden et al. (2006) is worth noting because of its long (mean of 7.1 years) follow-up and relatively large sample size (153 women). The authors retrospectively assessed outcomes using four different validated questionnaires and found that 72% of women were continent and only 3.3% required reoperation because of SUI within the follow-up period.

Much of the contemporary data regarding autologous PVS are derived from the Stress Incontinence Surgical Treatment Efficacy (SISTEr) trial, a multicenter, randomized clinical trial comparing the rectus fascial PVS in 326 women with Burch colposuspension in 329 women (Albo et al., 2007). The two primary outcomes were resolution of overall urinary incontinence (no subjective incontinence, increase of less than15 g in 24-hour pad weight, and no medical or surgical treatment for incontinence) and resolution of SUI (no subjective SUI and negative stress test). The authors found that, whereas the PVS was more effective at curing SUI (47% vs. 38%, $P < 0.001$), it was associated with a significantly higher rate of postoperative voiding dysfunction and cystitis. Of note, all 20 of the surgical procedures for bladder outlet obstruction (BOO) were performed in the PVS group, and two women in the Burch group experienced intraoperative ureteral injuries. In the long-term observational extension of the SISTEr trial, Brubaker et al. (2012) cited 5-year continence rates of 31% versus 24% ($P = 0.002$) in the PVS and Burch groups, respectively. Satisfaction at 5 years was related to continence status and was higher in the PVS group (83% vs. 73%, $P = 0.04$). While satisfaction decreased with time ($P = 0.001$), it still remained higher in the sling group ($P = 0.03$). The two groups had similar rates of adverse events (Burch 10% vs. PVS 9%) and similar numbers of participants with adverse events (Burch 23 vs. PVS 22). Both studies were especially noteworthy for their prospective, randomized design and seemingly low overall success rates for the PVS, which is most likely related to the strict definition of success and vigilant follow-up regimen. **The disparity between subjective patient outcomes and strict objective cure is another important observation, indicating that postoperative satisfaction is possible even in absence of complete dryness.**

A 2011 study by Athanasopoulos et al. (2011) was one of the earliest and largest studies to describe the outcomes of the PVS in patients in whom MUS had failed. In this study of 264 women, 30% had a prior history of MUS, and all of the women underwent partial sling excision at the time of PVS. The authors reported an 85% overall success rate (markedly improved or cured incontinence) and a history of previous anti-incontinence surgery had no effect on success rates. Additional studies have corroborated their conclusions (see Table 125.2).

Lee et al. (2015) performed a retrospective study with one of the longest follow-up periods after PVS sling surgery. At a median follow-up of 89 months, 63% of 84 women were improved or cured per validated questionnaire. As in earlier studies, the authors found no difference in outcomes between women with previous anti-incontinence surgery and those undergoing primary PVS.

While rectus fascia is the most commonly used autologous material, intermediate-term outcomes of fascia lata PVS appear to be comparable. In a retrospective study of 170 women with recurrent SUI, Beck et al. (1988) noted an impressive 92% cure rate measured by an absence of leakage on a postoperative cough test. It is interesting to note that the authors tested intraoperative urethral pressure to ensure that the slings could create pressures of 80 to 90 cm H_2O. A study by Govier et al. (1997) using fascia lata grafts is noteworthy because the authors compared outcomes of a chart review with responses to a questionnaire and found that the latter yielded poorer, but likely more accurate, outcomes (87.5% vs. 70%, respectively). This patient satisfaction–derived cure rate was similar to the questionnaire-based outcomes noted by Brown and Govier (2000). All of the women in this study had thigh pain at 1 to 2 weeks, and 11% described persistent thigh pain at 6 weeks. Latini et al. (2004) used the Crawford fascial stripper to obtain fascia lata, and, at 1 week, 20% of women had localized numbness at the harvest site, 7% had harvest site pain, and 5% had tendinitis in the harvest site leg. Despite this, 83% of respondents indicated that the procedure had a positive effect on their life, 82% would recommend the surgery to a friend, and 83% would undergo the procedure again. This evaluation remains the only study of fascia lata PVS with a mean follow-up greater than or equal to 48 months.

A Cochrane systematic review of PVS procedures included 26 trials involving 2284 women, most of whom had follow-up periods less than 24 months (Rehman et al., 2017). Twelve of these trials addressed the comparison between PVS and MUS, and the analysis concluded that these procedures were equally effective in the short term (RR for incontinence within first year 0.97, 95% CI 0.78 to 1.20). However, MUS surgery was associated with shorter operating times, fewer perioperative complications (other than bladder perforation) and less postoperative voiding and storage dysfunction. Finally, six trials compared one type of PVS with another, with porcine dermis, lyophilized dura mater, fascia lata, vaginal wall, autologous dermis, and rectus fascia represented. Subjective improvement rates within the first year favored the autologous fascial

PVS over other biologic materials (RR 0.45, 95% CI 0.21 to 0.98).

In summary, **success rates after PVS are typically high, with the wide range of continence rates in the literature (24% to 97%) depending intimately on the study patient population and definition of success.** In general, there is no direct correlation between universally accepted objective and subjective measures of improvement or cure for anti-incontinence procedures (Padmanabhan and Nitti, 2006). The most commonly cited reason for failure relates to other urinary storage symptoms, and UUI at follow-up is a common reason for patient dissatisfaction. **Postoperative de novo or urgency incontinence rates range from 2% to 22%** (Albo et al., 2007; Brubaker et al., 2012; Chaikin et al., 1998; Cross et al., 1998b; Flynn and Yap, 2002; Groutz et al., 2001; Haab et al., 1997; Hassouna and Ghoniem, 1999; Khan et al., 2015; Mason and Roach, 1996; Mitsui et al., 2007; Morgan et al., 2000; Onur et al., 2008; Parker et al., 2016; Zaragoza, 1996).

Allograft Pubovaginal Slings

While the autologous fascial PVS remains the gold standard treatment for SUI because of its efficacy and durability, it is associated with potential harvest site morbidity. Hence, cadaveric allograft slings were introduced in an effort to replicate the tissue integration of an autologous PVS and reduce its harvest site morbidity (Table 125.3). In general**, the outcome data are limited, and the efficacy and durability of these slings are questionable**. Early literature cited frozen or freeze-dried cadaveric fascia lata (CFL) with a variety of methods to secure the sling, such as suture fixation and bone anchors (Almeida et al., 2004; Amundsen et al., 2000b; Brown and Govier, 2000; Carbone et al., 2001; Fitzgerald et al., 1999; Flynn and Yap, 2002; Handa et al., 1996; Howden et al., 2006; O'Reilly and Govier, 2002; Richter et al., 2003; Walsh et al., 2002; Wright et al., 1998). Experience has shown that these tissue-processing techniques can have deleterious effects on cadaveric sling outcomes (Nazemi et al., 2008). **Failure rates for frozen or freeze-dried (FD) grafts range from 6% to 38%, often in the short-term.**

TABLE 125.3

Outcomes of Allograft Pubovaginal Slings

	AGE	FOLLOW-

STUDY	N	TISSUE	(MEAN OR MEDIAN YEARS)	GSI	UP (MEAN OR MEDIAN MONTHS)	CURED, IMPROVED, OR FAILED	ASSESSM OF OUTCOM
Handa et al., 1996	16	FF or FD	52–83	NR	6.2–11.8	Subjective: 86% cured Objective: 79% cured	CR; stress t
Wright et al., 1998	59	FD	60	52%	9.6	98% cured	CR
Fitzgerald et al., 1999	35	FD	NR	NR	0.2–9	82.8% cured	CR; stress t
Amundsen et al., 2000b	104	FD	61.7	35%	19.4	54% cured 21% improved	VQ; pad tes
Brown and Govier, 2000	121	FD	62	50%	12	74% cured 19% improved	Mailed VQ
Elliott and Boone, 2000	26	SD	56	NR	15	77%	CR; pad nu
Huang et al., 2001	18	SD	51.7	61%	9.2	72% cured or improved	Mailed VQ
Carbone et al., 2001	154	FD	60	NR	10.6	62% cured or improved	VQ; telepho interview
Soergel et al., 2001	12	FD	65.5	0%	1–6	33%	CR; stress t
Flynn and Yap, 2002	63	FD	54	4.8%	29	71% cured 13% improved	CR
O'Reilly and Govier, 2002	121	120 FF 1 SD	62	100%	6.5	86% cured	Mailed VQ
Walsh et al., 2002	31	FD	63	26%	13.5	94% cured	VD; VQ
Richter et al., 2003	102	FD	63.1	NR	35	75% cured or improved	VQ

Carey and Leach, 2004	265	SD	(<80 y) 61.2	44%	24.3	61% cured or improved	VQ
			(>80 y) 82.8	32%	21.4	55% cured or improved	
Almeida et al., 2004	30	FD	53.4	NR	36	40% cured 28% improved	CR
Owens and Winters, 2004	25	DG	62	72%	14.8	32% cured 36% improved	CR; telepho interview
Crivellaro et al., 2004	253	DG	58.3	38.3%	18	53% cured 25% improved	VQ; VD
Onur and Singla, 2005	25	SD	62	60%	12	80% cured 20% failed	VQ
Frederick and Leach, 2005	251	SD	66	61%	24	76% cured or improved	VQ
Howden et al., 2006	150	FD	63	NR	43.2	60% cured or improved	VQ; stress t
Pianezza et al., 2007	37	NR	60.2	54%	45.6	75.8 mean UDI score	VQ
Nazemi et al., 2008	358	SD	38–97	NR	24–60	34% cured 48% improved	VQ
Onur et al., 2008	25	SD	61	NR	13	79% cured or improved	VQ

[a] Retention defined as catheterization longer than 2 weeks.

CR, Chart review; *DG,* dermal graft; *FD,* freeze dried; *FF,* fresh frozen; *GSI,* genuine stress urinary incontinence; *NR,* not recorded; *SD,* solvent dehydrated; *UDI,* Urogenital Distress Inventory; *UUI,* urgency urinary incontinence; *VD,* voiding diary; *VQ,* validated questionnaire.

Several groups have commented on the status of cadaveric tissues at reoperation for sling failure. Fitzgerald et al. (1999) cited an early failure rate (within 1 week to 5 months) of 17% in 35 women who underwent irradiated CFL sling. Histopathologic analyses of the retrieved material indicated the following ongoing processes in the failed graft: disorganized remodeling, areas of graft degeneration, and evidence of immune reaction. These findings led the researchers to conclude that freeze-dried, irradiated CFL grafts should not be used for urogynecologic procedures because of the high material failure rate. Since then, additional groups have documented high failure rates with freeze-dried allografts. Carbone et al. (2001) reported a 38% failure rate and a 17% reoperation rate at a follow-up of 11 months after CFL secured with titanium bone anchors to the pubic symphysis. The average time to reoperation was 9 months (range 3 to 15), and intraoperative findings at reoperation revealed the entire allograft to be fragmented, attenuated, or simply absent. O'Reilly and Govier (2002) found that 8 of their 121 patients had recurrent SUI at a mean of 6.5 months (range 4 to 13 months). Seven of the 8 women had multiple comorbidities, including neurologic disease, diabetes, previous pelvic irradiation, and previous anti-incontinence and pelvic surgery. Based on these results and findings by Lemer et al. (1999), this group also discontinued the use of fresh-frozen grafts and switched to solvent-dehydrated cadaveric fascia and dermal grafts.

Graft deterioration and failure has also been reported with solvent-dehydrated CFL and cadaveric dermis (CD). Huang et al. (2001) reported a 28% failure rate with full recurrence of SUI with short-term follow-up. On reoperation with an autologous PVS, the remaining allograft was rudimentary and very friable. Histologic examination of the retrieved allograft revealed wavy collagen fibers with loosely packed fibroblasts and focal areas of degeneration. Owens and Winters (2004) observed promising initial results in women treated with CD slings with dry and improved rates of 68% and 24%, respectively. However, at intermediate follow-up, only 32% of the women were dry, and 36% noted improvement. Surgical re-exploration revealed almost complete absence of graft material, without evidence of infection or excessive inflammatory response.

Six studies have compared the outcomes of women undergoing PVS procedures using either autologous or cadaveric allograft fascia (Almeida et al., 2004; Brown and Govier, 2000; Flynn and Yap, 2002; Howden et al., 2006; Onur et al., 2008; Wright et al., 1998). Four groups found the outcomes comparable with similarly high success rates and no negligible difference in complications. They concluded that allograft fascia lata may be used as an alternative to autologous fascia for PVS to reduce operative time and decrease postoperative pain and disability (Brown and Govier, 2000; Flynn and Yap, 2002; Onur et al., 2008; Wright et al., 1998). With long-term follow-up, two groups noted superior continence outcomes in the autologous group (Almeida et al., 2004; Howden et al., 2006). Almeida et al. (2004) did not report adverse outcomes in either group, and Howden et al. (2006) found that recurrent symptoms occurred in a higher proportion in the cadaveric group (40%) compared with the autologous group (28%) (*P* = 0.04). The reoperation rate was also higher for the allograft group (13% vs. 3%, *P* = 0.003). As mentioned in the previous section, the subjective improvement rates within the first year favor autologous fascial PVS over other biologic materials in the systematic review of randomized controlled trials (RCTs) by Rehman et al. (2017).

Some studies support the efficacy of solvent-dehydrated fascial slings (Frederick and Leach, 2005; Nazemi et al., 2008; Onur and Singla, 2005; Pianezza et al., 2007), yet previously reported failures coupled with the consistent success and rapid adoption of synthetic MUS have led to near-complete abandonment of all types of cadaveric allografts at most centers. Hence, there is an almost complete absence of long-term outcomes for solvent-dehydrated allograft slings (Nazemi et al., 2008).

Synthetic Pubovaginal Slings

Although there were multiple single-center, retrospective studies describing synthetic PVS placed at the bladder neck, there are few randomized studies evaluating outcomes. One of those studies is a prospective, randomized trial comparing the ePTFE PVS with the Burch colposuspension (Sand et al., 2000). Seventeen women were randomized to sling, and the authors concluded that the synthetic suburethral sling had equivalent results to the modified Burch procedure after 3 months of follow-up. It is interesting to note that, although the authors reported no problems with exposure or perforation, they state in their discussion section that they stopped using this type of sling because of complications reported in 1995 by Weinberger and Ostergard. In that study, 108 women were treated with an ePTFE PVS for SUI. Forty percent developed a wound complication and 21% required complete or partial sling removal (10 with sinus tract formation, 4 with persistent vaginal granulation, 3 with prosthetic exposure, and 1 with groin pain). Clearly ePTFE is not an ideal synthetic sling material because of its microporous nature. Likewise, there have also been problems with other synthetic sling materials (polyethylene and polypropylene) with less-than-ideal physical properties placed under tension at the bladder neck (Drutz et al., 1990; Wohlrab et al., 2009; Young et al., 2001).

Xenograft Pubovaginal Slings

Xenografts represented an attractive surgical option because of the morbidity of autologous fascial harvest, high failure rates of allografts, and high exposure and perforation rates after synthetic PVS. **In general, xenografts are associated with a low rate of infection, exposure, and perforation because of their incorporation into host tissue** (Rutner et al., 2003). The majority of studies in the literature report on gamma-sterilized, porcine dermis (Pelvicol, C.R. Bard), porcine small-intestinal submucosa (SIS), and bovine dermis for use in PVS surgery (Abdel-Fattah et al., 2004; Arunkalaivanan and Barrington, 2003; Barrington et al., 2002; Broussard et al., 2013; Giri et al., 2006; Holstead et al., 2013; Khan et al., 2015; Rutner et al., 2003; Wiedemann and Otto, 2004; Wilson et al., 2008) (Table 125.4).

TABLE 125.4

Outcomes With Xenograft Pubovaginal Slings

STUDY	N	TYPE	AGE	FOLLOW-UP (MONTHS)	CURED, IMPROVED, OR FAILED	ASSESSMENT OF OUTCOME	DE NO URGE
Barrington et al., 2002	40	Pelvicol	56	6–18	85%	Subjective improvement >90%	NR
Rutner et al., 2003	152	SIS	NR	27.6	93% cured 2% improved	CR	NR
Abdel-Fattah et al., 2004	74	Pelvicol	53	36	78% cured 10% improved	Mailed VQ	17.6%
Giri et al., 2006	51	Pelvicol	46	36	31% cured 23% improved	Mailed VQ; telephone interview	2%
Wilson et al., 2008	37	Xenform Matrix[a]	67.7	19.5	84% SUI cured 54% global cure	Stress test; VQ	NR

Broussard et al., 2013	70	Pelvicol	53.8	62.1	43% SUI cured 11% global cure	Stress test; VQ	NR
Holstead et al., 2013	41	Xenform Matrix[a]	67.6	36	81% SUI cure	Stress test; VQ	2.4%
Khan et al., 2015	38	Pelvicol	62	120 (median)	15.7% dry, 58% improved	Subjective; VQ	0%

[a] Xenform Matrix is an acellular bovine dermis.

CR, Chart review; *NR,* not recorded; *SIS,* small intestinal submucosa; *SUI,* stress urinary incontinence; *VQ,* validated questionnaire.

Rutner et al. (2003) were first to describe the bone-anchored porcine SIS in 152 women with long-term follow-up and reported cure rates comparable to those of the autologous PVS. Among the 7 failures (5%), 5 women had recurrent SUI within 3 months of surgery, and the other 2 had recurrences after 9 and 11 months. At reoperation, grossly no evidence of the implanted SIS material was found; however, biopsies of the periurethral tissue did reveal fibrosis and muscular tissue with a few remnants of SIS. Wiedemann and Otto (2004) performed the first extensive histopathologic examination of porcine SIS in a series of 15 women. Biopsy specimens from the SIS band under the vaginal mucosa revealed only focal residues of SIS without any evidence of tissue reaction. Evidence of a significant immunologic or chronic inflammatory reaction was absent. These authors concluded that the advanced incorporation of the implant would lend to good biocompatibility.

Arunkalaivanan and Barrington (2003) first reported on Pelvicol PVS in a randomized, short-term trial comparing the xenograft with TVT. Questionnaire-based cure rates were comparable between the two: 85% in the TVT group and 89% in the Pelvicol group. Abdel-Fattah et al. (2004) presented 3-year follow-up data for this prospective trial, and cure rates remained high and comparable between the two groups: 79% for the TVT and 78% for Pelvicol. There was no statistical difference with regard to complication rates or postoperative pad score. Giri et al. (2006) compared the 3-year efficacy of Pelvicol versus autologous PVS in 101 consecutive, nonrandomized patients, and, although there was less surgical morbidity in the porcine dermis group, long-term cure rates were significantly lower than for the autologous PVS group. Repeat urodynamic studies indicated recurrent SUI as the cause of treatment failure in 18 of 20 (90%) patients treated with porcine dermis but in only 3 of 8 (37.5%) with a rectus PVS.

Bovine dermis is the most recently reported material used for a xenograft PVS (Wilson et al., 2008). Women with a high risk for sling failure (advanced age, previous surgical failure, and ISD) underwent either a bovine dermis or autologous rectus fascia PVS procedure with short-term follow-up. Global cure rates (completely dry and satisfied) and SUI cure rates were not statistically different between the two groups. Four women (8%) in the autologous PVS group underwent reoperation with periurethral bulking and repeat autologous PVS. Two women (5%) in the bovine dermis group underwent additional interventions with periurethral bulking and an autologous PVS. Biopsies of the bovine dermis sling material during reoperation (for SUI recurrence at 3 months) revealed that the sling had been replaced by fibrosis, hemorrhage, and mild chronic inflammatory infiltrate, with no acellular component. Tissue breakdown, represented by intermittent areas of myxoid degeneration, was present and may have indicated evidence of early graft failure. The same group reported an SUI cure rate of 80.5% and a low complication rate at a minimum follow-up of 36 months (Holstead et al., 2013).

Outcomes of Autologous Pubovaginal Slings for Mixed Urinary Incontinence

The treatment of women with SUI and concomitant urgency and UUI is complicated and often involves a combination of anticholinergic therapy and surgery. Medical therapy for MUI is associated with significant resolution of the urgency component in only two-thirds of patients (Nordling et al., 1979; Stephenson and Mundy, 1994). Anticholinergic therapy alone does not address the bladder outlet and would not be expected to achieve complete dryness in those with a significant stress component. **However, anti-incontinence surgery may cure, improve, or aggravate storage symptoms. Furthermore, even an "uncomplicated" sling may lead to de novo urgency. This aspect of anti-incontinence surgery is unpredictable and a major cause of patient dissatisfaction.**

Fulford et al. (1999) were the first group to use video-urodynamics in assessing the impact of a PVS on MUI. In this study, 69% of 85 women had MUI. Although 97% of the women were continent, only 78% were satisfied with the surgical result because of persistent or de novo urgency symptoms. Among these 27 women, 41% had an open bladder neck at rest compared with only 8% of those without postoperative UUI ($P < 0.01$). The storage symptoms eventually resolved in 69% of the women, almost all of whom had a closed bladder neck at rest. Of note, the **postoperative urgency symptoms were not significantly associated with any preoperative clinical or urodynamic variables.**

Schrepferman et al. (2000) tried to use preoperative video-urodynamics to predict urinary urgency resolution after a PVS procedure. Women with MUI were divided into two groups: a sensory urgency group (28 women without DO) and a motor urgency group (41 women with DO). The authors concluded that there was a significantly greater resolution of urgency symptoms in those women with low-pressure DO than in those with high-pressure DO or no DO. Overall, urgency resolved in 51% of women with MUI. Also in 2000, Serels et al. reviewed the records of 36 women with stress-induced DO. In this study, 75% of women had resolution of UUI, and 92% achieved a cure. Again, ALPPs measured during urodynamic studies did not correlate with outcomes.

Osman (2003) compared the outcomes of PVS and Burch colposuspension in women with MUI without DO and a control group of women with SUI. The

Burch arm consisted of 24 women (8 SUI, 16 MUI) with an ALPP greater than 90 cm H_2O, and the PVS arm consisted of 26 women (12 SUI, 14 MUI) with an ALPP less than 90 cm H_2O. In the PVS group, the incidence of persistent UUI in the MUI group was 12%, and the incidence of de novo UUI in the SUI group was 20%. The incidence of residual urgency was not significantly higher than that of de novo urgency in those with SUI.

Chou et al. (2003) used a validated questionnaire, voiding diary, and pad testing to report the outcomes of PVS for MUI and SUI. Forty-seven percent of 98 women had SUI, and 53% had MUI (26% with DO). The cure or improvement rates were 97% in the SUI group and 93% in the MUI group ($P = 0.33$). More urgency and UUI episodes on preoperative voiding diary correlated directly with surgical failure, whereas voiding frequency was associated with cure. The authors postulated that these women may have adopted preemptive voiding preoperatively to minimize incontinence episodes.

Stoffel et al. (2008) found no difference in preoperative video-urodynamics between women with MUI and DO and those without DO. However, MUI patients with DO had less improvement in UDI-6 scores than those without DO despite a similar reduction in pad use. The authors concluded that the presence of preoperative DO on urodynamic findings may relate to decreased QoL and decreased urgency resolution after a PVS.

To date, women with MUI have no consistent video-urodynamic parameters that correlate with outcomes after a PVS. **However, the presence of residual urgency is similar to de novo urgency after a PVS. Also, increasing episodes of urgency and UUI may correlate with surgical failure. Overall, the PVS remains an effective treatment option for women with MUI, with cure rates similar to those of women with SUI only.**

Outcomes of Autologous Pubovaginal Slings for Urethral Reconstruction

An autologous PVS serves an important role in the reconstruction of the urethra after anatomic damage (tissue loss) ranging from the relatively mild deformity of urethrovaginal fistulae and diverticula to the more severe, traumatic absence of the urethra or bladder neck. Causes of damage may also include protracted obstetric deliveries, anti-incontinence surgeries, aggressive transurethral resections of the bladder neck, long-term indwelling urethral catheters, pelvic trauma, tumors, and radiation (Blaivas and Jacobs, 1991). The goals of surgical repair are to restore function and anatomy while fashioning an unobstructed, continent urethra (Blaivas and Heritz, 1996).

Swierzewski and McGuire (1993) reviewed the outcomes of 14 women who underwent urethral diverticulectomy during a 3-year period, 8 of whom had preoperative symptoms of SUI. Seven of these women had SUI documented on preoperative urodynamic studies, and only these seven women underwent a combined urethral diverticulectomy and autologous PVS. All 14 women were cured of their SUI with a mean follow-up of 17 months (3 to 21 months). The authors concluded that the presence of a urethral diverticulum does not compromise the successful cure of SUI by a PVS.

Chancellor et al. (1994) performed obstructing PVS in 14 women with neurogenic bladder dysfunction who had destroyed urethras secondary to long-term, indwelling Foley catheters. Ten women had simultaneous bladder augmentations or diversions, and two had concurrent suprapubic tube placement. The other two had adequate preoperative bladder capacity and compliance. All women achieved continence after a mean follow-up of 24 months. The authors concluded that obstructing PVS is simpler and avoids the risk for fistula formation associated with bladder neck closure, which has historically been used in the aforementioned patient population.

Blaivas and Heritz (1996) reported on 49 women who underwent a one-stage urethral reconstruction to repair extensive damage to the urethra or bladder neck (45% from prior urethral diverticulectomy). Forty-one of these women had a concomitant PVS placed for preoperative SUI. At a mean follow-up of 4 years after PVS, none had postoperative SUI, and only one woman experienced obstruction and urgency symptoms requiring sling incision. She was continent at last follow-up. On the other hand, three of the five women who had modified Pereyra suspensions developed postoperative SUI requiring staged PVS. All three were continent at last follow-up. **This study illustrates that PVS in the setting of urethral reconstruction has excellent results when compared with other anti-incontinence surgeries.**

Faerber (1998) reported on 16 women who underwent urodynamic evaluation before simultaneous PVS and diverticulectomy. All were either significantly improved (12%) or cured (88%) of incontinence, and only two patients developed de novo urgency. A Foley catheter was left in place for urethral healing for the initial 2 weeks, and the mean time for complete bladder emptying was 5 weeks.

Rovner and Wein (2003) reported on 9 women undergoing circumferential urethral diverticulum repair who received either end-to-end urethroplasties or dorsal urethroplasties. Based on preoperative SUI status or evidence of an open bladder neck on preoperative cystography, seven women underwent concurrent rectus fascial PVS and one had a porcine PVS. All women were continent postoperatively, except for the one who refused PVS surgery and developed de novo SUI.

Flisser and Blaivas (2003) evaluated the results of 74 women with urethral pathology who required vaginal flap reconstructions, mostly for a diverticulum or urethral fistula secondary to iatrogenic causes. Fifty-six underwent a concomitant PVS, and 73% considered themselves cured postoperatively. Three of the four women with persistent SUI failed a modified Pereyra procedure, but were cured at reoperation. One woman was continent after operative revision of PVS for obstruction and significant UUI.

More recently, autologous PVS have been employed for urethral reconstruction in the setting of MUS urethral perforation. In a retrospective review of 19 women, Kowalik et al. (2018) treated seven with a concomitant ARF PVS. Although 54% rated their postoperative condition as “very much better” or “much better” on the PGI-I at a mean of 25 months of follow-up, much of the cohort required adjunctive measures to treat their persistent urinary tract symptoms.

Key Points: Pubovaginal Sling Outcomes

- Cure rates after autologous PVS range from 31% to 97% depending on the definition of success and outcomes measured. De novo urgency and UUI rates are likewise variable.

- No preoperative risk factors consistently predict outcomes after a PVS.
- The reported cure rate of PVS surgery for recurrent SUI is excellent. In randomized trials, porcine dermis was associated with significantly inferior long-term cure rates compared with the autologous PVS.
- Treatment of women with MUI is complicated and may involve a combination of anticholinergic therapy and surgery.
- The PVS is an effective treatment option for stress-induced DO, with cure rates similar to those of PVS for SUI. The presence of preoperative DO may be associated with decreased postoperative QoL and lower urgency resolution rates after a PVS.
- An autologous PVS is a valuable adjunct for providing continence and robust tissue coverage in urethral reconstruction caused by urethral fistula, diverticulum, urethral perforation after MUS, or devastated urethra.

Voiding Dysfunction Secondary to Bladder Outlet Obstruction After Pubovaginal Sling Surgery

Depending on the definition, the incidence of voiding dysfunction after PVS surgery varies widely (2.5% to 35%) (Carr and Webster, 1997; Chaliha and Stanton, 1999; Cross et al., 1998b; Foster and McGuire, 1993), and iatrogenic bladder outlet obstruction after PVS may be related to DO and impaired detrusor contractility. Morgan et al. (2000) reported a prolonged urinary retention rate of only 2.4% of 252 women at 4-year follow-up. A meta-analysis by the AUA Stress Urinary Incontinence Clinical Guidelines Panel reported that the incidence of urinary retention more than 4 weeks after PVS placement was 8%, and the risk for permanent retention “generally does not exceed 5%” (Leach et al., 1997). It must be noted that the most recent AUA SUI guidelines panel did not note this (Kobashi et al., 2017). Overall, the rate of retention is approximately 2% unless the sling is purposefully overtensioned.

The PVS is known to be associated with higher rates of voiding dysfunction than the Burch colposuspension (Stanton et al., 1983), and this finding was again confirmed in the randomized SISTEr trial (Albo et al., 2007). Success rates were higher for women who underwent the autologous PVS compared with the Burch, but women undergoing PVS experienced significantly greater postoperative voiding dysfunction (63% vs. 47%, $P < 0.001$), UTIs, difficulty voiding, and postoperative UUI.

The presentation of a woman with postoperative bladder outlet obstruction may be quite variable. She may have purely voiding symptoms (e.g., decreased force of stream, positional emptying, elevated PVR volume, and urinary retention), storage symptoms (urgency, UUI), or a combination of both. Obstruction may also cause recurrent UTIs, prolonged suprapubic pain, and painful voiding, even if emptying is completed and PVR volumes are low. Nitti et al. (2002) found that 16% of women who required urethrolysis after PVS did not have voiding symptoms or retention. Some studies report that persistent postoperative UUI and urgency after PVS constitute a more common presentation for obstruction than frank retention (8% vs. 25%) (Cross et al., 1998b). The risk for iatrogenic obstruction is usually related to technical factors such as placement of sutures or sling material under excessive tension. Unfortunately, there is often a fine line between inadequate and excessive sling tension and no consistent way of determining perfect tension for the individual woman. If the sling is too loose, the bladder neck and proximal urethra are inadequately supported and the potential for persistent SUI is greater. Conversely, there may be excessive elevation of the bladder neck toward the pubic bone, causing hypersuspension or overcorrection of the urethrovesical angle and increasing the potential for obstruction.

Not surprisingly, the presence of preoperative voiding dysfunction affects a woman's ability to empty after anti-incontinence surgery. Subclinical impaired detrusor contractility may manifest symptomatically with a relative obstruction when bladder outlet resistance is increased after anti-incontinence surgery. Dysfunctional voiding, or failure of relaxation of the external (striated) urethral sphincter, may also affect emptying after surgery (FitzGerald and Brubaker, 2001). Likewise, a woman who habitually voids by abdominal straining may theoretically have difficulty emptying postoperatively, as the sling provides dynamic resistance with increases in intra-abdominal pressure. Because of the variability of presenting symptoms after PVS surgery, a thorough history is invaluable in ascertaining the chronology, character, and bother of the predominant symptoms.

If a woman has postoperative urethral obstruction, physical examination may reveal abnormal urethral angulation, a foreshortened nonpliable vagina, or a nonmobile urethra. However, hypersuspension may not be clearly evident on physical examination. The PVR volume is very important in the evaluation of voiding dysfunction, although no clear cutoff values for obstruction exist (Siddighi and Karram, 2007). Cystoscopy is useful to rule out bladder pathology, sling perforation, and a hypersuspended urethra. Video-urodynamics may be useful in selected cases at the physician's discretion; however, a classic high-pressure, low-flow pattern that is pathognomonic for obstruction is frequently absent. **The temporal relationship between the onset of voiding or storage symptoms and the surgical procedure remains the most important criterion influencing the decision to incise a PVS or perform urethrolysis.**

Several studies have attempted to identify risk factors that may be predictive of postoperative voiding dysfunction. Weinberger and Ostergard (1996) studied 108 women receiving synthetic PVS and found that impaired detrusor contractility predicted postoperative urinary retention. Similarly, Miller et al. (2003) noted that women who underwent allograft PVS and voided with minimal or no increase in detrusor pressure (19%) had a significantly higher risk for postoperative retention. In contrast, no woman with a normal detrusor contraction developed retention postoperatively. However, other researchers have not confirmed this proposed association (McLennan et al., 1998). Mitsui et al. (2007) found that women with a PVR greater than 100 mL ($P = 0.05$) or Qmax less than or equal to 20 mL/sec ($P = 0.09$) on preoperative urodynamic studies were more likely to require prolonged CIC after surgery. In this group, 28% needed CIC for 4 to 40 months. In the SISTEr trial, urodynamic findings did not predict voiding dysfunction after surgery (Lemack et al., 2008). **Although urodynamic studies are useful in understanding the voiding dynamics of incontinent women, low detrusor pressure and Valsalva voiding preoperatively should not exclude women from having an anti-incontinence procedure.**

In general, although postoperative urgency and UUI (voiding dysfunction) are strongly related to failure, there are few preoperative risk factors that consistently predict these outcomes after PVS surgery. What is known is that preoperative DO on urodynamics (Alperin et al., 2008), high-pressure DO (Schrepferman et al., 2000), preexisting urgency, frequency, and nocturia (Alperin et al., 2008; Gamble et al., 2008; Kenton et al., 2009), and preoperative anticholinergic use (Barber et al., 2008; Kenton et al., 2009) have all been found to be independent predictors of postoperative urgency and UUI. These findings underscore the importance of preoperative counseling and obtaining a detailed history of all storage symptoms before sling surgery.

A key factor in assessing voiding dysfunction is the presence of POP that was either uncorrected at time of surgery or that occurred postoperatively. Prolapse of sufficient size may kink, angulate, or externally compress the urethra causing obstruction, and postoperative POP in all three compartments (apical, anterior, and posterior) must be ruled out as a cause of obstruction. Kobashi et al. (2002) reported on a technique of combined cystocele repair and PVS using a single piece of cadaveric fascia in 132 women. At a mean follow-up of 12 months, only one woman developed persistent obstruction that required urethrolysis. Barnes et al. (2002) reported on 38 women with grade 3 or 4 POP and occult SUI who underwent concurrent PVS with prolapse repair. No woman developed permanent urinary retention, and two developed de novo UUI. Preoperative UUI resolved in 45%. The authors concluded that concurrent surgery had little negative effect on postoperative bladder emptying. In general, there is a paucity of literature on the effects of concurrent PVS and prolapse repair on postoperative emptying and voiding symptoms.

Surgical Management of Voiding Dysfunction After Pubovaginal Sling Surgery

Although transient urinary retention is common, most women return to spontaneous and efficient voiding within the first 10 days (Cross et al., 1998b; Zaragoza, 1996). Obstruction after an autologous PVS usually improves or resolves with time, and, for this reason, most clinicians historically wait up to 3 months before considering surgical intervention. Obstruction after MUS is different and will be discussed later in this chapter. **It is appropriate to initially treat persistent postoperative voiding dysfunction conservatively.** This includes temporary indwelling catheter drainage, CIC, timed voiding, double voiding, biofeedback, PFMT, and anticholinergic therapy.

If the woman is in complete retention, sling revision may be undertaken sooner. In the first 6 weeks after autologous PVS, there may be success with loosening the sling in the operating room using spinal or general anesthesia. This is performed by inserting a cystoscope into the bladder and then gently applying inferior pressure to the urethra; **however, this procedure is not advised with synthetic slings.** Other anecdotal evidence also shows improvement in obstruction with urethral dilation and downward traction after autologous PVS; however, results may range from temporary relief to worsening of the urethral rigidity secondary to periurethral fibrosis (Beck et al., 1988; Zimmern et al., 1987). Transurethral resection or incision of the bladder neck is likely to fail because the sling is extraluminal, and transurethral resection may damage the sphincter or bladder neck or cause periurethral fibrosis, leading to worsened incontinence or a bladder neck contracture (Ghoniem and Elgamasy, 1995). After 6 weeks, or when conservative measures fail, sling incision or a formal urethrolysis is indicated.

Surgical management of bladder outlet obstruction after a PVS has traditionally involved complete urethrolysis by a retropubic, transvaginal, or suprameatal approach, with success rates ranging from 65% to 93% (Carr and Webster, 1997; Cross et al., 1998a; Goldman et al., 1999; Foster and McGuire, 1993; Petrou et al., 1999). Most of these series include women with obstruction after different anti-incontinence procedures, and only two groups stratified their results specifically for PVS (Foster and McGuire, 1993; Petrou et al., 1999). Foster and McGuire (1993) reported that transvaginal urethrolysis was successful in 50% of obstructions from PVS, which was lower than that for both needle suspensions (75%) and retropubic urethropexy (63%). Their conclusion was that transvaginal lateral dissection is insufficient in relieving the direct suburethral compressive force of the sling. Petrou et al. (1999) concluded that the suprameatal approach is superior to the transvaginal approach because the former allows access and division of the lateral wings of the sling. In their series, 8 of 12 women had successful results. In another series of 12 women, Petrou and Young (2002) reported resolution of obstruction in 10 women after retropubic urethrolysis. Of note, 2 of these 10 women subsequently developed SUI. Carr and Webster (1997) reported significant or complete resolution of symptoms in 86% of women after retropubic urethrolysis. Overall, recurrent SUI after formal urethrolysis is reported to range from 0% to 19% (Table 125.5).

TABLE 125.5

Result of Therapy for Bladder Outlet Obstruction After Pubovaginal Sling Surgery

---

STUDY	N	MANAGEMENT	MEAN TIME TO TREATMENT (MONTHS)	SUCCESS RATE	RECURRENT SUI	S T
Foster and McGuire, 1993	10	Transvaginal urethrolysis	25.9	50%	0%	N
Carr and Webster, 1997	51	Retropubic, vaginal, or infrapubic urethrolysis	15	Retropubic, 86% Vaginal, 73% Infrapubic, 25%	13.7%	N
Cross et al., 1998a	15	Transvaginal urethrolysis	16	72%	6.7%	F
Goldman et al., 1999	11	Transvaginal urethrolysis	14	84%	19%	N
Petrou et al., 1999	12	Suprameatal transvaginal urethrolysis	18	66.7%	0%	N
Defreitas and Herschorn,	16	Lateral sling lysis	NR	94%	34%	N

2000						
Amundsen et al., 2000a	32	Transvaginal urethrolysis, 22 Sling lysis, 10	9.8	84%	12.5%	C
Kusuda, 2001	5	Sling lysis	1.5–24	100%	0%	N
Nitti et al., 2002	19	Sling lysis	10.6	84%	17%	
Goldman, 2003	14	Sling lysis	8.6	93%	21%	M
Scarpero et al., 2003	24	Repeat transvaginal urethrolysis (23), retropubic urethrolysis (1)	9	92%	18%	C
Thiel et al., 2005a	13	Sling lysis	2.2	45% cured 45% improved	7.7%	N

MUS, Mid-urethral sling; *NR,* not recorded; *PVS,* pubovaginal sling; *SUI,* stress urinary incontinence.

Sling incision is associated with comparable success rates (84% to 100%), shorter operative time, and less morbidity than formal urethrolysis (Amundsen et al., 2000a; Goldman, 2003; Kusuda, 2001; McLennan and Bent, 1997; Nitti et al., 2002; Shenassa et al., 2000; Thiel et al., 2005a). Most series report the outcomes of a single midline PVS incision; however, incision of the sling in conjunction with the interposition of autologous graft between the cut ends of the sling has been described to successfully prevent recurrent SUI (Ghoniem and Elgamasy, 1995). Others, however, have found that this technique does not live up to expectations. Shenassa et al. (2000) and McLennan and Bent (1997) used vaginal wall interposition in 12 and 4 women, respectively. Successful relief of obstruction was achieved in 92% and 100%, respectively, but SUI recurred in 25% of women in each series.

Several authors have reported on successful midline or lateral sling incision without graft interposition. Defreitas and Herschorn (2000) had a 94% success rate in 16 women after lateral sling incision, with a 34% rate of recurrent SUI Kusuda (2001) reported successful outcomes in five women who underwent a similar procedure. A lateral incision theoretically minimizes the chance of urethral injury in those cases when the sling is identified, but the dissection plane between the urethra and sling cannot be established safely. Amundsen et al. (2000a) used a midline PVS incision in 10 of 32 women in whom the sling was easily identified and a formal transvaginal urethrolysis with entrance into the retropubic space in the remainder. The overall success rate was 84%, but the results were not stratified between sling incision and formal urethrolysis. Of note, in 9 of the 12 women with obstructing autologous slings, the sling material could not be identified and was replaced by dense fibrosis. Nitti et al. (2002) reported on 19 women who underwent PVS incision and cited an 84% success rate with a 17% rate of recurrent SUI. Two of the three women with urethrolysis failure underwent subsequent successful retropubic urethrolysis, which allowed for complete release of all retropubic scarring, which likely contributed to the initial failure of sling incision. Goldman (2003) performed simple sling incision in 14 women with iatrogenic urethral obstruction, three of whom had a MUS. Ninety-three percent had complete or significant improvement of voiding dysfunction, and one woman required subsequent formal urethrolysis. Three women (21%) developed recurrent SUI; however, only one required treatment with a repeat MUS. Thiel et al. (2005a) reported long-term results after simple sling incision for 13 women with catheter-dependent urinary retention after PVS. At 5 years of follow-up, 45% of women reported cure, and 45% were improved. Eight percent noted recurrent SUI but chose not to pursue further therapy.

There are no preoperative or urodynamic parameters that consistently predict success or failure of urethrolysis. Foster and McGuire (1993) found that women with DO had a higher rate of failure, but later studies contradicted this. Carr and Webster (1997) found that the only parameter predictive of success was no prior urethrolysis, and Nitti and Raz (1994) found that failure was related to higher PVR volume; however, these factors have not been confirmed by others.

Persistence of storage or voiding symptoms after urethrolysis may be caused by persistent or recurrent obstruction, DO, impaired detrusor contractility, or learned voiding dysfunction. Recurrent obstruction may result from periurethral fibrosis and scarring or intrinsic damage to the urethra that has occurred from previous urethrolyses. The most common reason for failure is likely insufficient dissection and lysis of the urethra. Scarpero et al. (2003) found that repeat urethrolysis after initial failure resolved obstruction in 92% of 24 women. Both transvaginal and retropubic approaches were employed depending on the clinical situation. Storage symptoms resolved in only 12%, and, even though improvement was often observed, 69% continued to require anticholinergic therapy. SUI recurred in 18% of the women. This supports the use of repeat urethrolysis in the face of initial failure, or in cases in which the aggressiveness of the initial dissection is in question. Finally, a retropubic urethrolysis may also be considered after an aggressive transvaginal urethrolysis has failed.

Refractory urinary storage symptoms after urethrolysis (>50%) affect patient satisfaction and QoL and constitute a treatment challenge (Starkman et al., 2008a). There are no predictors of this outcome after urethrolysis, yet preoperative DO may suggest an increased likelihood of refractory OAB. Likewise, there are no established guidelines for optimal management. Starkman et al. (2007) evaluated 25 women with UUI after pelvic surgery (19 PVS, 3 retropubic suspension, and 3 transperitoneal vesicovaginal fistula repair) of whom 4 required further urethrolysis. The authors found that 80% of the women reported greater than 50% improvement in their symptoms, and 6 were continent after subsequent sacral neuromodulation (SNM). There were no significant differences in response based on age, duration of symptoms, type of surgery, and urodynamic parameters. One year later, Starkman et al. (2008b) evaluated the value of SNM in the management of 8 women who had undergone at least one urethrolysis. Six women had a favorable response during test stimulation, and all six remained significantly improved after implantation of an implantable pulse generator. Hence, in addition to anticholinergics, SNM should be considered as an option for de novo or refractory urgency and urgency incontinence after urethrolysis.

With FDA approval of onabotulinumtoxinA for both idiopathic and neurogenic DO, this modality has also been employed for treatment of persistent and de novo OAB symptoms after sling surgery. Miotla et al. (2016) prospectively enrolled 53 women with idiopathic and 49 with de novo OAB symptoms after MUS and administered 100 Units of onabotulinumtoxinA. At 12 weeks, 41.5% of the women in the idiopathic group and 38.8% in the de novo group were completely dry. In both groups, there was a significant improvement ($P < 0.001$) in the daily number of voids (–2.39 and –2.0) and incontinence episodes (–1.38 and –1.44), with no significant difference between groups. Mean voided volume increased by >90 mL in both groups, and urinary retention was observed in four women. It must be noted that these women did not undergo sling revision first, and there are no studies specific for intravesical injection of onabotulinumtoxinA for persistent or de novo OAB symptoms after bladder neck slings.

Key Points: Voiding Dysfunction After Pubovaginal Sling

- Obstruction, DO, and impaired detrusor contractility are manifestations of voiding dysfunction from iatrogenic outlet obstruction after a PVS.
- The incidence of permanent urinary retention is usually less than or equal to 5%.
- Persistent urgency and UUI (8% to 25%) present more commonly as symptoms of bladder outlet obstruction after a PVS compared with frank urinary retention.
- A temporal relationship between the anti-incontinence surgery and the onset of voiding dysfunction is the key to diagnosis. Urodynamic studies may be helpful in these cases for diagnosis and to assist in making an appropriate treatment plan.
- Transient urinary retention usually resolves within 10 days, and obstruction from a PVS may improve or resolve with time. Therefore, most surgical interventions should be postponed until at least 3 months after surgery.
- Reported success rates of the surgical management of bladder outlet obstruction after a PVS procedure are 65% to 93%. The rate of recurrent SUI after urethrolysis is 0 to 19%.
- There are no preoperative variables that predict success or failure of urethrolysis. OAB symptoms are refractory in 50% of affected women after urethrolysis and contribute to a significant portion of reported failures.

Complications of Pubovaginal Slings

Pubovaginal Sling Perforation and Exposure

The incidence of PVS perforation and exposure is partially dependent on the composition of sling material. **Synthetic slings perforate 15 times more often into the urethra and are exposed 14 times more often in the vagina than autologous, allograft, and xenograft slings** (Blaivas and Sandhu, 2004). These numbers are based on a meta-analysis of 287 peer-reviewed articles (Leach et al., 1997). In this study, the urethral perforation rate was 0.02%, and the vaginal exposure rate was 0.007% in 1515 women who received synthetic slings. This is in contrast with a 0.003% urethral perforation incidence and 0.0001% vaginal exposure incidence in 1715 women who underwent autologous and allograft sling procedures. In subsequent studies, most perforations and exposures were associated with synthetic slings, particularly woven polyester slings (Amundsen et al., 2003; Bent et al., 1993; Chin and Stanton, 1995; Clemens et al., 2000; Duckett and Constantine, 2000; Kobashi et al., 1999; Myers and LaSala, 1998; Summit et al., 1992; Weinberger and Ostergard, 1995). Several cases of autologous and allograft sling perforations and exposures have been published (Amundsen et al., 2003; Blaivas and Sandhu, 2004; Bradley et al., 2003; Golomb et al., 2001; Handa and Stone, 1999).

Most urethral perforations are diagnosed 1 to 18 months after the original surgery, with a mean presentation time of approximately 9 months (Blaivas and Sandhu, 2004). Presenting symptoms often include urinary retention, urgency, and MUI. In addition, synthetic sling perforations and exposures may also be associated with vaginal discharge, vaginal pain, suprapubic pain, and recurrent UTIs. The etiology of these symptoms is usually multifactorial and may be related to the woman's tissue quality, surgical technique, or the sling material. Local tissue quality may be suboptimal from postsurgical scarring, urethral atrophy, estrogen deficiency, and radiation-induced ischemia. Errors in surgical technique include excessive sling tension, dissection too close to the urethra, or perforation of the urethra or bladder.

Urinary tract perforation by an autologous PVS is rare, with only four cases documented in the peer-reviewed literature. Golomb et al. (2001) and Handa and Stone (1999) each reported an individual case of an autologous PVS eroding through the mid-urethra. Possible contributing factors include misplacement or incorrect technique in sling passage or positioning, excessive tension, or traumatic urethral instrumentation after placement of a PVS (e.g., for clot evacuation or surveillance cystoscopy). In both aforementioned cases, the perforated portion of the sling was excised and the urethra was repaired. Clemens et al. (2000) described two cases of bladder dome perforation by an autologous rectus fascial PVS. The women had recurrent UTIs, dysuria, and UUI. One woman had a bladder calculus on the sling material visible on cystoscopy. The other had edema and visible suture at the dome. Both cases were likely caused by a missed bladder perforation after Stamey needle passage, underscoring the need for vigilant cystoscopy with 30- and 70-degree lenses during PVS surgery. Both cases were successfully managed with endoscopic removal of stitches and treatment of the stone. No further treatments were necessary.

Management of autologous and allograft sling urethral perforation usually involves incision or excision of the intraluminal sling portion and simple closure of the urethra (Blaivas and Sandhu, 2004). Rarely, additional coverage with measures such as a Martius flap may be required. **Because urinary tract perforation and vaginal exposure of synthetic PVS are more common and associated with significant morbidity, synthetic material is no longer used for bladder neck slings.** In fact, the ProteGen sling (Boston Scientific) was withdrawn from the market in January 1999 possibly because of the high urinary tract perforation rates (Clemens et al., 2000). Some authors believe that synthetic PVS sling perforation into the urinary tract necessitates complete removal of the sling and all other foreign materials (sutures, bone anchors, screws) whenever present (Blaivas and Sandhu, 2004). However, we believe that, as long as the synthetic material is no longer under tension, excised far away from the bladder and urethra, and not associated with infection or pain, it is not necessary to remove all of the foreign material. The technique for this removal is discussed in the Mid-Urethral Slings section later in this chapter.

The incidence of recurrent SUI after synthetic PVS removal in cases of urethral perforation is 44% to 100%, and treatment often involves a secondary PVS (Amundsen et al., 2003; Clemens et al., 2000; Kobashi et al., 1999). Flisser and Blaivas (2003) reported an 87% continence rate when perforations were managed with concurrent placement of a new PVS. Blaivas and Sandhu (2004) also noted that secondary procedures such as periurethral bulking agents and PVSs are successful in a majority of patients. However, if the bladder neck is involved with the perforation, the authors noted a much lower overall continence rate, even with the use of concomitant autologous slings at the time of reconstruction.

Pubovaginal Sling Nonurologic Complications

While the most common complications of PVS surgery are related to the urinary tract, significant nonurologic complications also occur. The authors of the 2009 update of the AUA guideline for SUI surgery performed an extensive meta-analysis of the literature and confirmed that the most common nonurologic complications were pulmonary, cardiovascular, neurologic, and gastrointestinal (bowel injury) (Appell et al., 2009). When considering all anti-incontinence procedures (retropubic and transvaginal suspensions, anterior colporrhaphy, and PVS), the panel estimated a death rate of approximately 3 per 10,000 procedures.

Anger et al. (2007a) analyzed Medicare claims data for short-term complications after sling surgery (mostly MUS) among female beneficiaries 65 years of age and older. A total of 1356 sling procedures were performed from 1999 to 2001, and, in the 3 months after surgery, 12.5% of women developed surgical or urologic complications and 34% were diagnosed with UTIs. One year after surgery, the following nonurologic complications were reported: bowel injury or obstruction (6.6%), cardiac complications (9.1%), thromboembolic complications (2.6%), pulmonary complications (15.3%), and other (22.1%). On multivariate analysis, nonwhite race was a risk factor for developing urologic and nonurologic postoperative complications. In addition, women 65 to 69 years of age were significantly less likely to experience nonurologic complications or undergo treatment for outlet obstruction or recurrent incontinence than women older than 75 years of age. In a similar review of greater than 21,000 female Medicare beneficiaries undergoing sling surgery between 2001 and 2011, Chughtai et al. (2016) cited rare adverse events within a 90-day postoperative window. The only exception was urinary retention, which was recorded in 11.3% of the women.

More specific information about the type of complications can be gleaned from the literature. In the SISTEr trial, rates of serious adverse events for the autologous PVS and Burch colposuspension groups were 13% and 10%, respectively (Albo et al., 2007). In the sling group, both deep venous thrombosis (DVT) and serious bleeding had an incidence of 0.3%. Although the authors did not describe the specific type of complication, there was also a 3.4% incidence of serious wound complications. The most common wound complications after autologous PVS surgery are wound infection, seroma, and incisional hernia. In their experience with over 500 patients, Blaivas and Chaikin (2011) reported wound infections and incisional hernias, each, in 1%. In another retrospective study of 247 women, the rate of incisional hernias was a similar 0.8% (Morgan et al., 2000). Although rare, incisional hernias related to harvesting the rectus fascia are an unfortunate serious complication of autologous PVS that usually require surgical correction.

Key Points: Complications of Pubovaginal Slings

- The incidence of perforation is dependent on the sling material, with synthetic slings being 15 times more likely to perforate into the urethra and 14 times more likely to become exposed in the vagina than other materials. For this reason, synthetic PVS are no longer used for support at the bladder neck.
- Vaginal exposures after synthetic slings typically manifest with vaginal discharge, pain, suprapubic pain, and recurrent UTIs and may require subtotal or total sling removal.
- The incidence of recurrent SUI after synthetic PVS urethral perforation is 44% to 100%, and treatment often involves a second (autologous) PVS.
- Perforation or exposure after autologous PVS is rare.

Mid-Urethral Slings

Mechanics, Anatomy, and Materials of Mid-Urethral Slings

Mechanics of the Mid-Urethral Sling

The integral theory posits that the most important factors in preserving continence are adequate function of the pubourethral ligaments, the suburethral vaginal hammock, and the pubococcygeus muscle (Petros and Ulmsten, 1990). An injury to any of these three components from surgery, parturition, aging, or hormonal deprivation can lead to impaired mid-urethral function and, subsequently, SUI. Urethral hypermobility is a sign of damage to these normal supporting structures of the urethra and not a cause of SUI.

Preoperative ultrasonography and MRI have demonstrated that the proximal urethra in women with SUI is often open at rest and, regardless of urethral mobility, movement of the anterior and posterior walls of the urethra during stress maneuvers most likely contributes to a shearing affect that opens the urethra and results in incontinence (Dietz and Wilson, 2004; Huang and Yang, 2003; Kociszewski et al., 2008; Masata et al., 2006; Sanders et al., 1994). Based on these observations, **it appears that a MUS works by impeding the movement of the posterior urethral wall above the sling, directing its motion in an anteroinferior or anterior direction. In addition, inward movement of the posterior urethral wall after placement of an MUS results in narrowing of the urethral lumen (compression).** This securing of the posterior wall of the urethra (with or without compression during stress maneuvers) is one theory of how MUS procedures achieve stress continence. In addition to this proposed mechanism for urethral support, some authors have proposed that MUS work through a mechanism of dynamic urethral kinking during stress events as seen on ultrasonography (Lo et al. 2001).

Ideally, a retropubic or transobturator MUS is placed loosely at the mid-urethra, and its function does not require the sling to be tight. The sling is anchored to the endopelvic fascia for retropubic-directed slings and to the obturator internus and externus muscle and fascia for transobturator-directed slings. Over time, the synthetic mesh sling becomes fixed in either of these two locations and provides support along its entire course inferior to the pubic symphysis and ischiopubic rami, and not just at the midline area posterior to the urethra. This broad support may be the reason why, in studies by Laurikainen and Killholma (2006), Gamé et al. (2006), Clifton et al., (2014) and Klutke et al. (2001), 50%, 70%, 79%, and 93% of women, respectively, remained continent after MUS incision for obstruction.

Several authors have found that lack of urethral mobility before retropubic and transobturator MUS is a prognostic factor for lower SUI cure rates, and that decreased urethral mobility postoperatively is associated with persistent incontinence (Haliloglu et al., 2010; Minaglia et al., 2005, 2009). Conversely, the postoperative persistence of significant urethral mobility is not associated with a poorer outcome. It appears that **lack of urethral mobility is a sign of a fixed urethra and ISD. Overall, women without urethral hypermobility do not respond as well to MUS surgery. A loosely placed MUS combined with a mobile urethra may allow the sling to compress the urethra during times of Valsalva and other stress maneuvers while remaining nonobstructive when the urethra is at rest.**

Despite the fact that transobturator and retropubic MUS are placed without tension, there is controversy about whether tension or resistance is ultimately created at the bladder outlet. In one study of over 400 retropubic MUS procedures, urodynamic studies before and after surgery confirmed a postoperative increase in voiding time but no difference in flow rate, urethral closure pressure, or urethral functional length (Meschia et al., 2001). A study by Lo et al. (2001) also showed no statistical difference in average flow, Qmax, PVR, MUCP, and functional urethral length in 82 women before and after retropubic MUS.

In contrast, urodynamics performed in 112 women before and after retropubic MUS showed consistent decreases in Qmax, increased mean PdetQmax, increased mean urethral resistance, and elevated PVR (Gateau et al., 2003). The authors concluded that retropubic MUS leads to obstructive changes in the bladder outlet. Sander et al. (2002) evaluated the voiding phase before and 1 year after retropubic MUS and found both subjective and objective changes in the voiding phase. Seventy-eight percent of women experienced more difficult voiding and significant decreases in Qmax, corrected Qmax, and average flow. PVR was also significantly increased, although no greater than 25% of capacity.

Unlike after retropubic and transobturator MUS, restriction of urethral mobility after SIMS may be associated with more favorable outcomes. Martan et al. (2009) analyzed 85 women after a SIMS with perineal ultrasonography, cough test, and validated questionnaires. Postoperatively, 62% had a negative cough test. The sling was noted to restrict urethral mobility, and a higher degree of restriction was associated with a higher likelihood of cure; however, this restrictive effect was noted to weaken within the first 3 months after surgery. A study of 57 women who underwent SIMS also showed that outcomes were poorer in women who had persistent urethral hypermobility after surgery (Spelzini et al., 2013). It is possible that SIMS efficacy is related to restriction of urethral mobility and that this restriction is required to secure the posterior urethral wall, achieve adequate urethral kinking, or compress the urethral lumen.

Anatomy of the Retropubic Mid-Urethral Sling

For a retropubic MUS, the trocars must pass through the retropubic space, which is also known as the *space of Retzius* or *prevesical space.* This space is bounded anteriorly by rectus abdominis muscles and the bony pelvis (pubic symphysis and ischiopubic rami). The lateral borders of the space are the bony pelvis and the obturator internus muscle. The bladder and proximal portion of the urethra lie posterior to this space. The endopelvic fascia (paravaginal connective tissue or pubocervical fascia) forms the inferolateral boundary of the prevesical space and is attached medially to the levator ani muscles at the bladder neck and inferior portion of the pubic symphysis. The endopelvic fascia is attached laterally to the ATFP and the ischiopubic rami. The endopelvic fascia separates the prevesical space from the vesicovaginal space. The prevesical space mainly contains loose connective tissue and adipose tissue. Obese women may have more adipose tissue in this space, and this anatomic finding may contribute to the lower rate of trocar-related bladder injuries seen in this patient population (Stav et al., 2010b).

The left and right dorsal nerves of the clitoris (DNC) run along the inferior surface of the ischiopubic rami and cross under the pubic bone approximately 1.4 cm from the midline (Achtari et al., 2006). After placing a retropubic MUS in 10 cadavers, the authors found that the sling was an average of 1.1 cm from the DNC at its closest point. The fact that the superior incisions for a retropubic MUS are typically made at least 2 cm from the midline should help ensure that the DNC are not injured by a trocar or sling. At a distance of 3.2 cm (laterally), the obturator vessels are the closest major vascular structures to a retropubic MUS (Muir et al., 2003).

The vesicovaginal space is the initial plane of dissection for a retropubic MUS. This space is bounded by the posterior wall of the bladder and the anterior wall of the vagina (Corton, 2013). The space extends to the proximal and middle urethra. Below this location, the posterior wall of the urethra and the anterior vaginal wall are fairly fused. A relatively thick periurethral fascia covers the posterior urethra. The female urethra is approximately 4 cm in length, and, therefore, an incision 1.5 cm from the meatus will provide access to the mid-urethra.

Anatomy of the Transobturator Mid-Urethral Sling

Like the retropubic MUS, transobturator MUS surgery begins with dissection in the vesicovaginal space. This dissection is carried out lateral to the urethra until the inferior border of the ischiopubic rami and pubic symphysis can be easily palpated. A trocar must traverse the obturator internus muscle, obturator membrane, and obturator externus muscle as it goes through the obturator foramen. Lateral to the obturator foramen are the adductor muscles (gracilis and adductor brevis muscles) of the thigh (Corton, 2013). The obturator nerve and vessels are located in the obturator canal at the superior aspect of the obturator foramen.

Several authors have performed cadaveric dissections to better understand the anatomic relationships of the transobturator MUS. Delmas et al. (2003) used the outside-in approach in 10 cadavers to detail the relevant pelvic anatomy in relation to the sling insertion path. In these dissections, the sling consistently passed 4 cm anterior and caudal to the obturator canal, confirming the relative safety of the obturator neurovascular structures. The authors also demonstrated that the sling traverses a plane between the perineal and levator ani musculature above the pudendal neurovascular pedicle.

Bonnet et al. (2005) performed the inside-out transobturator technique as described by de Leval (2003) in 13 cadavers to determine the sling path and proximity to surrounding structures. The authors noted that the sling never penetrated the adductor longus muscle and was a safe distance from neurovascular structures. However, in approximately 70% of cases, the implanted material traversed the adductor magnus, adductor brevis, and gracilis muscles during its path into the pelvis. At the level of the obturator foramen, the sling traverses the obturator externus and internus muscles as well as the obturator membrane. The distance between an inserted sling and the obturator nerve and vessels at the level of the obturator foramen ranged from 2.2 cm to 3 cm. The authors stated that hyperflexion of the hip and the rotational trajectory of the helical passer help ensure this separation. Also, the anterior branches of the obturator artery and vein are protected from injury by the bony architecture of the inferior pubic rami. Medially, the transobturator MUS enters the anterior compartment of the ischiorectal fascia, in the area of the levator ani membrane and obturator internus muscle. A properly placed sling remains outside the pelvic space and does not penetrate the levator ani muscular group. Lastly, transobturator MUS remain above the perineal membrane at all times, and the DNC, which is found caudal to the perineal membrane, is protected from injury during trocar passage.

A study by Whiteside and Walters (2004) further evaluated the obturator anatomy in relationship to sling insertion in 6 cadavers. The authors found that the mesh, on average, passed 2.4 cm inferior and medial to the obturator canal and that anterior and posterior divisions of the obturator nerve were 3.4 cm and 2.8 cm, respectively, away from the path of the trocar. However, they also noted that the trocar passed, on average, within 1.1 cm of the most medial and anterior branches of the obturator vessels (located behind the inferior pubic rami, as described by Bonnet et al., 2005). These authors concluded that a risk for injury does exist, and appropriate caution should be exercised.

The anatomic variations between the inside-out and outside-in transobturator MUS approaches have been compared, especially with regard to their association with adverse outcomes. The mean distance from the vaginal incision to the obturator membrane was 4.0 cm and 6.75 cm from the vaginal incision to the obturator neurovascular bundle in cadaver dissections after an inside-out transobturator MUS (Raders et al., 2005). At the obturator membrane, the closest point of the passer is only a mean distance of 2 cm from the obturator neurovascular bundle. This is the reason the curved passer is directed away from these structures and advanced. Also, an anterior branch of the obturator artery coursed medially along the exterior edge of the obturator foramen in 60% of the cadavers. However, similar to Bonnet et al. (2005), Raders et al. (2005) felt that the exterior bony rim of the obturator foramen protected this artery during an inside-out pass. However, they also postulated that this vessel could be potentially injured during an outside-in approach.

Anatomy of the Single-Incision Mid-Urethral Slings

For a SIMS, the plane of dissection is only in the vesicovaginal space. Although the trocars are much shorter, they are passed into the retropubic space or through the obturator foramen. As with other MUS procedures, cadaveric dissection aids in the anatomic localization of the SIMS. Using 14 embalmed and 5 fresh-frozen female bodies, Hubka et al. (2009) placed SIMS trocars bilaterally and measured the distances from the obturator bundle (obturator nerve and vessels). They found that the mean distances of the sling from the obturator nerve and vessels were 3.05 cm and 3.07 cm, respectively. Perforation of the fascia of obturator internus muscle occurred in 4.4%, and the authors felt that vascular injury, albeit unlikely, could theoretically occur. The position of the SIMS was not found to change with repositioning of the legs.

Mid-Urethral Sling Materials

In their initial description of the MUS, Ulmsten and Petros (1995) used Mersilene, Gore-Tex, Teflon, and Lyodura (cadaveric dura mater). However, because of complications related to other synthetic materials in the general surgery hernia literature, Ulmsten et al. (1998) eventually settled on a polypropylene, multifilamentous woven mesh and termed the procedure *intravaginal slingplasty* (IVS; Tyco Healthcare, Mansfield, MA). **Currently, almost all of the MUS products are constructed from a soft, loosely woven, polypropylene monofilament mesh with a pore size exceeding 75 µm.** As previously discussed, this material allows for optimal migration of host inflammatory components (leukocytes and macrophages) into the mesh for purposes of infectious surveillance and host wound healing (imbibition and inosculation). It has also been found that this material is optimal for inciting fibrous tissue ingrowth. This type of mesh is known as a type I mesh (Amid classification) and has previously been described in the general surgical literature as being favorable from the standpoints of its mechanical properties such as stretch and elasticity (Dietz et al., 2001, 2003).

UraTape (Mentor-Porgés, Le Plessis-Robinson, France) was the first transobturator MUS, and Delorme et al. (2003) were first to report initial outcomes. UraTape is a polypropylene, microporous sling with a central silicone core, and was eventually replaced by ObTape (Mentor-Porgés) because of a high rate of vaginal exposure likely related to the silicone core. However, possibly because of its semi-microporous (<50 µm) nature, vaginal exposures have also been reported with ObTape (Siegel, 2005; Yamada et al., 2006). A second-generation transobturator MUS developed by Mentor-Porgés (Aris transobturator tape) has a larger, 200-µm pore size that allows improved tissue ingrowth with less encapsulation. A unique transobturator mesh is the BioArc, which has a biologic (porcine dermis, InteXen) graft material that is sutured on either end to the polypropylene mesh. The biologic material actually occupies a suburethral position (de Leval, 2003; Delorme et al., 2003). While many retropubic and transobturator MUS products have been removed from the market, the available products are made of monofilament, macroporous woven polypropylene.

Key Points: Mechanics, Anatomy, and Materials of Mid-Urethral Slings

- The integral theory states that the most important factors to preserve continence are adequate function of the pubourethral ligaments, the suburethral vaginal hammock, and the pubococcygeus muscle. An injury to any of these three components from surgery, parturition, aging, or hormonal deprivation can lead to impaired mid-urethral function and, subsequently, urinary incontinence.
- Urethral hypermobility is a symptom of damage to the normal supporting structures of the urethra and not a cause of SUI.
- Initial MUS products were constructed of materials with smaller pore sizes. Currently, the majority of MUS are made of loosely woven, macroporous, monofilament polypropylene.

Mid-Urethral Sling Operative Procedures

Mid-Urethral Sling Patient Counseling

Because MUS surgery involves the implantation of a synthetic prosthesis, surgeons should thoroughly counsel their patients about the permanent nature of these products, and, although infrequent, unique and sometimes serious complications related to their use may occur. As with the PVS, women should also be counseled about the risk for transient and permanent voiding dysfunction after surgery. This should include a discussion of postoperative difficulty emptying the bladder and de novo urinary storage symptoms.

Mid-Urethral Sling Anesthesia, Patient Positioning, and Preparation

MUS surgery can be performed using local (with or without sedation), spinal, or general anesthesia, but the decision is based on patient, surgeon, and anesthesia provider preference. In the original description of the MUS, local anesthesia was used so that the woman would be able to perform an intraoperative cough stress test as a method of adjusting sling tension. It was believed that this would minimize the incidence of obstruction. However, several studies have failed to show a difference in the efficacy or safety of MUS performed under local versus spinal anesthesia (Adamiak et al., 2002; Wang and Chen, 2001). In one of these studies, 67 women underwent MUS under local anesthesia and 36 under spinal anesthesia, and there was no difference in the success rate after MUS or in the incidence of complications between the groups (Adamiak et al., 2002). The inability to perform a cough test in the spinal anesthesia group did not result in an increased incidence of postoperative obstruction. Hence, tensioning the sling according to cough stress test may not improve outcomes. Antibiotic and DVT prophylaxis, vaginal preparation, and patient positioning are performed as for the PVS procedure. Additional thigh flexion (≥70 degrees) may be beneficial during this procedure.

Surgical Approach for Retropubic Mid-Urethral Slings

The standard MUS consists of two specially curved 5-mm diameter insertion trocars and a 40-cm long and 1.1 cm wide segment of polypropylene mesh, although the width and length of the mesh and trocar diameter may vary slightly by manufacturer. The sling is typically covered with a clear plastic sheath, which protects the mesh from contamination and allows easy passage through host tissues. For the bottom-up technique, a rigid catheter guide is typically placed in the urethra with an 18-Fr Foley catheter to help deflect the bladder away from the path of trocar insertion. An ergonomic handle is attached to the trocar to aid in its manipulation. Fig. 125.8 shows some of the various types of slings and trocars that have been historically available. It must be noted that some of thes products may no longer be available on the market.

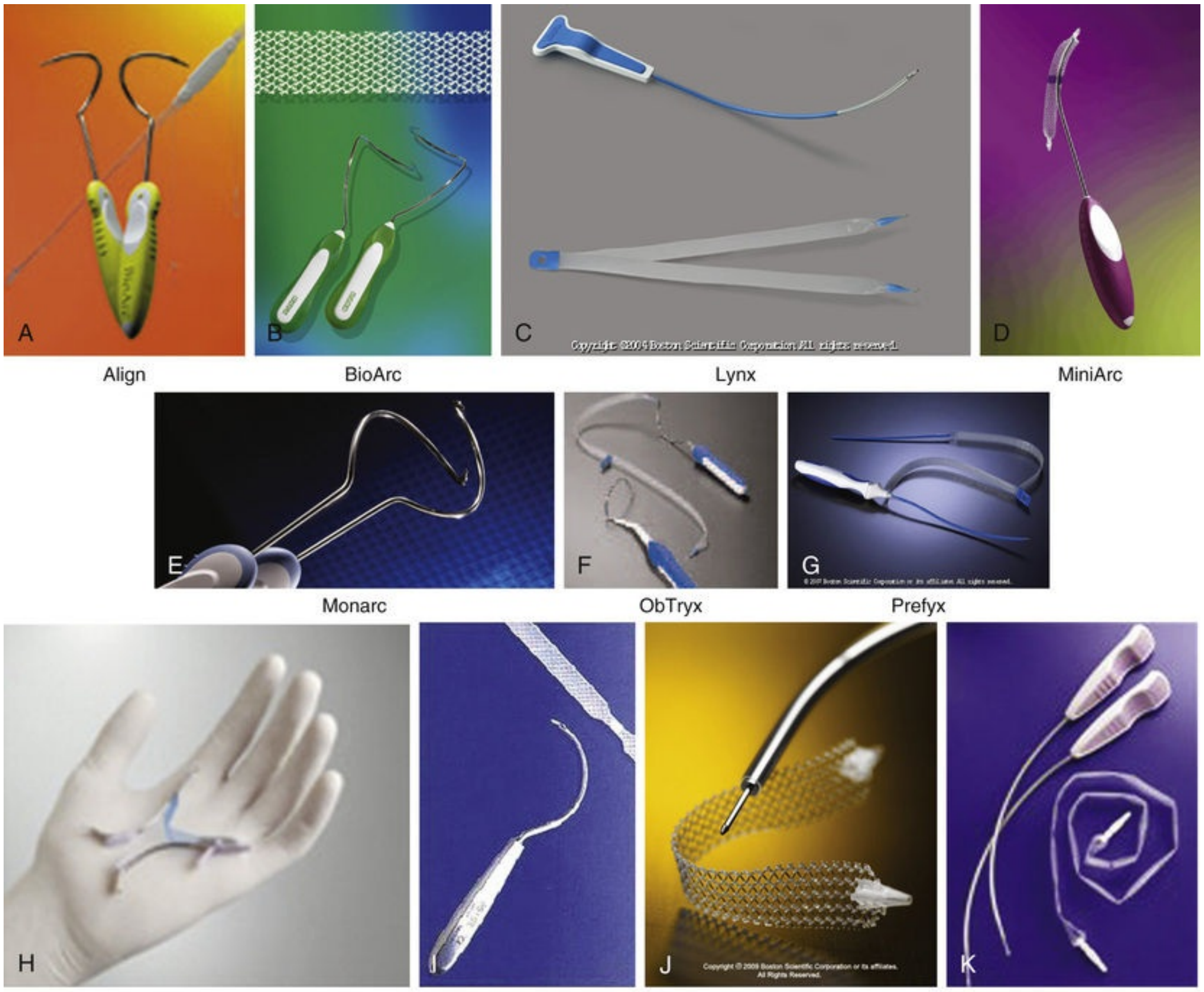
A
B
C
Copyright ©2004 Boston Scientific Corporation All rights reserved.
D
E
F
G
H
J
K

Align BioArc Lynx MiniArc

Monarc ObTryx Prefyx

TVT Secur UraTape Solyx SPARC

FIG. 125.8 (A to K) Mid-urethral sling trocars and prosthetics.

For MUS insertion under local anesthesia, approximately 5 mL of local anesthetic is injected into the vaginal area and into the planned suprapubic insertion skin sites. An additional 20 mL of local anesthetic is injected into the area along the posterior aspect of the pubic bone to the level of the urogenital diaphragm to anesthetize the retropubic space. Additional vaginal infiltration includes 10 mL injected on either side of the urethra to the level of the urogenital diaphragm.

After appropriate anesthesia, two small suprapubic stab incisions are created just above the level of the symphysis pubis, approximately 2 cm lateral to the midline. A third incision is made in the vaginal mucosa in the midline approximately 1.5 cm long and 1.5 cm proximal to the external urethral meatus. After the vaginal incision is created, minimal dissection is performed using Metzenbaum scissors under the vaginal flaps on either side to elevate the vaginal epithelium from the underlying periurethral tissue to the level of the pubocervical (endopelvic) fascia, which is not perforated. For the bottom-top technique, the trocar is then placed in the dissection tunnel immediately beneath the vaginal epithelium on one side of the urethra with the trocar tip situated in close proximity to the lower rim of the pubic ramus. With controlled pressure, the trocar is elevated through the endopelvic fascia, into the space of Retzius, through the rectus muscles, and through the previously created suprapubic skin incision. During this maneuver, the trocar is kept in close contact with the inferior surface of the pubic bone to avoid perforation of the lower urinary tract and also to avoid intraperitoneal entry. Tactile contact with the bone and slow graded pressure during trocar advancement ensure direct apposition of metal to bone and avoidance of bladder injuries.

Simultaneous deflection of the lower urinary tract is accomplished during insertion using the catheter guide and catheter with pelvic viscera deflected away from the site of needle insertion. The same maneuver is performed contralaterally so that each trocar exits through the appropriate skin incision. The technique for top-down trocar passage is very similar; however, a catheter guide with Foley in the urethra is typically not used, and the tip of the trocar is guided onto the index finger of the opposite hand and out of the vaginal incision lateral to the urethra.

Cystoscopy is performed to exclude trocar penetration of the lower urinary tract. The use of a 70-degree lens is essential, as is complete distention of the bladder with irrigant to exclude subtle tangential injury. **If perforation is noted, the trocar is withdrawn and passed once more with an effort to avoid further perforation.** Once cystoscopy has demonstrated no evidence of bladder injury, the bladder is drained and the mesh is brought through the incisions and the sling is tensioned. Tension adjustment is commonly performed by inserting a surgical instrument (clamp) or metallic sound between the sling and urethra while the protective plastic sheath is removed from the field. **In general, a MUS should be placed loosely at the mid-urethra because its function is not primarily related to compression.** Redundant mesh is then excised at the level of the suprapubic skin incisions, and the vaginal incision is closed with delayed absorbable suture. The skin incisions may be left open or closed per surgeon preference. (Fig. 125.9).

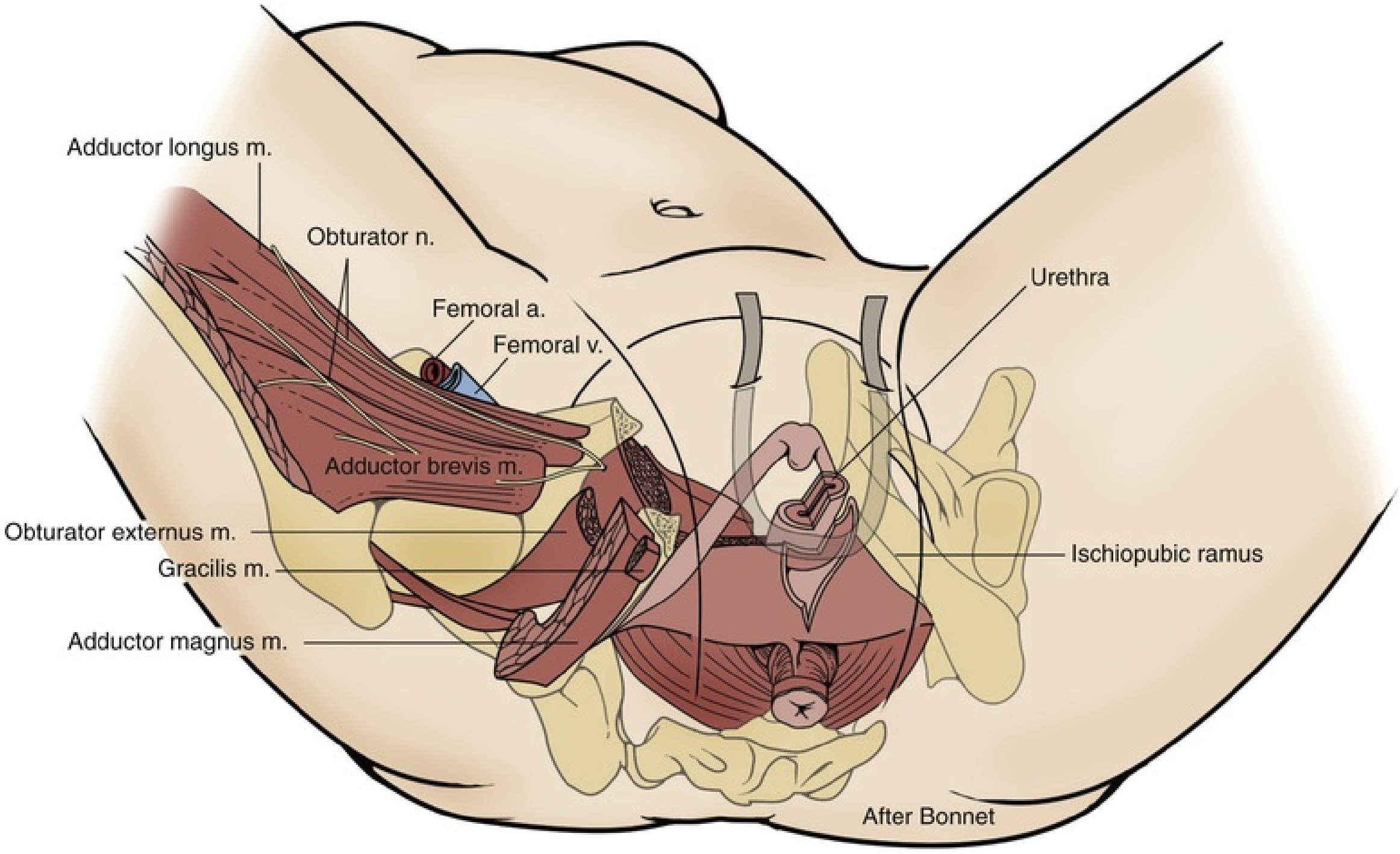
Adductor longus m.
Obturator n.
Femoral a.
Femoral v.
Urethra
Adductor brevis m.
Obturator externus m.
Gracilis m.
Ischiopubic ramus
Adductor magnus m.
After Bonnet

FIG. 125.9 Mid-urethral sling as placed via the retropubic approach.

Surgeons' views on sling tensioning vary considerably. A total of 596 surgeons (63% gynecologists, 37% urologists) from 56 different countries completed an Internet survey, with greater than 30% of respondents performing greater than 50 slings annually (Borazjani et al., 2017). Use of objective intraoperative tension evaluation methods was 15.6%, 7.8%, and 1.9% for intraoperative stress tests, cystoscopic evaluation of urethral coaptation, or Q-tip tests, respectively. Sixty-three percent indicated that they tension retropubic and transobturator MUS similarly, whereas 26.2% placed transobturator MUS under more tension, and 10.4% placed more tension on retropubic MUS. Those with fellowship training were 66% more likely to utilize leak point pressure results to inform the degree of tensioning (OR 1.66, CI 1.04 to 2.66).

Surgical Approach for Transobturator Outside-in Slings

The woman is placed in the dorsal lithotomy position with legs in hyperflexion (120 degrees). A small 1.5-cm midline vaginal incision is created 1.5 cm from the meatus as with the retropubic MUS, and dissection is carried out laterally to the ischiopubic ramus. A puncture incision is made in the crease between the labia majora and the thigh, at the notch along the internal edge of the inferior pubic ramus and the adductor longus tendon. With the woman in hyperflexion, the adductor longus tendon can be pinched with the thumb and index finger and the skin incision typically corresponds to location of the thumb. The obturator membrane is perforated, at which point resistance is noted by the operative surgeon. Using the nondominant index finger and identifying the landmarks of ramus and the obturator internus muscle, the trocar is turned in a medial orientation and advanced on the tip of the index finger and brought out through the vaginal incision. Inspection is carried out at this point to exclude inadvertent penetration of the vaginal fornix or associated urinary structures. The procedure is then repeated on the contralateral side. Cystoscopy to rule out urethral and bladder injury is recommended after trocar passage, and **it is important not to neglect a careful examination of the urethra.** The synthetic material is then attached to the trocar and brought out through the inner thigh stab wound. Tension is set on the sling by passing a clamp between the sling and urethra such that a surgical clamp can be passed easily between these two structures. Excess material is then cut at the skin puncture site, and the incisions are closed according to the surgeon's preference.

Surgical Approach for Transobturator Inside-Out Slings

The vaginal component of the procedure is the same as in the outside-in technique. Stab incisions are created approximately 2 cm superior to the horizontal line level with the urethra and 2 cm lateral to the labial folds, which will be the exit point for the helical passer. Once the device is inserted through the urethra and the upper part of the ischiopubic ramus is reached with the device, the obturator membrane is perforated sharply with scissors. The introducer is then passed at a 45-degree angle relative to the midline sagittal plane until it reaches and perforates the obturator membrane. The open side of the introducer is passed out facing the surgeon. The more distal end of the tubing is then mounted on the spiral segment of the helical passer and slipped along the open gutter of the introducer. The passer is aligned parallel to the sagittal axis and rotated so that the tip of the tubing exits the interthigh stab incision. The tubing is then removed from the passer until the first few centimeters of the mesh become externalized, and the procedure is repeated on the contralateral side. Next, cystoscopy is performed to ensure no injury to the bladder or urethra. All plastic covering sheaths are then removed simultaneously from the sling while maintaining no tension on the sling itself, using the technique previously described. Operative technique varies with insertion method (Fig. 125.10).

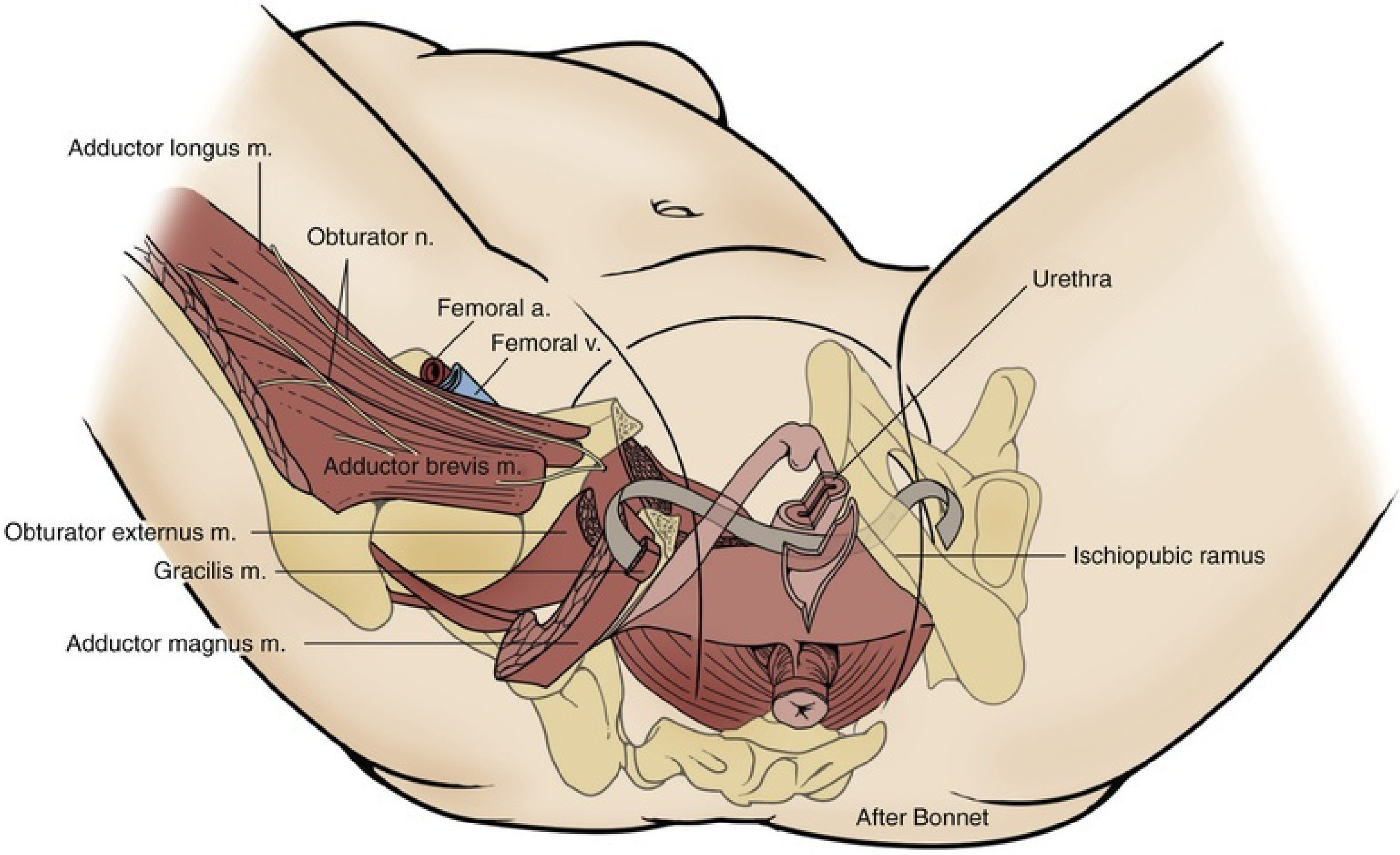
Adductor longus m.
Obturator n.
Femoral a.
Femoral v.
Urethra
Adductor brevis m.
Obturator externus m.
Ischiopubic ramus
Gracilis m.
Adductor magnus m.
After Bonnet

FIG. 125.10 Mid-urethral sling as placed via the transobturator approach.

Surgical Approach for Single-Incision Slings

Each of the SIMS has a proprietary method of placement that varies by manufacturer. In general, the sling devices consist of a short segment of loosely woven polypropylene mesh with two harder, pointed ends that allow it to anchor in place. A curved stainless steel trocar or other type of applicator device is used to push the ends of the sling into a secure position. The sling is placed under the mid-urethra and can be fixed in the hammock position (Fig. 125.11A) into the obturator internus muscle or in the U-shaped position (see Fig. 125.11B) into the connective tissue of the urogenital diaphragm (endopelvic fascia) behind the pubic bone (Meschia et al., 2009).

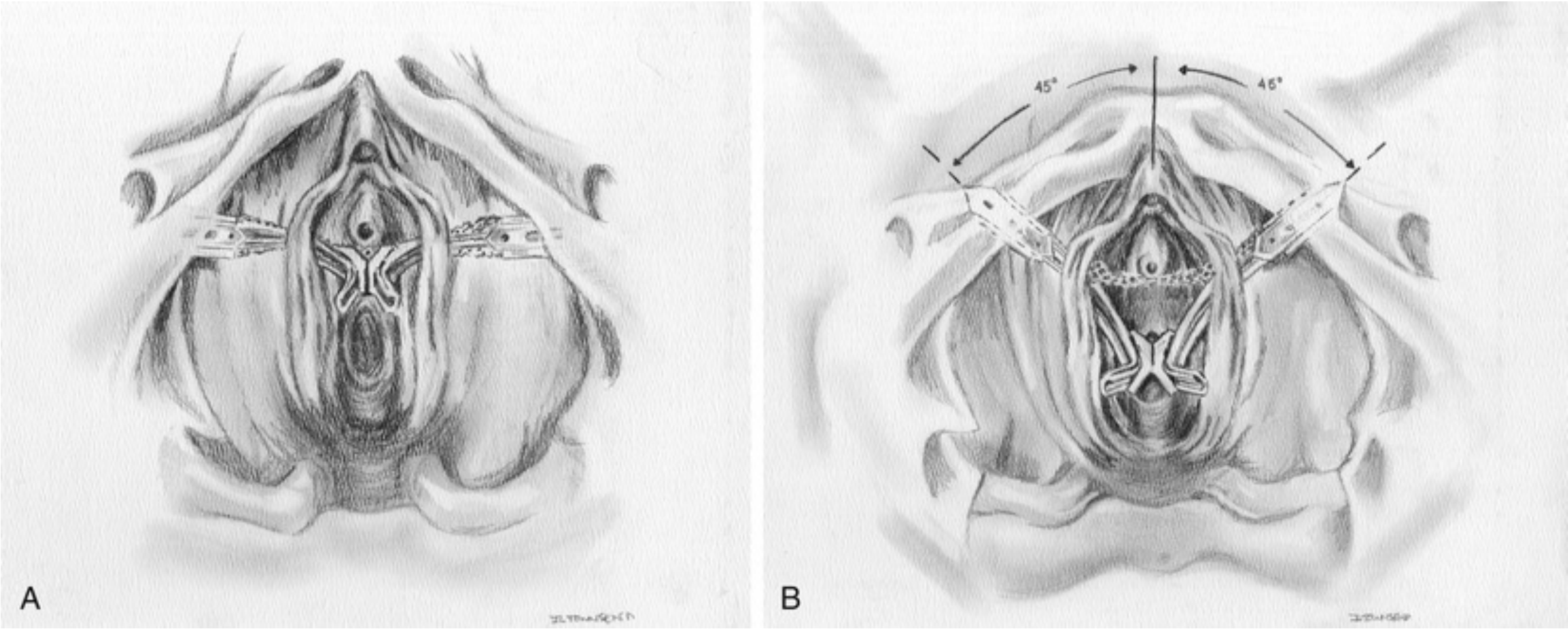

FIG. 125.11 Mid-urethral sling as placed via a single-incision approach. (A) Hammock style. (B) U position.

The procedure is performed with the patient in the dorsal lithotomy position (with sequential compression devices in place) with a significant degree of thigh flexion (≥70 degrees). A Foley catheter is placed before the procedure to ensure that the bladder is fully decompressed before passage of the device. As previously described, the patient receives parenteral sedation, and approximately 5 mL of 0.9% normal saline is used to hydrodistend the anterior vagina. After the vaginal incision is created, minimal dissection is performed using Metzenbaum scissors under the vaginal flaps on either side to elevate the vaginal epithelium from the underlying periurethral tissue to the level of the pubocervical fascia, which is not perforated. One trocar of the device is placed in the right dissection tunnel immediately beneath the vaginal epithelium and advanced up to the ischiopubic bone and into the obturator internus muscle, where the trocar holder anchors the sling edges. The left side is introduced in the same way, creating a hammock-shaped sling. Definitive sling tension is achieved when the tip of a hemostat is easily passed between the urethra and the sling. Cystoscopy with a 30-degree rigid cystoscope should be performed before completion of the procedure. This step is essential to avoid the future morbidity of repeat surgery for intravesical or urethral mesh. Urinary efflux from both ureteric orifices is confirmed. **Our experience suggests that the tension of the SIMS should be tighter than the classic retropubic or transobturator MUS surgeries to**

achieve the same result.

Outcomes of Mid-Urethral Slings for Predominantly Stress Urinary Incontinence

In reviewing the extensive outcomes for the MUS, several caveats must be mentioned. Outcomes are reported in varying fashions using different tools, durations of follow-up, and overall definitions of success and failure. Furthermore, studies may include women who have undergone previous anti-incontinence procedures or those who are undergoing concomitant POP repair. These factors should be kept in mind when attempting to compare different groups and procedural nuances.

Outcomes for Retropubic Mid-Urethral Slings in Patients With Predominantly Stress Urinary Incontinence

The initial study of the retropubic MUS reported an 80% author-defined success rate (Ulmsten et al., 1996). A subsequent prospective multicenter trial that included 130 women with SUI revealed success, improvement, and failure rates of 91%, 7%, and 2%, respectively, at 1 year (Ulmsten et al., 1998). In this first multicenter study, complication rates were low, but did include one bladder mesh perforation and one wound infection possibly associated with mesh exposure. The rate of voiding dysfunction was also relatively low, with only one woman experiencing retention for 12 days, which resolved spontaneously, and three women with less than 3 days of voiding dysfunction that required short-term CIC.

Nilsson and Kuuva (2001) evaluated 161 consecutive retropubic MUS operations (28% of whom had failed prior anti-incontinence surgery, 11% had ISD, and 37% had MUI). At a mean follow-up of 16 months, the overall objective cure rate was 87%, with 7% of women significantly improved, and another 5% considered failures. The trocar bladder puncture rate at the time of insertion was 3.7%, and 4.3% of women experienced short-term de novo voiding dysfunction. Urgency symptoms arising after surgery occurred in 3% of women, yet 80% of those who had preoperative urgency symptoms had relief of those symptoms at their 16-month visit. No serious complications were noted.

Since then, the MUS (and most notably the TVT) has become the most studied surgical procedure in the incontinence literature. Several single-center studies have reported outcomes at follow-up periods exceeding 10 years (Table 125.6). Success rates range from 48% to 97% depending on the definition, but typically approach 85%. There does appear to be a tendency for higher failure rates in older women and those with ISD in the long-term. The rate of complications continues to be low, and the Austrian Urogynecology Working Group reported no serious complications and no mortality from data compiled within the Austrian central registry, beginning in 1998 (Tamussino et al., 2001). It is interesting to note that 363 (45%) of the women in the registry had an MUS in combination with other procedures such as POP repair.

TABLE 125.6

Outcomes[a] With Retropubic Mid-Urethral Slings

STUDY	N	TYPE	FOLLOW-UP (YEARS)	CURED	ASSESSMENT OF OUTCOME	DE NOVO URGENCY	A U R
Nilsson et al., 2008	90	TVT	11	90% Obj 77% Subj 97% PGII	Pad test, CST, VQ	NR	0
Olsson et al., 2010	124	TVT	11.5 (10–13)	84% Obj 77% Subj	Pad test, CST, questionnaire	21%	3.
Aigmueller et al., 2011	141	TVT	10	84% Obj 57% Subj	Pad test, CST, UD, VQ	20%	0
Groutz et al., 2011a	52	TVT	10	65% Subj	Telephone interview	28%	N
Rogo-Gupta et al., 2012	30	DUPS	11	48% Subj	Questionnaire, VQ	NR	N
Serati et al., 2012	58	TVT	10	93% Obj 90% Subj 91% UD	CST, questionnaire, UD	19%	3.
Nilsson et al., 2013	58	TVT	17	91% Obj 79% Subj	CST, VQ	NR	1.

				87% PGII			
Svenningsen et al., 2013	327	TVT	10	90% Obj 76% Subj	Pad test, CST, questionnaire	15%	2
Khan et al., 2015	63	TVT	10	73% Improved 32% Dry	Subjective; VQ	1.6%	4.
Serati et al., 2017b	55	TVT	13	91% Obj 86% Subj 89% UD	CST, questionnaire, UD	18%	1.

[a] >10 years of follow-up.

CST, Cough stress test; *DUPS*, distal urethral polypropylene sling; *NR,* not recorded; *Obj,* objective; *Subj,* subjective; *TVT,* tension-free vaginal tape; *VQ,* validated questionnaire; *UD,* urodynamic.

The efficacy of the retropubic MUS has been amply compared with other anti-incontinence procedures. Among the retropubic MUS versus Burch colposuspension comparisons, the trials by Ward and Hilton enrolled the greatest number of patients and reported data at short-, medium-, and long-term follow-up periods (Ward and Hilton, 2002, 2004, 2008). After 6 months, the 175 women randomized to retropubic MUS and 169 to Burch had no significant difference in cure rates. The MUS was associated with more operative complications (i.e., bladder trocar injury), and the colposuspension was associated with more postoperative complications and longer recovery. At 2 years of follow-up, the overall cure rates noted were relatively low, with 63% of the MUS patients and 51% of colposuspension patients being cured. Also, there were significantly more women in the colposuspension group needing CIC ($P < 0.0045$) and surgery for pelvic organ prolapse ($P < 0.0042$) than in the MUS group. At long-term follow-up (5 years), there was no difference in cure rates and, consistent with earlier studies, POP was seen more commonly in the Burch group. Unlike earlier reports of high (27%) rates of de novo urgency and urgency incontinence in the literature after colposuspension (Jarvis, 1994), Ward and Hilton (2008) reported that less than 2% of women experienced this problem after MUS and less than 5% of women after colposuspension. In another comparison between retropubic MUS and Burch colposuspension, El-Barky et al. (2005) found operative time, duration of hospital stay, and time until return to normal activity significantly shorter in the MUS groups.

A MUS has also been compared in RCTs to other MUS procedures, with a recent systematic review including 81 trials with 12,113 women (Ford et al., 2017). The transobturator and retropubic approaches were compared in 55 trials with 8652 women. With follow-up periods of up to 1 year, the rate of subjective cure of both approaches are similar (RR 0.98, 95% CI 0.96 to 1.00; 36 trials, 5514 women), ranging from 62% to 98% in the transobturator group and from 71% to 97% in the retropubic group. Short-term objective cure was likewise similar (RR 0.98, 95% CI 0.96 to 1.00; 40 trials, 6145 women). Fewer trials reported medium-term (1 to 5 years) and longer term (over 5 years) data, but subjective cure was similar between the groups (RR 0.97, 95% CI 0.87 to 1.09; 5 trials, 683 women; and RR 0.95, 95% CI 0.80 to 1.12; 4 trials, 714 women). In the long term, subjective cure rates ranged from 43% to 92% in the transobturator group and from 51% to 88% in the retropubic group. The retropubic MUS appears to be more effective than the transobturator MUS in women with ISD (Rechberger et al., 2009). Likewise, Schierlitz et al. (2008) observed that, at 6-month follow-up, 13% of the women who underwent transobturator MUS for ISD required further surgery, compared with 0% of those who underwent retropubic MUS.

Retropubic MUS were associated with higher morbidity, but the overall rate of adverse events remained low. The rate of bladder perforation was lower, as expected, after transobturator MUS (0.6% vs. 4.5%; RR 0.13, 95% CI 0.08 to 0.20; 40 trials, 6372 women), as were major vascular/visceral injuries, mean operating time, operative blood loss, and length of hospital stay. Postoperative voiding dysfunction was also less frequent after transobturator MUS (RR 0.53, 95% CI 0.43 to 0.65; 37 trials, 6200 women). Rates of groin pain were higher in the transobturator group (6.4% vs. 1.3%; RR 4.12, 95% CI 2.71 to 6.27; 18 trials, 3221 women), but suprapubic pain was lower in the transobturator group (0.8% vs. 2.9%; RR 0.29, 95% CI 0.11 to 0.78). The overall rate of vaginal tape erosion/exposure/extrusion was low in both groups: 24/1000 instances with transobturator compared with 21/1000 for retropubic MUS (RR 1.13, 95% CI 0.78 to 1.65; 31 trials, 4743 women). There was limited evidence to suggest that repeat incontinence surgery in the long term was more likely after transobturator MUS (RR 8.79, 95% CI 3.36 to 23.00; 4 trials, 695 women). A retropubic bottom-top route was more effective than the top-down approach in terms of subjective cure (RR 1.10, 95% CI 1.01 to 1.19; 3 trials, 477 women), and it was associated with significantly lower rates of voiding dysfunction, bladder perforations, and vaginal tape exposures (Andonian et al., 2005; Lord et al., 2006; Tseng et al., 2005).

Several additional randomized comparisons have been performed between the down-to-up retropubic MUS (TVT) and other slings. Arunkalaivanan and Barrington (2003) compared the TVT with the Pelvicol PVS in a questionnaire-based study and found no difference in subjective cure rates at both 12-month and 36-month follow-up. TVT was compared in three studies with IVS, a multifilament, microporous polypropylene mesh material passed in a top-to-down manner. Rechberger et al. (2003) reported no differences in cure rates at 13 months of follow-up with 50 women in each group. Complications were similar, except for acute postoperative urinary retention occurring significantly more commonly in the TVT group. Meschia et al. (2006) compared the TVT and IVS with intermediate follow-up and reported subjective cure rates of 80% for TVT and 78% for IVS, and objective cure rates of 85% for TVT and 72% for IVS. Eight (9%) of the women who underwent IVS experienced vaginal erosion, compared with none in the TVT group. Lim et al. (2005) compared the TVT with the IVS and SPARC (a monofilament, macroporous polypropylene MUS passed in a top-to-down approach) in the SUSPEND trial. There was no significant difference between the cure rates between TVT (87.9%), IVS (81.5%), and SPARC (71.4%). There was a significantly greater rate of mesh exposure in the SPARC group. Balakrishnan et al. (2007) followed a subgroup of IVS patients from the Lim group (2005) for up to 30 months and found 13% with sling erosions, requiring removal. Of the 29 women (47%) from this initial IVS group seen 12 to 34 months postoperatively, 24% experienced sling erosion with associated sinus formation, requiring sling removal.

Outcomes for Transobturator Mid-Urethral Slings in Patients With Predominantly Stress Urinary Incontinence

Since its initial description by Delorme (2001), the transobturator approach MUS has become a viable method for effectively treating female SUI. Long-term continence rates have overall been high (Table 125.7). Because of its relatively recent introduction, 10-year outcome data have only recently become available, and reported continence rates range from 43% to 92% based on a variety of subjective (questionnaires and QoL single-item assessment) and objective (cough stress test, physical examination) measures**. Overall, the**

outcomes of transobturator MUS procedures in patients with predominantly SUI are similar to those of the retropubic MUS.

TABLE 125.7

Long-Term Outcomes With Transobturator Mid-Urethral Slings[a]

STUDY	N	TYPE	FOLLOW-UP (MONTHS)	CURED	ASSESSMENT OF OUTCOME	DE NOVO URGENCY	ANY URIN RET
Angioli et al., 2010	31	TVT-O	60 (median)	73% Obj	CST, questionnaire	6.4%	0%
Groutz et al., 2011b	61	TVT-O	60	74%	CST, questionnaire	NR	NR
Cheng & Liu, 2012	100	TVT-O	65 (mean)	92% Obj 90% Subj	CST, VQ	NR	4%
Sivaslioglu et al., 2012	36	I-Stop TOS	64 (mean)	75%	Stress test	NR	5.5%
Serati et al., 2013	185	TVT-O	60	91% Obj 90% Subj	Stress test, VQ	19.5%	0.5%
Athanasiou et al., 2014	124	TVT-O	90 (median)	82% Obj 83% Subj	Stress test, VQ	7%	0.8%
Laurikainen et al., 2014	123	TVT-O	60	80% Obj 86% Subj	Pad test, stress test, VQ	2.4%	0.8%
Kenton et al., 2015	90	TO MUS	60	43%	VQ	NR	NR
Tommasselli et al., 2015	47	TOT	99 (median)	70% Obj 60% Subj	Pad test, stress test, VQ	17%	0%
Al-Zahrani & Gajewski, 2016	202	TO MUS	11.9 years (median)	57%	VQ	5.9%	0%

Ulrich et al., 2016	71	TVT-O	10 years	69% Obj 64% Subj	CST, questionnaire, VQ	26%	7%
Ben-Zvi et al., 2017	34	TVT-O	60	NR	Pad test, VQ	2.9%	0%
Serati et al., 2017[a]	160	TVT-O	10 years	92% Obj 97% Subj	CST, VQ	14%	0.6%

[a]>5 years.

Minimal follow-up period included, unless otherwise noted.

CST, Cough stress test; *MUS,* mid-urethral sling; *NR,* not recorded; *Obj,* objective; *Subj,* subjective; *UDS,* urodynamic studies; *VQ,* validated questionnaire.

In 2010, Richter et al., published results of a large prospective, randomized trial comparing the retropubic MUS (*n* = 298) with the transobturator MUS (*n* = 299) with 12 months of follow-up. The objective cure rates as determined by a negative stress test, pad test, and no retreatment for the retropubic and transobturator groups were 80.8% and 77.7%, respectively (no statistically significant difference). The rate of voiding dysfunction requiring surgery was significantly higher in the retropubic group (2.7% vs. 0%). Of the 597 women in the original trial, 404 (68%) were enrolled in a 5-year observational cohort (Kenton et al., 2015). At the 5-year mark, the success was approximately 8% greater in women who underwent the retropubic MUS (51.3% vs. 43.4%, 95% CI –1.4, 17.2), not meeting prespecified criteria for equivalence. Satisfaction decreased during the 5 years but remained high and similar between arms (79% for the retropubic MUS and 85% for the transobturator MUS, *P* = 0.15). Additional RCTs have confirmed similar short- and medium-term success rates between the two approaches, as discussed in the previous section (Ford et al., 2017). The AUA SUI guideline cited Grade A evidence and made a Moderate recommendation that, in index patients who select MUS surgery, physicians may offer either the retropubic or transobturator MUS (Kobashi et al., 2017).

Short- and medium-term subjective cure rates between transobturator MUS passed using an in-to-out technique compared with an out-to-in approach were similar (RR 1.00, 95% CI 0.96 to 1.06; 6 trials, 759 women; and RR 1.06, 95% CI 0.91 to 1.23; 2 trials, 235 women) (Ford et al., 2017). Voiding dysfunction was more frequent in the inside-out group (RR 1.74, 95% CI 1.06 to 2.88; 8 trials, 1121 women), but vaginal perforation was less frequent in the inside-out approach (RR 0.25, 95% CI 0.12 to 0.53; 3 trials, 541 women). The SUI guidelines panel also state that, when performing transobturator MUS in women with stress-predominant urinary incontinence, surgeons may perform either the in-to-out or out-to-in technique (Kobashi et al., 2017).

Outcomes for Single-Incision Mid-Urethral Slings in Patients With Predominantly Stress Urinary Incontinence

Surgical treatment of SUI has expanded to include SIMS. This technology was first approved by the FDA in 2006 (TVT-Secur [TVT-S], Gynecare, Ethicon). Neuman (2008) performed a prospective observational study of 100 consecutive women with a hammock-style SIMS and compared postoperative outcomes between the first 50 women and the last 50. At 12 months, the objective failure rate went down from 20% to 8% between the two groups, with the sling being placed closer to the urethra. Four women in the first group had vaginal perforation with the inserter, and this complication was avoided in the second group by widening the submucosal tunnel. The mesh exposure rate decreased from 12% to 8% by the creation of deeper submucosal tunnels. There was one case of a paravesical self-remitting hematoma. Otherwise, the authors reported no cases of bladder or urethral perforation, urinary tract infection (UTI), wound infection, or intraoperative bleeding. At 12-month follow-up, the objective cure rates in the two groups were 88.6% and 93.5%.

In 2009, Dmochowski et al. reported preliminary results from one of the largest trials of the SIMS, with 29 sites participating in 8 countries. Effectiveness was measured by a standing cough stress test and an Incontinence Quality-of-Life (I-QoL) instrument. In this study of 642 women, 64.5% had a SIMS in a hammock (fixed into the obturator internus muscle) position, and 35.5% had it in the U position (fixed into the endopelvic fascia toward the retropubic space). Also, 65.3% had SUI and 34.7% had stress-predominant MUI. Intraoperative complications included one bladder perforation (0.2%) and three cases of bleeding greater than 200 mL (0.5%). Postoperatively, there was 1 reported case of retention (0.2%), 10 UTIs (1.6%), 6 cases of voiding dysfunction (0.9%), and 15 cases of de novo urgency (2.3%). There were five cases of mesh erosion (0.8%). Improvements in QoL at 3 months were sustained at 12 months. Objective continence via the cough test was 89% at 6 months and 87.5% at 12 months.

As befitting a relatively new approach, there is currently a dearth of long-term outcome data. However, there are a number of randomized trails comparing the "SIMS" to the transobturator MUS. Zhang et al. (2015) performed a systematic review of five RCTs encompassing 678 women who underwent SIMS (*n* = 361; Ajust™, CR Bard Inc., Covington, GA, USA) and TVT-O/TOT (*n* = 317) (Dati et al., 2012; Grigoriadis et al., 2013; Masata et al., 2013; Mostafa et al., 2013; Schweitzer et al., 2012). Three of these studies were available only in abstract form, and one compared 2 SIMS procedures, Ajust and TVT-Abbrevo (Dati et al., 2012). The authors' meta-analysis did not reveal a significant difference in patient-reported or objective cure rates between the two procedures (RR = 0.95, 95% CI 0.87 to 1.04, $P > 0.05$; and, RR = 0.97, 95% CI 0.90 to 1.05, $P > 0.05$, respectively). There were no significant differences between the two procedures in terms of postoperative pain, lower urinary tract injuries, postoperative voiding dysfunction, de novo or worsening of preoperative urgency, vaginal exposure, and need for repeat anti-incontinence surgery. The SIMS group had significantly less groin pain.

Since that publication, several additional studies have addressed the comparison between SIMS and transobturator MUS. Schellart et al. (2018) randomized 97 women to MiniArc and 96 to Monarc, with 77% and 78% of the original cohorts meeting 3-year follow-up, respectively. The subjective cure rates were not significantly different between the SIMS and transobturator MUS, 86% vs. 87% (risk difference –0.6%, 95% CI –12% to 11%), respectively. The objective cure rates were also not significantly different, 89% vs. 89% (risk difference 1.3%, 95% CI –9% to 11%), respectively. Complication rates were low in both groups. Likewise, Masata et al. (2016) randomized women to undergo TVT-O and Ajust, and at 1 year, 47 women in the TVT-O group and 49 in the Ajust group were available for evaluation. No differences in subjective cure rates or objective cure rates were observed. In the Ajust and TVT-O groups, the rates for subjective cure were 89.8 % and 91.5 %, respectively ($P = 1.0$, OR 1.22, 95% CI 0.24 to 6.58), and the rates for a negative stress test were 89.8 % and 87.2 %, respectively ($P = 0.76$, OR 0.77, 95% CI 0.17 to 3.32). In the Ajust group, two women reported de novo pain during sexual intercourse. Chang et al. (2015) performed a retrospective analysis of 136 women, 76 of whom underwent transobturator MUS (Align) and 60 who underwent a SIMS (Ajust). Women treated with SIMS had statistically significantly shorter operation time ($P = 0.003$), less intent to treat ($P < 0.05$), and earlier postoperative discharge ($P =$

0.001), and estimated operative blood loss, postoperative pain, and complications were similar between the two groups. Subjective and objective cure rates were not significantly different between the two groups (93% vs. 88% success rate in each group). Bianchi-Ferraro et al. (2014) randomized 56 women to TVT-O and 66 to TVT-S. At 2-year follow-up, objective cure rates for TVT-S and TVT-O groups were 77.3% and 83.6%, respectively, and subjective cure rates were 75.7% and 80.3% respectively, with no statistically significant differences between the groups. There was a significant improvement in all KHQ domains in both groups ($P < 0.001$). The most common perioperative complication was thigh pain associated with TVT-O, and vaginal exposure was observed in 5.3% and 7.5% of TVT-O and TVT-S cases, respectively.

A recent Cochrane systematic review by Nambiar et al. (2017) identified 31 RCTs or quasi-RCTs involving 3290 women that compared outcomes after SIMS compared with other anti-incontinence procedures. The following SIMS were included in this review: TVT-S; MiniArc (American Medical Systems, Minnetonka, MN); Ajust; Needleless (Mayumana Healthcare, Lisse, The Netherlands); Ophira (Promedon, Cordoba, Argentina); Tissue Fixation System (TFS PTY Ltd., Sydney, Australia), and CureMesh (DMed Co. Inc., Seoul, Korea). No studies compared SIMS versus no treatment, conservative treatment, colposuspension, laparoscopic procedures, or traditional PVS.

Women were more likely to have persistent or recurrent incontinence after SIMS than after retropubic MUS (121/292, 41% vs. 72/281, 26%; RR 2.08, 95% CI 1.04 to 4.14). SIMS was associated with higher risk for de novo urgency (RR 2.39, 95% CI 1.25 to 4.56). SIMS resulted in higher incontinence rates compared with inside-out transobturator MUS (30% vs. 11%; RR 2.55, 95% CI 1.93 to 3.36). The adverse event profile was also significantly worse with higher risks for vaginal exposure (RR 3.75, 95% CI 1.42 to 9.86) and bladder and/or urethral erosion (RR 17.79, 95% CI 1.06 to 298.88). Postoperative pain was less common with SIMS (RR 0.29, 95% CI 0.20 to 0.43), and rates of long-term pain or discomfort were marginally lower, but the clinical significance of these differences is questionable. Subanalysis revealed that the higher risk for incontinence was principally associated with use of the TVT-S, and this device has since been withdrawn from the market. The evidence was insufficient to reveal a difference in incontinence rates with other SIMS compared with inside-out or outside-in transobturator MUS. Risks of postoperative and long-term groin/thigh pain were slightly lower with SIMS, but overall evidence was insufficient to suggest a significant difference in the adverse event profile for

SIMS compared with transobturator MUS. Evidence was also insufficient to permit a meaningful sensitivity analysis of the other SIMS compared with transobturator MUS. The only significant differences were observed in rates of postoperative and long-term pain, and in duration of the operation, which marginally favored SIMS. Overall, results show that TVT-S is considerably inferior to retropubic and inside-out transobturator MUS, but additional evidence is required to allow any reasonable comparison of other SIMS and transobturator MUS. When two SIMS procedures were compared, there was insufficient evidence to suggest a significant difference between any of the available products.

Likewise, Song et al. (2018) analyzed 45 RCTs with 7295 participants that compared different MUS procedures. TVT, TOT, and Ajust had a higher objective cure rate than TVT-O (OR = 0.76, 95% CI 0.61 to 0.94) and TVT-S (OR = 0.41, 95% CI 0.28 to 0.60). TVT, TOT, and TVT-O had a superior subjective cure rate than TVT-S (OR = 0.29, 95% CI 0.15 to 0.56) and Ajust (OR = 0.45, 95% CI 0.20 to 0.91). With TVT as the reference, TVT-S had a statistically lower postoperative complication rate (OR = 0.39, 95% CI 0.16 to 0.89) and TVT-O, TVT-S, and TOT had significantly lower bladder perforation rates. There were no obvious differences between the five treatments for tape erosion. The AUA SUI guidelines panel cited Grade B evidence and made a Conditional recommendation that physicians may offer the SIMS to index patients undergoing MUS surgery with the patient informed as to the immaturity of evidence regarding their efficacy and safety (Kobashi et al., 2017).

There is some evidence in the literature that SIMS may have decreasing efficacy with longer follow-up. In a study of 96 women prospectively followed after TVT-S, the subjective cure rate decreased significantly between years 1 and 3 (85.4% to 72.9%) (Han et al., 2012). In another study by Masata et al. (2012) with 2 years of follow-up, 197 women were randomized to receive SIMS or transobturator MUS. The authors found that the SIMS had significantly lower objective (69% vs. 93%) and subjective (75% vs. 90%) cure rates.

Outcomes of Mid-Urethral Slings for Mixed Urinary Incontinence

Evidence suggests that MUS are successful for women with MUI symptoms as well. However, interpretation of these studies should be done with caution because many outcomes are reported on the basis of symptoms only with no urodynamic substantiation. In a retrospective analysis of 112 consecutive women with SUI and MUI by Jeffry et al. (2002), the objective cure rate measured by clinical and urodynamic examination was 89.3% at a mean follow-up of 25 months. Objective cure was defined as no evidence of stress incontinence, a negative stress test result, and no urinary retention or PVR volume greater than 150 mL. No difference was found in the objective cure rate between women with SUI and those with MUI. The overall subjective cure rate via the Contilife questionnaire was 66% and was lower than the objective cure in both women with SUI (69.3%) and those with MUI (54.2%). The type of incontinence did not alter the incidence of postoperative voiding difficulty. Ten of the 24 women with MUI had persistent urgency symptoms.

Holmgren et al. (2005) evaluated the outcome of the retropubic MUS in women with SUI and MUI with mailed questionnaires 2 to 8 years postoperatively. This was a large cohort of 970 women, and the 78% response rate was remarkable. Ultimately, 580 women with SUI and 112 women with MUI were eligible for analysis. Categorization of incontinence was based only on a positive stress test and a history of leakage immediately preceded by urgency, and urodynamic studies were not performed. Women with MUI were significantly older than the women with SUI (mean age 67 years vs. 61.2 years), and adjustment for age was made in the analysis. In addition, women with MUI had a statistically significant higher body mass index (BMI), rate of cesarean delivery, history of radiation, and prevalence of urinary frequency than those with SUI. The SUI cohort had a durable 85% subjective cure rate after 3 and 8 years of follow-up; however, only 60% of the 112 women with MUI were cured 3 years after surgery, and outcomes declined steadily thereafter. By 6 to 8 years postoperatively, the cure rate in women with MUI was only 30%. In addition, urgency and episodes of urgency incontinence increased with time after the MUS. The study design inherently limits the interpretation of results, as the lower cure rate in the MUI cohort may be a function of the confounding variables such as age, radiation, and higher BMI.

In a similar Finnish study, 191 women who had undergone MUS were evaluated by examination or telephone interview at a mean follow-up of 17 months (Laurikainen and Killholma, 2003). Sixty-four (34%) had preoperative subjective MUI, and postoperative cure was based on self-reporting of complete dryness in any stress situation. None underwent preoperative urodynamic evaluation. At latest follow-up, 88% of the 191 women were completely cured, with the cure rate in women with MUI being significantly lower than in those with SUI (69% vs. 97%). Undergoing concomitant surgery did not impact cure rates compared with women having MUS alone, and 60% of the women with MUI considered their urgency and UUI improved, as well. The authors suggested that, on the basis of these results, preoperative urodynamic studies should be performed in women with MUI before anti-incontinence surgery.

Segal et al. (2004) evaluated 98 women after MUS explicitly to answer the question of what happens to UUI postoperatively. The outcomes included subjective symptoms, rate of anticholinergic use before and after MUS, and QoL questionnaires, and women who had concomitant surgery were excluded from analysis. Sixty-five women were identified as having UUI, and follow-up occurred at 3 months and 1 year. On the basis of preoperative subjective symptoms, the urgency component resolved in 63% after MUS. Two women with complaints of subjective UUI only and urodynamic SUI had persistent UUI requiring anticholinergic drug treatment. Seventy-five women had preoperative urinary frequency and urgency, which resolved in 57% after MUS. Thirty (58%) of the 52 women using anticholinergics preoperatively no longer needed medication after surgery. Only 4 women (4.1%) began anticholinergics for the first time after MUS. Women with prior anti-incontinence surgery were eight times more likely to have postoperative OAB requiring use of an anticholinergic. MUS surgery resulted in statistically significant improvement in QoL scores postoperatively in women with stress-predominant MUI and SUI with urinary frequency and urgency.

Rezapour and Ulmsten (2001) retrospectively reported the efficacy and safety of MUS in 80 women with MUI without preoperative urodynamic evidence of DO. At 5-year follow-up, 85% were cured, and an additional 4% were improved on the basis of pad testing and symptom questionnaire. The researchers concluded that urodynamic studies were essential before surgery to analyze presenting symptoms. Only one woman had prolonged urinary retention (6 weeks), and 8% were found to have small hematomas with one woman undergoing exploration for bleeding.

In 2008, Paick et al. reported short-term outcomes of retropubic and transobturator MUS surgeries in women with MUI and found no significant difference in cure rates for the SUI component. Preoperative DO was an independent risk factor for treatment failure of the UUI component. Athanasiou et al. (2009) compared the efficacy of retropubic and transobturator MUS for treatment of urinary incontinence in women with MUI and idiopathic DO. There were no subjective differences in outcome, yet women undergoing retropubic

MUS were less likely to have persistent DO postoperatively. Kulseng-Hanssen et al. (2008) evaluated outcomes of retropubic MUS in 1113 women with MUI based on the woman's most bothersome concern (i.e., SUI, UUI, or equal stress and urgency components) and observed no difference in cure rates among the three groups. Women with predominantly SUI had significantly better results at 7 and 38 months than the other two groups, especially the patients reporting mainly UUI. Eleven percent of women had an increase in UUI at 38-month follow-up. The authors concluded that patients with predominant urgency incontinence have poorer results than those with predominantly stress incontinence.

In women with urodynamic SUI and subjective OAB undergoing retropubic MUS, Leron et al. (2009) noted an 89% cure rate and 9% improvement in SUI, with 62% improvement in OAB symptoms. There was no change in the severity of symptoms in one-third of the women and de novo OAB symptoms developed in 6%.

Ballert et al. (2008) found no difference in storage, voiding, or total score on the AUA Symptom Index between women with SUI and those with MUI, or those undergoing retropubic versus transobturator MUS. Sinha et al. (2008) used the Medical, Epidemiologic, and Social Aspects of Ageing (MESA) questionnaire and other outcome measures for short-term evaluation of the retropubic MUS in women with MUI. SUI and UUI were either cured or improved in 78% and 75% of women, respectively. The postoperative global impression of outcome noted great or moderate improvement in 75% of patients and reduction in mean MESA scores of 69% ($P < 0.001$). Duckett et al. (2008) used perineal ultrasonography in 77 women with DO and urodynamic SUI to determine whether the position of a retropubic MUS has any effect on the resolution of irritative symptoms. They found that resolution of urinary storage symptoms is not dependent on placement of the sling under a specific portion of the urethra.

Three studies have attempted to correlate preoperative variables with outcomes of retropubic MUS procedures in women with MUI (Duckett and Basu, 2007; Gamble et al., 2008; Panayi et al., 2009). Duckett and Basu (2007) compared pressure-flow studies before and after the MUS and observed that a significantly decreased Qmax after MUS was associated with persistent OAB symptoms. Women with DO resolution postoperatively had significantly higher flow rates compared with those with persistent DO, supporting a possible partial obstruction in women with persistent DO. Gamble et al. (2008) found that age, nocturia, maximum capacity, and choice of sling procedure affected the persistence of DO and UUI. The lowest rate of DO was seen after transobturator MUS, followed by retropubic MUS and then PVS. Panayi et al. (2009) found higher median preoperative opening detrusor pressure in women with DO after MUS surgery (33 vs. 26 cm H_2O, $P < 0.05$).

Four groups have focused on treatment of MUI with a transobturator MUS (Abdel-Fattah et al., 2014; Botros et al., 2007; Paick et al., 2008; Tahseen and Reid, 2009). Botros et al. (2007) compared the de novo urgency and resolution of DO and UUI among women undergoing the Monarc (125), TVT (99), and SPARC (52) procedures. De novo urgency was significantly lower in the Monarc group (8% vs. 33% for TVT and 17% for SPARC, $P = 0.04$); however, rates of de novo DO and resolution of preoperative DO and UUI did not differ among the three groups. Paick et al. (2008) performed 72 TVT, 22 SPARC, and 50 transobturator MUS in women with MUI. The authors found no significant differences in SUI cure rates or overall incontinence cure rates among the three groups. The presence of preoperative DO was associated with high UUI persistence in all three groups. Tahseen and Reid (2009) performed a transobturator MUS in 58 women and found 77% and 19% SUI and improvement rates, respectively. Additionally, UUI was persistent, improved, and cured in 21%, 36%, and 43% of women with MUI, respectively.

Overall, although most studies have reported that women with SUI have a higher cure rate than those with MUI, MUS procedures appear to be an effective treatment for those women with concomitant urgency and UUI. In addition, several studies have demonstrated improvement in OAB symptoms and less need for anticholinergic medications in women with MUI after MUS surgery. It must be noted that women with urge-predominant MUI are more likely to require combination therapy addressing both stress and urge symptoms. Finally, de novo urgency and UUI may develop after any sling procedure.

Outcomes of Mid-Urethral Slings for Intrinsic Sphincteric Deficiency

ISD has been an important risk factor for failure of conventional anti-incontinence procedures. It is difficult to evaluate the efficacy of surgical treatment for ISD because no universally accepted definition presently exists. However, as previously stated in the Pubovaginal Sling section, ISD is often defined urodynamically as an ALPP less than 60 cm H_2O or an MUCP less than 20 cm H_2O. **What is clear from the current literature is that the success of MUS is lower in women with a fixed urethra (no urethral mobility) and low leak point pressures. In addition, a preoperatively fixed urethra seems to be more predictive of a poorer outcome (no cure) than a low leak point pressure.** Thus, women with fixed urethrae have poor outcomes after MUS surgery regardless of leak point pressure.

In 2001, Rezapour et al. (2001) published a prospective 4-year follow-up of 49 women with ISD who underwent retropubic MUS. Forty-one of these women had urethral hypermobility, and the remainder had immobile urethrae. In the entire cohort, 74% of women were cured, and 12% were improved. None of the women with fixed urethrae were cured, and only three improved. Other studies support lower cure rates of retropubic MUS in women with low leak point pressures when rates of urethral hypermobility (fixed vs. nonfixed urethras) are not statistically different (Paick et al., 2004). Urethral mobility before MUS procedures has been shown to be predictive of success, and the greater the mobility in the proximal urethra with Valsalva, the higher the incontinence cure rate (Fritel et al., 2002). Leak point pressures alone have not been shown to predict outcome after an MUS procedure (Gutierrez Banos et al., 2004; Rodriguez et al., 2004). Therefore, **low leak point pressures are not necessarily a contraindication to retropubic MUS surgery.** Leak point pressures in the era of the MUS should be correlated with the woman's physical examination and used to counsel patients about their risk for a reduced chance of success.

Several additional studies have been performed to assess the clinical effectiveness of the retropubic MUS procedure in women with ISD (Bai et al., 2007; Ghezzi et al., 2006; O'Connor et al., 2006; Rechberger et al., 2009). In all of these studies, women had urodynamic SUI with Valsalva leak point pressure (VLPP) less than 60 cm H_2O. Ghezzi et al. (2006) noted a 94% cure rate in 35 women seen at 12.5-month follow-up. Two of the three women in whom the procedure failed were noted to have a fixed urethra preoperatively. Bai et al. (2007) compared 1-year treatment outcomes of the retropubic MUS in women with ISD (31) and non-ISD (80). Whereas there was a significant difference in cure rates between the ISD (87%) and non-ISD groups (100%) at the 1-month follow-up, there was no significant difference by 1 year after surgery. Rechberger et al. (2009) conducted a prospective, randomized trial with a follow-up of 18 months comparing the clinical effectiveness of retropubic and transobturator MUS, and, although the efficacy of both techniques was comparable, the retropubic route was more efficacious in the ISD group.

Although Delorme (2001) and Mellier et al. (2004) noted ISD in 15.6% and 28% of their transobturator MUS cohorts, respectively, outcomes were similar to their non-ISD populations. O'Connor et al. (2006) were the first group to examine the early outcomes of the transobturator approach in women stratified by high (>60 cm H_2O) and low (<60 cm H_2O) VLPP categories. The odds of continued SUI after transobturator MUS surgery were 12 times greater for women with low VLPP compared with those with high VLPP. In general, no preoperative predictors of outcomes using either clinical or urodynamic parameters have been established to determine overall results of MUS procedures. Even though the Richter et al. (2010) study comparing retropubic and transobturator MUS was not designed to look at ISD, all of the women underwent preoperative urodynamic studies. The authors found that VLPP and MUCP had no effect on the outcomes of the sling surgeries; however, the degree of urethral mobility was not recorded.

The evidence from RCTs regarding MUS outcomes specifically for ISD is sparse. A recent systematic review encompassed 55 RCTs comparing retropubic and transobturator MUS, 12 of which included women with ISD (Ford and Ogah, 2016). Only 8 of these trials of 399 women reported data specifically for this cohort (Deffieux et al., 2010; Karateke et al., 2009; Kim et al., 2005; Oliveira et al., 2008; Porena et al., 2007; Rechberger et al., 2009; Schierlitz et al., 2008; Tanuri et al., 2010). Six of the trials used VLPP less than or equal to 60 H_2O, 1 trial used either VLPP less than or equal to 60 H_2O or MUCP less than or equal to 20 H_2O, and 1 trial used MUCP less than or equal to 30 H_2O for their definitions of ISD. At short- and medium-term follow-up, 150 of 199 (75.4%) and 171 of 200 (85.5%) in the transobturator and retropubic MUS groups, respectively, were subjectively cured. This represents a 12% relative risk reduction in achieving cure with the transobturator route. Objective cure was reported by five trials of 324 women and reported no statistically significant difference between the two groups, with 69.2% of 159 women achieving cure after transobturator MUS and 76.4% of 165 after the retropubic MUS. Postoperative voiding dysfunction and de novo urgency and UUI were not statistically different between the two groups. The authors found that the need to undergo repeat incontinence surgery in the long-term was higher in the cohort undergoing transobturator MUS (147 women; RR 14.4, 95% CI 1.95 to 106).

More recently, Wlazlak et al. (2017) cited an 81.6% success rate after TVT in

109 women with ISD at 6 months of follow-up. Patients with a relative tape position toward one-half of urethral length had a higher cure rate ($P = 0.0003$), and cure rates decreased significantly with decreasing urethral mobility. Kim et al. (2016) likewise found that TVT (95.2%) was more effective than TOT (82.7%; $P = 0.009$) in 157 women with ISD.

Overall, **clinical experience with the MUS suggests that it is beneficial in the management of SUI in women with ISD, as long as there is preoperative urethral mobility.** In addition, the absolute reported rates of cure and improvement for women with ISD are within the range of reported results experienced with other types of procedures.

Outcomes of Mid-Urethral Slings for Recurrent Stress Urinary Incontinence

There are limited data specifically addressing the efficacy of MUS procedures as secondary surgery in women with recurrent incontinence. Several small studies with relatively short follow-up addressed the issue (Azam et al., 2001; Kuuva and Nilsson, 2002, 2003; Lo et al., 2002; Rardin et al., 2002a;; Rezapour and Ulmsten, 2001). As with the majority of SUI literature, comparison of these studies is hampered by differences in the definitions of cure, improvement, and failure and outcome criteria. Also, the population of patients in most studies of recurrent SUI may be biased by the inclusion of women in whom bulking agents had failed. Despite these limitations, cure rates of MUS surgery after prior failed anti-incontinence surgery range from 81% to 90%. Upon further review of these articles, several trends emerge. The procedure can be performed in the same way as it is performed for primary SUI. The complication rates are similar to that of retropubic MUS done for primary SUI, but the risk for bladder perforation appears to be higher in women who have had one or more prior retropubic suspensions. Also, as is the case with primary surgery, the failure rate is higher in women with immobile urethrae.

Rezapour and Ulmsten (2001) have one of the longest follow-up periods (4 years) for a cohort of women undergoing retropubic MUS for recurrent SUI. The 34 women had undergone 64 different anti-incontinence surgeries, and exclusion criteria included presence of significant prolapse, DO, or ISD (MUCP <20 cm H_2O). Twenty-four women had a hypermobile urethra, and 10 had a less-mobile urethra. Twenty-eight (82%) were cured by objective and subjective parameters, and 9% were improved. Only one bladder perforation occurred in a woman with a prior Marshall-Marchetti-Krantz (MMK), and no significant complications were encountered. Postoperative voiding dysfunction was negligible with no change in PVR urine after 8 weeks. These results were durable for up to 5 years.

Only a few series present the outcomes of women treated with a repeat MUS for recurrent SUI (Biggs et al., 2009; Lee et al., 2007a; Riachi et al., 2002; Tsivian et al., 2007; Villet et al., 2002). In these studies, the cure rates for women with recurrent SUI are higher for retropubic than for transobturator MUS. Tsivian et al. (2007) found that, in 12 women undergoing repeat MUS, the only procedure that failed was a repeat transobturator MUS. In another study, the cure rate for the repeat transobturator approach was 63% compared with 92% after repeat retropubic MUS (Lee et al., 2007a). A possible explanation for this difference is the angle of the sling, as the retropubic MUS has a U shape, which may provide more lateral support and, hence, more dynamic obstruction during increases in intra-abdominal pressure. In addition, the outside-in approach to the transobturator MUS may require wider dissection of the periurethral area, leading to potential sling migration. Salvage procedures are performed in some women in whom the initial MUS failed because of underlying ISD or who now have a fixed urethra from the initial surgery. This is consistent with the evidence of high success with retropubic slings for patients with a component of ISD.

In 2010, Stav et al. reported the outcomes in 1035 women after primary MUS surgery and 75 women after repeat MUS surgery (Stav et al., 2010a). Repeat MUS surgery was significantly less effective at curing incontinence than a primary sling (62% vs. 86%, $P < 0.001$). The rates of complications were similar between the two groups; however, the repeat group had a significantly higher rate of de novo urgency and UUI. All of the women underwent preoperative urodynamic studies, and the rate of preoperative MUI was similar between the two groups. It is interesting to note that the rate of preoperative ISD was significantly higher in the repeat MUS group (31% vs. 13%, $P < 0.001$). In 2013, Agur et al. performed a meta-analysis of the 10 RCTs of MUS that addressed recurrent SUI. The review included 350 women with a mean follow-up of 18.1 months. The authors found no significant difference in subjective cure rates in these women between retropubic and transobturator MUS surgery.

Key Points: Mid-Urethral Slings for Recurrent Stress Urinary Incontinence

- A repeat mid-urethral synthetic sling procedure for persistent or recurrent SUI is a viable option for select patients in whom the initial procedure has failed.
- Some studies show cure rates to be higher for retropubic slings than for transobturator slings. This may be the result of unequal rates of ISD in different study populations.

Outcomes of Mid-Urethral Slings in Patients With Pelvic Organ Prolapse

A large proportion of women with SUI have associated POP, and several studies have explored the outcomes of concomitant MUS and POP surgery. The advantage of using a synthetic MUS over an autologous PVS or retropubic suspensions at the time of POP repair is that operative time is reduced and blood loss from the MUS portion is less. **However, a theoretical risk for MUS with concomitant transvaginal surgery is that the increased dissection will increase exposure of the graft, leading to greater rates of infection, perforation, or vaginal exposure. Additionally, increased blood loss or anatomic distortion from the concomitant POP procedures could increase the rate of sling migration, postoperative voiding dysfunction, or obstruction. Finally, appropriate MUS tensioning in women with occult SUI (only seen with POP reduction) may be challenging.**

Although most studies tend to be small and have short-term follow-up, **results suggest that the MUS can be added to POP surgery with minimal morbidity and high success rates** (73% to 93%) (Jomaa, 2001; Huang et al., 2003; Meltomaa et al., 2004; Wei et al., 2012). Even in questionnaire-based assessments 3 years after surgery, the data do not show a statistical difference in the cure rate of SUI and incidence of urgency symptoms after MUS surgery alone or in combination with other vaginal surgery (Meltomaa et al., 2004). While transient urinary retention occurred more often in women undergoing combined surgery, rates of urethrolysis were low and not statistically different between groups. The reporting of urinary retention rates is limited by variations in the definition of retention, and, thus, caution must be exercised when interpreting outcomes.

Gordon et al. (2001) performed a “prophylactic” retropubic MUS during POP repair in 30 women with occult SUI. None of the women had undergone prior anti-incontinence surgery, and all had urethral hypermobility. At a mean follow-up of 14 months, no woman developed symptomatic SUI, but three had a positive stress test during postoperative urodynamic assessment. Six of nine women had persistent urgency, and four developed de novo urgency without evidence of obstruction. No woman had urinary retention lasting more than 2 weeks.

Five-year data from a prospective analysis of a large group of women undergoing MUS surgery for occult SUI combined with transvaginal repair of second- or third-degree POP revealed a low incidence of complications (Groutz et al., 2004). One bladder perforation was managed conservatively without consequence, and two women experienced extended voiding difficulty requiring catheterization for greater than 7 days. However, urethrolysis was not necessary in either case. Three cases of vaginal erosion were documented. Two women developed recurrent symptomatic SUI, and another 15 were found to have asymptomatic, urodynamically confirmed SUI. Eight women developed de novo UUI, and 72% of the 18 women with preoperative UUI had persistent UUI postoperatively.

The Cochrane Group found 16 randomized or quasi-randomized controlled trials that included significant data on bladder outcomes after a variety of POP surgeries (Maher et al., 2013). The authors concluded that women undergoing POP repair may benefit from having concomitant anti-incontinence, especially if they had overt SUI or if they were continent and had occult SUI demonstrated preoperatively. Following POP repair, 12% of women developed de novo urgency and UUI, and 9% developed de novo voiding dysfunction. Previous Cochrane reviews concluded that the addition of a retropubic MUS to transvaginal or abdominal POP surgery may reduce the incidence of postoperative SUI, but issues of cost and associated adverse effects were unclear (Maher et al., 2008). More recently, van der Ploeg et al. (2016) randomized 47 women with occult SUI to POP surgery alone and 43 to POP surgery with MUS. At 12 months, a greater number of women in the MUS group reported absence of SUI (86% vs. 48%; RR 1.79, 95% CI 1.29 to 2.48). No women in the MUS group received additional treatment for postoperative SUI, and 13% of women in the control group had a secondary MUS.

Although concurrent surgery does not appear to alter continence rates after MUS, its impact on efficient voiding or postoperative retention remains in question. Sokol et al. (2005) noted no significant difference in median days to voiding and incidence of urinary retention based on prolapse repair status in 267 women (66% having concurrent POP repair). However, increasing age, decreasing BMI, and postoperative UTI were independent predictors of longer time to adequate voiding. A history of incontinence surgery was the only predictor of urinary retention, but there was a significant difference in the rate of urethrolysis between the group undergoing MUS alone and the group undergoing MUS with POP repair.

Unlike most reports, Partoll (2002) found that urinary retention is far more common after combined procedures than MUS alone. While the 11-month cure rate was 94%, the rate of urinary retention in those women with concurrent anterior or posterior repair was an alarming 43%. It must be noted that urinary retention was defined as not meeting the criteria for catheter removal on postoperative day 2. Rather than the more flexible expectations in other studies, it is the expectation of efficient voiding 48 hours of surgery that most likely accounts for the higher rate of retention in this study. Of the 1356 sling cases from a Medicare claims database, Anger et al. (2008) isolated 467 (34%) who underwent concomitant POP repairs. Women in this group were significantly more likely to be diagnosed with postoperative outlet obstruction (9.4% vs. 5.5%, $P < 0.007$), but less likely to undergo a reoperation for SUI or POP within 1 year of follow-up.

When MUS are placed for urodynamic or occult SUI at time of prolapse repair, the risk for intervention for obstruction is equivalent to the risk for intervention for SUI if no MUS was placed (8.5% and 8.3%, respectively) (Ballert et al., 2009). Likewise, the risk for intervention for SUI in women with clinical (i.e., subjective) SUI but no urodynamic or occult SUI and no MUS was 30%.

MUS placed with either transvaginal or laparoscopic-assisted vaginal hysterectomy and anterior or posterior colporrhaphy have been shown to have success rates similar to those in published series of MUS surgery alone (Huang et al., 2005). Complication rates are also in accordance with other MUS series, with 2% bladder trocar injury, 11% postoperative urgency, and 11% postoperative voiding difficulty. A study specifically looking at the complications and cure rates of MUS performed with or without vaginal hysterectomy found that there was no overall difference (Darai et al., 2002). There was a trend in the MUS-hysterectomy group toward more bladder perforations and lower postoperative urinary flow rates, but these relationships were not statistically significant. Objective and subjective cures for this group were 93% and 75%, respectively, which was not significantly different from the MUS-alone group.

Anger et al. (2007b) evaluated the relationship between provider specialty and outcomes of sling surgery, specifically related to concurrent prolapse management. Using 1999 to 2000 Medicare data, the researchers found that urologists performed 1063 sling procedures, and gynecologists performed 246. Urologists performed concomitant POP repairs in 29% of cases versus 56% among gynecologists ($P < 0.0001$). Postoperatively, urologists were more likely to perform a repeat anti-incontinence procedure (9% vs. 5%, $P = 0.024$) and POP repair (26% vs. 12%, $P < 0.0001$). These findings suggest that urologists should identify and manage prolapse at the time of evaluation of urinary incontinence to avoid the morbidity and cost of repeat surgery.

Wei et al. (2012) presented their results of the Outcomes Following Vaginal Prolapse Repair and Midurethral Sling (OPUS) trial. This trial attempted to determine whether the use of a concomitant “prophylactic” retropubic MUS prevents the development of SUI in women undergoing POP surgery who had no clinical (subjective) SUI preoperatively. Sham incisions were made in the control arm. A total of 327 women without clinical incontinence completed 1-year follow-up, and urinary incontinence (allowing for subsequent treatment of incontinence) was present in 27% and 43% of women in the sling and sham groups, respectively ($P = 0.002$). The number needed to treat with a sling to prevent one case of SUI at 12 months was 6.3. The rates of trocar bladder injury, UTI, and bleeding, although low, were all significantly higher in the MUS group. It is important to note that some of the women in the sham group (without subjective SUI) may have had occult SUI and, thus, contributed to the higher failure rate in this group.

The practice of placing a true “prophylactic” MUS (i.e., in a woman with no subjective, overt, occult, or urodynamic SUI) at the time of POP surgery is controversial. Proponents cite the minimally invasive nature and low complication rate of the MUS and the potential to minimize the chance of postoperative SUI, and opponents cite the possibility of creating postoperative obstruction and de novo storage symptoms in a woman with a preoperative absence of these symptoms. The literature regarding this topic is sparse. A systematic review by Matsuoka et al. (2015) identified seven studies addressing a prophylactic anti-incontinence procedure at the time of POP repair, three of which employed a TVT and one a TVT-O. Based on these limited findings, the authors concluded that prophylactic MUS reduced the risk for SUI after surgical correction of severe POP. Conversely, Dillon et al. (2012) reported complications such as mid-urethral strictures, infected MUS components, and secondary incontinence/POP requiring surgery in a group of 10 women who underwent revisions of “prophylactic” MUS. **Neither of the authors advocates the placement of a true “prophylactic” MUS**.

Outcomes of Mid-Urethral Slings in Elderly Women

Although there is a large body of literature that demonstrates the efficacy and low morbidity of MUS, there is a paucity of data evaluating the effect of advanced age on outcomes. Aging affects the lower urinary tract both anatomically and functionally. **The aging lower urinary tract may have a higher rate of DO, UUI, and ISD, and emptying abnormalities related to impaired contractility are also more common in elderly persons.** Older women are more likely to have had prior procedures for incontinence and therefore may have higher rates of urethral fixation. More severe vaginal atrophy related to long-standing lack of salubrious estrogen support in the older woman could pose a greater risk for poor or delayed healing and mesh exposure after MUS surgery. In addition, older patients may be at greater anesthetic risk as a result of medical comorbidities that could complicate the surgery, the surgical outcome, or the postoperative course.

A few small studies have evaluated the safety and efficacy of MUS in older women (>70 years of age). The most robust of the studies was a prospective comparison of 460 consecutive women who underwent MUS surgery with a mean follow-up of 26 months (Gordon et al., 2005). In this study 157 (34%) were elderly, and all women underwent urodynamic evaluations preoperatively and 3 months after surgery. Significantly higher rates of preoperative MUI were seen in the elderly cohort (31% vs. 23%). Intraoperative complications were infrequent in either group, although there were significantly fewer bladder trocar injuries in the elderly population. The incidence of postoperative fever, UTI, wound infection, and hematoma formation was similar in the two groups. Older women did experience more perioperative morbidities, such as pulmonary embolism (2), cardiac arrhythmia (2), DVT (1), and pneumonia (1), whereas there was only a single case of cardiac arrhythmia in a younger woman. Older women experienced no increased risk for vaginal exposure, and the rates of postoperative voiding dysfunction necessitating catheterization for greater than 1 week were low and similar between groups. Cure rates in the elderly and younger patients were 93% and 94%, respectively. Rates of UUI were similar between groups, but the rate of de novo UUI was significantly greater in the older patients (18% vs. 4%).

A smaller study of 76 women documented a similar rate of postoperative de novo UUI (18.4%) in elderly women undergoing MUS (Sevestre et al., 2003). One strength of this study is that the degree of urethral hypermobility was characterized. Of these women, 53% had urethral hypermobility (positive Q-tip deflection >30 degrees), 29% had undergone prior anti-incontinence procedures, and 4 (5.3%) had urodynamic DO. At a mean follow-up of 24.6 months, 67% of the women were cured as determined by questionnaire and examination, and 10 (13%) failed, and all of these women had negative Q-tip tests preoperatively. Satisfaction with the procedure was 82%, and rates of dissatisfaction were higher in those with de novo UUI. For the older women with a negative Q-tip test, the cure rate was 71%, compared with 100% in those with a positive Q-tip test. The rate of immediate urinary retention was 26%, but only 1 woman had urinary retention for more than 1 week.

Liapis et al. (2006) also correlated the degree of urethral hypermobility and outcomes of MUS surgery in women 65 to 85 years of age. The overall cure rate of 76% correlated positively with greater bladder neck mobility. In women in whom the Q-tip displacement was less than 30 degrees, 42% became continent, whereas 90% of those with a greater than 30-degree deflection were continent. Eighty percent of those women with an angle less than 10 degrees remained incontinent. Cure rates were similar in women older than 70 years of age and younger women after Burch colposuspension and MUS (Pugsley et al., 2005). There was an increased incidence of UTI in the elderly Burch colposuspension and MUS patients, and older women also required more long-term CIC after Burch colposuspension.

The cure rates in older women with urethral hypermobility appear to be comparable to those in younger women. Complication rates vary, with some studies citing a higher rate of age-related morbidities but no apparent increase in intraoperative complications. Jha et al. (2009) found that age did not significantly affect outcomes for SUI reduction or improvement in QoL after retropubic MUS. **Postoperative voiding dysfunction and increased de novo urgency do appear to be more common in older women and may affect older women more significantly.** Postoperative urgency symptoms have been reported in as many as 60% of older women, and 44% develop the symptom de novo (Allahdin et al., 2004). Bafghi et al. (2005) noted higher cure rates (98% vs. 79%; $P = 0.001$) and higher satisfaction rates (93% vs. 67%) in younger women. This difference was attributed to higher rates of de novo and persistent UUI in the older age group.

Another important measure of MUS success in elderly women is assessment of QoL. At a mean of 22 months after retropubic MUS, 67 women were evaluated with a validated health-related QoL instrument, the King's Health Questionnaire (Walsh et al., 2004). Statistically significant improvement was demonstrated in SUI, frequency, urgency, and UUI in both age groups. SUI was improved by 91% and 80% in the younger and older groups ($P = 0.037$ and $P = 0.046$, respectively). There was also significant improvement in both age groups in incontinence impact, role limitations, physical limitations, social limitations, emotions, and severity measures. Although MUS surgery was overall successful in the elderly, the hospital stay was 6 days, suggesting that the postoperative morbidity in this age group was significant. Campeau et al. (2007) compared elderly women who either underwent a retropubic MUS or had to wait 6 months for surgery. The women who underwent surgery had a significantly higher QoL ($P < 0.0001$), but, not surprisingly, only the group that underwent MUS experienced bladder perforation (23%) and urinary retention (13%).

Hellberg et al. (2007) mailed a questionnaire to 970 women who underwent MUS with a mean follow-up of 5.7 years. Older women were significantly more often on hormone replacement therapy, had lower education, and had a history of recurrent UTIs, previous vaginal repair, and previous anti-incontinence surgery. Likewise, older women more commonly had MUI and required longer hospitalization postoperatively. The unfavorable cure rate among the older women (56% vs. 80%, $P = 0.0001$) was a result of a higher failure rate for SUI rather than for urgency symptoms.

A multicenter, prospective randomized clinical trial was performed to compare MUS surgery versus delaying surgery for 6 months (control group) in 69 older women with SUI (Campeau et al., 2007). The main outcome measures included the I-QoL, the Patient Satisfaction Questionnaire, and the Urinary Problems Self-Assessment Questionnaire. At 6 months after randomization, the group who underwent immediate MUS surgery had significant improvement in QoL and patient satisfaction and had fewer urinary concerns compared with the group of women waiting for the same surgery. It is important to note that no age-related morbidity was observed in the immediate surgery group.

The rate of persistent SUI after retropubic or transobturator MUS appears to be higher in the elderly population, potentially caused by preoperative factors such as concomitant UUI or less urethral mobility. The elderly population also has a higher incidence of de novo urgency and UUI after MUS surgery. Additionally, although there may be some initial increase in perioperative morbidity, MUS surgery does appear to be safe in the elderly. Lastly, although the literature is insufficient to support one anti-incontinence procedure over another for the elderly woman, it can be concluded that **elderly women should not be excluded from potentially curative MUS surgery based on their age alone.**

Outcomes of Mid-Urethral Slings in Obese Patients

Obesity has an intimate relationship with SUI, and the prevailing connection is attributed to increased intra-abdominal pressure (Cummings and Rodning, 2000; Subak et al., 2009). Additionally, neurologic and metabolic mechanisms have been proposed, likely supporting a multifactorial pathophysiology (Callaghan et al., 2016; Heliövaara, 1987). As such, obese women may frequently develop SUI and may benefit from corrective anti-incontinence surgery.

Two reviews evaluated the existing literature regarding MUS procedures in the obese (Fuselier et al., 2018; Osborn et al., 2013). In total, the authors identified 30 studies that evaluated retropubic, transobturator, and single-incision MUS in the obese population. Several conclusions can be drawn from the data. First, both retropubic and transobturator MUS procedures are associated with success rates exceeding 80% in obese women and vary somewhat depending on the definition of cure. Second, success rates in obese women appear to be lower when compared with non-obese women, with several long-term observational studies suggesting that obesity is a risk factor for TVT failure (Aigmueller et al., 2011; Serati et al., 2012, 2017b). Likewise, a 5-year secondary analysis of an RCT evaluating retropubic and transobturator MUS revealed that obese women continued to experience lower cure rates than nonobese women (Brennand et al., 2017). Of the women in the nonobese group, 87.4% of 95 women were objectively cured according to the 1-hour pad test, in comparison to 65.9 % out of 44 obese women ($P = 0.003$). Subjective cure also differed between the two cohorts, with 76.7% out of 116 nonobese women being cured compared with 53.6% of 56 of the obese women ($P = 0.002$). Third, the few studies evaluating SIMS in the obese reveal conflicting outcomes. While Meschia et al. (2013) found poorer outcomes in the obese population after SIMS, Tommaselli et al. (2016) did not. It must be noted that nearly one-half of the 206 women in the former study underwent the TVT-S (which has been associated with higher failure rates), and the latter study used the BMI cutoff of 25 kg/m^2, thus grouping overweight women with the obese. Finally, outcomes in morbidly obese women (BMI >35 kg/m^2) appear to be lower than those in the overweight and obese population (McKenna et al., 2016; Yonguc et al., 2015).

While it was originally thought that obese women may be prone to more surgical complications after undergoing MUS, the data largely refute this. In a systematic review of pooled data from 13 studies, Weltz et al. (2015) did not detect a significant difference in rates of urinary retention or sling excision between obese and nonobese women. Chen et al. (2007) also found no statistical difference in the proportion of women who had at least one perioperative complication (20% [obese] vs. 15% [non-obese]) after undergoing vaginal surgery. As may be expected, obese women were more likely to have an operative site infection (adjusted OR: 5.5; 95% CI 1.7 to 24.7; $P = 0.01$]. Bladder punctures during RP MUS appear to be less common in the obese (Dunivan et al., 2009; Revicky et al., 2011; Weltz et al., 2015). On the other hand, Zyczynski et al. (2015) found that a BMI greater than or equal to 30 reduced the likelihood of OAB symptom improvement after SUI surgery (OR 0.57; 95% CI 0.36 to 0.88). Additionally, Cadish et al. (2017) found that, after adjusting for age and activity level, overweight and obese women had significantly increased risk for postoperative-onset pain vs. normal BMI women undergoing in-to-out TO MUS.

Key Points: Mid-Urethral Sling Surgery Outcomes in Patients With Concomitant Prolapse Repair and in Elderly and Obese Women

- The literature supports the use of MUS in a variety of special populations of women. Efficacy and safety of MUS are not compromised in the elderly, the obese, or those undergoing concomitant vaginal surgery.
- A few small studies suggest that concomitant vaginal surgery places a patient at higher risk for delayed return to normal voiding and urinary retention. However, limitations in study design prevent a strict comparison of the data.
- Current sling data is difficult to interpret because of the lack of standard

definitions of cure and improvement and lack of standard outcome measures.

- Absolute conclusions about the use of MUS in special populations should not be made until larger prospective multicenter studies have been performed.

Complications of Retropubic, Transobturator, and Single-Incision Mid-Urethral Slings

Over the past 10 years, there has been a 27% increase in the rate of surgery for SUI, and a large portion of that increase is directly caused by the growing popularity of the MUS (Jonsson Funk et al., 2012). However, in 2010 the FDA released a revised statement alerting the public to safety concerns regarding the use of synthetic mesh for POP and SUI surgery (FDA, 2010). The FDA became aware of problems related to synthetic mesh because of information contained in the Manufacturer and User Facility Device Experience (MAUDE) database. According to MAUDE data, from 2008 to 2010 there were 1371 voluntary and involuntary self-reported medical device reports of complications related to MUS, and a significant portion of those were mesh perforation and exposure (FDA, 2011).

While the **overall incidence of complications with all MUS procedures is low,** it is important to note that postoperative QoL may be affected just as much by the incidence of postoperative voiding difficulties, UTIs, and other adverse consequences of the surgery itself as it is by SUI cure or improvement. The Finnish MUS registry demonstrated a pronounced learning curve for surgeons adopting the new MUS technology (Kuuva and Nilsson, 2003). This registry is unique in that all of the nation's MUS procedures are recorded in a single data bank, and, therefore, the results are reflective of the entire national experience with this novel procedure. Another registry in Austria includes greater than 5000 cases but does not involve all of the surgeons in the country (Tamussino et al., 2001). **The rates of bladder trocar injury in the two aforementioned national registries were 2.7% and 3.8%, respectively, and the rates of voiding dysfunction and wound healing problems were 7.6% and 1%, respectively.** A more comprehensive look at complications in randomized prospective trials and large retrospective studies is presented in eTable 125.8.

---

eTABLE 125.8

Review of Randomized Prospective Trials and Large Retrospective Studies for Mid-Urethral Sling Complications

REFERENCE	PATIENTS	HEMATOMA OR SIGNIFICANT HEMORRHAGE	BLADDER OR URETHRA TROCAR INJURY	VAGINAL MESH EXPOSURE	MESH PERFOR OF THE URETHR
Tamussino et al., 2001[a]	RPS 2795	2.3%	2.7%	NR	NR
Persson et al., 2002	RPS 38	5.3%	NR	2.6%	NR
Ward and Hilton, 2002	RPS 175	2.3%	8.8%	2.3%	0%
Liapis et al., 2002	RPS 36	0%	11.1%	NR	NR
Kuuva and Nilsson, 2002[b]	RPS 1455	2.4%	3.8%	0.7%	0%
Rechberger et al., 2003	RPS 100	4%	6%	0%	0%
Levin et al., 2004	RPS 313	1.3%	5.1%	1.3%	0%
Paraiso et al., 2004	RPS 33	5.5%	6.1%	3%	NR
Abdel-Fattah et al., 2004	RPS 68	2.9%	0%	0%	0%
David-Montefiore et al., 2006	RPS 42	4.8%	9.5%	NR	NR
	TOS 46	0%	0%		
Lim et al., 2005	RPS 181	NR	5.5%	6.1%	NR
Andonian et al., 2005	RPS 84	1.2%	23.8%	1.2%	NR
Hammad et al., 2005[d]	RPS 1459	NR	NR	1.2%	0.6%[e]
Tseng et al., 2005	RPS 62	12.9%[f]	6.4%	8.1%	NR
Foote et al., 2006	RPS 49	NR	10.2%	NR	NR
Meschia et al., 2006	RPS 179	2.1%	3.2%	4.2%	NR
Lord et al., 2006	RPS 301	3.3%	7.6%	NR	NR
Wang et al.,	RPS 29	3.4%	3.4%	3.4%	NR

2006	TOS 31	0%	0%	0%	
Tamussino et al., 2007	TOS 2543	3.3%	0.5%	0.4%	NR
Zullo et al., 2007	RPS 35	2.8%	5.7%	0%	NR
	TOS 37	0%	0%	0%	
Lee et al., 2007b	RPS 60	0%	3.3%	0%	0%
	TOS 60	0%	0%	0%	0%
Porena et al., 2007	RPS 73	1.4%	2.7%	1.4%	0%
	TOS 75	0%	1.3%	4%	
Rinne et al., 2008	RPS 134	NR	NR	0%	0%
	TOS 131			0.8%	
Rechberger et al., 2009	RPS 201	2.0 %	6.5%	2.0%	0%
	TOS 197	0%	0%	2.5%	
Basu and Duckett, 2010	RPS 33	NR	0%	0%	0%
	SS 37		2.7%	5.4%	
Richter et al., 2010	RPS 298	0.3%	5.4%	4%	0%
	TOS 299	0%	0%	1.3%	0%
Hinoul et al., 2011	TOS 85	1%	0%	1%	0%
	SS 75	0%	0%	7%	0%
Tincello et al., 2011	RPS 437	2.1%	0.4%	1.5%	0%
	TOS 238	0.4%	0.4%	0.4%	
	SS 659	0.1%	0.7%	1.2%	
Pushkar et al., 2011	RPS 187	9.1%	5.4%	0.5%	0%
	TOS 537	1.5%	0.6%	1.5%	
Teo et al., 2011	RPS 66	1.5%	0%	5.3%	0%
	TOS 61	1.6%	0%	2%	
Bianchi-Ferraro et al., 2013	TOS 54	0%	2.7%	0.5%	0%
	SS 63	1.5%	3.0%	1.5%	

[a] Retrospective study of gynecologists in Austria (one bowel perforation).

[b] Retrospective survey of pelvic surgeons in Finland.

[c] Eight patients (nine patients had intravesical mesh recognized and removed at the time of sling surgery).

[d] Retrospective survey of pelvic surgeons in Australia and New Zealand.

[e] Nine patients.

[f] Postoperative suprapubic ultrasonography performed on all patients.

NR, No record or authors did not comment on this complication; *RPS,* retropubic sling; *SS,* single-incision sling; *TOS,* transobturator sling.

Modified from Osborn DJ, Kaufman MR, Dmochowski RR. Complications after surgery for stress urinary incontinence. *Urologické Listy* 4:39–44, 2013.

As previously mentioned, the term *perforation* means that the polypropylene mesh has either entered the urinary tract (urethra, bladder, or ureters) or has penetrated bowel. The term *exposure* refers to the occurrence of visible or palpable mesh in the vagina or skin that is not covered by overlying tissue. For the purpose of this discussion, *trocar injury* refers to the passage of the trocar into the urethra or bladder at the time of sling placement.

The exact cause of these complications is debatable, but it most likely arises from a combination of patient and technical factors. These factors include patient body habitus, subclinical infection, poor tissue ingrowth into the sling, disturbed wound healing, rolling or twisting of the sling, excessive friction between host tissue and the sling, sling material properties, iatrogenic injury, and surgeon technical error (Domingo et al., 2005; Kobashi and Govier, 2003; Stav et al., 2010b)**. Biomechanical properties of the sling material have also been shown to play a major role in the incidence of complications related to mesh exposure.** Although various materials have been historically used for sling implants, there has been a trend in the contemporary literature toward the use of macroporous, polypropylene slings. The increased pore size of these materials allows for excellent tissue ingrowth, promotes integration with the surrounding host tissues, and decreases encapsulation and infection (Dietz et al., 2001, 2003; Slack et al., 2005). Adherence to meticulous surgical technique and use of polypropylene mesh with favorable biomechanical properties should help the surgeon minimize complications.

Mid-Urethral Sling Mesh Exposure

Vaginal mesh exposure is a rare complication after the MUS (Fig. 125.12). In a review of prospective trials and large retrospective studies, **the rate of vaginal mesh exposure was 0.5% to 8.1%** (see eTable 125.8). Most cases of vaginal mesh exposure manifest within a few weeks to a few months after the MUS procedure. **Symptoms** of vaginal exposure include vaginal discharge (with variable constituents and different amounts of blood and inflammatory components), a palpable rough surface in the vagina, sexual discomfort (including partner related), pelvic pain, inguinal discomfort, and lower urinary tract symptoms (urgency, frequency, persistent incontinence, and hematuria). Symptoms are often nonspecific, and, therefore, a high index of suspicion is required. In cases of mesh exposure, careful vaginal examination usually identifies an area on the anterior vaginal wall with separated epithelial edges and visible mesh. **The management of this complication is not standardized,** and there are various reports claiming successful outcomes with observation, partial sling excision, complete sling excision, and reapproximation of the vaginal mucosa over the exposed mesh (Table 125.9).

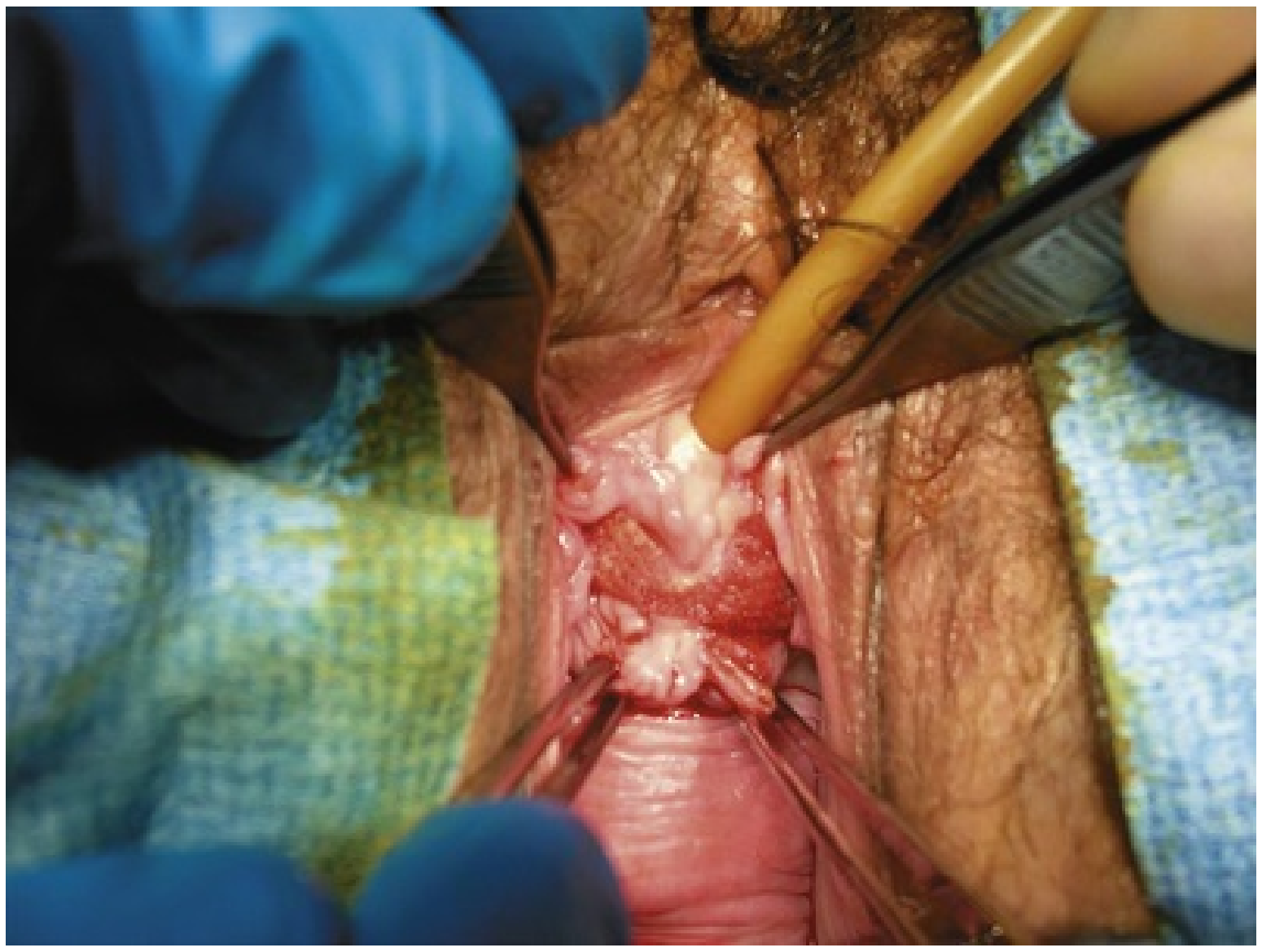

FIG. 125.12 Vaginal mesh exposure.

TABLE 125.9

Management of Vaginal Mesh Exposure

	TOTAL PATIENTS	CONSERVATIVE MANAGEMENT	FINAL MANAGEMENT	SYMPTOM RESOLUTION[a]	CON
Meschia et al., 2001	2	0%	2 resutured vagina	100%	100%
Kuuva and Nilsson, 2002	10	30%	4 resutured vagina 3 observation 2 partial mesh excision 1 unknown	NR	NR
Volkmer et al.,	1	0%	1 partial mesh excision	100%	0%

2003					
Karram et al., 2003	3	33%	1 partial mesh excision 1 vaginal advancement flap 1 antibiotics	100%	67%
Kobashi and Govier, 2003	4	100%	4 observation	NR	100%
Tsivian et al., 2004	5	20%	4 partial mesh excision 1 observation	100%	80%
Levin et al., 2004	4	0%	4 partial mesh excision	NR	NR
Sharma and Oligobo, 2004	3	0%	3 partial mesh excision	100%	NR
Huang et al., 2005	6	0%	6 partial mesh excision	100%	100%
Hammad et al., 2005	17	0%	17 partial mesh excision	65%	NR
Starkman et al., 2006	11	0%	11 partial mesh excision	100%	NR
Giri et al., 2007	5	0%	5 resutured vagina	100%	NR
Ordorica et al., 2008	11	0%	11 complete mesh excision	100%	82%
Lapouge et al., 2009	12	0%	12 partial mesh excision	83%	33%
Al-Wadi and Al-Badr, 2009	1	0%	1 partial mesh excision and Martius flap	100%	100%
Hinoul et al., 2011	7	0%	7 resutured vagina	100%	NR

Teo et al., 2011	3	0%	2 resutured vagina 1 partial mesh excision (failed resuturing twice)	100%	NR
Bianchi-Ferraro et al., 2013	3	33%	1 resutured vagina 1 partial mesh excision 1 topical conjugated estrogen	100%	NR

[a] Most common presenting symptoms were vaginal pain, dyspareunia, palpable mesh, urinary tract infection, and vaginal discharge.

NR, Not recorded.

It appears that the material composition of mesh is particularly important in the event of mesh exposure. Domingo et al. (2005) reported a relatively high incidence of vaginal exposure in their series using either the ObTape or UraTape. They attributed their exposure rate to the characteristics of the particular mesh and, specifically, the reduced pore size among other mechanical properties of the mesh. The authors noted a slightly higher risk for exposure after the ObTape compared with UraTape (19% vs. 12%) and felt that this was most likely because of reduction in pore size and a higher degree of encapsulation. They also concluded that synthetic mesh with larger pore sizes facilitates vascular and tissue ingrowth, optimizing mesh incorporation. In this series, sling exposure was usually managed by removal through the transvaginal approach alone or in combination with a transobturator approach. Despite mesh removal, 78% of the women were continent. High rates of vaginal exposure (up to 15%) after ObTape or UraTape MUS have been reported by other authors (Al-Singary et al., 2007; Babalola et al., 2005; Deval et al., 2006; Dobson et al., 2007; Domingo et al., 2005; Giberti et al., 2007; Juma and Brito, 2007; Karsenty et al., 2007).

In a series of 17 vaginal exposures in an Australasian cohort, 35% were asymptomatic and identified by vaginal examination only (Hammad et al., 2005). Symptomatic women reported palpable mesh, vaginal discharge, local pain, UTI, and dyspareunia.

Newer, macroporous polypropylene slings have a much lower incidence of exposure and infectious complications (Lee et al., 2009; Neuman, 2007; Rechberger et al., 2009; Waltregny et al., 2008). Two groups reported no evidence of mesh exposure at 1-year (Lee et al., 2009) and 3-year (Waltregny et al., 2008) follow-up. Waltregny et al. (2008) reported one intraoperative vaginal sulcus laceration, which was closed uneventfully. Lee et al. (2009) proposed that a modified canal transobturator sling (creating a suburethral tunnel between two oblique lateral incisions in the anterior vaginal wall) decreases the incidence of vaginal exposure compared with the classic single midline incision. The value of this technique needs to be confirmed by a randomized trial. Chen et al. (2008) assessed risk factors for vaginal exposure that developed in 6 of 239 women (2.5%) after synthetic MUS and found that diabetic women were 8.3 times more at risk. These authors encourage counseling women with diabetes of the risk for exposure.

Management of Mid-Urethral Sling Mesh Exposure

Management of mesh exposure is within the scope of practice of most pelvic surgeons; however, mesh perforation of the bladder or urethra may require a tertiary referral. Some authors propose observing any exposure of mesh that is less than 1 cm because the area may heal spontaneously (Kobashi and Govier, 2003; Tijdink et al., 2011). Four women (one after TVT and three after SPARC) with vaginal exposure were treated in a conservative fashion (Kobashi et al., 1999). All women had serial physical examinations and spontaneously re-epithelialized by 3 months. The authors attributed their success to the macroporous characteristics of the polypropylene mesh, which facilitated excellent tissue ingrowth. Conservative management is less likely to be successful with older, less-used sling materials, such as Gore-Tex, polyethylene terephthalate, and silicone. **In general, small areas of mesh exposure should be treated with sequentially increasing invasiveness. The first treatment should involve observation and then the addition of conjugated estrogen and, possibly, antibiotic creams. The next step should be limited excision and trimming of the exposed mesh and reapproximation of vaginal epithelial edges. If these options fail, excision of most of the mesh from a transvaginal approach should be pursued in most cases.** Table 125.9 reviews the management of mesh exposure in the literature.

In a review by Huang et al. (2005), six vaginal exposures and one bladder perforation after polypropylene MUS were initially managed expectantly. In four women with exposure of less than 1 cm, conservative management was initiated for a 3-month period. One of these women was observed for 24 months without adverse sequelae. In contrast with the results seen by Kobashi and Govier (2003), none of the women in this review had vaginal epithelialization over the area of exposure. Therefore, all six underwent transvaginal mesh excision in conjunction with an excision of all fibrotic vaginal tissue. Symptoms resolved in all women, and all were continent at their last follow-up. Although all women ultimately required surgical intervention, the authors felt that a trial of conservative management in appropriately selected patients (i.e., exposure <1 cm) was reasonable, and, if no epithelialization occurs after 3 months of follow-up, the mesh should be surgically removed.

If conservative measures fail, the next step for intervention should be operative management and will ultimately depend on the surgeon's preference and the size of the exposure. In the series by Tijdink et al. (2011), only 6 of 48 women with mesh exposure (12.5%) had persistent exposure after partial mesh excision. **Operative management typically involves excision of the exposed mesh, undermining of vaginal mucosal flaps, thorough irrigation with antibiotic solution, and reapproximation of vaginal edges with delayed, absorbable sutures.** The addition of topical antibiotics and conjugated estrogen cream may, theoretically, improve tissue quality before pursuing surgical intervention.

In a review of mesh-related complications in 200 women, Tsivian et al. (2004) observed five vaginal exposures after MUS (Tsivian et al., 2004). Four women required surgical excision of the exposed mesh, and one asymptomatic woman was being treated conservatively without adverse outcomes. Exposure resolved in all women after partial mesh excision and judicious vaginal debridement.

In the Finish nationwide review of 1455 MUS procedures, 10 women had vaginal polypropylene sling exposure. Three were managed without surgical intervention with favorable results and maintained continence (Kuuva and Nilsson, 2002). Four women had the vaginal mucosa resutured over the exposed mesh, and two women required partial mesh excision. One was lost to follow-up, and her management was unknown at the time of their report. According to this national registry, continence was maintained in all women regardless of management. Among 166 MUS surgeries performed by Giri et al. (2007), five women (3%) developed vaginal exposure 4 to 40 months postoperatively. Women reported vaginal discharge, pain, bleeding, and dyspareunia. In the operating room, the eroded margin of vaginal mucosa was trimmed and closed over the mesh. All of the women were subsequently symptom free at 12-month follow-up.

Ordorica et al. (2008) reported on 11 vaginal exposures after nonautologous sling placement (33 retropubic, 2 with bone anchors, 3 transobturator). In all cases, the involved sling and sutures were excised; however, the bone anchors were unable to be removed. An autologous sling was placed in the same setting if the woman complained of SUI at presentation. Two women had recurrent or persistent SUI, two had de novo urgency or frequency, and one developed osteitis pubis.

Kuhn et al. (2009b) used a validated questionnaire to determine the sexual function of women after correction of MUS exposure (Female Sexual Function Index [FSFI]). Among 21 exposures, 3 healed with topical estrogen, and 18 women with larger defects required operative intervention. Two women developed recurrent exposure after initial vaginal closure failed, with one undergoing repeat vaginal closure and the other having partial sling excision and closure. The domains of desire, arousal, lubrication, satisfaction, and pain improved significantly, and orgasm remained unchanged.

Key Points: Mid-Urethral Sling Mesh Exposure

- Conservative management is a plausible option in well-selected patients who are relatively asymptomatic and have small-caliber exposures (<1 cm). Favorable results have also been observed in selected patients with vaginal advancement flaps and suture approximation of the debrided vaginal mucosa over the exposed mesh.
- Even with partial excision of the mesh, continence is maintained in the majority of women.
- Observation should never be considered when there is urethral or intravesical perforation. More data supporting specific management strategies are necessary before a given approach can be advocated for patients with this complication.
- We recommend initial judicious observation for small vaginal exposures and, when appropriate, addition of topical conjugated estrogen cream. Excision should be reserved for failure of conservative therapy or when local symptoms, such as bothersome dyspareunia, mitigate against observational management.

Mid-Urethral Sling Trocar Injury to the Urinary Tract

In the majority of the literature, results listed for perforation (or injury) of the bladder or urethra refer to trocar passage into the urinary tract at the time of surgery. In these studies, the trocar injury is recognized at the time of surgery, and the trocar is passed again safely with continuation of the surgical case. **Trocar injury is generally considered to be a benign condition, and no study has shown a link between trocar injury and perioperative hemorrhage, hematomas, or subsequent mesh perforation of the bladder or urethra.** Because of the nature of trocar passage, **the rate of trocar injury is generally lower with transobturator MUS. In randomized trials, the rate of bladder or urethral trocar injury at the time of retropubic MUS falls between 2.7% and 23.8%** (Andonian et al., 2005; Porena et al., 2007).

Although initial reports described the risk with the transobturator MUS approach as being negligible, the rate of bladder or urethral trocar injury at the time of transobturator MUS surgery in randomized studies falls between 0% and 1.3% (Porena et al., 2007; Richter et al., 2010). Minaglia et al. (2004) reported three cases of intraoperative bladder injury while performing the transobturator insertion method. They identified all injuries intraoperatively because of their use of cystoscopy as an adjunct to all insertion procedures. All injuries were managed with catheter placement for 1 week postoperatively, and these authors noted no complications after sling removal and reinsertion at that same setting. It is possible that bladder trocar injuries are more likely to occur with out-to-in transobturator slings. With 10 of 11 bladder injuries occurring with the out-to-in technique in their study, Tamussino et al. (2007) concluded that trocar injury was more likely with this method.

Urethral Perforation During Mid-Urethral Sling Mesh Placement

Urethral perforation is defined as presence of sling material within the urethral lumen (Fig. 125.13). **The incidence of urethral perforation after MUS (transobturator and retropubic) surgery was 0% to 0.6%, respectively, in a review of randomized prospective and large retrospective studies (see** eTable 125.8). **Factors thought to contribute to urethral perforation include compromised urethral blood supply (e.g., from radiation therapy or estrogen deficiency), excessive sling tension, extensive dissection in close proximity to the urethra with subsequent urethral devascularization, iatrogenic urethral injury at time of device insertion, and traumatic urethral dilation. Furthermore, twisting or rolling of the sling can create a ridge that leads to pressure necrosis and perforation through the urethra** (Dell and O'Kelley, 2005). **Management of this complication is extremely challenging** and may be associated with significant morbidity, because access to the sling is traditionally gained by incising the urethra. Endoscopic management has been described, but medium- and long-term outcomes are unknown.

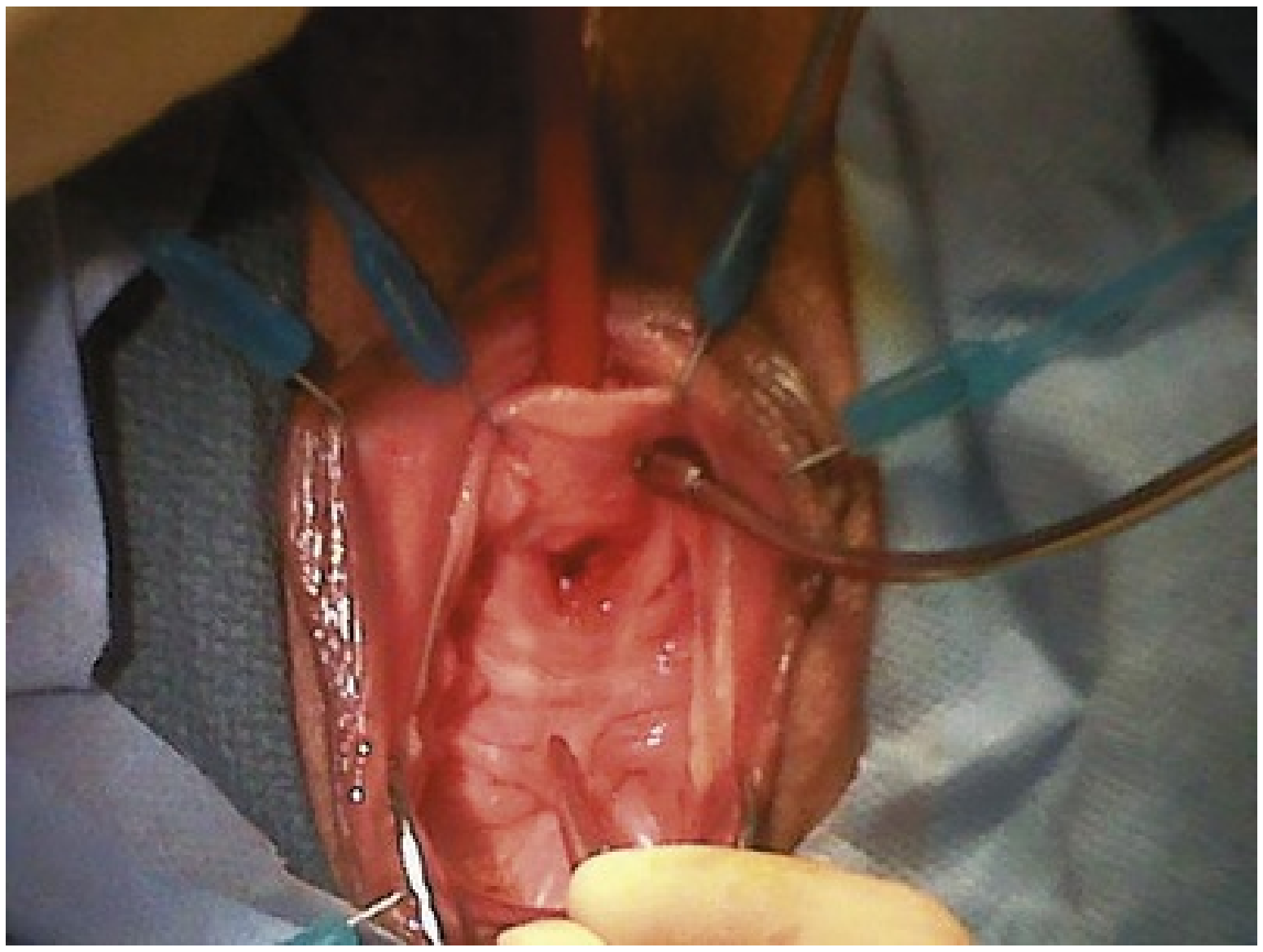

FIG. 125.13 Urethral mesh perforation and urethrovaginal fistula.

Instances of urethral perforation are rarely asymptomatic and **typical presenting symptoms** include urgency, UUI, obstructive voiding, urinary retention, recurrent UTI, and persistent urinary incontinence (Glavind and Sander, 2004; Haferkamp et al., 2002; Lieb and Das, 2003; Madjar et al., 2002; McLennan, 2004; Pit, 2002; Sweat et al., 2002; Tsivian et al., 2004; Vassallo et al., 2003; Wai et al., 2004). There is often a history of CIC and postoperative urethral dilations, and diagnosis is often delayed in these women for an extended period. In a review by Amundsen et al. (2003), the average time from placement of the initial PVS to diagnosis of urethral perforation was 9 months.

Confirming the presence of mesh within the urethral lumen during cystoscopy is diagnostic. Voiding cystourethrography has also been useful adjunctively by documenting a dilated proximal urethra related to high-grade obstruction caused by the eroded sling (Lieb and Das, 2003). A review of urethral perforation management is presented in Table 125.10.

TABLE 125.10

Management of Mesh Urethral Perforation

	TOTAL PATIENTS	CONSERVATIVE MANAGEMENT	FINAL MANAGEMENT	SYMPTOM RESOLUTION[a]	CO
Pit, 2002	2	0%	2 transvaginal partial mesh excision, reconstruction, Martius flap, and MUS	100%	100
Haferkamp et al., 2002	1	0%	1 transvaginal partial mesh excision and reconstruction	100%	100
Sweat et al., 2002	2	0%	1 transvaginal near-complete mesh excision and reconstruction and Martius flap 1 transvaginal retropubic near-complete mesh excision and reconstruction	NR	100
Madjar et al., 2002	1	0%	1 transvaginal partial mesh excision and reconstruction	100%	100
Lieb and Das, 2003	1	0%	1 transvaginal partial mesh excision and reconstruction	NR	0%

Vassallo et al., 2003	1	0%	1 transvaginal partial mesh excision and reconstruction	100%	10
Wai et al., 2004	1	0%	1 endoscopic and transvaginal partial mesh excision and reconstruction.	100%	0%
Glavind and Sander, 2004	1	0%	1 transvaginal partial mesh excision and reconstruction	0%	0%
Baracat et al., 2005	5	0%	5 endoscopic partial mesh excision	100%	10
Hammad et al., 2005	9	44%	5 transvaginal partial mesh excision and reconstruction 4 observation	NR	N
Starkman et al., 2006	5	0%	3 transvaginal partial mesh excision, reconstruction, and PVS 2 transvaginal partial mesh excision and reconstruction	100%	10
Powers et al., 2006	2	0%	2 transvaginal partial mesh excision and reconstruction	50%	10
Mesens et al., 2007	1	0%	1 transvaginal partial mesh excision and reconstruction	100%	10
Sokol and Urban, 2008	1	0%	1 transvaginal partial mesh excision and reconstruction	100%	10
Velemir et	8	12%	2 transvaginal	88%	50

al., 2008			partial mesh excision and reconstruction 4 endoscopic partial mesh excision 1 endoscopic and transvaginal partial mesh excision and reconstruction 1 observation		
Wijffels et al., 2009	3	0%	3 endoscopic partial mesh excision	100%	67
Jo et al., 2011	3	0%	2 endoscopic partial mesh excision 1 endoscopic and transvaginal partial mesh excision and reconstruction	100%	67
Shah et al., 2013	14	0%	8 transvaginal and retropubic complete mesh excision and reconstruction 6 transvaginal partial mesh excision and reconstruction	100%	72
Kowalik et al., 2018	19	0%	19 transvaginal partial mesh excision	60% (pain)	8%

[a] Most common presenting symptoms were urinary tract infection, urethral obstruction, urge urinary incontinence, pain, incontinence, urgency, dysuria, and hematuria.

MUS, Mid-urethral sling; *NR,* not recorded; *PVS,* pubovaginal sling.

Nine urethral perforations (0.6%) were reported in the Australasian database, with 89% being symptomatic and 30% manifesting greater than 1 year after surgery (Hammad et al., 2005). Presenting symptoms included urinary retention, bleeding, and local pain, and one case was discovered incidentally on cystoscopy. Unlike the reported vaginal exposures, 33% of the urethral perforations occurred when the polypropylene sling procedure followed another anti-incontinence procedure. Four (44%) were managed nonoperatively, as two of these women were too frail to undergo operative intervention. Five women (56%) had transvaginal excision, and all five were cured and dry postoperatively.

Management of Mid-Urethral Sling Mesh Perforation of the Urethra

Several studies have reported the successful treatment of urethral mesh perforation endoscopically (see Table 125.10). **Although we prefer transvaginal surgical excision as a first-line treatment, endoscopic management of small areas of mesh perforation appears to be a reasonable initial option based on a review of the literature. If endoscopic treatment fails, the next step in management of urethral perforation typically involves transvaginal urethrotomy and excision of the perforated mesh. An autologous fascial sling or a Martius labial fat pad graft can be used at the discretion of the surgeon.**

For endoscopic management, McLennan (2004) successfully managed an MUS urethral perforation by using hysteroscopic scissors to transect the mesh flush with the urethral mucosa. Catheter drainage was continued postoperatively for 72 hours. The woman remained symptom-free and continent at 10 months of follow-up. Wijffels et al. (2009) used an endoscopic transurethral approach successfully in three cases of urethral perforation. The visible mesh was grasped with forceps and cut while on traction with scissors on both sides of the urethra. One woman had recurrent SUI and subsequently underwent placement of another MUS. Baracat et al. (2005) successfully used a similar approach for five urethral perforations.

In our opinion, although it is relatively easy to remove a small portion of perforated mesh with endoscopic scissors or to ablate the mesh with a holmium laser, these women are likely to experience recurrence and require further surgeries. Endoscopic excision does not release the tension on the mesh that may be contributing to the perforation and does not provide any interposing tissue. **For surgical excision, we will often remove the mesh so that it is no**

longer in close proximity to the bladder or urethra and no longer under tension. The approach and type of incision depend on the location of the perforation.

Other authors have described transvaginal excision of perforated mesh. Pit (2002) described the management of two cases of urethral perforation by incising the urethra and cutting the mesh at the level of the mucosa. The mesh was then dissected on its medial edge toward the inferior ischiopubic ramus and cut bilaterally, which allowed the mesh to be removed from the periurethral fascia. A Martius graft was placed over the urethra in one case, and a cadaveric fascia lata graft was used in the second. A second MUS was then placed over the tissue bolsters without complication.

Glavind and Sander (2004) reported a urethrovaginal fistula caused by polypropylene mesh urethral perforation. Transvaginal mesh excision failed to resolve the fistula, and the woman required two transabdominal fistula repairs until closure and symptom resolution occurred. Persistent SUI was subsequently managed by conservative means with satisfactory results. Sokol and Urban (2008) reported use of the internal urinary sphincter for covering the defect after sling resection. They suggested that this may reduce the risk for fistula formation and be a less morbid option than a Martius flap. Four additional case reports reported excellent results with use of a midline transvaginal approach with partial mesh excision and closure of the urethra (Haferkamp et al., 2002; Lieb and Das, 2003; Madjar et al., 2002; Wai et al., 2004). The postoperative outcomes reported by each group were excellent, with all women achieving symptom resolution after surgical intervention. In two women, mild recurrent SUI was successfully managed with biofeedback (Glavind and Sander, 2004; Wai et al., 2004). In two women, continence was achieved with an intraoperative fascial sling, and, in a single case, a staged fascial sling resulted in satisfactory continence (Vassallo et al., 2003; Wai et al., 2004). It is important to note that, despite effective healing of the urethra after mesh removal, eventual incontinence and inadequate symptom resolution may occur (Kowalik et al., 2018). Long-term follow-up and additional treatment options are warranted in this population.

During surgical intervention for slings that perforate into the urethra, we prefer an inverted-U incision because this allows for excellent exposure of the proximal urethra, bladder neck, and endopelvic fascia. Likewise, this incision provides a vaginal epithelial flap that avoids overlapping suture lines, theoretically decreasing the risk for a fistula. The distal portion of the inverted U should be distal to the site of the urethral perforation, and the proximal portions of the U should extend to the level of the bladder neck in most cases. **We will frequently use a Martius labial fat pad flap to further prevent fistula formation. An autologous PVS is routinely placed if dissection of the sling out of the urethra creates a large defect or a defunctionalized urethra. Mesh excision is typically carried out to the level of the pubic bone or ischiopubic rami.** This type of excision leaves behind the arms of the mesh that tunnel into the retropubic space or obturator fossa. It is not typically necessary to enter these spaces because the mesh at this location is no longer under tension and is far from the urethra. We typically leave a Foley catheter for 3 weeks after repair of the urethra.

Mid-Urethral Sling Mesh Perforation of the Bladder

The finding of synthetic mesh within the lumen of the urinary bladder is a rare, but distressing complication (Fig. 125.14; Table 125.11). **The incidence falls between 0.5% and 0.6%** (Kuuva and Nilsson, 2002; Ward and Hilton, 2002)**. The majority of intravesical mesh perforations are most likely the result of an unrecognized cystotomy or placement of the mesh within the urinary bladder at the time of surgery.** True migration of the mesh across the seromuscular wall of the bladder into the lumen is much less likely, and this **underscores the importance of performing a complete and thorough cystoscopic examination of the bladder with adequate hydrodistention to minimize this complication.** We have found that the trocar may sometimes telescope the bladder wall during insertion and obscure visible bladder perforation.

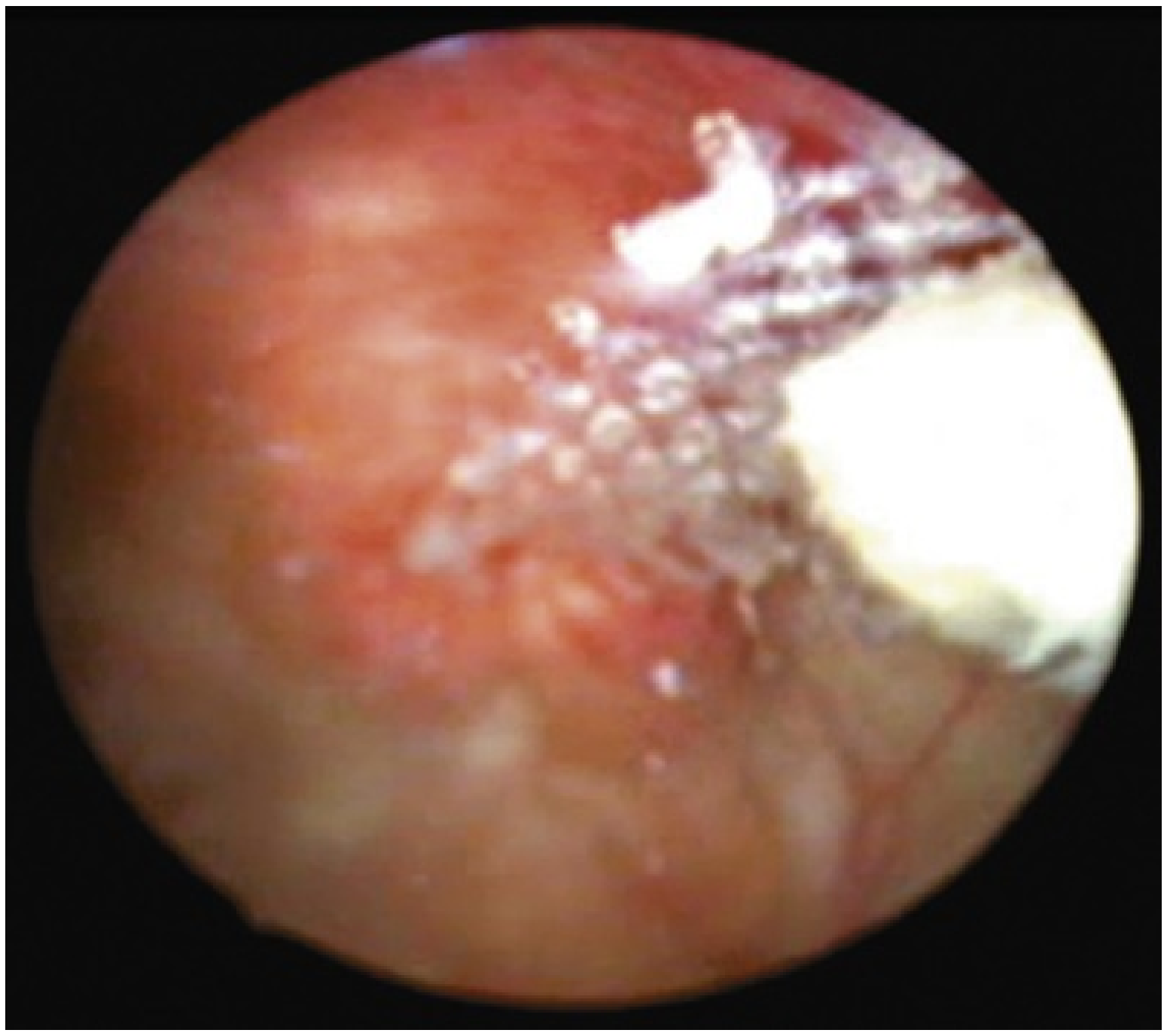

FIG. 125.14 Cystoscopic view of intravesical retropubic sling perforation.

TABLE 125.11

Management of Mesh Bladder Perforation

	TOTAL PATIENTS	CONSERVATIVE MANAGEMENT	FINAL MANAGEMENT	SYMPTOM RESOLUTION[a]
Wyczolkowski et al., 2001	1	0%	1 retropubic partial mesh excision	100%
Sweat et al., 2002	1	0%	1 transvaginal and retropubic partial mesh excision and reconstruction	100%
Jorion, 2002	1	0%	1 endoscopic partial mesh excision	100%
Volkmer et al., 2003	2	0%	2 complete transvaginal mesh excision and reconstruction	100%
Levin et al., 2004	2	0%	2 endoscopic partial mesh	NR

			excision		
Tsivian et al., 2004	1	0%	1 endoscopic and retropubic partial mesh excision and reconstruction	100%	
Huang et al., 2005	1	0%	1 transvaginal and retropubic complete mesh excision and reconstruction	100%	
Negoro et al., 2005	1	0%	1 retropubic partial mesh excision and reconstruction	0%	
Irer et al., 2005	1	0%	1 endoscopic partial mesh excision	100%	
Giri et al., 2005	3	0%	3 endoscopic partial mesh excision	100%	
Baracat et al., 2005	6	0%	6 endoscopic partial mesh excision	100%	
Siow et al., 2005	1	0%	1 transabdominal laparoscopic partial mesh excision and reconstruction	50%	
Starkman et al., 2006	7	0%	7 transvaginal and retropubic partial mesh excision and reconstruction	NR	
Mustafa and Wadie, 2007	1	0%	1 endoscopic partial mesh excision	100%	
Ordorica et al., 2008	2	0%	1 retropubic partial mesh excision and reconstruction (extravesical) 1 retropubic partial mesh	100%	

			excision and reconstruction	
Huwyler et al., 2008	5	0%	5 endoscopic partial mesh excision	100%
Rehman et al., 2008	2	0%	2 extraperitoneal laparoscopic partial mesh excision and reconstruction	100%
Shrotri et al., 2010	1	0%	1 endoscopic partial mesh excision	100%
Oh and Ryu, 2009	14	0%	14 endoscopic partial mesh excision	100%
Foley et al., 2010[b]	9	0%	7 endoscopic partial mesh excision 2 endoscopic and retropubic partial mesh excision	100%
Zivanovic et al., 2014[c]	3	0%	2 endoscopic and transvaginal partial mesh excision 1 endoscopic partial mesh excision	100%
Shah et al., 2013	7	0%	7 transvaginal and retropubic complete mesh excision and reconstruction	100%

[a] Most common presenting symptoms were urinary tract infection, urge urinary incontinence, pain, incontinence, urgency, hematuria, bladder stone, and dysuria.

[b] Includes one patient who had an I-Stop out-to-in transobturator mid-urethral sling.

[c] All were TVT-Secur slings.

NR, Not recorded.

Women with MUS bladder perforation typically report a variety of **symptoms.** A review of seven reported cases in the literature by Negoro et al. (2005) found that the typical symptoms are lower abdominal pain, intermittent gross hematuria, recurrent UTI, urgency, frequency, dysuria, and urinary incontinence. Diagnosis is made by cystoscopic examination of the bladder. Imaging modalities such as computed tomography scans and cystography may help in difficult cases but are not a substitute for cystoscopic examination.

Theoretically, transobturator slings should have a lower rate of mesh perforation into the bladder than retropubic slings; however, intravesical mesh perforation after transobturator MUS and cystocele repair has been reported (Parekh et al., 2006). The woman did not undergo cystoscopy intraoperatively. She initially had mesh on the left side of the bladder, then 6 months later had sling material on the right side of the bladder. She underwent a successful transurethral, transvaginal, and suprapubic mesh resection.

Management of Mid-Urethral Sling Mesh Perforation of the Bladder

Observational treatment is not recommended for mesh perforation of the bladder because the mesh often becomes encrusted, leading to stone formation, persistent lower urinary tract storage and voiding symptoms, recurrent UTIs, and intermittent gross hematuria. Different techniques and surgical approaches have been advocated with varying levels of invasiveness, complexity, and success.

For small areas of mesh perforation, the literature supports endoscopic excision with scissors or ablation with the holmium laser as an appropriate initial step. In 14 women with intravesical mesh, Oh and Ryu (2009) transurethrally resected the mesh deep into the perivesical fat. The women had dysuria, hematuria, pelvic pain, and urgency preoperatively, and six women had stone encasing the mesh at the time of transurethral excision. With a mean follow-up of 18 months, 13 (93%) had no recurrence. One woman had recurrent bladder stones, and one had mild SUI and UUI, which were controlled with anticholinergics. No further treatment for SUI was performed.

In a case report, Jorion (2002) excised the mesh endoscopically using an offset nephroscope transurethrally and a 5-mm laparoscopic trocar placed suprapubically. Laparoscopic grasping forceps were used to grasp the mesh, and endoscopic shears excised the mesh flush with the bladder mucosa, allowing for easy mesh removal. Cystoscopy at 1 month revealed healed mucosa, and the woman was continent and symptom-free. In another report, the mesh was initially cut endoscopically, but because of an adherent calculus, the mesh could not be extracted endoscopically (Tsivian et al., 2004). Therefore, a suprapubic approach was required to remove the stone and intravesical mesh.

Holmium:yttrium-aluminum-garnet (Ho:YAG) laser excision (or vaporization) of encrusted intravesical MUS has been used successfully in several cases (Baracat et al., 2005; Giri et al., 2005; Hodroff et al., 2004; Huwyler et al., 2008; Lane et al., 2005; Shrotri et al., 2010). Since stones frequently form on the intravesical portions of the sling, Irer et al. (2005) and Mahmoud and Wadie (2007) described successful endoscopic laser lithotripsy of the calculi and transurethral resection of the sling material. **We reserve endoscopic (holmium laser) management of intravesical mesh perforation for very small areas of perforation in select patients.**

If endoscopic excision is attempted and fails, removal of perforated bladder mesh can be removed through a transvaginal or retropubic approach. For slings that perforate into the bladder at or below the trigone, we prefer an inverted-U incision similar to the aforementioned management of urethral perforation because this allows for exposure of the proximal urethra, bladder neck, and endopelvic fascia. Furthermore, this incision provides a vaginal epithelial flap that avoids overlapping suture lines, theoretically decreasing the risk for fistula. Similar to the management of urethral perforations, we do not excise the entire sling as long as it is no longer under tension and is well away from the bladder.

For slings that perforate the bladder dome or other areas of the bladder not accessible from a transvaginal approach, we remove the mesh transabdominally. The sling can usually easily be seen entering the bladder in the retropubic space. Although not always necessary, opening the bladder in the midline usually aids with closure and identification of the exact area of bladder perforation. **In general, reconstruction should involve nonoverlapping suture lines and may benefit from interposition of tissue such as a labial fat pad, greater omentum, peritoneum, or autologous fascial sling.**

In a report by Negoro et al. (2005), a retropubic approach was used to resect the intravesical portion of the mesh. The bladder was closed with absorbable suture, and catheter drainage was maintained postoperatively. The woman was symptom free and continent at 10-month follow-up. Volkmer et al., (2003), Sweat et al. (2002), and Huang et al. (2005) used a combined transvaginal and abdominal approach to remove the sling in its entirety. One woman had residual urgency and frequency treated with anticholinergics, and three women had resolution of symptoms but recurrent SUI. One woman was managed with periurethral collagen injection, and two underwent pelvic floor muscle training and estrogen.

There are several reported cases of successful laparoscopic removal of intravesical mesh after retropubic sling placement. One of these cases used a three-port intraperitoneal approach (Siow et al., 2005), and the other two used a three-port extraperitoneal approach (Rehman et al., 2008). All of the women were symptom free and dry after the mesh removal. **The authors have also had success with an intraperitoneal robotic-assisted approach in women with bladder dome or posterior wall perforation.**

Key Points: Mid-Urethral Sling Mesh Perforation of the Urethra and Bladder

- Overall, the incidence of urethral and bladder mesh sling perforation is extremely low in the MUS literature.
- As the number of synthetic MUS surgeries continues to increase, physicians need to be mindful of the potential complications, have a high index of suspicion, and be aware of the management options available to treat the woman with urinary tract perforation.
- Conservative observational treatment is not an option for urethral and bladder mesh perforation.
- At the present time, transvaginal (or transabdominal) excision of the mesh with closure of the urethrotomy or bladder is our preferred first-line treatment in most cases of urethral and bladder perforation.
- If the repair is tenuous, a vascularized Martius labial fat pad graft can bolster the repair. Furthermore, an autologous fascial sling can be placed at the time of surgery to augment the repair or in a delayed fashion to treat recurrent SUI.

Infection and Pain After Mid-Urethral Sling Surgery

Groin and suprapubic pain are potential sequelae after MUS. Thigh and groin pain appear to be more commonly associated with the transobturator approach. A randomized controlled study from Finland revealed that 16% of women in the transobturator (in-to-out) group had groin pain compared with only 1.5% of those who underwent retropubic MUS (Laurikainen et al., 2007). In addition, groin pain may persist for a longer period after the transobturator MUS (Daneshgari et al., 2008). Long et al. (2009) and Wang et al. (2009) also found that women in the transobturator group have significantly more postoperative groin and thigh pain. Doo et al. (2006) noted persistent suprapubic pain in three (2%) women at 5-year follow-up after a retropubic MUS. In the Cochrane systematic review, Ford et al. (2017) estimated the rate of groin pain after transobturator MUS to be 6.4% from 18 trials involving 3221 women.

de Leval (2003) reported that 16% of women after transobturator MUS surgery had temporary groin pain that resolved after the second postoperative day. Similarly, Krauth et al. (2005) reported 14 cases (2%) of postoperative perineal and groin pain after transobturator MUS surgery, but also noted it to be transient and responsive to nonsteroidal anti-inflammatories in all but one case. The authors hypothesized that the cause of the pain was either subclinical hematoma or a transient neuropathic phenomenon. A randomized controlled trial by Teo et al. (2011) comparing the retropubic and transobturator MUSs was aborted because of a 26% incidence of leg pain in the transobturator MUS group (compared with 1.7% after retropubic MUS).

Fortunately, chronic groin and leg pain is an uncommon complication after MUS surgery. Roth (2007) found that steroids and local anesthetic were effective for pain relief with no side effects in three women with persistent groin pain 3 months postoperatively. Wolter et al. (2008) reported a case of refractory medial thigh pain after transobturator MUS, which ultimately required medial thigh and transobturator exploration by orthopedic surgery and sling excision.

Wound-related complications include **minor superficial cutaneous infections and pelvic abscesses.** Ward and Hilton (2002) found a 2% rate of vaginal wound infection after retropubic MUS, and Richter et al. (2010) found a 0.7% rate of vaginal wound infection in both the retropubic and transobturator MUS arms. Connolly (2004) reported a case of necrotizing fasciitis in an obese, diabetic woman that resolved after intensive resuscitation. It is interesting to note that a review of necrotizing fasciitis in gynecologic surgery found that obesity (88%), hypertension (65%), and diabetes (47%) were all risk factors for postoperative fasciitis (Gallup et al., 2002).

Fortunately, severe infection is a rare complication after MUS surgery; however, the diagnosis of this complication is variable and can be delayed by up to several years (Choi et al., 2011; Yenilmez et al., 2013). Mahajan et al. (2006) reported one case of failed sling and vaginal exposure that was associated with severe groin pain, fever, and chills 10 days postoperatively. The sling was easily removed through a vaginal incision, and mesh cultures were positive for *Bacteroides fragilis.* Complete symptom resolution occurred within 1 week of mesh removal. Abscesses and adductor myositis have also been reported, manifesting as leg pain, difficulty ambulating, and cellulitis (DeSouza et al., 2007; Goldman, 2006; Karsenty et al., 2007; Leanza et al., 2008; Zumbé et al., 2008). Gamé et al. (2004) reported an infected obturator hematoma after placement of an ObTape sling that required exploration and drainage. ObTape is no longer available for implantation. In general, severe infectious complications appear to be more common with the older, non–loosely woven polypropylene slings (Babalola et al., 2005).

Management of Severe Infection or Pain After Mid-Urethral Sling

In most cases, postoperative groin or leg pain after MUS can be managed with nonsteroidal anti-inflammatory medications, rest, and even physical therapy. Duckett and Jain (2005) reviewed different strategies for managing groin pain after retropubic MUS or similar MUS procedures in five women. Initial conservative management was successful in most women, with four women with persistent or severe pain treated with a combination of steroid and local anesthetic injections. Two women developed recurrent pain and had significant pain relief after sling excision. Medial thigh pain is a common problem after transobturator MUS surgery and, as with retropubic MUS, can usually be managed conservatively. A prospective study of 100 women who underwent transobturator MUS revealed a 24.4% incidence of early groin pain; however, the incidence of persistent groin pain 12 months after surgery after conservative management was only 3.7% (Lim et al., 2006).

In instances of chronic pain and severe infection after mesh MUS, and failure of nonoperative therapy, it may be necessary to attempt a complete mesh excision from both sides of the bone. In the case of retropubic mesh, this involves an abdominal and vaginal incision, and in the case of transobturator mesh, this involves incisions in the medial thigh and vagina. **For the complete excision of transobturator mesh, we typically consult an orthopedic surgeon**

to aid with lateral dissection of the sling. Reynolds et al. (2012) published their results with chronic groin pain after transobturator MUS that necessitated mesh excision from the obturator foramen. Five of the eight women were cured of their pain after a median follow-up of 8 months.

Voiding Dysfunction After Mid-Urethral Sling Surgery

Voiding dysfunction is a common problem after MUS surgery. **These voiding symptoms are typically the result of obstruction from the sling being placed too tightly, in the wrong location (too proximally), or associated with POP (unrecognized preoperatively or de novo). However, some women may have voiding dysfunction without evidence of obstruction.** Based on anecdotal experience after removing hundreds of chronically obstructive slings, we have found that obstructive slings are most likely to be found close to the bladder neck. In addition, we have found that progression of anterior and apical prolapse can cause a nonobstructive sling to become obstructive 10 years or more after placement of the sling. If the diagnosis of sling obstruction is in doubt, urodynamics can be performed to provide confirmation (Levin et al., 2004; Volkmer et al., 2003). Although most cases of voiding dysfunction after MUS surgery are the result of sling obstruction, not all women will have obstruction on urodynamic evaluation. Table 125.12 displays a literature review of the management of voiding dysfunction after MUS surgery.

TABLE 125.12

Management of Voiding Dysfunction From Obstruction After Mid-Urethral Sling Surgery

	TOTAL PATIENTS IN SERIES	PATIENTS WITH RETENTION OR SYMPTOMS OF OBSTRUCTION	FINAL MANAGEMENT	TIME TO SURGERY (MEAN OR MEDIAN)	RESOLU OF RETEN AFTER SURGIC MANAG
Klutke et al., 2001	600	17 (2.8%)	17 transvaginal loosening or midline sling transection	64 days	100%

Meschia et al., 2001	404	17 (4.0%)	15 observation or CIC 2 midline sling transection	NR	100%
Rardin et al., 2002b	1175	23 (2.0%)	17 midline sling transection 2 urethrolysis 4 segmental resection	121 days	100%
Kuuva and Nilsson, 2002	1455	34 (2.3%)	33 observation or CIC 1 midline sling transection	90 days	100%
Hong et al., 2003	375	32 (8.5%)	28 observation or CIC 4 midline sling transection	90 days	100%
Karram et al., 2003	350	17 (4.9%)	11 CIC 6 midline sling transection	42 days	100%
Volkmer et al., 2003	—	3	2 midline sling transection 1 segmental resection	214 days	100%
Long et al., 2004	71	7 (9.9%)	7 right-sided lateral transection (J-sling)	28 days	86%
Levin et al., 2004	313	8 (2.6%)	7 catheter 1 segmental resection and urethrolysis	60 days	100%
Tsivian et al., 2004	—	8	5 midline sling	420 days	100%

			transection 3 segmental resection		
Zubke et al., 2004	—	3	3 midline sling transection and mesh lengthening	NR	100%
Abouassaly et al., 2004	241	47 (19.5%)	37 CIC 7 midline sling transection 3 segmental resection	NR	100%
Hammad et al., 2005	1459	95 (6.5%)	62 CIC or catheter 19 midline sling transection 7 urethrolysis 7 transvaginal loosening	NR	NR
Sokol et al., 2005	267	29 (10.9%)	13 urethrolysis 11 CIC or catheter 5 urethral dilation	42 days	NR
Nguyen, 2005	163	10 (6%)	10 transvaginal loosening	5 days	100%
Laurikainen and Killholma, 2006	9040	50 (0.6%)	50 midline sling transection or bilateral transection	197 days	88%
Gamé et al., 2006	—	30	30 lateral sling transection	381 days	70%
Glavind and Glavind, 2007	143	10 (7%)	5 transvaginal loosening 3 CIC 2 midline sling transection	92 days	100%
Hinoul et al., 2011	98	2 (2%)	2 midline sling transection	NR	100%

Bianchi-Ferraro et al., 2013	117	4 (3.4%)	4 CIC	NR	100%

CIC, Clean intermittent catheterization; *NR,* not recorded.

In general, the rates of de novo urgency and perioperative urinary retention are similar among the different types of MUS. The most common symptoms of obstruction are an inability to void (urinary retention), incomplete emptying, and de novo urgency and frequency. The urinary storage symptoms and pain become more prevalent over weeks to months as the bladder attempts to adjust to the obstruction. **The optimal evaluation for women with postoperative voiding dysfunction is poorly defined in the literature. The decision to perform urethrolysis or sling incision is usually based on a clear temporal relationship between onset of symptoms and the surgical procedure.** Urodynamic studies can be useful in selected cases at the physician's discretion. However, it appears that the temporal relationship correlating symptoms with an antecedent surgical procedure should be the primary criterion in selecting women for sling-release procedures. **Cystoscopy is useful to rule out bladder pathology, urethral mesh perforation, and a hypersuspended bladder neck.**

In older, nonrandomized studies, there did not appear to be a significant difference in postoperative voiding dysfunction between retropubic and transobturator MUS surgeries (de Tayrac et al., 2004; Mansoor et al., 2003). More recently, Nguyen et al. (2012) cited rates of sling incision or loosening to be 1.2% and 1.9% after retropubic MUS and TOT, respectively. **However, in a more recent randomized controlled trial by Richter et al.** (2010)**, there was a significantly higher rate of voiding dysfunction necessitating surgery (or permanent catheterization) after a retropubic MUS compared with transobturator MUS (2.7% vs. 0%).** The rate of urinary retention (defined as catheterization for greater than 6 weeks) was also higher in the retropubic MUS group (3.7% vs. 0.7%). Another study evaluating 188,000 MUS surgeries with follow-up of up to 9 years cited a sling revision or removal rate of 1.3% (Jonsson Funk et al., 2013).

When selecting women for the retropubic MUS procedure, it might be helpful to identify preoperative factors predictive of postoperative voiding dysfunction and urinary retention. In a study by Hong et al. (2003), 32 of 375 women (8.5%) required catheterization for greater than or equal to 72 hours after surgery. Twenty-eight of these women resumed normal voiding within 3 months, and 4 women required a transvaginal sling release. On multivariate analysis, only peak flow rate predicted urinary retention. In 2004, a small study of 14 patients showed that low detrusor pressure at maximum flow (PdetQmax) on a preoperative pressure-flow study correlated with elevated PVR urine in three women who had retropubic MUS (Kawashima et al., 2004).

Tsivian et al. (2009) found that women having transobturator MUS alone had no voiding dysfunction postoperatively, whereas seven (11%) of those who had undergone additional pelvic surgery experienced voiding dysfunction. However, Sokol et al. (2005) did not find this same trend in a similar cohort undergoing retropubic MUS. The median time to voiding (8 days vs. 5 days) and rate of urinary retention were similar between women with and without POP repair. However, increasing age, decreasing BMI, and postoperative UTI were independent predictors of increased time to adequate voiding. Previous history of anti-incontinence surgery was the only independent variable predictive of urinary retention. In summary, **there does not appear to be a consensus in the literature regarding preoperative factors that contribute to voiding dysfunction after MUS surgery.**

Management of Voiding Dysfunction After Mid-Urethral Sling Surgery

Urinary obstruction after MUS surgery is frequently transient and can be managed with short-term CIC, although occasionally symptoms mandate sling release. Long-term retention after retropubic MUS surgery is a rare complication. In these cases, removal or incision of the sling usually improves the woman's symptoms.

In most cases, postoperative voiding dysfunction can be successfully treated conservatively. In the literature, temporary indwelling catheter drainage, CIC, timed voiding, biofeedback, PFMT, and selective medical therapy have all been successful to some degree in managing postoperative voiding dysfunction. In the Kuuva and Nilsson (2002) analysis of the Finnish database, 20 of 34 women with urinary retention resumed a normal voiding pattern after less than 14 days of conservative management. However, two women took an additional 5 and 6 weeks to return to normal voiding. Only one of the 34 women required midline sling lysis with subsequent normal voiding. Also in that study, there were 111 women with voiding dysfunction but no urinary retention. Thirteen of these women had voiding dysfunction that lasted up to 4 months, and two women required surgical transection of the sling to achieve a normal voiding pattern

(Kuuva and Nilsson, 2002, 2003). Pharmacotherapy with α-adrenergic antagonists may decrease bladder outlet resistance enough to relieve minimal or mild BOO without more invasive therapies (Patel et al., 2012).

Several reports have shown some benefit of urethral dilation or loosening the sling under anesthesia (Hong et al., 2003; Klutke et al., 2001; Mishra et al., 2005; Ozel et al., 2004). Mishra et al. (2005) performed urethral dilation in 3 of 52 women who had retention 3 months after MUS, and two of the three voided effectively after urethral dilation. In this series, the postoperative retention rate was significantly higher (23%) than in other published data. There are concerns about the potentially traumatic nature of dilation, which could induce scarring of the urethra or lead to mesh perforation. **It is our opinion that urethral dilation may be detrimental to the urethra and should not be performed.** Formal sling loosening may be performed by opening the vaginal incision and placing a right-angle clamp between the sling and urethra. Downward traction on the sling for 1 to 2 cm may lead to a significant improvement in greater than 95% of obstructed patients (Rautenberg et al., 2014). It must be noted that this technique is optimal when performed early in the postoperative period before tissue ingrowth takes place (Brucker and Malacarne, 2016).

Several methods of sling incision have been described in the literature, including lateral and bilateral approaches (Tran and Rutman, 2018). **Cutting the MUS in the midline through a single vertical vaginal incision is the preferred method to manage persistent voiding dysfunction that results from an obstructive sling within the first 3 months after surgery.** Compared with autologous PVS, in our opinion, the MUS after 3 months is fixed along its entire course, and midline sling incision may not achieve enough sling relaxation to resolve voiding dysfunction. In these cases, we perform a more formal sling excision and urethrolysis similar to that described earlier for sling excision after perforation.

Reassuringly, studies by Laurikainen and Killholma (2006), Gamé et al. (2006), Clifton et al. (2014), and Klutke et al. (2001) found that 50%, 70%, 79%, and 94% of women, respectively, remained continent after sling lysis. In the large review by Klutke et al. (2001), 17 of 600 women (3%) required reoperation secondary to urinary retention and persistent obstructive symptoms after retropubic MUS. In their series, sling release was performed at a mean of 64 days after MUS surgery. The sling was identified and either released with downward traction for 1 cm or cut in the midline. There was one urethral injury, which was repaired without sequelae. After sling release, symptoms resolved in all women, all women voided to completion, and 16 woman remained continent. In a nationwide retrospective review of 9040 women who had MUS, approximately 50% of the 48 women who required sling lysis were cured of their voiding dysfunction and remained continent (Laurikainen and Killholma, 2006). However, 4 (8.3%) continued to have retention after lysis. There was no difference in continence rates based on interval between MUS placement and sling lysis. Repeat sling lysis or urethrolysis was used to treat refractory retention. Lastly, Gamé et al. (2006) presented results of 30 women who required sling lysis with a lateral sling incision over a 4-year period, of whom 70% remained continent.

Zubke et al. (2004) managed three women with urethral obstruction after MUS surgery by using a novel surgical technique. They cut the sling in the midline with a transvaginal approach and sutured the edges of the sling to a polypropylene mesh, thus lengthening the sling. All three women were continent and resumed normal voiding after intervention.

The exact timing of sling incision varies in the literature; however, most authors recommend waiting at least 2 weeks (Glavind and Glavind, 2007; Long et al., 2004) before sling incision in cases of urethral obstruction. Even though Kuuva and Nilsson (2002) reported return to normal voiding after 6 weeks of conservative management, the majority of studies do not support waiting more than 4 weeks. **In our opinion, in cases of significant obstruction or retention, the sling should be incised within 4 weeks of surgery.** Also, in our experience, even though some women may return to "normal voiding" with conservative management, they often have persistent urgency and frequency.

Key Points: Mid-Urethral Sling Voiding Dysfunction

- Based on the available data, it appears that long-term urinary retention and obstructive voiding dysfunction are both rare after the MUS procedure.
- Although definitions of urinary retention and indications for management vary in the reported literature, most patients may be initially managed conservatively.
- Anecdotal cases have shown modest benefit from urethral dilation.
- For patients with persistently elevated residual urine and bothersome symptoms refractory to conservative management, transvaginal sling

release procedures consistently provide resolution of symptoms with maintenance of continence in the majority of women. We recommend a waiting period of at least 2 to 4 weeks before sling release.

- Sling release should be attempted through a small midline vaginal incision using minimal dissection.

Sexual Dysfunction After Mid-Urethral Sling Surgery

Varying degrees of sexual impairment have been reported after MUS surgery, with rates approaching 20% in some studies. In the study by Mazouni et al. (2004), 71 women were prospectively followed after they underwent retropubic MUS. In this study, 55 women had no sexual impairment before surgery, 14.5% of the women developed dyspareunia, and 5.4% experienced decreased libido after surgery. However, in a more recent study of 1112 women by Stav et al. (2010b) not designed to specifically look at sexual dysfunction, the rate of de novo dyspareunia after MUS was only 3%.

Marszalek et al. (2007) performed a cross-sectional analysis and noted that a 14.3% deterioration in sexual function was significantly associated with de novo urgency, dyspareunia, and the sensation of incomplete emptying. In 2008, Demirkesen et al. (2008) compared sexual satisfaction after MUS surgery and Burch colposuspension. In that study, 54% expressed a negative change, with most reporting dyspareunia. The MUS appeared to more adversely affect sexual satisfaction, but the difference was not significant. Kuhn et al. (2009a) reviewed the impact of sling removal on postoperative female de novo dyspareunia and found that the pain improved significantly.

There is also evidence that treatment of urinary incontinence can improve sexual function after surgery. In the randomized trial by Ward and Hilton (2008), the rate of dyspareunia actually decreased from 34% preoperatively to 13% 5 years after sling surgery. In 2009, Bekker et al. (2009) published the results of a retrospective evaluation of sexual function in 136 women after MUS surgery. The authors found that 21.3% of women reported improved sexual intercourse after surgery, and 5.9% reported worsened sexual intercourse. The authors mostly attributed the improved sexual function to a significant decrease in coital incontinence.

Other Complications After Mid-Urethral Sling Surgery

A diverse group of complications have been reported with the MUS, in addition to those mentioned previously. These include infection, bleeding, vascular injury, bowel perforation, and death. UTI is probably the most common and easily treatable complication of MUS surgery. Rates of UTI after MUS surgery range from 22% to 31% in large randomized trials (Richter et al. 2010; Ward and Hilton, 2002). In a retrospective review of the National Surgical Quality Improvement Program (NSQIP) database of 9,022 MUS surgeries from 2006 to 2014, Vigil et al. (2017) cited a UTI incidence of 2.6%. Factors independently associated with an increased infection risk included age older than 65 years (OR 1.54, 95% CI 1.07 to 1.22), BMI greater than 40 kg/m^2 (OR 1.89, 95% CI 1.23 to 2.92), and hospital admission (OR 2.06, 95% CI 1.37 to 3.11). MUS surgery performed by urologists carried a reduced risk for infection compared with the surgery performed by gynecologists (OR 0.52, 95% CI 0.40 to 0.69).

Another less common complication is intraoperative and postoperative **bleeding.** This complication is usually inconsistently reported in the literature. A review of the literature reveals that **severe bleeding or hematoma occurs in approximately 2% to 3% of women and can usually be managed with observation or local compression** (see eTable 125.8). This table also shows that in 8 of 10 studies comparing different MUS approaches, bleeding complications occurred more commonly after retropubic MUS. In their study, Wei et al. (2012) found the average estimated blood loss after MUS to be 156 mL. In 2004, Flock et al. (2004) reported that 4.1% of 249 women experienced a hemorrhage of 300 mL or more and required surgical intervention after retropubic MUS. Tseng et al. (2005) performed ultrasonography on all 62 women after MUS and found that 8 (12.9%) women had significant retropubic hematomas greater than 5 cm on the day after surgery. Only one patient required hematoma evacuation, and, in the remainder, repeat ultrasonographic examinations 1 month after surgery revealed that the hematomas had resolved. **Of interest, this study revealed that a postoperative hematoma may be a relatively common asymptomatic event after trocar passage.**

Serious complications such as vascular perforation, intestinal perforation, or even death remain extremely rare. The rate of serious vascular complications in the Finnish registry was 0.07% (Kuuva and Nilsson, 2002). Comparably, the Austrian registry reported a bowel perforation rate of 0.04% (Tamussino et al., 2001). In 2007, Deng et al. (2007) reviewed the complications reported to the FDA MAUDE database. The authors found that of 928 reported complications, 161 were considered major. The major complications included 39 vascular injuries, 38 bowel injuries, and 10 deaths.

Management of Recurrent or Persistent Stress Urinary Incontinence After Mid-Urethral Sling Surgery

Persistent SUI (no dry period after MUS) after otherwise routine MUS surgery may be caused by poor surgical technique, wrong choice of procedure, or suboptimal patient selection. On the other hand, recurrent SUI (SUI resolved, but then recurred) is thought to occur most commonly because of various patient-associated factors, such as age, obesity, concomitant preoperative UUI, and postoperative change in POP. The exact length of time separating persistent and recurrent post-MUS SUI is not clear, but the chance of undergoing repeat surgery is estimated to be 6% (Zimmern et al., 2016).

The evaluation of women with persistent or recurrent SUI is much like that of a woman being considered for primary anti-incontinence surgery. A focused history and pelvic examination should be performed to evaluate urethral mobility and the presence of POP. A urinalysis and PVR should be performed, and cystoscopy should be strongly considered for women with concomitant OAB symptoms or hematuria. Furthermore, urodynamic evaluation (with the possible addition of video) may assist in identifying DO or ISD.

The options for retreatment of persistent or recurrent SUI are: conservative management (including PFMT with biofeedback), tightening the previous MUS, or repeat anti-incontinence surgery (colposuspension, MUS, autologous PVS, and urethral bulking). In a review of the British Society of Urogynaecology database, Patil et al. (2011) found that a repeat retropubic MUS was the most common surgical reintervention after any failed MUS (54%; 170/313). Bulking, TVT-O, TOT, colposuspensions, and Aldridge slings were performed in 14%, 12%, 8%, 6%, and 2%, respectively. Overall, the data guiding the choice of procedure is woefully inadequate, with a Cochrane systematic review identifying 12 trials, but none meeting eligibility criteria (Bakali et al., 2013). Six of these trials were RCTs but were not eligible because the previous incontinence surgery was not a MUS.

There are essentially no data supporting nonsurgical means for curing post-MUS SUI, and the data regarding sling tightening is limited to case reports. Gaddi et al. (2014) suggested periurethral bulking as salvage therapy after failed sling. In a retrospective analysis of 6914 MUS, 165 women underwent a repeat procedure for recurrent SUI, including 98 MUS and 67 urethral bulking procedures. Eleven of the 98 women who underwent MUS were considered failures (11.2%), and 26 of the 67 women (38.8%) in the urethral bulking group failed ($P = 0.004$). There were no differences in perioperative complications or adverse events between the groups. In multivariable logistic regression, risk for failure was significantly higher in those undergoing urethral bulking compared with those undergoing mid-urethral sling (OR 3.49, 95% CI 1.34 to 9.09, $P = 0.01$).

Repeat MUS is certainly an option for primary MUS failure, and the expected success rates are 62% to 89% (Gaddi et al., 2014). This option is appealing because of its minimal attendant morbidity and overall high success rates, even as a secondary procedure. Risk factors for failure of the secondary MUS are lack of urethral mobility, preoperative ISD, and TO MUS as the secondary procedure. Finally, autologous PVS is an option for recurrent and persistent SUI. The advantage of this surgical option is that it places the sling in a location/vector that is distinctly different from that of the MUS. The downside is that there is a greater chance for postoperative voiding dysfunction and harvest site morbidity. The literature suggests that the use of autologous PVS for primary MUS failure is increasing. Zimmern et al. (2016) noted that, of those women in the TOMUS trial undergoing secondary treatment for primary MUS failure, one-half underwent urethral bulking, and one-half underwent autologous PVS. Other small studies support the upward trend of autologous PVS for this indication (McCoy et al., 2016; Milose et al., 2015; Petrou et al., 2016). The three retrospective studies included 147 women, and subjective cure utilizing different outcome measures was 52% to 76% at follow-up periods of up to 3 years. Objective cure was 91% in the study by McCoy et al. (2016), however 22% of the patients in their cohort required a mean of 1.8 subsequent interventions at an average of 6.5 months after autologous PVS placement. Furthermore, some women in these cohorts had evidence of mesh-related complications and underwent concomitant MUS revision at the time of PVS.

In a recent study, Singla et al. (2017) described their cohort of 99 women who underwent MUS removal for various indications over a 10-year period. Seventy percent and 20% originally underwent retropubic and transobturator MUS, respectively. After subtotal sling excision, 72 (72%) experienced some form of incontinence at a mean of 58 months, with SUI, UUI, and MUI present in 36%, 19%, and 44%, respectively. The success rate after a single minimally invasive intervention for incontinence after sling excision was 81%, 86%, and 75% in women with SUI, UUI, and MUI, respectively.

Regulatory and Legal Issues Related to Sling Mesh Complications

The FDA approved the first MUS for use through the 510(k) approval process in 1998. It is interesting to note that all subsequent MUS products have also been approved for use through this process (Secunda, 2011). The 510(k) approval process for class II products (mesh products fall into this class) allows medical device manufacturers to bypass the normal premarket approval (PMA) procedure as long as the new device is substantially equivalent to an existing product (FDA, 2013a, 2013b). Once the FDA determines that a product is substantially equivalent to an existing product, the company receives a letter of approval to market the new device.

The success of MUS for female urinary incontinence led to the development of transvaginal mesh products for POP repair. Subsequently, the FDA determined that these products were substantially equivalent to existing mesh products already approved, and, in turn, the 510(k) approval process led to the rapid approval of these products as well. The FDA and many physicians believe that the 510(k) approval process is a necessary and important practice that allows for medical device advances to occur more rapidly. Of note, through the Freedom of Information Act (5 U.S.C. § 552(a)(2) (Title 5 United States Code section 552 subsection a2), all FDA letter communications to manufacturers are available online.

However, although the use of transvaginal mesh for POP repairs has increased, so too have complications related to its use. In October 2008, the FDA released a public health notification (PHN) alerting the public about “rare” complications and problems related to transvaginal mesh products used for POP. **In 2011, the FDA modified this alert by removing the term “rare” and stating that surgical mesh for POP repair does not conclusively improve outcomes over traditional nonmesh or native tissue repairs and is associated**

with unique potentially serious adverse outcomes (FDA, 2011).

The FDA convened an advisory panel in September of 2011 to solicit recommendations on potential actions regarding urogynecologic surgical mesh for transvaginal POP repair. If a product approved by the FDA through the 510(k) process is found to have potential serious adverse health consequences, the FDA can require the manufacturer to perform costly 522 postmarket surveillance studies. In the case of mesh for pelvic surgery, the FDA was alerted to potential serious adverse events through the MAUDE database and reports in the urologic and gynecologic literature. In January 2012, the FDA mandated that all manufacturers of synthetic prosthetic mesh and biologic graft materials marketed for POP repair and SIMS perform 522 postmarket surveillance studies. Approximately 100 orders were sent to 35 vaginal mesh manufacturers to conduct such studies.

MUS products (except SIMS) were excluded from this mandate because the FDA advisory panel deemed existing MUS products “safe and effective” and recommended that these products not undergo 522 postmarket surveillance. For future MUS products, the FDA determined that the 510(k) approval process is still applicable as long as well-designed bench or animal studies are included with the 510(k) application. However, premarket clinical studies for new SUI products may be required if the FDA determines that there is a need for clinical information to demonstrate substantial equivalence to an existing product (Baxley, 2011).

The FDA subsequently issued two proposed orders in May 2014: (1) to reclassify the transvaginal surgical mesh for POP repair from class II to class III and reclassify instrumentation for the placement of such mesh products from class I to class II, and (2) require those manufacturers who wish to continue to market these products to submit a PMA application within 30 months of reclassification (January 4, 2016). Without such a PMA, commercial distribution of the device would have to cease, unless the manufacturer obtained an application for an investigational device exemption (IDE). The reclassification and PMA orders did not, and do not currently, apply to full-length retropubic or transobturator MUS.

As a class II device, mesh products or kits were deemed safe without premarket studies, and only required issuance of performance standards, postmarket surveillance, patient registries, guidelines, and recommendations. However, a class III device is one for which insufficient information exists to determine a reasonable assurance of safety and effectiveness, and for which there may be a potential unreasonable risk for illness or injury. (Effective Date of Requirement for PreMarket Approval for Surgical Mesh for Transvaginal Pelvic Organ Prolapse Repair. Federal Register, Vol 79, No. 84; pp 24642-24648, May 1, 2014.; Reclassification of Surgical Mesh for Transvaginal Pelvic Organ Prolapse Repair and Surgical Instrumentation for Urogynecologic Surgical Mesh Procedures: Designations of Special Controls for Urogynecologic Surgical Mesh Instrumentation. Federal Register, Vol 79, No. 84; p 23634–24642, May 1, 2014.)

On January 4, 2016, the FDA issued two final orders to manufacturers and the public regarding the use of surgical mesh for transvaginal POP repair. The FDA issued one order to reclassify these medical devices from class II, which generally includes moderate-risk devices, to class III, which includes high-risk devices. The second order requires manufacturers to submit a PMA application to support the safety and effectiveness of surgical mesh for transvaginal POP repair. The PMA pathway will require manufacturers to address safety concerns, including severe pelvic pain and organ perforation, to demonstrate safety and effectiveness.

These orders do not apply to surgical mesh used for other indications. Full-length MUS and mesh for sacral colpopexy remain class II devices, and SIMS are currently undergoing postmarket surveillance 522 order studies. The PMA requirements for class III devices must now include at least 1 year of outcome data with an additional 2 to 4 years of postmarket follow-up, more robust physician labeling (warnings and precautions), and patient labeling that must include an explanation of POP, treatment options, clinical trial data, a statement that surgical mesh is permanent, instructions for postoperative care, and a notice of availability of the FDA Safety Communication. All existing transvaginal mesh POP products will be required to complete the 522 order studies. The 510(k) process will no longer be used for new products, as all new products will be deemed class III and must undergo the PMA process.

Even though the FDA has determined that existing MUS products are safe and effective, this unfortunately has not prevented MUS from being caught up in the fervor of litigation related to products used for pelvic organ prolapse repair. In June 2010, a settlement was reached to halt the first class-action lawsuit against the manufacturer of ObTape (Mentor-Porgés) (Chapple et al., 2013). To date, AMS (Endo Pharmaceuticals), Ethicon (Gynecare, Johnson & Johnson), Boston Scientific, and C.R. Bard have all been targeted by multidistrict federal litigation for complications related to their MUS products.

The increase in litigation has been accompanied by MUS products being removed from the market. In June 2012, Ethicon withdrew four products, including TVT-S, stating that the move “was not a recall, but was based on the products’ commercial viability in light of changing market dynamics, and is not related to safety or efficacy.” Ethicon asked the FDA for permission to discontinue sales of the devices and to suspend requirements for additional studies on its Gynecare line of products. No official recall of devices was formally issued by the FDA since manufacturers voluntarily withdrew certain mesh products that they did not want to enroll into postmarket surveillance studies. Bard Medical Division discontinued the distribution and sale of the Align and Align TO MUS products in the United States as of June 1, 2016, and Endo International/Astora (SPARC and Monarc) discontinued commercial and manufacturing operations by March 31, 2016. Currently, most litigation is directed at device manufacturers; however, this could change.

It is important for pelvic surgeons to continue to thoroughly counsel their patients about the permanent nature of mesh products and the potentially serious complications related to their use. The AUA has come out with a position statement supporting the safety and efficacy of polypropylene MUS (AUA Position Statement on the Use of Vaginal Mesh for the Surgical Treatment of Stress Urinary Incontinence [SUI]).

Extensive data exist to support the use of synthetic polypropylene mesh suburethral slings for the treatment of female SUI, with minimal morbidity compared with alternative surgeries. Advantages include shorter operative time/anesthetic need, reduced surgical pain, reduced hospitalization, and reduced voiding dysfunction. Mesh-related complications can occur after polypropylene sling placement, but the rate of these complications is acceptably low. Furthermore, it is important to recognize that many sling-related complications are not unique to mesh surgeries and are known to occur with nonmesh sling procedures as well. It is the AUA's opinion that any restriction of the use of synthetic polypropylene mesh suburethral slings would be a disservice to women who choose surgical correction of SUI. Additionally, **both the Society of Urodynamics, Female Pelvic Medicine and Urogenital Reconstruction (SUFU) and the AUA support the use of multi-incision monofilament mid-urethral slings for the treatment of SUI in properly selected patients who are appropriately counseled regarding this surgical procedure by surgeons who are trained in the placement of such devices, and the recognition and management of potential complications associated with their use.**

Multiple case series and randomized controlled trials attest to the efficacy of synthetic polypropylene mesh slings at 5 to 10 years. This efficacy is equivalent or superior to other surgical techniques. There is no significant increase in adverse events observed over this period of follow-up. Based on these data, the AUA guideline for the Surgical Management of Stress Urinary Incontinence concluded that synthetic slings are an appropriate treatment choice for women with stress incontinence, with similar efficacy but less morbidity than conventional nonmesh sling techniques (Appell et al., 2009). The AUA guideline also indicates that intra-operative cystoscopy should be performed during all synthetic sling procedures to identify urinary tract injury. The most recent AUA/SUFU SUI guidelines have echoed these statements (Kobashi et al., 2017).

The AUA strongly agrees with the FDA that a thorough informed consent should be conducted before synthetic sling surgery. The AUA also agrees that surgeons who wish to perform synthetic sling surgery should:

- Undergo rigorous training in the principles of pelvic anatomy and pelvic surgery.
- Be properly trained in specific sling techniques.
- Be able to recognize and manage complications associated with synthetic mesh sling placement.

Finally, as carcinogenic potential must be considered for any surgical implant, several authors have addressed this topic. Of 2361 MUS procedures performed at the Cleveland Clinic over a 10-year period, bladder cancer was diagnosed in one woman (0.04%) (King et al., 2014). Likewise, Linder et al. (2016) diagnosed only two pelvic cancers (vaginal melanoma 3 years after MUS and an ovarian tumor 1 year after MUS) in a 10-year experience of 2474 women from the Mayo Clinic. Reviews of the literature confirm the absence of association between polypropylene mesh and carcinogenesis (Adel et al., 2017; King and Goldman, 2014).

Videos 125.1 to 125.5 show procedures related to this chapter.

Suggested Readings

Abouassaly R, Steinberg J, Lemieux M, et al. Complications of tension-free vaginal tape surgery: a multi-institutional review. *BJU Int*. 2004;94:110–113.

Albo ME, Richter HE, Brubaker L, et al. Burch colposuspension versus fascial sling to reduce urinary stress incontinence. *N Engl J Med*. 2007;356:2143–2155.

Anger JT, Weinberg AE, Albo ME, et al. Trends in surgical management of stress urinary incontinence among female Medicare beneficiaries. *Urology*. 2009;74:283–287.

Blaivas JG, Sandhu J. Urethral reconstruction after erosion of slings in women. *Curr Opin Urol*. 2004;14:335–338.

Brubaker L, Richter HE, Norton PA, et al. Urinary Incontinence Treatment Network. 5-year continence rates, satisfaction and adverse events of burch urethropexy and fascial sling surgery for urinary incontinence. *J Urol*. 2012;187:1324–1330.

Campeau L, Tu LM, Lemieux MC, et al. A multicenter, prospective, randomized clinical trial comparing tension-free vaginal tape surgery and no treatment for the management of stress urinary incontinence in elderly women. *Neurourol Urodyn*. 2007;26:990–994.

Chaikin DC, Rosenthal J, Blaivas JG. Pubovaginal fascial sling for all types of stress urinary incontinence: long-term analysis. *J Urol*. 1998;160(4):1312–1316.

Chou EC, Flisser AJ, Panagopoulos G, et al. Effective treatment for mixed urinary incontinence with a pubovaginal sling. *J Urol*. 2003;170:494–497.

de Tayrac R, Deffieux X, Droupy S, et al. A prospective randomized trial comparing tension-free vaginal tape and transobturator suburethral tape for surgical treatment of stress urinary incontinence. *Am J Obstet Gynecol*. 2004;190:602–

608.

Delorme E. Transobturator urethral suspension: mini-invasive procedure in the treatment of stress urinary incontinence in women. *Prog Urol*. 2001;11:1306–1313.

Doo CK, Hong B, Chung BJ, et al. Five-year outcomes of the tension-free vaginal tape procedure for treatment of female stress urinary incontinence. *Eur Urol*. 2006;50:333–338.

Dumoulin C, Hay-Smith EJ, Mac Habée-Séguin G, et al. Pelvic floor muscle training versus no treatment, or inactive control treatments, for urinary incontinence in women: a short version Cochrane systematic review with meta-analysis. *Neurourol Urodyn*. 2015;34:300–308.

Ford AA, Rogerson L, Cody JD, et al. Mid-urethral sling operations for stress urinary incontinence in women. *Cochrane Database Syst Rev*. 2017;(7) [CD006375].

Fuselier A, Hanberry J, Margaret Lovin J, et al. Obesity and stress urinary incontinence: impact on pathophysiology and treatment. *Curr Urol Rep*. 2018;19(1):10.

Klutke C, Siegel S, Carlin B, et al. Urinary retention after tension-free vaginal tape procedure: incidence and treatment. *Urology*. 2001;58:697–701.

Kobashi KC, Albo ME, Dmochowski RR, et al. Surgical treatment of female stress urinary incontinence: AUA/SUFU guideline. *J Urol*. 2017;198:875–883.

Kulseng-Hanssen S, Husby H, Schiotz HA. Follow-up of TVT operations in 1,113 women with mixed urinary incontinence at 7 and 38 months. *Int Urogynecol J Pelvic Floor Dysfunct*. 2008;19:391–396.

Kuuva N, Nilsson C. A nationwide analysis of complications associated with the tension-free vaginal tape (TVT) procedure. *Acta Obstet Gynecol Scand*. 2002;81:72–77.

Kuuva N, Nilsson C. Tension-free vaginal tape procedure: an effective minimally invasive operation for the treatment of recurrent stress urinary incontinence? *Gynecol Obstet Invest*. 2003;56:93–98.

Laurikainen E, Killholma P. A nationwide analysis of transvaginal tape release for urinary retention after tension-free vaginal tape procedure. *Int Urogynecol J Pelvic Floor Dysfunct*. 2006;17:111–119.

Leach G, Dmochowski R, Appell R, et al. Female Stress Urinary Incontinence Clinical Guidelines Panel summary report on surgical management of female stress urinary incontinence. The American Urological Association. *J Urol*. 1997;158:875–880.

Lee KS, Han DH, Choi YS, et al. A prospective trial comparing tension-free vaginal tape and transobturator vaginal tape inside-out for the surgical treatment of female stress urinary incontinence: 1-year follow-up. *J Urol*. 2007;177:214–218.

Lemack GE, Krauss S, Litman H, et al. Normal postoperative urodynamic testing does not predict voiding dysfunction after Burch colposuspension versus pubovaginal sling. *J Urol*. 2008;180:2076–2080.

Mansoor A, Vedrine N, Darcq C. Surgery of female urinary incontinence using trans-obturator tape (TOT): a prospective randomized comparative study with TVT. *Neurourol Urodyn*. 2003;22:488–489.

Meltomaa S, Backman T, Haarala M. Concomitant vaginal surgery did not affect outcome of the tension-free vaginal tape operation during a prospective 3-year follow-up study. *J Urol*. 2004;172:222–226.

Nambiar A, Cody JD, Jeffery ST, et al. Single-incision sling operations for urinary incontinence in women. *Cochrane Database Syst Rev*. 2017;(7) [CD008709].

Neuman M. TVT-Obturator: short-term data on the operative procedure for the cure of female stress urinary incontinence performed on 300 patients. *Eur Urol*. 2007;51:1083–1088.

Nilsson C, Falconer C, Rezapour M. Seven-year follow-up of the tension-free vaginal tape procedure for treatment of urinary incontinence. *Obstet Gynecol*. 2004;104:1259–1262.

Osborn DJ, Strain M, Gomelsky A, et al. Obesity and female stress urinary incontinence. *Urology*. 2013;82:759–763.

Petros P, Ulmsten U. An integral theory and its method for the diagnosis and management of female urinary incontinence. *Scand J Urol Nephrol Suppl*. 1993;153:1–93.

Porena M, Constantini E, Frea B, et al. Tension-free vaginal tape versus transobturator tape as surgery for stress urinary incontinence: results of a multicentre randomised trial. *Eurn Urol*. 2007;52:1481–1491.

Rehman H, Bezerra CA, Bruschini H, et al. Traditional suburethral sling operations for urinary incontinence in women. *Cochrane Database Syst Rev*. 2017;(7) [CD001754].

Richter HE, Albo ME, Zyczynski HM, et al. Retropubic versus transobturator midurethral slings for stress incontinence. *N Engl J Med*. 2010;362:2066–2076.

Sokol A, Jelovsek J, Walters M, et al. Incidence and predictors of prolonged urinary retention after TVT with and without concurrent prolapse surgery. *Am J Obstet Gynecol*. 2005;192:1537–1543.

Tamussino K, Hanzal E, Kölle D, et al. Tension-free vaginal tape operation: results of the Austrian registry. *Obstet Gynecol*. 2001;98:732–736.

Waltregny D, Gaspar Y, Reul O, et al. TVT-O for the treatment of female stress urinary incontinence: results of prospective study after a 3-year minimum follow-up. *Eur Urol*. 2008;53:401–410.

Ward K, Hilton P. Tension-free vaginal tape versus colposuspension for primary urodynamic stress incontinence: 5-year follow-up. *BJOG*. 2008;115:226–233.

Woodruff AJ, Cole EE, Dmochowski RR, et al. Histologic comparison of pubovaginal sling graft materials: a comparative study. *Urology*. 2008;72(1):85–89.

References

Abdel-Fattah M, Barrington JW, Arunkalaivanan AS. Pelvicol pubovaginal sling versus tension-free vaginal tape for treatment of urodynamic stress incontinence: a prospective randomized three-year follow-up study. *Eur Urol*. 2004;46:629–635.

Abdel-Fattah M, Ford JA, Lim CP, et al. Single-incision mini-slings versus standard midurethral slings in surgical management of female stress urinary incontinence: a meta-analysis of effectiveness and complications. *Eur Urol*. 2011;60:468–480.

Abdel-Fattah M, Hopper LR, Mostafa A. Evaluation of transobturator tension-free vaginal tapes in the surgical management of mixed urinary incontinence: 3-year outcomes of a randomized controlled trial. *J Urol*. 2014;191:114–119.

Abouassaly R, Steinberg J, Lemieux M, et al. Complications of tension-free vaginal tape surgery: a multi-institutional review. *BJU Int*. 2004;94:110–113.

Achtari C, McKenzie BJ, Hiscock R, et al. Anatomical study of the obturator foramen and dorsal nerve of the clitoris and their relationship to minimally invasive slings. *Int Urogynecol J Pelvic Floor Dysfunct*. 2006;17:330–334.

Adamiak A, Milart P, Skorupski P, et al. The efficacy and safety of the tension-free vaginal tape procedure do not depend on the method of analgesia. *Eur Urol*. 2002;42:29–33.

Adel E, Shapiro R, Zaslau S. Carcinogenic potential of polypropylene mid-urethral slings: what do we know so far? *Int Urogynecol J*. 2017;28:657–660.

Agur W, Riad M, Secco S, et al. Surgical treatment of recurrent stress urinary incontinence in women: a systematic review and meta-analysis of randomised controlled trials. *Eur Urol*.

2013;64:323–336.

Aigmueller T, Trutnovsky G, Tamussino K, et al. Ten-year follow-up after the tension-free vaginal tape procedure. *Am J Obstet Gynecol*. 2011;205:496.e1–496.e5.

Albo ME, Richter HE, Brubaker L, et al. Burch colposuspension versus fascial sling to reduce urinary stress incontinence. *N Engl J Med*. 2007;356:2143–2155.

Aldridge AH. Transplantation of fascia for relief of urinary stress incontinence. *Am J Obstet Gynecol*. 1942;44:398.

Allahdin S, McKinley C, Mahmood T. Tension free vaginal tape: a procedure for all ages. *Acta Obstet Gynecol Scand*. 2004;83:937–940.

Almeida SH, Gregório E, Grando JP, et al. Pubovaginal sling using cadaveric allograft fascia for the treatment of female urinary incontinence. *Transplant Proc*. 2004;36:995–996.

Alperin M, Abrahams-Gessel S, Wakamatsu M. Development of de novo urge incontinence in women post sling: the role of preoperative urodynamics in assessing the risk. *Neurourol Urodyn*. 2008;27:407–411.

Al-Singary W, Shergill IS, Allen SE, et al. Trans-obturator tape for incontinence: a 3-year follow-up. *Urol Int*. 2007;78:198–201.

Al-Wadi K, Al-Badr A. Martius graft for the management of tension-free vaginal tape vaginal erosion. *Obstet Gynecol*. 2009;114:489–491.

Al-Zahrani A, Gajewski J. Long-term patient satisfaction after retropubic and transobturator mid-urethral slings for female stress urinary incontinence. *J Obstet Gynaecol Res*. 2016;42:1180–1185.

American College of Obstetricians and Gynecologists (ACOG). Women's Health Care Physicians; Committee on Gynecologic Practice. Committee Opinion No. 571: solutions for surgical preparation of the vagina. *Obstet Gynecol*. 2013;122(3):718–

720.

Amid PK, Shulman AG, Lichtenstein IL. Selecting synthetic mesh for the repair of groin hernia. *Postgrad Gen Surg*. 1992;4:1505.

Amid PK. Classification of biomaterials and their related complications in abdominal wall hernia surgery. *Hernia*. 1997;1:15–21.

Amundsen CL, Flynn BJ, Webster GD. Urethral erosion after synthetic and nonsynthetic pubovaginal slings: differences in management and continence outcome. *J Urol*. 2003;170:134–137.

Amundsen CL, Guralnick ML, Webster GD. Variations in strategy for the treatment of urethral obstruction after a pubovaginal sling procedure. *J Urol*. 2000;164:434–437.

Amundsen CL, Visco AG, Ruiz H, et al. Outcome in 104 pubovaginal slings using freeze-dried allograft fascia lata from a single tissue bank. *Urology*. 2000;56(Suppl 6A):2–8.

Andonian S, Chen T, St-Denis B, et al. Randomized clinical trial comparing suprapubic arch sling (SPARC) and tension-free (TVT): one-year results. *Eur Urol*. 2005;47:537–541.

Anger JT, Litwin MS, Wang Q, et al. Complications of sling surgery among female Medicare beneficiaries. *Obstet Gynecol*. 2007;109:707–714.

Anger JT, Litwin MS, Wang Q, et al. Variations in stress incontinence and prolapsed management by surgeon specialty. *J Urol*. 2007;178:1411–1417.

Anger JT, Litwin MS, Wang Q, et al. The effect of concomitant prolapse repair on sling outcomes. *J Urol*. 2008;180:1003–1006.

Anger JT, Weinberg AE, Albo ME, et al. Trends in surgical management of stress urinary incontinence among female Medicare beneficiaries. *Urology*. 2009;74:283–287.

Angioli R, Plotti F, Muzii L, et al. Tension-free vaginal tape versus transobturator suburethral tape: five-year follow-up results of a prospective, randomised trial. *Eur Urol*. 2010;58:671–677.

Appell RA, Dmochowski RR, Blaivas JG, et al. *AUA guideline for the surgical management of female stress urinary incontinence*. [update; Available from] https://www.auanet.org/Documents/education/clinical-guidance/Incontinence.pdf; 2009.

Appell RA. In situ vaginal wall sling. *Urology*. 2000;56:499–503.

Arunkalaivanan AS, Barrington JW. Randomized trial of porcine dermal sling (Pelvicol implant) versus tension-free vaginal tape (TVT) in the surgical treatment of stress incontinence: a questionnaire-based study. *J Urol*. 2003;14:17–23.

Asmussen M, Ulmsten U. On the physiology of continence and pathophysiology of stress incontinence in the female. *Contrib Gynecol Obstet*. 1983;10:32–50.

Athanasiou S, Grigoriadis T, Kalamara E, et al. Mixed urodynamic incontinence: TVT or TVT-O? *Int Urogynecol J*. 2009;20 [34th Annual IUGA Meeting, abstract 173 (S218].

Athanasiou S, Grigoriadis T, Zacharakis D, et al. Seven years of objective and subjective outcomes of transobturator (TVT-O) vaginal tape: why do tapes fail? *Int Urogynecol J*. 2014;25:219–225.

Athanasopoulos A, Gyftopoulos K, McGuire EJ. Efficacy and preoperative prognostic factors of autologous fascia rectus sling for treatment of female stress urinary incontinence. *Urology*. 2011;78:1034–1038.

AUA Position Statement on the Use of Vaginal Mesh for the Surgical Treatment of Stress Urinary Incontinence (SUI). [Available from:] http://www.auanet.org/guidelines/use-of-vaginal-mesh-for-the-surgical-treatment-of-stress-urinary-incontinence.

Austin PF, Westney OL, Leng WW, et al. Advantages of rectus fascial slings for urinary incontinence in children with neuropathic bladders. *J Urol*. 2001;165:2369–2371.

Azam U, Frazier M, Kozman E, et al. The tension-free vaginal tape procedure in women with previous failed stress incontinence surgery. *J Urol*. 2001;166:554–556.

Babalola EO, Famuyide AO, McGuire LJ, et al. Vaginal erosion, sinus formation and ischiorectal abscess following transobturator tape: ObTape implantation. *Int Urogynecol J Pelvic Floor Dysfunct*. 2005;17:418–421.

Bafghi A, Valerio L, Trastour C, et al. Evaluation of the TVT technique according to age. *J Gynecol Obstet Biol Reprod (Paris)*. 2005;34:47–52.

Bai SW, Jun YH, Jeon MJ, et al. Treatment outcome of tension-free vaginal tape in stress urinary incontinence: comparison of intrinsic sphincter deficiency and nonintrinsic sphincter deficiency patients. *Int Urogynecol J*. 2007;18:1431–1434.

Bakali E, Buckley BS, Hilton P, et al. Treatment of recurrent stress urinary incontinence after failed minimally invasive synthetic suburethral tape surgery in women. *Cochrane Database Syst Rev*. 2013;(2) [CD009407].

Balakrishnan S, Lim YN, Barry C, et al. Sling distress: a subanalysis for the IVS tapes from the SUSPEND trial. *Aust N Z J Obstet Gynaecol*. 2007;47:496–498.

Ballert KN, Biggs GY, Isenalumhe A Jr, et al. Managing the urethra at transvaginal pelvic organ prolapse repair: a urodynamic approach. *J Urol*. 2009;181:679–684.

Ballert KN, Kanofsky JA, Nitti VW. Effect of tension-free vaginal tape and TVT-obturator on lower urinary tract symptoms other than stress urinary incontinence. *Int Urogynecol J Pelvic Floor Dysfunct*. 2008;19:335–340.

Baracat F, Mitre AI, Kanashiro H, et al. Endoscopic treatment of vesical and urethral perforations after tension-free vaginal tape (TVT) procedure for female stress urinary incontinence. *Clinics (Sao Paulo)*. 2005;60:397–400.

Barber MD, Kleeman S, Karram MM, et al. Risk factors associated with failure 1 year after retropubic or transobturator midurethral slings. *Am J Obstet Gynecol*. 2008;199:666.e1–666.e7.

Barnes HHF. Round ligament sling operation for stress incontinence. *Obstet Gynaecol Br Emp*. 1950;57:404–407.

Barnes NM, Dmochowski RR, Park R, et al. Pubovaginal sling and pelvic prolapse repair in women with occult stress urinary incontinence: effect on postoperative emptying and voiding symptoms. *Urology*. 2002;59:856–860.

Barrington JW, Edwards G, Arunkalaivanan AS, et al. The use of porcine dermal implant in a minimally invasive pubovaginal sling procedure for genuine stress incontinence. *BJU Int*. 2002;90:224–227.

Basu M, Duckett J. A randomised trial of a retropubic tension-free vaginal tape versus a mini-sling for stress incontinence. *BJOG*. 2010;117:730–735.

Baxley J. *Guidance for industry and FDA staff—clinical investigations of devices indicated for the treatment of urinary incontinence: March 8*. [Available from:] www.fda.gov/medicaldevices/deviceregulationandguidance/g 2011.

Beck RP, McCormick S, Nordstrom L. The fascia lata sling procedure for treating recurrent genuine stress incontinence of urine. *Obstet Gynecol*. 1988;72:699–703.

Bekker M, Beck J, Putter H, et al. Sexual function improvement following surgery for stress incontinence: the relevance of coital incontinence. *J Sex Med*. 2009;6:3208–3213.

Bent AE, Ostergard DR, Zwick-Zaffuto MT. Tissue reaction to expanded polytetrafluoroethylene suburethral sling for urinary incontinence: clinical and histologic study. *Am J Obstet Gynecol*. 1993;169:1198–1204.

Ben-Zvi T, Moore K, Haidar N, et al. An in-house Composix™-based pubovaginal sling trial for female stress urinary incontinence: five-year comparative followup to tension-free and transobturator vaginal tapes. *Cam Urol Assoc J*. 2017;11:275–280.

Bergman A, Bhatia NN. Urodynamic appraisal of the Marshall-Marchetti test in women with stress urinary incontinence. *Urology*. 1987;29:458–462.

Bianchi-Ferraro AM, Jarmy-Di Bella ZI, Castro Rde A, et al. Single-incision sling compared with transobturator sling for treating stress urinary incontinence: a randomized controlled trial. *Int Urogynecol J*. 2013;24(9):1459–1465.

Bianchi-Ferraro AM, Jarmy-DiBella ZI, de Aquino Castro R, et al. Randomized controlled trial comparing TVT-O and TVT-S for the treatment of stress urinary incontinence: 2-year results. *Int Urogynecol J*. 2014;25:1343–1348.

Bidmead J, Cardozo L. Sling techniques in the treatment of genuine stress incontinence. *BJOG*. 2000;107:147–156.

Biggs GY, Ballert KN, Rosenblum N, et al. Patient-reported outcomes for tension-free vaginal tape-obturator in women treated with a previous anti-incontinence procedure. *Int Urogynecol J*. 2009;20:331–335.

Blaivas JG, Chaikin DC. Pubovaginal fascial sling for the treatment of all types of stress urinary incontinence: surgical technique and long-term outcome. *Urol Clin North Am*. 2011;38:7–15.

Blaivas JG, Heritz DM. Vaginal flap reconstruction of the urethra and vesical neck in women: a report of 49 cases. *J Urol*. 1996;155:1014–1017.

Blaivas JG, Jacobs BZ. Pubovaginal fascial sling for the treatment of complicated stress urinary incontinence. *J Urol*.

1991;145:1214–1218.

Blaivas JG, Olsson CA. Stress incontinence: classification and surgical approach. *J Urol*. 1988;139:727–731.

Blaivas JG, Sandhu J. Urethral reconstruction after erosion of slings in women. *Curr Opin Urol*. 2004;14:335–338.

Bobyn JD, Wilson GJ, MacGregor DC, et al. Effect of pore size on the peel strength of attachment of fibrous tissue to porous-surfaced implants. *J Biomed Mater Res*. 1982;571–584.

Bohrer JC, Walters MD, Park A, et al. Pelvic nerve injury following gynecologic surgery: a prospective cohort study. *Am J Obstet Gynecol*. 2009;201:531.e1–531.e7.

Bonnet P, Waltregny D, Reul O, et al. Transobturator vaginal tape inside out for the surgical treatment of female stress urinary incontinence: anatomical considerations. *J Urol*. 2005;173:1223–1228.

Borazjani A, Pizarro-Berdichevsky J, Li J, et al. Surgeons' views on sling tensioning during surgery for female stress urinary incontinence. *Int Urogynecol J*. 2017;28:1489–1495.

Botros SM, Miller JJ, Goldberg RP, et al. Detrusor overactivity and urge urinary incontinence following transobturator versus midurethral slings. *Neurourol Urodyn*. 2007;26:42–45.

Bradley CS, Morgan MA, Arya LA, et al. Vaginal erosion after pubovaginal sling procedures using dermal allografts. *J Urol*. 2003;169:286–287.

Brennand EA, Tang S, Birch C, et al. Calgary Women's Pelvic Health Research Group. Five years after midurethral sling surgery for stress incontinence: obesity continues to have an impact on outcomes. *Int Urogynecol J*. 2017;28:621–628.

Broussard AP, Reddy TG, Frilot CF 2nd, et al. Long-term follow-up of porcine dermis pubovaginal slings. *Int Urogynecol J*. 2013;24:583–587.

Brown SL, Govier FE. Cadaveric versus autologous fascia lata for the pubovaginal sling: surgical outcome and patient satisfaction. *J Urol*. 2000;164:1633–1637.

Brubaker L, Richter HE, Norton PA, et al. Urinary Incontinence Treatment Network. 5-year continence rates, satisfaction and adverse events of burch urethropexy and fascial sling surgery for urinary incontinence. *J Urol*. 2012;187:1324–1330.

Brucker BM, Malacarne DR. Bladder outlet obstruction after incontinence surgery. *Curr Bladder Dysfunct Rep*. 2016;11:45–52.

Cadish LA, Hacker MR, Modest AM, et al. Association between body mass index and pain following transobturator sling. *J Obstet Gynaecol*. 2017;37:766–769.

Callaghan BC, Xia R, Reynolds E, et al. Association between metabolic syndrome components and polyneuropathy in an obese population. *JAMA Neurol*. 2016;73:1468–1476.

Campeau L, Tu LM, Lemieux MC, et al. A multicenter, prospective, randomized clinical trial comparing tension-free vaginal tape surgery and no treatment for the management of stress urinary incontinence in elderly women. *Neurourol Urodyn*. 2007;26:990–994.

Carbone JM, Kavaler E, Hu JC, et al. Pubovaginal sling using cadaveric fascia and bone anchors: disappointing early results. *J Urol*. 2001;165:1605–1611.

Carey J, Leach GE. Transvaginal surgery in the octogenarian using cadaveric fascia for pelvic prolapsed and stress incontinence: minimal one-year results compared to younger patients. *Urology*. 2004;63:665–670.

Carr LK, Webster GD. Voiding dysfunction following incontinence surgery: diagnosis and treatment with retropubic or vaginal urethrolysis. *J Urol*. 1997;157:821–823.

Chaikin DC, Rosenthal J, Blaivas JG. Pubovaginal fascial sling for all types of stress urinary incontinence: long-term analysis. *J Urol*. 1998;160:1312–1316.

Chaliha C, Stanton SL. Complications of surgery for genuine stress incontinence. *Br J Obstet Gynaecol*. 1999;106:1238–1245.

Chancellor MB, Erhard MJ, Kiilholma PJ, et al. Functional urethral closure with pubovaginal sling for destroyed female urethra after long-term urethral catheterization. *Urology*. 1994;43:499–505.

Chang CP, Chang WH, Hsu YM, Task Force on Gyn-Urodynamic Research Group, et al. Comparison of single-incision mini-slings (Ajust) and standard transobturator midurethral slings (Align) in the management of female stress urinary incontinence: a 1-year follow-up. *Taiwan J Obstet Gynecol*. 2015;54:726–730.

Chapple CR, Raz S, Brubaker L, et al. Mesh sling in an era of uncertainty: lessons learned and the way forward. *Eur Urol*. 2013;64:525–529.

Chen CC, Collins SA, Rodgers AK, et al. Perioperative complications in obese women vs. normal-weight women who undergo vaginal surgery. *Am J Obstet Gynecol*. 2007;197:98.e1–98.e8.

Chen HY, Ho M, Hung YC, et al. Analysis of risk factors associated with vaginal erosion after synthetic sling procedures for stress urinary incontinence. *Int Urogynecol J Pelvic Floor Dysfunct*. 2008;19:117–121.

Cheng D, Liu C. Tension-free vaginal tape-obturator in the treatment of stress urinary incontinence: a prospective study with five-year follow-up. *Eur J Obstet Gynecol Reprod Biol*. 2012;161:228–231.

Chin YK, Stanton SL. A follow up of silastic sling for genuine stress incontinence. *Br J Obstet Gynaecol*. 1995;102:143–147.

Choe JM, Bell T. Genetic material is present in cadaveric dermis and cadaveric fascia lata. *J Urol*. 2001;166:122–124.

Choi H, Bae JH, Lee JG. Severe thigh abscess two years after transobturator sling operation. *LUTS*. 2011;3:51–54.

Chou EC, Flisser AJ, Panagopoulos G, et al. Effective treatment for mixed urinary incontinence with a pubovaginal sling. *J Urol*. 2003;170:494–497.

Chughtai B, Buck J, Anger J, et al. Trends and reinterventions in the surgical management of stress urinary incontinence among female Medicare beneficiaries. *Urol Pract*. 2016;3:349–354.

Clemens JQ, DeLancey JO, Faerber GJ, et al. Urinary tract erosions after synthetic pubovaginal slings: diagnosis and management strategy. *Urology*. 2000;56:589–595.

Clemons JL, La Sala CA. The tension-free vaginal tape in women with a nonhypermobile urethra and low maximum urethral closure pressure. *Int Urogynecol J Pelvic Floor Dysfunct*. 2007;18:727–732.

Clifton MM, Linder BJ, Lightner DJ, et al. Risk of repeat anti-incontinence surgery following sling release: a review of 93 patients. *J Urol*. 2014;191(3):710–714.

Connolly TP. Necrotizing surgical site infection after tension-free vaginal tape. *Obstet Gynecol*. 2004;104:1275–1276.

Corton MM. Critical anatomic concepts for safe surgical mesh. *Clin Obstet Gynecol*. 2013;56:247–256.

Crivellaro S, Smith JJ, Kocjancic E, et al. Transvaginal sling using acellular human dermal allograft: safety and efficacy in 253 patients. *J Urol*. 2004;172:1374–1378.

Cross CA, Cespedes RD, McGuire EJ. Treatment results using pubovaginal slings in patients with large cystoceles and stress incontinence. *J Urol*. 1997;158:431–434.

Cross CA, Cespedes RD, English SF, et al. Transvaginal urethrolysis for urethral obstruction after antiincontinence surgery. *J Urol*. 1998;159:1199–1201.

Cross CA, Cespedes RD, McGuire EJ. Our experience with pubovaginal slings in patients with stress urinary incontinence. *J Urol*. 1998;159:1195–1198.

Cummings JM, Rodning CB. Urinary stress incontinence among obese women: review of pathophysiology therapy. *Int Urogynecol J*. 2000;11:41–44.

Dallosso HM, McGrother CW, Matthews RJ, et al. The association of diet and other lifestyle factors with overactive bladder and stress incontinence: a longitudinal study in women. *BJU Int*. 2003;92:69–77.

Daneshgari F, Kong W, Swartz M. Complications of mid urethral slings: important outcomes for future clinical trials. *J Urol*. 2008;180:1890–1897.

Darai E, Jeffry L, Deval B, et al. Results of tension-free vaginal tape in patients with or without vaginal hysterectomy. *Eur J Obstet Gynecol Reprod Biol*. 2002;103:163–167.

Dati S, Rombola P, Cappella S, et al. Single-incision minisling (AJUST) vs obturator tension-free vaginal shortened tape (TVTABBREVO) in surgical management of female stress urinary incontinence. *Int J Gynecol Obstet*. 2012;119:S670.

David-Montefiore E, Frobert JL, Grisard-Anaf M, et al. Peri-operative complications and pain after the suburethral sling procedure for urinary stress incontinence: a French prospective randomized multicenter study comparing the retropubic and transobturator routes. *Eur Urol*. 2006;49:133–138.

de Leval J. Novel surgical technique for the treatment of female stress urinary incontinence: transobturator vaginal tape inside-out. *Eur Urol*. 2003;44:724–730.

de Tayrac R, Deffieux X, Droupy S, et al. A prospective randomized trial comparing tension-free vaginal tape and transobturator suburethral tape for surgical treatment of stress urinary incontinence. *Am J Obstet Gynecol*. 2004;190:602–608.

Deffieux X, Daher N, Mansoor A, et al. Transobturator TVT-O versus retropubic TVT: results of a multicenter randomized controlled trial at 24 months follow-up. *Int Urogynecol J*. 2010;21:1337–1345.

Defreitas G, Herschorn S. Unilateral pubovaginal sling release: a minimally invasive transvaginal approach. *J Urol*. 2000;163(Suppl):74.

DeLancey JO. Structural support of the urethra as it relates to stress urinary incontinence: the hammock hypothesis. *Am J Obstet Gynecol*. 1994;170:1713–1723.

Dell J, O'Kelley K. TVT erosion secondary to a twist in tape. *Int Urogynecol J Pelvic Floor Dysfunct*. 2005;16:168–169.

Delmas V, Hermieu J, Dompeyre P, et al. The UraTape transobturator sling in the treatment of female stress urinary incontinence: mechanism of action. *Eur Urol*. 2003;196.

Delorme E, Droupy S, de Tayrac R, et al. Transobturator tape (UraTape). A new minimally invasive method in the treatment of urinary incontinence in women. *Prog Urol*. 2003;13:656–659.

Delorme E. Transobturator urethral suspension: mini-invasive procedure in the treatment of stress urinary incontinence in women. *Prog Urol*. 2001;11:1306–1313.

Deming CL. Transplantation of the gracilis muscle for incontinence of urine. *JAMA*. 1926;86:822.

Demirkesen O, Onal B, Tunc B, et al. Ceinele B. Does vaginal anti-incontinence surgery affect sexual satisfaction? A comparison of TVT and Burch-colposuspension. *Int Braz J Urol*. 2008;34:214–219.

Deng DY, Rutman M, Raz S, et al. Presentation and management of major complications of midurethral slings: are complications under-reported? *Neurourol Urodyn*. 2007;26:46–52.

Descurtins M, Buchmann P. Bovine pericardium—a new graft material for hernia repair [author's transl]. *Res Exp Med*

(Berl). 1982;180:11–14.

DeSouza R, Shapiro A, Westney OL. Adductor brevis myositis following transobturator tape procedure: a case report and review of the literature. *Int Urogynecol J Pelvic Floor Dysfunct*. 2007;18:817–820.

Deval B, Ferchaux J, Berry R, et al. Objective and subjective cure rates after trans-obturator tape (ObTape) treatment of female urinary incontinence. *Eur Urol*. 2006;49:373–377.

Dietz H, Vancaillie P, Svehla M, et al. Mechanical properties of urogynecologic implant materials. *Int Urogynecol J Pelvic Floor Dysfunct*. 2003;14:239–243.

Dietz HP, Vancaille P, Svehla M, et al. *Mechanical properties of implant materials used in incontinence surgery*. [Proceedings of the International Continence Society 31st Annual Meeting. Seoul, South Korea] 2001.

Dietz HP, Wilson PD. The “iris effect”: how two-dimensional and three-dimensional ultrasound can help us understand anti-incontinence procedure. *Ultrasound Obstet Gynecol*. 2004;23:267.

Dillon BE, Gurbuz C, Zimmern PE. Long term results after complication of “prophylactic” suburethral tape placement. *Can J Urol*. 2012;19:6424–6430.

Dmochowski RR, Grier D, Franco N. One year results from a world-wide registry of TVT-Secur in women with stress urinary incontinence. *J Urol*. 2009 [Annual Meeting abstract 181, 544 (abstract 1520)].

Dobson A, Robert M, Swaby C, et al. Trans-obturator surgery for stress urinary incontinence: 1-year follow-up of a cohort of 52 women. *Int Urogynecol J Pelvic Floor Dysfunct*. 2007;18:27–32.

Domingo S, Alama P, Ruiz N, et al. Diagnosis, management and prognosis of vaginal erosion after transobturator suburethral tape procedure using a nonwoven thermally bonded polypropylene mesh. *J Urol*. 2005;173:1627–1630.

Doo CK, Hong B, Chung BJ, et al. Five-year outcomes of the tension-free vaginal tape procedure for treatment of female stress urinary incontinence. *Eur Urol*. 2006;50:333–338.

Dora CD, Dimarco DS, Zobitz ME, et al. Time dependent variations in biomechanical properties of cadaveric fascia, porcine dermis, porcine small intestine submucosa, polypropylene mesh, and autologous fascia in the rabbit model. *J Urol*. 2004;171:1970–1973.

Drutz HP, Buckspan M, Flax S, et al. Clinical and urodynamic re-evaluation of combined abdominovaginal Marlex sling operations for recurrent stress urinary incontinence. *Int Urogynecol J*. 1990;1:70–73.

Dubiel WT, Wigren A. Functional status of the lower extremity after resection of fascia lata. A clinical and physiological follow-up study in patients with fascia lata heart valve replacement. *Acta Orthop Scand*. 1974;45:599–613.

Duckett J, Aggarwal I, Patil A, et al. Effect of tension-free vaginal tape position on the resolution of irritative bladder symptoms in women with mixed incontinence. *Int Urogynecol J Pelvic Floor Dysfunct*. 2008;19:237–239.

Duckett J, Basu M. The predictive value of preoperative pressure-flow studies in the resolution of detrusor overactivity and overactive bladder after tension-free vaginal tape insertion. *BJU Int*. 2007;99:1439–1442.

Duckett JR, Constantine G. Complications of silicone insertion for stress urinary incontinence. *J Urol*. 2000;163:1835–1837.

Duckett JR, Jain S. Groin pain after a tension-free vaginal tape or similar suburethral sling: management strategies. *BJU Int*. 2005;95:95–97.

Dumoulin C, Hay-Smith J, Frawley H, International Continence Society, et al. 2014 consensus statement on improving pelvic floor muscle training adherence: International Continence

Society 2011 State-of-the-Science Seminar. *Neurourol Urodyn*. 2015;34:600–605.

Dumoulin C, Hay-Smith EJ, Mac Habée-Séguin G, et al. Pelvic floor muscle training versus no treatment, or inactive control treatments, for urinary incontinence in women: a short version Cochrane systematic review with meta-analysis. *Neurourol Urodyn*. 2015;34:300–308.

Dunivan GC, Connolly A, Jannelli ML, et al. Body mass index as a risk factor for cystotomy during suprapubic placement of mid-urethral slings. *Int Urogynecol J Pelvic Floor Dysfunct*. 2009;20:1127–1131.

Dwyer NT, Kreder KJ. Fascia lata sling. Raz S, Rodriguez LV. *Female urology*. ed 3. Saunders: Philadelphia; 2008:409–410.

El-Barky E, El-Shazly A, El-Wahab OA, et al. Tension free vaginal tape versus Burch colposuspension for treatment of female stress urinary incontinence. *Int Urol Nephrol*. 2005;37:277–281.

Elliott DS, Boone TB. Is fascia lata allograft material trustworthy for pubovaginal sling repair? *Urology*. 2000;56:772–776.

Enhorning G. Simultaneous recording of the intravesical and intraurethral pressure. *Acta Obstet Gynecol Scand*. 1961;276:1–69.

Faerber GJ. Urethral diverticulectomy and pubovaginal sling for simultaneous treatment of urethral diverticulum and intrinsic sphincter deficiency. *Tech Urol*. 1998;4:192–197.

FitzGerald ML, Brubaker L. The etiology of urinary retention after surgery for genuine stress incontinence. *Neurourol Urodyn*. 2001;20:13.

Fitzgerald MP, Mollenhauer J, Brubaker L. Failure of allograft suburethral slings. *BJU Int*. 1999;84:785–788.

Fitzgerald MP, Mollenhauer J, Brubaker L. The fate of rectus fascia suburethral slings. *Am J Obstet Gynecol*.

2000;183:964–966.

Flisser AJ, Blaivas JG. Outcome of urethral reconstruction surgery in series of 74 women. *J Urol*. 2003;169:2246–2249.

Flock F, Reich A, Muche R, et al. Hemorrhagic complications associated with tension-free vaginal tape procedure. *Obstet Gynecol*. 2004;104:989–994.

Flynn BJ, Yap WT. Pubovaginal sling using allograft fascia lata versus autograft fascia for all types of stress urinary incontinence: 2-year minimum follow-up. *J Urol*. 2002;167:608–612.

Foley C, Patki P, Boustead G. Unrecognized bladder perforation with mid-urethral slings. *BJU Int*. 2010;106:1514–1518.

Foote AJ, Maughan V, Carne C. Laparoscopic colposuspension versus vaginal suburethral slingplasty: a randomised prospective trial. *Aust N Z J Obstet Gynaecol*. 2006;46:517–520.

Ford AA, Ogah JA. Retropubic or transobturator mid-urethral slings for intrinsic sphincter deficiency-related stress urinary incontinence in women: a systematic review and meta-analysis. *Int Urogynecol J*. 2016;27:19–28.

Ford AA, Rogerson L, Cody JD, et al. Mid-urethral sling operations for stress urinary incontinence in women. *Cochrane Database Syst Rev*. 2017;(7) [CD006375].

Forrest J, Clemens J, Finamore P, et al. AUA best practice policy statement for the prevention of deep venous thrombosis in patients undergoing urologic surgery. *J Urol*. 2009;3:1170–1177 [Available from:] https://www.jurology.com/doi/full/10.1016/j.juro.2008.12.027

Foster HE, McGuire EJ. Management of urethral obstruction with transvaginal urethrolysis. *J Urol*. 1993;150:1448–1551.

Frangenheim P. Zur operative Behaundlung der Inkontinenz der Mannlichen Harnohre. *Verh Dtsch Ges Chir*. 1914;43:149–158.

Frederick RW, Leach GE. Cadaveric prolapsed repair with sling: intermediate outcomes with 6 months to 5 years of followup. *J Urol*. 2005;173:1229–1233.

Fritel X, Fauconnier A, Pigne A. Circumstances of leakage related to low urethral closure pressure. *J Urol*. 2008;180:223–226.

Fritel X, Zabak K, Pigne A, et al. Predictive value of urethral mobility before suburethral tape procedure for urinary stress incontinence in women. *J Urol*. 2002;168:2472–2475.

Fulford SC, Flynn R, Barrington J, et al. An assessment of the surgical outcome and urodynamic effects of the pubovaginal sling for stress incontinence and the associated urge syndrome. *J Urol*. 1999;162:135–137.

Fuselier A, Hanberry J, Lovin JM, et al. Obesity and stress urinary incontinence: impact on pathophysiology and treatment. *Curr Urol Rep*. 2018;19:10.

Gaddi A, Guaderrama N. Bassioni N. Repeat midurethral sling compared with urethral bulking for recurrent stress urinary incontinence. *Obstet Gynecol*. 2014;123:1207–1212.

Gallantine ML, Cespedes RD. Review of cadaveric allografts in urology. *Urology*. 2002;59:318.

Gallup DG, Freedman MA, Meguiar RV, et al. Necrotizing fasciitis in gynecologic and obstetric patients: a surgical emergency. *Am J Obstet Gynecol*. 2002;187:305–310.

Gamble TL, Botros SM, Beaumont JL, et al. Predictors of persistent detrusor overactivity after transvaginal sling procedures. *Am J Obstet Gynecol*. 2008;199:696.e1–696.e7.

Gamé X, Mouzin M, Vaessen C, et al. Obturator infected hematoma and urethral erosion following transobturator tape implantation. *J Urol*. 2004;171:1629.

Gamé X, Soulié M, Malavaud B, et al. Treatment of bladder outlet obstruction secondary to suburethral tape by section of the tape. *Prog Urol*. 2006;16:67–71.

Gateau T, Faramarzi-Roques R, Le Normand L, et al. Clinical and urodynamic repercussions after TVT procedure and how to diminish patient complaints. *Eur Urol*. 2003;44:372–376.

Ghezzi F, Serati M, Cromi A, et al. Tension-free vaginal tape for the treatment of urodynamic stress incontinence with intrinsic sphincter deficiency. *Int Urogynecol J*. 2006;17:335–339.

Ghoniem GH, Elgamasy A. Simplified surgical approach to bladder outlet obstruction following pubovaginal sling. *J Urol*. 1995;154:181–183.

Ghoniem GH, Hassouna ME. Bladder neck prop using vaginal wall island for intrinsic sphincteric deficiency in elderly patients: a new technique. *Urology*. 1998;52:668–671.

Ghoniem GM. Modified pubovaginal sling for treatment of complicated stress urinary incontinence in females. *AUA Today*. 1991;4:5.

Giberti C, Gallo F, Cortese P, et al. Transobturator tape for treatment of female stress urinary incontinence: objective and subjective results after a mean follow-up of two years. *Urology*. 2007;69:703–707.

Giri SK, Drumm J, Saunders JA, et al. Day-case sling surgery for stress urinary incontinence: feasibility and safety. *BJU Int*. 2005;95:827–832.

Giri SK, Hickey JP, Sil D, et al. The long-term results of pubovaginal sling surgery using acellular cross-linked porcine dermis in the treatment of urodynamic stress incontinence. *J Urol*. 2006;175:1788–1793.

Giri SK, Sil D, Narasimhulu G, et al. Management of vaginal extrusion after tension-free vaginal tape procedure for urodynamics stress incontinence. *Urology*. 2007;69:1077–1080.

Glavind K, Glavind E. Treatment of prolonged voiding dysfunction after tension-free vaginal tape procedure. *Acta Obstet Gynecol Scand*. 2007;86:357–360.

Glavind K, Sander P. Erosion, defective healing and extrusion after tension-free urethropexy for the treatment of stress urinary incontinence. *Int Urogynecol J Pelvic Floor Dysfunct*. 2004;15:179–182.

Goebel R. Zur operativen beseitigung der angeborenen incontinenz vesicae. *Ztsch Gynakol Urol*. 1910;2:187–191.

Goldman HB, Rackley RR, Appell RA. The efficacy of urethrolysis without re-suspension for iatrogenic urethral obstruction. *J Urol*. 1999;161:1268–1271.

Goldman HB. Large thigh abscess after placement of synthetic transobturator sling. *Int Urogynecol J Pelvic Floor Dysfunct*. 2006;17:295–296.

Goldman HB. Simple sling incision for the treatment of iatrogenic urethral obstruction. *Urology*. 2003;62:713–718.

Golomb J, Groutz A, Mor Y, et al. Management of urethral erosion caused by a pubovaginal fascial sling. *Urology*. 2001;57:159–160.

Gomelsky A, Scarpero HM, Dmochowski RR. Sling surgery for stress urinary incontinence in the female: what surgery, which material? *AUA Update Ser*. 2003;267–275.

Gordon D, Gold R, Pauzner D, et al. Tension-free vaginal tape in the elderly: is it a safe procedure? *Urology*. 2005;65:479–482.

Gordon D, Gold RS, Pauzner D, et al. Combined genitourinary prolapse repair and prophylactic tension-free vaginal tape in women with severe prolapse and occult stress urinary incontinence: preliminary results. *Urology*. 2001;58:547–550.

Gormley EA, Bloom DA, McGuire EJ, et al. Pubovaginal slings for management of urinary incontinence in female adolescents. *J Urol*. 1994;152:822–825.

Govier FE, Gibbons RP, Correa RJ, et al. Pubovaginal slings using fascia lata for the treatment of intrinsic sphincter deficiency. *J Urol*. 1997;157:117–121.

Grigoriadis C, Bakas P, Derpapas A, et al. Tension-free vaginal tape obturator versus Ajust adjustable single incision sling procedure in women with urodynamic stress urinary incontinence. *Eur J Obstet Gynecol Reprod Biol*. 2013;170:563–566.

Groutz A, Blaivas JG, Hyman MJ, et al. Pubovaginal sling surgery for simple stress urinary incontinence: analysis by an outcome score. *J Urol*. 2001;165:1597–1600.

Groutz A, Gold R, Pauzner D, et al. Tension-free vaginal tape (TVT) for the treatment of occult stress urinary incontinence in women undergoing prolapse repair: a prospective study of 100 consecutive cases. *Neurourol Urodyn*. 2004;23:632–635.

Groutz A, Rosen G, Cohen A, et al. Ten-year subjective outcome results of the retropubic tension-free vaginal tape for treatment of stress urinary incontinence. *J Minim Invasive Gynecol*. 2011;18:726–729.

Groutz A, Rosen G, Gold R, et al. Long-term outcome results of the inside-out transobturator tension-free vaginal tape: efficacy and risk factors for surgical failure. *J Womens Health (Larchmt)*. 2011;20:1525–1528.

Gutierrez Banos JL, Martin Garcia B, Portillo Martin JA, et al. Usefulness of abdominal leak point pressure determination in the diagnosis of female urinary incontinence in the TVT era]. *Actas Urol Esp*. 2004;28:506–512.

Haab F, Trockman BA, Zimmern PE, et al. Results of pubovaginal sling for the treatment of intrinsic sphincter deficiency determined by questionnaire analysis. *J Urol*. 1997;1738–1741.

Haferkamp A, Steiner G, Muller S, et al. Urethral erosion of tension-free vaginal tape. *J Urol*. 2002;167:250.

Haliloglu B, Karateke A, Coksuer H, et al. The role of urethral hypermobility and intrinsic sphincteric deficiency on the outcome of transobturator tape procedure: a prospective study with 2-year follow-up. *Int Urogynecol J*. 2010;21:173–178.

Hammad FT, Kennedy-Smith A, Robinson RG. Erosions and urinary retention following polypropylene synthetic sling: Australasian survey. *Eurn Urol*. 2005;47:641–647.

Han JY, Park J, Choo MS. Efficacy of TVT-Secur and factors affecting cure of female stress urinary incontinence: 3-year follow-up. *Int Urogynecol J*. 2012;23:1721–1726.

Handa V, Jensen JK, Germain MM, et al. Banked human fascia lata for suburethral sling procedure: a preliminary report. *Obstet Gynecol*. 1996;88:1045–1049.

Handa V, Stone A. Erosion of a fascial sling into the urethra. *Urology*. 1999;54:923.

Hassouna ME, Ghoniem GM. Long-term outcome and quality of life after modified pubovaginal sling for intrinsic sphincteric deficiency. *Urology*. 1999;53:287–291.

Hathaway JK, Choe JM. Intact genetic material is present in commercially processed cadaveric allografts used for pubovaginal slings. *J Urol*. 2002;168:1040–1043.

Haylen BT, Freeman RM, Swift SE, et al. An International Urogynecological Association (IUGA)/International Continence Society (ICS) joint terminology and classification of the complications related directly to the insertion of prostheses (meshes, implants, tapes) and grafts in female pelvic floor surgery. *Neurourol Urodyn*. 2011;30:2–12.

Heliövaara M. Body height, obesity, and risk of herniated lumbar intervertebral disc. *Spine*. 1987;12:469–472.

Hellberg D, Holmgren C, Lanner L, et al. The very obese women and the very old women: tension-free vaginal tape for the treatment of stress urinary incontinence. *Int Urogynecol J*. 2007;18:423–429.

Hinoul P, Vervest HA, den Boon J, et al. A randomized, controlled trial comparing an innovative single incision sling with an established transobturator sling to treat female stress urinary incontinence. *J Urol*. 2011;185:1356–1362.

Hinton R, Jinnah RH, Johnson C, et al. A biomechanical analysis of solvent-dehydrated and freeze dried human fascia lata allograft. A preliminary report. *Am J Sports Med*. 1992;20:607–612.

Ho KL, Witte M, Bird ET. 8-ply small intestinal submucosa tension-free sling: spectrum of postoperative inflammation. *J Urol*. 2004;171:268–271.

Hodgkinson CP, Kelly WT. Urinary stress incontinence in the female. Round ligament technic for retropubic suspension of the urethra. *Obst Gynec*. 1957;10:493.

Hodroff M, Portis A, Siegel S. Endoscopic removal of intravesical polypropylene sling with the holmium laser. *J Urol*. 2004;172:1361–1362.

Holmgren C, Nilsson S, Lanner L, et al. Long term results with tension-free vaginal tape on mixed and stress urinary incontinence. *Obstet Gynecol*. 2005;106:38–43.

Holstead JP, Williams BJ, Gomelsky A. Long term follow up of bovine dermis pubovaginal slings. *Can J Urol*. 2013;20:6721–6725.

Hong B, Park S, Kim HS, et al. Factors predictive of urinary retention after a tension-free vaginal tape procedure for female stress urinary incontinence. *J Urol*. 2003;170:852–856.

Howden NS, Zyczynski HM, Moalli PA, et al. Comparison of autologous rectus fascia and cadaveric fascia in pubovaginal sling continence outcomes. *Am J Obstet Gynecol*. 2006;194:1444–1449.

Huang KH, Kung FT, Liang HM, et al. Concomitant surgery with tension-free vaginal tape. *Acta Obstet Gynecol Scand*. 2003;82:948–953.

Huang KH, Kung FT, Liang HM, et al. Management of polypropylene mesh erosion after intravaginal midurethral sling operation for female stress urinary incontinence. *Int Urogynecol J Pelvic Floor Dysfunct*. 2005;16:437–440.

Huang WC, Yang JM. Bladder neck funneling on ultrasound cystourethrography in primary stress urinary incontinence: a sign associated with urethral hypermobility and intrinsic sphincter deficiency. *Urology*. 2003;61:936–941.

Huang Y, Lin AT, Chen K, et al. High failure rate using allograft fascia lata in pubovaginal sling surgery for female stress urinary incontinence. *Urology*. 2001;58:943–946.

Hubka P, Masata J, Nanka O, et al. Anatomical relationship and fixation of tension-free vaginal tape Secur. *Int Urogynecol J Pelvic Floor Dysfunct*. 2009;20:681–688.

Huwyler M, Springer J, Kessler TM, et al. A safe and simple solution for intravesical tension-free vaginal tape erosion: removal by standard transurethral resection. *BJU Int*. 2008;102:582–585.

Ingelman-Sundberg A. Urinary incontinence in women. *Nord Med*. 1953;50:1149–1152.

Iosif CS. Porcine corium sling in the treatment of urinary stress incontinence. *Arch Gynecol*. 1987;240:131–136.

Irer B, Aslan G, Cimen S, et al. Development of vesical calculi following tension-free vaginal tape procedure. *Int Urogynecol J Pelvic Floor Dysfunct*. 2005;16:245–246.

Jarvis GJ. Surgery for genuine stress incontinence. *Br J Obstet Gynecol*. 1994;101:371–374.

Jeffcoate TN. The results of the Aldridge sling operation for stress incontinence. *J Obstet Gynaecol Br Emp*. 1956;63(1):36–39.

Jeffry L, Deval B, Birsan A, et al. Objective and subjective cure rates after tension-free vaginal tape for treatment of urinary incontinence. *J Urol*. 2002;58:702–706.

Jha S, Jones G, Radley S, et al. Factors influencing outcome following the tension-free vaginal tape (TVT). *Eur J Obstet*

Gynecol Reprod Biol. 2009;144:85–87.

Jo DJ, Lee YS, Oh TH, et al. Outcomes of transurethral removal of intravesical or intraurethral mesh following midurethral sling surgery. *Korean J Urol*. 2011;52:829–834.

John TT, Aggarwl N, Singla AK, et al. Intense inflammatory reaction with porcine small intestine submucosa pubovaginal sling or tape for stress urinary incontinence. *Urology*. 2008;72:1036–1039.

Jomaa M. Combined tension-free vaginal tape and prolapse repair under local anaesthesia in patients with symptoms of both urinary incontinence and prolapse. *Gynecol Obstet Invest*. 2001;51:184–186.

Jonsson Funk M, Levin PJ, Wu JM. Trends in the surgical management of stress urinary incontinence. *Obstet Gynecol*. 2012;119:845–851.

Jonsson Funk M, Siddiqui NY, Pate V, et al. Sling revision/removal for mesh erosion and urinary retention: long-term risk and predictors. *Am J Obstet Gynecol*. 2013;208:73.e1–73.e7.

Jorion J. Endoscopic treatment of bladder perforation after tension-free vaginal tape procedure. *J Urol*. 2002;168:197.

Juma S, Brito CG. Transobturator (TOT): two years follow-up. *Neurourol Urodyn*. 2007;26:37–41.

Kalota SJ. Small intestinal submucosa tension-free sling: postoperative inflammatory reactions and additional data. *J Urol*. 2004;172:1349–1350.

Karateke A, Haliloglu B, Cam C, et al. Comparison of TVT and TVT-O in patients with stress urinary incontinence: short-term cure rates and factors influencing the outcome. A prospective randomised study. *Aust N Z J Obstet Gynaecol*. 2009;49:99–105.

Karram M, Segal J, Vassallo BJ, et al. Complications and untoward effects of the tension-free vaginal tape procedure.

Obstet Gynecol. 2003;101:929–932.

Karram MM, Bhatia NN. Patch procedure: modified transvaginal fascia lata sling for recurrent or severe stress urinary incontinence. *Obstet Gynecol*. 1990;75:461–463.

Karsenty G, Boman J, Elzayat E, et al. Severe soft tissue infection of the thigh after vaginal erosion of transobturator tape for stress urinary incontinence. *Int Urogynecol J Pelvic Floor Dysfunct*. 2007;18:207–212.

Kasdon SC. Use of uterine ligament in repair of stress urinary incontinence. *Urol Cutan Rev*. 1951;55:597–601.

Kawashima H, Hirai K, Okada N, et al. The importance of studying pressure-flow for predicting postoperative voiding difficulties in women with stress urinary incontinence: a preliminary study that correlates low Pdet × Qave with postoperative residual urine. *Urol Res*. 2004;32:84–88.

Kenton K, Richter H, Litman H, et al. Urinary Incontinence Treatment Network. Risk factors associated with urge incontinence after continence surgery. *J Urol*. 2009;182:2805–2809.

Kenton K, Stoddard AM, Zyczynski H, et al. 5-Year longitudinal followup after retropubic and transobturator mid urethral slings. *J Urol*. 2015;193:203–210.

Khan ZA, Nambiar A, Morley R, et al. Long-term follow-up of a multicentre randomised controlled trial comparing tension-free vaginal tape, xenograft and autologous fascial slings for the treatment of stress urinary incontinence in women. *BJU Int*. 2015;115:968–977.

Kim HG, Park HK, Paick SH, et al. Comparison of effectiveness between tension-free vaginal tape (TVT) and trans-obturator tape (TOT) in patients with stress urinary incontinence and intrinsic sphincter deficiency. *PLoS ONE*. 2016;11:e0156306.

Kim YW, Na YG, Sul CK. Randomized prospective study between pubovaginal sling using SPARC sling system and MONARC sling system for the treatment of female stress urinary incontinence: short term results. *Korean J Urol*. 2005;46:1078–1082.

King AB, Goldman HB. Current controversies regarding oncologic risk associated with polypropylene midurethral slings. *Curr Urol Opin*. 2014;15:453.

King AB, Zampini A, Vasavada S, et al. Is there an association between polypropylene midurethral slings and malignancy. *Urology*. 2014;84:789–792.

Kirchin V, Page T, Keegan PE, et al. Urethral injection therapy for urinary incontinence in women. *Cochrane Database Syst Rev*. 2017;(7) [CD003881].

Klutke C, Siegel S, Carlin B, et al. Urinary retention after tension-free vaginal tape procedure: incidence and treatment. *Urology*. 2001;58:697–701.

Kobashi KC, Albo ME, Dmochowski RR, et al. Surgical treatment of female stress urinary incontinence: AUA/SUFU guideline. *J Urol*. 2017;198:875–883.

Kobashi KC, Dmochowski R, Mee SL, et al. Erosion of woven polyester pubovaginal sling. *J Urol*. 1999;162:2070–2072.

Kobashi KC, Govier F. Management of vaginal erosion of polypropylene mesh slings. *J Urol*. 2003;169:2242–2243.

Kobashi KC, Leach GE, Chon J, et al. Continued multicenter followup of cadaveric prolapse repair with sling. *J Urol*. 2002;168:2063–2068.

Kociszewski J, Rautenberg O, Perucchini D, et al. Tape functionality: sonographic tape characteristics and outcome after TVT incontinence surgery. *Neurourol Urodyn*. 2008;27:485–490.

Konig JE, Pannek J, Martin W, et al. Severe postoperative inflammation following implantation of a Sratatsis sling. *Urologe A*. 2004;43:1541–1543.

Kowalik CG, Cohn JA, Kakos A, et al. Road to recovery after transvaginal surgery for urethral mesh perforation: evaluation of outcomes and subsequent procedures. *Int Urogynecol J*. 2018;29(6):887–892.

Kraatz H. Use of nylon sling in urinary incontinence. *Zentralbl Gynakol*. 1953;75:1486–1487.

Krauth JS, Rasoamiaramanana H, Barletta H, et al. Sub-urethral tape treatment of female urinary incontinence—morbidity assessment of the trans-obturator route and a new tape (I-STOP): a multi-centre experiment involving 604 cases. *Eur Urol*. 2005;47:102–107.

Kubricht WS, Williams J, Eastham JA, et al. Tensile strength of cadaveric fascia lata compared to small intestinal submucosa using suture pull through analysis. *J Urol*. 2001;165:486–490.

Kuhn A, Burkhard F, Eggemann C, et al. Sexual function after suburethral sling removal for dyspareunia. *Surg Endosc*. 2009;23:765–768.

Kuhn A, Eggeman C, Burkhard F, et al. Correction of erosion after suburethral sling insertion for stress incontinence: results and related sexual function. *Eur Urol*. 2009;5:371–377.

Kulseng-Hanssen S, Husby H, Schiotz HA. Follow-up of TVT operations in 1,113 women with mixed urinary incontinence at 7 and 38 months. *Int Urogynecol J Pelvic Floor Dysfunct*. 2008;19:391–396.

Kuru M. Nervous control of micturition. *Physiol Rev*. 1965;45:425–494.

Kusuda L. Simple release of pubovaginal sling. *Urology*. 2001;57:358–359.

Kuuva N, Nilsson C. A nationwide analysis of complications associated with the tension-free vaginal tape (TVT) procedure. *Acta Obstet Gynecol Scand*. 2002;81:72–77.

Kuuva N, Nilsson C. Tension-free vaginal tape procedure: an effective minimally invasive operation for the treatment of recurrent stress urinary incontinence? *Gynecol Obstet Invest*. 2003;56:93–98.

Lane B, Singh D, Meraney A, et al. Novel endourologic applications for holmium laser. *Urology*. 2005;65:991–993.

Lapouge O, Bram R, Hocke C, et al. Management of erosive complications after tension-free vaginal tape procedure]. *Prog Urol*. 2009;19(3):193–201.

Latini JM, Lux MM, Kreder KJ. Efficacy and morbidity of autologous fascia lata sling cystourethropexy. *J Urol*. 2004;171:1180–1184.

Laurikainen E, Killholma P. A nationwide analysis of transvaginal tape release for urinary retention after tension-free vaginal tape procedure. *Int Urogynecol J*. 2006;17:111–119.

Laurikainen E, Killholma P. The tension-free vaginal tape procedure for female urinary incontinence without preoperative urodynamic evaluation. *J Am Coll Surg*. 2003;196:579–583.

Laurikainen E, Valpas A, Aukee P. Five-year results of a randomized trial comparing retropubic and transobturator midurethral slings for stress incontinence. *Eur Urol*. 2014;65:1109–1114.

Laurikainen E, Valpas A, Kivelä A, et al. Retropubic compared with transobturator tape placement in treatment of urinary incontinence: a randomized controlled trial. *Obstet Gynecol*. 2007;109:4–11.

Leach G, Dmochowski R, Appell R, et al. Female Stress Urinary Incontinence Clinical Guidelines Panel summary report on surgical management of female stress urinary incontinence. The American Urological Association. *J Urol*. 1997;158:875–880.

Leanza V, Garozzo V, Accardi M, et al. A late complication of transobturator tape procedures: abscess and myositis. *Minerva Ginecol*. 2008;60:91–94.

Lee D, Murray S, Bacsu CD, et al. Long-term outcomes of autologous pubovaginal fascia slings: is there a difference between primary and secondary slings? *Neurourol Urodyn*. 2015;34:18–23.

Lee JH, Yoon JH, Lee SJ, et al. Modified transobturator tape (canal transobturator tape) surgery for female stress urinary incontinence. *J Urol*. 2009;181:2616–2621.

Lee KS, Chin KD, Deok HH, et al. Outcomes following repeat mid urethral synthetic sling after failure of the initial sling procedure: rediscovery of the tension-free vaginal tape procedure. *J Urol*. 2007;178:1370–1374.

Lee KS, Han DH, Choi YS, et al. A prospective trial comparing tension-free vaginal tape and transobturator vaginal tape inside-out for the surgical treatment of female stress urinary incontinence: 1-year follow-up. *J Urol*. 2007;177:214–218.

Lemack GE, Krauss S, Litman H, et al. Normal postoperative urodynamic testing does not predict voiding dysfunction after Burch colposuspension versus pubovaginal sling. *J Urol*. 2008;180:2076–2080.

Lemer ML, Chaikin DC, Blaivas JG. Tissue strength analysis of autologous and cadaveric allografts for the pubovaginal sling. *Neurourol Urodyn*. 1999;18:497–503.

Leng WW, McGuire EJ. Management of female urethral diverticula: a new classification. *J Urol*. 1998;160:1297–1300.

Leron E, Steiner N, Peri Z, et al. Long term follow-up and prevalence of persistent, de novo and improvement of overactive bladder symptoms after tension free vaginal tape. *Int Urogynecol J*. 2009;20 [34th Annual IUGA Meeting, abstract 132 (S186–S187)].

Levin I, Groutz A, Gold R, et al. Surgical complications and medium-term outcome results of tension-free vaginal tape: a prospective study of 313 consecutive patients. *Neurourol Urodyn*. 2004;23:7–9.

Liapis A, Bakas P, Christopoulos P, et al. Tension-free vaginal tape for elderly women with stress urinary incontinence. *Int J Gynaecol Obstet*. 2006;92:48–51.

Liapis A, Bakas P, Creatsas G. Burch colposuspension and tension-free vaginal tape in the management of stress urinary incontinence in women. *Eur Urol*. 2002;41:469–473.

Lieb J, Das A. Urethral erosion of tension-free vaginal tape. *Scand J Urol Nephrol*. 2003;37:184–185.

Lim JL, Cornish A, Carey MP. Clinical and quality-of-life outcomes in women treated by the TVT-O procedure. *BJOG*. 2006;113:1315–1320.

Lim YN, Muller R, Corstiaans A, et al. Suburethral slingplasty evaluation study in North Queensland, Australia: the SUSPEND trial. *Aust N Z J Obstet Gynaecol*. 2005;45:52–59.

Linder BJ, Trabuco EC, Carranza DA, et al. Evaluation of the local carcinogenic potential of mesh used in the treatment of female stress urinary incontinence. *Int Urogynecol J*. 2016;27:1333–1336.

Lo T, Horng S, Chang C, et al. Tension-free vaginal tape procedure after previous failure in incontinence surgery. *Urology*. 2002;60:57–61.

Lo TS, Wang A, Horng S, et al. Ultrasonographic and urodynamic evaluation after tension free vagina tape procedure (TVT). *Acta Obstet Gynecol Scand*. 2001;80:65–70.

Long C, Lo T, Liu CM, et al. Lateral excision of tension-free vaginal tape for the treatment of iatrogenic urethral obstruction. *Obstet Gynecol*. 2004;104:1270–1274.

Long CY, Hsu CS, Wu MP, et al. Comparison of tension-free vaginal tape and transobturator tape procedure for the treatment of stress urinary incontinence. *Curr Opin Obstet Gynecol*. 2009;21:342–347.

Lord HE, Taylor JD, Finn JC, et al. A randomized controlled equivalence trial of short-term complications and efficacy of tension-free vaginal tape and suprapubic urethral support sling for treating stress incontinence. *BJU Int*. 2006;98:367–376.

Loughlin KR. Epithelial inclusion cyst formation after free vaginal wall swing sling procedure for stress urinary incontinence. *J Urol*. 1998;159:208.

Lucas MG, Bosch RJ, Burkhard FC. at al; European Association of Urology. EAU guidelines on surgical treatment of urinary incontinence. *Actas Urol Esp*. 2013;37:459–472.

Madjar S, Tchetgen M, Van Antwerp A, et al. Urethral erosion of tension-free vaginal tape. *Urology*. 2002;59:601.

Mahajan ST, Kenton K, Bova DA, et al. Transobturator tape erosion associated with leg pain. *Int Urogynecol J Pelvic Floor Dysfunct*. 2006;17:66–68.

Maher C, Baessler K, Glazener CM, et al. Surgical management of pelvic organ prolapsed in women: a short version Cochrane review. *Neurourol Urodyn*. 2008;27:3–12.

Maher C, Feiner B, Baessler K, et al. Surgical management of pelvic organ prolapse in women. *Cochrane Database Syst Rev*. 2013;(4) [CD004014].

Mahmoud M, Wadie BS. Bladder erosion of tension-free vaginal tape presented as vesical stone; management and review of literature. *Int Urol Nephrol*. 2007;39:453–455.

Mansoor A, Vedrine N, Darcq C. Surgery of female urinary incontinence using trans-obturator tape (TOT): a prospective randomized comparative study with TVT. *Neurourol Urodyn*. 2003;22:488–489.

Marszalek M, Roehlich M, Racz U, et al. Sexual function after tension-free vaginal tape procedure. *Urol Int*. 2007;78:126–129.

Martan A, Svabik K, Masata J, et al. Correlation between changes in ultrasound measurements and clinical curative effect of tension-free vaginal tape-SECUR procedure. *Int Urogynecol J Pelvic Floor Dysfunct*. 2009;20:533–539.

Martius H. Sphincter-und Harnrohrnplastik aus dem Musculus Bulbocavernosus. *Chirurg*. 1929;1:769.

Masata J, Martan A, Svabik K, et al. Ultrasound imaging of the lower urinary tract after successful tension-free vaginal tape (TVT) procedure. *Ultrasound Obstet Gynecol*. 2006;28:221.

Masata J, Svabik K, Hubka P, et al. Comparison of the safety and peri-operative complications of transobturator introduced tension-free vaginal tape (TVT-O) and single-incision tape with adjustable length and anchoring mechanism (Ajust) in a randomized trial: short-term results. *Int Urogynecol J*. 2013;24:S114–S115.

Masata J, Svabik K, Zvara K, et al. Comparison of the efficacy of tension-free vaginal tape obturator (TVT-O) and single-incision tension-free vaginal tape (Ajust™) in the treatment of female stress urinary incontinence: a 1-year follow-up randomized trial. *Int Urogynecol J*. 2016;27:1497–1505.

Masata J, Svabik K, Zvara K, et al. Randomized trial of a comparison of the efficacy of TVT-O and single-incision tape TVT Secur systems in the treatment of stress urinary incontinent women—2-year follow-up. *Int Urogynecol J*. 2012;23:1403–1412.

Mason RC, Roach M. Modified pubovaginal sling for treatment of intrinsic sphincteric deficiency. *J Urol*. 1996;156:1991–1994.

Matsuoka PK, Pacetta AM, Baracat EC, et al. Should prophylactic anti-incontinence procedures be performed at the time of prolapse repair? Systematic review. *Int Urogynecol J*. 2015;26:187–193.

Mazouni C, Karsenty G, Bretelle F, et al. Urinary complications and sexual function after the tension-free vaginal tape procedure. *Acta Obstet Gynecol Scand*. 2004;83:955–961.

McCoy O, Vaughan T, Nickles SW, et al. Outcomes of autologous fascia pubovaginal sling for patients with transvaginal mesh related complications requiring mesh removal. *J Urol*. 2016;196:484–489.

McGuire EJ, Bennett CJ, Konnak JA, et al. Experience with pubovaginal slings for urinary incontinence at the University of Michigan. *J Urol*. 1987;138:525–526.

McGuire EJ, Fitzpatrick CC, Wan J, et al. Clinical assessment of urethral sphincter function. *J Urol*. 1993;150:1452–1454.

McGuire EJ, Lytton B. Pubovaginal sling procedure for stress incontinence. *J Urol*. 1978;119:82–84.

McGuire EJ, O'Connell HE. Surgical treatment of intrinsic urethral dysfunction. Slings. *Urol Clin North Am*. 1995;22:657–664.

McGuire EJ, Wang CC, Usitalo H, et al. Modified pubovaginal sling in girls with myelodysplasia. *J Urol*. 1986;135:94–96.

McGuire EJ. Urodynamic findings in patient after failure of stress incontinence operations. *Prog Clin Biol Res*. 1981;78:351–360.

McIndoe GAJ, Jones RW, Grieve BW. The Aldridge sling procedure in the treatment of urinary stress incontinence. *Aust N Z J Obstet Gynaecol*. 1987;27:238–239.

McKenna JB, Parkin K, Cheng Y, et al. Objective efficacy of the tension-free vaginal tape in obese/morbidly obese women versus non-obese women, at median five year follow up. *Aust N Z J Obstet Gynaecol*. 2016;56:628–632.

McLaren HC. Fascial slings for stress incontinence. *J Obstet Gynaecol Br Emp*. 1957;64:673–681.

McLaren HC. Late results from sling operations. *J Obstet Gynaecol Br Commonw*. 1968;75:10–13.

McLennan M. Transurethral resection of transvaginal tape. *Int Urogynecol J Pelvic Floor Dysfunct*. 2004;15:360–362.

McLennan MT, Bent AE. Sling incision with associated vaginal wall interposition for obstructed voiding secondary to suburethral sling procedure. *Int Urogynecol J Pelvic Floor Dysfunct*. 1997;8:168–172.

McLennan MT, Melick CF, Bent AE. Clinical and urodynamic predictors of delayed voiding after fascia lata suburethral sling. *Obstet Gynecol*. 1998;92:608.

Mellier G, Benayed B, Bretones S, et al. Suburethral tape via the obturator route: is the TOT a simplification of the TVT? *Int Urogynecol J Pelvic Floor Dysfunct*. 2004;15:227–232.

Meltomaa S, Backman T, Haarala M. Concomitant vaginal surgery did not affect outcome of the tension-free vaginal tape operation during a prospective 3-year follow-up study. *J Urol*. 2004;172:222–226.

Meschia M, Barbacini P, Ambrogi V, et al. TVT-Secur: a minimally invasive procedure for the treatment of primary stress urinary incontinence. One year data from a multi-centre prospective trial. *Int Urogynecol J*. 2009;20:313–317.

Meschia M, Pifarotti P, Bernasconi F, et al. Tension-free vaginal tape: analysis of outcomes and complications in 404 stress incontinent women. *Int Urogynecol J Pelvic Floor Dysfunct*. 2001;12(Suppl 2):S24–S27.

Meschia M, Pifarotti P, Bernasconi F, et al. Tension-free vaginal tape (TVT) and intravaginal slingplasty (IVS) for stress urinary incontinence: a multicenter randomized trial. *Am J Obstet Gynecol*. 2006;195:1338–1342.

Meschia M, Rossi G, Bertini S, et al. Single incision mid-urethral slings: impact of obesity on outcomes. *Eur J Obstet Gynecol Reprod Biol*. 2013;170:571–574.

Mesens T, Aich A, Bhal PS. Late erosions of mid-urethral sling tapes for stress urinary incontinence—need for long-term follow-up? *Int Urogencol J Pelvic Floor Dysfunct*. 2007;18:1113–1114.

Miller EA, Amundsen CL, Toh KL, et al. Preoperative urodynamic evaluation may predict voiding dysfunction in women undergoing pubovaginal sling. *J Urol*. 2003;169:2234.

Miller NF. The surgical treatment of urinary incontinence in the female. *JAMA*. 1932;98:628–632.

Milose JC, Sharp KM, He C, et al. Success of autologous pubovaginal sling after failed synthetic mid urethral sling. *J Urol*. 2015;193:916–920.

Minaglia S, Ozel B, Hurtado E, et al. Effect of transobturator tape procedure on proximal urethral mobility. *Urology*. 2005;65:55–59.

Minaglia S, Ozel B, Klutke C, et al. Bladder injury during transobturator sling. *Urology*. 2004;64:376–377.

Minaglia S, Urwitz-Lane R, Wong M, et al. Effectiveness of transobturator tape in women with decreased urethral mobility. *J Reprod Med*. 2009;54:15–19.

Miotla P, Futyma K, Cartwright R, et al. Effectiveness of botulinum toxin injection in the treatment of de novo OAB symptoms following midurethral sling surgery. *Int Urogynecol J*. 2016;27:393–398.

Mishra VC, Mishra N, Karim OM, et al. Voiding dysfunction after tension-free vaginal tape: a conservative approach is often successful. *Int Urogynecol J Pelvic Floor Dysfunct*. 2005;16:210–214.

Mitsui T, Tanaka H, Moriya K, et al. Clinical and urodynamic outcomes of pubovaginal sling procedure with autologous rectus fascia for stress urinary incontinence. *Int J Urol*. 2007;14:1076–1079.

Morgan TO, Westney OL, McGuire EJ. Pubovaginal sling: 4-year outcome analysis and quality of life assessment. *J Urol*. 2000;163:1845–1848.

Mostafa A, Agur W, Abdel-All M, et al. Multicenter prospective randomized study of single-incision mini-sling vs. tension-free vaginal tape-obturator in management of female stress urinary incontinence: a minimum of 1-year follow-up. *Urology*. 2013;82:552–559.

Muir TW, Tulikangas PK, Fidela Paraiso M, et al. The relationship of tension-free vaginal tape insertion and the vascular anatomy. *Obstet Gynecol*. 2003;101:933–936.

Mustafa M, Wadie B. Bladder erosion of tension-free vaginal tape presented as vesical stone; management and review of literature. *Int Urol Nephrol*. 2007;39:453–455.

Myers DL, LaSala CA. Conservative surgical management of Mersilene mesh suburethral sling erosion. *Am J Obstet Gynecol*. 1998;179:1424–1429.

Nager CW, Brubaker L, Litman HJ, et al. Urinary Incontinence Treatment Network. A randomized trial of urodynamic testing before stress-incontinence surgery. *N Engl J Med*. 2012;366:1987–1997.

Nager CW, FitzGerald M, Kraus SR, et al. Urodynamic measures do not predict stress continence outcomes after surgery for stress urinary incontinence in selected women. *J Urol*. 2008;179:1470–1474.

Nager CW, Sirls L, Litman HJ, et al. Baseline urodynamic predictors of treatment failure 1 year after mid urethral sling surgery. *J Urol*. 2011;186:597–603.

Nambiar A, Cody JD, Jeffery ST, et al. Single-incision sling operations for urinary incontinence in women. *Cochrane Database Syst Rev*. 2017;(7) [CD008709].

Nambiar AK, Bosch R, Cruz F, et al. EAU guidelines on assessment and nonsurgical management of urinary incontinence. *Eur Urol*. 2018;73:596–609.

Narik G, Palmrich AH. A simplified sling operation suitable for routine use. *Am J Obstet Gynecol*. 1962;84:400.

Nazemi TM, Rapp DE, Govier FE, et al. Cadaveric fascial sling with bone anchors: minimum of 24 months of follow-up. *Urology*. 2008;71:834–838.

Negoro H, Kawakita M, Imai Y. Intravesical tape erosion following the tension-free vaginal tape procedure for stress urinary incontinence. *Int J Urol*. 2005;12:696–698.

Neuman M. Perioperative complications and early follow-up with 100 TVT-SECUR procedures. *J Minim Invasive Gynecol*. 2008;15:480–484.

Neuman M. TVT-Obturator: short-term data on the operative procedure for the cure of female stress urinary incontinence performed on 300 patients. *Eur Urol*. 2007;51:1083–1088.

Nguyen JN, Jakus-Waldman SM, Walter AJ, et al. Perioperative complications and reoperations after incontinence and prolapse surgeries using prosthetic implants. *Obstet Gynecol*. 2012;119:539–546.

Nguyen JN. Tape mobilization for urinary retention after tension-free vaginal tape procedures. *Urology*. 2005;66:523–526.

Niknejad K, Plzak LS, Staskin DR, et al. Autologous and synthetic urethral slings for female incontinence. *Urol Clin North Am*. 2002;29:597–611.

Nilsson CG, Kuuva N. The tension-free vaginal tape procedure is successful in the majority of women with indications for surgical treatment of urinary stress incontinence. *BJOG*. 2001;108:414–419.

Nilsson CG, Palva K, Aarnio R, et al. Seventeen years' follow-up of the tension-free vaginal tape procedure for female stress urinary incontinence. *Int Urogynecol J*. 2013;24:1265–1269.

Nilsson CG, Palva K, Rezapour M, et al. Eleven years prospective follow-up of the tension-free vaginal tape procedure for treatment of stress urinary incontinence. *Int Urogynecol J Pelvic Floor Dysfunct*. 2008;19:1043–1047.

Nitti VW, Carlson KV, Blaivas JG, et al. Early results of pubovaginal sling lysis by midline sling incision. *Urology*. 2002;59:47–51.

Nitti VW, Raz S. Obstruction following anti-incontinence procedures: diagnosis and treatment with transvaginal urethrolysis. *J Urol*. 1994;152:93–98.

Nordling J, Meyhoff H, Andersen JT, et al. Urinary incontinence in the female. The value of detrusor reflex activation procedures. *Br J Urol*. 1979;51:110–113.

Norton PA, Nager CW, Brubaker L, et al. The cost of preoperative urodynamics: a secondary analysis of the ValUE trial. *Neurourol Urodynam*. 2016;35:81.

Novara G, Galfano A, Boscolo-Berto R, et al. Complication rates of tension-free midurethral slings in the treatment of female stress urinary incontinence: a systematic review and meta-analysis of randomized controlled trials comparing tension-free midurethral tapes to other surgical procedures and different devices. *Eur Urol*. 2008;53:288–308.

O'Connor RC, Nanigian DK, Lyon MB, et al. Early outcomes of mid-urethral slings for female stress urinary incontinence stratified by Valsalva leak point pressure. *Neurourol Urodyn*. 2006;25:685–688.

Oh T, Ryu D. Transurethral resection of intravesical mesh after midurethral sling procedures. *J Endourol*. 2009;23:1–5.

Oliphant SS, Wang L, Bunker CH, et al. Trends in stress urinary incontinence inpatient procedures in the United States, 1979–2004. *Am J Obstet Gynecol*. 2009;521.e1–521.e6.

Oliveira LM, Sartori M, Castro R, et al. A prospective randomized study to compare TVT, TVT-O and pre-pubic TVT for the treatment of women with stress urinary incontinence, with or without intrinsic sphincter deficiency. *Int Urogynecol J*. 2008;19:S173–S174.

Olsson I, Abrahamsson AK, Kroon UB. Long-term efficacy of the tension-free vaginal tape procedure for the treatment of urinary incontinence: a retrospective follow-up 11.5 years post-operatively. *Int Urogynecol J Pelvic Floor Dysfunct*. 2010;21:679–683.

Onur R, Singla A, Kobashi KC. Comparison of solvent-dehydrated allograft dermis and autograft rectus fascia for pubovaginal sling: questionnaire-based analysis. *Int Urol Nephrol*. 2008;40:45–49.

Onur R, Singla A. Solvent-dehydrated cadaveric dermis: a new allograft for pubovaginal sling surgery. *Int J Urol*. 2005;12:801–805.

Ordorica R, Rodriguez AR, Coste-Delvecchio F, et al. Disabling complications with slings for managing female stress urinary incontinence. *BJU Int*. 2008;102:333–336.

O'Reilly KJ, Govier FE. Intermediate term failure of pubovaginal slings using cadaveric fascia lata: a case series. *J Urol*. 2002;167:1356–1358.

Osborn DJ, Kaufman MR, Dmochowski RR. Complications after surgery for stress urinary incontinence. *Urologické Listy*. 2013;4:39–44.

Osborn DJ, Strain M, Gomelsky A, et al. Obesity and female stress urinary incontinence. *Urology*. 2013;82:759–763.

Osman T. Stress incontinence surgery for patients presenting with mixed incontinence and a normal cystometrogram. *BJU Int*. 2003;92:964–968.

Owens DC, Winters JC. Pubovaginal sling using Duraderm graft: intermediate follow-up and patient satisfaction. *Neurourol Urodyn*. 2004;23:115–118.

Ozel B, Minaglia S, Hurtado E, et al. Treatment of voiding dysfunction after transobturator tape procedure. *Urology*.

2004;64:1030.

Padmanabhan P, Nitti VW. Female stress urinary incontinence: how do patient and physician perspectives correlate in assessment of outcomes? *Curr Opin Urol*. 2006;16:212–218.

Paick JS, Ku JH, Shin JW, et al. Tension-free vaginal tape procedure for urinary incontinence with low Valsalva leak point pressure. *J Urol*. 2004;172:1370–1373.

Paick JS, Oh SJ, Kim SW, et al. Tension-free vaginal tape, suprapubic arc sling and transobturator tape in the treatment of mixed urinary incontinence in women. *Int Urogynecol J Pelvic Floor Dysfunct*. 2008;19:123–129.

Panayi DC, Duckett J, Digesu GA, et al. Pre-operative opening detrusor pressure is predictive of detrusor overactivity following TVT in patients with pre-operative mixed urinary incontinence. *Neurourol Urodyn*. 2009;28:82–85.

Paraiso M, Walters M, Karram M, et al. Laparoscopic Burch colposuspension versus tension-free vaginal tape: a randomized trial. *Obstet Gynecol*. 2004;104:1249–1258.

Parekh MH, Minassian VA. Poplawsky D. Bilateral bladder erosion of a transobturator tape mesh. *Obstet Gynecol*. 2006;108:713–715.

Parker WP, Gomelsky A, Padmanabhan P. Autologous fascia pubovaginal slings after prior synthetic anti-incontinence procedures for recurrent incontinence: a multi-institutional prospective comparative analysis to de novo autologous slings assessing objective and subjective cure. *Neurourol Urodyn*. 2016;35:604–608.

Partoll L. Efficacy of tension-free vaginal tape with other pelvic reconstructive surgery. *Am J Obstet Gynecol*. 2002;186:1292–1298.

Patel BN, Kobashi KC, Staskin D. Iatrogenic obstruction after sling surgery. *Nat Rev Urol*. 2012;9:429–434.

Patil A, Moran P, Duckett J. British Society of Urogynaecology

Audit Committee. How do urogynaecologists treat failed suburethral slings? Experience from the British Society of Urogynaecology database and literature review. *J Obstet Gynaecol*. 2011;31:514–517.

Persson J, Teleman P, Eten-Bergqvist C, et al. Cost-analyses based on a prospective, randomized study comparing laparoscopic colposuspension with tension-free vaginal tape procedure. *Acta Obstet Gynecol Scand*. 2002;81:1066–1073.

Petros P, Ulmsten U. An integral theory of female urinary incontinence: experimental and clinical considerations. *Acta Obstet Gynecol Scand*. 1990;69(S153):7–31.

Petrou SP, Brown JA, Blaivas JG. Suprameatal transvaginal urethrolysis. *J Urol*. 1999;161:1268–1271.

Petrou SP, Davidiuk AJ, Rawal B, et al. Salvage autologous fascial sling after failed synthetic midurethral sling: greater than 3-year outcomes. *Int J Urol*. 2016;23:178–181.

Petrou SP, Frank I. Complications and initial continence rates after a repeat pubovaginal sling procedure for recurrent stress urinary incontinence. *J Urol*. 2001;165:1979–1981.

Petrou SP, Young PR. Rate of recurrent SUI after retropubic urethrolysis. *J Urol*. 2002;167(2 Pt 1):613–615.

Pianezza ML, Joffe R, Chugh T, et al. Long-term patient satisfaction following cadaveric pubovaginal sling incontinence surgery using the UDI and IIQ-7 questionnaires. *Neurourol Urodyn*. 2007;26:185–189.

Pit M. Rare complications of tension-free vaginal tape procedure: late intraurethral displacement and early misplacement of tape. *J Urol*. 2002;167:647.

Porena M, Constantini E, Frea B, et al. Tension-free vaginal tape versus transobturator tape as surgery for stress urinary incontinence: results of a multicentre randomised trial. *Eur Urol*. 2007;52:1481–1491.

Powers K, Lazarou G, Greston W. Delayed urethral erosion after tension-free vaginal tape. *Int Urogynecol J*. 2006;17:422–425.

Price PB. Plastic operations for incontinence of urine and feces. *Arch Surg*. 1933;26:1043–1053.

Pugsley H, Barbrook C, Mayne CJ, et al. Morbidity of incontinence surgery in women over 70 years old: a retrospective cohort study. *BJOG*. 2005;112:786–790.

Pushkar DY, Godunov BN, Gvozdev M, et al. Complications of mid-urethral slings for treatment of stress urinary incontinence. *Int J Gynaecol Obstet*. 2011;113:54–57.

Rardin C, Kohli N, Rosenblatt PL, et al. Tension-free vaginal tape: outcomes among women with primary versus recurrent stress urinary incontinence. *Obstet Gynecol*. 2002;100:893–897.

Rardin CR, Rosenblatt PL, Kohli N, et al. Release of tension-free vaginal tape for the treatment of refractory postoperative voiding dysfunction. *Obstet Gynecol*. 2002;100:898–902.

Rautenberg O, Kociszewski J, Welter J, et al. Ultrasound and early tape mobilization—a practical solution for treating postoperative voiding dysfunction. *Neurourol Urodyn*. 2014;33:1147–1151.

Raz S, Siegel AL, Short JL, et al. Vaginal wall sling. *J Urol*. 1989;141:143–146.

Rechberger T, Futyma K, Jankiewicz K, et al. The clinical effectiveness of retropubic (IVS-02) and transobturator (IVS-04) midurethral slings: randomized trial. *Eur Urol*. 2009;56:24–30.

Rechberger T, Rzeźniczuk K, Skorupski P, et al. A randomized comparison between monofilament and multifilament tapes for stress incontinence surgery. *Int Urogynecol J Pelvic Floor Dysfunct*. 2003;14:432–436.

Rehman H, Bezerra CA, Bruschini H, et al. Traditional suburethral sling operations for urinary incontinence in women. *Cochrane Database Syst Rev*. 2017;(7) [CD001754].

Rehman J, Chugtai B, Sukkarieh T, et al. Extraperitoneal laparoscopic removal of eroded midurethral sling: a new technique. *J Endourol*. 2008;22:365–368.

Revicky V, Mukhopadhyay S, de Boer F, et al. Obesity and the incidence of bladder injury and urinary retention following tension-free vaginal tape procedure: retrospective cohort study. *Obstet Gynecol Int*. 2011;2011:746393.

Reynolds WS, Kit LC, Kaufman MR, et al. Obturator foramen dissection for excision of symptomatic transobturator mesh. *J Urol*. 2012;187:1680–1684.

Rezapour M, Falconer C, Ulmsten U. Tension free vaginal tape (TVT) in stress incontinent women with intrinsic sphincter deficiency (ISD): a long term follow-up. *Int Urogynecol J Pelvic Floor Dysfunct*. 2001;12(Suppl 2):512–514.

Rezapour M, Ulmsten U. Tension-free vaginal tape (TVT) in women with mixed urinary incontinence-a long-term follow-up. *Int Urogynecol J Pelvic Floor Dysfunct*. 2001;12(Suppl 2):S15–S18.

Riachi L, Kohli N, Miklos J. Repeat tension-free transvaginal tape (TVT) sling for the treatment of recurrent stress urinary incontinence. *Int Urogynecol J*. 2002;13:133–135.

Richter HE, Albo ME, Zyczynski HM, et al. Retropubic versus transobturator midurethral slings for stress incontinence. *N Engl J Med*. 2010;362:2066–2076.

Richter HE, Burgio KL, Holley RL, et al. Cadaveric fascia lata sling for stress urinary incontinence: a prospective quality-of-life analysis. *Am J Obstet Gynecol*. 2003;189:1590–1596.

Richter HE, Diokno A, Kenton K, et al. Predictors of treatment failure 24 months after surgery for stress urinary incontinence. *J Urol*. 2008;179:1024–1030.

Richter HE, Varner E, Sanders E, et al. Effects of pubovaginal sling procedure on patients with urethral hypermobility and intrinsic sphincteric deficiency: would they do it again? *Am J Obstet Gynecol*. 2001;184:14–19.

Rinne K, Laurikainen E, Kivelä A, et al. A randomized trial comparing TVT with TVT-O: 12-month results. *Int Urogynecol J*. 2008;19:1049–1054.

Robert M, Mainprize TC. Long-term assessment of the incontinence ring pessary for the treatment of stress incontinence. *Int Urogynecol J Pelvic Floor Dysfunct*. 2002;13:326–329.

Rodriguez LV, de Almeida F, Dorey F, et al. Does Valsalva leak point pressure predict outcome alter the distal urethral polypropylene sling? Role of urodynamics in the sling era. *J Urol*. 2004;172:210–214.

Raders J, Rogers R, Lucente V. Paper 26: anatomic considerations for the TVT-obturator approach for the correction of female stress urinary incontinence. Abstract. *J Pelvic Med Surg*. 2005;11:S12–S13.

Rogo-Gupta L, Baxter ZC, Le NB, et al. Long-term durability of the distal urethral polypropylene sling for the treatment of stress urinary incontinence: minimum 11-year followup. *J Urol*. 2012;188:1822–1827.

Roth TM. Management of persistent groin pain after transobturator slings. *Int Urogynecol J*. 2007;18:1371–1373.

Rovner ES, Wein AJ. Diagnosis and reconstruction of the dorsal or circumferential urethral diverticulum. *J Urol*. 2003;170:82–86.

Rutner AB, Levine SR, Schmaelzle JF. Processed porcine small intestine submucosa as a graft material for pubovaginal sling: durability and results. *Urology*. 2003;62:805–809.

Sand PK, Bowen LW, Panganiban R, et al. The low pressure urethra as a factor in failed retropubic urethropexy. *Obstet Gynecol*. 1987;69:399–402.

Sand PK, Winkler H, Blackhurst DW, et al. A prospective randomized study comparing modified Burch retropubic urethropexy and suburethral sling for treatment of genuine stress incontinence with low-pressure urethra. *Am J Obstet Gynecol*. 2000;182:30–34.

Sander P, Moller LM, Rudnicki PM, et al. Does the tension-free vaginal tape procedure affect the voiding phase? Pressure-flow studies before and 1 year after surgery. *BJU Int*. 2002;89:694–698.

Sanders R, Genadry R, Yang A, et al. Imaging the female urethra with ultrasound. *Ultrasound Q*. 1994;12:167–183.

Scarpero HM, Dmochowski RR, Nitti VW. Repeat urethrolysis after failed urethrolysis for iatrogenic obstruction. *J Urol*. 2003;169:1013–1016.

Schellart RP, Zwolsman SE, Lucot JP, et al. A randomized, nonblinded study of single-incision versus transobturator midurethral sling in women with stress urinary incontinence. *Int Urogynecol J*. 2018;29:37–44.

Schierlitz L, Dwyer PL, Rosamilia A, et al. Three-year follow-up of tension-free vaginal tape compared with transobturator tape in women with stress urinary incontinence and intrinsic sphincter deficiency. *Obstet Gynecol*. 2012;119:321.

Schierlitz L, Dwyer PL, Rosamilia A, et al. Effectiveness of tension-free vaginal tape compared with transobturator tape in women with stress urinary incontinence and intrinsic sphincter deficiency. *Obstet Gynecol*. 2008;112:1253–1261.

Schrepferman CG, Griebling TL, Nygaard IE, et al. Resolution of urge symptoms following sling cystourethropexy. *J Urol*. 2000;164:1628–1631.

Schweitzer KJ, Cromheecke GJ, Milani AL, et al. A randomized controlled trial comparing the TVT-O with the Ajust as primary surgical treatment of female stress urinary incontinence. *Int Urogynecol J*. 2012;23:S77–S78.

Secunda J. *Update on surgical mesh for stress urinary* *incontinence (SUI)*. [FDA Meeting of the Obstetric and Gynecologic Devices Panel; Available from:] www.fda.gov/downloads/AdvisoryCommittees/CommitteesM 2011.

Segal J, Vassallo B, Kleeman S, et al. Prevalence of persistent de novo overactive bladder symptoms after the tension-free vaginal tape. *Obstet Gynecol*. 2004;104:1263–1269.

Serati M, Ghezzi F, Cattoni E, et al. Tension-free vaginal tape for the treratment of urodynamic stress incontinence: efficacy and adverse effects at 10-year follow-up. *Eur Urol*. 2012;61:939–946.

Serati M, Bauer R, Cornu JN, et al. TVT-O for the treatment of pure urodynamic stress incontinence: efficacy, adverse effects, and prognostic factors at 5-year follow-up. *Eur Urol*. 2013;63:872–878.

Serati M, Braga A, Athanasiou S, et al. Tension-free vaginal tape-obturator for treatment of pure urodynamic stress urinary incontinence: efficacy and adverse effects at 10-year follow-up. *Eur Urol*. 2017;71:674–679.

Serati M, Sorice P, Bogani G, et al. TVT for the treatment of urodynamic stress incontinence: efficacy and adverse effects at 13-year follow-up. *Neurourol Urodyn*. 2017;36:192–197.

Serels SR, Rackley RR, Appell RA. In situ slings with concurrent cystocele repair. *Tech Urol*. 1999;5:129–132.

Serels SR, Rackley RR, Appell RA. Surgical treatment for stress urinary incontinence associated with Valsalva induced detrusor instability. *J Urol*. 2000;163:884–887.

Sevestre S, Ciofu C, Deval B, et al. Results of the tension-free vaginal tape technique in the elderly. *Eur Urol*. 2003;44:128–131.

Shah K, Nikolavsky D, Gilsdorf D, et al. Surgical management of lower urinary mesh perforation after mid-urethral polypropylene mesh sling: mesh excision, urinary tract reconstruction and concomitant pubovaginal sling with autologous rectus fascia. *Int Urogynecol J*. 2013;24:2111–2117.

Sharma B, Oligbo N. Delayed vaginal erosion of the tape—a rare complication with TVT. *J Obstet Gynaecol*. 2004;24:96–98.

Shenassa B, Novak T, Ghoniem GM. Management of obstructing sling with transvaginal urethrolysis and vaginal patch interposition. *J Urol*. 2000;163:74.

Shrotri K, Shervington J, Shrotri N. Laser excision of encrusted intra-vesical tension-free vaginal tape (TVT). *Int Urogynecol J*. 2010;21:375–377.

Shutkin NM. Homologous-serum hepatitis following the use of refrigerated bone-bank bone. *J Bone Joint Surg Am*. 1954;35:160–162.

Siddighi S, Karram MM. Surgical and nonsurgical approaches to treat voiding dysfunction following antiincontinence surgery. *Curr Opin Obstet Gynecol*. 2007;19:490–495.

Siegel AL. Vaginal mesh extrusion associated with use of Mentor transobturator sling. *Urology*. 2005;66:995–999.

Singla N, Aggarwal H, Foster J, et al. Management of urinary incontinence following suburethral sling removal. *J Urol*. 2017;198:644–649.

Sinha D, Blackwell A, Moran PA. Outcome measures after TVT for mixed urinary incontinence. *Int Urogynecol J Pelvic Floor Dysfunct*. 2008;19:927–931.

Siow A, Morris AR, Lam A. Laparoscopic treatment of tension free vaginal tape erosion. *Aust N Z J Obstet Gynaecol*. 2005;45:333–336.

Sivaslioglu AA, Unlubilgin E, Aydogmus S, et al. A prospective randomized controlled trial of the transobturator tape and tissue fixation mini-sling in patients with stress urinary incontinence: 5-year results. *J Urol*. 2012;188:194–199.

Slack M, Sandhu J, Staskin D, et al. In vivo comparison of suburethral sling materials. *Int Urogynecol J Pelvic Floor Dysfunct*. 2005;17:106–110.

Soergel TM, Shott S, Heit M. Poor surgical outcomes after fascia lata allograft slings. *Int Urogynecol J*. 2001;12:247–253.

Sokol A, Jelovsek J, Walters M, et al. Incidence and predictors of prolonged urinary retention after TVT with and without concurrent prolapse surgery. *Am J Obstet Gynecol*. 2005;192:1537–1543.

Sokol ER, Urban R. Novel repair of tension-free midurethral sling erosion into the urethra. *J Minim Invasive Gynecol*. 2008;15:755–757.

Song P, Wen Y, Huang C, et al. The efficacy and safety comparison of surgical treatments for stress urinary incontinence: a network meta-analysis. *Neurourol Urodyn*. 2018;37:1199–1211.

Spelzini F, Cesana MC, Verri D, et al. Three-dimensional ultrasound assessment and middle term efficacy of a single-incision sling. *Int Urogynecol J*. 2013;24:1391–1397.

Squier JB. Postoperative urinary incontinence. *Med Rec*. 1911;79:868.

Stanton SL, Ozsoy C, Hilton P. Voiding difficulties in the female: prevalence, clinical and urodynamic review. *Obstet Gynecol*. 1983;61:144–147.

Starkman JS, Christopher WE, Scarpero HM, et al. Management of refractory urinary urge incontinence following urogynecological surgery with sacral neuromodulation. *Neurourol Urodyn*. 2007;26:29–35.

Starkman JS, Duffy JW III, Wolter CE, et al. The evolution of obstruction induced overactive bladder symptoms following urethrolysis for female bladder outlet obstruction. *J Urol*. 2008;179:1018–1023.

Starkman JS, Duffy JW III, Wolter CE, et al. Refractory overactive bladder after urethrolysis for bladder outlet obstruction: management with sacral neuromodulation. *Int Urogynecol J Pelvic Floor Dysfunct*. 2008;19:277.

Starkman JS, Wolter C, Gomelsky A, et al. Voiding dysfunction following removal of eroded synthetic mid-urethral slings. *J Urol*. 2006;176:1040–1044.

Staskin D, Bavendam T, Miller J, et al. Effectiveness of a urinary control insert in the management of stress urinary incontinence: early results of a multicenter study. *Urology*. 1998;47:829–836.

Stav K, Dwyer PL, Rosamilia A, et al. Repeat synthetic mid urethral sling procedure for women with recurrent stress urinary incontinence. *J Urol*. 2010;183:241–246.

Stav K, Dwyer PL, Rosamilia A, et al. Risk factors of treatment failure of midurethral sling procedures for women with urinary stress incontinence. *Int Urogynecol J*. 2010;21:149–155.

Stephenson TP, Mundy AT. The urge syndrome. Mundy AT, Stephenson TP, Wien AJ. *Urodynamics. Principles, practice and application*. ed 2. Churchill Livingstone: New York, NY; 1994:263–276.

Stoeckel W. Uber die Verwendung der Musculi pyramidales bei der operativen Behandlung der Incontinentia Urinae. *Zentralbl Gynakol*. 1917;41:11–19.

Stoffel JT, Smith JJ, Crivellaro S, et al. Mixed incontinence: does preoperative urodynamic detrusor overactivity affect postoperative quality of life after pubovaginal sling? *Int Braz J Urol*. 2008;34:765–771.

Studdiford WE. Transplantation of abdominal fascia for the relief of urinary stress incontinence. *Am J Obstet Gynecol*. 1944;47:764–775.

Subak L, Wing R, West D, et al. Weight loss to treat urinary incontinence in overweight and obese women. *N Engl J Med*. 2009;360:481–490.

Subak LL, Richter HE, Hunskaar S. Obesity and urinary incontinence: epidemiology and clinical research update. *J Urol*. 2009;182:S2–S7.

Summit RL, Bent AE, Ostergard DR, et al. Suburethral sling procedure for genuine stress incontinence and low urethral closure pressure: a continued experience. *Int Urogynecol J*. 1992;3:18–21.

Svenningsen R, Staff AC, Schiotz HA, et al. Long-term follow-up of the retropubic tension-free vaginal tape procedure. *Int Urogynecol J*. 2013;24:1271–1278.

Sweat S, Itano N, Clemens J, et al. Polypropylene mesh tape for stress urinary incontinence: complications of urethral erosion and outlet obstruction. *J Urol*. 2002;168:144–146.

Swierzewski SJ 3rd, McGuire EJ. Pubovaginal sling for treatment of female stress urinary incontinence complicated by urethral diverticulum. *J Urol*. 1993;149:1012–1014.

Tahseen S, Reid P. Effect of transobturator tape on overactive bladders symptoms and urge urinary incontinence in women with mixed urinary incontinence. *Obstet Gynecol*. 2009;113:617–623.

Tamussino K, Hanzal E, Kölle D, et al. Tension-free vaginal tape operation: results of the Austrian registry. *Obstet Gynecol*. 2001;98:732–736.

Tamussino K, Hanzal E, Kölle D, et al. Transobturator tapes for stress urinary incontinence: results of the Austrian registry. *Am J Obstet Gynecol*. 2007;197:634.e1–634.e5.

Tanuri AL, Feldner PC Jr, Bella ZI, et al. Retropubic and transobturator sling in treatment of stress urinary incontinence. *Rev Assoc Med Bras*. 2010;56:348–354.

Teo R, Moran P, Mayne C, et al. Randomized trial of tension-free vaginal tape and tension-free vaginal tape-obturator for urodynamic stress incontinence in women. *J Urol*. 2011;185:1350–1355.

Thiel DD, Pettit PD, McClellan WT, et al. Long-term urinary continence rates after simple sling incision for relief of urinary retention following fascia lata pubovaginal slings. *J Urol*. 2005;174:1878–1881.

Thiel M, Rodrigues PP, Riccetto CL, et al. A stereological analysis of fibrosis and inflammatory reaction induced by 4 different synthetic slings. *BJU Int*. 2005;95:833–837.

Thompson R. A case of epispadias associated with complete incontinence treated by rectus transplantation. *Br J Dis Child*. 1923;20:146–151.

Tijdink MM, Vierhout ME, Heesakkers JP, et al. Surgical management of mesh-related complications after prior pelvic floor reconstructive surgery with mesh. *Int Urogynecol J*. 2011;22:1395–1404.

Tincello DG, Botha T, Grier D, et al. The TVT Worldwide Observational Registry for Long-Term Data: safety and efficacy of suburethral sling insertion approaches for stress urinary incontinence in women. *J Urol*. 2011;186:2310–2315.

Tommaselli GA, D'Afiero A, Di Carlo C, et al. Tension-free vaginal tape-obturator and tension-free vaginal tape-Secur for the treatment of stress urinary incontinence: a 5-year follow-up randomized study. *Eur J Obstet Gynecol Reprod Biol*. 2015;185:151–155.

Tommaselli GA, Napolitano V, Di Carlo C, et al. Efficacy and safety of the trans-obturator TVT-Abbrevo device in normal weight compared to overweight patients affected by stress urinary incontinence. *Eur J Obstet Gynecol Reprod Biol*. 2016;197:116–119.

Tran H, Rutman M. Female outlet obstruction after anti-incontinence surgery. *Urology*. 2018;112:1–5.

Tseng LH, Wang AC, Lin YH, et al. Randomized comparison of the suprapubic arc sling procedure vs. tension-free vaginal taping for stress incontinent women. *Int Urogynecol J Pelvic Floor Dysfunct*. 2005;16:230–235.

Tsivian A, Benjamin S, Tsivian M, et al. Transobturator tape procedure with and without concomitant vaginal surgery. *J Urol*. 2009;182:1068–1071.

Tsivian A, Kessler O, Mogutin B, et al. Tape related complications of the tension-free vaginal tape procedure. *J Urol*. 2004;171:762–764.

Tsivian A, Menahem N, Yulish E, et al. Redo midurethral synthetic sling for female stress urinary incontinence. *Int Urogynecol J*. 2007;18:23–26.

U.S. Food and Drug Administration. *FDA public health notification: serious complications associated with transvaginal placement of surgical mesh in repair of pelvic organ prolapse and stress urinary incontinence*. [Available from:] www.fda.gov/MedicalDevices/Safety/AlertsandNotices/Publi 2010.

U.S. Food and Drug Administration. *Urogynecologic surgical mesh: update on the safety and effectiveness of transvaginal placement for pelvic organ prolapse*. [Available from:] www.fda.gov/downloads/medicaldevices/safety/alertsandnoti 2011.

U.S. Food and Drug Administration. *510(k) clearances*. [Available from:] www.fda.gov/medicaldevices/productsandmedicalprocedures 2013.

U.S. Food and Drug Administration. *FDA safety communication: update on serious complications associated with transvaginal placement of surgical mesh for pelvic organ prolapse*. [Available from:] www.fda.gov/MedicalDevices/Safety/AlertsandNotices/ucm2

2013.

Ulmsten U, Ekman G, Giertz G, et al. Different biochemical composition of connective tissue in continent and stress incontinent women. *Acta Obstet Gynecol Scand*. 1987;66:455–457.

Ulmsten U, Falconer C, Johnson P, et al. A multicenter study of tension-free vaginal tape (TVT) for surgical treatment of stress urinary incontinence. *Int Urogynecol J Pelvic Floor Dysfunct*. 1998;9:210–213.

Ulmsten U, Henriksson L, Johnson P, et al. An ambulatory surgical procedure under local anesthesia for treatment of female urinary incontinence. *Int Urogynecol J*. 1996;7:81–86.

Ulmsten U, Petros P. Intravaginal slingplasty (IVS): an ambulatory surgical procedure for treatment of female urinary incontinence. *Scand J Urol Nephrol*. 1995;29:75–82.

Ulrich D, Tammaa A, Holbfer S, et al. Ten-year followup after tension-free vaginal tape-obturator procedure for stress urinary incontinence. *J Urol*. 2016;196:1201–1206.

van der Ploeg JM, Rengerink KO, van der Steen A, et al. on behalf of the Dutch Urogynaecology Consortium. Vaginal prolapse repair with or without a midurethral sling in women with genital prolapse and occult stress urinary incontinence: a randomized trial. *Int Urogynecol J*. 2016;27:1029–1038.

Vasavada SP, Rackley R. Pubovaginal sling. *EMed Urol*. 2009.

Vassallo B, Kleeman S, Segal J, et al. Urethral erosion of a tension-free vaginal tape. *Obstet Gynecol*. 2003;101:1055–1058.

Velemir L, Amblard J, Jacquetin B, et al. Urethral erosion after suburethral synthetic slings: risk factors, diagnosis, and functional outcome after surgical management. *Int Urogynecol J*. 2008;19:999–1006.

Vigil HR, Mallick R, Nitti VW, et al. Risk factors for urinary tract infection following mid urethral sling surgery. *J Urol*.

2017;197:1268–1273.

Villet R, Ercoli A, Atallah D, et al. Second tension-free vaginal tape procedure and mesh retensioning: two possibilities of treatment of recurrent-persistent genuine stress urinary incontinence after a primary tension-free vaginal tape procedure. *Int Urogynecol J*. 2002;13:377–379.

Volkmer BG, Nesslauer T, Rinnab L, et al. Surgical intervention for complications of tension-free vaginal tape procedure. *J Urol*. 2003;169:570–574.

Von Giordano D. *Twentieth IEME Congress*. [Franco de Chirug] 1907:506.

Wai C, Atnip S, Williams K, et al. Urethral erosion of tension-free vaginal tape presenting as recurrent stress urinary incontinence. *Int Urogynecol J Pelvic Floor Dysfunct*. 2004;15:353–355.

Walsh IK, Nambirajan T, Donellan SM, et al. Cadaveric fascia lata pubovaginal slings: early results on safety, efficacy and patient satisfaction. *BJU Int*. 2002;90:415–419.

Walsh K, Generao S, White M, et al. The influence of age on quality of life outcome in women following a tension-free vaginal tape procedure. *J Urol*. 2004;171:1185–1188.

Waltregny D, Gaspar Y, Reul O, et al. TVT-O for the treatment of female stress urinary incontinence: results of prospective study after a 3-year minimum follow-up. *Eur Urol*. 2008;53:401–410.

Wang AC, Chen MC. Randomized comparison of local versus epidural anesthesia for tension-free vaginal tape operation. *J Urol*. 2001;165:1177–1180.

Wang AC, Lin YH, Tseng LH, et al. Prospective randomized comparison of transobturator suburethral sling (Monarc) vs. suprapubic arc (Sparc) sling procedures for female urodynamic stress incontinence. *Int Urogynecol J Pelvic Floor Dysfunct*. 2006;17:439–443.

Wang W, Zhu L, Lang J. Transobturator tape procedure versus tension-free vaginal tape for treatment of stress urinary incontinence. *Int J Gynaecol Obstet*. 2009;104:113–116.

Ward K, Hilton P. A prospective multicenter randomized trial of tension-free vaginal tape and colposuspension for primary stress incontinence. Two-year follow-up. *Am J Obstet Gynecol*. 2004;190:324–331.

Ward K, Hilton P. Tension-free vaginal tape versus colposuspension for primary urodynamic stress incontinence: 5-year follow-up. *BJOG*. 2008;115:226–233.

Ward KL, Hilton P. Prospective multicentre randomised trial of tension-free vaginal tape and colposuspension as primary treatment for stress incontinence. *BMJ*. 2002;325:67–70.

Webster TM, Gerridzen RG. Gone in 24 hours: the feasibility of performing pubovaginal sling surgery with an overnight hospital stay. *Can J Urol*. 2003;10:1905–1909.

Wei JT, Nygaard I, Richter HE, et al. A midurethral sling to reduce incontinence after vaginal prolapse repair. *N Engl J Med*. 2012;366:2358–2367.

Weinberger MW, Ostergard DR. Long-term clinical and urodynamic outcomes of polytetrafluoroethylene suburethral sling for treatment of genuine stress incontinence. *Obstet Gynecol*. 1995;86:92–96.

Weinberger MW, Ostergard DR. Postoperative catheterization, urinary retention, and permanent voiding dysfunction after polytetrafluoroethylene suburethral sling placement. *Obstet Gynecol*. 1996;87:1–162.

Weltz V, Guldberg R, Lose G. Efficacy and perioperative safety of synthetic mid-urethral slings in obese women with stress urinary incontinence. *Int Urogynecol J*. 2015;26:641–648.

Westby M, Asmussen M, Ulmsten U. Location of maximum intraurethral pressure related to urogenital diaphragm in the female studied by simultaneous urethrocystometry and voiding urethrocystography. *Am J Obstet Gynecol*. 1982;144:408–412.

Wheatcroft SM, Vardy SJ, Tyers AG. Complications of fascia lata harvesting for ptosis surgery. *Br J Ophthalmol*. 1997;81:581–583.

White RA, Hirose FM, Sproat RW, et al. Histopathology observations after short-term implantation of two porous elastomers in dogs. *Biomaterials*. 1981;2:171–176.

White RA. The effect of porosity and biomaterial on the healing and long-term mechanical properties of vascular prostheses. *ASAIO Trans*. 1988;11:95–100.

Whiteside JL, Walters MD. Anatomy of the obturator region: relations to a trans-obturator sling. *Int Urogynecol J Pelvic Floor Dysfunct*. 2004;15:223–226.

Wiedemann A, Otto M. Small intestinal submucosa for pubourethral sling suspension for the treatment of stress incontinence: first histopathological results in humans. *J Urol*. 2004;172:215–218.

Wijffels S, Elzevier W, Lyklama a Nijeholt AA. Transurethral mesh excision after urethral erosion of tension-free vaginal tape: report of three cases and review of literature. *Int Urogynecol J*. 2009;20:261–263.

Wilson CM, Williams BJ, Bilello S, et al. Bovine dermis: a novel biologic substitute for autologous tissue in sling surgery. *Int Urogynecol J*. 2008;19:1671–1676.

Wlazlak E, Viereck V, Kociczewski J, et al. Role of intrinsic sphincter deficiency with and without urethral hypomobility on the outcome of tape insertion. *Neurourol Urodyn*. 2017;36:1910–1916.

Wohlrab KJ, Erekson EA, Myers DL. Postoperative erosions of the Mersilene suburethral sling mesh for antiincontinence surgery. *Int Urogynecol J Pelvic Floor Dysfunct*. 2009;20:417–420.

Wolf S, Bennett C, Dmochowski R, et al. *AUA Best practice statement on urologic surgery antimicrobrial prophylaxis*. [Available from:] www.auanet.org/common/pdf/education/clinical-guidance/Antimicrobial-Prophylaxis.pdf; 2008.

Wolter C, Starkman J, Scarpero H, et al. Removal of transobturator midurethral sling for refractory thigh pain. *Urology*. 2008;72:461.e1–461.e3.

Woodruff AJ, Cole EE, Dmochowski RR, et al. Histologic comparison of pubovaginal sling graft materials: a comparative study. *Urology*. 2008;72(1):85–89.

Wright EJ, Iselin CE, Carr LK, et al. Pubovaginal sling using cadaveric allograft fascia for the treatment of intrinsic sphincter deficiency. *J Urol*. 1998;160:759–762.

Wu JM, Gandhi MP, Shah AD, et al. Trends in inpatient urinary incontinence surgery in the USA, 1998–2007. *Int Urogynecol J*. 2011;22(11):1437–1443.

Wyczolkowski M, Klima W, Piasecki Z. Reoperation after complicated tension-free vaginal tape procedures. *J Urol*. 2001;166:1004–1005.

Yamada BS, Govier FE, Stefanovic KB, et al. High rate of vaginal erosions associated with the mentor ObTape. *J Urol*. 2006;176:651–654 [discussion 654].

Yenilmez A, Baseskioglu B, Kaya C. Groin abscess due to a forgotten midurethral sling connector. *Int Urogynecol J*. 2013;24:1059–1061.

Yonguc T, Degirmenci T, Bozkurt IH, et al. Effectiveness of transobturator tape procedure in obese and severely obese women: 3-year follow-up. *Urology*. 2015;86:244–248.

Young SB, Howard AE, Baker SP. Mersilene mesh sling: short- and long-term clinical and urodynamic outcomes. *Am J Obstet Gynecol*. 2001;185:32–40.

Zaragoza MR. Expanded indications for the pubovaginal sling:

treatment of type 2 or 3 stress incontinence. *J Urol*. 1996;156:1620–1622.

Zhang P, Fan B, Zhang P, et al. Meta-analysis of female stress urinary incontinence treatments with adjustable single-incision mini-slings and transobturator tension-free vaginal tape surgeries. *BMC Urol*. 2015;15:64.

Zimmern PE, Gormley EA, Stoddard AM, et al. Management of recurrent stress urinary incontinence after burch and sling procedures. *Neurourol Urodyn*. 2016;35:344–348.

Zimmern PE, Hadley HR, Leach GE, et al. Female urethral obstruction after Marshall-Marchetti-Krantz operation. *J Urol*. 1987;138:517.

Zivanovic I, Kociszewski J, Eberhard J, et al. Bladder perforation after TVT-Secur procedure: how secure is TVT-Secur? *Arch Gynecol Obstet*. 2014;289:131–134.

Zubke W, Becker S, Kramer B, et al. Persistent urinary retention after tension-free vaginal tape: a new surgical solution. *Eur J Obstet Gynecol Reprod Biol*. 2004;115:95–98.

Zullo MA, Plotti F, Calcagno M, et al. One-year follow-up of tension-free vaginal tape (TVT) and trans-obturator suburethral tape from inside to outside (TVT-O) for surgical treatment of female stress urinary incontinence: a prospective randomised trial. *Eur Urol*. 2007;51:1376–1382 [discussion 1383–1384].

Zumbé J, Porres D, Degiorgis PL, et al. Obturator and thigh abscess after transobturator tape implantation for stress urinary incontinence. *Urol Int*. 2008;81:483–485.

Zyczynski HM, Albo ME, Goldman HB, et al. Urinary Incontinence Treatment Network. Change in overactive bladder symptoms after surgery for stress urinary incontinence in women. *Obstet Gynecol*. 2015;126:423–430.

Complications Related to the Use of Mesh and Their Repair

Anne P. Cameron MD, FRCSC, FPMRS

The use of mesh in urology and urogynecologic procedures is one of the most controversial topics in the field of female pelvic medicine and reconstruction. Currently there are several class action lawsuits against manufacturers, and lawyers are directly targeting women who have had these procedures via advertising. Because of the risk of litigation, some mesh kit manufacturers have removed their products from the market. There have also been three iterations of the US Food and Drug Administration (FDA) Public Health Notifications surrounding the use of vaginal mesh. The unbalanced depiction of mesh and its use in the media has further frightened patients and has led some surgeons to stop performing these procedures. In spite of these challenges, well-trained urologists should not be dissuaded from using these effective products in the care of their patients.

A recent consensus statement from the Society of Urodynamics, Female Pelvic Medicine and Urogenital Reconstruction in conjunction with the American Urogynecologic Society (Nager et al., 2014) states that **“The polypropylene mesh midurethral sling is the recognized worldwide standard of care for the surgical treatment of stress urinary incontinence. The procedure is safe, effective, and has improved the quality of life for millions of women.”** This statement was issued to clarify expert opinion in light of the ongoing controversy regarding mesh use. Multiple incision mesh slings are the most extensively studied procedure for stress urinary incontinence (SUI) with more than 200 clinical trials studies describing the safety and effectiveness of this procedure (Ford et al., 2015; SCENIHR, 2015). Success rates surpass 90% and are maintained at up to 20-year follow-up with low complication rates. They remain the most commonly performed procedure for SUI in women and are recommended as a primary surgical treatment for SUI by the 2017 American Urological Association Guidelines (Kobashi et al., 2017) and the 2016 European

Association of Urology Guidelines (Burkhard et al., 2017).

Contrary to the widespread fears of mesh complications, adverse events with mesh mid-urethral sling (MUS) are uncommon. In a landmark population-based study of all incontinence procedures performed in Scotland from 1997 to 2016, mesh slings had fewer immediate complications and lower risk of future prolapse surgery than Burch colposuspension (Morling et al., 2017). Of course, no surgery is without risks, and surgeons must understand how to appropriately counsel patients before undergoing surgery and to diagnose and treat complications should they occur. In this chapter, we address the complications of polypropylene type I mesh used for the treatment of stress incontinence in women and men, as well as mesh-augmented repairs for prolapse of the anterior and posterior compartment in women as well as vault prolapse repair with abdominal sacrocolpopexy (ASC) mesh.

The terminology surrounding mesh-related complications has varied over time. The International Urogynecological Association (IUGA) and the International Continence Society (ICS) jointly have proposed a system of definitions of mesh complications that will be used in this chapter (Haylen et al., 2011). “Erosion” is a generic term that implies that tissue has been “worn away by friction or pressure” (*Stedman's*, 2005); hence it should not be used. **Exposure** is a “condition of displaying, revealing, exhibiting or making accessible” (*Stedman's*, 2005), which correctly defines mesh that is visible through separated or non-healing vaginal epithelium (Fig. 126.1A). **Extrusion** is the “passage gradually out of a body structure or tissue” (*Stedman's*, 2005), such as a loop of mesh sling protruding in the vagina or bladder not via the surgical incision site (Fig. 126.1B), and **perforation** is an “abnormal opening into a hollow organ or viscus” (Fig. 126.2) (*Stedman's*, 2005). **Contraction** is when the mesh exhibits “shrinkage or reduction in size,” and **prominence** occurs when there are “parts that protrude beyond the surface.” such as with wrinkling, bunching, or folding of the mesh without evidence of epithelial defect.

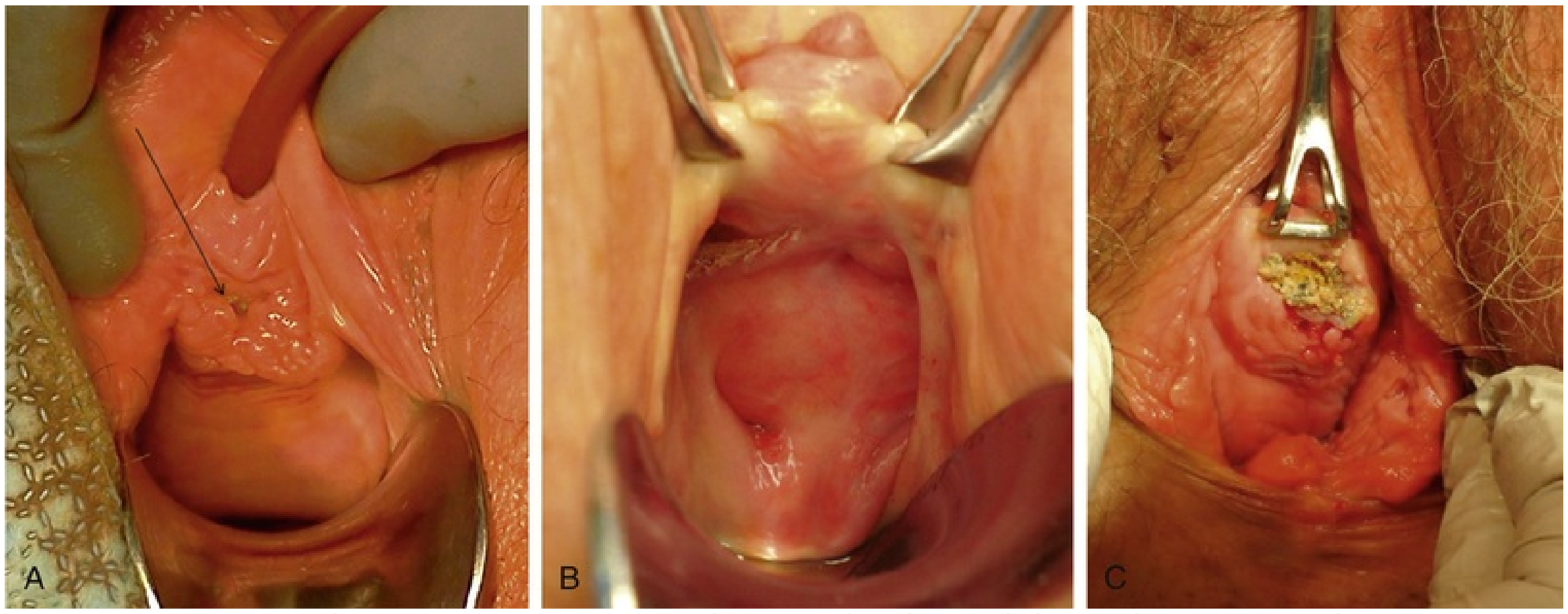

FIG. 126.1 Three examples of mesh complications. (A) Mesh exposure in the vagina from a mid-urethral sling. The incision for placement of the sling has separated and the mesh is visible. A vertical incision to access this mesh would allow for excision. (B) Mesh sling extrusion, where the mesh has gradually passed out of the vaginal epithelium away from the original incision. A horizontal incision along the area of the mesh would allow excision. (C) A pelvic organ prolapse mesh exposure/extrusion that is significantly calcified. The mesh became exposed at the original incision but has continued to become more extruded over time. Note a small central defect in the mesh where it has been trimmed in the office previously. This will require a maximal vaginal mesh excision to resolve.

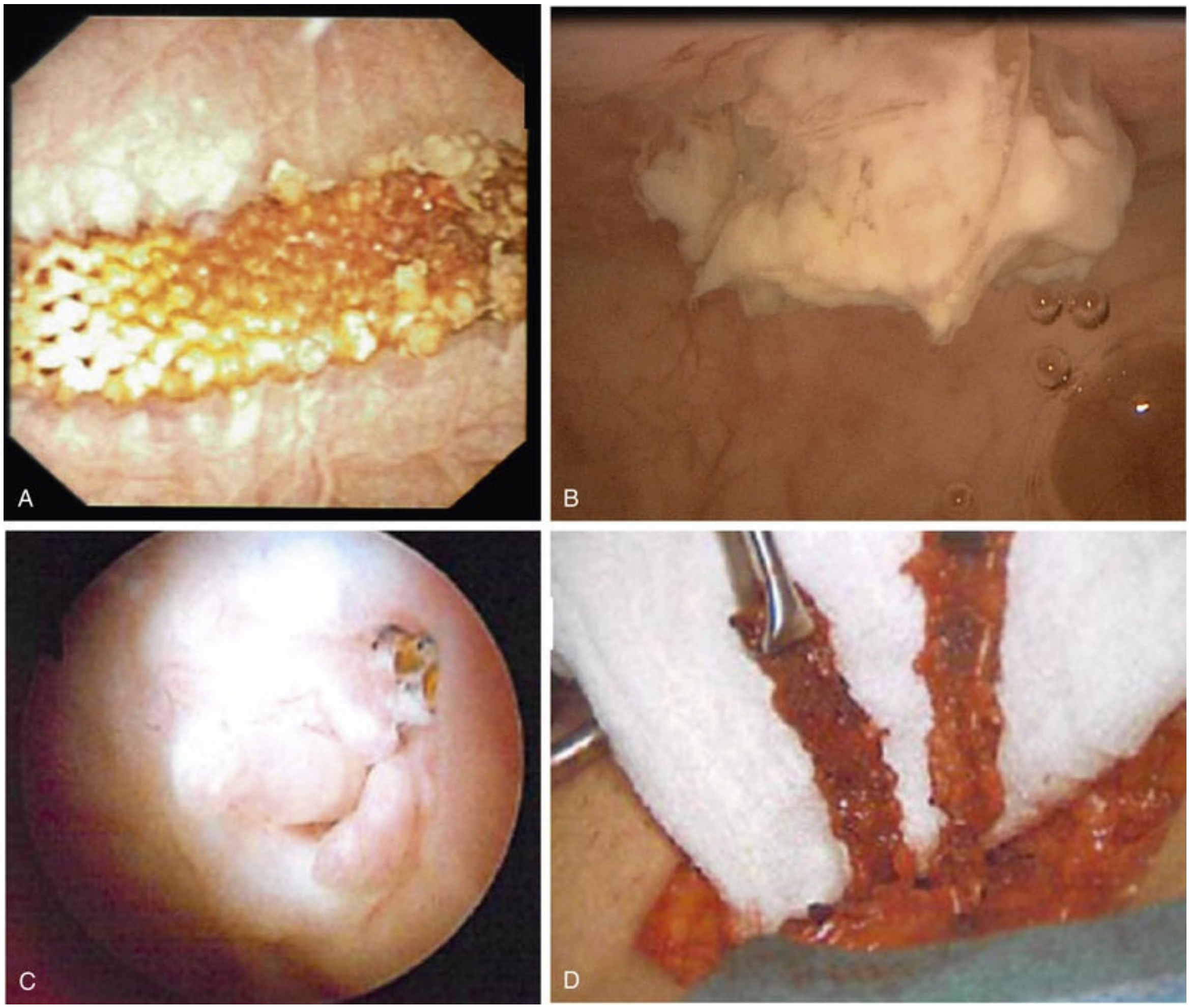

FIG. 126.2 These are all examples of bladder perforations of mesh slings. (A) A calcified mesh sling perforating the lateral bladder wall. This was discovered on computed tomography for other purposes. (B) Mesh sling at the dome seen on cystoscopy for hematuria and urgency. (C) Small mesh perforation of a mesh sling in the lateral wall of the bladder. The patient had severe pelvic pain with voiding and wanted the entire abdominal mesh removed. The arms have been located and are being dissected down to the bladder in (D).

Mesh and Its Properties

Polypropylene mesh has been widely used in surgical procedures for more than 50 years. Its success at preventing hernia recurrence has led to its use in other body compartments. Unlike the abdominal wall, the vagina has unique properties that may complicate mesh implantation, such as its significant physiologic stretch; proximity to the bladder, urethra, and rectum; and abundant microbiota.

Numerous adverse outcomes have been described with vaginal mesh implantation, including mesh infection, chronic pain, dyspareunia, vaginal exposure of the mesh, mesh shrinkage, perforation of mesh into surrounding structures, and lower urinary tract symptoms. However, there are also clear advantages to mesh over native tissue or cadaveric tissue/xenografts, including avoidance of potentially morbid harvests, lack of human or animal products that put the patient at risk for disease transmission, moderate cost, versatility, and durability (Chughtai et al., 2017).

Several mesh products have been used as mesh slings over the years with varying success and complications. According to the system proposed by Amid (1997), meshes are classified as types I to IV based on pore size. Type I mesh is macroporous with pore size greater than 75 µm. Examples of type I mesh are polypropylene and Marlex. Marlex is a woven monofilament polypropylene. It is one of the stiffest mesh materials with a propensity to wrinkle and a high extrusion rate (Morgan et al., 1995). In contrast, polypropylene is a monofilament knitted graft that is softer and more compliant than woven configurations and has larger interstices resulting from the loose knit (1500 vs. 600 µm), increasing elasticity (Gomelsky and Dmochowski, 2007). In addition, its melting point of 160°C allows it to be autoclaved. It is currently the only recommended implantable vaginal mesh for slings and pelvic organ prolapse (POP) (Chapple et al., 2017).

Type II meshes are microporous and include polytetrafluoroethylene, also known as Gore-Tex. Gore-Tex is polytetrafluoroethylene (Teflon) that has been thermomechanically expanded into a microporous mesh with a pore sized 10 µm. It becomes encapsulated in the body, which deters tissue integration, preventing adhesions. Despite success with small patch slings, more than 30% of full-length slings have required excision (Weinberger and Ostergard, 1996). Type III grafts, such as Mycromesh, have large macropores or perforations in a microporous base material (Gomelsky and Dmochowski, 2007). Other examples of type III mesh include Mersilene, which is a knitted polyethylene (polyester) that has interlinks in each fiber junction, creating elasticity in both directions. With vaginal use, complications from Mersilene, such as extrusion requiring excision and voiding symptoms, approached 20% (Young et al., 2001). Type IV grafts have submicronic pore size and include silicone grafts and silicone-coated mesh. Vaginal extrusion and sinus formation have been reported in up to 40% of cases with the use of type IV grafts (Comiter and Colegrove, 2004).

Pore size is critical to wound healing and mesh integration by the body. Smaller pore size in woven grafts allows bacteria (1 µm) to enter but restricts entry of host macrophages and lymphocytes (50 µm), impeding immune response. When pores are large, such as with polypropylene type I mesh (approximately 1500 µm), fibrocollagenous tissue ingrowth can occur, which allows the mesh to integrate into the local tissue, providing strength and support (Gomelsky and Dmochowski, 2007). Modifications have been attempted to improve tissue acceptance, such as injection of bovine collagen (ProteGen) or novel welding techniques (Urotype/Obtape), but these have produced unacceptably high rates of exposure and fistula formation (Domingo et al., 2005; Kobashi et al., 1999).

With long-term use of mesh in the vagina there has been the opportunity to follow women over many years for complications. Mesh has been hypothesized to increase cancer risk because of chronic foreign body response. This theory has been disproved with population-based studies **that showed no increase in pelvic or any other cancer diagnoses in women followed for 6 years after implant** (Chughtai et al., 2017). **Similarly mesh implantation has not been associated with the development of autoimmune diseases over long-term follow-up** (Chughtai et al., 2017). There is, however, moderate vaginal tissue fibrosis in more than half of patients, and almost all have giant cell reaction that occurs after vaginal mesh placement. Interestingly, those patients with extrusion or pain have less inflammation noted on histopathology than patients with voiding dysfunction, but overall mild inflammation predominates (Hill et al., 2015).

The USFDA approved surgical mesh for repair of POP and SUI in 2002, and these techniques were rapidly adopted. The FDA released its first Public Health Notification 6 years later, after more than 1000 mesh-related complications had been reported (FDA, 2011). This 2008 statement advised care providers that mesh has the potential for complications. In a more forceful warning in 2011, the FDA stated “serious adverse events associated with mesh use are not rare” and that “transvaginal mesh placement in pelvic organ prolapse repair does not conclusively improve clinical outcomes over traditional non-mesh repair in all patients with POP and it may expose patients to greater risk” (FDA, 2011). This warning did address ASC and concluded that “mesh placed abdominally for POP repair appears to result in lower rates of mesh complications compared with transvaginal POP surgery with mesh.” Public hearings after this warning led to an order in 2016 to reclassify POP mesh medical devices from class II, which generally includes moderate-risk devices, to class III, which identifies high-risk devices, and a second order that requires manufacturers to submit a premarket approval (PMA) application to support the safety and effectiveness of surgical mesh for the transvaginal repair of POP. The 2011 notification did not address slings for SUI, and an update was issued in 2013 to address mesh slings specifically. In contrast to its caution regarding POP mesh, **the FDA stated that “the safety and effectiveness of multi-incision slings is well-established in clinical trials that followed patients for up to one-year.”** Mesh slings for SUI remain class II devices.

These warnings have had an impact on clinical practice, particularly for POP. In a Medicare population the use of mesh in prolapse repair was only 2% in 2005 and increased to 35% in 2008. With the 2008 warning mesh use plateaued and then started to decrease in 2011 (Wang et al., 2015).

Following FDA guidelines and informing all patients that mesh will be used for their procedure is mandatory as well as providing them with written information on their product. Given the medicolegal controversy surrounding mesh, before any mesh excision it is advisable to have a standard consent form for mesh removal as well as an institutional policy for the handling of mesh being returned to patients if they desire it.

It is important to keep in mind that mesh removal is not without its own complications and the more mesh removed the greater the risks. It has been shown that more mesh removal leads to an increase in recurrent prolapse (Marcus-Braun and Theobald, 2010) and incontinence as well as excess bleeding (Pickett et al., 2015). Mesh becomes embedded in tissue and does require significant dissection to remove.

Key Point: How Much to Remove

- Surgeons should aim to remove enough mesh to correct the problem and prevent future mesh complications. Removal of all the mesh is rarely required, and removing asymptomatic mesh is never indicated.

Mesh Slings for Stress Urinary Incontinence

Unfortunately, pelvic floor dysfunction is very common: stress incontinence affects approximately one in three women and POP one in nine (Slieker-ten Hove et al., 2009). Both are strongly related to obesity, smoking, childbearing, and advancing age, and their prevalence appears to be increasing. Over the last 20 years, the lifetime risk of a woman requiring surgery for POP or SUI has risen from 11% to approximately 20% (Gyhagen et al., 2013; Smith and Koelbl, 2010).

Stress incontinence can be treated conservatively with pelvic floor physical therapy, vaginal inserts, or a pessary, but if these are not effective, a surgical approach is the next step. There are four well-established surgical treatments: urethral bulking agents, Burch colposuspension, autologous fascial pubovaginal slings (AFPVS), and multi-incision synthetic mesh mid-urethral slings (MUS) (Kobashi et al., 2017). In regard to single-incision, or “mini-slings,” “physicians may offer single-incision slings to index patients undergoing mid-urethral sling surgery with the patient informed as to the immaturity of evidence regarding their efficacy and safety” (Kobashi et al., 2017). Synthetic MUS are the most commonly performed procedure for SUI in women because they are equally as effective as the Burch and AFPVS with less surgical morbidity.

Risk Factors for Mesh Sling Complications

Avoiding mesh complications is by far the best strategy for the surgeon performing mesh MUS. There are clear contraindications to mesh implantation in the vagina, including women who are having a simultaneous urethrovaginal fistula, mesh urethral perforation, or urethral diverticulum repaired given the extensive urethral dissection in these procedures (Kobashi et al., 2017).

Other less well-defined risk factors for mesh exposure or extrusion include prior (not concurrent) urethral fistula repair, prior diverticula surgery, pelvic radiation or the presence of significant scarring, and poor tissue quality. Other potential patient risk factors include extremes of age, smoking, obesity, and low estrogenization of the vagina. These should be considered in the decision to use a mesh or non-mesh approach.

Risk factors for urinary retention after a mesh sling procedure include having had a prior SUI surgery and having concomitant vaginal apical suspension (Unger et al., 2016). Women with increased medical comorbidities (Charlson comorbidity index ≥1) are also at greater risk of failing their initial voiding trial (Ripperda et al., 2016).

Mesh Complications Among the Three Slings

Intraoperative bladder injuries occur in 4.8% of retropubic tension free vaginal tape (TVT) sling procedures. Transobturator (TOT) sling and mini-sling approaches have much lower rates of bladder injury (0–0.6% for obturator slings and mini-slings) (Fusco et al., 2017). Vaginal mucosal injury occurs in 1.6% to 7.1% of slings. Blood loss for all sling procedures is typically less than 50 mL; however, major vessel injury can occur with the retropubic approach (<1/1000) and may be life threatening (Ford et al., 2015; Kenton et al., 2015; Martinez Franco and Amat Tardiu, 2015; Mostafa et al., 2014). In addition, symptomatic pelvic hematomas occur more often in retropubic slings (1.7% vs. 0.3% in TOT slings) (Fusco et al., 2017).

Several randomized controlled trials (RCTs) showed similar mesh exposure rates with the three configurations of slings (0.7%–4.4% at 1 year) (Ford et al., 2015). This is in contrast to the mesh used in vaginal prolapse repair, in which the rate is much higher at 10% to 12% (Abed et al., 2011; Glazener et al., 2017), likely because of the greater surface area of mesh placed.

Groin pain is much more common after obturator (12%–26%) and mini-sling (~1.5%) approaches and likely relates to passage of the tape near the adductor muscles, but groin pain has been reported after retropubic sling. Voiding dysfunction resulting from obstruction is more common after retropubic slings (0.3%–7%) than the TOT slings (0–4%) or mini-slings (1.4%–1.7%). De novo symptoms of overactive bladder occur in 0 to 7% of cases and may be related to obstruction, which should be ruled out (Ford et al., 2015; Fusco et al., 2017; Kenton et al., 2015; Mostafa et al., 2014). Rarer complications include bowel perforation, nerve injury, and obturator/vaginal abscess (all <1%). Overall in long-term population studies 5.9% of women will require a mesh revision over 5 years (Keltie et al., 2017).

A thorough history including review of prior operative reports (from mesh implantation and attempts at excision) as well as a good speculum pelvic examination are required in all cases of suspected mesh complication. Cystoscopy can be performed if there is any suspicion of mesh perforation into the bladder. These perforations can be accompanied by hematuria, recurrent infections, LUTS, or sharp bladder pain, particularly when voiding. The time elapsed from surgery does not exclude the possibility of a complication: patients who had slings placed decades ago can still have new mesh exposures (Khanuengkitkong et al., 2013).

Bladder Outlet Obstruction and New Urgency and Urgency Incontinence

Bladder outlet obstruction (BOO) can easily be diagnosed in the woman after sling placement who has frank retention or elevated postvoid residuals. Also women with new obstructive urinary symptoms such as straining, double voiding, slow stream, or the need to assume unusual positions such as crouching to void are obvious and often do not require urodynamics to diagnose. It is important to determine the temporal association of the retention. **Women with prior difficulty emptying may have underlying pathology such as detrusor underactivity or diabetes, but in women who voided well before sling placement the cause is most likely the sling. In contrast, new or worsening urgency urinary incontinence (UUI) or urgency may be secondary to BOO from the sling, or it may simply be the result of bladder overactivity**. Women without overt retention often take longer to diagnose (on average 6 months) (Crescenze et al., 2016), which is concerning because irreversible bladder remodeling can occur with long-term bladder obstruction (Leng and Chancellor, 2004). Urodynamics are required in this instance, particularly in the woman who has failed a short course of antimuscarinics for urgency after sling placement. New-onset recurrent urinary tract infections after a sling may also be the presentation of BOO, and urodynamics are indicated to determine if this is the case.

Urethral dilation is ineffective in the setting of BOO from an obstructing sling and puts the patient at risk for urethral extrusion of the mesh with the dilation traumatizing the tissue over the inflexible mesh (Velemir et al., 2008). If the patient is improving, short-term voiding dysfunction can be managed expectantly for up to 6 weeks. However, if the patient is in retention, intervention should be much sooner because it is unlikely to resolve (Committee Opinion 694, 2017). If done within the first week, the sling can be loosened by opening the vaginal incision, placing an instrument around the mesh, and tugging. If the sling is embedded in the tissue and does not loosen, then the sling can simply be divided. Any frayed edges should be trimmed away from the incision. Before division of the sling, the amount of urethral mobility can be assessed by pulling on the catheter; after division, this should be appreciably improved.

Vaginal Mesh Exposure and Extrusion

Mesh exposure and extrusion likely occur as a result of a delayed infection of the incision or mesh, a vaginal hematoma that leads to separation of the incision, excess tension on the graft, or inadvertent injury to the vagina with mesh placed too superficially within the vaginal wall (Chermansky and Winters, 2012). **Exposures and extrusion occur with persistent bleeding, vaginal discharge, dyspareunia, partner pain, recurrent UTIs, or pelvic pain.** All of these concerns warrant a pelvic exam (Committee Opinion 694, 2017). Small exposures can sometimes spontaneously re-epithelialize, especially in the early postsurgical period, and this can be facilitated with short-term topical estrogen (Committee Opinion 694, 2017).

Different approaches have been reported, such as laparoscopic mesh removal (Rouprêt et al., 2010); however, **most surgeons aim to only remove the offending part of the sling, which can be accomplished vaginally in most cases.** Surgical excision of the mesh is typically performed under general anesthetic. If the mesh location is visibly exposed or obvious on palpation, an incision can be made either vertically midline or along the mesh horizontally (particularly if there is a large exposure) (see Fig. 126.1B). If the mesh is not appreciated on exam, an inverted U-shaped incision offers maximal exposure to explore for the mesh and allows the flap to be extended proximally as needed. Before incision, hydrodissection with 1% lidocaine with epinephrine facilitates flap creation by maximizing epithelial thickness over the mesh. The surgeon should not accidentally divide the mesh while making the vaginal incision because this makes mesh localization difficult. If the mesh is not easily palpated, a metal instrument can be used to sound over the dissected space because mesh can be “felt” as a scratching over the area. Alternatively, intraoperative translabial ultrasound can localize mesh very accurately (Staack et al., 2014). Mesh is not always located in its expected location mid-urethrally. It can be found as distal as the urethral meatus and can migrate proximally past the bladder neck. Once the mesh is found, careful blunt and sharp dissection is performed to expose the full width of the sling lateral to the urethra. This careful exposure allows easy passage of an instrument behind the sling, avoiding injury to the urethra. The instrument is then spread and the sling cut. Each arm can be dissected laterally to the lateral sulcus of the vagina and with tension divided as far as the surgeon can safely pass the scissors. If the mesh exposure is small, the surgeon can consider removing at least a centimeter of mesh around the defect (Fig. 126.3). Care must be taken not to blindly dissect laterally, especially with obturator slings, because there are many vessels in this location and a postoperative hematoma of the vulva can result (Fig. 126.4). Care must also be taken not to injure the urethra when passing the instrument behind the sling. If the urethra is injured, it should be repaired in layers and a catheter left in place. The vaginal mucosa is closed with a running 3-0 absorbable suture. Patients can have their catheters removed before discharge, unless bladder or urethral injury is noted.

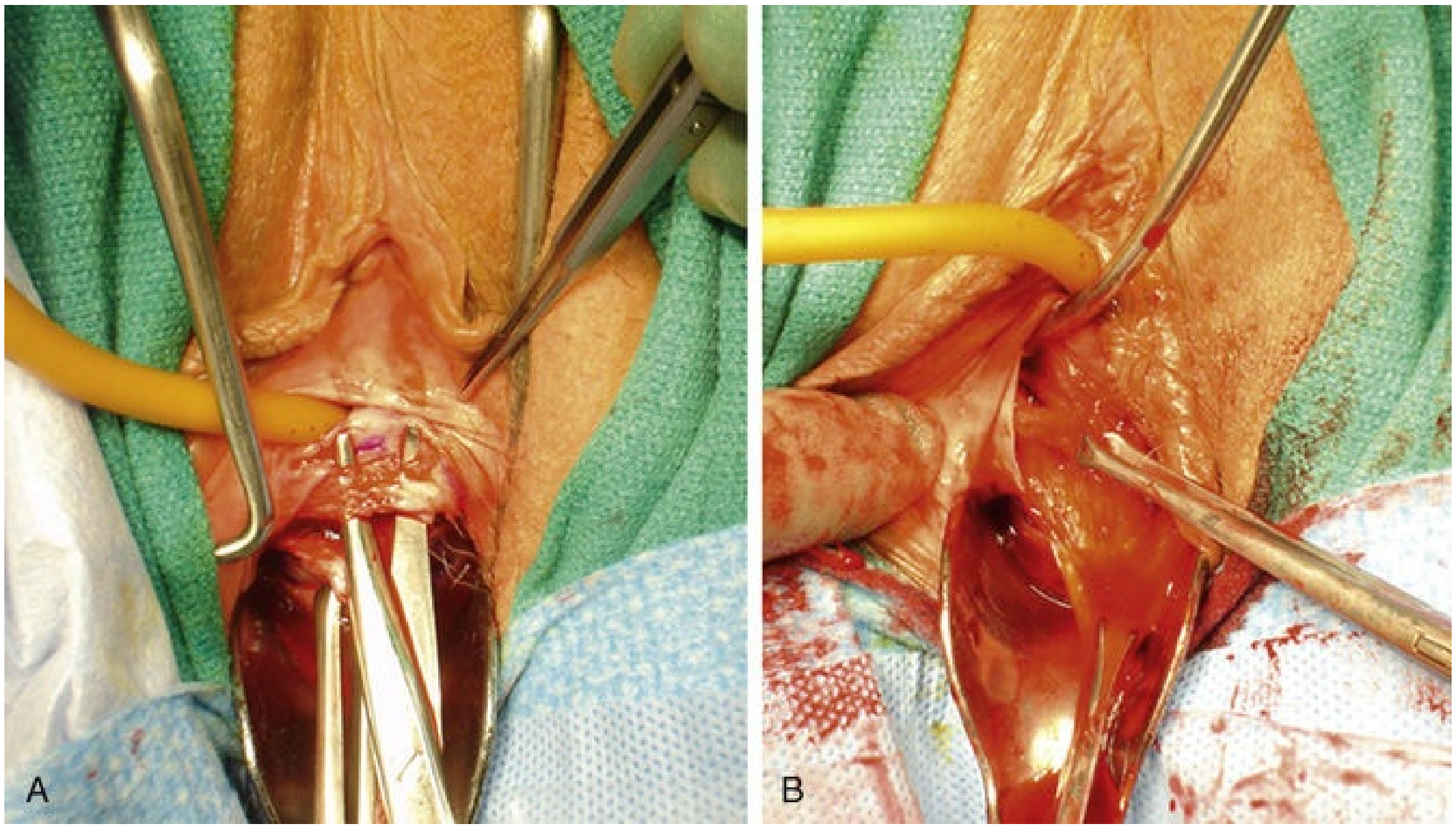

FIG. 126.3 This is the “divide-and-conquer” technique for mesh sling removal. (A) Once the mesh is found and the edges defined, an instrument (with sharp tips pointing out) is passed behind the sling lateral to the urethra and divided. (B) The arms can then be used for traction to easily dissect them as far as needed for resection.

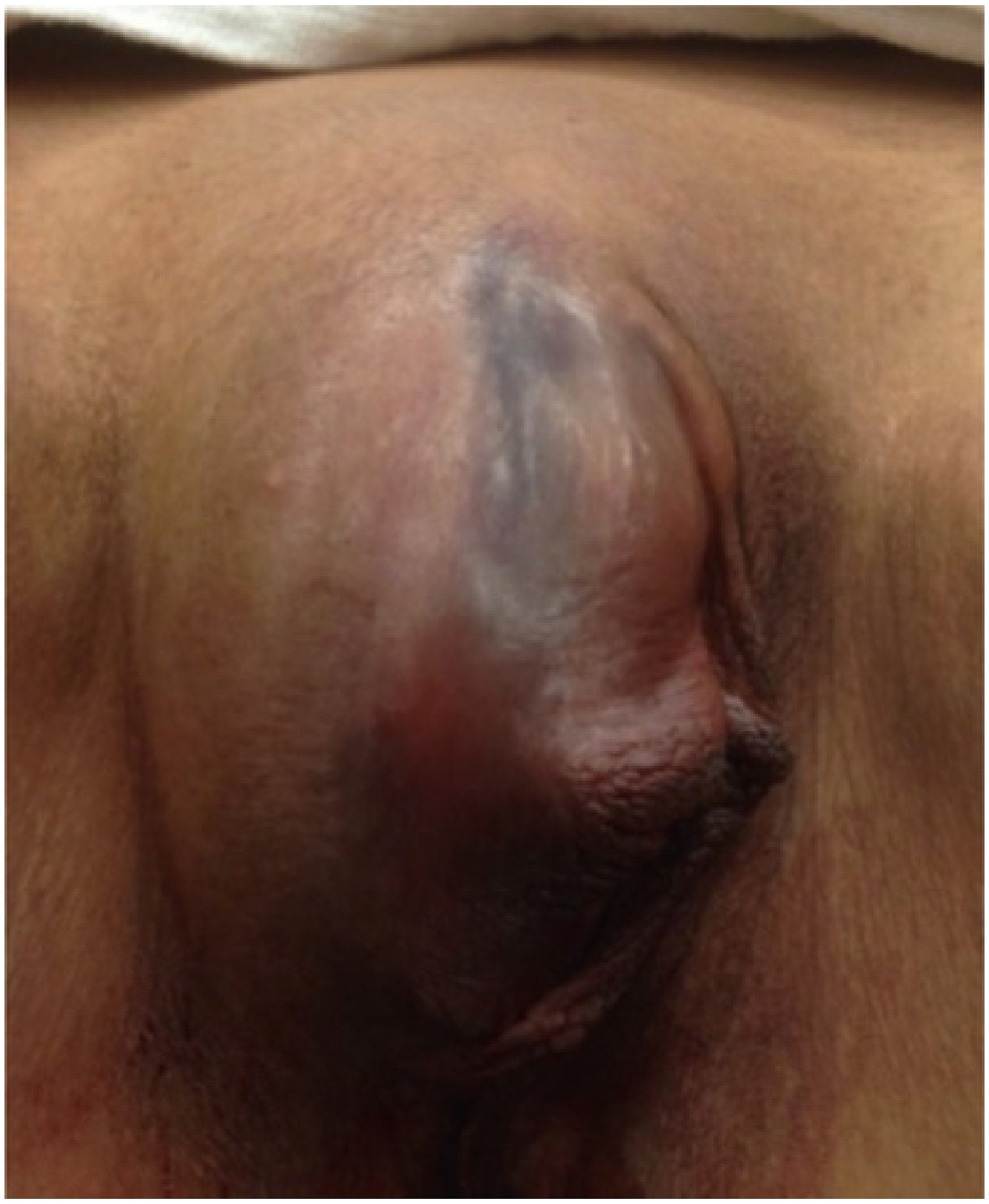

FIG. 126.4 This is a rapidly expanding vulvar hematoma after vaginal removal of an obturator sling. Patient required open evacuation via the vaginal incision, and the bleeding resolved with suture ligation of bleeding and vaginal packing.

Vaginal, Pelvic, and Thigh Pain

Pain after an MUS in the absence of other complications such as exposure or retention is a diagnostic challenge. It requires a detailed history of prior pain conditions (fibromyalgia, endometriosis, dyspareunia) and a focused physical exam of the pelvic floor attempting to isolate the source of the pain.

Preoperative risk factors for the development of pain after a sling include younger age, pain conditions such as fibromyalgia, or preexisting pelvic pain (Geller et al., 2017). Pain has been proposed to be caused by mesh shrinkage, excess tension on surrounding structures, obturator neuralgia, or muscle hypertonia from mesh being placed through pelvic floor muscles (Rigaud et al., 2010).

Pain that is severe and occurs acutely after a sling placement in the absence of other complications should be evaluated immediately. Many chronic mesh pain patients describe their pain as occurring immediately postprocedure. Although this is untested, it would seem legitimate to consider rapidly removing a mesh sling in the case of severe postoperative pain because mesh removal procedures are straightforward before tissue ingrowth (Rigaud et al., 2010). Before proceeding with mesh removal, the urologist should obtain cross-sectional imaging to rule out hematomas, because they are a common cause of discomfort and will likely resolve over time.

Diffuse pelvic floor hypertonicity or unilateral levator hypertonicity will benefit from oral analgesia and pelvic floor physical therapy or trigger point injections as a first step. Dyspareunia can also be the result of vaginal atrophy and lack of lubrication rather than the sling, and a trial of vaginal estrogen should be considered in postmenopausal women. Point tenderness over the sling or failed conservative treatment warrants consideration of mesh excision.

Removal of the entire vaginal portion of the sling reduced pain from 5.3 to 1.5 (on a 10-point scale), and 81% of women considered themselves pain free. If the indication for mesh removal is vaginal pain, it is important that as much vaginal mesh as possible is removed because persistent pain can be very difficult to treat if mesh is left behind. Patients with persistent pain after mesh removal tend to report diffuse pelvic pain (Hou et al., 2014) and should be treated conservatively with anti-inflammatory agents, topical estrogen, or physical therapy.

Groin Pain

Transient groin pain occurs frequently after TOT sling but typically lasts only a few weeks. Pain that is persistent and recalcitrant to conservative therapy such as oral analgesia, local injection, or steroid/nerve blocks can be treated with TOT excision of mesh. This can be accomplished via TOT foramen dissection combined with a vaginal dissection (Reynolds et al., 2012). Lateral groin incisions are made over the inferior pubic ramus at the level of the obturator foramen. This approach requires division of the adductor brevis medially, which is the most superficial muscle over the foramen. The obturator externus is directly below, and the mesh can be found within. After vaginal exposure of the mesh and dissection vaginally to the obturator foramen, traction on the mesh can facilitate localization of the mesh in the thigh. In the case of prior vaginal mesh removal, obturator exploration alone can be performed but is very challenging without the vaginal end for traction (Reynolds et al., 2012). Once the mesh is found, it is dissected medially toward the vaginal end of the mesh, and it is removed in a single segment. In a small case series, obturator foramen dissection resulted in complete pain resolution in 5 of 8 patients (Reynolds et al., 2012). This is not a straightforward dissection and may be unfamiliar to the urologist; orthopedic surgery assistance can be of value.

Complications of Vaginal Mesh Removal

Vaginal mesh sling removal can cause bleeding or injury to the vagina, bladder, or urethra, and mesh can become re-exposed over time. Severe bleeding is rare, but hematomas can be difficult to manage because they take significant time to resolve. Storage voiding symptoms can be refractory to sling excision. In women who develop UUI secondary to BOO from a sling 76% have persistent UUI after sling division (Crescenze et al., 2016). In women undergoing sling revision for BOO without concomitant urgency, up to 45% may develop de novo UUI after surgery.

After sling division or excision, the risk of recurrent SUI is not negligible. Reported rates of recurrent SUI vary from 20% to 74% (Clemens et al., 2000; Marcus-Braun and Theobald, 2010; Misrai et al., 2009; Moore and Goldman, 2013) and up to one-third will require another surgical procedure to treat it (Ramart et al., 2017). Bulking agents (Gaddi et al., 2014), repeat mesh sling (Parden et al., 2013), and autologous pubovaginal sling (Milose et al., 2016) have demonstrated success in women with recurrent or persistent incontinence after MUS or recurrent incontinence after sling removal. It is an individualized decision, but many patients with a sling complication requiring excision will be hesitant to have mesh implanted again.

After a simple sling division 95% of patients will have resolution of retention requiring catheterization, and 75% will have resolution of their obstructive symptoms (Crescenze et al., 2016). Persistent obstructive symptoms may be the result of continued obstruction from the sling, detrusor underactivity, or voiding dysfunction. Urodynamic studies are the most effective method of differentiating between these causes and determining the best course of action. If a repeat sling excision is indicated, a larger section of sling should be removed and a more aggressive urethrolysis performed to avoid continued obstruction.

Key Points: Mesh Removal Principles

- Mesh slings should be circumscribed and divided lateral to the urethra.
- The amount of mesh removed depends on the indication: retention requires only simple division; for exposure/extrusion, divide and remove mesh to at least a centimeter from defect; pain requires maximal vaginal removal and rarely, pubic or obturator arms.

Bladder Injury and Perforation/Extrusion

Bladder injury is far more common with retropubic than TOT trocars (4.8% vs. 0.6%) (Fusco et al., 2017) and is typically diagnosed on cystoscopy with a 70-degree lens during the sling placement. The trocar is seen at the dome/lateral wall of the bladder. **Complete filling of the bladder is required to evaluate for injuries because an underfilled bladder may obscure a small perforation.** Risk factors for trocar perforation include low body mass index (BMI; < 30) because there is less adipose tissue in the retropubic space displacing the bladder away from the pubic bone (Osborn et al., 2014) and prior incontinence surgery. Surgeons should ensure the bladder is completely drained before trocar passage and that the trocars remain in contact with the pubic bone during passage. The trocar must be rolled back and forth and the bladder mucosa examined to rule out intramuscular trocar placement, which is indicated by tethering or a trocar visible through thin mucosa. If not replaced, this can predispose a patient to future mesh extrusion into the bladder lumen. If a trocar perforation is detected in the bladder, the trocar is simply removed and replaced with great care (Fig. 126.5). Even if recognized and replaced correctly, bladder perforation does increase the risk of mesh extrusion into the bladder (Osborn et al., 2014). Missed bladder perforation can occur with pelvic or vaginal hematoma in the perioperative period; therefore if this complication does occur, suspicion for an unrecognized injury should be high (Osborn et al., 2014).

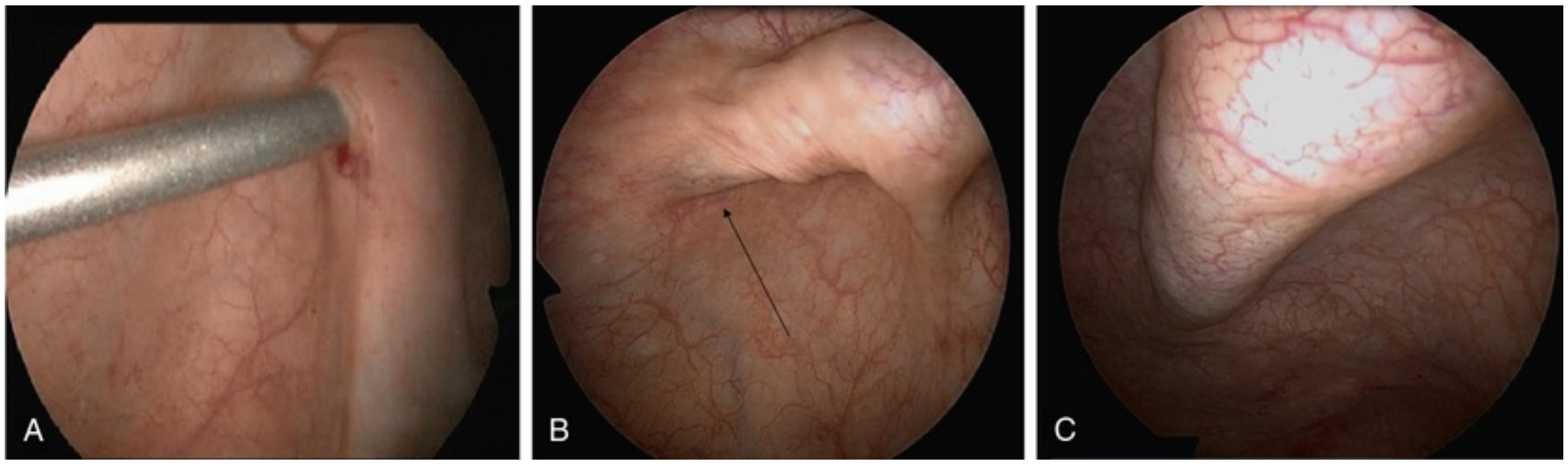

FIG. 126.5 These are different cystoscopic appearances of retropubic mesh sling trocars. (A) Clear perforation of the bladder with the metal trocar and requires removal and replacement. (B) Trocar in the detrusor muscle. It has not perforated the mucosa, but the metal is visible through the mucosa *(arrow)* and the bladder wall is wrinkled. (C) Same patient after removal and replacement of the trocar. The bladder is maximally filled and the indent in the bladder rolls smoothly; this is the correct placement of a trocar.

Bladder perforation/extrusion can present with irritative voiding symptoms (41%): vesicovaginal fistula, recurrent UTI, vaginal pain/dyspareunia, and hematuria (Osborn et al., 2014; Padmanabhan et al., 2012). These symptoms often occur immediately after sling placement and warrant a cystoscopy (Deng et al., 2007). If mesh is exposed to urine for prolonged periods, it will often form calculi that are seen on imaging (see Fig. 126.2A).

Bladder perforations can be treated with endoscopic resection or open cystotomy. Those bladder injuries that are close to the bladder neck or are after TOT sling placement can often be approached vaginally similarly to urethral injury. Endoscopic management has been performed with holmium laser, hysteroscopic scissors, or transurethral resection of the mesh with electrocautery loop into the bladder wall. If there is significant stone burden on the mesh, it should be treated first to clear the mesh. This approach is low morbidity and will often resolve symptoms (Foley et al., 2010). Following an endoscopic approach, the mesh is still embedded in the detrusor wall and will require monitoring for subsequent extrusion. If this occurs, open excision is advisable (Padmanabhan et al., 2012).

Transvesical removal of a larger section of mesh within and outside the bladder is a more definitive approach but has greater morbidity. It has been performed laparoscopically (Misrai et al., 2009) or via open abdominal incision (Foley et al., 2010; Shah et al., 2013).

With the patient under general anesthetic the prior pubic exit incisions from the retropubic sling can be marked as reference for where the arm of the sling will be expected. A cystoscopy confirms the laterality of the mesh perforation and allows placement of a ureteral access catheter if the mesh removal potentially compromises the ureteric orifice. A Pfannenstiel incision is made through skin and down to fascia and the superficial fascia exposed because the arms can often be found superficial to it. The offending arm once found can be used as traction and the fascia opened and the arm tracked down along the bladder. Only the mesh and its pseudocapsule are excised with an aim to remove no native tissue. Once the bladder is entered, the sling must be dissected past the defect and for another 2 cm to prevent the bladder closure from incorporating mesh. If the patient is not having vaginal pain, then the vaginal portion nor the contralateral arm need be removed. The resulting bladder defect can be closed in two layers with absorbable suture and the repair tested by filling the bladder via the catheter. With this approach there is almost no risk of re-extrusion of the mesh. If a patient had preexisting stress incontinence, this is an ideal opportunity to perform an autologous sling (Shah et al., 2013). The catheter can be removed 2 to 3 weeks postoperatively after a cystogram.

Mesh Perforation/Extrusion at Bladder Neck or Urethra

Mesh perforation or later extrusion at the bladder neck or into the urethra is a rare complication. It occurs because of an injury to the urethra or bladder neck during either the vaginal dissection or trocar passage. **If an intraoperative urethral injury is noted during dissection for placement of the sling, the surgeon must abandon mesh placement** (Kobashi et al., 2017). One should repair the urethral injury with absorbable suture and allow healing before undertaking any mesh procedure, given the extraordinary high risk of urethral extrusion of the mesh. Aggressive sling over-tensioning may also result in late urethral mesh extrusion, as can urethral dilations. As such, it is best to avoid urethral dilations and proceed to sling division if a patient is obstructed after sling placement.

Women with mesh in the urethra experience sharp pain during voiding or dysuria; retention; urgency; pelvic, urethral, and vaginal pain; hematuria; and recurrent infections. Symptoms often begin immediately after surgery (Deng et al., 2007; Velemir et al., 2008). A careful urethroscopy will reveal the mesh perforation (Fig. 126.6).

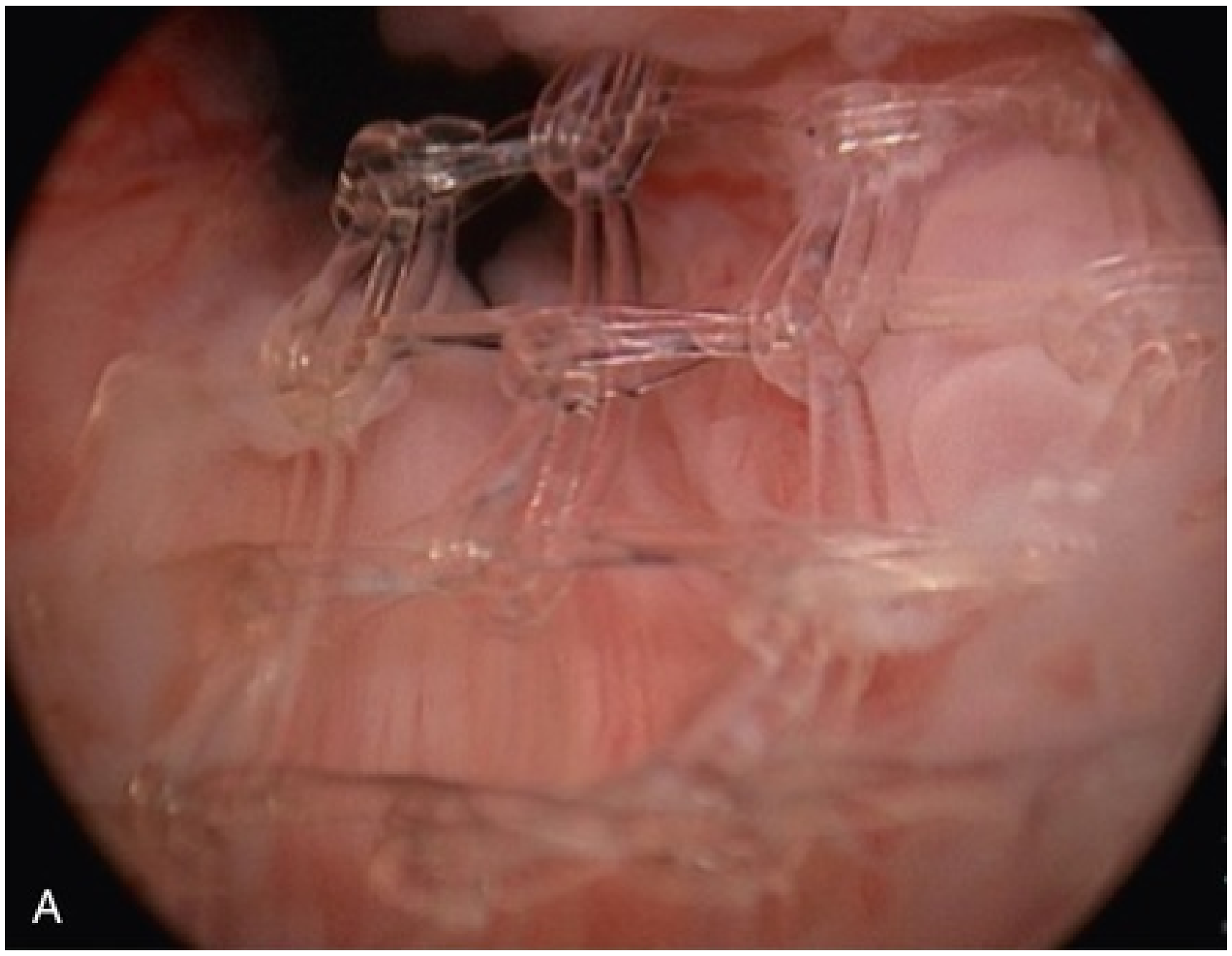

These are cystoscopic appearances of mesh perforation of the urethra. (A) Mesh perforating along the diameter of the urethra. This patient had minimal symptoms and was successfully treated with endoscopic scissors. (Courtesy J. Quentin Clemens.)

Velemir et al., 2008).

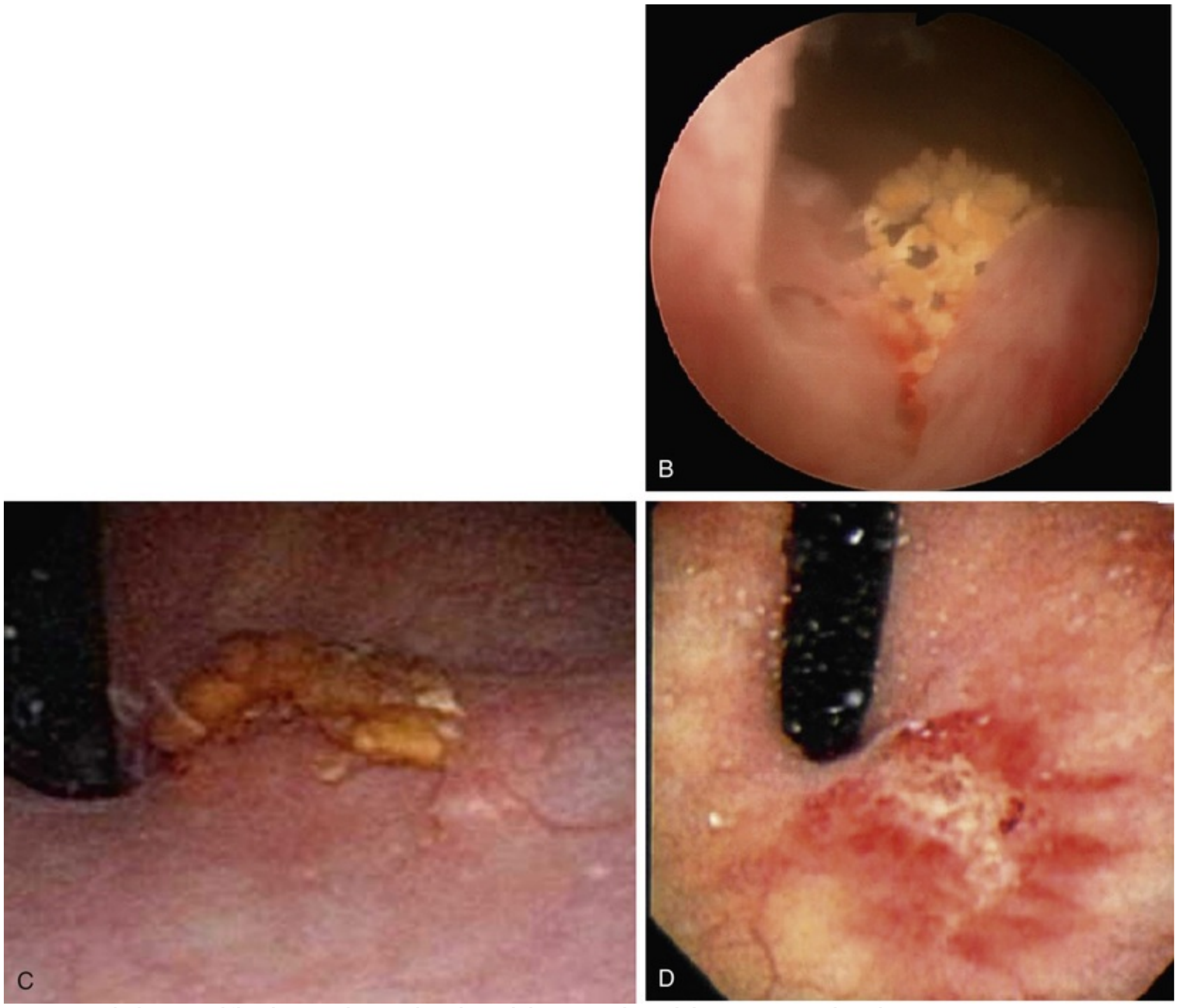

(B) Calcified mesh at the bladder neck. This woman had worsening of her incontinence after the sling placement along with severe voiding pain and recurrent urinary tract infections. She required urethrolysis and complete vaginal removal of the sling. (C and D) Mini sling. The perforated trigone/bladder neck was covered in stones on image C even after stone removal was symptomatic; hence it was removed vaginally (see Fig. 126.7). Note the proximity to the ureteric orifice in the right corner of image D.

FIG. 126.6

Endoscopic removal has been reported and can be accomplished with endoscopic scissors or a holmium laser. This is facilitated by traction placed on the mesh with an instrument passed along the cystoscope. Alternatively, a small nasal speculum can be used to directly access the mesh in the urethra for excision. This approach does leave mesh in the urethral wall that can extrude into the lumen in the future but is minimally invasive (Baracat et al., 2005; Velemir et al., 2008).

Urethrolysis with removal of entire vaginal mesh is a more definitive approach because no mesh is left near the urethra. After cystoscopy confirming the location of the injury, an inverted U-shaped flap is created after hydrodissection with 1% lidocaine. The mesh is found lateral to the urethra on the opposite side of the mesh injury if possible. The arm on the uninjured side is dissected up to the lateral sulcus and divided. The mesh is then carefully peeled off the urethra, knowing that it traverses the urethra proper, taking care to not excise any tissue and just remove the sling. Once the urethra is entered, care must be taken to create the smallest defect possible. Overdissection of the urethra can injure the continence mechanism or increase the risk for stricture. In the case of mesh in the bladder neck, if the initial cystoscopy reveals mesh near the ureteric orifice, a temporary ureteral access catheter can be placed for safety.

If the mesh perforates the urethra along its diameter, the urethra may have to be entered via a midline urethrotomy to facilitate complete extraction of the mesh. Alternatively, the mesh can be divided in the lumen with a cystoscope and hysteroscopic scissors and the arms dissected lateral to the urethra and pulled through each side, leaving only two small defects where the mesh was perforating (see Fig. 126.6).

Careful closure is necessary to prevent urethrovaginal fistula formation. The urethra is closed primarily with absorbable suture and a periurethral fascial layer developed and closed over the injury where possible (Deng et al., 2007). If there was a fistula associated with the mesh in the urethra or tissue quality is poor, the surgeon may consider a Martius flap to cover the defect, particularly if the patient will desire a future sling. The vaginal flap is then advanced and closed using a running absorbable suture avoiding overlapping suture lines. If the patient has a concomitant urethral stricture, a formal urethroplasty with buccal mucosa can be performed to correct the defect (Fig. 126.7).

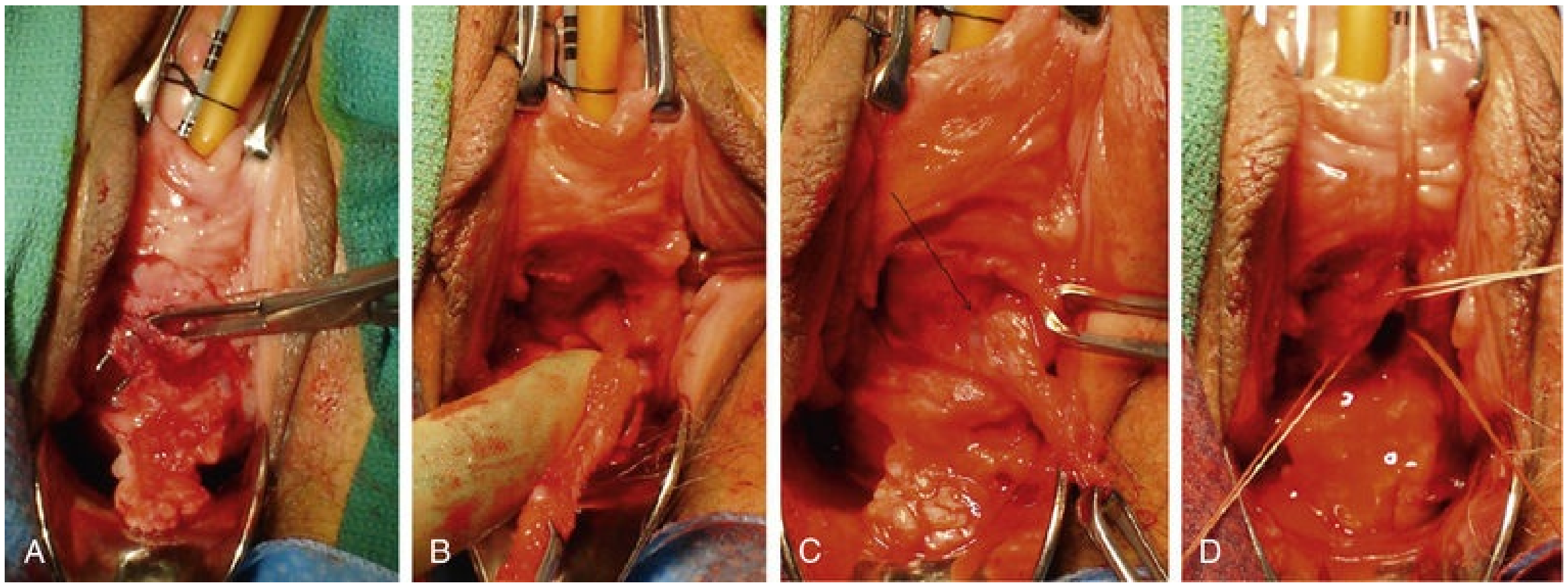

FIG. 126.7 These are the steps of mesh excision from the urethra/bladder neck from Fig. 126.6C and 126.6D. (A) The mesh has been localized and is being circumcised and divided. Note the ureteric access catheter placed to allow localization of the ureter. (B) The uninvolved right side of the sling has been excised, and the left arm is being dissected toward its perforation. (C) The mucosa of the bladder neck *(arrow)* is visible as the perforation is just about to be entered. (D) The resulting defect is closed after the mesh is removed.

Forty-two percent of patients develop SUI after intraurethral mesh excision (Starkman et al., 2006); however, the simultaneous placement of an autologous fascial pubovaginal sling significantly lowers that risk. New or persistent urgency and urgency incontinence is also very common (Starkman et al., 2006).

Key Point: Bladder and Urethral Perforations

- Bladder and urethral perforations are difficult complications to treat and can be managed endoscopically or open; the open approach is more thorough but associated with potentially greater morbidity.

Transvaginal (Anterior and Posterior Wall) Mesh Complications

Mesh kits for the treatment of anterior and posterior compartment prolapse have been used since 2004. Although anterior mesh was decreasing in use since the FDA warnings (Wang et al., 2015); both anterior and posterior mesh have been withdrawn from the market; many patients have already had these implants and may be seen at a later date with complications requiring treatment.

Nearly all surgical mesh devices used for these procedures are composed of nonabsorbable synthetic macroporous polypropylene (type I). Many different manufacturer kits are available with different shapes, anchoring devices, and configurations and are placed via midline vaginal incision on the anterior or posterior vaginal wall. Because each product has variations in its attachments, obtaining the original operative report of mesh placement is extremely valuable (Committee Opinion 694, 2017).

Mesh kits were developed to increase the ease and durability of POP repair. Native tissue repairs have been reported to have failure rates as high as 30% to 97% in the anterior compartment (Maher et al., 2016). However, this perceived inferiority has been brought into question with a recent large randomized controlled trial comparing primary transvaginal anterior or posterior repair using native tissue, biologic graft, or mesh placed transvaginally. This largest trial of its kind ($n = 1358$) found that after 2 years there were no differences in POP symptom scores or POP-related quality of life. Non–mesh-related adverse events such as UTI, urinary retention, and dyspareunia were not different between groups (~7%); however, 12% of the mesh group suffered a mesh-related complication, and three-quarters required either total or partial surgical excision (Glazener et al., 2017).

Mesh exposure or extrusion can present with serosanguineous or seropurulent discharge, dyspareunia, pelvic pain, or irritation to the partner's penis from exposed mesh (hispareunia) (Khrucharoen et al., 2018). Extrusions have been reported to occur up to 8 years after mesh placement; therefore any patient with mesh and symptoms requires an examination (Marcus-Braun and Theobald, 2010). Small mesh exposures (<1 cm) can be asymptomatic in up to 60% of women (Cheng et al., 2017). The rate of exposure is 10.3% to 12% (Abed et al., 2011; Glazener et al., 2017), with 5.1% to 8% requiring mesh removal (Dandolu et al., 2017; Diwadkar et al., 2009; Glazener et al., 2017).

Mesh contraction (shrinkage) occurs in 11.7% (Caquant et al., 2008) and is unique to POP mesh because a much larger volume of mesh is implanted. It can cause dyspareunia, vaginal shortening, and vaginal tightening. Another unique complication of POP mesh is folding and wrinkling of the mesh, creating a prominence that has no epithelial separation but can cause patient or partner pain with intercourse. This is seen on examination as palpable tight bands or heaped up areas that are tender to palpation. Patients can also have vaginal constriction or obstructed defecation after transvaginal mesh (Abbott et al., 2014).

Mesh perforation into the bladder (Altman et al., 2011; Caquant et al., 2008)

(0.7%–3.5%) in the case of anterior compartment POP repair and into the rectum (Caquant et al., 2008) (0.15%) from posterior repair can occur with pain, fistula formation, or, in the case of bladder perforation, recurrent hematuria, UTIs, or voiding-related pain. This is fortunately rare with a fistula rate of 0.2% reported (Caquant et al., 2008; Diwadkar et al., 2009). Other rare complications include pelvic hematoma (1.9%) and pelvic abscess (0.29%). Most patients (70%) experience multiple symptoms, and it is uncommon to have only one distinct complaint (Abbott et al., 2014).

Surgical risk factors for mesh exposure are a higher volume of mesh implanted (such as dual-compartment or POP mesh combined with a mesh sling) (Chughtai et al., 2017; Dandolu et al., 2017; Rac et al., 2017) and inadequate depth of vaginal dissection (Altman et al., 2011). Patient risk factors include smoking, diabetes, hypertension, extremes of age, being sexually active, concurrent hysterectomy, prior hysterectomy, and previous prolapse repair (Caquant et al., 2008; Cheng et al., 2017; Dandolu et al., 2017).

Treatment of Prolapse Mesh Complications

Mesh exposures in the vagina can be treated conservatively, particularly if the woman has few symptoms, there are no signs of infection, and the exposure is less than 0.5 to 1 cm. Treatments include observation only or topical estrogen cream (Committee Opinion 694, 2017), which may promote epithelialization. Notably there is no risk to observing an asymptomatic monofilament macroporous mesh exposure. Other minimally invasive approaches include in-office cautery with silver nitrate or in-office trimming of the mesh. In series in which a conservative approach is discussed, 25% to 36% of patients with mesh exposure do not require surgical excision (Cheng et al., 2017; Glazener et al., 2017). No patient factors such as age, BMI, smoking status, or menopausal status predicted success of conservative approaches to mesh exposure except size of the exposure (Cheng et al., 2017). Office-based excision with local anesthetic can be challenging because of limited visualization and patient discomfort. Close follow-up should be planned in these cases because up to 60% will require surgical treatment, and of those women who have in-office trimming, 73% eventually require excision in the operating room (Abbott et al., 2014).

Dyspareunia and pelvic pain in the absence of exposure or mesh abnormalities such as folding or prominence on exam are not well described in the literature. Given their normal physical exam systemic analgesics can be attempted in the short term and physical therapy particularly if there is pelvic floor hypertonicity contributing to the pain. Nerve block or trigger point injections can also be attempted in women who want to avoid surgical excision of the mesh (Warembourg et al., 2017). **Pelvic pain related to non-exposed POP mesh is a complex problem and may not resolve after mesh removal** (Committee Opinion 694, 2017); therefore conservative treatments are worth an attempt. In one series that assessed pain resolution after vaginal mesh removal in women without exposure, 67% were pain free after maximal transvaginal mesh excision (Hou et al., 2014).

Surgical Mesh Removal

If a woman is symptomatic or has a large exposure that will not heal conservatively, excision is the next step. Patients must be counseled about the risks of mesh removal, including the need for repeat mesh excision. Also patients need to be aware that, no matter how thorough the mesh removal, small areas of mesh will likely remain. The best approach is to aim to remove enough mesh to resolve symptoms and prevent future mesh complications while avoiding causing complications for the sake of removing more mesh.

A good exam under anesthesia should be performed at the beginning of any mesh excision as well as a cystoscopy if there is any suspicion of bladder perforation and rectal examination or proctoscopy in the case of posterior mesh. The limits of the mesh can typically be palpated on the exam, but if they are difficult to locate, a vaginal ultrasound can be performed intraoperatively.

For anterior and posterior wall mesh typically a midline full-thickness vaginal incision is made over the expected location of the mesh to be removed. Before incision hydrodissection over the entire area of excision with 1% lidocaine with epinephrine will assist with creation of a vaginal flap and control bleeding. A self-retaining retractor along with a weighted vaginal speculum can assist with exposure. The vaginal epithelium is opened with a scalpel and flaps of vaginal epithelium developed sharply superficial to the mesh with an aim to make the flap as thick as possible to prevent tears or buttonholes. The superior and inferior edges of the mesh must be identified and dissected free of the vaginal epithelium. A right angle or tonsil clamp is carefully passed behind the mesh and the mesh is then divided. This is a critical part of the procedure because bladder or rectal injuries are most likely to occur during this portion of the dissection, which is relatively blind. Once the mesh is divided in the midline, each portion can be used for traction to carefully dissect the rectum or bladder off of the mesh. The dissection is done sharply with scissors (tips pointing away from the bladder or rectum) and with gentle blunt dissection. Dissection is carried out to the lateral arms of the mesh and, once visualized, strong tension is applied while these arms are cut, maximizing the amount of mesh removed. At the location of arm excision, bleeding is often encountered, and the surgeon must be ready to suture ligate bleeding vessels. Excess pursuit of lateral arms can result in hematoma formation. During dissection in the ischiorectal fossa a finger placed in the rectum can assist in preventing inadvertent entry. Before closure a native tissue anterior colporrhaphy with absorbable suture or posterior repair can be undertaken to prevent prolapse recurrence in this compartment. The vaginal incision is trimmed of any devitalized tissue and closed using a running locked absorbable suture (Ridgeway et al., 2008). Cases with smaller areas of exposure without pain, infection, or fistulas can be tailored to remove less mesh, provided a healthy, thick flap of vaginal epithelium free of mesh for at least 1 cm can be obtained.

Complications of transvaginal mesh removal include UTI, vaginal yeast infection, and temporary urinary retention. Later common complications include cystocele recurrence (19%) (Marcus-Braun and Theobald, 2010), new-onset incontinence, or the need for repeat surgery to remove more mesh (20%) (Marcus-Braun and Theobald, 2010). Rare complications include bladder injury (1%), hematoma formation (2%), and vesicovaginal fistula (3%) (Warembourg et al., 2017).

No specific patient factors such as diabetes, age, obesity, or smoking predict complication after mesh removal (Rac et al., 2017), but **patients with pre-existing chronic pain conditions have a greater risk of persistent vaginal pain after excision** (Crosby et al., 2014). Those with persistent pain tend to have diffuse pelvic pain rather than pain at a specific site (Hou et al., 2014). When more mesh is removed, the risk of prolapse recurrence is greater (Marcus-Braun and Theobald, 2010), but partial mesh removal incurs a greater risk of subsequent mesh excisions. Patients who have mesh excised from multiple compartments simultaneously have a threefold estimated blood loss (50 mL vs. 150 mL) with a ninefold increased risk of transfusion (1% vs. 9%) (Pickett et al., 2015). Hematomas can be managed expectantly or with antibiotics if there is suspicion for infection. However, if the hematoma is rapidly expanding or the patient shows signs of acute blood loss, she should return to the operating room for evacuation and hemostasis.

Long term, patients may have persistent symptoms, including discharge (22%), bleeding (15%), and dyspareunia or pain even after complete resolution of mesh exposure. Patients must be counseled that mesh removal, even if a "success," may not resolve these bothersome symptoms. Persistent sexual dysfunction is especially common, and 45% of women report sexual abstinence after mesh removal because of mesh-related problems. This must be particularly emphasized in women who have other chronic pain diagnoses because their pain is more likely to be unresponsive to mesh excision (Crosby et al., 2014).

Key Point: Prolapse Mesh Complications

- Transvaginal prolapse mesh has a higher rate of mesh exposure/extrusion than slings, given the larger volume of mesh. Small exposures can be treated conservatively. Large exposures and pain are treated with vaginal mesh excision; typically the entire vaginal mesh is excised, leaving only the arms in place. Vaginal pain/dyspareunia is the most difficult to treat, given the multifactorial cause of pain.

Apical Mesh Complications

ASC using polypropylene mesh is an extremely durable prolapse repair with a reoperation rate for prolapse of only 2.2% (Diwadkar et al., 2009; Gupta et al., 2018). Non–mesh-related complications that are commonly reported include inadvertent cystotomy (2.6%) and wound infection (2.4%). Other less common complications include ureteral injury, small bowel obstruction (0.7%), enterotomy (0.3%), and port site herniation (0.3%) (Gupta et al., 2017: Hudson et al., 2014).

Mesh-related complications can be either exposures (in the setting of concomitant hysterectomy or vaginal repair) or extrusion into the vagina, typically at the apex where the mesh is anchored. Less common mesh complications include pain (2.3%) (Hudson et al., 2014); mesh perforation into the bladder or bowel after surgery, which are likely secondary to unrecognized cystotomy or enterotomy; pelvic abscess; and discitis (Gupta et al., 2017). The rate of mesh exposure after ASC was initially believed to be far less than with vaginal placement of mesh, but with increasing follow-up in large, well-designed studies, the rate of exposure increases over time with the probability at 7 years being 10.5% (Nygaard et al., 2013).

Several risk factors for extrusion of mesh after ASC have been consistently reported. Patients having a uterine or cervical-sparing ASC are at very low risk of extrusion because the cervix acts as an anatomic barrier. Conversely having a concomitant total hysterectomy at the time of ASC significantly increases the risk of exposure compared with women having ASC post-hysterectomy (23% vs. 5%) (Tan-Kim et al., 2011). Greater stage of prolapse (3–4) and undergoing multiple concomitant procedures also increase the risk of mesh extrusion. Other risk factors such as smoking, diabetes, age, BMI, bowel resection, posterior repair, and hormonal status have variably been shown to affect extrusion risk (Cundiff et al., 2008; Diwadkar et al., 2009; Visco et al., 2001).

Mesh extrusion/exposure occurs in a similar fashion as in other compartments of the vagina, with purulent or bloody vaginal discharge, dyspareunia, granulation tissues in the vagina, palpable mesh by patient or sexual partner, and pelvic pain. Abdominal or vaginal cuff abscess can occur within a few weeks to several months after ASC with abdominal or pelvic pain, foul vaginal discharge, and fever (Akyol et al., 2014). Because a large portion of the mesh after ASC is not accessible via vaginal exam or transvaginal ultrasound, cross-sectional imaging is often required. MRI provides the best visualization because the mesh is visible; with CT the mesh is not seen.

Treatment of Mesh Exposure

The simplest mesh complication to treat is suture extrusion into the vagina. Most ASC are secured to the abdominal side of the vagina with several nonabsorbable sutures such as expanded polytetrafluoroethylene (ePTFE, Gore-Tex), polypropylene, or polyester. These soft sutures can present as an extrusion early or late and have similar, albeit often less severe, symptoms as mesh extrusion. They are diagnosed with a good speculum exam (Fig. 126.8).

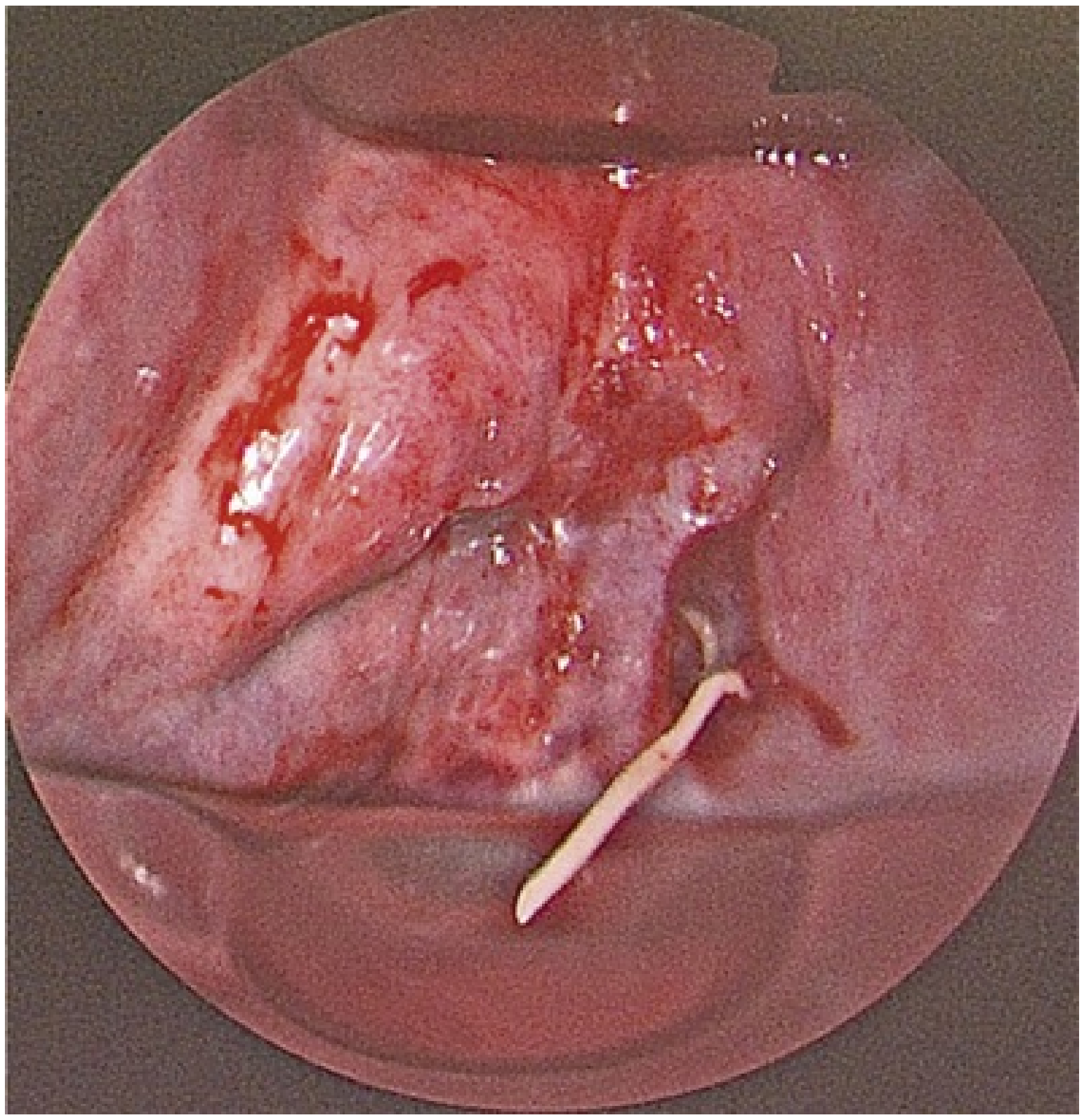

FIG. 126.8 An extruded permanent suture from an abdominal sacrocolpopexy. Symptoms included bleeding and discharge. It was treated by a simple division of the stitch below the knot.

These are straightforward to treat because the suture can be grasped and the suture cut deep to the knot to release the entire suture. Typically, the vaginal defect is so small that no suturing is required. The patient should be treated with vaginal estrogen to promote healing after the suture is removed. The ability to put traction on the suture makes this feasible and effective as an office procedure (Cundiff et al., 2008; Nygaard et al., 2013).

For small mesh exposures, topical estrogen cream applied with the vaginal applicator to achieve good tissue penetration at the superior portion of the vagina, where the exposure is located, has very little prospective or comparative data. A 6- to 8-week trial of this therapy is reasonable particularly with a small mesh exposure without any significant inflammation or in the patient who is minimally bothered (Committee Opinion 694, 2017; Cundiff et al., 2008). The available evidence notes a 14% resolution (Deffieux et al., 2006).

Mesh excision vaginally is a less invasive approach than mesh removal abdominally. In contrast to extruded sutures, these excisions can be far more challenging. A vaginal epithelium incision is required. The mesh is very difficult to manipulate because of its high attachment in the abdomen, and most of these women have excellent anatomic support of the vault, which makes access more difficult. As with anterior and posterior meshes, simply trimming the exposed mesh is bound to fail because the mesh burden is so high adjacent to the incision. The vaginal approach does carry a high risk of mesh extrusion recurrence and in some series required up to three attempts to resolve (South et al., 2007). A technique involving a partial colpocleisis has been reported to be successful in 50% of cases (Quiroz et al., 2008). The authors describe placing a suture for traction through the exposed mesh with sharp dissection of the vaginal epithelium for at least a centimeter around the exposure until healthy vaginal tissue well ingrown with mesh is encountered. A maximal amount of mesh is excised, and the remaining mesh is inverted and closed with absorbable suture. The vaginal epithelium is then closed with a delayed absorbable suture.

Abdominal mesh removal is sometimes indicated after failed vaginal approach or for patients with intractable mesh-related pain, abscess/infected upper portion of the mesh, or discitis. **In the case of infection, the entire mesh should always be removed because residual infected mesh after a failed partial excision causes significant morbidity including chronic infection, sinus tracts, abscess, and fistula formation.** These will require a repeat excision typically via laparotomy, and this is usually a very difficult and morbid procedure (Cundiff et al., 2008). The abdominal approach also allows for the concomitant correction of other abdominal complications such as ureteral obstruction or ureterovaginal fistula and would be the preferred approach in these instances.

During abdominal removal the mesh must be detached all the way from the sacral promontory to the vaginal cuff, including removal of any nonabsorbable attachment suture. The mesh is often in a retroperitoneal location because many surgeons “re-peritonealize” the ASC mesh during initial placement. The mesh is often very adherent to adjacent tissue. The mesh is typically found in the expected location; however, case series have reported mesh found near the coccyx or in other locations very distal to the sacral promontory (Oliver et al., 2017), and the surgeon must proceed with care. Partial vaginectomy or trachelectomy to remove the entire mesh is frequently necessary (74%) (Oliver et al., 2017) because the mesh is deeply embedded in the vagina. Blood loss can be substantial, ranging from 200 to 1000 mL when performed in an open fashion (Oliver et al., 2017). Other complications include bowel injury in up to 29% (South et al., 2007) of cases and sepsis. Given the morbidity of the abdominal approach, most authors recommend complete mesh excision because a repeat abdominal excision would be needed in the event of recurrent exposure, infection, or pain and subsequent procedure are even more difficult. Case series in which the mesh is completely removed abdominally as an initial procedure have reported up to 100% symptom resolution (South et al., 2007).

Laparoscopic approaches have also been described (South et al., 2007), but given the difficulty of this procedure being performed, open laparoscopic approach would be even more challenging. Individual surgeons must judge their own ability with advanced laparoscopic techniques when deciding on an approach for this uncommon surgical procedure. South et al. (2007) reported no difference in complications between the two approaches to remove ASC mesh, but these patients were selected for the most appropriate approach on a case-by-case basis.

Key Point: Abdominal Sacrocolpopexy Mesh Removal

- ASC sutures are easily removed vaginally; however, mesh is very difficult to effectively remove transvaginally, often requiring multiple attempts. Open abdominal mesh removal is a potentially morbid procedure with high risk of bowel injury, vaginal tissue loss, and significant blood loss.

Male Mesh Slings

Men are also affected by SUI, occurring most commonly after radiation or radical prostatectomy for prostate cancer. Men have a very low reported incontinence mesh complication rate in the literature, and the use of mesh in men is much less controversial than in females. The lower rate of complications likely occurs because the incision is in the perineum, which is a sterile procedure with no expected bacterial contamination in contrast with the vaginal route for women. Also the mesh is placed deep to the epidermis and underlying subcutaneous adipose tissue with several layers of closure over the mesh. Furthermore, the bulbar urethra is very thick ventrally where the mesh is placed in contrast to female urethras, resulting in a very low urethral extrusion rate.

Perineal bone-anchored slings (**AMS Invance**, Minnetonka, MN) involve securing a 4- × 7-cm silicone-coated polypropylene mesh to the inferior rami with four to six titanium bone screws attached to a polypropylene suture via a perineal incision. Although this procedure is no longer performed, the urologist may encounter the need to remove or divide one of these devices for complications or to allow placement of an artificial sphincter. Removal is relatively straightforward because the coated mesh is not as ingrown with patient tissue as woven type I polypropylene, and, if infected, will be even less ingrown. The prior perineal incision can be opened sharply and dissection carried down to the mesh. Once the mesh is found, the superior and inferior edges should be dissected and an instrument passed behind the sling, taking care to avoid the urethra. The mesh can be divided and each arm dissected toward the pubic rami. The bony anchors (2–3 on each rami) can be challenging to remove if the bone is intact and could be removed with a rongeur; however, because these are surgical steel, they rarely needed to be taken. The mesh can be extracted from the bony screw entirely with careful dissection. Sling division without actual removal is sometimes needed when placing an artificial sphincter and can be performed simultaneously without difficulty (Fisher et al., 2007).

The Virtue Quadratic male sling (Coloplast, Humbebaek, Denmark) has TOT components as well as prepubital arms that relocate the urethra and provide perineal urethral compression to achieve continence (Comiter et al., 2014). It is made of large-pore knitted monofilament polypropylene with four arms and a central portion placed over the bulbospongiosus muscle.

Three studies have reported on medium-term outcomes and complications

(Comiter et al., 2014; Ferro et al., 2017; McCall et al., 2016). **Short-term urinary retention occurs in 0 to 44% of patients but only persists for up to 3 days.** No cases required any intervention other than extending the duration of catheterization. **Short-term paresthesia has been reported in up to 12% of men, and perineal and scrotal pain is very common postprocedure, occurring in 14% to 17%. Chronic perineal pain has been described in 0 to 7% of men and has been treated with sling removal.** No urethral perforations or infections of the sling have been reported in the literature, but this is the newest of the male slings with a small overall number of procedures. Removal of the perineal portion of the sling has been reported and can be accomplished to allow for placement of an artificial sphincter in the case of sling failure.

The Advance TOT sling (Boston Scientific, formerly American Medical Systems) is a macroporous knitted monofilament polypropylene sling. A second-generation sling, the Advance XP was launched in 2010 with integrated tensioning fibers and a broad center portion to allow fixation to the corpus spongiosum. It functions by repositioning the native sphincter into its original presurgical position without compressing the urethra (Bauer et al., 2011). The sling is placed directly on the bulbar urethra with no bulbourethral muscle intervening. It is the most commonly used sling in North America. Between **14% and 21% of men experience acute urinary retention** after removal of the catheter (Bauer et al., 2010; Serra et al., 2013). **Most resolve within a few days once the edema from the procedure abates, but 0.5% to 1% of men have chronic retention lasting more than 12 weeks. Men with cystoprostatectomy and neobladder as the cause of their incontinence are at particularly high risk of retention** (100% in one study; Bauer et al., 2010). Retention can also occur as do novo overactivity with urgency incontinence. This can be diagnosed urodynamically and treated with sling transection on one or both sides of the urethra. Avoidance of transection immediately over the urethra reduces risk of urethra injury.

Perineal pain has been reported in 2.2% to 8% (Bauer et al., 2010; Serra et al., 2013) **and has been treated with oral analgesia with persistent pain occurring in 0.4% to 1% with none requiring mesh explant.**

Urethral extrusion of mesh is one of the more severe complications of any of the male slings and is accompanied by urinary retention, pain, hematuria, and urinary tract infections. It is easily diagnosed with urethroscopy, and any male with persistent retention should receive a cystoscopy as part of his workup. In case series in which it has been reported, it occurred in procedures in which cystoscopy was not performed during the procedure and was believed to result from a urethral perforation during the procedure (Bauer et al., 2010). This author has two cases: one with no cystoscopy during the procedure and the other with traumatic catheterization after sling placement in the presence of prior radiation (Fig. 126.9).

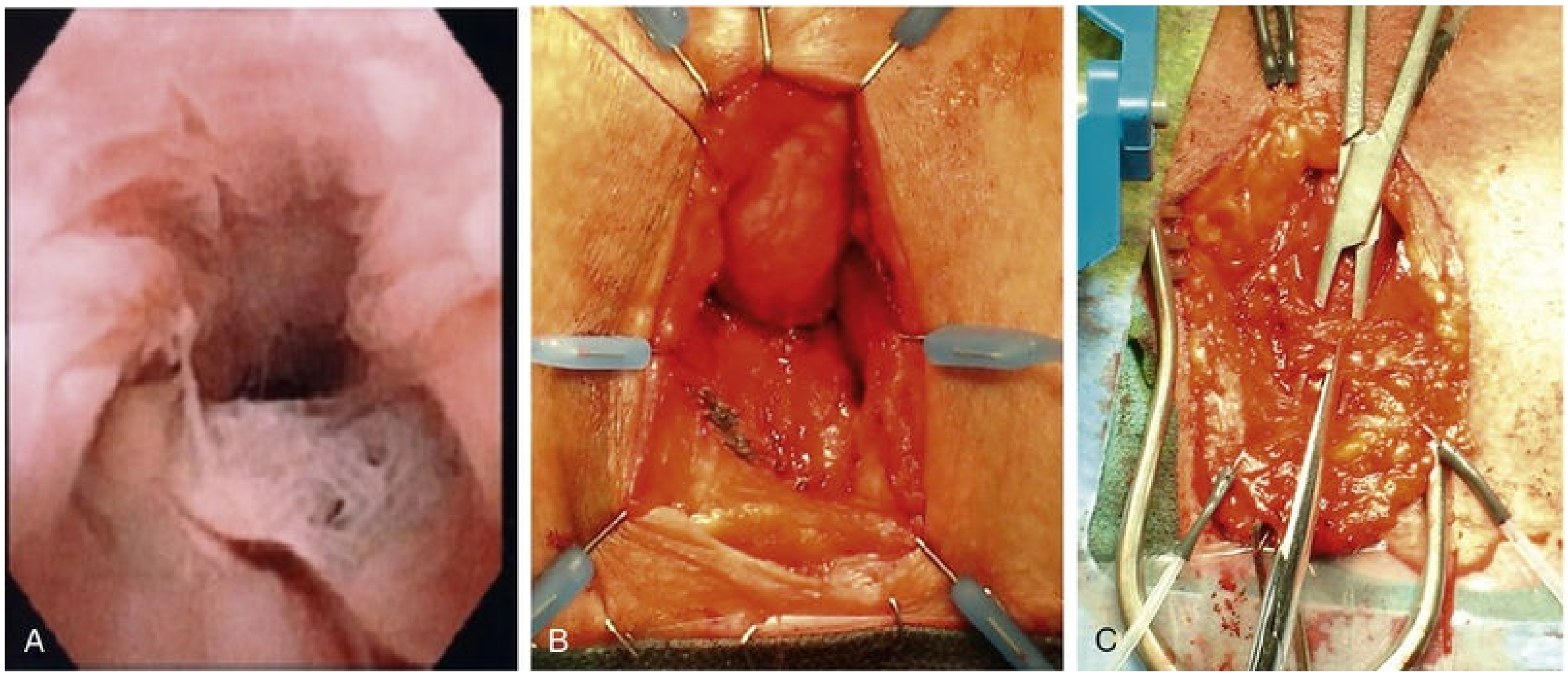

FIG. 126.9 (A) Male sling that has perforated and is obstructing the urethra. The patient experienced pyuria and retention. (B) This is the appearance of the sling before it was divided. (C) Division of the sling lateral to the urethra. The mesh was later dissected out of the bulbar urethra and the defect repaired primarily because there was little stricture.

Excision is performed by circumscribing the mesh lateral to the urethra on both sides and dissecting toward the urethra with an aim to preserve the urethra maximally. If the urethra is extensively involved or there is stricture accompanying the mesh perforation, consideration should be made for an augmented ventral buccal graft. Given the patient's prior urethral transection during radical prostatectomy, avoiding transecting the urethra seems prudent.

Key Point: Male Slings and Retention

- Male slings often have temporary retention that typically resolves over time. It is uncommon to require mesh division to resolve it, and urodynamics are helpful in determining obstruction versus bladder dysfunction as the cause.

References

Abbott S, Unger CA, Evans JM, et al. Evaluation and management of complications from synthetic mesh after pelvic reconstructive surgery: a multicenter study. *Am J Obstet Gynecol*. 2014;210:163.e1–163.e8 http://dx.doi.org/10.1016/j.ajog.2013.10.012 [(online journal)].

Abed H, Rahn DD, Lowenstein L, et al. Incidence and management of graft erosion, wound granulation, and dyspareunia following vaginal prolapse repair with graft materials: a systematic review. *Int Urogynecol J*. 2011;22:789–798.

Akyol A, Akca A, Ulker V, et al. Additional surgical risk factors and patient characteristics for mesh erosion after abdominal sacrocolpopexy. *J Obstet Gynaecol Res*. 2014;40:1368–1374.

Altman D, Väyrynen T, Engh ME, et al. Nordic Transvaginal mesh group. anterior colporrhaphy versus transvaginal mesh for pelvic-organ prolapse. *N Engl J Med*. 2011;364:1826–1836 http://www.ncbi.nlm.nih.gov/pubmed/21561348%0Ahtt [(online journal)].

Amid PK. Classification of biomaterials and their related complications in abdominal wall hernia surgery. *Hernia*. 1997;1:15–21 http://link.springer.com/10.1007/BF02426382 [(online journal)].

Baracat F, Mitre AI, Kanashiro H, et al. Endoscopic treatment of vesical and urethral perforations after tension-free vaginal tape (TVT) procedure for female stress urinary incontinence. *Clinics (Sao Paulo)*. 2005;60:397–400.

Bauer RM, Mayer ME, May F, et al. Complications of the AdVance transobturator male sling in the treatment of male stress urinary incontinence. *Urology*. 2010;75:1494–

1498 http://dx.doi.org/10.1016/j.urology.2009.12.012 [(online journal)].

Bauer RM, Soljanik I, Füllhase C, et al. Results of the AdVance transobturator male sling after radical prostatectomy and adjuvant radiotherapy [Internet]. *Urology*. 2011;77:474–480 [Available from:] http://dx.doi.org/10.1016/j.urology.2010.07.541.

Burkhard FC, Bosch JLHR, Cruz F, et al. *EAU Guidelines on Urinary Incontinence in Adults*. 2017.

Caquant F, Collinet P, Debodinance P, et al. Safety of Trans Vaginal Mesh procedure: retrospective study of 684 patients. *J Obstet Gynaecol Res*. 2008;34:449–456.

Chapple CR, Cruz F, Deffieux X, et al. Consensus statement of the European Urology Association and the European Urogynaecological Association on the use of implanted materials for treating pelvic organ prolapse and stress urinary incontinence. *Eur Urol*. 2017;72:424–431 http://dx.doi.org/10.1016/j.eururo.2017.03.048 [(online journal)].

Cheng YW, Su TH, Wang H, et al. Risk factors and management of vaginal mesh erosion after pelvic organ prolapse surgery. *Taiwan J Obstet Gynecol*. 2017;56:184–187 http://dx.doi.org/10.1016/j.tjog.2016.02.021 [(online journal)].

Chermansky CJ, Winters JC. Complications of vaginal mesh surgery. *Curr Opin Urol*. 2012;22:287–291.

Chughtai B, Sedrakyan A, Mao J, et al. Is vaginal mesh a stimulus of autoimmune disease? *Am J Obstet Gynecol*. 2017;216:495.e1–495.e7 http://dx.doi.org/10.1016/j.ajog.2016.12.021 [(online journal)].

Chughtai B, Sedrakyan A, Mao J, et al. Challenging the myth: transvaginal mesh is not associated with carcinogenesis. *J*

Urol. 2017;198:884–889 http://dx.doi.org/10.1016/j.juro.2017.04.099 [(online journal)].

Clemens JQ, Delancey JO, Faerber GJ, et al. Urinary tract erosions after synthetic pubovaginal slings: diagnosis and management strategy. *Urology*. 2000;56:589–594.

Comiter CV, Colegrove PM. High rate of vaginal extrusion of silicone-coated polyester sling. *Urology*. 2004;63:1066–1070.

Comiter CV, Rhee EY, Tu LM, et al. The virtue sling—a new quadratic sling for postprostatectomy incontinence—results of a multinational clinical trial. *Urology*. 2014;84:433–438 http://dx.doi.org/10.1016/j.urology.2014.02.062 [(online journal)].

Committee Opinion 694. Summary: management of mesh and graft complications in gynecologic surgery. *Obstet Gynecol*. 2017;129:773–774.

Crescenze IM, Abraham N, Li J, et al. Urgency incontinence before and after revision of a synthetic mid urethral sling. *J Urol*. 2016;196:478–483 http://dx.doi.org/10.1016/j.juro.2016.01.091 [(online journal)].

Crosby EC, Abernethy M, Berger MB, et al. Symptom resolution after operative management of complications from transvaginal mesh. *Obstet Gynecol*. 2014;123:134–139.

Cundiff GW, Varner E, Visco AG, et al. Risk factors for mesh/suture erosion following sacral colpopexy. *Am J Obstet Gynecol*. 2008;199:1–5.

Dandolu V, Akiyama M, Allenback G, et al. Mesh complications and failure rates after transvaginal mesh repair compared with abdominal or laparoscopic sacrocolpopexy and to native tissue repair in treating apical prolapse. *Int Urogynecol J*. 2017;28:215–222.

Deffieux X, Huel C, de Tayrac R, et al. [Vaginal mesh extrusion after transvaginal repair of cystocele using a prosthetic mesh: treatment and functional outcomes]. *J Gynecol Obstet Biol Reprod (Paris)*. 2006;35:678–684 http://www.ncbi.nlm.nih.gov/pubmed/17088768 [(online journal)].

Deng DY, Rutman M, Raz S, et al. Presentation and management of major complications of midurethral slings: are complications under-reported? *Neurourol Urodyn*. 2007;26(1):46–52.

Diwadkar GB, Barber MD, Feiner B, et al. Complication and reoperation rates after apical vaginal prolapse surgical repair: a systematic review. *Obstet Gynecol*. 2009;113:367–373.

Domingo S, Alamá P, Ruiz N, et al. Diagnosis, management and prognosis of vaginal erosion after transobturator suburethral tape procedure using a nonwoven thermally bonded polypropylene mesh. *J Urol*. 2005;173:1627–1630.

Food and Drug Administration (FDA). FDA safety communication: urogynecologic surgical mesh: update on the safety and effectiveness of transvaginal placement for pelvic organ prolapse. *Rev Lit Arts Am*. 2011 [Available from:] https://www.fda.gov/medical-devices/urogynecologic-surgical-mesh-implants/fdas-activities-urogynecologic-surgical-mesh.

Ferro M, Bottero D, D'Elia C, et al. Virtue male sling for post-prostatectomy stress incontinence: a prospective evaluation and mid-term outcomes. *BJU Int*. 2017;119:482–488.

Fisher MB, Aggarwal N, Vuruskan H, et al. Efficacy of artificial urinary sphincter implantation after failed bone-anchored male sling for postprostatectomy incontinence. *Urology*. 2007;70:942–944.

Foley C, Patki P, Boustead G. Unrecognized bladder perforation with mid-urethral slings. *BJU Int*. 2010;106:1514–1518.

Ford A, Rogerson L, Cody J, et al. Mid-urethral sling operations for stress urinary incontinence in women. *Cochrane Database Syst Rev*. 2015;(7) [CD006375].

Fusco F, Abdel-Fattah M, Chapple CR, et al. Updated systematic review and meta-analysis of the comparative data on colposuspensions, pubovaginal slings, and midurethral tapes in the surgical treatment of female stress urinary incontinence. *Eur Urol*. 2017;72:567–591 http://dx.doi.org/10.1016/j.eururo.2017.04.026 [(online journal)].

Gaddi A, Guaderrama N, Bassiouni N, et al. Repeat midurethral sling compared with urethral bulking for recurrent stress urinary incontinence. *Obstet Gynecol*. 2014;123:1207–1212 http://content.wkhealth.com/linkback/openurl?sid=WKPTLP:landingpage&an=00006250-201406000-00010 [(online journal)].

Geller EJ, Babb E, Nackley AG, et al. Incidence and risk factors for pelvic pain after mesh implant surgery for the treatment of pelvic floor disorders. *J Minim Invasive Gynecol*. 2017;67–73.

Glazener CM, Breeman S, Elders A, et al. Mesh, graft, or standard repair for women having primary transvaginal anterior or posterior compartment prolapse surgery: two parallel-group, multicentre, randomised, controlled trials (PROSPECT). *Lancet*. 2017;389:381–392 http://dx.doi.org/10.1016/S0140-6736(16)31596-3 [(online journal)].

Gomelsky A, Dmochowski RR. Biocompatibility assessment of synthetic sling materials for female stress urinary incontinence. *J Urol*. 2007;178:1171–1181.

Gupta P, Ehlert M, Bartley J, et al. Perioperative outcomes, complications, and efficacy of robotic-assisted prolapse repair: a single institution study of 196 patients. *Female Pelvic Med Reconstr Surg*. 2018;24(6):408–411.

Gyhagen M, Bullarbo M, Nielsen TF, et al. Prevalence and risk factors for pelvic organ prolapse 20 years after childbirth: a national cohort study in singleton primiparae after vaginal or caesarean delivery. *BJOG*. 2013;120:152–160.

Haylen BT, Freeman RM, Swift SE, et al. An International Urogynecological Association (IUGA) / International Continence Society (ICS) joint terminology and classification of the complications related directly to the insertion of prostheses (meshes, implants, tapes) & grafts in female pelvic floor surgery. *Int Urogynecol J*. 2011;22:3–15.

Hill AJ, Unger CA, Solomon ER, et al. Histopathology of excised midurethral sling mesh. *Int Urogynecol J Pelvic Floor Dysfunct*. 2015;26:591–595.

Hou JC, Alhalabi F, Lemack GE, et al. Outcome of transvaginal mesh and tape removed for pain only. *J Urol*. 2014;192:856–860 http://dx.doi.org/10.1016/j.juro.2014.04.006 [(online journal)].

Hudson CO, Northington GM, Lyles RH, et al. Outcomes of robotic sacrocolpopexy: a systematic review and meta-analysis. *Female Pelvic Med Reconstr Surg*. 2014;20:252–260.

Keltie K, Elneil S, Monga A, et al. Complications following vaginal mesh procedures for stress urinary incontinence: an 8 year study of 92,246 women [Internet]. *Sci Rep*. 2017;7:1–9 http://dx.doi.org/10.1038/s41598-017-11821-w [(online journal)].

Kenton K, Stoddard AM, Zyczynski H, et al. 5-Year longitudinal followup after retropubic and transobturator mid urethral slings. *J Urol*. 2015;193:203–210 http://dx.doi.org/10.1016/j.juro.2014.08.089 [(online journal)].

Khanuengkitkong S, Lo TS, Dass AK. Delayed vaginal and urethral mesh exposure: 10 years after TVT surgery. *Int*

Urogynecol J Pelvic Floor Dysfunct. 2013;24:519–521.

Khrucharoen U, Ramart P, Choi J, et al. Clinical predictors and risk factors for vaginal mesh extrusion. *World J Urol*. 2018;36:299–304 https://doi.org/10.1007/s00345-017-2137-y [(online journal)].

Kobashi KC, Albo ME, Dmochowski RR, et al. Surgical treatment of female stress urinary incontinence: AUA/SUFU Guideline. *J Urol*. 2017;198:875–883 http://linkinghub.elsevier.com/retrieve/pii/S00225347177 [(online journal)].

Kobashi KC, Dmochowski R, Mee SL, et al. Erosion of woven polyester pubovaginal sling. *J Urol*. 1999;162:2070–2072.

Leng WW, Chancellor MB. Recognition and treatment of bladder outlet syndrome after sling surgery. *Rev Urol*. 2004;6:29–33.

Maher C, Feiner B, Baessler K, et al. Transvaginal mesh or grafts compared with native tissue repair for vaginal prolapse. *Cochrane Database Syst Rev*. 2016;(2) [CD012079].

Marcus-Braun N, Von Theobald P. Mesh removal following transvaginal mesh placement: a case series of 104 operations. *Int Urogynecol J*. 2010;21:423–430.

Martinez Franco E, Amat Tardiu L. Contasure-Needleless single incision sling compared with transobturator TVT-O for the treatment of stress urinary incontinence: long-term results. *Int Urogynecol J*. 2015;26:213–218.

McCall AN, Rivera ME, Elliott DS. Long-term follow-up of the virtue quadratic male sling. *Urology*. 2016;93:213–216 http://dx.doi.org/10.1016/j.urology.2016.03.012 [(online journal)].

Milose JC, Sharp KM, He C, et al. Success of autologous pubovaginal sling after failed synthetic mid urethral sling. *J Urol*. 2016;193.

Misrai V, Rouprêt M, Xylinas E, et al. Surgical resection for suburethral sling complications after treatment for stress urinary incontinence. *J Urol*. 2009;181:2198–2203 http://dx.doi.org/10.1016/j.juro.2009.01.036 [(online journal)].

Moore CK, Goldman HB. Simple sling incision for the treatment of iatrogenic bladder outlet obstruction. *Int Urogynecol J Pelvic Floor Dysfunct*. 2013;2145–2146.

Morgan JE, Heritz DM, Stewart FE, et al. The polypropylene pubovaginal sling for the treatment of recurrent stress urinary incontinence. *J Urol*. 1995;154:1013–1015.

Morling JR, McAllister DA, Agur W, et al. Adverse events after first, single, mesh and non-mesh surgical procedures for stress urinary incontinence and pelvic organ prolapse in Scotland, 1997-2016: a population-based cohort study. *Lancet*. 2017;389:629–640 http://dx.doi.org/10.1016/S0140-6736(16)32572-7 [(online journal)].

Mostafa A, Lim CP, Hopper L, et al. Single-incision mini-slings versus standard midurethral slings in surgical management of female stress urinary incontinence: an updated systematic review and meta-analysis of effectiveness and complications. *Eur Urol*. 2014;65:402–427 http://dx.doi.org/10.1016/j.eururo.2013.08.032 [(online journal)].

Nager C, Tulikangas P, Miller D, et al. Position statement on mesh midurethral slings for stress urinary incontinence. *Female Pelvic Med Reconstr Surg*. 2014;20:123–125.

Nygaard I, Brubaker L, Zyczynski HM, et al. Long-term outcomes following abdominal sacrocolpopexy for pelvic organ prolapse. *J Am Med Assoc*. 2013;309:2016–2024.

Oliver JL, Chaudhry ZQ, Medendorp AR, et al. Complete excision of sacrocolpopexy mesh with autologous fascia sacrocolpopexy. *Urology*. 2017;106:65–69 http://dx.doi.org/10.1016/j.urology.2017.04.040 [(online

journal)].

Osborn DJ, Dmochowski RR, Harris CJ, et al. Analysis of patient and technical factors associated with midurethral sling mesh exposure and perforation. *Int J Urol*. 2014;21:1167–1170.

Padmanabhan P, Hutchinson RC, Reynolds WS, et al. Approach to management of iatrogenic foreign bodies of the lower urinary tract following reconstructive pelvic surgery. *J Urol*. 2012;187:1685–1690.

Parden AM, Gleason JL, Jauk V, et al. Incontinence outcomes in women undergoing primary and repeat midurethral sling procedures. *Obstet Gynecol*. 2013;273–278.

Pickett SD, Barenberg B, Quiroz LH, et al. The significant morbidity of removing pelvic mesh from multiple vaginal compartments. *Obstet Gynecol*. 2015;125:1418–1422.

Quiroz LH, Gutman RE, Fagan MJ, et al. Partial colpocleisis for the treatment of sacrocolpopexy mesh erosions. *Int Urogynecol J*. 2008;19:261–266.

Rac G, Greiman A, Rabley A, et al. Analysis of complications of pelvic mesh excision surgery using the Clavien-Dindo Classification System. *J Urol*. 2017;198:638–643 http://dx.doi.org/10.1016/j.juro.2017.04.078 [(online journal)].

Ramart P, Ackerman AL, Cohen SA, et al. The risk of recurrent urinary incontinence requiring surgery after suburethral sling removal for mesh complications. *Urology*. 2017;106:203–209 http://dx.doi.org/10.1016/j.urology.2017.01.060 [(online journal)].

Reynolds WS, Kit LC, Kaufman MR, et al. Obturator foramen dissection for excision of symptomatic transobturator mesh. *J Urol*. 2012;187:1680–1684 http://dx.doi.org/10.1016/j.juro.2011.12.065 [(online journal)].

Ridgeway B, Walters MD, Paraiso MFR, et al. Early experience with mesh excision for adverse outcomes after transvaginal mesh placement using prolapse kits. *Am J Obstet Gynecol*. 2008;199.

Rigaud J, Pothin P, Labat JJ, et al. Functional results after tape removal for chronic pelvic pain following tension-free vaginal tape or transobturator tape. *J Urol*. 2010;184:610–615 http://dx.doi.org/10.1016/j.juro.2010.03.132 [(online journal)].

Ripperda CM, Kowalski JT, Chaudhry ZQ, et al. Predictors of early postoperative voiding dysfunction and other complications following a midurethral sling. *Am J Obstet Gynecol*. 2016;215:656.e1–656.e6 http://dx.doi.org/10.1016/j.ajog.2016.06.010 [(online journal)].

Rouprêt M, Misraï V, Vaessen C, et al. Laparoscopic surgical complete sling resection for tension-free vaginal tape-related complications refractory to first-line conservative management: a single-centre experience. *Eur Urol*. 2010;58:270–274.

Scientific Committee on Emerging and Newly Identified Health Risks (SCENIHR). *Opinion on the safety of surgical meshes used in urogynecological surgery*. [(website)] http://ec.europa.eu/health/scientific_committees/emerging/Op
2015.

Serra AC, Folkersma LR, Domínguez-Escrig JL, et al. Ad Vance/Ad Vance XP transobturator male slings: preoperative degree of incontinence as predictor of surgical outcome. *Urology*. 2013;81:1034–1039.

Shah K, Nikolavsky D, Gilsdorf D, et al. Surgical management of lower urinary mesh perforation after mid-urethral polypropylene mesh sling: mesh excision, urinary tract reconstruction and concomitant pubovaginal sling with autologous rectus fascia. *Int Urogynecol J Pelvic Floor Dysfunct*. 2013;24:2111–2117.

Slieker-ten Hove MCP, Pool-Goudzwaard AL, Eijkemans MJC, et al. Symptomatic pelvic organ prolapse and possible risk factors in a general population. *Am J Obstet Gynecol*. 2009;200:184.e1–184.e7.

Smith ARB, Koelbl H. Is mid-urethral placement of synthetic minimal access tapes important in stress urinary incontinence surgery? *Neurourol Urodyn*. 2010;29:676–678.

South MMT, Foster RT, Webster GD, et al. Surgical excision of eroded mesh after prior abdominal sacrocolpopexy. *Am J Obstet Gynecol*. 2007;197:1–5.

Staack A, Vitale J, Ragavendra N, et al. Translabial ultrasonography for evaluation of synthetic mesh in the vagina. *Urology*. 2014;83:68–74.

Starkman JS, Wolter C, Gomelsky A, et al. Voiding dysfunction following removal of eroded synthetic mid urethral slings. *J Urol*. 2006;176:1040–1044.

Stedman's medical dictionary. ed 3. Lippincott, Williams and Wilkins: Baltimore; 2005.

Tan-Kim J, Menefee SA, Luber KM, et al. Prevalence and risk factors for mesh erosion after laparoscopic-assisted sacrocolpopexy. *Int Urogynecol J*. 2011;22:205–212.

Unger CA, Rizzo AE, Ridgeway B. Indications and risk factors for midurethral sling revision. *Int Urogynecol J*. 2016;27:117–122.

Velemir L, Amblard J, Jacquetin B, et al. Urethral erosion after suburethral synthetic slings: risk factors, diagnosis, and functional outcome after surgical management. *Int Urogynecol J*. 2008;19:999–1006.

Visco AG, Weidner AC, Barber MD, et al. Vaginal mesh erosion after abdominal sacral colpopexy. *Am J Obstet Gynecol*. 2001;184:297–302.

Wang LC, Al Hussein Al Awamlh B, Hu JC, et al. Trends in mesh use for pelvic organ prolapse repair from the Medicare database. *Urology*. 2015;86:885–891.

Warembourg S, Labaki M, de Tayrac R, et al. Reoperations for mesh-related complications after pelvic organ prolapse repair: 8-year experience at a tertiary referral center. *Int Urogynecol J*. 2017;28:1139–1151.

Weinberger MW, Ostergard DR. Postoperative catheterization, urinary retention, and permanent voiding dysfunction after polytetrafluoroethylene suburethral sling placement. *Obstet Gynecol*. 1996;87:50–54.

Young SB, Howard AE, Baker SP. Mersilene mesh sling: Short- and long-term clinical and urodynamic outcomes. *Am J Obstet Gynecol*. 2001;185:32–40.

127

Additional Therapies for Storage and Emptying Failure

Timothy B. Boone MD, PhD, Julie N. Stewart MD, Laura M. Martinez MD

Disorders of the storage and emptying phases of micturition result in voiding dysfunction and often lead to bothersome urinary symptoms. The location of the storage or emptying failure may occur at the bladder, the bladder outlet, or a combination of both. Storage failure originating from the bladder results from poor bladder compliance, decreased capacity, detrusor overactivity (DO), and/or altered bladder sensation. Failure of the bladder outlet to store urine is due to an incompetent closure mechanism. Emptying disorders can similarly be classified by location. At the bladder level, impaired or absent detrusor contractility leads to emptying failure. At the bladder outlet, emptying difficulties are caused by anatomic obstruction or sphincter dyssynergia/dysfunction. In previous chapters, numerous therapies for bladder storage and emptying failure have already been discussed, illustrating the complexities of voiding dysfunction management.

This chapter covers additional therapies to improve bladder storage and emptying, including contemporary augmentation cystoplasty techniques for adults, surgical and nonsurgical management of the incompetent bladder outlet, and modified cystoplasty incorporating a catheterizable channel.

Additional Therapies for Storage Failure at the Bladder Level

Failure of the filling/storage phase of micturition often results in urinary symptoms of frequency, urgency, and/or incontinence. In addition, poor bladder compliance and reduced capacity may lead to renal function deterioration. **The goals of therapy for storage failure are urine accommodation in the bladder at low pressures, improved bladder capacity, decreased incontinence related to DO, and preservation of renal function.**

Augmentation Cystoplasty

Augmentation cystoplasty is a well-established technique that typically involves adding an enteric segment to the bladder to increase its size. This can improve bladder compliance and capacity, preserve renal function, and minimize incontinence resulting from severe DO. **Augmentation cystoplasty may be performed in patients who have failed or who are not candidates for more conservative forms of intervention such as anticholinergics, intravesical instillation of medication, intravesical injection of botulinum toxin, and/or clean intermittent catheterization (CIC).** The contemporary indications for augmentation cystoplasty are narrowing with the rising efficacy of these conservative therapies, especially botulinum toxin, and their ability to improve bladder compliance and capacity (Karsenty et al., 2008). However, augmentation cystoplasty plays an important role in the management of refractory patients. In the appropriate patients, augmentation cystoplasty is an excellent treatment option that can enhance bladder function and improve patients’ quality of life.

Historical Perspective

First reported in canines by Tizzoni and Foggi (1888), augmentation ileocystoplasty was performed in humans 1 year later by Von Mikulicz (1889). After 1972, with the introduction of CIC and the wider use of enteric segments in urologic procedures, the technique of augmentation cystoplasty gained popularity (Biers et al., 2012). In 1982 Bramble's technique of clam cystoplasty (1982), further popularized by Mundy and Stephenson (1985), established the use of augmentation cystoplasty in the urologic community.

More recently, the number of augmentation cystoplasty procedures being performed has declined. Data from the United Kingdom show a 38% reduction in augmentation cystoplasty operations from 2000 to 2010. This reduction appears to coincide with a dramatic increase in the use of intravesical botulinum toxin (Biers et al., 2012). The decline also may be related to increasing concern for complications associated with augmentation cystoplasty, including malignancy, spontaneous bladder perforation, and metabolic changes (Schlomer et al., 2013). However, in a prospective study of 30 patients with refractory neurogenic bladder resulting from spinal cord injury (SCI), quality-of-life and continence rates were significantly higher in patients who had augmentation cystoplasty versus those managed with intravesical botulinum toxin; complete continence was achieved in 87.5% vs. 42.3% ($P = 0.0187$) (Anquetil et al., 2016).

Indications for Augmentation Cystoplasty

The key indications for augmentation cystoplasty are poor bladder compliance, reduced bladder capacity, and significant refractory DO.

Bladder Compliance.

It is well known that patients with poor bladder compliance and/or subsequent increases in detrusor pressures of greater than 40 cm H_2O without leakage during bladder filling are at risk for vesicoureteral reflux and upper tract deterioration (McGuire et al., 1981). Patients with poor compliance require intervention to reduce storage pressures, thereby preserving renal function. Multiple studies show that augmentation cystoplasty successfully reduces detrusor pressures and improves bladder compliance. In the literature, there is a reported 65% to 82% reduction in mean maximum detrusor pressure after augmentation cystoplasty (Gurung et al., 2012; Khastgir et al., 2003; Quek and Ginsberg, 2003). In addition, long-term data with 6 to 14 years of postoperative follow-up show this improvement in compliance to be sustained over time (Gurung et al., 2012; Khastgir et al., 2003; Quek and Ginsberg, 2003). After augmentation cystoplasty, resolution or marked improvement in vesicoureteral reflux is also reported (Khastgir et al., 2003).

Capacity.

Reduced bladder capacity, found in conjunction with poor bladder compliance and/or severe DO, is another indication for augmentation cystoplasty. **Patients with significantly reduced bladder capacities are bothered by incontinence, frequent urination, and/or the frequent need to perform CIC to avoid leakage.** These bothersome lower urinary tract symptoms (LUTS) negatively affect patients' social, psychological, and physical quality of life (Ku, 2006; Liu et al., 2010). Patients who have undergone augmentation cystoplasty have improvements in bladder capacity with an increase in mean cystometric capacity from 200 mL to more than 500 mL postoperatively (Gurung et al., 2012; Khastgir et al., 2003; Khavari et al., 2012; Quek and Ginsberg, 2003). In addition, after augmentation cystoplasty, patients have significant improvement in their quality of life and a 93% to 96% satisfaction rate (Gurung et al., 2012; Khastgir et al., 2003).

Detrusor Overactivity.

Augmentation cystoplasty is also indicated in patients with severe DO refractory to anticholinergics, intravesical botulinum toxin, and/or neuromodulation. **DO is a urodynamic finding characterized by involuntary detrusor contractions during filling cystometry.** DO can result in significant urinary urgency, frequency, and/or incontinence. A systematic review demonstrated that patients with neurogenic DO incontinence scored lower on various health-related quality-of-life instruments measuring physical, emotional, and psychological parameters when compared with their continent counterparts (Tapia et al., 2013). Overall continence rates in patients with neurogenic DO also improve after augmentation cystoplasty and range from 80% to 100% (Biers et al., 2012). Although augmentation cystoplasty is not commonly performed for idiopathic DO, data show similar continence and satisfaction rates of 78% to 90% in this population (Edlund et al., 2001). Not surprisingly, urinary incontinence from neurogenic DO also negatively affects patients' sexual function (Valtonen et al., 2006).

Augmentation Cystoplasty Techniques

Many gastrointestinal tract segments have been used for bladder augmentation. These segments include ileum, sigmoid colon, cecum, and stomach. Each is associated with its own advantages and disadvantages. A more detailed discussion of various augmentation techniques and complications may be found in Chapter 37.

Ileocystoplasty is the most common type of augmentation cystoplasty because of the reconstructive urologist's familiarity with ileum and the ileum's ability to easily reach to the pelvis. Although hyperchloremic metabolic acidosis can occur after using ileum or colon for bladder substitution, the use of ileum for augmentation seems to result in less significant metabolic disturbances. Patients with SCI followed for more than 10 years after ileocystoplasty had no evidence of metabolic abnormalities (Gurung et al., 2012). Normal electrolyte and arterial blood gas levels were also found after long-term follow-up of 25 pediatric patients with ileocystoplasty. However, 12% of these patients had mild osteopenia, a potential sequela of chronic acidosis (Hafez et al., 2003). Although patients may develop metabolic acidosis after ileocystoplasty or colocystoplasty, this acidosis is often clinically insignificant and only 16% require oral bicarbonate therapy (Biers et al., 2012).

Colon has also been successfully used for augmentation cystoplasty. The sigmoid can be redundant in chronically constipated neurogenic patients, is easy to position on the bladder, and has a large lumen and abundant mesenteric blood supply. One advantage of using cecum, or the ileocecocystoplasty technique, is the ability to use the ileocecal valve along with terminal ileum to create a continent catheterizable channel (Sarosdy, 1992; Sutton et al., 1998). **Disadvantages of using large bowel instead of small bowel for augmentation include more significant metabolic disturbances** (Vaida et al., 2003)**, increased mucus production, and a theoretic heightened risk for malignancy. Before augmentation cystoplasty, colonoscopy is recommended in all patients in whom colon will be used. Using the terminal ileum for ileocecocystoplasty also puts patients at risk for vitamin B_{12} deficiency. Thus levels must be monitored over the long term.**

When small or large bowel is unavailable or metabolic acidosis is present, **stomach is an option** for use in bladder augmentation. **The advantages of gastrocystoplasty are decreased mucus production and less bacterial colonization.** The popularity of gastrocystoplasty has waned with increasing awareness of associated complications. **Hematuria-dysuria syndrome occurs in up to 70% of patients with gastrocystoplasty** and is characterized by suprapubic pain, dysuria, bladder spasms, and hematuria. However, only 4% of patients with this syndrome will require chronic treatment with H_2 blockers or proton pump inhibitors (Leonard et al., 2000). **Other complications include peptic ulcers in the bladder, augment perforation, hyperchloremic hyponatremic alkalosis, increased gastrin production, and malignancy** (Biers et al., 2012)**.**

Contraindications to Augmentation Cystoplasty

Augmentation cystoplasty is contraindicated in patients who have diseases of the bowel (i.e., inflammatory bowel disease, irradiated bowel, short gut syndrome) or bladder pathologic conditions that would preclude using the bladder (Sajadi and Goldman, 2012). Patients or caregivers also must be willing and able to perform CIC for the long term. A patient with a progressive neurologic disease, such as multiple sclerosis, may not have the ability to perform CIC in the future. Noncompliance with CIC puts the patient at risk for life-threatening spontaneous bladder perforation. Renal disease also may be a relative contraindication to augmentation cystoplasty. Baseline renal insufficiency can worsen with the absorption and electrolyte changes that result from exposure of bowel to urine. However, if augmentation cystoplasty is indicated for renal impairment, renal function is expected to stabilize or improve. The series by Ivancić et al. (2010) of pediatric patients with chronic renal insufficiency showed either improvement or no change in renal function after augmentation cystoplasty.

Key Points: Additional Therapies for Storage Failure at the Bladder Level

- The goals of therapy for storage failure are low pressure storage, improved bladder capacity, decreased incontinence resulting from DO, and preservation of renal function.
- Augmentation cystoplasty is an option after failed conservative management such as pharmacologic therapy, intravesical botulinum toxin injection, or CIC.
- Use of large bowel versus small bowel may lead to more significant metabolic disturbance, increased mucus production, and theoretic heightened risk of malignancy.

Additional Therapies for Storage Failure at the Bladder Outlet

The inability to store urine can be the result of an incompetent bladder outlet arising from hypermobility of the urethrovesical junction, intrinsic sphincteric deficiency, denervation of the sphincteric musculature, or frank urethral loss resulting from urethral erosion in women after prolonged urethral catheter use, radiation, or refractory urethral fistulae. The following sections discuss alternative treatments for urine storage failure at the bladder outlet that have not been covered in depth in other chapters in this text.

Urethral Bulking Agents

The goal of injectables is to augment or restore urethral mucosal coaptation and its "hermetic seal effect" contribution to the continence mechanism (Appell and Winters, 2007) **and to maintain coaptation during periods of increased abdominal pressure** (Reynolds and Dmochowski, 2012). **The ideal injectable urethral bulking agent provides luminal coaptation and should be nonantigenic, biocompatible, and cause little or no inflammatory reaction** (Kershen and Atala, 1999) **or fibrotic response** (Dmochowski and Appell, 2000). **It should consist of particles large enough to prevent migration to distant sites (diameter > 80 µm), which are durable enough to produce long-lasting results** (Kirchin et al., 2017). **No material has met all of these requirements.**

Use of Injectable Agents for Female Stress Urinary Incontinence

In the late 1990s injection therapy was the most commonly performed anti-incontinence procedure in women with stress urinary incontinence (SUI), at a rate of 3649 procedures per 100,000 women (Nygaard et al., 2014). By 2007 the rate had fallen to 2236 procedures per 100,000 (Rogo-Gupta et al., 2013). Possible reasons for the decline in numbers include less-than-optimal long-term results and the availability of other minimally invasive options (Kong and Vasavada, 2009).

Table 127.1 lists the bulking agents that are discussed in this section. Collagen was once the most widely used and studied injectable agent, but its production was discontinued in 2010 because of the development of hyaluronic acid fillers. There are currently three FDA-approved urethral bulking agents: Durasphere, Macroplastique, and Coaptite.

TABLE 127.1

Urethral Bulking Agent Materials for Stress Urinary Incontinence

BRAND NAME	MATERIAL	FDA APPROVAL	MAJOR RCT	DISADVAN
CURRENTLY USED				
Durasphere	Carbon-coated zirconium beads	1999	Noninferior to collagen (Lightner et al., 2001)	Particle migratio original formulat (Pannek 2001) Reports periuret mass for (Madjar 2006)
Macroplastique	Silicone microimplants (polydimethylsiloxane)	2006	Noninferior to collagen (Ghoniem et al., 2009)	Requires spe delivery dev (gun)
Coaptite	Calcium hydroxyapatite	2005	Noninferior to collagen (Mayer et al., 2007)	High pa density Reporte vaginal erosion (et al., 20 urethral prolapse al., 2008 et al., 20
Bulkamid	Polyacrylamide hydrogel	Not available in US	Noninferior to collagen (Sokol et al., 2014)	
Urolastic	Polydimethylsiloxane (polymerizes in situ)	Not available in US	No comparative	

			trials Few observational Dutch studies	
NO LONGER USED				
Contigen	Glutaraldehyde cross-linked (GAX) bovine collagen	1993	Lower success rate than surgery (Corcos et al., 2005)	Disconti due to emergen hyaluron fillers (Schwan 2010) Allergic reaction requirin test
N/A	Autologous fat	No	No better than placebo saline (Lee et al., 2001)	Fatal pulmo embolus (Le 2001)
Polytef	Polytetrafluoroethylene	No	No comparative trials	Distant parti migration an granuloma f (Malizia et a
Tegress, Uryx	Ethylene vinyl alcohol	2004	Noninferior to collagen (Karram et al., 2003)	Voluntarily from market high rate (37 urethral eros (Hurtado et 2007)
Zuidex	Dextranomer/hyaluronic acid	No	Midurethral Zuidex inferior to proximal urethral collagen (Lightner et al., 2009)	High rate (1 15%) of pseudoabsce to market withdrawal (Lightner et 2009, 2010)

Urethral bulking agents create artificial urethral cushions to restore urethral mucosal coaptation (Appell and Winters, 2007) **and to maintain continence during periods of increased abdominal pressure** (Reynolds and Dmochowski, 2012). Thus bulking agent injection therapy is well suited for women with intrinsic sphincter dysfunction (ISD). Proper placement of the injectable, just below the bladder neck, rather than actual quantity of the agent (Khullar et al., 1997) improves ISD. **Although initially it was thought that these agents would be most effective in patients with ISD alone, multiple reports have shown clinical efficacy in patients with hypermobility** (Bent et al., 2001a; Herschorn et al., 1996; Lose et al., 2010; Steele et al., 2000).

Patient Selection, Indications, and Contraindications

The American Urological Association (AUA) guideline for surgical treatment of female SUI (http://www.auanet.org/guidelines/stress-urinary-incontinence-(sui)-new-(aua/sufu-guideline-2017) **includes bulking agent therapy as a viable treatment option. However, there are few long-term data with difficulty in measuring long-term outcomes, and inadequate data to recommend one injectable agent over another. The panel recommends that patients should be counseled on the expected need for repeat injections. Bulking agents may still play a role in patients who do not wish to undergo more invasive surgery, who are wishing to avoid a lengthier recovery, or who do not achieve sufficient improvement after a previous anti-incontinence procedure** (Kobashi et al., 2017).

Other considerations may include patients who cannot stop anticoagulation, desire nonsurgical therapy using only local anesthesia, desire more children, have SUI and poor bladder emptying, or have mild SUI associated with exercise (Cespedes and Serkin, 2009).

Contraindications include active urinary infection and hypersensitivity to the injectable material. Caution is warranted in patients with a history of radiation or surgery because severe urethral scarring may affect mucosal pliability by preventing bulking and retention of the injectable in the urethra.

Injection Techniques

Urethral bulking agent injection can be performed using local anesthesia with cystoscopic guidance. **Periurethral** and **transurethral** approaches can be used to implant the agent into the urethral submucosa at the bladder neck or proximal urethra. The technique for injection is shown in Figs. 127.1 and 127.2. The goal is to create mucosal apposition at the end of treatment.

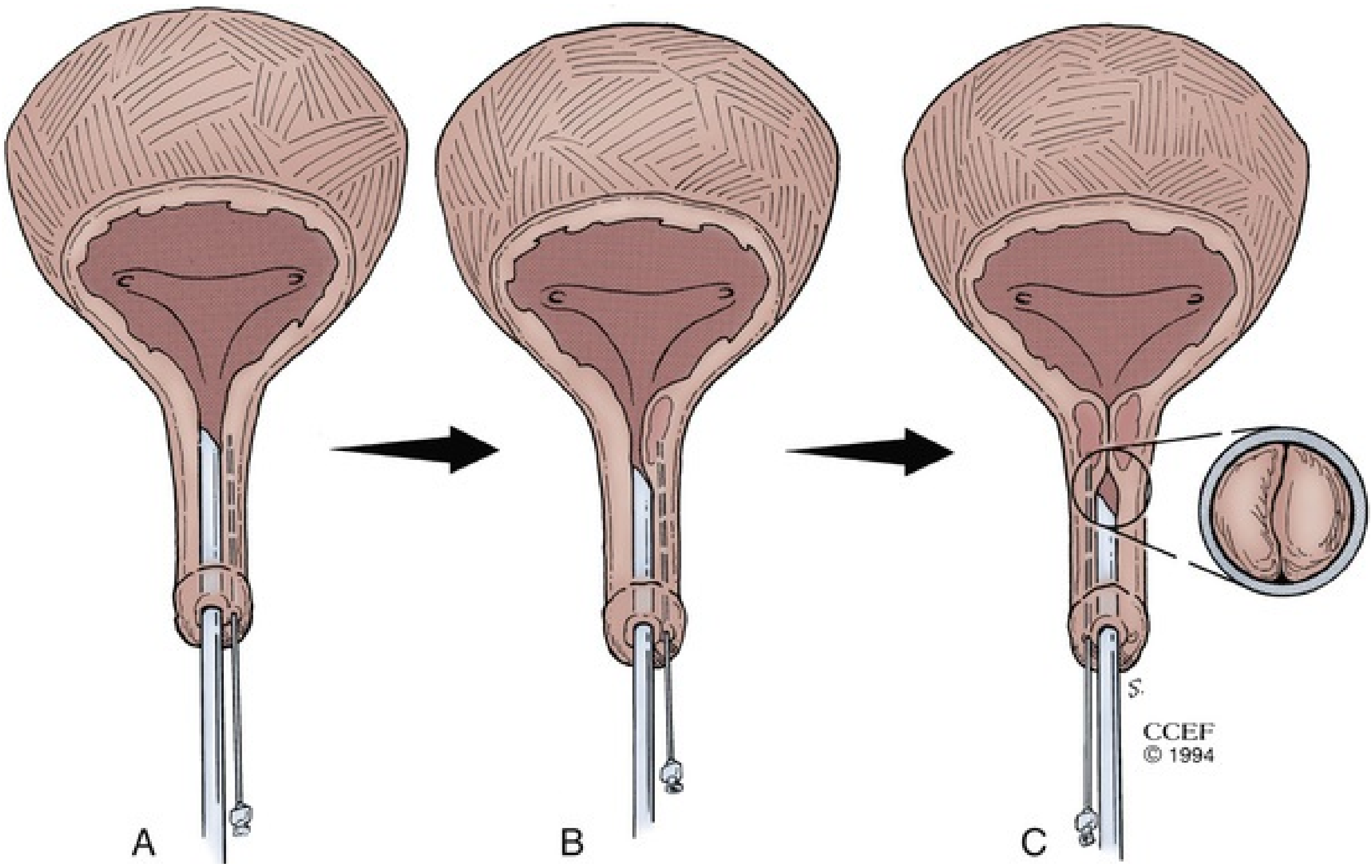

FIG. 127.1 Periurethral collagen injection. The 20-Fr cystoscope with a 30-degree lens is positioned in the urethra while the substance is injected into the bladder neck region. (A) Appearance of the urethra before treatment. (B) Periurethral needle positioned in the proximal urethra below the bladder neck. (C) Appearance of the urethra after injection. (Reprinted with permission, Cleveland Clinic Center for Medical Art & Photography. Copyright 1994-2011. All rights reserved.)

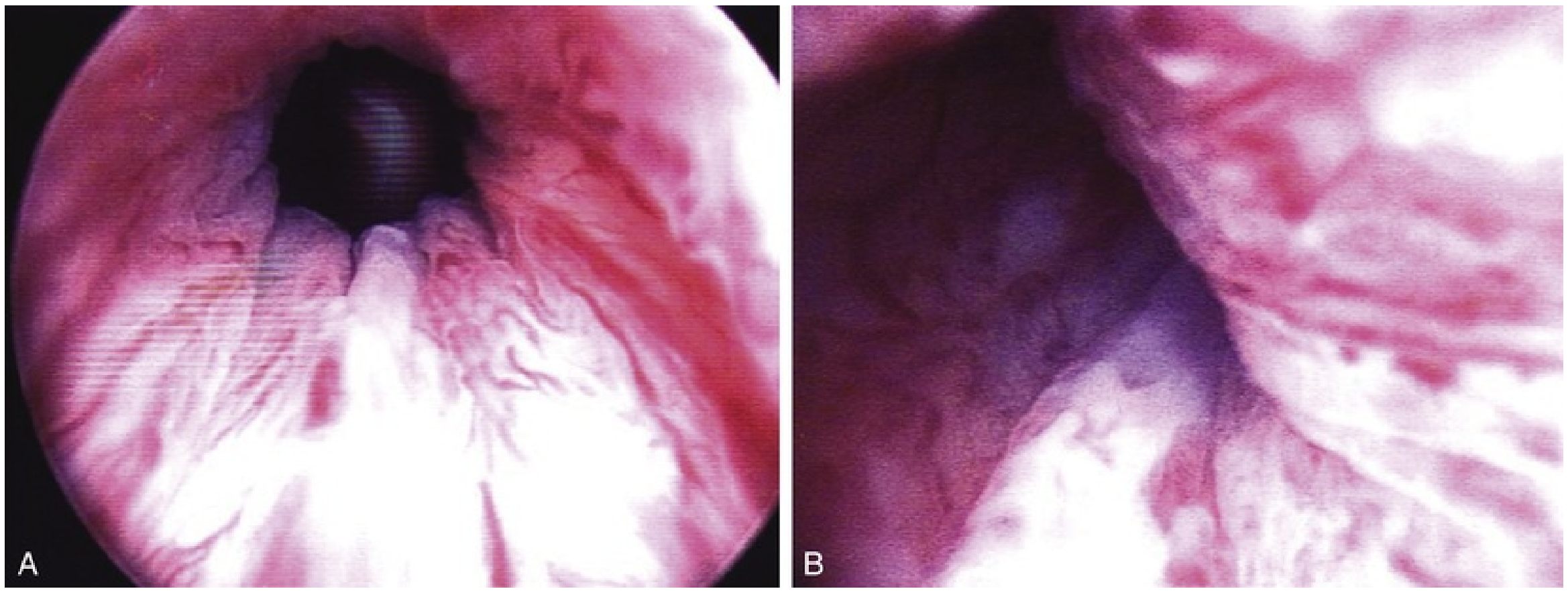

FIG. 127.2 (A) Cystoscopic view of the open bladder neck region before injection. (B) Collagen has been injected via the periurethral route on the patient's left side. Note the intraluminal bulking effect of the bulking agent.

Periurethral Technique.

The patient is placed in the lithotomy position and prepared and draped in the usual sterile fashion. Topical 2% urethral lidocaine jelly is instilled into the meatus. Perimeatal blebs are raised with 1% or 2% aqueous lidocaine approximately 3 to 4 mm lateral to the urethral meatus. A rigid cystoscope with 30-degree lens is inserted into the urethra. The periurethral needle is introduced and advanced parallel to the endoscope sheath until its position can be seen cystoscopically just below the bladder neck within the mucosa. Care must be taken to prevent the needle from entering the urethral lumen and causing extravasation of the agent. If penetration of the mucosa occurs, the needle should be removed and repositioned. The substance is injected either unilaterally or bilaterally to create the appearance of "prostatic" lobes (Fig. 127.3). Transvaginal injection with the needle placed through the biopsy port of an ultrasound probe has also been described (Appell, 1996).

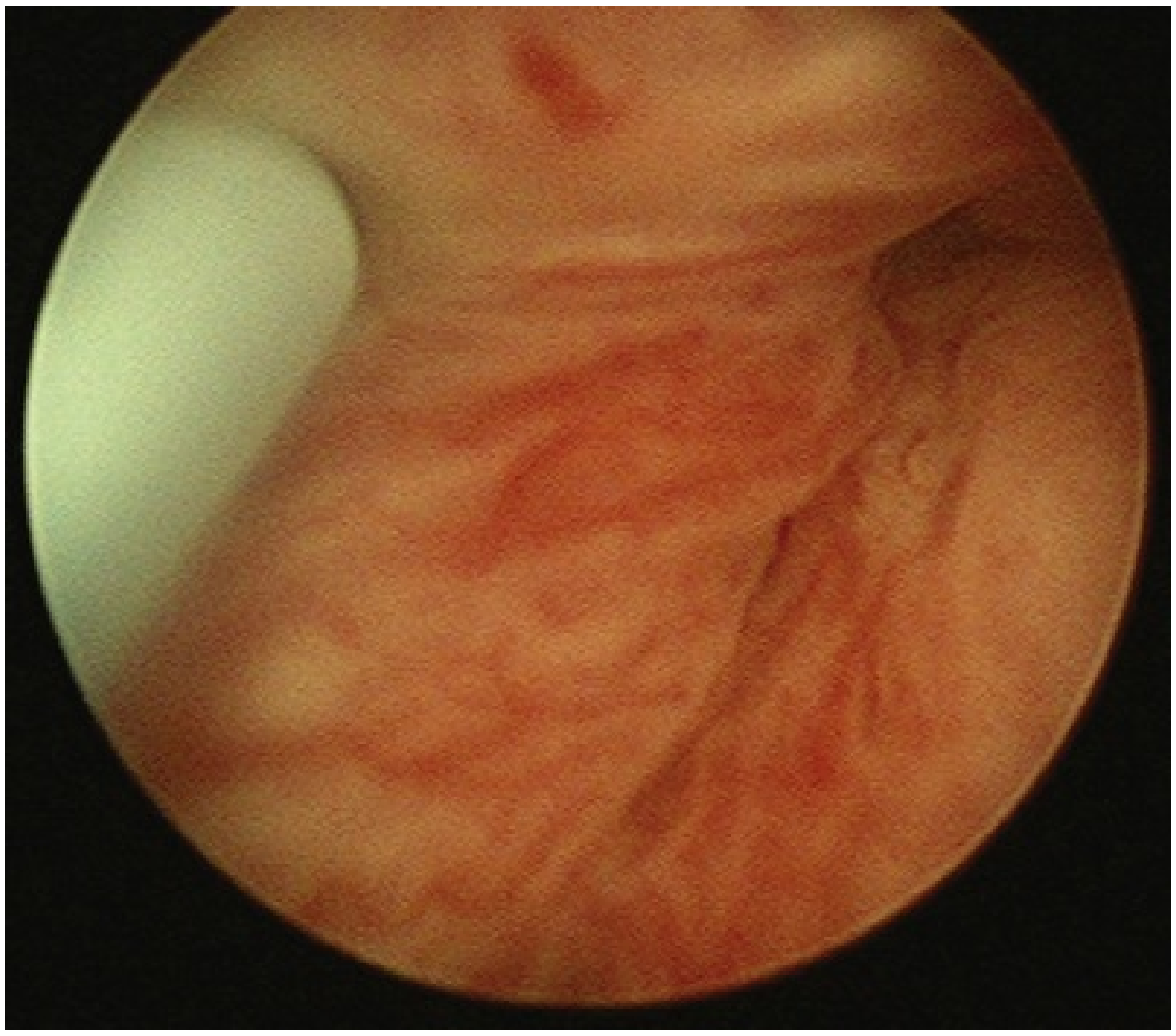

FIG. 127.3 Appearance of urethra after injection of collagen with a transurethral needle, shown on the left. Both sides of the urethra have been injected, giving the appearance of an occlusive prostate.

Transurethral Techniques.

The implant can also be injected transurethrally. The injection needle is inserted through the cystoscope into the urethral mucosa at a 30- to 45-degree angle. The point of penetration of the urethra has to be at a distance below the bladder neck of more than the length of the needle to prevent extravasation of material into the bladder. Injections can be given at the 3-, 6-, and 9-o'clock positions until mucosal apposition is achieved. The cystoscope should not be advanced through the bulked up urethra and bladder neck to avoid compressing or causing extravasation of the injected material.

The periurethral and transurethral approaches for collagen injection were first compared by Faerber et al. (1998), **who reported no significant difference in success rates and numbers of injections required in 24 patients with transurethral treatment versus 21 with a periurethral approach. However, significantly more collagen was required for the periurethral approach. Schulz et al.** (2004) **reported similar findings in 40 women randomly assigned to either technique. Furthermore, the Cochrane review concluded that there are insufficient data to determine whether the transurethral approach is superior to the periurethral approach and whether mid-urethral injection offers any benefit over bladder neck injection** (Kirchin et al., 2017). **The transurethral approach is now more commonly reported than the periurethral approach.**

Periprocedure Care

Postprocedure urinary retention can be treated by insertion of a small caliber Foley catheter (12 to 14 Fr or smaller) overnight or intermittent catheterization. Although not specifically reported, an indwelling Foley catheter may cause molding of the agent and lead to early failure, so long-term catheterization should be avoided.

If stress incontinence persists or recurs after the procedure, reinjection may be performed. The minimum timing for reinjections is variable and depends on the agent. Although bovine glutaraldehyde cross-linked (GAX) collagen (Contigen) could be reinjected within 7 days, most clinicians have waited at least 4 weeks to assess response and the need for reinjection (Appell and Winters, 2007).

Efficacy of Urethral Injection Therapy for Female Stress Urinary Incontinence

The Stamey grading system (0 to 3) (Stamey, 1979) (Table 127.2) for SUI has been recommended as the primary outcome measure by the US Food and Drug

Administration (FDA) since the original US collagen trial (McGuire and Appell, 1994). Although the scale has been used extensively, there is little evidence that it is as valid or reliable as other measures such as voiding diaries, pad tests, and leak point measurements (Payne et al., 2009).

TABLE 127.2

Stamey Incontinence Grading System

GRADE	DESCRIPTION
0	Continent
1	Patient loses urine with sudden increases in abdominal pressure but not when supine
2	Patient loses urine with physical stress (walking; changing from a reclining to a standing position; sitting up in bed)
3	Patient has total incontinence; urine loss unrelated to physical activity and/or position

The Cochrane Database of Systematic Reviews published an updated review of injectable agents in women in 2017 (Kirchin et al., 2017). The authors reviewed the findings of 14 randomized controlled trials (RCTs) including 2004 women and concluded that there are still insufficient data to guide practice. There has only been one placebo-controlled trial comparing autologous fat injection to saline, which demonstrated no difference in cure or improvement between treatment and placebo arms at 3 months (22% vs. 21%, respectively) (Lee et al., 2001). This is likely due to the fact that fat biodegrades rapidly. Because of the lack of efficacy and risk of fatal adverse events (pulmonary fat emboli), autologous fat is no longer used.

Two RCTs demonstrated that injectable therapy had lower success rates than surgical therapy. In one trial comparing collagen versus sling or retropubic suspension, the success rate (dry 24-hour pad test) of collagen injection was significantly lower than surgery at 12 months (53.1% vs. 72.2%, respectively; 95% CI −36.2% to −2%) (Corcos et al., 2005). However, there was no significant difference in satisfaction (67.2% collagen vs. 79.6% surgery, $P = 0.228$), and the patients in the collagen arm had significantly fewer adverse events (36 events in 23 collagen patients vs 84 events in 34 surgery patients, $P = 0.03$). In another trial comparing Macroplastique versus autologous pubovaginal sling in 55 women with ISD, there was a significant difference in objective cure, defined as no leakage resulting from SUI on urodynamics at 6 months (9%

Macroplastique vs 81% surgery, $P < 0.0001$) (Maher et al., 2005). However, there was no significant difference in subjective cure (77% injection vs. 90% sling, $P = 0.41$) or patient satisfaction (60% injection vs. 81% sling, $P = 0.41$). The average cost of Macroplastique (accounting for reinjections) was also found to be more expensive than that of pubovaginal sling ($P < 0.0001$).

Based on the Cochrane analysis, there were no conclusive data to recommend one agent over another based on efficacy; the majority of these trials demonstrated noninferiority of the particular material to collagen (Andersen, 2002; Ghoniem et al., 2009; Lightner et al., 2001; Mayer et al., 2007).

Adverse Events

Common adverse events after urethral bulking agent injection tend to be transient and include urinary retention (0–12%) or elevated postvoid residual (55%–75%), irritative voiding symptoms (17%–46%), hematuria (8%–40%), dysuria (9%–46%), and urinary tract infection (UTI; 0–23%) (Andersen, 2002; Corcos et al., 2005; Ghoniem et al., 2009; Lightner et al., 2001; Maher et al., 2005; Mayer et al., 2007; ter Meulen et al., 2009).

Urethral erosion is a less common adverse event, seen in 1.6% of patients undergoing Macroplastique with collagen in an RCT (Ghoniem et al., 2009). A higher rate (37%) was observed with injection of ethylene vinyl alcohol polymer (Tegress), which was voluntarily removed from the market after initial FDA approval in 2004 (Hurtado et al., 2007).

Particle migration is a possible adverse event, especially when particle size is less than 80 μm. Polytetrafluoroethylene (Teflon) consists of particles 4 to 100 μm and was shown to have distant migration and granulomatous reaction in pelvic lymph nodes, lung, and brain in an animal study (Malizia et al., 1984). The authors concluded that periurethral Teflon injections should not be performed in children or adults of normal life expectancy. Particle migration into urethral mucosa and regional and distant lymph nodes has been demonstrated with the original formulation of Durasphere (200–550 μm) (Pannek et al., 2001). This was subsequently attributed to the high pressure necessary to inject the viscous material with large particles, resulting in material displacement into vascular or lymphatic spaces (Appell et al., 2006).

Summary of Specific Agents

Glutaraldehyde Cross-Linked (GAX) Bovine Collagen (Contigen).

Until it was discontinued in 2010 because of development of hyaluronic acid as an alternative material for cosmetic fillers (Schwanke, 2010), GAX collagen was the most widely used and best-studied urethral injectable agent. It was the standard against which all new injectables were compared.

Contigen was easily injectable through a 22-gauge needle and was supplied in 3-mL syringes. One to three syringes were typically used per treatment. A skin test was required 30 days before treatment because of the 3% rate of allergic reaction.

The use of GAX collagen was first reported by Shortliffe et al. (1989), and since then, there have been numerous reports of its efficacy, safety, ease of administration, and relative lack of morbidity (Corcos and Fournier, 1999; Cross et al., 1998; Gorton et al., 1999; Herschorn et al., 1992; Khullar et al., 1997; Winters and Appell, 1995). Herschorn and Radomski (1997) performed a Kaplan-Meier analysis showing that the probability of remaining dry after the last collagen injection was 72% at 1 year, 57% at 2 years, and 45% at 3 years (Fig. 127.4). Most patients needed one or two treatment sessions with a mean of 5.6 to 15 mL of collagen.

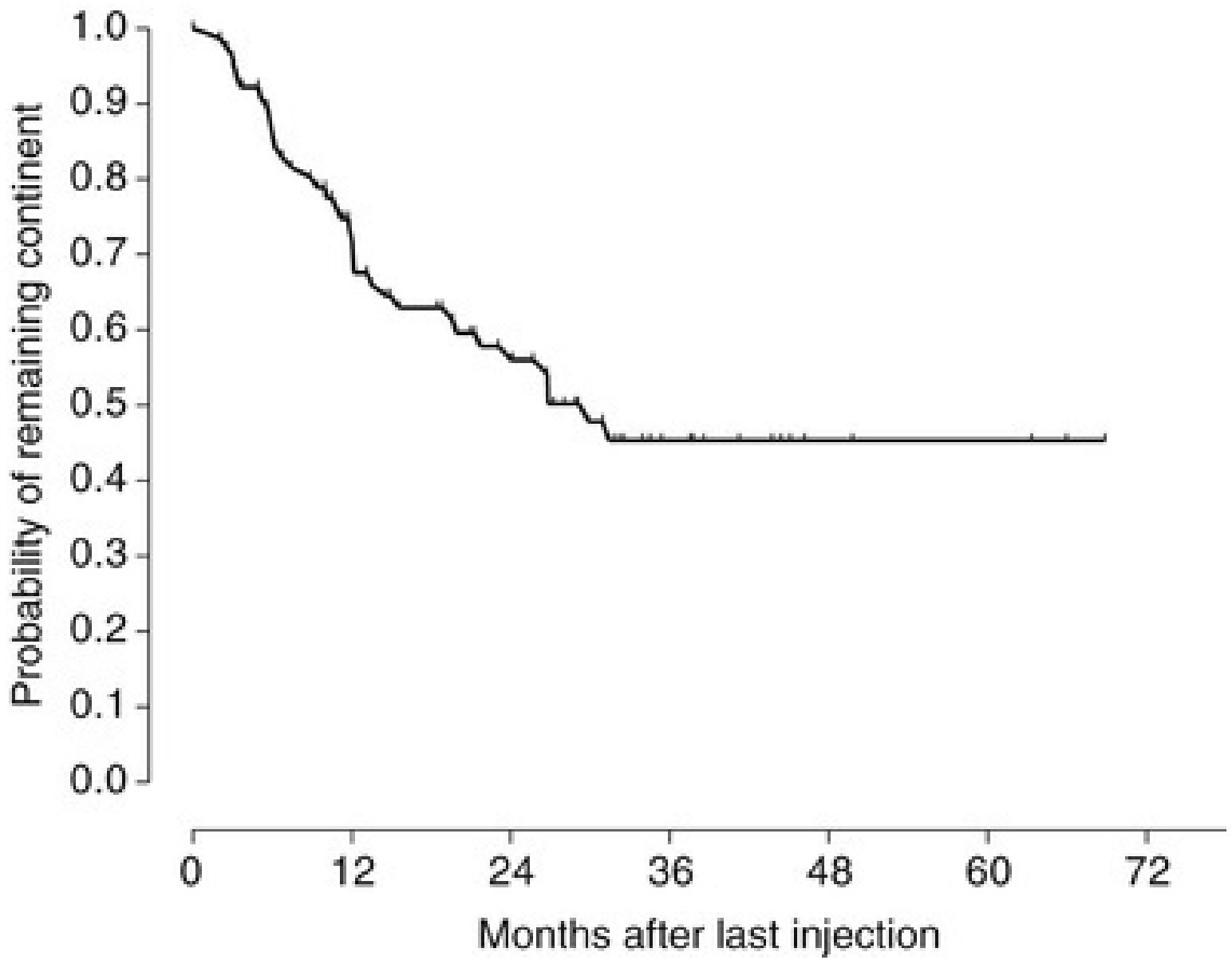

FIG. 127.4 Durability: Kaplan-Meier curve showing durability of cure of incontinence after the last collagen injection in 78 patients. (From Herschorn S, Radomski SB: Collagen injections for genuine stress urinary incontinence: patient selection and durability. *Int Urogynecol J Pelvic Floor Dysfunct* 8[1]:18–24, 1997.)

Carbon-Coated Zirconium Beads (Durasphere).

Durasphere consists of pyrolytic carbon-coated zirconium beads suspended in 2.8% glucan. The original formulation of Durasphere was highly viscous (particle size 200–550 µm) and required high pressure to inject. Durasphere-EXP was later introduced to address this issue, with particle size 95 to 200 µm.

In the original multicenter randomized 235-patient clinical trial of Durasphere versus collagen, Lightner et al. (2001) reported similar 12-month continence grade improvement rates between the two agents (66.1% Durasphere vs. 65.8% collagen, $P = 1.000$). However, the injected initial and repeat injection volumes of Durasphere were significantly less than those of collagen. Another RCT by Andersen (2002) demonstrated similar results: 80% (20 of 25) of Durasphere patients versus 61.9% (13 of 21) of collagen patients had a continence grade improvement ($P = 0.205$) after a mean of 2.6 and 2.8 years, respectively.

Rare but reported adverse events include urethral mucosal prolapse (Ghoniem and Khater, 2006), periurethral mass formation requiring drainage in 2.9% in a series of 135 patients (Madjar et al., 2006), and a pseudoabscess found 5 years after injection (Berger and Morgan, 2012).

Silicone Microimplants (Macroplastique).

Macroplastique consists of solid polydimethylsiloxane particles suspended in inert bio-excretable gel. Because of its high viscosity, injection of Macroplastique requires the use of a ratcheted injection gun (Fig. 127.5).

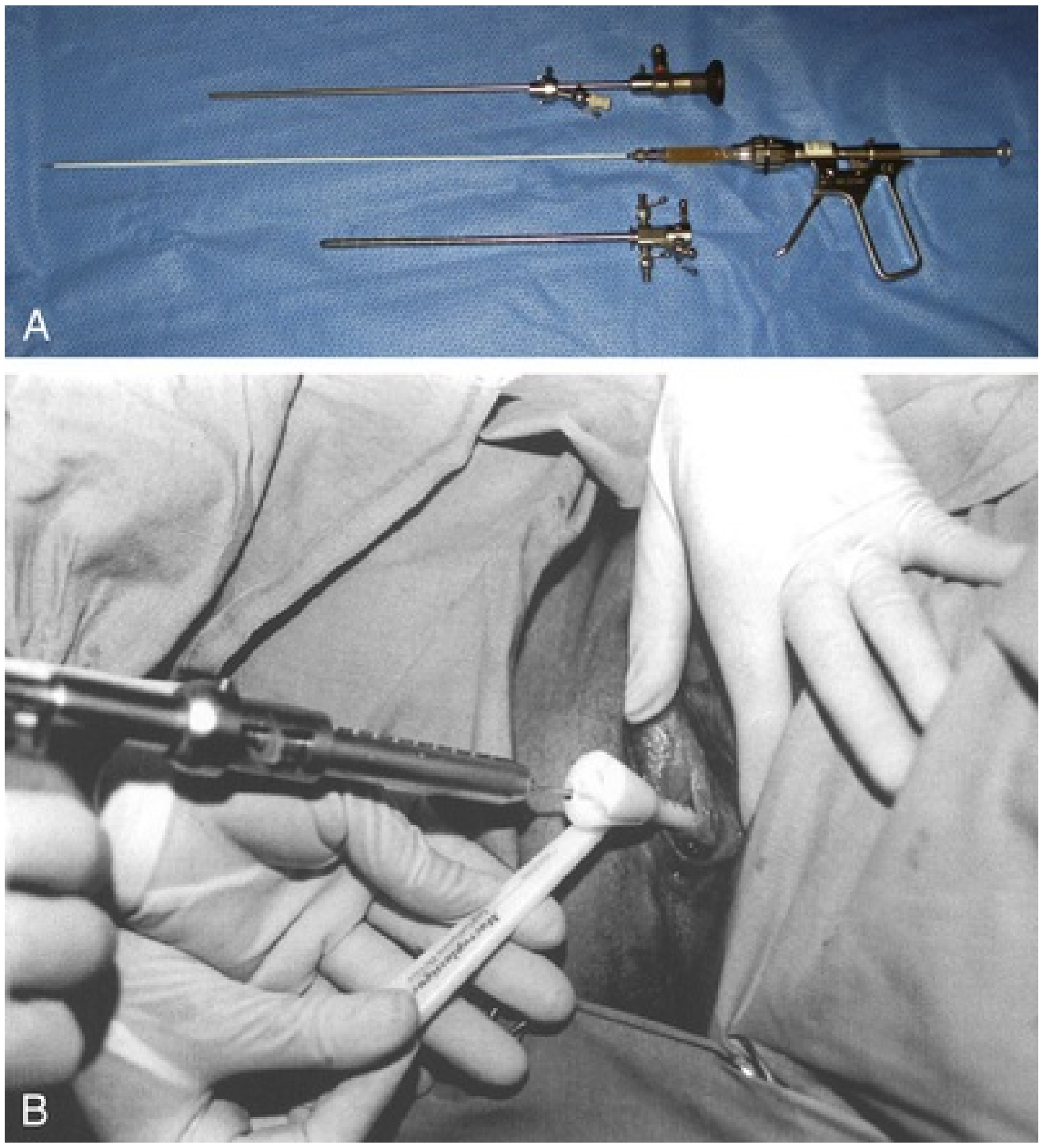

FIG. 127.5 (A) Silicone macroparticle injection gun. The injection needle is 7 Fr with a 10-mm, 18-gauge needle tip. (B) The implantation procedure. The bulking agent is injected through the device using the injection gun and a rigid needle. (From Tamanini JT, D'Ancona CA, Netto NR Jr: Treatment of intrinsic sphincter deficiency using the Macroplastique Implantation System: two-year follow-up. *J Endourol* 18[9]:906–911, 2004.)

A systematic review and meta-analysis of Macroplastique series from 1990 to 2010 was reported by Ghoniem and Miller (2013)**. The authors included 24 published articles with a total of 958 patients. Short-term (<6 months) cure and improvement rates were 43% and 75%, respectively. Medium-term (6 to 18 months) rates were 37% and 73%. Long-term (>18 months) rates were 36% and 64%. The median reinjection rate was 30%, and higher reinjection rates resulted in improved long-term outcomes.**

In a multicenter randomized trial of Macroplastique versus collagen in 247 women with ISD, Macroplastique was shown to have a significantly higher cure rate (36.9% vs. 24.8%, $P < 0.05$) (Ghoniem et al., 2009). However, there were no significant differences in pad weight testing, quality-of-life scale, or adverse events. The same authors subsequently reported follow-up results in the Macroplastique patients who had successful outcome at 12 months, showing

84% sustained success at 24 months (Ghoniem et al., 2010). Another RCT demonstrated Macroplastique injection to be superior to pelvic floor exercises in patients with SUI and urethral hypermobility (ter Meulen et al., 2009).

The systematic review by Ghoniem and Miller (2013) noted the absence of any serious reported adverse events over the 20 years of global experience.

Calcium Hydroxylapatite (Coaptite).

Coaptite consists of calcium hydroxylapatite (CaHA) particles in a carboxymethylcellulose gel carrier (Mayer et al., 2007). Calcium hydroxylapatite is a normal constituent of bone and thus nonimmunogenic. Coaptite is more viscous than collagen; it is currently supplied in 1-mL syringes and can be injected via a transurethral approach through a 21-gauge needle.

In a randomized prospective trial of CaHA versus collagen in 231 women with ISD only and 12-month follow-up, Mayer et al. (2007) demonstrated no significant difference in the primary outcome measure: improvement of at least one Stamey grade in 63.4% of CaHA patients versus 57% ($P = 0.34$). There was also no difference in overall cure rate (39% CaHA vs. 37% collagen, $P = 0.78$). However, more CaHA patients required only one injection, and the total average injected volume was lower (4.0 mL vs. 6.6 mL respectively; $P < 0.0001$).

Overall, CaHA was shown to have a similar safety profile to collagen (Mayer et al., 2007). Rare complications include vaginal wall erosion, dissection of the material beneath the trigone (Mayer et al., 2007), urethral mucosal prolapse (Lai et al., 2008; Palma et al., 2006), and injection site granuloma (Gafni-Kane and Sand, 2011).

Agents Available Outside the United States.

Bulkamid (polyacrylamide hydrogel) and Urolastic (polydimethylsiloxane [PDMS-U]) are currently used injectable agents found in Europe and are mentioned in Table 127.1.

Adjustable Continence Therapy

The Adjustable Continence Therapy (ACT) device was developed as an alternative to bulking agents that would not migrate (Kocjancic et al., 2008). It consists of two inflatable silicone balloons attached to silicone tubing with a titanium and silicone port (Fig. 127.6). The procedure can be done using local, regional, or general anesthesia. The balloons are placed into the periurethral space at the bladder neck with introducer devices inserted through 1-cm incisions in the labial sulci. The procedure is carried out under fluoroscopic guidance with a contrast-filled Foley balloon positioned at the bladder neck. After the correct position is ascertained, the device balloons are inflated with 1 to 1.5 mL of an isotonic solution (sterile water and contrast material). The aim is to increase urethral resistance and support the bladder neck with the inflated balloons (Stecco et al., 2006). The ports are buried in the subcutaneous tissue of the labia to enable postoperative reinjection of the balloons if necessary (Kocjancic et al., 2008). Beginning at 6 weeks, additional fluid, usually in increments of 2 mL, can be added to the balloons by percutaneous injection through the port sites. Each balloon has a capacity of 8 mL.

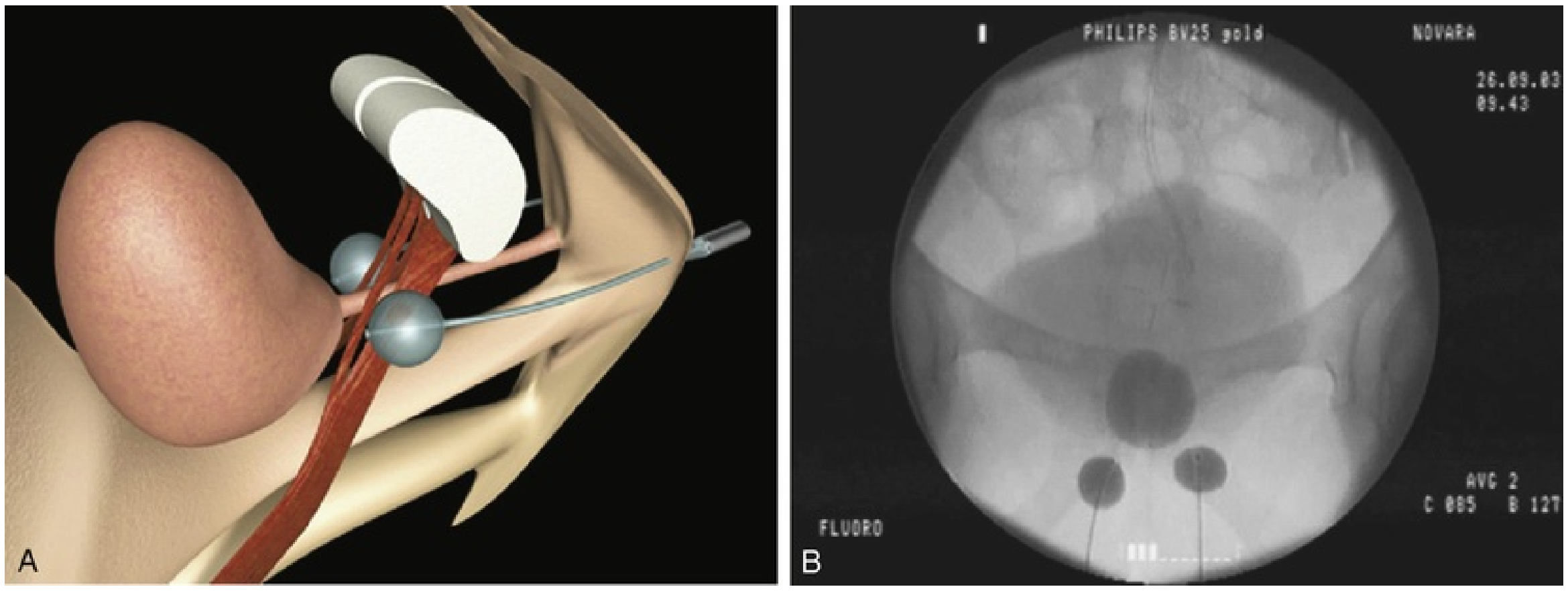

FIG. 127.6 Illustration of Adjustable Continence Therapy balloon device for women. (A) Schematic diagram showing percutaneous placement of the balloons on both sides of the bladder neck. (B) Fluoroscopic picture showing contrast agent in the bladder, Foley catheter, and balloons. (From Aboseif SR, Franke EI, Nash SD, et al.: The Adjustable Continence Therapy system for recurrent female stress urinary incontinence: 1-year results of the North America Clinical Study Group. *J Urol* 2009;181[5]:2187–91.)

Outcomes

Use of ACT in female patients with SUI was first reported in a prospective study by Chartier-Kastler et al. (2007). Of the 29 women followed for a mean of 2 years, 87% were dry or improved. There have been several studies on the use of ACT in recurrent SUI after anti-incontinence procedures, demonstrating dry rate of 44% to 68% (Cross et al., 1998; Gorton et al., 1999; Kocjancic et al., 2008;

Wachter et al., 2008). The longest term results were reported by Kocjancic et al. (2010). In 29 patients with a mean follow-up of 6 years, 68% considered themselves dry. On the Patient Global Impression of Improvement questionnaire, 64% of patients rated their symptoms as very much improved, 23% as much improved, and 13% as minimally improved or unchanged.

Rate of balloon adjustment has been reported as 62% to 69% (Kocjancic et al., 2008; Wachter et al., 2008), and Aboseif et al. (2009) reported a mean of 2.3 balloon adjustments per patient within the first 9 months.

There has been one comparative study on ACT. A French retrospective study compared outcomes of ACT versus artificial urinary sphincter (AUS) placement in 61 patients with SUI resulting from ISD (Freton et al., 2018). At baseline, the patients in the ACT group were older and had more comorbidities. The AUS group had better functional outcomes (dry rate 71.4% AUS vs. 21.7% ACT, $P < 0.001$), but a higher rate of intraoperative complications, longer operative time, and longer hospital stay.

Similar to urethral bulking agents, ACT may represent a reasonable option for treatment of SUI in patients who have recurrent SUI after anti-incontinence procedures as well as in older patients who may not be candidates for more invasive procedures.

Complications

The complication rate has been reported to be 24% (Aboseif et al., 2009) to 39% (Wachter et al., 2008), with most classified as mild to moderate. Reported intraoperative perforation rates are 3.7% to 45% (Phe et al., 2014). During the first year postoperatively, reported complications include balloon migration (6.5% to 17.5%) or dysfunction (0.6% to 8.9%), urethral erosion (2% to 15%), cutaneous erosion of the port (3% to 75%), device infection (0.6% to 6%), treatment failure or worsening of incontinence (2.5% to 11.7%), dysuria or retention (1.5% to 6.8%), and de novo urgency (10.5%) (Phe et al., 2014).

The explantation rate is 15% to 38% (Chartier-Kastler et al., 2007; Phe et al., 2014). The reimplantation rate is up to 50% in various studies (Phe et al., 2014).

Cell-Based Therapy

Cell-based therapy for SUI represents a new frontier in regenerative medicine. Autologous stem cells can be injected into the urethral sphincter with the goal of regenerating deficient anatomic components of the urethral continence mechanism. Stem cell therapy has the potential to restore the external (striated muscle) and internal (smooth muscle) urethral sphincter, neuromuscular synapse, and blood supply (Hart et al., 2015). Because of its mechanism, this therapy is thought to be best suited for patients with ISD. As of 2017, the AUA guideline mentions stem cell therapy as a potential future option for treatment of female SUI but states it should not be offered outside of investigational protocols (Kobashi et al., 2017). Advantages of cell-based therapy for SUI include treatment of the cause rather than just the symptom as well as lack of immunologic reaction with the use of autologous cells. In addition, needle biopsy and urethral injection can be performed in a minimally invasive fashion under local anesthesia.

The use of adult stem cells derived from skeletal muscle, bone marrow, umbilical cord, and adipose tissue has been investigated in animal and human studies (Williams et al., 2016). The majority of clinical trials have involved autologous muscle-derived cells (AMDCs).

Human Studies

In their pilot North American study, Carr et al. (2008) reported on their 1-year experience with urethral injection of AMDCs ($18–22 \times 10^6$) isolated from quadriceps biopsies in 8 women with SUI. Clinical improvement was reported in 5 of 8 women; one achieved complete continence. Onset of improvement was seen between 3 and 8 months after injection, with sustained improvement at a median of 10 months. In the subsequent prospective dose ranging study, 38 women underwent periurethral injection of low ($1, 2, 4, 8$, of 16×10^6) or high doses ($32, 64$, or 128×10^6) of AMDCs with promising results (Carr et al., 2013). In the high-dose group, a higher percentage of patients experienced 50% or greater reduction in pad weight (88.9% high dose vs. 61.5% low dose), 50% or greater reduction in diary-reported stress leaks (77.8% vs. 53.3%), and had 0 to 1 leak in a 3-day period (88.9% vs. 33.3%) at 12-month follow-up.

Peters et al. (2014) reported the safety and 12-month efficacy outcomes of two pooled phase II studies of AMDCs using four increasing doses ($10, 50, 100$, and 200×10^6). They also found that higher-dose groups tended to have greater percentages of patients with at least a 50% reduction in stress leaks and pad weight. All groups had statistically significant improvements in Urogenital Distress Inventory-6 and IIQ-7 scores.

Randomized controlled trials on use of AMDCs for urinary sphincter repair have yet to be published. Preliminary data from a Phase III double-blind RCT in 143 women with SUI (50 placebo, 93 AMDCs at dose 150×10^6) were recently presented (Carr et al., 2017). The patients were randomized 2 : 1 to receive intrasphincteric injection at a dose of 150×10^6 or placebo, and within the treatment group, randomized 1 : 1 to receive 1 versus 2 treatments (second treatment being performed at 6 months). At 12 months, all patients were unblinded, and those receiving placebo could opt to receive AMDC injection. With their preliminary data, the authors concluded that AMDCs may provide durable reduction in incontinence episode frequency (IEF). The aforementioned studies were sponsored by Cook Myosite, Incorporated (Pittsburgh, PA).

Additional studies using AMDCs have shown promising results. Mitterberger et al. (2007) reported on 123 women with SUI who underwent transurethral ultrasound (TUUS)–guided injection of autologous fibroblasts into the urethral submucosa and myoblasts into the rhabdosphincter, using cells cultured from biceps biopsies. One year after therapy, 94 women (79%) were cured, 16 (13%) were substantially improved, and 9 (7%) were slightly improved; 4 were lost to follow-up. TUUS and electromyography evaluation demonstrated significant improvement in thickness and contractility of the rhabdosphincter. Stangel-Wojcikiewicz et al. (2014) reported 2-year outcomes of transurethral sphincter injections of autologous muscle-derived stem cells (MDSCs) harvested from the deltoid in 16 women with SUI. After 2 years, 8 (50%) were dry and an additional 4 (25%) were improved; in 4, the treatment failed. The authors noted that the mean time for initial improvement was 4.7 months. They also noted that success was seen with a relatively small number of cells ($0.6 – 25 \times 10^6$). Cornu et al. (2014) reported the long-term outcome of autologous MDSC injection in 12 women, 11 of whom had recurrent SUI after anti-incontinence procedures. Of the 2 patients who were dry at 1 year, both were still dry at 6 years. Of the 5 who were considered improved at 1 year, all worsened, but 3 remained satisfied. There were 5 failures.

To avoid the need for expensive cell preparation technology, Gras et al. (2014) tested the effect of intraurethral injection of minced autologous skeletal muscle tissue in 20 women with uncomplicated and 15 with complicated SUI. After 12 months, cure and improvement were noted in 25% and 63% of the uncomplicated group and 7% and 57% of the complicated group, respectively. The results appear similar to reports with harvested stem cells.

In Phase II trials, there were no serious adverse events (Peters et al., 2014). There were biopsy-related adverse events in 4 patients: wound hematoma (2), procedural dizziness (2), postoperative bleeding requiring sutures (1), and joint swelling (1). Injection–procedure-related adverse events occurred in 18% (14 of 80): dysuria (7), pelvic/abdominal pain (4), vulvovaginal pruritus (3), urinary urgency (2), and transient hematuria (2). There were no reports of urinary retention, which distinguishes this therapy from existing procedures for SUI.

Other cell types have also been studied. The first human study of cell therapy for SUI involved injecting autologous ear chondrocytes as a urethral bulking agent in 32 women (Bent et al., 2001b). After 1 year, 81% were improved and 50% were dry. Lee et al. (2010) reported the outcome of transurethral injection of a 2-mL suspension of umbilical cord blood stem cells in 36 women. After 12 months, 26 (72.2%) were cured or improved, and in 10 (27.8%), the procedure failed. In a study using autologous adipose derived cells in 5 females with SUI, one patient was continent at 6 months and an additional 2 were continent at 12 months; the authors used the cough test as their primary end point (Kuismanen et al., 2014). **The technology looks promising and may provide advantages over bulking agents. However, there are no large or comparative studies, and no long-term data are available yet. Furthermore, the ultimate cost of the technology will determine whether it becomes a feasible alternative.**

Use of Injectable Agents for Male Stress Urinary Incontinence

Urethral bulking agents may also be used to treat male patients with SUI, the majority of whom have postprostatectomy incontinence (PPI). **Several agents have been used including bovine collagen (Contigen) and silicone microparticles (Macroplastique). All agents share similar problems including the need for multiple injections, deterioration of effect over time, and low cure rates.**

Evaluation of postprostatectomy patients is discussed in detail in Chapter 131. **Before bulking agent injection, cystourethroscopy is recommended to verify integrity of the urethral wall and bladder neck and the status of the bladder (e.g., trabeculation, stones, diverticula). Injectables are not effective with scarred supramembranous urethras because the tissues cannot expand with the agent.**

Injection Techniques

Retrograde Injection.

Urethral bulking agent injection may be performed transurethrally under cystoscopic guidance using local, regional, or general anesthesia (Fig. 127.7A). A 20- or 22-Fr cystoscope sheath is used with a 0-degree or 30-degree lens. The needle is advanced under the urethral mucosa with the beveled portion facing the urethral lumen to allow for layering of the material. The injectable material is then delivered, creating a bleb under the urethral mucosa that protrudes into the urethral lumen. This is performed in a circumferential manner in four quadrants. After completion, the urethral mucosa should be completely coapted, creating the appearance of an obstructed urethra. The postprostatectomy urethra is frequently scarred and not very pliable; thus several needle insertions may be needed to deposit sufficient material for urethral coaptation. Extrusion of the injectable agent into the urethral lumen may be prevented by leaving the needle in place for at least 30 seconds or by flushing the material with saline. The loss of additional material is diminished by preventing advancement of the cystoscope proximal to the injection sites.

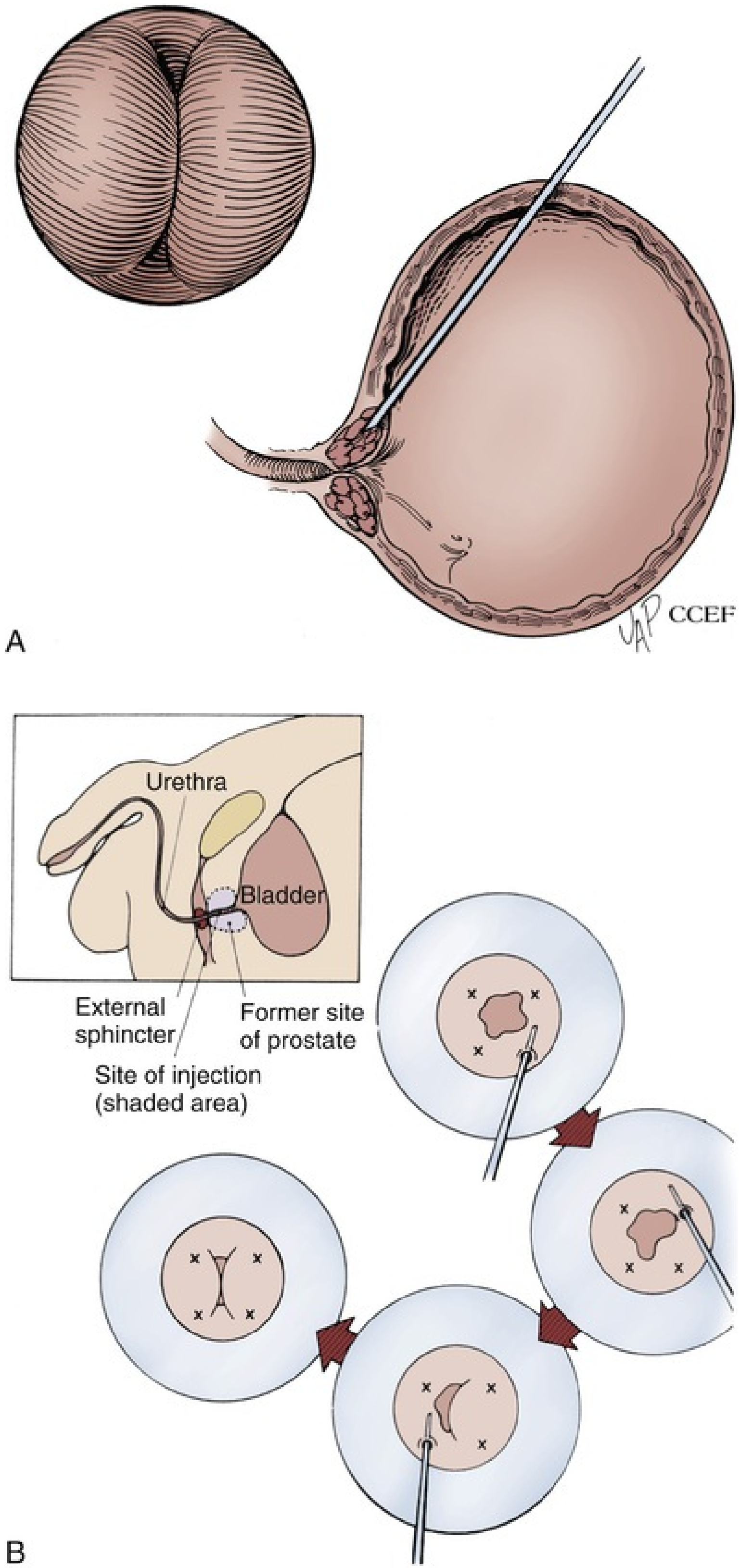
CCEF
A
Urethra
Bladder
External sphincter
Site of injection (shaded area)
Former site of prostate
B

FIG. 127.7 (A) Retrograde urethral injection technique in men. Schematic representation of transurethral circumferential injection in a male after prostatectomy. (B) Antegrade urethral technique injection in the male after radical prostatectomy. (A, Reprinted with permission, Cleveland Clinic Center for Medical Art & Photography. Copyright 1994–2011. All rights reserved.)

Antegrade Injection.

Because of less-than-optimal results, an alternative method of injecting collagen in men was introduced, involving a suprapubic antegrade approach. The antegrade approach has the advantage of direct visualization of the bladder neck and the injection of material into a more supple, less scarred urethra (Fig. 127.7B). The patient is placed in the lithotomy position and flexible cystoscopy is carried out, simultaneously filling the bladder. A percutaneous suprapubic puncture allows placement of two guidewires into the bladder. The site is dilated to 16 Fr with Amplatz dilators. A sheath may be used, but commonly the cystoscope (flexible or rigid pediatric) can be advanced over one of the guidewires into the bladder. A small red rubber catheter or the flexible cystoscope can be used to assist in localization of the bladder neck. The needle is placed just under the urethral mucosa at the level of the bladder neck and advanced proximally, meaning it is pulled back toward the bladder. The bladder neck closes off completely as the material is injected on either side. A small suprapubic tube (SPT) can be placed to avoid the possible necessity of urethral catheterization.

Collagen.

For collagen, success rates for PPI range from 36% to 69%, with 4% to 20% of patients reporting being dry (Aboseif et al., 1996; Cespedes et al., 1999; Cummings et al., 1996; Klutke et al., 1999; McGuire and Appell, 1994; Sanchez-Ortiz et al., 1997; Smith et al., 1998a; Tiguert et al., 1999). Unfortunately, the end points in most of these studies are subjectively based, making comparisons difficult; however, it is clear that cure rates (total dryness) are low, and multiple injections are required to achieve modest rates of subjective improvement. There is no advantage of delivery technique (retrograde vs. antegrade).

Collagen injection does not adversely affect outcomes of artificial sphincter implantation and does not increase the complication rate (Gomes et al., 2000), nor does it adversely affect outcomes of bone-anchored male sling placement (Comiter, 2002; Onur and Singla, 2006).

Silicone Microimplants (Macroplastique).

Use of Macroplastique in PPI was first reported by Colombo et al. (1997), who followed 6 men for a mean of 15.5 months. Of 6 patients, 5 became dry and 1 was substantially improved. Although initial success has been demonstrated, results have been shown to deteriorate over time (Bugel et al., 1999; Kylmala et al., 2003).

In a randomized trial of AUS implantation versus Macroplastique injection, Imamoglu et al. (2005) demonstrated no difference in success with AUS versus Macroplastique in men with mild incontinence (the vast majority had SUI after benign prostatic hyperplasia [BPH] surgery, with more than one-third of the cohort having SUI after open radical prostatectomy). However, in patients with more severe incontinence, the AUS was superior, with minimal improvement seen after transurethral Macroplastique.

Cell-Based Therapy.

Use of autologous muscle-derived cells has also been studied in male patients with postprostatectomy SUI. Mitterberger et al. (2008) injected autologous fibroblasts and myoblasts into the rhabdosphincter of 63 patients with postprostatectomy SUI. The authors reported continence in 41 of 63 patients, improvement in 17, and lack of improvement in 5, as well as improvements in thickness and contractility of the rhabdosphincter on transurethral ultrasound. In a study of 222 patients undergoing transurethral injection of AMDCs with at least 12-month follow-up, 12% were continent, 42% showed improvement, and in 46%, therapy was ineffective (Gerullis et al., 2012). There have been 3 trials on autologous adipose-derived regenerative cells (ADRCs) in a total of 20 males with incontinence after prostate surgery (Choi et al., 2016; Gotoh et al., 2014; Yamamoto et al., 2012). In the largest of these studies ($n = 11$) with 1 year follow-up, 8 patients demonstrated progressive improvement in SUI and 1 achieved total continence (Gotoh et al., 2014). Also, enhanced ultrasonography showed a progressive increase in blood flow at the area of injection, suggesting an angiogenesis effect.

Use of Injectable Agents After Urinary Diversion

There are increasing numbers of reports in the literature about the use of injectables after diversion. In a canine study, Izes et al. (1997) demonstrated that GAX collagen injected circumferentially into the lumen of the ileocecal valve can increase the leak point pressure for up to 1 month. Subsequently, Smith et al. (1998b) reported results of collagen use in 6 patients with incontinence after Indiana pouch; 5 of 6 remained dry after a mean follow-up of 26 months.

Macroplastique has also been used for treatment of incontinent catheterizable channels. Guys et al. (2002) reported on the use of Macroplastique in 6 patients (4 appendix and 2 ileum) with a mean of 6 (3 to 8) mL. One had a second injection after 3 months. Four of 6 were continent after a mean of 11 (8 to 18) months. Halachmi et al. (2004) reported cure in 3, improvement in 1, and no change in 1 of 5 patients with stoma leakage. Kass-Ilya et al. (2015) reported a 50% success rate in 24 patients after a mean of 30 months. Three were dry and 9 were improved. Five of the 9 improved patients went on to surgery at a mean of 41 months.

Prieto et al. (2006) treated 14 patients with leaking stomas with 2 to 6 mL (mean 3.7 mL) of dextranomer/hyaluronic acid (DHA). With a mean follow-up of 1 year, 10 were dry after one injection, 1 was dry after two injections, and 3 had treatment failure. Welk et al. (2008) achieved success in 2 of 4 patients with DHA injections. Injectable agents appear to be a benefit for stomal incontinence in more than 50% of reported patients and may obviate or delay surgical revision.

Injectables have been reported in women with urethral incontinence after neobladder construction. Tchetgen et al. (2001) reported on 3 women with SUI after cystectomy and orthotopic neobladder. An average of two collagen injections were given, with a cure in 1 patient, improvement in 1, and no change in 1. Wilson et al. (2004) administered transurethral collagen to 11 patients and Durasphere to 1 patient with SUI after cystectomy and neobladder. After a mean of 22.5 months, 2 patients (16.7%) were dry, although they continued to have urinary frequency. Four patients (33.3%) were improved and 6 were unchanged. The authors concluded that the treatment response was not optimal or durable.

New-onset vesicovaginal fistula was reported in two patients who had undergone collagen injection for SUI after cystectomy and neobladder (Pruthi et al., 2000). Both patients underwent transvaginal fistula repair with pubovaginal sling.

Bladder Outlet Closure: Functional and Complete

In certain instances, when other surgical interventions have failed, urethral or bladder neck closure is necessary to treat refractory incontinence resulting from urethral erosion, severe stress incontinence, bladder neck incompetence, or difficult urethral fistulae. One familiar clinical scenario is that of a neurogenic female patient managed with a long-term indwelling urethral catheter. Over time, the catheter balloon causes pressure necrosis and urethral/bladder neck destruction, leaving a very patulous, incompetent urethra. Chancellor et al. (1994c) reported their results with **functional bladder neck closure using an obstructing autologous pubovaginal sling** in 14 female patients with neurogenic, end-stage bladders and a destroyed bladder outlet from chronic indwelling Foley use. All women had an intact bladder neck and at least 1 cm of viable proximal urethra. With a mean follow-up of 24 months, all patients had success with minimal incontinence and a low rate of complications. **This type of functional bladder neck closure avoids complete closure of the urinary system, providing a "pop-off" valve for leakage at higher pressures and allows access for possible future instrumentation.** In this type of scenario, in which the sling is meant to obstruct the bladder outlet, autologous or cadaveric slings are superior to mesh slings, which would be much more likely to erode into the urethra. However, several studies have described using mesh slings in a "spiral" fashion to wrap the urethra circumferentially for refractory patients with stress urinary incontinence (Mourtzinos et al., 2008; Rodriguez et al., 2010; Rutman et al., 2006). This technique, first described by Rutman et al. (2006), involves a transvaginal urethrolysis to gain access to the urethra circumferentially. A polypropylene mesh sling with sutures attached to each of the ends is completely wrapped around the urethra, crossing at the ventral urethra, and then the ends are passed retropubically and tied above the fascia. Success of 72% to 87%, or overall improvement in symptoms, was reported in these small series with few complications noted (Mourtzinos et al., 2008; Rodriguez et al., 2010; Rutman et al., 2006).

When preservation of a functional bladder outlet is not a viable option, transvaginal, transabdominal (retropubic), or combined bladder neck closure along with LUT reconstruction to the abdominal wall is indicated. **Closure of the bladder neck is more challenging than a simple cystorrhaphy. The bladder neck is hyperactive in neurogenic patients, and stress is placed on the bladder neck closure with every voiding reflex.** It is imperative to have a multilayer, watertight closure and use postoperative drains to avoid fistula formation (Fig. 127.8). In addition, an adequate time of continuous bladder drainage and use of anticholinergics will limit the stress on the bladder neck suture line.

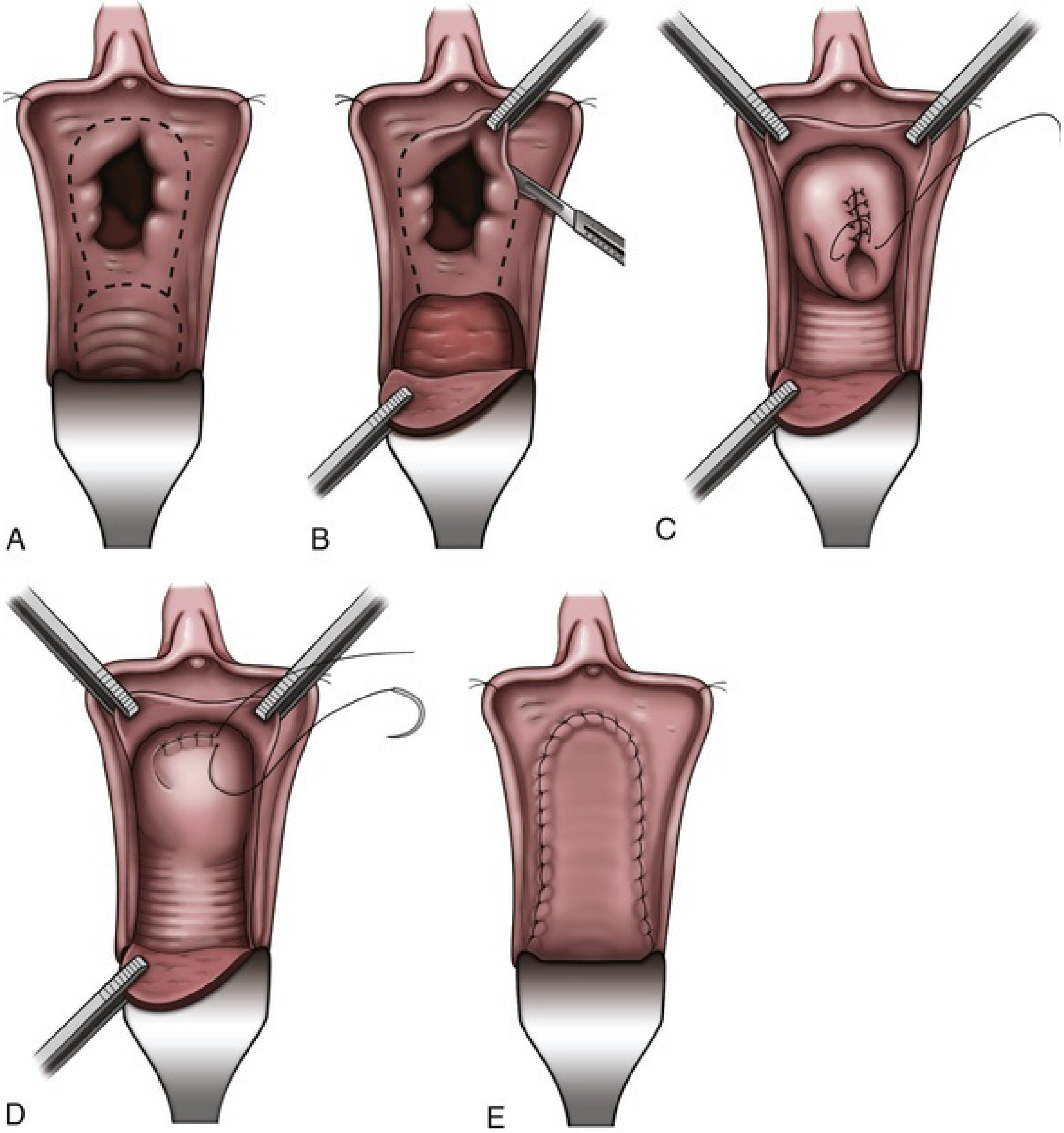

FIG. 127.8 (A) After injection of normal saline solution into the anterior vaginal wall, an incision is made around the urethral opening to create the vaginal wall flap. (B) The urethral meatus is dissected free, and the vaginal wall flap is created. (C) The bladder neck wall musculature is vertically closed in a running fashion after the mucosal layer has a watertight closure. (D) The final muscular layer is closed in a horizontal fashion and rotated superiorly behind the pubis. (E) The vaginal epithelium is advanced over the entire defect and closed with a running suture.

Levy et al. (1994) reported a 40% success rate using a transvaginal bladder neck closure. They subsequently modified the approach, using a combined transvaginal-transabdominal approach and reported a 100% success rate at a mean 16-month follow-up for the subsequent 10 patients. Shpall and Ginsberg (2004) reported on 39 patients who underwent a combined transabdominal bladder neck closure and various continent and incontinent diversions. At a mean of 37 months, 6 patients (15%) developed fistulae; however, 4 patients underwent successful repair for an overall 95% cure rate. In addition, O'Connor et al. (2005) reported on 35 patients with a mean 79-month follow-up who underwent a transabdominal bladder neck closure for refractory incontinence. They were initially successful in 28 (83%) patients, with an overall 94% cure rate after one revision. Most recently, Kavanagh et al. (2012) reported with a median follow-up of 69 months on 28 pediatric or adolescent patients who underwent concomitant transabdominal bladder neck closure with enterocystoplasty and Mitrofanoff diversion. Bladder neck closure was successful in 96.4% of patients, with only one requiring repair of a postoperative vesicovaginal fistula. In addition, there was no evidence of progressive or new hydronephrosis in their cohort. **Ultimately, closure of the bladder outlet with simultaneous LUT reconstruction is often required and can be highly successful in certain refractory patients who have failed other surgical treatments for their destroyed bladder outlet.**

In a retrospective study of 64 patients, transvaginal and transabdominal (retropubic) approaches were shown to have similar urethral continence rates (85.7% transvaginal vs. 81.5% retropubic, $P = 0.74$) (Willis et al., 2015). However, transvaginal bladder neck closure was associated with shorter operative time, decreased length of hospital stay, and fewer short-term complications.

Bladder neck closure is definitive, and patients need to understand the importance of adhering to consistent bladder drainage to avoid the complication of spontaneous bladder perforation. Although rare, concerns also arise over the potential difficulty in accessing the bladder acutely because of an emergency situation or possible stomal stenosis; reported rates of stenosis are 6% to 19.5% (Ardelt et al., 2012; Leslie et al., 2011; Welk et al., 2008). One group discusses equipping all their patients with MedicAlert bracelets and instructing them on how to decompress their bladder if need be via percutaneous needle aspiration (Kavanagh et al., 2012).

Key Points: Additional Therapies for Storage Failure at the Bladder Outlet

- Goal of urethral injection therapy is to restore urethral mucosal coaptation and its hermetic seal effect, especially during periods of increased abdominal pressure.
- Injectable agents are an option for patients who are not candidates for more invasive procedures. Efficacy and durability are generally inferior to surgery.
- Functional urethral closure with pubovaginal sling provides pop-off valve for leakage at higher pressures and allows access for transurethral instrumentation.
- Bladder neck closure with simultaneous LUT reconstruction may be successful in refractory patients with destroyed bladder outlet.

Additional Therapies for Emptying

Continent Catheterizable Channels

Some neurogenic patients require CIC to empty but have difficulty accessing the native urethra. This can be the case in patients with limited upper extremity dexterity or in patients who are wheelchair-bound and find it troublesome to position themselves for CIC. Often these patients depend on caregivers to assist them with CIC, have impaired self-esteem and body image, and ultimately desire more independence. Walsh et al. (2004) studied quadriplegic female patients who underwent surgery for creation of continent catheterizable channels. The authors show that these patients had significant improvements in quality-of-life measures and had increased efficiency in catheterizing (decrease in time to catheterize from 27 [range 10 to 40] to 7.8 [range 1 to 15] minutes). Another study by Zommick et al. (2003) reviewed outcomes of continent LUT reconstruction in 21 patients with cervical SCI and varying degrees of upper extremity dexterity. These patients reported improvements in quality of life because of eradication of urinary drainage bags, increased continence, more freedom, and improved body image. In addition, a majority (95%) were able to maintain CIC long term by themselves or with the help of a caregiver. Furthermore, neurogenic patients undergoing augmentation cystoplasty who also have severe incontinence resulting from urethral erosion or bladder neck incompetence may benefit from concomitant bladder outlet surgery and formation of a continent catherizable channel at the time of LUT reconstruction.

Urethral loss also can necessitate creation of a continent catheterizable channel to maintain bladder access and continence. **In addition to neurogenic patients, patients with non-neurogenic benign disease processes such as recalcitrant bladder neck contracture, urethral loss from stricture or radiation damage, and refractory urethral fistulae are candidates for continent LUT reconstruction.**

Various techniques, many using the flap-valve mechanism for continence, have been described: the Mitrofanoff appendicovesicostomy (Mitrofanoff, 1980); a transverse ileal tube (Yang-Monti) (Monti et al., 1997; Yang, 1993); tapered ileum implanted into a serous-lined extramural tunnel (Abol-Enein and Ghoneim, 1999); and the ileocecocystoplasty, which uses the ileocecal valve to provide continence (Sarosdy, 1992; Sutton et al., 1998) (Fig. 127.9). These channels are not free of complications, and long-term issues with catheterization, incontinence, and stomal stenosis can occur. A large retrospective study by Leslie et al. (2011) analyzed the long-term outcomes of 169 pediatric patients after either Mitrofanoff appendicovesicostomy or transverse ileal (Monti) tube. The authors report a 39% revision rate (8% stricture, 4% prolapse, 10% incontinence, 17% stomal stenosis at skin level). Despite revisions, 96% of channels were still functional at last follow-up. Most recently, in a cohort of 81 pediatric patients, Jacobsen et al. (2017) demonstrated that channel-associated complications cluster within the first 2 years postoperatively, followed by a significant decline. They also demonstrated a higher complication rate for ileal versus appendiceal channels. The choice of continent channel technique is often influenced by patient anatomy and surgeon preference.

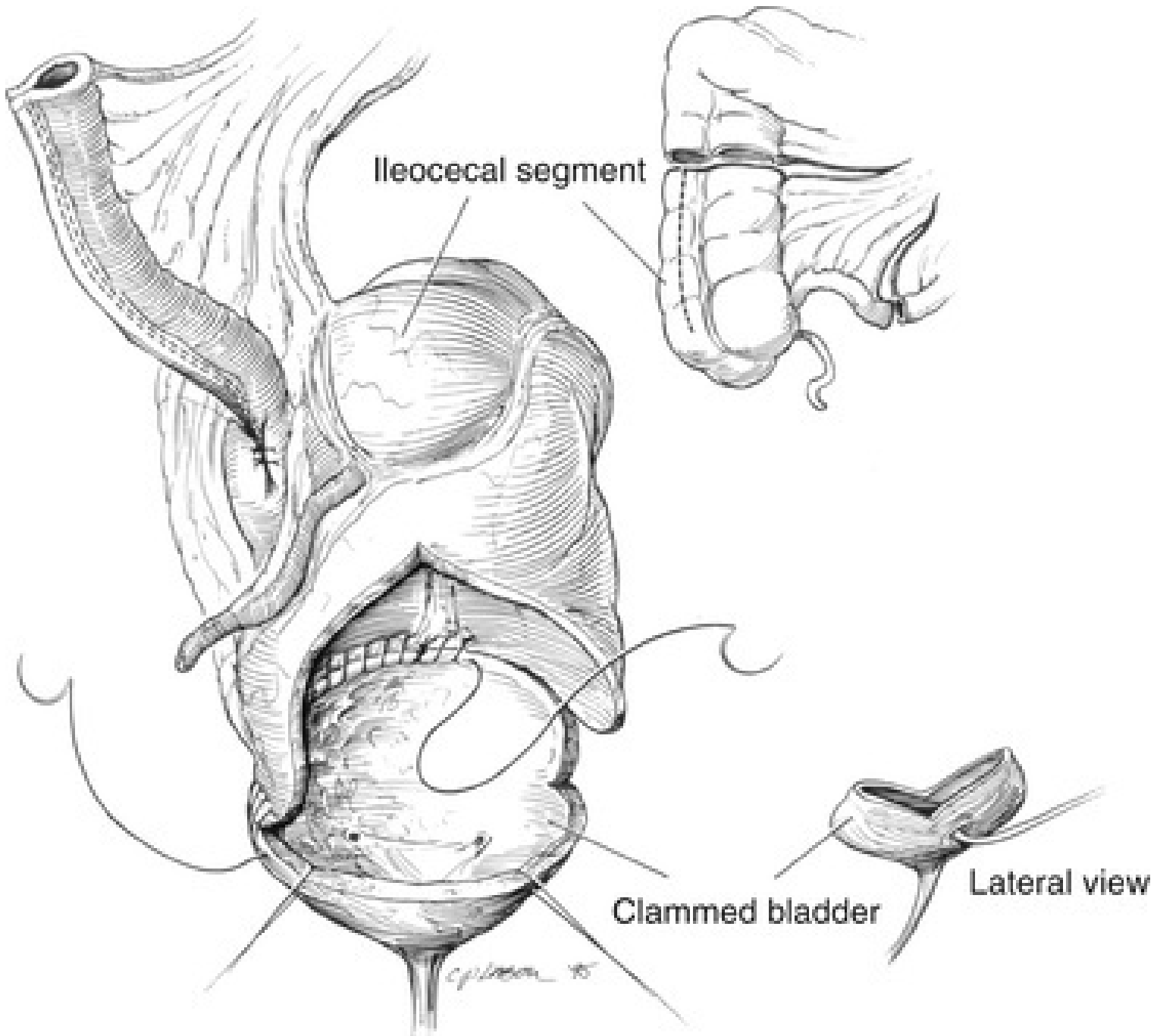

FIG. 127.9 Diagram of the continent ileocecal augmentation cystoplasty with the bowel segment used (right cecum and distal ileum) in the upper right corner and a view of the bivalved bladder in the lower right corner. (From Sutton MA, Hinson JL, Nickell KG, et al.: Continent ileocecal augmentation cystoplasty. *Spinal Cord* 36:246–251, 1998.)

Catheterization

Catheterization, in its many forms, is an effective method of bladder emptying and is a useful adjunct when efforts to increase intravesical pressure and/or decrease outlet resistance have been unsuccessful. Catheterization may also be a useful adjunct in patients who have filling/storage failure caused by bladder overactivity and/or sphincteric incontinence (Wein and Barrett, 1988). The common goals, irrespective of the mode of catheterization, are to provide low-pressure storage, preserve continence, avoid renal deterioration, minimize complications, and maintain quality of life.

Indwelling urethral catheters are generally used for short-term bladder drainage, and careful use of a small-bore catheter for a short time is unlikely to adversely affect the ultimate outcome, especially in initial bladder management after SCI (Lloyd et al., 1986). Long-term bladder drainage may be achieved by intermittent catheterization or by an indwelling suprapubic or urethral catheter. The most appropriate form of bladder drainage in patients requiring prolonged bladder management has long been debated. Most studies on catheterization have been retrospective and in patients with SCI, who represent the majority of patients requiring long-term catheterization. The main area of controversy concerns whether long-term indwelling catheterization in neurologically impaired patients is associated with an inferior outcome compared with CIC, specifically regarding urinary tract complications or quality of life.

Although CIC is currently the preferred management for patients requiring prolonged bladder drainage, it is a recent innovation. Intermittent catheterization was first introduced as a sterile procedure in 1949 by Guttman and, at the time, challenged the beliefs of most urologists (Guttman, 1949; Guttmann and Frankel, 1966). It was not until Lapides et al. (1972) introduced the concept of CIC that widespread usage became more common. **As the popularity of CIC grew, long-term indwelling catheterization was condemned, based on infectious risks and a perceived increased risk for other urologic complications.** Weld and Dmochowski (2000) reported a retrospective review of 316 patients with SCI with a mean follow-up of 18.3 years. Bladder management methods included chronic urethral catheterization in 114 patients, CIC in 92, spontaneous voiding in 74, and suprapubic catheterization in 36. Complications were classified as infectious complications (epididymitis and pyelonephritis), renal and bladder calculi, urethral complications (stricture and periurethral abscess), and radiographic abnormalities (vesicoureteral reflux and abnormal urographic findings). Overall, there were 398 complications identified, of which 236 developed in 61 patients (53.5%) on chronic urethral catheterization, 48 in 16 patients (44.4%) on suprapubic catheterization, 57 in 24 patients (32.4%) who voided spontaneously, and 57 in 25 patients (27.2%) on CIC. Separate bar graphs for each type of complication suggest the overall superiority of CIC as the least problematic long-term form of bladder management (Fig. 127.10).

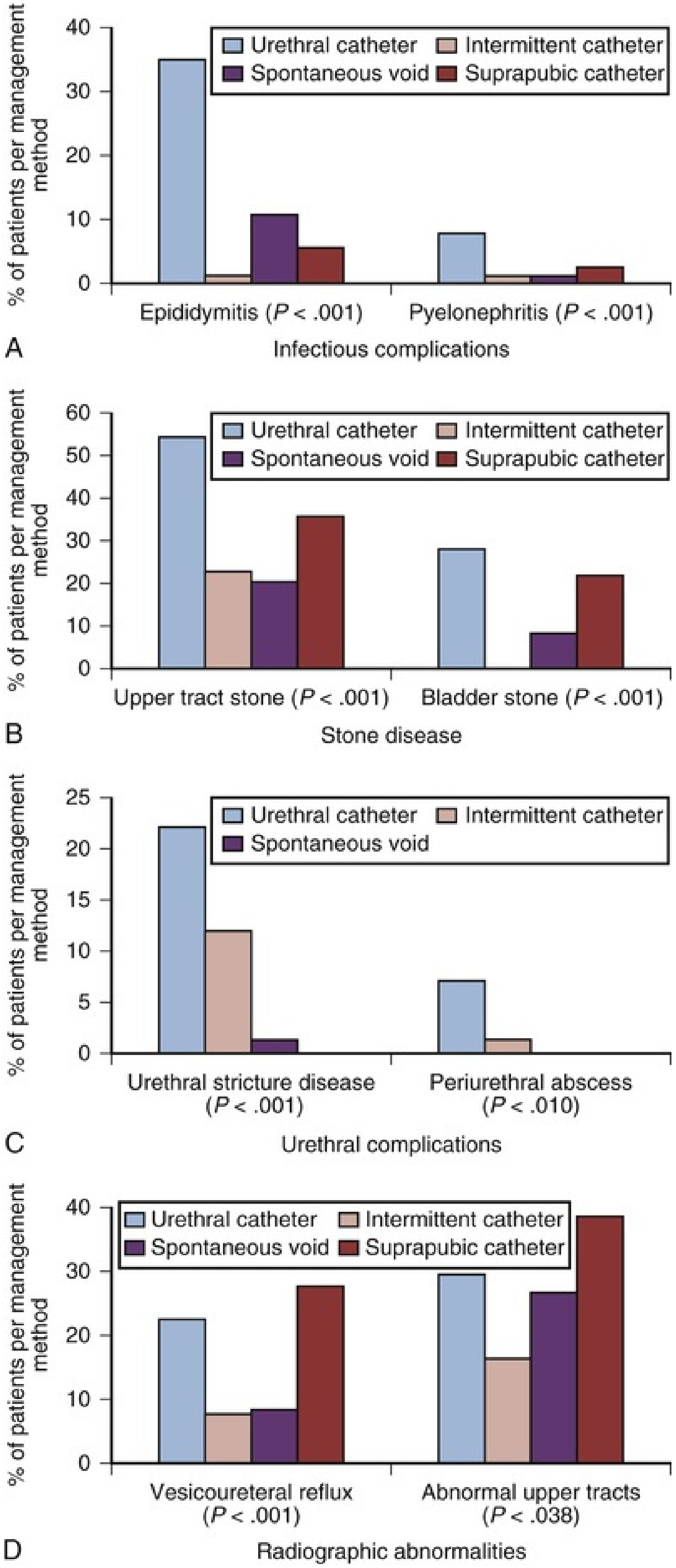
% of patients per management method
40
30
20
10
0
Urethral catheter
Intermittent catheter
Spontaneous void
Suprapubic catheter
Epididymitis (P < .001)
Pyelonephritis (P < .001)
A
Infectious complications
% of patients per management method
60
50
40
30
20
10
0
Urethral catheter
Intermittent catheter
Spontaneous void
Suprapubic catheter
Upper tract stone (P < .001)
Bladder stone (P < .001)
B
Stone disease
% of patients per management method
25
20
15
10
5
0
Urethral catheter
Intermittent catheter
Spontaneous void
Urethral stricture disease (P < .001)
Periurethral abscess (P < .010)
C
Urethral complications
% of patients per management method
40
30
20
10
0
Urethral catheter
Intermittent catheter
Spontaneous void
Suprapubic catheter
Vesicoureteral reflux (P < .001)
Abnormal upper tracts (P < .038)
D
Radiographic abnormalities

FIG. 127.10 Complications related to specific bladder management methods: infectious (A); stone disease (B); urethral (C); radiographic abnormalities (D). (Modified from Weld KJ, Dmochowski RR: Effect of bladder management on urological complications in spinal cord injured patients. *J Urol* 163:768–772, 2000.)

The exact cause of upper tract deterioration in patients with long-term indwelling catheters is unclear because the bladder should be well drained by a catheter; however, it is likely related to chronic "occult" or subclinical DO in the face of sphincteric dyssynergy providing a functional obstruction. Regardless of the cause, it is clinically heralded by the development of poor detrusor compliance demonstrated on urodynamic studies. Jamil et al. (1999) reported on ambulatory urodynamics in 30 patients with SCI managed with an indwelling urethral catheter. They found that freely draining indwelling catheters did not guarantee consistently low intravesical pressure, observing intermittent detrusor contractions causing intravesical pressure greater than 40 cm H_2O in 11 patients (37%). Renal scarring was seen in 9 patients, 6 of whom demonstrated abnormal bladder contractions. **The authors concluded that suppression of high-pressure contractions in chronically catheterized patients may play a role in preventing renal deterioration.**

Periodic upper and lower tract evaluation using renal ultrasonography and cystoscopy should be considered in all patients who require prolonged bladder management. The use of urodynamics to monitor the bladder in neurologically impaired individuals is controversial**. At a minimum, we believe that urodynamics should be performed after the initial neurologic injury is stable and whenever any significant changes in continence or voiding function occur. The initial urodynamics is useful to direct early bladder management, while subsequent urodynamics evaluations are performed to determine if LUT changes, such as the development of dyssynergia, have occurred.**

Although bacteriuria is common in all forms of bladder catheterization, symptomatic infection is not. The presence of asymptomatic bacteriuria does not usually require treatment and should be distinguished from an invasive, symptomatic UTI. Treatment of asymptomatic bacteriuria has not proved beneficial, and the use of continuous prophylactic antibiotics is rarely indicated (Gribble and Puterman, 1993). Nevertheless, infectious complications are the most common complications associated with prolonged catheterization, and frequent catheter changes should be considered to reduce these complications (Weld and Dmochowski, 2000; Wyndaele, 2002). Much interest has recently been generated with catheter-associated infections in hospitalized patients. Under new rules by the Centers for Medicare and Medicaid Services, hospitals will not be compensated for catheter-associated UTIs, causing many hospitals to intensify their efforts in implementing preventive measures (Saint et al., 2009). For more information regarding bacteriuria and catheter-associated UTI, see Chapter 55.

Clean Intermittent Catheterization

CIC has proved to be the most effective and practical means of attaining a catheter-free state in the majority of patients who are unable to empty their bladders spontaneously. CIC is based on a theory proposed by Lapides that high intravesical pressure or bladder overdistention is primarily responsible for the development of UTI, not the bacteriuria. Theoretically, reduced blood flow to the bladder can lead to increased host susceptibility to bacterial invasion and UTI. Bacteria introduced by CIC would be neutralized by the host, and relatively sterile urine would be maintained as long as bladder distention and high intraluminal pressures were avoided. The long-term efficacy and safety of such a program has been demonstrated by Lapides and others (Weld and Dmochowski, 2000).

Whereas indwelling catheter drainage requires little input from the patient, **a cooperative, well-motivated patient or caregiver is a requirement for CIC.** The patient must have adequate hand control, or a family member must be willing to perform the catheterization. In addition, **there must be adequate urethral exposure.** In addition, proper selection of equipment for the patient's intelligence and financial level will increase patient acceptance of and compliance with a self-catheterization program. Successful CIC is intimately associated with patient compliance, and therefore patients should be monitored periodically to ensure catheterization is performed properly. **CIC should be used cautiously in patients known to have autonomic dysreflexia.**

Intermittent catheterization may be performed by clean, aseptic, or sterile techniques (Hudson and Murahata, 2005). CIC historically involved reusing a catheter several times before disposal. It is washed, generally with soap and water, and allowed to air-dry before storage. When reusing catheters, some have advocated boiling or microwaving for sterilization (Douglas et al., 1990). **In April 2008, in an attempt to decrease the incidence of UTIs in patients**

performing intermittent catheterization, Medicare policy regarding intermittent catheterization changed. Any patient requiring intermittent catheterization may obtain up to 200 sterile catheters per month for one-time use. This change in policy has negated the need for reusing catheters in most patients. **For adult patients, catheterization is typically performed at a minimum of every 4 to 6 hours to minimize bacterial dwell time. In most cases, catheterizations should be timed to maintain bladder volumes below the normal 400- to 500-mL capacity** to minimize bladder wall pressure. Even smaller volumes may be required if they have poor detrusor compliance. Pharmacologic therapy should be considered when urine leakage occurs between catheterization intervals or if high storage pressures develop.

Catheter choice is variable, but a 12- to l6-Fr soft catheter may be used for males and shorter catheters are available for females. Rigid catheters have the potential to injure the urethra in insensate males because they may not “make the bend” at the prostate, causing a false passage such that CIC may be difficult or impossible. In men, hydrophilic-coated catheters have been found to reduce the incidence of UTI and hematuria and have higher patient satisfaction rates than conventional plastic catheters (De Ridder et al., 2005; Vapnek et al., 2003). Larger catheters may be required in patients with augmentation cystoplasty who require bladder irrigation. Patients with recurrent UTIs, despite the use of single-use catheters, may obtain sterile catheter kits for sterile intermittent catheterization.

Continuous Catheterization

Long-term indwelling catheters should be considered when anatomic, functional, or caregiver limitations prohibit performance of intermittent catheterization. Continuous catheterization also may be indicated in patients with complications from persistent incontinence or autonomic dysreflexia or when a small bladder capacity prohibits effective CIC. Long-term catheterization may be accomplished by a urethral or suprapubic catheter. The basics of urethral catheterization, including the technique of suprapubic tube (SPT) insertion, are covered in Chapter 11.

In males, the benefits of an indwelling SPT over urethral catheterization include a lower incidence of epididymitis and urethral stricture disease (Weld and Dmochowski, 2000) and preserved sexual function (Rutkowski et al., 1995) (see Fig. 127.5). Furthermore, a meta-analysis by Han et al. (2017) demonstrated that bladder drainage with either suprapubic tube or intermittent catheterization was associated with a lower rate of UTI than transurethral catheterization when catheterization duration was longer than 5 days in the postoperative setting. Overall, suprapubic catheters have been associated with high rates of patient satisfaction. Barnes et al. (1993) concluded that long-term suprapubic catheters were well tolerated by patients with neuropathic bladders. Of 32 patients, 84% were satisfied; however, follow-up was short (mean 23 months), and in 2 of 12 patients assessable at more than 2 years, creatinine levels increased. Other problems included recurrent catheter blockage in 38%, recurrent symptomatic urinary infections in 23%, and displaced catheters requiring reinsertion in the operating room in 15%. Urethral leakage occurred in 8 of 14 females with a suprapubic catheter alone and in 6 of 16 males. Patients using a suprapubic catheter should be advised that urinary incontinence may commence or worsen in the setting of sphincteric incontinence or reflex DO, because active opening of the sphincteric unit will occur in the absence of dyssynergia.

A controversial issue, common to all long-term indwelling catheters, is the development of bladder cancer. **The long-term risk of carcinoma in the patient with SCI with a chronic catheter has been estimated to be 8% to 10%** (Delnay et al., 1999; Locke et al., 1985). Kaufman et al. (1977) were among the first to recognize that patients with SCI and chronic indwelling catheters had an increased incidence of bladder cancer, particularly squamous cell carcinoma (SCC). Several others reported similar findings (Chao et al., 1993; Stonehill et al., 1996). Since then, the association between chronic indwelling catheterization and the development of bladder carcinoma has been debated. **No associations with intermittent catheterization have been identified.** Chronic inflammation is the most likely causative factor and may be caused by the indwelling catheter, bladder calculi, and/or recurrent infections. It is not clear whether earlier treatment of these conditions or better follow-up will lessen the risk for bladder carcinoma. A mechanism for the development of bladder carcinoma secondary to long-term inflammation was described by Wall et al. (2001). **According to their report, inducible nitric oxide synthase expressed by inflammatory macrophages in areas of chronic inflammation may lead to the formation of potentially carcinogenic nitrosamines in the bladder.** For more on the development of carcinoma related to chronic catheterization, see Chapter 135.

When SCC is identified in patients with SCI, it is often advanced and commonly fatal; however, routine screening cystoscopy for at-risk patients with SCI is controversial. **Although some authors suggest that screening**

cystoscopy conveys a survival advantage by identifying bladder cancer at an earlier stage (Navon et al., 1997)**, others have found no advantage for screening** (Hamid et al., 2003; Yang and Clowers, 1999). Cytologic examination, although commonly performed, is not useful for detecting SCC (Bejany et al., 1987). In addition, SCC may not always be cystoscopically detectable (Kaufman et al., 1977). For this reason, routine random biopsies have been advocated by some (Stonehill et al., 1996). **Despite the lack of data in patients without SCI, most urologists recommend all patients with chronic catheters undergo annual screening, generally starting after 8 years** (Stonehill et al., 1996)**. Gross hematuria has been reported as the most common manifesting symptom in patients eventually diagnosed with bladder cancer** (Hess et al., 2003). Despite disparate opinions regarding screening, certainly all would agree that patients with new-onset gross hematuria should be evaluated with upper tract imaging, urine cytology, cystoscopy, and perhaps random biopsies. **Other patients to consider for close surveillance include those known risk factors for the development of carcinoma, such as recurrent UTIs or bladder stones.**

Increasing Intravesical Pressure or Facilitating Bladder Contractility

External Compression (Credé) and Valsalva Maneuver

The Credé maneuver (manual compression of the bladder) is most effective in patients with decreased bladder tone who can generate an intravesical pressure greater than 50 cm H_2O and have decreased bladder outlet resistance (Wein and Barrett, 1988). The open-handed Credé method involves placement of the thumbs of each hand over the anterior superior iliac spines and the digits over the suprapubic area, and downward compression on the fundus of the bladder with the fingertips. For some patients, this maneuver can be accomplished more efficiently by using a closed fist or a rolled-up towel. Straining as the Credé maneuver is applied is generally counterproductive because this increases intra-abdominal pressure and causes bulging of the abdominal wall, which then lifts the compressing hands off the fundus of the bladder. If the guarding reflex arc is intact, this also may produce a striated sphincter contraction. The Credé maneuver is much easier in a patient with a lax, lean abdominal wall than in one with a taut or obese one, and it is more readily performed in a child than an adult.

A similar increase in intravesical pressure may be achieved by abdominal straining (Valsalva maneuver). The proper technique involves sitting and letting the abdomen protrude forward on the thighs. During straining in this position, hugging of the knees and legs may be advantageous to prevent any bulging of the abdomen. To increase intravesical pressure in this manner requires voluntary control of the abdominal wall and diaphragmatic muscles.

"Voiding" by the Credé or Valsalva maneuver is generally discouraged, because it is nonphysiologic and is resisted by the same forces that normally resist stress incontinence. In many cases, an increase in outlet resistance may occur reflexively with external compression maneuvers. If adequate emptying does not occur in the properly selected patient, other types of therapy to decrease outlet resistance may be considered; however, these treatments may adversely affect urinary continence.

The best chance for success with this mode of therapy is in the patient with an areflexic bladder and some degree of outlet denervation. This is most commonly seen in the patient with an autonomous neurogenic bladder (Lapides classification), T11 through L2 SCI in whom the sympathetic nervous supply is damaged, or after outlet resistance is decreased surgically or by botulinum toxin injection. Most of these patients already have stress incontinence, and the Credé or Valsalva maneuver simply helps the patient overcome outlet resistance to empty the bladder at a convenient time. These techniques also may be useful to decompress a neobladder when the outlet resistance is low either by volitional sphincteric relaxation or when surgically induced.

Vesicoureteral reflux is a relative contraindication to external compression or the Valsalva maneuver, especially in patients capable of generating a high intravesical pressure. The most flagrant misuse of this form of management is in the patient with a neurogenic bladder and poor detrusor compliance, because the increased storage pressures can cause upper tract deterioration with minimal filling. External compression or Valsalva maneuvers will only further aggravate this already dangerous situation.

Even when the patient has a flaccid bladder and/or low detrusor leak point pressures, close follow-up and periodic evaluation are necessary to avoid upper tract deterioration. Chang et al. (2000) reported the long-term urologic complications and residual volumes of 74 SCI patients with flaccid bladders who routinely performed the Credé maneuver as their primary form of bladder management for more than 20 years. Residual urine volume was greater than 100 mL in 93% of patients, and 50% were greater than 300 mL. The authors also reported that 59.5% developed ureteral dilation, 35.1% developed hydronephrosis, and 16.2% suffered renal deterioration. Males were significantly more likely to develop these complications than females, probably because of increased outlet resistance. Other complications included recurrent UTIs, pyuria, urolithiasis, epididymo-orchitis, genital-rectal prolapse, and hemorrhoids (Chang et al., 2000; Wyndaele, 2008).

Promotion or Initiation of Reflex Contractions

In patients with SCI and an intact sacral spinal cord, voiding can be elicited by exploiting existing spinal reflexes. The sacral micturition reflex occurs when tension receptors within the bladder wall are stimulated by bladder filling and activate sensory afferent neurons. Motor efferents from the spinal cord respond by generating a reflexive bladder contraction and, when of adequate magnitude, will result in voiding. Bladder contractions obtained in this manner are often involuntary and sporadic. In some cases, patients with SCI may be able to trigger this reflex voluntarily by manual stimulation of areas within the sacral or lumbar dermatomes. **According to the classic reference by Glahn** (1974)**, the most effective method of initiating a reflex contraction is rhythmic suprapubic manual pressure (seven or eight pushes every 3 seconds). Quick repetitive stimulation in this manner is thought to produce a summation effect on the tension receptors in the bladder wall, resulting in activation of the bladder reflex arc. Other commonly used maneuvers to induce reflex detrusor contraction include pulling the skin or hair of the pubis, scrotum, or thigh; squeezing the clitoris; or digital rectal stimulation** (Wein and Barrett, 1988). Patients able to void in such a way are encouraged to find their own optimal trigger points and position for urination. Reflex voiding depends on the ability to stimulate detrusor contractions and may be most suitable for patients with SCI or conditions characterized by DO. Surgical procedures to reduce outlet resistance should be considered if significant obstruction or sphincter dyssynergia are present. Complications with this voiding technique are most often related to the use of external collection devices or from the development of high-pressure storage resulting in upper tract deterioration. To ensure compliance, periodic surveillance should be performed with regular urodynamic evaluation.

Intraurethral Valve-Pump for Women With Impaired

Detrusor Contractility

The inFlow intraurethral valve-pump was FDA approved in 2014 for use in adult females with incomplete bladder emptying resulting from impaired detrusor contractility (IDC). It is a silicone device containing a miniature internal pump available in lengths ranging from 3 to 7 cm and diameter of 24 or 28 Fr. Initial sizing and placement is performed by the physician and must be changed every 29 days. Subsequent insertions may be performed by the patient or caregiver. The device is inserted into the urethra using a disposable introducer and fixed in place by silicone fins at the level of the bladder neck and a flexible flange at the urethral meatus. To void, the patient places a remote control (inFlow activator) over the suprapubic area and presses a button, which magnetically activates an internal pump to generate a urine flow of 10 to 12 mL/s. When the button is released, the valve closes to restore continence.

In a multi-center single-arm crossover study, use of inFlow resulted in significant improvements in quality-of-life scores compared with baseline CIC in the 77 patients who completed the 16-week inFlow treatment phase (Chen et al., 2005). Postvoid residual was comparable during baseline CIC and inFlow treatment phases (20.3 cc vs. 16.1 cc, respectively). However, there was a large early withdrawal rate of 61.9% (169/273), mainly resulting from initial discomfort and leakage. In a cohort of 92 patients with long-term (1 year) follow-up, Madjar et al. (2000) also reported a high dropout rate (77.1% overall) but a 100% satisfaction rate in the 21 patients who were still using the device at 1 year. Adverse events included device migration into the bladder ($n = 4$), asymptomatic bacteriuria ($n = 15$), and symptomatic UTIs ($n = 4$). With a protocol of pre-insertion patient education and post-insertion nursing support, a higher rate of device acceptance may be achieved (Lynch et al., 2003).

Stimulated Myoplasty for Bladder Emptying

Few treatment options are available for patients with detrusor underactivity except for self-intermittent catheterization. Restoration of bladder contractility remains an elusive goal for most patients with this condition. The first animal feasibility studies to augment bladder contractility used a unilateral rectus abdominis muscle wrap over the bladder to facilitate bladder emptying (Chancellor et al., 1994a). The rectus muscle, with intact neurovascular pedicle, was dissected free at one end and wrapped over the bladder to create a spherical configuration housing the bladder. Evaluation of the transposed muscle showed no damage to the blood supply or innervation of the rectus muscle, and the underlying bladder retained its volume despite neurogenically induced underactivity. This model was touted as the precursor for a clinical trial in which the patient would learn to contract his rectus muscle voluntarily and create sufficient extrinsic pressure to void. The first case report of rectus myoplasty involved a 33-year-old man with an L4 SCI from a gunshot wound 10 years before enterocystoplasty covered by the left rectus muscle transposed over the bladder (Chancellor et al., 1994b). One month later, the patient could void by contracting his rectus muscle, generating 50 cm H_2O detrusor pressure. This ability persisted for 11 months until the case was reported in the literature. Use of rectus muscle for myoplasty in humans was not reported again for 23 years. In a case series of 5 patients with acontractile bladder resulting from SCI, complete spontaneous voiding was achieved in all patients after rectus abdominus detrusor myoplasty (Agarwal et al., 2017). At 6 months, the authors demonstrated a statistically significant decrease in postvoid residual and statistically significant increases in urine flow rate, bladder contractility, and detrusor pressure.

Latissimus dorsi has also been used for myoplasty. Von Heyden et al. (1998) studied free latissimus dorsi muscle flaps for bladder myoplasty in dogs; revascularization and electrical stimulation of the thoracodorsal nerve successfully induced pressures sufficient for partial evacuation of the bladder. The advantage of a singular nerve supply with ample geometry provided by the latissimus dorsi free flap led to the first clinical application in 1998 by Stenzl et al. (1998). Three patients with bladder acontractility were treated with latissimus dorsi myoplasty, and all three were able to void by abdominal straining. In a larger clinical study using the free transfer of the latissimus dorsi muscle to restore voluntary voiding, 14 of 20 patients were able to void spontaneously with postvoid residual volumes of less than 100 mL (Ninkovic et al., 2003). **The largest latissimus dorsi detrusor myoplasty experience was reported by Gakis et al.** (2011) **in 24 patients with detrusor underactivity requiring CIC and a mean follow-up of 46 months. Latissimus dorsi detrusor myoplasty resulted in complete voluntary voiding in 71% of patients with a 91% reduction in UTIs. Three patients reduced the frequency of catheterization by 50%, and 4 patients had no improvement.**

Key Points: Additional Therapies for Emptying

- Indications for catheterizable channel include difficulty catheterizing per urethra, urethral scarring, and urethral incompetence requiring outlet closure.
- Complications of continent catheterizable channels include long-term issues with catheterization, incontinence, and stomal stenosis.
- Asymptomatic bacteriuria is common in catheterized patients and does not require treatment unless the patient becomes symptomatic.
- Chronic catheterization (CIC or indwelling) may lead to poor bladder compliance and upper tract deterioration; thus periodic surveillance is recommended.
- Credé and Valsalva maneuvers may elevate intravesical pressure enough to cause upper tract deterioration, especially in setting of poor detrusor compliance.
- Reflex voiding depends on the ability to stimulate detrusor contractions and may be most suitable for patients with SCI or neurogenic DO.

Additional Therapies for Storage and Emptying Failure: Circumventing the Problem

Patients with urinary incontinence may choose to wear an external collecting device or absorbent pad to manage leakage. For some, their incontinence is minimal, or they are unwilling or unable to undergo more definitive treatment. However, in some instances, patients have failed multiple anti-incontinence procedures and external collecting devices or pads are the only management options available.

External Collecting Devices

No external urinary collecting device for females has been successful or effective. The female urethral meatal anatomy has made it difficult to design a leak-proof apparatus that is easy to apply and maintain. **However, external collecting devices for men—the condom catheter, penile sheath, or Texas catheter—are generally effective in urine collection. For male patients who are unable to perform CIC because of cognitive impairment, quadriplegia, or lack of reliable assistance from a caregiver, the condom catheter may be preferable over an indwelling urethral catheter.** A study by Saint et al. (2006) reported the results of a randomized controlled trial of 75 hospitalized male veterans in which 41 men were managed with indwelling urethral catheter and 34 men with condom catheter. The median hospital stay was 3 days. **Condom catheters were associated with a lower incidence of bacteriuria, symptomatic UTIs, and death compared with the use of an indwelling urethral catheter. Patients also reported that external urinary collection devices were more comfortable and less restrictive on daily activities than indwelling catheters.** Despite the reduced incidence of adverse outcomes, the use of external collection devices and absorbent products is associated with a higher risk for UTIs compared with cases in which no appliances are used (Sturmann and O'Grady, 1989). It is generally recommended that condom catheters be changed daily because the risk for UTI is increased when catheters are changed less frequently (Waites et al., 1993; Zimakoff et al., 1996). **The use of a condom catheter is not free of complications. It can cause allergic**

reactions, skin maceration, and/or penile edema. Furthermore, the penile skin and glans should be examined at every catheter change to ensure no skin breakdown or contact reactions have occurred (Newman, 1999). These devices have the potential to cause pressure necrosis of the penis and, when severe, may even damage the urethra (Golji, 1981). **Pressure-related complications are more likely to occur in patients with impaired sensation, such as those with neurogenic LUT dysfunction** (Golji, 1981). External urine collecting devices also are prone to dislodge or fall off, especially if the patient is wearing an inappropriate size. In addition, patients with SCI may have reflex penile retraction and paralysis associated with pelvic bending, making it difficult to maintain the device. Van Arsdalen et al. (1981) reported on the use of a malleable penile prosthesis in this type of patient to facilitate applying and maintaining a condom catheter. Zermann et al. (2006) describe the long-term results of penile prosthetic surgery for urinary incontinence and/or erectile dysfunction in neurologically impaired patients. At a mean follow-up of 7.2 years, 90.3% of urinary management problems were resolved. The overall infection rate was 5%, and the rate of explantation was 7.7%, which is comparable with the explantation rate in non-neurogenic patients.

Absorbent Products

Urinary incontinence can be a socially debilitating problem leading to fear of odor, discovery, and embarrassment. Many patients with urinary incontinence wear some type of absorbent product, which may include pads, shields, drip collectors, guards, undergarments, briefs, diapers, or underpads. **Consumers spend billions of dollars on these products** (Erekson et al., 2008; Getliffe et al., 2007) **and for the majority, selection is often based on trial and error, cost, convenience, and manufacturers' claims** (Baker and Norton, 1996; Fantl et al., 1996). Recently, the National Association for Continence (NAFC) formed a council of experts with the goal of establishing national, independent quality performance standards for disposable adult absorbent products. The full recommendations of the NAFC Council include nine performance assessment parameters: "rewet rate (product's ability to withstand multiple incontinent episodes between changes), rate of acquisition (the speed at which urine is drawn away from the skin by a product), product retention capacity (product's capacity to hold fluid without rewetting the skin), sizing options, absorbency levels, product safety, closure technology, breathable zones (air permeability across a textile-like fabric at a controlled differential pressure), and elasticity” (Muller and McInnis, 2013). More research is needed to evaluate the impact of these parameters on cost and quality of care.

Often recognized as the authority in the management of the incontinent patient, urologists should acknowledge the basic nursing principles and skin care recommendations that may significantly contribute to patient care. Absorbent products should be changed frequently to help avoid buildup of odor and limit exposure of the skin to urine. Prolonged exposure of the skin to a wet environment may lead to supersaturation and disruption of the skin's protective barriers, promoting skin maceration, dermatitis, and possibly infection. **Incontinence-associated dermatitis (IAD) can be defined as inflammation of the surface of the skin with redness, edema, and, in some cases, bullae containing clear exudate** (Gray et al., 2007)**. IAD predominately occurs in skin folds and may promote candidiasis or bacterial skin infections.** Gray et al. (2007) published an excellent review of the epidemiology, pathophysiology, and management of IAD with recommendations for prevention and treatment.

Further information regarding the types of absorbent products available for males and females, including a review of skin care management, external collection, and urethral compression devices can be found in the book by Newman and Wein (2009) and the comprehensive resource guide available from the NAFC (2008) (http://www.nafc.org).

Key Points: Circumventing the Problem

- Condom catheter use is associated with lower rate of bacteriuria, symptomatic UTIs, and death than indwelling Foley; it is also more comfortable and less restrictive.
- Complications of condom catheter include allergic reactions, penile edema, and higher risk for pressure sores in patients with impaired sensation or cognition.
- Consumers spend billions of dollars on absorbent products; selection is often based on trial and error, cost, convenience, and manufacturers’ claims.
- IAD is inflammation of skin with redness, edema, and/or bullae with clear exudate; it is often in skin folds and may promote candidiasis or bacterial

skin infections.

Summary

Disorders of the storage and emptying phases of micturition have various causes and can be classified by the location of the dysfunction, either at the bladder level or the bladder outlet. Treatment strategies are numerous and often combine medical and surgical management. Continued research is warranted to further our understanding of the pathophysiology of storage and emptying failure so that we may continue to improve patients’ quality of life.

Suggested Readings

Biers SM, Venn SN, Greenwell TJ. The past, present and future of augmentation cystoplasty. *BJU Int*. 2012;109:1280–1293.

Ghoniem GM, Miller CJ. A systematic review and meta-analysis of Macroplastique for treating female stress urinary incontinence. *Int Urogynecol J*. 2013;24(1):27–36.

Kirchin V, Page T, Keegan PE, et al. Urethral injection therapy for urinary incontinence in women. *Cochrane Database Syst Rev*. 2017;(7) [CD003881].

Kobashi KC, Albo ME, Dmochowski RR, et al. *Surgical treatment of female stress urinary incontinence (SUI): AUA/SUFU Guideline*. [website] http://www.auanet.org/guidelines/stress-urinary-incontinence-(sui)-new-(aua/sufu-guideline-2017; 2017.

Lapides J, Diokno A, Silber S, et al. Clean intermittent self-catheterization in the treatment of urinary tract disease. *J Urol*. 1972;107:458–465.

Peters KM, Dmochowski RR, et al. Autologous muscle derived cells for treatment of stress urinary incontinence in women. *J Urol*. 2014;192(2):469–476.

Wein AJ, Barrett DM. *Voiding function and dysfunction: a logical and practical approach*. Year Book Medical: Chicago; 1988.

Weld KJ, Dmochowski RR. Effect of bladder management on urological complications in spinal cord injured patients. *J Urol*. 2000;163:768–772.

References

Abol-Enein H, Ghoneim MA. Serous lined extramural ileal valve: a new continent urinary outlet. *J Urol*. 1999;161:786–791.

Aboseif SR, Franke EI, et al. The Adjustable Continence Therapy system for recurrent female stress urinary incontinence: 1-year results of the North America Clinical Study Group. *J Urol*. 2009;181(5):2187–2191.

Aboseif SR, O'Connell HE, et al. Collagen injection for intrinsic sphincteric deficiency in men. *J Urol*. 1996;155(1):10–13.

Agarwal P, Husain S, Wankhede S, et al. Rectus abdominis detrusor myoplasty (RADM) for acontractile/hypocontractile bladder in spinal cord injury patients: preliminary report. *J Plast Reconst Aesthet Surg*. 2017;S1748-6815(17):30514.

Andersen RCM. Long-term follow-up comparison of Durasphere and Contigen in the treatment of stress urinary incontinence. *J Low Genit Tract Dis*. 2002;6(4):239–243.

Anquetil C, Abdelhamid S, Gelis A, et al. Botulinum toxin therapy for neurogenic detrusor hyperactivity versus augmentation enterocystoplasty: impact on the quality of life of patients with SCI. *Spinal Cord*. 2016;54:1031–1035.

Appell R. Collagen injections. Raz S. *Female urology*. Saunders: Philadelphia; 1996:399–405.

Appell RA, Dmochowski RR, et al. Urethral injections for female stress incontinence. *BJU Int*. 2006;98(Suppl 1):27–30 [discussion 31].

Appell RA, Winters JC. Injection therapy for urinary incontinence. Wein A, Kavoussi LR, Novick AC, et al. *Campbell-Walsh urology*. 9th ed. Saunders: Philadelphia; 2007:2272–2287.

Ardelt PU, Woodhouse CR, Riedmiller H, et al. The efferent segment in continent cutaneous urinary diversion: a comprehensive review of the literature. *BJU Int*. 2012;109:288–297.

Baker J, Norton P. Evaluation of absorbent products for women with mild to moderate urinary incontinence. *Appl Nurs Res*. 1996;9:29–33.

Barnes DG, Shaw PJ, Timoney AG, et al. Management of the neuropathic bladder by suprapubic catheterization. *Br J Urol*. 1993;72:169–174.

Bejany DE, Lockhart JL, Rhamy RK. Malignant vesical tumors following spinal cord injury. *J Urol*. 1987;138:1390.

Bent AE, Foote J, et al. Collagen implant for treating stress urinary incontinence in women with urethral hypermobility. *J Urol*. 2001;166(4):1354–1357.

Bent AE, Tutrone RT, et al. Treatment of intrinsic sphincter deficiency using autologous ear chondrocytes as a bulking agent. *Neurourol Urodyn*. 2001;20(2):157–165.

Berger MB, Morgan DM. Delayed presentation of pseudoabscess secondary to injection of pyrolytic carbon-coated beads bulking agent. *Female Pelvic Med Reconstr Surg*. 2012;18(5):303–305.

Biers SM, Venn SN, Greenwell TJ. The past, present and future of augmentation cystoplasty. *BJU Int*. 2012;109:1280–1293.

Bramble FJ. The treatment of adult enuresis and urge incontinence by enterocystoplasty. *Br J Urol*. 1982;54:693–696.

Bugel H, Pfister C, et al. Intraurethral macroplastic injections in the treatment of urinary incontinence after prostatic surgery. *Prog Urol*. 1999;9(6):1068–1076.

Carr LK, Robert M, Kultgen PL, et al. Autologous muscle derived cell therapy for stress urinary incontinence: a prospective, dose ranging study. *J Urol*. 2013;189(2):595–601.

Carr LK, Steele D, Steele S, et al. 1-year follow-up of autologous muscle-derived stem cell injection pilot study to treat stress urinary incontinence. *Int Urogynecol J Pelvic Floor Dysfunct*. 2008;19(6):881–883.

Carr LK, Tu LM, Robert M, et al. Randomized, double-blind, placebo-controlled study of autologous muscle derived cells for urinary sphincter repair. *J Urol*. 2017;197(4S):e609–e610.

Cespedes RD, Leng WW, et al. Collagen injection therapy for postprostatectomy incontinence. *Urology*. 1999;54(4):597–602.

Cespedes RD, Serkin FB. Is injection therapy for stress urinary incontinence dead? No. *Urology*. 2009;73(1):11–13.

Chancellor MB, Erhard JM, Kilholma P, et al. Functional urethral closure with pubovaginal sling for destroyed female urethra after long-term catheterization. *Urology*. 1994;43:499–504.

Chancellor MB, Rivas DA, Acosta R, et al. Detrusor-myoplasty, innervated rectus muscle transposition study, and functional effect on spinal cord injury rat model. *Neurourol Urodyn*. 1994;13:547–557.

Chancellor MB, Rivas DA, Salzman SK. Detrusor-myoplasty to restore micturition. *Lancet*. 1994;343:669.

Chang SM, Hou CL, Dong DQ, et al. Urologic status of 74 spinal cord injury patients from the 1976 Tangshan earthquake, and managed for over 20 years using the Credé maneuver. *Spinal Cord*. 2000;38:552–554.

Chao R, Clowers D, Mayo ME. Fate of upper tracts in patients with indwelling catheter after spinal cord surgery. *Urology*. 1993;42:259–264.

Chartier-Kastler E, Costa P, Ben Naoum K, et al. French multicentre prospective study of the use of ACT balloons (Uromedica, Inc., Plymouth, Min, U.S.A.; Medtronic, Minneapolis, U.S.A.) for the treatment of female stress urinary incontinence. *Prog Urol*. 2007;17(7):1372–1377.

Chen TY-H, Ponsot Y, Carmel M, et al. Multi-centre study of intraurethral valve-pump catheter in women with hypocontractile or acontractile bladder. *Eur Urol*. 2005;48:628–633.

Choi JY, Kim TH, Yang JD, et al. Adipose-derived regenerative cell injection therapy for postprostatectomy incontinence: a phase I clinical study. *Yonsei Med J*. 2016;57(5):1152–1158.

Colombo T, Augustin H, Breinl E, et al. The use of polydimethylsiloxane in the treatment of incontinence after radical prostatectomy. *Br J Urol*. 1997;80(6):923–926.

Comiter CV. The male sling for stress urinary incontinence: a prospective study. *J Urol*. 2002;167(2 Pt 1):597–601.

Corcos J, Collet JP, Shapiro S, et al. Multicenter randomized clinical trial comparing surgery and collagen injections for treatment of female stress urinary incontinence. *Urology*. 2005;65(5):898–904.

Corcos J, Fournier C. Periurethral collagen injection for the treatment of female stress urinary incontinence: 4-year follow-up results. *Urology*. 1999;54(5):815–818.

Cornu JN, Lizee D, Pinset C, et al. Long-term follow-up after regenerative therapy of the urethral sphincter for female stress urinary incontinence. *Eur Urol*. 2014;65(1):256–258.

Cross CA, English SF, Cespedes RD, et al. A followup on transurethral collagen injection therapy for urinary incontinence. *J Urol*. 1998;159(1):106–108.

Cummings JM, Boullier JA, et al. Transurethral collagen injections in the therapy of post-radical prostatectomy stress incontinence. *J Urol*. 1996;155(3):1011–1013.

De Ridder DJ, Everaert K, Fernández LG, et al. Intermittent catheterization with hydrophilic-coated catheters (SpeediCath) reduces the risk of clinical urinary tract infection in spinal cord injured patients: a prospective randomized parallel comparative trial. *Eur Urol*. 2005;48:991–995.

Delnay K, Stonehill W, Goldman H, et al. Bladder histological changes associated with chronic indwelling urinary catheter. *J Urol*. 1999;161:1106–1109.

Dmochowski RR, Appell RA. Injectable agents in the treatment of stress urinary incontinence in women: where are we now? *Urology*. 2000;56(6 Suppl 1):32–40.

Douglas C, Burke B, Kessler OL, et al. Microwave: practical cost effective method for sterilizing urinary catheters in the home. *Urology*. 1990;35:219–224.

Edlund C, Peeker R, Fall M. Clam ileocystoplasty: successful treatment of severe bladder overactivity. *Scand J Urol Nephrol*. 2001;35:190–195.

Erekson EA, Meyer SA, Melick C, et al. Incontinence pads: recommending the best product-based wetback performance and price. *Int Urogynecol J Pelvic Floor Dysfunct*. 2008;19:1411–1414.

Faerber GJ, Belville WD, Ohl DA, et al. Comparison of transurethral versus periurethral collagen injection in women with intrinsic sphincter deficiency. *Tech Urol*. 1998;4(3):124–127.

Fantl JA, Newman DK, Colling J, et al. Managing acute and chronic urinary incontinence. AHCPR urinary incontinence in adults guideline update panel. *Am Fam Physician*. 1996;54:1661–1672.

Freton L, Tondut L, Enderle I, et al. Comparison of adjustable continence therapy periurethral balloons and artificial urinary sphincter in female patients with stress urinary incontinence due to intrinsic sphincter deficiency. *Int Urogynecol J*. 2018; 10.1007/s00192-017-3544-8.

Gafni-Kane A, Sand PK. Foreign-body granuloma after injection of calcium hydroxylapatite for type III stress urinary incontinence. *Obstet Gynecol*. 2011;118(2 Pt 2):418–421.

Gakis G, Ninkovic M, Gommert A, et al. Functional detrusor myoplasty for bladder acontractility: long-term results. *J Urol*. 2011;185:593–599.

Gerullis H, Eimer C, Georgas E, et al. Muscle-derived cells for treatment of iatrogenic sphincter damage and urinary incontinence in men. *ScientificWorldJournal*. 2012;2012:898535.

Getliffe K, Fader M, Cottenden A, et al. Absorbent products for incontinence: “treatment effects” and impact on quality of life. *J Clin Nurs*. 2007;16:1936–1945.

Ghoniem G, Corcos J, Comiter J, et al. Cross-linked polydimethylsiloxane injection for female stress urinary incontinence: results of a multicenter, randomized, controlled, single-blind study. *J Urol*. 2009;181(1):204–210.

Ghoniem G, Corcos J, Comiter C, et al. Durability of urethral bulking agent injection for female stress urinary incontinence: 2-year multicenter study results. *J Urol*. 2010;183(4):1444–1449.

Ghoniem GM, Khater U. Urethral prolapse after durasphere injection. *Int Urogynecol J Pelvic Floor Dysfunct*. 2006;17(3):297–298.

Ghoniem GM, Miller CJ. A systematic review and meta-analysis of Macroplastique for treating female stress urinary incontinence. *Int Urogynecol J*. 2013;24(1):27–36.

Glahn BE. Neurogenic bladder in spinal cord injury: management of patients in Hornback, Denmark. *Urol Clin North Am*. 1974;1:163–176.

Golji H. Complications of external condom drainage. *Paraplegia*. 1981;19:189–194.

Gomes CM, Broderick GA, Sanchez-Ortiz RF, et al. Artificial urinary sphincter for post-prostatectomy incontinence: impact of prior collagen injection on cost and clinical outcome. *J*

Urol. 2000;163(1):87–90.

Gorton E, Stanton S, Monga A, et al. Periurethral collagen injection: a long-term follow-up study. *BJU Int*. 1999;84(9):966–971.

Gotoh M, Yamamoto T, Kato M, et al. Regenerative treatment of male stress urinary incontinence by periurethral injection of autologous adipose-derived regenerative cells: 1-year outcomes in 11 patients. *Int J Urol*. 2014;21(3):294–300.

Gras S, Klarskov N, Lose G. Intraurethral injection of autologous minced skeletal muscle: a simple surgical treatment for stress urinary incontinence. *J Urol*. 2014;192(3):850–855.

Gray M, Bliss DZ, Doughty DB, et al. Incontinence-associated dermatitis. *J Wound Ostomy Continence Nurs*. 2007;34:45–54.

Gribble MJ, Puterman ML. Prophylaxis of urinary tract infection in persons with recent spinal cord injury: a prospective, randomized, double-blind, placebo-controlled study of trimethoprim-sulfamethoxazole. *Am J Med*. 1993;95:141–152.

Gurung PM, Attar KH, Abdul-Rahman A, et al. Long-term outcomes of augmentation ileocystoplasty in patients with spinal cord injury: a minimum of 10 years of follow-up. *BJU Int*. 2012;109:1236–1242.

Guttman L. Management of paralysis. *Br Surg Pract*. 1949;6:445.

Guttmann L, Frankel H. The value of intermittent catheterisation in the early management of traumatic paraplegia and tetraplegia. *Paraplegia*. 1966;4:63–83.

Guys JM, Fakhro A, Haddad M, et al. Endoscopic cure of stomal leaks in continent diversion. *BJU Int*. 2002;89(6):628–629.

Hafez AT, McLorie G, Gilday D, et al. Long-term evaluation of metabolic profile and bone mineral density after ileocystoplasty in children. *J Urol*. 2003;170:1639–1641.

Halachmi S, Farhat W, et al. Efficacy of polydimethylsiloxane injection to the bladder neck and leaking diverting stoma for urinary continence. *J Urol*. 2004;171(3):1287–1290.

Hamid R, Bycroft J, Arya M, et al. Screening cystoscopy and biopsy in patients with neuropathic bladder and chronic suprapubic indwelling catheters: is it valid? *J Urol*. 2003;170:425–427.

Han CS, Kim S, Radadia KD, et al. Comparison of urinary tract infection rates associated with transurethral catheterization, suprapubic tube and clean intermittent catheterization in the postoperative setting: a network meta-analysis. *J Urol*. 2017;198:1353–1358.

Hart ML, Izeta A, Herrera-Imbroda B, et al. Cell therapy for stress urinary incontinence. *Tissue Eng Part B Rev*. 2015;21:365–376.

Herschorn S, Radomski SB, Steele DJ, et al. Early experience with intraurethral collagen injections for urinary incontinence. *J Urol*. 1992;148(6):1797–1800.

Herschorn S, Steele DJ, Radomski S, et al. Follow up of intraurethral collagen for female stress urinary incontinence. *J Urol*. 1996;156(4):1305–1309.

Herschorn S, Radomski SB. Collagen injections for genuine stress urinary incontinence: patient selection and durability. *Int Urogynecol J Pelvic Floor Dysfunct*. 1997;8(1):18–24.

Hess MJ, Zhan EH, Foo DK, et al. Bladder cancer in patients with spinal cord injury. *J Spinal Cord Med*. 2003;26:322.

Hudson H, Murahata RI. The “no touch” method of intermittent urinary catheter insertion: can it reduce the risk of bacteria entering the bladder? *Spinal Cord*. 2005;43:611–614.

Hurtado E, McCrery R, Appell R. The safety and efficacy of ethylene vinyl alcohol copolymer as an intra-urethral bulking agent in women with intrinsic urethral deficiency. *Int Urogynecol J Pelvic Floor Dysfunct*. 2007;18(8):869–873.

Imamoglu MA, Tuygun C, Bakirtas H, et al. The comparison of artificial urinary sphincter implantation and endourethral Macroplastique injection for the treatment of postprostatectomy incontinence. *Eur Urol*. 2005;47(2):209–213.

Ivancić V, DeFoor W, Jackson E, et al. Progression of renal insufficiency in children and adolescents with neuropathic bladder is not accelerated by lower urinary tract reconstruction. *J Urol*. 2010;184:1768–1774.

Izes JK, Bihrle W 3rd, et al. Ileocecal valve resistance augmentation using glutaraldehyde cross-linked collagen: a canine model for endoscopic salvage of the leaking Indiana reservoir. *J Urol*. 1997;158(4):1369–1371.

Jacobsen DL, Thomas JC, Pope J, et al. Update on continent catheterizable channels and the timing of their complications. *J Urol*. 2017;197:871–876.

Jamil F, Williamson M, Ahmed YS, et al. Natural fill urodynamics in chronically catheterized patients with spinal cord injury. *BJU Int*. 1999;83:396–399.

Karram M, Bent A, Kennelly M. Multicenter randomized controlled study to evaluate URYX urethral bulking agent in treating female stress urinary incontinence. *Int Urogynecol J*. 2003;14:S62–S63.

Karsenty G, Denys P, Amarenco G, et al. Botulinum toxin A (Botox) intradetrusor injections in adults with neurogenic detrusor overactivity/neurogenic overactive bladder: a systematic literature review. *Eur Urol*. 2008;53:275–287.

Kass-Ilya A, Rashid T, et al. Long-term efficacy of polydimethylsiloxane (Macroplastique) injection for Mitrofanoff leakage after continent urinary diversion surgery. *BJU Int*. 2015;115(3):461–465.

Kaufman JM, Fam B, Jacobs SC, et al. Bladder cancer and squamous metaplasia in spinal cord injury patients. *J Urol*. 1977;118:967–972.

Kavanagh A, Afshar K, Scott H, et al. Bladder neck closure in conjunction with enterocystoplasty and Mitrofanoff diversion for complex incontinence: closing the door for good. *J Urol*. 2012;188:1561–1565.

Kershen RT, Atala A. New advances in injectable therapies for the treatment of incontinence and vesicoureteral reflux. *Urol Clin North Am*. 1999;26(1):81–94 [viii].

Khastgir J, Hamid R, Arya M, et al. Surgical and patient reported outcomes of “clam” augmentation ileocystoplasty in spinal cord injured patients. *Eur Urol*. 2003;43:263–269.

Khavari R, Fletcher SG, Liu J, et al. A modification to augmentation cystoplasty with catheterizable stoma for neurogenic patients: technique and long-term results. *Urology*. 2012;80:460–464.

Khullar V, Cardozo LD, Abbott D, et al. GAX collagen in the treatment of urinary incontinence in elderly women: a two year follow up. *Br J Obstet Gynaecol*. 1997;104(1):96–99.

Kirchin V, Page T, Keegan PE, et al. Urethral injection therapy for urinary incontinence in women. *Cochrane Database Syst Rev*. 2017;(7) [CD003881].

Klutke JJ, Subir C, Andriole G, et al. Long-term results after antegrade collagen injection for stress urinary incontinence following radical retropubic prostatectomy. *Urology*. 1999;53(5):974–977.

Kobashi KC, Albo ME, Dmochowski RR, et al. *Surgical Treatment of Female Stress Urinary Incontinence (SUI): AUA/SUFU Guideline*. [website] http://www.auanet.org/guidelines/stress-urinary-incontinence-(sui)-new-(aua/sufu-guideline-2017; 2017.

Kocjancic E, Crivellaro S, Smith JJ, et al. Adjustable continence therapy for treatment of recurrent female urinary incontinence. *J Endourol*. 2008;22(7):1403–1407.

Kocjancic E, Crivellaro S, Ranzoni S, et al. Adjustable Continence Therapy for severe intrinsic sphincter deficiency and recurrent female stress urinary incontinence: long-term experience. *J Urol*. 2010;184(3):1017–1021.

Kong WG, Vasavada SP. Is injection therapy for stress urinary incontinence dead? Yes. *Urology*. 2009;73(1):9–10.

Ku JH. The management of neurogenic bladder and quality of life in spinal cord injury. *BJU Int*. 2006;98:739–745.

Kuismanen K, Sartoneva R, Haimi S, et al. Autologous adipose stem cells in treatment of female stress urinary incontinence: results of a pilot study. *Stem Cells Transl Med*. 2014;3(8):936–941.

Kylmala T, Tainio H, Raitanen M, et al. Treatment of postoperative male urinary incontinence using transurethral Macroplastique injections. *J Endourol*. 2003;17(2):113–115.

Lai HH, Hurtado EA, Apell RA, et al. Large urethral prolapse formation after calcium hydroxylapatite (Coaptite) injection. *Int Urogynecol J Pelvic Floor Dysfunct*. 2008;19(9):1315–1317.

Lapides J, Diokno A, Silber S, et al. Clean intermittent self-catheterization in the treatment of urinary tract disease. *J Urol*. 1972;107:458–465.

Lee CN, Jang JB, Drutz HP, et al. Human cord blood stem cell therapy for treatment of stress urinary incontinence. *J Korean Med Sci*. 2010;25(6):813–816.

Lee PE, Kung RC, Drutz HP. Periurethral autologous fat injection as treatment for female stress urinary incontinence: a randomized double-blind controlled trial. *J Urol*. 2001;165(1):153–158.

Leonard MP, Dharamsi N, Williot PE. Outcome of gastrocystoplasty in tertiary pediatric urology practice. *J*

Urol. 2000;164:947–950.

Leslie B, Lorenzo AJ, Moore K, et al. Long-term followup and time to event outcome analysis of continent catheterizable channels. *J Urol*. 2011;185:2298–2302.

Levy JB, Jacobs JA, Wein AJ. Combined abdominal and vaginal approach for bladder neck closure and permanent suprapubic tube: urinary diversion in the neurologically impaired woman. *J Urol*. 1994;152:2081–2084.

Lightner D, Calvosa C, Andersen R, et al. A new injectable bulking agent for treatment of stress urinary incontinence: results of a multicenter, randomized, controlled, double-blind study of Durasphere. *Urology*. 2001;58(1):12–15.

Lightner D, Rovner E, Corcos J, et al. Randomized controlled multisite trial of injected bulking agents for women with intrinsic sphincter deficiency: mid-urethral injection of Zuidex via the Implacer versus proximal urethral injection of Contigen cystoscopically. *Urology*. 2009;74(4):771–775.

Lightner DJ, Fox J, Klingele C. Cystoscopic injections of dextranomer hyaluronic acid into proximal urethra for urethral incompetence: efficacy and adverse outcomes. *Urology*. 2010;75(6):1310–1314.

Liu CW, Attar KH, Gall A, et al. The relationship between bladder management and health-related quality of life in patients with spinal cord injury in the UK. *Spinal Cord*. 2010;48:319–324.

Lloyd LK, Kuhlemeier LV, Fine PR, et al. Initial bladder management in spinal cord injury: does it make a difference? *J Urol*. 1986;135:523–527.

Locke JR, Hall DE, Walzer Y. Incidence of squamous cell carcinoma in patients with long-term catheter drainage. *J Urol*. 1985;133:1034–1038.

Lose G, Sorensen HC, Axelsen SM, et al. An open multicenter study of polyacrylamide hydrogel (Bulkamid) for female stress and mixed urinary incontinence. *Int Urogynecol J*. 2010;21(12):1471–1477.

Lynch WJ, Testa GA, Bell D. A study to determine subjective and objective benefits of a remote-controlled intra-urethral device for the management of female acontractile bladder. *Brit J Urol*. 2003;92:960–963.

Madjar S, Halachmi S, Wald M, et al. Long-term follow up of the inFlow^{TM} intraurethral insert for the treatment of women with voiding dysfunction. *Eur Urol*. 2000;38:161–166.

Madjar S, Sharma AK, Walzer WC, et al. Periurethral mass formations following bulking agent injection for the treatment of urinary incontinence. *J Urol*. 2006;175(4):1408–1410.

Maher CF, O'Reilly BA, Dwyer PL, et al. Pubovaginal sling versus transurethral Macroplastique for stress urinary incontinence and intrinsic sphincter deficiency: a prospective randomised controlled trial. *BJOG*. 2005;112(6):797–801.

Malizia AA Jr, Reiman HM, Meyers RP, et al. Migration and granulomatous reaction after periurethral injection of polytef (Teflon). *J Am Med Assoc*. 1984;251(24):3277–3281.

Mayer RD, Dmochowski RR, Appell RA, et al. Multicenter prospective randomized 52-week trial of calcium hydroxylapatite versus bovine dermal collagen for treatment of stress urinary incontinence. *Urology*. 2007;69(5):876–880.

McGuire EJ, Appell RA. Transurethral collagen injection for urinary incontinence. *Urology*. 1994;43(4):413–415.

McGuire EJ, Woodside JR, Borden TA, et al. Prognostic value of urodynamic testing in myelodysplastic patients. *J Urol*. 1981;126:205–209.

Mitrofanoff P. Trans-appendicular continent cystostomy in the management of the neurogenic bladder. *Chir Pediatr*. 1980;21:297–305.

Mitterberger M, Marksteiner R, et al. Autologous myoblasts and fibroblasts for female stress incontinence: a 1-year follow-up in 123 patients. *BJU Int*. 2007;100(5):1081–1085.

Mitterberger M, Marksteiner R, Margreiter E, et al. Myoblast and fibroblast therapy for post-prostatectomy urinary incontinence: 1-year followup of 63 patients. *J Urol*. 2008;179(1):226–231.

Monti PR, Lara RC, Dutra MA, et al. New techniques for construction of efferent conduits based on the Mitrofanoff principle. *Urology*. 1997;49:112–115.

Mourtzinos A, Maher MG, Raz S, et al. Spiral sling salvage anti-incontinence surgery for women with refractory stress urinary incontinence: surgical outcome and satisfaction determined by patient-driven questionnaires. *Urology*. 2008;72:1044–1048.

Muller N, McInnis E. The development of national quality performance standards for disposable absorbent products for adult incontinence. *Ostomy Wound Manage*. 2013;59:40–55.

Mundy AR, Stephenson TP. “Clam” ileocystoplasty for the treatment of refractory urge incontinence. *Br J Urol*. 1985;57:641–646.

National Association for Continence. *National Association for Continence resource guide*. 14th ed. National Association for Continence: Spartanburg (SC); 2008.

Navon JD, Soleman H, Khonsari F, et al. Screening cystoscopy and survival of spinal cord injured patients with squamous cell carcinoma of the bladder. *J Urol*. 1997;157:2109–2111.

Newman DK, Wein AJ. *Managing and treating urinary incontinence*. 2nd ed. Health Professions Press: Baltimore; 2009.

Newman DK. *The urinary incontinence sourcebook*. 2nd ed. McGraw-Hill: New York; 1999.

Ninkovic M, Stenzl A, Schwabegger A, et al. Free neurovascular transfer of latissimus dorsi muscle for the treatment of bladder acontractility. II. Clinical results. *J Urol*. 2003;169:1379–1383.

Nygaard I, Thom DH, et al. Urinary incontinence in women. Litwin MS, Saigal CS. *Urologic diseases in America*. US Department of Health and Human Services, Public Health Service, National Institutes of Diabetes and Digestive and Kidney Diseases. US Government Publishing Office: Washington, DC; 2014:87–103.

O'Connor RC, Stapp EC, Donnellan SM, et al. Long-term results of suprapubic bladder neck closure for treatment of the devastated outlet. *Urology*. 2005;66:311–315.

Onur R, Singla A. Comparison of bone-anchored male sling and collagen implant for the treatment of male incontinence. *Int J Urol*. 2006;13(9):1207–1211.

Palma PC, Riccetto CL, et al. Massive prolapse of the urethral mucosa following periurethral injection of calcium hydroxylapatite for stress urinary incontinence. *Int Urogynecol J Pelvic Floor Dysfunct*. 2006;17(6):670–671.

Pannek J, Brands FH, et al. Particle migration after transurethral injection of carbon coated beads for stress urinary incontinence. *J Urol*. 2001;166(4):1350–1353.

Payne C, Brown J, et al. Research. Abrams P, Cardozo L, Khoury S. *Incontinence—4th International Consultation*. Health Publications Ltd: Paris, France; 2009:1713–1766.

Peters KM, Dmochowski RR, et al. Autologous muscle derived cells for treatment of stress urinary incontinence in women. *J Urol*. 2014;192(2):469–476.

Phe V, Nguyen K, et al. A systematic review of the treatment for female stress urinary incontinence by ACT(R) balloon placement (Uromedica, Irvine, CA, USA). *World J Urol*. 2014;32(2):495–505.

Prieto JC, Perez-Brayfield M, et al. The treatment of catheterizable stomal incontinence with endoscopic implantation of dextranomer/hyaluronic acid. *J Urol*. 2006;175(2):709–711.

Pruthi RS, Petrus CD, et al. New onset vesicovaginal fistula after transurethral collagen injection in women who underwent cystectomy and orthotopic neobladder creation: presentation and definitive treatment. *J Urol*. 2000;164(5):1638–1639.

Quek ML, Ginsberg DA. Long-term urodynamics followup of bladder augmentation for neurogenic bladder. *J Urol*. 2003;169:195–198.

Reynolds WS, Dmochowski RR. Urethral bulking: a urology perspective. *Urol Clin North Am*. 2012;39(3):279–287.

Rodriguez AR, Hakky T, Hoffman M, et al. Salvage spiral sling techniques: alternatives to manage disabling recurrent urinary incontinence in females. *J Urol*. 2010;184:2429–2433.

Rogo-Gupta L, Litwin MS, et al. Trends in the surgical management of stress urinary incontinence among female Medicare beneficiaries, 2002-2007. *Urology*. 2013;82(1):38–41.

Rutkowski SB, Middleton JW, Truman G, et al. The influence of bladder management on fertility in spinal cord injured males. *Paraplegia*. 1995;33:263–266.

Rutman MP, Deng DY, Shah SM, et al. Spiral sling salvage anti-incontinence surgery in female patients with a nonfunctional urethra: technique and initial results. *J Urol*. 2006;175:1794–1798.

Saint S, Kaufman SR, Rogers MA, et al. Condom versus indwelling urinary catheters: a randomized trial. *J Am Geriatr Soc*. 2006;54:1055–1061.

Saint S, Meddings JA, Calfee D, et al. Catheter-associated urinary tract infection and the Medicare rule changes. *Ann Intern Med*. 2009;150:877–884.

Sajadi KP, Goldman HB. Bladder augmentation and urinary diversion for neurogenic LUTS: current indication. *Curr Urol Rep*. 2012;13:389–393.

Sanchez-Ortiz RF, Broderick GA, et al. Collagen injection therapy for post-radical retropubic prostatectomy incontinence: role of Valsalva leak point pressure. *J Urol*. 1997;158(6):2132–2136.

Sarosdy MF. Continent urinary diversion using cutaneous ileocecocystoplasty. *Urology*. 1992;40:102–106.

Schlomer BJ, Saperston K, Baskin L. National trends in augmentation cystoplasties in the 2000s and factors associated with patient outcomes. *J Urol*. 2013;190:1352–1357.

Schulz JA, Nager CW, et al. Bulking agents for stress urinary incontinence: short-term results and complications in a randomized comparison of periurethral and transurethral injections. *Int Urogynecol J Pelvic Floor Dysfunct*. 2004;15(4):261–265.

Schwanke J. *Dermatologists prepare for departure of collagen from U.S. market*. [website] http://dermatologytimes.modernmedicine.com/dermatology-times/news/modernmedicine/modern-medicine-feature-articles/dermatologists-prepare-depart?page=full; 2010.

Shortliffe LM, Freiha FS, et al. Treatment of urinary incontinence by the periurethral implantation of glutaraldehyde cross-linked collagen. *J Urol*. 1989;141(3):538–541.

Shpall AI, Ginsberg DA. Bladder neck closure with lower urinary tract reconstruction: technique and long-term followup. *J Urol*. 2004;172:2296–2299.

Smith DN, Appell RA, et al. Collagen injection therapy for post-prostatectomy incontinence. *J Urol*. 1998;160(2):364–367.

Smith JJ 3rd, Swierzewski SJ 3rd, et al. Endoscopic injection of glutaraldehyde cross-linked collagen for efferent limb incompetence in the Indiana reservoir. *J Urol*. 1998;159(3):804–805.

Sokol ER, Karram MM, et al. Efficacy and safety of polyacrylamide hydrogel for the treatment of female stress incontinence: a randomized, prospective, multicenter North American study. *J Urol*. 2014;192(3):843–849.

Stamey TA, et al. Urinary incontinence in the female. Harrison JH, Gittes RF, Stamey TA. *Campbell's urology*. Saunders: Philadelphia; 1979:2272–2293.

Stangel-Wojcikiewicz K, Jarocha D, et al. Autologous muscle-derived cells for the treatment of female stress urinary incontinence: a 2-year follow-up of a Polish investigation. *Neurourol Urodyn*. 2014;33(3):324–330.

Stecco A, Saponaro A, et al. Can MRI predict which patients are most likely to benefit from percutaneous positioning of volume-adjustable balloon devices? *Urol Int*. 2006;76(3):240–246.

Steele AC, Kohli N, et al. Periurethral collagen injection for stress incontinence with and without urethral hypermobility. *Obstet Gynecol*. 2000;95(3):327–331.

Stenzl A, Ninkovic M, Kolle D, et al. Restoration of voluntary emptying of the bladder by transplantation of innervated free skeletal muscle. *Lancet*. 1998;351:1483–1485.

Stonehill WH, Dmochowski RR, Patterson AL, et al. Risk factors for bladder tumors in spinal cord injury patients. *J Urol*. 1996;155:248–250.

Sturmann D, O'Grady S, D’mello V. Management of urinary incontinence: a comparative study in a continuing care facility. *Infect Control Can*. 1989;4:4.

Sutton MA, Hinson JL, Nickell KG, et al. Continent ileocecal augmentation cystoplasty. *Spinal Cord*. 1998;36:246–251.

Tapia CI, Khalaf K, Berenson K, et al. Health-related quality of life and economic impact of urinary incontinence due to detrusor overactivity associated with a neurologic condition: a systematic review. *Health Qual Life Outcomes*. 2013;11:13.

Tchetgen MB, Sanda MG, et al. Collagen injection for the treatment of incontinence after cystectomy and orthotopic neobladder reconstruction in women. *J Urol*. 2001;163:212 [Abstr].

ter Meulen PH, Berghmans LC, et al. Effects of Macroplastique Implantation System for stress urinary incontinence and urethral hypermobility in women. *Int Urogynecol J Pelvic Floor Dysfunct*. 2009;20(2):177–183.

Tiguert R, Gheiler EL, et al. Collagen injection in the management of post-radical prostatectomy intrinsic sphincteric deficiency. *Neurourol Urodyn*. 1999;18(6):653–658.

Tizzoni F, Foggi A. Die wiederhestellung der harnblase. *Zentralbl Chir*. 1888;15:921–924.

Vaida P, Pinter AB, Harangi F, et al. Metabolic findings after colocystoplasty in children. *Urology*. 2003;62:542–546.

Valtonen K, Karlsson AK, Siösteen A, et al. Satisfaction with sexual life among persons with traumatic spinal cord injury and meningomyelocele. *Disabil Rehabil*. 2006;28:965–976.

Van Arsdalen KN, Klein FA, Hackler RH. Penile implants in spinal cord injury patients for maintaining external appliances. *J Urol*. 1981;126:1117–1123.

Vapnek JM, Maynard FM, Kim J. A prospective randomized trial of the Lofric hydrophilic coated catheter versus conventional plastic catheter for clean intermittent catheterization. *J Urol*. 2003;169:994–998.

Von Heyden B, Anthony JP, Brock GB, et al. The latissimus dorsi bladder myoplasty to assist detrusor function. *Urol Res*. 1998;26:215–221.

Von Mikulicz J. Zur operation der angebarenen blaßen-Spalte.

Zentralbl Chir. 1889;20:641–643.

Wachter J, Henning A, et al. Adjustable continence therapy for female urinary incontinence: a minimally invasive option for difficult cases. *Urol Int*. 2008;81(2):160–166.

Waites KB, Canupp KC, DeVivo MJ. Epidemiology and risk factors for urinary tract infection following spinal cord injury. *Arch Phys Med Rehabil*. 1993;74:691–695.

Wall BM, Dmochowski RR, Malecha M, et al. Inducible nitric oxide synthase in the bladder of spinal cord injured patients with a chronic indwelling urinary catheter. *J Urol*. 2001;165:1457–1461.

Walsh K, Troxel SA, Stone AR. An assessment of the use of a continent catheterizable stoma in female tetraplegics. *BJU Int*. 2004;94:595–597.

Wein AJ, Barrett DM. *Voiding function and dysfunction: a logical and practical approach*. Year Book Medical: Chicago; 1988.

Weld KJ, Dmochowski RR. Effect of bladder management on urological complications in spinal cord injured patients. *J Urol*. 2000;163:768–772.

Welk BK, Afshar K, Rapoport D, et al. Complications of the catheterizable channel following continent urinary diversion: their nature and timing. *J Urol*. 2008;180:1856–1860.

Williams JK, Dean A, Badlani G, et al. Regenerative medicine therapies for stress urinary incontinence. *J Urol*. 2016;196:1619–1626.

Willis H, Safiano NA, Lloyd LK. Comparison of transvaginal and retropubic bladder neck closure with suprapubic catheter in women. *J Urol*. 2015;193:196–202.

Wilson S, Quek ML, et al. Transurethral injection of bulking agents for stress urinary incontinence following orthotopic neobladder reconstruction in women. *J Urol*. 2004;172(1):244–246.

Winters JC, Appell R. Periurethral injection of collagen in the treatment of intrinsic sphincteric deficiency in the female patient. *Urol Clin North Am*. 1995;22(3):673–678.

Wyndaele JJ. Complications of intermittent catheterization: their prevention and treatment. *Spinal Cord*. 2002;40:536–541.

Wyndaele JJ. Conservative treatment of patients with neurogenic bladder. *Eur Urol*. 2008;(Suppl 7):557–565.

Yamamoto T, Gotoh M, Kato M, et al. Periurethral injection of autologous adipose-derived regenerative cells for the treatment of male stress urinary incontinence: report of three initial cases. *Int J Urol*. 2012;19(7):652–659.

Yang CC, Clowers DE. Screening cystoscopy in chronically catheterized spinal cord injury patients. *Spinal Cord*. 1999;37:204–207.

Yang WH. Yang needle tunneling technique in creating antireflux and continent mechanisms. *J Urol*. 1993;150:830–834.

Zermann DH, Kutzenberge J, Sauerwein D, et al. Penile prosthetic surgery in neurologically impaired patients: long-term followup. *J Urol*. 2006;175(3 Pt 1):1041–1044.

Zimakoff J, Stickler DJ, Pontoppidan B, et al. Bladder management and urinary tract infections in Danish hospitals, nursing homes, and home care: a national prevalence study. *Infect Control Hosp Epidemiol*. 1996;17:215–221.

Zommick JN, Simoneau AR, Skinner DG, et al. Continent lower urinary tract reconstruction in the cervical spinal cord injured population. *J Urol*. 2003;169:2184–2187.

Aging and Geriatric Urology

Tomas L. Griebling MD, MPH

Aging is a universal process that affects all living organisms. Alterations in anatomy and physiology associated with the normal aging process lead to functional changes in all aspects of human medicine including the genitourinary system. This chapter focuses on human aging and the associated alterations in structure and function that affect urologic care for older adults.

Dr. Ignatz Leo Nacher was the first to use *geriatrics* as a clinical term in a scientific publication in 1909 (Nacher, 1909). That article highlighted early concepts about considering care for older adults as a distinct branch of medicine. More than a century later, geriatrics is a recognized and respected distinct specialty not only within general medicine but also in multiple other health care disciplines, including nursing, pharmacy, physical and occupational therapy, social work, and others. More recently, the growing need for geriatrics expertise in all of the medical and surgical specialties including urology has been recognized (Bell et al., 2011; Drach and Griebling, 2003). Research efforts and educational materials have been developed that have helped to expand knowledge about the unique aspects of medical needs and care delivery for older adults with urologic health problems (Griebling 2009a, 2009b, 2014a; Guzzo et al., 2013; Reuben et al., 2014; Webb and Duthie, 2008).

In clinical medicine, the term ***geriatrics* is most commonly used to refer to care of patients 65 year of age or older.** In part, this is a social construct because this is the age when Medicare and Social Security benefits have traditionally started for people in the United States. The World Health Organization (WHO) actually classifies people over the age of 60 as being “elderly,” because life expectancy is still shorter in many parts of the developing world. With continuing advances in medical care, and extended longevity in many developed countries, many would argue that clinical geriatrics now encompasses an even older population, often focused on those 70 years and older. However, in many circumstances, **chronologic age may be a much less**

important factor compared with physiologic or functional age.

One of the basic principles in geriatric medicine is a focus on patient-centered care. This places the goals of care for patients, their caregivers, and other loved ones at the core of clinical evaluation and treatment. In some cases the goal may be treatment with curative intent. However, in many instances this may not be possible. In all cases, there should be an **emphasis on quality of life and stabilization or improvement in functional status.** This frequently includes a goal to maintain independence as long as possible and to reduce the need for assistance or care from others to the extent possible. Promotion of urinary continence and improved bladder function is a good example of this type of care within the scope of urologic practice. Improvement in independent toileting and continence status can reduce the need for caregiver assistance and may in turn decrease the risk of need for nursing home placement (Andel et al., 2007).

Biology and Principles of Aging

There are several plausible theories about why people age and experience changes over time. The **Hayflick "limit"** describes the phenomenon of limitations in the number of cellular replication cycles inherent to most cell types (Hayflick and Moorhead, 1961). This may be due to a variety of factors. **Telomere shortening** has been identified as a common cellular change seen with aging. **Activation of various tumor suppressor genes** or other genetic pathways may also either promote or suppress cellular senescence. **Release of free radicals and other types of oxidative stress increase with aging** and can lead to mitochondrial damage and other intracellular changes. Some cell types exhibit **apoptosis or programmed cell death.** Numerous inflammatory biomarkers have been shown to increase with age and could potentially accelerate the aging process. These **accumulated changes can lead to the alterations in tissue and organ function commonly seen with advancing age.** These types of changes can influence clinical outcomes, including tissue and wound healing, restoration of function, and outcomes of reconstructive urologic surgical procedures (Griebling, 2009a).

Physiologic Aging

Changes in function with increasing age can be seen in essentially all organ systems. Generalized changes can be exacerbated by specific disease progression. A number of these different processes have direct impact on genitourinary health, urologic function, and clinical decision making relative to urologic care.

Renal blood flow decreases with aging. This can be caused by atherosclerotic plaque formation in the renal arteries and other vascular diseases. Kidney mass also decreases progressively after 65 years of age. This leads to a **concomitant decrease in the glomerular filtration rate of approximately 10 mL/min per decade,** reaching about 50% by age 80. Approximately 26% of all adults over the age of 70 have some degree of chronic renal impairment. **This can have substantial impact on dosing of medications cleared by renal metabolism** (Hanlon et al., 2009). In many cases, lower doses will be adequate to achieve clinical effects, and doses typically used in younger patients may lead to toxicity or untoward side effects. Renal concentrating ability is also reduced, and older adults tend to make a larger volume of more dilute urine (Sands, 2003).

Accurate estimation of renal function in older adults can be challenging. **Serum creatinine levels alone may not reflect actual renal function,** particularly in frail older adults or those with reduced lean body mass. In these cases, serum creatinine measurements will tend to overestimate function, and underestimate the degree of renal impairment (Giannelli et al., 2007). Measures that calculate estimated glomerular filtration rates, including the Cockcraft-Gault equation, will tend to be more accurate in this elderly population (Scrutinio et al., 2009). Routine assessment and reporting of estimated GFR can help to improve prescribing accuracy for drugs that require renal metabolism (Kurtal et al., 2009).

The diurnal pattern of water consumption and urine production also changes with aging. Total water intake appears to decrease among older adults with aging, with population studies indicating only 19% to 27% of geriatric patients actually reach the daily recommended levels of fluid consumption (Zizza et al., 2009). Endogenous secretion of arginine vasopressin decreases with age. Because of this, older adults tend to excrete the majority of their fluid output at night, which can lead to symptomatic nocturia (Tani et al., 2008). This relative nocturnal polyuria can be a major contributing factor to clinically bothersome symptoms (Natsume et al., 2009).

Cardiac compliance and elasticity decrease with aging, which leads to decreased cardiac output and stroke volume. This can have important implications, particularly when considering older adults as candidates for urologic surgery. Hypertension is also a common condition seen with aging, which can negatively influence functional reserve capacity. Hypertension in older adults can be caused by a myriad of factors, including renovascular and other causes.

The **respiratory system** undergoes substantial changes with aging. Pulmonary surface area for oxygen diffusion decreases leading to changes in ventilation and perfusion ratio. Chest wall elasticity and respiratory muscle strength both decrease, and there is decreased maximal expansion. Pulmonary fibrosis and chronic obstructive pulmonary disease are common conditions seen with aging that can also negatively influence respiratory function. Cigarette smoking increases these risks and exacerbates age-related changes. Increased cough may worsen symptoms among patients with concomitant stress urinary incontinence. As with cardiovascular disease, alterations in pulmonary function play a major role in consideration for surgical therapy in older adults. **Although the majority of deaths in the perioperative period in geriatric patients are due to cardiovascular events** such as myocardial infarction and stroke, **the majority of prolonged hospitalizations are due to pulmonary problems** such as pulmonary embolism, pneumonia, and respiratory failure and difficulty weaning from ventilator support (Somme et al., 2003).

Hepatic function also declines with time. Loss of hepatocytes leads to **decreased metabolic efficiency for drugs cleared by hepatic metabolism.** Alterations in the cytochrome P450 mechanism are common and can be influenced by a variety of medications. This can alter hepatic metabolism and may require dose adjustment of medications cleared by the liver. It is also important to consider drug-drug interactions that may be influenced by changes in the cytochrome P450 pathway. Certain foods, particularly grapefruit, can also interfere with the cytochrome P450 pathway and potentially impair drug metabolism.

Immunologic function, particularly T-cell mediated immunity, tends to slowly decline with age. This leads to a generalized increase in the risk of infections among older adults including a greater risk for upper and lower urinary tract infections (UTIs) and pneumonia.

Gastroenterologic changes include a generalized slowing of bowel motility, which can lead to alterations in stool frequency and consistency. **Altered water reabsorption from the colon can increase risk for constipation.** This can be particularly affected by anticholinergic and other medications, which may slow bowel motility. This in turn increases the risk for constipation and fecal impaction with aging. These conditions can be exacerbated by medications used in the treatment of some urologic conditions such as antimuscarinics prescribed for overactive bladder, urinary urgency and frequency, and urgency UI (Kim et al., 2014).

Vascular changes are common with aging. These include changes in peripheral vasculature, cardiac and central nervous system vascular anatomy, and renal perfusion. Hypertension, tobacco use, and diabetes contribute to vascular disorders seen more commonly with aging. Plaque formation and atherosclerotic disease may limit circulation to the kidneys, bladder, penis, and other genitourinary organs. Decreased penile blood flow can lead to erectile dysfunction in elderly men (Justo et al., 2010). Pelvic ischemia has also been linked to the subsequent development of lower urinary tract symptoms (LUTS) in older adults (Kim et al., 2010; Pinggera et al., 2008). Color Doppler ultrasound demonstrates diminished arterial blood flow is associated with pelvic ischemia and higher rates of lower urinary tract symptoms. Animal models show that pelvic ischemia is associated with increased levels of proinflammatory cytokines and other biomarkers suggesting that oxidative stress plays a role in this process (Nomiya et al., 2012). Free radical release and oxidative stress may cause ultrastructural damage that can lead to neurodegeneration and other anatomic and functional abnormalities (Azadzoi et al., 2007, 2010, 2011; Tyagi et al., 2014b). Early research suggests that melatonin and other compounds such as free radical scavengers could be potential agents to prevent urologic sequelae from this type of ischemia (Nomiya et al., 2013).

Metabolic changes are common with aging. Rates of the metabolic syndrome and type II diabetes mellitus increase substantially with advancing age. These conditions can contribute to multiple clinical conditions, including vascular insufficiency, erectile dysfunction, renal impairment, and bladder dysfunction (Park et al., 2008). With aging, there is a **relative increase in adipose tissue and a loss of lean body mass and muscle.** This influences fluid distribution and drug metabolism and increases the rate of accumulation of lipophilic metabolites. **Because of this, many lipophilic drugs must be dose titrated in older adults.** Obesity and overweight have reached epidemic proportions in the United States, and this is associated with increased rates of associated medical conditions, including diabetes and metabolic syndrome.

Aging and the Lower Urinary System

Many of the common genitourinary conditions occur with higher incidence and prevalence rates in older adults, but these should not necessarily be considered a normal or inevitable part of the aging process. Examples include UTIs, urinary incontinence, erectile and sexual dysfunction, and many urologic malignancies. Various changes commonly occur in the genitourinary tract as a result of the normal aging process. **One of the greatest challenges in geriatric urology is to differentiate between normal aging and pathologic processes** that can affect the genitourinary system and lead to associated symptoms.

Several structural changes that occur in the bladder with aging have been linked to functional changes that can cause specific clinical symptoms (DuBeau, 2006). The ratio of smooth muscle to collagen in the wall of the bladder decreases, which may lead to decreased contractile strength. Studies using electron microscopy and other structural imaging modalities have demonstrated these changes as well as development of dense bands and loss of caveolae (Elbadawi et al., 1993; Lowalekar et al., 2012). These alterations have been linked to increased involuntary detrusor contractions and changes in contraction strength and velocity. Functional bladder innervation also appears to diminish over time with chronic obstruction or overactivity (Fry et al., 2011). Changes in detrusor anatomy can also lead to a decrease in elasticity and compliance, defined as the change in bladder volume related to bladder pressure. These alterations can lead to changes in urine storage and bladder emptying (Elbadawi et al., 1997). Sensory changes may be caused by alterations in the epithelium and associated receptors and neurotransmitters. Oxidative stress damage may also occur as a result of the aging process and may be associated with symptomatic bladder dysfunction (Aybek et al., 2011). Bladder capacity tends to remain relatively stable or decrease only slightly with advancing age (Pfisterer et al., 2006a, 2006b).

Progressive anatomic changes in pelvic floor support and muscle strength can also occur with aging. Cadaveric studies using biopsies of the urogenital diaphragm have documented that striated muscle tissue is substantially reduced or absent in many older women relative to connective tissue (Betschart et al., 2008). However, aging may not be the sole risk factor, and other variables including parity and history of vaginal delivery should be considered (Weemhoff et al., 2010). Bony structural support in the pelvis may also contribute to these changes and can potentially be influenced by geriatric skeletal disorders such as osteopenia or osteoporosis (Richter et al., 2013). **Pelvic floor muscle dysfunction is common among elderly women,** and research indicates many of them may not be able to generate voluntary muscle contractions on initial examination (Talasz et al., 2012). Some of this observed change in pelvic floor support may be due to apoptotic cellular changes in these tissues (Saatli et al., 2014).

Decreased striated muscle density in the rhabdosphincter can lead to an increased propensity for stress urinary incontinence, particularly in elderly women. These anatomic changes may be caused, at least in part, by apoptosis associated with aging (Strasser et al., 1999, 2000). This can subsequently lead to a loss of the normal circumferential anatomy and appropriate urethral resistance and closure pressures (Klauser et al., 2004; Kurihara et al., 2004).

Demographics of Aging

Aging and Population Trends

The overall population of the United States, and many other developed countries, is aging at a very rapid pace. This is due to a number of factors, including improved longevity, decreased overall birth rates, and enhanced medical technology that makes effective treatment for many conditions possible. Older adults, defined as those 65 years of age and older, currently account for approximately 13% of the total US population. However, it is estimated that this will increase to at least 20% by the year 2030 (Fig. 128.1). **Those over the age of 85 represent the fastest-growing segment of the United States population.** The aging of the “Baby Boom” generation, including those born between 1946 and 1964, is also contributing to this demographic trend. Approximately 10,000 people per day now turn 65 years of age in the United States. This is a global phenomenon and is occurring in almost all portions of the world with the exception of sub-Saharan Africa, where mean life expectancy is still relatively shorter. Worldwide, approximately 420 million people were over the age of 65 in 2000, and it is estimated that this will increase to more than 973 million by 2030 (Centers for Disease Control and Prevention, 2014). Remaining life expectancy for those already aged 65 continues to steadily increase in the United States and many developed countries worldwide.

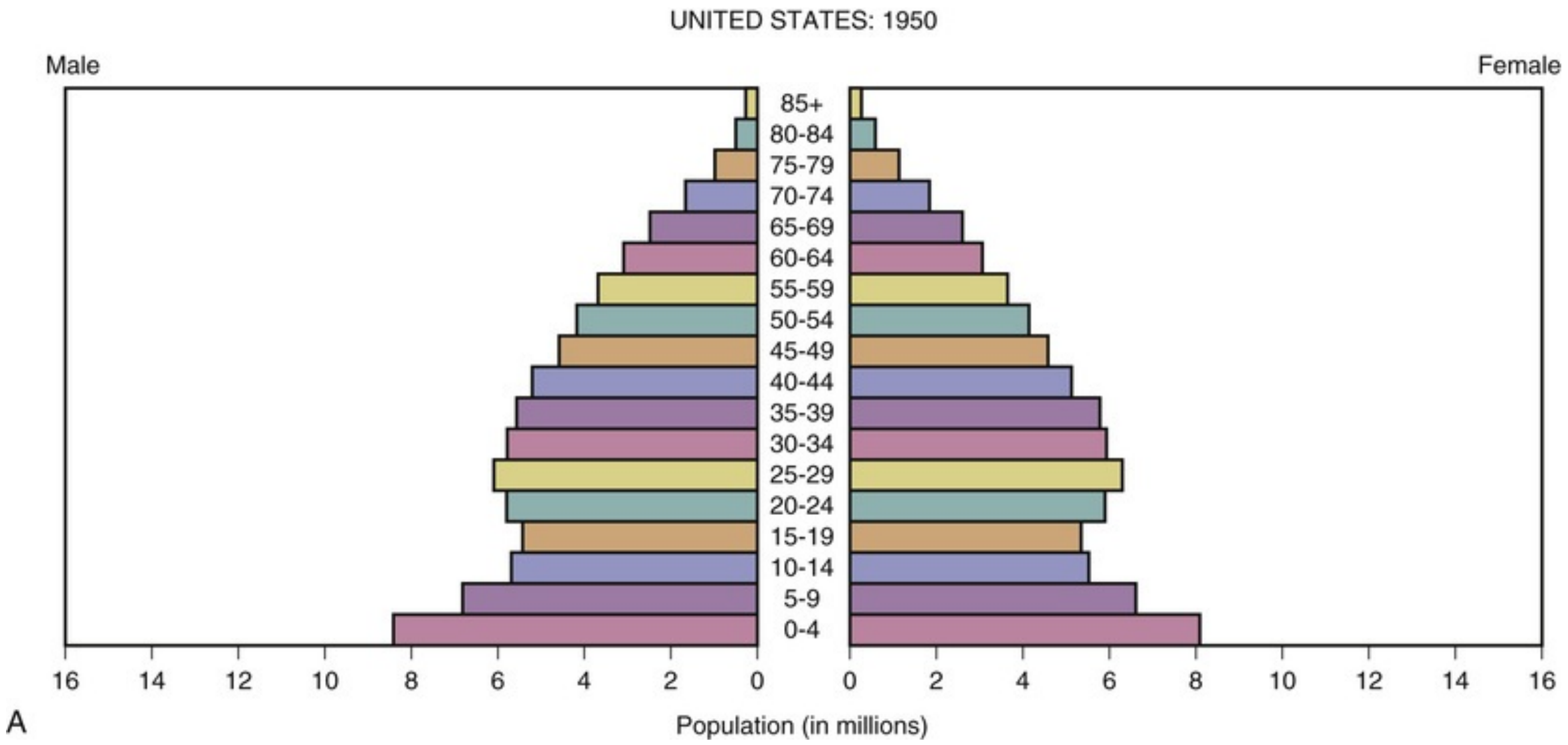

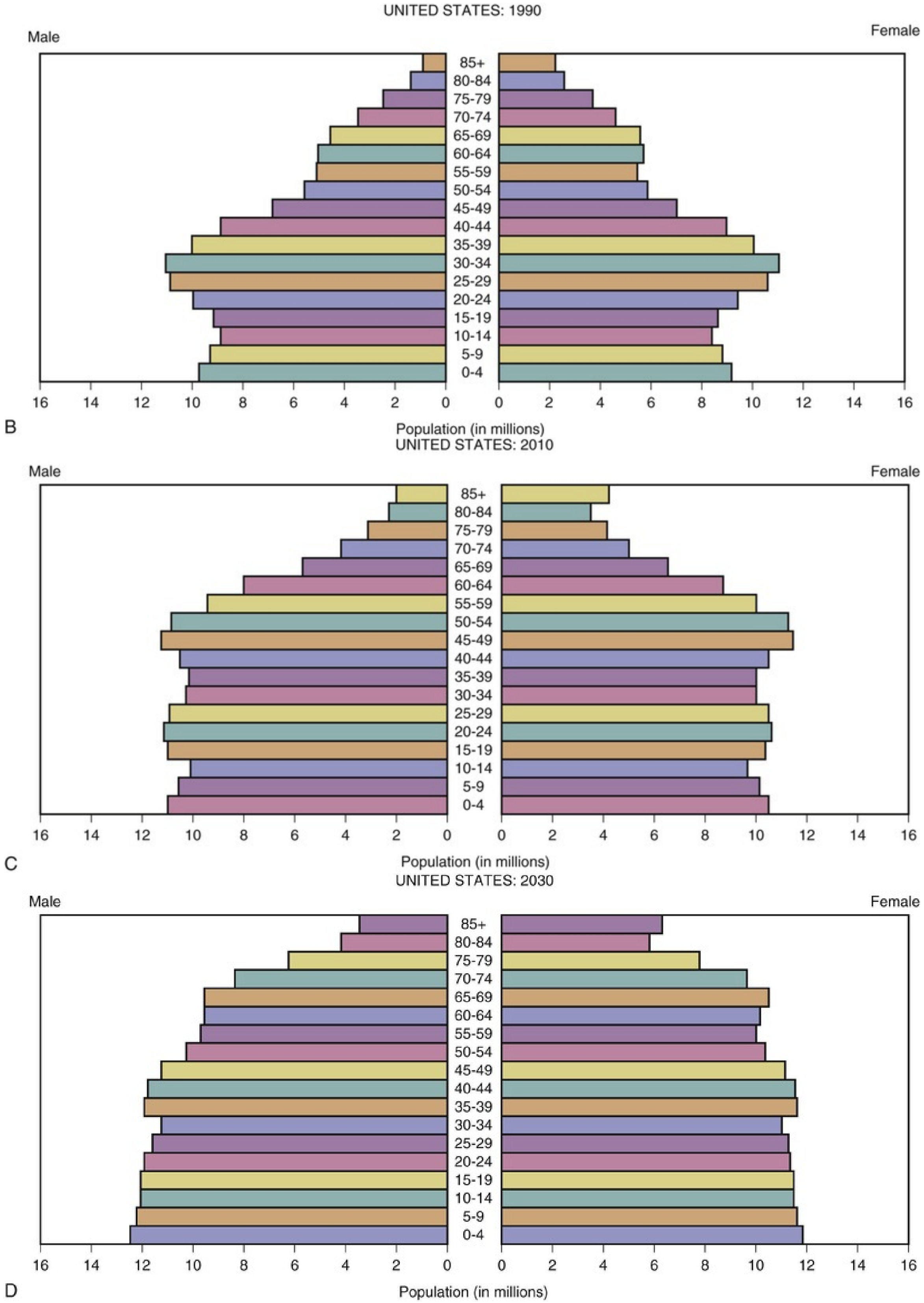

FIG. 128.1 Age-sex population pyramids based on United States Census data. (A) 1950 census. (B) 1990 census. (C) 2010 census. (D) 2030

(projected). Note the sizeable increase in total population and the progressive change over time from a pyramid shape, where the majority of the total population is relatively young, to a rectangular shape, where a substantially larger portion of the population is more than 65 years of age. The pronounced bulge in the graphs for 1990 and 2010 represents the "Baby Boom" generation. (Source: United States Census Bureau, https://www.census.gov).

The majority of older adults continue to live in the community, with only a minority requiring residential long-term care in nursing home or other types of facilities. The need for nursing home services does increase with advancing age, with approximately 15% of those over 85 years of age living in long-term care facilities (Federal Interagency Forum on Aging-Related Statistics, 2012).

Global Implications for Urologic Health Care

As the population ages, there will be an increased need for health care providers with specific knowledge and skills to evaluate and treat clinical conditions in this heterogeneous and complex patient population. In many ways, urology is by its very nature, a geriatric specialty. Except for those who exclusively practice pediatric or adolescent urology, most urologists in general practice have a majority of patients in their practice who are more than 65 years old. **Urology consistently ranks among the top three specialties in the United States in terms of the total volume of older adults seen in clinical practice.** Only ophthalmology and cardiology outrank urology in terms of the total volume of geriatric care provided in the specialty (Drach and Griebling, 2003). There has been recommendation that geriatric competencies be incorporated into surgical training and included as part of board certification and continued maintenance of certification broadly across surgical disciplines (Bell et al., 2011). Surgical trainees have indicated that they are interested in learning more about geriatric care as part of their education (Shipway et al., 2015). As the medical workforce ages, there will be a growing need for more urologists with understanding and specific training on geriatrics principles (Gaither et al., 2016).

Epidemiologic studies have consistently shown that **incidence and prevalence rates for the most common urologic conditions tend to increase substantially with advancing age.** This includes urinary incontinence and lower urinary tract dysfunction, pelvic organ prolapse (POP), UTI, bladder outlet obstruction (BOO), and benign prostatic hyperplasia (BPH). With the exception of testicular cancers, all of the urologic malignancies have a predilection to occur in older adults. Sexual health problems are more common among older men and women than younger patients. **Increased population growth among older adults will mean that more elderly patients will develop urologic disorders,** and in turn will likely translate into increased rates of surgical care among geriatric patients (Takao et al., 2008). All of these factors contribute to the expanding need for expertise in geriatric urology (Drach and Griebling, 2003).

Clinical Evaluation of the Geriatric Urology Patient

Older adults frequently have more complex health needs compared with younger patients. This is in part due to changes associated with aging and to the increase in comorbidity seen in elderly patients. **Physiologic alterations associated with aging can lead to loss of functional reserve capacity,** which in turn leads to impaired response to stressors such as infection, surgery, chemotherapy, or other urologic conditions or treatments (Fig. 128.2). The concept of the body trying to restore or remain in balance in response to internal or external stressors has been termed *homeostasis*. In geriatrics, the decline in functional reserve capacity associated with aging is sometimes described using the term *homeostenosis*, an analogy to the narrowing of arteries with atherosclerosis. For a given stressor, older adults with lower baseline functional reserve capacity may not be able to respond as well or may actually have a more exaggerated response compared with younger patients with more reserve. An example would be the development and progression of a postoperative pneumonia. In a healthier younger patient, this may be relatively indolent and self-limited and may promptly resolve with appropriate antibiotic therapy. However, in a more debilitated older adult with less functional reserve capacity, the same level of pneumonia could result in a much more profound illness that could require more intense treatment and time to resolve. It could also have a higher likelihood of progression to more serious disease.

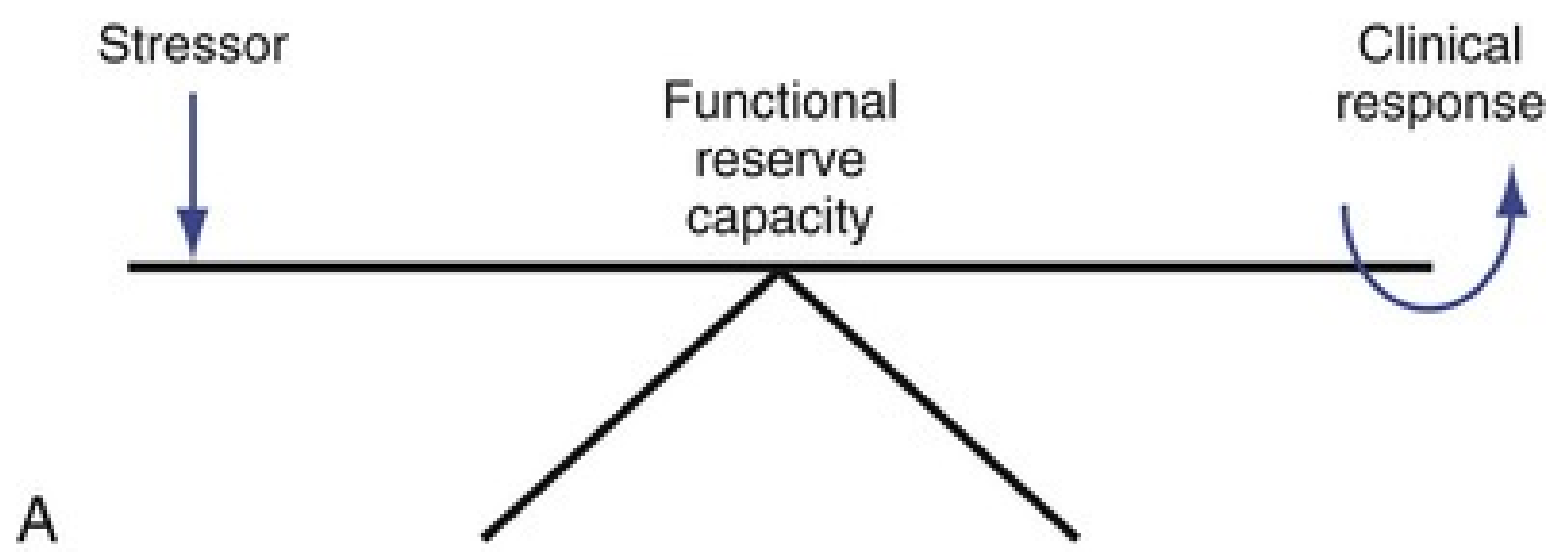

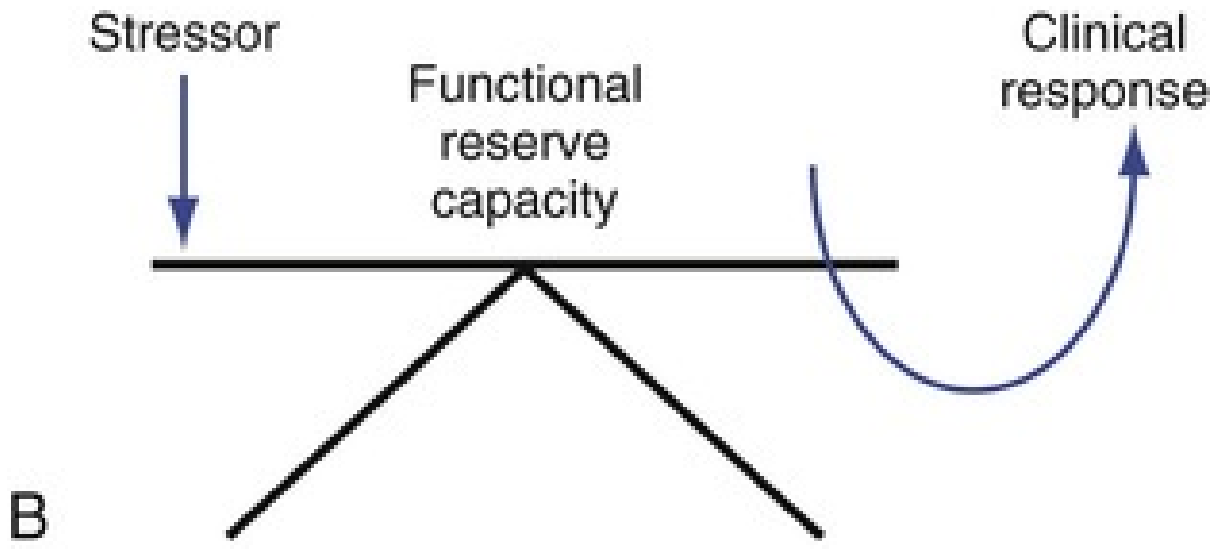

FIG. 128.2 Changes in functional reserve capacity with aging. With aging, there is a progressive decline in functional reserve capacity. This diagram demonstrates the conceptual model of homeostasis (A), in which the body tries to maintain balance in response to various stressors such as disease or clinical treatment. Progression to homeostenosis (B) is caused by relative decline in functional reserve capacity. In this case, response to identical stressors may be more difficult or complications more pronounced because of loss of functional reserve capacity.

One of the most commonly used measures of comorbidity is the **Charlson Comorbidity Index (CCI).** This was initially developed to identify underlying disease conditions that could help to predict subsequent mortality risk (Charlson et al., 1987). The instrument assigns points to each chronic condition, with a sum score indicating level of risk based on comorbidity. The CCI has been used extensively and has been validated for use in surgical patients. It has been applied recently to some urologic conditions such as kidney cancer to help make clinical decisions between surveillance and surgery in elderly patients (O'Connor et al., 2009). Self-reported health is an important predictive factor among geriatric patients. **Poor self-reported health among older adults has been linked to increased overall and disease-specific mortality and has in some cases been found to be a stronger negative predictor than physician-rated health status** (Giltay et al., 2012).

Because of this, older adults often require more involved clinical evaluation in relation to their urologic treatment. This includes a number of specific areas that are somewhat unique to geriatrics but that influence overall care for the patient. Development of comorbid chronic health conditions is common with aging. **The majority of adults over 65 years of age have at least one chronic medical condition, and more than 50% have at least two** (Wolff et al., 2002).

Functional Assessment

Functional assessment in geriatrics includes a number of components designed to evaluate reserve capacity and levels of dependence or independence. This includes evaluation of an older adult's ability to independently perform specific tasks. **A clear understanding of an individual patient's baseline functional status is vital to his or her care** (Dunlop et al., 2002). This provides a framework to better understand subsequent changes associated with surgery or other treatments. **Baseline functional status has been shown to be predictive of other health care outcomes,** including remaining life expectancy, morbidity, and mortality (Lubitz et al., 2003). There is wide heterogeneity among older adults, and this is not specifically related to chronologic age. Progression of clinical disorders and response to treatments can lead to changes in functional status, and the clinician must be able to identify these alterations compared with baseline function. The following components form the basic parts of functional assessment in geriatric patients.

Activities of Daily Living

Activities of daily living (ADLs) include basic tasks people need to do to function and interact in the world. These include bathing, dressing, grooming, use of the toilet, feeding, and physical ambulation. Each of these factors is evaluated on a scale ranging from complete independence to needing full assistance (Lawton and Brody, 1969). Alterations in ADLs are among the most predictive factors for need of caregiving assistance with aging. Although there can be variations in the pattern of progressive need for help with ADLs, bathing is typically the one for which people first need assistance. Feeding tends to be preserved the longest, even in people who are otherwise debilitated. A simple way to determine if people are beginning to need assistance with their ADLs is to ask if someone is able to shower or bathe independently. This can be an early sign of alterations in overall status that may be predictive of future change.

Instrumental Activities of Daily Living

The **instrumental activities of daily living (IADLs)** add a higher cognitive and executive function component to the basic ADLs. These include shopping, preparing food, housekeeping tasks, doing laundry, managing finances, using telephone or other communication devices, managing medications, and using transportation. As people age, it is common for them to need some assistance with the IADLs before they need help with ADLs, although there can be variation in these change patterns. Many community and home-based services are available to help with ADL and IADL needs as people age.

ADL and IADL function can be predictive of overall health status and future health variables. Using data from the Medicare Current Beneficiary Survey from 1992 to 1998, Lubitz et al. (2003) examined nearly 17,000 people aged 70 at the time of enrollment and studied longitudinal outcomes stratified by functional status. Those who were independent in all ADL and IADL variables had an estimated remaining life expectancy of 14.3 years and annual health care costs of $4600 (in 1998 dollars). Loss of independence in one IADL reduced expected remaining life expectancy to 12.4 years and increased annual health care expenditures to $8500. Needing assistance with at least one of the basic ADLs led to a reduction of remaining life expectancy to 11.6 years and increased annual health care expenditures to $14,000. These data clearly demonstrate that loss of functional independence is linked to reduced life expectancy and increased health care costs. Understanding baseline ADL and IADL function also helps clinicians to monitor changes in status over time and with treatments.

Mobility

Limitations in mobility can have a substantial impact on overall functional status for older adults. **Mobility impairment is frequently associated with urologic issues,** including the development of what is termed “functional” incontinence. In these cases, urinary incontinence is due to factors other than the bladder such as impaired mobility or cognition. Improvement in the underlying factors such as return of independent mobility could help to improve or resolve the urinary incontinence.

One of the most commonly used and well-validated clinical assessments for mobility is the **Timed Up and Go (TUG) test** (Podsiadlo and Richardson, 1991). To perform this test, the patients are seated in a stationary, hard-backed chair with arms. They are asked to stand, walk 3 m, turn, return to the chair, and sit down. If they normally use assistive devices such as a walker or cane for ambulation, they are allowed to use these. Most older adults without mobility limitations can complete this task in 10 seconds or less. More frail older adults who still maintain good mobility independence can complete this in 20 seconds or less. Inability to complete the test, or needing more than 20 seconds indicates a higher level of dependence for mobility. Although it seems simple, the TUG test measures a number of complex components associated with independent mobility. These include the ability to follow directions, quadriceps strength in standing from the seated position, gait, balance, and coordination. Diminished quadriceps strength is recognized as an early sign of decreased overall muscle function.

One of the newer conceptual models that expands on the complexity of the concept of mobility is the **Life Space Assessment** (Baker et al., 2003). This examines the degree to which a person is able to independently interact with his or her world. Measurements range from the extremes of being confined to one's bedroom to being fully able to travel and go out independently into the greater community and world at large. This can have important implications for urologic function. For example, people who are limited to their bedrooms may require complete assistance for toileting. An understanding of baseline life space capabilities also helps to better evaluate postoperative function in people undergoing surgery (Stewart et al., 2009).

Slower gait speed in elderly patients has been closely linked to reductions in remaining life expectancy, chronic disability, nursing home placement, and injurious falls (Hardy et al., 2007; Rothman et al., 2008). **It has been shown to be one of the strongest predictors of mortality and other negative health outcomes among older adults** (Seino et al., 2013). It is likely that this represents a marker condition that includes changes in other functional status components, including muscle strength and sarcopenia, nutritional status, and baseline levels of activity. Fatigue and easy exhaustion with physical activity are also associated with increased risk of mortality in elderly patients (Hardy and Studenski, 2008). These factors, including diminished levels of physical activity, a sense of easy exhaustion, and reduced gait speed, are clinical components of the frailty phenotype (Fried et al., 2001).

Cognition

Cognitive changes in older adults are common and can be acute or chronic. **An appreciation of baseline cognitive status for an individual patient is important, particularly in relation to changes that can be observed longitudinally over time, or directly related to various therapies.** Alterations in cognitive status may be associated with delirium or dementia, and recognition of these factors is important for correct diagnosis and subsequent treatment.

Various methods can be used to assess cognitive status. The most commonly used validated instruments include the **Folstein Mini-Mental State Examination (MMSE) and the Mini-Cog** (Borson et al., 2000; Folstein et al., 1975). Both instruments provide valuable information on the cognitive status of patients. The MMSE provides a brief cognitive assessment in several domains, including orientation, ability to follow directions, visual-spatial capacity, and short-term memory. It can be influenced by educational status, with more highly educated individuals tending to score higher at baseline. The instrument is graded on a scale from 0 to 30 with scores of 24 or less generally considered positive for dementia.

The Mini-Cog assesses ability to follow directions, visual-spatial cognition, and short-term memory and executive function. It is less influenced by educational level than the MMSE. Advantages of the Mini-Cog include ease of administration and shorter time required to complete assessment. It can usually be done within about 3 minutes and includes two components: a three-item short-term repetition with recall and a clock-drawing test. Subjects are asked to repeat and remember three words. These should be unrelated items and should not include abstract ideas, emotions, colors, or terms that modify or describe each other. Examples of words often used in testing are “apple, penny, and table.” These are also somewhat more complex because they each have two syllables. After patients attempt to repeat the words, they are asked to draw the face of a clock including all 12 numbers, and to set the hands to a specified time (usually 11 : 10). They may be provided with a paper that already includes the circle or they may draw the circle and complete the clock (Fig. 128.3). After they have finished drawing the clock, they are asked to repeat the three previously presented and repeated words. This concludes the test. Zero to three points are assigned for the short-term recall, one for each correctly repeated word. Either zero or two points are assigned for the clock drawing, depending on whether all components were correctly completed. A total score of 0 to 2 is positive for possible dementia, and a score or 3 to 5 is considered negative. The Mini-Cog has been validated in a variety of settings, does not require specialized equipment, is relatively quick and easy to administer, and is less influenced by language and educational status compared with other available tests.

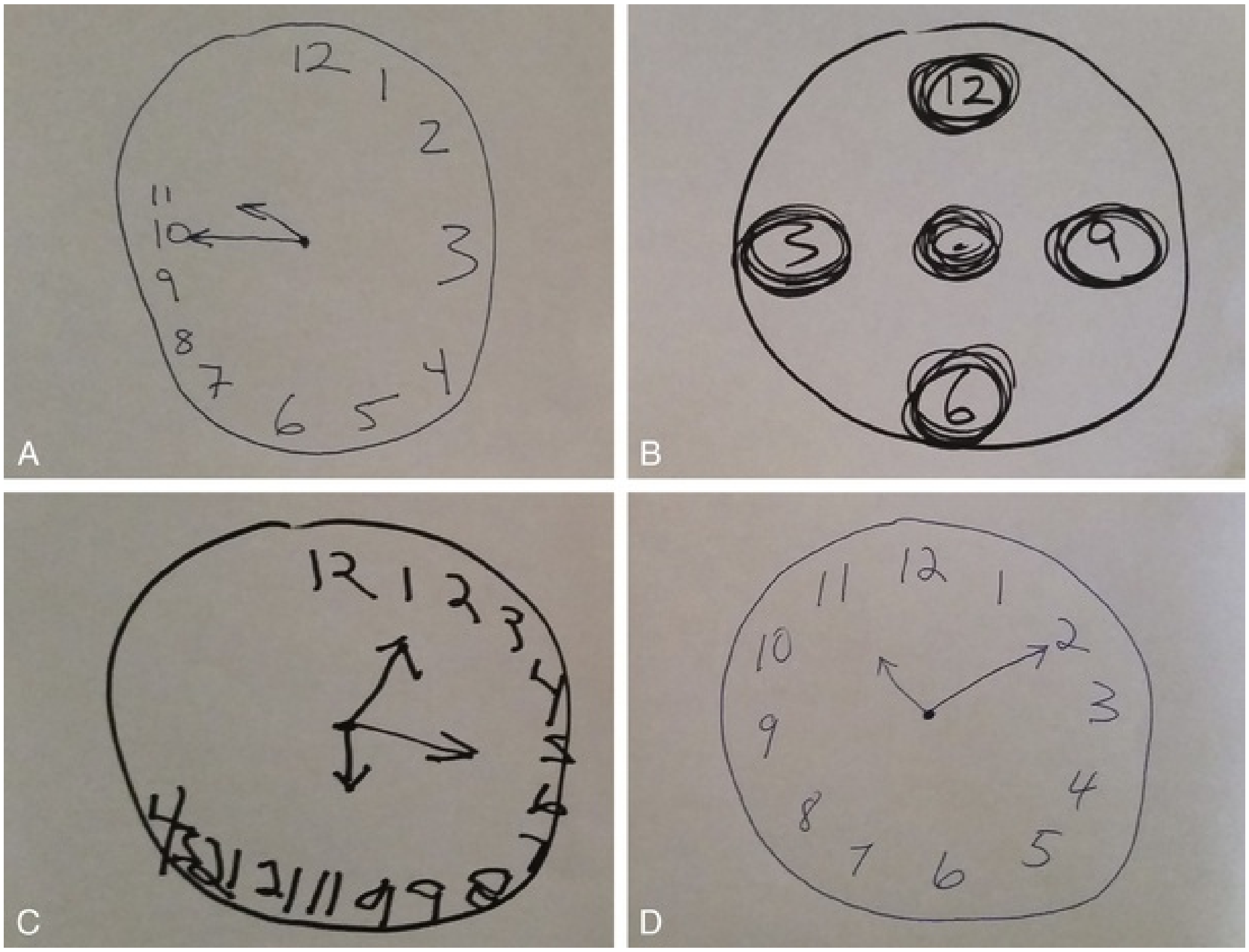

FIG. 128.3 Mini-Cog clock drawing test results (abnormal and normal). Examples of the clock drawing test from the Mini-Cog assessment. (A) Abnormal: Note the incorrect spatial orientation of the numbers and placement of the hands. (B) Abnormal: Only four numbers are included and no hands are drawn to show time. Note the perseveration on drawing the circles around the numbers. (C) Abnormal: Note the incorrect spatial orientation of the numbers, repetition of part of the numerical sequence, and incorrect number and placement of hands. (D) Normal: Note the correct spatial orientation of the numbers and placement of the hands to indicate time per the instructions.

Understanding preoperative cognitive function is important for several reasons. It can help gauge the capacity for patients to provide informed consent for treatment and as a comparison for later observed cognitive status. **Advanced directives and informed decision making regarding health care are an important part of geriatric practice.** Reduced baseline cognitive function has been associated with worse postoperative outcomes in elderly surgical patients. Examples include a higher incidence of delirium (78% vs. 37%; $P < 0.001$), longer hospital stays (15 ± 14 vs. 9 ± 9 days; $P = 0.008$), higher rate of discharge institutionalization (42% vs. 18%; $P = 0.001$), and higher 6-month mortality

(13% vs. 5%; *P* = 0.040) (Robinson et al., 2012).

Potentially reversible causes of memory loss in patients should be considered and addressed if appropriate. Conditions commonly seen in urologic practice include vitamin B_{12} deficiency, hypothyroidism, and medication side effects. Patients with a history of urinary diversion using small intestine can be at particular risk for vitamin B_{12} deficiency, and replacement therapy may be necessary. Although not necessarily reversible, tertiary neurosyphilis can be associated with memory loss and neurogenic bladder and voiding dysfunction.

Depression

Depression is a very common condition among older adults. Like other conditions, the incidence and prevalence increase with advancing age, but depression should not be considered a normal or expected part of the aging process. A number of **urologic health conditions have been associated with increased rates of depression, including urinary incontinence and various genitourinary malignancies.** The **Geriatric Depression Scale (GDS)** is a short, validated screening tool to assess for possible depression in older adults (Sheikh and Yesavage, 1986). The instrument consists of 15 items with yes/no responses. A score of 0 to 2 points is considered normal. If someone scores 3 or more points, the screening test is considered positive for possible depression. This could alert the provider to the potential need for additional evaluation. Input from the patient's primary care provider or consultation with either a geriatrician or geriatric psychiatrist may be indicated.

Examples of urologic conditions that occur at higher rates in geriatric patients and tend to be associated with risk for depression include urinary incontinence, POP, prostate cancer, and sexual dysfunction (Kafri et al., 2013; Kahn et al., 2013; McCabe and Althof, 2014; Ravi et al., 2014). Urinary incontinence has been shown to be undertreated in the general older adult population and has substantial negative effects on multiple health domains (Chang et al., 2008). Additional research is needed to identify the role of treatment of urologic conditions on mental health outcomes.

Surgical Risk and Medical Optimization

Surgical therapy remains one of the mainstays of urologic treatment for many of the clinical conditions that affect geriatric patients. Unfortunately, many clinicians and patients seem to have an inherent bias against surgical therapy for older adults. However, **with careful planning, surgical therapy may be an appropriate option for treatment of many urologic conditions seen in older adults.** The development of minimally invasive surgical techniques has opened up a new avenue for potential therapy for many patients. Age by itself should not be a limiting factor, and in most cases clinical comorbidity is a much more influential issue. However, even in these cases, careful preoperative planning and medical optimization can potentially reduce risk of complications after urologic surgery (Takao et al., 2008).

One of the primary tasks of the urologic surgeon planning operative care for a geriatric patient is to identify potential risks and benefits associated with surgery. **Preoperative optimization should be carefully considered.** Although it is technically not possible to "clear" someone for surgery, there are a wide variety of steps that can be taken to optimize health status in different realms before surgery. The American College of Surgeons and the American Geriatrics Society (AGS) recently collaborated on a project to help outline evaluations that should be used before surgery in older adults and in the perioperative period (Chow et al., 2012; Mohanty et al., 2016). These recommendations are grounded on evidence-based data regarding evaluation of each organ system and various functional components. The goals of these evidence-based recommendations are to help identify risks and improve status before surgical intervention. This includes several targeted components in addition to basic functional assessment with ADLs, IADLs, cognitive status, and mobility that have been previously described (Box 128.1; Chow et al., 2012). Data obtained from the National Surgical Quality Improvement Program were used to construct recommendations highlighted in this document. A more recent publication has focused on perioperative optimization (Mohanty et al., 2016). Specific activities that can promote improved outcomes are highlighted in Box 128.2. Ongoing research has enhanced and optimized these types of data sets to maximize information that can be used in developing optimal models of surgical care for older adults (Berian et al., 2017).

Box 128.1

Preoperative Assessment Recommendations for Older Adults

- Assess cognitive ability and capacity
- Screen for depression
- Identify risk factors for delirium
- Screen for alcohol and other substance use
- Cardiac evaluation (American College of Cardiology/American Heart Association)
- Pulmonary risk assessment
- Document functional status and risk of falls
- Determine baseline frailty score
- Assess baseline nutritional status (consider preoperative replacement/supplementation)
- Detailed medication history and monitor for polypharmacy
- Determine patient's treatment goals and expectations
- Determine familial and social support systems
- Order appropriate diagnostics tests/labs as clinically indicated

Modified from Chow WB, Rosenthal RA, Merkow RP, et al.: Optimal preoperative assessment of the geriatric surgical patient: a best practices guideline from the American College of Surgeons National Surgical Quality Improvement Program and the American Geriatrics Society. *J Am Coll Surg* 215:453–466, 2012.

Box 128.2

Optimal Perioperative Management of the Geriatric Patient

Immediate Preoperative Management

Discuss goals of care and treatment preferences with patients and family
Ensure geriatric patients have advance directives in place
Consider early palliative care consultation for those with poor prognosis (especially if <6 months estimated remaining life expectancy)
Carefully consider the times for preoperative fasting based on type of surgery and types of food or fluids

Ensure careful medication review

Intraoperative Management

Collaborate closely with anesthesia colleagues to optimize choice of anesthetic type

Judicious management of intraoperative status (e.g., fluids, temperature, positioning)

Peri- and Postoperative Management

Analgesics should be administered based on patient-specific needs and indications

Preventive treatment and management of nausea and vomiting to help avoid aspiration risk

Screen and monitor for delirium or other cognitive changes

Implement strategies to prevent postoperative pulmonary complications

Assess for fall risk and implement fall prevention strategies

Evaluate fluid and nutritional status, particularly in those with perioperative dietary restrictions, and provide replacement as clinically indicated

Employ methods to reduce risk of urinary tract infection (e.g., remove catheters as soon as possible)

Implement measures to prevent functional decline such as early mobilization and referral to physical therapy

Assess for pressure ulcer risk and implement multicomponent interventions for prevention and treatment

Engage the patient, family and caregivers, and social services and nursing staff in planning for transitions of care

Modified from Mohanty S, Rosenthal RA, Russell MM, et al.: Optimal perioperative management of the geriatric patient: a best practices guideline from the American College of Surgeons NSQIP and the American Geriatrics Society. *J Am Coll Surg* 222:930–947, 2016.

Chronologic age is usually not identified as an independent risk factor in most research examining morbidity and mortality outcomes from surgery.

However, extensive surgical time and poor baseline ASA classification status have been linked to worse outcomes in elderly urologic surgical patients (Peled et al., 2009). In addition, compared with elective cases, urgent and emergent surgical procedures have been shown to be associated with greater overall morbidity and mortality among geriatric patient undergoing urologic surgery (Peled et al., 2009).

Nutritional assessment is important for overall health and wound healing. One problem is that no single measure has proven adequate for complete preoperative assessment (Griebling, 2004). Different questionnaires and various biomarkers have been used. Albumin and prealbumin measure protein nutrition and are the most commonly used serum markers. Data on preoperative nutrition supplementation in geriatric patients have been variable (Evans et al., 2014). One question is if improved nutrition can help contribute to pressure ulcer prevention (Hill-Brown, 2011). Although nutrition is a contributor to this condition, other factors such as tissue pressure and shear forces may play a stronger role. Good nutrition does appear to influence wound healing (Jaul, 2010; Rosenthal, 2004). Postoperative wound infections are a common and often preventable complication of surgery in older adults. They tend to increase length of hospital stay and associated costs. **Elderly surgical patients who experience a surgical site infection have been found to have a 3.5 times greater risk of mortality compared with those who do not develop this type of infection** (Kaye et al., 2009). The Centers for Medicare and Medicaid Services (CMS) have included surgical site infections as one of the “never events” for which hospitals will not be reimbursed. Diminished functional status has been shown to be associated with an increased risk of surgical wound infections (Chen et al., 2010). This is likely due to a reduction in overall functional reserve capacity, which is associated with changes in immunity and other organ system response.

Postoperative urinary retention is another very common problem that occurs frequently in geriatric patients. A wide variety of factors can increase the risk for postoperative urinary retention, including medication effects, opioid narcotics, decreased mobility, delirium, cognitive impairment, and a history of pre-existing lower urinary tract anatomic and functional issues. Correction of the underlying cause often leads to resolution of the problem, and time is an important factor in many cases (Darrah et al., 2009; Johansson and Christensson, 2010).

Anesthesia

Anesthetic considerations are important in planning for surgical interventions in geriatric urologic patients. Patients often ask is if regional anesthesia would be a safer alternative compared with general anesthesia. Most studies have not shown significant differences in either morbidity or mortality among older adults undergoing surgery using regional blocks versus general anesthesia (Mason et al., 2010; Tognoni et al., 2011).

Other important anesthetic considerations include thermoregulation during surgery, fluid balance, and patient positioning. **Hypothermia during noncardiac surgery increases risk for cardiovascular and thromboembolic events,** including myocardial infarction, deep vein thrombosis, and stroke. Intraoperative hypothermia has also been associated with risk of postoperative wound infection (Leeds et al., 2014). Maintenance of appropriate intraoperative patient temperatures has been identified as an essential goal and is one of the variables that is tracked for quality of hospital care in the United States. Proper fluid balance is also important, and care must be taken to avoid fluid overadministration, which can induce pulmonary edema or congestive heart failure in older adults. Patient positioning requires careful attention to padding pressure points to prevent neuropathy and adjusting to limitations in joint flexibility in patients with arthritis (Akhavan et al., 2010; Rozet and Valilala, 2007). Positioning patients awake before induction of anesthesia can be useful in these circumstances to prevent injury.

Cognitive changes are frequently seen immediately after anesthesia in geriatric patients. Reported rates can be as high as 56%, with 25% still having some change compared with baseline at 3 months after general anesthesia (Price et al., 2008). Although this usually resolves, in some cases cognitive changes can be more prolonged. Among older adults undergoing noncardiac surgery, advancing age, history of stroke, and lower baseline educational levels have been associated with postoperative cognitive decline (Monk et al., 2008).

Prehabilitation

Recent research has examined the potential utility of preoperative conditioning and strength-building exercise in older adults. Termed *prehabilitation,* these efforts focus on improving overall conditioning, stamina, and endurance for activity. This may help to improve or at least slow the decline in functional reserve capacity. Nutritional interventions generally focus on improving protein reserves before surgical intervention. **General assessments or "eyeballing" the patient to determine level of frailty may not be adequate, and more precise measures are useful for preoperative evaluation of risk** (Hubbard and Story, 2014). Preoperative interventions have shown mixed results, and additional research will be necessary to identify optimal targets for intervention and appropriate candidates for these types of treatments.

Comprehensive Geriatric Assessment

Comprehensive geriatric assessment (CGA) is a structured method of complete health care analysis for older adults. This type of evaluation is usually conducted by a geriatrician specialized in the primary care of older adults in conjunction with other multidisciplinary health care providers, including nurses, pharmacists, social workers, physical and occupational therapists, and others. Some primary care practitioners may offer CGA as part of their clinical care for geriatric patients. **Consultation and partnering with a geriatrician** in care of older adults with complex medical problems can help facilitate what can sometimes be a complex process. Similarly, **working with anesthesiology colleagues** for preoperative assessment can help to clarify clinical needs and choices of anesthetic technique in an attempt to optimize care.

There is great interest in the role of expanded assessment of geriatric patients undergoing major surgery and influence on subsequent outcomes. One study of 62 elderly women undergoing pelvic floor reconstructive surgery showed no statistically significant difference in multiple outcomes between those randomized to an enhanced CGA and those who underwent routine preoperative evaluation (Richter et al., 2005). However, the researchers noted that this may have been due to the overall high functional and health status of women in this study. Studies with more frail and functionally impaired older adults may yield different results. Information gleaned from CGA has been shown to be predictive of morbidity and mortality risk after surgery (Kim et al., 2013). Geriatric patients undergoing radical cystectomy have been found to have increased complications and length of hospital stay related to underlying comorbidity and functional limitations that can be identified on careful preoperative assessment (Prentis et al., 2013). Additional research on this topic will help to elucidate the most important factors that should be included in these types of evaluations to help optimize outcomes in geriatric surgical patients.

Major Geriatric Syndromes and Urology

“Geriatric syndromes” are defined as conditions that are complex in nature, tend to occur more commonly among older adults, are typically multifactorial, and can have substantial clinical or other outcomes for affected patients. Successful prevention or treatment often requires a multicomponent approach. Examples of geriatric syndromes include frailty, falls, pressure ulcers, polypharmacy, delirium, and urinary incontinence. Different syndromes can interact and influence each other. For example, frailty is linked to falls, and both conditions are closely associated with urinary incontinence. Each of these syndromes can have direct and indirect effects on urologic health in older adults (McRae et al., 2014). Data from the Health and Retirement Study on more than 11,000 older adults living in the community and nursing homes demonstrated that 49.9% had at least one geriatric syndrome, and presence of multiple geriatric syndromes was common (Cigolle et al., 2007). Prevalence rates for geriatric syndromes are particularly high in homeless older adults who may be vulnerable overall (Brown et al., 2017). Geriatric syndromes strongly increased risk of dependency on others for completion of ADLs even after controlling for demographic factors and chronic diseases. One geriatric syndrome led to an adjusted risk ratio of 2.1 (95% confidence interval [CI], 1.9–2.4), for two syndromes this increased to 3.6 (95% CI 3.1–4.1), and for three or more syndromes 5.6 (95% CI 56–7.6). In a cross-sectional analysis of 12,480 older adults, prevalence of geriatric syndromes among those with cancer was 60.3% compared with 53.2% in those without a history of cancer ($P < 0.001$) (Mohile et al., 2011). This highlights the complexity of these conditions and overlap with other health issues associated with aging.

Frailty

Frailty is a complex condition frequently seen in elderly patients that is becoming better understood with ongoing research. It is not age dependent and can also occur in younger people, although incidence and prevalence increase with advancing age. **It overlaps but is not completely identical to the concepts of comorbidity or disability** (Fig. 128.4). Comorbidity refers to presence of other health states or conditions. Examples include diabetes or hypertension. Disability refers to need for assistance from others to accomplish various tasks. An example would be the need to have someone help with bathing, dressing, or using the toilet. Potential relationships between preoperative frailty and postoperative outcomes have recently garnered increased research attention (Revenig et al., 2013).

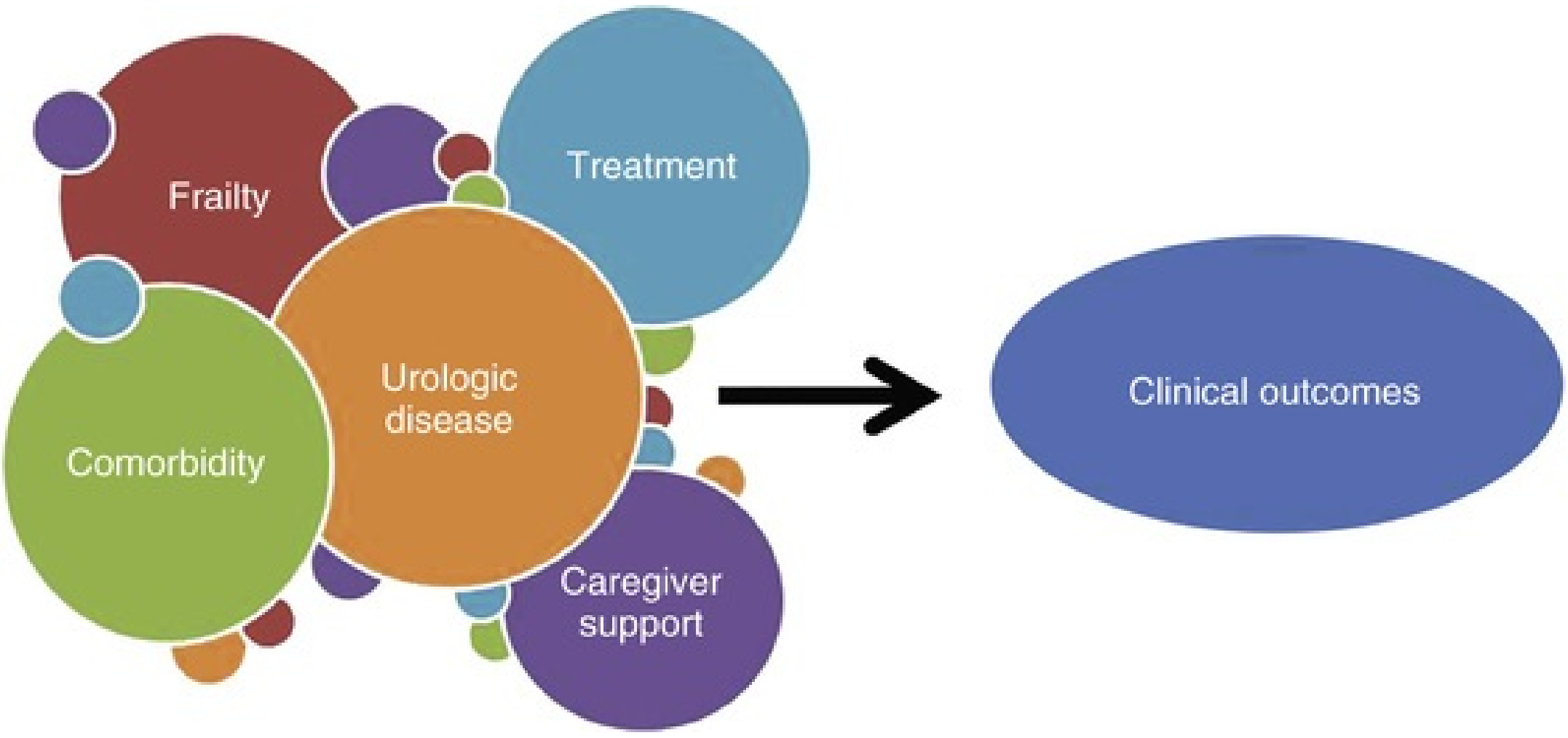

FIG. 128.4 Conceptual model of health complexity and clinical outcomes in geriatrics. This schematic highlights the interrelated nature of urologic disease, comorbidity, frailty, treatment, caregiver support, and other variables. Note that these are related and influence each other but are distinct entities that do not completely overlap. Numerous other factors can contribute and interact with these variables to influence overall clinical outcomes.

Several different definitions and conceptual models of frailty exist, and these differ somewhat based on theoretical components they include. One causation theory is an accumulated deficits model. In this conceptual framework, multisystem deterioration is combined with reduced functional reserve capacity. Accumulated deficits can be counted numerically, and increased summative scores indicate a higher degree of frailty. In this model, frailty tends to progress with cyclic deterioration over time and with more added deficits. The Deficit Accumulation Index (DAI) has been used in an attempt to identify preoperative levels of frailty and predict subsequent outcomes (Braden and Bergstrom, 1994; Cohen et al., 2012). However, DAI has not been found to be statistically predictive of outcomes in this study. This indicates a simple numeric scoring of deficits may not be adequate, and interactions between components are more complex.

Although different operational definitions of frailty have been proposed, one of the more commonly used is the conceptual model developed by Fried et al. (2001), which includes measurable changes for five different components. **This frailty phenotype includes unintentional weight loss of more than 10 pounds or more than 5% of total body weight in 1 year, reduced grip strength, slowing of gait speed and mobility, decreased overall levels of activity, and a sense of easy exhaustion with activity.** Individuals with three or more components are considered “frail,” those with one or two components are classified as “pre-frail,” and those with none of the components are “non-frail.”

The predictive value of frailty assessment in older urologic patients, particularly those being considered for surgery, has been the subject of recent research. Frailty evaluation can be accomplished relatively easily in outpatient clinical settings, and results can be predictive of morbidity and mortality outcomes in elderly surgical patients (Kim et al., 2014; Makary et al., 2010; Ravaglia et al., 2008). Data derived from electronic medical records can be used, although this may not provide complete information in all cases (Amrock et al., 2014). Inclusion of cognitive changes in addition to physical assessment has been shown to improve predictive value for clinical outcomes among hospitalized older adults (Wou et al., 2013). Frailty has been associated with substantial increased risk of developing new-onset incontinence among hospitalized patients (Chong et al., 2018)

Translational research studies have attempted to identify a relationship between various inflammatory biomarkers and the frailty phenotype. Increased levels of IL-6, d-dimer, C-reactive protein, white blood cell count, and others have been described in correlation with increased frailty (Chang et al., 2012; Fontana et al., 2013). There is some debate over whether low levels of inflammatory response may actually be beneficial, particularly for wound healing, but that higher levels may be destructive because of oxidative stress.

Delirium

Delirium is an extremely important geriatric syndrome to consider in older urologic patients. **Delirium is defined as an acute confusional state characterized by fluctuations in mental status and inattention. In addition, patients must exhibit either disorganized thinking or an altered level of consciousness.** This most commonly manifests in the form of agitation; however, a hypoactive form can also occur. Patients may experience hallucinations or delusions. These symptoms can be disturbing to patients, loved ones, and clinical care providers. Agitated patients tend to act out physically or emotionally, and the behavior can usually be easily recognized. The hypoactive form of delirium can be much more subtle and difficult to diagnose. However, data suggest that hypoactive delirium actually may be more dangerous in terms of negative sequelae, including risk for mortality (DeCrane et al., 2011).

Delirium is highly prevalent and is associated with substantial negative outcomes. However, the condition is often underrecognized in this population

(Vollmer et al., 2010). **Rates of developing postoperative delirium range from 10% to 15% after noncardiac surgery and increase in cases of either urgent or emergency surgical procedures** (Demeure et al., 2006). **Patients who develop delirium postoperatively have a two- to threefold increase in the risk of mortality within the first year after surgery** (Ely et al., 2004; McCusker et al., 2002). There is also an increased risk of progressive cognitive decline and potential need for placement in nursing home care at the time of hospital discharge in patients who develop an episode of delirium (Popejoy et al., 2013; Rudolph et al., 2008).

There are multiple risk factors for development of delirium in geriatric patients, including around the time of surgery (Tai et al., 2015). Examples include electrolyte abnormalities, pain, sensory impairment, immobility, dehydration, sleep deprivation, pneumonia or other infections, and alcohol withdrawal. Having had a prior episode of delirium is also a strong risk factor for future delirium. Patients with underlying dementia are also at higher risk. Acute UTIs in older adults may be a cause for delirium, and urinary samples including cultures should be checked as part of the evaluation if this is suspected (Eriksson et al., 2010). In a study of urologic surgical patients, poorer baseline functional status and older age were identified as risk factors for delirium, but type of anesthesia (regional vs. general) and mode of surgery (open vs. endoscopic) were not (Tognoni et al., 2011). Some medications, including statins, have been identified as another potential risk factor in surgical patients (Redelmeier et al., 2008).

Inoyue and colleauges developed and validated the Confusional Assessment Method (CAM) as a way to identify and diagnose delirium (Inouye et al., 1990). These diagnostic criteria require that patients exhibit an acute change in mental status with a fluctuating course and inattention. In addition, they must also exhibit either disorganized thinking or an altered level of consciousness. The CAM has been used in numerous clinical settings and has been shown to be easy to use and interpret. Using these criteria, delirium can be diagnosed with a 94% to 100% sensitivity and a 90% to 95% specificity (Inouye, 2006).

Several studies have examined the effects of delirium on clinical outcomes in older adults including those developing the condition after surgery. In one study of 49 geriatric patients undergoing radical cystectomy, the incidence of postoperative delirium was 29%, and readmission and reoperation rates were higher in those who developed delirium compared with those who did not (Large et al., 2013).

Prevention of delirium is key, and clinicians should have a high index of suspicion for diagnosis in patients who exhibit signs or symptoms of the condition. Some medications are known to substantially increase the risk of delirium in older adults, including sedative hypnotics, anticholinergics, and opioid narcotics. Care must be taken to control pain but also avoid inducing delirium caused by medications. Pain is a risk factor for development of delirium, and this must be carefully assessed and managed. In patients with underlying cognitive impairment such as dementia, pain can be difficult to assess accurately (Horgas et al., 2009). Patient-controlled analgesia (PCA) offers the potential benefit of avoiding overdosing of medication, provided only the patient is pushing the dosing button on the device. However, proper use of a PCA requires a cognitively intact patient who understands the therapy and is able to self-administer medication when needed to control pain.

Treatment for delirium includes methods to reduce disruption and improve sensory interaction with the patient and his or her surroundings. This includes maintaining proper sleep-wake cycles, minimizing distractions including alarms and other loud noises, having family or other loved ones at the bedside to help reorient the patient, making sure a patient's hearing aids and glasses are provided, and assisting with mobility. Underlying fluid and electrolyte imbalances should be corrected. In patients who present a physical danger to themselves or care workers, temporary physical or chemical restraint may be necessary. **The preferred medication treatment is haloperidol administered intravenously in small doses, usually starting at 0.25 or 0.5 mg.** Doses may be repeated at approximately 15-minute intervals until the patient is calm. A total dose of 1 to 2 mg or more may be required, but it is safer to administer this in progressive small quantities and monitor for response rather than giving a large bolus dose, which could be too sedating. Other benzodiazepines or sedative hypnotics should generally be avoided because of potential adverse effects, including worsening of delirium, severe sedation, or an increase in associated delusions or hallucinations. Physical restraints should be used only with extreme caution and for short time periods and are indicated only if patients are in imminent danger of harming themselves or others.

Costs associated with postoperative delirium in geriatric surgical patients are high. Development of delirium, even subsyndromal delirium, is associated with increased rates of hospital readmission, reoperation, caregiver requirements, and need for institutionalization (Cole et al., 2008; Large et al., 2013). Economic analysis has shown an approximately 2.5-fold increase in costs for elderly patients who experience an episode of delirium while in the hospital compared with those who do not develop delirium (Leslie et al., 2008).

Falls

Older adults are at an increased risk for falls and associated injuries, including long bone and hip fractures. **Urinary incontinence and use of indwelling urinary catheters have been identified as risk factors for potentially injurious falls** (Brown et al., 2000; Chiarelli et al., 2009; Foley et al., 2012). In addition, there have been data suggesting a potential association between anticholinergic use and falls in elderly women (Marcum et al., 2016). LUTS including overactive bladder have been shown to increase fall risk in community-dwelling older adults and those requiring home care services (Hunter et al., 2013; Kurita et al., 2013). In long-term care facilities, urinary incontinence and behavioral changes associated with cognitive decline and dementia have been identified as independent risk factors for falls in older adults (Hasegawa et al., 2010). Nocturia can also play a role (Galizia et al., 2012). Contributing clinical and environmental factors include orthostatic or postural hypotension, vertigo, gait and balance problems, poor lighting, physical obstacles, or long distance between the bed and toilet. Urinary urgency is a common risk factor for falls because of nocturia or urgency UI. When older adults attempt to rush to the toilet, fall risk increases. Slipping on wet floors caused by urine leakage can also occur. Additional identified risk factors for falls include visual and other sensory impairments, alterations in cognitive status, and delirium.

Urinary catheters have been shown to increase risk of falls in older adults. Similarly, other **physical restraints** have been associated not only with increased falls but also with other potentially dangerous injuries including strangulation and accidental death. **Physical restraints should be avoided if at all possible,** and efforts targeted at reducing their use have been beneficial in nursing home and other care settings. Other interventions designed to improve overall care in long-term care facilities have also been shown to improve outcomes and decrease risk of falls associated with urinary incontinence in this setting (Min et al., 2011).

Elderly men on androgen deprivation therapy are at particularly increased risk for fractures and other injuries associated with falls (Bylow et al., 2008). Hormonal manipulation with androgen deprivation is associated with decreases in bone mineral density and an increased risk of development of osteopenia and osteoporosis. This causes bones to be more brittle and increases risk of fracture during falls. Elderly men with associated LUTS resulting from BPH or other conditions have been shown to have higher rates of falls and fractures compared with men without these urologic conditions (Parsons et al., 2009).

Pressure Ulcers

Pressure ulcers are areas of localized tissue necrosis that typically occur over bony prominences because of prolonged pressure against a hard surface. Tissue shearing can also occur with movement and transfers. Changes in skin anatomy and integrity occur as a part of the general aging process with a decrease in the amount of elastic tissue and alterations in collagen and other connective tissue quality. In addition, older adults often have decreased sensation in cutaneous tissues and may be prone to increased rates of underlying skin infections. These factors increase the risk of pressure ulcer formation in older adults. **Urinary incontinence is another common factor that increases pressure ulcer risk in older adults.** Maceration of tissues resulting from chronic moisture can lead to progressive tissue loss, particularly when combined with physical pressure or shearing forces.

Positioning and transfers during surgery in older adults are especially important. Care must be taken to adequately pad all pressure points during surgery, and efforts made to eliminate shearing effects during transfers between beds and transport carts. Many older adults suffer from arthritis, and this can make positioning for surgery challenging, particularly in the dorsal lithotomy position. In these cases, positioning the patient while awake before induction of anesthesia can be useful to help confirm a comfortable position and prevent injury.

Early mobilization and physical activity after surgery are important for many reasons, including reducing the risk of pneumonia, deep vein thrombosis, pulmonary embolus, and pressure ulcers. Even among healthy younger people, extended bed rest is associated with substantial loss of mobility, aerobic capacity, and lower extremity strength (Coker et al., 2015; Kortebein et al., 2008). These negative effects are compounded in older adults, who may start at diminished baseline functional levels. Frequent turning of patients who are in bed or using a wheelchair is another important prevention method. Use of specialized air mattresses or other pressure reduction methods also helps reduce risk.

Pressure ulcers are staged based on clinical characteristics. Stage I ulcers include nonblanching erythema of intact skin. Stage II ulcers include partial thickness skin loss but do not involve muscle or other deeper tissues. These can appear as an abrasion, blister, or shallow crater. Stage III ulcers involve full-thickness skin loss, which may extend to but not through the underlying fascia. Stage IV ulcers are characterized by extension into deeper tissues, including muscle or bone with possible exposure of supporting structures such as tendons.

It is important to carefully document skin integrity in older adults being admitted to hospital care. The CMS have designated new pressure ulcer formation as one of the “never events,” which is considered preventable in essentially all cases. As such, they will not reimburse facilities or providers for care for new pressure ulcers.

The prevalence of pressure ulcers among hospitalized elderly patients has been reported to be as high as 8.9% (Barrois et al., 2008). **Urinary, fecal, and dual incontinence have been identified among the strongest risk factors for the development of pressure ulcers in the elderly population.** Clinicians should have a high index of suspicion for the risk of pressure ulcers, and careful examination should be performed as part of the routine physical examination in older adults with bladder and bowel incontinence. Among hospitalized older adults, increased length of time waiting in the emergency room, immobilizing procedures or medications, and intensive care unit stays have been identified to increase the risk of developing pressure ulcers (Baumgarten et al., 2008).

Polypharmacy and Medication Optimization

Polypharmacy is a highly prevalent and complex geriatric syndrome that has been defined in a number of different ways. The simplest definition is the use of multiple medications. More recent definitions include the concepts of increased regimen complexity and use of potentially inappropriate medications. More complex medical regimens may be difficult for older adults to follow correctly and can lead to poorer compliance with prescribed therapy. Risk of drug interactions increases exponentially with increased numbers of medications. Use of inappropriate medications can lead to untoward side effects and other negative outcomes (O'Connor et al., 2012). Rates of potentially inappropriate medication prescription among older adults are high, with approximately 25% of more than 272,000 in one study being on these types of drugs in the perioperative period (Finlayson et al., 2011). The ultimate goal is to optimize pharmacotherapy and minimize risk in older adults using medications. **The practice of medication reconciliation during hospitalization and clinical evaluation has become a**

common practice and is an important step in helping to reduce or eliminate polypharmacy in geriatric patients. During this process, all medications including prescription and non-prescription medications are assessed. Clinical indications for each medicine are verified, and response determined. Ideally, medications without a clear clinical indication should be discontinued. Potentially inappropriate medications should also be identified, and safer agents substituted if possible. In addition, medication underuse can occur with elderly patients, and it is important to recognize when medications may be clinically indicated based on guidelines or other evidence-based practice.

In 1993 the late Dr. Mark Beers convened a consensus panel to develop a list of potentially inappropriate medications for use in older adults in nursing home settings. This original list has been updated and expanded to include all older adults and is no longer limited by location or type of clinical care. **The AGS has recently published a revised version of the Beers criteria** (American Geriatrics Society Beers Criteria Update Expert Panel, 2015). This is a highly evidence-based document that categorizes medications into different groups based on characteristics and considerations for use in older adults. The most recent version includes information regarding level of evidence used to make recommendations, and overall strength of the recommendation from the expert panel. This document is being maintained and updated on a regular basis as new data emerge. It is important that urologists be familiar with the Beers criteria and the concept of potentially inappropriate medications (PIMs). This can help them to make more informed decisions about medication use in older adults, which can help improve the care they provide (Griebling et al., 2016; Steinman et al., 2015). Identification of alternate medications or treatment strategies may be helpful in this regard (Hanlon et al., 2015).

Some medications are considered always inappropriate for elderly patients and should be avoided in all cases. An example of such a medication often used in urologic practice is meperidine (Demerol). This drug was included because of the significant potential risks for delirium and other adverse events caused by accumulation of a toxic metabolite, poor overall efficacy, and availability of other more clinically useful alternatives. Other urologic medications are included in portions of the AGS Beers criteria document. For example, antimuscarinic agents used in treatment of overactive bladder (OAB) and urgency UI are included in a group of medications to avoid with specific comorbid conditions. In this case, these medications should be avoided or used with caution in older adults with a history of chronic constipation or cognitive impairment. Nitrofurantoin is included as a medication to avoid in older adults with impaired renal function (GFR < 30 mL/min) or for chronic prophylaxis resulting from the potential risk of pulmonary fibrosis. It is acceptable for treatment of acute UTIs and other short-term indications in patients with adequate renal function. A summary of medications commonly used in urologic practice included in the 2015 AGS Beers criteria is presented in Table 128.1.

TABLE 128.1

Select Medications Commonly Used in Urology Included in the 2015 Beers Criteria

MEDICATION	RECOMMENDATION	RATIONALE	QUALITY OF EVIDENCE	ST R
Peripheral α_1 blockers • Doxazosin • Prazosin • Terazosin	Avoid use as an antihypertensive (all patients) Avoid use in women with stress UI	Not recommended as routine treatment for hypertension; alternative agents have superior risk/benefit profile; high risk of orthostatic hypotension; may aggravate stress UI in women	Moderate	St
Nitrofurantoin	Avoid for long-term antibacterial suppression Avoid in patients with CrCl < 30 mL/min	Safer alternatives available; potential for pulmonary toxicity hepatotoxicity, and peripheral neuropathy; lack of efficacy in patients with CrCl < 30 mL/min because of inadequate drug concentration in urine	Low	St
Tertiary tricyclic antidepressants, alone or in	Avoid	Highly anticholinergic, sedating, and cause	High	St

combination • Amitriptyline • Imipramine		orthostatic hypotension		
First-generation antihistamines (as single agent or as part of combination products) • Diphenhydramine (oral) • Hydroxyzine • Promethazine	Avoid	Highly anticholinergic clearance reduced with advanced age, and tolerance develops when used as a hypnotic; anticholinergic effects and toxicity. Use of diphenhydramine in special situations such as acute treatment of severe allergic reaction may be appropriate	Moderate	St
Androgens • Methyltestosterone • Testosterone	Avoid unless indicated for confirmed moderate to severe hypogonadism with clinical symptoms	Potential for cardiac problems and contraindicated in men with prostate cancer	Moderate	W
Estrogens with or without progestins	Avoid oral or topical patch; Topical vaginal cream is acceptable use for management of dyspareunia, lower urinary tract infections and other vaginal symptoms	Evidence of carcinogenic potential (breast and endometrium) and aggravation of UI for oral or transdermal; lack of cardioprotective effect and cognition protection in older women Evidence that vaginal estrogens for treatment of	High: oral and patch Moderate: topical	

		vaginal dryness is safe and effective in women with breast cancer, especially at dosages of estradiol < 25 mcg twice weekly		
Anticholinergics Benzodiazepines (short and long acting)	Avoid	Older adults have increased sensitivity to this class of drugs; decreased metabolism of long-acting agents can induce or worsen delirium, falls, fractures	Moderate	St
Meperidine	Avoid as an analgesic, especially in individuals with chronic kidney disease	Not an effective oral analgesic in commonly used doses; may have higher risk of neurotoxicity including dementia than other opioids; safer alternatives available	Moderate	St
Oral antimuscarinics for UI • Darifenacin • Fesoterodine • Oxybutynin (oral) • Solifenacin • Tolterodine • Trospium	Be aware of anticholinergic properties and potential effects	Potential anticholinergic effects may include dry mouth, constipation, confusion, etc.		
Desmopressin	Avoid for treatment of nocturia or nocturnal polyuria	High risk of hyponatremia; safer alternative treatments available	Moderate	St

Note: This is not a complete listing of all medications included in the 2015 Beers criteria.

BPH, Benign prostatic hyperplasia; *CrCl,* creatinine clearance; *LUTS,* lower urinary tract symptoms; *UI,* urinary incontinence.

Modified from American Geriatrics Society (AGS) Beers Criteria Update Expert Panel: American Geriatrics Society updated Beers criteria for potentially inappropriate medication use in older adults. *J Amer Geriatr Soc* 63:2227–2246, 2015. Please see this source for detailed information.

Medications with anticholinergic effects deserve special mention. There are a large number of different medications that can have potential anticholinergic effects in older adults. This is due in part to cross-reactivity between different types of receptors located in different organs including salivary gland, bowel, and bladder. Common anticholinergic effects in older adults include dry mouth, constipation, dry eye, and confusion. Serum studies have shown total anticholinergic burden can be measured, although lists of medications must be used in conjunction with this to improve diagnostic accuracy (Lampela et al., 2013). Increased anticholinergic burden can worsen underlying cognitive function, memory, and associated comorbid conditions such as Alzheimer disease (Fox et al., 2011a, 2011b; Han et al., 2008; Koyama et al., 2014). Increased anticholinergic load has been associated with increased risk of mortality and decline in physical function (Fox et al., 2014). It has also been linked to changes in bladder function (De La Cruz et al., 2015). Attempts should be made to reduce or eliminate use of anticholinergics to the extent possible. Reductions in overall anticholinergic burden have been associated with improvements in behavioral and cognitive outcomes in affected elderly patients (Kersten et al., 2013). In cases in which these medications are used for a clinically indicated purpose, response should be closely monitored to determine if an appropriate effect is achieved, and the medication discontinued or changed if warranted.

A basic principle for prescribing medications in the geriatric patient population is to “start low and go slow.” This refers to the fact that lower medication dosages may be effective in older adults compared with younger patients and that high initial doses can often have adverse effects. Starting with lower doses and gradually increasing medication dosing with time can help to alleviate some of these potential problems. **One caveat that must be considered is that medication dose may have to be increased to reach the point of clinically efficacy.** Therefore care should be taken to avoid keeping doses of medications so low that they are not actually effective for symptoms they are prescribed to treat. Dose escalation should be continued until a clinically effective end point, maximum dosing for a particular medication, or intolerable side effects are reached.

It is also important for clinicians to avoid the "prescribing cascade." In these cases, a patient is prescribed a medication for a clinical problem. Because of side effects from this medication, they develop new symptoms that are attributed to a different cause, leading to prescription of a second medication to treat the side effects. To avoid this problem, clinicians should consider whether a new symptom may be due to a medication side effect rather than another cause. The AGS has included the concept that a medication review should be performed any time a new prescription is given as part of their "Choosing Wisely" list (AGS Choosing Wisely Workgroup, 2014).

Urinary Incontinence

The International Continence Society defines urinary incontinence (UI) as the involuntary loss of urine (Abrams et al., 2002). **From a clinical perspective, UI can be considered a specific diagnosis and a geriatric syndrome.** This is particularly true among frail older adults who may have multiple chronic conditions and geriatric syndromes (DuBeau et al., 2010; Fonda et al., 2005; Wagg et al., 2017). Urologists and gynecologists tend to view UI as a clinical diagnosis in contrast to geriatricians who conceptualize it more as a geriatric syndrome. As previously described, geriatric syndromes are defined as common conditions seen in older adults that are complex in nature, are usually multifactorial, and can have substantial clinical or other negative health outcomes for affected patients.

The incidence and prevalence of UI increase in older adults with more advanced age (Rohrmann et al., 2016)**. However, incontinence should not be considered a normal or inevitable part of the aging process.** Just because someone is elderly or frail does not mean that he or she should experience UI. This is a common myth among health care providers and patients that must be dispelled. **UI is more commonly associated with underlying medical conditions or other factors rather than chronologic age.**

Geriatric Specific Risk Factors for Urinary Incontinence

Several etiologic factors for UI and other forms of voiding dysfunction are unique to older adults and deserve special consideration**. Impairments in functional status, including dependence on others for ADLs, have been**

closely linked to increased prevalence of UI (Huang et al., 2007; Jenkins and Fultz, 2005; Khatutsky et al., 2013). Mobility impairment with diminished walking speed and balance may be important contributors to declines in ADL function and risk of UI (Fritel et al., 2013). Alterations in IADLs appear to have less influence on continence status compared with ADLs (Omli et al., 2013). Older adults are more likely to have multiple comorbidities that increase risk of developing UI. These include diabetes, metabolic syndrome, hypertension, and heart disease (Khatutsky et al., 2013; Smith et al., 2010). Risk factors for UI in elderly men and women can differ as a result of multiple factors, including anatomic differences, prior medical and surgical history, and lifestyle variables (Tikkinen et al., 2013).

Modifiable risk factors including smoking and alcohol use have been identified as risk factors for UI in geriatric cohort studies (Hirayama et al., 2009; Ikeda et al., 2011). Obesity and overweight are also linked to risk of UI in older adults. This may be due to increased intra-abdominal pressure and mobility impairments associated with morbid obesity. High body mass index (BMI) and increased waist circumference have been associated with UI in elderly patients (Byles et al., 2009; Krause et al., 2010).

Cognitive impairment, particularly after stroke or because of underlying dementia, presents a substantial risk for development of UI among older adults (Hatta et al., 2011). Among geriatric patients with dementia living at home, reported prevalence of UI ranges from 1% to 38%, and those with more severe symptoms require more specialized home care services (Drennan et al., 2013). Alzheimer dementia tends to be associated with loss of short-term memory, which can impair the ability of affected older adults to recognize sensations associated with a full bladder and need to void, accurately identify the toilet, and be able to adjust clothing or perform other tasks needed to maintain continence. Vascular dementia has been linked to diminished inhibitory control, which may influence continence status (Haruta et al., 2013).

Congestive heart failure (CHF) can cause UI for several reasons. Affected patients tend to make more atrial natriuretic peptide, which in turn leads to increased urine production. They also tend to have more problems with peripheral edema, which can increase urine output, particularly at night. **Increased CHF severity has been linked to increased UI severity in clinical studies** (Chiu et al., 2012; Palmer et al., 2009). More severe CHF is also associated with increased distress and increased use of absorbent pads and products to deal with the leaking (Meng et al., 2016). Diuretics are frequently used in management of CHF, and these can worsen UI because of increased urine output. Decreased pulmonary status with reductions in functional lung capacity have been associated with worse UI (Hirayama et al., 2009). Common neurologic disorders in older adults such as Parkinson disease can cause detrusor overactivity (DO) and associated urgency UI (Araki et al., 2000; Winge and Nielsen, 2012).

The term "aging in place" has been used to describe what is often considered an ideal paradigm in geriatrics. The goal is to help keep older adults living in their own homes as long as possible with as much independence as is feasible. Changes in ADL status including development of UI can be limiting factors in some cases. Older adults with UI and other ADL impairment may have greater needs for home health services compared with continent and more functionally independent elders (DuMoulin et al., 2009). Those living in residential care facilities have also been shown to have increased UI prevalence and care needs compared with community-dwelling older adults (DeGagne et al., 2013). In settings where public health resources are limited, older adults simply may not have access to these types of services (Burti et al., 2012).

Costs of Incontinence

The direct and indirect financial costs of UI are staggering. Medicare expenditure data showed that costs of care for UI nearly doubled from $128 million in 1992 to $234 million in 1998 (Anger et al., 2006). This represents a 15% per capita increase in treatment costs once adjusted for inflation. Other economic analysis has shown an estimated national cost of evaluation and care for overactive bladder with urgency UI of $65.9 billion in 2007 with projected increases to $76.2 billion in 2015 and $82.6 in 2020 (Coyne et al., 2014). This includes care for patients of all ages, not just older adults. Recent analysis has shown increasing rates of office visits, hospitalization, and other resource use for UI, which also tend to drive up associated costs (Thom et al., 2005). The estimated annualized cost in 2000 for nursing home admissions resulting from UI was $6.0 billion (Morrison and Levy, 2006). In addition, there are substantial environmental costs associated with use of absorbent pads and products going into landfills. Costs associated with care for OAB are particularly high among more vulnerable older adults with complex comorbidities. Recent estimates show an approximately $7000 increase per year in health care costs for these medically vulnerable geriatric patients with OAB (Chuang et al., 2018).

Negative Impacts of Urinary Incontinence

UI can have substantial negative health outcomes in older adults (Dugan et al., 2000). **The condition is associated with social isolation, depression, stigmatization, and embarrassment for many affected patients** (Lim et al., 2018). Many people discontinue activities that they enjoy because of urinary leakage. They may stop going out to the theater or movies, stop attending church or temple, or stop visiting friends because of the condition. Many people with UI feel a sense of embarrassment or shame, which can delay their choice to seek help for the condition (Vethanayagam et al., 2017). This has been shown to be true in multiple different cultures (Hamid et al., 2015). UI can lead to negative consequences, including physical, emotional, and financial costs for caregivers of affected individuals (Santini et al., 2016).

Incontinence can also have important negative physical effects. Chronic incontinence can be associated with skin irritation and breakdown, development or worsening of pressure ulcers, UTIs, and falls and fractures. UI also affects mental health, including increased rates of depression among affected older adults (Laganà et al., 2014). Research has shown that **UI has a stronger negative influence on overall levels of happiness than many other common chronic conditions in older adults, including diabetes, hypertension, arthritis, and osteoporosis among others** (Angner et al., 2009). Only chronic debilitating pain has been shown to be a stronger negative predictor of diminished happiness.

UI can have a substantial negative effects on general and health-related quality of life (HRQoL) in older adults. It limits the ability of people to participate in leisure activities and engage with others in the community (Kwong et al., 2010). Many older adults stop participating in activities they enjoy because of fear or embarrassment about urinary leakage. The associated psychosocial effects can be substantial and include problems with depression and social isolation (Chung RY et al., 2013; Lee YI et al., 2013; Pintarelli et al., 2011; Sahin-Onat et al., 2014; Yip et al., 2013). Depression can be particularly problematic among older adults and can cause issues in other facets of life, including mental health domains, nutrition and eating, sleep quality, and happiness (Angner et al., 2009; Sexton et al., 2011).

UI can cause significant psychological distress for elderly patients, often because of their reduction in other activities (deVries et al., 2012). Many older adults require assistance with toileting and other ADLs. Levels of caregiver burden can also be substantially higher among those with associated UI, particularly if other ADL impairments are present (Gotoh et al., 2009; Miu et al., 2010; Tamanini et al., 2011). The type of UI may influence outcomes related to quality of life, particularly for those with mixed symptoms (Frick et al., 2009). However, other epidemiologic studies in older adults have shown the degree of incontinence as measured by severity appears to be more influential on HRQoL outcomes compared with type of UI (Aguilar-Navarro et al., 2012; Barentsen et al., 2012).

Among those older adults living in nursing homes, UI has been shown to have negative impacts on a number of important quality-of-life parameters, including dignity, autonomy, and mood (Xu and Kane, 2013). Successful treatment of UI has been shown to substantially improve HRQoL outcomes (Fonda et al., 1995).

Established Versus Transient Incontinence

Established Urinary Incontinence.

Established or chronic UI is an extremely common problem seen in geriatric patients. Recent epidemiologic data show that of all people over 65 years of age, 43.8% report a history of any urinary leakage (Gorina et al., 2014). Among community-dwelling elderly women, 12% report severe or very severe UI. More than half of community-dwelling women and about a quarter of men report experiencing UI. Overall, 36.6% of those in residential care facilities, not including nursing homes, experienced UI, and women were 1.2 times as likely to report this than men (95% CI 1.03–1.4). Similarly, of those older adults receiving home care services, 40.2% reported problems with bladder control, and women were 1.7 times more likely to experience this compared with men (95% CI 1.3–2.1) (Gorina et al., 2014).

Transient Versus Established Urinary Incontinence.

Urinary incontinence in older adults is frequently transient. In fact, studies indicate that **up to 30% of UI in community-dwelling older adults and nearly 50% of UI in elderly patients admitted to acute care hospitals may be caused by transient conditions** (Herzog and Fultz, 1990; Resnick et al., 1988). The identification of transient incontinence among elderly patients is important because it highlights the interplay between various organ systems and genitourinary function. For example, if a patient develops worsening peripheral edema because of an exacerbation of CHF, this could increase nocturnal urinary production and associated nocturia or nocturnal enuresis. Similarly, temporary mobility impairment from lower extremity cellulitis in a patient with DO and urinary urgency may lead to development of urgency UI. Although no direct changes occurred in bladder function in either example, changes in fluid volume or mobility status led to urinary leakage. Treatment of underlying causative conditions could result in improvement or complete resolution of UI. Prospective evaluation and treatment for these conditions in elderly patients has been shown to be effective (Resnick, 1989).

A wide variety of conditions can lead to associated transient UI. Patients with sudden or new onset of UI symptoms should be screened for possible associated causative conditions. However, even patients with longstanding urinary incontinence can suffer if these underlying conditions have been present but untreated over time. Multiple causes are frequently involved in geriatric patients.

Transient Urinary Incontinence.

UTI causes an inflammatory reaction in the urothelium, which can lead to increased sensations of bladder filling. This causes urinary frequency and, in some cases, UI. This should be considered symptomatic and evaluated and treated appropriately. In contrast, true asymptomatic bacteriuria does not by itself cause UI and does not require antibiotic therapy. Atrophic vaginitis or urethritis is common in elderly women and may be associated with dysuria or a burning sensation with voiding. Physical examination reveals thinning and loss of rugation of vaginal mucosa, although inflammatory changes with erythema and mucosal hemorrhage may also be seen in a minority of patients. In elderly women who are sexually active, atrophic vaginitis can lead to dyspareunia. Treatment with vaginal estrogens can help ameliorate symptoms of this condition and may help improve continence status in affected individuals. It also helps reduce incidence of symptomatic UTIs in postmenopausal women (Goldstein et al., 2013).

Fecal impaction is frequently seen in older adults. This can be caused by slow transit time through the gut or increased water reuptake in the colon. Fecal incontinence and diarrhea may be presenting symptoms because liquid stool proximal to the impaction moves around the impacted stool bolus. Disimpaction often results in resolution of urinary and fecal symptoms. Chronic constipation is a common problem in older adults. Treatment and prevention with a bowel regimen can help. This typically involves multiple modalities including stool softeners, increase in dietary or supplemental fiber, increased fluid intake, and judicious use of products such as polyethylene glycol (Miralax) (Schnelle et al.,

2010).

Numerous different medications can cause transient incontinence in older adults including psychotropics, diuretics, benzodiazepines, angiotensin-converting enzyme (ACE) inhibitors, calcium channel blockers, tricyclic antidepressants, methylxanthines, alpha-blockers, and narcotic analgesics among others (Kashyap et al., 2013; Landi et al., 2002; Tsakiris et al., 2008). Polypharmacy is a common problem in older adults, which has also been linked to increased risk of UI (Talasz and Lechleitner, 2012). Diuretics are commonly prescribed for treatment of hypertension or peripheral edema but cause an increase in urinary production that can overwhelm the bladder and cause urinary urgency, frequency, and urgency UI (Peron et al., 2012). If taken at night, diuretics can potentially induce nocturia and nocturnal enuresis. The ACE inhibitors, also used to treat hypertension, can induce cough and worsen stress UI, particularly in older women. Combinations of these medications for treatment of hypertension have been shown to have synergistic effects in worsening UI in older adults (Peron et al., 2012). Opioids and narcotic analgesics tend to decrease detrusor contractility and can cause urinary retention with associated incontinence. Cholinesterase inhibitors prescribed to help slow progression of memory loss in Alzheimer dementia can increase detrusor contractility, leading to symptomatic UI (Hashimoto et al., 2000). Tricyclic antidepressants can exert a strong anticholinergic effect and decrease detrusor contractility leading to difficulty voiding or urinary retention. The alpha-adrenergic receptor antagonists cause smooth muscle relaxation and can worsen stress urinary incontinence, particularly in women.

Data from the Women's Health Initiative Study demonstrated that systemic administration of estrogen was actually associated with increased rates of UI (Hendrix et al., 2005). It is one reason that systemic estrogen is usually not encouraged in elderly women. The most recent update of the AGS Beers criteria also includes a recommendation to avoid systemic estrogens in elderly women because of this increased risk of UI (American Geriatrics Society Beers Criteria Update Expert Panel, 2012). Alcohol and other substance abuse should also be considered as potential causes of UI. Anticholinergic medications can worsen UI by exacerbating urinary retention and incomplete bladder emptying. This in turn can lead to more urinary frequency as the bladder reaches capacity quickly even after voiding. In addition, older adults may have decreased salivary secretions, which can be worsened by anticholinergic medications. Increased fluid intake in response to this dry mouth can worsen incontinence symptoms. Over-the-counter decongestant medications used to treat colds and flu often have strong anticholinergic properties. These can worsen urinary retention, particularly in men with underlying BPH and some degree of BOO.

Psychological or behavioral factors including depression or anxiety can lead to changes in continence status (Steers and Lee, 2001). Successful treatment of underlying psychological issues may help reduce or resolve UI. Similarly, delirium or dementia can cause incontinence resulting from cognitive changes. In delirium, these are typically associated with acute confusion and fluctuation in status and inattention. Dementia tends to be more longstanding and progressive over time but can also be associated with substantial cognitive change and inattention to voiding (Lee et al., 2014). Although dementia may not be reversible, acute delirium is typically treatable and UI may resolve with abatement of acute cognitive changes.

Mobility impairment can cause problems with UI (Kim et al., 2015). This can be due to either acute or chronic conditions. Hip and long bone fractures, arthritis, joint deformities, spinal stenosis, and claudication can significantly limit mobility. Other gait and balance problems include disequilibrium, vertigo, orthostatic or other forms of hypotension, generalized deconditioning, and muscle weakness. Visual impairment and other sensory limitations can increase fear of falling and result in reduction of mobility. Stroke often leads to mobility impairment, which may or may not improve with time and rehabilitation. Normal pressure hydrocephalus is a condition seen more commonly in older adults. The condition is characterized by a triad of symptoms, including ataxic gait, cognitive dysfunction, and urinary incontinence. Ventriculoperitoneal (VP) shunt placement is the main therapy for NPH and may lead to complete resolution of symptoms, particularly if patients are treated relatively early after onset of symptoms (Akiguchi et al., 2008). Other neurologic disorders can lead to problems with UI in elderly patients. Parkinson disease is often associated with sleep disorders and may increase nocturia (Vaughan et al., 2013). It also increases risk of urinary urgency and DO. UI is particularly common in older adults with Alzheimer disease, Lewy body dementia, and vascular dementia (Ransmayr et al., 2008; Sakakibara et al., 2005). A recent epidemiologic study showed a 6.2% incidence rate for UI in patients with underlying Alzheimer disease (Lee et al., 2017). Involvement of the frontal lobe(s) of the brain appears to be particularly important in the association between Alzheimer disease and UI (Sugimoto et al., 2017).

Excess urinary output, polyuria, can also lead to transient UI. In addition to diuretics, other potential causes include metabolic derangements, CHF, pulmonary edema, venous insufficiency, malnutrition with hypoalbuminemia, diabetes insipidus, a syndrome of inappropriate antidiuretic hormone (SIADH) production, or excessive fluid intake resulting from psychogenic polydipsia or other factors. Peripheral edema can cause increased urine production when the patient moves to a recumbent position and tissue fluid recirculates leading to increased urinary production. Affected patients may benefit from elevating their legs above heart level late in the afternoon to offload some of this excess fluid before retiring to bed, thus reducing nocturia. Numerous medications can also exacerbate the development of peripheral edema including thiazolidinediones or glitazone medications used to treat diabetes, amantadine used to treat Parkinson disease, beta-blockers, calcium channel blockers, or nonsteroidal anti-inflammatory drugs (NSAIDs).

Types of Established Urinary Incontinence.

The major categories of established UI in older adults are similar to those in younger people, although some important clinical caveats must be noted (Diokno, 1990).

Urgency UI is the most common form of established incontinence among elderly people. This is typically associated with symptoms of urinary urgency and frequency. DO is often seen on urodynamic evaluation and is a common cause among older adults (Griebling, 2013b). The International Continence Society (ICS) defines urgency incontinence as the complaint of involuntary leakage accompanied by or immediately preceded by urgency, and DO as a urodynamic observation characterized by involuntary detrusor contractions during the filling phase that may be spontaneous or provoked (Abrams et al., 2002). Although the exact cause of DO is unclear, a number of different theories and mechanisms associated with aging have been explored. These include bladder and pelvic organ ischemia, free radical release and tissue damage from oxidative stress, inflammatory effects, changes in central and peripheral neural control, and cellular dysfunction (Chancellor, 2014; Smith, 2010; Tyagi et al., 2014a; Young et al., 2013).

Normal urine storage and voiding is a complex process that requires synchronous interaction between the bladder and peripheral and central nervous systems. Interaction between brain activity and bladder function in older adults has been the subject of recent research interest (Griffiths et al., 2005, 2007). Studies have used static and functional magnetic resonance imaging (MRI), sometimes done in conjunction with urodynamics, to assess these relationships (Krhut et al., 2012; Morris, 2013; Tadic et al., 2012). Normative data examining continent younger and elderly women have been obtained using functional MRI scanning during bladder filling and voiding (Griffiths et al., 2009). This includes data on motor and sensory changes in control patients associated with small filling volumes often associated with urgency in symptomatic patients (Tadic et al., 2013). In contrast to asymptomatic controls, patients with a history of urinary urgency, frequency, and UI tend to have an increase in white matter hyperintensities on brain MRI (Kuchel et al., 2009; Wehrberger et al., 2013). These findings support the hypothesis that alterations in brain anatomy and physiology may play a crucial role in urinary control in older adults. Additional research will help to further elucidate these complex processes and may identify future targets for therapy.

UI is particularly common after stroke. **Approximately 70% of stroke survivors experience problems with bladder control** (Marinkovic and Badlani, 2001). **Stroke severity is closely linked with development of UI, and those with more severe strokes tend to have more severe incontinence problems** (Panfili et al., 2017). Ischemic and hemorrhagic stroke can cause subsequent incontinence. Continued UI in those who were previously dry is a marker condition for increased morbidity and mortality after stroke (Patel et al., 2001). Stroke laterality and hemispheric dominance have generally not been found to be associated with differences in UI patterns or severity (Gupta et al., 2009; Kim et al., 2010). However, brainstem strokes that affect the pontine micturition center tend to cause worse incontinence. DO is the predominant urodynamic finding in patients with post-stroke incontinence and is typically associated with urinary urgency, frequency, and urgency UI. However, some patients experience poor detrusor contractions and chronic urinary retention with associated incontinence. Continued UI after stroke is associated with greater levels of functional dependence and higher overall care needs (Mizrahi et al., 2011). Post-stroke incontinence has been linked to poorer overall quality of life and alterations in sense of well-being (Tibaek et al., 2011). Fecal incontinence is also a common finding in patients with post-stroke UI resulting from overlap in neural control mechanisms (Brittain et al., 2006; Kovindha et al., 2009). Interaction between cognitive and mobility impairment after stroke and associated UI and voiding dysfunction is complex. Among those with mobility impairment, decreased mobility velocity has been linked to worse LUTS severity (Tibaek et al., 2009).

The term *precipitancy* has been used to describe the symptom that occurs with DO in older adults (Resnick, 1990). In patients with no sensation of warning, precipitant leakage may be experienced as an unconscious or reflex episode of incontinence. In contrast, in those with a warning sensation, precipitancy is the abrupt sensation of imminent leakage, regardless of time interval or the amount of urine loss (Resnick, 1990).

DO may exist in with or without other comorbid disease. **Underlying neurologic disorders such as Parkinson disease, Alzheimer disease, multiple sclerosis, spinal stenosis, or prior stroke tend to be associated with DO and related urinary dysfunction.** Sometimes bladder symptoms are among the earliest signs of some conditions such as multiple sclerosis (Chesnel et al., 2018). However, in many cases, no specific cause for DO can be identified. This makes evaluation and targeted treatment of DO in older adults more challenging.

The term *OAB* is used to describe the symptom complex experienced by patients. This includes “urgency, with or without urge incontinence, usually with frequency and nocturia” (Wein and Rovner, 2002). This can be further subdivided into OAB-dry, in which patients experience urinary urgency and frequency symptoms but do not actually leak urine, and OAB-wet, in which urgency UI also occurs. Older adults often develop specific coping mechanisms to deal with their symptoms of OAB, including voiding on a schedule or identifying and mapping where toilets are when they go out of their home (Blasco et al., 2017).

One form of bladder dysfunction that is unique in the geriatric population is detrusor hyperactivity with impaired contractility (DHIC) (Resnick and Yalla, 1987). In this condition, the patient experiences DO with bladder filling, which is associated with the typical symptoms of urinary urgency, frequency, and potentially with urgency UI. However, during the voiding effort, the bladder does not contract efficiently or with sufficient force to completely empty. In some ways, this represents a functional combination of overactive and underactive bladder. Brain imaging studies have shown hypoperfusion abnormalities that localize to the frontal and global cortical areas and are often associated with cognitive impairment (Griffiths et al., 2002). In some cases, detrusor contraction strength may actually be increased, particularly in presence of urgency UI. Monotherapy with antimuscarinic medications or other bladder relaxants can worsen urinary retention and promote development of chronic urinary retention with associated incontinence. Successful treatment often requires multimodal therapy including behavioral interventions and medications to inhibit DO and clean intermittent catheterization (CIC) to empty the bladder. Intentional induction of urinary retention with antimuscarinic medications to control hyperactivity, combined with CIC performed on a regular schedule to empty the bladder, can be a successful method for clinical management in some patients. Future research will be needed to help develop more optimal forms of management for this complex condition (Smith et al., 2014; Taylor and Kuchel, 2006).

Stress urinary incontinence (SUI) is common in older people and may occur in men and women. **In women, stress UI is usually due to either urethral hypermobility or intrinsic sphincter deficiency.** Pelvic floor support and urethral closure pressure tend to decrease with advancing age, and this increases risk of urethral hypermobility and intrinsic sphincter deficiency (ISD) in elderly women. Urethral atrophy associated with decreased tissue estrogenization, and other age-related factors can exacerbate ISD and stress UI in this population. Stress UI in men is often related to prior surgical therapy for either BPH or prostate cancer. Transurethral resection of the prostate (TURP) and radical prostatectomy have been associated with increased risk of stress UI in men. Enhancements in surgical technique and targeted therapy with pelvic floor muscle exercise (PFME) and other behavioral interventions may potentially reduce overall incidence and prevalence of postprostatectomy UI in older men (Goode et al., 2011; Kojima et al., 2013; Mirza et al., 2011).

Detrusor underactivity, sometimes called “underactive bladder” can be caused by a wide variety of conditions. Often the cause is idiopathic, but recent research has led to emerging data on this condition (Chancellor, 2014; Griebling, 2013a; Griebling et al., 2014b). Poorly controlled diabetes can lead to impairment of bladder contractility and a “diabetic cystopathy.” Patients can develop impairments in bladder sensation leading to behavioral changes and a prolongation of the intervoiding interval. This cyclic but chronic bladder overdistention may be associated with subclinical bladder ischemia, which leads to progressive muscle dysfunction. Pelvic atherosclerosis is associated with diminished arterial blood flow to the bladder, which could cause ischemic changes. This in turn can promote development and release of free radicals and accumulation of oxidative stress causing damage to cells and tissues.

Untreated chronic BOO can lead to detrusor dysfunction and chronic urinary retention in men, although this is less common with early detection and targeted interventions. Anatomic urethral obstruction in women is uncommon and most typically caused by prior urethral trauma. Large POP can cause functional obstruction with urethral kinking or angulation. Many of these women describe having to manually reduce prolapse with a finger in the vagina to void to completion. Use of a pessary or surgical prolapse repair can help treat this type of voiding dysfunction. Iatrogenic urinary retention can occur after surgical therapy for stress UI and may require surgical revision of the prior repair (Anger et al., 2007a, 2007b).

The term *functional incontinence* is sometimes used to describe urinary leakage caused primarily by factors other than the bladder. The ICS does not specifically define or recognize this term, but it is commonly used in research and clinical practice. **The most common factors associated with functional incontinence in geriatric patients include mobility limitations and cognitive impairments.** Care must be exercised to consider potentially reversible causes of transient UI other than restricted mobility and cognitive changes because these can coexist in patients thought to have functional incontinence. The identification of a functional component should also not presume that underlying lower urinary tract function is normal. Indeed, older adults with mobility or cognitive impairment and functional incontinence may have other underlying urologic pathology that predisposes them to UI. **Neither cognitive impairment nor immobility mean that UI will be an inevitable outcome. In fact, the majority of older adults with mobility limitation and cognitive impairments are actually continent.** In one study of nursing home residents, 17% with severe dementia were continent, and if they were able to transfer between the bed and a chair, half were continent (Resnick et al., 1988). It is also important to consider these functional limitations because, although they may not directly cause UI, they can certainly contribute to the condition in otherwise susceptible individuals. Even multiple small improvements in various functional components can substantially improve or resolve UI and associated clinical problems.

Incontinence in the Nursing Home Setting

UI is one of the most common conditions found in older adults living in nursing homes and other long-term care settings. Based on national data, reported prevalence of bladder incontinence is 46.1% for short-term nursing home residents and 75.8% for long-term care residents (Gorina et al., 2014). Similar rates have been observed in other countries with more than 50% of nursing home residents experiencing chronic incontinence (Jerez-Roig et al., 2016). UI is often considered one of the primary factors that necessitates facility placement among older adults. Using national data, the calculated attributable fraction of nursing home admissions resulting from UI is approximately 0.10 (95% CI 0.08–0.13) for men and 0.06 (95% CI 0.05–0.09) for women (Morrison and Levy, 2006; Thom et al., 1997). However, **new onset of UI is also a common finding among nursing home residents after admission to care facilities** (Ouslander et al., 1993; Palmer et al., 1991). Efforts have helped to substantially reduce use of indwelling urinary catheters in nursing homes, and most facilities now report relatively low rates of 7.3% among long-term residents, and 13.9% in short-term residents (Gorina et al., 2014). Short-term urinary catheters can be useful, particularly in older adults with associated clinical problems such as mobility limitation from lower extremity or pelvic fractures. However, even in these circumstances, rates of catheter associated infections of more than 30% have been reported (Kamdar et al., 2009).

Efforts to decrease rates of catheter-associated urinary tract infections (CAUTIs) have taken priority in acute care settings and nursing homes (Averch et al., 2015). This includes application of standard definitions to establish the diagnosis (Armbruster et al., 2017). Enhanced awareness of the appropriate indicates and uses for catheters can help with this (Hu et al., 2015). Reduction in CAUTIs has been associated with decreased overall costs of care (Hutton et al., 2018).

All nursing home residents undergo a comprehensive evaluation, including an assessment of urinary control and continence status, at the time of admission. Additional assessments are performed at least quarterly and more frequently if clinically indicated. Completion of the Minimum Data Set (MDS), a comprehensive multidimensional clinical assessment and documentation tool, is required for every nursing home resident in facilities that receive reimbursement from Medicare and/or Medicaid. It is completed within the first 2 weeks of admission, and at least annually. A short form is completed quarterly and in cases of substantial clinical change. Nursing homes in the United States are under strict regulatory control, and frequent inspections are required. F-Tag 315 is the national quality measure that examines UI and catheter use in nursing homes (Johnson and Ouslander, 2006). It is used to help facility surveyors assess care for UI and catheter use in long-term care facilities. In a survey study of nursing home staff and state surveyors there were substantial differences in knowledge about UI and attitudes toward this federal regulation (DuBeau et al., 2007). Other research has shown similar variation in levels of understanding and attitudes about UI by nursing home staff (Saxer et al., 2009). **Organizational**

factors can be as important as clinical medicine and nursing issues in this setting (Yoon et al., 2012). This highlights the need to include nursing home staff and administrators in quality improvement. Process change in nursing home settings can be challenging, and ongoing research seeks to improve these methods (Grabowski et al., 2014).

Catheters are generally not used for UI management in this setting. Rather, they are used for treatment of chronic urinary retention, particularly among older adults who would not otherwise tolerate clean intermittent catheterization (CIC) because of physical or cognitive issues or in cases of significant caregiver burden (Jonsson et al., 2011b; Lin et al., 2011). **Continued use of indwelling catheters in nursing home residents is subject to intense scrutiny and must be clinically justified in each specific case** (Gammack, 2003). Management of UI and other voiding dysfunction among morbidly obese nursing home residents can be particularly problematic. These individuals often suffer from multiple comorbid conditions, and mobility and transfers may be severely limited (Bradway et al., 2010). Catheter use may be considered in select cases.

The need for continued Foley catheter drainage among older adults discharged from acute care hospitalization has been associated with substantially increased rates of short-term mortality and need for institutional placement at time of discharge (Bootsma et al., 2013). However, caution must be used to balance risk and benefit. Bacterial colonization is common with 98% of indwelling catheters among geriatric nursing home residents affected (Jonsson et al., 2011a).

Absorbent pads and products are often used as part of a “check and change” approach to management of UI in geriatric nursing home residents, particularly in cases in which more active forms of therapy may not be feasible because of cognitive or other functional impairments. Although many nursing home residents prefer scheduled toileting and active interventions, use of pads and products can be effective in select cases (Pfisterer et al., 2007). Research has shown, however, that pad-per-day usage does not necessarily correlate well with actual UI volumes or severity (Omli et al., 2010).

Urologic consultation in nursing home settings can be useful for evaluation and management of complex genitourinary conditions, or to supplement ongoing therapies administered by nursing home staff (Watson et al., 2010). This can obviate the need to transport older adults from their place of residence to outpatient clinics or hospital settings. However, in the current national model of physician reimbursement, this type of onsite consultation service can be difficult to maintain over time because of administrative and cost barriers.

Targeted protocols to treat UI in long-term care settings have proved successful. Prompted toileting can be used with residents who have adequate mobility and cognitive function to use toilet facilities independently. Patients are prompted by caregivers or staff to use the toilet on a regular schedule. Timing is adjusted based on specific individual needs. In those older adults with mobility and/or cognitive impairment, assisted toileting procedures may be necessary. These involve having staff physically assist older adults to the toilet and guiding them through the process of adjusting clothing, using the toilet, and cleaning after voiding and/or defecation. Individually devised plans may be needed for each resident depending on his or her condition. Use of bladder scan ultrasound may be useful in this process to help identify when subjects need to use the toilet (Iwatsubo et al., 2014). This has been successfully combined with prompted toileting programs (Suzuki et al., 2016). The use of assistive toileting devices such as handheld urinals or bedside commodes may be necessary depending on functional status. Functional incidental training (FIT) has been used as a successful model of assisted toileting with older nursing home residents. In the FIT model, residents combine physical activity and mobility training with scheduled and assisted toileting (Schnelle et al., 1995).

Clinical Evaluation of Incontinence.

Clinical evaluation of UI in older adults requires special consideration of associated health factors and can differ substantially from standard evaluation in younger and healthier patients. In particular, **careful attention must be paid to potential contributions of comorbidity, either as a causative factor or an effect from UI.** Evaluation should seek to identify any of the previously described reversible transient causes of incontinence. It should also assess caregiver and social support, and the environmental setting where the older adult resides. The evaluation could also identify other serious urologic conditions that can be associated with UI including bladder cancer, benign or malignant prostate disease, neurologic disorders, or stone disease.

Evaluation should be individually tailored to the clinical needs and goals of the patient and his or her caregivers. In some cases, complete resolution of UI may not be feasible, but even small improvements in the condition can yield substantial functional results. For example, improvement in volume or frequency of urinary leaking may allow someone who was previously confined to the home the ability to get out and interact in social settings more easily.

Simple interventions can sometime have substantial positive effects. In most clinical guidelines, these form the cornerstone of initial therapies. However, a comprehensive approach is often the most effective when addressing the complex topic of UI in older adults.

History.

A detailed history is essential to proper diagnosis and selection of therapy for UI in older adults. The characteristics of incontinence, including duration, frequency and volume, should be determined. Any exacerbating factors such as physical activity, coughing, laughing, sneezing, or other factors should be assessed. A review of medical records can be extremely valuable. This would include any prior treatments that have been attempted, and prior surgical records if available. Some patients will be unable to provide their own historical information, and portions of, or in some cases the entire, history may have to be obtained from caregivers or surrogates. A telephone call to the patient's geriatrician or primary care provider can be valuable for obtaining historical information. For those older adults who reside in long-term care facilities, a call to the nursing staff member most familiar with them can help put clinical questions into better context. This can also help clarify goals of evaluation and treatment.

In some cases, a careful history will allow the clinician to determine the type(s) of UI a given patient experiences. However, this is not always true, particularly for elderly patients who may have more complex voiding dysfunction. The symptom of urinary urgency is extremely common but is neither particularly sensitive nor specific for DO. This may or may not be accompanied by actual urinary leakage. Similarly, urinary frequency is a common complaint that must be placed in clinical context. This may be caused by true DO, sensory changes that results in frequency of urination, or incomplete urination leading to rapid refilling of the bladder. In some cases this is a learned behavior or purposeful technique to avoid UI that may occur near bladder capacity. Voiding diaries can be helpful in gaining more insight into these clinical complaints.

Identifying the most bothersome component or characteristics of UI is particularly important in older adults. This can help to target treatments that can yield clinically meaningful improvements even if urinary leakage cannot be completely eliminated and is one of the main components of patient-centered therapy.

Physical Examination.

The physical examination is a crucial part of overall assessment of older adults with UI. In addition to routine aspects of physical examination including pelvic examination in women and genital and rectal examination in men, several unique components are also included for older adults with incontinence. The general physical examination should include identification of conditions associated with fluid overload and associated incontinence including peripheral edema, congestive heart failure, and pulmonary edema.

Neurologic examination includes gait and balance, mobility, and ability to transfer between positions. This includes ability to get on and off a chair, which can be similar to getting on and off the toilet. Clinical signs associated with common rheumatologic and neurologic disorders in older adults should also be evaluated. These include changes from arthritis and joint disorders, Parkinson disease, multiple sclerosis, prior stroke, spinal stenosis, cord compression, vertebral disc herniation, acute or chronic back pain, dementia, and delirium.

Perineal sensation should be tested and may be diminished or asymmetric, particularly in those with a history of underlying neurologic disease. For example, patients with a history of stroke and associated hemiparesis may have asymmetric perineal sensation. Tissue quality should be assessed, including presence or lack of rugation of the vaginal mucosa. Atrophic vaginitis is common in postmenopausal women and is usually due to lack of estrogen. This can also lead to fusion or agglutination of the labia minora or labia majora. In some cases this can cause voiding dysfunction and BOO (Chang et al., 2012). Vaginal narrowing or stenosis is another common finding on pelvic examination in elderly women. This is sometimes associated with a prior history of pelvic radiation therapy.

Pelvic examination in women should be performed with the bladder moderately full to evaluate for stress UI. Many older women wish to void before pelvic examination because it makes this more comfortable, and they may be used to doing so before routine gynecologic examinations. In some cases, women want to void before examination to avoid potential embarrassment with urine leakage in front of the clinician. However, if the patient voids to completion before the examination, determination of stress leakage with cough or Valsalva will be severely limited. Gentle reassurance of the importance of doing the examination with urine in the bladder and objective identification of stress leakage can be very useful and can help put the patient at ease.

Rectal examination may reveal signs associated with chronic constipation or fecal impaction. The bulbocavernosus reflex may be absent in older adults, although this change may or may not be associated with underling neurologic pathology. Prostate enlargement or nodularity may be palpable, although prostate size on rectal examination does not necessarily correlate with symptoms. Rectal cancers are more common among older adults, and the majority of lesions are palpable on digital rectal examination. Stool guaiac testing should also be considered and can help to identify otherwise silent pathology in some patients (Goetzl et al., 2008).

Having the patient void as part of the physical examination can be particularly useful in geriatric patients. This may include actually taking the patients to the toilet to observe their behaviors and level of need for assistance. Are patients able to recognize the toilet? Are they able to identify the sensations provided by a full bladder and respond appropriately to these signals? Are they able to adjust their clothing independently to allow use of the toilet? This can provide insight into potential issues of cognitive or physical functional impairment that could change the course of recommended therapy.

Assessment of Postvoid Residual Volume.

Many older adults do not completely empty the bladder with voiding. **Elevation of the postvoid residual (PVR) is common in older adults. However, no specific volume is considered pathological, and there is a great deal of controversy surrounding the importance of elevated PVR in older adult patients** (Huang et al., 2011; Shimoni et al., 2015).

Measurement of PVR can be accomplished with either ultrasound scan or bladder catheterization. Ultrasound is convenient and eliminates the need for urethral instrumentation. However, the device is expensive, and not all clinics will have this equipment available. Some nursing homes, outpatient clinics, emergency rooms, and other facilities that provide care for older adults have invested in this type of technology (Omli et al., 2008).

Measurement should ideally be completed immediately after a voluntary void rather than after an incontinent episode. However, in some patients, particularly those with cognitive impairment, this may not be feasible. Measurement of PVR after an incontinent leakage episode can be useful, particularly if the volume is low because this indicates complete bladder evacuation.

Voiding Diaries.

The use of voiding diaries can be particularly helpful in assessing UI and other forms of voiding dysfunction in older adults. They can help identify patterns of voiding in terms of time and associated factors. This can be useful to differentiate the type of UI in some cases. It can also be helpful in identifying cases of daytime or nocturnal polyuria. Research has shown diaries completed over 3 days can be valid for analysis, and this eliminates need for extended 7-day or longer diaries (Dmochowski et al., 2005). Most diaries are completed using paper forms, although electronic diaries are also available and are frequently employed in clinical research trials. If clinicians are going to use voiding diaries with older adult patients, care should be used to make sure the font is large and easily readable and that adequate instructions are provided for proper completion.

Findings from the voiding diary can be very useful in helping to guide treatment for UI in older adults. The voiding diary can help identify voiding patterns and provides an objective tool to validate subjective symptoms. It can be particularly helpful in patients with nocturia to differentiate nocturnal polyuria from some of other causes of the condition (Udo et al., 2009; Weiss and Blaivas, 2000). In some cases, recording fluid intake may be useful, but this increases the complexity of data the older adult is asked to complete. Information on fluid intake is particularly useful to identify polydipsia or fluid restriction, which could be causing voiding problems.

Laboratory Testing.

Geriatric patients need some special considerations for laboratory testing related to urologic health. Urinalysis and urine cultures should be obtained when clinically indicated and can help to identify underlying comorbidity. **The American Urological Association (AUA) Guidelines recommend checking a urinalysis as part of the initial evaluation for UI** (Dmochowski et al., 2010; Gormley et al., 2012). Gross or persistent microhematuria warrants additional evaluation, including in those older adults who are on anticoagulation therapy (Davis et al., 2012). Urine cultures are important to help diagnose the cause of UTIs and guide therapeutic choices. Persistent sterile pyuria should raise suspicion for possible genitourinary tuberculosis in older adults who can harbor this infection without other signs or symptoms (Kulchavenya et al., 2013).

Measurement of serum creatinine alone frequently does not adequately reflect true renal function in geriatric patients. This is due to natural loss of muscle mass with aging, which influences observed serum creatinine levels. Several options have been developed to correct for this measurement disparity

(Aucella et al., 2010). A 24-hour urine collection will provide the most accurate information but may be difficult to obtain for many patients, particularly those with substantial UI. The most commonly used estimation equations include the Cockcroft-Gault and Modification of Diet in Renal Disease (MDRD) models. Correction factors for age and body habitus can help improve accuracy of these estimates of glomerular filtration rate (Schaeffner et al., 2012; Van Pottelbergh et al., 2014; Zhu et al., 2014).

Serum electrolytes should be checked in patients with delirium because this can be a causative and potentially reversible factor in some cases. Glucose measurement is useful in diagnosing underlying diabetes that could be associated with renal, lower urinary tract, and sexual health disorders.

Urodynamics.

Urodynamics can be useful in the evaluation of select elderly patients with urinary incontinence and other forms of voiding dysfunction (Diokno, 1990). The AUA recently published guidelines regarding the use of urodynamics for assessment of voiding dysfunction (Winters et al., 2012). **Primary indications for urodynamics, particularly in older adults, include failed prior therapy, underlying neurologic or other comorbid conditions that could influence voiding function, and planned genitourinary reconstruction.** It is important to consider if and how findings from urodynamic testing may change treatments. If different urodynamic results would not alter therapy, then testing would not be warranted. However, if different treatment options would be considered based on the observed results from the testing, then it would be justified. Pressure-flow urodynamics can be particularly helpful to differentiate between functional obstruction and underactive bladder with poor contractility and incomplete bladder emptying.

Several factors must be specifically considered for geriatric patients who may undergo urodynamic testing. Although minimally invasive, the study is in some ways an interventional procedure and must be conducted in this context. The test is interactive, and patients need to be able to follow directions and describe what they are feeling at various points. They need to be able to be positioned adequately and undergo catheter placement. Older adults with cognitive or mobility limitations may have difficulty participating in urodynamic testing, which could compromise the quality of the findings. **Ideally, the symptoms being targeted for analysis and treatment should be reproduced during urodynamic testing.** This can be difficult to achieve in the urodynamic laboratory, but a variety of techniques can be employed to help with standardization of methodology. The importance of good urodynamic technique and testing quality cannot be overemphasized (Schäfer et al., 2002). Most urodynamic testing is conducted in hospital- or clinic-based facilities, although portable and ambulatory urodynamic evaluation can be performed in select cases. The role of urodynamic testing in the nursing home and other care settings is relatively limited and should be reserved for specific cases in which results of the testing would substantially influence treatment considerations. Staffing and reimbursement may also be a limiting factor for studies done in mobile settings such as nursing homes.

In a large cohort study of urodynamic findings in 100 community-dwelling elderly women, the most common clinical conditions identified include DO and DHIC (Valentini et al., 2010). These tended to be strongly correlated with patient symptoms. However, other studies have contradicted this finding and suggest that in some older adults the observed correlation between clinical symptoms and urodynamic findings may be lower (Bromage et al., 2010). This likely reflects alterations in anatomy or physiology and overall heterogeneity of changes seen with advancing age among older adults.

Treatment of Incontinence.

Treatments of UI must be carefully tailored to the individual patient. This is particularly true among geriatric patients in whom there can be substantial heterogeneity between individuals based on comorbidities, functional status, and goals of care. Because causes of established UI in geriatric patients are multifactorial, treatment also frequently requires multiple components and approaches. **In many cases, the actual target of therapy may be outside of the lower urinary tract to address contributions from comorbidities and other contributing clinical conditions.** Behavioral therapies are a mainstay of treatment of UI in geriatrics, although medications and surgeries can also be used successfully in this population.

Behavioral Therapies.

Behavioral therapies are considered the mainstay of therapy for treatment of UI in older adults. They offer the advantage of good clinical efficacy while avoiding potential side effects often associated with medications or surgery (Parker and Griebling, 2015).

Some older adults choose to limit fluid intake in an attempt to reduce urgency incontinence or urinary urgency or frequency episodes (Miller et al., 2011; Segal et al., 2011). Although this can be useful in select cases, particularly at night in those with symptomatic nocturia, care must be taken to avoid dehydration. **Reduced fluid consumption can exacerbate UI and constipation. In addition, restriction of fluids can lead to production of a stronger and more concentrated urine, which is actually more irritating to the epithelium.** Although total urine volume is reduced, increased urinary concentration can actually worsen urge symptoms. Other common dietary recommendations including avoidance of foods or beverages that tend to trigger urinary urgency and frequency symptoms. These include caffeine, carbonated beverages, alcohol, and spicy or acidic foods (Gleason et al., 2013).

Timed or scheduled toileting can be useful in some patients with urinary urgency and frequency. Many older adults have worse symptoms near bladder capacity. **Voiding on a more regular schedule before reaching capacity may help to limit urge sensations and associated leaking.** Bladder retraining, a series of steps to increase the intervoiding interval, can also be useful in select cases. This can help to slowly increase functional bladder capacity and response to sensations of bladder filling. One clinical trial demonstrated a mean reduction of 57% for urgency incontinence frequency in elderly women (Fantl et al., 1991). Delayed voiding is similar except that patients do not follow a predetermined time interval but instead base their schedule on sensations as they experience them (Burgio et al., 2011). Biofeedback training is sometime used in combination with this type of intervention (Newman, 2014). Urge suppression methods are frequently combined with other types of therapy as a form of habit retraining to improve UI symptoms (Ostaszkiewicz et al., 2004).

PFME is one of the primary forms of behavioral therapy used to treat UI in older adults. Numerous studies have shown that men and women with various types of UI can benefit. However, simply telling people to do Kegel or pelvic muscle exercises is unlikely to be successful. **Most older adults require specific training for these methods to work.** Cognitive impairment may limit practicality of this therapy in some patients. It requires a motivated patient who is willing to do the exercises and is able to follow guided instruction. In a study of hospitalized older women (mean age 78.2 ± 6.3 years), the majority (74.5%) were unable to voluntarily contract their pelvic floor muscles (Talasz et al., 2012). With proper instruction, PFME has been shown to improve UI more than just bladder training and timed voiding alone (Sherburn et al., 2011). PFME is often used in combination with other forms of behavioral or pharmacological therapies, and effects may be additive or synergistic (Burgio et al., 2000; Ghoniem et al., 2005). In some cases, patients may be able to decrease or discontinue medications for UI, depending on success of PFME and behavioral treatments (Burgio et al., 2008). It has also been shown to be effective in men with a history of postprostatectomy incontinence and in patients with symptomatic nocturia (Goode et al., 2011; Johnson et al., 2005).

PFME appears to have a direct effect on pelvic anatomy and physiology. It has been shown to improve pelvic floor muscle morphology and dynamic function over time (DuMoulin et al., 2009; Madill et al., 2013). A variety of teaching methods have been developed and advocated for PFME instruction in older adults. These have been used successfully in nursing home settings (Engel et al., 1990; Vinsnes et al., 2012). Group instruction is feasible and has been shown to have good outcomes (Lajiness et al., 2007; Sampselle et al., 2005). This may be particularly useful for older adult patients who may benefit not only from direct instruction but also from interaction and support of the group learning PFME together. It may also be a more efficient and cost-effective way to disseminate this type of clinical education for multiple patients. This has been shown to be effective in a nursing home setting where participants also experienced improvements in overall functional status (Tak et al., 2012). Online instruction with Internet-based teaching and interactive support forums have been shown to be successful in early trials (Sjöström et al., 2013).

Vaginal cones can be used to augment pelvic floor exercise and may help patients to identify the muscles used in this technique. However, randomized controlled trials have not shown statistically significant differences in continence outcomes with or without cones (Pereira et al., 2012, 2013). Electrical stimulation of pelvic floor muscles can also be used, but results of this treatment compared with PFME alone have been mixed (Castro et al., 2008; Correia et al., 2014). Weight loss has been shown to be effective at improving stress UI and FI in elderly women with obesity (Markland et al., 2011; Subak et al., 2009).

Pharmacotherapies.

Medications are widely used in treatment of UI. The specific drug selected is typically based on the type and cause of UI experienced by the patient. Unfortunately, there are currently no pharmacologic agents available in the United States that are particularly effective for treatment of stress UI in older adults. Medications with alpha agonist properties such as pseudoephedrine have been tried but tend to have substantial side effects and limited clinical efficacy in geriatric patients. The older medication phenylpropanolamine was removed from the market by the FDA because of increased risk of serious side effects including hemorrhagic stroke and other thromboembolic events (Meadows, 2001). Duloxetine, a balanced serotonin and noradrenaline reuptake inhibitor, also has α-adrenergic properties and has been considered as a possible treatment option for stress UI (Basu and Duckett, 2009). Although it is used in some parts of the world, it is not approved by the United States FDA for this purpose.

The majority of medications have been designed to treat OAB, including urinary urgency, frequency, and urgency UI. These are mostly antimuscarinic, anticholinergic medications that act by blocking muscarinic receptors in the bladder, which in turn decreases detrusor contractions. The classic medication in this group is oxybutynin. Although it can be effective for management of bladder symptoms, it has strong anticholinergic properties, which can cause problematic side effects in older adults. The most common include dry mouth and constipation, although dry eye, headache, confusion, and other anticholinergic effects may also occur (Moga et al., 2013; Pagoria et al., 2011). It is important to remember that a wide variety of medications may cause dry mouth and other adverse effects (Tan et al., 2018). **Some of the newer selective antimuscarinic agents and the β_3 agonists may help reduce these problems.** These medications can be used in men and women, and all have been shown to have relatively similar efficacy (Madhuvrata et al., 2012).

Several of the newer medications have theoretical advantages for use in older adults. In some cases these may have a real physiologic effect, but to some extent the primary purpose has been differentiation in marketing for various drugs. Differences between medications have been based on a variety of factors including lipophilicity, molecular size, selective affinity for various muscarinic receptor subtypes, drug half-life, and other metabolic effects. For example, trospium is a quaternary amine, unlike the other agents which are tertiary amines. Animal studies have shown that trospium may be less likely to cross the blood-brain barrier and may therefore decrease the potential cognitive side effects from this medication (Kranz et al., 2013). However, changes in the blood-brain barrier with aging increase permeability and may alter drug efflux in older adults (Chancellor et al., 2012). Studies of these types of medications in older adults must examine cognitive side effects (Kay et al., 2006; Paquette et al., 2011). Improved selectivity of muscarinic receptor binding is another focus in drug development. The goal is to target the bladder (M_2 and M_3) but avoid the salivary gland and bowel (both M_3), which may help reduce the risk of dry mouth and constipation (Abrams and Andersson, 2007).

The route of administration and type of drug delivery system are also important considerations for several of these medications. These can influence pharmacokinetics and pharmacodynamics of these preparations. Immediate release drugs offer quick onset of action, but long-acting or time-released agents may have a benefit of more stable steady-state of circulating medication. Transdermal preparations avoid the first pass effect through the liver and may be useful in patients with hepatic insufficiency. They are also useful in patients with swallowing difficulties that can prevent effective use of oral tablet or capsule formulations. Liquid oxybutynin is available and can be administered through feeding or gastric tubes in patients unable to swallow liquids or other formulations.

One of the challenges is that older adults are frequently excluded from clinical trials used to approved medications and other treatments because of their underlying comorbidity and heterogeneity (Beers et al., 2014; Briggs et al., 2012). **However, the reality is that these drugs are widely prescribed in this type of patient population in routine clinical practice** (Kraus et al., 2010). This means that potential side effects and interactions between medications and underlying comorbidity have been studied in less detail, which makes clinical decisions and prediction of outcomes more difficult. **Several recent studies have examined use of antimuscarinic medications specifically in older adult cohorts.** Fesoterodine was demonstrated to have good clinical efficacy in a 12-week randomized, placebo-controlled trial in a group of 562 elderly patients with a mean age 75, and 50.4% 75 years old or older (DuBeau et al., 2014). This group had high baseline rates of comorbidity, polypharmacy, and functional impairment, which mirror real-world prescribing challenges. The medication was generally well tolerated, and overall adverse events were similar to those seen in younger patient populations. These results were also demonstrated in a similar trial of fesoterodine conducted with geriatric patients in Europe (Wagg et al., 2015). This medication has also been shown to be safe in older women with hypertension (Yokoyama et al., 2018). Studies on older adults have also shown relatively good efficacy and tolerability for tolterodine, solifenacin, darifenacin, and trospium (Chapple et al., 2007; Griebling et al., 2009c; Lipton et al., 2005; Sand et al., 2011; Wagg et al., 2006, 2013). One study of fixed low-dose, extended-release oxybutynin in cognitively impaired older adults living in nursing homes did not seem to worsen cognition and decreased the number of wet pad checks by 38% but failed to show a significant benefit for UI overall

(Lackner et al., 2011). An earlier study had also shown relatively good tolerability with no increase in rates of delirium in a cohort of cognitively impaired nursing home residents (Lackner et al., 2008).

Most of these medications undergo either hepatic or renal metabolism, and caution is warranted in patients with liver or kidney impairment. Use of the lowest clinically effective dose is generally recommended. Drug-drug interactions tend to occur with other drugs that undergo hepatic metabolism. Drug-food interactions have also been identified, particularly with alcohol and grapefruit, which can lead to inhibition of the cytochrome P450 pathway. **Use of the antimuscarinic and anticholinergic medications is also contraindicated in patients with closed angle (narrow) glaucoma.** Consultation with a patient's ophthalmologist or optometrist may be needed in these cases before prescribing these medications. Open-angle glaucoma is much more common, and this by itself is not a contraindication to use of the antimuscarinic anticholinergic medications for treatment of urinary symptoms.

Adverse effects of antimuscarinic medications are one of the primary limiting factors for ongoing use, particularly among older adults (Sears et al., 2010; Wagg et al., 2012). Discontinuation of medication is common, and several different medications may have to be tried to find one that is acceptable for an individual patient. Urinary retention is a theoretical risk with all of these medications, although this is not commonly seen in clinical practice. Monitoring of postvoid residual volumes after initiation of therapy may be considered.

A new class of agents for treatment of OAB are β_3-adrenoceptor agonists. Mirabegron is the only agent in this class currently approved in the United States and is available in 25-mg and 50-mg doses taken once daily. This acts on detrusor smooth muscle to decrease contractility and reduce symptoms associated with overactivity. Studies in older adults have demonstrated good clinical efficacy with relatively few side effects (Lee and Kuo, 2018; Wagg et al., 2014). Although some data suggest it can increase blood pressure, this medication has been demonstrated to be safe in general from a cardiovascular perspective (Rosa et al., 2016). This class of medications offers the potential advantage of reducing bladder symptoms without the risk of anticholinergic side effects.

Regimen compliance and continuation can be problematic with the antimuscarinic medications, particularly among older adults. Discontinuation rates are relatively high, ranging up to 50% to 86% at 1 year (Mauseth et al., 2013; Sicras-Mainar et al., 2014; Wagg et al., 2012).

Newer data suggest that these rates may be even lower at around 30% at 1 year (Kosilov et al., 2017). Although all of the available medications have been shown to be effective in clinical trials, the response of an individual patient to a specific medication is difficult if not impossible to predict. Patient perception of the degree of improvement is very important in their decision to continue or stop pharmacotherapy (Basra et al., 2008). Older adults frequently discontinue these types of medications because of either a lack of perceived efficacy or development of adverse effects such as dry mouth, constipation, or confusion.

Cost is also an important consideration when using pharmacotherapy for UI in older adults (Armstrong et al., 2012; Perimenis et al., 2006). Many geriatric patients are on a fixed income, and they may or may not have insurance coverage for prescription medications. Coverage varies widely among different policies and between different drugs. Even under Medicare Part D benefit, older adults may have a substantial out-of-pocket expense, particularly if they are on multiple medications and have used the extent of their available benefits. Different medications may have different preferred formulary status with different coverage plans. Patients often need help navigating these complexities with their insurance providers and pharmacies.

Use of antimuscarinic medications in patients with underlying cognitive impairment, or dual use in those on cholinesterase inhibitors requires special consideration. These drugs theoretically act in pharmacologic opposition and may influence symptoms of the other disease process (Green et al., 2017). There have been anecdotal reports of patients developing UI after initiation of a cholinesterase inhibitor, and conversely cognitive decline has been reported in some patients after initiation of an anticholinergic medication for treatment of urinary symptoms (Hashimoto et al., 2000; Siegler and Reidenberg, 2004; Starr, 2007). This can be associated with an increased risk of polypharmacy in these older adults (Modi et al., 2009). In fact **initiation of one medication may lead to symptoms that prompt subsequent prescription of the other class of medications, an example of the “prescribing cascade”** (Boudreau et al., 2011; Johnell and Fastbom, 2008). Larger observational studies have shown that combined use of these medications can lead to progressive cognitive decline in some older adults (Sink et al., 2008). In these cases, it can be helpful to consult directly with the treating geriatrician or neurologist to determine which medication should take priority based on the overall clinical situation. Risks and benefits of medications must be balanced with observed outcomes in regard to urologic and neurocognitive function. Risks of cognitive change or confusion with anticholinergic medications are real, although overall reported incidence is relatively small. Discontinuation of medication usually results in resolution of the cognitive side effects.

Potential cardiac risks are also a consideration with specific antimuscarinic agents. For example, high doses of tolterodine may cause Q-T prolongation that can lead to symptomatic bradycardia, and even Torsade de pointes. Maximum dosing for specific medications should be carefully considered and should not be exceeded (Rosa, 2013). Anticholinergic medications also have a potential risk of inducing tachycardia, although this has not been reported as a common clinical adverse event of currently available medications. The β_3-adrenoceptor agonist mirabegron has been associated with slight increases in blood pressure and should be used carefully in older adults with a history of hypertension (Sanford, 2013). Underlying cardiovascular disease plays an important role in these cases and should be considered when prescribing of medications for treatment of OAB.

Surgical Therapies.

A number of different forms of surgical therapy are used for treatment of UI in older adults. These include surgical procedures for stress and urgency UI. Many older adults want to avoid surgery as a possible treatment option for UI, POP, or other urologic conditions. Similarly, many clinicians may not consider surgical options for geriatric patients because of concerns about potential risks and complications resulting from age (Griebling, 2011). However, **there is a growing body of evidence that indicates surgery may be safe and effective for carefully selected older adults with UI and other genitourinary disorders. Age alone is rarely a significant risk factor for postoperative outcomes, which tend to be more closely related to comorbidity and functional status.** In fact, considering surgery earlier in the treatment algorithm may be appropriate in some cases. For example, prolapse repair performed earlier after menopause in older women has been shown to have improved outcomes compared with those in which surgery is substantially delayed (Ahn et al., 2010). Development of newer, less-invasive effective surgical procedures have made some surgical options more viable for use in elderly patients (Atiemo et al., 2006). In addition, efforts to better optimize older adults medically before surgery may help to improve outcomes (Chow et al., 2012).

Bulking agent injections have been used to treat stress UI in older women (Keegan et al., 2007; Lightner et al., 2002). They offer the advantage of a minimally invasive technique with relatively good success rates. However, overall success is somewhat more limited compared with other surgical techniques because of longevity of the effect and need to repeat the procedure. Conversely, the ability to repeat treatment can also be seen as a clinical advantage to bulking agent injections. A variety of materials have been used for this purpose including cross-linked bovine collagen, synthetic gels, and microbeads (Khullar et al., 1997; Lightner et al., 2001; Vecchioli-Scaldazza et al., 2014; Winters et al., 2000). **Bulking agent injection therapy may be particularly appealing in elderly women with stress UI who may not be candidates for more involved surgical therapy.** The use of bulking agents in men has shown substantially less overall success compared with efficacy in women (Griebling et al., 1997).

Sling procedures are used for treatment of stress UI. Slings for treatment in women include pubovaginal and mid-urethral procedures. Various graft materials have been used for this purpose, including autologous fascial grafts, other biologic grafts using either cadaveric fascia or xenografts, and synthetic mesh. Slings have also been developed for treatment of stress UI in men. There have been a number of published studies that have examined safety and efficacy of sling procedures for treatment of stress UI in geriatric patients. These have generally shown good outcomes with no significant difference in complication rates compared with younger patients (Jun et al., 2012; Serati et al., 2013; Stav et al., 2010). However, other clinical reports suggest older women may be at increased risk for perioperative UTIs and other complications (Groutz et al., 2011). Continence outcomes may also differ with one study reporting inferior rates of improvement in elderly women compared with younger patients after mid-urethral mesh sling (Kim et al., 2011). In this study, elderly women had higher rates of parity, hysterectomy, and prior anti-incontinence or prolapse surgery. This could have influenced observed results. An analysis of Medicare beneficiary data demonstrated that elderly women appear to have a higher risk of urinary retention, urinary urgency, and other complications after sling surgery compared with younger women (Anger et al., 2007a, 2007b). Some surgeons may avoid using mesh specifically in elderly women because of potentially increased risks of erosion or other complications after this type of surgery (Reynolds et al., 2013).

Artificial urinary sphincter (AUS) implantation is often used for treatment of stress UI in men. AUS devices are not commonly used in women any longer because of advances in sling procedures, bulking agent injections, and other minimally invasive surgical options. Cognitive status and manual dexterity must be carefully considered in elderly men being considered for AUS placement because they will need to operate the device several times daily to effectively manage incontinence and void. In select patients this therapy can be effective (O'Connor et al., 2007). Sling procedures for treatment of UI in men have been developed, but there are no clinical data examining outcomes specifically in geriatric patients.

Neuromodulation uses electrical stimulation of the nerves that control detrusor contractility to treat voiding dysfunction. Two forms of neuromodulation are currently available, including sacral neuromodulation with implantable electrodes (InterStim, Medtronic) or peripheral tibial nerve stimulation (Urgent PC, Uroplasty). Both have shown good success in research trials and clinical practice. Studies on use of these therapies in geriatric patients have been somewhat limited; however, reported results are promising (Griebling, 2010; Schreiner et al., 2010; White et al., 2009). Success rates up to 83.3% at 1 year have been reported in geriatric patients among those who went on to generator placement (Angioli et al., 2013). Reported complication rates are low, even in elderly patients with multiple comorbidities (Chughtai et al., 2015). Age by itself does not appear to substantially influence overall success of therapy (Peters et al., 2013). Posterior tibial nerve stimulation has been used successfully for older adults in a residential care setting, and in patients with a history of voiding dysfunction related to prior stroke (Booth et al., 2013; Monteiro et al., 2014). Successful use of neuromodulation therapy requires that the patient be able to identify characteristics of his or her symptoms and participate in ongoing programming and adjustment of the device as needed. In some cases, if patients are unable to do this themselves, assistance from a caregiver may be required.

Chemodenervation of the detrusor muscle is used to treat urinary urgency, frequency, and urgency UI. This has typically been reserved for use in cases that are refractory to other forms of therapy, including behavioral or pharmacologic interventions. The most commonly used agent for this purpose is onabotulinumtoxin A. Studies in older adults have been relatively limited but have shown clinical efficacy and overall safety (White et al., 2008). The major concern of this particular therapy is the risk of urinary retention, which could necessitate CIC or indwelling catheter drainage at least temporarily.

Urinary diversion is another possible option for treatment of intractable UI in highly selected older adults. In some elderly patients, use of a urinary conduit with management of a stomal appliance is preferable to UI. **Care must be taken**

to evaluate potential risks of surgery and balance this with the potential benefits of independent urinary control provided by urinary diversion (Osborn et al., 2014). In select patients, creation of a continent catheterizable diversion may also be an option (Gowda, 2008).

Use of indwelling catheters is generally avoided in older adults because of associated risks of UTI, catheter colonization, urinary tract stones, or tissue erosion (Drinka, 2006; Leuck et al., 2012; Ouslander et al., 1987). Chronic use of indwelling catheters after discharge from acute hospitalization in older adults has been linked to negative outcomes including an increased risk of mortality (Holroyd-Leduc et al., 2007). Catheters should be removed as soon as feasible to help prevent these negative outcomes. Indwelling catheters are also not particularly helpful in management of DO because they tend to exacerbate bladder contractions and can make symptoms worse. They should also be avoided for simple convenience or fluid monitoring in most patients in acute care settings.

However, use of indwelling catheters can be useful in highly select cases. These include patients with chronic urinary retention and incomplete bladder emptying who are unable to undergo CIC for various reasons. Other examples include those with morbid obesity, severe extremity contractures, or other body habitus changes that prevent catheterization. Older adults with dementia or severe cognitive impairment, severe urethral stricture disease not amenable to surgical correction, or other anatomic changes may not tolerate CIC. In this case, use of an indwelling catheter may be more appropriate. Patients with sacral pressure ulcers or other skin breakdown may also benefit from temporary indwelling catheter drainage to keep the affected area dry and allow for tissue healing. Temporary urinary catheter drainage can also be useful after flap placement or other reconstructive surgery to keep the surgical site dry during the healing process.

In cases in which chronic catheterization is necessary, placement of a suprapubic catheter is generally preferred over urethral catheterization. This helps prevent bladder neck and urethral erosion in all patients and decreases rates of epididymitis and prostatitis in men. Once the tract is healed, the suprapubic tube may be easier for staff to change and may also be more comfortable for the patient. This also positions the catheter out of the urethra and genital tract and allows patients to be sexually active if so desired. The catheter should be changed at least monthly or more often if necessary based on individual clinical variables (Wilde, 2013). Cystoscopy is generally recommended on at least an annual basis, particularly after the first several years of use, to evaluate for any mucosal changes such as squamous metaplasia or development of stones. **If patients have problems with urinary leakage around the catheter or from the urethra, treatment should be focused on reducing bladder contractions with antimuscarinic or other agents and ensuring adequate catheter drainage. It is strongly recommended that providers NOT increase the caliber of the tube.** Increasing the diameter of the catheter will not solve the underlying cause of the urinary leakage and will only dilate the suprapubic (SP) tract or urethra. This can lead to severe problems with erosion and catheter extrusion. Catheters of 16 or 18 Fr are generally adequate for use as an SP tube.

Urine Containment and Absorbent Products.

A variety of devices and products are available to help manage urinary leakage. Although these should not be considered a curative treatment option, they can be useful for management of symptomatic urine loss. In some cases, use of these types of products can allow affected individuals opportunity to participate in social activities they would otherwise avoid because of embarrassment or other factors associated with UI.

Absorbent pads and products come in a wide array of designs. These range from small pads to extra absorbent briefs and can be used for light and heavier volumes of urinary leakage (Fader et al., 2007, 2008). There are some differences in products available for men and women with designs specific for leakage target zones based on anatomy. Advances in technology have continued to improve products, including better management of odor and absorbency (White et al., 2003). Gel-based products may offer better odor control and have good overall absorbency, although they may not be able to control large volume leakage as well as products using wood pulp or fiber. Pads may be particularly effective in helping to reduce associated dermatologic complications such as urea dermatitis of the perineum (Sugama et al., 2012). Pads and absorbent products are frequently used in the UI management scheme of nursing home residents and can be a useful adjunct in this setting (Pfisterer et al., 2007). Use in acute care settings should be relatively limited if possible and has been shown to potentially increase rates of UI (Zisberg et al., 2011).

Condom catheters, also known as urinary sheaths, can be a useful adjunct for management of urinary leakage in men. These disposable devices surround the penis and are connected to a urinary drainage collection bag. Some men use these in selective settings such as when they go out of their home or participate in social activities. They can also be used at night to help control urinary leakage and decrease bother from nocturia, particularly in men with mobility limitations that make traveling to the toilet difficult or dangerous. Proper sizing of condom catheters and good skin hygiene are essential for successful use. Skin breakdown or necrosis can occur if the device is not properly maintained or if the condom is too small or placed too tightly around the penile shaft.

Urethral clamps and plugs are available in a wide variety of styles. Cunningham and other types of penile clamps should be used only during the daytime and must be moved to different locations on the penile shaft every few hours to prevent tissue injury or necrosis. Men need to have adequate hand dexterity and cognitive function to use these types of devices successfully. Urethral caps and plugs have been developed for use in women. These offer the advantage of a nonsurgical option but can be difficult to use because of disposable design, which requires removal and replacement with every void and associated costs. They also require adequate hand dexterity for routine use. These types of devices may be most useful when used selectively to prevent urinary leakage during exercise or other physical activities, or when leaving the home environment.

Other Lower Urinary Tract Dysfunction, Urinary Tract Infections, Pelvic Floor Conditions, and Genitourinary Trauma

A wide variety of other lower urinary tract and pelvic floor conditions can affect older adults and require special considerations for geriatric patients.

Bladder Outlet Obstruction

BOO, particularly resulting from BPH or urethral stricture disease, is more common in elderly than in younger patients. Incidence and prevalence rates for BPH, UI, and other forms of voiding dysfunction in men increase with advancing age (Griebling, 2008; Irwin et al., 2011; Parsons et al., 2008). Evidence-based guidelines for evaluation and management have been developed (McVary et al., 2011). However, there still appears to be a bit of variation in initial evaluation and management among different practices (Erickson et al., 2014; Strope et al., 2011).

Measurement of PVR volume is a key component of most evaluations, but how this changes with time is somewhat unclear. Recent population-based data suggest that for men with initially low PVR measurements, few will require future treatment compared with those with baseline PVR of more than 400 mL in whom 75% needed intervention over time (Noguchi et al., 2018).

The spectrum of medical and surgical therapies should be considered, and decisions based on each patient's unique situation. In many cases, men want to start with medications before considering surgical therapy. Recent research has led to an increased use of combination therapy with alpha-blockers and other forms of medication, including PDE-5 inhibitors, antimuscarinic agents, and 5-alpha-reductase inhibitors (Chung et al., 2011; Regadas et al., 2013).

Tissue ischemia caused by oxidative stress and diminished blood flow to the pelvic organs and prostate is a factor, which theoretically could worsen BOO symptoms. Animal studies have suggested that an antioxidant diet may help to reduce the negative effects of this condition (Bisogni et al., 2012). There is great interest to determine if similar results may be possible in humans.

Surgical therapies can be very useful, particularly in men with a history of acute urinary retention resulting from BOO, or in those who have not experienced sufficient improvement on pharmacotherapies. In addition to traditional transurethral resection, laser surgery and other minimally invasive forms of therapy have been used successfully in elderly men with BPH (Elshal et al., 2013; Kuntz et al., 2008). Bipolar plasmakinetic TURP has been used to reduce bleeding during surgery in elderly men with larger prostate glands (Coskuner et al., 2014). However, TURP may not be successful in all elderly men. In fact, a recent study showed 64% of elderly male nursing home residents who were underwent TURP for urinary retention were still catheter dependent postoperatively, and 32% died in the first year after surgery (Suskind et al., 2017). There has also been some early interest in embolization of the prostatic arteries as a minimally invasive therapy for symptomatic BPH (Wang et al., 2016).

Care must be taken when considering treatment of elderly men with BPH, particularly in those with associated neurologic conditions such as Parkinson disease, Shy-Drager syndrome, multiple sclerosis, or other underlying disorders. These can exacerbate bladder storage and voiding problems and may increase risk for UI and other negative outcomes. Even after relief of BOO, DO may not completely resolve. This can be frustrating to patients and may continue to require therapy to control bothersome symptoms. TURP has traditionally been avoided in men with combined BOO and detrusor underactivity, although newer data have been challenging this long-held concept (Ou et al., 2012).

In select patients who are not good surgical candidates, urethral stents may be considered as an option (Milroy and Allen, 1996). Complications of urethral stents include technical issues and difficulty with tissue overgrowth and urethral strictures. However, in select men who may otherwise be dependent on indwelling catheter drainage, urethral stents may offer a viable treatment alternative (Bozkurt et al., 2013; Gesenberg and Sintermann, 1998). Urethral reconstruction may be feasible in select elderly men, and good outcomes have been reported using dorsal onlay skin grafts among other techniques (Schwentner et al., 2010).

Ophthalmic side effects of medications used to treat BOO must be considered carefully in elderly men. The “floppy iris syndrome” is a condition that causes billowing of the iris during surgical cataract extraction and lens implantation (Bell et al., 2009; Friedman et al., 2009). It is important that elderly men on tamsulosin and other medications for treatment of BOO inform their eye surgeon before any procedure. These medications may have to be discontinued for at least a week before planned cataract surgery.

Underactive Bladder, Neurogenic Bladder, and Urinary Retention

Underactive bladder (UAB) is a condition characterized by poor bladder emptying that is not necessarily caused by BOO. It likely encompasses multiple causes and clinical conditions (Taylor and Kuchel, 2006). This may be related to a failure of the detrusor muscles to contract and a failure of the neural pathways to properly stimulate the bladder (Smith, 2010). The ICS defines the term *detrusor underactivity* as “a contraction of reduced strength and/or duration, resulting in prolonged bladder emptying and/or a failure to achieve complete emptying within a normal time span” (Abrams et al., 2002).

Research on UAB is relatively new, and there are few epidemiologic studies on the condition (Griebling, 2013a). In a population-based survey, 23% of 633 respondents indicated they had difficulty emptying the bladder (Valente et al., 2014). In a similar study of older adults who had undergone urodynamic testing for voiding dysfunction, 40.2% of men and 13.3% of women were diagnosed with detrusor underactivity (Jeong et al., 2012). **Structural and functional changes appear to lead to development of underactive bladder.**

Ultrastructural studies have demonstrated that aging is associated with an increased deposition of collagen and a reduction in the ratio of smooth muscle to connective tissue (Elbadawi et al., 1993, 1997).

Progression of prior OAB or BOO may be involved in this process (Chancellor, 2014). Alterations in active contraction and passive muscle stretch appear to play an important role as well (Young et al., 2013). Bladder ischemia has been linked to subsequent development of detrusor dysfunction and UAB. Studies using color flow Doppler ultrasound have shown there is a quantifiable decrease in pelvic arterial blood flow in some elderly patients with LUTS. This may be due to atherosclerosis or other vascular insufficiency (Kim et al., 2010; Pinggera et al., 2008). The development of animal models of UAB will help advance future research on this topic (Tyagi et al., 2014a).

Several different forms of UAB have been identified in geriatric patients, and this can manifest in several different ways. Detrusor failure can be caused by sacral nerve injury with development of cauda equina syndrome. Patients typically experience lower extremity weakness and problems with gait and mobility. Some may develop frank paraplegia. In these cases, the bladder typically has a low pressure during filling and does not contract well to void.

Acute urinary retention can be caused by BOO or detrusor failure. Decompression with an indwelling urinary catheter is usually required initially with careful monitoring for postobstructive diuresis and electrolyte fluctuations. Evaluation for renal insufficiency or hydronephrosis is also warranted. **Avoid catheter clamping before removal because this has not been shown to be of any clinical benefit and will only induce discomfort.** In men with a history of BOO from BPH, initiation of medical therapy with alpha-blockers or 5-alpha-reductase inhibitors can be considered.

DHIC is one of the more common conditions seen in geriatric practice (Resnick and Yalla, 1987; Yalla et al., 2007). This condition is characterized by urinary urgency and frequency resulting from DO during bladder filling and storage. However, during the voiding effort, the bladder contracts poorly and does not empty well. Because of this, patients experience urinary urgency and frequency but incomplete voiding and urinary retention.

Adequate treatment of UAB can be complex. In many cases, this may require intermittent bladder catheterization. However, in some patients this may be difficult or impossible because of comorbidity such as severe hand arthritis or cognitive impairment. Augmented voiding techniques including the Credé maneuver or bladder tapping may be used by some patients (Ersoz et al., 2013). Care should be taken to monitor the upper urinary tracts in these patients for development of hydronephrosis or other evidence of clinical deterioration.

Unfortunately, there is currently no effective pharmacologic therapy that improves bladder emptying in the case of underactive bladder. Theoretically, the cholinergic medications should lead to improved smooth muscle contraction in the urinary bladder. But **medications such as bethanechol have failed to demonstrate clinically efficacy.** A recent Cochrane review concluded that this medication should not be used for the treatment of urinary retention or underactive bladder (Lapitan et al., 2013).

Early qualitative studies have demonstrated the negative impacts on overall and health-related quality of life in people with UAB (Uren et al., 2017). Continued research and education on UAB will help advance our understanding of the clinical condition in geriatric patients (Dewulf et al., 2017; Griebling et al., 2014b).

Spinal cord injury is also a major cause of voiding dysfunction including urinary retention in older adults. Neurogenic bladder management with urinary retention typically involves CIC in patients who are able to do this. However, some patients with spinal injuries may require urinary diversion. The overall clinical needs of geriatric patients with neurogenic bladder resulting from spinal cord injury must be considered in the context of their overall health, and particularly their comorbidities and functional status (Chan et al., 2018).

Nocturia

Nocturia is one of the most common and bothersome urinary conditions that occurs in elderly patients (Wehrberger et al., 2012; Weiss and Blaivas, 2000). The ICS defines nocturia as “getting up from sleep in order to void” (Abrams et al., 2002). This is generally preceded and followed by additional episodes of sleep. Polysomnography studies have documented that a majority of episodes of nocturia occur during superficial rapid eye movement (REM) sleep (Bal et al., 2012; Krystal et al., 2010). However, waking to urinate can also lead to difficulty getting back to sleep with 46% of older adults in one survey reporting this as a substantial clinical problem (Endeshaw, 2009). Affected older adults also report worse disease burden, poor overall sleep quality, and an increased rate of falls compared with those who fall back to sleep more easily. Sleep duration is often decreased in older adults, and this has been identified as an independent risk factor for nocturia in elderly patients (Udo et al., 2009). Several biochemical processes appear to influence nocturia and nocturnal polyuria. Obstructive sleep apnea results in decreased antidiuretic hormone (ADH) secretion and increased brain natriuretic peptide (BNP), which can lead to nocturnal polyuria (Hoshiyama et al., 2014). Nighttime melatonin secretion is inversely proportional to nocturia in older adults (Obayashi et al., 2014). Worse nocturia severity has also been linked to progression of underlying neurologic disorders such as Parkinson disease (Vaughan et al., 2013). Improved understanding of these complex associations between comorbid conditions and nocturia may help to improve future options for diagnosis and treatment.

The epidemiology of nocturia is complex and is linked to underlying risk factors associated with the condition. There appear to be some underlying differences in nocturia between men and women resulting from a variety of anatomic and physiologic factors (Bing et al., 2007, 2008; Tikkinen et al., 2006). An epidemiologic survey of 6000 people in Finland revealed multiple associated conditions, including urinary urgency, snoring, BPH in men, and overweight and obesity (Tikkinen et al., 2009). At an individual level, urinary urgency appears to be one of the strongest correlated conditions. However, none of the conditions studies accounted for more than 50% of cases, even in age-adjusted risk analysis. Some modifiable behavioral factors have also been associated with nocturia, including alcohol consumption and cigarette smoking (Lee et al., 2012). Symptoms of nocturia can change over time and may resolve spontaneously in some cases (Pesonen et al., 2016).

Nocturia can have a substantial negative impact on quality of life. In general, one episode of nocturia per night is well tolerated by most people and is usually considered normal. However, **two or more episodes of nocturia nightly have been linked to diminished sleep quality, reduced overall and health-related quality of life, and other detrimental clinical outcomes** (Tikkinen et al., 2010). Nocturia has also been linked to depression in longitudinal research (Obayashi et al., 2017). Increased rates of morbidity and mortality have been linked to nocturia (van Doorn et al., 2012). **Worse nocturia severity has been directly correlated with increased rates of complication including falls, fractures, and other negative clinical outcomes** (Bing et al., 2007, 2008). This association appears to be independent of age and is more associated with severity of nocturia (Temml et al., 2009). This is true in community-dwelling older adults and those living in nursing homes and other facilities (Galizia et al., 2012). **Falls are associated with increased rates of hip and long bone fractures, which in turn increase the risk for immobility and mortality** (Nakagawa et al., 2010). Fat embolization from bone fractures can cause stroke and pulmonary embolus. Falls associated with nocturia can be caused by a number of factors, including problems with balance and gait, attempting to travel to the toilet in the dark, navigating obstacles that may be in the path to the bathroom, and other factors.

Even in younger people, increased rates of nocturia have been associated with increased mortality (Fitzgerald et al., 2007; Kupelian et al., 2011; Nakagawa et al., 2010). **This is likely due to the fact that nocturia may be a marker condition of other comorbid diseases,** including cardiovascular and pulmonary diseases among others. Elderly patients with nocturia who also suffer from being underweight are at increased risk of mortality compared with heavier patients (Negoro et al., 2015).

A careful history is useful in helping to identify potential causes of nocturia. Multiple different conditions can contribute to nocturia (Denys et al., 2017). These include nocturnal polyuria, medications that increase urine production or disrupt sleep, diabetes insipidus, the syndrome of inappropriate antidiuretic hormone (SIADH) production, hypertension, congestive heart failure, pulmonary or peripheral edema, obstructive sleep apnea, and other sleep-related disorders (Burgio et al., 2010; Guilleminault et al., 2004). A fluid intake and output diary can be helpful in differentiating causes of nocturia in many older patients.

Successful treatment of nocturia in elderly patients can be challenging and complex. **Because the cause of nocturia is typically multifactorial, single therapies provided in isolation are often ineffective, and multimodal therapy targeting different causes may be required.** Behavioral therapies and medications have been shown to be more effective in combination and should be focused on the underlying mechanisms of nocturia (Vaughan et al., 2009). Behavioral strategies that have shown promise include limiting evening fluid consumption, PFME training, delayed voiding methods, and urge-suppression techniques (Johnson et al., 2013). Use of diuretics during the earlier portions of the day may help to off-load excess fluid. Patients with peripheral edema may benefit from lying in a recumbent position earlier in the day to create a postural diuresis and offload some of this excess fluid before retiring to bed for the night. Use of pressure gradient stockings may also be helpful.

Obstructive sleep apnea is often treated with continuous positive airway pressure (CPAP) ventilation support. In patients with incomplete bladder emptying and nocturia, CIC performed at bedtime may permit better sleep by improving functional bladder capacity at night, thus allowing the bladder more time to fill during sleep. Use of assistive devices such as bedside commodes or handheld urinals can help to reduce difficulties associated with nocturia in older adults. This can be particularly useful in those with mobility limitations or where there is a strong risk for falls during nighttime toileting.

Desmopressin has been advocated as a potential pharmacologic treatment for nocturia caused by nocturnal polyuria. The overall expression of vasopressin receptors appears to increase with aging in the urinary bladder and the kidney (Birder et al., 2018). This makes it a potential pharmacologic target for treatment of nocturia. However, substantial caution should be exercised when using this medication, particularly in geriatric patients. Older adults tend to have less capacity for compensatory regulation of electrolyte imbalance. Hyponatremia is one of the major risks associated with use of desmopressin in elderly patients (Rembratt et al., 2006; Weatherall, 2004). Development of clinically significant hyponatremia can occur even several months after starting medication (Bae et al., 2007). In addition to potential hyponatremia, there are multiple other potential contraindications for use of vasopressin in older adults. These include risk of exacerbation of underlying heart failure, renal insufficiency, alterations in potassium and calcium excretion, and other electrolyte disturbances.

The primary risk is hyponatremia, which can be profound in some cases and can lead to negative outcomes including agitation, confusion, or coma. Staggered dosing of desmopressin and furosemide has been shown in short-term research to improve outcomes and possibly reduce associated risks of electrolyte abnormalities (Fu et al., 2011). Newer formulations with rapidly dissolving oral preparations or “melts,” which do not require water consumption for administration may be associated with lower rates of complications. Low-dose therapy (<0.2 mg) appears to be effective in many cases (Song et al., 2014). Dosing requirements may differ in men and women because of underlying physiologic differences, with older women appearing to require lower baseline dosages (Yamaguchi et al., 2013). Desmopressin was actually added to the most recent Beers criteria as a medication to avoid in older adults based on older research data (American Geriatrics Society, 2015). Clinical trials of desmopressin for treatment of nocturia in elderly patients are ongoing. Early data from clinical trials suggest that newer formulations with minimal dosing may be safe and effective for treatment of nocturia in the geriatric population (Kaminetsky et al., 2018).

Bowel Dysfunction and Fecal Incontinence

Older adults commonly experience difficulty with bowel function. This can be caused by changes in motility, absorption, and other physiologic alterations associated with the aging process. Fecal impaction can actually appear to be diarrhea because of liquid material oozing around a stool bolus leading to fecal incontinence, particularly in those with low anal closure pressures. Elderly patients often experience dual bowel and bladder incontinence because the same neural pathway controls both of these processes. **Fecal incontinence (FI) can be particularly problematic among older adults** (Hayden and Weiss, 2011; Quander et al., 2005). Health care providers must specifically ask about bowel function during clinical assessment. Older patients may not voluntarily provide information regarding bowel problems because of embarrassment or other personal reasons. Increased levels of functional dependence and a variety of other factors are associated with increased risk of developing fecal incontinence, particularly among nursing home residents (Bliss et al., 2018; Jerez-Roig et al., 2015).

Reported prevalence rates of FI range from 17% of community-dwelling women over the age of 85 to 43% of elderly women residing in nursing home facilities (Townsend et al., 2013). More recent data confirm these prevalence rates with 17.3% of community-dwelling older adults reporting having experienced accidental bowel leakage (Gorina et al., 2014). Among those receiving home health care services, FI was reported by 13.1% of those aged 65 to 74 years, and 20.8% for those aged 85 years and older. Patients in hospice care have reported prevalence of UI of 9.9%, FI 24.0%, and dual incontinence 28.0% (Gorina et al., 2014). **UI is highly correlated with FI, and older adults with either one of these conditions are at increased risk for developing the other problem.** Rectal hypersensitivity and anatomic defects of the anal sphincter muscle complex have been identified as additional risk factors for development of FI (Lewicky-Gaupp et al., 2009).

Constipation and FI are highly prevalent among nursing home residents. In one study, 81.1% of elderly nursing home residents had an average of 3 bowel movements every 5 days, and only 29% were classified as continent (Schnelle et al., 2009). These rates improved substantially with 74% “continent” using relatively simple targeted therapies, including prompted toileting. Multimodal therapy may also be useful in older adults with UI and FI and has been shown to substantially reduce problems with constipation (Schnelle et al., 2010).

Continence Promotion and Advocacy

Education of patients and providers is a critical aspect of continence promotion for older adults (Newman et al., 2017). There are a number of common myths about UI in geriatrics that hamper appropriate evaluation and treatment in many cases. **UI should never be considered a normal or inevitable part of the aging process.** Patients and providers need to be aware that there are often treatments that can substantially improve and in some cases completely eliminate incontinence. Many of these successful therapies involve nonsurgical methods. Surgery may be an appropriate and successful treatment option for some select patients with specific clinical indications.

Enhanced public awareness may improve access to and use of care services. An analysis of data on more than 82,000 elderly Medicare beneficiaries demonstrated a 37% prevalence of UI, but only 41% of those who experienced UI had spoken with a health care professional about their symptoms (Chang et al., 2008). Some have argued that systematic screening for UI may be beneficial among older women (Visser et al., 2013). In a survey study, elderly women indicated that they did not seek help because they did not feel their symptoms were severe enough to justify treatment (73.4%), they had already found a way to cope with symptoms (57.3%), they thought UI was a normal part of aging (46.9%), they thought there was no cure or effective treatment available (23.8%), or their general practitioner did not ask about UI (20.3%) (Visser et al., 2012). These findings demonstrate that there is a role for improved public and professional education and a need for advocacy on this topic.

Targeted continence promotion programs for older adults have been successful in the community setting. These can increase knowledge among patients suffering from incontinence and have been shown to encourage help seeking and self-treatment behaviors (Tannenbaum et al., 2010). Evidence-based self-management tools have been developed and can be useful in this process for motivated patients (Holroyd-Leduc et al., 2011). Future research will help improve understanding of the best methods for dissemination of this type of information among older adults suffering from UI and other urologic conditions.

Pelvic Organ Prolapse

POP is a common clinical condition seen in elderly women. Incidence and prevalence of POP increase with advancing age, but like other conditions it should not be considered an expected or normal part of the aging process. **Risk factors for POP in elderly women include history of prior pregnancy and vaginal delivery, prior pelvic trauma, and changes in tissue quality and structure.** Biopsy studies have shown that with advancing age, there is a progressive loss of smooth and striated muscle and an increase in collagen and other connective tissues in the urogenital diaphragm (Betschart et al., 2008). Apoptotic changes in pelvic floor tissues also occur that can predispose to prolapse (Saatli et al., 2014). These changes lead to laxity of pelvic floor architecture and subsequent loss of support.

Evaluation of POP in elderly women requires careful history and physical examination. Many older women describe the sensation of a vaginal bulge. This is often worse after physical activity or in the late afternoon or evening after being up and about during the day. **Severe prolapse can be associated with difficulties with urination or defecation because of urethral angulation or anatomic changes in rectal configuration.** Some women, particularly with a large prolapse, describe a need to manually reduce the bulge with their fingers to void or defecate. The clinician should attempt to reduce the prolapse during pelvic examination. The position of the uterus if present, and the vaginal cuff should be assessed. Prolapse of the vaginal apex may require specific surgical fixation to either the sacrospinous or uterosacral ligaments.

Pessaries can be useful in treatment of POP in elderly women (Griebling, 2016a). These come in a wide variety of shapes and sizes and must be individually fit to the patient. When the pessary is correctly sized, the patient is usually unable to feel it in the vagina. If the pessary is too small, it will tend to fall out with physical activity or straining. If it is too large, the pessary will tend to be uncomfortable and may cause tissue irritation or erosion over time. Pessaries should be removed and cleaned periodically, and the tissue integrity checked (Khaja and Freeman, 2014). In patients with limited hand dexterity or cognitive impairment, this may require assistance from a care provider. Visiting nurse services can sometime help with pessary management. It is important that the pessary be routinely checked to avoid complications associated with neglect, including erosion into surrounding structures or vaginal infections. Concomitant use of vaginal estrogen can be useful to help prevent some of these complications.

Pessaries offer potential advantages of avoiding surgery and allowing patients self-control over the clinical situation. Many older women do very well with pessaries and will continue to use them over time (Ramsay et al., 2016). Factors associated with increased long-term success include age of at least 72 years, careful fitting, and provision of clear instructions for use (Friedman et al., 2010). Successful pessary use has been associated with improved overall and health-related quality of life and improved body image in elderly women with POP

(Patel et al., 2010). However, some older women do not like using pessaries or do not want to be bothered with having to remove and replace the device on a regular basis. If the pessary improves genitourinary symptoms but the patient does not like using the device, this may indicate that she could experience a good functional outcome with surgery.

Surgical repairs for POP are feasible even in elderly women, and most women recover to their baseline functional status after surgery (Oliphant et al., 2014). These procedures can be done using vaginal, laparoscopic, robotic, or open surgical techniques. A variety of native tissue repairs and procedures using biologic or mesh grafts can be used. Several studies have shown that mesh repairs can be successful for treatment of POP even in elderly women (Gabriel et al., 2010; Shah et al., 2004). However, as with any surgical treatment, patients do have to be very carefully counseled about use of mesh grafts and potential risks and benefits associated with this technique (Mohammed et al., 2013; Reynolds et al., 2013). Surgical repair with native tissue grafts such as autologous or cadaveric fascia has also been successfully used in elderly women with POP and UI (Carey and Leach, 2004). Many older women may choose to avoid or delay surgery for POP. However, in those who do eventually undergo surgical repair, there is evidence to suggest that increased time between development of symptoms, particularly after menopause, and subsequent surgery is associated with poorer subjective postoperative improvements (Ahn et al., 2010). Recent data show low rates of complications (5.6%) for elderly women undergoing surgical repair for POP (Körnig et al., 2018).

One surgical option that can be considered for select older women with POP is colpocleisis with perineoplasty. This procedure essentially reduces the prolapse and closes the vaginal introitus. This should be considered a permanent and nonreversible procedure. Two different surgical techniques are used. In women who still have their uterus, the procedure is generally performed leaving lateral channels on each side of the vaginal vault to permit uterine drainage. Total colpocleisis is used in women after hysterectomy and consists of a denudation of the vaginal mucosa and subsequent reduction and conical closure of the prolapse. Perineoplasty is performed to reduce the size of the vaginal introitus and prevent recurrence of bulging from the outlet. Women must be expressly counseled that penetrative sexual activity will not be possible after this type of surgery. However, it does not preclude other forms of erotic or sexual activity. Reported success rates with colpocleisis have been high, and rates of subsequent regret after having the procedure are low (Koski et al., 2012; Vij et al., 2014). Colpocleisis has been shown to improve bladder and bowel symptoms in women with a history of significant prolapse (Gutman et al., 2010; Vij et al., 2014).

Urethral caruncle is a protrusion of tissue from the urethra and is seen more commonly in elderly than in younger women. In most cases these are painless and benign. **Unless they are large, they often do not affect voiding function** (Ozkurkcugil et al., 2010). Topical estrogen therapy is useful and often leads to tissue contraction and involution of the caruncle. Surgical excision is not typically necessary. However, if surgery is performed, care must be taken to avoid damage to the external urethral sphincter, which could lead to stress UI.

Urinary Tract Infections and Asymptomatic Bacteriuria

UTI is one of the most common clinical conditions seen in older adults, and particularly in elderly women. **It is important to distinguish between symptomatic UTIs and asymptomatic bacteriuria.** Overtreatment of asymptomatic bacteriuria has been associated with negative outcomes, including potential medication side effects and increased bacterial resistance (Köves et al., 2017). Symptomatic infections require evaluation and treatment, usually with antibiotic therapy. **Urinary cultures are strongly recommended to verify the infection, determine the associated bacterial organism, and identify antibiotic susceptibility or resistance patterns.** Empiric treatment with antibiotics may have to be modified depending on the results of the urine culture and drug susceptibility panels. If older adults have difficulty providing a clean-catch urine specimen, a catheterized urine sample should be obtained to help with accurate diagnosis (Gordon et al., 2013).

Symptoms of acute UTI may include urinary urgency and frequency, cloudy or foul-smelling urine, fever, bladder pain, and dysuria. However, many older adults may not show these symptoms because of alterations in the immunologic or other systems (Arinzon et al., 2012). Instead, **elderly patients may experience what have been called “atypical” symptoms in other populations. These include confusion, agitation, lethargy, and anorexia among others** (Juthani-Mehta et al., 2009). Acute UTIs in older adults can lead to clinically symptomatic delirium (Eriksson et al., 2011). Urine cultures should be checked to determine if an associated UTI is present, and appropriate antibiotic therapy initiated if indicated.

More complex UTIs such as pyelonephritis are often associated with underlying comorbidity, including diabetes, anemia, and urolithiasis (Kang et al., 2008). Antibiotic therapy should be instituted in most cases and should be based on culture and drug susceptibility results. **Urosepsis in elderly patients can be serious, and increased mortality is seen in this population.** Associated factors that increase the risk of mortality from bacteremia in geriatric patients include advanced age (≥85 years), chronic renal disease, severe cognitive impairment, and hypothermia (Rebelo et al., 2011). Hospital-acquired UTIs also appear to be a greater risk for mortality compared with community-acquired infections, at least among older adults in acute hospital settings (Chin et al., 2011). Treatment of these serious infections typically requires directed antibiotic therapy and fluid resuscitation. Fungal UTIs occur more commonly with advanced age, and particularly in patients with reduced immune status, including those with a history of transplant, advanced human immunodeficiency virus (HIV) disease or acquired immunodeficiency syndrome, and those with poorly controlled diabetes. Treatment with antifungal agents such as fluconazole can be effective in many cases (Fraisse et al., 2011). Antibiotic treatment in nursing home settings should be done judiciously based on culture results to help reduce the risk of developing increased antibiotic resistance in this setting (Sundvall et al., 2014).

In contrast, **asymptomatic bacteriuria is very common in older adults and generally does not require therapy. Approximately 10% to 20% of all older women living in the community will have bacteria in their urine on routine analysis, and rates are typically higher in long-term care and other institutional settings** (Varli et al., 2012). Although less common than in women, rates of asymptomatic bacteriuria still approach about 10% in community-dwelling elderly men (Juthani-Mehta, 2007). Asymptomatic bacteriuria has been associated with increased serum and urinary inflammatory cytokines, but this does not necessitate antibiotic therapy (Chang et al., 2012). Dipstick urinalysis can be useful in diagnosis, particularly in long-term care settings, with a goal to correctly differentiate symptomatic UTI and asymptomatic bacteriuria and reduce overuse of antibiotics when not clinically indicated (Bonnal et al., 2008; Sundvall and Gunnarsson, 2009). The AGS has included avoidance of antimicrobial therapy for asymptomatic bacteriuria as one of their original five things to avoid or question as part of the Choosing Wisely campaign (AGS Choosing Wisely Workgroup, 2013).

A variety of clinical factors increase risk of UTIs in older adults. CAUTIs are one of the most prevalent types of infection seen in acute care hospitals and other inpatient settings (Daniels et al., 2014). CIC can reduce infection rates in patients with chronic urinary retention, although one study of elderly stroke survivors did show a trend toward increased infection rates (Stott et al., 2009). However, this association disappeared after controlling for stroke severity. Body mass index has been linked to UTI in older adults with obese and significantly underweight elderly patients having higher rates of infection (Dorner et al., 2010).

Administration of vaginal estrogens can be useful in reducing rates of symptomatic UTIs in elderly women. After menopause, there is loss of the natural acidification of vaginal fluid. This increased alkalinity prevents growth of *Lactobacillus* sp., the natural flora in the vaginal vault. *Lactobacillus* sp. is an important part of the natural host-defense mechanism to prevent UTI. **Addition of topical vaginal estrogens can help reacidify vaginal fluid, which permits growth of *Lactobacillus* sp.** This in turn helps to kill off pathogenic bacteria that cause symptomatic UTI. The medication comes in several different forms, including vaginal creams, vaginal tablets or suppositories, and a small ring-shaped device that releases estrogen continuously over several months. If using creams, a small amount with fingertip application in the vagina is usually sufficient administered three times weekly at bedtime. Vaginal estrogens are generally contraindicated in women with a personal history of either breast or uterine cancer. However, emerging data suggest that women with known estrogen receptor negative (ER−) breast cancers may be able to safely use this type of therapy. The amount of estrogen absorbed systemically is usually low. Patients with this type of history should consult with their oncologist before starting therapy.

The use of cranberry juice or other cranberry supplements is popular with many people as a form of UTI prophylaxis. This works by interaction between fructose and proanthocyanidins in cranberry and bacterial cell walls, which leads to inhibition of adherence to the urothelium. Although many people describe clinical efficacy, results in scientific studies have been mixed. Recent data from a randomized, double-blind, placebo-controlled trial in nursing home residents showed there were reductions in infection rates, but these were limited to those patients with a previous high-rate of infections (Caljouw et al., 2014). The overall cost effectiveness of cranberry therapy also appears to be limited based on observed clinical outcomes and economic analysis, which demonstrated an estimated cost of more than $5200 annually to prevent one clinically significant UTI (van den Hout et al., 2014).

Chronic antibiotic use for UTI prophylaxis should be avoided unless no

other options are available because of an increased risk of development of resistant organisms. The choice of antibiotics is also important. Although it can be useful for short treatment of acute infections, nitrofurantoin should be avoided for chronic prophylaxis because of risks of pulmonary fibrosis and associated complications in older adults. In addition, it should be avoided in those with impaired renal function defined as creatinine clearance (CrCl) less than 30 mL/min (American Geriatrics Society Beers Criteria Update Expert Panel 2015; Leung et al., 2007).

Evaluation and management of UTIs in nursing home and assisted care settings require special consideration. Overuse of antibiotics is very common in these locations, and this may be due to the substantial challenge of correctly diagnosing symptomatic UTIs in older nursing home residents who may have subtle or atypical symptoms (D'Agata et al., 2013; Juthani-Mehta et al., 2007; Kistler et al., 2013). In addition to avoiding treatment of asymptomatic bacteriuria, careful antibiotic selection is important. **Use of antibiograms based on local prevalence of specific organisms can help guide therapy.** Guidelines from professional organizations can also help to reduce overuse of specific antibiotics that may increase the risk of developing drug-resistant infection in given locations (Daneman et al., 2011; Fagan et al., 2012). As with acute care hospitals, data suggest that environmental contamination in nursing homes may increase the risk of some types of infections, including methicillin-resistant *Staphylococcus aureus* (Murphy et al., 2012). Strict hand washing and other infection prevention methods can help to substantially reduce this risk.

However, several studies have recently shown less than 10% of UTIs diagnosed in nursing home settings actually met established surveillance guidelines that include symptoms and culture results (Ryan et al., 2018).

The costs associated with evaluation and treatment of UTIs in the United States are staggering and surpass almost all of the other major genitourinary disorders (Griebling, 2005a, 2005b). This is due to multiple factors including a high incidence and prevalence of UTIs but also excess evaluation and overtreatment of conditions that may not require therapy including asymptomatic bacteriuria. A sizeable volume of clinical care for UTIs is provided in emergency room settings, which exponentially increases associated costs.

Hematuria

Hematuria is a common clinical condition seen in elderly patients,

particularly those on anticoagulants. Patients with gross or persistent microhematuria should undergo clinical evaluation (Davis et al., 2012). The use of anticoagulation is common in older adults, particularly for prevention of stroke in those with atrial fibrillation and other arrhythmias, deep vein thrombosis, and other hematologic disorders. Supratherapeutic anticoagulation, particularly with warfarin, has been associated with an increased risk of developing acute kidney injury (AKI) (Lim and Campbell, 2013).

Genitourinary Trauma

Evaluation and management of genitourinary trauma in elderly patients requires some special considerations. **Compared with younger adults, elderly patients are more likely to experience blunt rather than penetrating traumatic injuries. Underlying comorbidity and clinical conditions associated with the aging process put geriatric patients at higher risk for poor outcomes.** For example, falls are one of the leading causes of traumatic injuries among older adults, with more than 2.3 million emergency room visits for this annually in the United States (CDC, 2010). The rate of genitourinary injuries resulting from falls in geriatric patients is 26.5% compared with 8.4% in younger adults ($P < 0.0001$) (Bjurlin et al., 2011).

The basic principles of management of genitourinary trauma do not differ considerably based solely on age. The decision for conservative versus more aggressive therapy should be based primarily on the nature of the injury. However, careful consideration of associated comorbidity with medical optimization of these other conditions is essential for successful management. For example, **older adults with osteoporosis may be at higher risk for pelvic fracture because of falls compared with those without this associated comorbidity.** Treatment in these patients may require different techniques including greater use of embolization therapy compared with younger or healthier patients (Kimbrell et al., 2004). **Men on androgen deprivation therapy are at higher risk for hip and long bone fractures because of changes in bone mineral density associated with hormonal therapy** (James et al., 2014). Treatment with agents such as alendronate or zoledronic acid may decrease this facture risk in these patients (Campbell et al., 2010; Planas et al., 2009).

Older adults are also more likely to require discharge to either a rehabilitation facility or nursing home (13.6% and 18.5%, respectively) compared with younger adults (8.6% and 3.1%, respectively) after acute management for genitourinary trauma (both, $P < 0.0001$) (Bjurlin et al., 2011). Geriatric trauma is a relatively new scientific field, and additional work will be needed to better identify specific protocols for this population. Early research has shown inclusion of data on chronic comorbidities in geriatric trauma patients may be superior to traditional measures of vital signs and injury pattern alone in decision-making and clinical outcomes (Brooks et al., 2014). In addition, there is interest in creating and validating an index of frailty specific for elderly trauma patients to see if this may influence evaluation, treatment, and outcomes (Joseph et al., 2014).

Genitourinary Malignancies

Almost all of the genitourinary cancers occur with greater incidence and prevalence in geriatric patients compared with their younger counterparts. The one exception is testis cancer, in which lymphoma is the most common histology seen in geriatric men.

Prostate Cancer

The evaluation and treatment of prostate cancer in elderly men differs somewhat from the general population. The US Preventive Services Task Force recommendation does not support routine screening for prostate cancer in any group, although this is highly controversial (Moyer et al., 2012; US Preventive Services Task Force, 2008). **When prostate cancer screening is performed, it is generally recommended that this be discontinued in men once they reach 70 to 75 years of age.** This is because definitive therapy for prostate cancer is typically reserved for men with an estimated remaining life expectancy of 10 or more years (Hoffman et al., 2010). Because the mean life expectancy for men in the United States is approximately 82 to 84 years, most clinicians would argue to limit use of definitive therapy with radical prostatectomy or radiation therapy to those aged 75 years or younger. Interestingly, in survey research, about a third of older adults indicate that they would rather not know either their predicted life expectancy or survival probability (Clarke et al., 2008). This can be problematic in relation to discussions about clinical decisions in this population.

Recent research has examined factors that can be associated with recommendations to stop screening, including prostate-specific antigen (PSA) velocity and genetics, and risk factor group profiles (Tang et al., 2010, 2011). Despite these recommendations, many older men choose to continue screening for various personal reasons (Caire et al., 2010; von Wagner et al., 2013). There is also some variation among practitioners in terms of following these guidelines for discontinuing screening in geriatric men (Bynum et al., 2010; Hudson et al., 2009; Whittle, 2010). **In contrast to routine screening, targeted diagnosis in select patients at risk for prostate cancer can help to guide therapy, even if it is not done with curative intent** (Abdollah et al., 2016; Paterson et al., 2013). This can help in the overall care and management of disease in older men.

There are a number of caveats that must be considered based on the overall clinical situation for each man. The AUA has published guidelines on treatment of clinically localized prostate cancer that include considerations related to overall health, comorbidity, and age (Thompson et al., 2007). The International Society of Geriatric Oncology recently published results of a study indicating importance of including assessment of ADL and IADL function in the care decisions for elderly men with prostate cancer (Droz et al., 2010). The combination of functional status and disease burden combined with predicted longevity and other parameters may help with this complex decision process.

Although prostate cancer in elderly men is often an indolent, slow-growing disease, some have more aggressive cancers (Kunz et al., 2013; Scosyrev et al., 2012). In addition, some studies have shown that elderly men tend to have higher-risk disease (Vatandoust et al., 2018). Various factors may predispose to more advanced prostate cancer in elderly men including a history of hypertriglyceridemia (Hayashi et al., 2012). However, other studies continue to show that most elderly men die of other diseases, including cardiovascular and pulmonary disorders (Jeong et al., 2009; Ketchandji et al., 2009). Multiple risk factors for prostate cancer in elderly men have been identified, including genetics and diet. Recently, an epidemiologic study has identified a potential association between Alzheimer disease and prostate cancer, which may be linked to androgen receptor reactivation resulting from oxidative stress (Lin et al., 2018). There is also evidence linking components of the metabolic syndrome with increased prostate cancer risk in elderly men (Zhang et al., 2015).

Several studies have shown that elderly men who undergo radical prostatectomy can have good clinical outcomes that in many cases are equivalent to those seen in younger men (Greco et al., 2009; Namiki et al., 2010; Pierorazio et al., 2010). However, other studies have demonstrated that elderly men are at higher risk for negative clinical outcomes, including upgrading and upstaging of their disease, greater risk for biochemical recurrence, and surgical complications (Ko et al., 2013; Richstone et al., 2008; Trinh et al., 2012). Radiation therapy is often used in elderly prostate cancer patients because it is considered to be less invasive. It has been associated with acceptable clinical outcomes including health-related quality of life, although as with any treatment there are risks for incontinence and erectile dysfunction among others (Mirza et al., 2011; Namiki et al., 2010). UI can be particularly bothersome in elderly men treated for prostate cancer. This can have substantial negative effects on activity, mood, and quality of life (Kopp et al., 2013; Park et al., 2012). Cryotherapy has been advocated as a possible treatment for elderly men with organ-confined prostate cancer who may not be candidates for more invasive forms of therapy (Dhar et al., 2011).

In elderly men with metastatic prostate cancer, hormonal therapy or chemotherapy may be used to reduce disease progression. Docetaxel has been shown to improve overall survival in early trials (Miyake et al., 2012). **Androgen deprivation therapy can certainly be useful in select patients but is also associated with potential adverse effects, particularly in elderly men.** ADT has been shown to increase the risk of cardiovascular disease, myocardial infarction, and diabetes in elderly men (Keating, 2013). Changes in bone mineral density are associated with increased risk of fractures because of osteoporosis and osteopenia (Shao et al., 2013). These effects can be tempered by use of agents such as alendronate and zoledronic acid (Campbell et al., 2010; Planas et al., 2009). Other negative side effects include decreased libido, gynecomastia, hot flashes, and sexual dysfunction. ADT has also been linked to development of sarcopenia in elderly men (Reis et al., 2009). ADT has been associated with an increased risk for depression and potential risk of suicidality (Chung et al., 2017; Welk et al., 2017; Zhang et al., 2017).

Finally the cost of ADT may be a barrier to ongoing therapy for some patients (Krahn et al., 2011).

Bladder Cancer

Bladder cancer is one of the most common urologic malignancies seen in the geriatric population, and incidence and prevalence increase substantially with advancing age. Because of the long latency of carcinogen exposure, age is one of the most important independent risk factors for development of bladder cancer with a median age at diagnosis of more than 70 years (Shariat et al., 2010b). In general, diagnosis is similar in elderly and younger patients. Diagnosis of bladder cancer is associated with negative effects on overall and health-related quality of life with reductions in physical and mental health domains (Fung et al., 2014). Conversely, increased rates of depression and other psychiatric illness are associated with worse survival outcomes in older adults treated for bladder cancer (Jazzar et al., 2018).

Guidelines have been developed for evaluation and management of bladder cancer, and an audit study showed that these are generally followed (88.8%) in elderly patients (Bolenz et al., 2010). The role of tumor restaging with repeat resection has been demonstrated in elderly patients, although rates have been shown to be low among Medicare beneficiaries (Skolarus et al., 2011). This can be very useful to help identify muscle-invasive disease, which may require different treatment. Interestingly, bacille Calmette-Guérin (BCG) therapy has shown decreased efficacy in elderly patients with non–muscle-invasive bladder cancer compared with younger patients (Margel et al., 2011). This may be due to an age-related decease in the immune system and reduced ability to mount an immune response to therapy in geriatric patients. A recent study examined extending the initial BCG dosing schedule to every other week for more frail older adults and demonstrated improved tolerability with no significant reduction in clinical survival outcomes (Racioppi et al., 2018).

Treatment for muscle-invasive bladder cancer has generally focused on surgical extirpation with radical cystectomy and urinary diversion. From a surgical standpoint, this is one of the most invasive and potentially morbid surgeries done in the field of urology. In addition, many of these patients have substantial underlying comorbidity. For example, the condition is strongly linked to a history of smoking, which can predispose to lung disorders such as chronic obstructive pulmonary disease (COPD) and restrictive airway disease. These increase the risk of anesthetic complications in this already vulnerable population.

Multiple studies have demonstrated that with careful preoperative planning and intraoperative and postoperative management, radical cystectomy can be accomplished safely even in elderly patients (Guillotreau et al., 2012; May et al., 2007). This appears to convey a potential survival advantage in many patients (Tyritzis et al., 2012). However, this must be evaluated within the context of overall health and comorbidity. **Many patients with bladder cancer may die of other competing conditions, and this must be considered when making treatment decisions for elderly patients with muscle-invasive bladder cancer** (Donat et al., 2010; Fisher et al., 2009; Resorlu et al., 2009). Some studies have shown an increased rate of peri- and postoperative complications in elderly patients undergoing radical cystectomy, likely resulting from other chronic disease and functional status (Liberman et al., 2011; Lund et al., 2010). Sarcopenia, a key component of the frailty phenotype, appears to be a predictor of postoperative complications in elderly women undergoing radical cystectomy (Smith et al., 2014). Diminished performance status has been shown to be a negative predictor of outcomes among geriatric patients treated for muscle-invasive bladder cancer (Weizer et al., 2007).

Bladder-sparing therapies with endoscopic resection and adjuvant chemotherapy and/or radiation have been examined (McPherson et al., 2017; Williams et al., 2018). Some studies have shown similar survival rates for more conservative therapy compared with radical cystectomy (Martini et al., 2013). However, overall time in hospital is often greater for those treated with bladder-sparing therapies, and this can have a negative impact on remaining quality of life (Wehrberger et al., 2010). Other data suggest very elderly patients and those with more clinical comorbidity have poorer outcomes in terms of overall and cancer-specific survival (Kohjimoto et al., 2010; Tran et al., 2009). A recent large database study demonstrated trimodal therapy had inferior survival compared with older adults who underwent radical cystectomy (Williams et al., 2018). Radiation therapy has been used mostly for palliation of significant bleeding in patients who are otherwise not suitable surgical candidates (Kouloulias et al., 2013). This therapy appears to be well tolerated in these select patients.

Kidney Cancer

Kidney cancer is often diagnosed as an incidental finding in geriatric patients undergoing abdominal imaging for other conditions. Over the past 30 years, there has been a steady increase of 2% to 3% annually in the incidence of kidney cancer diagnoses (Chow et al., 1999). **Although increased rates of kidney cancer have been seen in all age groups, the largest have been identified in those in the seventh and eighth decades of life** (Katz et al., 1994). In elderly patients with small tumors, surveillance is feasible and may preclude the need for invasive surgery (O'Malley et al., 2010). Advanced age over 75 years has been identified as a risk for more advanced disease, and older adults may need to be watched with greater caution. It is important to consider overall health and comorbidity when making treatment decisions. Use of measures such as the CCI can be useful in this regard and can help identify those who may be at substantially higher risk with treatment (Charlson et al., 1987; O'Connor et al., 2009).

Older adults have been shown to tolerate radical and partial nephrectomy (Sandberg et al., 2014). In general, complication rates do not appear to be substantially influenced by chronologic age but more by comorbidity (Roos et al., 2008; Sun et al., 2012). Laparoscopic and robotic procedures for partial nephrectomy appear to be well tolerated by older adults with similar clinical outcomes and complication rates compared with younger patients (Guzzo et al., 2009; Hillyer et al., 2012; Thomas et al., 2009). However, rates of use of partial nephrectomy in elderly patients still lag behind younger cohorts (Kates et al., 2011). The reasons for this are unclear but may be based on concern over underlying clinical conditions and ability to perform surgery in more frail older adults.

In patients with more advanced disease, cytoreductive nephrectomy has been used successfully in elderly individuals, although some complications including need for transfusion are higher in geriatric patients (Kader et al., 2007; Sun et al., 2012). Subsequent immunotherapy may be difficult in some patients, particularly if they have functional impairments and decreased overall performance status. Radical nephroureterectomy has been described in geriatric patients with upper tract urothelial cancers, although reported cancer-specific survival has been lower in those older than 80 years of age compared with younger patients (Shariat et al., 2010a).

Testis Cancer

Although testis cancer can occur at any age, most germ cell tumors occur in young men between the ages of 15 and 35. **In geriatric men, the most common testicular malignancy is lymphoma** (Shih et al., 2014). **This should be evaluated and treated as a systemic condition because isolated testicular involvement is rare.** When germ cell tumors of the testis do occur in elderly men, evaluation and general treatment principles should follow those of younger men. One important caveat is that doses of chemotherapeutic agents may have to be adjusted based on comorbidity that affects renal, hepatic, or pulmonary function. This highlights the need for a thorough geriatric assessment in these patients. With successful treatment, life expectancy approaches that of other elderly men without testis cancer (Wheater et al., 2011).

Urologic Cancers and Other Health Issues in Older Adults

A diagnosis of cancer can have substantial impacts on overall health, including multiple domains of health-related quality of life. Psychological stress of dealing with a cancer diagnosis and the associated treatments can be substantial for patients and their family and friends (Dräger et al., 2017). Increased research efforts are being targeted at cancer survivors and caregivers to help ease this process.

Sexual Health in Elderly Women and Men

Sexual health is an important part of life for most adults, even at advanced age, and has been linked to improved overall quality of life and an improved sense of well-being (Flynn and Gow, 2015; Lee DM et al., 2016). **Many older adults wish to remain sexually active through their life** (Hyde et al., 2010). Data from the National Survey of Sexual Health and Behavior (NSSHB) in 2009 demonstrated that 20% to 30% of all older adult men and women remained sexually active well into their 80s (Schick et al., 2010). **A common myth is that older adults are not able or interested in participating in sexual activity. Forms of sexual expression may change with time over the lifespan** (Lindau et al., 2007). Lack of a partner is a limiting factor for many older adults. Penetrative sexual activity may become less important for some older adults, and there may be an increased emphasis on intimacy and other types of erotic interaction. Masturbation may become an important form of sexual expression for many older adults.

Comorbidity plays an important role in sexual health for many older adults (Appa et al., 2014). Those with better overall health tend to be more sexually active than those with poorer functional health status (Bach et al., 2013; Lindau and Gavrilova, 2010). **Changes in sexual health may be a sign or symptom of underlying systemic disorders.** Multiple studies have linked obesity, diabetes, cardiovascular disease, and neurologic disorders such as Parkinson disease and stroke to erectile dysfunction in elderly men (Garimella et al., 2013; Justo et al., 2010; Marinkovic and Badlani, 2001; Riedner et al., 2006; Seftel, 2003). Alterations in sex hormones and testis function have been shown to influence erectile function and cardiovascular health in elderly men (Rastrelli et al., 2013). UI and other LUTS can negatively influence sexual health for many older adults (Griebling, 2006; Tannenbaum et al., 2006). Prevalence of UI during sexual activity in women has been shown to be as high as 26% (Visser et al., 2014). **Frailty affects multiple physical and psychosocial domains and has been shown to be linked to worse sexual health status** (Lee et al., 2013). Other physical health issues may influence the ability to engage in sexual activity. Severe arthritis may make some positions for intercourse painful or impossible. Atrophic vaginitis can cause dyspareunia in elderly women. Use of water-based lubricants and vaginal estrogen replacement therapy may be useful in these cases. Many chronic diseases that affect sexual health tend to be underreported and underdiagnosed among older adults. For example, hypogonadism, erectile dysfunction, and osteoporosis are conditions that influence sexuality and overall health that frequently remain undiagnosed in elderly men (Frost et al., 2012).

Sexual health has also been closely linked to mental health in older adults, with higher rates of depression noted in those with erectile or sexual dysfunction (Cheng et al., 2007; Korfage et al., 2009). Satisfactory sexual function has been linked to improved sense of well-being in older men and women (Lee et al., 2016). Cognitive impairment may also negatively influence sexuality in elderly people (Wright and Jenks, 2016). Body image is an important factor with regard to sexual satisfaction and mental health regarding sexuality (Carr et al., 2013). This can be affected by a number of factors including weight, body mass index, and history of prior genitourinary cancer surgery or stoma formation. In longitudinal studies of men, regular sexual activity has been identified as a protective factor in continued sexual health and is associated with lower rates of subsequent erectile dysfunction (Koskimäki et al., 2008).

There are important differences in human sexuality between men and women. In comparison with the plethora of data on evaluation and treatment of erectile dysfunction in men, there has been much less research conducted examining sexual response and health needs in elderly women. **Population-based research does show that many elderly women remain interested in sex and have sexual health care concerns that deserve clinical attention** (Huang et al., 2009; Schick et al., 2010). As with men, comorbid disease such as metabolic syndrome and diabetes can have a negative influence on sexual health (Kim et al., 2011). Older women have been found to place strong emphasis on relationships and psychosocial aspects of sexuality including intimacy (Kim and Jeon, 2013). Improved sexual function has been linked to better self-rated health and life satisfaction in cohort studies of geriatric women (Thompson et al., 2011; Woloski-Wruble et al., 2010). In women who have undergone prior treatment for urologic or gynecologic disease, treatment of the underlying pathology can have a substantial impact on sexual health, and this must be considered in evaluation and treatment (Ratner et al., 2011).

Environmental factors can influence sexual health for many older adults. In some cases, elderly persons may live with extended family or be in situations where privacy for sexual activity may be an issue. **Sexual health in nursing home residents deserves special consideration.** There has been an increased awareness and understanding of this in recent years, and many nursing homes work to accommodate this for residents (Mroczek et al., 2013). This may include allowing couples to live in the same room and share a bed, providing privacy and time free from interruptions or medical care, and offering specific medical and nursing care for sexual health needs. Recent research has worked to develop and validate an assessment instrument specific for sexual health in nursing home residents (Bauer et al., 2014). **In patients with dementia and other cognitive impairment, inappropriate displays of sexual behavior may occur and can be problematic. Ethical considerations include assessment of the broadly defined capacity for a person to make decisions regarding sexual activity** (Wilkins, 2015)**. Specific evaluation and treatment tailored to these issues can be useful in these cases** (Bardell et al., 2011).

Treatment of sexual health problems should be designed to address the needs of each individual patient. This must be done in the context of overall health and comorbidity. For example, elderly men with heart disease may not be candidates for PDE-5 inhibitors if they have a history of chest pain and use nitrates or take medications that contradict use of this treatment. However, in carefully selected patients, oral medications for treatment of ED may be safe and effective (Oelke et al., 2017). Some elderly men may have physical or cognitive impairments that limit the use of other therapies such as penile injections or vacuum erection devices. Surgery with placement of a penile prosthesis may be an option for some patients but could be limited in those who are poor surgical candidates. Some men do well with this, and advanced age alone should not be the deciding factor for selection for surgery (Al-Najar et al., 2009).

Some adults may engage in relatively high-risk sexual behaviors, and this can put them at risk for transmission of sexually transmitted diseases including HIV. Condom use in this age group has been reported to be relatively low overall and may increase risk for some people (Choe et al., 2011; Schick et al., 2010). This generation was never really targeted in public health campaigns about safer sex, and specific counseling about this is warranted. Some health care providers may lack awareness or expertise about geriatric sexuality. **Clinicians need to appreciate their own level of comfort and knowledge in providing sexual health care in the geriatric population and seek additional information or**

consultation with others if needed.

Sexual orientation is an important factor to consider in sexual health care. To date there has been relatively little research on the specific sexual health needs or goals of elderly lesbian, gay, or bisexual persons (Griebling, 2016b). There has recently been increased interest in this area, and a national summit identified research and clinical needs specific to this population in relation to cancer care (Burkhalter et al., 2016). Additional work in this field will help to increase understanding to improve quality of care. Transgender older adults may also have unique urologic needs, including hormonal replacement and care after reconstructive surgery (Gooren and Lips, 2014). Cultural and religious views play an important role in human sexuality and should be considered and respected in the evaluation and treatment of sexual health in the older adult population. **The goal should be to provide sexual health care that is respectful of each patient's needs, desires, and goals of therapy.**

Discharge Planning and Care Coordination

Successful management of geriatric urology patients, particularly those undergoing surgical therapy, requires careful coordination and planning. Within this context, discharge planning is vitally important. **Many older adults admitted to hospital or who undergo surgery will lose independence of at least one of the ADLs at least temporarily. Some may manifest new onset or exacerbation of previously existing complex geriatric syndromes** (Bell et al., 2016). This may necessitate assistance from caregivers or transition to another place for care. A variety of options are available after discharge from the acute care hospital including home health nursing or other care services, inpatient or outpatient rehabilitation, and placement in a skilled care facility. Nearly $40 billion dollars are spent annually on this type of post-discharge care, which represents about 10% of the total Medicare budget (Robinson et al., 2011). Full recovery to pre-hospitalization baseline levels can occur but is less common than some level of continued impairment (Gill et al., 2009).

High-quality communication between acute care discharging hospital staff and receiving staff at long-term care facilities can greatly facilitate these transitions (King et al., 2013). Goals of care must be carefully considered, and needs and abilities of family or other loved ones to assist in the process must be assessed. Cost is an important factor, and options may be determined in part by coverage available to individual patients**. Ideally, discharge planning should begin as**

early as possible when treatment determinations are being made. If the patients are to return to their home in the community, what is the environment like and how will this influence function? Are there stairs in the home and are they able to maneuver them safely? What are the toilet facilities like in the home, and are modifications such as grab bars, a bedside commode, or other accommodations needed? Input from professionals in multiple health care disciplines including urology, nursing, physical and occupational therapy, social services, and others can be extremely helpful. The psychological and emotional needs of the patient and caregivers should also be considered (Farage et al., 2008; Gotoh et al., 2009). Development of UI can be particularly stressful for older adults who may already have substantial other requirements (deVries et al., 2012). Particularly in cases in which care needs are significant or require extensive time, caregiver burden must be considered (Tamanini et al., 2011).

Elder Mistreatment

Mistreatment of older adults is an unfortunate but common problem that requires vigilance and a high index of suspicion for optimal diagnosis and intervention. **Screening for elder mistreatment is a responsibility of all health care providers.** In the United States and many other countries, health care providers are mandatory reporters for suspected abuse or neglect. Clinicians who report suspected elder mistreatment in good faith are typically protected from liability or retaliation. Increasingly, urologists and other urologic health care providers are seeing older adults on an ongoing basis for treatment of chronic conditions. Therefore these clinicians may be in an excellent position to identify potential abuse and neglect among elderly patients. **There are a variety of types of elderly mistreatment that must be considered including physical abuse, emotion and psychological abuse, sexual abuse, financial exploitation, and neglect by caregivers or self-neglect.**

A careful history and physical examination is essential to diagnose and document suspected elder mistreatment. Ideally, the interview and examination should be conducted privately with the older adult, but this can be difficult particularly if the patient has impairments in cognition, vision, speech, or hearing. **Providers need to be alert to potential signs of abuse or neglect,** including overall appearance, poor hygiene, distractions, or nervous interactions particularly with accompanying caregivers, or social withdrawal and avoidance of questions. Other physical signs of abuse and neglect include bruises, abrasions or lacerations, or physical findings that are out of proportion to the described mechanism of injury. A careful genitourinary and pelvic examination should be performed in cases of suspected sexual abuse, and screening for sexually transmitted infections should be considered.

Identification of sexual mistreatment of older adults is particularly in the realm of urologic care. It is defined by the National Center on Elder Abuse as "nonconsensual sexual contact of any kind" (Department of Health and Human Services, 2014). Clinicians should be alert for signs and symptoms of sexual abuse, including genital lacerations or other injuries, unusual or unexpected infection patterns including sexually transmitted infections, and avoidance behavior or fear on the part of the patient. Changes from prior observed behavior may be particularly noticeable if the clinician has been following an older adult patient longitudinally over time.

UI has been identified as a risk factor for increased rates of psychosocial abuse against elderly people (Garre-Olmo et al., 2009). Increased rates were also noted in those with depression and social isolation, conditions that are often associated with incontinence. **UI has been identified as a risk factor for neglect of older adults by their caregivers** (Heath et al., 2005). Self-neglect by older adults is also a common but frequently undiagnosed problem. **Increased rates of self-neglect have been associated with higher levels of self-reported disability and impairments in baseline physical function** (Dong et al., 2009). The question of whether successful treatment of UI among older adult patients will help prevent or reduce rates of associated abuse and neglect deserves additional research attention.

End-of-Life Care and Urology

Palliative and end-of-life care is an important part of urologic health for many older adults. Some of the urologic malignancies may progress to a point where palliative care is appropriate. **When cure of the condition is no longer possible, treatment can shift to a palliative care mode. This does not mean that all treatment is withdrawn or that it is less focused or intense than curative therapy. Indeed, aggressive symptom management is one of the hallmark goals of palliative care** for most patients. Urologists and other urologic health care providers play an key role in the care of patients at the end of life who have genitourinary disorders (Sinclair et al., 2015).

Important aspects of high-quality palliative care include pain and symptom management, realization of personal goals for the patient and family, and coordination of care (Agar et al., 2009). Surgical therapy may play a role in select cases in which cytoreductive therapy for a large tumor burden, or removal of tumor for intractable bleeding or pain may help to relieve symptoms. In some cases, urinary or bowel diversion may be indicated for this purpose. Selective radiation therapy for painful bone metastases may be useful. Treatment is highly selective and tailored specifically to the needs of each individual patient. Integrated health care delivery models that include providers from multiple disciplines is feasible and can help to improve the delivery of care in these circumstances (Bergman et al., 2016). Among older adults in assisted living facilities, **use of hospice services has been shown to reduce need for nursing home or other institutional placement** (Dobbs et al., 2012). This can allow patients to remain living at home as long as possible and can increase quality-of-life outcomes in this setting. Consultation with trained, dedicated palliative care specialists can be extremely helpful in providing necessary care for older adults near the end of life.

Summary

The aging process can have substantial effects on the genitourinary system in men and women. Care for older adult patients must be tailored to their specific requirements based on a careful assessment and understanding of overall health and comorbid conditions. **Many clinical conditions seen in the specialty of urology occur with greater incidence and prevalence in elderly patients. In some ways, this makes urology, by definition, a "geriatric specialty."** Some facets of urologic care differ significantly between elderly and younger patients. **Clinical principles of geriatrics are not always intuitive, and the body of evidence related to care for elderly patients is growing rapidly.** Additional research and education on these topics will help enhance our ability to provide high-quality care for the older adults whom we serve.

Key Points

- Multiple biologic processes contribute to the phenomenon of normal human aging.
- Aging affects the structure and function of all organ systems, including the genitourinary system.
- The geriatric population is growing at an extremely rapid pace in the United States and in most developed countries worldwide.
- In addition to considering overall health status, functional assessment in geriatric patients includes evaluation of ADLs, IADLs, mobility, cognition, and other health domains.
- Increased comorbidity and decreased functional reserve capacity are common with aging and strongly influence clinical outcomes.
- Comorbidity and changes in functional status tend to be stronger predictors of clinical outcomes in older adults than chronologic age.
- Careful optimization of medical conditions before surgery or other treatment may help improve clinical outcomes and reduce complications in geriatric urology patients.
- Geriatric syndromes are complex, multifactorial conditions that can

negatively affect elderly patients. Examples include frailty, falls, pressure ulcers, polypharmacy, delirium, and urinary incontinence.

- Established urinary incontinence is associated with substantial negative effects in elderly patients, including limitation of activities, depression, and social isolation. Evaluation and treatment plans should be individualized and can help improve or resolve symptoms in many cases.
- Transient urinary incontinence is common in older adult patients and can be caused by many different factors. Successful treatment of the underlying condition will often help to improve or resolve the incontinence.
- Lower urinary tract and bowel dysfunction including BOO, underactive bladder, urinary retention, nocturia, and fecal incontinence are common in geriatric patients.
- POP is common among elderly women and can be successfully treated using either surgical or nonsurgical methods.
- Asymptomatic bacteriuria in geriatric patients does not typically require antibiotic therapy and must be differentiated from symptomatic UTIs.
- Most genitourinary malignancies have higher incidence and prevalence with advancing age.
- Sexuality remains an important part of overall and health-related quality of life for most older adults. Symptoms of sexual dysfunction may be signs of other underlying comorbidity such as heart disease, diabetes, or neurologic conditions.
- Urologists and urologic health care providers can play a key role in identifying elder mistreatment and neglect and are considered mandatory reporters in most locales.
- High-quality palliative and end-of-life care is an important part of geriatric urology practice.
- Patient-centered care is a central focus in geriatrics, and clinical evaluation and treatment should be tailored to meet the needs and goals of each individual, family, and caregiver.

Suggested Readings

American Geriatrics Society. 2015 Beers Criteria Update Expert Panel: American Geriatrics Society 2015 updated Beers criteria for potentially inappropriate medication use in older adults. *J Am Geriatr Soc*. 2015;63:2227–2246.

Averch TD, Stoffel J, Goldman HB, et al. AUA white paper on catheter associated urinary tract infections: definitions and significance in the urological patient. *Urol Pract*. 2015;2:321–328.

Chan LW, Griebling TL, Arnold EP, et al. Special considerations in the urological management of the older spinal cord injury patient. *World J Urol*. 2018;36(10):1603–1611.

Chow WB, Rosenthal RA, Merkow RP, et al. Optimal preoperative assessment of the geriatric surgical patient: a best practices guideline from the American College of Surgeons National Surgical Quality Improvement Program and the American Geriatrics Society. *J Am Coll Surg*. 2012;215:453–466.

Fried L, Tangen CM, Walston J, et al. Frailty in older adults: evidence for a phenotype. *J Gerontol A Biol Sci Med Sci*. 2001;56:M146–M156.

Gorina Y, Schappert S, Bercovitz A, et al. Prevalence of incontinence among older Americans. *Vital Health Stat 3*. 2014;(36) [US Department of Health and Human Services, Centers for Disease Control and Prevention, National Center for Health Statistics].

Griebling TL. *Geriatric urology*. Springer: New York; 2014.

Griebling TL, Dineen MK, DuBeau CE, et al. AUA white paper on the Beers criteria for potentially inappropriate medication use in older adults. *Urol Pract*. 2016;3:102–111.

Hanlon JT, Semla TP, Schmader KE. Alternative medications for medications in the use of high-risk medications in the elderly and potentially harmful drug-disease interactions in the elderly quality measures. *J Am Geriatr Soc*. 2015;63(12):e8–e18.

Newman DK, Cockerell R, Griebling TL, et al. Primary prevention, continence promotion, models of care and education (Committee 21). Abrams P, Cardozo L, Wagg A, et al. *Incontinence: 6th International Consultation on Incontinence*. ed 6. ICS and ICUD: Tokyo; 2017:2427–2478.

Revenig LM, Canter DKJ, Taylor MD, et al. Too frail for surgery? Initial results of a large multidisciplinary prospective study examining preoperative variables predictive of poor surgical outcomes. *J Am Coll Surg*. 2013;217:665–670.

Sinclair CT, Kalender-Rich JL, Griebling TL, et al. Palliative care of urologic patients at end of life. *Clin Geriatr Med*. 2015;31(4):667–678.

Steinman MA, Beizer JL, DuBeau CE, et al. How to use the American Geriatrics Society 2015 Beers criteria: a guide for patients, clinicians, health systems, and payors. *J Am Geriatr Soc*. 2015;63(12):e1–e7.

Wagg A, Chen LK, Johnson T 2nd, et al. Incontinence in frail older persons. Abrams P, Cardozo L, Wagg A, et al. *Incontinence: 6th International Consultation on Incontinence*. ed 6. ICS and ICUD: Tokyo; 2017:1309–1442.

References

Abdollah F, Ye Z, Miller DC, et al. Understanding the use of prostate biopsy among men with limited life expectance in a statewide quality improvement collaborative. *Eur Urol*. 2016;70:854–861.

Abrams P, Andersson KE. Muscarinic receptor antagonists for overactive bladder. *BJU Int*. 2007;100:987–1006.

Abrams P, Cardozo L, Fall M, et al. The standardisation of terminology of lower urinary tract function: report from the Standardisation Subcommittee of the International Continence Society. *Neurourol Urodyn*. 2002;21:167–178.

Agar M, Currow D, Plummer J, et al. Changes in anticholinergic load from regular prescribed medications in palliative care as death approaches. *Palliat Med*. 2009;23:257–265.

AGS Choosing Wisely Workgroup. American Geriatrics Society identifies five things that healthcare providers and patients should question. *J Am Geriatr Soc*. 2013;61:622–631.

AGS Choosing Wisely Workgroup. American Geriatric Society identifies another five things that healthcare providers and patients should question. *J Am Geriatr Soc*. 2014;62:950–960.

Aguilar-Navarro S, Navarrete-Reyes AP, Grados-Chavarria BH, et al. The severity of urinary incontinence decreases health-related quality of life among community-dwelling elderly. *J Gerontol A Biol Sci Med Sci*. 2012;67:1266–1271.

Ahn KH, Kim T, Hur JY, et al. Years from menopause-to-surgery is a major factor in the post-operative subjective outcome for pelvic organ prolapse. *Int Urogynecol J*. 2010;21:969–975.

Akhavan A, Gainsburg DM, Stock JA. Complications associated with patient positioning in urologic surgery. *Urology*. 2010;76:1309–1316.

Akiguchi I, Ishii M, Watanabe Y, et al. Shunt-responsive Parkinsonism and reversible white matter lesions in patients with idiopathic NPH. *J Neurol*. 2008;255:1392–1399.

Al-Najar A, Naumann CM, Kaufmann S, et al. Should being aged over 70 years hinder penile prosthesis implantation? *BJU Int*. 2009;104:834–837.

American Geriatrics Society 2015 Beers Criteria Update Expert Panel. American Geriatrics Society 2015 updated beers criteria for potentially inappropriate medication use in older adults. *J Am Geriatr Soc*. 2015;63:2227–2246.

Amrock LG, Meuman MD, Lin HM, et al. Can routine preoperative data predict adverse outcomes in the elderly? Development and validation of a simple risk model incorporating a chart-derived frailty score. *J Am Coll Surg*. 2014;219:684–694.

Andel R, Hyer K, Slack A. Risk factors for nursing home placement in older adults with and without dementia. *J Aging Health*. 2007;19:213–228.

Anger J, Saigal C, Madison R, et al. Increasing costs of urinary incontinence among female Medicare beneficiaries. *J Urol*. 2006;176:247–251.

Anger JT, Litwin MS, Wang Q, et al. Complications of sling surgery among female Medicare beneficiaries. *Obstet Gynecol*. 2007;109:707–714.

Anger JT, Litwin MS, Wang Q, et al. The effect of age on outcomes of sling surgery for urinary incontinence. *J Am Geriatr Soc*. 2007;55(12):1927–1931.

Angioli R, Montera R, Plotti F, et al. Success rates, quality of life, and feasibility of sacral nerve stimulation in elderly patients: 1-year follow-up. *Int Urogynecol J*. 2013;24:789–794.

Angner E, Ray MN, Saag KG, et al. Health and happiness among older adults: a community-based study. *J Health Psychol*. 2009;14:503–512.

Appa AA, Creasman J, Brown JS, et al. The impact of multimorbidity on sexual function in middle-aged and older women: beyond the single disease perspective. *J Sex Med*. 2014;11:2744–2755.

Araki I, Kitahara M, Oida T, et al. Voiding dysfunction and Parkinson's disease: urodynamic abnormalities and urinary symptoms. *J Urol*. 2000;164:1640–1643.

Arinzon Z, Shabat S, Peisakh A, et al. Clinical presentation of urinary tract infection (UTI) differs with aging in women. *Arch Gerontol Geriatr*. 2012;55:145–147.

Armbruster CE, Prenovost K, Mobley HLT, et al. How often do clinically diagnosed catheter-associated urinary tract infections in nursing homes meet standardized criteria? *J Am Geriatr Soc*. 2017;65:395–401.

Armstrong EP, Malone DC, Bui CN. Cost-effectiveness analysis of anti-muscarinic agents for the treatment of overactive bladder. *J Med Econ*. 2012;15(Suppl 1):35–44.

Atiemo H, Griebling TL, Danishgari F. Advances in geriatric female pelvic surgery. *BJU Int*. 2006;98(Suppl 1):90–94.

Aucella F, Guida CC, Lauriola V, et al. How to assess renal function in the geriatric population. *J Nephrol*. 2010;23(Suppl 15):S46–S54.

Averch TD, Stoffel J, Goldman HB, et al. AUA white paper on catheter associated urinary tract infections: definitions and significance in the urological patient. *Urol Pract*. 2015;2:321–328.

Aybek H, Aybek Z, Abban G, et al. Preventive effects of vitamin E against oxidative damage in aged diabetic rat bladders. *Urology*. 2011;77(2):508 [e10–14].

Azadzoi KM, Chen BG, Radisavljevic ZM, et al. Molecular reactions and ultrastructural damage in the chronically ischemic bladder. *J Urol*. 2011;186:2115–2122.

Azadzoi KM, Radisavljevic ZM, Golabek T, et al. Oxidative modification of mitochondrial integrity and nerve fiber density in the ischemic overactive bladder. *J Urol*. 2010;183:362–369.

Azadzoi KM, Yalla SV, Siroky MB. Oxidative stress and neurodegeneration in the ischemic overactive bladder. *J Urol*. 2007;178:710–715.

Bach LE, Mortimer JA, Vandeweerd C, et al. The association of physical and mental health with sexual activity in older adults in a retirement community. *J Sex Med*. 2013;10:2671–2678.

Bae JH, Oh MM, Shim KS, et al. The effects of long-term administration of oral desmopressin on the baseline secretion of antidiuretic hormone and serum sodium concentration for the treatment of nocturia: a circadian study. *J Urol*. 2007;178:200–203.

Baker PS, Bodner EV, Allman RM. Measuring life-space mobility in community-dwelling older adults. *J Am Geriatr Soc*. 2003;51:1610–1614.

Bal K, Ayik S, Issi Y, et al. Sleep analysis of patients with nocturia and benign prostatic obstruction. *Urology*. 2012;80:383–388.

Bardell A, Lau T, Fedoroff JP. Inappropriate sexual behavior in a geriatric population. *Int Psychogeriatr*. 2011;23:1182–1188.

Barentsen JA, Visser E, Hofstetter H, et al. Severity, not type, is the main predictor of decreased quality of life in elderly women with urinary incontinence: a population-based study as part of a randomized controlled trial in primary care. *Health Qual Life Outcomes*. 2012;10:153.

Barrois B, Labalette C, Rousseau P, et al. A national prevalence study of pressure ulcers in French hospital inpatients. *J Wound Care*. 2008;17:373–376 [378–379].

Basra RK, Wagg A, Chapple C, et al. A review of adherence to drug therapy in patients with overactive bladder. *BJU Int*. 2008;102:774–779.

Basu M, Duckett JR. Update on duloxetine for the management of stress urinary incontinence. *Clin Interv Aging*. 2009;4:25–30.

Bauer M, Fetherstonhaugh D, Tarzia L, et al. Supporting residents’ expression of sexuality: the initial construction of a sexuality assessment too for residential aged care facilities. *BMC Geriatr*. 2014;14:82.

Baumgarten M, Margolis DJ, Localio AR, et al. Extrinsic risk factors for pressure ulcers early in the hospital stay: a nested case-control study. *J Gerontol A Biol Sci Med Sci*. 2008;63:408–413.

Beers E, Moerkerken DC, Leufkens HG, et al. Participation of older adults in preauthorization trials of recently approved medicines. *J Am Geriatr Soc*. 2014;62:1883–1890.

Bell CM, Hatch WV, Fischer HD, et al. Association between tamsulosin and serious ophthalmic adverse events in older men following cataract surgery. *J Am Med Assoc*. 2009;301:1991–1996.

Bell RH Jr, Drach GW, Rosenthal RA. Proposed competencies in geriatric patient care for use in assessment for initial and continued board certification of surgical specialists. *J Am Coll Surg*. 2011;213:683–690.

Bell SP, Vasilevskis EE, Saraf AA, et al. Geriatric syndromes in hospitalized older adults discharged to skilled nursing facilities. *J Am Geriatr Soc*. 2016;64:715–722.

Bergman J, Ballon-Landa E, Lorenz KA, et al. Community-partnered collaboration to build an integrated palliative care clinic: the view from urology. *Am J Hosp Palliat Med*. 2016;33:164–170.

Berian JR, Zhou L, Hornor MA, et al. Optimizing surgical quality datasets to care for older adults: lessons from the American College of Surgeons NSQIP Geriatric Surgery Pilot. *J Am Coll Surg*. 2017;225:702–712.

Betschart C, Scheiner D, Maake C, et al. Histomorphological analysis of the urogenital diaphragm in elderly women: a cadaver study. *Int Urogynecol J Pelvic Floor Dysfunct*. 2008;19:1477–1481.

Bing MH, Moller LA, Jennum P, et al. Nocturia and associated morbidity in a Danish population of men and women aged 60-80 years. *BJU Int*. 2008;102:808–814 [discussion 814–815].

Bing MH, Moller LA, Jennum P, et al. Pathophysiological aspects of nocturia in a Danish population of men and women age 60 to 80 years. *J Urol*. 2007;178:552–557.

Birder LA, Wolf-Johnston AS, Jackson EK, et al. Aging increases the expression of vasopressin receptors in both the kidney and urinary bladder. *Neurourol Urodyn*. 2018 https://onlinelibrary.wiley.com/doi/pdf/10.1002/nau.238 [(online journal)].

Bisogni S, Ferreira FT, Amstalden Neto A, et al. Influence of oxidative stress on inducing micturition dysfunction following chronic infravesical obstruction and the protective role of an antioxidant diet: association of in vivo and in vitro studies in rats. *Int Braz J Urol*. 2012;38:552–560.

Bjurlin MA, Goble SM, Fantus RJ, et al. Outcomes in geriatric genitourinary trauma. *J Am Coll Surg*. 2011;213:415–421.

Blasco P, Valdivia MI, Oña MR, et al. Clinical characteristics, beliefs and coping strategies among older patients with overactive bladder. *Neurourol Urodyn*. 2017;36:774–779.

Bliss DZ, Gurvich OV, Eberly LE, et al. Time to and predictors of dual incontinence in older nursing home admissions. *Neurourol Urodyn*. 2018;37:229–236.

Bolenz C, Ho R, Nuss GR, et al. Management of elderly patients with urothelial carcinoma of the bladder: guideline concordance and predictors of overall survival. *BJU Int*. 2010;106:1324–1329.

Bonnal C, Baune B, Mion M, et al. Bacteriuria in a geriatric hospital: impact of an antibiotic improvement program. *J Am Med Dir Assoc*. 2008;9:605–609.

Booth J, Hagen S, McClurg D, et al. A feasibility study of transcutaneous posterior tibial nerve stimulation for bladder and bowel dysfunction in elderly adults in residential care. *J Am Med Dir Assoc*. 2013;14:270–274.

Bootsma AM, Buurman BM, Geerlings SE, et al. Urinary incontinence and indwelling urinary catheters in acutely admitted elderly patients: relationship with mortality, institutionalization, and functional decline. *J Am Med Dir Assoc*. 2013;14:147 [e7–12].

Borson S, Scanlan J, Brush M, et al. The Mini-Cog: a cognitive ‘vital signs’ measure for dementia screening in multi-lingual elderly. *Int J Geriatr Psychiatry*. 2000;15:1021–1027.

Boudreau DM, Yu O, Gray SL, et al. Concomitant use of cholinesterase inhibitors and anticholinergics: prevalence and outcomes. *J Am Geriatr Soc*. 2011;59:2069–2076.

Bozkurt IH, Yalcinkaya F, Sertcelik MN, et al. A good alternative to indwelling catheter owing to benign prostate hyperplasia in elderly: memotherm prostatic stent. *Urology*. 2013;82:1004–1007.

Braden BJ, Bergstrom N. Predictive validity of the Braden Scale for pressure sore risk in a nursing home population. *Res Nurs Health*. 1994;17:459–470.

Bradway C, Miller E, Heivly A, et al. Continence care for obese nursing home residents. *Urol Nurs*. 2010;30:121–129.

Briggs R, Robinson S, O'Neill D. Ageism and clinical research. *Ir Med J*. 2012;105:311–312.

Brittain K, Perry S, Shaw C, et al. Isolated urinary, fecal, and double incontinence: prevalence and degree of soiling in stroke survivors. *J Am Geriatr Soc*. 2006;54:1915–1919.

Bromage SJ, Dorkin TJ, Chan L, et al. Urodynamics in the octogenarian female: is it worthwhile? *Int Urogynecol J*. 2010;21:1117–1121.

Brooks SE, Mukherjee K, Gunter OL, et al. Do models incorporating comorbidities outperform those incorporating vital signs and injury pattern for predicting mortality in geriatric trauma? *J Am Coll Surg*. 2014;219:1020–1027.

Brown JS, Vittinghoff E, Wyman JF, et al. Urinary incontinence: does it increase risk for falls and fractures? *J Am Geriatr Soc*. 2000;48:721–725.

Brown RT, Hemati K, Riley ED, et al. Geriatric conditions in a population-based sample of older homeless adults. *Gerontologist*. 2017;57:757–766.

Burgio K, Goode P, Johnson TM II, et al. Behavioral versus drug treatment for overactive bladder in men: the Male Overactive Bladder Treatment In Veterans (MOTIVE) Trial. *J Am Geriatr Soc*. 2011;59:209–2216.

Burgio KL, Johnson TM 2nd, Goode PS, et al. Prevalence and correlates of nocturia in community-dwelling older adults. *J Am Geriatr Soc*. 2010;58:861–866.

Burgio KL, Kraus SR, Menefee S, et al. Behavioral therapy to enable women with urge incontinence to discontinue drug treatment: a randomized trial. *Ann Intern Med*. 2008;149(3):161–169.

Burgio KL, Locher JL, Goode PS. Combined behavioral and drug therapy for urge incontinence in older women. *J Am Geriatr Soc*. 2000;48(4):370–374.

Burkhalter JE, Margolies L, Sigurdsson HO, et al. The national LGBT Cancer Action Plan: a white paper of the 2014 National Summit on Cancer in the LGBT Communities. *LGBT Health*. 2016;3:19–31.

Burti JS, Santos AM, Pereira RM, et al. Prevalence and clinical characteristics of urinary incontinence in elderly individuals of a low income. *Arch Gerontol Geriatr*. 2012;54:e42–e46.

Byles J, Millar CJ, Sibbritt DW, et al. Living with urinary incontinence: a longitudinal study of older women. *Age Ageing*. 2009;38:333–338 [discussion 251].

Bylow K, Dale W, Mustian K, et al. Falls and physical performance deficits in older patients with prostate cancer undergoing androgen deprivation therapy. *Urology*. 2008;72:422–427.

Bynum J, Song Y, Fisher E. Variation in prostate-specific antigen screening in men aged 80 and older in fee-for-service Medicare. *J Am Geriatr Soc*. 2010;58:674–680.

Caire AA, Sun L, Robertson CN, et al. Public survey and survival data do not support recommendations to discontinue prostate-specific antigen screening in men at age 75. *Urology*. 2010;75:1122–1127.

Caljouw MA, van den Hout WB, Putter H, et al. Effectiveness of cranberry capsules to prevent urinary tract infections in vulnerable older persons: a double-blind randomized placebo-controlled trial in long-term care facilities. *J Am Geriatr Soc*. 2014;62:103–110.

Campbell SC, Bhoopalam N, Moritz TE, et al. The use of zoledronic acid in men receiving androgen deprivation therapy for prostate cancer with severe osteopenia or osteoporosis. *Urology*. 2010;75:1138–1143.

Carey JM, Leach GE. Transvaginal surgery in the octogenarian using cadaveric fascia for pelvic prolapse and stress incontinence: minimal one-year results compared to younger patients. *Urology*. 2004;63:665–670.

Carr D, Murphy LF, Batson HD, et al. Bigger is not always better: the effect of obesity on sexual satisfaction and behavior of adult men in the United States. *Men Masculin*.

2013;16:452–477.

Castro RA, Arruda RM, Zanetti MR, et al. Single-blind, randomized, controlled trial of pelvic floor muscle training, electrical stimulation, vaginal cones, and no active treatment in the management of stress urinary incontinence. *Clinics (Sao Paulo)*. 2008;63:465–472.

Centers for Disease Control and Prevention. *Public Health and Aging: Trends in Aging – United States and Worldwide*. [(website)] www.cdc.gov/mmwr/preview/mmwrhtml/mm5206a2.htm; 2014.

Centers for Disease Control and Prevention (CDC). *National estimates of the 10 leading causes of nonfatal injuries treated in hospital emergency departments, United States, 2010. Web-Based Injury Statistics Query and Reporting System (WISQARS)*. [(website)] www.cdc.gov/Injury/wisqars/pdf/National_Estim_10_Leading
ED_US2010-a.pdf; 2010.

Chan LW, Griebling TL, Arnold EP, et al. Special considerations in the urological management of the older spinal cord injury patient. *World J Urol*. 2018; 10.1007/s00345-018-2326-3 [epub ahead of print].

Chancellor MB. The overactive bladder progression to underactive bladder hypothesis. *Int Urol Nephrol*. 2014;46(Suppl 1):S23–S27.

Chancellor MB, Staskin DR, Kay GG, et al. Blood-brain barrier permeation and efflux exclusion of anticholinergics used in the treatment of overactive bladder. *Drugs Aging*. 2012;29(4):259–273.

Chang CH, Gonzalez CM, Lau DT, et al. Urinary incontinence and self-reported health among the U.S. Medicare managed care beneficiaries. *J Aging Health*. 2008;20:405–419.

Chang CH, Fan YH, Tong-Long Lin A, et al. Bladder outlet obstruction due to labial agglutination. *J Chin Med Assoc*. 2012;75:40–42.

Chang HT, Juang SJ, Liang YJ, et al. Asymptomatic bacteriuria among the elderly residents of long-term care facilities in Taiwan. *Age Ageing*. 2012;41:795–798.

Chang SS, Weiss CO, Xue QL, et al. Association between inflammatory-related disease burden and frailty: results from the Women's Health and Aging Studies (WHAS) I and II. *Arch Gerontol Geriatr*. 2012;54:9–15.

Chapple C, DuBeau C, Ebinger U, et al. Darifenacin treatment of patients > or = 65 years with overactive bladder: results of a randomized, controlled, 12-week trial. *Curr Med Res Opin*. 2007;23(10):2347–2358.

Charlson ME, Pompei P, Aless KL, et al. A new method of classifying prognostic comorbidity in longitudinal studies: development and validation. *J Chronic Dis*. 1987;40:373–383.

Chen TY, Anderson DJ, Chopra T, et al. Poor functional status is an independent predictor of surgical site infections due to methicillin-resistant staphylococcus aureus in older adults. *J Am Geriatr Soc*. 2010;58:527–532.

Cheng JY, Ng EM, Ko JS. Depressive symptomatology and male sexual functions in late life. *J Affect Disord*. 2007;104:225–229.

Chesnel C, Charlanes A, Hentzen C, et al. Lower urinary tract symptoms in elderly population with multiple sclerosis. *Int Neurourol J*. 2018;22:58–64.

Chiarelli PE, Mackenzie LA, Osmotherly PG. Urinary incontinence is associated with an increase in falls: a systematic review. *Aust J Physiother*. 2009;55(2):89–95.

Chin BS, Kim MS, Han SH, et al. Risk factors of all-cause in-hospital mortality among Korean elderly bacteremic urinary tract infection (UTI) patients. *Arch Gerontol Geriatr*.

2011;52:e50–e55.

Chiu AF, Liao CH, Wang CC, et al. High classification of chronic heart failure increases risk of overactive bladder syndrome and lower urinary tract symptoms. *Urology*. 2012;79:260–265.

Choe HS, Lee SJ, Kim CS, et al. Prevalence of sexually transmitted infections and the sexual behavior of elderly people presenting to health examination centers in Korea. *J Infect Chemother*. 2011;17:456–461.

Chong E, Chan E, Lim WS, et al. Frailty predicts incident urinary incontinence among hospitalized older adults: a 1-year prospective cohort study. *J Am Med Dir Assoc*. 2018;19:422–427.

Chow WB, Rosenthal RA, Merkow RP, et al. Optimal preoperative assessment of the geriatric surgical patient: a best practices guideline from the American College of Surgeons National Surgical Quality Improvement Program and the American Geriatrics Society. *J Am Coll Surg*. 2012;215:453–466.

Chow WH, Devesa SS, Warren JL, et al. Rising incidence of renal cell cancer in the United States. *J Am Med Assoc*. 1999;281:1628–1631.

Chuang CC, Yang E, Zou KH, et al. Health and functional status, health events, use of healthcare services and costs associated with overactive bladder among the medically complex vulnerable elderly in the US. *Int J Clin Pract*. 2018 https://onlinelibrary.wiley.com/doi/abs/10.1111/ijcp.132 [(online journal)].

Chughtai B, Sedrakyan A, Isaacs A, et al. Long term safety of sacral nerve modulation in Medicare beneficiaries. *Neurourol Urodyn*. 2015;34:659–663.

Chung RY, Leung JC, Chan DC, et al. Lower urinary tract symptoms (LUTS) as a risk factor for depressive symptoms in elderly men: results from a large prospective study in southern Chinese men. *PLoS ONE*. 2013;8:e76017.

Chung SD, Chang HC, Chiu B, et al. The efficacy of additive tolterodine extended release for 1-year in older men with storage symptoms and clinical benign prostatic hyperplasia. *Neurourol Urodyn*. 2011;30:568–571.

Chung SD, Kao LT, Lin HC, et al. Patients receiving androgen deprivation therapy for prostate cancer have an increased risk of depressive disorder. *PLoS ONE*. 2017; 10.1371/journal.pone.0173266.

Cigolle CT, Langa KM, Kabeto MU, et al. Geriatric conditions and disability: the Health and Retirement Study. *Ann Intern Med*. 2007;147(3):156–164.

Clarke MG, Kennedy KP, MacDonagh RP. Discussing life expectancy with surgical patients: do patients want to know and how should this information be delivered? *BMC Med Inform Decis Mak*. 2008;8:24.

Cohen RR, Lagoo-Deenadayalan SA, Heflin MT, et al. Exploring predictors of complication in older surgical patients: a deficit accumulation index and the Braden scale. *J Am Geriatr Soc*. 2012;60:1609–1615.

Coker RH, Hays MP, Williams RH, et al. Bed rest promotes reductions in walking speed, functional parameters, and aerobic fitness in older, healthy adults. *J Gerontol A Biol Sci Med Sci*. 2015;70:91–96.

Cole MG, McCusker J, Ciampi A, et al. The 6- and 12-month outcomes of older medical inpatients who recover from subsyndromal delirium. *J Am Geriatr Soc*. 2008;56:2093–2099.

Correia GN, Pereira VS, Hirakawa HS, et al. Effects of surface and intravaginal electrical stimulation in the treatment of women with stress urinary incontinence: randomized controlled trial. *Eur J Obstet Gynecol Reprod Biol*.

2014;173:113–118.

Coskuner ER, Ozkan TA, Koprulu S, et al. The role of the bipolar plasmakinetic TURP over 100 g prostate in the elderly patients. *Int Urol Nephrol*. 2014;46:2071–2077.

Coyne KS, Wein A, Nicholson S, et al. Economic burden of urgency urinary incontinence in the United States: a systematic review. *J Manag Care Pharm*. 2014;20:130–140.

D'Agata E, Loeb MB, Mitchell SL. Challenges in assessing nursing home residents with advanced dementia for suspected urinary tract infections. *J Am Geriatr Soc*. 2013;61:62–66.

Daneman N, Gruneir A, Newman A, et al. Antibiotic use in long-term care facilities. *J Antimicrob Chemother*. 2011;66:2856–2863.

Daniels KR, Lee GC, Frei CR. Trends in catheter-associated urinary tract infections among a national cohort of hospitalized adults, 2001-2010. *Am J Infect Control*. 2014;42:17–22.

Darrah DM, Griebling TL, Silverstein JH. Postoperative urinary retention. *Anesthesiol Clin*. 2009;27:465–484.

Davis R, Jones JS, Barocas DA, et al. Diagnosis, evaluation and follow-up of asymptomatic microhematuria (AMH) in adults: AUA Guideline. *J Urol*. 2012;188:2473–2481.

DeCrane SK, Culp KR, Wakefield B. Twelve-month mortality among delirium subtypes. *Clin Nurs Res*. 2011;20:404–421.

DeGagne JC, So A, Oh J, et al. Sociodemographic and health indicators of older women with urinary incontinence: 2010 National Survey of Residential Care Facilities. *J Am Geriatr Soc*. 2013;61:981–986.

De La Cruz JF, Kisby C, Wu JM, et al. Impact of anticholinergic load on bladder function. *Int Urogynecol J*. 2015;26:545–549.

deVries HF, Northington GM, Bogner HR. Urinary incontinence (UI) and new psychological distress among community dwelling older adults. *Arch Gerontol Geriatr*. 2012;55:49–54.

Demeure MJ, Fain MJ. The elderly surgical patient and postoperative delirium. *J Am Coll Surg*. 2006;203:752–757.

Denys MA, Decalf V, Kumps C, et al. Pathophysiology of nocturnal lower urinary tract symptoms in older patients with urinary incontinence. *Int J Urol*. 2017;24:808–815.

Department of Health and Human Services. *Administration on Aging, National Center on Elder Abuse*. [(website)] http://ncea.acl.gov; 2014.

Dewulf K, Abraham N, Lamb LE, et al. Addressing challenges in underactive bladder: recommendations and insights from the Congress on Underactive Bladder (CURE-UAB). *Int Urol Nephrol*. 2017;49:777–785.

Dhar N, Ward JF, Cher ML, et al. Primary full-gland prostate cryoablation in older men (> age of 75 years): results from 860 patients tracked with the COLD registry. *BJU Int*. 2011;108:508–512.

Diokno AC. Diagnostic categories of incontinence and the role of urodynamic testing. *J Am Geriatr Soc*. 1990;38:300–305.

Dmochowski RR, Blaivas JM, Gormley EA, et al. Update of the AUA Guideline on the surgical management of female stress urinary incontinence. *J Urol*. 2010;183:1906–1914.

Dmochowski RR, Sanders SW, Appell RA, et al. Bladder-health diaries: an assessment of 3-day vs 7-day entries. *BJU Int*. 2005;96:1049–1054.

Dobbs D, Meng H, Hyer K, et al. The influence of hospice use on nursing home and hospital use in assisted living among dual-eligible enrollees. *J Am Med Dir Assoc*. 2012;13(2):189 [e9–e13].

Donat SM, Siegrist T, Cronin A, et al. Radical cystectomy in octogenarians: does morbidity outweigh the potential survival benefits? *J Urol*. 2010;183:2171–2177.

Dong X, Mendes de Leon CF, Evans DA. Is greater self-neglect severity associated with lower levels of physical function? *J Aging Health*. 2009;21:596–610.

Dorner TE, Schwarz F, Kranz A, et al. Body mass index and the risk of infections in institutionalised geriatric patients. *Br J Nutr*. 2010;103:1830–1835.

Drach GW, Griebling TL. Geriatric urology. *J Am Geriatr Soc*. 2003;51:S355–S358.

Dräger DL, Protzel C, Hakenberg OW. Psychological stress in geriatric patients with genito-urinary cancers. *J Geriatr Oncol*. 2017;8:216–219.

Drennan VM, Rait G, Cole L, et al. The prevalence of incontinence in people with cognitive impairment or dementia living at home: a systematic review. *Neurourol Urodyn*. 2013;32:314–324.

Drinka PJ. Complications of chronic indwelling urinary catheters. *J Am Med Dir Assoc*. 2006;7:388–392.

Droz JP, Balducci L, Bolla M, et al. Management of prostate cancer in older men: recommendations of a working group of the International Society of Geriatric Oncology. *BJU Int*. 2010;106:462–469.

DuBeau CE. The aging lower urinary tract. *J Urol*. 2006;175:S11–S15.

DuBeau CE, Kraus SR, Griebling TL, et al. Effect of fesoterodine in vulnerable elderly subjects with urgency incontinence: a double-blind, placebo-controlled trial. *J Urol*. 2014;191:395–404.

DuBeau CE, Kuchel GA, Johnson T 2nd, et al. Incontinence in the frail elderly. Report from the 4th International Consultation on Incontinence. *Neurourol Urodyn*. 2010;29(1):165–178.

DuBeau CE, Ouslander JG, Palmer MH. Knowledge and attitudes of nursing home staff and surveyors about the revised federal guidance for incontinence care. *Gerontologist*.

2007;47:468–479.

Dugan E, Cohen SJ, Bland DR, et al. The association of depressive symptoms and urinary incontinence among older adults. *J Am Geriatr Soc*. 2000;48(4):413–416.

DuMoulin MF, Hamers JP, Ambergen AW, et al. Urinary incontinence in older adults receiving home care diagnosis and strategies. *Scand J Caring Sci*. 2009;23:222–230.

Dunlop DD, Manheim LM, Sohn MW, et al. Incidence of functional limitation in older adults: the impact of gender, race, and chronic conditions. *Arch Phys Med Rehabil*. 2002;83(7):964–971.

Elbadawi A, Hailemariam S, Yalla SV, et al. Structural basis of geriatric voiding dysfunction. VII. Prospective ultrastructural/urodynamic evaluation of its natural evolution. *J Urol*. 1997;157:1814–1822.

Elbadawi A, Yalla SV, Resnick NM. Structural basis of geriatric voiding dysfunction. II. Aging detrusor: normal versus impaired contractility. *J Urol*. 1993;150:1657–1667.

Elshal AM, Elmansy HM, Elhilali MM. Transurethral laser surgery for benign prostate hyperplasia in octogenarians: safety and outcomes. *Urology*. 2013;81:634–639.

Ely EW, Shintani A, Truman B, et al. Delirium as a predictor of mortality in mechanically ventilated patients in the intensive care unit. *J Am Med Assoc*. 2004;291:1753–1762.

Endeshaw Y. Correlates of self-reported nocturia among community-dwelling older adults. *J Gerontol A Biol Sci Med Sci*. 2009;64:142–148.

Engel BT, Burgio LD, McCormick KA. Behavioral treatment of incontinence in the long-term care setting. *J Am Geriatr Soc*. 1990;38:361–363.

Erickson BA, Lu X, Vaughan-Sarrazin M, et al. Initial treatment of men with newly diagnosed lower urinary tract dysfunction in the Veterans Health Administration. *Urology*.

2014;83:304–311.

Eriksson I, Gustafson Y, Fagerstrom L, et al. Prevalence and factors associated with urinary tract infections (UTIs) in very old women. *Arch Gerontol Geriatr*. 2010;50:132–135.

Eriksson I, Gustafson Y, Fagerstrom L, et al. Urinary tract infection in very old women is associated with delirium. *Int Psychogeriatr*. 2011;23:496–502.

Ersoz M, Erhan B, Akkoc Y, et al. An evaluation of bladder emptying methods and the effect of demographic and clinical factors on spontaneous voiding frequency in stroke patients. *Neurol Sci*. 2013;34:729–734.

Evans DC, Martindale RG, Kiraly LN, et al. Nutrition optimization prior to surgery. *Nutr Clin Pract*. 2014;29:10–21.

Fader M, Cottenden AM, Getliffe K. Absorbent products for light urinary incontinence in women. *Cochrane Database Syst Rev*. 2007;(2) [CD001406].

Fader M, Cottenden AM, Getliffe K. Absorbent products for moderate-heavy urinary and/or faecal incontinence in women and men. *Cochrane Database Syst Rev*. 2008;(4) [CD007408].

Fagan M, Maehlen M, Lindbaek M, et al. Antibiotic prescribing in nursing homes in an area with low prevalence of antibiotic resistance: compliance with national guidelines. *Scan J Prim Health Care*. 2012;30:10–15.

Fantl JA, Wyman JA, McClish DK, et al. Efficacy of bladder training in older women with urinary incontinence. *J Am Med Assoc*. 1991;265:609–613.

Farage MA, Miller KW, Berardesca E, et al. Psychosocial and societal burden of incontinence in the aged population: a review. *Arch Gynecol Obstet*. 2008;277(4):285–290.

Federal Interagency Forum on Aging-Related Statistics. *Older Americans 2012: Key indicators of well-being. Federal* *interagency forum on aging-related statistics*. U.S. Government Printing Office: Washington, DC; 2012.

Finlayson E, Maselli J, Steinman MA, et al. Inappropriate medication use in older adults undergoing surgery: a national study. *J Am Geriatr Soc*. 2011;59:2139–2144.

Fisher MB, Svatek RS, Hegarty PK, et al. Cardiac history and risk of post-cystectomy cardiac complications. *Urology*. 2009;74:1085–1089.

Fitzgerald MP, Litman HJ, Link CL, BACH Survey Investigators, et al. The association of nocturia with cardiac disease, diabetes, body mass index, age and diuretic use: results from the BACH Survey. *J Urol*. 2007;177:1385–1389.

Flynn TJ, Gow AJ. Examining associations between sexual behaviours and quality of life in older adults. *Age Ageing*. 2015;44:823–828.

Foley AL, Loharuka S, Barrett JA, et al. Association between the geriatric giants of urinary incontinence and falls in older people using data from the Leicestershire MRC Incontinence Study. *Age Ageing*. 2012;41:35–40.

Folstein MF, Folstein SE, McHugh PR. Mini-mental state: a practical method for grading the cognitve state of patients for the clinicians. *J Psychiatr Res*. 1975;12:189–198.

Fonda D, DuBeau CE, Harari D, et al. Incontinence in the frail elderly. Abrams P, Cardozo L, Khoury S, et al. *Incontinence*. ed 3. Health Publications: Plymouth (UK); 2005:1163–1239.

Fonda D, Woodward M, D'Astoli M, et al. Sustained improvement of subjective quality of life in older community-dwelling people after treatment of urinary incontinence. *Age Ageing*. 1995;24:283–286.

Fontana L, Addante F, Copetti M, et al. Identification of a metabolic signature for multidimensional impairment and mortality risk in hospitalized older patients. *Aging Cell*. 2013;12:459–466.

Fox C, Livingston G, Maidment ID, et al. The impact of anticholinergic burden in Alzheimer's dementia: the Laser-AD study. *Age Ageing*. 2011;40:730–735.

Fox C, Richardson K, Maidment ID, et al. Anticholinergic medication use and cognitive impairment in the older population: the Medical Research Council Cognitive Function and Ageing Study. *J Am Geriatr Soc*. 2011;59:1477–1483.

Fox C, Smith T, Maidment I, et al. Effect of medications with anti-cholinergic properties on cognitive function, delirium, physical function and mortality: a systematic review. *Age Ageing*. 2014;43:604–615.

Fraisse T, Crouzet J, Lachaud L, et al. Candiduria in those over 85 years old: a retrospective study of 73 patients. *Intern Med*. 2011;50:1935–1940.

Frick AC, Huang AJ, Van den Eeden SK, et al. Mixed urinary incontinence: greater impact on quality of life. *J Urol*. 2009;182:596–600.

Fried L, Tangen CM, Walston J, et al. Frailty in older adults: evidence for a phenotype. *J Gerontol A Biol Sci Med Sci*. 2001;56:M146–M156.

Friedman AH. Tamsulosin and the intraoperative floppy iris syndrome. *J Am Med Assoc*. 2009;301:2044–2045.

Friedman S, Sandhu KS, Wang C, et al. Factors influencing long-term pessary use. *Int Urogynecol J*. 2010;21:673–678.

Fritel X, Lachal L, Cassou B, et al. Mobility impairment is associated with urge but not stress urinary incontinence in community-dwelling older women: results from the Ossébo Study. *BJOG*. 2013;120:1566–1574.

Frost M, Wraae K, Gudex C, et al. Chronic diseases in elderly men: underreporting and underdiagnosis. *Age Ageing*. 2012;41:177–183.

Fry CH, Bayliss M, Young JS, et al. Influence of age and bladder dysfunction on the contractile properties of isolated human detrusor smooth muscle. *BJU Int*. 2011;108:E91–E96.

Fu FG, Lavery HJ, Wu DL. Reducing nocturia in the elderly: a randomized placebo-controlled trial of staggered furosemide and desmopressin. *Neurourol Urodyn*. 2011;30:312–316.

Fung C, Pandya C, Guancial E, et al. Impact of bladder cancer on health related quality of life in 1,476 older Americans: a cross-sectional study. *J Urol*. 2014;192:690–695.

Gabriel B, Rubod C, Cordova LG, et al. Prolapse surgery in women of 80 years and older using the Prolift technique. *Int Urogynecol J*. 2010;21:1463–1470.

Galizia G, Langellotto A, Cacciatore F, et al. Association between nocturia and falls-related long-term mortality risk in the elderly. *J Am Med Dir Assoc*. 2012;13:640–644.

Gaither TW, Awad MA, Fang R, et al. The near-future impact of retirement on the urologic workforce: results from the American Urological Association census. *Urology*. 2016;94:85–89.

Gammack JK. Use and management of chronic urinary catheters in long-term care: much controversy, little consensus. *J Am Med Dir Assoc*. 2003;4(Suppl):S53–s59.

Garimella PS, Paudel ML, Ensrud KE, et al. Osteoporotic fractures in men research G: association between body size and composition and erectile dysfunction in older men: osteoporotic Fractures in Men Study. *J Am Geriatr Soc*. 2013;61:46–54.

Garre-Olmo J, Planas-Pujol X, Lopez-Pousa S, et al. Prevalence and risk factors of suspected elder abuse subtypes in people aged 75 and older. *J Am Geriatr Soc*. 2009;57:815–822.

Gesenberg A, Sintermann R. Management of benign prostatic hyperplasia in high risk patients: long-term experience with the Memotherm stent. *J Urol*. 1998;160:72–76.

Ghoniem GM, Van Leeuwen JS, Elser DM, et al. A randomized controlled trial of duloxetine alone, pelvic floor muscle training alone, combined treatment and no active treatment in women with stress urinary incontinence. *J Urol*. 2005;173:1647–1653.

Giannelli SV, Patel KV, Windham BG, et al. Magnitude of underascertainment of impaired kidney function in older adults with normal serum creatinine. *J Am Geriatr Soc*. 2007;55:816–823.

Gill TM, Gahbauer EA, Han L, et al. Factors associated with recovery of prehospital function among older persons admitted to a nursing home with disability after an acute hospitalization. *J Gerontol A Biol Sci Med Sci*. 2009;64:1296–1303.

Giltay EJ, Vollaard AM, Kromhout D. Self-rated health and physician-rated health as independent predictors of mortality in elderly men. *Age Ageing*. 2012;41:165–171.

Gleason JL, Richter HE, Redden DT, et al. Caffeine and urinary incontinence in US women. *Int Urogynecol J*. 2013;24:295–302.

Goetzl MA, Outman JE, Griebling TL, et al. Digital fecal occult blood testing in the ambulatory urology clinic. *J Am Coll Surg*. 2008;206:144–147.

Goldstein I, Dicks B, Kim NN, et al. Multidisciplinary overview of vaginal atrophy and associated genitourinary symptoms in postmenopausal women. *Sex Med*. 2013;1:44–53.

Goode PS, Burgio KL, Johnson TM 2nd, et al. Behavioral therapy with or without biofeedback and pelvic floor electrical stimulation for persistent postprostatectomy incontinence: a randomized controlled trial. *J Am Med Assoc*. 2011;305:151–159.

Gooren L, Lips P. Conjectures concerning cross-sex hormone treatment of aging transsexual persons. *J Sex Med*. 2014;11:2012–2019.

Gordon LB, Waxman MJ, Ragsdale L, et al. Overtreatment of presumed urinary tract infection in older women presenting to the emergency department. *J Am Geriatr Soc*. 2013;61:788–792.

Gorina Y, Schappert S, Bercovitz A, et al. Prevalence of incontinence among older Americans. *Vital Health Stat 3*. 2014;(36) [US Department of Health and Human Services, Centers for Disease Control and Prevention, National Center for Health Statistics].

Gormley EA, Lightner DJ, Burgio KL, et al. Diagnosis and treatment of overactive bladder (non-neurogenic) in adults: AUA/SUFU Guideline. *J Urol*. 2012;188:2455–2463.

Gotoh M, Matsukawa Y, Yoshikawa Y, et al. Impact of urinary incontinence on the psychological burden of family caregivers. *Neurourol Urodyn*. 2009;28:492–496.

Gowda BD, Agarwal V, Harrison SC. The continent, catheterizable abdominal conduit in adult urological practice. *BJU Int*. 2008;102:1688–1692.

Grabowski DC, O'Malley AJ, Afendulis CC, et al. Culture change and nursing home quality of care. *Gerontologist*. 2014;54:S35–S45.

Greco KA, Meeks JJ, Wu S, et al. Robot-assisted radical prostatectomy in men aged > or =70 years. *BJU Int*. 2009;104:1492–1495.

Green AR, Segal J, Tian J, et al. Use of bladder antimuscarinics in older adults with impaired cognition. *J Am Geriatr Soc*. 2017;65:390–394.

Griebling TL. Detrusor underactivity and urinary retention in geriatric patients: evaluation, management and recent research. *Curr Bladder Dysfunct Rep*. 2013;8:92–100.

Griebling TL. *Geriatric urology*. Springer: New York; 2014.

Griebling TL. Incontinence guidelines: is lack of adherence a form of ageism? *Nat Rev Urol*. 2011;8:655–657.

Griebling TL. Overactive bladder in elderly men: epidemiology, evaluation, clinical effects, and management. *Curr Urol Rep*. 2013;14:418–425.

Griebling TL. Perioperative nutrition and metabolism in geriatric surgical patients. *Curr Surg*. 2004;61:275–280.

Griebling TL. Reconstructive urology and geriatrics: issues in older adults. *Curr Opin Urol*. 2009;19:577–581.

Griebling TL. Sacral nerve stimulation in the elderly. *Int Urogynecol J*. 2010;21(Suppl 2):S485–S489.

Griebling TL. Sexuality and aging: a focus on lesbian, gay, bisexual, and transgender (LGBT) needs in palliative and end of life care. *Curr Opin Support Palliat Care*. 2016;10:95–101.

Griebling TL. The impact of urinary incontinence on sexual health in older adults. *J Am Geriatr Soc*. 2006;54:1290–1292.

Griebling TL. Urinary incontinence and voiding dysfunction in elderly men. *Curr Bladder Dysfunct Rep*. 2008;3:241–246.

Griebling TL. Urological Diseases in America Project: trends in resource use for urinary tract infections in men. *J Urol*. 2005;173:1288–1294.

Griebling TL. Urologic Diseases in America Project: trends in resource use for urinary tract infections in women. *J Urol*. 2005;173:1281–1287.

Griebling TL. Urological issues in older adults. Arenson C, Busby-Whitehead J, Brummel-Smith K, et al. *Reichel's care of the elderly: clinical aspects of aging*. ed 6. Cambridge University Press: New York; 2009:266–279.

Griebling TL. Vaginal pessaries for treatment of pelvic organ prolapse in elderly women. *Curr Opin Urol*. 2016;26:201–206.

Griebling TL, Dineen MK, DuBeau CE, et al. AUA white paper on the Beers criteria for potentially inappropriate medication use in older adults. *Urol Pract*. 2016;3:102–111.

Griebling TL, DuBeau CE, Kuchel G, et al. Defining and advancing education and conservative therapies of underactive bladder. *Int Urol Nephrol*. 2014;46(Suppl 1):S29–S34.

Griebling TL, Kraus SR, Richter HE, et al. Tolterodine extended release is well tolerated in older subjects. *Int J Clin Pract*. 2009;63:1198–1204.

Griebling TL, Kreder KJ Jr, Williams RD. Transurethral collagen injection for treatment of postprostatectomy urinary incontinence in men. *Urology*. 1997;49:907–912.

Griffiths D, Derbyshire S, Stenger A, et al. Brain control of normal and overactive bladder. *J Urol*. 2005;174:1862–1867.

Griffiths D, Tadic SD, Schaefer W, et al. Cerebral control of the bladder in normal and urge-incontinent women. *Neuroimage*. 2007;37(1):1–7.

Griffiths DJ, McCracken PN, Harrison GM, et al. Urge incontinence and impaired detrusor contractility in the elderly. *Neurourol Urodyn*. 2002;21:126–131.

Griffiths DJ, Tadic SD, Schaefer W, et al. Cerebral control of the lower urinary tract: how age-related changes might predispose to urge incontinence. *Neuroimage*. 2009;47:981–986.

Groutz A, Cohen A, Gold R, et al. The safety and efficacy of the “inside-out” trans-obturator TVT in elderly versus younger stress-incontinent women: a prospective study of 353 consecutive patients. *Neurourol Urodyn*. 2011;30:380–383.

Guilleminault C, Lin CM, Goncalves MA, et al. A prospective study of nocturia and the quality of life of elderly patients with obstructive sleep apnea or sleep onset insomnia. *J Psychosom Res*. 2004;56(5):511–515.

Guillotreau J, Miocinovic R, Game X, et al. Outcomes of laparoscopic and robotic radical cystectomy in the elderly patients. *Urology*. 2012;79:585–590.

Gupta A, Taly AB, Srivastava A, et al. Urodynamics post stroke in patients with urinary incontinence: Is there correlation between bladder type and site of lesion? *Ann Indian Acad Neurol*. 2009;12:104–107.

Gutman RE, Bradley CS, Ye W, et al. Effects of colpocleisis on bowel symptoms among women with severe pelvic organ prolapse. *Int Urogynecol J*. 2010;21:461–466.

Guzzo TJ, Allaf ME, Pierorazio PM, et al. Perioperative outcomes of elderly patients undergoing laparoscopic renal procedures. *Urology*. 2009;73:572–576.

Guzzo TJ, Drach GW, Wein AJ. *Primer of geriatric urology*. Springer: New York; 2013.

Hamid TA, Pakgohar M, Ibrahim R, et al. Stain in life”: the meaning of urinary incontinence in the context of Muslim postmenopausal women through hermeneutic phenomenology. *Arch Gerontol Geriatr*. 2015;60:514–521.

Han L, Agostini JV, Allore HG. Cumulative anticholinergic exposure is associated with poor memory and executive function in older men. *J Am Geriatr Soc*. 2008;56:2203–2210.

Hanlon JT, Aspinall SL, Semla TP, et al. Consensus guidelines for oral dosing of primarily renally cleared medications in older adults. *J Am Geriatr Soc*. 2009;57:335–340.

Hanlon JT, Semla TP, Schmader KE. Alternative medications for medications in the use of high-risk medications in the elderly and potentially harmful drug-disease interactions in the elderly quality measures. *J Am Geriatr Soc*. 2015;63(12):e8–e18.

Hardy SE, Perera S, Roumani YF, et al. Improvement in usual gait speed predicts better survival in older adults. *J Am Geriatr Soc*. 2007;55:1727–1734.

Hardy SE, Studenski SA. Fatigue predicts mortality in older adults. *J Am Geriatr Soc*. 2008;56:1910–1914.

Haruta H, Sakakibara R, Ogata T, et al. Inhibitory control task is decreased in vascular incontinence patients. *Clin Auton Res*. 2013;23:85–89.

Hasegawa J, Kuzuya M, Iguchi A. Urinary incontinence and behavioral symptoms are independent risk factors for recurrent and injurious falls, respectively, among residents in long-term care facilities. *Arch Gerontol Geriatr*. 2010;50:77–81.

Hashimoto M, Imamura T, Tanimukai S, et al. Urinary incontinence: an unrecognised adverse effect with donepezil. *Lancet*. 2000;356:568.

Hatta T, Iwahara A, Ito E, et al. The relation between cognitive function and UI in healthy, community-dwelling, middle-aged and elderly people. *Arch Gerontol Geriatr*. 2011;53:220–224.

Hayashi N, Matsushima M, Yamamoto T, et al. The impact of hypertriglyceridemia on prostate cancer development in patients aged >/=60 years. *BJU Int*. 2012;109:515–519.

Hayden DM, Weiss EG. Fecal incontinence: etiology, evaluation, and treatment. *Clin Colon Rectal Surg*. 2011;24(1):64–70.

Hayflick L, Moorhead PR. The serial cultivation of human diploid cell strains. *Exp Cell Res*. 1961;25:585–621.

Heath JM, Brown M, Kobylarz FA, et al. The prevalence of undiagnosed geriatric health conditions among adult protective services clients. *Gerontologist*. 2005;45:820–823.

Hendrix SL, Cochrane BB, Nygaard IE, et al. Effects of estrogen with and without progestin on urinary incontinence. *J Am Med Assoc*. 2005;293:935–948.

Herzog AR, Fultz NH. Prevalence and incidence of urinary incontinence in community-dwelling populations. *J Am Geriatr Soc*. 1990;38:273–281.

Hill-Brown S. Reduction of pressure ulcer incidence in the home healthcare setting. *Home Healthc Nurse*. 2011;29:311–325.

Hillyer SP, Autorino R, Spana G, et al. Perioperative outcomes of robotic-assisted partial nephrectomy in elderly patients: a matched-cohort study. *Urology*. 2012;79:1063–1067.

Hirayama F, Lee AH, Binns CW, et al. Association of impaired respiratory function with urinary incontinence. *Respirology*. 2009;14:753–756.

Hoffman KE, Hguyen PL, Ng KA, et al. Prostate cancer screening in men 75 years old or older: an assessment of self-reported health status and life expectancy. *J Urol*. 2010;183:1798–1802.

Holroyd-Leduc JM, Sen S, Bertenthal D, et al. The relationship of indwelling urinary catheters to death, length of hospital stay, functional decline, and nursing home admission in hospitalized older medical patients. *J Am Geriatr Soc*. 2007;55:227–233.

Holroyd-Leduc JM, Straus S, Thorpe K, et al. Translation of evidence into a self-management tool for use by women with urinary incontinence. *Age Ageing*. 2011;40:227–233.

Horgas AL, Elliott AF, Marsiske M. Pain assessment in persons with dementia: relationship between self-report and behavioral observation. *J Am Geriatr Soc*. 2009;57:126–132.

Hoshiyama F, Hirayama A, Tanaka M, et al. The impact of obstructive sleep apnea syndrome on nocturnal urine production in older men with nocturia. *Urology*. 2014;84:892–897.

Hu FW, Yang DC, Huang CC, et al. Inappropriate use of urinary catheters among hospitalized elderly patients: clinician awareness is key. *Geriatr Gerontol Int*. 2015;15:1235–1241.

Huang AJ, Brown JS, Boyko EJ, et al. Clinical significance of postvoid residual volume in older ambulatory women. *J Am*

Geriatr Soc. 2011;59:1452–1458.

Huang AJ, Brown JS, Thom DH, et al. Urinary incontinence in older community-dwelling women: the role of cognitive and physical function decline. *Obstet Gynecol*. 2007;109:909–916.

Huang AJ, Subak LL, Thom DH, et al. Sexual function and aging in racially and ethnically diverse women. *J Am Geriatr Soc*. 2009;57:1362–1368.

Hubbard RE, Story DA. Patient frailty: the elephant in the operating room. *Anaesthesia*. 2014;69(Suppl 1):26–34.

Hudson SV, Ohman-Strickland P, Ferrante JM, et al. Prostate-specific antigen testing among the elderly in community-based family medicine practices. *J Am Board Fam Med*. 2009;22:257–265.

Hunter KF, Voaklander D, Hsu ZY, et al. Lower urinary tract symptoms and falls risk among older women receiving home support: a prospective cohort study. *BMC Geriatr*. 2013;13:46.

Hutton DW, Krein SL, Saint S, et al. Economic evaluation of a catheter-associated urinary tract infection prevention program in nursing homes. *J Am Geriatr Soc*. 2018;66:742–747.

Hyde Z, Flicker L, Hankey GJ, et al. Prevalence of sexual activity and associated factors in men aged 75 to 95 years: a cohort study. *Ann Intern Med*. 2010;153:693–702.

Ikeda Y, Nakagawa H, Ohmori-Matsuda K, et al. Risk factors for overactive bladder in the elderly population: a community-based study with face-to-face interview. *Int J Urol*. 2011;18:212–218.

Inouye SK. Delirium in older persons. *N Engl J Med*. 2006;354:1157–1165.

Inouye SK, van Dyck CH, Alessi CA, et al. Clarifying confusion: the Confusion Assessment Method: a new method for detection of delirium. *Arch Intern Med*. 1990;113:941–

948.

Irwin DE, Kopp ZS, Agatep B, et al. Worldwide prevalence estimates of lower urinary tract symptoms, overactive bladder, urinary incontinence and bladder outlet obstruction. *BJU Int*. 2011;108:1132–1139.

Iwatsubo E, Suzuki M, Igawa Y, et al. Individually tailored ultrasound-assisted prompted voiding for institutionalized older adults with urinary incontinence. *Int J Urol*. 2014;21:1253–1257.

James H III, Aleksic I, Bienz MN, et al. Comparison of fracture risk assessment tool score to bone mineral density for estimating fracture risk on patients with advanced prostate cancer on androgen deprivation therapy. *Urology*. 2014;84:164–168.

Jaul E. Assessment and management of pressure ulcers in the elderly: current strategies. *Drugs Aging*. 2010;27:311–325.

Jazzar U, Yong S, Klaassen Z, et al. Impact of psychiatric illness on decreased survival in elderly patients with bladder cancer in the United States. *Cancer*. 2018;124:3127–3135.

Jenkins KR, Fultz NH. Functional impairment as a risk factor for urinary incontinence among older Americans. *Neurourol Urodyn*. 2005;24(1):51–55.

Jeong CW, Ku JH, Kwak C, et al. Chronic pulmonary disease negatively influences the prognosis of patients with advanced prostate cancer. *World J Urol*. 2009;27:643–652.

Jeong SJ, Kim HJ, Lee YJ, et al. Prevalence and clinical features of detrusor underactivity among elderly with lower urinary tract symptoms: a comparison between men and women. *Korean J Urol*. 2012;53:342–348.

Jerez-Roig J, Santos MM, Souza DLB, et al. Prevalence of urinary incontinence and associated factors in nursing home residents. *Neurourol Urodyn*. 2016;35:102–107.

Jerez-Roig J, Souza DLB, Amaral FLJS, et al. Prevalence of fecal incontinence (FI) and associated factors in institutionalized older adults. *Arch Gerontol Geriatr*. 2015;60:425–430.

Johansson RM, Christensson L. Urinary retention in older patients in connection with hip fracture surgery. *J Clin Nurs*. 2010;19:2110–2116.

Johnell K, Fastbom J. Concurrent use of anticholinergic drugs and cholinesterase inhibitors: register-based study of over 700,000 elderly patients. *Drugs Aging*. 2008;25:871–877.

Johnson TM 2nd, Ouslander JG. The newly revised F-Tag 315 and surveyor guidance for urinary incontinence in long-term care. *J Am Med Dir Assoc*. 2006;7(9):594–600.

Johnson TM II, Markland AD, Goode PS, et al. Efficacy of adding behavioral treatment or antimuscarinic drug therapy to α-blocker therapy in men with nocturia. *BJU Int*. 2013;112:100–108.

Johnson TM, Burgio KL, Redden TR, et al. Effects of behavioral and drug therapy on nocturia in older incontinent women. *J Am Geriatr Soc*. 2005;53:846–850.

Jonsson K, Claesson BE, Hedelin H. Urine cultures from indwelling bladder catheters in nursing home patients: a point prevalence study in a Swedish county. *Scan J Urol Nephrol*. 2011;45:265–269.

Jonsson K, Emanuelsson-Loft AL, Nasic S, et al. A prospective registration of catheter life and catheter interventions in patients with long-term indwelling urinary catheters. *Scan J Urol Nephrol*. 2011;45:401–405.

Joseph B, Pandit V, Zangbar B, et al. Validating trauma-specific frailty index for geriatric trauma patients: a prospective analysis. *J Am Coll Surg*. 2014;219:10–18.

Jun KK, Oh SM, Choo GY, et al. Long-term clinical outcomes of the tension-free vaginal tape procedure for the treatment of stress urinary incontinence in elderly women over 65. *Korean*

J Urol. 2012;53:184–188.

Justo D, Arbel Y, Mulat B, et al. Sexual activity and erectile dysfunction in elderly men with angiographically documented coronary artery disease. *Int J Impot Res*. 2010;22:40–44.

Juthani-Mehta M. Asymptomatic bacteriuria and urinary tract infection in older adults. *Clin Geriatr Med*. 2007;23:585–594.

Juthani-Mehta M, Quagliarello V, Perrelli E, et al. Clinical features to identify urinary tract infection in nursing home residents: a cohort study. *J Am Geriatr Soc*. 2009;57:963–970.

Juthani-Mehta M, Tinetti M, Perrelli E, et al. Diagnostic accuracy of criteria for urinary tract infection in a cohort of nursing home residents. *J Am Geriatr Soc*. 2007;55:1072–1077.

Kader AK, Tamboli P, Luongo T, et al. Cytoreductive nephrectomy in the elderly patient: the M.D. Anderson Cancer Center experience. *J Urol*. 2007;177:855–860 [discussion 860–861].

Kafri R, Kodesh A, Shames J, et al. Depressive symptoms and treatment of women with urgency urinary incontinence. *Int Urogynecol J*. 2013;24:1953–1959.

Kahn ZA, Whittal C, Mansol S, et al. Effect of depression and anxiety on the success of pelvic floor muscle training for pelvic floor dysfunction. *J Obstet Gynaecol*. 2013;33:710–714.

Kamdar A, Yahya A, Thangaraj L. Retrospective observational study of the incidence of short-term indwelling urinary catheters in elderly patients with neck of femur fractures. *Geriatr Gerontol Int*. 2009;9:131–134.

Kaminetsky J, Fein S, Dmochowski R, et al. Efficacy and safety of SER120 nasal spray in patients with nocturia: pooled analysis of 2 randomized, double-blind, placebo controlled, phase 3 trials. *J Urol*. 2018;200(3):604–611.

Kang SC, Tsao HM, Liu CT, et al. The characteristics of acute pyelonephritis in geriatric patients: experiences in rural northeastern Taiwan. *Tohoku J Exp Med*. 2008;214:61–67.

Kashyap M, Tu LM, Tannenbaum C. Prevalence of commonly prescribed medications potentially contributing to urinary symptoms in a cohort of older patients seeking care for incontinence. *BMC Geriatr*. 2013;13:57.

Kates M, Badalato G, Pitman M, et al. Persistent overuse of radical nephrectomy in the elderly. *Urology*. 2011;78:555–559.

Katz DL, Zheng T, Holford TR, et al. Time trends in the incidence of renal carcinoma: analysis of Connecticut tumor registry data, 1935-1989. *Int J Cancer*. 1994;58:57–63.

Kay G, Crook T, Rekeda L, et al. Differential effects of the antimuscarinic agents darifenacin and oxybutynin ER on memory in older subjects. *Eur Urol*. 2006;50(2):317–326.

Kaye KS, Anderson DJ, Sloane R, et al. The effect of surgical site infection on older operative patients. *J Am Geriatr Soc*. 2009;57:46–54.

Keating NL, O'Malley AJ, Freedland SJ, et al. Does comorbidity influence the risk of myocardial infarction or diabetes during androgen-deprivation therapy for prostate cancer? *Eur Urol*. 2013;64:159–166.

Keegan PE, Atiemo K, Cody J, et al. Periurethral injection therapy for urinary incontinence in women. *Cochrane Database Syst Rev*. 2007;(3) [CD003881].

Kersten H, Molden E, Tolo IK, et al. Cognitive effects of reducing anticholinergic drug burden in a frail elderly population: a randomized controlled trial. *J Gerontol A Biol Sci Med Sci*. 2013;68:271–278.

Ketchandji M, Kuo YF, Shahinian VB, et al. Cause of death in older men after the diagnosis of prostate cancer. *J Am Geriatr*

Soc. 2009;57:24–30.

Khaja A, Freeman RM. How often should shelf / Gellhorn pessaries be changed? A survey of IUGA urogynaecologists. *Int Urogynecol J*. 2014;25:941–996.

Khatutsky G, Walsh EG, Brown DW. Urinary incontinence, functional status, and health-related quality of life among Medicare beneficiaries enrolled in the Program for All-Inclusive Care for the Elderly and dual eligible demonstration special needs plans. *J Ambul Care Manage*. 2013;36:35–49.

Khullar V, Cardozo LD, Abbott D, et al. GAX collagen in the treatment of urinary incontinence in elderly women: a two year follow up. *Br J Obstet Gynaecol*. 1997;104:96–99.

Kim H, Higgins PA, Canaday DH, et al. Frailty assessment in the geriatric outpatient clinic. *Geriatr Gerontol Int*. 2014;14:78–83.

Kim H, Yoshida H, Hu X, et al. Association between self-reported urinary incontinence and musculoskeletal conditions in community-dwelling elderly women: a cross-sectional study. *Neurourol Urodyn*. 2015;34:322–326.

Kim J, Lucioni A, Govier F, et al. Worse long-term surgical outcomes in elderly patients undergoing SPARC retropubic midurethral sling placement. *BJU Int*. 2011;108:708–712.

Kim KI, Park KH, Koo KH, et al. Comprehensive geriatric assessment can predict postoperative morbidity and mortality in elderly patients undergoing elective surgery. *Arch Gerontol Geriatr*. 2013;56:507–512.

Kim M, Dam A, Green J. Common GI drug interactions in the elderly. *Curr Treat Options Gastroenterol*. 2014;12:292–309.

Kim O, Jeon HO. Gender differences in factors influencing sexual satisfaction in Korean older adults. *Arch Gerontol Geriatr*. 2013;56:321–326.

Kim S, Jeong JY, Choi YJ, et al. Association between lower urinary tract symptoms and vascular risk factors in aging men: the Hallym Aging Study. *Korean J Urol*. 2010;51:477–482.

Kim TG, Yoo KH, Jeon SH, et al. Effect of dominant hemispheric stroke on detrusor function in patients with lower urinary tract symptoms. *Int J Urol*. 2010;17:656–660.

Kim YH, Kim SM, Kim JJ, et al. Does metabolic syndrome impair sexual function in middle- to old-aged women? *J Sex Med*. 2011;8:1123–1130.

Kimbrell BJ, Velmahos GC, Chan LS, et al. Angiographic embolization for pelvic fractures in older patients. *Arch Surg*. 2004;139:728–733.

King BJ, Gilmore-Bykovskyi AL, Roiland RA, et al. The consequences of poor communication during transitions from hospital to skilled nursing facility: a qualitative study. *J Am Geriatr Soc*. 2013;61:1095–1102.

Kistler CE, Sloane PD, Platts-Mills TF, et al. Challenges of antibiotic prescribing for assisted living residents: perspectives of providers, staff, residents, and family members. *J Am Geriatr Soc*. 2013;61:565–570.

Klauser A, Frauscher F, Strasser H, et al. Age-related rhabdosphincter function in female urinary stress incontinence: assessment of intraurethral sonography. *J Ultrasound Med*. 2004;23:631–637.

Ko J, Falzarano SM, Walker E, et al. Prostate cancer patients older than 70 years treated by radical prostatectomy have higher biochemical recurrence rate than their matched younger counterpart. *Prostate*. 2013;73:897–903.

Kohjimoto Y, Iba A, Shintani Y, et al. Impact of patient age on outcome following bladder-preserving treatment for non-muscle-invasive bladder cancer. *World J Urol*. 2010;28:425–430.

Kojima Y, Takahashi N, Haga N, et al. Urinary incontinence after robot-assisted radical prostatectomy: pathophysiology and intraoperative techniques to improve surgical outcome. *Int J Urol*. 2013;20:1052–1063.

Kopp RP, Marshall LM, Wang PY, et al. The burden of urinary incontinence and urinary bother among elderly prostate cancer survivors. *Eur Urol*. 2013;64:672–679.

Korfage IJ, Pluijm S, Roobol M, et al. Erectile dysfunction and mental health in a general population of older men. *J Sex Med*. 2009;6:505–512.

Körnig M, Brühlmann E, Günthert A, et al. Intra-, peri- and postoperative complications in pelvic organ prolapse surgery in geriatric women. *Eur J Obstet Gynecol Reprod Biol*. 2018;224:142–145.

Kortebein P, Symons TB, Ferrando A, et al. Functional impact of 10 days of bed rest in healthy older adults. *J Gerontol A Biol Sci Med Sci*. 2008;63:1076–1081.

Kosilov KV, Loparev SA, Kuzina IG, et al. Long-term adherence to antimuscarinic drugs when treating overactive bladder in the older: subjective reason and objective factors. *Investig Clin Urol*. 2017;58:109–116.

Koski ME, Chow D, Bedestani A, et al. Colpocleisis for advanced pelvic organ prolapse. *Urology*. 2012;80:542–546.

Koskimäki J, Shiri R, Tammela T, et al. Regular intercourse protects against erectile dysfunction: Tampere Aging Male Urologic Study. *Am J Med*. 2008;121:592–596.

Kouloulias V, Tolia M, Kolliarakis N, et al. Evaluation of acute toxicity and symptoms palliation in a hypofractionated weekly schedule of external radiotherapy for elderly patients with muscular invasive bladder cancer. *Int Braz J Urol*. 2013;39:77–82.

Köves B, Cai T, Veeratterapillay R, et al. Benefits and harms of treatment of asymptomatic bacteriuria: a systematic review and meta-analysis by the European Association Of Urology Urological Infection Guidelines Panel. *Eur Urol*.

2017;72:865–868.

Kovindha A, Wattanapan P, Dejpratham P, et al. Prevalence of incontinence in patients after stroke during rehabilitation: a multi-centre study. *J Rehabil Med*. 2009;41:489–491.

Koyama M, Steinman K, Ensrud T, et al. Long-term cognitive and functional effects of potentially inappropriate medications in older women. *J Gerontol A Biol Sci Med Sci*. 2014;69:423–429.

Krahn M, Bremner KE, Tomlinson G, et al. Androgen deprivation therapy in prostate cancer: are rising concerns leading to falling use? *BJU Int*. 2011;108:1588–1596.

Kranz J, Petzinger E, Geyer J. Brain penetration of the OAB drug trospium chloride is not increased in aged mice. *World J Urol*. 2013;31:219–224.

Kraus SR, Bavendam T, Brake T, et al. Vulnerable elderly patients and overactive bladder syndrome. *Drugs Aging*. 2010;27:697–713.

Krause MP, Albert SM, Elsangedy HM, et al. Urinary incontinence and waist circumference in older women. *Age Ageing*. 2010;39:69–73.

Krhut J, Tintera J, Holý P, et al. A preliminary report on the use of functional magnetic resonance imaging with simultaneous urodynamics to record brain activity during micturition. *J Urol*. 2012;188:474–479.

Krystal AD, Preud'homme XA, Amundsen CL, et al. Detrusor overactivity persisiting at night and preceding nocturia in patients with overactive bladder syndrome: a nocturnal cystometrogram and polysomnogram study. *J Urol*. 2010;184:623–628.

Kuchel GA, Moscufo N, Guttmann CR, et al. Localization of brain white matter hyperintensities and urinary incontinence in community-dwelling older adults. *J Gerontol A Biol Sci Med Sci*. 2009;64:902–909.

Kulchavenya E, Zhukova I, Kholtobin D. Spectrum of urogenital tuberculosis. *J Infect Chemother*. 2013;19:880–883.

Kuntz RM, Lehrich K, Ahyai SA. Holmium laser enucleation of the prostate versus open prostatectomy for prostates greater than 100 grams: 5-year follow-up results of a randomized clinical trial. *Eur Urol*. 2008;53:160–166.

Kunz I, Musch M, Roggenbuck U, et al. Tumour characteristics, oncological and functional outcomes in patients aged >/= 70 years undergoing radical prostatectomy. *BJU Int*. 2013;111:E24–E29.

Kupelian V, Fitzgerald MP, Kaplan SA, et al. Association of nocturia and mortality: results from the Third National Health and Nutrition Examination Survey. *J Urol*. 2011;185:571–577.

Kurihara M, Murakami G, Kajiwara M, et al. Lack of the complete circular rhabdosphincter and a distinct circular smooth muscle layer around the proximal urethra in elderly Japanese women: an anatomical study. *Int Urogynecol J Pelvic Floor Dysfunct*. 2004;15:85–94.

Kurita N, Yamazaki S, Fukumori N, et al. Overactive bladder syndrome severity is associated with falls in community-dwelling adults: LOHAS Study. *BMJ Open*. 2013;3.

Kurtal H, Schwenger V, Azzaro M, et al. Clinical value of automatic reporting of estimated glomerular filtration rate in geriatrics. *Gerontology*. 2009;55:288–295.

Kwong PW, Cumming RG, Chan L, et al. Urinary incontinence and quality of life among older community-dwelling Australian men: the CHAMP Study. *Age Ageing*. 2010;39:349–354.

Lackner TE, Wyman JF, McCarthy TC, et al. Efficacy of oral extended-release oxybutynin in cognitively impaired older nursing home residents with urge urinary incontinence: a randomized placebo-controlled trial. *J Am Med Dir Assoc*. 2011;12:639–647.

Lackner TE, Wyman JF, McCarthy TC, et al. Randomized, placebo-controlled trial of the cognitive effect, safety, and tolerability of oral extended-release oxybutynin in cognitively impaired nursing home residents with urge urinary incontinence. *J Am Geriatr Soc*. 2008;56(5):862–870.

Laganà L, Bloom DW, Ainsworth A. Urinary incontinence: its assessment and relationship to depression among community-dwelling multiethnic older women. *ScientificWorldJournal*. 2014;2014:708564.

Lajiness MD, Wolfert C, Hall S, et al. Group session teaching of behavioral modification program for urinary incontinence: establishing the teachers. *Urol Nurs*. 2007;27:124–127.

Lampela P, Lavikainen P, Garcia-Horsman JA, et al. Anticholinergic drug use, serum anticholinergic activity, and adverse drug events among older people: a population-based study. *Drugs Aging*. 2013;30:321–330.

Landi F, Cesari M, Russo A, et al. Benzodiazepines and the risk of urinary incontinence in frail older persons living in the community. *Clin Pharmacol Ther*. 2002;72(6):729–734.

Lapitan MCM, Buckley BS, Lascano R. Abalajon MJ. Drugs for the prevention of postoperative urinary retention in adults (Protocol). *Cochrane Database Syst Rev*. 2013;(10); 10.1002/14651858.CD010759 [Art. No.: CD010759].

Large MC, Reichard C, Williams JT, et al. Incidence, risk factors, and complications of postoperative delirium in elderly patients undergoing radical cystectomy. *Urology*. 2013;81:123–128.

Lawton MP, Brody EM. Assessment of older people: self-maintaining and instrumental activities of daily living. *Gerontologist*. 1969;9:179–186.

Lee DM, Tajar A, Ravindrarajah R, et al. Frailty and sexual health in older European men. *J Gerontol A Biol Sci Med Sci*. 2013;68:837–844.

Lee DM, Vanhoutte B, Nazroo J, et al. Sexual health and positive subjective well-being in partnered older men and women. *J Gerontol B Psychol Sci Soc Sci*. 2016;71:698–710.

Lee HY, Li CC, Juan YS, et al. Urinary incontinence in Alzheimer's disease: a population-based cohort study in Taiwan. *Am J Alzheimers Dis Other Demen*. 2017;32:51–55.

Lee SH, Cho ST, Na HR, et al. Urinary incontinence in patients with Alzheimer's disease: relationship between symptoms status and urodynamic diagnosis. *Int J Urol*. 2014;21:683–687.

Lee YI, Kim JW, Bae SR, et al. Effect of urgency symptoms on the risk of depression in community-dwelling elderly men. *Korean J Urol*. 2013;54:762–766.

Lee YJ, Jeong SJ, Byun SS, et al. Prevalence and correlates of nocturia in community-dwelling older men: results from the Korean Longitudinal Study on Health and Aging. *Korean J Urol*. 2012;53:263–267.

Lee YK, Kuo HC. Safety and therapeutic efficacy of mirabegron 25 mg in older patients with overactive bladder and multiple comorbidities. *Geriatr Gerontol Int*. 2018;18:1330–1333.

Leeds IL, Wick EC, Melton GB. Does close temperature regulation affect surgical site infection rates? *Adv Surg*. 2014;48:65–76.

Leslie DL, Marcantonio ER, Zhang Y, et al. One-year health care costs associated with delirium in the elderly population. *Arch Intern Med*. 2008;168:27–32.

Leuck AM, Wright D, Ellingson L, et al. Complications of Foley catheters: is infection the greatest risk? *J Urol*. 2012;187:1662–1666.

Leung SX, Xu QL, Tian J, et al. Inflammation and frailty in older women. *J Am Geriatr Soc*. 2007;55:864–871.

Lewicky-Gaupp C, Hamilton Q, Ashton-Miller J, et al. Anal sphincter structure and function relationships in aging and fecal incontinence. *Am J Obstet Gynecol*. 2009;200(559):e551–e555.

Liberman D, Lughezzani G, Sun M, et al. Perioperative mortality is significantly greater in septuagenarian and octogenarian patients treated with radical cystectomy for urothelial carcinoma of the bladder. *Urology*. 2011;77:660–666.

Lightner D, Calvosa C, Andersen R, et al. A new injectable bulking agent for treatment of stress urinary incontinence: results of a multicenter, randomized, controlled, double-blind study of Durasphere. *Urology*. 2001;58:12–15.

Lightner DJ, Itano NB, Sweat DS, et al. Injectable agents: present and future. *Curr Urol Rep*. 2002;3:408–413.

Lim AK, Campbell DA. Haematuria and acute kidney injury in elderly patients admitted to hospital with supratherapeutic warfarin anticoagulation. *Int Urol Nephrol*. 2013;45:561–570.

Lim YM, Lee SR, Choi EJ, et al. Urinary incontinence is strongly associated with depression in middle-aged and older Korean women: data from the Korean Longitudinal Study of Ageing. *Eur J Obstet Gynecol Reprod Biol*. 2018;220:69–73.

Lin CS, Jao FC, Shin PW, et al. Evaluating the potential of removing long-term urinary catheters among home care recipients in Taiwan. *J Clin Gerontol Geriatr*. 2011;2:105–108.

Lin H, Kao LT, Chung SD, et al. Alzheimer's disease is associated with prostate cancer: a population-based study. *Oncotarget*. 2018;9:7616–7622.

Lindau ST, Gavrilova N. Sex, health, and years of sexually active life gained due to good health: evidence from two US population based cross sectional surveys of ageing. *BMJ*.

2010;340:c810.

Lindau ST, Schumm LP, Laumann EO, et al. A study of sexuality and health among older adults in the United States. *N Engl J Med*. 2007;357:762–774.

Lipton RB, Kolodner K, Wesnes K. Assessment of cognitive function of the elderly population: effects of darifenacin. *J Urol*. 2005;173:493–498.

Lowalekar SK, Cristofaro V, Radisavljevic ZM, et al. Loss of bladder smooth muscle caveolae in the aging bladder. *Neurourol Urodyn*. 2012;31:586–592.

Lubitz J, Cai L, Kramarow E, et al. Health, life expectancy, and health care spending among the elderly. *N Engl J Med*. 2003;349:1048–1055.

Lund L, Jacobsen J, Clark P, et al. Impact of comorbidity on survival of invasive bladder cancer patients, 1996-2007: a Danish population-based cohort study. *Urology*. 2010;75:393–398.

Madill SJ, Pontbriand-Drolet S, Tang A, et al. Effects of PFM rehabilitation on PFM function and morphology in older women. *Neurourol Urodyn*. 2013;32:1086–1095.

Madhuvrata P, Cody JD, Ellis G, et al. Which anticholinergic drug for overactive bladder symptoms in adults. *Cochrane Database Syst Rev*. 2012;(1) [CD005429].

Margel D, Alkhateeb SS, Finelli A, et al. Diminished efficacy of Bacille Calmette-Guerin among elderly patients with nonmuscle invasive bladder cancer. *Urology*. 2011;78:848–854.

Makary MA, Segev DL, Pronovost PJ, et al. Frailty as a predictor of surgical outcomes in older patients. *J Am Coll Surg*. 2010;210:901–908.

Marcum ZA, Wirtz HS, Pettinger M, et al. Anticholinergic medication use and falls in postmenopausal women: findings from The Women's Health Initiative Cohort Study. *BMC*

Geriatr. 2016;16:76.

Marinkovic SP, Badlani G. Voiding and sexual dysfunction after cerebrovascular accidents. *J Urol*. 2001;165:359–370.

Markland AD, Richter HE, Burgio KL, et al. Weight loss improves fecal incontinence severity in overweight and obese women with urinary incontinence. *Int Urogynecol J*. 2011;22:1151–1157.

Martini T, Mayr R, Wehrberger C, et al. Comparison of radical cystectomy with conservative treatment in geriatric (>/=80) patients with muscle-invasive bladder cancer. *Int Braz J Urol*. 2013;39:622–630.

Mason SE, Noel-Storr A, Ritchie CW. The impact of general and regional anesthesia on the incidence of post-operative cognitive dysfunction and post-operative delirium: a systematic review with meta-analysis. *J Alzheimers Dis*. 2010;22(Suppl 3):67–79.

Mauseth SA, Skurtveit S, Spigset O. Adherence, persistence and switch rates for anticholinergic drugs used for overactive bladder in women: data from the Norwegian Prescription Database. *Acta Obstet Gynecol Scand*. 2013;92:1208–1215.

May M, Fuhrer S, Braun KP, et al. Results from three municipal hospitals regarding radical cystectomy on elderly patients. *Int Braz J Urol*. 2007;33:764–773 [discussion 774–766].

McCabe MP, Althof SE. A systematic review of the psychosocial outcomes associated with erectile dysfunction: does the impact of erectile dysfunction extend beyond a man's inability to have sex? *J Sex Med*. 2014;11:347–363.

McCusker J, Cole M, Abrahamowicz M, et al. Delirium predicts 12-month mortality. *Arch Intern Med*. 2002;162:457–463.

McPherson VA, Rodrigues G, Bauman G, et al. Chemoradiotherapy in octogenarians as primary treatment for muscle-invasive bladder cancer. *Can Urol Assoc J*. 2017;11:24–30.

McRae PJ, Peel NM, Walker PJ, et al. Geriatric syndromes in individuals admitted to vascular and urology surgical units. *J Am Geriatr Soc*. 2014;62:1105–1109.

McVary KT, Roehrborn C, Avins A, et al. Update on AUA Guideline on the management of benign prostatic hyperplasia. *J Urol*. 2011;185:1793–1803.

Meadows M. FDA issues public health advisory on phenylpropanolamine in drug products. *FDA Consum*. 2001;35:9.

Meng Q, Busby-Whitehead J, Palmer MH. Absorbent products use and symptom distress in women who have urinary incontinence and heart failure. *Int J Clin Pract*. 2016;70:1019–1026.

Miller JM, Guo Y, Rodseth SB. Cluster analysis of intake, output, and voiding habits collected from diary data. *Nurs Res*. 2011;60:115–123.

Milroy E, Allen A. Long-term results of Urolume urethral stent for recurrent urethral strictures. *J Urol*. 1996;155:904–908.

Min LC, Reuben DB, Adams J, et al. Does better quality of care for falls and urinary incontinence result in better participant-reported outcomes? *J Am Geriatr Soc*. 2011;59:1435–1443.

Mirza M, Griebling TL, Kazer MW. Erectile dysfunction and urinary incontinence after prostate cancer treatment. *Semin Oncol Nurs*. 2011;27:278–289.

Miu DK, Lau S, Szeto SS. Etiology and predictors of urinary incontinence and its effect on quality of life. *Geriatr Gerontol Int*. 2010;10:177–182.

Miyake H, Sakai I, Harada K, et al. Significance of docetaxel-based chemotherapy as treatment for metastatic castration-resistant prostate cancer in Japanese men over 75 years old. *Int Urol Nephrol*. 2012;44:1697–1703.

Mizrahi EH, Waitzman A, Arad M, et al. Bladder management and the functional outcome of elderly ischemic stroke patients. *Arch Gerontol Geriatr*. 2011;53:e125–e128.

Modi A, Weiner M, Craig BA, et al. Concomitant use of anticholinergics with acetylcholinesterase inhibitors in Medicaid recipients with dementia and residing in nursing homes. *J Am Geriatr Soc*. 2009;57:1238–1244.

Moga DC, Carnahan RM, Lund BC, et al. Risks and benefits of bladder antimuscarinics among elderly residents of Veterans Affairs community living centers. *J Am Med Dir Assoc*. 2013;14:749–760.

Mohammed N, Raschid Hoda M, Fornara P. Prolapse surgery in octogenarians: are we pushing the limits too far? *World J Urol*. 2013;31:623–628.

Mohanty S, Rosenthal RA, Russell MM, et al. Optimal perioperative management of the geriatric patient: a best practices guideline from the American College of Surgeons NSQIP and the American Geriatrics Society. *J Am Coll Surg*. 2016;222:930–947.

Mohile SG, Fan L, Reeve E, et al. Association of cancer with geriatric syndromes in older Medicare beneficiaries. *J Clin Oncol*. 2011;29:1458–1464.

Monk TG, Weldon BC, Garvan CW, et al. Predictors of cognitive dysfunction after major noncardiac surgery. *Anesthesiology*. 2008;108:18–30.

Monteiro ÉS, de Carvalho LBC, Fukujima MM, et al. Electrical stimulation of the posterior tibialis nerve improves symptoms of poststroke neurogenic overactive bladder in men: a randomized controlled trial. *Urology*. 2014;84:509–514.

Morris CL. Urge urinary incontinence and the brain factor. *Neurourol Urodyn*. 2013;32:441–448.

Morrison A, Levy R. Fraction of nursing home admissions attributable to urinary incontinence. *Value Health*. 2006;9(4):272–274.

Moyer VA, US Preventive Services Task Force. Screening for prostate cancer: U.S. Preventive Services Task Force recommendation statement. *Ann Intern Med*. 2012;157:120–134.

Mroczek B, Kurpas D, Gronowska M, et al. Psychosexual needs and sexual behaviors of nursing care home residents. *Arch Gerontol Geriatr*. 2013;57:32–38.

Murphy CR, Eells SJ, Quan V, et al. Methicillin-resistant staphylococcus aureus burden in nursing homes associated with environmental contamination of common areas. *J Am Geriatr Soc*. 2012;60:1012–1018.

Nakagawa H, Niu K, Hozawa A, et al. Impact of nocturia on bone fracture and mortality in older individuals: a Japanese longitudinal cohort study. *J Urol*. 2010;184:1413–1418.

Namiki S, Ishidoya S, Kawamura S, et al. Quality of life among elderly men treated for prostate cancer with either radical prostatectomy or external beam radiation therapy. *J Cancer Res Clin Oncol*. 2010;136:379–386.

Nacher IL. Geriatrics. *NY Med J*. 1909;90:358–359.

Natsume O, Kaneko Y, Hirayama A, et al. Fluid control in elderly patients with nocturia. *Int J Urol*. 2009;16:307–313.

Negoro H, Sugino Y, Nishizawa K, et al. Underweight body mass index is a risk factor for mortality in outpatients with nocturia in Japan. *BMC Res Notes*. 2015;8:490.

Newman DK. Pelvic floor muscle rehabilitation using biofeedback. *Urol Nurs*. 2014;34:193–202.

Newman DK, Cockerell R, Griebling TL, et al. Primary prevention, continence promotion, models of care and education (Committee 21). Abrams P, Cardozo L, Wagg A, et al. *Incontinence: 6th International Consultation on Incontinence*. ed 6. ICS and ICUD: Tokyo; 2017:2427–2478.

Noguchi N, Chan L, Cumming RG, et al. Natural history of post-void residual urine volume over 5 years in community-dwelling older men: the Concord Health and Ageing in Men

Project. *Neurourol Urodyn*. 2018;37:1068–1073.

Nomiya M, Burmeister DM, Sawada N, et al. Effect of melatonin on chronic bladder-ischaemia-associated changes in rat bladder function. *BJU Int*. 2013;112:E221–E230.

Nomiya M, Sagawa K, Yazaki J, et al. Increased bladder activity is associated with elevated oxidative stress markers and proinflammatory cytokines in a rat model of atherosclerosis-induced chronic bladder ischemia. *Neurourol Urodyn*. 2012;31:185–189.

Obayashi K, Saeki K, Kurumatani N. Associations between melatonin secretion and nocturia in elderly individuals: a cross-sectional study of the HEIJO-KYO cohort. *J Urol*. 2014;191:1816–1821.

Obayashi K, Saeki K, Negoro H, et al. Nocturia increases the incidence of depressive symptoms: a longitudinal study of the HEIJO-KYO cohort. *BJU Int*. 2017;120:280–285.

O'Connor KM, Davis N, Lennon GM, et al. Can we avoid surgery in elderly patients with renal masses by using the Charlson Comorbidity Index? *BJU Int*. 2009;103:1492–1495.

O'Connor MN, Gallagher P, Byrne S, et al. Adverse drug reactions in older patients during hospitalisation: are they predictable? *Age Ageing*. 2012;41:771–776.

O'Connor RC, Nanigian DK, Patel BN, et al. Artificial urinary sphincter placement in elderly men. *Urology*. 2007;69(1):126–128.

Oelke M, Wagg A, Takita Y, et al. Efficacy and safety of tadalafil 5 mg once daily in the treatment of lower urinary tract symptoms associated with benign prostatic hyperplasia in men aged ≥ 75 years: integrated analyses of pooled data from multinational, randomized, placebo-controlled clinical studies. *BJU Int*. 2017;119:793–803.

Oliphant SS, Lowder JL, Lee M, et al. Most older women recover baseline functional status following pelvic organ prolapse surgery. *Int Urogyencol J*. 2014;25:1425–1432.

O'Malley RL, Godoy G, Phillips CK, et al. Is surveillance of small renal masses safe in the elderly? *BJU Int*. 2010;105:1098–1101.

Omli R, Hunskaar S, Mykletun A, et al. Urinary incontinence and risk of functional decline in older women: data from the Norwegian HUNT-Study. *BMC Geriatr*. 2013;13:47.

Omli R, Skotnes LH, Mykletun A, et al. Residual urine as a risk factor for lower urinary tract infection: a 1-year follow-up study in nursing homes. *J Am Geriatr Soc*. 2008;56:871–874.

Omli R, Skotnes LH, Romild U, et al. Pad per day usage, urinary incontinence and urinary tract infections in nursing home residents. *Age Ageing*. 2010;39:549–554.

Osborn DJ, Dmochowski RR, Kaurman MR, et al. Cystectomy with urinary diversion for benign disease: indications and outcomes. *Urology*. 2014;83:1433–1437.

Ostaszkiewicz J, Johnston L, Roe B. Habit retraining for the management of urinary incontinence in adults. *Cochrane Database Syst Rev*. 2004;(2) [CD002801].

Ou R, Pan C, Chen H, et al. Urodynamically diagnosed detrusor hypocontractility: should transurethral resection of the prostate be contraindicated? *Int Urol Nephrol*. 2012;44:35–39.

Ouslander JG, Greengold B, Chen S. Complications of chronic indwelling urinary catheters among male nursing home patients: a prospective study. *J Urol*. 1987;138:1191–1195.

Ouslander JG, Palmer MH, Rovner BW, et al. Urinary incontinence in nursing homes: incidence, remission, and associated factors. *J Am Geriatr Soc*. 1993;41:1083–1089.

Ozkurkcugil C, Ozkan L, Tarcan T. The effect of asymptomatic urethral caruncle on micturition in women with urinary incontinence. *Korean J Urol*. 2010;51:257–259.

Pagoria D, O'Connor RC, Guralnick ML. Antimuscarinic drugs:

review of the cognitive impact when used to treat overactive bladder in elderly patients. *Curr Urol Rep*. 2011;12:351–357.

Palmer MH, German PS, Ouslander JG. Risk factors for urinary incontinence one year after nursing home admission. *Res Nurs Health*. 1991;14:405–412.

Palmer MH, Hardin SR, Behrend C, et al. Urinary incontinence and overactive bladder in patients with heart failure. *J Urol*. 2009;182:196–202.

Panfili Z, Metcalf M, Griebling TL. Contemporary evaluation and treatment of poststroke lower urinary tract dysfunction. *Urol Clin North Am*. 2017;44:403–414.

Paquette A, Gou P, Tannenbaum C. Systematic review and meta-analysis: do clinical trials testing antimuscarinic agents for overactive bladder adequately measure central nervous system adverse events? *J Am Geriatr Soc*. 2011;59:1332–1339.

Park HK, Lee HW, Lee KS, et al. Relationship between lower urinary tract symptoms and metabolic syndrome in a community-based elderly population. *Urology*. 2008;72:556–560.

Park SW, Kim TN, Nam JK, et al. Recovery of overall exercise ability, quality of life, and continence after 12-week combined exercise intervention in elderly patients who underwent radical prostatectomy: a randomized controlled study. *Urology*. 2012;80:299–305.

Parker WP, Griebling TL. Nonsurgical treatment of urinary incontinence in elderly women. *Clin Geriatr Med*. 2015;31(4):471–485.

Parsons JK, Bergstrom J, Silberstein J, et al. Prevalence and characteristics of lower urinary tract symptoms in men aged > or = 80 years. *Urology*. 2008;72:318–321.

Parsons JK, Mougey J, Lambert L, et al. Lower urinary tract symptoms increase the risk of falls in older men. *BJU Int*.

2009;104(1):63–68.

Patel M, Coshall C, Rudd AG, et al. Natural history and effects on 2-year outcomes of urinary incontinence after stroke. *Stroke*. 2001;32:122–127.

Patel M, Mellen C, O'Sullivan DM, et al. Impact of pessary use on prolapse symptoms, quality of life, and body image. *Am J Obstet Gynecol*. 2010;202(499):e491–e494.

Paterson AL, Sut MK, Khan AR, et al. Prostatic biopsies in selected men aged 75 years and older guide key clinical management decisions. *Int Urol Nephrol*. 2013;45:1539–1544.

Peled E, Keren Y, Halachmi S, et al. Patients aged 80 and older undergoing orthopedic or urologic surgery: a prospective study focusing on perioperative morbidity and mortality. *Gerontology*. 2009;55:517–522.

Pereira VS, de Melo MV, Correia GN. Driusso P: Long-term effects of pelvic floor muscle training with vaginal cone in post-menopausal women with urinary incontinence: a randomized controlled trial. *Neurourol Urodyn*. 2013;32:48–52.

Pereira VS, de Melo MV, Correia GN, et al. Vaginal cone for postmenopausal women with stress urinary incontinence: randomized, controlled trial. *Climacteric*. 2012;15:45–51.

Perimenis P, Konstantinopoulos A, Giannitsas K, et al. Cost implications of antimuscarinic drugs in the treatment of overactive bladder syndrome. *Expert Opin Pharmacother*. 2006;7:539–544.

Peron EP, Zheng Y, Perera S, et al. Antihypertensive drug class use and differential risk of urinary incontinence in community-dwelling older women. *J Gerontol A Biol Sci Med Sci*. 2012;67:1373–1378.

Pesonen JS, Cartwright R, Mangera A, et al. Incidence and remission of nocturia: a systematic review and meta-analysis.

Eur Urol. 2016;70:372–381.

Peters KM, Killinger KA, Gilleran J, et al. Does patient age impact outcomes of neuromodulation? *Neurourol Urodyn*. 2013;32:30–36.

Pfisterer MH, Griffiths DJ, Rosenberg L, et al. The impact of detrusor overactivity on bladder function in younger and older women. *J Urol*. 2006;175(5):1777–1783 [discussion 1783].

Pfisterer MH, Griffiths DJ, Schaefer W, et al. The effect of age on lower urinary tract function: a study in women. *J Am Geriatr Soc*. 2006;54(3):405–412.

Pfisterer MH, Johnson TM 2nd, Jenetzky E, et al. Geriatric patients' preferences for treatment of urinary incontinence: a study of hospitalized, cognitively competent adults aged 80 and older. *J Am Geriatr Soc*. 2007;55:2016–2022.

Pierorazio PM, Humphreys E, Walsh PC, et al. Radical prostatectomy in older men: survival outcomes in septuagenarians and octogenarians. *BJU Int*. 2010;106:791–795.

Pinggera GM, Mitterberger M, Steiner E, et al. Association of lower urinary tract symptoms and chronic ischaemia of the lower urinary tract in elderly women and men: assessment using colour Doppler ultrasonography. *BJU Int*. 2008;102:470–474.

Pintarelli VL, Perchon LF, Lorenzetti F, et al. Elderly men's quality of life and lower urinary tract symptoms: an intricate relationship. *Int Braz J Urol*. 2011;37:758–765.

Planas J, Trilla E, Raventos C, et al. Alendronate decreases the fracture risk in patients with prostate cancer on androgen-deprivation therapy and with severe osteopenia or osteoporosis. *BJU Int*. 2009;104:1637–1640.

Podsiadlo D, Richardson S. The timed 'Up & Go': a test of basic functional mobility for frail elderly persons. *J Am*

Geriatr Soc. 1991;39:142–148.

Popejoy LL, Dorman Marek K, Scott-Cawiezell J. Patterns and problems associated with transitions after hip fracture in older adults. *J Gerontol Nurs*. 2013;39:43–52.

Prentis JM, Trenell MI, Vasdev N, et al. Impaired cardiopulmonary reserve in an elderly population is related to postoperative morbidity and length of hospital stay after radical cystectomy. *BJU Int*. 2013;112:e13–e319.

Price CC, Garvan CW, Monk TG. Type and severity of cognitive decline in older adults after noncardiac surgery. *Anesthesiology*. 2008;108:8–17.

Quander CR, Morris MC, Melson J, et al. Prevalence of and factors associated with fecal incontinence in a large community study of older adults. *Am J Gastroenterol*. 2005;100(4):905–909.

Racioppi M, Di Gianfrancesco L, Ragonese M, et al. The challenges of bacillus of Calmette-Guerin (BCG) therapy for high risk non muscle invasive bladder cancer treatment in older patients. *J Geriatr Oncol*. 2018;9:507–512.

Ramsay S, Tu LM, Tannenbaum C. Natural history of pessary use in women aged 65–74 versus 75 years and older with pelvic organ prolapse: a 12-year study. *Int Urogynecol J*. 2016;27:1201–1207.

Ransmayr GN, Holliger S, Schletterer K, et al. Lower urinary tract symptoms in dementia with Lewy bodies, Parkinson disease, and Alzheimer disease. *Neurology*. 2008;70:299–303.

Rastrelli D, Corona G, Lotti F, et al. Relationship of testis size and LH levels with incidence of major adverse cardiovascular events in older men with sexual dysfunction. *J Sex Med*. 2013;10:2761–2773.

Ratner ES, Erekson EA, Minkin MJ, et al. Sexual satisfaction in the elderly female population: a special focus on women with gynecologic pathology. *Maturitas*. 2011;70:210–215.

Ravaglia G, Forti P, Lucicesare A, et al. Development of an easy prognostic score for frailty outcomes in the aged. *Age Ageing*. 2008;37:161–166.

Ravi P, Karakiewicz PI, Roghmann F, et al. Mental health outcomes in elderly men with prostate cancer. *Urol Oncol*. 2014;32:1333–1340.

Rebelo M, Pereira B, Lima J, et al. Predictors of in-hospital mortality in elderly patients with bacteremia admitted to an internal medicine ward. *Int Arch Med*. 2011;4:33.

Redelmeier DA, Thiruchelvam D, Daneman N. Delirium after elective surgery among elderly patients taking statins. *Can Med Assoc J*. 2008;179:645–652.

Regadas RP, Reges R, Cerqueira JBG, et al. Urodynamic effects of the combination of tamsulosin and daily tadalafil in men with lower urinary tract symptoms secondary to benign prostatic hyperplasia: a randomized, placebo-controlled clinical trial. *Int Urol Nephrol*. 2013;45:39–43.

Reis C, Liberman S, Pompeo AC, et al. Body composition alterations, energy expenditure and fat oxidation in elderly males suffering from prostate cancer, pre and post orchiectomy. *Clinics*. 2009;64:781–784.

Rembratt A, Riis A, Norgaard JP. Desmopressin treatment in nocturia: an analysis of risk factors for hyponatremia. *Neurourol Urodyn*. 2006;25(2):105–109.

Resnick NM. Noninvasive diagnosis of the patient with complex incontinence. *Gerontology*. 1990;36(Suppl 2):8–18.

Resnick NM. Diagnosis and treatment of incontinence in the institutionalized elderly. *Semin Urol*. 1989;7:117–123.

Resnick NM, Baumann MM, Scott M, et al. Risk factors for incontinence in the nursing home: a multivariate study. *Neurourol Urodyn*. 1988;7:274–276.

Resnick NM, Yalla SV. Detrusor hyperactivity with impaired contractile function. An unrecognized but common cause of incontinence in elderly patients. *J Am Med Assoc*. 1987;257:3076–3081.

Resorlu B, Beduk Y, Baltaci S, et al. The prognostic significance of advanced age in patients with bladder cancer treated with radical cystectomy. *BJU Int*. 2009;103:480–483.

Reuben DB, Herr KA, Pacala JT, et al. *Geriatrics at your fingertips: 2014*. ed 16. The American Geriatrics Society: New York; 2014.

Revenig LM, Canter DKJ, Taylor MD, et al. Too frail for surgery? Initial results of a large multidisciplinary prospective study examining preoperative variables predictive of poor surgical outcomes. *J Am Coll Surg*. 2013;217:665–670.

Reynolds WS, Gold KP, Ni S, et al. Immediate effects of the initial FDA notification on the use of surgical mesh for pelvic organ prolapse surgery in Medicare beneficiaries. *Neurourol Urodyn*. 2013;32:330–335.

Richstone L, Bianco FJ, Shah HH, et al. Radical prostatectomy in men aged >or=70 years: effect of age on upgrading, upstaging, and the accuracy of a preoperative nomogram. *BJU Int*. 2008;101:541–546.

Richter HE, Morgan SL, Gleason JL, et al. Pelvic floor symptoms and bone mineral density in women undergoing osteoporosis evaluation. *Int Urogynecol J*. 2013;24:1663–1669.

Richter HE, Redden DT, Duxbury AS, et al. Pelvic floor surgery in the older woman: enhanced compared with usual preoperative assessment. *Obstet Gynecol*. 2005;105:800–807.

Riedner CE, Rhoden EL, Ribeiro EP, et al. Central obesity is an independent predictor of erectile dysfunction in older men. *J Urol*. 2006;176:1519–1523.

Robinson TN, Wallace JI, Wu DS, et al. Accumulated frailty characteristics predict postoperative discharge institutionalization in the geriatric patient. *J Am Coll Surg*. 2011;213:37–42 [discussion 42–34].

Robinson TN, Wu DS, Pointer LF, et al. Preoperative cognitive dysfunction is related to adverse postoperative outcomes in the elderly. *J Am Coll Surg*. 2012;215:12–17.

Rohrmann S, Katzke V, Kaaks R. Prevalence and progression of lower urinary tract symptoms in an aging population. *Urology*. 2016;95:158–163.

Roos FC, Pahernik S, Melchior SW, et al. Renal tumour surgery in elderly patients. *BJU Int*. 2008;102:680–683.

Rosa GM, Bauckneht M, Scala C, et al. Cardiovascular effects of antimuscarinic agents in overactive bladder. *Expert Opin Drug Saf*. 2013;12:815–827.

Rosa GM, Ferrero S, Nitti VW, et al. Cardiovascular safety of β3-adrenoceptor agonists for the treatment of patients with overactive bladder syndrome. *Eur Urol*. 2016;69:311–323.

Rosenthal RA. Nutritional concerns in the older surgical patient. *J Am Coll Surg*. 2004;199:785–791.

Rothman MD, Leo-Summers L, Gill TM. Prognostic significance of potential frailty criteria. *J Am Geriatr Soc*. 2008;56:2211–2216.

Rozet I, Valilala MS. Risks and benefits of patient positioning during neurosurgical care. *Anesthesiol Clin*. 2007;25:631–653.

Rudolph JL, Marcantonio ER, Culley DJ, et al. Delirium is associated with early postoperative cognitive dysfunction. *Anaesthesia*. 2008;63:941–947.

Ryan S, Gillespie E, Stuart RL. Urinary tract infection surveillance in residential aged care. *Am J Infect Control*. 2018;46:67–72.

Saatli B, Kizildag S, Cagliyan E, et al. Alteration of apoptosis-related genes in postmenopausal women with uterine prolapse. *Int Urogynecol J*. 2014;25:971–977.

Sahin-Onat S, Güzel O, Uçar D. Relationship between urinary incontinence and quality of life/depression in elderly patients. *J Clin Gerontol Geriatr*. 2014;5:86–90.

Sakakibara R, Ito T, Uchiyama T, et al. Lower urinary tract function in dementia of Lewy body type. *J Neurol Neurosurg Psychiatry*. 2005;76(5):729–732.

Sampselle CM, Messer KL, Seng JS, et al. Learning outcomes of a group behavioral modification program to prevent urinary incontinence. *Int Urogynecol J Pelvic Floor Dysfunct*. 2005;16:441–446.

Sand PK, Johnson TM 2nd, Rovner ES, et al. Trospium chloride once-daily extended release is efficacious and tolerated in elderly subjects (aged >/= 75 years) with overactive bladder syndrome. *BJU Int*. 2011;107:612–620.

Sandberg JM, Krane LS, Hemal AK. A nonrandomized prospective comparison of robotic-assisted partial nephrectomy in the elderly to a younger cohort: an analysis of 339 patients with intermediate-term follow-up. *Urology*. 2014;84:838–843.

Sands JM. Urine-concentrating ability in the aging kidney. *Sci Aging Knowledge Environ*. 2003;18:pe15.

Sanford M. Mirabegron: a review of its use in patients with overactive bladder syndrome. *Drugs*. 2013;73:1213–1225.

Santini S, Andersson G, Lamura G. Impact of incontinence on the quality of life of caregivers of older persons with incontinence: a qualitative study in four European countries. *Arch Gerontol Geriatr*. 2016;63:92–101.

Saxer S, de Bie RA, Dassen T, et al. Knowledge, beliefs, attitudes, and self-reported practice concerning urinary incontinence in nursing home care. *J Wound Ostomy Continence Nurs*. 2009;36:539–544.

Schäfer W, Abrams P, Liao L, et al. Good urodynamic practices:

uroflowmetry, filling cystometry, and pressure-flow studies. *Neurourol Urodyn*. 2002;21:261–274.

Schaeffner ES, Ebert N, Delanaye P, et al. Two novel equations to estimate kidney function in persons aged 70 years or older. *Ann Intern Med*. 2012;157:471–481.

Schick V, Herbenick D, Reece M, et al. Sexual behaviors, condom use, and sexual health of Americans over 50: implications for sexual health promotion for older adults. *J Sex Med*. 2010;7(Suppl 5):315–329.

Schnelle JF, Leung FW, Rao SS, et al. A controlled trial of an intervention to improve urinary and fecal incontinence and constipation. *J Am Geriatr Soc*. 2010;58:1504–1511.

Schnelle JF, MacRae PG, Ouslander JG, et al. Functional Incidental Training, mobility performance and incontinence care with nursing home residents. *J Am Geriatr Soc*. 1995;43:1356–1362.

Schnelle JF, Simmons SF, Beuscher L, et al. Prevalence of constipation symptoms in fecally incontinent nursing home residents. *J Am Geriatr Soc*. 2009;57:647–652.

Schreiner L, dos Santos TG, Knorst MR, et al. Randomized trial of transcutaneous tibial nerve stimulation to treat urge urinary incontinence in older women. *Int Urogynecol J*. 2010;21:1065–1070.

Schwentner C, Seibold J, Colleselli D, et al. Dorsal onlay skin graft urethroplasty in patients older than 65 years. *Urology*. 2010;76:465–470.

Scosyrev E, Messing EM, Mohile S, et al. Prostate cancer in the elderly: frequency of advanced disease at presentation and disease-specific mortality. *Cancer*. 2012;118:3062–3070.

Scrutinio D, Passantino A, Santoro D, et al. Prognostic value of formulas estimating excretory renal function in the elderly with systolic heart failure. *Age Ageing*. 2009;38:296–301.

Sears CL, Lewis C, Noel K, et al. Overactive bladder medication adherence when medication is free to patients. *J Urol*. 2010;183:1077–1081.

Seftel AD. Erectile dysfunction in the elderly: epidemiology, etiology and approaches to treatment. *J Urol*. 2003;169:1999–2007.

Segal S, Saks EK, Arya LA. Self-assessment of fluid intake behavior in women with urinary incontinence. *J Womens Health (Larchmt)*. 2011;20:1917–1921.

Seino S, Yabushita N, Kim MJ, et al. Physical performance measures as a useful indicator of multiple geriatric syndromes in women aged 75 years and older. *Geriatr Gerontol Int*. 2013;13:901–910.

Serati M, Braga A, Cattoni E, et al. Transobturator vaginal tape for the treatment of stress urinary incontinence in elderly women without concomitant pelvic organ prolapse: is it effective and safe? *Eur J Obstet Gynecol Reprod Biol*. 2013;166:107–110.

Sexton CC, Coyne KS, Thompson C, et al. Prevalence and effect on health-related quality of life of overactive bladder in older Americans: results from the Epidemiology of Lower Urinary Tract Symptoms Study. *J Am Geriatr Soc*. 2011;59:1465–1470.

Shah DK, Paul EM, Rastinehad AR, et al. Short-term outcome analysis of total pelvic reconstruction with mesh: the vaginal approach. *J Urol*. 2004;171:261–263.

Shao YH, Moore DF, Shih W, et al. Fracture after androgen deprivation therapy among men with a high baseline risk of skeletal complications. *BJU Int*. 2013;111:745–752.

Shariat SF, Godoy G, Lotan Y, et al. Advanced patient age is associated with inferior cancer-specific survival after radical nephroureterectomy. *BJU Int*. 2010;105:1672–1677.

Shariat SF, Sfakianos JP, Droller MJ, et al. The effect of age and gender on bladder cancer: a critical review of the literature.

BJU Int. 2010;105:300–308.

Sheikh J, Yesavage J. *Geriatric Depression Scale (GDS) recent evidence and development of a shorter version. In: clinical gerontology: a guide to assessment and intervention*. The Hawthorne Press: New York, NY; 1986:165–173.

Sherburn M, Bird M, Carey M, et al. Incontinence improves in older women after intensive pelvic floor muscle training: an assessor-blinded randomized controlled trial. *Neurourol Urodyn*. 2011;30:317–324.

Shih HJ, Shih LY, Chang H, et al. Clinical features of testicular lymphoma. *Acta Haematol*. 2014;131:187–192.

Shimoni Z, Fruger E, Froom P. Measurement of post-void residual bladder volumes in hospitalized older adults. *Am J Med*. 2015;128:77–81.

Shipway DJH, Partridge JSL, Foxton CR, et al. Do surgical trainees believe they are adequately trained to manage the ageing population? A UK survey of knowledge and beliefs in surgical trainees. *J Surg Educ*. 2015;72:641–647.

Sicras-Mainar A, Rejas J, Navarro-Artieda R, et al. Antimuscarinic persistence patterns in newly treated patients with overactive bladder: a retrospective comparative analysis. *Int Urogynecol J*. 2014;25:485–492.

Siegler EL, Reidenberg M. Treatment of urinary incontinence with anticholinergics in patients taking cholinesterase inhibitors for dementia. *Clin Pharmacol Ther*. 2004;75:484–488.

Sinclair CT, Kalender-Rich JL, Griebling TL, et al. Palliative care of urologic patients at end of life. *Clin Geriatr Med*. 2015;31(4):667–678.

Sink KM, Thomas J 3rd, Xu H, et al. Dual use of bladder anticholinergics and cholinesterase inhibitors: long-term functional and cognitive outcomes. *J Am Geriatr Soc*. 2008;56(5):847–853.

Sjöström M, Umefjord G, Stenlund H, et al. Internet-based treatment of stress urinary incontinence: a randomized controlled study with focus on pelvic floor muscle training. *BJU Int*. 2013;112:362–372.

Skolarus TA, Ye Z, Montgomery JS, et al. Use of restaging bladder tumor resection for bladder cancer among Medicare beneficiaries. *Urology*. 2011;78:1345–1349.

Smith AB, Deal AM, Yu H, et al. Sarcopenia as a predictor of complications and survival following radical cystectomy. *J Urol*. 2014;191:1714–1720.

Smith AL, Wang PC, Anger JT, et al. Correlates of urinary incontinence in community-dwelling older Latinos. *J Am Geriatr Soc*. 2010;58:1170–1176.

Smith PP. Aging and the underactive detrusor: a failure of activity or activation? *Neurourol Urodyn*. 2010;29:408–412.

Smith PP, Tyagi P, Kuchel GA, et al. Advanced therapeutic directions to treat the underactive bladder. *Int Urol Nephrol*. 2014;46(Suppl 1):S35–S44.

Somme D, Maillet JM, Gisselbrecht M, et al. Critically ill old and the oldest-old patients in intensive care: short- and long-term outcomes. *Intensive Care Med*. 2003;29:2137–2143.

Song M, Hong BS, Chun JY, et al. Safety and efficacy of desmopressin for the treatment of nocturia in elderly patients: a cohort study. *Int Urol Nephrol*. 2014;46:1495–1499.

Starr JM. Cholinesterase inhibitor treatment and urinary incontinence in Alzheimer's disease. *J Am Geriatr Soc*. 2007;55(5):800–801.

Stav K, Dwyer PL, Rosamilia A, et al. Midurethral sling procedures for stress urinary incontinence in women over 80 years. *Neurourol Urodyn*. 2010;29:1262–1266.

Steers WD, Lee KS. Depression and incontinence. *World J Urol*. 2001;19:351–357.

Steinman MA, Beizer JL, DuBeau CE, et al. How to use the

American Geriatrics Society 2015 Beers criteria: a guide for patients, clinicians, health systems, and payors. *J Am Geriatr Soc*. 2015;63(12):e1–e7.

Stewart CM, Wheeler TL 2nd, Markland AD, et al. Life-space assessment in urogynecology and gynecological oncology surgery patients: a measure of perioperative mobility and function. *J Am Geriatr Soc*. 2009;57:2263–2268.

Stott DJ, Falconer A, Miller H, et al. Urinary tract infection after stroke. *QJM*. 2009;102:243–249.

Strasser H, Tiefenthaler M, Steinlechner M, et al. Urinary incontinence in the elderly and age-dependent apoptosis of rhabdosphincter cells. *Lancet*. 1999;354:918–919.

Strasser H, Tiefenthaler M, Steinlechner M, et al. Age dependent apoptosis and loss of rhabdosphincter cells. *J Urol*. 2000;164:1781–1785.

Strope SA, Elliott SP, Smith A, et al. Urologist practice styles in the initial evaluation of elderly men with benign prostatic hyperplasia. *Urology*. 2011;77:535–540.

Subak LL, Wing R, West DS, et al. Weight loss to treat urinary incontinence in overweight and obese women. *N Engl J Med*. 2009;360(5):481–490.

Sugama J, Sanada H, Shigeta Y, et al. Efficacy of an improved absorbent pad on incontinence-associated dermatitis in older women: cluster randomized controlled trial. *BMC Geriatr*. 2012;12:22.

Sugimoto T, Yoshida M, Ono R, et al. Frontal lobe function correlates with one-year incidence of urinary incontinence in elderly with Alzheimer disease. *J Alzheimers Dis*. 2017;56:567–574.

Sun M, Abdollah F, Schmitges J, et al. Cytoreductive nephrectomy in the elderly: a population-based cohort from the USA. *BJU Int*. 2012;109:1807–1812.

Sundvall P, Elm M, Gunnarsson R, et al. Antimicrobial resistance in urinary pathogens among Swedish nursing home residents remains low: a cross-sectional study comparing antimicrobial resistance from 2003 to 2012. *BMC Geriatr*. 2014;14:30.

Sundvall PD, Gunnarsson RK. Evaluation of dipstick analysis among elderly residents to detect bacteriuria: a cross-sectional study in 32 nursing homes. *BMC Geriatr*. 2009;9:32.

Suskind AM, Walter LC, Zhao S, et al. Functional outcomes after transurethral resection of the prostate in nursing home residents. *J Am Geriatr Soc*. 2017;65:699–703.

Suzuki M, Iguchi Y, Igawa Y, et al. Ultrasound-assisted prompted voiding for management of urinary incontinence of nursing home residents: efficacy and feasibility. *Int J Urol*. 2016;23:786–790.

Tadic SD, Griffiths D, Schaefer W, et al. Brain activity underlying impaired continence control in older women with overactive bladder. *Neurourol Urodyn*. 2012;31:652–658.

Tadic SD, Tannenbaum C, Resnick NM, et al. Brain responses to bladder filling in older women without urgency incontinence. *Neurourol Urodyn*. 2013;32:435–440.

Tai S, Xu L, Zhang L, et al. Preoperative risk factors of postoperative delirium after transurethral prostatectomy for benign prostatic hyperplasia. *Int J Clin Exp Med*. 2015;8:4569–4574.

Tak EC, van Hespen A, van Dommelen P, et al. Does improved functional performance help to reduce urinary incontinence in institutionalized older women? A multicenter randomized clinical trial. *BMC Geriatr*. 2012;12:51.

Takao T, Tsujimura A, Kiuchi H, et al. Urological surgery in patients aged 80 years and older: a 30-year retrospective clinical study. *Int J Urol*. 2008;15:789–793.

Talasz H, Jansen SC, Kofler M, et al. High prevalence of pelvic floor muscle dysfunction in hospitalized elderly women with urinary incontinence. *Int Urogynecol J*. 2012;23:1231–1237.

Talasz H, Lechleitner M. Polypharmacy and incontinence. *Z Gerontol Geriatr*. 2012;45(6):464–467.

Tamanini JT, Santos JL, Lebrao ML, et al. Association between urinary incontinence in elderly patients and caregiver burden in the city of Sao Paulo, Brazil: health, Wellbeing, and Ageing Study. *Neurourol Urodyn*. 2011;30:1281–1285.

Tan ECK, Lexomboon D, Sandborgh-Englund G, et al. Medications that cause dry mouth as an adverse effect in older people: a systematic review and metaanalysis. *J Am Geriatr Soc*. 2018;66:76–84.

Tang P, Sun L, Uhlman MA, et al. Prostate-specific antigen-based risk-adapted discontinuation of prostate cancer screening in elderly African American and Caucasian American men. *Urology*. 2010;76:1058–1062.

Tang P, Sun L, Uhlman MA, et al. Prostate-specific antigen velocity based risk-adapted discontinuation of prostate cancer screening in elderly men. *BJU Int*. 2011;108:44–48.

Tani M, Hirayama A, Fujimoto K, et al. Increase in 24-hour urine production/weight causes nocturnal polyuria due to impaired function of antidiuretic hormone in elderly men. *Int J Urol*. 2008;15:151–154 [discussion 155].

Tannenbaum C, Corcos J, Assalian P. The relationship between sexual activity and urinary incontinence in older women. *J Am Geriatr Soc*. 2006;54:1220–1224.

Tannenbaum C, Drali R, Holroyd-Leduc J, et al. Lessons learned: impact of a continence promotion activity for older community-dwelling women. *Neurourol Urodyn*. 2010;29:540–544.

Taylor JA 3rd, Kuchel GA. Detrusor underactivity: clinical features and pathogenesis of an underdiagnosed geriatric condition. *J Am Geriatr Soc*. 2006;54(12):1920–1932.

Temml C, Ponholzer A, Gutjahr G, et al. Nocturia is an age-independent risk factor for hip-fractures in men. *Neurourol Urodyn*. 2009;28:949–952.

Thom DH, Haan MN, Van Den Eeden SK. Medically recognized urinary incontinence and risks of hospitalization, nursing home admission and mortality. *Age Ageing*. 1997;26:367–374.

Thom DH, Nygaard IE, Calhoun EA. Urologic Diseases in America Project: urinary incontinence in women: national trends in hospitalizations, office visits, treatment and economic impact. *J Urol*. 2005;173:1295–1301.

Thomas AA, Aron M, Hernandez AV, et al. Laparoscopic partial nephrectomy in octogenarians. *Urology*. 2009;74:1042–1046.

Thompson I, Thrasher JB, Aus G, et al. Guideline for the management of clinically localized prostate cancer: 2007 update. *J Urol*. 2007;177:2106–2131.

Thompson WK, Charo L, Vahia IV, et al. Association between higher levels of sexual function, activity, and satisfaction and self-rated successful aging in older postmenopausal women. *J Am Geriatr Soc*. 2011;59:1503–1508.

Tibaek S, Dehlendorff C, Iversen HK, et al. Is well-being associated with lower urinary tract symptoms in patients with stroke? *Scan J Urol Nephrol*. 2011;45:134–142.

Tibaek S, Gard G, Klarskov P, et al. Are activity limitations associated with lower urinary tract symptoms in stroke patients? A cross-sectional, clinical survey. *Scan J Urol Nephrol*. 2009;43:383–389.

Tikkinen KA, Auvinen A, Johnson TM 2nd, et al. A systematic evaluation of factors associated with nocturia: the population-based FINNO study. *Am J Epidemiol*. 2009;170:361–368.

Tikkinen KA, Johnson TM 2nd, Tammela TL, et al. Nocturia frequency, bother, and quality of life: how often is too often? A population-based study in Finland. *Eur Urol*. 2010;57:488–

496.

Tikkinen KA, Tammela TL, Huhtala H, et al. Is nocturia equally common among men and women? A population based study in Finland. *J Urol*. 2006;175:596–600.

Tikkinen KAO, Agarwal A, Griebling TL. Epidemiology of male urinary incontinence. *Curr Opin Urol*. 2013;23:502–508.

Tognoni P, Simonato A, Robutti N, et al. Preoperative risk factors for postoperative delirium (POD) after urological surgery in the elderly. *Arch Gerontol Geriatr*. 2011;52:e166–e169.

Townsend MK, Matthews CA, Whitehead WE, et al. Risk factors for fecal incontinence in older women. *Am J Gastroenterol*. 2013;108:113–119.

Tran E, Souhami L, Tanguay S, et al. Bladder conservation treatment in the elderly population: results and prognostic factors of muscle-invasive bladder cancer. *Am J Clin Oncol*. 2009;32:333–337.

Trinh QD, Schmitges J, Sun M, et al. Open radical prostatectomy in the elderly: a case for concern? *BJU Int*. 2012;109:1335–1340.

Tsakiris P, Oelke M, Michel MC. Drug-induced urinary incontinence. *Drugs Aging*. 2008;25(7):541–549.

Tyagi P, Smith PP, Kuchel GA, et al. Pathophysiology and animal modeling of underactive bladder. *Int Urol Nephrol*. 2014;46(Suppl 1):S11–S21.

Tyagi P, Tyagi V, Xianggui Q, et al. Association of inflammaging (inflammation + aging) with higher prevalence of OAB in elderly population. *Int Urol Nephrol*. 2014;46:871–877.

Tyritzis SI, Anastasiou I, Stravodimos KG, et al. Radical cystectomy over the age of 75 is safe and increases survival. *BMC Geriatr*. 2012;12:18.

Udo Y, Nakao M, Honjo H, et al. Sleep duration is an independent factor in nocturia: analysis of bladder diaries. *BJU Int*. 2009;104:75–79.

Uren AD, Cotterill N, Harding C, et al. Qualitative exploration of the patient experience of underactive bladder. *Eur Urol*. 2017;72:402–407.

US Preventive Services Task Force. Screening for prostate cancer: US Preventive Services Task Force recommendation statement. *Ann Intern Med*. 2008;148:185–191.

Valente S, DuBeau C, Chancellor D, et al. Epidemiology and demographics of the underactive bladder: a cross-sectional survey. *Int Urol Nephrol*. 2014;46(Suppl 1):S7–S10.

Valentini FA, Robain G, Marti BG, et al. Urodynamics in a community-dwelling population of females 80 years or older. Which motive? Which diagnosis? *Int Braz J Urol*. 2010;36:218–224.

van den Hout WB, Caljouw MA, Putter H, et al. Cost-effectiveness of cranberry capsules to prevent urinary tract infection in long-term care facilities: economic evaluation with a randomized controlled trial. *J Am Geriatr Soc*. 2014;62:111–116.

van Doorn B, Kok ET, Blanker MH, et al. Mortality in older men with nocturia: a 15-year followup of the Krimpen Study. *J Urol*. 2012;187:1727–1731.

Van Pottelbergh G, Vaes B, Adriaensen W, et al. The glomerular filtration rate estimated by new and old equations as a predictor of important outcomes in elderly patients. *BMC Med*. 2014;12:27.

Vatandoust S, Kichenadasse G, O'Callaghan M, et al. Localised prostate cancer in elderly men aged 80-89 years: findings from a population-based registry. *BJU Int*. 2018;121(Suppl 3):48–54.

Varli M, Guruz H, Aras S, et al. Asymptomatic bacteriuria among the elderly living in the community: prevalence, risk factors and characteristics. *Eur Geriatr Med*. 2012;3:87–91.

Vaughan CP, Endeshaw Y, Nagamia Z, et al. A multicomponent behavioural and drug intervention for nocturia in elderly men: rationale and pilot results. *BJU Int*. 2009;104:69–74.

Vaughan CP, Juncos JL, Trotti LM, et al. Nocturia and overnight polysomnography in Parkinson disease. *Neurourol Urodyn*. 2013;32:1080–1085.

Vecchioli-Scaldazza C, Morosetti C, Azizi B, et al. Polyacrylamide hydrogel (Bulkamid®) in female patients of 80 or more years with urinary incontinence. *Int Braz J Urol*. 2014;40:37–43.

Vethanayagam N, Orrell A, Dahlberg L, et al. Understanding help-seeking in older people with urinary incontinence: an interview study. *Health Soc Care Community*. 2017;25:1061–1069.

Vij M, Bombieri L, Dua A, et al. Long-term follow-up after colpocleisis: regret, bowel and bladder function. *Int Urogynecol J*. 2014;25:811–815.

Vinsnes AG, Helbostad JL, Nyronning S, et al. Effect of physical training on urinary incontinence: a randomized parallel group trial in nursing homes. *Clin Interv Aging*. 2012;7:45–50.

Visser E, de Bock GH, Kollen BJ, et al. Systematic screening for urinary incontinence in older women: who could benefit from it? *Scan J Prim Health Care*. 2012;30:21–28.

Visser E, de Bock GH, Berger MY, et al. Impact of urinary incontinence on sexual functioning in community-dwelling older women. *J Sex Med*. 2014;11:1757–1765.

Visser E, Dekker JH, Vermeulen KM, et al. The effect of systematic screening of older women for urinary incontinence on treatment uptake: the URINO trial. *Maturitas*. 2013;74:334–340.

Vollmer CM, Bond J, Eden BM, et al. Incidence, prevalence, and under-recognition of delirium in urology patients. *Urol Nurs*. 2010;30:235–241 [254].

von Wagner C, Macedo A, Campbell C, et al. Continuing cancer screening later in life: attitudes and intentions among older adults in England. *Age Ageing*. 2013;42:770–775.

Wagg A, Cardozo L, Nitti VW, et al. The efficacy and tolerability of the β3-adrenoceptor agonist mirabegron for the treatment of symptoms of overactive bladder in older patients. *Age Ageing*. 2014;43:666–675.

Wagg A, Chen LK, Johnson T 2nd, et al. Incontinence in frail older persons. Abrams P, Cardozo L, Wagg A, et al. *Incontinence: 6th International Consultation on Incontinence*. ed 6. ICS and ICUD: Tokyo; 2017:1309–1442.

Wagg A, Compion G, Fahey A, et al. Persistence with prescribed antimuscarinic therapy for overactive bladder: a UK experience. *BJU Int*. 2012;110:1767–1774.

Wagg A, Dale M, Tretter R, et al. Randomised, multicenter, placebo-controlled, double-blind crossover study investigating the effect of solifenacin and oxybutynin in elderly people with mild cognitive impairment: the SENIOR Study. *Eur Urol*. 2013;64:74–81.

Wagg A, Darekar A, Arumi D, et al. Factors associated with dose escalation of fesoterodine for treatment of overactive bladder in people > 65 years of age: a post hoc analysis of data from the SOFIA Study. *Neurourol Urodyn*. 2015;34:438–443.

Wagg A, Wyndaele JJ, Sieber P. Efficacy and tolerability of solifenacin in elderly subjects with overactive bladder syndrome: a pooled analysis. *Am J Geriatr Pharmacother*. 2006;4(1):14–24.

Wang MQ, Wang Y, Yan JY, et al. Prostatic artery embolization for the treatment of symptomatic benign prostatic hyperplasia in men ≥ 75 years: a prospective single-center study. *World J Urol*. 2016;34:1275–1283.

Watson RA, Suchak N, Steel K. A doctor in the house: rationale for providing on-site urological consultation to geriatric patients in nursing health care facilities. *Urology*. 2010;76:277–281.

Weatherall M. The risk of hyponatremia in older adults using desmopressin for nocturia: a systematic review and meta-analysis. *Neurourol Urodyn*. 2004;23:302–305.

Webb TP, Duthie E Jr. Geriatrics for surgeons: infusing life into an aging subject. *J Surg Educ*. 2008;65:91–94.

Weemhoff M, Shek KL, Dietz HP. Effects of age on levator function and morphometry of the levator hiatus in women with pelvic floor disorders. *Int Urogynecol J*. 2010;21:1137–1142.

Wehrberger C, Berger I, Marszalek M, et al. Bladder preservation in octogenarians with invasive bladder cancer. *Urology*. 2010;75:370–375.

Wehrberger C, Jungwirth S, Fischer P, et al. The relationship between cerebral white matter hyperintensities and lower urinary tract function in a population based, geriatric cohort. *Neurourol Urodyn*. 2013;33:431–436.

Wehrberger C, Madersbacher S, Jungwirth S, et al. Lower urinary tract symptoms and urinary incontinence in a geriatric cohort: a population-based analysis. *BJU Int*. 2012;110:1516–1521.

Wein AJ, Rovner ES. Definition and epidemiology of overactive bladder. *Urology*. 2002;60(5 Suppl 1):7–12.

Weiss JP, Blaivas JG. Nocturia. *J Urol*. 2000;163:5–12.

Weizer AZ, Joshi D, Daignault S, et al. Performance status is a predictor of overall survival of elderly patients with muscle invasive bladder cancer. *J Urol*. 2007;177:1287–1293.

Welk B, McArthur E, Ordon M, et al. Association of suicidality and depression with 5α-reductase inhibitors. *JAMA Intern Med*. 2017;177:683–691.

Wheater MJ, Manners J, Nolan L, et al. The clinical features and management of testicular germ cell tumours in patients aged 60 years and older. *BJU Int*. 2011;108:1794–1799.

White CF. Engineered structures for use in disposable incontinence products. *Proc Inst Mech Eng H*. 2003;217:243–251.

White WM, Mobley JD 3rd, Doggweiler R, et al. Sacral nerve stimulation for refractory overactive bladder in the elderly population. *J Urol*. 2009;182:1449–1452.

White WM, Pickens RB, Doggweiler R, et al. Short-term efficacy of botulinum toxin A for refractory overactive bladder in the elderly population. *J Urol*. 2008;180:2522–2526.

Whittle J. How can rates of prostate-specific antigen screening be reduced in men aged 80 and older? *J Am Geriatr Soc*. 2010;58:757–759.

Wilde MH, McDonald MV, Brasch J, et al. Long-term urinary catheter users self-care practices and problems. *J Clin Nurs*. 2013;2:356–367.

Wilkins JM. More than capacity: alternatives for sexual decision making in individuals with dementia. *Gerontologist*. 2015;55:716–723.

Williams SB, Shan Y, Jazzar U, et al. Comparing survival outcomes and costs associated with radical cystectomy and trimodal therapy for older adults with muscle-invasive bladder cancer. *JAMA Surg*. 2018;153:881–889.

Winge K, Nielsen KK. Bladder dysfunction in advanced Parkinson's disease. *Neurourol Urodyn*. 2012;31:1279–1283.

Winters JC, Chiverton A, Scarpero HM, et al. Collagen injection therapy in elderly women: long-term results and patient satisfaction. *Urology*. 2000;55(6):856–861.

Winters JC, Dmochowski RR, Goldman HB, et al. Urodynamic studies in adults: AUA/SUFU guideline. *J Urol*. 2012;188:2464–2472.

Wolff JL, Starfield B, Anderson G. Prevalence expenditures, and complications of multiple chronic conditions in the elderly. *Arch Intern Med*. 2002;162:2269–2276.

Woloski-Wruble AC, Oliel Y, Leefsma M, et al. Sexual activities, sexual and life satisfaction, and successful aging in women. *J Sex Med*. 2010;7:2401–2410.

Wou F, Gladman JR, Bradshaw L, et al. The predictive properties of frailty-rating scales in the acute medical unit. *Age Ageing*. 2013;42:776–781.

Wright H, Jenks RA. Sex on the brain! Associations between sexual activity and cognitive function in older age. *Age Ageing*. 2016;45:313–317.

Xu D, Kane RL. Effect of urinary incontinence on older nursing home residents' self-reported quality of life. *J Am Geriatr Soc*. 2013;61:1473–1481.

Yalla SV, Sullivan MP, Resnick NM. Update on detrusor hyperactivity with impaired contractility. *Curr Bladder Dysfunct Rep*. 2007;2(4):191–196.

Yamaguchi O, Nishizawa O, Juul KV, et al. Gender difference in efficacy and dose response in Japanese patients with nocturia treated with four different doses of desmopressin orally disintegrating tablet in a randomized, placebo-controlled trial. *BJU Int*. 2013;111:474–484.

Yip SO, Dick MA, McPencow AM, et al. The association between urinary and fecal incontinence and social isolation in older women. *Am J Obstet Gynecol*. 2013;208(146):e141–e147.

Yokoyama O, Yamagami H, Hiro S, et al. Efficacy and safety of fesoterodine treatment overactive bladder symptoms in elderly women with and without hypertension. *Int J Urol*.

2018;25:251–257.

Yoon JY, Lee JY, Bowers BJ, et al. The impact of organizational factors on the urinary incontinence care quality in long-term care hospitals: a longitudinal correlational study. *Int J Nurs Stud*. 2012;49:1544–1551.

Young JS, Johnston L, Soubrane C, et al. The passive and active contractile properties of the neurogenic, underactive bladder. *BJU Int*. 2013;111:355–361.

Zhang JQ, Geng H, Ma M, et al. Metabolic syndrome components are associated with increased prostate cancer risk. *Med Sci Monit*. 2015;21:2387–2396.

Zhang Z, Yang L, Xie D, et al. Depressive symptoms are found to be potential adverse effects of androgen deprivation therapy in older prostate cancer patients: a 15-month prospective, observational study. *Psychooncology*. 2017;26:2238–2244.

Zhu Y, Ye X, Zhu B, et al. Comparisons between the 2012 new CKD-EPI (Chronic Kidney Disease Epidemiology Collaboration) equations and other four approved equations. *PLoS ONE*. 2014;9.

Zisberg A, Sinoff G, Gur-Yaish N, et al. In-hospital use of continence aids and new-onset urinary incontinence in adults aged 70 and older. *J Am Geriatr Soc*. 2011;59:1099–1104.

Zizza CA, Ellison KJ, Wernette CM. Total water intakes of community-living middle-old and oldest-old adults. *J Gerontol A Biol Sci Med Sci*. 2009;64:481–486.

129

Urinary Tract Fistulae

Dirk J.M.K. De Ridder MD, PhD, FEBU, Tamsin Greenwell MD, PhD

A fistula is an abnormal or surgically made passage between a hollow or tubular organ and the body surface, or between two hollow or tubular organs. **Although most fistulae in patients in the industrialized world are iatrogenic, they may also occur as a result of congenital anomalies, malignancy, inflammation and infection, radiation therapy, iatrogenic (surgical) or external tissue trauma, ischemia, parturition, and a variety of other processes. The continuous leakage of urine and/or fecal material can have a devastating effect on the quality of life of the patient. Except for a palliative setting, the active treatment of fistulae is always warranted.** Although some types of urinary fistulae heal with conservative management, surgery is usually necessary for a definitive repair. Repair and reconstruction of urinary fistulae are sometimes complex. These should be approached on a case-by-case basis, because repair may involve some innovative and even improvisational maneuvers in the operating room. The surgeon should be familiar with a variety of approaches and techniques, because one approach will not be optimal for all patients with a given type of urinary fistula.

General Considerations

Prevention of Fistula

In the developed world the increasing frequency of gynecologic surgery as well as pelvic radiation, forgotten vaginal foreign bodies, or uninhibited cancer growth are the modern causes for vesicovaginal fistulae (VVF) in elderly patients (Hampel et al., 2015). Careful planning and execution of gynecologic or cancer surgery and/or radiotherapy reduce the risk of iatrogenic fistula formation, although there is little research on the impact of preventive measures on this type of fistulae. Even in stage IV cervical cancer, treated with radiotherapy, clear risk factors could not be established (Biewenga et al., 2010).

In the developing world poor perinatal care and the lack of timely cesarean sections for women with an increased risk for obstetric fistula (OF) formation are the main causes in some regions of Africa, Asia, and South America. The risk factors for obstructed labor are well known: illiteracy, low economic status, and short stature (<150 cm) (Kasamba et al., 2013; Tebeu et al., 2012). Recently an increase in obstetric fistulae has been noted in the UK (Hilton, 2016). The finding of a persistent fistula after presumably definitive treatment may suggest the existence of other contributing host factors, such as malignancy, nutritional issues, the possibility of an unrecognized foreign body, tissue ischemia, or surgical factors such as inadequate postoperative urinary drainage, persistent distal urinary obstruction, or technical problems with the surgery (Arrowsmith et al., 1996; Malik et al., 2018).

Preparation and Optimization of Patient

Prevention of urinary fistulae is, of course, paramount; however, nutrition, infection, and malignancy are important considerations not only when assessing a patient for the risk of creation of a fistula during any given intervention but also during an evaluation for the repair of an existing urinary fistula. Although the majority of urinary fistulae in the industrialized world occur in healthy, well-nourished individuals, a nutritional assessment may be an important factor in some patients with fistulae, such as those patients with malignancies. Ensuring adequate nutrition is integral to surgical healing in general but is especially important in the setting of a urinary fistula. Not uncommonly, the catabolic processes contributing to the lack of healing, which may have been a contributing factor in the initial fistula formation, are often ongoing. This is especially relevant in fistulae related to radiation therapy or in debilitated patients.

Medicolegal Aspects

Acquired urinary fistulae in the industrialized world are almost universally unexpected and may result in a great deal of inconvenience, discomfort, and physical disability for the affected individual. They are most often acquired as a result of a medical or surgical intervention for an unrelated problem, and, consequently, considerable emotional and psychological distress often accompany the diagnosis and subsequent treatment. Often medicolegal issues occur with a high risk for litigation (Thomas and Williams, 2000). Nevertheless, minimizing patient discomfort, maintaining a positive and honest patient-physician relationship while providing constant reassurance, and, finally, and perhaps most important, pursuing expeditious and successful treatment of the fistula most often result in a mutually satisfying long-term outcome.

Notably, after the initial early diagnosis of a urinary fistula, which results in external urinary leakage, immediate management or control of the urinary leakage is vital. Addressing this quickly will reduce skin breakdown and related complications, as well as alleviate much of the psychological distress. The judicious use of catheters, pads, skin care, and odor control products and appliances can be very helpful in this regard. These simple measures can often deflect the anger of an otherwise very disaffected patient, thereby reducing the potential for further aggravating an already difficult medical and, possibly, litigious situation.

The principles of repair of urinary fistulae are outlined in Box 129.1 and can be applied to almost any type of fistula involving the urinary tract.

Box 129.1

Principles of Urinary Fistula Management

Ensure adequate nutrition.
Eliminate infection.
Achieve unobstructed urinary drainage and/or stenting.

Remove or bypass distal urinary obstruction.
Beware of malignant cause of fistula.

Principles of surgical management of urinary fistulae are outlined in Box 129.2.

Box 129.2

Principles of Surgical Repair of Urinary Fistulae

Adequate exposure of the fistula tract with debridement of devitalized and ischemic tissue
Removal of involved foreign bodies or synthetic materials from region of fistula, if applicable
Careful dissection and/or anatomic separation of the involved organ cavities
Watertight closure
Use of well-vascularized, healthy tissue flaps for repair (atraumatic handling of tissue)
Multiple-layer closure
Tension-free, non-overlapping suture lines
Adequate urinary tract drainage and/or stenting after repair
Treatment and prevention of infection (appropriate use of antimicrobials)
Maintenance of hemostasis

Key Points: Presentation

- Urinary fistulae are often associated with considerable physical and psychological distress for the patient and can have medicolegal consequences.
- Nutrition, infection, malignancy, urinary obstruction, and the presence of a foreign body are important factors to consider in the initial approach to urinary fistula and in those patients in whom primary therapy has failed.

Vesicovaginal Fistulae

Vesicovaginal fistula (VVF) is the most common acquired fistula of the urinary tract (Gerber and Schoenberg, 1993) **and has been known since ancient times** (Fig. 129.1).

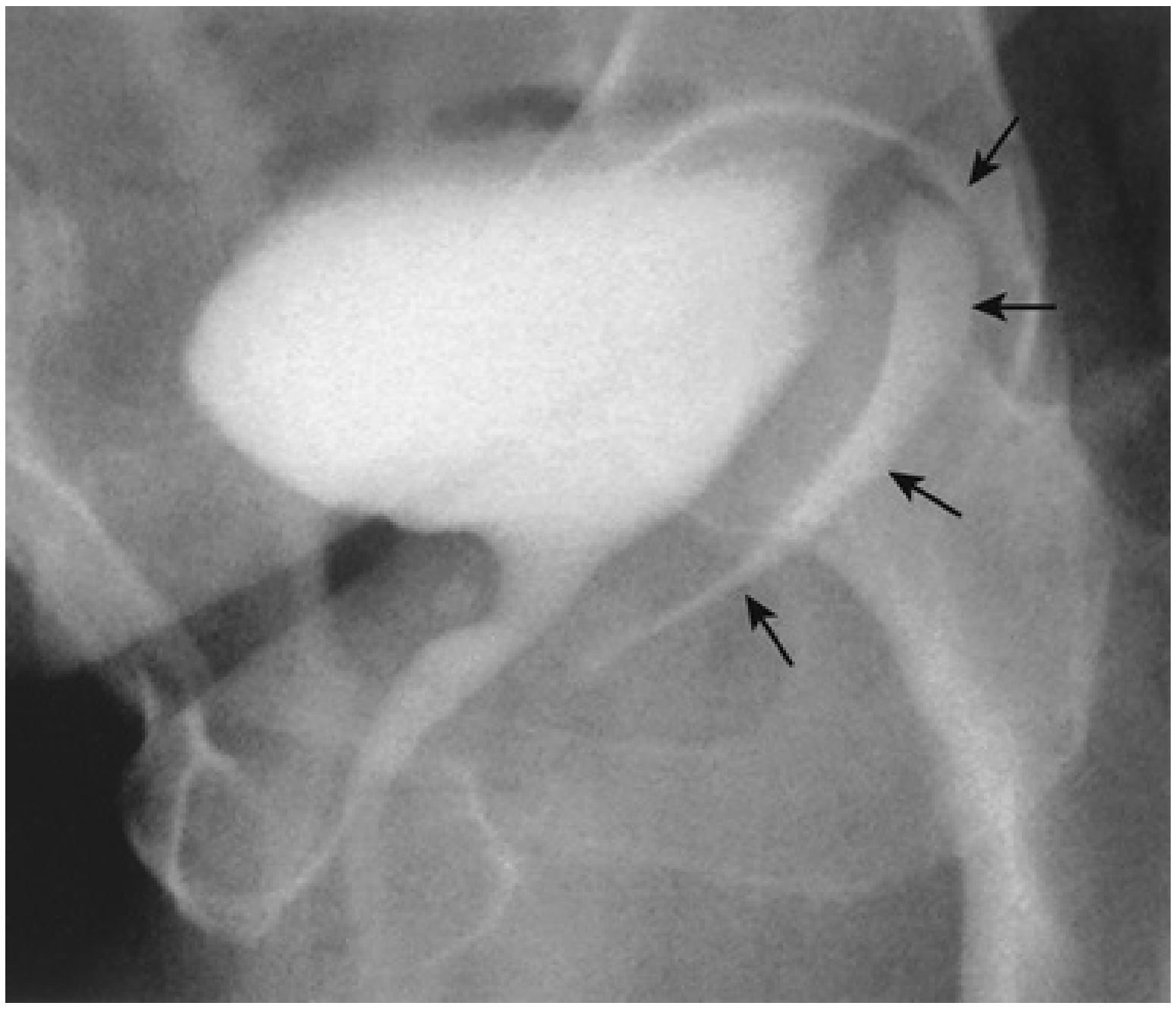

FIG. 129.1 Voiding cystourethrogram demonstrates filling of the vagina *(arrows)* with voiding as a result of a posthysterectomy vesicovaginal fistula.

The first surgical repair was described in 1663 by Hendrik von Roonhuyse denuding the fistula margins and then approximating them with sharpened stiff swan quills (Margolis and Mercer, 1994). Johann Fatio is generally credited with the first successful VVF repair, in 1675, using von Roonhuyse's technique (Falk and Tancer, 1954). In 1838, using leaden sutures, John Peter Mettauer was the first US surgeon to claim a successful VVF closure (Kight, 1967). In 1852 James Marion Sims published his surgical series describing his method of surgical treatment of VVF using silver wire in a transvaginal approach (Sims, 1852). He achieved success at his 30th attempt. The technique was subsequently modified as a partial colpocleisis by Latzko (1942) and the more commonly used dissection and repair in layers or “flap-splitting” technique (variously attributed to Hayward, Collis, and Lawson Tait) (Wall, 2005). **Sims remains the subject of considerable debate regarding his ethics,** because it is unknown whether the patients in his surgical series were willing and consenting participants (all were African-American slaves in pre–Civil War America) (Sur et al., 2017). **The first successful transabdominal approach to VVF repair was reported by Trendelenburg in 1888,** and the concept of **an interpositional flap was first proposed and reported in 1928 by Martius,** who used a labial fat pad.

Etiology and Prevalence

The cause of VVF differs in various parts of the world. In the developing world, VVF is the most common fistula (>75%) and occurs mainly from obstetric complications. As resources increase within these countries, the number of obstetric fistulae seems to decrease, but those of iatrogenic fistulae seem to increase (Tebeu et al., 2012; Wright et al., 2016). **In the industrialized world, the most common cause (>75%) of VVF is injury to the bladder at the time of gynecologic, urologic, or other pelvic surgery** (De Ridder, 2011; Ozdemir et al., 2011; Pal et al., 2016; Tancer, 1992).

Obstetric Fistulae

Epidemiologic studies on obstetric fistulae (OF) are inadequate (De Ridder et al., 2017). A recent systematic review by Adler et al. (2013) found 19 studies that could be evaluated. The studies included data from West Africa, Bangladesh, Turkey, Jordan, Ethiopia, Egypt, and India. The number of new fistulae ranged from 0.09 per 1000 recently pregnant women in community-based studies to 0.66 per 1000 pregnancies in hospital-based studies. Cowgill et al. (2015) performed another systematic review, also looking at the association of stillbirth (SB) and fistulae. They included 62 studies. Incidence estimates ranged from 0 to 4.09 OF cases per 1000 deliveries, whereas prevalence estimates were judged more prone to bias and ranged from 0 to 81.0 of cases per 1000 women. Reported frequency of SB associated with OF ranged from 32.3% to 100%, with estimates from the largest studies around 92%. The major risk factors for both appear to be age at first marriage, short stature, pregnancy with a male child rather than a female child, failure to attend antenatal care, low socioeconomic status, low social class, lack of employment, and illiteracy. Misconceptions on the cause of persist, mostly in rural areas and mostly in men.

The consequences of obstetric fistula include divorce (16%–92%), social isolation, worsening poverty, malnutrition, sexual dysfunction, mental illness (including anxiety/depression), insomnia, general ill health, and thoughts of worthlessness and suicide (Farid et al., 2013; Imoto et al., 2015).

OF most commonly occurs as a result of prolonged obstructed labor resulting from cephalopelvic disproportion, with resulting pressure necrosis to the anterior vaginal wall, bladder, bladder neck, and proximal urethra from the baby (Fig. 129.2; Arrowsmith et al., 1996). **The constellation of problems resulting from obstructed labor is not limited to VVF and has been termed the *obstructed labor injury complex;* it includes varying degrees of each of the following: urethral loss, stress incontinence, hydroureteronephrosis, renal failure, rectovaginal fistula, rectal atresia, anal sphincter incompetence, cervical destruction, amenorrhea, pelvic inflammatory disease, secondary infertility, vaginal stenosis, osteitis pubis, and foot drop.**

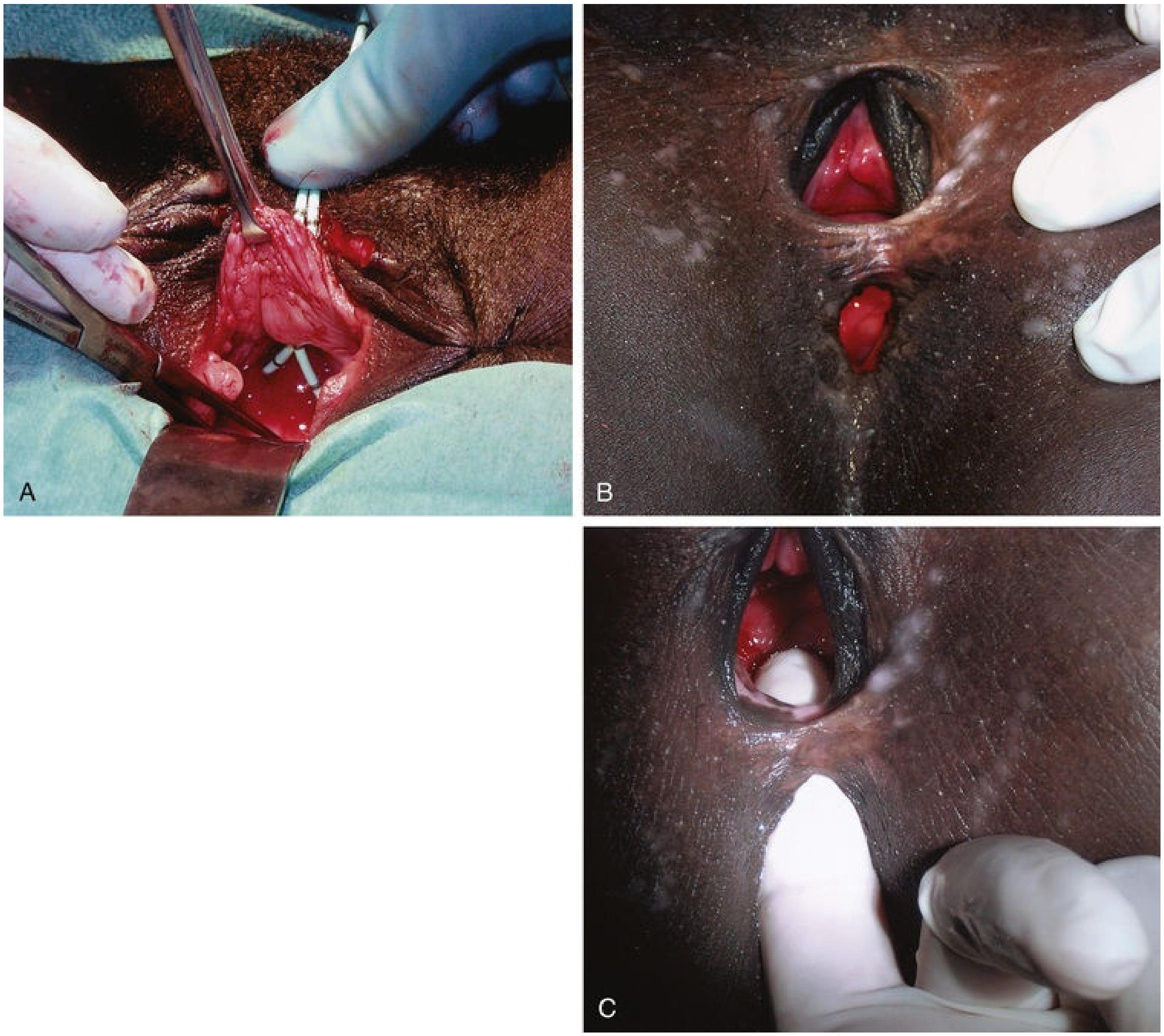

FIG. 129.2 Vesicovaginal fistula (VVF) secondary to obstructed labor. (A) Note the complete loss of the proximal urethra and bladder neck. The ureteral catheters have been passed through the urethra and delineate the ureteric orifices before repair. (B) Large VVF and rectovaginal fistula caused by obstructed labor. (C) Same patient as in B. Digital examination confirms rectovaginal and vesicovaginal fistulae in this patient. (A to C, Courtesy Mark Morgan, MD, Department of Obstetrics and Gynecology, Hospital of the University of Pennsylvania, Philadelphia, PA.)

OF tend to be larger and located distally in the vagina and may involve large portions of the bladder neck and proximal urethra. Even in experienced hands, these VVF are often very difficult to repair because of the extensive soft-tissue loss, as well as the ischemia and fibrosis of adjacent tissues (Arrowsmith, 1994; Arrowsmith et al., 2013; De Ridder, 2011; Kayondo et al., 2011). OF are devastating injuries in the developing world, with significant socioeconomic ramifications (Wall et al., 2004). The affected individuals, commonly young teens, are often ostracized and shunned by family and friends and become permanent outcasts in society.

There are few detailed reports documenting these women's obstructed labors. The time of onset of labor is rarely recorded, and reports from delivery locations may disregard the fact that the woman has labored at home for days before attending the delivery location. The reason for the woman not receiving help rarely differentiates between the absence of health-seeking behavior and the lack of services. A recent study looked at the pathway these patients followed. The mean duration of the fistula was 4 years, and the entire care process took up to 2.7 years, of which 7 months were spent at the repair center (Maulet et al., 2013, 2015).

Misuse of family planning, intercourse during the menstruation, curses by relatives, and sexually transmitted diseases (STDs) are still erroneously seen as potential causes of OF (Kasamba et al., 2013). Education programs should be directed against these misconceptions. Health system causes such as poor quality obstetric care, staff unaccountability, late referral, and poor nursing standards are prevalent in sub-Saharan Africa and rural areas of Pakistan and other parts of Asia (Jokhio et al., 2014; Mselle and Kohi, 2015; Mwini-Nyaledzigbor et al., 2013).

With improvements in the delivery of prenatal care in some areas of the developing world, it appears that the incidence of VVF from obstetric causes may be decreasing as a subset of all VVF, with a proportional increase in the rate of iatrogenic gynecologic fistulae approaching that seen in industrialized nations (Malik et al., 2017; Venkatramani et al., 2014; Wright et al., 2016). Another important cause of VVF in some parts of the world is traditional folk treatments such as “gishiri or guriya cutting,” which may account for up to 13% of VVFs in some series (Ampofo et al., 1990; Ouedraogo et al., 2018b; Tahzib, 1985). This ritual practice involves using a knife to incise the anterior vagina as a treatment for a variety of conditions, including infertility, dyspareunia, dysuria, and back pain.

Iatrogenic Fistulae

Surgical injury to the lower urinary tract most commonly occurs in the setting of hysterectomy (Fig. 129.3). The most common causes of VVF as a consequence of surgery, in developed countries is an injury to the urinary tract during hysterectomy for benign conditions (60%–75%), followed by hysterectomy for malignant conditions (30%), cesarean section (6%), and obstetric injuries (1%) (Hadzi-Djokic et al., 2009; Tancer, 1992). The remainder are related to general surgical procedures in the pelvis, anterior colporrhaphy or cystocele repair, anti-incontinence surgery, or other urologic procedures. Overall, the risk of pelvic organ fistula after hysterectomy has been reported to be between 0.1% and 4% (Forsgren and Altman, 2010). It is important to recognize that most urinary tract injuries do not result in a fistula.

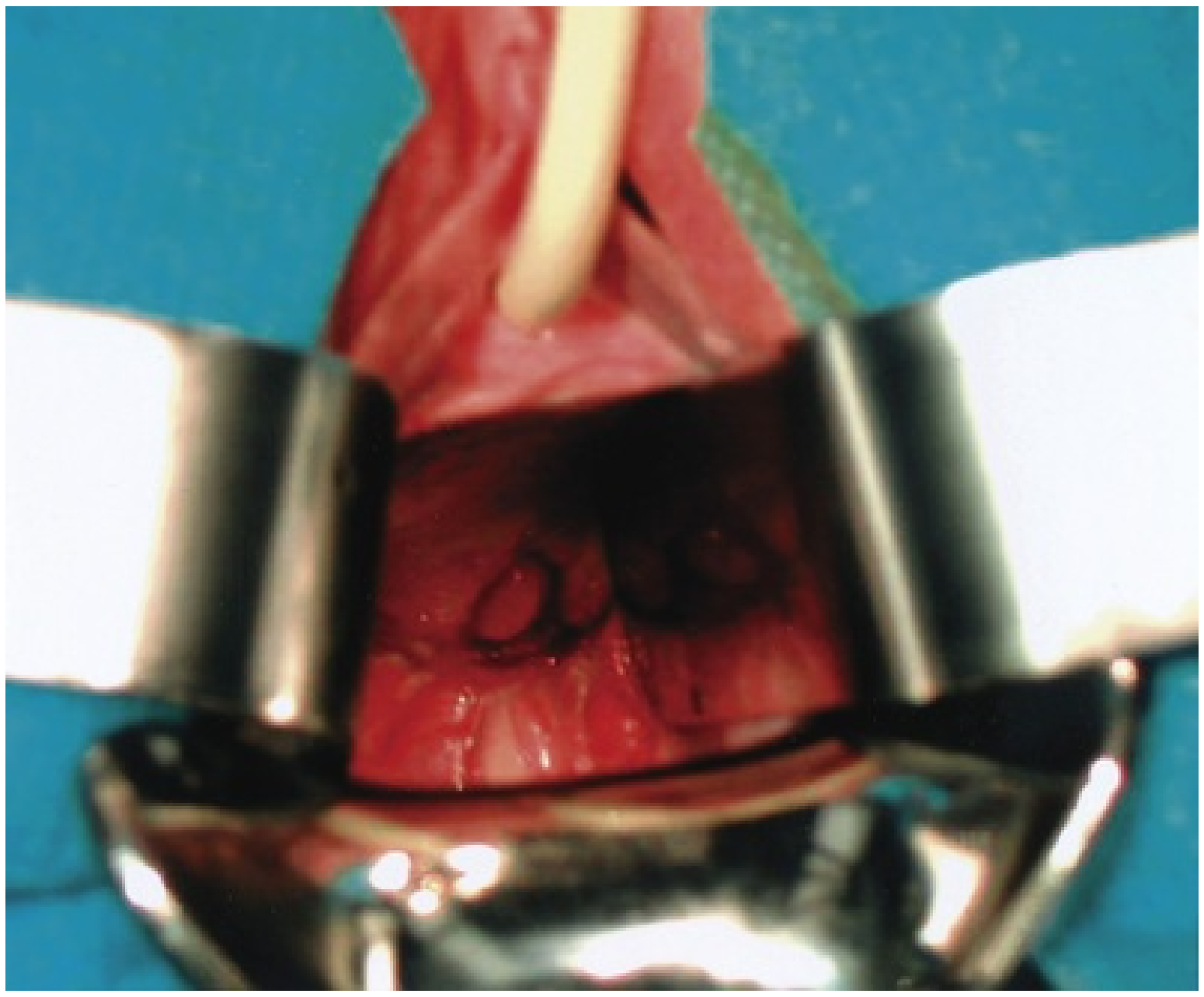

FIG. 129.3 Posthysterectomy vesicovaginal fistula (VVF). Retraction with a weighted speculum and Heaney right-angled retractors to provide lateral retraction are needed to visualize this posthysterectomy VVF in a nulliparous woman.

The prevalence of genitourinary (GU) injury and fistulae vary slightly from center to center. In one US retrospective study from the Mayo clinic, gynecologic surgery was responsible for 82% of the fistulas, obstetric procedures for 8%, and various forms of irradiation for 6%, and trauma or fulguration for 4%. The majority of fistulae followed treatment for benign conditions (Lee et al., 1988). The relative proportions of the types of urinary fistula have changed with urethral fistulae having increased, whereas ureteral, bladder and/or urethral fistulae have decreased.

At the Zekai Tahir Burak center in Turkey, 25,998 gynecologic and obstetric operations were performed over a 3-year period. The bladder was the most frequently injured organ. Urinary tract injury rates were reported to be 0.49% for the bladder and 0.24% for the ureter in gynecologic operations, and 0.18% for the bladder and 0.01% for the ureter in obstetric operations (Ozdemir et al., 2011). The use of vaginal mesh for prolapse repair may also result in VVF (Amundsen et al., 2003; Blaivas and Mekel, 2014; Kasyan et al., 2014; Mishra et al., 2016; Ridgeway et al., 2008). **Posthysterectomy VVFs are thought to result most commonly from an incidental unrecognized iatrogenic cystotomy near the vaginal cuff** (Kursh et al., 1988). If unrecognized intraoperatively, a pelvic urinoma may develop and ultimately drain out through the vaginal cuff. Ongoing urinary drainage along this tract results in a fistula. **Other potential mechanisms for posthysterectomy VVF include tissue necrosis from cautery, a suture placed through the bladder and vaginal wall during closure of the vaginal cuff, or an attempt to control pelvic bleeding by suture ligature.** Tissue ischemia and then necrosis promote fibrosis and induration, finally resulting in an epithelial or mucosal lining of the tract and the development of a fistula tract. It is likely that factors other than an isolated suture placed through the bladder and vagina are necessary for posthysterectomy VVF formation because, at least in an animal model, deliberate suture fixation of the bladder to the vagina does not invariably result in VVF in the absence of infection, urinary extravasation, or other complicating factors (Meeks et al., 1997).

The degree of bladder injury appears to be a major factor in iatrogenic fistula formation. In one study, 1317 benign hysterectomies were reviewed (46% abdominal, 48% vaginal, and 6% laparoscopically assisted vaginal) with reference to risk factors for VVF after intraoperative injury to the urinary tract. In all, 34 cystotomies occurred with 4 (11.7%) developing into a VVF. Patients who developed a VVF were more likely to have a large cystotomy and these individuals trended toward greater tobacco use, larger uterine size, and more operative blood loss (Duong et al., 2009). In another study involving 3076 vaginal hysterectomies with or without additional gynecologic procedures, 1 ureteral injury and 54 bladder lacerations were noted, yielding a total of 4 VVF. The bladder lacerations occurred during the hysterectomy portion of the surgery in 61% of cases and during the additional procedures in 39% (Mathevet et al., 2001). Iatrogenic fistula also in developing countries. Raassen et al. (2014) found 805 iatrogenic fistula in a series of 5959 (13.5%) patients in 11 countries. Most fistulae occurred as a consequence of caesarean section, surgical intervention, or hysterectomy for ruptured uterus (Raassen et al., 2014; Roberto Martinez et al., 2007).

The rate of urogenital fistulae associated with simple abdominal hysterectomy for benign disease is often described as being approximately 1 in 1000. In a national study from Sweden the rate of women undergoing any fistula surgery was reported as 0.26% in women having had a hysterectomy compared with 0.0007% in those not exposed to hysterectomy, with the "number needed to harm" being estimated at 5700 (Forsgren et al., 2009). From Finland the rate of vesicovaginal fistula was reported to be 1 in 1250 after all hysterectomies, 1 in 455 after laparoscopic, 1 in 1000 after total abdominal, and 1 in 5000 after vaginal hysterectomy (Harkki-Siren et al., 1998). The publicly available tables from the national hospital database in England give similar figures of 1 in 600 after total abdominal hysterectomy, and 1 in 5000 after vaginal hysterectomy (Herbert et al., 2017; Hilton, 2011). More detailed longitudinal analysis of patient-level information from the same data set suggests a rate of 1 in 788 for all types of hysterectomy, 1 in 540 for abdominal hysterectomy for benign disease, 1 in 896 after vaginal hysterectomy for benign disease (excluding prolapse), and 1 in 3861 after vaginal hysterectomy for prolapse (Hilton and Cromwell, 2012).

Other causes of VVF include urologic or gynecologic instrumentation, including percutaneous procedures (Armenakas et al., 2004; Pruthi et al., 2000); retroperitoneal, vascular, or pelvic surgery; infectious and inflammatory diseases such as tuberculosis (TB) (Borjas and Rodriguez Diaz, 1949) or other infections (Starownik et al., 2013); congenital VVF (Zeineddine et al., 2014); sexual trauma (Friedman et al., 2017; Roy et al., 2002); vaginal laser procedures (Nwabineli and Davis, 1992); and external violence (Box 129.3).

Box 129.3

Cause of Vesicovaginal Fistulae

- Traumatic
    - Postsurgical
    - Abdominal hysterectomy
    - Vaginal hysterectomy
    - Anti-incontinence surgery
    - Anterior vaginal wall prolapse surgery (e.g., colporrhaphy)
    - Vaginal biopsy
    - Bladder biopsy, endoscopic resection, laser therapy
    - Other pelvic surgery (e.g., vascular, rectal)
    - External trauma (e.g., penetrating, pelvic fracture, sexual)
- Radiation therapy
- Advanced pelvic malignancy
- Infectious or inflammatory cause
- Foreign body
- Obstetric
    - Obstructed labor
    - Forceps laceration
    - Uterine rupture
    - Cesarean section injury to bladder
- Congenital

Foreign bodies such as pessaries, sex toys, herbs, and cups can be also be a cause of VVF (Adaji et al., 2013; Bansal et al., 2016, Birge et al., 2016; Donaldson et al., 2014; Gauta, 2017; Paul et al., 2013; Penrose et al., 2014; Powers et al., 2008). Often their presentation is delayed (up to 15 months). Ketamine abuse can lead to not only severe changes in the bladder wall structure but also fistula formation, as was shown in 14.8% of 27 patients undergoing a computed tomography (CT) urography (Huang et al., 2014).

Intraoperative Risk Factors for Iatrogenic Vesicovaginal Fistulae

Clearly, intraoperative injury to the urinary bladder is a primary risk factor for subsequent development of a postoperative VVF. Other risk factors for postoperative VVF formation include prior uterine surgery (cesarean section), endometriosis, infection, diabetes, arteriosclerosis, pelvic inflammatory disease, obesity, and prior radiation therapy (Hilton and

Cromwell, 2012; Likic et al., 2008, Raassen et al., 2014). **The American Association for the Surgery of Trauma (AAST) grade of the bladder trauma is the strongest predictor of subsequent VVF formation.** Two of 3 patients developing a VVF had a grade V injury, compared with only 1 of 48 who did not develop a VVF. A grade V bladder injury as defined by the AAST involves injury to the trigone. It postulated that the proximity of the injury to the vaginal cuff serves as an avenue for VVF formation because the site of the bladder injury comes in direct contact with the healing cuff (Duong et al., 2011). **The operative approach to hysterectomy is an important factor, because bladder injuries are at least three times more common during abdominal hysterectomy compared with vaginal hysterectomy.** Hilton calculated the risk for fistula formation in radical hysterectomy for cervical cancer to be 1 of 87, whereas in vaginal hysterectomy for prolapse, the risk was only 1 of 3861 (Hilton and Cromwell, 2012). Intraoperative recognition and repair of bladder injury are paramount in prevention of VVF; however, despite intraoperative repair, VVF may still occur in a substantial number of patients. In 1969 Hutch emphasized five factors in the prevention of VVF during gynecologic surgery: (1) immediate detection of bladder injury using vital dyes if necessary; (2) watertight closure of the bladder; (3) satisfactory extravesical drain placement; (4) avoidance of a vaginal incision, if possible, after recognition of the bladder injury; and (5) prolonged, uninterrupted postoperative bladder drainage (Hutch and Noll, 1970).

It has been suggested that patients with severe abdominal pain, distention, paralytic ileus, hematuria, or symptoms of severe irritability of the bladder after abdominal hysterectomy be investigated early for a possible bladder injury (Kursh et al., 1988).

Evaluation and Diagnosis

VVF must be distinguished from other causes, including urinary incontinence, stress (urethral) incontinence, urgency (bladder) incontinence, and overflow incontinence, as well as ureterovaginal fistula.

Presentation

The most common complaint in patients with VVF is constant urinary drainage from the vagina. The amount of urinary leakage can vary considerably from patient to patient and may be proportional to the size of the fistula tract. Patients may void a variable amount, depending on the position and size of the fistula, and the volume of urinary leakage. For example, when a large VVF is present, patients may not void at all and simply have continuous leakage of urine into the vagina. Small, pinpoint fistulae may cause intermittent wetness, which is positional in nature. In the supine position, when sleeping, the amount of leakage reported by the patient may be minimal, but on rising to a seated or standing position the amount of leakage may increase precipitously. Patients may also report recurrent cystitis, perineal skin irritation from constant wetness, vaginal fungal infections, or rarely pelvic pain. In fact, **pain is an uncommon finding in patients with VVF unless there is considerable skin irritation or the VVF occurred as a result of radiation therapy.**

VVF after hysterectomy or other surgical procedures may manifest after removal of the urethral catheter, or the VVF may be seen 1 to 3 weeks later with urinary drainage from the vagina. It may be possible to identify some patients at high risk for VVF in the immediate postoperative period. Kursh et al. (1988) noted that patients who developed VVF after hysterectomy more commonly had postoperative ileus, hematuria, bladder irritability, and elevated white blood cell count compared with a cohort of patients who did not develop VVF. Occasionally posthysterectomy VVF may go undiagnosed for an extended period of time because postoperative clear or serosanguineous vaginal discharge is often attributed to the surgery.

As noted previously, VVF resulting from radiation therapy may not manifest for months to years after completion of radiation.

Physical Examination

A pelvic examination with a speculum should always be performed in the evaluation of VVF. The vaginal speculum examination usually provides a precise assessment of VVF including the location, size, and number of fistulae. Identification can be easier with a dye in the bladder. Vaginoscopy has been suggested as an adjunct measure, in some cases, using a modified endoscope or flexible cystoscope to visualize precisely the fistula tract (Andreoni et al., 2003). **Most commonly, VVFs after hysterectomy are located along the anterior vaginal wall at the level of the vaginal cuff** (Fig. 129.4)**. A visual and manual assessment of inflammation surrounding the fistula is necessary, because it may affect timing of the repair**. Significant inflammation, infection, or induration around the fistula may mitigate against immediate repair. **Relevant vaginal anatomy, including depth, associated**

prolapse, atrophy, and introital size are carefully recorded, because these may affect the surgical approach to repair. Anatomically, fistulae located high in the vagina, at the level of the hysterectomy cuff in a deep narrow vagina, may be best approached by some surgeons abdominally because a vaginal approach in these patients can be challenging. Postmenopausal vaginal atrophy may be treated with preoperative topical estrogen replacement, thereby optimizing the health and vascularity of potential reconstructive flaps. Palpation for masses or other pelvic pathology, which may require attention at the time of fistula repair, is also performed. Notation of prior incisions in the perineum, lower abdomen, and thigh is necessary because these tissues may be required for flap reconstruction when definitive repair is undertaken.

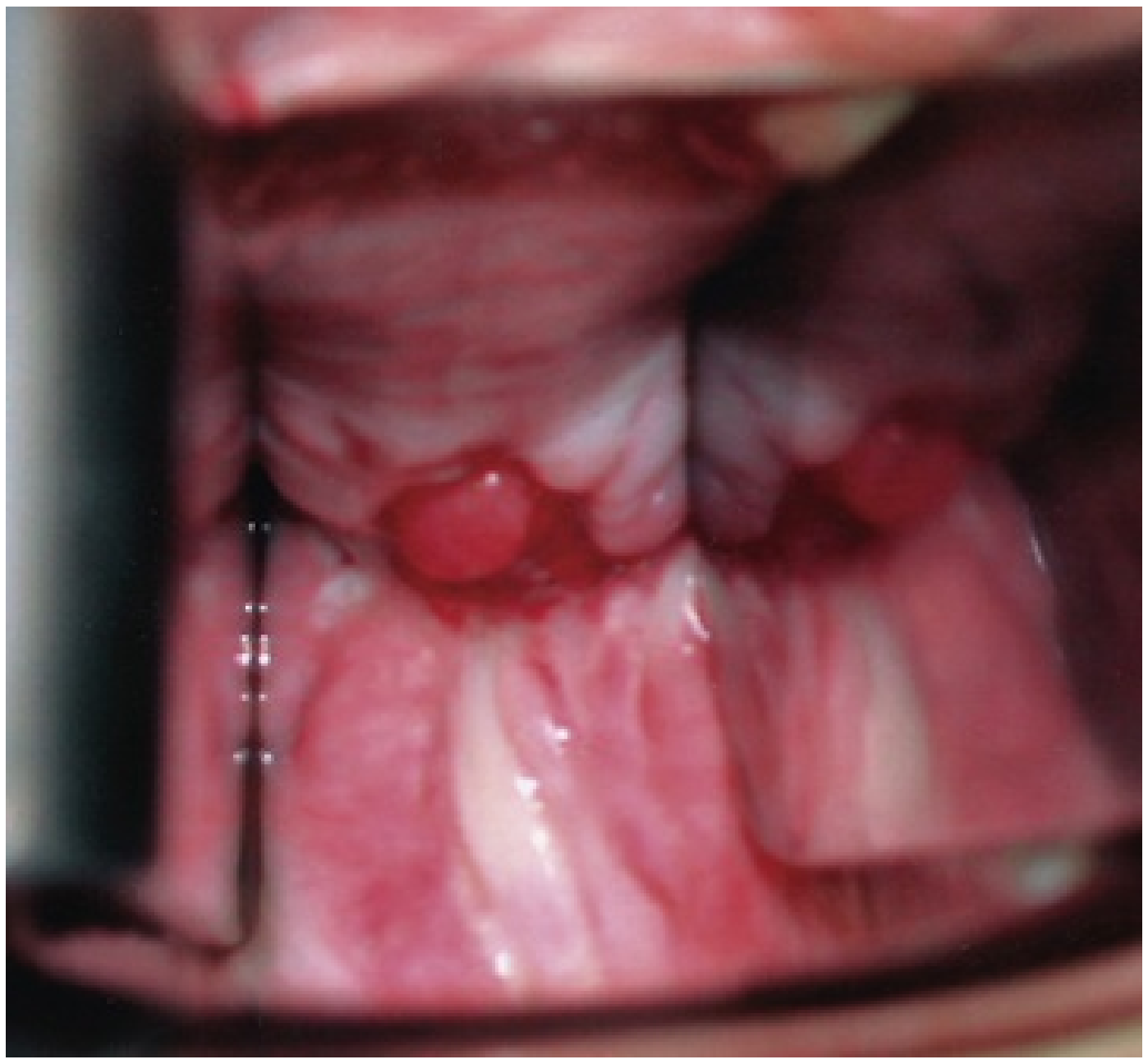

FIG. 129.4 Vesicovaginal fistula (VVF) on physical examination. A large VVF is seen at the apex of the vagina after hysterectomy. The VVF in this image is seen as reddish pink bladder mucosa prolapsing into the vagina. Handheld Heaney right-angled retractors provide lateral retraction in this image.

The presence of a VVF may be confirmed by instilling a vital blue dye into the bladder per urethra and observing whether vaginal drainage is discolored. Small or occult fistulae may be identified in this fashion (Drutz and Mainprize, 1988; Hanash et al., 2003). The vagina may be packed with gauze (3-swab test) or directly inspected for blue-tinged leakage (Gannon, 1990). If blue-tinged leakage is not apparent and the diagnosis of VVF is in doubt, the sensitivity of this test may be improved by ambulating the patient for a short period of time. Staining at the introital (distal) end of the packing suggests urinary incontinence or a urethrovaginal fistula, whereas proximal staining suggests a VVF. **If the vaginal packing remains dye free with this maneuver, then the possibility of a ureterovaginal fistula can be investigated with the use of clean vaginal packing, intravenous indigo carmine (or other vital dye), and a repeat pad test. Blue staining at the proximal end of the pad after this maneuver suggests the presence of a ureterovaginal fistula.**

A double dye or tampon test may confirm the diagnosis of urinary fistula, as well as suggesting the possibility of an associated ureterovaginal or urethrovaginal fistula (Hanash et al., 2003; Moir, 1973; Raghavaiah, 1974**)**. In one variation of the double dye test, a tampon is placed in the vagina. Oral phenazopyridine is administered, and vital blue dye is instilled into the bladder. If the tampon is discolored yellow-orange at the top, it is suggestive of a ureterovaginal fistula. Blue discoloration in the midportion of the tampon suggests VVF, whereas blue staining at the bottom suggests a urethrovaginal fistula.

Clear vaginal discharge after hysterectomy does not invariably represent a urinary fistula or incontinence. Other than normal vaginal secretions, less common causes include a peritoneovaginal fistula (Ginsberg et al., 1998), lymphatic fistula (Lau and Wong, 1994), vaginitis, and fallopian tube fluid (Maloney et al., 2016). Incontinence after cesarean section, in which a VVF has been excluded, may suggest the possibility of a ureterovaginal or vesicouterine fistula.

Cystoscopy

An endoscopic examination should be performed in patients for whom a suspicion of VVF is present (Fig. 129.5). Immature fistulae may appear as areas of localized bullous edema without distinct ostia. Mature fistulae may have smooth margins with variably sized ostia. In some cases, multiple pits and cavities along an area of the traumatized posterior bladder wall, in the setting of a small VVF, may make it difficult to identify the exact fistula tract. In these cases, a guidewire or ureteral catheter may be placed through the working channel of the cystoscope and into the fistula tract (Fig. 129.6). Visualization of the wire in the vagina confirms the exact location of the VVF on the bladder and genital sides. Cystourethroscopy can confirm the presence of the fistula but also may reveal the size of the tract, the presence of collateral fistulae, and the location of the ureteric orifices in relation to the fistula. **In the setting of a prior history of pelvic malignancy, a biopsy of the fistula is often done to evaluate for the possibility of a recurrent malignancy.** Fistulae located near or at the ureteric orifice may require ureteral reimplantation at the time of VVF repair. This type of requirement would usually mitigate against a completely transvaginal attempt at repair.

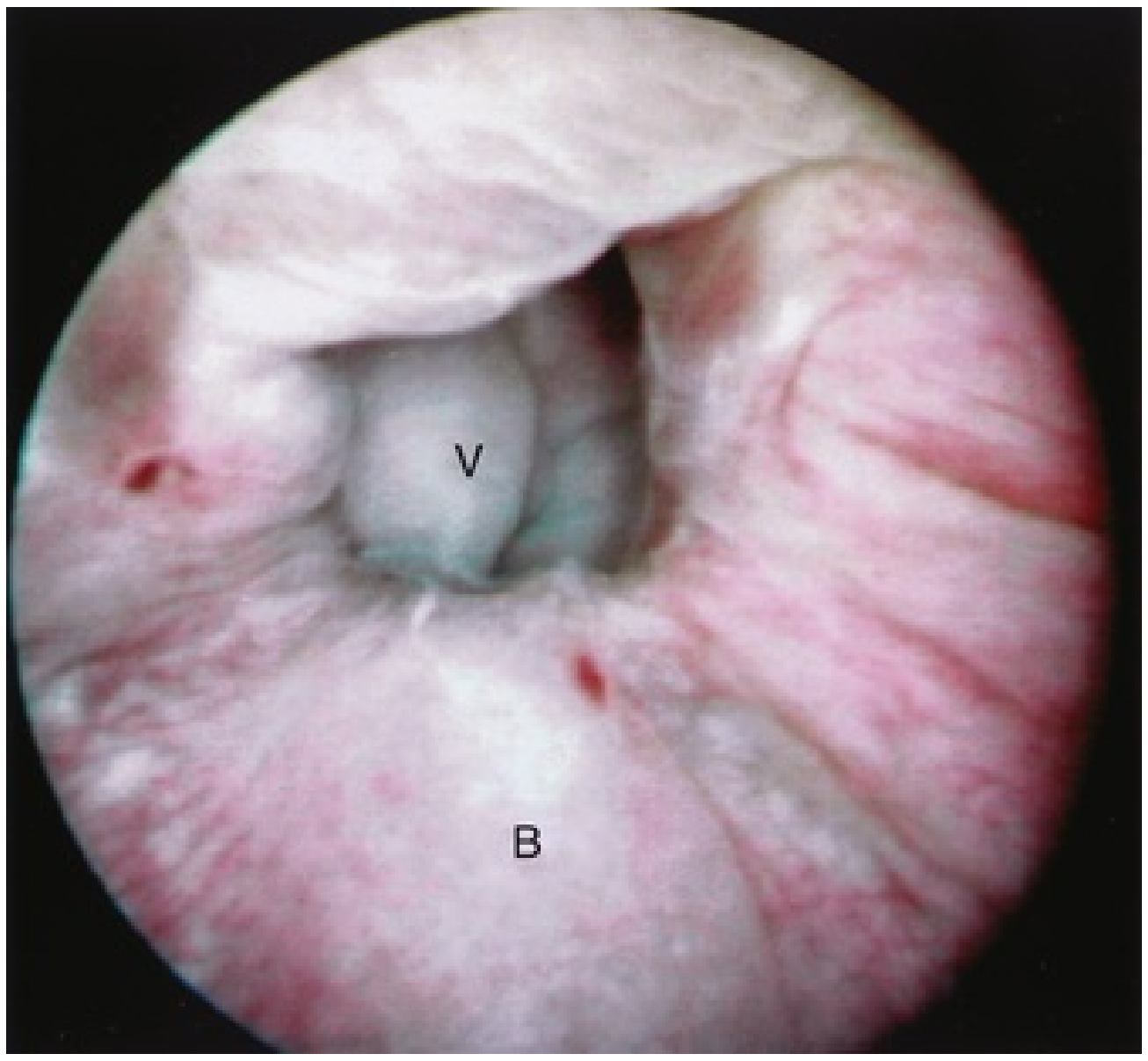

FIG. 129.5 Endoscopic view of vesicovaginal fistula (VVF). The fistula is now seen from the bladder side. This VVF is large enough to allow one to see directly into the vagina *(V)* through the bladder *(B).*

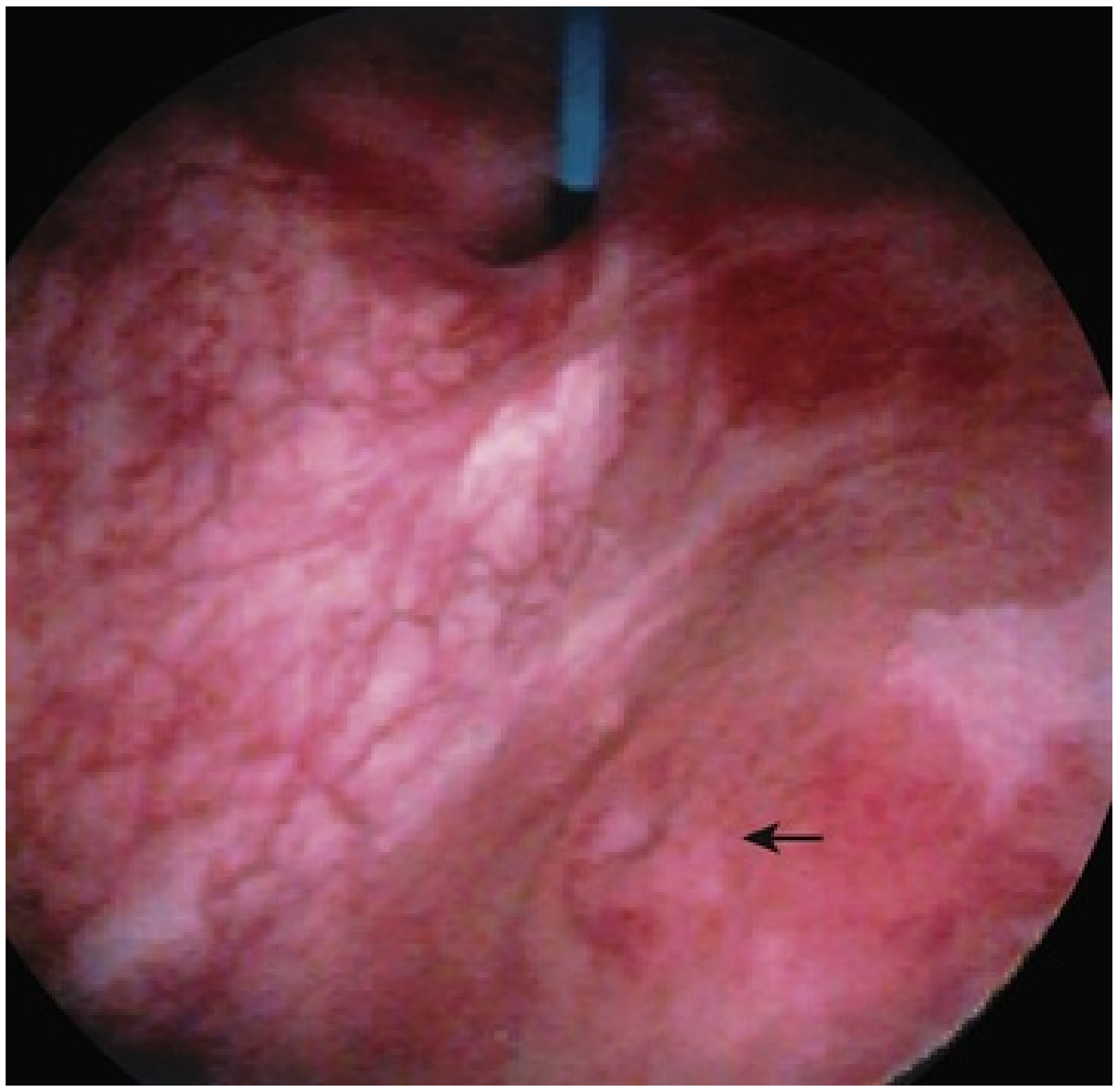

FIG. 129.6 Confirmation of a vesicovaginal fistula (VVF). A 4-Fr ureteral catheter traverses the fistula tract in this endoscopic photograph. The VVF is high on the posterior bladder wall, the typical location for a posthysterectomy VVF. The right ureter can be seen *(arrow)*.

Imaging

Contrast CT or magnetic resonance imaging (MRI) examination is usually performed if fistulae are suspected (Abou-El-Ghar et al., 2012; Verma et al., 2012). Delayed CT visualization of contrast within the vagina is considered highly suspicious for VVF in the majority of cases (Fig. 129.7). In cases of suspected VVF, CT should be performed with only intravenous contrast, or, alternatively, a CT cystogram can be performed to isolate the bladder. A vaginal tampon placed per vagina during intravenous urography (IVU) or CT scan may improve the sensitivity for finding small or occult VVF in patients with an otherwise negative evaluation. **Cross-sectional imaging may also be helpful in assessing for recurrent malignant disease in those with such a history. A cystogram and/or voiding cystourethrogram (VCUG) and an upper tract study can be performed in patients being evaluated for a VVF, if MRI or CT is not available.** The cystogram may objectively determine the presence and location of the fistula. VVFs are often best seen in the lateral projection (Fig. 129.8) in which the bladder and vagina are not superimposed (Fig. 129.9). **However, voiding images may be necessary in some patients with small**

fistulae to demonstrate the VVF. A cystogram that fails to demonstrate a suspected VVF but lacks voiding images or postvoid images should be considered nondiagnostic. During voiding, care should be taken to exclude vaginal voiding or reflux of contrast from the introital region cephalad into the vagina, which would produce a falsely positive image. An involuntary bladder contraction can be provoked with rapid filling during cystography, and if the intravesical pressure rises sufficiently, this may also be sufficient to demonstrate a VVF when the filling images of the cystogram failed to demonstrate it. In some instances, a cystogram can also permit an assessment of bladder capacity (important in the setting of prior radiotherapy), cystocele, bladder neck competence, and vesicoureteral reflux, any of which may have an impact on operative repair.

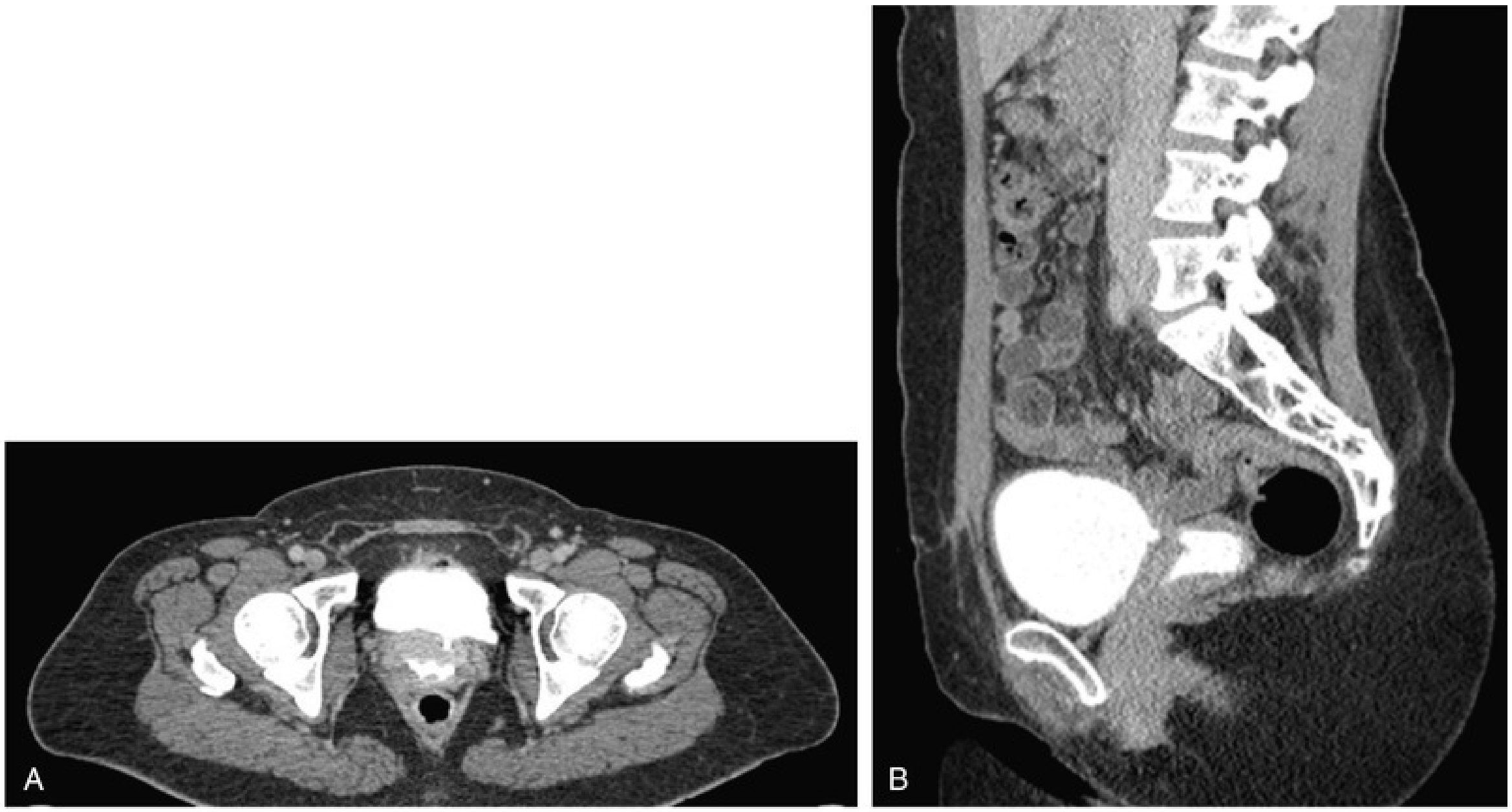

FIG. 129.7 Computed tomography (CT) scan of vesicovaginal fistula (VVF). (A) After intravenous administration of the contrast agent, there is high-density material in the bladder and vagina consistent with a VVF. The fistulous connection is between the bladder anteriorly and the vagina posteriorly. (B) Sagittal CT reconstruction demonstrating VVF.

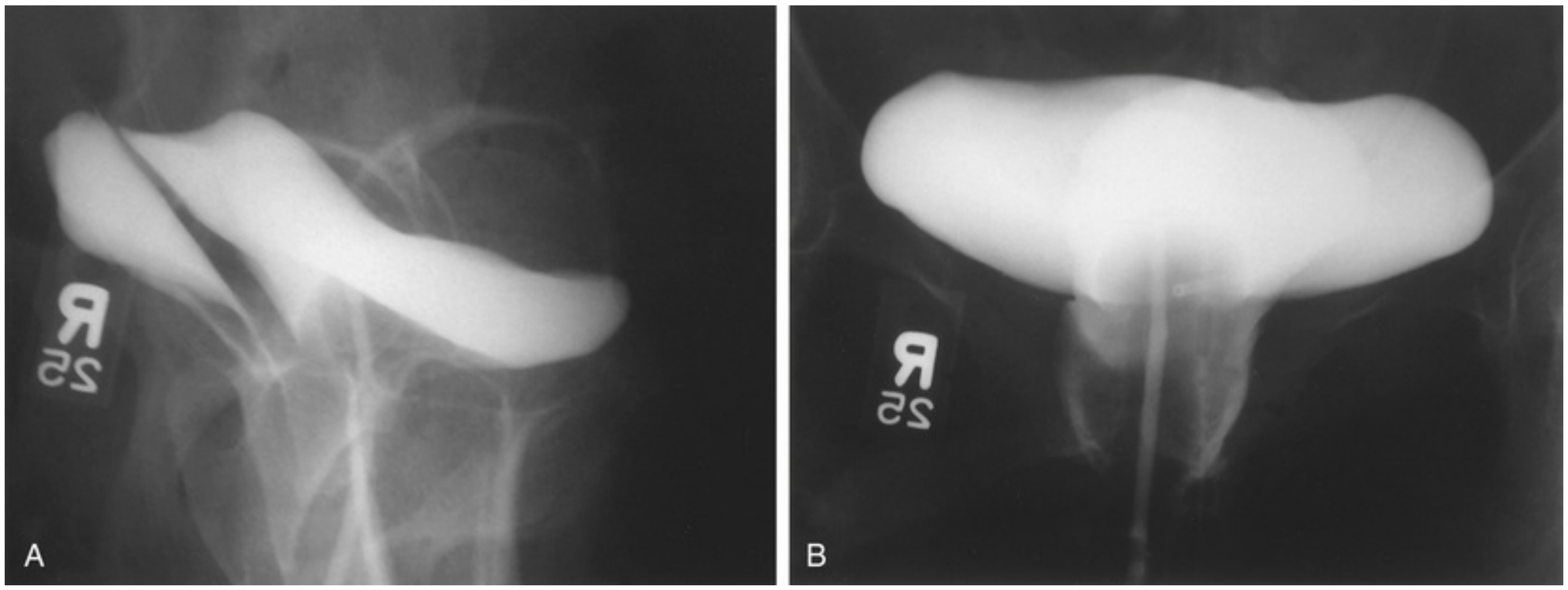

FIG. 129.8 Cystogram demonstrating a vesicovaginal fistula (VVF). (A) Lateral image demonstrates a posthysterectomy VVF. (B) Anteroposterior view. The contrast agent is seen opacifying and outlining the vagina, superimposed on the bladder.

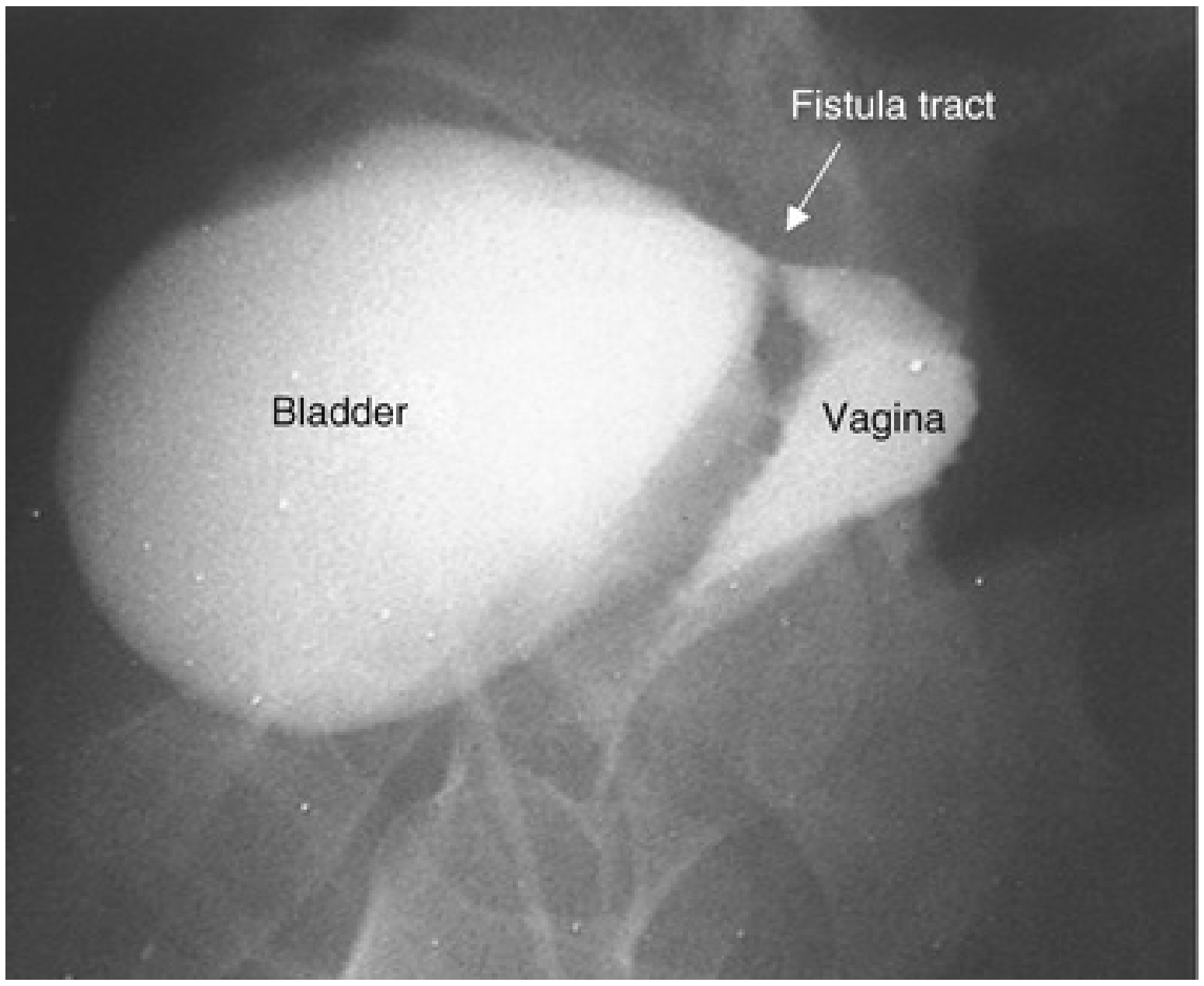

FIG. 129.9 Lateral image during cystography demonstrates the vesicovaginal fistula tract.

VVFs can be associated with ureteral injury or ureterovaginal fistula; thus upper urinary tract evaluation is important. CT urography or MRI studies reveal the combined fistulae (Botsikas et al., 2012; Lopez et al., 2005). IVU (Gerber and Schoenberg, 1993) may be an alternative if CT or MRI is not available.

Ultrasound examination has also been used as diagnostic tool but remains user dependent (Volkmer et al., 2000).

Other Studies

Appropriate urine studies including culture, and cytology when indicated, are performed. Urine may extravasate externally or internally. Creatinine levels in the urine are higher than serum levels. Therefore, in the setting of a suspected fistula, testing the creatinine level in either the extravasated fluid or the accumulated ascites and comparing this value with the serum creatinine levels will confirm urinary leakage but not the location of the fistula. Likewise, testing potassium levels will show higher levels compared with serum levels. When infection is detected, appropriate antibiotic coverage is initiated. Urodynamics, including video-urodynamics, are generally not necessary in the evaluation of routine posthysterectomy VVF. However, in the setting of a prior history of radiation or radical pelvic surgery (e.g., radical hysterectomy) or in those with preexisting neurogenic vesicourethral dysfunction, a urodynamic evaluation can be used to evaluate for significant detrusor dysfunction, including impaired bladder compliance, although the impact of these diagnoses on the management of VVF is not clear (Goh et al., 2013; Hilton, 1998).

Classification of Fistulae

An ideal fistula classification system should correlate with the outcome and prognosis of the eventual fistula treatment. The Waaldijk and Goh classifications are the only ones that have been used to document sufficient numbers of obstetric fistula patients. The Waaldijk classification assesses mainly the extent of the urethral involvement and whether the injury to the urethra is circumferential. Fistulae are classified into types I (distance between the distal edge of the fistula and the urethral meatus > 4 cm with no involvement of the urethral closure mechanism), II (distance between the distal edge of the fistula and the urethral meatus 1–4 cm [type IIA] or 0.5–1 cm [type IIB] with involvement of the urethral closing mechanism at the bladder neck and mid-urethral level), and III. Type III fistulae are those fistulae other than vesicovaginal fistulae and include rectovaginal fistulae and ureterovaginal fistulae.

Similarly, the Goh classification looks at three of the four proven variables known to affect the outcome for obstetric fistula repair: the location of the fistula (assessing the extent of urethral involvement), the size of the fistula, and the amount of scarring (including whether or not it is circumferential) (Browning, 2006; Goh, 2004; Goh et al., 2008). Bladder capacity or size is also known to affect outcome, but because this is difficult or even impossible to measure preoperatively, it has not been included in the Goh classification (Fig. 129.10).

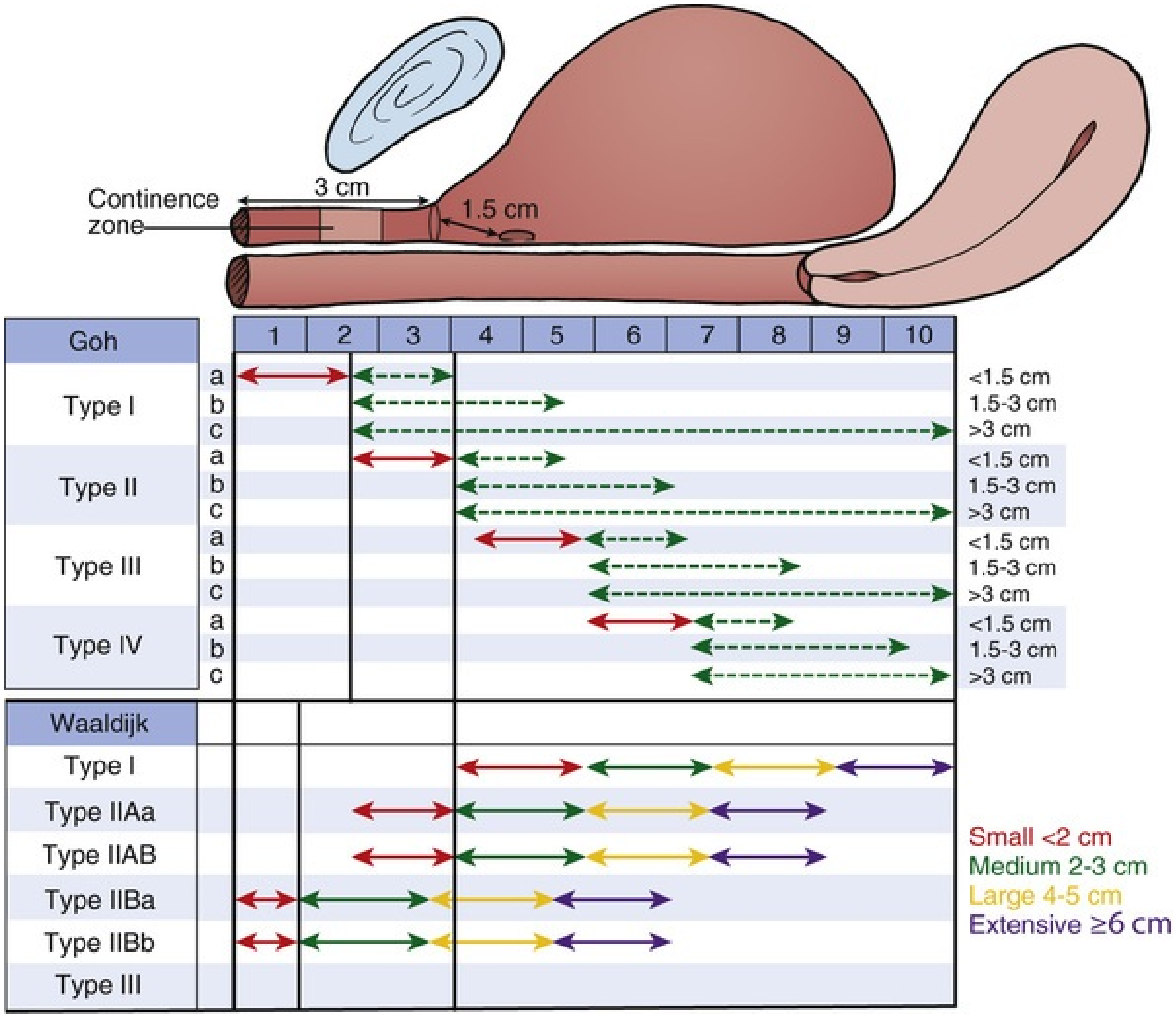
Continence zone
3 cm
1.5 cm
Goh
1
2
3
4
5
6
7
8
9
10
Type I
Type II
Type III
Type IV
a
b
c
<1.5 cm
1.5-3 cm
>3 cm
Waaldijk
Type I
Type IIAa
Type IIAB
Type IIBa
Type IIBb
Type III
Small <2 cm
Medium 2-3 cm
Large 4-5 cm
Extensive ≥6 cm

FIG. 129.10 Goh classification.

There has been one comparative study showing that the Goh system is superior to the Waaldijk in terms of predicting closure (Capes et al., 2012; Goh et al., 2009). Frajzyngier et al. (2013), in a prospective cohort study, compared the classification systems of Lawson, Tafesse, Goh, Waaldijk, and the World Health Organization (WHO). They included 1274 patients in 11 centers. The predictive accuracy for fistula closure was 0.63 for the WHO score, 0.62 for Goh, and 0.60 for the Tafesse score. The Waaldijk and Lawson systems fared worse. They propose a new empirical and simplified scoring system. They also suggested including other items in a prognostic scoring systems such as HIV status, malnutrition, malaria, and genital cutting.

Classification systems have been developed for an obstetric fistula population. For iatrogenic fistulae the classification is highly variable. Most centers use their own classification. It may be possible to use OF classifications for iatrogenic fistula as well, although a recent study indicated that this is not the case for the Goh classification (Beardmore-Gray et al., 2017).

Treatment

Conservative and Minimally Invasive Therapy

The goal of treatment of VVF is the rapid cessation of urinary leakage with return of normal and complete urinary and genital function. The physical and psychological impact of a VVF can be overwhelming because of the continual wetness, undesirable odor, vaginal and bladder infections, and their related discomfort. Bladder catheterization may temporize some of these effects until definitive repair is undertaken but often will not completely eradicate leakage, especially in those with a large fistula or those with significant detrusor overactivity. Furthermore, catheterization may provoke additional irritation and pelvic pain and is a constant reminder to the patient of an iatrogenic insult.

Before epithelialization is complete, an abnormal communication between viscera will tend to close spontaneously, provided that the natural outflow is unobstructed. **A trial of indwelling catheterization and anticholinergic medication for at least 2 to 6 weeks may be warranted in selected patients with newly diagnosed VVF, because spontaneous healing may result.**

Bazi (2007) reported a non-systematic review of papers including information on the spontaneous fistula closure of VVF. Although quality of the data was poor, he identified 30 studies from which 12 could be included (Bazi, 2007). Few studies described catheter drainage in large fistulae, although it seemed that those of less than 1 cm diameter were most likely to heal spontaneously. The time between the insult and institution of drainage in cases of nonsurgical closure varied widely, although in most cases this was less than 3 weeks. Similarly, the duration of catheterization before the initiation of conservative treatment was deemed to have been unsuccessful and varied considerably, making true estimates of the effectiveness of this approach impossible; generally this varied between 10 days and 3 months. Reported success rates varied between 0 and 100% (but 5 series had a sample size of 1), although in several series it was difficult to determine how many women had attempted conservative management.

In large series of obstetric fistulae in which a consistent approach to conservative management has been applied, spontaneous healing has been reported in up to 28% of cases (Waaldijk, 1994, 1997, 2004). In one series of urogenital fistulae of varying causes, spontaneous closure was seen in 19 of 238 or 8.0% of surgical cases, 4 of 38 or 10.5% of obstetric cases, 1 of 36 or 2.8% of miscellaneous (largely traumatic cases), and 0 of 34 or 0.0 of radiotherapy-related cases (Hilton, 2011). Oakley et al. (2014) studied 226 patients, of whom 116 underwent immediate surgery and 60 were treated with catheterization for 12 weeks. Of the conservative treatment group only 11.7% resolved spontaneously, the remainder required surgery. It is possible that in this, and many other reported, series data are an underestimate of the value of this approach to management (Hilton, 2011); nevertheless, combining available data gives an overall spontaneous closure rate from 348 surgical fistulae treated by initial catheterization of 13% ± 23% (Chittacharoen and Theppisai, 1993; Davits and Miranda, 1991; Dogra and Nabi, 2001; Falk and Orkin, 1957; Frang and Jilling, 1983; Gorrea et al., 1985; Hilton, 2011; Latzko, 1942; Lentz, 2005; Mathevet et al., 2001; Milicic et al., 2001; Soong and Lim, 1997, Tancer, 1992). Patients with ongoing, continuous vaginal leakage despite a functioning indwelling catheter should be spared prolonged catheter drainage and proceed with more definitive repair as soon as medically appropriate (Fig. 129.11).

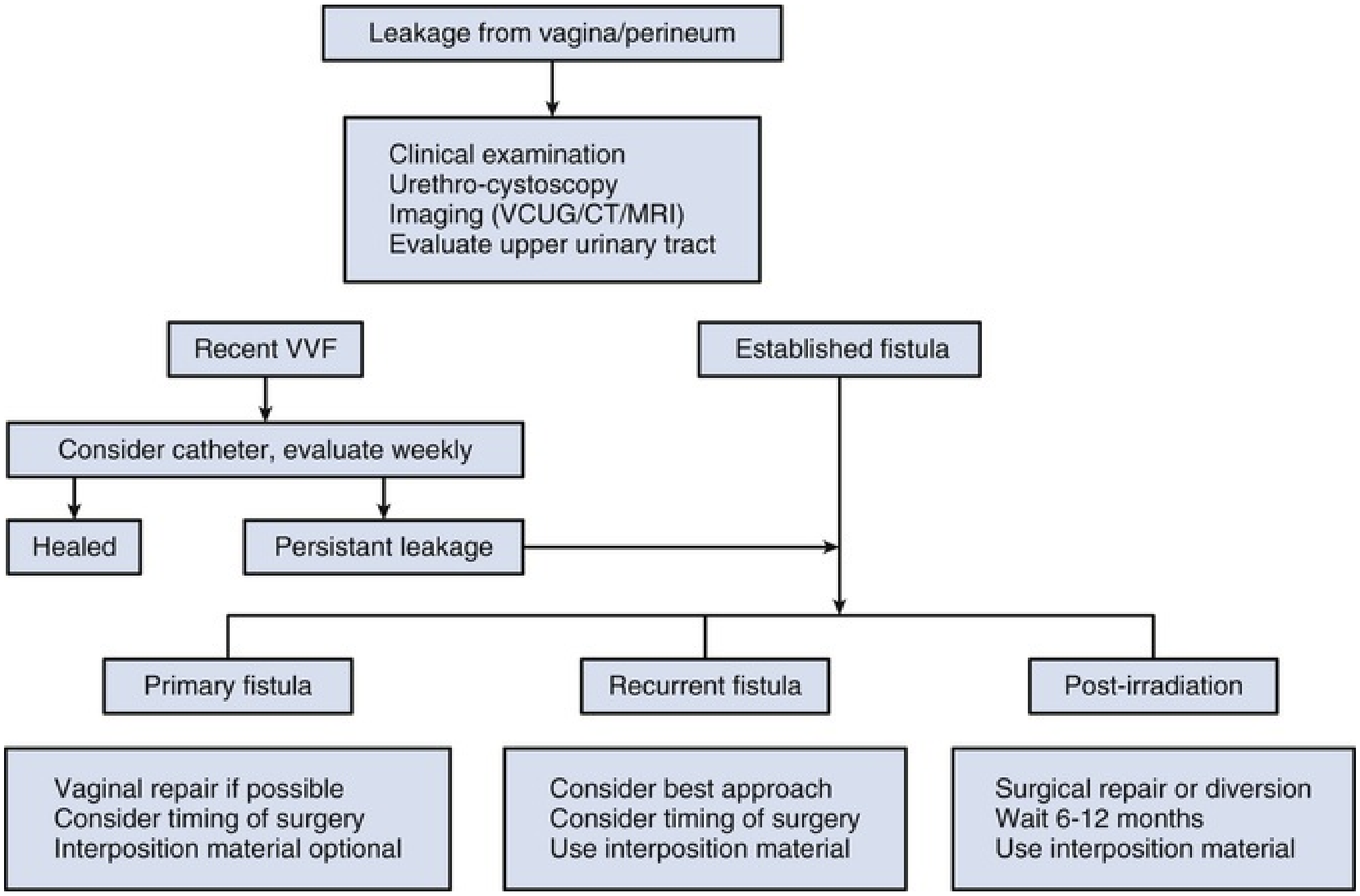
Leakage from vagina/perineum
Clinical examination
Urethro-cystoscopy
Imaging (VCUG/CT/MRI)
Evaluate upper urinary tract
Recent VVF
Established fistula
Consider catheter, evaluate weekly
Healed
Persistant leakage
Primary fistula
Recurrent fistula
Post-irradiation
Vaginal repair if possible
Consider timing of surgery
Interposition material optional
Consider best approach
Consider timing of surgery
Use interposition material
Surgical repair or diversion
Wait 6-12 months
Use interposition material

FIG. 129.11 Algorithm for the diagnosis of vesicovaginal fistula (VVF). *CT,* Computed tomography; *RPG,* retrograde pyelography; *VCUG,* voiding cystourethrogram.

Patients with small epithelialized fistulae may benefit from a minimally invasive treatment involving disruption of the epithelial layer of the fistula tract. Catheterization may be combined with minimally invasive electrocoagulation of the fistula tract. In this approach, a small cautery electrode is passed into the fistula tract endoscopically as far as possible. The electrode is slowly withdrawn from the tract with the electrode set on coagulation. The edges of the fistula tract should blanch. This approach was advocated by O'Conor as far back as 1938 for small, highly situated fistulae (O'Conor and Sokol, 1951) and has been reported in several small case series. In patients with fistulae less than 3.5 mm in diameter, 11 of 15 had successful fistula tract ablation with cauterization and catheter drainage in a study by Stovsky et al. (1994). Endoscopic transvesical VVF fulguration may be a safe and effective procedure for small VVFs on a day care basis, with decreased morbidity, improved cosmesis, and decreased hospital stay (Shah, 2010). Also, laser welding has been tried with success in a small series of women with fistula smaller than 3 mm (Dogra and Saini, 2011). All successfully treated patients had VVF less than 3 mm in diameter; in two patients with 6-mm VVF this approach failed. In patients with a thin vesicovaginal septum, large VVF, a nonoblique fistula tract, or significant inflammation around the fistula tract, fulguration risks failure and the possibility of enlarging the size of the fistula. This approach may also devitalize adjacent tissues, thereby compromising their future use as flaps. Fibrin sealant has been used as an adjunctive measure to treat VVF. The fibrin sealant may be injected directly into the fistula tract after fulguration as described earlier. The bladder is then drained for several weeks. Presumably, the gel-like nature of the fibrin sealant plugs the hole until tissue ingrowth occurs from the edges of the fistula (D'Arcy and Jaffry, 2010; Dolay et al., 2007; Kanaoka et al., 2001; Pettersson et al., 1979). In general, these conservative measures are useful for small, oblique fistulae (usually less than 2 to 3 mm in diameter), in patients who are agreeable to this course of therapy.

Surgical Repair

It has been stated that the best opportunity to achieve successful repair of VVF is with the initial operation (Elkins, 1994). Previous failed attempts at repair produce scarring and anatomic distortion and may compromise potential reconstructive flaps. Therefore careful preoperative planning is essential to maximize the chances for a successful result. **There is no “best” approach for all patients with VVF.**

Timing: Immediate Versus Delayed Repair

The timing of VVF repair is somewhat controversial. **Repair of VVF should be as expeditious as possible to minimize patient suffering; however, optimal timing for repair should allow consideration of certain medical and surgical factors.** It is generally accepted that VVF resulting from obstructed labor should be associated with a 3- to 6-month delay before definitive repair (Arrowsmith, 1994; Waaldijk, 1994; Wein et al., 1980) to allow maximum demarcation of ischemic tissue and resolution of the associated edema and inflammatory reaction. Longer periods of time, up to 6 to 12 months, have been advocated for radiation-induced fistulae, which are often associated with severe obliterative endarteritis and reduced tissue vascularity.

In the classical teaching of VVF, a minimal waiting period of several months is suggested—from the inciting event before the definitive repair attempt—to allow reduced tissue edema and inflammation, and optimal pliability of the tissues (Lawson, 1972; Persky et al., 1979). O'Conor (1973) recommended a waiting period of 3 to 6 months for suprapubic VVF repairs. In this setting, reduced inflammation and edema permit easier identification of tissue planes (and therefore flap development), less bleeding, and less tension on the reapproximated suture lines. **There is no consensus in the literature as to the definition of "early"** in this context, with different studies either failing to specify at all, or giving a broad range of definition. Although some studies have used the terms "immediate" (Lee et al., 2010), "less than 2 weeks" (Shelbaia and Hashish, 2007), or "less than 30 days" (Soong and Lim, 1997), most reports have considered either less than 6 weeks (Badenoch et al., 1987; Blandy et al., 1991; Kam et al., 2003) or less than 3 months (Moriel et al., 1993; Radoja et al., 2010; Wang and Hadley, 1990) as their definition of early intervention. **The enthusiasm for delayed management has waned, and, in general, uncomplicated postgynecologic urinary fistulae may be repaired as soon as they are identified and confirmed, thereby minimizing patient discomfort and anguish** (Blaivas et al., 1995; Kostakopoulos et al., 1998; Nagraj et al., 2007). Early repair can be considered within 2 to 3 weeks after the occurrence of the fistula. If that time window has passed, a waiting period of 2 to 3 months is considered to be safe. There are no good comparative studies to offer more guidance. Nevertheless, in some cases, the timing of a VVF repair is best tailored to the individual patient (Blaivas et al., 1995). If an abdominal approach is being considered after a particularly difficult or complicated abdominal surgery that resulted in the VVF (e.g., complicated by abscess, urinoma), then a delay may be warranted to allow resolution of active inflammation. Another potential reason to delay repair is to treat ongoing infection or inflammation at the level of the vaginal cuff. Periodic reexamination of the vaginal tissues can be performed every 1 to 2 weeks, and definitive repair scheduled when suitable pliability is noted (Carr and Webster, 1996).

A vaginal approach can be attempted as soon as 2 to 3 weeks after the initial injury, if conservative therapy fails (i.e., the patient remains wet when a Foley catheter is in place to provide adequate drainage of the bladder) and the patient is in good general health. The vaginal tissues are usually relatively undisturbed from the prior causative surgery, especially if the surgery was transabdominal. Wide, healthy vaginal flaps can usually be obtained. In the rare circumstance in which a VVF is seen within the first 24 to 48 hours postoperatively, an immediate repair can be attempted (Margolis and Mercer, 1994).

Approach: Abdominal Versus Vaginal

VVF may be repaired through a transvaginal or transabdominal (transvesical) approach. Each approach has merits depending on the particular circumstances of the fistula, and excellent outcomes can be expected with both approaches (Table 129.1). **Next to factors such as size, location, and the need for adjunctive procedures often influence the choice of approach, also the experience of the operating surgeon must be taken into account.** There are no randomized studies comparing abdominal and vaginal approaches, although there are recent retrospective studies comparing vagina and abdominal approaches. The fistula closure rate seems to be similar for both approaches (Gedik et al., 2015; Rajamaheswari et al., 2012; Tatar et al., 2017). Also the postoperative sexual function is similar in both approaches (Mohr et al., 2014). However, the abdominal route is characterized by higher morbidity (22% vs. 7%), prolonged length of stay (3.5 days ± 2.3 vs. 1.6 days ± 2), more sepsis (4.3% vs. 0), a higher transfusion need (7.1% vs. 0.8%), and a higher readmission rate (10.1% vs. 0.8%), when compared with the vaginal approach (Theofanides et al., 2017). **The abdominal approach is a significant predictor of complications at 30 days. Therefore a vaginal approach is to be recommended or referral to a skilled vaginal surgeon should be offered.**

TABLE 129.1

Abdominal Versus Transvaginal Repair of Vesicovaginal Fistulae

	ABDOMINAL	**TRANSVAGINAL**
Incision	Abdominal incision	Vaginal incision(s) can be done immediately in the absence of infection or other complications.
Timing of repair (elapsed time from fistula creation)	Eventually within 2–3 weeks, but often delayed 3–6 months	
Exposure	Fistula located low on the trigone or near the bladder neck may be difficult to expose transabdominally.	Fistula located high at the vaginal cuff may be difficult to expose transvaginally.
Location of ureters relative to fistula tract	Fistula located near ureteric orifice may necessitate reimplantation.	Reimplantation may not be necessary even if fistula tract is located near ureteric orifice.

Sexual function	No change in vaginal depth	Risk of vaginal shortening (e.g., Latzko technique)
Use of adjunctive flaps	Omentum, peritoneal flap, rectus abdominis flap	Labial fat pad (Martius fat pad), peritoneal flap, gluteal skin or gracilis myocutaneous flap
Relative indications	Large fistulae, location high in a deep narrow vagina, radiation fistulae, failed transvaginal approach, small-capacity bladder requiring augmentation, need for ureteral reimplantation, inability to place patient in the lithotomy position	Uncomplicated fistulae, low fistulae
Complications	Higher morbidity Increased length of stay Higher transfusion need Higher readmission rate Higher risk for sepsis	Vaginal shortening
Cost	High	Low

Potential disadvantages of the transvaginal approach include the relative lack of familiarity of the vaginal cuff anatomy to many urologists; the potential for vaginal shortening, especially with the Latzko approach; and, finally, the difficulty in exposing high or retracted fistulae located near the vaginal cuff, especially in deep, narrow vaginas, or in those without any apical prolapse, such as that found in nulliparous females (see Fig. 129.3).

The abdominal approach to VVF repair can be indicated in several circumstances. If the VVF is associated with **other intra-abdominal pathology requiring repair—**including an associated ureteral injury (i.e., ureterovaginal fistula) or a complex fistula, including those involving another intra-abdominal organ—then a transabdominal approach is indicated to address the problems simultaneously. In patients with **a small-capacity or poorly compliant bladder (often secondary to radiation) requiring augmentation cystoplasty,** an abdominal approach is indicated, because both procedures can be performed using the same incision. Currently the open abdominal approach is often being replaced by laparoscopic or robotic repairs (see later).

Handling of Fistula Tract: Excision Versus No Excision

A long-held tenet for successful fistula closure, dating back to the original description by Sims in 1852, involves complete excision of the fistulous scar tissue and tract (Persky and Rabin, 1973). This approach ensures clean, well-vascularized viable edges to be approximated for the initial layer of repair but increases the fistula size. **However, excision of the fistula tract is not always necessary and may even compromise the repair in some patients** (Raz et al., 1993; Shaker et al., 2011). There is only a single randomized trial comparing aspects of surgical technique; Shaker et al. (2011) reported a randomized controlled trial (RCT) comparing trimming of the fistula edge with no trimming. Although there was no statistical difference in success rates between the two groups, in patients in whom repair was unsuccessful and trimming had been undertaken, the fistula tended to become larger, whereas fistulae wherein there was no trimming were more likely to be smaller on recurrence. There are several potential disadvantages of excision of the fistula tract. First, this creates a larger soft-tissue defect to be repaired. Excision of the fibrous tract may lead to bleeding, which, if cautery is used, may result in tissue necrosis and impede healing (Eilber et al., 2003).

If the VVF is adjacent to the ureter, then excision of the tract may mandate reimplantation of the ureter. Alternatively, if the tract is left in situ, the ureter may be catheterized for the repair and then left undisturbed during a transvaginal operation, obviating the need for reimplantation. In addition, in chronic fistulae, a strong fibrous ring forms outside the epithelialized tract, which maintains some strength through the repair if this layer is incorporated into the closure. This can be an important consideration in patients with significant detrusor overactivity postoperatively from either the repair or the indwelling drainage catheters.

Use of Adjuvant Flaps or Grafts: Type and Application

Before embarking on surgical repair, the surgeon should be familiar with a variety of adjuvant flaps and grafts that allow for the interposition of healthy tissue during VVF repair. It is often not possible to predict which patients will require these procedures. The literature consists of retrospective cohort series or small comparative studies, and thus there is no evidence that a Martius or any other interposition graft improves the outcome in primary fistula repair. Likewise there is no evidence that it does not.

The indications for tissue interposition are not well defined, but these measures are most commonly used in the setting of irradiated tissues, obstetric fistulae, failed prior repairs, large fistulae, and patients with

tenuous repairs. A variety of other flaps including gracilis muscle flaps, labial myocutaneous flaps, seromuscular intestinal flaps, and rectus abdominis flaps, as well as free grafts of bladder mucosa, have been used as adjunctive measures in the repair of complex VVF (Brandt et al., 1998; Izes et al., 1992; Menchaca et al., 1990; Mraz and Sutory, 1994; Ostad et al., 1998; Sharifi-Aghdas et al., 2002; Symmonds and Hill, 1978; Viennas et al., 1995). The various types of flaps are discussed in more detail later in the chapter.

Other Considerations

There is no evidence that preoperative estrogen supplementation is beneficial in the postmenopausal patient with vaginal atrophy and VVF. There is some evidence that estrogen supplementation may improve spontaneous closure of fistulae (Goh et al., 2001; Park et al., 2015), but there is no proven effect on the outcome of surgical repairs.

Perioperative antibiotics are administered, according to the existing American Urological Association or European Association of Urology guidelines on vaginal surgery. Specifically for obstetric fistula Muleta et al. (2010) showed in an RCT that a single prophylactic dose of gentamycin was as effective as the extended use of amoxicillin, chloramphenicol, or cotrimoxazole. Treatment of existing infection based on preoperative urine culture is potentially beneficial in preventing bacteremia during surgery.

Sexual activity should be documented preoperatively. Patients should be specifically queried regarding sexual function and dyspareunia occurring before the onset of the event that resulted in the fistula. Fistula repair usually improves sexuality (Mohr et al., 2014), but women need to be counseled that some types of vaginal procedures for the repair of VVF (such as Latzko partial colpocleisis) and abdominal repairs may result in vaginal shortening and postoperative dyspareunia. Preoperative documentation of this preexisting condition can be invaluable. Furthermore, adjuvant procedures that may alter vaginal appearance or function, such as the harvesting of a Martius fibrofatty labial flap or an episiotomy, should be carefully discussed with the patient in advance, especially regarding sexual function, although the impact on sexuality of the Martius flap is limited (Malde et al., 2017; Wilson et al., 2017).

Finally, postoperative drainage after VVF repair should be offered by a transurethral catheter (Leng et al., 1998), a suprapubic catheter (Blaivas et al., 1995), or a combination of both (Eilber et al., 2003). The duration of catheterization is variable. Ruminjo et al. (2014) did a survey among African and

Asian fistula centers and showed that catheters are kept between 14 and 29 days. Nardos showed that 10 days of catheterization are not inferior to 14 days (Nardos et al., 2012). A cystography may be used to establish the optimal timing of catheter removal (Bochenska and Zyczynski, 2016).

Preoperative Counseling and Indications for Surgery

Surgical repair of a VVF is indicated after confirmation of the diagnosis. As noted previously, a trial of conservative management may be warranted in selected cases, especially in those with a newly diagnosed, small, uncomplicated fistula in which the vaginal leakage significantly improves or resolves with catheter drainage. When conservative measures fail or if after adequate counseling the patient requests repair before a trial of conservative management, surgical treatment is pursued. Before surgery, patients should be counseled that VVFs in the industrialized world are repaired on the first attempt in more than 85% of cases; however, prolonged postoperative urinary catheter drainage is necessary after surgery. Postoperative urinary urgency and frequency are common for a period of time after removal of the catheter but are usually self-limited. Finally, the patient should be aware that it may be necessary to alter the surgical plan intraoperatively as a result of a variety of factors encountered during the operation, and that interpositional flaps or grafts may be used. Comparing the outcomes of treatment between different reports and different methods is made difficult by the inconsistent and relatively inefficient outcome measures used. These have ranged from the apparent achievement of a watertight repair based on dye-testing in the operating theatre, to patient reported symptoms at the time of discharge from hospital. Follow-up in obstetric fistula patients is inevitably difficult in many developing world centers, but even among surgical or radiotherapy cases in the developed world, relatively few reports describe examination findings or symptoms at later postoperative review. Long-term outcomes and quality-of-life measures have only rarely been reported (Browning and Menber, 2008, Dolan et al., 2008).

Vaginal Techniques

Common vaginal approaches to the repair of uncomplicated VVF are described. The merits of the vaginal approach are reviewed in Table 129.1. There are two main types of closure technique applied to the repair of urinary fistulae: the *classical saucerization* technique described by Sims (1852) and subsequently modified as a *partial colpocleisis* by Latzko (1942) and the more commonly used *dissection and repair in layers* or “*flap-splitting*” technique (variously attributed to Hayward, Collis, and Lawson Tait) (Wall, 2005). Individual surgeons inevitably employ these techniques somewhat variably, and in different situations, and there are no data comparing their outcomes.

Vaginal Flap or Flap-Splitting Technique.

The vaginal flap or flap-splitting approach popularized by Raz and colleagues (Raz et al., 1993; Zimmern et al., 1985) results in a three-layer closure without the use of an adjuvant flap, and a four-layer closure if a flap is used (Fig. 129.12). It can be performed as an outpatient procedure and is applicable to most simple, uncomplicated VVFs (Fig. 129.13). The number of layers to be used is not an absolute given. Good dissection of the vaginal wall and the fistula, allowing for tension-free closure of well vascularized bladder wall and vaginal wall, seems to be more important than the use of additional layers or interposition flaps (Browning, 2006; Miklos et al., 2015).

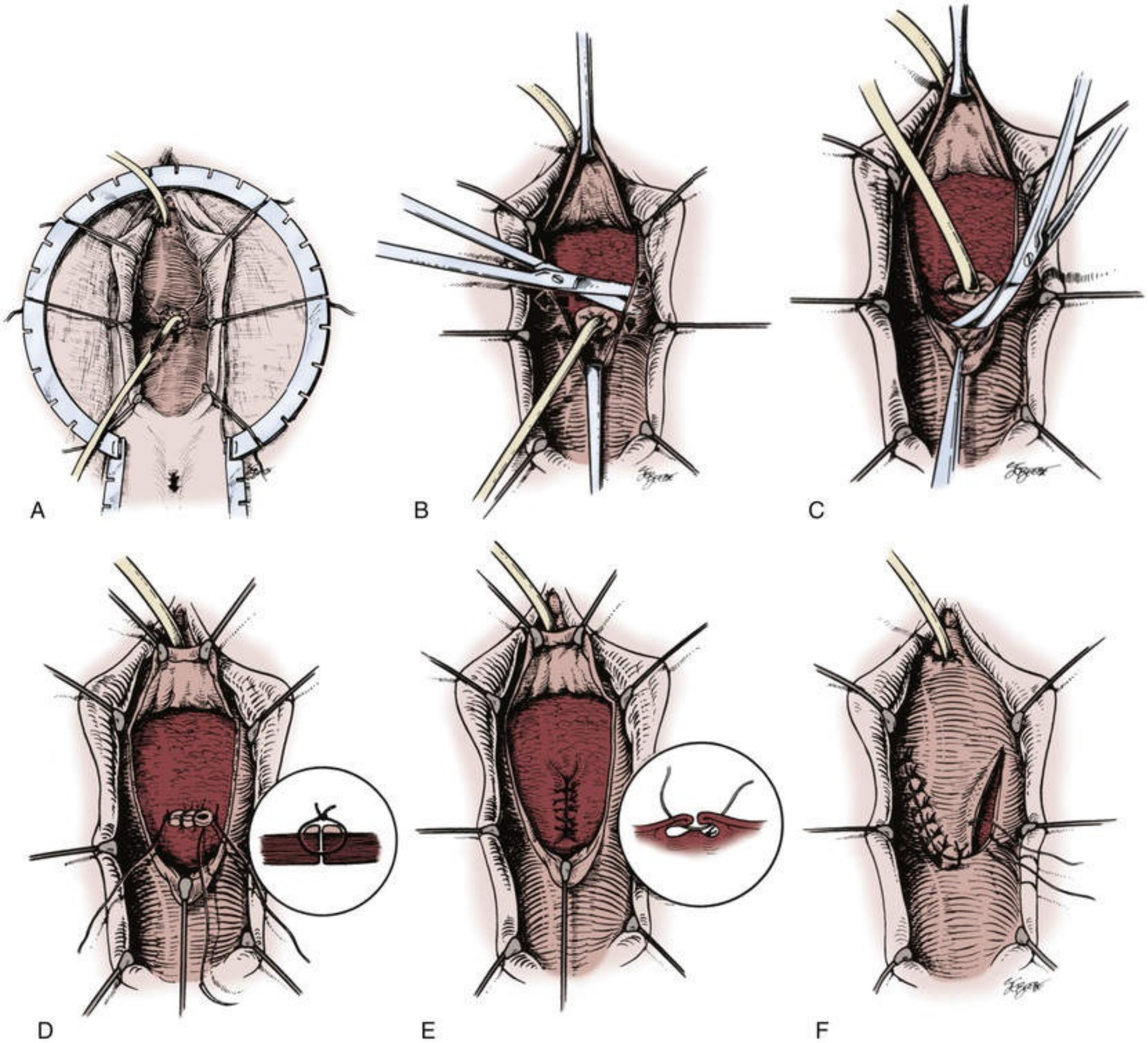

FIG. 129.12 Technique of vaginal repair of a posthysterectomy vesicovaginal fistula (VVF). (A) Retraction including ring retractor, vaginal speculum, and Foley catheter in the VVF tract. A Foley catheter is seen in the VVF tract providing traction on the vaginal cuff. (B) Mobilization of anterior vaginal wall flap. Lateral flaps are developed as well, thereby isolating the VVF tract. (C) Mobilization of posterior vaginal wall flap. (D) Initial layer of closure is performed without excising the edges of the fistula tract. (E) The perivesical fascia is closed with Lembert-type sutures. This line of closure is perpendicular to the initial suture line. (F) The vaginal wall flaps are advanced to avoid overlapping suture lines. (From Ganabathi K, Sirls L, Zimmern P, et al.: Vesicovaginal fistulae: reconstructive techniques. In McAninch J, editor: *Traumatic and reconstructive urology,* Philadelphia, 1996, Saunders; p 317.)

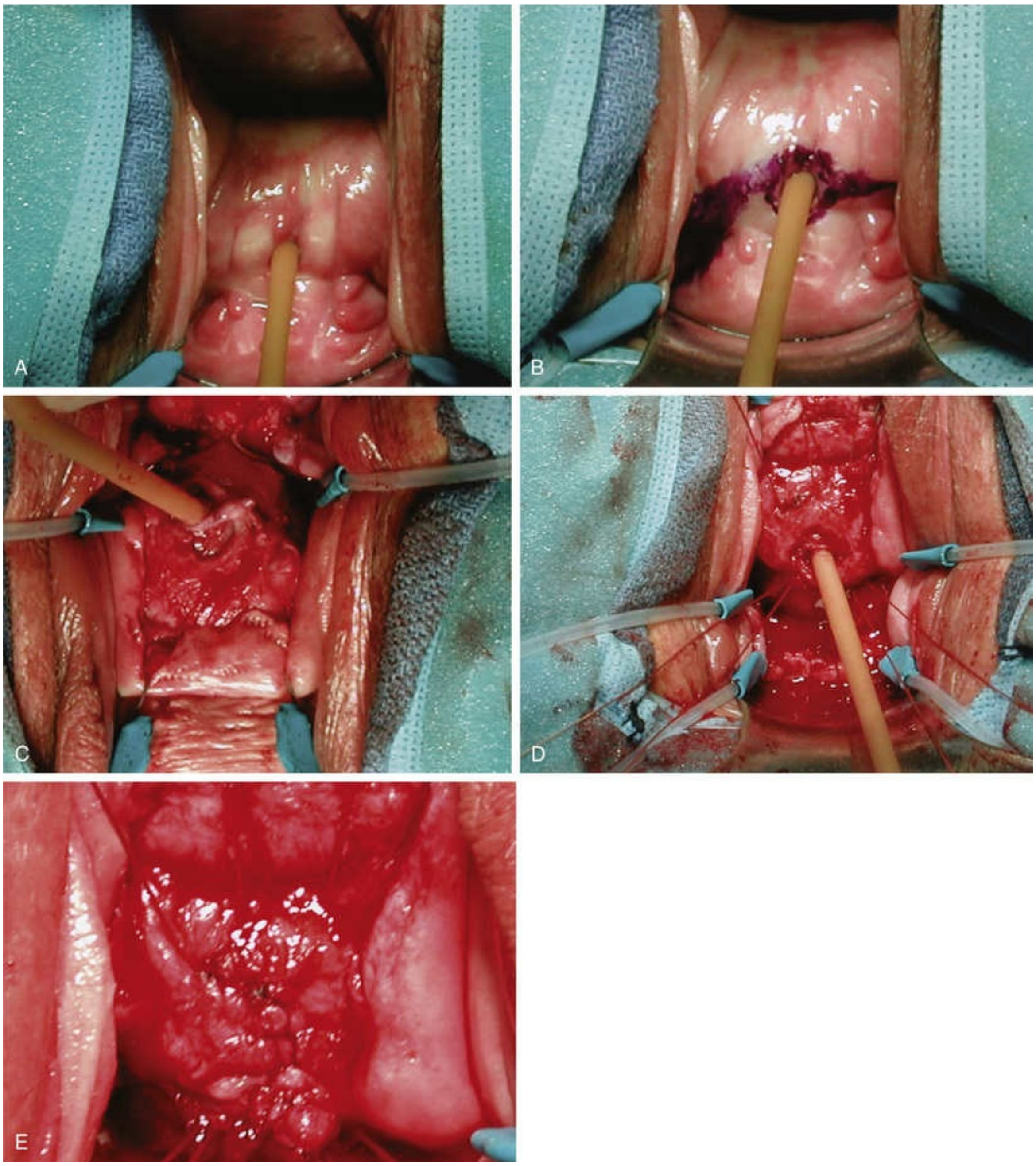

FIG. 129.13 Operative repair of vesicovaginal fistula. (A) Foley catheter in fistula providing retraction. (B) Posterior vaginal flap is marked. (C) The vaginal flaps have been developed and are retracted behind the hooks of the ring retractor. Note that the fistula tract is intact surrounding the Foley catheter. (D) The first layer of sutures has been placed. The Foley catheter will be removed from the fistula tract and the sutures tied down. (E) The second layer of closure is performed by reapproximating the perivesical fascia over the first suture line.

Complications.

Proper surgical technique is critical in avoiding complications. Dissection in the proper surgical planes ensures minimal bleeding. When significant bleeding is encountered during the dissection, it is possible that an improper plane of dissection was entered. Careful intraoperative inspection and reevaluation of the surgical planes are warranted. Furthermore, excessive use of cautery may compromise the vascular supply of the tissue flaps used for repair. This may become evident only in the postoperative period with ischemic flaps and recurrence of the fistula. Intraoperative bleeding should be controlled with fine absorbable suture whenever possible. **The possibility of ureteral injury is a concern if the VVF is located adjacent to the insertion of the ureter.** If there is doubt regarding a ureteral injury, then cystoscopy should be performed after the intravenous administration of indigo carmine. Blue efflux from the ureteric orifice confirms ureteral patency. Alternatively, retrograde imaging can be performed, because the ureter can be patent but partially obstructed.

Long-term complications from transvaginal VVF repair include vaginal shortening and stenosis. Careful attention to flap mobilization and reconstruction will minimize this complication. In addition, excessive resection of the vaginal wall should be avoided during reconstruction to avoid vaginal shortening or scarring.

The most important complication of VVF repair is recurrence of the fistula. A repeat transvaginal approach can be attempted with satisfactory success. A careful review of potential factors leading to failure of the initial repair is undertaken, and any remediable factors (e.g., inadequate nutrition, vaginal atrophy, excessive postoperative bladder spasms) are addressed. Strong consideration should be given to the use of adjuvant flaps in repeat VVF repairs in which tissue quality may be suboptimal.

Other Transvaginal Techniques.

There are multiple variations to transvaginal fistula repair, including those originally described by Latzko in 1914. The Latzko high-partial colpocleisis is a very popular approach among some reconstructive surgeons, with reported success rates in excess of 90% (Tancer, 1992). This approach may not be as successful as the vaginal flap technique for large obstetric fistulae (Elkins, 1994). In this procedure, the fistula tract is isolated, and the tissue surrounding the VVF tract is denuded of vaginal “epithelium” circumferentially for a distance of 1 to 2 cm. Care is taken to avoid deeply “denuding” the vaginal tissues to avoid entry into the bladder or perivesical fascia. The denuded areas are then reapproximated over the fistula tract with a series of interrupted absorbable sutures. Sutures are not placed into the detrusor or vesical mucosa, but rather in the bladder serosa. The edges of the vaginal wall are then reapproximated as a second layer, creating a partial colpocleisis in some patients. Advantages of the Latzko procedure include minimal blood loss, no need for ureteral reimplantation (even for a fistula adjacent to the ureter, because sutures are not placed through the bladder), and a short convalescence. Potential disadvantages include the possibility of vaginal shortening (Enzelsberger and Gitsch, 1991), as well as the creation of directly overlapping suture lines.

Webster and colleagues reported excellent results with a transvaginal approach to VVF by vaginal cuff excision (Flynn et al., 2004; Iselin and Webster, 1998). In this approach, the fistula tract is isolated, and the entire epithelialized portion of the tract is excised in the fashion of a wide inverted cone, leaving a funnel-shaped defect from the vesical to the vaginal side of the fistula. The defect is then closed in three or four layers using absorbable suture. The principal advantages of this technique are that mobilization of vaginal flaps is not required, and vaginal shortening is minimal.

Abdominal Techniques

VVF may be repaired transabdominally, and this is the preferred approach in those cases requiring augmentation cystoplasty or ureteral reimplantation. Compared with the vaginal approach, the abdominal approach to VVF repair is associated with a longer recovery time and in-patient hospitalization, greater blood loss, more cosmetic deformity, and, in general, greater morbidity. Abdominal repair of VVF may be performed intraperitoneally or extraperitoneally, as well as transvesically.

Suprapubic Intraperitoneal or Extraperitoneal Approach.

The patient is positioned in a low lithotomy position with access to the vagina in the sterile operative field. Ureteral catheters may be placed preoperatively or intraoperatively to assist in identification of the ureters, especially if the VVF is in close proximity to the ureteric orifices. A lower midline incision is carried out. As classically described by O'Conor and colleagues (Chibber et al., 2005; O'Conor, 1980; O'Conor and Sokol, 1951), the bladder is approached extraperitoneally; however, in some cases, the peritoneum will be entered. The bladder is opened vertically, and the cystotomy is extended down to the opening of the VVF (Fig. 129.14). As the dissection proceeds distally, stay sutures placed on the bladder edges greatly assist in retraction. In addition, a curved sponge stick placed per vagina with gentle upward traction can provide excellent exposure of the VVF. With the bladder having been bivalved down to the level of the VVF, the VVF tract is excised, and the dissection is continued beyond the fistula tract to develop the vesicovaginal space (Fig. 129.15). The vagina is carefully dissected and separated from the bladder for a distance of 2 to 3 cm beyond the VVF. **The key to the operation is the mobilization of the bladder from the vagina caudal to (beyond) the VVF tract.** After wide mobilization from the bladder, the vagina is closed with a running absorbable suture. At this point, if an interpositional flap of greater omentum is to be used, it is mobilized and then secured 1 to 2 cm distally beyond the excised VVF tract (see later discussion) (Wein et al., 1980).The bladder is then closed in one or several layers. A suprapubic tube and urethral catheter are usually left for postoperative drainage. Anticholinergic agents are used liberally in the postoperative period to minimize bladder irritability, which may be problematic.

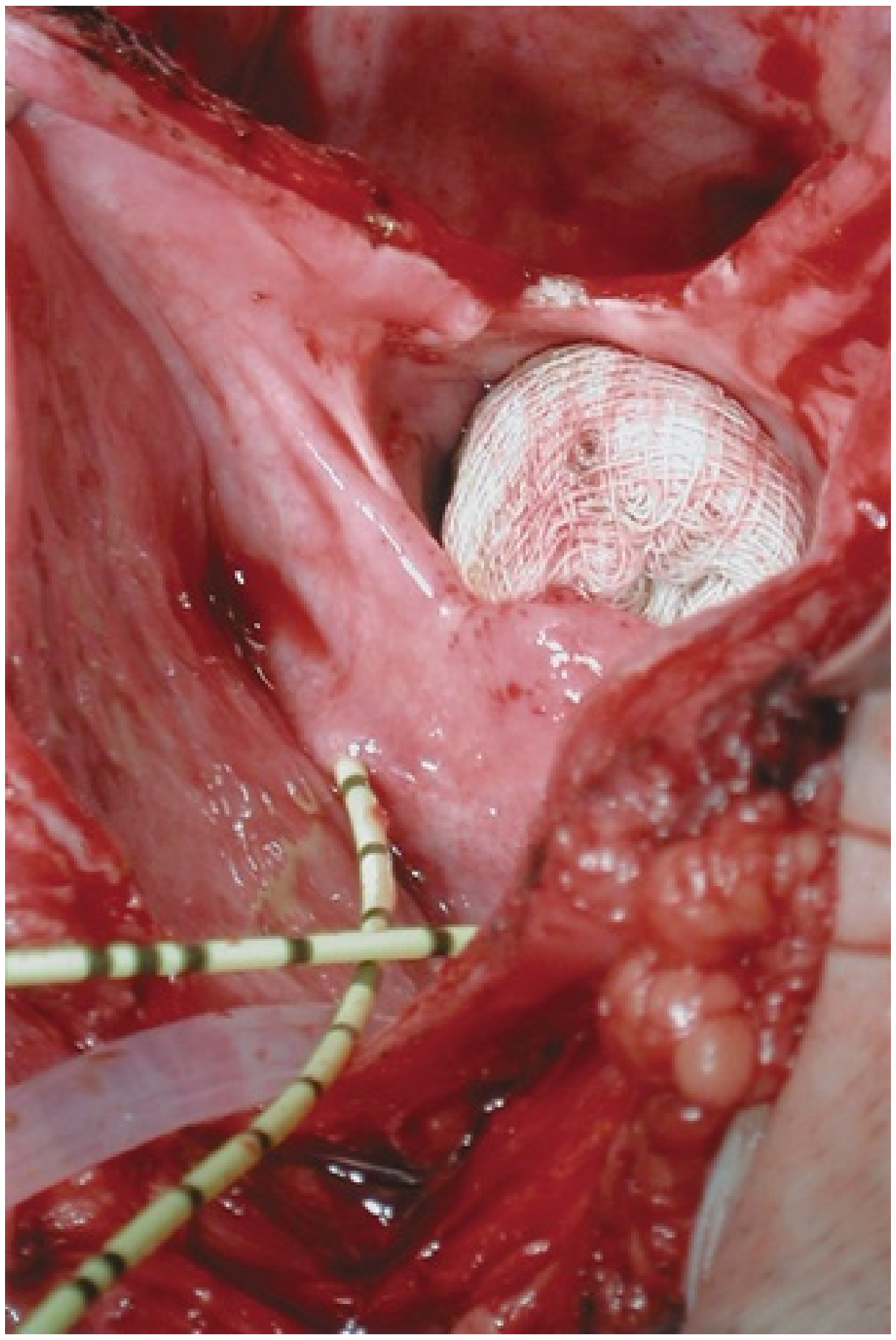

FIG. 129.14 Intraoperative photograph from a suprapubic vesicovaginal fistula (VVF) repair. The bladder has been opened anteriorly and bivalved in the midline down to the level of a very large VVF. The gauze packing lies in the vagina. The ureteral catheters were placed to identify the ureters intraoperatively.

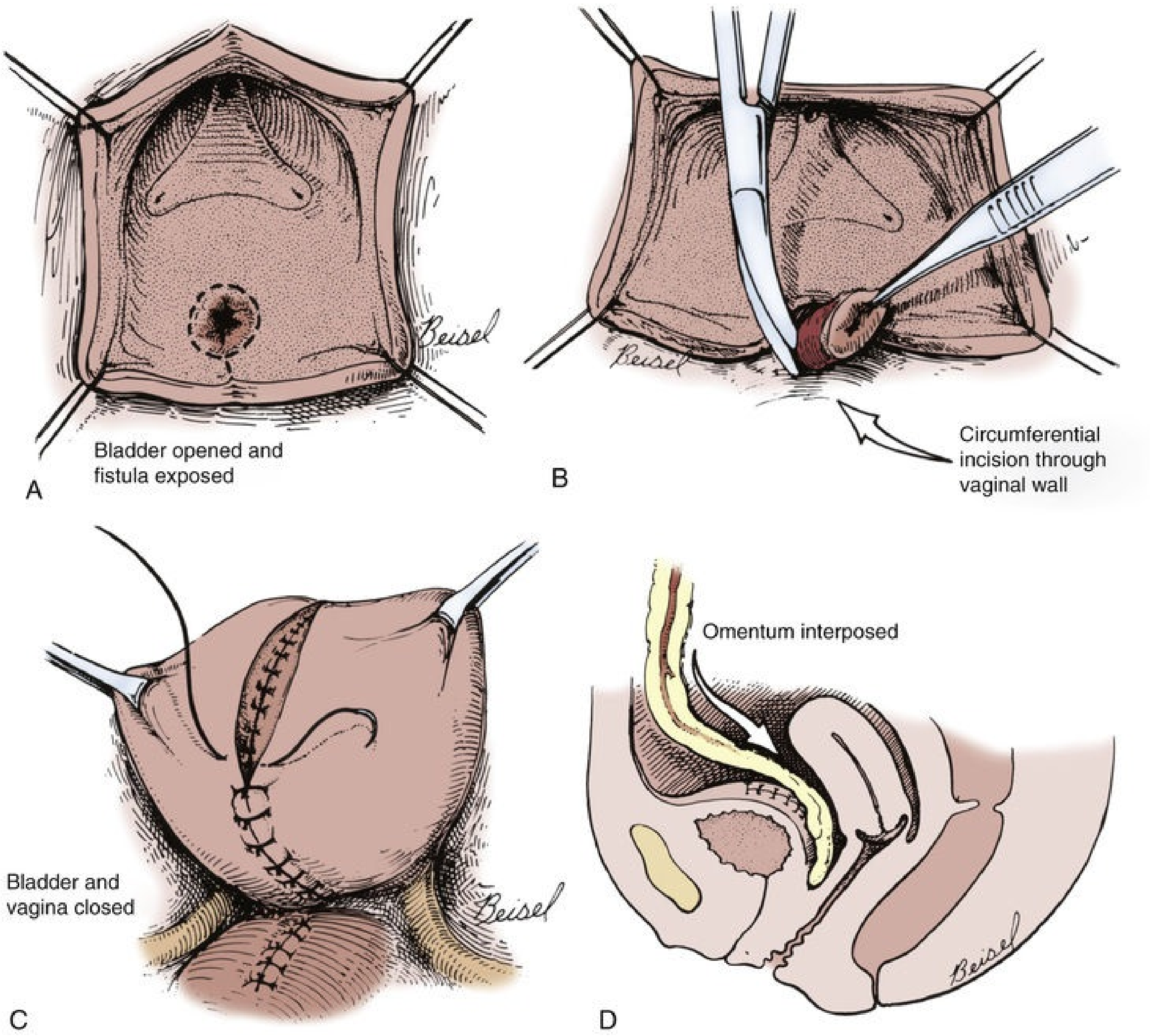
Beisel
Bladder opened and
fistula exposed
A
Beisel
B
Circumferential
incision through
vaginal wall
Bladder and
vagina closed
Beisel
C
Omentum interposed
Beisel
D

FIG. 129.15 Diagrams of suprapubic repair of vesicovaginal fistula (VVF). (A) The bladder opened and bivalved down to the level of the VVF. (B) The VVF tract is excised. (C) After closure of the vagina, the bladder is closed in multiple layers. (D) Omentum is interposed between the bladder and vaginal closures. (From Ganabathi K, Sirls L, Zimmern P, et al.: Vesicovaginal fistulae: reconstructive techniques. In McAninch J, editor: *Traumatic and reconstructive urology,* Philadelphia, 1996, Saunders, p 315.)

Bladder augmentation or ureteral reimplantation, if necessary, can be incorporated into the suprapubic approach before closure of the bladder. Large or small bowel may be used for augmentation cystoplasty, depending on the clinical circumstances.

Transvesical.

A suprapubic transvesical approach to VVF repair has also been described (Cetin et al., 1988; Gil-Vernet et al., 1989; Landes, 1979). In this approach, the bladder is opened through a vertical cystotomy but is not bivalved down to the VVF tract. From a transvesical approach, the VVF tract is circumscribed and excised transvesically. The vaginal edges are then carefully mobilized from the bladder. The vagina and bladder are closed sequentially. A V-shaped flap of adjacent posterior bladder wall may be brought down as a flap to close a large gap or to minimize overlapping suture lines (Gil-Vernet et al., 1989). This approach has been successful in simple and complex fistula (Gil-Vernet et al., 1989; Leng et al., 1998), and modifications have been described incorporating an omental flap (Hellenthal et al., 2007).

Laparoscopic and Robotic Approaches

Laparoscopic VVF repair is an alternative to the classical open approach described previously. Compared with the transabdominal approach, laparoscopic repair is reported to be associated with less surgical trauma, shorter convalescence, and lower morbidity without compromising the results (Ghosh et al., 2016; Nezhat et al., 1994; von Theobald et al., 1998; Xiong et al., 2016). Laparoscopic VVF repair is most useful in the same scenarios as the transabdominal repair, such as in the setting of a high VVF in which a vaginal operation would be anatomically challenging. Dense pelvic adhesions and/or inflammation from prior abdominal surgery can make this approach less desirable in some patients.

Successful robotic VVF repair was first reported in 2005 (Melamud et al., 2005), and several small case series have been subsequently reported with or without the use of interposition flaps (Kelly et al., 2017; Martini et al., 2016; Watts et al., 2017). A five-port technique has been described using a vaginal pack to maintain pneumoperitoneum throughout the case (Hemal et al., 2008; Sundaram et al., 2006). Removal of the vaginal packing without loss of pneumoperitoneum confirms successful closure. Advantages of the robotic technique include three-dimensional (3D) visualization, wristed instrumentation reducing the severe angulation required for laparoscopic VVF repair, and technically simpler intracorporeal knot tying. There is no level 1 evidence to prove superiority of one approach over another. Outcomes depend on the surgeon's experience and practice. Minimally invasive series demonstrate efficacy in primary VVF repair with acceptable success rates. Two retrospective studies described transition from open to laparoscopic repair and found that the latter was minimally invasive with similar success (Ou et al., 2004). In another retrospective case-matched study of 32 patients, Gupta et al. (2010) evaluated robotic-assisted laparoscopic versus open repair for recurrent VVF without any significant statistical difference in success rate (100% vs. 90%), mean operative time, complication rate, use of interpositional flap (omental vs. peritoneum), or complications (0 vs. 10%). The most significant difference between the two groups was shorter average hospitalization (3.1 vs. 5 days) favoring the robotic-assisted group, with decreased morbidity as opposed to open surgery (Gupta et al., 2010).

Miklos et al. (2015) performed a systematic review on laparoscopic and robotic fistula repair and concluded that the outcome of a transperitoneal approach is equal to a transvesical approach and that the number of layers or the use of interposition material had no influence on the fistula closure. Intraoperative integrity testing of the bladder led to better outcome (Table 129.2).

TABLE 129.2

Outcome of Conventional Laparoscopic and Robot-Assisted Repair of Vesicovaginal Fistulae

		LAPAROSCOPIC		ROBOTIC	
AUTHORS	**DATE**	**N**	**CURE RATE**	**N**	**CURE RATE**
Nezhat et al.	1994	1	100%		
Phipps	1996	6	100%		
Miklos et al.	1999	1	100%		
Chibber et al.	2005	8	100%		
Sotelo et al.	2005	15	93%		
Wong et al.	2006	2	100%		
Das Mahapatra et al.	2007	12	92%		
Otsuka et al.	2008	7	86%		
Gazen et al.	2009	3	100%		
Porpiglia et al.	2009	4	100%		
Shah	2009	25	72%		
Lee et al.	2010	5	100%		
Rizvi et al.	2010	8	100%		
Abdel-Karim et al.	2011	15	100%		
Abdel-Karim et al.	2011	5	100%		
Melamud et al.	2005			1	100%
Sundaram et al.	2006			5	100%

Schimpf et al.	2007			1	100%
Hemal et al.	2008			7	100%
Kurz et al.	2012			3	100%
Bragayrac	2014			4	100%
Oderda	2014			1	100%
Agrawal	2015			10	100%
Gellhaus et al.	2015			10	100%
Jairath et al.	2016			8	100%
Martini et al.	2016			1	100%
Price et al.	2016			1	100%
Kelly et al.	2017			1	100%
Machen	2017			11	100%
Watts	2017			1	100%
TOTAL		117	96%	65	100%

Although there have been no direct comparisons among the classical transabdominal VVF repair, transvaginal VVF repair, and the minimally invasive robotic and laparoscopic techniques, **it is doubtful that a single procedure will emerge as the optimal surgery for all patients with VVF, given the variability in the nature of the condition, the patients in whom it occurs, and the expertise of individual surgeons, but considering the morbidity and costs of abdominal approaches, vagina repair should be considered first, if possible.**

Adjuvant Procedures in the Repair of Vesicovaginal Fistulae: Tissue Interposition

The interposition of a healthy, well-vascularized tissue flap during VVF repair may be beneficial under certain circumstances. **Tissue flaps are especially helpful in the setting of complex fistulae, such as those that have recurred after a prior attempt at repair, those related to previous radiotherapy, ischemic or obstetric fistulae, large fistulae, and, finally, those associated with a difficult or tenuous closure because of poor tissue quality. In primary fistulae, adequate dissection allowing tension free and watertight closure of the bladder wall and vaginal wall are more important than the use of interposition material.** For VVFs repaired transvaginally, a labial fat pad (Martius flap) or a peritoneal flap is most commonly used. From a transabdominal approach, omentum or peritoneum is often used as an interpositional flap.

Martius Flap.

For low or distal fistulae, a Martius fibrofatty labial flap is a reliable source of tissue. The fibrofatty labial flap was first described by Heinrich Martius in 1928. **This flap consists of adipose tissue and connective tissue and is the preferential tissue for fistulae involving the trigone, bladder neck, and urethra** (Boronow, 1986; Ghoniem and Monga, 1995; Patil et al., 1980; Punekar et al., 1999). **The blood supply to the flap derives inferiorly from the posterior labial vessels (off the internal pudendal artery), superiorly from the external pudendal artery, and laterally from the obturator artery.** The lateral blood supply is sacrificed during mobilization of the flap; the flap may be divided at either its most superior or inferior margin (basing the blood supply on the inferior or superior vascular pedicle, respectively), depending on where the flap will be transferred (Figs. 129.16 and 129.17).

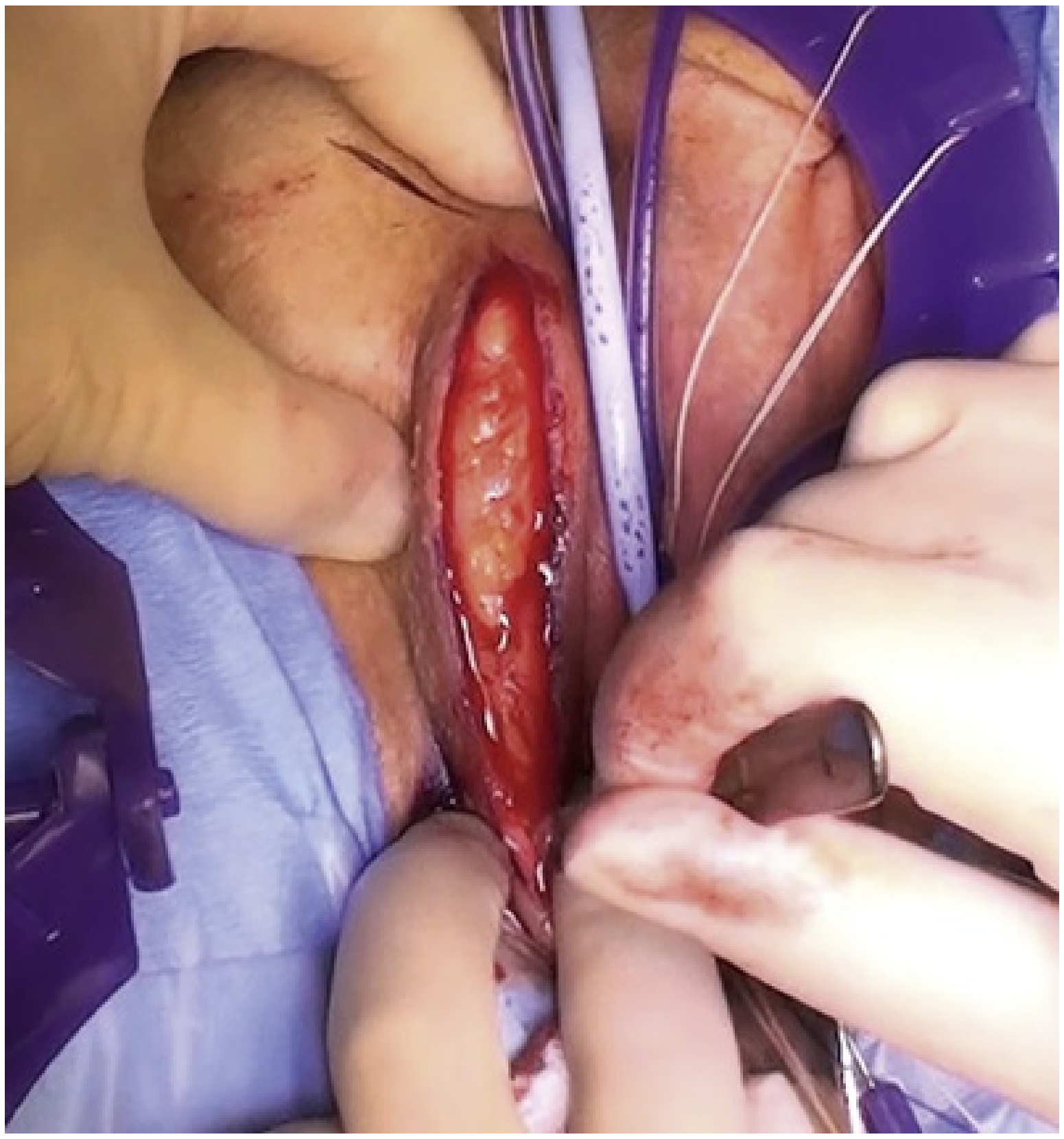

FIG. 129.16 Harvesting of a Martius flap. The incision is made in the labia. A large flap may be obtained (see Fig. 129.17).

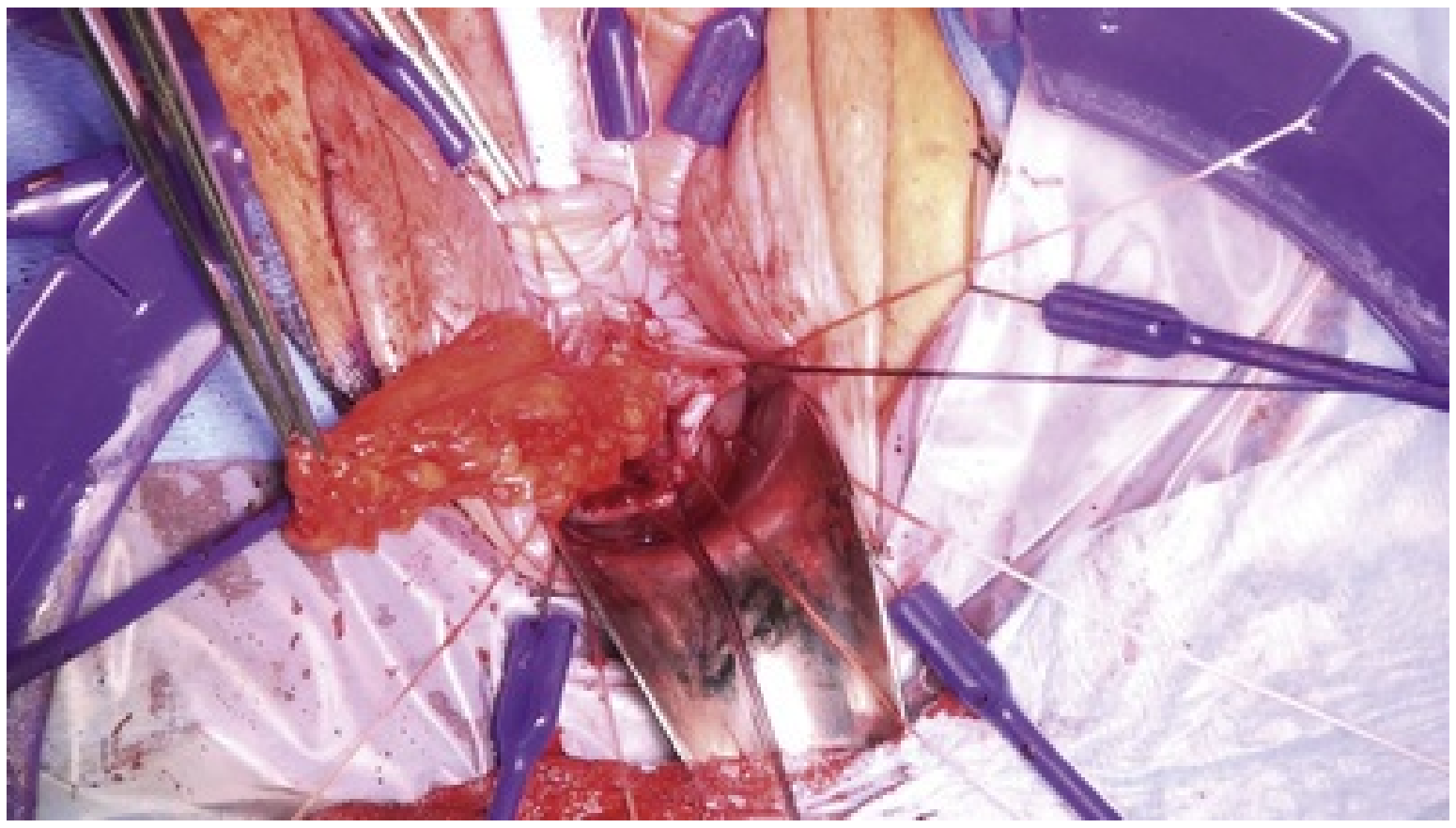

FIG. 129.17 Tunneling of the Martius flap. (From Raz S: Vesicovaginal fistulae. In Raz S, editor: *Atlas of transvaginal surgery,* Philadelphia, 1992, Saunders, p 158.)

Rangnekar et al. (2000) reported on the usefulness of the Martius flap in urethrovaginal fistulae and VVFs, the majority of which (32 of 46) were a result of obstetric trauma (Rangnekar et al., 2000). Of the VVF repairs, 4 of 21 repairs without a Martius flap failed, compared with none of the 13 procedures that included an adjuvant Martius flap. Eilber et al. (2003) reported that 33 of 34 (97%) patients undergoing repair of a distal VVF with a Martius flap were cured after the first operation.

For posthysterectomy fistulae, the distance from the labial harvesting site of the Martius flap to the fistula at the apex of the vagina may be considerable. Mobilizing and then tunneling the Martius flap to reach this location may compromise its blood supply and viability. In these cases, a peritoneal flap can be used (Raz et al., 1993).

Peritoneal Flap.

The use of a peritoneal flap during transvaginal repair of a complex VVF is a simple procedure that does not require extravaginal harvesting of the flap. **This technique is used primarily in conjunction with repair of a high-lying posthysterectomy VVF** (Eilber et al., 2003; Raz et al., 1993). Notably, peritoneal flaps may also be used as an adjunctive measure during transabdominal repair of VVF, although the approach and technique are vastly different (Chen, 1981; Eisen et al., 1974; Lentz, 2005).

After a two-layer closure as described previously, the peritoneum is identified posteriorly. The peritoneum and preperitoneal fat are identified, isolated, and mobilized from the caudal origin of the vaginal wall flap using sharp dissection.

Usually, dissection just beyond the posterior wall of the bladder will expose the edge of the peritoneum in the anterior cul-de-sac (Raz et al., 1993). The peritoneum is identified as a distinct layer from the bladder. The peritoneum is not opened but is mobilized and then advanced over the fistula repair and secured with interrupted absorbable sutures in a tension-free manner (Fig. 129.18). If a peritoneotomy is made during dissection or mobilization, the peritoneal defect can be closed as the flap is secured to the perivesical fascia over the fistula repair. The vaginal flap is then advanced and closed as previously described.

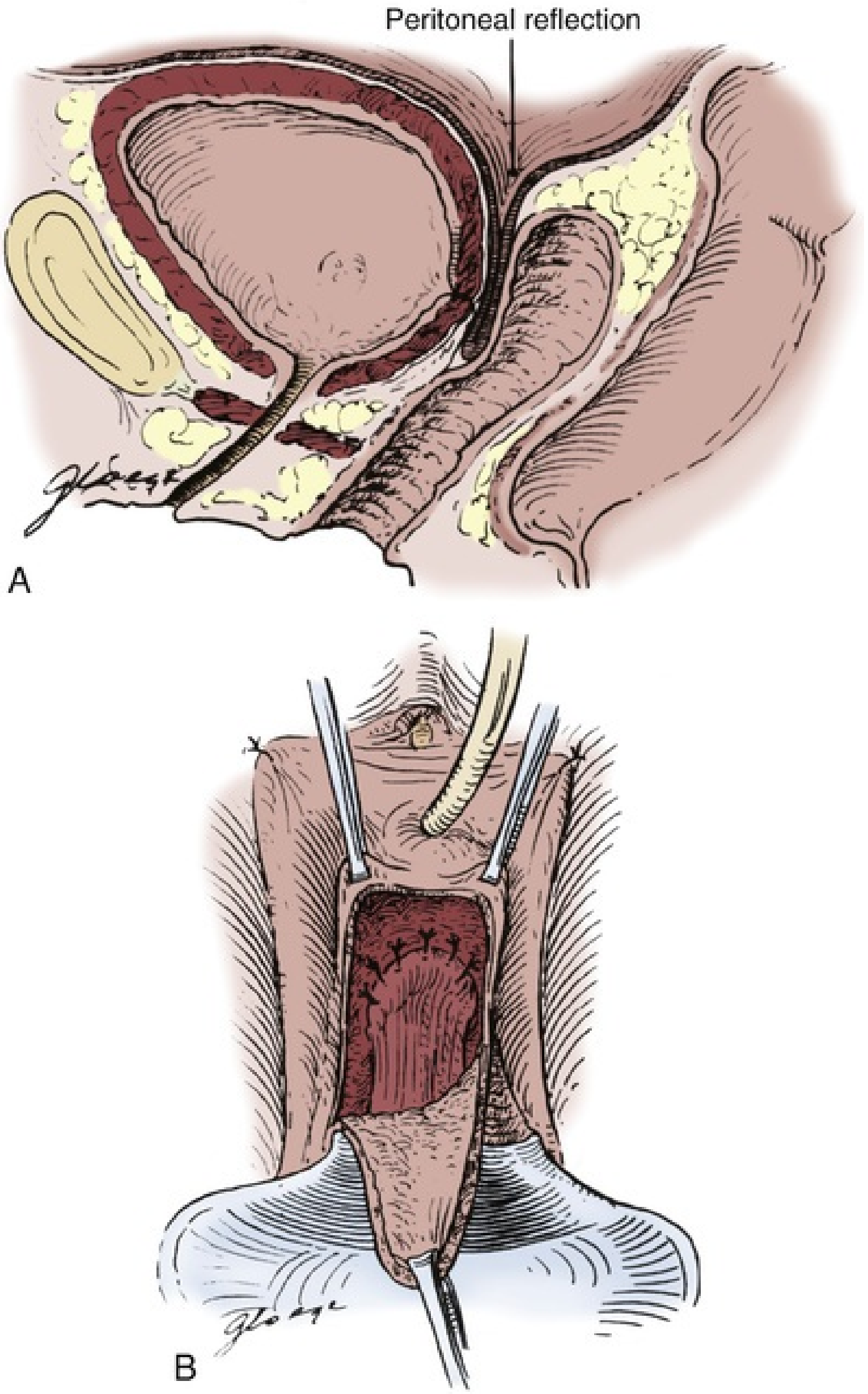

FIG. 129.18 Peritoneal flap. (A) Diagrammatic representation of the location of the peritoneal flap during vesicovaginal fistula repair. (B) Diagram of peritoneal flap advanced over fistula repair. (A and B, From Raz S: Fistulae: transvaginal repair of vesicovaginal and urethrovaginal fistulae. In Raz S, editor: *Atlas of transvaginal surgery*, ed 2, Philadelphia, 2002, Saunders, p 242.)

Greater Omentum.

The omentum is a particularly useful structure in the repair of VVF. **Although most commonly used as an adjunct during transabdominal VVF repair (an**

interpositional layer between the bladder and vagina), it has occasional usefulness in transvaginal VVF repair, if it had been brought down into the pelvis during a prior surgical procedure. **Favorable properties of the omentum include its ability to be mobilized on a well-vascularized pedicle into the deep pelvis without tension, its inherent lymphatic properties, its ability to contribute to healing even in the presence of infection, and the ease with which epithelialization occurs on its surface** (Turner-Warwick, 1975; Wein et al., 1980).

The use of interposition material is controversial and clear guidance cannot be given. There are no prospective RCTs and the case series only represent the author's personal experiences. Several authors advocate the use of several interposition materials (omentum, Martius flap, buccal mucosa, peritoneum) in open, vaginal, laparoscopic, and robotic repairs (Chen, 1981; Javed et al., 2015; Mahdy, 2014; Malde et al., 2017; Singh et al., 2013; Tobias-Machado et al., 2014; Watts et al., 2017), whereas others showed that the interposition of tissue did not influence the outcome (Kelly et al., 2017; Martini et al., 2016; Miklos et al., 2015; Price and Price, 2016; Tebeu et al., 2012; Wahab et al., 2016).

Other Flap and Graft Techniques.

A variety of flaps including gracilis muscle flaps (Izes et al., 1992), labial myocutaneous flaps (Symmonds and Hill, 1978), seromuscular intestinal flaps (Mraz and Sutory, 1994), and rectus abdominis flaps (Menchaca et al., 1990) have been used as adjunctive measures in the repair of complex VVF. Obstetric fistulae associated with significant urethral loss may be repaired, in part, with the use of anterior or posterior bladder flaps (Elkins, 1994; Hanash and Sieck, 1983; Khanna, 1992). The gracilis muscle in the medial thigh is a convenient adjunct to repair large soft-tissue defects, especially those associated with radiation therapy (Heckler et al., 1980; Obrink and Bunne, 1978). The gracilis muscle is in proximity to the vagina and has a reliable blood supply. The muscle is mobilized through a thigh incision from its distal attachment on the tibial condyle, with care taken to preserve its blood supply. It is tunneled cephalad into the vagina subcutaneously and secured over the fistula. Bilateral gracilis muscle flaps can be used for total vaginal reconstruction (Fig. 129.19).

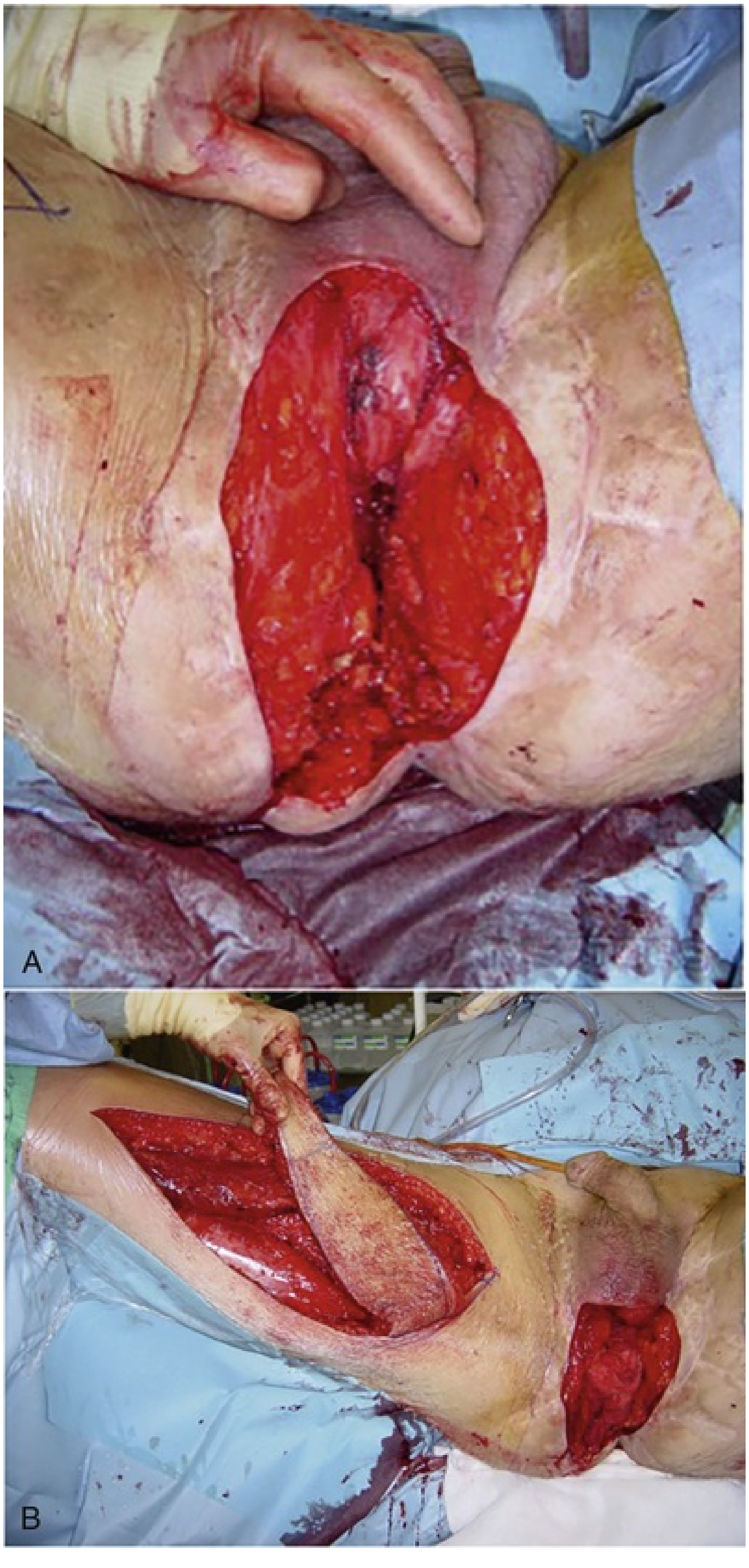
A
B

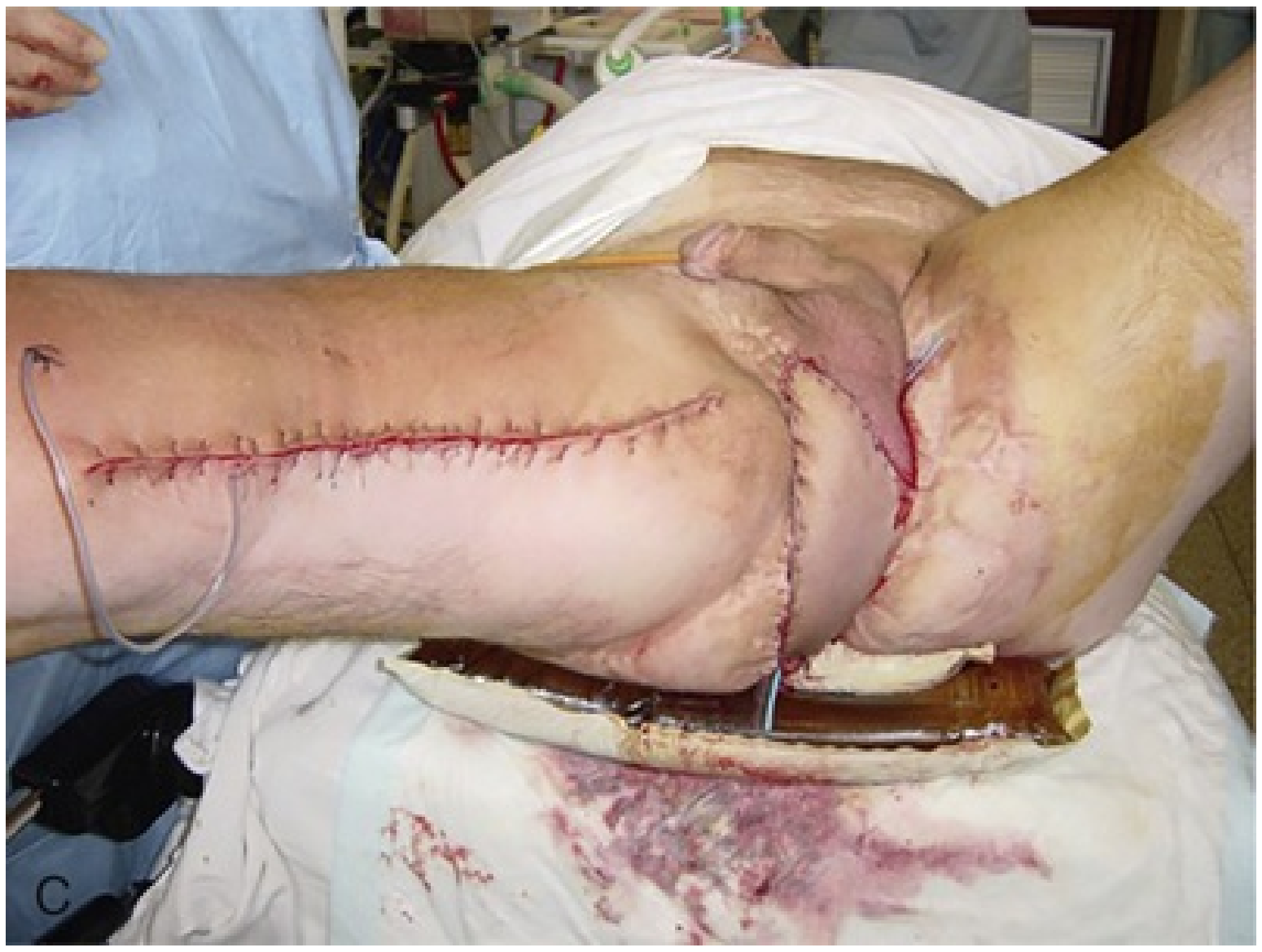

FIG. 129.19 (A) Large perineal defect. (B) Harvesting of a pedicled musculocutaneous gracilis flap that can be used to close perineal wounds after fistula repair. Can also be harvested as a pedicled muscular flap if the skin defect of the acceptor site can be closed easily. (C) Closure of the perineal wound by gracilis musculocutaneous flap. (Courtesy Professor AR Mundy, UCLH, London, UK.)

Bladder mucosa as a free graft has been used for repair of VVF (Brandt et al., 1998; Ostad et al., 1998; Fig. 129.20). The bladder is approached extraperitoneally and a small cystotomy is performed. The fistula tract is identified and denuded of mucosa circumferentially for approximately 1 cm. A free graft of bladder mucosa is harvested from the edge of the cystotomy and placed over the denuded VVF tract and secured in place with absorbable suture. Brandt et al. (1998) reported a 96.3% success rate in 80 patients. Ostad et al. (1998) reported on 6 patients with complex, high, irradiated, large or recurrent VVF, all of whom were cured by this technique. Buccal mucosa has been used as interposition material in 2 recurrent fistulae (Hadzi-Djokic et al., 2015).

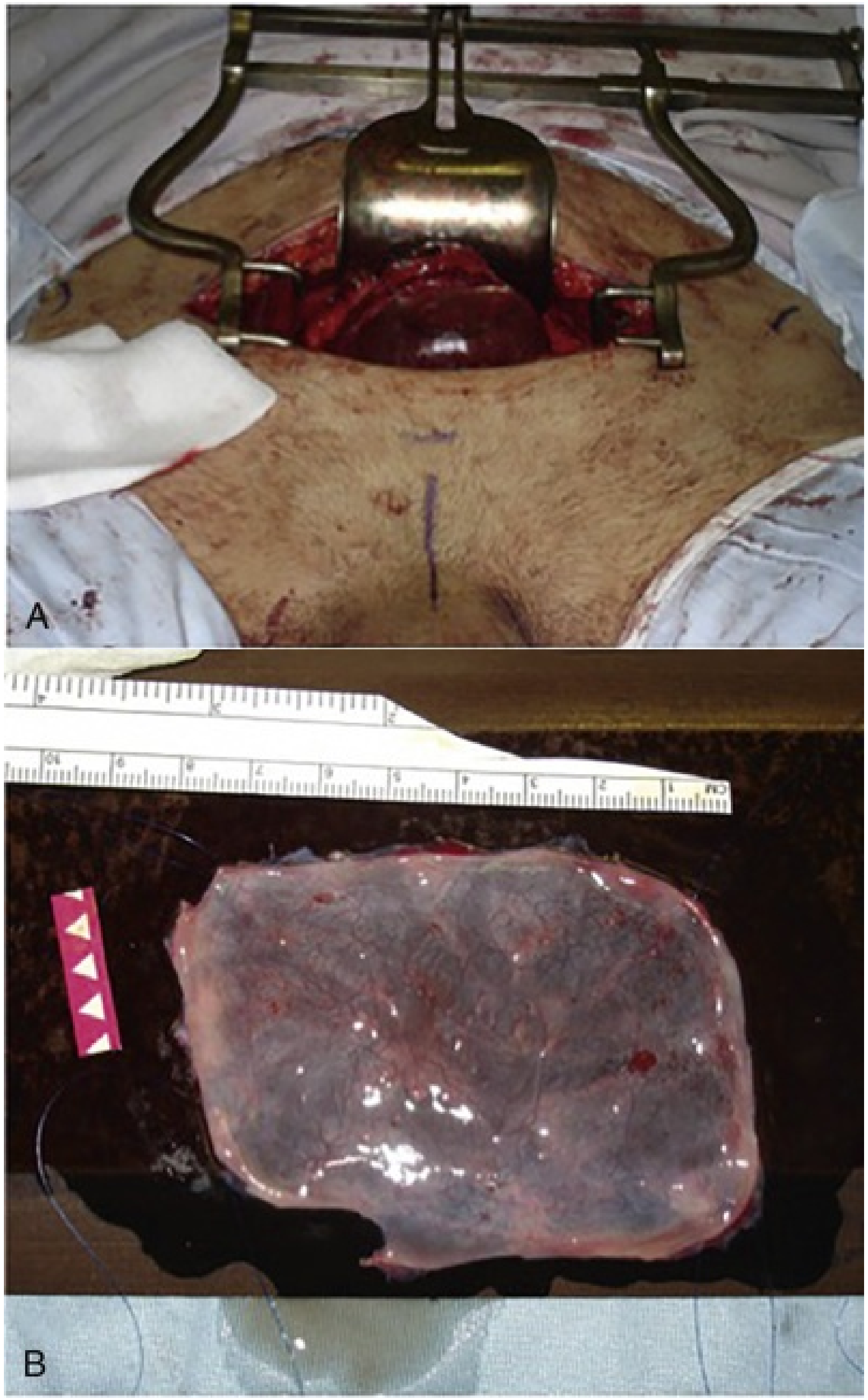

FIG. 129.20 (A) Bladder mucosal flap harvested by open detrusorectomy. (B) Bladder mucosa spread out, ready to be used as free flap. (Courtesy PCB Anderson, Russell's Hall Hospital, Dudley, UK.)

Vesicovaginal Fistulae and Urinary Diversion.

In some patients, repair of VVF is not possible or multiple surgical attempts have failed. This is probably most commonly associated with existing pelvic malignancy, severe radiation damage, and/or large soft-tissue loss, especially in the setting of obstetric fistula. However, some patients may simply not be candidates for repair because of coexistent medical morbidities, making them a prohibitive surgical risk. **In the former group, urinary diversion in the form of either a urinary conduit** (Kisner and Kesner, 1987) **or a continent reservoir can be considered. Fistulae in patients who are not candidates for surgical intervention may be managed by percutaneous ureteral occlusion and permanent nephrostomy** (Amsellem-Ouazana et al., 2006; Boudghene et al., 1988; Farrell et al., 1997; Franke et al., 2015; Hubner et al., 1992; Kim et al., 2008; Papanicolaou et al., 1985).

In the developing world, where catheters and ostomy appliances are either too expensive or completely unavailable, continent urinary diversion or incontinent urostomies are often not practical, which presents ethical issues with the alternative treatments (Arrowsmith, 2007; Wall et al., 2008). In these situations, internal urinary diversion with ureterosigmoidostomy has some application in patients with unreconstructable lower urinary tracts (El-Lamie, 2001; Kontturi and Larmi, 1972; Lassey et al., 2002; Lentz and Homesley, 1995; Mayer, 1951; Radopoulos et al., 2008). This is clearly a last-resort operation because of its significant metabolic and neoplastic potential.

Outcomes of Vesicovaginal Fistula Repair

The success rate reported for a simple VVF repair in the modern era, whether through an abdominal or vaginal approach, is in excess of 85%. Long-term follow-up suggests that the majority of patients are greatly improved, although minimally bothersome symptoms may persist in a minority of patients over the long term, causing little impact on quality of life (Dolan et al., 2008). Complicated VVFs including those resulting from obstetric causes, larger fistulae, and those associated with radiation therapy generally have lower success rates or have persisting (stress) incontinence despite a closed fistula (Alling Møller et al., 2000; Hillary et al., 2016; Hood, 2016; Karp et al., 2017; Loposso et al., 2016; Naidoo et al., 2017, Ouedraogo et al., 2018a; Raassen et al., 2017; Reisenauer, 2017; Tatar et al., 2017; Wall and Arrowsmith, 2007). Hillary et al. (2016) showed, in a systematic review of patients undergoing repairs in well-resourced countries, that the median overall closure rate was 94.6%, whereas in low-resourced countries this was 87.0%. Closure was significantly more likely to be achieved using a transvaginal approach than a transabdominal technique (90.8% success vs. 83.9%, Fisher's exact test; $P = 0.0176$) (Hillary et al., 2016). **In patients with obstetric fistulae associated with loss of the bladder neck and proximal urethra, relatively high rates of persistent severe sphincteric incontinence are noted despite successful**

repair of the VVF (Browning, 2004, 2006), **and this type of fistula is involved in the majority of treatment failures** (Frajzyngier et al., 2013; Goh et al., 2008). Thus despite a technically successful VVF repair, functionally, from the patient's perspective, some of these individuals may not be significantly improved after the repair because of severe stress urinary incontinence (SUI). Pubovaginal slings and periurethral injectable agents are often beneficial in these patients once the VVF has been surgically closed (Arrowsmith, 1994; Browning, 2004). In the developing world, access to synthetic mid-urethral slings is limited. Furthermore, the safety of using such materials in the setting of extensive reconstruction, such as that after repair of an obstetric fistula, is not established.

Key Points: Vesicovaginal Fistulae

- VVF is the most common acquired fistula of the urinary tract.
- In the industrialized world, surgical injury to the bladder is the most common cause of VVF, most commonly seen after hysterectomy. In the developing world, VVF is most commonly related to complications from obstructed labor.
- VVFs caused by radiation therapy are usually complex.
- VVF occurring in the setting of a history of pelvic malignancy should undergo biopsy before repair to exclude recurrent malignancy as a cause of the fistula.
- Diagnosis of VVF can be confirmed on CT, MRI, and VCUG.
- Upper tract imaging is obtained after a diagnosis of VVF to exclude injury to the ureter(s).
- Small, oblique fistulae may respond to conservative therapy, including prolonged urinary catheterization with or without fulguration of the fistula tract.
- There is no optimal method for the surgical repair of all VVFs. In the properly selected patient, transabdominal and transvaginal approaches to fistula repair have similar success rates. Laparoscopic and robotic approaches for VVF repair are advancing the field. Adjuvant tissue flaps may be useful to prevent surgical failure in the setting of complex or recurrent fistula, radiation fistula, obstetric fistula, and fistulae with tenuous repairs.

Ureteric Fistulae

Etiology and Presentation

Ureteral fistulae to the genital tract in the female most often connect with the vagina but have also been reported to connect with other genital structures, including the fallopian tube or uterus (Billmeyer et al., 2001; Crochet et al., 2008). **Risk factors for the development of ureterovaginal fistulae (Box 129.4) include endometriosis, obesity, pelvic inflammatory disease, radiation therapy, and pelvic malignancy** (Brandes et al., 2004; Drake and Noble, 1998; Leonard et al., 2007; Mteta et al., 2006). A large prospective case series from Finland found an incidence of ureteric injury associated with hysterectomy for benign pathology of 0.2% (10/5279) with the lowest rate associated with vaginal hysterectomy and no difference between open and laparoscopic abdominal hysterectomy (Brummer, 2011). The incidence of immediate and delayed ureteric injury during radical hysterectomy was found to be 1.3% (7/536) and 2.4% (13/536), respectively, in a series from Serbia; injuries appeared more common after prolonged surgery and in patients with diabetes, obesity, or wound infection (Likic, 2008). A registry study from the United States found an overall incidence of ureteric injury during radical hysterectomy of 0.8% (Frankman, 2010). Case series from referral centers in India, Pakistan, and Egypt showed that the proportion of urinary tract injuries resulting from obstetric or gynecologic surgical trauma that primarily affected the ureter varied from 1% to 23% (El-Tabey, 2011; Kumar et al., 2009; Nawaz, 2010; Sachdev, 2009).

Box 129.4

Cause of Ureterovaginal Fistulae

Gynecologic Surgery

Abdominal hysterectomy
Vaginal hysterectomy
Radical hysterectomy
Cesarean section
Anterior colporrhaphy (cystocele repair)

Other Pelvic Surgical Procedures

- Vascular surgery
- Urologic surgery including retropubic bladder neck suspensions
- Colon surgery

Other Causes

- Locally advanced malignancy
- Radiation therapy
- Pelvic trauma
- Chronic inflammatory diseases (e.g., actinomycosis)

Ureteric fistulae can also occur as a consequence of open and laparoscopic endometriosis or colorectal surgery (Alves et al., 2017; Chang et al., 2016).

Ureteroarterial fistulae are uncommon but can be life threatening because of massive bleeding in the ureter (see later). They have a high mortality rate (Melegari et al., 2016). Predisposing factors are radiation therapy, vascular pathology and/or ureteral stenting. Das et al. (2016) reviewed the literature and found 61 cases. In terms of treatment, endovascular stenting has emerged as an appealing initial modality and should be considered in stable patients with less favorable candidacy for open surgical intervention secondary to pre-existing comorbidities (Das et al., 2016).

The mechanism of injury resulting in iatrogenic postoperative ureterovaginal fistulae includes ureteral laceration or transection, blunt avulsion, crush injury, partial or complete suture ligation, and, finally, ischemia caused by operative devitalization of the ureteral vascular supply and/or cautery injury. Overall, the ureter is most commonly injured during gynecologic surgery in the distal one-third or pelvic portion, which is, accordingly, the only location at which a ureteral injury may result in a ureterovaginal fistula. Not uncommonly this occurs inadvertently during an attempt by the surgeon to control active bleeding using clamps or suture ligation of large tissue segments in the deep pelvis.

The pelvic ureter is intimately related to the female genital tract throughout its course. **In the deep pelvis, the ureter passes at the lateral edge of the uterosacral ligament and ventral to the uterine artery and then passes just lateral to the cervix and fornix of the vagina.** In close apposition to these structures, the ureter must be carefully avoided during any gynecologic procedure in the deep pelvis. **Any injury to the ureter that exposes the ureteral lumen (i.e., laceration) or results in delayed necrosis of a portion of the ureter (i.e., suture ligation) and subsequent urinary extravasation may lead to a fistula.** A ureterovaginal fistula may result from a sequence of events, including urinary extravasation from the ureteral injury, urinoma formation, subsequent extension along non-anatomic planes created during surgery, and eventual drainage through the vaginal incision or an ischemic area of the vaginal cuff. Infection, prior radiation therapy, or other factors that may impede healing probably promote the development of ureterovaginal fistulae under these circumstances.

The most common presenting symptom is the onset of constant urinary incontinence 1 to 4 weeks after surgery (Mandal et al., 1990). This may have been preceded by several days of flank or abdominal pain, nausea, and low-grade fever, presumably as a result of urinoma and/or obstruction of the kidney (Lee et al., 1988). Flank pain will often be masked in the postoperative period because of the use of postoperative narcotic analgesics. **Of importance, and in direct contrast to VVF, in the setting of continuous urine leakage from a ureterovaginal fistula, patients will continue to report normal voiding habits because bladder filling is maintained from the contralateral, presumably undamaged, upper urinary tract.**

Prevention of this type of fistula is usually done by preventive stenting of the ureters. A randomized study involving 3141 women undergoing open or laparoscopic gynecologic surgery lasting for longer than 30 minutes found that the incidence of ureteral injury after prophylactic insertion of ureteral stents (1.2%) was similar to controls (1.1%) (Chou et al., 2009). A previous cost analysis from the US perspective suggested that stenting was worthwhile only if the risk of injury was higher than 3.2% (Schimpf et al., 2008). If injury does occur, many cases, even those involving bilateral injury, can be managed by endoscopic techniques.

Diagnosis and Management

Unfortunately, intraoperative diagnosis of a GU or GI injury is made in only about half of the cases that result in fistula (Ostrzenski Ostrzenska, 1998). In one study, 36% of VVFs were found within 1 week of a laparoscopic hysterectomy and 50% in the second week. Most patients who had undergone transabdominal hysterectomies had leakage in the second week (90%) (Kochakarn and Pummangura, 2007).

Diagnosis and confirmation of a ureterovaginal fistula can usually be accomplished with a combination of a relevant history, physical examination, and appropriate radiologic studies, including cross-sectional imaging (such as a CT urogram), IVU, and retrograde pyelography (Mandal et al., 1990; Fig. 129.21). Urine may extravasate externally or internally. Creatinine levels in the urine are higher than serum levels. Therefore, in the setting of a suspected fistula, testing the creatinine level in either the extravasated fluid or the accumulated ascites and comparing this value to the serum creatinine levels will confirm urinary leakage but not the location of the fistula. Likewise, testing potassium levels will show higher levels compared with serum levels.

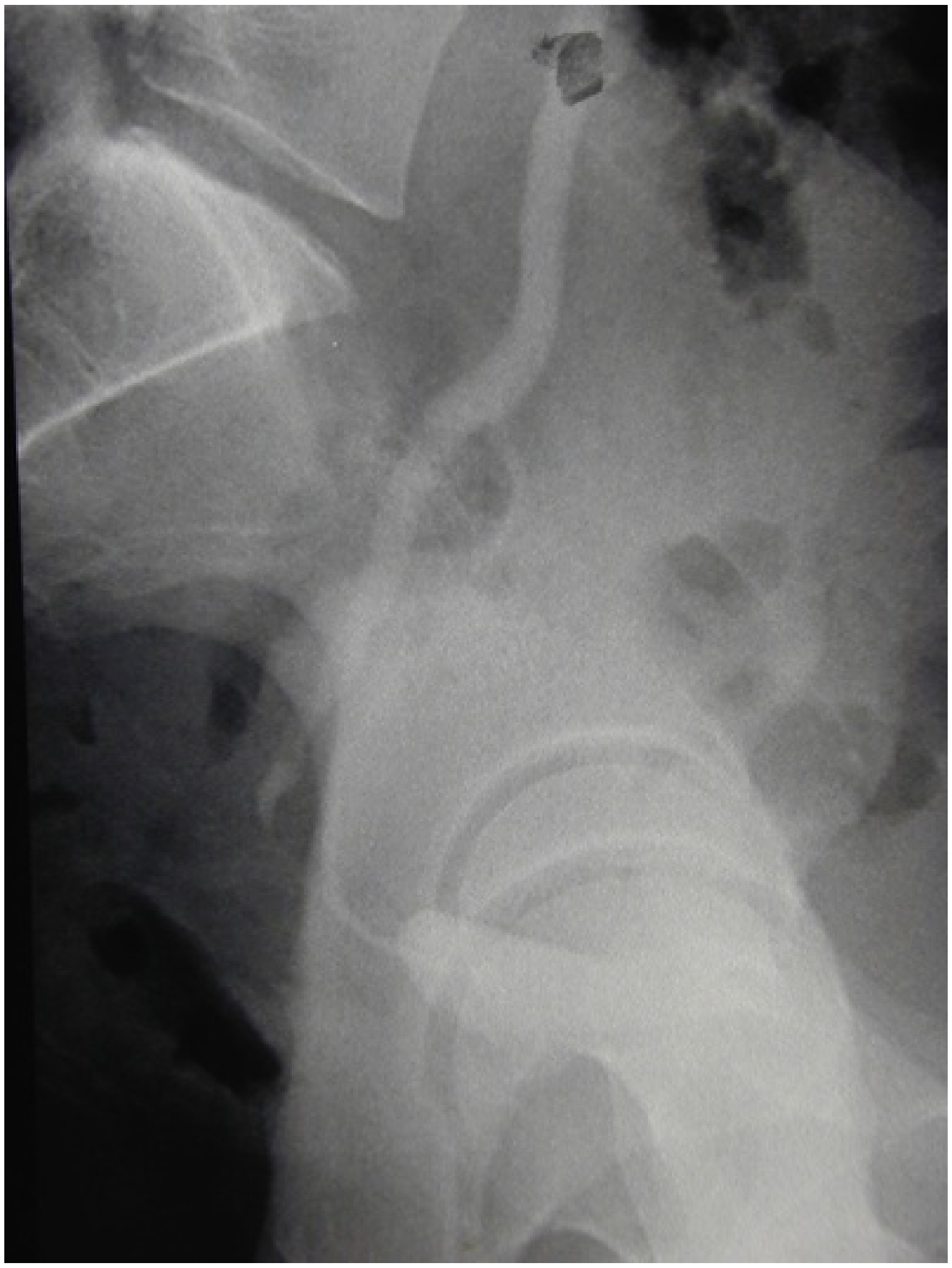

FIG. 129.21 Diagnosis of ureterovaginal fistula. Retrograde pyelogram

demonstrates a distal ureteral stricture with a small fistula tract with contrast in the vagina superimposed on contrast in the bladder from the contralateral retrograde ureterogram.

A double dye test may be of some value in differentiating between a ureterovaginal fistula and VVF as a cause of ongoing urinary leakage (Raghavaiah, 1974). Suspicion of a ureterovaginal fistula should prompt upper tract imaging (Badenoch et al., 1987). **The IVU or CT urogram most commonly will demonstrate some degree of ureteral obstruction and associated caliectasis or ureteral dilation** (Selzman et al., 1995). **These findings in the presence of constant vaginal drainage strongly suggest a ureterovaginal fistula.** Alternatively, if the fistula is mature and large, the upper urinary tract may appear completely unremarkable; however, urine will be seen opacifying the vagina before the postvoid image (Fig. 129.22). Antegrade pyelography after nephrostomy tube decompression of a partially obstructed ureter may be associated with similar findings (Fig. 129.23). **A high oblique or lateral film may be necessary to differentiate the contrast in the bladder from that in the vagina.** A retrograde pyelogram may show the ureter and fistula well or may demonstrate an abrupt termination of the ureter 2 to 4 cm from the ureteric orifice. **If retrograde pyelography demonstrates the fistula, as well as ureteral continuity, then an attempt at stenting is warranted. Cystography is performed primarily to exclude a coexistent VVF.** A cystogram will not demonstrate the ureterovaginal fistula unless there is preexisting vesicoureteral reflux. Ureterovaginal fistulae may be seen on CT urography or MRI (Fig. 129.24); however, an additional role for such cross-sectional imaging is to evaluate for an associated pelvic abscess or undrained urinoma. An unstructured review by Narayanan et al. (2009) suggested that MRI, particularly with T2 weighting, provided optimal diagnostic information regarding fistula associated with pelvic malignancy, with contrast-enhanced CT with late excretory phase an acceptable alternative. These newer modalities were considered to be superior to other x-ray contrast techniques and ultrasonography. MRI is also used more widely (Abou-El-Ghar et al., 2012).

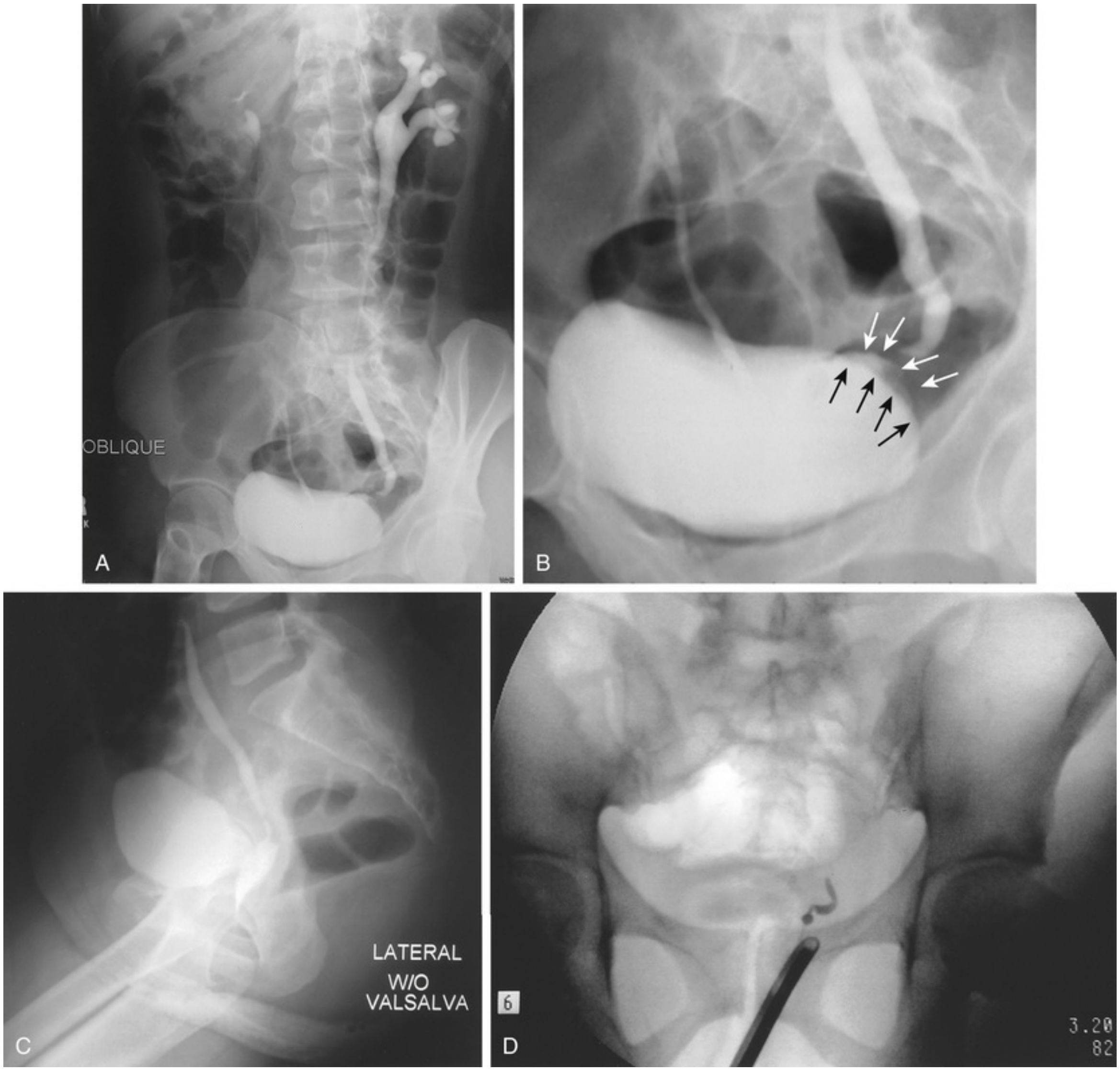

FIG. 129.22 Ureterovaginal fistula. (A) Oblique view on intravenous urography shows mild left-sided hydroureteronephrosis associated with a distal tapering of the ureter. (B) Faint and subtle opacification of the vagina *(white arrows)* is somewhat obscured by bladder filling (bladder edge indicated by *black arrows*) on this oblique image. (C) Lateral view demonstrates the ureter clearly entering the vagina. (D) Retrograde pyelogram demonstrates abrupt termination of the distal ureter.

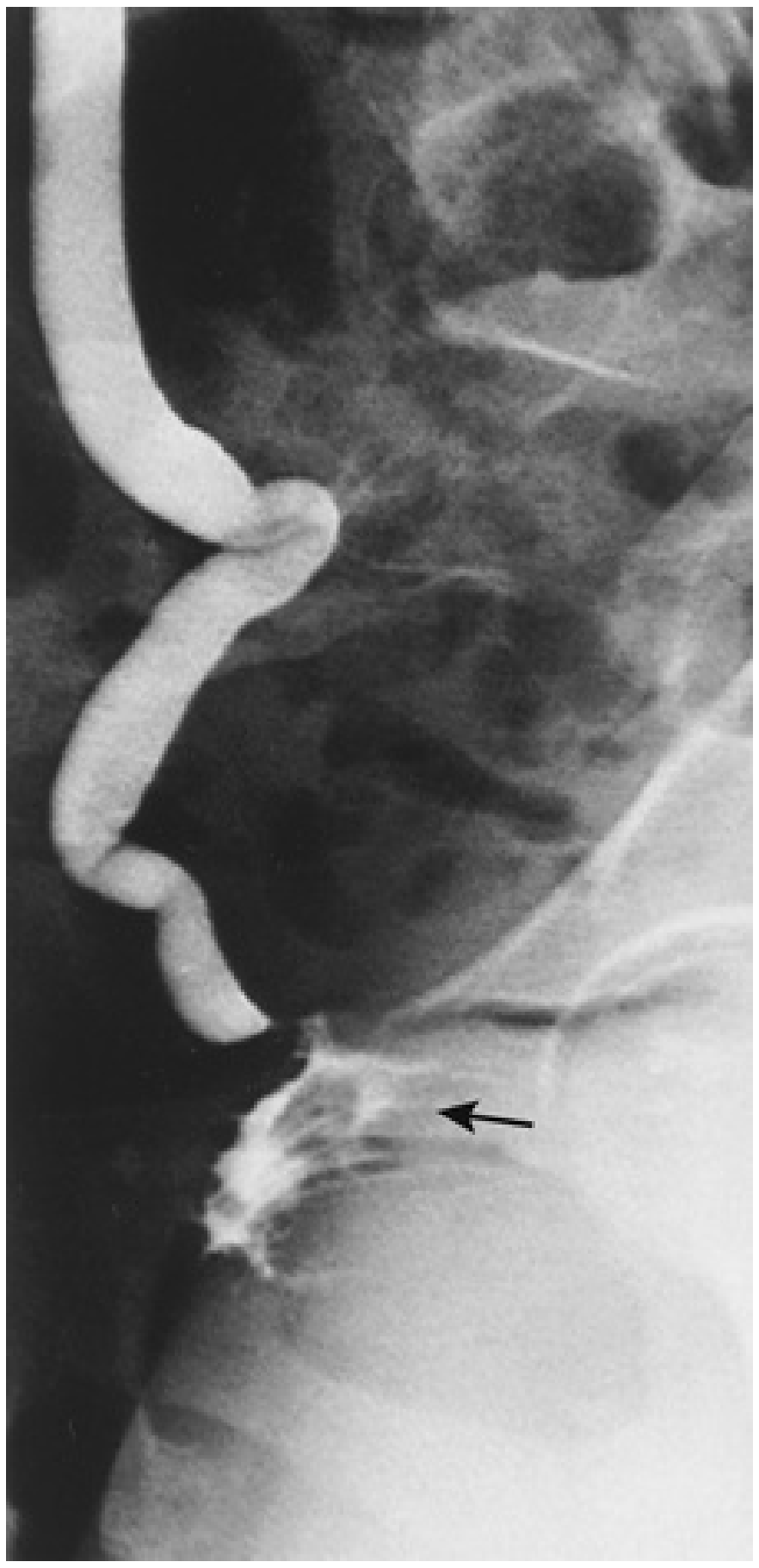

FIG. 129.23 Ureterovaginal fistula. Antegrade nephrostogram demonstrates mild ureterectasis with opacification of the vagina *(arrow).*

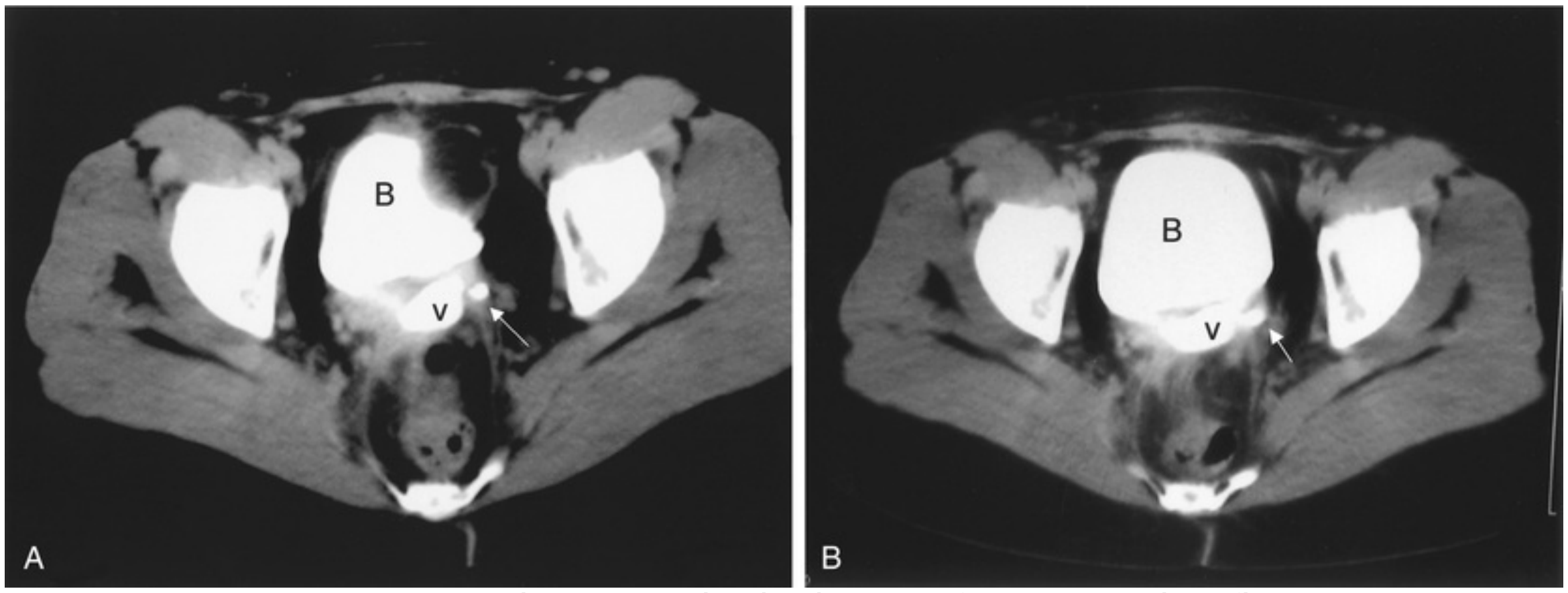

FIG. 129.24 Computed tomography (CT) scan of ureterovaginal fistula. (A) CT scan demonstrates contrast material within the bladder *(B)* and vagina *(v).* The ureter is visible *(arrow)* adjacent to the vagina. (B) This image shows the ureter *(arrow)* entering the vagina.

The goal of therapy is the expeditious resolution of urinary leakage, avoidance of urosepsis, and preservation of renal function. Once the diagnosis is made, prompt drainage of the affected upper urinary tract is essential (Gerber and Schoenberg, 1993), **because partial ureteral obstruction is often present.** An attempt at ureteral stenting or percutaneous nephrostomy tube decompression is warranted as soon as possible (Dowling et al., 1986) if direct open surgical repair is not immediately considered. Occasionally, conservative, nonoperative management alone will result in fistula closure in patients with ureteral continuity and a normal-appearing ureter beyond the fistula (Alonso Gorrea et al., 1985), although this is unusual. Endoscopic management, including ureteral stenting, may be sufficient to promote closure of the fistula in some cases. The use of ureteric stenting in patients with ureterovaginal fistulae was reported in 11 studies, including 126 patients in total (Andriole et al., 1984; Barton et al., 1992; Beaghler et al., 1997; Campbell et al., 1993; Dowling et al., 1986; Koonings et al., 1992; Lang, 1984; Lingeman et al., 1995; Mandal et al., 1990; Narang et al., 2007; Ustunsoz et al., 2008); this resulted in closure in 63 cases altogether. Success rates were between 6% and 100%, although the overall closure rate across all series is calculated at 50% ± 18%.

Where retrograde stenting proves impossible, percutaneous nephrostomy and antegrade stenting may be considered if there is some degree of pelvicalyceal dilatation. Ureteroscopy may also be helpful (Koonings et al., 1992; Narang et al., 2007), and a technique for combined antegrade and retrograde ureteroscopic cannulation has been reported (Beaghler et al., 1997). In one report all cases of ureterovaginal fistula were managed by temporary diversion using a percutaneous nephrostomy followed by delayed repair 4 to 6 weeks later (Onuora et al., 1993), and a similar approach was taken in the management of one ureterouterine fistula (Wang and Hung, 1997).

If endoluminal techniques fail or result in secondary stricture, the abdominal approach to repair is standard and may require end-to-end anastomosis, re-implantation into the bladder using psoas hitch or Boari flap, or replacement with bowel segments with or without reconfiguration. Recent case series suggest that this standard surgery can be performed safely and with reasonable operative times using laparoscopic or robotic techniques if the relevant skills and facilities are available (Laungani, 2008; Modi, 2008; Puntambekar, 2006). A recent case report has suggested that open repair through the vagina is possible if abdominal access is problematic (Chen, 2007).

If ureteral stenting is unsuccessful because of complete ureteral occlusion

or if prolonged leakage persists despite stenting, then formal surgical repair is indicated (Fig. 129.25). **Timing of the repair of ureterovaginal fistulae is controversial.** Some authors advocate early repair (Pal et al., 2016; Sakellariou et al., 2002; Yu et al., 2013), whereas others recommend a delay of 4 to 8 weeks (Demirci et al., 2013). More recent literature suggests that early repair is preferred and is not associated with an increase in morbidity or higher failure rates, if the damage is not too severe (Drake and Noble, 1998; Hampel et al., 2015).

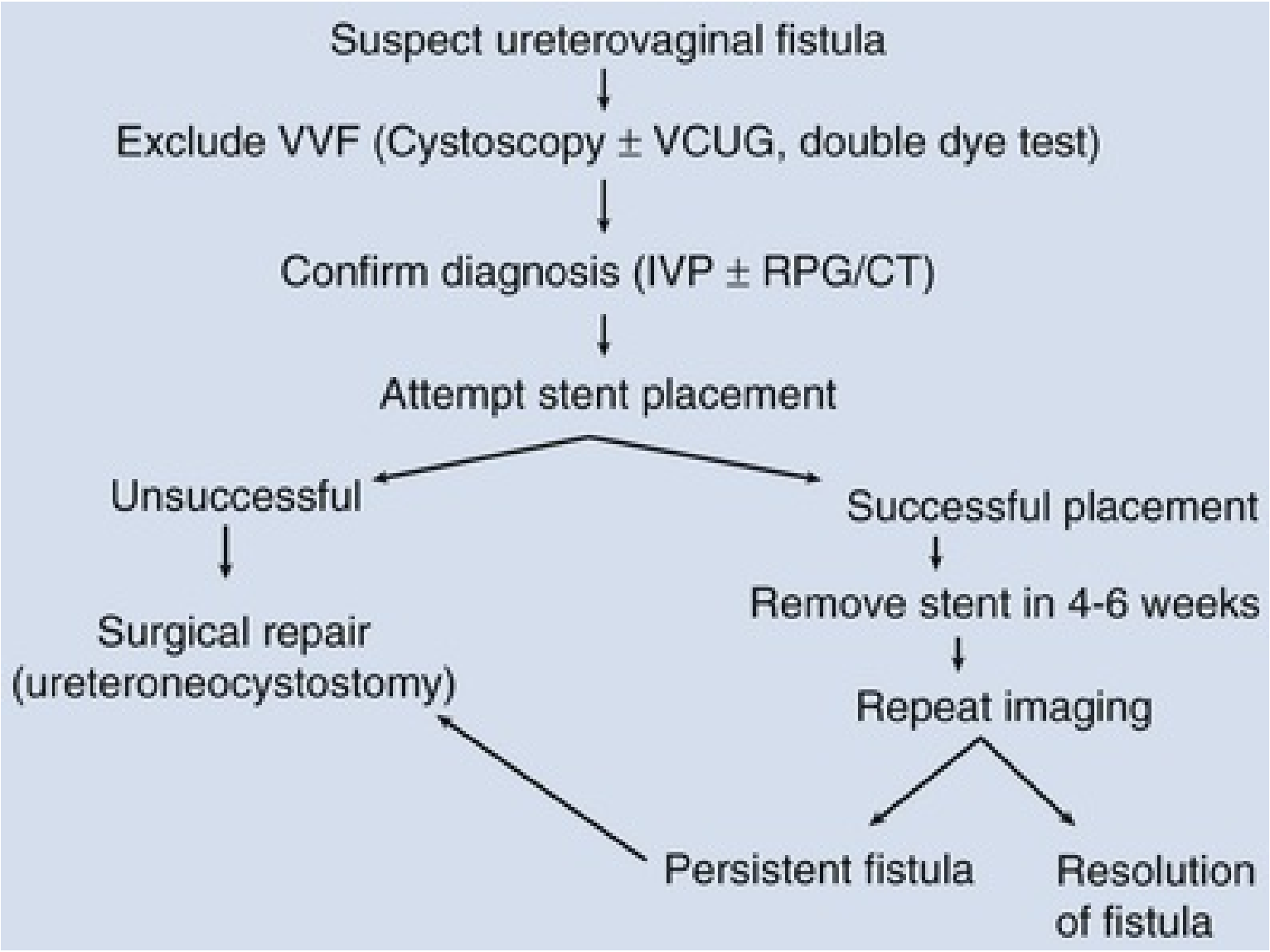
Suspect ureterovaginal fistula
Exclude VVF (Cystoscopy ± VCUG, double dye test)
Confirm diagnosis (IVP ± RPG/CT)
Attempt stent placement
Unsuccessful
Surgical repair (ureteroneocystostomy)
Successful placement
Remove stent in 4-6 weeks
Repeat imaging
Persistent fistula
Resolution of fistula

FIG. 129.25 Algorithm for diagnosis and management of ureterovaginal fistula. *CT,* Computed tomography; *IVP,* intravenous pyelography; *RPG,* retrograde pyelography; *VCUG,* voiding cystourethrography; *VVF,* vesicovaginal fistula.

As noted previously, ureterovaginal fistulae most commonly result from injury to the distal one-third of the ureter below the level of the iliac vessels. **The usual site of the injury in the very distal ureter and the surrounding fibrosis and inflammation usually preclude primary repair of the fistula. Therefore open surgical repair most commonly involves ureteroneocystostomy.** The ureter is located and dissected as distally as possible in the pelvis. Care is taken to preserve the periureteral adventitial layer to prevent ureteral ischemia. The ureter is divided distally, and a ureteroneocystostomy is performed with or without a psoas hitch. It is not important to create a tunneled anastomosis. Occasionally a Boari flap or replacement with bowel segments (with or without reconfiguration) may be necessary because of extensive ureteral injury. **Robotic and**

laparoscopic repairs using the same principles as open repair have been reported (Miklos et al., 2015; Modi et al., 2006; Watts et al., 2017), **with the potential benefits of shorter hospitalization and quicker convalescence.** Rarely, transureteroureterostomy, ileal substitution of the ureter, or renal autotransplantation is required. In patients with a normal contralateral kidney in whom there is extensive renal damage because of obstruction or infection, nephrectomy may be the most expeditious method of management.

Successful repair of ureterovaginal fistulae is expected in more than 90% of cases. Blandy et al. (1991) reported on early repair of iatrogenic injury to the ureter in 43 cases including 30 ureterovaginal fistulae. All patients were cured using a combination of techniques including the Boari flap.

Ureteral fistulae to other gynecologic organs have been reported. Ureterouterine fistulae may occur as a result of cesarean section, uterine malignancy, and elective abortion (Billmeyer et al., 2001; Lo et al., 2016). Uretero–fallopian tube fistulae have also been reported as a consequence of laparoscopic fulguration of endometriosis (Chene et al., 2015; Crochet et al., 2008; Ingber et al., 2010).

Key Points: Ureterovaginal Fistulae

- Ureterovaginal fistulae occur more commonly after benign hysterectomy than after radical hysterectomy.
- Patients have constant urinary leakage but usually a normal voiding pattern.
- In the setting of ureteral patency, a trial of an indwelling ureteral stent may result in resolution of the fistula.
- If conservative management fails or if there is complete obstruction of the distal ureter, then ureteral reimplantation with or without a psoas hitch is usually curative.

Vesicouterine Fistulae

Etiology and Presentation

Vesicouterine fistulae are among the least common urogynecologic fistulae (Benchekroun et al., 1999; Tancer, 1986). However, the incidence of this condition is increasing in parallel with the rising numbers of low-segment cesarean sections being done worldwide (Kumar et al., 1988; Porcaro et al., 2002). **Cesarean section is by far the most common cause of this unusual fistula** (Tancer, 1986). Tancer related that of the 74 cases of vesicouterine fistulae reported from 1947 to 1986, 57 followed low-segment cesarean section, 7 followed vaginal operative delivery, and the remaining cases were related to a variety of disparate scenarios, including induced abortion, hysterectomy, and dilation and curettage (D&C). Jozwik et al. (1998) reported that 21 of 24 vesicouterine fistulae treated over a 12-year period occurred after cesarean section, the majority of which were repeat cesarean sections. Those undergoing vaginal birth after prior cesarean section (VBAC) are also at risk for vesicouterine fistula (Gil and Sultana, 2001). Vesicouterine fistulae may occur spontaneously as a result of a ruptured uterus during obstructed labor. In these cases, the posterior bladder wall may tear along the uterine rupture line creating the potential for a fistula. Bladder wall invasion by chorionic villi penetrating beyond the uterine serosa, placenta percreta, may also create a vesicouterine fistula (Krysiewicz et al., 1988). A foreign body such as an intrauterine device (IUD) (Schwartzwald et al., 1986), uterine artery embolization (Sultana et al., 2002), brachytherapy (Memon et al., 1998), traumatic bladder catheterization (Futter and Baker, 1995), Meyer-Rokitansky syndrome (Okusanya and Garba, 2010), and endometrial ablation (Rooney and Cholhan, 2010) have been reported to cause vesicouterine fistula. **In most cases, simultaneous injury to the bladder and uterus is the inciting event.** An unrecognized and unrepaired (occult) bladder injury, or incorporation of a portion of the bladder during closure of the uterus during any number of operations, may result in a vesicouterine fistula. **Anatomically, the most common location of the fistula is along the posterior bladder wall in the midline, or from the genital side, just cephalad to the internal cervical os.**

Unlike other types of urogynecologic fistulae, vesicouterine fistulae may or may not manifest with constant urinary incontinence because of the

sphincter-like activity of the cervix; the exception is in the setting of an incompetent cervix, wherein urinary leakage is constant. In this clinical setting, which typically occurs after vaginal delivery, urine flows from the bladder through the fistula into the uterine cavity and then into the vagina through an incompetent cervical os. However, in the setting of a relevant clinical history, vesicouterine fistulae also manifest with menouria and cyclic hematuria in the setting of urinary continence. **Youssef syndrome describes the presenting symptom complex of vesicouterine fistula: menouria, cyclic hematuria with associated apparent amenorrhea, infertility, and urinary *continence*** (Youssef, 1957) **in a patient who has undergone prior low-segment cesarean section.** Endometriosis of the bladder in which cyclic hematuria may be present must be differentiated from this condition.

Diagnosis and Management

Diagnosis of vesicouterine fistula can be made by a combination of cystoscopy and radiographic studies, although a high degree of suspicion is necessary to pursue the diagnosis if initial radiographic studies prove negative (Smayra et al., 2005). Cystoscopy may demonstrate a midline lesion along the posterior bladder wall (Fig. 129.26). Urine cytology may reveal endothelial cells. Instillation of contrast material into the bladder (cystogram) will outline the uterine cavity (Fig. 129.27), whereas a hysterosalpingogram will demonstrate filling of the bladder. MRI, CT (Fig. 129.28), and ultrasonography have been used in the diagnosis and evaluation of vesicouterine fistulae as well (Huang et al., 1996; Mercader et al., 1995; Murphy et al., 1999). IVU or contrast-enhanced CT can be used to exclude concomitant ureteral injury.

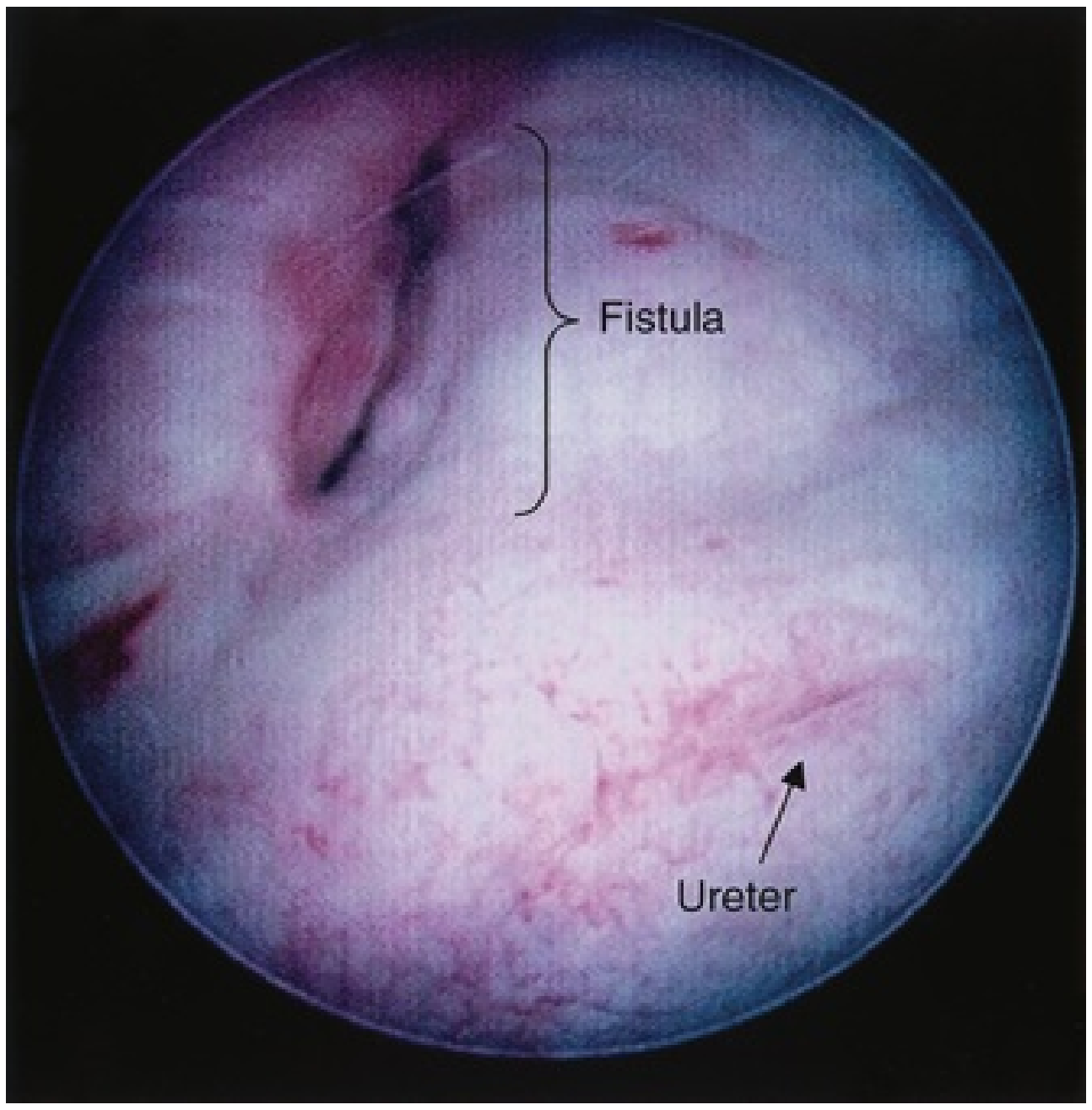
Fistula
Ureter

FIG. 129.26 Cystoscopic view of vesicouterine fistula before repair.

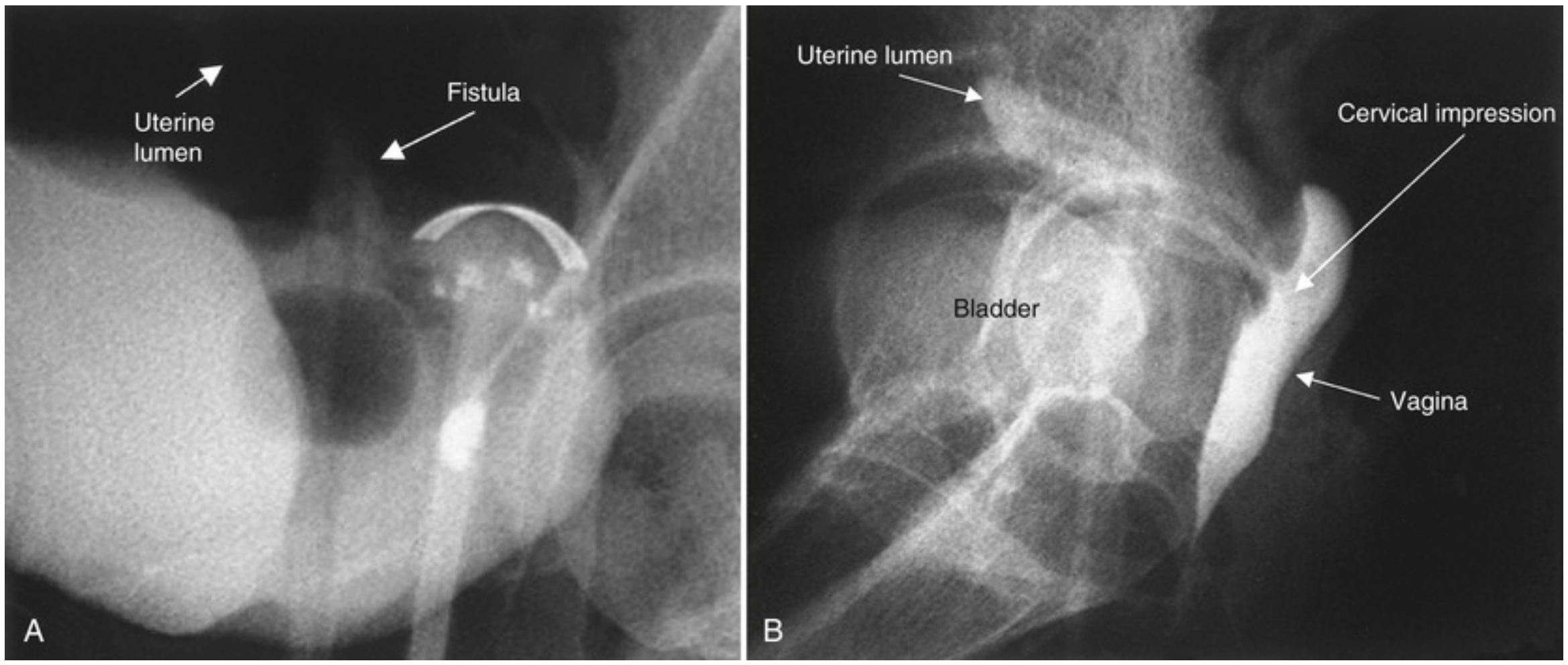
Uterine lumen
Fistula
A
Uterine lumen
Cervical impression
Bladder
Vagina
B

FIG. 129.27 Cystogram demonstrating vesicouterine fistula in a postpartum woman. (A) Filling of the bladder demonstrates a small amount of contrast material cephalad to the tip of the Foley catheter. The uterine cavity is faintly seen. (B) Postvoid image demonstrates filling of the uterine cavity and cervical canal. The bladder is not well demonstrated. This patient's status is immediately postpartum. Contrast material in the vagina outlines the incompetent cervical canal and os.

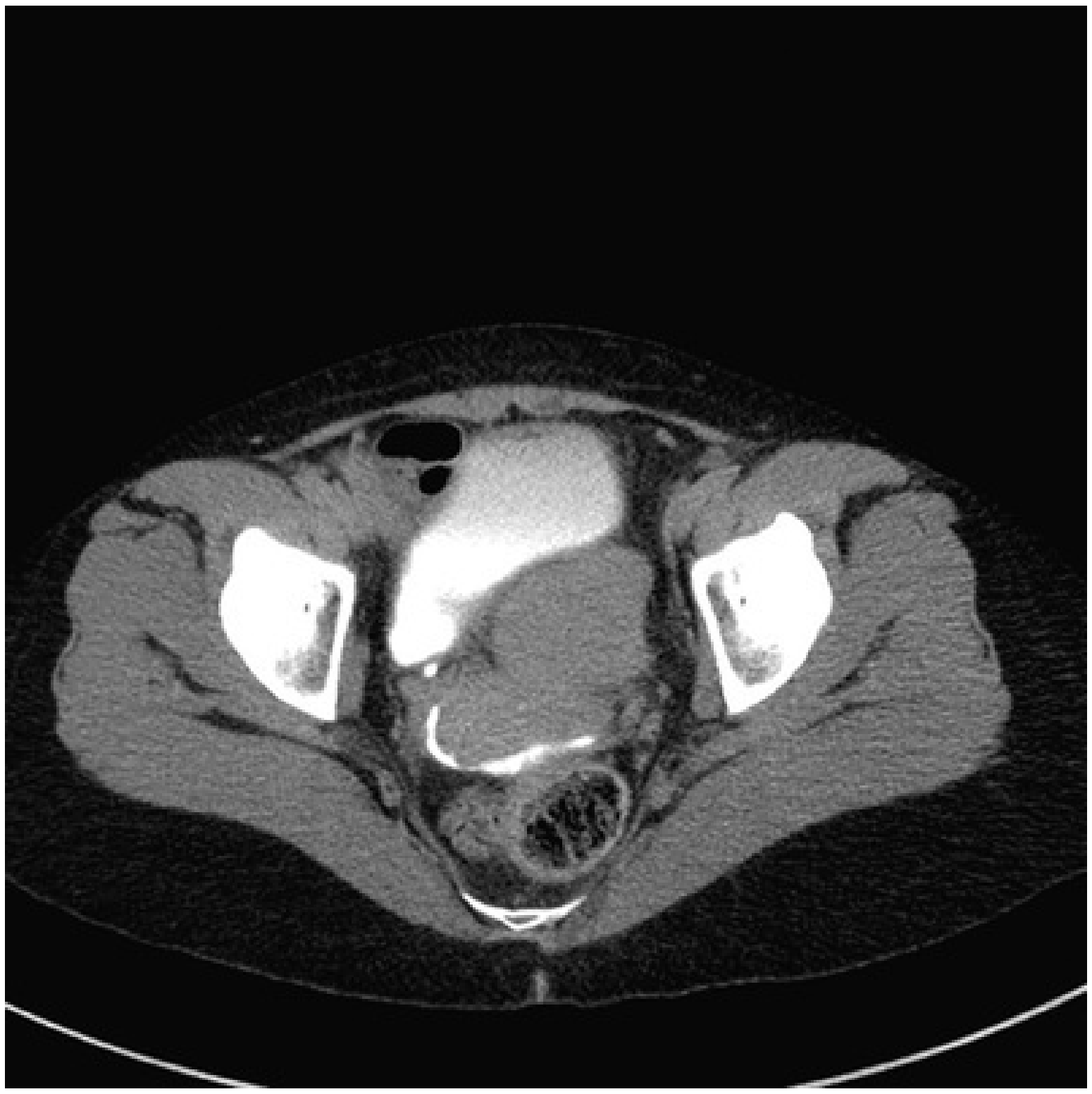

FIG. 129.28 Computed tomography scan with contrast enhancement demonstrating a vesicouterine fistula. Contrast material is layering in the partially filled urinary bladder; contrast opacification of the uterine canal suggests a vesicouterine fistula.

Several different approaches have been advocated for the treatment of vesicouterine fistulae. **Prolonged indwelling bladder catheterization or fulguration of the fistula tract followed by bladder drainage may be successful in select cases, especially in patients with small, immature fistulae** (Graziotti et al., 1978; Ravi et al., 2003; Rouzi et al., 2016). **Hormonal induction of menopause will induce involution of the puerperal uterus, and this principle has been used with some success in treating this condition as well** (Ravi et al., 2003). Jozwik and Jozwik (1999) reported successful treatment in eight of nine patients with use of hormonal manipulation.

Surgical therapy for vesicouterine fistulae is often contingent on the specific reproductive wishes of the patient, **as well as other surgical factors,** but is considered definitive therapy. Vaginal repair is feasible in selected patients, but many will require an abdominal approach (Milani et al., 2017; Rajamaheswari and Chhikara, 2013). **For the patient who desires preservation of fertility, uterine-sparing surgery can be considered.** In a manner similar to an O'Conor transabdominal VVF repair, the bladder is opened and bivalved down to the fistula tract. Careful dissection allows separation of the bladder from the uterus beyond the fistula tract. The fistula tract is excised from both structures, the uterus and bladder are closed individually, and an interpositional flap, usually omentum, is secured between the two organs (Sapmaz et al., 2003). Fertility is possible after repair of vesicouterine fistula. Lotocki et al. (1996) reported five pregnancies with four full-term deliveries in a cohort of 16 patients who had undergone uterine-sparing surgery for vesicouterine fistulae. Minimally invasive laparoscopic and robotic surgical approaches to the repair of vesicouterine fistulae have been reported (Alamoudi et al., 2017; Maioli et al., 2015). **If there is no further desire for childbearing, then transabdominal hysterectomy and bladder closure should be considered. Ureteral stents can be placed to facilitate identification of the ureters intraoperatively.** After performance of the hysterectomy, the fistula tract on the posterior bladder wall is excised and the bladder is closed primarily. An omental flap can be placed into the deep pelvis to buttress the bladder closure and separate the bladder closure from the vaginal closure to reduce the possibility of a postoperative VVF.

Key Points: Vesicouterine Fistulae

- The most common cause of vesicouterine fistulae is low-segment caesarean section.
- Vesicouterine fistulae do not always manifest with urinary incontinence.
- Nonsurgical management of vesicouterine fistulae is possible by hormonally inducing involution of the uterus with maintenance of urinary drainage.
- Management of vesicouterine fistulae is contingent on the reproductive wishes of the patient. Hysterectomy followed by repair of the bladder is indicated for the individual who no longer desires fertility. Uterine-sparing procedures can be used, and successful pregnancy is possible after vesicouterine fistula repair.

Urethrovaginal Fistulae

Etiology and Presentation

In the developing world, urethrovaginal fistulae may occur as a result of obstructed labor with or without associated VVF. In industrialized countries urethrovaginal fistulae in adults mostly have an iatrogenic cause.

In feminizing genital reconstructions in children with ambiguous genitalia and surgical repairs of cloacal malformations, urethrovaginal fistulae can occur as early or late complications (Dhabalia et al., 2009; Levitt and Pena, 2010, Levitt et al., 2011; Oguzkurt et al., 2009; Park et al., 2011). Also in transsexual adults undergoing female to male reconstruction, urethrovaginal fistulae have been reported (Hage et al., 1993).

In the surgical treatment of stress incontinence in women with bulking agents (Carlin and Klutke, 2000; Hilton, 2009) or synthetic slings several cases of urethrovaginal fistulae have been reported (Blaivas and Mekel, 2014; Estevez et al., 2010a, 2010b; Glavind and Larsen, 2001; Lee and Zimmern, 2016; Morton and Hilton, 2009; Reisenauer et al., 2007, 2014). Even conservative treatment of prolapse with pessaries can lead to the formation of fistula, if these pessaries are neglected for an extended period of time, although fistula formation after only 2 weeks of pessary use has been described (Hilton and Cromwell, 2012; Walker et al., 2011).

Trauma, including inappropriate catheterization, and foreign bodies are obvious causes of fistulae (Blaivas and Purohit, 2008; Cameron and Atiemo, 2009; Holland et al., 2001; Kobayashi et al., 2010; Liu et al., 2008; Parkhurst et al., 1981; Thrumurthy et al., 2010).

Urethral diverticulae and their surgical repair may also lead to urethrovaginal fistulae (Ben Amna et al., 2002; Ganabathi et al., 1994; Greenwell and Spilotros, 2015, Lo et al., 2017; Porpiglia et al., 2002).

Urethrovaginal fistulae have also been described in some Behçet patients with vasculitis and local necrosis of the urethrovaginal septum (Chung et al., 2005; Waidelich et al., 1994).

Irradiation complications can also result in the formation of urethrovaginal fistula (Flottorp and Inversen, 1960) (Figs. 129.29 and 129.30). **Other causes of urethrovaginal fistulae include trauma (including pelvic fracture) and vaginal neoplasms.** A final important cause in the long-term–care setting is urethral catheter erosion (Andrews and Shah, 1998; Trop and Bennett, 1992). In patients with poor sensation, especially the cognitively or otherwise neurologically impaired patient, pressure necrosis from a chronically indwelling catheter may result in traumatic hypospadias and urethrovaginal fistula. If the condition is not recognized, over time the catheter may erode to the level of the bladder neck and beyond, effectively creating a bivalved urethra and a urethrovesicovaginal fistula (Fig. 129.31). For that reason suprapubic catheters are to be preferred in patients with cognitive and/or neurologic impairment.

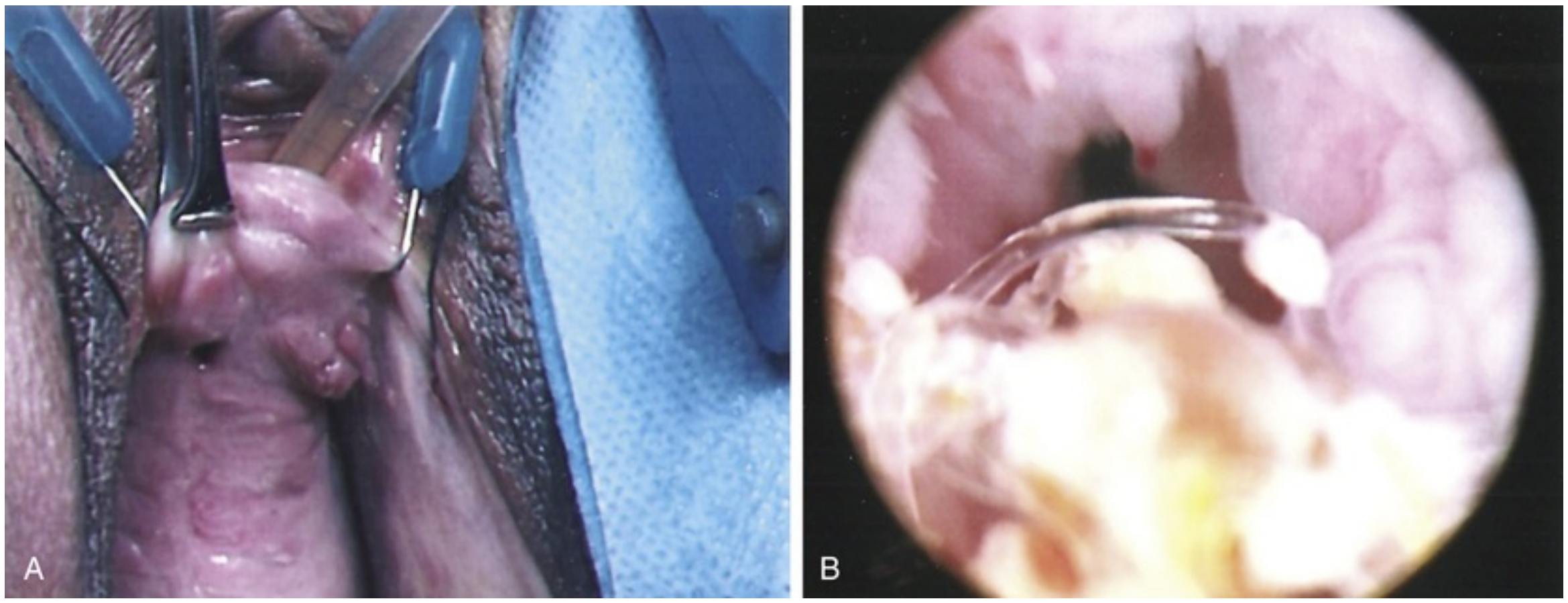

FIG. 129.29 Urethrovaginal fistula after mid-urethral synthetic sling procedure. (A) Intraoperative view demonstrating a urethrovaginal fistula at the bladder neck after a mid-urethral sling procedure. (B) Cystoscopy demonstrates intraurethral sling material with calcified material.

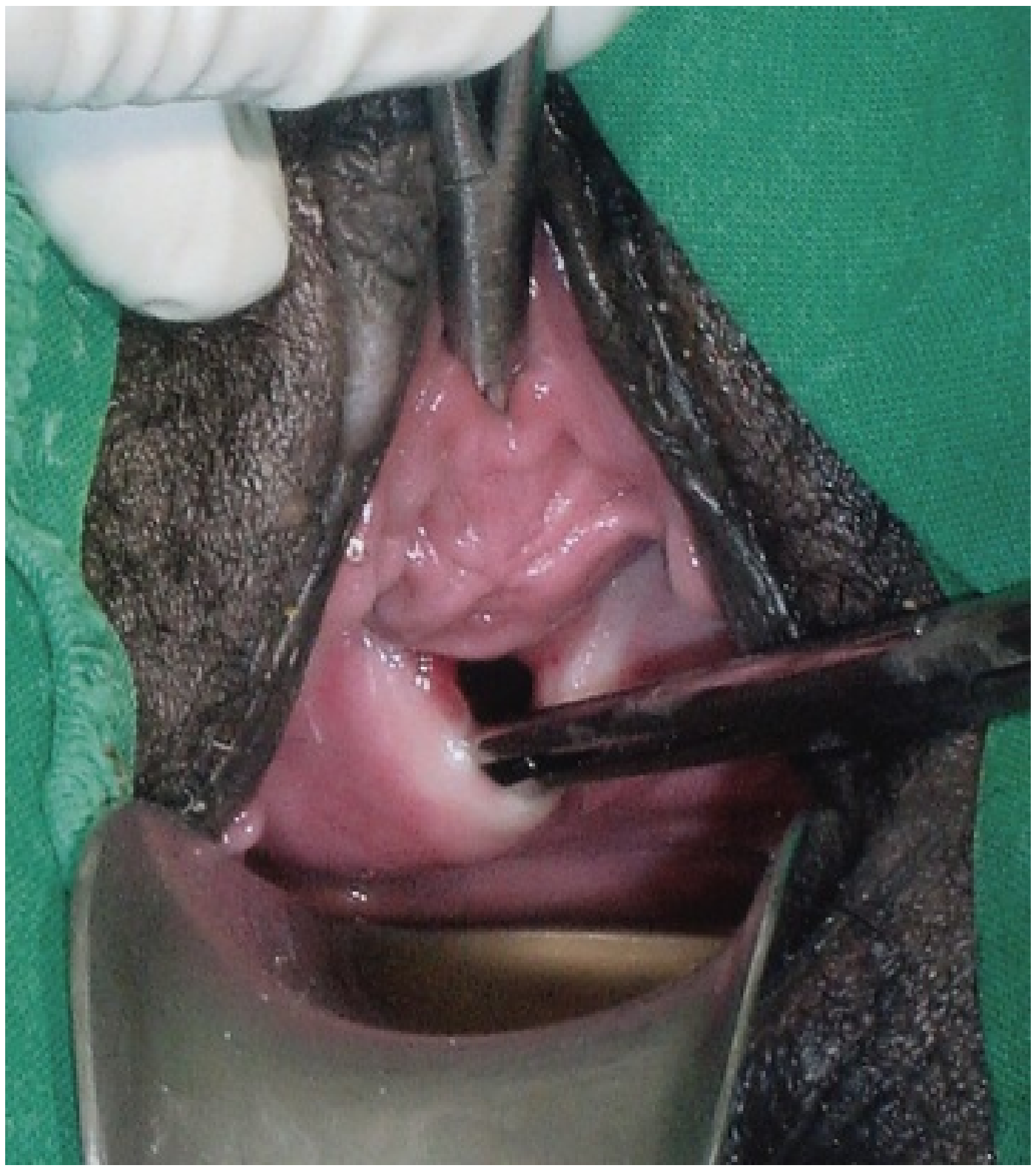

FIG. 129.30 Urethrovaginal fistula at the bladder neck from obstructed labor. A hemostat is shown entering the urethral meatus. (Courtesy Mark Morgan, MD, Department of Obstetrics and Gynecology, Hospital of the University of Pennsylvania, Philadelphia, PA.)

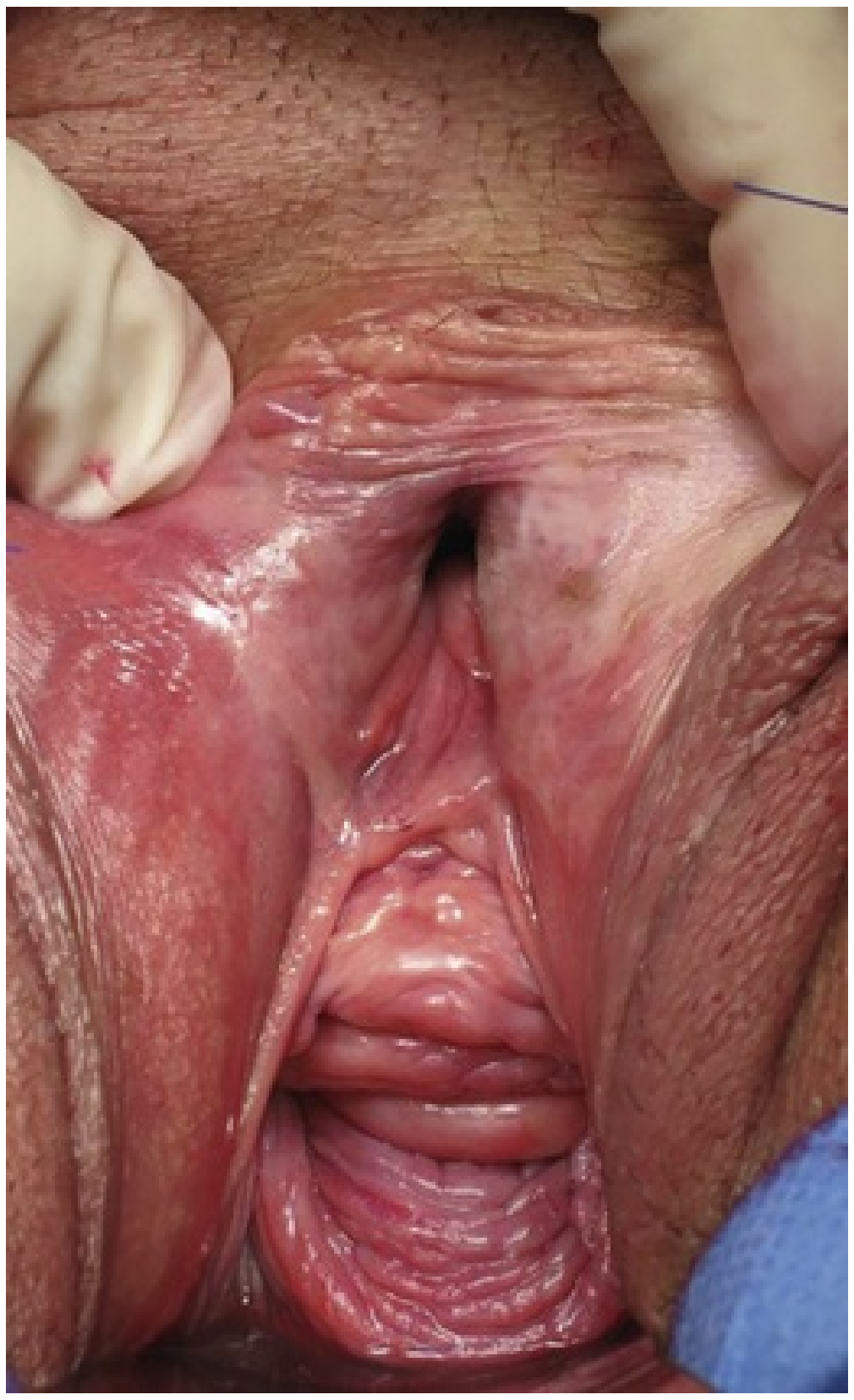

FIG. 129.31 Severe complete erosion of the urethra secondary to chronic indwelling urinary catheter. This patient with advanced multiple sclerosis underwent surgical bladder neck closure and ileovesicostomy (ileal chimney).

Symptoms of urethrovaginal fistulae are largely dependent on the size and location of the fistula along the urethral lumen. A small fistula may produce only minimal leakage, whereas a large urethrovaginal fistula can cause continuous urine drainage. **Proximal fistulae can be associated with stress incontinence, or, continuous incontinence neck similar to that associated with VVF if they are located at the bladder. Distal fistulae beyond the sphincteric mechanism may be completely asymptomatic or may be associated with a splayed urinary stream.** Occasionally, distal fistulae are associated with vaginal voiding and pseudo-incontinence, so called because the patient reports urinary incontinence that occurs only when rising from a seated position after voiding. This occurs as a result of urine accumulation in the vagina during voiding, with emptying occurring on standing—so-called vaginal voiding or vaginal reflux (Fig. 129.32).

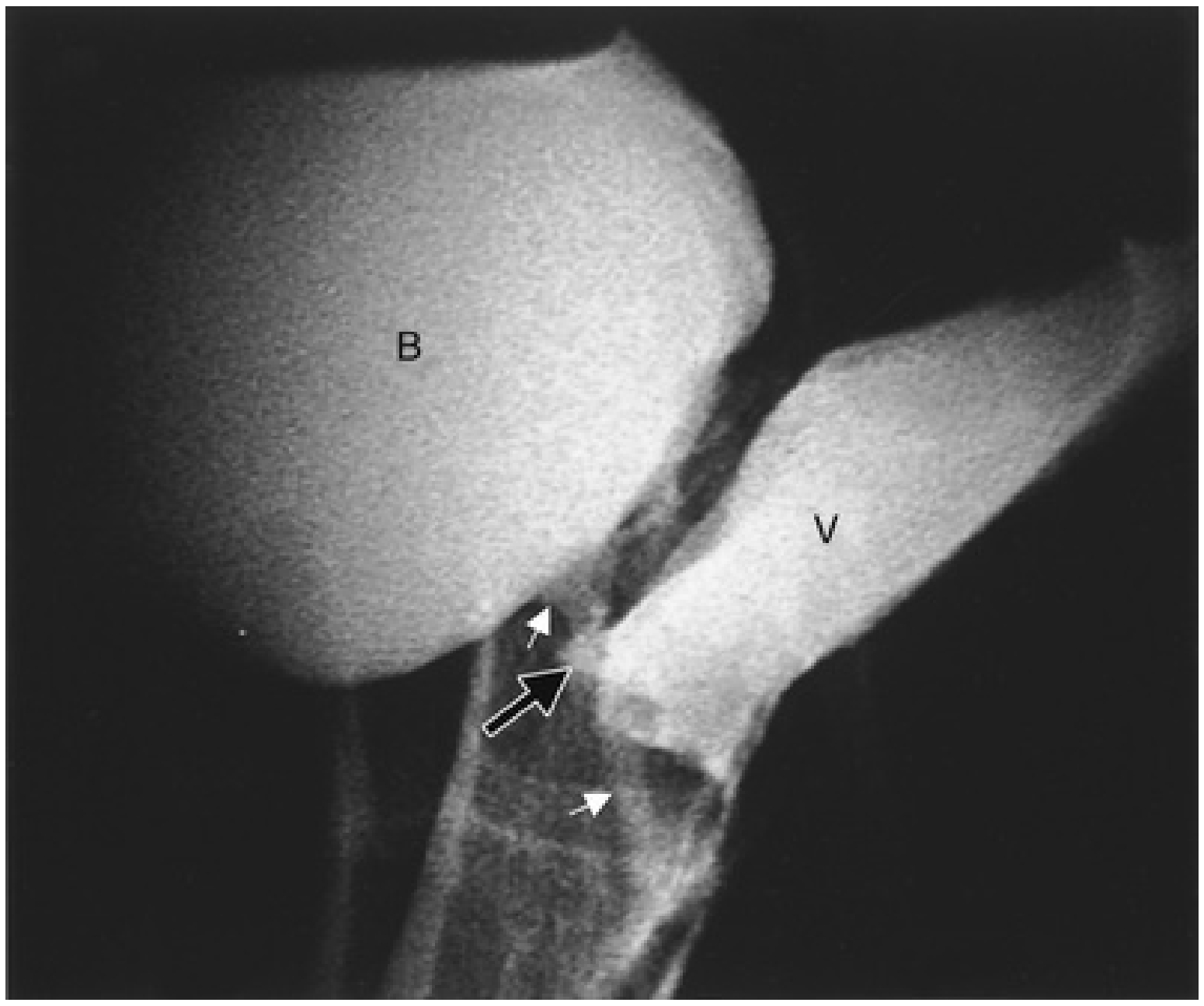

FIG. 129.32 Urethrovaginal fistula on lateral voiding image from voiding cystourethrography demonstrates fistula *(black arrow)* in this patient with a primary symptom of vaginal voiding. The urethra proximal and distal to the fistula is well opacified *(white arrows). B,* Bladder; *V,* vagina.

Diagnosis

The diagnosis of urethrovaginal fistula can often be made on physical examination and cystourethroscopy; however, voiding cystourethrography is extremely useful (Fig. 129.33), especially in complex cases. Double-balloon urethrography is the classic examination to show urethral diverticulum and urethrovaginal fistula, but 3D MRI or CT scan is being used more widely (Abet et al., 1983; Quiroz et al., 2010; Schoellnast et al., 2004). Ultrasound can be useful as well (Ying et al., 2010). Small fistulae may be very difficult to locate on physical examination, even with a speculum, because of the surrounding vaginal rugation (Fig. 129.34). An associated VVF will be found in up to 20% of cases, and therefore a thorough evaluation of the entire lower urinary tract is warranted (Lee et al., 1988).

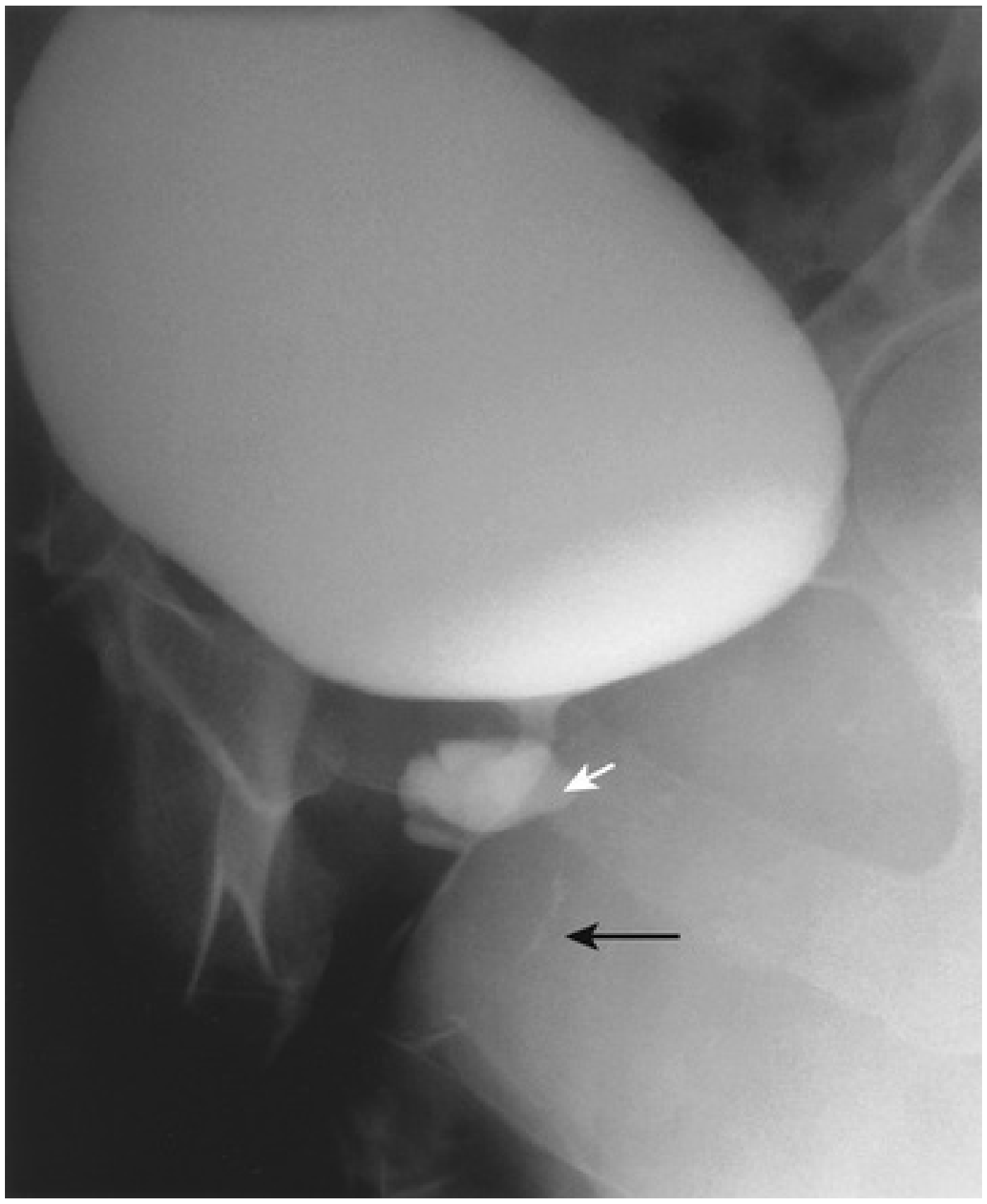

FIG. 129.33 This patient was referred for the evaluation of persistent incontinence after urethral diverticulectomy. A voiding cystourethrogram demonstrates incomplete resection of the urethral diverticulum *(white arrow)* with a pinpoint postoperative urethrovaginal fistula (*black arrow* shows a small amount of contrast material faintly outlining the anterior vaginal wall). Resection of the residual diverticulum with repair of the fistula by a Martius flap was curative.

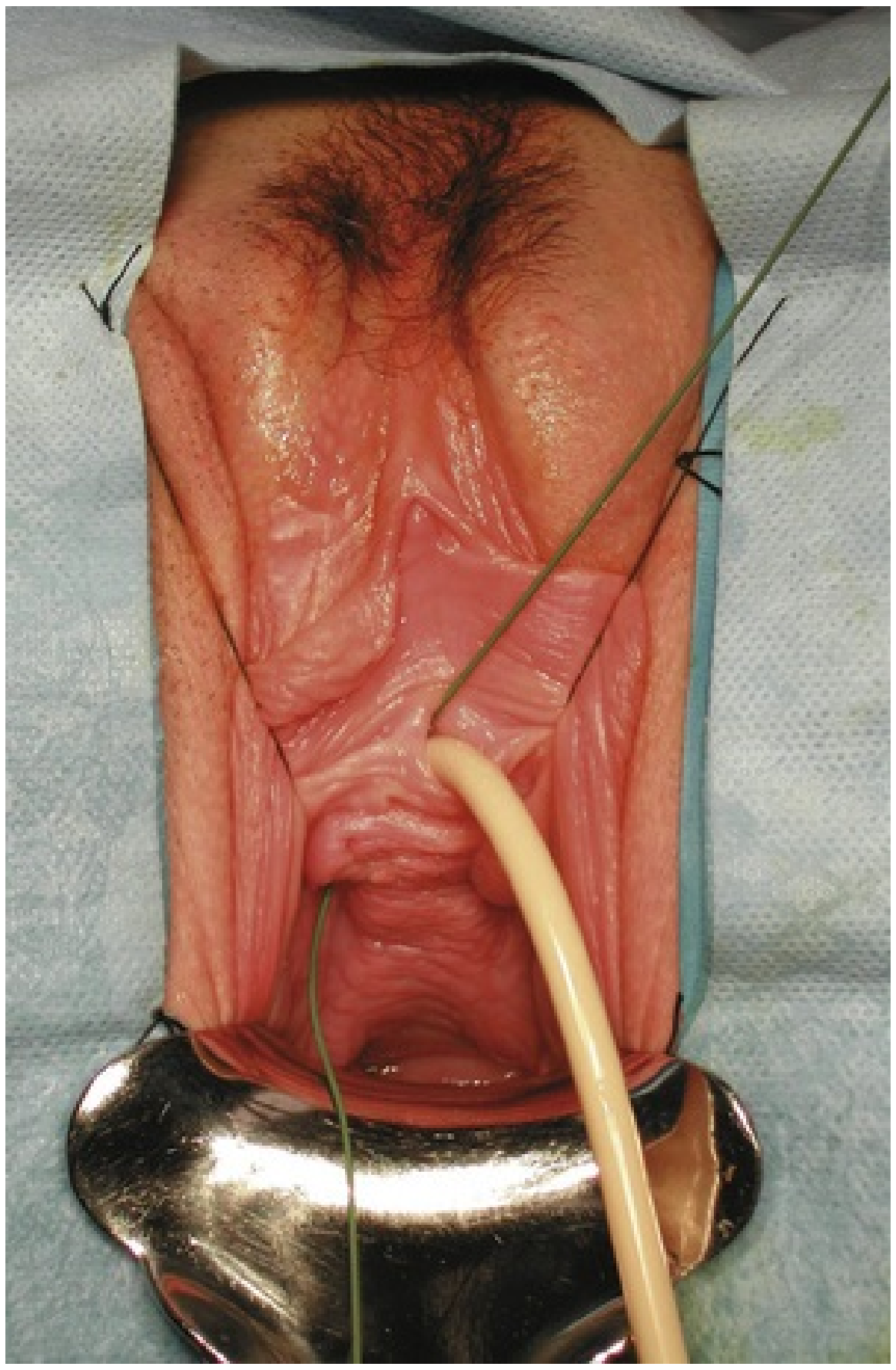

FIG. 129.34 Urethrovaginal fistula. Identification of the exact fistula tract can be difficult in redo cases. Passage of a flexible wire endoscopically from the urethral lumen into the vagina can aid in locating the fistula tract.

Endoscopic examination of the urethra should be performed. However, because of its short length, the female urethra may be difficult to fully examine with a standard rigid cystoscope, because the irrigation fluid is discharged 1 to 2 cm proximal to the lens. A flexible cystoscope or a specially designed female cystoscope with a short beak is very helpful in visualizing the entire urethral lumen, because the irrigation fluid is discharged next to the lens, distending the adjacent urethral lumen (Fig. 129.35). Once the diagnosis is made on cystoscopy, the bladder is examined for additional fistulae.

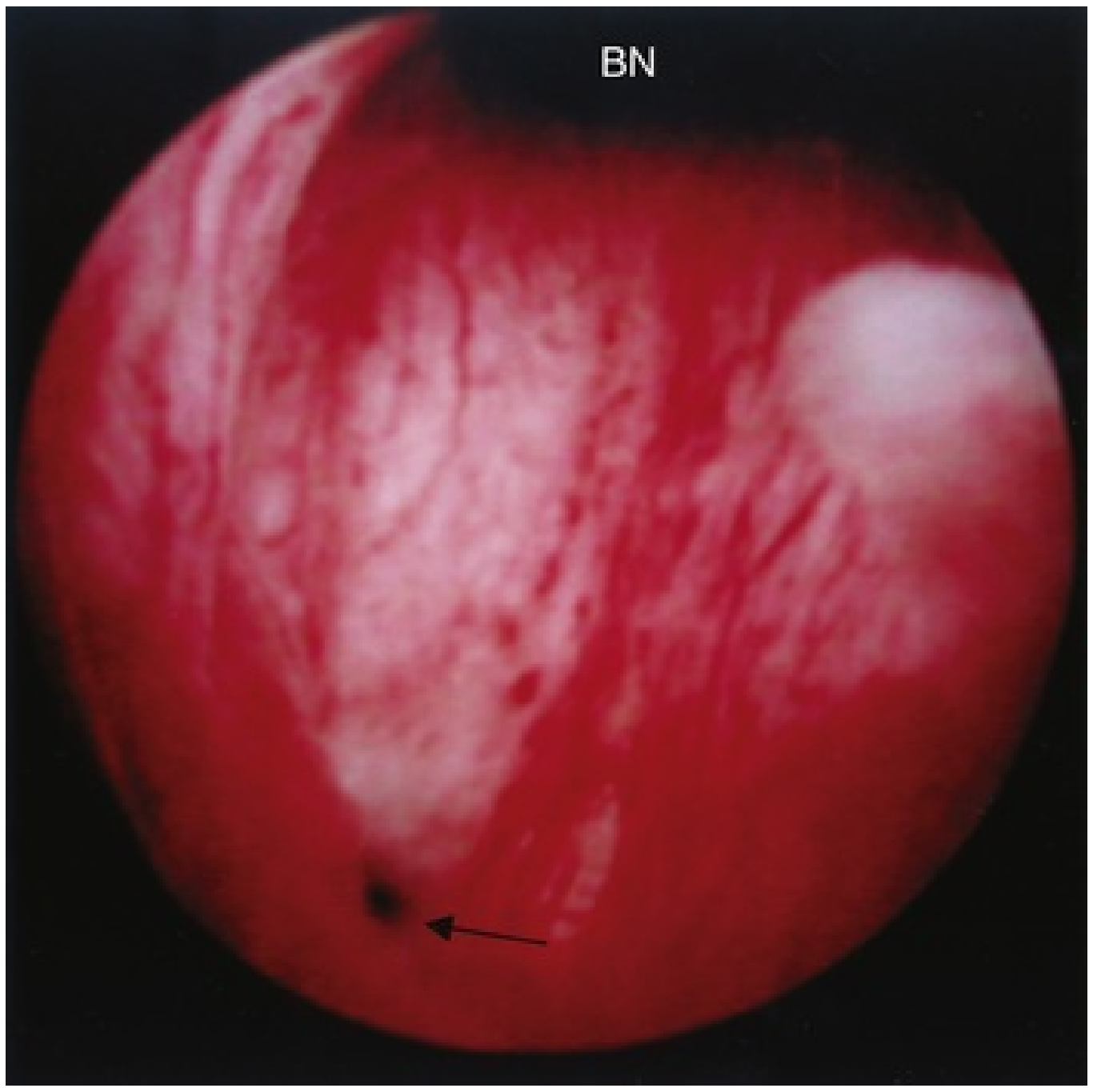

FIG. 129.35 Endoscopic view of a urethrovaginal fistula *(arrow).* This patient reported ongoing urinary incontinence for 10 years after an endoscopic bladder neck suspension. *BN,* Bladder neck.

Video-urodynamics may accurately characterize any associated incontinence, including that associated with detrusor dysfunction, although this will not often influence the decision to close the fistula. This study also allows assessment of the anatomic relationship of the fistula to the bladder neck and urethra, as well as examination for associated VVF.

Treatment of Urethrovaginal Fistulae

Several techniques for urethrovaginal fistula closure have been described. A vaginal approach is mostly used. Surgical correction intends to create a continent urethra that permits volitional, painless, and unobstructed passage of urine. Depending on the size, localization, and cause of the fistula and the amount of tissue loss, urethral reconstruction techniques may be necessary to restore the urethra and to achieve postoperative continence (Blaivas and Purohit, 2008).

Vaginal Approach

Goodwin and Scardino (1980) described in their series that a vaginal approach yielded a success rate of 70% at first attempt and 92% at second attempt, but that an abdominal approach only leads to a successful closure in 58% of cases. A vaginal approach required less operating time and had less blood loss and a shorter hospitalization time.

Most authors describe surgical principles that are identical to those of vesicovaginal fistula repair: identifying the fistula, creation of a dissection plane between vaginal wall and urethra, watertight closure of urethral wall, eventual interposition of tissue, and closure of the vaginal wall. Primary closure rates of 53% to 95.4% have been described. Pushkar et al. (2006) described a series of 71 women, treated for urethrovaginal fistula; 90.1% of fistulae were closed at the first vaginal intervention. In addition, 7.4% were closed at a second vaginal intervention. Despite successful closure, stress incontinence developed in 52%. The stress incontinent patients were treated with synthetic or autologous slings, and nearly 60% became dry and an additional 32% improved. Urethral obstruction occurred in 5.6% and was managed by urethral dilation or urethrotomy (Pushkar et al., 2006).

Advancement flaps of the vaginal wall can be used to cover the urethral suture line. In some cases more advanced methods are used to close or to protect the urethral closure.

In cases of difficult dissection and visualization, urethral sectioning has been advocated (Parks, 1965). This technique is also being used in the repair of complex urethral diverticula (Rovner and Wein, 2003). Fistulae that are located in the distal third of the urethra may also be marsupialized without compromising the continence mechanism (Lamensdorf et al., 1977). Distal urethrovaginal fistula may be entirely without symptoms, and in such cases, repair is not mandated.

Blaivas advocates that vaginal flaps are usually the best option in dealing with urethral reconstruction, next to the possibility of offering anterior or posterior bladder flaps. Options for vaginal repair of fistula include primary closure, peninsula flaps, bilateral labial pedicle flaps, and labial island flaps. Outcomes are optimized by using exacting surgical principles during repair and careful postoperative management by an experienced reconstructive surgeon (Blaivas and Purohit, 2008). Patients with urethrovaginal fistulae resulting from synthetic slings should be counselled that de novo or persisting stress incontinence can occur and that additional conservative or surgical treatment may be necessary (Blaivas and Mekel, 2014; Lee and Zimmern, 2016; Reisenauer, 2015).

Labial and Vaginal Flaps and Neourethra

The simplest flap is a vaginal advancement flap (Fall, 1995).

Labial tissue can be harvested as a pedicled skin flap. This labial skin can be used as a patch to cover the urethral defect but can also be used to create a tubular neo-urethra (Jiang et al., 2017; Pushkar, 2009; Xu et al., 2009). The construction of a neo-urethra has mostly been described in traumatic causes. In some cases a transpubic approach has been used (Huang et al., 2003). The numbers of patients reported are small, and there are no data on the long-term outcome of fistula closure and continence rates. The underlying bulbocavernosus tissue can be incorporated in the pedicled flap and probably offers a better vascularization and more bulking to the repair. This could allow a safer placement of a sling afterward, in those cases in which bothersome stress incontinence would occur postoperatively (Candiani et al., 1993; McKinney, 1979).

Martius Flap.

Although in obstetric fistula repair it was not found to have any benefit in a large retrospective study in 440 women, the labial bulbocavernosus muscle/fat flap originally described by Martius is still considered by some to be an important adjunctive measure in the treatment of GU fistulae where additional bulking with well vascularized tissue is needed (Browning, 2006). Rangnekar et al. (2000) reported on 12 patients with urethrovaginal fistula of whom 8 were treated with a Martius flap and 4 with a conventional repair. Only 1 out of the 8 had a fistula recurrence, while 3 out of 4 of the conventional repairs broke down; however, these cases were not randomized between surgical techniques (Rangnekar et al., 2000). Punekar et al. (1999) described 15 patients with complex and recurrent fistula, using the skin island flap modification with excellent results. Radopoulos et al. (2008) published a small series of 5 recurrent and complex urethrovaginal fistulas that all healed using a Martius flap. The series of non-obstetric cause are small, and all of them are retrospective. There are no prospective data or randomized studies (Baskin et al., 2005; Birkhoff et al., 1977). The indications for Martius flap in the repair of all types of fistula remain unclear. In some cases the fistula repair can be combined with a Martius flap and an autologous sling with good results (Chodisetti et al., 2016).

Rectus Muscle Flap.

Rectus abdominis muscle flaps have been described by some authors (Atan et al., 2007; Bruce et al., 2000). Transvaginal urethrovaginal fistula closure was performed followed by a pedicled rectus abdominis muscle flap interposed between the fistula closure and vaginal suture line. The muscle flap was based on the inferior epigastric vessels and provided additional support to the urethra, bladder neck, and bladder base. Urethrovaginal fistula repair with the rectus abdominis muscle flap was successful in all cases without recurrence. Of the patients 5 (83%) were continent and able to void to completion at a mean follow-up of 23 months (range 2 to 66).

Other Interposition Material.

A range of nontraditional interposition flaps and grafts have been reported by several authors. All of the publications only report on small patient numbers without long-term outcomes or continence data.

Golomb et al. (2006) reported the use of a fascial patch, while adding a rectus fascia sling to a urethrovaginal fistula repair. Omentum is extensively used in abdominal approaches to VVF, but Janez et al. (1985) used it during a vaginal approach in three patients with good results.

The gracilis muscle can be used as well, although experience is limited. The graciloplasty was described by Ingelman-Sundberg in 1947 and has been adapted by other surgeons in the treatment of fistula. The number of patients reported is low as is the quality of the evidence (Hamlin and Nicholson, 1969; Ingelman-Sundberg, 1947; Patil et al., 1980).

Non-autologous material has been used as well. Lowman et al. (2007) described the use of porcine dermis interposition and a synthetic sling in an irradiated patient. Other biodegradable materials have been used, although the quality of available data is low and is insufficient to advocate their use (Lowman et al., 2007; Scott et al., 1991). Nonvascularized tissue grafts should be used with caution in such cases because the cause of the initial tissue damage resulting in fistula is often ischemic.

Posterior Approach

In cases of high fistula with difficult vaginal access, a perineal pararectal approach has been described. Some variations exist in the incisions and dissection planes. The anterior sagittal transrectal approach (ASTRA technique) and the posterior sagittal pararectal approach only have been reported in small observational series (Domini et al., 2000; Mauermann et al., 2004; Nikolaev and Bizhanova, 1998; Pena, 1989; Rossi et al., 1998).

Abdominal Approach

Female urethral injuries may cause serious morbidity with loss of the entire urethra in some cases. Ahmed et al. (2000) reported the results of construction of a neourethra by the flipped anterior bladder-tube technique in 5 girls aged 3 to 18 years (mean 8 years). All had pelvic fractures. Three patients came with a suprapubic cystostomy, 1 was totally incontinent, and another had an urethrovaginal fistula. Three had an associated vaginal injury. All 5 patients underwent construction of a neourethra using a flipped anterior bladder-wall tube (FABWT) and were followed for 18 to 80 months (mean 44 months). All patients were continent in the daytime, and 3 were voiding spontaneously without the need for catheterization. Two were managed by clean intermittent catheterization (CIC), one per urethram, and other via a continent abdominal stoma (Mitrofanoff) (Ahmed and Kardar, 2000).

A retropubic retrourethral technique has been described by Koraitim (1985). This approach allows a urethrovesical flap tube to be fashioned to form a continent neourethra. Urodynamic studies showed that the proximal vesical and distal urethral components of the neourethra contribute to sphincteric function. For larger fistula an enwrapping technique has been described as well (Massoudnia, 1974).

Complications

Little information can be found on complications after urethrovaginal fistula repair. A short report on 4 cases by Tehan et al. (1980) describes a disappointing experience in the transvaginal repair of these fistulae. These authors advocate a suprapubic bladder flap or bladder tube technique to achieve a functioning urethra. Complications after surgical repair have been fistula recurrence, urethral shortening and retraction, persistent reflux, bladder calculi, and bladder cancer (Tehan et al., 1980).

Follow-Up

In most series of urogenital fistula repair, follow-up is of very short duration. Dolan et al. (2008) investigated urinary and sexual symptoms and quality of life in a group of 31 women 50 months (median) after successful repair of urogenital fistula using the Bristol Female Lower Urinary Tract Symptom questionnaire. All women had undergone urodynamic investigation before their repair surgery, and only 36% had normal findings. Almost all women reported one or more symptoms, and for 65%, these caused at least “a bit of a problem,” although 87%

said that their urinary symptoms had little or no impact on their quality of life. Symptoms were similar in urethrovaginal and vesicovaginal fistulae and were not significantly associated with prior functional abnormality. Lee and Zimmern (2016) published 4- to 5-year results in 18 women with a 95% successful repair, although 33% of them had to be re-operated for minor complications.

Operative Technique

The repair of urethrovaginal fistulae is conceptually very similar to the vaginal flap repair of VVF described previously. The patient is positioned in the dorsal lithotomy position, and urethral and suprapubic catheters are placed. A ring retractor is helpful for exposure. Allis clamps are used to reflect the vaginal wall cephalad, exposing the fistula. In some patients an episiotomy may facilitate exposure of the fistula, improving visualization for repair (Webster et al., 1984). However, because of the distal (with respect to the vagina) location of these lesions, this is not usually necessary.

After infiltration of the fistula margins with injectable saline or local anesthetic with adrenaline, the fistula tract is circumscribed through the vaginal wall (Fig. 129.36). The fistula tract and immediate surrounding epithelium are not typically excised, because this will create a larger defect in the urethra that will be more difficult to close without undue tension. However, the vaginal wall is dissected several millimeters from the edge of the circumscribed fistula tract in a radial orientation. An inverted U- or J-shaped incision is marked along the anterior vaginal wall, with the base of the U or J at the margin of the circumscribed fistula tract. This is infiltrated with injectable saline, and the anterior vaginal wall flap is developed, exposing the underlying periurethral fascia to the level of the bladder neck or beyond, depending on the size and location of the fistula. If a concomitant anti-incontinence procedure is planned, dissection may be carried out laterally from the edges of the flap at the level of the bladder neck and the retropubic space entered.

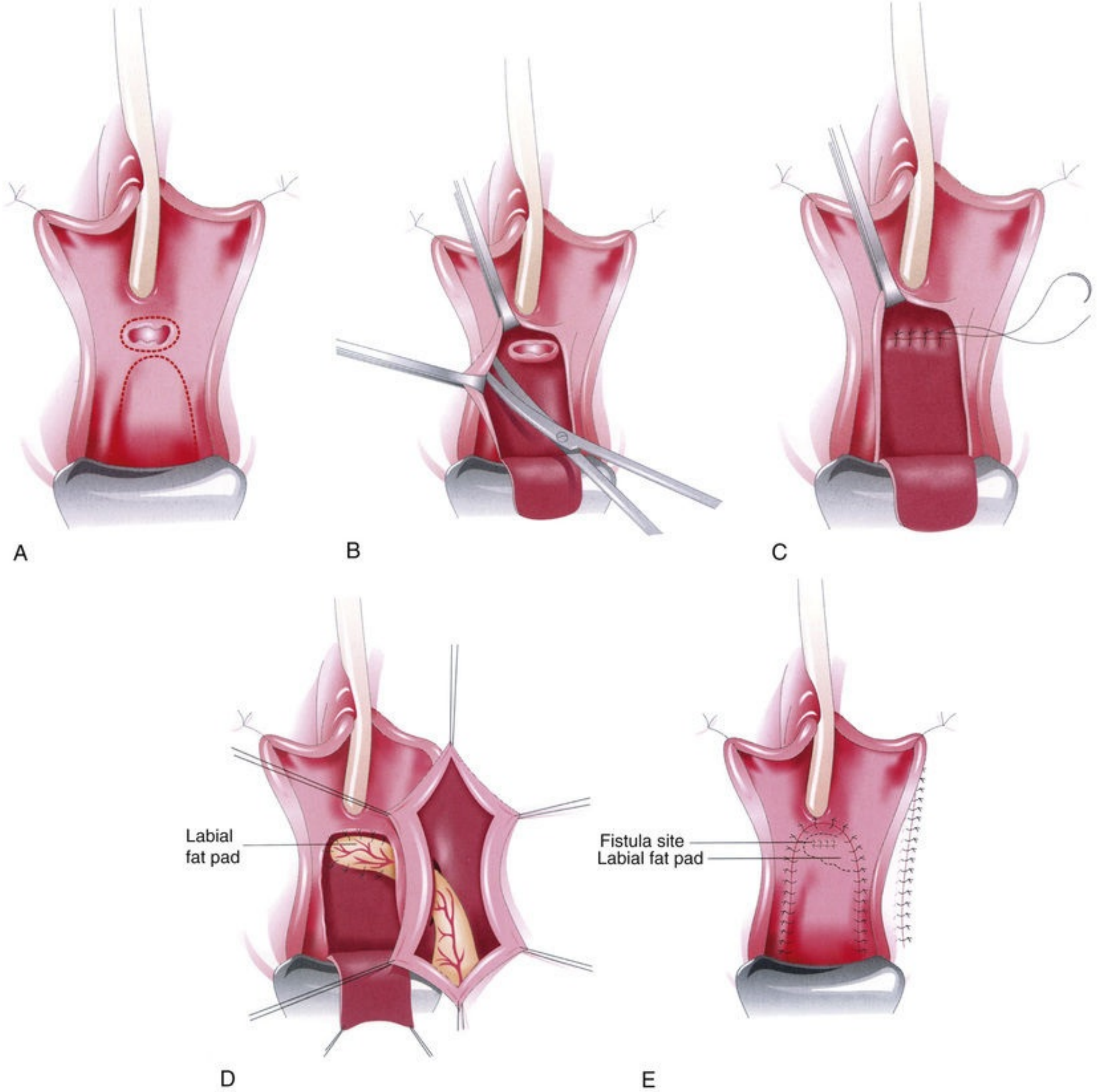

FIG. 129.36 Operative diagram of urethrovaginal fistula repair. (A) Inverted U incision is made in the anterior vaginal wall with the base of the U at the proximal margin of the fistula. The fistula is circumscribed. (B) The anterior vaginal wall flap is mobilized, exposing the periurethral fascia. Dissection is also carried out laterally and distally from the margins of the fistula. The edges of the fistula tract are not excised. (C) The epithelialized margins of the fistula tract are reapproximated with absorbable suture for the initial layer of closure. The periurethral fascia may be closed as a second layer, imbricating the initial layer of closure (not shown). (D) A Martius flap may be harvested from the labia majora and tunneled as an additional layer of closure. (E) The anterior vaginal wall flap is advanced over the closure and secured with absorbable suture. (From Leach GE, Kobashi KC: Urethral diverticulum and fistula. In: Cardozo L, Staskin D, editors. *Textbook of female urology and urogynecology*, London, 2001, Isis Medical Media, pp 721–745.)

The edges of the circumscribed tract are reflected over the fistula and apposed with absorbable suture to create the first layer of closure. The periurethral fascia is then reapproximated in a perpendicular suture to the first layer of closure, thereby minimizing overlap. At this point, a Martius flap or other adjuvant flap can be secured over the periurethral fascia. Finally, the anterior vaginal wall flap is brought over the repair, including a Martius flap if used, and secured beyond the original fistula tract.

Suprapubic as opposed to urethral catheterization postoperatively for at least 14 days to allow adequate healing has been suggested (Tehan et al., 1980), although the use of only a single drainage catheter postoperatively is not universally agreed on. Other authors use a suprapubic and a urethral catheter (Leach, 1991). Anticholinergics are administered liberally to reduce bladder irritability. Usually a VCUG with contrast administered through the suprapubic tube is obtained to document resolution of the fistula.

SUI may persist after repair of urethrovaginal fistulae. Whether repair of SUI should be done concomitantly with the fistula surgery or should be deferred until after repair of the fistula is controversial. Blaivas (1989) argued that sphincteric incontinence should be repaired at the time of fistula surgery, with a Martius flap interposed between the fistula repair and a pubovaginal fascial sling. Webster et al. (1984) suggested that SUI associated with a proximal or mid-urethral urethrovaginal fistula should not be corrected until the fistula is closed and the patient reassessed for persistent incontinence. These authors suggest, however, that SUI associated with distal urethrovaginal fistula can be repaired concomitantly.

Overall, the success rate of urethrovaginal fistula repair is variable but is not generally considered to be as high as that for VVF repair (Gerber and Schoenberg, 1993). Not uncommonly, two or more procedures may be necessary to achieve a satisfactory result (Webster et al., 1984).

Key Points: Urethrovaginal Fistulae

- Distal urethrovaginal fistulae are often asymptomatic, whereas proximal fistulae may cause intermittent or constant urinary leakage.
- Urethrovaginal fistulae caused by surgical trauma may be difficult to visualize on physical examination or cystoscopy.

- Diagnosis of a urethrovaginal fistula is best made with VCUG.
- Repair of urethrovaginal fistulae can be challenging and often involves an interpositional tissue flap because of the relative lack of surrounding connective tissue in the mid-urethra and distal urethra.

Uroenteric Fistulae

Etiology and Presentation

The most common non-obstetric causes of fistula involving the gastrointestinal tract are diverticular disease, Crohn disease, and malignant disease or its treatment (Chadha et al., 2008). **Less common causes include radiation, infection, and trauma (external penetrating trauma), as well as iatrogenic surgical trauma.** There are few data on the incidence of fistula formation in these conditions, although published estimates are in the range of 2% to 6% in Crohn disease (Ben-Ami et al., 2002; Greenstein et al., 1984; Margolin and Korelitz, 1989) and 20% in diverticular disease (Woods et al., 1988).

The peak incidence of vesicoenteric fistula occurs at 55 to 65 years of age, although fistulae from Crohn disease manifest much earlier (Badlani et al., 1980). Approximately 2% of patients with diverticulitis may experience a colovesical fistula as a complication of their disease (Hafner et al., 1962). In a multi-institutional retrospective review of 400 patients with Crohn disease over a 10-year period, 8 patients (2%) were found to have enterovesical fistulae, 7 had ileovesical, and 1 had colovesical fistulae (Gruner et al., 2002). The underlying GI tract disease strongly influences the type of fistula (Najjar et al., 2004); **ileovesical fistulae are more common in Crohn disease than in cancer, and colovesical fistulae are usually a result of diverticulitis.**

Intestinal fistulae in Crohn disease most typically involve the small bowel, although communication with urinary tract and large bowel are also found; involvement of the bladder was reported in 27% and of the colon in 14% in one series (Glass et al., 1985). Three large series examining the urologic complications in association with Crohn disease reported that although a majority of patients were female, the most serious complications were seen in males; most significantly, 30 of 31 or 93% of the ileovesical fistulae described in these series were in men (Ben-Ami et al., 2002; Kyle, 1980; Saint-Marc et al., 1995).

Although clearly diverticular disease involves the large bowel primarily in all cases, diverticular fistulae have been reported to communicate with the bladder in 65% of cases, the vagina or uterus in 28%, and small bowel in 7% (Woods et al., 1988). Diverticular disease is the most common cause of colovesical fistula in most reports, accounting for up to 75% of cases (Ferguson et al., 2008; Garcea et al., 2006; McBeath et al., 1994; Mileski et al., 1987; Najjar et al., 2004; Pokala et al., 2005; Pollard et al., 1987; Schofield, 1988), with colon cancer, bladder cancer, radiotherapy, and Crohn disease accounting for the remainder (Golabek et al., 2013).

Previous hysterectomy appears to be a significant factor in the incidence of fistula associated with diverticular disease (Bahadursingh and Longo, 2003). In a national case-controlled study from Sweden involving a total of 783,245 women over a 30-year period, the risk of undergoing fistula surgery increased 4-fold in hysterectomized women without diverticulitis, 7-fold in women with diverticulitis without hysterectomy, and 25-fold in hysterectomized women with diverticulitis (Altman et al., 2010; Table 129.3).

TABLE 129.3

Causes of Vesicoenteric Fistulae

Diverticulitis	65%–75%
Malignancy	10%–15%
Crohn disease	5%–6%
Other (trauma, appendiceal abscess, foreign body)	<5%

Data from Morse and Dretler, 1974; Amendola et al., 1984; Pollard et al., 1987; Schofield, 1988; Walker et al., 2002.

Symptoms of vesicoenteric fistulae may originate from the urinary or GI tract; however, in general, lower urinary tract symptoms are more common at presentation (Morse and Dretler, 1974). In the early stages, symptoms are nonspecific and relate to lower urinary tract dysfunction. Lower urinary tract symptoms include pneumaturia, frequency, urgency, suprapubic pain, recurrent urinary tract infections (UTIs), and hematuria (Table 129.4). **Pneumaturia is considered the most common presenting symptom noted in 50% to 70% of cases** (Morse and Dretler, 1974; Solem et al., 2002). GI symptoms may include fecaluria and tenesmus. **The classic presentation of vesicoenteric fistula is described as Gouverneur syndrome and consists of suprapubic pain, urinary frequency, dysuria, and tenesmus** (Chebli et al., 2014; Vidal Sans et al., 1986). Recurrent UTIs or cystitis refractory to antibiotic therapy may suggest a colovesical fistula (Rao et al., 1987). Although it is rare for enterovesical fistulae to have sepsis as the presenting sign (Woods et al., 1988), patients with sepsis are found to have urinary obstruction in approximately 70% of cases (Mileski et al., 1987).

TABLE 129.4

Presenting Symptoms of Vesicoenteric Fistulae

Pneumaturia	52%–77%
Fecaluria	36%–51%
Urinary tract infection symptoms (frequency, urgency, dysuria)	44%–45%
Fever and chills	41%
Abdominal pain	25%
Nonspecific gastrointestinal symptoms	25%
Hematuria	5%–22%
Orchitis	10%
Urine per rectum	5%

Data from Morse and Dretler, 1974; Pontari et al., 1992; Najjar et al., 2004.

Pyeloenteric Fistulae

Pyelointestinal fistulae represent an epithelialized connection between the renal pelvis or collecting system of the kidney and the GI tract. **Chronic inflammatory disease, such as xanthogranulomatous pyelonephritis or other infectious diseases involving the kidney or bowel, historically has been the most common cause of this condition** (Hui Wu et al., 2014; Majeed et al., 1997; Yildiz et al., 1993)**. However, iatrogenic surgical trauma, especially that related to percutaneous renal surgery and percutaneous nephrolithotomy (PCNL), has been associated with an increasing number of such fistulae** (Padovani et al., 2015; Un et al., 2015; Fig. 129.37). Penetrating external trauma, malignancy, ulcer disease, ingested foreign bodies, and complex calculous disease may also result in pyeloenteric fistulae (Atalla et al., 2009; Cooper et al., 1997, Hernandez et al., 2007; McDougal and Persky, 1972). **Right-sided pyeloenteric fistulae most often involve the duodenum because of their close anatomic relationship, whereas left-sided pyeloenteric fistulae most commonly involve the descending colon.**

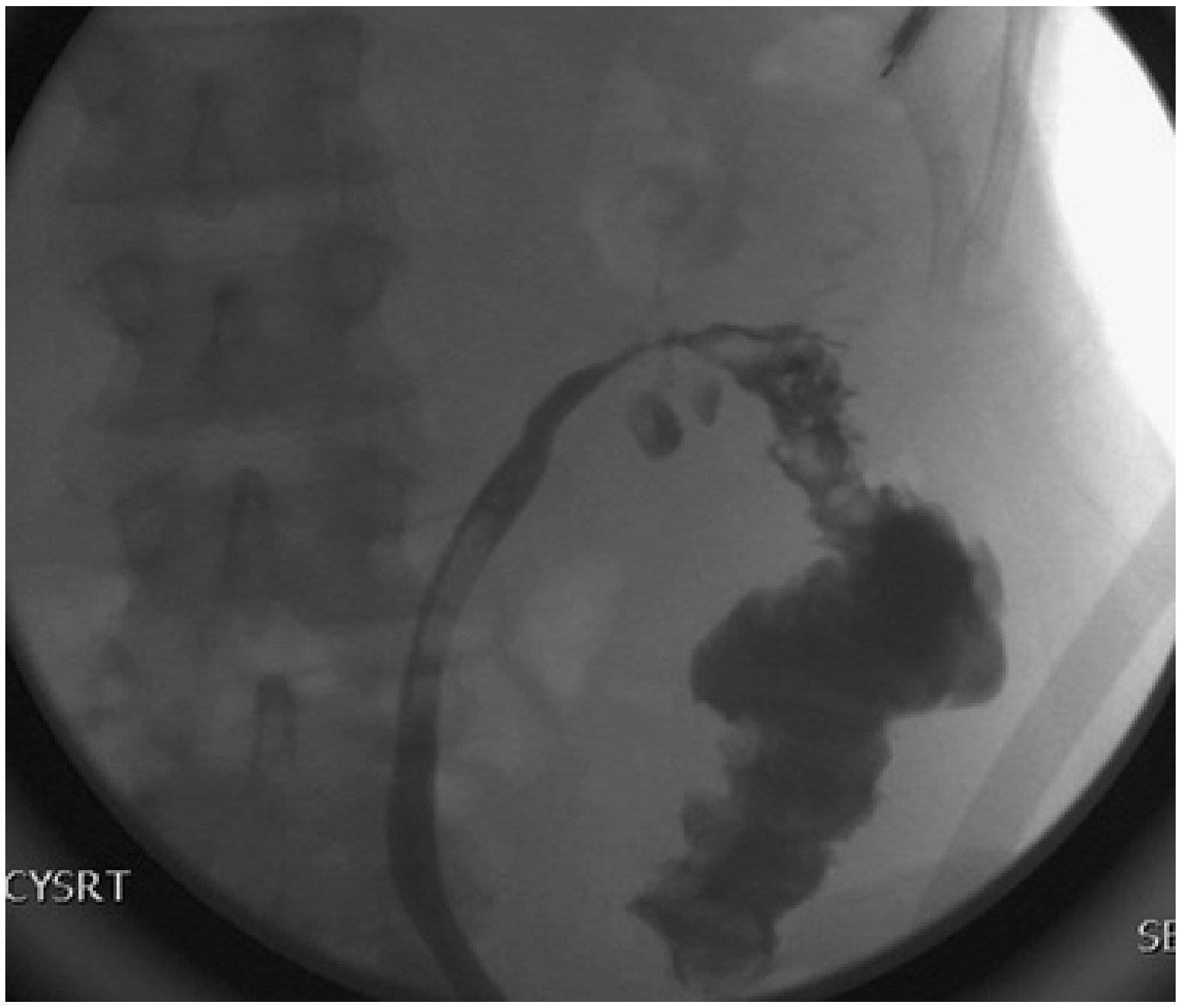

FIG. 129.37 Pyelocolonic fistula after cryosurgical ablation of a renal tumor. Retrograde pyeloureterogram demonstrates contrast extravasation into the colon.

Diagnosis

Many studies exist for the diagnosis of enterovesical fistulae; however, there are significant problems with false negatives and false positives among the diagnostic modalities, and thus the diagnosis is often made on clinical grounds. **Cystoscopy has the highest yield in identifying a potential lesion, with some type of abnormality noted on endoscopic examination in more than 90% of cases** (Morse and Dretler, 1974; Fig. 129.38). **However, the findings on cystoscopy are often nonspecific and include localized erythema, papillary, or bullous change; a definitive diagnosis using cystoscopy can be made in only 35% to 46% of cases** (Pontari et al., 1992; Woods et al., 1988). Cystoscopy and biopsy of abnormal-appearing tissue or an established fistula tract in the setting of a history of malignancy are indicated to evaluate for the possibility of a malignant fistula.

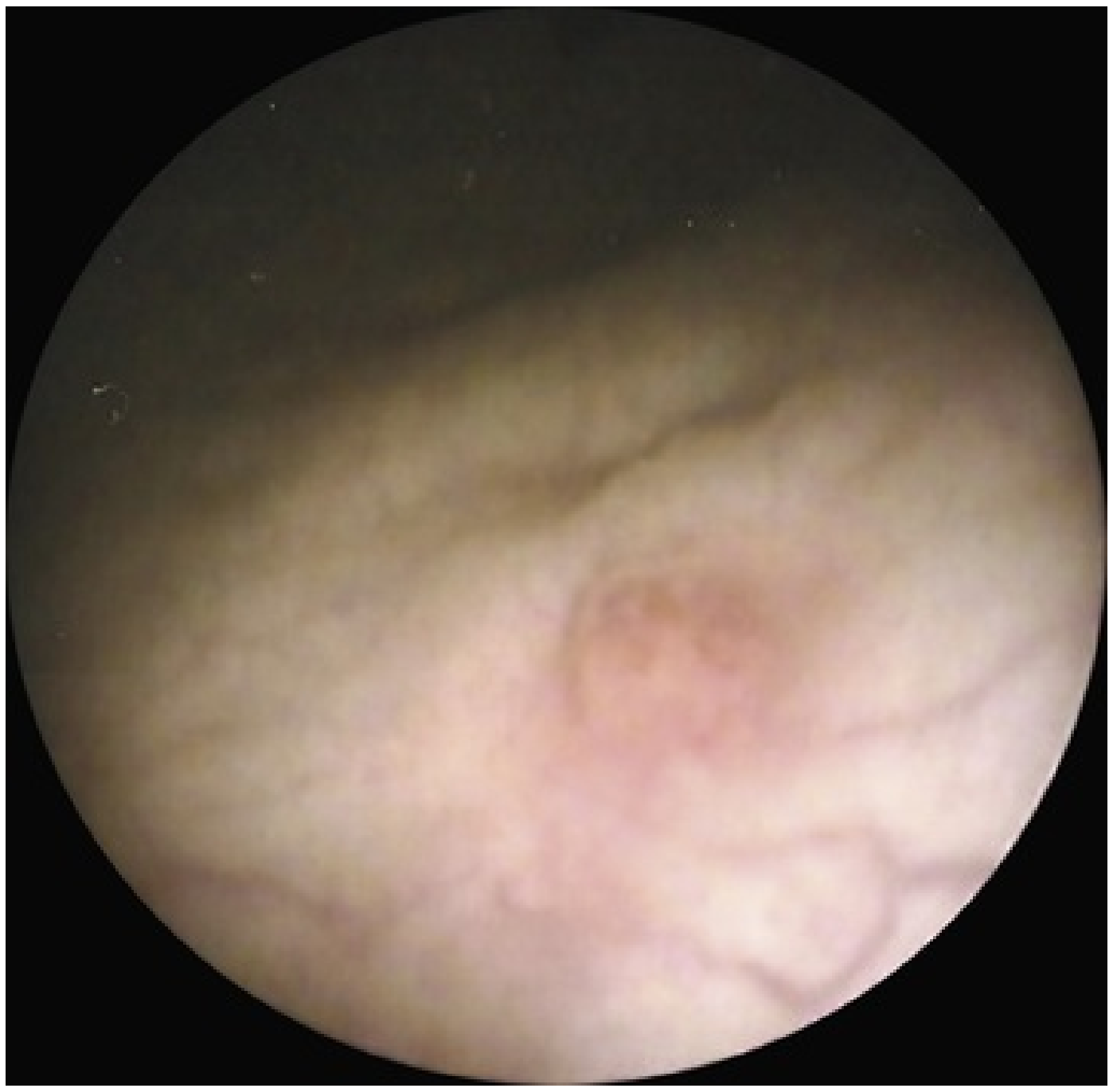

FIG. 129.38 Cystoscopic view of a chronic long-standing colovesical fistula. Unlike the majority of these fistulae, there is minimal inflammation around the fistula tract.

Cross-sectional imaging, especially CT scanning, has become the imaging modality of choice (Golabek et al., 2013). **The triad of findings on CT that**

are suspicious for colovesical fistulae consist of (1) bladder wall thickening adjacent to a loop of thickened colon, (2) air in the bladder (in the absence of previous lower urinary manipulation), and (3) the presence of colonic diverticula (Fig. 129.39). Ultrasonography has also been reported to be useful in the diagnosis of colovesical fistulae. A characteristic "beak" sign may be noted; however, this study is not usually performed in the routine evaluation of the patient with a suspected enterovesical fistula (Chen et al., 1990).

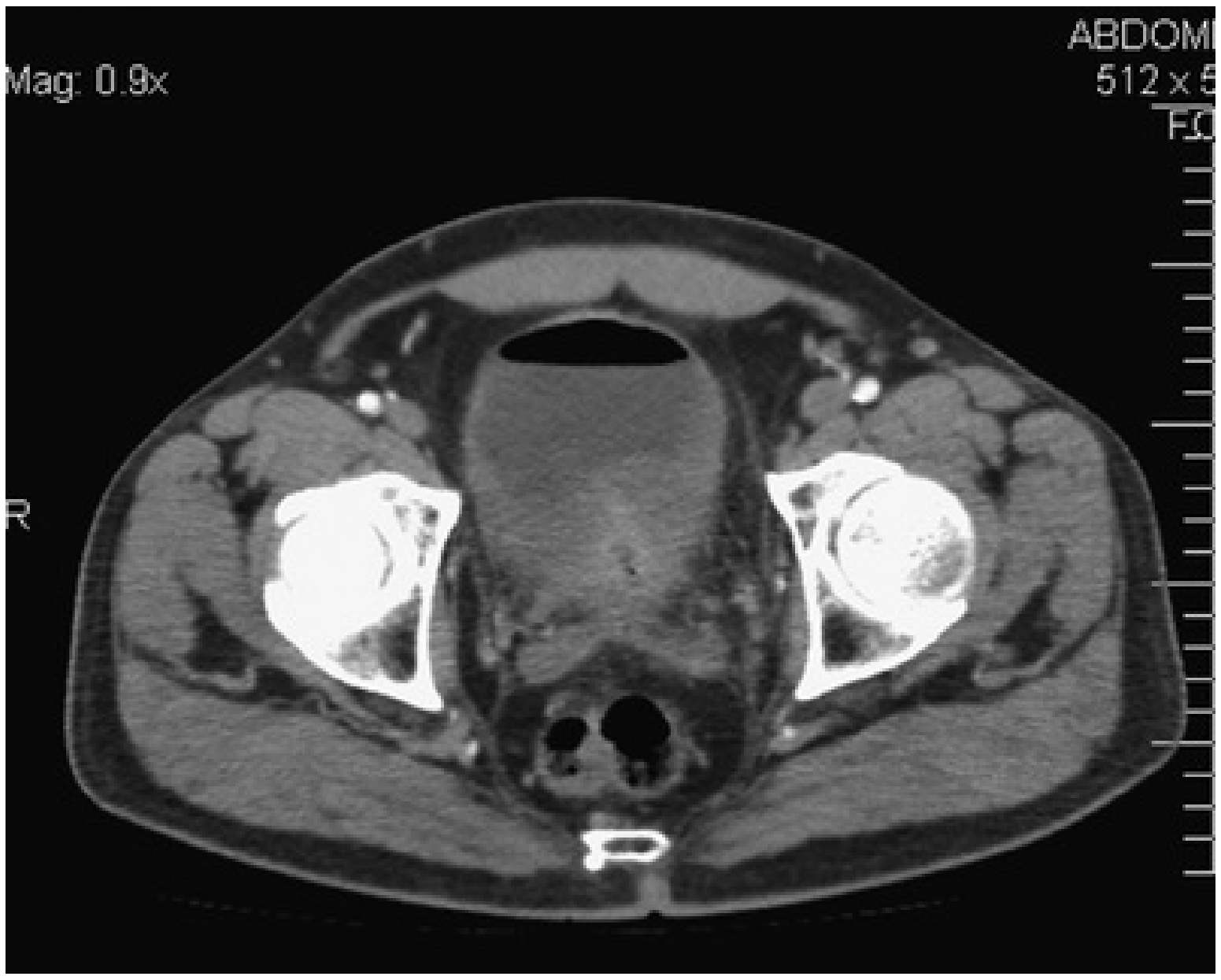

FIG. 129.39 Computed tomography scan of colovesical fistula. Note the air in the bladder with the thickened posterior bladder wall.

Cystography and transrectal contrast studies (e.g., barium enema) are in general less likely to demonstrate the fistula (Pindoria et al., 2014).

Management

Nonoperative management is a viable option in selected patients with vesicoenteric fistula. Solkar et al. (2005) and Radwan et al. (2013) reported on more than 80 patients that were diagnosed with CVF. Those managed conservatively were older and more frail. At 1 and 3 years after diagnosis there was no difference in mortality between these two groups (Radwan et al., 2013; Solkar et al., 2005). **In nontoxic, minimally symptomatic patients with nonmalignant causes of enterovesical fistulae, a trial of medical therapy**

including intravenous total parenteral nutrition, bowel rest, and antibiotics may be warranted. This may be the preferred initial approach, especially in patients with Crohn disease, in whom the notion of immediate exploratory laparotomy and bowel resection is often discouraged because of the chronic relapsing nature of the disease (Evans et al., 2003)**. There is also the potential for successful medical management of other fistulae resulting from inflammatory bowel disease** (Mahadevan et al., 2003). Ileovesical fistula in Crohn disease may be managed with antibiotics, nutritional support, often including total parenteral nutrition, and various combinations of immunomodulatory agents. In a nonsystematic review of the management of internal fistulae in Crohn disease, Levy and Tremaine (2002) described the drugs that have been reported to close internal fistulae partially or completely, including azathioprine, 6-mercaptopurine, mycophenolate mofetil, cyclosporine A, tacrolimus, and infliximab.

One case series of 500 patients with Crohn disease included 17 with enterovesical fistulae; all received sulfasalazine, most were treated with corticosteroids and antibiotics intermittently, and 8 in addition received 6-mercaptopurine. Although it is not clear that their fistulae closed completely, 6 continued on medical treatment alone for several years (Margolin and Korelitz, 1989).

Present et al. (1999) reported a placebo-controlled randomized trial of the tumor necrosis factor-α (TNF-α) neutralizing agent infliximab, a murine-human chimeric monoclonal antibody that binds the soluble subunit and the membrane-bound precursor of TNF-α, in patients with externally draining fistulae associated with Crohn disease. Adverse events were very common, but complete resolution of all fistulae was achieved in 55%, and 50% reduction in fistulous drainage was achieved in 68% of patients on 5-mg infliximab. This study did not include intestinovesical fistulae, although a case of successful use of infliximab in an ileovesical fistula has been reported (Game et al., 2003).

The goal of operative management is to separate and close the involved organs with minimal anatomic disruption and normal long-term function of both systems. Unfortunately, enterovesical fistulae may be complicated by intense pelvic inflammation, pelvic abscess, and phlegmon formation (in some cases), requiring complex staged reconstructions (Shackley et al., 2000). Bowel resection and/or partial cystectomy may be necessary to obtain viable tissue margins to ensure adequate, watertight closure of the involved viscera. An interpositional flap of greater omentum is often placed between the repaired bowel and urinary bladder to prevent overlapping suture lines and provide a well-vascularized surface for healing.

Single and multistage procedures have been advocated, depending on the clinical circumstances (Harris et al., 2017; Mileski et al., 1987; Morse and Dretler, 1974). A one-stage procedure involves removal of the fistula, closure of the involved organs, and primary reanastomosis of the bowel after resection of the involved bowel segment. A two-stage approach advocates removal of the fistula, closure of the involved organs, and creation of a temporary proximal diverting colostomy, with a later return to the operating room for colostomy takedown once the fistula tract has been demonstrated to be closed. **The choice of whether to proceed with a one-stage or two-stage repair is influenced by the location and cause of the fistula, the patient's general condition, the presence of a pelvic abscess, and the presence of colonic obstruction**. **Patients with an inflammatory cause of the fistula but without gross contamination can be treated with a one-stage procedure, whereas those with an unprepared bowel, gross contamination, or abscess may require a multistage procedure** (Mileski et al., 1987). As noted previously, most patients with colovesical fistulae present themselves electively with lower urinary tract symptoms, not emergently in extremis with sepsis. Therefore adequate preoperative support, eventually including bowel preparation, nutritional supplementation, and appropriate antibiotics, can be used in the majority of patients, allowing an elective one-stage approach.

The authors of many case series have advocated a one-stage approach in the majority of cases but have indicated that this should be limited to patients whose nutritional state is good and in whom there is no evidence of severe inflammation, radiation injury, advanced malignancy, intestinal obstruction, major medical problem, or advanced age. More recent series have tended to imply a greater advocacy of the one-stage approach; Garcea et al. (2006) in a series of 90 patients with colovesical fistula reported primary anastomosis in 61 of 65 (94%) cases wherein left colon resection was undertaken. Balaguera et al. (2006) argued against diverting colostomy or Hartmann procedure as being unnecessary and possibly resulting in additional morbidity.

In addition to the aforementioned criteria, it is intuitive that the more complex a fistula tract, the more relevant a phased approach to treatment becomes. Shackley et al. (2000) described a series of 10 patients with highly complex fistulae involving 3 to 6 separate organs and surfaces. They advocate a three-stage multidisciplinary management package, involving (1) an acute stage involving proximal defunctioning and distal drainage of the GI and urinary tracts to isolate the fistula, together with the eradication of sepsis; (2) a recovery stage consisting of total parenteral nutrition, organ support, radiologic planning of surgical reconstruction, and intensive nursing; (3) joint urologic and GI reconstructive surgery when the patient was stable and nutritionally replenished and the sepsis was controlled. The mean time to reconstruction was 5 (1 to 20) months; the fistulae were treated successfully in all patients, with functional restoration in 4 and/or diversion of the GI and urologic tracts in 6 (Shackley et al., 2000).

Laparoscopic management of colovesical fistulae has been reported, albeit with a relatively high rate of conversion to open repair (Badic et al., 2017; Marcucci et al., 2017). Several reports have described a laparoscopic approach to one-stage treatment of colovesical fistulae. The overall conversion rate was seen to be higher for fistulae involving the duodenum, vagina, and sigmoid colon than for those involving the bladder (10%), although a low threshold for conversion to open surgery was advocated in one series (Pokala et al., 2005).

Key Points: Vesicoenteric Fistulae

- The most common cause of vesicoenteric fistulae is diverticulitis.
- Presenting symptoms are usually urinary, most commonly pneumaturia.
- Diagnosis is generally made with a combination of cystoscopy and cross-sectional imaging, including a CT scan.
- Repair of colovesical fistulae involves a single-stage or multistage procedure, depending on a number of clinical factors, including the presence of gross fecal contamination and infection.

Rectourethral Fistulae

Acquired rectourethral fistula (RUF) may occur in the male under a variety of clinical circumstances, including those related to prostatectomy for benign or malignant disease (Harris et al., 2017)**, cryotherapy, pelvic radiotherapy, anorectal surgery, external penetrating trauma** (Bukowski et al., 1995; Kucera et al., 2017), **urethral instrumentation** (Thompson and Marx, 1990), **locally advanced prostatic or rectal malignancy, infection** (e.g., TB) (Okaneya et al., 1988), **ruptured prostatic abscess, or inflammatory disease (e.g., Crohn disease)**.

Etiology and Presentation

The incidence of RUF after radical retropubic, laparoscopic, or robotic prostatectomy (RRP) is low, but because of the frequency with which the operation is performed, it is the most common cause of RUF in most modern series (Buckley, 2011; Masuda et al., 2010; Wedmid et al., 2011; Yildirim et al., 2012**)**. **Rectal injury during radical prostatectomy occurs in less than 1% to 2% of patients** (Borland and Walsh, 1992; Guillonneau et al., 2003). In a Mayo RRP series, there were 27 documented rectal injuries in 2212 patients (McLaren et al., 1993). In this series, 26 of 27 injuries were recognized intraoperatively and repaired. Six patients underwent temporary colostomy, and 4 patients developed RUF. Guillonneau et al. (2003) reported a 1.3% incidence of rectal injury in 1000 consecutive patients undergoing laparoscopic radical prostatectomy. In a German series of 2447 radical prostatectomies, the incidence of RUF was 0.53%. The risk of rectourethral fistulas was 3.06-fold higher (P = 0.074) for perineal (7 of 675, 1.04%) than for retropubic prostatectomy (6 of 1772, 0.34%). In robotic radical prostatectomy the incidence of RUF was 0.17% (11 in 6650 cases) in a multicenter study by Wedmid et al. and 0.2% in a series of 4440 patients. Cases in which rectal injury was identified intraoperatively required fewer surgical repeat interventions but ultimately each group had acceptable long-term urinary and bowel function results (Kheterpal et al., 2011; Wedmid et al., 2011).

In the setting of radical prostatectomy, a prior history of pelvic radiation therapy, rectal surgery, or transurethral resection of the prostate (TURP) is associated with an increased risk of RUF (Thompson and Marx, 1990). RUF that occurs after radical prostatectomy is usually seen at the vesicourethral anastomosis and is often caused by an unrecognized rectal injury at the time of surgery. However, when a rectal injury is recognized and repaired intraoperatively, RUF is extremely uncommon. Borland and Walsh (1992) reported 10 rectal injuries in 1000 non-irradiated patients undergoing radical prostatectomy at Johns Hopkins Hospital; however, no patient developed an RUF. Nine of 10 patients had a two-layer closure performed with an omental interpositional flap at the time of injury. One patient underwent a temporary diverting colostomy; the rectal injury was diagnosed and repaired on postoperative day 2. Anal sphincter dilation was performed on all patients, and they received 7 to 14 days of postoperative antibiotics. Also in robotic series primary closure of RUF has been described with good outcome (Wedmid et al., 2011).

The reported incidence of RUF after cryosurgical ablation as primary therapy for localized carcinoma of the prostate is 0.5% to 5% (Hanna et al., 2014; Zippe, 1996). Partial gland cryotherapy yields less RUF than total gland cryotherapy (0 vs. 1.2%) (Tay et al., 2016, 2017). The **rate of RUF after cryotherapy as salvage therapy for prostate cancer is somewhat higher at approximately 3.3% to 9%** (Vora et al., 2016). **The incidence of RUF after brachytherapy for prostate cancer as reported by** Theodorescu et al. (2000) **is 0.4%.** RUFs have also been reported to follow high-intensity focused ultrasound (HIFU) treatment (Uchida et al., 2015), HIFU combined with external beam radiotherapy (6% incidence) (Gelet et al., 2004; Uchida et al., 2011), laparoscopic radical prostatectomy (Guillonneau et al., 2003), and transurethral thermotherapy for benign prostatic hyperplasia (BPH) (Norby and Frimodt-Moller, 2000). The incidence of RUF in Crohn disease is estimated to be approximately 0.3% (Fig. 129.40). Fistulae caused by Crohn disease are complex, and management should be individualized (Cools et al., 1996; Zwintscher et al., 2015).

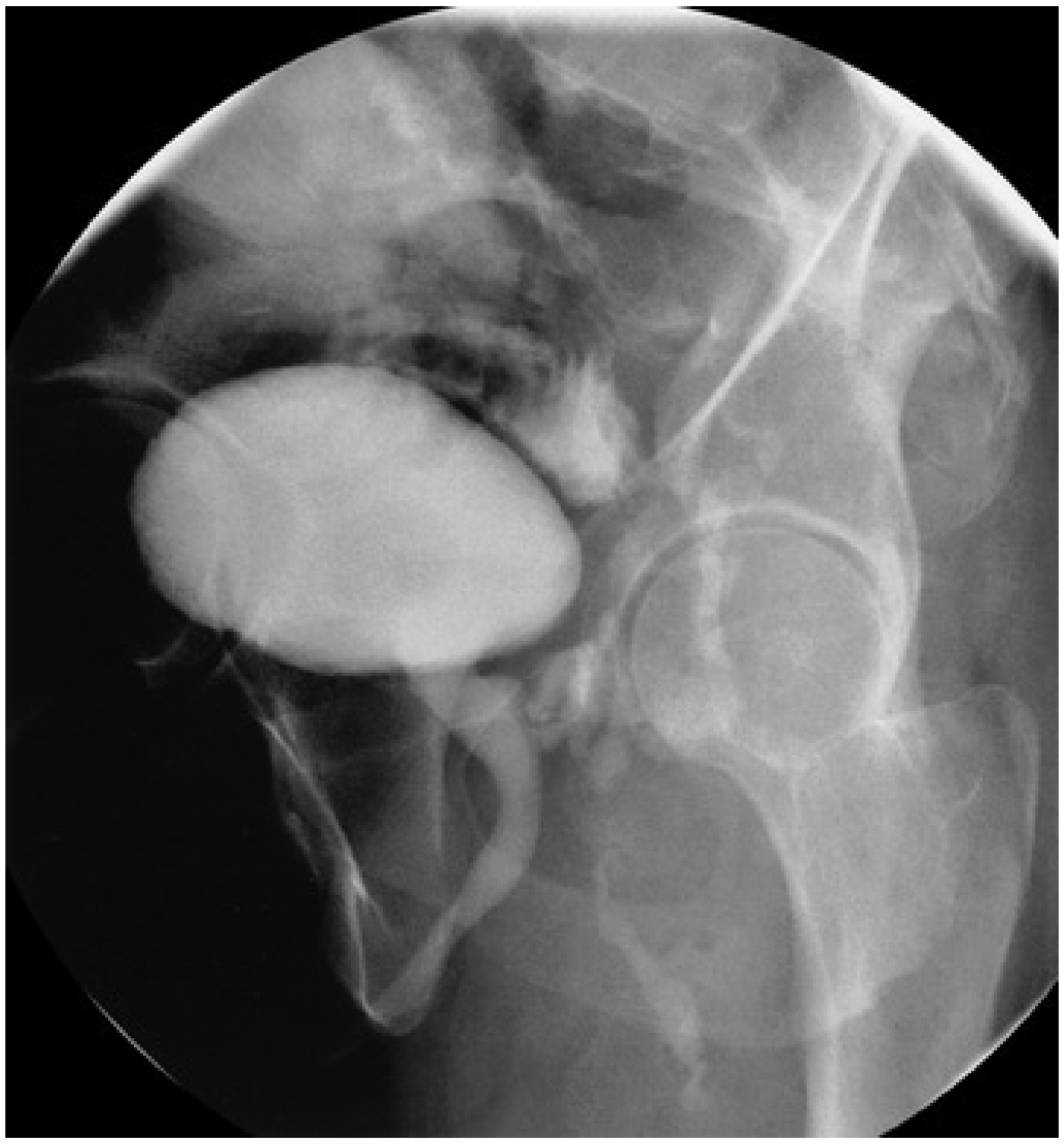

FIG. 129.40 Rectourethral fistula caused by Crohn disease. Contrast material is seen posterior to the bladder on this voiding image from voiding cystourethrography. (Courtesy Nancy Curry, MD, Department of Radiology, Medical University of South Carolina, Charleston, SC.)

The presentation of RUF is variable. **Symptoms may include fecaluria, hematuria, UTI, nausea, vomiting, and fever.** Peritonitis and sepsis may occur as well. Digital rectal examination often permits palpation of the fistula tract along the anterior rectal wall. **Cystoscopy and sigmoidoscopy visualize the fistula tract in the majority of cases and provide a mechanism for biopsy. In patients with a history of pelvic malignancy, biopsy of the fistula is suggested to evaluate for a local recurrence of the tumor** (Shin et al., 2000). A VCUG or retrograde urethrogram (RUG) usually provides a definitive diagnosis of RUF (Fig. 129.41). The exact anatomic location and size of the fistula are also usually well delineated on the VCUG or RUG, providing important information in surgical planning. Lateral projections may be necessary to visualize small fistulae, because contrast in the rectum or urethra can sometimes obscure extremely thin fistulous tracts (Karsten et al., 2016). Also PET/CT and MRI have a place in the imaging of RUF (Nguyen and Collins, 2011). **Upper tract imaging should be performed in patients with RUF to exclude a related ureteral injury. It is important to make an assessment of continence and sphincteric function in patients with RUF after radical**

prostatectomy. Given the location of most RUFs at or near the vesicourethral anastomosis and the membranous urethra, there is a risk for persistent severe stress incontinence postoperatively after RUF repair (Harris et al., 2017; Keller et al., 2015). In many patients with RUF and severe stress incontinence, closure of the RUF may not be sufficient to bring about continence. Additional procedures may be needed to bring about a satisfactory result in these patients; this is an important issue to discuss in preoperative patient counseling. Artificial sphincters are a feasible option after RUF repair (Selph et al., 2015).

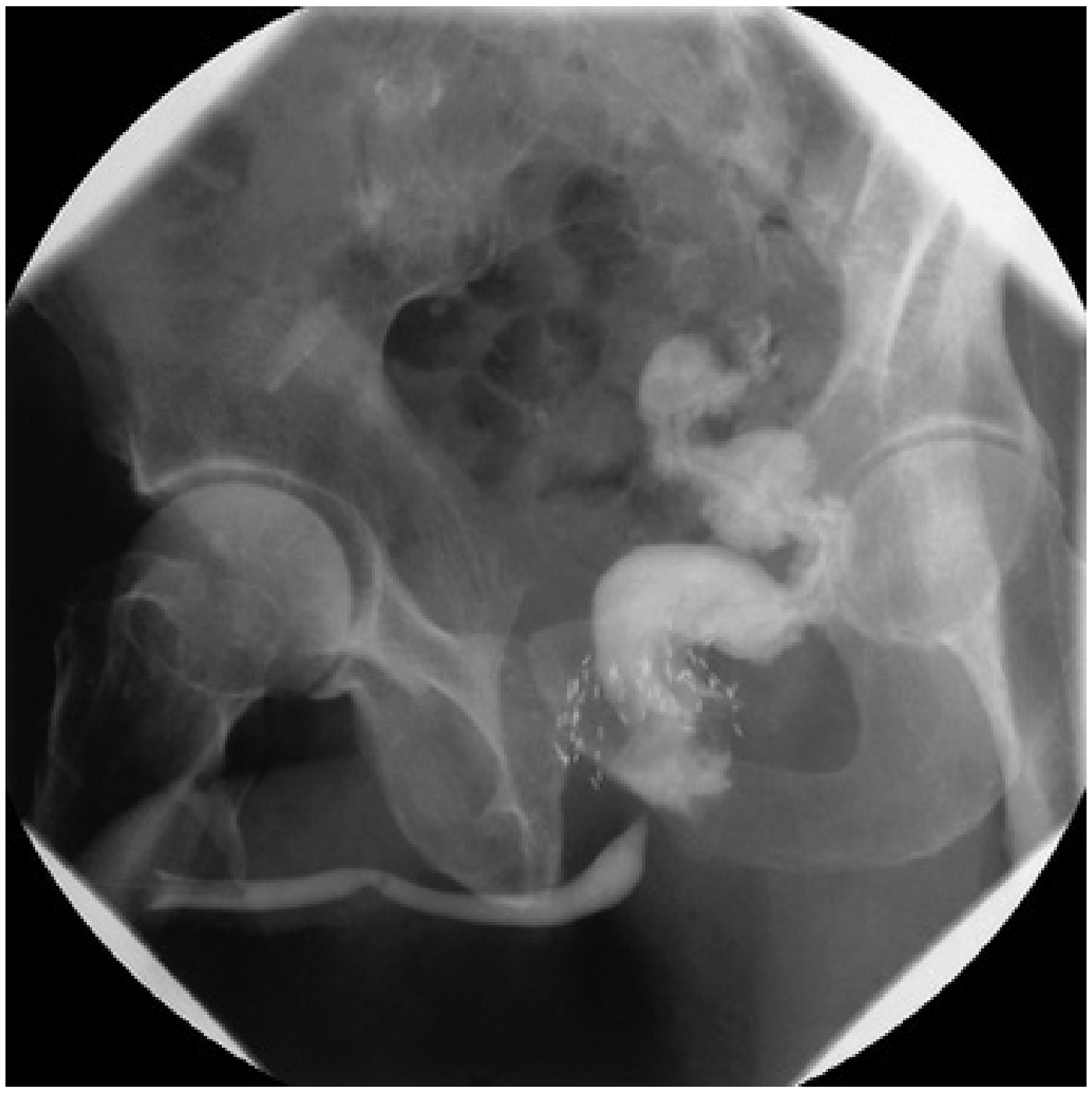

FIG. 129.41 Rectourethral fistula after brachytherapy for carcinoma of the prostate. A retrograde urethrogram demonstrates filling of the rectum in this patient who was seen several years after brachytherapy with fecaluria. The bladder is not opacified. The brachytherapy seeds can be seen in the area of the prostate.

A large patient cohort was published by Harris et al. (2017). After prostate cancer treatment 201 patients underwent rectourethral fistula repair. The fistula developed in 97 men (48.2%) after radical prostatectomy alone and in 104 (51.8%) who received a form of energy ablation. In the ablation group 84% of patients underwent bowel diversion before rectourethral fistula repair compared with 65% in the prostatectomy group. An interposition flap or graft was placed in 91% and 92% of the 2 groups, respectively. Concomitant bladder neck contracture or urethral stricture developed in 26% of patients in the ablation group and in 14% in the prostatectomy group. Postoperatively the rates of urinary incontinence and complications were higher in the energy ablation group at 35% and 25% versus 16% and 11%, respectively. The ultimate success rate of fistula repair in the energy ablation and radical prostatectomy groups was 87% and 99% with 92% overall success (Harris et al., 2017).

Thirty males (mean age 63 years) were reviewed. Prostate cancer treatment was the most common fistula cause (97%). Urinary drainage consisted of urethral catheter in all patients and suprapubic catheter in 14 (47%). The rate of fecal diversion was 67%. During a mean follow-up of 72 months, healing rate was 90% and recurrence rate 0. Spontaneous healing was achieved in 14 patients (47%): 8 (27%) without fecal diversion and 6 (20%) after fecal diversion. Thirteen patients (43%) required definitive intervention. The majority of operated patients underwent transanal or transperineal flap (endorectal, dartos, or gracilis) successfully. Only 2 patients (7%) required an abdominal approach (positive oncologic margins or nonfunctioning bladder). Fifteen out of the 20 patients (75%) who underwent fecal diversion had stoma closure with an overall permanent stoma rate of 17%. Long-term urinary incontinence was noted in 11 patients (37%). Six patients (20%) required permanent urinary diversion or drainage catheters. Algorithm-based treatment approach for rectourethral fistula is useful in the management of this rare condition. Selective fecal diversion is possible, and majority of patients who require definitive intervention can be treated with a transanal or transperineal approach. The rate of permanent stoma is low, but long-term urinary dysfunction is frequent (Keller et al., 2015).

Management

Most RUFs require surgical repair (Hanna et al., 2014; Harris et al., 2017), although it is clear that some close with conservative management. **RUF that follows open or laparoscopic prostatectomy may heal spontaneously with catheter drainage, bowel rest, and intravenous hyperalimentation. In some cases, fecal diversion is necessary.** Rassweiler et al. (2003) reported that 6 of 8 RUF patients were treated successfully in such a manner. Two patients required a temporary colostomy. Masuda (2010) and Thomas et al. (2010) reported spontaneous closure with the use of a protective temporary colostomy.

Harris et al. (2017) reviewed 201 patients from 4 high-volume centers. The fistula developed in 97 men (48.2%) after radical prostatectomy alone and in 104 (51.8%) who received a form of energy ablation. In the ablation group 84% of patients underwent bowel diversion before rectourethral fistula repair compared with 65% in the prostatectomy group. An interposition flap or graft was placed in 91% and 92% of the 2 groups, respectively. Concomitant bladder neck contracture or urethral stricture developed in 26% of patients in the ablation group and in 14% in the prostatectomy group. Postoperatively the rates of urinary incontinence and complications were higher in the energy ablation group at 35% and 25% versus 16% and 11%, respectively. The ultimate success rate of fistula repair in the energy ablation and radical prostatectomy groups was 87% and 99% with 92% overall success (Harris et al., 2017).

An algorithm-based approach has been advocated by Keller et al (2015). Thirty males (mean age 63 years) were reviewed. Prostate cancer treatment was the most common fistula cause (97%). Urinary drainage consisted of urethral catheter in all patients and suprapubic catheter in 14 (47%). The rate of fecal diversion was 67%. During a mean follow-up of 72 months, healing rate was 90% and recurrence rate 0. Spontaneous healing was achieved in 14 patients (47%): 8 (27%) without fecal diversion, and 6 (20%) after fecal diversion. Thirteen patients (43%) required definitive intervention. The majority of operated patients underwent transanal or transperineal flap (endorectal, dartos, or gracilis) successfully. Only 2 patients (7%) required an abdominal approach (positive oncologic margins or nonfunctioning bladder). Fifteen out of the 20 patients (75%) who underwent fecal diversion had stoma closure with an overall permanent stoma rate of 17%. Long-term urinary incontinence was noted in 11 patients (37%). Six patients (20%) required permanent urinary diversion or drainage catheters.

Surgical repair of RUF can be challenging, and the basic tenets of operative fistula repair are especially relevant in these cases (see Box 129.2). Several surgical approaches have been advocated and are outlined later. **Single and staged repairs have been described for the repair of RUF.** The controversy surrounding the staged repair centers on the issue of whether to perform fecal diversion at all, or whether to perform it before or at the time of repair of the urinary tract. Some authors have advocated fecal diversion and staged repair of all RUFs (Shin et al., 2000). This is considered the standard conservative approach and, in combination with an indwelling urethral catheter, permits a trial of spontaneous healing of the fistula without open manipulation of the urinary tract. In support of the single-stage repair, a successful one-stage approach limits the potential morbidity and cost of multiple procedures that, by design, accompany the staged repair. **Suggested guidelines for cases in which a one-stage approach may be appropriate include surgically induced, small RUFs not associated with infection or abscess** (Harris et al., 2017; Thomas et al., 2010). **Staged repairs may be considered in cases of large fistulae, those associated with radiation therapy, uncontrolled local or systemic infection, immunocompromised states, or inadequate bowel preparation at the time of definitive repair.**

Transrectal approaches with and without division of the anal sphincter have been described for the operative repair of RUF. A recent systematic review by Hechenbleikner et al. (2013) identified 416 patients, including 169 (40%) who had previous pelvic irradiation and/or ablation. Most patients (90%) underwent 1 of 4 categories of repair: transanal (5.9%), transabdominal (12.5%), transsphincteric (15.7%), and transperineal (65.9%). Tissue interposition flaps, predominantly gracilis muscle, were used in 72% of repairs. The fistula was successfully closed in 87.5%. Overall permanent fecal and/or urinary diversion rates were 10.6% and 8.3%, respectively. Most high-volume centers (≥25 patients) performed transperineal repairs with tissue flaps in 100% of cases. Regardless of complexity, rectourethral fistulas have an initial closure rate approaching 90% when the transperineal approach is used. Permanent fecal and/or urinary diversion should be a last resort in patients with devastated, nonfunctional fecal and urinary systems.

The York-Mason procedure is a transrectal, transsphincteric approach that has been found to be effective and to have low morbidity. Classically, this is a staged repair with fecal diversion performed before repair of the RUF. However, in patients with small, nonirradiated fistulae, a single-stage approach can be used, provided that a vigorous bowel preparation and broad-spectrum antibiotics are used (Renschler and Middleton, 2003). For repair of the urinary tract, the patient is placed prone on the operating room table in the jackknife position. A full-thickness incision through the posterior anus and dorsal rectal wall is performed and deepened down to the level of the coccyx through the external anal sphincter. Care is taken to mark or tag each layer of the anal sphincter as it is divided. Later in the procedure during closure, careful anatomic reapproximation of the layers of the external anal sphincter is necessary to avoid the devastating complication of anal incontinence postoperatively. The anorectal incision as described provides excellent exposure of the fistula in the anterior rectal wall. The fistula tract is excised, and the anterior rectal wall is mobilized circumferentially around the fistula margins. The urethra is closed, and then the anterior rectal wall is closed. Finally, the rectal mucosa is reapproximated, providing a three-layer closure. Alternatively, after excision of the RUF, an anterior rectal wall flap can be developed and advanced over the fistula (al-Ali et al., 1997), similar to the transvaginal repair of VVF using the vaginal wall (see the previous discussion under VVF repair). Closure of the incision is performed by reapproximating the posterior rectal wall and then sequentially closing the layers of the anal sphincter in an anatomic fashion. Results with the York-Mason procedure have been excellent. In the largest series of patients undergoing the York-Mason procedure, Renschler and Middleton (2003) reported a successful repair in 22 of 24 patients. One of the two failures was subsequently repaired with another York-Mason procedure. No serious complications were reported, and no patient developed anal incontinence or anal stenosis. Similar excellent results have been noted by other authors (Forest et al., 2014; Hechenbleikner et al., 2013).

In contrast to the transrectal, transsphincteric approach, the **transanal approach** to RUF repair does not involve division of the anal sphincter. Exposure of the fistula is provided by dilation of the anus and fixed retraction. The Latzko procedure is one such approach (Hata et al., 2002). Similar to the Latzko method described previously for transvaginal VVF repair (see prior discussion), the fistula tract and surrounding rectal mucosa are denuded in all four quadrants. The fistula is then closed in three layers. The major disadvantage to this approach is the relatively poor exposure and lack of maneuverability within the operative field.

A **perineal approach** to RUF has been advocated by some authors in selected cases of RUF (Harris et al., 2017; Nyam and Pemberton, 1999; Zmora et al., 2003). Anatomically, this is a familiar approach for many urologists and has the added advantage of local access to a variety of potential interpositional flaps. Excellent results have been obtained with the perineal approach in combination with an interpositional flap, including gracilis muscle (Choi et al., 2014; Zmora et al., 2006) and pedicled Dartos muscle (Youssef et al., 1999). Transabdominal approaches to RUF have been described with limited success (Bukowski et al., 1995; Shin et al., 2000). The principal advantage of this technique is the availability of greater omentum for an interpositional flap. Potential disadvantages include the morbidity and prolonged postoperative convalescence associated with a laparotomy incision, poor exposure of the operative field (with limited maneuverability in the deep pelvis), and the risk of urinary and fecal incontinence.

The repair of RUF after external beam radiotherapy, **combined radiotherapy**, **brachytherapy, or cryosurgical ablation of the prostate can be especially difficult.** These fistulae may be large and are associated with considerable induration, fibrosis, and ischemia for a variable distance around the fistula, limiting reconstructive options. Repair of rectourethral fistulas caused by radiation has a significantly higher wound infection rate and median time to healing, and lower overall stomal reversal rate than nonradiation-induced rectourethral fistulas. Patients who had irradiated rectourethral fistulas required significantly more complex operations, likely contributing to the higher morbidity, mortality, and lower fistula closure rate (Hanna et al., 2014). In another group of 45 patients, those with prior radiation/ablation were significantly more likely to require permanent colostomy (25 of 29 [86%] vs. 0, $P < 0.0001$) and permanent urinary diversion as part of fistula management (27 of 29 [93%] vs. 1 of 16 [6%], $P < 0.0001$) (Linder et al., 2013). Similar findings were published by Beddy et al. (2013). Urinary reconstruction may not be possible in some of these cases, necessitating urinary diversion (Faris et al., 2014).

Key Points: Rectourethral Fistulae

- Rectourethral fistula is an uncommon outcome that results most commonly from the surgical treatment of localized prostate cancer.
- Diagnosis of RUF can be confirmed with VCUG.
- Treatment of RUF most commonly involves surgical repair; however, select patients may respond to conservative therapy, including Foley catheter drainage.

Urovascular Fistulae

Ureteroarterial fistulae are uncommon but can be life threatening because of massive bleeding in the ureter. They have a high mortality rate (Melegari et al., 2016). Predisposing factors are radiation therapy, vascular pathology, and ureteral stenting. Das et al. (2016) reviewed the literature and found 61 cases. In terms of treatment, endovascular stenting has emerged as an appealing initial modality and should be considered in stable patients with less favorable candidacy for open surgical intervention secondary to pre-existing comorbidities (Das et al., 2016).

Fistulae between the urinary tract and the vascular system are rare but have increased in frequency with the rapid integration of minimally invasive interventions in the upper urinary tract. These fistulae include communications between the upper urinary tract, including the collecting system or ureter, and an artery or vein.

Renovascular and Pyelovascular Fistulae

The most common causes of renovascular or pyelovascular fistulae are procedures in which percutaneous renal access is required, such as PCNL (Kyriazis et al., 2015**)**. Typically, these fistulae are created through puncture of an intrarenal vascular structure during creation or dilation of the nephrostomy tract. The damaged vessel may bleed on puncture or may not hemorrhage immediately because of external compression and tamponade from the catheter in the nephrostomy tract. However, on removal of the catheter, brisk bleeding may be noted into the relatively lower-pressure renal collecting system (Patterson et al., 1985). Alternatively, a long-term indwelling nephrostomy tube may lead to pyelovascular fistula formation. In this setting, a chronic indwelling large-bore nephrostomy tube may result in erosion into an adjacent renal vessel with resulting hemorrhage on removal of the tube. Lee et al. (1987) reported an 11.2% incidence of bleeding requiring transfusion and 1.2% incidence of bleeding requiring surgical or angiographic intervention after PCNL in 582 patients. Patterson et al. (1985) reported a vascular injury in 0.9% of 1032 patients undergoing percutaneous renal stone surgery. Other causes of renovascular fistula include external penetrating and blunt trauma (Stower et al., 1989), infection, and open renal surgery, including partial nephrectomy. Previous renal surgery is a risk factor (Yesil et al., 2013).

Patients with renovascular fistulae may have life-threatening hemorrhage and hypovolemic shock, or intermittent gross hematuria. After PCNL these fistulae may appear on removal of the nephrostomy tube with brisk bleeding out of the flank from the nephrostomy tube tract in combination with brisk hematuria, or they may manifest several days to weeks later with only hematuria (Clayman et al., 1984). CT scan is mostly used to make the diagnosis (Ganpule et al., 2013).

Treatment of renovascular fistulae is contingent on the presentation, cause, and hemodynamic stability of the patient. Patients with severe hemorrhage on removal of the nephrostomy tube can be temporized in some instances by replacing the tube, or, in large mature tracts, by placing a Foley catheter to tamponade the bleeding. In patients with ongoing bleeding, transcatheter angiographic embolization of the lacerated vessel is recommended. Even repeat arteriographic treatment can be necessary in case of persistent bleeding, which can be caused by missed pseudoaneurysm and the recanalization of the embolized vessels or new renal vascular lesion. The cause of these new renal vascular lesions is unknown. The lesion may be missed during the initial arteriography because of arterial spasm. Progressive deterioration of the injured vessel integrity could be the other possibility (Zhaohui et al., 2016).

Occasionally, flank exploration is necessary with partial or simple nephrectomy to control hemorrhage.

Ureterovascular Fistulae

Rarely reported before the advent of indwelling ureteral stents, ureterovascular fistulae are becoming increasingly common. **Most reported ureterovascular fistulae are ureteroiliac artery fistulae, although ureteroiliac vein fistulae have been reported as well** (Teuton et al., 1987). Ureteroaortic fistulae (and perigraft fistulae) are rare and have a high mortality (Deem et al., 2007; Nomoto et al., 2009; Ota et al., 2005). Usually endovascular treatment is used. Also aorto-ileal conduit fistula have been described (Ishibashi et al., 2007).

Most cases of ureteroarterial fistulae are reported in patients with a prior history of vascular disease, radiation therapy, and/or pelvic surgery, especially in the setting of indwelling ureteral stents (Aslam et al., 2010; McCullough et al., 2012).

A multidisciplinary approach is highly preferable for treating potentially life-threatening UIAF. Endovascular treatment with stent grafts is currently recommended in selected patients whenever possible, but open surgical treatment is required in certain patients with enteric contamination, abscess, local sepsis, or previously failed endovascular treatment (Hong et al., 2016).

Ureteral arterial fistula (UAF) is an uncommon condition characterized by a direct fistulous communication between a ureter and an iliac artery resulting in bleeding into the ureter, which can be massive and life threatening because of hemodynamic instability, as confirmed by the high mortality rate (7%–23% overall). This condition is actually increasing in frequency because of its relation to predisposing factors such as vascular pathology, previous radiation therapy, previous surgery, and necessity of ureteral stenting. Diagnosis is often challenging, as in most patients, the only symptom is hematuria and the treatment may require a multidisciplinary approach, including the expertise of the urologist, vascular surgeon, and interventional radiologist. Endovascular approach offers advantages over open surgery, decreasing morbidity (reduced risk of injury to adjacent structure) and shortening hospital stays. There is no consensus regarding the safety of intentional occlusion of the hypogastric artery: proximal occlusion of a hypogastric artery typically produces little or no clinical symptoms because of well-collateralized pelvic arterial networks. On the contrary, significant complications, such as colonic ischemia, spinal cord paralysis, buttock claudication, or erectile dysfunction, are well-recognized adverse events after hypogastric artery embolization, especially in bilateral cases. We describe our experience of a bilateral UAF treated with bilateral endovascular approach (Melegari et al., 2016).

Ureterovascular fistulae may manifest with microscopic hematuria, intermittent gross hematuria, or life-threatening exsanguinating hemorrhage. The key to the diagnosis of ureteroarterial fistulae is a high index of suspicion in an at-risk patient with gross hematuria (Batter et al., 1996)**. Intermittent gross hematuria or the sudden onset of massive hematuria in a patient with an indwelling stent and a history of previous iliac artery surgery or radiation should raise the suspicion of a ureteroarterial fistula**.

The routine urologic and radiologic evaluation of hematuria will not generally provide evidence of ureterovascular fistula (Quillin et al., 1994). This is especially true in patients with intermittent hematuria in whom there is no active bleeding at the time of the radiographic investigation, presumably because of thrombus over the site of the fistula. Selective or subselective arteriography of the iliac vessels may be more revealing in suspected cases, and provocative maneuvers, such as stent removal, or mechanical friction of the ureteral lumen by manipulation of the stent may be necessary to demonstrate the fistulous connection in patients without active bleeding who are undergoing angiography. **However, these adjuvant maneuvers should be performed only with extreme caution in an appropriate setting where immediate angiographic or surgical intervention is possible.** In the review by Batter et al. (1996), retrograde pyelography was diagnostic for only 6 of 10 patients in whom it was performed, and arteriography was diagnostic for a ureterovascular fistula in only 4 of 14 cases. Indirect evidence of a ureteroarterial fistula can be found on CT, but findings are usually nonspecific and only suspicious in retrospect after a confirmed diagnosis achieved by other means (Baum et al., 1987; Bergqvist et al., 2001). **Nevertheless, in a stable patient with a suspected ureterovascular fistula, a full radiographic evaluation may be pursued not only for diagnostic purposes but also to evaluate potential reconstructive options** (Batter et al., 1996) **and, in select cases, to perform therapeutic angiographic embolization procedures.**

Because these patients may be in extremis with hypotension and severe hemorrhage, surgical intervention must be considered early, especially because radiographic evaluation may be nondiagnostic. **In cases in which angiography is pursued for diagnosis, an endovascular stent graft may be placed** (Aarvold et al., 2008; Araki et al., 2008; Atmaca et al., 2013; Bergqvist et al., 2001; Brizuela et al., 2013; Copelan et al., 2014; Das et al., 2016; Sherif et al., 2002).

The management of these fistulae must be multidisciplinary. Endovascular stenting is the preferred initial treatment, but open surgical interventions with urologic and vascular reconstructions may be necessary (Das et al., 2016). A systematic literature review found reports of 139 cases of ureteroarterial fistula published from 1899 to 2008 (van den Bergh et al., 2009). All patients had hematuria; 25% also had other urinary symptoms or back pain. Almost all patients had a relevant past surgical history, particularly pelvic cancer surgery (54%) and arterial surgery with graft insertion (31%), and 61% had a ureteric stent in situ. The majority affected the iliac segment, and preoperative imaging was not always diagnostic. A total of 18 (13%) patients died as a result of the fistula. Many vascular and urologic interventions were used either alone or in combination. Later cases suggested that endovascular repair of the arterial defect gave the best results with lower mortality. Another, more recent, case series of 20 patients also showed a high mortality of 10% to 20% but did not find any difference in outcome between open or endovascular graft insertion techniques (Fox et al., 2011).

Key Points: Urovascular Fistulae

- Pyelovascular fistulae most commonly result from percutaneous interventional procedures to the upper urinary tract.
- Patients with suspected ureteroarterial fistulae usually have one or more risk factors including a history of pelvic radiotherapy, indwelling ureteral stents, prior pelvic surgery, and/or vascular disease.
- Ureteroarterial fistulae are difficult to diagnose radiographically with standard imaging, including CT scan and retrograde pyelography.
- Patients suspected of having a ureteroarterial fistula based on history and the presence of significant risk factors should be treated expeditiously and aggressively on presentation.

Oncologic and Radiation Fistulae

In the oncologic context, fistulae may occur as a result of primary or recurrent malignancy or as a consequence of cancer treatment by surgery, radiotherapy, chemotherapy, or a combination of therapies.

In one study, 536 women underwent a radical hysterectomy for invasive cervical cancer. More advanced stage of disease, obesity, diabetes, and postoperative surgical infection were predisposing factors to urinary tract complications. In this study, ureteral injury occurred in 1.32%, bladder injury in 1.49% with VVF forming in 2.61% and ureterovaginal fistula in 2.43% of cases, respectively (Likic et al., 2008). In a similar report, 1092 women with cervical cancer underwent a radical hysterectomy with obligatory pelvic lymphadenectomy. A VVF occurred in 0.3% and a ureterovaginal fistula occurred in 1.4% (Baltzer et al., 1980). The rate of GU injury likely varies between centers. For example, in one report of 479 women undergoing different methods of radical hysterectomy for cervical cancer over a 15-year period, 52 (10.8%) had urologic complications (17 bladder and ureter injuries, 35 fistulae and strictures) (Bostofte and Serup, 1981). In contrast, one institution reported that, with modifications and careful dissection, ureteric and bladder injury have almost been eliminated (Draca, 1979).

In two recently published case series, one of fistulae specifically associated with gynecologic cancers (Narayanan et al., 2009) and one of urogenital fistula from all causes (Hilton, 2011), those relating directly to primary cancer were uncommon (2/20 = 10% [Narayanan et al., 2009] and 2/348 = 0.6% *−2/66 = 3% of the oncologic cases in this series* [Hilton, 2011], respectively). Fistulae associated with cancer surgery (3/20 = 15% and 30/348 = 8.6%*−30/66 = 45% of the oncologic cases in this series*) or radiotherapy (15/20 = 75% and 34/348 = 9.8%*−34/66 = 52% of the oncologic cases in this series*) made up a much larger proportion of both series.

Immune deficiency may be a further contributory factor, and enterovesical fistula has previously been reported in association with non-Hodgkin lymphoma in HIV-AIDS (Genta et al., 1993), and vesicovaginal fistula has been seen in association with classical Hodgkin affecting the vagina in a long-term pessary user (Murdoch and Hilton, 2012).

Cancer Surgery

It is likely that all operations carried out in the pelvis can be complicated by genital tract fistula in some circumstances (Hilton, 2011). Operations carried out with the intention of curing malignant disease will inevitably carry a higher risk of subsequent fistula formation as compared with those undertaken with less radical intent.

After radical hysterectomy for cervical cancer (Wertheim-Meigs procedure) the rate of fistula formation reported from case series is between 0.6% and 4.4% (Averette et al., 1993; Hallum et al., 2000; Hatch et al., 1984; Jones et al., 1984; Likic et al., 2008; Ralph et al., 1990; Riss et al., 1988). These data are heterogeneous, some reporting all types of fistula together. Where they are reported separately, the rates of vesicovaginal and ureterovaginal fistula appear to be of the same magnitude with both being reported in between 0.9% and 2.5% of cases (Chen et al., 2008; Likic et al., 2008; Yan et al., 2009). The data from UK cited above suggests a urogenital fistula rate of 1 in 95 after radical abdominal hysterectomy in women with malignant disease as compared with 1 in 540 for total (simple) abdominal hysterectomy for benign disease, and 1 in 2041 for vaginal hysterectomy for all benign disease (including prolapse) (Hilton and Cromwell, 2012). Overall, the rate of urogenital fistula appears to be approximately 9 times higher after radical hysterectomy in women with malignant disease as compared with that after simple hysterectomy (abdominal or vaginal) in women with benign conditions (Hilton and Cromwell, 2012).

The risk of visceral injury or subsequent fistula formation after radical hysterectomy undertaken in pregnancy, or immediately after cesarean section is not obviously increased over those carried out electively in nonpregnant individuals. Monk and Montz (1992) described inadvertent cystotomy followed by vesicovaginal fistula in 1 of 21 women operated on during or immediately after pregnancy.

Several modifications to the conventional Wertheim-Meig procedure of radical hysterectomy have been described in an effort to reduce the associated morbidity. None of them seems to offer a benefit regarding fistula formation (Blythe et al., 1988; Bostofte and Serup, 1981).

Given the increased risk associated with radical surgery for malignancy, it is intuitive that the risks would increase with the stage of disease and with the extent of the surgery undertaken. There are few published reports of fistula after exenterative surgery. One study noted a 16% vesicovaginal fistula rate in 19 women after exenteration for vulvar carcinoma (Hopkins and Morley, 1992), whereas another describes a 15% bowel fistula rate and an 8% urinary fistula rate from a series of 75 exenterations for recurrent cervical cancer (Berek et al., 2005). In contrast, Ungar et al. describe only one ureterovaginal fistula and one pouch–vaginal fistula in 212 women undergoing exenteration out of a total of 2540 women treated for cervix cancer in 1 center over a 13-year period (0.9%) (Ungar et al., 2008).

Bladder-sparing techniques during pelvic exenteration can carry a risk for fistula formation (Liedl et al., 2014). Also when the bladder has been removed and a neo-bladder has been constructed, fistulae between the neo-bladder and the vagina may occur (Bailey et al., 2016; Carmel et al., 2016).

The introduction of laparoscopic surgery within oncology is seen to have considerable advantages in terms of patient recovery; the risk of operative injury to bowel and the urinary tract, and subsequent fistula formation may, however, remain a concern in such cases. Although some studies, case series, and nonrandomized cohorts describe similar rates of injury to those described after open radical surgery (Chen et al., 2008; Langebrekke et al., 2002; Marchiole et al., 2007; Xu et al., 2007; Yan et al., 2009), others have reported injury or fistula rates several times higher after laparoscopic radical hysterectomy (Hallum et al., 2000; Kadar and Reich, 1993).

The risk of urinary tract injury from minor surgical interventions is, in general, low, although the use of repeat procedures may confer a significant increase in risk. Vesicovaginal fistula has been reported after repeated use of CO_2 laser for vaporization of vaginal condylomata (Colombel et al., 1995) and after cone biopsy of the cervix (Nwabineli and Davis, 1992). In 1 personal series of 370 urogenital fistulae, 4 were associated with large loop excision of the transformation zone (LLETZ) of cervix, 3 of which followed a second LLETZ procedure (Hilton, personal communication).

Rarely, localized malignancies have been associated with VVF. One example is a primary mixed müllerian vaginal tumor reported in a 48-year female (Ahuja et al., 2011). The mechanism for fistula formation is likely to be direct invasion into the bladder.

Genitourinary injuries during colorectal surgery are rare. Eswara et al. (2015) described 75 GU injuries in 42570 colorectal surgeries: cystotomy (35%), incomplete ureteral transection (29%), ureteral injuries (15%). Preoperative external beam radiotherapy or chemotherapy and delayed repair were associated with worse outcome (Eswara et al., 2015).

Radiation Fistulae

Pelvic irradiation can be delivered by external beam as well as locally (intracavitary/brachytherapy). Fistula formation appears to be slightly higher for postoperative external radiation (1.9%) compared with intravaginal brachytherapy (0.8%) (Kucera et al., 1984). It does not appear that pretreatment factors accurately predict those who will develop fistula related to radiotherapy (Biewenga et al., 2010). **The three most common locally advanced malignancies that result in VVF include cervical, vaginal, and endometrial carcinoma, which in aggregate account for approximately 3% to 5% of VVFs in the industrialized world. Treatment of vaginal cancer is associated with a high complication rate;** up to 30% of patients develop significant complications including rectovaginal fistula or VVF, grade III to IV proctitis, cystitis, and vaginal stricture (Gunderson et al., 2013).

The literature in this area is particularly heterogeneous, with wide variation in (and some lack of clarity over) the tumor type and stage being treated, the form of radiation, and the site and dose delivered. In a series of urogenital fistulae from the UK, 34 of 348 or 9.8% were associated with previous radiotherapy; of those related to gynecologic cancer, 34 of 66, or 52%, had undergone radiotherapy (Hilton, 2011). In a further series of cases specifically related to gynecologic malignancy, 15 of 20, or 75%, had undergone previous radiotherapy (Narayanan et al., 2009). In both series most cases followed radiation used for the treatment of cervical cancer, although, 5 of 34, or 15%, followed treatment of endometrial cancer, and 1 of 34, or 3%, followed treatment of a multifocal gynecologic cancer in 1 series (Hilton, 2011). Among a series of 216 radiation-induced fistulae, the time to diagnosis of the fistula was made between 3 months and 10 years (mean 21 months) after radiation (Pushkar et al., 2009). In other series fistulae have been reported to develop or present up to 30 years after the “causative” influence (Hilton, 2011; Zoubek et al., 1989).

The incidence of any deleterious clinical impact on the gastrointestinal and urinary tracts after radiation varies in the literature between 1% and 12% (Cochrane et al., 1981; Demanes et al., 2000; Denton et al., 2002; de Crevoisier et al., 2007; Emmert and Kohler, 1996; Krause et al., 1987; Maier et al., 1997; Monk et al., 1994), with fistula rates of 1% to 5% (Angioli et al., 2003; Narayanan et al., 2009). In a retrospective review of 2096 patients treated for cervical cancer over a 10-year period using unspecified regimen(s) of radiotherapy, 38 patients (1.8%) were found to have developed fistulae, all of whom had stage IIIa/b or IV disease at presentation (Emmert and Kohler, 1996). Of these cases, approximately three-fourths involved the rectum, with one-third being combined rectovaginal and vesicovaginal fistulae; one-fourth were vesicovaginal only (Emmert and Kohler, 1996).

Following a clearly defined regimen of external beam radiation plus brachytherapy for the treatment of primary squamous cell carcinoma of vagina in 91 women, de Crevoisier et al. reported 10.0% grade 2 to 3 urinary tract toxicity (using the Franco-Italian glossary) (Chassagne et al., 1993) and 12.1% grade 2 to 3 gastrointestinal toxicity (de Crevoisier et al., 2007). Unsurprisingly, they found anterior tumor location to be correlated with increased risk of bladder toxicity and decreased rectal toxicity. Two women in this series developed rectovaginal fistulae (2%) and one ureterovaginal fistula (1%) (de Crevoisier et al., 2007).

In a series of 10,709 women treated by telebrachytherapy (67.5 Gy) for a range of gynecologic cancers in 1 center over a 22-year period, 133 (1.2%) developed urologic complications of which 35 (0.3%) developed fistulae (Maier et al., 1997).

In a series of 28 women treated by brachytherapy for recurrent corpus or cervix cancer, four patients developed chronic morbidities related to treatment. Three fistulae were reported in two patients (7.1%): one combined rectovaginal and vesicovaginal fistula and one ureterointestinal fistula; a further patient developed a ureteric stricture and small bowel obstruction requiring resection (Monk et al., 1994).

These data tend to suggest a higher rate of fistula formation after the application of radiotherapy in locally recurrent disease than in primary disease. From a small series of urologic complications after radiotherapy for gynecologic cancers, 14 patients had developed vesicovaginal fistula; of these, 4 (29%) had evidence of tumor recurrence (Krause et al., 1987). In the series reported by Jones at al. (1984) 326 of 1161 (28%) developed urologic complications over a 20-year period; 46 developed fistulae (4%), of whom 33 (72%) had evidence of active malignant disease.

In prostate cancer patients, recto-urethral fistula are described after cryotherapy (0.1%–4%) (Shah et al., 2014), HIFU (0.7%) (Ganzer et al., 2013), and brachytherapy (2%) (Park et al., 2013).

When a fistula occurs after radiotherapy, it is considered good clinical practice to exclude tumor recurrence before attempting a fistula closure. Feddock et al.

(2014) found 27 fistulae in 325 patients after post-radiation biopsies for cervical cancer. The fistula were toxicity-related in 51.9%, a consequence of primary disease in 22.2% and of recurrent disease in 25.9%. The residual or recurrent cancer found in the biopsies was only 31.5%. Elevated radiotherapy doses to the rectum, advanced tumor stage, and post-radiotherapy biopsy were considered risk factors for fistula formation.

Injury to the GI or urinary tract may arise after therapeutic radiation, with the incidence of complications increasing when the dose exceeds 50 Gy. The obliterative endarteritis associated with ionizing radiation in therapeutic doses may proceed over many years and may result in fistula formation long after the primary malignancy has been treated (Hilton, 2012). The associated devascularization in the adjacent tissues means that conventional surgical repair has a high likelihood of failure and may also result in re-presentation with several fistulae over a period of many years. If abdominal repair surgery or urinary diversions are undertaken, a high risk of GI anastomotic leak and progressive sepsis has been reported, perhaps related either to inadequate resection of irradiated bowel or to damage to other organs at operation (Cochrane et al., 1981). All these factors often make the management of postradiation fistulae more challenging than that of postsurgical or even obstetric fistulae. Modified surgical techniques are often required, and indeed, where the same techniques have been applied to surgical and postradiation fistulae, the results from the latter have been consistently poorer (Jovanovic et al., 2010). Spontaneous healing seems rarely if ever to occur (Hilton, 2012) and only one case report was identified, of presentation of a radiation fistula 22 years after initial treatment, in which healing occurred after cauterization (for biopsy) and prolonged catheter drainage (Madjar and Gousse, 2001). In some cases, hyperbaric oxygen therapy could be helpful, although there are no recent data to support this treatment option (Williams et al., 1992).

Management of Radiation Fistulae: Diversion Procedures

Because of the wide field abnormality surrounding many radiotherapy-associated fistulae, several authors have suggested that urinary and/or fecal diversion should be seen as the treatment of choice in such cases (Eswara et al., 2015; Langkilde et al., 1999; Lentz and Homesley, 1995). Others have employed a routine policy of preliminary urinary and fecal diversion, with later undiversion in selected cases (Vanni et al., 2010). In a nonrandomized cohort of rectourethral fistula repairs, Vanni et al. (2010) reported 100% closure at first operation in 35 nonirradiated patients, compared with 84% in 39 irradiated patients. In addition, 97% of the nonirradiated patients subsequently underwent undiversion, whereas 31% of the irradiated patients required permanent fecal diversion because of a noncompliant rectum or severe sphincter dysfunction (Vanni et al., 2010).

Some authors have emphasized the place of repair in carefully selected cases of radiotherapy-associated fistulae (Hilton, 2012). Of 36 radiation-associated or malignant fistulae in the series reported by Hilton, although 11 patients declined surgery or died before treatment and 6 underwent primary diversion, of the 19 (53%) who underwent repair, closure was achieved in 18 (95%) at first operation (Hilton, 2012). Finally, some authors seem to take the view that diversion has little or no place in the management of radiation-induced VVF in particular (Pushkar et al., 2009). Of 216 radiation-induced fistulae managed over a 47-year period by Pushkar et al. (2009), 210 patients underwent a vaginal and 6 an abdominal repair procedure (this is a retrospective case series, and although not stated in the paper, it is possible that other patients not included in this review actually underwent diversion). However, with this almost exclusive use of the vaginal repair procedure, although a cumulative closure rate of 80% was eventually achieved after four or more operations, closure was achieved in only 48% after first repair, in 40% after a second operation, in 52% after a third operation, and in 35% after a fourth operation.

In view of the anastomotic problems associated with radiation-induced fistula, the transverse colon has often been favored over ileum as a conduit in this context to avoid the risk of employing irradiated bowel and distal ureter (Schmidt and Buchsbaum, 1986). Although these benefits seem clear, high perioperative morbidity (37%) and reoperation rates (20%) have been reported from this procedure (Ravi et al., 1994).

As an alternative to the latter operation, wherein urinary and fecal diversion are proposed, Hampson et al. (1994) described the technique of left colic urinary diversion with distal transverse end colostomy. This technique allows a shorter operative time and avoids the necessity for an intestinal anastomosis. In patients wishing to remain sexually active after such procedures, the residual bladder or rectal wall may be used to augment the vagina (Leissner et al., 2000). Where VVF coexists with significant bladder contracture after surgery or radiation, an abdominal (transperitoneal) repair may be considered, along with simultaneous ileocystoplasty or coloplasty (Mao et al., 2017; Mayersak et al., 1995, Tabakov and Slavchev, 2004). Fistula repair performed concurrently with vaginal reconstruction using sigmoidovaginoplasty has also been described by Verbaeys et al. (2007). Although one may anticipate very high operative and postoperative morbidity from such complex multiple procedures, the outcome in the very small numbers reported appears to have been good.

Management of Radiation Fistulae: Repair Techniques

Several different techniques for the vaginal repair of fistulae have been reported, although the methods of flap-splitting or dissection and repair in layers (variously attributed to Hayward, Collis, and Lawson Tait) (Wall, 2005) and partial colpocleisis (Latzko, 1942) have been the most widely advocated in radiation-associated fistulae. When patients do not wish to maintain sexual function, complete colpocleisis may be used to good effect (Hilton, 2012). In a nonrandomized cohort study, Hilton (2012) reported anatomic closure by colpocleisis in 94.7% of patients with radiation-associated fistulae, compared with 96.1% for a range of repair procedures in fistulae of surgical cause.

The technique of sigmoid exclusion or isolation has been described for the management of radiation-associated colovesical or enterovesical and colovaginal or enterovaginal fistulae (Levenback et al., 1994). Although the results have generally been good, with the avoidance of a permanent urinary or fecal stoma, Levenback et al. (1994) reported poorer results than after resection of the affected bowel, largely related to bleeding from the isolated segment and bacterial infection.

The interpositional grafts mentioned earlier are particularly useful in radiation-induced fistulae.

Other Management Approaches

In patients with intractable urinary incontinence from radiation-associated fistula, percutaneous nephrostomy or ureterostomy may be considered (Krause et al., 1987). This may in some cases extend life perhaps inappropriately, and where life expectancy is deemed to be very short, ureteral occlusion may be more appropriate. Several methods have been described, including the insertion of coils (Amsellem-Ouazana et al., 2006) and other devices (Asvadi and

Arellano, 2015; Kim et al., 2008; Pieper et al., 2014). These were reviewed by Avritscher et al. (2004) with success rates ranging from 50% to 100% for the different methods, and with an overall success rate of 77% in 150 cases from 9 papers reviewed.

Recommendations

Although diversion is used more widely in radiation-associated fistulae of all types as compared with nonirradiated fistulae, there is low-level evidence that repair procedures can achieve successful fistula closure and continence in appropriately selected cases.

Where urinary and/or fecal diversions are required, attempts should be made to avoid using irradiated tissues whenever possible and to minimize the potential for anastomotic complications.

There is low-level evidence to support the use of interpositional grafts when repair of radiation-associated fistula is undertaken.

In patients with intractable urinary incontinence from radiation-associated fistula in whom life expectancy is very short, ureteral occlusion may be considered; there is insufficient evidence to recommend any particular technique.

Chemotherapy

There are few reports of fistula formation in association with the use of chemotherapy. One case report described a patient who developed a vesicovaginal fistula having undergone abdominal hysterectomy for atypical endometrial hyperplasia while taking *tamoxifen* after a previous modified radical mastectomy. Surgical repair of the fistula was initially unsuccessful, although after discontinuing the *tamoxifen* and continued bladder drainage, healing occurred (Caputo and Copeland, 1996). It was hypothesized that the impaired healing was a result of the administration of the hormone therapy.

Combination Therapies

Adjuvant or neoadjuvant therapies are used to increase the efficacy of the primary treatment compared with its use in isolation. It may be anticipated that this would also increase the range and magnitude of adverse effects.

In a case control study examining the urinary tract complications of radical hysterectomy only a single vesicovaginal fistula was seen in 50 patients (2%), in a patient receiving preoperative irradiation (45–50 Gy) (Behtash et al., 2005). A small case series found 2 of 20 or a 10% rate of urinary fistulae after preoperative irradiation and radical hysterectomy in a heterogeneous group of “high-risk” cervix cancers (Monk et al., 1993). A further case series described the impact of combined external whole pelvic irradiation (50 Gy) and intravaginal cone boost (20–26 Gy) after radical hysterectomy in 108 women. The overall rate of fistula formation was 3.7%, 2.2% after “prophylactic” radiation, and 10.5% in “salvage” cases in which recurrent disease was present (Mitsuhashi et al., 1995).

Modarress et al. (2005) reported a randomized comparison of preoperative combined chemoradiation (cisplatin plus external beam therapy) and neoadjuvant chemotherapy (cisplatin plus vincristine) followed by radical hysterectomy in stage IB-IIB bulky cervical cancer. Four patients developed hydronephrosis (3 in the chemoradiation group, 13.3%) and two vesicovaginal fistula (both in the chemoradiation group, 6.7%) (Modarress et al., 2005). Two further case series reported 2 of 36 or a 5.6% rate of fistulae after preoperative chemoradiation (cisplatin plus brachytherapy) followed by radical hysterectomy (Koumantakis et al., 1998), and 4 of 46 or 8.7% rate of fistulae after the use of neoadjuvant and postoperative chemotherapy using irinotecan, cisplatin, and nedaplatin (Matsumura et al., 2010). In a recent series of chemoradiotherapy for cervical cancer, fistula were reported in only 1.6% of cases (Jakubowicz et al., 2014).

Other Urinary Fistulae

Urinary fistulae have been reported between the kidneys and thoracic cavity with a number of causes, including infection, trauma, and stone disease. Infectious causes include xanthogranulomatous pyelonephritis, TB, and renal abscess (Arida, 1977; Blight, 1980; Liu et al., 2016). Fortunately, nephropleural and nephrobronchial fistulae are uncommon. **Percutaneous access to the kidney for endourologic procedures may be complicated by nephropleural fistula** (Hyatt et al., 2017). Lallas et al. (2004) reported a 1% incidence of nephropleural fistulae in 375 patients undergoing percutaneous access procedures. All of the affected patients had a supracostal access tract performed; none of the patients with a subcostal access tract developed this complication. Presenting symptoms may include cough, a urine-like taste in the mouth, fever, and flank pain.

Treatment of nephropleural or nephrobronchial fistulae typically involves percutaneous drainage of any associated abscess (if present), treatment of associated infection and/or urinary obstruction, and surgical exploration with interposition of healthy tissue. **Iatrogenic fistulae resulting from percutaneous access procedures can be managed nonoperatively in some cases** (Lallas et al., 2004). **Nephrectomy is indicated in poorly functioning renal units.**

Cutaneous fistulae from the urinary tract may arise from the kidney, ureter, bladder, or urethra. Renocutaneous fistulae may occur as a result of chronic infection, especially in the setting of calculous disease (Haney et al., 1992). Often the associated renal unit is poorly functioning, and thus definitive treatment is provided by nephrectomy. External trauma or iatrogenic surgical trauma, such as percutaneous renal surgery or partial nephrectomy, may also result in a renocutaneous fistula. Prompt treatment with internal ureteral stenting is usually successful by providing unobstructed antegrade urinary drainage. Most ureterocutaneous and vesicocutaneous fistulae are iatrogenic or otherwise purposefully surgically created to facilitate urinary drainage. Other uncommon causes include external penetrating trauma, malignancy, and chronic infection.

For newly diagnosed urocutaneous fistulae, it is imperative to evaluate for distal urinary obstruction. If present, the obstruction should be treated, if possible, or bypassed. **Individuals with nonhealing urocutaneous fistulae caused by chronic infection not only should be evaluated for an occult source of the infection but also should undergo a nutritional evaluation**

because these individuals may be catabolic, immunosuppressed, and unable to mobilize adequate metabolic reserves to initiate wound closure. Other considerations in individuals with nonhealing urocutaneous fistulae include occult malignancy or an undiscovered foreign body.

Urinary Leak After Renal Preservation Surgery

A large case series identified urinary fistula, defined as urinary drainage from a drain site more than 14 days postoperatively, in 4% (45 of 1118) of patients undergoing partial nephrectomy (Kundu et al., 2010). This was associated with larger tumors, greater blood loss, and longer ischemia time, but not the mode of surgery (laparoscopic vs. open). The majority resolved without intervention, but 30% required ureteral stent insertion or percutaneous drainage. A poor-quality quasi-randomized study involving 16 patients with persistent leakage after pelvicalyceal surgery despite stenting found that use of intranasal desmopressin 40 µg daily resulted in a shorter time to resolution of leak compared with controls (Razzaghi et al., 2009).

Urinary Leak After Renal Transplantation

A case series from Brazil observed a fistula rate of 3.0% (31 of 1046) at a mean of 28 (1 to 131) days after transplantation predominantly as a result of distal ureteral necrosis and with most cases requiring open repair (Mazzucchi et al., 2006). Fistula occurred more commonly in patients with diabetes and was associated with lower graft survival and 2 deaths from sepsis. A case series from China observed fistula development in 3.5% (43 of 1223) of patients at a mean of 6 (range 3 to 20) days after transplantation, again primarily a result of necrosis of the distal transplanted ureter (Nie et al., 2009). Open intervention with reimplantation of the ureter into the bladder or native ureter was required in 34 patients, with 1 other patient requiring transplant nephrectomy. The occurrence of a fistula did not appear to prejudice graft or patient survival. Initial implantation of the transplant ureter into the native ureter appeared to result in a lower rate of fistula. A further case series from Serbia found a fistula rate after renal transplantation of 2.2% (5 of 224), and all required open repair (Basic et al., 2011).

See Videos 129.1 to 129.4 for procedures related to this chapter.

Key Points: Other Fistulae

- Nephropleural or nephrobronchial fistulae are uncommon and may occur secondary to percutaneous access procedures to the upper urinary tract.
- Urocutaneous fistulae may originate from multiple locations within the urinary tract.

Acknowledgments

The authors are grateful to Gopal H Badlani, MD, FACS, Jayadev Reddy Mettu, MD, MBBS, and Eric S. Rovner, MD, who co-authored the previous edition of this chapter with D. De Ridder. Much of their text and illustrations have been used.

Suggested Readings

Arrowsmith S, Hamlin EC, Wall LL. Obstructed labor injury complex: obstetric fistula formation the multifaceted morbidity of maternal birth trauma in the developing world. *Obstet Gynecol Surv*. 1996;51(9):568–574.

Blaivas JG, Heritz DM, Romanzi LJ. Early versus late repair of vesicovaginal fistulae: vaginal abdominal approaches. *J Urol*. 1995;153(4):1110–1112.

De Ridder D, Browning A, Mourad MS, et al. Fistula. Abrams P, Cardozo L, Wagg A, et al. *Incontinence*. 6th ed. ICI-ICS: Bristol, UK; 2017.

Miklos JR, Moore RD, Chinthakanan O. Laparoscopic and robotic-assisted vesicovaginal fistula repair: a systematic review of the literature. *J Minim Invasive Gynecol*. 2015;22(5):727–736.

References

Aarvold A, Wales L, Papadakos N, et al. Arterio-ureteric fistula following iliac angioplasty. *Cardiovasc Intervent Radiol*. 2008;31(4):821–823.

Abet L, Richter J, Lenk S, et al. [Double-balloon urethrography in the female]. *Z Urol Nephrol*. 1983;76(1):19–28.

Abou-El-Ghar ME, El-Assmy AM, Refaie HF, et al. Radiological diagnosis of vesicouterine fistula: role of magnetic resonance imaging. *J Magn Reson Imaging*. 2012;36(2):438–442.

Adaji SE, Bature SB, Shittu OS. Vaginally inserted herbs causing vesico-vaginal fistula and vaginal stenosis. *Int Urogynecol J*. 2013;24(6):1057–1058.

Adler AJ, Ronsmans C, Calvert C, et al. Estimating the prevalence of obstetric fistula: a systematic review and meta-analysis. *BMC Pregnancy Childbirth*. 2013;13:246.

Ahmed S, Kardar AH. Construction of a neourethra in girls: follow-up results. *Pediatr Surg Int*. 2000;16(8):584–585.

Ahuja A, Safaya R, Prakash G, et al. Primary mixed mullerian tumor of the vagina–a case report with review of the literature. *Pathol Res Pract*. 2011;207(4):253–255.

al-Ali M, Kashmoula D, Saoud IJ. Experience with 30 posttraumatic rectourethral fistulas: presentation of posterior transsphincteric anterior rectal wall advancement. *J Urol*. 1997;158(2):421–424.

Alamoudi OJ, AlTheneyan MA, Aldhaam N, et al. Early robotic repair of vesicouterine fistula: a case report and literature review. *Urol Case Rep*. 2017;11:76–78.

Alling Møller L, Lose G, Jorgensen T. Risk factors for lower urinary tract symptoms in women 40 to 60 years of age. *Obstet Gynecol*. 2000;96(3):446–451.

Alonso Gorrea M, Fernandez Zuazu J, Mompo Sanchis JA, et al. Spontaneous healing of uretero-vesico-vaginal fistulas. *Eur Urol*. 1985;11(5):341–343.

Altman D, Forsgren C, Hjern F, et al. Influence of hysterectomy on fistula formation in women with diverticulitis. *Br J Surg*. 2010;97(2):251–257.

Alves J, Puga M, Fernandes R, et al. Laparoscopic management of ureteral endometriosis and hydronephrosis associated with endometriosis. *J Minim Invasive Gynecol*. 2017;24(3):466–472.

Amendola MA, Agha FP, Dent TL, et al. Detection of occult colovesical fistula by the Bourne test. *AJR Am J Roentgenol*. 1984;142(4):715–718.

Ampofo EK, Omotara BA, Otu T, et al. Risk factors of vesico-vaginal fistulae in Maiduguri, Nigeria: a case-control study. *Trop Doct*. 1990;20(3):138–139.

Amsellem-Ouazana D, Cornud F, Conquy S, et al. Management of a malignant urinary fistula by ureteral embolization with coils. *Urology*. 2006;68(2):427.e421–427.e423.

Amundsen CL, Flynn BJ, Webster GD. Urethral erosion after synthetic and nonsynthetic pubovaginal slings: differences in management and continence outcome. *J Urol*. 2003;170(1):134–137 [discussion 137].

Andreoni C, Bruschini H, Truzzi JC, et al. Combined vaginoscopy-cystoscopy: a novel simultaneous approach improving vesicovaginal fistula evaluation. *J Urol*. 2003;170(6 Pt 1):2330–2332.

Andrews HO, Shah PJ. Surgical management of urethral damage in neurologically impaired female patients with chronic indwelling catheters. *Br J Urol*. 1998;82(6):820–824.

Andriole GL, Bettmann MA, Garnick MB, et al. Indwelling double-J ureteral stents for temporary and permanent urinary drainage: experience with 87 patients. *J Urol*.

1984;131(2):239–241.

Angioli R, Penalver M, Muzii L, et al. Guidelines of how to manage vesicovaginal fistula. *Crit Rev Oncol Hematol*. 2003;48(3):295–304.

Araki T, Nagata M, Araki T, et al. Endovascular treatment of ureteroarterial fistulas with stent-grafts. *Radiat Med*. 2008;26(6):372–375.

Arida EJ. Splenic arteriovenous fistula with portal hypertension, varices, and ascites. *N Y State J Med*. 1977;77(6):987–990.

Armenakas NA, Pareek G, Fracchia JA. Iatrogenic bladder perforations: longterm followup of 65 patients. *J Am Coll Surg*. 2004;198(1):78–82.

Arrowsmith SD. Genitourinary reconstruction in obstetric fistulas. *J Urol*. 1994;152(2 Pt 1):403–406.

Arrowsmith SD. Urinary diversion in the vesico-vaginal fistula patient: general considerations regarding feasibility, safety, and follow-up. *Int J Gynaecol Obstet*. 2007;99(Suppl 1):S65–S68.

Arrowsmith SD, Barone MA, Ruminjo J. Outcomes in obstetric fistula care: a literature review. *Curr Opin Obstet Gynecol*. 2013;25(5):399–403.

Arrowsmith S, Hamlin EC, Wall LL. Obstructed labor injury complex: obstetric fistula formation and the multifaceted morbidity of maternal birth trauma in the developing world. *Obstet Gynecol Surv*. 1996;51(9):568–574.

Aslam MZ, Kheradmund F, Patel N, et al. Uretero-iliac artery fistula: a diagnostic and therapeutic challenge. *Adv Urol*. 2010;276497.

Asvadi NH, Arellano RS. Transrenal antegrade ureteral occlusion: clinical assessment of indications, technique and outcomes. *J Urol*. 2015;194(5):1428–1432.

Atalla MA, Tajkarimi K, Vinh D, et al. Pyeloduodenal fistula. *J Urol*. 2009;181(6):2733–2734.

Atan A, Tuncel A, Aslan Y. Treatment of refractory urethrovaginal fistula using rectus abdominis muscle flap in a six-year-old girl. *Urology*. 2007;69(2):384 e311–384 e383.

Atmaca AF, Canda AE, Gumus M, et al. Delayed massive hemorrhage due to external iliac artery pseudo-aneurysm and uretero-iliac artery fistula following robotic radical cystectomy and intracorporeal Studer pouch reconstruction: endovascular management of an unusual complication. *Can Urol Assoc J*. 2013;7(9–10):E605–E608.

Averette HE, Nguyen HN, Donato DM, et al. Radical hysterectomy for invasive cervical cancer. A 25-year prospective experience with the Miami technique. *Cancer*. 1993;71(4 Suppl):1422–1437.

Avritscher R, Madoff DC, Ramirez PT, et al. Fistulas of the lower urinary tract: percutaneous approaches for the management of a difficult clinical entity. *Radiographics*. 2004;24(Suppl 1):S217–S236.

Badenoch DF, Tiptaft RC, Thakar DR, et al. Early repair of accidental injury to the ureter or bladder following gynaecological surgery. *Br J Urol*. 1987;59(6):516–518.

Badic B, Leroux G, Thereaux J, et al. Colovesical fistula complicating diverticular disease: a 14-year experience. *Surg Laparosc Endosc Percutan Tech*. 2017;27(2):94–97.

Badlani G, Sutton AP, Abrams HJ, et al. Enterovesical fistulas in Crohn disease. *Urology*. 1980;16(6):599–600.

Bahadursingh AM, Longo WE. Colovaginal fistulas. Etiology and management. *J Reprod Med*. 2003;48(7):489–495.

Bailey GC, Blackburne A, Ziegelmann MJ, et al. Outcomes of surgical management in patients with stress urinary incontinence and/or neovesicovaginal fistula after orthotopic neobladder diversion. *J Urol*. 2016;196(5):1478–1483.

Balaguera CJ, Camunas Segovia J, Pena Gamarra L, et al. Colovesical fistula complicating diverticular disease: one-stage resection. *Int Surg*. 2006;91(1):17–23.

Baltzer J, Kaufmann C, Ober KG, et al. Complications in 1,092 radical abdominal hysterectomies with pelvic lymphadenectomies (author's transl). *Geburtshilfe Frauenheilkd*. 1980;40(1):1–5.

Bansal A, Kumar M, Goel S, et al. Vesicovaginal fistula following insertion of a foreign body in the vagina for sexual gratification: could it be catastrophic? *BMJ Case Rep*. 2016;2016.

Barton DP, Morse SS, Fiorica JV, et al. Percutaneous nephrostomy and ureteral stenting in gynecologic malignancies. *Obstet Gynecol*. 1992;80(5):805–811.

Basic D, Djokic JH, Milutinovic D, et al. Ureteral fistulae after kidney transplantation: experience with 224 cases. *Acta Chir Iugosl*. 2011;58(1):89–94.

Baskin D, Tatlidede S, Karsidag SH. Martius repair in urethrovaginal defects. *J Pediatr Surg*. 2005;40(9):1489–1491.

Batter SJ, McGovern FJ, Cambria RP. Ureteroarterial fistula: case report and review of the literature. *Urology*. 1996;48(3):481–489.

Baum ML, Baum RD, Plaine L, et al. Computed tomography in the diagnosis of fistula between the ureter and iliac artery. *J Comput Assist Tomogr*. 1987;11(4):719–721.

Bazi T. Spontaneous closure of vesicovaginal fistulas after bladder drainage alone: review of the evidence. *Int Urogynecol J Pelvic Floor Dysfunct*. 2007;18(3):329–333.

Beaghler MA, Taylor FC, McLaughlin KP. A combined antegrade and retrograde technique for reestablishing ureteral continuity. *Tech Urol*. 1997;3(1):44–48.

Beardmore-Gray A, Pakzad M, Hamid R, et al. Does the Goh classification predict the outcome of vesico-vaginal fistula repair in the developed world. *Int Urogynecol J*.

2017;28(6):937–940.

Beddy D, Poskus T, Umbreit E, et al. Impact of radiotherapy on surgical repair and outcome in patients with rectourethral fistula. *Colorectal Dis*. 2013;15(12):1515–1520.

Behtash N, Ghaemmaghami F, Ayatollahi H, et al. A case-control study to evaluate urinary tract complications in radical hysterectomy. *World J Surg Oncol*. 2005 [Feb 16 20005 (online journal)] http://dx.doi.org/10.1186/1477-7819-3-12.

Ben Amna M, Hajri M, Moualli SB, et al. [The female urethral diverticula: apropos of 21 cases]. *Ann Urol (Paris)*. 2002;36(4):272–276.

Ben-Ami H, Ginesin Y, Behar DM, et al. Diagnosis and treatment of urinary tract complications in Crohn's disease: an experience over 15 years. *Can J Gastroenterol*. 2002;16(4):225–229.

Benchekroun A, Lachkar A, Soumana A, et al. [Vesico-uterine fistulas. Report of 30 cases]. *Ann Urol (Paris)*. 1999;33(2):75–79.

Berek JS, Howe C, Lagasse LD, et al. Pelvic exenteration for recurrent gynecologic malignancy: survival and morbidity analysis of the 45-year experience at UCLA. *Gynecol Oncol*. 2005;99(1):153–159.

Bergqvist D, Parsson H, Sherif A. Arterio-ureteral fistula–a systematic review. *Eur J Vasc Endovasc Surg*. 2001;22(3):191–196.

Biewenga P, Mutsaerts MA, Stalpers LJ, et al. Can we predict vesicovaginal or rectovaginal fistula formation in patients with stage IVA cervical cancer? *Int J Gynecol Cancer*. 2010;20(3):471–475.

Billmeyer BR, Nygaard IE, Kreder KJ. Ureterouterine and vesicoureterovaginal fistulas as a complication of cesarean section. *J Urol*. 2001;165(4):1212–1213.

Birge O, Arslan D, Kinali E, et al. A rare complication of colporraphy anterior procedure: vesicovaginal fistula due to foreign body. *Clin Exp Obstet Gynecol*. 2016;43(2):297–299.

Birkhoff JD, Wechsler M, Romas NA. Urinary fistulas: vaginal repair using a labial fat pad. *J Urol*. 1977;117(5):595–597.

Blaivas JG. Vaginal flap urethral reconstruction: an alternative to the bladder flap neourethra. *J Urol*. 1989;141(3):542–545.

Blaivas JG, Mekel G. Management of urinary fistulas due to midurethral sling surgery. *J Urol*. 2014;192(4):1137–1142.

Blaivas JG, Purohit RS. Post-traumatic female urethral reconstruction. *Curr Urol Rep*. 2008;9(5):397–404.

Blaivas JG, Heritz DM, Romanzi LJ. Early versus late repair of vesicovaginal fistulas: vaginal and abdominal approaches. *J Urol*. 1995;153(4):1110–1112 [discussion 1112–1113].

Blandy JP, Badenoch DF, Fowler CG, et al. Early repair of iatrogenic injury to the ureter or bladder after gynecological surgery. *J Urol*. 1991;146(3):761–765.

Blight EM Jr. Case profile: nephrobronchial fistula due to tuberculosis. *Urology*. 1980;15(5):526–527.

Blythe JG, Hodel KA, Wahl TP. A comparison between peritoneal sheathing of the ureters (Ohkawa technique) and retroperitoneal pelvic suction drainage in the prevention of ureteral damage during radical abdominal hysterectomy. *Gynecol Oncol*. 1988;30(2):222–227.

Bochenska K, Zyczynski HM. Utility of postoperative voiding cystourethrogram after lower urinary tract repair. *Female Pelvic Med Reconstr Surg*. 2016;22(5):369–372.

Borjas A, Rodriguez Diaz LH. Vesicovaginal fistula of tuberculous origin. *J Int Coll Surg*. 1949;12(6):840–842.

Borland RN, Walsh PC. The management of rectal injury during radical retropubic prostatectomy. *J Urol*. 1992;147(3 Pt 2):905–907.

Boronow RC. Repair of the radiation-induced vaginal fistula utilizing the Martius technique. *World J Surg*. 1986;10(2):237–248.

Bostofte E, Serup J. Urological complications of Okabayashi's operation for cervical cancer. *Acta Obstet Gynecol Scand*. 1981;60(1):39–42.

Botsikas D, Caviezel A, Becker CD, et al. A new MDCT technique for the detection and anatomical exploration of urogenital fistulas. *AJR Am J Roentgenol*. 2012;198(2):W160–W162.

Boudghene F, Lukacs B, Carette MF, et al. [Transrenal ureteral occlusion using detachable balloons. An alternative to cutaneous ureterostomy in the treatment of vesicovaginal fistula]. *Ann Urol (Paris)*. 1988;22(6):425–427.

Brandes S, Coburn M, Armenakas N, et al. Diagnosis and management of ureteric injury: an evidence-based analysis. *BJU Int*. 2004;94(3):277–289.

Brandt FT, Lorenzato FR, Albuquerque CD. Treatment of vesicovaginal fistula by bladder mucosa autograft technique. *J Am Coll Surg*. 1998;186(6):645–648.

Browning A. Prevention of residual urinary incontinence following successful repair of obstetric vesico-vaginal fistula using a fibro-muscular sling. *BJOG*. 2004;111(4):357–361.

Browning A. Lack of value of the Martius fibrofatty graft in obstetric fistula repair. *Int J Gynaecol Obstet*. 2006;93(1):33–37.

Browning A. Risk factors for developing residual urinary incontinence after obstetric fistula repair. *BJOG*. 2006;113(4):482–485.

Browning A, Menber B. Women with obstetric fistula in Ethiopia: a 6-month follow up after surgical treatment. *BJOG*. 2008;115(12):1564–1569.

Bruce RG, El-Galley RE, Galloway NT. Use of rectus abdominis muscle flap for the treatment of complex and refractory urethrovaginal fistulas. *J Urol*. 2000;163(4):1212–1215.

Brummer TH, Jalkanen J, Fraser J, et al. FINHYST, a prospective study of 5279 hysterectomies: complications and their risk factors. *Hum Reprod*. 2011;26:1741–1751.

Buckley JC. Complications after radical prostatectomy: anastomotic stricture and rectourethral fistula. *Curr Opin Urol*. 2011;21(6):461–464.

Bukowski TP, Chakrabarty A, Powell IJ, et al. Acquired rectourethral fistula: methods of repair. *J Urol*. 1995;153(3 Pt 1):730–733.

Cameron AP, Atiemo HO. Unusual presentation of an obstetrical urethrovaginal fistula secondary to improper catheter placement. *Can Urol Assoc J*. 2009;3(4):E21–E22.

Campbell SC, Streem SB, Zelch M, et al. Percutaneous management of transplant ureteral fistulas: patient selection and long-term results. *J Urol*. 1993;150(4):1115–1117.

Candiani P, Austoni E, Campiglio GL, et al. Repair of a recurrent urethrovaginal fistula with an island bulbocavernous musculocutaneous flap. *Plast Reconstr Surg*. 1993;92(7):1393–1396.

Capes T, Stanford EJ, Romanzi L, et al. Comparison of two classification systems for vesicovaginal fistula. *Int Urogynecol J*. 2012;23(12):1679–1685.

Caputo RM, Copeland LJ. Gynecologic effects of tamoxifen: case reports and review of the literature. *Int Urogynecol J*. 1996;7(4):179–184.

Carlin BI, Klutke CG. Development of urethrovaginal fistula following periurethral collagen injection. *J Urol*. 2000;164(1):124.

Carmel ME, Goldman HB, Moore CK, et al. Transvaginal neobladder vaginal fistula repair after radical cystectomy with orthotopic urinary diversion in women. *Neurourol Urodyn*.

2016;35(1):90–94.

Carr LK, Webster GD. Abdominal repair of vesicovaginal fistula. *Urology*. 1996;48(1):10–11.

Cetin S, Yazicioglu A, Ozgur S, et al. Vesicovaginal fistula repair: a simple suprapubic transvesical approach. *Int Urol Nephrol*. 1988;20(3):265–268.

Chadha R, Agarwal K, Choudhury SR, et al. The colovesical fistula in congenital pouch colon: a histologic study. *J Pediatr Surg*. 2008;43(11):2048–2052.

Chang KH, Bourke MG, Kavanagh DO, et al. A systematic review of the role of re-laparoscopy in the management of complications following laparoscopic colorectal surgery. *Surgeon*. 2016;14(5):287–293.

Chassagne D, Sismondi P, Horiot JC, et al. A glossary for reporting complications of treatment in gynecological cancers. *Radiother Oncol*. 1993;26(3):195–202.

Chebli JM, Figueiredo AA, Gaburri PD. Gouverneur's syndrome in a patient with abdominal pain: mind Crohn's disease!. *Rev Assoc Med Bras (1992)*. 2014;60(3):196–197.

Chen SS, Yang S-H, Yang J-M, et al. Transvaginal repair of ureterovaginal fistula by Latzko technique. *Int Urogynecol J*. 2007;18:1381–1383.

Chen DM. [Pedicle graft of omentum or pre-peritoneal fat in repair of vesico-vaginal fistula (author's transl)]. *Zhonghua Wai Ke Za Zhi*. 1981;19(7):437–438.

Chen SS, Chou YH, Tiu CM, et al. Sonographic features of colovesical fistula. *J Clin Ultrasound*. 1990;18(7):589–591.

Chen Y, Xu H, Li Y, et al. The outcome of laparoscopic radical hysterectomy and lymphadenectomy for cervical cancer: a prospective analysis of 295 patients. *Ann Surg Oncol*. 2008;15(10):2847–2855.

Chene G, Lamblin G, Marcelli M, French College of Obstetrics and Gyneacology, et al. [Urinary, infectious and digestive adverse events related to benign hysterectomy and the associated surgery on the Fallopian tube: guidelines]. *J Gynecol Obstet Biol Reprod (Paris)*. 2015;44(10):1183–1205.

Chibber PJ, Shah HN, Jain P. Laparoscopic O'Conor's repair for vesico-vaginal and vesico-uterine fistulae. *BJU Int*. 2005;96(1):183–186.

Chittacharoen A, Theppisai U. Urological injury during gynecologic surgical procedures. *J Med Assoc Thai*. 1993;76(Suppl 1):87–91.

Chodisetti S, Boddepalli Y, Kota MR. Concomitant repair of stress urinary incontinence with proximal urethrovaginal fistula: our experience. *Indian J Urol*. 2016;32(3):229–231.

Choi JH, Jeon BG, Choi SG, et al. Rectourethral fistula: systemic review of and experiences with various surgical treatment methods. *Ann Coloproctol*. 2014;30(1):35–41.

Chou MT, Wang CJ, Lien RC. Prophylactic ureteral catheterization in gynecologic surgery: a 12-year randomized trial in a community hospital. *Int Urogynecol J Pelvic Floor Dysfunct*. 2009;20(6):689–693.

Chung HJ, Goo BC, Lee JH, et al. Behcet's disease combined with various types of fistula. *Yonsei Med J*. 2005;46(5):625–628.

Clayman RV, Surya V, Hunter D, et al. Renal vascular complications associated with the percutaneous removal of renal calculi. *J Urol*. 1984;132(2):228–230.

Cochrane JP, Yarnold JR, Slack WW. The surgical treatment of radiation injuries after radiotherapy for uterine carcinoma. *Br J Surg*. 1981;68(1):25–28.

Colombel M, Pedron P, Missirlu A, et al. Vesicovaginal fistula after laser vaporization of vaginal condyloma. *J Urol*. 1995;154(5):1860.

Cools P, Vanderputte S, Van der Stighelen Y, et al. Rectourethral fistula due to Crohn's disease. *Acta Urol Belg*.

1996;64(3):47–48.

Cooper CS, Rier K, Donovan JF Jr. Pyeloduodenal fistula associated with a ureteropelvic junction obstruction. *Surgery*. 1997;121(3):355–356.

Copelan A, Chehab M, Cash C, et al. Endovascular management of ureteroarterial fistula: a rare potentially life threatening cause of hematuria. *J Radiol Case Rep*. 2014;8(7):37–45.

Cowgill KD, Bishop J, Norgaard AK, et al. Obstetric fistula in low-resource countries: an under-valued and under-studied problem–systematic review of its incidence, prevalence, and association with stillbirth. *BMC Pregnancy Childbirth*. 2015;15:193.

Crochet P, Savoie PH, Agostini A, et al. Uretero-fallopian fistula after gynecological surgery for endometriosis: a case report. *J Minim Invasive Gynecol*. 2008;15(1):108–109.

D'Arcy FT, Jaffry S. The treatment of vesicovaginal fistula by endoscopic injection of fibrin glue. *Surgeon*. 2010;8(3):174–176.

Das A, Lewandoski P, Laganosky D, et al. Ureteroarterial fistula: a review of the literature. *Vascular*. 2016;24(2):203–207.

Davits RJ, Miranda SI. Conservative treatment of vesicovaginal fistulas by bladder drainage alone. *Br J Urol*. 1991;68(2):155–156.

de Crevoisier R, Sanfilippo N, Gerbaulet A, et al. Exclusive radiotherapy for primary squamous cell carcinoma of the vagina. *Radiother Oncol*. 2007;85(3):362–370.

De Ridder D. An update on surgery for vesicovaginal and urethrovaginal fistulae. *Curr Opin Urol*. 2011;21(4):297–300.

De Ridder D, Browning A, Mourad MS, et al. Fistula. Abrams P, Cardozo L, Wagg A, et al. *Incontinence*. 6th ed. ICI-ICS: Bristol, UK; 2017.

Deem S, Stone P, Schlarb C. Ureteral perigraft fistula. *Vasc Endovascular Surg*. 2007;41(4):352–354.

Demanes DJ, Schutz KL, Quackenbush JJ, et al. Low dose rate brachytherapy in vaginal carcinoma: long-term outcome and morbidity. *J Brachyther Int*. 2000;16(1):11–24.

Demirci U, Fall M, Gothe S, et al. Urovaginal fistula formation after gynaecological and obstetric surgical procedures: clinical experiences in a Scandinavian series. *Scand J Urol*. 2013;47(2):140–144.

Denton AS, Clarke N, Maher J. Non-surgical interventions for late radiation cystitis in patients who have received radical radiotherapy to the pelvis [Systematic Review]. *Cochrane Database Syst Rev*. 2002;(3) [CD001773].

Dhabalia JV, Nelivigi GG, Satia MN, et al. Congenital urethrovaginal fistula with imperforate hymen: a first case report. *J Obstet Gynaecol Can*. 2009;31(7):652–653.

Dogra PN, Saini AK. Laser welding of vesicovaginal fistula–outcome analysis and long-term outcome: single-centre experience. *Int Urogynecol J*. 2011;22(8):981–984.

Dogra PN, Nabi G. Laser welding of vesicovaginal fistula. *Int Urogynecol J Pelvic Floor Dysfunct*. 2001;12(1):69–70.

Dolan LM, Dixon WE, Hilton P. Urinary symptoms and quality of life following urogenital fistula repair: a long-term follow-up study. *BJOG*. 2008;115(12):1570–1574.

Dolan LM, Dixon WE, Hilton P. Urinary symptoms and quality of life in women following urogenital fistula repair: a long-term follow-up study. *BJOG*. 2008;115(12):1570–1574.

Dolay K, Aras B, Tugcu V, et al. Combined treatment of iatrogenic rectourethral fistula with endoscopic fibrin glue application and clipping. *J Endourol*. 2007;21(4):433–436.

Domini M, Aquino A, Rossi F, et al. Recurrent posttraumatic urethrovaginal fistula: a new application for ASTRA. *J Pediatr Surg*. 2000;35(3):522–525.

Donaldson JF, Tait C, Rad M, et al. Obstructive uropathy and vesicovaginal fistula secondary to a retained sex toy in the vagina. *J Sex Med*. 2014;11(10):2595–2600.

Dowling RA, Corriere JN Jr, Sandler CM. Iatrogenic ureteral injury. *J Urol*. 1986;135(5):912–915.

Draca P. Wertheim hysterectomy: a ten year experience. *Int Surg*. 1979;64(5):59–63.

Drake MJ, Noble JG. Ureteric trauma in gynecologic surgery. *Int Urogynecol J Pelvic Floor Dysfunct*. 1998;9(2):108–117.

Drutz HP, Mainprize TC. Unrecognized small vesicovaginal fistula as a cause of persistent urinary incontinence. *Am J Obstet Gynecol*. 1988;158(2):237–240.

Duong TH, Taylor DP, Meeks GR. A multicenter study of vesicovaginal fistula following incidental cystotomy during benign hysterectomies. *Int Urogynecol J Pelvic Floor Dysfunct*. 2011;22(8):975–979.

Duong TH, Gellasch TL, Adam RA. Risk factors for the development of vesicovaginal fistula after incidental cystotomy at the time of a benign hysterectomy. *Am J Obstetr Gynecol*. 2009;201(5):512.e511–512.e514.

Eilber KS, Kavaler E, Rodriguez LV, et al. Ten-year experience with transvaginal vesicovaginal fistula repair using tissue interposition. *J Urol*. 2003;169(3):1033–1036.

Eisen M, Jurkovic K, Altwein JE, et al. Management of vesicovaginal fistulas with peritoneal flap interposition. *J Urol*. 1974;112(2):195–198.

Elkins TE. Surgery for the obstetric vesicovaginal fistula: a review of 100 operations in 82 patients. *Am J Obstet Gynecol*. 1994;170(4):1108–1118 [discussion 1118–1120].

El-Lamie IK. Preliminary experience with Mainz type II pouch in gynecologic oncology patients. *Eur J Gynaecol Oncol*. 2001;22(1):77–80.

El-Tabey NA, Ali-El-Dein B, Shaaban AA, et al. Urological trauma after gynecological and obstetric surgeries. *Scand J Urol Nephrol*. 2011;185:945–950.

Emmert C, Kohler U. Management of genital fistulas in patients with cervical cancer. *Arch Gynecol Obstet*. 1996;259(1):19–24.

Enzelsberger H, Gitsch E. Surgical management of vesicovaginal fistulas according to Chassar Moir's method. *Surg Gynecol Obstet*. 1991;173(3):183–186.

Estevez JP, Cosson M, Boukerrou M. An uncommon case of urethrovaginal fistula resulting from tension-free vaginal tape. *Int Urogynecol J*. 2010;21(7):889–891.

Estevez JP, Colin P, Lucot JP, et al. [Urethrovaginal fistulae resulting from sub-urethral slings for stress urinary incontinence treatment. A report of two cases and review of the literature]. *J Gynecol Obstet Biol Reprod (Paris)*. 2010;39(2):151–155.

Eswara JR, Raup VT, Heningburg AM, et al. Pelvic radiation is associated with urinary fistulae repair failure and need for permanent urinary diversion. *Urology*. 2015;85(4):932–936.

Eswara JR, Raup VT, Potretzke AM, et al. Outcomes of iatrogenic genitourinary injuries during colorectal surgery. *Urology*. 2015;86(6):1228–1233.

Evans LA, Ferguson KH, Foley JP, et al. Fibrin sealant for the management of genitourinary injuries, fistulas and surgical complications. *J Urol*. 2003;169(4):1360–1362.

Falk HC, Orkin LA. Nonsurgical closure of vesicovaginal fistulas. *Obstet Gynecol*. 1957;9(5):538–541.

Falk HC, Tancer ML. Vesicovaginal fistula; an historical survey. *Obstet Gynecol*. 1954;3(3):337–341.

Fall M. Vaginal wall bipedicled flap and other techniques in complicated urethral diverticulum and urethrovaginal fistula. *J Am Coll Surg*. 1995;180(2):150–156.

Farid FN, Azhar M, Samnani SS, et al. Psychosocial experiences of women with vesicovaginal fistula: a qualitative approach. *J Coll Physicians Surg Pak*. 2013;23(10):828–829.

Faris SF, Milam DF, Dmochowski RR, et al. Urinary diversions after radiation for prostate cancer: indications and treatment. *Urology*. 2014;84(3):702–706.

Farrell TA, Wallace M, Hicks ME. Long-term results of transrenal ureteral occlusion with use of Gianturco coils and gelatin sponge pledgets. *J Vasc Intervent Radiol*. 1997;8(3):449–452.

Feddock J, Randall M, Kudrimoti M, et al. Impact of post-radiation biopsies on development of fistulae in patients with cervical cancer. *Gynecol Oncol*. 2014;133(2):263–267.

Ferguson GG, Lee EW, Hunt SR, et al. Management of the bladder during surgical treatment of enterovesical fistulas from benign bowel disease. *J Am Coll Surg*. 2008;207(4):569–572.

Flottorp J, Inversen S. [Vesicovaginal and urethrovaginal fistulas treated at the Norwegian Radium Hospital 1940-1952 and in the gynecological department of the Rikshospitalet 1953-1959]. *Tidsskr Nor Laegefor*. 1960;80:597–599.

Flynn MK, Peterson AC, Amundsen CL, et al. Functional outcomes of primary and secondary repairs of vesicovaginal fistulae via vaginal cuff scar excision. *Int Urogynecol J Pelvic Floor Dysfunct*. 2004;15(6):394–398 [discussion 398].

Forest S, Fassi Fehri H, Glachant S, et al. [Management of rectourethral fistulas with the York Mason procedure: surgical techniques and outcomes]. *Prog Urol*. 2014;24(5):276–281.

Forsgren C, Altman D. Risk of pelvic organ fistula in patients undergoing hysterectomy. *Curr Opin Obstet Gynecol*. 2010;22(5):404–407.

Forsgren C, Lundholm C, Johansson AL, et al. Hysterectomy for benign indications and risk of pelvic organ fistula disease.

Obstetr Gynecol. 2009;114(3):594–599.

Fox JA, Krambeck A, McPhail EF, et al. Ureteroarterial fistula treatment with open surgery versus endovascular management: long-term outcomes. *J Urol*. 2011;185(3):945–950.

Frajzyngier V, Li G, Larson E, et al. Development and comparison of prognostic scoring systems for surgical closure of genitourinary fistula. *Am J Obstet Gynecol*. 2013;208(2):112 e111.

Frang D, Jilling A. Techniques for surgical repair of vesicovaginal fistulae. *Int Urol Nephrol*. 1983;15(2):161–169.

Franke M, Winand S, Chang DH, et al. Urinary tract fistulas: transrenal reversible ureteral occlusion with detachable semicompliant balloons. *Urology*. 2015;86(2):388–393.

Frankman EA, Wang L, Bunker CH, et al. Lower urinary tract injury in women in the united states, 1979–2006. *Am J Obstet Gynecol*. 2010;202:495.e491–495.e495.

Friedman MA, Shaw JS, McGary K, et al. Vesicovaginal fistula: an unexpected consequence of changing sexual practices? *Sex Health*. 2017;14(4):396.

Futter NG, Baker K. A vesicouterine fistula caused by catheterization during delivery. *Can J Urol*. 1995;2(1):107–108.

Game X, Malavaud B, Alric L, et al. Infliximab treatment of Crohn disease ileovesical fistula. *Scand J Gastroenterol*. 2003;38(10):1097–1098.

Ganabathi K, Leach GE, Zimmern PE, et al. Experience with the management of urethral diverticulum in 63 women. *J Urol*. 1994;152(5 Pt 1):1445–1452.

Gannon MJ. The three swab test using knots for urovaginal fistula. *Surg Gynecol Obstet*. 1990;170(2):171.

Ganpule AP, Shah DH, Ganpule SA, et al. Role of multidetector computed tomography (MDCT) in management of post percutaneous nephrolithotomy (PCNL) bleeding. *F1000Res*. 2013;2:253.

Ganzer R, Fritsche HM, Brandtner A, et al. Fourteen-year oncological and functional outcomes of high-intensity focused ultrasound in localized prostate cancer. *BJU Int*. 2013;112(3):322–329.

Garcea G, Majid I, Sutton CD, et al. Diagnosis and management of colovesical fistulae; six-year experience of 90 consecutive cases. *Colorectal Dis*. 2006;8(4):347–352.

Gauta J. Pessary migration into the bladder: a rare episode of removal and repair of a vesicovaginal fistula. *Int Urogynecol J*. 2017;28(6):965–966.

Gedik A, Deliktas H, Celik N, et al. Which surgical technique should be preferred to repair benign, primary vesicovaginal fistulas? *Urol J*. 2015;12(6):2422–2427.

Gelet A, Chapelon JY, Poissonnier L, et al. Local recurrence of prostate cancer after external beam radiotherapy: early experience of salvage therapy using high-intensity focused ultrasonography. *Urology*. 2004;63(4):625–629.

Genta RM, Ramchandani MK, Gyorkey F, et al. Enterovesical fistula due to non-Hodgkin lymphoma in AIDS. *J Clin Gastroenterol*. 1993;16(4):333–335.

Gerber GS, Schoenberg HW. Female urinary tract fistulas. *J Urol*. 1993;149(2):229–236.

Ghoniem GM, Monga M. Modified pubovaginal sling and Martius graft for repair of the recurrent vesicovaginal fistula involving the internal urinary sphincter. *Eur Urol*. 1995;27(3):241–245.

Ghosh B, Wats V, Pal DK. Comparative analysis of outcome between laparoscopic versus open surgical repair for vesico-vaginal fistula. *Obstet Gynecol Sci*. 2016;59(6):525–529.

Gil A, Sultana CJ. Vesicouterine fistula after vacuum delivery and two previous cesarean sections. A case report. *J Reprod Med*. 2001;46(9):853–855.

Gil-Vernet JM, Gil-Vernet A, Campos JA. New surgical approach for treatment of complex vesicovaginal fistula. *J Urol*. 1989;141(3):513–516.

Ginsberg DA, Rovner ES, Raz S. Posthysterectomy vaginal cuff fistula: diagnosis and management of an unusual cause of “incontinence. *Urology*. 1998;52(1):61–64 [discussion 64–65].

Glass RE, Ritchie JK, Lennard-Jones JE, et al. Internal fistulas in Crohn's disease. *Dis Colon Rectum*. 1985;28(8):557–561.

Glavind K, Larsen EH. Results and complications of tension-free vaginal tape (TVT) for surgical treatment of female stress urinary incontinence. *Int Urogynecol J Pelvic Floor Dysfunct*. 2001;12(6):370–372.

Goh JT. A new classification for female genital tract fistula. *Aust N Z J Obstet Gynaecol*. 2004;44:502–504.

Goh JT, Browing A, Berhan B, et al. Predicting the risk of failure of closure of obstetric fistula and residual urinary incontinence using a classification system. *Int Urogynecol J Pelvic Floor Dysfunct*. 2008;19(12):1659–1662.

Goh JT, Krause HG, Browning A, et al. Classification of female genito-urinary tract fistula: inter- and intra-observer correlations. *J Obstet Gynaecol Res*. 2009;35:160–163.

Goh JT, Krause H, Tessema AB, et al. Urinary symptoms and urodynamics following obstetric genitourinary fistula repair. *Int Urogynecol J*. 2013;24(6):947–951.

Goh JT, Howat P, de Costa C. Oestrogen therapy in the management of vesicovaginal fistula. *Aust N Z J Obstet Gynaecol*. 2001;41(3):333–334.

Golabek T, Szymanska A, Szopinski T, et al. Enterovesical fistulae: aetiology, imaging, and management. *Gastroenterol Res Pract*. 2013;2013:617967.

Golomb J, Leibovitch I, Mor Y, et al. Fascial patch technique for repair of complicated urethrovaginal fistula. *Urology*. 2006;68(5):1115–1118.

Goodwin WE, Scardino PT. Vesicovaginal and ureterovaginal fistulas: a summary of 25 years of experience. *J Urol*. 1980;123(3):370–374.

Gorrea AM, Zuazu FJ, Sanchis MJA, et al. Spontaneous healing of uretero-vesico-vaginal fistulas. *Eur Urol*. 1985;11(5):341–343.

Graziotti P, Lembo A, Artibani W. Spontaneous closure of vesicouterine fistula after cesarean section. *J Urol*. 1978;120(3):372.

Greenstein AJ, Sachar DB, Tzakis A, et al. Course of enterovesical fistulas in Crohn's disease. *Am J Surg*. 1984;147(6):788–792.

Greenwell TJ, Spilotros M. Urethral diverticula in women. *Nat Rev Urol*. 2015;12(12):671–680.

Gruner JS, Sehon JK, Johnson LW. Diagnosis and management of enterovesical fistulas in patients with Crohn's disease. *Am Surg*. 2002;68(8):714–719.

Guillonneau B, Gupta R, El Fettouh H, et al. Laparoscopic [correction of laproscopic] management of rectal injury during laparoscopic [correction of laproscopic] radical prostatectomy. *J Urol*. 2003;169(5):1694–1696.

Gunderson CC, Nugent EK, Yunker AC, et al. Vaginal cancer: the experience from 2 large academic centers during a 15-year period. *J Low Genit Tract Dis*. 2013;17(4):409–413.

Gupta NP, Mishra S, Hemal AK, et al. Comparative analysis of outcome between open and robotic surgical repair of recurrent supra-trigonal vesico-vaginal fistula. *J Endourol*. 2010;24(11):1779–1782.

Hadzi-Djokic J, Pejcic TP, Acimovic M. Vesico-vaginal fistula: report of 220 cases. *Int Urol Nephrol*. 2009;41(2):299–302.

Hadzi-Djokic J, Pejcic T, Stamenkovic V, et al. Buccal mucosal graft interposition in the treatment of recurrent vesicovaginal fistula: a report on two cases. *Taiwan J Obstet Gynecol*. 2015;54(6):773–775.

Hafner CD, Ponka JL, Brush BE. Genitourinary manifestations of diverticulitis of the colon. A study of 500 cases. *J Am Med Assoc*. 1962;179:76–78.

Hage JJ, Bouman FG, Bloem JJ. Construction of the fixed part of the neourethra in female-to-male transsexuals: experience in 53 patients. *Plast Reconstr Surg*. 1993;91(5):904–910 [discussion 911–903].

Hallum IAV, Hatch KD, Nour M, et al. Comparison of radical abdominal hysterectomy with laparoscopic-assisted radical vaginal hysterectomy for treatment of early cervical cancer. *J Gynecol Tech*. 2000;6(1):3–6.

Hamlin RH, Nicholson EC. Reconstruction of urethra totally destroyed in labour. *Br Med J*. 1969;2(5650):147–150.

Hampel C, Neisius A, Thomas C, et al. [Vesicovaginal fistula. Incidence, etiology and phenomenology in Germany]. *Urologe A*. 2015;54(3):349–358.

Hampson SJ, Morris SB, Gordon EM, et al. Management of inoperable pelvic carcinomas with complex fistulas: a new approach. *Ann R Coll Surg Engl*. 1994;76(3):188–189.

Hanash KA, Sieck U. Successful repair of a large vesicovaginal fistula with associated urethral loss using the anterior bladder flap technique. *J Urol*. 1983;130(4):775–776.

Hanash KA, Al Zahrani H, Mokhtar AA, et al. Retrograde vaginal methylene blue injection for localization of complex urinary fistulas. *J Endourol*. 2003;17(10):941–943.

Haney PT, Bihrle R, Kopecky KK. Percutaneous management of a nephrocutaneous fistula due to a pyelocaliceal diverticular calculus. *J Urol*. 1992;148(3 Pt 2):1105–1107.

Hanna JM, Peterson AC, Mantyh C. Rectourethral fistulas in the cancer survivor. *Curr Opin Urol*. 2014;24(4):382–388.

Hanna JM, Turley R, Castleberry A, et al. Surgical management of complex rectourethral fistulas in irradiated and nonirradiated patients. *Dis Colon Rectum*. 2014;57(9):1105–1112.

Harkki-Siren P, Sjoberg J, Tiitinen A. Urinary tract injuries after hysterectomy. *Obstet Gynecol*. 1998;92(1):113–118.

Harris CR, McAninch JW, Mundy AR, et al. Rectourethral fistulas secondary to prostate cancer treatment: management and outcomes from a multi-institutional combined experience. *J Urol*. 2017;197(1):191–194.

Hata F, Yasoshima T, Kitagawa S, et al. Transanal repair of rectourethral fistula after a radical retropubic prostatectomy: report of a case. *Surg Today*. 2002;32(2):170–173.

Hatch KD, Parham G, Shingleton HM, et al. Ureteral strictures and fistulae following radical hysterectomy. *Gynecol Oncol*. 1984;19(1):17–23.

Hechenbleikner EM, Buckley JC, Wick EC. Acquired rectourethral fistulas in adults: a systematic review of surgical repair techniques and outcomes. *Dis Colon Rectum*. 2013;56(3):374–383.

Heckler FR, Aldridge JE Jr, Songcharoen S, et al. Muscle flaps and musculocutaneous flaps in the repair of urinary fistulas. *Plast Reconstr Surg*. 1980;66(1):94–101.

Hellenthal NJ, Nanigian DK, Ambert L, et al. Limited anterior cystotomy: a useful alternative to the vaginal approach for vesicovaginal fistula repair. *Urology*. 2007;70(4):797–798.

Hemal AK, Kolla SB, Wadhwa P. Robotic reconstruction for recurrent supratrigonal vesicovaginal fistulas. *J Urol*. 2008;180(3):981–985.

Herbert A, Wijlaars L, Zylbersztejn A, et al. Data resource profile: hospital episode statistics admitted patient care (HES APC). *Int J Epidemiol*. 2017;46(4) [1093–1093i].

Hernandez DJ, Schaeffer EM, Allaf ME. Pyeloduodenal fistula due to advanced upper tract malignancy. *Urology*. 2007;69(6):1206–1207.

Hillary CJ, Osman NI, Hilton P, et al. The aetiology, treatment, and outcome of urogenital fistulae managed in well- and low-resourced countries: a systematic review. *Eur Urol*. 2016;70(3):478–492.

Hilton P. Urodynamic findings in patients with urogenital fistulae. *Br J Urol*. 1998;81(4):539–542.

Hilton P. Urethrovaginal fistula associated with ‘sterile abscess’ formation following periurethral injection of dextranomer/hyaluronic acid co-polymer (Zuidex) for the treatment of stress urinary incontinence–a case report. *BJOG*. 2009;116(11):1527–1530.

Hilton P. Urogenital fistula in the UK - a personal case series managed over 25 years. *BJU Int*. 2011 [online journal] http://dx.doi.org/10.1111/j.1464-410X.2011.10630.x.

Hilton P. Urogenital fistula in the UK: a personal case series managed over 25 years. *BJU Int*. 2012;110(1):102–110.

Hilton P. Trends in the aetiology of urogenital fistula: a case of ‘retrogressive evolution. *Int Urogynecol J*. 2016;27(6):831–837.

Hilton P, Cromwell DA. The risk of vesicovaginal and urethrovaginal fistula after hysterectomy performed in the English National Health Service–a retrospective cohort study examining patterns of care between 2000 and 2008. *BJOG*. 2012;119(12):1447–1454.

Holland AJ, Cohen RC, McKertich KM, et al. Urethral trauma in children. *Pediatr Surg Int*. 2001;17(1):58–61.

Hong SY, Noh M, Ko GY, et al. Management strategy for ureteral-iliac artery fistula. *Ann Vasc Surg*. 2016;36:22–27.

Hood J. Repairing obstetric fistulas. *Nurs N Z*. 2016;22(1):4.

Hopkins MP, Morley GW. Pelvic exenteration for the treatment of vulvar cancer. *Cancer*. 1992;70(12):2835–2838.

Huang CR, Sun N, Wei p, et al. The management of old urethral injury in young girls: analysis of 44 cases. *J Pediatr Surg*. 2003;38(9):1329–1332.

Huang LK, Wang JH, Shen SH, et al. Evaluation of the extent of ketamine-induced uropathy: the role of CT urography. *Postgrad Med J*. 2014;90(1062):185–190.

Huang SC, Yao BL, Chou CY. Transvaginal ultrasonographic findings in vesico-uterine fistula. *J Clin Ultrasound*. 1996;24(4):209–212.

Hubner W, Knoll M, Porpaczy P. Percutaneous transrenal ureteral occlusion: indication and technique. *Urol Radiol*. 1992;13(3):177–180.

Hui Wu J, Xu Y, Qiang Xu Z, et al. Severe anemia and melena caused by pyeloduodenal fistula due to renal stone-associated squamous cell carcinoma. *Pak J Med Sci*. 2014;30(2):443–445.

Hutch JA, Noll LE. Prevention of vesicovaginal fistulas. *Obstet Gynecol*. 1970;35(6):924–927.

Hyatt E, Park H, Srinivasa R, et al. Nephropleural fistula. *J Vasc Interv Radiol*. 2017;28(10):1472.

Imoto A, Matsuyama A, Ambauen-Berger B, et al. Health-related quality of life among women in rural Bangladesh after surgical repair of obstetric fistula. *Int J Gynaecol Obstet*. 2015;130(1):79–83.

Ingber MS, Firoozi F, Goldman HB, et al. Fallopian tube prolapse presenting as a peritoneovaginal fistula. *Can J Urol*. 2010;17(2):5117–5119.

Ingelman-Sundberg A. An extravaginal technic in the operation for urethro-vaginal and vesico-vaginal fistulas. *Gynaecologia*. 1947;123(6):380–385.

Iselin CE, Webster GD. Office management of female urinary incontinence. *Urol Clin North Am*. 1998;25(4):625–645 [ix].

Ishibashi H, Ohta T, Sugimoto I, et al. Successful treatment of an aorto-ileal-conduit fistula with an endovascular stent graft: report of a case. *Surg Today*. 2007;37(4):305–307.

Izes J, Smith J, Zinman L. The gracilis muscle in repair of complex lower urinary tract fistulae (15 year experience). *J Urol*. 1992;147(Suppl):281A.

Jakubowicz J, Blecharz P, Skotnicki P, et al. Toxicity of concurrent chemoradiotherapy for locally advanced cervical cancer. *Eur J Gynaecol Oncol*. 2014;35(4):393–399.

Janez J. [Use of the great epiploon in the treatment of complex vesico- and urethro-vaginal fistulae]. *Ann Urol (Paris)*. 1985;19(4):267–268.

Javed A, Abdullah A, Faruqui N, et al. Doctor! Will I be dry? Factors determining recurrence after vesicovaginal fistula repair. *J Pak Med Assoc*. 2015;65(9):954–959.

Jiang D, Chen Z, He L, et al. Repair of urethrovaginal fistula secondary to pelvic fracture with a labia minora skin flap in young girls. *Urology*. 2017;103:227–229.

Jokhio AH, Rizvi RM, Rizvi J, et al. Prevalence of obstetric fistula: a population-based study in rural Pakistan. *BJOG*. 2014;121(8):1039–1046.

Jones CR, Woodhouse CR, Hendry WF. Urological problems following treatment of carcinoma of the cervix. *Br J Urol*. 1984;56(6):609–613.

Jovanovic MD, Milovic N, Aleksic P, et al. Efficiency of urinary fistulas surgical treatment. *Eur Urol Suppl*. 2010;9(6):572.

Jozwik M, Jozwik M. Spontaneous closure of vesicouterine fistula. Account for effective hormonal treatment. *Urol Int*. 1999;62(3):183–187.

Jozwik M, Jozwik M, Lotocki W. Actual incidence and cause of vesico-uterine fistula. *Br J Urol*. 1998;81(2):341–342.

Kadar N, Reich H. Laparoscopically assisted radical Schauta hysterectomy and bilateral laparoscopic pelvic lymphadenectomy for the treatment of bulky stage IB carcinoma of the cervix. *Gynaecol Endosc*. 1993;2(3):135–142.

Kam MH, Tan YH, Wong MY. A 12-year experience in the surgical management of vesicovaginal fistulae. *Singapore Med J*. 2003;44(4):181–184.

Kanaoka Y, Hirai K, Ishiko O, et al. Vesicovaginal fistula treated with fibrin glue. *Int J Gynaecol Obstet*. 2001;73(2):147–149.

Karp NE, Kobernik EK, Berger MB, et al. Do the surgical outcomes of rectovaginal fistula repairs differ for obstetric and nonobstetric fistulas? A retrospective cohort study. *Female Pelvic Med Reconstr Surg*. 2019;25(1):36–40.

Karsten K, Rothe K, Marzheuser S. Voiding cystourethrography in the diagnosis of anorectal malformations. *Eur J Pediatr Surg*. 2016;26(6):494–499.

Kasamba N, Kaye DK, Mbalinda SN. Community awareness about risk factors, presentation and prevention and obstetric fistula in Nabitovu village, Iganga district, Uganda. *BMC Pregnancy Childbirth*. 2013;13:229.

Kasyan G, Abramyan K, Popov AA, et al. Mesh-related and intraoperative complications of pelvic organ prolapse repair. *Cent European J Urol*. 2014;67(3):296–301.

Kayondo M, Wasswa S, Kabakyenga J, et al. Predictors and outcome of surgical repair of obstetric fistula at a regional referral hospital, Mbarara, western Uganda. *BMC Urol*. 2011;11:23.

Keller DS, Aboseif SR, Lesser T, et al. Algorithm-based multidisciplinary treatment approach for rectourethral fistula. *Int J Colorectal Dis*. 2015;30(5):631–638.

Kelly E, Wu MY, MacMillan JB. Robotic-assisted vesicovaginal fistula repair using an extravesical approach without interposition grafting. *J Robot Surg*. 2017;12(1):173–176.

Khanna S. Posterior bladder flap plasty for repair of vesicourethrovaginal fistula. *J Urol*. 1992;147(3):656–657.

Kheterpal E, Bhandari A, Siddiqui S, et al. Management of rectal injury during robotic radical prostatectomy. *Urology*. 2011;77(4):976–979.

Kight JR. John Peter Mettauer and the first successful closure of vesicovaginal fistula in the United States. *Am J Obstet Gynecol*. 1967;99(7):885–892.

Kim SK, Lee YR, Kyung MS, et al. Transrenal ureteral occlusion with the use of microcoils in five patients with ureterovaginal fistulas. *Abdom Imaging*. 2008;33(5):615–620.

Kisner CD, Kesner KM. Use of the transverse colon conduit for vesicovaginal fistula in late-stage carcinoma of the cervix. *Br J Urol*. 1987;59(3):234–238.

Kobayashi K, Otoshi T, Madono K, et al. [A case of urethrovaginal fistula caused by a foreign body in the vagina]. *Hinyokika Kiyo*. 2010;56(7):389–391.

Kochakarn W, Pummangura W. A new dimension in vesicovaginal fistula management: an 8-year experience at Ramathibodi hospital. *Asian J Surg*. 2007;30(4):267–271.

Kontturi M, Larmi TK. Utilization of the intestine in surgery for major urological complications following gynaecological cancer. *Ann Chir Gynaecol Fenn*. 1972;61(6):306–311.

Koonings PP, Huffman JL, Schlaerth JB. Ureteroscopy: a new asset in the management of postoperative ureterovaginal fistulas. *Obstetr Gynecol*. 1992;80(3 Pt 2):548–549.

Koraitim M. A new retropubic retrourethral approach for large vesico-urethrovaginal fistulas. *J Urol*. 1985;134(6):1122–1123.

Kostakopoulos A, Deliveliotis C, Louras G, et al. Early repair of injury to the ureter or bladder after hysterectomy. *Int Urol Nephrol*. 1998;30(4):445–450.

Koumantakis E, Haralambakis Z, Koukourakis M, et al. A pilot study on concurrent platinum chemotherapy and intracavitary brachytherapy for locally advanced cancer of the uterine cervix. *Br J Radiol*. 1998;71(MAY):552–557.

Krause S, Hald T, Steven K. Surgery for urologic complications following radiotherapy for gynecologic cancer. *Scand J Urol Nephrol*. 1987;21(2):115–118.

Krysiewicz S, Auh YH, Kazam E. Vesicouterine fistula associated with placenta percreta. *Urol Radiol*. 1988;10(4):213–215.

Kucera H, Skodler W, Weghaupt K. Complications of postoperative radiotherapy in uterine cancer]. *Geburtshilfe Frauenheilkd*. 1984;44(8):498–502.

Kucera WB, Jezior JR, Duncan JE. Management of post-traumatic rectovesical/rectourethral fistulas: case series of complicated injuries in wounded warriors and review of the literature. *Mil Med*. 2017;182(3):e1835–e1839.

Kumar A, Goyal NK, Das SK, et al. Our experience with genitourinary fistulae. *Urol Int*. 2009;82(4):404–410.

Kumar A, Vaidyanathan S, Sharma SK, et al. Management of vesico-uterine fistulae: a report of six cases. *Int J Gynaecol Obstet*. 1988;26(3):453–457.

Kundu SD, Thompson RH, Kallingal GJ, et al. Urinary fistulae after partial nephrectomy. *BJU Int*. 2010;106(7):1042–1044.

Kursh ED, Morse RM, Resnick MI, et al. Prevention of the development of a vesicovaginal fistula. *Surg Gynecol Obstet*. 1988;166(5):409–412.

Kyle J. Urinary complications of Crohn's disease. *World J Surg*. 1980;4(2):153–160.

Kyriazis I, Panagopoulos V, Kallidonis P, et al. Complications in percutaneous nephrolithotomy. *World J Urol*. 2015;33(8):1069–1077.

Lallas CD, Delvecchio FC, Evans BR, et al. Management of nephropleural fistula after supracostal percutaneous nephrolithotomy. *Urology*. 2004;64(2):241–245.

Lamensdorf H, Compere DE, Begley GF. Simple surgical correction of urethrovaginal fistula. *Urology*. 1977;10(2):152–153.

Landes RR. Simple transvesical repair of vesicovaginal fistula. *J Urol*. 1979;122(5):604–606.

Lang EK. Antegrade ureteral stenting for dehiscence, strictures, and fistulae. *AJR Am J Roentgenol*. 1984;143(4):795–801.

Langebrekke A, Istre O, Hallqvist AC, et al. Comparison of laparoscopy and laparotomy in patients with endometrial cancer. *J Am Assoc Gynecol Laparosc*. 2002;9(2):152–157.

Langkilde NC, Pless TK, Lundbeck F, et al. Surgical repair of vesicovaginal fistulae–a ten-year retrospective study. *Scand J Urol Nephrol*. 1999;33(2):100–103.

Lassey AT, Peterson CF, Ampofo K. Pregnancy and delivery after ureterosigmoidotomy for vesicovaginal fistula. *Int J Gynaecol Obstet*. 2002;79(1):25–26.

Latzko W. Postoperative vesicovaginal fistulas: genesis and therapy. *Am J Surg*. 1942;58:211–218.

Lau TK, Wong WS. Lymphatic vaginal fistula after Wertheim-Taussig hysterectomy: a case report. *Gynecol Oncol*. 1994;52(3):411–412.

Laungani R, Patil N, Krane LS, et al. Robotic-assisted ureterovaginal fistula repair: report of efficacy and feasibility. *J Laparoendosc Adv Surg Techn*. 2008;18:731–734.

Lawson J. Vesical fistulae into the vaginal vault. *Br J Urol*. 1972;44:623–631.

Leach GE. Urethrovaginal fistula repair with Martius labial fat pad graft. *Urol Clin North Am*. 1991;18(2):409–413.

Lee D, Zimmern PE. Long-term functional outcomes following non-radiated urethrovaginal fistula repair. *World J Urol*. 2016;34(2):291–296.

Lee JH, Choi JS, Lee KW, et al. Immediate laparoscopic nontransvesical repair without omental interposition for vesicovaginal fistula developing after total abdominal hysterectomy. *JSLS*. 2010;14(2):187–191.

Lee RA, Symmonds RE, Williams TJ. Current status of genitourinary fistula. *Obstet Gynecol*. 1988;72(3 Pt 1):313–319.

Lee WJ, Snyder JA, Smith AD. Staghorn calculi: endourologic management in 120 patients. *Radiology*. 1987;165(1):85–88.

Leissner J, Black P, Filipas D, et al. Vaginal reconstruction using the bladder and/or rectal walls in patients with radiation-induced fistulas. *Gynecol Oncol*. 2000;78(3 Pt 1):356–360.

Leng WW, Amundsen CL, McGuire EJ. Management of female genitourinary fistulas: transvesical or transvaginal approach? *J Urol*. 1998;160(6 Pt 1):1995–1999.

Lentz SS. Transvaginal repair of the posthysterectomy vesicovaginal fistula using a peritoneal flap: the gold standard. *J Reprod Med*. 2005;50(1):41–44.

Lentz SS, Homesley HD. Radiation-induced vesicosacral fistula: treatment with continent urinary diversion. *Gynecol Oncol*. 1995;58(2):278–280.

Leonard F, Fotso A, Borghese B, et al. Ureteral complications from laparoscopic hysterectomy indicated for benign uterine pathologies: a 13-year experience in a continuous series of 1300 patients. *Hum Reprod*. 2007;22(7):2006–2011.

Levenback C, Gershenson DM, McGehee R, et al. Enterovesical fistula following radiotherapy for gynecologic cancer. *Gynecol Oncol*. 1994;52(3):296–300.

Levitt MA, Pena A. Cloacal malformations: lessons learned from 490 cases. *Semin Pediatr Surg*. 2010;19(2):128–138.

Levitt MA, Bischoff A, Pena A. Pitfalls and challenges of cloaca repair: how to reduce the need for reoperations. *J*

Pediatr Surg. 2011;46(6):1250–1255.

Levy C, Tremaine WJ. Management of internal fistulas in Crohn's disease. *Inflamm Bowel Dis*. 2002;2:106–111.

Liedl B, Khoder WY, Ruhdorfer-Metz B, et al. Outcomes of a bladder preservation technique in female patients undergoing pelvic exenteration surgery for advanced gynaecological tumours. *Int Urogynecol J*. 2014;25(7):953–960.

Likic IS, Kadija S, Ladjevic NG, et al. Analysis of urologic complications after radical hysterectomy. *Am J Obstetr Gynecol*. 2008;199:644.e641–644.e643.

Likic IS, Kadija S, Ladjevic NG, et al. Analysis of urologic complications after radical hysterectomy. *Am J Obstet Gynecol*. 2008;199(6):644 [e641–643].

Linder BJ, Umbreit EC, Larson D, et al. Effect of prior radiotherapy and ablative therapy on surgical outcomes for the treatment of rectourethral fistulas. *J Urol*. 2013;190(4):1287–1291.

Lingeman JE, Wong MYC, Newmark JR. Endoscopic management of total ureteral occlusion and ureterovaginal fistula. *J Endourol*. 1995;9(5):391–396.

Liu GC, Xia HM, Wen YQ, et al. Considerations before repair of acquired rectourethral and urethrovaginal fistulas in children. *World J Pediatr*. 2008;4(1):53–57.

Liu XQ, Wang CC, Liu YB, et al. Renal and perinephric abscesses in West China Hospital: 10-year retrospective-descriptive study. *World J Nephrol*. 2016;5(1):108–114.

Lo TS, Jaili SB, Ibrahim R. A complicated urethrovaginal fistula following an inappropriate urethral diverticulum management. *Taiwan J Obstet Gynecol*. 2017;56(4):534–537.

Lo TS, Wijaya T, Lo LM, et al. Clinical relevance and treatment selection of ureteral injury after cesarean section. *Female Pelvic Med Reconstr Surg*. 2016;22(5):303–306.

Lopez C, Balogun M, Ganesan R, et al. MRI of vaginal conditions. *Clin Radiol*. 2005;60(6):648–662.

Loposso M, Hakim L, Ndundu J, et al. Predictors of recurrence and successful treatment following obstetric fistula surgery. *Urology*. 2016;97:80–85.

Lotocki W, Jozwik M, Jozwik M. Prognosis of fertility after surgical closure of vesicouterine fistula. *Eur J Obstet Gynecol Reprod Biol*. 1996;64(1):87–90.

Lowman J, Moore RD, Miklos JR. Tension-free vaginal tape sling with a porcine interposition graft in an irradiated patient with a past history of a urethrovaginal fistula and urethral mesh erosion: a case report. *J Reprod Med*. 2007;52(6):560–562.

Madjar S, Gousse A. Postirradiation vesicovaginal fistula completely resolved with conservative treatment. *Int Urogynecol J Pelvic Floor Dysfunct*. 2001;12(6):405–406.

Mahadevan U, Marion JF, Present DH. Fistula response to methotrexate in Crohn's disease: a case series. *Aliment Pharmacol Ther*. 2003;18(10):1003–1008.

Mahdy A. Interposition flaps in vesicovaginal fistula repairs can optimize cure rate. *Urol Ann*. 2014;6(1):98.

Maier U, Ehrenbock PM, Hofbauer J. Late urological complications and malignancies after curative radiotherapy for gynecological carcinomas: a retrospective analysis of 10,709 patients. *J Urol*. 1997;158(3 Pt 1):814–817.

Maioli RA, Macedo AR, Garcia AR, et al. Laparoscopic repair for vesicouterine fistulae. *Int Braz J Urol*. 2015;41(5):1030–1031.

Majeed HA, Mohammed KA, Salman HA. Renocolic fistula as a complication to xanthogranulomatous pyelonephritis. *Singapore Med J*. 1997;38(3):116–119.

Malde S, Spilotros M, Wilson A, et al. The uses and outcomes of the Martius fat pad in female urology. *World J Urol*. 2017;35(3):473–478.

Malik MA, Sohail M, Malik MT, et al. Changing trends in the etiology and management of vesicovaginal fistula. *Int J Urol*. 2018;25(1):25–29.

Maloney TG, Kavanagh A, Khavari R. Vesicosalpingo fistula: a case presentation and review of the literature. *Female Pelvic Med Reconstr Surg*. 2016;22(6):501–503.

Mandal AK, Sharma SK, Vaidyanathan S, et al. Ureterovaginal fistula: summary of 18 years' experience. *Br J Urol*. 1990;65(5):453–456.

Mao Q, Luo J, Fang J, et al. Management of radiation-induced rectovesical fistula in a woman using ileum: a case report and review of the literature. *Medicine (Baltimore)*. 2017;96(46):e8553.

Marchiole P, Benchaib M, Buenerd A, et al. Oncological safety of laparoscopic-assisted vaginal radical trachelectomy (LARVT or Dargent's operation): a comparative study with laparoscopic-assisted vaginal radical hysterectomy (LARVH). *Gynecol Oncol*. 2007;106(1):132–141.

Marcucci T, Giannessi S, Giudici F, et al. Management of colovesical and colovaginal diverticular fistulas: our experience and literature reviewed. *Ann Ital Chir*. 2017;88:55–61.

Margolin ML, Korelitz BI. Management of bladder fistulas in Crohn's disease. *J Clin Gastroenterol*. 1989;11(4):399–402.

Margolis T, Mercer LJ. Vesicovaginal fistula. *Obstet Gynecol Surv*. 1994;49(12):840–847.

Martini A, Dattolo E, Frizzi J, et al. Robotic vesico-vaginal fistula repair with no omental flap interposition. *Int Urogynecol J*. 2016;27(8):1277–1278.

Martius H. Die operative wiederherstellung der vollkommen fehlenden harnrohre ande schliessmuskels derselbel. *Zentralbl Gynakol*. 1928;52.

Massoudnia N. [G. Doderlein's “enwrapping plasty” for the surgical treatment of large bladder- and urethrovaginal fistulas]. *Zentralbl Gynakol*. 1974;96(20):624–629.

Masuda T, Kinoshita H, Nishida S, et al. Rectal injury during laparoscopic radical prostatectomy: detection and management. *Int J Urol*. 2010;17(5):492–495.

Mathevet P, Valencia P, Cousin C, et al. Operative injuries during vaginal hysterectomy. *Eur J Obstet Gynecol Reprod Biol*. 2001;97(1):71–75.

Matsumura M, Takeshima N, Ota T, et al. Neoadjuvant chemotherapy followed by radical hysterectomy plus postoperative chemotherapy but no radiotherapy for Stage IB2-IIB cervical cancer–irinotecan and platinum chemotherapy. *Gynecol Oncol*. 2010;119(2):212–216.

Mauermann J, Gonzalez R, Franc-Guimond J, et al. The anterior sagittal transrectal approach for traumatic urethrovaginal fistula closure. *J Urol*. 2004;171(4):1650–1651.

Maulet N, Berthe A, Traore S, et al. Obstetric fistula “disease” and ensuing care: patients’ views in West-Africa. *Afr J Reprod Health*. 2015;19(1):112–123.

Maulet N, Keita M, Macq J. Medico-social pathways of obstetric fistula patients in Mali and Niger: an 18-month cohort follow-up. *Trop Med Int Health*. 2013;18(5):524–533.

Mayer L. [Ureterosigmoid anastomosis in large vesicovaginal fistulas and cancer of the bladder]. *Brux Med*. 1951;31(48):2527–2528.

Mayersak JS, Viviano CJ, Babiarz JW. Cervical cancer radiation injury to the urinary bladder and ureters: management by cecal augmentation to a previous ileal augmentation cystoplasty. *Wis Med J*. 1995;94(6):300–304.

Mazzucchi E, Souza GL, Hisano M, et al. Primary reconstruction is a good option in the treatment of urinary fistula after kidney transplantation. *Int Braz J Urol*. 2006;32(4):398–403 [discussion 403–394].

McBeath RB, Schiff M Jr, Allen V, et al. A 12-year experience with enterovesical fistulas. *Urology*. 1994;44(5):661–665.

McCullough MC, Oh EE, Lucci JA 3rd, et al. Ureteroarterial fistula. *J Obstet Gynaecol*. 2012;32(7):617–620.

McDougal WS, Persky L. Traumatic and spontaneous pyeloduodenal fistulas. *J Trauma*. 1972;12(8):665–670.

McKinney DE. Use of full thickness patch graft in urethrovaginal fistula. *J Urol*. 1979;122(3):416.

McLaren RH, Barrett DM, Zincke H. Rectal injury occurring at radical retropubic prostatectomy for prostate cancer: etiology and treatment. *Urology*. 1993;42(4):401–405.

Meeks GR, Sams JO 4th, Field KW, et al. Formation of vesicovaginal fistula: the role of suture placement into the bladder during closure of the vaginal cuff after transabdominal hysterectomy. *Am J Obstet Gynecol*. 1997;177(6):1298–1304.

Melamud O, Eichel L, Turbow B, et al. Laparoscopic vesicovaginal fistula repair with robotic reconstruction. *Urology*. 2005;65(1):163–166.

Melegari S, Paparella S, Follini ML, et al. Bilateral ureteroarterial fistula: a case report and review of literature. *Urologia*. 2016;83(3):168–172.

Memon MA, Zieg DA, Neal PM. Vesicouterine fistula twenty years following brachytherapy for cervical cancer. *Scand J Urol Nephrol*. 1998;32(4):293–295.

Menchaca A, Akhyat M, Gleicher N, et al. The rectus abdominis muscle flap in a combined abdominovaginal repair of difficult vesicovaginal fistulae. A report of three cases. *J Reprod Med*. 1990;35(5):565–568.

Mercader VP, McGuckin JF Jr, Caroline DF, et al. CT of vesicocorporeal fistula with menouria: a complication of uterine biopsy. *J Comput Assist Tomogr*. 1995;19(2):324–326.

Miklos JR, Moore RD, Chinthakanan O. Laparoscopic and robotic-assisted vesicovaginal fistula repair: a systematic review of the literature. *J Minim Invasive Gynecol*. 2015;22(5):727–736.

Milani R, Cola A, Frigerio M, et al. Repair of a vesicouterine fistula following cesarean section. *Int Urogynecol J*. 2017;29(2):309–311.

Mileski WJ, Joehl RJ, Rege RV, et al. One-stage resection and anastomosis in the management of colovesical fistula. *Am J Surg*. 1987;153(1):75–79.

Milicic D, Sprem M, Bagovic D. A method for the repair of vesicovaginal fistulas. *Int J Gynaecol Obstet*. 2001;73(1):35–39.

Mishra VV, Tanvir T, Choudhary S, et al. A transvaginal removal and repair of vesicovaginal fistula due to mesh erosion. *J Midlife Health*. 2016;7(2):97–99.

Mitsuhashi N, Takahashi M, Yamakawa M, et al. Results of postoperative radiation therapy for patients with carcinoma of the uterine cervix: evaluation of intravaginal cone boost with an electron beam. *Gynecol Oncol*. 1995;57(3):321–326.

Modarress M, Maghami FQ, Golnavaz M, et al. Comparative study of chemoradiation and neoadjuvant chemotherapy effects before radical hysterectomy in stage IB-IIB bulky cervical cancer and with tumor diameter greater than 4 cm. *Int J Gynecol Cancer*. 2005;15(3):483–488.

Modi P, Gupta R, Rizvi SJ. Laparoscopic ureteroneocystostomy and psoas hitch for post-hysterectomy ureterovaginal fistula. *J Urol*. 2008;180:615–617.

Modi P, Goel R, Dodia S. Laparoscopic repair of vesicovaginal fistula. *Urol Int*. 2006;76(4):374–376.

Mohr S, Brandner S, Mueller MD, et al. Sexual function after vaginal and abdominal fistula repair. *Am J Obstet Gynecol*. 2014;211(1):74 e71–74 e76.

Moir JC. Vesico-vaginal fistulae as seen in Britain. *J Obstet Gynaecol Br Commonw*. 1973;80(7):598–602.

Monk BJ, Montz FJ. Invasive cervical cancer complicating intrauterine pregnancy: treatment with radical hysterectomy. *Obstet Gynecol*. 1992;80(2):199–203.

Monk BJ, Walker JL, Tewari K, et al. Open interstitial brachytherapy for the treatment of local-regional recurrences of uterine corpus and cervix cancer after primary surgery. *Gynecol Oncol*. 1994;52(2):222–228.

Monk BJ, Solh S, Johnson MT, et al. Radical hysterectomy after pelvic irradiation in patients with high risk cervical cancer or uterine sarcoma: morbidity and outcome. *Eur J Gynaecol Oncol*. 1993;14(6):506–511.

Moriel EZ, Meirow D, Zilberman M, et al. Experience with the immediate treatment of iatrogenic bladder injuries and the repair of complex vesico-vaginal fistulae by the transvesical approach. *Arch Gynecol Obstet*. 1993;253(3):127–130.

Morse FP 3rd, Dretler SP. Diagnosis and treatment of colovesical fistula. *J Urol*. 1974;111(1):22–24.

Morton HC, Hilton P. Urethral injury associated with minimally invasive mid-urethral sling procedures for the treatment of stress urinary incontinence: a case series and systematic literature search. *BJOG*. 2009;116(8):1120–1126.

Mraz JP, Sutory M. An alternative in surgical treatment of post-irradiation vesicovaginal and rectovaginal fistulas: the seromuscular intestinal graft (patch). *J Urol*. 1994;151(2):357–359.

Mselle LT, Kohi TW. Perceived health system causes of obstetric fistula from accounts of affected women in rural Tanzania: a qualitative study. *Afr J Reprod Health*. 2015;19(1):124–132.

Mteta KA, Mbwambo J, Mvungi M. Iatrogenic ureteric and bladder injuries in obstetric and gynaecologic surgeries. *East*

Afr Med J. 2006;83(2):79–85.

Muleta M, Tafesse B, Aytenfisu HG. Antibiotic use in obstetric fistula repair: single blinded randomized clinical trial. *Ethiop Med J*. 2010;48(3):211–217.

Murdoch M, Hilton P (2012). “Classical Hodgkin's lymphoma presenting as vesicovaginal fistula.” (submitted).

Murphy JM, Lee G, Sharma SD, et al. Vesicouterine fistula: MRI diagnosis. *Eur Radiol*. 1999;9(9):1876–1878.

Mwini-Nyaledzigbor PP, Agana AA, Pilkington FB. Lived experiences of Ghanaian women with obstetric fistula. *Health Care Women Int*. 2013;34(6):440–460.

Nagraj HK, Kishore TA, Nagalaksmi S. Early laparoscopic repair for supratrigonal vesicovaginal fistula. *Int Urogynecol J Pelvic Floor Dysfunct*. 2007;18(7):759–762.

Naidoo TD, Moodley J, Naidoo S. Genital tract fistula: a case series from a tertiary centre in South Africa. *Int Urogynecol J*. 2017;29(3):383–389.

Najjar SF, Jamal MK, Savas JF, et al. The spectrum of colovesical fistula and diagnostic paradigm. *Am J Surg*. 2004;188(5):617–621.

Narang V, Sinha T, Karan SC, et al. Ureteroscopy: savior to the gynecologist? Ureteroscopic management of post laparoscopic-assisted vaginal hysterectomy ureterovaginal fistulas. *J Minim Invas Gynecol*. 2007;14(3):345–347.

Narayanan P, Nobbenhuis M, Reynolds KM, et al. Fistulas in malignant gynecologic disease: etiology, imaging, and management. *Radiographics*. 2009;29(4):1073–1083.

Nardos R, Menber B, Browning A. Outcome of obstetric fistula repair after 10-day versus 14-day Foley catheterization. *Int J Gynaecol Obstet*. 2012;118(1):21–23.

Nawaz H, Khan M, Tareen FM, et al. Retrospective study of 213 cases of female urogenital fistulae at the Department of Urology & Transplantation Civil Hospital Quetta, Pakistan. *J*

Pak Med Assoc. 2010;60:28–32.

Nezhat CH, Nezhat F, Nezhat C, et al. Laparoscopic repair of a vesicovaginal fistula: a case report. *Obstet Gynecol*. 1994;83(5 II):899–901.

Nguyen BD, Collins JM. F-18 FDG PET/CT and MR imaging of rectourethral fistula. *Clin Nucl Med*. 2011;36(4):e8–e10.

Nie ZL, Zhang KQ, Li QS, et al. Treatment of urinary fistula after kidney transplantation. *Transplant Proc*. 2009;41(5):1624–1626.

Nikolaev VV, Bizhanova DA. High posttraumatic vaginal stricture combined with urethrovaginal fistula and urethral stricture in girls: reconstruction using a posterior sagittal pararectal approach. *J Urol*. 1998;160(6 Pt 1):2194–2196.

Nomoto T, Tanaka Y, Yamamoto K. Uretero-aortic fistula: a case report. *Tokai J Exp Clin Med*. 2009;34(1):12–14.

Norby B, Frimodt-Moller PC. Development of a urethrorectal fistula after transurethral microwave thermotherapy for benign prostatic hyperplasia. *BJU Int*. 2000;85(4):554–555.

Nwabineli NJ, Davis JA. Fistula injury to the bladder at repeat cone biopsy by laser. *Eur J Obstet Gynecol Reprod Biol*. 1992;43(3):245–246.

Nyam DC, Pemberton JH. Management of iatrogenic rectourethral fistula. *Dis Colon Rectum*. 1999;42(8):994–997 [discussion 997–999].

Oakley SH, Brown HW, Greer JA, et al. Management of vesicovaginal fistulae: a multicenter analysis from the Fellows' Pelvic Research Network. *Female Pelvic Med Reconstr Surg*. 2014;20(1):7–13.

Obrink A, Bunne G. Gracilis interposition in fistulas following radiotherapy for cervical cancer. A retrospective study. *Urol Int*. 1978;33(5):370–376.

O'Conor VJ, Sokol JK. Vesicovaginal fistula from the standpoint of the urologist. *J Urol*. 1951;66(4):579–585.

O'Conor VJ Jr. Review of experience with vesicovaginal fistula repair. *J Urol*. 1980;123(3):367–369.

O'Conor VJ Jr, Sokol JK, Bulkley GJ, et al. Suprapubic closure of vesicovaginal fistula. *J Urol*. 1973;109(1):51–54.

Oguzkurt P, Ince E, Ezer SS, et al. Primary vaginal calculus secondary to urethrovaginal fistula with imperforate hymen in a 6-year-old girl. *J Pediatr Surg*. 2009;44(7):e11–e13.

Okaneya T, Ogawa A, Wajiki M. Tuberculous rectourethral fistula. *Urology*. 1988;31(5):424–426.

Okusanya BO, Garba KK. Vesico-vaginal fistula in a patient with Meyer-Rokitansky-Kuster-Hauser syndrome. *Niger Postgrad Med J*. 2010;17(1):64–66.

Onuora VC, al-Mohalhal S, Youssef AM, et al. Iatrogenic urogenital fistulae. *Br J Urol*. 1993;71(2):176–178.

Ostad M, Uzzo RG, Coleman J, et al. Use of a free bladder mucosal graft for simple repair of vesicovaginal fistulae. *Urology*. 1998;52(1):123–126.

Ostrzenski A, Ostrzenska KM. Bladder injury during laparoscopic surgery. *Obstet Gynecol Surv*. 1998;53(3):175–180.

Ota T, Tsuji Y, Kawasaki R, et al. Endovascular treatment of aortoureteric fistula. *J Endovasc Ther*. 2005;12(3):411–413.

Ou CS, Huang UC, Tsuang M, et al. Laparoscopic repair of vesicovaginal fistula. *J Laparoendosc Adv Surg Tech A*. 2004;14(1):17–21.

Ouedraogo I, Payne C, Nardos R, et al. Obstetric fistula in Niger: 6-month postoperative follow-up of 384 patients from the Danja Fistula Center. *Int Urogynecol J*. 2018;29(3):345–351.

Ouedraogo I, McConley R, Payne C, et al. Gurya cutting and female genital fistulas in Niger: ten cases. *Int Urogynecol J*. 2018;29(3):363–368.

Ozdemir E, Ozturk U, Celen S, et al. Urinary complications of gynecologic surgery: iatrogenic urinary tract system injuries in obstetrics and gynecology operations. *Clin Exp Obstet Gynecol*. 2011;38(3):217–220.

Padovani GP, Vicentini FC, Marchini GS, et al. Peripyelitis: a risk factor for urinary fistula after tubeless PCNL. *Int Braz J Urol*. 2015;41(1):177–178.

Pal DK, Wats V, Ghosh B. Urologic complications following obstetrics and gynecologicai surgery: our experience in a tertiary care hospital. *Urol Ann*. 2016;8(1):26–30.

Papanicolaou N, Pfister RC, Yoder IC. Percutaneous occlusion of ureteral leaks and fistulae using nondetachable balloons. *Urol Radiol*. 1985;7(1):28–31.

Park DS, Gong IH, Choi DK, et al. Radical prostatectomy versus high dose permanent prostate brachytherapy using iodine-125 seeds for patients with high risk prostate cancer: a matched cohort analysis. *World J Urol*. 2013;31(6):1511–1517.

Park SH, Park WH, Kim HG. Successful case of conservative treatment of vesicovaginal fistula by hodge pessary insertion. *Low Urin Tract Symptoms*. 2015;7(2):118–120.

Park S, Ha SH, Kim KS. Long-term follow-up after feminizing genital reconstruction in patients with ambiguous genitalia and high vaginal confluence. *J Korean Med Sci*. 2011;26(3):399–403.

Parkhurst JD, Coker JE, Halverstadt DB. Traumatic avulsion of the lower urinary tract in the female child. *J Urol*. 1981;126(2):265–267.

Parks J. Section of the urethral wall for correction of urethrovaginal fistulae and urethral diverticula. *Am J Obstet Gynecol*. 1965;93(5):683–692.

Patil U, Waterhouse K, Laungani G. Management of 18 difficult vesicovaginal and urethrovaginal fistulas with modified Ingelman-Sundberg and Martius operations. *J Urol*.

1980;123(5):653–656.

Patterson DE, Segura JW, LeRoy AJ, et al. The etiology and treatment of delayed bleeding following percutaneous lithotripsy. *J Urol*. 1985;133(3):447–451.

Paul S, Singh V, Sinha RJ, et al. Vesicovaginal fistula due to vaginal herb for primary infertility: could it be devastating? *BMJ Case Rep*. 2013;2013.

Pena A. The surgical management of persistent cloaca: results in 54 patients treated with a posterior sagittal approach. *J Pediatr Surg*. 1989;24(6):590–598.

Penrose KJ, Ma Yin J, Tsokos N. Delayed vesicovaginal fistula after ring pessary usage. *Int Urogynecol J*. 2014;25(2):291–293.

Persky L, Rabin R. Experiences with vesicovaginal fistulas. *Am J Surg*. 1973;125(6):763–766.

Persky L, Herman G, Guerrier K. Nondelay in vesicovaginal fistula repair. *Urology*. 1979;13(3):273–275.

Pettersson S, Hedelin H, Jansson I, et al. Fibrin occlusion of a vesicovaginal fistula. *Lancet*. 1979;1(8122):933.

Pieper CC, Meyer C, Hauser S, et al. Transrenal ureteral occlusion using the Amplatzer vascular plug II: a new interventional treatment option for lower urinary tract fistulas. *Cardiovasc Intervent Radiol*. 2014;37(2):451–457.

Pindoria K, Reyad A, Youssef Y. Foley catheter through a colovesical fistula: an unusual method of diagnosis. *BMJ Case Rep*. 2014;2014.

Pokala N, Delaney CP, Brady KM, et al. Elective laparoscopic surgery for benign internal enteric fistulas: a review of 43 cases. *Surg Endosc*. 2005;19(2):222–225.

Pollard SG, Macfarlane R, Greatorex R, et al. Colovesical fistula. *Ann R Coll Surg Engl*. 1987;69(4):163–165.

Pontari MA, McMillen MA, Garvey RH, et al. Diagnosis and treatment of enterovesical fistulae. *Am Surg*. 1992;58(4):258–

263.
Porcaro AB, Zicari M, Zecchini Antoniolli S, et al. Vesicouterine fistulas following cesarean section: report on a case, review and update of the literature. *Int Urol Nephrol*. 2002;34(3):335–344.
Porpiglia F, Destefanis P, Fiori C, et al. Preoperative risk factors for surgery female urethral diverticula. Our experience. *Urol Int*. 2002;69(1):7–11.
Powers K, Grigorescu B, Lazarou G, et al. Neglected pessary causing a rectovaginal fistula: a case report. *J Reprod Med*. 2008;53(3):235–237.
Present DH, Rutgeerts P, Targan S, et al. Infliximab for the treatment of fistulas in patients with Crohn's disease. *N Engl J Med*. 1999;340(18):1398–1405.
Price DT, Price TC. Robotic repair of a vesicovaginal fistula in an irradiated field using a dehydrated amniotic allograft as an interposition patch. *J Robot Surg*. 2016;10(1):77–80.
Pruthi RS, Petrus CD, Bundrick WJ. New onset vesicovaginal fistula after transurethral collagen injection in women who underwent cystectomy and orthotopic neobladder creation: presentation and definitive treatment. *J Urol*. 2000;164(5):1638–1639.
Punekar SV, Buch DN, Soni AB, et al. Martius' labial fat pad interposition and its modification in complex lower urinary fistulae. *J Postgrad Med*. 1999;45(3):69–73.
Puntambekar S, Palep RJ, Gurjar AM, et al. Laparoscopic ureteroneocystostomy with psoas hitch. *J Minim Invas Gynecol*. 2006;13:302–305.
Pushkar D. Editorial comment on: transpubic access using pedicle tubularized labial urethroplasty for the treatment of female urethral strictures associated with urethrovaginal fistulas secondary to pelvic fracture. *Eur Urol*. 2009;56(1):200.

Pushkar DY, Dyakov VV, Kasyan GR. Management of radiation-induced vesicovaginal fistula. *Eur Urol*. 2009;55(1):131–137.

Pushkar DY, Dyakov VV, Kosko JW, et al. Management of urethrovaginal fistulas. *Eur Urol*. 2006;50(5):1000–1005.

Quillin SP, Darcy MD, Picus D. Angiographic evaluation and therapy of ureteroarterial fistulas. *AJR Am J Roentgenol*. 1994;162(4):873–878.

Quiroz LH, Shobeiri SA, Nihira MA. Three-dimensional ultrasound imaging for diagnosis of urethrovaginal fistula. *Int Urogynecol J*. 2010;21(8):1031–1033.

Raassen TJ, Ngongo CJ, Mahendeka MM. Iatrogenic genitourinary fistula: an 18-year retrospective review of 805 injuries. *Int Urogynecol J*. 2014;25(12):1699–1706.

Raassen T, Ngongo CJ, Mahendeka MM. Diagnosis and management of 365 ureteric injuries following obstetric and gynecologic surgery in resource-limited settings. *Int Urogynecol J*. 2017;29(9):1303–1309.

Radoja I, Sudarevic B, Perkovic J, et al. Our experience with vesicovaginal fistula repair surgery. *Eur Urol Suppl*. 2010;9(6):637.

Radopoulos DK, Dimitriadis GP, Vakalopoulos IK, et al. Our experience with salvage genitourinary fistulae repair: technique and outcomes. *Int Urol Nephrol*. 2008;40(1):57–63.

Radwan R, Saeed ZM, Phull JS, et al. How safe is it to manage diverticular colovesical fistulation non-operatively? *Colorectal Dis*. 2013;15(4):448–450.

Raghavaiah NV. Double-dye test to diagnose various types of vaginal fistulas. *J Urol*. 1974;112(6):811–812.

Rajamaheswari N, Chhikara AB. Vesicouterine fistulae: our experience of 17 cases and literature review. *Int Urogynecol J*. 2013;24(2):275–279.

Rajamaheswari N, Bharti A, Seethalakshmi K. Vaginal repair of supratrigonal vesicovaginal fistulae–a 10-year review. *Int Urogynecol J*. 2012;23(12):1675–1678.

Ralph G, Tamussino K, Lichtenegger W. Urological complications after radical hysterectomy with or without radiotherapy for cervical cancer. *Arch Gynecol Obstet*. 1990;248(2):61–65.

Rangnekar NP, Imdad Ali N, Kaul SA, et al. Role of the Martius procedure in the management of urinary-vaginal fistulas. *J Am Coll Surg*. 2000;191(3):259–263.

Rao PN, Knox R, Barnard RJ, et al. Management of colovesical fistula. *Br J Surg*. 1987;74(5):362–363.

Rassweiler J, Seemann O, Schulze M, et al. Laparoscopic versus open radical prostatectomy: a comparative study at a single institution. *J Urol*. 2003;169(5):1689–1693.

Ravi B, Schiavello H, Abayev D, et al. Conservative management of vesicouterine fistula. A report of 2 cases. *J Reprod Med*. 2003;48(12):989–991.

Ravi R, Dewan AK, Pandey KK. Transverse colon conduit urinary diversion in patients treated with very high dose pelvic irradiation. *Br J Urol*. 1994;73(1):51–54.

Raz S, Bregg KJ, Nitti VW, et al. Transvaginal repair of vesicovaginal fistula using a peritoneal flap. *J Urol*. 1993;150(1):56–59.

Razzaghi MR, Rezaei A, Javanmard B, et al. Desmopressin as an alternative solution for urinary leakage after ureterocaliceal surgeries. *Urol J*. 2009;6(2):120–122.

Reisenauer C. Vesicovaginal fistulas: a gynecological experience in 41 cases at a German pelvic floor center. *Arch Gynecol Obstet*. 2015;292(2):245–253.

Reisenauer C. Presentation and management of vesicovaginal fistulae after delivery at a German women's hospital. *Arch Gynecol Obstet*. 2017;296(1):1–3.

Reisenauer C, Wallwiener D, Stenzl A, et al. Urethrovaginal fistula–a rare complication after the placement of a suburethral sling (IVS). *Int Urogynecol J Pelvic Floor Dysfunct*. 2007;18(3):343–346.

Reisenauer C, Janowitz J, Wallwiener D, et al. Urethrovaginal fistulae associated with tension-free vaginal tape procedures: a clinical challenge. *Int Urogynecol J*. 2014;25(3):319–322.

Renschler TD, Middleton RG. 30 years of experience with York-Mason repair of recto-urinary fistulas. *J Urol*. 2003;170(4 Pt 1):1222–1225 [discussion 1225].

Ridgeway B, Walters MD, Paraiso MF, et al. Early experience with mesh excision for adverse outcomes after transvaginal mesh placement using prolapse kits. *Am J Obstet Gynecol*. 2008;199(6):703 e701–703 e707.

Riss P, Koelbl H, Neunteufel W, et al. Wertheim radical hysterectomy 1921-1986: changes in urologic complications. *Arch Gynecol Obstet*. 1988;241(4):249–253.

Roberto Martinez P, Rodríguez Colorado SE, Escobar del Barco L, et al. Vesicovaginal fistula. Experience at the Instituto Nacional de Perinatologia. *Ginecol Obstet Mex*. 2007;75(1):31–34.

Rooney KE, Cholhan HJ. Vesico-uterine fistula after endometrial ablation in a woman with prior cesarean deliveries. *Obstet Gynecol*. 2010;115(2 Pt 2):450–451.

Rossi F, De Castro R, Ceccarelli PL, et al. Anterior sagittal transanorectal approach to the posterior urethra in the pediatric age group. *J Urol*. 1998;160(3 Pt 2):1173–1177.

Rouzi AA, Sahly N, Mansouri N, et al. Urinary catheterization as a successful treatment option for post-cesarean section vesicouterine fistula. *Clin Exp Obstet Gynecol*. 2016;43(1):143–145.

Rovner ES, Wein AJ. Diagnosis and reconstruction of the dorsal or circumferential urethral diverticulum. *J Urol*. 2003;170(1):82–86 [discussion 86].

Roy KK, Vaijyanath AM, Sinha A, et al. Sexual trauma–an unusual cause of a vesicovaginal fistula. *Eur J Obstet Gynecol Reprod Biol*. 2002;101(1):89–90.

Ruminjo JK, Frajzyngier V, Bashir Abdullahi M, et al. Clinical procedures and practices used in the perioperative treatment of female genital fistula during a prospective cohort study. *BMC Pregnancy Childbirth*. 2014;14:220.

Sachdev PS, Hassan N, Abbasi RM, et al. Genito-urinary fistula: a major morbidity in developing countries. *J Ayub Med Coll Abbottabad*. 2009;21:8–11.

Saint-Marc O, Frileux P, Vaillant JC, et al. [Enterovesical fistulas in Crohn disease: diagnosis and treatment]. *Ann Chir*. 1995;49(5):390–395.

Sakellariou P, Protopapas AG, Voulgaris Z, et al. Management of ureteric injuries during gynecological operations: 10 years experience. *Eur J Obstet Gynecol Reprod Biol*. 2002;101(2):179–184.

Sapmaz E, Celik H, Semercioz A. Omental graft use in Youssef syndrome. *Eur J Obstet Gynecol Reprod Biol*. 2003;109(1):92–96.

Schimpf MO, Gottenger EE, Wagner JR. Universal ureteral stent placement at hysterectomy to identify ureteral injury: a decision analysis. *BJOG*. 2008;115(9):1151–1158.

Schmidt JD, Buchsbaum HJ. Transverse colon conduit diversion. *Urol Clin North Am*. 1986;13(2):233–239.

Schoellnast H, Lindbichler F, Riccabona M. Sonographic diagnosis of urethral anomalies in infants: value of perineal sonography. *J Ultrasound Med*. 2004;23(6):769–776.

Schofield PF. Colovesical fistulas. *Br J Hosp Med*. 1988;39(6):483–487.

Schwartzwald D, Mooppan UM, Tancer ML, et al. Vesicouterine fistula with menouria: a complication from an intrauterine contraceptive device. *J Urol*. 1986;136(5):1066–

1067.

Scott R, Gorham SD, Aitcheson M, et al. First clinical report of a new biodegradable membrane for use in urological surgery. *Br J Urol*. 1991;68(4):421–424.

Selph JP, Madden-Fuentes R, Peterson AC, et al. Long-term artificial urinary sphincter outcomes following a prior rectourethral fistula repair. *Urology*. 2015;86(3):608–612.

Selzman AA, Spirnak JP, Kursh ED. The changing management of ureterovaginal fistulas. *J Urol*. 1995;153(3 Pt 1):626–628.

Shackley DC, Brew CJ, Bryden AA, et al. The staged management of complex entero-urinary fistulae. *BJU Int*. 2000;86(6):624–629.

Shah SJ. Role of day care vesicovaginal fistula fulguration in small vesicovaginal fistula. *J Endourol*. 2010;24(10):1659–1660.

Shah TT, Ahmed H, Kanthabalan A, et al. Focal cryotherapy of localized prostate cancer: a systematic review of the literature. *Expert Rev Anticancer Ther*. 2014;14(11):1337–1347.

Shaker H, Saafan A, Yassin M, et al. Obstetric vesico-vaginal fistula repair: should we trim the fistula edges? A randomized prospective study. *Neurourol Urodyn*. 2011;30(3):302–305.

Sharifi-Aghdas F, Ghaderian N, Payvand A. Free bladder mucosal autograft in the treatment of complicated vesicovaginal fistula. *BJU Int*. 2002;89(Suppl 1):54–56.

Shelbaia AM, Hashish NM. Limited experience in early management of genitourinary tract fistulas. *Urology*. 2007;69(3):572–574.

Sherif A, Karacagil S, Magnusson A, et al. Endovascular approach to treating secondary arterioureteral fistula. *Scand J Urol Nephrol*. 2002;36(1):80–82.

Shin PR, Foley E, Steers WD. Surgical management of rectourinary fistulae. *J Am Coll Surg*. 2000;191(5):547–553.

Sims J. On the treatment of vesico-vaginal fistula. *Am J Med Sci*. 1852;XXIII:59–82.

Singh V, Sinha RJ, Mehrotra S, et al. Transperitoneal transvesical laparoscopic repair of vesicovaginal fistulae: experience of a tertiary care centre in northern India. *Curr Urol*. 2013;7(2):75–82.

Smayra T, Ghossain MA, Buy JN, et al. Vesicouterine fistulas: imaging findings in three cases. *AJR Am J Roentgenol*. 2005;184(1):139–142.

Solem CA, Loftus EV Jr, Tremaine WJ, et al. Fistulas to the urinary system in Crohn's disease: clinical features and outcomes. *Am J Gastroenterol*. 2002;97(9):2300–2305.

Solkar MH, Forshaw MJ, Sankararajah D, et al. Colovesical fistula–is a surgical approach always justified? *Colorectal Dis*. 2005;7(5):467–471.

Soong Y, Lim PH. Urological injuries in gynaecological practice–when is the optimal time for repair? *Singapore Med J*. 1997;38(11):475–478.

Starownik R, Michalak J, Bar K, et al. An uncommon case of inflammatory infiltration of the urinary bladder in the long-term process of the purulent inflammation of the cervix and vaginal fornix, complicated with vesicovaginal fistula of unknown etiology. *Cent European J Urol*. 2013;66(1):101–103.

Stovsky MD, Ignatoff JM, Blum MD, et al. Use of electrocoagulation in the treatment of vesicovaginal fistulas. *J Urol*. 1994;152(5 Pt 1):1443–1444.

Stower MJ, Wyatt MG, Jeans WD. Arteriocaliceal fistula controlled by trans-catheter occlusion. *Br J Urol*. 1989;64(4):436–437.

Sultana CJ, Goldberg J, Aizenman L, et al. Vesicouterine fistula after uterine artery embolization: a case report. *Am J Obstet Gynecol*. 2002;187(6):1726–1727.

Sundaram BM, Kalidasan G, Hemal AK. Robotic repair of vesicovaginal fistula: case series of five patients. *Urology*. 2006;67(5):970–973.

Sur MD, Muller D, Angelos P, et al. J. Marion Sims, MD: a controversial legacy. *Bull Am Coll Surg*. 2017;102(7):84–85.

Symmonds RE, Hill LM. Loss of the urethra: a report on 50 patients. *Am J Obstet Gynecol*. 1978;130(2):130–138.

Tabakov ID, Slavchev BN. Large post-hysterectomy and post-radiation vesicovaginal fistulas: repair by ileocystoplasty. *J Urol*. 2004;171(1):272–274.

Tahzib F. Vesicovaginal fistula in Nigerian children. *Lancet*. 1985;2:1291–1293.

Tancer ML. Vesicouterine fistula—a review. *Obstet Gynecol Surv*. 1986;41(12):743–753.

Tancer ML. Observations on prevention and management of vesicovaginal fistula after total hysterectomy. *Surg Gynecol Obstet*. 1992;175(6):501–506.

Tatar B, Oksay T, Selcen Cebe F, et al. Management of vesicovaginal fistulas after gynecologic surgery. *Turk J Obstet Gynecol*. 2017;14(1):45–51.

Tay KJ, Polascik TJ, Elshafei A, et al. Propensity score-matched comparison of partial to whole-gland cryotherapy for intermediate-risk prostate cancer: an analysis of the cryo on-line data registry data. *J Endourol*. 2017;31(6):564–571.

Tay KJ, Polascik TJ, Elshafei A, et al. Primary cryotherapy for high-grade clinically localized prostate cancer: oncologic and functional outcomes from the COLD registry. *J Endourol*. 2016;30(1):43–48.

Tebeu PM, Fomulu JN, Khaddaj S, et al. Risk factors for obstetric fistula: a clinical review. *Int Urogynecol J*. 2012;23(4):387–394.

Tehan TJ, Nardi JA, Baker R. Complications associated with surgical repair of urethrovaginal fistula. *Urology*.

1980;15(1):31–35.

Teuton ME, Viner NA, Zuckerman HL, et al. Ureteroiliac vein fistula associated with a polyethylene indwelling ureteral stent. *J Urol*. 1987;137(5):975–976.

Theodorescu D, Gillenwater JY, Koutrouvelis PG. Prostatourethral-rectal fistula after prostate brachytherapy. *Cancer*. 2000;89(10):2085–2091.

Theofanides MC, Sui W, Sebesta EM, et al. Vesicovaginal fistulas in the developed world: an analysis of disease characteristics, treatments, and complications of surgical repair using the ACS-NSQIP database. *Neurourol Urodyn*. 2017;36(6):1622–1628.

Thomas C, Jones J, Jager W, et al. Incidence, clinical symptoms and management of rectourethral fistulas after radical prostatectomy. *J Urol*. 2010;183(2):608–612.

Thomas K, Williams G. Medicolegal aspects of vesicovaginal fistulae. *BJU Int*. 2000;86(3):354–359.

Thompson IM, Marx AC. Conservative therapy of rectourethral fistula: five-year follow-up. *Urology*. 1990;35(6):533–536.

Thrumurthy SG, Hill SR, Islam S. Iatrogenic urethrovaginal fistula from catheterization in labour. *Br J Hosp Med*. 2010;71(7):414.

Tobias-Machado M, Mattos PA, Castro PR, et al. Laparoscopic treatment of vesicovaginal fistula. *Int Braz J Urol*. 2014;40(3):435–discussion 436.

Trop CS, Bennett CJ. Complications from long-term indwelling Foley catheters in female patients with neurogenic bladders. *Semin Urol*. 1992;10(2):115–120.

Turner-Warwick R. The use of the omental pedicle graft in urinary tract reconstruction. *Trans Am Assoc Genitourin Surg*. 1975;67:126–132.

Uchida T, Shoji S, Nakano M, et al. High-intensity focused ultrasound as salvage therapy for patients with recurrent prostate cancer after external beam radiation, brachytherapy or proton therapy. *BJU Int*. 2011;107(3):378–382.

Uchida T, Tomonaga T, Kim H, et al. Improved outcomes with advancements in high intensity focused ultrasound devices for the treatment of localized prostate cancer. *J Urol*. 2015;193(1):103–110.

Un S, Cakir V, Kose O, et al. Colon perforation during percutaneous nephrolithotomy and fistula closure with Spongostan following conservative therapy. *Can Urol Assoc J*. 2015;9(5–6):E313–E315.

Ungar L, Palfalvi L, Novak Z. Primary pelvic exenteration in cervical cancer patients. *Gynecol Oncol*. 2008;111(2 Suppl):S9–S12.

Ustunsoz B, Ugurel S, Duru NK, et al. Percutaneous management of ureteral injuries that are diagnosed late after cesarean section. *Korean J Radiol*. 2008;9(4):348–353.

van den Bergh RC, Moll FL, de Vries JP, et al. Arterioureteral fistulas: unusual suspects-systematic review of 139 cases. *Urology*. 2009;74(2):251–255.

Vanni AJ, Buckley JC, Zinman LN. Management of surgical and radiation induced rectourethral fistulas with an interposition muscle flap and selective buccal mucosal onlay graft. *J Urol*. 2010;184(6):2400–2404.

Venkatramani V, Shanmugasundaram R, Kekre NS. Urogenital fistulae in India: results of a retrospective analysis. *Female Pelvic Med Reconstr Surg*. 2014;20(1):14–18.

Verbaeys C, Hoebeke P, Oosterlinck W. Complicated postirradiation vesicovaginal fistula in young women: keep off or try reconstruction? *Eur Urol*. 2007;51(1):243–246 [discussion 246].

Verma A, Vyas S, Patwari S, et al. Magnetic resonance fistulogram demonstration of urethrovesicovaginal fistula in a case of mullerian agenesis due to traumatic urethral coitus. *J*

Minim Invasive Gynecol. 2012;19(2):259–261.

Vidal Sans J, Pradell Teigell J, Palou Redorta J, et al. Review of 31 vesicointestinal fistulas: diagnosis and management. *Eur Urol*. 1986;12(1):21–27.

Viennas LK, Alonso AM, Salama V. Repair of radiation-induced vesicovaginal fistula with a rectus abdominis myocutaneous flap. *Plast Reconstr Surg*. 1995;96(6):1435–1437.

Volkmer BG, Kuefer R, Nesslauer T, et al. Colour Doppler ultrasound in vesicovaginal fistulas. *Ultrasound Med Biol*. 2000;26(5):771–775.

von Theobald P, Hamel P, Febbraro W. Laparoscopic repair of a vesicovaginal fistula using an omental J flap. *Br J Obstet Gynaecol*. 1998;105(11):1216–1218.

Vora A, Agarwal V, Singh P, et al. Single-institution comparative study on the outcomes of salvage cryotherapy versus salvage robotic prostatectomy for radio-resistant prostate cancer. *Prostate Int*. 2016;4(1):7–10.

Waaldijk K. The immediate surgical management of fresh obstetric fistulas with catheter and/or early closure. *Int J Gynaecol Obstet*. 1994;45(1):11–16.

Waaldijk K. Immediate indwelling bladder catheterisation at postpartum urine leakage - personal experience of 1200 patients. *Trop Doct*. 1997;27:227–228.

Waaldijk K. The immediate management of fresh obstetric fistulas. *Am J Obstet Gynecol*. 2004;191(3):795–799.

Wahab F, Nasir A, Manan F. Outcome of VVF repair without omental interposition. *J Pak Med Assoc*. 2016;66(5):590–592.

Waidelich RM, Brunschweiger SM, Schmeller NT. Urethrovaginal fistula in Behcet disease]. *Urologe A*. 1994;33(2):163–166.

Walker KF, Dasgupta J, Cust MP. A neglected shelf pessary resulting in a urethrovaginal fistula. *Int Urogynecol J*. 2011;22(10):1333–1334.

Walker KG, Anderson JH, Iskander N, et al. Colonic resection for colovesical fistula: 5-year follow-up. *Colorectal Dis*. 2002;4(4):270–274.

Wall LL. Dr. George Hayward (1791-1863): a forgotten pioneer of reconstructive pelvic surgery. *Int Urogynecol J Pelvic Floor Dysfunct*. 2005;16(5):330–333.

Wall LL, Arrowsmith SD. The “continence gap”: a critical concept in obstetric fistula repair. *Int Urogynecol J Pelvic Floor Dysfunct*. 2007;18(8):843–844.

Wall LL, Arrowsmith SD, Hancock BD. Ethical aspects of urinary diversion for women with irreparable obstetric fistulae in developing countries. *Int Urogynecol J*. 2008;19(7):1027–1030.

Wall LL, Karshima JA, Kirschner C, et al. The obstetric vesicovaginal fistula: characteristics of 899 patients from Jos, Nigeria. *Am J Obstet Gynecol*. 2004;190(4):1011–1019.

Wang AC, Hung CF. Endourologic diagnosis and treatment of ureterouterine fistula. *Int Urogynecol J Pelvic Floor Dysfunct*. 1997;8(3):164–167.

Wang Y, Hadley HR. Nondelayed transvaginal repair of high lying vesicovaginal fistula. *J Urol*. 1990;144(1):34–36.

Watts KL, Ho R, Ghavamian R, et al. Robot-assisted extravesical vesicovaginal fistula repair utilizing laparoscopically mobilized omental flap interposition. *Int Urogynecol J*. 2017;28(4):641–644.

Webster GD, Sihelnik SA, Stone AR. Urethrovaginal fistula: a review of the surgical management. *J Urol*. 1984;132(3):460–462.

Wedmid A, Mendoza P, Sharma S, et al. Rectal injury during robot-assisted radical prostatectomy: incidence and management. *J Urol*. 2011;186(5):1928–1933.

Wein AJ, Malloy TR, Greenberg SH, et al. Omental transposition as an aid in genitourinary reconstructive procedures. *J Trauma*. 1980;20(6):473–477.

Wein AJ, Malloy TR, Carpiniello VL, et al. Repair of vesicovaginal fistula by a suprapubic transvesical approach. *Surg Gynecol Obstet*. 1980;150(1):57–60.

Williams JA Jr, Clarke D, Dennis WA, et al. The treatment of pelvic soft tissue radiation necrosis with hyperbaric oxygen. *Am J Obstet Gynecol*. 1992;167(2):412–415 [discussion 415–416].

Wilson A, Pillay S, Greenwell T. How and why to take a Martius labial interposition flap in female urology. *Transl Androl Urol*. 2017;6(Suppl 2):S81–S87.

Woods RJ, Lavery IC, Fazio VW, et al. Internal fistulas in diverticular disease. *Dis Colon Rectum*. 1988;31(8):591–596.

Wright J, Ayenachew F, Ballard KD. The changing face of obstetric fistula surgery in Ethiopia. *Int J Womens Health*. 2016;8:243–248.

Xiong Y, Tang Y, Huang F, et al. Transperitoneal laparoscopic repair of vesicovaginal fistula for patients with supratrigonal fistula: comparison with open transperitoneal technique. *Int Urogynecol J*. 2016;27(9):1415–1422.

Xu H, Chen Y, Li Y, et al. Complications of laparoscopic radical hysterectomy and lymphadenectomy for invasive cervical cancer: experience based on 317 procedures. *Surg Endosc*. 2007;21(6):960–964.

Xu YM, Sa YL, Fu Q, et al. Transpubic access using pedicle tubularized labial urethroplasty for the treatment of female urethral strictures associated with urethrovaginal fistulas secondary to pelvic fracture. *Eur Urol*. 2009;56(1):193–200.

Yan X, Li G, Shang H, et al. Complications of laparoscopic radical hysterectomy and pelvic lymphadenectomy–experience of 117 patients. *Int J Gynecol Cancer*.

2009;19(5):963–967.

Yesil S, Ozturk U, Goktug HN, et al. Previous open renal surgery increased vascular complications in percutaneous nephrolithotomy (PCNL) compared with primary and secondary PCNL and extracorporeal shock wave lithotripsy patients: a retrospective study. *Urol Int*. 2013;91(3):331–334.

Yildirim M, Goktas C, Horuz R, et al. Rectal injury during radical prostatectomy. *Ulus Travma Acil Cerrahi Derg*. 2012;18(3):250–254.

Yildiz M, Atan A, Aydoganli L, et al. Renocolic fistula secondary to chronic pyelonephritis. *Int Urol Nephrol*. 1993;25(3):229–233.

Ying T, Li Q, Shao C, et al. Value of transrectal ultrasonography in female traumatic urethral injuries. *Urology*. 2010;76(2):319–322.

Youssef AF. Menouria following lower segment cesarean section; a syndrome. *Am J Obstet Gynecol*. 1957;73(4):759–767.

Youssef AH, Fath-Alla M, El-Kassaby AW. Perineal subcutaneous dartos pedicled flap as a new technique for repairing urethrorectal fistula. *J Urol*. 1999;161(5):1498–1500.

Yu S, Wu H, Xu L, et al. Early surgical repair of iatrogenic ureterovaginal fistula secondary to gynecologic surgery. *Int J Gynaecol Obstet*. 2013;123(2):135–138.

Zeineddine HA, Nassif J, El-Hout Y, et al. Congenital vesicovaginal fistula: spontaneous or forced? Two cases and literature review. *Int Urogynecol J*. 2014;25(9):1167–1172.

Zhaohui H, Hanqi L, Xiongbing L, et al. Analysis of repeated renal arteriography after percutaneous nephrolithotomy. *Urolithiasis*. 2016.

Zimmern PE, Hadley HR, Staskin DR, et al. Genitourinary fistulae. Vaginal approach for repair of vesicovaginal fistulae.

Urol Clin North Am. 1985;12(2):361–367.

Zippe CD. Cryosurgery of the prostate: techniques and pitfalls. *Urol Clin North Am*. 1996;23(1):147–163.

Zmora O, Potenti FM, Wexner SD, et al. Gracilis muscle transposition for iatrogenic rectourethral fistula. *Ann Surg*. 2003;237(4):483–487.

Zmora O, Tulchinsky H, Gur E, et al. Gracilis muscle transposition for fistulas between the rectum and urethra or vagina. *Dis Colon Rectum*. 2006;49:1316–1321.

Zoubek J, McGuire EJ, Noll F, et al. The late occurrence of urinary tract damage in patients successfully treated by radiotherapy for cervical carcinoma. *J Urol*. 1989;141(6):1347–1349.

Zwintscher NP, Shah PM, Argawal A, et al. The impact of perianal disease in young patients with inflammatory bowel disease. *Int J Colorectal Dis*. 2015;30(9):1275–1279.

Bladder and Female Urethral Diverticula

Lindsey Cox MD, Eric S. Rovner MD

Bladder Diverticula

The term *bladder diverticulum* is usually reserved for a subjectively large herniation of the bladder urothelium through the muscularis propria of the bladder wall. This results in a thin-walled, urine-filled structure adjacent to and connecting with the bladder lumen through a variably sized neck, or ostium. Histologically **the diverticulum wall is composed of mucosa, subepithelial connective tissue or lamina propria, some scattered thin muscle fibers, and an adventitial layer** (Fig. 130.1) (Gil-Vernet, 1998; Peterson et al., 1973). A **fibrous capsule or pseudocapsule outer shell is often present and may be a useful surgical plane for excision**. The outside wall of the bladder diverticulum often contains some residual scattered strands or bundles of smooth muscle; however, these are disorganized and nonfunctional. Therefore bladder diverticula generally empty poorly during micturition, leaving a large postvoid residual urine volume that results in the characteristic findings on presentation and imaging.

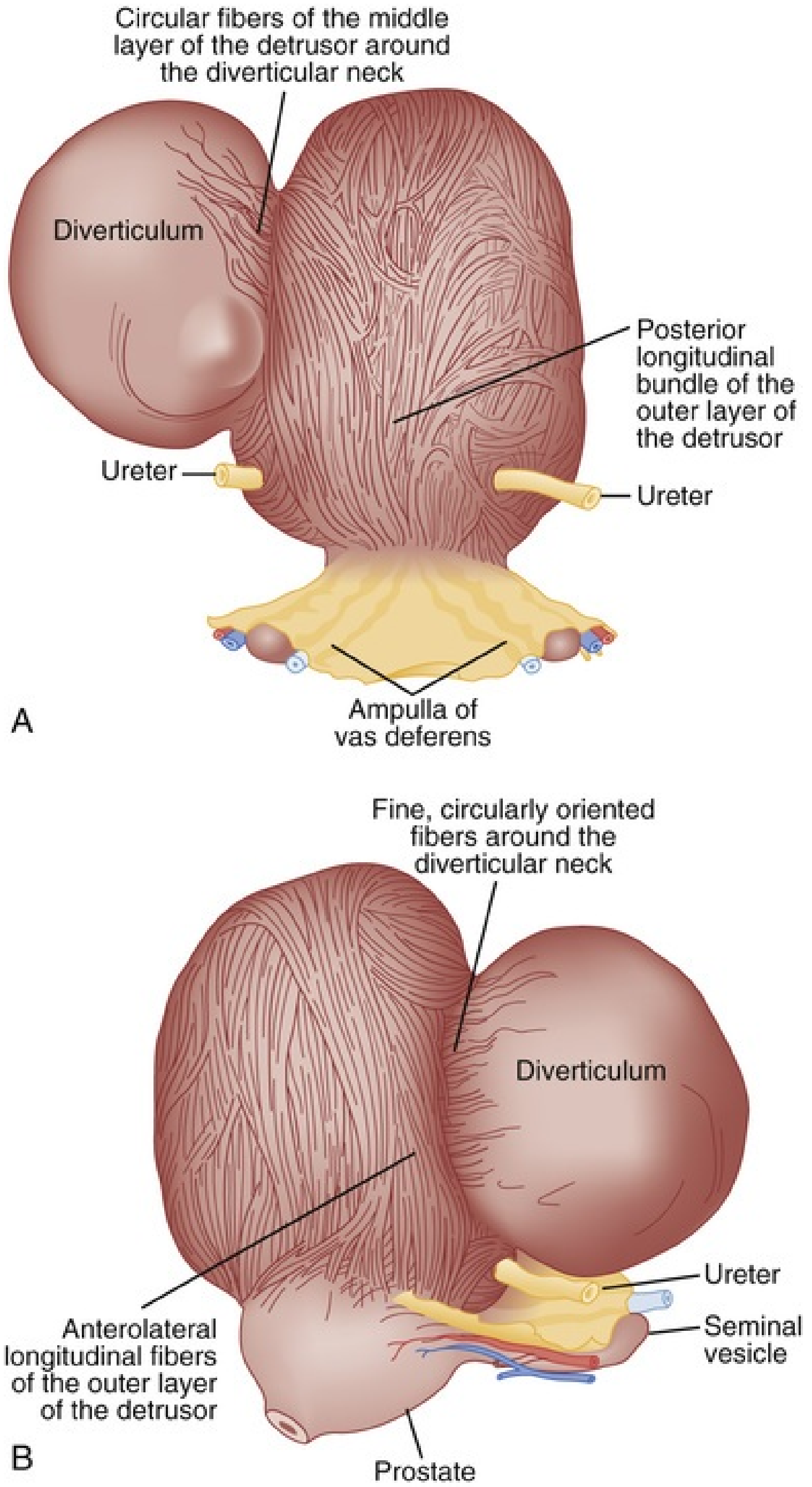
Circular fibers of the middle layer of the detrusor around the diverticular neck
Diverticulum
Posterior longitudinal bundle of the outer layer of the detrusor
Ureter
Ureter
Ampulla of vas deferens
A
Fine, circularly oriented fibers around the diverticular neck
Diverticulum
Ureter
Seminal vesicle
Anterolateral longitudinal fibers of the outer layer of the detrusor
B
Prostate

FIG. 130.1 Drawing of bladder diverticulum. (A) Posterior view. (B) Lateral view.

Classification, Pathophysiology, and Etiology

Bladder diverticula may occur in adults or children, but overall approximately

90% of bladder diverticula occur in adults (Psutka and Cendron, 2013). In addition, these lesions are far more common in males than females, with a ratio of approximately 9 : 1 in the adult and pediatric age groups (Idrees et al., 2013).

Bladder diverticula may be classified as either congenital or acquired. Pathophysiology, presentation, clinical implications, and imaging may differentiate these two types. **Congenital diverticula usually are seen during childhood, with a peak incidence in those younger than 10 years old** (Boechat and Lebowitz, 1978). **These are usually solitary, occur most commonly in males** (Evangelidis et al., 2005; Garat et al., 2007; Idrees et al., 2013; Sarihan and Abes, 1998; Stage and Tank, 1992), **and are located lateral and posterior to the ureteral orifice, often in association with vesicoureteral reflux** (Evangelidis et al., 2005; Garat et al., 2007). **In contrast to adults, in whom coexistent lower urinary tract neurogenic dysfunction or obstruction is almost always present, the primary causation in the pediatric age group is generally thought to be a congenital weakness of the detrusor muscle, most often at the level of the ureterovesical junction with or without coexistent lower urinary tract abnormalities** (Hutch, 1961; Hutch et al., 1961; Johnston, 1960; Psutka and Cendron, 2013; Stephens, 1979). Approximately 90% of pediatric or congenital bladder diverticula occur in the vicinity of the ureterovesical junction (Psutka and Cendron, 2013). Congenital bladder diverticula may occur in the presence of normal voiding dynamics in the absence of bladder outlet obstruction (Barrett et al., 1976; Blane et al., 1994; Cendron et al., 1972); however, up to 60% of congenital bladder diverticula may be associated with an underlying syndrome, neuropathic voiding dysfunction, or outlet obstruction (Blane et al., 1994). Blane et al. (1994) reported the incidence of bladder diverticula in children to be approximately 1.7% in a pediatric genitourinary database of more than 5000 cases. Congenital bladder diverticula are usually relatively larger in comparison with those associated with obstruction or neurogenic bladder dysfunction (Gearhart, 2002).

The most common presentation of congenital bladder diverticula is acute urinary tract infection (UTI) resulting from stasis (Bauer and Retik, 1974; Evangelidis et al., 2005; Garat et al., 2007; Pieretti and Pieretti-Vanmarcke, 1999). Less common presentations include enuresis, pyelonephritis, acute retention, and stones. Notably, secondary bladder outlet obstruction may occur when the diverticulum extends distally toward the bladder neck (Epstein et al., 1982; Oge et al., 2002; Taylor et al., 1979; Verghese and Belman, 1984). **Typically, congenital bladder diverticula are found in smooth-walled**

bladders and are not associated with significant trabeculation on cystoscopic examination (Hutch, 1961). In patients with prune-belly syndrome or posterior urethral valves, bladder diverticula may be located at the dome and be associated with aberrant voiding dynamics and/or anatomy. These are to be distinguished from the urachal diverticula seen in some pediatric urologic conditions. **Importantly, unlike secondary or adult bladder diverticula, there is almost no increased association with malignancy in congenital diverticula** (Alexander et al., 2012; Idrees et al., 2013; Tamas et al., 2009).

Congenital bladder diverticula have been noted in association with a number of congenital syndromes, including Menkes syndrome (kinky hair or copper deficiency syndrome) (Daly and Rabinovitch, 1981; Harcke et al., 1977; Hebert and Martin, 2015), Williams syndrome (Babbitt et al., 1979; Blane et al., 1994; Schulman et al., 1996), Ehlers-Danlos syndrome (Bade et al., 1994; Breivik et al., 1985; Burrows et al., 1998; Cuckow et al., 1994; Levard et al., 1989; Rabin et al., 1991; Schippers and Dittler, 1989), and fetal alcohol syndrome (Lewis and Woods, 1994). Whether there is a genetic predisposition to the formation of bladder diverticula in individuals without congenital syndromes is unclear, although congenital bladder diverticula have been reported in twins (Beall and Berger, 1978) and possibly as an autosomal dominant trait in a family (Hofmann et al., 1984). Because of the association of congenital bladder diverticula with genetic syndromes, it has been suggested that chromosomal testing should be pursued in such patients (Blane et al., 1994); however, this testing is generally not recommended in children with a single simple lesion (Hebert and Martin, 2015; Psutka and Cendron, 2013).

Acquired (also termed “secondary”) diverticula occur most commonly in the setting of bladder outlet obstruction or neurogenic vesicourethral dysfunction. Similar to the congenital type, these diverticula are located most commonly at the ureterovesical hiatus (Van Arsdalen and Wein, 1992) but also occur elsewhere in the bladder. **Acquired diverticula in males usually occur after age 60, which corresponds to the age of the development of prostatic enlargement** (Fig. 130.2). Bladder outlet obstruction (including that resulting from benign and malignant disease of the prostate), bladder neck obstruction (e.g., bladder neck hypertrophy, bladder neck contracture), and urethral stricture are commonly associated factors in adults, although obstruction is not considered to be present in all cases (Blacklock et al., 1983). Approximately 70% of bladder diverticula are associated with benign prostatic hyperplasia (Gerridzen and Futter, 1982). Historically, the reported prevalence of moderate-to large-sized bladder diverticula in association with "prostatism" is approximately 1% to 6% (Burns, 1944). **Acquired diverticula are often multiple, typically found in association with significant bladder trabeculation** (Wesselhoeft et al., 1963), **and much more common in males than females** (Pool and Hacker, 1966; Senger et al., 1952). Bladder diverticula in females are relatively uncommon and often associated with bladder outlet obstruction (Gillon et al., 1988). When found in the female, careful evaluation of the bladder outlet often reveals a cause for obstruction such as dysfunctional voiding, vaginal prolapse, bladder neck hypertrophy, urethral stricture, or iatrogenic obstruction resulting from anti-incontinence surgery (Safir et al., 1998; Fig. 130.3). Acquired bladder diverticula may also be found in children and young adults secondary to a number of conditions, including bladder neck dysfunction, posterior urethral valves, and neurogenic vesicourethral dysfunction. **If the diverticulum is located superolateral to the ureteral orifice, without involving the trigone in the setting of a neuropathic bladder and vesicoureteral reflux, it is termed a "Hutch" diverticulum, named after the individual who described this finding in a series of paraplegic individuals** (Hutch, 1952). These diverticula may also occur in the setting of dysfunctional voiding.

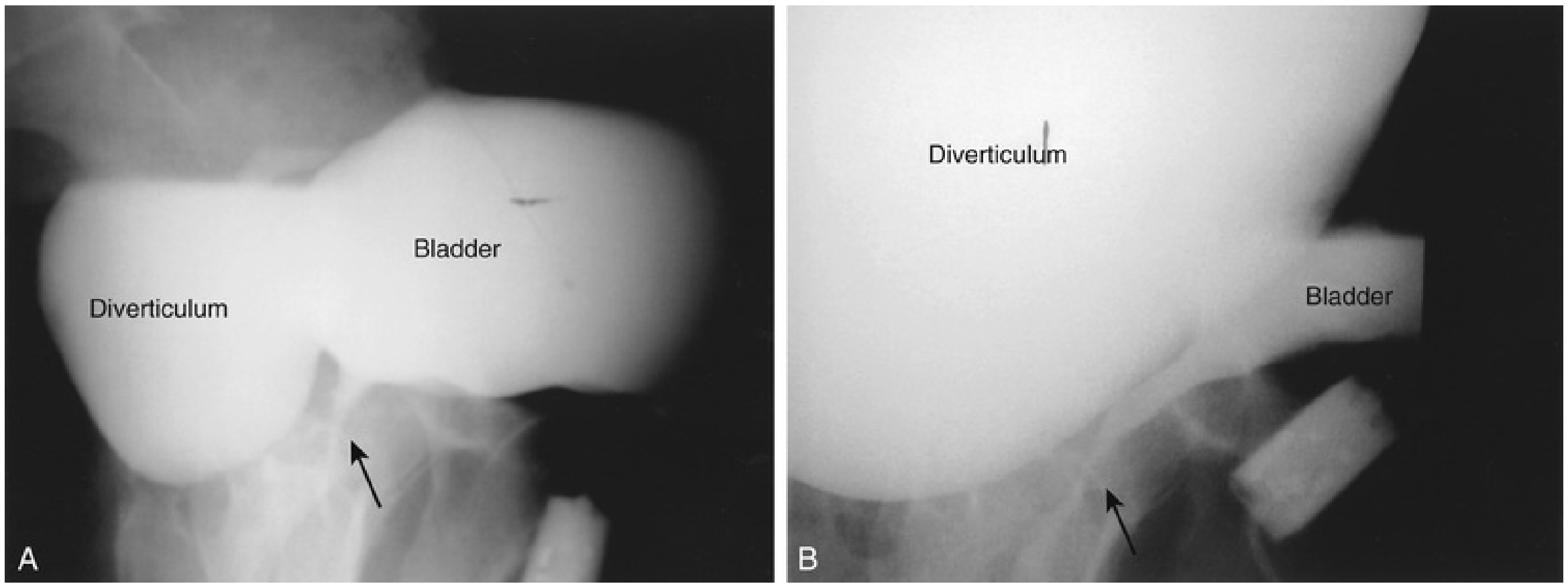

FIG. 130.2 Voiding cystourethrogram (VCUG) demonstrating a bladder diverticulum in a male. (A) The diverticulum is seen posterior to the bladder on this lateral voiding image (*arrow* points to urethra). There is a fluid-fluid level within the diverticulum representing the relatively denser contrast media settling below the urine. (B) Later image from the VCUG demonstrates near emptying of the bladder with enlargement of the diverticulum (*arrow* points to urethra).

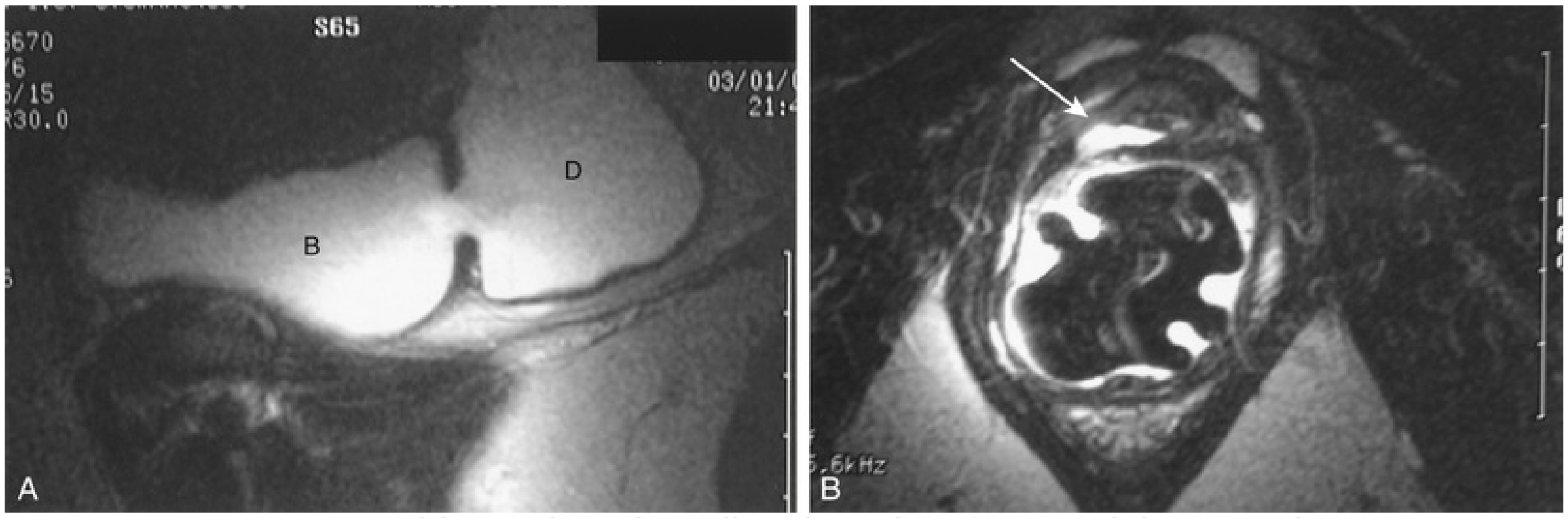

FIG. 130.3 Bladder and urethral diverticula in a female. (A) Magnetic resonance imaging (MRI) of a bladder *(B)* diverticulum *(D).* (B) Endoluminal MRI demonstrating urethral diverticulum (*arrow* points to urethral diverticulum).

Bladder diverticula may also be iatrogenic (Chertin and Prat, 2008; Hernández et al., 1997; Suzuki et al., 2002). Inadequate closure of the muscular layers of the bladder wall after a cystotomy for any indication may result in formation of a bladder diverticulum at a weak point of the suture line. “Iatrogenic” bladder diverticula may also occur after ureteral reimplantation surgery at the ureteroneocystostomy site (Ahmed et al., 1982; Sheu et al., 1998).

Diagnosis

Presentation and Evaluation

Acquired bladder diverticula do not typically produce specific symptoms and are most often found incidentally in the evaluation of other signs and symptoms, especially UTI (Fig. 130.4). Because large bladder diverticula empty poorly or incompletely during voiding, symptoms and signs, if present, are usually attributed to urinary stasis within the diverticulum or, alternatively, to its mass effect in the lower abdomen and pelvis. Retrospectively, when queried, patient symptoms such as incomplete bladder emptying, lower abdominal fullness, and double voiding may be attributed to some large bladder diverticula. These symptoms, however, are nonspecific and can be due to prostatic enlargement, obstruction, or a number of other lower urinary tract conditions. **Most bladder diverticula are found during the investigation of nonspecific lower urinary symptoms, hematuria, or infection—or, alternatively, noted incidentally during radiographic or endoscopic investigation of these conditions.** As noted previously, congenital bladder diverticula most often occur with UTI (Bauer and Retik, 1974; Evangelidis et al., 2005; Garat et al., 2007;

Pieretti and Pieretti-Vanmarcke, 1999), but hematuria, abdominal pain, or an abdominal mass may be present as well. Inguinal hernias containing bladder diverticula have also been reported (Bolton and Joyce, 1994; Buchholz et al., 1998; Scardino and Upson, 1953; Schewe et al., 2000).

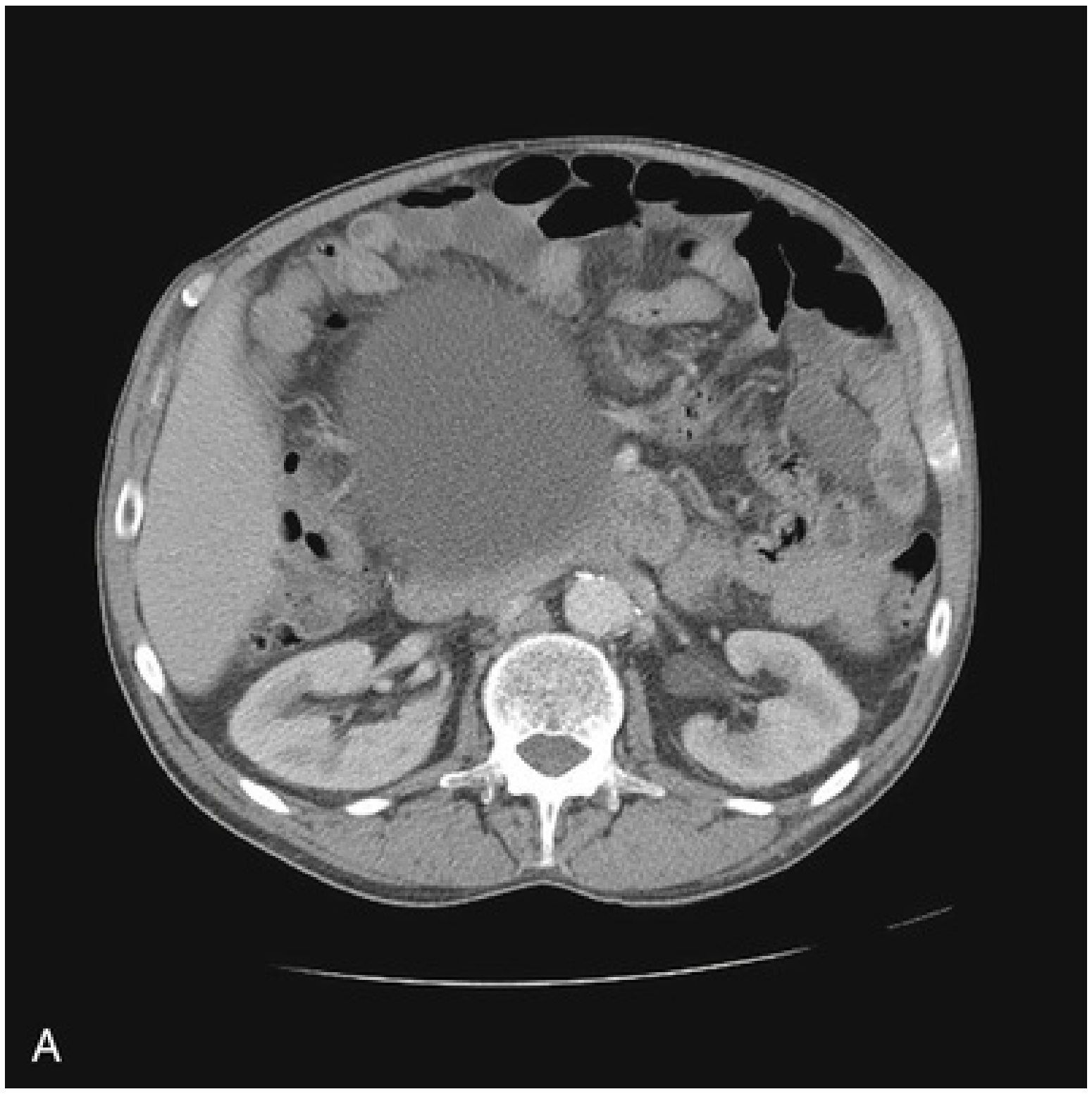

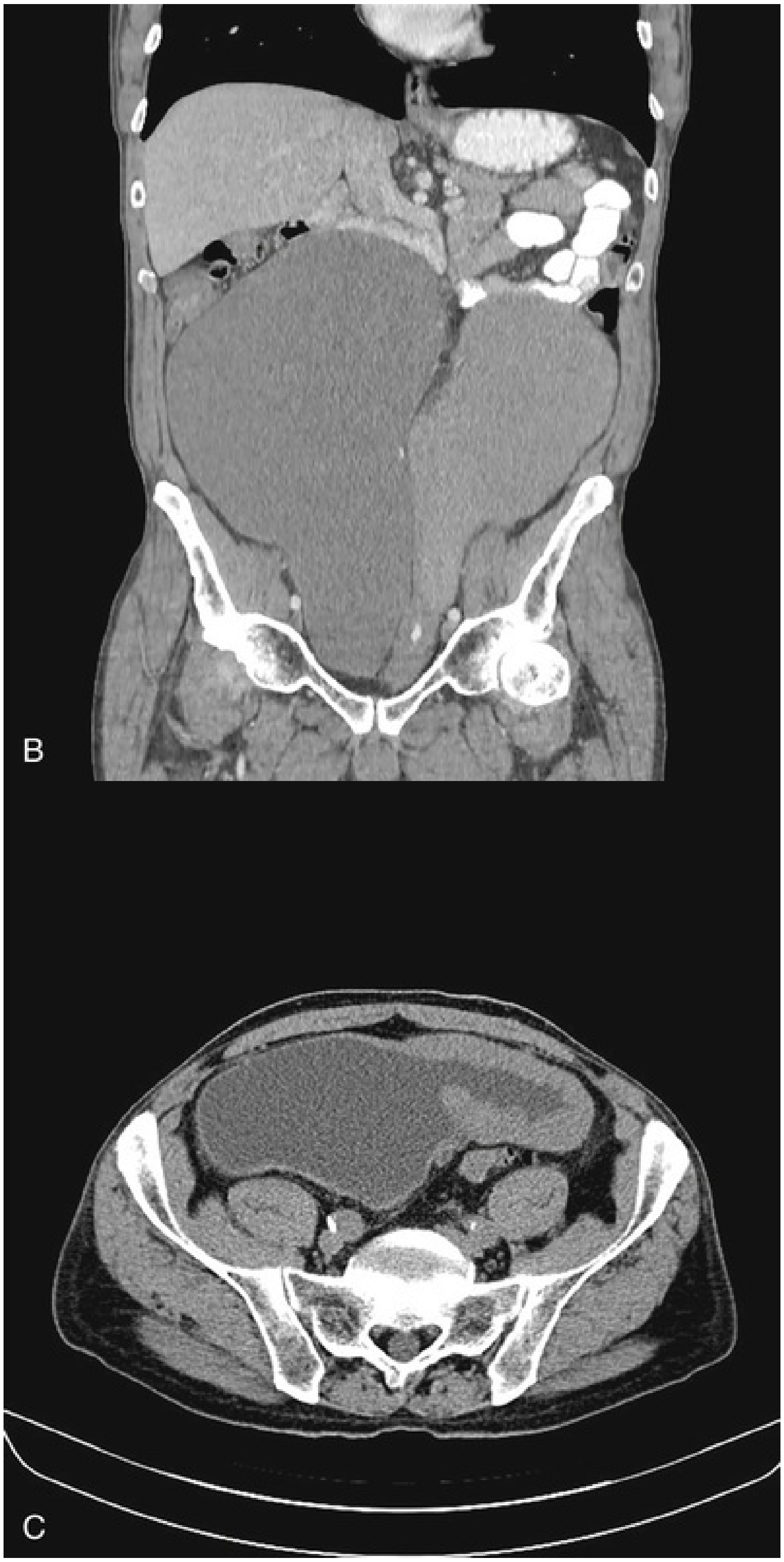

FIG. 130.4 Computed tomography (CT) scan of an enormous bladder diverticulum found initially on a CT scan of the chest in evaluation of pulmonary complaints. The patient had no lower urinary tract symptoms nor history of urinary tract infection. (A) CT chest scan showing fluid-filled structure below the diaphragm. (B) Coronal CT scan of abdomen/pelvis

showing fluid-filled structure. (C) Axial CT image showing partially distended bladder and pelvic viscera displaced by bladder diverticulum.

UTI in the male has been associated with bladder diverticula because it is often an infection in a male that provides the impetus for further clinical investigation uncovering a diverticulum. A bladder diverticulum and subsequent urinary stasis may result in a predisposition for UTI and may confer an increased difficulty in eradicating an existing infection (Shah, 1979; Taylor et al., 1979).

The initial evaluation of a bladder diverticulum includes a thorough history and physical examination, including digital rectal examination. In the male, prostate-specific antigen testing is pursued where appropriate. The history should quantitate lower urinary tract symptoms, query potential occult sources of neurogenic vesicourethral dysfunction (e.g., spinal surgery), and properly characterize any prior lower urinary tract surgery.

Urine analysis and urine culture as well as urine cytology should be considered in most patients with bladder diverticula, especially when nonoperative management is being considered. Abnormalities of the urine sediment are common in patients with bladder diverticula. Pyuria and hematuria are often present. In fact, relapsing or persistent pyuria unresponsive to antibiotic therapy may be an indication for bladder diverticulectomy in an otherwise asymptomatic patient. **The finding of a bladder diverticulum in an adult should prompt further evaluation for bladder outlet obstruction or occult neuropathic vesicourethral dysfunction, as well as endoscopic examination and imaging of the lower and upper urinary tract.**

Imaging

The diagnosis of bladder diverticula relies on radiographic and endoscopic findings. Bladder diverticula are part of the radiologic continuum that includes cellules and saccules. Cellules, saccules, and bladder diverticula are thought to represent increasingly larger and therefore more severe manifestations of the same pathological process involving elevated intravesical voiding pressure (Talner et al., 2000). **Cellules and saccules represent small outpouchings between hypertrophied bands of bladder muscle, with saccules generally being larger than cellules. However, there are no universally agreed upon minimum size requirements that distinguish cellules, saccules, and bladder diverticula, and the differentiation among these three entities is often**

subjective and arbitrary (Talner et al., 2000).

As noted previously, bladder diverticula are often found incidentally in the radiographic investigation of recurrent UTIs or other nonspecific lower urinary tract symptoms or signs. The differential diagnosis of a fluid-filled structure adjacent to the bladder is lengthy and includes müllerian cysts; uterine, ovarian, and fallopian tube abnormalities; urachal cysts; ectopic ureter or ureterocele; and postsurgical changes, including lymphocele.

Fluoroscopically monitored voiding cystourethrography (VCUG) is an excellent study to detect bladder diverticula; however, false negatives are possible (Hernanz-Schulman and Lebowitz, 1985). **A VCUG with anterior-posterior, oblique, and lateral images provides information regarding anatomy, location, and size of the diverticulum. It also assesses for associated vesicoureteral reflux and, importantly, evaluates for adequate emptying of the bladder diverticulum with voiding.** Vesicoureteral reflux may be found in up to 13% of patients with congenital bladder diverticula (Barrett et al., 1976). The finding of vesicoureteral reflux associated with bladder diverticula in the pediatric population has historically prompted ureteroneocystostomy in all cases; however, recently authors have pursued a more selective approach, reimplanting only those ureters associated with complicating factors such as renal scarring or progressive renal function deterioration (Afshar et al., 2005). Anomalous voiding into the diverticulum during a detrusor contraction may result in paradoxic enlargement of the bladder diverticulum during micturition (Wesselhoeft et al., 1963) (see Fig. 130.2). Presumably, this occurs during the detrusor contraction as the contrast flows from an area of relatively high pressure in the bladder through the diverticula ostia and into the diverticulum, which represents an area of relatively low pressure. In some instances the bladder may empty or discharge partly into the diverticulum and partly through the urethra. Often, with continued observation under fluoroscopy after the cessation of voiding, the empty bladder will start to refill as the diverticulum discharges back into the bladder. The amount of postvoid residual urine in the bladder diverticulum and bladder should be noted.

Cross-sectional imaging of the lower urinary tract may provide useful information regarding bladder diverticula and critical information regarding the surrounding anatomy. **Review of the radiographic films should accurately characterize the number, anatomy, and location of the diverticula as well as assess for masses within the diverticulum.** Filling defects within the diverticula or other bladder abnormalities should prompt further investigation

(Fig. 130.5). If the neck of the diverticulum is obstructed from a tumor or otherwise not patent, cross-sectional imaging may be required for diagnosis and further evaluation (Dondalski et al., 1993). Finally, cross-sectional imaging provides surgically relevant information, including the location of the ureters and surrounding structures (e.g., rectum), which can be distorted because of the space-occupying nature of some large bladder diverticula.

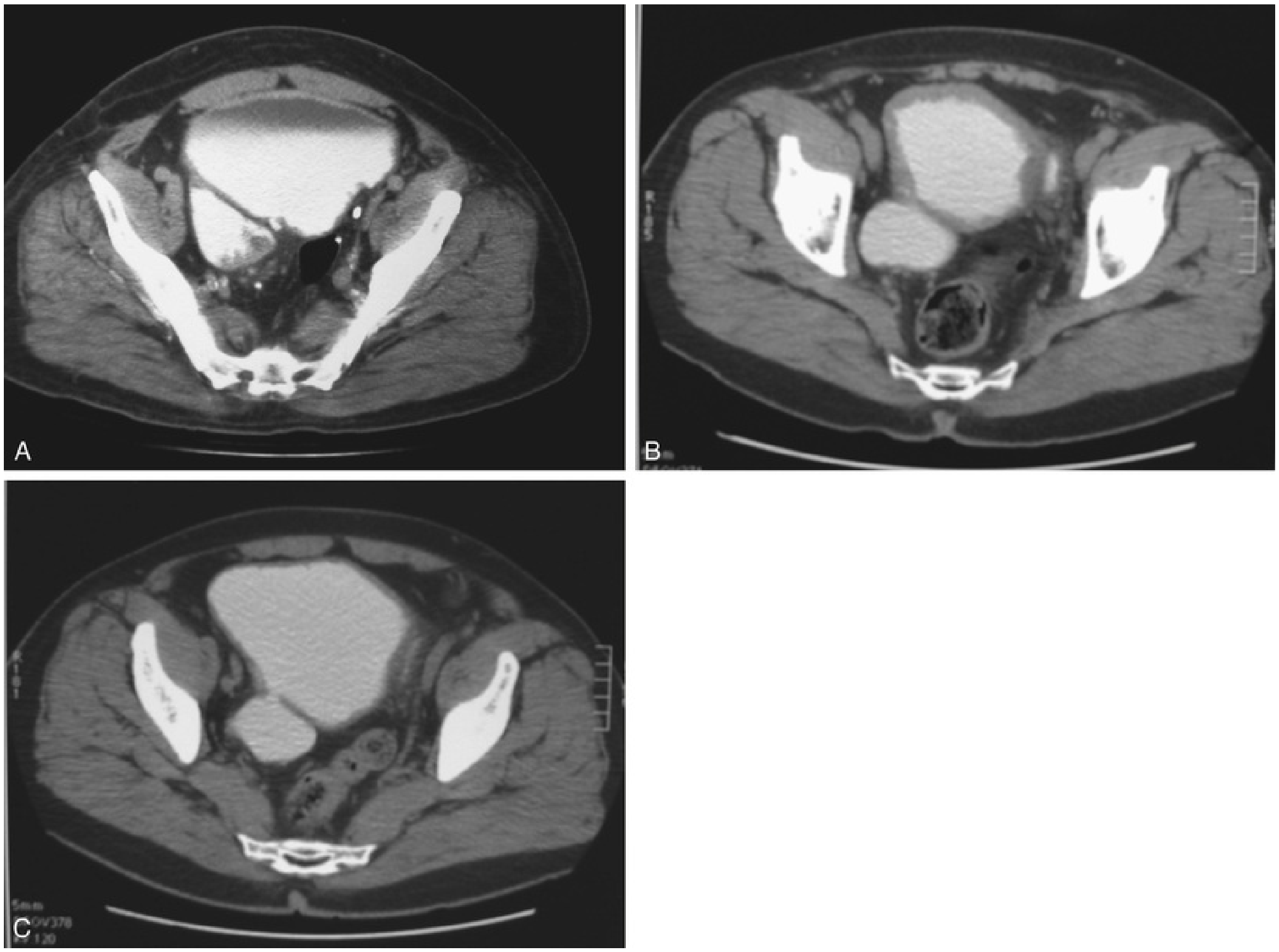

FIG. 130.5 Computed tomography (CT) scans demonstrating several abnormalities in the setting of a bladder diverticulum. (A) Diverticulum with multiple filling defects. Cystoscopy and biopsy revealed urothelial carcinoma. (B) Diffusely thickened and irregular bladder wall resulting from chronic bladder outlet obstruction in association with two diverticula. Cystoscopy confirmed trabeculation without mucosal abnormalities. (C) Asymmetrical bladder wall thickening in association with a bladder diverticulum. The ostium of the diverticulum is seen connecting to the bladder.

Imaging of the upper urinary tract may include intravenous pyelography, ultrasonography, computed tomography (CT), or magnetic resonance imaging (MRI). **In the absence of hematuria or a known or suspected urinary tract**

malignancy, the goal of upper tract imaging in the adult is to evaluate for asymptomatic or silent hydroureteronephrosis related to the diverticulum (Lebowitz et al., 1979; Sharma et al., 1997) which has been reported to be present in up to almost 7% of cases in one series (Fox et al., 1962). In children with bladder diverticula the reported incidence of upper tract abnormalities, including renal scarring, dysplasia, and hydronephrosis, has been reported to be as high as 30% (Gotoh et al., 1987; Tokunaka et al., 1980). Hydronephrosis may be related to obstruction of the ureter (Kwan and Lowe, 1992; Livne and Gonzales, 1985), an underlying urodynamic abnormality that resulted in the formation of the diverticulum, vesicoureteral reflux in association with the diverticulum, and inflammation (Bellinger et al., 1985), or may be completely unrelated to the bladder diverticulum (Fig. 130.6). A multichannel urodynamic study in combination with a VCUG or, alternatively, a video-urodynamic study is useful in this setting to differentiate upper from lower urinary tract causes of the hydronephrosis.

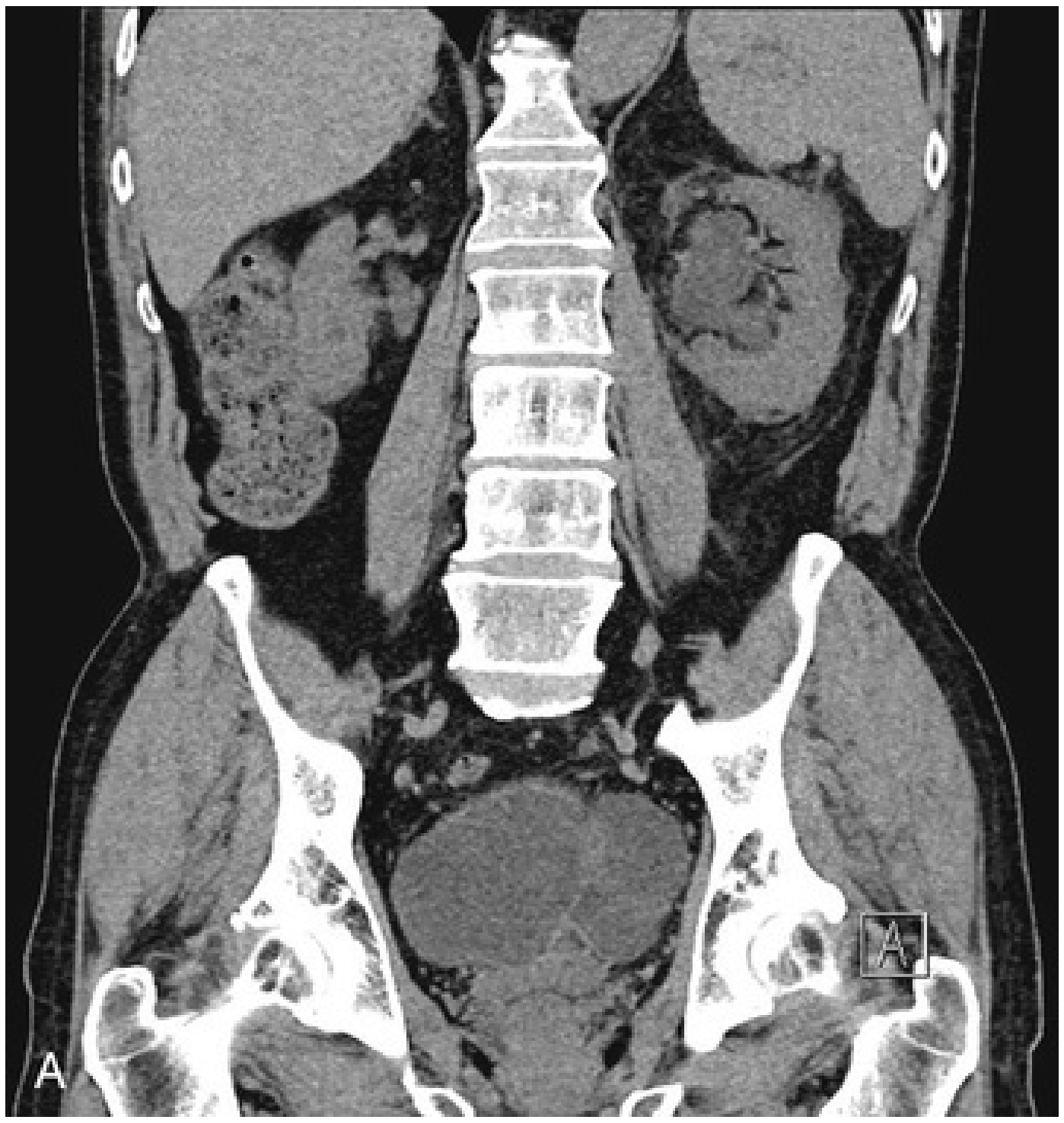

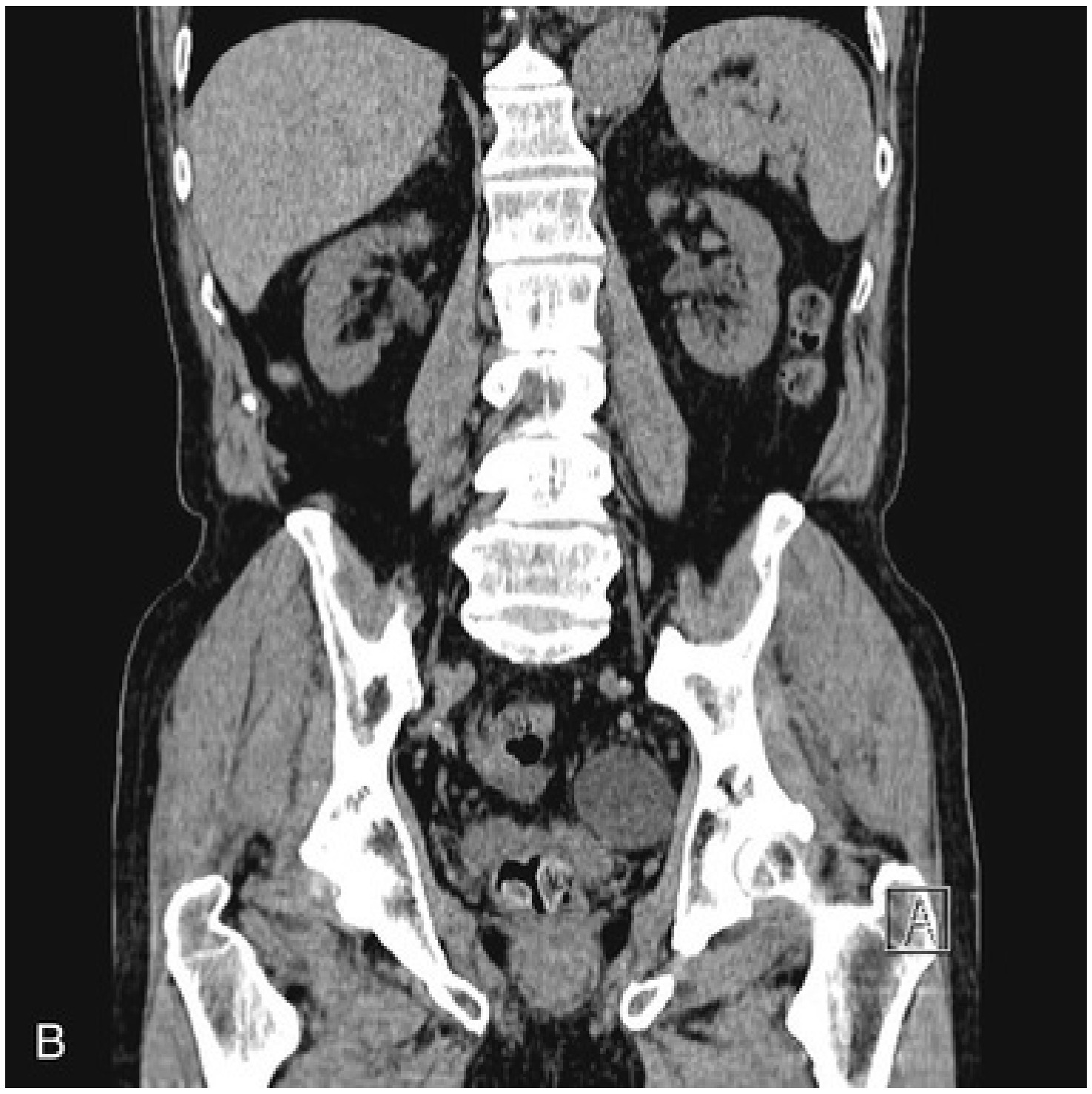

FIG. 130.6 Hydronephrosis related to a bladder diverticulum and bladder outlet obstruction. (A) Computed tomography scan of left-sided hydronephrosis related to ipsilateral bladder diverticulum and urinary retention. (B) Resolution of the hydronephrosis after treatment of the bladder outlet obstruction. The bladder diverticulum was persistent but smaller after transurethral resection of the prostate, which relieved the hydronephrosis.

A bladder diverticulum may cause deviation with or without compression of the ipsilateral ureter. **Medial deviation of the pelvic ureter is most commonly seen; however, lateral deviation may also occur** (Talner et al., 2000; Fig. 130.7). Such information is important in determining surgical approach and whether to place ureteric stents preoperatively. Furthermore, a bladder diverticulum that encompasses the ureteral orifice may create a functionally shortened intramural ureteral segment and result in vesicoureteral reflux (see later discussion).

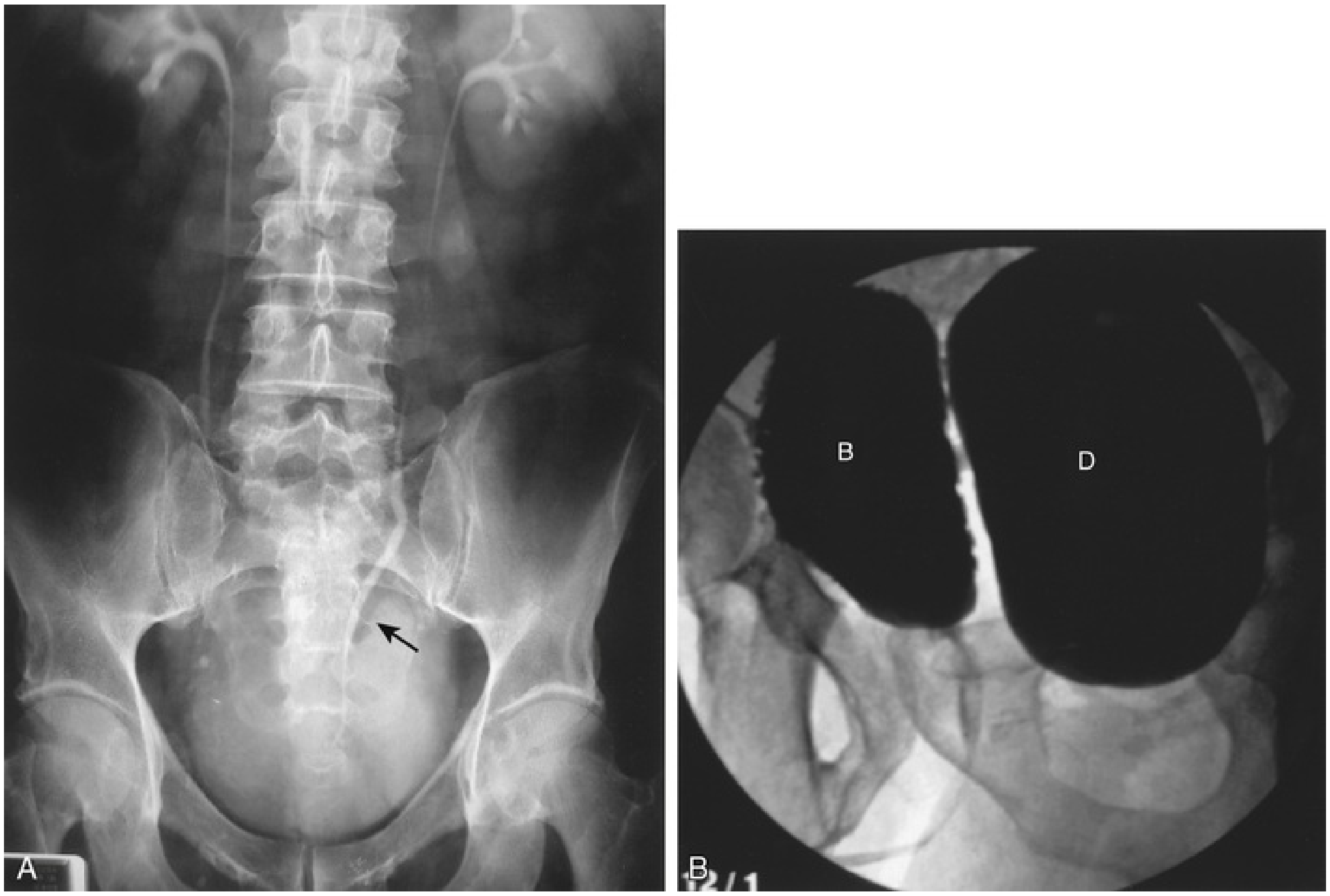

FIG. 130.7 Bladder diverticulum with deviation of the ureter. This patient had a long history of recurrent urinary tract infections as a result of presumed prostatitis. (A) Image from 10-minute intravenous urogram demonstrating medial deviation of the pelvic ureter *(arrow)*. (B) Voiding image from the voiding cystourethrogram revealed a large, smooth-walled bladder *(B)* diverticulum *(D)* emanating from the trabeculated bladder.

Urodynamics

In the adult, bladder outlet obstruction and/or neurogenic voiding dysfunction may result in the formation of bladder diverticula. A video-urodynamic study can be very helpful in the investigation of these patients (Adot Zurbano et al., 2005). The role of urodynamics in the evaluation of congenital bladder diverticula is less well defined (Psutka and Cendron, 2013). However, **failure to identify and treat an existing underlying urodynamic abnormality before or concomitantly with definitive surgical therapy for bladder diverticula, especially in an adult may result in a high risk of recurrent diverticula or other problems after surgery. Therefore such an evaluation is critical.** Furthermore, successful treatment of the urodynamic abnormality may improve bladder emptying and potentially result in resolution of the symptoms and/or complications without the need for bladder diverticulectomy.

Bladder outlet obstruction, impaired contractility, elevated postvoid residual urine, and detrusor overactivity are some of the urodynamic findings associated with bladder diverticula. Importantly, **bladder contractility may appear to be diminished on urodynamics because of the "pressure sink" effect of the bladder diverticulum.** This artifact occurs as the detrusor contracts and the intravesical contents are decompressed through the path of least resistance into the bladder diverticulum as opposed to the urethra (Wilson and Klufio, 1985). Nevertheless, when carefully measured, bladder contractility is not significantly different from that in individuals with benign prostatic hyperplasia without bladder diverticula (Adot Zurbano et al., 2005). In addition, elevated postvoid residual urine may be present as a result of retained urine in the diverticulum regardless of the presence or absence of impaired bladder contractility or bladder outlet obstruction.

Endoscopic Examination

Endoscopically, the entire interior of each bladder diverticulum should be thoroughly inspected for stones or abnormal-appearing epithelium. Flexible cystoscopy is often required to examine the entire interior of some diverticula. The location of the diverticula relative to the ureters and bladder outlet is noted, and the size of each diverticulum is carefully recorded (Fig. 130.8). Ideally, urine cytology should be obtained from the diverticulum during endoscopic examination. **Any abnormal-appearing epithelium or lesions within the diverticulum are carefully biopsied** (Fig. 130.9)**. Extreme care must be taken during the biopsy to prevent perforation, because the wall of the diverticulum is very thin because of the lack of a muscularis propria layer. All epithelial lesions under consideration for biopsy should be considered malignant until proven otherwise. Perforation of the diverticular wall during biopsy risks tumor seeding into the perivesical fat with potential adverse prognostic implications.**

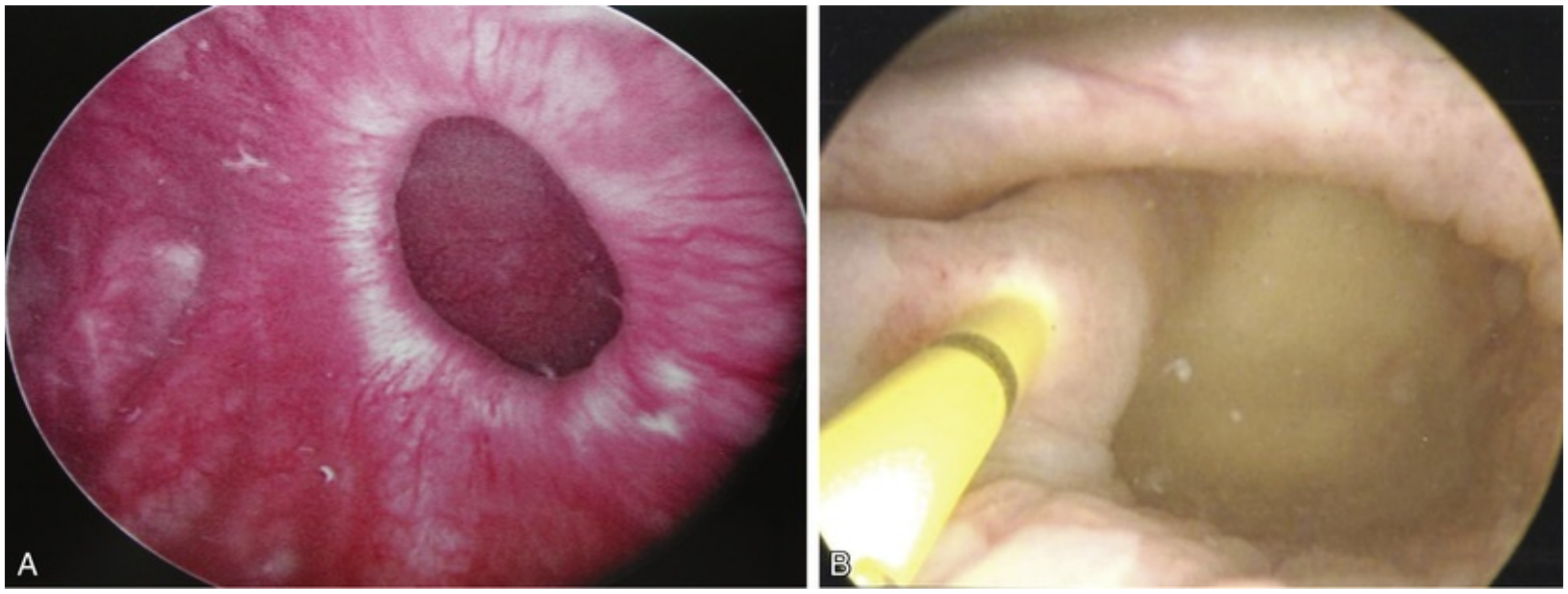

FIG. 130.8 Endoscopic views of bladder diverticula. (A) Lateral wall diverticulum in a male with bladder outlet obstruction. (B) Paraureteral diverticulum in an adult female with vesicoureteral reflux and urinary tract infections. The right ureter is intubated with a catheter.

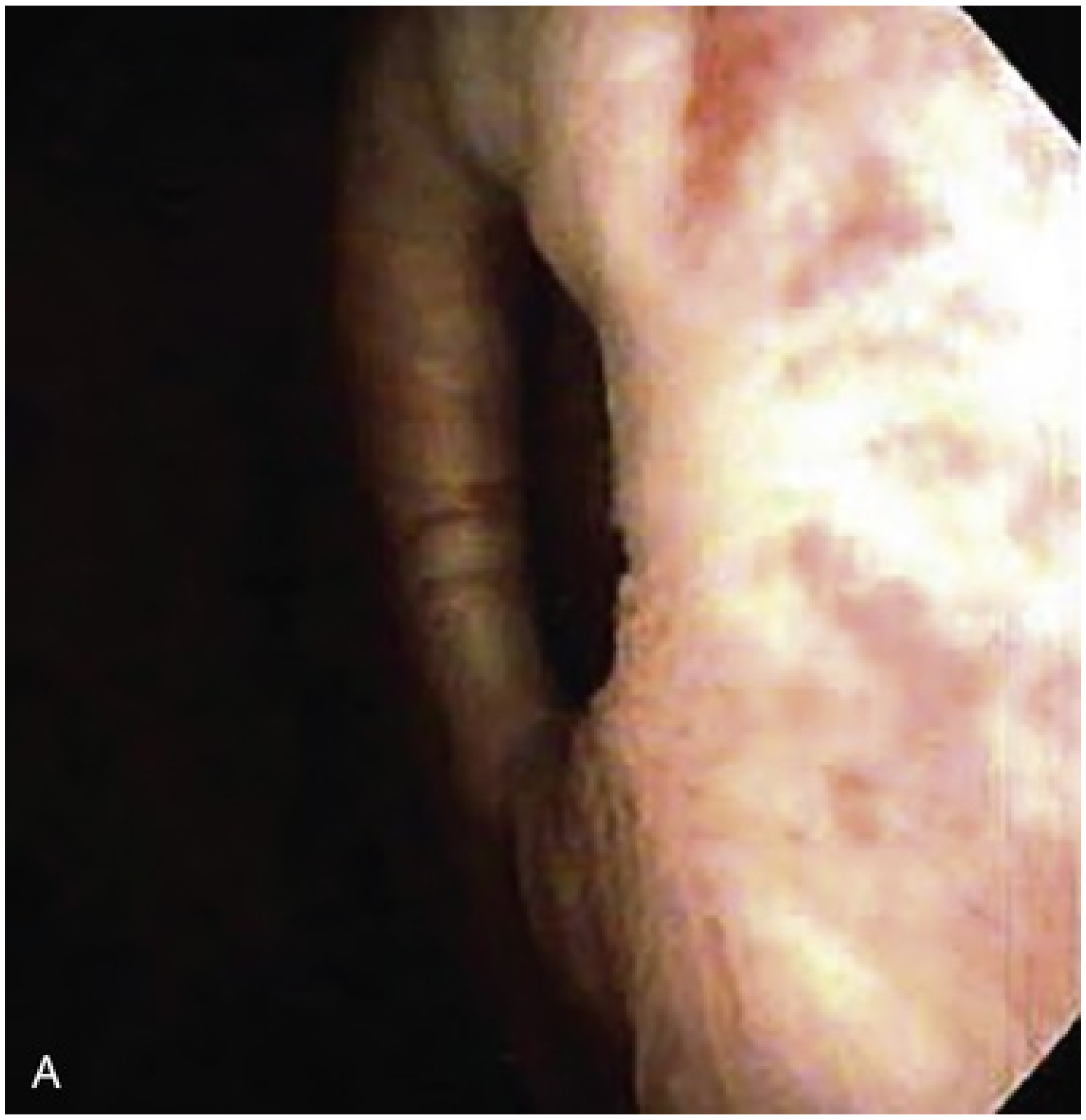

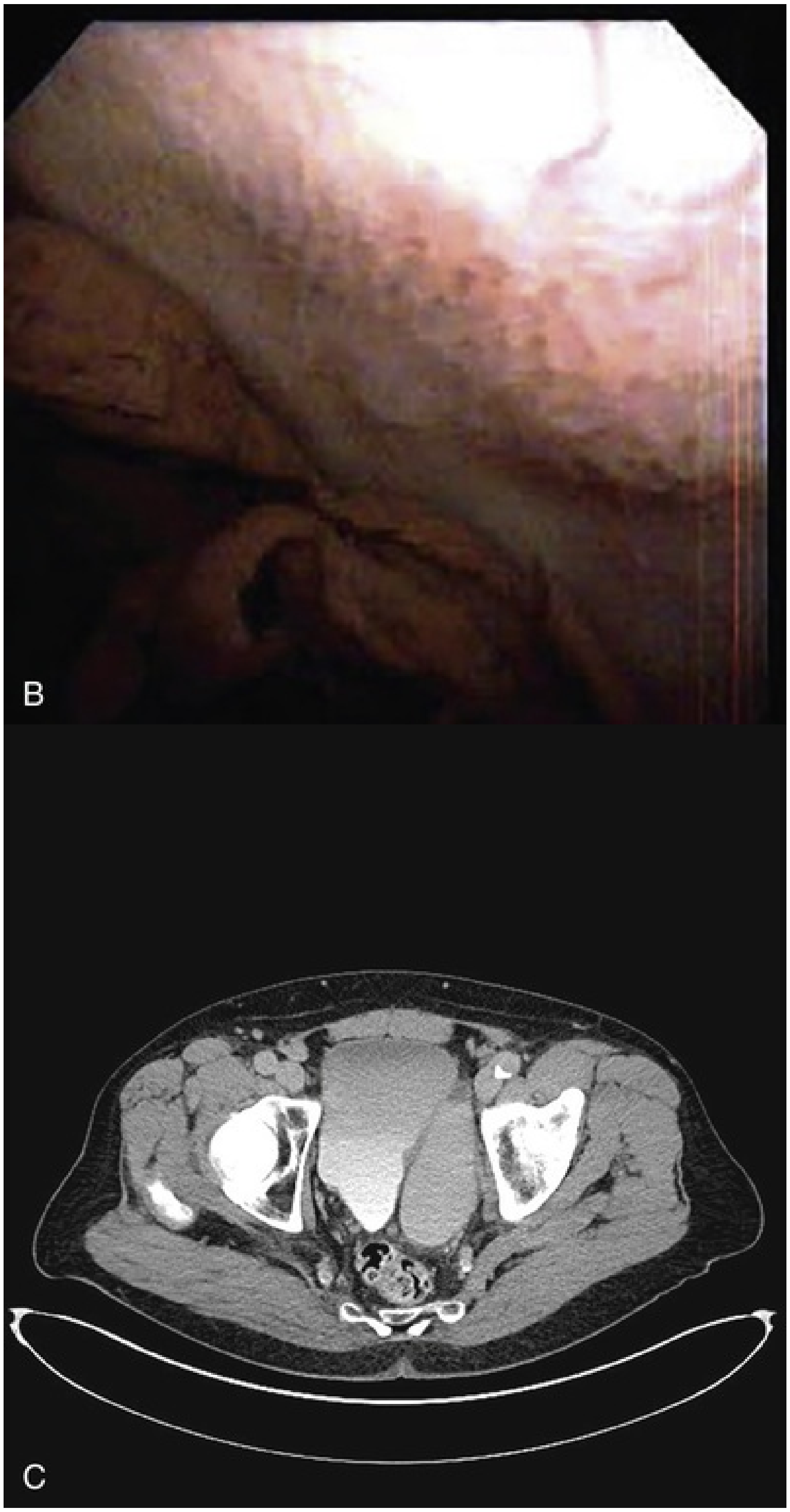

FIG. 130.9 Papillary urothelial malignancy in a bladder diverticulum. (A) Endoscopic view of the ostia of the bladder diverticulum. (B) Endoscopic view of the papillary lesion within the diverticulum. (C) Axial computed tomography scan of bladder diverticulum showing no mass.

Patients who elect nonoperative management of bladder diverticula are

usually followed closely with periodic endoscopic examinations and cytology. The natural history of untreated bladder diverticula is unknown, but the possibility of malignant transformation over time because of urinary stasis within the diverticulum should be considered.

Associated Conditions

Bladder Outlet Obstruction

Acquired bladder diverticula are commonly found to exist in the setting of bladder outlet obstruction. Common causes of bladder outlet obstruction in the male include benign and malignant disease of the prostate and urethral stricture disease. Less common causes include bladder neck hypertrophy (primary bladder neck obstruction), vesicourethral anastomotic stricture after prostatectomy, and functional obstruction as a result of neurogenic vesicourethral dysfunction (bladder neck and/or striated sphincter dyssynergia). Strong consideration should be given toward management of bladder outlet obstruction before or concomitant with treatment of the bladder diverticulum. Whether such procedures should be done concomitantly or staged is controversial (Powell and Kreder, 2009). **In some patients, especially those with small diverticula, treatment of bladder outlet obstruction alone may subsequently allow low pressure and complete emptying of the bladder diverticulum with micturition, thus reducing the potential for complications associated with these lesions and possibly avoiding the need for future operative intervention in the form of surgical diverticulectomy.**

Malignancy

Much has been written about the association of bladder diverticula and malignancy. **Historically, the risk of malignancy in bladder diverticula has been reported to be elevated. This increased risk of bladder cancer in diverticula has been attributed to urinary stasis and to chronic inflammation that is often found on pathological examination of bladder diverticulum tissue** (Idrees et al., 2013; Kelalis and McLean, 1967). Forty-five percent to 80% of bladder diverticulectomy specimens harbor inflammatory changes to the urothelium (Gerridzen and Futter, 1982; Idrees et al., 2013; Kong et al., 2013). **The overall prevalence of malignant tumors within a bladder diverticulum has been reported as ranging from 0.8% to 10%** (Baniel and

Vishna, 1997; Golijanin et al., 2003; Melekos et al., 1987; Mićić and Ilić, 1983; Montague and Boltuch, 1976). **However, it is likely that the prevalence of bladder diverticula overall is under-reported and, as such, the prevalence of tumors within diverticula is probably considerably smaller than that noted here. Nevertheless, the most common histologic type of malignancy seen within bladder diverticula is urothelial cell carcinoma in approximately 70% to 80% of cases, followed by squamous cell carcinoma in 20% to 25% of cases** (Baniel and Vishna, 1997; Golijanin et al., 2003; Mićić and Ilić, 1983; Montague and Boltuch, 1976; Redman et al., 1976; Van Arsdalen and Wein, 1992; Yu et al., 1993). Tumors in bladder diverticula occur almost exclusively in adults, with a peak occurrence between ages 65 and 75 (Ostroff et al., 1973).

In addition to the potentially increased risk of bladder cancer, **the finding of a neoplasm within a bladder diverticulum has particularly important diagnostic and therapeutic considerations because the bladder diverticulum wall lacks a well-developed muscularis propria layer,** and such tumors are at greater risk of being high grade and invasive as compared with non-diverticular bladder cancers (Kong et al., 2013). Therefore such a finding may portend a poorer prognosis because of the potential for rapid transmural involvement of invasive bladder cancer and extravesical extension. **In addition, the lack of a defined muscular wall risks early dissemination of tumor cells into an extravesical location during transurethral resection of these lesions and makes precise pathological staging difficult** (Idrees et al., 2013).

The prognosis for patients with these tumors has been historically reported as poor (Das and Amar, 1986; Faysal and Freiha, 1981; Melekos et al., 1987; Mićić and Ilić, 1983), although some reports may suggest otherwise in selected patients (Baniel and Vishna, 1997; Bourgi et al., 2016; Montague and Boltuch, 1976). The poor prognosis has been attributed to delayed diagnosis and advanced stage at presentation (Faysal and Freiha, 1981; Fellows, 1978; Mićić and Ilić, 1983; Ostroff et al., 1973). Historically, this has supported the prophylactic surgical treatment of all bladder diverticula, including asymptomatic and minimally symptomatic lesions (Kelalis and McLean, 1967). However, **more recently it has been suggested that such management is not warranted, and observation with careful follow-up and periodic endoscopic surveillance is acceptable in asymptomatic individuals without evidence of dysplastic or malignant changes** (Fellows, 1978).

Accurate identification of tumors within bladder diverticula has been demonstrated using a variety of radiographic techniques, including CT, MRI, and ultrasonography (Dondalski et al., 1993; Dragsted et al., 1985; Durfee et al., 1997; Lowe et al., 1989; Mallampati and Siegelman, 2004; Saez et al., 1985; Williams and Gooding, 1985) (see Fig. 130.5). Whether these modalities can reliably predict extravesical invasion and therefore affect staging and prognosis is not clear, although one small series suggests that certain radiographic features, including tumor length and width on CT, correlate with survival (Di Paolo et al., 2015). **It has been suggested that clinical stage at presentation is the most important prognostic factor for patients with tumors in bladder diverticula, with 5-year actuarial survival ranging from 83% ± 9% in patients with superficial disease to 45% ± 14% in those with extradiverticular disease** (Golijanin et al., 2003). One small series suggests that aggressive individualized multimodal therapy in these patients, including surgery, chemotherapy, and radiation therapy, may improve prognosis (Garzotto et al., 1996). Because pathological staging after transurethral resection is difficult and often inaccurate, some authors have suggested a very aggressive approach to these tumors. This surgical staging approach involves an open exploration and partial or radical cystectomy without a prior transurethral resection (Redman et al., 1976). Others have advocated a selective individualized approach, taking into account the clinical stage and pathological grade of the tumor (Golijanin et al., 2003). Radical cystectomy has similar outcomes for tumors within diverticula as for tumors in other locations. Hu et al. (2015) found that there was no difference in recurrence-free survival or overall survival after radical cystectomy in patients with or without urothelial carcinoma in a bladder diverticulum when stratified by stage.

Low-grade, low-stage tumors may be successfully treated with diverticulectomy alone (Baniel and Vishna, 1997; Bourgi et al., 2016; Sulaiman et al., 1998); however, it is important to recognize that the ability to reliably predict stage and grade preoperatively is limited, and therefore this approach should be undertaken only with caution in select cases, with adequate counseling and follow-up.

The role for less invasive treatment strategies of low-grade bladder tumors found in bladder diverticula is not well defined. As noted earlier, the potential risk of perforation with transurethral resection is higher with these tumors because of the lack of a defined muscularis propria layer. However, whether these patients can be safely treated with biopsy and fulguration with or without intravesical chemotherapy/immunotherapy and interval cystoscopic surveillance for low-grade tumors, is unclear.

Other Associated Conditions

The location of many bladder diverticula at the level of the ureterovesical junction may explain the high incidence of associated ipsilateral ureteral abnormalities. For a ureter found within a diverticulum, the lack of a muscular backing to the diverticulum results in a functionally shortened intramural tunnel (see Fig. 130.7). **A very high prevalence of ipsilateral vesicoureteral reflux has been noted in association with congenital bladder diverticula** (Amar, 1972; Barrett et al., 1976). Other considerations in the evaluation and management of bladder diverticula include the potential development of stones within the diverticulum, ureteral obstruction (Bellinger et al., 1985; Khan et al., 1994; Kwan and Lowe, 1992; Lebowitz et al., 1979; Sharma et al., 1997), and even the potential for the rare but life-threatening complication of perforation and/or rupture of the bladder diverticulum (Itoh and Kounami, 1994; Jorion and Michel, 1999; Keeler and Sant, 1990; Mitchell and Hamilton, 1971).

Key Points: Bladder Diverticula: Diagnosis

- Bladder diverticula do not contain a defined functional muscularis propria layer, and therefore larger ones generally empty poorly with micturition.
- In the adult, bladder diverticula are often associated with bladder outlet obstruction or neurogenic vesicourethral dysfunction.
- Many bladder diverticula are found in a paraureteric location.
- Bladder diverticula are most often diagnosed incidentally in the evaluation of nonspecific lower urinary tract symptoms or infection.
- Patients with bladder diverticula should be evaluated for bladder outlet obstruction, and, if this is present, it should be addressed in advance of or concomitantly with definitive treatment of the bladder diverticulum.
- Malignancy can occur within a bladder diverticulum, and consideration should be given to the possibility of early extravesical disease extension because of the lack of a defined muscularis propria.

Management

In general, if the cause of the bladder diverticulum is believed to be consistent with bladder outlet obstruction and there are no other

complicating factors, definitive treatment of the bladder outlet is indicated before formal diverticulectomy. This approach allows reassessment of the diverticulum after relief of outlet obstruction and, if bladder emptying is satisfactory and symptoms resolve, then the diverticulum may not require surgical excision. However, simultaneous open bladder diverticulectomy/open prostatectomy as well as simultaneous bladder diverticulectomy/transurethral prostatectomy can be performed (Porpiglia et al., 2004). If treatment of the obstruction is pursued initially and results in satisfactory emptying of the diverticulum postoperatively, and complicating factors such as reflux, infection, malignancy, or stones are absent, then ongoing surveillance of the diverticulum may be all that is required. Emptying of the diverticulum after relief of outlet obstruction may be assessed on VCUG, video-urodynamics, or cross-sectional imaging such as ultrasound.

Management options in the treatment of bladder diverticula include observation, endoscopic management, and surgical excision; however, there are many factors to consider during the evaluation of these lesions before deciding on appropriate therapy (Fig. 130.10).

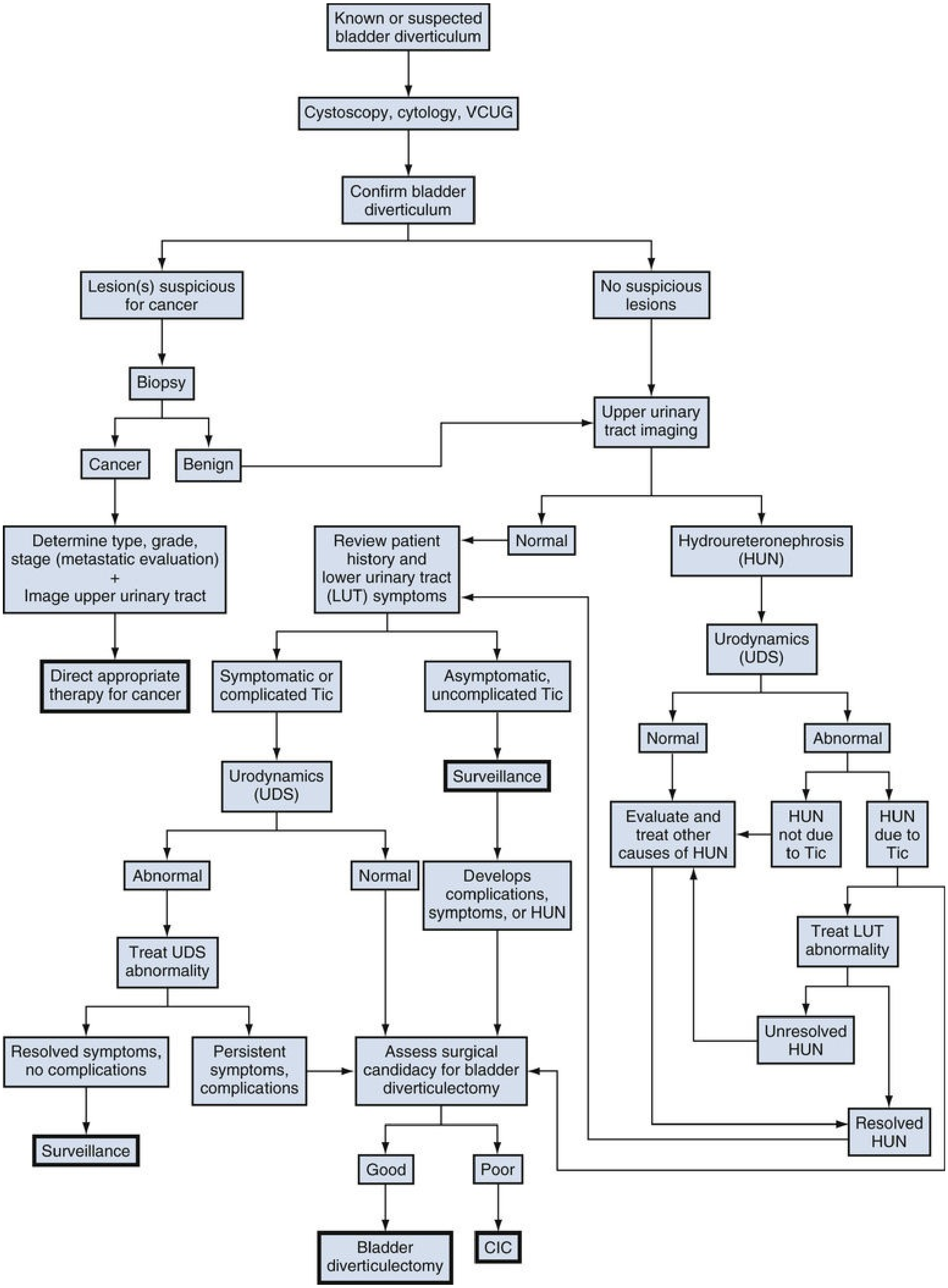
Known or suspected bladder diverticulum
Cystoscopy, cytology, VCUG
Confirm bladder diverticulum
Lesion(s) suspicious for cancer
No suspicious lesions
Biopsy
Upper urinary tract imaging
Cancer
Benign
Determine type, grade, stage (metastatic evaluation) + Image upper urinary tract
Review patient history and lower urinary tract (LUT) symptoms
Normal
Hydroureteronephrosis (HUN)
Direct appropriate therapy for cancer
Symptomatic or complicated Tic
Asymptomatic, uncomplicated Tic
Urodynamics (UDS)
Normal
Abnormal
Urodynamics (UDS)
Surveillance
Evaluate and treat other causes of HUN
HUN not due to Tic
HUN due to Tic
Abnormal
Normal
Develops complications, symptoms, or HUN
Treat LUT abnormality
Treat UDS abnormality
Unresolved HUN
Resolved symptoms, no complications
Persistent symptoms, complications
Assess surgical candidacy for bladder diverticulectomy
Resolved HUN
Surveillance
Good
Poor
Bladder diverticulectomy
CIC

FIG. 130.10 Algorithm for the evaluation and therapy of bladder diverticula. Bold-outlined boxes are potential end points in the algorithm.

CIC, Clean intermittent catheterization; *Tic,* bladder diverticulum; *VCUG,* voiding cystourethrogram. (Modified from Rovner ES, Wein AJ: Bladder diverticula in adults. In Resnick M, Elder JA, Spirnak JP, editors: *Decision making in urology,* ed 3, Hamilton, Ontario, 2004, BC Decker, pp 260–263.)

Observation and Nonsurgical Management

Adult patients with minimal symptoms and no complicating factors may opt for observation with surveillance. These patients should be counseled regarding the potentially increased risk of malignancy and the need for periodic reassessment as well as the unpredictable course and potentially aggressive nature of malignancy if subsequently found in this setting. They should also be counseled regarding the symptoms and signs that indicate progression, including increasing lower urinary tract symptoms, hematuria, and UTI. **The optimal schedule and type of surveillance for those individuals choosing observation is not well defined but consists of a periodic reassessment of symptoms, urine studies (including cytology), and endoscopic examination of the lower urinary tract** (Yu et al., 1993).

Patients who have poor bladder emptying after relief of obstruction and remain symptomatic, or those who are unable or unwilling to undergo surgical excision of the bladder diverticulum, may be effectively treated with clean intermittent catheterization (CIC) or an indwelling catheter. In this setting, and in the absence of future complicating factors, ongoing CIC and periodic surveillance of the bladder diverticulum may be acceptable.

Indications for bladder diverticulectomy in children are similar to those in adults. However, in children with multiple bladder diverticula associated with a chromosomal syndrome, observation and medical management are usually preferred because of the inherent connective tissue disorders found in these patients, which impair postoperative wound healing, increase perioperative surgical risk, and predispose to recurrence (Psutka and Cendron, 2013).

Indications for Intervention

Many patients with incidentally found congenital or acquired bladder diverticula are managed expectantly and with periodic surveillance. Bladder diverticula can vary tremendously in size and, in some instances, are larger than the bladder. The size of the diverticulum does not appear to correlate with symptoms or complications and therefore cannot be used as an absolute indication to proceed with surgery. **Bladder diverticulectomy is indicated for**

the treatment of lower urinary tract symptoms related to the diverticulum that are not otherwise responsive to medical therapy, or for the major complications directly related to it: persistent symptoms, chronic relapsing UTI, stones within the diverticulum, carcinoma or premalignant change, and upper urinary tract deterioration as a result of obstruction or reflux. Symptoms or complications related to bladder diverticula are most often due to poor emptying of the diverticulum and urinary stasis. Therefore excision of the diverticula would be expected to improve emptying of the lower urinary tract, provided that the primary problem that resulted in the formation of the bladder diverticulum (i.e., obstruction) has been adequately addressed.

Excision of bladder diverticula is most commonly elective. The relative merits of surgical excision versus surveillance should be carefully considered and discussed with each patient individually. The patient should be in relatively good health and be a reasonable surgical risk before considering the procedure. Preoperative medical status should be assessed and reversible risk factors (e.g., nutritional, renal, cardiac, pulmonary) corrected and/or optimized. Preoperative UTI should be treated. Patients who have prohibitive surgical risks because of concurrent medical illness or other factors should not undergo surgical excision but may be candidates for CIC or endoscopic treatment.

Endoscopic Management

Endoscopic management of bladder diverticulum may be considered in patients who are aged or somewhat debilitated, those who are not good candidates for an open operative approach, or those undergoing transurethral resection of the prostate in whom there exists an associated poorly draining diverticulum (Orandi, 1977; Vitale and Woodside, 1979).

Transurethral resection of the diverticular neck has been reported to be successful in select cases (Vitale and Woodside, 1979). This technique is usually performed with a standard resectoscope. The neck of the diverticulum is incised using the resectoscope loop or Collins knife. Incisions are carried down to the muscular fibers of the bladder at the level of the ostium of the diverticulum. Circumferential resection of the entire neck may be performed. When successful, this procedure enlarges the neck of the diverticulum, disrupting the narrow sphincteric-like properties of its connection to the bladder lumen and thereby permitting improved emptying of the diverticulum during micturition. Although generally safe and well tolerated, this technique has resulted in urinary retention because of a reversal of flow during micturition and “venting” of the bladder contents into the diverticulum postoperatively (Schulze and Hald, 1983). This technique has been reported to be less successful in those individuals with large diverticula (Orandi, 1977; Vitale and Woodside, 1979). **Transurethral resection of the diverticular neck may be combined with fulguration of the entire urothelial lining of the diverticulum** (Adachi et al., 1991a,b; Clayman et al., 1984; Yamaguchi et al., 1992). Fulguration of the lining of the diverticulum should result in obliteration of the diverticulum or a considerable reduction in its size.

Operative Excision

Operative excision may be performed through an open, laparoscopic, or robotic approach with or without concomitant treatment of associated bladder outlet obstruction.

Key Points: Bladder Diverticula: Management

- Bladder diverticulectomy is not indicated in all cases. Surgical treatment should be reserved for the treatment of symptoms related to the diverticulum, chronic relapsing UTI stones within the diverticulum, carcinoma or premalignant change, and upper urinary tract deterioration as a result of obstruction or reflux.
- Surgical diverticulectomy can be performed with a variety of approaches, including minimally invasive techniques, and treatment of concomitant bladder outlet obstruction, if present, should be considered.

Female Urethral Diverticula

Urethral diverticula (UD) in female patients are variably sized, urine-filled periurethral cystic structures adjacent to the urethra within the confines of the pelvic fascia, connected to the urethra via an ostium. Such lesions represent some of the most challenging diagnostic and reconstructive problems in female urology. UD are notable for a bewildering array of clinical presentations ranging from completely asymptomatic, incidentally noted lesions on physical examination or imaging, to very debilitating, painful vaginal masses associated with incontinence, stones, severe dyspareunia, and/or tumors. Anatomic variations between patients and in the location, size, and complexity of these lesions ensure that each case is unique.

Although described as early as the 19th century (Hey, 1805), the modern era of female UD began in the 1950s with the advent of positive-pressure urethrography (PPU) by Davis and Cian (1956). Over the next several years, there was a dramatic increase in number of cases of UD reported in the literature. A published series of 121 cases by Davis and TeLinde (1958) approximately doubled the number of cases reported during the previous 60 years. Development of adjuvant imaging techniques such as ultrasonography and surface coil/endoluminal MRI have contributed greatly to further understanding of UD (Fig. 130.11).

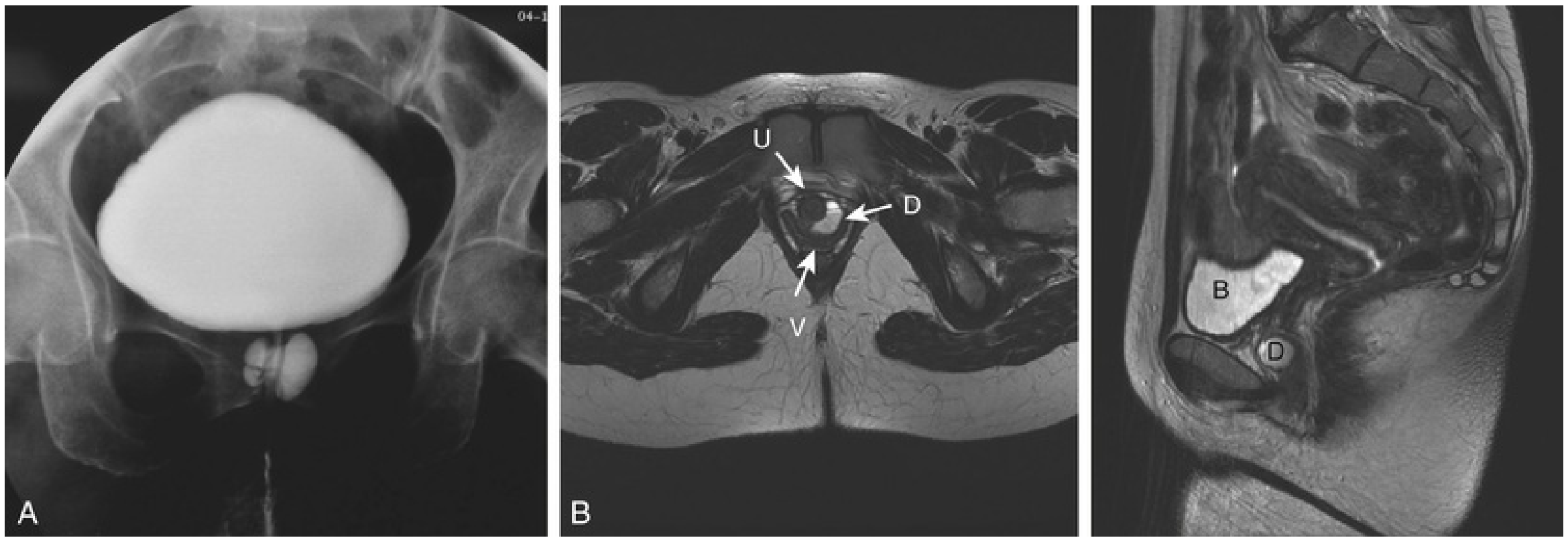

FIG. 130.11 Imaging of urethral diverticula. (A) Anterior-posterior view from a voiding cystourethrogram demonstrating a collection of contrast below the bladder, suggesting a urethral diverticulum. (B) Surface coil magnetic resonance image with sagittal *(left)* and axial *(right)* T2 images demonstrating the relevant anatomy of a patient with a urethral diverticulum

(D). B, Bladder; *U,* urethra; *V,* vagina.

Anatomy of the Female Urethra

The normal female urethra is a musculofascial tube approximately 3 to 4 cm in length, extending from the bladder neck to the external urethral meatus, suspended from the pelvic sidewall and pelvic fascia (tendinous arc of the obturator muscle) by a sheet of connective tissue known as the urethropelvic ligament. The urethropelvic ligament is composed of two layers of fused pelvic fascia that extend toward the pelvic sidewall bilaterally (Fig. 130.12). This structure can be considered to have an abdominal side (the endopelvic fascia) and a vaginal side (the periurethral fascia). **Within and between these two leaves of fascia lie the urethra and the location of most UD.**

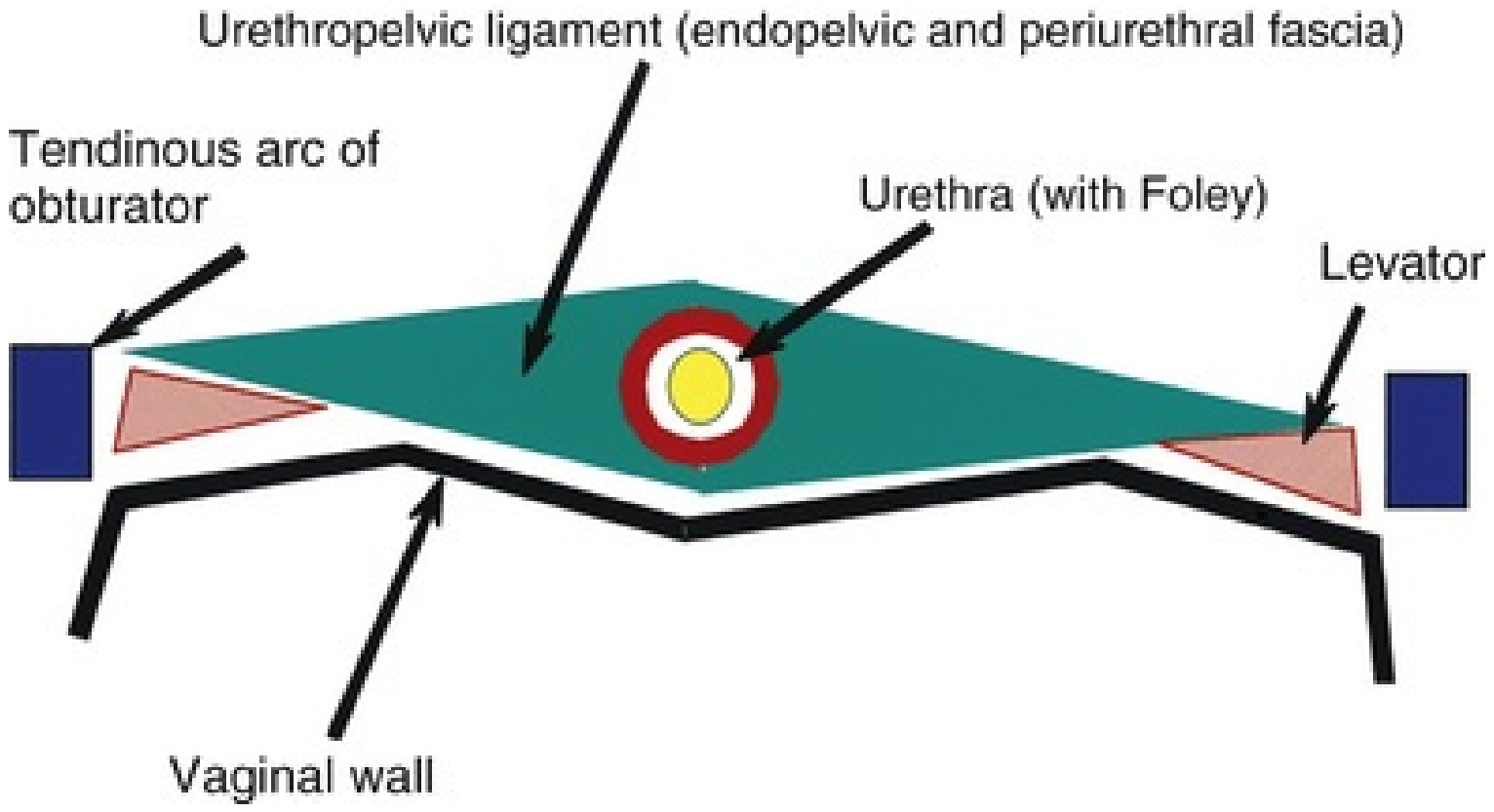
Urethropelvic ligament (endopelvic and periurethral fascia)
Tendinous arc of obturator
Urethra (with Foley)
Levator
Vaginal wall

FIG. 130.12 Schematic diagram of the anatomy of the mid-urethra in the coronal plane.

The urethral lumen is lined by a urothelial layer proximally and a nonkeratinized stratified squamous cell type distally. The urethra may be conceptualized as a rich, vascular, spongy cylinder surrounded by an envelope consisting of smooth and skeletal muscle and fibroelastic tissue (Young and Wahle, 1996). **Within the thick, vascular lamina propria/submucosal layer are the periurethral glands** (Fig. 130.13). These tubuloalveolar glands exist over the entire length of the urethra posterolaterally; however, **they are most prominent over the distal two-thirds,** with the majority of the glands draining into the distal one-third of the urethra. **It is from pathological processes involving the periurethral glands that most acquired female UD are thought**

to originate. The Skene glands are the largest and most distal of these glands and are sometimes called the *paraurethral glands*. These paraurethral glands drain outside the urethral lumen, lateral to the urethral meatus.

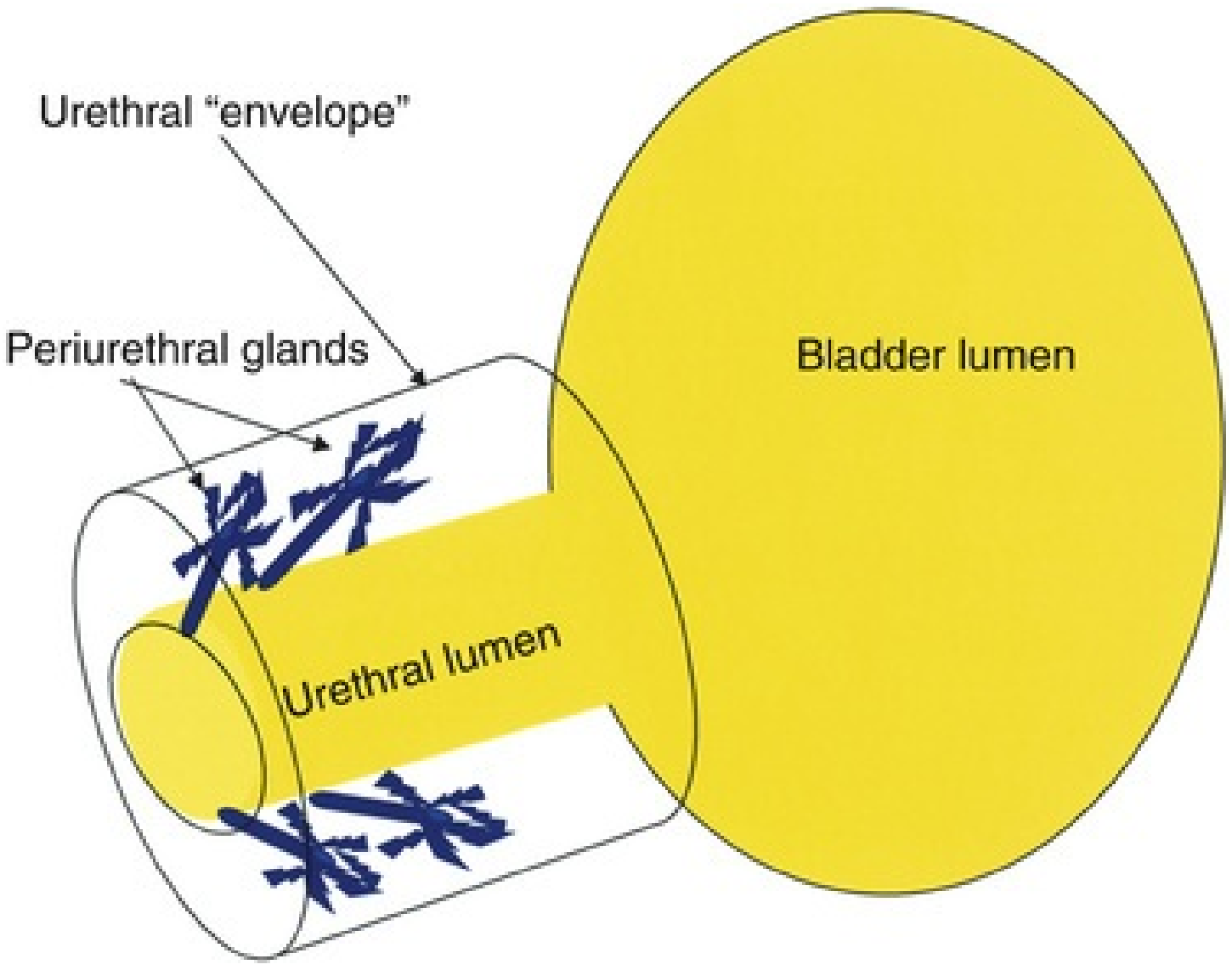

FIG. 130.13 Periurethral glands are located within the submucosa of the urethra deep to the muscular envelope, draining distally but arborizing proximally.

The urethra has several muscular layers: an internal longitudinal smooth muscle layer, an outer circular smooth muscle layer, and a skeletal muscle layer. The skeletal muscle component spans much of the length of the urethra but is more prominent in the middle third. It has a U-shaped configuration, deficient dorsally. Ventral to the urethra, but separated from it by the periurethral fascia, lies the anterior vaginal wall (see Fig. 130.12). **The location and competence of the urethral sphincters have important implications when considering surgical repair of UD because of the anatomic overlap of these two entities.**

Arterial inflow to the urethra derives from two sources. **The proximal urethra has a blood supply similar to the adjacent bladder, whereas the distal urethra derives its blood supply from the terminal branches of the inferior vesical artery through the vaginal artery that runs along the superior lateral aspect of the vagina** (Hinman, 1993). **Lymphatic drainage of the female urethra is to the external and internal iliac nodes from the proximal urethra and to the superficial and deep inguinal lymph nodes from the distal urethra. Innervation to the female urethra is from the**

pudendal nerve (S2 to S4), and afferents from the urethra travel through the pelvic splanchnic nerves.

Urethral Diverticula

Pathophysiology and Etiology

As conceptualized by Young and Wahle (1996), UD represent a cavity dissecting within the confines of the fascia of the urethropelvic ligament. This defect is often an isolated cystlike appendage with a single discrete connection to the urethral lumen known as the neck, or ostium (Fig. 130.14). **However, complicated anatomic patterns may exist, and in certain cases the UD may extend partially (saddlebag UD) around the urethra, anterior to the urethra** (Vakili et al., 2003)**, or circumferentially around the entire urethra** (Rovner and Wein, 2003; Fig. 130.15).

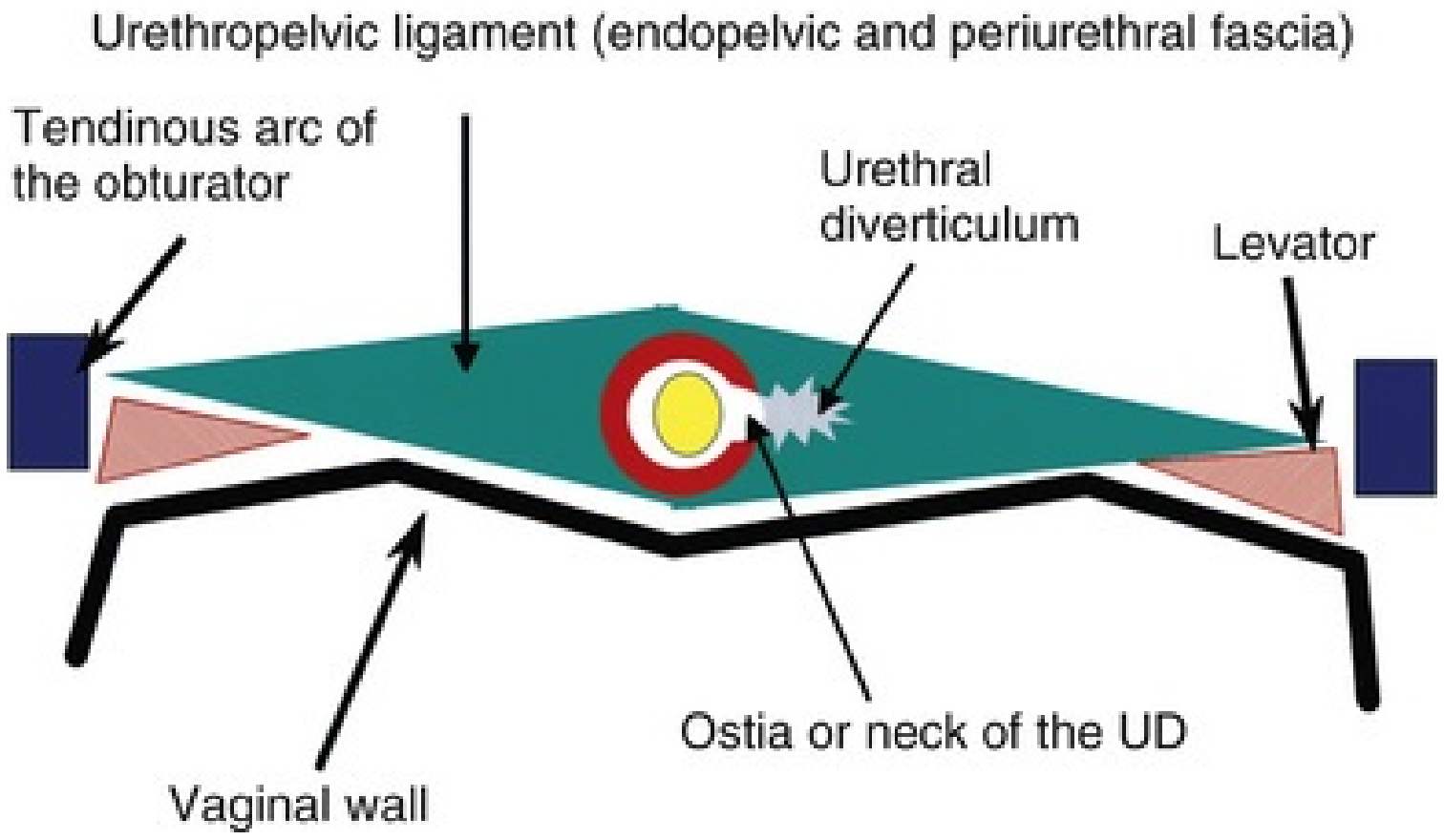
Urethropelvic ligament (endopelvic and periurethral fascia)
Tendinous arc of the obturator
Urethral diverticulum
Levator
Ostia or neck of the UD
Vaginal wall

FIG. 130.14 Diagram of urethral diverticulum *(UD),* which forms within and between the layers of the urethropelvic ligament.

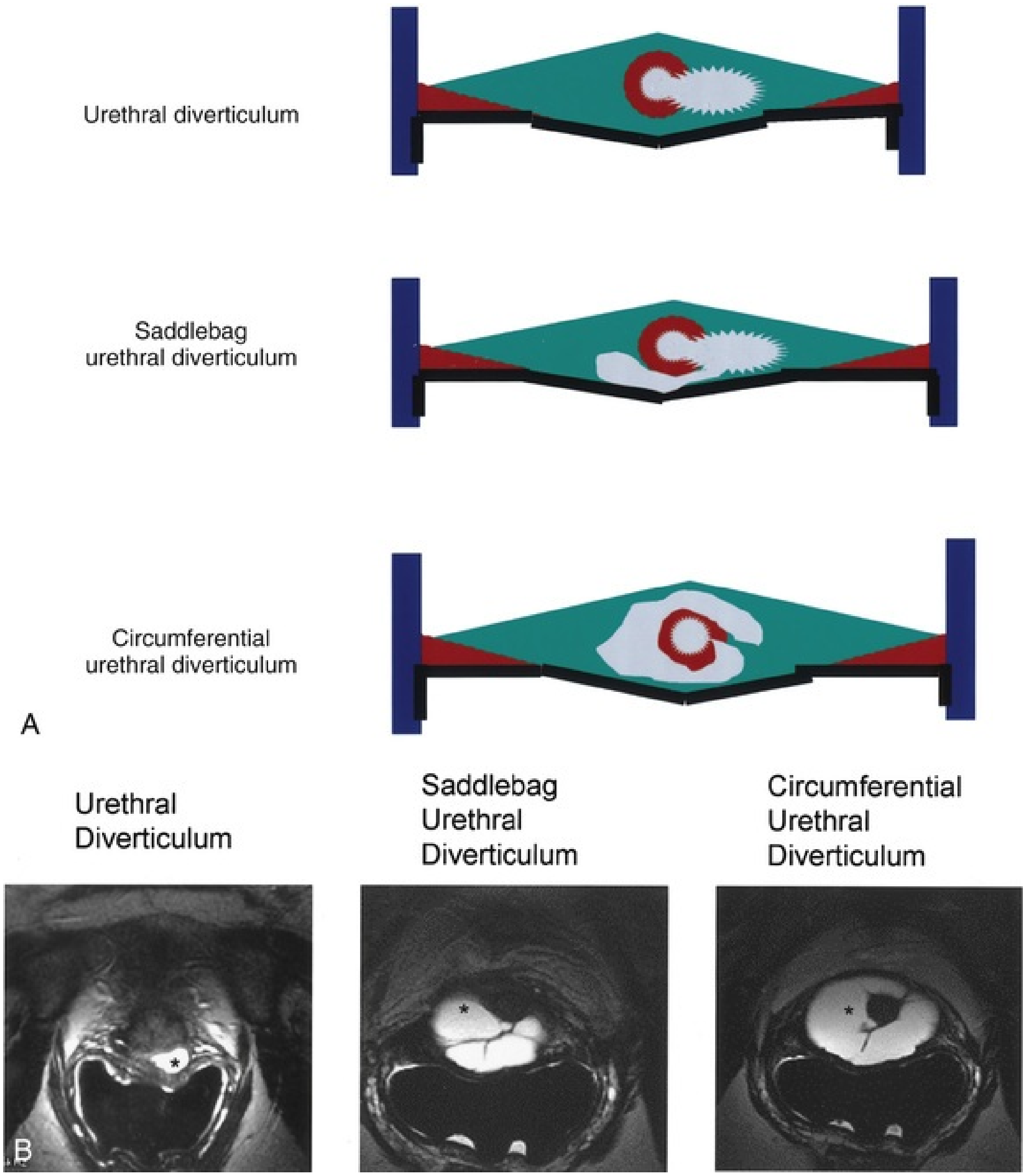
Urethral diverticulum
Saddlebag urethral diverticulum
Circumferential urethral diverticulum
A
Urethral Diverticulum
Saddlebag Urethral Diverticulum
Circumferential Urethral Diverticulum
*
*
*
B

FIG. 130.15 Multiple different morphologies of urethral diverticulum (UD) may exist. (A) Schematic diagrams representing three different morphologies of UD. (B) Endoluminal magnetic resonance images corresponding to each of the configurations in three different patients (*asterisk* indicates UD).

The exact origin of UD is still unproven. A major debate in the early part of the 20th century focused on whether UD were congenital or acquired lesions (Gilbert and Rivera Cintron, 1954; Johnson, 1938; Pinkerton, 1963). Although this condition exists in children, the diagnosis may represent a different clinical entity from adult female UD. Scattered reports of congenital UD in female infants have been described (Glassman et al., 1975). Marshall (1981) reported five cases of UD in young females, of whom three experienced spontaneous regression. Congenital anterior UD is a well-described entity in boys (Kaneti et al., 1984; Kirks and Grossman, 1981; Lau and Ong, 1981), but this is considered to be an entirely different clinical entity from UD in the female. Congenital Skene gland cysts have been reported (Kimbrough and Vaughan Jr., 1977; Lee and Kim, 1992) but are considered extremely rare. Diverticula in the pediatric population have been attributed to a number of congenital anomalies, including an ectopic ureter draining into a Gartner duct cyst and a forme fruste of urethral duplication (Boyd and Raz, 1993; Silk and Lebowitz, 1969; Vanhoutte, 1970). **The vast majority of UD, however, are classified as acquired and are diagnosed in adult females.** In two large series of UD, there were no patients reported who were younger than 10 years of age (Davis et al., 1958, 1970), arguing against a congenital cause for these lesions. A congenital defect in patients that results in or represents a precursor to UD, which then only becomes symptomatic later in life, may exist; however, this is still unproven.

There are multiple theories regarding the formation of acquired UD. For many years, acquired UD were believed to be most likely the result of trauma from vaginal childbirth (McNally, 1935). It was postulated that mechanical trauma during vaginal delivery resulted in herniation of the urethral mucosa through the muscular layers of the urethra with the subsequent development of a UD. However, up to 20% to 30% of patients in some UD series are nulliparous (Ganabathi et al., 1994; Lee, 1984), which may significantly discount parity as a risk factor. Trauma with forceps delivery, however, has been reported to cause UD (Kłyszejko et al., 1985), and the radiographic appearance of periurethral injectable agents, including collagen (Bridges et al., 2005; Clemens and Bushman, 2001) and other injectable agents (Castillo-Vico et al., 2007; Gaines et al., 2017), can simulate a UD.

The periurethral glands are thought to be the probable site of origin of acquired UD (Young and Wahle, 1996). Huffman's anatomic work (1948) with wax models of the female urethra was critical to the early theories regarding the pathophysiology of UD and the involvement of the periurethral glands. By reviewing 10-μm transverse sections, he refuted earlier anatomic descriptions of the glandular anatomy of the female. He characterized the periurethral glands as located primarily dorsolateral to the urethra, arborizing proximally along the urethra, and yet draining into ducts located in the distal one-third of the urethra (see Fig. 130.13). Furthermore, he noted that periductal and interductal inflammation was found commonly. **In support of these observations and an infectious (acquired) cause of UD, in more than 90% of UD cases the ostium is located posterolaterally in the mid- or distal urethra, which corresponds to the anatomic location of the periurethral glands** (Lang and Davis, 1959; Mackinnon et al., 1959).

Although there are probably other unknown factors that may facilitate the initiation, formation, or propagation of UD, infection of the periurethral glands seems to the most generally accepted common etiologic factor in most cases. Peters and Vaughan (1976) found a strong association with concurrent or previous infection with *Neisseria gonorrhoeae* and UD. However, the initial infection and, especially, subsequent reinfections may originate from a variety of sources, including *Escherichia coli* and other coliform bacteria as well as vaginal flora. **Nevertheless, UD have been attributed historically to recurrent infection of the periurethral glands, with obstruction, suburethral abscess formation, and subsequent rupture of these infected glands into the urethral lumen.** Continual filling and pooling of urine in the resultant cavity may lead to stasis, recurrent infection, and eventual epithelialization of the cavity, forming a permanent UD. This concept was first popularized by Routh (1890) more than a century ago and has now become the most widely accepted theory regarding the formation of female UD. **Reinfection, inflammation, and recurrent obstruction of the neck of the cavity are theorized to result in patient symptoms and enlargement of the diverticulum.** Daneshgari et al. (1999) have reported noncommunicating UD diagnosed by MRI. Whether this lesion represents a forme fruste of UD or simply a UD with an obstructed ostium is unclear.

Young and Wahle (1996) have formulated a modern hypothesis regarding the pathogenesis of UD through extensive clinical experience with this entity, including the diagnosis, imaging, and surgical repair of UD. **These authors have proposed that acquired UD results from infection and obstruction of the periurethral glands.** These glands are normally found in the submucosal layer of the spongy tissue of the distal two-thirds of the urethra. **Repeated infection and abscess formation in these obstructed glands eventually result in enlargement and expansion.** Initially the expanding mass displaces the spongy tissue of the urethral wall and then enlarges to disrupt the muscular envelope of the urethra. This results in herniation into the periurethral fascia. The enlarging cavity can then expand and dissect within the leaves of the periurethral fascia and urethropelvic ligament. **This expansion occurs most**

commonly ventrally, resulting in the classic anterior vaginal wall mass palpated on physical examination in some patients with UD. However, these may also expand laterally, or even dorsally, about the urethra. **Eventually, the abscess cavity ruptures into the urethral lumen, resulting in the communication between the UD and the urethral lumen.**

This proposed pathophysiology appears to adequately explain the anatomic location and configuration of many UD and is supported by the work of Huffman noted previously. However, it is not without critics. Some have argued that UD represent one form in the continuum of periurethral cysts (Tsivian et al., 2009). In addition, about one-third of UD occur in the proximal portion of the urethra (Thomas et al., 2008), which is not consistent with the location of the majority of the drainage ducts for the periurethral glands. Finally, if this proposed pathophysiology were true, the finding of periurethral abscesses as a result of infection and enlargement of the periurethral glands should be at least as common as UD, but such lesions are indeed rarely seen clinically.

Prevalence

Moore (1952) **stated that UD as an entity is "found in direct proportion to the avidity with which it is sought."** Although it is not considered a rare lesion today, less than 100 cases of UD were reported in the literature before 1950. With the development of sophisticated imaging techniques, including PPU in the 1950s, the diagnosis of UD became increasingly common.

The true prevalence of female UD, however, is not known; it is reported to occur in up to 1% to 6% of adult females in some series. Determining the true prevalence of UD would require appropriate screening and imaging of a large number of symptomatic and asymptomatic adult female subjects in a primary care setting, which has not been done. Bruning (1959) found UD in 3 of 500 female autopsy specimens. In 1967 Andersen reported the results of PPU done for 300 women with cervical cancer but without lower urinary tract symptoms and found UD in 3%. Aldridge et al. (1978) reported a prevalence of UD of 1.4% in women with incontinence and related symptoms. Stewart et al. (1981) found UD in 16 of 40 highly symptomatic females investigated with PPU. Endorectal coil MRI was performed on 140 consecutive female patients with lower urinary tract symptoms, and the incidence of UD was approximately 10% (Lorenzo et al., 2003). However, this represented a series of *symptomatic* females at a tertiary referral center and therefore probably is not reflective of the general population. Burrows et al. (2005) reviewed US hospital and ambulatory surgery databases and concluded that the rate of urethral diverticulectomy surgery from 1994 to 1996 was approximately 6.7 per 1 million females. However, this is well below the historical prevalence figures cited previously. A population-based study of women in Olmstead County, Minnesota, by El-Nashar et al. (2014) found that the incidence of UD is less than 0.02% per year. Further complicating an accurate assessment of the epidemiology of UD is that the condition can be asymptomatic and is often misdiagnosed or overlooked. A population-based study of women in Olmstead County, Minnesota, by El-Nashar et al. (2014) found that the incidence of UD is less than 0.02% per year.

Some series have suggested a racial predilection, with African-Americans being as much as six times as likely to develop UD as their Caucasian counterparts (Davis et al., 1970). This distribution was historically believed to be attributed to an urban bias because most of the clinical series of these cases were reported from academic medical centers in large cities. However, a recent retrospective series from the Cleveland Clinic revealed that approximately two-thirds of urethral diverticulectomies performed at that institution over a 26-year period were in Caucasians. Nevertheless, inpatient surgery for UD in the United States occurred threefold more commonly in African-Americans than in whites from 1979 to 1997 (Burrows et al., 2005).

Diverticular Anatomy and Histology

The interior surface of UD may be urothelial, squamous, columnar, or cuboidal epithelium, or mixed (Tsivian et al., 2009)**. In some cases, the epithelium is absent and the wall of the UD consists of only fibrous tissue. Two-thirds of resected UD demonstrate inflammatory changes** (Thomas et al., 2008).

Most UD demonstrate benign histopathology, but premalignant and malignant changes can be seen. Approximately 10% of urethral diverticulectomy specimens may demonstrate significant histopathologic abnormalities, including metaplasia, dysplasia, or frank carcinoma, which require long-term follow-up or additional therapy (Thomas et al., 2008)**. Fewer than 100 cases of carcinoma within UD have been reported in the English-language literature** (Rajan et al., 1993)**. The most common malignant pathology in UD is adenocarcinoma, followed by urothelial cell and squamous cell carcinomas** (Rajan et al., 1993; Thomas et al., 2008)**. This**

is in direct contrast to primary urethral carcinoma, in which the primary histologic type is squamous cell carcinoma. Some authors have suggested that UD is associated with the development of urethral adenocarcinoma in the female (Oliva and Young, 1996). If this is true, then observational management or nonexcisional therapy of UD, such as marsupialization or endoscopic incision, should always be combined with a biopsy to rule out malignancy (McLoughlin, 1975). **There is no consensus on proper treatment in these cases of malignancy associated with UD, and recurrence rates are high with local treatment alone** (Rajan et al., 1993). The incidental finding of malignancy in these cases can be particularly troubling when found intraoperatively, or even more disturbing on the postoperative pathology report. Although it is interesting to speculate, **it has not been conclusively demonstrated that any particular preoperative imaging modality, such as ultrasonography or MRI** (Chung et al., 2010), **can reliably and prospectively diagnose a small malignancy arising in a UD.** In consideration of curative therapy, it is unclear whether extensive surgery, including cystourethrectomy with or without adjuvant external beam radiotherapy, is superior to local excision followed by radiotherapy (Patanaphan et al., 1983).

Multiple benign lesions, including nephrogenic adenoma and endometriosis, have been described within UD (Laudano et al., 2014; Paik and Lee, 1997; Palagiri, 1978; Peterson and Matsumoto, 1978; Piazza et al., 1987). Pathologically, nephrogenic adenoma can be difficult to differentiate from adenocarcinoma (Laudano et al., 2014).

Calculi within UD are not uncommon and may be diagnosed in 4% to 10% of cases (Ginesin et al., 1988; Romanzi et al., 2000; Ward et al., 1967) and are most likely caused by urinary stasis and/or infection (Fig. 130.16). They may be suspected by physical examination findings or noted incidentally on imaging evaluation. **The presence of a stone will not significantly alter the evaluation or surgical approach and can be considered an incidental finding.** The stone is removed with the UD specimen at the time of surgery.

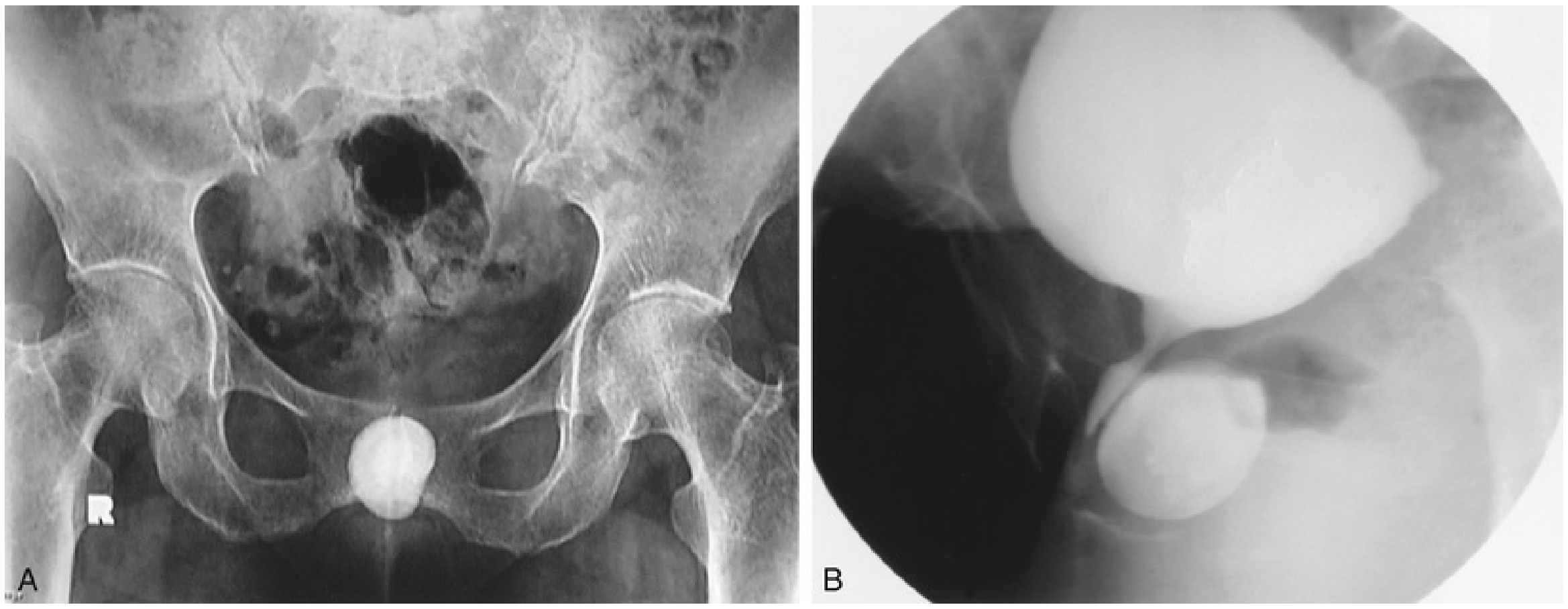

FIG. 130.16 Calculi within a urethral diverticulum. (A) Scout film shows a calcified density overlying the symphysis pubis. (B) Voiding image from a voiding cystourethrogram demonstrates that the density seen on the scout film represents a stone within a urethral diverticulum.

UD are found within the periurethral fascia bordered by the anterior vaginal wall ventrally. **The size of the lesion may vary from only a few millimeters to several centimeters.** In addition, the size may vary over time as a result of inflammation, intermittent obstruction of the ostium, and subsequent drainage into the urethral lumen. In the sagittal plane, UD are most often located and centered at the level of the middle third of the urethra, with the luminal connection, or ostium, located posterolaterally. They may extend distally along the vaginal wall almost to the urethral meatus, or proximally up to and beyond the bladder neck underneath the trigone of the bladder (Fig. 130.17). A bewildering array of configurations can be noted on imaging and at surgical exploration (Table 130.1). In the axial plane, the UD cavity may extend laterally along the urethral wall and, in some cases, around to the dorsal side of the urethra or may wrap circumferentially around the entire urethra. UD may be bilobed (dumbbell shaped), extending across the midline in a so-called saddlebag configuration (see Fig. 130.15). Multiple loculations are not uncommon, and approximately 6% of patients have multiple UD at presentation (Thomas et al., 2008). Varying degrees of sphincteric compromise may exist because of the location of diverticulum relative to the proximal and distal urinary sphincter mechanisms, or sphincteric compromise may coexist with UD as a result of other factors. This is important to note when considering surgical repair, as discussed later.

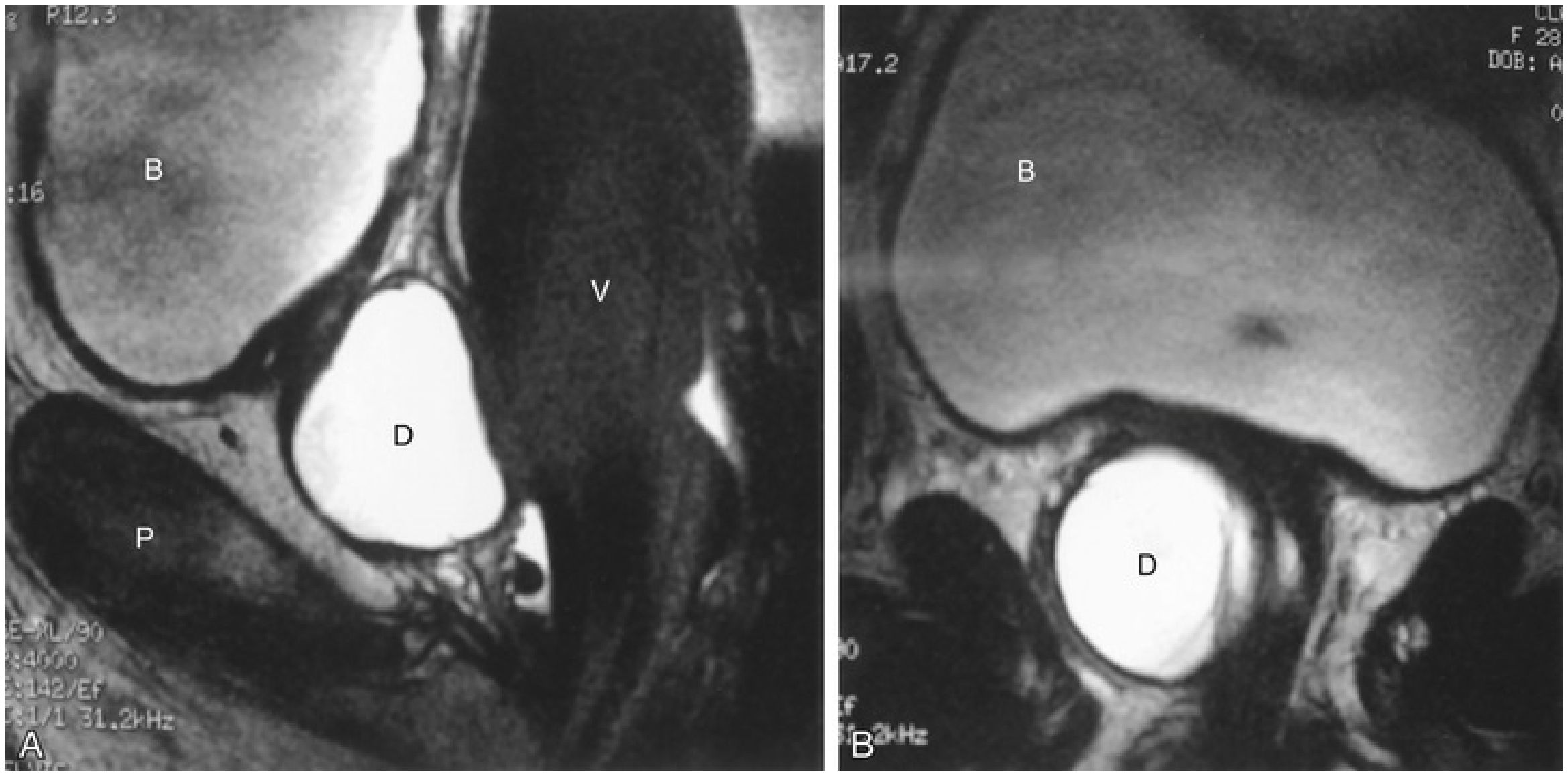

FIG. 130.17 T2 magnetic resonance image demonstrating a large urethral diverticulum *(D)* extending to the trigone of the bladder *(B)* in the sagittal (A) and coronal (B) planes. *P,* Symphysis pubis; *V,* vagina.

TABLE 130.1

Diverticular Morphology and Characteristics

AUTHOR/COUNTRY	PATIENT NUMBER MEAN/MEDIAN AGE LENGTH OF FOLLOW-UP	CONFIGURATION, NUMBER, AND COMMUNICATION WITH URETHRA	SIZE RANGE	I M S
Romanzi 2000 USA	N = 46 36 y/o (17–67)		20–80 mm	
Blander 2001 USA	N. = 27		-	
Porpiglia 2001	N. = 18	Lateral 6/18	-	

Italy	47 y/o (25–65) Time to diagnosis (4–72 months)	Posterior 10/18 Horseshoe 2/18 Proximal 4/18 Mid-urethral 10/18 Distal 4/18		
Rovner 2003 USA	N. = 41 50 y/o	Simple 32/41 Circumferential 9/41	-	-
Rufford 2004 UK	N. = 18 42 y/o (22–67) Time to diagnosis (9.5 months 2–96)		-	V
Ljungqvist 2007 Sweden	N. = 68 44 y/o (21–85)	Single 53/68 Multiple 15/68 Multiloculated 17/68 Simple 31/58 Horseshoe 19/68 Proximal: 8/56 Mid-urethral: 33/56 Distal: 12/56	9 mm–size of a plum	
Han 2007 Korea	N. = 30 46 y/o (31–73) 29 months	Single 26/30 Multiple 4/30 Simple 17/30 U shaped 3/30 Circumferential 10/30 Proximal 23/30 Distal 7/30	2.3 mL mean	M
Foster 2007 USA	N. = 27 47 y/o (21–76) Symptom duration 47 months (0–360)	-	-	M M m
Chang 2008 Taiwan	N. = 14 47 y/o (22–65) Symptom			

	duration 78 months (1–30 months)			
Ockrim 2008 UK	N. = 30 40 y/o (23–61)	Single 10/16 Multiloculated 6/16 Simple 19/26 Partial horseshoe 5/26 Horseshoe 2/26 Proximal 4/16 Middle 9/16 Distal 3/16	-	
Stav 2008 Australia and Israel	N. = 25 42 y/o ±12	Partial horseshoe 2/25 Proximal: 5/25 Mid-urethra: 7/25 Distal: 12/25	9-43 mm Mean = 22.8 mm	
Chung 2010 USA	N. = 41		12–48 mm	
Cassanova 2011 USA	N. = 30 40 y/o (16–65)	True diverticula 24/30 Pseudodiverticula 6/30 all had prior sling surgery	-	-
Ingberg 2011/Thomas 2008 USA	N. = 122 46y/o ± 11	Single 103/122 Multiple 19/122 Simple 57/122 Horseshoe/saddlebag 30/122 Circumferential 18/122 Proximal 31/122 Middle 33/122 Distal 22/122	3–50 mm mean 17 mm	-
Dwarkasing 2011	N. = 60 women,		4–33 mm	

Netherlands	20 had diverticula 44 y/o			
Portnoy 2013 Israel	N. = 11 44 y/o (20–69)		9–33 mm	
Dai 2013 China	N. = 14 43 y/o (30–60)			C U l (i c b
Pathi 2013 USA	N. = 36 37 y/o (27–47)	-	-	
Laudano 2014 USA	N. = 29	Single 15/16 Multiple 1/16	Mean = 23 mm (±14)	-

Nickles 2014 USA	N. = 43 52 y/o	<75% circumference (simple) 32/43	-	M
Reeves 2014 UK	N. = 89 42 y/o (17–71)	Simple 72/89 Multiloculated 12/89 Saddle 5/89 Proximal 17/89 Mid-urethra 47/89 Distal 24/89 Full length 2/89	8–48 mm (Mean = 24 mm)	
Gugliotta 2015 Italy	N. = 20 46 y/o (35–55)	Simple 15/20 Multiloculated 4/20 Saddle 1/20	28 mm (8–50)	T 1
Enemchukwu 2015 USA	N. = 38 50 y/o (29–71) Symptom duration 56.7 months (5–150)	-	-	
Summary	Age: 16–85 y/o Mean range: 36–52 years old Symptom duration: range mean 7–78 months (range 0–360) Total 873 patients	Single: 294/361 Multiple: 67/361 Simple: 282/386 Saddlebag:65/386 Circumferential:39/386 Proximal: 64/261 Mid-urethra: 132/261 Distal:65/261	Mean = 21.1 mm Range: 3–80 mm	

Presentation

The majority of patients with UD are seen initially between the third and seventh decades of life (Ganabathi et al., 1994; Ginsburg and Genadry, 1983; Johnson, 1938; Moore, 1952; Pathak and House, 1970). The presenting symptoms and signs in patients with UD are protean (Box 130.1). **The classic presentation of UD has been described historically as the "three Ds"—dysuria, dyspareunia, and dribbling (postvoid)—but this presentation is**

only infrequently seen, with recent series showing that only 5% of contemporary cases have all three (Baradaran et al., 2016). Such a designation is of historical interest only because it was coined in the period before extensive radiologic imaging was available (Lee and Fynes, 2005). However, individually or collectively, these symptoms are neither sensitive nor specific for UD. **Although presentation is highly variable, the most common symptoms are irritative lower urinary tract symptoms (e.g., frequency, urgency), pain, and infection** (Baradaran et al., 2016; Davis et al., 1958, 1970; Leach et al., 1986; Nickles et al., 2014; Peters III and Vaughan Jr, 1976). **Dyspareunia will be noted by 12% to 24% of patients** (Davis et al., 1958, 1970). **Approximately 5% to 32% of patients will complain of postvoid dribbling** (Davis et al., 1970; Ganabathi et al., 1994), and one-third will have associated incontinence (Ganabathi et al., 1994). **Recurrent cystitis or UTI is also a frequent presentation, seen in one-third of subjects** (Davis et al., 1970; Ganabathi et al., 1994), **probably as a result of urinary stasis in the UD. Multiple bouts of recurrent cystitis should alert the clinician to the possibility of a UD. Other complaints include pain, a vaginal mass, hematuria, vaginal discharge, obstructive symptoms, or urinary retention.** Patients may complain of a tender or nontender anterior vaginal wall mass, which upon gentle compression may reveal retained urine or purulent discharge per the urethral meatus. Although spontaneous rupture of these lesions is extremely rare, urethrovaginal fistula may result under these circumstances (Nielsen et al., 1987). **Notably, up to 10% to 20% of patients diagnosed with UD may be completely asymptomatic, having the lesions diagnosed incidentally on imaging or physical examination** (Baradaran et al., 2016).

Box 130.1

Signs and Symptoms of Urethral Diverticula

Symptoms

Vaginal or pelvic mass
Pelvic pain
Urethral pain
Dysuria
Urinary frequency

- Postvoid dribbling
- Dyspareunia
- Urinary urgency
- Incontinence
- Urinary hesitancy
- Vaginal or urethral discharge
- Double voiding
- Sense of incomplete emptying

Signs

- Recurrent urinary tract infection
- Hematuria
- Vaginal or perineal tenderness
- Urinary retention
- Vaginal mass
- Urethral discharge with stripping of anterior vaginal wall

The size and complexity of the UD do not correlate with symptoms (Nickles et al., 2014). In some cases, very large UD may result in minimal symptoms, and, conversely, some UD that are nonpalpable may result in considerable patient discomfort and distress. Finally, symptoms may wax and wane and even resolve for long periods of time. The reasons for these exacerbations and remissions are poorly understood but may be related to periodic and repeated episodes of infection and inflammation.

Because many of the symptoms associated with UD are nonspecific, patients may often be misdiagnosed and treated for years for a number of unrelated conditions before the diagnosis of UD is made. This may include therapies for interstitial cystitis, recurrent cystitis, vulvodynia, endometriosis, and vulvovestibulitis. In one series of 46 consecutively examined women eventually diagnosed with UD, the mean interval from onset of symptoms to diagnosis was 5.2 years (Romanzi et al., 2000). In this series, women consulted with an average of nine physicians before the definitive diagnosis being made, despite the fact that 52% of women had a palpable mass on examination. This underscores the importance of a baseline level of suspicion and a thorough pelvic examination in female patients complaining of lower urinary tract symptoms or other symptoms that may be associated with UD.

UD has also been reported to present during pregnancy. Moran et al. (1998) reported four cases of UD diagnosed during pregnancy. Conservative treatment included antibiotics and aspiration or incision and drainage. Two women delivered vaginally and the other two delivered by cesarean section for unrelated reasons. In one patient, drainage was performed during labor to facilitate delivery. Three of the four women had definitive repair performed after delivery. It is not known if pregnancy is associated with formation of UD, although patients may be more likely to become symptomatic during this period. Usually, conservative management with antibiotics may be desirable until after delivery to avoid precipitating premature labor, although successful surgical treatment during pregnancy has been reported (Wittich, 1997). Transvaginal aspiration of symptomatic lesions also can be considered.

Evaluation and Diagnosis

The diagnosis of UD can be made with a combination of a thorough history, physical examination, appropriate urine studies (including urine culture and analysis), endoscopic examination of the bladder and urethra, and selected radiologic imaging. A urodynamic study may also be helpful in completing the evaluation in selected cases.

History and Physical Examination

A thorough history is essential in patients with a diagnosis of UD as well as those without an established diagnosis. Although the presenting symptoms and signs are nonspecific for UD, a thorough accounting of lower urinary tract symptoms, signs (e.g., hematuria), prior diagnostic studies, and response to therapy is critical. Such an approach will permit appropriate counseling regarding improvement or resolution of symptoms in those individuals with a diagnosis of UD and may suggest such a diagnosis in those with diagnostic dilemmas. Important historical data include prior pelvic surgery, especially incontinence procedures; bulking agents may appear as UD on imaging (Gaines et al., 2017; Kumar et al., 2011); and prior sling surgery may present difficulties in accessing and surgically repairing the UD. The presence or absence of urinary incontinence and pad usage, as well as the type of incontinence (e.g., urge vs. stress vs. postvoid dribbling) should be recorded. Sexual function and dyspareunia should be documented as well because vaginal reconstructive surgery may have adverse (or favorable) effects on these individuals’ symptoms.

During physical examination, the anterior vaginal wall should be carefully palpated for masses and tenderness. The location, size, and consistency of any suspected UD should be recorded. **Most UD are located ventrally over the middle and proximal portions of the urethra, corresponding to the area of the anterior vaginal wall 1 to 3 cm inside the introitus** (Fig. 130.18). More distal lesions near the urethral meatus or those distorting the urethral meatus are likely Skene gland cysts or abscesses. Only about one-third of UD are seen initially with a tender anterior vaginal wall mass (Ganabathi et al., 1994). **However, UD may also be located anterior to the urethra or extend partially or completely around the urethral lumen. UD may also extend proximally toward the bladder neck.** These UD may produce distortion of the bladder outlet and trigone of the bladder on cystoscopy or on radiographic imaging. Special care should be taken during surgical excision and reconstruction in such cases because of concerns for intraoperative bladder and ureteral injury, as well as the potential development of postoperative voiding dysfunction and urinary incontinence.

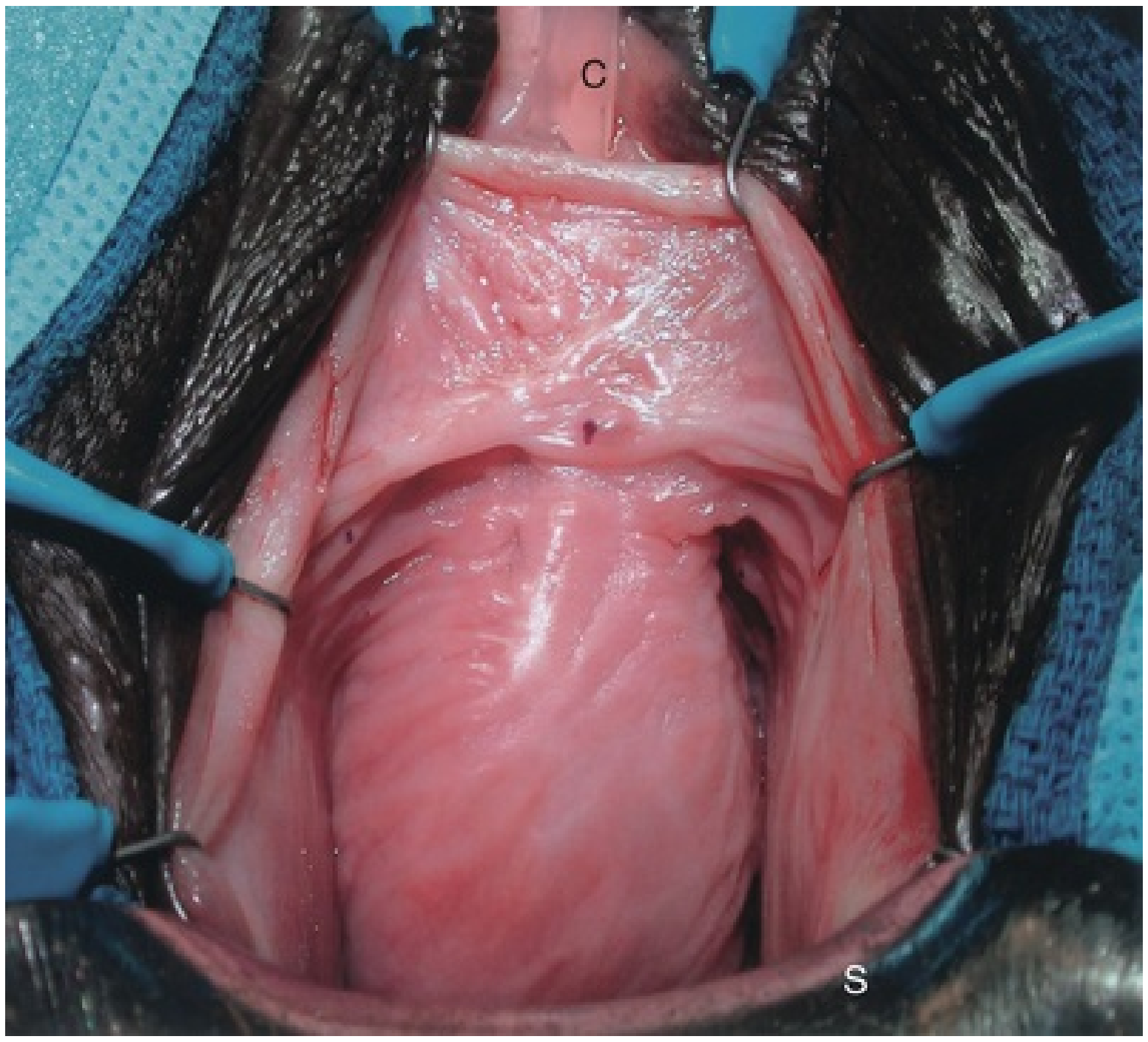

FIG. 130.18 Large anterior vaginal wall mass. The urethral catheter *(C)* is seen superiorly, and a weighted vaginal speculum *(S)* is seen inferiorly. Scott retractor hooks are seen exposing the anterior vaginal wall in this intraoperative photograph.

Distal vaginal masses or perimeatal masses may represent other lesions, including abnormalities of Skene glands (see later discussion). The differentiation between these lesions sometimes cannot be made on the basis of a physical examination alone and may require additional radiologic imaging. **A particularly hard anterior vaginal wall mass may indicate a calculus or malignancy within the UD and mandates further investigation. During physical examination, the urethra may be gently "stripped" or "milked" distally in an attempt to express purulent material or urine from within the UD cavity.** Although often described for the evaluation of UD, this maneuver is not successful in producing the characteristic discharge per urethral meatus in the majority of patients (Leach and Bavendam, 1987).

The vaginal walls are assessed for atrophy, rugation, and elasticity. Poorly estrogenized, atrophic tissues are important to note if surgery is being considered for definitive treatment. These tissues are mobilized intraoperatively and may be used for flaps during excision and reconstruction. Topical estrogens may be administered preoperatively in such cases to improve the quality of these tissues for possible reconstruction intraoperatively. The distal vagina and vaginal introitus are also assessed for capacity. These factors may have an impact on surgical planning because a narrow introitus can make surgical exposure difficult and may mandate an episiotomy or other measures. Finally, during physical examination a provocative maneuver to elicit stress incontinence should be performed, as well as an assessment of the presence or absence of any vaginal prolapse.

Urine Studies

Urine analysis and culture should be performed. The most common organism isolated in patients with UD is *E. coli*. However, other gram-negative enteric flora, as well as *N. gonorrhoeae*, *Chlamydia*, streptococci, and staphylococci, are often present (Davis et al., 1958; Hoffman and Adams, 1965). A sterile urine culture does not exclude infection, because these patients are often on antibiotic therapy at presentation. In patients with irritative symptoms or in whom a malignancy is suspected, urine cytology can be performed.

Cystourethroscopy

Cystourethroscopy is performed in an attempt to visualize the UD ostium as well as to evaluate for other causes for the patient's lower urinary tract

symptoms. A flexible fiberoptic cystoscope or specially designed rigid female cystoscope can be extremely helpful in evaluating the female urethra. The short beak of the rigid female cystoscope and the lack of a beak on a flexible cystoscope maintain the discharge of the irrigation solution immediately adjacent to the lens and thus aid in distention of the relatively short (as compared with the male) urethra, permitting improved luminal visualization when attempting to locate the ostium of the UD. It may also be advantageous to compress the bladder neck while an assistant simultaneously applies pressure to the diverticular sac with a finger. Luminal discharge of purulent material can often be seen with this maneuver or with simple digital compression of the UD during urethroscopy. **The UD ostium is most often located posterolaterally at the 4 and 8 o'clock positions at level of the mid-urethra but can be very difficult to identify in some patients** (Fig. 130.19). The success in identifying a diverticular ostium on cystourethroscopy is highly variable and is reported to range from 15% to 89% (Davis et al., 1970; Ganabathi et al., 1994; Leach and Bavendam, 1987). As a note of caution, patients with UD are often highly symptomatic, and endoscopic examination can be very difficult to initiate or complete without anesthesia. Notably, a positive examination may help in surgical planning; however, the failure to locate an ostium on cystourethroscopy should not influence the decision to proceed with further investigations or surgical repair.

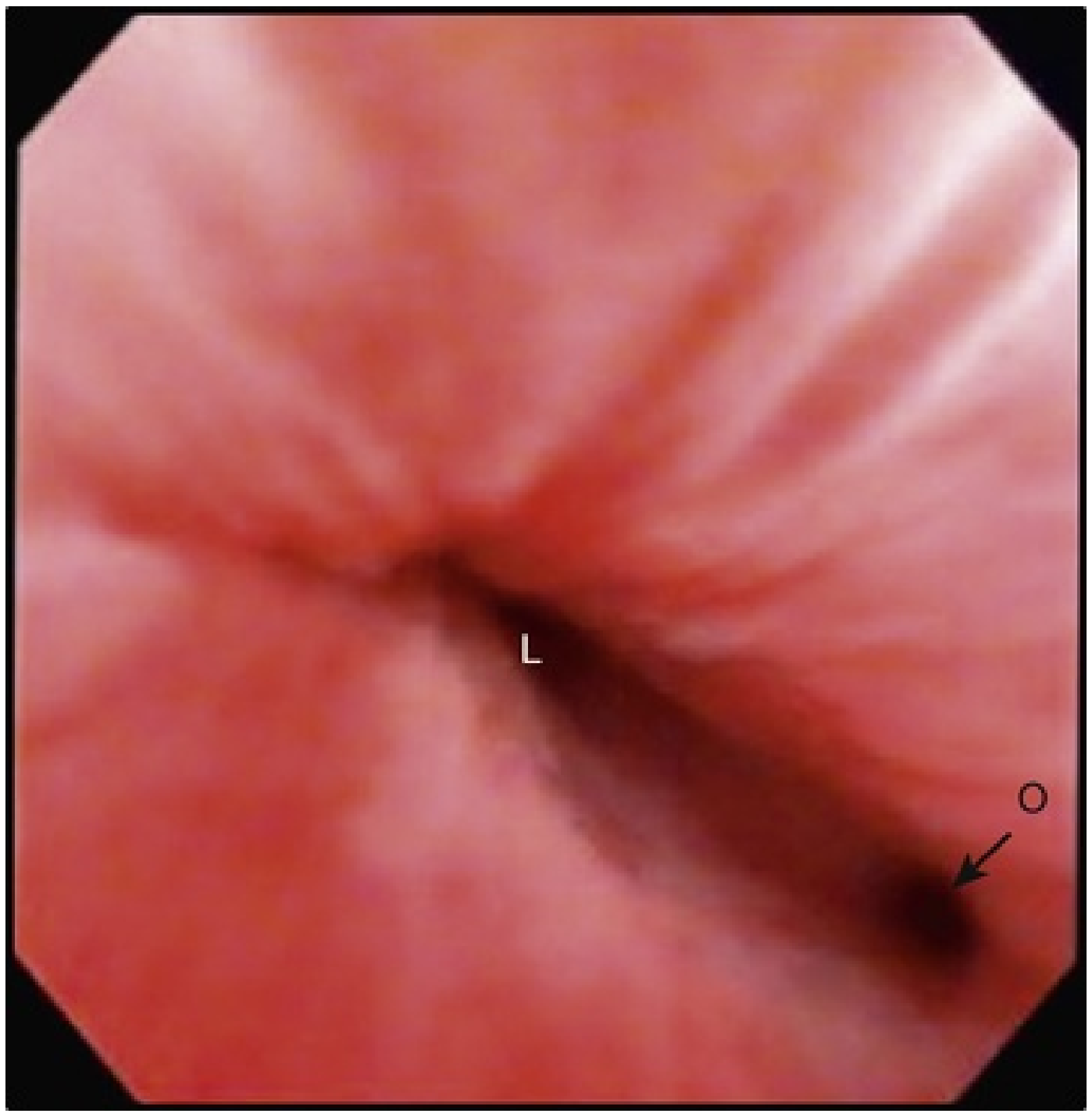

FIG. 130.19 Cystoscopic view of the ostium *(O)* of a urethral diverticulum, which is often difficult to visualize endoscopically. *L,* Lumen of the urethra.

Urodynamics

For patients with UD and urinary incontinence or significant voiding dysfunction, a urodynamic study may be helpful in accurately characterizing these symptoms (Bhatia et al., 1981; Reid et al., 1986; Summitt and Stovall, 1992). Urodynamics may document the presence or absence of stress urinary incontinence (SUI) before repair. **Approximately one-third of women with UD are seen initially with symptoms of urinary incontinence, and up to 50% of women with UD demonstrate SUI on urodynamic evaluation** (Bass and Leach, 1991; Ganabathi et al., 1994). A video-urodynamic study is optimal because it combines a VCUG and a urodynamic study, thus consolidating the diagnostic evaluation and decreasing the number of required urethral catheterizations during the patient's clinical workup (Greiman et al., 2018).

Urethral pressure profilometry has also been used by some authors to assess and/or diagnose patients with UD, noting a biphasic pattern or pressure drop at the level of the lesion during the study (Bhatia et al., 1981; Summitt and Stovall, 1992; Wagner et al., 1986).

Alternatively, a small number of patients may have evidence of bladder outlet obstruction on urodynamic evaluation because of the obstructive or mass effects of the UD on the urethra. SUI may coexist with obstruction (Bradley and Rovner, 2004), but nevertheless both conditions can be treated successfully with a carefully planned and executed operation.

Imaging

High-quality preoperative imaging is important in the diagnosis and therapy of female UD. **Aside from its utility as a diagnostic entity, radiologic imaging should also provide an accurate reflection of the relevant anatomy of the UD, including its relationship to the proximal urethra and bladder neck.**

Diagnostic Contrast Radiography

A number of imaging techniques have been applied to the study of female UD, and no single study can be considered the gold standard or optimal imaging study for the evaluation of UD. Each technique has relative advantages and disadvantages, and the ultimate choice of diagnostic study in many centers often depends on several factors, including local availability, cost, and the experience and expertise of the radiologist. Currently available techniques for the evaluation of UD include double-balloon PPU, VCUG, intravenous urography, ultrasonography, and MRI with or without an endoluminal coil.

Historically, **double-balloon PPU** had been considered to be the optimal study for the diagnosis and assessment of female UD (Davis and Cian, 1956; Davis et al., 1958; Ganabathi et al., 1994; Greenberg et al., 1981). In this technique, a highly specialized catheter (Trattner catheter) with two balloons separated by several centimeters is inserted into the female urethra (Fig. 130.20). This catheter contains a channel that exits through a side hole between the two balloons. One balloon is positioned adjacent to the external urethral meatus, and the other balloon is situated at the bladder neck. Both balloons are inflated, creating a seal about the urethral lumen. Contrast is then infused through the channel under slight pressure, distending the urethral lumen between the two balloons and forcing contrast into the UD, thereby opacifying the cavity. **This highly specialized study provides outstanding images of the urethra and UD and importantly, unlike VCUG, is not dependent on the patient successfully voiding during the study.** However, PPU is not widely performed clinically and the specialized Trattner catheter is not widely available.

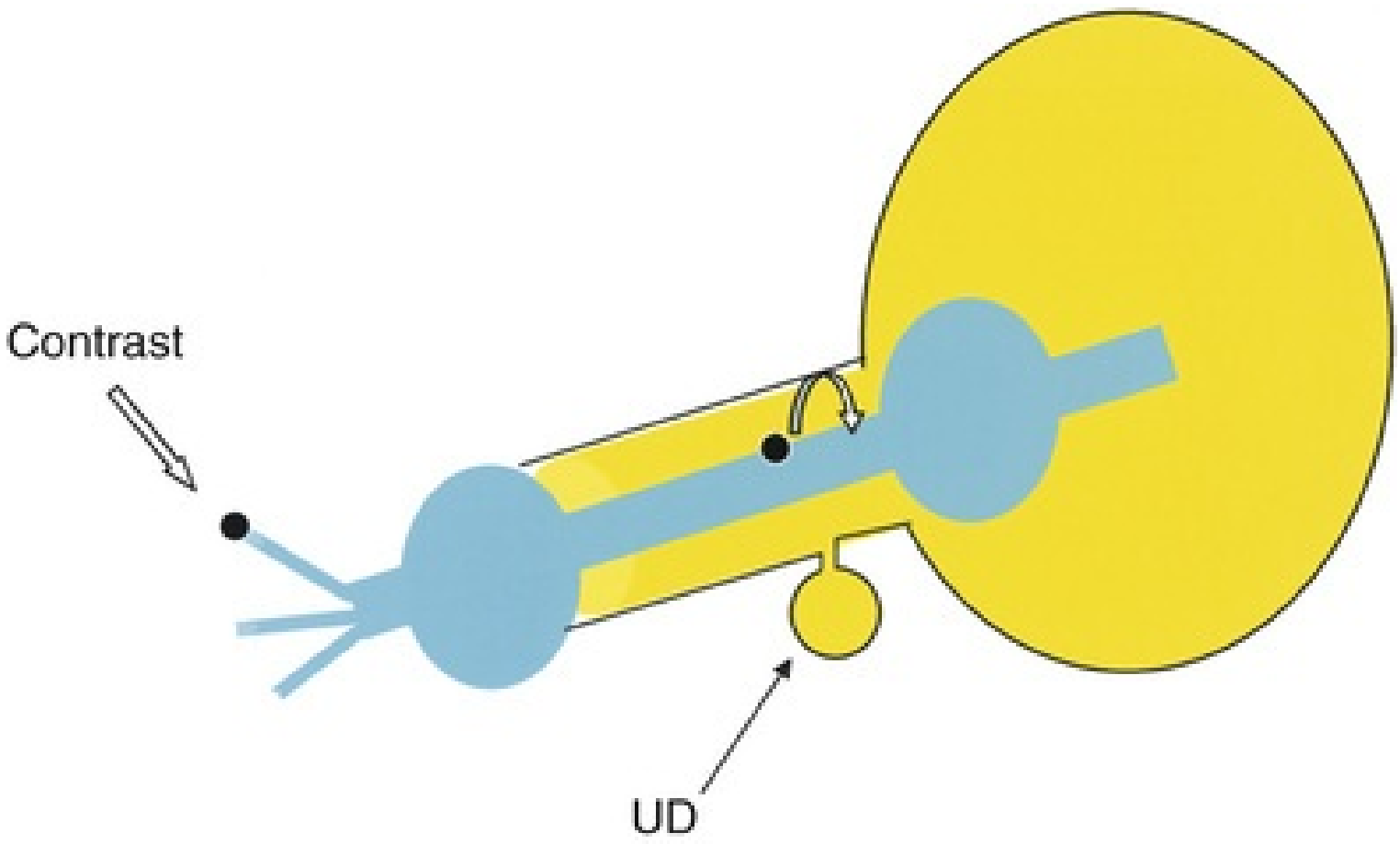

FIG. 130.20 Schematic diagram of a double-balloon catheter. The *curved white arrow* represents flow of the contrast as it enters the urethral lumen. *UD,* Urethral diverticulum.

As an alternative to PPU, **VCUG** may provide excellent imaging of UD (Fig. 130.21). It is widely available and is a familiar diagnostic technique to most radiologists. Sensitivity for UD with this technique varies from 44% to 95% (Ganabathi et al., 1994; Jacoby and Rowbotham, 1999). Patients often will have difficulty in initiating micturition in the radiology suite because of the pain associated with urethral catheterization, psychogenic inhibition attributable to voiding in the presence of others, or other factors. In the absence of voiding, the UD will often not be seen. **Therefore a VCUG that does not demonstrate a UD but did not contain voiding images or postvoid images is nondiagnostic.** If the patient is unable to void under fluoroscopy during the VCUG, an attempt should be made to void in the privacy of an adjacent bathroom. If voiding in private was successful, a postvoid film taken under these circumstances will likely show a collection of contrast inferior to the bladder demonstrating the UD. Unfortunately, an inability to generate an adequate flow rate during the VCUG will result in suboptimal filling of the UD and an underestimation of its size and complexity (Fig. 130.22). Three-dimensional CT VCUG with reconstructions is a novel imaging technique for UD but is not yet widely used clinically (Kim et al., 2005; Lee et al., 2014; Zhao et al., 2017).

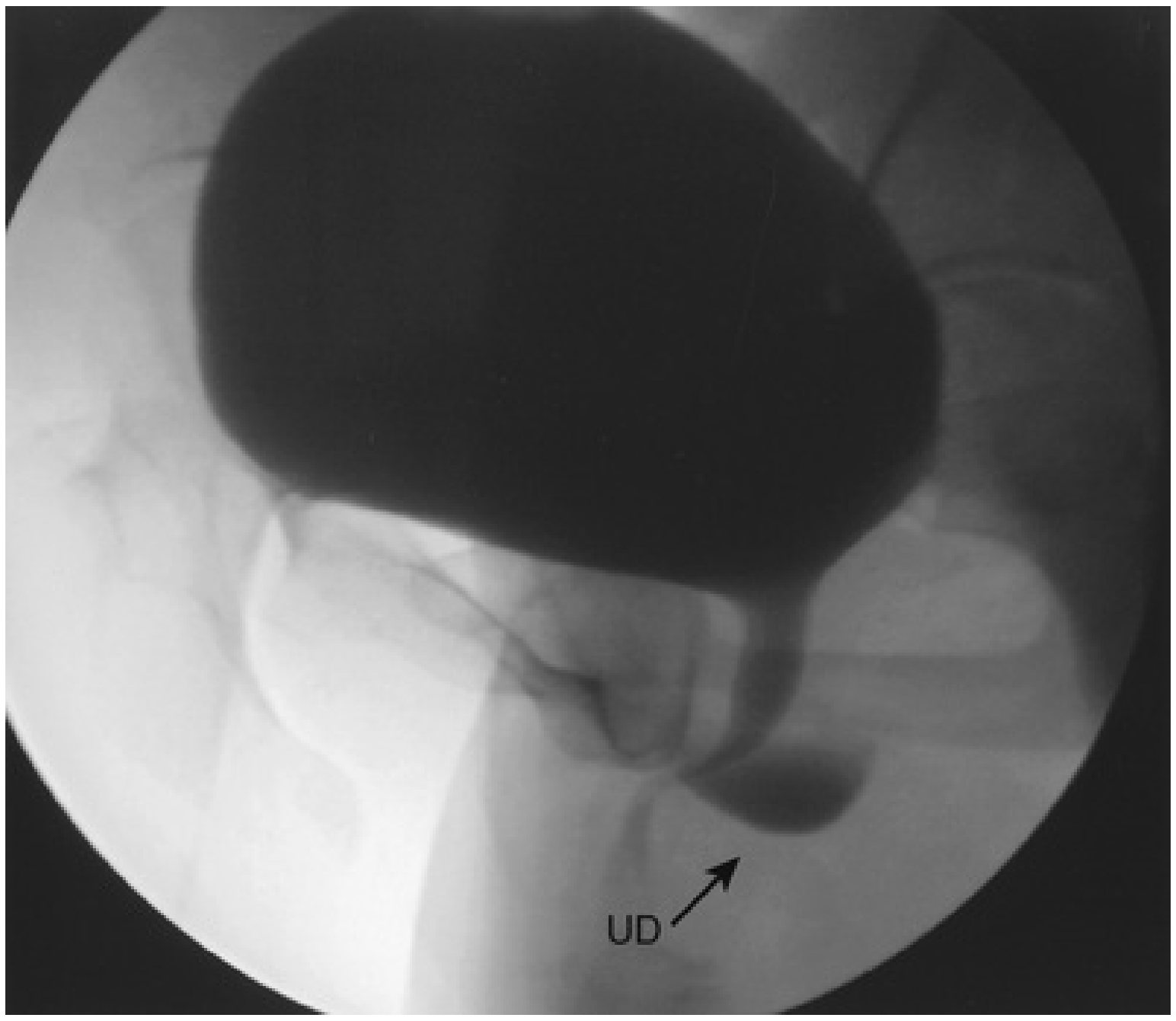

FIG. 130.21 Voiding image from a voiding cystourethrogram demonstrating a urethral diverticulum *(UD).*

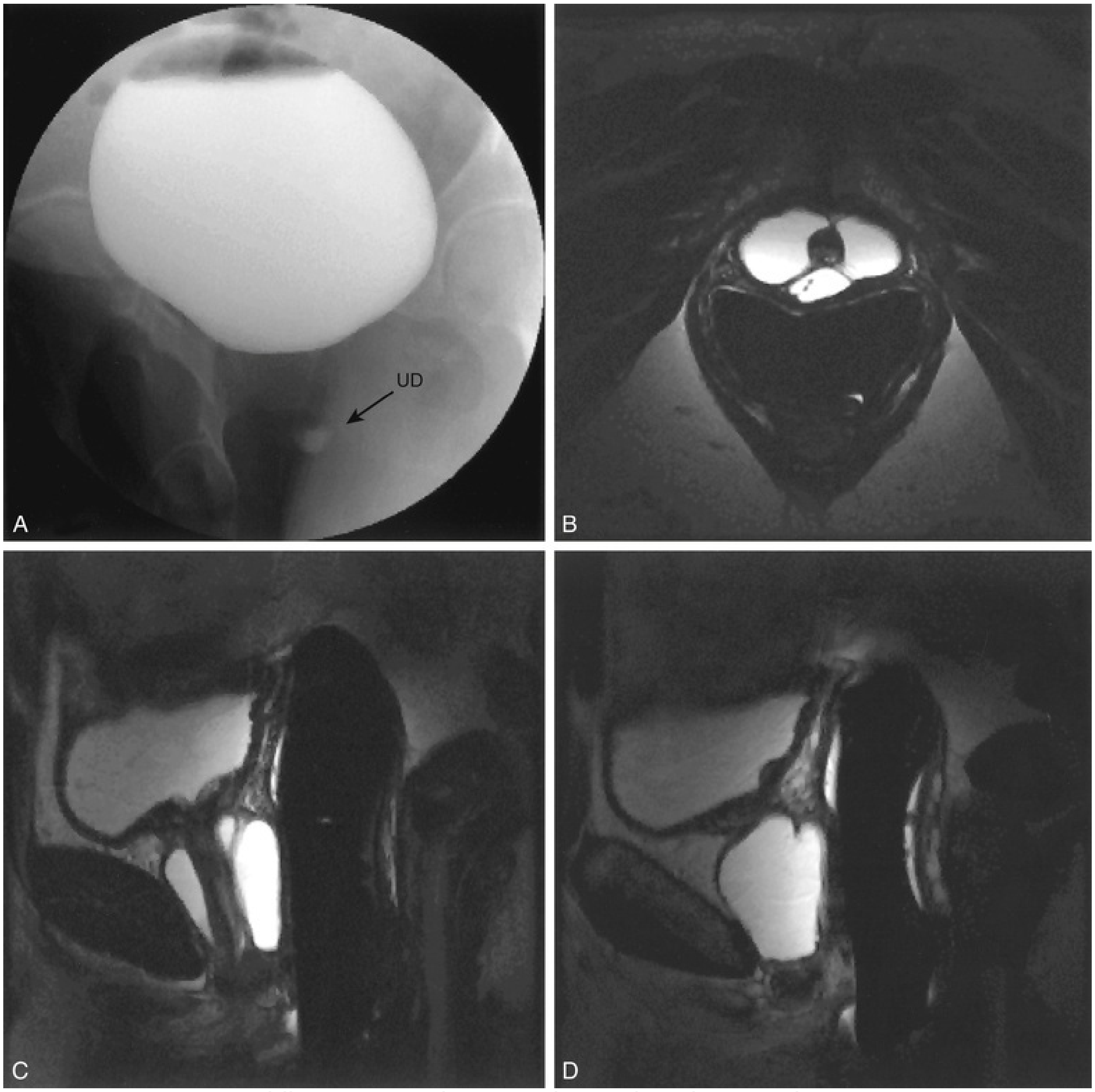

FIG. 130.22 Voiding cystourethrogram (VCUG) and magnetic resonance image (MRI) from a patient with a large circumferential urethral diverticulum *(UD)*. (A) The voiding image from the VCUG shows poor opacification of the proximal urethra with suboptimal distention of the UD as a result of a poor voiding effort. (B to D) The endoluminal MRI demonstrates the full extent and complexity of the lesion on the T2 axial (B), midline sagittal (C), and parasagittal (D) images.

Intravenous urography or CT urogram may be considered in patients in whom it is necessary to delineate the upper urinary tract or to evaluate for the possibility of a congenital ectopic ureteral anomaly as the cause of an anterior vaginal wall mass (Blacklock et al., 1982). The postvoid film of the intravenous urogram can be helpful for the diagnosis of UD in some patients (Goldfarb et al., 1981; Stern and Patel, 1976).

Ultrasonography.

This study has been advocated for the preoperative assessment of vaginal masses and UD by multiple authors (Baert et al., 1992; Chancellor et al., 1995; Dmochowski, 2001; Fortunato et al., 2001; Gerrard et al., 2003; Lee and Keller, 1977; Lee et al., 2001; Mårtensson and Duchek, 1994; Vargas-Serrano et al., 1997; Wexler and McGovern, 1980). Abdominal, transvaginal, translabial, and transurethral techniques have been described. **Transvaginal imaging often provides information regarding the size and location of UD.** On ultrasonographic imaging, the UD appears as an anechoic or hypoechoic area with enhanced through-transmission. Ultrasonography is relatively noninvasive and does not expose the patient to radiation. Another significant advantage of ultrasonography is that successful imaging of UD does not require voiding. However, ultrasonography may not produce detailed high-resolution images that demonstrate precise surgical anatomy. Transvaginal contrast-enhanced sonourethrography has been proposed as a way to improve accuracy of US imaging but requires the use of a catheter, making it as invasive as VCUG, and it requires a skilled sonographer (Dai et al., 2013).

Magnetic Resonance Imaging.

As an alternative to the radiologic investigations noted previously, MRI permits relatively noninvasive, high-resolution, multiplanar imaging of UD. **UD appear as areas of decreased signal intensity on T1 images compared with the surrounding soft tissues and have high signal intensity on T2 images**. **A distinct advantage of MRI compared with VCUG is that successful imaging of UD is wholly independent of voiding and that it is free from ionizing radiation.** Surface coil (Hricak et al., 1991; Kim et al., 1993; Fig. 130.23) and endoluminal (Blander et al., 2001; Lorenzo et al., 2003; Siegelman et al., 1997; Wang and Wang, 1997) techniques have been described. Endoluminal magnetic resonance imaging (eMRI) places the magnetic coil into a body cavity adjacent to the area of interest. This location produces an improved signal-to-noise ratio and high-resolution imaging of these areas (Blander et al., 2001; Siegelman et al., 1997) with excellent sensitivity and specificity for the diagnosis of UD (Dwarkasing et al., 2011). For the evaluation of UD, the eMRI coil is placed intravaginally or intrarectally. **Surface coil MRI and eMRI appear to be superior to VCUG and/or PPU in the evaluation of UD** (Blander et al., 2001; Kim et al., 1993; Neitlich et al., 1998), but the technology is expensive and not widely available. In a series of 17 patients undergoing both PPU and MRI, Portnoy et al. (2013) found that the modalities agreed with 88% correlation on diagnosis of UD, with complexity, location, and demonstration of connection to the urethra also reasonably well correlated (67%, 67%, and 56%, respectively). **Notably, there are several lesions, including periurethral bulking agents, that can be misdiagnosed as UD on MRI** (Gaines et al., 2017)**, and this imaging technique may be inadequate in the diagnosis of malignancy within UD, a rare but important finding** (Chung et al., 2010).

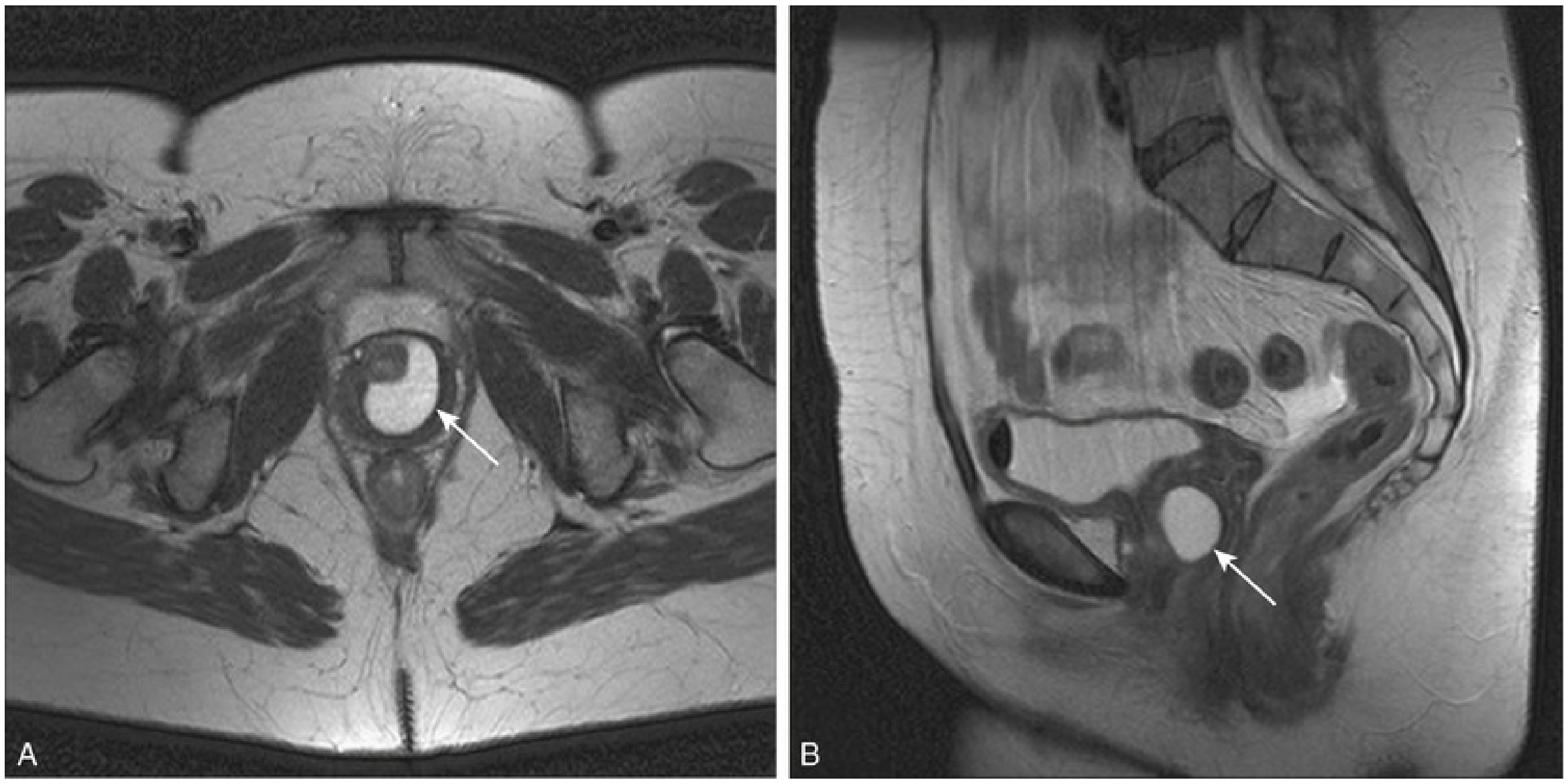

FIG. 130.23 Surface coil T2 magnetic resonance image demonstrating a urethral diverticulum *(arrows)* in the sagittal (A) and axial (B) planes.

Contraindications to MRI for UD are few; these include metallic foreign body fragments, claustrophobia, and an inability to tolerate the endoluminal probe.

Differential Diagnosis: Periurethral Masses Other Than Urethral Diverticula

Periurethral masses other than UD comprise a wide spectrum of conditions that must be differentiated from each other and UD. It may often be possible to make a definitive diagnosis based on history and physical examination alone; in other cases, judicious use of radiographic and cystoscopic studies are necessary to exclude UD.

Vaginal Leiomyoma.

Vaginal leiomyomata are benign mesenchymal tumors of the vaginal wall that arise from smooth muscle elements. They commonly are seen as a smooth, firm, round mass on the anterior vaginal wall (Fig. 130.24). Vaginal leiomyoma is an uncommon lesion, with approximately 300 cases reported in the literature (Young et al., 1991). In a recent series of 79 patients with periurethral masses, 4 (5%) were found to have vaginal leiomyoma (Blaivas et al., 2004). These masses were all apparent on physical examination as freely mobile, firm, nontender masses on the anterior vaginal wall. They may be misdiagnosed as UD (Shirvani and Winters, 2000). Symptoms, if they exist, are usually related to the size of the lesion and include a mass effect, obstruction, pain, and dyspareunia. They commonly occur in the fourth to fifth decade. Similar to uterine leiomyoma, these lesions are usually estrogen dependent and have been demonstrated to regress during menopause (Liu, 1988). Excision or enucleation (Young et al., 1991) through a vaginal approach is often curative and is recommended to confirm the diagnosis, to exclude malignant histology, and also to alleviate symptoms.

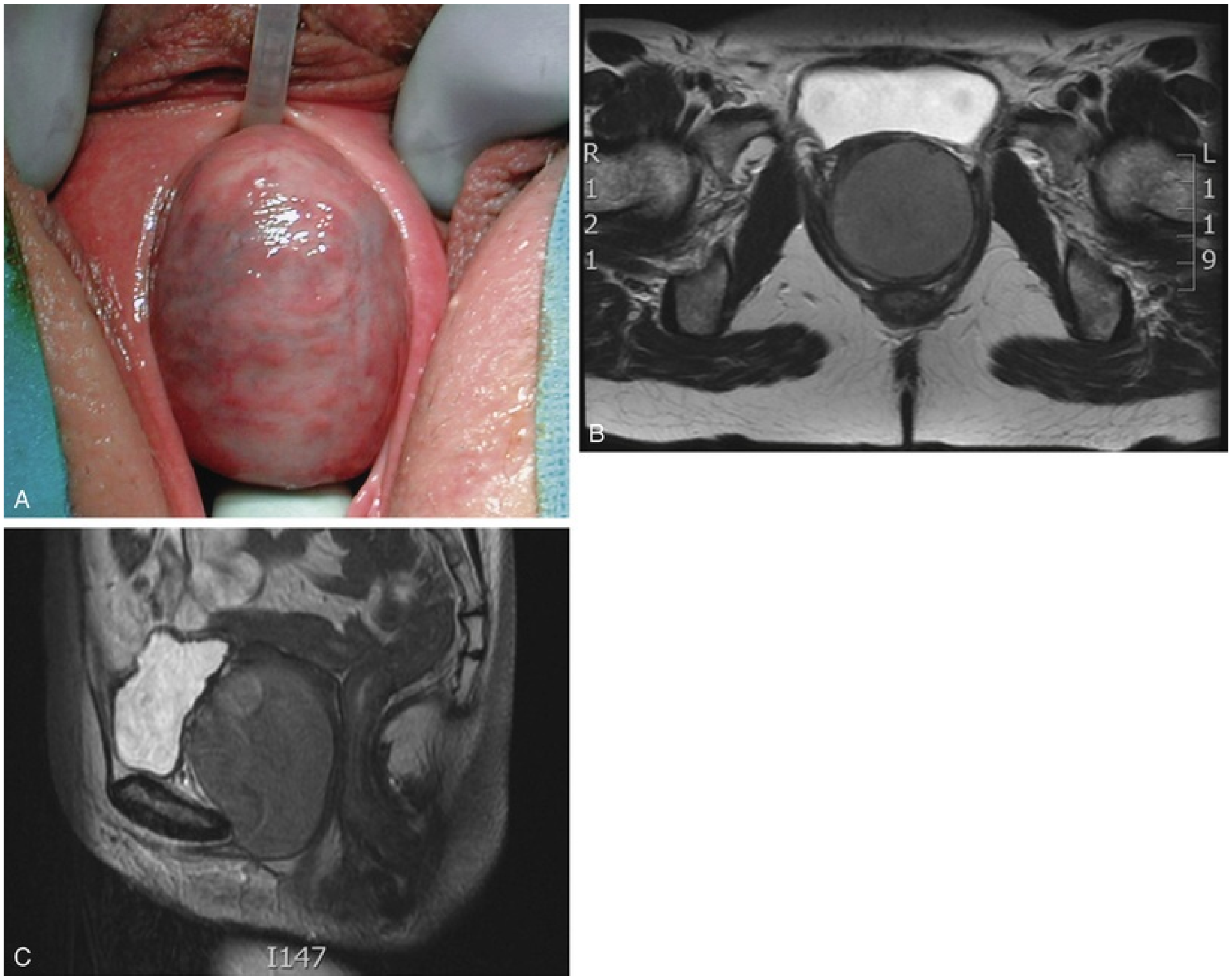

FIG. 130.24 (A) Large anterior vaginal wall leiomyoma. (B and C) Axial (B) and sagittal (C) magnetic resonance images of anterior vaginal wall leiomyoma.

Skene Gland Abnormalities.

Skene gland cysts and abscesses are similar lesions that are differentiated based on clinical findings (Fig. 130.25). Both lesions generally occur as small, cystic masses just lateral or inferolateral to the urethral meatus. They may be lined with transitional or stratified squamous epithelium. Abscesses may be extremely tender and inflamed, and, in some cases, purulent fluid can be expressed from the ductular orifice. **Classically, in contrast to UD, these lesions do not communicate with the urethral lumen.** Skene gland cysts are not uncommonly noted in neonatal girls and young to middle-age female patients (Lee and Kim, 1992). Symptoms may include dysuria, dyspareunia, obstruction, and pain. **Differentiation from UD can often be made on physical examination, because these lesions are located relatively distally on the urethra, often distorting the urethral meatus, as compared with UD, which most commonly occur over the mid- and proximal urethra and do not deform the urethral meatus.** Various treatments for Skene gland abnormalities have been described, including aspiration, marsupialization, incision and drainage, and simple excision. Surgical excision is curative.

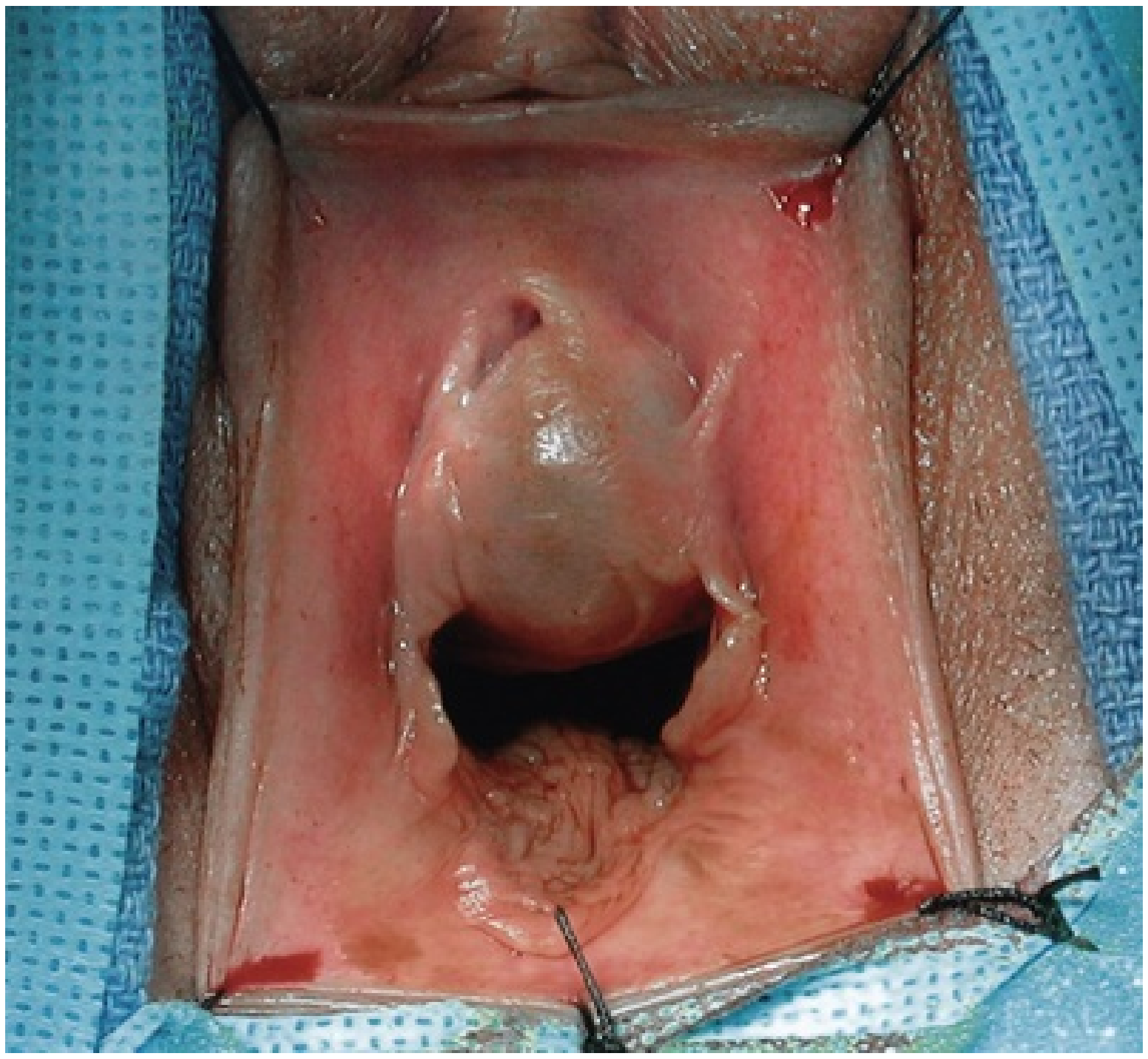

FIG. 130.25 Skene gland cyst in a 19-year-old female. Note the large periurethral mass with displacement of the urethral meatus.

Adenocarcinoma arising in Skene glands has been reported. Because of homology with the prostate, these patients may demonstrate elevated prostate-specific antigen levels that normalize with treatment (Dodson et al., 1994).

Gartner Duct Abnormalities.

Gartner duct cysts represent mesonephric remnants and are found on the anterolateral vaginal wall from the cervix to the introitus. Because these are mesonephric remnants, they may drain ectopic ureters from poorly functioning or nonfunctioning upper pole moieties in duplicated systems (Fig. 130.26). They have also been reported with single-system ectopia, although this is much less common in females (Currarino, 1982; Gadbois and Duckett, 1974). **It is not clear what proportion of patients with Gartner duct cysts will have ipsilateral renal abnormalities, but upper tract evaluation is recommended.** In contrast, approximately 6% of subjects with unilateral renal agenesis have a Gartner duct cyst (Eilber and Raz, 2003). Up to 50% of patients with Gartner duct cysts and renal dysplasia may also have ipsilateral müllerian duct obstruction (Sheih et al., 1998).

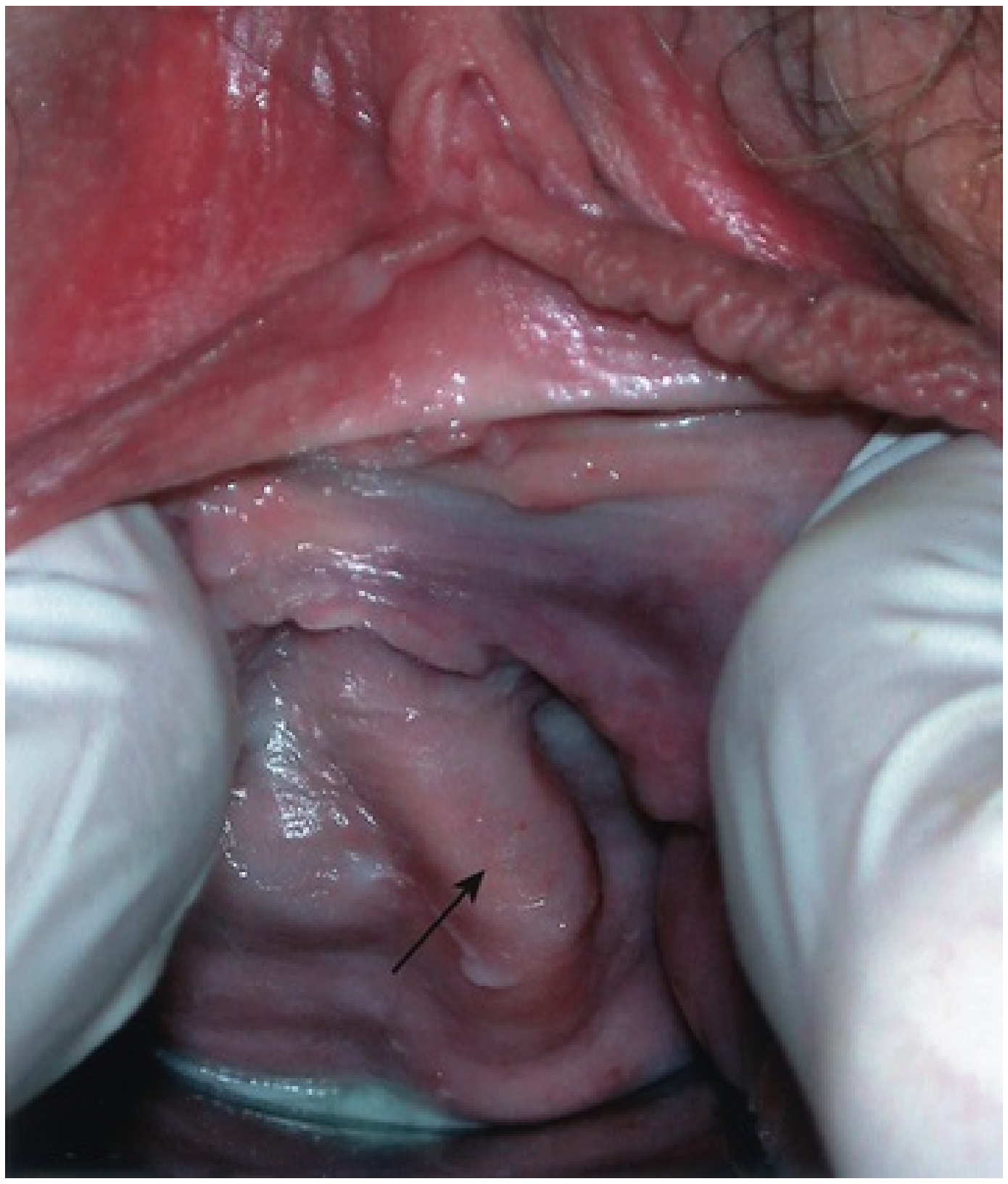

FIG. 130.26 Upper pole ectopic ureter in a 39-year-old female being evaluated for lifelong urinary incontinence and recurrent pyelonephritis. A tubelike structure *(arrow)* representing the turgid, debris-filled ectopic ureter is seen on the anterior vaginal wall.

Treatment depends on symptoms and association with ectopic ureters. If the lesions are asymptomatic and are associated with a nonfunctioning renal moiety, they can be observed. Aspiration followed by sclerotherapy has been successful (Abd-Rabbo and Atta, 1991). Simple excision or marsupialization has also been recommended for symptomatic lesions. If the cyst is associated with a functioning renal moiety, treatment must be individualized.

Vaginal Wall Cysts.

Vaginal wall cysts usually occur as small asymptomatic masses on the anterior vaginal wall (Deppisch, 1975) but may enlarge to cause lower urinary tract symptoms or dyspareunia (Fig. 130.27). They may arise from multiple cell types: mesonephric (Gartner duct cysts), paramesonephric (müllerian), endometriotic, urothelial, or epidermoid (inclusion cyst). A specific diagnosis cannot be reliably made until the specimen is removed and examined by a pathologist. The histologic subtype is usually of little consequence, although epidermoid cysts are usually associated with previous trauma or vaginal surgery. Pradhan and Tobon described the pathological characteristics of 43 vaginal cysts removed over a 10-year period from 41 women (Pradhan and Tobon, 1986). The derivation of the cyst was müllerian in 44%, epidermoid in 23%, and mesonephric in 11%. The remainder were a Bartholin gland type, endometriotic, and indeterminate. As with other periurethral masses, they must be differentiated from UD. Treatment is usually by simple excision in symptomatic patients.

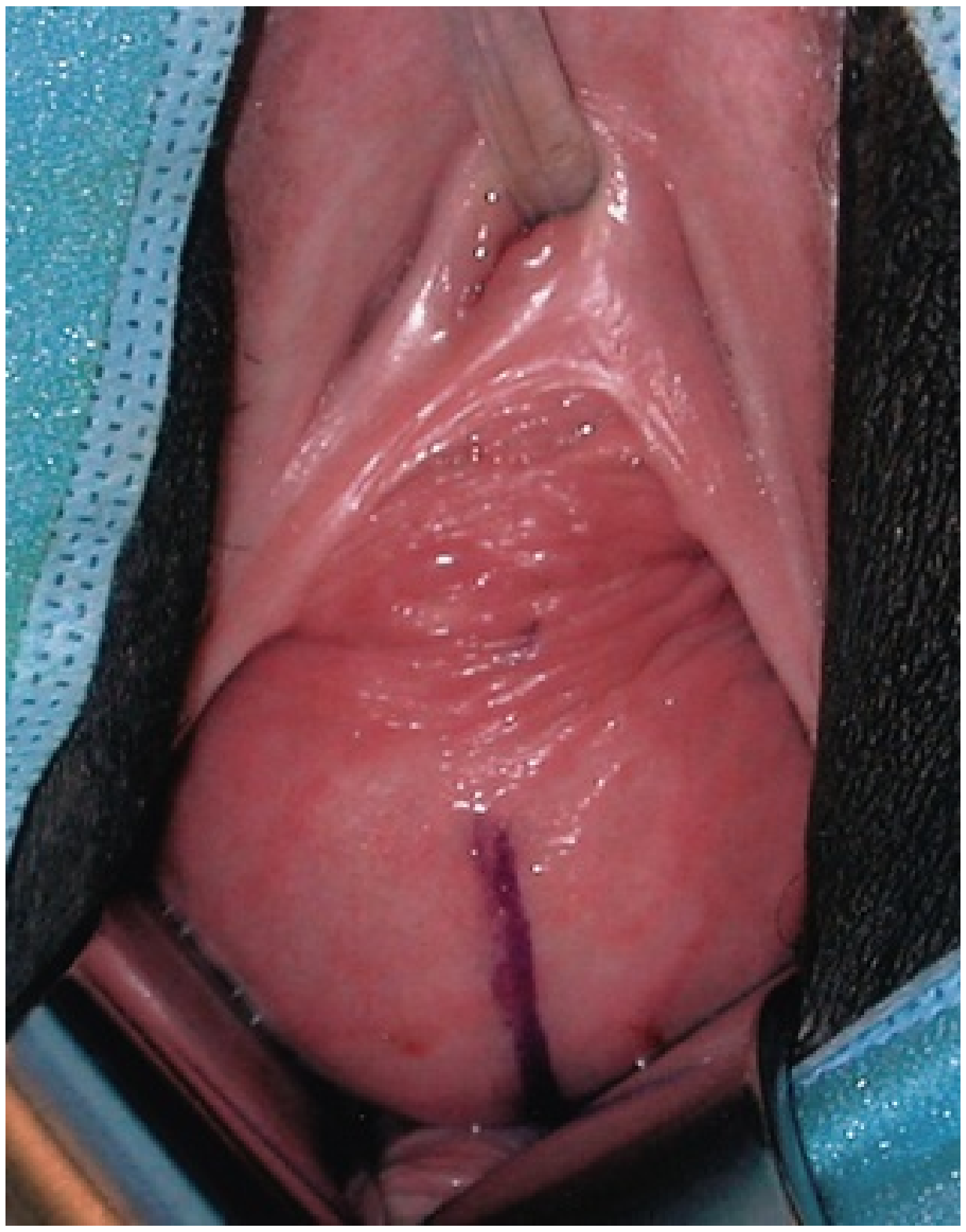

FIG. 130.27 Anterior vaginal wall cyst before planned excision. This mass was misdiagnosed as a cystocele and followed for many years in this patient with considerable lower urinary tract symptoms. A midline incision has been marked out before operative repair.

Urethral Mucosal Prolapse.

Urethral prolapse is seen as a circumferential herniation or eversion of the urethral mucosa at the urethral meatus. The prolapsed mucosa commonly appears as a beefy red, doughnut-shaped lesion that completely surrounds the urethral meatus. It may be asymptomatic or occur with bleeding, spotting, pain, or urinary symptoms. **It is commonly noted in two separate populations:**

postmenopausal women and prepubertal girls. Although thought to be more common in young African-American girls, more recent series do not confirm this predilection (Fernandes et al., 1993; Rudin et al., 1997). In children, it is often causally related to Valsalva voiding or constipation. Eversion of the mucosa may then occur as a result of a pathologically loose attachment between smooth muscle layers of the urethra (Lowe et al., 1986). Cause is much less clear for postmenopausal women, although it has been epidemiologically linked to estrogen deficiency. Treatment may be medical or surgical. **Medical treatment involves topical creams (estrogen, anti-inflammatory) and/or sitz baths. Various surgical techniques have been described, including cauterization, ligation around a Foley catheter, and complete circumferential excision.** Circumferential excision with suture reapproximation of the remaining urethral mucosa to the vaginal wall can be performed with few complications. Rudin et al. (1997) reported outcomes in 58 girls with urethral prolapse. Medical treatment was initially successful in 20 patients among whom there were 5 recurrences. The remaining 38 patients failed initial conservative management and underwent surgical excision with 4 complications, including urethral stenosis in 2 patients. Jerkins et al. (1984) found superior results in surgically treated patients when compared with medical management or catheter ligation.

Urethral Caruncle.

Urethral caruncle is an inflammatory lesion of the distal urethra that is most commonly diagnosed in postmenopausal women. It usually appears as a reddish exophytic mass at the urethral meatus, which is covered with mucosa. These lesions are often symptomatic and noted incidentally on gynecologic examination. When irritated, they may cause underwear spotting or become painful. Less commonly they may cause voiding symptoms. Rarely, these lesions may thrombose, resulting in a discolored periurethral mass (Fig. 130.28). **Etiologically, they are related to mucosal prolapse.** Chronic irritation contributes to hemorrhage, necrosis, and inflammatory growth of the tissue that corresponds to the histology of excised lesions. If the lesion is atypical in appearance or behavior, excision may be warranted to exclude other entities. Intestinal metaplasia, tuberculosis, melanoma, and lymphoma have been reported to either coexist with or mimic urethral caruncles (Atalay et al., 1998; Indudhara et al., 1992; Khatib et al., 1993; Lopez et al., 1993; Willett and Lack, 1990).

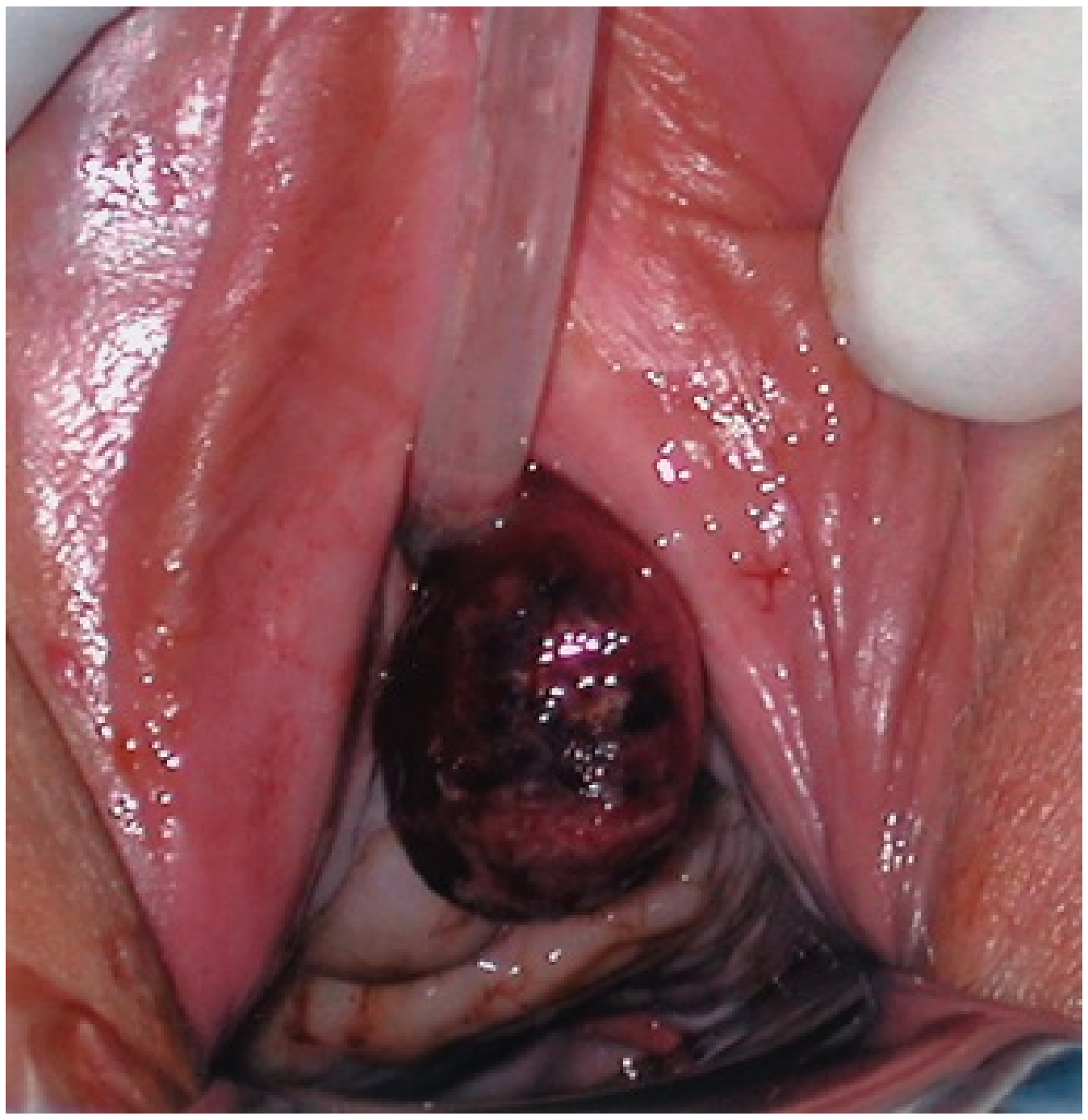

FIG. 130.28 Thrombosed urethral caruncle in a postmenopausal female. The Foley catheter is seen in the urethra. Simple excision was curative.

There is a paucity of literature regarding optimal treatment of urethral caruncle. Most authors recommend initial conservative management with topical estrogen or anti-inflammatory creams and sitz baths. Large or refractory lesions may be managed with simple excision. The tip of the lesions should be grasped and traction employed to fully expose the base of the caruncle. The lesion can then easily be excised. If a large defect remains, the mucosa may be reapproximated with absorbable suture. In most instances, the urethral mucosa will heal around a Foley catheter, which may be left in place for several days.

Periurethral Bulking Agents.

The transurethral or periurethral injection of bulking agents for the treatment of stress incontinence may result in an anterior vaginal wall mass that appears cystic on imaging, consistent with a UD (Bridges et al., 2005; Castillo-Vico et al., 2007; Clemens and Bushman, 2001). These radiographic lesions are often misdiagnosed as such (Gaines et al., 2017). A careful history will elicit this possibility. Typically, these lesions do not communicate with the urethra and are largely asymptomatic. Symptomatic lesions may be surgically excised transvaginally (Kumar et al., 2011).

Classification of Urethral Diverticula

Although not yet widely adopted, a classification system for UD has been proposed by Leach et al. (1993).This staging system for UD, termed the *L/N/S/C3 classification system*, is similar to that used for cancer staging and is based on several characteristics of UD, including location, number, size, anatomic configuration, site of communication to the urethral lumen, and continence status of the patient. This system attempts to standardize description of UD, but currently it has not been prospectively applied or validated by other authors. Another proposed classification scheme uses the location of the UD as the primary determinant of surgical approach, with distal lesions undergoing marsupialization and more proximal lesions undergoing excision and reconstruction (Ginsburg and Genadry, 1983).

Finally, a classification system proposed by Leng and McGuire divides UD into two categories based on the presence or absence of a preserved periurethral fascial layer (Leng and McGuire, 1998). In some patients with UD who have undergone prior vaginal or urethral surgery, the periurethral fascial layer may be deficient, resulting in a pseudodiverticulum. These authors suggest that the recognition of this anatomic configuration has important implications for surgical reconstruction. These patients may require additional reconstruction or interposition of a tissue flap or graft for reconstruction.

Key Points: Female Urethral Diverticula: Diagnosis

- Female UD are often diagnosed in the evaluation of nonspecific lower urinary tract symptoms, including dysuria, pelvic pain, vaginal mass, dyspareunia, and recurrent UTIs.
- Multiple imaging modalities may be used in the diagnosis and evaluation of female UD, including PPU, VCUG, ultrasonography, and MRI; each of these techniques has inherent advantages and disadvantages.
- The differential diagnosis of periurethral vaginal masses is extensive. A careful history, physical examination, and appropriate diagnostic studies are usually adequate to provide a definitive preoperative diagnosis.

Surgical Repair of Female Urethral Diverticula

Indications for Repair

Although often highly symptomatic, not all UD mandate surgical excision. Some patients may be asymptomatic at presentation, with the lesion incidentally diagnosed on imaging for another condition or, perhaps, incidentally noted on routine physical examination. Other patients may be unwilling or medically unable to undergo surgical removal. **Very little is known regarding the natural history of untreated UD. Whether these lesions will progress in size, symptomatology, or complexity with time is unknown.** For these reasons, lack of symptoms in selected cases, and the risks of surgical intervention including de novo urinary incontinence, urethral stricture, and vaginal scarring, some patients may not desire surgical excision. However, **there are multiple reports in the literature of carcinomas arising in UD** (Gonzalez et al., 1985; Hickey et al., 2000; Marshall and Hirsch, 1977; Patanaphan et al., 1983; Prudente de Toledo et al., 1978; Rajan et al., 1993; Seballos and Rich, 1995; Tesluk, 1981; Thomas and Maguire, 1991; Tines et al., 1982). It is possible that certain carcinomas arising in UD are asymptomatic and may not be initially or prospectively identified on radiologic imaging (Chung et al., 2010). **Thus patient counseling is necessary with patients who elect primary nonoperative management.** Patients electing nonoperative management can be treated with low-dose antibacterial suppressants and digital stripping of the anterior vaginal wall after micturition to prevent postvoid dribbling and reduce the risk of UTI resulting from stasis in the UD. Whether long-term surveillance for the development of cancer is required in these patients, with periodic physical examinations, radiographic imaging, or endoscopic examination, is unknown.

Symptomatic patients, including those with dysuria, refractory bothersome postvoid dribbling, recurrent UTIs, dyspareunia, and pelvic pain, may be offered surgical excision.

Urethral Diverticula and Stress Urinary Incontinence

As noted previously SUI may co-exist with UD. In addition, significant de novo SUI may occur in between 7% and 16% of individuals undergoing urethral diverticulectomy surgery without a concomitant anti-incontinence surgery (Han et al., 2007; Ljungqvist et al., 2007; Reeves et al., 2014; Stav et al., 2008). Lee et al. (2008) noted at least minor de novo SUI in 49% of patients after urethral diverticulectomy, the majority of which was minor and did not require additional therapy. In this series, only 10% of affected individuals underwent a subsequent SUI operation (Lee et al., 2008). Risk factors for de novo SUI may include the size of the diverticulum (>30 mm), more proximal location (Kim et al., 2013; Stav et al., 2008), as well as circumferential configuration (Malde et al., 2017). Furthermore, in a retrospective review of MRI findings, Malde et al. (2017) suggest that a complex circumferential UD configuration is associated with a greater risk of postoperative SUI (20%) as compared with a simple UD (0) in the absence of a concomitant anti-incontinence procedure, but this has not been consistently found in the literature (Nickles et al., 2014). However, it is not universally agreed that all UD patients should undergo simultaneous SUI surgery. The additional operative time and expense, as well as the potential morbidity of concomitant SUI surgery, should be balanced against the convenience of performing both surgeries synchronously. **Nevertheless, for patients undergoing surgery for UD who have coexistent symptomatic bothersome SUI, a concomitant anti-incontinence surgery can be offered** (Fig. 130.29). Multiple authors have described successful repair of UD and stress incontinence in the same operative setting (Bass and Leach, 1991; Faerber, 1998; Ganabathi et al., 1994; Lockhart et al., 1990; Swierzewski and McGuire, 1993). Patients without SUI or who have mild non-bothersome SUI can be counseled that it is reasonable to perform urethral diverticulectomy surgery alone, and then re-evaluate later for the development of bothersome postoperative SUI after recovery from the UD surgery (Greiman et al., 2018).

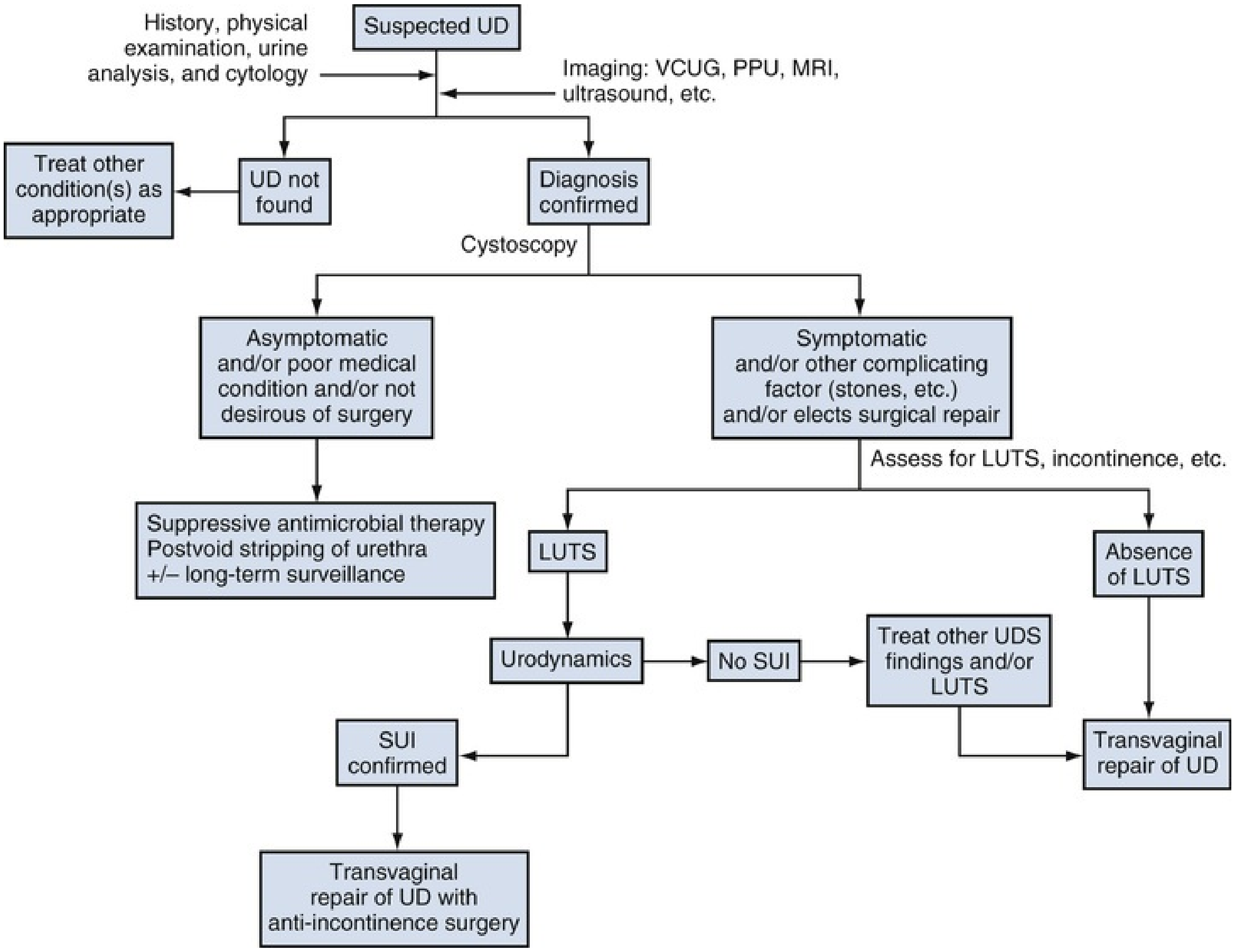
History, physical examination, urine analysis, and cytology
Suspected UD
Imaging: VCUG, PPU, MRI, ultrasound, etc.
Treat other condition(s) as appropriate
UD not found
Diagnosis confirmed
Cystoscopy
Asymptomatic and/or poor medical condition and/or not desirous of surgery
Symptomatic and/or other complicating factor (stones, etc.) and/or elects surgical repair
Assess for LUTS, incontinence, etc.
Suppressive antimicrobial therapy
Postvoid stripping of urethra
+/– long-term surveillance
LUTS
Absence of LUTS
Urodynamics
No SUI
Treat other UDS findings and/or LUTS
SUI confirmed
Transvaginal repair of UD
Transvaginal repair of UD with anti-incontinence surgery

FIG. 130.29 Algorithm for treatment of urethral diverticula. *LUTS,* Lower urinary tract symptoms; *MRI,* magnetic resonance imaging; *PPU,* positive-pressure urethrography; *SUI,* stress urinary incontinence; *UD,* urethral diverticulum; *UDS,* urodynamics; *VCUG,* voiding cystourethrography.

Synthetic materials (e.g., mid-urethral polypropylene mesh) should not be used in an anti-incontinence procedure synchronously with UD surgery because of the potentially increased risk of urethral erosion and infection (Dmochowski et al., 2010). Whether such material can be safely used months or years after successful UD surgery in patients with de novo or persistent SUI is unknown. Contemporary series have demonstrated that autologous pubovaginal fascial slings provide satisfactory outcomes as a concomitant procedure at the time of UD excision (Enemchukwu et al., 2015; Faerber, 1998; Romanzi et al., 2000; Swierzewski and McGuire, 1993).

Techniques for Repair

Alternative Techniques.

A variety of surgical interventions for UD have been reported since 1805 when Hey described transvaginal incision of the UD and packing the resulting cavity with lint. Approaches have included transurethral (Davis et al., 1970) and open (Roehrborn, 1988; Spence and Duckett, 1970) marsupialization, endoscopic unroofing (Lapides, 1978; Spencer and Streem, 1987), fulguration (Saito, 2000), incision and obliteration with oxidized cellulose (Ellick, 1957) or polytetrafluoroethylene (Mizrahi and Bitterman, 1988), coagulation (Mizrahi and Bitterman, 1988), and excision with reconstruction. **Most commonly, a complete excision and reconstruction is performed as described later.** However, for distal lesions, a transvaginal marsupialization as described by Spence and Duckett may reduce operative time, blood loss, and recurrence rate (Roehrborn, 1988; Spence and Duckett, 1969, 1970). **During this procedure, care must be taken to avoid aggressively extending the incision proximally, which could result in vaginal voiding or potentially damage the proximal and distal sphincteric mechanism, resulting in SUI.** Another potentially significant complication with the Spence-Duckett procedure is that, in sexually active women, a pseudoseptum may be created by the marsupialization of the urethra with respect to the anterior vaginal wall, which may result in dyspareunia. Therefore this approach is probably only applicable to UD in very select cases involving the distal one-third of the urethra in patients who are not sexually active. It is not commonly performed.

Excision and Reconstruction.

Excision and reconstruction is probably the most common surgical approach to UD in the modern era. The principles of the urethral diverticulectomy operation have been well described (Box 130.2). There are only a few minor issues about which some surgeons may disagree, including the type of vaginal incision (midline vs. inverted “U” vs. inverted “T”), whether it is necessary to remove the entire mucosalized portion of the lesion, and, finally, the optimal type of postoperative catheter drainage (urethra only vs. urethra and suprapubic tube).

Box 130.2

Principles of Transvaginal Urethral Diverticulectomy

Mobilization of a well-vascularized anterior vaginal wall flap(s)
Preservation of the periurethral fascia as a separate layer
Identification and excision of the neck or ostium of the UD
Removal of entire UD wall or sac (epithelium)
Watertight urethral closure
Multilayered, nonoverlapping closure with absorbable suture
Closure of dead space
Preservation or creation of continence

UD, Urethral diverticulum.

Complex urethral reconstructive techniques for the repair of UD have been described. Fall (1995) described the use of a bipedicled vaginal wall flap for urethral reconstruction in patients with UD and urethrovaginal fistula. Laterally based vaginal flaps have also been used as an initial approach to UD (Appell et al., 1982; Woodhouse et al., 1980). Complex anatomic configurations may exist, and many novel approaches have been described for complicated anteriorly located or circumferential lesions (Clyne and Flood, 2002; Rovner and Wein, 2003; Vakili et al., 2003). Recently, a laparoscopic/robotic approach to an anterior urethral diverticulum has been described (Sivarajan et al., 2015).

The technique described herein is similar to that described by Leach et al. (1986), based on earlier work by Benjamin et al. (1974) and Busch and Carter (1973). A systematic review of surgical techniques for treating UD in 1947 patients determined that the literature lacks sufficient data to describe differences in outcomes and complications among the surgical techniques (Bodner-Adler et al., 2016). A systematic review of surgical techniques for treating urethral diverticula in 1947 patients determined that the literature lacks sufficient data to describe differences in outcomes and complications among the surgical techniques (Bodner-Adler et al., 2016).

Preoperative Preparation.

The urine should be sterile preoperatively. Surgery should not proceed in the setting of an acute UTI. Prophylactic antibiotics are often used preoperatively to ensure sterile urine at the time of surgery. Patients can also be encouraged to strip the anterior vaginal wall after voiding, thereby consistently emptying the UD and preventing urinary stasis and recurrent UTIs. This may not be possible in those with noncommunicating UD or in those who have significant pain related to the UD. **In some patients with postmenopausal atrophic vaginitis, application of topical estrogen creams for several weeks before surgery may be beneficial in improving the overall quality of the tissues with respect to planned operative dissection and mobilization. Preoperative parenteral antibiotics are administered especially for those with recurrent or persistent UTIs.**

Urethral diverticulectomy surgery is complex and sometimes technically challenging. Further complicating these cases are the associated preoperative symptoms such as pain, dyspareunia, voiding dysfunction, UTIs, and urinary incontinence. These associated symptoms are often, but not always, improved or eliminated with surgical repair despite a technically successful surgery. Therefore the importance of appropriate preoperative patient counseling regarding surgery and postoperative expectations of cure cannot be overemphasized.

As noted previously, patients with symptomatic SUI can be offered simultaneous anti-incontinence surgery. Preoperative video-urodynamics may be helpful in evaluating the anatomy of the UD, assessing the competence of the bladder neck, and confirming the diagnosis of SUI. Video-urodynamics can often accurately differentiate and characterize true SUI from postvoid dribbling, vaginal voiding, and false incontinence resulting from urine discharge from a urine-filled UD.

Procedure.

The patient is placed in the lithotomy position with all pressure points well padded. The use of padded adjustable stirrups for the lower extremities greatly enhances operative access to the female perineum. A standard vaginal antiseptic preparation is applied. A weighted vaginal speculum and Scott retractor with hooks aid in exposure. **A posterolateral episiotomy may be beneficial in some patients for additional exposure, although the mid-urethral (and therefore somewhat distal in the vaginal canal) location of most UD usually precludes the need for this type of adjunctive procedure.** A Foley catheter is placed per urethra. If desired, a suprapubic tube is placed at the start of the procedure, either using the Lowsley retractor or proceeding percutaneously under direct transurethral cystoscopic visual guidance. Placement of the suprapubic tube at the end of the case is not advisable because this will require traversing the fresh urethral suture line and risk disruption of the repair.

An inverted U is marked along the anterior vaginal wall with the base of the U at the level of the distal urethra and the limbs extending to the bladder neck or beyond (Fig. 130.30A). Care is taken to ensure that the limbs of the U are progressively wider proximally (toward the bladder neck) to ensure adequate vascularity at the distal lateral margins of the anterior vaginal wall flap. Compared with the inverted T incision, the inverted U incision provides excellent exposure laterally at the level of the mid-vagina and can be extended proximally as needed for lesions that extend beyond the bladder neck. Injectable saline can be infused along the lines of the incision to facilitate dissection. An anterior vaginal wall flap is created by careful dissection in the potential space between the vaginal wall and the periurethral fascia. **The use of sufficient countertraction during this portion of the procedure is important in maintaining the proper plane of dissection. Care is taken to preserve the periurethral fascia and avoid inadvertent entry into the UD.**

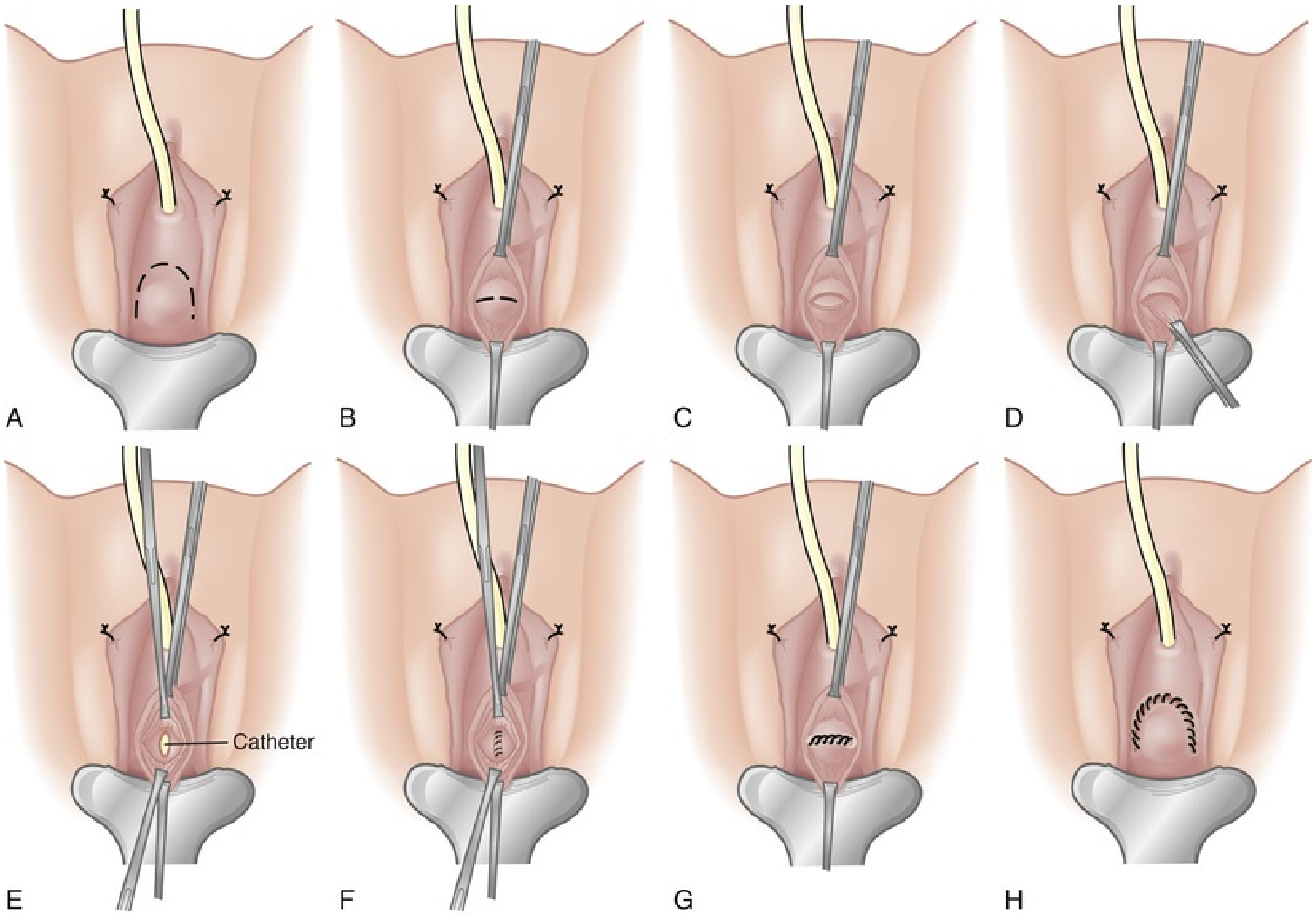

FIG. 130.30 (A) An inverted U incision is marked on the anterior vaginal wall. Retraction is aided by the use of Allis clamps and a ring retractor with hooks. (B) After reflection of the anterior vaginal wall, a transverse incision is made in the periurethral fascia. The *dotted line* represents the intended incision line. (C) The periurethral fascia is incised and dissected from the underlying urethral diverticulum. (D) The diverticular sac is freed from the

periurethral fascia. (E) The urethral catheter is seen after complete excision of the diverticular sac. (F) The urethra is closed with absorbable suture. (G) The periurethral fascia is closed with care to obliterate any dead space. (H) The anterior vaginal wall flap is advanced over the periurethral suture line and secured with running interlocking absorbable suture.

A distinct layer of periurethral fascia is usually interposed between the vaginal wall and the UD. Preservation and later reconstruction of this layer is paramount to prevent recurrence, close dead space, and avoid urethrovaginal fistula formation postoperatively. Pseudodiverticula have been described wherein this layer of tissue is considerably attenuated or even absent (Leng and McGuire, 1998). In these patients, an interpositional Martius flap or a graft such as a pubovaginal fascial sling may be used for reconstruction.

The periurethral fascia is incised transversely (Fig. 130.30B). Proximal and distal layers of periurethral fascia are carefully developed, avoiding entrance into the UD. The UD is then grasped and dissected back to its origin on the urethra within the leaves of the periurethral fascia (Fig. 130.30C). In many cases, it is necessary to open the UD to facilitate dissection from the surrounding tissues. The ostium or connection to the urethra is identified and the walls of the UD are completely removed. Every effort should be made to remove the entire mucosalized surface of the UD to prevent recurrence (Fortunato et al., 2001; Ganabathi et al., 1994). This may involve removing small adherent or inflamed portions of the urethral wall, especially in the area of the ostium (Fig. 130.30D). All abnormal tissue in the area of the ostium should be removed, if possible, to ensure that no mucosal elements of the UD wall remain, which could result in postoperative urine leakage and recurrence. Elaborate methods of identifying the full extent of the UD cavity have been described, including catheterization of the UD with urinary (Kohorn and Glickman, 1992; Moore, 1952) and Fogarty (Wear, 1976) catheters, packing the UD with gauze (Hyams and Hyams, 1939), infusing and staining the UD with methylene blue (Gilbert and Rivera Cintron, 1954), and the use of silicone (Hirschhorn, 1964) or cryoprecipitate (Feldstein, 1981) to create a solid mass and ease dissection. However, these measures are mostly of historical interest only and are usually not necessary in modern UD surgery (Ganabathi et al., 1994; Leach and Bavendam, 1987).

The Foley catheter is often seen transvaginally through the operative site after complete excision of UD (Fig. 130.30E). The urethra can be reconstructed over as small as a 12-Fr Foley catheter without long-term risk of urethral stricture (Young and Wahle, 1996) and should be closed in a watertight fashion with absorbable suture (Fig. 130.30F). The closure should be tension free. Uncommonly, a UD may extend circumferentially around the urethra and require segmental resection of the involved portion of the urethra and complex reconstruction (Rovner and Wein, 2003; Tamada et al., 2000).

The periurethral fascial flaps are reapproximated with absorbable suture in a perpendicular orientation to the urethral closure line to minimize overlap and the risk of postoperative urethrovaginal fistula formation (Fig. 130.30G). Care is taken to secure the periurethral fascial flaps so that all dead space is closed.

If desired, a fibrofatty labial (Martius) flap can be harvested at this point and placed over the periurethral fascia as an additional layer of closure (Dmochowski, 2001). **Indications for such a flap are not universally agreed upon. However, in those patients with poor-quality tissues, with attenuated periurethral fascia, or in whom significant inflammation is encountered intraoperatively, a well-vascularized adjuvant flap (e.g., Martius flap) may reduce the risk of wound breakdown and subsequent complications such as urethrovaginal fistula.** Malde et al. (2017a,b) report a low rate of complication for Martius flap (<2%) with good cosmetic results.

The anterior vaginal wall flap is then repositioned and reapproximated with absorbable suture (Fig. 130.30H). This completes a three-layer closure (four layers if a Martius flap is used). An antibiotic-impregnated vaginal pack is placed.

For the rare anteriorly located UD without a posterior component, a suprameatal, infrapubic incision is made, and the dissection and reconstruction proceed as described earlier with the same principles including removal of the diverticulum, identification and closure of the ostia, and re-approximation of the periurethral fascia.

Postoperative Care.

Antibiotics are continued for 24 hours postoperatively. The vaginal packing is removed and the patient discharged home with closed urinary drainage. Antispasmodics are used liberally to reduce bladder spasms. A pericatheter VCUG is obtained at 14 to 21 days postoperatively. If there is no extravasation, the catheters are removed. If extravasation is seen, then repeat pericatheter VCUGs are performed weekly until resolution is noted. In the vast majority of cases, extravasation will resolve in several weeks with this type of conservative management (Schwab and Rovner, 2003).

Complications.

Careful adherence to the principles of transvaginal urethral diverticulectomy should minimize postoperative complications. Nevertheless, complications may arise (Table 130.2). Raup et al. (2015) described 30-day complications of diverticulectomy in the multi-institutional cohort derived from the National Surgical Quality Improvement Program user files. They found that out of 2.3 million cases in the database, there were 122 female urethral diverticulectomy cases reported between 2007 and 2012. Minor complications occurred in 3.3% of cases, with urinary tract infection being most common (4 patients), and one each of superficial wound infection and hemorrhage requiring transfusion (Raup et al., 2015).

TABLE 130.2

Complications of Transvaginal Urethral Diverticulectomy

COMPLICATION	RANGE OF REPORTED INCIDENCE
Urinary incontinence	1.7%–16.1%
Urethrovaginal fistula	0.9%–8.3%
Urethral stricture	0–5.2%
Recurrent urethral diverticula	10%–22%
Recurrent urinary tract infection	0–31.3%
Other:	
Hypospadias/distal urethral necrosis	Not available
Bladder or ureteral injury	Not available
Vaginal scarring or narrowing: dyspareunia, etc.	Not available

Modified from Dmochowski R: Surgery for vesicovaginal fistula, urethrovaginal fistula, and urethral diverticulum. In Walsh PC, Retik AB, Vaughan ED Jr, et al., editors: *Campbell's urology*, ed 8, Philadelphia, 2002, Saunders.

Overall, common complications include recurrent UTIs, urinary incontinence, or recurrent UD. Urethrovaginal fistula is an uncommon but distressing complication of urethral diverticulectomy and deserves special mention. A urethrovaginal fistula located beyond the sphincteric mechanism should not be associated with symptoms other than perhaps a split urinary stream and/or vaginal voiding. Therefore an asymptomatic distal urethrovaginal fistula may not require repair, although some patients may request repair. Conversely, a proximal fistula located at the bladder neck or at the mid-urethra in patients with an incompetent bladder neck will likely result in considerable symptomatic urinary leakage. These patients should undergo repair with consideration for the use of an adjuvant tissue flap, such as a Martius flap, to provide a well-vascularized additional tissue layer if needed. The actual timing of the repair relative to the initial procedure is controversial. Meticulous attention to surgical technique, good hemostasis, avoidance of infection, preservation of the periurethral fascia (Fig. 130.31), a well-vascularized anterior vaginal wall flap, and a multilayered closure with nonoverlapping suture lines should minimize the potential for postoperative urethrovaginal fistula formation.

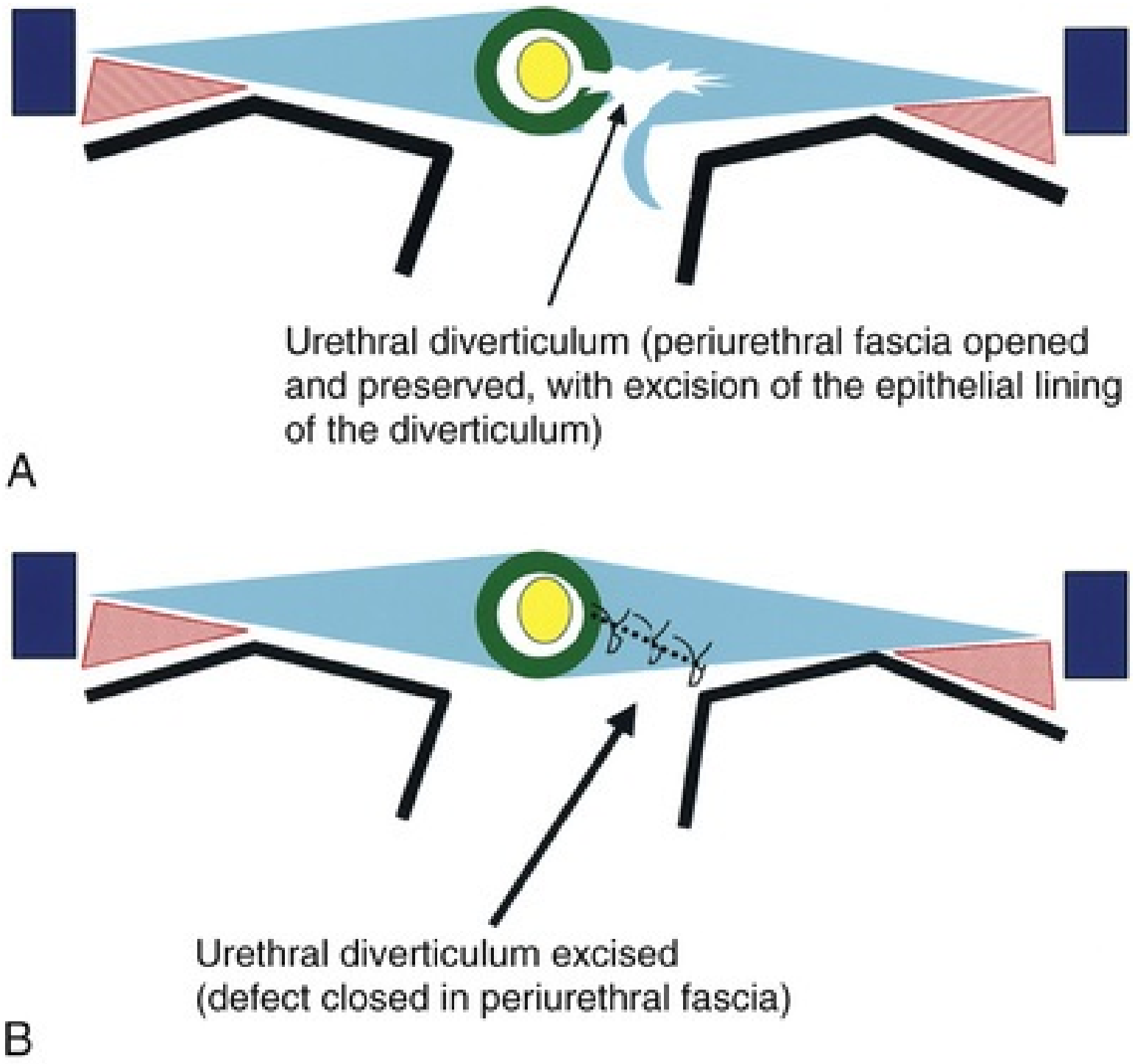
Urethral diverticulum (periurethral fascia opened and preserved, with excision of the epithelial lining of the diverticulum)
A
Urethral diverticulum excised (defect closed in periurethral fascia)
B

FIG. 130.31 Diagrams demonstrating the importance of preserving and reconstructing the periurethral fascia. (A) The periurethral fascia has been opened and the urethral diverticulum has been excised. (B) The periurethral fascia has been closed.

One small series suggested that large diverticula (>4 cm) or those associated with a lateral or horseshoe configuration may be associated with a greater likelihood of postoperative complications (Porpiglia et al., 2002), whereas other series (Nickles et al., 2014) show similar complication rates, except for increased rate of UTI after repair of complex diverticula as compared with simple diverticula.

Persistence or Recurrence of Symptoms After Urethral Diverticulectomy.

Although complete resolution of obstructive and irritative urinary symptoms after UD excision may occur, some patients have persistence or recurrence of their preoperative symptoms postoperatively (Bodner-Adler et al., 2016; Stav et al., 2008). These symptoms may be a result of surgery, and if so, may resolve over time. Such symptoms should be carefully investigated, because they could result from a recurrent UD, a new UD, or urethral stricture among other possibilities.

Lack of resolution of some or all symptoms after UD surgery may occur in a substantial number of patients regardless of anatomic complexity of the UD, surgical approach, or technically successful excision (Nickles et al., 2014). One series suggests that excision of recurrent UD are associated with less likelihood of resolution of preoperative symptoms (Ljungqvist et al., 2007).

The finding of a UD after a presumably successful urethral diverticulectomy may occur as a result of a new UD, or, alternatively, as a result of recurrence of the original lesion. Recurrence of UD may be due to incomplete removal of the UD, inadequate closure of the urethra or residual dead space, or other technical factors. The risk of long-term recurrence is approximately 10% to 22% (Han et al., 2007; Ingber et al., 2011; Ko et al., 2017; Lee, 1983; Ljungqvist et al., 2007; Popat and Zimmern, 2016; Zhou et al., 2017). Lee noted recurrent UD in 8 of 85 patients at follow-up of 2 to 15 years from the initial UD resection (Lee, 1983), whereas Ljungqvist et al. (2007) reported recurrence in 11 of 68 patients during a 26-year follow-up. The risk of recurrence of UD after transvaginal excision may be related to the complexity of the anatomic configuration and location. Han et al. (2007) reported no recurrent UD in 17 patients with simple UD, but of the 10 patients with circumferential UD, recurrence was noted in 6 (60%). Notably in this series, secondary procedures were not as successful in completely removing the UD (Han et al., 2007). Ockrim et al. (2009) similarly cured all 19 patients with simple UD on the first attempt, but the 11 patients with complex anatomic configurations required a total of 17 procedures for success. Popat and Zimmern (2016) reported a series of 12 patients with horseshoe diverticula with recurrence in 1 patient with a mean follow-up of 52 months. Ko et al. (2017) reported a series of 68 patients with a recurrence rate of 22% for primary urethral diverticulectomy, and multivariate analysis showed that circumferential configuration was independently associated with recurrence. Proximal location and multiple UD at presentation are also potential risk factors for recurrence

(Ingber et al., 2011). In a meta-analysis of contemporary series, Cameron (2015) reported the rate of diverticulum recurrence after surgical repair to be 9.8%. **Repeat urethral diverticulectomy surgery can be challenging because of altered anatomy, scarring, and the difficulty in identifying the proper anatomic planes.** Complications such as fistula and recurrence of the UD are more common in reoperative cases (Ljungqvist et al., 2007; Zhou et al., 2017).

Key Points: Female Urethral Diverticula: Management

- Concomitant urinary incontinence symptoms should be thoroughly investigated preoperatively, and strong consideration should be given to surgical treatment of bothersome SUI at the time of urethral diverticulectomy.
- Transvaginal excision and urethral reconstruction is the most common approach to the treatment of UD in the female patient.

Suggested Readings

Bladder Diverticula

Bauer SB, Retik AB. Bladder diverticula in infants and children. *Urology*. 1974;3:712–715.

Garzotto MG, Tewari A, Wajsman Z. Multimodal therapy for neoplasms arising from a vesical diverticulum. *J Surg Oncol*. 1996;62:46–48.

Gil-Vernet JM. Bladder diverticulectomy. Graham SD Jr. *Glenn's urologic surgery*. 5th ed. Lippincott-Raven: Philadelphia; 1998:205–209.

Urethral Diverticula

Eilber KS, Raz S. Benign cystic lesions of the vagina: a literature review. *J Urol*. 2003;170:717–722.

Lee RA. Diverticulum of the urethra: clinical presentation, diagnosis, and management. *Clin Obstet Gynecol*. 1984;27:490–498.

Patel AK, Chapple CR. Female urethral diverticula. *Curr Opin Urol*. 2006;16:248–254.

Scarpero HM, Dmochowski RR, Leu PB. Female urethral diverticula. *Urol Clin North Am*. 2011;38:65–71.

References

Abd-Rabbo MS, Atta MA. Aspiration and tetracycline sclerotherapy: a novel method for management of vaginal and vulval Gartner cysts. *Int J Gynaecol Obstet*. 1991;35:235–237.

Adachi M, Nakada T, Suzuki H, et al. Successful repair of huge bladder diverticulum with a transurethral fulguration. Report of a case. *Urol Int*. 1991;46:87–89.

Adachi M, Nakada T, Yamaguchi T, et al. Transurethral treatment of bladder diverticula. *Eur Urol*. 1991;19:104–108 [(online journal)] http://www.ncbi.nlm.nih.gov/pubmed/1902416.

Adot Zurbano JM, Salinas Casado J, Dambros M. [Urodynamics of the bladder diverticulum in the adult male]. *Arch Esp Urol*. 2005;58:641–649.

Afshar K, Malek R, Bakhshi M, et al. Should the presence of congenital para-ureteral diverticulum affect the management of vesicoureteral reflux? *J Urol*. 2005;174:1590–1593 [(online journal)] http://www.ncbi.nlm.nih.gov/pubmed/16148659.

Ahmed S, Tan HJ. Complications of transverse advancement ureteral reimplantation: diverticulum formation. *J Urol*. 1982;127:970–973.

Aldridge CW, Beaton JH, Nanzig RP. Review of office urethroscopy and cystometry. *Am Gynecol*. 1978;131:432–437.

Alexander RE, Kum JB, Idrees M. Bladder diverticulum: clinicopathologic spectrum in pediatric patients. *Pediatr Dev Pathol*. 2012;15:281–285.

Amar A. Vesicoureteral reflux associated with congenital bladder diverticulum in boys and young men. *J Urol*.

1972;107:966–968.

Andersen M. The incidence of diverticula in the female urethra. *J Urol*. 1967;98:96–98.

Appell RA, Suarez BC. Experience with a laterally based vaginal flap approach for urethral diverticulum. *J Urol*. 1982;127:677–678.

Atalay AC, Karaman MI, Basak T, et al. Non-Hodgkin's lymphoma of the female urethra presenting as a caruncle. *Int Urol Nephrol*. 1998;30:609–610 [(online journal)] http://www.ncbi.nlm.nih.gov/pubmed/9934806.

Babbitt D, Dobbs J, Boedecker R. Multiple bladder diverticula in Williams “elfin-facies” syndrome. *Pediatr Radiol*. 1979;8:29–31.

Bade J, Ypma A, van Elk P. A pelvic mass: bladder diverticulum with haemorrhage in Ehlers-Danlos patient. *Scand J Urol Nephrol*. 1994;28:319–321.

Baert L, Willemen P, Oyen R. Endovaginal sonography: new diagnostic approach for urethral diverticula. *J Urol*. 1992;147:464–466.

Baniel J, Vishna T. Primary transitional cell carcinoma in vesical diverticula. *Urology*. 1997;50:697–699.

Baradaran N, Chiles LR, Freilich DA, et al. Female urethral diverticula in the contemporary era: is the classic triad of the ‘3Ds’ still relevant? *Urology*. 2016;94:53–56 [(online journal)] http://dx.doi.org/10.1016/j.urology.2016.04.005.

Barrett DM, Malek RS, Kelalis PP. Observations on vesical diverticulum in childhood. *J Urol*. 1976;116:234–236.

Bass JS, Leach GE. Surgical treatment of concomitant urethral diverticulum and stress incontinence. *Urol Clin North Am*. 1991;18:365–373.

Bauer SB, Retik AB. Bladder diverticula in infants and children. *Urology*. 1974;3:712–715.

Beall M, Berger M. Congenital bladder diverticula in adult twins. *Urology*. 1978;11:498–499.

Bellinger MF, Gross GW, Boal DK. Bladder diverticulum associated with ureteral obstruction. *Pediatr Radiol*. 1985;15:207–228.

Benjamin J, Elliott L, Cooper JF, et al. Urethral diverticulum in adult female. Clinical aspects, operative procedure, and pathology. *Urology*. 1974;3:1–7 [(online journal)] http://www.ncbi.nlm.nih.gov/pubmed/4204835.

Bhatia NN, McCarthy TA, Ostergard DR. Urethral pressure profiles of women with urethral diverticula [Internet]. *Obstet Gynecol*. 1981;58:375–378 [(online journal)] http://journals.lww.com/greenjournal/abstract/1981/09000/ure

Blacklock AR, Geddes JR, Shaw RE. The treatment of large bladder diverticula. *Br J Urol*. 1983;55:17–20.

Blacklock AR, Shaw RE, Geddes JR. Late presentation of ectopic ureter. *Br J Urol*. 1982;54:106–110.

Blaivas JG, Flisser AJ, Bleustein CB. Periurethral masses: etiology and diagnosis in a large series of women. *Obs Gynecol*. 2004;103:842–847.

Blander D, Rovner E, Schnall M. Endoluminal magnetic resonance imaging in the evaluation of urethral diverticula in women. *Urology*. 2001;57:660–665.

Blane CE, Zerin JM, Bloom DA. Bladder diverticula in children. *Radiology*. 1994;190:695–697.

Blane CE, Zerin JM, Bloom DA, et al. Bladder diverticula in children. *Pediatr Radiol*. 1994;190:695–697.

Bodner-Adler B, Halpern K, Hanzal E. Surgical management of urethral diverticula in women: a systematic review. *Int Urogynecol J*. 2016;27:993–1001 [(online journal)] http://dx.doi.org/10.1007/s00192-015-2862-y.

Boechat MI, Lebowitz RL. Diverticula of the bladder in children. *Pediatr Radiol*. 1978;7:22–28.

Bolton DM, Joyce G. Vesical diverticulum extending into an inguinal hernia. *Br J Urol*. 1994;73:323–324.

Bourgi A, Ayoub E, Merhej S. Diverticulectomy in the management of intradiverticular bladder tumors: a twelve-year experience at a single institution. *Adv Urol*. 2016;2016.

Boyd SD, Raz S. Ectopic ureter presenting in midline urethral diverticulum. *Urology*. 1993;41:571–574.

Bradley CS, Rovner ES. Urodynamically defined stress urinary incontinence and bladder outlet obstruction can coexist in women. *J Urol*. 2004;171:757–760 [NaN–1].

Breivik N, Refsum SJ, Oppedal B. Ehlers-Danlos syndrome and diverticula of the bladder. *Z Kinderchir*. 1985;40:243–246.

Bridges MD, Petrou SP, Lightner DJ. Urethral bulking agents: imaging review. *Am J Roentgenol*. 2005;185:257–264.

Bruning EJ. *Die Pathologie der weiblichen urethra und des parurethrium*. Stuttgart Enke. 1959.

Buchholz NP, Biyabani R, Talati J. Bladder diverticulum as an unusual content of a femoral hernia. *Br J Urol*. 1998;82:457–458 [(online journal)] http://www.ncbi.nlm.nih.gov/pubmed/9772895.

Burns E. Diverticula of the urinary bladder. *Ann Surg*. 1944;119:656.

Burrows LJ, Howden NLS, Meyn L, et al. Surgical procedures for urethral diverticula in women in the United States, 1979-1997. *Int Urogynecol J Pelvic Floor Dysfunct*. 2005;16:158–161 [(online journal)] http://www.ncbi.nlm.nih.gov/pubmed/15789149.

Burrows NP, Monk BE, Harrison JB. Giant bladder diverticulum in Ehlers-Danlos syndrome type I causing outflow obstruction. *Clin Exp Dermatol*. 1998;23:109–112.

Busch FM, Carter FH. Vaginal flap incision for urethral diverticula [abstract]. *Western section meeting*. American Urological Association: Honolulu, HI; 1973.

Cameron AP. Urethral diverticulum in the female: a meta-analysis of modern series. *Minerva Ginecol*. 2015 [(online journal)] http://www.ncbi.nlm.nih.gov/pubmed/26545036.

Castillo-Vico M, Checa-Vizcaíno M, Payà-Panadés A. Periurethral granuloma following injection with dextranomer/hyaluronic acid copolymer for stress urinary incontinence. *Int Urogynecol J Pelvic Floor Dysfunct Floor Dysfunct*. 2007;18:95–97.

Cendron J, Alain JL. Bladder diverticulum in children without obstruction of the lower urinary tract. Apropos of 43 cases [in French]. *J Urol Nephrol*. 1972;78:793–805.

Chancellor MB, Liu JB, Rivas DA. Intraoperative endo-luminal ultrasound evaluation of urethral diverticula. *J Urol*. 1995;153:72–75.

Chertin B, Prat O. Iatrogenic bladder diverticula following caesarean section. *Int Urogynecol J Pelvic Floor Dysfunct*. 2008;19:1707–1709 [(online journal)] http://www.ncbi.nlm.nih.gov/pubmed/18458802.

Chung DE, Purohit RS, Girshman J, et al. Urethral diverticula in women: discrepancies between magnetic resonance imaging and surgical findings. *J Urol*. 2010;183:2265–2269 [(online journal)] http://www.ncbi.nlm.nih.gov/pubmed/20400161.

Clayman RV, Shahin S, Reddy P, et al. Transurethral treatment of bladder diverticula. Alternative to open diverticulectomy. *Urology*. 1984;23:573–577 [(online journal)] http://www.ncbi.nlm.nih.gov/pubmed/6428024.

Clemens JQ, Bushman W. Urethral diverticulum following transurethral collagen injection. *J Urol*. 2001;166:626 [(online journal)] http://www.ncbi.nlm.nih.gov/pubmed/11458094.

Clyne OJ, Flood HD. Giant urethral diverticulum: a novel approach to repair. *J Urol*. 2002;167:1796 [(online journal)] http://www.ncbi.nlm.nih.gov/pubmed/11912422.

Cuckow PM, Blackhall RJ, Mouriquand PD. Huge bladder diverticula associated with Ehlers-Danlos syndrome. *J R Soc Med*. 1994;87:290–291 [(online journal)] http://www.ncbi.nlm.nih.gov/pubmed/8207727.

Currarino G. Single vaginal ectopic ureter and Gartner's duct cyst with ipsilateral renal hypoplasia and dysplasia (or agenesis). *J Urol*. 1982;128:988–993 [(online journal)] http://www.ncbi.nlm.nih.gov/pubmed/7176066.

Dai Y, Wang J, Shen H, et al. Diagnosis of female urethral diverticulum using transvaginal contrast-enhanced sonourethrography. *Int Urogynecol J Pelvic Floor Dysfunct*. 2013;24:1467–1471.

Daly WJ, Rabinovitch HH. Urologic abnormalities in Menkes' syndrome. *J Urol*. 1981;126:262–264 [(online journal)] http://www.ncbi.nlm.nih.gov/pubmed/7265378.

Daneshgari F, Zimmern PE, Jacomides L. Magnetic resonance imaging detection of symptomatic noncommunicating intraurethral wall diverticula in women. *J Urol*. 1999;161:1259–1261–2 [(online journal)] http://www.ncbi.nlm.nih.gov/pubmed/10081881.

Das S, Amar AD. Vesical diverticulum associated with bladder carcinoma: therapeutic implications. *J Urol*. 1986;136:1013–1014 [(online journal)] http://www.ncbi.nlm.nih.gov/pubmed/3095564.

Davis BL, Robinson DG, Davis HJ, et al. Diverticula of the female urethra: assay of 120 cases. *J Urol*. 1970;104:850–853.

Davis HJ, Cian LG. Positive pressure urethrography: a new diagnostic method. *J Urol*. 1956;75:753–757 [(online journal)] http://www.ncbi.nlm.nih.gov/pubmed/13307784.

Davis HJ, TeLinde RW. Urethral diverticula: an assay of 121 cases. *J Urol*. 1958;80:34–39.

Deppisch LM. Cysts of the vagina: classification and clinical correlations. *Obstet Gynecol*. 1975;45:632–637 [(online journal)] http://www.ncbi.nlm.nih.gov/pubmed/1143723.

Di Paolo PL, Vargas HA, Karlo CA, et al. Intradiverticular bladder cancer: CT imaging features and their association with clinical outcomes. *Clin Imaging*. 2015;39:94–98 [(online journal)] http://dx.doi.org/10.1016/j.clinimag.2014.10.004.

Dmochowski R. Urethral diverticula: evolving diagnostics and improved surgical management. *Curr Urol Rep*. 2001;2:373–378.

Dmochowski R, Blaivas J, Gormley E, et al. Female stress urinary incontinence update panel of the American Urological Association Education and Research, Inc. Update of AUA guideline on the surgical management of female stress urinary incontinence. *J Urol*. 2010;183:1906–1914.

Dodson MK, Cliby WA, Keeney GL, et al. Skene's gland adenocarcinoma with increased serum level of prostate-specific antigen. *Gynecol Oncol*. 1994;55:304–307 [(online journal)] http://www.ncbi.nlm.nih.gov/pubmed/7525428.

Dondalski M, White EM, Ghahremani GG. Carcinoma arising in urinary bladder diverticula: imaging findings in six patients. *Am J Roentgenol*. 1993;161:817–820.

Dragsted J, Nilsson T. Urothelial carcinoma in a bladder diverticulum evaluated by transurethral ultrasonography. *Scand J Urol Nephrol*. 1985;19:153–154.

Durfee SM, Schwartz LH, Panicek DM. MR imaging of carcinoma within urinary bladder diverticulum. *Clin Imaging*. 1997;21:290–292.

Dwarkasing RS, Dinkelaar W, Hop WC. MRI evaluation of urethral diverticula and differential diagnosis in symptomatic women. *Am J Roentgenol*. 2011;197:676–682.

Eilber KS, Raz S. Benign cystic lesions of the vagina: a literature review. *J Urol*. 2003;170:717–722 [(online journal)] http://www.ncbi.nlm.nih.gov/sites/entrez?Db=pubmed&DbFrom=pubmed&Cmd=Link&LinkName=pu

Articles&IdsFromResult=12913681&ordinalpos=3&itool=En

El-Nashar SA, Bacon MM, Kim-Fine S, et al. Incidence of female urethral diverticulum: a population-based analysis and literature review. *Int Urogynecol J*. 2014;25:73–79 [(online journal)] http://www.ncbi.nlm.nih.gov/pubmed/23857063.

Ellick M. Diverticulum of the female urethra: a new method of ablation. *J Urol*. 1957;77:243–246.

Enemchukwu E, Lai C, Reynolds WS, et al. Autologous pubovaginal sling for the treatment of concomitant female urethral diverticula and stress urinary incontinence. *Urology*. 2015;85:1300–1303 [(online journal)] http://dx.doi.org/10.1016/j.urology.2015.02.022.

Epstein ES, Siegel MJ, Manley CB. Acute urinary retention caused by vesical diverticula. *Urol Radiol*. 1982;4:263–265 [(online journal)] http://www.ncbi.nlm.nih.gov/sites/entrez?
Db=pubmed&DbFrom=pubmed&Cmd=Link&LinkName=pu
Articles&IdsFromResult=6820210&ordinalpos=3&itool=Entr

Evangelidis A, Castle EP, Ostlie DJ, et al. Surgical management of primary bladder diverticula in children. *J Pediatr Surg*. 2005;40:701–703 [(online journal)]
http://www.ncbi.nlm.nih.gov/sites/entrez?
Db=pubmed&DbFrom=pubmed&Cmd=Link&LinkName=pu
Articles&IdsFromResult=15852283&ordinalpos=3&itool=En

Faerber GJ. Urethral diverticulectomy and pubovaginal sling for simultaneous treatment of urethral diverticulum and intrinsic sphincter deficiency. *Tech Urol*. 1998;4:192–197 [(online journal)] http://www.ncbi.nlm.nih.gov/pubmed/9892000.

Fall M. Vaginal wall bipedicled flap and other techniques in complicated urethral diverticulum and urethrovaginal fistula. *J Am Coll Surg*. 1995;180:150–156 [(online journal)]
http://www.ncbi.nlm.nih.gov/sites/entrez?
Db=pubmed&DbFrom=pubmed&Cmd=Link&LinkName=pu
Articles&IdsFromResult=7850047&ordinalpos=3&itool=Entr

Faysal MH, Freiha FS. Primary neoplasm in vesical diverticula. A report of 12 cases. *Br J Urol*. 1981;53:141–143 [(online journal)] http://www.ncbi.nlm.nih.gov/pubmed/6786409.

Feldstein MS. Cryoprecipitate coagulum as an adjunct to surgery for diverticula of the female urethra. *J Urol*. 1981;126:698–699 [(online journal)] http://www.ncbi.nlm.nih.gov/pubmed/6795366.

Fellows FJ. The association between vesical carcinoma and diverticulum of the bladder. *Eur Urol*. 1978;4:185–186 [(online journal)] http://www.ncbi.nlm.nih.gov/sites/entrez?Db=pubmed&DbFrom=pubmed&Cmd=Link&LinkName=pu Articles&IdsFromResult=95952&ordinalpos=3&itool=Entrez

Fernandes ET, Dekermacher S, Sabadin MA, et al. Urethral prolapse in children. *Urology*. 1993;41:240–242 [(online journal)] http://www.ncbi.nlm.nih.gov/sites/entrez?Db=pubmed&DbFrom=pubmed&Cmd=Link&LinkName=pu Articles&IdsFromResult=8442306&ordinalpos=3&itool=Entr

Fortunato P, Schettini M, Gallucci M. Diagnosis and therapy of the female urethral diverticula. *Int Urogynecol J Pelvic Floor Dysfunct*. 2001;12:51–57 [(online journal)] http://www.ncbi.nlm.nih.gov/pubmed/11294533.

Fox M, Power RF, Bruce AW. Diverticulum of the bladder—presentation and evaluation of treatment of 115 cases. *Br J Urol*. 1962;34:286–298.

Gadbois WF, Duckett JW. Gartner's duct cyst and ipsilateral renal agenesis. *Urology*. 1974;4:720–721 [(online journal)] http://www.ncbi.nlm.nih.gov/pubmed/4454113.

Gaines N, Gupta P, Khourdaji AS, et al. Radiographic misdiagnoses after periurethral bulking agents. *Female Pelvic Med Reconstr Surg*. 2017;19:210–213 [(online journal)] http://www.ncbi.nlm.nih.gov/pubmed/28657999.

Ganabathi K, Leach GE, Zimmern PE, et al. Experience with the management of urethral diverticulum in 63 women. *J*

Urol. 1994;152:1445–1452.

Garat JM, Angerri O, Caffaratti J, et al. Primary congenital bladder diverticula in children. *Urology*. 2007;70:984–988 [(online journal)] http://www.ncbi.nlm.nih.gov/sites/entrez?Db=pubmed&DbFrom=pubmed&Cmd=Link&LinkName=pul Articles&IdsFromResult=18068458&ordinalpos=3&itool=En

Garzotto MG, Tewari A, Wajsman Z. Multimodal therapy for neoplasms arising from a vesical diverticulum. *J Surg Oncol*. 1996;62:46–48 [(online journal)] http://www.ncbi.nlm.nih.gov/sites/entrez?Db=pubmed&DbFrom=pubmed&Cmd=Link&LinkName=pul Articles&IdsFromResult=8618401&ordinalpos=3&itool=Entr

Gearhart JP. Exstrophy, epispadias, and other bladder anomalies. Walsh P, Retik A, Vaughan E Jr. *Campbell's urology*. Saunders: Philadelphia; 2002:2136–2196.

Gerrard E, Lloyd L, Kubricht W. Transvaginal ultrasound for the diagnosis of urethral diverticulum. *J Urol*. 2003;169:1395–1397.

Gerridzen RG, Futter NG. Ten-year review of vesical diverticula. *Urology*. 1982;20:33–35 [(online journal)] http://www.ncbi.nlm.nih.gov/sites/entrez?Db=pubmed&DbFrom=pubmed&Cmd=Link&LinkName=pul Articles&IdsFromResult=6810528&ordinalpos=3&itool=Entr

Gil-Vernet JM. Bladder diverticulectomy. Graham SD Jr. *Glenn's urologic surgery*. Lippincott-Raven: Philadelphia; 1998:205–209.

Gilbert C, Rivera Cintron F. Urethral diverticula in the female; review of the subject and introduction of a different surgical approach. *Am J Obs Gynecol*. 1954;67:616–627.

Gillon G, Nissenkorn I, Servadio C. Bladder diverticula in elderly females with urgency, dysuria and incontinence. *Eur Urol*. 1988;14:34–36 [(online journal)] http://www.ncbi.nlm.nih.gov/sites/entrez?

Db=pubmed&DbFrom=pubmed&Cmd=Link&LinkName=pul
Articles&IdsFromResult=3125054&ordinalpos=3&itool=Entr

Ginesin Y, Bolkier M, Nachmias J, et al. Primary giant calculus in urethral diverticulum. *Urol Int*. 1988;43:47–48 [(online journal)] http://www.ncbi.nlm.nih.gov/pubmed/131944.

Ginsburg D, Genadry R. Suburethral diverticulum: classification and therapeutic considerations. *Obstet Gynecol*. 1983;61:685–688 [(online journal)] http://www.ncbi.nlm.nih.gov/pubmed/6405333.

Glassman TA, Weinerth JL, Glenn JF. Neonatal female urethral diverticulum. *Urology*. 1975;5:249–251 [(online journal)] http://www.ncbi.nlm.nih.gov/sites/entrez?
Db=pubmed&DbFrom=pubmed&Cmd=Link&LinkName=pul
Articles&IdsFromResult=803731&ordinalpos=3&itool=Entre

Goldfarb S, Mieza M, Leiter E. Postvoid film of intravenous pyelogram in diagnosis of urethral diverticulum. *Urology*. 1981;17:390–392 [(online journal)] http://www.ncbi.nlm.nih.gov/sites/entrez?
Db=pubmed&DbFrom=pubmed&Cmd=Link&LinkName=pul
Articles&IdsFromResult=6784320&ordinalpos=3&itool=Entr

Golijanin D, Yossepowitch O, Beck SD, et al. Carcinoma in a bladder diverticulum: presentation and treatment outcome. *J Urol*. 2003;170:1761–1764 [(online journal)] http://www.ncbi.nlm.nih.gov/sites/entrez?
Db=pubmed&DbFrom=pubmed&Cmd=Link&LinkName=pul
Articles&IdsFromResult=14532771&ordinalpos=3&itool=En

Gonzalez MO, Harrison ML, Boileau MA. Carcinoma in diverticulum of female urethra. *Urology*. 1985;26:328–332 [(online journal)] http://www.ncbi.nlm.nih.gov/sites/entrez?
Db=pubmed&DbFrom=pubmed&Cmd=Link&LinkName=pul
Articles&IdsFromResult=3931322&ordinalpos=3&itool=Entr

Gotoh T, Koyanagi T, Tokunaka S. Pathology of ureterorenal units in various ureteral anomalies with particular reference to the genesis of renal dysplasia. *Int Urol Nephrol*. 1987;19:231–243 [(online journal)] http://www.ncbi.nlm.nih.gov/sites/entrez?Db=pubmed&DbFrom=pubmed&Cmd=Link&LinkName=pu Articles&IdsFromResult=3667135&ordinalpos=3&itool=Entr

Greenberg M, Stone D, Cochran ST, et al. Female urethral diverticula: double-balloon catheter study. *Am J Roentgenol*. 1981;136:259–264 [(online journal)] http://www.ncbi.nlm.nih.gov/pubmed/6781244.

Greiman A, Rittenberg L, Freilich D, et al. Outcomes of treatment of stress urinary incontinence associated with female urethral diverticula: a selective approach. *Neurourol Urodyn*. 2018;37:478–484 [(online journal)] http://www.ncbi.nlm.nih.gov/pubmed/28660723.

Han DH, Jeong YS, Choo M-S, et al. Outcomes of surgery of female urethral diverticula classified using magnetic resonance imaging. *Eur Urol*. 2007;51:1664–1670 [(online journal)] http://www.ncbi.nlm.nih.gov/pubmed/17335961.

Harcke H, Capitanio M, Grover W. Bladder diverticula and Menkes' syndrome. *Radiology*. 1977;124:459–461.

Hebert KL, Martin AD. Management of bladder diverticula in Menkes syndrome: a case report and review of the literature. *Urology*. 2015;86:162–164 [(online journal)] http://dx.doi.org/10.1016/j.urology.2015.03.030.

Hernández J, Waguespack RL, Horton M, et al. Acute urinary retention due to an iatrogenic bladder diverticulum. *J Urol*. 1997;158:1907 [(online journal)] http://www.ncbi.nlm.nih.gov/sites/entrez?Db=pubmed&DbFrom=pubmed&Cmd=Link&LinkName=pu Articles&IdsFromResult=9334630&ordinalpos=3&itool=Entr

Hernanz-Schulman M, Lebowitz RL. The elusiveness and importance of bladder diverticula in children. *Pediatr Radiol*. 1985;15:399–402 [(online journal)] http://www.ncbi.nlm.nih.gov/sites/entrez?Db=pubmed&DbFrom=pubmed&Cmd=Link&LinkName=pul Articles&IdsFromResult=3932949&ordinalpos=3&itool=Entr

Hey W. *Practical observations in surgery*. James Humphries: Philadelphia; 1805.

Hickey N, Murphy J, Herschorn S. Carcinoma in a urethral diverticulum: magnetic resonance imaging and sonographic appearance. *Urology*. 2000;55:588–589 [(online journal)] http://www.ncbi.nlm.nih.gov/sites/entrez?Db=pubmed&DbFrom=pubmed&Cmd=Link&LinkName=pul Articles&IdsFromResult=10736510&ordinalpos=3&itool=En

Hinman F. Female genital tract and urethra. Hinman FJ. *Atlas of urosurgical anatomy*. Saunders: Philadelphia; 1993:389–416.

Hirschhorn RC. A new surgical technique for removal of urethral diverticula in the female patient. *J Urol*. 1964;92:206–209 [(online journal)] http://www.ncbi.nlm.nih.gov/pubmed/14213537.

Hoffman MJ, Adams WE. Recognition and repair of urethral diverticula: a report of 60 cases. *Am J Obstet Gynecol*. 1965;92:106–111 [(online journal)] http://www.ncbi.nlm.nih.gov/pubmed/14280900.

Hofmann R, Hegemann M, Mauermayer W, et al. Hereditary autosomal dominant form of bladder diverticula in male patients. *J Urol*. 1984;131:338–339 [(online journal)] http://www.ncbi.nlm.nih.gov/sites/entrez?Db=pubmed&DbFrom=pubmed&Cmd=Link&LinkName=pul Articles&IdsFromResult=6422057&ordinalpos=3&itool=Entr

Hricak H, Secaf E, Buckley DW, et al. Female urethra: MR imaging. [Internet]. *Radiology*. 1991;178:527–535 [(online journal)] http://www.ncbi.nlm.nih.gov/pubmed/1898991.

Hu B, Satkunasivam R, Schuckman A, et al. Urothelial carcinoma in bladder diverticula: outcomes after radical cystectomy. *World J Urol*. 2015;33:1397–1402 [(online journal)] http://dx.doi.org/10.1007/s00345-014-1472-5.

Huffman JW. The detailed anatomy of the para-urethral ducts in the adult human female. *Am J Obstet Gynecol*. 1948;55:86–101 [(online journal)] http://www.ncbi.nlm.nih.gov/pubmed/18918954.

Hutch JA. Vesico-ureteral reflux in the paraplegic: cause and correction. *J Urol*. 1952;68:457–469 [(online journal)] http://www.ncbi.nlm.nih.gov/pubmed/14955874.

Hutch JA. Saccule formation at the ureterovesical junction in smooth walled bladders. *J Urol*. 1961;86:390–399 [(online journal)] http://www.ncbi.nlm.nih.gov/pubmed/14450230.

Hutch JA, Ayers RD, Loquvam GS. The bladder musculature with special reference to the ureterovesical junction. *J Urol*. 1961;85:531–539 [(online journal)] http://www.ncbi.nlm.nih.gov/pubmed/13717039.

Hyams JA, Hyams MN. A new operative procedure for the treatment of diverticulum of the female urethra. *Urol Cut Rev*. 1939;43:573–577.

Idrees MT, Alexander RE, Kum JB, et al. The spectrum of histopathologic findings in vesical diverticulum: implications for pathogenesis and staging. *Hum Pathol*. 2013;44:1223–1232 [(online journal)] http://www.ncbi.nlm.nih.gov/pubmed/23375647.

Indudhara R, Vaidyanathan S, Radotra BD. Urethral tuberculosis. *Urol Int*. 1992;48:436–438 [(online journal)] http://www.ncbi.nlm.nih.gov/sites/entrez?Db=pubmed&DbFrom=pubmed&Cmd=Link&LinkName=pu
Articles&IdsFromResult=1413309&ordinalpos=3&itool=Entr

Ingber MS, Firoozi F, Vasavada SP, et al. Surgically corrected urethral diverticula: long-term voiding dysfunction and reoperation rates. *Urology*. 2011;77:65–69 [(online journal)] http://www.ncbi.nlm.nih.gov/pubmed/20800882.

Itoh N, Kounami T. Spontaneous rupture of a bladder

diverticulum: ultrasonographic diagnosis. *J Urol*. 1994;152:1206–1207 [(online journal)]
http://www.ncbi.nlm.nih.gov/sites/entrez?
Db=pubmed&DbFrom=pubmed&Cmd=Link&LinkName=pu
Articles&IdsFromResult=8072099&ordinalpos=3&itool=Ent

Jacoby K, Rowbotham RK. Double balloon positive pressure urethrography is a more sensitive test than voiding cystourethrography for diagnosing urethral diverticulum in women. *J Urol*. 1999;162:2066–2069 [(online journal)]
http://www.ncbi.nlm.nih.gov/sites/entrez?
Db=pubmed&DbFrom=pubmed&Cmd=Link&LinkName=pu
Articles&IdsFromResult=10569571&ordinalpos=3&itool=En

Jerkins GR, Verheeck K, Noe HN. Treatment of girls with urethral prolapse. *J Urol*. 1984;132:732–733 [(online journal)] http://www.ncbi.nlm.nih.gov/sites/entrez?
Db=pubmed&DbFrom=pubmed&Cmd=Link&LinkName=pu
Articles&IdsFromResult=6540815&ordinalpos=3&itool=Ent

Johnson C. Diverticula and cyst of the female urethra. *J Urol*. 1938;39:506–516.

Johnston JH. Vesical diverticula without urinary obstruction in childhood. *J Urol*. 1960;84:535–543.

Jorion JL, Michel M. Spontaneous rupture of bladder diverticula in a girl with Ehlers-Danlos syndrome. *J Pediatr Surg*. 1999;34:483–484 [(online journal)]
http://www.ncbi.nlm.nih.gov/sites/entrez?
Db=pubmed&DbFrom=pubmed&Cmd=Link&LinkName=pu
Articles&IdsFromResult=10211661&ordinalpos=3&itool=En

Kaneti J, Sober I, Bar-Ziv J, et al. Congenital anterior urethral diverticulum. *Eur Urol*. 1984;10:48–52 [(online journal)]
http://www.ncbi.nlm.nih.gov/pubmed/6698087.

Keeler LL, Sant GR. Spontaneous rupture of a bladder diverticulum. *J Urol*. 1990;143:349–351 [(online journal)]
http://www.ncbi.nlm.nih.gov/sites/entrez?

Db=pubmed&DbFrom=pubmed&Cmd=Link&LinkName=pul
Articles&IdsFromResult=2105399&ordinalpos=3&itool=Entr

Kelalis PP, McLean P. The treatment of diverticulum of the bladder. *J Urol*. 1967;98:349–352 [(online journal)] http://www.ncbi.nlm.nih.gov/sites/entrez?
Db=pubmed&DbFrom=pubmed&Cmd=Link&LinkName=pul
Articles&IdsFromResult=4963798&ordinalpos=3&itool=Entr

Khan MS, Uwechue EJ, O'Brien A. Acute renal failure due to bladder diverticula. *Br J Urol*. 1994;73:466–467 [(online journal)] http://www.ncbi.nlm.nih.gov/sites/entrez?
Db=pubmed&DbFrom=pubmed&Cmd=Link&LinkName=pul
Articles&IdsFromResult=8199845&ordinalpos=3&itool=Entr

Khatib RA, Khalil AM, Tawil AN, et al. Non-Hodgkin's lymphoma presenting as a urethral caruncle. *Gynecol Oncol*. 1993;50:389–393 [(online journal)] http://www.ncbi.nlm.nih.gov/pubmed/8406208.

Kim B, Hricak H, Tanagho EA. Diagnosis of urethral diverticula in women: value of MR imaging. *Am J Roentgenol*. 1993;161:809–815 [(online journal)] http://www.ncbi.nlm.nih.gov/sites/entrez?
Db=pubmed&DbFrom=pubmed&Cmd=Link&LinkName=pul
Articles&IdsFromResult=8372765&ordinalpos=3&itool=Entr

Kim JH, Lee KW, Kim JM, et al. Risk factors for de novo mixed urinary incontinence and stress urinary incontinence following surgical removal of a urethral diverticulum. *Low Urin Tract Symptoms*. 2013;5:154–158 [(online journal)] http://www.ncbi.nlm.nih.gov/pubmed/26663452.

Kim SH, Kim SH, Park BK, et al. CT voiding cystourethrography using 16-MDCT for the evaluation of female urethral diverticula: initial experience. *Am J Roentgenol*. 2005;184:1594–1596 [(online journal)] http://www.ncbi.nlm.nih.gov/sites/entrez?
Db=pubmed&DbFrom=pubmed&Cmd=Link&LinkName=pul

Articles&IdsFromResult=15855122&ordinalpos=3&itool=En

Kimbrough H, Vaughan E Jr. Skene's duct cyst in a newborn: case report and review of the literature. *J Urol*. 1977;117:387–388.

Kirks DR, Grossman H. Congenital saccular anterior urethral diverticulum. *Radiology*. 1981;140:367–372 [(online journal)] http://www.ncbi.nlm.nih.gov/sites/entrez?Db=pubmed&DbFrom=pubmed&Cmd=Link&LinkName=pul Articles&IdsFromResult=6789371&ordinalpos=3&itool=Entr

Kłyszejko C, Ilnicki W, Kłyszejko D, et al. [Development of a urethral diverticulum after forceps delivery]. *Ginekol Pol*. 1985;56:766–769 [(online journal)] http://www.ncbi.nlm.nih.gov/sites/entrez?Db=pubmed&DbFrom=pubmed&Cmd=Link&LinkName=pul Articles&IdsFromResult=3938749&ordinalpos=3&itool=Entr

Ko KJ, Suh YS, Kim TH, et al. Surgical outcomes of primary and recurrent female urethral diverticula. *Urology*. 2017;105:181–185 [(online journal)] http://dx.doi.org/10.1016/j.urology.2017.02.040.

Kohorn EI, Glickman MG. Technical aids in investigation and management of urethral diverticula in the female. *Urology*. 1992;40:322–325 [(online journal)] http://www.ncbi.nlm.nih.gov/pubmed/1413348.

Kong MX, Zhao X, Kheterpal E, et al. Histopathologic and clinical features of vesical diverticula. *Urology*. 2013;82:142–147 [(online journal)] http://www.ncbi.nlm.nih.gov/pubmed/23540860.

Kumar D, Kaufman MR, Dmochowski RR. Case reports: periurethral bulking agents and presumed urethral diverticula. *Int Urogynecol J*. 2011;22:1039–1043 [(online journal)] http://link.springer.com/10.1007/s00192-011-1377-4.

Kwan DJ, Lowe FC. Congenital bladder diverticulum: an unusual presentation with abdominal mass, urinary retention, and renal failure in a young adult. *Urol Radiol*. 1992;14:194–196 [(online journal)] http://www.ncbi.nlm.nih.gov/sites/entrez?Db=pubmed&DbFrom=pubmed&Cmd=Link&LinkName=pul Articles&IdsFromResult=1290210&ordinalpos=3&itool=Entr

Lang EK, Davis HJ. Positive pressure urethrography: a roentgenographic diagnostic method for urethral diverticula in the female. *Radiology*. 1959;72:401–405 [(online journal)] http://www.ncbi.nlm.nih.gov/pubmed/13634402 LK - link%7Chttp://www.ncbi.nlm.nih.gov/pubmed/13634402 SRC - BaiduScholar FG - 0.

Lapides J. Transurethral treatment of urethral diverticula in women. *Trans Am Assoc Genitourin Surg*. 1978;70:135–137 [(online journal)] http://www.ncbi.nlm.nih.gov/sites/entrez?Db=pubmed&DbFrom=pubmed&Cmd=Link&LinkName=pul Articles&IdsFromResult=111388&ordinalpos=3&itool=Entre

Lau JT, Ong GB. Congenital diverticulum of the anterior urethra. *Aust N Z J Surg*. 1981;51:305–306 [(online journal)] http://www.ncbi.nlm.nih.gov/sites/entrez?Db=pubmed&DbFrom=pubmed&Cmd=Link&LinkName=pul Articles&IdsFromResult=6789810&ordinalpos=3&itool=Entr

Laudano MA, Jamzadeh AE, Dunphy C, et al. Pathologic outcomes following urethral diverticulectomy in women. *Adv Urol*. 2014;2014.

Leach GE, Bavendam TG. Female urethral diverticula. *Urology*. 1987;30:407–415 [(online journal)] http://www.ncbi.nlm.nih.gov/pubmed/3118546.

Leach GE, Schmidbauer CP, Hadley HR, et al. Surgical treatment of female urethral diverticulum. *Semin Urol*. 1986;4:33–42 [(online journal)] http://www.ncbi.nlm.nih.gov/pubmed/3083495.

Leach GE, Sirls LT, Ganabathi K, et al. L N S C3: a proposed classification system for female urethral diverticula.

Neurourol Urodynamics. 1993;12:523–531 [(online journal)] http://europepmc.org/abstract/MED/8312937 LK - link%7Chttp://europepmc.org/abstract/MED/8312937 SRC - BaiduScholar FG - 0.

Lebowitz RL, Colodny AH, Crissey M. Neonatal hydronephrosis caused by vesical diverticula. *Urology*. 1979;13:335–341 [(online journal)] http://www.ncbi.nlm.nih.gov/sites/entrez?Db=pubmed&DbFrom=pubmed&Cmd=Link&LinkName=pu
Articles&IdsFromResult=108831&ordinalpos=3&itool=Entre

Lee DI, Bagley DH, Liu JB. Experience with endoluminal ultrasonography in the urinary tract. [Internet]. *J Endourol*. 2001;15:67–74 [(online journal)] http://www.ncbi.nlm.nih.gov/sites/entrez?Db=pubmed&DbFrom=pubmed&Cmd=Link&LinkName=pu
Articles&IdsFromResult=11248923&ordinalpos=3&itool=En

Lee JWS, Fynes MM. Female urethral diverticula. *Best Pract Res Clin Obstet Gynaecol*. 2005;19:875–893 [(online journal)] http://www.ncbi.nlm.nih.gov/sites/entrez?Db=pubmed&DbFrom=pubmed&Cmd=Link&LinkName=pu
Articles&IdsFromResult=16181809&ordinalpos=3&itool=En

Lee NH, Kim SY. Skene's duct cysts in female newborns. *J Pediatr Surg*. 1992;27:15–17 [(online journal)] http://www.ncbi.nlm.nih.gov/sites/entrez?Db=pubmed&DbFrom=pubmed&Cmd=Link&LinkName=pu
Articles&IdsFromResult=1552435&ordinalpos=3&itool=Entr

Lee RA. Diverticulum of the female urethra: postoperative complications and results. *Obstet Gynecol*. 1983;61:52–58 [(online journal)] http://www.ncbi.nlm.nih.gov/pubmed/6401854.

Lee RA. Diverticulum of the urethra: clinical presentation, diagnosis, and management. *Clin Obstet Gynecol*. 1984;27:490–498 [(online journal)]

http://www.ncbi.nlm.nih.gov/sites/entrez?Db=pubmed&DbFrom=pubmed&Cmd=Link&LinkName=pu
Articles&IdsFromResult=6430620&ordinalpos=3&itool=Entr

Lee TG, Keller FS. Urethral diverticulum: diagnosis by ultrasound. *Am J Roentgenol*. 1977;128:690–691 [(online journal)] http://www.ncbi.nlm.nih.gov/sites/entrez?Db=pubmed&DbFrom=pubmed&Cmd=Link&LinkName=pu
Articles&IdsFromResult=403810&ordinalpos=3&itool=Entre

Lee UJ, Goldman H, Moore C, et al. Rate of de novo stress urinary incontinence after urethal diverticulum repair. *Urology*. 2008;71:849–853 [(onine journal)] http://www.ncbi.nlm.nih.gov/pubmed/18355904.

Lee YJ, Son SJ, Paick J-S, et al. Preoperative CT voiding cystourethrography using 16-multidetector CT in female urethral diverticulum. *PLoS ONE*. 2014;9:e107448 [(online journal)] http://dx.plos.org/10.1371/journal.pone.0107448.

Leng WW, McGuire EJ. Management of female urethral diverticula: a new classification. *J Urol*. 1998;160:1297–1300 [(online journal)] http://www.ncbi.nlm.nih.gov/sites/entrez?Db=pubmed&DbFrom=pubmed&Cmd=Link&LinkName=pu
Articles&IdsFromResult=9751339&ordinalpos=3&itool=Entr

Levard G, Aigrain Y, Ferkadji L, et al. Urinary bladder diverticula and the Ehlers-Danlos syndrome in children. *J Pediatr Surg*. 1989;24:1184–1186 [(online journal)] http://www.ncbi.nlm.nih.gov/sites/entrez?Db=pubmed&DbFrom=pubmed&Cmd=Link&LinkName=pu
Articles&IdsFromResult=2509670&ordinalpos=3&itool=Entr

Lewis DD, Woods SE. Fetal alcohol syndrome. *Am Fam Physician*. 1994;50:1025–1032 [1035; (online journal)] http://www.ncbi.nlm.nih.gov/sites/entrez?Db=pubmed&DbFrom=pubmed&Cmd=Link&LinkName=pu
Articles&IdsFromResult=7942401&ordinalpos=3&itool=Entr

Liu MM. Fibromyoma of the vagina. *Eur J Obstet Gynecol*

Reprod Biol. 1988;29:321–328 [(online journal)] http://www.ncbi.nlm.nih.gov/sites/entrez?Db=pubmed&DbFrom=pubmed&Cmd=Link&LinkName=pu Articles&IdsFromResult=3229545&ordinalpos=3&itool=Entr

Livne PM, Gonzales ET. Congenital bladder diverticula causing ureteral obstruction. *Urology*. 1985;25:273–276 [(online journal)] http://www.ncbi.nlm.nih.gov/sites/entrez?Db=pubmed&DbFrom=pubmed&Cmd=Link&LinkName=pu Articles&IdsFromResult=3919483&ordinalpos=3&itool=Entr

Ljungqvist L, Peeker R, Fall M. Female urethral diverticulum: 26-year followup of a large series. *J Urol*. 2007;177:219–224 [discussion 224; (online journal)] http://www.ncbi.nlm.nih.gov/pubmed/17162049.

Lockhart JL, Ellis GF, Helal M, et al. Combined cystourethropexy for the treatment of type 3 and complicated female urinary incontinence. *J Urol*. 1990;143:722–725 [(online journal)] http://www.ncbi.nlm.nih.gov/pubmed/2107335.

Lopez JI, Angulo JC, Ibañez T. Primary malignant melanoma mimicking urethral caruncle. Case report. *Scand J Urol Nephrol*. 1993;27:125–126 [(online journal)] http://www.ncbi.nlm.nih.gov/sites/entrez?Db=pubmed&DbFrom=pubmed&Cmd=Link&LinkName=pu Articles&IdsFromResult=8388121&ordinalpos=3&itool=Entr

Lorenzo AJ, Zimmern P, Lemack GE, et al. Endorectal coil magnetic resonance imaging for diagnosis of urethral and periurethral pathologic findings in women. *Urology*. 2003;61:1129–1133 [(online journal)] http://linkinghub.elsevier.com/retrieve/pii/S00904295030026

Lowe FC, Goldman SM, Oesterling JE. Computerized tomography in evaluation of transitional cell carcinoma in bladder diverticula. *Urology*. 1989;34:390–395 [(online journal)] http://www.ncbi.nlm.nih.gov/sites/entrez?

Db=pubmed&DbFrom=pubmed&Cmd=Link&LinkName=pu
Articles&IdsFromResult=2595887&ordinalpos=3&itool=Entr

Lowe FC, Hill GS, Jeffs RD, et al. Urethral prolapse in children: insights into etiology and management. *J Urol*. 1986;135:100–103 [(online journal)] http://www.ncbi.nlm.nih.gov/sites/entrez?
Db=pubmed&DbFrom=pubmed&Cmd=Link&LinkName=pu
Articles&IdsFromResult=3941438&ordinalpos=3&itool=Entr

Mackinnon M, Pratt JH, Pool TL. Diverticulum of the female urethra. *Surg Clin North Am*. 1959;39:953–962 [(online journal)] http://www.ncbi.nlm.nih.gov/sites/entrez?
Db=pubmed&DbFrom=pubmed&Cmd=Link&LinkName=pu
Articles&IdsFromResult=13676011&ordinalpos=3&itool=En

Malde S, Naaseri S, Kavia R, et al. Preliminary report on the effect of urethral diverticulum magnetic resonance imaging configuration on the incidence of new onset urodynamic stress urinary incontinence following excision. *Urol Ann*. 2017;9:321–323 [(online journal)] http://www.ncbi.nlm.nih.gov/pubmed/29118531.

Malde S, Sihra N, Naaseri S, et al. Urethral diverticulectomy with Martius labial fat pad interposition improves symptom resolution and reduces recurrence. *BJU Int*. 2017;119:158–163.

Malde S, Spilotros M, Wilson A, et al. The uses and outcomes of the Martius fat pad in female urology. *World J Urol*. 2017;35:473–478.

Mallampati GK, Siegelman ES. MR imaging of the bladder. *Magn Reson Imaging Clin N Am*. 2004;12:545–555 [vii; (online journal)] http://www.ncbi.nlm.nih.gov/sites/entrez?
Db=pubmed&DbFrom=pubmed&Cmd=Link&LinkName=pu
Articles&IdsFromResult=15271370&ordinalpos=3&itool=En

Marshall S. Urethral diverticula in young girls. *Urology*. 1981;17:243–245 [(online journal)]

http://www.ncbi.nlm.nih.gov/sites/entrez?
Db=pubmed&DbFrom=pubmed&Cmd=Link&LinkName=pu
Articles&IdsFromResult=6782736&ordinalpos=3&itool=Entr

Marshall S, Hirsch K. Carcinoma within urethral diverticula. *Urology*. 1977;10:161–163 [(online journal)]
http://www.ncbi.nlm.nih.gov/sites/entrez?
Db=pubmed&DbFrom=pubmed&Cmd=Link&LinkName=pu
Articles&IdsFromResult=408951&ordinalpos=3&itool=Entre

Mårtensson O, Duchek M. Translabial ultrasonography with pulsed colour-Doppler in the diagnosis of female urethral diverticula. *Scand J Urol Nephrol*. 1994;28:101–104 [(online journal)] http://www.ncbi.nlm.nih.gov/sites/entrez?
Db=pubmed&DbFrom=pubmed&Cmd=Link&LinkName=pu
Articles&IdsFromResult=8009181&ordinalpos=3&itool=Entr

McLoughlin MG. Carcinoma in situ in urethral diverticulum: pitfalls of marsupialization alone. *Urology*. 1975;6:343 [(online journal)] http://www.ncbi.nlm.nih.gov/pubmed/808888.

McNally A. Diverticula of the female urethra. *Am J Surg*. 1935;28:177.

Melekos MD, Asbach HW, Barbalias GA. Vesical diverticula: etiology, diagnosis, tumorigenesis, and treatment. Analysis of 74 cases. *Urology*. 1987;30:453–457 [(online journal)]
http://www.ncbi.nlm.nih.gov/sites/entrez?
Db=pubmed&DbFrom=pubmed&Cmd=Link&LinkName=pu
Articles&IdsFromResult=3118548&ordinalpos=3&itool=Entr

Mićić S, Ilić V. Incidence of neoplasm in vesical diverticula. *J Urol*. 1983;129 [(online journal)] http://www.ncbi.nlm.nih.gov/pubmed/6405057 LK - link%7Chttp://www.ncbi.nlm.nih.gov/pubmed/6405057 SRC - BaiduScholar FG - 0.

Mitchell RJ, Hamilton SG. Spontaneous perforation of bladder diverticula. *Br J Surg*. 1971;58:712 [(online journal)] http://www.ncbi.nlm.nih.gov/sites/entrez?Db=pubmed&DbFrom=pubmed&Cmd=Link&LinkName=pul Articles&IdsFromResult=4999028&ordinalpos=3&itool=Entr

Mizrahi S, Bitterman W. Transvaginal, periurethral injection of polytetrafluoroethylene (polytef) in the treatment of urethral diverticula. *Br J Urol*. 1988;62:280 [(online journal)] http://www.ncbi.nlm.nih.gov/sites/entrez?Db=pubmed&DbFrom=pubmed&Cmd=Link&LinkName=pul Articles&IdsFromResult=3142633&ordinalpos=3&itool=Entr

Montague DK, Boltuch RL. Primary neoplasms in vesical diverticula: report of 10 cases. *J Urol*. 1976;116:41–42 [(online journal)] http://www.ncbi.nlm.nih.gov/sites/entrez?Db=pubmed&DbFrom=pubmed&Cmd=Link&LinkName=pul Articles&IdsFromResult=819660&ordinalpos=3&itool=Entre

Moore TD. Diverticulum of female urethra; an improved technique of surgical excision. *J Urol*. 1952;68:611–616 [(online journal)] http://www.ncbi.nlm.nih.gov/pubmed/12991357.

Moran PA, Carey MP, Dwyer PL. Urethral diverticula in pregnancy. *Aust N Z J Obstet Gynaecol*. 1998;38:102–106 [(online journal)] http://www.ncbi.nlm.nih.gov/sites/entrez?Db=pubmed&DbFrom=pubmed&Cmd=Link&LinkName=pul Articles&IdsFromResult=9521406&ordinalpos=3&itool=Entr

Neitlich JD, Foster HE, Glickman MG, et al. Detection of urethral diverticula in women: comparison of a high resolution fast spin echo technique with double balloon urethrography. *J Urol*. 1998;159:408–410 [(online journal)] http://www.ncbi.nlm.nih.gov/sites/entrez?Db=pubmed&DbFrom=pubmed&Cmd=Link&LinkName=pul Articles&IdsFromResult=9649250&ordinalpos=3&itool=Entr

Nickles SW, Ikwuezunma G, Maclachlan L, et al. Simple vs complex urethral diverticulum: presentation and outcomes. *Urology*. 2014;84:1516–1520 [(online journal)] http://dx.doi.org/10.1016/j.urology.2014.07.070.

Nielsen VM, Nielsen KK, Vedel P. Spontaneous rupture of a diverticulum of the female urethra presenting with a fistula to the vagina. *Acta Obstet Gynecol Scand*. 1987;66:87–88 [(online journal)] http://www.ncbi.nlm.nih.gov/sites/entrez?Db=pubmed&DbFrom=pubmed&Cmd=Link&LinkName=pu
Articles&IdsFromResult=3111165&ordinalpos=3&itool=Entr

Ockrim JL, Greenwell TJ, Foley CL, et al. A tertiary experience of vesico-vaginal and urethro-vaginal fistula repair: factors predicting success. *BJU Int*. 2009;103:1122–1126 [(online journal)] http://www.ncbi.nlm.nih.gov/pubmed/19154500.

Oge O, Gemalmaz H, Ozeren B. Acute urinary retention in a child caused by a congenital bladder diverticulum. *J Pediatr Surg*. 2002;37:926–927 [(online journal)] http://www.ncbi.nlm.nih.gov/sites/entrez?Db=pubmed&DbFrom=pubmed&Cmd=Link&LinkName=pu
Articles&IdsFromResult=12037767&ordinalpos=3&itool=En

Oliva E, Young RH. Clear cell adenocarcinoma of the urethra: a clinicopathologic analysis of 19 cases. *Mod Pathol*. 1996;9:513–520 [(online journal)] http://www.ncbi.nlm.nih.gov/sites/entrez?Db=pubmed&DbFrom=pubmed&Cmd=Link&LinkName=pu
Articles&IdsFromResult=8733766&ordinalpos=3&itool=Entr

Orandi A. Transurethral fulguration of bladder diverticulum: new procedure. *Urology*. 1977;10:30–32 [(online journal)] http://www.ncbi.nlm.nih.gov/sites/entrez?Db=pubmed&DbFrom=pubmed&Cmd=Link&LinkName=pu
Articles&IdsFromResult=406705&ordinalpos=3&itool=Entre

Ostroff EB, Alperstein JB, Young JD. Neoplasm in vesical diverticula: report of 4 patients, including a 21-year-old. *J Urol*. 1973;110:65–69 [(online journal)] http://www.ncbi.nlm.nih.gov/pubmed/4197343.

Paik SS, Lee JD. Nephrogenic adenoma arising in an urethral

diverticulum. *Br J Urol*. 1997;80:150 [(online journal)] http://www.ncbi.nlm.nih.gov/sites/entrez?
Db=pubmed&DbFrom=pubmed&Cmd=Link&LinkName=pul
Articles&IdsFromResult=9240199&ordinalpos=3&itool=Entr

Palagiri A. Urethral diverticulum with endometriosis. *Urology*. 1978;11:271–272 [(online journal)] http://www.ncbi.nlm.nih.gov/sites/entrez?
Db=pubmed&DbFrom=pubmed&Cmd=Link&LinkName=pul
Articles&IdsFromResult=416537&ordinalpos=3&itool=Entre

Patanaphan V, Prempree T, Sewchand W, et al. Jaiwatana J. Adenocarcinoma arising in female urethral diverticulum. *Urology*. 1983;22:259–264 [(online journal)] http://www.ncbi.nlm.nih.gov/pubmed/6312661.

Pathak UN, House MJ. Diverticulum of the female urethra. *Obstet Gynecol*. 1970;36:789–794 [(online journal)] http://www.ncbi.nlm.nih.gov/pubmed/4990773.

Peters WA III, Vaughan ED Jr. Urethral diverticulum in the female: etiologic factors and postoperative results. *Obs Gynecol*. 1976;47:549–552.

Peterson LJ, Matsumoto LM. Nephrogenic adenoma in urethral diverticulum. *Urology*. 1978;11:193–195 [(online journal)] http://www.ncbi.nlm.nih.gov/sites/entrez?
Db=pubmed&DbFrom=pubmed&Cmd=Link&LinkName=pul
Articles&IdsFromResult=415400&ordinalpos=3&itool=Entre

Peterson LJ, Paulson DF, Glenn JF. The histopathology of vesical diverticula. *J Urol*. 1973;110:62–64 [(online journal)] http://www.ncbi.nlm.nih.gov/sites/entrez?
Db=pubmed&DbFrom=pubmed&Cmd=Link&LinkName=pul
Articles&IdsFromResult=4197342&ordinalpos=3&itool=Entr

Piazza R, Aragona F, Pizzarella M, et al. Nephrogenic adenoma in urethral diverticulum: an unusual finding. *Urol Int*. 1987;42:69–70 [(online journal)] http://www.ncbi.nlm.nih.gov/sites/entrez?

Db=pubmed&DbFrom=pubmed&Cmd=Link&LinkName=pul
Articles&IdsFromResult=3590407&ordinalpos=3&itool=Entr

Pieretti R V, Pieretti-Vanmarcke RV. Congenital bladder diverticula in children. *J Pediatr Surg*. 1999;34:468–473 [(online journal)] http://www.ncbi.nlm.nih.gov/sites/entrez?Db=pubmed&DbFrom=pubmed&Cmd=Link&LinkName=pul
Articles&IdsFromResult=10211656&ordinalpos=3&itool=En

Pinkerton JH. Urethral diverticula in women. *Br Med J*. 1963;2:1204–1205 [(online journal)] http://www.ncbi.nlm.nih.gov/pubmed/14060934.

Pool TL, Hacker PK. Vesical diverticulum of the urinary bladder in the female. *Arch Surg*. 1966;92:266–268 [(online journal)] http://www.ncbi.nlm.nih.gov/sites/entrez?Db=pubmed&DbFrom=pubmed&Cmd=Link&LinkName=pul
Articles&IdsFromResult=4955211&ordinalpos=3&itool=Entr

Popat S, Zimmern PE. Long-term outcomes after the excision of horseshoe urethral diverticulum. *Int Urogynecol J*. 2016;27:439–444.

Porpiglia F, Destefanis P, Fiori C, et al. Preoperative risk factors for surgery female urethral diverticula. Our experience. *Urol Int*. 2002;69:7–11 [(online journal)] http://www.ncbi.nlm.nih.gov/pubmed/12119431.

Porpiglia F, Tarabuzzi R, Cossu M, et al. Is laparoscopic bladder diverticulectomy after transurethral resection of the prostate safe and effective? Comparison with open surgery. *J Endourol*. 2004;18:73–76 [(online journal)] http://www.ncbi.nlm.nih.gov/sites/entrez?Db=pubmed&DbFrom=pubmed&Cmd=Link&LinkName=pul
Articles&IdsFromResult=15006059&ordinalpos=3&itool=En

Portnoy O, Kitrey N, Eshed I, et al. Correlation between MRI and double-balloon urethrography findings in the diagnosis of female periurethral lesions. *Eur J Radiol*. 2013;82:2183–2188 [(online journal)] http://dx.doi.org/10.1016/j.ejrad.2013.08.005.

Powell CR, Kreder KJ. Treatment of bladder diverticula, impaired detrusor contractility, and low bladder compliance. *Urol Clin North Am*. 2009;36:511–525 [vii; (online journal)] http://www.ncbi.nlm.nih.gov/sites/entrez?Db=pubmed&DbFrom=pubmed&Cmd=Link&LinkName=pu Articles&IdsFromResult=19942049&ordinalpos=3&itool=En

Pradhan S, Tobon H. Vaginal cysts: a clinicopathological study of 41 cases. *Int J Gynecol Pathol*. 1986;5:35–46 [(online journal)] http://www.ncbi.nlm.nih.gov/sites/entrez?Db=pubmed&DbFrom=pubmed&Cmd=Link&LinkName=pu Articles&IdsFromResult=3957551&ordinalpos=3&itool=Ent

Prudente de Toledo W, Dias Montellato NI, Arap S, et al. Carcinoma in diverticulum of female urethra. *Urol Int*. 1978;33:393–398 [(online journal)] http://www.ncbi.nlm.nih.gov/pubmed/106501.

Psutka SP, Cendron M. Bladder diverticula in children. *J Pediatr Urol*. 2013;9:129–138 [(online journal)] http://www.ncbi.nlm.nih.gov/sites/entrez?Db=pubmed&DbFrom=pubmed&Cmd=Link&LinkName=pu Articles&IdsFromResult=22658330&ordinalpos=3&itool=En

Rabin JM, Hirschfield L, Badlani GH. Type IX Ehlers-Danlos syndrome: bladder diverticula with transitional cell carcinoma. *Urology*. 1991;38:563–566 [(online journal)] http://www.ncbi.nlm.nih.gov/sites/entrez?Db=pubmed&DbFrom=pubmed&Cmd=Link&LinkName=pu Articles&IdsFromResult=1746090&ordinalpos=3&itool=Ent

Rajan N, Tucci P, Mallouh C, et al. Carcinoma in female urethral diverticulum: case reports and review of management. *J Urol*. 1993;150:1911–1914 [(online journal)] http://www.ncbi.nlm.nih.gov/pubmed/8230535.

Raup VT, Hess DS, Hanske J, et al. Patient characteristics and perioperative outcomes of female urethral diverticulectomy:

analysis of a multi-institutional prospective database. *Urology*. 2015;86:712–715 [(online journal)] http://dx.doi.org/10.1016/j.urology.2015.07.007.

Redman JF, McGinnis TB, Bissada NK. Management of neoplasms in vesical diverticula. *Urology*. 1976;7:492–494 [(online journal)] http://www.ncbi.nlm.nih.gov/sites/entrez?Db=pubmed&DbFrom=pubmed&Cmd=Link&LinkName=pul Articles&IdsFromResult=1274006&ordinalpos=3&itool=Entr

Reeves FA, Inman RD, Chapple CR. Management of symptomatic urethral diverticula in women: a single-centre experience. *Eur Urol*. 2014;66:164–172 [(online journal)] http://www.ncbi.nlm.nih.gov/pubmed/24636677.

Reid RE, Gill B, Laor E, et al. Role of urodynamics in management of urethral diverticulum in females. *Urology*. 1986;28:342–346.

Roehrborn CG. Long term follow-up study of the marsupialization technique for urethral diverticula in women. *Surg Gynecol Obstet*. 1988;167:191–196 [(online journal)] http://www.ncbi.nlm.nih.gov/sites/entrez?Db=pubmed&DbFrom=pubmed&Cmd=Link&LinkName=pul Articles&IdsFromResult=3413648&ordinalpos=3&itool=Entr

Romanzi LJ, Groutz A, Blaivas JG. Urethral diverticulum in women: diverse presentations resulting in diagnostic delay and mismanagement. *J Urol*. 2000;164:428–433 [(online journal)] http://www.ncbi.nlm.nih.gov/pubmed/10893602.

Routh A. Urethral diverticula. *Br Med J*. 1890;1(SRC–B):361–362.

Rovner ES, Wein AJ. Diagnosis and reconstruction of the dorsal or circumferential urethral diverticulum. *J Urol*. 2003;170:82–86 [discussion 86; (online journal)] http://www.ncbi.nlm.nih.gov/pubmed/12796650.

Rudin JE, Geldt VG, Alecseev EB. Prolapse of urethral mucosa in white female children: experience with 58 cases. *J Pediatr*

Surg. 1997;32:423–425 [(online journal)] http://www.ncbi.nlm.nih.gov/sites/entrez?Db=pubmed&DbFrom=pubmed&Cmd=Link&LinkName=pul Articles&IdsFromResult=9094008&ordinalpos=3&itool=Entr

Saez F, Peña JM, Martinez A, et al. Reyzabal J. Carcinomas in vesical diverticula: the role of ultrasound. *J Clin Ultrasound*. 1985;13:45–48 [(online journal)] http://www.ncbi.nlm.nih.gov/sites/entrez?Db=pubmed&DbFrom=pubmed&Cmd=Link&LinkName=pul Articles&IdsFromResult=3920256&ordinalpos=3&itool=Entr

Safir MH, Gousse AE, Raz S. Bladder diverticula causing urinary retention in a woman without bladder outlet obstruction. *J Urol*. 1998;160:2146–2147 [(online journal)] http://www.ncbi.nlm.nih.gov/sites/entrez?Db=pubmed&DbFrom=pubmed&Cmd=Link&LinkName=pul Articles&IdsFromResult=9817345&ordinalpos=3&itool=Entr

Saito S. Usefulness of diagnosis by the urethroscopy under anesthesia and effect of transurethral electrocoagulation in symptomatic female urethral diverticula. *J Endourol*. 2000;14:455–457 [(online journal)] http://www.ncbi.nlm.nih.gov/pubmed/10958571.

Sarihan H, Abes M. Congenital bladder diverticula in infants. *Eur Urol*. 1998;33:101–110 [(online journal)] http://www.ncbi.nlm.nih.gov/sites/entrez?Db=pubmed&DbFrom=pubmed&Cmd=Link&LinkName=pul Articles&IdsFromResult=9471050&ordinalpos=3&itool=Entr

Scardino PL, Upson TE. Inguinal hernia and bladder diverticulum. *J Urol*. 1953;69:282–283 [(online journal)] http://www.ncbi.nlm.nih.gov/pubmed/13023823.

Schewe J, Brands EH, Pannek J. The inguinal bladder diverticulum: a rare differential diagnosis of hernias. *Int Urol Nephrol*. 2000;32:255–256 [(online journal)] http://www.ncbi.nlm.nih.gov/sites/entrez?

Db=pubmed&DbFrom=pubmed&Cmd=Link&LinkName=pu
Articles&IdsFromResult=11229643&ordinalpos=3&itool=En

Schippers E, Dittler HJ. Multiple hollow organ dysplasia in Ehlers-Danlos syndrome. *J Pediatr Surg*. 1989;24:1181–1183 [(online journal)] http://www.ncbi.nlm.nih.gov/sites/entrez?Db=pubmed&DbFrom=pubmed&Cmd=Link&LinkName=pu
Articles&IdsFromResult=2509669&ordinalpos=3&itool=Ent

Schulman SL, Zderic S, Kaplan P. Increased prevalence of urinary symptoms and voiding dysfunction in Williams syndrome. *J Pediatr*. 1996;129:466–469 [(online journal)] http://www.ncbi.nlm.nih.gov/sites/entrez?Db=pubmed&DbFrom=pubmed&Cmd=Link&LinkName=pu
Articles&IdsFromResult=8804343&ordinalpos=3&itool=Ent

Schulze S, Hald T. Voiding inability after transurethral resection of a bladder diverticulum. *Scand J Urol Nephrol*. 1983;17:377–378 [(online journal)] http://www.ncbi.nlm.nih.gov/sites/entrez?Db=pubmed&DbFrom=pubmed&Cmd=Link&LinkName=pu
Articles&IdsFromResult=6417773&ordinalpos=3&itool=Ent

Schwab CW, Rovner ES. Utility of radiologic imaging and prolonged catheterization following complex lower urinary tract reconstruction [abstract]. *Mid Atl Sect Meet Am Urol Assoc*. 2003 [Boca Raton, FL].

Seballos RM, Rich RR. Clear cell adenocarcinoma arising from a urethral diverticulum. *J Urol*. 1995;153:1914–1915 [(online journal)] http://www.ncbi.nlm.nih.gov/sites/entrez?Db=pubmed&DbFrom=pubmed&Cmd=Link&LinkName=pu
Articles&IdsFromResult=7752352&ordinalpos=3&itool=Ent

Senger FL, Bottone JJ, Rothfeld SH. Bladder diverticulum in the female. *J Urol*. 1952;68:699–702 [(online journal)] http://www.ncbi.nlm.nih.gov/sites/entrez?Db=pubmed&DbFrom=pubmed&Cmd=Link&LinkName=pu
Articles&IdsFromResult=12991377&ordinalpos=3&itool=En

Shah KJ. Bladder diverticulum: an uncommon cause of acute retention of urine in a male child. *Br J Radiol*. 1979;52:504–506.

Sharma R, Mondal A, Sherigar R, et al. Giant diverticulum of urinary bladder causing bilateral hydronephrosis in an adult. Diagnostic features on radionuclide scintigraphy. *Clin Nucl Med*. 1997;22:385–387 [(online journal)] http://www.ncbi.nlm.nih.gov/sites/entrez?Db=pubmed&DbFrom=pubmed&Cmd=Link&LinkName=pul
Articles&IdsFromResult=9193809&ordinalpos=3&itool=Entr

Sheih CP, Li YW, Liao YJ, et al. Diagnosing the combination of renal dysgenesis, Gartner's duct cyst and ipsilateral müllerian duct obstruction. *J Urol*. 1998;159:217–221 [(online journal)] http://www.ncbi.nlm.nih.gov/sites/entrez?Db=pubmed&DbFrom=pubmed&Cmd=Link&LinkName=pul
Articles&IdsFromResult=9400484&ordinalpos=3&itool=Entr

Sheu JC, Huang YH, Chang PY, et al. Results of surgery for vesicoureteral reflux in children: 6 years’ experience in an Asian country. *Pediatr Surg Int*. 1998;13:138–140 [(online journal)] http://www.ncbi.nlm.nih.gov/sites/entrez?Db=pubmed&DbFrom=pubmed&Cmd=Link&LinkName=pul
Articles&IdsFromResult=9563026&ordinalpos=3&itool=Entr

Shirvani AR, Winters JC. Vaginal leiomyoma presenting as a urethral diverticulum. *J Urol*. 2000;163:1869 [(online journal)] http://www.ncbi.nlm.nih.gov/pubmed/10799207.

Siegelman ES, Banner MP, Ramchandani P, et al. Multicoil MR imaging of symptomatic female urethral and periurethral disease. *Radiographics*. 1997;17:349–365 [(online journal)] http://www.ncbi.nlm.nih.gov/sites/entrez?Db=pubmed&DbFrom=pubmed&Cmd=Link&LinkName=pul
Articles&IdsFromResult=9084077&ordinalpos=3&itool=Entr

Silk MR, Lebowitz JM. Anterior urethral diverticulum. *J Urol*. 1969;101:66–67 [(online journal)]

http://www.ncbi.nlm.nih.gov/sites/entrez?Db=pubmed&DbFrom=pubmed&Cmd=Link&LinkName=pu
Articles&IdsFromResult=4973448&ordinalpos=3&itool=Entr

Sivarajan G, Glickman L, Faber K, et al. Transabdominal robot-assisted laparoscopic urethral diverticulectomy of a complex anterior horseshoe diverticulum of the proximal urethra. *J Endourol Case Rep*. 2015;1:33–35 [(online journal)] http://www.ncbi.nlm.nih.gov/pubmed/27579382.

Spence HM, Duckett JW. Motion picture: simple operation for cure of diverticula of female urethra. *Trans Am Assoc Genitourin Surg*. 1969;61:78–79 [(online journal)] http://www.ncbi.nlm.nih.gov/pubmed/4981869.

Spence HM, Duckett JW. Diverticulum of the female urethra: clinical aspects and presentation of a simple operative technique for cure. *J Urol*. 1970;104:432–437 [(online journal)] http://www.ncbi.nlm.nih.gov/pubmed/4990033.

Spencer WF, Streem SB. Diverticulum of the female urethral roof managed endoscopically. *J Urol*. 1987;138:147–148 [(online journal)] http://www.ncbi.nlm.nih.gov/pubmed/3110434.

Stage KH, Tank ES. Primary congenital bladder diverticula in boys. *Urology*. 1992;40:536–538 [(online journal)] http://www.ncbi.nlm.nih.gov/sites/entrez?Db=pubmed&DbFrom=pubmed&Cmd=Link&LinkName=pu
Articles&IdsFromResult=1466108&ordinalpos=3&itool=Entr

Stav K, Dwyer PL, Rosamilia A, et al. Urinary symptoms before and after female urethral diverticulectomy–can we predict de novo stress urinary incontinence? *J Urol*. 2008;180:2088–2090 [(online journal)] http://www.ncbi.nlm.nih.gov/pubmed/18804229.

Stephens FD. The vesicoureteral hiatus and paraureteral diverticula. *J Urol*. 1979;121:786–791 [(online journal)] http://www.ncbi.nlm.nih.gov/sites/entrez?

Db=pubmed&DbFrom=pubmed&Cmd=Link&LinkName=pu
Articles&IdsFromResult=110945&ordinalpos=3&itool=Entre

Stern AJ, Patel SK. Diverticulum of the female urethra. The value of the post-void bladder film during excretory urography. [Internet]. *Radiology*. 1976;121:222 [Available from] http://www.ncbi.nlm.nih.gov/sites/entrez?Db=pubmed&DbFrom=pubmed&Cmd=Link&LinkName=pu
Articles&IdsFromResult=822475&ordinalpos=3&itool=Entre

Stewart M, Bretland PM, Stidolph NE. Urethral diverticula in the adult female. *Br J Urol*. 1981;53:353–359 [(online journal)] http://www.ncbi.nlm.nih.gov/sites/entrez?Db=pubmed&DbFrom=pubmed&Cmd=Link&LinkName=pu
Articles&IdsFromResult=6789922&ordinalpos=3&itool=Entr

Sulaiman MN, Buchholz NP, Khan MA. Carcinoma in a bladder diverticulum: the place of diverticulectomy. *Arch Ital Urol Androl*. 1998;70:195–197 [(online journal)] http://www.ncbi.nlm.nih.gov/sites/entrez?Db=pubmed&DbFrom=pubmed&Cmd=Link&LinkName=pu
Articles&IdsFromResult=9823668&ordinalpos=3&itool=Entr

Summitt RL, Stovall TG. Urethral diverticula: evaluation by urethral pressure profilometry, cystourethroscopy, and the voiding cystourethrogram. *Obstet Gynecol*. 1992;80:695–699 [(online journal)] http://www.ncbi.nlm.nih.gov/pubmed/1407897.

Suzuki K, Tanaka O, Saito T, et al. Giant bladder diverticulum due to previous bullet injury: findings of gadolinium-enhanced magnetic resonance imaging. *Int J Urol*. 2002;9:517–519 [discussion 520; (online journal)] http://www.ncbi.nlm.nih.gov/sites/entrez?Db=pubmed&DbFrom=pubmed&Cmd=Link&LinkName=pu
Articles&IdsFromResult=12410933&ordinalpos=3&itool=En

Swierzewski SJ, McGuire EJ. Pubovaginal sling for treatment of female stress urinary incontinence complicated by urethral diverticulum. *J Urol*. 1993;149:1012–1014 [(online journal)] http://www.ncbi.nlm.nih.gov/pubmed/8483202.

Talner L, O'Reilly P, Roy C. Specific causes of obstruction. Pollack H, McClennan B, Dyer R, et al. *Clinical urography*. Saunders: Philadelphia; 2000:1967–2136 [(electronic resource)] http://www.researchgate.net/publication/291125124_Specific_ LK - link%7Chttp://www.researchgate.net/publication/291125124_ SRC - BaiduScholar FG - 0.

Tamada S, Iwai Y, Tanimoto Y, et al. [Urethral diverticula surrounding the urethra in women: report of 2 cases]. *Hinyokika Kiyo*. 2000;46:639–642 [(online journal)] http://www.ncbi.nlm.nih.gov/pubmed/11107536.

Tamas EF, Stephenson AJ, Campbell SC, et al. Histopathologic features and clinical outcomes in 71 cases of bladder diverticula. *Arch Pathol Lab Med*. 2009;133:791–796 [(online journal)] http://www.ncbi.nlm.nih.gov/sites/entrez?Db=pubmed&DbFrom=pubmed&Cmd=Link&LinkName=pu Articles&IdsFromResult=19415955&ordinalpos=3&itool=En

Taylor WN, Alton D, Toguri A, et al. Bladder diverticula causing posterior urethral obstruction in children. *J Urol*. 1979;122:415 [(online journal)] http://www.ncbi.nlm.nih.gov/sites/entrez?Db=pubmed&DbFrom=pubmed&Cmd=Link&LinkName=pu Articles&IdsFromResult=112263&ordinalpos=3&itool=Entre

Tesluk H. Primary adenocarcinoma of female urethra associated with diverticula. *Urology*. 1981;17:197–199 [(online journal)] http://www.ncbi.nlm.nih.gov/sites/entrez?Db=pubmed&DbFrom=pubmed&Cmd=Link&LinkName=pu Articles&IdsFromResult=6781117&ordinalpos=3&itool=Entr

Thomas AA, Rackley RR, Lee U, et al. Urethral diverticula in 90 female patients: a study with emphasis on neoplastic alterations. *J Urol*. 2008;180:2463–2467 [(online journal)] http://www.ncbi.nlm.nih.gov/pubmed/18930487.

Thomas RB, Maguire B. Adenocarcinoma in a female urethral diverticulum. *Aust N Z J Surg*. 1991;61:869–871.

Tines SC, Bigongiari LR, Weigel JW. Carcinoma in diverticulum of the female urethra. *Am J Roentgenol*. 1982;138:582–585 [(online journal)] http://www.ncbi.nlm.nih.gov/sites/entrez?Db=pubmed&DbFrom=pubmed&Cmd=Link&LinkName=pu
Articles&IdsFromResult=6801939&ordinalpos=3&itool=Entr

Tokunaka S, Koyanagi T, Matsuno T, et al. Paraureteral diverticula: clinical experience with 17 cases with associated renal dysmorphism. *J Urol*. 1980;124:791–796 [(online journal)] http://www.ncbi.nlm.nih.gov/sites/entrez?Db=pubmed&DbFrom=pubmed&Cmd=Link&LinkName=pu
Articles&IdsFromResult=6777506&ordinalpos=3&itool=Entr

Tsivian M, Tsivian A, Shreiber L, et al. Female urethral diverticulum: a pathological insight. *Int Urogynecol J Pelvic Floor Dysfunct*. 2009;20:957–960 [(online journal)] http://www.ncbi.nlm.nih.gov/pubmed/19582385.

Vakili B, Wai C, Nihira M. Anterior urethral diverticulum in the female: diagnosis and surgical approach. *Obstet Gynecol*. 2003;102:1179–1183 [(online journal)] http://www.ncbi.nlm.nih.gov/pubmed/14607049.

Van Arsdalen K, Wein AJ. Bladder diverticulectomy. Droller M. *Surgical management of urologic disease: an anatomic approach*. Mosby Year Book: St. Louis; 1992:629–639.

Vanhoutte JJ. Ureteral ectopia into a Wolffian duct remnant (Gartner's ducts or cysts) presenting as a urethral diverticulum in two girls. *Am J Roentgenol Radium Ther Nucl Med*. 1970;110:540–545 [(online journal)] http://www.ncbi.nlm.nih.gov/sites/entrez?Db=pubmed&DbFrom=pubmed&Cmd=Link&LinkName=pu

Articles&IdsFromResult=4992386&ordinalpos=3&itool=Entr

Vargas-Serrano B, Cortina-Moreno B, Rodríguez-Romero R, et al. Transrectal ultrasonography in the diagnosis of urethral diverticula in women. *J Clin Ultrasound*. 1997;25:21–28 [(online journal)] http://www.ncbi.nlm.nih.gov/sites/entrez?Db=pubmed&DbFrom=pubmed&Cmd=Link&LinkName=pub Articles&IdsFromResult=9010804&ordinalpos=3&itool=Entr

Verghese M, Belman AB. Urinary retention secondary to congenital bladder diverticula in infants. *J Urol*. 1984;132:1186–1188 [(online journal)] http://www.ncbi.nlm.nih.gov/sites/entrez?Db=pubmed&DbFrom=pubmed&Cmd=Link&LinkName=pub Articles&IdsFromResult=6438352&ordinalpos=3&itool=Entr

Vitale PJ, Woodside JR. Management of bladder diverticula by transurethral resection: re-evaluation of an old technique. *J Urol*. 1979;122:744–745 [(online journal)] http://www.ncbi.nlm.nih.gov/sites/entrez?Db=pubmed&DbFrom=pubmed&Cmd=Link&LinkName=pub Articles&IdsFromResult=117122&ordinalpos=3&itool=Entre

Wagner U, Debus-Thiede G, Christ F. [Significance of the urethral pressure profile in the diagnosis of urethral diverticulum]. *Geburtshilfe Frauenheilkd*. 1986;46:456–458 [(online journal)] http://www.ncbi.nlm.nih.gov/sites/entrez?Db=pubmed&DbFrom=pubmed&Cmd=Link&LinkName=pub Articles&IdsFromResult=3093308&ordinalpos=3&itool=Entr

Wang AC, Wang CR. Radiologic diagnosis and surgical treatment of urethral diverticulum in women. *J Reprod Med*. 1997;377–382.

Ward JN, Draper JW, Tovell HM. Diagnosis and treatment of urethral diverticula in the female. *Surg Gynecol Obstet*. 1967;125:1293–1300 [Available from] http://www.ncbi.nlm.nih.gov/pubmed/4965149.

Wear JB. Urethral diverticulectomy in females. *Urol Times*.

1976;4:2–3.

Wesselhoeft CW, Perlmutter AD, Berg S, et al. Pathogenesis and surgical treatment of diverticulum of the urinary bladder. *Surg Gynecol Obstet*. 1963;116:719–725 [(online journal)] http://www.ncbi.nlm.nih.gov/pubmed/14000076.

Wexler JS, McGovern TP. Ultrasonography of female urethral diverticula. *Am J Roentgenol*. 1980;134:737–740 [(online journal)] http://www.ncbi.nlm.nih.gov/sites/entrez?Db=pubmed&DbFrom=pubmed&Cmd=Link&LinkName=pul Articles&IdsFromResult=6767359&ordinalpos=3&itool=Entr

Willett GD, Lack EE. Periurethral colonic-type polyp simulating urethral caruncle. A case report. *J Reprod Med*. 1990;35:1017–1018 [(online journal)] http://www.ncbi.nlm.nih.gov/pubmed/2277363.

Williams MJ, Gooding GA. Sonographic diagnosis of a neoplasm in a bladder diverticulum. *J Ultrasound Med*. 1985;4:203–204 [(online journal)] http://www.ncbi.nlm.nih.gov/sites/entrez?Db=pubmed&DbFrom=pubmed&Cmd=Link&LinkName=pul Articles&IdsFromResult=3921722&ordinalpos=3&itool=Entr

Wilson B, Klufio G. The radiological and urodynamic significance of large bladder diverticula. *Clin Radiol*. 1985;36:521–524 [(online journal)] http://www.ncbi.nlm.nih.gov/pubmed/3935356.

Wittich AC. Excision of urethral diverticulum calculi in a pregnant patient on an outpatient basis. *J Am Osteopath Assoc*. 1997;97:461–462 [(online journal)] http://www.ncbi.nlm.nih.gov/sites/entrez?Db=pubmed&DbFrom=pubmed&Cmd=Link&LinkName=pul Articles&IdsFromResult=9284614&ordinalpos=3&itool=Entr

Woodhouse CR, Flynn JT, Molland EA, et al. Urethral diverticulum in females. *Br J Urol*. 1980;52:305–310 [(online journal)] http://www.ncbi.nlm.nih.gov/sites/entrez?

Db=pubmed&DbFrom=pubmed&Cmd=Link&LinkName=pu
Articles&IdsFromResult=6775728&ordinalpos=3&itool=Entr

Yamaguchi K, Kotake T, Nishikawa Y, et al. Transurethral treatment of bladder diverticulum. *Urol Int*. 1992;48:210–212 [(online journal)] http://www.ncbi.nlm.nih.gov/sites/entrez?
Db=pubmed&DbFrom=pubmed&Cmd=Link&LinkName=pu
Articles&IdsFromResult=1585517&ordinalpos=3&itool=Entr

Young G, Wahle G. Female urethral diverticulum. Raz S. *Female urology*. Saunders: Philadelphia; 1996:477–489.

Young SB, Rose PG, Reuter KL. Vaginal fibromyomata: two cases with preoperative assessment, resection, and reconstruction. *Obstet Gynecol*. 1991;78:972–974 [(online journal)] http://www.ncbi.nlm.nih.gov/sites/entrez?
Db=pubmed&DbFrom=pubmed&Cmd=Link&LinkName=pu
Articles&IdsFromResult=1923243&ordinalpos=3&itool=Entr

Yu CC, Huang JK, Lee YH, et al. Intradiverticular tumors of the bladder: surgical implications–an eleven-year review. *Eur Urol*. 1993;24:190–196 [(online journal)] http://www.ncbi.nlm.nih.gov/sites/entrez?
Db=pubmed&DbFrom=pubmed&Cmd=Link&LinkName=pu
Articles&IdsFromResult=8375438&ordinalpos=3&itool=Entr

Zhao YX, Wang JP, Li JM, et al. Preoperative 3D and 4D-CT imaging using 640-Multislice CT (640-MSCT) in diagnosis of female urethral diverticulum. *World J Urol*. 2017;35:1133–1139.

Zhou L, Luo DY, Feng SJ, et al. Risk factors for recurrence in female urethral diverticulectomy: a retrospective study of 66 patients. *World J Urol*. 2017;35:139–144.

131

Surgical Procedures for Sphincteric Incontinence in the Male

Hunter Wessells MD, FACS, Alex J. Vanni MD, FACS

Urinary incontinence (UI), the complaint of any involuntary leakage of urine (Abrams et al., 2002), may be the result of congenital anomalies, injury, genitourinary surgery, and other conditions. The most common cause of sphincteric UI in men is radical prostatectomy (RP), with the primary mechanism being failure to store urine secondary to inadequate resistance of the outlet sphincter. The burden of disease from post-RP UI in the United States remains high because of continued large numbers of RP performed annually, although it may decline because of improvements in surgical technique, reduced use of surgery after the US Preventive Services Task Force recommendations against screening with PSA in 2012 (Halpern et al., 2017), and greater adoption of active surveillance (Chen et al., 2018).

UI significantly compromises health-related quality of life in men (Coyne et al., 2003, 2012) and can be improved by surgical treatment including transurethral bulking agents, bulbar urethral slings, and the artificial urinary sphincter (AUS). These procedures prevent involuntary urinary loss by increasing outlet resistance. **Although bulking agents have been used in the past as first-line treatment for male sphincteric UI, the severity of incontinence and postsurgical scarring in the vesicourethral region post-prostatectomy have made surgical correction first-line treatment for the majority of cases.**

After a number of generations, bulbar urethral slings have been established as effective treatment for male UI. Long-term follow-up is now available for these slings, allowing patients to make informed decisions about treatment, particularly for mild to moderate incontinence. However, **the AUS remains the gold standard for the treatment of UI in males because of its long-term durability and effectiveness across the spectrum of moderate and severe degrees of urine loss.**

The recently published *Incontinence after Prostate Treatment: AUA/SUFU Guideline* (Sandhu et al., 2019) offers the urologic community a systematic literature review with evidence-based guideline statements for the evaluation and management of men with sphincteric urinary incontinence due to prostate surgery. In this chapter, we emphasize relevant information as it pertains to a given topic by referencing Sandhu et al. verbatim.

Classification, Pathophysiology, and Etiology

Urinary continence in the male depends on a compliant and contractile bladder body, functional posterior urethra including the bladder neck and prostate (internal sphincter), and an intact rhabdosphincter (external sphincter). Thus stress urinary incontinence develops only in men with concomitant internal and external sphincter impairment. Internal sphincter incompetence results from pelvic surgery, bladder neck injury, specific sympathetic neuropathic dysfunction, or embryologic disruption. **Incompetence of the external sphincter occurs most frequently after RP** but also can result from pelvic fracture urethral injuries, traumatic and acquired myelopathy, and congenital disorders such as spinal dysraphism, sacral agenesis, and the exstrophy/epispadias complex. **Associated bladder dysfunction including decreased compliance or detrusor overactivity may complicate or confound the diagnosis and management of male UI and requires careful evaluation (see later).**

Male incontinence is rare in the general population, affecting only 5% to 6% of older men (Bortolotti et al., 2000; Wu et al., 2015). The incidence of UI in men parallels the rate of various surgical procedures and urologic conditions listed earlier. **Incontinence after transurethral resection of the prostate (TURP) may reflect persistent bladder overactivity but rarely results from damage to the external sphincter during transurethral resection.** In the classic Veterans Affairs Cooperative Study (Wasson et al., 1995) the rate of de novo UI after transurethral resection of the prostate (TURP) was no different than in the watchful waiting group.

The historical incidence of incontinence after RP varies from 2.5% to 87% (Foote et al., 1991). Wide variation in reported UI rates after RP reflect patient- and surgeon-specific factors as well as methodology of data collection (Flynn and Webster, 2004). Rates of incontinence are higher when calculated from self-report instruments as compared with chart review or physician-recorded outcomes (Carlson and Nitti, 2001; Flynn and Webster, 2004). Progressive improvement in urinary control has been reported to occur up to 2 years after surgery: in one study the percentage of men that used one pad or less after RP was 71%, 87%, 92%, and 98.5% at 3, 6, 12, and 24 months, respectively (Lepor and Kaci, 2004). Nerve-sparing techniques pioneered by Walsh (Eggleston and Walsh, 1985) have been associated with a reduced incidence of postoperative UI (Wei et al., 2000a,b). Although the mechanism of this effect remains debated, sensory and motor pudendal innervation of the rhabdosphincter are generally preserved post-RP; in contrast, autonomic afferent denervation and impaired membranous urethral sensitivity seem to be associated with post-RP UI (Catarin et al., 2008). In systematic review and meta-analysis, nerve sparing techniques have been associated with more rapid return of continence, although not final continence status, after RP (Reeves et al., 2015).

Other proposed mechanisms of post-RP UI besides nerve injury include damage to the external urethral rhabdosphincter, pelvic floor, and bladder neck. A functional and anatomic study (Cameron et al., 2015) comparing continent and incontinent men post-RP found no differences between resting urethral pressure profile (UPP) or length of the pressure zone. However, the peak UPP with Kegel and magnetic resonance imaging (MRI) urethral length were significantly higher in the continent group. Furthermore, the authors found a greater degree of funneling at the bladder neck along with distortion and loss of symmetry of the sphincter area. Modifications to the posterior reconstruction of the rhabdosphincter during RP have been proposed to accelerate return to continence but are not associated with improved long-term continence (Rocco et al., 2012).

Bladder neck stenosis is associated with a reduced continence rate after RP, likely because of secondary surgical intervention (Park et al., 2001). Urethral anastomotic fibrosis (Tuygun et al., 2006) is hypothesized to lead to reduced coaptation of the urethra and sphincter; the endoscopic finding of a “sector defect” or loss of the normal radiating folds of the external sphincter may be the correlate of the earlier-mentioned MRI finding of sphincteric distortion or loss of symmetry.

History and Development of Devices

Devices to control urinary incontinence in men have been described since antiquity (Schultheiss et al., 2000). One of the first modern prosthetic devices to treat incontinence in men was reported by Berry in 1964. This acrylic prosthesis was designed to kink and compress the bulbar urethra, but poor results, pain, and fistula formation led to its abandonment (Engel and Wade, 1969). In 1970 Kaufman reported the first of several procedures to provide continence by compressing the urethra with the Kaufman I procedure. This was modified by incorporating a tetrafluoroethylene mesh tape in the Kaufman II and a silicone-gel–filled hemispheric prosthesis in the Kaufman III, giving a success rate of 70%.

Slings to treat stress UI in men were introduced in 1975 by Kishev, who described the placement of a pliable prosthetic “wad” under the bulbar urethra. Schaeffer then described a bulbourethral sling that used bolsters suspended from the rectus fascia (Clemens et al., 1999a,b; Schaeffer et al., 1998). Another report documented results with a composite graft of polypropylene and porcine skin collagen placed suburethrally (John, 2004). Male bulbourethral slings have continued to evolve with the development of bone screws for stable fixation of synthetic mesh to the inferior pubic ramus (InVance, American Medical Systems, Minnetonka, MN), transobturator fixation (AdVance and AdVance XP, Boston Scientific, formerly AMS, Marlborough, MA) and a combined prepubic and transobturator sling (Virtue, Coloplast, Minneapolis, MN). The bone-anchored sling is no longer commercially available in the United States, which reduces options for complex cases involving failure of a transobturator sling or AUS.

In 1976 Rosen designed the first model of an AUS, but hydraulic failure and fistula formation approached 100%, and this device was abandoned (Fowler and Auld, 1985). Scott presented his initial report with the AMS 721 (American Medical Systems, Minnetonka, MN), noting a 79% success rate (Scott, 1978; Timm et al., 1976). Over the next 10 years, further developments in design of the AUS included automatic cuff closure after cuff decompression (AMS 742), a silicone rubber cuff and a deactivation button (AMS 791, 792) (Scott, 1989), and deactivation button within the control pump (AMS 800). In 1987 the narrow-backed cuff was introduced (Fig. 131.1A), which, by improving pressure transmission from the cuff pressure to the underlying tissue, greatly decreased the incidence of urethral erosion and tissue atrophy (Light and Reynolds, 1992).

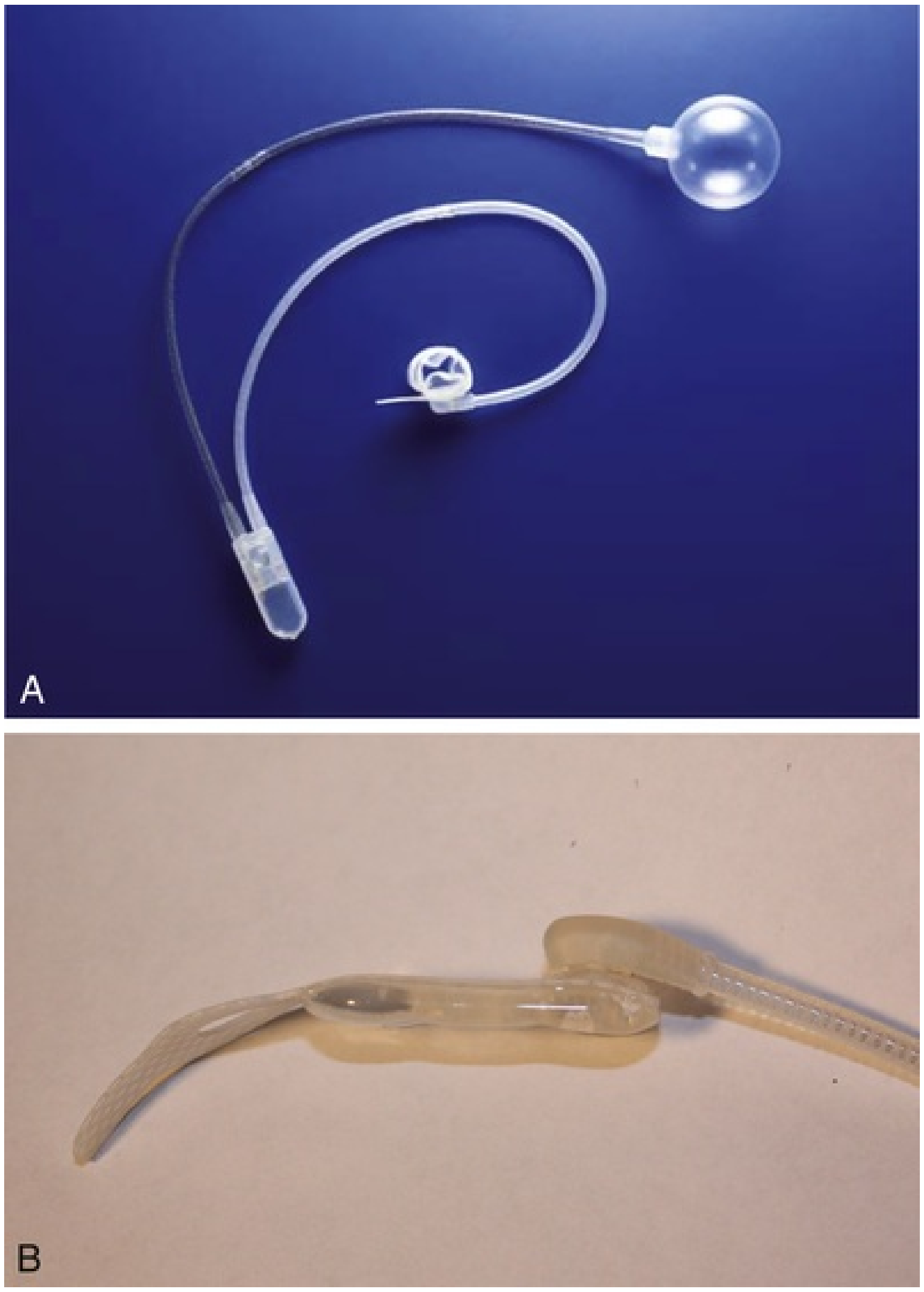

FIG. 131.1 AMS 800 narrow backed artificial urinary sphincter. (A) Cuff, pump, and pressure-regulating balloon. (B) Close-up view of a 3.5-cm cuff. Note the subtle folds of the three-cushion design unique to the 3.5-cm cuff.

The most recent modification of the AMS 800 is the addition of the 3.5-cm cuff to the size options for the device. This has allowed placement in cases with atrophy of the urethra and revision cases necessitating placement of the cuff distally, whereas the urethra is naturally much smaller in diameter. The 3.5-cm cuff has very specific design characteristics (Fig. 131.1B) that were needed to achieve a concentric compression of the urethra in this small diameter (see later). Other strategies developed to address bulbar atrophy include fascial wrapping and transcorporal cuff placement (see later).

Innovations and Emerging Concepts in Device

Design

Although slings and AUS have been available for decades, innovation is necessary because both types of devices have significant limitations and need improvement. The AUS Consensus Group recently developed ideas for several important innovations in sphincter technology that would improve the device (Biardeau et al., 2016). One would be to make the sphincter easier to use so that a patient's manual dexterity was not a prerequisite for implantation. In addition, the device should be simple to deactivate, have cuff pressures that modulate in real-time to the needs of the patient, have system pressures easily modified without the need for revision surgery, and be implantable with minimally invasive techniques. Attempts at overcoming these limitations have progressed by creating an adaptive device that is wirelessly controlled (Lamraoui, 2010; Ruthmann et al., 2010; Valerio et al., 2013). Although a number of these new devices, hydro-mechanical and mechanical, have been studied in humans (Knight et al., 2006; Schiavini et al., 2010; Staerman, 2013), none are approved by the U.S. Food and Drug Administration (FDA), and further refinements are needed to advance beyond current technology.

Adjustable balloon devices may be offered to patients with mild stress urinary incontinence after prostate treatment (Sandhu et al., 2019). The Prostate Adjustable Continence Therapy device (ProACT; Uromedica, Plymouth, MN) consists of two balloons, placed on both sides of the bladder neck to increase outlet resistance. Percutaneous adjustment of the pressure applied to the bladder neck is performed through titanium ports within the scrotum. Hübner and Schlarp showed significantly improved continence as they used this device over time, which stimulated the use of the ProACT device in centers in Europe (Hubner and Schlarp, 2005; Trigo-Rocha et al., 2006). More recent studies show deterioration in success (Venturino et al., 2015). The pivotal trial in the US associated with FDA approval determined that 60% of patients met the primary endpoint and had a greater than 50% reduction in leakage as measured by pad weights (Nash et al., 2018).

Slings are continually developed and studied in the hopes of providing a cure for male UI with the advantage of being easier to implant, not requiring patient hand dexterity, and with fewer potential complications as compared with the AUS. Adjustable slings (e.g., the Adjustable Transobturator Male System [ATOMS], Remeex [not available in the United States]) have been studied in hopes of improving upon existing slings (Advance, Virtue) currently available in the United States. The ATOMS device, available in Canada and Europe, is an adjustable transobturator sling with short-term results demonstrating a 73% dry rate at 2 years' follow-up and may perform better than the Advance sling in radiated patients (Angulo et al., 2017). The ATOMS device involves mesh arms that provide four-point fixation in the pelvis and a silicone cushion in the midportion of the tape. The cushion provides pressure on the ventral aspect of the bulbar urethra and can be adjusted with volume at any time via a port.

The Advance XP was developed in 2010 and has recently undergone clinical trials in Europe as an update to the existing Advance sling (Bauer et al., 2015; Kretschmer et al., 2016). The Advance XP has an updated mesh with integrated tensioning wires and chevron anchors on the mesh arms. A multicenter trial with 3-year follow-up demonstrated outcomes similar to the standard device: post-RP UI cure improved in 66% and 23% of patients respectively; the result did not diminish over time (Bauer et al., 2017).

A number of further refinements in sling technology are needed. Improved efficacy of slings is needed to shift the risk-benefit ratio toward sling in men with moderate to severe incontinence, history of radiation therapy, and those with prior urethral surgery. AUS placement in these men has a significantly greater potential for complications. In addition, if new sling design allowed easier implantation with less potential for variability in placement, it would allow a larger number of urologists to treat patients and potentially improve surgical outcomes. Last, although slings have a lower complication profile compared with AUS, there are postoperative problems related to postoperative urinary retention, perineal/groin pain, and rarely urethral erosion. Sling design should continue to improve upon existing technologies to mitigate these risks to improve the quality of life of our patients.

Mechanisms of Continence With Surgical Devices

Slings have evolved from simple obstructive foreign bodies to sophisticated devices that rely on interaction with the bony pelvis to compress or reposition the male urethra (Fig. 131.2). The mechanism of continence with the bone-anchored sling was thought to be from compression of the urethra, as demonstrated by an increase in fixed resistance of the urethra (Ullrich and Comiter, 2004). Further support for this proposed mechanism was the development of techniques to optimize tensioning of the sling, which also reduce the risk of urinary retention (Comiter, 2002).

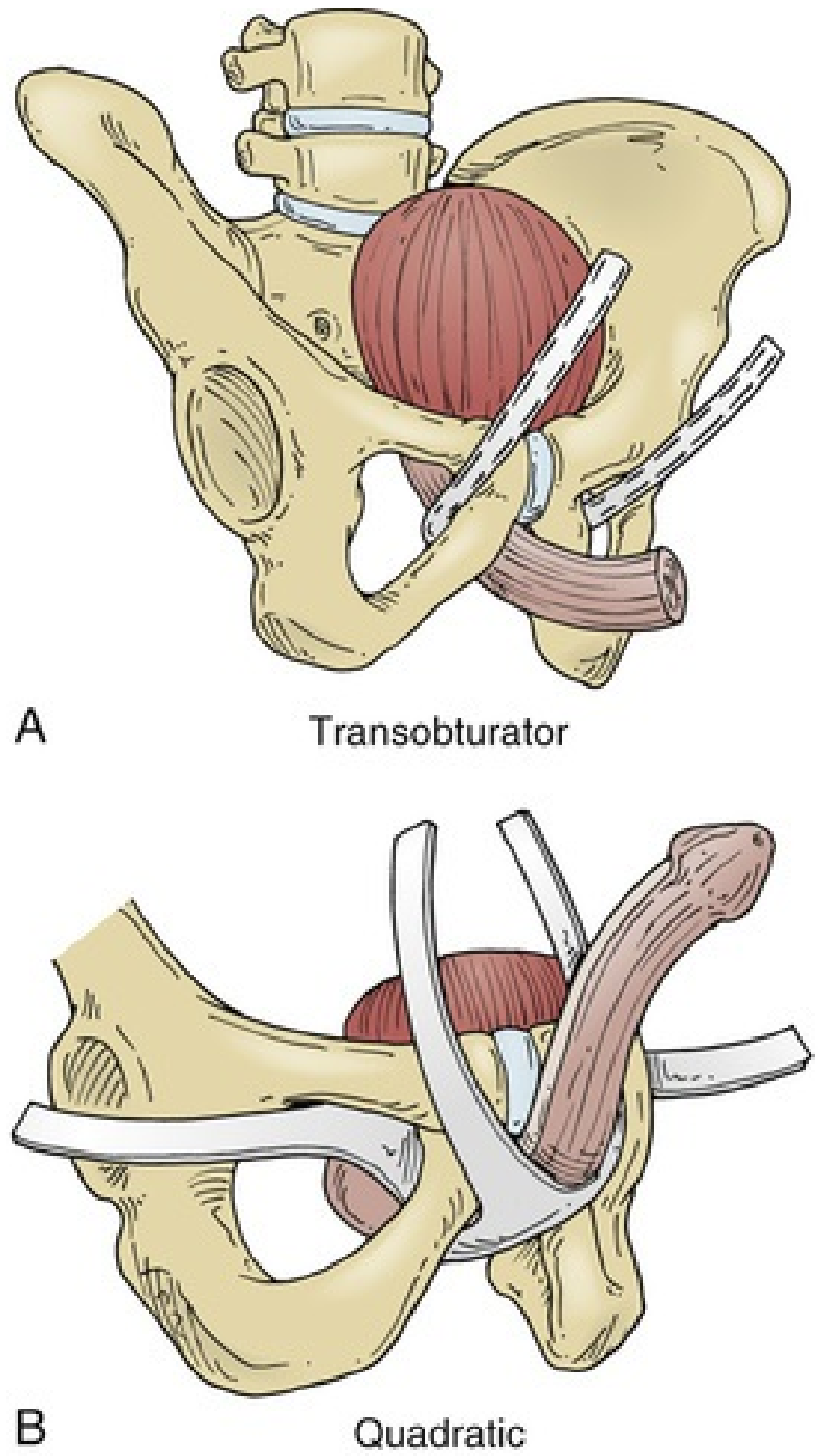

FIG. 131.2 Proposed mechanism of slings. (A) Transobturator. (B) Quadratic fixation.

Transobturator slings are hypothesized to enhance rhabdosphincter function by repositioning and lengthening the membranous urethra without significant compression. Urodynamic studies show an increase in abdominal leak point pressure without other urodynamic evidence of obstruction (Davies et al., 2009; Soljanik et al., 2011). Fluoroscopic studies and magnetic resonance imaging further demonstrate an increase in membranous urethral length and elevation of the bladder neck, posterior bladder wall, and rhabdosphincter (Firrozi and Vasavada, 2009, Soljanik et al., 2013).

The Virtue sling is a four-armed mesh device (quadratic fixation) that provides a long segment of urethral compression against the urogenital diaphragm and a separate elevation component resulting from the prepubic

and transobturator arms, respectively (Comiter et al., 2012).

The AUS (AMS 800) consists of a fluid-filled cuff placed around the bladder neck or bulbar urethra, which provides a 2-cm zone of circumferential compression. The degree of compression is determined by the compliance of the pressure-regulating balloon (PRB), the pressure of which is selected based on patient tissue characteristics and location of the cuff. **The standard PRB for bulbar AUS, namely 61 to 70 cm H_2O, optimally balances the need for occlusion with the risk for erosion. Lower pressures provide reduced continence rates but may be advisable if risk of erosion is considered excessive.** The degree of occlusion provided by standard 61 to 70 cm H_2O is similar in magnitude to that measured in successful male sling surgery. However, when the cuff is opened, urethral resistance drops to negligible levels, thus allowing men without significant detrusor contractility to empty via straining or Crede. Interestingly, the amount of urethral lengthening achieved with the AdVance male sling, 1.2 cm post-tensioning, is significantly less compared with the 2-cm zone of compression with AUS (Soljanik et al., 2013)**.**

Evaluation and Diagnosis

The initial evaluation of a man with UI requires a detailed history, physical examination, postvoid residual measurement, and urinalysis. AUA/SUFU Guidelines also recommend appropriate diagnostic modalities to categorize type and severity of incontinence and degree of bother (Sandhu et al., 2019). **Cystoscopy and pressure flow urodynamics can be used to evaluate potential bladder neck stenosis, residual sphincteric function, and bladder storage function as indicated.** Fig. 131.3 shows the AUA/SUFU evaluation algorithm.

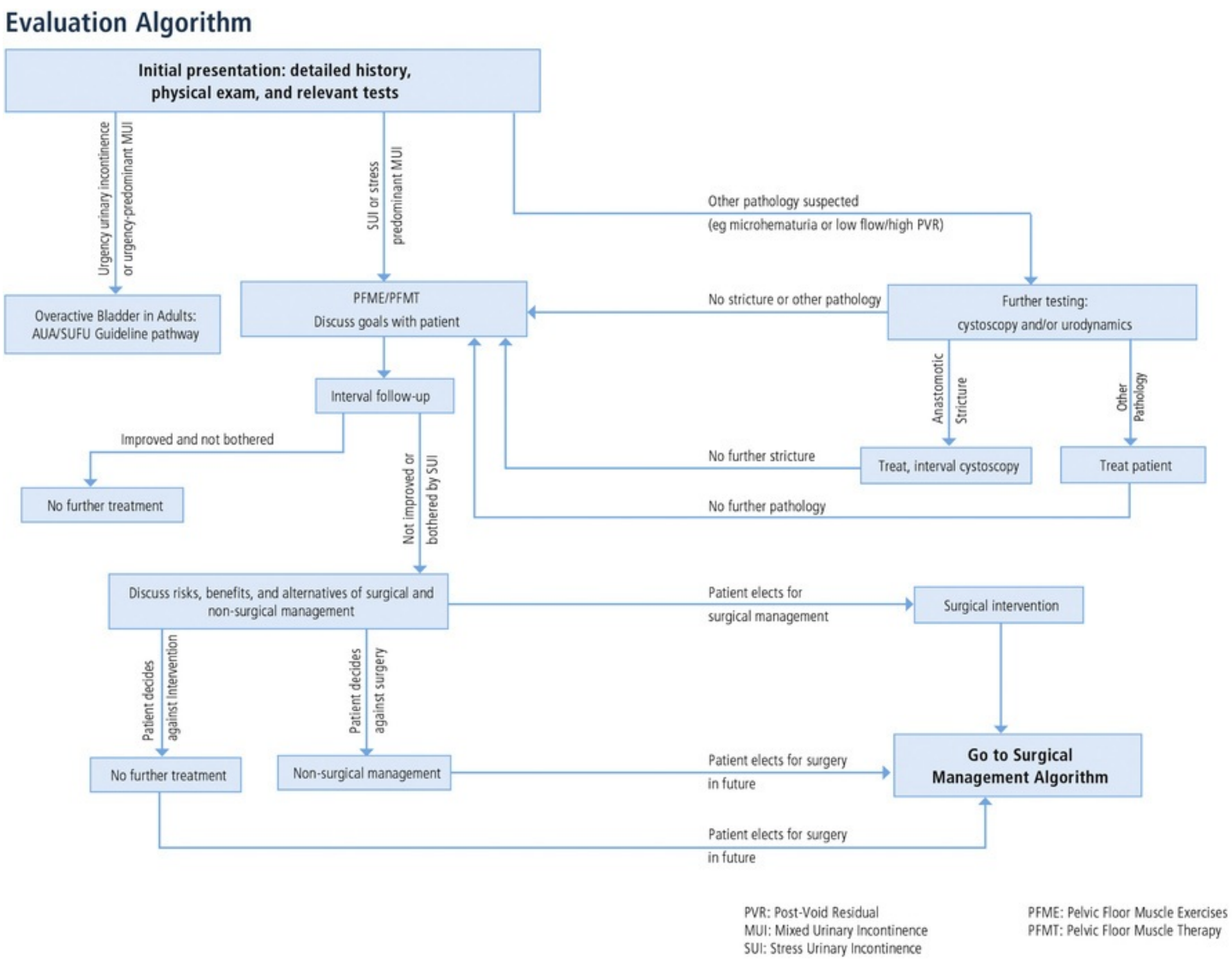
Evaluation Algorithm
Initial presentation: detailed history, physical exam, and relevant tests
Urgency urinary incontinence or urgency-predominant MUI
SUI or stress predominant MUI
Other pathology suspected (eg microhematuria or low flow/high PVR)
Overactive Bladder in Adults: AUA/SUFU Guideline pathway
PFME/PFMT Discuss goals with patient
No stricture or other pathology
Further testing: cystoscopy and/or urodynamics
Anastomotic Stricture
Other Pathology
Interval follow-up
Improved and not bothered
No further treatment
Not improved or bothered by SUI
No further stricture
Treat, interval cystoscopy
Treat patient
No further pathology
Discuss risks, benefits, and alternatives of surgical and non-surgical management
Patient elects for surgical management
Surgical intervention
Patient decides against intervention
Patient decides against surgery
No further treatment
Non-surgical management
Patient elects for surgery in future
Go to Surgical Management Algorithm
Patient elects for surgery in future
PVR: Post-Void Residual
MUI: Mixed Urinary Incontinence
SUI: Stress Urinary Incontinence
PFME: Pelvic Floor Muscle Exercises
PFMT: Pelvic Floor Muscle Therapy

FIG. 131.3 AUA/SUFU Guideline Evaluation Algorithm for Incontinence after Prostate Treatment. (Reproduced from Sandhu et al., 2019, with permission.)

History

The medical history should focus on the type, degree, and severity of UI; previous surgical procedures; and symptoms of neurologic disease. Specific evaluation of the failed AUS will be considered at the end of this section. **Differentiation between stress and urgency UI is important and can be aided by the voiding diary and pad test, simple inexpensive assessments of urinary incontinence that are recommended before proceeding with invasive testing** (Flynn and Webster, 2004). The 2- to 7-day voiding diary reliably assesses the number of incontinent episodes and may uncover significant urgency and urgency incontinence (Groutz et al., 2000). Self-reported daily pad usage varies considerably with only moderate concordance with urinary incontinence volume (Dylewski et al., 2007). Thus the 24-hour home pad weight test, which objectively measures the magnitude of the incontinence, may be helpful in directing appropriate therapy. However, because the effectiveness of current surgical therapies has not been stratified according to measures of UI severity, the most important current use for the pad test may be as an outcome measure postoperatively.

Patient-Reported Measures

The severity and symptom impact of UI is thought to be an important factor in selection of surgical approach. Patient-reported measures (PRMs) help elucidate the presence and severity of patient symptoms and bother and thus may serve as an important adjunct to the history and physical examination. Validated disease-specific questionnaires such as the UCLA Prostate Cancer Index (PCI) (Litwin et al., 1998) or the Expanded Prostate Cancer Index Composite (Wei et al., 2000a,b) capture symptoms of stress and urgency incontinence in men post-RP, and have traditionally been used in research and as part of retrospective or prospective cohort series. The performance of such instruments in clinical practice and in demonstrating responsiveness to treatment has not, however, been formally assessed. Similarly, the Incontinence Symptom Index and Incontinence Impact Questionnaire-7 have been used to measure AUS outcomes, although neither of these were developed for assessment of male UI (Wingate et al., 2017). Nitti and the SUFU Pad Weight Study Group (Nitti, 2014) developed a questionnaire that uses pad size, number, and degree of wetness to estimate incontinence. It correlates well with actual urine loss and may offer an alternative method that does not require pad weights. Patient-reported outcome measures that closely correlate with pad weight, other symptoms, and patient bother from UI continue to be unmet needs and remain important future directions for the field of male incontinence.

Physical Examination

A complete examination of the abdomen, back, genitalia, perineum, rectum, and neurologic system is essential to identify conditions associated with specific causes of UI. The patient's manual dexterity should be evaluated if considering placement of an AUS. Clinicians should ensure that patients have adequate physical and cognitive abilities to operate the device (Sandhu et al., 2019). The skin should be inspected for signs of breakdown or secondary fungal or bacterial infection, which must be treated before surgery. **Previous surgical incisions should be noted when planning AUS PRB placement. Likewise, inguinal**

hernias should be identified, and if contralateral PRB placement is not possible, concomitant repair is advisable. Scrotal examination will detect pathology that may influence pump placement such as hydrocele, hernias, and scrotal masses. Having the patient perform a Valsalva maneuver in the office may be helpful in demonstrating stress UI.

Laboratory

Urine analysis and culture are required before surgical correction of male UI, and all abnormalities need complete investigation. UTI must be appropriately evaluated and eradicated. Serum creatinine and PSA should be obtained to assess renal function and cancer status post-RP. Renal insufficiency requires careful evaluation before proceeding with surgical intervention.

Cystoscopy

Detection of vesicourethral anastomotic stricture, bladder neck stenosis, and bulbar urethral stricture before planned surgery may be achieved by history or uroflowmetry in most cases (Yurkanin et al., 2001). **Because unrecognized urethral or bladder neck pathology can significantly complicate all surgical approaches, prior to surgical intervention for stress urinary incontinence, cystourethroscopy should be performed to assess for urethral and bladder pathology that may affect outcomes of surgery. A corollary to this is that patients with symptomatic vesicourethral anastomotic stenosis or bladder neck contracture should be treated prior to surgery for incontinence after prostate treatment** (Sandhu et al., 2019). Cystoscopic evaluation of the degree of residual function of the external sphincter may help identify appropriate candidates for transobturator sling procedures (see later and Fig. 131.4). Furthermore, in patients with recurrent incontinence after AUS implantation, cystoscopy may aid in differentiating mechanical failure from other causes such as urethral atrophy. Finally, when an AUS or sling (Harris et al., 2009) has been removed because of infection or erosion, repeat evaluation of the urethra before reimplantation is recommended to identify stricture, diverticulum, and other urethral complications.

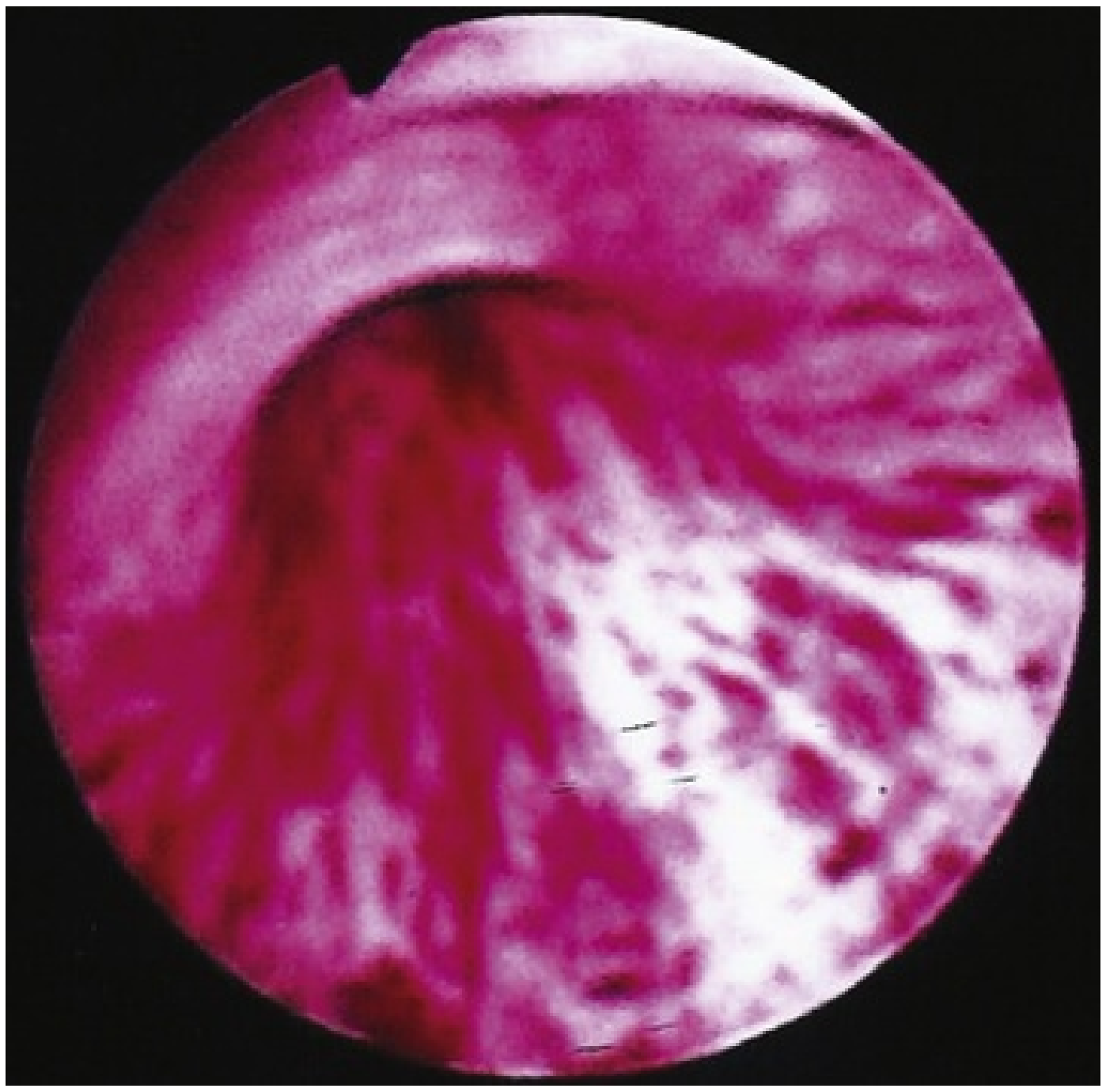

FIG. 131.4 Appearance of external sphincter of a man with post-radical prostatectomy urinary incontinence showing quadrant defect from 9 to 12 o'clock with incomplete circumferential coaptation. Such a patient may not be an ideal candidate for the transobturator sling, which relies on repositioning of a functional external sphincter unit.

Urodynamics

Assessment of bladder capacity, compliance, and contractility is required before considering surgical correction of UI. A careful history and voiding diary may be sufficient to assess the adequacy of bladder function. Noninvasive studies with uroflowmetry and postvoid residual urine volume, when normal, confirm bladder capacity, completeness of bladder emptying, and the absence of bladder neck stenosis. When more comprehensive evaluation is required, however, clinicians may perform urodynamic testing in a patient prior to surgical intervention for stress urinary incontinence in cases where it may facilitate diagnosis or counseling (Sandhu et al., 2019). Intrinsic sphincter deficiency (ISD) will be identified in almost all cases. **Although 40% to 45% of men with UI post-RP have bladder dysfunction, it is the sole cause of incontinence in a very small percentage** (Ficazzola and Nitti, 1998; Leach et al., 1996). Filling cystometry can be difficult in men with severe incontinence, and occlusion of the bladder neck with a balloon catheter may be required to assess compliance and detrusor function. Decreased bladder capacity was a predictor of worse outcomes from male sling surgery in one series (Warner et al., 2012). **Detrusor overactivity, although not a contraindication to surgery for UI if discovered, requires realistic counseling regarding the likelihood of successful outcome.** Patients with urgency urinary incontinence or urgency predominant mixed urinary incontinence should be offered treatment options per the American Urological Association Overactive Bladder guideline (Guideline 10: Clinical Principle). Reduced bladder compliance presents a more serious concern because prolonged storage at high pressures may lead to deteriorating renal function. Notably, such urodynamic findings do not reliably predict worse post-AUS continence (Lai et al., 2009; Trigo-Rocha et al., 2008). This effectiveness in spite of adverse urodynamic findings could portend silent upper tract deterioration. Conversely, **detrusor hypocontractility on pressure flow urodynamics may indicate the need for AUS if adequate detrusor function does not exist to overcome the potential increased outlet resistance of a sling** (Comiter, 2007).

The American Urological Association guidelines on the use of urodynamics for the patient with stress incontinence state at minimum that surgeons considering invasive therapy in patients with stress UI should assess the postvoid residual (PVR) urine volume (Winters et al., 2012). Furthermore, clinicians may perform multi-channel urodynamics in patients with symptoms and physical findings of stress incontinence who are considering invasive, potentially morbid, or irreversible treatments, which include placement of the male sling or AUS.

Evaluation of Persistent Incontinence After Artificial Urinary Sphincter and Sling

The diagnostic evaluation of recurrent UI after AUS must differentiate between inadvertent deactivation, insufficient urethral compression (oversizing of cuff), mechanical failure with fluid loss, cuff erosion, bladder storage failure, urethral or bladder neck atrophy under the cuff, as well as rare causes such as a plugged delay-fill resistor or kinked tubing (Montague et al., 2001). In patients with persistent or recurrent urinary incontinence after artificial urinary sphincter or sling, clinicians should again perform history, physical examination, and/or other investigations to determine the cause of incontinence (Sandhu et al., 2019). The evaluation includes the same general approach described for de novo UI as shown in Figs. 131.3 and 131.5. A history of sudden loss of continence suggests deactivation or mechanical failure. Active cycling of the device excludes inadvertent deactivation. If the pump is deactivated with inadequate fluid to cycle, passive filling can be achieved by squeezing the pump on its lateral edges, pushing on the pump with a cotton-tip applicator opposite the deactivation button, or holding down the button for at least 30 seconds. Fluid loss from the device implies mechanical failure and leak. Plain radiography (for contrast-filled systems) or ultrasonography (for saline-filled systems) of the PRB during cycling can help differentiate fluid loss from cuff atrophy. If the PRB size changes with cycling, and refills passively, mechanical failure is less likely, thus suggesting cuff atrophy (Lorentzen et al., 1987; Taylor and Lebowitz, 1985). Cystoscopy, in addition to excluding erosion, can be used to visualize the cuff during cycling and give insight into the likelihood of atrophy. Urodynamics should be performed when bladder storage failure is suspected, or in cases where it is difficult to determine if incontinence is primarily due to detrusor overactivity. It is axiomatic that in patients with persistent or recurrent stress urinary incontinence after artificial urinary sphincter, revision should be considered (Sandhu et al., 2019).

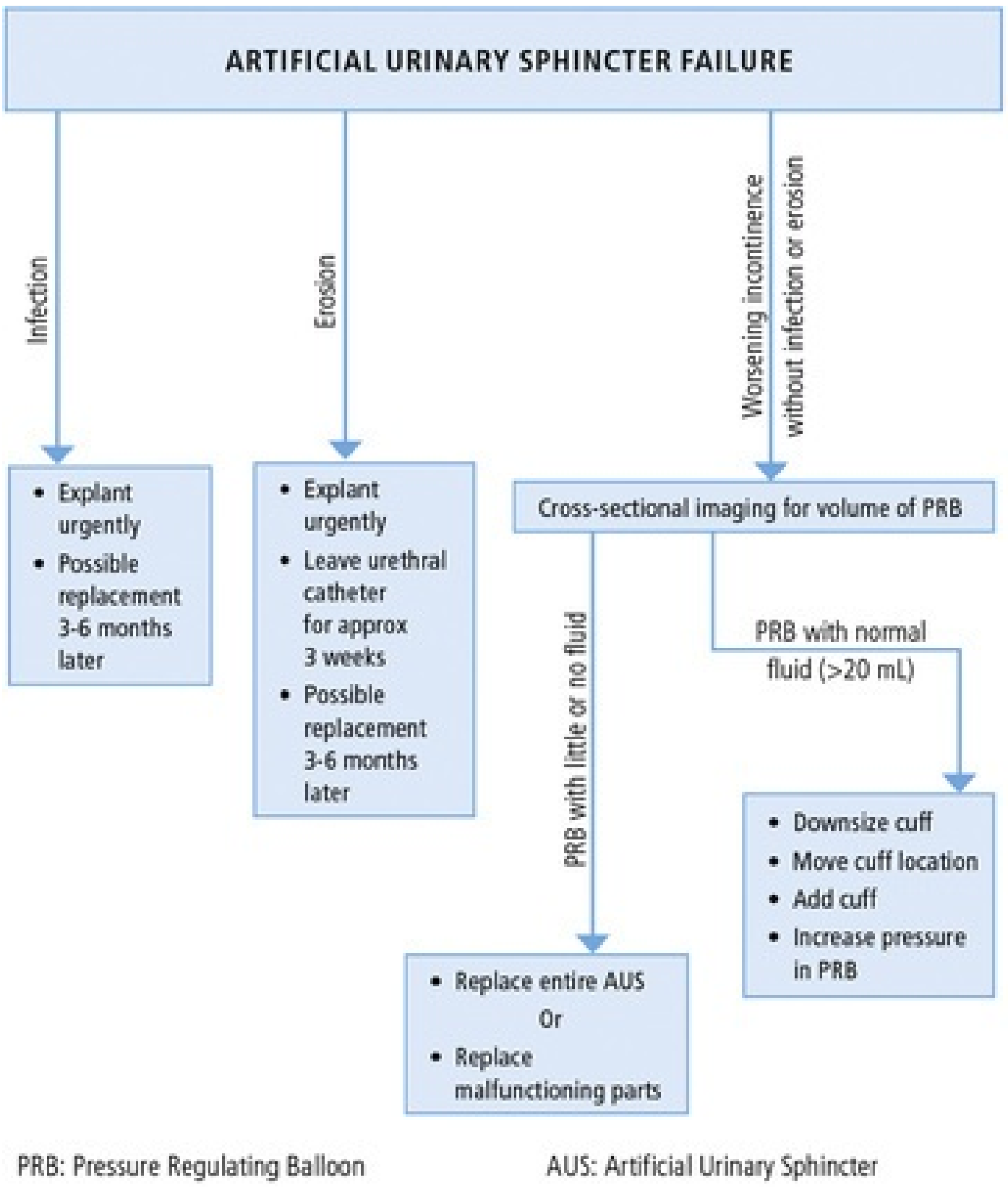
ARTIFICIAL URINARY SPHINCTER FAILURE
Infection
Erosion
Worsening incontinence without infection or erosion
• Explant urgently
• Possible replacement 3-6 months later
• Explant urgently
• Leave urethral catheter for approx 3 weeks
• Possible replacement 3-6 months later
Cross-sectional imaging for volume of PRB
PRB with little or no fluid
PRB with normal fluid (>20 mL)
• Downsize cuff
• Move cuff location
• Add cuff
• Increase pressure in PRB
• Replace entire AUS
Or
• Replace malfunctioning parts
PRB: Pressure Regulating Balloon
AUS: Artificial Urinary Sphincter

FIG. 131.5 AUA/SUFU Algorithm for Artificial Urinary Sphincter Failure. (Reproduced from Sandhu et al., 2019, with permission.)

Evaluation of the patient who underwent prior urethral sling is similar to the evaluation after AUS placement with several caveats. Identifying the type of sling placed (Advance vs. Virtue vs. bone anchored), and the timing of the incontinence are important. In the case of the Advance sling, it is important to determine whether the patient may have loosened the sling in the first 6 weeks postoperatively, whether the incontinence is persistent (ongoing stress UI without improvement), or the result of detrusor overactivity. If patients give a history of improved UI and a loosening of the sling in the first 6 weeks postoperatively, re-exploration is appropriate. The perineum is opened, the arms of the sling lateral to the bulbar urethra are identified, and each arm is cut. The remaining central portion of the sling should be removed from the surface of the corpus spongiosum of the bulbar urethra. This maneuver may require an extensive dissection if the initial sling surgery achieved a significant degree of elevation and invagination of the corpus spongiosum. Another sling can then be placed in the same manner as described later.

In patients with persistent or delayed stress UI after sling placement (i.e., no loosening of the Advance sling in the early postoperative period), evaluation should determine if the incontinence is a result of detrusor overactivity or stress UI. If persistent stress UI (i.e., sling failure) occurs, placement of an AUS is the "gold standard" and can be performed with similar outcomes compared with first-time AUS placement (Lentz et al., 2012; Ziegelmann et al., 2016). Placement of a second Advance sling in cases of late failure of the first sling is feasible in select patients and has been reported with a success rate of 56% at 17.5 months' follow-up (Martinez et al., 2015). We recommend this only in very selected cases when AUS is contraindicated or the patient refuses.

Key Points

- A careful history and voiding diary characterize the type and severity of urinary incontinence in most men.
- Uroflowmetry and postvoid residual urine volume measurement should be assessed at minimum.
- Suspected outlet obstruction, significant bladder overactivity, or impaired bladder contractility should prompt urodynamic studies.
- Patients with suspected urethral, vesicourethral, or bladder neck pathology should undergo cystoscopy.

- Urinalysis (and culture if indicated) are required before surgical treatment.

Indications for Surgery

Surgical correction of UI is indicated in male patients with irreversible sphincter incompetence and bothersome involuntary leakage of urine. In patients seeking treatment for incontinence after radical prostatectomy, pelvic floor muscle exercises or pelvic floor muscle training should be offered (Sandhu et al., 2019); however, the benefit of extensive or one-to-one pelvic floor muscle training after RP or TURP remains uncertain (Anderson et al., 2015; Campbell et al., 2012). Because progressive improvement in continence occurs after RP, some authors recommend a 1-year observation period (Flynn and Webster, 2004; Peyromaure et al., 2002). However, in patients with bothersome stress urinary incontinence after prostate treatment, surgery may be considered as early as six months if incontinence is not improving despite conservative therapy (Sandhu et al., 2019). Patients with incontinence after prostate treatment should be counseled that efficacy is low and cure is rare with urethral bulking agents (Abrams et al., 2009; Herschorn et al., 2010; Kuznetsov et al., 2000; Montague and Angermeier, 2000; Sandhu et al., 2019.)**. Thus AUS and slings should be considered as first-line surgical therapy for sphincteric incontinence in most men, although a trial of a bulking agent may be appropriate in cases of neurogenic male stress UI.**

Once the diagnostic evaluation has been completed (see Fig. 131.3), patients should be informed of management options for their incontinence, including surgical and non-surgical options (see Fig. 131.6). Physicians should discuss risk, benefits, and expectations of different treatments using the shared decision-making model (Sandhu et al., 2019). **Factors to consider include the severity of UI and associated bother; patient characteristics including body mass index, prior surgical procedures including urethroplasty, primary or adjuvant radiation therapy, bladder function, and cystoscopic findings; manual dexterity and cognitive function; efficacy of the various implants; long-term risk of complications and reoperation; and patient preference. Absolute contraindications to surgical correction of male UI are few and include bladder disorders that jeopardize renal function such as diminished vesical compliance and vesicoureteral reflux at low intravesical pressure. Inadequate tissue integrity at the bladder neck or urethra to accommodate a sling or AUS may require bladder neck closure or urinary diversion.** A urinary diversion can be considered in patients who are unable to obtain long-term quality of life after incontinence after prostate treatment and who are appropriately motivated and counseled (Sandhu et al., 2019). **In addition, urinary tract abnormalities that require future transurethral management, such as bladder cancer or refractory vesicourethral anastomotic strictures, should be considered relative contraindications to surgery.** In such cases, an AUS or sling procedure could impair transurethral access, and repeated instrumentation may put the devices at risk for infection or erosion. Although metastatic prostate cancer is not a contraindication to surgical correction of UI, improvements in quality of life must be balanced against performance status and life expectancy.

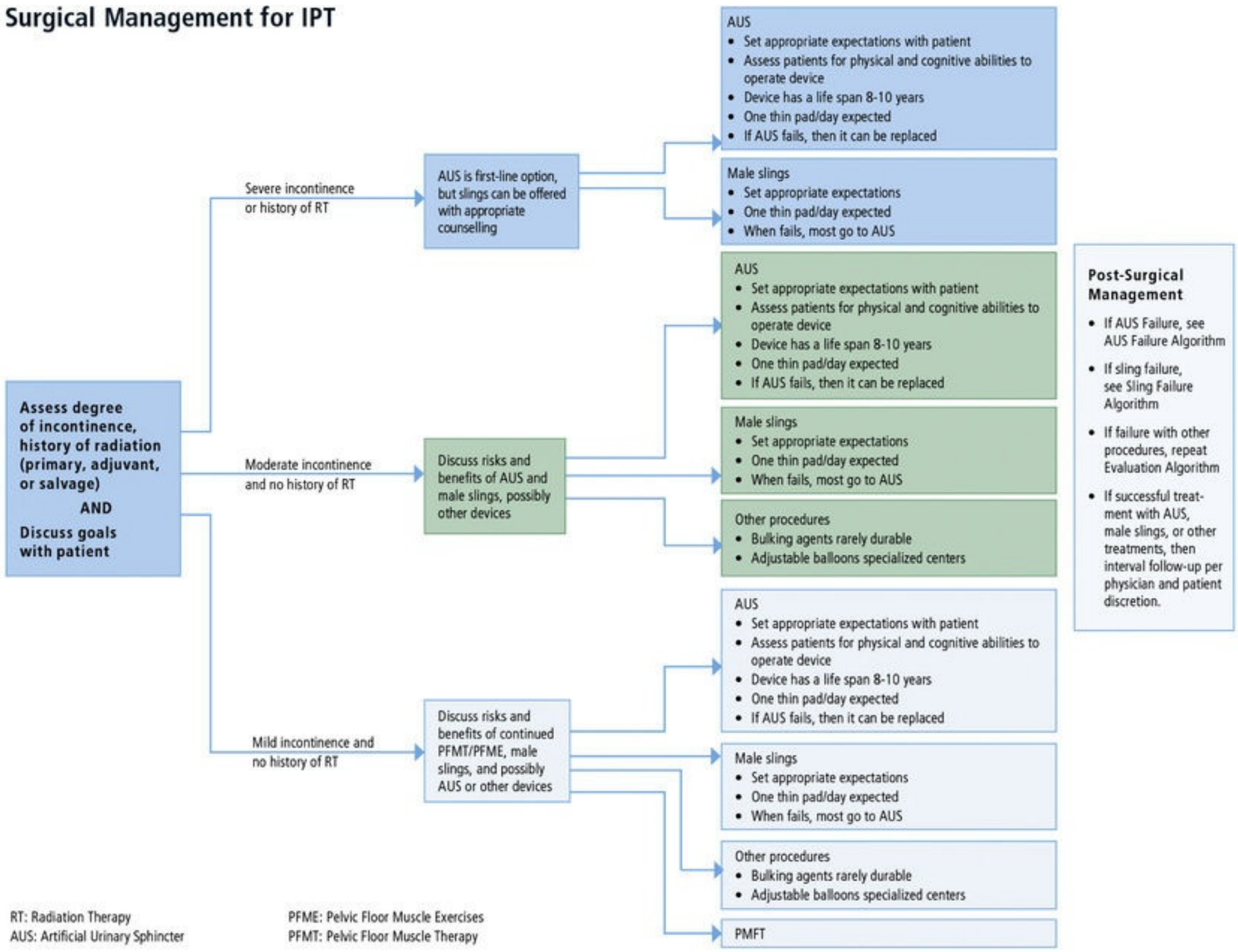
Surgical Management for IPT
Assess degree of incontinence, history of radiation (primary, adjuvant, or salvage) AND Discuss goals with patient
Severe incontinence or history of RT
AUS is first-line option, but slings can be offered with appropriate counselling
AUS
Set appropriate expectations with patient
Assess patients for physical and cognitive abilities to operate device
Device has a life span 8-10 years
One thin pad/day expected
If AUS fails, then it can be replaced
Male slings
Set appropriate expectations
One thin pad/day expected
When fails, most go to AUS
Moderate incontinence and no history of RT
Discuss risks and benefits of AUS and male slings, possibly other devices
AUS
Set appropriate expectations with patient
Assess patients for physical and cognitive abilities to operate device
Device has a life span 8-10 years
One thin pad/day expected
If AUS fails, then it can be replaced
Male slings
Set appropriate expectations
One thin pad/day expected
When fails, most go to AUS
Other procedures
Bulking agents rarely durable
Adjustable balloons specialized centers
Mild incontinence and no history of RT
Discuss risks and benefits of continued PFMT/PFME, male slings, and possibly AUS or other devices
AUS
Set appropriate expectations with patient
Assess patients for physical and cognitive abilities to operate device
Device has a life span 8-10 years
One thin pad/day expected
If AUS fails, then it can be replaced
Male slings
Set appropriate expectations
One thin pad/day expected
When fails, most go to AUS
Other procedures
Bulking agents rarely durable
Adjustable balloons specialized centers
PMFT
Post-Surgical Management
If AUS Failure, see AUS Failure Algorithm
If sling failure, see Sling Failure Algorithm
If failure with other procedures, repeat Evaluation Algorithm
If successful treatment with AUS, male slings, or other treatments, then interval follow-up per physician and patient discretion.
RT: Radiation Therapy
AUS: Artificial Urinary Sphincter
PFME: Pelvic Floor Muscle Exercises
PFMT: Pelvic Floor Muscle Therapy

FIG. 131.6 AUA/SUFU Algorithm for Surgical Management. (Reproduced from Sandhu et al., 2019, with permission.)

Artificial urinary sphincter should be considered for patients with bothersome stress urinary incontinence after prostate treatment (Sandhu et al., 2019). **It AUS remains the established device for treatment of moderate to severe UI, supported by numerous publications documenting its benefits.** Advantages include reproducible and reliable outcomes, ability of patients to empty the bladder without detrusor contraction, and proven efficacy after pelvic irradiation. A national study using validated questions from the UCLA PCI provides useful data on AUS results (Dalkin et al., 2003). Few men after AUS implantation have severe degrees of incontinence (9%), but many continue to use pads and report a moderately high urinary bother. There is evidence that men who are completely dry after RP have significantly better health-related quality of life compared with those who wear one pad daily (Cooperberg et al., 2003). Whether this is also the case after AUS remains unknown. **Long-term durability of the AUS is well established, although a revision rate of 16% and 28% at 2 and 5 years, respectively, highlights the limitations of the devices** (Dalkin et al., 2003) and is consistent with other single institution series in which 72% to 75% had the original sphincter in place and functioning at or beyond 5 years (Elliott and Barrett, 1998; Lai et al., 2007).

Perineal slings have been established as an alternative to AUS and should be considered as treatment options for mild to moderate stress urinary incontinence (Sandhu et al., 2019). A transobturator sling introduced by AMS (AdVance) in 2007 has been shown to be effective in short-term to intermediate-term follow-up of well-characterized case series. In selected populations, approximately 75% of patients are cured or significantly improved, with results persisting at 12 to 36 months (Kowalik et al., 2015). Thus **male sling procedures represent an established part of the surgical armamentarium for UI by providing an alternative to AUS for mild to moderate UI.**

AUA/SUFU Guidelines provide a moderate recommendation based on lower level evidence that "male slings should not be routinely performed in patients with severe stress incontinence" (Sandhu et al., 2019). Slings can be seen as alternatives for correction of more severe UI in those who refuse AUS from fear of infection, erosion, or mechanical failure as well as those with limited physical or cognitive capacity. In two small case series of patients with neurogenic stress incontinence, 28% to 65% of patients with UI improved (Groen et al., 2012; Vainrib et al., 2015). Although slings have a lower complication profile, one study showed that 30% of patients needed the sling removed for either infection or perineal wound breakdown (Vainrib et al., 2015). **The trade-off between risk and efficacy must be considered, with most authors recommending AUS for more severe UI. For mild UI, bulbar sling procedures become a preferred alternative, whereas AUS may represent therapeutic overkill. Thus the transobturator slings should be primarily used in cases with mild to**

moderate incontinence, which can be defined as a 24-hour pad weight of less than 150 g for mild UI (Flynn and Webster, 2004) **and less than 400 g for moderate UI** (Collada Serra et al., 2013; Fischer et al., 2007). In men with stress urinary incontinence after primary, adjuvant, or salvage radiotherapy who are seeking surgical management, artificial urinary sphincter is preferred over male slings or adjustable balloons (Sandhu et al., 2019). **A sling procedure should be offered with caution to those with prior radiation therapy or urethral erosion, because the degree of urine loss that exists in this group usually exceeds the limits of the procedure** (Castle et al., 2005; Dikranian et al., 2004; Giberti et al., 2009; Schaeffer et al., 1998; Torrey et al., 2013). One reason for the lower efficacy in these patients may be the lack of appropriate tissue elasticity for deformation/elongation/compression of the rhabdosphincter apparatus.

When deciding between the two devices (AUS vs. sling) men follow surgeon recommendations. However, when given the choice, men most often choose the sling to avoid the perceived risks of mechanical malfunction, revision surgeries, and device-associated problems (Kumar et al., 2009). This tendency may lead to a higher rate of failure with slings. In light of these choices made by patients and clinicians, a subset of men is predicted to require reoperation after placement of a transobturator male sling, because of inadequate treatment of incontinence.

Key Points

- Surgical intervention is indicated for stress urinary incontinence resulting from ISD that fails to improve with conservative management.
- Implant selection depends on the severity of UI; prior surgical procedures; bladder function; cystoscopic findings; manual dexterity and cognitive function; long-term risk of complications and reoperation; and patient preference.
- Slings should only be used very selectively in cases of radiation and severe gravitational UI.
- AUS should not be used in cases of poor manual dexterity, cognitive disability, poor urethral tissue integrity, or severely reduced bladder compliance.

Technique of Device Implantation

Operative Preparation

The entire operative site is shaved and ideally should incorporate chlorhexidine-alcohol skin preparation, including the lower abdomen, genitals, and perineum (Darouiche et al., 2010; Yeung et al., 2013). Surgery is conducted under general or spinal anesthesia with the patient in the low lithotomy position. **Intravenous antibiotics including an aminoglycoside (5 mg/kg) and a first- or second-generation cephalosporin or vancomycin are administered within 60 minutes before skin incision according to the American Urological Association (AUA) Best Practice Statement on antimicrobial prophylaxis** (Wolf et al., 2008). A chlorhexidine scrub for 10 minutes followed by Iodine Povacrylex (0.7% available Iodine) and isopropyl alcohol, 74% w/w (DuraPrep) was shown in one recent study to reduce postpreparation bacterial skin culture rates compared with povidone-iodine, although clinical implant infection rates were similar between groups (Yeung et al., 2013). The patient is then carefully draped; a urethral catheter may be placed to drain the bladder and facilitate identification and dissection of the urethra.

Artificial Urinary Sphincter

In the patient who selects artificial urinary sphincter, a single cuff perineal approach is preferred (Sandhu et al., 2019). The aim is to place the cuff as proximal on the bulbar urethra as possible, proximal to the fusion of the two corporal bodies (Fig. 131.7A). This location allows safe circumferential dissection of the urethra, provides protection of the cuff from opening while sitting, and exposes the largest diameter of corpus spongiosum for placement of the cuff. A **trans-scrotal approach popularized by Wilson et al.** (2003) **demonstrated suboptimal results for the control of incontinence, and required modification** (see later).

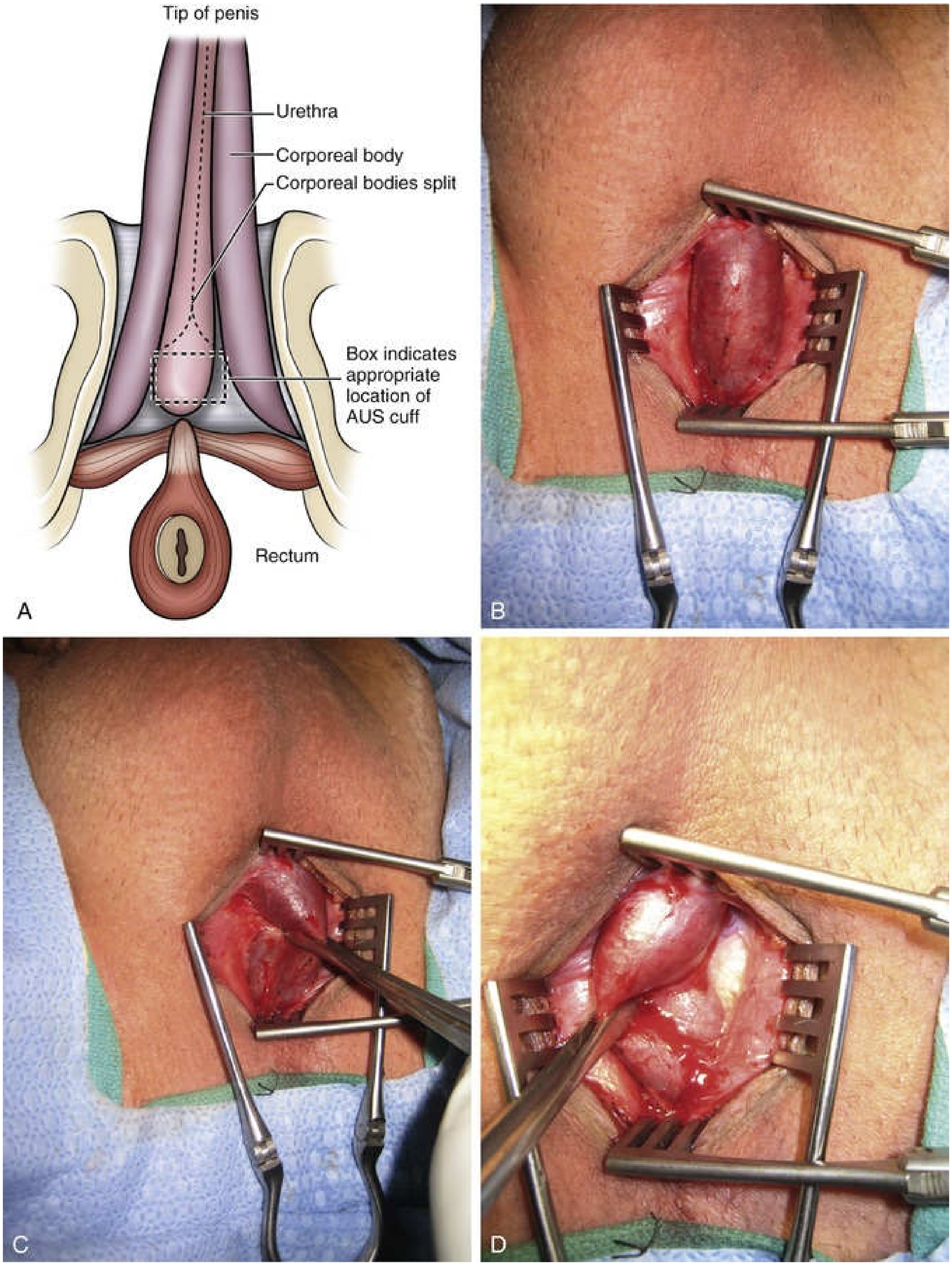
Tip of penis
Urethra
Corporeal body
Corporeal bodies split
Box indicates appropriate location of AUS cuff
Rectum
A
B
C
D

FIG. 131.7 Perineal anatomy and bulbar urethral dissection. (A) Preferred location for first-time bulbar cuff proximal to convergence of corpora cavernosa. Note box indicating ideal cuff placement. (B) Exposure of the corpus spongiosum after division of the bulbospongiosus muscle. (C) Dissection at interface between spongiosum and right crus of the

cavernosum. (D) Dissection at interface between spongiosum and left crus of the cavernosum. *AUS,* Artificial urinary sphincter.

After incision of the skin, Colles fascia, and bulbospongiosus muscle, Buck fascia is incised as it reflects off the bulbar urethra onto the diverging corporal bodies (Fig. 131.7B through D). A 2-cm wide tunnel is created under direct vision using sharp dissection dorsal to Buck fascia over the roof of the urethra. A right-angle clamp is then passed through this tunnel. Blunt spreading dissection is discouraged in this area because it risks injury to the urethra, especially in reoperative cases. **The circumference of the urethra is measured around the corpus spongiosum to guide selection of cuff size, most commonly 4.0 or 4.5 cm.** Surgeons should develop a standardized approach to cuff sizing. Whether to remove the urethral catheter before measurement (our choice) is less important than consistently applying a method and developing familiarity with the fit of the cuff compared with the tape measurement. As a rule of thumb, the actual cuff is slightly tighter than the tape measure. If the cuff size is obviously incorrect, the appropriate next size should be selected. Although some authors advocate selecting a cuff size 0.5 to 1 cm smaller than the measured circumference of the urethra to compensate for postoperative sub-cuff atrophy of the spongiosum, a recent study suggests that cuffs that are *less tight* have better continence outcomes (Rothschild et al., 2014). The best test of cuff fit is the visual and endoscopic appearance after it has been placed around the urethra (Fig. 131.8A and B). The tubing from the AUS cuff is passed through the overlying bulbospongiosus muscle into the deep perineal space beneath Colles fascia.

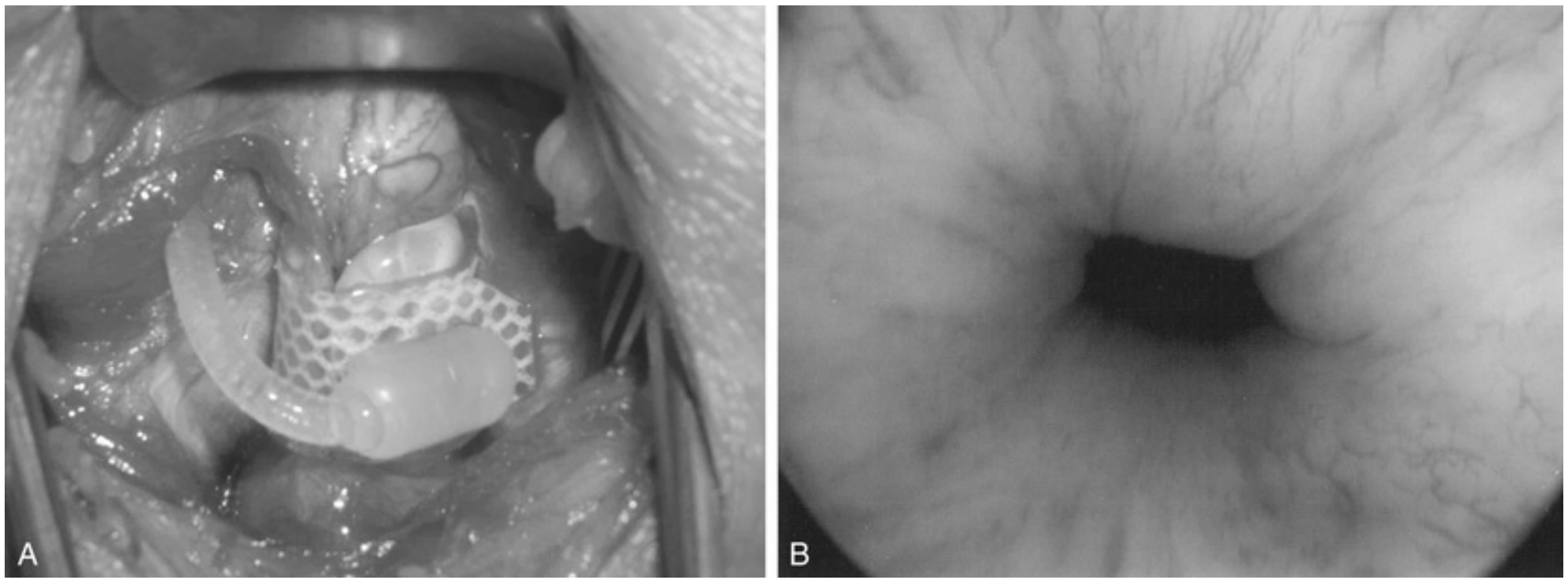

FIG. 131.8 Appropriate appearance of cuff. (A) Perineal placement encircling the bulbar urethra. (B) Endoscopic appearance with cuff activated.

The cuffs are available in various sizes, starting at 3.5 cm and range up to 11 cm (3.5, 4.0, 4.5, 5.0, 5.5, 6.0, 6.5, 7.0, 7.5, 8.0, 9.0, 10.0, 11.0). The larger sizes are reserved for bladder neck implantation. The 3.5-cm cuff allows the surgeon to further downsize devices to obtain better urethral coaptation in patients with significant urethral atrophy from prior AUS placement and those needing very distal placement of cuffs because of multiple revisions. Use of the 3.5-cm size has resulted in an increased risk of erosion in patients with a prior history of radiation therapy (Brant et al., 2014; Simhan et al., 2015). Patients with radiation therapy or other adverse risk factors and significant urethral atrophy should be considered for transcorporal placement rather than a 3.5-cm cuff (see later).

Pressure-Regulating Balloon

The placement of the PRB may be achieved through a scrotal, perineal, or abdominal incision, depending on prior surgical incisions, body habitus, and surgeon preference. Implanters should be familiar with each approach. For abdominal placement, a horizontal lower quadrant incision is made in the abdomen ipsilateral to pump placement. The rectus or external oblique fascia is incised, allowing the surgeon to split the underlying muscle and access the preperitoneal or intraperitoneal space. Digital dissection creates the space required for the PRB, which is small. **We place a 61- to 70-cm H_2O PRB in bulbar AUS and reserve the 71 to 80 cm H_2O PRB for bladder neck cuff placement.** The abdominal wall fascia is closed around the tubing.

Alternatively, the PRB can be placed via the external inguinal ring, using techniques adapted from penile implant surgery. With use of either a scrotal or perineal incision, the external ring is identified and used to provide access to the retropubic space by penetrating through the floor of the inguinal canal with a finger tip or instrument. No sutures are required because the transversalis fascia provides a natural barrier to PRB extrusion. Contraindications to this approach include mesh hernia repairs, radical cystectomy, and other extensive abdominal surgery. In such cases, the abdominal approach reduces the risk of inadvertent bladder or intestinal injury.

The PRB is filled with 23 mL of sterile normal saline or contrast material, unless a bladder neck cuff is used, which requires additional fluid volume according to manufacturer instructions. Filling solutions include 0.9% normal saline, Cysto-Conray 60 cc of contrast diluted with 15 cc of sterile water, or

Hypaque 25% 50 cc contrast diluted with 60 cc of sterile water. To provide an isotonic solution, contrast solutions should always be diluted with sterile water. Contrast media are contraindicated if the patient has an iodine or contrast allergy.

Control Pump Placement

The pump assembly is placed into the anterior scrotum from the inguinal, scrotal, or perineal incision. When the PRB has been placed abdominally, dissection proceeds inferiorly to the scrotum above the abdominal wall fascia accessing the anterior scrotum deep to Scarpa fascia. A finger placed outside the dependent portion of the scrotum then invaginates this skin upward into the inguinal incision, allowing the fascial layers to be stripped off the dartos layer with an instrument, creating a small pocket for the pump (Fig. 131.9). The pump is then placed into that position. For the single-incision approaches, a small subdartos pouch is created directly from the scrotal or perineal incision, orienting the pump accordingly toward the foot (scrotal) or head (perineal), respectively.

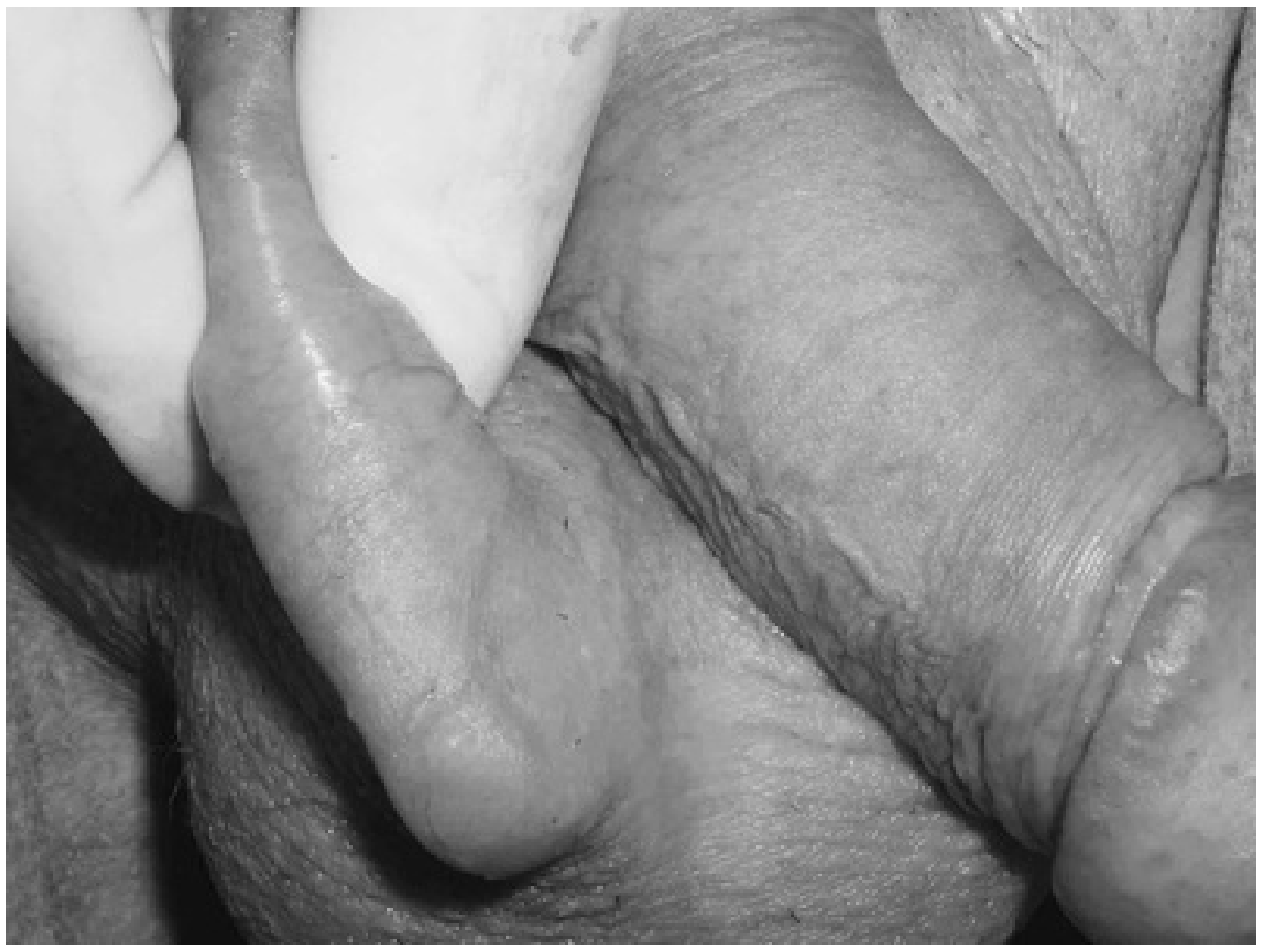

FIG. 131.9 Placement of the pump beneath the skin in a subdartos pocket.

Making the Connections

Connections are typically made in the abdominal incision, when used, protecting the connections from excess wear and allowing easy exploration at a later date. **The quick connectors supplied by the manufacturer provide excellent, secure, and watertight connections for newly implanted devices. However, they are not recommended for revision surgeries because a biofilm on the tubing interferes with watertight connection.** Therefore one must use hand-tie connectors in revision cases in which the entire device is not being replaced.

After the connections are complete, the device is cycled several times through the activation and deactivation states. We verify adequate coaptation of the urethra via urethroscopy. The closed cuff should cause slight blanching of the urethral tissue, indicating adequate urethral coaptation, filling and connection of the device (see Fig. 131.8B). Conversely, the deactivated cuff should cause minimal coaptation. If coaptation is deemed excessive in this circumstance, replacement with a larger diameter cuff should be considered.

Tandem Cuff Artificial Urinary Sphincter

Up to 11% of men may have significant incontinence after single-cuff AUS placement, despite significant improvements in AMS 800 design and implantation techniques (Montague and Angermeier, 2000). In such patients, when the cause of persistent UI is incomplete urethral occlusion, the addition of a second cuff around the bulbar urethra (Fig. 131.10A and C) can yield satisfactory continence (Brito et al., 1993; DiMarco and Elliott, 2003; Kabalin, 1996; O'Connor et al., 2003). **Indiscriminate use of the tandem cuff approach as first-line surgical treatment should be tempered by higher rates of erosion associated with the distal cuff in several series** (Bell and Mulcahy, 2000; Kowalczyk et al., 1996a,b)**. In addition, many patients undergoing AUS placement require subsequent AUS revision surgery, and tandem cuff placement limits available urethral locations for future cuff placement**.

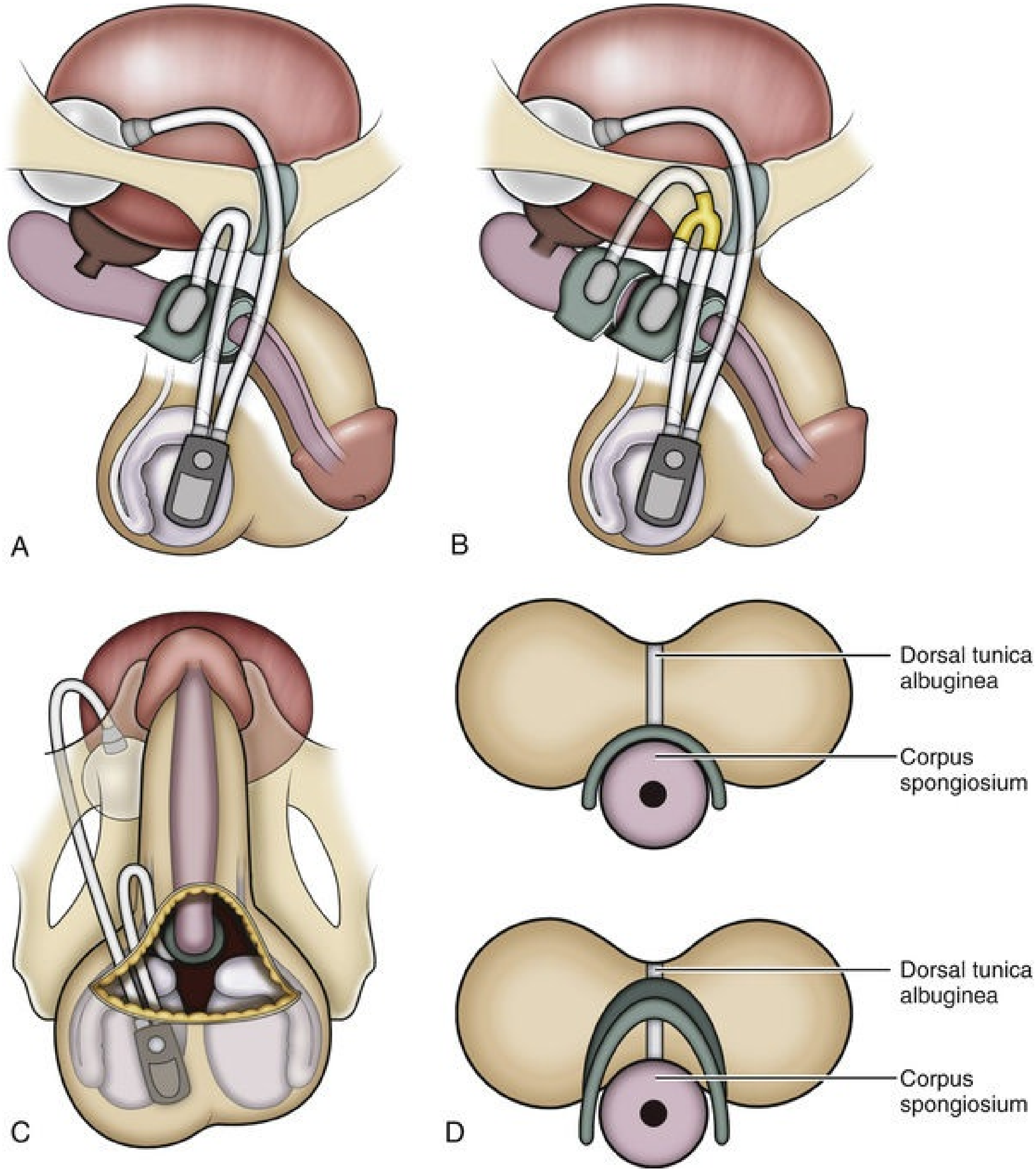
A
B
Dorsal tunica albuginea
Corpus spongiosum
C
D
Dorsal tunica albuginea
Corpus spongiosum

FIG. 131.10 Diagram of the artificial urinary sphincter implantation techniques including perineal (A), scrotal (B), tandem (C), and transcorporal (D) approaches. Note the incorporation of the ventral tunica albuginea with the corpus spongiosum in the transcorporeal approach.

Placement of the second cuff can be accomplished via the perineal incision. After circumferential dissection around the distal bulbar urethra, at least 1.5 to 2 cm distal to the primary cuff, a new cuff is placed. **Connection to the existing device requires division of the existing cuff tubing and use of a metal** Y-

connector. An additional 3 mL of fluid must be added to the system. When a new cuff is added to an existing system, the tubing must be connected with hand ties as described earlier. The entire device is left deactivated for 6 weeks postoperatively.

Transcorporal Artificial Urinary Sphincter Cuff

The transcorporal placement of the AUS provides another approach to difficult initial or revision surgery (Guralnick et al., 2002). Placing a transcorporal cuff after prior erosion or urethroplasty should be performed at a different location along the bulbar urethra (Biardeau et al., 2016). Rather than dissecting between the corpus spongiosum and the ventral surface of the corpora cavernosa, this technique leaves the ventral tunica albuginea attached to the dorsum of the spongiosum (see Fig. 131.10D). Parallel longitudinal incisions in the tunica albuginea of the corpora cavernosa, near the interface with the corpus spongiosum, allows the plane of dissection to pass through the septum of the corpora from one side to the other (Fig. 131.11A). The lateral edges of the tunica albuginea are imbricated *behind* the urethra before cuff measurement (see Fig. 131.11B). Closing the tunica albuginea this way reduces the risk of surgical site hematoma. Although there is a theoretical risk of impaired sexual function with the transcorporal approach, two small series have demonstrated that erectile function can be preserved in most sexually active men (Smith et al., 2013; Wiedemann et al., 2013). An operative video in the AUA video series details the technique.

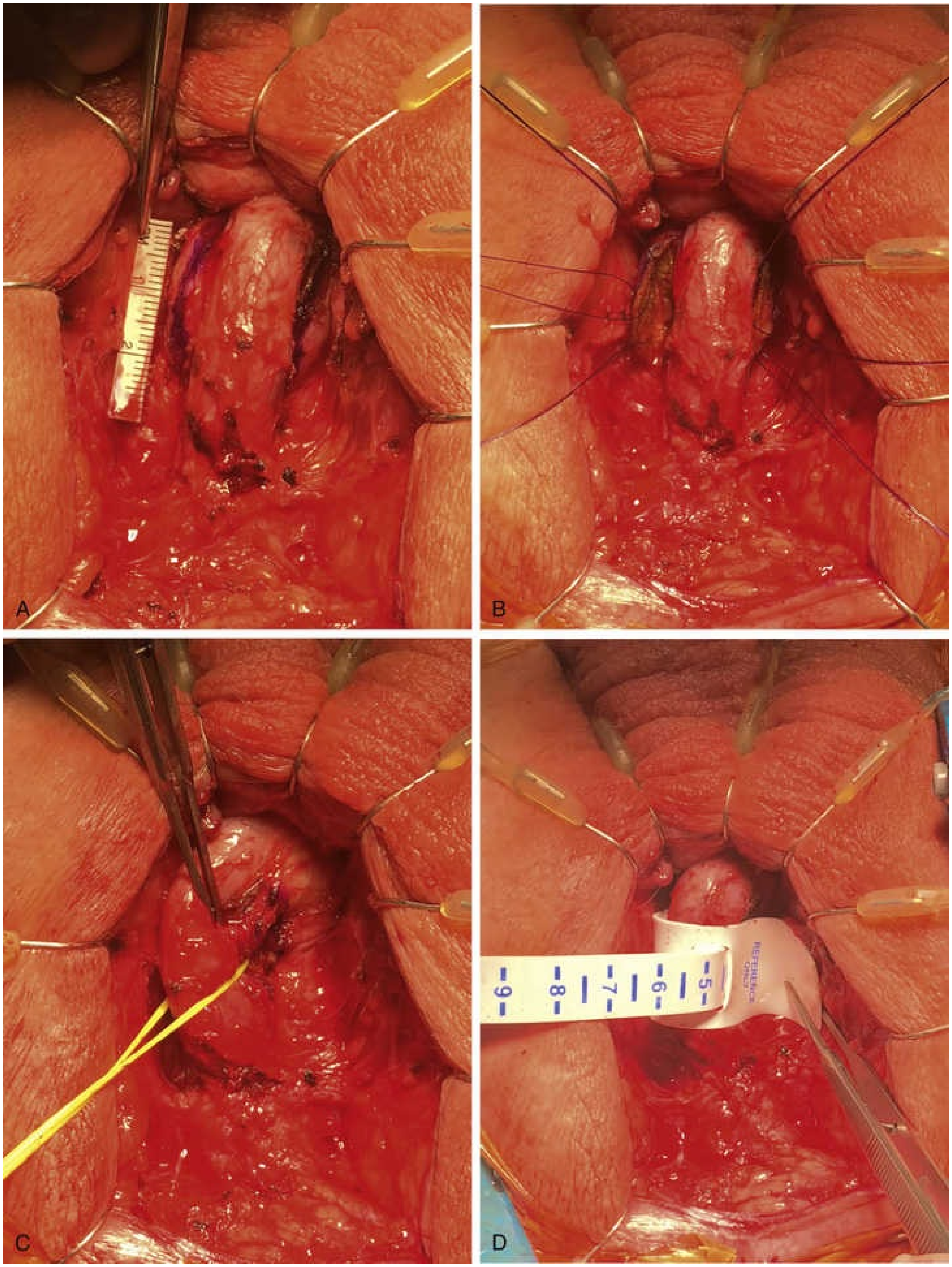
A
B
C
D
REFERENCE ONLY
5
6
7
8
9

FIG. 131.11 Transcorporal cuff placement. (A) Marking the tunica albuginea. (B) Bilateral incisions in tunica albuginea of each corporal body. (C) After imbrication of the lateral edges. (D) Measurement of the cuff size.

Advantages of the transcorporal approach include reduced risk of urethral injury during reoperation after prior erosion, urethra injury, urethroplasty, or rectourethral fistula repair; better cuff fit because of the increased bulk of the urethra; and *potential* reduction in erosion risk in high-risk patients (see Fig. 131.10). The technique is particularly useful when proximal cuff atrophy occurs leaving a small caliber urethra (e.g., 3.5-cm cuff or smaller) available distally. A prospective study evaluating urethral erosion with AUS found that men with prior radiation therapy, prior AUS erosion, and 3.5-cm cuff had an increased risk of cuff erosion (Brant et al., 2014). Patients undergoing transcorporal AUS are more likely to have transient urinary retention requiring suprapubic cystostomy placement (Smith et al., 2013). Transcorporal placement may yield AUS continence results similar to those in Table 131.1. Rates of cure or improvement in UI in patients undergoing transcorporal placement in high risk patients has been reported between 76% and 84%, without urethral erosion (Guralnick et al., 2002; Wiedemann et al., 2013). Literature on the effectiveness of this approach remains sparse with most series reporting a combination of both the standard and transcorporal techniques (Hoy and Rourke 2015; Sathianathen et al., 2014; Smith et al., 2013).

TABLE 131.1

Outcomes of Surgical Therapy for Male Sphincteric Urinary Incontinence

DEVICE	OUTCOMES (%)			
	CURED OR IMPROVED	CURED	IMPROVED	FAILED
Artificial urinary sphincter	82–89	73–76[a]	13–16	18–25
Transobturator sling	70–84	40–80[b]	13–30	16–30
Quadratic sling	32–100	32–70[c]	24–32	30–68

[a] Defined as 0–1 pad.

[b] Defined as no pads. Not included are results from series that included higher proportion of men with history of adjuvant radiotherapy.

[c] No consensus definition among studies.

Based on Haab, 1997; Hajivassiliou, 1999; Montague, 2000; Venn, 2000; Montague, 2001; Dalkin, 2003; Raj, 2005; Bauer, 2009; Hudak, 2011; Lai, 2012; Li, 2013; Rehder, 2012, 2013; Torrey, 2013; Brant, 2014; Comiter, 2014; Zuckerman, 2014; Kowalik, 2015; Simhan, 2015; McCall, 2016; Chen, 2017; Ferro, 2017; Wingate, 2017; Grabbert, 2019.

Trans-Scrotal Artificial Urinary Sphincter

Wilson et al. (2003) described a technique in which all components of the AUS are placed through a transverse scrotal incision. Originally developed for reoperative surgery because of urethral atrophy, it allowed placement of a more distal cuff in tandem or with the transcorporal technique (see Fig. 131.10B). Although the initial report was favorable in terms of continence outcomes, several reports suggest that the trans-scrotal technique yields inferior continence results (Henry et al., 2008; Stone et al., 2003). One possible explanation is that it does not allow equivalent placement of the cuff around the proximal, larger diameter bulbar urethra when compared with the perineal approach. Corroborative evidence comes from data on implanted cuff size. In a large series, 267 of the 272 perineal cuffs measured 4.5 cm, whereas the remaining cuffs were 5.0 cm (Elliott and Barrett, 1998). Conversely, in the trans-scrotal series, 32 of the 37 cuffs measured 4.0 cm and the remaining cuffs were 4.5 cm (Wilson et al., 2003). A modified version of the trans-scrotal approach, using enhanced exposure (Wilson et al., 2010), has allowed the use of larger cuff sizes around the proximal bulbar urethra and may address the concerns raised in the literature. The authors prefer the more proximal location achieved with perineal cuff placement, leaving the more distal implantation sites available for subsequent revision surgeries.

Bladder Neck Artificial Urinary Sphincter

Bladder neck AUS remains an optional, more invasive, and technically challenging method of cuff placement in those men with sphincteric UI in whom the prostate is without external surgical or traumatic disruption. Thus for causes of myelomeningocele and other neuropathic disorders it should be considered as an alternative to bulbar AUS (Herndon et al., 2003)**. Its use is contraindicated after RP.** Advantages include lower likelihood of erosion and cuff atrophy. Placement of the cuff is more complex, requiring a lower abdominal incision, exposure of the bladder base, and circumferential dissection of the vesicoprostatic junction. Opening the endopelvic fascia helps to develop of the plane of dissection; a catheter placed in the urethra and another in the rectum helps in identifying these structures. If necessary, cystotomy with placement of a finger in the lumen of the bladder neck may also assist the dissection. Similarly, the procedure can also be completely robotic, allowing dissection of the posterior plane between the bladder and seminal vesicles under direct vision and potentially avoiding the need for a lower abdominal incision (Yates et al., 2013). The bladder neck in adults requires a much larger cuff implant (usually 8 cm or greater), higher PRB pressure (usually 71–80 cm H_2O), and a larger fluid volume in the system. Manufacturer packaging includes details relevant to implantation, including determination of the extra fluid required in the system. In children, cuff and PRB characteristics may have to be altered significantly (Ruiz et al., 2006).

Key Points

- Standard implantation of the bulbar AUS places the cuff around the corpus spongiosum proximal to the convergence of the corporal bodies.
- Pressure-regulating balloon of 61 to 70 cm H_2O is advised for bulbar urethral cuffs. Placement may be via abdominal, scrotal, or perineal approach.
- Postoperative deactivation of the cuff for 4 to 6 weeks is essential for proper healing without erosion.
- Prolonged urinary retention requires suprapubic cystostomy drainage.
- Revision surgery for nonmechanical causes may require transcorporal cuff placement or other modifications such as using 3.5-cm or tandem cuff.

Transobturator Bulbourethral Sling

Rehder and Gozzi (2007) described a male transobturator sling that provides an alternative surgical technique for suburethral placement. Its use has been primarily for post-RP male UI, although indications have been broadened to include UI after TURP and laser enucleation (Barnard et al., 2014; Kretschmer et al., 2016) because the surgical management of stress urinary incontinence after treatment of benign prostatic hyperplasia is the same as that for patients after radical prostatectomy (Sandhu et al., 2019). **Transobturator male slings are designed to reposition and lengthen the membranous urethra.** After exposing the corpus spongiosum in a manner identical to the AUS described earlier, freeing the bulbospongiosus muscle off the spongiosum at a convenient starting point, the corpus spongiosum is dissected along its ventral surface proximally to the level of the perineal body, which is marked for later sling positioning and then taken down to release the most proximal bulb. The corpus spongiosum is thus released from the bulbospongiosus muscle to allow appropriate repositioning with tensioning of the sling. The next step is to develop the space between the corpus spongiosum and diverging corpus cavernosum on each side. It is important that the surgeon can feel the inferior pubic ramus *behind* each crus so that the trochar can be received safely onto the fingertip as it comes around.

Using the inferior margin of the adductor longus muscle as a landmark, a small stab wound is made approximately 1 fingerbreadth below the muscle on each side, in the groin crease. A spinal needle locates the obturator foramen immediately lateral to the pubic ramus. Then, using an outside-inside direction, the surgeon inserts the appropriate left- or right-sided helical passing device from the thigh through the obturator foramen and out of the perineal wound medial to the ipsilateral corporal body. The surgeon will feel two "pops" as the trochar passes through the various layers before turning the trochar. The trochar should be brought out as close as possible to the superior aspect of the angle formed by the corpus spongiosum medially and the ipsilateral inferior pubic ramus laterally. Once this has been completed, the polypropylene mesh is loosely positioned in the perineum, attached to the passing device on each side in turn, and pulled out of the obturator foramen to the medial thigh without tension. The proximal aspect of the sling is positioned at the pre-marked area of the distal aspect of the perineal body (Fig. 131.12A). **The sling is then fixed to the corpus spongiosum with 4 to 6 permanent or absorbable sutures. Once fixed in place, the arms of the sling are then steadily and equally pulled up to tension the device. With tensioning, the perineal body and proximal bulbar urethra should move proximally and cephalad 3 to 4 cm to achieve appropriate positioning** (Fig. 131.12B). The maneuver can also be performed during cystoscopic visualization of the external sphincter region, to verify the cephalad repositioning of the membranous urethra (Fig. 131.12C and D). Once in position, final tensioning is achieved after removing the plastic covering of the sling arms. The tail ends of the sling are tunneled by pulling the device ends into the main perineal incision without trimming excess length. The perineal incision is closed in layers, including the bulbospongiosus muscle, Colles fascia, and skin. Overnight catheter drainage is usually sufficient for decompression of the bladder.

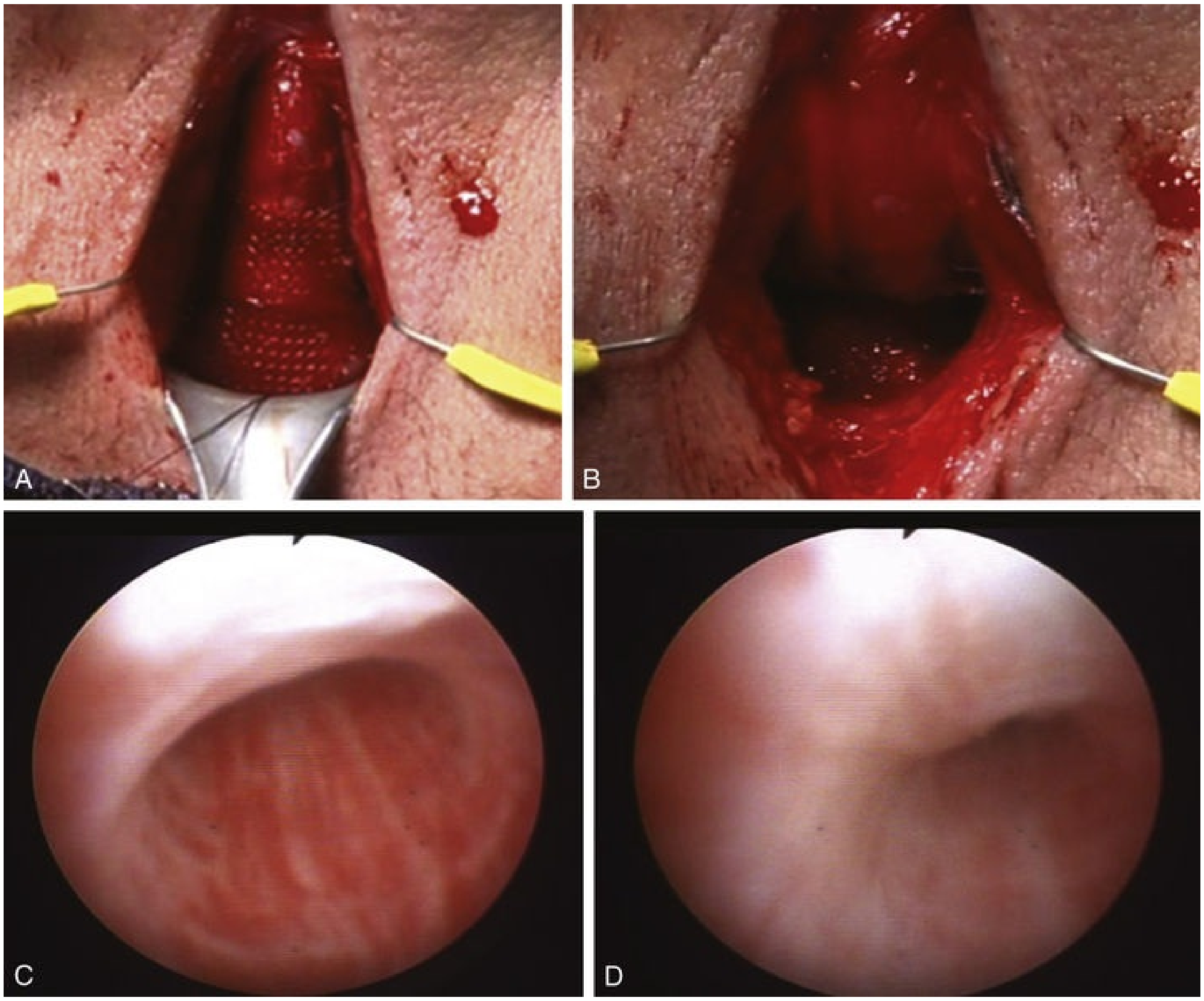

FIG. 131.12 Transobturator sling. (A) Perineal appearance of sling in place on corpus spongiosum before tensioning. (B) Perineal appearance of sling after tensioning. (C) Endoscopic appearance before tensioning. (D) Endoscopic appearance after tensioning.

Four-Arm Sling

A four-arm sling with two lateral strips for transobturator urethral elevation in addition to two prepubic arms designed to provide concomitant compression (see Fig. 131.2) yielded acceptable results (Comiter, 2007) leading to FDA approval. The device offers quadratic fixation and is marketed by Coloplast as Virtue (Comiter et al., 2012). A subsequent report emphasized the importance of sling fixation prepubically (Comiter et al., 2014). A small prospective cohort study of patients with mild UI showed significant improvement with durable outcomes at 3 years (Ferro et al., 2017). Its role in the treatment armamentarium has not been fully defined, but because of its compressive mechanism, the device may potentially be used across a range of UI severity and a wider spectrum of causes in addition to RP.

Key Points

- Male bulbar urethral slings are indicated in men with mild to moderate sphincteric UI, intact bladder contractility, and well-vascularized, nonradiated urethral anatomy.
- Transobturator slings reposition and elongate the membranous urethra and depend on the intact external sphincter.
- Quadratic fixation provides an alternative to the two-arm devices with limited data on efficacy and durability.

Artificial Urinary Sphincter Complications

Urinary Retention

Urinary retention after AUS is rare but more frequent with transcorporal and 3.5-cm cuffs compared with larger cuffs (Smith et al., 2013). Retention in the immediate postoperative period should be managed by transurethral bladder drainage with a small (10-Fr or 12-Fr) catheter for 24 to 48 hours. Cuff deactivation must be confirmed before catheterization. **If the patient fails a voiding trial at 48 hours, suprapubic cystostomy drainage is recommended to reduce the risk of urethral erosion.** Ultrasound or fluoroscopic guidance is recommended to prevent puncture or potential contamination of the PRB. Retention persisting beyond several weeks implies undersizing of the cuff; in such cases reoperation and cuff replacement may be required. Correlation with preoperative urodynamic findings is advised in such case. Late-onset urinary retention mandates endoscopic and urodynamic evaluation to rule out proximal urethral obstruction, erosion, or detrusor failure.

Artificial Urinary Sphincter Infection

Infection remains a serious and devastating complication of any implant surgery. The rate of infection with initial AUS surgery is 1% to 3% (Gundian et al., 1989; Litwiller et al., 1996; Marks and Light, 1989; Montague and Angermeier, 2000) but may be as high as 10% in high-risk patients (see earlier). **Skin pathogens are the most commonly cultured organism, usually *Staphylococcus epidermidis* and *S. aureus*** (Licht et al., 1995). The introduction of the InhibiZone surface treatment combining rifampin and minocycline hydrochloride to the AUS cuff and pump was postulated to lead to a reduction in postoperative infection rates, although the reduced infection rate seen with penile implants (Carson, 2004) has not been replicated in the AUS literature (de Cógáin and Elliott, 2013). Late infections (>4 months) may represent indolent organisms introduced at the time of infection or by hematogenous spread. Therefore, **in men with AUS, antibiotics should be considered before urinary tract manipulation in accordance with AUA Best Practice Statements** (Wolf et al., 2008, updated 2012).

The initial presentation of an early postoperative AUS infection is usually scrotal pain, although erythema, edema, and frank purulence commonly accompany this symptom. **Because implant infections are generally not amenable to antibiotic therapy, in a patient presenting with infection or erosion of an artificial urinary sphincter or sling, explantation should be performed and reimplantation should be delayed** (Sandhu et al., 2019). Figs. 131.6 and 13 show the AUA/SUFU algorithm for AUS and male sling failure, respectively.

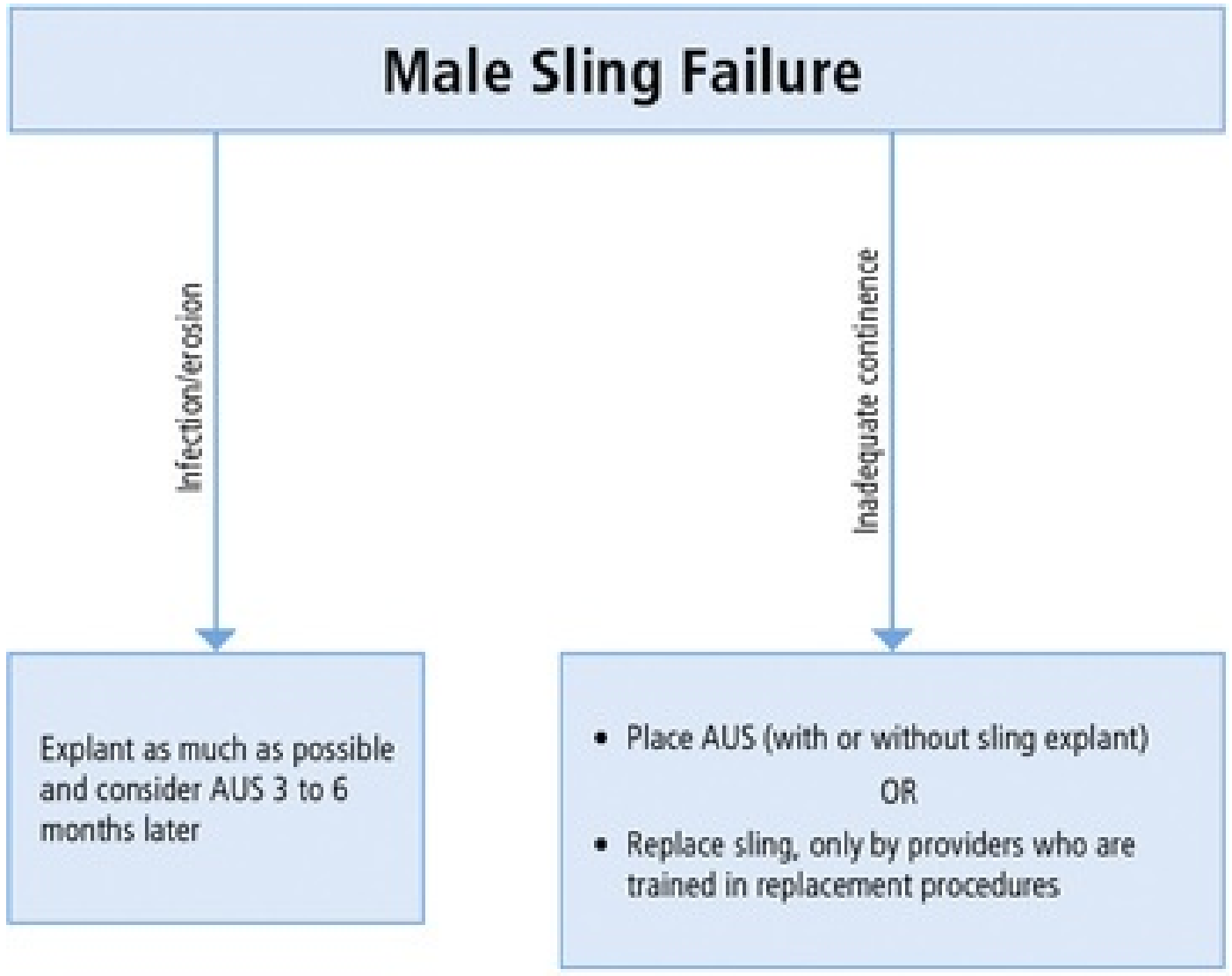
Male Sling Failure
Infection/erosion
Inadequate continence
Explant as much as possible and consider AUS 3 to 6 months later
• Place AUS (with or without sling explant)
OR
• Replace sling, only by providers who are trained in replacement procedures

AUS: Artificial Urinary Sphincter

FIG. 131.13 AUA/SUFU Algorithm for Sling Failure. (Reproduced from Sandhu et al., 2019, with permission.)

Immediate salvage of infected non-eroded AUS can be accomplished with complete device removal, antiseptic irrigation, and immediate reimplantation (Bell and Mulcahy, 2000; Bryan et al., 2002; Kowalczyk et al., 1996a,b). This procedure includes an irrigation regimen used in penile prosthesis salvage protocols (Mulcahy et al., 1995). Mulcahy and associates used this approach to salvage 7 of 8 patients with infected non-eroded AUS in a total of 9 operations (Bryan et al., 2002). In all cases the entire AUS was removed and the wounds were copiously irrigated according to a seven-solution protocol before a new system being implanted. Contraindications to prosthesis salvage include sepsis, ketoacidosis, necrotizing infection, device erosion, immunosuppression, and the finding of gross purulent material at the time of explantation.

Urethral Erosion

Urethral erosion is reported in 5% to 10% of AUS implantations and is as high as 35% in patients with multiple risk factors described earlier (Brant et al., 2014; Mock, 2015). Furlow introduced the concept of postoperative deactivation during the healing process to decrease pressure-induced ischemia and necrosis (Furlow and Barrett, 1985). **Delayed activation has lowered the risk of urethral erosion, especially in cases of reimplantation.** The secondary urethral erosion dropped from 18% to 1.3% with this technique (Motley and Barrett, 1990). Multiple well-established risk factors of erosion include prior radiation, hypertension, coronary artery disease, diabetes, and prior AUS revisions (Brant et al., 2014; Raj et al., 2006; Rivera et al., 2016). In addition, urethral catheterization (with or without cuff deactivation) is also a risk factor for urethral erosion (Seideman, 2013).

Although a recent study reported that only 25% of PRBs left in place at the time of AUS cuff explant because of erosion became infected (Rozanski et al., 2018), **we advocate for immediate removal of all the components in cases of erosion, because they are assumed to be infected** (Biardeau et al., 2016)**. Urethral injury has traditionally been managed with urethral catheter drainage and or suprapubic cystostomy** (Flynn and Webster, 2004; Kowalczyk et al., 1996a,b). Perineal wounds are considered infected and loosely approximated or allowed to close by secondary intention.

In an effort to decrease the risk of subsequent urethral stricture, several centers have evaluated the management of acute erosion with urethrorrhaphy or urethroplasty. The type of urethroplasty performed at the time of erosion has not been well studied and likely depends on the degree of urethral loss at the time of device explantation. Patients who underwent in situ urethral repair, with ventral approximation of the urethral mucosa without mobilization of the urethra, developed a urethral stricture in 38% of patients compared with 85% of patients who had urethral catheter drainage alone (Rozanski et al., 2014). In contrast, a multi-institutional study demonstrated a higher risk of stricture formation in patients with complete cuff erosion and did not demonstrate a statistically significant difference in stricture rate among patients who had their erosion managed with catheter (29%), urethrorrhaphy (repair of capsule) (40%), or anastamotic urethroplasty (14%) (Gross et al., 2017). This is a complex, heterogeneous group of patients with variable degrees of urethral loss resulting from cuff erosion. Further study is needed to identify which patients may be best suited for acute erosion urethroplasty or whether catheter placement alone is sufficient.

AUS reimplantation is considered only after urethral healing is confirmed by urethrography and a delay of 3 to 6 months is observed. Urethral patency must be confirmed after urethral erosion and cuff removal by cystoscopy or retrograde urethrogram before attempted device replacement (Frank et al., 2000; Kowalczyk et al., 1996a,b; Motley and Barrett, 1990). A new cuff should be placed either proximal or distal to the previous site. Significant scarring as well as a compromised vascular supply makes replacement of the cuff at the erosion site difficult and risky (Kowalczyk et al., 1996a,b; Motley and Barrett, 1990). The risk of repeat cuff erosion in patients undergoing AUS reimplantation has been shown to be as high as 35% in the first 6.7 months (Raj et al., 2006). Frank et al. (2000) **recommended nightly deactivation of the AUS in cases of reimplantation for prior erosion** and reported a successful outcome in 87% of de novo reimplantation after erosion or infection, with recurrent urethral erosion in 8.7%. **Use of the transcorporal approach in such cases may reduce the risk of urethral injury during the secondary surgery as well as potentially provide greater protection against subsequent erosion.**

Urethral Atrophy

Patients should be counseled that artificial urinary sphincters will likely lose effectiveness over time, and reoperations are common (Sandhu et al., 2019). **Urethral atrophy results from the chronic compression of the spongy tissue under the occlusive cuff. In contrast to device failure, the symptoms may be insidious in onset and progress slowly. This is considered one of the most common reasons for revision of the AUS. Treatment options include cuff downsizing, movement of the cuff to a more proximal or distal location, where the spongiosum may be thicker, transcorporal placement, or placement of a second cuff in tandem.** Simple replacement of the PRB with a higher-pressure reservoir to overcome urethral atrophy is no longer recommended because of risk of erosion (Raj et al., 2005).

Our approach is to downsize the cuff in the same location when possible. If the existing cuff is 4.0 cm, we reposition the cuff more proximally, when feasible, or more distally using the transcorporal technique if necessary, and measure the appropriate size cuff. Saffarian et al. (2003) reported a significant improvement in daily pad usage from 3.9 to 0.5 in 17 patients with urethral atrophy undergoing AUS. In a large series of secondary AUS surgery, the cuff was replaced in 142 cases of which 33% of cuffs were placed distal to the original location, 11% were placed proximal, and 52% were placed at the original cuff location (Raj et al., 2005). The cuffs were downsized in 56% of cases, unchanged in 30% and upsized in 13%, reflecting the new locations.

Recently the concept of subcuff atrophy has been questioned, and one high-volume center obtains acceptable results by assuming that all cases are mechanical failure and replaces the device with the same size cuff (Bugeja et al., 2016). In contrast, Srivastava et al. (2018) used retrograde urethral pressure profilometry to assess cuff coaptation and identified atrophy as the cause of AUS failure in 22% of cases.

Mechanical Failure

The historical incidence of mechanical failure has diminished substantially after introduction of the narrow-backed cuff (Elliott and Barrett, 1998). The change in design resulted in a decrease in nonmechanical failure from 17% to 9%, primarily because of a reduction in urethral atrophy. A decrease in mechanical failure from 21% to 7.6% was primarily the result of a reduction in cuff leak along with improvements in the synthetic material, which lessened the risk of fracture or kinking of the device. **Patients can generally expect a 7- to 10-year device life for the AUS. In the absence of infection or erosion, replacement of an isolated malfunctioning component may be feasible if the revision occurs within 3 years of implantation. These will most often be pump or cuff failures, which occur at a median of a year or less** (Srivastava et al., 2018)**. However, a slow leak from the PRB may be difficult to diagnose intraoperatively, and, if in doubt, total device replacement is prudent. Devices more than 3 years old most likely fail at the PRB; we generally replace the device in toto; however, approaches to selectively interrogate the PRB first, either with an ohmmeter** (Selph et al., 2015) **or a burette** (Srivastava et al., 2018)**, may allow the experienced implanter to avoid total replacement.**

Special Circumstances

The management of **urethral and vesicourethral anastomotic stricture** encountered *after* AUS implantation proposes a unique challenge. Stricture at the site of the AUS cuff may result from compression or ischemia and may indicate impending urethral erosion. One such bulbar urethral stricture was successfully managed with periodic dilation (Debell and Wessells, 2001). Others have successfully treated strictures proximal to an AUS with balloon dilation (Westney et al., 1992) or holmium laser through a flexible cystoscope or ureteroscope (Anger et al., 2005). In the event significant endoscopic manipulation is required proximal to the cuff site (e.g., transurethral resection of bladder tumor), our practice is to surgically uncouple the cuff for the duration of the endoscopic procedure.

The incidence of **urethral stricture after catheter management of erosion** is unknown, with no large series on AUS reporting this outcome. Patients who develop a significant urethral stricture after erosion may require urethroplasty before subsequent AUS placement. Patients with stress urinary incontinence following urethral reconstructive surgery may be offered artificial urinary sphincter and should be counseled that complications rates are higher (Sandhu et al., 2019). Patients undergoing AUS reimplantation 6 months after successful urethroplasty have an expected risk of erosion of 24% at 2 years' follow-up (Keihani et al., 2017). Transcorporal AUS placement in patients undergoing revision AUS may reduce the risk of subsequent erosion.

UI after cystectomy and neobladder reconstruction is a well-known entity. AUS placement in this group of patients is feasible, but not without a significant rate of complication. Patients with elevated postvoid residual were taught clean intermittent catheterization (CIC) after cuff deactivation. Incontinence improved in 76% of patients but with a 60% revision rate (O'Connor et al., 2002). This revision rate is likely due to the high bacterial colonization rate as well as risk associated with CIC. An important technical aspect in this group of patients is to avoid placing the PRB adjacent to the neobladder because of the risk of erosion into the neobladder or other adjacent bowel. We advocate making a counter-incision lateral away from the midline and placing the PRB posterior to the rectus muscle.

In patients with incontinence after prostate treatment and erectile dysfunction, a concomitant or staged procedure may be offered (Sandhu et al., 2019). **Dual implantation of AUS and inflatable penile prosthesis** is safe, feasible, and cost-effective for patients with UI and erectile dysfunction. Although the literature is limited, several small case series have shown that synchronous implantation of both devices can be performed, albeit with longer operative times (Kendirci et al., 2006; Rolle et al., 2012). Implantation can be performed through 1 penoscrotal incision or 2 incisions (penoscrotal, perineal).

Patients who have **an inflatable penile prosthesis requiring placement of a transcorporal AUS** represent a potentially complex scenario for the implant surgeon. Surgeons should attempt to avoid opening the capsule of the penile prosthesis to prevent potential contamination and direct contact of the two silicone devices. If this is unavoidable, separation of the two implants can be achieved by closing the tunical defect with tutoplast, donor pericardium, or other similar off-the-shelf material.

Sling Complications

The most commonly reported complications of male slings are perineal pain, urinary retention, infection, and rare cases of erosion. Retention is short lived and resolves within several weeks. Isolated cases have required release of the sling. **Large series with longer-term follow-up suggest rates of erosion and infection of 1% to 2%** (Cerruto et al., 2013; Zuckerman et al., 2014). Patients should be counseled as to the possibility of persistent pain and dysuria after slings, although such complications are extremely rare. Pain is typically related to the trocar introduction sites on the thigh and generally subsides; persistent severe pain may imply that the sling has been placed through the tendon of to adductor longus muscle and should be evaluated with appropriate imaging.

Key Points

- Device infection typically requires total explantation, but salvage procedures in select patients with device removal, antibiotic regimen washout, and reimplantation are feasible.
- Device erosion requires total explantation and catheter drainage.
- Troubleshooting of recurrent UI post-AUS requires a systematic and exhaustive evaluation.
- Cuff atrophy requires downsizing, repositioning, tandem cuff, or transcorporal surgery.

Long-Term Results of Artificial Urinary Sphincters and Slings

Outcomes of surgical correction of male UI depend on patient and device characteristics. First in importance is the severity of UI. Many urologic surgeons reserve sling surgery for mild to moderate degrees of incontinence, but severity is poorly characterized by pad number (see earlier). A difference in baseline incontinence between studies introduces unmeasured bias and makes comparisons of case series difficult. We have summarized available data in Table 131.1.

Montague and Angermeier (2000) reviewed the results of the AUS in 286 patients from 5 centers noting that on average 76% of patients were dry (dry 0–1 pads/day) and 13% were improved, for an overall success rate of 89% at a mean follow-up of 18 to 44 months. Revision of the device occurred because of erosion 5%, infection 3%, and mechanical failure 15%. Other studies have confirmed these results (Hajivassiliou, 1999; Venn et al., 2000). Although many patients still need minor protection with urinary pads, most are satisfied with the long-term outcome of the AUS (Dalkin et al., 2003; Haab et al., 1997; Montague and Angermeier, 2001; Wingate et al., 2017). Success rates for revision surgery compare favorably with initial surgery, although infection and erosion rates are higher (Raj et al., 2005). Differences among centers may be related to surgical volume, inclusion of secondary implants, as well as the sensitivity and accuracy of outcome measures. The long-term fate of patients implanted with transcorporal cuffs and the newly introduced 3.5-cm cuff remain to be determined (Hudak and Morey, 2011). The 3.5-cm cuff is an option for patients with urethral atrophy except in cases of prior radiation therapy or erosion (Brant et al., 2014; Lai and Boone, 2012; Simhan et al., 2015).

Initial success rates with transobturator slings are high, and outcomes appear to be durable beyond 3 years. One surgeon did not identify a learning curve in adoption of the transobturator male sling (Zuckerman et al., 2013), but other centers with less extensive experience with male urethral surgery, AUS, or female sling surgery may note greater variation in outcomes with initial cases.

The role of the transobturator AdVance sling in the armamentarium has been firmly established. Early promising results (Bauer et al., 2009) have been confirmed by other centers, and a persistent benefit with only modest deterioration over time (Li et al., 2012; Rehder et al., 2012; Zuckerman et al., 2014). Incontinence improvement at 3 years is reported between 73% and 77% in appropriately selected patients (Kowalik et al., 2015; Rehder et al., 2012; Zuckerman et al., 2014). Patient selection criteria are evolving, particularly with regard to cutoffs based on incontinence severity (e.g., pad number or weight). The poorer prognosis for patients having undergone prior adjuvant radiotherapy has been replicated in additional series (Torrey et al., 2013).

A recently performed meta-analysis supports multiple prior studies on the effectiveness of the AUS and Advance sling. This analysis did not compare effectiveness of the AUS to the sling, rather the published outcomes that are usually based on surgeon decision. Both devices reduced the pad number used per day by 3, with approximately 60% of men cured of UI and another 25% improved (Chen et al., 2017).

Success rates reported for the Virtue Quadratic Sling range from 32% to 100% based on UI severity, technique (fixation or no fixation), and primary outcome measure (Comiter et al., 2014; Ferro et al., 2017; McCall et al., 2016). In the longest running study (Ferro et al., 2017) all patients used a pad or less at 36 months, and improvements in most measures were significant. However, other studies used alternative definitions of success, such as no pad use, which makes comparison across studies difficult. In the only study without industry support, success was much lower (32%). Larger, rigorously designed studies, including principles enunciated by the FDA in its *Guidance for Industry and Food and Drug Administration Staff* (FDA, 2011), are necessary before more widespread dissemination of Virtue can be recommended.

The approach to failure of male sling is also evolving. Repeat male sling surgery was effective in several studies, with the caveat that selection criteria must be carefully considered (Martinez et al., 2015; Soljanik et al., 2010). Reoperation and implantation of AUS has been shown to have outcomes similar to those in surgically naive patients (Lentz et al., 2012), and in patients with persistent or recurrent stress urinary incontinence after sling, an artificial urinary sphincter is recommended (see Figure 131.13) (Sandhu et al., 2019).

The less-consistent outcomes seen with male perineal sling surgery may reflect variation in residual rhabdosphincter function or implantation techniques. In the future, quantitative assessment of rhabdosphincter function may be important in selection of patients for sling surgery or AUS. Finally, sling implantation inherently introduces greater variability in technique. Many factors are at play, including location of sling placement along the bulbar urethra, pelvic bony anatomy, degree of tension placed on the device, and other unmeasured influences. In contrast, the AUS occludes the bulbar urethra with a very high degree of reproducibility and mechanical reliability, allowing consistent results regardless of the degree of incontinence or experience of the surgeon.

Key Points

- AUS continues to provide a reliable solution to male UI of all degrees of severity across the range of first-time implantation to complex reoperative and high-risk patients.
- Transobturator slings such as AdVance and newer devices provide long-term durable outcomes for mild to moderate male UI after RP.

Future Directions

Improving the Quality of Evidence

It is estimated that more than 150,000 men have undergone AUS implant or sling device for the treatment of male stress incontinence (Van der Aa et al., 2013). Despite the large number of patients, the preponderance of clinical studies evaluating the long-term outcomes related to device implantation are small, retrospective single institution case series. This is highlighted by two recent reviews evaluating the quality of articles on surgical procedures for male stress UI. A Cochrane database review found only 1 randomized controlled trial evaluating surgery for male stress UI, whereas another review found that there have been no high-quality studies performed as defined by randomized controlled trial data or data registry data (IDEAL framework 3-4) (Barski et al., 2017; Silva et al., 2014). Consequently, there are many critical questions that remain unanswered or have been studied with insufficient power to properly direct patient and surgeon practice. Patient-reported outcome measures used to assess AUS outcomes have not been designed or validated for men with UI (Wingate et al., 2017). Other gaps include evaluation of the impact of radiotherapy on AUS and sling outcomes, how to best manage AUS erosions (i.e., in situ urethroplasty vs catheter), and how to manage urethral strictures after AUS erosion (Chertack et al., 2017; DeLay et al., 2018; Keihani et al., 2017; Rozanski et al., 2014; Srivastava et al., 2018).

Patients and urologic surgeons are likely to benefit from greater collaboration among institutions by participating in device registries and/or multi-institutional research studies, which offer the power to answer the field's most difficult questions regarding outcomes of male UI device surgery and the impact on patients' health-related quality of life. Patients are being accrued in the randomized controlled MASTER (male synthetic sling vs. AUS trial for men with urodynamic stress incontinence after prostate surgery) trial in the UK. The trial objective is to determine whether the Advance sling is non-inferior to the AUS for post-prostatectomy male UI based on clinical outcomes, complications, and cost-effectiveness (Constable et al., 2018). In addition, the European Urology Association Research Foundation in collaboration with Boston Scientific Corporation is enrolling a registry of patients in Europe with male UI undergoing AUS or sling placement. The primary outcome endpoint is cure rate, with secondary outcomes evaluating the time being incontinence free, time from revision, change in quality of life, and complications (US National Library of Medicine).

Training Paradigms

Implantation of AUS and sling can dramatically improve male UI, yet only 20% to 30% of urologists in the US continue to perform this surgery after training (Poon et al., 2012). Several hurdles limit the adoption of these procedures amongst practicing urologists: unclear indications for sling versus AUS; low case numbers in training; limited familiarity with perineal dissection; and lack of standardization of device implantation techniques. Strategies to increase dissemination are therefore needed during and after training. These may include innovations in preoperative assessment of sphincteric function to optimize assignment to sling surgery; development of simulation curricula or standardized cadaver-based training during graduate medical education; and invention of novel tools to improve intraoperative cuff sizing, sling tensioning, and other critical steps in device implantation.

Summary

The continued high rate of surgery for localized prostate cancer portends that male sphincteric UI will remain prevalent and require surgical treatment to improve symptoms and quality of life. The initial evaluation must include a focused history and physical examination, voiding diary, pad weight test, uroflowmetry and postvoid residual measurement, and in selected cases cystoscopy and pressure flow urodynamics. The AUS remains the gold standard treatment for moderate to severe male UI, especially in complex cases, with excellent overall success and acceptable complication rates. For mild to moderate UI in the absence of prior urethral surgery, radiation therapy, or detrusor acontractility, male slings provide efficacious alternatives. The outcomes after AUS and male sling cannot be fully compared because of differences in baseline incontinence severity, end points, follow-up, and patient numbers. Nevertheless, **regardless of severity, nearly 90% of men with sphincteric UI will have minimal leakage and acceptable quality of life related to urinary symptoms after surgical treatment with AUS.** Similar cured and improved rates for post-RP UI have been reported with transobturator slings. However, several caveats exist. It is likely that selection bias regarding UI severity and other factors exists in choosing a sling versus AUS at most institutions. Results of slings in radiated patients are inferior. The appropriateness of standard transobturator slings for incontinence of other causes (e.g., TURP, neurogenic, post-traumatic) requires further demonstration. No sling has been compared with AUS in a controlled clinical trial. Furthermore, perineal **sling implantation depends on subtle technical maneuvers relating to positioning and tensioning. Conversely, once the urethra has been circumferentially mobilized and measured, the effectiveness of AUS is largely independent of technique.** Thus the occasional implanter will be more likely to achieve success with AUS versus sling procedures, although the potential for erosion and mechanical failure will continue to drive the need for alternative solutions.

See Videos 131.1 and 131.2 for procedures related to this chapter.

Acknowledgment

The authors would like to acknowledge Dr. Andrew C. Peterson for his contributions to prior editions of this chapter.

Suggested Readings

Biardeau X, Aharony S, Group AUSC, et al. Artificial urinary sphincter: report of the 2015 Consensus Conference. *Neurourol Urodyn*. 2016;35 Suppl 2:S8–S24.

Herschorn S, Bruschini H, Comiter C, et al. Committee of the International Consultation on Incontinence. Surgical treatment of stress incontinence in men. *Neurourol Urodyn*. 2010;29:179–190.

Martinez EJ, Zuckerman JM, Henderson K, et al. Evaluation of salvage male transobturator sling placement following recurrent stress urinary incontinence after failed transobturator sling. *Urology*. 2015;85(2):478–482.

Nitti VW, Mourtzinos A, Brucker BM, et al. Correlation of patient perception of pad use with objective degree of incontinence measured by pad test in men with post-prostatectomy incontinence: the SUFU Pad Test Study. *J Urol*. 2014;192(3):836–842.

Rehder P, Gozzi C. Transobturator sling suspension for male urinary incontinence including post-radical prostatectomy. *Eur Urol*. 2007;52:860–866.

Sandhu JS, Breyer B, Comiter C, et al. Incontinence after prostate treatment: AUA/SUFU guideline. *J Urol*. 2019;202(2):369–378.

Van der Aa F, Drake MJ, Kasyan GR, et al. Young Academic Urologists Functional Urology Group. The artificial urinary sphincter after a quarter of a century: a critical systematic review of its use in male non-neurogenic incontinence. *Eur Urol*. 2013;63(4):681–689.

References

Abrams P, Cardozo L, Fall M, et al. The standardization of terminology of lower urinary tract function: report for the Standardisation Sub-committee of the International Continence Society. *Neurourol Urodyn*. 2002;21:167–178.

Abrams P, et al. Evaluation and treatment of urinary incontinence, pelvic organ prolapse and faecal incontinence. Abrams P, Cardozo C, Khoury K, et al. *Incontinence*. ed 21. Health Publications, Ltd.: Distributor, Paris; 2009:1767–1821.

Anderson CA, Omar MI, Campbell SE, et al. Conservative management for postprostatectomy urinary incontinence. *Cochrane Database Syst Rev*. 2015;(1) [CD001843].

Anger JT, Raj GV, Delvecchio FC, et al. Anastomotic contracture and incontinence after radical prostatectomy: a graded approach to management. *J Urol*. 2005;173:1143–1146.

Angulo JC, Arance I, Esquinas C, et al. Outcome measures of adjustable transobturator male system with pre-attached scrotal port for male stress urinary incontinence after radical prostatectomy: a prospective study. *Adv Ther*. 2017;34(5):1173–1183.

Angulo JC, Cruz F, Esquinas C, et al. Treatment of male stress urinary incontinence with the adjustable transobturator male system: outcomes of a multi-center Iberian study. *Neurourol Urodyn*. 2018.

Barnard J, van Rij S, Westenberg AM. A Valsalva leak-point pressure of >100 cmH_2O is associated with greater success in AdVance sling placement for the treatment of post-prostatectomy urinary incontinence. *BJU Int*. 2014;114(Suppl 1):34–37.

Barski D, Gerullis H, Otto T. Review of surgical implant procedures for male incontinence after radical prostatectomy according to IDEAL framework. *Updates Surg*. 2017;69(3):327–338.

Bauer RM, Grabbert MT, Klehr B, et al. 36-month data for the AdVance XP((R)) male sling: results of a prospective multicentre study. *BJU Int*. 2017;119(4):626–630.

Bauer RM, Kretschmer A, Stief CG, et al. AdVance and AdVance XP slings for the treatment of post-prostatectomy incontinence. *World J Urol*. 2015;33(1):145–150.

Bauer RM, Mayer ME, Gratzke C, et al. Prospective evaluation of the functional sling suspension for male postprostatectomy stress urinary incontinence: results after 1 year. *Eur Urol*. 2009;56:928–933.

Bell BB, Mulcahy JJ. Management of cuff erosion of the double cuff artificial urinary sphincter. *J Urol*. 2000;163:85–86.

Berry JL. Evaluation of a new procedure for correction of postprostatectomy urinary incontinence. *Bull N Y Acad Med*. 1964;40:790–794.

Biardeau X, Aharony S, Group AUSC, et al. Artificial urinary sphincter: report of the 2015 Consensus Conference. *Neurourol Urodyn*. 2016;35 Suppl 2:S8–S24.

Bortolotti A, Bernardini B, Colli E, et al. Prevalence and risk factors for urinary incontinence in Italy. *Eur Urol*. 2000;37:30–35.

Brant WO, Erickson BA, Elliott SP, et al. Risk factors for erosion of artificial urinary sphincters: a multicenter prospective study. *Urology*. 2014;84(4):934–938.

Brito CG, Mulcahy JJ, Mitchell ME, et al. Use of a double cuff AMS800 urinary sphincter for severe stress incontinence. *J Urol*. 1993;149:283–285.

Bryan DE, Mulcahy JJ, Simmons GR. Salvage procedure for infected noneroded artificial urinary sphincters. *J Urol*.

2002;168:2464–2466.

Bugeja S, Ivaz SL, Frost A, et al. Urethral atrophy after implantation of an artificial urinary sphincter: fact or fiction? *BJU Int*. 2016;117(4):669–676.

Cameron AP, Suskind AM, Neer C, et al. Functional and anatomical differences between continent and incontinent men post radical prostatectomy on urodynamics and 3T MRI: a pilot study. *Neurourol Urodyn*. 2015;34(6):527–532.

Campbell SE, Glazener CM, Hunter KF, et al. Conservative management for postprostatectomy urinary incontinence. *Cochrane Database Syst Rev*. 2012;(1) [CD001843].

Carlson KV, Nitti VW. Prevention and management of incontinence following radical prostatectomy. *Urol Clin North Am*. 2001;28:595–612.

Carson CC. Efficacy of antibiotic impregnation of inflatable penile prostheses in decreasing infection in original implants. *J Urol*. 2004;171:1611–1614.

Castle EP, Andrews PE, Itano N, et al. The male sling for post-prostatectomy incontinence: mean followup of 18 months. *J Urol*. 2005;173:1657–1660.

Catarin MV, Manzano GM, Nobrega JA, et al. The role of membranous urethral afferent autonomic innervation in the continence mechanism after nerve sparing radical prostatectomy: a clinical and prospective study. *J Urol*. 2008;180:2527–2531.

Cerruto MA, D'Elia C, Artibani W. Continence and complications rates after male slings as primary surgery for post-prostatectomy incontinence: a systematic review. *Arch Ital Urol Androl*. 2013;85(2):92–95.

Chen J, Oromendia C, Halpern JA, et al. National trends in management of localized prostate cancer: a population based analysis 2004-2013. *Prostate*. 2018;78(7):512–520.

Chen YC, Lin PH, Jou YY, et al. Surgical treatment for urinary incontinence after prostatectomy: a meta-analysis and systematic review. *PLoS ONE*. 2017;12(5).

Chertack N, Gill BC, Angermeier KW, et al. Predicting success after artificial urinary sphincter: which preoperative factors drive patient satisfaction postoperatively? *Transl Androl Urol*. 2017;6(6):1138–1143.

Clemens JQ, Bushman W, Schaeffer AJ. Questionnaire based results of the bulbourethral sling procedure. *J Urol*. 1999;162:1972–1976.

Clemens JQ, Bushman W, Schaeffer AJ. Urodynamic analysis of the bulbourethral sling procedure. *J Urol*. 1999;162:1977–1981.

Collado Serra A, Resel Folkersma L, Domínguez-Escrig JL, et al. AdVance/AdVance XP transobturator male slings: preoperative degree of incontinence as predictor of surgical outcome. *Urology*. 2013;81:1034–1039.

Comiter CV, Nitti V, Elliot C, et al. A new quadratic sling for male stress incontinence: retrograde leak point pressure as a measure of urethral resistance. *J Urol*. 2012;187:563–568.

Comiter CV, Rhee EY, Tu LM, et al. The virtue sling–a new quadratic sling for postprostatectomy incontinence–results of a multinational clinical trial. *Urology*. 2014;84(2):433–438.

Comiter CV. Surgery Insight: surgical management of postprostatectomy incontinence—the artificial urinary sphincter and male sling. *Nat Clin Pract Urol*. 2007;4:615–624.

Comiter CV. The male sling for stress urinary incontinence: a prospective study. *J Urol*. 2002;167:597–601.

Constable L, Cotterill N, Cooper D, et al. Male synthetic sling versus artificial urinary sphincter trial for men with urodynamic stress incontinence after prostate surgery (MASTER): study protocol for a randomised controlled trial. [(Chief Investigator) for the; MASTER Study Group] *Trials*.

2018;19(1):131.

Cooperberg MR, Master VA, Carroll PR. Health related quality of life significance of single pad urinary incontinence following radical prostatectomy. *J Urol*. 2003;170:512–515.

Coyne KS, Kvasz M, Ireland AM, et al. Urinary incontinence and its relationship to mental health and health-related quality of life in men and women in Sweden, the United Kingdom, and the United States. *Eur Urol*. 2012;61:88–95.

Coyne KS, Zhou Z, Thompson C, et al. The impact on health-related quality of life of stress, urge and mixed urinary incontinence. *BJU Int*. 2003;92:731–735.

Dalkin BL, Wessells H, Cui H. A national survey of urinary and health related quality of life outcomes in men with an artificial urinary sphincter for post-radical prostatectomy incontinence. *J Urol*. 2003;169:237–239.

Darouiche RO, Wall MJ Jr, Itani KM, et al. Chlorhexidine-alcohol versus povidone-iodine for surgical-site antisepsis. *N Engl J Med*. 2010;362(1):18–26.

Davies TO, Bepple JL, McCammon KA. Urodynamic changes and initial results of the AdVance male sling. *Urology*. 2009;74:354–357.

de Cógáin MR, Elliott DS. The impact of an antibiotic coating on the artificial urinary sphincter infection rate. *J Urol*. 2013;190:113–117.

Debell M, Wessells H. Recurrent bulbar urethral stricture in the region of an artificial urinary sphincter. *J Urol*. 2001;166:1006–1007.

DeLay KJ, Haney NM, Chiang J, et al. Comparison of adjuvant radiation therapy before or after artificial urinary sphincter placement: a multi-institutional, retrospective analysis. *Urology*. 2018;113:160–165.

Dikranian AH, Chang JH, Rhee EY, et al. The male perineal sling: comparison of sling materials. *J Urol*. 2004;172:608–

610.

DiMarco DS, Elliott DS. Tandem cuff artificial urinary sphincter as a salvage procedure following failed primary sphincter placement for the treatment of post-prostatectomy incontinence. *J Urol*. 2003;170:1252–1254.

Dylewski DA, Jamison MG, Borawski KM, et al. A statistical comparison of pad numbers versus pad weights in the quantification of urinary incontinence. *Neurourol Urodyn*. 2007;26:3–7.

Eggleston JC, Walsh PC. Radical prostatectomy with preservation of sexual function: pathological findings in the first 100 cases. *J Urol*. 1985;134:1146–1148.

Elliott DS, Barrett DM. Mayo Clinic long-term analysis of the functional durability of the AMS 800 artificial urinary sphincter: a review of 323 cases. *J Urol*. 1998;159:1206–1208.

Engel RM, Wade JC. Experience with Berry prosthesis. *J Urol*. 1969;102:78–80.

Erickson BA, Meeks JJ, Roehl KA, et al. Bladder neck contracture after retropubic radical prostatectomy: incidence and risk factors from a large single-surgeon experience. *BJU Int*. 2009.

Ferro M, Bottero D, D'Elia C, et al. Virtue male sling for post-prostatectomy stress incontinence: a prospective evaluation and mid-term outcomes. *BJU Int*. 2017;119(3):482–488.

Ficazzola MA, Nitti VW. The etiology of post-radical prostatectomy incontinence and correlation of symptoms with urodynamic findings. *J Urol*. 1998;160:1317–1320.

Firrozi F, Vasavada S. Editorial comment. Urodynamic changes and initial results of the AdVance male sling. *Urology*. 2009;74:357–358.

Fischer MC, Huckabay C, Nitti VW. The male perineal sling: assessment and prediction of outcome. *J Urol*.

2007;177:1414–1418.

Flynn BJ, Webster GD. Evaluation and surgical management of intrinsic sphincter deficiency after radical prostatectomy. *Rev Urol*. 2004;6:180–186.

Food and Drug Administration. *Guidance for Industry and Food and Drug Administration Staff*. [Clinical investigations of devices indicated for the treatment of urinary incontinence, 2011 (website)] https://www.fda.gov/MedicalDevices/ucm070852.htm.

Foote J, Yun S, Leach G. Postprostatectomy incontinence. Pathophysiology, evaluation, and management. *Urol Clin North Am*. 1991;18:229–241.

Fowler JW, Auld CD. The control of male stress incontinence by implantable prostheses. *Br J Urol*. 1985;57:175–180.

Frank I, Elliott DS, Barrett DM. Success of de novo reimplantation of the artificial genitourinary sphincter. *J Urol*. 2000;163:1702–1703.

Furlow WL, Barrett DM. The artificial urinary sphincter: experience with the AS 800 pump-control assembly for single-stage primary deactivation and activation–a preliminary report. *Mayo Clin Proc*. 1985;60:255–258.

Giberti C, Gallo F, Schenone M, et al. The bone anchor suburethral synthetic sling for iatrogenic male incontinence: critical evaluation at a mean 3-year followup. *J Urol*. 2009;181:2204–2208.

Groen LA, Spinoit AF, Hoebeke P, et al. The AdVance male sling as a minimally invasive treatment for intrinsic sphincter deficiency in patients with neurogenic bladder sphincter dysfunction: a pilot study. *Neurourol Urodyn*. 2012;31(8):1284–1287.

Gross MS, Broghammer JA, Kaufman MR, et al. Urethral stricture outcomes after artificial urinary sphincter cuff erosion: results from a multicenter retrospective analysis.

Urology. 2017;104:198–203.
Groutz A, Blaivas J, Chaikin D, et al. Noninvasive outcome measures of urinary incontinence and lower urinary tract symptoms: a multicenter study of micturition diary and pad tests. *J Urol*. 2000;164:698–701.
Gundian JC, Barrett DM, Parulkar BG. Mayo Clinic experience with use of the AMS800 artificial urinary sphincter for urinary incontinence following radical prostatectomy. *J Urol*. 1989;142:1459–1461.
Guralnick ML, Miller E, Toh KL, et al. Transcorporal artificial urinary sphincter cuff placement in cases requiring revision for erosion and urethral atrophy. *J Urol*. 2002;167:2075–2078.
Haab F, Trockman BA, Zimmern PE, et al. Quality of life and continence assessment of the artificial urinary sphincter in men with minimum 3.5 years of followup. *J Urol*. 1997;158:435–439.
Hajivassiliou CA. A review of the complications and results of implantation of the AMS artificial urinary sphincter. *Eur Urol*. 1999;35:36–44.
Halpern JA, Shoag JE, Artis AS, et al. National trends in prostate biopsy and radical prostatectomy volumes following the US Preventive Services Task Force Guidelines Against Prostate-Specific Antigen Screening. *JAMA Surg*. 2017;152(2):192–198.
Harris SE, Guralnick ML, O'Connor RC. Urethral erosion of transobturator male sling. *Urology*. 2009;73(443):e19–e20.
Henry GD, Graham SM, Cleves MA, et al. Perineal approach for artificial urinary sphincter implantation appears to control male stress incontinence better than the transscrotal approach. *J Urol*. 2008;179:1475–1479.
Herndon CD, Rink RC, Shaw MB, et al. The Indiana experience with artificial urinary sphincters in children and young adults.

J Urol. 2003;169:650–654.

Herschorn S, Bruschini H, Comiter C, et al. Committee of the International Consultation on Incontinence. Surgical treatment of stress incontinence in men. *Neurourol Urodyn*. 2010;29:179–190.

Hoy NY, Rourke KF. Artificial urinary sphincter outcomes in the “fragile urethra”. *Urology*. 2015;86(3):618–624.

Hubner WA, Schlarp OM. Treatment of incontinence after prostatectomy using a new minimally invasive device: adjustable continence therapy. *BJU Int*. 2005;96:587–594.

Hudak SJ, Morey AF. Impact of 3.5 cm artificial urinary sphincter cuff on primary and revision surgery for male stress urinary incontinence. *J Urol*. 2011;186:1962–1966.

Infection. *J Urol*. 2013 [S0022-5347: 05337-05338].

John H. Bulbourethral composite suspension: a new operative technique for post-prostatectomy incontinence. *J Urol*. 2004;171:1866–1870.

Kabalin JN. Addition of a second urethral cuff to enhance performance of the artificial urinary sphincter. *J Urol*. 1996;156:1302–1304.

Keihani S, Chandrapal JC, Peterson AC, et al. Outcomes of urethroplasty to treat urethral strictures arising from artificial urinary sphincter erosions and rates of subsequent device replacement. *Urology*. 2017;107:239–245.

Kendirci M, Gupta S, Shaw K, et al. Synchronous prosthetic implantation through a transscrotal incision: an outcome analysis. *J Urol*. 2006;175(6):2218–2222.

Knight SL, Susser J, Greenwell T, et al. A new artificial urinary sphincter with conditional occlusion for stress urinary incontinence: preliminary clinical results. *Eur Urol*. 2006;50(3):574–580.

Kowalczyk JJ, Nelson R, Mulcahy JJ. Successful reinsertion of the artificial urinary sphincter after removal for erosion or infection. *Urology*. 1996;48:906–908.

Kowalczyk JJ, Spicer DL, Mulcahy JJ. Long-term experience with the double-cuff AMS 800 artificial urinary sphincter. *Urology*. 1996;47:895–897.

Kowalik CG, DeLong JM, Mourtzinos AP. The advance transobturator male sling for post-prostatectomy incontinence: subjective and objective outcomes with 3 years follow up. *Neurourol Urodyn*. 2015;34(3):251–254.

Krambeck AE, DiMarco DS, Rangel LJ, et al. Radical prostatectomy for prostatic adenocarcinoma: a matched comparison of open retropubic and robot-assisted techniques. *BJU Int*. 2009;103:448–453.

Kretschmer A, Buchner A, Leitl B, et al. Long-term outcome of the retrourethral transobturator male sling after transurethral resection of the prostate. *Int Neurourol J*. 2016;20(4):335–341.

Kumar A, Litt ER, Ballert KN, et al. Artificial urinary sphincter versus male sling for post-prostatectomy incontinence—what do patients choose? *J Urol*. 2009;181:1231–1235.

Kuznetsov DD, Kim HL, Patel RV, et al. Comparison of artificial urinary sphincter and collagen for the treatment of postprostatectomy incontinence. *Urology*. 2000;56:600–603.

Lai HH, Boone TB. Complex artificial urinary sphincter revision and reimplantation cases–how do they fare compared to virgin cases? *J Urol*. 2012;187:951–955.

Lai HH, Hsu EI, Boone TB. Urodynamic testing in evaluation of postradical prostatectomy incontinence before artificial urinary sphincter implantation. *Urology*. 2009;73:1264–1269.

Lai HH, Hsu EI, Teh BS, et al. 13 years of experience with artificial urinary sphincter implantation at Baylor College of Medicine. *J Urol*. 2007;177(3):1021–1025.

Lamraoui H, Bonvilain A, Robain G, et al. Rectus abdominis electromyography and MechanoMyoGraphy comparison for the detection of cough. *Conf Proc IEEE Eng Med Biol Soc*. 2010;2010:6502–6505.

Leach GE, Trockman B, Wong A, et al. Post-prostatectomy incontinence: urodynamic findings and treatment outcomes. *J Urol*. 1996;155:1256–1259.

Lentz AC, Peterson AC, Webster GD. Outcomes following artificial sphincter implantation after prior unsuccessful male sling. *J Urol*. 2012;187:2149–2153.

Lepor H, Kaci L. The impact of open radical retropubic prostatectomy on tontinence and lower urinary tract symptoms: a prospective assessment using validated self-administered outcome instruments. *J Urol*. 2004;171:1216–1219.

Li H, Gill BC, Nowacki AS, et al. Therapeutic durability of the male transobturator sling: midterm patient reported outcomes. *J Urol*. 2012;187:1331–1335.

Licht MR, Montague DK, Angermeier KW, et al. Cultures from genitourinary prostheses at reoperation: questioning the role of Staphylococcus epidermidis in periprosthetic infection. *J Urol*. 1995;154:387–390.

Light JK, Reynolds JC. Impact of the new cuff design on reliability of the AMS800 artificial urinary sphincter. *J Urol*. 1992;147:609–611.

Litwiller SE, Kim KB, Fone PD, et al. Post-prostatectomy incontinence and the artificial urinary sphincter: a long-term study of patient satisfaction and criteria for success. *J Urol*. 1996;156:1975–1980.

Litwin MS, Hays RD, Fink A, et al. The UCLA Prostate Cancer Index: development, reliability, and validity of a health-related quality of life measure. *Med Care*. 1998;36:1002–1012.

Lorentzen T, Dorph S, Hald T. Artificial urinary sphincters. Radiographic evaluation. *Acta Radiol*. 1987;28:63–66.

Madjar S, Jacoby K, Giberti C, et al. Bone anchored sling for the treatment of post-prostatectomy incontinence. *J Urol*. 2001;165:72–76.

Marks JL, Light JK. Management of urinary incontinence after prostatectomy with the artificial urinary sphincter. *J Urol*. 1989;142:302–304.

Martinez EJ, Zuckerman JM, Henderson K, et al. Evaluation of salvage male transobturator sling placement following recurrent stress urinary incontinence after failed transobturator sling. *Urology*. 2015;85(2):478–482.

McCall AN, Rivera ME, Elliott DS. Long-term follow-up of the Virtue quadratic male sling. *Urology*. 2016;93:213–216.

Mock S, Dmochowski RR, Brown ET, et al. The impact of urethral risk factors on transcorporeal artificial urinary sphincter erosion rates and device survival. *J Urol*. 2015;194(6):1692–1696.

Montague DK, Angermeier KW, Paolone DR. Long-term continence and patient satisfaction after artificial sphincter implantation for urinary incontinence after prostatectomy. *J Urol*. 2001;166:547–549.

Montague DK, Angermeier KW. Artificial urinary sphincter troubleshooting. *Urology*. 2001;58:779–782.

Montague DK, Angermeier KW. Postprostatectomy urinary incontinence: the case for artificial urinary sphincter implantation. *Urology*. 2000;55:2–4.

Motley RC, Barrett DM. Artificial urinary sphincter cuff erosion. Experience with reimplantation in 38 patients. *Urology*. 1990;35:215–218.

Mulcahy JJ, Brant MD, Ludlow JK. Management of infected penile implants. *Tech Urol*. 1995;1:115–119.

Nash S, Aboseif S, Gilling P, et al. Treatment with an adjustable long-termimplant for post-prostatectomy stress incontinence: the ProACT™ pivotal trial. *Neurourol Urodyn*.

2018;37:2854–2859.

Nitti VW, Mourtzinos A, Brucker BM, et al. Correlation of patient perception of pad use with objective degree of incontinence measured by pad test in men with post-prostatectomy incontinence: the SUFU Pad Test Study. *J Urol*. 2014;192(3):836–842.

O'Connor RC, Gerber GS, Avila D, et al. Comparison of outcomes after single or double-cuff artificial urinary sphincter insertion. *Urology*. 2003;62:723–726.

O'Connor RC, Kuznetsov DD, Patel RV, et al. Artificial urinary sphincter placement in men after cystectomy with orthotopic ileal neobladder: continence, complications, and quality of life. *Urology*. 2002;59(4):542–545.

Park R, Martin S, Goldberg JD, et al. Anastomotic strictures following radical prostatectomy: insights into incidence, effectiveness of intervention, effect on continence, and factors predisposing to occurrence. *Urology*. 2001;57:742–746.

Peyromaure M, Ravery V, Boccon-Gibod L. The management of stress urinary incontinence after radical prostatectomy. *BJU Int*. 2002;90:155–161.

Poon SA, Silberstein JL, Savage C, et al. Surgical practice patterns for male urinary incontinence: analysis of case logs from certifying American urologists. *J Urol*. 2012;188(1):205–210.

Raj GV, Peterson AC, Toh KL, et al. Outcomes following revisions and secondary implantation of the artificial urinary sphincter. *J Urol*. 2005;173:1242–1245.

Raj GV, Peterson AC, Webster GD. Outcomes following erosions of the artificial urinary sphincter. *J Urol*. 2006;175:2186–2190.

Reeves F, Preece P, Kapoor J, et al. Preservation of the neurovascular bundles is associated with improved time to continence after radical prostatectomy but not long-term continence rates: results of a systematic review and meta-analysis. *Eur Urol*. 2015;68(4):692–704.

Rehder P, Gozzi C. Transobturator sling suspension for male urinary incontinence including post-radical prostatectomy. *Eur Urol*. 2007;52:860–866.

Rehder P, Haab F, Cornu JN, et al. Treatment of postprostatectomy male urinary incontinence with the transobturator retroluminal repositioning sling suspension: 3-year follow-up. *Eur Urol*. 2012;62:140–145.

Rivera ME, Linder BJ, Ziegelmann MJ, et al. The impact of prior radiation therapy on artificial urinary sphincter device survival. *J Urol*. 2016;195:1033–1037.

Rocco B, Cozzi G, Spinelli MG, et al. Posterior musculofascial reconstruction after radical prostatectomy: a systematic review of the literature. *Eur Urol*. 2012;62:779–790.

Rolle L, Ceruti C, Sedigh O, et al. Surgical implantation of artificial urinary device and penile prosthesis through trans-scrotal incision for postprostatectomy urinary incontinence and erectile dysfunction: synchronous or delayed procedure? *Urology*. 2012;80(5):1046–1050.

Rothschild J, Chang Kit L, Seltz L, et al. Difference between urethral circumference and artificial urinary sphincter cuff size, and its effect on postoperative incontinence. *J Urol*. 2014;191(1):138–142.

Rozanski AT, Tausch TJ, Ramirez D, et al. Immediate urethral repair during explantation prevents stricture formation after artificial urinary sphincter cuff erosion. *J Urol*. 2014;192(2):442–446.

Rozanski AT, Viers BR, Shakir NA, et al. Is removal of the pressure-regulating balloon necessary after artificial urinary sphincter cuff erosion? *Urology*. 2018;113:225–229.

Ruiz E, Puigdevall J, Moldes J, et al. 14 years of experience with artificial urinary sphincter in children and adolescents without spina bifida. *J Urol*. 2006;176:1821–1825.

Ruthmann O, Richter S, Seifert G, et al. The first teleautomatic low-voltage prosthesis with multiple therapeutic applications: a new version of the German artificial sphincter system. *Artif Organs*. 2010;34(8):635–641.

Saffarian A, Walsh K, Walsh IK, et al. Urethral atrophy after artificial urinary sphincter placement: is cuff downsizing effective? *J Urol*. 2003;169:567–569.

Sandhu JS, Breyer B, Comiter C, et al. Incontinence after prostate treatment: AUA/SUFU guideline. *J Urol*. 2019;202(2):369–378.

Sathianathen NJ, McGuigan SM, Moon DA. Outcomes of artificial urinary sphincter implantation in the irradiated patient. *BJU Int*. 2014;113(4):636–641.

Schaeffer AJ, Clemens JQ, Ferrari M, et al. The male bulbourethral sling procedure for post-radical prostatectomy incontinence. *J Urol*. 1998;159:1510–1515.

Schiavini JL, Damiao R, de Resende Junior JA, et al. Treatment of post-prostate surgery urinary incontinence with the periurethral constrictor: a retrospective analysis. *Urology*. 2010;75(6):1488–1492.

Schultheiss D, Hofner K, Oelke M, et al. Historical aspects of the treatment of urinary incontinence. *Eur Urol*. 2000;38:352–362.

Scott FB. The artificial sphincter in the management of incontinence in the male. *Urol Clin North Am*. 1978;5:375.

Scott FB. The artificial urinary sphincter. Experience in adults. *Urol Clin North Am*. 1989;16:105.

Seideman CA, Zhao LC, Hudak SJ, et al. Is prolonged catheterization a risk factor for artificial urinary sphincter cuff erosion? *Urology*. 2013;82(4):943–946.

Selph JP, Belsante MJ, Gupta S, et al. The ohmmeter identifies the site of fluid leakage during artificial urinary sphincter revision surgery. *J Urol*. 2015;194(4):1043–1048.

Silva LA, Andriolo RB, Atallah ÁN, et al. Surgery for stress urinary incontinence due to presumed sphincter deficiency after prostate surgery. *Cochrane Database Syst Rev*. 2014;(9) [CD008306].

Simhan J, Morey AF, Singla N, et al. 3.5 cm artificial urinary sphincter cuff erosion occurs predominantly in irradiated patients. *J Urol*. 2015;193(2):593–597.

Smith PJ, Hudak SJ, Scott JF, et al. Transcorporal artificial urinary sphincter cuff placement is associated with a higher risk of postoperative urinary retention. *Can J Urol*. 2013;20:6773–6777.

Soljanik I, Bauer RM, Becker AJ, et al. Morphology and dynamics of the male pelvic floor before and after retrourethral transobturator sling placement: first insight using MRI. *World J Urol*. 2013;31:629–638.

Soljanik I, Becker AJ, Stief CG, et al. Repeat retrourethral transobturator sling in the management of recurrent postprostatectomy stress urinary incontinence after failed first male sling. *Eur Urol*. 2010;58:767–772.

Soljanik I, Becker AJ, Stief CG, et al. Urodynamic parameters after retrourethral transobturator male sling and their influence on outcome. *Urology*. 2011;78:708–712.

Srivastava A, Joice GA, Patel HD, et al. Causes of artificial urinary sphincter failure and strategies for surgical revision: implications of device component survival. *Eur Urol Focus*. 2018.

Srivastava A, Joice GA, Patel HD, et al. Impact of adjuvant radiation on artificial urinary sphincter durability in postprostatectomy patients. *Urology*. 2018.

Stanford JL, Steophenson RA, Coyle LM, et al. *Prostate cancer trends 1973-1995*. [SEER Program, National Cancer Institute

NIH Pub 99] 1999.

Staerman F, G-Llorens C, Leon P, et al. ZSI 375 artificial urinary sphincter for male urinary incontinence: a preliminary study. *BJU Int*. 2013;111(4 Pt B):E202–E206.

Stone AR, Nguyen M, Tse V. Re: new surgical technique for sphincter urinary control system using upper transverse scrotal incision. *J Urol*. 2003;170:550–551.

2017. *Surg*. 2017;69(3):327–338.

Taylor GA, Lebowitz RL. Artificial urinary sphincters in children: radiographic evaluation. *Radiology*. 1985;155:91–97.

Timm GW, Bradley WE, Scott FB. Development of an implantable artificial urinary sphincter. *Urologe A*. 1976;15:176–179.

Torrey R, Rajeshuni N, Ruel N, et al. Radiation history affects continence outcomes after Advance transobturator sling placement in patients with post-prostatectomy incontinence. *Urology*. 2013;82:713–717.

Trigo-Rocha F, Gomes CM, Mitre AI, et al. A prospective study evaluating the efficacy of the artificial sphincter AMS 800 for the treatment of postradical prostatectomy urinary incontinence and the correlation between preoperative urodynamic and surgical outcomes. *Urology*. 2008;71:85–89.

Trigo-Rocha F, Gomes CM, Pompeo AC, et al. Prospective study evaluating efficacy and safety of Adjustable Continence Therapy (ProACT) for post radical prostatectomy urinary incontinence. *Urology*. 2006;67:965–969.

Tuygun C, Imamoglu A, Keyik B, et al. Significance of fibrosis around and/or at external urinary sphincter on pelvic magnetic resonance imaging in patients with postprostatectomy incontinence. *Urology*. 2006;68(6):1308–1312.

Ullrich NF, Comiter CV. The male sling for stress urinary incontinence: urodynamic and subjective assessment. *J Urol*. 2004;172:204–206.

Vainrib M, Reyblat P, Ginsberg D. Outcomes of male sling mesh kit placement in patients with neuropathic stress urinary incontinence: a single institution experience. *Urol Int*. 2015;95(4):406–410.

Valerio M, Jichlinski P, Dahlem R, et al. Experimental evaluation of an electromechanical artificial urinary sphincter in an animal model. *BJU Int*. 2013;112(4):E337–E343.

Van der Aa F, Drake MJ, Kasyan GR, et al. Young Academic Urologists Functional Urology Group. The artificial urinary sphincter after a quarter of a century: a critical systematic review of its use in male non-neurogenic incontinence. *Eur Urol*. 2013;63(4):681–689.

Venn SN, Greenwell TJ, Mundy AR. The long-term outcome of artificial urinary sphincters. *J Urol*. 2000;164:702–706.

Venturino L, Dalpiaz O, Pummer K, et al. Adjustable continence balloons in men: adjustments do not translate into long-term continence. *Urology*. 2015;85(6):1448–1452.

Warner JN, Grimsby GM, Tyson MD, et al. Bladder capacity on preoperative urodynamics may impact outcomes on transobturator male slings. *Neurourol Urodyn*. 2012;31:1124–1127.

Wasson JH, Reda DJ, Bruskewitz RC, et al. A comparison of transurethral surgery with watchful waiting for moderate symptoms of benign prostatic hyperplasia. The Veterans Affairs Cooperative Study Group on Transurethral Resection of the Prostate. *N Engl J Med*. 1995;332:75–79.

Wei J, Dunn R, Marcovich R, et al. Prospective assessment of patient reported urinary continence after radical prostatectomy. *J Urol*. 2000;164:744–748.

Wei JT, Dunn RL, Litwin MS, et al. Development and validation of the expanded prostate cancer index composite

(EPIC) for comprehensive assessment of health-related quality of life in men with prostate cancer. *Urology*. 2000;56:899–905.

Westney OL, Del Terzo MA, McGuire EJ. Balloon dilation of posterior urethral stricture secondary to radiation and cryotherapy in a patient with a functional artificial urethral sphincter. *J Endourol*. 1992;13:585–586.

Wiedemann L, Cornu JN, Haab E, et al. Transcorporal artificial urinary sphincter implantation as a salvage surgical procedure for challenging cases of male stress urinary incontinence: surgical technique and functional outcomes in a contemporary series. *BJU Int*. 2013;112(8):1163–1168.

Wilson SK, Delk JR, Henry GD, et al. New surgical technique for sphincter urinary control system using upper transverse scrotal incision. *J Urol*. 2003;169:261–264.

Wilson SK, Aliotta PJ, Salem EA, et al. New enhancements of the scrotal one-incision technique for placement of artificial urinary sphincter allow proximal cuff placement. *J Sex Med*. 2010;7(10):3510–3515.

Wingate JT, Erickson BA, Murphy G, et al. Multicenter analysis of patient reported outcomes following artificial urinary sphincter placement for male stress urinary incontinence. *J Urol*. 2017;199(3):785–790.

Winters JC, Dmochowski RR, Goldman HB, et al. Urodynamic studies in adults: AUA/SUFU guideline. *J Urol*. 2012;188:2464–2472.

Wolf JS Jr, Bennett CJ, Dmochowski RR, et al. Best practice policy statement on urologic surgery antimicrobial prophylaxis. *J Urol*. 2008;179:1379–1390.

Wu JM, Matthews CA, Vaughan CP, et al. Urinary, fecal, and dual incontinence in older U.S. adults. *J Am Geriatr Soc*. 2015;63(5):947–953.

Yates DR, Phe V, Roupret M, et al. Robot-assisted laparoscopic artificial urinary sphincter insertion in men with neurogenic stress urinary incontinence. *BJU Int*. 2013;111(7):1175–1179.

Yeung LL, Grewal S, Bullock A, et al. A comparison of chlorhexidine-alcohol versus povidone-iodine for eliminating skin flora before genitourinary prosthetic surgery: a randomized controlled trial. *J Urol*. 2013;189:136–140.

Yurkanin JP, Dalkin BL, Cui H. Evaluation of cold knife urethrotomy for the treatment of anastomotic stricture after radical retropubic prostatectomy. *J Urol*. 2001;165:1545–1548.

Ziegelmann MJ, Linder BJ, Rivera ME, et al. The impact of prior urethral sling on artificial urinary sphincter outcomes. *Can Urol Assoc J*. 2016;10(11–12):405–409.

Zuckerman JM, Edwards B, Henderson K, et al. Extended outcomes in the treatment of male stress urinary incontinence with a transobturator sling. *Urology*. 2014;83(4):939–945.

Zuckerman JM, Henderson K, McCammon K. Transobturator male sling: is there a learning curve? *Can J Urol*. 2013;20:6768–6772.

PART XIV

Benign and Malignant Bladder Disorders

OUTLINE

132 Bladder Surgery for Benign Disease

133 Genital and Lower Urinary Tract Trauma

134 Special Urologic Considerations in Transgender Individuals

135 Tumors of the Bladder

136 Management Strategies for Non–Muscle-Invasive Bladder Cancer (Ta, T1, and CIS)

137 Management of Muscle-Invasive and Metastatic Bladder Cancer

138 Surgical Management of Bladder Cancer Transurethral, Open, and Robotic

139 Use of Intestinal Segments in Urinary Diversion

140 Cutaneous Continent Urinary Diversion

141 Orthotopic Urinary Diversion

142 Minimally Invasive Urinary Diversion

Bladder Surgery for Benign Disease

Paras H. Shah MD, Lee Richstone MD

Surgery of the urinary bladder and distal ureter often involves significant extirpative as well as reconstructive techniques, demanding skill and experience from the urologic surgeon. As a result of these technical challenges, bladder surgery is associated with significant potential for complication in inexperienced hands. In an attempt to minimize the morbidity of open surgery, minimally invasive techniques for surgery of the urinary bladder have been introduced and refined. Laparoscopic and robotic techniques can be used for essentially every bladder operation. In most cases, improved cosmetic results are accompanied by reductions in associated pain, duration of hospitalization, and recovery times. Nevertheless, open surgery remains a widely utilized strategy with proven long-standing efficacy with respect to outcomes.

Technology continues to drive the field forward, and natural orifice transluminal endoscopic surgery and laparoendoscopic single-site surgery (LESS) techniques have been employed to reduce further the incisions and morbidity associated with surgery of the urinary bladder. This chapter describes open, conventional laparoscopic, robotic, and LESS approaches to surgery of the distal ureter and the bladder, focusing on indications, techniques, complications, and outcomes (Box 132.1).

Box 132.1

Open and Minimally Invasive Surgery of the Bladder and Distal Ureter

Bladder diverticulectomy
Ureteral reimplantation
Psoas hitch, Boari flap, and bladder advancement flaps
Enterocystoplasty

Partial cystectomy and urachal surgery
Bladder stone and foreign-body removal

Bladder Anatomy and Surgical Considerations

The bladder is located in the anterior pelvis situated within the extraperitoneal compartment. The space of Retzius, also referred to as the *retropubic space*, separates the bladder from the pubic bone and transversalis fascia anteriorly and is composed of loose areolar tissue. Dissection of this space provides access to the anterior bladder wall.

The parietal peritoneum lining the anterior abdominal wall folds over the dome of the bladder, forming the peritoneal reflection and effectively separating the pelvic and abdominal cavities. Laterally, this peritoneal fold forms the peritoneal wings, which serve as the superior border of the lateral paravesical fossa and overlie the ductus deferens in males or form the broad ligament in females. These peritoneal attachments to the bladder can be divided to aid in bladder mobilization. Redundancy of the peritoneal reflection on the superior surface of the bladder can be appreciated posteriorly when the bladder is empty and is referred to as the *transverse vesical fold.*

The bladder is bordered on this lateral surface by the perivesical fat, which, when swept medially, exposes the lateral paravesical fossa in which reside the pelvic muscular sidewall, the obturator fossa, and the external and internal iliac vessels.

Within males, the most dependent portion of the peritoneal reflection occurs at the interface between the rectum and posterior bladder wall, referred to as the *rectovesical pouch.* The corresponding region in females is shallower and occurs between the anterior uterus and posterior bladder wall, referred to as the *vesicouterine pouch.* Incision of the peritoneal fold in these locations enables mobilization of the posterior bladder wall through caudal dissection within the fascial partition separating the bladder and prostate from the rectum in males or the bladder from the uterus and anterior vaginal wall in females.

The bladder derives the majority of its blood supply from the internal iliac artery, which provides blood flow through a rich vascular network emanating from the superior and inferior vesical arteries. The superior vesical artery originates off the umbilical artery, which itself is a branch of the internal iliac artery. Ligation of the contralateral superior vesical artery often allows for cephalad mobilization of the bladder. The inferior vesical artery branches directly off the anterior division of the internal iliac artery, although in females, it is considered a branch of the vaginal artery emanating off of the internal iliac artery. The ureter enters the bladder parallel to this pedicle.

The ureters course over the bifurcation of the common iliac arteries after which they deviate medially within the pelvic cavity to insert into the posterolateral aspect of the base of the bladder. Several aspects to the ureteral anatomy within the pelvis deserve mention. The umbilical artery may be ligated in some cases to support caudal ureteral dissection. In males, the ureter courses under the vas deferens in close proximity to the tip of the seminal vesicles before entering the bladder. In females, the ureters course below the uterine vessels, which originate off the anterior division of the internal iliac and travel through the broad ligament as part of the cardinal ligament.

Bladder Diverticulectomy

Description

Bladder diverticula are outpouchings of the bladder wall devoid of a functional muscularis propria lining (Kelalis and McLean, 1967). The primary layers constituting the wall of diverticula are the mucosa and underlying lamina propria tissue. Beyond this, scattered detrusor muscle fibers may be observed in an architecturally disorganized fashion, precluding coordinated contraction of the diverticulum (Kelalis and McLean, 1967). As such, urinary stasis and associated sequela may prompt clinical symptoms and the need for intervention (Fox et al., 1962). Overlying the exterior of diverticula is the adventitial layer of the bladder wall around which a fibrous capsule may form. This capsule serves an important role during surgical dissection if resection of the diverticulum is undertaken (Kelalis and McLean, 1967).

Among adults, acquired bladder diverticula are most frequently encountered in the setting of bladder outlet obstruction as a result of high voiding pressures. A male predominance is reported as benign prostate hyperplasia is responsible for the majority of acquired diverticula, although urethral stricture disease and pelvic organ prolapse may also cause outlet obstruction in women (Kelalis and McLean, 1967). Individuals with neurogenic bladder who have poor wall compliance may also have high intravesical pressures contributing to the formation of bladder diverticula. Diverticula acquired in the context of outlet obstruction or poor bladder compliance can be multiple in nature and vary in size, factors that strongly influence the ultimate need for intervention and treatment selection.

Most acquired diverticula are asymptomatic and thus discovered incidentally on imaging or cystoscopic examination for alternative reasons, including for conditions that underlie their formation. Symptoms related to the presence of diverticula are primarily caused by the associated urinary stasis and include urinary tract infection and formation of bladder calculi (Melekos et al., 1987) (Fig. 132.1). As diverticula may hold larges volume of urine, they may also contribute to the sensation of incomplete bladder emptying. Less often, large-caliber diverticula may extrinsically compress the ureter near its insertion into the bladder, resulting in ureteral obstruction and hydronephrosis (Livne and Gonzales, 1985). Several studies have also observed increased risk for bladder cancer within diverticula (Faysal and Freiha, 1981); a thorough evaluation is thus necessary before any intervention.

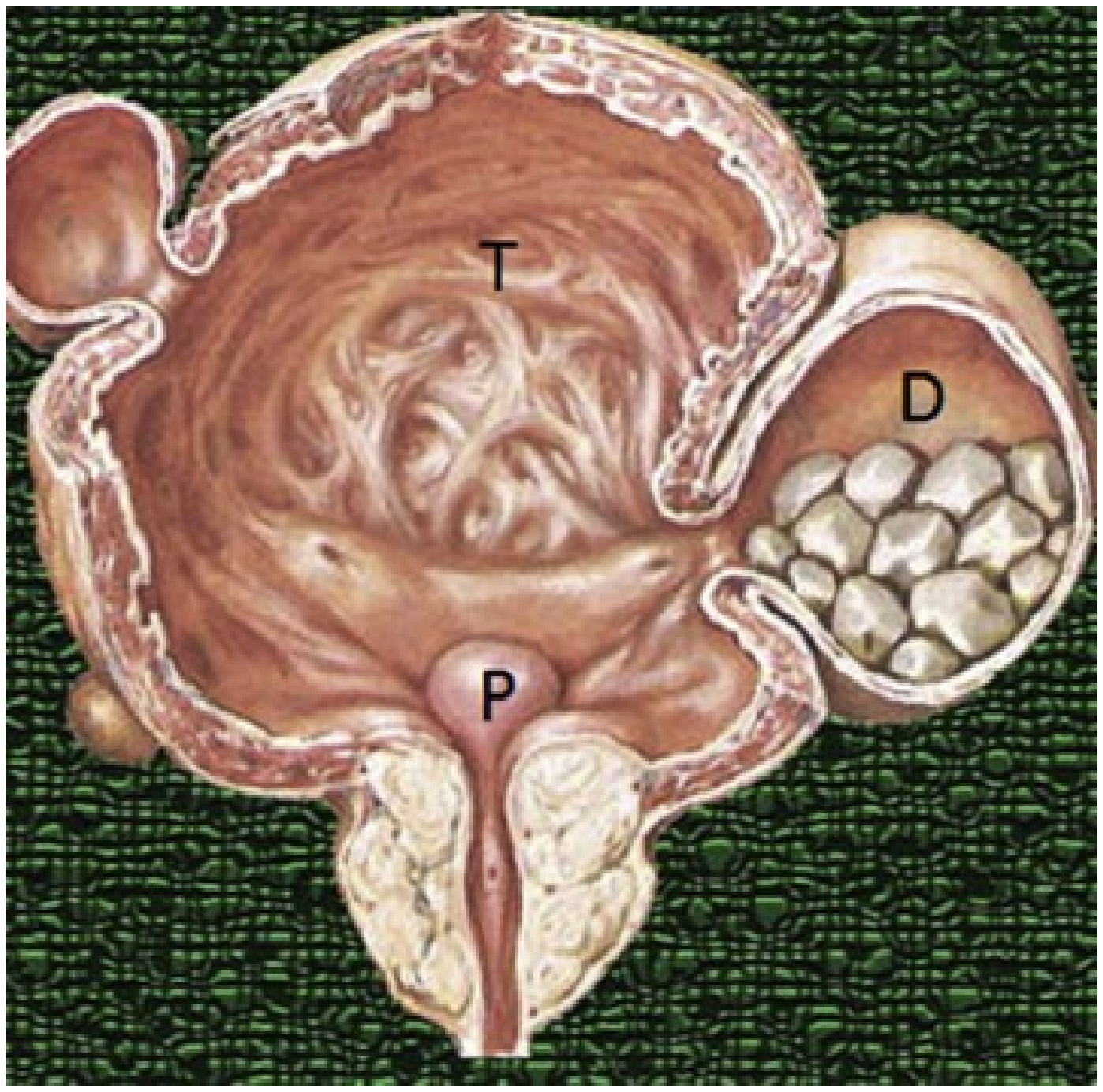

FIG. 132.1 Large left bladder diverticulum *(D)* seen with calculus secondary to stasis. Trabeculations in bladder wall *(T)* indicate diverticula formation in setting of bladder outlet obstruction caused by benign prostate hyperplasia *(P).*

A congenital bladder diverticulum is more commonly encountered in the pediatric population. Contrary to acquired diverticula in adults, the underlying mechanism involves an intrinsic weakness in the bladder musculature rather than outlet obstruction or neurogenic pathology (Blane et al., 1994). Nevertheless, a substantial proportion of individuals with congenital diverticula have voiding dysfunction syndromes, necessitating an evaluation for bladder outlet obstruction and neurogenic dysfunction in these populations as well.

Congenital diverticula are often solitary in nature and situated posterolaterally within the bladder in close proximity to the ureterovesical interface, in which case they are referred to as *Hutch diverticula* (Pieretti et al., 1999). As a consequence of the detrusor dysfunction associated with herniation of the bladder wall in this location, vesicoureteral reflux (VUR) is generally present and may contribute to clinical manifestations such as hydronephrosis or pyelonephritis. This is an important consideration when managing such diverticula as surgical planning should involve ureteral reimplantation.

Less common scenarios associated with the formation of bladder diverticula in adults include pediatric neurogenic and bladder outlet obstruction conditions (e.g., posterior urethral valves or prune belly syndrome), genetic connective tissue disorders (e.g., Ehlers-Danlos or Williams syndrome), and iatrogenic disruption of the bladder, most often in women who have undergone anti-incontinence procedures.

Evaluation and Surgical Indications

The evaluation of bladder diverticula is multifaceted, particularly when intervention is planned. Cystoscopy is a central component to the workup as it enables direct anatomic inspection of the diverticulum and permits evaluation for the presence of bladder malignancy, which may alter the treatment landscape. Important features to note during cystoscopy include the nearness of the diverticulum mouth to the ureteral orifices, the number of diverticula present, the size of the diverticulum mouth, and an approximate volume calibration. All diverticula should be entered if possible and every effort made to inspect the wall as an increased risk for bladder cancer has been reported. Additionally, urinary stasis within the diverticulum may contribute to the formation of bladder stones, which can be managed simultaneously with diverticulectomy. Trabeculations along the bladder wall may offer insight into the disease process contributing to the formation of diverticula as their presence may indicate bladder outlet obstruction. At the time of cystoscopy, the presence of prostatic lobar hypertrophy (particularly an intravesical component) and urethral stricture or bladder neck contracture should be noted as these would likely require management before or at the time of diverticulum treatment.

Voiding cystourethrogram (VCUG) may be performed as it offers a wealth of information regarding the structural properties of diverticula (e.g., location, number) and the anatomic aspects of any underlying conditions (Fig. 132.2). A reliable estimate of diverticulum size is offered by VCUG, which will influence treatment selection. In addition, diverticula that may have been missed on cystoscopic examination, particularly in the setting of heavy bladder trabeculation, may be elucidated. The concomitant presence of reflux and the proximity of the diverticulum to the ureter can be reliably evaluated on VCUG as well; this offers insight into whether preoperative stent placement is necessary to aid in identification and/or protection of the ureter or if a simultaneous ureteral reimplantation is necessary. Information on the presence of bladder neck obstruction, such as that caused by bladder neck hypertrophy, function bladder neck obstruction, detrusor-bladder neck dyssynergia, posterior urethral valves, or urethral stricture disease, can also be garnered from this study.

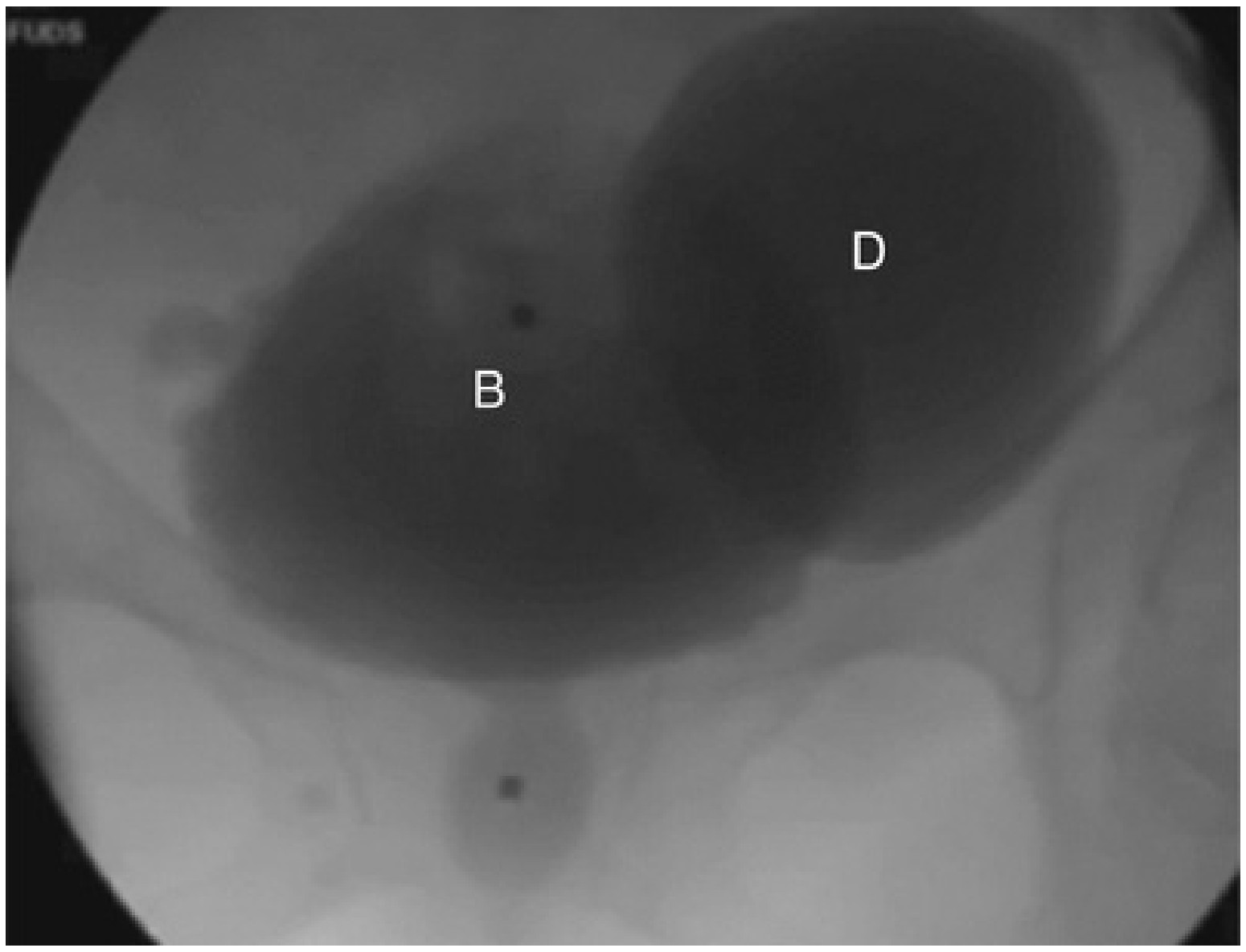

FIG. 132.2 Voiding cystourethrogram delineating bladder diverticulum *(D)* and bladder *(B).* (Modified from Chandhoke RA, Ghoniem GM. Transurethral electrovaporization of bladder diverticulum: an alternative to open or laparoscopic bladder diverticulectomy. *J Endourol Case Rep* 1[1]:11–13, 2015.)

The final study necessary before treatment planning involves imaging of the upper tracts. Ideally, triphasic computed tomography (CT) of the abdomen and pelvis, placing emphasis on excretory-phase imaging, helps characterize the concomitant presence of hydronephrosis, which may result from VUR or extrinsic ureteral compression by the diverticulum (Fig. 132.3). The proximity of the ureter to the diverticulum is also nicely delineated in this study (Fig. 132.4). CT imaging of the pelvis represents an invaluable tool in the workup as it enables evaluation of the number, size, and location of diverticula. In the event a contrast study cannot be performed, ultrasonography or noncontrast CT imaging of the kidneys should be done to evaluate for hydronephrosis combined with intraoperative retrograde pyelogram and cystogram to more comprehensively characterize the anatomic proximity of the diverticulum and ureter and evaluate for ureteral obstruction. Magnetic resonance urography may also be considered.

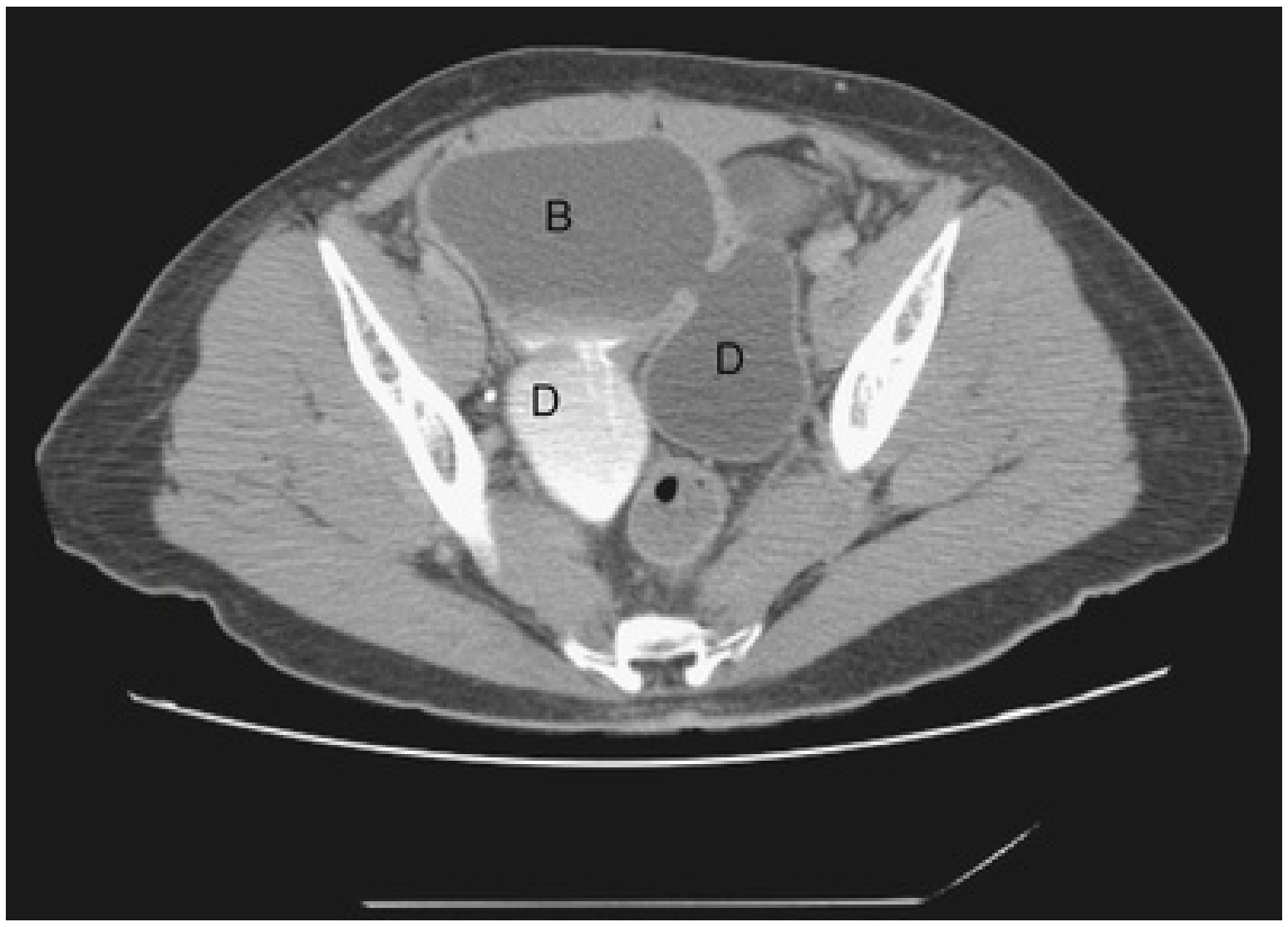

FIG. 132.3 Computed tomography urogram of the abdomen/pelvis demonstrating four bladder diverticula. Contiguity between true bladder *(B)* and two posterior bladder diverticula *(D)* is demonstrated.

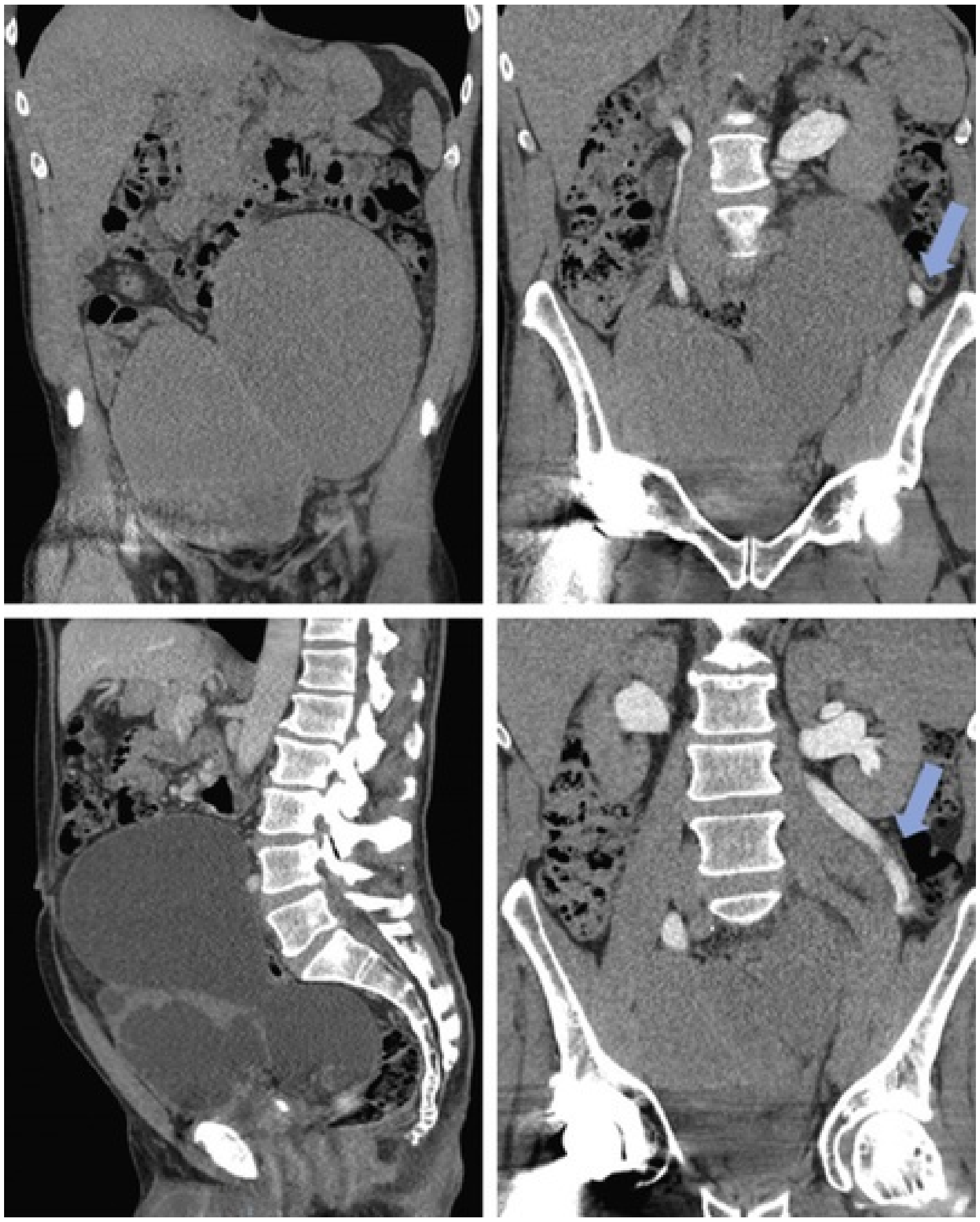

FIG. 132.4 Computed tomography of the abdomen/pelvis demonstrating large bladder diverticula in coronal *(top, left)* and sagittal *(bottom, left)* planes. Lateral displacement of the ureter *(arrow)* caused by the diverticulum can be appreciated on excretory phase imaging *(right).* (Courtesy of Lee Richstone, MD.)

As the majority of acquired bladder diverticula form in the setting of bladder outlet obstruction, and less often neurogenic dysfunction, ancillary studies should be performed to better characterize these conditions, as treatment for these disease states is necessary before or at the same time the bladder diverticulum is managed. In this regard, patients may undergo measurement of their urinary flow rate or undergo formal urodynamics testing to characterize detrusor contractile capacity and voiding pressures. Transrectal ultrasonography may be used to estimate prostate volume in patients undergoing procedural evaluation for benign prostatic hyperplasia (BPH), although CT imaging and cystoscopy, performed as part of the workup for a diverticulum, may also offer information regarding prostate size and extent of obstruction.

A urine cytology should be done in all patients given the association with bladder cancer. A negative urine culture should be confirmed before any surgical intervention.

Small, asymptomatic bladder diverticula without associated complications can be observed or treated with cystoscopic fulgaration (Clayman et al., 1984; Orandi, 1977; Vitale and Woodside, 1979) or resection. Diverticulectomy is indicated for large diverticula with incomplete emptying, chronic or repeated urinary tract infection, bladder calculi, or pain. Bladder diverticulum that result in ureteral reflux or obstruction also require diverticulectomy, often combined with ureteral reimplantation. The presence of bladder malignancy within a diverticulum is an indication for partial or radical cystectomy (Golijanin et al., 2003).

Surgical Technique

Since Czerny's first description of diverticulectomy in 1897 (Knappenberger et al., 1960), the surgical treatment of bladder diverticula has evolved from open surgery, to endoscopic procedures, to laparoscopic and robotic techniques.

Transperitoneal laparoscopic bladder diverticulectomy (LBD) was first introduced in 1992 (Das, 1992; Parra et al., 1992), and, since then, numerous subsequent reports have demonstrated the reproducibility of this technique via transvesical and extravesical approaches (Flasko et al., 2007; Nadler et al., 1995; Shah et al., 2006). Robotic bladder diverticulectomy (RBD) was subsequently described in 2007 (Macejko et al., 2008; Meeks et al., 2009; Myer and Wagner, 2007; Rao et al., 2007; Tareen et al., 2008) and mimics the laparoscopic technique, aids the surgeon without extensive laparoscopic experience, and provides a comfortable ergonomic platform for working in the deep pelvis.

When an open approach is utilized, it is possible to remain extraperitoneal, including for posteriorly situated diverticula, whereas during laparoscopic and robotic surgery, a transperitoneal approach may be preferable given this provides a wide and generous working space, and fewer reports exist detailing outcomes associated with an extravesical approach (Flasko et al., 2007; Nadler et al., 1995; Shah et al., 2006). Extraperitoneal surgery has the advantage of reducing risk for visceral injury and intraperitoneal urine leak, which can be a major source of morbidity.

The choice of surgical technique for bladder diverticulectomy depends on numerous factors, including the number and location of diverticula, proximity of the diverticulum to the ureter, and the need for concomitant ureteral or bladder outlet surgery. Complex (large, posteriorly situated) and multiple diverticula requiring concomitant ureteral reimplantation traditionally are managed with an open approach, although a laparoscopic or robotic approach may be pursued, provided the surgeon has sufficient experience and skill.

Various alternative approaches to laparoscopic diverticulectomy have been described in attempts to minimize morbidity further. Transvesical pneumovesicoscopic diverticulectomy has been described involving the cystoscopic establishment of carbon dioxide pneumovesicum, with subsequent transabdominal trocar placement directly into the bladder (Badawy et al., 2008; Marte et al., 2010). LESS surgery has been employed to address bladder diverticula as well via a transabdominal (Stolzenburg et al., 2011) and transvesical approach (Roslan et al., 2012a).

The underlying cause of diverticula formation should be addressed before or at the time of diverticulectomy, including relief of bladder outlet obstruction or augmentation cystoplasty in cases of neurogenic bladder. When bladder outlet obstruction is caused by BPH, surgery can be performed concomitantly, either immediately before or after resection of the diverticulum. Options for management include transurethral endoscopic procedures or extirpative interventions such as suprapubic prostatectomy, particularly for a higher burden of disease. Laparoscopic or robotic simple prostatectomy also can be performed at the time of LBD or RBD (Magera et al., 2008). If endoscopic management is pursued for bladder outlet obstruction, it should be performed before diverticulectomy to avoid risking perforation of the bladder from tension being placed on the suture lines by irrigation fluid.

Open Technique

Intravesical Approach.

The patient is placed on the operating table in a supine position with the anterior superior iliac spine positioned over the break of the table. The table is placed into slight flexion to facilitate entry into the retropubic space of Retzius (Fig. 132.5A). The genitalia and intraumbilical aspect of the abdomen is prepped and draped in the standard sterile fashion. An 18-Fr Foley catheter is placed into the bladder on the sterile field. The bladder is distended with approximately 200 mL of sterile water, and the catheter is plugged to retain irrigant fluid within the bladder. Alternatively, flexible cystoscopy can be performed at the beginning of the case, and a guidewire can be used to catheterize the diverticulum with a Councill-tip catheter; instillation of fluid would permit distension of the diverticulum and aid in intraoperative localization (Fig. 132.6). In cases in which the bladder diverticulum is in close proximity to the ureter, a ureteral catheter may be placed.

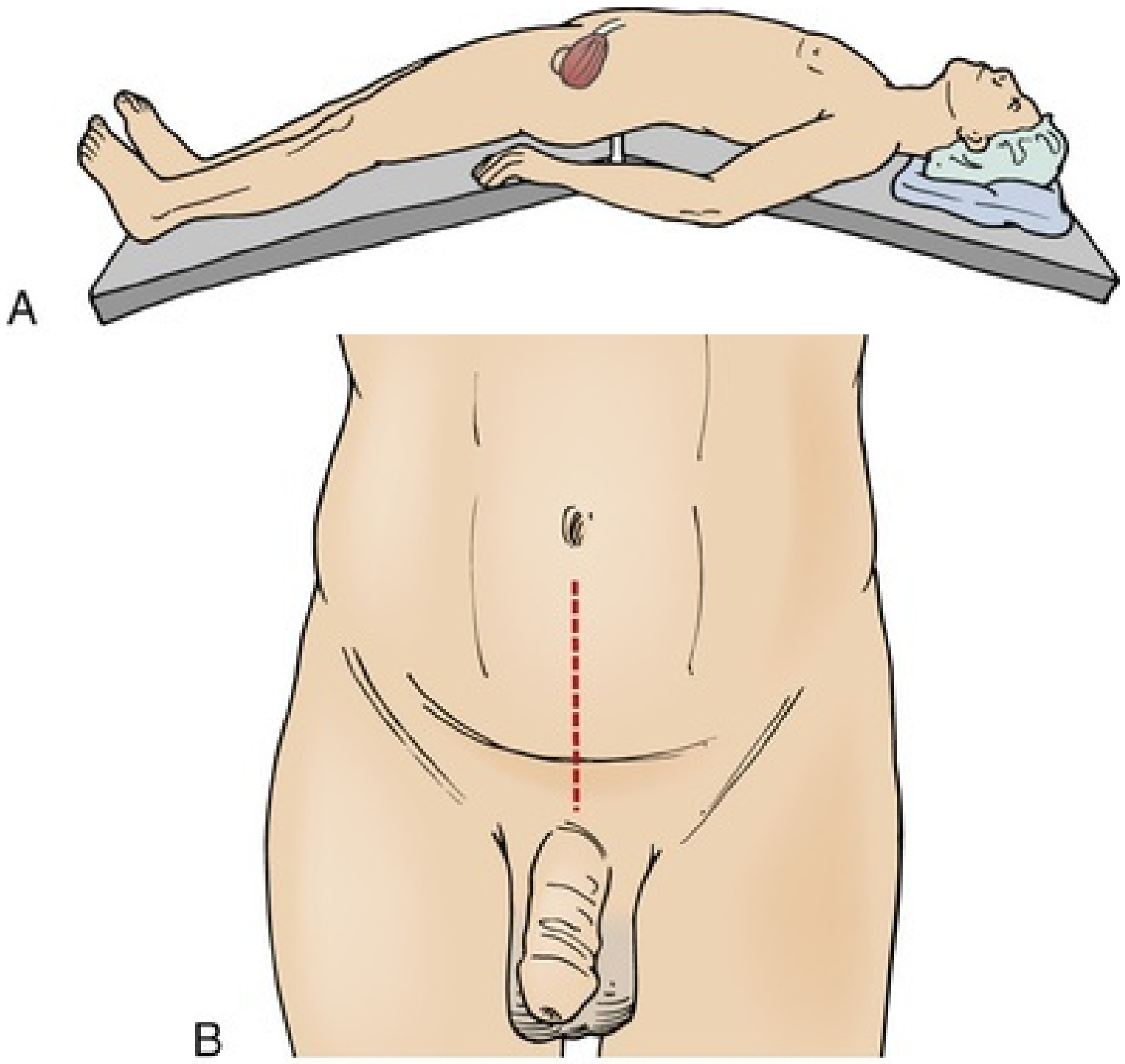

FIG. 132.5 Patient positioning and incision for open diverticulectomy. (A) Patient placed supine with operating table flexed. (B) Lower midline incision.

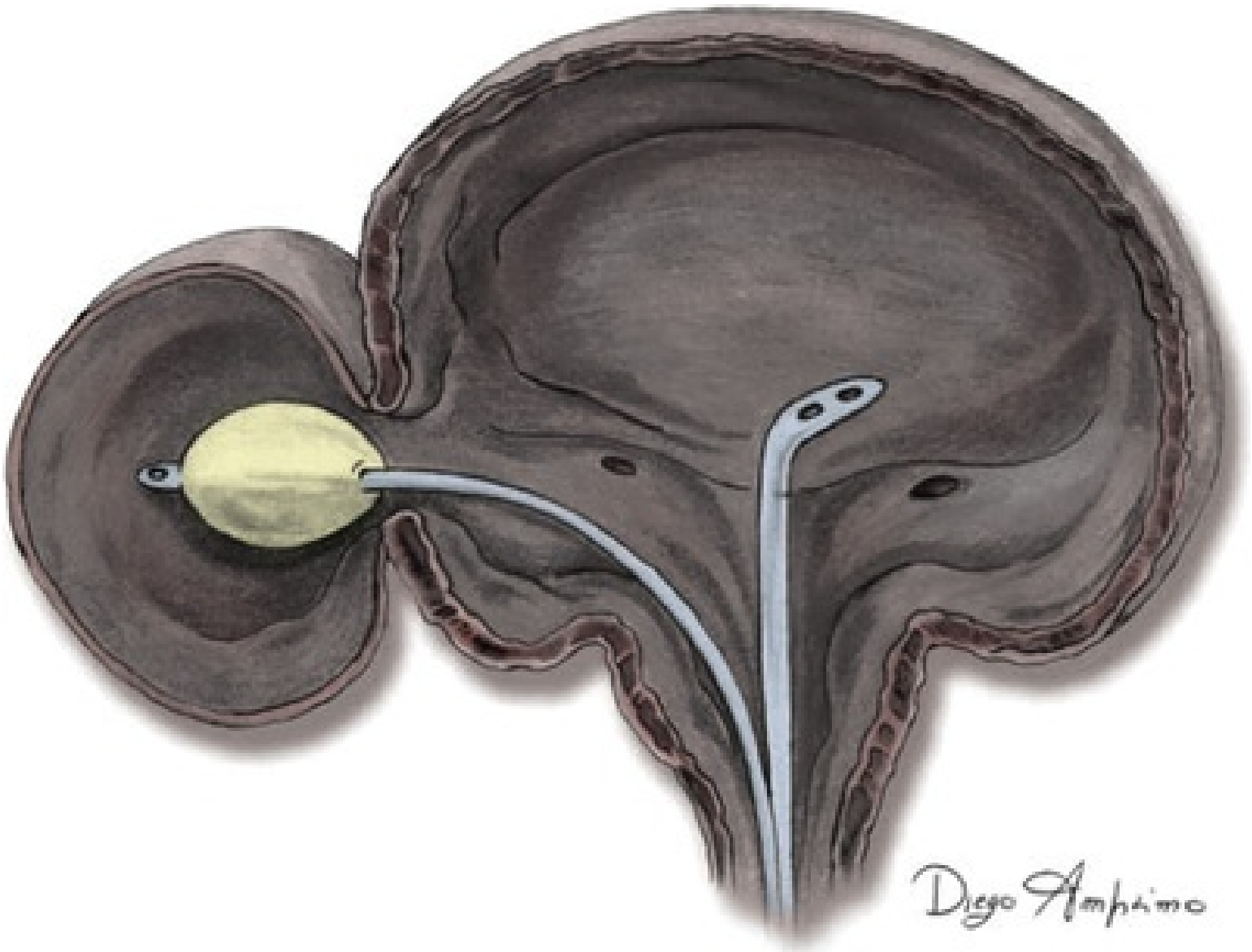

FIG. 132.6 Selective catheterization of the bladder diverticulum with a Councill catheter. A Foley catheter in the bladder permits selective distention of the diverticulum to aid in diverticular identification and dissection. Ureteral catheterization aids in ureteral identification to avoid injury. (Modified from Porpiglia F, Tarabuzzi R, Cossu M, et al. Sequential transurethral resection of the prostate and laparoscopic bladder diverticulectomy: comparison with open surgery. *Urology* 60[6]:1045–1049, 2002.)

A midline infraumbilical incision is made down to the level of the pubic symphysis (see Fig. 132.5B). The subcutaneous tissue is divided with electrocautery down to the rectus fascia. The rectus fascia is divided the length of the incision along the linea alba, exposing the underlying rectus abdominus muscle. The bellies of the rectus abdominus muscle are split the length of the incision after which the transversalis fascia is incised to reveal the preperitoneal fat above and the space of Retzius below. Distension of the bladder will have displaced the peritoneal reflection cephalad, enabling easier entry into the space of Retzius. The bladder may be distended further at this time to facilitate cephalad displacement of the peritoneum. Using a sponge-stick, the space of Retzius is developed bluntly as are the lateral pelvic gutters on either side of the bladder by pushing the perivesical fat medially. During this maneuver, the peritoneal reflection can be swept upward further off the bladder dome to minimize risk for inadvertent entry into the peritoneal cavity. At this time, a self-retaining retractor is placed to aid in exposure.

With the bladder distended, electrocautery is used to make a vertical cystotomy down the midline from the anterior dome of bladder to just proximal to the bladder neck. The irrigant fluid within the bladder should be aspirated with a suction device as the cystotomy is lengthened. A 2-0 polyglactin suture is placed transmurally at the apices of the bladder incision to minimize risk for tearing the bladder wall. At this time, all irrigant fluid should be aspirated from the bladder and the bladder mucosa carefully inspected to ensure that there are no suspicious lesions. Deeper blades can be placed on the self-retaining retractor to gently retract the bladder walls and facilitate exposure; alternatively, this can be done with a handheld deep blade retractor.

The ureteral orifices should be identified and their proximity to the bladder diverticulum noted. If there is concern regarding nearness of the ureter to the diverticulum, a 5-Fr ureteral catheter can be inserted into the ureter. Once the mouth of the diverticulum is identified, an attempt can be made to evert the diverticulum into the bladder lumen by passing an Allis clamp through the neck of the diverticulum and grasping its base. Once the diverticulum is everted, the mucosa is incised circumferentially around the neck of the diverticulum with an approximate 0.5-cm margin and continued down through to the submucosal connective tissue, freeing the diverticulum off the bladder wall.

If eversion of the diverticulum is not possible, a circumferential incision of the mucosa approximately 0.5 cm from the mouth of the diverticulum is made and carried down into the submucosal connective tissue (Fig. 132.7A). As diverticula often have a fibrous pseudocapsule that has formed around the adventitial layer, a combination of blunt and sharp dissection is used to exploit this plane and dissect the diverticulum free from its overlying capsule (see Fig. 132.7B). An Allis clamp placed on the neck of the diverticulum after incision of the mucosa can be used to generate countertraction as this cleavage plane is created between the diverticular sac and the fibrous capsule; The Allis clamp can be repositioned as needed around the perimeter of the diverticular neck to provide appropriate countertraction as the diverticulum is mobilized in a circumferential manner. Eventually, the diverticulum will be freed from its overlying capsule and removed in its entirety (see Fig. 132.7C).

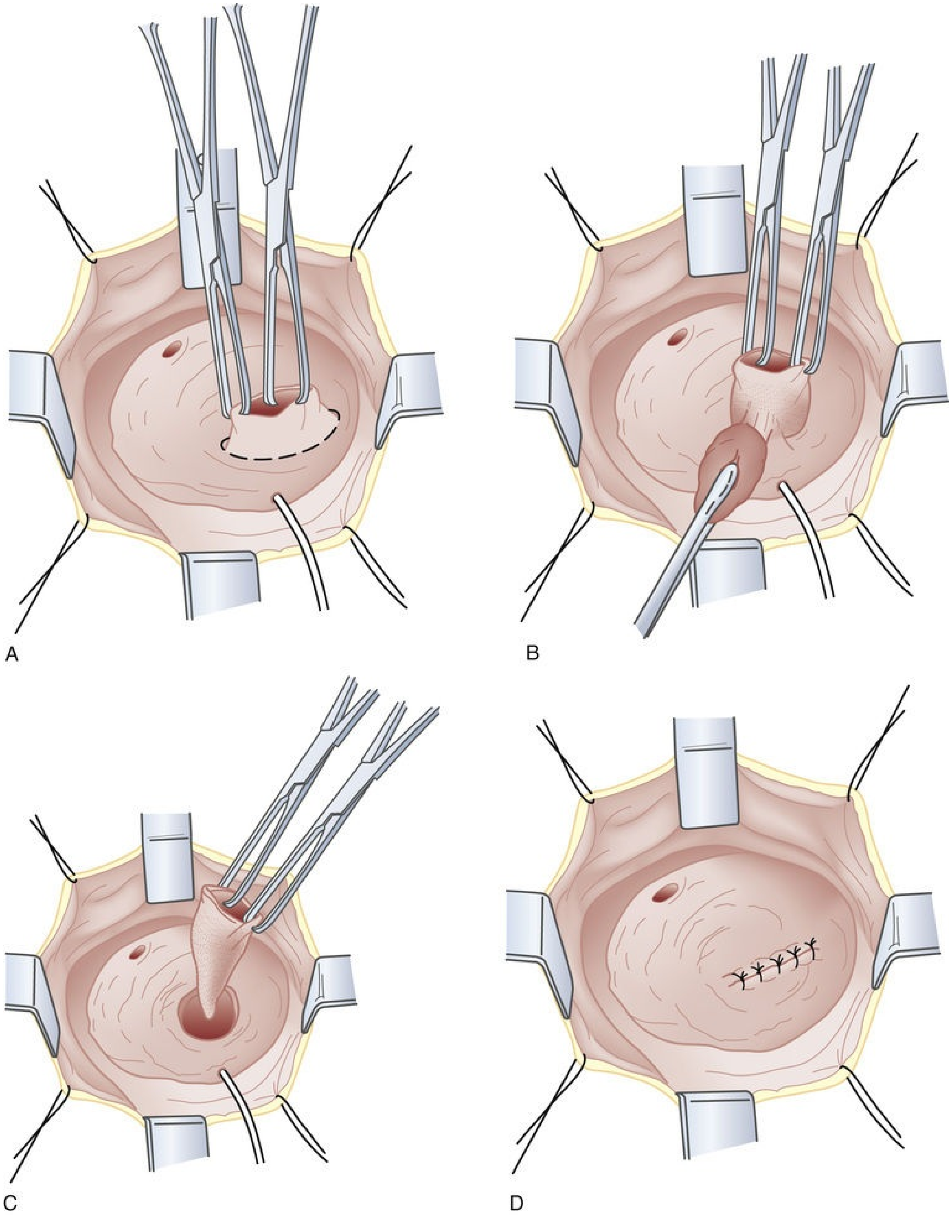

FIG. 132.7 Intravesical technique for bladder diverticulectomy. (A) The neck of the bladder diverticulum is identified intravesically. With the aid of Allis clamps, a circumferential incision is made through the mucosa into underlying connective tissue later. (B) The cleavage plane between the adventitial wall of the diverticulum and the overlying capsule is developed

with sharp and blunt dissection. (C) The diverticulum is freed from its overlying capsule and delivered into the bladder. (D) The bladder wall defect closed. No drain has to be left in remnant capsule.

The bladder wall defect at the site of diverticular resection should be closed in a two-layer running fashion using 2-0 polyglactin suture, with care taken to ensure a secure seromuscular closure to minimize the risk for recurrence (see Fig. 132.7D). The initial urinary catheter is exchanged for a larger-bore Foley catheter (e.g., 22-Fr). With the catheter in position, the cystotomy is closed in a two-layer running fashion with 2-0 polyglactin suture; the closure should allow for apposition of the mucosal layer first followed by the seromuscular layer. The integrity of the cystotomy closure and the bladder wall defect at the site of diverticulum removal should be tested by gently filling the bladder with 300 mL of sterile water. Any areas of fluid extravasation should be reinforced with figure-of-eight 2-0 polyglactin suture.

Placement of a suprapubic catheter is generally not necessary but may be placed at the surgeon's discretion to maximize drainage and minimize tension on the suture lines at the site of bladder closure. A separate punch cystotomy should be made lateral to the midline cystotomy before closure. The suprapubic catheter should be threaded into the bladder under direct visualization and secured to the bladder wall using 2-0 polyglactin suture in a purse-string fashion. Under direct visualization, a separate stab incision is made through the skin and underlying fascia lateral to the rectus belly with the aid of a tonsil clamp. The suprapubic catheter is brought out to the skin and secured with nonabsorbable suture.

A pelvic drain should be placed, ideally, anterior to the cystotomy curving into the lateral pelvic gutter lateralized to the site of diverticulectomy. This is brought out through the skin through a separate stab incision and secured using nonabsorbable suture. The drain should be placed to self-suction.

The fascia may be closed in either a continuous or interrupted fashion. The subcutaneous wound is irrigated, after which the skin is closed.

Combined Intra-Extravesical Approach.

The combined intra-extravesical approach to excision of a bladder diverticulum begins with many of the same initial steps involved in the intravesical technique. Once the cystotomy is made and the mouth of the bladder diverticulum identified, a circumferential incision of the mucosa approximately 0.5 cm from the mouth of the diverticulum is made and carried down into the submucosal connective tissue.

Subsequently, a finger or blunt curved instrument (e.g., metal suction tip) can be placed into the diverticular sac to allow anterior traction to be applied on the diverticular sac in a manner that brings the extravesical portion into surgical view (Fig. 132.8A). A Kittner dissection sponge can be used to gently tease the perivesical fat off the external surface of the diverticular sac and free it from surrounding tissue. This enables better visualization of the interface between the external surface of the diverticulum and the extravesical bladder surface.

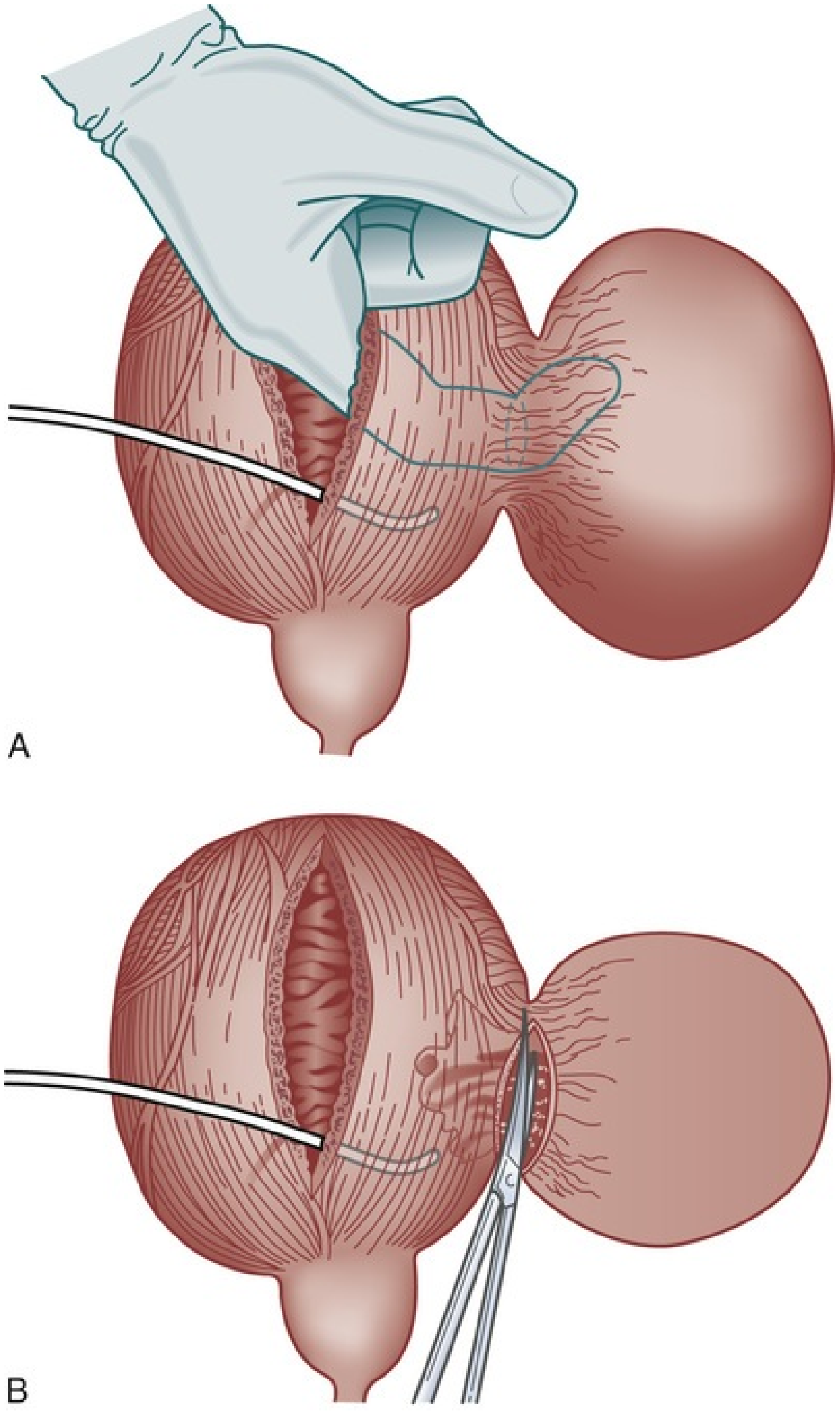

FIG. 132.8 Combined intra-extravesical technique for bladder diverticulectomy. (A) After gaining access to the bladder, the bladder neck is identified and circumferential incision is made through the mucosa into the underlying connective tissue. (B) A finger is placed into the diverticulum sac to allow for anterior displacement into the surgical field, and an incision is made circumferentially around the neck of the diverticulum along its extravesical surface. The diverticulum and overlying capsule are dissected free from surrounding tissue and removed. Alternatively, the detached diverticulum is dissected off its overlying capsule and removed.

With the neck of the diverticulum having been circumscribed intravesically with electrocautery, placement of anterior-outward traction on the diverticular sac should more readily expose the extravesical surface of the diverticular neck. The extravesical surface of the diverticular neck is circumferentially incised with electrocautery, freeing the diverticulum off the bladder wall (see Fig. 132.8B). It is important to bear in mind that as the diverticular neck is incised circumferentially on its extravesical surface, continuity should be established with the intravesically incised mucosal rim around the diverticular neck. Failure to do this may create a new dissection plane during extravesical dissection that leads to resection of excess bladder wall tissue.

Once the diverticulum neck is freed from the bladder wall, it remains within the surrounding pseudocapsule, which itself can be adherent to the surrounding perivesical tissue. The diverticular sac is dissected free from the pseudocapsule using a combination of blunt (i.e., a Kittner dissection sponge) and sharp dissection. Placement of Allis clamps at the neck of the disconnected diverticulum will offer countertraction to aid in dissection of the diverticulum off the overlying capsule.

The bladder wall defect can be closed using either the intravesical or extravesical route in a two-layer running fashion using 2-0 polyglactin suture.

Laparoscopic and Robotic Techniques

The patient is placed in a dorsal lithotomy position with the arms secured to the side and hips abducted (Fig. 132.9). The abdomen up to the level of umbilical and the groin are prepped and draped.

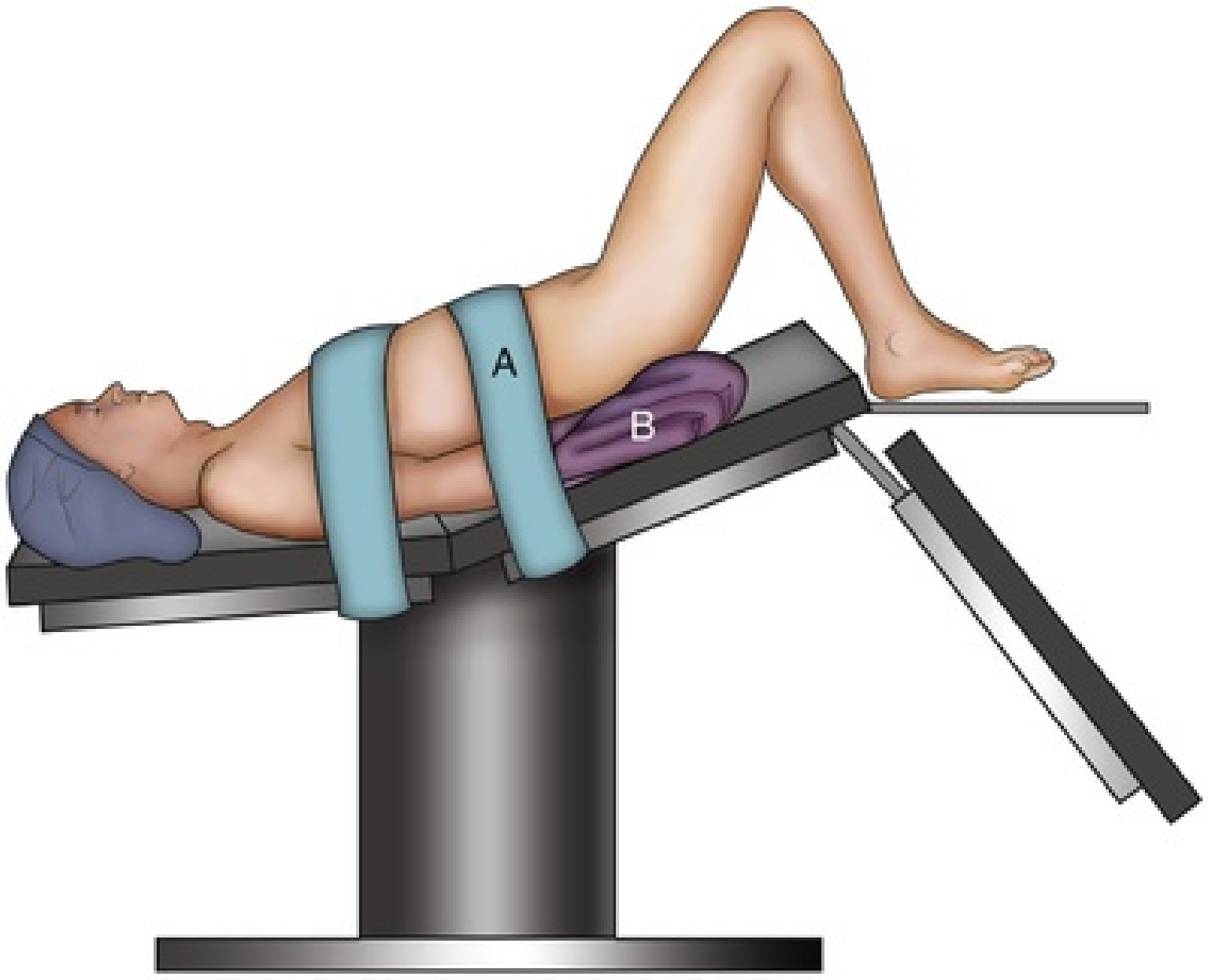

FIG. 132.9 Positioning for robotic and laparoscopic diverticulectomy. The patient is positioned in the dorsal lithotomy position using standard operative stirrups and then placed into the Trendelenburg position. All pressure points are protected using standard egg crate foam padding. (A) Cross-shoulder harness made by four strips of egg-crate foam padding. Each strip is 6 × 24 inches, and two strips are used on each side of the patient creating an "X" configuration across the patient's chest. The pads are secured to the operating table using cloth tape.

Before port placement, flexible cystoscopy can be performed for ureteral catheterization if necessary. Selective catheterization of the diverticulum can also be performed by placing a Councill-tip catheter over a guidewire into the diverticulum and a separate Foley catheter into the bladder proper for selective filling and intraoperative identification of bladder diverticula (Khonsari et al., 2004; Nadler et al., 1995; Porpiglia et al., 2002), as depicted in Fig. 132.6.

Alternatively, real-time illumination of the diverticulum with a flexible cystoscope is a useful aid in identifying the diverticulum, as described later (Jarrett et al., 1995; Nadler et al., 1995; Parra et al., 1992). In our experience, this is particularly valuable in patients with multiple diverticula in whom separate catheterization of each diverticulum is not practical. Intravesical methylene blue also has been described as an aid to identify the bladder neck during robotic diverticulectomy (Moore et al., 2012).

For both LBD and RBD being performed by a transperitoneal approach, a Veress needle is placed through the umbilicus into the peritoneal cavity, and pneumoperitoneum of 15 mm Hg is established. Alternatively, a subcostal location may be used for placement of the Veress needle in patients with prior history of abdominal surgery (Gaunay et al., 2016). The table is subsequently placed into the steep Trendelenburg position, which aids in visualization of the pelvic cavity by displacing the intestinal contents cephalad (see Fig. 132.9).

Trocars for LBD and RBD are positioned as depicted in Fig. 132.10. In the case of robotic surgery, the ports are placed beginning with the camera port in the midline approximately 2 cm above the umbilicus (see Fig. 132.10A); the incision for camera port placement should reflect the model of the DaVinci (Intuitive Surgical, Sunnyvale, CA) surgical system being used, as the Si unit utilizes a 12-mm port and the Xi unit uses an 8-mm port. The endoscope is inserted, and the abdominal cavity is inspected to ensure that there is no injury. The remaining 8-mm robotic ports should be placed under direct visualization.

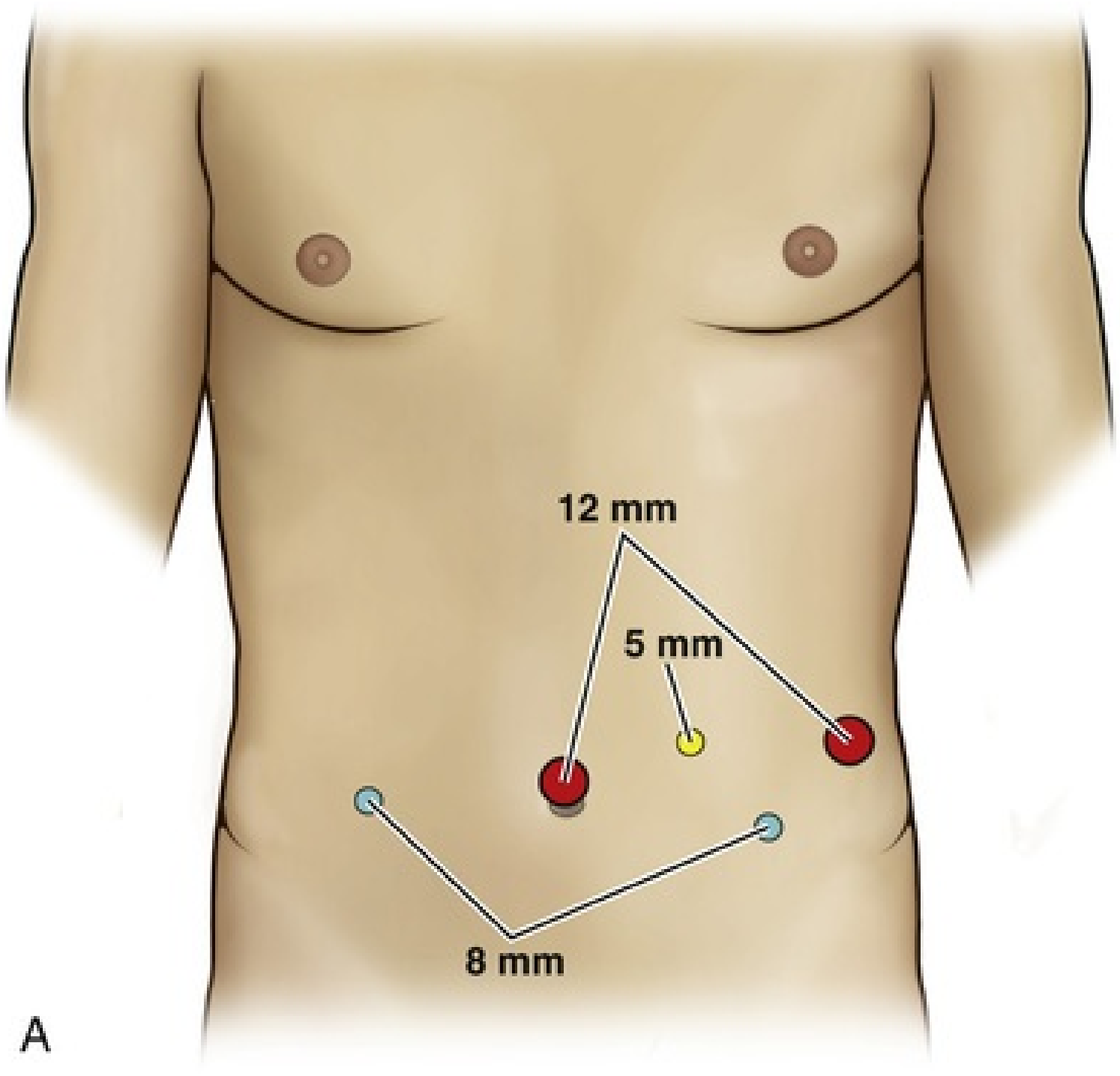

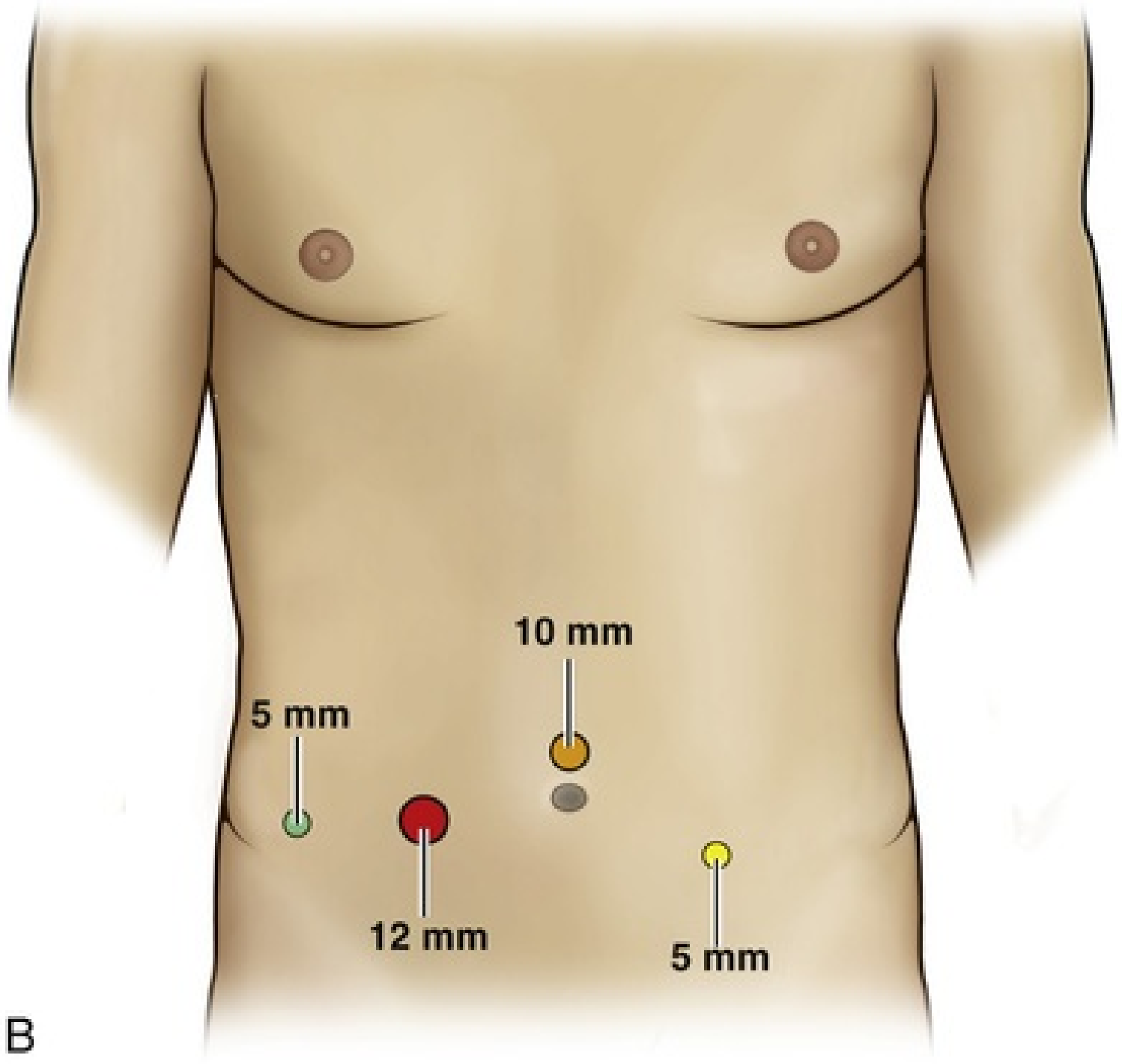

FIG. 132.10 Port placement. (A) Robotic bladder diverticulectomy. A 12-mm port at the umbilicus is employed for the endoscope. Two 8-mm robotic trocars are placed 10 cm inferolaterally at the pararectus location. At the surgeon's discretion, assistant ports are placed as needed; options include a 5-mm trocar (placed halfway between the camera and robotic trocar) and/or a 12-mm trocar (two fingerbreadths above the anterior superior iliac spine). If needed, an additional 8-mm trocar can be used for the fourth arm of the robot two fingerbreadths above the contralateral anterior superior iliac spine. (B) Laparoscopic bladder diverticulectomy. A 10-mm port at the umbilicus is employed for the endoscope. For a right-handed surgeon, working ports include a 12-mm and a 5-mm trocar at the right and left pararectus location, respectively. An optional 5-mm trocar can be placed approximately 2 cm cephalad and medial to the anterior superior iliac spine (depicted in *green*).

Two 8-mm robotic ports are placed on either side of midline caudal to the camera port and at the level of the umbilicus. These should be placed 10 cm inferolaterally to the midline camera port in a pararectus location. The fourth arm of the robot can be used, based on surgeon preference, and would require placement of another 8-mm robotic port approximately 8 cm lateral to one of the pararectus ports and two fingerbreadths above the anterior superior iliac spine, on the same side as the diverticulum (not shown). This will allow placement of a lateral 12-mm assistant port on the side contralateral to the diverticulum approximately two fingerbreadths above the anterior superior iliac spine. This configuration provides the assistant direct access to the region of interest compared with ipsilateral placement of the assistant port, which may limit freedom of motion because of the iliac bone. An additional 5-mm assistant port may be placed in the upper abdomen on the side contralateral to the diverticulum. It should be situated in a triangulated distance of 8 cm from the camera port and paramedian robotic port (see Fig. 132.10A).

After placement of the ports, the robotic is docked either on the side of the patient for the Xi model or in between the legs for the Si model.

Both LBD and RBD begin with an incision of the peritoneum overlying the diverticulum, which can be identified with the aid of either selective catheterization and filling or cystoscopic transillumination (Fig. 132.11). For larger or multiple diverticula, the bladder can be mobilized by incising the peritoneum lateral to the obliterated umbilical ligament bilaterally, dividing the urachus, and then “dropping” the bladder posteriorly to enter into the space of Retzius. The 10-mm LigaSure device (ValleyLab, Boulder, CO) can be used during LBD, and a combination of monopolar and bipolar cautery instrumentation is employed during RBD.

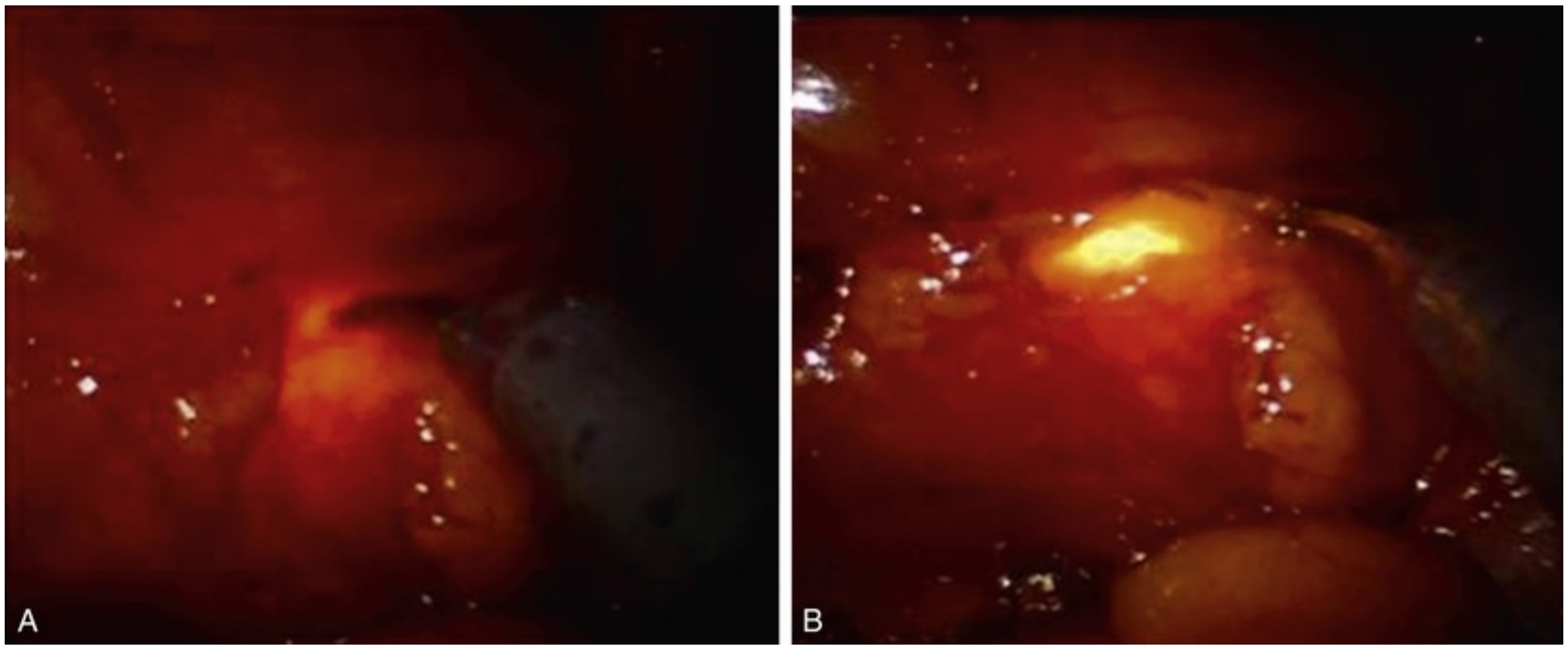

FIG. 132.11 Identification of diverticulum during minimally invasive diverticulectomy. (A) Cystoscopic illumination of diverticulum with flexible cystoscope within the diverticular neck (scissors point to center of diverticulum). (B) Cystoscope repositioned to selected point of bladder entry, anterior to the diverticular neck with ample margin.

Peridiverticular adhesions are transected and the diverticulum is dissected down to its neck (Fig. 132.12A). The extravesical surface of the neck of the diverticulum is circumscribed, either with a monopolar hook during LBD or monopolar scissors during RBD (see Fig. 132.12B). Traction can be applied to the diverticulum sac to facilitate dissection and resection using either robotic Prograsp forceps for RBD or atraumatic bowel grasping forceps for LBD (see Fig. 132.12C). The incision is carried through the wall of the bladder enabling complete excision of the diverticulum. Constant vigilance is required to prevent injury to the ureter or ureteral orifice. In some cases, this may require careful dissection of the ureter off the external surface of the diverticulum. The diverticulum once detached from the bladder is placed in an EndoCatch (Covidien, Mansfield, MA) specimen bag.

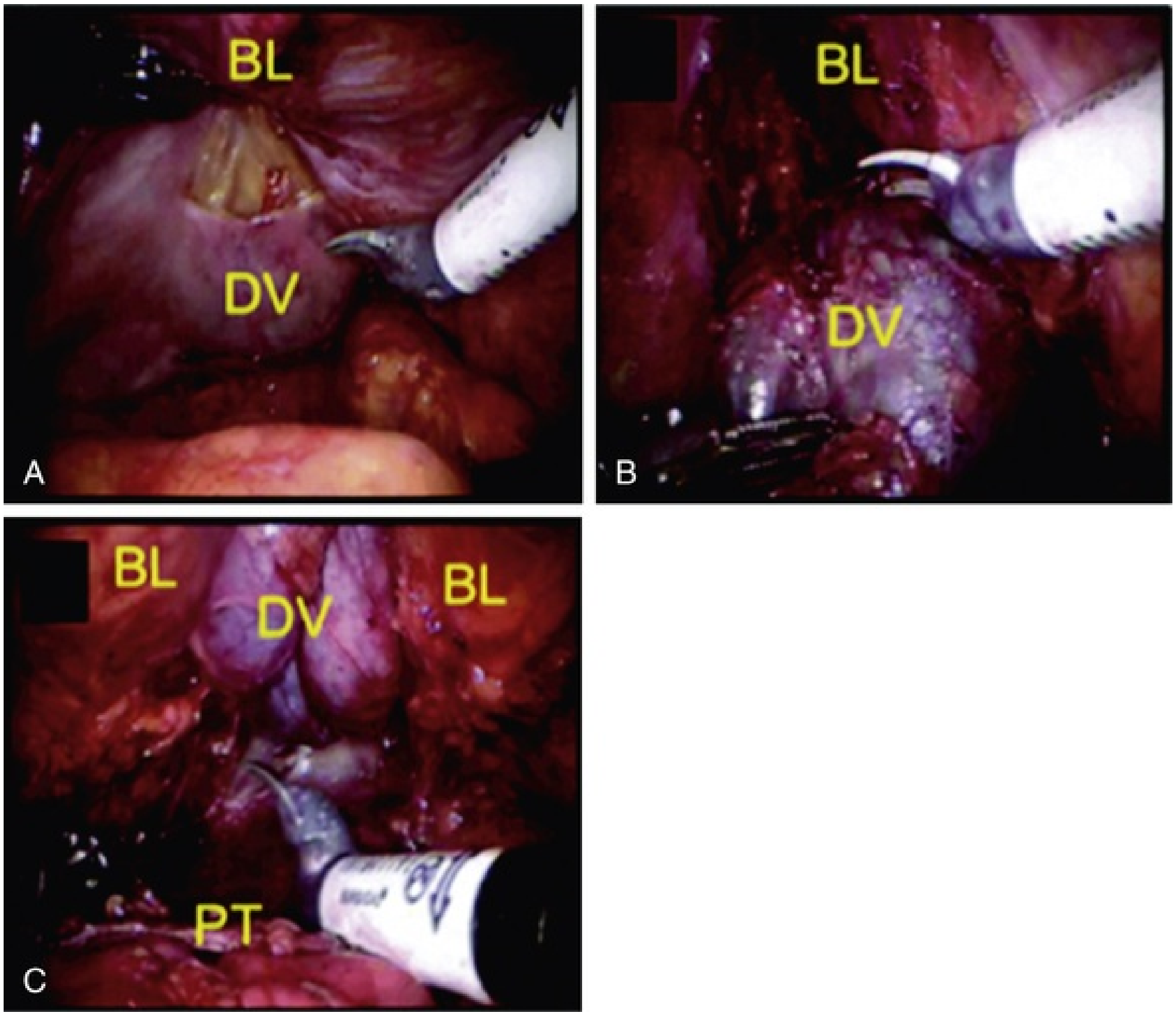

FIG. 132.12 Extravesical robotic bladder diverticulectomy. (A) Distension of diverticulum allows identification from transperitoneal view. Peritoneum overlying diverticulum in vicinity of the neck is incised. (B) Diverticulum is dissection free of peridiverticular connective tissue adhesions down to its neck. An incision is made circumferentially around the neck, beginning anteriorly. (C) Anterior traction placed on the diverticulum allows circumferential incision, seen here on its posterior neck. (Modified from Abreu AL, Chopra S, Dharmaraja A, et al. Robot-assisted bladder

diverticulectomy. *J Endourol* 28[10]:1159–1164, 2014.)

If necessary, a transvesical approach can be employed. After the bladder is dropped, the bladder is opened at its midline. To maintain the pneumoperitoneum, the Foley catheter is plugged externally. The diverticulum mouth is identified, and the diverticulum is pulled into the bladder; inversion can be facilitated by pushing inward on the extravesical surface of the diverticular sac while simultaneously grasping and pulling on the inner mucosal surface from within the bladder. Once inverted, the mucosal lining the neck of the diverticulum is circumscribed, and the incision is carried deeper to allow detachment of the diverticulum from the bladder wall.

In either approach, the bladder wall defect, including the site of diverticular resection and, for the transvesical approach, the site of cystotomy is closed in two layers with 2-0 polyglactin suture. The bladder may be hitched anteriorly to aid in visualization of the defect. During LBD, freehand intracorporeal suturing can be employed. Alternatively, an Endo Stitch device (Covidien, Mansfield, MA) can be used as a suturing aid. An Endo GIA stapler (Covidien, Mansfield, MA) can also be used for excision; however, this carries with it the theoretical risk for bladder stone formation (Kerbl et al., 1993). The bladder is filled to ensure watertight closure. If needed, ureteral reimplantation secondary to reflux, obstruction, or iatrogenic injury is performed as described in the following section. The peritoneum may be reconstituted to recompartmentalize the intraperitoneal and extraperitoneal spaces.

A pelvic drain is placed via one of the trocar sites to avoid an unnecessary additional incision. It is secured to the skin with nonabsorbable suture and placed to self-suction. The pneumoperitoneum is released. The specimen is extracted through an extension of the midline camera-port incision. The fascia of the extraction site and 12-mm assistant port are closed with figure-of-eight 0-polyglactin suture. The skin incisions are closed.

The extraperitoneal approach to LBD involves similar principles as used for the transperitoneal LBD. The extraperitoneal space is first accessed by making an incision 2 cm below the umbilicus and carried through the fascia and linea alba. Blunt finger dissection is used to develop the extraperitoneal space. A dilating balloon inserted into this space can be used to further develop this space. A Hasson port is then placed into this location after which insufflation with CO_2 is used to establish the preperitoneal and retropubic space. Two additional ports, either 5 mm or 12 mm, are placed in the pararectus location inferior to the infraumbilical incision. An additional assistant port (5 mm or 12 mm) may be placed as necessary in the midline between the pubic symphysis and the umbilicus, below the camera port.

LESS has been demonstrated as an approach to diverticulectomy with excellent cosmetic outcomes (Roslan et al., 2012a; Stolzenburg et al., 2011). After single-site access in the transabdominal approach, the operation follows the same basic steps as described earlier for LBD and RBD (Stolzenburg et al., 2011). During transvesical single-site diverticulectomy, the procedure begins with cystoscopy-guided placement of a single-port access device transvesically, followed by the establishment of pneumovesicum (Roslan et al., 2013). The diverticular neck is circumscribed with a monopolar scissors or hook, and the diverticulum is excised. Retraction can be aided by transurethral and/or cystoscopic instrumentation. The defect is subsequently closed, and the specimen is extracted (Roslan et al., 2013).

Postoperative Care and Complications

The Foley catheter is kept to drainage for approximately 1 week postsurgery to allow for adequate healing of the bladder closure. Output from the pelvic drain is monitored because high output may indicate a urinary leak. If the output is low and there is adequate urine output from the Foley catheter, the drain may be removed, typically 48 hours after surgery. Some surgeons may opt to measure a drain fluid creatinine to confirm the integrity of the bladder closure. Before outpatient removal of the Foley catheter, a cystogram should be performed to confirm the absence of contrast extravasation; periprocedural antibiotics are optional to reduce the risk for transient bacteremia.

Complications after bladder diverticulectomy are similar for both open and minimally invasive techniques. The most common complication is urinary extravasation, which may manifest only as high fluid output from the pelvic drain or symptomatically with abdominal pain and fever secondary to an infected urinoma; if performed via a transperitoneal approach, urinary extravasation may present with ileus and electrolyte abnormalities. If still present, a drain serum creatinine can be measured to confirm leak. Cross-sectional imaging can be performed to characterize the degree and location of extravasation. If asymptomatic, the Foley catheter and pelvic drain should be left in place to facilitate healing. Symptomatic presentation may require placement of a percutaneous drain. A drain study and cystogram should be performed before removal of the drain and Foley catheter. Persistence of a urinary leak despite these measures may require placement of percutaneous nephrostomy tubes.

Ureteral injury sustained during diverticular dissection may go unrecognized until the postoperative period, at which time it may present as acute kidney injury or with symptoms of urinary extravasation (e.g., fever, abdominal pain, ileus, electrolyte abnormalities) or flank pain. Excretory urography, and if necessary retrograde imaging, should be performed to confirm and characterize the ureteral injury, visualize hydronephrosis, and identify the presence of a urinoma, which may require percutaneous draining. An attempt at retrograde stent placement should be undertaken; if this fails, a percutaneous nephrostomy should be placed with plans for delayed ureteral repair. Other complications include urinary tract infection, urinary fistula formation, bladder spasms, wound infection, and bowel injury.

Outcomes

Open surgery remains the gold standard for management of bladder diverticula, although increased experience with minimally invasive techniques has enabled use of these strategies for treatment of even complex bladder diverticula, including those that are large in size or multiple in nature (Khonsari et al., 2004).

The majority of comparisons to open surgery are in the form of single-institutional series. Porpiglia et al. studied perioperative outcomes in 12 patients undergoing sequential transurethral resection of the protate followed by transperitoneal LBD versus 13 patients undergoing conventional open diverticulectomy and transvesical prostatectomy (Porpiglia et al., 2004). Diverticula between groups were similar in size and position, and prostatic adenomas were similar in volume. Although operative time was significantly longer in the minimally invasive group (240 vs. 136 minutes), blood loss, postoperative pain, and hospital length of stay was significantly less compared with open surgery. No complications were noted with either approach, and postoperative urinary flow rates were equivalent (Porpiglia et al., 2004).

A case series involving 13 patients who underwent transperitoneal LBD without simultaneous management of bladder outlet obstruction revealed only one postoperative complication in the form of extravasation from the suture line that resolved with conservative management (Abdel-Hakim et al., 2007). In those patients who had diverticular disease secondary to BPH, TURP was successfully performed shortly after LBP without complications. Postoperative follow-up at 3 months revealed significant improvement in International Prostate Symptom Score (IPSS) and uroflowmetry; a normal postvoid residual urine volume was appreciated in all cases. Additionally, no patients had experienced urinary tract infection after their procedure (Abdel-Hakim et al., 2007). Sequential holmium laser enucleation of the prostate and laparoscopic extraperitoneal bladder diverticulectomy has also been performed with favorable outcomes (Shah et al., 2006). As such, laparoscopic bladder diverticulectomy has been shown to be a safe and effective alternative to open diverticulectomy and may in fact be associated with decreased hospital stay.

Robotic bladder diverticulectomy has also been demonstrated to be effective, with excellent perioperative outcomes and hospital stays approximating 2 to 3 days (Abreu et al., 2014; Altunrende et al., 2011; Davidiuk et al., 2015; Eyraud et al., 2013; Kural et al., 2009). A study of 10 patients undergoing transperitoneal RBD using either an extravesical or transvesical approach revealed a median estimated blood loss of 75 mL and operative time of 210 minutes. At 18-month follow-up, median IPSS had decreased by 57% (Abreu et al., 2014). Of note, one (10%) major complication was noted in this series in a patient who had undergone concomitant RBD and robotic suprapubic prostatectomy. Eyraud et al. reviewed 13 series of RBD involving a total of 44 patients (Eyraud et al., 2013). Median size of the treated diverticulum was 8.3 cm. The authors noted favorable operative times (median 186 minutes) and blood loss (86 mL) as well relatively short median hospital length of stay of only 2 days. Time to removal of the Foley catheter ranged between 7 and 14 days and was similar to that reported in open series. Two patients experienced a postoperative complication; one involved development of a urinary tract infection managed with antibiotics, and the other was a urinary leak across the suture lines requiring longer duration of catheterization (Eyraud et al., 2013). Davidiuk et al. more recently reported on 16 consecutive patients who underwent RBD (Davidiuk et al., 2015). Median operative time ranged between 149 and 228 minutes, and no major complications were seen in their cohort at 30-day follow-up. Additionally, significant reductions in postvoid residual volume (458 mL preoperatively to 214 mL postoperatively) and American Urological Association Symptom Score (AUASS) (18 preoperative to 7 postoperatively) were observed (Davidiuk et al., 2015).

When considered in aggregate, the published literature on RBD indicates the ability to achieve favorable outcomes with low risk for complications and operative times shorter than that seen with laparoscopic techniques.

Ureteral Reimplantation

Description

Ureteral reimplantation in adults may be required for a multitude of reasons in both the acute and elective setting. More urgent circumstances arise in the context of either trauma situations, in which case an open approach to repair is preferable, or with recognized iatrogenic injury during pelvic and retroperitoneal procedures (Dowling et al., 1986; Vakili et al., 2005), for which open or minimally invasive attempts at reconstruction may be employed depending on the approach of the index procedure and the magnitude of injury.

Elective procedures aimed at restoring continuity between the ureter and bladder occur most frequently in the setting of ureteral stricture disease or unrecognized iatrogenic ureteral injury with delayed clinical manifestation (Dowling et al., 1986; Roberts et al., 1998; Vakili et al., 2005; Weinberg et al., 1987). Less often in adults is ureteral reimplantation performed for primary vesicoureteral reflux. Ureteral reimplantation also may be performed in a single-stage fashion as part of a planned procedural intervention for separate indication, such as bladder diverticulectomy, partial cystectomy, or distal ureterectomy for upper tract urothelial carcinoma.

Described here are approaches to ureteral reimplantation primarily in the context of nonmalignancy states.

Evaluation and Surgical Indications

The importance of careful intraoperative and, in instances of elective repair, preoperative evaluation cannot be overstated as a successful reimplantation of the ureter is highly contingent on a tension-free anastomosis with the bladder (Dowling et al., 1986); as such, accurate characterization of the length and location of the defect is necessary.

In the acute setting, direct inspection of the ureter allows for an accurate assessment of the magnitude of injury, in which case intraoperative imaging may not be required. Careful attention should be placed on the health of both the ureteral tissue and periureteral blood supply. Information on the mechanism of injury helps inform judgement regarding ureteral viability as debridement of tissue with gross normal appearance may be required, especially in cases of thermal or high-velocity projectile injury. When encountering incomplete transection or ureteral contusion, an intraoperative retrograde pyelogram may be performed to evaluate for the presence, magnitude, and location of extravasation. Alternatively, methylene blue may be injected into the ureter directly from a proximal location.

For elective ureteral reimplantation, both antegrade and retrograde imaging should be utilized to properly characterize the length and location of the diseased ureteral segment (Fig. 132.13). Antegrade imaging may involve use of CT urography, although if a nephrostomy tube is in place, antegrade nephrostogram can be performed (Fig. 132.14). Multiplicity of diseased ureteral segments should be noted on imaging as this would increase the overall length of the defect despite normal appearing intervening segments.

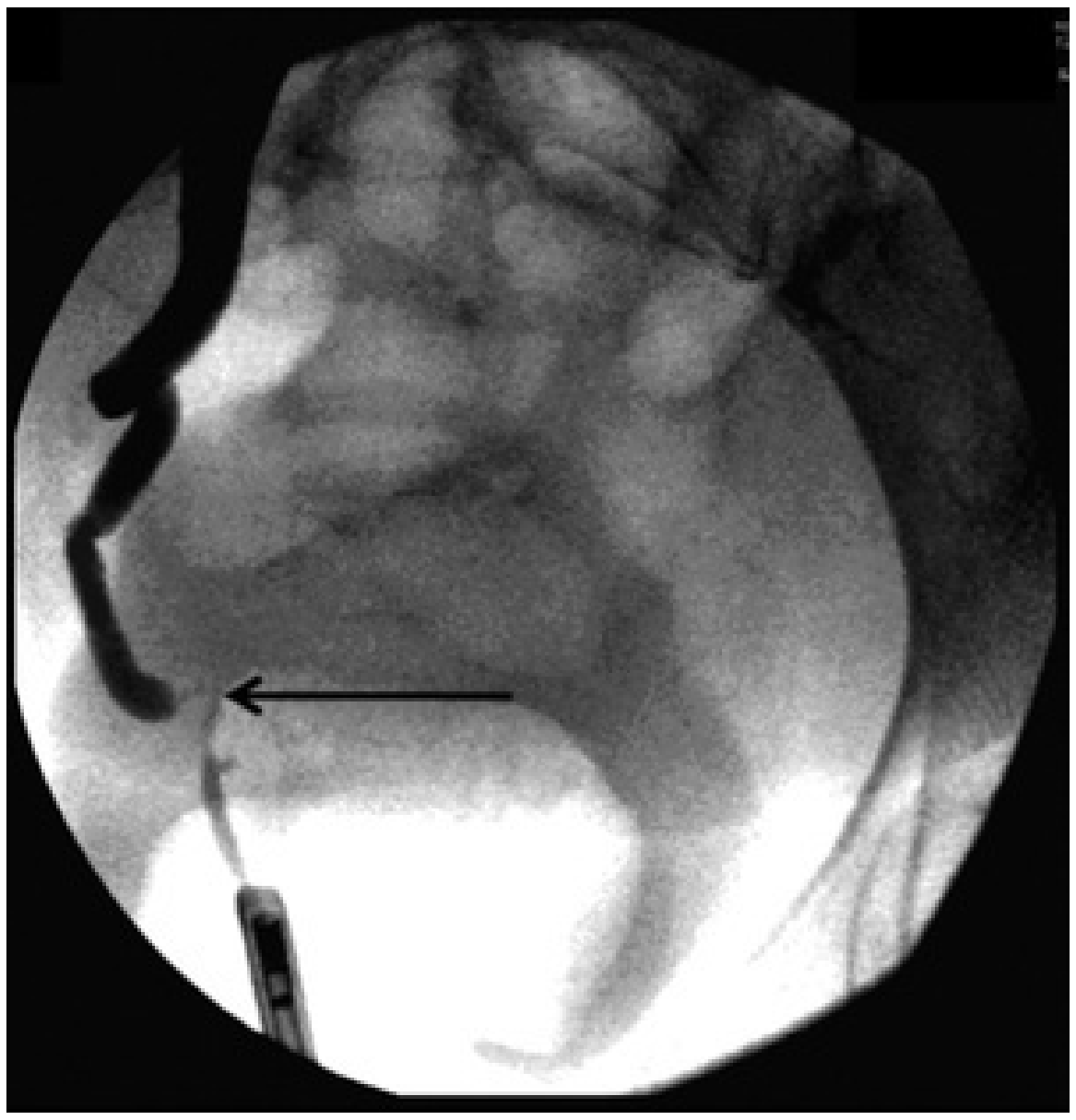

FIG. 132.13 Retrograde pyelogram demonstrating an abrupt cutoff of the right distal ureter consistent with distal ureteral injury sustained during hysterectomy performed 8 days earlier *(arrow).* (Modified from Kalisvaart JF, Finley DS, Ornstein DK. Robotic-assisted repair of iatrogenic ureteral ligation following robotic-assisted hysterectomy. *JSLS* 12[4]:414–416, 2008.)

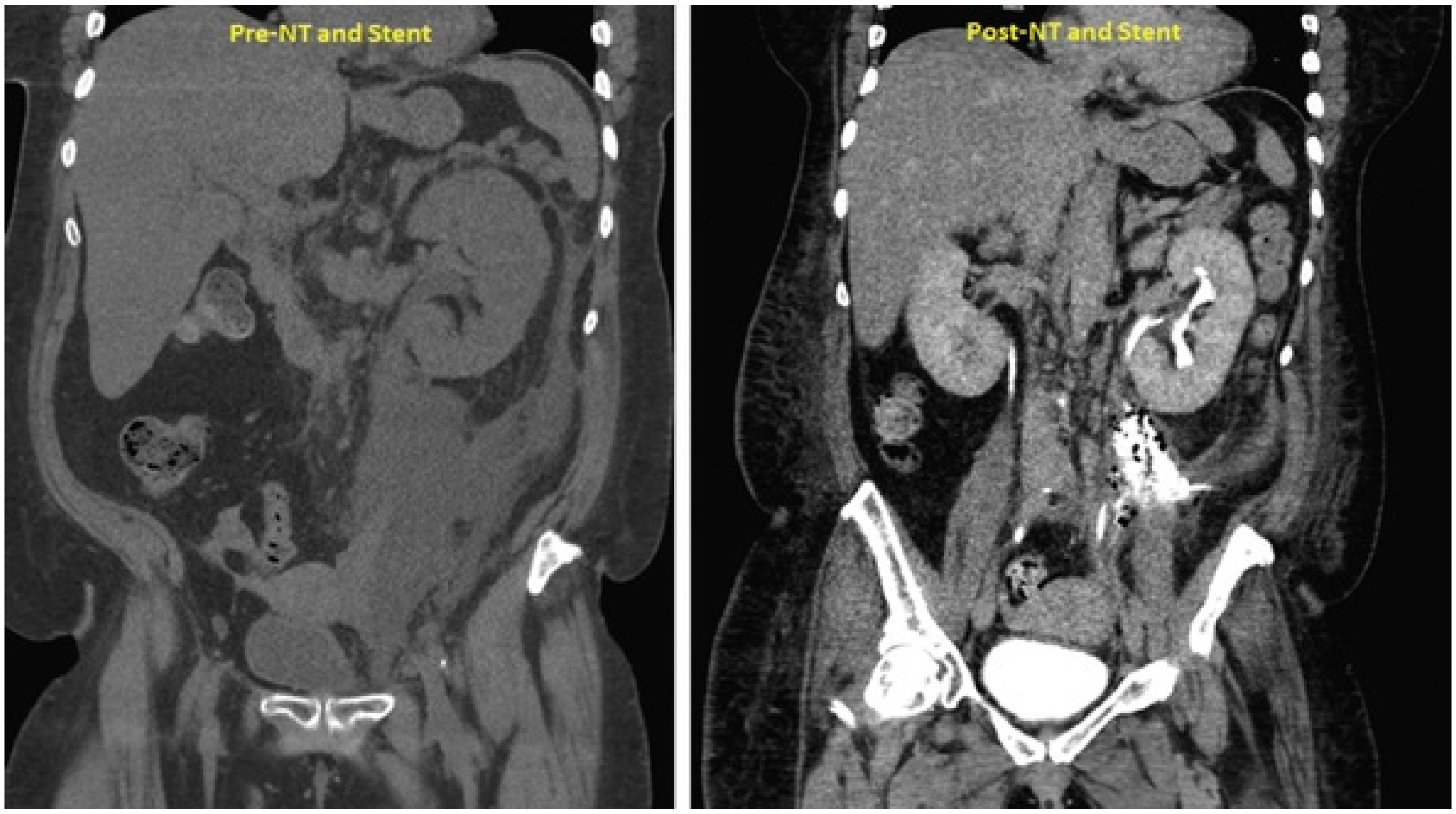

FIG. 132.14 Delayed presentation of ureteral injury sustained during ureteroscopy. *Left,* Large periureteral fluid collection consistent with urinoma. *Right,* Despite 6 weeks of ureteral stent placement and percutaneous drain, persistence of extravasation is seen on excretory phase of computed tomography urography.

Ureteral stricture disease may occur secondary to the presence of an impacted stone, history of pelvic or abdominal radiation, or chronic infection or inflammation. It is important that malignancy is ruled out before intervention. This may involve urine cytology and, in high-risk individuals (e.g., smoking history, older age), endoscopic evaluation with biopsy. Additionally, a resected stricture specimen may be sent for intraoperative frozen section.

Evidence of renal atrophy on imaging, particularly in the setting of chronic obstruction, may require a nuclear renography to be performed to not only document obstruction, but also to evaluate renal function. In cases of severe obstruction, a nephrostomy tube may be placed to enable more accurate characterization of renal function after relief of obstruction. Ureteral reimplantation should not be performed if poor function of the ipsilateral renal unit is demonstrated.

In circumstances in which a ureteral stent had been placed for ureteral contusion or partial ureteral transection sustained during trauma or iatrogenic injury, retrograde pyelography or CT urography should be performed before removal of the stent. If retrograde pyelogram is performed, the stent should be exchanged for a guidewire to maintain continuity across the bladder and ureter.

The presence of urinary extravasation despite adequate duration of stent placement indicates persistence of ureteral injury and is an indication for ureteral reimplantation (see Fig. 132.14). In such cases, a ureteral catheter should be advanced into the renal pelvis over a guidewire and a retrograde pyelogram performed with gradual withdrawal of ureteral catheter during contrast injection. This will enable complete opacification of the ureter and help better characterize the extent and location of injury.

Surgical Technique

The approach to ureteral reimplantation depends partly on the indication for which it is being performed. As the majority of cases in adults are for ureteral injury, stricture disease, or reimplantation during partial cystectomy or diverticulectomy, dissection of the intramural segment of ureter is generally not necessary (Elliott and McAninch, 2006). Instead, the ureter may be divided proximal to the diseased portion with the distal stump tied. For cases in which there is concern over inadequate ureteral length, advancement flaps constructed from the bladder wall offer a means to establish a tension-free ureterovesical anastomosis.

A nonrefluxing anastomosis is generally not necessary in adults, as vesicoureteral reflux is rarely the primary indication for surgery. Several studies confirm that use of a refluxing anastomosis does not necessarily place individuals at risk for accelerated decline in renal function or risk for stenosis when compared with nonrefluxing anastomoses (Stefanovic et al., 1991). Whether a difference in infectious complications exists remains understudied, although long-term studies in adults undergoing a refluxing anastomosis do not seem to indicate increased risk for infection (Wenske et al., 2013).

Irrespective of the technique used, several cardinal principles must be obeyed to optimize the chance for a successful postoperative outcome. The ureter should be delicately manipulated to minimize devascularization injury. In similar regard, a conscious effort should be made during extravesical mobilization of the ureter to preserve the periureteral fibroadipose tissue and avoid excessive skeletonization, which may also compromise the blood supply. The creation of a tension-free ureterovesical anastomosis is also of paramount importance. Primary reimplantation of the ureter into the bladder is generally feasible for defects of the distal ureter up to 4 cm in length. For longer-sized defects of the distal ureter, a psoach hitch and/or Boari flap should be considered to avoid unnecessary stretch on the ureterovesical anastomosis. Renal mobilization and downward nephropexy may also be attempted as this can add up to 5 cm in ureteral length. Lastly, reimplantation of the ureter into the bladder should avoid excessive angulation near its entry into the bladder as this may lead to postoperative obstruction. As a general rule, the ureter should be inserted into the bladder in a path directed toward the bladder neck.

As alluded to earlier, the technique used for ureteral reimplantation depends in part on the clinical circumstances surrounding ureteral injury and the preference of the treating surgeon. Open surgery is preferred for trauma situations as this allows direct inspection of the abdomen and pelvis for associated injuries. Iatrogenic injury recognized intraoperatively may be managed using the same approach as the index procedure, although this depends on the comfort of the surgeon and the established surgical setup.

Open Technique

Ureteral Mobilization.

The patient is placed on the operating table in the supine position with the anterior superior iliac spine positioned over the break of the table. The table is placed into slight flexion to facilitate entry into the retropubic space of Retzius (see Fig. 132.5A). The external genitalia and abdomen are sterilely prepped and draped to just above the level of the umbilicus. A 16-Fr catheter is placed into the bladder on the sterile field.

A midline infraumbilical incision is made down to the level of the pubic symphysis (see Fig. 132.5B). The subcutaneous tissue is divided with electrocautery down to the level of the rectus fascia. The rectus fascia is divided in the midline at the linea alba along the length of the incision. The underlying bellies of rectus abdominus muscles are subsequently split, permitting access to the transversalis fascia, which is divided the length of the incision to allow entry into the space of Retzius. Care should be taken to avoid inadvertent entry into the peritoneal cavity.

The bladder is identified through palpation of the Foley catheter balloon, and the lateral pelvic gutters are developed with blunt dissection using a sponge stick, sweeping the perivesical fat medially.

Adequate exposure of the great pelvic vessels will facilitate identification of the ureters. The external iliac artery can be traced proximal toward the bifurcation of the common iliac artery, where the ureter is identified as it crosses over from lateral to medial (Fig. 132.15A). Alternatively, the ureter may be localized as it courses underneath the obliterated umbilical artery near its origin off of the proximal internal iliac artery. Using a right-angle clamp, the ureter is dissected circumferentially, allowing for placement of a vessel loop. Extravesical dissection of the ureter is then commenced caudad and cephalad taking care to avoid overskeletonization.

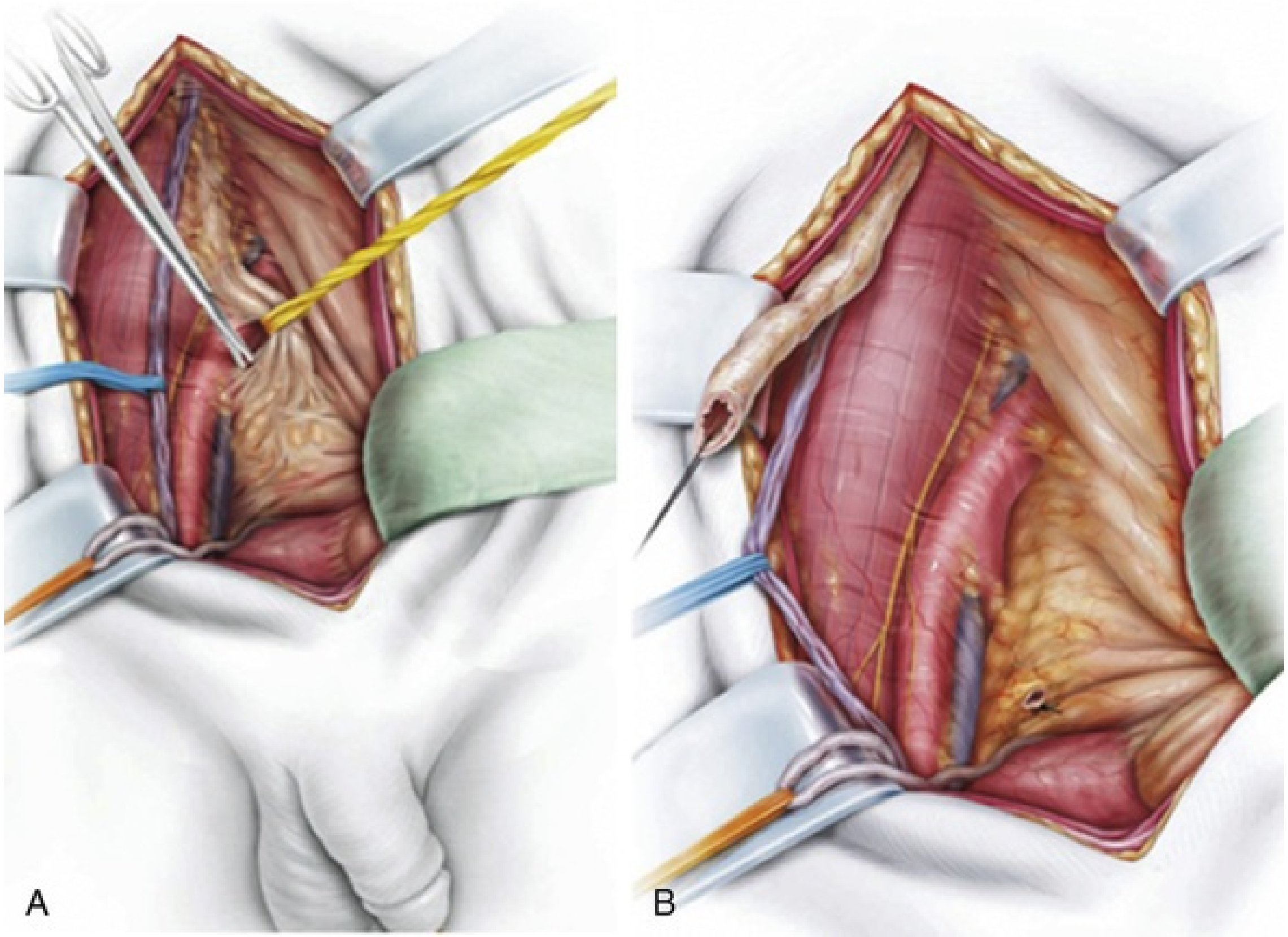

FIG. 132.15 Ureteral mobilization. (A) The ureter is identified as it crosses over the bifurcation of the iliac vessels and subsequently mobilized both cephalad and caudad, ensuring preservation of periureteral tissue. (B) The ureter is transected above the diseased segment with the distal ureter tied or clipped. Stay sutures are placed on the transected proximal ureter. (Modified from Stein R, Rubenwolf P, Ziesel C, et al. Psoas hitch and Boari flap ureteroneocystostomy. *BJU Int* 112[1]:137–155, 2013.)

In cases of ureteral stricture disease or iatrogenic injury, the diseased ureteral segment is identified and resected. Before transection, the distal ureteral stump is sealed using a metal clip. A metal clip may also be placed across the ureter proximal to the diseased area as this will allow for passive ureteral distension and aid in subsequent reimplantation. A 4-0 poliglecaprone suture tag is placed on the end of the ureter at the 6 o'clock position to aid with manipulation (see Fig. 132.15B). In the case of stricture disease, a margin of the transected ureter is sent for frozen-section analysis to rule out malignancy.

Bladder Mobilization.

Dissection within the lateral pelvic gutters is carried out superiorly, enabling cephalad displacement of peritoneal reflection off the bladder dome. The bladder should be disengaged from the overlying peritoneal reflection as much as possible using a gentle sweeping motion of the sponge stick in a cephalad-medial direction. This may involve transection of the ipsilateral medial umbilical ligaments and urachus at the dome of the bladder (Fig. 132.16).

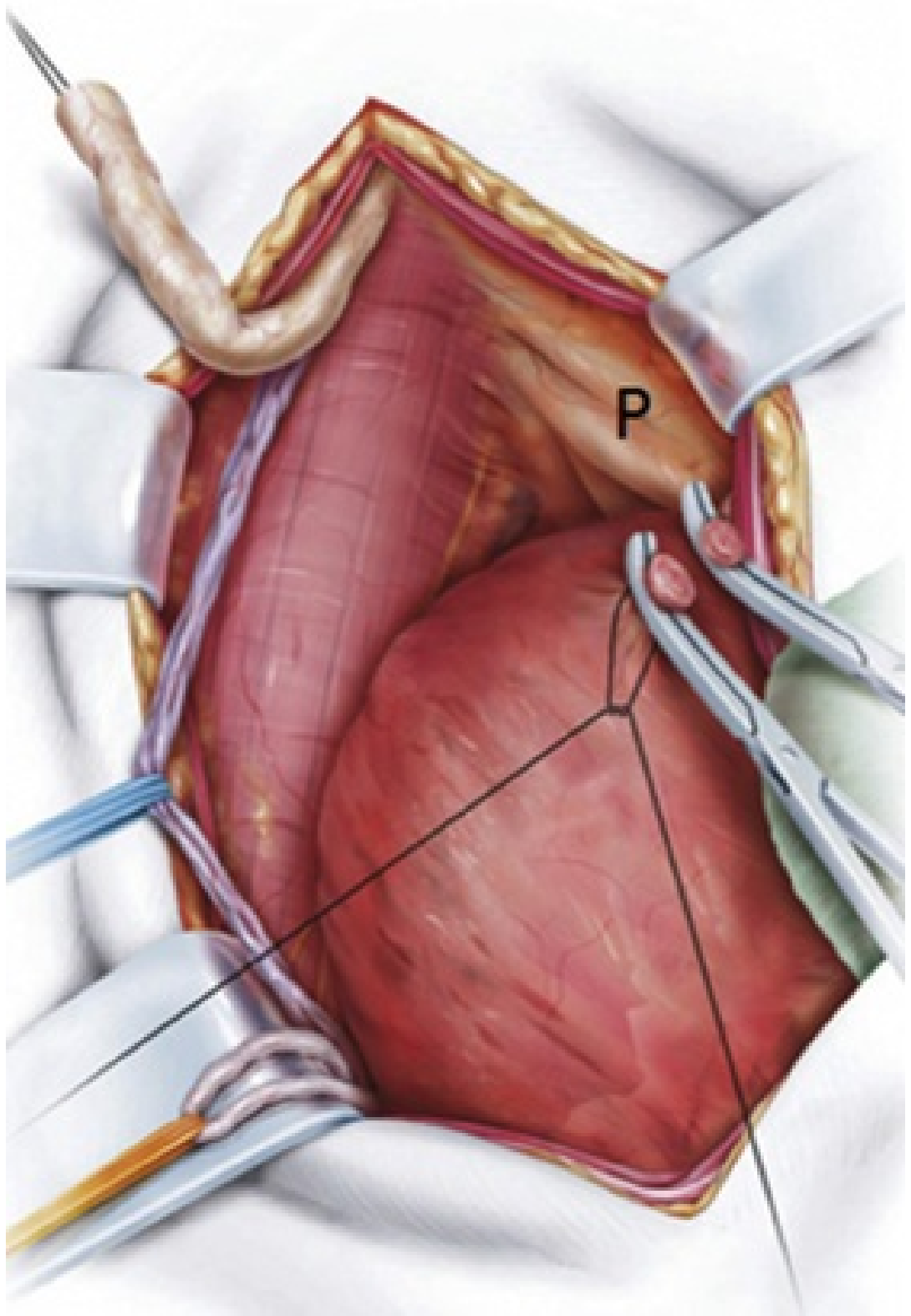

FIG. 132.16 Bladder mobilization. The bladder is mobilized in the extravesical space, pushing the peritoneal reflection *(P)* off the dome. This may involve transection of the ipsilateral medial umbilical ligament (and potentially the urachus). (Modified from Stein R, Rubenwolf P, Ziesel C, et al. Psoas hitch and Boari flap ureteroneocystostomy. *BJU Int* 112[1]:137–155, 2013.)

If a refluxing anastomosis is planned, the bladder does not require the same level of mobilization as is needed for a nonrefluxing anastomosis; this is because the ureter will be reimplanted into the posterior bladder dome, a location more accessible than that needed for nonrefluxing, tunneled anastomoses.

At this point, the feasibility of performing a primary ureteroneocystostomy should be assessed by approximating the ureter to the decompressed bladder dome and ensuring that no tension is present. In some cases in which the ureteral length falls short, the ureter can be mobilized further cephalad, although this increases the risk for devascularization and future stricture disease.

If a primary ureteroneocystotomy is pursued, multiple techniques for reimplantation may be implemented via both an extravesical and intravesical approach in either a refluxing or nonrefluxing fashion.

Nonrefluxing Ureteral Reimplantation—Extravesical Approach (Modified Lich-Gregoir)

The bladder is partially distended with 150 mL of sterile water. This aids not only in reimplantation, but also dissection of the bladder off the overlying peritoneal attachments. Ideally, the bladder should be mobilized enough so such that medial retraction of the bladder on the side of the ureteral pathology enables visualization of the native ureterovesical junction. Ureteral reimplantation should occur on the posterior bladder wall in a location superior and medial to the original ureterovesical junction as placement in a more lateral location would risk kinking, particularly during bladder distension.

A transmural cystotomy is made at the anticipated site of the new ureteral orifice (neo-orifice), with the size of the mucosal defect being slightly wider than the caliber of the transected ureteral lumen (Fig. 132.17B). A longitudinal incision is subsequently made in the serosal and detrusor layers of the bladder, sparing the underlying urothelium, with the directionality of this incision aimed toward the bladder neck (see Fig. 132.17A). The detrusor layer is dissected off the underlying urothelium perpendicularly, effectively allowing the creation of a submucosal tunnel via an extravesical approach. The length of the submucosal tunnel should be roughly three to five times the diameter of the ureter to be reimplanted. Inadvertent entry into the urothelium during creation of the tunnel via an extravesical approach may be closed with 4-0 poliglecaprone suture reapproximating the mucosal edges.

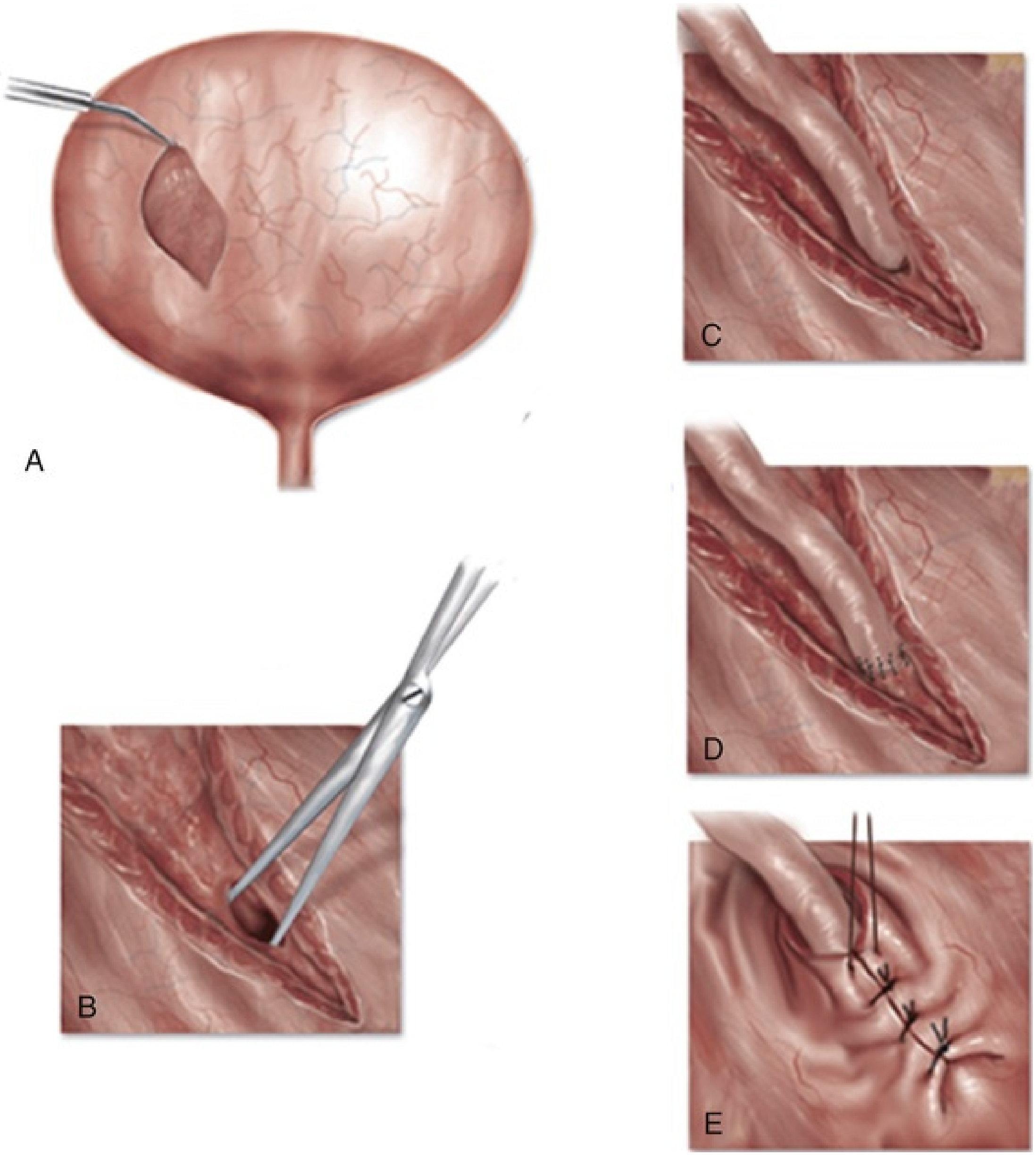

FIG. 132.17 Extravesical, nonrefluxing (tunneled) ureteral reimplant—modified Lich-Gregoir. (A) The detrusor is incised extravesically, sparing the underlying mucosa, to create a submucosal tunnel. (B) A mucosal defect is created at the end of the tunnel wide enough for ureteral reimplantation. (C) The ureter placed in the submucosal tunnel. (D) The distal end of the ureter is spatulated and anastomosed to the neo-orifice. (E) The detrusor muscle is closed to create the antirefluxing submucosal tunnel.

In preparation for reimplantation of the ureter, the distal end of the transected ureter is excised and the new distal end is spatulated anteriorly using sharp tenotomy scissors. The apex of the spatulated ureter is anchored to the mucosa of the neo-orifice at the 12 o'clock position using 4-0 poliglecaprone suture (see Fig. 132.17C). It is critical that sutures placed through the ureter are transmural and those placed through the bladder incorporate the edges of the bladder mucosa and some of the detrusor layer; this ensures proper apposition of the mucosal surfaces. Additionally, the sutures should be placed such that the knots fall external to the anastomosis. The posterior ureter is then anchored to the neo-orifice on the bladder at the 6 o'clock position after which sutures are placed circumferentially in an interrupted fashion to complete the ureterovesical anastomosis (see Fig. 132.17D). Before completion of the anastomosis, a 6-Fr by 26- or 28-cm indwelling double pigtail stent is placed retrograde across the anastomosis.

The anastomosed ureter is placed within the submucosal tunnel over which the serosal-detrusor flaps, created previously to generate the submucosal tunnel, are closed using 2-0 polyglactin suture (see Fig. 132.17E).

A large-bore Foley catheter is placed, and the bladder is filled with 200 mL of sterile water to test the adequacy of the anastomosis. A pelvic drain is placed in the vicinity of the anastomosis and brought out to the skin through a separate stab incision. It is secured to the skin with nonabsorbable suture and placed to self-suction. The fascia and skin are closed in the standard fashion.

Nonrefluxing Ureteral Reimplantation—Transvesical Approach (Modified Politano-Leadbetter)

The bladder is mobilized in a manner similar to the extravesical approach. With the bladder partially distended, a midline cystotomy is made along the anterior surface to gain intravesical access. A suction device is used to aspirate fluid from the bladder as the cystotomy is created.

The location for the neo-orifice should be selected such that it is situated on the posterior bladder wall superior and medial to the native ureteral orifice. Once this site has been determined, the bladder mucosa is circumferentially scored and a mucosal defect generated. The diameter of the neo-orifice should be slightly larger than the diameter of the ureter to be reimplanted (approximately 1.5 cm). A submucosal tunnel is subsequently developed using Metzenbaum scissors, starting at the neo-orifice. The tunnel should be oriented longitudinally in the direction of the bladder neck, with the length of this tunnel being 3 to 5 times the caliber of the ureteral lumen.

Once a submucosal tunnel of appropriate length has been generated, the Metzenbaum scissors are exchanged for a right-angle clamp. The beak of the right-angle clamp is directed posteriorly, and an incision is made through the posterior bladder wall onto the clamp; this will serve as the new entry site for the ureter into the bladder. The location of this new ureterovesical junction should be cephalad and medial to the native ureterovesical junction as this will allow the ureter to be oriented almost longitudinally as it courses through the submucosal tunnel. The right-angle clamp is advanced through the posterior bladder wall and used to grasp the ureteral stay sutures (Fig. 132.18B). The ureter is delivered through the submucosal tunnel and out of the neo-orifice into the bladder.

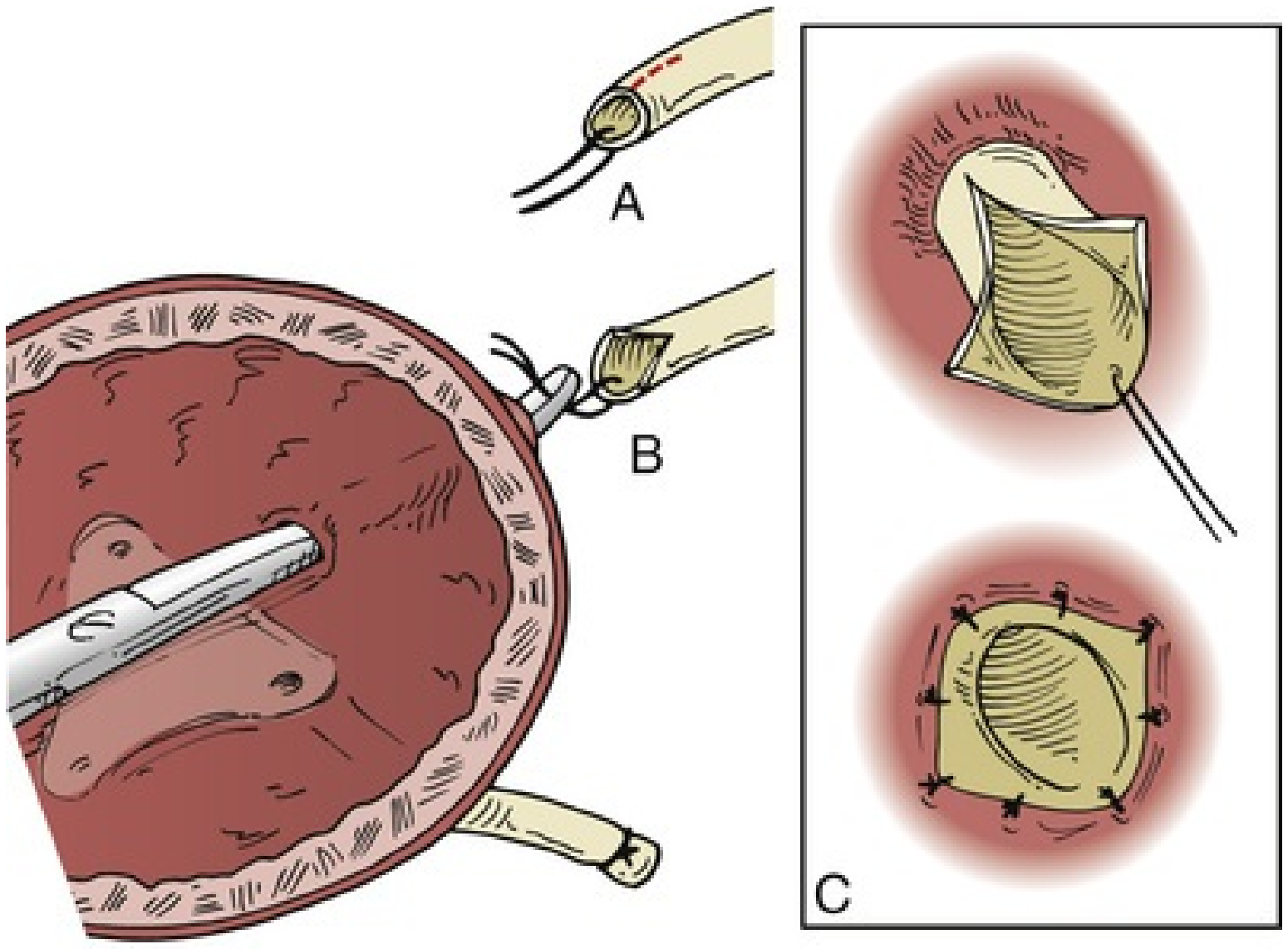

FIG. 132.18 Transvesical, nonrefluxing (tunneled) ureteral reimplant—modified Politano-Leadbetter. (A) Stay sutures are placed on the distal end of the transected ureter. (B) The neo-orifice is delineated on the intravesical bladder surface, and a submucosal tunnel is created with sharp dissection. A cystotomy is made through the posterior bladder wall, and the ureter is delivered into the bladder, traversing through the tunnel and neo-orifice. (C) The ureter is spatulated anterior and anastomosed in a interrupted fashion to the neo-orifice. (Modified from Yeomans ER, Hoffman BL, Gilstrap 3rd LC, Cunningham FG. *Cunningham and Gilstrap's operative obstetrics*. 3rd ed. McGraw-Hill Education; 2017.)

The ureter is spatulated and anastomosed to the mucosa of the neo-orifice with stent placement in a manner similar to that described earlier (Fig. 132.18C).

A large-bore Foley catheter is placed, and the cystotomy is closed in the standard two-layer fashion using 2-0 polyglactin suture. The bladder is filled with 200 mL of sterile water to test the adequacy of closure and anastomosis. A pelvic drain placed in the vicinity of the bladder wall closure and anastomosis is brought out to the skin through a separate stab incision and placed to self-suction. The fascia and skin are closed in the standard fashion.

Refluxing Ureteral Reimplantation—Extravesical Approach

The dome of the bladder is grasped with Allis clamps, and a transmural cystotomy is created in the posterior dome lateralized to the side of ureteral pathology. The diameter of the defect should be wide enough to accommodate the transected ureter.

After excising the distal end of the transected ureter, the new distal end is spatulated anteriorly and reanastomosed to the bladder in a manner similar to that described earlier for the nonrefluxing, extravesical approach (Fig. 132.19).

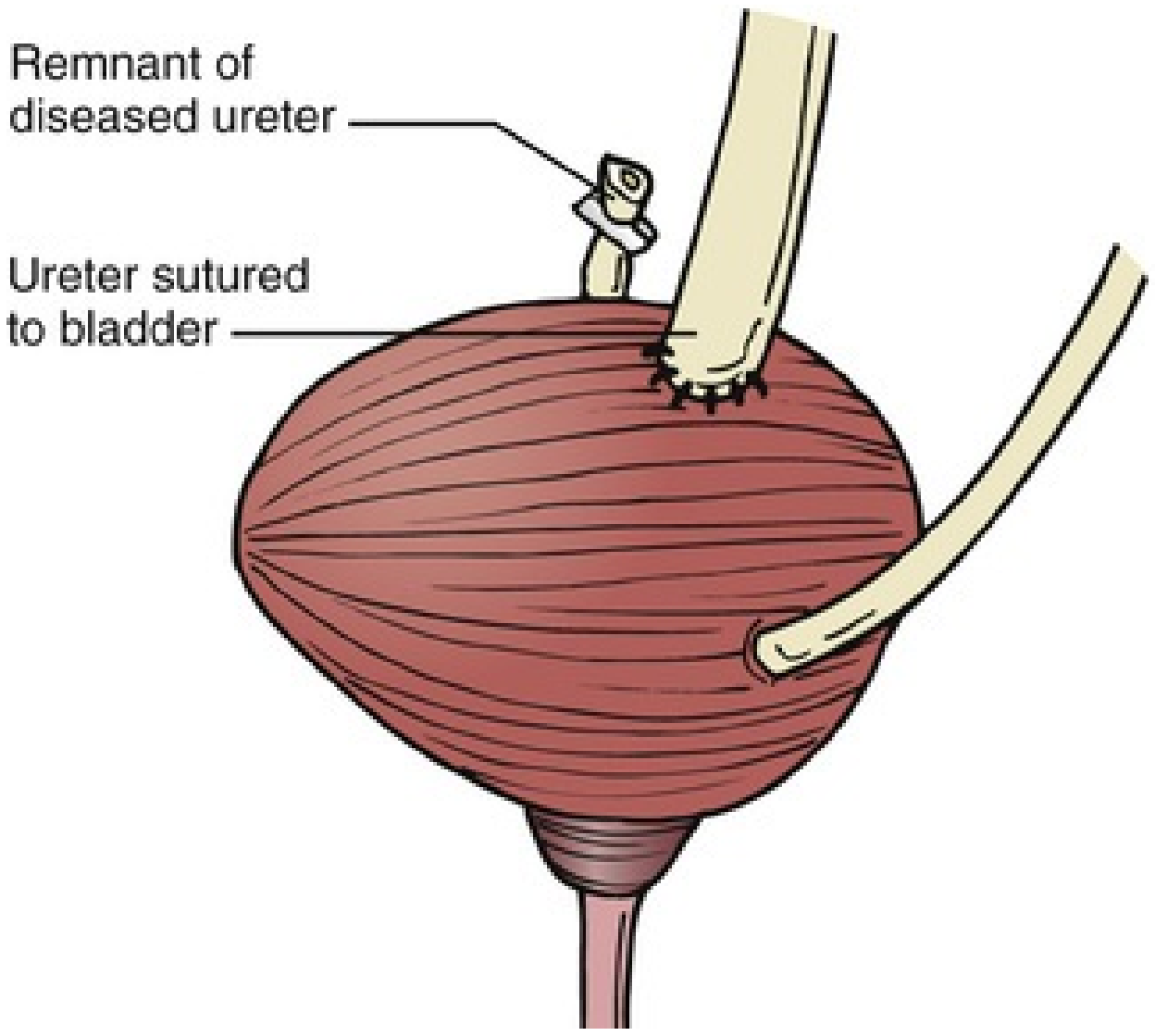

FIG. 132.19 Extravesical, refluxing ureteral reimplant. The healthy transected portion of the proximal ureter is reimplanted into the dome of the bladder.

A large-bore Foley catheter and pelvic drain are placed as described earlier. The bladder should be irrigated to test for adequacy of the anastomosis.

Refluxing Ureteral Reimplantation—Transvesical Approach

With the bladder partially distended, an anterior midline cystotomy is made to gain intravesical access. A Kelly clamp is placed through the cystotomy and directed posteriorly against the posterior bladder dome lateralized to the side of the ureteral pathology. A cystotomy is created over the Kelly clamp large enough to accommodate the transected ureter. The Kelly clamp is advanced posteriorly through the bladder wall defect and used to grasp the stay sutures on the distal end of transected ureter. The ureter is brought into the bladder through the posterior bladder wall defect as the Kelly clamp is withdrawn. This will effectively serve as the new ureterovesical junction and associated neo-orifice.

The ureter once delivered into the bladder is spatulated and anastomosed to the mucosa of the neo-orifice in a manner similar to that described earlier.

A large-bore Foley catheter is placed, and the cystotomy is closed in the standard two-layer fashion using 2-0 polyglactin suture. The bladder is filled with 200 mL of sterile water to test the adequacy of closure and anastomosis.

A pelvic drain placed in the vicinity of the bladder wall closure and anastomosis is brought out to the skin through a separate stab incision and placed to self-suction. The fascia and skin are closed in the standard fashion.

Laparoscopic and Robotic Techniques

Minimally invasive approaches to distal ureteral reconstruction are widely utilized in contemporary practice given extensive accumulated experience that has enabled near-replication of open techniques (Ehrlich et al., 1994; Janetschek et al., 1995; Reddy and Evans, 1994; Schimpf and Wagner, 2008).

A transperitoneal, extravesical approach offers a wide working space and permits creation of both refluxing and nonrefluxing anastomoses. Additionally, the technical feasibility to perform a psoas hitch and bladder advancement flaps using a minimally invasive platform allows experienced surgeons to utilize laparoscopy and robotic surgery for management of longer ureteral defects.

We routinely perform laparoscopic ureteral reimplantation using a three-trocar approach as depicted in Fig. 132.20. Patient positioning and typical port site placement for robotic ureteral reimplant is similar to that employed for bladder diverticulectomy (see Fig. 132.10A). It is important to keep in mind that placement of the assistant ports for robotic reimplantation occurs on the side contralateral to the ureteral pathology as this allows the assistant more direct access.

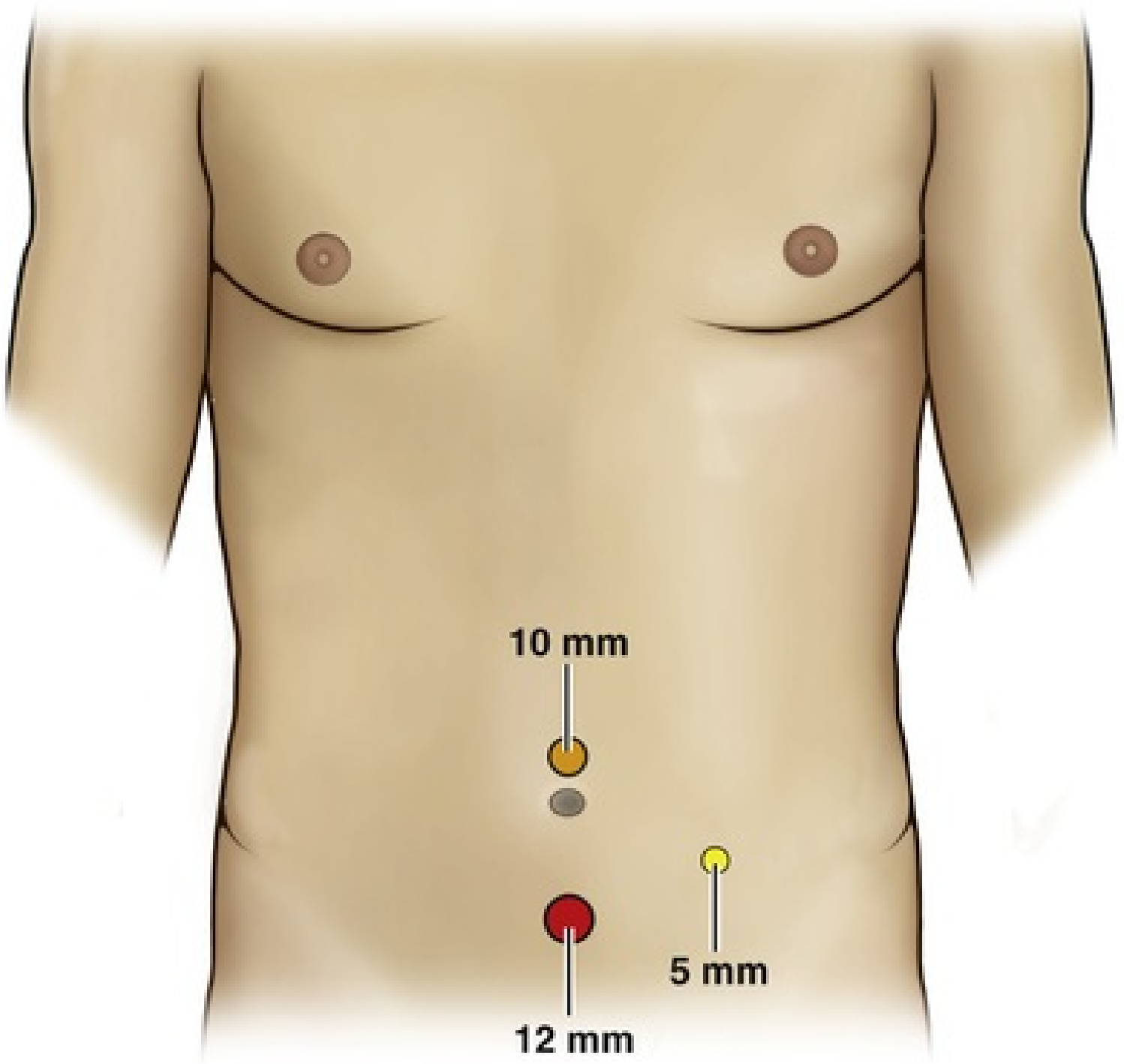

FIG. 132.20 Port placement for laparoscopic ureteral reimplantation (left-sided). Trocar placement for left ureteral reimplantation includes a 10-mm umbilical camera port and a 12-mm working port placed halfway between the umbilicus and the symphysis pubis. A 5-mm working port is placed at the lateral edge of the rectus muscle at the level of the umbilicus on the ipsilateral side of the procedure.

The ureter is identified medial to the obliterated umbilical ligament, and the overlying peritoneum is incised. Alternatively, the parietal peritoneum may be incised more proximally where the ureter courses over the bifurcation of the common iliac artery. The ureter is mobilized caudally toward the ureterovesical junction, preserving periureteric tissue to ensure adequate vascular supply. The ipsilateral vas deferens in males or broad ligament in females may be divided to facilitate identification and exposure of the distal ureter. An incision may also be made lateral to the ipsilateral obliterated umbilical ligament to enter the space of Retzius and allow for medial rotation of the bladder, which remains suspended as the contralateral ligament is kept intact.

The diseased segment of ureter is identified, and a metal Hem-o-lok clip (Teleflex, Morrisville, NC) is placed at this distal edge (if possible), effectively closing off the distal ureteral stump. The diseased segment is then excised. In the case of stricture disease, a margin of the transected ureter is sent for frozen-section analysis to rule out malignancy. A metal clip may be placed on the end of the proximally transected ureter to allow for passive ureteral dilation that can aid in subsequent reimplantation. A 4-0 suture may also be placed at the distal end of the transected ureter to enable atraumatic manipulation.

The bladder is dropped and the space of Retzius accessed in a manner similar to that described earlier for robotic diverticulectomy. The feasibility of a tension-free anastomosis is assessed by approximating the ureter to the ipsilateral dome of a nondistended bladder.

Nonrefluxing Ureteral Reimplantation—Extravesical Approach (Modified Lich-Gregoir)

When performing a extravesical nonrefluxing anastomosis, the location of the proposed tunnel is determined with the bladder filled with approximately 250 to 300 mL of saline. Care should be taken to orient the tunnel in the direction of the bladder neck and select a location that is superior and medial to the native ureterovesical junction, as a more lateral location risks kinking of the ureter during filling. A 5 : 1 tunnel-to-ureteral diameter is maintained. Taking care to avoid perforation of the bladder mucosa, the detrusor muscle is incised to create a sufficient trough. A cystotomy is then made at the distal end of the tunnel to create the neo-orifice.

The ureter is spatulated along its anterior surface, and its apex is anchored to the mucosa of the neo-orifice at the 12 o'clock position using 4-0 poliglecaprone suture. As is the case with the open approach, sutures passed through the ureter are transmural, whereas those passed through the bladder should capture the bladder mucosa and detrusor fibers. Additionally, the knots should fall external to the ureteral lumen. The posterior ureter is then anchored to the neo-orifice on the bladder at the 6 o'clock position after which sutures are placed circumferentially in an interrupted fashion to complete the ureterovesical anastomosis. Before completion of the anastomosis, a 6-Fr by 26- or 28-cm indwelling double pigtail stent is placed retrograde across the anastomosis with the assistance of a guidewire.

The ureter is then placed within the trough, and the detrusor is closed over it, using a series of interrupted 2-0 absorbable sutures (Fig. 132.21) (Gundeti et al., 2008; Hedican et al., 1999; Lakshmanan and Fung, 2000; Reddy and Evans, 1994).

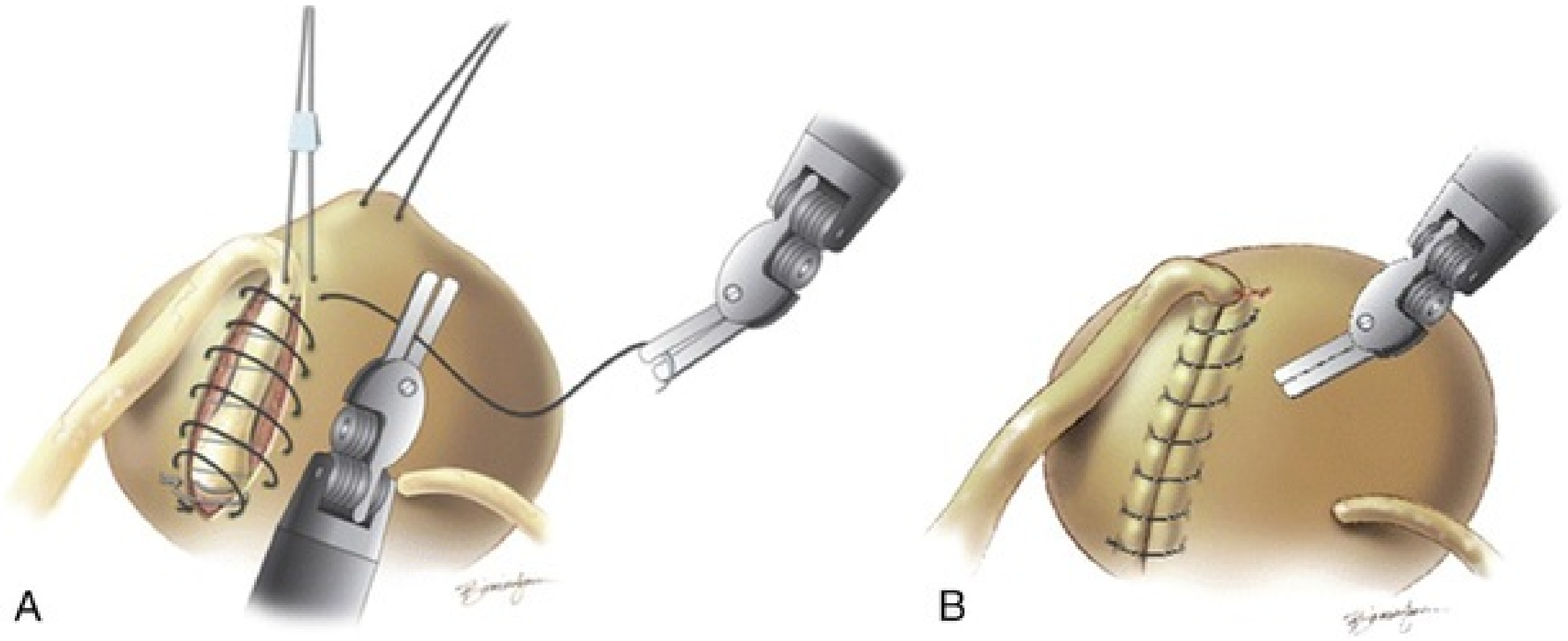

FIG. 132.21 Robotic extravesical nonrefluxing (tunneled) ureteral reimplantation. A tunnel is made in the detrusor muscle for the ureter, completing the antirefluxing mechanism. (A) After anastomosis of the spatulated ureter to the bladder mucosa, detrusorrhaphy is initiated. (B) Completed extravesical reimplantation. (From Gundeti MS, Kojima Y, Haga N, Kiriluk K. Robotic-assisted laparoscopic reconstructive surgery in the lower urinary tract. *Curr Urol Rep* 14[4]:333–341, 2013.)

A large-bore Foley catheter is placed, and the bladder is filled with 200 mL of sterile water to test the adequacy of the anastomosis. A pelvic drain is placed in the vicinity of the anastomosis and brought out through the lateral port. It is secured to the skin with nonabsorbable suture and placed to self-suction. The pneumoperitoneum is released. The fascia of all 12-mm ports are closed with figure-of-eight 0-polyglactin suture. Skin incisions are closed.

Refluxing Ureteral Reimplantation—Extravesical Approach

For cases in which a refluxing reimplantation is planned, the length of ureter needed for a tension-free anastomosis is less than that required for a nonrefluxing anastomosis given the absence of the submucosal tunnel (Seideman et al., 2009). As such, the ureter may be mobilized to a lesser degree.

A new ureteral hiatus is created at the anterior dome of the bladder, slightly lateralized to the site of ureteral pathology. The ureter is spatulated and reimplanted with 4-0 absorbable sutures in an interrupted fashion as described earlier.

A large-bore Foley catheter is placed, and the bladder is filled with 200 mL of sterile water to test the adequacy of the anastomosis. A pelvic drain is placed in the vicinity of the anastomosis and brought out through the lateral port. It is secured to the skin with nonabsorbable suture and placed to self-suction. The pneumoperitoneum is released. The fascia of all 12-mm ports are closed with figure-of-eight 0-polyglactin suture. Skin incisions are closed.

Postoperative Care and Complications

The Foley catheter is kept to drainage for approximately 1 week postsurgery with a cystogram performed before removal to ensure that there is no extravasation. The pelvic drain is removed typically after 48 hours once the output has decreased; a drain creatinine measurement is optional and should be interpreted in the context of the drain output. The ureteral stent is left in place for 6 weeks to provide adequate time for healing of the anastomosis.

Urinary extravasation may complicate the postoperative course of either open or minimally invasive ueteroneocystotomy. This may clinically manifest with fever and abdominal pain, particularly with infection of the urinoma. Ileus or electrolyte abnormalities may occur in the setting of intraperitoneal urinary ascites. Anastomotic leak may result from the lack of a watertight anastomosis or impending ischemia. Excretory urography may help characterize the location and degree of extravasation and the presence of a urinoma that may require percutaneous drainage. Management involves continuing the Foley catheter and ureteral stent to facilitate maximal antegrade drainage. If extravasation occurs after removal of the stent, replacement of the stent is necessary. Placement of a percutaneous nephrostomy tube should be considered for cases refractory to these measures.

Ureteral obstruction is a late complication that can manifest after removal of the stent. It may be detected incidentally on follow-up imaging (e.g., hydronephrosis on ultrasonography) or present with symptoms of flank pain or pyelonephritis. Obstruction typically results from ureteral ischemia because of excessive skeletonization during ureteral mobilization, tension on the ureterovesical anastomosis, the creation of a narrow neo-orifice, inadequate spatulation of the anterior ureter, or prior radiation exposure, which may have perturbed the ureteral blood supply at baseline. Antegrade and retrograde imaging should be used to characterize the size and extent of the strictured segment. Endoscopic interventions to restore patency of the ureteroneocystotomy may be attempted initially, particularly for short-length strictures, although repeat surgery may be necessary for high-grade obstruction (Goldfischer and Gerber, 1997; Hafez and Wolf, 2003; Kwak et al., 1995). Less often, obstruction may occur secondary to reimplantation of the ureter into a more lateral location on the bladder, which risks kinking during bladder distension.

Other complications include development of urinary tract infection, urinary fistula formation, bladder spasms, stent colic, wound infection, and bowel injury.

Outcomes

The open surgical technique for ureteroneocystotomy remains the gold standard for management of distal ureteral disease in adults. Open surgery allows tremendous versality in approach, including the ease of staying entirely extraperitoneal, ability to perform reimplantation via extravesical or transvesical means, option of performing a nonrefluxing or refluxing anastomosis, and the ability to readily integrate procedures such as psoas hitch or Boari flap to ensure a tension-free anastomosis.

Larger studies with long-term follow-up are available primarily for the open surgical approach and confirm the ability to achieve favorable outcomes in the vast majority of individuals with distal ureteral obstruction. Wenske et al. reported on their institutional experience with 100 cases of open distal ureteral surgery performed for ureteral obstruction or injury (Wenske et al., 2013). Primary ureteroneocystotomy, psoas hitch, and Boari flap procedures were performed in 24, 58, and 18 cases, respectively. At a median follow-up of 5 years, 81% of patients with preoperative hydronephrosis had complete resolution. However, 15.3% of patients did require chronic ureteral stent placement to maintain kidney function (Wenske et al., 2013). Complications were rare in this series, with urinary extravasation requiring extended drainage occurring in only 3% of patients.

On the other hand, clinical experience with laparoscopic and robotic ureteroneocystostomy continues to evolve. Small feasibility studies prevail; however, a few larger studies with intermediate-term follow-up data support the efficacy of minimally invasive approaches (Modi et al., 2005; Pompeo et al., 2013; Seideman et al., 2009).

The largest series of laparoscopic ureteral reimplantation in adults was reported by Seideman et al., who described perioperative and functional outcomes in 45 patients undergoing laparoscopic ureteral reimplantation for distal ureteral stricture disease, the mean length of which was 3 cm (Seideman et al., 2009). The authors reported excellent perioperative outcomes, with no cases requiring open conversion, mean blood loss having been 150 mL, and hospital length approximating 3 days. Three patients (6.7%) experienced a low-grade complication, namely urinary extravasation, which were managed conservatively. Success rate, defined as radiographic evidence of no residual obstruction, resolution of symptoms, absence of worsened renal function, and no subsequent intervention, was 96% with 2-year follow-up. Two patients had recurrence of stricture disease, whereas one patient required nephrectomy for chronic pain (Seideman et al., 2009). A more recent series describing laparoscopic ureteroneocystotomy for ureteral injuries after open hysterectomy demonstrated similar findings with a 100% ureteral patency rate on long-term follow-up (Pompeo et al., 2013).

A direct comparison between laparoscopic and open ureteral reimplantation was performed by Rassweiler et al., who studied 10 patients undergoing laparoscopic ureteral reimplantation versus 10 patients treated using conventional open techniques for distal ureteral stricture disease (Rassweiler et al., 2007). The mean length of the ureteral stricture was 2.85 cm in the laparoscopic group versus 2.5 cm in the open group. The authors observed an advantage to the laparoscopic approach as it was associated with lower blood loss, lower analgesic requirements, less time to oral intake, shorter hospital stay, and shorter convalescence time. Additional, procedural success was seen for all 10 patients undergoing laparoscopy, whereas two patients undergoing open surgery had a major postoperative complication, including one who had recurrence of stricture (Rassweiler et al., 2007). Similarly, Simmons et al. (2007) retrospectively compared 12 laparoscopic versus 34 open ureteral reimplantation procedures, demonstrating reduced blood loss and shorter hospitalization associated with laparoscopy. Complication rates and ureteral patency rates were equivalent at a mean follow-up of nearly 2 years (Simmons et al., 2007).

The advent of the robotic platform has generated significant interest recently in robotic-assisted ureteral reimplantation, particularly given the ergonomics of use, enhanced three-dimensional magnification, and availability of articulating joints with six degrees of freedom, which shallows the learning curve for tasks such as intracorporeal suturing. Several authors have reported the feasibility of this approach (Patil et al., 2008; Uberoi et al., 2007; Yohannes et al., 2003a). A recent comparison of robotic ($N = 13$) and laparoscopic ($N = 6$) ureteral reimplantation for benign ureteral stricture disease demonstrated highly comparable perioperative outcomes with intermediate follow-up (Baldie et al., 2012). No major postoperative complications were observed in either arm, although two (15.3%) open conversions were performed in the robotic group and one (16.7%) in the laparoscopic group. Mean operative time (259 vs. 278 min), blood loss (171 vs. 150 mL), and length of stay (2.5 vs. 2.7) was similar between both groups, with all patients having had successful outcomes on both radiographic and clinical assessment at time of last follow-up (Baldie et al., 2012).

Contemporary comparisons between open and robotic reimplantation for benign stricture disease further supports the feasibility and efficacy of the robotic approach as an alternative to open surgery (Isac et al., 2013; Kozinn et al., 2012). In a series by Kozinn et al., 10 patients undergoing robotic distal ureteral reconstruction were compared with 10 matched controls undergoing open surgery (Kozinn et al., 2012). In total, four neocystostomies, four psoas hitches, and two Boari flaps were performed in the robotic arm versus six neocystostomies, three psoas hitches, and one Boari flap performed in the open group. No intraoperative conversion to open surgery was necessary in the robotic cohort. Additionally, blood loss (30.6 vs. 327.5 mL) and hospital length of stay (2.4 vs. 5.1 days) were significantly lower in the robotic group versus the open group with no differences observed in operative time. All patients had successful treatment of their stricture disease based on radiologic and clinical assessment at 24- and 30-month follow-up in the robotic and open groups, respectively (Kozinn et al., 2012). A subsequent comparison of 25 robotic ureteroneocystostomies versus 41 open procedures performed between 2000 and 2010 revealed significantly shorter operative times with the open technique (200 vs. 279 minutes), but less blood loss (100 vs. 150 mL), shorter hospital length of stay (3 vs. 5 days), and less postoperative narcotic pain requirement with the robotic approach. Additionally, no differences were observed in rate of reoperation for disease stricture recurrence (Isac et al., 2013).

Most recently, Elsamra et al. provided a single-institutional review of perioperative outcomes associated with 130 open (N = 25), laparoscopic (N = 85), and robotic (N = 25) cases of ureteroneocystotomy (Elsamra et al., 2014). The authors demonstrated significantly lower operative blood loss and hospital length of stay in patients undergoing minimally invasive versus open surgery, and a numerically higher readmission and 90-day complication rate in the open cohort. These results further support a role for minimally invasive techniques in distal ureteral reconstruction for adults.

LESS surgery has also emerged as a technique with the potential for improved cosmetic outcomes and perhaps reduced pain and convalescence. LESS ureteroneocystostomy has been reported, but larger series are needed to validate the efficacy and safety of the approach (Desai et al., 2009). Roslan et al. reported a case of a LESS ureteroneocystotomy (Roslan et al., 2012b). Khanna et al. reported on three cases of LESS ureteral reimplantation (Khanna et al., 2012). With a median follow-up of 29 months, none of the three patients required revision or had recurrent stricture disease. There are clear technical challenges, and most surgeons reporting on LESS ureteral reimplantations have had broader experiences in LESS nephrectomy and other types of LESS reconstructive surgeries.

Psoas Hitch and Boari Flap

Description

When faced with minimal distal ureteral loss, simple ureteroneocystostomy is sufficient to reestablish urinary continuity. However, more extensive gaps require more complex reconstructive techniques.

A psoas hitch, first described by Zimmerman et al. (1960) and Warwick and Worth (1969), may be utilized to bring the bladder cephalad enough to enable a tension-free anastomosis with the healthy ureteral segment (Ehrlich et al., 1978). If a tension-free anastomosis is not possible using a psoas hitch alone, a Boari flap can be performed in conjunction to bridge the ureteral gap. This situation is most often encountered for ureteral disease extending up to the mid-ureter (Ockerblad, 1947).

The Boari bladder flap was introduced for bridging larger gaps between the ureter and bladder in a canine model in 1894 and in humans in 1947 (Ockerblad, 1947), with the capability of bridging ureteral gaps up to 15 cm in length. Minimally invasive techniques mimicking the open approach have since emerged and expanded the treatment armamentarium for patients with longer segments of ureteral discontinuity. Laparoscopic Boari flap creation was first described in humans in 2001, whereas reports of Boari flap using the robotic platform first emerged in 2008 (Fergany et al., 2001; Fugita and Kavoussi, 2001; Schimpf and Wagner, 2008). The robotic approach can ease the technical burdens of extensive intracorporeal suturing required for Boari flap creation (Allaparthi et al., 2010; Schimpf and Wagner, 2008).

Although these techniques are used more often for defects involving the distal and middle third of the ureter, in select cases, they may be used to bridge defects as high as the proximal ureter and/or renal pelvis, although ureteroureterostomy, transureteroureterostomy, autotransplantation, or ileal ureteral substitution should also be considered in these circumstances.

Evaluation and Surgical Indication

A psoas hitch and Boari flap are indicated when the degree of ureteral loss precludes simple ureteroureterostomy or ureteroneocystostomy. Preoperative evaluation is similar to that described earlier for ureteroneocystostomy and includes antegrade and retrograde urography to estimate the extent of disease and aid in planning for the surgical approach. A small-volume bladder is a contraindication to a psoas hitch and Boari flap. Ultimately, intraoperative findings dictate the need for a Boari flap and/or psoas hitch.

Surgical Technique

Open Technique

Psoas Hitch.

The bladder is mobilized on the side ipsilateral to the ureteral pathology as described for ureteral reimplantation (see Fig. 132.16). The ipsilateral bladder dome is then pulled cephalad and positioned over the ipsilateral psoas muscle above the bifurcation of the common iliac artery. The transected proximal ureteral segment, which has also been mobilized, is placed onto the superior lateral surface of the bladder dome to ensure the ability to create a tension-free ureterovesical anastomosis. Extra mobility of the bladder can be achieved by dividing the round ligament in females or vas deferens in males. If necessary, the bladder may be freed from contralateral perivesical attachments as this may facilitate further cephalad displacement. This may involve ligation of the contralateral superior vesical artery and less often middle vesical arteries and opening of the contralateral endopelvic fascia.

Stay sutures are placed on the anterior dome of the bladder after which an oblique cystotomy is made across the anterior dome at site of its maximum diameter (Fig. 132.22A). The length of this cystotomy should span approximately one-half of the anterior dome as a shorter incision may compromise the degree of cephalad bladder displacement. The surgeon's finger is placed into the bladder and used to displace the ipsilateral posterolateral dome onto the ipsilateral psoas muscle above the common iliac artery bifurcation (see Fig. 132.22B). If further length is necessary, incisions horizontal to the initial oblique cystotomy can be made to release the ipsilateral dome.

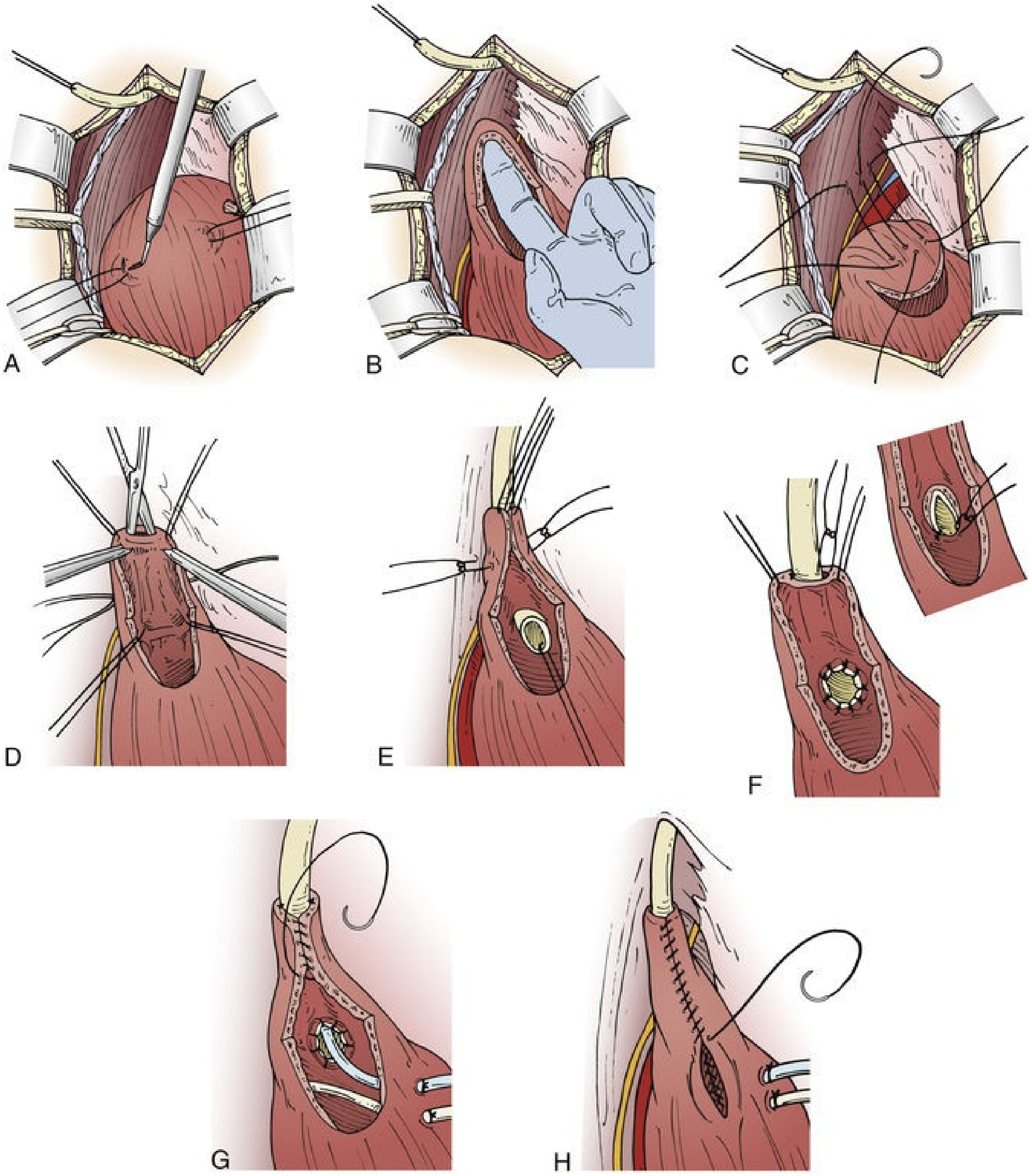

FIG. 132.22 Psoas hitch procedure. (A) A transverse-oblique cystotomy is made on the posterior bladder dome ipsilateral to the ureteral pathology. (B) The bladder dome is displaced cephalad to the ipsilateral psoas muscle. (C) The posterior wall of the bladder dome is sutured to the psoas minor tendon. (D) A tunneled ureteral anastomosis can be created by submucosal dissection toward the neo-orifice. (E) The ureter is delivered through the submucosal tunnel into the bladder. (F) The ureter is spatulated anteriorly and anastomosed to the neo-orifice in an interrupted fashion. The ureter may be loosely anchored to the extravesical surface of the bladder at its point of entry. (G) A ureteral stent is placed and a two-layer closure is commenced by first performing a mucosal closure. (H) The

detrusor is closed. (Modified from Stein R, Rubenwolf P, Ziesel C, et al. Psoas hitch and Boari flap ureteroneocystostomy. *BJU Int* 112[1]:137–155, 2013.)

The extravesical bladder wall surface is anchored to the psoas muscle using four to six 2-0 polyglactin sutures placed through the psoas minor muscle tendon and the bladder detrusor muscle (see Fig. 132.22C). Sutures should be placed superficially through the tendon of the psoas minor parallel to the direction of the muscle fibers so as to minimize the risk for disrupting the genitofemoral nerve, situated superficially on the psoas muscle, or the femoral nerve, located deeper in the belly of the muscle.

Before tying the anchoring sutures, the site for the ureteroneocysostomy should be determined and the ureter delivered into the bladder (see Fig. 132.22E). Ideally, the ureter should be reimplanted on the superior-lateral aspect of the displaced bladder dome segment as this would allow for it to follow its native trajectory and be positioned on a relatively immobile portion of the bladder, reducing the likelihood for kinking.

If a nonrefluxing anastomosis is planned, a submucosal tunnel is generated via either an extravesical or intravesical approach as described earlier (see Fig. 132.22D). Shorter ureteral segments may require creation of a refluxing anastomosis.

4-0 polyglactin sutures are placed extravesically to loosely anchor the adventitia of the ureter to the detrusor wall of the bladder at the site of ureteral entry (see Fig. 132.22F).

The cystotomy is subsequently closed in a two-layer fashion with 2-0 polyglactin suture (see Fig. 132.22G, H).

Boari Flap.

The Boari flap is first outlined and should be oriented obliquely downward across the anterior bladder wall such that the base is ipsilateral to the side of ureteral pathology (Fig. 132.23A). The base of the flap should measure at least 4 cm in width, with longer flaps requiring a wider base to ensure adequate blood supply. The apex of the flap should measure at least 3 cm in width. The length of the flap should approximate the size of the ureteral defect, although longer flaps (usually an additional 3 cm in length) may be used if ureteral tunneling is planned for a nonrefluxing anastomosis. It is critical that the ratio of length to-base width does not exceed 3 : 1 as this risks ischemia to the flap. Flap measurements should be taken with the bladder nondistended.

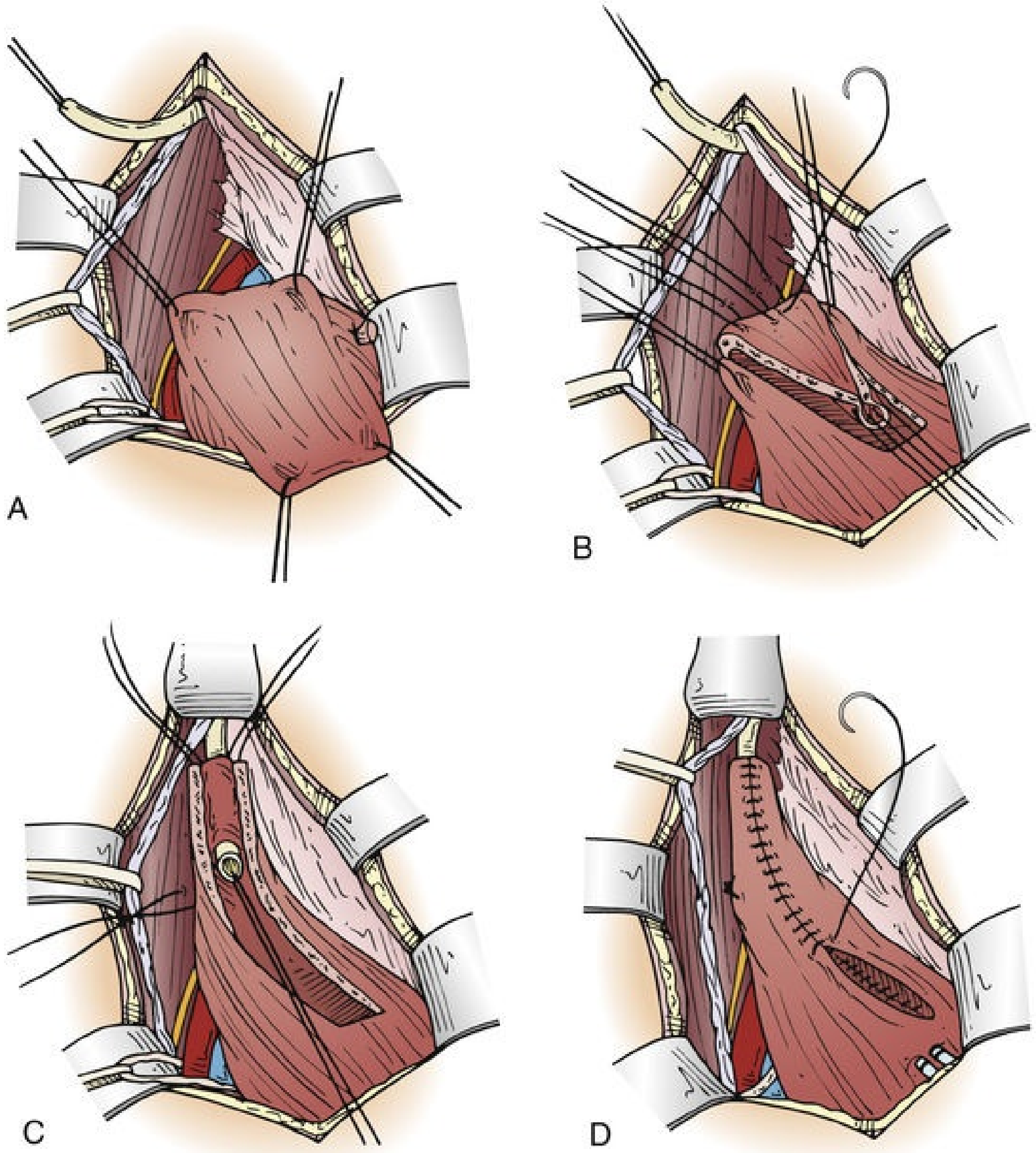

FIG. 132.23 Creation of a Boari flap. (A) An obliquely oriented flap is outlined spanning across the dome of the bladder. (B) After transmural incision along the outline of the flap, the flap is raised and the back wall of its base is sutured to the psoas minor tendon. (C) The ureter is tunneled through the Boari flap and anastomosed to the neo-orifice. (D) After placement of a ureteral stent, the bladder is closed in two layers. (Modified from Stein R, Rubenwolf P, Ziesel C, et al. Psoas hitch and Boari flap ureteroneocystostomy. *BJU Int* 112[1]:137–155, 2013.)

Electrocautery is used to incise along the planned outline of the flap, after which the flap is raised up to the ureter. The base of the flap is anchored to the psoas muscle tendon in a manner similar to that described for the psoas hitch (see Fig. 132.23B). Combining the Boari flap with a psoas hitch will reduce the size of the flap required to bridge the ureteral defect and thus help preserve bladder capacity.

In cases in which a nonrefluxing anastomosis is planned, there should be approximately 3 cm of overlap between the flap and the ureter to be reimplanted. A submucosal tunnel approximating 3 cm in length is generated via either an extravesical or intravesical approach as described earlier, with the ureter being delivered into the bladder through the posterior wall of the bladder flap just below its apex (see Fig. 132.23C). After completion of the ureterovesical anastomosis, the Boari flap is tubularized and closed with 2-0 polyglactin suture in a two-layer fashion (see Fig. 132.23D). 4-0 polyglactin sutures are placed extravesically to loosely anchor the adventitia of the ureter to the posterior wall of the bladder flap at its site of entry.

When the ureter is reimplanted in a refluxing manner, the spatulated end of ureter is anastomosed directly to the mucosal edges of the tubularized flap with 4-0 poliglecaprone suture. To avoid anastomotic stenosis, the width of the flap apex should be approximately three times the diameter of the ureter.

The cystotomy is subsequently closed in a two-layer fashion with 2-0 polyglactin suture.

In cases in which the Boari flap fails to adequately bridge the ureteral gap, the kidney may be mobilized and displaced downward.

Laparoscopic and Robotic Technique

Psoas Hitch.

Trocar placement for laparoscopic psoas hitch or advancement flap is similar to that for ureteral reimplantation and is depicted in Fig. 132.20. Trocar placement for the robotic approach is identical to that used for diverticulectomy, as seen in Fig. 132.10A. A transperitoneal approach is preferred.

The procedure begins by incising the ipsilateral white line of Toldt and identifying the ureter as it crosses the iliac vessels. The ureter is mobilized distally (Fig. 132.24A), and the diseased segment is excised, ensuring that the distal margin is well vascularized and healthy. In the case of stricture disease, a margin of the transected ureter is sent for frozen-section analysis to rule out malignancy. As described for primary ureteral reimplantation, a metal clip may be placed on the end of the transected ureter to permit passive dilation (see Fig. 132.24B). The bladder is filled with 200 mL of normal saline and mobilized by incising the peritoneum lateral to the obliterated umbilical ligaments bilaterally and transecting the urachus. Blunt dissection allows the bladder to “drop” posteriorly, and the space of Retzius is entered.

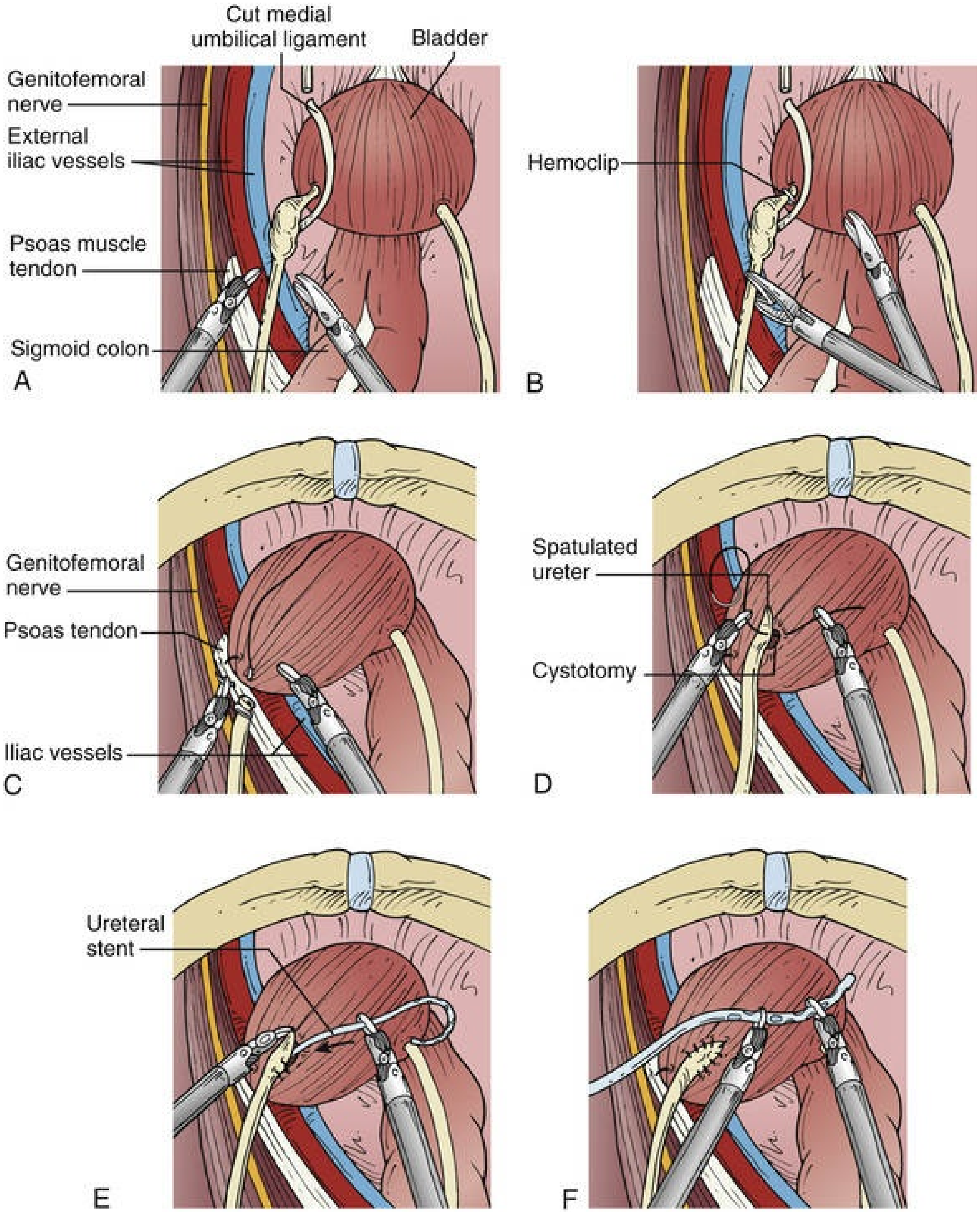
Cut medial umbilical ligament
Bladder
Genitofemoral nerve
External iliac vessels
Psoas muscle tendon
Sigmoid colon
A
Hemoclip
B
Genitofemoral nerve
Psoas tendon
Iliac vessels
C
Spatulated ureter
Cystotomy
D
Ureteral stent
E
F

FIG. 132.24 Robotic psoas hitch with extravesical ureteroneocystotomy. (A) The ureter is mobilized and the diseased area is identified. (B) A clip is placed distal to the diseased segment to close off the distal ureteral stump.

A clip on the end of the proximal transected ureteral segment may also be placed. (C) The ipsilateral bladder dome is displaced cephalad and sutured to the psoas minor tendon. (D) The ureter is spatulated and anastomosed to a cystotomy created in the ipsilateral posterior dome. (E) Before completion of anastomosis, a ureteral stent is placed in a retrograde fashion. (F) A pelvic drain is placed into the retropubic space. (Modified from Pugh J, Farkas A, Su LM. Robotic distal ureterectomy with psoas hitch and ureteroneocystostomy: Surgical technique and outcomes. *Asian J Urol* 2[2]:123–127, 2015.)

With the bladder mobilized, the posterior wall of the bladder is sutured to the psoas minor tendon with 2-0 polyglactin sutures to take any tension off the ureteral reimplantation (see Fig. 132.24C). This tendon may be identified superior and lateral to the ipsilateral common iliac vessels. Generally, division of the contralateral vascular pedicle to the bladder is not required, however, if further mobilization of the bladder is necessary, the superior and middle vesical arteries on the contralateral side can be ligated with and Endo GIA stapler. In a manner similar to open techniques, sutures should be placed through the psoas minor tendon superficially and oriented parallel to the direction of the muscle fibers so as to avoid entrapment of the genitofemoral nerve and deeper femoral nerve. Sutures in the posterior bladder wall should capture the detrusor muscle.

The ureter is reimplanted on the superior-lateral aspect of the displaced bladder dome segment in a refluxing, extravesical fashion as described earlier (see Fig. 132.24D,E). Placement of the ureter in this location allows for it to follow its native trajectory and be positioned on a relatively immobile portion of the bladder, reducing the likelihood for kinking.

The bladder is filled to 300 mL to identify any sites of anastomotic leakage, and a pelvic drain is placed through the 5-mm trocar site (see Fig. 132.24F).

Boari Flap.

The laparoscopic Boari flap was first described in humans by Fugita and Kavoussi (2001) in a series of three patients with distal ureteral obstruction (Fig. 132.25). The robotic-assisted laparoscopic approach was first reported several years later (Schimpf and Wagner, 2008). Trocar placement for laparoscopic Boari flap or advancement flap is similar to that for ureteral reimplantation and depicted in Fig. 132.20. Trocar placement for the robotic approach is identical to that used for diverticulectomy, as seen in Fig. 132.10A.

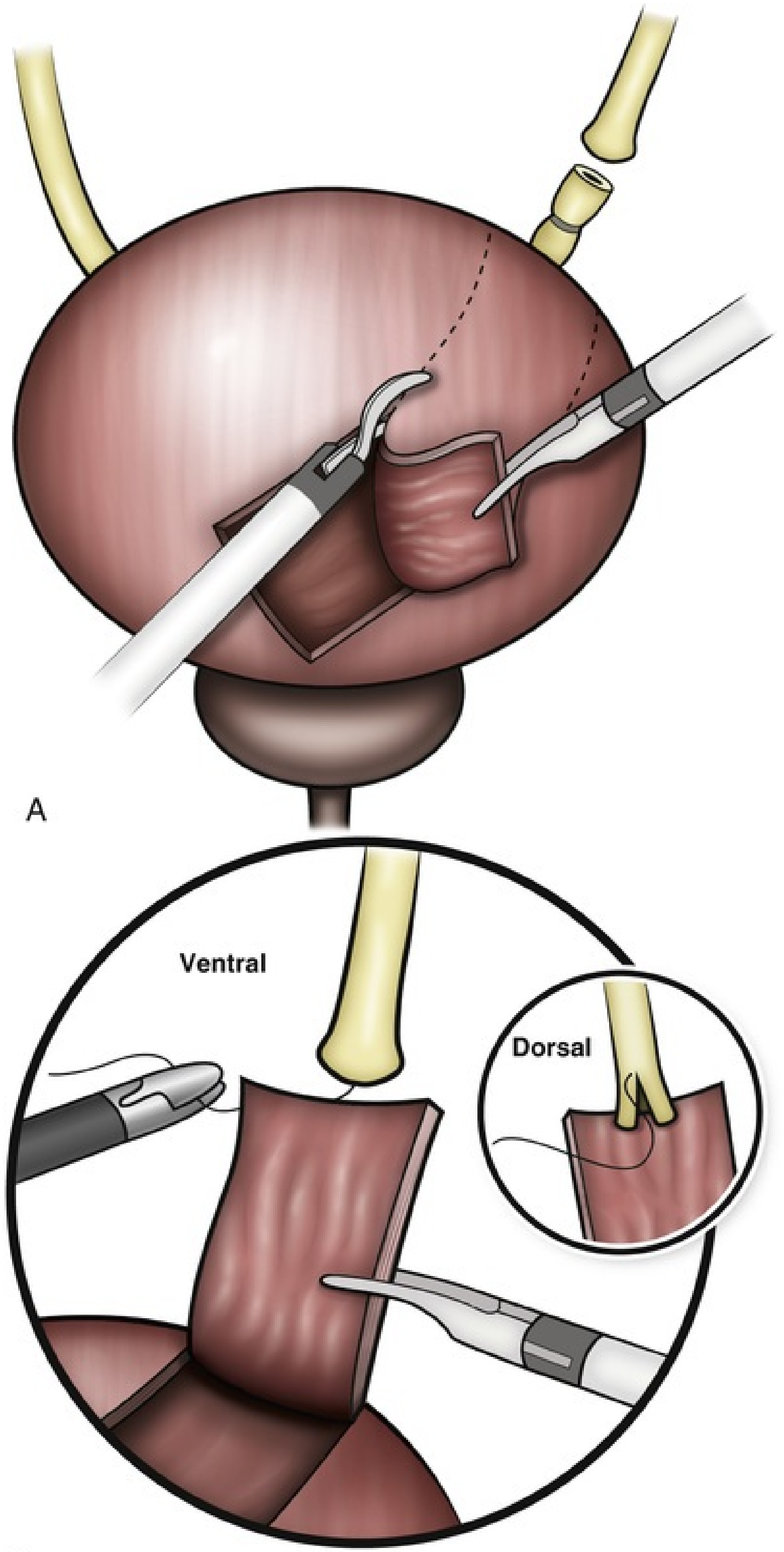
A
Ventral
Dorsal
B

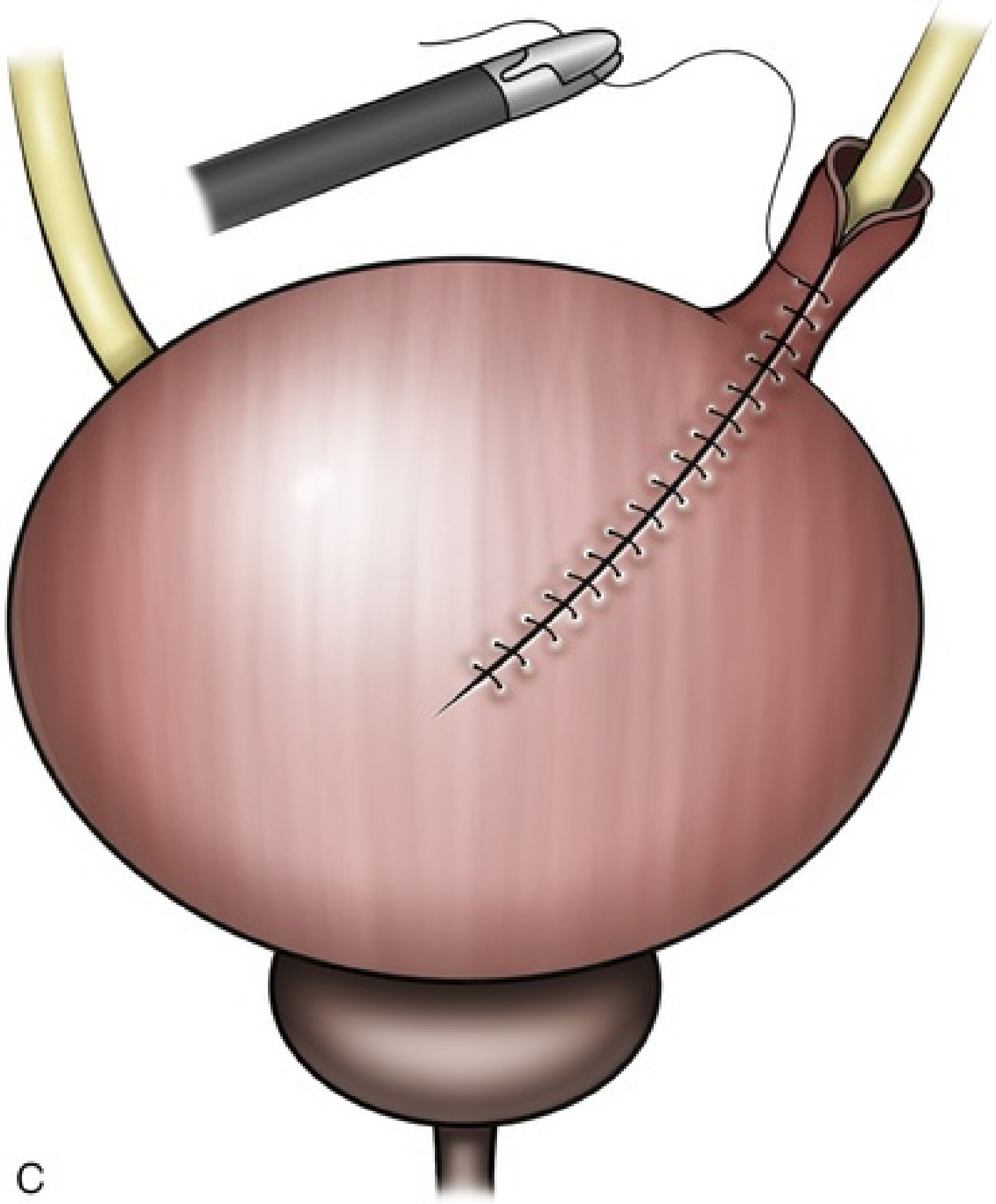

FIG. 132.25 Laparoscopic Boari flap. (A) An anterior flap is created beginning 2 cm from the bladder neck and extending to the bladder dome. (B) The spatulated ureter is anastomosed to the apex of the flap with interrupted 4-0 absorbable suture. (C) The flap is closed in a running fashion. (Modified from Fugita OE, Kavoussi L. Laparoscopic ureteral reimplantation for ureteral lesion secondary to transvaginal ultrasonography for oocyte retrieval. *Urology* 58[2]:281, 2001.)

As alluded to earlier, ligation of the contralateral bladder pedicle with an Endo GIA stapler and psoas hitch using 2-0 polyglactin suture often can provide enough mobilization to perform a ureteroneocystostomy (Modi et al, 2005; Schimpf and Wagner, 2008). If this maneuver does not suffice, a Boari flap or bladder advancement flap is performed.

Using electrosurgical scissors or a 10-mm LigaSure device, an anterior bladder flap is created beginning approximately 2 cm from the bladder neck and extending to the ipsilateral bladder dome; the apex of the flap is approximately 3 cm, and the base of the flap is approximately 4 cm (Fig. 132.26C) (Fugita and Kavoussi, 2001). Care should be taken to confirm that the base of the flap is wide enough to ensure adequate vascularity. The Boari flap is raised cephalad (see Fig. 132.26D), and its base is sutured to the psoas tendon (or muscle) (see Fig. 132.26E,F).

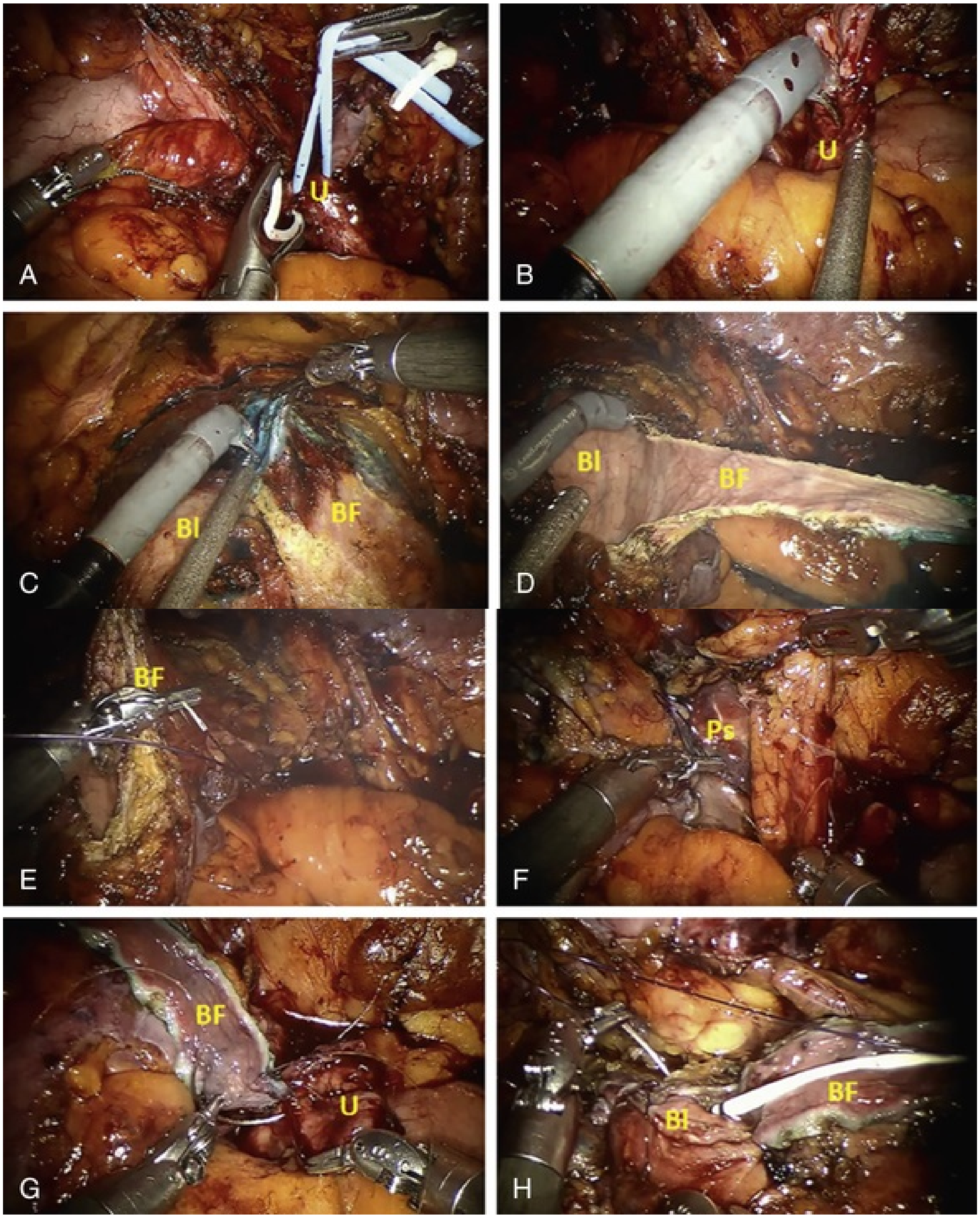
U
A
U
B
Bl
BF
C
Bl
BF
D
BF
E
Ps
F
BF
U
G
BF
Bl
H

FIG. 132.26 Robotic Boari flap with psoas hitch fixation. (A) A vessel loop is placed around the ureter *(U)* during mobilization. The diseased segment is identified, and the ureter is transected proximally. (B) The ureter *(U)* is

spatulated. (C) After the bladder is mobilized, the bladder is distended with methylene blue. A transmural incision is made along the outline of the Boari flap *(BF)* made across the bladder dome *(Bl).* (D) The boari flap *(BF)* is raised cephalad and approximated to the transected ureter to ensure a tension-free anastomosis. (E) Suture is placed through the detrusor layer at the base of the flap *(BF)* on the extravesical surface. (F) Suture is placed through the psoas muscle *(Ps)* to hitch the bladder flap to the psoas muscle. (G) The ureter *(U)* is anastomosed to the apex of the flap *(BF)* in a refluxing manner. (H) The cystotomy *(Bl)* is closed and the flap *(BF)* is tubularized after a stent is placed across the anastomosis. (Procedure performed by Alejandro R. Rodriquez, MD. Chief of Urology, Director of Robotic and Minimally Invasive Surgery, Samaritan Medical Center. Watertown, NY.)

The distal end of transected ureter is then spatulated (see Fig. 132.26B) and anastomosed to the apex of the flap with interrupted 4-0 absorbable suture (see Fig. 132.26G). After placement of a 7-Fr double-pigtail catheter over a guidewire, the flap is closed in a running fashion in two layers with 2-0 polyglactin suture or with the assistance of an Endo Stitch device (see Fig. 132.26H). The bladder is filled to 300 mL to identify any sites of anastomotic leakage, and a pelvic drain is placed through the 5-mm trocar site.

Advancement Flap.

The laparoscopic bladder advancement flap was first described by Lima et al. (2005) as a simplified alternative to a Boari flap. The bladder is opened with a transverse incision, placed one-third of the distance from the dome to the bladder neck (Fig. 132.27). The spatulated ureter is anastomosed to the bladder flap in a fashion similar to a Boari flap, described earlier. Because of its simplicity and versatility and the ability to gain considerable length that is on par with the Boari flap, it is the authors’ opinion that advancement flaps be utilized in lieu of the Boari flap to bridge longer ureteral defects not amenable to primary ureteroneocystostomy or psoas hitch (Fig. 132.28).

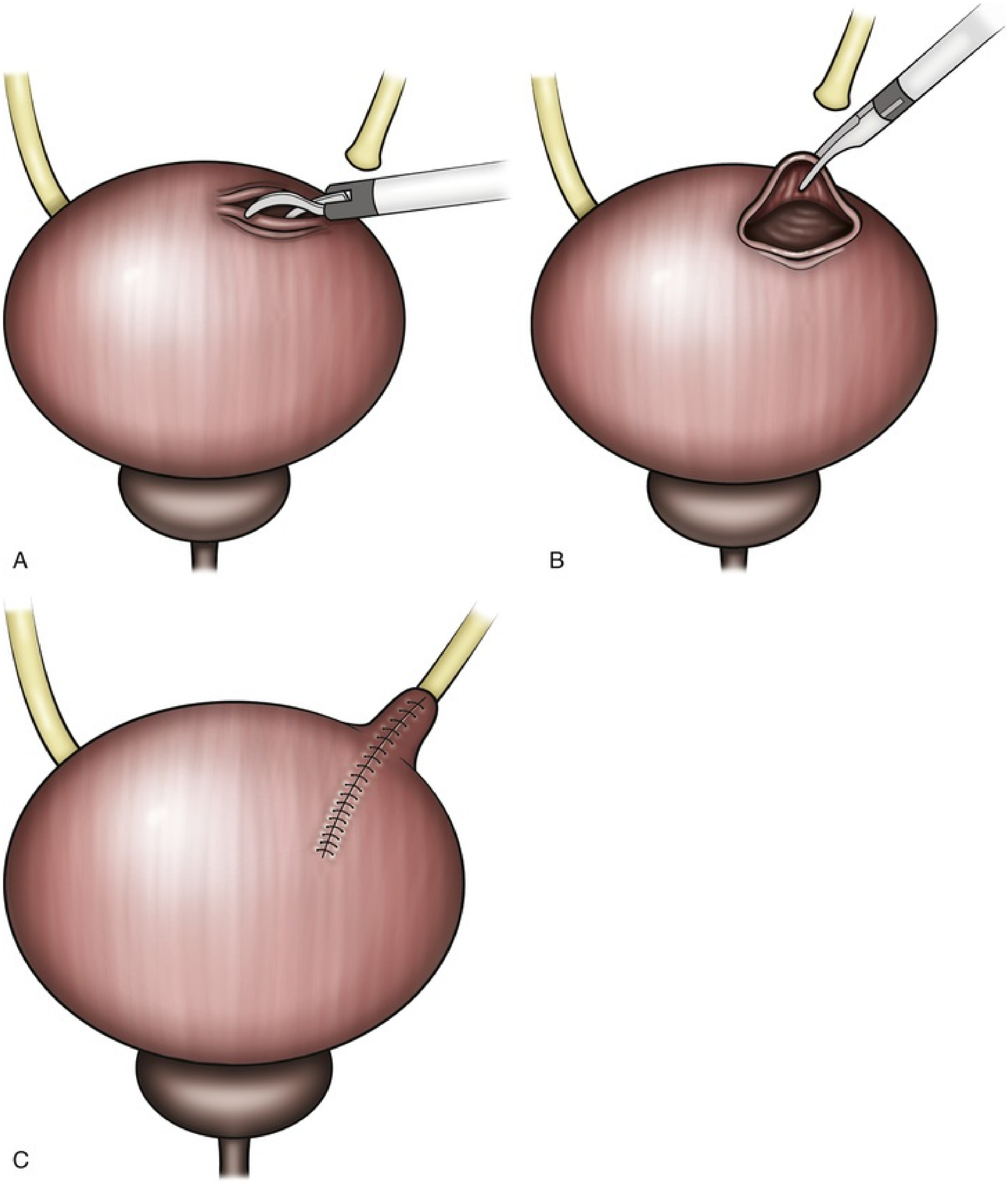

FIG. 132.27 Laparoscopic bladder advancement flap. (A) After spatulation of the ureter, a transverse opening is made on the anterior surface of the bladder one-third from the bladder dome. (B) As the incision is widened, the advancement flap is extended to the ureter. (C) The ureter is anastomosed to the advancement flap. (Modified from Lima GC, Rais-Bahrami S, Link RE, Kavoussi LR. Laparoscopic ureteral reimplantation: a simplified dome advancement technique. *Urology* 66[6]:1307, 2005.)

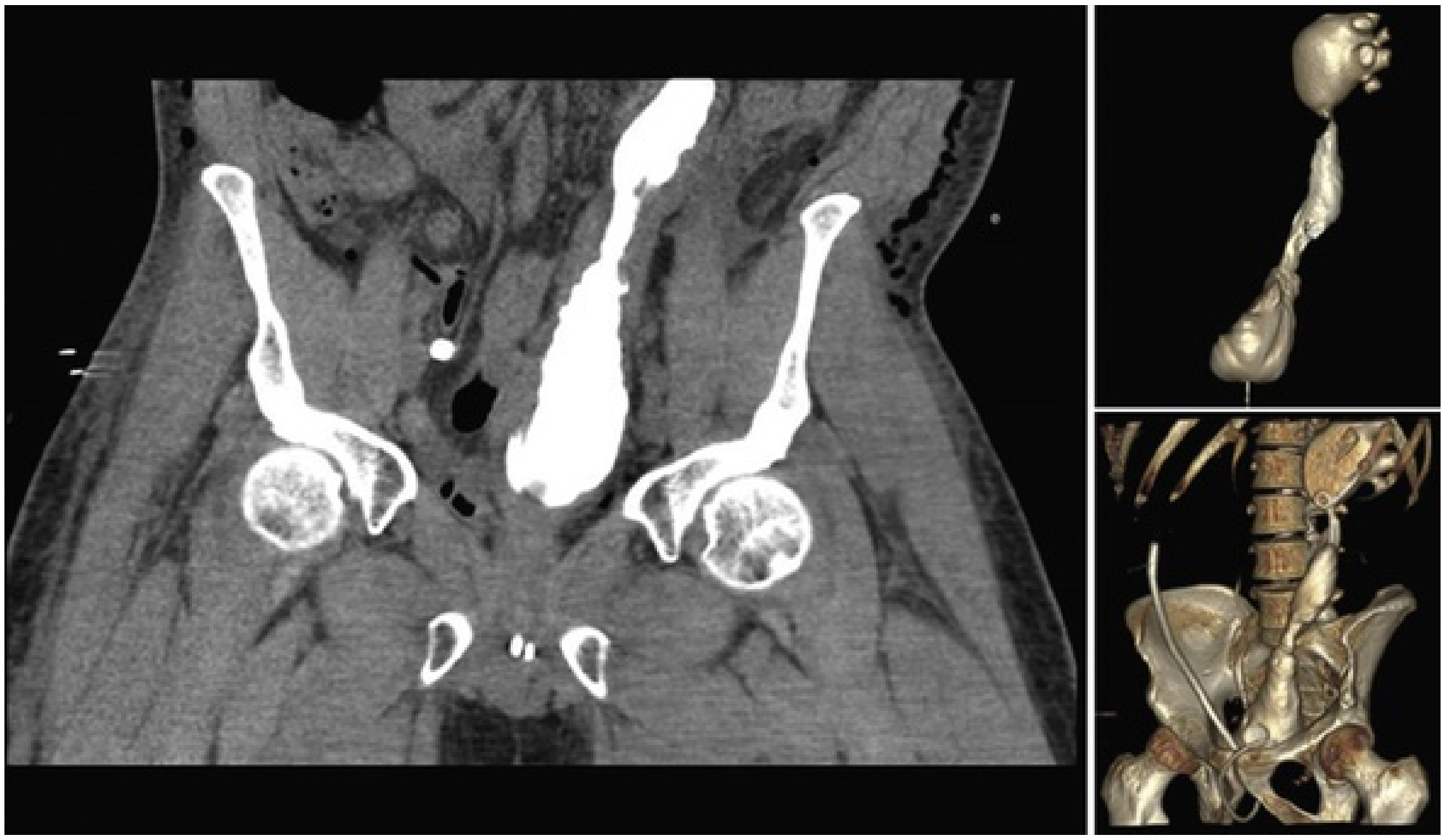

FIG. 132.28 Bladder advancement flap. Computed tomography (CT) cystogram demonstrating a "mega"-advancement flap used to bridge a large ureteral defect extending to the proximal ureter *(left).* A three-dimensional CT reconstruction demonstrating the considerable reach of a bladder advancement flap *(right).* (Courtesy of Lee Richstone, MD.)

Laparoendoscopic Single-Site (LESS) Surgery Boari Flap.

The LESS Boari flap has been described and may improve cosmetic results. Either a homemade or a manufactured multichannel LESS port is used. Alternatively, multiple standard trocars can be introduced through a single site, typically the umbilicus. A robotic-assisted LESS approach also can be used. After access is obtained, the procedure is performed identically to laparoscopic and robotic flap creation (Khoder et al., 2011).

Postoperative Care and Complications

Postoperative management follows the same course as for ureteroneocystotomy described earlier. The nature of complications following the psoas hitch procedure and Boari flap creation are also similar to those described earlier for primary ureteral reimplantation.

Additional considerations include the potential for neuropraxy resulting from injury to the genitofemoral nerve or femoral nerve during bladder fixation to the psoas minor tendon. This can be averted by placing sutures superficially through the tendon in the direction of the muscle fibers. Injury to the iliac vessels may also occur as the bladder is displaced cephalad over the bifurcation of the common iliac artery. In the case of Boari flap creation, anastomotic stricture caused by ischemia may occur in the setting of a flap, which has a narrow base relative to its length; risk for ischemia can be minimized by obeying the 3 : 1 ratio between flap length and flap base width.

An overall reduction in bladder capacity may also result after creation of a Boari flap, which may lead to irritative voiding symptoms including urgency, frequency, and incontinence.

Outcomes

Since its first description in the mid-20th century, the open approach to the psoas hitch procedure has been widely utilized to gain up to 5 cm of additional length during distal ureteral reconstruction (Ehrlich et al., 1978; Warwick and Worth, 1969; Zimmerman et al., 1960). Among the largest of open series describing long-term outcomes after open psoas hitch reconstruction is that provided by Mathews and Marshal (1997), in which 20 patients who underwent psoas hitch ureteral reimplantation had follow-up data for a mean of 6 years after surgery. The majority of cases were performed for distal ureteral injury sustained during surgery. Surgical success, defined by the lack of need for further intervention, resolution of symptoms, and presence of normal or stable renal function, was noted in 17 patients, with one patient having continued flank pain despite a negative urologic workup (Mathews and Marshall, 1997). A separate single-institutional series of 24 open psoas hitch procedures performed for distal ureteral obstruction, the majority of cases resulting from operative injury, also revealed high success rates at a mean 33-month follow-up (Ahn and Loughlin, 2001). No patients had persistence of severe hydronephrosis or experienced deterioration in renal function, flank pain, or recurrent pyelonephritis after surgery. Additionally, the authors noted no difference in outcomes between immediate versus delayed repair (Ahn and Loughlin, 2001).

The use of a Boari flap has been shown to bridge longer ureteral defects, including those approaching 15 cm in length, while averting the need for more complex, higher-risk procedures such as ileal interposition or auto-transplantation (Benson et al., 1990). Motiwala et al. (1990) presented their initial experience with Boari flap ureteral substitution in 12 patients with ureteric injury sustained primarily during gynecologic procedures. The authors observed 1 major postoperative complication, although all patients had resolution of their obstruction on follow-up. A high success rate with low perioperative morbidity was also reported by Wenske et al. (2013) in a more contemporary series of 18 Boari flap ureteral reimplantations.

The ability to reproduce open techniques for psoas hitch ureteral reimplantation using laparoscopy has been also demonstrated by several authors (Ghosh et al., 2016; Gozen et al., 2010; Riedmiller et al., 1984). Nezhat et al. (2004) reported on their experience with six women who had undergoing laparoscopic psoas hitch ureteral reimplantation for distal ureteral pathology in the setting on infiltrative endometriosis. In this series, no patients experienced an intraoperative or 30-day postoperative complication. Additionally, imaging studies revealed no evidence of obstruction at 1-year follow-up in all patients. A similar series by Puntambekar et al. (2006) in five women undergoing laparoscopic psoas hitch ureteral reimplantation for injury sustained during gynecologic procedures reported favorable perioperative outcomes including a mean surgical time of 220 minutes, mean estimated blood loss of 150 mL, and an average hospital length of stay of 3 days. No complications were observed, and follow-up urography demonstrated resolution of obstruction with no evidence of reflux on cystogram. The authors did, however, stress the importance of a proper intracorporeal suturing technique to facilitate surgical success. More contemporary series on laparoscopic distal ureteral reconstruction routinely consider patients undergoing primary ureteroneocystotomy in aggregate with those undergoing psoas hitch reimplantation, indicating its more widespread integration into the minimally invasive treatment armamentarium for distal ureteral defects (Gozen et al., 2010; Pompeo et al., 2013; Rassweiler et al., 2007).

In a similar regard, laparoscopic techniques for Boari flap creation are being utilized for ureteral reconstruction in the setting of longer-segment ureteral defects (Ghosh et al., 2016; Gozen et al., 2010). The first clinical series of laparoscopic ureteral reimplantation with a Boari flap was reported in 2001 and involved three patients (Fugita and Kavoussi, 2001). The approach was demonstrated to be feasible with a mean operative time of 220 minutes and estimated blood loss ranging from 400 to 600 mL. With a mean follow-up period of 11 months, all patients had resolution of obstruction. Castillo et al. (2005) reported a slightly larger series of laparoscopic Boari flap in eight patients. Operative times (mean 157 minutes), blood loss (mean 124 mL), and hospital stay (mean 3 days) further validated the feasibility of the technique. Two complications occurred, including one pulmonary embolism and one episode of urinary leakage at the anastomosis requiring laparoscopic repair. With a mean follow-up of 18 months, all patients had resolution of obstruction (Castillo et al., 2005).

Seideman et al. (2009) reported the largest single-center series of laparoscopic Boari flap in 21 of 45 patients undergoing laparoscopic ureteral reimplantation with significant follow-up (mean 24 months). Median length of stay was 3 days, and median estimated blood loss was 150 mL. Complications included small bowel obstruction in one patient, *Clostridium difficile* colitis and respiratory distress in one patient, and urinary leakage in two patients that was managed conservatively in both cases. In a multi-institutional series of 30 patients undergoing a laparoscopic Boari flap procedure, excellent outcomes were achieved (Castillo et al., 2013). In this series, mean operative time was 161 minutes, and mean estimated blood loss was 123 mL with no intraoperative complications or conversion to open surgery. Postoperative complications occurred in 17% of patients, with a success rate of 97% at a mean follow-up of 32 months (Castillo et al., 2013).

Increased utilization of the robotic platform for urologic surgery has generated considerable interest in its use for more complex reconstructive procedures involving longer defects of the distal and mid-ureter (Allaparthi et al., 2010; Musch et al., 2013; Schimpf and Wagner, 2008, 2009). A multi-institutional review of 12 cases of robotic ureteral reimplantation with psoas hitch performed by three experienced robotic surgeons for benign indications demonstrated high efficacy of the procedure with a mean operating time of 173 minutes, mean blood loss of 48 mL, and hospital stay of 4.3 days (Patil et al., 2008). Additionally, no intraoperative or postoperative complications were encountered with all procedures having been completed robotically. All patients were asymptomatic after a mean follow-up of 15.5 months, with imaging demonstrating no hydronephrosis in 10 patients and only mild residual hydronephrosis in two patients (Patil et al., 2008).

In a subsequent series of 16 patients undergoing robotic-assisted reconstruction of the distal ureter, Musch et al. (2013) reported on outcomes associated with seven cases in which psoas hitch was performed and four cases for which a Boari flap was also created. Open surgery was required in one case because of massive peritoneal adhesions from a previous pancreatectomy, and two patients experienced a major postoperative complication, characterized by prolonged urinary leak in one case and bladder insufficiency with urinary leak in the second. At a medium follow-up of 10.2 months, however, 94% of patients remained without evidence of urinary tract obstruction, and 81% were free of any clinical symptomatology (Musch et al., 2013). A similar investigation of robotic Boari flap ureteral reimplantation performed in eight patients for benign ureteral stricture disease revealed similar efficacy, with a mean operative time of 171.9 minutes, blood loss of 161.3 mL, and no intraoperative complications or occurrences of open conversion (Do et al., 2014). One postoperative anastomotic leak was observed, which resolved with conservative management.

Thus, although the majority of laparoscopic and robotic series to date are small in study size, they indicate that, in experienced hands, excellent results can be achieved with minimally invasive techniques.

Enterocystoplasty

Description

Bladder augmentation in adults is most frequently indicated in the setting of neurogenic bladder (either congenital or acquired) when more conservative attempts at improving bladder compliance are unsuccessful (Wiener et al., 2011). Less often, augmentation cystoplasty is performed after partial cystectomy when resection has led to a significant reduction in bladder capacity. The intrinsic distensibility of bowel makes its use ideal for reducing intravesical pressures and improving reservoir function of the bladder, although it is critical that the isolated segment is adequately detubularized to subvert coordinated peristaltic contractions that may mitigate this purpose.

Traditionally performed via an open approach, there has been a gradual evolution in the use of minimally invasive techniques for enterocystoplasty (Docimo et al., 1995; Gill et al., 2000). Over the past decade, ileocystoplasty has emerged as the most widely employed technique. Reports of laparoscopic, robotic, and LESS bladder augmentation have documented the reproducibility of these techniques by purely intracorporeal and partly extracorporeal approaches.

Evaluation and Surgical Indication

Among patients with known neurogenic dysfunction of the bladder, there has been considerable evolution in noninvasive management strategies that have made the need for enteroplasty a more advanced option. Indeed, continuous intermittent catheterization, anticholinergics, intravesical injections with botulinum toxin, and sacral neuromodulation form the mainstay of therapy in these patients (Apostolidis et al., 2009; Cardenas et al., 2011; Jamison et al., 2013; Sadiq and Brucker, 2015). However, in situations in which noncompliance of the bladder persists despite these measures, augmentation cystoplasty with bowel should be considered, particularly if there is evidence of upper tract deterioration, hydronephrosis, or significant incontinence (Utomo et al., 2014).

Urodynamics is an important tool in this patient population as measurement of detrusor leak point pressure is a strong indicator of the elastic properties of the bladder and risk for renal deterioration. Video-urodynamics is often preferred as this allows for simultaneous evaluation of bladder contour, the presence of associated anomalies (e.g., diverticula), and presence of vesicoureteral reflux. Ultrasonography should also be routinely performed as the development of hydronephrosis or parenchymal atrophy indicates poor bladder wall compliance.

Symptoms of frequency, urgency, nocturia, or incontinence in patients who have previously undergone partial cystectomy may indicate a significant reduction in bladder capacity. Conservative measures, similar to those for neurogenic bladder dysfunction, should be implemented initially, with enterocystoplasty reserved only for cases of refractory symptomatology. Ideally, preoperative screening will have selected against those patients at risk for clinically significant reduction in bladder capacity. Urodynamics may be utilized in these patients to better characterize bladder function and response to noninvasive interventions.

Resection of the intestine and subsequent integration into the urinary tract carries the potential for metabolic derangement. As such, a full serum chemistry is necessary before surgical planning. In particular, with ileum being most often utilized for bladder augmentation, careful screening for Vitamin B_{12} and fat-soluble vitamin deficiency is necessary. Additionally, perturbations in acid balance resulting from the interaction of urine with intestinal mucosa warrants careful consideration, particularly in patients with renal failure caused by compromised ability to regulate serum pH. As ileum is most widely utilized for purposes of bladder augmentation, primary concern relates to the development of a chronic metabolic acidosis state in these individuals and associated risk for bone demineralization.

Technical considerations when determining candidacy for augmentation enterocystoplasty include a careful understanding of the patient's medical history. Presence of Crohn's disease or previous intestinal surgery may place patients at risk for short gut syndrome after further bowel resection. Prior radiation exposure to the bowel may preclude ability to isolate an intestinal segment with a durable blood supply. The need for continuous intermittent catheterization will remain in the majority of cases where augmentation cystoplasty is performed, thus manual dexterity and anatomic feasibility to catheterize must be confirmed before treatment, especially when being performed for neurogenic dysfunction.

The need for concomitant interventions should also be factored into surgical planning. Patients with neurogenic dysfunction with stress urinary incontinence may undergo simultaneous placement of a sling or artificial sphincter. In individuals undergoing creation of a continent catheterizable stoma, bladder neck closure may be planned, particularly in the context of incontinence. Nonrefluxing ureteral reimplantation for high-grade reflux may be planned in cases of renal dysfunction and concern for relative persistence of high intravesical pressures despite augmentation cystoplasty.

Nearly any portion of the gastrointestinal system can be utilized for purposes of bladder augmentation. However, the ileum is most often utilized given its abundance, ease of mobilization resulting from the intraperitoneal location and long mesentery, and rich vascular supply. If a continent catheterizable channel is desired, particularly in cases in which the bladder neck has been closed, an ileocecal segment may be used. Sigmoid colon is attractive in patients with neurogenic dysfunction as there is often redundancy of the mesentery, which facilitates mobilization. Patients in whom colon is being used for augmentation should receive colonoscopy to ensure no malignancy is present.

Presented here are techniques for performing open, laparoscopic, and robotic ileocystoplasty. The general principles demonstrated here apply when harvesting other intestinal segments.

Surgical Technique

Open Technique

The patient is placed supine on the operating table with the table flexed at the anterior superior iliac spine. When using ileal or colonic segments of bowel, the patient is prepped from the thigh to just above the umbilicus; the incision may need to be carried more cephalad if a gastric segment is utilized.

A midline skin incision is made from the umbilicus to the pubic symphysis and carried down through the subcutaneous tissue to the level of the rectus fascia. The fascia is incised in the midline the length of the incision, exposing the underlying rectus muscle. The bellies of the muscle are split at the midline linea alba, and the transversalis fascia is incised. The peritoneum is entered sharply and incised the length of the incision.

The space of Retzius is developed with blunt dissection. Extensive dissection of the lateral pelvic gutters is not necessary as transposition of the isolated bowel segment generally occurs onto the most cephalad portion of the bladder.

A 25-cm length of ileum is isolated approximately 20 cm proximal to the ileocecal valve to reduce malabsorption risk related to resection of the terminal ileum (Fig. 132.29A). The candidate segment of ileum is brought down into the pelvis and approximated onto the dome of the bladder to ensure feasibility for a tension-free anastomosis.

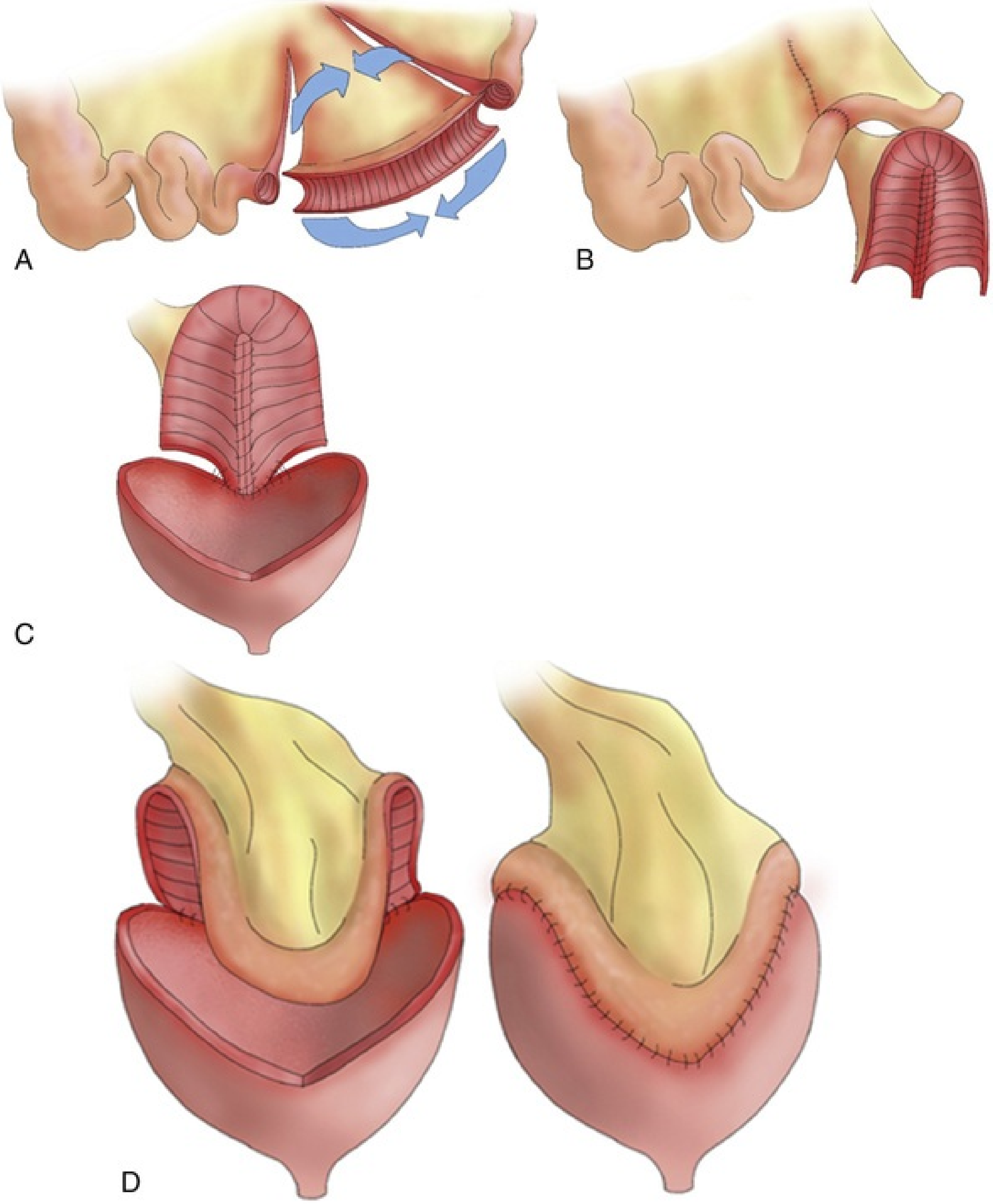

FIG. 132.29 Open enterocystoplasty. (A) A 25-cm segment of ileum is isolated after which is it detubularized along its antimesenteric surface. (B) The bowel segment is folding into a U-shape to form an intestinal flap. (C) The bladder is bivalved by incision along the midline dome. (D) The U-shaped intestinal flap is anastomosed to the bladder dome allowing for a

wide-mouth anastomosis. (Modified from Breen M, Phelps A, Estrada C, Chow JS. The role of imaging in pediatric bladder augmentation. *Pediatr Radiol* 45[10]:1440–1447, 2015.)

Before harvesting the intestinal segment, the mesentery is transilluminated to visualize the vascular supply and ensure isolation of a bowel segment with an adequate arterial arcade, extending ideally to the edges of the segment. 2-0 silk stay sutures are loosely placed on the antimesenteric surface of the intestine to demarcate the boundaries of resection. A small mesenteric window is made along the mesenteric surface of the intestine at the marked boundaries of resection. An Endo GIA stapler is inserted through this window and used to divide the intestinal segment to be used for bladder augmentation. The mesentery is divided toward its root with a 10-mm LigaSure device or Endo GIA stapler (see Fig. 132.29A). Care should be taken to avoid blood vessels during division of the mesentery. Additionally, the mesenteric base of the isolated intestinal segment should be kept broad to minimize the risk for torsion of the pedicle.

Continuity of the intestinal segments is reestablished via a side-to-side anastomosis using an Endo GIA stapler. Allis clamps are used to appose the edges of the intestinal wall defect at the elbow of the anastomosis under which a TA stapler (Covidien, Mansfield, MA) is used to complete the anastomosis staple line. The mesenteric defect is closed with 2-0 polyglactin sutures placed longitudinally through the mesentery to avert internal herniation. The intestine with the closed mesenteric trap should be situated on top of the isolated segment of bowel that is to be used for bladder augmentation.

The staple lines are resected off the ends of isolated intestinal segments, and the segment is copiously irrigated. The segment is then detubularized by incising its antimesenteric surface transmurally with electrocautery (see Fig. 132.29A). The detubularized intestinal patch is subsequently configured into a U-arrangement, and the sides are sutured with full-thickness 2-0 polyglactin suture in a running fashion (see Fig. 132.29B).

A longitudinal incision is made along the dome of the bladder from anterior to posterior, essentially bivalving the bladder. The bladder wall defect should be patent enough to facilitate a wide-mouth anastomosis as this will allow the intestinal patch to better assume the reservoir function of the bladder (see Fig. 132.29C). The U-shaped detubularized intestinal patch is sutured to the edges of the bladder dome defect circumferentially, ensuring that transmural sutures are placed through the intestinal segment and bladder wall (see Fig. 132.29D).

Before completion of the vesiointestinal anastomosis, a suprapubic tube should be placed through a separate cystotomy and brought out through the skin. Additionally, if the bladder neck is open, a large-bore Foley catheter should be placed under visualization. The integrity of the anastomosis is assessed by irrigating the bladder through the Foley catheter and/or suprapubic tube. Any sites of leakage should be reinforced with figure-of-eight 2-0 polyglactin suture. A pelvic drain is placed in the retropubic space and secured to the skin. The fascia and skin are closed in the standard fashion.

Laparoscopic and Robotic Techniques

The procedure begins with cystoscopic evaluation and placement of bilateral open-ended or single-J ureteral catheters, which are secured to a urethral catheter. Pneumoperitoneum is established. Laparoscopic or robotic enterocystoplasty is performed using three to five trocars depending on the surgeon's experience and preference (Fig. 132.30A).

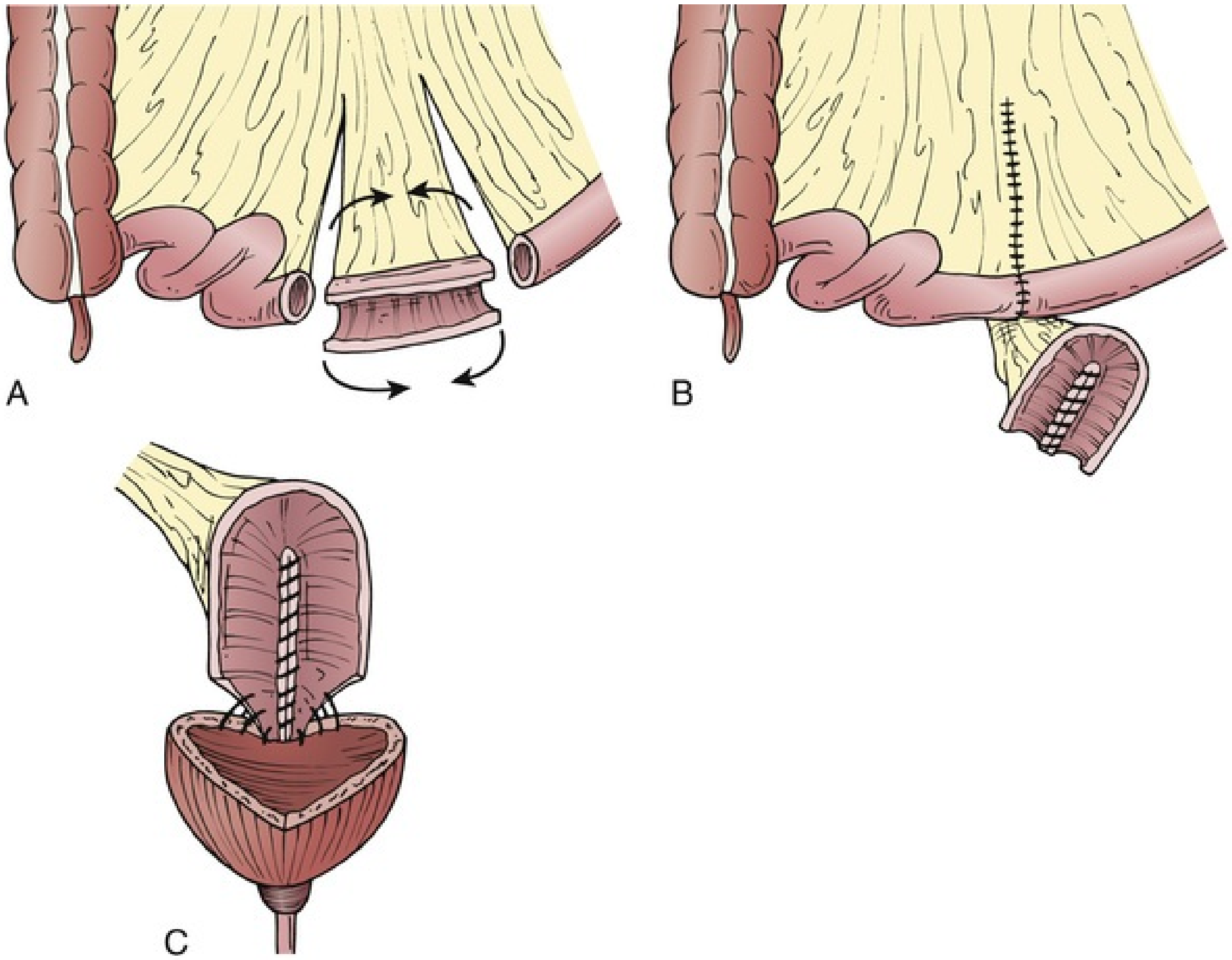

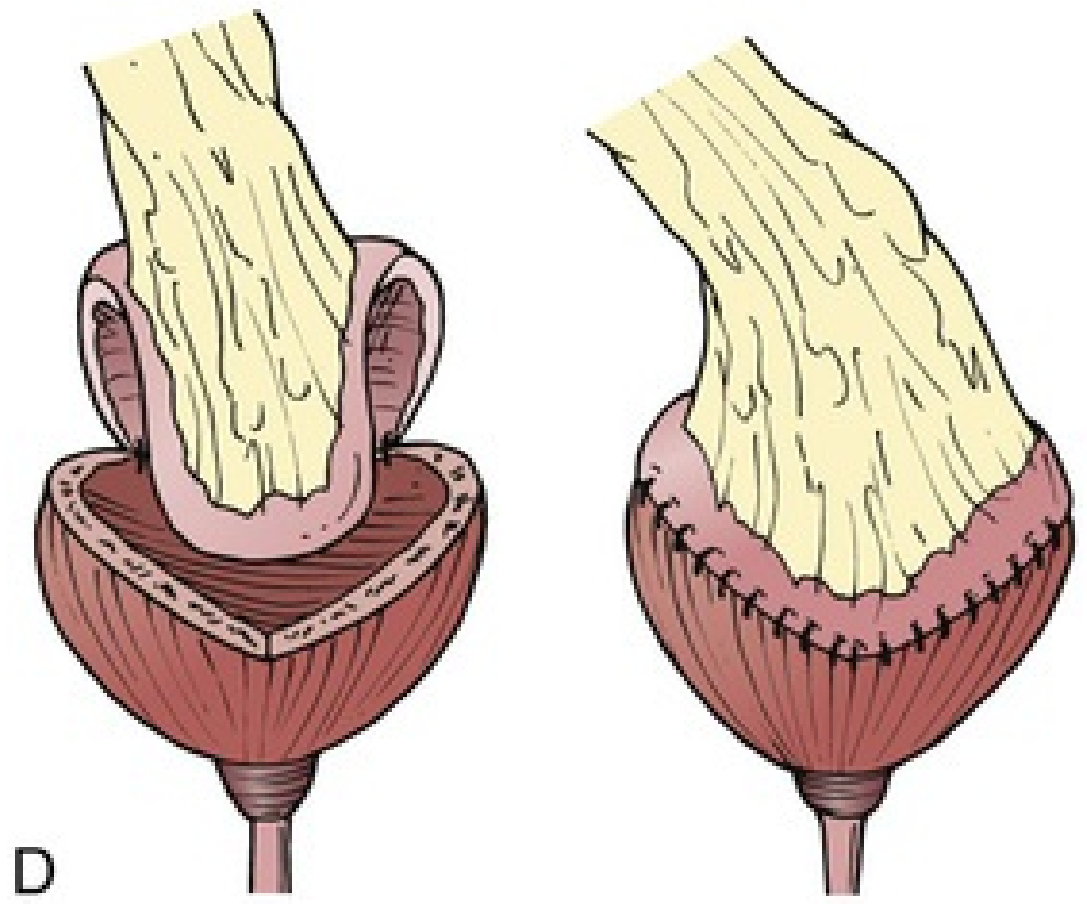

FIG. 132.30 Technique for minimally invasive enterocystoplasty. (A) Four-port transperitoneal technique is employed including an umbilical port, one port at each lateral border of the rectus muscle at the level of the umbilicus, and a port in the iliac fossa at the level of the anterior superior iliac spine. (B) The selected bowel segment (≈20 cm) is exteriorized through an extension of the umbilical port incision. Alternatively, the bowel work can be performed intracorporeally. The anteroposteriorly bivalved bladder is shown. (C) Ileoileal reanastomosis is performed cephalad (anterior) to the isolated bowel segment, which is detubularized and cleansed. Proper orientation of the bowel mesentery must be maintained. (D) Ileovesical anastomosis is performed in a circumferential manner with continuous, full-thickness, freehand laparoscopic suturing with 2-0 polyglactin suture on a CT-1 needle. The completed augmentation ileocystoplasty is shown in the inset. (Reprinted with permission from The Cleveland Clinic Foundation. From Gill IS, Rackley RR, Meraney AM, et al. Laparoscopic enterocystoplasty. *Urology* 55[2]:178–181, 2000.)

The bladder is fully mobilized by incising the peritoneum lateral to the obliterated umbilical ligament bilaterally, and the urachus is divided to “drop” the bladder posteriorly and enter the space of Retzius. An appropriate 15- to 20-cm segment of bowel is chosen taking care to ensure an adequate vascular pedicle and that the segment will reach to the bladder neck (see Fig. 132.30B). The bowel work can be completed via a purely laparoscopic approach (Meng et al., 2002) or extracorporeally by extending the length of the umbilical incision (Gill et al., 2000) as described later in this chapter.

In either approach, the segment is harvested using an Endo GIA stapler, and the mesentery can be divided with additional reloads of the Endo GIA stapler or with a 10-mm LigaSure device, as described earlier for the open technique. Bowel continuity is reestablished with a side-to-side anastomosis using the Endo GIA stapler. The anastomosis is completed using a TA stapler if performed extracorporeally and with a series of Lembert sutures if performed using intracorporeal suturing (see Fig. 132.30C). The mesenteric window, or “trap,” is closed to prevent internal herniation.

The bowel segment is irrigated copiously, the staple lines are excised on each end, and the segment is then opened along the antimesenteric border. The sides of the now detubularized ileal bowel segment are approximated to form a *U*-shaped segment with running 2-0 polyglactin suture, as described for the open technique. At this time, the bladder is filled with saline and bivalved at the midsagittal line. The segment is brought down to the pelvis without tension or torsion of the mesenteric pedicle (see Fig. 132.30D).

With the bowel segment oriented so that the apex of the *U* is positioned anteriorly at the bladder neck, the patch is sutured to the bladder in a running continuous fashion with 2-0 polyglactin suture, beginning posteriorly and ending anteriorly (see Fig. 132.30D) (Elliott et al., 2002; Gill et al., 2000; Meng et al., 2002). The integrity of the completed augmentation is confirmed by irrigating the bladder via the Foley catheter, and finally a pelvic drain is positioned through an established port.

Laparoscopic and robotic ileocecocystoplasty with creation of a catheterizable stoma also have been described (Gill et al., 2000; Gundeti et al., 2008). As an alternative to vesicoplasty for select patients, appendicovesicostomy has been performed laparoscopically (Hsu and Shortliffe, 2004; Lorenzo et al., 2007) and with robotic assistance (Lendvay et al., 2008). More recently, LESS enterocystoplasty has been reported, but larger series are needed to validate the efficacy and safety of the approach (Desai et al., 2009).

Postoperative Care and Complications

Postoperatively, a Foley catheter is kept to drainage for approximately 1 week with a cystogram performed before removal. The pelvic drain is removed typically after 48 hours once the output has decreased; a drain creatinine measurement is optional and should be interpreted in the context of the drain output.

Patients undergoing enterocystoplasty are subject to complications similar to bladder diverticulectomy. Urinary extravasation across the suture lines may result from inadequate suturing or ischemia of the intestinal flap; it is for this latter reason that a robust vascular arcade be preserved during flap harvest. Clinical presentation and management of urine leak are described earlier in the section for bladder diverticulectomy. Patients undergoing enterocystoplasty are also subject to urinary tract infection, bowel injury, and urinary fistula formation. Intraabdominal infectious complications in particular may occur during irrigation of the bowel segment and detubularization, particularly if proper isolation precautions are not used during this portion of the procedure.

Complications unique to enterocystoplasty include bladder perforation, stone formation, systemic metabolic derangements, and neoplasia (pertinent to cases in which colon segment is used). Continuous intermittent catheterization is imperative in patients undergoing augmentation cystoplasty as failure to do so risks perforation. Preoperative operative planning should account for the manual dexterity of patients as this will also influence type of augmentation performed; individuals with unfavorable body habitus who cannot catheterize at the bladder neck may be better served with a continent ileocecocystoplasty, whereas individuals unable to catheterize or who demonstrate poor compliance can undergo an incontinent ileovesicostomy. Bladder perforation should be suspected in cases of abdominal pain, fever, or acute abdominal distension and should prompt CT of the abdomen and pelvis; a high index of suspicion is required in the neurogenic population as sensory deficits may be present. Perforation is a surgical emergency and requires exploration.

Higher propensity for bladder stone formation is multifactorial and involves mucus production by the interposed intestinal segment, the higher burden of bacterial colonization and risk for infection, and urinary stasis (DeFoor et al., 2004). Irrigation is thought to reduce retention of mucus within the bladder, although the true benefit remains the subject of debate (Hensle et al., 2004). Symptomatic bacterial infections should be treated with antibiotics. Increased risk for cancer has been reported in augmented bladders, although the exact incidence is difficult to discern. Nevertheless, bladders augmented with bowel segments appear to be at risk for not only adenocarcinoma but also urothelial carcinoma (Austen and Kalble, 2004). Surveillance endoscopy is recommended after 10 years of initial surgery. Routine blood work is necessary to screen for metabolic derangements, including vitamin deficiencies.

Outcomes

Open augmentation cystoplasty is a widely utilized treatment option for patients with neurogenic dysfunction (Wiener et al., 2011). Given minimally invasive techniques have only recently emerged, long-term outcome studies are available primarily for procedures performed using open techniques (Gurung et al., 2012; Herschorn and Hewitt, 1998).

The earliest of reports detailing the efficacy of enterocystoplasty involving use of the cecum or ileum were provided by Linder et al. (1983), who described their outcomes at a mean 38-month follow-up for 18 patients treated for neurogenic dysfunction. The authors cited high success related to the procedure as 82% of patient remained continent at last follow-up (Linder et al., 1983). Longer-term follow-up was provided by Gurung et al. (2012) in 19 adult patients (mean age 28.9) undergoing ileocystoplasty for detrusor overactivity secondary to spinal cord injury. At a mean 14-year follow-up, the authors demonstrated significant improvement in bladder capacity and reduction in intravesical pressures using video-urodynamic testing. Additionally, the authors demonstrated a very high-level of patient satisfaction on quality-of-life questionnaire, with no reports of change in bowel or sexual function. Of note, over 50% of patients experienced a complication related to their augmentation procedure at some time point; the majority were related to the formation of bladder stones (Gurung et al., 2012).

These results echo the findings of a similar report by Quek and Ginsberg (2003) describing long-term outcomes in a cohort of patients undergoing enterocystoplasty for neurogenic bladder. In their series of 26 patients, a mean 8-year follow-up demonstrated resolution of incontinence in 96% of patients and a significant improvement in bladder capacity. Urodynamics studies performed in all patients revealed a reduction in mean maximum detrusor pressures of appropriately 61 cm H_2O. Additionally, patient satisfaction after the procedure was nearly 100%, with very few patients reporting bowel dysfunction. The authors did note, however, that efficacy of the procedures was observed in the context of a secondary procedure in almost 50% of patients at some time point after the initial surgery (Quek and Ginsberg, 2003).

These results indicate that open augmentation cystoplasty is an effective treatment strategy for patients with neurogenic dysfunction experiencing refractory voiding symptoms (e.g., incontinence, overactivity) or at risk for upper tract dysfunction secondary to high intravesical pressures. Although there is a relatively high risk for complications with long-term follow-up, the majority pose low morbidity and are manageable with secondary interventions.

The data on minimally invasive procedures are less robust, although small series do report feasibility and efficacy with intermediate follow-up (Gould and Stoffel, 2011). Docimo et al. performed the first pure laparoscopic gastrocystoplasty in a patient with a five-port technique (Docimo et al., 1995). The procedure involved almost 11 hours of operating time and a 13-day hospitalization. A laparoscopic-assisted approach, in which the laparoscopic work was largely limited to bowel mobilization, followed (Chung et al., 2004; Hedican et al., 1999). Gill et al. reported the first laparoscopic ileocystoplasty, sigmoidocystoplasty, and cecocoloplasty (Gill et al., 2000). Bowel harvest and anastomotic work was done extracorporeally with a four-port approach. In this series of three patients, operative times of 5 to 8 hours and blood loss of 50 to 200 mL were reported. A rectus sheath hematoma was the only complication that occurred.

The first purely laparoscopic ileocystoplasty in a human was reported in 2002 (Elliott et al., 2002; Meng et al., 2002). The patient underwent a 9-hour procedure and required a 13-day hospitalization secondary to prolonged ileus. A subsequent larger series of laparoscopic cystoplasty comprised six patients who underwent pure laparoscopic ileocystoplasty and an antegrade continence enema procedure (Shadpour et al., 2005). Operative times were 5 to 8.5 hours, with a median hospitalization of 5 days. Complications included one ileal anastomotic leak that resolved conservatively and one appendiceal stomal stenosis requiring revision. With intermediate-term follow-up (13 to 16 months), all patients were continent of urine between catheterizations, and nearly all had perfect fecal continence.

Purely intracorporeal robotic augmentation ileocystoplasty with and without Mitrofanoff appendicovesicostomy has also been described (Al-Othman et al., 2008; Gundeti et al., 2008). The technique is essentially identical to the laparoscopic approach, but it may facilitate the learning curve for intracorporeal suturing. In a recent series of five cases of robotic ileocystoplasty reported by Gould and Stoffel (2011), mean operative time was 6.4 hours, blood loss was 180 mL, and length of stay was 7 days. Only one patient experienced a postoperative complication involving formation of urinoma causing ileus; this resolved spontaneously with conservative management. At last follow-up, all patients were continent and had normal upper tract imaging (Gould and Stoffel, 2011). Flum et al. (2014) recently published a larger, more contemporary review of their experience performing robotic augmentation enterocystoplasty, in which the entirety of the procedure was performed intracorporeally. Of 22 patients treated, 15 underwent enterocystoplasty alone, whereas seven patients additionally received a continent catheterizable channel. Mean operative time was 365 minutes, and blood loss was only 110 mL. One conversion to open surgery was necessary, and four major complications were reported. At a mean follow-up of 38.9 months, mean cystometric capacity increased by 52% and mean maximal detrusor pressure decreased by 40 cm H_2O on urodynamic testing

(Flum et al., 2014).

These results indicate that continued experience with minimally invasive techniques for augmentation cystoplasty may be allowing for improvement in perioperative and postoperative outcomes.

Partial Cystectomy and Urachal Surgery

Description

Partial cystectomy is most frequently utilized for select patient populations with muscle-invasive urothelial carcinoma or urachal adenocarcinoma who are amenable to bladder preservation (Knoedler et al., 2012; Wadhwa et al., 2006). However, there are several benign indications for which partial cystectomy is performed as well.

The majority of benign bladder tumors can either be managed conservatively, with removal of the offending stimulus, or using transurethral resection. However, certain tumors that grow large in size, demonstrate a locally infiltrative growth pattern, or manifest with refractory local symptomatology may require surgical resection. The most common tumors exhibiting such properties are bladder leiomyomas and paragangliomas (Agarwal et al., 2002). Other benign processes for which partial cystectomy is indicated include bladder endometriosis, urachal anomalies, and colovesicular or vesicovaginal fistulas that have failed conservative management strategies.

Evaluation and Surgical Indications

Selection criteria when partial cystectomy is performed for benign indication are not as stringent as for cases of malignancy. Issues of tumor multiplicity, concomitant presence of premalignant lesions (e.g., CIS), and prior history of recurrence patterns are generally less relevant in these circumstances. The primary consideration is whether partial resection of the bladder wall would decrease bladder capacity to the point of compromising postoperative quality of life. As such, partial cystectomy should be avoided in patients with a small-volume bladder or who have severe dysfunctional voiding symptoms at baseline.

The presence of bladder malignancy must be ruled out as there are some important technical aspects to surgery that differ between benign and malignant disease processes (e.g., wide margins and lymph node dissection when performed for malignancy). In this regard, a workup that is similar to that for bladder malignancy is generally pursued in all individuals before surgery. This includes cross-sectional excretory-phase imaging, cytology, cystoscopy, and, in most cases, bladder biopsy to establish a histologic diagnosis. It is important to note tumor location as this may influence the feasibility of partial cystectomy, particularly for lesions located near the bladder base. If the lesion is situated near the ureteral orifice, simultaneous ureteral reimplantation may be necessary. Considerations specific to the type of pathology are described in the following section.

Leiomyoma

Leiomyomas of the bladder are rare smooth muscle tumors that have been reported primarily in women of childbearing age (Knoll et al., 1986). Histologically, they are similar in appearance to fibroids that occur most commonly in the uterus. The etiology is poorly understood given their rarity, however, hormonal imbalances or chronic detrusor irritation are speculated (Cornella et al., 1997). As these tumors may grow large in size, typical symptoms associated with their presence include urinary outlet or ureteral obstruction, irritative voiding symptoms, pelvic pain, and hematuria (Bazeed and Aboulenien, 1988; Belis et al., 1979). Morphologically, leiomyomas of the bladder can have a predominant endovesical, intramural, or extravesical pattern of growth (Fig. 132.31). As such, transvaginal ultrasonography and less often magnetic resonance imaging (MRI) can be used to characterize lesions (Illescas et al., 1986; Maya and Slywotzky, 1992). Whereas small-sized endovascular lesions may be amenable to transurethral resection, larger lesions or those with intramural composition may necessitate wide local resection to minimize the risk for tumor regrowth (Belis et al., 1979).

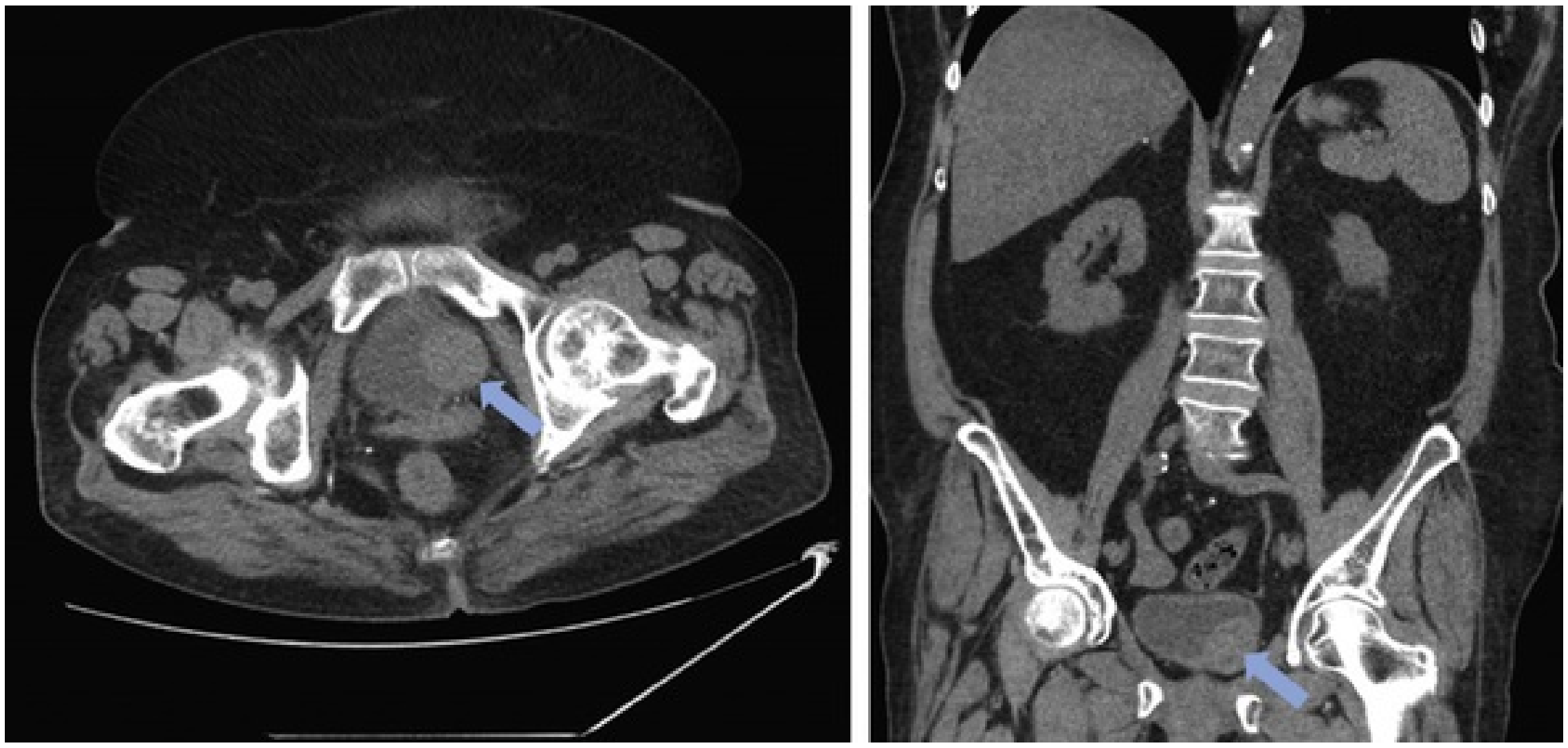

FIG. 132.31 Bladder leiomyoma. Computed tomography scan demonstrating a well-circumscribed extraluminal lesion *(arrow)* invested within the detrusor muscle. Resection of the lesion demonstrated a leiomyoma. (Courtesy of Lee Richstone, MD.)

Paraganglioma

Paragangliomas, which represent extra-adrenal tumors originating from chromaffin cells of the sympathetic nervous system, occur most commonly along the sympathetic chain, although benign tumors of the bladder have been described (Leestma and Price, 1971). The majority exhibit functional properties related to the release of catecholamines and thus may manifest with episodic bouts of hypertension, tachycardia, palpitations, diaphoresis, or tremors. Unique to bladder wall paragangliomas is the occurrence of hypotension and syncope related to micturition or sexual activity (Al-Zahrani, 2010).

Despite the functional properties of these tumors, bladder wall paragangliomas often present with nonspecific symptoms such as painless hematuria or may be recognized incidentally on cross-sectional imaging as a bladder wall thickening (Leestma and Price, 1971). In this context, bladder instrumentation or transurethral manipulation of these tumors without appropriate preoperative alpha-adrenergic blockage, particularly in asymptomatic patients, may result in a dangerous intraoperative catecholamine surge (Chen et al., 2009). As such, a preoperative workup involving measurement of plasma metanephrines and functional imaging of the bladder lesion is necessary if these tumors are suspected (Fig. 132.32).

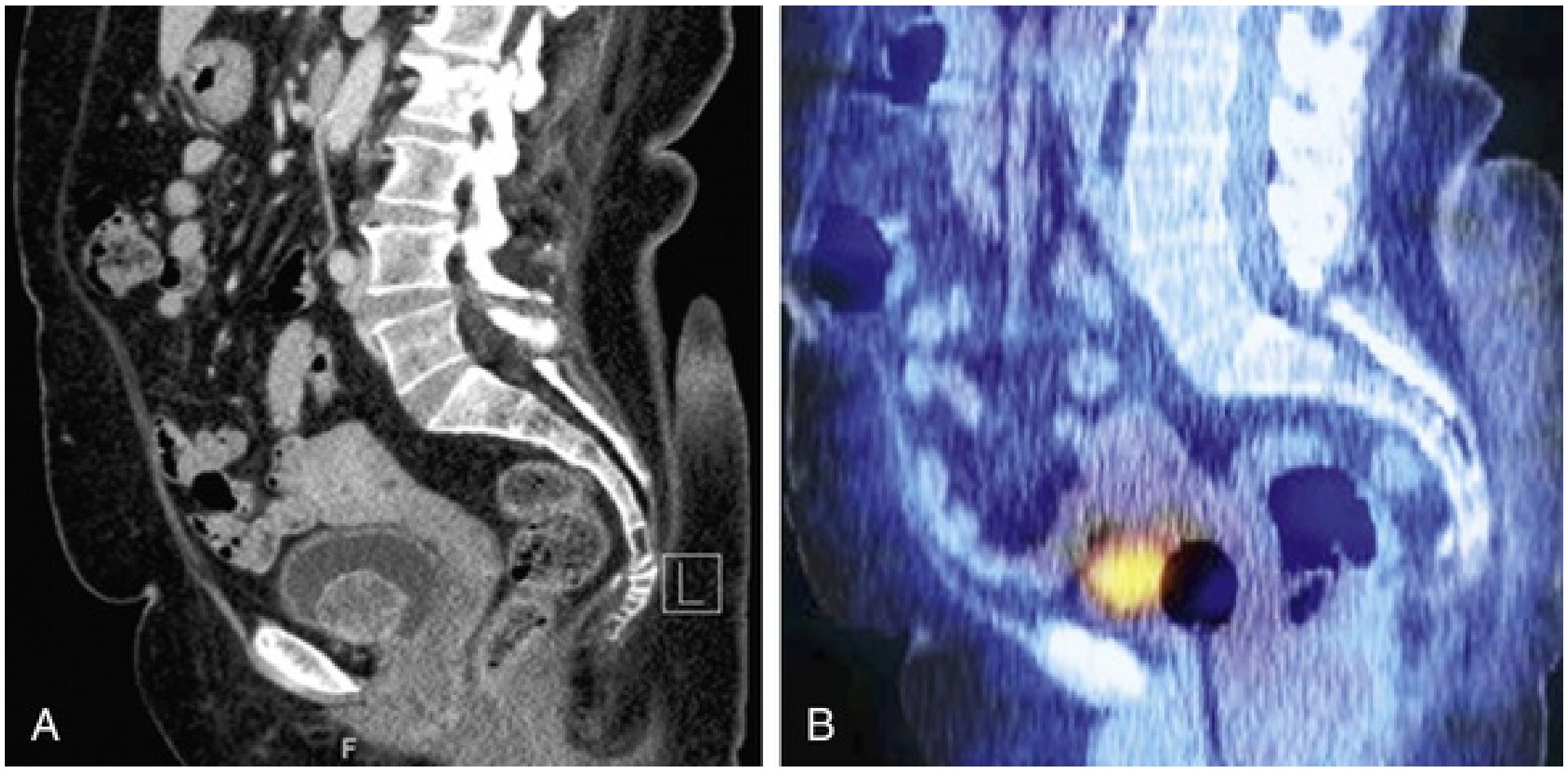

FIG. 132.32 Bladder paraganglioma. (A) A bladder mass seen at base of bladder on sagittal computed tomography. (B) Positive metaiodobenzylguanidine (MIBG) scan confirming functional bladder mass, consistent with paraganglioma. (Modified from El-Tholoth HS, Al Rasheedi S, Alharbi F, et al. Paraganglioma of urinary bladder managed by laparoscopic partial cystectomy in conjunction with flexible cystoscopy: a case report. *J Endourol Case Rep* 4(1):15–17, 2018.)

Cystoscopically, paragangliomas appear as yellow regions of raised mucosa as they tend to be situated within the detrusor muscle (Al-Zahrani, 2010). Partial cystectomy is preferred over transurethral resection, including for benign lesions, as there is a high tendency for local recurrence in cases of inadequate extirpation (Dahm and Gschwend, 2003).

Endometriosis

Endometriosis of the bladder can be primary in nature or occur secondary to iatrogenic dissemination during pelvic surgery (Vercellini et al., 2002). Classical symptoms include cyclic patterns of hematuria or irritative voiding symptoms that coincide with menses. As ectopic involvement of the bladder by endometrial tissue is generally extravesical in nature, cystoscopy is of limited utility in the evaluation of these patients, although it does enable assessment for mucosal involvement. Instead, transabdominal ultrasonography, often coupled with transvaginal ultrasonography can help gauge lesion size and degree of bladder involvement. MRI may also help delineate the level of disease (Fig. 132.33) (Beaty et al., 2006). Partial cystectomy is the primary form of treatment for these lesions, again given the extravesical pattern of distribution (Komar, 2004).

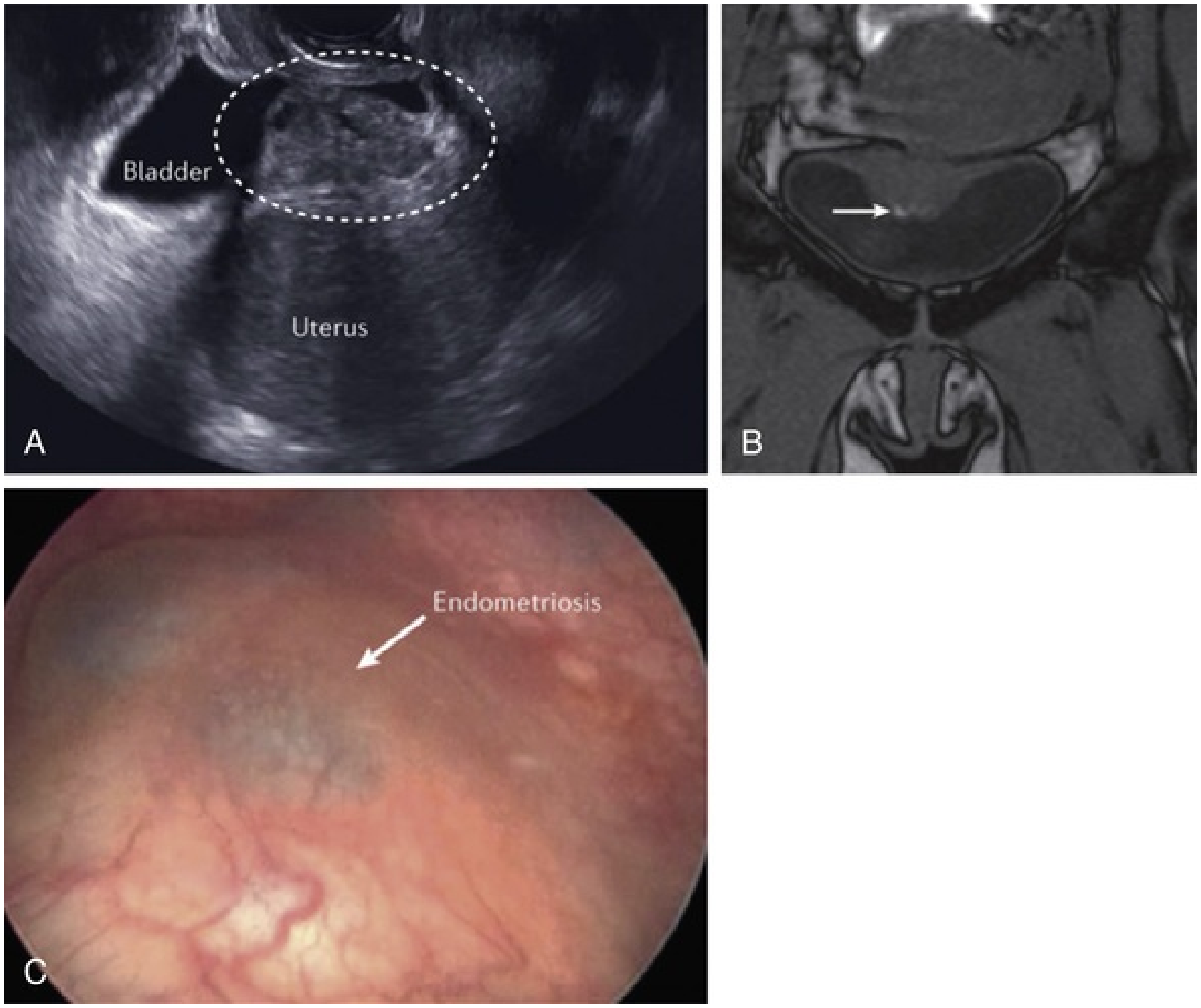

FIG. 132.33 Bladder endometriosis. (A) Ultrasound scan demonstrating deeply infiltrative mass protruding into bladder lumen, appearing contiguous with the uterus. (B) T1-weighted imaging demonstrating high signal intensity within the mass *(arrow),* consistent with bladder endometriosis. (C) Endometriosis situated in the detrusor fibers of the bladder wall, appearing as a submucosal bladder lesion with a bluish hue and neovascularization. (Modified from Nezhat C, Falik R, McKinney S, et al. Pathophysiology and management of urinary tract endometriosis. *Nat Rev Urol* 14[6]:359–372, 2017.)

Urachal Abnormalities

The urachus is the embryologic remnant of the allantois and provides ligamentous support from the dome of the bladder to the umbilicus. Benign pathology related to the urachus are most frequently encountered in the pediatric population, although delayed onset of symptoms may cause clinical manifestations in adults (Berman et al., 1988). The primary benign urachal conditions seen in adults that may warrant partial cystectomy include urachal cysts, vesico-urachal diverticula, a patent urachus, and urachal sinus (Berman et al., 1988; Sheldon et al., 1984). Communication with the bladder, as is seen for vesico-urachal diverticula and parent urachus, may result in hematuria, mucinuria, or urine leakage from the umbilicus. Nonspecific symptoms resulting from either of these conditions include fever, abdominal pain, or peri or infraumbilical fluctuant mass secondary to infection of stagnant urine or fluid (Blichert-Toft and Nielsen, 1971). Less often, a calculus may form. The gravest of concerns relates to malignant transformation of remnant urachal tissue (Herr, 1994).

As the majority of urachal anomalies are asymptomatic, they are often incidentally detected on cross-sectional imaging. When symptomatic, they can be evaluated using ultrasonography or CT (Fig. 132.34A). A VCUG or sinogram may be performed to evaluate communication with the bladder, particularly in cases of urinary symptoms or skin drainage. The bladder dome and anterior bladder wall should be carefully inspected to ensure that no suspicion lesions are present (see Fig. 132.34B).

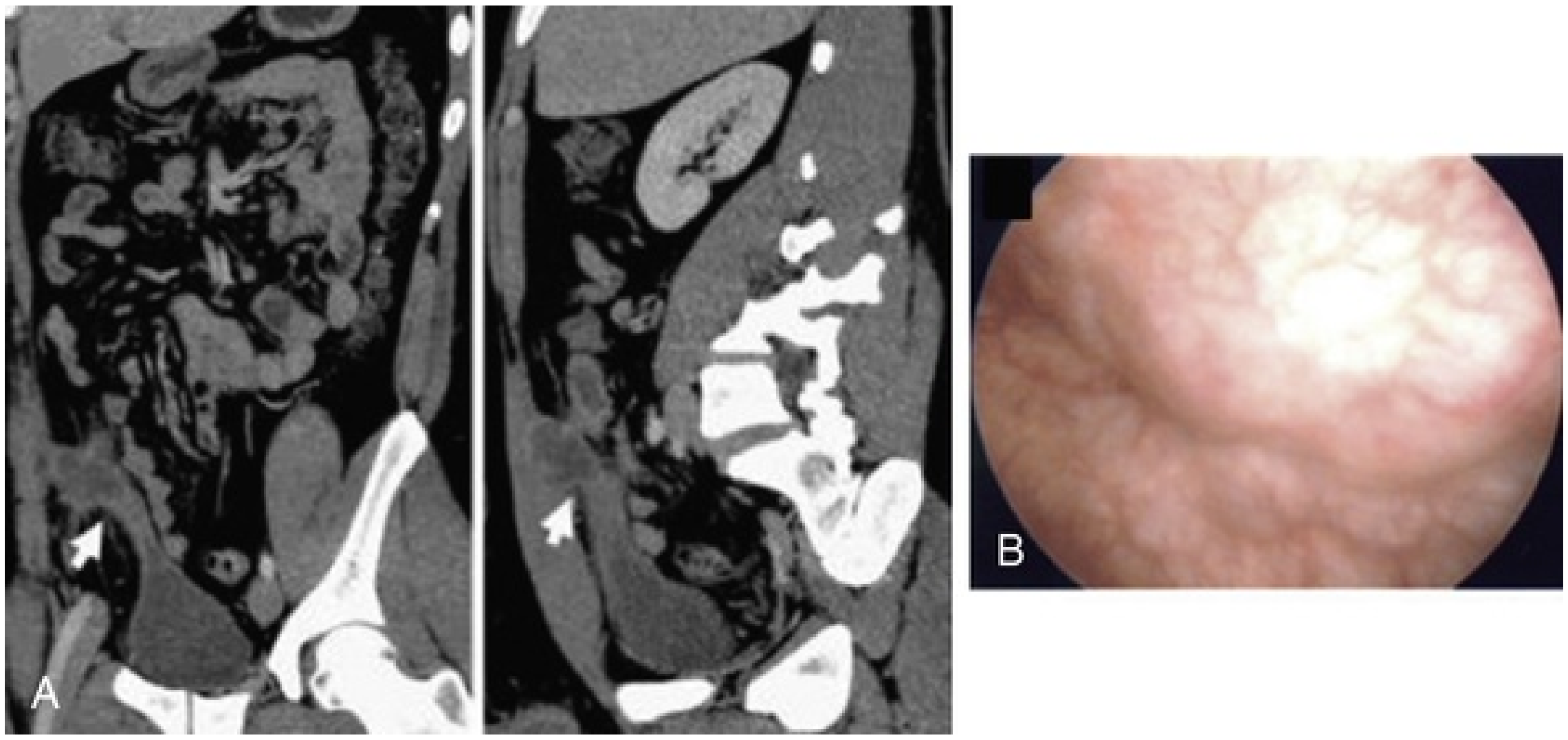

FIG. 132.34 (A) Contrast-enhanced computed tomography scan demonstrating heterogenous enhancing lesion posterior to the abdominal wall with tubular connection to the bladder dome. The lesion was found to be an infected urachal remnant on resection. (B) Submucosal bladder dome lesion protruding into the lumen is found to be a urachal cyst. (A, Modified from Liu WC, Hsiang CW, Hsu HH, et al. An infected urachal remnant in a young man. *Intern Med* 53[5]:523, 2014; B, Modified from Madeb R, Knopf JK, Nicholson C, et al. The use of robotically assisted surgery for treating urachal anomalies. *BJU Int* 98[4]:838–842, 2006.)

Treatment is indicated for symptomatic or infected urachal anomalies. In the setting of inflammation or infection, patients should be treated with oral or intravenous antibiotics. Swab culture of the umbilicus and urine cultures should be sent before initiating antibiotics. In the setting of a fluctuant umbilicus, local incision and drainage can be performed. If the infection resolves with complete relief of symptoms, no further intervention is required. In the setting of recurrent infected urachal anomalies, surgical excision is indicated (Navarrete et al., 2005; Stone et al., 1995; Yohannes et al., 2003b). The entire urachus should be excised including a small area on the dome of the bladder. The practice of incorporating a bladder cuff into the surgical specimen is thought to ensure that no residual tissue is left in the vicinity of the bladder apex as this may risk recurrence of symptoms or malignant transformation.

Surgical Technique

Open partial cystectomy remains most widely used for treatment of select bladder tumors given the accrued experience with this approach. However, use of laparoscopic and robotic techniques have gained significant momentum in the management of not only bladder and urachal malignancies, but also benign bladder processes as they represent a particularly attractive low-morbidity alternative to open surgery for lesions that require more extensive resection than can be safely achieved by endoscopic means (Cadeddu et al., 2000; Madeb et al., 2006; Mettler et al., 2008).

Open

The approach to partial cystectomy is contingent on the location of the lesion to be resected. Lesions on the dome or anterior bladder wall are amenable to an extraperitoneal approach, whereas tumors situated along the posterior bladder wall are better managed with an intraperitoneal approach.

Extraperitoneal Approach to Partial Cystectomy

The initial steps to extraperitoneal open partial cystectomy are similar to open ureteral reimplantation (described earlier), including patient positioning, preparation, initial incision, and extraperitoneal bladder mobilization. A pelvic lymph node dissection is usually not necessary for benign indication and thus can be deferred at this time. With the bladder having been adequately mobilized bilaterally, intraoperative cystoscopy is performed to confirm the location of a lesion, particularly if found to be situated intravesically on preoperative evaluation. For conditions that are primarily extravesical or submucosal within the detrusor, intraoperative ultrasonography can be used to help demarcate the location and extent of the lesion.

Stay sutures are placed on the bladder wall distant from the location of the lesion, and a longitudinal cystotomy is made to gain access to the bladder. The bladder may be partially distended as the cystotomy is made, although it is critical that the intravesical fluid be aspirated so as to avoid spillage into the field because even some benign processes have a tendency for local recurrence. The cystotomy incision is lengthened enough to provide good visualization of the site of bladder pathology. Before resection, careful inspection of the bladder mucosa is necessary to rule out presence of any abnormalities concerning malignancy.

Once the borders of the lesion are defined, a circumferential transmural incision is made around the lesion with electrocautery. Despite this being a benign process, a margin of normal bladder wall is necessary as some disease processes have a high tendency to recur in the setting of inadequate resection. Additionally, the perivesical fat overlying the lesion should be preserved. If the bladder capacity permits, we recommend a 2-cm margin of normal tissue. Biopsies of the normal appearing bladder wall should be taken to ensure adequate resection.

In cases in which the lesion encroaches on or involves the ureteral orifice, the ureter should be mobilized and reimplanted in a refluxing or nonrefluxing manner as described earlier.

The bladder wall defect is subsequently closed in a two-layer running fashion with 2-0 polyglactin suture, ensuring proper mucosal apposition with the first layer of closure. The cystostomy is subsequently closed in a similar fashion.

A perivesical drain is placed in the retropubic space, ideally crossing over the bladder wall defect and cystotomy site. This is brought out through a separate stab incision lateral to the rectus muscle and secured to the skin with nonabsorbable suture. A 22-Fr Foley catheter is left in place within the bladder. The bladder should be irrigated to assess adequacy of closure. The abdominal fascia and incision are closed in the usual fashion.

Transperitoneal Approach to Partial Cystectomy

After incising the transversalis fascia, the peritoneum is entered sharply in the midline and opened the length of the incision. A self-retaining retractor is placed and used to pack the abdominal content cephalad to provide access to the peritoneal fold overlying the dome of the bladder. The space of Retzius and lateral pelvic gutters are developed with blunt dissection.

Mobilization of the ureter is often necessary as partial cystectomy of the posterior bladder wall may necessitate ureteral reimplantation. The peritoneum overlying the bifurcation of the iliac vessels is incised, and the ureter is identified. The ureter is dissected caudally toward its entry into the bladder. Care is taken to preserve the periureteral tissue, which harbors the periureteral blood supply.

The posterior bladder is mobilized enough to support adequate resection of the tumor. In women, this may involve incision of the peritoneal fold overlying the vesicoureterine pouch and development of the pubocervical fascia with sharp dissection. In men, the peritoneum of the rectovesical pouch may be incised to develop Denonvillier's fascia, particularly for very posteriorly situated lesions near the bladder base.

Resection of the lesion is performed in a manner similar to the extraperitoneal approach described earlier.

Urachal Surgery

In cases in which partial cystectomy is being performed as part of resection of the urachal remnant, an initial periumbilical incision is made that is carried down the midline. After incision of the tranversalis fascia, the peritoneum is identified. A circumferential incision is made around the umbilicus at the level of the skin down to the peritoneum. The peritoneal cavity is entered sharply above the umbilicus. With anterior traction placed on the umbilical segment, the urachus is excised with generous peritoneal wings down to the level of the bladder dome. The bladder is distended with sterile water to facilitate a transmural incision in the apical bladder dome circumferentially around insertion of the urachus into the bladder. A wide margin of resection around the site of urachal insertion is not necessary for benign indication. The bladder wall defect is subsequently closed in a two-layer manner with 2-0 polyglactin suture. A large-bore Foley catheter and pelvic drain are placed, as described earlier. The bladder should be irrigated to assess adequacy of closure.

Of note, when the urachal remnant is being excised for infection or inflammation, if proper incision and drainage of any subcutaneous fluid has been performed, it is unnecessary to remove the umbilicus in the absence of malignancy.

Laparoscopic and Robotic Techniques

Transperitoneal Approach to Partial Cystectomy

Positioning and port placement in patients undergoing laparoscopic or robotic partial cystectomy is similar to that for robotic diverticulectomy (see Fig. 132.10).

The bladder is first mobilized off the anterior abdominal wall, and the space of Retzius is accessed by incising lateral to the obliterated umbilical ligaments and transecting the urachus. Once the bladder is mobilized, the bedside assistant performs flexible cystoscopy to transilluminate the bladder and allow the surgeon to delineate the site of bladder pathology from an intraperitoneal perspective (Fig. 132.35). The robotic/laparoscopic intraperitoneal light is dimmed to aid in visualization. For tumors situated along the posterior bladder wall, the bladder does not need to be mobilized off the anterior abdominal wall; instead, intraoperative cystoscopy can help identify the site of pathology with the bladder suspended, and the peritoneum directly overlying this region of disease is dissected. Lesions situated intramurally or on the extravesical surface of the bladder may be characterized with a laparoscopic ultrasound instrument.

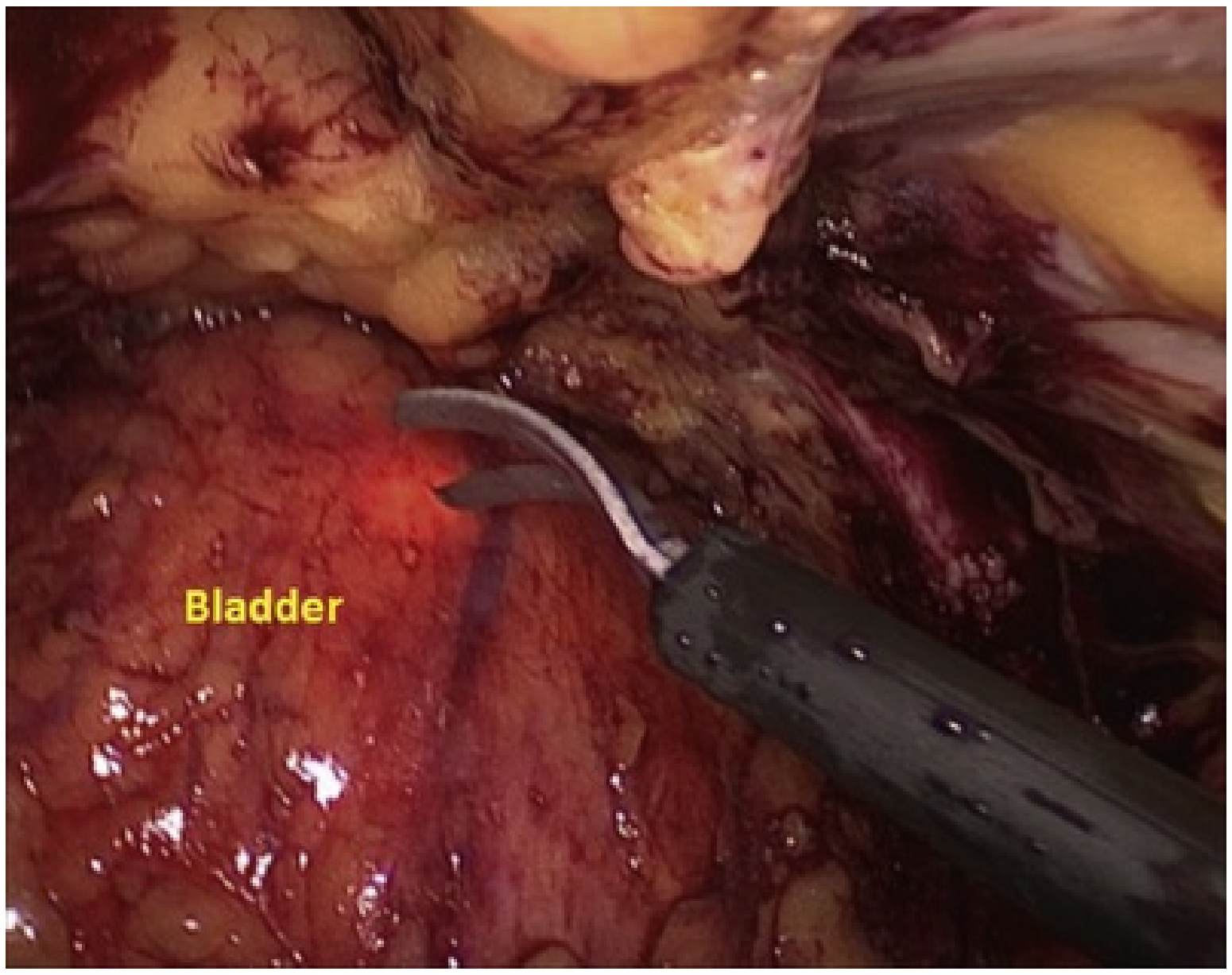

FIG. 132.35 Intraoperative cystoscopy to delineate bladder lesion from transperitoneal view and help guide location for cystotomy. (Modified from El-Tholoth HS, Al Rasheedi S, Alharbi F, et al. Paraganglioma of urinary bladder managed by laparoscopic partial cystectomy in conjunction with flexible cystoscopy: A case report. *J Endourol Case Rep* [1]:15–17, 2018.)

Electrocautery can be used to outline the area of resection on the outside of the bladder to ensure that adequate margins of resection are achieved. When electrocautery is complete, the cystoscope is removed, and a Foley catheter is placed. The Foley catheter is plugged to permit bladder distension.

With the bladder distended, a longitudinal cystotomy is made superior/anterior to the identified lesions, and the bladder is entered. Care should be taken to aspirate fluid within the bladder as it is entered to avoid spillage of intravesical contents. The Foley balloon is taken down, and the bladder mucosa is inspected. The site of the bladder lesion is noted as is the proximity to the ureteral orifices. A ureteral catheter may be placed retrograde at this time to help protect the ureter. Alternatively, if there is concern over ureteral disruption, reimplantation may be pursued after resection of the lesion.

Using electrocautery, full-thickness resection of the lesion is carried out circumferentially via an intravesical perspective (Fig. 132.36). The perivesical fat overlying the lesion should be preserved. Attempts should be made at attaining an adequate margin of normal-appearing bladder mucosa given the propensity for some lesions to locally recur in cases of inadequate resection. Once disconnected from the bladder, the specimen is placed into a 10- or 15-cm EndoCatch bag. Frozen sections of the resection margins may be performed to ensure adequacy of excision. A large-bore Foley catheter is placed, and the bladder wall defect and the cystotomy are closed in the standard two-layer fashion using 2-0 polyglactin suture. The bladder is filled with 200 mL of sterile water to test the adequacy of closure; defects in the closure can be reinforced with full-thickness figure-of-eight 2-0 polyglactin suture.

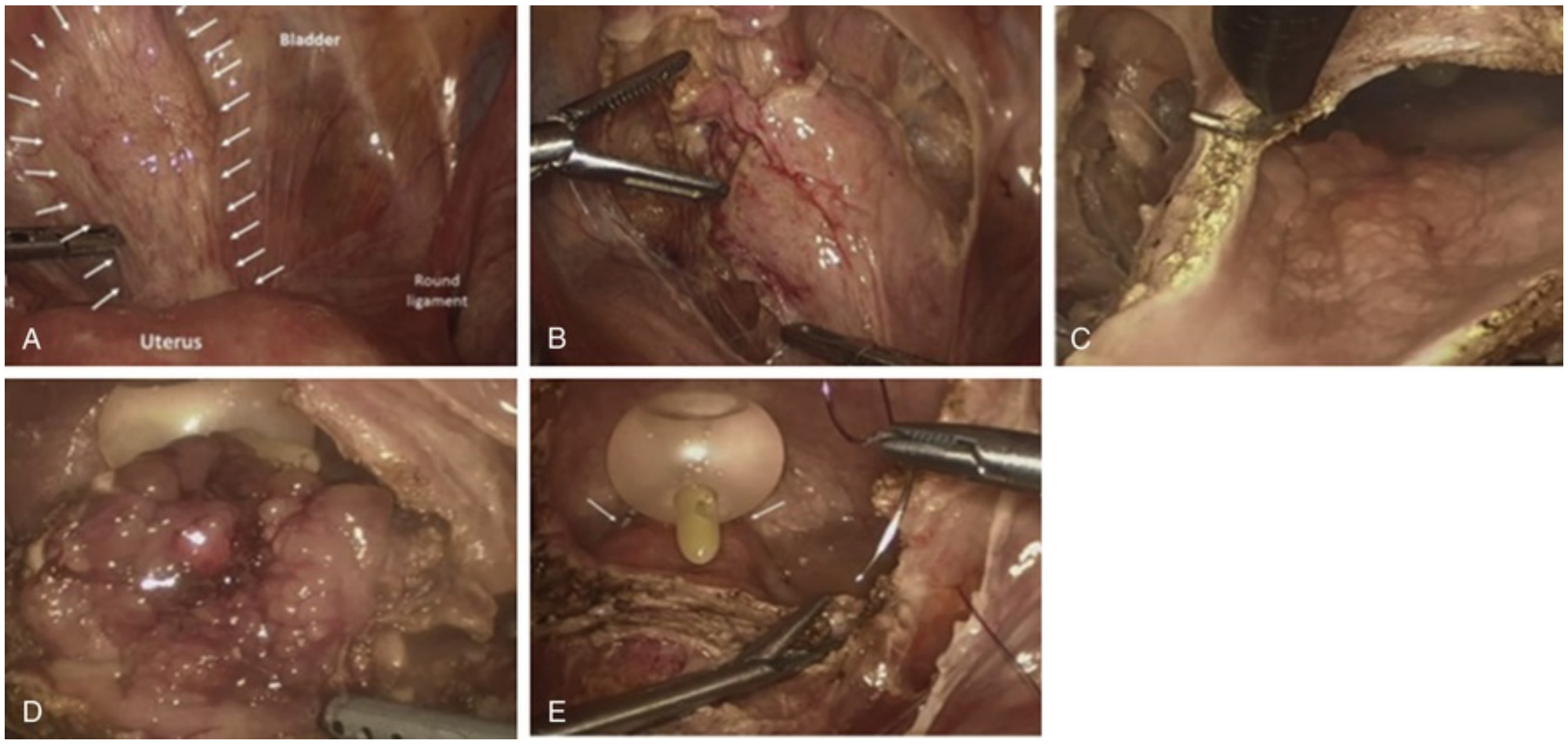

FIG. 132.36 Laparoscopic partial cystectomy. (A) The location of the bladder pathology is identified along the posterior-lateral dome of the bladder. (B) Given the posterior location of the lesion, the bladder was left suspended to the anterior abdominal wall. The peritoneum around the area of the lesion is incised. (C) A cystotomy is made to allow a normal margin of tissue around the lesion, and circumferential incision is commenced. (D) Posterior attachments of lesion to the bladder wall are excised. (E) The bladder wall defect is closed in two layers. The ureteral catheters can be visualized *(white arrow).* (Modified from Koukoura O, Alevra Z, Pavlakis K, Pistofidis G. Laparoscopic excision of an inflammatory myofibroblastic tumour of the bladder disguised as deep infiltrating endometriosis. *BMJ Case Rep* 2017.)

A pelvic drain is placed in the vicinity of the bladder wall closure and brought out through the lateral port. It is secured to the skin with nonabsorbable suture and placed to self-suction. The pneumoperitoneum is released. The specimen is extracted through an extension of the midline camera-port incision. The fascia of the extraction site and the fascia of the 12-mm assistant port are closed with figure-of-eight 0-polyglactin suture. Skin incisions are closed.

Urachal Surgery

When performing partial cystectomy as part of surgery to remove the urachal remnant, the 12-mm camera port is inserted 5 cm above and 2 cm to the left of the umbilicus. In contrast with conventional open surgery, the urachus is dissected out last when performing partial cystectomy for urachal disease. The laparoscopic/robotic surgeon should leave the bladder attached to the anterior abdominal wall during the initial dissection to maximize visualization and exposure. The bladder can be filled with approximately 200 to 300 mL of sterile water to better define the anatomy.

Using electrocautery, a small rim of bladder segment around insertion of the urachus is scored, and dissection proceeds through all layers of the bladder with the exception of the bladder mucosa. Before dividing the bladder mucosa, the entire urachus with peritoneal wings is dissected all the way to the level of the umbilicus. The urachus is divided at this level, and the umbilicus can be removed at the end of the case if necessary, although it is not required for benign indication. When the entire urachus is dissected free, the bladder is opened, and the bladder wall is excised circumferentially around the site of urachal insertion (Fig. 132.37). The specimen is placed in an EndoCatch bag. Frozen section of the bladder wall resection margin is not necessary for benign indication.

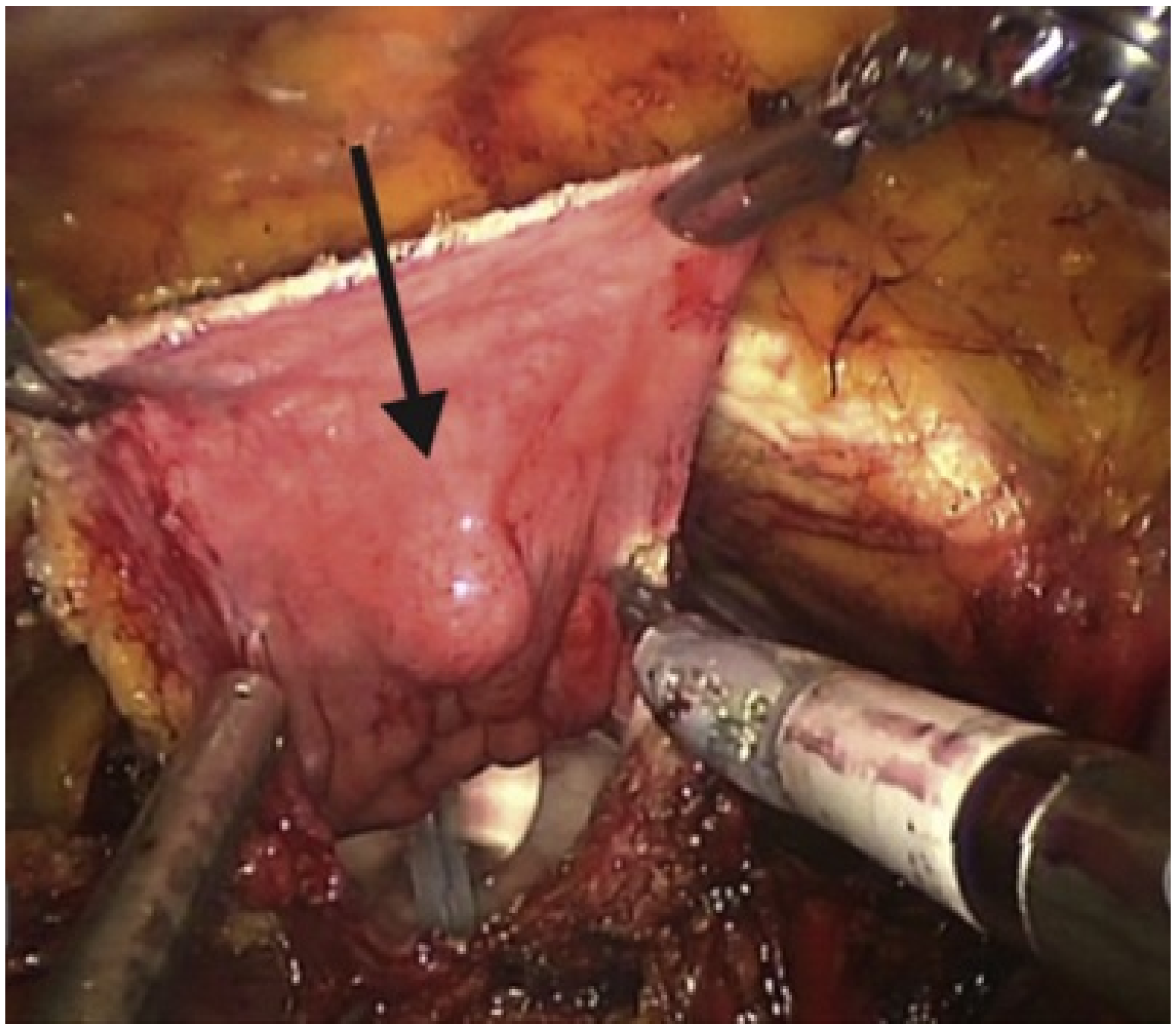

FIG. 132.37 Laparoscopic resection of urachal anomaly *(arrow).* (Modified From Kim DK, Lee JW, Park SY, et al. Initial experience with robotic-assisted laparoscopic partial cystectomy in urachal disease. *Korean J Urol* 51[5]:318–322, 2010.)

The bladder is closed in two layers using 2-0 polyglactin suture. A large-bore Foley catheter is placed, and the closure is tested with instillation of 200 mL of sterile water. A pelvic drain is placed and brought out to the skin through the lateral port. The specimen is extracted through an extension of the midline camera-port incision. In some cases, the specimen bag may be removed directly through the lateral 12-mm assistant port without the need for extending the midline incision. The fascia, including that of the 12-mm assistant port, is closed with figure-of-eight 0-polyglactin suture. Skin incisions are closed.

Postoperative Care and Complications

The Foley catheter is kept to drainage for approximately 1 week postsurgery with a cystogram performed before removal. The pelvic drain is removed typically after 48 hours once the output has decreased; a drain creatinine measurement is optional and should be interpreted in the context of the drain output.

Complications after partial cystectomy are similar for both open and minimally invasive techniques and essentially mimic those seen for bladder diverticulectomy (see earlier discussion). Urinary extravasation from either the site of resection or cystotomy is the most common complication, followed by ureteral injury. A full description of the presentation and management of these complications is provided earlier in this chapter in the Bladder Diverticulectomy section.

Patient selection and counseling regarding complications is important as resection of bladder wall segment can decrease bladder capacity and cause irritative voiding symptoms that may require future intervention. Other complications include urinary tract infection, bladder spasms, urinary fistula formation, wound infection, and bowel injury.

Outcomes

Experience with treatment of benign bladder tumors and urachal lesions using partial cystectomy are generally limited to small case series given the rarity of these conditions in adults. Nevertheless, partial cystectomy, performed using conventional open techniques or a minimally invasive platform, has demonstrated considerable success in management of the pathologies mentioned earlier, offering high rates of cure while enabling preservation of bladder function (Albert, 1981; Cadeddu et al., 2000; Madeb et al., 2006; Mettler et al., 2008).

Bladder Stones and Foreign-Body Removal

Description

Bladder calculi, although encountered far less frequently than kidney and ureteral stones, represent a distinct pathologic entity with substantial potential to disrupt quality of life. The primary biologic underpinning of bladder stone formation is thought to be urinary stasis; as such, bladder calculi are encountered most often in the setting of either bladder outlet obstruction syndromes, particularly benign prostate hyperplasia in men, or neurogenic bladder. Less commonly, bladder calculi can form in the setting of bladder substitution or augmentation with bowel, as a result of a multitude of factors including incomplete emptying and associated stasis, high bacterial burden within the urinary system, metabolic alterations in urinary composition, and possibly increased mucus production. The presence of foreign body within the bladder, usually introduced via an iatrogenic route, may also serve as a nidus for stone formation.

Evaluation and Surgical Indication

As the majority of bladder stones are asymptomatic, incidental detection is often the case during diagnostic workup for associated conditions. Alternatively, symptoms such as hematuria, irritative voiding patterns, recurrent urinary tract infections, incontinence, or urinary retention may prompt cystoscopy or imaging of the bladder, at which time bladder stones may be discovered as offending agents.

Before surgical intervention for bladder stones, a proper diagnostic evaluation should be undertaken to not only characterize stone burden, as this will inform the most appropriate management strategy, but also understand concomitant conditions ultimately responsible for stone formation. This will enable the implementation of strategies to prevent reoccurrence of bladder stones and aid in operative planning, particularly if a concomitant procedure to address the underlying cause is necessary.

Noncontrast CT provides the most reliable assessment of stone volume and stone size, of which accurate measurement is critical given their role in guiding treatment selection. Additionally, cross-sectional imaging with CT may help understand anatomy as it relates to underlying disease states associated with bladder stone formation, such as prostate volume in the case of BPH, or presence of hydronephrosis in the setting of neurogenic bladder. Cystoscopy for direct visualization of bladder stones before procedural intervention is not necessary unless indicated for other reasons, such as gross hematuria, concern for bladder malignancy, or anatomic evaluation of prostatic lobar hyperplasia and prostatic urethral length. Before treatment of bladder stones, urodynamics may be utilized if neurogenic bladder is suspected or as part of treatment planning in individuals with BPH.

Surgical Technique

Open cystolithotomy has historically served as the gold standard procedure for management of bladder calculi. Transurethral and more recently percutaneous endoscopic techniques, however, have largely supplanted this approach in contemporary practice primarily because of perceived advantages in cosmesis and duration of postprocedural catheterization times. Nevertheless, relatively large-sized bladder calculi or high-volume stone burden may be best managed by cystolithotomy to maximize the chance for stone-free outcome and minimize operative duration, particularly as prolonged transurethral instrumentation can pose a risk for urethral stricture.

The nature of simultaneous procedures planned for associated disease states should also be factored in when deciding treatment approach for bladder stones. For example, a very enlarged prostate gland that is not amenable to transurethral resection or vaporation may be better managed with a simple prostatectomy, ideally through a transvesical route; in this case, cystolithotomy may be preferred to manage bladder stones in tandem. A large bladder diverticulum necessitating diverticulectomy to diminish risk for urinary stasis may also encourage the use cystolithotomy. In patients with neurogenic bladder who have evidence of poor compliance that is refractory to conservative measures such as anticholinergic therapy or intravesical botulinum toxin injection, enterocystoplasty may be considered, at which time cystolithotomy may be performed.

Additional considerations involve history of prior bladder or abdominal surgery as alterations in the local pelvic anatomy may preclude percutaneous approaches for larger stones over concern of bowel injury during initial puncture and establishment of the access tract. This is particularly relevant among individuals with bladder stones in the setting of a urinary diversion or augmented bladder.

The laparoscopic and robotic techniques that have emerged for cystolithotomy offer a minimally invasive alternative to the traditional open approach while not compromising on the ability to remove larger stone burden. Improved experience, particularly with minimally invasive approaches to transvesical simple prostatectomy and bladder diverticulectomy, makes this an attractive option for addressing bladder stones when multiple procedures are necessary in a single-stage setting.

Percutaneous cystolithotripsy offers another minimally invasive option for the management of large bladder calculi. Access into the bladder via a single small suprapubic incision enables enhanced cosmesis relative to open cystolithotomy and offers lower morbidity given the creation of a smaller cystotomy when compared with open and laparoscopic procedures. Shorter catheterization time and hospital stay have also been reported for the percutaneous technique (Demirel et al., 2006). Furthermore, the larger diameter of the nephroscope and its wider working channel improves visualization and allows for use of a versatile array of instruments that permit more efficient stone fragmentation over shorter operative durations when compared with conventional transurethral cystoscopic procedures (Aron et al., 2003). In this regard, the percutaneous approach to endoscopic bladder stone surgery virtually eliminates the risk for urethral stricture disease, which has been reported after prolonged urethral instrumentation time during transurethral cystolitholapaxy.

In addition to bladder stones, foreign bodies within the bladder can be removed using open techniques as well laparoscopically, via a transperitoneal or transvesical LESS approach, or robotically. Procedures for removal of foreign bodies have been described for objects including surgical materials and mesh (Kim et al., 2012; Macedo et al., 2013; Maher and Feiner, 2011; Roslan et al., 2013; Yoshizawa et al., 2011), migrated intrauterine devices, broken sewing needles (Lee et al., 2010), and electrical wires (Ko et al., 2010).

Open

The patient is placed in a supine position with the anterior superior iliac spine positioned over the break of the table. The table is placed into slight flexion to facilitate entry into the space of Retzius (see Fig. 132.5A). The genitalia and intraumbilical aspect of the abdomen is prepped and draped in the standard sterile fashion. An 18-Fr Foley catheter is placed into the bladder on the sterile field. The bladder is distended with approximately 200 mL of sterile water, and the catheter is plugged.

Using either a midline infraumbilical incision (see Fig. 132.5B) or transverse Pfannenstiel incision, the subcutaneous tissue is divided with electrocautery down to the level of the rectus fascia. The type of incision used to access the extravesical space depends in part on whether additional procedures will be performed concomitantly, such as bladder diverticulectomy or simple prostatectomy.

The rectus fascia is divided the length of the incision exposing the underlying rectus abdominus muscle. The bellies of the rectus abdominus muscle is split longitudinally at the midline, and the space of Retzius is developed with blunt dissection. Distension of the bladder displaces the peritoneal reflection cephalad and permits easier entry into the space of Retzius. Extensive mobilization of the bladder from lateral perivesical attachments is not necessary.

With the bladder distended, electrocautery is used to make a vertical cystotomy across the midline bladder dome toward the bladder neck (Fig. 132.38A). Fluid within the bladder is aspirated as the cystotomy is lengthened. A 2-0 polyglactin stay suture is placed transmurally at the apices of the cystotomy to prevent tearing of the bladder wall as the bladder is accessed. Deeper blades can be placed on the self-retaining retractor to gently retract the bladder walls and facilitate exposure; alternatively, this can be done with a handheld deep blade retractor.

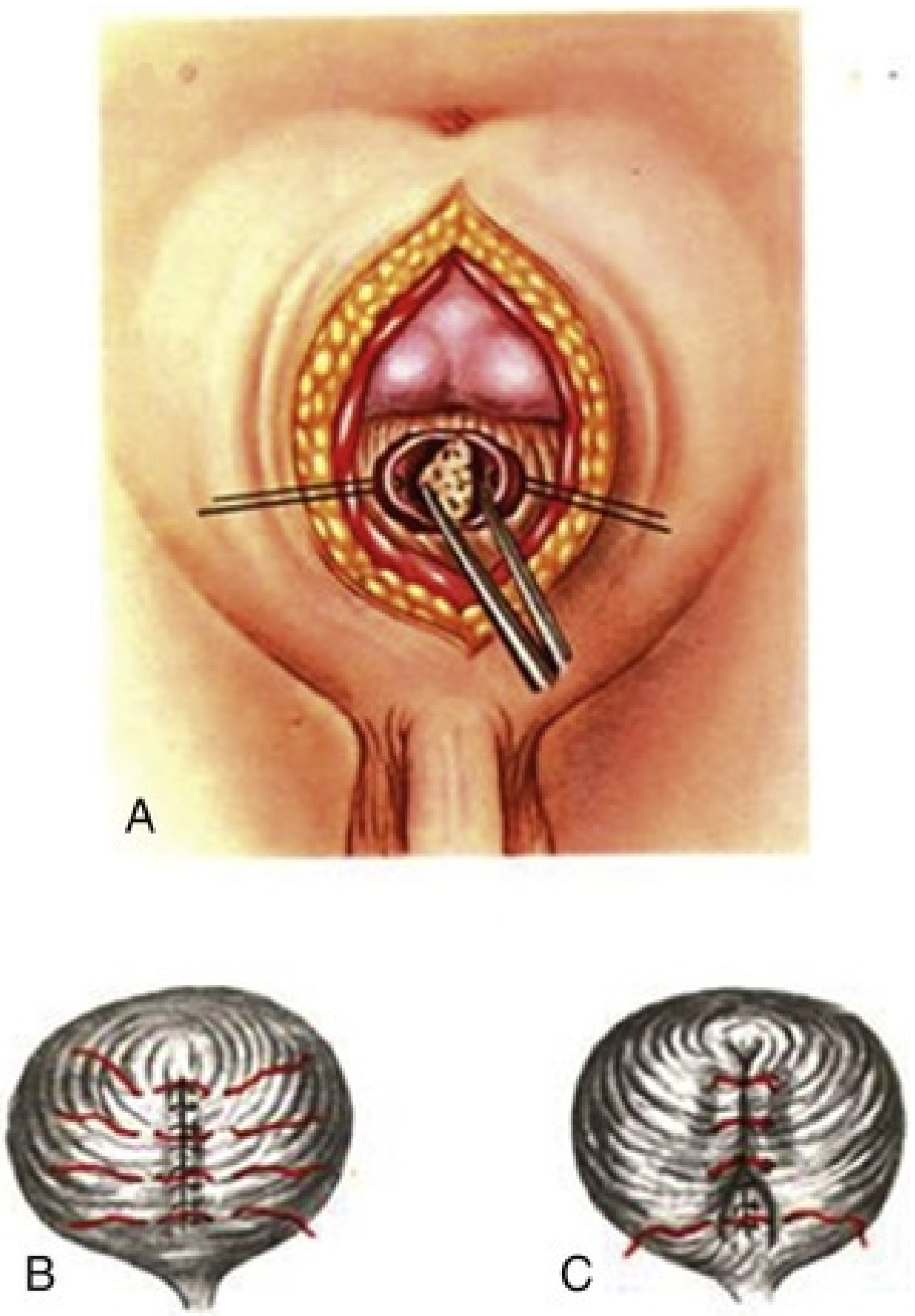

FIG. 132.38 Open cystolithotomy. (A) A vertical cystotomy is made on the bladder dome allowing access to the bladder. The calculus is visualized and removed. (B) A two-layer closure is done, beginning with the mucosal layer. (C) Imbricating sutures are used to perform the second layer of closure and bury the mucosal closure sutures.

Bladder stones (or other foreign bodies) are removed under direct visualization. The bladder should be inspected to characterize any suspicious mucosal lesions and the presence of intravesical prostatic lobe, which may be causing outlet obstruction. Any additional procedures to address outlet obstruction (e.g., suprapubic prostatectomy) or urinary stasis (e.g., diverticulectomy) can be performed at this time.

A large-bore catheter is placed to facilitate postoperative drainage. The bladder is closed in a two-layer running fashion using 2-0 polyglactin suture (see Fig. 132.38B,C). A suprapubic catheter may be placed before closure, although this is not necessary. After bladder wall closure, a pelvic drain is situated anterior to the cystostomy in the retropubic space and secured to the skin placed to self-suction. The fascia is closed with 0-loop polydioxanone suture after which the skin is closed.

Laparoscopic and Robotic

A transperitoneal approach is the most straightforward technique to laparoscopic and robotic cystolithotomy or foreign-body excision. Patient positioning and port placement are similar to that described in Fig. 132.10 (Macedo et al., 2013; Maher and Feiner, 2011). A fourth robotic arm is not necessary and is up to the discretion of the surgeon.

The bladder is mobilized off the anterior wall as described earlier. An anterior vertical or transverse cystotomy is made with electrocautery, and the bladder stone or foreign body is visualized. Ureteral catheterization is performed if needed, and the bladder stone or foreign body is removed or excised. The bladder is closed in a two-layer fashion with 2-0 polyglactin suture (Fig. 132.39). A large-core Foley catheter is placed, and the closure is tested with instillation of fluid. A pelvic drain is placed over the cystotomy and placed to self-suction.

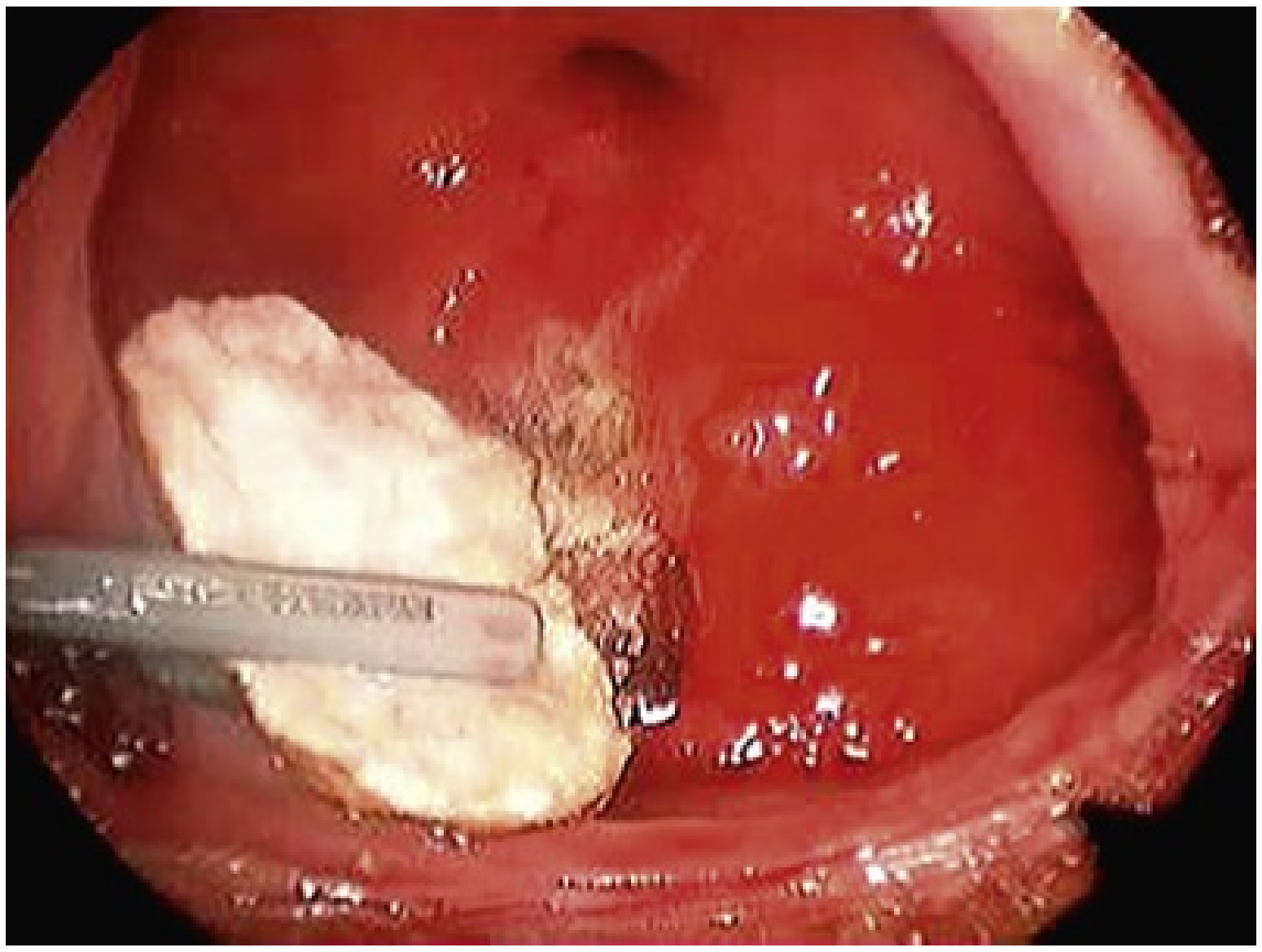

FIG. 132.39 Transperitoneal laparoscopic mesh excision. After establishment of pneumoperitoneum, transabdominal trocars are placed via traditional techniques. The bladder is opened, and mesh, stones, or foreign bodies are removed. The bladder is closed in two layers with absorbable sutures. An intravesical mesh is shown with associated large bladder calculi.

The abdominal cavity can be avoided by using a transvesical approach, which can be performed with multiple trocars (Fig. 132.40) (Kim et al., 2012; Yoshizawa et al., 2011). After cystoscopy and saline instillation into the bladder, a 5-mm trocar is placed into the bladder under direct vision, the bladder is drained, and pneumovesicum is established at 8 to 12 mm Hg. Two additional trocars are placed, and the bladder stone is removed or the foreign body is excised.

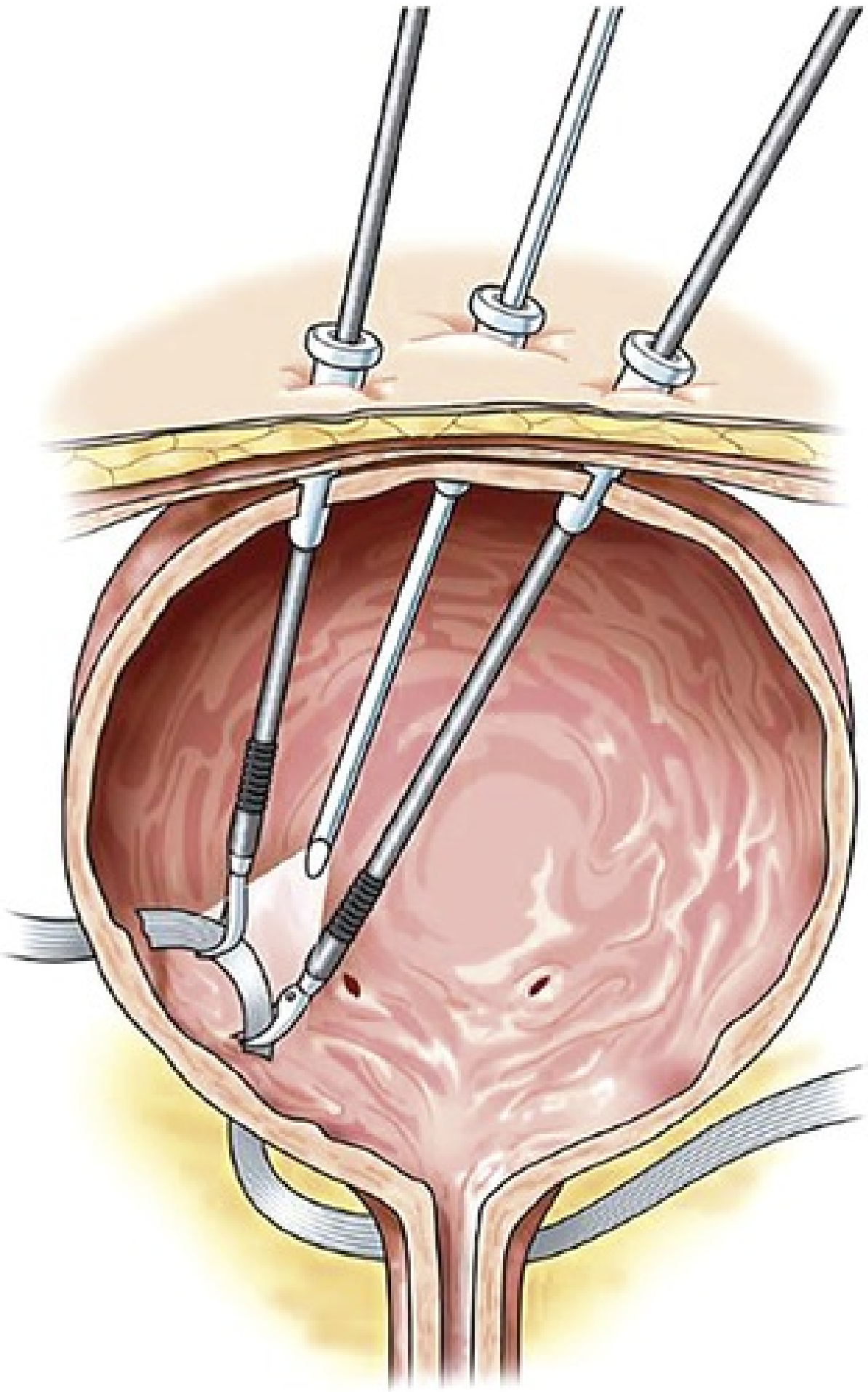

FIG. 132.40 Transvesical laparoscopic mesh excision. After cystoscopy, transvesical trocars are placed directly into the bladder. Pneumovesicum is established and maintained. Mesh or other foreign bodies are excised, and the bladder is closed with absorbable suture. (Modified from Yoshizawa T, Yamaguchi K, Obinata D, et al. Laparosocopic transvesical removal of erosive mesh after transobturator tape procedure. *Int J Urol* 18[12]:861, 2011.)

Transvesical excision of foreign bodies and/or mesh also can be performed via a transvesical single-site method (Fig. 132.41) (Ingber et al., 2009; Roslan et al., 2013). After cystoscopy and saline instillation, a single-site device is deployed, and the foreign body is identified and excised followed by bladder closure. To aid in retraction, a grasper can be placed transurethrally (Roslan et al., 2013).

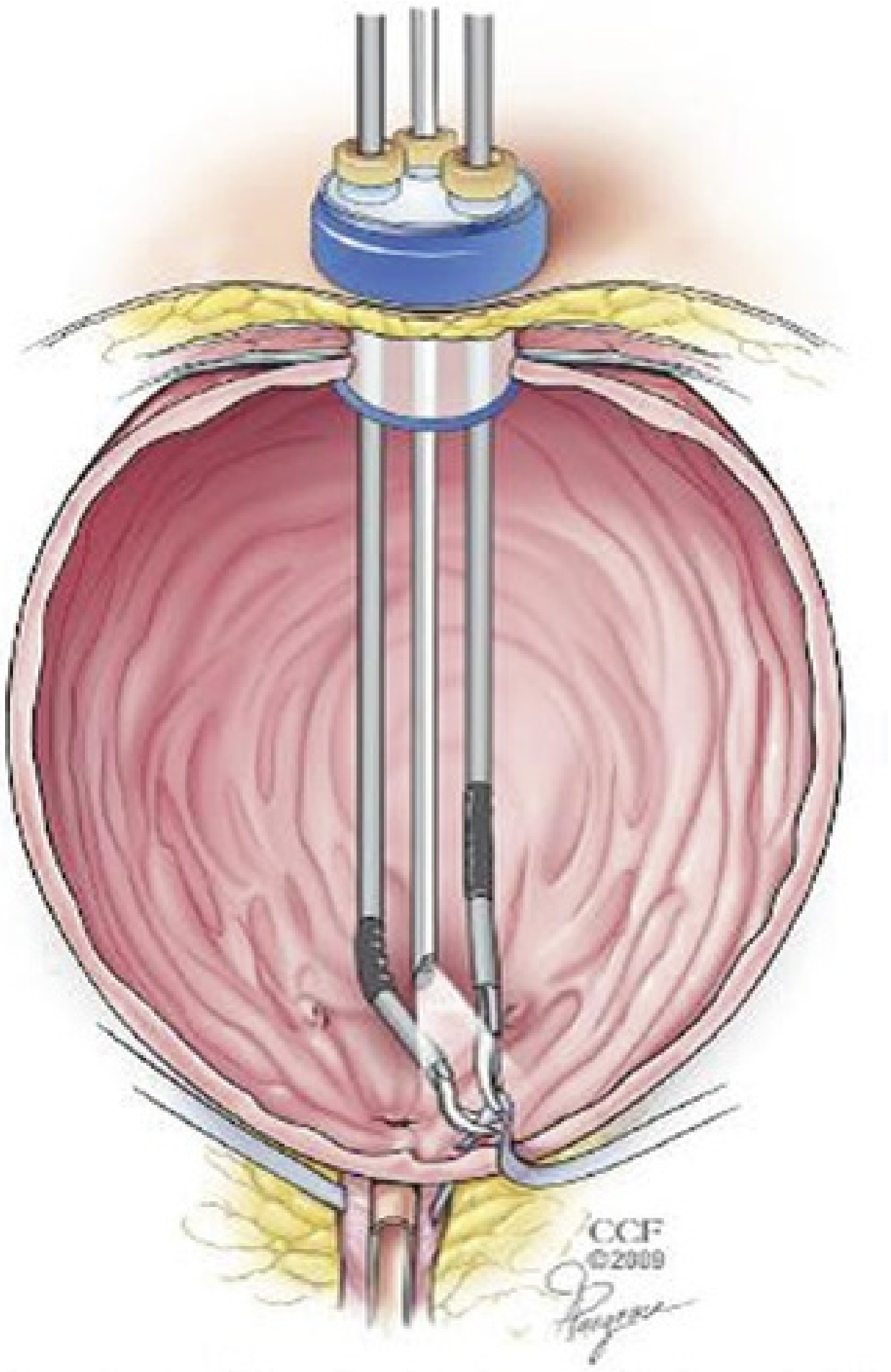

FIG. 132.41 Transvesical single-site mesh excision. After cystoscopy, the bladder is distended with saline. A single-site access port is placed directly in the bladder, and pneumovesicum is established. Transvesical single-site mesh excision is performed, and the bladder is closed. (From Ingber MS, Stein RJ, Rackley RR, et al. Single-port transvesical excision of foreign body in the bladder. *Urology* 74[6]:1347–1350, 2009.)

Percutaneous

The patient may be placed in either a dorsal lithotomy or supine position. The perineum and lower abdomen are prepped and draped, ideally with an apparatus that has a fluid control pouch.

A Foley catheter is placed transurethrally, and the bladder is distended with 300 mL of sterile saline. A 1-cm skin incision is made approximately two fingerbreadths above the pubic symphysis. An 18-gauge trocar needle placed through the incision is used to puncture into the bladder. This step may be done under ultrasound guidance. Alternatively, access into the bladder may be established under direct visualization with flexible cystoscopy. In patients with a prior history of abdominal surgery, preoperative cross-sectional imaging or real-time ultrasound may be performed to ensure that there is no interposing bowel segment between the skin and bladder.

The inner obturator of the needle is removed to evaluate for the return of urine, which confirms access into the bladder. An Amplatz Super Stiff polytetrafluoroethylene-coated 0.038-inch J-tip guidewire (Boston Scientific, Marlborough, MA) is cannulated through the needle trocar to allow curling within the bladder, after which the trocar is subsequently removed over the wire. Amplatz renal dilators (Cook Medical, Bloomington, IN) are introduced over the wire and used to sequentially dilate the percutaneous tract up to 30 Fr. A 30-Fr sheath is positioned across the suprapubic percutaneous tract through which a 24-Fr or 26-Fr nephroscope is inserted. The wider caliber of the access sheath relative to the nephroscope permits continuous bladder irrigation and thus aids in visualization.

For stones less than 1 cm, a rigid grasping forceps can be used to retrieve the stone without the need for fragmentation. Alternatively, larger stones may be fragmented or comminuted with a pneumatic or ultrasonic lithotripter under direct visualization through the nephroscope. A rigid grasping forceps can be used subsequently to grasp residual stone fragments.

Once the stone burden has been adequately cleared, a suprapubic catheter is inserted into the bladder over the guidewire and placed to gravity drainage. Alternatively, a large-bore transurethral Foley may be placed in lieu of a suprapubic tube.

Tan et al. (2014) reported on the use of a laparoscopic entrapment bag to aid in stone sequestration and clearance during percutaneous cystolithotripsy. In a series of 21 patients, the authors introduced a laparoscopic entrapment bag into the bladder through the 30-Fr Amplatz access sheath. With the aid of a flexible cystoscope, the bag is maneuvered intravesically to capture the stone(s). The bag is cinched and exteriorized to the level of the skin with the Amplatz sheath removed. The bag, which now carries the stone within it, is opened, and the 30-F Amplatz sheath is reintroduced directly into the bag. The nephroscope and lithotripter are inserted into the bag through the sheath and used to fragment the stone. Once the stone has been sufficiently fragmented, the bag can be pulled directly across the percutaneous tract. A suprapubic catheter is inserted into the bladder over the guidewire, which had been left in place traversing the percutaneous tract.

Postoperative Care and Complications

The Foley catheter is kept to drainage for approximately 1 week postsurgery to allow for adequate healing of the bladder closure. Output from the pelvic drain is monitored as high-output may indicate a urinary leak. If the output is low and there is adequate urine output from the Foley catheter, the drain may be removed, typically 48 hours after surgery. Drain fluid creatinine is not necessary unless high output is encountered. A cystogram should be performed before removal of the catheter to ensure that there is no extravasation present.

In cases of percutaneous cystolithotripsy in which a suprapubic tube has been placed, the tube may be clamped for between 24 and 48 hours following the procedure to allow for a trial of void. Once the patient has successfully voided, the suprapubic tube may be removed. If a urethral catheter is in place, it may be removed between 24 and 48 hours after the procedure to allow for a trial of void.

Key Points: Bladder Diverticulectomy

- The success of surgery is contingent on a meticulous preoperative workup that characterizes the number, size, and location of diverticula. Specifically, the anatomy relative to the ureter should be defined to ensure the preservation of ureteral integrity during repair.
- The disease process underlying formation of the bladder diverticulum should be managed before or at the time of diverticulum repair.
- The fibrous pseudocapsule surrounding the diverticulum serves as a cleavage plane to free the diverticulum from surrounding extravesical tissue.
- During minimally invasive bladder diverticulectomy, selective catheterization of the diverticulum with a Councill-tip catheter placed over a guidewire allows for selective filling of the diverticulum and aids in intraoperative identification.

Ureteral Reimplantation

- Avoid aggressive skeletonizing of the ureter during mobilization as this may lead to ischemia and ureteral stricture formation.
- A tension-free anastomosis between the bladder and ureter is critical because the presence of tension risks anastomotic stricture formation.
- The ureter should be adequately spatulated before creation of the anastomosis.
- When performing a nonrefluxing ureteral reimplant, the length of a submucosal tunnel should be three to five times the caliber of the ureteral lumen.
- Longer ureteral defects may be bridged through maneuvers such as ligation of the contralateral medial umbilical ligament, dissection of the peritoneal reflection off the bladder dome, or ligation of the contralateral bladder pedicle, all of which are conducive to cephalad displacement of the bladder.

Psoas Hitch and Boari Flap

- During creation of a psoas hitch, sutures that fix the extravesical surface of the bladder to the psoas minor tendon should be placed superficially and parallel to the direction of the muscle fibers to avoid entrapment of the femoral and genitofemoral nerves, respectively.
- Reimplantation of the ureter should be performed before tying the anchoring sutures to the psoas muscle tendon during psoas hitch creation.
- The base of a Boari flap should measure at least 4 cm in width, with longer flaps requiring wider base measurement to maintain adequate blood supply; in this regard, the length-to-base ratio should not exceed 3 : 1.
- If a nonrefluxing anastomosis is planned into a Boari flap, there should be at least 3 cm of overlap between the flap and the ureteral segment.
- Because of its relative simplicity and versality, advancement flaps may be used in lieu of Boari flaps to bridge longer ureteral defects.

Enterocystoplasty

- The ileum is most frequently utilized for bladder augmentation given its abundance, ease of mobilization, and robust blood supply.

- The ileum should be isolated approximately 20 cm proximal to the ileocecal valve to spare the terminal ileum and avoid risk for bile salt and vitamin B_{12} malabsorption.
- Detubularization of the isolated intestinal segment is necessary to reduce coordinated peristaltic contractions, which may otherwise contribute to high intravesical pressures.
- A broad mesenteric base to the isolated intestinal segment should be maintained to avoid torsion of the pedicle and preserve a rich blood supply.
- The bladder should be generously bivalved along its dome so as to facilitate a wide-mouth anastomosis with the intestinal patch; a narrow-mouth anastomosis would result in the creation of a pseudo-diverticulum that may poorly empty and cause complications.
- Patients should be counseled regarding the importance of continuous intermittent catheterization as the failure to do so risks perforation.

Partial Cystectomy and Urachal Surgery

- Preoperative evaluation should confirm the presence of adequate bladder capacity and the absence of significant voiding symptoms before proceeding with partial cystectomy.
- Partial cystectomy for benign disease processes still requires adequate margins of resection given the infiltrative nature of many conditions and the propensity for recurrence in cases of inadequate excision.
- During minimally invasive partial cystectomy, intraoperative flexible cystoscopy by the bedside assistant can aid the surgeon in identification of the site of bladder pathology.
- Urachal surgery, when being performed for benign indication, does not require a wide margin of resection of the bladder dome around the site of urachal insertion.

Bladder Stone Surgery

- Approach to bladder stone surgery depends on the size and number of calculi and the presence of any associated processes contributing to stone formation that may need to be simultaneously addressed.
- Percutaneous cystolithotripsy is a minimally invasive alternative to

management of large bladder calculi; percutaneous access, however, may be prohibited in patients with prior pelvic or abdominal surgery given concern over intestinal injury.

References

Bladder Diverticulectomy

Abdel-Hakim AM, El-Feel A, Abouel-Fettouh H, et al. Laparoscopic vesical diverticulectomy. *J Endourol*. 2007;21(1):85–89.

Abreu AL, Chopra S, Dharmaraja A, et al. Robot-assisted bladder diverticulectomy. *J Endourol*. 2014;28(10):1159–1164.

Altunrende F, Autorino R, Patel NS, et al. Robotic bladder diverticulectomy: technique and surgical outcomes. *Int J Urol*. 2011;18(4):265–271.

Badawy H, Eid A, Hassouna M, et al. Pneumovesicoscopic diverticulectomy in children and adolescents: is open surgery still indicated? *J Pediatr Urol*. 2008;4(2):146–149.

Baldie K, Angell J, Ogan K, et al. Robotic management of benign mid and distal ureteral strictures and comparison with laparoscopic approaches at a single institution. *Urology*. 2012;80(3):596–601.

Blane CE, Zerin JM, Bloom DA. Bladder diverticula in children. *Radiology*. 1994;90(3):695–697.

Clayman RV, Shahin S, Reddy P, et al. Transurethral treatment of bladder diverticula. Alternative to open diverticulectomy. *Urology*. 1984;23(6):573–577.

Das S. Laparoscopic removal of bladder diverticulum. *J Urol*. 1992;148(6):1837–1839.

Davidiuk AJ, Meschia C, Young PR, et al. Robotic-assisted bladder diverticulectomy: assessment of outcomes and modifications of technique. *Urology*. 2015;85(6):1347–1351.

Desai MM, Stein R, Rao P, et al. Embryonic natural orifice transumbilical endoscopic surgery (E-NOTES) for advanced reconstruction: initial experience. *Urology*. 2009;73(1):182–187.

Dowling RA, Corriere JN Jr, Sandler CM. Iatrogenic ureteral injury. *J Urol*. 1986;135(5):912–915.

Ehrlich RM, Gershman A, Fuchs G. Laparoscopic vesicoureteroplasty in children: initial case reports. *Urology*. 1994;43(2):255–261.

Elliott SP, McAninch JW. Ureteral injuries: external and iatrogenic. *Urol Clin North Am*. 2006;33(1):55–66 [vi].

Elsamra SE, Theckumparampil N, Garden BB, et al. Open, laparoscopic, and robotic ureteroneocystotomy for benign and malignant ureteral lesions: a comparison of over 100 minimally invasive cases. *J Endourol*. 2014;28(12):1455–1459.

Eyraud R, Laydner H, Autorino R, et al. Robot-assisted laparoscopic bladder diverticulectomy. *Curr Urol Rep*. 2013;14(1):46–51.

Faysal MH, Freiha FS. Primary neoplasm in vesical diverticula. A report of 12 cases. *Br J Urol*. 1981;53(2):141–143.

Flasko T, Toth G, Benyo M, et al. A new technical approach for extraperitoneal laparoscopic bladder diverticulectomy. *J Laparoendosc Adv Surg Tech A*. 2007;17(5):659–661.

Fox M, Power RF, Bruce AW. Diverticulum of the bladder—presentation and evaluation of treatment of 115 cases. *Br J Urol*. 1962;34:286–298.

Gaunay GS, Elsamra SE, Richstone L. Trocars: site selection, instrumentation, and overcoming complications. *J Endourol*. 2016;30(8):833–843.

Goldfischer ER, Gerber GS. Endoscopic management of ureteral strictures. *J Urol*. 1997;157(3):770–775.

Golijanin D, Yossepowitch O, Beck S, et al. Carcinoma in a bladder diverticulum: presentation and treatment outcome. *J Urol*. 2003;170(5):1761–1764.

Gundeti MS, Eng MK, Reynolds WS, et al. Pediatric robotic-assisted laparoscopic augmentation ileocystoplasty and Mitrofanoff appendicovesicostomy: complete intracorporeal—initial case report. *Urology*. 2008;72(5):1144–1147 [discussion 1147].

Hafez KS, Wolf JS Jr. Update on minimally invasive management of ureteral strictures. *J Endourol*. 2003;17(7):453–464.

Hedican SP, Schulam PG, Docimo SG. Laparoscopic assisted reconstructive surgery. *J Urol*. 1999;161(1):267–270.

Isac W, Kaouk J, Altunrende F, et al. Robot-assisted ureteroneocystostomy: technique and comparative outcomes. *J Endourol*. 2013;27(3):318–323.

Janetschek G, Radmayr C, Bartsch G. Laparoscopic ureteral anti-reflux plasty reimplantation. First clinical experience. *Ann Urol (Paris)*. 1995;29(2):101–105.

Jarrett TW, Pardalidis NP, Sweetser P, et al. Laparoscopic transperitoneal bladder diverticulectomy: surgical technique. *J Laparoendosc Surg*. 1995;5(2):105–111.

Kelalis PP, McLean P. The treatment of diverticulum of the bladder. *J Urol*. 1967;98(3):349–352.

Kerbl K, Chandhoke P, McDougall E, et al. Laparoscopic stapled bladder closure: laboratory and clinical experience. *J Urol*. 1993;149(6):1437–1439 [discussion 1439–1440].

Khanna R, Isac W, Laydner H, et al. Laparoendoscopic single site reconstructive procedures in urology: medium term results. *J Urol*. 2012;187(5):1702–1706.

Khonsari S, Lee DI, Basillote JB, et al. Intraoperative catheter management during laparoscopic excision of a giant bladder diverticulum. *J Laparoendosc Adv Surg Tech A*. 2004;14(1):47–50.

Knappenberger ST, Uson AC, Melicow MM. Primary neoplasms occurring in vesical diverticula: a report of 18 cases. *J Urol*. 1960;83:153–159.

Kozinn SI, Canes D, Sorcini A, et al. Robotic versus open distal ureteral reconstruction and reimplantation for benign stricture disease. *J Endourol*. 2012;26(2):147–151.

Kural AR, Atug F, Akpinar H, et al. Robot–assisted laparoscopic bladder diverticulectomy combined with photoselective vaporization of prostate: a case report and review of literature. *J Endourol*. 2009;23(8):1281–1285.

Kwak S, Leef JA, Rosenblum JD. Percutaneous balloon catheter dilatation of benign ureteral strictures: effect of multiple dilatation procedures on long–term patency. *Am J Roentgenol*. 1995;165(1):97–100.

Lakshmanan Y, Fung LC. Laparoscopic extravesicular ureteral reimplantation for vesicoureteral reflux: recent technical advances. *J Endourol*. 2000;14(7):589–593 [discussion 593–584].

Livne PM, Gonzales ET Jr. Congenital bladder diverticula causing ureteral obstruction. *Urology*. 1985;25(3):273–276.

Macejko AM, Viprakasit DP, Nadler RB. Cystoscope- and robot-assisted bladder diverticulectomy. *J Endourol*. 2008;22(10):2389–2391 [discussion 2391–2382].

Magera JS Jr, Adam Childs M, Frank I. Robot-assisted laparoscopic transvesical diverticulectomy and simple prostatectomy. *J Robot Surg*. 2008;2(3):205–208.

Marte A, Sabatino MD, Borrelli M, et al. Pneumovesicoscopic treatment of congenital bladder diverticula in children: our experience. *J Laparoendosc Adv Surg Tech A*. 2010;20(1):87–90.

Meeks JJ, Hagerty JA, Lindgren BW. Pediatric robotic-assisted laparoscopic diverticulectomy. *Urology*. 2009;73(2):299–301 [discussion 301].

Melekos MD, Asbach HW, Barbalias GA. Vesical diverticula: etiology, diagnosis, tumorigenesis, and treatment. Analysis of

74 cases. *Urology*. 1987;30(5):453–457.

Modi P, Goel R, Dodiya S. Laparoscopic ureteroneocystostomy for distal ureteral injuries. *Urology*. 2005;66(4):751–753.

Moore CR, Shirodkar SP, Avallone MA, et al. Intravesical methylene blue facilitates precise identification of the diverticular neck during robot-assisted laparoscopic bladder diverticulectomy. *J Laparoendosc Adv Surg Tech A*. 2012;22(5):492–495.

Myer EG, Wagner JR. Robotic assisted laparoscopic bladder diverticulectomy. *J Urol*. 2007;178(6):2406–2410 [discussion 2410].

Nadler RB, Pearle MS, McDougall EM, et al. Laparoscopic extraperitoneal bladder diverticulectomy: initial experience. *Urology*. 1995;45(3):524–527.

Orandi A. Transurethral fulguration of bladder diverticulum: new procedure. *Urology*. 1977;10(1):30–32.

Parra RO, Jones JP, Andrus CH, et al. Laparoscopic diverticulectomy: preliminary report of a new approach for the treatment of bladder diverticulum. *J Urol*. 1992;148(3):869–871.

Patil N, Mottrie A, Sundaram B, et al. Robotic-assisted laparoscopic ureteral reimplantation with psoas hitch: a multi-institutional, multinational evaluation. *Urology*. 2008;72(1):47–50 [discussion 50].

Pieretti RV, Pieretti-Vanmarcke RV. Congenital bladder diverticula in children. *J Pediatr Surg*. 1999;34(3):468–473.

Pompeo A, Molina WR, Sehrt D, et al. Laparoscopic ureteroneocystostomy for ureteral injuries after hysterectomy. *JSLS*. 2013;17(1):121–125.

Porpiglia F, Tarabuzzi R, Cossu M, et al. Sequential transurethral resection of the prostate and laparoscopic bladder diverticulectomy: comparison with open surgery. *Urology*. 2002;60(6):1045–1049.

Porpiglia F, Tarabuzzi R, Cossu M, et al. Is laparoscopic bladder diverticulectomy after transurethral resection of the prostate safe and effective? Comparison with open surgery. *J Endourol*. 2004;18(1):73–76.

Rao R, Nayyar R, Panda S, et al. Surgical techniques: robotic bladder diverticulectomy with the da Vinci-S surgical system. *J Robot Surg*. 2007;1(3):217–220.

Rassweiler JJ, Gozen AS, Erdogru T, et al. Ureteral reimplantation for management of ureteral strictures: a retrospective comparison of laparoscopic and open techniques. *Eur Urol*. 2007;51(2):512–522 [discussion 522–513].

Reddy PK, Evans RM. Laparoscopic ureteroneocystostomy. *J Urol*. 1994;152(6 Pt 1):2057–2059.

Roberts WW, Cadeddu JA, Micali S, et al. Ureteral stricture formation after removal of impacted calculi. *J Urol*. 1998;159(3):723–726.

Roslan M, Markuszewski MM, Klacz J, et al. Laparoendoscopic single-port transvesical diverticulectomy: preliminary clinical experience. *J Endourol*. 2012;26(8):975–979.

Roslan M, Markuszewski MM, Klacz J, et al. Laparoendoscopic single-site transvesical ureteroneocystostomy for vesicoureteral reflux in an adult: a one-year follow-up. *Urology*. 2012;80(3):719–723.

Roslan M, Markuszewski M, Klacz J, et al. Suprapubic transvesical laparoendoscopic single-port bladder diverticulectomy: points of technique with medium-term surgical outcomes. *J Endourol*. 2013;27(6):688–692.

Schimpf MO, Wagner JR. Robot-assisted laparoscopic Boari flap ureteral reimplantation. *J Endourol*. 2008;22(12):2691–2694.

Seideman CA, Huckabay C, Smith KD, et al. Laparoscopic ureteral reimplantation: technique and outcomes. *J Urol*.

2009;181(4):1742–1746.

Shah HN, Shah RH, Hegde SS, et al. Sequential holmium laser enucleation of the prostate and laparoscopic extraperitoneal bladder diverticulectomy: initial experience and review of literature. *J Endourol*. 2006;20(5):346–350.

Simmons MN, Gill IS, Fergany AF, et al. Laparoscopic ureteral reconstruction for benign stricture disease. *Urology*. 2007;69(2):280–284.

Stefanovic KB, Bukurov NS, Marinkovic JM. Non-antireflux versus antireflux ureteroneocystostomy in adults. *Br J Urol*. 1991;67(3):263–266.

Stolzenburg JU, Do M, Kallidonis P, et al. Laparoendoscopic single-site bladder diverticulectomy: technique and initial experience. *J Endourol*. 2011;25(1):85–90.

Tareen BU, Mufarrij PW, Godoy G, et al. Robot-assisted laparoscopic partial cystectomy and diverticulectomy: initial experience of four cases. *J Endourol*. 2008;22(7):1497–1500.

Uberoi J, Harnisch BB, Sethi AS, et al. Robot-assisted laparoscopic distal ureterectomy and ureteral reimplantation with psoas hitch. *J Endourol*. 2007;21(4):368–373 [discussion 372–363].

Ureteral Reimplantation

Vakili BB, Chesson RR, Kyle BL, et al. The incidence of urinary tract injury during hysterectomy: a prospective analysis based on universal cystoscopy. *Am J Obstet Gynecol*. 2005;192(5):1599–1604.

Vitale PJ, Woodside JR. Management of bladder diverticula by transurethral resection: re-evaluation of an old technique. *J Urol*. 1979;122(6):744–745.

Weinberg JJ, Ansong K, Smith AD. Complications of ureteroscopy in relation to experience: report of survey and author experience. *J Urol*. 1987;137(3):384–385.

Wenske S, Olsson CA, Benson MC. Outcomes of distal ureteral reconstruction through reimplantation with psoas hitch, Boari flap, or ureteroneocystostomy for benign or malignant ureteral obstruction or injury. *Urology*. 2013;82(1):231–236.

Yohannes P, Chiou RK, Pelinkovic D. Rapid communication: pure robot-assisted laparoscopic ureteral reimplantation for ureteral stricture disease: case report. *J Endourol*. 2003;17(10):891–893.

Ureteral Reconstruction

Ahn M, Loughlin KR. Psoas hitch ureteral reimplantation in adults—analysis of a modified technique and timing of repair. *Urology*. 2001;58(2):184–187.

Allaparthi S, Ramanathan R, Balaji KC. Robotic distal ureterectomy with boari flap reconstruction for distal ureteral urothelial cancers: a single institutional pilot experience. *J Laparoendosc Adv Surg Tech A*. 2010;20(2):165–171.

Benson MC, Ring KS, Olsson CA. Ureteral reconstruction and bypass: experience with ileal interposition, the Boari flap-psoas hitch and renal autotransplantation. *J Urol*. 1990;143(1):20–23.

Castillo OA, Litvak JP, Kerkebe M, et al. Early experience with the laparoscopic boari flap at a single institution. *J Urol*. 2005;173(3):862–865.

Castillo OA, Travassos J, Escobar JF, et al. Laparoscopic ureteral replacement by Boari flap: multi-institutional experience in 30 cases. *Actas Urol Esp*. 2013;37(10):658–662.

Do M, Kallidonis P, Qazi H, et al. Robot-assisted technique for boari flap ureteral reimplantation: is robot assistance beneficial? *J Endourol*. 2014;28(6):679–685.

Ehrlich RM, Melman A, Skinner DG. The use of vesico-psoas hitch in urologic surgery. *J Urol*. 1978;119(3):322–325.

Fergany A, Gill IS, Abdel-Samee A, et al. Laparoscopic bladder flap ureteral reimplantation: survival porcine study. *J Urol*. 2001;166(5):1920–1923.

Fugita OE, Kavoussi L. Laparoscopic ureteral reimplantation for ureteral lesion secondary to transvaginal ultrasonography for oocyte retrieval. *Urology*. 2001;58(2):281.

Ghosh B, Biswal DK, Bera MK, et al. Laparoscopic extravesical lich-gregoir ureteroneocystostomy with psoas hitch for the management of ureterovaginal fistula in post-hysterectomy patients. *Urol Int*. 2016;96(2):171–176.

Gozen AS, Cresswell J, Canda AE, et al. Laparoscopic ureteral reimplantation: prospective evaluation of medium-term results and current developments. *World J Urol*. 2010;28(2):221–226.

Khoder WY, Schlenker B, Trottmann M, et al. Single-incision laparoscopic surgery (SILS) in reconstructive urological cases. *Surg Technol Int*. 2011;21:35–40.

Lima GC, Rais-Bahrami S, Link RE, et al. Laparoscopic ureteral reimplantation: a simplified dome advancement technique. *Urology*. 2005;66(6):1307–1309.

Mathews R, Marshall FF. Versatility of the adult psoas hitch ureteral reimplantation. *J Urol*. 1997;158(6):2078–2082.

Modi P, Goel R, Dodiya S. Laparoscopic ureteroneocystostomy for distal ureteral injuries. *Urology*. 2005;66(4):751–753.

Motiwala HG, Shah SA, Patel SM. Ureteric substitution with Boari bladder flap. *Br J Urol*. 1990;66(4):369–371.

Musch M, Hohenhorst L, Pailliart A, et al. Robot-assisted reconstructive surgery of the distal ureter: single institution experience in 16 patients. *BJU Int*. 2013;111(5):773–783.

Nezhat CH, Malik S, Nezhat F, et al. Laparoscopic ureteroneocystostomy and vesicopsoas hitch for infiltrative endometriosis. *JSLS*. 2004;8(1):3–7.

Ockerblad NF. Reimplantation of the ureter into the bladder by a flap method. *J Urol*. 1947;57(5):845–847.

Patil NN, Mottrie A, Sundaram B, et al. Robotic-assisted laparoscopic ureteral reimplantation with psoas hitch: a multi-institutional, multinational evaluation. *Urology*. 2008;72(1):47–50 [discussion 50].

Pompeo A, Molina WR, Sehrt D, et al. Laparoscopic ureteroneocystostomy for ureteral injuries after hysterectomy. *JSLS*. 2013;17(1):121–125.

Puntambekar S, Palep RJ, Gurjar AM, et al. Laparoscopic ureteroneocystostomy with psoas hitch. *J Minim Invasive Gynecol*. 2006;13(4):302–305.

Rassweiler JJ, Gozen AS, Erdogru T, et al. Ureteral reimplantation for management of ureteral strictures: a retrospective comparison of laparoscopic and open techniques. *Eur Urol*. 2007;51(2):512–522 [discussion 522–513].

Riedmiller H, Becht E, Hertle L, et al. Psoas-hitch ureteroneocystostomy: experience with 181 cases. *Eur Urol*. 1984;10(3):145–150.

Schimpf MO, Wagner JR. Robot-assisted laparoscopic Boari flap ureteral reimplantation. *J Endourol*. 2008;22(12):2691–2694.

Schimpf MO, Wagner JR. Robot-assisted laparoscopic distal ureteral surgery. *JSLS*. 2009;13(1):44–49.

Seideman CA, Huckabay C, Smith KD, et al. Laparoscopic ureteral reimplantation: technique and outcomes. *J Urol*. 2009;181(4):1742–1746.

Warwick RT, Worth PH. The psoas bladder-hitch procedure for the replacement of the lower third of the ureter. *Br J Urol*. 1969;41(6):701–709.

Wenske S, Olsson CA, Benson MC. Outcomes of distal ureteral reconstruction through reimplantation with psoas hitch, Boari flap, or ureteroneocystostomy for benign or malignant ureteral obstruction or injury. *Urology*. 2013;82(1):231–236.

Zimmerman IJ, Precourt WE, Thompson CC. Direct uretero-cysto-neostomy with the short ureter in the cure of ureterovaginal fistula. *J Urol*. 1960;83:113–115.

Enterocystoplasty

Al-Othman KE, Al-Hellow HA, Al-Zahrani HM, et al. Robotic augmentation enterocystoplasty. *J Endourol*. 2008;22(4):597–600 [discussion 600].

Apostolidis A, Dasgupta P, Denys P, et al. Recommendations on the use of botulinum toxin in the treatment of lower urinary tract disorders and pelvic floor dysfunctions: a European consensus report. *Eur Urol*. 2009;55(1):100–119.

Austen M, Kalble T. Secondary malignancies in different forms of urinary diversion using isolated gut. *J Urol*. 2004;172(3):831–838.

Cardenas DD, Moore KN, Dannels-McClure A, et al. Intermittent catheterization with a hydrophilic-coated catheter delays urinary tract infections in acute spinal cord injury: a prospective, randomized, multicenter trial. *PM R*. 2011;3(5):408–417.

Chung SY, Meldrum K, Docimo SG. Laparoscopic assisted reconstructive surgery: a 7-year experience. *J Urol*. 2004;171(1):372–375.

DeFoor W, Minevich E, Reddy P, et al. Bladder calculi after augmentation cystoplasty: risk factors and prevention strategies. *J Urol*. 2004;172(5 Pt 1):1964–1966.

Desai MM, Stein R, Rao P, et al. Embryonic natural orifice transumbilical endoscopic surgery (E–NOTES) for advanced reconstruction: initial experience. *Urology*. 2009;73(1):182–

187.

Docimo SG, Moore RG, Adams J, et al. Laparoscopic bladder augmentation using stomach. *Urology*. 1995;46(4):565–569.

Elliott SP, Meng MV, Anwar HP, et al. Complete laparoscopic ileal cystoplasty. *Urology*. 2002;59(6):939–943.

Flum AS, Zhao LC, Kielb SJ, et al. Completely intracorporeal robotic-assisted laparoscopic augmentation enterocystoplasty with continent catheterizable channel. *Urology*. 2014;84(6):1314–1318.

Gill IS, Rackley RR, Meraney AM, et al. Laparoscopic enterocystoplasty. *Urology*. 2000;55(2):178–181.

Gould JJ, Stoffel JT. Robotic enterocystoplasty: technique and early outcomes. *J Endourol*. 2011;25(1):91–95.

Gundeti MS, Eng MK, Reynolds WS, et al. Pediatric robotic-assisted laparoscopic augmentation ileocystoplasty and Mitrofanoff appendicovesicostomy: complete intracorporeal—initial case report. *Urology*. 2008;72(5):1144–1147 [discussion 1147].

Gurung PM, Attar KH, Abdul-Rahman A, et al. Long-term outcomes of augmentation ileocystoplasty in patients with spinal cord injury: a minimum of 10 years of follow-up. *BJU Int*. 2012;109(8):1236–1242.

Hedican SP, Schulam PG, Docimo SG. Laparoscopic assisted reconstructive surgery. *J Urol*. 1999;161(1):267–270.

Hensle TW, Bingham J, Lam J, et al. Preventing reservoir calculi after augmentation cystoplasty and continent urinary diversion: the influence of an irrigation protocol. *BJU Int*. 2004;93(4):585–587.

Herschorn S, Hewitt RJ. Patient perspective of long-term outcome of augmentation cystoplasty for neurogenic bladder. *Urology*. 1998;52(4):672–678.

Hsu TH, Shortliffe LD. Laparoscopic Mitrofanoff appendicovesicostomy. *Urology*. 2004;64(4):802–804.

Jamison J, Maguire S, McCann J. Catheter policies for management of long term voiding problems in adults with neurogenic bladder disorders. *Cochrane Database Syst Rev*. 2013;(11) [CD004375].

Lendvay TS, Shnorhavorian M, Grady RW. Robotic-assisted laparoscopic mitrofanoff appendicovesicostomy and antegrade continent enema colon tube creation in a pediatric spina bifida patient. *J Laparoendosc Adv Surg Tech A*. 2008;18(2):310–312.

Linder A, Leach GE, Raz S. Augmentation cystoplasty in the treatment of neurogenic bladder dysfunction. *J Urol*. 1983;129(3):491–493.

Lorenzo AJ, Chait PG, Wallis MC, et al. Minimally invasive approach for treatment of urinary and fecal incontinence in selected patients with spina bifida. *Urology*. 2007;70(3):568–571.

Meng MV, Anwar HP, Elliott SP, et al. Pure laparoscopic enterocystoplasty. *J Urol*. 2002;167(3):1386.

Quek ML, Ginsberg DA. Long-term urodynamics followup of bladder augmentation for neurogenic bladder. *J Urol*. 2003;169(1):195–198.

Sadiq A, Brucker BM. Management of neurogenic lower urinary tract dysfunction in multiple sclerosis patients. *Curr Urol Rep*. 2015;16(7):44.

Shadpour P, Simforoosh N, Magsudi R, et al. Totally laparoscopic combined freehand ileocystoplasty and Malone procedures. *J Endourol*. 2005;19(4):471–475.

Utomo E, Groen J, Blok BF. Surgical management of functional bladder outlet obstruction in adults with neurogenic bladder dysfunction. *Cochrane Database Syst Rev*. 2014;(5) [CD004927].

Wiener JS, Antonelli J, Shea AM, et al. Bladder augmentation versus urinary diversion in patients with spina bifida in the

United States. *J Urol*. 2011;186(1):161–165.

Partial Cystectomy and Urachal Surgery

Agarwal N, Kriplani A, Parul, et al. Intramural bladder endometriosis after caesarean section: diagnostic and therapeutic aspects. *J Gynecol Surg*. 2002;18:69–73.

Albert NE. Leiomyoma of bladder. Preoperative diagnosis by ultrasound. *Urology*. 1981;17(5):486–487.

Al-Zahrani AA. Recurrent urinary bladder paraganglioma. *Adv Urol*. 2010;2010:912125.

Bazeed MA, Aboulenien H. Leiomyoma of the bladder causing urethral and unilateral ureteral obstruction: a case report. *J Urol*. 1988;140(1):143–144.

Beaty SD, Silva AC, De Petris G. Bladder endometriosis: ultrasound and MRI findings. *Radiol Case Rep*. 2006;1(3):92–95.

Belis JA, Post GJ, Rochman SC, et al. Genitourinary leiomyomas. *Urology*. 1979;13(4):424–429.

Berman SM, Tolia BM, Laor E, et al. Urachal remnants in adults. *Urology*. 1988;31(1):17–21.

Blichert-Toft M, Nielsen OV. Diseases of the urachus simulating intra-abdominal disorders. *Am J Surg*. 1971;122(1):123–128.

Cadeddu JA, Boyle KE, Fabrizio MD, et al. Laparoscopic management of urachal cysts in adulthood. *J Urol*. 2000;164(5):1526–1528.

Chen CH, Boag AH, Beiko DT, et al. Composite paraganglioma-ganglioneuroma of the urinary bladder: a rare neoplasm causing hemodynamic crisis at tumour resection. *Can Urol Assoc J*. 2009;3(5):E45–E48.

Cornella JL, Larson TR, Lee RA, et al. Leiomyoma of the female urethra and bladder: report of twenty-three patients and review of the literature. *Am J Obstet Gynecol*. 1997;176(6):1278–1285.

Dahm P, Gschwend JE. Malignant non-urothelial neoplasms of the urinary bladder: a review. *Eur Urol*. 2003;44(6):672–681.

Herr HW. Urachal carcinoma: the case for extended partial cystectomy. *J Urol*. 1994;151(2):365–366.

Illescas FF, Baker ME, Weinerth JL. Bladder leiomyoma: advantages of sonography over computed tomography. *Urol Radiol*. 1986;8(4):216–218.

Knoedler JJ, Boorjian SA, Kim SP, et al. Does partial cystectomy compromise oncologic outcomes for patients with bladder cancer compared to radical cystectomy? A matched case-control analysis. *J Urol*. 2012;188(4):1115–1119.

Knoll LD, Segura JW, Scheithauer BW. Leiomyoma of the bladder. *J Urol*. 1986;136(4):906–908.

Komar PD. Urinary tract endometriosis. *Ind J Surg*. 2004;66:41–43.

Leestma JE, Price EB Jr. Paraganglioma of the urinary bladder. *Cancer*. 1971;28(4):1063–1073.

Madeb R, Knopf JK, Nicholson C, et al. The use of robotically assisted surgery for treating urachal anomalies. *BJU Int*. 2006;98(4):838–842.

Maya MM, Slywotzky C. Urinary bladder leiomyoma: magnetic resonance imaging findings. *Urol Radiol*. 1992;14(3):197–199.

Mettler L, Gaikwad V, Riebe B, et al. Bladder endometriosis: possibility of treatment by laparoscopy. *JSLS*. 2008;12(2):162–165.

Navarrete S, Sanchez Ismayel A, Sanchez Salas R, et al. Treatment of urachal anomalies: a minimally invasive surgery technique. *JSLS*. 2005;9(4):422–425.

Sheldon CA, Clayman RV, Gonzalez R, et al. Malignant urachal lesions. *J Urol*. 1984;131(1):1–8.

Stone NN, Garden RJ, Weber H. Laparoscopic excision of a urachal cyst. *Urology*. 1995;45(1):161–164.

Vercellini P, Frontino G, Pisacreta A, et al. The pathogenesis of bladder detrusor endometriosis. *Am J Obstet Gynecol*. 2002;187(3):538–542.

Wadhwa P, Kolla SB, Hemal AK. Laparoscopic en bloc partial cystectomy with bilateral pelvic lymphadenectomy for urachal adenocarcinoma. *Urology*. 2006;67(4):837–843.

Yohannes P, Bruno T, Pathan M, et al. Laparoscopic radical excision of urachal sinus. *J Endourol*. 2003;17(7):475–479 [discussion 479].

Bladder Stone and Foreign-Body Removal

Aron M, Agarwal MS, Goel A. Comparison of percutaneous with transurethral cystolithotripsy in patients with large prostates and large vesical calculi undergoing simultaneous transurethral prostatectomy. *BJU Int*. 2003;91(3):293–295.

Demirel F, Cakan M, Yalcinkaya F, et al. Percutaneous suprapubic cystolithotripsy approach: for whom? Why? *J Endourol*. 2006;20(6):429–431.

Ingber MS, Stein RJ, Rackley RR, et al. Single-port transvesical excision of foreign body in the bladder. *Urology*. 2009;74(6):1347–1350.

Kim JH, Doo SW, Yang WJ, et al. Laparoscopic transvesical excision and reconstruction in the management of mid-urethral tape mesh erosion and stones around the bladder neck: initial experiences. *BJU Int*. 2012;110(11 Pt C):E1009–E1013.

Ko YH, Kang SG, Kang SH, et al. Removal of long, complex foreign bodies from bladder using single laparoscopic port under pneumovesicum. *J Laparoendosc Adv Surg Tech A*. 2010;20(7):639–642.

Lee JT, Ha HK, Shin DG, et al. Laparoscopic removal of a broken sewing needle in a patient with irritative bladder symptoms. *Int Neurourol J*. 2010;14(4):272–274.

Macedo FI, O'Connor J, Mittal VK, et al. Robotic removal of eroded vaginal mesh into the bladder. *Int J Urol*. 2013;20(11):1144–1146.

Maher C, Feiner B. Laparoscopic removal of intravesical mesh following pelvic organ prolapse mesh surgery. *Int Urogynecol J*. 2011;22(12):1593–1595.

Roslan M, Markuszewski M, Klacz J, et al. Suprapubic transvesical laparoendoscopic single-port bladder diverticulectomy: points of technique with medium-term surgical outcomes. *J Endourol*. 2013;27(6):688–692.

Tan YK, Gupta DM, Weinberg A, et al. Minimally invasive percutaneous management of large bladder stones with a laparoscopic entrapment bag. *J Endourol*. 2014;28(1):61–64.

Yoshizawa T, Yamaguchi K, Obinata D, et al. Laparoscopic transvesical removal of erosive mesh after transobturator tape procedure. *Int J Urol*. 2011;18(12):861–863.

133

Genital and Lower Urinary Tract Trauma

Allen F. Morey MD, FACS, Jay Simhan MD, FACS

The lower urinary tract may sustain injury through a wide variety of mechanisms. Although rarely life-threatening, mismanagement of these injuries can lead to devastating long-term morbidity and, in some cases, permanent disability. The best outcomes can be achieved by employing appropriate imaging and identifying the optimal timing and approach for intervention.

In the acute setting, it is important to distinguish between scenarios when immediate reconstruction is appropriate, such as testicular rupture, and when reconstruction is best offered in the delayed setting, such as cases of pelvic fracture urethral injury. Appropriate management at the time of injury also facilitates delayed reconstruction, such as initial placement of a large-bore suprapubic tube for urethral injury followed by delayed posterior urethroplasty.

Improved technology and wider availability have made imaging more useful in lower urinary tract trauma, allowing for prompt and accurate diagnosis of injury. Better localization of the site of injury also allows the surgeon to select more direct or minimally invasive approaches for repair. Ultrasonography is routinely performed for scrotal trauma and is being performed more widely for confirming diagnosis of penile fracture. High-resolution computed tomography (CT) cystography can pinpoint the site of bladder rupture, facilitating diagnosis and making laparoscopic or robotic repair an excellent option. Retrograde urethrography can diagnose pelvic fracture urethral injury and differentiate between injuries in which primary realignment is feasible and those in which suprapubic tube placement is the better alternative.

Injuries of the External Genitalia

Penis

Traumatic injuries to the genitalia are uncommon, in part because of the mobility of the penis and scrotum. Blunt phallic traumatic injury is usually of concern only with an erect penis, when fracture of the tunica albuginea may result. In general, prompt surgical reconstruction of most penile injuries usually leads to adequate and acceptable cosmetic and functional results.

Fracture

Etiology.

Penile fracture is the disruption of the tunica albuginea with rupture of the corpus cavernosum. Fracture typically occurs during vigorous sexual intercourse, when the rigid penis slips out of the vagina and strikes the perineum or pubic bone, producing a buckling injury.

The tunica albuginea is a bilaminar structure (inner circular, outer longitudinal) composed of collagen and elastin. The outer layer determines the strength and thickness of the tunica, which varies in different locations along the shaft and is thinnest ventrolaterally (Brock et al., 1997; Hsu et al., 1994). When the erect penis bends abnormally, the abrupt increase in intracavernosal pressure exceeds the tensile strength of the tunica albuginea, and a transverse laceration of the proximal shaft usually results.

Although penile fracture has been reported most commonly with sexual intercourse with the “doggy style” position being the most common (Barros et al., 2017), it also has been described with masturbation, rolling over or falling onto the erect penis, and other scenarios (Al Ansari et al., 2013). Penile fracture may occur more frequently in “stressful situations” such as extramarital sex (Kramer, 2011). In the Middle East, self-inflicted fractures predominate resulting from the practice of “taqaandan,” in which the erect penis is forcibly bent during masturbation or as a means to achieve rapid detumescence after coitus (Zargooshi, 2009).

Cultural factors likely contribute to the varying etiologies of penile fracture. Mydlo (2001) reported that 94% of fractures in Philadelphia, Pennsylvania, were a result of sexual intercourse; Zargooshi (2009) described 76% of fractures in

Kermanshah, Iran, as being caused by self-manipulation. The tunical tear is usually transverse and 1 to 2 cm in length (Asgari et al., 1996; Mydlo, 2001). The injury is usually unilateral, although tears in both corporeal bodies occur in 10% of injuries (El-Taher et al., 2004; Mydlo, 2001). Bilateral corporeal injuries are more commonly associated with urethral injury (Koifman et al., 2010). **Although the site of rupture can occur anywhere along the penile shaft, fractures are most often distal to the suspensory ligament. Injuries associated with coitus are usually ventral or lateral** (Lee et al., 2007; Mydlo, 2001)**, where the tunica albuginea is the thinnest** (Hsu et al., 1994).

Diagnosis and Imaging.

The diagnosis of penile fracture is often straightforward and can be made reliably by history and physical examination. Patients usually describe a cracking or popping sound as the tunica tears, followed by pain, rapid detumescence, and discoloration and swelling of the penile shaft (American Urological Association [AUA] Urotrauma Guidelines, Statement 26). If Buck's fascia remains intact, the penile hematoma remains contained between the skin and tunica, resulting in a typical “eggplant deformity.” If Buck's fascia is disrupted, the hematoma can extend to the scrotum, perineum, and suprapubic regions (eFig. 133.1). The swollen, ecchymotic phallus often deviates to the side opposite the tunical tear because of the resultant hematoma and mass effect. The fracture line in the tunica albuginea may be palpable. Because fear and embarrassment are common, the patient's presentation to the emergency department or clinic is sometimes significantly delayed.

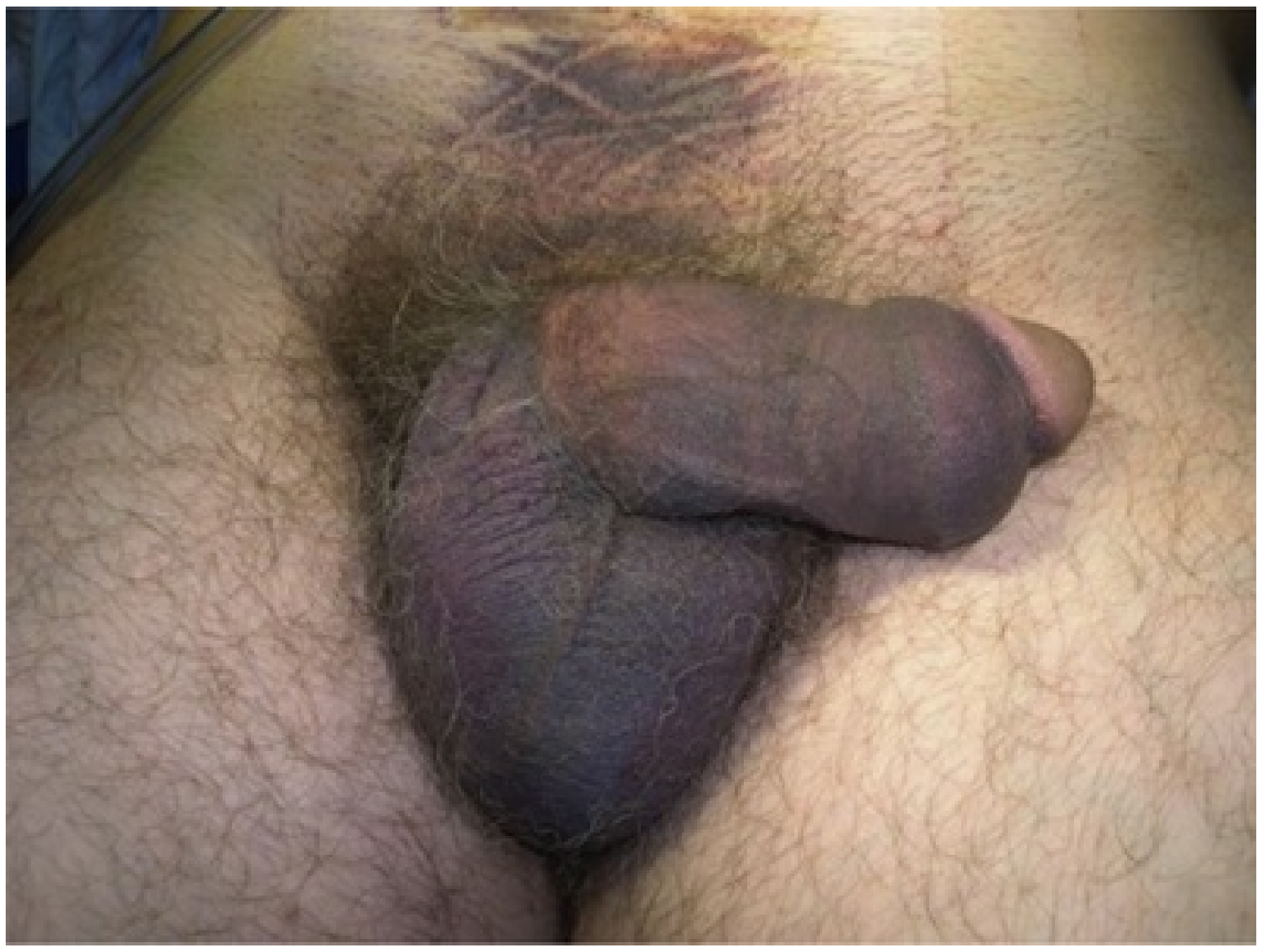

EFIG. 133.1 Eggplant deformity—the classic appearance of a penile fracture sustained during intercourse, with hematoma of the penile shaft and ecchymosis extending into the scrotum.

The incidence of urethral injury is significantly higher in the United States and Europe (20%) than in Asia, the Middle East, and the Mediterranean region (3%), probably because of the different etiology—intercourse trauma versus self-inflicted injury (Derouiche et al., 2008; Eke, 2002; Jack et al., 2004; Zargooshi, 2009). Most urethral injuries are associated with gross hematuria, blood at the meatus (eFig. 133.2), or inability to void, although the absence of these findings does not definitively rule out urethral injury (Jack et al., 2004; Koifman et al., 2010; Mydlo, 2001; Tsang and Demby, 1992). In cases that are suspicious of penile fracture with concomitant urethral injury, urethral evaluation is compulsory. **Given that urethral injury occurs frequently** (Pariser et al., 2015)**, preoperative urethrography can be considered when urethral injury is suspected. However, because urethrography can be time-consuming and inaccurate** (Kamdar et al., 2008)**, intraoperative flexible cystoscopy is now often performed routinely just before catheter placement at the time of penile exploration when urethral injury is suspected** (AUA Urotrauma Guidelines, Statement 29).

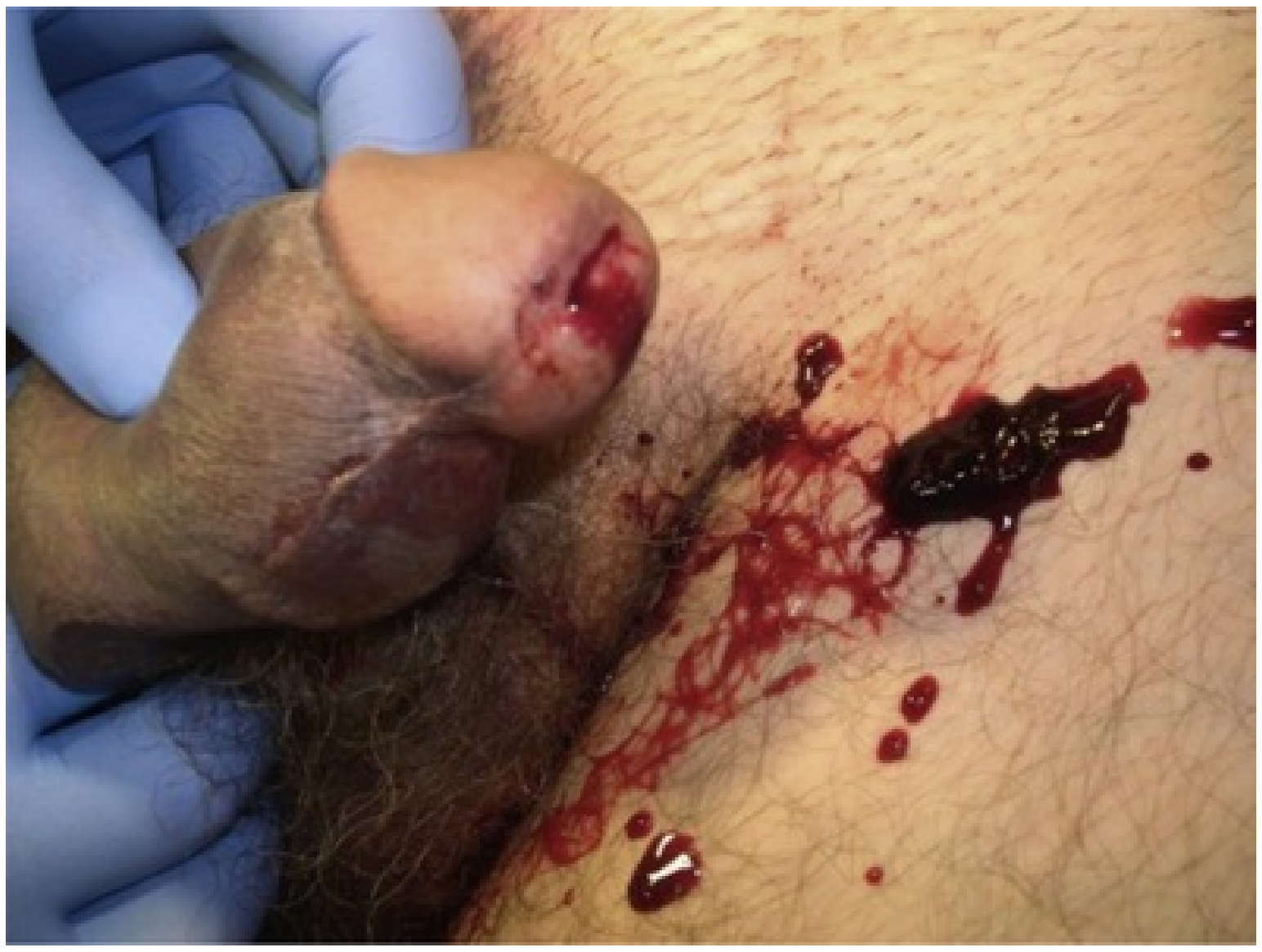

EFIG. 133.2 Blood at the urethral meatus noted in this patient with a penile fracture sustained during intercourse.

The typical history and clinical presentation of penile fracture usually make adjunctive imaging studies unnecessary. However, when the history and physical examination are equivocal for penile fracture, ultrasonography can establish the diagnosis (AUA Urotrauma Guidelines, Statement 28; Koifman et al., 2010). **Ultrasonography (Fig. 133.3) has become the preferred imaging study to evaluate for equivocal penile fracture because it is rapid, readily available, noninvasive, inexpensive, and accurate. Penile ultrasonography is most useful for ruling out fracture in patients with low clinical suspicion** or to identify the location of the tear, potentially guiding the choice of incision (El-Assmy et al., 2011).

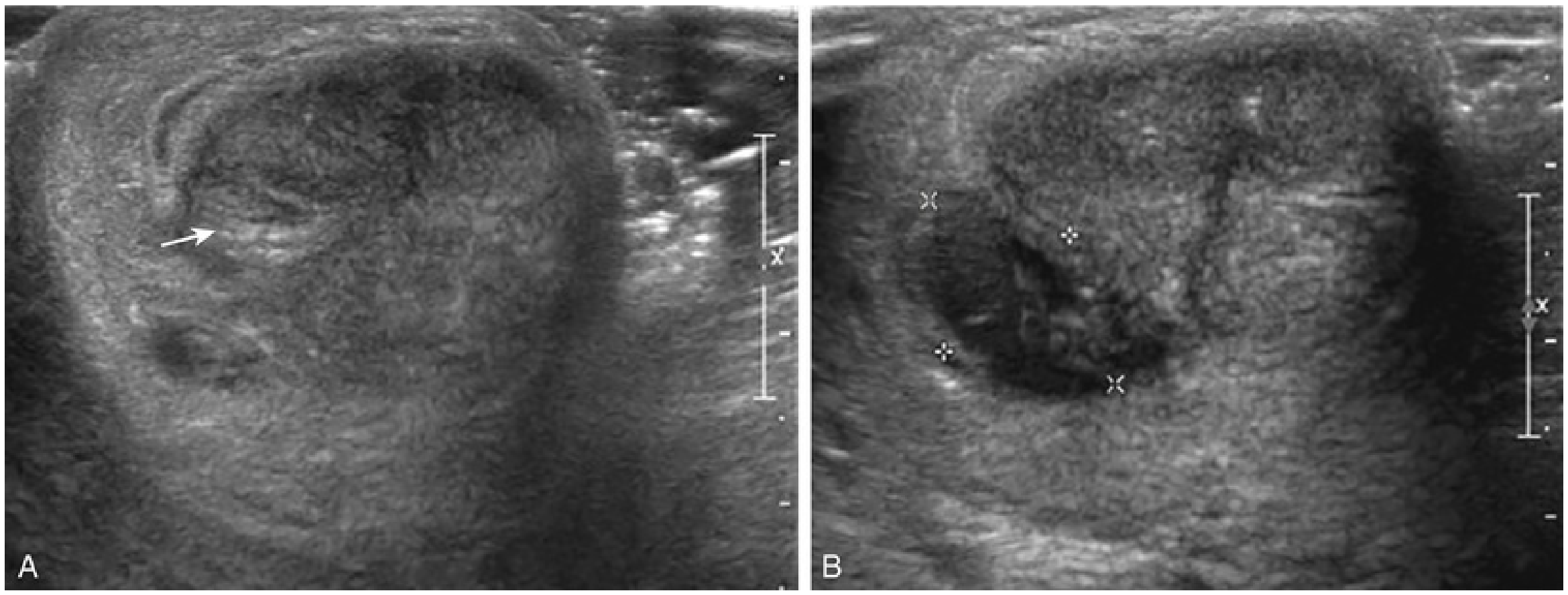

FIG. 133.3 (A) Ultrasound examination demonstrates ruptured tunica

albuginea *(arrow)* in a patient with a suspected penile fracture. (B) Hematoma adjacent to ruptured tunica.

Magnetic resonance imaging (MRI) has been reported to be a noninvasive and accurate alternative means of demonstrating disruption of the tunica albuginea (Antonini et al., 2014; Fedel et al., 1996; Uder et al., 2002). However, because of the expense, limited availability, and time requirements involved, **MRI has not been employed widely for the evaluation of patients with symptoms and physical findings suggestive of penile fracture. AUA guidelines recommend MRI in the setting of equivocal ultrasound findings for penile fracture** (El-Assmy et al., 2011)**. Cavernosography is discouraged in the evaluation of a suspected penile fracture because it is time-consuming and unfamiliar to most urologists and radiologists** (Beysel et al., 2002; Morey et al., 2004).

False fracture has been reported in patients who present with penile swelling and ecchymosis, and some even describe the classic “snap-pop” or rapid detumescence typically associated with fracture (Feki et al., 2007). Physical examination may be inadequate for definitive diagnosis of a corporeal tear in these circumstances (Shah et al., 2003). Surgical exploration (eFig. 133.4) or evaluation with MRI should be considered (El-Assmy et al., 2010). Another condition that may mimic penile fracture is rupture of the dorsal penile artery or vein during sexual intercourse (Armenakas et al., 2001; Bar-Yosef et al., 2007).

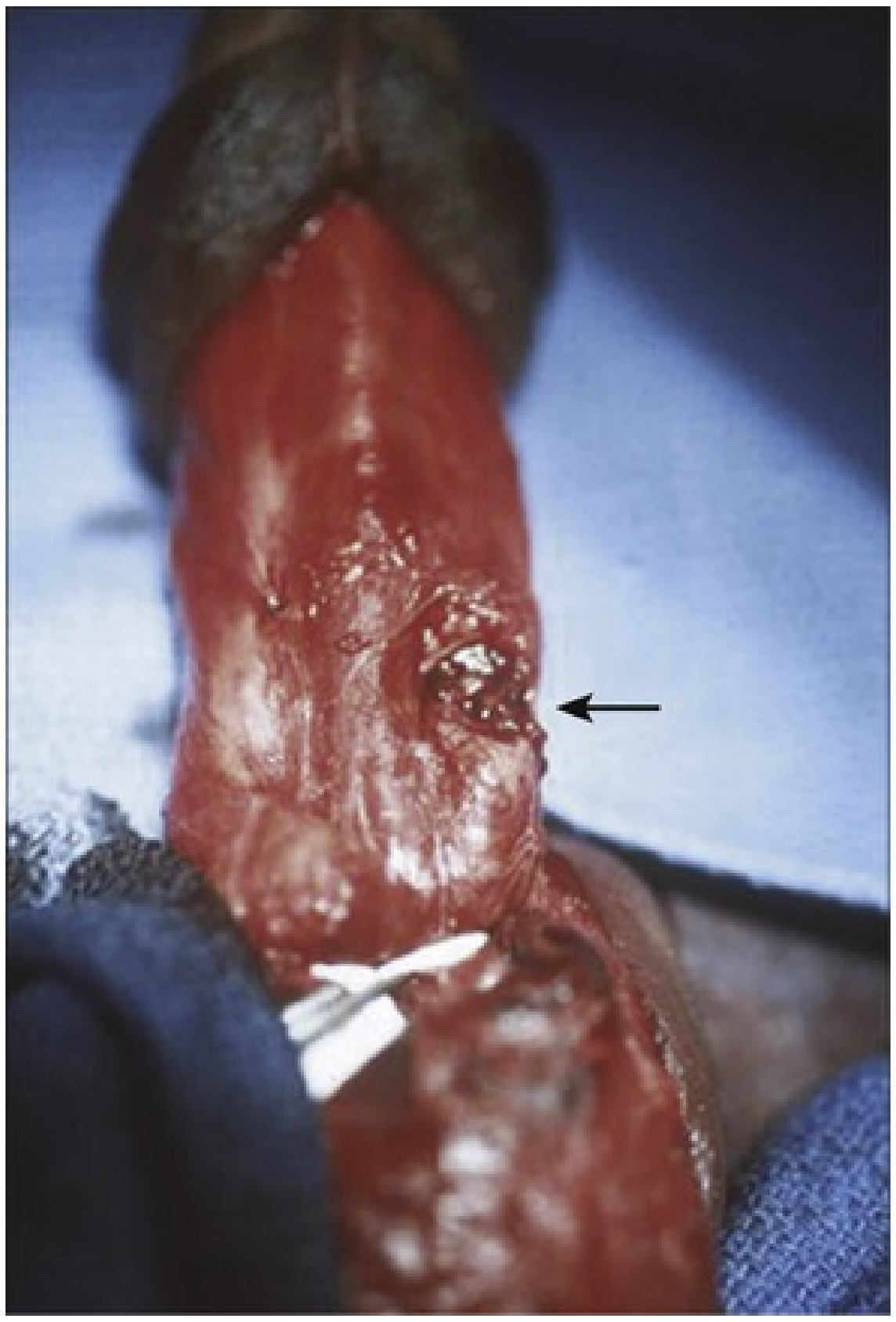

EFIG. 133.4 Transverse laceration of left corpus cavernosum *(arrow)* associated with penile fracture, successfully repaired through a circumcision incision.

Management.

Multiple contemporary publications recommend that suspected penile fractures be promptly explored and surgically repaired (AUA Urotrauma Guidelines, Statement 27)**. Because most penile fractures occur ventrally or laterally, a ventral vertical penoscrotal incision is usually preferred for direct exposure to the fracture (Fig. 133.5)** (Mazaris et al., 2009)**. Alternatively, small lateral incisions may be used for localized hematomas or palpable tunical defects** (El-Bahnasawy and Gomha, 2000; Nasser and Mostafa, 2008)**. The distal circumcising incision may be appropriate when the location of the fracture is uncertain because it provides exposure to all three penile compartments. Closure of the tunical defect with interrupted 2-0 or 3-0 absorbable sutures is recommended; deep corporeal vascular ligation and excessive debridement of the delicate underlying erectile tissue should be avoided.**

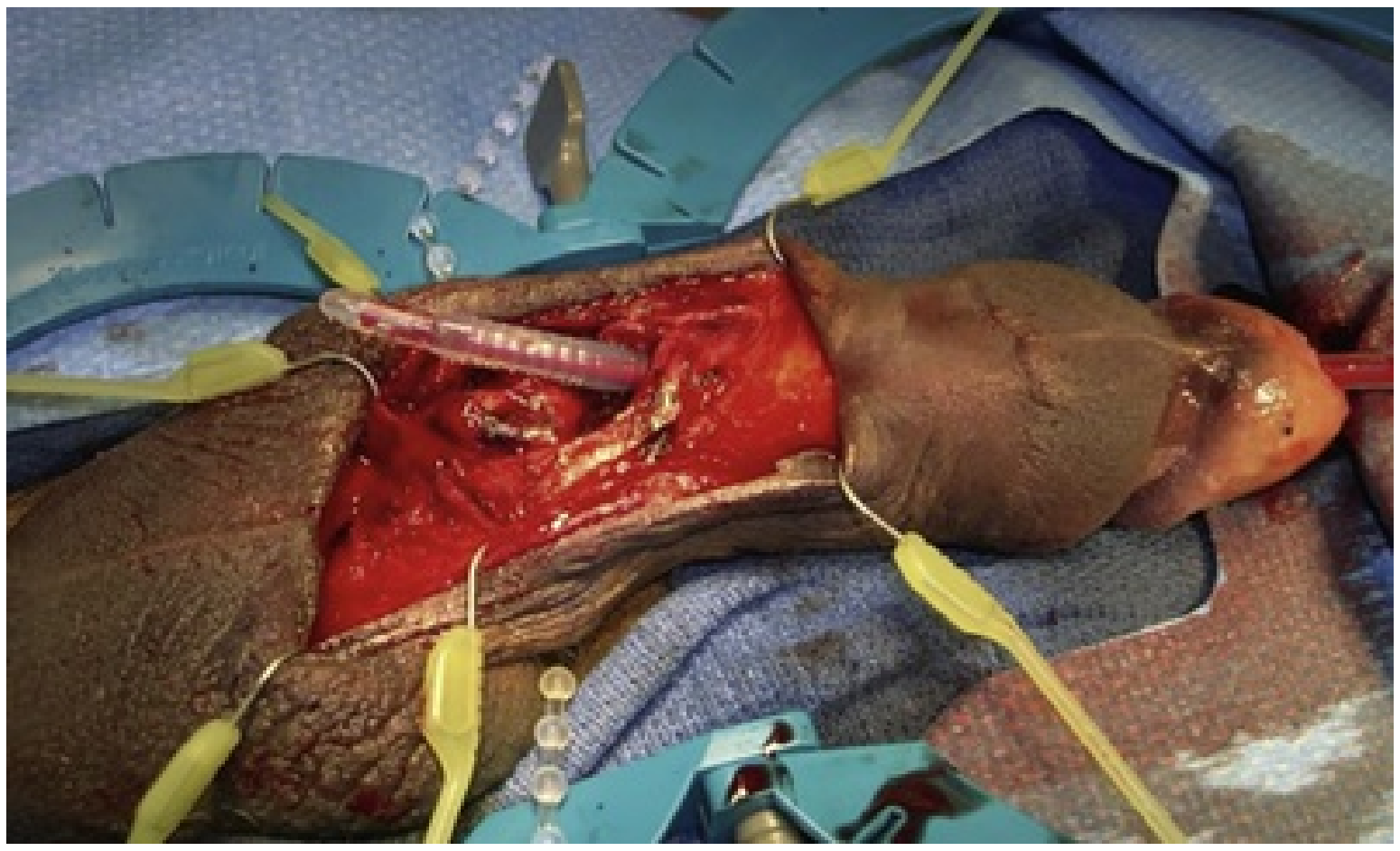

FIG. 133.5 Surgical exploration through a ventral vertical incision showing excellent exposure of the site of the tunical tear and associated urethral injury.

Induction of an artificial erection with saline or colored dye may aid in locating the corporal laceration (Shaeer, 2006). Partial urethral injuries should be oversewn with fine absorbable suture over a urethral catheter. Complete urethral injuries should be debrided, mobilized, and repaired in a tension-free manner over a catheter (Fig. 133.6). After urethral repair, the catheter is often maintained for 2 to 3 weeks while therapy with broad-spectrum antibiotics and 1 month of sexual abstinence are recommended. In uncircumcised patients, the distal circumcising incision may place the distal prepuce at risk for ischemia. Although a ventral vertical incision is preferred, if a distal circumcising incision is required, performing limited circumcision at the conclusion of the repair should be strongly considered.

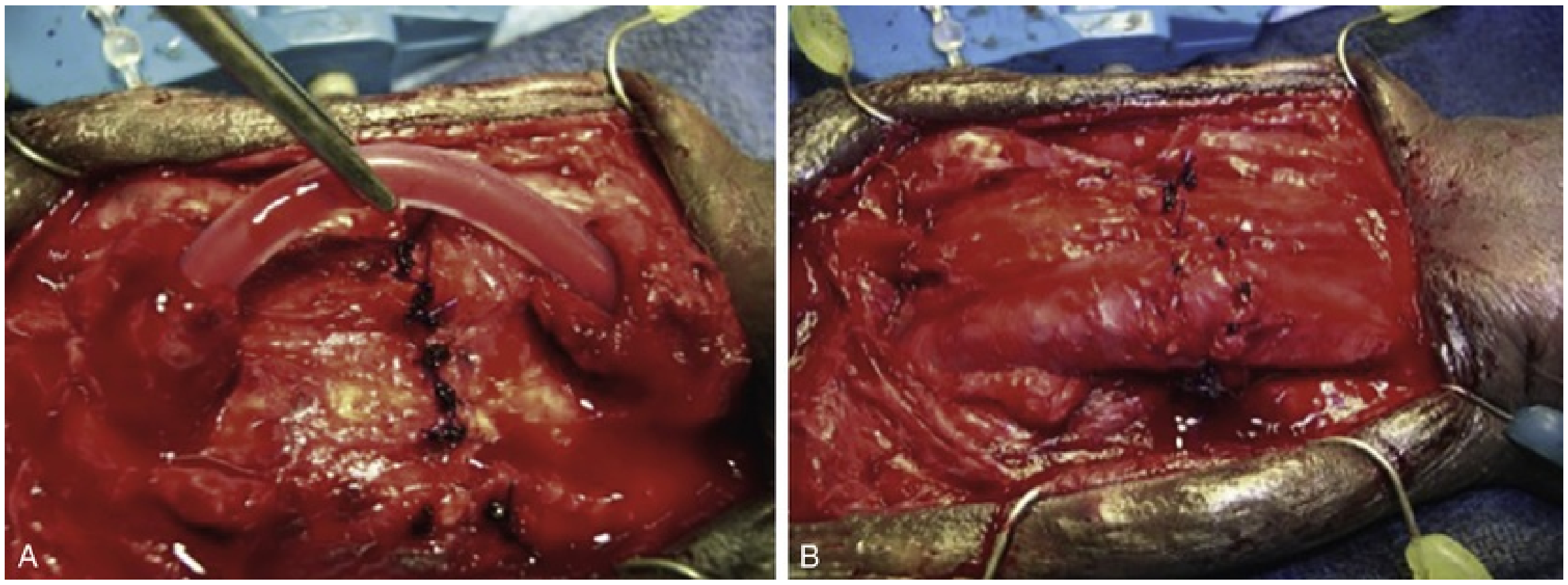

FIG. 133.6 (A) Completely transected urethra secondary to penile fracture. Repair of bilateral tunical rupture was performed previously. (B)

Anastomotic repair of the urethra after urethral mobilization.

Outcome and Complications.

Surgical reconstruction results in faster recovery, decreased morbidity, lower complication rates, and lower incidence of long-term penile curvature (AUA Urotrauma Guidelines, Statement 27; El-Taher et al., 2004; Hinev, 2002; Muentener et al., 2004; Nicolaisen et al., 1983; Orvis and McAninch, 1989). Although repair results in penile curvature in less than 5% of patients (El Atat et al., 2008), conservative management of penile fracture has been associated with penile curvature in more than 10% of patients, abscess or debilitating plaques in 25% to 30%, and significantly longer hospitalization times and recovery (Kalash and Young, 1984; Meares, 1971; Nicolaisen et al., 1983; Orvis and McAninch, 1989). Zargooshi (2009) reported in a surgical series of 352 patients that surgical management of penile fractures resulted in erectile function in nearly all patients. **Although surgery is better than conservative management, surgical delay of up to 7 days after the time of injury does not adversely affect the results of repair** (El-Assmy et al., 2011; Kozacioglu et al., 2011).

Gunshot and Penetrating Injuries

Gunshot Wounds.

Most penetrating wounds to the genitalia are caused by gunshots (Bjurlin et al., 2013; Mohr et al., 2003; Phonsombat et al., 2008), and most require surgical exploration. **Treatment principles include immediate exploration, copious irrigation, excision of foreign matter, antibiotic prophylaxis, and surgical closure.** Gunshot injuries to the phallus are rarely isolated wounds—nearly all victims have significant associated injuries, including abdominal, pelvic, lower extremity, vascular, or additional genitourinary injuries (Bandi and Santucci, 2004; Kunkle et al., 2008; Najibi et al., 2010). Excellent cosmetic and functional outcomes can be expected with immediate reconstruction (Cavalcanti et al., 2006; Gomez et al., 1993). An artificial erection may be induced to ensure penile straightness and no tunical violation, and plication techniques may be used to correct any curvature resulting from closure of a large corporal injury (Kunkle et al., 2008).

Urethral injuries have been reported in 15% to 50% of penile gunshot wounds (Cinman et al., 2013; Goldman et al., 1996; Miles et al., 1990; Mohr et al., 2003). **Retrograde urethrography should be strongly considered in any patient with penetrating injury to the penis, especially with high-velocity missile injuries, blood at the meatus, or difficulty voiding and when the trajectory of the bullet was near the urethra** (Bandi and Santucci, 2004; Cerwinka and Block, 2009; Goldman et al., 1996; Mohr et al., 2003; Phonsombat et al., 2008). Alternatively, intraoperative retrograde urethral injection of methylene blue or indigo carmine may identify the site of injury and the adequacy of closure. If a catheter has already been placed, pericatheter injection may help to ascertain urethral integrity.

Urethral injuries resulting from penetrating trauma should be closed primarily by use of standard urethroplasty principles whenever possible; excellent results have been reported (Bandi and Santucci, 2004; Miles et al., 1990). Patients with urethral injury and extensive tissue damage from high-velocity weapons or close-range shotgun blasts may require staged repair and suprapubic urinary diversion (Bandi and Santucci, 2004), especially injuries located in the penile urethra (Cavalcanti et al., 2006).

Animal and Human Bites.

The morbidity of animal bites is directly related to the severity of the initial wound. Most victims are boys, and dog bites are the most common injury (Gomes et al., 2001; Van der Horst et al., 2004). Infectious complications are unusual because treatment is sought early. **Initial management of dog bites includes copious irrigation, debridement, and immediate primary closure along with prophylactic use of a broad-spectrum antibiotic** (Bertozzi et al., 2009; Cummings and Boullier, 2000; Wolf et al., 1993). Tetanus and rabies immunizations should be used as appropriate. Because of the risk for polymicrobial infection and the antimicrobial susceptibilities of typical organisms, recommended empirical antimicrobial therapy choices include a β-lactam antibiotic with a β-lactamase inhibitor (i.e., amoxicillin-clavulanic acid), a second-generation cephalosporin with anaerobic efficacy (i.e., cefoxitin, cefotetan), or clindamycin with a fluoroquinolone (Talan et al., 1999).

Human bites produce contaminated wounds that often should not be closed primarily. Most individuals with human bite injuries seek medical attention after a substantial delay and are more likely to present with gross infection. Empirical antibiotic administration is warranted with amoxicillin/clavulanic acid or moxifloxacin (Talan et al., 2003).

Penile Amputation.

Traumatic amputation of the penis, although rare, is usually the result of genital self-mutilation. Psychosis is present in 65% to 87% of patients performing genital self-mutilation (Aboseif et al., 1993; Greilsheimer and Groves, 1979; Romilly and Isaac, 1996). Psychiatric consultation should be sought in all such cases.

Reconstruction of the urethra and reanastomosis of the corporeal bodies with microsurgical repair of dorsal penile vessels and nerves achieves remarkably good results. Patients should be transferred to a facility with microsurgical capabilities; however, if such a facility is unavailable, macroscopic anastomosis of the urethra and corporeal bodies can be performed with good erectile results, albeit with potential compromise of sensation and skin loss (Bhanganada et al., 1983; Razzaghi et al., 2009). Every attempt should be made to locate, clean, and preserve the severed portion in a "double bag" technique. The distal penis should be rinsed in saline solution, wrapped in saline-soaked gauze, and sealed in a sterile plastic bag, and the bag should be placed into an outer bag with ice or slush (AUA Urotrauma Guidelines, Statement 32; Jezior et al., 2001). **Hypothermic injury to the amputated segment can occur if it is in direct contact with ice for a prolonged period.** Successful reimplantation is possible after 16 hours of cold ischemia time or 6 hours of warm ischemia (Lowe et al., 1991). If the severed part is unavailable, the penile stump should be formalized by closing the corpora and spatulating the urethral neomeatus, similar to a partial penectomy procedure for malignant disease.

Microvascular reconstruction of the dorsal arteries, vein, and nerves is the preferred method of repair for an amputated penis. Adequate erectile function is possible with microvascular reanastomosis and macroscopic replantation, with more than 50% of men able to achieve erection with either technique (Aboseif et al., 1993; Bhanganada et al., 1983; Lowe et al., 1991; Morrison et al., 2017). However, **complications such as urethral strictures, skin loss, and sensory abnormalities all are less common with microvascular repair** (Jezior et al., 2001; Morrison et al., 2017).

Normal penile sensation returns in 0 to 10% of patients after macroscopic replantation (Bhanganada et al., 1983; Lowe et al., 1991), whereas sensation is present in more than 80% of patients with microscopic replantations (Jezior et al., 2001; Jordan and Gilbert, 1989; Lowe et al., 1991; Morrison et al., 2017). Penile skin necrosis, sometimes complete, is often a troublesome problem, although it is less common with microsurgical repair. This is because the blood supply of the skin is independent of the corporeal bodies and because without repair of the superficial vascular structures, the penile skin is essentially a free graft (Jezior et al., 2001). Split-thickness skin grafts are applied when the native skin becomes necrotic, usually after several weeks of observation, resuscitation, and debridement (Ozturk et al., 2009). An alternative strategy is to denude the phallus of all skin and bury it in the scrotum, leaving the glans exposed, followed by separation of the structures after 2 months (Bhanganada et al., 1983; Jordan and Gilbert, 1989). Adjuvant techniques after penile replantation include the use of hyperbaric oxygen to promote healing (Landström et al., 2004; Zhong et al., 2007) or medical leeches on the penis after macroreplantation to augment venous outflow and decrease edema (Mineo et al., 2004). Additionally, emerging techniques to manage total penile loss include utilization of radial artery–based forearm free flaps for total phallic reconstruction (Falcone et al., 2016).

Key Points: Step-by-Step Approach to Penile Reattachment

- Suprapubic cystostomy
- Closure of the tunica albuginea with 2-0 absorbable suture
- Urethral closure over a catheter with 4-0 absorbable suture
- Minimal dissection along the neurovascular bundle to identify severed vessels and nerves
- Microscopic anastomosis of dorsal artery with 11-0 nylon; microscopic dorsal vein repair with 9-0 nylon; microscopic epineural repair of dorsal nerve with 10-0 nylon
- Skin coverage

Zipper Injuries.

Zipper injuries to the penis more often happen to impatient boys or intoxicated men. Multiple maneuvers are available to free the entrapped skin and to remove the mechanism. After a penile block, the zipper slider and adjacent skin can be lubricated with mineral oil, followed by a single attempt to unzip and untangle the skin (Kanegaye and Schonfeld, 1993; Mydlo, 2000). The cloth material connected to the zipper can be incised with perpendicular cuts in between each zipper tooth to release the lateral support of the zipper, allowing the device to fall apart and release the trapped skin (Oosterlinck, 1981). A bone cutter or similar tool can be used to cut the median bar (diamond-shaped connection) of the slider. This maneuver allows separation of the upper and lower shields of the slider, and the entire zipper falls apart (Flowerdew et al., 1977; Saraf and Rabinowitz, 1982). Alternatively, a screwdriver may be placed between the upper and lower shields of the slider, and a twisting action separates the two shields from the median bar and unravels the zipper (Raveenthiran, 2007). Another technique involves cutting the anterior shield with a wire cutter (Maurice and Cherullo, 2013). Some children may require more than local anesthesia or sedation; circumcision or an elliptical skin excision can be performed in the operating room under anesthesia (Mydlo, 2000; Yip et al., 1989).

Strangulation Injuries.

Accidental injuries with thread, hair, or rubber bands occur in children, but child abuse must be considered in such cases. Any child with unexplained penile swelling, erythema, or difficulty voiding should be examined closely for a hidden strangulating hair or string. Adults may place objects around the shaft as a means of sexual pleasure or to prolong an erection. The constricting device can reduce blood flow, cause edema, and induce ischemia; gangrene and urethral injury may develop in delayed presentations. Emergent treatment requires decompression of the constricted penis to allow blood flow and micturition.

String, hair, and rubber bands should be incised promptly. Initial attempts to remove a solid constricting device causing penile strangulation involve lubrication of the shaft and foreign body and attempted direct removal. Edema distal to the strangulation often makes removal difficult. A string or latex tourniquet can be wrapped around the distal shaft to decrease swelling and to improve the odds of removing the device with lubrication. If the constricting object cannot be severed or removed, a string technique should be considered (Browning and Reed, 1969; Vahasarja et al., 1993; Noh et al., 2004). A thick silk suture or umbilical tape is passed proximally under the strangulation object and wound tightly around the penis distally toward the glans. The tag of suture or tape proximal to the ring is grasped; unwinding from the proximal end pushes the object distally. Glanular puncture with a needle or blade allows escape of dark trapped blood and improves the odds of removing the object with the string method (Browning and Reed, 1969; Noh et al., 2004).

Plastic constricting devices can be incised with a scalpel or an oscillating cast saw (Pannek and Martin, 2003), but metal objects present a more difficult challenge. Readily available hospital equipment (ring cutters, bolt cutters, dental drills, commercially available rotary tools, orthopedic and neurosurgical operative drills) may be inadequate to cut through heavy iron or steel items. The use of industrial drills, steel saws, hacksaws, saber saws, and high-speed electric drills is often required (Perabo et al., 2002; Santucci et al., 2004). Occasionally, fire department and emergency medical services equipment may be required to cut through iron and steel rings. The phallus should be protected from thermal injury, sparks, and the cutting blade by use of tongue depressors, sponges, or malleable retractors; continuous saline irrigation may be used for cooling (Video 133.1). Such elaborate undertakings are best accomplished in the operating room under anesthesia. If decompression is delayed and the patient is distended and unable to void, a suprapubic bladder catheter should be placed. Outcomes are generally favorable with device removal alone, although the surgeon should be prepared to consider reconstructive techniques such as skin grafting if the strangulation injury causes skin necrosis (Gaspar et al., 2015; Ivanovski et al., 2007).

Testis

Etiology

Although the testis is relatively protected by the mobility of the scrotum, reflexive cremasteric muscle contraction, and the tough fibrous tunica albuginea, blunt injury (usually the result of assault, sports-related events, and motor vehicle accidents) can result in rupture of the tunica albuginea, contusion, hematoma, dislocation, or torsion of the testis. Testicular injury results from blunt trauma in about 75% of cases (Cass and Luxenberg, 1991; McAninch et al., 1984), whereas penetrating injuries secondary to firearms, explosions, or impalement account for the remaining cases.

Although only 1.5% of blunt testis injury involves both gonads, about 30% of penetrating scrotal trauma results in bilateral injury (Cass and Luxenberg, 1988, 1991). Similar to penetrating urethral injuries, penetrating scrotal trauma (roughly 80%) usually involves neighboring structures, including the thigh, penis, perineum, bladder, urethra, or femoral vessels (Cline et al., 1998; Gomez et al., 1993; Simhan et al., 2012). In contemporary military conflicts, genital wounds account for a larger percentage of urologic injuries because of the powerful explosive weapons involved and absence of protective body armor over the genitalia (Janak et al., 2017; Thompson et al., 1998; Waxman et al., 2009). Blast injuries are typically associated with extensive scrotal skin loss, multiple projectile injuries of both testes, and concomitant extensive destruction of the lower extremities and abdomen.

Diagnosis

Rupture of the testis must be considered in all cases of blunt scrotal trauma. Most patients complain of exquisite scrotal pain and nausea. **Swelling and ecchymosis are variable, and the degree of hematoma may not correlate with the severity of testicular injury; absence does not entirely rule out testicular rupture, and contusion without fracture can manifest as significant bleeding.** Scrotal hemorrhage and hematocele along with tenderness to palpation often limit a complete physical examination. Concomitant urethral injury should be suspected and evaluated when examination reveals blood at the meatus or if the mechanism of injury or hematuria suggests this possibility. Penetrating injuries mandate careful examination of surrounding structures, especially the femoral vessels.

Ultrasonography can be helpful to assess the integrity and vascularity of the testis in equivocal cases. Ultrasonography is rapid, readily available, and noninvasive. Because it may be operator dependent, false-positive and false-negative studies range from 56% to 94% (Corrales et al., 1993; Dreitlein et al., 2001; Fournier et al., 1989; Herbener, 1996). **Ultrasound findings suggestive of testicular fracture include a heterogeneous echo pattern of the testicular parenchyma and disruption of the tunica albuginea (Fig. 133.7)** (Bjurlin et al., 2013; Buckley and McAninch, 2006; Micallef et al., 2001)**. Although ultrasonography may assist in detection of testicular fracture or hematoma** (Guichard et al., 2008)**, a normal or equivocal ultrasound study should not delay surgical exploration when physical examination findings suggest testicular damage; definitive diagnosis is often made in the operating room** (AUA Urotrauma Guidelines, Statement 30). Although MRI may effectively demonstrate testicular integrity, its widespread use is not the norm because of expense, limited availability, and potential delay in definitive surgical care of the patient (Kim et al., 2009; Muglia et al., 2002; Serra et al., 1998).

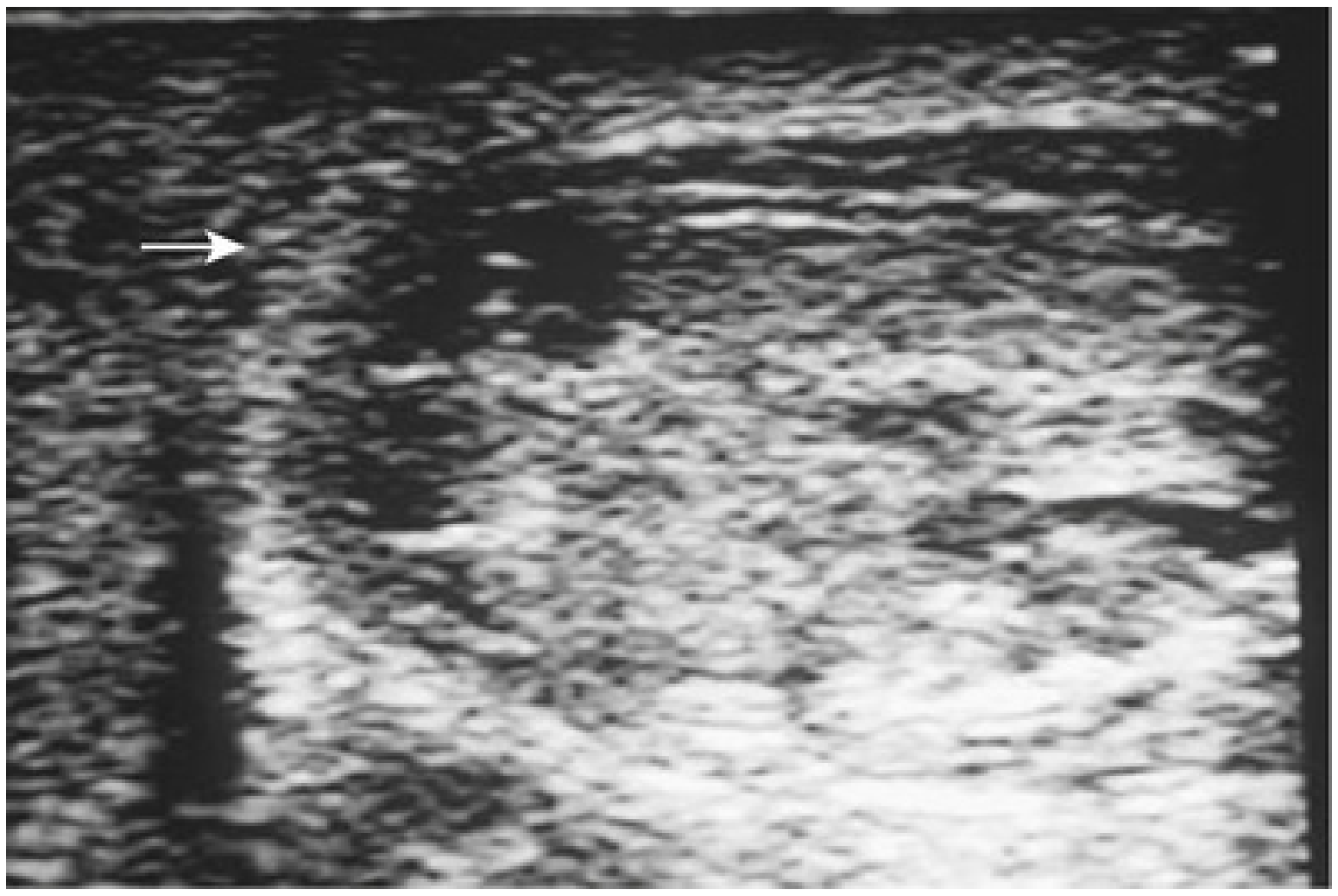

FIG. 133.7 Ultrasound examination demonstrates hypoechoic intratesticular areas *(arrow)* consistent with testicular rupture sustained by blunt trauma. Scrotal exploration revealed a large hematocele and exposed seminiferous tubules.

Differential diagnosis of testicular fracture includes hematocele without rupture, torsion of the testis or an appendage, reactive hydrocele, hematoma of the epididymis or spermatic cord, and intratesticular hematoma. A nonpalpable testis in a trauma patient should raise the possibility of dislocation outside the scrotum. This entity usually occurs after motorcycle crashes when extreme forces on the scrotum expel the testis into surrounding tissues such as the superficial inguinal pouch (50%) or to a pubic, penile, pelvic, abdominal, or perineal location (Bromberg et al., 2003; Schwartz and Faerber, 1994). Bilateral dislocation after trauma has been reported (Bromberg et al., 2003; O'Brien et al., 2004). Manual or surgical reduction of the displaced testis is indicated. Finally, approximately 5% of spermatic cord torsions are thought to be precipitated by trauma; torsion should be considered in all cases of significant scrotal pain without signs or symptoms of major scrotal trauma (Elsaharty et al., 1984; Lrhorfi et al., 2002; Manson, 1989).

Management

Early exploration and repair of testicular injury is associated with increased testicular salvage, reduced convalescence and disability, faster return to normal activities, and preservation of fertility and hormonal function (Kukadia et al., 1996). Minor scrotal injuries without testicular damage can be managed with ice, elevation, analgesics, and irrigation and closure in some circumstances.

The objectives of surgical exploration and repair are testicular salvage, prevention of infection, control of bleeding, and reduced convalescence. Either transverse or vertical scrotal incisions can be performed for successful exploration. **The tunica albuginea should be closed with small absorbable sutures after removal of necrotic and extruded seminiferous tubules.** Even small defects in the tunica albuginea should be closed primarily because progressive swelling and any rise in intratesticular pressure can continue to extrude seminiferous tubules over time. Every attempt to salvage the testis should be performed. Loss of capsule tissue may require removal of additional parenchyma to allow closure of the remaining tunica albuginea. A flap or graft of tunica vaginalis may be used to cover a large defect in the tunica albuginea in an otherwise salvageable testis (Fig. 133.8); synthetic grafts are not recommended for this purpose (Ferguson and Brandes, 2007). Significant intratesticular hematomas should be explored and drained, even in the absence of testicular rupture to prevent progressive pressure necrosis and atrophy, delayed exploration (40%), and orchiectomy (15%) (Cass and Luxenberg, 1988). Significant hematoceles should also be explored, regardless of imaging studies, because up to 80% are caused by testicular rupture (Buckley and McAninch, 2006; Vaccaro et al., 1986).

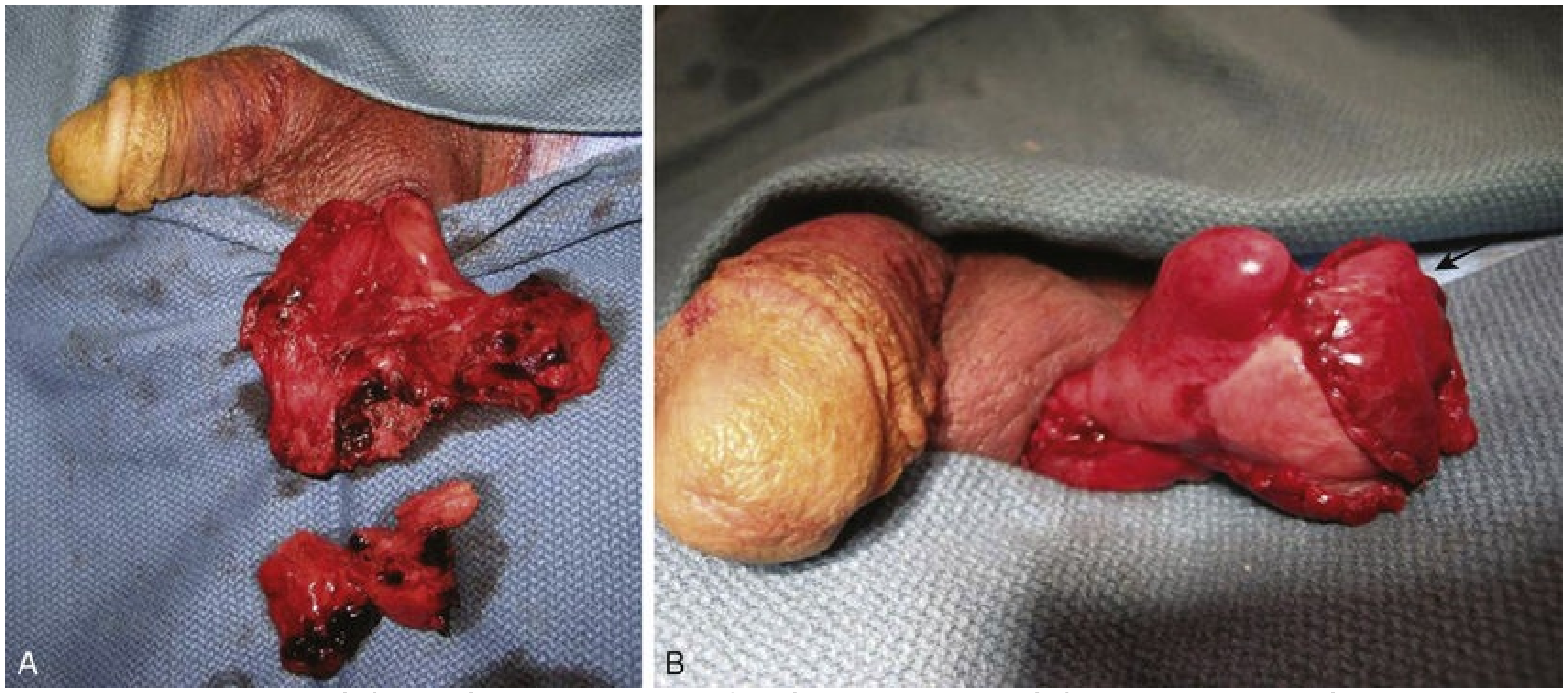

FIG. 133.8 (A) Testicular rupture after blunt trauma. (B) Reconstructed testis after debridement and closure. *Arrow* indicates placement of a tunica vaginalis graft.

Penetrating scrotal injuries should be surgically explored to inspect for vascular and vasal injury; the same principles of salvage, hemostasis, and reconstruction apply as in blunt trauma. The vas deferens is injured in 7% to 9% of scrotal gunshot wounds (Brandes et al., 1995; Gomez et al., 1993). The injured vas should be ligated with nonabsorbable suture, and delayed reconstruction should be performed if necessary. Depending on the mechanism and trajectory of the projectile, scrotal exploration of the contralateral testis should be considered (Simhan et al., 2012).

Outcome and Complications

Nonoperative management of testicular rupture is frequently complicated by infection, atrophy, necrosis, chronic unrelenting pain, and delayed orchiectomy. **Testicular salvage rates exceed 90% with exploration and repair within 3 days of injury** (Cass and Luxenberg, 1991; Del Villar et al., 1973; Fournier et al., 1989; Schuster, 1982)**, whereas orchiectomy rates are threefold to eightfold higher with conservative management and delayed surgery** (Cass and Luxenberg, 1991). Indicative of the benefits of early intervention, testicular salvage rates with conservative management approach only 33%, with delayed orchiectomy rates between 21% and 55% (Cass and Luxenberg, 1991; McAleer and Kaplan, 1995; Schuster, 1982). Timely surgical intervention for testis injury is also probably warranted as roughly one-half of patients initially managed conservatively fail and will ultimately undergo surgical exploration for pain, infection, and persistent hematoma (Cass and Luxenberg, 1991; Del Villar et al., 1973). Convalescence and time of return to normal activities are significantly reduced after early surgical repair.

In contrast with blunt testis rupture, for which salvage rates are very high, penetrating testicular trauma has historically been associated with gonad salvage in only 32% to 65% of cases in historic cohorts (Bickel et al., 1990; Brandes et al., 1995; Cline et al., 1998; Gomez et al., 1993). However, likely secondary to heightened provider awareness, improved salvage rates as high as 86% have been reported in more recent civilian series (Bjurlin et al., 2013; Phonsombat et al., 2008; Simhan et al., 2012) and combat series (Al-Azzawi et al., 2014; Janak et al., 2017; Waxman et al., 2009). Most surgical patients have adequate preservation of hormonal and fertility function (Kukadia et al., 1996). Sperm production has been documented in men with appropriately repaired bilateral testis rupture and bilateral penetrating injuries (Brandes et al., 1995; Pohl et al., 1968).

Urologists may be consulted for opinion and guidance with regard to boys with a solitary testis who play a contact sport. Testicular injuries are exceedingly rare in boys involved in individual or team contact sports and recreational activities (McAleer et al., 2002; Wan et al., 2003a, 2003b). Parents should be appropriately counseled, and a protective cup device should be recommended, but it also must be made clear that the benefits of continued physical activity far outweigh any concerns for potential complications (Diokno and Rowe, 2010). Further, the American Academy of Pediatrics Committee on Sports Medicine and Fitness has definitively recommended that children with a solitary testicle be allowed to participate universally in noncontact and full-contact sports (Rice, et al., 2008).

Genital Skin Loss

Etiology

Necrotizing gangrene secondary to polymicrobial infection in the genital area, or Fournier gangrene, is the most common cause of extensive genital skin loss (McAninch et al., 1984). Skin loss is iatrogenic, caused by the necessity for acute debridement of necrotic genital skin and optimization of infection control.

Penile skin loss can result from traction by mechanical devices, such as farm or industrial machinery, or by suction devices, such as vacuum cleaners. Because the superficial penile tissue is loose areolar tissue, it is often torn free without damage to the underlying structures. Significant scrotal skin loss resulting from penetrating trauma is uncommon, but it can be seen more commonly in explosive injuries (Fig. 133.9) (Janak et al., 2017).

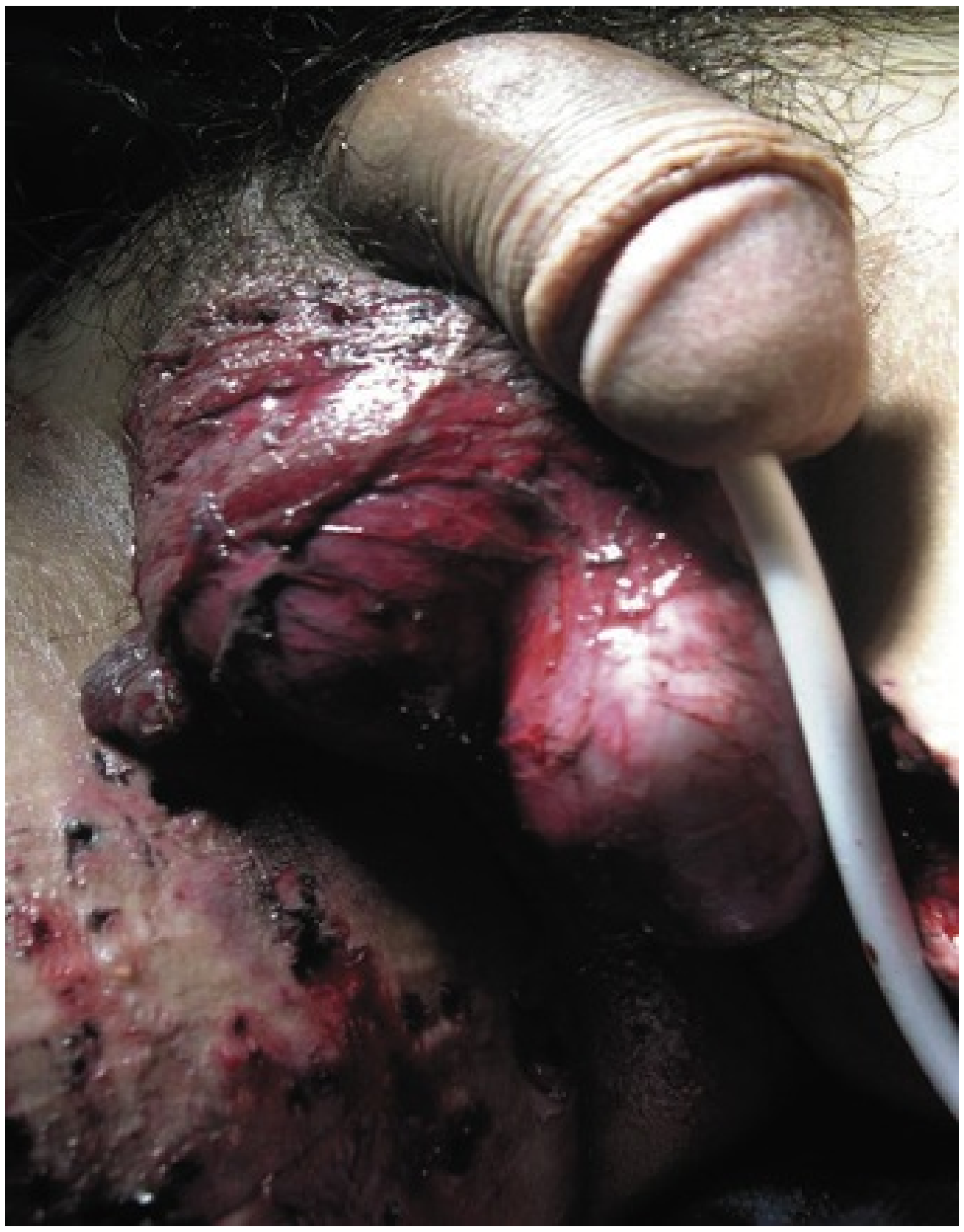

FIG. 133.9 Extensive loss of scrotal skin from explosive blast injury. Note numerous concomitant shrapnel injuries to the thigh.

Penile burns, although rare, are often full-thickness burns because the penile skin is so thin (Horton and Dean, 1990). Constricting bands placed on the penis can result in significant skin loss, although a more common injury involves direct pressure necrosis under the band, which usually heals well with device removal alone.

Diagnosis and Initial Management

Although both cellulitis and Fournier gangrene are commonly associated with significant genital edema and erythema, skin ischemia with crepitus is the hallmark of Fournier gangrene. The finding of loss of scrotal rugae is highly suggestive of tissue necrosis. Scrotal ultrasonography (Kane et al., 1996; Morrison et al., 2005) and CT may reveal subcutaneous air, a helpful indicator of necrotizing infection (Fig. 133.10).

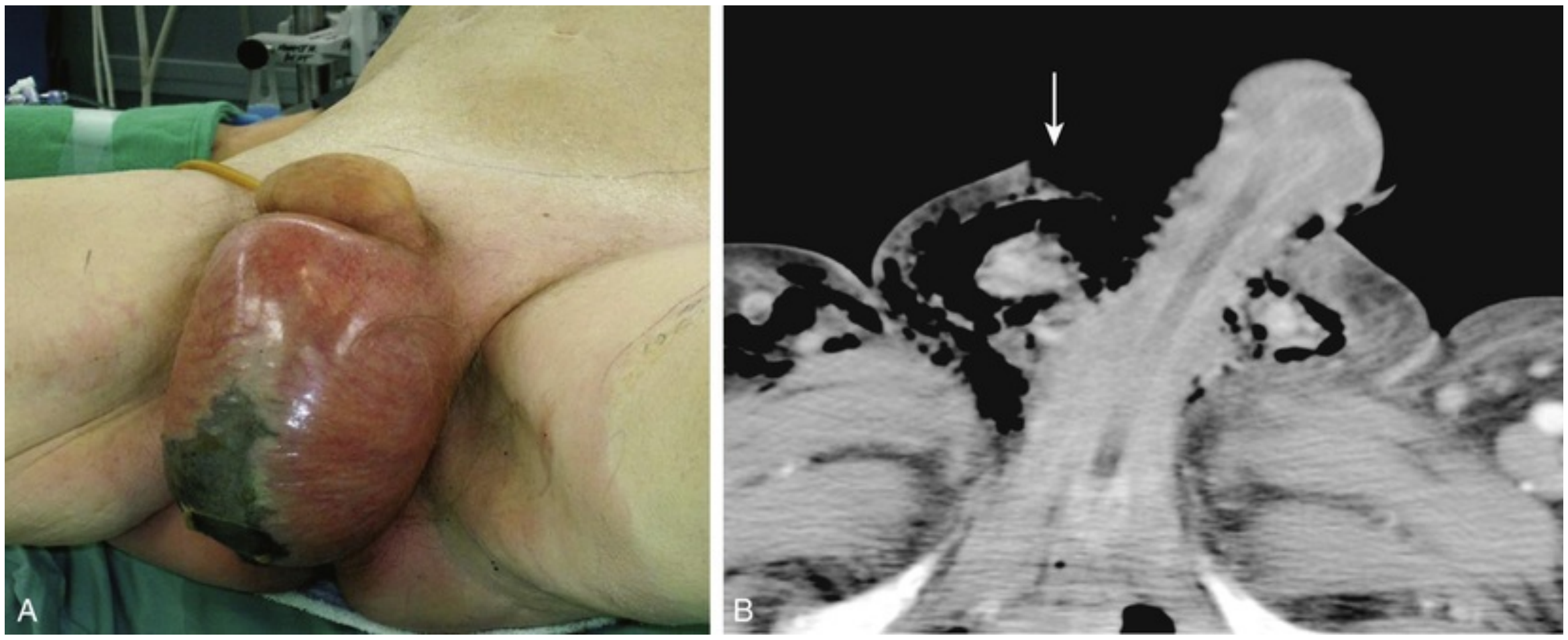

FIG. 133.10 (A) Large erythematous scrotum with central necrosis suggestive of necrotizing infection. (B) Computed tomography scan reveals subcutaneous air in the scrotum *(arrow)* secondary to Fournier gangrene.

In most cases of Fournier gangrene, multiple debridements of ischemic or frankly necrotic skin are required over a period of several days until active infection is controlled (AUA Urotrauma Guidelines, Statement 31). Wounds are treated with frequent wet-to-dry dressing changes or with vacuum-assisted closure therapy (Czymek et al., 2009) until primary coverage is planned. Inspection at least daily by the surgical team is mandatory. **Early suprapubic urinary diversion should be strongly considered for extensive injuries to simplify wound care and to prevent urethral complications related to prolonged catheterization.** Hyperbaric oxygen treatment has been advocated as an adjunctive measure to promote wound healing, although we do not recommend this because of the considerable increased expense and logistical complexity in the absence of proven benefit (Mindrup et al., 2005). Negative-pressure wound care therapy can also be utilized in complex cases of Fournier gangrene with large wound surface areas to reduce mortality and theoretically promote wound granulation (Czymek et al., 2009).

Genital burns are largely treated similarly to other burns, with early resection of burn eschar and coverage with split-thickness skin grafts when possible. Partial-thickness skin loss or genital burns may be treated with silver sulfadiazine cream. For deep penile electrical burns, a conservative approach is warranted because the ultimate outcome usually is autopenectomy and/or death as a result of extensive concurrent injuries (Medendorp et al., 2007).

Penile Reconstruction

In selected uncircumcised patients, mobilization of redundant foreskin may allow primary closure of middle to distal penile skin loss (Horton and Dean, 1990). Scrotal rotation flaps can also be used for more proximal defects if skin loss is limited, but the hair-bearing nature of scrotal skin risks an unacceptable cosmetic result (Zhao et al., 2009). Local flaps, such as from the abdomen and thigh, can be used but are cosmetically inferior to split-thickness skin grafts. Skin coverage with avulsed skin should be avoided because it often becomes necrotic.

Thick (0.012- to 0.015-inch), nonmeshed, split-thickness skin grafts (McAninch et al., 1984) **are preferred for penile reconstruction.** Meshed grafts can be used but have a tendency to contract and are cosmetically inferior to unmeshed grafts. Grafts are usually harvested from the anterior thigh with a pneumatic dermatome. **If grafts are to be used, care must be taken to remove any subcoronal skin remaining after debridement. Lymphatic obstruction of this distal foreskin, if it is not excised, results in circumferential lymphedema** (McDougal, 2003). Graft stabilization in the immediate postoperative period may be achieved with either a tie-over-bolster technique or with a circumferential vacuum dressing (Senchenkov et al., 2006; Weinfeld et al., 2005). Skin grafts placed on the penile shaft never regain normal sensation (Horton and Dean, 1990), although sexual function is often preserved because of intact sensation in the glans and maintenance of corporal anatomy without alteration of blood flow.

Scrotal Reconstruction

Scrotal skin loss defects of up to 50% can often be closed directly. For extensive injuries, the testes may be placed in thigh pouches, treated with wet dressings, or placed under vacuum pressure dressings until reconstruction (Cuccia et al., 2009; Cummings and Boullier, 2000; Gomes et al., 2001). **Utilization of thigh pouches is often a historic maneuver that is not recommended initially because transmission of the infectious process into uninvolved tissues may occur.** During scrotal reconstruction, local skin flaps should be mobilized initially to cover as much of the tissue defect as possible (eFig. 133.11). Meshed split-thickness skin grafts can be employed for remaining reconstruction. In addition to providing an excellent cosmetic result, meshing allows exudate to escape from the interstices, improving graft take. The spermatic cords and testes are sewn together in multiple areas before grafting to prevent a bifid neoscrotum

(Tan et al., 2011). The neoscrotum may appear unnaturally tight initially, but after 6 to 12 months the testes eventually occupy a more natural dependent position. Thigh flaps can be used to reconstruct the scrotum when the testes have been buried in the thighs after traumatic or surgical scrotal removal (Morey and McAninch, 1999). Fibrin sealant has proven useful as a tissue glue to promote healing and to reduce drainage during complex genital reconstruction cases (Morris et al., 2006).

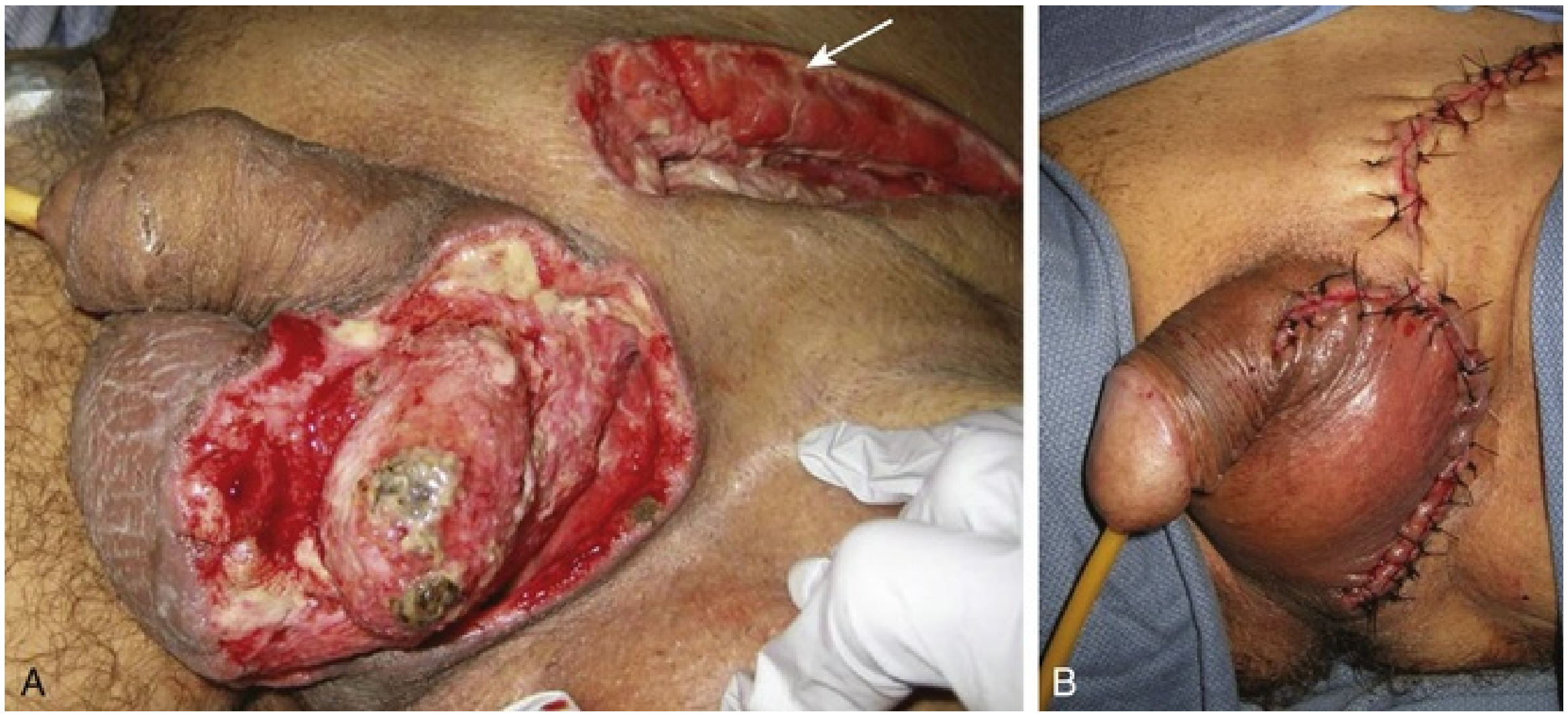

EFIG. 133.11 (A) Scrotal defect before final debridement and closure of left hemiscrotum for Fournier gangrene. *Arrow* indicates an inguinal counterincision made because of extension of infection to the inguinal canal. (B) Delayed primary closure. The right testis and tunica vaginalis were mobilized off the overlying scrotal tissue, which was then used to close the scrotal defect.

Key Points: Genital Trauma

- Although penile fracture can be diagnosed based on history and physical examination, penile ultrasonography is readily available, inexpensive, and rapid in equivocal cases.
- Gunshot wounds to the penis should be repaired primarily to prevent deformity and erectile dysfunction.
- Animal bites should be irrigated, debrided, and closed primarily, whereas most human bites should be left open.

- Blunt scrotal injury can be evaluated by ultrasonography for testicular rupture.
- Penetrating scrotal injuries should undergo surgical exploration to assess and repair deep tissues and remove contamination.

Bladder Injury

Etiology

The urinary bladder is generally protected from external trauma because of its deep location in the bony pelvis. Most blunt bladder injuries are the result of rapid-deceleration motor vehicle collisions, but many also occur with falls, crush injuries, assault, and blows to the lower abdomen. Disruption of the bony pelvis tends to tear the bladder at its fascial attachments, but bone fragments also can directly lacerate the organ. Other important causes of bladder rupture include penetrating trauma, iatrogenic surgical complications, and spontaneous rupture in patients with a history of neuropathic disease, preexisting bladder disease, or prior urologic surgery.

Bladder injuries that occur with blunt external trauma are rarely isolated injuries—80% to 94% of patients have significant associated nonurologic injuries (Bjurlin et al., 2009; Cass, 1984; Hsieh et al., 2002; Parry et al., 2003; Volpe et al., 1999). Mortality in these patients with multiple injuries is usually related to nonurologic injuries and ranges from 8% to 44% (Alli et al., 2003; Carroll and McAninch, 1984; Cass and Luxenberg, 1987; Corriere and Sandler, 1989; Parry et al., 2003; Volpe et al., 1999). **The most common associated injury is pelvic fracture, which is associated with 83% to 95% of bladder injuries** (Cass, 1989; Corriere and Sandler, 1989; Morey et al., 2001; Parry et al., 2003). Conversely, bladder injury has been reported to occur in only 5% to 10% of pelvic fractures (Aihara et al., 2002; Cass, 1989; Peters, 1989). Sudden force applied to a full bladder may result in a rapid increase in intravesical pressures and lead to rupture without pelvic fracture.

Penetrating bladder trauma is also associated with significant nonurologic injuries and mortality rate. Nearly one-half of all bladder injuries are iatrogenic (Dobrowolski et al., 2002); **obstetric and gynecologic complications are the most common causes of bladder injuries during open surgery** (Dobrowolski et al., 2002; Gomez et al., 2004).

Diagnosis and Radiographic Imaging

Extraperitoneal bladder injury is usually associated with pelvic fracture. Intraperitoneal injuries can be associated with pelvic fracture but are more commonly caused by penetrating injuries or burst injuries at the dome by direct blow to a full bladder. Appropriate diagnostic imaging is important because of the marked influence on management.

After blunt external trauma, the absolute indication for immediate cystography is gross hematuria associated with pelvic fracture; approximately 29% of patients presenting with this combination of findings have bladder rupture (AUA Urotrauma Guidelines, Statement 14; Morey et al., 2001). Relative indications for cystography after blunt trauma include gross hematuria without pelvic fracture and microhematuria with pelvic fracture. **The diagnosis of bladder rupture is extremely low in these atypical groups (e.g., 0.6% in patients with pelvic fracture and microhematuria), but the index of suspicion should be raised by associated clinical indicators of bladder injury. Conversely, penetrating injuries of the buttock, pelvis, or lower abdomen with *any* degree of hematuria warrant cystography.**

Key Points: Clinical Indicators of Bladder Injury

- Suprapubic pain or tenderness
- Free intraperitoneal fluid on CT or ultrasound examination
- Inability to void or low urine output
- Clots in urine or clots noted in bladder on CT
- Enlarged scrotum with ecchymosis
- Abdominal distention or ileus

Retrograde or stress cystography is nearly 100% accurate for bladder injury if performed appropriately. The bladder should be filled in cooperative and conscious patients to a sense of discomfort and otherwise to 350 mL. For a plain film technique, three images are obtained: one before administration of a contrast agent, one full-bladder anteroposterior film, and one drainage film. Posterior extravasation of the contrast medium can be missed without a drainage film. Significant bladder distention is required to visualize small tears. False-negative studies have been reported with retrograde instillation of only 250 mL (Morey and Carroll, 1997; Peters, 1989). Although hematuria and mechanism of injury mandate consideration of upper tract imaging studies, upper and lower urinary tract injuries are almost never coincident (0.4%) (Cass and Luxenberg,

1990).

A dense, flame-shaped collection of contrast material in the pelvis is characteristic of extraperitoneal extravasation (Fig. 133.12). Depending on fascial integrity, contrast material may extend beyond the confines of the pelvis and be visualized in the retroperitoneum, scrotum, phallus, thigh, or abdominal wall. The amount of extravasation is not always proportional to the extent of bladder injury. **Intraperitoneal extravasation is identified when contrast material outlines loops of bowel and/or the lower lateral portion of the peritoneal cavity.**

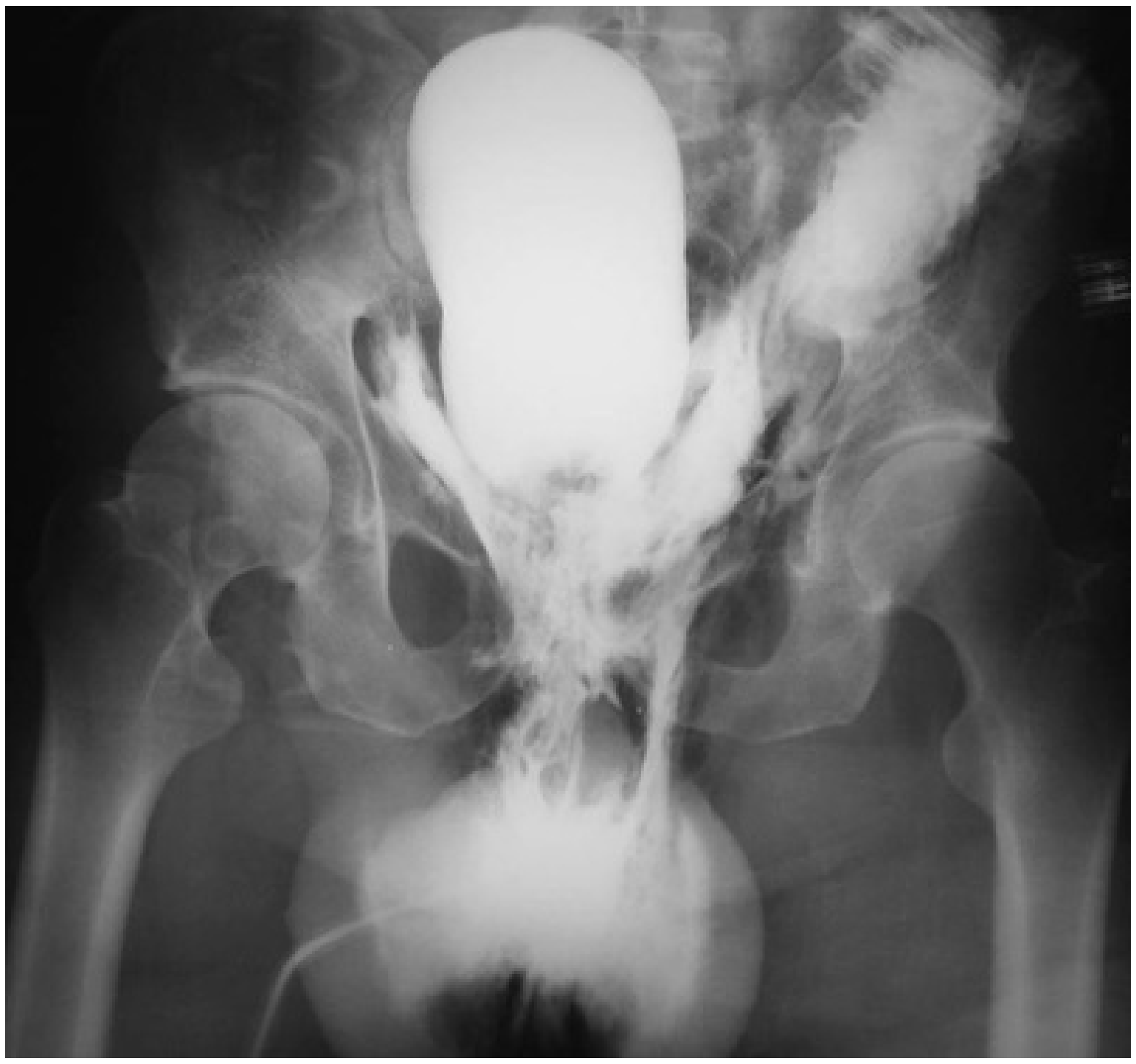

FIG. 133.12 Plain film cystogram reveals extraperitoneal bladder rupture with extravasation into the scrotum. Surgical exploration revealed anterior bladder neck and prostatic urethral laceration.

Because CT is now routinely used to assess trauma patients, concomitant CT cystography is frequently selected as a more efficient means to assess the bladder. CT cystography is as accurate and reliable as plain film cystography in evaluation of suspected bladder injury (Fig. 133.13), as long as the bladder is filled in retrograde fashion with contrast material diluted to 2% to 4% (6 : 1 dilution with saline) to a volume of 350 mL (Hsieh et al., 2002; Peng et al., 1999). Drainage films are not required after CT cystography because the retrovesical space can be well visualized with axial images (Morey and Carroll, 1997). Dilution of the contrast material is mandatory because undiluted contrast material is so dense that the CT quality is compromised by scatter artifact. **Clamping the urethral catheter in an attempt to allow antegrade distention of the bladder by intravenous contrast medium is notoriously inadequate for diagnosis of bladder rupture; retrograde filling is mandatory.** Conventional abdominal CT of a trauma patient may show findings suggestive of bladder injury, but it is not considered to be adequate for bladder evaluation without retrograde contrast distention (Hsieh et al., 2002; Mee et al., 1987; Udekwu et al., 1996).

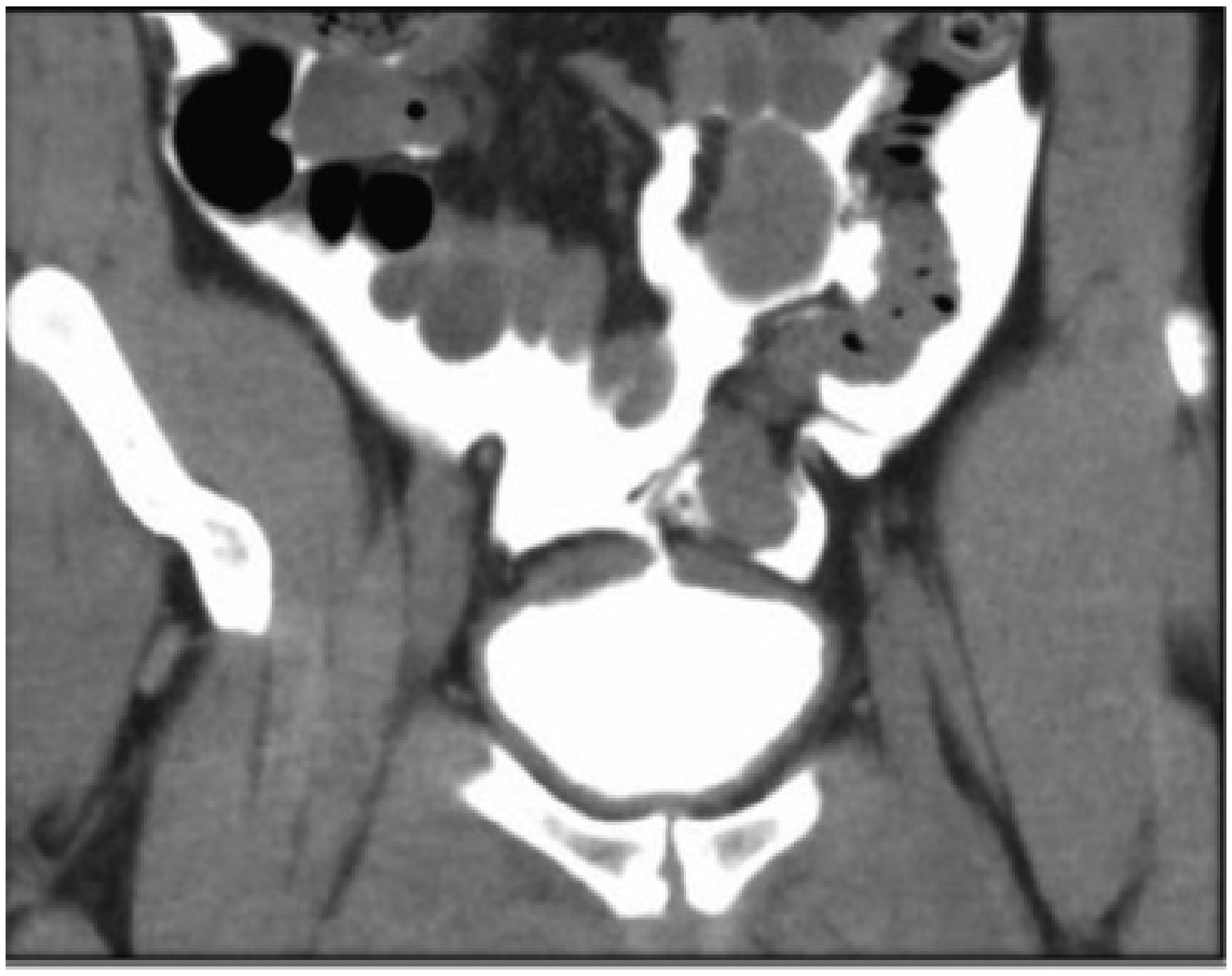

FIG. 133.13 Computed tomography cystogram demonstrates contrast material surrounding loops of bowel consistent with intraperitoneal bladder rupture.

Clinical Signs and Symptoms

Bladder rupture does not occur as an isolated, asymptomatic event in normal individuals. Conscious patients present with pronounced nonspecific symptoms such as suprapubic pain combined with the inability to void. Physical signs include suprapubic tenderness, lower abdominal bruising, muscle guarding and rigidity, and diminished bowel sounds. Associated abdominal and pelvic injuries may mask bladder symptoms. Higher suspicion for bladder injury is similarly warranted in patients who are unresponsive because of intoxication or altered sensorium.

Immediate catheterization should be performed when blunt bladder rupture is suspected. **The most reliable indicator is gross hematuria, which is present in nearly all cases** (Gomez et al., 2004; Hsieh et al., 2002; Iverson and Morey, 2001; Parry et al., 2003)**. If blood is noted at the meatus or the catheter does not pass easily, retrograde urethrography should be performed first because urethral injuries occur concomitantly in 10% to 29% of patients with bladder rupture** (Cass, 1989; Dobrowolski et al., 2002).

Management

The usual treatment of uncomplicated extraperitoneal bladder ruptures, when conditions are ideal, is conservative management with urethral catheter drainage alone (Fig. 133.14) (AUA Urotrauma Guidelines, Statement 16). A large-bore (22-Fr) Foley catheter should be used to promote adequate drainage; if output is poor, fluoroscopic cystography should be considered to ensure proper catheter placement. Cystography is necessary to verify complete healing before catheter removal 14 days after injury. If extravasation persists, continuation of urethral catheter drainage is maintained for several weeks, after which radiographic confirmation of healing is essential. Bone spicules within the bladder wall (eFig. 133.15) may compromise healing and thus prompt open repair. Antimicrobial agents are instituted on the day of injury and continued for at least 1 week to prevent infection of the pelvic hematoma.

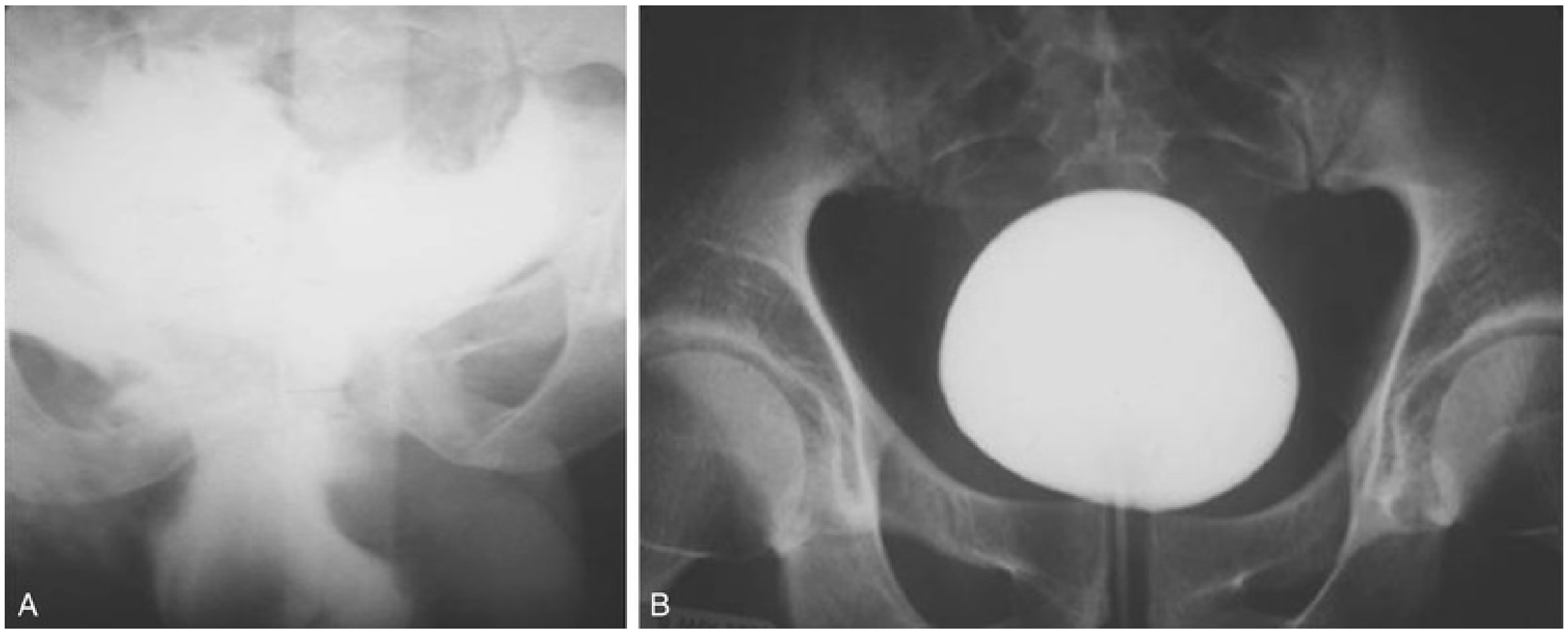

FIG. 133.14 (A) Dense flame-shaped pattern of contrast extravasation in the pelvis secondary to extraperitoneal bladder rupture. (B) Repeat

cystogram in the same patient after 2 weeks of catheter drainage shows a completely healed bladder.

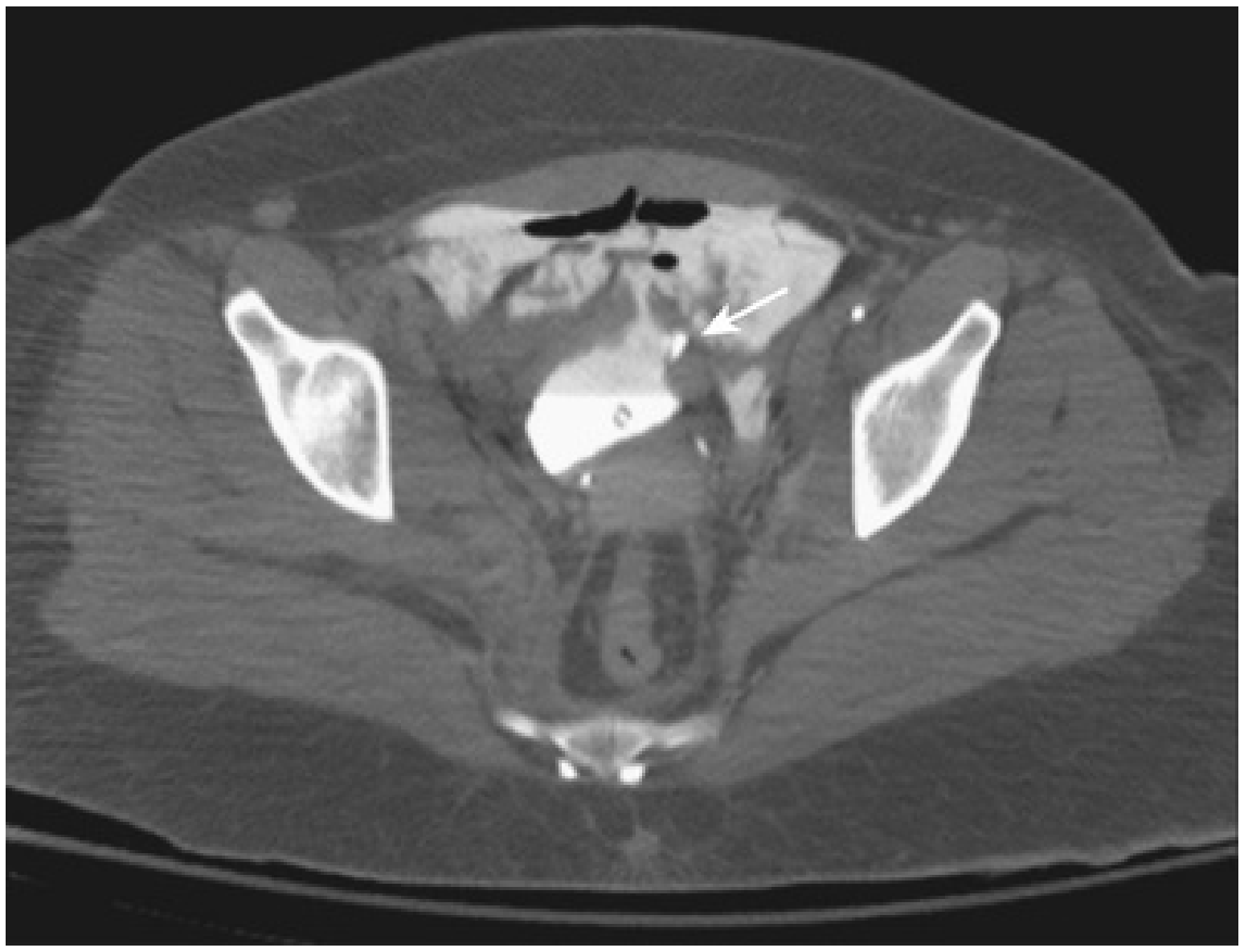

EFIG. 133.15 Computed tomography cystogram of a patient with extraperitoneal bladder rupture after a motor vehicle/pedestrian collision and extensive pelvic fracture. *Arrow* indicates a fragment of bone in the bladder, removed at the time of laparotomy and repair of the bladder.

Several series have reported fewer complications, such as fistula, failure to heal, clot retention, and sepsis, with open repair versus conservative management for patients with blunt extraperitoneal bladder injuries (Cass, 1989; Kotkin and Koch, 1995). In a recent contemporary series comparing operative and conservative management, cystorrhaphy performance resulted in fewer urologic complications such as fistula formation, decreased hospital length of stay, and a decreased time to negative cystography (Johnsen et al., 2016). **For this reason, blunt extraperitoneal injuries in the presence of complicating features (see Key Points in this section) warrant immediate open repair to prevent complications such as fistula, abscess, and prolonged leak.**

For patients undergoing exploratory laparotomy for other associated injuries or internal fixation of pelvic fracture, it is prudent to perform surgical repair of the extraperitoneal rupture at the same setting. The anterior bladder wall is entered directly in the midline, and the tear is closed intravesically with absorbable suture. The perivesical pelvic hematoma should not be disturbed. When internal fixation of pelvic fractures is performed, concomitant bladder repair is recommended because urine leakage from the injured bladder onto the orthopedic fixative hardware is prevented, reducing the risk for hardware infection. Drainage of the repaired bladder can be safely accomplished with a large-bore Foley catheter alone, and cystography performed 1 week after repair should verify bladder healing.

Key Points: Indications for Immediate Repair of Bladder Injury

- Intraperitoneal injury from external trauma
- Penetrating or iatrogenic nonurologic injury
- Inadequate bladder drainage or clots in urine
- Bladder neck injury
- Rectal or vaginal injury
- Open pelvic fracture
- Pelvic fracture requiring open reduction and internal fixation
- Selected stable patients undergoing laparotomy for other reasons
- Bone fragments projecting into the bladder

Penetrating or intraperitoneal injuries resulting from external trauma should be managed by immediate operative repair. In a national study of patients with bladder trauma, operative repair was associated with a 59% reduction in mortality (Deibert and Spencer, 2011). These injuries are often larger than suggested on cystography and are unlikely to heal spontaneously. A prolonged leak of urine may cause a chemical peritonitis or abscess. Select patients with isolated intraperitoneal bladder injuries may undergo laparoscopic repair (Kim et al., 2008). **When bladder injuries are explored after penetrating trauma without preliminary imaging, the ureteral orifices should be inspected for clear efflux; ureteral integrity also may be ensured by intravenous administration of indigo carmine, methylene blue, fluorescein green, or retrograde passage of a ureteral catheter.** Any penetrating injury involving the ureteral orifice or intramural ureter warrants primary closure with stented reimplantation of the ureter and a perivesical drain. In patients with intraperitoneal rupture, antimicrobial agents are administered for

3 days in the perioperative period only. If the bladder has been repaired, a cystogram can be obtained 7 to 10 days after surgery (Corriere and Sandler, 1989). **Several additional studies have shown that suprapubic tube drainage provides no benefit over urethral catheter drainage alone** (Alli et al., 2003; Parry et al., 2003; Thomae et al., 1998; Volpe et al., 1999), thus recent guidelines have suggested catheter drainage alone to be sufficient for management (AUA Urotrauma Guidelines, Statement 18). When concurrent rectal or vaginal injuries exist, the organ walls should be separated, overlapping suture lines should be avoided, and every attempt should be made to interpose viable tissue in between the repaired structures. Fibrin sealant injected over the bladder wall closure may help reduce complications when intervening tissue is unavailable (Evans et al., 2003).

Outcomes and Complications

Prompt diagnosis and appropriate management of bladder injuries promote excellent results and minimal morbidity. Serious complications are usually associated with delayed diagnosis or treatment because of misdiagnosis, delayed presentation, or complex injuries resulting from devastating pelvic trauma. Unrecognized bladder injuries may manifest as acidosis, azotemia, fever and sepsis, low urine output, peritonitis, ileus, urinary ascites, or respiratory difficulties. Unrecognized bladder neck, vaginal, and rectal injury associated with bladder rupture can result in incontinence, fistula, stricture, and difficult delayed major reconstruction. Severe pelvic fractures may cause a transient or permanent neurologic injury and result in voiding difficulties despite an adequate bladder repair.

Urethral Injury

Posterior Urethral Injuries

Etiology

Pelvic fracture urethral injury (PFUI) typically occurs in conjunction with multisystem trauma from motor vehicle accidents, falls, or industrial accidents. Fracture of the anterior pelvic ring or pubic diastasis is usually present when urethral disruption is encountered, and a greater degree of displacement has been correlated to a higher risk for urethral injury (Basta et al., 2007). **“Straddle fractures” (eFig. 133.16) involving all four pubic rami and fractures resulting in vertical and rotational pelvic instability are associated with the highest risk for urologic injury** (Brandes and Borelli, 2001; Koraitim, 1999; Mundy, 1996). Urethral injury has been reported to occur in approximately 10% of male patients and up to 6% of female patients with pelvic fractures (Black et al., 2006; Koraitim, 1999). Girls younger than 17 years of age have a higher risk for urethral injury compared with women, perhaps because of greater compressibility of the pelvic bones (Hemal et al., 1999).

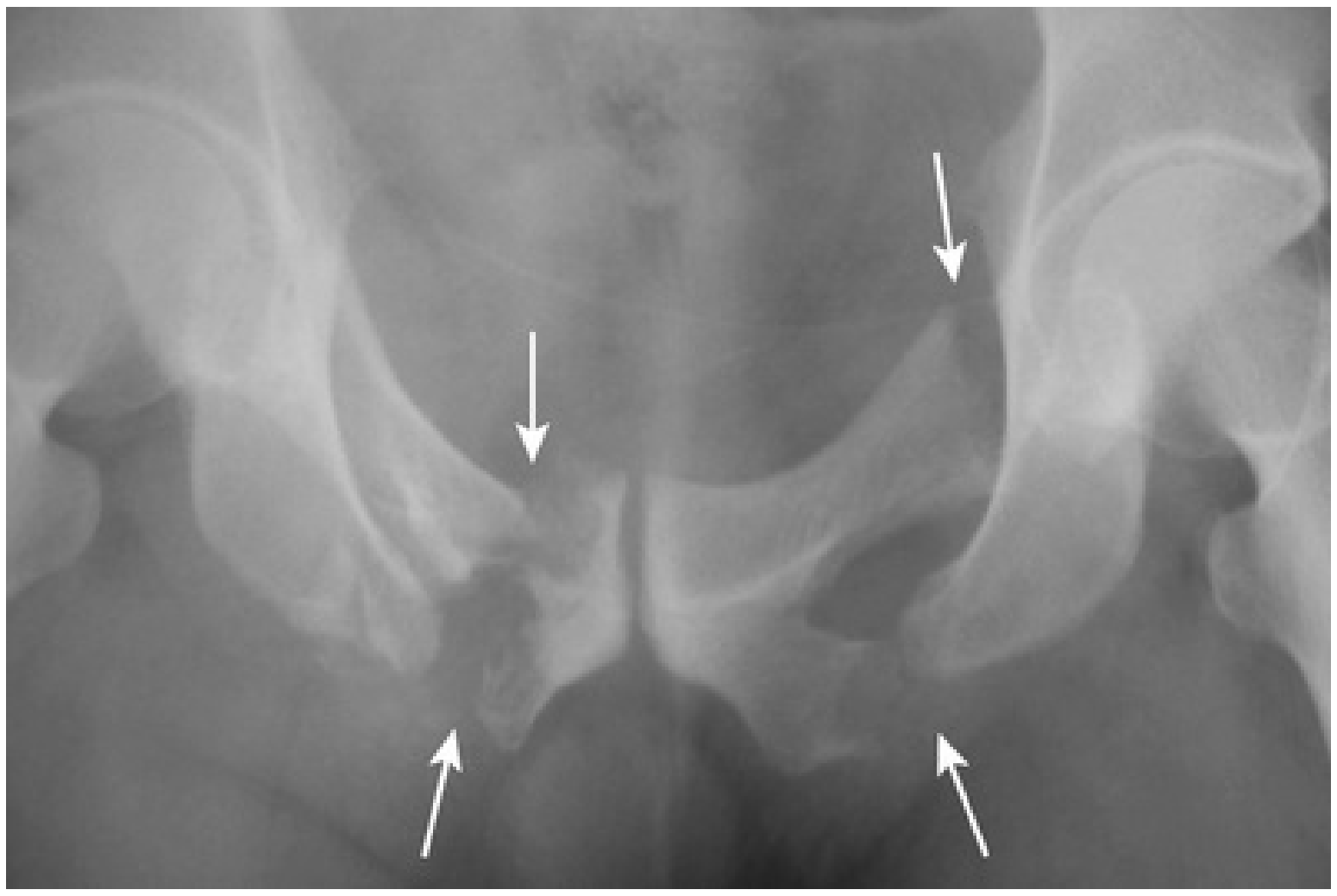

EFIG. 133.16 Anteroposterior film of the pubis shows a straddle fracture involving all four pubic rami *(arrows)* in a patient with a posterior urethral disruption in whom initial perineal posterior urethroplasty failed because of severe bone distortion. Reconstruction was successfully performed by an abdominoperineal technique.

Because the posterior urethra is densely adherent to the pubis via the urogenital diaphragm and the puboprostatic ligaments, the bulbomembranous junction is more vulnerable to injury during pelvic fracture than the prostatomembranous junction (Brandes and Borelli, 2001; Colapinto and McCallum, 1977)**. Endoscopic and urodynamic evaluation has confirmed that the membranous urethral sphincter complex tends to remain functionally intact while being avulsed vertically, posteriorly, or laterally from the underlying bulb** (Andrich and Mundy, 2001; Mundy, 1997). In children, injuries are less common (Tarman et al., 2002) but are more likely to extend proximally to the bladder neck because of the rudimentary nature of the prostate (Al-Rifaei et al., 1991; Boone et al., 1992; Devine et al., 1989).

Diagnosis

Examination.

Urethral disruption is heralded by the triad of an inability to urinate, blood at the meatus, and a palpably full bladder. Because these and other classic findings, such as a “high-riding” prostate or a “butterfly” perineal hematoma, may frequently be absent or difficult to discern (Esposito et al., 2005; Sandler and Corriere, 1989), urethral disruption is often first detected when a urethral catheter cannot be placed by the trauma team or when it is misplaced into a pelvic hematoma. Pelvic hematoma often obscures the prostatic contour, resulting in misdiagnosis of an impalpable prostate (Koraitim et al., 1996). Although more rare than in male counterparts, female patients also may develop proximal urethral avulsion injuries. They present with vulvar edema (Fig. 133.17) and blood at the vaginal introitus, indicating the need for careful vaginal examination in all female patients with pelvic fracture (Perry and Husmann, 1992).

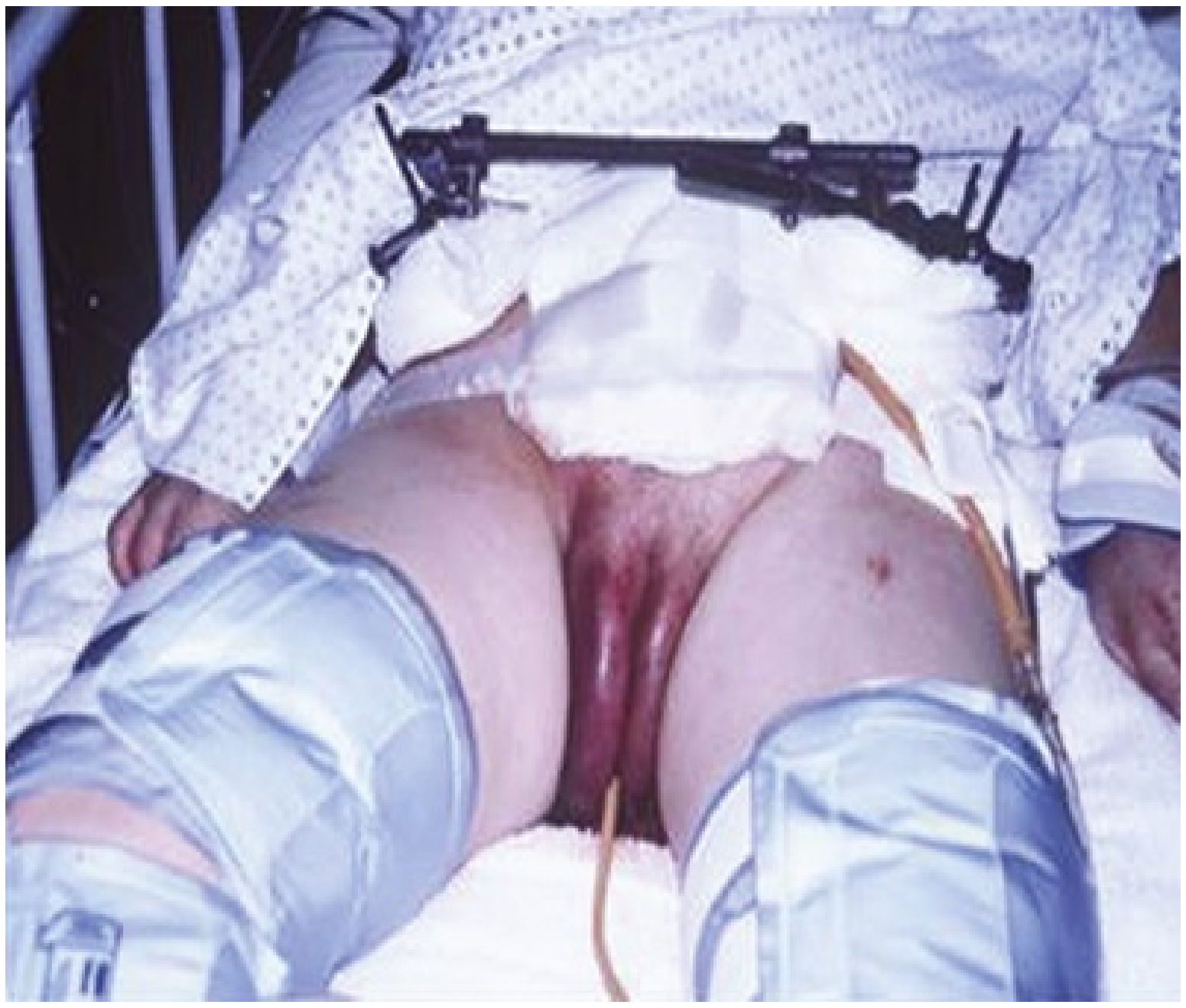

FIG. 133.17 Pelvic fracture urethral disruption injury and marked vulvar edema and ecchymosis in a female patient.

Urethrography.

When blood at the urethral meatus is discovered, an immediate retrograde urethrogram should be performed to rule out urethral injury (Fig. 133.18) (AUA Urotrauma Guidelines, Statement 19). A small-bore (16-Fr) urethral catheter is placed unlubricated 1 cm into the fossa navicularis, and the balloon is filled with 3 mL of water to achieve a snug fit (Sandler and Corriere, 1989). Alternatively, a Brodney clamp or rolled gauze bandage can be used to provide penile traction. Patients should be placed in an oblique or lateral decubitus position, and it is preferable to perform the study under fluorography when it is available; 25 mL of contrast medium is injected gently by a 60-mL catheter-tip syringe, and the film is taken during injection. **Direct inspection by urethroscopy is suggested in lieu of urethrography in female patients with suspected urethral injury** (Koraitim, 1999; Perry and Husmann, 1992).

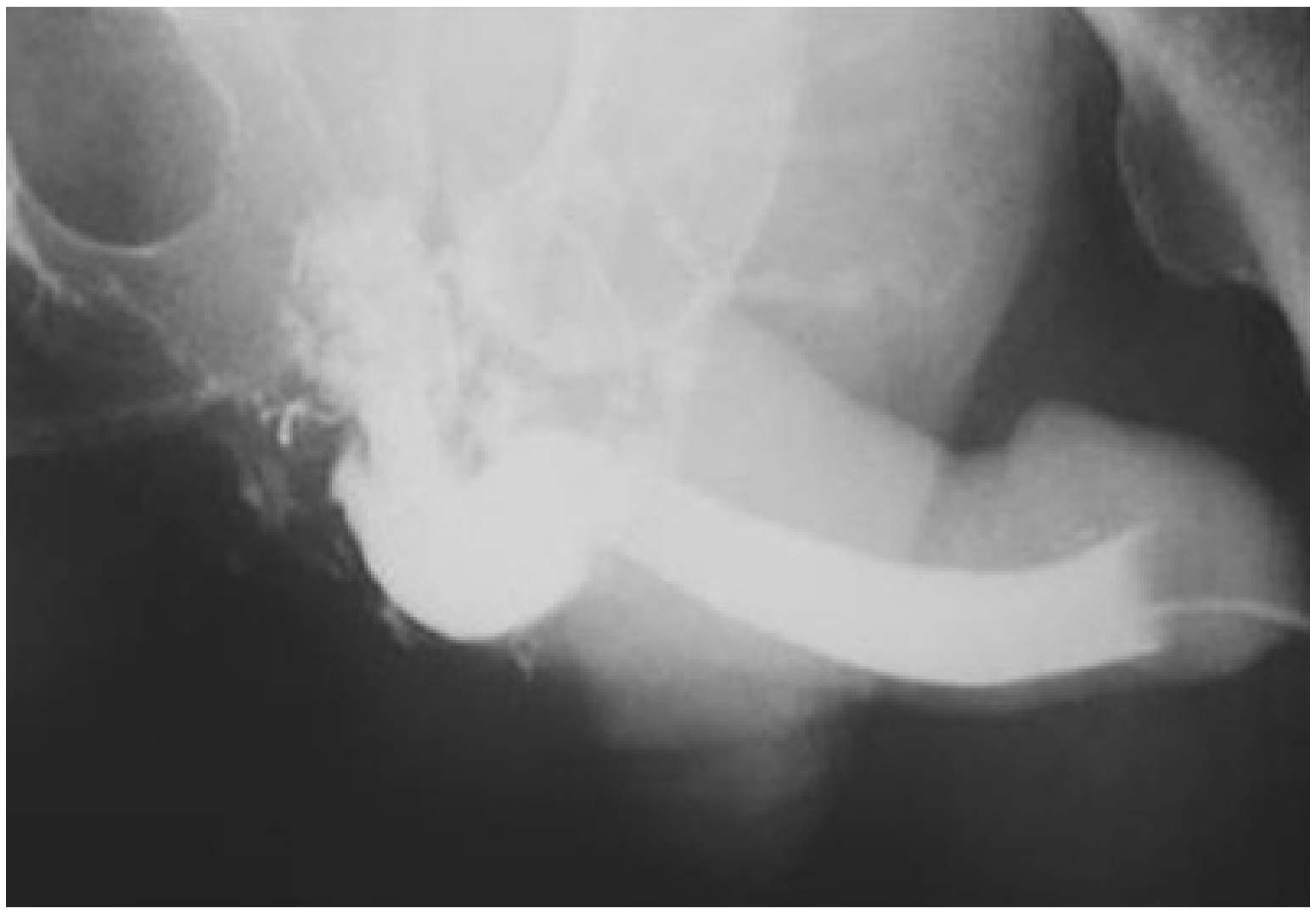

FIG. 133.18 Retrograde urethrogram in a patient with a pelvic fracture shows complete disruption of the posterior urethra.

Initial Management

Initial Management: Suprapubic Cystostomy With Planned Delayed Reconstruction.

Immediate suprapubic tube placement remains the standard of care in men with severe posterior urethral injuries. Percutaneous suprapubic tube placement is safe and expedient when the bladder is obviously distended and no other indications for surgery exist. We prefer a 16-Fr Foley catheter placed via a peel-away sheath trochar in the lower midline, using a preliminary 18G spinal needle and Trendelenberg positioning as adjuncts. Smaller “punch” suprapubic tubes are less robust, tending to fracture or obstruct with debris requiring urgent replacement within several weeks. Alternatively, an infraumbilical incision allows direct inspection and repair of concomitant bladder injury with placement of a large-bore catheter at the bladder dome. Delayed urethral reconstruction may then be performed on an elective basis within several months when the patient is ambulatory.

Increasingly, patients with pelvic ring fracture undergo early surgical fixation by orthopedists to decrease bleeding, improve healing, and speed ambulation (Connor et al., 2003)**. Although orthopedists may suggest that a suprapubic tube not be placed if anterior pubic hardware is anticipated because of concern that the suprapubic tube will lead to hardware infection** (Patterson, 1995)**, we and others** (Bepple et al., 2007; Borrelli and Brandes, 2004) **have**

repeatedly found that suprapubic cystostomy can be used safely without complications throughout the course of care (Fig. 133.19) (AUA Urotrauma Guidelines, Statement 21). When transurethral access to the bladder is compromised because of injury, and the pelvic fracture is managed by open reduction internal fixation, we place a large-bore (24-Fr) Foley catheter in the bladder, tunneled through the skin as high on the lower abdominal midline to keep the tube away from the plated symphysis.

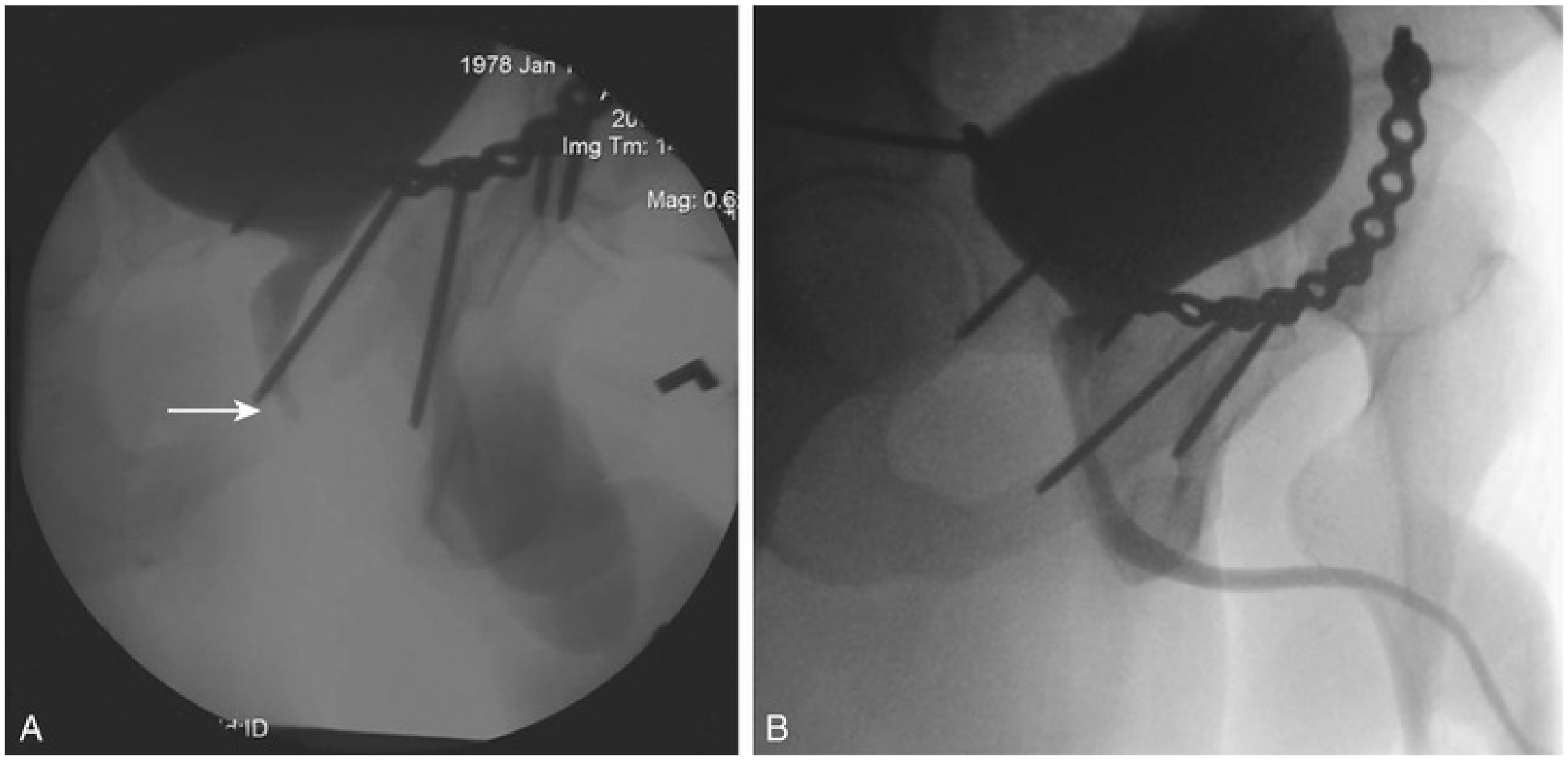

FIG. 133.19 (A) Defect in the urethra *(arrow)* seen on an antegrade urethrogram in a patient after pelvic fracture urethral disruption and internal fixation of anterior pelvic fracture. (B) Postoperative voiding urethrogram demonstrates normal-caliber urethra after perineal urethroplasty.

Initial Management: Primary Realignment.

A brief attempt at primary realignment of the urethral injury is recognized as an alternative option in patients whose condition is stable (AUA Urotrauma Guidelines, Statement 22; Elliott and Barrett, 1997) **and can be done either acutely or within several days of injury.** Combined retrograde and anterograde flexible cystoscopes have been advocated for realignment (Asci et al., 1999; Elliott and Barrett, 1997; Follis et al., 1992; Hadjizacharia et al., 2008; Leddy et al 2012; Mouraviev et al., 2005; Porter et al., 1997; Routt et al., 1996), although prolonged endoscopic realignment attempts risk infection (Morey et al., 1999) and are thus not recommended (Fig. 133.20, AUA Urotrauma Guidelines, Statement 22).

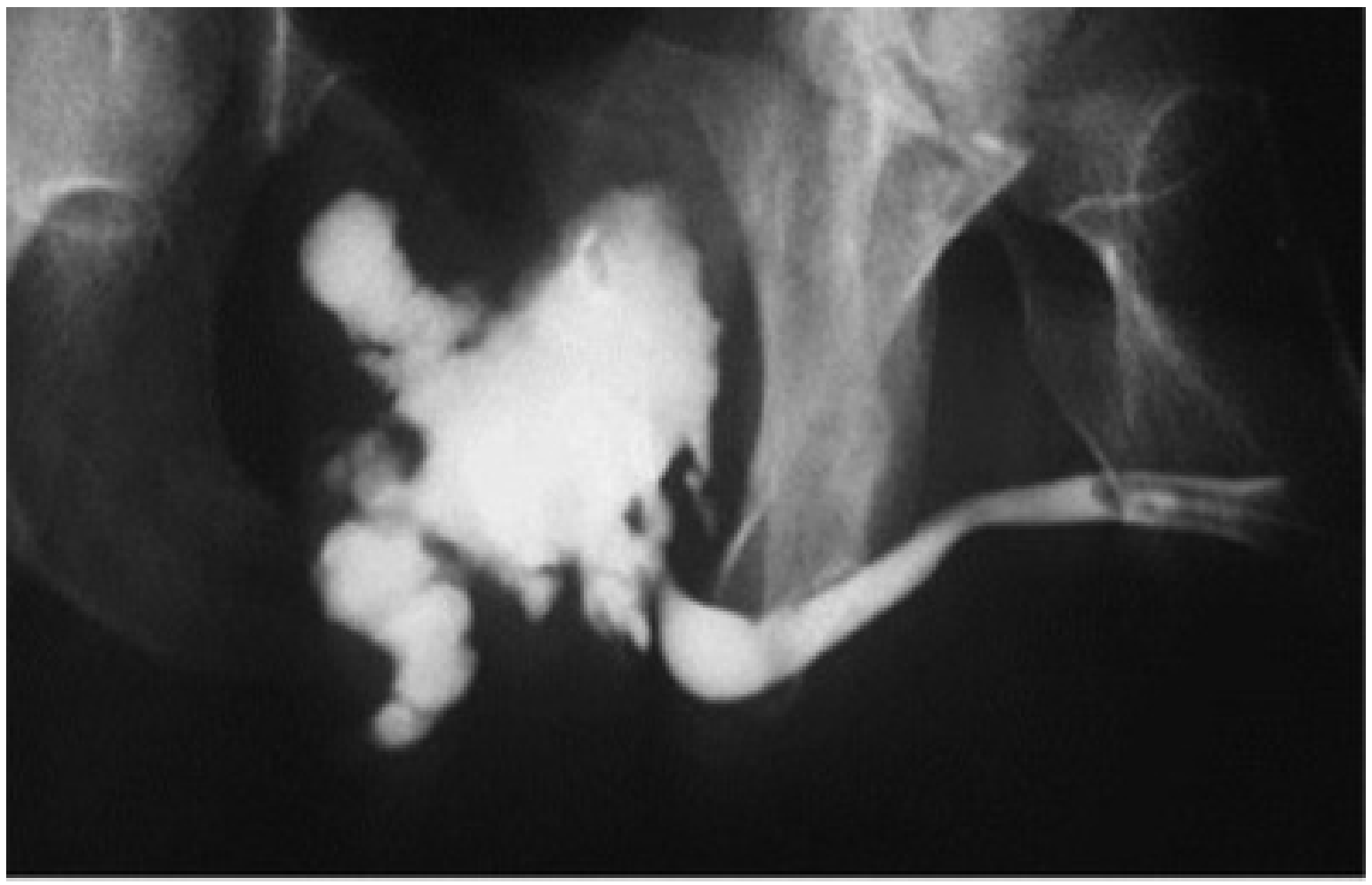

FIG. 133.20 Pelvic abscess diagnosed on retrograde urethrogram in a patient who underwent initial primary endoscopic realignment for urethral disruption.

After realignment, when the urethral catheter is removed after 4 to 6 weeks, it is imperative to retain a suprapubic catheter because an overwhelming majority of patients, despite realignment, will develop posterior urethral stenosis (Chung et al., 2018; Leddy et al., 2012). If the patient voids satisfactorily through the urethra, the suprapubic catheter can be removed 7 to 14 days later. Primary realignment rarely heals without stricture (Elliott and Barrett, 1997; Leddy et al., 2012). Whether realigned or not, urethral stenosis 1 to 2 cm in length typically ensues in an overwhelming majority of PFUI patients (Asci et al., 1999; Chung et al., 2018; Kotkin and Koch, 1996; Routt et al., 1996), requiring elective delayed posterior urethroplasty (Kotkin and Koch, 1996; Mouraviev et al., 2005). Further endoscopic treatments or dilations of PFUI are recognized as being costly and prone both to failure and adding complexity to the eventual repair (Horiguchi et al., 2017; Tausch et al., 2017). Multi-institutional investigation is currently underway to further assess the comparative treatment efficacy of immediate realignment to immediate suprapubic tube placement with delayed urethroplasty.

Incomplete urethral tears are best treated by stenting with a urethral catheter. Various investigators (Al-Ali and Husain, 1983; Kotkin and Koch, 1996; Mundy, 1991) **have not identified evidence that a gentle attempt at urethral catheterization converts an incomplete transection into a complete transection.** Caution is warranted because misplacement outside the bladder is theoretically possible; radiographic confirmation of adequate positioning is imperative. In no case should traction be used after urethral catheter placement as it may cause incontinence (Asci et al., 1999).

Delayed Reconstruction

In posterior urethral disruption, the rupture defect between the two severed ends fills with scar tissue, resulting in a complete lack of urethral continuity. This separation is not a stricture; it is a true urethral stenosis filled with fibrosis. **At 2 to 3 months, scar tissue at the urethral disruption site is stable enough to allow posterior urethroplasty to be undertaken safely, provided that associated injuries are stabilized and the patient is ambulatory.** Suprapubic cystostomy drainage should be maintained until any associated injuries have healed and the patient can be appropriately positioned for the reconstructive procedure.

Preoperative Evaluation.

Before the reconstructive procedure is planned, imaging studies are necessary to delineate the characteristics of the urethral rupture defect. **A cystogram and retrograde urethrogram should be obtained simultaneously ("up-and-down-o-gram," Fig. 133.21).** The patient is asked to attempt to void with the bladder filled. Ideally, the prostatic urethra should be visualized as the bladder neck opens, enabling measurement of the distance between the severed urethral ends. If the bladder neck does not open, flexible endoscopy should be used to supplement radiographic imaging (Mundy, 1997). The appearance of the bladder neck on preoperative imaging may not correlate with bladder neck behavior postoperatively (Koraitim, 2010; Mundy, 1997), making it difficult to predict bladder neck incompetence or obstruction. MRI has been employed to define the length of the defect and to determine the extent and direction of urethral dislocation (Dixon et al., 1992) and the extent of prostatic displacement, and it may help in planning the surgical approach (Koraitim and Reda, 2007).

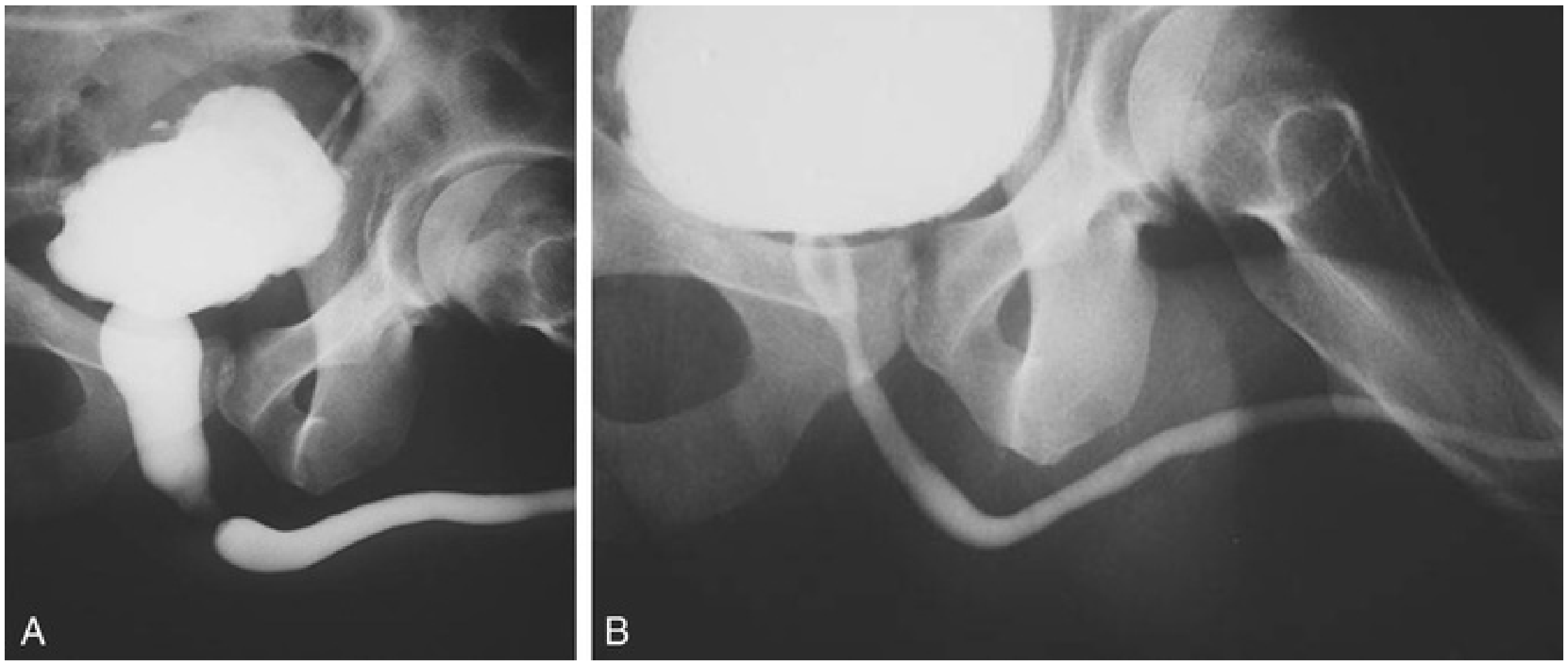

FIG. 133.21 (A) Combined cystogram and urethrogram 4 months after pelvic fracture shows complete posterior urethral disruption injury. (B) Postoperative appearance reveals normal urethral caliber.

Endoscopic Treatment

Endoscopic treatments such as direct-vision internal urethrotomy are best reserved for select short, incomplete urethral stenoses, such as partial distraction injuries for which early catheterization has maintained initial urethral continuity. When preoperative evaluation indicates defects 1 cm or longer, endoscopic procedures such as cutting through the pelvic scar to provide a channel between the two ends of the avulsed urethra ("cut-to-the-light" procedure) tend to be ineffective. Aggressive endoscopic treatments have been associated with complications such as coring of a false passage that inadvertently bypasses the bladder neck (Turner-Warwick, 1989). Cut-to-the-light or similar core-through procedures typically require multiple urethrotomies or long-term dilation by the patient and/or urologist to keep the channel open. Inevitably, the fibrosis contracts, leading to difficult self-catheterization, false passage, and/or acute urinary retention. In such cases, a 2- to 3-month period of "urethral rest" via suprapubic urinary diversion is advised before open reconstruction (Terlecki et al., 2011).

Surgical Reconstruction

Open posterior urethroplasty through a perineal anastomotic approach is the treatment of choice for most urethral distraction injuries because it definitively cures the patient without the need for multiple procedures. When preoperative studies have determined that the prostatic urethral apex can be reached by a perineal approach, the patient is placed in the high lithotomy position, and a midline or lambda-shaped incision is made. The bulbar urethra is freed and mobilized from the site of urethral rupture to the midscrotum. The scar tissue of the urethral rupture defect is excised, and the prostatic urethra is identified at the apex of the prostate. Care must be taken to excise carefully and meticulously all fibrotic tissue from the proximal urethral margin until at least a 28-Fr bougie passes without resistance (eFig. 133.22) (Morey and McAninch, 1997; Turner-Warwick, 1989). The bulbar urethra is then anastomosed in a tension-free manner to the prostatic urethra.

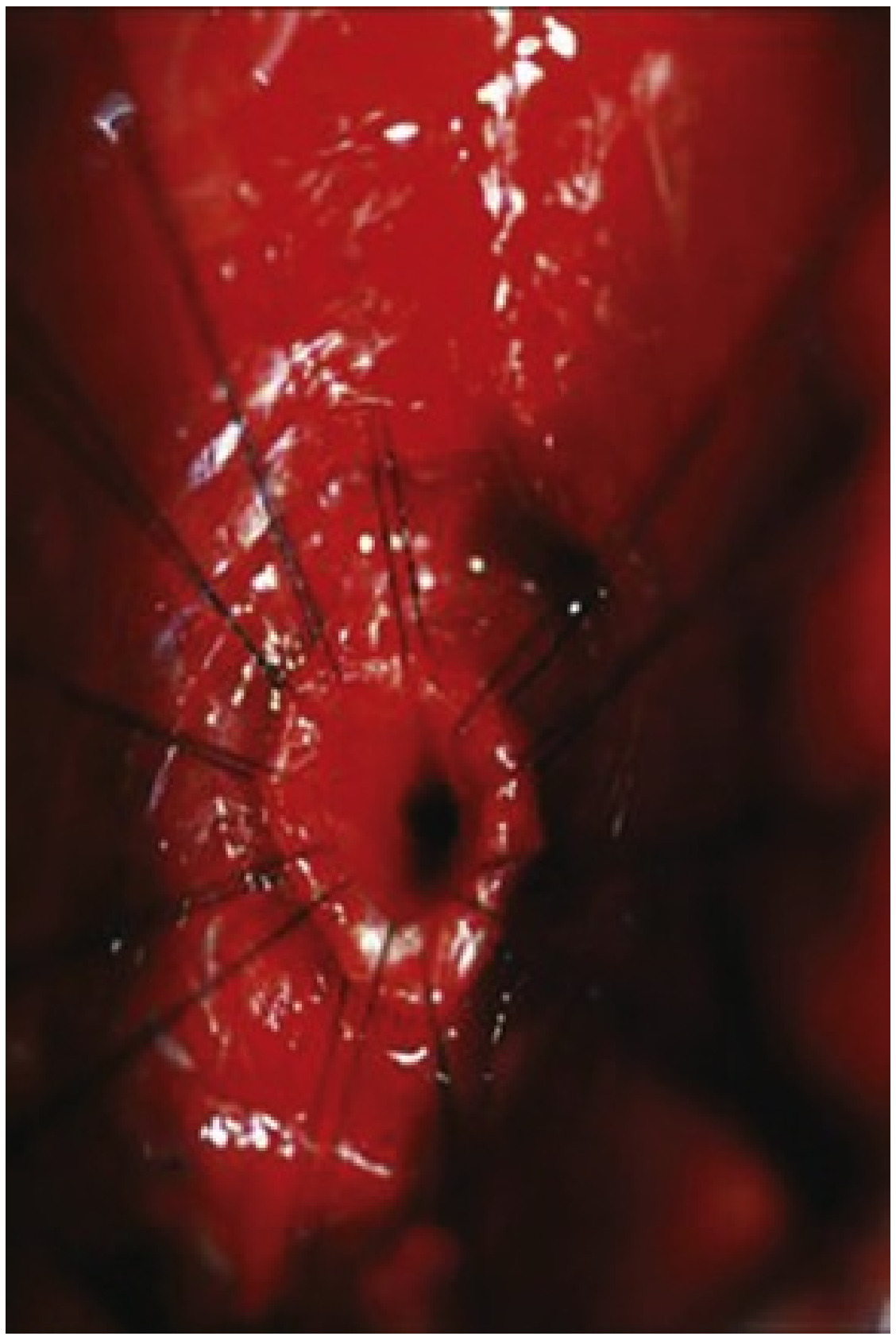

EFIG. 133.22 Intraoperative view of normal membranous urethra after fibrotic tissue was excised during perineal bulbomembranous urethroplasty.

Posterior urethral anastomosis is successfully achieved in a majority of cases through a perineal approach alone (Carr and Webster, 1997; Kizer et al., 2007)**. Adjunctive maneuvers such as corporal splitting, inferior pubectomy, and corporal rerouting are often implemented if direct anastomosis proves difficult** (Flynn et al., 2003; Mundy, 1997)**. Others have found these**

maneuvers, especially supracrural rerouting, to be unnecessary and/or unhelpful in many cases (Cooperberg et al., 2007; Kizer et al., 2007; Morey and McAninch, 1997; Rosenstein and Jordan, 2003).

Total removal of the symphysis pubis, first reported by Pierce in 1962, has been recommended when severe injuries result in complicating features such as fistula or marked displacement or retropubic fixation of the prostate (Asci et al., 1999; McAninch, 1989; Netto, 1985; Pierce, 1962). **Alternatively, a combined abdominoperineal approach (with or without partial pubectomy) has proven helpful in cases of severe fibrosis, fistula, previous failed anastomotic urethroplasty, and associated bladder neck injury, and in pediatric cases** (Al-Rifaei et al., 1991; Koraitim, 2003, 2005; Pratap et al., 2006; Waterhouse, 1976). It is important to limit the lithotomy time to 5 hours or less to prevent lower extremity complications when any complex urethral reconstruction is undertaken (Anema et al., 2000).

Complications: Erectile Dysfunction.

Some degree of impotence is noted in as many as 82% of patients with pelvic fracture and urethral distraction injury (Flynn et al., 2003)**, although the average reported rate is approximately 50%** (Asci et al., 1999; Blaschko et al., 2015; Corriere et al., 1994; Elliott and Barrett, 1997; Koraitim, 2005; Routt et al., 1996)**. The etiology is multifactorial and variably attributed to cavernous nerve injury, arterial insufficiency, venous leak, and direct corporal injury** (Munarriz et al., 1995; Narumi et al., 1993; Shenfeld et al., 2003). Factors that correspond to the severity of the injury, such as diastasis of the pubic symphysis, lateral displacement of the urethra, and long urethral gap, have been found to correlate with erectile dysfunction (Feng et al., 2008; Koraitim, 2013).

Some surgical series have shown a small number of patients with new-onset or worsened erectile dysfunction after reconstruction (Tunc et al., 2000); however, the complications of the original pelvic injury are difficult to differentiate from the complications of attempts to repair urethral and bladder injuries. Accounts of greater risk for erectile dysfunction and incontinence with primary realignment were published before the advent of flexible endoscopes (Koraitim et al., 1996). Several studies have shown that patients treated with modern techniques of primary endoscopic realignment have rates of impotence and incontinence similar to those of patients who have had either no treatment or delayed open reconstruction (Asci et al., 1999; Koraitim, 2005; Kotkin and

Koch, 1996; Mouraviev et al., 2005). **These studies support the conclusion that these complications are usually the result of the injury itself and not of the treatment** (Barrett et al., 2014; Corriere, 2001; Elliott and Barrett, 1997; Follis et al., 1992; Porter et al., 1997). Some patients who become impotent after injury spontaneously recover erectile function 1 or 2 years later (Koraitim, 2005; Morey and McAninch, 1997; Turner-Warwick, 1989).

Many patients who become impotent as a result of pelvic fracture have some degree of arterial insufficiency (Armenakas et al., 1993; Matthews et al., 1995). **Because patients with impotence may be more vulnerable to restenosis after posterior urethroplasty as a result of bulbar urethral ischemia, some experts have suggested that "at-risk" patients undergo preoperative penile arterial duplex Doppler studies to identify candidates who are suitable for initial penile revascularization** (Matthews et al., 1995; Rosenstein and Jordan, 2003; Zuckerman et al., 2012). However, indications for penile revascularization as a treatment for post-traumatic erectile dysfunction are extremely limited (Kawanishi et al., 2004). Overall rates of incontinence, anejaculation, and areflexic bladder are low (2% to 4%) (Anger et al., 2008; Asci et al., 1999; Corriere et al., 1994; Elliott and Barrett, 1997), although these conditions along with erectile dysfunction must be monitored for at least 1 year after urethral injury (AUA Urotrauma Guidelines, Statement 23).

Complications: Recurrent Stenosis.

After posterior urethroplasty, 5% to 15% of patients have recurrent stenosis at the anastomosis (Cooperberg et al., 2007; Flynn et al., 2003; Koraitim 2005; Mundy, 1996). Endoscopic treatment (e.g., with direct-vision internal urethrotomy) is often successful in this setting because most fibrotic tissue has been eliminated (Cooperberg et al., 2007; Koraitim 2003; Netto et al., 1989).

Complications: Incontinence.

Urinary continence after urethral distraction is the rule rather than the exception, despite destruction of the external sphincter from either the injury itself or the subsequent repair. Incontinence rates after reconstruction are low—less than 4% (Koraitim, 2005). The mechanism of continence is thought to be largely attributable to bladder neck function (Iselin and Webster, 1999). Urodynamic data show that a significant proportion of patients also have identifiable distal rhabdosphincteric function (Whitson et al., 2008).

Anterior Urethral Injuries

Etiology

In contrast with posterior urethral distraction, anterior injuries are most often isolated (Kiracofe et al., 1975). Most occur after straddle injury and involve the bulbar urethra, which is susceptible to compressive injury because of its fixed location beneath the pubis. A smaller percentage of injuries to the anterior urethra are the result of direct penetrating injury to the penis.

As with posterior urethral injury, a high index of suspicion must be maintained in all patients with blunt or penetrating trauma in the urogenital region, and urethrography should be performed in any case of suspected urethral injury (Husmann et al., 1993). Clinical signs of anterior urethral injuries include blood at the meatus, perineal hematoma, gross hematuria, and urinary retention. Similar to pelvic fracture urethral injury cases, prompt urinary drainage must be established through either suprapubic tube placement or urethral catheterization with fluoroscopic assistance (AUA Urotrauma Guidelines, Statement 25). In severe trauma, Buck's fascia may be disrupted, resulting in blood and urinary extravasation into the scrotum (eFig. 133.23). **The primary morbidity of straddle injury is urethral stricture, which may become symptomatic years later** (Park and McAninch, 2004).

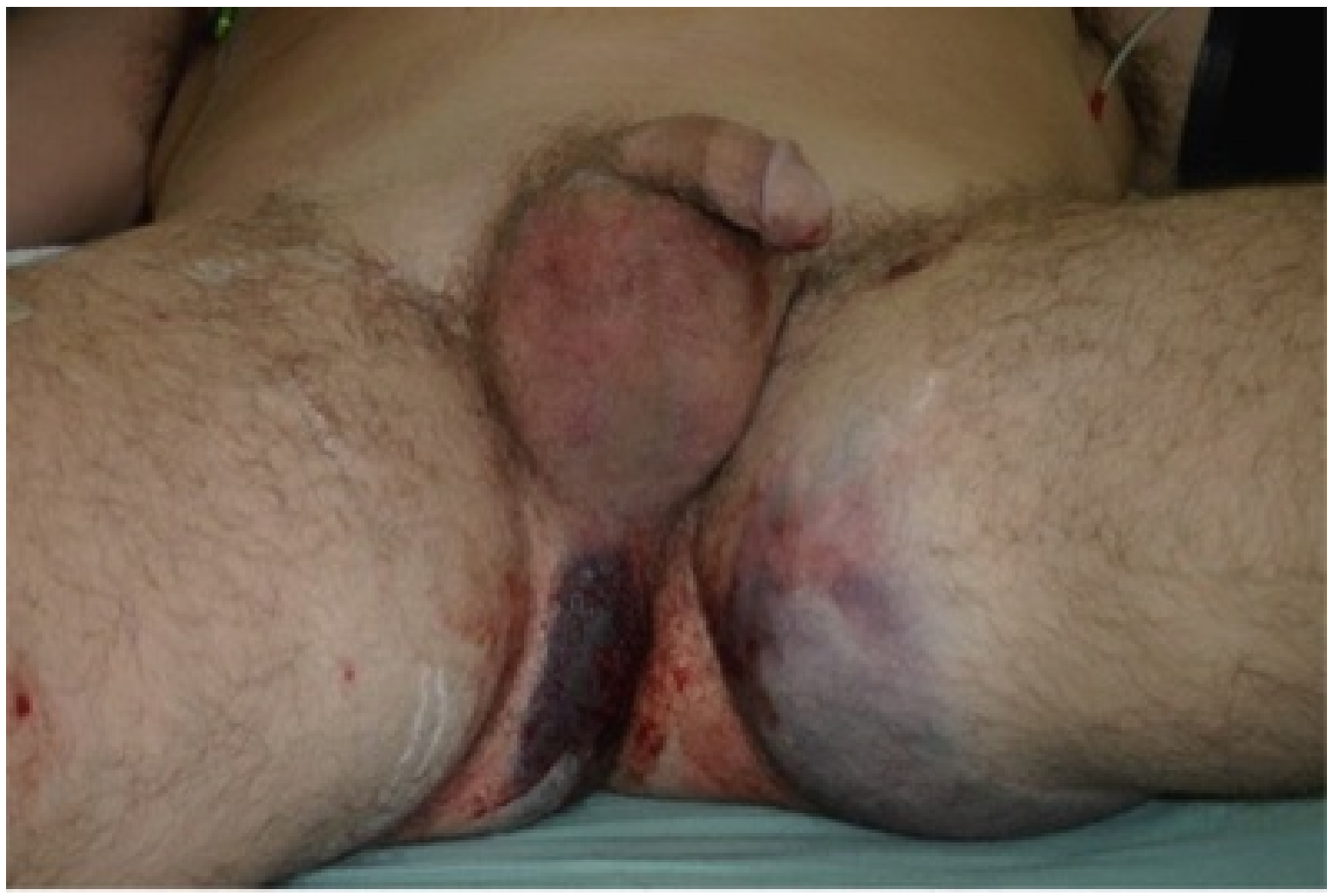

EFIG. 133.23 Extravasation of blood in the scrotum and perineum seen on physical examination in a patient with a straddle injury.

Initial Management

Armenakas and McAninch (1996) proposed a simple, practical classification scheme dividing anterior urethral injuries on the basis of radiographic findings into contusion, incomplete disruption, and complete disruption. Contusions and incomplete injuries can be treated with urethral catheter diversion alone. **Initial suprapubic cystostomy is the standard of care for major straddle injuries involving the urethra** (Park and McAninch, 2004); however, primary anterior urethral realignment has shown promising results with respect to stricture rate and erectile dysfunction in patients with straddle injuries of lesser magnitude (Ying-Hao et al., 2000; Yu et al., 2007).

Primary surgical repair is recommended for low-velocity urethral gunshot injuries (Kunkle et al., 2008); catheter alignment alone is associated with a far worse stricture rate (Husmann et al., 1993). Debridement of the corpus spongiosum after trauma should be limited because corporal blood supply is usually robust, enabling spontaneous healing of most contused areas (Kiracofe et al., 1975; Husmann et al., 1993). Initial suprapubic urinary diversion is recommended after high-velocity gunshot wounds to the urethra, followed by delayed reconstruction.

Delayed Reconstruction

Before any planned procedure, a retrograde urethrogram and voiding cystourethrogram should be obtained to define the site and length of the obliterated urethra clearly. Urethral ultrasound examination may help delineate the length and severity of stricture. Retrograde injection of saline combined with antegrade bladder filling fills the urethra proximally and distally, and a 10-MHz sonogram clearly defines the nondistensible segment to be excised. Dense fibrous tissue from trauma often demonstrates a fixed, nondistensible appearance sonographically with significant shadowing (Morey and McAninch, 2000). **Ultrasound imaging of urethral strictures is more accurate than retrograde urethrography** (Mitterberger et al., 2007), although it is highly operator dependent and not widely used at the present time.

Anastomotic urethroplasty is the procedure of choice in the totally obliterated bulbar urethra after a straddle injury. The typical scar is 1.5 to 2 cm long and can be readily completely excised. The proximal and distal urethra can be mobilized for a tension-free, end-to-end anastomosis. This is a highly successful procedure in more than 95% of cases (Jordan et al., 2010; Santucci et

al., 2002).

Endoscopic incision of saddle injuries through the scar tissue of an obliterated urethra is a hopeless procedure doomed to failure. Partial urethral narrowing can initially be treated by endoscopic incision or dilation with greater success. **Repeated endoscopic manipulation is neither clinically effective nor cost-effective for the treatment of urethral strictures** (Greenwell et al., 2004). Patients who undergo repeated endoscopic procedures are also more likely to require complex reconstructive procedures such as grafts (Hudak et al., 2012; Park and McAninch, 2004). Open repair should be delayed for several weeks after instrumentation to allow the urethra to stabilize, and a 2-month period of suprapubic urinary diversion may be prudent preoperatively to optimize conditions for repair of complex or recurrent strictures that have been catheter dependent (Terlecki et al., 2011). Finally, UroLume stents (now “off the market” in the United States) are contraindicated in the setting of traumatic urethral strictures (Wilson et al., 2002).

Key Points: Lower Genitourinary Tract Injuries

- Although most bladder injuries are associated with pelvic fractures, only 10% of patients with pelvic fracture have bladder injuries.
- Intraperitoneal bladder injury from external trauma requires urgent operative repair.
- Prompt suprapubic catheter drainage is recommended for initial management of pelvic fracture urethral disruption injury.
- Primary realignment may be performed in stable patients; close follow-up is essential because of the high rate of stricture formation.
- Posterior urethroplasty by excision and primary anastomosis is the treatment of choice for urethral distraction injuries.
- Anastomotic urethroplasty is the procedure of choice for straddle injury–related anterior urethral stricture.

Suggested Readings

Andrich DE, Mundy AR. The nature of urethral injury in cases of pelvic fracture urethral trauma. *J Urol*. 2001;165:1492–1495.

Black PC, Miller EA, Porter JR, et al. Urethral and bladder neck injury associated with pelvic fracture in 25 female patients. *J Urol*. 2006;175:2140–2145.

Buckley JC, McAninch JW. Use of ultrasonography for the diagnosis of testicular injuries in blunt scrotal trauma. *J Urol*. 2006;175:175–178.

Cooperberg MR, McAninch JW, Alsikafi NF, et al. Urethral reconstruction for traumatic posterior urethral disruption: outcomes of a 25-year experience. *J Urol*. 2007;178:2006–2010.

Morey AF, Brandes SB, Dugi DD, et al. Urotrauma: AUA Guideline. *J Urol*. 2014;192:327–335.

Morey AF, Iverson AJ, Swan A, et al. Bladder rupture after blunt trauma: guidelines for diagnostic imaging. *J Trauma*. 2001;51:683–686.

Morey AF, Metro MJ, Carney KJ, et al. Consensus on genitourinary trauma. *BJU Int*. 2004;94:507–515.

Tausch TJ, Morey AF, Scott JF, et al. Unintended negative consequences of primary endoscopic realignment for men with pelvic fracture urethral injuries. *J Urol*. 2014;192:1720–1724.

References

Injuries of the External Genitalia

Aboseif S, Gomez R, McAninch JW. Genital self-mutilation. *J Urol*. 1993;150:1143–1146.

Aihara R, Blansfield JS, Millham FH, et al. Fracture locations influence the likelihood of rectal and lower urinary tract injuries in patients sustaining pelvic fractures. *J Trauma*. 2002;52:205–209.

Al Ansari A, Talib RA, Shamsodini A, et al. Which is guilty in self-induced penile fractures: marital status, culture or geographic region? A case series and literature review. *Int J Impot Res*. 2013;25:221–223.

Al-Ali IH, Husain I. Disrupting injuries of the membranous urethra—the case for early surgery and catheter splinting. *Br J Urol*. 1983;55:716–720.

Al-Azzawi IS, Koraitim MM. Lower genitourinary trauma in modern warfare: the experience from civil violence in Iraq. *Injury*. 2014;45(5):885–889.

Alli MO, Singh B, Moodley J, et al. Prospective evaluation of combined suprapubic and urethral catheterization to urethral drainage alone for intraperitoneal bladder injuries. *J Trauma*. 2003;55:1152–1154.

Al-Rifaei MA, Gaafar S, Abdel-Rahman M. Management of posterior urethral strictures secondary to pelvic fractures in children. *J Urol*. 1991;145:353–356.

Andrich DE, Mundy AR. The nature of urethral injury in cases of pelvic fracture urethral trauma. *J Urol*. 2001;165:1492–1495.

Anema JG, Morey AF, McAninch JW, et al. Complications related to the high lithotomy position during urethral reconstruction. *J Urol*. 2000;164:360–363.

Anger JT, Sherman ND, Webster GD. Ejaculatory profiles and fertility in men after posterior urethroplasty for pelvic fracture-urethral distraction defect injuries. *BJU Int*. 2008;102:351–353.

Antonini G, Vicini P, Sansalone S, et al. Penile fracture: penoscrotal approach with degloving of penis after Magnetic Resonance Imaging (MRI). *Arch Ital Urol Androl*. 2014;86(1):39–40.

Armenakas NA, Hochberg DA, Fracchia JA. Traumatic avulsion of the dorsal penile artery mimicking a penile fracture. *J Urol*. 2001;166:619.

Armenakas NA, McAninch JW, Lue TF, et al. Posttraumatic impotence: magnetic resonance imaging and duplex ultrasound in diagnosis and management. *J Urol*. 1993;149:1272–1275.

Armenakas NA, McAninch JW. Acute anterior urethral injuries: diagnosis and initial management. McAninch JW. *Traumatic and reconstructive urology*. Saunders: Philadelphia, PA; 1996:543–550.

Asci R, Sarikaya S, Buyukalpelli R, et al. Voiding and sexual dysfunctions after pelvic fracture urethral injuries treated with either initial cystostomy and delayed urethroplasty or immediate primary urethral realignment. *Scand J Urol Nephrol*. 1999;33:228–233.

Asgari MA, Hosseini SY, Safarinejad MR, et al. Penile fractures: evaluation, therapeutic approaches and long-term results. *J Urol*. 1996;155:148–149.

Bandi G, Santucci RA. Controversies in the management of male external genitourinary trauma. *J Trauma*. 2004;56:1362–1370.

Barrett K, Braga LH, Farrokhyar F, et al. Primary realignment vs suprapubic cystostomy for the management of pelvic fracture-associated urethral injuries: a systematic review and meta-analysis. *Urology*. 2014;83(4):924–929.

Barros R, Schulze L, Ornellas AA, et al. Relationship between sexual position and severity of penile fracture. *Int J Impot Res*. 2017;29(5):207–209.

Bar-Yosef Y, Greenstein A, Beri A, et al. Dorsal vein injuries observed during penile exploration for suspected penile fracture. *J Sex Med*. 2007;4:1142–1146.

Basta AM, Blackmore CC, Wessells H. Predicting urethral injury from pelvic fracture patterns in male patients with blunt trauma. *J Urol*. 2007;177:571–575.

Bepple JL, Virasoro R, Williams MB, et al. Incidence of infection in patients with orthopedic interventions for a pelvic fracture and a suprapubic catheter placed secondary to a posterior urethral distraction injury. *J Urol*. 2007;77 [abstract 115].

Bertozzi M, Prestipino M, Nardi N, et al. Scrotal dog bite: unusual case and review of pediatric literature. *Urology*. 2009;74:595–597.

Beysel M, Tekin A, Gürdal M, et al. Evaluation and treatment of penile fractures: accuracy and clinical diagnosis and the value of corpus cavernosography. *Urology*. 2002;60:492–496.

Bhanganada K, Chayavatana T, Pongnumkul C, et al. Surgical management of an epidemic of penile amputations in Siam. *Am J Surg*. 1983;146:376–382.

Bickel A, Mata J, Hochstein LM, et al. Bowel injury as a result of penetrating scrotal trauma: review of associated injuries. *J Urol*. 1990;143:1017–1018.

Bjurlin MA, Fantus RJ, Mellett MM, et al. Genitourinary injuries in pelvic fracture morbidity and mortality using the National Trauma Data Bank. *J Trauma*. 2009;67:1033–1039.

Bjurlin MA, Kim DY, Zhao LC, et al. Clinical characteristics and surgical outcomes of penetrating external genital injuries.

J Trauma Acute Care Surg. 2013;74:839–844.

Bladder Injuries and Urethral Injuries

Blaschko SD, Sanford MT, Schlomer BJ, et al. The incidence of erectile dysfunction after pelvic fracture urethral injury: a systematic review and meta-analysis. *Arab J Urol*. 2015;13(1):68–74.

Boone TB, Wilson WT, Husmann DA. Postpubertal genitourinary function following posterior urethral disruptions in children. *J Urol*. 1992;148:1232–1234.

Borrelli J, Brandes SB. Pelvic fractures: assessment and management for the urologist. *AUA Update Series*. 2004;23:82–86.

Brandes SB, Borelli J. Pelvic fracture and associated urologic injuries. *World J Surg*. 2001;25:1578–1587.

Brandes SB, Buckman RF, Chelsky MJ, et al. External genitalia gunshot wounds: a ten-year experience with fifty-six cases. *J Trauma*. 1995;39:266–271.

Brock G, Hsu G, Nunes L, et al. The anatomy of the tunica albuginea in the normal penis and Peyronie's disease. *J Urol*. 1997;157:276–281.

Bromberg W, Wong C, Kurek S, et al. Traumatic bilateral testicular dislocation. *J Trauma*. 2003;54:1009–1011.

Browning WH, Reed DC. A method of treatment for incarceration of the penis. *J Urol*. 1969;101:189–190.

Buckley JC, McAninch JW. Use of ultrasonography for the diagnosis of testicular injuries in blunt scrotal trauma. *J Urol*. 2006;175:175–178.

Carr LK, Webster GD. Posterior urethral reconstruction. *Atlas Urol Clin North Am*. 1997;5:125–137.

Carroll PR, McAninch JW. Major bladder trauma: mechanisms of injury and a unified method of diagnosis and repair. *J Urol*.

1984;132:254–257.

Cass AS, Luxenberg M. Features of 164 bladder ruptures. *J Urol*. 1987;138:743–745.

Cass AS, Luxenberg M. Value of early operation in blunt testicular contusion with hematocele. *J Urol*. 1988;139:746–747.

Cass AS, Luxenberg M. Simultaneous upper and lower urinary tract injury from external trauma. *Urology*. 1990;36:226–227.

Cass AS, Luxenberg M. Testicular injuries. *Urology*. 1991;37:528–530.

Cass AS. Diagnostic studies in bladder rupture. *Urol Clin North Am*. 1989;16:267–273.

Cass AS. The multiple injured patient with bladder trauma. *J Trauma*. 1984;24:731–734.

Cavalcanti AG, Krambeck R, Araujo A, et al. Penile lesion from gunshot wound: a 43-case experience. *Int Braz J Urol*. 2006;32:56–63.

Cerwinka WH, Block NL. Civilian gunshot injuries of the penis: the Miami experience. *Urology*. 2009;73:877–880.

Chung PH, Wessells H, Voelzke BB. Updated outcomes of early endoscopic realignment for pelvic fracture urethral injuries at a level 1 trauma center. *Urology*. 2018;112:191–197.

Cinman NM, McAninch JW, Porten SP, et al. Gunshot wounds to the lower urinary tract: a single-institution experience. *J Trauma Acute Care Surg*. 2013;74:725–730 [discussion 730–731].

Cline KJ, Mata JA, Venable DB, et al. Penetrating trauma to the male external genitalia. *J Trauma*. 1998;44:492–494.

Colapinto V, McCallum RW. Injury to the male posterior urethra in fractured pelvis: a new classification. *J Urol*. 1977;118:575–580.

Connor GS, McGwin G, MacLennan PA, et al. Early versus delayed fixation of pelvic ring fractures. *Am Surg*.

2003;69:1019–1024.

Cooperberg MR, McAninch JW, Alsikafi NF, et al. Urethral reconstruction for traumatic posterior urethral disruption: outcomes of a 25-year experience. *J Urol*. 2007;178:2006–2010.

Corrales JG, Corbel L, Cipolla B, et al. Accuracy of ultrasound diagnosis after blunt testicular trauma. *J Urol*. 1993;150:1834–1836.

Corriere JN, Rudy DC, Benson GS. Voiding and erectile function after delayed one-stage repair of posterior urethral disruptions in 50 men with a fractured pelvis. *J Trauma*. 1994;37:587–589.

Corriere JN, Sandler CM. Management of extraperitoneal bladder rupture. *Urol Clin North Am*. 1989;16:275–277.

Corriere JN. 1-Stage delayed bulboprostatic anastomotic repair of posterior urethral rupture: 60 patients with 1-year followup. *J Urol*. 2001;165:404–407.

Cuccia G, Mucciardi G, Morgia G, et al. Vacuum-assisted closure for the treatment of Fournier's gangrene. *Urol Int*. 2009;82:426–431.

Cummings JM, Boullier JA. Scrotal dog bites. *J Urol*. 2000;164:57–58.

Czymek R, Schmidt A, Eckmann C, et al. Fournier's gangrene: vacuum-assisted closure versus conventional dressings. *Am J Surg*. 2009;197:168–176.

Deibert CM, Spencer BA. The association between operative repair of bladder injury and improved survival: results from the National Trauma Data Bank. *J Urol*. 2011;186:151–155.

Del Villar RG, Ireland GW, Cass AS. Early exploration following trauma to the testicle. *J Trauma*. 1973;13:600–601.

Derouiche A, Belhaj K, Hentati H, et al. Management of penile fractures complicated by urethral rupture. *Int J Impot Res*. 2008;20:111–114.

Devine CJ Jr, Jordan GH, Devine PC. Primary realignment of the disrupted prostatomembranous urethra. *Urol Clin North Am*. 1989;16:291–295.

Diokno E, Rowe D. Medical and orthopedic conditions and sports participation. *Pediatr Clin North Am*. 2010;57(3):839–847.

Dixon CM, Hricak H, McAninch JW. Magnetic resonance imaging of traumatic posterior urethral defects and pelvic crush injuries. *J Urol*. 1992;148:1162–1165.

Dobrowolski ZF, Lipczynski W, Drewniak T, et al. External and iatrogenic trauma of the urinary bladder: a survey in Poland. *BJU Int*. 2002;89:755–756.

Dreitlein DA, Suner S, Basler J. Genitourinary trauma. *Emerg Med Clin North Am*. 2001;19:569–590.

Eke N. Fracture of the penis. *Br J Surg*. 2002;89:555–565.

El Atat R, Sfaxi M, Renslama MR, et al. Fracture of the penis: management and long-term results of surgical treatment. Experience in 300 cases. *J Trauma*. 2008;64:121–125.

El-Assmy A, el-Tholoth HS, Abou-El-Ghar ME, et al. False penile fracture: value of different diagnostic approaches and long-term outcome of conservative and surgical management. *Urology*. 2010;75:1353–1356.

El-Assmy A, el-Tholoth HS, Mohsen T, et al. Does timing of presentation of penile fracture affect outcome of surgical intervention? *Urology*. 2011;77:1388–1391.

El-Bahnasawy MS, Gomha MA. Penile fractures: the successful outcome of immediate surgical management. *Int J Impot Res*. 2000;12:273–277.

Elliott DS, Barrett DM. Long-term followup and evaluation of primary realignment of posterior urethral disruptions. *J Urol*. 1997;157:814–816.

Elsaharty S, Pranikoff K, Magoss IV, et al. Traumatic torsion of the testis. *J Urol*. 1984;132:1155–1156.

El-Taher AM, Aboul-Ella HA, Sayed MA, et al. Management of penile fracture. *J Trauma*. 2004;56:1138–1140.

Esposito TJ, Ingraham A, Luchette FA, et al. Reasons to omit digital rectal exam in trauma patients: no fingers, no rectum, no useful additional information. *J Trauma*. 2005;59:1314–1319.

Evans LA, Ferguson KH, Foley JP, et al. Fibrin sealant for the management of genitourinary injuries, fistulas, and surgical complications. *J Urol*. 2003;169:1360–1362.

Falcone M, Garaffa G, Raheem A, et al. Total phallic reconstruction using the radial artery based forearm free flap after traumatic penile amputation. *J Sex Med*. 2016;13(7):1119–1124.

Fedel M, Venz S, Andreessen R, et al. The value of magnetic resonance imaging in the diagnosis of suspected penile fracture with atypical clinical findings. *J Urol*. 1996;155:1924–1927.

Feki W, Derouiche A, Belhaj K, et al. False penile fracture: report of 16 cases. *Int J Impot Res*. 2007;19:471–473.

Feng C, Xu YM, Yu JJ, et al. Risk factors for erectile dysfunction in patients with urethral strictures secondary to blunt trauma. *J Sex Med*. 2008;5(11):2656–2661.

Ferguson GG, Brandes S. Gunshot wound injury of the testis: the use of tunica vaginalis and polytetrafluoroethylene grafts for reconstruction. *J Urol*. 2007;178:2462–2465.

Flowerdew R, Fishman IJ, Churchill BM. Management of penile zipper injury. *J Urol*. 1977;117:671.

Flynn BJ, Delvecchio FC, Webster GD. Perineal repair of pelvic fracture urethral distraction defects: experience in 120 patients during the last 10 years. *J Urol*. 2003;170:1877–1880.

Follis HW, Koch MO, McDougal WS. Immediate management of prostatomembranous urethral disruptions. *J Urol*.

1992;147:1259–1262.

Fournier GR, Laing FC, McAninch JW. Scrotal ultrasonography and the management of testicular trauma. *Urol Clin North Am*. 1989;16:377–385.

Gaspar SS, Dias JS, Martins F, et al. Sexual urological emergencies. *Sex Med Rev*. 2015;3(2):93–100.

Goldman HB, Dmochowski RR, Cox CE. Penetrating trauma to the penis. *J Urol*. 1996;155:551–553.

Gomes CM, Ribeiro-Filho L, Giron AM, et al. Genital trauma due to animal bites. *J Urol*. 2001;165:80–83.

Gomez RG, Castanheira AC, McAninch JW. Gunshot wounds to the male external genitalia. *J Urol*. 1993;150:1147–1149.

Gomez RG, Ceballos L, Coburn M, et al. Consensus statement on bladder injuries. *BJU Int*. 2004;94:27–32.

Greenwell TJ, Castle C, Andrich DE, et al. Repeat urethrotomy and dilation for the treatment of urethral stricture are neither clinically effective nor cost-effective. *J Urol*. 2004;172:275–277.

Greilsheimer H, Groves JE. Male genital self-mutilation. *Arch Gen Psychiatry*. 1979;36:441–446.

Guichard G, El Ammari J, Del Coro C, et al. Accuracy of ultrasonography in diagnosis of testicular rupture after blunt scrotal trauma. *Urology*. 2008;71:52–56.

Hadjizacharia P, Inaba K, Teixeira PGR, et al. Evaluation of immediate endoscopic realignment as a treatment for traumatic urethral injuries. *J Trauma*. 2008;64:1443–1450.

Hemal AK, Singh I, Chahal R, et al. Core through internal urethrotomy in the management of post-traumatic isolated bladder neck and prostatic urethral strictures in adults: a report of 4 cases. *Int Urol Nephrol*. 1999;31:703–708.

Herbener TE. Ultrasound in the assessment of the acute scrotum. *J Clin Ultrasound*. 1996;24:405–421.

Hinev AI. Re: Penile injury [letter]. *J Urol*. 2002;167:1802–

1803.

Horiguchi A, Shinchi M, Masunaga A, et al. Primary realignment for pelvic fracture urethral injury is associated with prolonged time to urethroplasty and increased stenosis complexity. *Urology*. 2017;108:184–189.

Horton CE, Dean JA. Reconstruction of traumatizing acquired defects of the phallus. *World J Surg*. 1990;14:757–762.

Hsieh C, Chen R, Fang J, et al. Diagnosis and management of bladder injury by trauma surgeons. *Am J Surg*. 2002;184:143–147.

Hsu GL, Brock G, Martinez-Pineiro L, et al. Anatomy and strength of the tunica albuginea: its relevance to penile prosthesis extrusion. *J Urol*. 1994;151:1205–1208.

Hudak SJ, Atkinson TH, Morey AF. Repeat transurethral manipulation of bulbar urethral strictures is associated with increased stricture complexity and prolonged disease duration. *J Urol*. 2012;187:1691–1695.

Husmann DA, Boone TB, Wilson WT. Management of low velocity gunshot wounds to the anterior urethra: the role of primary repair versus urinary diversion alone. *J Urol*. 1993;150:70–72.

Iselin CE, Webster GD. The significance of the open bladder neck associated with pelvic fracture urethral distraction defects. *J Urol*. 1999;162:347–351.

Ivanovski O, Stankov O, Kuzmanoski M, et al. Penile strangulation: two case reports and review of the literature. *J Sex Med*. 2007;4:1775–1780.

Iverson AJ, Morey AF. Radiographic evaluation of suspected bladder rupture following blunt trauma: critical review. *World J Surg*. 2001;25:1588–1591.

Jack GS, Garraway I, Reznichek R, et al. Current treatment options for penile fractures. *Rev Urol*. 2004;6:114–120.

Janak JC, Orman JA, Soderdahl DW, et al. Epidemiology of genitourinary injuries among male U.S. service members deployed to Iraq and Afghanistan: early findings from the Trauma Outcomes and Urogenital Health (TOUGH) project. *J Urol*. 2017;197(2):414–419.

Jezior JR, Brady JD, Schlossberg SM. Management of penile amputation injuries. *World J Surg*. 2001;25:1602–1609.

Johnsen NV, Young JB, Reynolds WS, et al. Evaluating the role of operative repair of extraperitoneal bladder rupture following blunt pelvic trauma. *J Urol*. 2016;195(3):661–665.

Jordan G, Chapple C, Heyns C. *Urethral strictures*. Presented at: An International Consultation on Urethral Strictures. 2010:86 [Marrakech, Morocco].

Jordan GH, Gilbert DA. Management of amputation injuries of the male genitalia. *Urol Clin North Am*. 1989;16:359–367.

Kalash SS, Young JD. Fracture of penis: controversy of surgical versus conservative treatment. *Urology*. 1984;24:21–24.

Kamdar C, Mooppan UM, Kim H, et al. Penile fracture: preoperative evaluation and surgical technique for optimal patient outcome. *BJU Int*. 2008;102:1640–1644.

Kane CJ, Nash P, McAninch JW. Ultrasonographic appearance of necrotizing gangrene: aid in early diagnosis. *Urology*. 1996;48:142–144.

Kanegaye JT, Schonfeld N. Penile zipper entrapment: a simple and less threatening approach using mineral oil. *Pediatr Emerg Care*. 1993;9:90–91.

Kawanishi Y, Kimura K, Nakanishi R, et al. Penile revascularization surgery for arteriogenic erectile dysfunction: the long-term efficacy rate calculated by survival analysis. *BJU Int*. 2004;94:361–368.

Kim FJ, Chammas MF Jr, Gewehr EV, et al. Laparoscopic management of intraperitoneal bladder rupture secondary to blunt abdominal trauma using intracorporeal single layer suturing technique. *J Trauma*. 2008;65:234–236.

Kim SH, Park S, Choi SH, et al. The efficacy of magnetic resonance imaging for the diagnosis of testicular rupture: a prospective preliminary study. *J Trauma*. 2009;66:239–242.

Kiracofe HL, Pfister RR, Peterson NE. Management of non-penetrating distal urethral trauma. *J Urol*. 1975;114:57–62.

Kizer WS, Armenakas NA, Brandes SB, et al. Simplified reconstruction of posterior urethral disruption defects: limited role of supracrural rerouting. *J Urol*. 2007;177:1378–1382.

Koifman L, Barros R, Júnior RAS, et al. Penile fracture: diagnosis, treatment and outcomes of 150 patients. *Urology*. 2010;76:1488–1492.

Koraitim MM, Marzouk ME, Atta MA, et al. Risk factors and mechanism of urethral injury in pelvic fractures. *Br J Urol*. 1996;77:876–880.

Koraitim MM, Reda IS. Role of magnetic resonance imaging in assessment of posterior urethral distraction defects. *Urology*. 2007;70:403–406.

Koraitim MM. Assessment and management of an open bladder neck at posterior urethroplasty. *Urology*. 2010;76:476–479.

Koraitim MM. Failed posterior urethroplasty: lessons learned. *Urology*. 2003;62:719–722.

Koraitim MM. On the art of anastomotic posterior urethroplasty: a 27-year experience. *J Urol*. 2005;173:135–139.

Koraitim MM. Pelvic fracture urethral injuries: the unresolved controversy. *J Urol*. 1999;161:1433–1441.

Koraitim MM. Predictors of erectile dysfunction post pelvic fracture urethral injuries: a multivariate analysis. *Urology*. 2013;81:1081–1085.

Kotkin L, Koch MO. Impotence and incontinence after immediate realignment of posterior urethral trauma: result of injury or management? *J Urol*. 1996;155:1600–1603.

Kotkin L, Koch MO. Morbidity associated with nonoperative management of extraperitoneal bladder injuries. *J Trauma*. 1995;38:895–898.

Kozacioglu Z, Degirmenci T, Arslan M, et al. Long-term significance of the number of hours until surgical repair of penile fractures. *Urol Int*. 2011;87:75–79.

Kramer AC. Penile fracture seems more likely during sex under stressful situations. *J Sex Med*. 2011;8:3414–3417.

Kukadia AN, Ercole CJ, Gleich P, et al. Testicular trauma: potential impact on reproductive function. *J Urol*. 1996;156:1643–1646.

Kunkle DA, Lebed BD, Mydlo JH, et al. Evaluation and management of gunshot wounds of the penis: 20-year experience at an urban trauma center. *J Trauma*. 2008;64:1038–1042.

Landström JT, Schuyler RW, Macris GP. Microsurgical penile replantation facilitated by postoperative HBO treatment. *Microsurgery*. 2004;24:49–55.

Leddy LS, Vanni AJ, Wessells H, et al. Outcomes of endoscopic realignment of pelvic fracture associated urethral injuries at a level 1 trauma center. *J Urol*. 2012;188:174–178.

Lee SH, Bak CW, Choi MH, et al. Trauma to male genital organs: a 10-year review of 156 patients, including 118 treated by surgery. *BJU Int*. 2007;101:211–215.

Lowe MA, Chapman W, Berger RE. Repair of a traumatically amputated penis with return of erectile function. *J Urol*. 1991;145:1267–1270.

Lrhorfi H, Manunta A, Rodriguez A, et al. Trauma induced testicular torsion. *J Urol*. 2002;168:2548.

Manson AL. Traumatic testicular torsion: case report. *J Trauma*. 1989;29:407–408.

Matthews LA, Herbener TE, Seftel AD. Impotence associated with blunt pelvic and perineal trauma: penile revascularization as a treatment option. *Semin Urol*.

1995;13:66–72.

Maurice MJ, Cherullo EE. A novel, nonoperative treatment for delayed penile zipper injury. *Am J Emerg Med*. 2013;31:419–420.

Mazaris EM, Livadas K, Chalikopoulos D, et al. Penile fractures: immediate surgical approach with a midline ventral incision. *BJU Int*. 2009;104:520–523.

McAleer IM, Kaplan GW, LoSasso BE. Renal and testis injuries in team sports. *J Urol*. 2002;168:1805–1807.

McAleer IM, Kaplan GW. Pediatric genitourinary trauma. *Urol Clin North Am*. 1995;22:177–188.

McAninch JW, Kahn RI, Jeffrey RB, et al. Major traumatic and septic genital injuries. *J Trauma*. 1984;24:291–298.

McAninch JW. Pubectomy in repair of membranous urethral stricture. *Urol Clin North Am*. 1989;16:297–302.

McDougal WS. Lymphedema of the external genitalia. *J Urol*. 2003;170:711–716.

Meares EM. Traumatic rupture of the corpus cavernosum. *J Urol*. 1971;105:407–408.

Medendorp AR, Albrecht MC, Morey AF. Natural history of extensive, full-thickness electrical burns involving the penis. *Urology*. 2007;70:588–589.

Mee SL, McAninch JW, Federle MP. Computerized tomography in bladder rupture: diagnostic limitations. *J Urol*. 1987;137:207–209.

Micallef M, Ahmad I, Ramesh N, et al. Ultrasound features of blunt testicular injury. *Injury*. 2001;32:23–26.

Miles BJ, Poffenberger RJ, Farah RN, et al. Management of penile gunshot wounds. *Urology*. 1990;36:318–321.

Mindrup SR, Kealey GP, Fallon B. Hyperbaric oxygen for the treatment of Fournier's gangrene. *J Urol*. 2005;173:1975–1977.

Mineo M, Jolley T, Rodriguez G. Leech therapy in penile replantation: a case of recurrent penile self amputation. *Urology*. 2004;63:981–983.

Mitterberger M, Christian G, Pinggera GM, et al. Gray scale and color Doppler sonography with extended field of view technique for the diagnostic evaluation of anterior urethral strictures. *J Urol*. 2007;177:992–996.

Mohr AM, Pham AM, Lavery RF, et al. Management of trauma to the male external genitalia: the usefulness of American Association for the Surgery of Trauma organ injury scales. *J Urol*. 2003;170:2311–2315.

Morey AF, Carroll PR. Evaluation and management of adult bladder trauma. *Contemp Urol*. 1997;9:13–22.

Morey AF, Hernandez J, McAninch JW. Reconstructive surgery for lower urinary tract trauma. *Urol Clin North Am*. 1999;26:49–60.

Morey AF, Iverson AJ, Swan A, et al. Bladder rupture after blunt trauma: guidelines for diagnostic imaging. *J Trauma*. 2001;51:683–686.

Morey AF, McAninch JW. Genital skin loss and scrotal reconstruction. Alter G, Ehrlich R. *Reconstructive and plastic surgery of the external genitalia*. Saunders: Philadelphia, PA; 1999:414–422.

Morey AF, McAninch JW. Reconstruction of posterior urethral disruption injuries: outcome analysis in 82 patients. *J Urol*. 1997;157:506–510.

Morey AF, McAninch JW. Sonographic staging of anterior urethral strictures. *J Urol*. 2000;163:1070–1075.

Morey AF, Metro MJ, Carney KJ, et al. Consensus on genitourinary trauma. *BJU Int*. 2004;94:507–515.

Morris MS, Morey AF, Stackhouse DA, et al. Fibrin sealant as tissue glue: preliminary experience in complex genital reconstructive surgery. *Urology*. 2006;67:688–691.

Morrison D, Blaivas M, Lyon M. Emergency diagnosis of

Fournier's gangrene with bedside ultrasound. *Am J Emerg Med*. 2005;23:544–547.

Morrison SD, Shakir A, Vyas KS, et al. Penile replantation: a retrospective analysis of outcomes and complications. *J Reconstr Microsurg*. 2017;33(4):227–232.

Mouraviev VB, Coburn M, Santucci RA. The treatment of posterior urethral disruption associated with pelvic fractures: comparative experience of early realignment versus delayed urethroplasty. *J Urol*. 2005;173:873–876.

Muentener M, Suter S, Hauri D, et al. Long-term experience with surgical and conservative treatment of penile fracture. *J Urol*. 2004;172:576–579.

Muglia V, Tucci S Jr, Elias J Jr, et al. Magnetic resonance imaging of scrotal diseases: when it makes the difference. *Urology*. 2002;59:419–423.

Munarriz RM, Yan QR, ZNehra A, et al. Blunt trauma: the pathophysiology of hemodynamic injury leading to erectile dysfunction. *J Urol*. 1995;153:1831–1840.

Mundy AR. Reconstruction of posterior urethral distraction defects. *Atlas Urol Clin North Am*. 1997;5:139–174.

Mundy AR. The role of delayed primary repair in the acute management of pelvic fracture injuries of the urethra. *Br J Urol*. 1991;68:273–276.

Mundy AR. Urethroplasty for posterior urethral strictures. *Br J Urol*. 1996;78:243–247.

Mydlo JH. Surgeon experience with penile fracture. *J Urol*. 2001;166:526–529.

Mydlo JH. Treatment of a delayed zipper injury. *Urol Int*. 2000;64:45–46.

Najibi S, Tannast M, Latini JM. Civilian gunshot wounds to the genitourinary tract: incidence, anatomic distribution, associated injuries, and outcomes. *Urology*. 2010;76:977–981 [discussion 981].

Narumi Y, Hricak H, Armenakas NA, et al. MR imaging of traumatic posterior urethral injury. *Radiology*. 1993;188:439–443.

Nasser TA, Mostafa T. Delayed surgical repair of penile fracture under local anesthesia. *J Sex Med*. 2008;5:2464–2469.

Netto NR Jr, Lemos GC, Claro JF. Internal urethrotomy as a complementary method after urethroplasties for posterior urethral stenosis. *J Urol*. 1989;141:50–51.

Netto NR Jr. The surgical repair of posterior urethral strictures by the transpubic urethroplasty or pull-through technique. *J Urol*. 1985;133:411–412.

Nicolaisen GS, Melamud A, Williams RD, et al. Rupture of the corpus cavernosum: surgical management. *J Urol*. 1983;130:917–919.

Noh J, Kang TW, Heo T, et al. Penile strangulation treated with the modified string method. *Urology*. 2004;64:591.

O'Brien MF, Collins DA, McElwain JP, et al. Traumatic retrovesical testicular dislocation. *J Urol*. 2004;171:798.

Oosterlinck W. Unbloody management of penile zipper injury. *Eur Urol*. 1981;7:365–366.

Orvis BR, McAninch JW. Penile rupture. *Urol Clin North Am*. 1989;16:369–375.

Ozturk E, Ozguc H, Yilmazlar T. The use of vacuum assisted closure therapy in the management of Fournier's gangrene. *Am J Surg*. 2009;197:660–665 [discussion 665].

Pannek J, Martin W. Penile entrapment in a plastic bottle. *J Urol*. 2003;170:2385.

Pariser JJ, Pearce SM, Patel SG, et al. National patterns of urethral evaluation and risk factors for urethral injury in patients with penile fracture. *Urology*. 2015;86(1):181–185.

Park S, McAninch JW. Straddle injuries to the bulbar urethra: management and outcomes in 78 patients. *J Urol*. 2004;171:722–725.

Parry NG, Rozycki GS, Feliciano DV, et al. Traumatic rupture of the urinary bladder: is the suprapubic tube necessary? *J Trauma*. 2003;54:431–436.

Patterson BM. Pelvic ring injury and associated urologic trauma: an orthopaedic perspective. *Semin Urol*. 1995;13:25–33.

Peng MY, Parisky YR, Cornwell EE 3rd, et al. CT cystography versus conventional cystography in evaluation of bladder injury. *Am J Roentgenol*. 1999;173:1269–1272.

Perabo FG, Steiner G, Albers P, et al. Treatment of penile strangulation caused by constricting devices. *Urology*. 2002;59:137.

Perry MO, Husmann DA. Urethral injuries in female subjects following pelvic fractures. *J Urol*. 1992;147:139–143.

Peters PC. Intraperitoneal rupture of the bladder. *Urol Clin North Am*. 1989;16:279–282.

Phonsombat S, Master VA, McAninch JW. Penetrating external genital trauma: a 30-year single institution experience. *J Urol*. 2008;180:192–196.

Pierce JM Jr. Exposure of the membranous and posterior urethra by total pubectomy. *J Urol*. 1962;88:256–257.

Pohl DR, Johnson DE, Robison JR. Bilateral testicular rupture. *J Urol*. 1968;99:772–773.

Porter JR, Takayama TK, Defalco AJ. Traumatic posterior urethral injury and early realignment using magnetic urethral catheters. *J Urol*. 1997;158:425–430.

Pratap A, Agrawal CS, Tiwari A, et al. Complex posterior urethral disruptions: management by combined abdominal transpubic urethroplasty. *J Urol*. 2006;175:1751–1754.

Raveenthiran V. Releasing of zipper-entrapped foreskin: a novel nonsurgical technique. *Pediatr Emerg Care*. 2007;23:463–464.

Razzaghi MR, Rezaei A, Mazloomfard MM, et al. Successful macrosurgical reimplantation of an amputated penis. *Urol J*. 2009;6:306–308.

Rice SG, American Academy of Pediatrics Council on Sports Medicine and Fitness. Medical conditions affecting sports participation. *Pediatrics*. 2008;121(4):841–848.

Romilly CS, Isaac MT. Male genital self-mutilation. *Br J Hosp Med*. 1996;55:427–431.

Rosenstein D, Jordan GH. The perineal approach to membranous urethral distraction injuries. *Atlas Urol Clin North Am*. 2003;11:51–63.

Routt ML, Simonian PT, Defalco AJ, et al. Internal fixation in pelvic fractures and primary repairs of associated genitourinary disruptions: a team approach. *J Trauma*. 1996;40:784–790.

Sandler CM, Corriere JN Jr. Urethrography in the diagnosis of acute urethral injuries. *Urol Clin North Am*. 1989;16:283–289.

Santucci RA, Deng D, Carney J. Removal of metal penile foreign body with a widely available emergency-medical-services-provided air-driven grinder. *Urology*. 2004;63:1183–1184.

Santucci RA, Mario LA, McAninch JW. Anastomotic urethroplasty for bulbar urethral stricture: analysis of 168 patients. *J Urol*. 2002;167:1715–1719.

Saraf P, Rabinowitz R. Zipper injury of the foreskin. *Am J Dis Child*. 1982;136:557–558.

Schuster G. Traumatic rupture of the testicle and a review of the literature. *J Urol*. 1982;127:1194–1196.

Schwartz SL, Faerber GJ. Dislocation of the testis as a delayed presentation of scrotal trauma. *Urology*. 1994;43:743–745.

Senchenkov A, Knoetgen J, Chrouser KL, et al. Application of vacuum-assisted closure dressing in penile skin graft reconstruction. *Urology*. 2006;67:416–419.

Serra AD, Hricak H, Coakley FV, et al. Inconclusive clinical and ultrasound evaluation of the scrotum: impact of magnetic resonance imaging on patient management and cost. *Urology*. 1998;51:1018–1021.

Shaeer O. Methylene blue-guided repair of fractured penis. *J Sex Med*. 2006;3:349–354.

Shah DK, Paul EM, Meyersfield SA, et al. False fracture of the penis. *Urology*. 2003;61:1259.

Shenfeld OZ, Kiselgorf D, Gofrit ON, et al. The incidence and causes of erectile dysfunction after pelvic fractures associated with posterior urethral disruption. *J Urol*. 2003;169:2173–2176.

Simhan J, Rothman J, Canter D, et al. Gunshot wounds to the scrotum: a large single-institutional 20-year experience. *BJU Int*. 2012;109:1704–1707.

Talan DA, Citron DM, Abrahamian FM, et al. Bacteriologic analysis of infected dog and cat bites. *N Engl J Med*. 1999;340:85–92.

Talan DA, Talan DA, Abrahamian FM, et al. Clinical presentation and bacteriologic analysis of infected human bites in patients presenting to emergency departments. *Clin Infect Dis*. 2003;37:1481–1489.

Tan B-K, Rasheed MZ, Wu WTL. Scrotal reconstruction by testicular apposition and wrap-around skin grafting. *J Plast Reconstr Aesthet Surg*. 2011;64:944–948.

Tarman GJ, Kaplan GW, Lerman SL, et al. Lower genitourinary injury and pelvic fractures in pediatric patients. *Urology*. 2002;59:123–126.

Tausch TJ, Lotan Y, Zhao LC, et al. Decision analysis model comparing cost of management strategies for pelvic fracture urethral injuries. *Urol Pract*. 2017;4:285–289.

Terlecki RP, Steele MC, Valadez C, et al. Urethral rest: role and rationale in preparation for anterior urethroplasty. *Urology*.

2011;77:1477–1481.
Thomae KR, Kilambi NK, Poole GV. Method of urinary diversion in nonurethral traumatic bladder injuries: retrospective analysis of 70 cases. *Am Surg*. 1998;64(1):77–80.
Thompson I, Flaherty S, Morey AF. Battlefield urologic injuries: the Gulf War experience. *J Am Coll Surg*. 1998;187:139–141.
Tsang T, Demby AM. Penile fracture with urethral injury. *J Urol*. 1992;147:466–468.
Tunc HM, Tefekli AH, Kaplancan T, et al. Delayed repair of post-traumatic posterior urethral distraction injuries: long-term results. *Urology*. 2000;55:837–841.
Turner-Warwick R. Prevention of complications resulting from pelvic fracture urethral injuries—and from their surgical management. *Urol Clin North Am*. 1989;16:335–358.
Udekwu PO, Gurkin B, Oller DW. The use of computed tomography in blunt abdominal injuries. *Am Surg*. 1996;62:56–59.
Uder M, Gohl D, Takahashi M, et al. MRI of penile fracture: diagnosis and therapeutic follow-up. *Eur Radiol*. 2002;12:113–120.
Vaccaro JA, Davis R, Belville WD, et al. Traumatic hematocele: association with rupture of the testicle. *J Urol*. 1986;136:1217–1218.
Vahasarja VJ, Hellstrom PA, Serlo W, et al. Treatment of penile incarceration by the string method: 2 case reports. *J Urol*. 1993;149:372–373.
Van der Horst C, Martinez Portillo FJ, Seif C, et al. Male genital injury: diagnostics and treatment. *BJU Int*. 2004;93:927–930.
Volpe MA, Pachter EM, Scalea TM, et al. Is there a difference in outcome when treating traumatic intraperitoneal bladder rupture with or without a suprapubic tube? *J Urol*.

1999;161:1103–1105.

Wan J, Corvino TF, Greenfield SP, et al. The incidence of recreational genitourinary and abdominal injuries in the western New York pediatric population. *J Urol*. 2003;170:1525–1527.

Wan J, Corvino TF, Greenfield SP, et al. Kidney and testicle injuries in team and individual sports: data from the national pediatric trauma registry. *J Urol*. 2003;170:1528–1532.

Waterhouse K. The surgical repair of membranous urethral strictures in children. *J Urol*. 1976;116:363–365.

Waxman S, Beekley A, Morey A, et al. Penetrating trauma to the external genitalia in Operation Iraqi Freedom. *Int J Impot Res*. 2009;21:145–148.

Weinfeld AB, Kelley P, Yuksel E, et al. Circumferential negative-pressure dressing (VAC) to bolster skin grafts in the reconstruction of the penile shaft and scrotum. *Ann Plast Surg*. 2005;54:178–183.

Whitson JM, Tanagho EA, Metro MJ, et al. Mechanism of continence after repair of posterior urethral disruption: evidence of rhabdosphincter activity. *J Urol*. 2008;179:1035–1039.

Wilson TS, Lemack GE, Dmochowski RR. UroLume stents: lessons learned. *J Urol*. 2002;167:2477–2480.

Wolf JS, Turzan C, Cattolica EV, et al. Dog bites to the male genitalia: characteristics, management and comparison with human bites. *J Urol*. 1993;149:286–289.

Ying-Hao S, Chuan-Liang X, Xu G, et al. Urethroscopic realignment of ruptured bulbar urethra. *J Urol*. 2000;164:1543–1545.

Yip A, Ng SK, Wong WC, et al. Injury to the prepuce. *Br J Urol*. 1989;63:535–538.

Yu JJ, Xu YM, Qiao Y, et al. Urethral cystoscopic realignment and early end-to-end anastomosis develop different influence on erectile function in patients with ruptured bulbous urethra. *Arch Androl*. 2007;53:59–62.

Zargooshi J. Sexual function and tunica albuginea wound healing following penile fracture: an 18-year follow-up study of 352 patients from Kermanshah, Iran. *J Sex Med*. 2009;6:1141–1150.

Zhao Y-Q, Zhang J, Yu M-S, et al. Functional restoration of penis with partial defect by scrotal skin flap. *J Urol*. 2009;182:2358–2361.

Zhong Z, Dong Z, Lu Q, et al. Successful penile replantation with adjuvant hyperbaric oxygen treatment. *Urology*. 2007;69:983.e3–983.e5.

Zuckerman JM, McCammon KA, Tisdale BE, et al. Outcome of penile revascularization for arteriogenic erectile dysfunction after pelvic fracture urethral injuries. *Urology*. 2012;80(6):1369–1373.

Special Urologic Considerations in Transgender Individuals

Nicolas Lumen MD, PhD, Anne-Françoise Spinoit MD, PhD, Piet Hoebeke MD, PhD

Gender identity is a person's sense of gender, which can be nonconforming with the sex a person was assigned at birth, inclusive of the associated gender role and/or primary and secondary sex characteristics. Whereas sex of a person refers to biologic differences (chromosomes, hormonal profiles, internal and external sex organs), **gender describes the characteristics that a society or culture delineates as masculine or feminine.**

When gender identity and sex do not match in a person, we discuss gender dysphoria (GD). When the GD reaches a significant level of distress, it can meet the criteria for a formal diagnosis: transsexualism in the International Classification of Diseases, 10th edition (ICD-10) or gender identity disorder (GID) in the Diagnostic and Statistical Manual of Mental Disorders, 4th edition (DSM-4) recently adapted in DSM-5 (American Psychiatric Association, 2013) to gender dysphoria (Black and Grant, 2014; De Cuypere et al., 2011; Dittmann et al., 1996).

The largest epidemiologic study and review about transsexualism reports prevalence ranging from 1 : 11,900 to 1 : 45,000 for male-to-female (transwomen) persons and 1 : 30,400 to 1 : 200,000 for female-to-male (transmen) persons (De Cuypere et al., 2007). Recently, an increase in prevalence is observed together with more public awareness and more research into the diagnosis and treatment. During the past decade, there is also an increase in transgender and gender nonconforming (TGN) youth (Steensma et al., 2011).

The etiology of transsexualism remains unknown but is thought to be multifactorial. Probably, its etiology is both biologic (“nature”), where brain, genetic factors, and hormones might play a role, and dependent on external psychological influence (“nurture”) (Bao and Swaab, 2011; Green, 2000; Hoekzema et al., 2015).

Since 1979, generally accepted treatment guidelines have been published by the World Professional Association for Transgender Health (WPATH), with the latest guidelines published in 2012 (WPATH Standards of Care Version 7: https://www.wpath.org/publications/soc) (Bockting et al., 2011).

In most but not all patients, treatment includes surgical management known as sex reassignment surgery (SRS) or gender-affirmation surgery (GAS), which can include genital surgery and removal of gonads, mastectomy or breast augmentation, facial feminization surgery, and speech modification surgeries. **Because of the close relationship between the genital and the urinary tract both in males and females, genital surgery includes modifications of the urinary tract. GAS can have an impact on the urinary tract, which justifies a chapter on specific urologic considerations in TGN individuals.** It is, however, important to note the difference between SRS and gender reassignment surgery (GRS). GRS refers to the whole body including the genitals; facial and body procedures are included. SRS refers only to the genital procedures (vaginoplasty, clitoroplasty, labioplasty, phalloplasty, penile-scrotal reconstruction). This chapter will focus only on SRS.

Urologic Issues in Gender Nonconforming Youths

In the past decades, more children and adolescents present to health care with gender nonconforming symptoms. There is a bimodal peak at presentation, with children presenting with severe gender dysphoria and adolescents who present at or just after puberty (Conard, 2017). Often these youths present with atypical symptoms like mood and behavior problems. Furthermore they often face bullying and harassment at home, at school, and in the community. One matched retrospective cohort study found a twofold to threefold increased risk for depression, anxiety disorder, suicidal ideation, suicide attempt, and self-harm (Reisner et al., 2015).

These patients will not present to urology or pediatric urology practices, but urologists should be aware that there are treatment guidelines for these youths covering social transition, the use of puberty blockers, and gender-affirming hormones and surgery (Hembree et al., 2009).

In most countries, surgery is only possible when the patient reaches the age of majority, although in some countries chest surgery and removal of gonads is possible from 16 years of age onward. It can be expected that with the wide availability of treatment in youths more and more adolescents will present for GAS.

So, in gender nonconforming youths, urologic issues are rare. We have, however, observed that some patients present with lower urinary tract symptoms (LUTS) because of changed toilet behavior. As some patients tend to avoid going to the toilet in public, they tend to develop detrusor underactivity (unpublished observations).

Puberty-blocking and gender-affirming hormones might have an impact on the techniques of GAS. We have observed in transwomen that, as a result of puberty blocking, the penis is underdeveloped and penile skin is lacking for penile inversion vaginoplasty, making additional bowel vaginoplasty necessary to obtain a functional vagina. In transmen, the estrogen naïvety of the vagina makes vaginectomy much more complicated. So the actual care of TGN youth can have an impact on future results of GAS (unpublished observations).

Urologic Issues in Male-to-Female Transsexuals (Transwomen)

Genital surgery in transwomen consists in **removal of the testes and penile body and the creation of a vaginal cavity and a clitoris.** Different techniques have been described, however, the penile inversion technique is the most often used technique to create the vaginal cavity (Selvaggi and Bellringer, 2011). During this reconstructive surgery, a cavity is created between the prostate and the rectum with the risk for damaging nerve supply to the sphincter and bladder and damaging the rectum and the bladder.

Effects of Sex Reassignment Surgery on Bladder Sphincter Function

Vaginoplasty in transwomen should create a perineogenital complex as feminine in appearance and function as possible. The urethra should be shortened in such a way that the urinary stream is downward in the sitting position and it should be free of stenosis. Shortening of a male urethra has low complication rates. The **neomeatus can develop meatal stenosis** typical for mucocutaneous connections. When the meatus is patent, there should be no long-term negative effect on the lower urinary tract.

During SRS in transwomen, the bulbospongiosus tissue needs to be resected. If it is not resected, obstruction to the vaginal cavity caused by erection on sexual stimulation and arousal can result. As the urethra is thin at this level, proper care should be taken not to damage the urethra while resecting the bulbospongiosus tissue.

The incidence of LUTS in transwomen is unknown. There have been some reports on meatal and urethral stenosis, infections, deviation of urinary stream, and incontinence (Hoebeke et al., 2005; Kuhn et al., 2007; Melloni et al., 2016).

In a study performed at our center, 16% of transwomen presented on the long-term symptoms of urinary incontinence (Hoebeke et al., 2005).

Fate of the Prostate in Transwomen

The prostate is **not removed** during SRS. After GAS, these transwomen can suffer prostatitis, benign prostatic hyperplasia (BPH), and prostate cancer. In transwomen who underwent vaginoplasty, the prostate can easily be palpated or examined by ultrasonography through the neovagina (Weyers et al., 2009).

Prostatitis

There is no literature on prostate infection in transwomen. Despite this lack of evidence from the literature, cases of prostatitis and a case of prostate abscess has been observed in our center. The lack of reports in the literature probably reflects the **very low incidence.** Prostatitis is often related to BPH, and BPH is rare because of the estrogen treatment. This is the most evident reason for the low incidence.

Benign Prostatic Hyperplasia

Two cases of BPH, requiring transurethral prostate resection, have been described in individuals who had been orchidectomized and treated with estrogens only for more than 20 years (Trum et al., 2015).

Prostate Cancer

Six cases of prostate cancer in transwomen taking estrogen have been reported (for a review, see Trum et al., 2015). It is not clear if these cancers were estrogen-sensitive or were present before the start of estrogen administration and then subsequently de-differentiated to become androgen-independent or estrogen-sensitive. Most of these patients were older than 50 years of age when they started cross-sex hormone treatment (with total androgen ablation). In most clinics, screening for elevated levels of prostate-specific antigen (PSA) is not done routinely. The question could be raised whether a digital rectal examination of the prostate in combination with measuring PSA should be recommended in the follow up of transwomen. The six reported cases of prostate cancers in an unknown number of transwomen set against this incidence **do not lead to an evidence-based recommendation on routine testing.** Most of the reported cases of prostate cancer in transwomen were in individuals who started cross-sex hormones late in life. So digital rectal examination and measurement of PSA may be limited to candidates with a late start of hormone treatment or those with a family history of prostate cancer. Whereas in a male population the upper limit of reference values for PSA is 4 ng/mL, in androgen-deprived people the upper limit should be 1.0 ng/mL and, as in men, the PSA velocity is a significant prognosticator of malignancy.

Urologic Issues in Female-to-Male Transsexuals (Transmen)

A transman can undergo a long care pathway with several invasive procedures in different stages. These procedures can include mastectomy, hysterectomy, ovariectomy, vaginectomy, scrotoplasty, urethroplasty, phalloplasty, and implantation of testicular and erectile prosthesis. According to standards of care, patients do not need to undergo all surgical steps, however, a majority of transmen want to reach the following goals by undergoing surgery (Hage and De Graaf, 1993; Monstrey et al., 2009; Perovic and Djordjevic, 2003):

- Normal-looking male genital appearance
- Voiding in a standing position
- Ability for sexual intercourse

To achieve these goals, participation of a dedicated urologist in the gender team is advisable.

Diagnosis and Preoperative Care

Because SRS in transmen has an impact on the lower urinary tract resulting from vaginectomy, pelvic floor reconstruction, and lengthening of the urethra, preoperative urologic screening is mandatory.

Diagnosis

Diagnosis of GD is made following the WPATH guidelines. Patients need to be referred at centers for GD, where a full multidisciplinary team composed of psychologists, psychiatrists, endocrinologists, gynecologists, social workers, plastic surgeons, and urologists will guide the patient through the diagnostic path that can end in SRS if wished by the patient. One of the important phases before considering SRS is the minimum of 2 years the patient has to live and work in the desired gender. This phase is called the “real-life experience.”

Once the diagnosis is confirmed, the real-life experience has taken place, and extensive counseling has been given about SRS, the patient might choose to undergo the surgical procedures related to it. Interestingly, some patients choose not to undergo SRS and prefer to go on in life in the new gender with their native genitals.

Preoperative Care

When considering SRS, the **urinary tract status should be checked beforehand.** When undergoing SRS, transmen will have significant lengthening of the urethra. Any preexisting lower urinary tract disorder (LUTD) might worsen after lengthening the urethra with a tube based on skin, after vaginectomy, or after pelvic floor reconstruction. Along with a urologic history, uroflowmetry with a postvoid volume is needed to assess preoperative status. Ultrasonography of the kidneys is performed at the same time to exclude any upper tract anomaly such as stones or hydronephrosis, which could be potentially more difficult to treat after SRS.

Transwomen, on the other hand, will only have a shortening of their urethra, which makes them less prone to postoperative LUTD. A preoperative ultrasound evaluation of the urinary tract is sufficient.

The **informed consent** process should include urologic complications. Urinary fistulae and strictures, damage to neighboring structures (e.g., rectum, bladder, urinary sphincter), lower urinary tract dysfunction, and urinary tract infection and complications related to the implants should all be included.

Sex Reassignment Surgery

SRS in transmen can be divided as follows:

1. Removal of female anatomic structures: mastectomy, oophorectomy, hysterectomy, and vaginectomy
2. Reconstruction of male anatomic urogenital structures (genitoperineal transformation): scrotoplasty, urethroplasty, and phalloplasty (or metoidioplasty)
3. Implantation of testicular implants and erectile implant.

Removal of Female Anatomic Structures

Mastectomy, Hysterectomy, and Ovariectomy

Mastectomy is usually the first surgical procedure that will be performed. A subcutaneous mastectomy is performed with removal of the glandular tissue but with preservation of overlying skin and (part of) the nipple. Different types of subcutaneous mastectomy are possible depending on the patient's anatomy and surgeon's experience/preference (Monstrey et al., 2008). To reduce morbidity and scar tissue, ovariectomy and hysterectomy are preferably performed by the laparoscopic approach. If this is not possible, or in case of need of conversion, a Pfannenstiel incision is advised to reduce visible scar tissue. **During hysterectomy, care must be taken not to injure the ureters.** The ureters cross the iliac vessels and run toward the bladder's trigone under the uterine artery. In case of injury to the ureter, the urologist must be asked for immediate repair. The type of repair depends on the extent and location of the injury (Serafetinides et al., 2015). During hysterectomy, there is a small risk for injury of the bladder. If a bladder injury is encountered, immediate repair with resorbable sutures is needed (Lumen et al., 2015). To facilitate the future vaginectomy, it is advised to remove the entire cervix and, if possible, the tip of the vagina during hysterectomy. To minimize the number of procedures, mastectomy, ovariectomy, and hysterectomy can be performed as a combined procedure. This will usually take an admission of 3 to 5 days (Weyers et al., 2010).

Vaginectomy

Vaginectomy is usually combined with genitoperineal transformation in transmen and not done as a separate procedure. The vaginectomy is a **hazardous procedure.** Potential major complications associated with vaginectomy are hemorrhage requiring re-intervention (5.7%), bladder injury (3.1%), and rectal injury (0.9%) (Weyers et al., 2010). Because the severity of these complications and because vaginectomy is not really necessary, it must be discussed with the patient whether or not to perform vaginectomy.

If vaginectomy is chosen, the risk for damage to neighboring organs is highest. The procedure is described in Fig. 134.1. Alternatively, the upper part of the vagina can be kept in place and the mucosa fulgurated to prevent the formation of a mucocele (Fig. 134.2). If it is decided not to perform vaginectomy, the plane between the female urethra and the anterior vaginal wall is dissected over 2 to 3 cm to allow lengthening of the urethra with enough separation from the anterior vaginal wall to prevent urethrovaginal fistulae (Fig. 134.3).

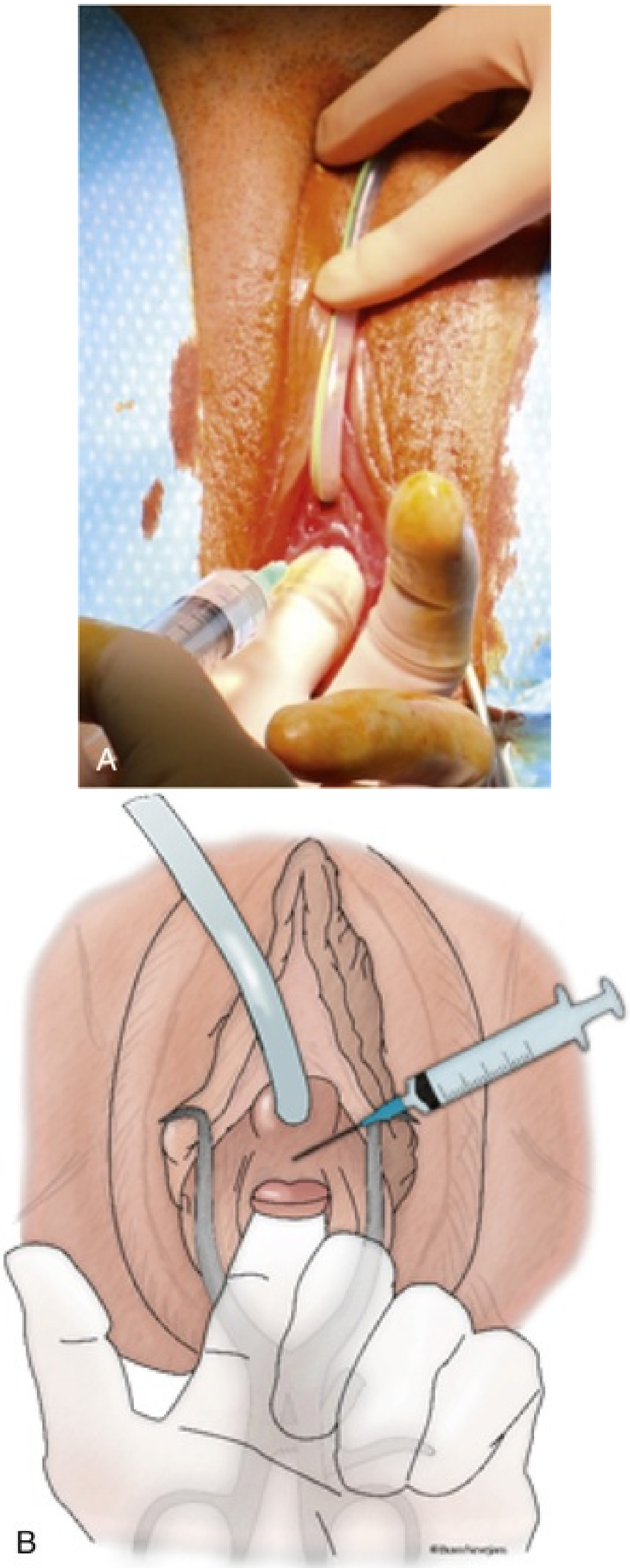

FIG. 134.1 (A and B) Total vaginectomy *(picture and schematic view).* The plane between the anterior vaginal wall and the urethra-bladder is infiltrated with a dilute solution of xylocaine. This hydrodissection will aid in the later

surgical development of this plane.

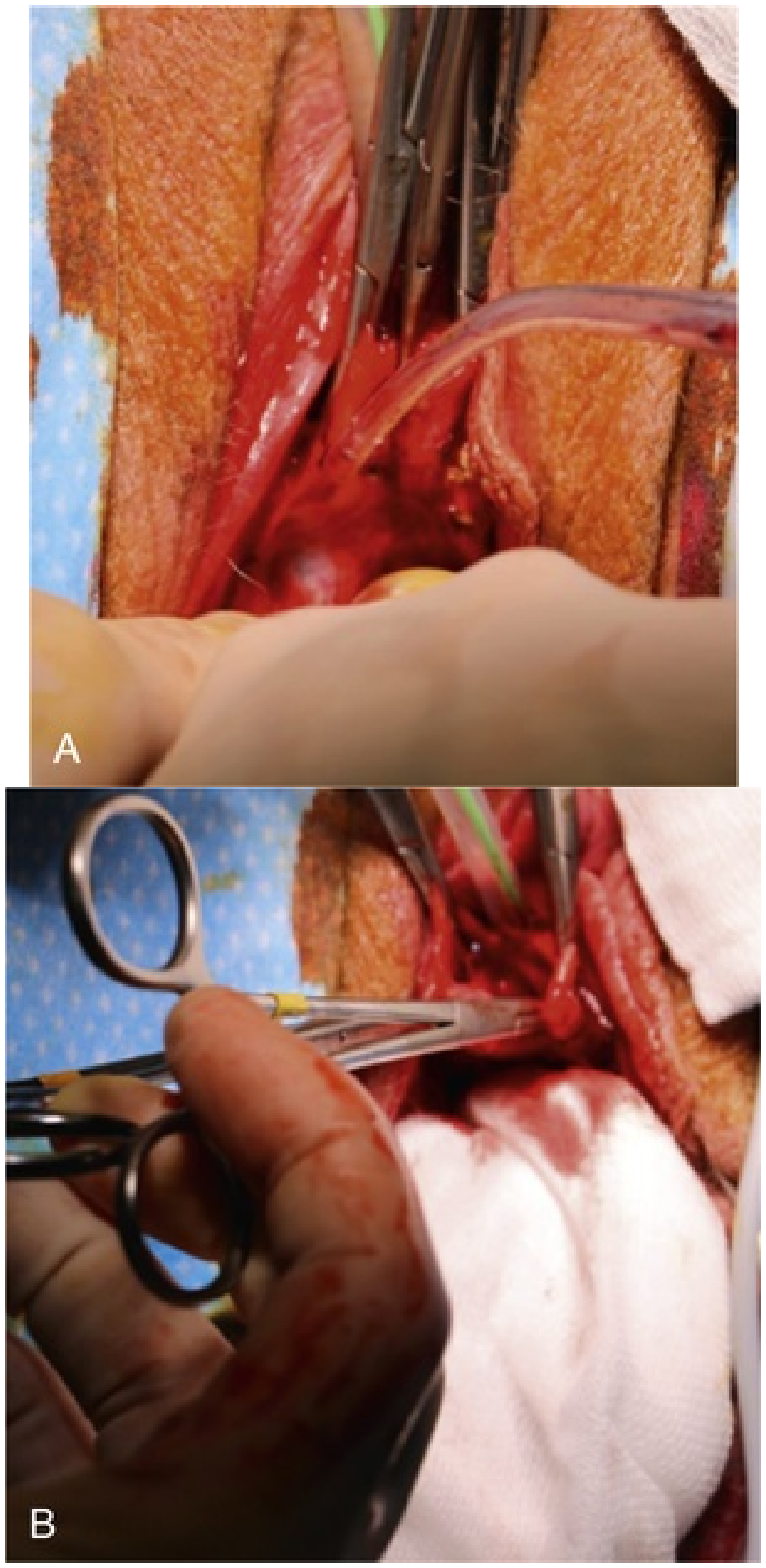

FIG. 134.2 (A) Blunt, digital dissection of the rectovaginal plane. (B) The rectum is protected by a gauze during further vaginectomy.

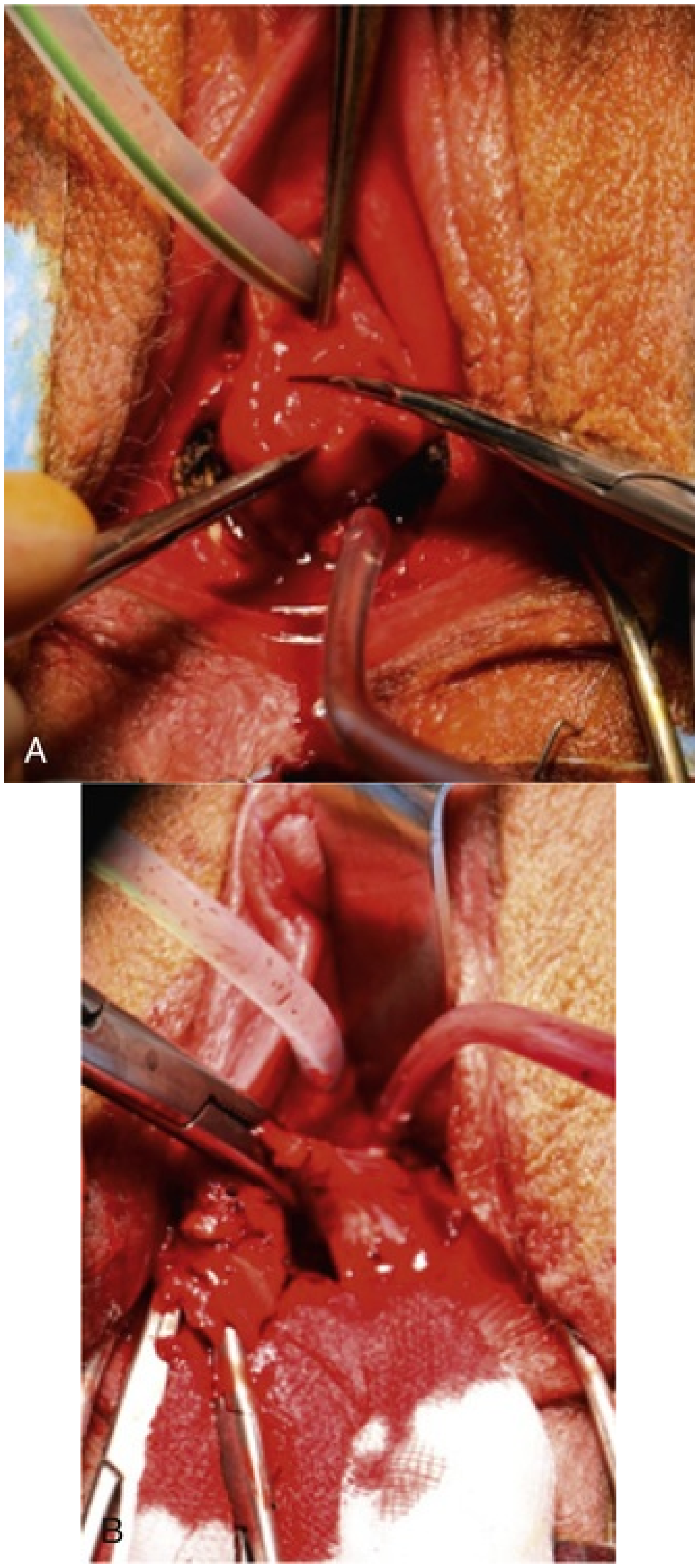

FIG. 134.3 (A) Sharp dissection of the urethrovaginal plane. (B) The lateral vaginal wall is grasped by a Jean-Louis Faure clamp, which facilitates exposure of the levator muscle.

The vaginal introitus is circumferentially incised, and the vagina is grasped with two mosquito clamps anterior and two posterior. The plane between the posterior vaginal wall and the rectum is usually easy to develop by blunt digital dissection. A gauze to protect the rectum is placed in the created space between the rectum and the posterior vaginal wall.

The mobilization between the anterior vaginal wall and the urethra is started with sharp dissection using tenotomy scissors. Diathermy must be avoided to prevent thermal damage to the sphincteric mechanism. Once this plane is finalized, the further plane between the bladder and anterior vaginal wall can be done by the combination of blunt and sharp dissection. A submucosal dissection of the vaginal wall prevents injury to the bladder wall. If injury to the bladder wall occurs, it is usually at the midline, and this must be closed primarily. If there is doubt about the integrity of the ureteric orifices, cystoscopy must be performed. Once the anterior and posterior vaginal walls are sufficiently mobilized, dissection of the lateral walls is started. The mosquito clamps are removed and replaced by two hysterectomy clamps. The levator muscle is dissected away from the lateral wall. High-energy cauterization is used for the lateral dissection to have sufficient hemostasis of the paravaginal plexus.

Although the upper vaginal part can be removed, it is not necessary and less hazardous. The vaginal mucosa is then cauterized to avoid mucosal retention cysts (Fig. 134.4).

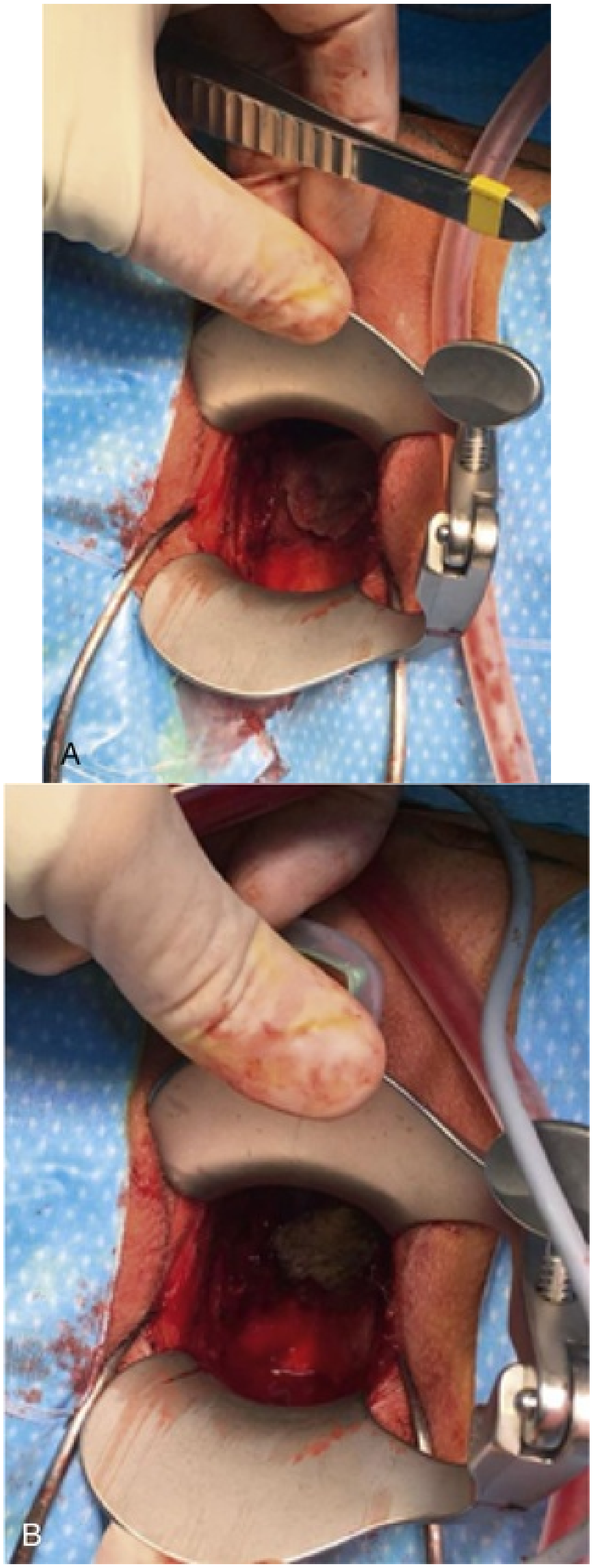

FIG. 134.4 Partial vaginectomy. Vaginal top before (A) and after (B) coagulation.

The gauze protecting the rectum is removed, and hemostasis is performed. Hemostatic agents in the space between the rectum and the bladder are useful at this stage. The medial borders of the left and right levator muscle are approximated with two to three Vicryl 1.0 sutures (Fig. 134.5). This to prevent future prolapse of the bladder and/or rectum.

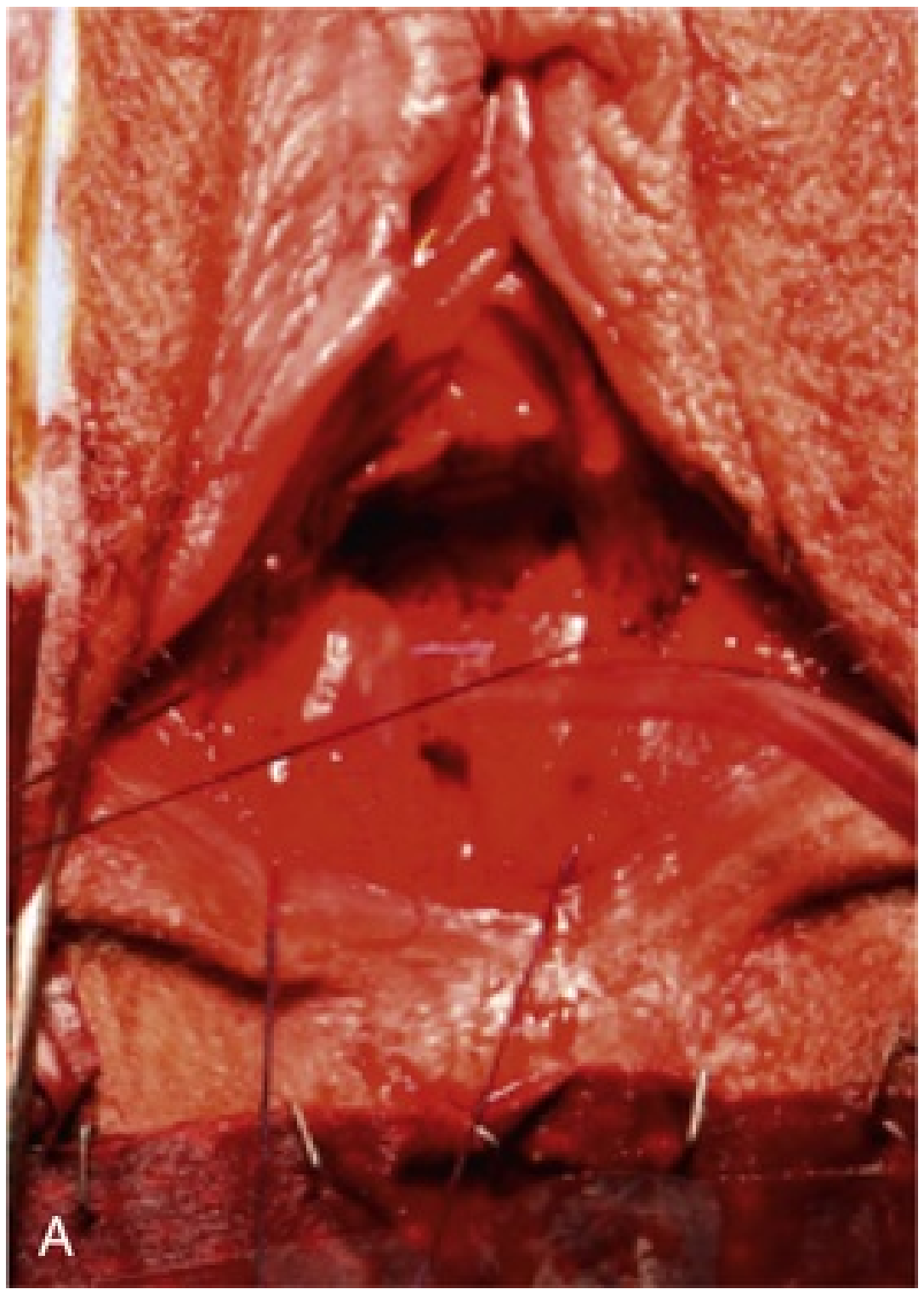

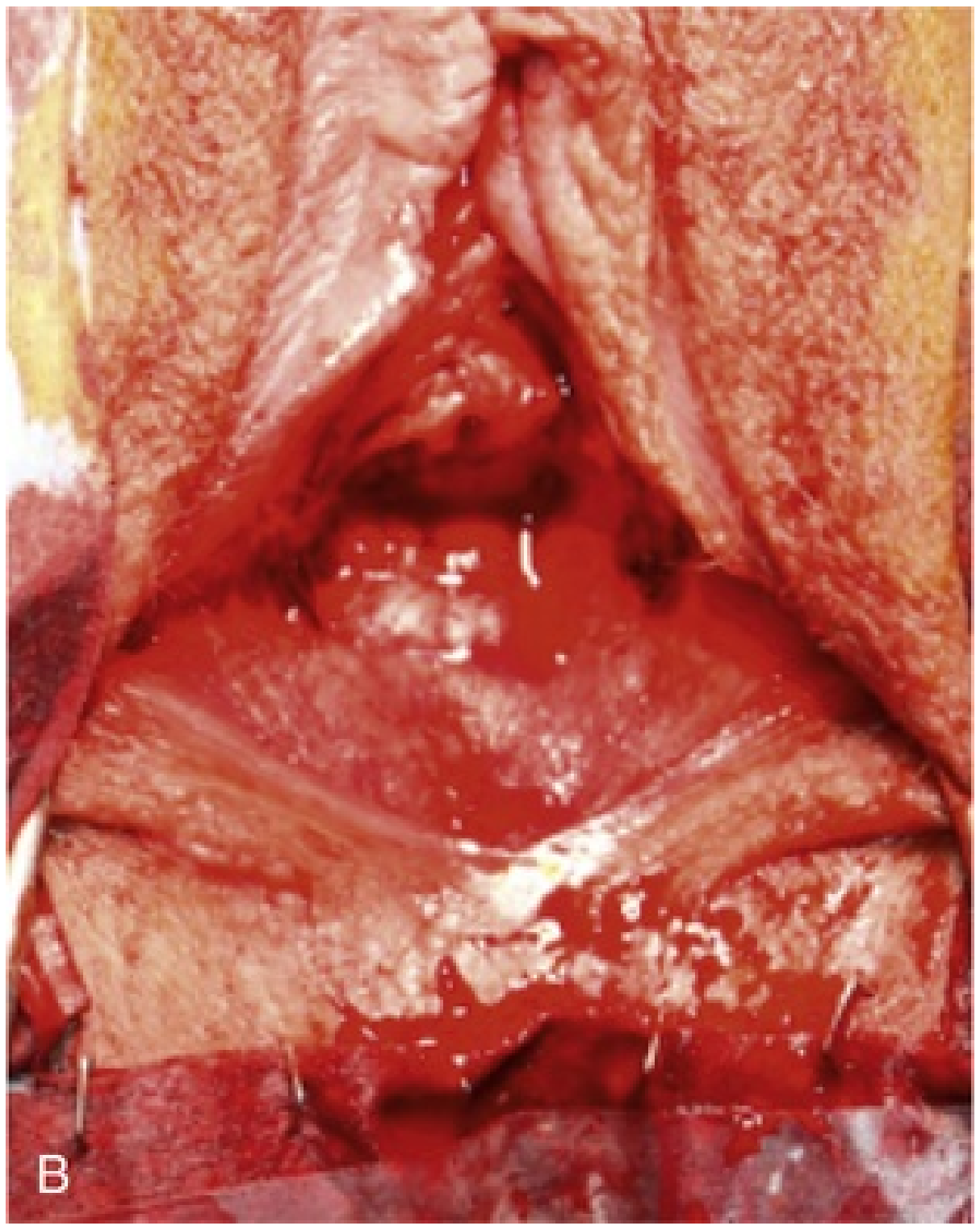

FIG. 134.5 Approximation of the levator muscle. (A) Sutures at the levator muscle. (B) After suturing.

The vaginal introitus is then partially closed from anterior to posterior (Figs. 134.6 and 134.7). A small opening (1-cm diameter) remains for evacuation of vaginal mucus.

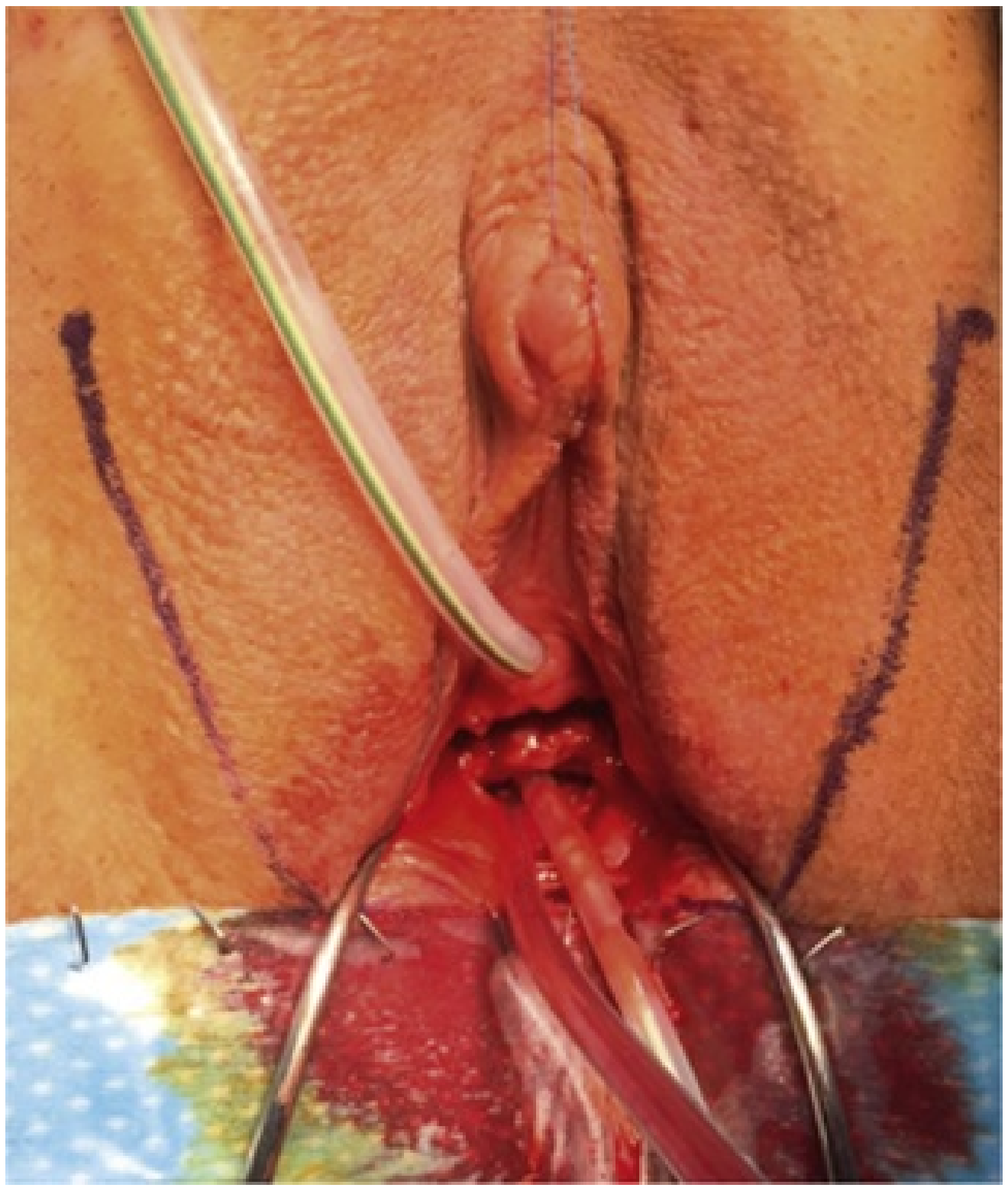

FIG. 134.6 Preservation of the vagina.

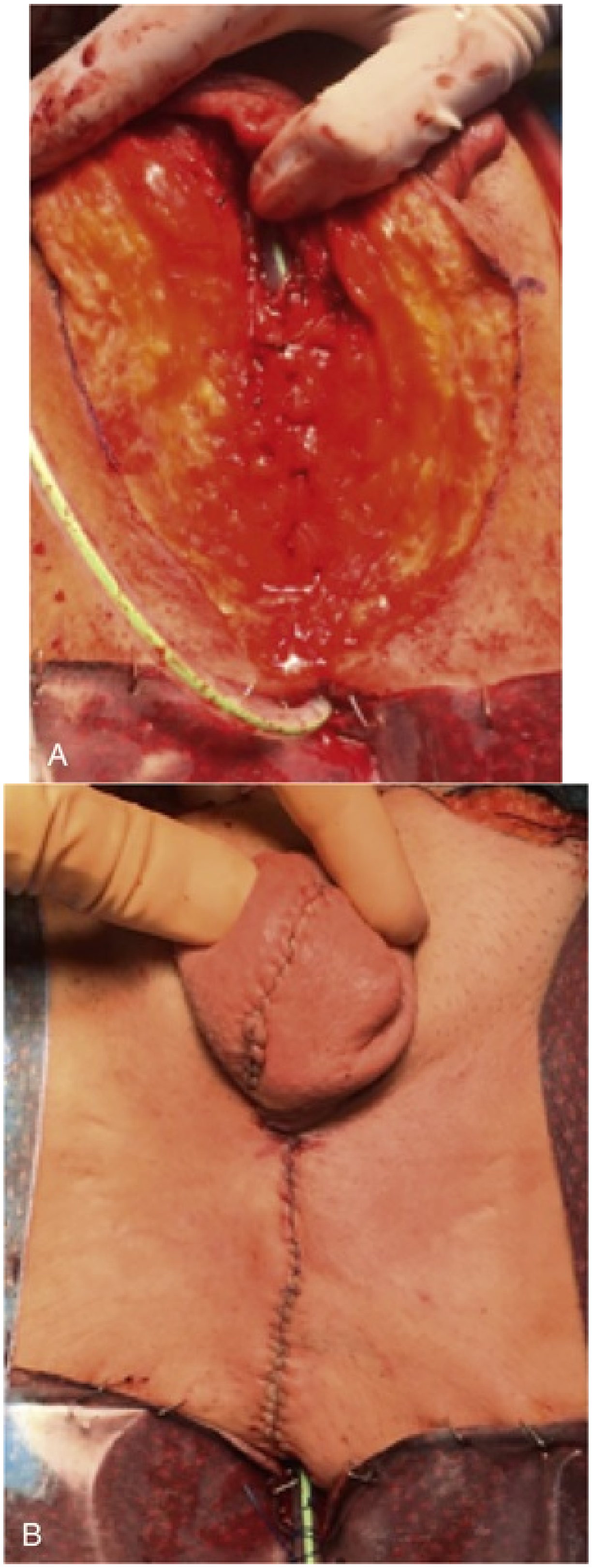

FIG. 134.7 Perineal area in which the vaginal introitus has been partially closed. The drain marks the introitus after creation of the fixed part of the urethra, with approximation of the bulbospongiosus muscle (A) and after

scrotoplasty and closure of the perineum (B).

The best time point to perform vaginectomy remains unclear:

- Vaginectomy can be performed during an “all-in-one” procedure in which full female removal (mastectomy, ovariectomy, hysterectomy, and vaginectomy) is combined with genitoperineal transformation. In the series by Weyers et al. (2010), where phalloplasty was performed, there were more major complications and a higher transfusion rate in case of an all-in-one-procedure. Stojanovic et al. (2017) reported no higher complication rate for the all-in-one-procedure compared with multistage surgery, however, in these series, metoidioplasty was performed instead of phalloplasty.
- Vaginectomy can also be performed at the time of hysterectomy and ovariectomy and combined with temporary metoidioplasty. The phalloplasty is then performed at a later stage. The potential advantage of this is that blood loss and hypotension related to the vaginectomy will not affect perfusion of the phalloplasty as it is not performed at the same time. However, this theoretical advantage needs prospective confirmation.
- The other option is to perform mastectomy, ovariectomy, and hysterectomy first, followed by vaginectomy and genitoperineal transformation in a second stage.

Genitoperineal Transformation

Urethroplasty

In transmen, the urethra can be divided in **three parts:** the native female urethra, the perineal urethra or fixed part, and the phallic urethra.

- The native urethra: this is the original female urethra from the bladder neck to the external meatal orifice
- The fixed part of the urethra: from the (original female) external

> meatal orifice, the urethra is lengthened under the enlarged clitoris using the vestibular mucosa on the ventral side of the clitoris between the female meatus and the glans clitoris and the inner side of the minor labia, creating a 3-cm-wide urethral plate tubularized around an 18-Fr silicone tube with a running 3.0 polyglactin suture. This fixed part of the urethra is the equivalent of the bulbar part of the urethra in males, however, it will not be surrounded by spongiosal tissue (Kim et al., 2010) (see Fig. 134.4).

Some techniques describe the use of an anterior vaginal mucosa flap to incorporate in the reconstructed urethra. The latter is only possible when performed at the time of vaginectomy (Kim et al., 2010).

After reconstruction of the fixed part of the urethra (Fig. 134.8 and Video 134.1), the mucosa of the clitoral glans is removed. Hydrodissection by submucosal infiltration of diluted xylocaine can aid to this. At this stage, one dorsal clitoral nerve is dissected for 2 to 3 cm. This nerve can be found at the 1 o'clock and 11 o'clock positions. The side of dissection depends on the side of vascular anastomosis of the phalloplasty. A prepubic incision is made at the side of future phalloplasty, and the clitoris is fixed onto the pubic symphysis with a Vicryl 2.0 suture (Fig. 134.9).

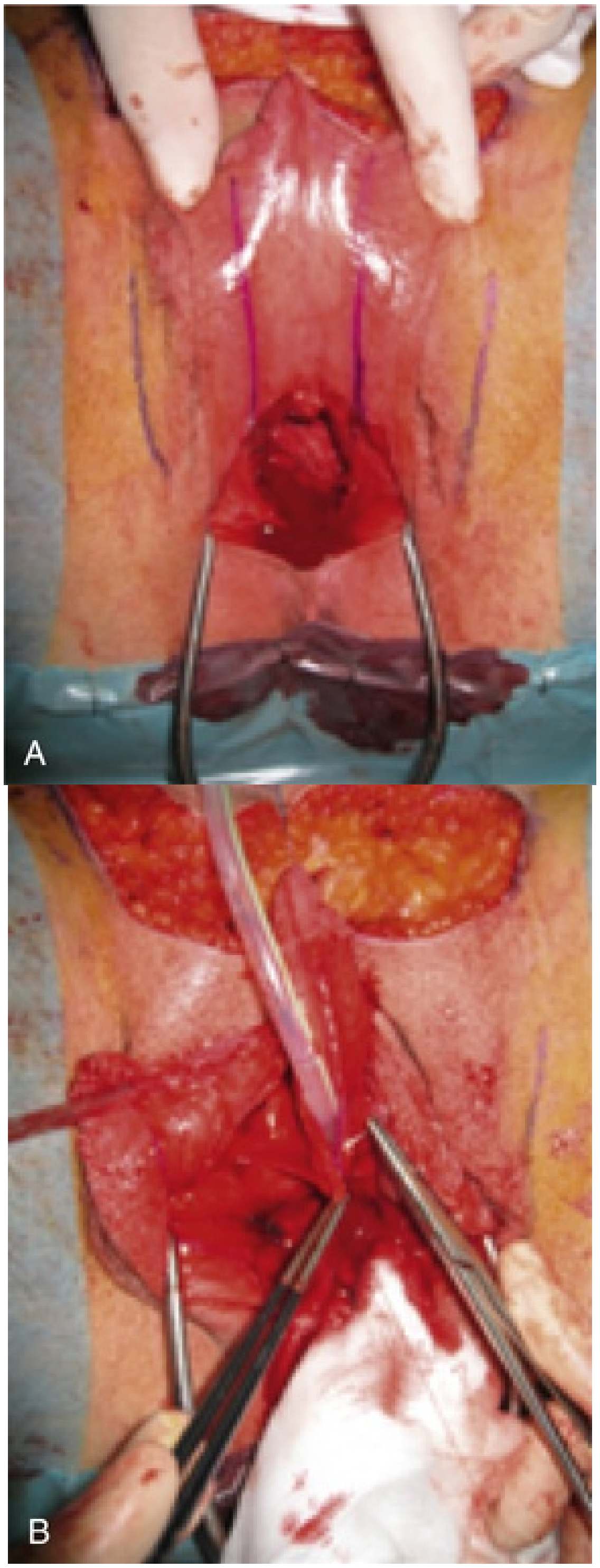
A
B

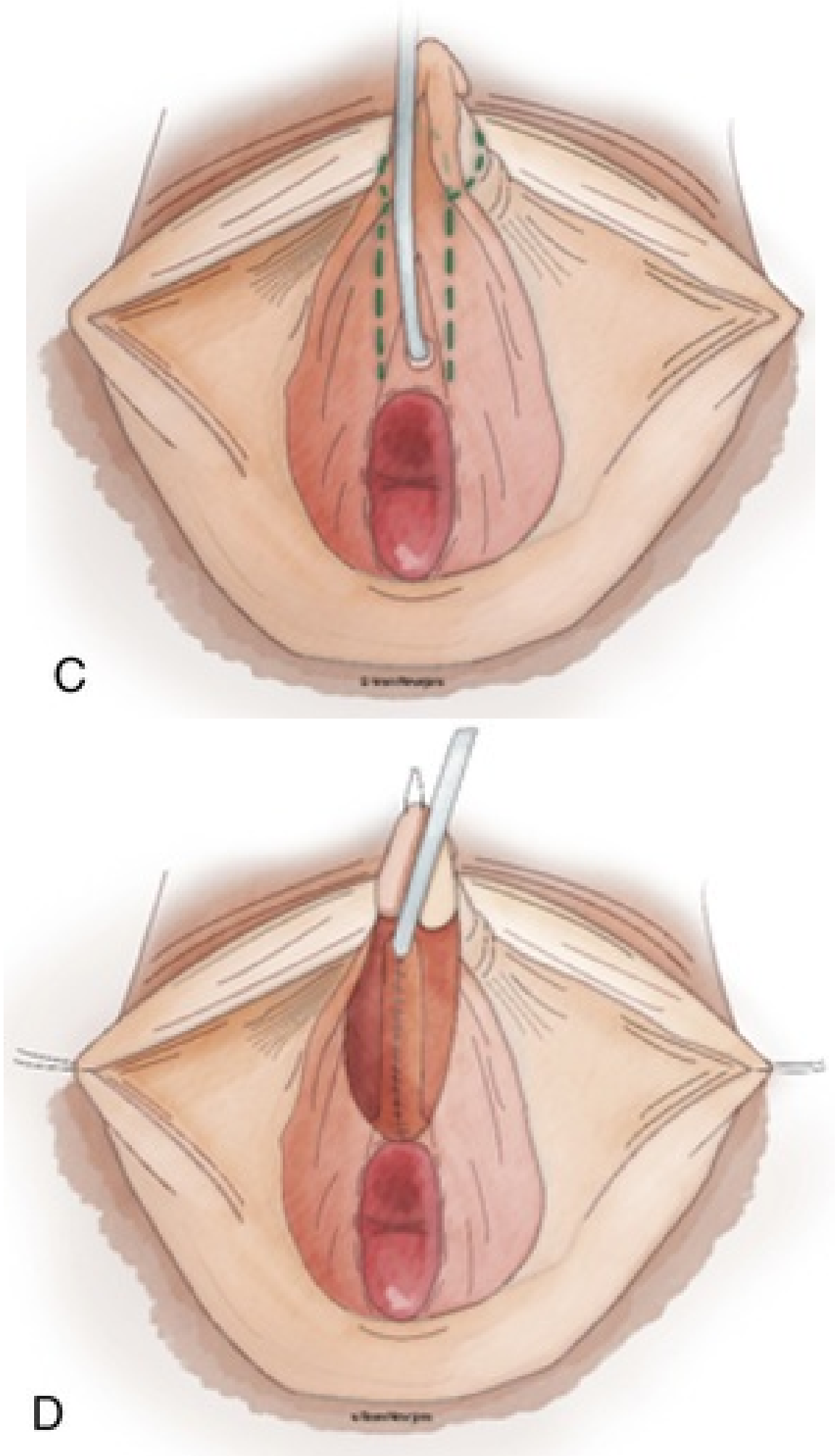

FIG. 134.8 (A to D) Reconstruction of the perineal urethra (pars fixa).

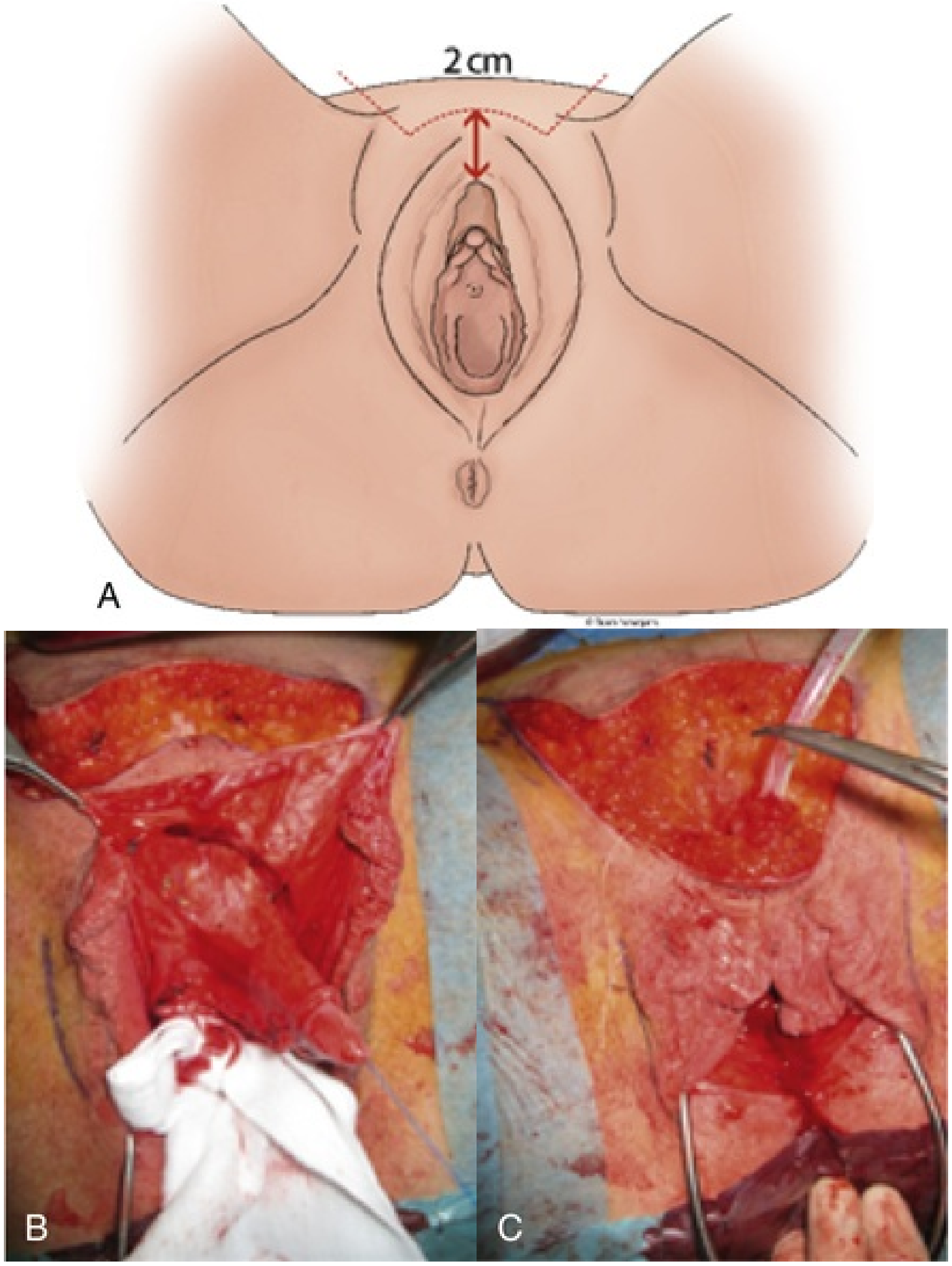

FIG. 134.9 (A to C) Denuding the glans clitoris, dissecting a clitoral nerve, and fixating the clitoris to the pubic bone.

The clitoral nerve will be connected to one of the cutaneous nerves of the flap after the vascular anastomosis has been completed. The distal end of the fixed part is prepared for the future anastomosis with the phallic urethra by placing separate polyglactin 4.0 sutures.

In the perineum, the bulbospongiosus muscles are sutured in the midline to cover the fixed part of the urethra (Fig. 134.10). This will provide a solid vascular support of this part of the urethra (with prevention of fistulae). Furthermore, these muscles can be used to evacuate the last drops of urine that stay in the urethra after micturition. This reduces the embarrassing phenomenon of postvoid dribbling in transmen (Hoebeke et al., 2005).

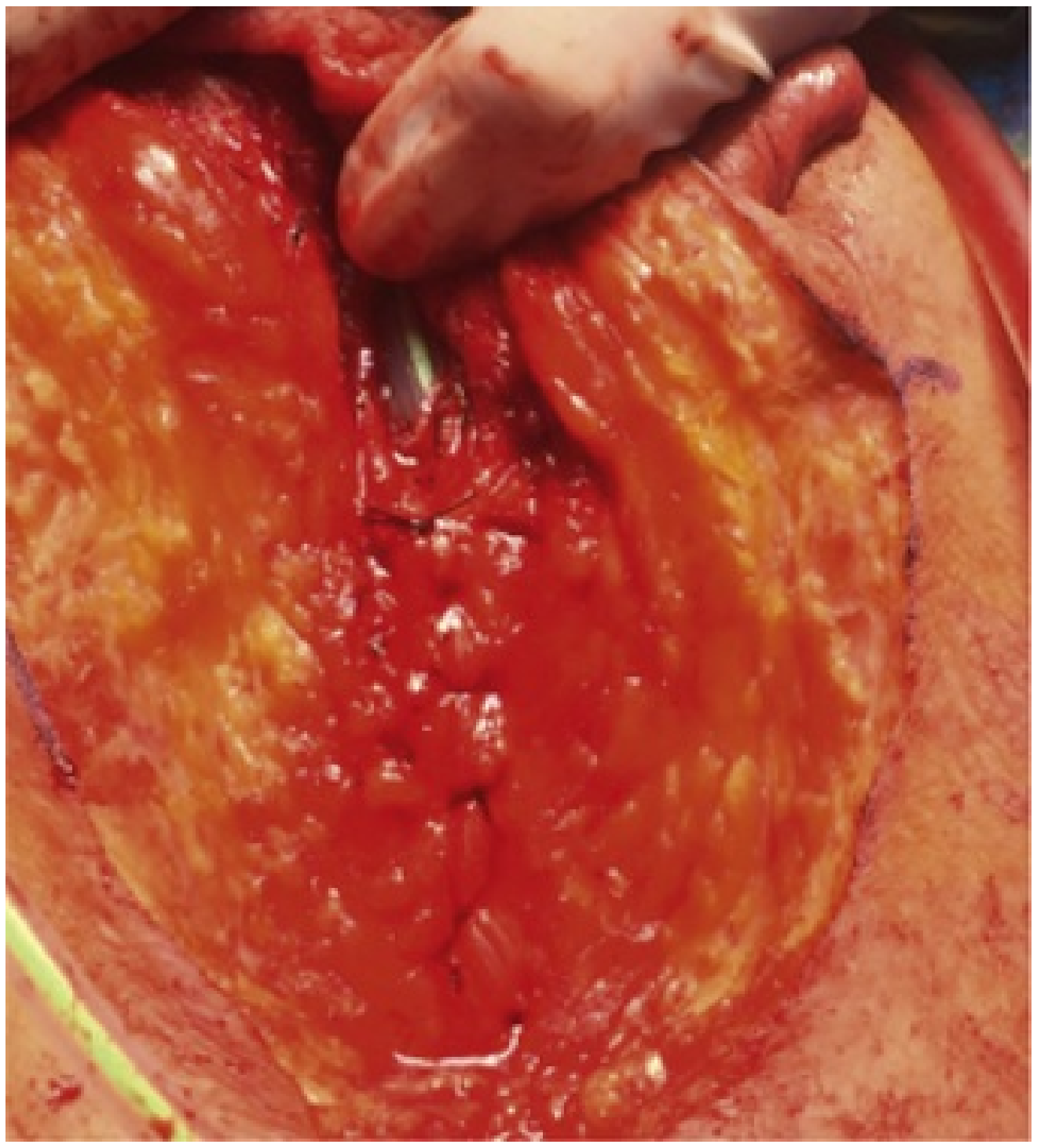

FIG. 134.10 Closure of the bulbospongiosus muscle around the fixed part of the urethra.

The Phallic Urethra

This part of the urethra is located in the phallic reconstruction and is equivalent to the penile urethra in males but again lacks surrounding spongiosal tissue (Fig. 134.11). The phallic urethra can be made using the tube-in-a-tube principle during phalloplasty. A 3-cm-wide skin island of the flap is wrapped around a catheter and tubularized by a polyglactin 3.0 running suture. The proximal end is connected to the fixed part with the interrupted polyglactin 4.0 sutures that are already in place after the neurovascular anastomosis has been performed (in case of free flap phalloplasty). The distal end is connected to the skin of the phallic reconstruction and will form the neomeatus of the transman. The phallic urethra can also be reconstructed by a separate flap (pedicled or free flap) using the same principles as described for the tube-in-a-tube technique.

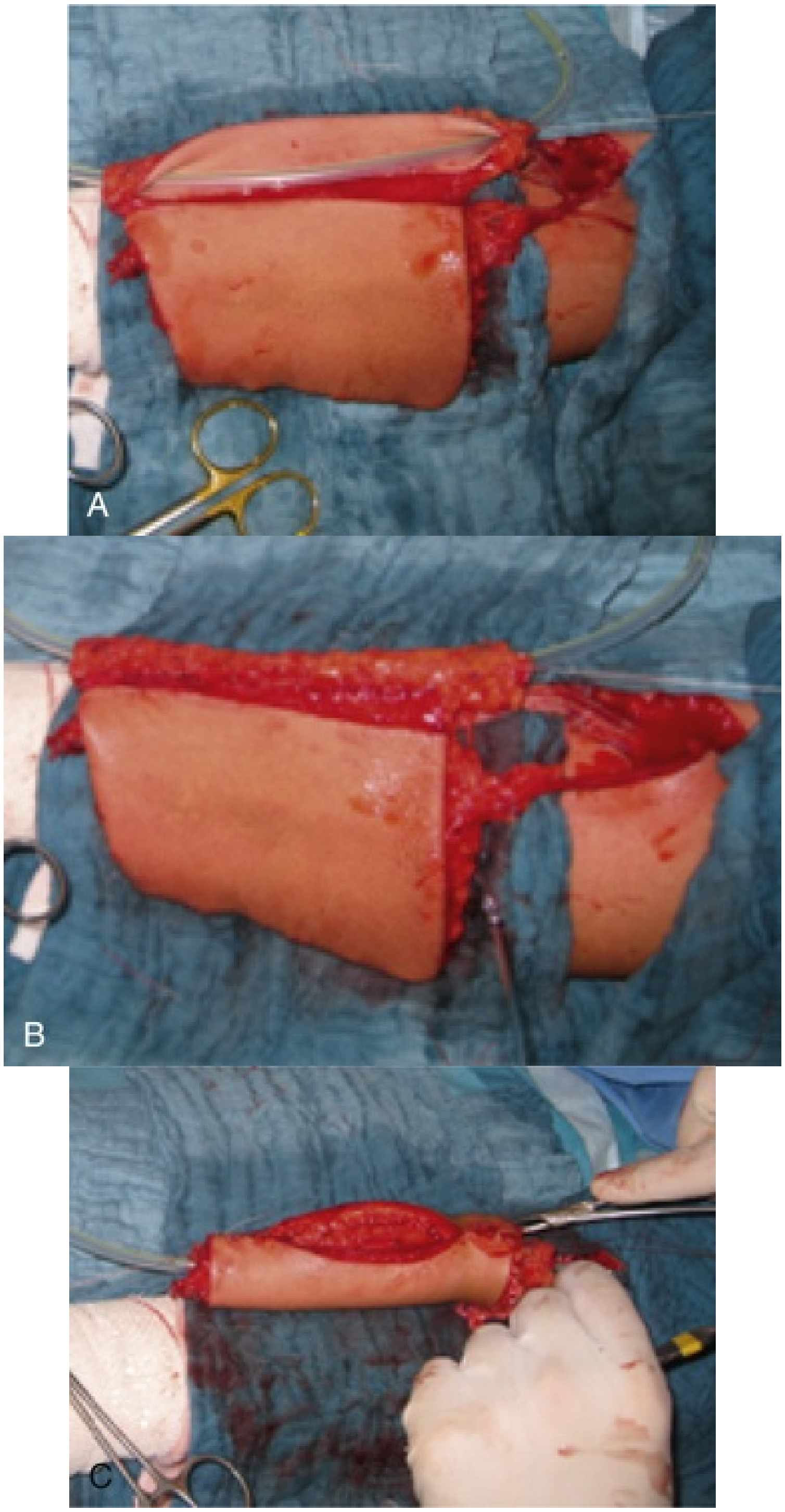
A
B
C

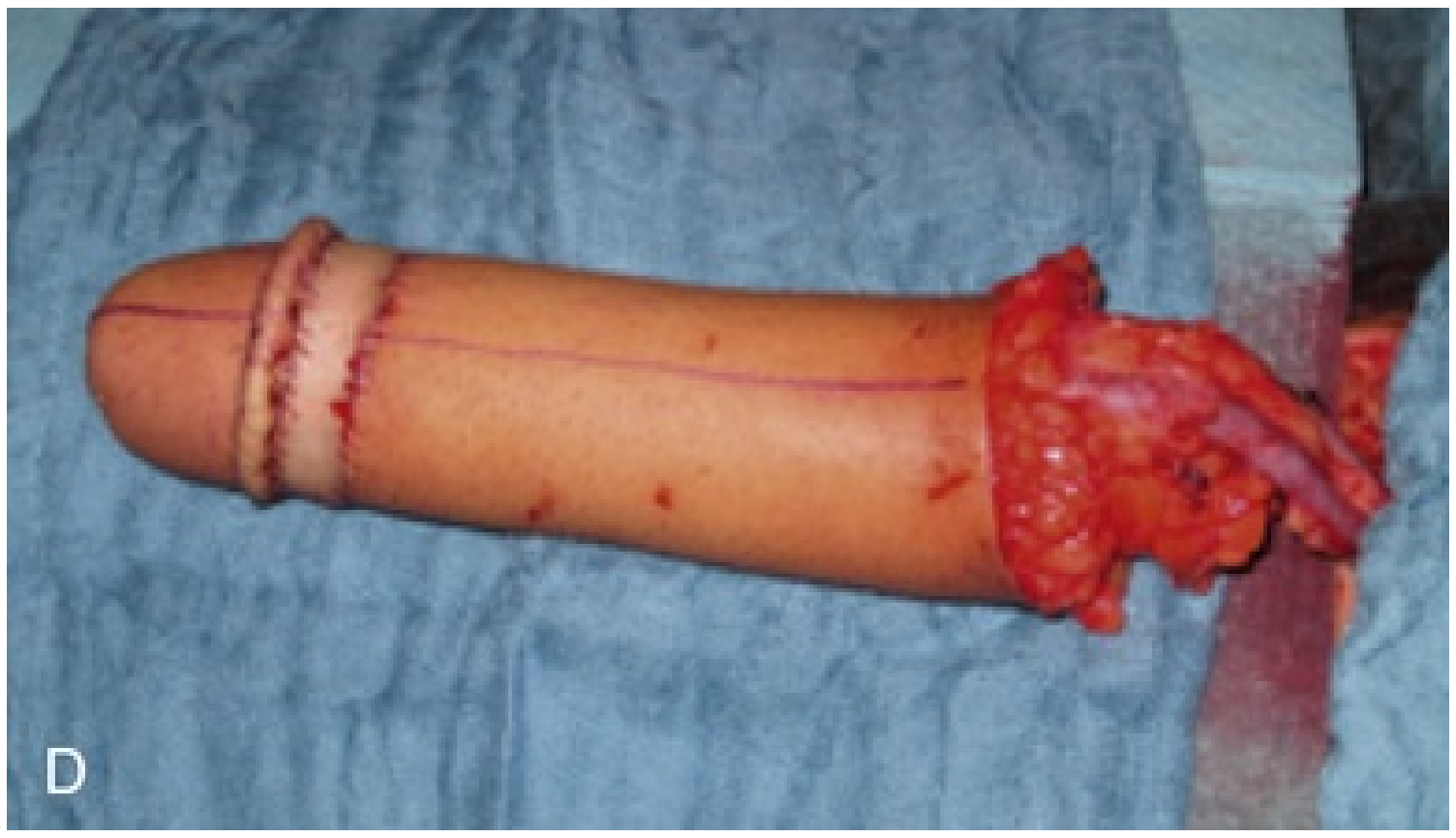

FIG. 134.11 (A to D) Reconstruction of the phallic urethra.

Scrotoplasty

The (hair-bearing) labia majora are used to construct the neoscrotum (Video 134.2▶). Simple midline closure of the labia majora over the former vaginal introitus at the perineum will result in an unaesthetic scrotum that is located between the transman's legs. As the scrotum in males is located in front of the legs, to mimic this, the labia majora are dorsally semi-circumferentially incised and mobilized. This creates bilateral labial flaps supplied by branches of the external pudendal artery. The remnants of the (non–hair-bearing) labia minora and clitoral foreskin are resected from these flaps. The **flaps are turned 180 degrees** and sutured at the top of the perineal skin (Selvaggi et al., 2009). The perineum is closed by subcutaneous polyglactin 1.0 sutures. These large-caliber sutures are needed because there is a lot of tension. The flaps are sutured to each other with resorbable 3.0 sutures. The perineal skin is also closed by resorbable 3.0 sutures (Selvaggi et al., 2009).

Phalloplasty

A **multitude of free and pedicled flaps** are described to reconstruct the phallus. This multitude of flaps indicates that no single flap is able to achieve the ideal goals of phalloplasty. The phalloplasty is done by the plastic surgeon. The choice between different types of flaps depends on the plastic surgeon's expertise, the patient's preference, and, sometimes, local anatomic considerations (e.g., previous surgery in the pelvic or genitoperineal area). Technical details on phalloplasty are beyond the scope of this chapter.

Metoidioplasty

Metoidioplasty is a **potential alternative to phalloplasty** in transmen for whom penetration during sexual intercourse is a secondary or no goal. Metoidioplasty was first described by Lebovic and Laub in 1999 and popularized by Perovic around the same time (Hage and De Graaf, 1993). In this method, a **micropenis** is reconstructed from the enlarged clitoris. With this technique, the fixed part of the urethra is reconstructed as described earlier. However, to lengthen the urethra onto the tip of the clitoral glans, a transverse preputial island flap is used. The neophallus reconstructed by this technique is relatively small (3 to 8 cm) but creates a realistic-appearing penis capable of engorgement with no loss of erotic sensation and, most often, the ability to void standing. There is **most often no ability to penetrate** because of short length, but it is sometimes preferred by transmen because of sexual spontaneity, erection, and sensitivity. Concerns for visible scars in standard phalloplasty may also be at the base of the choice (Monstrey et al., 2008).

Surgically, metoidioplasty relies on straightening of the hypertrophied clitoris by dividing the chordae, releasing the clitoris from the attachments with the labiae minorae, and release of the wide urethral plate on the ventral side by which the clitoris is bent downward. After release of the urethral plate, maximal length can be obtained, but the urethra needs to be lengthened. In our center, we use the transverse preputial island flap to tubularize and use for extension of the urethra.

The **complications** of metoidioplasty can be categorized as minor (Clavien-Dindo grade I and II) or major (Clavien-Dindo III to V). Minor complications such as hematoma, infection, and delayed wound healing do not need surgical reintervention, and major complications including urethral fistulae, urethral stenosis, or flap necrosis need surgical revision. There is only limited experience reported in the literature. Complication rates for minor complications are between 17% and 35%, and major complications account for 7% to 15% of complications (Monstrey et al., 2008; Perovic and Djordjevic, 2003).

Testicular Implants and Erectile Prosthesis

Implantation of testicular and erectile prostheses is done as a **separate procedure. Testicular prostheses can be implanted as early as 6 months after scrotoplasty,** when the scrotum is healed. The size of the scrotum usually allows for the implantation of a 17-mL prostheses. A small incision is made at the base of the scrotum, and a pouch is created bluntly. To avoid displacement, fixation of the prosthesis is advised. Testicular prostheses are usually implanted together with an erectile prosthesis in case the patient also desires the latter.

Implantation of an erectile prosthesis is done as early as 1 year after phalloplasty, if the phallus is endowed with protective sensation and if there are no urethral problems. Although implantation of two cylinders is possible, the bulk of two cylinders can cause ischemia to the skin and the underlying urethra, with an elevated risk for erosion and perforation. One cylinder is usually sufficient to obtain axial rigidity to allow for sexual intercourse. A specific problem in transmen is the lack of a tunica albuginea in which the cylinder can be fixated. For this, the cylinder is fixed at the periosteum of the pubic bone just lateral to the urethra. Malleable and inflatable prostheses are possible in these patients. However, malleable prostheses are technically easier and have a lower risk for technical failure compared with inflatable prostheses. Given the relative hypovascularity of the phallus compared with the native penis and the poor coverage of the prosthesis, **the rate of infection and/or erosion is relative high (20%).** In case of these complications, urgent explantation is needed with subsequent reimplantation at earliest 6 months later. **Technical malfunction (up to 25%) and malposition (up to 15%) are other frequent complications** and reasons for surgical revision (Hoebeke et al., 2003, 2010). Today a specific prosthesis for phalloplasty (ZSI 475 FTM; Zephyr Surgical Implants, Switzerland) has been designed consisting of one larger cylinder with a silicone glans cap and titanium plate at the base that can be sutured to the pubic bone (Fig. 134.12). The implantation technique is shown in ▶Video 134.3.

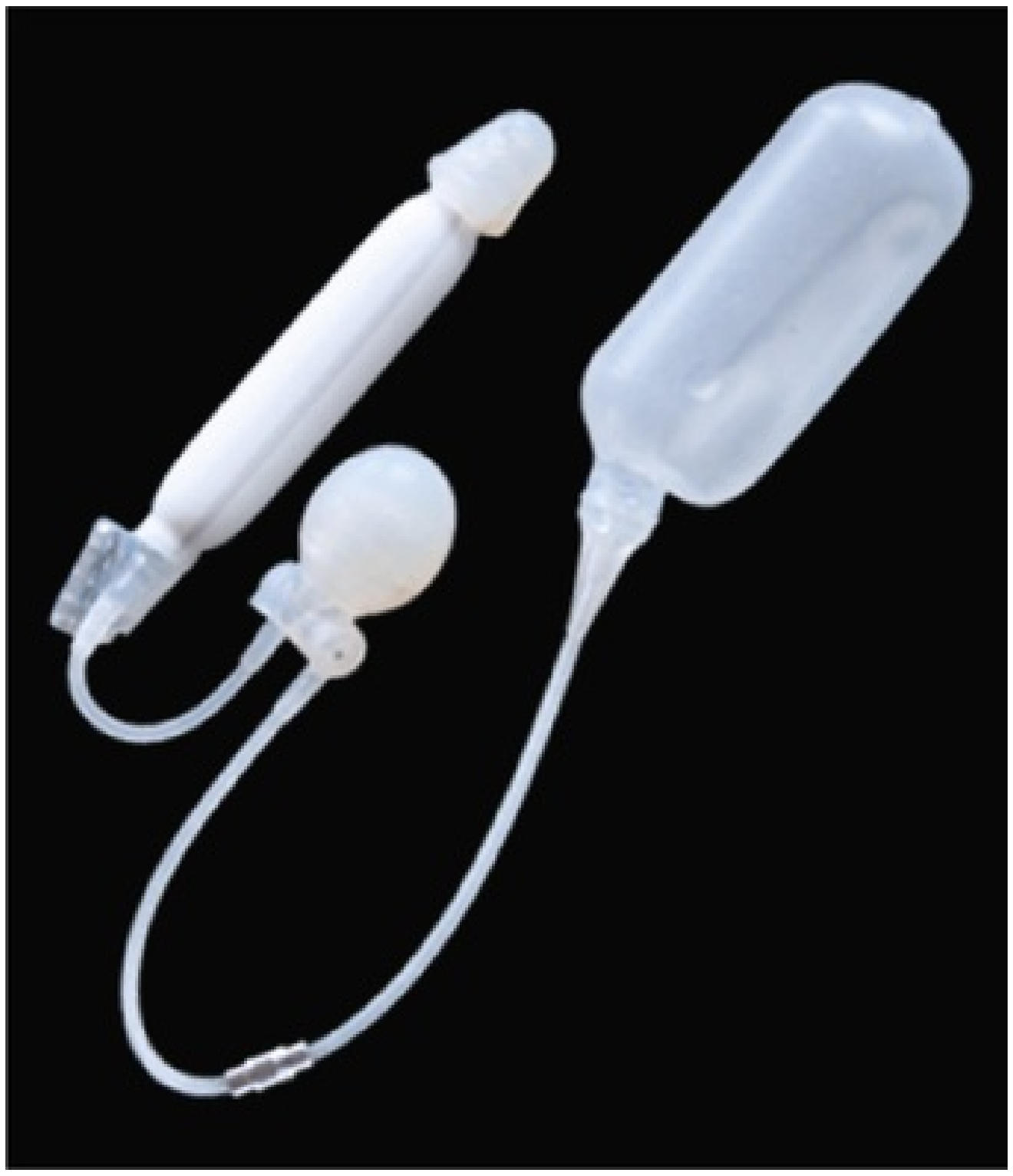

FIG. 134.12 The ZSI 475 FTM inflatable penile implant (Zephyr Surgical Implants, Switzerland).

Postoperative Care, Follow-Up, and Urethral Complications

Early Postoperative Care

Early postoperative care focuses on recovery of micturition after genitourinary reconstruction. In transmen, a suprapubic catheter and a trans-neo-urethral tube are left in situ. After 12 days, the trans-neo-urethral catheter is removed and the patient starts to void. Sometimes, because of significant swelling or a neurogenic impairment to the bladder after vaginectomy, the ability to void and empty completely can be delayed. The suprapubic catheter is then used until normal function is acquired.

In transwomen, a bladder catheter is left in situ for 10 days. After removal, patients usually can void to completion, however, there can be some delay because of neurogenic impairment of bladder function after the creation of the vaginal cavity between the rectum and bladder.

Further early postoperative care is standard as in most urogenital surgical procedures.

Transurethral Catheterization in Transmen

Insertion of a transurethral catheter in transmen is not as easy as in males. The curve toward the native urethra is abrupt, and two small sinuses toward the orifices of Bartholin glands are present bilaterally from this native urethral meatus in which the tip of the catheter can get stuck.

In elective cases, transurethral catheterization must be done by the urologist. One attempt of blind catheterization with a Tiemann tip catheter can be performed, but this attempt must be aborted in case of any problems. A second attempt can be performed with the use of a Freudenberg mandarin by which the sharp curve at the native female urethral meatus can be passed easily. However, in case of any difficulties, it is better to stop and do a flexible cystoscopy with placement of a guidewire into the bladder to avoid provoking urethral trauma (and subsequent stricture formation). An open tip catheter is then placed over this guidewire.

In emergencies, placement of a suprapubic catheter is always a good

solution.

Urethral Complications in Transmen

Up to 40% of patients will suffer urethral complications after phalloplasty.

Urethral Fistula

A urethral fistula is a very common early postoperative complication (35%) (Monstrey et al., 2009). It is related to delayed wound healing of the phallus. The most common location is at the base of the phallus followed by fistulae at the shaft of the phallus. Perineal fistulae are rare because of the better coverage of the urethra with local tissues at this location. However, if vaginectomy has not been performed, urethrovaginal fistulae can arise (Fig. 134.13).

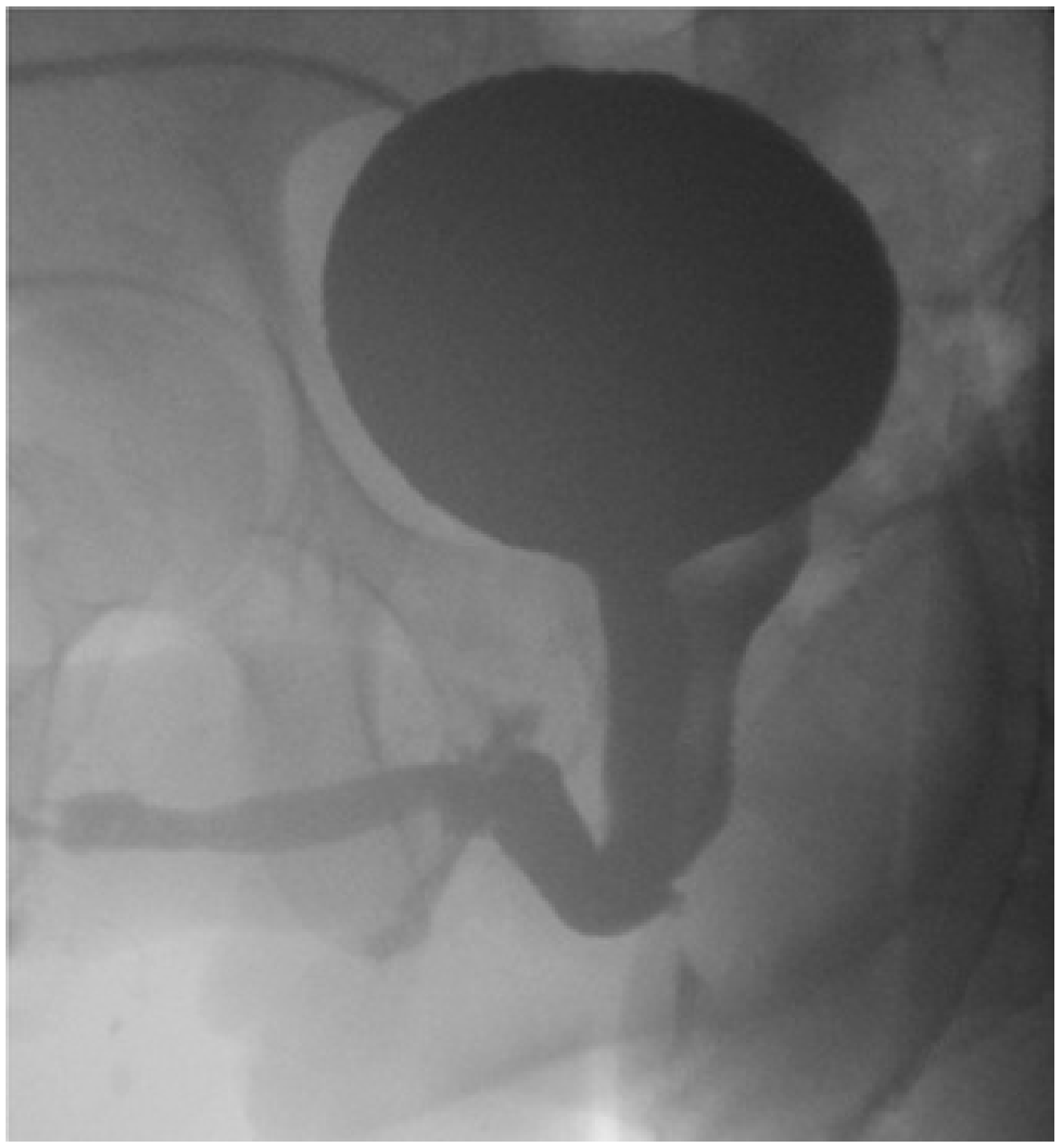

FIG. 134.13 Urethrovaginal fistula on voiding cystography.

In the early postoperative period, the fistula is evident if the urethral catheter is visible through the wound dehiscence. As there is usually an association with delayed healing of the phallus, further maceration of the wound should be avoided. For this purpose, the urinary diversion (transurethral or suprapubic catheter) is maintained until this issue is resolved. After this period, the urinary diversion can be removed, and the patient can start to void through the fistula. **Smaller fistulas have a high chance (up to 70%) of spontaneous closure** (Monstrey et al., 2009). If the fistula persists for longer than 3 months, it is assumed to be permanent, and a surgical closure will be required. The principles of fistula closure must be respected for these patients as well. The fistulous tract is excised with closure of the urethra and skin and with interpositioning of a healthy layer between both. As no dartos layer is available in these patients, only local fatty tissue can be used for coverage. After fistula repair, a catheter is maintained for 10 to 12 days. Compared with the male urethra, which consists of mucosa in spongiosal tissue, the phallic urethra is based on skin from the flap in which healing is delayed.

Urethral Stricture

Incidence.

The risk for urethral stricture is **about 20%** (Monstrey et al., 2009). Again, stricture formation is usually related to healing problems of the phallus and most commonly occurs at areas with a poorer blood supply. This is the reason why the majority of strictures are located at the phallic part of the urethra, the anastomosis, or the external meatus (Lumen et al., 2011). This is a mucocutaneous junction that is prone to stricture formation enforced by delayed healing as a result of poorer blood supply at the extremities of the flap. Most of the strictures at the anastomotic site are short and will usually appear short after phallic reconstruction. Clinical signs and symptoms are the same as in males with urethral stricture.

Diagnosis.

As in males, transmen with urethral stricture will present with a typical plateau curve on uroflowmetry. **Retrograde urethrography (RUG)** is necessary in case of suspicion of urethral stricture. RUG is able to confirm the diagnosis and will provide valuable information about the location and length of the stricture. The three parts of the urethra (the native female urethra, the perineal urethra or fixed part, and the phallic urethra) can be clearly distinguished during RUG (Fig. 134.14). In case of any doubt, urethroscopy can be performed.

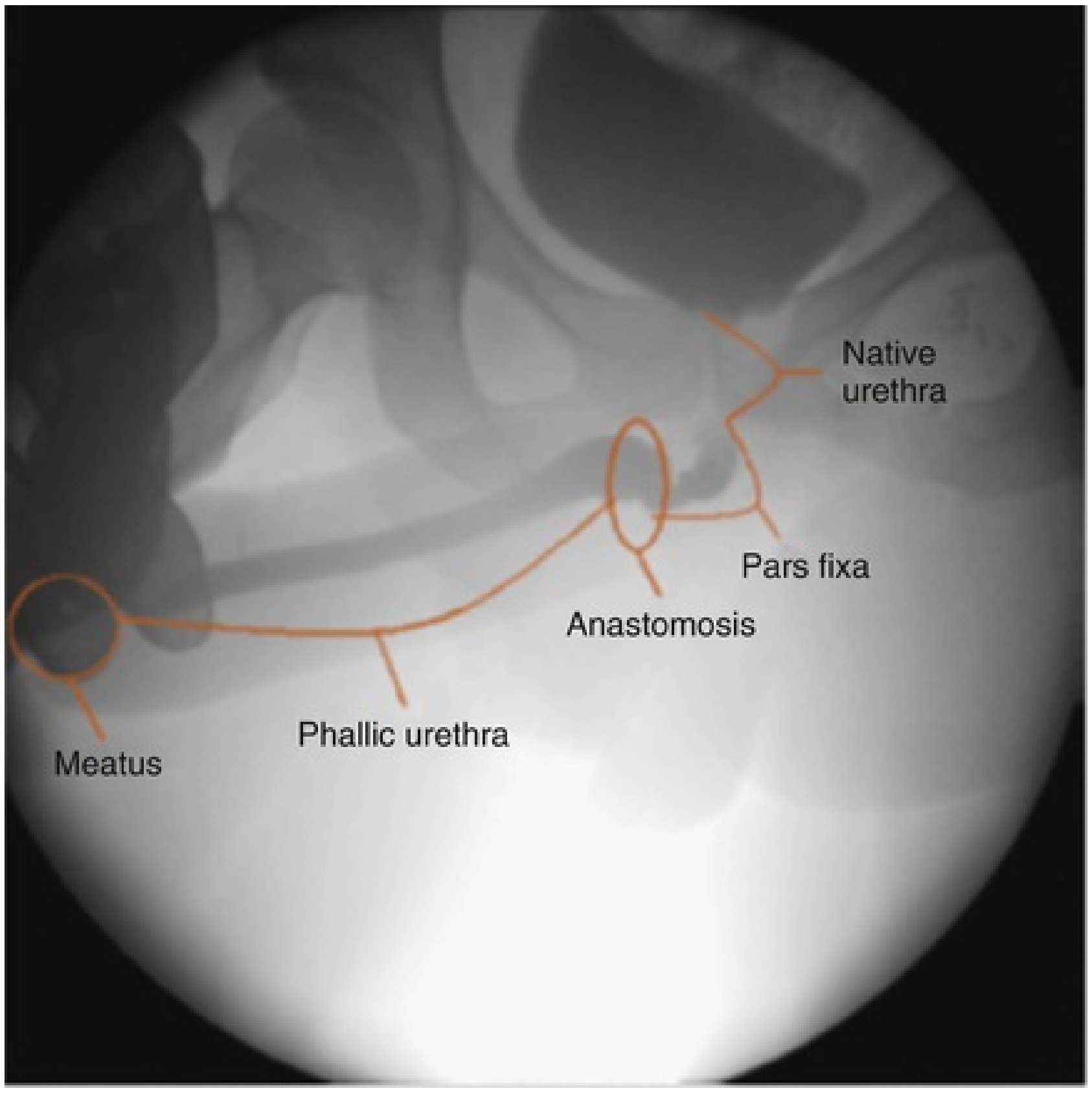

FIG. 134.14 The three parts of the urethra (native female urethra, perineal urethra or fixed part, and phallic urethra) in transmen after phalloplasty as seen on retrograde urethrography.

Management.

Any form of treatment of urethral stricture disease should be **postponed for at least 3 months and preferably 6 months after phallic reconstruction,** at the time wound healing of the phallus has stabilized. It is useless to perform reconstruction during the acute phase of inflammation and wound healing. In case of invalidating obstructive symptoms or retention, a suprapubic catheter is inserted as first-line treatment. A perineostomy is an option if a long interval for definitive urethral reconstruction is expected, in case of severe complaints related to the suprapubic catheter (e.g., bladder spasms), or in case of refusal of the suprapubic catheter. This perineostomy can be closed at the time of urethral reconstruction or in a later phase if the urethral reconstruction appears to be successful.

The type of treatment depends on previous interventions, stricture location, stricture length, and concomitant problems related to the phallus (e.g., flap contracture).

Urethral Dilation

Intermittent urethral dilation is an option for **low-grade meatal stenosis.** The interval of dilation is dictated by the interval of stricture recurrence. A single dilation is possible for a **short flimsy stricture at the anastomosis** between the phallic and fixed part. This dilation is preferably done with fluoroscopic guidance to avoid creating a false passage at the urethra. A guidewire is placed through the stricture, and progressive dilation is performed until it is 18-Fr (if possible). This can be done without anesthesia. **Repetitive dilations for anastomotic strictures are not curative.**

Endoscopic Incision (Direct Vision Internal Urethrotomy)

Endoscopic incision is done under sedation (if the phallus is not sensitive yet) or under spinal/general anesthesia. Again, a guidewire is passed through the stricture to avoid false passage. Direct cold-knife incision at the 4 o'clock, 8 o'clock, and 12 o'clock positions is performed until the underlying fatty tissue is reached and passage of the resectoscope is possible. An 18-Fr transurethral catheter is left in place for 2 weeks. This period is required as it is skin that needs healing and not urethral mucosa, surrounded by spongiosal tissue. **Endoscopic incision has a success rate of 44%. Repetitive endoscopic incisions are of no value.** The sooner after phallic reconstruction, the lower the chance of success (Lumen et al., 2009).

Urethral Reconstruction

Urethral reconstruction is performed for short (<3 cm) strictures refractory to dilation or endoscopic incision and for longer strictures at any segment of the urethra in transmen. Compared with urethral reconstruction in native males, a higher recurrence rate is observed (25% to 61.9%) (Lumen et al., 2011).

Meatotomy

This is indicated for **short meatal strictures** in which dilation is not possible or wanted by the patient. The ventral side of the stenotic meatus in incised until healthy urethra is reached. The skin of the phallus is sutured to the skin of the urethra. The meatus will become slightly hypospadiac with this technique.

Heineke-Mikulicz Urethroplasty

This is an option for **short, nonobliterative strictures** at any segment of the urethra. The urethra is incised longitudinally and closed transversely.

Excision and Primary Anastomosis

This is reserved for **short strictures at the anastomotic site** between the fixed and the phallic part of the urethra. An incision is made at the penoscrotal angle. A metal sound is introduced through the meatus and marks the distal end of the stricture. The urethra is incised ventrally and further opened until healthy proximal urethra at the fixed part is encountered. In case of complete obstruction, the proximal end of the stricture can be marked by passing a metal sound through the perineostomy or the suprapubic tract. The stenotic segment is completely resected, and both urethral ends are spatulated. Both ends are mobilized to allow for a tension-free anastomosis.

Free Graft Urethroplasty

This is of limited value in transmen. The phallic urethra is only surrounded by fatty tissue and does not sufficiently support a graft. The results are, as a consequence, disappointing. At the fixed part, a graft can be placed after incision of the urethral plate as a dorsal inlay procedure. The graft is quilted against the corporal body of the clitoris. The need for this technique is, however, exceptional seen the low incidence of stricture at this site.

Two-Stage Urethroplasty

This is a **standard technique to treat longer strictures** at the phallic urethra. The urethra is opened, and marsupialization is obtained by suturing the borders of the urethra to the borders of the skin incision. In case of a narrow and/or severely scarred urethral plate, the plate can be resected and replaced or augmented by a full-thickness skin graft or by oral mucosa. At least 3 months later, if the urethral plate has healed well, the borders of the marsupialized urethra are incised and retubularized around a urethral catheter.

Flap Urethroplasty

Substitution urethroplasty with local phallic or scrotal skin flaps is of limited use seen the paucity of mobile local tissues and the risk for penile/scrotal deformities after local flap harvest. **For complex or recurrent stricture at the phallic urethra, a complete urethral substitution at this part needs to be performed.** Options are a radial forearm free flap or a superficial circumflex iliac artery free or pedicled groin flap. Other problems at the phallus (e.g., graft contracture) can be managed at the same time with additional grafting or flap procedures.

Definitive Perineostomy

The technique is the same as for contemporary perineostomy in the early postoperative phase. The perineum is incised at the midline until the fixed part of the urethra is reached. The fixed part of the urethra is opened longitudinally over 4 to 5 cm. The borders of the urethra are sutured to the borders of the perineal skin. This is an option for patients with refractory urethral strictures who do not wish further urethral reconstruction (Fig. 134.15).

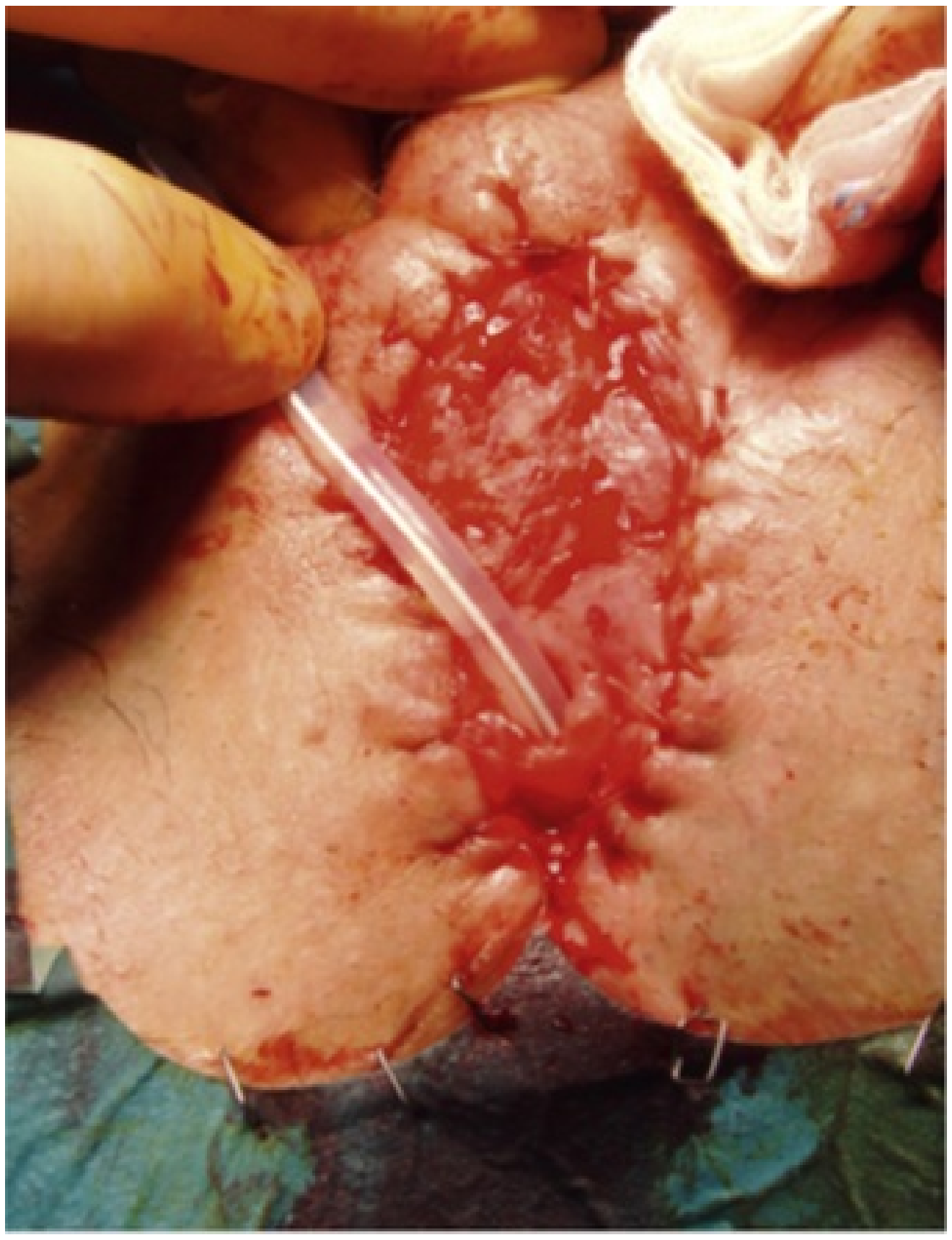

FIG. 134.15 Contemporary perineostomy.

Urethral Hair Growth

In case the urethra is made from skin flaps (which is usually the case), hair growth can occur in the urethra. This is usually without any consequences. Prevention is of utmost importance. If a skin flap will be used for the phallic urethra, a flap from a region with no or minimal hair growth is harvested (e.g., ulnar side in case of radial forearm flap). If this is not possible, preoperative laser epilation is strongly recommended.

In case of substantial hair growth, a hairball with stone formation is possible. Related symptoms are difficulty voiding, local irritation, and urethral discharge. Once it has formed, the phallic urethra is opened at the ventral side with removal of the stone (if present). The borders of the urethra are sutured to the borders of opened skin of the phallus. The hairs at the urethra can be treated subsequently with **laser epilation.** In the next stage, the urethral plate is tubularized as during the second stage of a two-stage urethroplasty.

Postvoid Dribbling

Nearly all transmen will experience some form of postvoid dribbling (Hoebeke et al., 2005). The urethra in transmen is merely a rigid tube as it lacks the elasticity from the surrounding spongiosus tissue in males. Furthermore, although reconstruction of the bulbospongiosus muscle is performed during phalloplasty (see earlier), this reconstructed muscle is not as effective to squeeze out the last drips of urine at the end of micturition. **Perineal pressure at the end of micturition combined with squeezing of the phallus** is an option in case of bothersome postvoid dribbling. In case of severe postvoid dribbling, urethrography or urethroscopy must be performed to exclude urethral sacculation or a pseudodiverticulum from a vaginal remnant. If this is the case, resection might resolve or at least reduce the problem.

Conclusion

Despite the fact that SRS is only carried out in a few specialized centers, the number of people who have undergone SRS is considerable. They can present themselves to each urologist with urologic problems, which is why insight into the reconstructive techniques and possible complications is useful for every urologist. The aim of this chapter was to provide any urologist with essential knowledge to be able to take care of acute urologic problems. Thereafter, referral to experienced centers for treatment of the complications is advisable.

Key Points

- The urologist has an important role in the treatment and follow-up of transgender individuals.
- Urinary incontinence is the most frequent complication in transwomen.
- It is important to be aware of prostate pathology in transwomen.
- Whether or not to perform vaginectomy in transmen should be discussed with the patient.
- Urethral fistula and stricture are frequent complications in transmen and most often occur at the anastomosis between the fixed part and phallic part of the urethra.
- Metoidioplasty is an alternative to phalloplasty in transmen who refuse to accept the complications of phalloplasty.
- Implantation of an erectile prosthesis in transmen is associated with a higher risk for complications compared with native males.

Suggested Readings

Conard LE. Supporting and caring for transgender and gender nonconforming youth in the urology practice. *J Pediatr Urol*. 2017;13(3):300–304.

De Cuypere G, Knudson G, Bockting W. World Professional Association for Transgender Health: mission and Vision. Response of WPATH to the proposed DSM 5 criteria for Gender Incongruence and Transvestic Disorder. *J Sex Med*. 2011;8 [112–112].

Hoebeke P, Selvaggi G, Ceulemans P, et al. Impact of sex reassignment surgery on lower urinary tract function. *Eur Urol*. 2005;47(3):398–402.

Hoebeke PB, Decaestecker K, Beysens M, et al. Erectile implants in female-to-male transsexuals: our experience in 129 patients. *Eur Urol*. 2010;57(2):334–340.

Lumen N, Monstrey S, Goessaert AS, et al. Urethroplasty for strictures after phallic reconstruction: a single-institution experience. *Eur Urol*. 2011;60(1):150–158.

Monstrey S, Hoebeke P, Selvaggi G, et al. Penile reconstruction: is the radial forearm flap really the standard technique? *Plast Reconstr Surg*. 2009;124(2):510–518.

Perovic SV, Djordjevic ML. Metoidioplasty: a variant of phalloplasty in female transsexuals. *BJU Int*. 2003;92(9):981–985.

Selvaggi G, Bellringer J. Gender reassignment surgery: an overview. *Nat Rev Urol*. 2011;8(5):274–282.

Trum HW, Hoebeke P, Gooren LJ. Sex reassignment of transsexual people from a gynecologist's and urologist's perspective. *Acta Obstet Gynecol Scand*. 2015;94(6):563–567.

Weyers S, De Sutter P, Hoebeke S, et al. Gynaecological aspects of the treatment and follow-up of transsexual men and women. *Facts Views Vis Obgyn*. 2010;2(1):35–54.

References

Bao AM, Swaab DF. Sexual differentiation of the human brain: relation to gender identity, sexual orientation and neuropsychiatric disorders. *Front Neuroendocrinol*. 2011;32(2):214–226.

Black DW, Grant JE. *DSM-5 guidebook: the essential companion to the Diagnostic and Statistical Manual of Mental Disorders, fifth edition*. [the; American Psychiatric Association] ed 1. American Psychiatric Association: Washington, DC; 2014.

Bockting W, Coleman E, De Cuypere G. Care of transsexual persons. *N Engl J Med*. 2011;364(26):2559–2560 [author reply 2560].

Conard LE. Supporting and caring for transgender and gender nonconforming youth in the urology practice. *J Pediatr Urol*. 2017;13(3):300–304.

De Cuypere G, Van Hemelrijck M, Michel A, et al. Prevalence and demography of transsexualism in Belgium. *Eur Psychiatry*. 2007;22(3):137–141.

De Cuypere G, Knudson G, Bockting W. Response of WPATH to the proposed DSM 5 criteria for Gender Incongruence and Transvestic Disorder. [the; World Professional Association for Transgender Health: Mission and Vision] *J Sex Med*. 2011;8 [112–112].

Dittmann V, Albus M, Grefe J. Disorders of adult personality and behaviour (F6). Results from the ICD-10 field trial of the Diagnostic Criteria for Research in German-speaking countries. *Psychopathology*. 1996;29(5):301–305.

Green R. Family cooccurrence of “gender dysphoria”: ten sibling or parent-child pairs. *Arch Sex Behav*. 2000;29(5):499–507.

Hage JJ, De Graaf FH. Addressing the ideal requirements by free flap phalloplasty: some reflections on refinements of technique. *Microsurgery*. 1993;14(9):592–598.

Hembree WC, Cohen-Kettenis P, Delemarre-van de Waal HA, et al. Endocrine treatment of transsexual persons: an Endocrine Society clinical practice guideline. *J Clin Endocrinol Metab*. 2009;94(9):3132–3154.

Hoebeke P, de Cuypere G, Ceulemans P, et al. Obtaining rigidity in total phalloplasty: experience with 35 patients. *J Urol*. 2003;169(1):221–223.

Hoebeke P, Selvaggi G, Ceulemans P, et al. Impact of sex reassignment surgery on lower urinary tract function. *Eur Urol*. 2005;47(3):398–402.

Hoebeke PB, Decaestecker K, Beysens M, et al. Erectile implants in female-to-male transsexuals: our experience in 129 patients. *Eur Urol*. 2010;57(2):334–340.

Hoekzema E, Schagen SE, Kreukels BP, et al. Regional volumes and spatial volumetric distribution of gray matter in the gender dysphoric brain. *Psychoneuroendocrinology*. 2015;55:59–71.

Kim SK, Moon JB, Heo J, et al. A new method of urethroplasty for prevention of fistula in female-to-male gender reassignment surgery. *Ann Plast Surg*. 2010;64(6):759–764.

Kuhn A, Hiltebrand R, Birkhauser M. Do transsexuals have micturition disorders? *Eur J Obstet Gynecol Reprod Biol*. 2007;131(2):226–230.

Lumen N, Oosterlinck W, Decaestecker K, et al. Endoscopic incision of short (<3 cm) urethral strictures after phallic reconstruction. *J Endourol*. 2009;23(8):1329–1332.

Lumen N, Monstrey S, Goessaert AS, et al. Urethroplasty for strictures after phallic reconstruction: a single-institution experience. *Eur Urol*. 2011;60(1):150–158.

Lumen N, Kuehhas FE, Djakovic N, et al. Review of the current management of lower urinary tract injuries by the EAU Trauma Guidelines Panel. *Eur Urol*. 2015;67(5):925–929.

Melloni C, Melloni G, Rossi M, et al. Lower urinary tract symptoms in male-to-female transsexuals: short terms results and proposal of a new questionnaire. *Plast Reconstr Surg Glob Open*. 2016;4(3):e655.

Monstrey S, Selvaggi G, Ceulemans P, et al. Chest-wall contouring surgery in female-to-male transsexuals: a new algorithm. *Plast Reconstr Surg*. 2008;121(3):849–859.

Monstrey S, Hoebeke P, Selvaggi G, et al. Penile reconstruction: is the radial forearm flap really the standard technique? *Plast Reconstr Surg*. 2009;124(2):510–518.

Perovic SV, Djordjevic ML. Metoidioplasty: a variant of phalloplasty in female transsexuals. *BJU Int*. 2003;92(9):981–985.

Reisner SL, Vetters R, Leclerc M, et al. Mental health of transgender youth in care at an adolescent urban community health center: a matched retrospective cohort study. *J Adolesc Health*. 2015;56(3):274–279.

Selvaggi G, Bellringer J. Gender reassignment surgery: an overview. *Nat Rev Urol*. 2011;8(5):274–282.

Selvaggi G, Hoebeke P, Ceulemans P, et al. Scrotal reconstruction in female-to-male transsexuals: a novel scrotoplasty. *Plast Reconstr Surg*. 2009;123(6):1710–1718.

Serafetinides E, Kitrey ND, Djakovic N, et al. Review of the current management of upper urinary tract injuries by the EAU Trauma Guidelines Panel. *Eur Urol*. 2015;67(5):930–936.

Steensma TD, Biemond R, de Boer F, et al. Desisting and persisting gender dysphoria after childhood: a qualitative follow-up study. *Clin Child Psychol Psychiatry*. 2011;16(4):499–516.

Stojanovic B, Bizic M, Bencic M, et al. One-stage gender-confirmation surgery as a viable surgical procedure for female-to-male transsexuals. *J Sex Med*. 2017;14(5):741–746.

Trum HW, Hoebeke P, Gooren LJ. Sex reassignment of transsexual people from a gynecologist's and urologist's perspective. *Acta Obstet Gynecol Scand*. 2015;94(6):563–567.

Weyers S, Decaestecker K, Verstraelen H, et al. Clinical and transvaginal sonographic evaluation of the prostate in transsexual women. *Urology*. 2009;74(1):191–196.

Weyers S, De Sutter P, Hoebeke S, et al. Gynaecological aspects of the treatment and follow-up of transsexual men and women. *Facts Views Vis Obgyn*. 2010;2(1):35–54.

135

Tumors of the Bladder

Max Kates MD, Trinity J. Bivalacqua MD, PhD

Epidemiology

Incidence, Prevalence, Mortality

Bladder cancer is a global disease, with 540,000 incident cases and 188,000 deaths in 2015 worldwide (Fig. 135.1). In the United States 81,190 patients will be diagnosed in 2018 and 17,240 will die from their disease (American Cancer Society, 2017). Although age-adjusted incidence and mortality rates initially declined in the 1990s and early part of 2000s, these rates have plateaued in recent years (Dy et al., 2017; Ferlay et al., 2014). Between 2005 and 2015 unadjusted incidence rates of bladder cancer grew 31%, which has been attributed to aging and population growth (Fitzmaurice et al., 2017). This increase in incidence has been attributed to the increase in life expectancy over time and the resultant aging of the global population. Adjusted for demographic changes, the incidence rates for bladder cancer have remained relatively stable (Fig. 135.2). The United States has seen a decline in incidence rates from 2005 to 2014 by 0.8% per year in men and women (American Cancer Society, 2017). The odds of developing bladder cancer are highest in high-income countries (1 in 36 men and 1 in 165 women) and lowest in low-income countries (1 in 122 men and 1 in 310 women). In 2015 age-specific incidence rates were highest in North American (31.6 per 100,000), Western Europe (26.0), and Central Europe (24.1), and lowest in Oceania (4.5), Andean Latin America (5.8), and Central Latin America (5.9). However, since 1990, developing countries have had an increasing burden of bladder cancer incidence compared with developed countries, which has been attributed to a narrowing gap in life expectancy between low- and high-income countries, with subsequent higher rates of cancer in an older population (Dy et al., 2017).

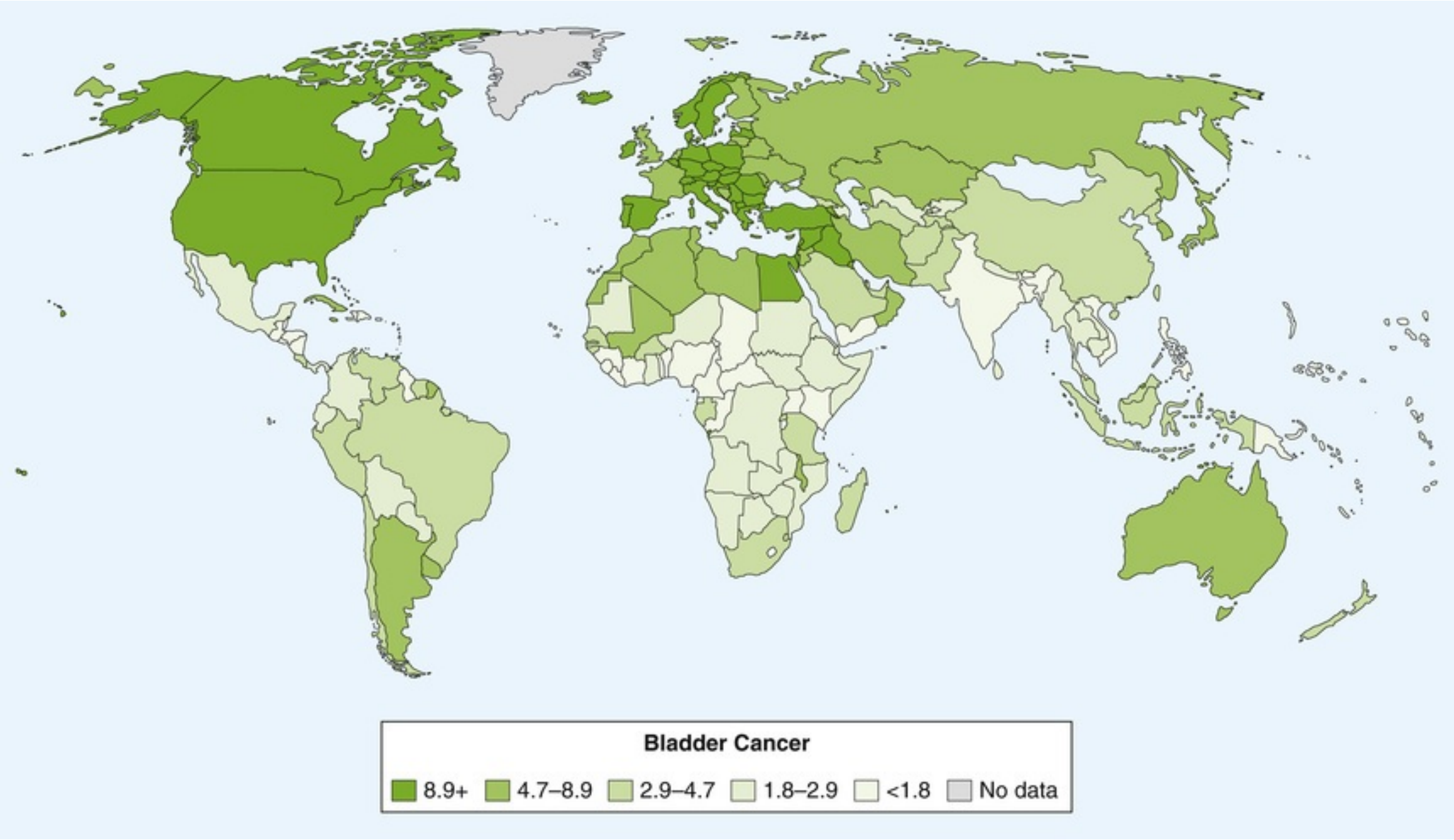
Bladder Cancer
8.9+
4.7–8.9
2.9–4.7
1.8–2.9
<1.8
No data

FIG. 135.1 Global incidence rates of bladder cancer. (Data from Ferlay J, Soerjomataram I, Ervik M, et al.: GLOBOCAN 2012 v1.1, Cancer incidence and mortality worldwide: IARC CancerBase No. 11. Lyon, *Fr. Int Agency Res Cancer,* 2014 [website]: http://globocan.iarc.fr)

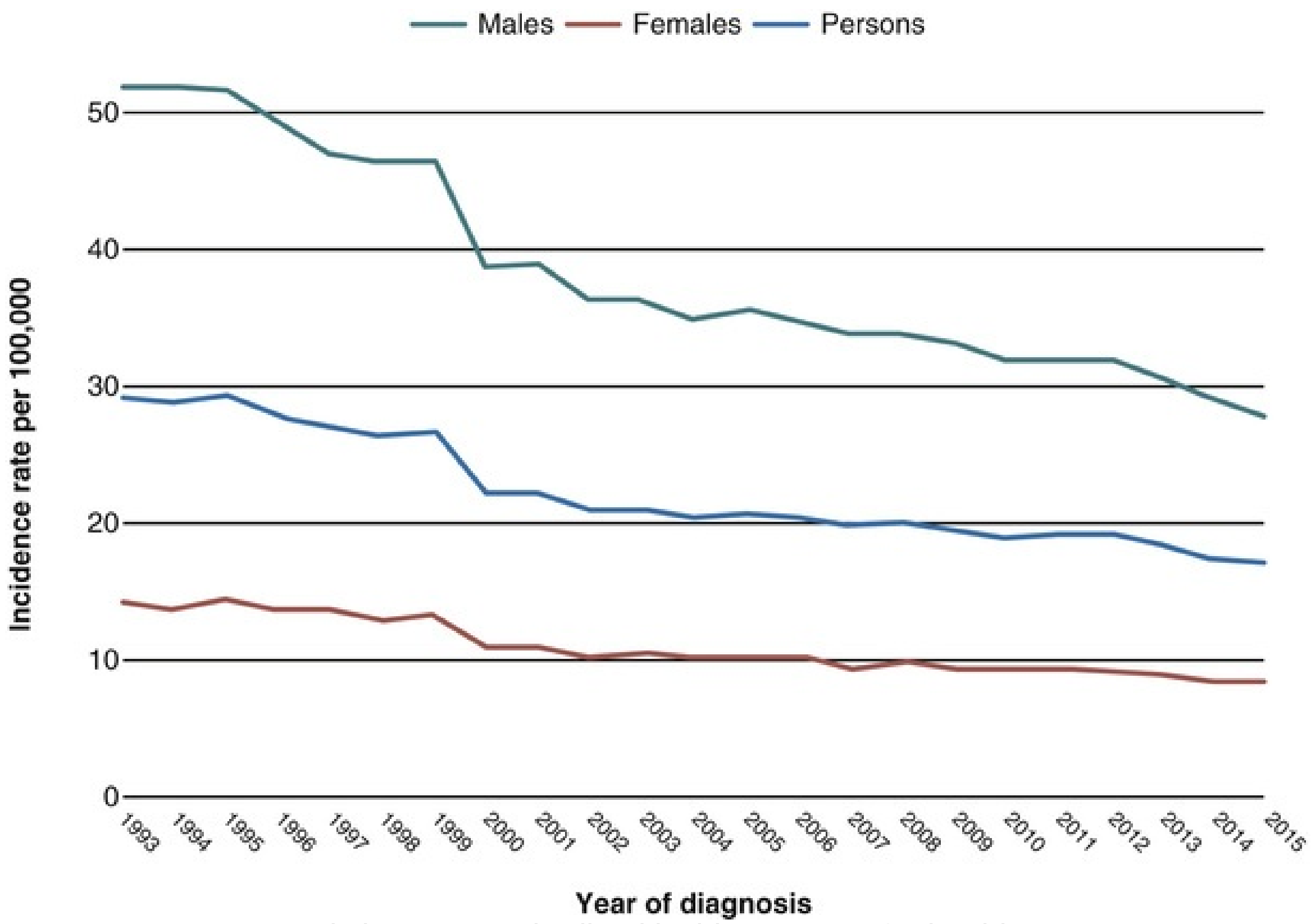

FIG. 135.2 Trends in age-standardized incidence rates for bladder cancer, 1993 to 2015. (Modified from Cancer Center UK: *Bladder cancer statistics,* 2018 [website]: https://www.cancerresearchuk.org/health-professional/cancer-statistics/statistics-by-cancer-type/bladder-cancer.)

Although incidence rates are highest in Europe and North America, more than 60% of all bladder cancer incidence, and nearly half of bladder cancer deaths occur in the developing world (Antoni et al., 2017). Disability-adjusted life-years (DALYs) are the primary way in which the World Health Organization (WHO) quantifies the burden of disease from mortality and morbidity. DALYs correspond to the years of life lost (number of deaths × remaining life expectancy) and the years lost because of disability. Bladder cancer causes approximately 3.4 million DALYs in 2015. Furthermore, although age-standardized DALYs rates for bladder cancer among both sexes decreased by 9%, incidence rates have remained steady among high-income countries.

Because bladder cancer has fewer deaths relative to incident cases compared with several other malignancies, bladder cancer is one of the world's most prevalent cancers. The global 5-year prevalence of bladder cancer is estimated to be 1,319,749, with 243,867 coming from the United States (Ferlay et al., 2014). However, 5-year prevalence may not fully reflect the number of bladder cancer survivors managing disease sequel, as an estimated 571,518 bladder cancer survivors lived in the United States in 2011 (Malats and Real, 2015). Among cancers affecting both sexes, bladder cancer ranks as the fourth most prevalent cancer globally, and in the top 5 in prevalence in individual countries of all income levels and all regions, including the United States (96.6 patients per 100,000), Argentina (32.6), Egypt (41.2), Belgium (158.6), Australia (59.7), and Japan (71.0) (Bray et al., 2013; Ferlay et al., 2014; see Fig. 135.2). Regional variations do exist, however. Bladder cancer was the most commonly diagnosed cancer in 2015 for men in Egypt primarily because of high rates of *Schistosoma haematobium* in that country, which causes squamous cell carcinoma (SCC) of the bladder. In Europe, the highest world age-standardized incidence rates for bladder cancer are in Belgium for men and Hungary for women (Ferlay et al., 2014, 2013). These regional differences are due to a combination of factors, including a country's demographic characteristics and environmental exposures.

Gender, Racial, and Age Differences

Bladder cancer typically arises from chronic, constant insults to the urinary tract over time. Urothelial cancer is a disease of aging and environmental exposures. As such, the incidence and prevalence increase with age. The average age of diagnosis is 73 in the United States with approximately 9 of 10 patients diagnosed after the age of 55. Age-specific incidence rates rise gradually around age 50 to 54 in males and females, with a sharper rise in males age 60 to 64. The highest age-adjusted incidence rates are in the 90+ age group for both sexes (Fig. 135.3).

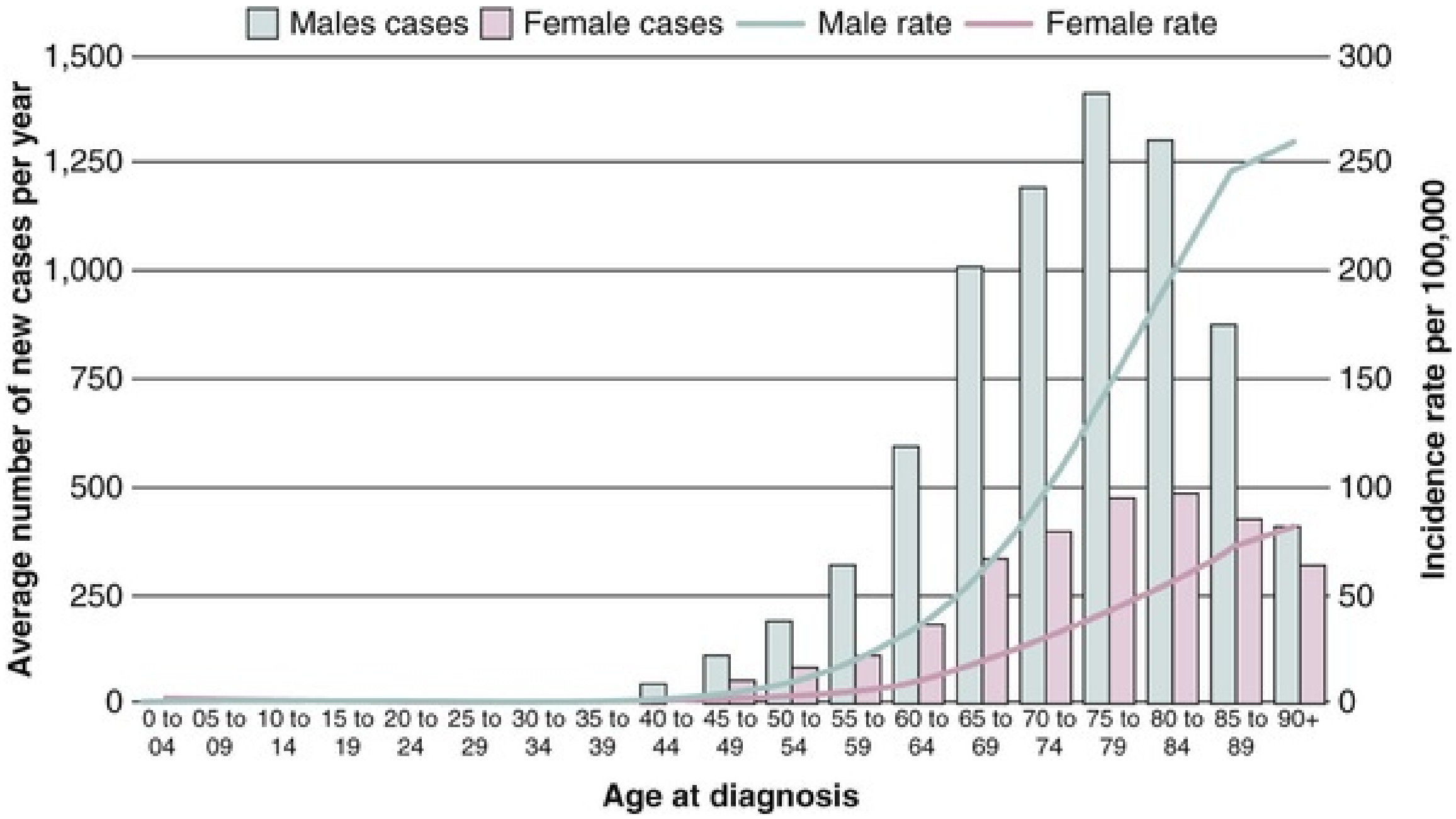

FIG. 135.3 Age-adjusted incidence rates for bladder cancer in the United Kingdom. (Data from Cancer Research UK: *Cancer stats,* 2017 [website]: https://www.cancerresearchuk.org/cancerstats.)

Nearly three-quarters of bladder cancer cases occur in males, who have a higher incidence rate (9.0 per 100,000) compared with women (2.2). In the United States, 1 in 27 men will develop bladder cancer over their lifetime, and 1 in 107 US men will die of bladder cancer. For women, 1 in 89 US women will develop bladder cancer, and 1 in 293 will die of their disease (American Cancer Society, 2017). Several hypotheses have been proposed for increased bladder cancer rates among men. First, globally smoking is much more common in men in comparison with women, with age-standardized prevalence declining in men from 41.2% in 1980 to 31.1% in 2012 in comparison with 10.6% to 6.2% among women (Chappidi et al., 2017). However, even when controlling for smoking, gender-related incidence disparities persist (Hartge et al., 1990). It has been hypothesized that although carcinogen exposure may not account for differences between genders, cellular metabolism of carcinogens may be different (Hemelt et al., 2009). Metabolic enzymes including 5′-diphosphoglucuronosyltransferase (UGT), which is involved in aromatic amine metabolism, and glutathione-*S*-transferase M1 (GSTM1), involved in foreign substance detoxification, have been implicated in bladder cancer–associated carcinogen metabolism. Both enzymes have been shown to be differentially expressed in men and women (Karagas et al., 2005; Zhang, 2013). As a result, gender differences in carcinogen metabolism may explain why even among similar carcinogen exposures (e.g., similar smoking pack-years), gender disparities in bladder cancer incidence persist.

In addition, gender differences have been explained by differences in sex steroid production and receptor expression. Among women, older age at menarche (≥15), parity (compared with nulliparous women), and use of estrogen or progestin therapy have been associated with decreased UCB risk, suggesting that sex steroid exposure mitigates bladder cancer risk (Daugherty et al., 2013). From a tumor biology standpoint, the androgen receptor (AR) has been implicated in bladder cancer development and progression. AR expression appears to be downregulated in immunohistochemical studies of bladder cancer, and this downregulation appears to increase with higher stage/grade tumors (Li et al., 2017). Transgenic and N-butyl-N-(4-hydroxybutyl)-nitrosamine (BBN) mouse models of bladder cancer have demonstrated that castration or direct AR knockout suppresses bladder cancer growth and development (Johnson et al., 2008; Miyamoto et al., 2007).

Although the disease is more prevalent in men, women are more likely to have more advanced tumors and a less-favorable prognosis (Scosyrev et al., 2009). Although men lose 26% of their remaining life expectancy to bladder cancer, women lose 36% (Scosyrev et al., 2012). The differences in stage presentation only account for approximately 30% of gender disparities in bladder cancer prognosis and mortality; women fare worse than men stage for stage (Aydin Mungan et al., 2000; Scosyrev et al., 2009). This gender disparity in the aggressiveness of bladder cancer at presentation has been attributed to differences in tumor biology, environmental exposures, and as well as implicit bias (also known as implicit social cognition), in which the conception of bladder cancer as a “male” disease leads to delays in diagnosis from initial hematuria symptoms to pathological diagnoses. Multiple series using insurance claims data have demonstrated that women have a delay from their initial hematuria claim to their bladder cancer claim compared with men and that women are more likely to be referred for urinary tract infection (UTI) evaluation and therefore have a delay in referral to a urologist (Buteau et al., 2014; Cohn et al., 2014; Garg et al., 2014). These delays in diagnosis may partially explain why women are more likely to present with advanced stage disease.

Bladder cancer is most common among Caucasian Americans, with an incidence rate 1.5 times that of African-Americans, twice that of Hispanic Americans, and six times that of Native Americans. However, similar to gender differences, African-American patients are more likely to have muscle-invasive disease compared with Caucasian patients (Scosyrev et al., 2009; Fig. 135.4). In addition, for reasons that are unclear, African-Americans, and African-American women in particular, have increased rates of non-urothelial histology. Rates of non-urothelial histology among African-American women (10.5%) are greater than African-American men (5.9%), Caucasian American men (2.3%), or Caucasian American women (4.3%) (Scosyrev et al., 2009). Stage for stage, 5-year relative survival rates are worse for African-Americans with localized disease (61% vs. 70%) and regionally advanced disease (28% vs. 36%) compared with all Americans (Siegel et al., 2018).

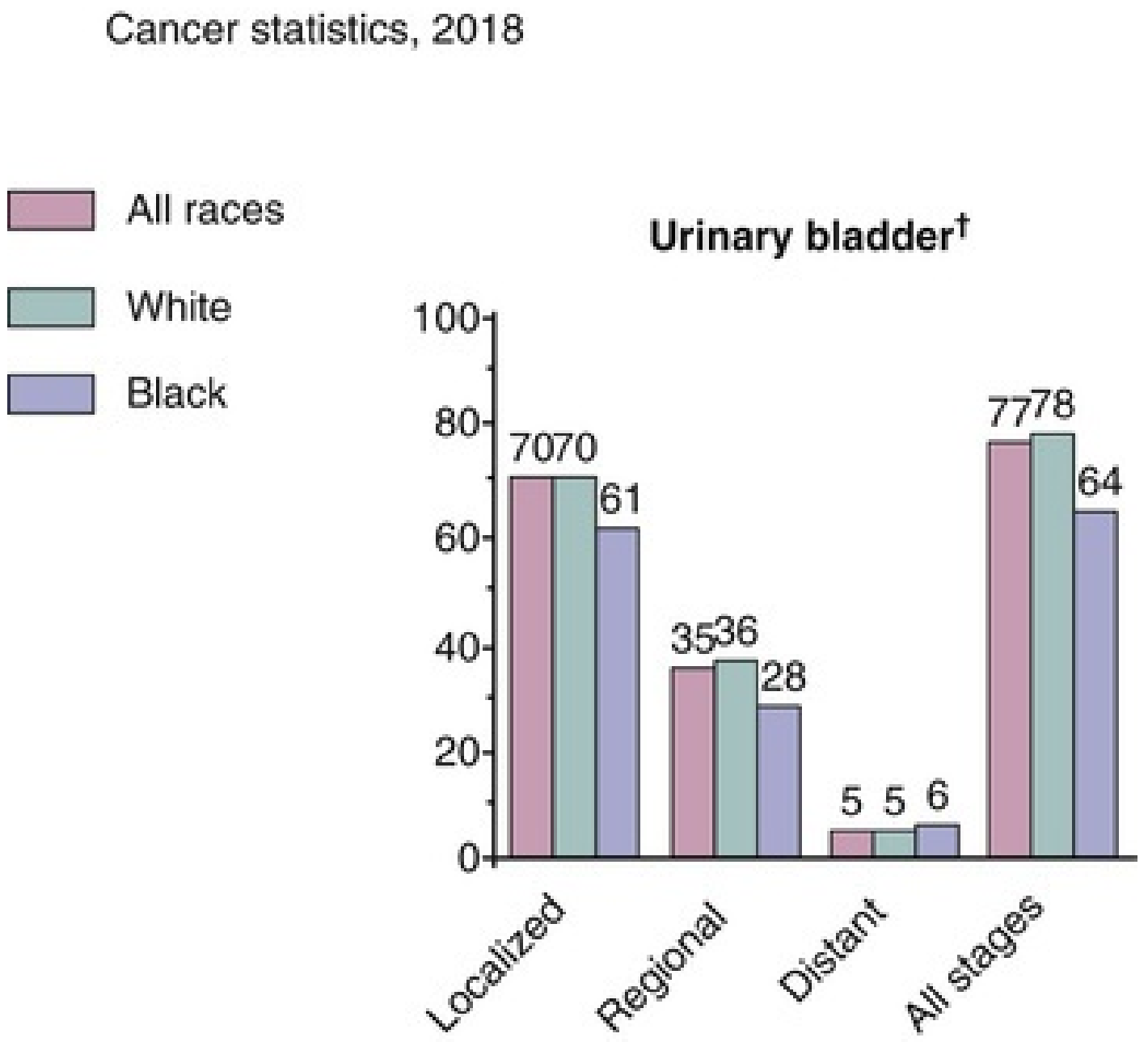

FIG. 135.4 Five-year relative survival rates for selected cancers by race and stage at diagnosis, United States, 2007 to 2013. The standard error is between 5 and 10 percentage points. †The survival rate for carcinoma in situ of the urinary bladder is 96% in all races, 96% in whites, and 91% in blacks. (Data from Siegel RL, Miller KD, Jemal A: Cancer statistics, 2018. *CA Cancer J Clin* 68:7–30, 2018.)

Economic Impact

Bladder cancer is the most expensive cancer to treat per patient over a patient's lifetime (Curtis, 2016). The lifetime treatment cost per patient is between $129,000 to $251,000. Annual directed medical costs are estimated to exceed $4 billion in the United States and €4.9 billion in the European Union (EU) (Curtis, 2016; Leal et al., 2016). However, bladder cancer health care costs vary widely between countries and disease states. For example in Latvia €2257 is spent per bladder cancer case compared with €11 937 in France (Leal et al., 2016). Europe as a whole spends €45 per 10 EU citizens compared with €97 per 10 US citizens. These variations between countries and between patients in the same country can be attributed to regional variations in the management of bladder cancer, particularly non–muscle-invasive disease. In addition, treatment costs vary by institution and region (Svatek et al., 2014). Two areas that have been proposed for future research and interventions to improve bladder cancer costs are in the management of patients with non–muscle-invasive bladder cancer (NMIBC) in whom intense surveillance strategies often lead to procedures and laboratory testing annually, and in patients with metastatic disease resulting from large costs of late-stage therapeutics and end-of-life care (Svatek et al., 2014).

Risk Factors

Like skin and lungs, the bladder is an organ that comes in constant contact with the environment and is therefore sensitive to environmental carcinogens and inflammation. Aromatic amines (2-naphthylamine, 4-aminobiphenyl, and benzidine) are thought to be the central causative agent in carcinogen-mediated bladder carcinogenesis. Tobacco smoking and occupation account for the two most frequent routes of environmental exposure. Tobacco smoke is full of aromatic amines, as are other environmental carcinogens implicated in bladder cancer. These amines, when hydroxylated, lead to DNA adduction and damage.

Genetics

The most-studied genes associated with bladder cancer are *N*-acetyltransferase 2 (NAT2) and a deletion of glutathione S-transferase μ (GSTM1) (Garcia-Closas et al., 2005; Golka et al., 1997; Karagas et al., 2005). Both of these genes are associated with the ability to metabolize aromatic amines and thus play an important role in the subset of individuals with environmental carcinogen exposure. NAT2 detoxifies nitrosamines, regulating the rate of acetylation of aromatic amine compounds found in cigarette smoke (Garcia-Closas et al., 2005). Recent evidence suggests that there are likely several underlying genetic risk factors, that when combined with occupational, environmental, and behavioral exposures, potentiate bladder cancer risk and development (Czerniak et al., 2016).

Hereditary

Although first-degree relatives of patients with bladder cancer have a twofold increased risk of developing urothelial bladder cancer, high-risk bladder cancer families are exceedingly rare. Hereditary bladder cancer does not seem to be associated with a Mendelian inheritance pattern, making classical family-tree linkage studies unhelpful. More likely the cause is multifactorial, in which certain genes magnify environmental exposures (Kiemeney, 2008). Patients with Lynch syndrome (hereditary non-polyposis colon carcinoma, HNPCC) are at increased risk of developing urothelial cancer. This increased risk is primarily found among the mismatch repair gene *MSH2* mutations carriers (van der Post et

al., 2010).

Smoking

Tobacco is the main known cause of bladder cancer and accounts for 30% to 40% of all urothelial carcinoma. Worldwide there are more than 1 billion current smokers, and smokers have a 2- to 3-fold increased risk of bladder cancer (Islami et al., 2015). Although cigarette smoking is the most common tobacco product associated with bladder cancer risk, pipe smoking and cigar smoking have also been associated with urothelial carcinoma formation (Cumberbatch et al., 2016). Current cigarette smoking among US adults declined from 20.9% (45.1 million US adults) in 2005 to 15.1% (36.5 million) in 2015. This represents a 27.7% decline in a 10-year period (Jamal et al., 2016). Aromatic amines are the primary carcinogens in tobacco smoke that lead to cancer. Persons with *NAT2* slow acetylation polymorphisms have been shown to be at a particularly high risk when they smoke cigarettes, because *NAT2* allows for the detoxification of these amines. Although there is some evidence that dietary beta-carotene may have protective effects, supplementary beta-carotene and vitamin supplementation (with C, E, or folate) have not been shown to mitigate bladder cancer risk among those with environmental exposures (Roswall et al., 2009). Smoking cessation has been shown to decrease the risk of urothelial cancer formation: smokers who have stopped for 1 to 3 years have a 2.6 relative risk compared with a 1.1 relative risk among those who have stopped smoking for more than 15 years (Koshiaris et al., 2017). Approximately 20% of patients with bladder cancer are smokers at the time of diagnosis, and these patients have an increased risk for local recurrence when actively smoking with NMIBC and increased risk of bladder cancer death when actively smoking with muscle-invasive bladder cancer (MIBC). In addition, many patients with smoking-related cancer continue to smoke even after their bladder cancer is discovered (Koshiaris et al., 2017). The survival benefit of quitting early after a bladder cancer diagnosis is controversial and still an area of active investigation. However, continued smoking increases the risk of a second primary cancer and the risk of other smoking-related diseases, including peripheral vascular disease and chronic obstructive pulmonary disorder (Health NC, 2014).

Body Mass Index

Increased body mass index (BMI) has been shown to be a risk factor for multiple cancers. Increasing BMI has been shown in multiple meta-analyses to be a risk factor for bladder cancer development (Choi et al., 2018; Koebnick et al., 2008; Sun et al., 2015; Zhao et al., 2017). One reason for this link is the strong association between smoking and obesity; however, BMI remains associated with bladder cancer even after controlling for smoking status. There is also a dose-response relationship in which bladder cancer risk appears to increase with BMI. Furthermore, among patients already diagnosed with bladder cancer, obesity appears to attenuate prognosis and is associated with an increased risk of tumor recurrence and a shorter time interval to recurrence (Wyszynski et al., 2014). The mechanism of excess weight contributing to cancer risk includes insulin resistance, chronic hyperinsulinemia, increased bioavailability of steroid hormones, and localized inflammation. Elevated insulin production may drive tumor growth and stimulate pro-inflammatory cytokines. The exact mechanism by which excess weight may contribute to bladder cancer risk is unknown and likely includes a multitude of inflammatory mediators.

Occupational Risk

Occupational exposures account for between 5% and 10% of all bladder cancer (Cumberbatch et al., 2015; Rushton et al., 2010; Table 135.1). Occupations that work directly with chemicals and dyes have the greatest lifetime risk. Particularly at-risk occupations that work with aromatic amines include tobacco, dye, and rubber workers, hairdressers, painters, and leather workers. Those that works with polycyclic aromatic hydrocarbons are also at risk, including chimney sweeps, nurses, waiters, alumni workers, petroleum workers, and seamen (Cumberbatch et al., 2015). Many of these professions are increasingly women, and it has been reported that occupational exposures may be increasing among women in particular.

TABLE 135.1

Relative Risk of Bladder Cancer by Occupation

OCCUPATION	RELATIVE RISK
Tobacco workers	1.72
Dye workers	1.58
Chimney sweeps	1.53
Nurses	1.49

Rubber workers	1.49
Waiters	1.43
Aluminum workers	1.41
Hairdressers	1.32
Plumbers	1.2
Metal workers	1.14
Fishermen	1.13
Physicians	1.11
Mechanics	1.11

Data from Cumberbatch MG, Cox A, Teare D, et al.: Contemporary occupational carcinogen exposure and bladder cancer: a systematic review and meta-analysis. *J Am Med Assoc Oncol* 1(9):1282–1290, 2015.

Medical Conditions

Medical conditions have the potential to increase bladder cancer risk directly or indirectly as a toxicity of treatment. Typically, direct carcinogenesis is mediated by chronic inflammation and the development of keratinizing squamous metaplasia. For example, patients with neurogenic bladder and spinal cord injuries who have chronic indwelling catheters are at a modestly increased risk of developing SCC of the bladder.

Bladder calculi, urinary outflow obstruction, recurrent UTIs, and inflammation from direct catheter trauma have been postulated to be additive in the development of keratinizing squamous metaplasia (Ho et al., 2015; West et al., 1999). In addition, the malignant potential of bladder exstrophy has been well documented, with the reported incidence of 3.3% to 7.5% of the general exstrophy population—several times higher than age-matched controls in the general population (Rieder et al., 2006; Smeulders and Woodhouse, 2001). Adenocarcinoma accounts for more than 90% of cases and squamous cell and urothelial carcinoma account for the remaining 10%. As patients with spinal cord injuries and congenital bladder abnormalities continue to live longer lives because of advances in the care of these individuals, rates of bladder cancer may rise as these patients age.

Schistosomiasis

Schistosomiasis is an infectious disease endemic in as many as 76 developing countries and affecting up to 218 million people (Word Health Organization, 2017). Despite widespread WHO-led eradication campaigns, schistosomiasis remains a major contributor to disease and bladder cancer in many tropical countries. Schistosomes are parasitic blood flukes that have mammalian hosts as well as intermediate hosts (e.g., freshwater snails). Of the four human schistosomes, *S. haematobium* is the one linked to squamous cell bladder cancer. *S. haematobium* live in the venules of the human urinary bladder, where they lay eggs, producing irritation and tissue fibrosis. The mechanism of SCC development likely involves a TH-2 type pro-inflammatory immune response (Bernardo et al., 2016). In addition, underlying *S. haematobium* infection seems to promote susceptibility to other bladder cancer risk factors—notably smoking.

Recurrent Infection

Multiple investigators have suggested that persistent or recurrent bacterial UTIs may increase the risk of bladder carcinogenesis. Multiple epidemiologic studies suggest that there may be a modest, increased risk of bladder cancer associated with chronic UTIs; however, these studies are confounded by chronic intermittent catheterization, chronic inflammatory bladder stone formation, and other risk factors including smoking status and occupational status (Jiang et al., 2009; Vermeulen et al., 2015). In addition, previous gonorrhea infections have been associated with bladder cancer formation. One prospective study found a nearly twofold relative risk of bladder cancer formation in men with a history of gonorrhea, and these tumors are more likely to be invasive (Michaud et al., 2007). The mechanism of action may be related to the production of carcinogens such as nitrosamines that can produce chronic UTIs. However, there have been no prospective studies examining the association between UTIs and bladder cancer risk, and much of the early data demonstrating a connection have not been validated in more contemporary cohorts. Furthermore, recent explorations into the microbiome of the urinary tract suggest that in some instances certain bacterial and viral colonization of the bladder epithelium have a protective effect against tumor formation. Host microbiota have been shown to be crucial to maintaining homeostasis in mucosal surfaces, including the gut and oral cavity; current efforts are underway to define these mechanisms in the bladder (Whiteside et al., 2015).

Indirect Medical Risk Factors

Indirect medical causes of bladder cancer are typically unintended side effects of treatment.

Pioglitazone

Pioglitazone is an antidiabetic drug in the thiazolidinedione class of drugs that lower glucose levels among patients with non–insulin-dependent diabetes. In 2005 the PROactive randomized trial reported an unexpected finding that the pioglitazone arm had higher cases of bladder cancer compared with placebo. These findings were controversial and were subsequently confirmed in some follow-up studies and refuted in others (Boice et al., 1985).

Radiation

The association of radiation exposure with bladder cancer has been noted since atomic bomb survivors were found to have markedly increased rates of urothelial carcinoma. In one study, the attributable risk for survivors exposed to more than 0.005 Gy was estimated to be 16% and rose to 60% for those with more than 1 Gy of exposure. Urothelial cancer formation after radiation therapy does not appear age related; however, the estimated latency period is estimated to be 15 to 30 years. External beam radiation for cervical cancer is associated with a two- to fourfold higher incidence of secondary bladder cancer compared with the nonirradiated population (Boice et al., 1985; Kleinerman et al., 1995). Studies regarding the use of external beam radiation therapy (EBRT) and brachytherapy are conflicting and likely confounded by other risk factors for bladder cancer. However, they do suggest that EBRT for prostate may denote a 1.5-fold to twofold increased risk of bladder cancer (Chrouser et al., 2005; Nieder et al., 2008). Brachytherapy appears to be associated with a smaller risk, and several investigators have suggested that intensity-modulated radiation therapy denotes little to no increased risk of bladder tumor formation (Hall and Wuu, 2003).

Chemotherapy

Chemotherapy destroys malignant cells by inducing DNA damage and cell death; however, in organs with rapid cell turnover, chemotherapy can induce dysregulation for normal cells. The only chemotherapy that has been shown to cause bladder cancer is cyclophosphamide. Phosphoramide mustard is the primary mutagenic metabolite that causes cyclophosphamide-associated bladder cancer. The risk of bladder cancer is 4.5-fold higher among patients who underwent cyclophosphamide treatment and appears to be dose dependent and most pronounced among those who receive more than 20 g. For patients who receive more than 50 g of cyclophosphamide, the excess risk increases to approximately 7 excess cases per 100 patients treated (Travis et al., 1995). In addition, the risk appears to increase after 5 years of cyclophosphamide treatment and peaks in years 10 to 14, with standardized incidence ratios of up to 15% (Faurschou et al., 2015).

Environmental Pollution

Exposure to arsenic in drinking water has been associated with the development of urothelial bladder cancer. Arsenic is a toxic metalloid that enters drinking water from weathering rock. West Bengal, Bangladesh, and Taiwan are the most affected regions worldwide with concentrations in excess of 4700 μg/L, a 470-fold increase over the recommended amount of 10 μg/L. Studies in these regions and parts of Chile, where arsenic exposure is particularly high, have confirmed a significantly higher rate of bladder cancer in these regions (Burger et al., 2013). The mechanism of arsenic-mediated carcinogenesis is thought to be multifactorial, including oxidative stress, epigenetic effects, and alterations in DNA repair.

Diet

Fluids

Similar to other cancers, dietary factors have been an area of much study with regard to bladder cancer risk. Fluid intake is one area of controversy, as initial retrospective studies demonstrated decreased bladder cancer risk with increased water consumption (Burger et al., 2013). However, these findings were not demonstrated in the European Prospective Investigation into Cancer and Nutrition (EPIC), which showed no link between total fluid intake and bladder cancer risk among 250,000 patients with a mean of 9 years follow-up (Ros et al., 2011). Similarly, caffeine consumption through ingestion of coffee and tea have not been shown to be associated with bladder cancer risk (Al-Zalabani et al., 2016). The studies that initially demonstrated a modest link between coffee consumption and bladder cancer were confounded by smoking (Villanueva et al., 2009). Alcohol is a known risk factor for several cancers primarily involving the gastrointestinal tract and the hepatobiliary system. However, there is currently no evidence to support a link between alcohol consumption and bladder cancer risk, regardless of the amount of alcohol consumed (Bagnardi et al., 2015).

Foods

In addition to fluid intake, many carcinogens are ingested via food and excreted in the urine resulting in direct exposure to the urothelium and potential for increased bladder cancer risk. **However, no conclusive data support consumption of a specific food or food group to mitigate bladder cancer risk.** In other malignancies dietary intake of meat has been associated with increased risk. However, among more than 500,000 persons in the EPIC study, red meat consumption was not associated with bladder cancer risk. Dietary intake of fruits and vegetables has been investigated because they are an abundant source of phytochemicals with purported anti-carcinogenic effects. In the EPIC study, a higher consumption of fruits and vegetables was associated with lower risk of bladder cancer among never and former smokers but not in current smokers. Furthermore, in meta-analyses adjusting for smoking status, no associations between bladder cancer and total fruits and vegetables, total vegetable, or total fruit intake were identified (Ros et al., 2011; Vieira et al., 2015).

Dietary Supplements

Similar to fluid and food intake, no supplemental vitamin and minerals have been shown to have carcinogenic or protective effects for bladder cancer. In a prospective series of 80,000 persons in the VITamins study, no supplements were identified to be related to bladder cancer risk. Similarly, in the Selenium and Vitamin E Cancer Prevention Trial (SELECT), no association between selenium and vitamin E and bladder cancer was identified.

Key Points

- Bladder cancer is related to age and exposure to environmental carcinogens.
- Smoking accounts for 30% to 40% of all urothelial carcinoma.
- Although bladder cancer is more than 3 times as prevalent in men, women are more likely to be seen initially with more advanced tumors and less

favorable prognosis.

- Bladder cancer is the most expensive cancer to treat per patient over a patient's lifetime.
- No dietary interventions have been successful at reducing risk from bladder cancer.

Detection of Urothelial Carcinoma

Unlike many cancers, bladder cancer is rarely incidentally discovered at the time of autopsy. Painless gross hematuria is present in 85% of patients with newly diagnosed bladder cancer, and microscopic hematuria is present in nearly all patients (Alishahi et al., 2002; Edwards et al., 2006). Hematuria is typically intermittent and can be related to Valsalva maneuvers. Importantly, any episode of gross hematuria must be evaluated even if subsequent urinalysis is negative. Use of anti-platelet therapy and anticoagulation should similarly not preclude a full hematuria evaluation (Davis et al., 2012). Irritative voiding symptoms (e.g., frequency, urgency) also may be signs of bladder cancer, particularly carcinoma in situ (CIS).

Approximately 50% of patients with gross hematuria have an identifiable cause, and the risk of malignancy in these patients is 20.4%. By comparison, the risk of malignancy among patients with microscopic hematuria is 2.6% to 5.2% (Davis et al., 2012; Khadra et al., 2000). The risk of malignancy among patients with recurrent gross or microscopic hematuria who had a complete negative hematuria workup is nearly 0 within the first 6 years. As a result, it is reasonable to delay a repeat hematuria evaluation in patients with persistent hematuria 3 to 5 years after their first negative evaluation (Davis et al., 2012; Khadra et al., 2000).

Hematuria is defined as the presence of red blood cells (RBCs) in the urine. The urine dipstick is a common test that screens for hematuria by using reagents that detect peroxidase activity of heme in RBCs. However, although the sensitivity is for urine dipsticks in detecting hematuria is 91% to 100%, the reported specificity of dipstick tests is 65%, which can lead to unnecessary hematuria evaluations (Liu et al., 2016). In contrast, microscopic urinalysis directly examines the urine sediment for the presence of RBCs. For this reason, urine dipstick is discouraged as the sole screening test for microhematuria and should be confirmed with microscopic urinalysis (American Urological Association, 2015).

A full hematuria evaluation for bladder cancer includes a focused history and physical, cystoscopy, upper tract imaging, and a urine culture. For patients with gross hematuria upper tract imaging should include a multi-phase computed tomography (CT) scan with delayed phase images for patients who can tolerate it. Although 2012 AUA guidelines suggest a CT urogram (CTU) for the evaluation of asymptomatic microhematuria (AMH) as well, recent studies suggest CTU can be safely replaced with a renal and bladder ultrasound in patients with AMH because upper tract malignancy is exceedingly rare in these patients (Tan et al., 2018). For patients with gross hematuria it is reasonable to obtain a urine cytology and/or urine markers. However, according to the AUA guidelines, providers should avoid obtaining urine cytology or urine markers as part of the routine evaluation of the asymptomatic patient with microhematuria (Davis et al., 2012). A focused history should inquire into patient risk factors as outlined earlier as well as family history. Although physical exam will rarely uncover a bladder tumor, a bimanual exam should be performed at the time of transurethral resection of the bladder tumor if the tumor appears invasive. A prostate-specific antigen (PSA) blood test may be considered after a discussion between the patient and provider because 10% of patients with recurrent gross hematuria will have prostate cancer.

Cystoscopy

The gold-standard test for the diagnosis of bladder cancer is cystoscopy and biopsy. All adult patients with gross hematuria and all patients 35 years and older with microscopic hematuria should undergo cystoscopic evaluation for malignancy. Flexible office cystoscopy is as reliable for the diagnosis of bladder cancer as rigid endoscopy (Grossfeld et al., 2001). Currently white light cystoscopy (WLC) remains the standard of care for the diagnosis of a bladder tumor and enables the urologist to map and resect all visible tumors. Although WLC has excellent sensitivity and specificity for the diagnosis of large papillary tumors, it is less reliable for diagnosing small papillary tumors and CIS. Porphyrin-induced fluorescence cystoscopy uses photoactive porphyrins, such as hexaminolevulinate (HAL), that accumulate preferentially in neoplastic tissue and emit red fluorescence under blue-wavelength light with a wavelength of 360 to 450 nm. Although HAL and 5-aminolevulinic acid (5-ALA) have been assessed in clinical studies, only HAL is FDA approved, with indications for bladder cancer surveillance for rigid and flexible cystoscopy (Video 135.1▶). In a meta-analysis assessing the utility of HAL-blue light cystoscopy (BLC), BLC detected 14.7% more Ta tumors and 40.8% more CIS lesions compared with WLC (Burger et al., 2013). In 26.7% of patients, CIS was detected only by BLC, and detection was significantly improved for primary bladder cancer diagnosis and recurrent cancer diagnosis. In the outpatient setting, flexible BLC identified a tumor recurrence not seen under WLC in 20.6% of patients (Daneshmand et al., 2018).

Narrow band imaging (NBI) is an endoscopic optical image enhancement technique that enhances contrast between mucosal surfaces and microvascular surfaces without the use of dyes. The depth of light penetration into the bladder wall increases with increasing wavelength. NBI illuminates the mucosal surface with light of a narrow bandwidth in the blue (415 nm) and green (540 nm) light spectrum, which are strongly absorbed by hemoglobin. Consequently the vascular structures appear dark brown or green against a pink or white mucosal background. Studies evaluating NBI have been performed primarily in single-institution settings or have been underpowered; nevertheless, NBI appears to improve the detection of CIS compared with WLC alone. However, in the most robust study performed thus far, a multicenter randomized trial comparing NBI-assisted transurethral resection of bladder tumor (TURBT) to conventional white light TURBT, NBI and WLC achieved similar overall 12-month recurrence rates (27% in WLC and 25.4% in NBI), but NBI-assisted TURBT significantly reduced disease recurrence in low-risk patients (27% in WLC vs. 5.6% in NBI) (Naito et al., 2016).

Urine Cytology

Since 1945, when George Papanicolaou first hypothesized that exfoliated cells in urine could reliably detect urinary tract malignancies, urine cytology has been a standard diagnostic test to aid in the diagnosis of bladder cancer. The contemporary sensitivity and specificity for urine cytology in detecting bladder cancer is 31% to 62% and 94% to 100%, respectively (Planz et al., 2005; Raitanen et al., 2002; van Rhijn et al., 2005). Furthermore, significant variation in cytologic reporting exists between institutions, further complicating the interpretation of this subjective diagnostic modality (Karakiewicz et al., 2006; Raitanen et al., 2002). In 2013 Paris Reporting System for urinary cytology was first introduced at the International Congress of Cytology to standardize cytologic interpretation of urine samples (Fig. 135.5; Rosenthal et al., 2017). This reporting schema emphasizes specific diagnostic categories and cytomorphologic criteria for the reliable diagnosis of high-grade urothelial carcinoma. Preliminary reports suggest that the Paris classification schema may decrease the rate of inconclusive “atypia” calls and improve risk stratification for patients with high-grade urothelial carcinoma (Cowan et al., 2017; Wang et al., 2018). Because urine cytology is highly specific, a cytology suspicious or positive for high-grade urothelial carcinoma should be investigated. In a patient with a negative cystoscopy and persistent positive high-grade urine cytology, it is therefore reasonable to perform random biopsies of the bladder and prostatic urethra, as well as ureteral washings for cytology with or without direct ureteroscopic inspection of the upper tracts.

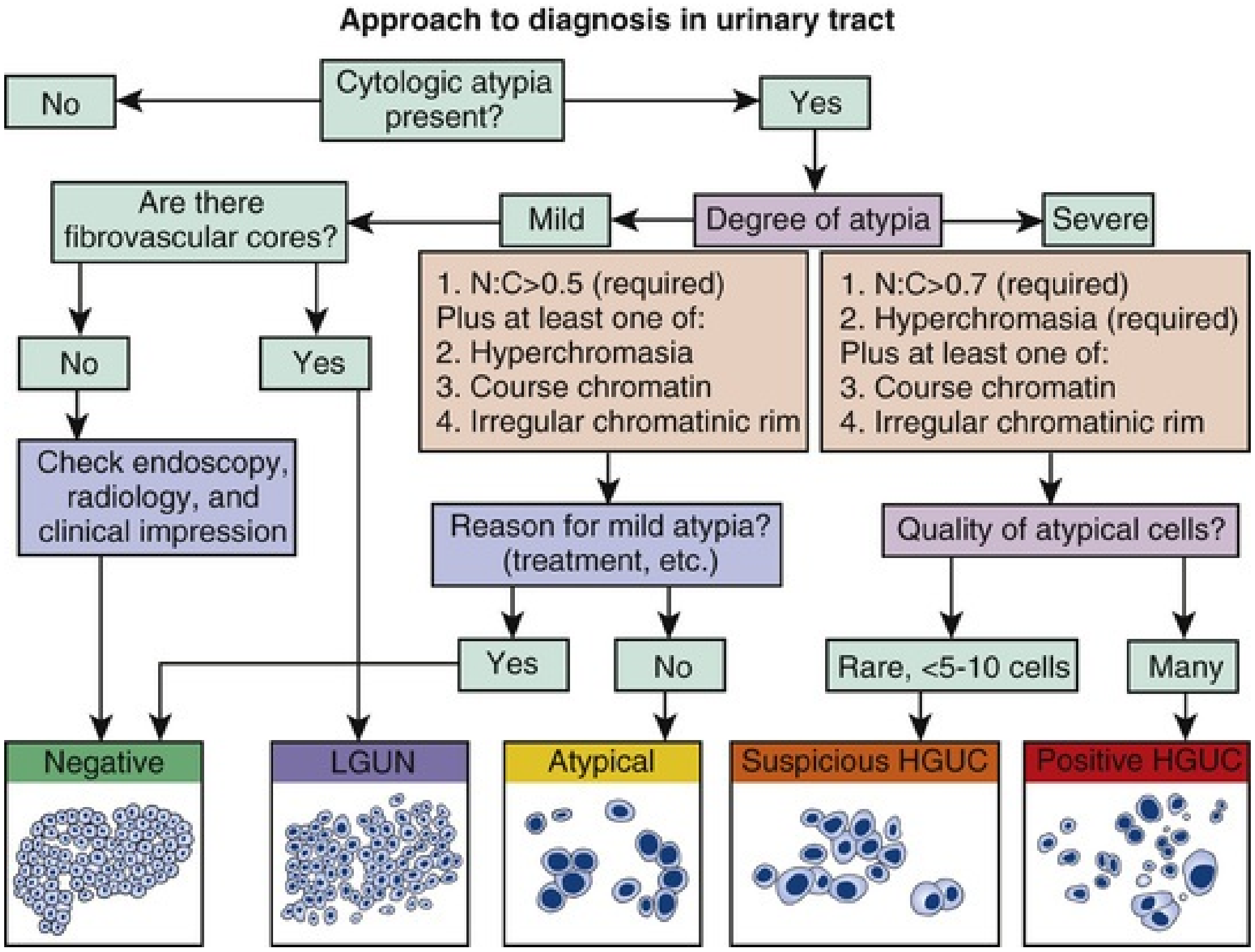
Approach to diagnosis in urinary tract
Cytologic atypia present?
No
Yes
Degree of atypia
Mild
Severe
Are there fibrovascular cores?
No
Yes
1. N:C>0.5 (required)
Plus at least one of:
2. Hyperchromasia
3. Course chromatin
4. Irregular chromatinic rim
1. N:C>0.7 (required)
2. Hyperchromasia (required)
Plus at least one of:
3. Course chromatin
4. Irregular chromatinic rim
Check endoscopy, radiology, and clinical impression
Reason for mild atypia? (treatment, etc.)
Quality of atypical cells?
Yes
No
Rare, <5-10 cells
Many
Negative
LGUN
Atypical
Suspicious HGUC
Positive HGUC

FIG. 135.5 Paris system for urine cytology. *HGUC,* High-grade urothelial carcinoma; *LGUN,* low-grade urothelial neoplasm; *N:C,* nucleus to cytoplasm ratio. (Modified from Barkan GA, Wojcik EM, Nayar R, et al.: The Paris System for reporting urinary cytology: the quest to develop a standardized terminology. *Acta Cytol* 60:185–197, 2016.)

Urine-based biomarkers have been developed as an adjunct to standard diagnostic modalities for bladder cancer diagnosis and monitoring. Noninvasive testing with improved sensitivity over urine cytology has been proposed as a desirable alternative to cystoscopy, which is costly and uncomfortable. Several urine-based biomarkers have been developed with improved sensitivity compared with urine cytology, although most have yet to reach its specificity. We will discuss the most widely available and reported urinary biomarkers that have relevance in current and future clinical practice (Table 135.2).

TABLE 135.2

Test Performance of Urinary Biomarkers for Diagnosis of Bladder Cancer

VARIABLE	SENSITIVITY		SPECIFICITY		POSITIVE LR (95% CI)	NEGATIVE LR (95% CI)
	Sensitivity (95% CI); Studies, n_τ^2 (*P* Value)		**Specificity (95% CI); Studies, n_τ^2 (*P* Value)**			
QUANTITATIVE NMP22						
Overall	0.69 (0.62–0.75); 0.33 (P = 0.0005)	19	0.77 (0.70–0.83); 0.62 ($P < 0.0001$)	19	3.05 (2.28–4.10)	0.40 (0.32–0.50)
Evaluation of symptoms	0.67 (0.55–0.77); 0.34 (P = 0.04)	9	0.84 (0.75–0.90); 0.45 (P = 0.02)	7	4.20 (2.65–6.67)	0.40 (0.29–0.55)
Surveillance	0.61 (0.49–0.71); 0.45 (P = 0.04)	10	0.71 (0.60–0.81); 0.54 (P = 0.01)	8	2.10 (1.58–2.80)	0.55 (0.44–0.69)
QUALITATIVE NMP22						
Overall	0.58 (0.39–0.75); 0.57 (P = 0.14)	4	0.88 (0.78–0.94); 0.50 (P = 0.13)	4	4.89 (3.23–7.40)	0.48 (0.33–0.71)
Evaluation of symptoms	0.47 (0.33–0.61); 0.12 (P = 0.38)	2	0.93 (0.81–0.97); 0.52 (P = 0.31)	2	6.27 (2.98–13.2)	0.58 (0.46–0.72)
Surveillance	0.70 (0.40–0.89); 0.74 (P = 0.36)	2	0.83 (0.75–0.89); 0.74 (P = 0.31)	2	4.20 (3.22–5.47)	0.36 (0.16–0.81)
QUALITATIVE BTA						
Overall	0.64 (0.58–0.69);	22	0.77 (0.73–0.81);	21	2.80 (2.31–3.39)	0.47 (0.30–0.55)

	0.26 (*P* <0.0001)		0.27 (*P* < 0.0001)			
Evaluation of symptoms	0.76 (0.67–0.83); 0.21 (*P* = 0.05)	8	0.78 (0.66–0.87); 0.50 (*P* = 0.02)	6	3.42 (2.04–5.74)	0.31 (0.21–0.46)
Surveillance	0.60 (0.55–0.65); 0.02 (*P* = 0.27)	11	0.76 (0.69–0.83); 0.26 (*P* = 0.02)	8	2.53 (1.92–3.34)	0.52 (0.47–0.59)
QUANTITATIVE BTA						
Overall	0.65 (0.54–0.75); 0.10 (*P* = 0.32)	4	0.74 (0.64–0.82); 0.14 (*P* = 0.27)	4	2.52 (1.86–3.41)	0.47 (0.37–0.61)
Evaluation of symptoms	0.76 (0.61–0.87)	1	0.53 (0.38–0.68)	1	1.61 (1.14–2.28)	0.46 (0.26–0.81)
Surveillance	0.58 (0.46–0.69); <0.0001 (*P* = 1.0)	2	0.79 (0.72–0.85); <0.0001 (*P* = 1.0)	2	2.77 (1.66–4.61)	0.54 (0.39–0.76)
FISH						
Overall	0.63 (0.50–0.75); 0.74 (*P* = 0.01)	11	0.87 (0.79–0.93); 0.90 (*P* = 0.003)	11	5.02 (2.93–8.60)	0.42 (0.30–0.59)
Evaluation of symptoms	0.73 (0.50–0.88); 0.36 (*P* = 0.40)	2	0.95 (0.87–0.98); <0.0001 (*P* = 1.0)	1	14.2 (5.2–39)	0.29 (0.14–0.60)
Surveillance	0.55 (0.36–0.72); 0.85 (*P* = 0.03)	7	0.80 (0.66–0.89); 0.80 (*P* = 0.03)	6	2.75 (1.95–3.89)	0.56 (0.42–0.76)
IMMUNOCYT						
Overall	0.78 (0.68–0.85); 0.71 (*P* = 0.003)	14	0.78 (0.72–0.82); 0.25 (*P* = 0.001)	14	3.49 (2.82–4.32)	0.29 (0.20–0.41)
Evaluation of symptoms	0.85 (0.78–0.90); 0.10 (*P* = 0.30)	6	0.83 (0.77–0.87); 0.11 (*P* = 0.07)	7	4.89 (3.79–6.30)	0.18 (0.12–0.26)
Surveillance	0.75 (0.64–	7	0.76 (0.70–	8	3.09 (2.56–	0.33 (0.24–

	0.83); 0.34 (P = 0.05)		0.81); 0.14 (P = 0.04)		3.72)	0.46)
CXBLADDER						
Evaluation of symptoms[a]	0.82 (0.70–0.90)	1	0.85 (0.81–0.88)	1	5.53 (4.28–7.15)	0.21 (0.13–0.36)

[a] Based on threshold selected for a specificity of 0.85.

BTA, Bladder tumor antigen; *CI,* confidence interval; *FISH,* fluorescence in situ hybridization; *LR,* likelihood ratio; *NMP22,* nuclear matrix protein 22.

Data from Chou R, Gore JL, Buckley D, et al.: Urinary biomarkers for diagnosis of bladder cancer: a systematic review and meta-analysis. *Ann Int Med* 2015 (online journal): http://annals.org/aim/fullarticle/2466370/urinary-biomarkers-diagnosis-bladder-cancer-systematic-review-meta-analysis.

Nuclear matrix protein 22 (NMP22) is part of a family of proteins that provides structure to cell nucleus and is 20 times more prevalent in malignant urothelial cells compared with normal cells. There are currently 2 NMP22 tests FDA approved for use in BC surveillance: the original NMP22 laboratory-based quantitative test and a point-of-care qualitative test. In a meta-analysis of 19 studies, sensitivity of quantitative NMP22 was 0.69 (95% CI 0.62–0.75), and specificity was 0.77 (95% CI 0.70–0.83). Diagnostic accuracy appears to be similar for initial diagnosis as well as surveillance. Sensitivity of the qualitative point of care NMP22 tests was 0.58 (95% CI 0.39–0.75) and specificity was 0.88 (95% CI 0.78 to 0.94), although these ranges are limited by relatively few studies.

Fluorescence in Situ Hybridization

Fluorescence in situ hybridization (FISH) has been designed for bladder cancer detection since 2000 and identified fluorescently labeled DNA probes that bind to intranuclear chromosomes (Sokolova et al., 2000). The current commercially available FISH assay (UroVysion) detects aneuploidy of chromosomes 3,7, and 17, and homozygous loss of the 9p21 locus in exfoliated urothelial cells. A positive test is defined as 5 or more urinary cells with gains of two or more chromosomes, 10 or more cells with gain of a single chromosome, or homozygous deletion of 9p21 in more than 20% of exfoliated cells. Overall sensitivity of FISH is 0.63 (95% CI 0.50–0.75) and specificity 0.87 (95% CI 0.79–0.93) (Chou et al., 2015). As a reflex test in the setting of an atypical cytology, a negative FISH correlates with benign cytologic changes. Among patients with an atypical cytology and a negative cystoscopy, 3-year recurrence-free survival increases from 34% to 67% in the setting of a positive FISH (Kim et al., 2014; Yoder et al., 2007). FISH has relative low sensitivity in detecting low-grade bladder tumors, and there continues to be a lack of consensus regarding criteria used to evaluate abnormal cells.

Bladder Tumor Antigen

The bladder tumor antigen (BTA) assay detects two basement membrane antigens, human complement factor H-related protein and complement factor H using monoclonal antibodies. Two forms of the BTA test are available and FDA approved for the diagnosis and follow-up of bladder cancer. The BTA stat test is a qualitative dipstick-based point-of-care test. Sensitivity of qualitative BTA was 0.64 (95% CI 0.58–0.69) across 22 studies, and specificity was 0.77 (95% CI 0.73–0.81). In addition, a quantitative, ELISA-based BTA assay (BTA TRAK) has also been developed, with reported sensitivity of 0.65 (95% CI 0.54–0.75) and specificity of 0.74 (95% CI 0.64 to 0.82). The high false positivity of both BTA assays could be related to the presence of cross-reactivity with red blood cells because complement factor H is present in high concentrations in serum and thus is associated with high false positives in hematuria (Longo et al., 2018).

Immunocyt

Immunocyt is a cell-based adjunct to urine cytology, developed in the late 1990s. Fluorescent-labeled antibodies are directed against three antigens that are commonly expressed by exfoliated urothelial cells: a glycosylated from of carcinoembryonic antigen (CEA) and two mucins. Across all studies, the sensitivity of ImmunoCyt was 0.78 (95% CI 0.68–0.85), and specificity was 0.78 (95% CI 0.72–0.82) (Chou et al., 2015). In one study, ImmunoCyt in combination with urine cytology improved sensitivity from 50% to 90%; however, specificity was lower (80% to 72%) when compared with cytology alone (Toma et al., 2004). Like urine cytology, the test is operator dependent, with high interobserver variability and poor agreement (Pode et al., 1999); one study has suggested that the variability in test performance can be overcome with adequate training (Messing et al., 2005).

CxBladder

CxBladder is a cell-based urine assay that comprises five mRNA fragments (HOXA13, CDC2, MDK, CXCR2, and IGFBP5) (Holyoake et al., 2008; O'Sullivan et al., 2012). With a limited number of studies performed thus far, test sensitivity is approximately 85% and specificity 85% (Kavalieris et al., 2015; O'Sullivan et al., 2012). Although still in need of validation in independent, multi-institutional datasets, initial comparative studies have suggested the CxBladder may have improved sensitivity and specificity over urine cytology and other protein-based assays (Breen et al., 2015; Lough et al., 2018).

The currently available urinary biomarkers to detect bladder cancer miss many patients with bladder cancer and yield false positives in others. Head-to-head comparisons of urinary biomarkers have been too limited thus far to reach firm conclusions about comparative effectiveness. It is thus our opinion and current practice that in the setting of microhematuria, the addition of any current urine biomarkers does not preclude a cystoscopy and thus does not change management. Similarly, in the case of gross hematuria, a negative test result is associated with an approximately 10% probability of having bladder cancer (Longo et al., 2018). As a result, a negative test would also not preclude a cystoscopy. Furthermore, the field is rapidly evolving with the discovery of novel genomics and bladder cancer subtypes. Multiplex gene assays have been developed by multiple teams and are in need of further validation. Because none of the currently available biomarkers have reached the necessary threshold for the diagnosis of bladder cancer, they are currently used in combination with cystoscopy as a surveillance strategy for patients with a known history of non–muscle-invasive bladder cancer.

Key Points

- Painless gross hematuria is the key presenting symptom of bladder cancer, occurring in 85% of newly diagnosed patients.
- A full hematuria evaluation for bladder cancer includes a focused history and physical, cystoscopy, upper tract imaging, and a urine culture.
- The gold-standard test for the diagnosis of bladder cancer is cystoscopy and biopsy. Increasingly, HAL BLC and narrow band imaging are being used as adjuncts to cystoscopy in identifying occult malignancy.

- There are various urine markers that can be used to evaluate secreted proteins or shed cells in the hope of noninvasively detecting bladder cancer. None of these markers has a high enough sensitivity or specificity to replace office cystoscopy.

Pathology

There are numerous benign tumors of the bladder, each with its own clinical presentation and disease burden.

Epithelial Metaplasia

Epithelial metaplasia is defined by focal area of transformed urothelium, with otherwise normal nuclear and cellular morphology. Typically, epithelial metaplasia is located on the trigone and may be composed of either squamous metaplasia or glandular metaplasia. Glandular metaplasia in particular consists of clumps of raised, red inflammatory areas that can be confused for cancer. Squamous metaplasia is very common, affecting up to 40% of women and 5% of men, and can be attributed to a history of urinary tract infection, trauma, and prior surgery (Ozbey et al., 1999). A biopsy to diagnose glandular or squamous metaplasia is unnecessary and no treatment is required or efficacious.

Papilloma and Inverted Papilloma

An inverted papilloma (Fig. 135.6) is a benign proliferative lesion that is associated with chronic inflammation or bladder outlet obstruction and can be located throughout the bladder but most commonly on the trigone, accounting for less than 1% of all bladder tumors. Painless gross hematuria is the most common representing symptom, with microscopic hematuria and irritative voiding symptoms also common. Inverted papillomas grow in an endophytic pattern along the lamina propria to form nests and anastomosing trabeculae. When diagnosed according to strictly defined criteria (e.g., lack of cytologic atypia), inverted papillomas behave in a benign fashion with a 1% chance of recurrence.

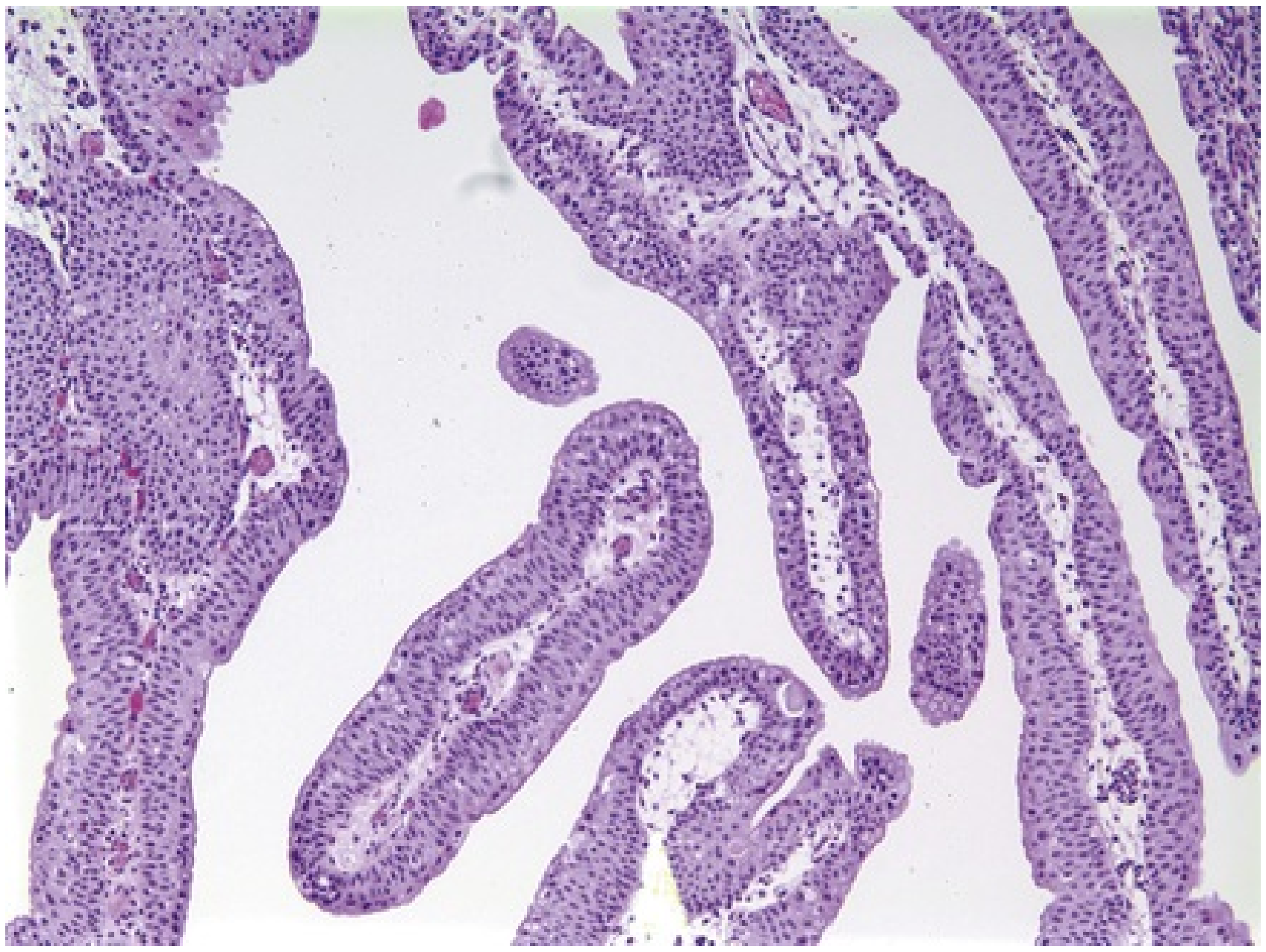

FIG. 135.6 Inverted papilloma.

Urothelial papilloma (Fig. 135.7) is characterized by a benign proliferative growth of delicate stalks lined by normal-appearing urothelium. Papillomas were historically characterized as low-grade Ta malignant bladder tumors but are now thought to be benign with no risk of local or systemic invasion. Although papillomas have fibroblast growth factor receptor-3 (FGFR3) mutations, which are commonly found in bladder cancer, they lack markers of aggressive behavior, including TP53 and RB mutations (Montironi and Lopez-Beltran, 2005).

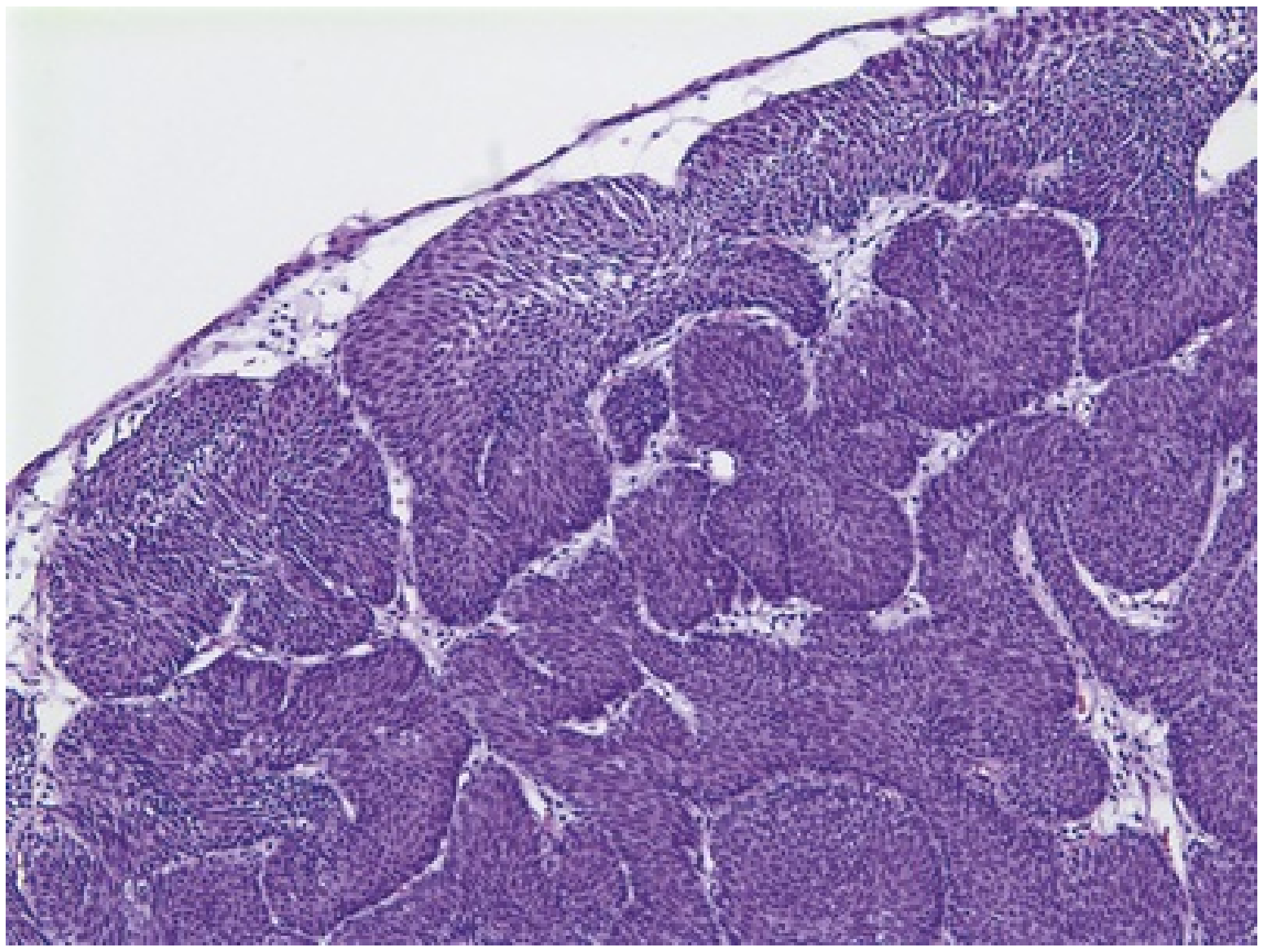

FIG. 135.7 Papilloma.

Nephrogenic Adenoma

Nephrogenic adenoma is a rare tumor caused by chronic irritation of the urothelium and can arise from trauma, prior surgery, renal transplantation, intravesical chemotherapy, stones, catheters, and infection. Nephrogenic adenoma is composed of glandular appearing tubules similar to renal tubules that involve mucosa and sub mucosa of the bladder. Cystoscopically, nephrogenic adenoma may appear like a papillary neoplasm and may be hard to distinguish from more aggressive bladder neoplasms. Lesions may cause dysuria hematuria, prompting cystoscopic investigation. Recurrence does occur but is uncommon and can be safely managed with repeat resection (Yi et al., 2018).

Leukoplakia

Leukoplakia of the bladder has similar features to squamous metaplasia with the additional characteristic of white, flaky plaques floating in the bladder. If not diagnosed incidentally, presenting symptoms are typically frequent, recurrent infections with urinary urgency and frequency. Histologic analyses demonstrate that the bladder mucosa is chronically inflamed, displaying diffuse squamous metaplasia of keratinizing type leukoplakia. Although on other squamous epithelial surfaces leukoplakia is premalignant, there exists some controversy as to whether bladder leukoplakia predisposes patients to malignancy. Historic reports described leukoplakia as premalignant, with 37% risk of carcinoma (Benson et al., 1984). However, more recently a connection between leukoplakia as an independent risk factor for bladder cancer has been disproven. Staack et al. (2006) performed cytogenic studies of bladder leukoplakia in 77 cases using DNA analysis for tumor suppressor gene TP52 and found no evidence to suggest that this condition was premalignant; therefore cystoscopy, biopsy, and further treatment were unnecessary.

Cystitis Cystica and Glandularis

Cystitis cystica and/or glandularis is a common finding in normal bladders, typically associated with inflammation or chronic obstruction. These benign lesions represent cystic nests that are lines by columnar or cuboidal cells and are generally associated with proliferation of Von Brunn nests (Fig. 135.8) (Semins and Schoenberg, 2007). Although cystitis glandularis (Fig. 135.9) can transform into adenocarcinoma, the risk is low; however, regular endoscopic evaluation of these entities is recommended. Treatment is transurethral resection and relief of the obstruction or inflammatory condition.

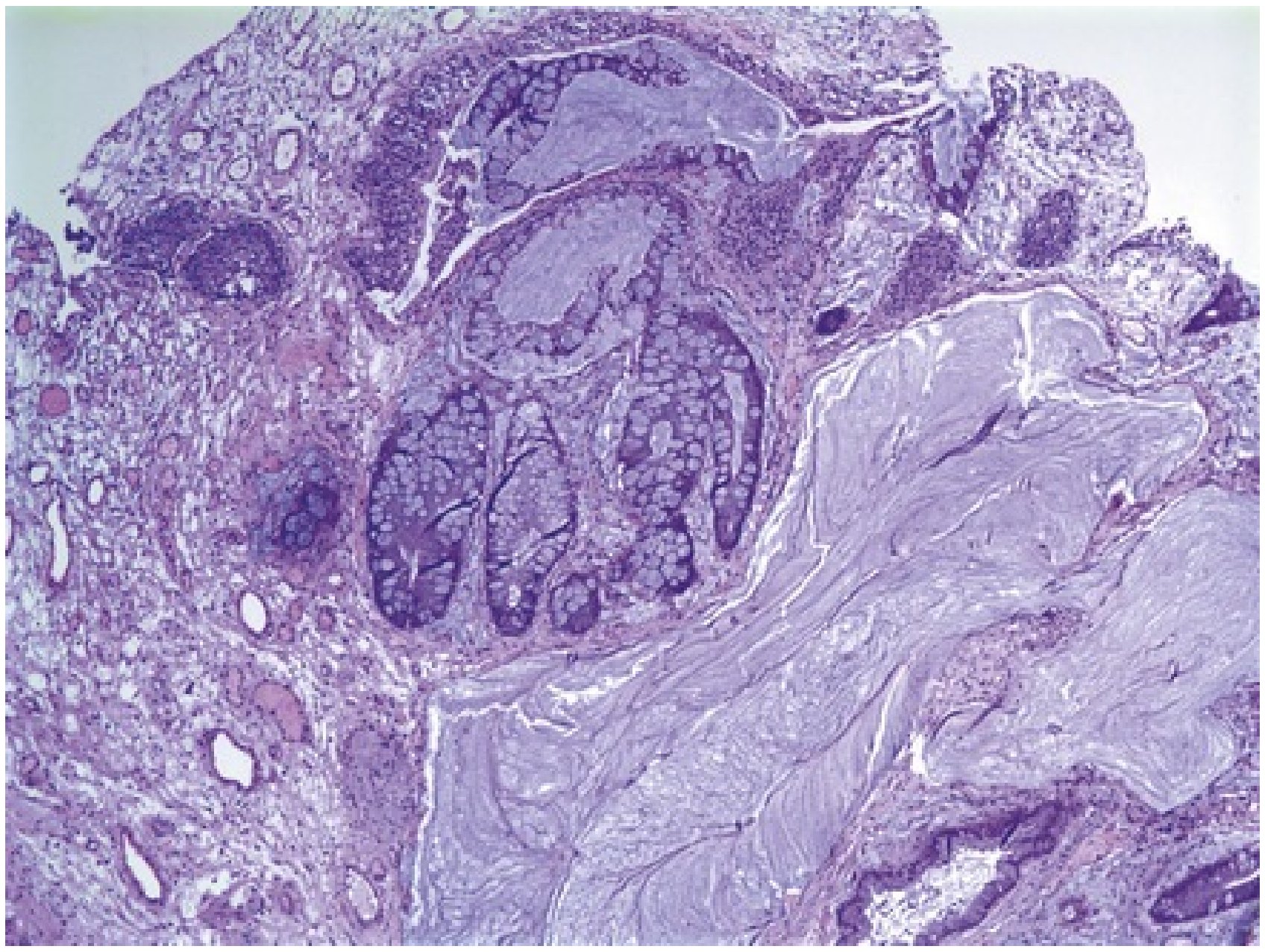

FIG. 135.8 Von Brunn nest with cystitis cystica.

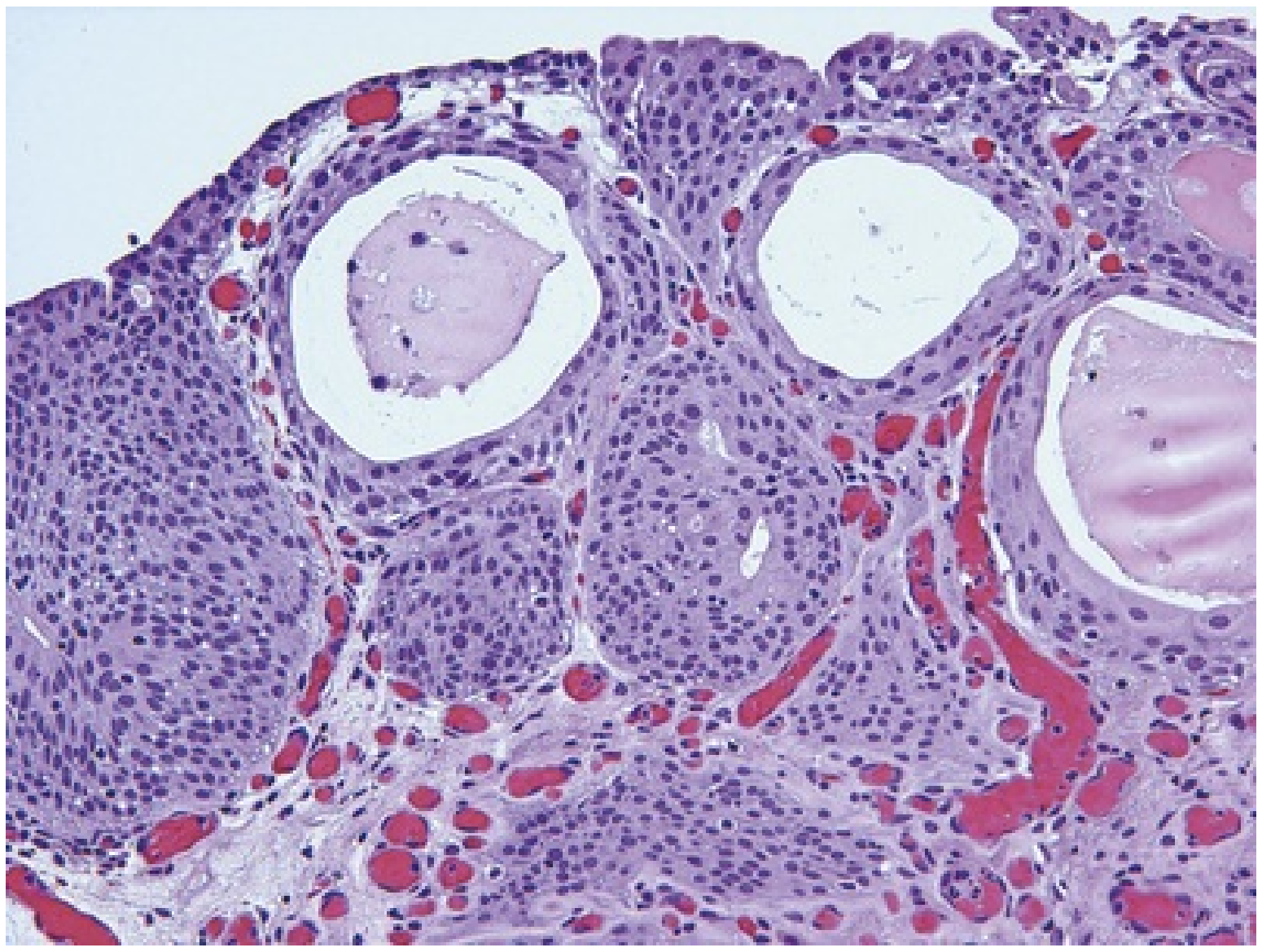

FIG. 135.9 Cystitis glandularis.

Precursor Malignant Lesions

Normal urothelium comprises multilayered mucosa, 4 to 7 cells thick, which features the transition between nonkeratinizing squamous and pseudostratified columnar epithelium. Cells mature from the basal basement membrane cells, which are small and cuboidal, to intermediate cells to superficial umbrella cells in an orderly fashion. The surface has large umbrella cells that may have nuclear atypia and form asymmetrical units. These umbrella cells form a urine bladder barrier preventing toxins from transforming urothelial cells. Precursor lesions are a continuum from hyperplasia to atypia to dysplasia and finally cancer. The 2004 World Health Organization classification system for urothelial neoplasia classifies pre-malignant lesions as urothelial hyperplasia (flat and papillary), reactive atypia, urothelial atypia of unknown significance (AUS), urothelial dysplasia, and low-grade intraurothelial neoplasia (Hodges et al., 2010).

Urothelial hyperplasia may be flat or papillary (Fig. 135.10) and is characterized by thickening of the mucosa to 10 or more cell layers. Although the nuclei may be slightly enlarged, no cytologic atypia is present and mitoses are absent. Although in isolation urothelial hyperplasia is not thought to have malignant potential, hyperplasia is frequently seen in conjunction with pre-malignant and malignant lesions. Hyperplastic flat lesions may be precursors to low-grade papillary tumors, evidenced by mutation in FGFR3, and loss of heterozygosity at 3q22-q24, 5q22-q31, 10q26, 13q14, and 17p13 in benign hyperplastic lesions from bladders with urothelial carcinoma (Majewski et al., 2008; van Oers et al., 2006). On cystoscopy, papillary urothelial hyperplasia can be indistinguishable from low-grade papillary lesions and is often present adjacent to low-grade papillary tumors.

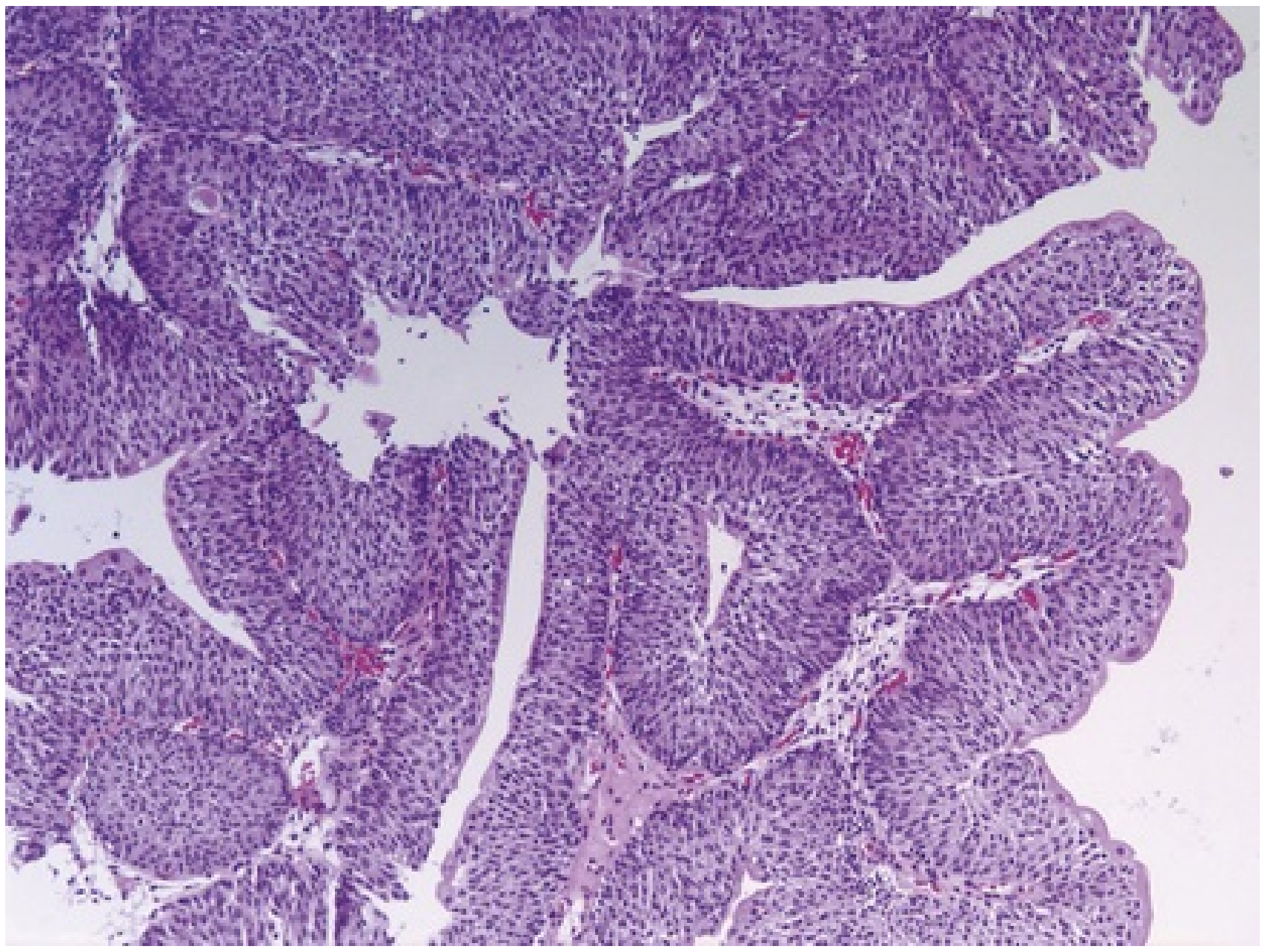

FIG. 135.10 Papillary urothelial hyperplasia.

Reactive atypia is characterized by nuclear abnormalities occurring in the background of an inflamed urothelium (Hodges et al., 2010). Typically patients have a history of chronic inflammation, regeneration, or reaction from noxious stimuli and have irritative voiding symptoms. Endoscopically, reactive atypia is edematous and inflamed appearing. Microscopically, although nuclei may be prominent and enlarged, the mucosa proceeds in an orderly fashion from basal to intermediate to superficial cell types, and nuclear polarity is maintained. Similar to hyperplasia, reactive atypia does not appear to independently evolve into carcinoma; however, atypia often coexists with dysplasia and carcinoma in situ and thus mandates rigorous investigation.

Atypia of unknown significance (AUS) is used when it is unclear whether observed urothelial changes are premalignant or reactive. Microscopically, AUS is characterized by inflammation of the lamina propria and nuclear atypia disproportionate to the degree of atypia. CK20 and CK44 immunohistochemical staining, which are positively expressed in AUS, can aid in distinguishing AUS from dysplasia (Kunju et al., 2005). AUS independently does not appear to lead to urothelial carcinoma and is a diagnosis of limited clinical utility.

Urothelial dysplasia is characterized by a normal urothelial thickness and an altered cytologic appearance of urothelial cells. Normal cytoplasmic clearing is lost particularly in basal and intermediate cells, with loss of nuclear polarity, nuclear enlargement, hyperchromosia, and nuclear membrane irregularity. The lamina propria is typically normal, and comparison with normal urothelium can help differentiate reactive atypia from dysplasia. Ck20 and P53 staining typically highlight the dysplastic cells. Umbrella cells are typically present with dysplasia but not with CIS. Dysplasia, although difficult to distinguish from CIS in some cases, is a good indication of urothelial instability and a marker of recurrence or progression in those with a history of urothelial cancer. Approximately 14% to 19% of patients with urothelial dysplasia will progress to urothelial cancer; however, in the setting of a prior history of bladder cancer, urothelial dysplasia will lead to CIS in 60% of cases (Baithun et al., 1988; Cheng et al., 1999, 2000).

Malignant Lesions

Urothelial carcinoma is the most common malignancy of the urinary tract and is the second most common cause of death among all genitourinary tumors. Non–muscle-invasive bladder cancer, comprising low- and high-grade noninvasive papillary neoplasms, CIS, and urothelial carcinoma with invasion into the lamina propria (T1), make up approximately 70% of all bladder urothelial carcinoma.

CIS (Fig. 135.11) is characterized by noninvasive, flat high-grade tumors. There is severe nuclear atypia, loss of cellular polarity, and a non-cohesive cellular structure. The cells are large, pleomorphic, chromatin clumping, and often with abnormal mitotic figures. A characteristic that separates dysplasia from CIS is the loss of umbrella cells. The genetic abnormalities of CIS are more similar to high-grade, invasive tumors of the urinary tract, furthering the concept that CIS is a precursor to high-grade invasive carcinoma. These include alterations to RB, TP53, and PTEN (Sanchez-Carbayo et al., 2002). Interestingly, no FGFR3 mutations have been reported in CIS, suggesting a very different tumor lineage from low-grade papillary tumors, which have frequent FGFR3 mutations (Zieger et al., 2009). Clinically, CIS in association with invasive tumors carries a worse prognosis, with a 45% to 65% 5-year mortality rate (Montironi et al., 2009).

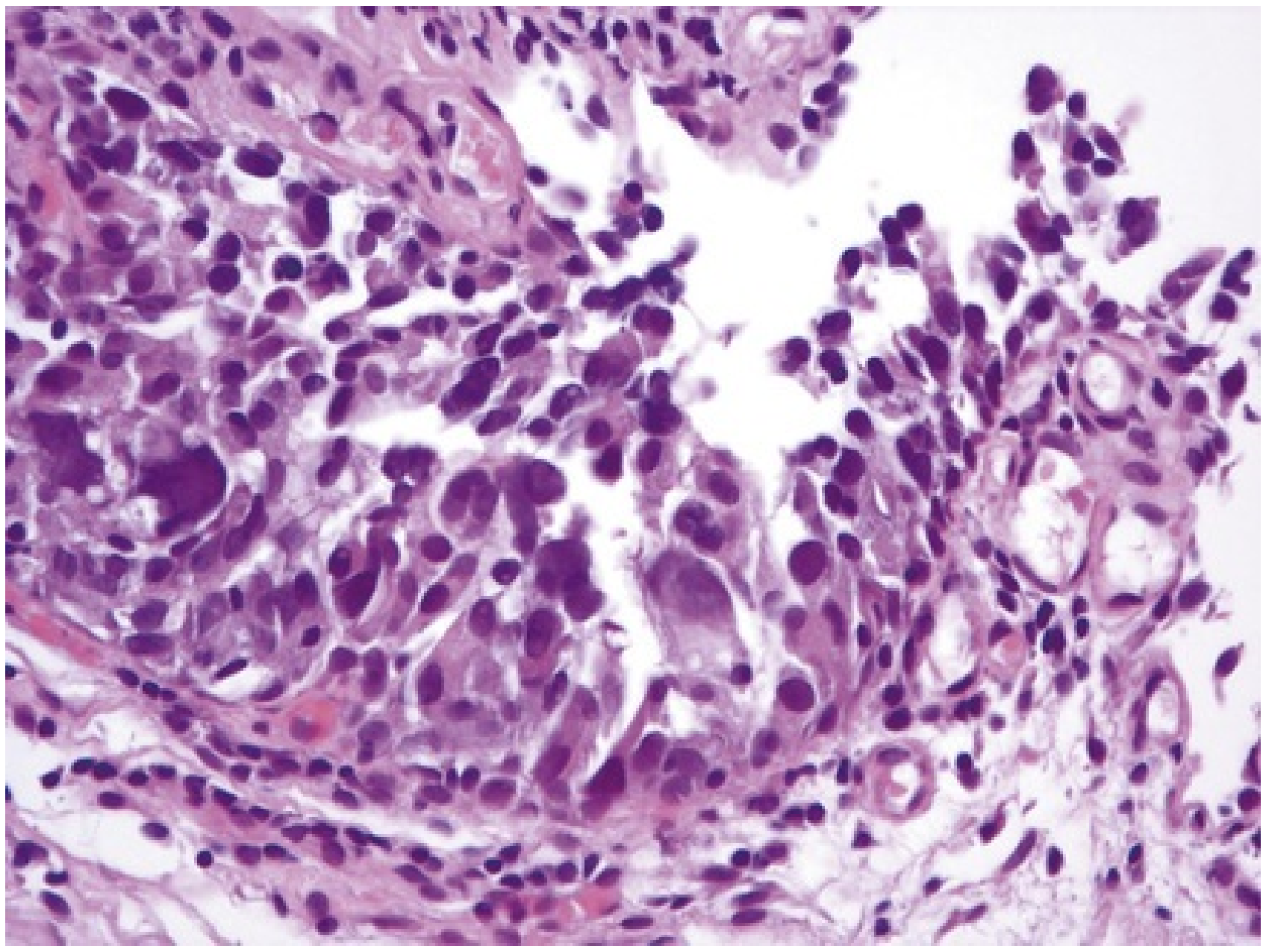

FIG. 135.11 Carcinoma in situ.

Papillary urothelial neoplasm of low malignant potential (PUNLMP) (Fig. 135.12) constitutes a diagnosis with particularly good prognosis, and there is controversy as to whether it should carry the label of cancer (Montironi and Lopez-Beltran, 2005; Sauter, 2004). PUNLMP is a papillary growth with minimal cytologic atypia that is more than seven cells thick, generally solitary, and typically located on the trigone. Cell polarity is maintained, and nuclei are mildly enlarged. Five-year recurrence rates after PUNLMP are estimated to be 20.1%, and these recurrences are nearly always PUNLMP or low-grade papillary lesions. Progression to MIBC among patients with PUNLMP is less than 1%, and it is unclear if these rare high-grade recurrences represent true stage progression or the presence of a new, separate bladder cancer (Maxwell et al., 2015). TERT promoter mutations and FGFR3 mutations have been identified in more than 60% of PUNLMP cases, which creates a similar profile to low-grade papillary Ta lesions. The low rate of HRAS mutations (3%) compared with the 33% incidence in other noninvasive urothelial tumors, however, may speak to the relative indolent, non-aggressive course of PUNLMP lesions (Rodriguez Pena et al., 2017).

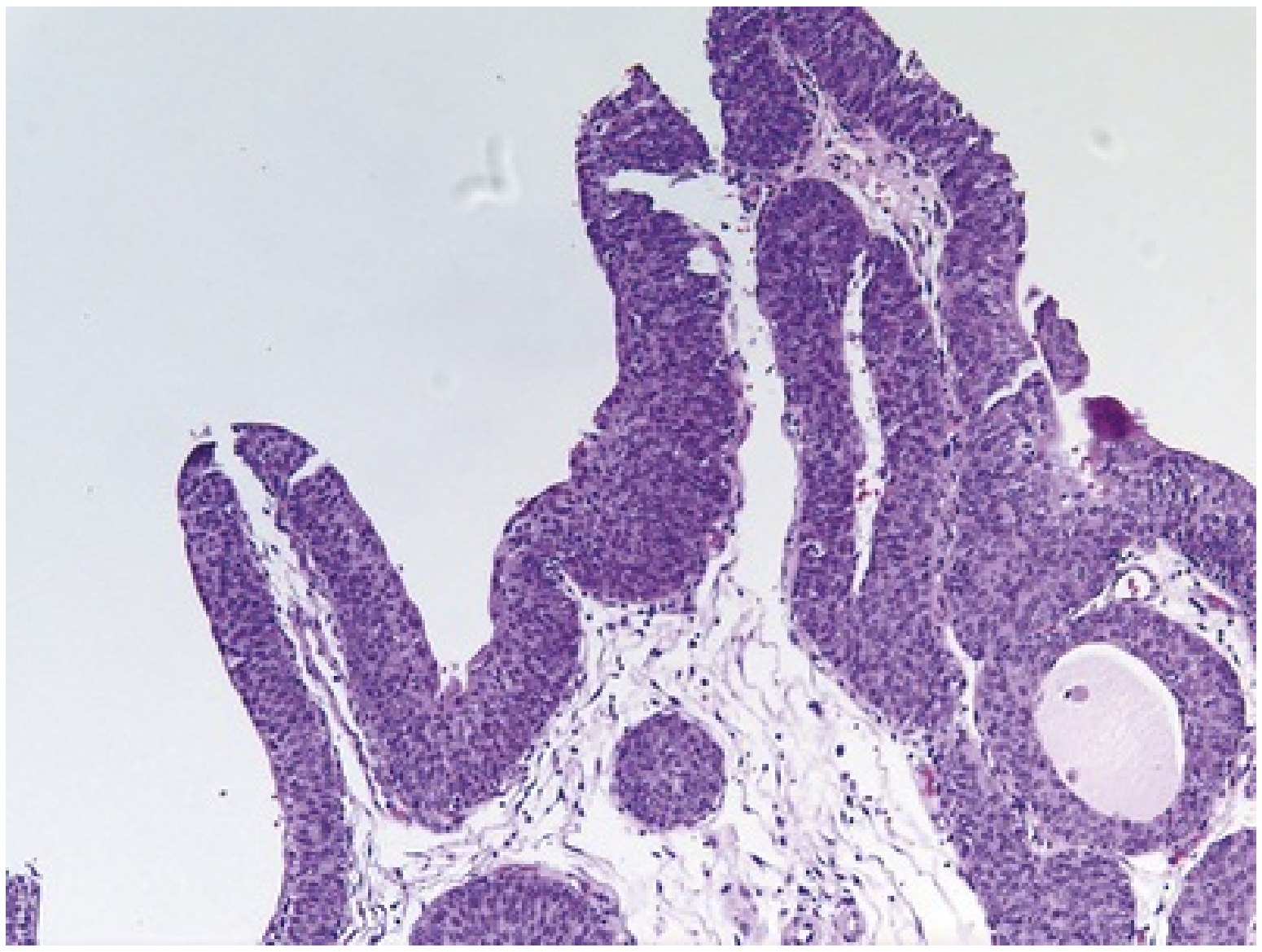

FIG. 135.12 Papillary urothelial neoplasm of low malignant potential.

Low-grade urothelial carcinoma is typically papillary (Fig. 135.13) with a fibrovascular stalk and frequent papillary branching with increased cellular size, some nuclear atypia, and occasional mitotic figures. These tumors almost universally display alterations of genes in chromosome 9 and frequent mutations in *FGFR3*, *PI3K* or, alternatively, *Ras* genes (Dinney et al., 2004; Lopez-Knowles et al., 2006; van Rhijn et al 2010). Low-grade Ta tumors frequently recur 48% to 71% of the time; however, stage or grade progression is relatively infrequent, occurring 2% to 12% of the time, depending on the series (Montironi and Lopez-Beltran, 2005).

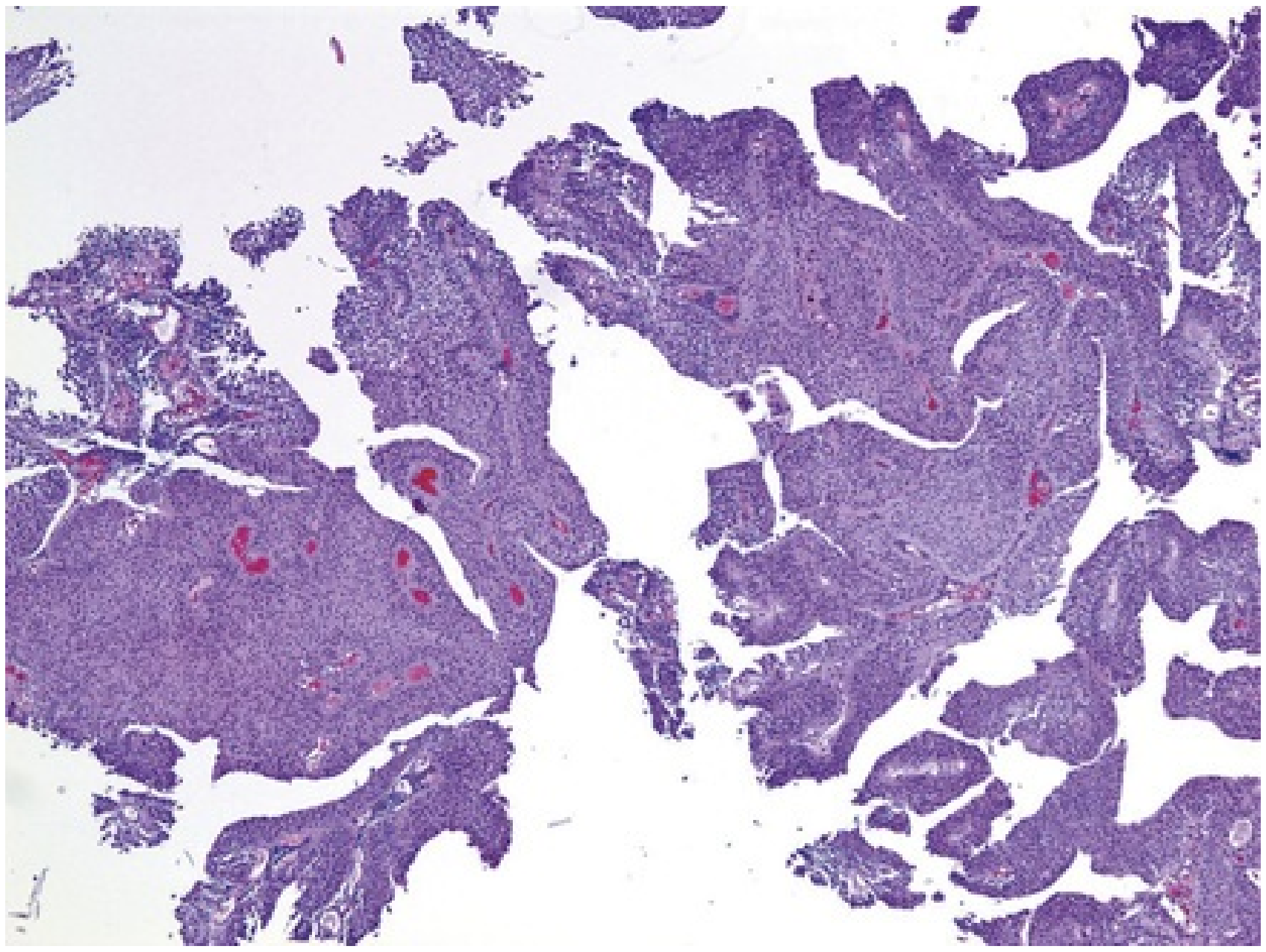

FIG. 135.13 Low-grade papillary urothelial neoplasm.

High-grade papillary urothelial cancer (Fig. 135.14) is composed of fused papillary stalk with high-grade cancer in the urothelial layer. There is a disordered growth pattern, numerous mitotic figures present, and there are pleomorphic cells with exaggerated nuclei. If left untreated, more than 80% of high-grade papillary tumors invade the underlying urothelial stroma. High-grade papillary tumors are considered biologically, and clinically, to be a precursor to invasive high-grade urothelial cancer.

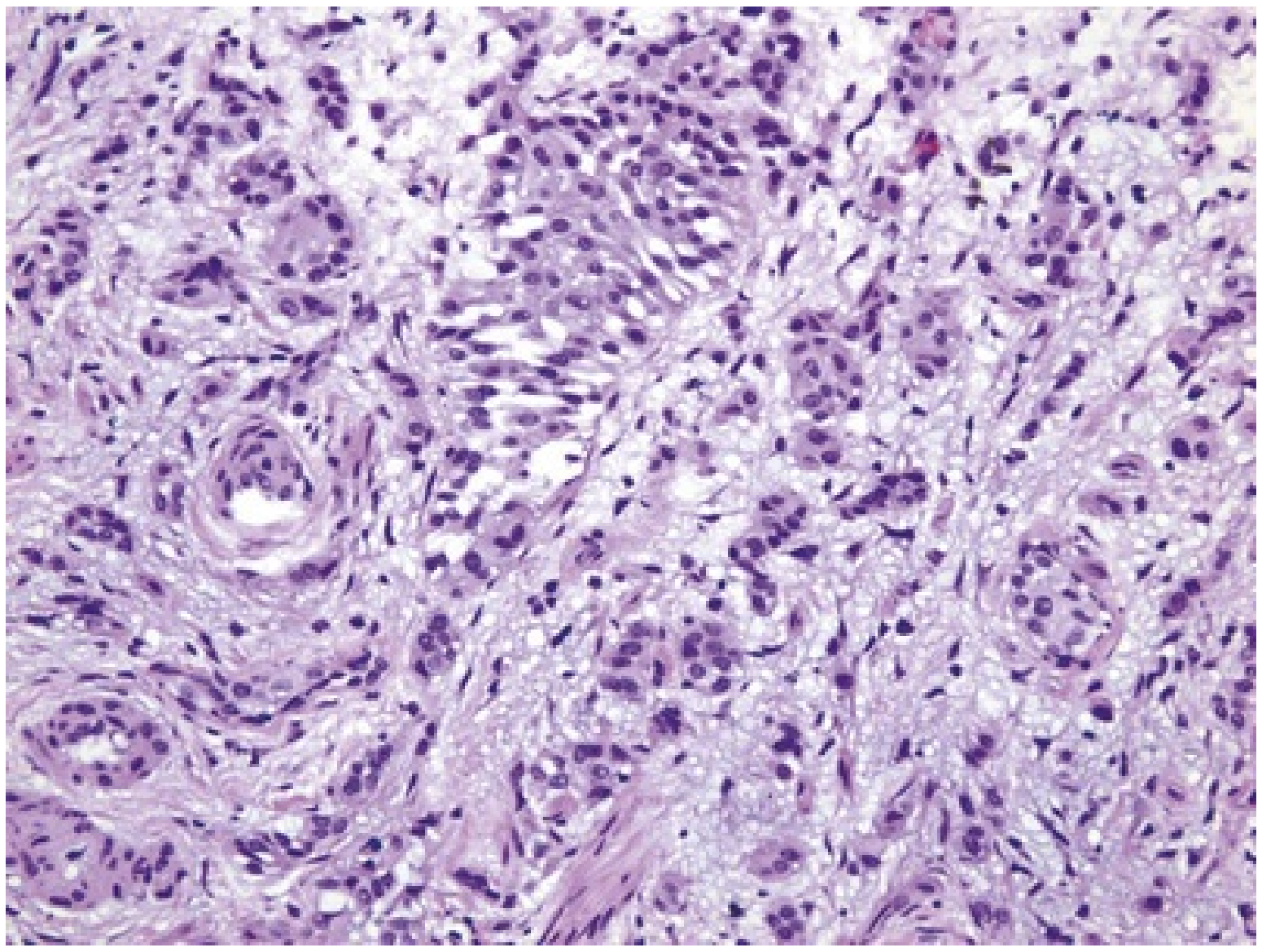

FIG. 135.14 High-grade urothelial cancer invading the lamina propria.

Staging

The American Joint Committee on Cancer (AJCC) in combination with the International Union Cancer Consortium meets regularly to determine tumor, nodes, and metastases (TNM) staging classification. The 2017 staging system is shown in Table 135.3 (Amin et al., 2017). Broadly speaking, non–muscle-invasive bladder cancer comprises stage 0 (noninvasive) and stage I (invasion into subepithelial connective tissue), muscle-invasive organ-confined bladder cancer is of stage II, muscle-invasive locally advanced bladder cancer is stage III, and metastatic disease is stage IV. Whereas prior AJCC editions viewed positive lymph nodes as stage IV regardless of the quantity or location, the 2017 AJCC staging update now views nodal disease in the absence of systemic metastases as stage III (Paner et al., 2018).

TABLE 135.3

American Joint Committee on Cancer/International Union Cancer Consortium 2017 Tumor, Nodes, and Metastases (TNM) Staging Classification

STAGE	STAGE GROUPING	STAGE DESCRIPTION
0a	**Ta**	The cancer is a noninvasive papillary carcinoma (Ta). It has grown toward the hollow center of the bladder but has not grown into the connective tissue or muscle of the bladder wall.
	N0	It has not spread to nearby lymph nodes (N0) or distant sites (M0).
	M0	
0is	**Tis**	The cancer is a flat, noninvasive carcinoma (Tis), also known as flat carcinoma in situ (CIS). The cancer is growing in the inner lining layer of the bladder only. It has not grown inward toward the hollow part of the bladder, nor has it invaded the connective tissue or muscle of the bladder wall.
	N0	It has not spread to nearby lymph nodes (N0) or distant sites (M0).
	M0	
I	**T1**	The cancer has grown into the layer of connective tissue under

		the lining layer of the bladder but has not reached the layer of muscle in the bladder wall (T1).
	N0	The cancer has not spread to nearby lymph nodes (N0) or to distant sites (M0).
	M0	
II	**T2a or T2b** **N0**	The cancer has grown into the inner (T2a) or outer (T2b) muscle layer of the bladder wall, but it has not passed completely through the muscle to reach the layer of fatty tissue that surrounds the bladder.
	M0	The cancer has not spread to nearby lymph nodes (N0) or to distant sites (M0).
IIIA	**T3a, T3b or T4a**	The cancer has grown through the muscle layer of the bladder and into the layer of fatty tissue that surrounds the bladder (T3a or T3b).
	N0	It may have spread into the prostate, uterus, or vagina, but it is not growing into the pelvic or abdominal wall (T4a).
	M0	The cancer has not spread to nearby lymph nodes (N0) or to distant sites (M0).
	OR	The cancer has:
	T1-4a	grown into the layer of connective tissue under the lining of the bladder wall (T1), OR
	N1	into the muscle layer of the bladder wall (T2), OR
	M0	into the layer of fatty tissue that surrounds the bladder, (T3a or T3b) OR
		it may have spread into the prostate, uterus, or vagina, but it is not growing into the pelvic or abdominal wall (T4a).
		AND the cancer has spread to a nearby lymph node in the true pelvis (N1).
		It has not spread to distant sites (M0).
IIIB		The cancer has:
	T1-T4a	grown into the layer of connective tissue under the lining of the bladder wall (T1), OR
	N2 or N3 **M0**	into the muscle layer of the bladder wall (T2), OR
		into the layer of fatty tissue that surrounds the bladder (T3a or T3b), OR
		it may have spread into the prostate, uterus, or vagina, but it is not growing into the pelvic or abdominal wall (T4a).
		AND the cancer has spread to 2 or more lymph nodes in the true pelvis (N2) or to lymph nodes along the common iliac arteries (N3).

		It has not spread to distant sites (M0).
IVA		The cancer has grown through the bladder wall into the pelvic or abdominal wall (T4b).
	T4b	The cancer has not spread to nearby lymph nodes (N0) or to distant sites (M0).
	N0	
	M0	
	OR	
	Any T	The cancer may or may not have grown through the wall of the bladder into nearby organs (Any T).
	Any N	It may or may not have spread to nearby lymph nodes (Any N).
	M1a	It has spread to a distant set of lymph nodes (M1a).
IVB	**Any T**	The cancer may or may not have grown through the wall of the bladder into nearby organs (Any T).
	Any N	It may or may not have spread to nearby lymph nodes (Any N).
	M1b	It has spread to 1 or more distant organs (such as the bones, liver or lungs) (M1b).

NMIBC is further subdivided into low-, intermediate-, and high-risk disease. Low-risk NMIBC comprises a primary (i.e., not recurrent), low-grade papillary (Ta), solitary tumors less than 3 cm. Intermediate-risk NMIBC is histologically confirmed by multiple and/or recurrent and/or large (>3 cm) low-grade Ta tumors. High-risk NMIBC involves tumors with any high-grade histologic features (i.e., CIS or T1) (Kamat et al., 2014). In addition, the 2017 AJCC recommends subcategorization of T1 urothelial carcinoma into T1a (superficial) and T1b (deep) lamina propria invasion (Fig. 135.15) to help stratify the heterogeneous group of T1 tumors, which are at a 50% risk of upstaging to T2 or higher and a 33% risk of being upstaged to non–organ confined (Badalato et al., 2011; Svatek et al., 2010). **These stratifications suggest that the deeper the tumor invades into the lamina propria, the worse the survival.**

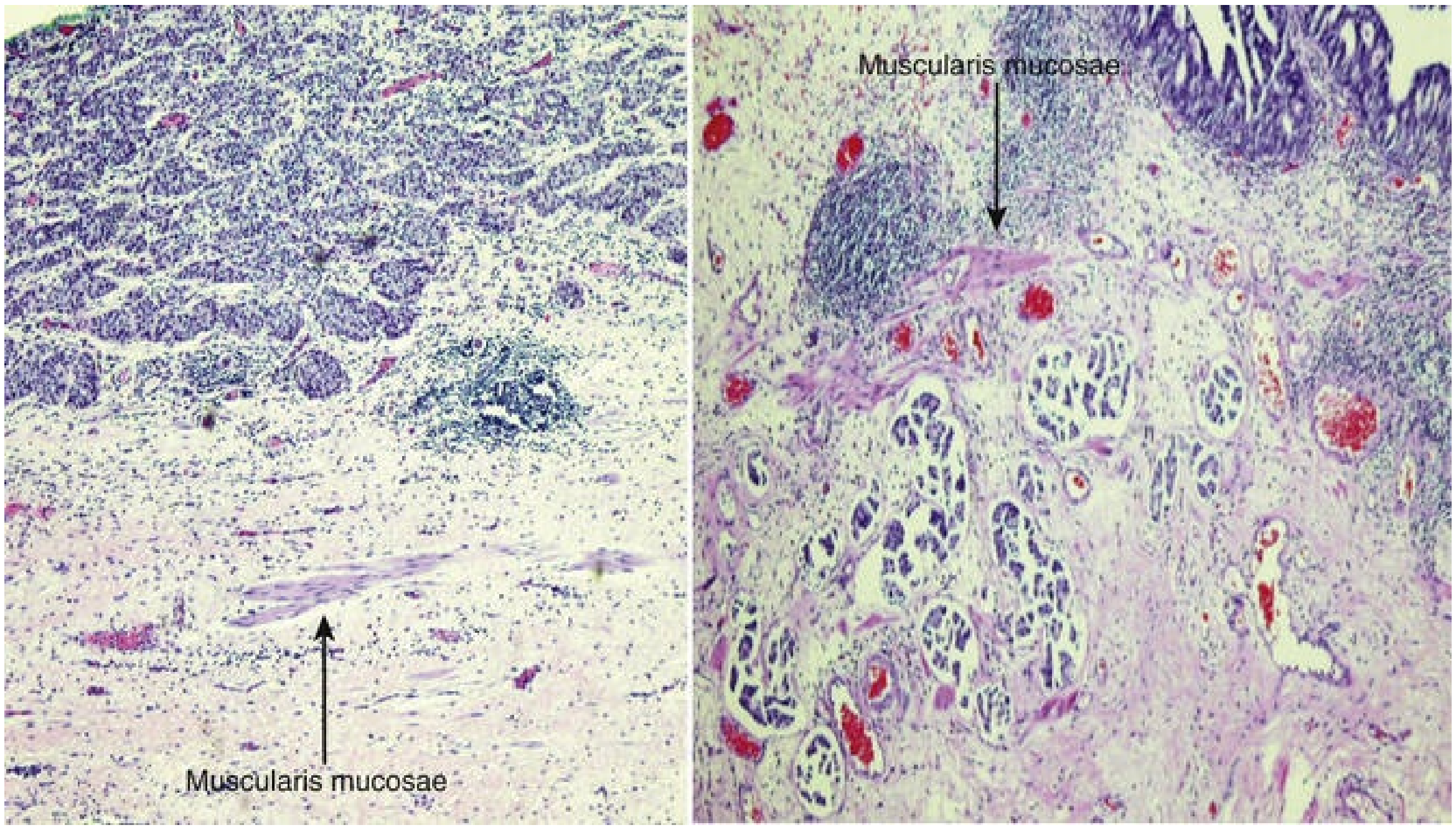

FIG. 135.15 High grade T1a *(left)* and Tlb *(right)* urothelial cancer.

Muscle-invasive disease is subdivided into T2a and T2b. T2a includes invasion into the inner half of the muscularis propria, although T2b is deeper into the outer half. It is controversial whether depth of muscle invasion makes significant impact on disease, and this is complicated by sampling variability of muscle on TURBT. For this reason, the AJCC staging guidelines view T2a and T2b as similar in the current staging schema. T3 disease constitutes invasion outside of the bladder proper into the periadipose tissue. T3a disease involves microscopic extension, whereas T3b is macroscopic extension. T4a disease is invasion of the prostatic stroma, uterus, or vagina, and T4b disease is invasion of the pelvic or abdominal wall.

Prostatic urethral cancer is associated with bladder cancer in 90% of cases, although among patients with primary bladder urothelial cancer, urethral involvement is relatively rare, occurring in 3% of patients. Most prostatic urethral urothelial carcinoma is CIS, and extension of the tumor into the prostatic urethra without stroma invasion does not carry an adverse prognosis for patients with known bladder cancer. These tumors can be difficult to treat with intravesical therapy, however, and as a result among patients undergoing frequent intravesical therapy, the rate of prostatic urethral CIS is elevated (Table 135.4; Mungan et al., 2005). Prostate stromal invasion, however, particularly if it is direct extension from the bladder through the muscle into the prostate, does carry a poor prognosis, with 5-year overall survival of less than 25% in historic series (Donat et al., 2001; Esrig et al., 1996). For this reason only patients with prostate stromal invasion are considered to be T4.

TABLE 135.4

Clinical Significance of Different Non–Muscle-Invasive Urothelial Cancer Categories in the World Health Organization 2004 Grading System

	PAPILLOMA	PAPILLARY NEOPLASM OF LOW MALIGNANT POTENTIAL	LOW-GRADE PAPILLARY CARCINOMA	HIGH-GRADE CARCINOMA (PAPILLARY AND CIS)
Recurrence (%)	0–8	27–47	48–71	55–58
Grade progression (%)	2	11	7	N/A
Stage progression (%)	0	0–4	2–12	27–61
Survival (%)	100	93–100	82–96	74–90

CIS, Carcinoma in situ; *N/A,* not applicable.

Data from Montironi R, Lopez-Beltran A: The 2004 WHO classification of bladder tumors: a summary and commentary. *Int J Surg Pathol* 13(2):143–53, 2005.

Molecular Biology

Major progress has been made in recent years toward improving our understanding of the molecular makeup of urothelial carcinoma. Several molecular alterations are common in bladder cancer, including FGFR3 alterations, PI3K pathway alterations, activation of mitogen-activated protein kinase (MAPK) signaling, defects in cell cycle regulation, and Hedgehog and WNT signaling (Knowles and Hurst, 2015).

Genes encoding proteins that control the cell cycle are frequently mutated in bladder cancer, particularly MIBC. Inactivation of *RB1*, and *CDKN2A* are very common, and *p53* inactivation occurs in as many as 76% of MIBCs (Cancer Genome Atlas Research Network, 2014). Similarly loss of the tumor suppressor gene *RB1* is common in MIBC and leads to amplification and overexpression of the oncogene *E2F3* (Knowles and Hurst, 2015). The genetic alterations that are the hallmark of NMIBC are alterations in the fibroblast growth factor receptor-3 *(FGFR3)* gene and deletions of chromosome regions 9p and 9q. Up to 80% of low-grade papillary (Ta) bladder tumors have activating point mutations in *FGFR3*, whereas approximately 10% to 20% of muscle-invasive bladder tumors have *FGFR3* mutations (Cappellen et al., 1999; Zieger et al., 2005). In normal bladder epithelium, FGFR3 is expressed in the IIIb isoform and binds to FGF1. In bladder cancer cell lines, a switch from the IIIb to the IIIc FGFR3 isoform may induce oncogenesis via paracrine and autocrine signaling (Tomlinson et al., 2005; Zhang et al., 2006). In addition, FGFR3 fusion proteins, which are present in many bladder tumors, comprise highly activated oncoproteins of FGFR3 fused to TACC3 or BAI1 (Williams et al., 2013).

The MAPK signaling pathway comprises another set of key genetic alterations in bladder cancer pathogenesis. *Ras* (HRAS or KRAS) pathway alterations are mutually exclusive from *FGFR3* mutations because they are in the same RAS-MEK-ERK pathway. *Ras* genes are from a family of transforming oncogenes that were originally identified in T24 bladder cancer cell lines (McBride et al., 1982). However, unlike *FGFR3*, *RAS* mutations occur with equal incidence in NMIBC and MIBC.

Point mutations in PIK3CA are found in 25% of NMIBC and less commonly in MIBC. FGFR3 and PIK3CA work together in a similar pathway, and thus both mutations are often seen in the same tumors. PI3K pathway alterations are critical in the PTEN pathway as PTEN negatively regulates PI3K. Downregulation of PTEN in MIBC is associated with TP53 alterations and poor prognosis (Platt et al., 2009; Puzio-Kuter et al., 2009). In a pre-clinical transgenic model of bladder cancer, dual deletion of the genes encoding p53 and PTEN leads to the development of metastatic bladder cancer (Knowles and Hurst 2015). It appears that the protein phosphatase activity of PTEN, and not its lipid activity, drives bladder cancer invasion and metastasis (Gildea et al 2004). Additional studies demonstrate that the WNT/b-catenin pathway often coordinates with PI3K/PTEN to promote bladder cancer development and growth. Three dimensional organoid cultures have revealed the importance of the WNT/b-catenin pathway in bladder cancer cell proliferation (Yoshida et al 2018). These studies confirmed earlier experiments showing that expression of activated b-catenin with PTEN deletion promoted bladder cancer development (Ahmad et al 2011).

A new framework is emerging for understanding the heterogeneity of bladder cancer and how that molecular diversity plays a role in treatment response. Historically, bladder tumors were thought to arise from two distinct pathways. In the first pathway, tumors arise from urothelial proliferation and differentiate into low-grade noninvasive papillary tumors. These tumors are enriched in *FGFR3* mutations and have a relatively low total mutational burden. In the second pathway, tumors start as dysplastic cells and transform into CIS and into high-grade invasive tumors.

However, recent genome-wide expression and sequencing studies have identified genes and pathways that are clear drivers in urothelial cancer development. A more complex picture with molecular subclasses that are agnostic to conventional tumor stage and grade has emerged.

In 2014, the comprehensive molecular characterization of MIBC was performed by the Cancer Genome Atlas (TCGA) (Network TCGAR 2014). In that analysis of mRNA, microRNA, and protein expression from 129 muscle invasive tumors, four distinct clusters were identified resembling intrinsic subtypes of breast cancer. Subdividing urothelial bladder cancer into intrinsic subtypes based on breast cancer was independently confirmed by groups from Lund, MDAnderson, and UNC (Sjodahl et al 2012; Choi et al 2014; Damrauer et al 2014). These systems partially overlap, and broadly speaking characterizes basal and luminal tumor subtypes (Fig. 135.16). The luminal group, characterized by high levels of *FGFR3,* GATA3, KRT20, and PPARG mutations was biologically less aggressive compared with the basal-squamous subtype, characterized by squamous differentiation, and expression of CK5, CK6, CK14, and low levels of FOXA1 and GATA3RNA and protein.

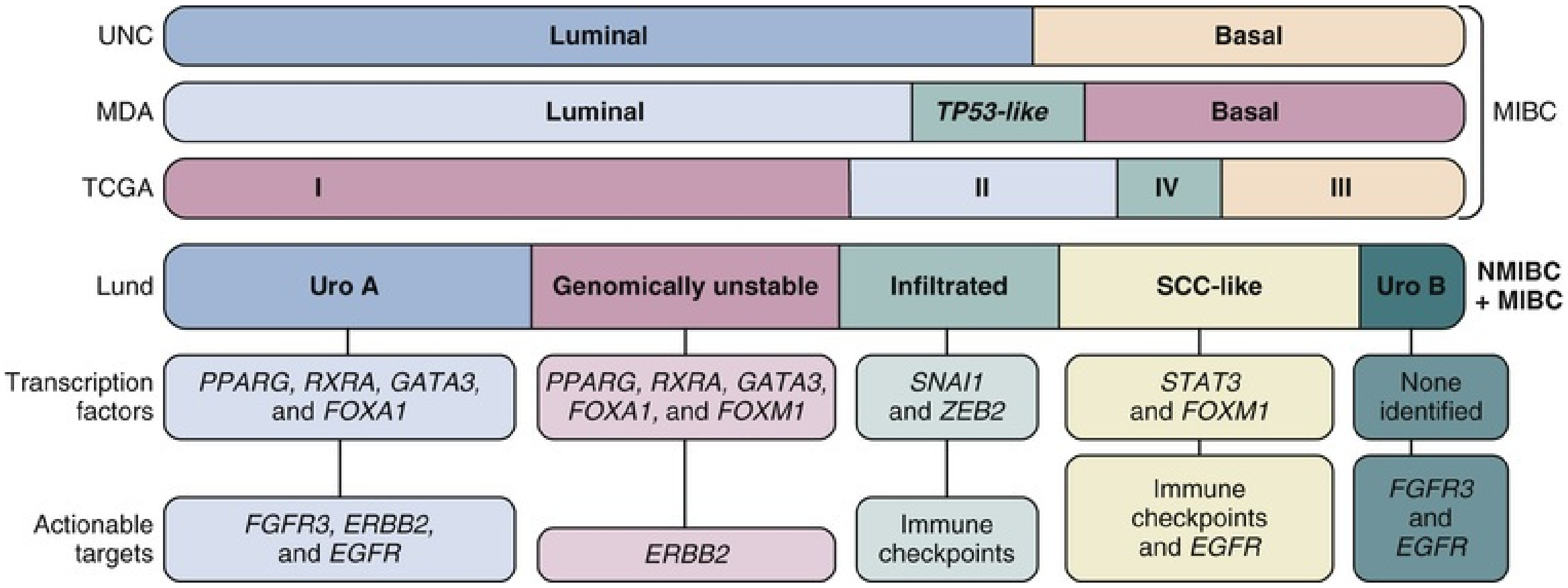
UNC
Luminal
Basal
MDA
Luminal
TP53-like
Basal
MIBC
TCGA
I
II
IV
III
Lund
Uro A
Genomically unstable
Infiltrated
SCC-like
Uro B
NMIBC + MIBC
Transcription factors
PPARG, RXRA, GATA3, and FOXA1
PPARG, RXRA, GATA3, FOXA1, and FOXM1
SNAI1 and ZEB2
STAT3 and FOXM1
None identified
Actionable targets
FGFR3, ERBB2, and EGFR
ERBB2
Immune checkpoints
Immune checkpoints and EGFR
FGFR3 and EGFR

FIG. 135.16 Molecular subtypes of bladder cancer. *MDA,* MD Anderson

Cancer Center nomenclature; *MIBC,* muscle-invasive bladder cancer; *NMIBC,* non–muscle-invasive bladder cancer; *SCC,* small cell carcinoma; *TCGA,* The Cancer Genome Atlas nomenclature; *UNC,* University of North Carolina nomenclature. (Modified from Compérat E, Varinot J, Moroch J, et al.: A practical guide to bladder cancer pathology. *Nat Rev Urol* 15:143–154, 2018.)

Ultimately, grouping bladder cancer into distinct molecular clusters may help identify certain patients that may benefit from specific therapies. For example, the MD Anderson classification identified a distinct subgroup of luminal tumors that they termed “P53-like”, that which were chemoresistant and associated with a poor prognosis (Choi et al., 2014). In addition, the UNC classification identified a claudin-low molecular subtype of MIBC enriched for RB1, EP300, and NCOR1, with decreased FGFR3, KDM6A, and PPARG amplification or expression. These claudin-low tumors are immune infiltrated and actively immune suppressed and may benefit from immune checkpoint inhibitors that have been FDA approved for the treatment of bladder cancer (Bai et al., 2016). **A 2017 follow-up study from the TCGA of 412 muscle-invasive tumors identified 5 expression subtypes that may stratify to different treatments** (Fig. 135.17). **In addition, that study identified a subset of patients with a high mutational load, driven by an APOBEC-mediated mutagenesis. APOEBEC comprises a family of cytidine deaminases that are involved in mRNA editing. This APOBEC related subset of patients had a 75% 5-year survival, far higher than the typical MIBC patient.**

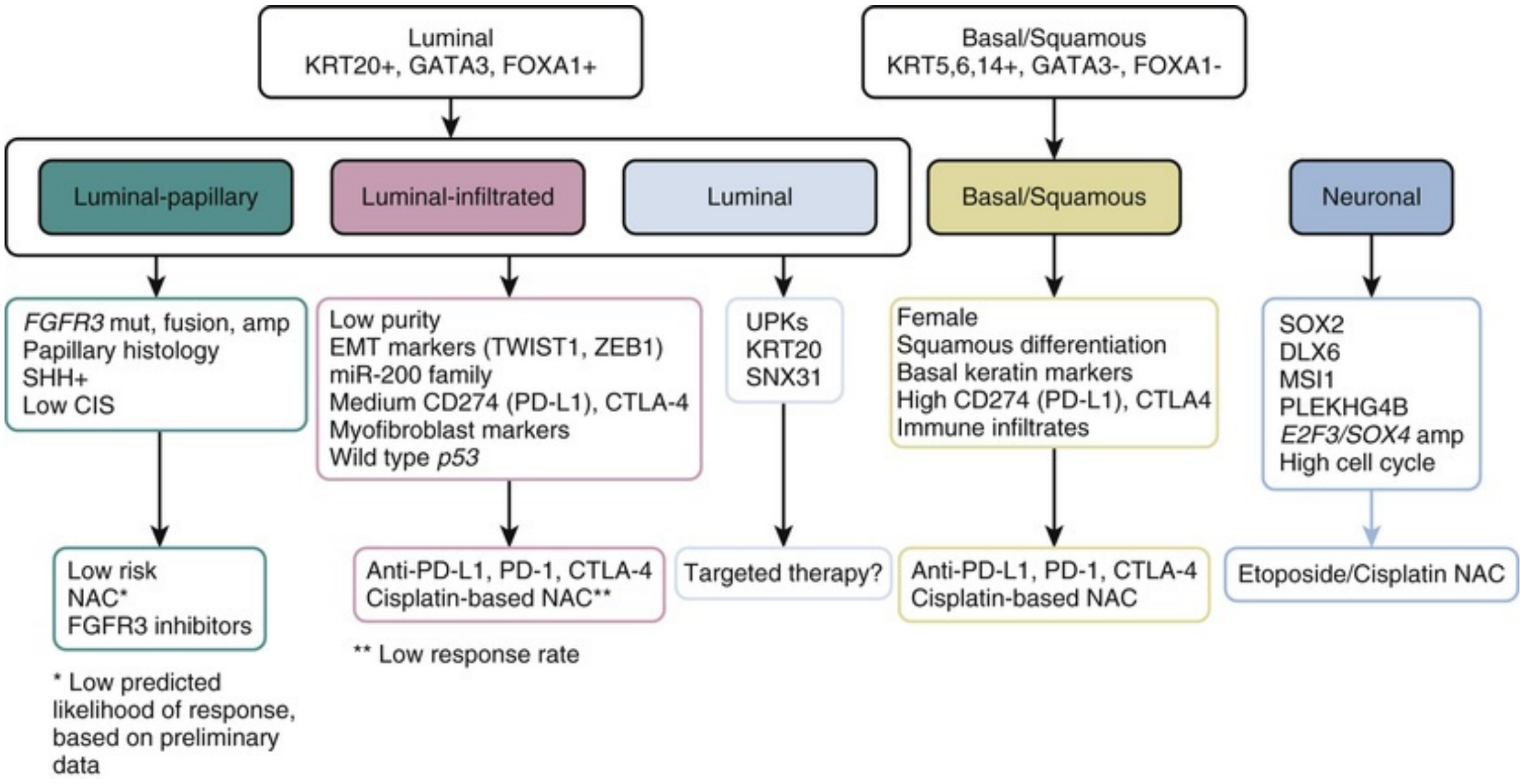
Luminal
KRT20+, GATA3, FOXA1+
Basal/Squamous
KRT5,6,14+, GATA3-, FOXA1-
Luminal-papillary
Luminal-infiltrated
Luminal
Basal/Squamous
Neuronal
FGFR3 mut, fusion, amp
Papillary histology
SHH+
Low CIS
Low purity
EMT markers (TWIST1, ZEB1)
miR-200 family
Medium CD274 (PD-L1), CTLA-4
Myofibroblast markers
Wild type *p53*
UPKs
KRT20
SNX31
Female
Squamous differentiation
Basal keratin markers
High CD274 (PD-L1), CTLA4
Immune infiltrates
SOX2
DLX6
MSI1
PLEKHG4B
E2F3/SOX4 amp
High cell cycle
Low risk
NAC*
FGFR3 inhibitors
Anti-PD-L1, PD-1, CTLA-4
Cisplatin-based NAC**
Targeted therapy?
Anti-PD-L1, PD-1, CTLA-4
Cisplatin-based NAC
Etoposide/Cisplatin NAC
* Low predicted likelihood of response, based on preliminary data
** Low response rate

FIG. 135.17 Proposed schema of expression-based, subtype-stratified therapeutic approach as a framework for prospective hypothesis testing in clinical trials. (From Robertson AG, Kim J, Al-Ahmadie H, et al.: Comprehensive molecular characterization of muscle-invasive bladder cancer. *Cell Press* 171:540–56.e25, 2017.)

Key Points

- Recent genome-wide expression and sequencing studies have identified genes and pathways that are clear drivers in urothelial cancer development.
- A molecular taxonomy is emerging broadly defined by urothelial cells types.
- The luminal phenotype is characterized by high levels of FGFR3, GATA3, KRT20, and PPARG mutations.
- The basal phenotype is characterized by squamous differentiation, and expression of CK5, CK6, CK14, and low levels of FOXA1 and GATA3 RNA and protein expression.

Histologic Variants of Urothelial Carcinoma

Urothelial carcinoma of the bladder had previously been labeled transitional cell carcinoma of the bladder because of its known propensity for cellular differentiation into other tumor types, such as SCC, adenocarcinoma, and clear cell carcinoma. Recently, a wider spectrum of histologic variants of urothelial cancer has been identified and investigated that includes distinct growth patterns of urothelial carcinoma, altered cellular differentiation of stromal reactions, and unique responses to treatment and external stimuli. The more common histologic variants are discussed here.

Micropapillary Variant

Micropapillary urothelial carcinoma was first described in 1994 and occurs in approximately 0.7% to 2.2% of all urothelial tumors (Amin et al., 1994; Johansson et al., 1999; Fig. 135.18). There is a strong male predominance associated with micropapillary urothelial cancer, with reports of a male-to-female ratio as high as 37:1. Micropapillary urothelial carcinoma is associated with advanced disease, as more than 50% are stage T3 or T4 at diagnosis; as such 5- and 10-year overall survival is 51% and 24%, lower than with other common histologies (Kamat et al., 2007). However, even among lower-stage bladder tumors, micropapillary variant is associated with a worse prognosis because these tumors are associated with a progression rate from non–muscle-invasive to muscle-invasive disease of 70%, with a high subsequent metastatic rate despite treatment (Kamat et al., 2007). Histologically, micropapillary urothelial carcinoma exhibit small tight clusters or thin papillae of atypical cells with eosinophilic to clear cytoplasm surrounded by prominent retraction artifact (Watts and Hansel, 2010). **Unlike other histologic subtypes, any amount of micropapillary urothelial carcinoma may be present for it to be defined as micropapillary and clinically managed as such.** The most effective therapy for all stages of micropapillary urothelial carcinoma is surgical resection. Treatment with transurethral resection and bacillus Calmette-Guérin therapy is ineffective unless the tumor is completely resected, and early cystectomy is encouraged for NMIBC, with a cancer-specific survival of 72% compared with 60% who undergo transurethral resection with intravesical BCG. Similarly, for muscle-invasive disease neoadjuvant chemotherapy does not appear to be effective, and immediate cystectomy is currently encouraged (Kamat et al., 2007). Molecular profiling of the micropapillary variant suggest that these tumors are characterized by ERBB2 amplification and activation of *miR-296* and *RUVBL1* target genes (Guo et al., 2016; Isharwal et al., 2018; Ross et al., 2014). The micropapillary variants appear to evolve almost exclusively through a luminal pathway, displaying enrichment of PPAR-gamma and suppression of *p63* genes. Similar to conventional luminal tumors, a subset of micropapillary cancers demonstrate activation of wild-type *p53,* and these represent the most aggressive phenotypes with the worst prognosis (Guo et al., 2016).

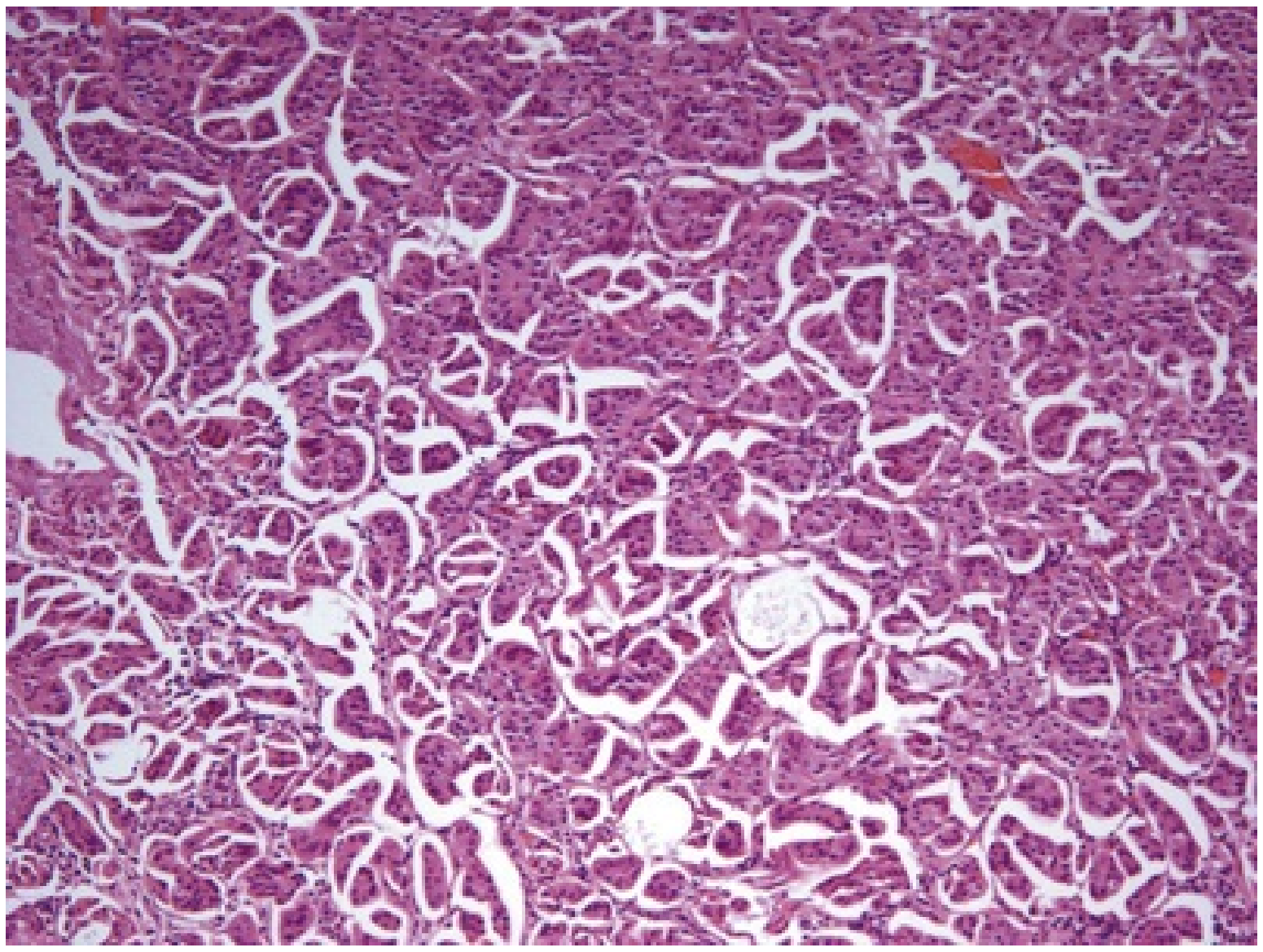

FIG. 135.18 Micropapillary urothelial cancer.

Sarcomatoid Variant

The sarcomatoid variant has a prevalence of 0.3% to 0.6% of all bladder cancers (Amin, 2009; Moschini et al., 2017a; Wright et al., 2007). Historically they were described separately as carcinosarcoma and sarcomatoid carcinoma, although molecular studies suggest that they have a common clonal origin (Armstrong et al., 2009; Gronau et al., 2002; Wright et al., 2007). Patients with the sarcomatoid variant are seen with large infiltrative masses, often at higher stages with a 5-year cancer-specific survival as low as 28.4% across all stages (Wang et al., 2010). Even when controlling for stage they have worse outcomes than pure urothelial tumors. These patients have a poor response to systemic chemotherapy, and thus immediate radical cystectomy is often considered when feasible; furthermore, our group and others have proposed intraoperative radiation therapy (IORT) at the time of radical cystectomy for these high-risk patients (Kates et al., 2017; Wang et al., 2010).

Plasmacytoid Variant

The plasmacytoid variant of urothelial carcinoma is rare, comprising less than 1% of all urothelial tumors (Lopez-Beltran et al., 2009; Moschini et al., 2017b). According to the 2016 WHO classification of urothelial carcinoma, plasmacytoid urothelial carcinoma now includes the signet ring variant, which is defined by the presence of cytoplasmic vacuoles with or without intracellular mucin. The plasmacytotic variant microscopically has increased eosinophilic cytoplasm, with eccentrically placed and enlarged hyperchromatic nuclei. These tumors typically are seen in an advanced stage with deep invasion into the bladder muscle and perivesical tissues, and with characteristic intraperitoneal metastatic spread. This aggressive phenotype is characterized by truncating somatic alterations in the *CDH1* gene, which occurs in 84% of cases according to one study (Al-Ahmadie et al., 2016). Although plasmacytoid variant is chemosensitive and thus treated with neoadjuvant chemotherapy whenever possible, relapses are common with median survival among non-metastatic patients just 17.7 months (Dayyani et al., 2013; Kaimakliotis et al., 2014; Ricardo-Gonzalez et al., 2012).

Nested Variant

The nested variant is a rare but aggressive cancer that has a male-to-female ratio of 6:1 and can be confused with benign lesions such as Von Brunn nests that are located in the lamina propria, cystitis cystica, and inverted papillomas (Fig. 135.19). Although the nested variant is typically upstaged at the time of cystectomy and found to be locally advanced at the time of presentation, stage-matched comparisons between nested variant and pure urothelial carcinoma suggest similar rates of recurrence and survival (Beltran et al., 2014; Linder et al., 2013).

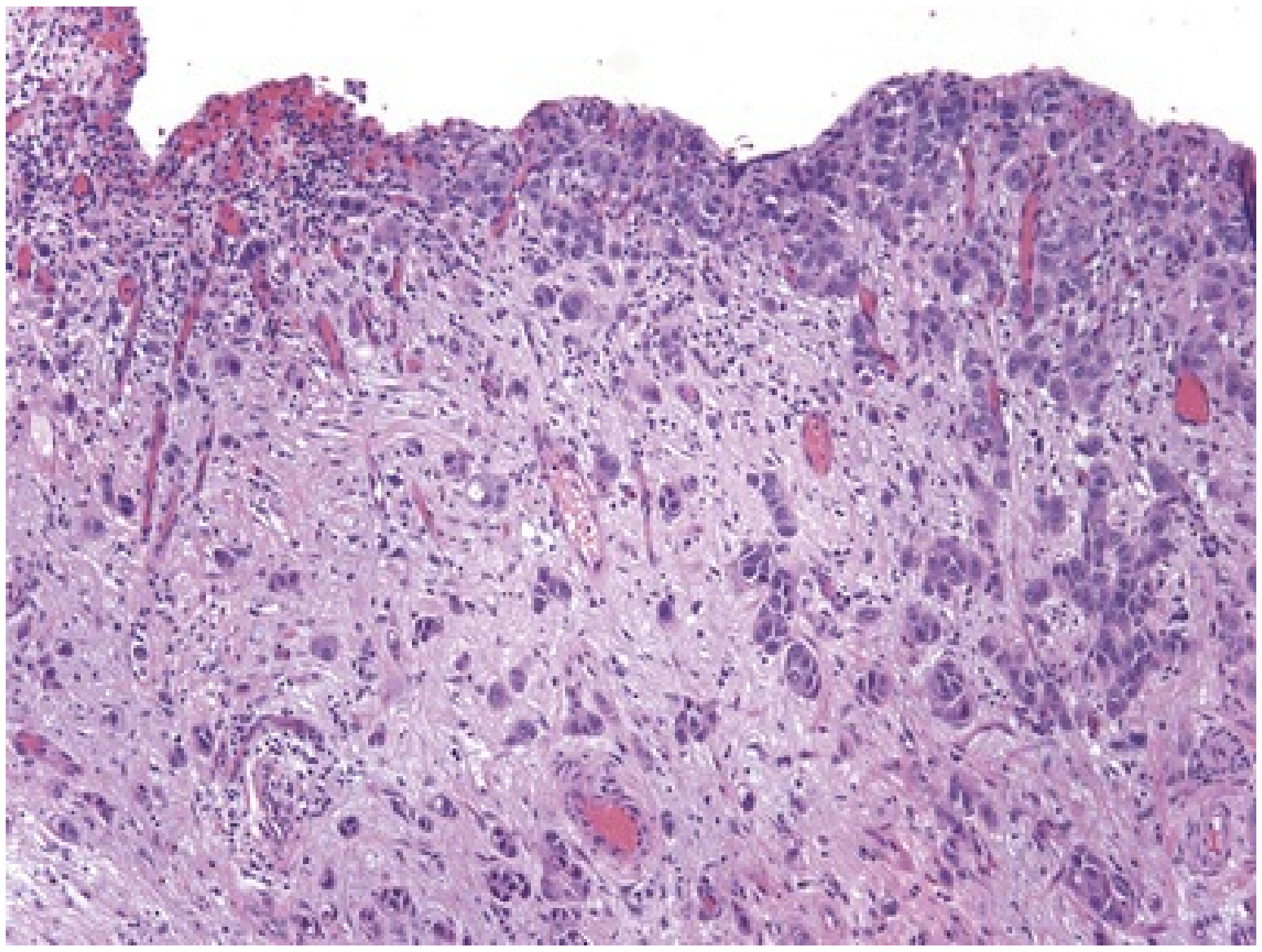

FIG. 135.19 Nested variant of urothelial cancer.

Urothelial Carcinoma With Divergent Differentiation

Urothelial carcinoma with squamous differentiation is present in up to 16% to 22% of patients with bladder cancer, although these may be underestimates, and studies suggest that up to 60% of bladder cancers have squamous elements (Black et al., 2009; Shanks and Iczkowski, 2009). The under-reporting of squamous differentiation and the percent of the tumor involved make it difficult to assess how this divergent histology affects clinical outcomes (Shah et al., 2013). Squamous differentiation is associated with the basal molecular subtype of bladder cancer, which is seen at a more advanced stage and is more focally aggressive (Choi et al., 2014). These tumors may be associated with recurrence and progression for patients with localized and advanced stages (Li et al., 2018; Minato et al., 2017).

Glandular differentiation comprises small tubular or gland-like spaces in otherwise conventional urothelial carcinoma and is present in approximately 10% of patients with urothelial bladder cancer. Similar to squamous differentiation, glandular differentiation is associated with a high stage at presentation and with clinical to pathological upstaging at the time of radical cystectomy; however, their clinical behavior does not appear to be different from conventional urothelial carcinoma, with similar rates of recurrence-free and overall survival (Kim et al., 2012; Mitra et al., 2014).

Nonurothelial Malignancy

Small Cell

Small cell carcinoma (Fig. 135.20) is a rare, poorly differentiated neuroendocrine neoplasm that primarily arises in the lung but can occur in extrapulmonary sites, including the prostate and bladder. Although patients typically are seen with hematuria, there have been reports of paraneoplastic syndromes associated with small cell carcinoma including hypercalcemia, Cushing syndrome, and sensory neuropathy. Small cell carcinoma of the bladder has a high somatic mutational burden driven by an APOBEC-mediated mutational process, and TP53, RB1, and TERT promoter mutations are frequently present (Chang et al., 2018). Evolutionary studies have suggested that small cell carcinoma of the bladder may represent a dedifferentiation from urothelial carcinoma, rather than having a shared lineage from small cell carcinoma of the lung.

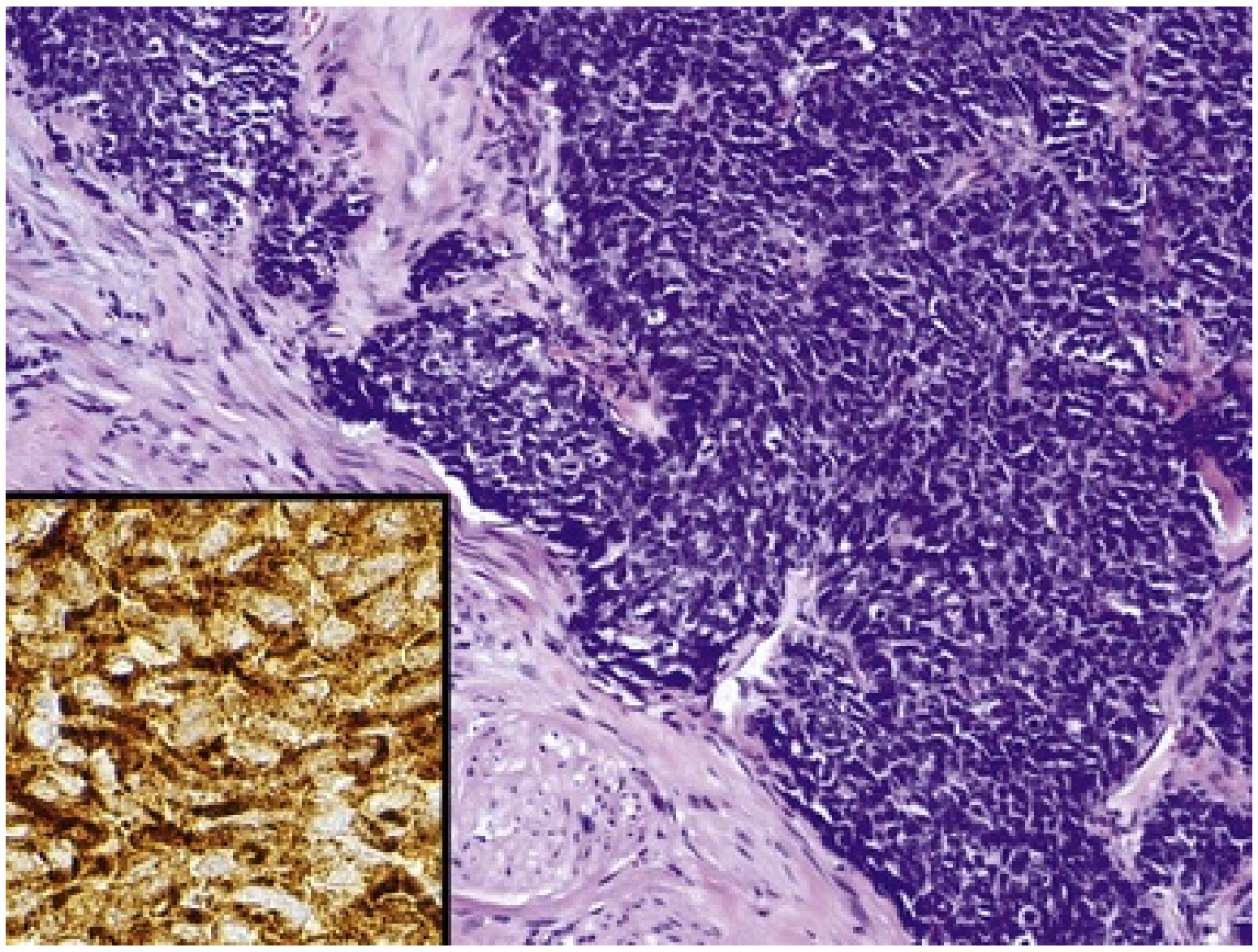

FIG. 135.20 Small cell carcinoma of the bladder. Tumor composed of sheets and nests of basophilic-appearing tumor cells with high nucleocytoplasmic ratio. Histologic features resemble small cell carcinoma seen in the lung. Tumor cells stain and show diffuse and strong immunoreactivity with neuroendocrine markers chromogranin *(inset)* and synaptophysin.

Small cell carcinoma of the bladder is clinically aggressive and chemosensitive. As such, platinum-based chemotherapy is recommended as the initial treatment regardless of the stage of presentation. A variety of chemotherapy regimens have been reported, but cisplatin and etoposide are the current treatment of choice based on the standard regimen for small cell carcinoma of the lung. Siefker-Radtke et al. (2004) reported that patients with primary small cell treated initially with cystectomy observed a 36% 5-year disease-free survival, which was not improved with adjuvant chemotherapy. However, patients who underwent neoadjuvant chemotherapy observed a cancer-specific survival of 78%. However, Kaushik et al. (2015) have demonstrated, in a separate study, that the aggressive features of small cell may be related to a high stage at diagnosis. Further, when matched stage-for-stage, small cell responds similarly to conventional urothelial carcinoma, and there may be a role for adjuvant chemotherapy. In addition, historically small cell was thought to be a nonsurgical entity and most appropriate for chemoradiation, whereas some groups still advocate for trimodal therapy. The combination of chemotherapy with cystectomy is associated with the highest response rates in published series, and further investigation into the safety of chemoradiation in small cell carcinoma is warranted (Bryant et al., 2016; Siefker-Radtke et al., 2004).

Squamous Cell Cancer

Chronic infection with *S. haematobium* or other bacteria leads to SCC of the bladder (Fig. 135.21). In countries with endemic schistosomiasis, SCC thus makes up the majority of bladder cancer and presents a unique growth pattern and treatment algorithm. In the United States and Europe SCC is more uncommon, occurring in 2% to 5% of all bladder cancers (Rausch et al., 2014). The central factor contributing to the development of SCC is chronic inflammation of the urinary tract. Historically patients with spinal cord injury requiring chronic catheterization had an incidence of SCC of 2.3%; however, this incidence rate has declined to 0.39% in contemporary series likely because of the trend toward intermittent self-catheterization. This supports the concept that chronic infection and foreign bodies can lead to bladder cancer formation. Data regarding the carcinogenesis of SCC are largely limited to schistosoma-induced SCC, detailed earlier in this chapter.

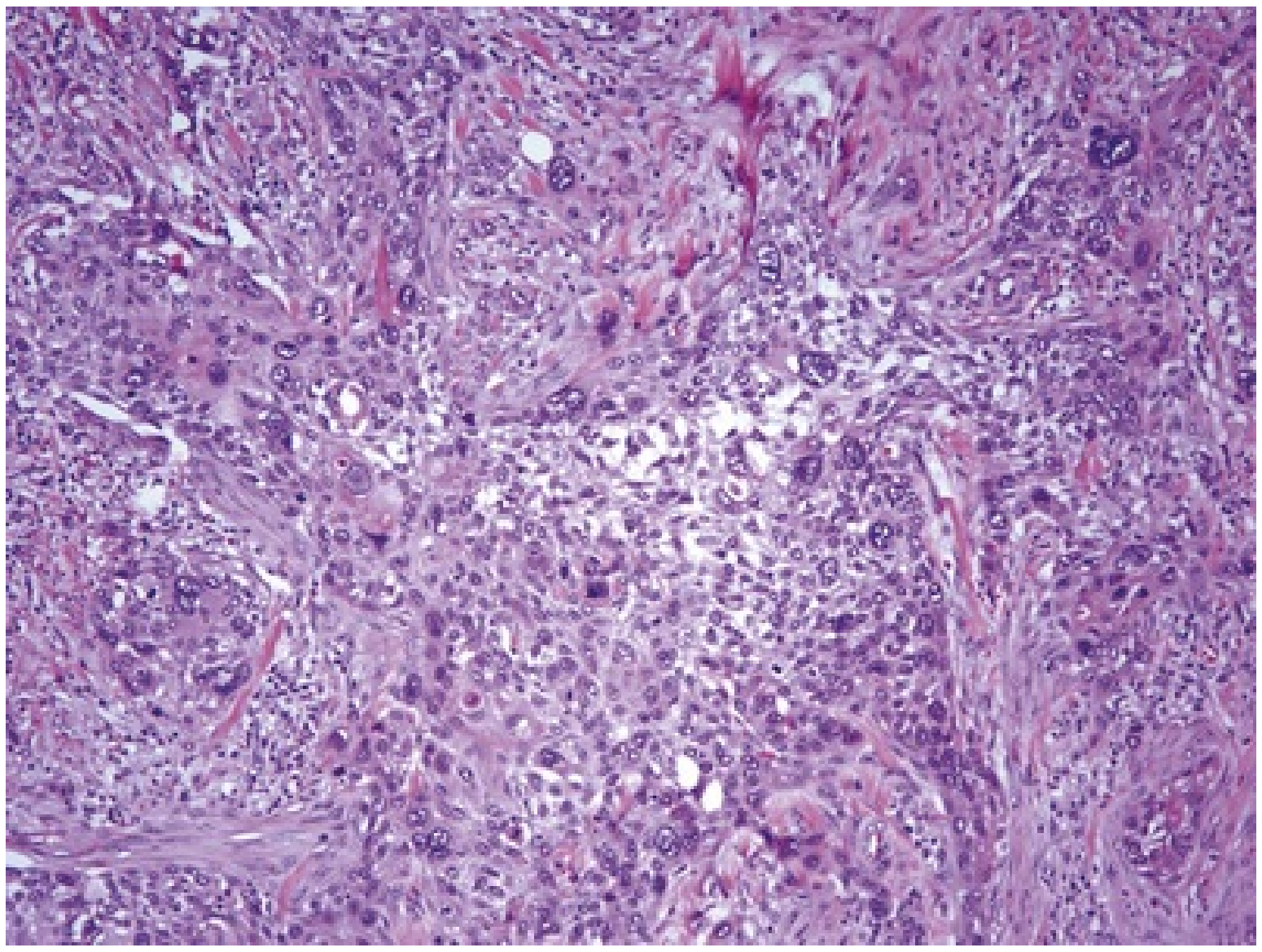

FIG. 135.21 Squamous cell cancer with associated urothelial cancer.

Despite having a lower incidence of nodal and metastatic disease, SCC often is seen initially at more advanced local stages than conventional urothelial carcinoma. Radical cystectomy is the mainstay treatment for SCC, and there is no clear consensus regarding the use of neoadjuvant chemotherapy before surgery. Preoperative radiation therapy was extensively studied in the 1970s and 1980s, but was associated with worse survival outcomes and thus should only be used if the patient is not undergoing cystectomy (Swanson et al 1990; Johnson et al 1976; Costello et al 1984). Adjuvant and intraoperative radiation therapy have also been proposed but there is no clear consensus on how or when it should be used. There is limited data regarding the molecular biology of SCC, particularly that which is not associated with schistosomiasis. Fibroblast growth factor (FGF2) has been shown to be associated with aggressive pathologic features and worse outcomes after radical cystectomy (Youssef et al 2015).

Adenocarcinoma

Adenocarcinoma (Fig. 135.22) may be a primary cancer arising from the bladder urothelium with a pure glandular phenotype, or may be a secondary cancer from a distant metastasis, or more commonly from direct extension from the colon, prostate, endometrium, or cervix. Although the urachus is not an anatomic component of the urinary bladder, urachal adenocarcinomas share similar pathologic and clinical features to bladder adenocarcinoma. Risk factors for adenocarcinoma are a history of bladder exstrophy, schistosomiasis, and chronic irritation or obstruction. Because secondary bladder adenocarcinomas are more common than primary adenocarcinomas, ruling out adenocarcinomas from other organs is recommended. At our center we have our patients undergo a colonoscopy whenever an adenocarcinoma is identified. Most primary bladder adenocarcinomas present with muscle invasive disease, and radical cystectomy is the standard treatment. Currently there is no level 1 data to support the use of chemotherapy or radiation therapy in the neoadjuvant or adjuvant setting. When chemotherapy is delivered the traditional MVAC or GC regimens used for conventional urothelial carcinoma are of little benefit. Often a regimen including 5-flourouracil and cisplatin is used based on experience with adenocarcinoma at other organ sites (Dadhania et al., 2015).

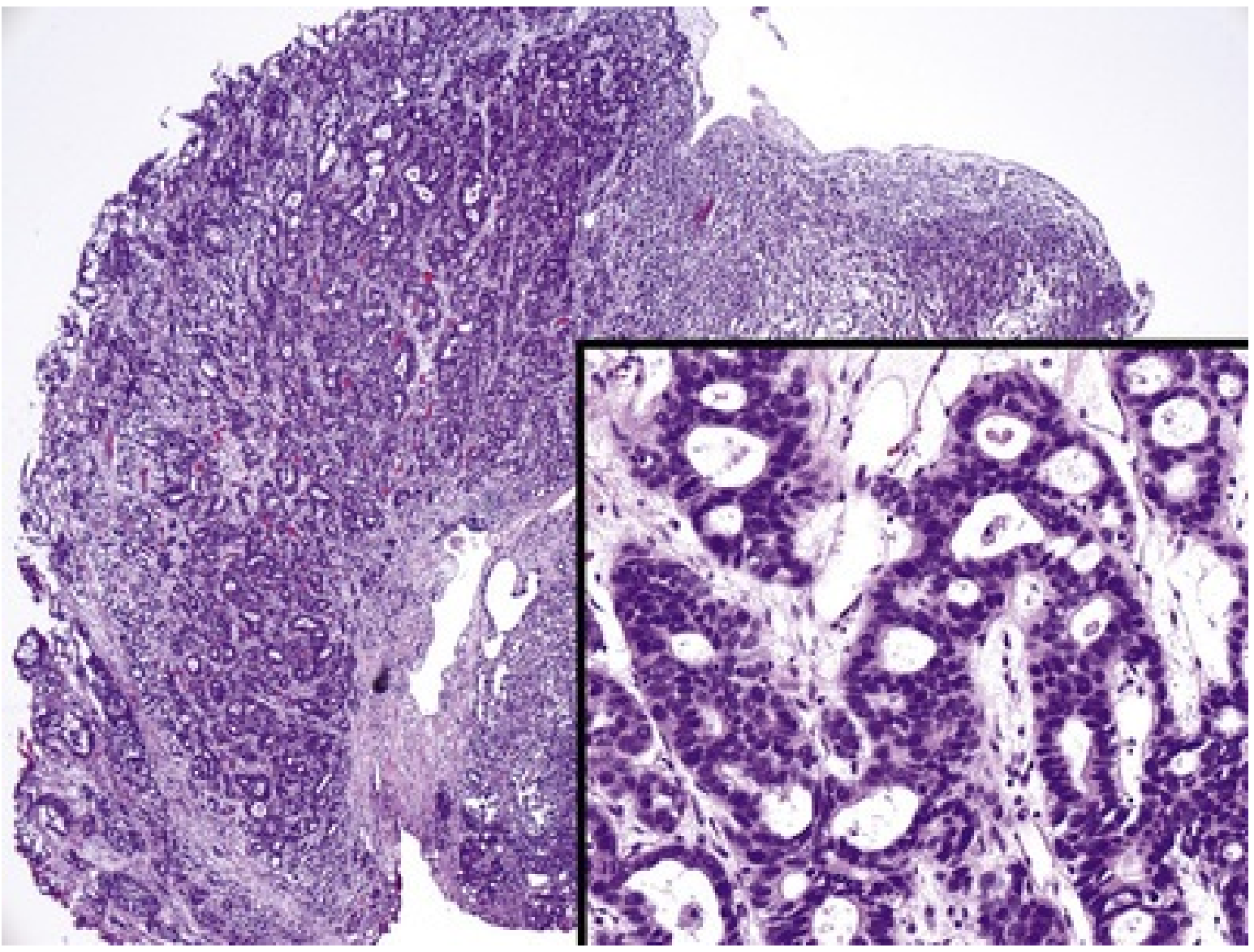

FIG. 135.22 Adenocarcinoma of the bladder. Transurethral resection of the prostate fragment showing extensive involvement by primary bladder adenocarcinoma. Note presence of cribriform and glandular architecture of tumor *(inset).*

Urachal Adenocarcinoma

Urachal adenocarcinoma is a rare cancer, accounting for approximately one-third of all bladder adenocarcinomas, that arises from the allantoic remnant that connects the bladder to the umbilical cord during embryogenesis. Although urachal remnants are typically lined by urothelial cells, urachal cancer is almost always adenocarcinoma in origin. The 2016 WHO classification introduced criteria for the diagnosis of urachal adenocarcinoma based on the work by Gopalan et al. (2009): the tumor should be located in the bladder dome or anterior abdominal wall, with the epicenter of the tumor occurring in the bladder wall; the tumor could not have widespread cystitis cystica, and there should be a thorough investigation for a secondary source for the adenocarcinoma. Urachal adenocarcinomas are difficult to stage using standard TNM staging because nearly all are muscle invasive because of their anatomic location. Staging of urachal carcinoma thus follows the system developed by Sheldon et al. (1984). Stage I tumors are carcinomas confined to the urachal mucosa, stage II tumors are confined to the urachus, stage III tumors are urachal tumors that extend locally into the bladder (IIIA), abdominal wall (IIIB), or peritoneum (IIIC), and stage IV tumors are metastatic (Sheldon et al., 1984). The standard treatment for urachal adenocarcinoma is en bloc resection of the bladder dome, urachal ligament, and umbilicus (Siefker-Radtke et al., 2003).

Key Points

- Eighty percent of urothelial carcinomas contain some mixed differentiation, most commonly squamous cell.
- Altered growth patterns, particularly micropapillary and nested variants, carry a poor prognosis, even for non–muscle-invasive disease.
- Neoadjuvant chemotherapy appears to be active in mixed tumors containing adenocarcinoma or squamous cell cancer but not against altered growth patterns such as in micropapillary and nested urothelial cancer.
- Small cell carcinoma of the bladder should be treated as metastatic disease with institution of chemotherapy followed by either radiation therapy or surgery for elimination of the local disease.

References

Ahmad I, Morton JP, Singh LB, et al. β-Catenin activation synergizes with PTEN loss to cause bladder cancer formation. *Oncogene*. 2011;30:178–189.

Al-Ahmadie HA, Iyer G, Lee BH, et al. Frequent somatic CDH1 loss-of-function mutations in plasmacytoid variant bladder cancer. *Nat Genet*. 2016;48:356–358.

Alishahi S, Byrne D, Goodman CM, et al. Haematuria investigation based on a standard protocol: emphasis on the diagnosis of urological malignancy. *J R Coll Surg Edinb*. 2002;47:422–427.

Al-Zalabani AH, Stewart KFJ, Wesselius A, et al. Modifiable risk factors for the prevention of bladder cancer: a systematic review of meta-analyses. *Eur J Epidemiol*. 2016;31:811–851.

American Cancer Society. *Cancer facts & figures 2017*. [website] https://www.cancer.org/research/cancer-facts-statistics/all-cancer-facts-figures/cancer-facts-figures-2017.html; 2017.

American Urological Association. *Five more things physicians and patients should question. Choosing Wisely*. [website] http://www.choosingwisely.org/wp-content/uploads/2015/02/AUA-Choosing-Wisely-List.pdf; 2015.

Amin MB, Edge SB. *American Joint Committee on Cancer. AJCC cancer staging manual*. 8th ed. Springer International Publishing; 2017.

Amin MB, Ro JY, el-Sharkawy T, et al. Micropapillary variant of transitional cell carcinoma of the urinary bladder. Histologic pattern resembling ovarian papillary serous carcinoma. *Am J Surg Pathol*. 1994;18:1224–1232.

Amin MB. Histological variants of urothelial carcinoma:

diagnostic, therapeutic and prognostic implications. *Mod Pathol*. 2009;22:96–118.

Antoni S, Ferlay J, Soerjomataram I, et al. Bladder cancer incidence and mortality: a global overview and recent trends. *Eur Urol*. 2017;71:96–108.

Armstrong AB, Wang M, Eble JN, et al. TP53 mutational analysis supports monoclonal origin of biphasic sarcomatoid urothelial carcinoma (carcinosarcoma) of the urinary bladder. *Mod Pathol*. 2009;22:113–118.

Aydin Mungan N, Kiemeney LALM, Van Dijck JAAM, et al. Gender differences in stage distribution of bladder cancer. *Urology*. 2000;55(3):368–371.

Badalato G, Patel T, Hruby G, et al. Does the presence of muscularis propria on transurethral resection of bladder tumour specimens affect the rate of upstaging in cT1 bladder cancer? *BJU Int*. 2011;108:1292–1296.

Bagnardi V, Rota M, Botteri E, et al. Alcohol consumption and site-specific cancer risk: a comprehensive dose–response meta-analysis. *Br J Cancer*. 2015;112:580–593.

Bai Y, Ni M, Cooper B, et al. Claudin-low bladder tumors are immune infiltrated and actively immune suppressed. *BMC Genomics*. 2016;15.

Baithun SI, Rogers HS, Martin JE, et al. Primary dysplasia of bladder. *Lancet*. 1988;1:483.

Beltran AL, Cheng L, Montironi R, et al. Clinicopathological characteristics and outcome of nested carcinoma of the urinary bladder. *Virchows Arch*. 2014;465:199–205.

Benson RC, Swanson SK, Farrow GM. Relationship of leukoplakia to urothelial malignancy. *J Urol*. 1984;131:507–511.

Bernardo C, Cunha MC, Santos JH, et al. Insight into the molecular basis of Schistosoma haematobium-induced bladder cancer through urine proteomics. *Tumor Biol*.

2016;37:11279–11287.

Black PC, Brown GA, Dinney CPN. The impact of variant histology on the outcome of bladder cancer treated with curative intent. *Urol Oncol*. 2009;27:3–7.

Boice JD, Day NE, Andersen A, et al. Second cancers following radiation treatment for cervical cancer. An international collaboration among cancer registries. *J Natl Cancer Inst*. 1985;74:955–975.

Bray F, Ren JS, Masuyer E, et al. Global estimates of cancer prevalence for 27 sites in the adult population in 2008. *Int J Cancer*. 2013;132:1133–1145.

Breen V, Kasabov N, Kamat AM, et al. A holistic comparative analysis of diagnostic tests for urothelial carcinoma: a study of Cxbladder Detect, UroVysion® FISH, NMP22® and cytology based on imputation of multiple datasets. *BMC Med Res Methodol*. 2015;15:45.

Bryant CM, Dang LH, Stechmiller BK, et al. Treatment of small cell carcinoma of the bladder with chemotherapy and radiation after transurethral resection of a bladder tumor. *Am J Clin Oncol*. 2016;39:69–75.

Burger M, Catto JWF, Dalbagni G, et al. Epidemiology and risk factors of urothelial bladder cancer. *Eur Urol*. 2013;63:234–241.

Burger M, Grossman HB, Droller M, et al. Photodynamic diagnosis of non–muscle-invasive bladder cancer with hexaminolevulinate cystoscopy: a meta-analysis of detection and recurrence based on raw data. *Eur Urol*. 2013;64:846–854.

Buteau A, Seideman CA, Svatek RS, et al. What is evaluation of hematuria by primary care physicians? Use of electronic medical records to assess practice patterns with intermediate follow-up. *Urol Oncol*. 2014;32:128–134.

Cancer Genome Atlas Research Network TCGAR.

Comprehensive molecular characterization of urothelial bladder carcinoma. *Nature*. 2014;507:315–322.

Cappellen D, De Oliveira C, Ricol D, et al. Frequent activating mutations of FGFR3 in human bladder and cervix carcinomas. *Nat Genet*. 1999;23:18–20.

Chang MT, Penson A, Desai NB, et al. Small-cell carcinomas of the bladder and lung are characterized by a convergent but distinct pathogenesis. *Clin Cancer Res*. 2018;24:1965–1973.

Chappidi MR, Kates M, Tosoian JJ, et al. Evaluation of gender-based disparities in time from initial haematuria presentation to upper tract urothelial carcinoma diagnosis: analysis of a nationwide insurance claims database. *BJU Int*. 2017;120.

Cheng L, Cheville JC, Neumann RM, et al. Flat intraepithelial lesions of the urinary bladder. *Cancer*. 2000;88:625–631.

Cheng L, Cheville JC, Neumann RM, et al. Natural history of urothelial dysplasia of the bladder. *Am J Surg Pathol*. 1999;23:443–447.

Choi JB, Lee EJ, Han K-D, et al. Estimating the impact of body mass index on bladder cancer risk: stratification by smoking status. *Sci Rep*. 2018;8:947.

Choi W, Porten S, Kim S, et al. Identification of distinct basal and luminal subtypes of muscle-invasive bladder cancer with different sensitivities to frontline chemotherapy. *Cancer Cell*. 2014;25:152–165.

Chou R, Gore JL, Buckley D, et al. Urinary biomarkers for diagnosis of bladder cancer a systematic review and meta-analysis. *Ann Intern Med*. 2015;163(12):922–932.

Chrouser K, Leibovich B, Bergstralh E, et al. Bladder cancer risk following primary and adjuvant external beam radiation for prostate cancer. *J Urol*. 2005;174:107–110.

Cohn JA, Vekhter B, Lyttle C, et al. Sex disparities in diagnosis of bladder cancer after initial presentation with hematuria: a nationwide claims-based investigation. *Cancer*.

2014;120:555–561.

Costello AJ, Tiptaft RC, England HR, et al. Squamous cell carcinoma of bladder. *Urology*. 1984;23:234–236.

Cowan ML, Rosenthal DL, VandenBussche CJ. Improved risk stratification for patients with high-grade urothelial carcinoma following application of the Paris System for Reporting Urinary Cytology. *Cancer Cytopathol*. 2017;125:427–434.

Cumberbatch MG, Rota M, Catto JWF, et al. The role of tobacco smoke in bladder and kidney carcinogenesis: a comparison of exposures and meta-analysis of incidence and mortality risks. *Eur Urol*. 2016;70:458–466.

Cumberbatch MGK, Cox A, Teare D, et al. Contemporary occupational carcinogen exposure and bladder cancer. *JAMA Oncol*. 2015;1:1282.

Curtis S. *MIlken Institute 2016 Report on Bladder Cancer*. [MIlken Inst] 2016.

Czerniak B, Dinney C, McConkey D. Origins of bladder cancer. *Annu Rev Pathol*. 2016;11:149–174.

Dadhania V, Czerniak B, Guo CC. Adenocarcinoma of the urinary bladder. *Am J Clin Exp Urol*. 2015;3:51–63.

Damrauer JS, Hoadley KA, Chism DD, et al. Intrinsic subtypes of high-grade bladder cancer reflect the hallmarks of breast cancer biology. *Proc Natl Acad Sci U S A*. 2014;111:3110–3115.

Daneshmand S, Patel S, Lotan Y, et al. Efficacy and Safety of blue light flexible cystoscopy with hexaminolevulinate in the surveillance of bladder cancer: a Phase III, Comparative, multicenter study. *J Urol*. 2018;199:1158–1165.

Daugherty SE, Lacey JV, Pfeiffer RM, et al. Reproductive factors and menopausal hormone therapy and bladder cancer risk in the NIH-AARP Diet and Health Study. *Int J Cancer*. 2013;133:462–472.

Davis R, Jones JS, Barocas DA, et al. Diagnosis, evaluation and follow-up of asymptomatic microhematuria (AMH) in adults: AUA Guideline. *J Urol*. 2012;188:2473–2481.

Dayyani F, Czerniak BA, Sircar K, et al. Plasmacytoid urothelial carcinoma, a chemosensitive cancer with poor prognosis, and peritoneal carcinomatosis. *J Urol*. 2013;189:1656–1661.

Dinney CPN, McConkey DJ, Millikan RE, et al. Focus on bladder cancer. *Cancer Cell*. 2004;6:111–116.

Donat SM, Genega EM, Herr HW, et al. Mechanisms of prostatic stromal invasion in patients with bladder cancer: clinical significance. *J Urol*. 2001;165:1117–1120.

Dy GW, Gore JL, Forouzanfar MH, et al. Global burden of urologic cancers, 1990-2013. *Eur Urol*. 2017;71:437–446.

Edwards TJ, Dickinson AJ, Natale S, et al. A prospective analysis of the diagnostic yield resulting from the attendance of 4020 patients at a protocol-driven haematuria clinic. *BJU Int*. 2006;97:301–305.

Esrig D, Freeman JA, Elmajian DA, et al. Transitional cell carcinoma involving the prostate with a proposed staging classification for stromal invasion. *J Urol*. 1996;156:1071–1076.

Faurschou M, Mellemkjaer L, Voss A, et al. Prolonged risk of specific malignancies following cyclophosphamide therapy among patients with granulomatosis with polyangiitis. *Rheumatology*. 2015;54:1345–1350.

Ferlay J, Soerjomataram I, Ervik M, et al. *GLOBOCAN 2012 v1.1, Cancer Incidence and Mortality Worldwide: IARC CancerBase No. 11 [Internet]*. [Lyon, Fr. Int. Agency Res. Cancer; Available from:] http://globocan.iarc.fr; 2014.

Ferlay J, Steliarova-Foucher E, Lortet-Tieulent J, et al. Cancer incidence and mortality patterns in Europe: estimates for 40 countries in 2012. *Eur J Cancer*. 2013;49:1374–1403.

Fitzmaurice C, Allen C, Barber RM, et al. Global, regional, and national cancer incidence, mortality, years of life lost, years lived with disability, and disability-adjusted life-years for 32 cancer groups, 1990 to 2015. *JAMA Oncol*. 2017;3:524.

Garcia-Closas M, Malats N, Silverman D, et al. NAT2 slow acetylation, GSTM1 null genotype, and risk of bladder cancer: results from the Spanish Bladder Cancer Study and meta-analyses. *Lancet*. 2005;366:649–659.

Garg T, Pinheiro LC, Atoria CL, et al. Gender disparities in hematuria evaluation and bladder cancer diagnosis: a population based analysis. *J Urol*. 2014;192:1072–1077.

Gildea JJ, Herlevsen M, Harding MA, et al. PTEN can inhibit in vitro organotypic and in vivo orthotopic invasion of human bladder cancer cells even in the absence of its lipid phosphatase activity. *Oncogene*. 2004;23:6788–6797.

Golka K, Reckwitz T, Kempkes M, et al. *N* -Acetyltransferase 2 (NAT2) and Glutathione S-Transferase μ (GSTM1) in bladder-cancer patients in a highly industrialized area. *Int J Occup Environ Health*. 1997;3:105–110.

Gopalan A, Sharp DS, Fine SW, et al. Urachal carcinoma. *Am J Surg Pathol*. 2009;33:659–668.

Gronau S, Menz CK, Melzner I, et al. Immunohistomorphologic and molecular cytogenetic analysis of a carcinosarcoma of the urinary bladder. *Virchows Arch*. 2002;440:436–440.

Grossfeld GD, Litwin MS, Wolf JS, et al. Evaluation of asymptomatic microscopic hematuria in adults: the American Urological Association best practice policy–part II: patient evaluation, cytology, voided markers, imaging, cystoscopy, nephrology evaluation, and follow-up. *Urology*. 2001;57:604–610.

Guo CC, Dadhania V, Zhang L, et al. Gene expression profile of the clinically aggressive micropapillary variant of bladder cancer. *Eur Urol*. 2016;70:611–620.

Hall EJ, Wuu C-S. Radiation-induced second cancers: the impact of 3D-CRT and IMRT. *Int J Radiat Oncol Biol Phys*. 2003;56:83–88.

Hartge P, Harvey EB, Linehan WM, et al. Unexplained excess risk of bladder cancer in men. *J Natl Cancer Inst*. 1990;82:1636–1640.

Health NC for CDP and HP (US) O on S and. *The Health Consequences of Smoking—50 Years of Progress [Internet]. Heal. Consequences Smoking—50 Years Prog. A Rep. Surg. Gen*. [Centers for Disease Control and Prevention (US); website] http://www.ncbi.nlm.nih.gov/pubmed/24455788; 2014.

Hemelt M, Yamamoto H, Cheng KK, et al. The effect of smoking on the male excess of bladder cancer: a meta-analysis and geographical analyses. *Int J Cancer*. 2009;124:412–419.

Ho C-H, Sung K-C, Lim S-W, et al. Chronic indwelling urinary catheter increase the risk of bladder cancer, even in patients without spinal cord injury. *Medicine (Baltimore)*. 2015;94:e1736.

Hodges KB, Lopez-Beltran A, Davidson DD, et al. Urothelial dysplasia and other flat lesions of the urinary bladder: clinicopathologic and molecular features. *Hum Pathol*. 2010;41:155–162.

Holyoake A, O'Sullivan P, Pollock R, et al. Development of a multiplex RNA urine test for the detection and stratification of transitional cell carcinoma of the bladder. *Clin Cancer Res*. 2008;14:742–749.

Isharwal S, Huang H, Nanjangud G, et al. Intratumoral heterogeneity of ERBB2 amplification and HER2 expression in micropapillary urothelial carcinoma. *Hum Pathol*. 2018;77:63–69.

Islami F, Stoklosa M, Drope J, et al. Global and regional patterns of tobacco smoking and tobacco control policies. *Eur Urol Focus*. 2015;1:3–16.

Jamal A, King BA, Neff LJ, et al. Current cigarette smoking among adults — United States, 2005–2015. *MMWR Morb Mortal Wkly Rep*. 2016;65:1205–1211.

Jiang X, Castelao JE, Groshen S, et al. Urinary tract infections and reduced risk of bladder cancer in Los Angeles. *Br J Cancer*. 2009;100:834–839.

Johansson SL, Borghede G, Holmäng S. Micropapillary bladder carcinoma: a clinicopathological study of 20 cases. *J Urol*. 1999;161:1798–1802.

Johnson AM, O'Connell MJ, Miyamoto H, et al. Androgenic dependence of exophytic tumor growth in a transgenic mouse model of bladder cancer: a role for thrombospondin-1. *BMC Urol*. 2008;8.

Johnson DE, Schoenwald MB, Ayala AG, et al. Squamous cell carcinoma of the bladder. *J Urol*. 1976;115:542–544.

Kaimakliotis HZ, Monn MF, Cheng L, et al. Plasmacytoid bladder cancer: variant histology with aggressive behavior and a new mode of invasion along fascial planes. *Urology*. 2014;83:1112–1116.

Kamat AM, Dinney CPN, Gee JR, et al. Micropapillary bladder cancer. *Cancer*. 2007;110:62–67.

Kamat AM, Witjes JA, Brausi M, et al. Defining and treating the spectrum of intermediate risk nonmuscle invasive bladder cancer. *J Urol*. 2014;192:305–315.

Karagas MR, Park S, Warren A, et al. Gender, smoking, glutathione-S-transferase variants and bladder cancer incidence: a population-based study. *Cancer Lett*. 2005;219(1):63–69.

Karakiewicz PI, Benayoun S, Zippe C, et al. Institutional variability in the accuracy of urinary cytology for predicting recurrence of transitional cell carcinoma of the bladder. *BJU*

Int. 2006;97:997–1001.

Kates M, Chappidi MR, Brant A, et al. High dose-rate intra-operative radiation therapy during high risk genitourinary surgery: initial observations and a proposal for its study in bladder cancer. *Bladder Cancer*. 2017;3:191–199.

Kaushik D, Frank I, Boorjian SA, et al. Long-term results of radical cystectomy and role of adjuvant chemotherapy for small cell carcinoma of the bladder. *Int J Urol*. 2015;22:549–554.

Kavalieris L, O'Sullivan PJ, Suttie JM, et al. A segregation index combining phenotypic (clinical characteristics) and genotypic (gene expression) biomarkers from a urine sample to triage out patients presenting with hematuria who have a low probability of urothelial carcinoma. *BMC Urol*. 2015;15:23.

Khadra MH, Pickard RS, Charlton M, et al. A prospective analysis of 1,930 patients with hematuria to evaluate current diagnostic practice. *J Urol*. 2000;163:524–527.

Kiemeney LALM. Hereditary bladder cancer. *Scand J Urol Nephrol*. 2008;42:110–115.

Kim PH, Sukhu R, Cordon BH, et al. Reflex fluorescence *in situ* hybridization assay for suspicious urinary cytology in patients with bladder cancer with negative surveillance cystoscopy. *BJU Int*. 2014;114(3):354–359.

Kim SP, Frank I, Cheville JC, et al. The impact of squamous and glandular differentiation on survival after radical cystectomy for urothelial carcinoma. *J Urol*. 2012;188:405–409.

Kleinerman RA, Boice JD, Storm HH, et al. Second primary cancer after treatment for cervical cancer. An international cancer registries study. *Cancer*. 1995;76:442–452.

Knowles MA, Hurst CD. Molecular biology of bladder cancer: new insights into pathogenesis and clinical diversity. *Nat Rev*

Cancer. 2015;15:25–41.

Koebnick C, Michaud D, Moore SC, et al. Body mass index, physical activity, and bladder cancer in a large prospective study. *Cancer Epidemiol Biomarkers Prev*. 2008;17:1214–1221.

Koshiaris C, Aveyard P, Oke J, et al. Smoking cessation and survival in lung, upper aero-digestive tract and bladder cancer: cohort study. *Br J Cancer*. 2017;117:1224–1232.

Kunju LP, Lee CT, Montie J, et al. Utility of cytokeratin 20 and Ki-67 as markers of urothelial dysplasia. *Pathol Int*. 2005;55:248–254.

Leal J, Luengo-Fernandez R, Sullivan R, et al. Economic burden of bladder cancer across the European Union. *Eur Urol*. 2016;69:438–447.

Li G, Hu J, Niu Y. Squamous differentiation in pT1 bladder urothelial carcinoma predicts poor response for intravesical chemotherapy. *Oncotarget*. 2018;9:217–223.

Li P, Chen J, Miyamoto H. Androgen receptor signaling in bladder cancer. *Cancers (Basel)*. 2017;9(2) http://www.ncbi.nlm.nih.gov/pubmed/28241422 [(online journal)].

Linder BJ, Frank I, Cheville JC, et al. Outcomes following radical cystectomy for nested variant of urothelial carcinoma: a matched cohort analysis. *J Urol*. 2013;189:1670–1675.

Liu J-J, Jones JS, Rao PK. Urinalysis in the evaluation of hematuria. *J Am Med Assoc*. 2016;315:2726.

Longo TA, Brousell SC, Inman BA. Urine cytology and existing urinary biomarkers for bladder cancer. Hansel D, Lerner S. *Precision molecular pathology of bladder cancer*. Springer: Switzerland; 2018:137–155.

Lopez-Beltran A, Requena MJ, Montironi R, et al. Plasmacytoid urothelial carcinoma of the bladder. *Hum Pathol*. 2009;40:1023–1028.

Lopez-Knowles E, Hernández S, Malats N, et al. PIK3CA Mutations are an early genetic alteration associated with FGFR3 mutations in superficial papillary bladder tumors. *Cancer Res*. 2006;66:7401–7404.

Lough T, Luo Q, O'Sullivan P, et al. Clinical utility of Cxbladder Monitor for patients with a history of urothelial carcinoma: a physician–patient real-world clinical data analysis. *Oncol Ther*. 2018;1–13 http://link.springer.com/10.1007/s40487-018-0059-5 [(online journal)].

Majewski T, Lee S, Jeong J, et al. Understanding the development of human bladder cancer by using a whole-organ genomic mapping strategy. *Lab Invest*. 2008;88:694–721.

Malats N, Real FX. Epidemiology of bladder cancer. *Hematol Oncol Clin North Am*. 2015;29:177–189.

Maxwell JP, Wang C, Wiebe N, et al. Long-term outcome of primary papillary urothelial neoplasm of low malignant potential (PUNLMP) including PUNLMP with inverted growth. *Diagn Pathol*. 2015;10:3.

McBride OW, Swan DC, Santos E, et al. Localization of the normal allele of T24 human bladder carcinoma oncogene to chromosome 11. *Nature*. 1982;300:773–774.

Messing EM, Teot L, Korman H, et al. Performance of urine test in patients monitored for recurrence of bladder cancer: a multicenter study in the United States. *J Urol*. 2005;174:1238–1241.

Michaud DS, Platz EA, Giovannucci E. Gonorrhoea and male bladder cancer in a prospective study. *Br J Cancer*. 2007;96:169–171.

Minato A, Fujimoto N, Kubo T. Squamous differentiation predicts poor response to cisplatin-based chemotherapy and unfavorable prognosis in urothelial carcinoma of the urinary bladder. *Clin Genitourin Cancer*. 2017;15:1063–1067.

Mitra AP, Bartsch CC, Bartsch G, et al. Does presence of squamous and glandular differentiation in urothelial carcinoma of the bladder at cystectomy portend poor prognosis? An intensive case-control analysis. *Urol Oncol*. 2014;32:117–127.

Miyamoto H, Yang Z, Chen Y-T, et al. Promotion of bladder cancer development and progression by androgen receptor signals. *J Natl Cancer Inst*. 2007;99:558–568.

Montironi R, Lopez-Beltran A, Scarpelli M, et al. 2004 World Health Organization classification of the noninvasive urothelial neoplasms: inherent problems and clinical reflections. *Eur Urol Suppl*. 2009;8(5):453–457.

Montironi R, Lopez-Beltran A. The 2004 WHO Classification of bladder tumors: a summary and commentary. *Int J Surg Pathol*. 2005;13:143–153.

Moschini M, D'Andrea D, Korn S, et al. Characteristics and clinical significance of histological variants of bladder cancer. *Nat Rev Urol*. 2017;14:651–668.

Moschini M, Dell'Oglio P, Luciano R, et al. Incidence and effect of variant histology on oncological outcomes in patients with bladder cancer treated with radical cystectomy. *Urol Oncol*. 2017;35:335–341.

Mungan M, Canda A, Tuzel E, et al. Risk Factors for mucosal prostatic urethral involvement in superficial transitional cell carcinoma of the bladder. *Eur Urol*. 2005;48:760–763.

Naito S, Algaba F, Babjuk M, et al. The Clinical Research Office of the Endourological Society (CROES) multicentre randomised trial of narrow band imaging–assisted transurethral resection of bladder tumour (TURBT) versus conventional white light imaging–assisted TURBT in primary non–muscle-invasive bladder cancer patients: trial protocol and 1-year results. *Eur Urol*. 2016;70:506–515.

Network TCGAR. Comprehensive molecular characterization of urothelial bladder carcinoma. *Nature*. 2014;507:315–322.

Nieder AM, Porter MP, Soloway MS. Radiation therapy for prostate cancer increases subsequent risk of bladder and rectal cancer: a population based cohort study. *J Urol*. 2008;180:2005–2010.

O'Sullivan P, Sharples K, Dalphin M, et al. A multigene urine test for the detection and stratification of bladder cancer in patients presenting with hematuria. *J Urol*. 2012;188:741–747.

Ozbey I, Aksoy Y, Polat Ö, et al. Squamous metaplasia of the bladder: findings in 14 patients and review of the literature. *Int Urol Nephrol*. 1999;31:457–461.

Paner GP, Stadler WM, Hansel DE, et al. Updates in the eighth edition of the tumor-node-metastasis staging classification for urologic cancers. *Eur Urol*. 2018;73:560–569.

Planz B, Jochims E, Deix T, et al. The role of urinary cytology for detection of bladder cancer. *Eur J Surg Oncol*. 2005;31:304–308.

Platt FM, Hurst CD, Taylor CF, et al. Spectrum of phosphatidylinositol 3-kinase pathway gene alterations in bladder cancer. *Clin Cancer Res*. 2009;15:6008–6017.

Pode D, Shapiro A, Wald M, et al. Noninvasive detection of bladder cancer with the BTA stat test. *J Urol*. 1999;161:443–446.

Puzio-Kuter AM, Castillo-Martin M, Kinkade CW, et al. Inactivation of p53 and Pten promotes invasive bladder cancer. *Genes Dev*. 2009;23:675–680.

Raitanen M-P, Aine R, Rintala E, et al. Differences between local and review urinary cytology in diagnosis of bladder cancer. an interobserver multicenter analysis. *Eur Urol*. 2002;41:284–289.

Rausch S, Lotan Y, Youssef RF. Squamous cell carcinogenesis and squamous cell carcinoma of the urinary bladder: a contemporary review with focus on nonbilharzial squamous cell carcinoma. *Urol Oncol*. 2014;32:32.e11–32.e16.

Ricardo-Gonzalez RR, Nguyen M, Gokden N, et al. Plasmacytoid carcinoma of the bladder: a urothelial carcinoma variant with a predilection for intraperitoneal spread. *J Urol*. 2012;187:852–855.

Rieder JMD, Parsons JK, Gearhart JP, et al. Primary squamous cell carcinoma in unreconstructed exstrophic bladder. *Urology*. 2006;67:199.e1–199.e2.

Rodriguez Pena MDC, Tregnago AC, Eich M-L, et al. Spectrum of genetic mutations in de novo PUNLMP of the urinary bladder. *Virchows Arch*. 2017;471:761–767.

Ros MM, Bas Bueno-de-Mesquita HB, Büchner FL, et al. Fluid intake and the risk of urothelial cell carcinomas in the European Prospective Investigation into Cancer and Nutrition (EPIC). *Int J Cancer*. 2011;128:2695–2708.

Rosenthal DL, Wojcik EM, Kurtycz DFI. *The Paris System for reporting urinary cytology*. [Springer Nature; website] https://link.springer.com/content/pdf/10.1007/978-3-319-22864-8.pdf; 2017.

Ross JS, Wang K, Gay LM, et al. A high frequency of activating extracellular domain ERBB2 (HER2) mutation in micropapillary urothelial carcinoma. *Clin Cancer Res*. 2014;20:68–75.

Roswall N, Olsen A, Christensen J, et al. Micronutrient intake and risk of urothelial carcinoma in a prospective Danish Cohort. *Eur Urol*. 2009;56:764–770.

Rushton L, Bagga S, Bevan R, et al. Occupation and cancer in Britain. *Br J Cancer*. 2010;102:1428–1437.

Sanchez-Carbayo M, Socci ND, Charytonowicz E, et al. Molecular profiling of bladder cancer using cDNA microarrays: defining histogenesis and biological phenotypes.

Cancer Res. 2002;62:6973–6980.

Sauter G. *Tumors of the urinary system in: World Health Organisation classification of tumors*. [Pathol Genet Tumors Urin Syst Male Genit Organs] 2004:110–123.

Scosyrev E, Golijanin D, Wu G, et al. The burden of bladder cancer in men and women: analysis of the years of life lost. *BJU Int*. 2012;109:57–62.

Scosyrev E, Noyes K, Feng C, et al. Sex and racial differences in bladder cancer presentation and mortality in the US. *Cancer*. 2009;115:68–74.

Semins MJ, Schoenberg MP. A case of florid cystitis glandularis. *Nat Clin Pract Urol*. 2007;4:341–345.

Shah RB, Montgomery JS, Montie JE, et al. Variant (divergent) histologic differentiation in urothelial carcinoma is under-recognized in community practice: impact of mandatory central pathology review at a large referral hospital. *Urol Oncol*. 2013;31:1650–1655.

Shanks JH, Iczkowski KA. Divergent differentiation in urothelial carcinoma and other bladder cancer subtypes with selected mimics. *Histopathology*. 2009;54:885–900.

Sheldon CA, Clayman RV, Gonzalez R, et al. Malignant urachal lesions. *J Urol*. 1984;131:1–8.

Siefker-Radtke AO, Dinney CP, Abrahams NA, et al. Evidence supporting preoperative chemotherapy for small cell carcinoma of the bladder: a retrospective review of the M. D. Anderson cancer experience. *J Urol*. 2004;172:481–484.

Siefker-Radtke AO, Gee J, Shen YU, et al. Multimodality management of urachal carcinoma: the M. D. Anderson Cancer Center Experience. *J Urol*. 2003;169:1295–1298.

Siegel RL, Miller KD, Jemal A. Cancer statistics, 2018. *CA Cancer J Clin*. 2018;68:7–30.

Sjodahl G, Lauss M, Lövgren K, et al. A molecular taxonomy for urothelial carcinoma. *Clin Cancer Res*. 2012;18:3377.

Smeulders N, Woodhouse CR. Neoplasia in adult exstrophy patients. *BJU Int*. 2001;87:623–628.

Sokolova IA, Halling KC, Jenkins RB, et al. The development of a multitarget, multicolor fluorescence in situ hybridization assay for the detection of urothelial carcinoma in urine. *J Mol Diagn*. 2000;2:116–123.

Staack A, Schlechte H, Sachs M, et al. Clinical value of vesical leukoplakia and evaluation of the neoplastic risk by mutation analyses of the tumor suppressor gene TP53. *Int J Urol*. 2006;13:1092–1097.

Sun J-W, Zhao L-G, Yang Y, et al. Obesity and risk of bladder cancer: a dose-response meta-analysis of 15 cohort studies. *PLoS ONE*. 2015 [(Website):] http://dx.plos.org/10.1371/journal.pone.0119313 [Koul HK, editor, Public Library of Science].

Svatek RS, Hollenbeck BK, Holmäng S, et al. The economics of bladder cancer: costs and considerations of caring for this disease. *Eur Urol*. 2014;66:253–262.

Svatek RS, Shariat SF, Novara G, et al. Discrepancy between clinical and pathological stage: external validation of the impact on prognosis in an international radical cystectomy cohort. *BJU Int*. 2010;107:898–904.

Swanson DA, Liles A, Zagars GK. Preoperative irradiation and radical cystectomy for stages T2 and T3 squamous cell carcinoma of the bladder. *J Urol*. 1990;143:37–40.

Tan WS, Sarpong R, Khetrapal P, et al. Can renal and bladder ultrasound replace CT urogram in patients investigated for microscopic hematuria? *J Urol*. 2018 http://linkinghub.elsevier.com/retrieve/pii/S0022534718 [(online journal)].

Toma M, Friedrich M, Hautmann S, et al. Comparison of the ImmunoCyt test and urinary cytology with other urine tests in the detection and surveillance of bladder cancer. *World J*

Urol. 2004;22:145–149.

Tomlinson DC, L'Hôte CG, Kennedy W, et al. Alternative splicing of fibroblast growth factor receptor 3 produces a secreted isoform that inhibits fibroblast growth factor–induced proliferation and is repressed in urothelial carcinoma cell lines. *Cancer Res*. 2005;65:10441–10449.

Travis LB, Curtis RE, Glimelius B, et al. Bladder and kidney cancer following cyclophosphamide therapy for non-Hodgkin's lymphoma. *J Natl Cancer Inst*. 1995;87:524–531.

van der Post RS, Kiemeney LA, Ligtenberg MJL, et al. Risk of urothelial bladder cancer in Lynch syndrome is increased, in particular among MSH2 mutation carriers. *J Med Genet*. 2010;47:464–470.

van Oers JMM, Adam C, Denzinger S, et al. Chromosome 9 deletions are more frequent thanFGFR3 mutations in flat urothelial hyperplasias of the bladder. *Int J Cancer*. 2006;119:1212–1215.

van Rhijn BWG, van der Poel HG, van der Kwast TH. Urine markers for bladder cancer surveillance: a systematic review. *Eur Urol*. 2005;47:736–748.

van Rhijn BWG, Zuiverloon TCM, Vis AN, et al. Molecular Grade (FGFR3/MIB-1) and EORTC risk scores are predictive in primary non–muscle-invasive bladder cancer. *Eur Urol*. 2010;58:433–441.

Vermeulen SH, Hanum N, Grotenhuis AJ, et al. Recurrent urinary tract infection and risk of bladder cancer in the Nijmegen bladder cancer study. *Br J Cancer*. 2015;112:594–600.

Vieira AR, Vingeliene S, Chan DSM, et al. Fruits, vegetables, and bladder cancer risk: a systematic review and meta-analysis. *Cancer Med*. 2015;4:136–146.

Villanueva CM, Silverman DT, Murta-Nascimento C, et al. Coffee consumption, genetic susceptibility and bladder cancer risk. *Cancer Causes Control*. 2009;20:121–127.

Wang J, Wang FW, LaGrange CA, et al. Clinical features of sarcomatoid carcinoma (carcinosarcoma) of the urinary bladder: analysis of 221 cases. *Sarcoma*. 2010;1–7.

Wang Y, Auger M, Kanber Y, et al. Implementing The Paris System for Reporting Urinary Cytology results in a decrease in the rate of the “atypical” category and an increase in its prediction of subsequent high-grade urothelial carcinoma. *Cancer Cytopathol*. 2018;126:207–214.

Watts KE, Hansel DE. Emerging concepts in micropapillary urothelial carcinoma. *Adv Anat Pathol*. 2010;17:182–186.

West DA, Cummings JM, Longo WE, et al. Role of chronic catheterization in the development of bladder cancer in patients with spinal cord injury. *Urology*. 1999;53:292–297.

Whiteside SA, Razvi H, Dave S, et al. The microbiome of the urinary tract—a role beyond infection. *Nat Rev Urol*. 2015;12:81–90.

Williams SV, Hurst CD, Knowles MA. Oncogenic FGFR3 gene fusions in bladder cancer. *Hum Mol Genet*. 2013;22:795–803.

Wright JL, Black PC, Brown GA, et al. Differences in survival among patients with sarcomatoid carcinoma, carcinosarcoma and urothelial carcinoma of the bladder. *J Urol*. 2007;178:2302–2307.

Wyszynski A, Tanyos SA, Rees JR, et al. Body mass and smoking are modifiable risk factors for recurrent bladder cancer. *Cancer*. 2014;120:408–414.

Yi Y, Wu A, Cameron AP. Nephrogenic adenoma of the bladder: a single institution experience assessing clinical factors. *Int Braz J Urol*. 2018;44:1–6.

Yoder BJ, Skacel M, Hedgepeth R, et al. Reflex UroVysion Testing of bladder cancer surveillance patients with equivocal or negative urine cytology. *Am J Clin Pathol*. 2007;127:295–301.

Yoshida T, Sopko NA, Kates M, et al. Three-dimensional organoid culture reveals involvement of Wnt/β-catenin pathway in proliferation of bladder cancer cells. *Oncotarget*. 2018;9.

Youssef RF, Kapur P, Mosbah A, et al. Role of fibroblast growth factor in squamous cell carcinoma of the bladder: prognostic biomarker and potential therapeutic target. *Urol Oncol*. 2015;33:111.e1–111.e7.

Zhang X, Ibrahimi OA, Olsen SK, et al. Receptor specificity of the fibroblast growth factor family. *J Biol Chem*. 2006;281:15694–15700.

Zhang Y. Understanding the gender disparity in bladder cancer risk: the impact of sex hormones and liver on bladder susceptibility to carcinogens. *J Environ Sci Health C Environ Carcinog Ecotoxicol Rev*. 2013;31:287–304.

Zhao L, Tian X, Duan X, et al. Association of body mass index with bladder cancer risk: a dose-response meta-analysis of prospective cohort studies. *Oncotarget*. 2017;8:33990–34000.

Zieger K, Dyrskjøt L, Wiuf C, et al. Role of activating fibroblast growth factor receptor 3 mutations in the development of bladder tumors. *Clin Cancer Res*. 2005;11:7709–7719.

Zieger K, Marcussen N, Borre M, et al. Consistent genomic alterations in carcinoma *in situ* of the urinary bladder confirm the presence of two major pathways in bladder cancer development. *Int J Cancer*. 2009;125:2095–2103.

Management Strategies for Non–Muscle-Invasive Bladder Cancer (Ta, T1, and CIS)

Joseph Zabell MD, Badrinath R. Konety MD, MBA [a]

Non–muscle-invasive bladder cancer (NMIBC) is the term commonly applied to malignant urothelial tumors that have not invaded the detrusor muscle of the bladder (Epstein et al., 1998; Smith et al., 1999). This terminology encompasses the relatively benign course of low-grade papillary tumors, the more aggressive clinical course of high-grade tumors including urothelial carcinoma in situ (CIS), and high-grade Ta and T1 tumors. **Approximately 70% to 80% of bladder tumors are non–muscle invasive at presentation with 60% to 70% as stage Ta, 20% to 30% as T1, and approximately 10% as CIS** (Fig. 136.1) (Aldousari and Kassouf, 2010; Ro et al., 1992).

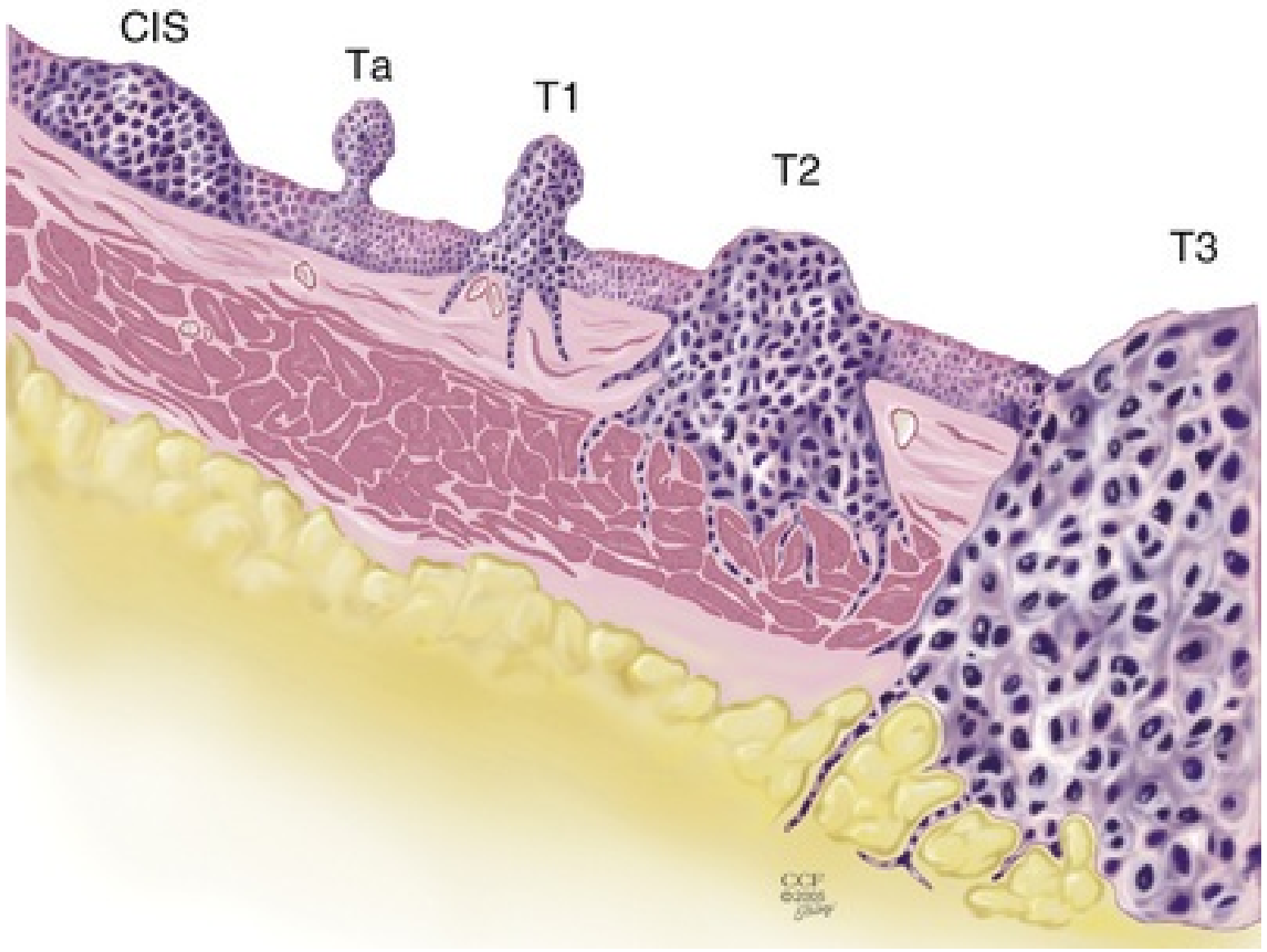

FIG. 136.1 Carcinoma in situ is a high-grade, flat malignancy confined to the urothelium. Papillary tumors confined to the urothelium are Ta, whereas papillary tumors invading lamina propria are T1. The T1 tumor here intertwines with the wispy fibers of the muscularis propria but by definition does not invade the smooth muscle fibers of the detrusor. T2 tumors invade the detrusor muscle, and T3 tumors are in extravesical fat as shown. *CIS,* Carcinoma in situ.

Painless hematuria (either visible or non-visible) is the most common presenting symptom of NMIBC. Patients with visible hematuria have reported rates of bladder cancer much higher than that observed in patients with non-visible (>3 RBC/hpf on microscopic urinalysis) hematuria (Tan et al., 2018)**. A recent prospective study of more than 3500 patients from 40 institutions found that 10.9% of patients with visible hematuria had bladder cancer, whereas non-visible hematuria was associated with bladder cancer in 2.5%** (Tan et al., 2018)**. Other studies have found a prevalence of bladder cancer in 0.3% to 4.7% of patients with non-visible or microscopic hematuria** (Kang et al., 2015; Khadra et al., 2000). Bladder cancer patients younger than 40 years are more likely to have visible hematuria rather than non-visible hematuria.

The degree of hematuria, whether visible or non-visible is not predictive of stage and grade of cancer (Tan et al., 2018). The **presence of irritative voiding symptoms in the absence of a urinary tract infection is also associated with CIS** with some studies reporting rates of up to 80% (Zincke et al., 1985). In a review of 600 patients diagnosed with interstitial cystitis, 1% of the patients had a missed diagnosis of urothelial carcinoma, although the majority of these patients did not have hematuria (Tissot et al., 2004). Thus **cystoscopy and upper tract imaging are indicated in patients with hematuria and/or unexplained irritative symptoms** (Davis et al., 2012; Grossfeld et al., 2001).

Recurrence is common in all patients with NMIBC but can often be managed with multimodal treatment, including transurethral surgery with or without intravesical immunotherapy and chemotherapy therapy. Risk of recurrence is typically approximately 40% to 60% but can be influenced by multiple clinical factors. Risk of progression, however, is of key concern in patients with NMIBC given the heterogeneity of tumors in this category with rates of progression as low as 6% in patients with low-grade Ta lesions (Leblanc et al., 1999) to as high as 17% in high-grade T1 tumors (Palou et al., 2012). The frequency of progression and death is shown in Table 136.1.

TABLE 136.1

Estimates of Disease Progression in Non–Muscle-Invasive Bladder Cancer: World Health Organization/International Society of Urologic Pathology Consensus Classification

TUMOR TYPE	RELATIVE FREQUENCY (%)	PROGRESSION (%)	DEATHS (%)
NONINVASIVE			
Papilloma	10	0–1	0
Papillary urothelial neoplasm of low malignant potential	20	3	0–1
Papillary cancer, low grade (TaG1)	20	5–10	1–5
Papillary cancer, high grade (TaG3)	30	15–40	10–25
INVASIVE			
Papillary cancer (T1G3)	20	30–50	33
CARCINOMA IN SITU			
Primary	10	>50	—
Secondary	90	—	—

From Donat SM: Evaluation and follow-up strategies for superficial bladder cancer. *Urol Clin North Am* 30:765–766, 2003.

Considerable work has been completed in an effort to develop clinical tools for risk stratification of patients with NMIBC. One previously published stratification system has been developed by the European Organization for Research and Treatment of Cancer (EORTC) with the goal of predicting probability of recurrence and progression at 1 and 5 years after treatment. Factors associated with recurrence include previous recurrence, number of tumors, and tumor size. For progression, significant factors for prognosis were T stage, presence of CIS, and grade (Sylvester et al., 2006). A similar model was developed by the Spanish Urological Club for Oncological Treatment/Club Urologico Espanol de Tratamiento Oncologico (CUETO) (Fernandez-Gomez et al., 2009). The EORTC model was limited by minimal use of bacille Calmette-Guérin (BCG) maintenance, perioperative mitomycin C (MMC), and restaging transurethral resection of bladder tumor (TURBT) in the patient cohorts used for model development. As a consequence, they tended to overestimate the rate of recurrence and progression. Using data from more recent trials incorporating patients who have received BCG maintenance therapy, the EORTC risk assessment tool has been updated (Cambier et al., 2016). However, the cohort is deficient in patients with CIS and requires further independent validation. More recently, the American Urological Association and Society of Urologic Oncology (AUA/SUO) Guideline for the Diagnosis and Treatment of Non–Muscle-Invasive Bladder Cancer has been published, which created a novel risk stratification schema (Table 136.2; Chang et al., 2016). Such risk stratification models allow for more nuanced evaluation of risk of recurrence and progression in patients with NMIBC, therefore allowing for risk-adapted treatment and surveillance strategies.

TABLE 136.2

American Urological Association Risk Stratification for Non–Muscle-Invasive Bladder Cancer

LOW RISK	INTERMEDIATE RISK	HIGH RISK
LG solitary Ta ≤ 3 cm	Recurrence within 1 year, LG Ta	HG T1
PUNLMP	Solitary LG Ta > 3 cm	Any recurrent, HG Ta
	LG Ta, multifocal	HG Ta, >3 cm (or multifocal)
	HG Ta, ≤ 3 cm	Any CIS
	LG T1	Any BCG failure in HG patient
		Any variant histology
		Any LVI
		Any HG prostatic urethral involvement

BCG, Bacille Calmette-Guérin; *CIS,* carcinoma in situ; *HG,* high grade; *LG,* low grade; *LVI,* lymphovascular invasion; *PUNLMP,* papillary urothelial neoplasm of low malignant potential.

From Chang et al: *Diagnosis and treatment of non-muscle invasive bladder cancer*, AUA/SUO Guideline, 2016.

Pathology: Grading and Staging

Pathological Staging

Tumor staging for urothelial carcinoma of the bladder is outlined by the American Joint Committee on Cancer (AJCC) criteria that include clinical and pathological staging outlines. Clinical stage reflects findings in TURBT as well as radiologic and physical exam findings with bimanual exam at time of TURBT. These findings allow the clinician to determine if lamina propria and/or muscularis propria are present or involved in the specimen and should assess for lymphovascular invasion (LVI), if possible. Pathological staging is based on surgical resection of the bladder via partial or radical cystectomy and pathological evaluation of pelvic lymph nodes.

The bladder has three main histologic layers: (1) urothelium, (2) suburothelial connective tissue called *lamina propria,* and (3) detrusor or muscularis propria (which is absent beneath the urothelium of diverticula). TNM staging for NMIBC includes noninvasive papillary tumors confined to urothelium regardless of grade (stage Ta), tumors invading the subepithelial tissue (lamina propria) (T1), and carcinoma in situ/tumor in situ (CIS/Tis). The TNM grading system is illustrated in Fig. 136.1.

Tumors invading the lamina propria can exhibit focal or extensive invasion. Several strategies have been used to sub-stratify T1 disease; extent of invasion is thought to correlate with progression to muscle-invasive disease (Leivo et al., 2018). One commonly used method includes evaluation of depth of invasion relative to the muscularis mucosae, which is a layer of discontinuous wispy bands of smooth muscle within the lamina propria. Tumors invading deep to the muscularis mucosae have been found to have a worse prognosis (Roubret et al., 2013). However, because of discontinuity of this layer and difficulty of orientation with some TURBT specimens, the depth of lamina propria invasion cannot be adequately assessed in all cases using this technique (Leivo et al., 2018). Recognition of the clinical importance of substaging of T1 tumors into T1a and T1b as part of the staging system has been proposed. The most recent *AJCC Staging Manual* emphasizes the importance of assessing the extent of lamina propria invasion; however, no specific approach to doing so is yet universally accepted (Amin et al., 2016).

Pathological Grading

Currently, the World Health Organization (WHO)/International Society of Urologic Pathology (ISUP) grading system from 2015 is widely accepted and commonly used (Moch et al., 2015). This system highlights the term *urothelial cancer* as being preferable to the previously common terminology of *transitional cell cancer*, although the former term is still occasionally used. Since the 2004 revised classification system was published, bladder cancer grade has been differentiated between low-grade tumors and high-grade tumors, rather than the previously published three-tiered WHO/Ash-Broder system. Currently used common classification includes hyperplasia (flat and papillary), reactive atypia, atypia of unknown significance, urothelial dysplasia, urothelial CIS, urothelial papilloma, papillary urothelial neoplasm of low malignant potential, non–muscle-invasive low-grade papillary urothelial carcinoma, and non–muscle-invasive high-grade papillary urothelial carcinoma.

Essentially benign papillary tumors with orderly cellular arrangement, minimal architectural abnormalities, and minimal nuclear atypia are distinct from those two grades and are designated papillary urothelial neoplasm of low malignant potential (PUNLMP), which are largely regarded as unlikely to progress and are considered essentially benign. However, on the basis of this low risk, the WHO recommends that such pathology reports contain the note, "Patients with these tumors are at risk of developing new bladder tumors ('recurrence'), usually of similar histology. However, occasionally these subsequent lesions manifest as urothelial carcinoma (UC), such that follow-up of the patient is warranted" (Epstein et al., 1998). Papillomas are truly benign and not associated with risk of progression (Figs. 136.2 through 136.5; also see Fig. 136.1).

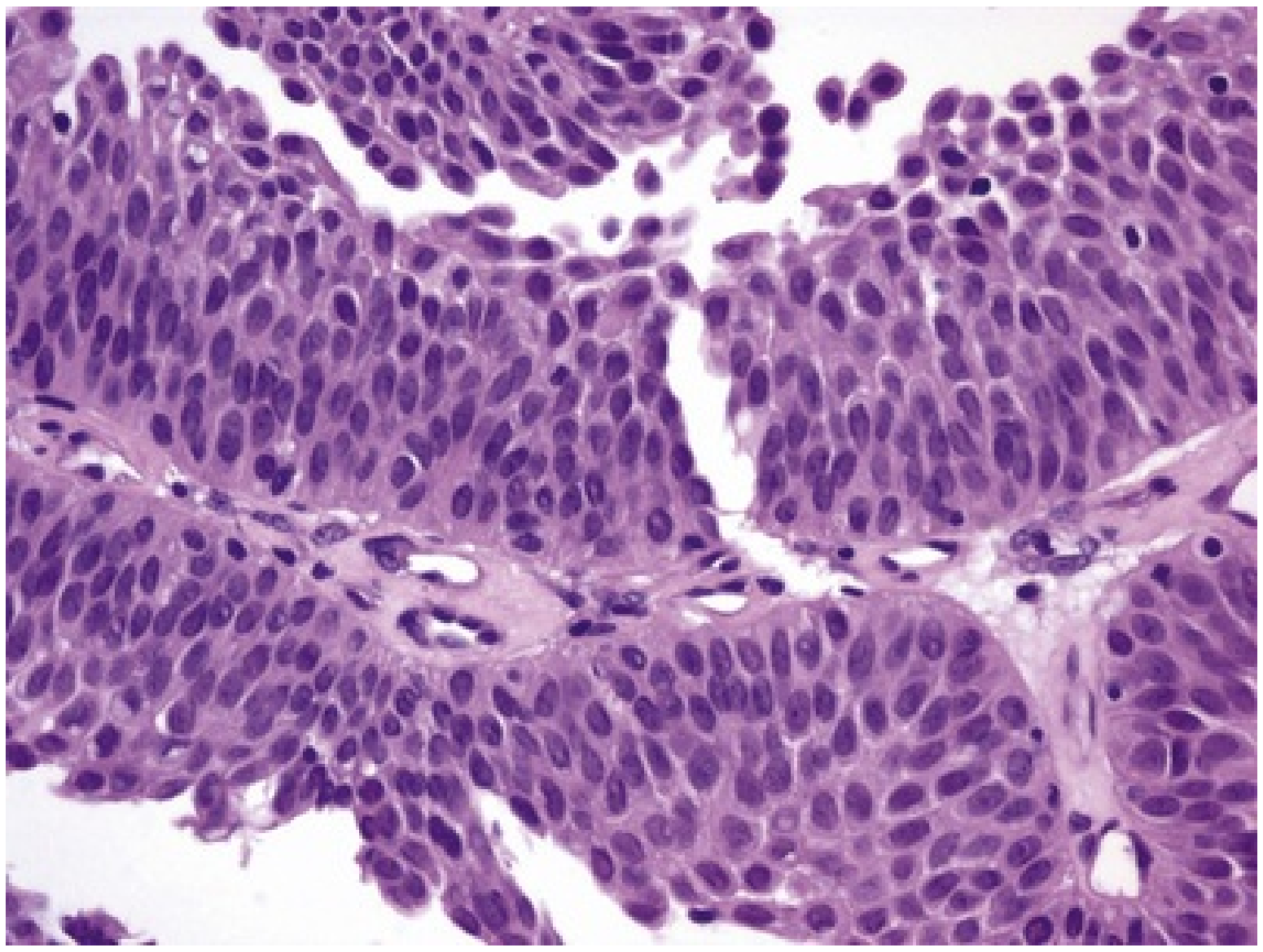

FIG. 136.2 The urothelium is thickened, but cells and nuclei are normal in papillary urothelial neoplasm of low malignant potential (×40).

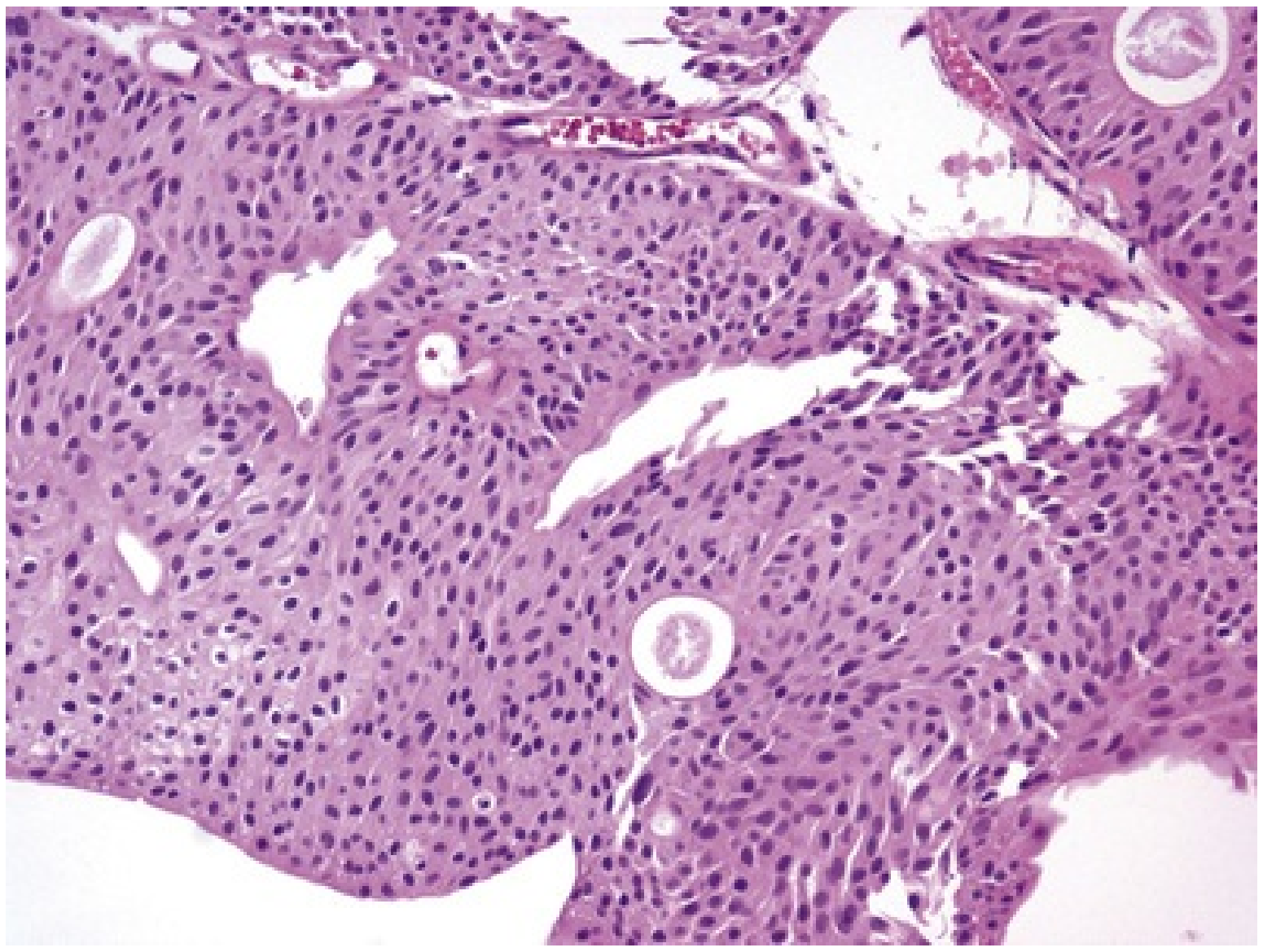

FIG. 136.3 Ta low-grade tumor (×40). Cells are relatively normal but exhibit irregularity and some nuclear differentiation.

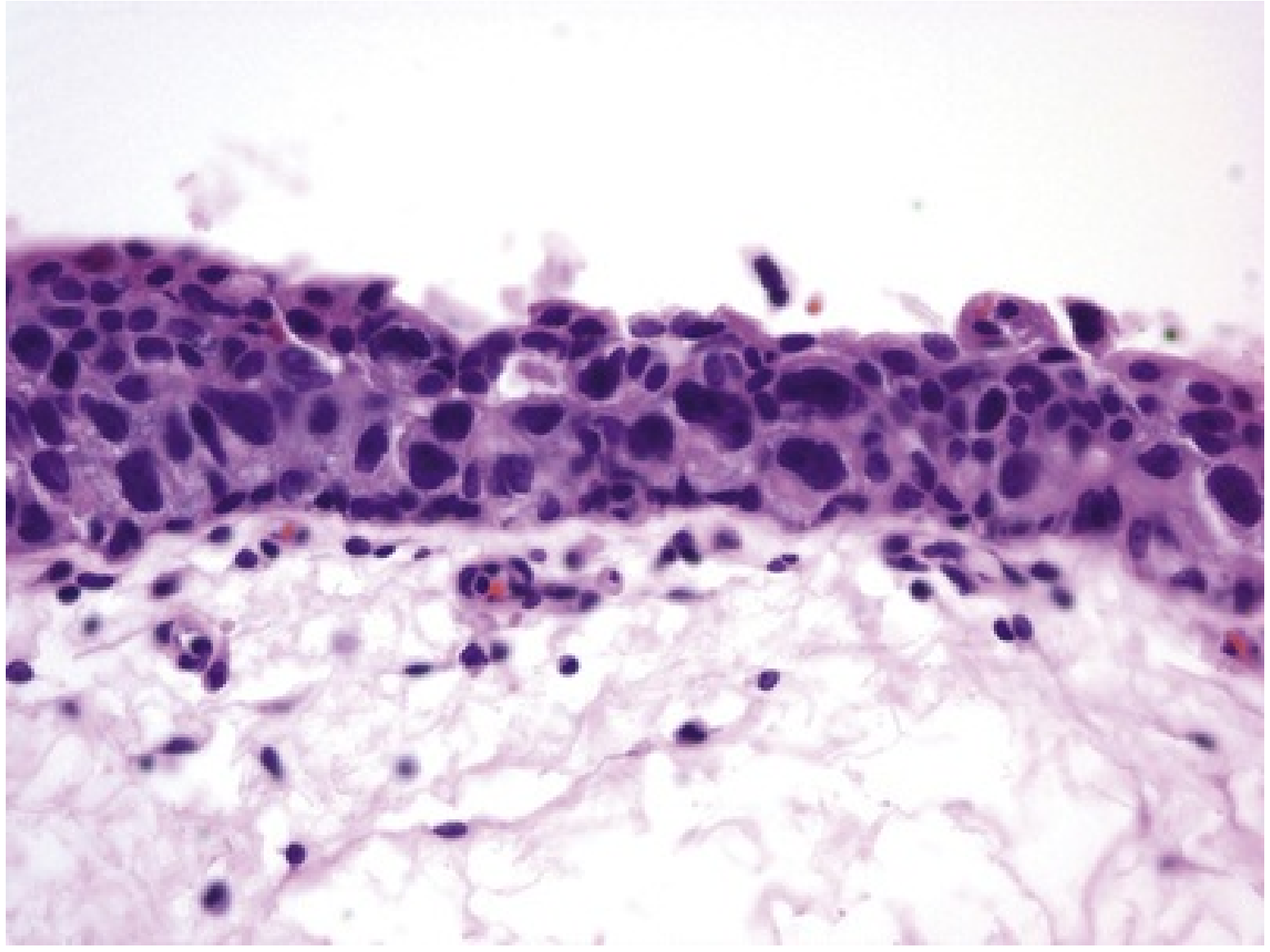

FIG. 136.4 Carcinoma in situ (×40) exhibits severe irregularity of cellular structure and nuclear pleomorphism, but there is no invasion of lamina propria.

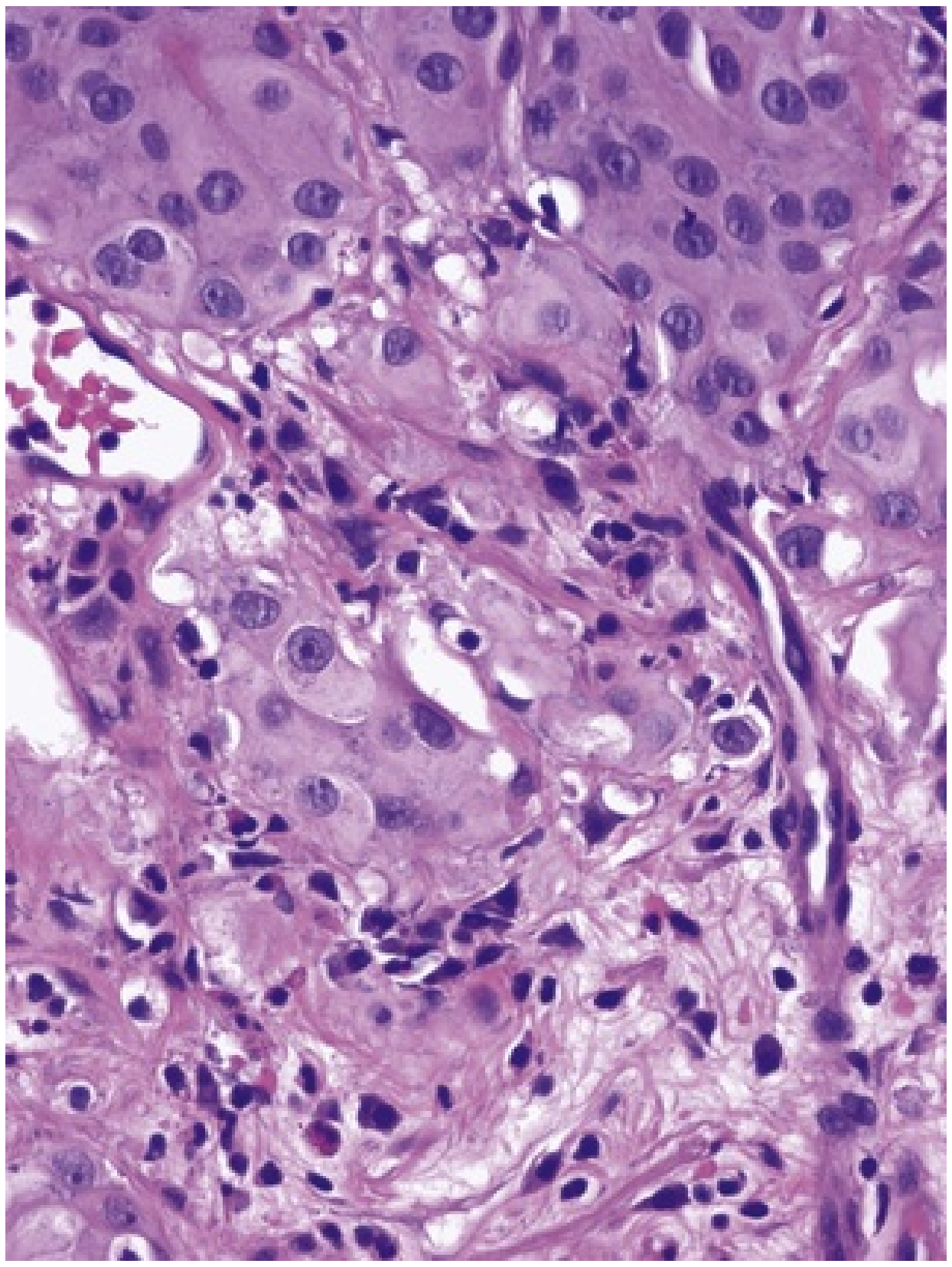

FIG. 136.5 T1 (×40) high-grade tumor exhibits nesting of abnormal cells and mitotic figures. Tumor cells can be seen invading the lamina propria in

the lower one-third of the photomicrograph.

Tumor Biology

Low-grade tumors and high-grade tumors have very different natural histories, consistent with grade being among the most important predictors of prognosis in NMIBC. **Low-grade Ta lesions recur at a rate of 50% to 70% and progress in less than 5% of cases. In contrast, high-grade T1 lesions recur in more than 80% of cases and progress in 50% of patients within 3 years.** This behavior is primarily grade dependent, rather than stage dependent: high-grade tumors progress with similar frequency regardless of whether they were invasive (T1) or noninvasive (Ta) (Herr, 2000b). **Prognosis also correlates with tumor size, multiplicity, papillary versus sessile configuration, presence or absence of lymphovascular invasion, and status of the remaining urothelium** (Althausen et al., 1976; Heney et al., 1983a, 1983b; Kunju et al., 2008; Lutzeyer et al., 1982).

The divergence in biologic behavior for low-grade versus high-grade lesions correlates with the known dual molecular lines of genetic development for these two pathways and supports the concept that **high-grade and low-grade cancers may essentially be considered different diseases** (Droller, 2005; Hasui et al., 1994). **Chromosomal alterations caused by oxidative DNA damage create two separate genetic pathways to the development of UC** (Cote and Chatterjee, 1999; Richter et al., 1997; Spruck et al., 1994). The first and more common (low grade) leads to noninvasive, papillary tumors. These usually follow an indolent course unless they convert to or are associated with a secondary tumor of a second higher-grade pathway (Kiemeney et al., 1993). Fibroblast growth factor receptor 3 *(FGFR3)* mutations, along with chromosome 9 deletions occur in the majority of papillomas and low-grade tumors and are related to the RAS pathway and cell proliferation (Wolff et al., 2005).

The second pathway leads to the development of high-grade cancer, including CIS, T1, and, ultimately, muscle-invasive carcinoma. Such genetic alterations can be evaluated using karyotyping, microsatellite analysis for allelic imbalance (Mao et al., 1996), comparative genomic hybridization (Kallioniemi et al., 1995), DNA ploidy analysis by flow cytometry (Bittard et al., 1996), and fluorescence in situ hybridization (FISH) (Degtyar et al., 2004). High-grade tumors tend to have numerous and greatly variable chromosomal gains and losses. In addition to their relatively predictable aneuploidy, high-grade tumors can also lose all or part of chromosome 9 (Richter et al., 1997). Although almost any chromosome can be affected, aneuploidy of chromosomes 7, 9, and 17 is associated with especially aggressive tumors (Degtyar et al., 2004; Olumi et al., 1990; Waldman et al., 1991). Specific mutations have been linked to risk of progression, including p53, p21, and pRb, which act in cooperative and synergistic ways to promote bladder cancer progression (Chatterjee et al., 2004).

Because of these differing genetic imprints, it has been suggested that papillary pTa tumors could almost be considered benign and may be a completely separate disease entity in contrast to high-grade tumors (Harnden, 2007; Sauter and Mihatsch, 1998). Nevertheless, high-grade and low-grade lesions are known to coexist. UC is traditionally considered a field change disease, with tumors arising at different times and sites. Rarely, patients who initially have low-grade tumors subsequently develop high-grade tumors, often years after the original tumors, so long-term surveillance is usually appropriate (Holmäng and Ströck, 2012).

Pathological Characteristics by Stage and Implications for Clinical Management

Stage Ta tumors are usually low grade. Although recurrence is common, especially in the setting of multiplicity, progression is rare. However, **2.9% to 18% of Ta tumors are high grade, with an average of 6.9%** (Sylvester et al., 2005). **The most important risk factor for progression is grade, not stage** (Millán-Rodríguez et al., 2000; Sylvester et al., 2005).

CIS is occasionally mischaracterized as "premalignant" (Sylvester et al., 2005), **but it is actually a flat, noninvasive UC that is high grade by definition and is regarded as a precursor to the development of invasive high-grade cancer.**

CIS lesions are composed of severely dysplastic urothelium. Microscopically, tumors demonstrate disorderly histology with nuclear atypia characteristic of high-grade malignancy; denudement of some or all of the mucosa as a result of loss of cellular cohesion sometimes complicates interpretation. A pathology report read as dysplasia or atypia can create confusion. Most pathologists consider mild examples of these entities to be benign. However, **lesions interpreted as severe/high-grade dysplasia are regarded as being the same entity as CIS** (Epstein et al., 1998).

From 40% to 83% of patients with CIS develop muscle invasion if

untreated, especially if associated with papillary tumors (Althausen et al., 1976). Among patients thought to have CIS alone, up to 20% who are treated with cystectomy are found to actually contain invasion on final pathology (Shariat et al., 2006). The presence of CIS in specimens from cystectomy performed for presumed T1 tumors was associated with upstaging in 55% of patients in one series, compared with 6% upstaging in patients without CIS (Masood et al., 2004). In a series of 1500 patients, CIS was the second most important prognostic factor after grade (Millán-Rodríguez et al., 2000). Multicentricity presents another ominous characteristic of CIS (Koch and Smith, 1996). The presence of irritative voiding symptoms has been associated with diffuse disease, invasion, and a compromised prognosis, but there is no consensus on this finding in the literature (Smith et al., 1999; Sylvester et al., 2005). The incidence of node-positive disease in patients with CIS only who undergo radical cystectomy can be up to 3% (Shariat et al., 2006).

T1 tumors are usually papillary and often have a narrow stalk; a **nodular or sessile appearance suggests deeper invasion. Deep penetration into the lamina propria, especially if involving muscularis mucosae, increases the risk of recurrence and progression in some reports. Lymphovascular invasion** (Kim et al., 2014; Streeper et al., 2009; Tilki et al., 2013), **pyuria** (Azuma et al., 2013), **and bladder neck involvement** (Kobayashi et al., 2014) **also increase this risk. Hydronephrosis often indicates muscle invasion.**

There is significant potential for understaging in patients with high-grade, apparently non–muscle-invasive tumors, especially those that appear to be stage T1. At time of cystectomy many tumors are found to be more extensive than what was indicated by the transurethral resection (TUR) specimen. Understaging errors ranging from 34% to 62% have been reported (Stein et al., 2001). Herr (1999) reported considerable rates of upstaging tumors on restaging TURBT of high-grade tumors, particularly T1 tumors where up to 49% of tumors were found to be muscle invasive on restaging TURBT. Studies addressing the risk of understaging of T1 tumors are shown in Table 136.3. These data highlight the importance of performing a more thorough second resection to accurately estimate the depth of invasion and reduce the likelihood of missing T1 tumors that are actually muscle invasive. This is particularly important in patients with absence of muscle in the initial resection specimen.

TABLE 136.3

Risk of Understaging When Cystectomy Is Performed for Presumed Non–

Muscle-Invasive Disease

STUDY	INSTITUTION	RISK (%) OF UNDERSTAGING
Stein et al., 2001	Southern California	39
Dutta et al., 2001	Vanderbilt University	40
Bianco et al., 2004	Wayne State University	27
Bayraktar et al., 2004	Vakif Gureba Hospital, Aksaray-Istanbul, Turkey	50
Huguet et al., 2005	Servicio de Urologia, Fundació Puigvert, Barcelona	27
Ficarra et al., 2005	University of Verona, Italy	43

Key Points: Pathology

- Malignant tumors are classified as low grade or high grade, regardless of invasion.
- High- and low-grade cancers are often considered essentially separate diseases based on disparate genetic development, biologic behavior, and management strategies.
- The most important risk factor for progression is grade.
- CIS is a precursor as well as a risk factor for progression, invasion, and metastasis.
- Papillary tumors with orderly cellular arrangement, minimal architectural abnormalities, and minimal nuclear atypia are designated PUNLMP.

Endoscopic Surgical Management

Procedures

Upon the identification of a bladder tumor during office-based cystoscopy, the location, number, and morphology of tumors are recorded, as is involvement of areas likely to reflect extravesical extension such as the ureteral orifices and bladder neck or prostatic urethra. Urinary cytology is typically obtained as a baseline and to establish the likelihood of high-grade disease. Positivity will encourage random bladder biopsy at the time of TUR, as discussed later.

Cross-sectional imaging to evaluate the upper urinary tract such as CT urography (Fig. 136.6) is commonly performed before TUR to identify other sources of hematuria and to assess the extravesical urothelium given the risk of concomitant upper tract disease secondary to the "field change" nature of UC, which can affect such tissue throughout the urinary tract**.** Retrograde pyelography or ureteroscopy can be planned for any upper tract abnormalities identified. CT urography, MR urography, or retrograde pyelography are typically used to evaluate for upper tract lesions, with ureteroscopy reserved for suspicious findings. Expert consensus is that patients with solitary or limited low-grade Ta lesions do not need upper tract imaging except at baseline because of the very low risk of extravesical disease (Chang et al., 2016; Davis et al., 2012; Goessl et al., 1997). The overall risk of identifying upper tract lesions in patients with known history of bladder cancer is low, and upper tract tumors occur in less than 5% of such patients. However, tumors at the trigone, the presence of concomitant CIS, and identification of high-risk disease are risk factors for the presence of upper tract disease (Millán-Rodriguez et al., 2000; Palou et al., 2005).

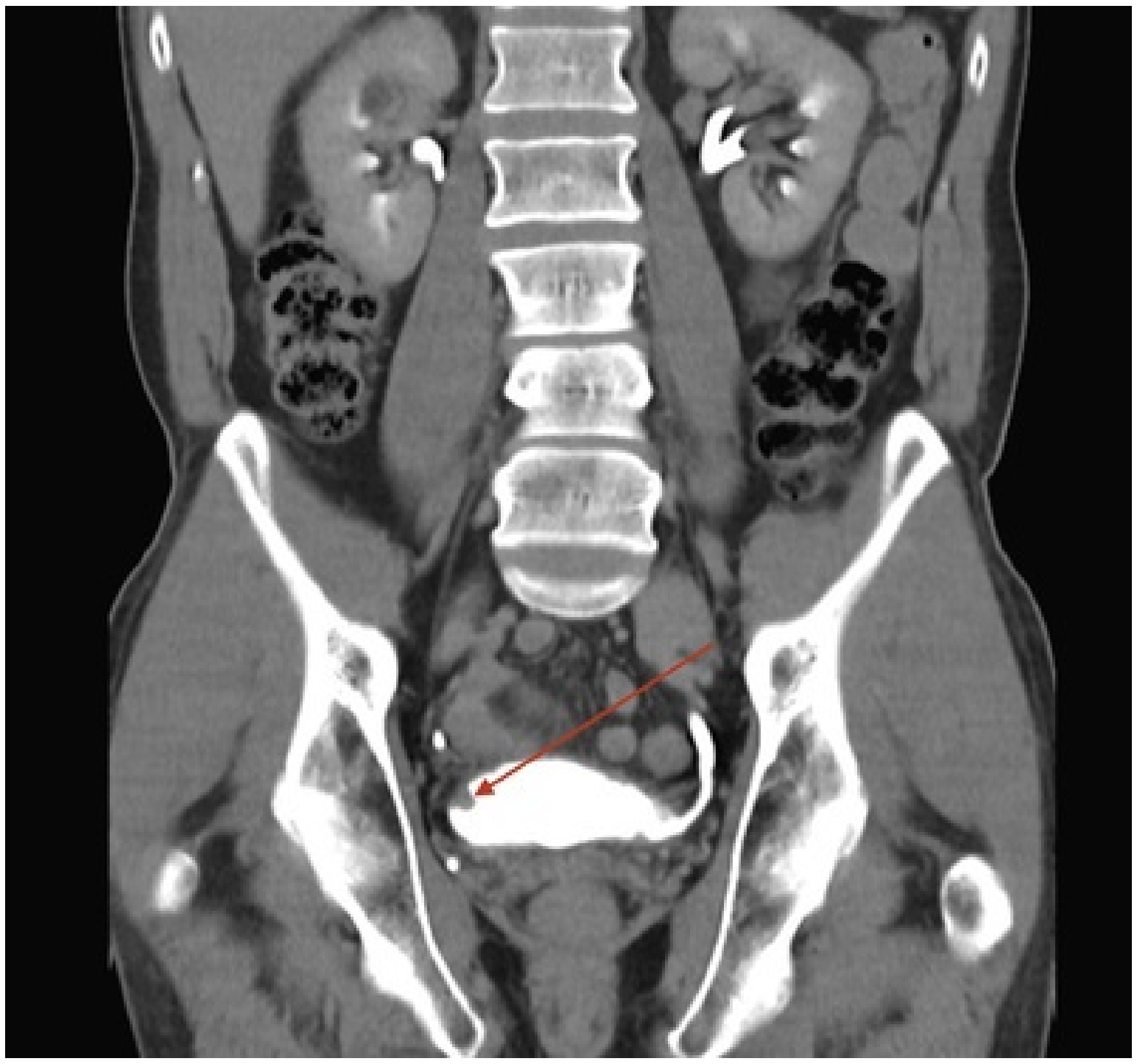

FIG. 136.6 CT urogram demonstrating a bladder tumor along the right lateral wall *(red arrow),* ultimately found to be a high-grade Ta bladder tumor.

TURBT under regional or general anesthesia is the initial treatment for visible lesions. This therapy is intended to be diagnostic and therapeutic by providing specimens to allow for pathological determination of stage and grade, while simultaneously removing and/or fulgurating all visible tumors. Bimanual examination of the bladder is often performed with the patient under anesthesia before preparation and draping and is repeated after resection to allow for appropriate clinical staging. Fixation or persistence of a palpable mass after resection suggests locally advanced disease, although the additional value of this maneuver in the era of modern imaging appears limited and may even be misleading (Ploeg et al., 2012).

Complete visualization of the bladder should be completed using a flexible cystoscope and/or the 30- and 70-degree rigid lens. Resection is typically performed using continuous flow **irrigation and resectoscope with the bladder filled only enough to visualize its contents. This minimizes bladder wall movement and lessens thinning of the detrusor through overdistention, thereby reducing the risk of perforation** (Koch and Smith, 1996). An outflow suction can be used, which allows for more refined control of bladder volume and avoids inadvertent overdistention, which could result in extravasation through microperforations in the bladder wall. Resection is performed piecemeal, delaying transection of tumor base or stalk until the majority of tumor burden has been resected. **Friable, low-grade tumors can often be removed without the use of electrical energy** because the non-powered cutting loop will break off such tumors. This minimizes the chance of bladder perforation and unnecessary cautery damage or loss of specimens. Higher grade, more solid tumors and the base of all tumors require the use of cutting current; cautery yields hemostasis once the entire tumor has been resected. **Lifting the tumor edge away from detrusor lessens the chance of perforation** (Holzbeierlein and Smith, 2000). There appears to be variability in completeness of resection among surgeons as demonstrated by previous data demonstrating variability in recurrence rates from 7.4% to 45.8% depending on the surgeon (Brausi et al., 2002).

After all visible tumor has been resected, an additional pass of the cutting loop or a cold-cup biopsy can be obtained to send to pathology separately to determine the presence of muscle invasion of the tumor base. An Ellik or similar chip evacuator can be used to gather the chips floating in the bladder, and final confirmation of hemostasis should be assessed in the presence of minimal irrigation after all chips have been removed.

Traditionally, TUR has been performed using sterile water because saline solutions conduct electricity and disperse energy from the monopolar cautery cutting loop. Bipolar energy, as opposed to monopolar energy, appears to offer some advantages. In a systematic review, Zhao et al. (2016) found that patients undergoing TUR with bipolar energy had shorter hospital stay, less blood loss, and fewer complications such as obturator reflex and bladder perforation. **The use of bipolar cautery allows use of saline irrigation,** which can decrease risk of TUR syndrome in cases of perforation and if the resection is prolonged. Data suggest that tissue preservation for pathological evaluation is at least as good as with monopolar resection, if not better. The use of general anesthesia with muscle-paralyzing agents also prevents obturator reflex in patients with tumors along the posterolateral bladder walls.

Resection of diverticular tumors presents significant risk of bladder wall perforation, and accurate staging is difficult to achieve given the absence of underlying detrusor. Invasion beyond the diverticular lamina propria immediately involves perivesical fat (stage T3a by definition). Resection in diverticula frequently leads to bladder perforation. **Low-grade diverticular tumors are best treated with a combination of conservative resection and**

fulguration of the base. This can be followed by subsequent repeat resection if the final pathological interpretation is high grade. High-grade tumors require adequate sampling of the tumor base, often including perivesical fat, despite the near certainty of bladder perforation. In such cases, an indwelling catheter should be left for several days to allow for urothelial healing. **Partial or radical cystectomy should be strongly considered for high-grade diverticular lesions because tumors can penetrate extravesically with relative ease given the lack of a muscularis layer in the diverticula.**

Anterior wall tumors and tumors at the dome in patients with large bladders can be difficult to reach. Minimal bladder filling combined with manual compression of the lower abdominal wall to bring the tumor toward the resectoscope facilitates removal. Extra-long resectoscopes available from many manufacturers are long enough to reach the entirety of most bladders. Rarely, the creation of a temporary perineal urethrostomy can be used to allow for better access, particularly in the obese patient with an anterior wall or dome tumor. Digital manipulation through the rectum or vagina or downward compression of the suprapubic area can occasionally facilitate resection.

Care must be taken during resection near the ureteral orifice to prevent obstruction from scarring after fulguration. **Pure cutting current causes minimal scarring and may be safely performed, including resection of the orifice if necessary.** Resection of the intramural ureter may lead to complete eradication of some tumors but risks reflux of malignant cells. The clinical implications of this are unclear (Palou et al., 1992).

As an alternative to formal TURBT, **many small tumors may be resected using the cold-cup biopsy forceps** alone. This is especially helpful in patients with thin-walled bladders, such as can be seen in elderly females, because of risk of perforation with traditional transurethral resection techniques. If perforation does occur in this circumstance, the biopsy forceps typically leads to a smaller perforation than the cutting loop, facilitating subsequent healing. A Bugbee cauterization electrode facilitates hemostasis.

En bloc resection of bladder tumors represents another alternative, relatively novel resection technique that can be performed with the traditional loop electrode, Hybrid-Knife, holmium laser, Thulium laser, or KTP laser (Kramer et al., 2015, 2017). This technique involves excision of the entire tumor with underlying segment of muscle with the specimen being resected and extracted intact, rather than piecemeal. The benefit of this derives from less cautery artifact, thereby allowing more accurate assessment of muscle invasion by pathology. This technique is most feasible in papillary tumors with a distinct stalk; however, specimen extraction after en bloc resection may become problematic in the case of large tumors, which may require fragmentation into pieces to allow extraction through the resectoscope. Because of this potential difficulty, it is thought that up to a third of tumors are not amenable to en bloc resection given tumor size or location. Further potential disadvantages of this technique include possible disruption of tissue at incision line, equipment acquisition costs, and risk of excessive tissue penetration depth (Kramer et al., 2017). Regardless, en bloc resection provides a viable approach to intravesical management of appropriately selected tumors. ▶Video 136.1 demonstrates this technique.

If a tumor appears to be muscle invasive, biopsies of the borders and base to establish invasion may be performed in lieu of complete resection, given the likelihood of subsequent cystectomy. Failure to demonstrate invasion necessitates repeat resection unless the decision is made to proceed to cystectomy based on factors other than muscle invasion. Using a 10-item checklist that meticulously documents all the important elements of the TUR can enhance adequacy of specimen that is obtained and the thoroughness of resection (Anderson et al., 2016).

Complications of Transurethral Resection of Bladder Tumor and Bladder Biopsy

Minor bleeding and irritative symptoms are common side effects in the immediate postoperative period. The major complications of uncontrolled hematuria and clinical bladder perforation occur in 1% to 6.7% of cases (Comploj et al., 2014), although up to 50% of patients can exhibit contrast agent extravasation indicative of minor perforation if cystography is performed (El Hayek et al., 2009). Perforations tend to occur in elderly patients with large posterior wall tumors, particularly in cases involving previous treatment with multiple courses of intravesical therapy (Golan et al., 2011). The incidence of perforation can be reduced by attention to technical details, avoiding overdistention of the bladder, and using anesthetic paralysis during the resection of significant lateral wall lesions to lessen an obturator reflex response. Moreover, large, bulky tumors and those that appear to be muscle invasive are often best resected in a staged manner because it is believed that repeat resection can more safely remove residual tumor if indicated.

The majority of perforations are extraperitoneal; however, intraperitoneal rupture is possible when tumors are resected at the dome (Collado et al., 2000)**. The risk of tumor seeding from perforation appears to be low** (Balbay et al., 2005). However, anecdotal reports have identified extravesical recurrences after perforation, theoretically caused by seeding (Mydlo et al., 1999). It has been suggested that the risk of tumor seeding is higher in patients who undergo surgical repair, but this may be related to patient selection because only serious intraperitoneal perforations are likely to be managed in this manner (Mydlo et al., 1999; Skolarikos et al., 2005). **Bladder perforation during TUR does appears to be associated with greater risk of recurrence and worse disease-free survival in a series published by Comploj et al.** (2014)**. However, neither cancer-specific nor overall survival were affected in this series because these patients were more likely to undergo radical cystectomy.**

Extraperitoneal bladder perforation during TURBT can typically be managed with prolonged urethral catheter drainage. Intraperitoneal perforation is less likely to close spontaneously and usually requires open or laparoscopic surgical repair. Decisions for surgical correction should be made on the basis of the extent of the perforation and the clinical status of the patient. On occasion, a frozen section of the resected specimen can be performed and if there is clear evidence of muscle invasion, a cystectomy could be advised in lieu of closure of bladder perforation. Open repair of an intraperitoneal perforation or cystectomy will also allow for more thorough washout of the abdomen to potentially reduce the likelihood of local seeding from extravasated tumor.

TUR syndrome from fluid absorption is uncommon, particularly with the use of bipolar energy, and managed in the same manner as during transurethral resection of the prostate (TURP).

As long as resection of the ureteral orifice is performed with pure cutting current, scarring is minimal and obstruction unlikely. Cystoscopy to visualize efflux, which can be aided by intravenous administration of indigo carmine or methylene blue or retrograde ureteropyelography, can aid in determination of potential obstruction. In tumors that are close to the ureteral orifice, placement of an open-ended ureteral catheter before resection will help avoid encroachment of the orifice during resection. If fluorescence cystoscopy is in use as described later, the urine jet will appear green and can thus be visualized as well. If the orifice is resected or coagulation current is used nearby, renal ultrasonography in the postoperative period can aid in identification of asymptomatic obstruction. In one series, risk of ureteral stricture formation was rare at approximately 4% after TUR of the ureteral orifice, and most cases of hydronephrosis either resolved spontaneously or were associated with invasive disease (Mano et al., 2012). Balloon dilation of the orifice or endoscopic incision can relieve obstruction, but failure to respond will occasionally necessitate reimplantation (Chang et al., 1989).

Repeat Transurethral Resection of Bladder Tumor

Complete tumor removal is not always possible, whether as a result of excessive tumor volume, anatomic inaccessibility, medical instability requiring premature cessation of initial resection, or risk of perforation. It is important to obtain adequate muscle in the biopsy specimen to evaluate muscle invasion, particularly in cases in which T1 disease is identified or invasive tumor is suspected. This may also be important for high-grade tumors, although that seems to be less critical. The AUA and the EAU guidelines recommend obtaining muscle for evaluation by performing a second TUR if necessary in cases of incomplete resection, if no muscle is present in the initial specimen and in high-grade T1 tumors, although more emphasis is placed on this approach for T1 tumors (Babjuk et al., 2017; Chang et al., 2016).

Incomplete initial resection is often noted in such circumstances, as evidenced by data suggesting that tumors are noted at the first cystoscopic evaluation in up to 45% of patients (Brausi et al., 2002) and that residual tumor is identified at the site of the initial resection at least 40% of the time when repeat TUR is performed within several weeks of original resection (Klan et al., 1991; Mersdorf et al., 1998; Vogeli et al., 1998). In a review, Miladi et al. (2003) found that a second TURBT detected residual tumor in 26% to 83% of patients and corrected clinical staging errors in half of those patients.

In the case of high-risk, high-grade Ta tumors, multiple series suggest that residual tumor can be identified in up to 50% of cases (Grimm et al., 2003; Herr, 1999), and upstaging is noted in up to 15% of patients on repeat TURBT (Vianello et al., 2011). Given these findings, AUA guidelines recommend consideration of repeat TURBT of the primary tumor site within 6 weeks of initial TURBT in the setting of high-risk, high-grade Ta tumors (Chang et al., 2016).

In the setting of high-grade T1 tumors, repeat TURBT is recommended

within 6 weeks of initial TURBT based on the well-established risk of identifying worse prognostic findings or upstaging to muscle-invasive disease in up to 25% to 30% of repeat TURBT specimens (Herr, 2015; Schwaibold et al., 2000). **This is especially important if no muscle is identified on initial pathology, where repeat resection of patients with T1 disease can identify upstaging to muscle-invasive disease in up to 49% of cases** (Herr, 1999). Understaging is much more likely in T1 tumors when muscle is absent compared with when muscle is present in the specimen (64% vs. 30%) (Dutta et al., 2001). Herr (1999) reported that a second resection changed treatment in one-third of patients. Survival was 63% in patients who underwent a second TURBT versus 40% for those who did not in a German observational study (Grimm et al., 2003), and recurrences appear to be lower after repeat TUR (Sfakianos et al., 2014). Randomized data have also demonstrated that patients with T1 disease at initial resection who undergo a second TUR demonstrate lower rates of recurrence and progression (Divrik et al., 2010). Furthermore, the efficacy of BCG in preventing recurrence and progression appears to be higher in patients with high-grade papillary tumors and CIS if a restaging TURBT was performed before instillation of BCG (Herr, 2005). Finally, if residual stage T1 is noted on repeat TURBT, risk of progression has been demonstrated to be as high as 80% (Herr et al., 2007), thereby suggesting potential benefit of early cystectomy in these patients.

Repeat resection also is helpful in the setting of a second opinion, unless clear evidence of muscle invasion is identified on the initial resection, especially if the outside pathology slides are not available for review. In addition, subspecialty pathological reinterpretation at the time of second opinion can yield information, potentially leading to a change in management in almost one-third of patients (Lee et al., 2010).

In summary, given the data presented earlier, patients with stage T1 tumors merit repeat TUR. Patients with no muscle present in the initial specimen appear to benefit most in terms of recurrence, progression, and cancer-specific and overall survival (Gontero et al., 2016). As such, **AUA guidelines recommend repeat TURBT of primary tumor site, to include muscularis propria, within 6 weeks of the initial TURBT in patients with incomplete initial resection, and patients with stage T1 disease. These guidelines also recommend consideration of repeat TURBT in patients with high-risk, high-grade Ta tumors** (Chang et al., 2016).

Random Bladder Biopsies

Biopsies of any suspicious areas are an important part of a complete evaluation. Cold-cup biopsies may not provide as much information regarding muscular invasion but provide tissue sampling without cautery artifact (Smith, 1986; Soloway et al., 1978).

The use of random biopsies to identify CIS in otherwise normal-appearing mucosa remains controversial. May et al. (2003) performed random biopsies in high-risk patients and found that the results were positive in 12.4% and altered treatment in 7%, including 14 of 1033 patients in whom the only positive tissue was in the random biopsy specimen, rather than the primary resected tumor. However, even when velvety red patches were sampled, only 11.9% of biopsy specimens were positive in one report (Swinn et al., 2004). A European Organisation for Research and Treatment of Cancer (EORTC) retrospective review found that 10% of random biopsy specimens were positive (3.5% CIS) and concluded that such biopsies were not warranted (van der Meijden et al., 1999). Fujimoto et al. (2003) prospectively evaluated the role of random biopsies of normal-appearing urothelium and found cancer in only 8 of 100 biopsy samples, 5 of which were CIS. They concluded that random biopsies are indicated only in the setting of multiple tumors or positive cytology. **The current consensus is that random biopsies are not indicated in low-risk patients** (i.e., those with low-grade papillary tumors and negative cytology), but there remains no consensus with regard to patients with high-grade disease, and many urologists perform random biopsies in this setting particularly if urine cytology is positive.

Prostatic urethral biopsy using the cutting loop may be performed, especially if neobladder creation is anticipated for high-risk disease, but bleeding may be more common (Holzbeierlein and Smith, 2000). The additional value of the information obtained from cold-cup and or loop resected urethral biopsies must be weighed against the theoretic risk that such biopsies provide an exposed bed to aid tumor implantation (Kiemeney et al., 1994; Yamada et al., 1996). **Traditional teaching is that TURP and TURBT of a low-grade bladder tumor may be performed at the same setting but that resection of a high-grade bladder tumor should not be performed coincident to TURP to avoid tumor seeding and possible intravasation of tumor cells** likely to metastasize. Despite anecdotal reports of low-grade tumors implanting in the prostatic urethra after simultaneous resection, this risk appears to be small (Tsivian et al., 2003).

Laser Resection

Laser coagulation allows minimally invasive ablation of small papillary tumors up to 2.5 cm. The neodymium : yttrium-aluminum-garnet (Nd : YAG) laser has the best properties for use in bladder cancer. **The most significant complication of laser therapy is forward scatter of laser energy to adjacent structures, resulting in perforation of a hollow, viscous organ such as overlying bowel.** This is rare but more commonly occurs with the Nd : YAG laser because of its deeper tissue penetration than with holmium (Ho):YAG and potassium titanyl phosphate (KTP) lasers (Smith, 1986). Unless higher energy is necessary for a very large tumor, **limiting energy to 35 W precludes exceeding 60°C on the outer bladder wall, minimizing the risk of perforation** (Hofstetter et al., 1994).

Laser therapy can be more expensive than resection because of the cost of laser fibers, but bleeding is negligible and there is no risk of obturator reflex. More recently en bloc resection of bladder tumors (EBRT) has been accomplished using a Thulium laser. Tumors from 1 to 5 cm have been resected using this technique, and it appears to be safe and comparable with standard electrical TUR with low incidence of bleeding and bladder perforation (Kramer et al., 2015). A systematic review of the literature has identified that en bloc resection provides more than 95% rates of detrusor muscle in specimen, allowing for high-quality pathological evaluation with similar perioperative morbidity and recurrence rates to conventional TURBT (Kramer et al., 2017).

Office-Based Endoscopic Management

Many patients with small (typically <0.5–1 cm), low-grade recurrences can be managed safely in the office setting with use of diathermy or laser ablation (Donat et al., 2004). Instillation of viscous or injectable 1% to 2% lidocaine mixed with bicarbonate through a catheter and a dwelling time of 15 to 30 minutes yields mucosal analgesia, although pain with fulguration of 1- to 5-mm tumors is often acceptable without analgesia. A prior tissue diagnosis and a negative cytology for the initial tumor occurrence are mandatory to determine whether the tumor is of high or low grade.

In addition, **many small, low-grade tumors can be safely observed until they exhibit significant growth because of the minimal risk of progression** (Pruthi et al., 2008; Soloway et al., 2003).

Enhanced Cystoscopic Techniques: Fluorescence Cystoscopy, Narrow Band Imaging, Optical Coherent Tomography, and Confocal Laser Endomicroscopy

Endoscopically, urologists can suspect malignancy based solely on the presence of visible changes such as tumors or “red spots.” However, a multicenter study found that 37% of the biopsies performed on the basis of suspicious endoscopic findings resulted in a false-negative biopsy, emphasizing the subjectivity and attendant false-positive and false-negative rates of cystoscopy (Riedl et al., 2001). **The imperfect sensitivity of cystoscopy potentially explains, at least in part, the high rate of cancer recurrence soon after complete removal of all visible tumors.** It is likely that in many such cases, cancer was already present but not visible at the time of resection and simply became visible at follow-up when it became morphologically abnormal enough to differentiate from adjacent normal urothelium. To aid in identification of such tumors or satellite lesions, numerous techniques have been developed to enhance the use of standard cystoscopy.

Photoactive porphyrins accumulate preferentially in neoplastic tissue. Under blue light they emit red fluorescence, which can help in the diagnosis of indiscernible malignant lesions. Originally, studies conducted using intravesical application of 5-aminolevulinic acid (5-ALA), a precursor of photoactive porphyrin, resulted in residual systemic photosensitization (Lange et al., 1999). Hexaminolevulanic acid is a derivative that avoids the systemic photosensitization. Hexaminolevulanic acid has been approved widely for use in fluorescence or “blue light” cystoscopy, also known as photodynamic diagnosis, or PDD.

When blue light technology is used, small papillary tumors and almost one-third more cases of CIS overlooked on cystoscopy are identified (Fradet et al., 2007; Jichlinski et al., 2003; Schmidbauer et al., 2004) (Fig. 136.7). In one study, 96% of all tumors were detected with hexaminolevulinate (HAL) imaging compared with 77% with standard cystoscopy. Detection was improved for CIS (95% vs. 68%), and papillary tumors (96% vs. 85%) (Jocham et al., 2005). The clinical impact of improved tumor detection seems intuitive, and prospective evidence has shown that this decreases recurrence rates in patients who undergo HAL fluorescence cystoscopy compared with controls (Denzinger et al., 2007;

Filbeck et al., 2003; Grossman, 2007; Rink et al., 2013). The impact appears to persist for at least 4 years. There may be an impact on progression, although one study that examined this was underpowered to prove this trend (Stenzl et al., 2010). Fluorescence cystoscopy can also be used in the office setting with flexible cystoscopy (Fig. 136.8). Studies have demonstrated that even with flexible cystoscopy about 20% more recurrent papillary tumors and 34% more areas of CIS can be detected using fluorescence cystoscopy (Daneshmand et al., 2017). Another advantage of fluorescence cystoscopy is the ability to more accurately assess thoroughness of TUR. This would allow for more complete resection at the initial setting and reduce recurrence rates. A meta-analysis of all the studies incorporating this technique suggests that fluorescence cystoscopy can decrease recurrence up to 1 year and beyond, but not all studies consistently demonstrate this finding (Chou et al., 2017).

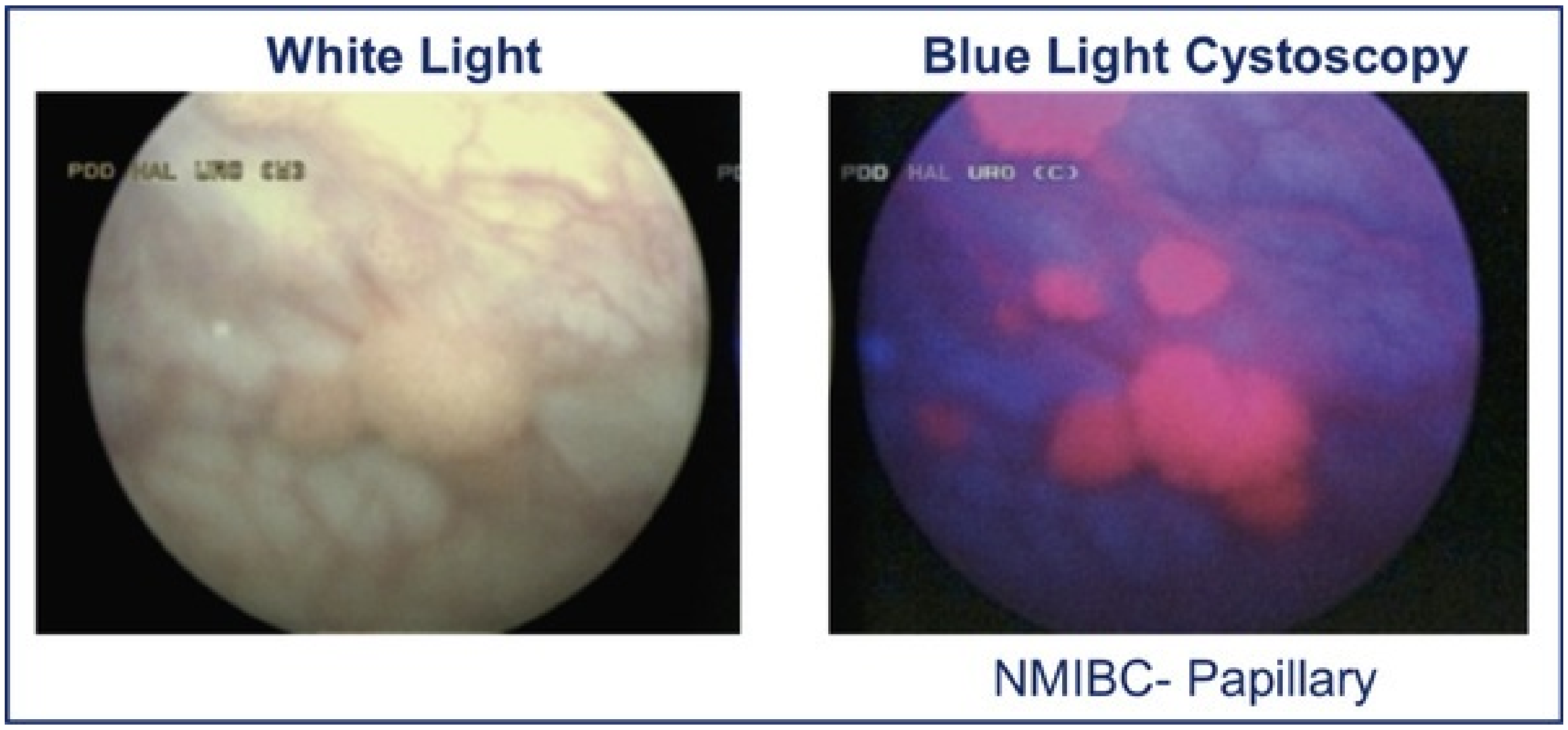

FIG. 136.7 White light cystoscopy reveals apparent normal-appearing mucosa juxtaposed with blue light cystoscopy demonstrating visual evidence of bladder cancer. Blue light cystoscopy reveals accumulation of hexaminolevulinate in the same area, ultimately found to contain non–muscle-invasive bladder cancer (NMIBC). (Image courtesy Dr. Siamak Daneshmand.)

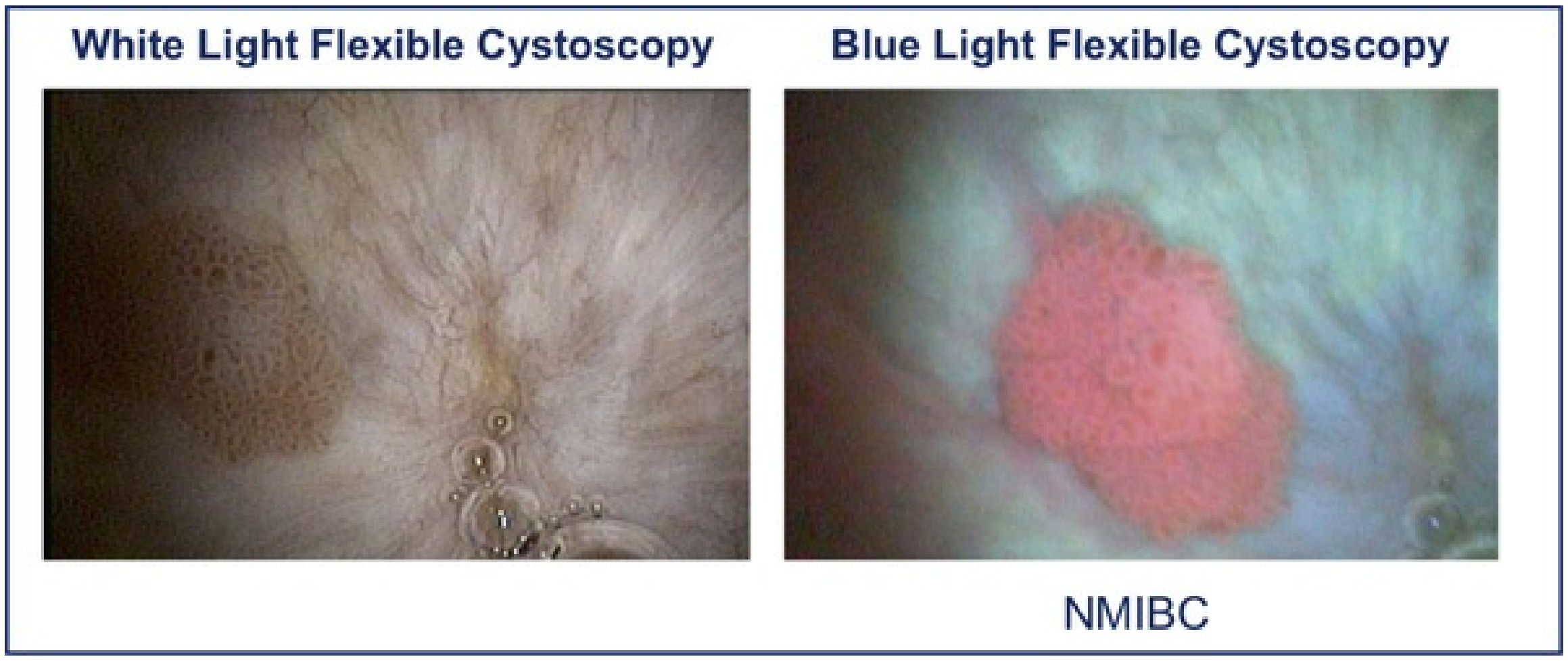
White Light Flexible Cystoscopy
Blue Light Flexible Cystoscopy
NMIBC

FIG. 136.8 White and blue light cystoscopy of non–muscle-invasive bladder cancer (NMIBC) using flexible cystoscopy after administration of hexaminolevulinate. (Image courtesy Dr. Siamak Daneshmand.)

Narrow band imaging (NBI) is an optical image enhancement technology intended to improve the visibility of blood vessels inherent to neoplastic processes. NBI light is composed of two specific wavelengths that are absorbed by hemoglobin; 415-nm light penetrates only the superficial mucosal layers, whereas 540-nm light penetrates more deeply. The combination allows improved visualization of tumors and enables distinguishing blood vessels on and below the surface from tumors. Several studies have been performed that reveal that NBI is able to detect more papillary tumors as well as CIS (Xiong et al., 2017). Initial studies suggest that about 13% more tumors could be diagnosed by NBI (Herr and Donat, 2008). More tumors were found using NBI compared with cystoscopy in 56% of cases. False-positive rates of NBI, however, are approximately 60%. TUR performed with NBI was also found to be more thorough, yielding reduced recurrence rates after TUR (Naselli et al., 2010, 2012). A more recent randomized trial conducted by Naito et al. (2016) demonstrated that the recurrence rates after TUR performed under white light cystoscopy and with NBI were no different. However, short-term recurrence rates at up to 3 months were reduced in low-risk tumors. This suggests that NBI-based resection may allow more thorough resection of surface tumors but cannot alter the pattern of recurrence in higher risk tumors.

Optical coherence tomography is a real-time imaging technology using near-infrared light (890–1300 nm) to provide cross-sectional images of biologic tissues. A small probe can be passed via cystoscope into bladder to allow real-time examination of bladder tumors. This technology is able to distinguish layers of urothelium and lamina propria as well as muscularis propria and distinguish between benign and malignant characteristics (Lerner and Goh, 2015). Early experience suggests more than 90% sensitivity, specificity, and negative predictive value with regard to detecting muscle invasion at time of cystoscopy (Lerner et al., 2008), which may facilitate determining appropriate depth of resection.

Confocal laser endomicroscopy involves administration of fluorescein and use of a 488-nm low-power laser to scan the tissue section of interest below the surface. Specific optical diagnostic criteria are then used to characterize tissue at the micro-architectural and cellular level to distinguish between normal urothelium, benign inflammatory lesions, and low- versus high-grade tumors (Chen et al., 2014).

Enhanced cystoscopic techniques are now included in the AUA guidelines (Chang et al., 2016) **as techniques to be considered for improving detection rates and for ensuring more complete TUR.**

Key Points: Endoscopic Surgical Management

- TURBT is performed to remove all visible tumors and to provide specimens for pathological examination to determine stage and grade.
- Repeat resection within 2 to 6 weeks is usually indicated in patients with high-grade disease, especially if no muscle was present in the initial TURBT.
- All suspicious lesions should be sampled, but random biopsies are not required in low-risk patients.
- Office-based fulguration and observation may be applied to certain low-risk patients.
- Fluorescence cystoscopy with 5-ALA derivatives and NBI improves the ability to visualize inconspicuous tumors and could reduce short- and long-term recurrence rates after TUR.

Intravesical Therapy

Perioperative Intravesical Therapy

It is believed that tumor cell implantation immediately after transurethral resection is responsible for many early recurrences, and this has been used to explain the observation that initial tumors are most commonly found on the floor and lower sidewalls of the bladder, whereas recurrences are often located near the dome as a result of "flotation" (Heney et al., 1981). Thus intravesical chemotherapy to kill such cells before implantation has been used for decades (Klan et al., 1991; Zincke et al., 1983).

Mitomycin C (MMC) appears to be the most effective adjuvant intravesical chemotherapeutic agent perioperatively, although epirubicin is used in Europe and direct comparative studies are lacking (Witjes and Hendricksen, 2008). **Consistent with its proposed mechanism of action to prevent tumor cell implantation, a single dose administered within 6 hours lessens recurrence rates, whereas a dose 24 hours later does not** (Duque and Loughlin, 2000; Isaka et al., 1992; Oosterlinck et al., 1993; Sekine et al., 1994; Solsona et al., 1999), and maintenance therapy does not reduce the risk further (Bouffioux et al., 1995; Tolley et al., 1996).

A meta-analysis of the use of perioperative chemotherapy found that low-risk patients experience a drop in the odds of recurrence from 48.4% to 36.7% at a median follow-up of 3.4 years. Patients with multiple tumors experienced a 56% reduction in the odds of recurrence. MMC, epirubicin, and pirarubicin significantly decreased the recurrence of single and multiple tumors. Thiotepa did not show the same benefit, but data were limited and some studies used diluted strengths (Sylvester et al., 2004). The number needed to treat (NNT) to prevent one recurrence in the meta-analysis was 8.5, so some authors have suggested that intravesical chemotherapy reduces overall cost of care by reducing the need for secondary resections. However, subsequent studies have shown that the tumors prevented are primarily smaller tumors that are often treated in the office or ambulatory surgery setting (Berrum-Svennung et al., 2008). In addition, the benefit appears limited to patients with low risk of recurrence (Gudjónsson et al., 2009), so the economic impact regarding recurrences remains controversial if recurrences are treated in any manner other than inpatient care (Lee et al., 2012; Rao and Jones, 2009). Randomized trial data have demonstrated that immediate intravesical instillation of mitomycin C reduces the risk of recurrence, even in patients treated with ongoing adjuvant instillations (Bosscheiter et al., 2018). **Hence, level 1 evidence demonstrates that a single-dose of mitomycin C or epirubicin instilled within 6 hours after resection reduces tumor recurrence, particularly for the initial presentation of a solitary papillary low-grade tumor.**

Studies using post-TUR instillation of gemcitabine have yielded mixed results. In one randomized study published by Böhle et al. (2009), recurrence-free survival at 1 year was no different in patients undergoing gemcitabine instillation vs saline. All patients in this study underwent more than 20-hour irrigation of the bladder with saline, thus raising the question of whether the continuous irrigation of the bladder post TUR can be helpful in reducing recurrence rates through mechanical extraction of floating cells. To this end, sterile water irrigation (Moskovitz et al., 1987) and normal saline continuous bladder irrigation have been evaluated and shown potential to reduce tumor recurrences after TURBT (Onishi et al., 2017). In a more recent phase III randomized trial completed by the Southwest Oncology Group (SWOG), intravesical administration of gemcitabine was again compared with saline in the immediate post-TURBT setting. In this trial, reported by Messing et al. (2017), gemcitabine demonstrated a 34% reduction in the likelihood of tumor recurrence with a very favorable side-effect profile. Hence gemcitabine remains an alternative option for perioperative intravesical chemotherapy.

The use of perioperative intravesical therapy is widespread in Europe but has achieved less frequent adoption in the United States (Madeb et al., 2009) potentially because of the cost, complexity, and potential for side effects, combined with the fact that it has not been shown to have adequate impact for recurrent, multiple, or high-grade tumors (Sylvester et al., 2004). A more detailed analysis of more than 2000 cases derived from 5 large practice sites in the United States revealed that post-TUR instillation of chemotherapy was used in an appropriate and judicious manner in up to 85% of cases and avoided mainly because of suspicion of perforation in many cases (Barocas et al., 2013).

Although local irritative symptoms are the most common complications of postoperative instillation, serious sequelae and rare deaths have also occurred, especially in patients with perforation during resection (Oddens et al., 2004). Other reported conditions associated with intravesical chemotherapy (with perioperative or multi-dose regimens) include chemical cystitis, cutaneous desquamation, decreased bladder capacity as a result of contractures, calcified eschars, and complications or added difficulty of subsequent cystectomy (Fig. 136.9; Cliff et al., 2000; Doherty et al., 1999; Nieuwenhuijzen et al., 2003; Oddens et al., 2004; Shapiro et al., 2006). **Chemotherapy should be withheld in patients with extensive resection or when there is concern about perforation.**

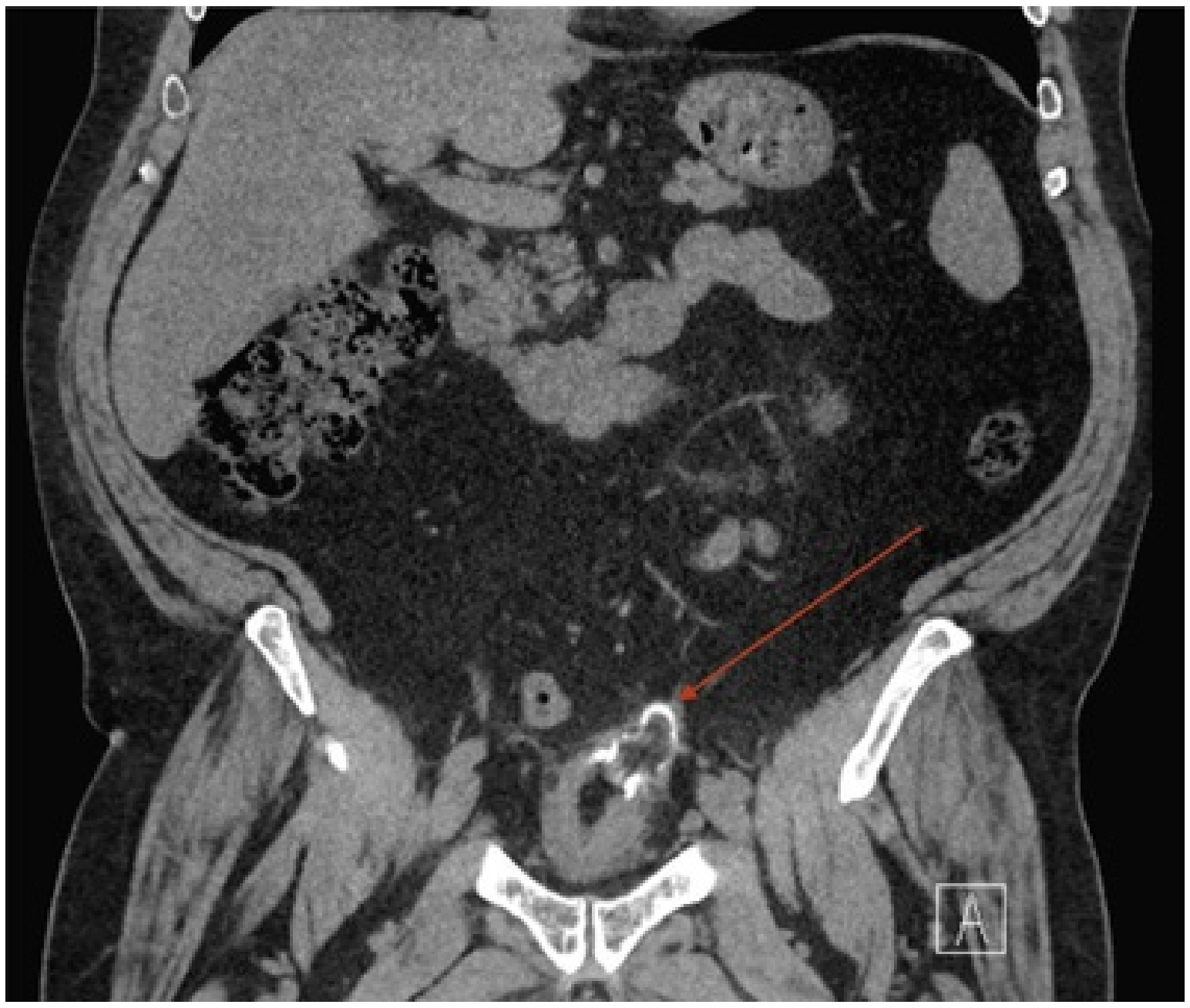

FIG. 136.9 CT image taken from image of a 59-year-old male who received perioperative administration of mitomycin C at time of transurethral resection of bladder tumor in the setting of extravesical perforation. This patient subsequently developed calcified, necrotic tissue associated with non-healing bladder ulcer (as pictured in image with *red arrow* pointing to calcified region) and ultimately required radical cystectomy with ileal neobladder secondary to refractory symptoms.

BCG can never be safely administered immediately after TUR because the risk of bacterial sepsis and death is high.

Key Points: Perioperative Intravesical Therapy to Prevent Tumor Implantation

- Single-dose intravesical chemotherapy administered within 6 hours of resection reduces recurrence of low-risk tumors with significant impact in the setting of initial presentation of solitary low-grade papillary tumors.

- The incremental benefit in patients with recurrent or multiple tumors is limited.
- No benefit has been found in patients with high-grade disease.

Intravesical Immunotherapy

Bacille Calmette-Guérin

BCG is an attenuated mycobacterium developed as a vaccine for tuberculosis that has demonstrated antitumor activity in several different cancers including UC (Morales et al., 1976). The original regimen described by Morales included a percutaneous dose, which was discontinued after success with a similar intravesical regimen by Brosman (1982).

BCG powdered vaccine is reconstituted with 50 mL of saline and is routinely administered through a urethral catheter. **Treatments are typically started 2 to 4 weeks after tumor resection, allowing time for re-epithelialization of the bladder after TURBT, thereby minimizing the potential for intravasation of live bacteria** (Lamm et al., 1992)**. A urinalysis is usually performed immediately before instillation to further confirm absence of infection or significant bleeding to decrease the likelihood of systemic uptake of BCG. In the event of a traumatic catheterization, the treatment should be delayed for at least several days,** depending on the extent of injury. Active urinary tract infection is often considered an indication to delay treatment until it has been managed; however, recent publications question the need to avoid BCG in the presence of asymptomatic bacteriuria (Herr, 2012). **After instillation, the patient should retain the solution for at least 1 to 2 hours.** Some clinicians have advocated that the patient turn from side to side to bathe the entire urothelium, but there is no scientific support for this practice. Fluid, diuretic, and caffeine restriction before instillation limits dilution of the agent by urine and facilitates adequate retention of the agent for 2 hours (Lamm et al., 2000b). Patients are commonly instructed to clean the toilet with bleach, although there is no demonstrable risk of close contact infection.

Mechanism of Action

Intravesical immunotherapy results in a robust local immune response characterized by induced expression of cytokines in the urine and bladder wall and by an influx of granulocytes and mononuclear and dendritic cells (Shen et al., 2008). **The initial step appears to be direct binding to fibronectin within the bladder wall,** subsequently leading to direct stimulation of cell-based immunologic response and an antiangiogenic state. Numerous cytokines involved in the initiation or maintenance of inflammatory processes including tumor necrosis factor-α (TNF-α), granulocyte-macrophage colony-stimulating factor (GM-CSF), interferon-γ (IFN-γ), and interleukin-1 (IL-1), IL-2, IL-5, IL-6, IL-8, IL-10, IL-12, and IL-18 have been detected in the urine of patients treated with intravesical BCG and other immunostimulatory agents. Release of tumor necrosis factor–related apoptosis inducing ligand (TRAIL) also appears to be a key event in propagation of the BCG response and is associated with response to BCG (Ludwig et al., 2004). **The observed pattern of cytokine induction with preferential upregulation of IFN-γ, IL-2, and IL-12 reflects induction of a T-helper type-1 (Th1) response.** This immunologic response activates cell-mediated cytotoxic mechanisms believed to underlie the efficacy of BCG and other agents in the prevention of recurrence and progression (Bohle and Brandau, 2003). BCG may concomitantly stimulate IL-10, resulting in the suppressive Th2 response. Overall, response to intravesical immunotherapy may be limited if a patient has an immunosuppressive disease or by advanced age (Joudi et al., 2006a, 2006b). More recent data, however, suggest that BCG can be used safely in patients who are immunosuppressed such as transplant recipients and those on systemic steroid therapy without significant increase in side effects or BCG sepsis (Herr and Dalbagni, 2013). Response to BCG therapy may not be as robust as seen in patients who are not similarly immunosuppressed.

Bacille Calmette-Guérin Treatment of Carcinoma in Situ

BCG is the most commonly used intravesical agent in the United States, whereas intravesical chemotherapy is more commonly used in other parts of the world. BCG is approved for intravesical treatment of NMIBC by the US Food and Drug Administration (FDA). Before the adoption of BCG intravesical therapy, CIS reportedly progressed at an average rate of 7% per year (Zincke et al., 1985). **The initial tumor-free response rate is as high as 84%** (Brosman, 1982; De Jager et al., 1991; Hudson and Herr, 1995; Lamm et al., 2000a, 2000b, 2000c). **Approximately 50% of patients experience a durable response for a median period of 4 years. Over a 10-year period, approximately 30% of patients remain free of tumor progression or recurrence, so close follow-up is**

mandatory. The majority of these occur within the first 5 years (Herr et al., 1992). Herr et al. (1989) **reported progression in 19% of initial responders at 5 years but found the rate to be 95% in nonresponders—findings confirmed by other investigators** (Coplen et al., 1990; Harland et al., 1992). **The current AUA guidelines panel recommends BCG as the preferred initial treatment option for high-risk bladder tumors and as a potential option either up front or preferably after intravesical chemotherapy for intermediate-risk tumors** (Chang et al., 2016).

BCG has gained a preeminent role in North America on the basis of higher efficacy reports compared with intravesical chemotherapy (O'Donnell, 2007). BCG is more effective than intravesical mitomycin C but only when comparing BCG induction + maintenance doses versus a 6-week induction course of mitomycin alone. Furthermore, intravesical BCG instillation is associated with reduced risk for recurrence as well as progression (Chou et al., 2017), whereas intravesical chemotherapy does not appear to affect progression. BCG instillation is, however, associated with a greater risk of adverse events including cystitis, dysuria, hematuria, and fever as compared with other intravesical therapies (Chou et al., 2017). In more than 600 patients, there was a 68% complete response rate to BCG and a 49% complete response rate to chemotherapy. In responders, 68% of patients treated with BCG remained free of disease as compared with 47% of patients receiving chemotherapy, on the basis of a median follow-up of 3.75 years. The overall disease-free rates were 51% and 27%, respectively (Sylvester et al., 2005). More recently, meta-analysis data have further identified that mitomycin C, doxorubicin, epirubicin, and thiotepa are associated with a decreased risk of recurrence. Unlike BCG, however, these intravesical chemotherapeutic agents do not appear to decrease the risk of progression (Chou et al., 2017).

Bacille Calmette-Guérin Treatment of Residual Tumor

Intravesical BCG can effectively treat residual papillary lesions but should not be used as a substitute for surgical resection. Investigators have demonstrated a nearly 60% response by residual tumor with intravesical BCG alone (Brosman, 1982; Coplen et al., 1990; Schellhammer et al., 1986).

Carcinoma of the mucosa or the superficial ducts of the prostate can be adequately treated by BCG with a 50% tumor-free rate. A limited TURP or fulguration can be effective in decreasing tumor burden and facilitating exposure of the prostate surface to BCG administration (Bretton et al., 1990;

Schellhammer et al., 1995).

Bacille Calmette-Guérin Prophylaxis to Prevent Recurrence

Early single-center studies demonstrated an advantage in decreased tumor recurrence of approximately 30% when a 6-week course of BCG was administered after recovery from TURBT (Brosman, 1982; Morales et al., 1992). In several larger series, tumor recurrence after TURBT was reduced by 20% to 65%, for an average of approximately 40% (Herr et al., 1992; Krege et al., 1996; Melekos et al., 1993; Pagano et al., 1991a, 1991b). A meta-analysis of 2000 patients with Ta, T1, and/or CIS disease found that patients receiving maintenance BCG had a statistically decreased rate of recurrence compared with those receiving induction therapy alone (Han and Pan, 2006). A subsequent reevaluation of the published data concluded that 3 years of maintenance therapy was supported by the literature but that patients with intermediate-risk disease may be equally managed with 1 year of maintenance (Ehdaie et al., 2013). A more recent meta-analysis further identifies a decreased risk of recurrence with BCG administration (Chou et al., 2017).

The efficacy of BCG after TURBT for high-risk papillary disease has been demonstrated in several series of T1 lesions, with recurrence rates of 16% to 40% and progression rates of 4.4% to 40%, a substantial improvement compared with TUR alone (Cookson and Sarosdy, 1992; Gohji et al., 1999; Herr, 1997; Hurle et al., 1999a, 1999b; Jimenez-Cruz et al., 1997; Pansadoro et al., 1995). Tumor multiplicity and associated CIS were associated with increased risk of progression. Substaging lesions on the basis of the presence or absence of muscularis mucosae invasion in a series of 49 patients did not improve prediction of recurrence (69% vs. 65%) or progression (22% vs. 29%) after BCG therapy (Kondylis et al., 2000).

Impact of Bacille Calmette-Guérin on Progression

Although reports of the impact of BCG on tumor recurrence are compelling, the greater need is the potential for impact on progression. In 403 patients with CIS, BCG reduced the risk of progression by 35% compared with intravesical chemotherapy (Sylvester et al., 2002).

In a randomized trial of 86 patients with high-risk superficial disease, Herr et al. (1988) demonstrated a greater delay in interval progression for BCG patients versus TUR controls. In addition, the cystectomy rate was significantly decreased for CIS patients treated with BCG (11% vs. 55% for controls), and time-to-cystectomy was delayed in the BCG group. However, only 27% of patients were alive with an intact functioning bladder after follow-up over 10 to 15 years, so this apparent advantage is temporary in many cases (Cookson et al., 1997). Available data suggest that BCG can delay progression of high-risk bladder cancer, yet the long-term survival advantage is not fully defined.

Nevertheless, meta-analyses have concluded that BCG reduces the risk of progression. Progression at 2.5 years' median follow-up was reduced by 27% (9.8% for BCG vs. 13.8% for non-BCG) in one (Sylvester et al., 2002) and by 23% (7.7% for BCG vs. 9.4% for MMC) at 26-month median follow-up in another analysis (Bohle and Bock, 2004). More recent meta-analysis data further identify reduced risk of progression in patients treated with BCG with an RR of 0.39 based on data from 4 trials (Chou et al., 2017). In each meta-analysis the **superior results with BCG were concentrated in trials using BCG maintenance therapy. In contrast, no chemotherapy trials have achieved a significant reduction in progression** (Chou et al., 2017; Grossman et al., 2008).

Determining Optimum Bacille Calmette-Guérin Treatment Schedule

The optimal treatment schedule and dose for BCG have not been established (Herr et al., 2011). In reality, **several studies and AUA guidelines suggest that a 6-week induction course alone is insufficient to obtain an optimal response in many patients and that maintenance therapy is requisite** (Chang et al., 2016; Lamm et al., 2000a,b,c; Palou et al., 2001).

The average additional response to a second induction course is 25% in those patients treated for prophylaxis and 30% in CIS patients (Bohle and Bock, 2004; Bretton et al., 1990; Coplen et al., 1990; Haaff et al., 1986; Kavoussi et al., 1988; Sylvester et al., 2002). However, **additional courses of BCG to treat refractory patients after a second 6-week course are accompanied by a significant risk of tumor progression in 20% to 50% of patients** (Nadler et al., 1994). Catalona et al. (1987) reported roughly a 7% actuarial risk of progression with every additional course of BCG therapy. **Response to BCG at 6 months can be used as a predictor of prognosis, with the number of patients developing progressive disease being significantly higher among nonresponders** (Orsola et al., 1998).

The **Southwest Oncology Group (SWOG)** reported the most significant impact of maintenance therapy. Patients received a **6-week induction course**

followed by 3 weekly instillations at 3 and 6 months and every 6 months thereafter for 3 years. Estimated median recurrence-free survival was 76.8 months in the maintenance arm and 35.7 months in the control arm (*P* = 0.0001). Average recurrence-free survival was 111.5 months in the control arm and could not be estimated in the maintenance arm (*P* = 0.04). Overall 5-year survival was 78% in the control arm and 83% in the maintenance arm. No toxicities above grade 3 were observed, yet **only 16% of patients tolerated the full dose-schedule regimen.** Two-thirds of the patients who stopped BCG because of side effects did so in the first 6 months, suggesting that the side effects do not increase appreciably with additional time on therapy. **Because of the fact that the treatment group fared better despite most patients having failed to complete the full course of therapy, the maximum benefit may have been achieved earlier. Shorter maintenance schedules and reduced dosages may accomplish the same results with less toxicity** (Lamm et al., 2000a).

More recent data from a randomized non-inferiority study published by Oddens et al. (2013) clarify the use of different durations of maintenance therapy based on risk stratification of the tumor. For patients with intermediate-risk disease, a 1-year course of maintenance BCG was administered at months 3, 6, and 12. In patients with high-risk disease, the instillations were continued every 6 months thereafter up to 3 years. Full dose and one-third dose of BCG were tested in this four-arm trial. The results demonstrated that patients with intermediate-risk disease benefited from 1 year of maintenance therapy with full-dose BCG, whereas patients with high-risk disease obtained the most benefit with 3 years of full-dose BCG therapy. Only 7.1% and 8.3% of patients who received 1 year of maintenance and 3 years of maintenance, respectively, had to discontinue treatment because of side effects. For high-grade T1 lesions or CIS, maintenance therapy has proven superior in multiple studies (Palou et al., 2001). **The determination of whether the optimal treatment schedule should be as described in the SWOG study, monthly, or on some other schedule remains undefined, and optimal duration of a monthly maintenance schedule, if chosen, is not definitively established. However, based on the trial reported by Oddens et al., it appears that the SWOG regimen yields the best results reported to date** (Lamm et al., 2000a, 2000b, 2000c; O'Donnell, 2005, Oddens et al., 2013).

Several investigators have evaluated the potential for BCG dose reduction (Martinez-Pineiro et al., 1995; Melekos et al., 1993; Morales et al., 1992; Pagano et al., 1995). In general, a decrease in toxicity with no statistical difference in efficacy has been noted in small series (Hurle et al., 1996; Mack and Frick, 1995; Pagano et al., 1991b), although multifocal and high-grade tumors may respond better to full dosage (Martinez-Pineiro et al., 2002). Recent meta-analysis data have not demonstrated clear differences between standard and lower doses of BCG in recurrence, progression, or risk of mortality (Chou et al., 2017). Some studies have shown an upregulation of the Th1 response with a lower dose of BCG. Lengthening of the instillation interval may decrease side effects without loss of efficacy (Bassi et al., 2000). Studies in Europe, where BCG inoculation for tuberculosis is more common than in North America, suggest that the dose may be safely reduced by half (Martinez-Pineiro et al., 2002). The difference in response to doing so in immunologically naive North Americans is unknown, but Morales et al. (1992) found a significant decrease in response rates (67% vs. 37%), especially for patients with CIS in combination with papillary tumors treated with the reduced dose. The results from the EORTC trial reported by Oddens et al. (2013), wherein worse responses were observed with one-third dose BCG raises questions about the difference in efficacy between the full-dose and reduced-dose BCG. **Given the variability of this data, the most recent AUA guidelines suggest there is insufficient evidence to prescribe a particular strength of BCG** (Chang et al., 2016).

Antibiotic therapy may have a beneficial effect in treating or preventing systemic side effects of BCG therapy, yet it may also inhibit the effectiveness of BCG therapy if it is given routinely for urinary tract prophylaxis during a course of BCG therapy (Durek et al., 1999a, 1999b). Quinolones were previously thought to affect the viability of BCG (Durek et al., 1999b; Boxes 136.1 and 136.2). However, subsequent randomized studies have demonstrated that short-term use of a quinolone antibiotic such as ofloxacin or prulifloxacin for 24 to 48 hour post-BCG can reduce the cystitis-related side effects of BCG instillation in up to 20% of patients with the most significant reduction in side effects grade II or higher seen in patients after the fourth instillation (Colombel et al., 2006; Damiano et al., 2009). Post-instillation use of quinolones also reduced treatment delays and discontinuations while not affecting recurrence or progression rates. Many urologists use this routinely as part of BCG instillation protocol. A single dose of isoniazid (INH) or a 24-hour duration of INH has been used before or around the time of BCG instillation to reduce side effects. The results of this approach have been mixed with one study demonstrating a reduction and another study showing no change (Al Khalifa et al., 2000; van der Meijden et al., 2001).

Box 136.1

Contraindications to Bacille Calmette-Guérin (BCG) Therapy

Absolute Contraindications

Immunosuppressed and immunocompromised patients[a]
Immediately after transurethral resection on the basis of the risk of intravasation and septic death
Personal history of BCG sepsis
Gross hematuria (intravasation risk)
Traumatic catheterization (intravasation risk)
Total incontinence (patient will not retain agent)

Relative Contraindications

Urinary tract infection (intravasation risk)
Liver disease (precludes treatment with isoniazid if sepsis occurs)
Personal history of tuberculosis (risk theorized but unknown)
Poor overall performance status
Advanced age

No or Insufficient Data on Potential Contraindications

Patients with prosthetic materials have not been shown to have increased risk of infectious or other complications in limited literature (Rosevear et al., 2010)
Ureteral reflux
Anti–tumor necrosis factor medications (theoretically predispose to BCG sepsis)

---

[a] Recent small series suggest this may not be an absolute contraindication (Herr, 2012).

From Ehlers S: Why does tumor necrosis factor targeted therapy reactivate tuberculosis? *J Rheumatol (Suppl)* 74:35–39, 2005.

Box 136.2

Management of Bacille Calmette-Guérin (BCG) Toxicity

Grade 1: Moderate Symptoms <48 Hours

Mild or moderate irritative voiding symptoms, mild hematuria, fever <38.5°C

Assessment

Possible urine culture to rule out bacterial urinary tract infection

Symptom Management

Anticholinergics, topical antispasmodics (phenazopyridine), analgesics, nonsteroidal anti-inflammatory drugs

(Asymptomatic prostatic granulomas that occur after BCG therapy can occasionally mimic prostate cancer clinically and/or radiographically. There is no evidence to support treatment in this setting [Suzuki et al., 2013].)

Grade 2: Severe Symptoms and/or >48 Hours

Severe irritative voiding symptoms, hematuria, or symptoms lasting >48 h

All maneuvers for grade 1, plus the following:

Assessment

Urine culture, chest radiograph, liver function tests

Management

Consider dose reduction to one-half to one-third of dose when instillations resume.
Treat culture results as appropriate.
Can also consider pre-treating with a single dose of isoniazid before each subsequent instillation

Antimicrobial Agents

Administer isoniazid and rifampin orally until symptom resolution.
Also use vitamin B6 or pyridoxine.
Do not use monotherapy.
Observe for rifampin drug-drug interactions (e.g., warfarin).
Monitor liver function tests.

Grade 3: Serious Complications (Hemodynamic Changes, Persistent High-Grade Fever)

Allergic Reactions (Joint Pain, Rash)

Perform all maneuvers described for grades 1 and 2, plus the following:
Isoniazid and rifampin, depending on response.
Also use vitamin B6 or pyridoxine.

Solid Organ Involvement (Liver, Lung, Kidney)

Stop BCG instillations. Initiate antimycobacterial therapy with isoniazid, rifampin. If symptoms persist, consult with Infectious Disease specialist with expertise in anti-tuberculous therapy. Can add ethambutol.
Cycloserine often causes severe psychiatric symptoms and is to be strongly discouraged.
BCG is almost uniformly resistant to pyrazinamide, so this drug has no role.
Consider prednisone when response is inadequate or for septic shock (never given without effective antibacterial therapy).

Assessing the response to BCG is a critical component to successful treatment with this agent. It is largely understood that the patient's immune response is a critical predictor for outcomes with BCG. As such, Kamat et al. (2016) have developed a nomogram to predict response to BCG based on a cytokine panel. This cytokine panel for response to intravesical therapy (CyPRIT) evaluates a number of urinary cytokines after BCG administration, with a nomogram based on these findings demonstrating prediction of recurrence with AUC of 86%. This and similar techniques have the potential to provide a useful tool for predicting response to immunotherapy.

Interferon

IFNs are glycoproteins produced in response to antigenic stimuli. These agents have multiple antitumor activities including inhibition of nucleotide synthesis; upregulation of tumor antigens, antiangiogenic properties; and stimulation of cytokine release with enhanced T- and B-cell activation, as well as enhanced natural killer cell activity (Naitoh et al., 1999). Among several subtypes, IFN-α has been the most extensively studied. It is most active in doses of at least 100 million units, although optimal dose and administration schedule have yet to be determined (Belldegrun et al., 1998; Torti et al., 1988).

IFN as a solitary agent is more expensive and less effective than BCG or intravesical chemotherapy in eradicating residual disease, preventing recurrence of papillary disease, and treating CIS (20% to 43% complete response). Its long-term efficacy for CIS is less than 15% (Belldegrun et al., 1998). A randomized trial demonstrated CIS responses from 5% at low doses (10 million units) to as high as 43% at high doses (100 million units) (Torti et al., 1988). As a prophylactic agent, IFN alone demonstrated recurrence rates that were inferior in general to those of BCG alone (from 60% to 16%) (Glashan, 1990; Kalble et al., 1994). It has demonstrated limited activity against T1 tumors (Malmstrom, 2001). However, it can occasionally be effective in patients in whom BCG has failed (15% to 20% complete response; see later).

IFN-α has also been studied in a combination treatment regimen with either chemotherapy or BCG (Bercovich et al., 1995; Stricker et al., 1996). There appeared to be additive effects with either epirubicin or MMC. **Several trials investigated the combination of BCG and IFN and suggested the potential superiority of the combination or the possibility of decreasing the dose of BCG, which may reduce side effects. Initial work by O'Donnell et al.** (1999) **reported a 63% disease-free rate at 12 months and 53% at 24 months with use of combination therapy.** A subsequent randomized trial conducted in BCG-naive patients compared BCG with BCG + interferon α-2b in a cohort of 670 patients (Nepple et al., 2010). Patients were also secondarily randomized to receiving megadose multivitamins or recommended daily allowance of multivitamins. There appeared to be no difference among all four groups, suggesting that the addition of interferon α-2b as well as megadose multivitamins did not significantly affect response to BCG. At this point the main benefit of adding interferon α-2b to BCG appears to be the fact that the dose of BCG can be reduced to a third or lower without compromising the efficacy of the regimen.

Investigational Immunotherapeutic Agents

A number of novel agents have shown potential, but none has reached clinical practice. Keyhole limpet hemocyanin (KLH) from the hemolymph of the mollusk *Megathura crenulata* is a nonspecific immune stimulant whose potential effectiveness in UC was identified serendipitously (Jurincic et al., 1989; Olsson et al., 1974). Recent work suggests continued promise for this agent but no clear superiority to available agents (Lammers et al., 2012). Mycobacterial cell wall DNA extract contains a mixture of immunostimulatory DNA attached to antigenic cell wall. Phase II trial results indicate success rates less than those achieved with BCG but with good tolerability; however, no agent is commercially available (Morales et al., 2001, 2009). A phase II single-arm study of this agent was conducted in 129 patients by Morales et al. (2015), which demonstrated an overall disease-free survival rate of 19% at 2 years. The disease-free survival was higher (35%) in patients with papillary-only tumors. A phase III study of the same agent was suspended because of poor accrual. Only 75 patients of an anticipated 450 patients were enrolled, and no significant difference between groups was noted.

IL-2 is highly expressed after BCG stimulation and is a key component of the Th1 immune response. Preclinical data suggest a potential benefit and little toxicity (Horinaga et al., 2005). Multiple studies have documented the potential use of either intravesical IL-2 alone, with BCG, or with BCG and IFN (Shapiro et al., 2007). Preclinical data identifying the efficacy of liposome-mediated intravesical IL-2 with biologic response modifiers have elucidated long-term T-cell memory against muscle-invasive bladder cancer and NMIBC (Horiguchi et al., 2000; Larchian et al., 2000). Combination therapy with BCG and intravesical interferon α-2b and IL-2 along with granulocyte colony-stimulating factor has been shown to yield surprisingly high response rates in patients who had previously failed intravesical BCG therapy (Steinberg et al., 2017).

Key Points: Immunotherapy

- Intravesical BCG has higher efficacy and side effects compared with intravesical chemotherapy.
- BCG should be used cautiously for patients with low-risk disease because of concern about side effects.
- Management of infectious complications of BCG is shown in Box 136.2.
- BCG is the only agent shown to delay or reduce high-grade tumor progression.
- The optimal dose and the treatment schedule for BCG are undetermined, but results are better with maintenance therapy, if tolerated.
- BCG is contraindicated in the setting of a disrupted urothelium because of the risk of intravasation and BCG sepsis.

Intravesical Chemotherapy

Induction therapy using chemotherapeutic agents instilled within 6 hours of TURBT has demonstrated a clear impact on recurrence rates, as described earlier and are recommended in current clinical guidelines (Chang et al., 2016). However, the role of chemotherapy in the adjuvant setting is less clear compared with the efficacy of BCG. A **SWOG trial that compared doxorubicin and BCG showed a 15% progression rate in patients receiving BCG compared with a 37% progression rate in patients receiving chemotherapy** (Lamm et al., 1991). In addition, data have suggested that BCG with maintenance confers a lower risk of recurrence compared with mitomycin C, doxorubicin, epirubicin, and thiotepa (Chou et al., 2017). Nevertheless, the risk of BCG infectious complications is nonexistent with chemotherapy, leading many urologists to continue using these agents. The main side effects of most chemotherapeutic agents appear to be local such as cystitis and dermatitis if the agent comes in contact with skin. On rare occasions systemic absorption can occur through the skin or bladder, resulting in hematopoietic side effects or nausea.

The agents are summarized in Table 136.4.

TABLE 136.4

Comparisons Among Intravesical Agents

AGENT	PERIOPERATIVE USE	RISK GROUP	CYSTITIS (%)	OTHER TOXICITY	DRO (%)
Doxorubicin (Adriamycin)	Yes	Low to intermediate	20–40	Fever, allergy, contracted bladder, 5%	2–16
Epirubicin	Yes	Low to intermediate	10–30	Contracted bladder rare	3–6
Thiotepa	Yes	Low to intermediate	10–30	Myelosuppression 8%–19%	2–11
Mitomycin	Yes	Low to intermediate	30–40	Rash 8%–19%, contracted bladder 5%	2–14
BCG	No	Intermediate to high	60–80	Serious infection, 5%	5–10
Interferon	No	Salvage	<5	Flulike symptoms 20%	Rare
Gemcitabine	Yes	Salvage	Mild	Occasional nausea	<10
Valrubicin	No	Salvage	Mild	UTI, abdominal pain, asthenia	<10

BCG, Bacille Calmette-Guérin; *UTI,* urinary tract infection.

Modified from O'Donnell MA: Practical applications of intravesical chemotherapy and immunotherapy in high-risk patients with superficial bladder cancer. *Urol Clin North Am* 32:121–131, 2005.

Thiotepa

Thiotepa (triethylenethiophosphoramide) is the only chemotherapeutic agent approved by the FDA specifically for the intravesical treatment of papillary bladder cancer. It is an alkylating agent and is not cell cycle specific. In controlled clinical trials ($n = 950$ patients), it has been shown to significantly decrease tumor recurrence in 6 of 11 studies by up to 41% (mean decrease, 16%). Systemic side effects can be seen because of its low molecular weight, resulting in up to half of administered doses being absorbed, risking hematopoietic toxicity (Thrasher and Crawford, 1992). As such, most centers have substituted its use with BCG or one of the aforementioned chemotherapeutic agents.

Doxorubicin

Doxorubicin (Adriamycin) is anthracycline antibiotic that acts by binding DNA base pairs, inhibiting topoisomerase II, and inhibiting protein synthesis. In a review, **doxorubicin demonstrated a 13% to 17% improvement over TUR in preventing recurrence but no advantage in preventing tumor progression (15.2% vs. 12.6%)** (Kurth et al., 1997). The principal side effect of intravesical doxorubicin is chemical cystitis, which can occur in up to half of the patients. Reduced bladder capacity has been reported in several series (Thrasher and Crawford, 1992).

The **doxorubicin derivative epirubicin decreases recurrence compared with TUR alone by 12% to 15%** (Oosterlinck et al., 1993). This was demonstrated with a single, immediate, perioperative dose, as well as in full 8-week courses of intravesical therapy. Epirubicin is available for use in patients with UC in Europe and is FDA approved but is unavailable for treatment of UC in the United States. At least one study conducted in Japan combined epirubicin with lactobacillus casei, a probiotic agent commonly used in Japan (Naito et al., 2008). Recurrence rates were reduced by 15% in patients using lactobacillus casei as an oral supplement during epirubicin instillation therapy.

Valrubicin

Valrubicin is a semisynthetic analogue of doxorubicin that was approved by the FDA for treatment of BCG-refractory CIS in patients who cannot tolerate cystectomy; the drug became available in 2009 in the United States (Greenberg et al., 1997; Grossman et al., 2008; Sweatman et al., 1991). In a cohort of 90 patients with BCG-refractory CIS, only 21% demonstrated a complete response (Steinberg et al., 2000), so its use is not widespread.

Mitomycin C

MMC is an alkylating agent that inhibits DNA synthesis. The drug is usually instilled weekly for 6 to 8 weeks at dose ranges from 20 to 60 mg. A meta-analysis of nine clinical trials compared its effect on disease progression with that of BCG. With a median follow-up of 26 months, **7.67% of the patients in the BCG group and 9.44% of the patients in the MMC group developed tumor progression** (Bohle and Bock, 2004). More recently, Chou et al. (2017), in a meta-analysis comparing MMC with BCG, identified no differences between BCG and MMC with regard to recurrence risk; however, BCG fared better in the subgroup of trials using maintenance (RR 0.79). MMC was also found to have higher risk of progression than BCG in this same study. **Another review found a 38% reduction in tumor recurrence with MMC. This was not as effective as BCG but was considered in most studies to make MMC a viable option for reduction in recurrence (but not for progression) in light of its lesser side effects** (Huncharek et al., 2001).

Optimization of MMC delivery can result in halving of the recurrence rate in some studies. This can be achieved by eliminating residual urine volume, fasting overnight, using sodium bicarbonate to reduce drug degradation, and increasing concentration to 40 mg in 20 mL (Au et al., 2001). The use of local microwave therapy in conjunction with MMC, 20 mg/50 mL, reduced recurrence rates from 57.5% to 17.1% in a multicenter trial. A study using microwave therapy with higher doses of 40 to 80 mg for 6 to 8 weeks in high-grade bladder cancer found a recurrence-free rate of 75% at 2 years (Gofrit et al., 2004; van der Heijden et al., 2004).

Electromotive intravesical MMC appears to improve drug delivery into bladder tissue by four- to sevenfold (Di Stasi and Riedl, 2009; DiStasi et al., 1999). The electromotive current is usually delivered as a pulsed current of 40 to 60 mA/sec to a maximum of 20 mA over 30 minutes through two cathode electrodes placed over the gel-smeared skin of the lower abdominal wall. With this treatment was reported reduction in recurrence rates with MMC from 58% to 31%, whereas patients in the BCG control arm had a 64% recurrence rate (Di Stasi et al., 2003). A randomized trial conducted in patients with primary and recurrent T1 urothelial carcinoma comparing BCG alone with a combination of BCG alternating with electromotive MMC reported lower recurrence and progression rates with the combination treatment as well as better overall and cancer-specific survival (Di Stasi et al., 2006). Peak plasma MMC was significantly higher in the electromotive group, supporting its presumed mechanism of action.

More recent approaches have used the approach of heating the bladder along with mitomycin instillation to incite a mild inflammation of the bladder wall, which potentiates the action of mitomycin but can also improve the effectiveness of BCG (DiStasi et al., 2011). The interior of the bladder can be heated to a temperature of about 42°C using radiofrequency needles emerging from the tip of a urethral catheter. The device is called the Synergo-RITE (Medical Enterprises Group, Amstelveen, The Netherlands). The intravesical heating enhances the absorption and activity of mitomycin C similar to when the electric current is delivered transabdominally. Several single arm studies have demonstrated encouraging results. Randomized studies comparing chemohyperthemia (as it is termed) to plain mitomycin instillation have demonstrated up to a threefold lower recurrence rate with electromotive mitomycin or chemohyperthermia (Colombo et al., 2011). However, a subsequent randomized study by Arends et al. (2016), which compared electromotive mitomycin to BCG instillation, demonstrated lower 2-year recurrence-free survival in those receiving electromotive mitomycin, although this difference was not statistically significant. There was an observed higher toxicity in those receiving the electromotive MMC. Gan et al. (2016) have also published work involving a combination protocol of BCG in conjunction with electromotive MMC demonstrating promising results of 87% initial complete response with 73% of their initial first responders remaining disease free at 2 years.

An alternative method of delivering heated mitomycin C into the bladder termed hyperthermic intravesical chemotherapy (HIVEC) can be delivered using the Bladder Recirculation System (BRC) developed by Combat Medical (Hertfordshire, United Kingdom). This method involves instilling a solution of mitomycin that is heated to 42°C into the bladder in the form of a continuously recirculating irrigation. Patients have been treated in a neoadjuvant fashion before TUR and in an adjuvant fashion after TUR (Sousa et al., 2016). Surprisingly, 62% of patients who received the treatment before TUR had chemoablation of their tumors and a negative biopsy at TUR. Of those who received the treatment in an adjuvant fashion, 2-year risk of recurrence was 12%. All treatments were focused on patients with intermediate-risk disease. Although these results are exciting, more data from randomized trials are needed before this approach can be incorporated into the current treatment paradigm (Jung et al., 2017).

Other Intravesical Therapeutic Agents

Gemcitabine and the taxanes **paclitaxel** and **docetaxel** have demonstrated activity against metastatic bladder cancer (Calabro and Sternberg, 2002). Intravesical gemcitabine can be safely administered either weekly or twice weekly for six to eight treatments. Minimal systemic absorption occurs through the bladder. Early small phase I and phase II studies demonstrated reduction of recurrence of 39% to 70%, including modest efficacy in heavily pretreated BCG-refractory patients (Maymi et al., 2004; O'Donnell, 2005). Di Lorenzo et al. (2010) completed a randomized phase II trial using intravesical gemcitabine versus re-induction course of BCG in patients who failed one course of BCG and identified improved 2-year disease-free survival but no significant difference in risk of progression or cystectomy rates. An additional SWOG phase II trial evaluated gemcitabine after two failed courses of intravesical BCG and identified a 2-year disease-free survival rate of 21% (Skinner et al., 2013). As such, gemcitabine appears to have a role, particularly in the setting of previous BCG failure.

Taxanes have also been formulated into an active intravesical treatment (Lu et al., 2004). Robins et al. (2017) have published a phase II trial using nanoparticle albumin-bound paclitaxel in patients with disease recurrence after BCG. This trial identified a complete response rate of 36% and recurrence-free survival rate of 18% with a median follow-up of 41 months. Although data remain limited, these and other agents remain under investigation for patients with BCG failure.

Apaziquone or EOquin is an indoloquinone that is derived from mitomycin C. It has a rather high molecular weight of 288 kD and hence does not easily penetrate the bladder epithelium. It is rapidly cleared in the systemic circulation and requires activation by a reductase that is found at relatively higher levels in bladder tumor tissue compared with normal bladder epithelium. A phase II study involving Ta/T1 marker lesions suggested an excellent pathological response rate of 67% (van der Heijden et al., 2006). Side effects mainly consisted of cystitis and hematuria with only 9% of patients experiencing grade 3 toxicity. Subsequent phase III trials using this agent for immediate perioperative instillation have not yielded expected results and further trials are currently ongoing.

Combination Therapy

Combining mechanisms of different agents is a logical and often successful approach to improve response rates for systemic therapy. However, studies have not identified clear benefit to doing so in intravesical therapy with a general theme of increased local side effects with modest outcome improvement (Isaka et al., 1992; Sekine et al., 1994).

There has been more interest in combination intravesical chemotherapy using mitomycin and gemcitabine in sequence as well as mitomycin and docetaxel. Breyer et al. (2010) demonstrated a good response rate to sequential mitomycin and gemcitabine in patients who were BCG refractory. This was confirmed in a larger multi-institutional study in which a durable recurrence-free rate of 38% was found in a cohort of 47 patients (Lightfoot et al., 2014). In this approach gemcitabine is instilled first at a dose of 1000 mg and left in place for 60 to 90 minutes. After draining the gemcitabine, this is followed by mitomycin C in the dose of 40 mg for another 60 to 90 minutes. It is important to instill the mitomycin second because it is a vesicant, and irritation caused by the mitomycin can make it hard for the patient to retain the gemcitabine as well as resulting in significantly greater local side effects. A combination of gemcitabine and docetaxel has also been used for sequential intravesical instillation (Steinberg et al., 2015). A 34% recurrence-free rate at 2 years has been achieved in a pilot study of 45 patients, indicating that this may be a promising approach. The main advantage of this regimen compared with other combination intravesical therapies may be the low incidence of side effects while maintaining a similar response. A combination of chemotherapy and BCG was evaluated in prospective trials by several investigators. The EORTC reported a 46% complete response rate when a solitary marker tumor was intentionally not resected and patients were subsequently given sequential MMC and BCG (van der Meijden et al., 1996). In a study of 188 patients with Ta and T1 lesions, no difference was seen with regard to recurrence, progression, or side effects in those patients treated with BCG and MMC compared with those treated with MMC alone. There was actually a significantly longer disease-free interval in the BCG monotherapy arm (55%) compared with the same combination arm (45%) in another study of 314 patients (Malmstrom et al., 1999; Solsona et al., 2002). **Thus no clear advantage is obtained with sequential therapy, or chemotherapy and BCG regimens in the absence of electromotive current using any of the combinations explored to date** (Nieder et al., 2005; Rintala et al., 1995, 1996; Witjes et al., 1998). **Salvage approaches using sequential combination chemotherapy using gemcitabine and mitomycin or docetaxel may yield reasonable response and recurrence-free survival in a subset of patients, although these data must be confirmed by larger studies.**

Key Points: Intravesical Chemotherapy

- Intravesical chemotherapy has a clear impact on tumor recurrence when immediately instilled after TURBT and in the adjuvant setting. There is no clear evidence of an impact on progression.
- Combinations of various chemotherapeutic agents and chemotherapy combined with BCG have not demonstrated major benefit combined with

single-agent treatment, with the exception of IFN.

- In general, side effects of chemotherapy tend to be less common and less severe than those for BCG, but BCG is more efficacious.
- Combination intravesical chemotherapy may have a role in treating BCG refractory cancers

Refractory High-Grade Disease

Recurrent or persistent disease after an initial 6-week course of BCG has been traditionally referred to as *BCG failure*, although this term has been poorly defined in the past. **Persistent disease after BCG therapy can be categorized as BCG refractory disease.** Current consensus is that BCG-refractory disease is defined in patients who have persistent disease despite receipt of 2 induction courses of BCG, induction plus maintenance (usually within 6 months), or intolerance of BCG (Jarrow et al., 2014). **BCG-refractory patients in particular are an especially high-risk group and should be strongly considered for immediate cystectomy if young and in generally good health** (Chang et al., 2016; Herr and Dalbagni, 2003). Additional intravesical therapy for BCG refractory disease should be reserved for patients who refuse or are too ill to undergo cystectomy or on defined investigational protocols.

The necessity of biopsy to determine BCG response is unclear, although it should be strongly considered in high-risk patients to determine disease status at this key point in time. Urine cytology can be useful in this setting. Dalbagni et al. (1999) reported minimal usefulness of routine biopsy after BCG if cystoscopy and urinary cytology were both negative. Whereas 5 of 11 patients with erythematous bladder mucosa and positive cytology had positive bladder biopsies, none of 37 with erythematous lesions and negative cytology were positive, and only 1 in 13 patients with a normal mucosa had a positive biopsy (Dalbagni et al., 1999). Other studies have suggested that the value of routine post-BCG biopsy is limited (Dalbagni et al., 1999). UroVysion FISH (Abbott Molecular, Chicago, IL) conversion from positive to negative has been shown to correlate with BCG response in single-center studies (Kipp et al., 2005; Whitson et al., 2009).

Declaring failure may take up to 6 months because the response rate for patients with high-grade bladder cancer treated with BCG rose from 57% to 80% 3 to 6 months after therapy (Herr and Dalbagni, 2003). This is particularly true for patients with CIS because it appears that there is a delayed resolution of CIS that can occur between 3 and 6 months. Clearly, the tumoricidal activity continues for some period after cessation of therapy. This has obvious implications not only for declaring BCG failure and the need for subsequent therapy, but also for interpretation of success rates of salvage protocols if administered soon after therapy.

Management of Refractory High-Grade Disease

Although most urologists will administer an initial 6-week course of intravesical therapy for high-risk patients, **management of patients with persistent disease after the first course is more complex. Such patients are at increased risk of progression, which is particularly likely in the event of early recurrence, progression while on therapy, or multiple recurrences.**

If the initial treatment was chemotherapy, a course of BCG should be considered. BCG has demonstrated superiority to repeat courses of chemotherapy in this setting because the latter will lead to only an approximately 20% disease-free survival (Malmstrom et al., 1999; Steinberg et al., 2000). **For patients who have failed BCG, a second course still gives a 30% to 50% response** (Brake et al., 2000; Pansadoro and De Paula, 1987). **A second course of BCG is recommended for patients with intermediate- or high-risk disease if persistent or recurrent Ta disease or CIS is noted after a single course of intravesical BCG in most recent AUA/SUO guidelines** (Chang et al., 2016). Patients who cannot tolerate BCG for any reason may be considered for salvage chemotherapy, but the risk of failure and progression is high.

Further courses of BCG or chemotherapy beyond two are not recommended because they will fail 80% of the time, although recent studies suggest some potential for newer agents (Skinner et al., 2013). **Rapid disease progression is common in such patients,** so salvage chemotherapy, investigational protocols, and IFN alone or in combination with reduced doses of BCG may be appropriate only for patients who are unwilling or unable to undergo surgery even after being informed of their risks (Catalona et al., 1987). Current guidelines recommend consideration of clinical trials as the first option followed by radical cystectomy. Repeated attempts at intravesical therapy beyond 2 years from initial tumor diagnosis should be discouraged because there is a significant drop in cancer-specific survival in patients with high-risk tumors (particularly T1) who wait longer than this duration despite ultimate performance of radical cystectomy (Herr and Sogani, 2001).

Role of Alternative Options for Refractory Disease

Photodynamic therapy (PDT) relies on a specific light interaction with a

photosensitized target tissue. This treatment is performed by administering a photosensitizing agent such as porfimer sodium (Photofrin) systemically or hexaminolevulinate (HAL) intravesically. The patient is then given an intravesical treatment with light irradiation. After excitation by light, the photosensitizer reacts with molecular oxygen to form free radicals and reactive singlet oxygen to have cytotoxic effect.

The response rate in CIS patients from combined series is 66%, with a duration of 37 to 84 months (Jocham et al., 1989; Nseyo et al., 1997, 1998; Walther, 2000). For patients with papillary disease, an overall response rate of 51% has been achieved with a median time to recurrence of 24 to 48 months (Naito et al., 1991; Nseyo et al., 1997, 1998; Walther, 2000). PDT has been limited by significant side effects such as bladder contracture or irritability (50%) and dermal sensitivity (19%) (Naito et al., 1991; Nseyo et al., 1997, 1998; Uchibayashi et al., 1995). More recent trials have demonstrated improved tolerability with HAL and an incoherent white light source for irradiation. One such trial involved 2 treatments with HAL-PDT 6 weeks apart with 2 of 17 patients tumor free at 21 months (Bader et al., 2013).

Research efforts have been directed at development of improved photosensitizers and modifications in laser dosimetry (Kriegmair et al., 1996a; Nseyo et al., 1997, 1998). HAL, a more lipophilic ester of 5-ALA, generates a sensitizer called *protoporphyrin IX* that appears more tumor specific, although clinical data are limited (Datta et al., 1998). Radachlorin is composed of three chlorins and appears promising, at least in the setting of BCG-refractory high-grade disease (Lee et al., 2013).

Radiation therapy in the treatment of NMIBC is typically restricted to individuals who refuse cystectomy after the failure of intravesical therapy or who are unsuitable for major surgery (Kim et al., 2000). A complete response to radiation therapy and TUR is attainable in 50% to 75% of patients, but the additional benefit of radiation to TUR remains unclear (De Neve et al., 1992; Jansson et al., 1998; Rozan et al., 1992). Five-year response rates are 44% to 60%. There is no significant effect on CIS. Because of reports that up to 50% of patients will develop progression and a high likelihood of death (Rödel et al., 2001), there is a limited role for radiation therapy other than for palliative purposes in this population. Combinations of radiation and chemotherapy have shown promise but have not reached widespread use (Gray et al., 2013).

Checkpoint inhibitors are a newer class of therapy under investigation for use in NIMBC. These agents represent systemic immunotherapy with a mechanism of action that involves disrupting the interaction between programmed death ligand-1 (PD-L1), and programmed cell death protein-1 (PD-1). In normal immune function, the interaction between these receptors and their ligands regulates T-cell activation and acts as an inhibitory signal in the generation of immune response against a tissue. A number of malignancies, including urothelial cell carcinoma, have been found to upregulate this interaction to prevent immune response against tumor cells. Over the past several years, monoclonal antibodies inhibiting this interaction, and thereby activating cytotoxic T-cell function against tumor cells, have been developed, with urothelial cell carcinoma exhibiting susceptibility to such therapy (Mukherjee et al., 2018).

Several agents such as atezolizumab (PD-L1 inhibitor) have been approved for patients with locally advanced or metastatic bladder cancer who progressed after chemotherapy (Rosenberg et al., 2016). Several additional agents including avelumab and durvalumab have also been approved for this indication. Nivolumab and pembrolizumab are PD-1 receptor monoclonal antibodies that are approved for similar indications in advanced disease, post-chemotherapy, and for patients not eligible for cisplatin.

Given the response of urothelial carcinoma in advanced disease as well as the long-standing role for BCG immunotherapy in NMIBC, several current trials are aiming to assess the value of checkpoint inhibitors in NMIBC. Current phase II clinical trials are ongoing in patients with BCG-refractory disease evaluating the potential benefit of atezolizumab, durvalumab, and pembrolizumab. Furthermore, additional trials are underway using checkpoint inhibitors in combination with concurrent intravesical BCG (Mukherjee et al., 2018). Although the efficacy of these agents in NMIBC remains under investigation, checkpoint inhibitors represent a promising new line of immunotherapy for this disease.

Key Points: Management of Refractory Disease

- Patients who experience failure of an initial course of intravesical therapy after TURBT are at high risk of recurrence or progression.
- Failure of initial chemotherapy or BCG is most appropriately treated with a subsequent course of BCG because its efficacy in this setting is significantly greater than that of chemotherapy.

- After failure of a second course of intravesical therapy, patients can be enrolled in clinical trials of new agents, consider combination intravesical therapy, or proceed to cystectomy.

Role of “Early” Cystectomy

Despite local therapy, many cases of high-grade NMIBC will progress to invasion and risk of cancer death. Although the initial response rate to BCG therapy in CIS patients can be above 80%, patients in whom treatment fails will have a 50% chance of disease progression and potential for disease-specific mortality (Catalona et al., 1987; Nadler et al., 1994). Early (3-month) failure for T1 tumors after BCG is associated with an 82% progression rate, compared with a 25% progression rate in patients who do not experience treatment failure at 3 months (Herr et al., 1997; Herr, 2000a). Up to 20% of patients with CIS die of UC within 10 years (Herr et al., 1989); each occurrence of T1 tumors is associated with a 5% to 10% chance of metastasis (Herr and Sogani, 2001), and residual tumor found on repeat resection in these patients is associated with an 82% chance of development of muscle invasion (Herr et al., 1997). These data offer compelling evidence of the potential to underestimate disease status in high-risk patients.

Cookson et al. (1997) reported that 27% of high-risk patients treated initially with aggressive intravesical therapy did well and died of other causes, and the same low number survived with an intact, functioning bladder 15 years after diagnosis. However, approximately half of patients experienced progression, and one-third died of their disease. In contrast, **patients who undergo immediate cystectomy for clinical T1 tumors benefit from more accurate pathological staging in addition to a 10-year disease-free survival of 92%, compared with 64% of those with clinical T1 tumors who were found to actually have muscle invasion at the time of cystectomy** (Bianco et al., 2004).

Despite the benign connotation of the term *superficial* formerly applied, up to 50% of patients with presumed non–muscle-invasive high-grade disease who undergo cystectomy will actually be found to have muscle-invasive disease. Such procedures have traditionally been termed *early cystectomy* on the basis of the fact that they are performed before the traditional surgical indication of documented muscle invasion. Up to 15% will already have micrometastases (Chang and Cookson, 2005) and a delay in cystectomy of even 12 weeks is associated with poorer survival; therefore some of these procedures do not seem to be early enough (Chamie et al., 2013; Sanchez-Ortiz et al., 2003).

The risk of progression must be weighed against the risk, morbidity, and impact on quality of life for cystectomy. Thus **a reasonable goal may be, as termed by Chang and Cookson** (2005), **"timely" cystectomy for patients at risk.**

Ten-year survival after cystectomy for non–muscle-invasive cancer can range from 67% to 92% (Amling et al., 1994; Freeman et al., 1995). **However, despite the bias that substantial progression can be averted with the benefit of early detection and close surveillance in patients whose tumors are identified before muscle invasion, it appears that such patients who progress to having muscle invasion may have a poorer prognosis than do those who have muscle-invasive disease on initial presentation** (Lee et al., 2007; Schrier et al., 2004). **Thus overconfidence in disease control status with high-risk patients on surveillance creates a false sense of security.**

The AUA guidelines suggest cystectomy as the first option for patients with refractory high-grade disease after an initial course of intravesical therapy (see later). Nevertheless, **fewer than one in five American urologists surveyed stated that they would recommend cystectomy for their patients with CIS refractory to two courses of intravesical BCG, a group with an 80% risk of failure or progression** (Joudi et al., 2006a). **Cystectomy in that setting, or for persistent high-grade papillary disease after two courses of intravesical therapy, is the standard of care and should not be considered "early."**

The role of surgical approaches involving potential oncologic concessions such as seminal and nerve-sparing cystectomy in such patients theoretically at lower risk of recurrence compared with patients with muscle invasion remains unknown (Hautmann and Stein, 2005). The availability of neobladder for less disfiguring urinary diversion has been reported to decrease the delay in treatment of such patients, potentially leading to significantly improved disease-free survival (Hautmann and Paiss, 1998). The impact on disease outcomes is unproven.

Cystectomy should also be considered in patients whose cancer cannot be reasonably controlled through resection: bulky tumors, inaccessible because of a large bladder or urethral stricture disease, or otherwise not amenable to safe removal endoscopically.

In summary, **radical cystectomy offers the most accurate pathological staging option and should be strongly considered for patients with NMIBCs that are high grade and invading deeply into lamina propria, exhibit**

lymphovascular invasion, are associated with diffuse CIS, are in diverticula, substantially involve the distal ureters or prostatic urethra, are refractory to initial therapy, or are too large or anatomically inaccessible to be removed in their entirety endoscopically. It can also be used in patients who understand the risks and benefits of bladder preservation versus cystectomy and request definitive therapy (Stein, 2003). **Current AUA guidelines suggest radical cystectomy in patients who are fit for surgery and have persistent high-grade T1 disease on repeat resection, or T1 tumors with associated CIS, LVI, or variant histologies. These same guidelines also suggest cystectomy in high-risk patients with persistent or recurrent disease within 1 year after treatment with two induction cycles of BCG or BCG maintenance** (Chang et al., 2016). Partial cystectomy has limited data but may be a bladder preservation option in appropriately selected patients, between the extremes of TURBT combined with intravesical therapy and radical cystectomy.

Key Points: Early Cystectomy

- Patients at high risk for progression should be considered for cystectomy.
- Failure to respond to an initial course of intravesical therapy is occasion to reconsider cystectomy.
- Failure to respond to a second course is an indication for immediate cystectomy unless contraindicated or the patient chooses to pursue clinical trials or newer proven intravesical options if evidence builds for their use.

Surveillance and Prevention

Although bladder cancer is less common than prostate cancer, expenditures are almost twice as high for bladder cancer because of its chronic nature and the need for long-term surveillance. According to the Agency for Healthcare Research and Quality, annual expenditures were $2.2 billion in 2003 for bladder cancer versus $1.4 billion for prostate cancer (Donat, 2003). A significant portion of this cost is associated with surveillance (Hedelin et al., 2002).

Surveillance strategies for UC recurrence have historically relied on the diagnostic combination of cystoscopy and urinary cytology. In clinical practice, only 40% of patients actually comply with a standard surveillance protocol (Schrag et al., 2003). Although the accuracy of both tests relies on subjective and operator-dependent interpretation of visible findings, their traditional presumed status as the gold standard has been widely accepted (Brown, 2000). The timing and frequency of surveillance cystoscopy, cytology, and upper tract imaging can be varied based on risk of recurrence and progression. To aid urologists in determining this risk for patients, several models and risk stratification algorithms exist, including AUA/SUO guideline stratification outlined in Table 136.2, and EORTC risk tables, which take into account number of tumors, tumor size, prior recurrence rate, T stage, CIS, and grade (Sylvester et al., 2006). Using these risk stratification systems surveillance can be tailored to individual patients, and a summary of suggested surveillance protocols consistent with most recent AUA/SUO guidelines is provided in Table 136.5.

TABLE 136.5

2016 AUA/SUO Guideline Suggested Surveillance Strategies

RISK	TUMOR STATUS	CYSTOSCOPY SCHEDULE	UPPER TRACT IMAGING
Low	Solitary Ta low grade	3 mo after initial resection Annually beginning 9 mo after initial surveillance if no recurrence Consider cessation at 5 or more years Consider cytology or tumor markers	Not necessary unless hematuria present

Intermediate	Multiple Ta low grade Large tumor Recurrence at 3 mo	Every 3–6 mo for 1-2 yr Every 6–12 mo for subsequent 2 yr Annual cystoscopy thereafter Consider cytology or tumor markers Restart clock with each recurrence	Consider imaging at 1- to 2-yr intervals, especially for recurrence Imaging for hematuria
High	Any high grade (including CIS)	Every 3–4 mo for 2 yr Semiannually for 2 yr Annually for lifetime Cytology at same schedule Consider tumor markers Restart clock with each recurrence	Imaging annually for 2 yr, then consider lengthening interval

CIS, Carcinoma in situ.

Modified from Chang et al.: *Diagnosis and treatment of non-muscle invasive bladder cancer*, AUA/SUO Guideline, 2016.

Cystoscopic Surveillance

Office-based cystoscopy offers rapid, relatively painless visual access to the urothelium. Papillary tumors arising from the smooth bladder surface are readily identified. CIS is classically described as a velvety red mucosal patch, although the reliability of such findings is less clear. Nevertheless, for office-based diagnosis it allows identification of the site and characteristics of most tumors. **There is a high positive predictive value with cystoscopy because most lesions believed to be malignant are proven so pathologically. The endoscopic appearance cannot reliably predict tumor stage or grade, although sessile morphology and/or the presence of necrosis suggests high-grade disease likely to be invasive.**

Cystoscopy is usually performed in the outpatient setting, often using digital flexible cystoscopes in most settings. Complete visualization of the bladder mucosa is possible in a matter of seconds in most patients. Using the same technology for flexible cystoscopy as described earlier for HAL fluorescence rigid cystoscopy, phase II studies have had mixed results but suggest that office-based fluorescence cystoscopy can improve the detection of CIS and papillary tumors (Loidl et al., 2005; Witjes et al., 2005).

The majority of men and women tolerate office-based cystoscopy with minimal discomfort. **Intraurethral injection of local anesthetics is almost universal among urologists. Data from randomized trials are contradictory** (Palit et al., 2003; Rodriguez-Rubio et al., 2004) **and one meta-analysis indicated no benefit (**Patel et al., 2008b**), whereas another indicated there was a benefit in pain reduction when anesthetic containing lubricating gel was used** (Aaronson et al., 2009). Two recent studies actually found that pain experience was higher with the use of local anesthetics than in patients cystoscoped using aqueous lubricant alone (Chen et al., 2005; Ho et al., 2003). Use of a video monitor allows patients to see and understand the findings, theoretically distracting them from any discomfort. Men who are able to do so tolerate the procedure with approximately 50% less pain than those who cannot see their findings on the monitor (Patel et al., 2007). Instillation of anesthetic gel into the urethra has not been found to be of significant benefit in women, probably because of the straighter urethra (Patel et al., 2008a).

The bladder should be emptied before cystoscopy. Aspiration with use of a 60-mL syringe attached to the irrigant port is occasionally necessary during the procedure. This can further lessen clouding. A systematic approach is mandatory to ensure that all urothelium is visualized.

The use of air cystoscopy, as opposed to fluid instillation, has also been evaluated and found to potentially aid in visualization during active hematuria (Ciudin et al., 2013) and may provide a viable alternative in settings where sterile fluid irrigant is unavailable (Dutta et al., 2017).

Attempts have been made to modify the previously described surveillance schedule with use of decision analysis tools (Abel, 1993; Kent et al., 1989). Several authors recommend termination of surveillance at 5 or more years for low-risk patients (Haukaas et al., 1999). However, the actual cost of surveillance cystoscopy was responsible for only 13% of the expenditures for bladder cancer care in one study, so the financial opportunity may be limited for such efforts (Hedelin et al., 2002; Schoenberg et al., 2000). In addition, the risk of recurrence and potential for progression exists beyond this period. Reports of late recurrences of high-grade cancer years after the original tumor temper some authors’ enthusiasm for terminating surveillance at any point (Leblanc et al., 1999; Morris et al., 1995; Thompson et al., 1993; Zieger et al., 2000). The AUA guidelines recommend cystoscopic surveillance based on risk stratification of the tumor into low-, intermediate- and high-risk categories. The recommended surveillance schedule is shown in Table 136.5. Current AUA guidelines indicate that surveillance beyond 10 years can be decided on a case-by-case basis after a discussion between the patient and the urologist (Chang et al., 2016).

Other investigators have examined the predictive impact of early or multiple recurrences and how this may affect surveillance (Holmäng et al., 1995; Parmar et al., 1989; Reading et al., 1995). **Tumor recurrence on initial 3-month cystoscopy and number of tumors on initial resection (single or multiple) provide the most predictive information with regard to recurrence in several studies. Absence of recurrence on the 3-month surveillance cystoscopy in patients with Ta low-grade tumors is associated with recurrence rates so low that annual cystoscopy appears safe even at that point (beginning 12 months after the initial resection)** (Fitzpatrick et al., 1986; Frydenberg et al., 2005; Olsen and Genster, 1995). Finally, patients with a negative cystoscopy and a negative UroVysion assay (see later) are at low risk of recurrence in the following 6 to 12 months, creating opportunity to individualize the surveillance schedule (Sarosdy et al., 2002).

Urine Cytology

Cytology involves microscopic evaluation of stained cellular smears from the urine. Unlike tumor markers, urinary cytology represents a pathologist's interpretation of the morphologic features of shed urothelial cells rather than an objective laboratory test. Poor cellular cohesion in high-grade tumors, especially CIS, enhances the yield.

Its high specificity is the most important feature of cytology because a **positive reading regardless of cystoscopic or radiographic findings suggests the existence of malignancy in the vast majority of patients.** Even in the setting of UC, of patients with a negative workup (cystoscopy and upper tract imaging) with a persistently positive cytology, 40% were found to have genitourinary cancer within 24 months (Nabi et al., 2004).

Although cytology has traditionally been believed to have high sensitivity for high-grade cancer, recent studies suggest that only 58% of bladder tumors are identified using cytology. Its low sensitivity is not limited to low-grade tumors because only 71% of high-grade cancers were identified. **Cumulative data from series published after 1990 reported that cytology actually identified (using the older grading system) 11% of grade 1, 31% of grade 2, and only 60% of grade 3 tumors** (Halling et al., 2000). In contrast, they observed that these recent findings were well below those reported before 1990, when the sensitivity of cytology was 94% for grade 3 tumors, but could find no explanation for this deterioration. These findings are supported by numerous other studies and emphasized by a recent multicenter study involving several institutions noted for bladder cancer expertise that found cytology had an overall sensitivity of 15.8% (Grossman et al., 2005).

Thus cytology has high specificity but low sensitivity for high-grade and low-grade tumors, including CIS.

Tumor Markers

Many attempts have been made to develop a UC biomarker test to complement or replace urinary cytology. Most of these have had adequate sensitivity but poor specificity, resulting in substantial false-positive readings, creating the need for further diagnostic testing. Current urinary markers have been developed to detect tumor-associated antigens, blood group antigens, growth factors, cell cycle and apoptosis, and extracellular matrix proteins. The most significant issue limiting widespread adoption of tumor markers is the lack of prospective data to support their impact on prognosis or disease management (Lokeshwar et al., 2005).

The qualitative point-of-care test **BTA stat** (Polymedco, Cortlandt Manor, NY) and the quantitative **BTA TRAK** (Polymedco) assay detect human complement factor H–related protein. The overall sensitivity of these tests ranges from 50% to 80%, whereas the specificity is between 50% and 75%. These tests are more sensitive than cytology particularly for low-grade tumors, but their results can be falsely positive in patients with inflammation, infection, or hematuria (Liou, 2006).

ImmunoCyt (DiagnoCure, Saint Foy, Canada) is a hybrid of cytology and an immunofluorescence assay. Three fluorescent-labeled monoclonal antibodies are targeted at a UC variant of carcinoembryonic antigen and two bladder mucins. Sensitivity and specificity are reported to be 86% and 79%, respectively. The assay has not been shown to be affected by benign conditions, but interpretation is complex and operator dependent (Têtu et al., 2005; Toma et al., 2004). This test may be helpful in adjudicating atypical cytology because it has a high negative predictive value in this setting (Odisho et al., 2013).

The **NMP22 BladderChek** Test (now marketed as the Alere NMP22 BladderChek, Alere, St. Louis, MO) is based on the detection of nuclear matrix protein 22, part of the mitotic apparatus released from urothelial nuclei on cellular apoptosis. The protein is elevated in UC, but it is also released from dead and dying urothelial cells. Benign conditions of the urinary tract such as stones, infection, inflammation, hematuria, and cystoscopy can cause a false-positive reading. A laboratory-based, quantitative immunoassay and a qualitative point-of-care test are available. The sensitivities and specificities range from 68.5% to 88.5% for sensitivity and from 65.2% to 91.3% for specificity (Liou, 2006). A multi-institutional trial involving 1331 patients showed that, overall, the NMP22 was more sensitive than cytology but less specific. Sensitivities were 50% and 90% for noninvasive and invasive cancer, respectively, with an overall sensitivity of 55.7%. Overall specificity was higher for cytology at 99.2% compared with NMP22 at 85.7%. The sensitivity of cystoscopy in this study was 88.6%, but when combined with NMP22, this increased to 93.7% (Grossman et al., 2005).

UroVysion (Abbott Molecular, Des Plaines, IL) is a cytology-based test that uses FISH of DNA probes or labels specifically chosen to identify certain chromosomal foci. Probes to identify aneuploidy of chromosomes 3, 7, and 17 are combined with a probe to the 9p21 locus. Probes can be developed to identify essentially any locus, but this combination has the best sensitivity and specificity (Halling et al., 2000). Cumulative data from comparative studies show sensitivity for cytology compared with FISH of 19% versus 58% for grade 1, 50% versus 77% for grade 2, and 71% versus 96% for grade 3. Similar findings occurred by stage, wherein cytology compared with FISH sensitivity was 35% versus 64% for Ta, 66% versus 83% for T1, and 76% versus 94% for muscle-invasive carcinoma (Jones et al., 2006; Fig. 136.10).

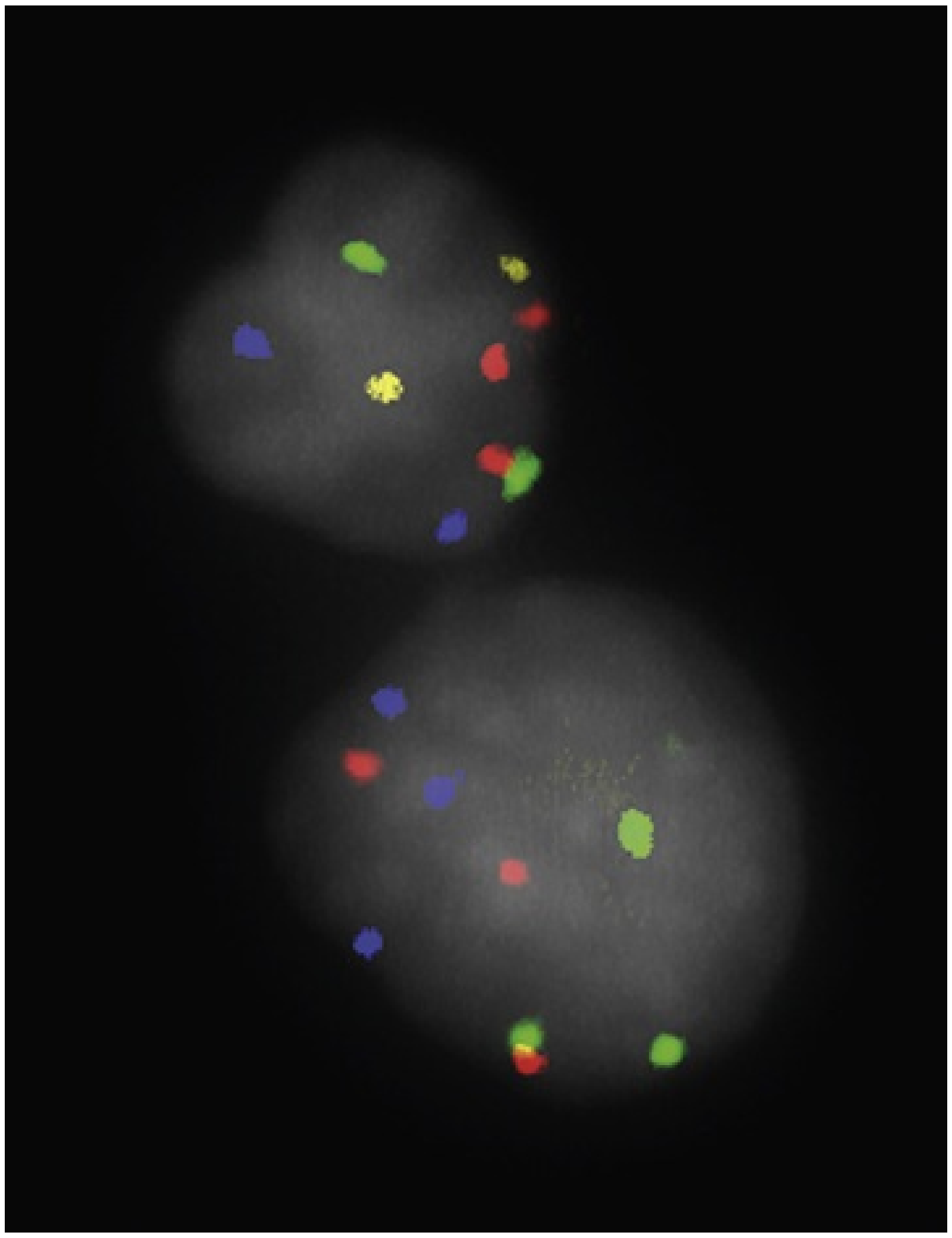

FIG. 136.10 An abnormal enlarged cell *(lower right)* demonstrates three copies of chromosome 3 *(red),* chromosome 7 *(green),* and chromosome 17 *(aqua)* on use of fluorescence in situ hybridization. Homozygous deletion of band 9p21 locus *(yellow)* is also present. (Courtesy Raymond Tubbs, MD, Department of Laboratory Pathology, Cleveland Clinic Foundation.)

Notably, cytology detected only 67% of patients with CIS versus 100% detection by FISH in comparative studies. **UroVysion has the highest specificity of the available tumor markers.** It will, however, detect chromosomal changes before the development of phenotypic expression of malignancy, so it leads to an “anticipatory positive” reading in some patients. Such readings are often not false positives and will lead to identification of clinical tumors within 3 to 15 months in the majority of cases (Sarosdy et al., 2002). Moreover, patients testing negative are unlikely to experience tumor recurrence in less than 1 year (Yoder et al., 2007). Previous studies have suggested that a persistently positive UroVysion FISH after BCG may predict a poor response to BCG with higher likelihood of recurrence and progression (Kamat et al., 2012). Thus the use of UroVysion FISH may allow identification of patients at risk of recurrence versus those unlikely to develop recurrence, and subsequent individualizing of surveillance and treatment protocols.

UroVysion has also been shown to clarify equivocal findings in patients with atypical or negative cytology (Skacel et al., 2003). It is not affected by hematuria, inflammation, or other factors that can cause false-positive readings with some tumor markers, so it appears to be useful as a marker of BCG response (Kipp et al., 2005; Whitson et al., 2009). “Non-diagnostic” UroVysion reports identifying limited cellularity or positive cells at numbers below defined standards can be regarded as negative and are not associated with increased risk of bladder cancer recurrence in the future compared with expectations with “normal” readings (Nguyen et al., 2009).

CxBladder Monitor is a noninvasive urine monitoring test using gene expression and clinical patient data to generate a test to assess for evidence of urothelial carcinoma. This test has been shown to outperform other studies such as cytology and NMP22 with a sensitivity of 91% and negative predictive value of 96% (Lotan et al., 2017).

A retrospective study suggests that a multiplex of eight biomarkers in combination may improve performance compared with currently available markers if validated in further studies (Rosser et al., 2013).

The usefulness of tumor markers and the choice of which one to use is not clear at this time. For example, if indication for biopsy in the operating room is the end point, then high specificity is desired to limit the number of negative biopsies. On the other hand, if increasing the interval of cystoscopic surveillance is the end point, then high sensitivity, particularly for high-grade tumors, is desired. Defining that a patient has a low likelihood of recurrence within the following year can allow individualization of surveillance protocols (see Table 136.5; Grossman et al., 2006).

Current AUA guidelines discourage the use of urinary markers to replace cytology for surveillance of NMIBC. They do, however, suggest consideration of urinary markers to assess response to intravesical therapy as well as for the adjudication of atypical or equivocal cytology results (Chang et al., 2016).

Extravesical Surveillance

The proportion of patients developing **upper tract UC** after treatment of non–muscle-invasive disease has been reported as 0.002% to 2.4% over intervals of 5 to 13 years (Holmäng et al., 1995; Oldbring et al., 1989; Sadek et al., 1999; Shinka et al., 1988), although the risk increases substantially over time to as high as 18% in very high-risk populations (Herr et al., 1997). Synchronous tumors were detected in no patients (0) with grade 1 (using the prior grading system) tumors, 1.1% with grade 2, and 1.3% with grade 3, as well as 0 for low-grade Ta and 7% for T1 (Herranz-Amo et al., 1999). **The Surveillance, Epidemiology, and End Results (SEER) database showed that only 0.8% of bladder cancer patients develop subsequent upper tract tumors, so surveillance is of limited value unless the patient has hematuria or a high-grade tumor, especially if it is near the ureteral orifice** (Wright et al., 2009). In a review of 591 patients with median follow-up of 86 months, upper tract recurrence was 0.9% in low-risk patients (solitary, low-grade, low-stage Ta/T1), 2.2% in patients at intermediate risk (recurrent or multifocal disease), and 9.8% in high-risk patients including intravesical chemotherapy failures (Hurle et al., 1998). **AUA guidelines suggest that clinicians should not perform routine surveillance upper tract imaging in asymptomatic patients with a history of low-risk NMIBC. In the setting of intermediate- or high-risk patients, guidelines suggest consideration of surveillance upper tract imaging at 1- to 2-year intervals, but there are few data evaluating the benefit of such imaging** (Chang et al., 2016).

Multiphasic CT urography has become the preferred technology for the evaluation of hematuria, but its role in the evaluation of patients with NMIBC has not been extensively reported (Davis et al., 2012; Herts, 2003). Magnetic resonance urography and renal ultrasound are potential alternatives in select patients. Retrograde ureteropyelography represents an additional alternative option to image the upper tracts in patients with NMIBC, particularly in those unable to undergo CT urography secondary to contrast allergies or renal insufficiency. Although this does require procedural instrumentation, it can often be done in the same setting with TURBT.

Although infrequent, the appearance of upper tract disease is associated with mortality rates of 40% to 70%. Patients with high-risk disease treated with BCG experience upper tract recurrence risk of 13% to 18% (Herr et al., 1997; Miller et al., 1993). The risk for recurrence in this population appears greatest over the first 5 years after treatment (median time to detection, 56 months) yet persists at least 15 years.

Selective cytology of the upper tract may increase the yield of upper tract lesions detected, but, in the presence of a bladder tumor, selective upper tract cytology may be falsely positive and is not recommended for most patients (Sadek et al., 1999; Zincke et al., 1983).

Secondary tumor involvement of the prostatic urethra and ducts by UC may be detected in 10% to 15% of patients with high-risk non–muscle-invasive disease within 5 years and in 20% to 40% within 10 years (Donat, 2003). Patients who have refractory disease are at risk for extravesical recurrence in the prostatic fossa in approximately one-third of cases, 44% of which are fatal (Herr et al., 1988). Involvement of the prostatic ducts by low-grade UC is usually be managed by complete TURP for disease eradication and to facilitate contact of intravesical therapy to the prostatic urethra. Involvement of the ducts by high-grade disease is best managed by radical cystoprostatectomy, and consideration of urethrectomy should be made, especially if tumor is present near or at the surgical margin (Liedberg et al., 2007).

In summary, surveillance strategies should be individualized on the basis of the risk of recurrence in the bladder and extravesical sites (see Table 136.5).

Secondary Prevention Strategies

Lifestyle changes and chemoprevention could potentially reduce the risk of recurrence and have been considered in the management of patients with non–muscle-invasive disease.

Lifestyle changes are particularly important because UC is directly linked to environmental factors in the majority of cases. **Smoking cessation, increased fluid intake, and a low-fat diet may reduce the risk of recurrence**; the former is paramount. **Increased hydration reduces the concentration and dwell time of carcinogens** and thereby reduces the risk of malignant transformation within the urothelium (Jiang et al., 2008). The Physician Health Study showed an inverse correlation between fluid intake and the incidence of UC on longitudinal follow-up, but this simple measure may also be of benefit for secondary prevention for patients who already have a history of UC (Michaud et al., 1999). **High fat and cholesterol intake are now firmly established as risk factors** for many cancers, although the mechanisms are not as well defined as for other malignancies (Steineck et al., 1990).

A variety of agents have been investigated for chemoprevention strategies for patients with UC, including retinoids (i.e., vitamin A and its analogues) (Becci et al., 1978; Eichholzer et al., 1996; Sporn et al., 1977; Steinmaus et al., 2000);

pyridoxine (vitamin B_6) (Byar and Blackard, 1977; Newling et al., 1995); α-tocopherol (Lotan et al., 2005; Virtamo et al., 2000); and difluoromethylornithine (DFMO) (Messing et al., 2005). However, none of these agents has proven useful in rigorous trials. Isoflavones were studied for the same purpose, but the studies were abandoned because of higher bladder cancer risk in the patients consuming greater amounts of soy products (Sun et al., 2004). High-dose multivitamins were shown to decrease the incidence of recurrence especially if administered along with intravesical BCG therapy (Lamm et al., 1994). However, a randomized trial conducted subsequently failed to confirm this initial finding (Nepple et al., 2010).

Key Points: Surveillance and Prevention

- Cystoscopy is the hallmark of surveillance. The surveillance schedule should be individualized on the basis of risk stratification of the most recently resected tumor.
- Table 136.5 demonstrates reasonable surveillance protocols based on clinical scenarios.
- A number of tumor markers have shown the ability to improve the sensitivity of cytology, but specificity is lower for most.
- Increased fluids, smoking cessation, and a low-fat diet are recommended.

Suggested Readings

Chamie K, Litwin MS, Bassett JC, Urologic Diseases in America Project, et al. Recurrence of high-risk bladder cancer: a population-based analysis. *Cancer*. 2013;119(17):3219–3227.

Chang SS, Boorjian SA, Chou R, et al. Diagnosis and treatment of non-muscle invasive bladder cancer: AUA/SUO Guideline. *J Urol*. 2016;196(4):1021–1029.

Chang SS, Cookson MS. Radical cystectomy for bladder cancer: the case for early intervention. *Urol Clin North Am*. 2005;32:147–155.

Chou R, Selph S, Buckley DI, et al. Intravesical therapy for the treatment of nonmuscle invasive bladder cancer: a systematic review and meta-analysis. *J Urol*. 2017;197(5):1189–1199.

Lamm DL, Blumenstein BA, Crissman JD, et al. Maintenance bacillus Calmette-Guérin immunotherapy for recurrent Ta,T1 and carcinoma in situ TCC of the bladder: a randomized SWOG study. *J Urol*. 2000;163:1124–1129.

O'Donnell MA. Practical applications of intravesical chemotherapy and immunotherapy in high-risk patients with superficial bladder cancer. *Urol Clin North Am*. 2005;32:121–131.

Sylvester RJ, Oosterlinck W, van der Meijden AP. A single immediate postoperative instillation of chemotherapy decreases the risk of recurrence in patients with stage Ta, T1 bladder cancer: a meta-analysis of published results of randomized clinical trials. *J Urol*. 2004;171:2186–2190.

References

Aaronson DS, Walsh TJ, Smith JF, et al. Meta-analysis: does lidocaine gel before flexible cystoscopy provide pain relief? *BJU Int*. 2009;104:506–509.

Abel PD. Follow-up of patients with “superficial” transitional cell carcinoma of the bladder: the case for a change policy. *Br J Urol*. 1993;72:135–142.

Al Khalifa M, Elfving P, Månsson W, et al. The effect of isoniazid on BCG-induced toxicity in patients with superficial bladder cancer. *Eur Urol*. 2000;37(Suppl 1):26–30.

Aldousari S, Kassouf W. Update on the management of non-muscle invasive bladder cancer. *Can Urol Assoc J*. 2010;4(1):56–64.

Althausen AF, Prout GR Jr, Daly JJ. Non-invasive papillary carcinoma of the bladder associated with carcinoma in situ. *J Urol*. 1976;116:575–580.

Amin MB, Edge SB, Greene FL, et al. *AJCC cancer staging manual*. ed 8. Springer: New York, NY; 2016.

Amling C, Thraser J, Frazier H, et al. Radical cystectomy for stages Ta, Tis, and T1 transitional cell carcinoma of the bladder. *J Urol*. 1994;151:31.

Anderson C, Weber R, Patel D, et al. A 10-item checklist improves reporting of critical procedural elements during transurethral resection of bladder tumor. *J Urol*. 2016;196:1014–1020.

Arends TJ, Nativ O, Maffezzini M, et al. Results of a randomised controlled trial comparing intravesical chemohyperthermia with mitomycin C versus bacillus Calmette-Guérin for adjuvant treatment of patients with intermediate- and high-risk non-muscle-invasive bladder cancer. *Eur Urol*. 2016;69:1046–1052.

Au JL, Badalament RA, Wientjes MG, et al. Methods to improve efficacy of intravesical mitomycin C: results of a randomized phase III trial. *J Natl Cancer Inst*. 2001;93:597–604.

Azuma T, Nagase Y, Oshi M. Pyuria predicts poor prognosis in patients with non–muscle-invasive bladder cancer. *Clin Genitourin Cancer*. 2013;11(3):331–336.

Babjuk M, Böhle A, Burger M, et al. EAU Guidelines on non-muscle-invasive urothelial carcinoma of the bladder: update 2016. *Eur Urol*. 2017;71:447–461.

Bader MJ, Stepp H, Beyer W, et al. Photodynamic therapy of bladder cancer – a phase I study using Hexaminolevulinate (HAL). *Urol Oncol*. 2013;31:1178–1183.

Balbay MD, Cimentepe E, Unsal A, et al. The actual incidence of bladder perforation following transurethral bladder surgery. *J Urol*. 2005;174:2260–2262.

Barocas DA, Liu A, Burks FN, et al. Practice based collaboration to improve the use of immediate intravesical therapy after resection of nonmuscle invasive bladder cancer. *J Urol*. 2013;190:2011–2016.

Bassi P, Spinadin R, Carando R, et al. Modified induction course: a solution to side-effects? *Eur Urol*. 2000;37(Suppl 1):31–32.

Bayraktar Z, Gurbuz G, Tasci AI, et al. Management of clinical T1 bladder transitional cell carcinoma by radical cystectomy. *Urol Oncol*. 2004;22:290–294.

Becci PJ, Thompson HJ, Grubbs CJ, et al. Inhibitory effect of 13-*cis*-retinoic acid on urinary bladder carcinogenesis induced in C57BL/6 mice by *N*-butyl-*N*-(4-hydroxybutyl)-nitrosamine. *Cancer Res*. 1978;38:4463–4466.

Belldegrun AS, Franklin JR, O'Donnell MA, et al. Superficial bladder cancer: the role of interferon-alpha. *J Urol*.

1998;159:1793–1801 [Review. Erratum in *J Urol* 160:1444, 1998].

Bercovich E, Deriu M, Manferrari F, et al. BCG vs. BCG plus recombinant alpha-interferon in superficial tumors of the bladder. *Arch Ital Urol Androl*. 1995;67:257–262.

Berrum-Svennung I, Granfors T, Jahnson S, et al. A single instillation of epirubicin after transurethral resection of bladder tumors prevents only small recurrences. *J Urol*. 2008;179(1):101–105.

Bianco FJ Jr, Justa D, Grignon DJ. Management of clinical T1 bladder transitional cell carcinoma by radical cystectomy. *Urol Oncol*. 2004;22:290–294.

Bittard H, Lamy B, Billery C. Clinical evaluation of cell deoxyribonucleic acid content measured by flow cytometry in bladder cancer. *J Urol*. 1996;155:1887–1891.

Bohle A, Bock PR. Intravesical bacille Calmette-Guérin versus mitomycin C in superficial bladder cancer: formal meta-analysis of comparative studies on tumor progression. *Urology*. 2004;63:682–686.

Bohle A, Brandau S. Immune mechanisms in bacillus Calmette-Guérin immunotherapy for superficial bladder cancer. *J Urol*. 2003;170:964–969.

Böhle A, Leyh H, Frei C, et al. Single postoperative instillation of gemcitabine in patients with non-muscle-invasive transitional cell carcinoma of the bladder: a randomised, double-blind, placebo-controlled phase III multicentre study. *Eur Urol*. 2009;56:495–503.

Bosscheiter J, Nieuwenhuijzen JA, van Ginkel T, et al. Value of an immediate intravesical instillation of Mitomycin C in patients with non-muscle-invasive bladder cancer: a prospective ulticentre randomized study in 2243 patients. *Eur Urol*. 2018;73:226–232.

Bouffioux C, Kurth KH, Bono A, et al. Intravesical adjuvant chemotherapy for superficial transitional cell bladder carcinoma: results of 2 European Organization for Research and Treatment of Cancer randomized trials with mitomycin C and doxorubicin comparing early versus delayed instillations and short-term versus long-term treatment. *J Urol*. 1995;153:934.

Brake M, Loertzer H, Horsch R. Long-term results of intravesical bacillus Calmette-Guérin therapy for stage T1 superficial bladder cancer. *Urology*. 2000;55:673–678.

Brausi M, Collette L, Kurth K, et al. Variability in the recurrence rate at first follow-up cystoscopy after TUR in stage Ta, T1 transitional cell carcinoma of the bladder: a combined analysis of seven EORTC studies. EORTC Genito-Urinary Tract Cancer Collaborative Group. *Eur Urol*. 2002;41:523–531.

Bretton PR, Herr HW, Kimmel M, et al. The response of patients with superficial bladder cancer to a second course of intravesical bacillus Calmette-Guérin. *J Urol*. 1990;143:710–712.

Breyer BN, Whitson JM, Carroll PR, et al. Sequential intravesical gemcitabine and mitomycin C chemotherapy regimen in patients with non-muscle invasive bladder cancer. *Urol Oncol*. 2010;28:510–514.

Brosman SA. Experience with bacillus Calmette-Guérin in patients with superficial bladder carcinoma. *J Urol*. 1982;128:27–30.

Brown FM. Urine cytology: is it still the gold standard for screening? *Urol Clin North Am*. 2000;27:25–37.

Byar D, Blackard C. Comparisons of placebo, pyridoxine, and topical thiotepa in preventing recurrence of stage I bladder cancer. *Urology*. 1977;10:556–562.

Calabro F, Sternberg CN. New drugs and new approaches for the treatment of metastatic urothelial cancer. *World J Urol*.

2002;20:158–166.

Cambier S, Sylvester RJ, Collette L, et al. EORTC nomograms and risk groups for predicting recurrence, progression, and disease-specific and overall survival in non-muscle-invasive stage Ta-T1 urothelial bladder cancer patients treated with 1-3 years of maintenance bacillus Calmette-Guérin. *Eur Urol*. 2016;69(1):60–69.

Catalona WJ, Hudson MA, Gillen DP. Risks and benefits of repeated courses of intravesical bacillus Calmette-Guérin therapy for superficial bladder cancer. *J Urol*. 1987;137:220–224.

Chamie K, Litwin MS, Bassett JC, Urologic Diseases in America Project, et al. Recurrence of high-risk bladder cancer: a population-based analysis. *Cancer*. 2013;119(17):3219–3227.

Chang R, Marshall FF, Mitchell S. Percutaneous management of benign ureteral strictures and fistulas. *J Urol*. 1989;137:1126.

Chang SS, Boorjian SA, Chou R, et al. Diagnosis and treatment of non-muscle invasive bladder cancer: AUA/SUO guideline. *J Urol*. 2016;196(4):1021–1029.

Chang SS, Cookson MS. Radical cystectomy for bladder cancer: the case for early intervention. *Urol Clin North Am*. 2005;32:147–155.

Chatterjee SJ, Datar R, Youssefzadeh D, et al. Combined effects of p53, p21, and pRb expression in the progression of bladder transitional cell carcinoma. *J Clin Oncol*. 2004;22:1007–1013.

Chen YT, Hsiao PJ, Wong WY, et al. Randomized double-blind comparison of lidocaine gel and plain lubricating gel in relieving pain during flexible cystoscopy. *J Endourol*. 2005;19:163–166.

Chen SP, Liao JC. Confocal laser endomicroscopy of bladder and upper tract urothelial carcinoma: a new era of optical diagnosis? *Curr Urol Rep*. 2014;15:437.

Chou R, Selph S, Buckley DI, et al. Comparative effectiveness of fluorescent versus white light cystoscopy for initial diagnosis or surveillance of bladder cancer on clinical outcomes: systematic review and meta-analysis. *J Urol*. 2017;197:548–558.

Chou R, Selph S, Buckley DI, et al. Intravesical therapy for the treatment of nonmuscle invasive bladder cancer: a systematic review and meta-analysis. *J Urol*. 2017;197:1189–1199.

Ciudin A, Diaconu MG, Gosalbez D, et al. Air cystoscopy is superior to water cystoscopy for the diagnosis of active hematuria. *J Urol*. 2013;190:2097–2101.

Cliff AM, Romaniuk CS, Parr NJ. Perivesical inflammation after early mitomycin C instillation. *BJU Int*. 2000;85(4):556–557.

Collado A, Chechile GE, Salvador J, et al. Early complications of endoscopic treatment for superficial bladder tumors. *J Urol*. 2000;164:1529–1532.

Colombel M, Saint F, Chopin D, et al. The effect of ofloxacin on bacillus calmette-guerin induced toxicity in patients with superficial bladder cancer: results of a randomized, prospective, double-blind, placebo controlled, multicenter study. *J Urol*. 2006;176:935–939.

Colombo R, Salonia A, Leib Z, et al. Long-term outcomes of a randomized controlled trial comparing thermochemotherapy with mitomycin-C alone as adjuvant treatment for non-muscle-invasive bladder cancer (NMIBC). *BJU Int*. 2011;107:912–918.

Comploj E, Dechet CB, Mian M, et al. Perforation during TUR of bladder tumours influences the natural history of superficial bladder cancer. *World J Urol*. 2014;32:1219–1223.

Cookson MS, Herr HW, Shang ZF, et al. The treated natural history of high risk superficial bladder cancer: 15 year outcome. *J Urol*. 1997;158:62–67.

Cookson MS, Sarosdy MJ. Management of stage T1 superficial bladder cancer with intravesical bacillus Calmette-Guérin. *J Urol*. 1992;148:797–801.

Coplen DE, Marcus MD, Myers JA, et al. Long-term follow-up of patients treated with 1 or 2, 6-week courses of intravesical bacillus Calmette-Guérin: analysis of possible predictors of response free of tumor. *J Urol*. 1990;144:652–657.

Cote R, Chatterjee SJ. Molecular determinants of outcome in bladder cancer. *Cancer J Sci Am*. 1999;5:1–15.

Dalbagni G, Rechtschaffen T, Herr HW. Is transurethral biopsy of the bladder necessary after 3 months to evaluate response to bacillus Calmette-Guérin therapy? *J Urol*. 1999;162:708–709.

Damiano R, De Sio M, Quarto G, et al. Short-term administration of prulifloxacin in patients with nonmuscle-invasive bladder cancer: an effective option for the prevention of bacillus Calmette-Guérin-induced toxicity? *BJU Int*. 2009;104:633–639.

Daneshmand S, Patel S, Lotan Y, et al. Efficacy and safety of blue light flexible cystoscopy with hexaminolevulinate in the surveillance of bladder cancer: a Phase III, comparative, multicenter study. *J Urol*. 2017; 10.1016/j.juro.2017.11.096 [pii: S0022-5347(17)78004-4].

Datta SN, Loh CS, MacRobert AJ, et al. Quantitative studies of the kinetics of 5-aminolaevulinic acid–induced fluorescence in bladder transitional cell carcinoma. *Br J Urol*. 1998;78:1113–1118.

Davis R, Jones JS, Barocas DA, et al. Diagnosis, evaluation and follow-up of asymptomatic microhematuria (AMH) in adults: AUA guidelines. *J Urol*. 2012;188:2473–2481.

De Jager R, Guinan P, Lamm DL, et al. Long-term complete remission in bladder carcinoma in situ with intravesical TICE bacillus Calmette-Guérin: overview analysis of six phase II clinical trials. *Urology*. 1991;38:507–513.

De Neve W, Lybeert ML, Goor C, et al. T1 and T2 carcinoma of the urinary bladder: long-term results with external, preoperative, or interstitial radiotherapy. *Int J Radiat Oncol Biol Phys*. 1992;23:299–304.

Degtyar P, Neulander E, Zirkin H, et al. Fluorescence in situ hybridization performed on exfoliated urothelial cells in patients with transitional cell carcinoma of the bladder. *Urology*. 2004;63:398–401.

Denzinger S, Burger M, Walter B, et al. Clinically relevant reduction in risk of recurrence of superficial bladder cancer using 5-aminolevulinic acid–induced fluorescence diagnosis: 8-year results of prospective randomized study. *Urology*. 2007;69(4):675–679.

Di Lorenzo G, Perdona S, Damiano R, et al. Gemcitabine versus Bacille Calmette-Guerin after initial bacilli Calmette-Guerin failure in non-muscle-invasive bladder cancer. *Cancer*. 2010;116:1893–1900.

Di Stasi SM, Giannantoni A, Giurioli A, et al. Sequential BCG and electromotive mitomycin versus BCG alone for high-risk superficial bladder cancer: a randomised controlled trial. *Lancet Oncol*. 2006;7:43–51.

Di Stasi SM, Giannantoni A, Massoud R, et al. Electromotive vs passive diffusion of Mitomycin C into human bladder wall: concentration-depth profile studies. *Cancer Res*. 1999;59:4912–4918.

Di Stasi SM, Giannantoni A, Stephen RL, et al. Intravesical electromotive mitomycin C versus passive transport mitomycin C for high risk superficial bladder cancer: a prospective randomized study. *J Urol*. 2003;170:777–782.

Di Stasi SM, Riedl C. Updates in intravesical electromotive drug administration of mitomycin-C for non-muscle invasive bladder cancer. *World J Urol*. 2009;27:325–330.

Di Stasi SM, Valenti M, Verri C, et al. Electromotive instillation of mitomycin immediately before transurethral resection for patients with primary urothelial non-muscle invasive bladder cancer: a randomised controlled trial. *Lancet Oncol*. 2011;12(9):871–879.

Divrik RT, Sahin AF, Yildirim U, et al. Impact of routine second transurethral resection on the long-term outcome of patients with newly diagnosed pT1 urotheilal carcinoma with respect to recurrence, progression rate, and disease-specific survival: a prospective randomized clinical trial. *Eur Urol*. 2010;58:185–190.

Doherty AP, Trendell-Smith N, Stirling R, et al. Perivesical fat necrosis after adjuvant intravesical chemotherapy. *BJU Int*. 1999;83(4):420–423.

Donat SM, North A, Dalbagni G, et al. Efficacy of office fulguration for recurrent low grade papillary bladder tumors less than 0.5 cm. *J Urol*. 2004;171:636–639.

Donat SM. Evaluation and follow-up strategies for superficial bladder cancer. *Urol Clin North Am*. 2003;30:765–766.

Droller MJ. Biological considerations in the assessment of urothelial cancer: a retrospective. *Urology*. 2005;66(5 Suppl):66–75.

Duque JL, Loughlin KR. An overview of the treatment of superficial bladder cancer: intravesical chemotherapy. *Urol Clin North Am*. 2000;27:125–134.

Durek C, Brandau S, Ulmer AJ, et al. Bacillus Calmette-Guérin (BCG) and 3D tumors: an in vitro model for the study of adhesion and invasion. *J Urol*. 1999;162:600–605.

Durek C, Rusch-Gerdes S, Jocham D, et al. Interference of modern antibacterials with bacillus Calmette-Guérin viability. *J Urol*. 1999;162:1959–1962.

Dutta R, Yoon R, Patel RM, et al. Clinical comparison of conventional and mobile endockscope videocystoscopy using an air or fluid medium. *J Endourol*. 2017;31:593–597.

Dutta SC, Smith JA Jr, Shappell SB. Clinical under staging of high risk non–muscle-invasive urothelial carcinoma treated with radical cystectomy. *J Urol*. 2001;166:490–493.

Ehdaie B, Sylvester R, Herr HW. Maintenance bacillus Calmette-Guérin treatment of non–muscle-invasive bladder cancer: a critical evaluation of the evidence. *Eur Urol*. 2013;64(4):579–585.

Eichholzer M, Stahelin HB, Gey KF, et al. Prediction of male cancer mortality by plasma levels of interacting vitamins: 17-year follow-up of the prospective Basel study. *Int J Cancer*. 1996;66:145–150.

El Hayek OR, Coelho RF, Dall'oglio MF, et al. Evaluation of the incidence of bladder perforation after transurethral bladder tumor resection in a residency setting. *J Endourol*. 2009;2:1183–1186.

Epstein JI, Amin MB, Reuter VR, et al. The World Health Organization/International Society of Urological Pathology consensus classification of urothelial (transitional cell) neoplasms of the urinary bladder. Bladder Consensus Conference Committee. *Am J Surg Pathol*. 1998;22:1435–1448.

Fernandez-Gomez J, Madero R, Solsona E, et al. Predicting nonmuscle invasive bladder cancer recurrence and progression in patients treated with bacillus Calmette-Guerin: the CUETO scoring model. *J Urol*. 2009;182(5):2195–2203.

Ficarra V, Dalpiaz O, Alrabi N, et al. Correlation between clinical and pathological staging in a series of radical cystectomies for bladder carcinoma. *BJU Int*. 2005;95:786–790.

Filbeck T, Pichlmeier U, Knuechel R, et al. Reducing the risk of superficial bladder cancer recurrence with 5-aminolevulinic acid–induced fluorescence diagnosis: results of a 5-year study. *Urologe A*. 2003;42:1366–1373.

Fitzpatrick JM, West AB, Butler MR, et al. Superficial bladder tumors (stage pTa, grades 1 and 2): the importance of recurrence pattern following initial resection. *J Urol*. 1986;135:920–922.

Fradet Y, Grossman HB, Gomella L, PC B302/01 Study Group, et al. A comparison of hexaminolevulinate fluorescence cystoscopy and white light cystoscopy for the detection of carcinoma in situ in patients with bladder cancer: a phase III, multicenter study. *J Urol*. 2007;178(1):68–73.

Freeman JA, Esrig D, Stein JP, et al. Radical cystectomy for high-risk patients with superficial bladder cancer in the era of orthotopic urinary reconstruction. *Cancer*. 1995;76:833–839.

Frydenberg M, Millar JL, Toner G, Urology Study Committee of the Victorian Co-operative Oncology Group, et al. Cancer Council of Victoria: management of superficial bladder cancer in Victoria: 1990 and 1995. *ANZ J Surg*. 2005;75:270–274.

Fujimoto N, Haradas S, Terado M, et al. Multiple biopsies of normal looking urothelium in patients with superficial bladder cancer: are they necessary? *Int J Urol*. 2003;10:631–635.

Gan C, Amery S, Chatterton K, et al. Sequential bacillus Calmette-Guerin/electromotive drug administration of Mitomycin C as the standard intravesical regimen in high risk nonmuscle invasive bladder cancer: 2-year outcomes. *J Urol*. 2016;195:1697–1703.

Glashan R. A randomized controlled study of intravesical alpha-2b interferon in carcinoma in situ of the bladder. *J Urol*. 1990;144:658.

Goessl C, Knispel HH, Millar K, et al. Is routine excretory urography necessary at first diagnosis of bladder cancer? *J Urol*. 1997;157:480–481.

Gofrit ON, Shapiro A, Pode D. Combined local bladder hyperthermia and intravesical chemotherapy for the treatment of high-grade superficial bladder cancer. *Urology*. 2004;63:466–471.

Gohji K, Nomi M, Okamoto M, et al. Conservative therapy for stage T1b, grade 3 transitional cell carcinoma of the bladder. *Urology*. 1999;53:308–313.

Golan S, Baniel J, Lask D, et al. Transurethral resection of bladder tumour complicated by perforation requiring open surgical repair - clinical characteristics and oncological outcomes. *BJU Int*. 2011;107:1065–1068.

Gontero P, Sylvester R, Pisano F, et al. The impact of re-transurethral resection on clinical outcomes in a large multicentre cohort of patients with T1 high-grade/Grade 3 bladder cancer treated with bacille Calmette-Guérin. *BJU Int*. 2016;118:44–52.

Gray PJ, Shipley WU, Efstathiou JA, et al. Recent advances and the emerging role for chemoradiation in nonmuscle invasive bladder cancer. *Curr Opin Urol*. 2013;23(5):429–434.

Greenberg RE, Bahnson RR, Wood D, et al. Initial report on intravesical administration of *N*-trifluoroacetyladriamycin-14-valerate (AD-32) to patients with refractory superficial transitional cell carcinoma of the urinary bladder. *Urology*. 1997;49:471–475.

Grimm MO, Steinhoff C, Simon X, et al. Effect of routine repeat transurethral resection for superficial bladder cancer: a long-term observational study. *J Urol*. 2003;170:433–437.

Grossfeld GD, Wolf JS Jr, Litwan MS, et al. Asymptomatic microscopic hematuria in adults: summary of the AUA best practice policy recommendations. *Am Fam Physician*. 2001;63:1145–1154.

Grossman HB, Blute ML, Dinney CP, et al. The use of urine-based biomarkers in bladder cancer. *Urology*. 2006;67(3 Suppl 1):62–64.

Grossman HB, Messing E, Soloway M, et al. Detection of bladder cancer using a point-of-care proteomic assay. *JAMA*. 2005;293(7):810–816.

Grossman HB, O'Donnell MA, Cookson MS, et al. Bacillus Calmette-Guérin failures and beyond: contemporary management of non–muscle-invasive bladder cancer. *Rev Urol*. 2008;10(4):281–289.

Grossman HB. A phase III, multicenter comparison of hexaminolevulinate fluorescence cystoscopy and WL cystoscopy for the detection of superficial papillary lesions in patients with bladder cancer. *J Urol*. 2007;178:62–67.

Gudjónsson S, Adell L, Merdasa F, et al. Should all patients with non-muscle-invasive bladder cancer receive early intravesical chemotherapy after transurethral resection? The results of a prospective randomised multicentre study. *Eur Urol*. 2009;55:773–780.

Haaff EO, Catalona WJ, Ratcliffe TL. Detection of interleukin 2 in the urine of patients with superficial bladder tumors after treatment with intravesical BCG. *J Urol*. 1986;136:970–974.

Halling K, King W, Sokolova I, et al. A comparison of cytology and fluorescence in situ hybridization for the detection of urothelial carcinoma. *J Urol*. 2000;164:1768–1775.

Han RF, Pan JG. Can intravesical bacillus Calmette-Guérin reduce recurrence in patients with superficial bladder cancer? A meta-analysis of randomized trials. *Urology*. 2006;67:1216–1223.

Harland SJ, Charig CR, Highman W, et al. Outcome in carcinoma in situ of bladder treatment with intravesical bacille Calmette-Guérin. *Br J Urol*. 1992;70:271.

Harnden P. A critical appraisal of the classification of urothelial tumours: time for a review of the evidence and a radical change? *BJU Int*. 2007;99(4):723–725.

Hasui Y, Osada Y, Kitada S. Significance of invasion to the muscularis mucosae on the progression of superficial bladder cancer. *Urology*. 1994;43:782–786.

Haukaas S, Daehlin L, Maartmann-Moe H, et al. The long-term outcome in patients with superficial transitional cell carcinoma of the bladder: a single-institutional experience. *BJU Int*. 1999;83:957–963.

Hautmann RE, Paiss T. Does the option of the ileal neobladder stimulate patient and physician decision toward earlier cystectomy? *J Urol*. 1998;159(6):1845–1850.

Hautmann RE, Stein JP. Neobladder with prostatic capsule and seminal-sparing cystectomy for bladder cancer: a step in the wrong direction. *Urol Clin North Am*. 2005;32:177–185.

Hedelin H, Holmäng S, Wiman L. The cost of bladder tumour treatment and follow-up. *Scand J Urol Nephrol*. 2002;36:344–347.

Heney NM, Ahmed S, Flanagan MJ, et al. Superficial bladder cancer: progression and recurrence. *J Urol*. 1983;130:1083–1086.

Heney NM, Nocks BN, Daly JJ, et al. Prognostic factors in carcinoma of the ureter. *J Urol*. 1981;125:632–636.

Heney NM, Proppe K, Prout GR, et al. Invasive bladder cancer: tumor configuration, lymphatic invasion and survival. *J Urol*. 1983;130:895–897.

Herr HW, Badalament RA, Amato DA, et al. Superficial bladder cancer treated with bacillus Calmette-Guérin: a multivariate analysis of factors affecting tumor progression. *J Urol*. 1989;141:22–29.

Herr HW, Cookson MS, Soloway SM. Upper tract tumors in patients with primary bladder cancer followed for 15 years. *J Urol*. 1997;156:1286–1287.

Herr HW, Dalbagni G, Donat SM. Bacillus Calmette-Guérin without maintenance therapy for high-risk non-muscle-invasive bladder cancer. *Eur Urol*. 2011;60(1):32–36.

Herr HW, Dalbagni G. Defining bacillus Calmette-Guérin refractory superficial bladder tumors. *J Urol*. 2003;169:1706–1708.

Herr HW, Dalbagni G. Intravesical bacille Calmette-Guérin (BCG) in immunologically compromised patients with bladder cancer. *BJU Int*. 2013;111:984–987.

Herr HW, Donat SM, Dalbagni G. Can restaging transurethral resection of T1 bladder cancer select patients for immediate cystectomy? *J Urol*. 2007;177:75–79.

Herr HW, Donat SM. A comparison of white-light cystoscopy and narrow-band imaging cystoscopy to detect bladder tumour recurrences. *BJU Int*. 2008;102:1111–1114.

Herr HW, Laudone VP, Badalament RA, et al. Bacillus Calmette-Guérin therapy alters the progression of superficial bladder cancer. *J Clin Oncol*. 1988;6:1450–1454.

Herr HW, Sogani PC. Does early cystectomy improve the survival of patients with high-risk superficial bladder tumors? *J Urol*. 2001;166:1296–1299.

Herr HW, Wartinger DD, Fair WR, et al. Bacillus Calmette-Guérin therapy for superficial bladder cancer: a 10-year follow-up. *J Urol*. 1992;147:1020–1023.

Herr HW. Intravesical bacillus Calmette-Guérin outcomes in patients with bladder cancer and asymptomatic bacteriuria. *J Urol*. 2012;187(2):435–437.

Herr HW. Restaging transurethral resection of high risk superficial bladder cancer improves the initial response to bacillus Calmette-Guérin therapy. *J Urol*. 2005;174:2134–2137.

Herr HW. Role of repeat resection in non-muscle invasive bladder cancer. *J Natl Compr Canc Netw*. 2015;13:1041.

Herr HW. The value of a second transurethral resection in evaluating patients with bladder tumors. *J Urol*. 1999;162:74–76.

Herr HW. Timing of a cystectomy for superficial bladder tumors. *Urol Oncol*. 2000;5:162–165.

Herr HW. Tumor progression and survival of patients with high grade, noninvasive papillary (TaG3) bladder tumors: 15-year outcome. *J Urol*. 2000;163:60–61 [discussion 61–62].

Herr HW. Tumour progression and survival in patients with T1G3 bladder tumours: 15-year outcome. *Br J Urol*. 1997;80:762–765.

Herranz-Amo F, Diaz-Cordero JM, Verdú-Tartajo F, et al. Need for intravenous urography in patients with primary transitional carcinoma of the bladder? *Eur Urol*. 1999;36:221–224.

Herts BR. Imaging for renal tumors. *Curr Opin Urol*. 2003;13:181–186.

Ho KJ, Thompson TJ, O'Brien A, et al. Lignocaine gel: does it cause urethral pain rather than prevent it? *Eur Urol*. 2003;43:194–196.

Hofstetter A, Kriegman M, Baumgartner R. Evaluation of laser treatment of bladder cancer. Smith JA Jr. *Lasers in urologic surgery*. Mosby–Year Book: Chicago; 1994:114–125.

Holmäng S, Hedelin H, Anderstrom C, et al. The relationship among multiple recurrences, progression and prognosis of patients with stages Ta and T1 transitional cell cancer of the bladder followed for at least 20 years. *J Urol*. 1995;153:1823–1827.

Holmäng S, Ströck V. Should follow-up cystoscopy in bacillus Calmette-Guérin–treated patients continue after five tumour-free years? *Eur Urol*. 2012;61(3):503–507.

Holzbeierlein JM, Smith JA Jr. Surgical management of noninvasive bladder cancer (stages Ta/T1/CIS). *Urol Clin*

North Am. 2000;27:15–24 [vii–viii].

Horiguchi Y, Larchian WA, Kaplinsky R, et al. Intravesical liposome-mediated interleukin-2 gene therapy in orthotopic murine bladder cancer model. *Gene Ther*. 2000;7:844–851.

Horinaga M, Harsch KM, Fukuyama R, et al. Intravesical interleukin-12 gene therapy in an orthotopic bladder cancer model. *Urology*. 2005;66:461–466.

Hudson MA, Herr HW. Carcinoma in situ of the bladder. *J Urol*. 1995;153:564–572.

Huguet J, Crego M, Sabate S, et al. Cystectomy in patients with high risk superficial bladder tumors who fail intravesical BCG therapy: pre-cystectomy prostate involvement as a prognostic factor. *Eur Urol*. 2005;48:53–59.

Huncharek M, McGarry R, Kupelnick B. Impact of intravesical chemotherapy on recurrence rate of recurrent superficial transitional cell carcinoma of the bladder: results of a meta-analysis. *Anticancer Res*. 2001;21:765–769.

Hurle R, Losa A, Manzetti A, et al. Intravesical bacille Calmette-Guérin in stage T1 grade 3 bladder cancer therapy: a 7-year follow-up. *Urology*. 1999;54:258–263.

Hurle R, Losa A, Manzetti A, et al. Upper urinary tract tumors developing after treatment of superficial bladder cancer: 7-year follow-up of 591 consecutive patients. *Urology*. 1999;53:1144–1148.

Hurle R, Losa A, Ranierie A, et al. Low dose Pasteur bacillus Calmette-Guérin regimen in stage T1, grade 3 bladder cancer therapy. *J Urol*. 1996;156:1602–1605.

Hurle R, Manzetti A, Losa A, et al. Intravesical instillation of mitomycin C in 242 patients with superficial bladder cancer at high risk of recurrence: long-term results. *Urol Int*. 1998;61:220–226.

Isaka S, Okano T, Abe K, et al. Sequential instillation therapy with mitomycin C and Adriamycin for superficial bladder cancer. *Cancer Chemother Pharmacol*. 1992;30:41.

Jansson OT, Morcos E, Brundin L, et al. The role of nitric oxide in bacillus Calmette-Guérin mediated anti-tumour effects in human bladder cancer. *Br J Cancer*. 1998;78:588–592.

Jarrow JP, Lerner SP, Kluetz PG, et al. Clinical trial design for the development of new therapies for nonmuscle-invasive bladder cancer: report of a food and drug administration and American Urological Association public workshop. *Urology*. 2014;83:262–265.

Jiang X, Castelao JE, Groshen S, et al. Water intake and bladder cancer risk in Los Angeles County. *Int J Cancer*. 2008;123(7):1649–1656.

Jichlinski P, Guillou L, Karlsen SJ, et al. Hexyl aminolevulinate fluorescence cystoscopy: new diagnostic tool for photodiagnosis of superficial bladder cancer—a multicenter study. *J Urol*. 2003;170:226–229.

Jimenez-Cruz JF, Vera-Donoso CD, Leiva O, et al. Intravesical immunoprophylaxis in recurrent superficial bladder cancer (stage T1): multicenter trial comparing bacille Calmette-Guérin and interferon-alpha. *Urology*. 1997;50:529–535.

Jocham D, Beer M, Baumgartner R, et al. Long-term experience with integral photodynamic therapy of TIS bladder carcinoma. *Ciba Found Symp*. 1989;146:198–205.

Jocham D, Witjes F, Wagner S, et al. Improved detection and treatment of bladder cancer using hexaminolevulinate imaging: a prospective, phase III multicenter study. *J Urol*. 2005;174:862–866.

Jones JS, Patel A, Angie M, et al. *Office cystoscopy more tolerated with patient visualized real-time video monitoring*. [Abstract 94765. Presented at: AUA annual meeting. Atlanta, GA] 2006.

Joudi FN, Smith BJ, O'Donnell MA, et al. The impact of age on the response of patients with superficial bladder cancer to intravesical immunotherapy. *J Urol*. 2006;175:1634–1639.

Joudi FN, Smith BJ, O'Donnell MA. Final results from a national multicenter phase II trial of combination bacillus Calmette-Guérin plus interferon alpha-2B for reducing recurrence of superficial bladder cancer. *Urol Oncol*. 2006;24:344–348.

Jung JH, Gudeloglu A, Kiziloz H, et al. Intravesical electromotive drug administration for non-muscle invasive bladder cancer. *Cochrane Database Syst Rev*. 2017;(9); 10.1002/14651858.CD011864 [CD011864].

Jurincic CC, Engelmann U, Gasch J, et al. Immunotherapy in bladder cancer with keyhole-limpet hemocyanin: a randomized study. *J Urol*. 1989;139:723–726.

Kalble T, Beer M, Mendoza E, et al. BCG vs. interferon A for prevention of recurrence of superficial bladder cancer: a prospective randomized study. *Urologe A*. 1994;33:133.

Kallioniemi A, Kallioniemi OP, Citro G, et al. Identification of gains and losses of DNA sequences in primary bladder cancer by comparative genomic hybridization. *Genes Chromosomes Cancer*. 1995;12:213–219.

Kamat AM, Briggman J, Urbauer DL, et al. Cytokine panel for response to intravesical therapy (CyPRIT): nomogram of changes in urinary cytokine levels predicts patient response to Bacillus Calmette-Guerin. *Eur Urol*. 2016;59:197–200.

Kamat AM, Dickstein RJ, Messetti F, et al. Use of fluorescence in situ hybridization to predict response to bacillus Calmette-Guerin therapy for bladder cancer: results of a prospective trial. *J Urol*. 2012;187(3):862–867.

Kang M, Lee S, Jeong SJ, et al. Characteristics and significant predictors of detecting underlying diseases in adults with asymptomatic microscopic hematuria: a large case series of a Korean population. *Int J Urol*. 2015;22:389–393.

Kavoussi LR, Torrence RJ, Gillen DP, et al. Results of 6 weekly intravesical BCG instillations on the treatment of superficial bladder tumors. *J Urol*. 1988;139:935–940.

Kent DL, Shachter R, Sox HC, et al. Efficient scheduling of cystoscopies in monitoring for recurrent bladder cancer. *Med Decis Making*. 1989;9:26–37.

Khadra MH, Pickard RS, Charlton M, et al. A prospective analysis of 1,930 patients with hematuria to evaluate current diagnostic practice. *J Urol*. 2000;163:524–527.

Kiemeney LA, Witjes JA, Hiejbroek RP, et al. Should random urothelial biopsies be taken from patients with primary superficial bladder cancer? A decision analysis. *Br J Urol*. 1994;73:164–171.

Kiemeney LA, Witjes JA, Verbeek AL, et al. The clinical epidemiology of superficial bladder cancer. Dutch South-East Cooperative Urological Group. *Br J Cancer*. 1993;67:806–812.

Kim HL, Steinberg GD. The current status of bladder preservation in the treatment of muscle invasive bladder cancer. *J Urol*. 2000;164(3 Pt 1):627–632.

Kim HS, Kim M, Jeong CW, et al. Presence of lymphovascular invasion in urothelial bladder cancer specimens after transurethral resections correlates with risk of upstaging and survival: a systematic review and meta-analysis. *Urol Oncol*. 2014;32(8):1191–1199.

Kipp BR, Karnes RJ, Brankley SM, et al. Monitoring intravesical therapy for superficial bladder cancer using fluorescence in situ hybridization. *J Urol*. 2005;173:401–404.

Klan R, Loy V, Huland H. Residual tumor discovered in routine second transurethral resection in patients with stage T1 transitional cell carcinoma of the bladder. *J Urol*. 1991;146:316–318.

Kobayashi S, Fujii Y, Koga F, et al. Impact of bladder neck involvement on progression in patients with primary non–

muscle invasive bladder cancer: a prospective validation study. *Urol Oncol*. 2014;32(1):38.e29–38.e36.

Koch MO, Smith JA Jr. Natural history and surgical management of superficial bladder cancer (stages Ta/T1/Tis). Vogelzang N, Miles BJ. *Comprehensive textbook of genitourinary oncology*. Lippincott Williams & Wilkins: Baltimore; 1996:405–415.

Kondylis FI, Demirci S, Ladaga L, et al. Outcomes after intravesical bacillus Calmette-Guérin are not affected by substaging of high grade T1 transitional cell carcinoma. *J Urol*. 2000;163:1120–1123.

Kramer MW, Altieri V, Hrule R, et al. Current evidence of transurethral en-bloc resection of nonmuscle invasive bladder cancer. *Eur Urol Focus*. 2017 http://dx.doi.org/10.1016/j.euf.2016.12.004.

Kramer MW, Rassweiler JJ, Klein J, et al. En bloc resection of urothelium carcinoma of the bladder (EBRUC): a European multicenter study to compare safety, efficacy, and outcome of laser and electrical en bloc transurethral resection of bladder tumor. *World J Urol*. 2015;33:1937–1943.

Krege S, Giani G, Meyer R, et al. A randomized multicenter trial of adjuvant therapy in superficial bladder cancer: transurethral resection only versus transurethral resection plus mitomycin C versus transurethral resection plus bacillus Calmette-Guérin. *J Urol*. 1996;156:962–966.

Kriegmair M, Baumgartner R, Knuchel R, et al. Detection of early bladder cancer by 5-aminolevulinic acid induced porphyrin fluorescence. *J Urol*. 1996;155:105–110.

Kunju LP, You L, Zhang Y, et al. Lymphovascular invasion of urothelial cancer in matched transurethral bladder tumor resection and radical cystectomy specimens. *J Urol*. 2008;180(5):1928–1932.

Kurth K, Tunn U, Ay R, et al. Adjuvant chemotherapy for superficial transitional cell bladder carcinoma: long-term results of an EORTC randomized trial comparing doxorubicin, ethoglucid and TUR alone. *J Urol*. 1997;158:378–384.

Lamm DL, Blumenstein BA, Crawford ED, et al. A randomized trial of intravesical doxorubicin and immunotherapy with bacille Calmette-Guérin for transitional cell carcinoma of the bladder. *N Engl J Med*. 1991;325:1205–1209.

Lamm DL, Blumenstein BA, Crissman JD, et al. Maintenance bacillus Calmette-Guérin immunotherapy for recurrent Ta, T1 and carcinoma in situ TCC of the bladder: a randomized SWOG study. *J Urol*. 2000;163:1124–1129.

Lamm DL, Dehaven JI, Riggs DR. Keyhole limpet hemocyanin immunotherapy of bladder cancer: laboratory and clinical studies. *Eur Urol*. 2000;37(Suppl 3):41–44.

Lamm DL, Riggs DR, Bugaj M, et al. Prophylaxis in bladder cancer: a meta-analysis. *J Urol*. 2000;163:151.

Lamm DL, Riggs DR, Shriver JS, et al. Megadose vitamins in bladder cancer: a double-blind clinical trial. *J Urol*. 1994;151:21–26.

Lamm DL, van der Meijden AD, Morales A, et al. Incidence and treatment of complications of bacillus Calmette-Guérin intravesical therapy in superficial bladder cancer. *J Urol*. 1992;147:596–600.

Lammers RJ, Witjes WP, Janzing-Pastors MH, et al. Intracutaneous and intravesical immunotherapy with keyhole limpet hemocyanin compared with intravesical mitomycin in patients with non–muscle-invasive bladder cancer: results from a prospective randomized phase III trial. *J Clin Oncol*. 2012;30(18):2273–2279.

Lange N, Jichlinski P, Zellweger M, et al. Photodetection of early human bladder cancer based on the fluorescence of 5-aminolaevulinic acid hexylester-induced protoporphyrin IX: a pilot study. *Br J Cancer*. 1999;80:185.

Larchian WA, Horiguchi Y, Nair SK, et al. Effectiveness of combined interleukin 2 and B7.1 vaccination strategy is dependent on the sequence and order; a liposome-mediated gene therapy treatment for bladder cancer. *Clin Cancer Res*. 2000;6:2913–2920.

Leblanc B, Duclos AJ, Bénard F, et al. Long-term follow-up of initial Ta grade 1 transitional cell carcinoma of the bladder. *J Urol*. 1999;162:1946–1950.

Lee CT, Barocas D, Globe DR, et al. Economic and humanistic consequences of preventable bladder tumor recurrences in nonmuscle invasive bladder cancer cases. *J Urol*. 2012;188(6):2114–2119.

Lee CT, Dunn RL, Ingold C, et al. Early-stage bladder cancer surveillance does not improve survival if high-risk patients are permitted to progress to muscle invasion. *Urology*. 2007;69(6):1068–1072.

Lee JY, Diaz RR, Cho KS, et al. Efficacy and safety of photodynamic therapy for recurrent, high grade nonmuscle invasive bladder cancer refractory or intolerant to bacille Calmette-Guérin immunotherapy. *J Urol*. 2013;190(4):1192–1199.

Lee M, Levin HL, Jones JS. The role of pathology review of transurethral bladder tumor resection specimens in the modern era. *J Urol*. 2010;183:921–928.

Leivo MZ, Sahoo D, Hamilton Z, et al. Analysis of T1 bladder cancer on biopsy and transurethral resection specimens: comparison and ranking of T1 quantification approaches to predict progression to muscularis propria invasion. *Am J Surg Pathol*. 2018;42(1):e1–e10.

Lerner SP, Goh A. Novel endoscopic diagnosis for bladder cancer. *Cancer*. 2015;121:169–178.

Lerner SP, Goh AC, Tresser NJ, et al. Optical coherence tomography as an adjunct to white light cystoscopy for intravesical real-time imaging and staging of bladder cancer. *Urology*. 2008;72:133–137.

Liedberg F, Chebil G, Månsson W. Urothelial carcinoma in the prostatic urethra and prostate: current controversies. *Expert Rev Anticancer Ther*. 2007;7(3):383–390.

Lightfoot AJ, Breyer BN, Rosevear HM, et al. Multi-institutional analysis of sequential intravesical gemcitabine and mitomycin C chemotherapy for non-muscle invasive bladder cancer. *Urol Oncol*. 2014;32:35.e15–35.e19.

Liou LS. Urothelial cancer biomarkers for detection and surveillance. *Urology*. 2006;67(3 Suppl 1):25–33.

Loidl W, Schmidbauer J, Susani M, et al. Flexible cystoscopy assisted by hexaminolevulinate induced fluorescence: a new approach for bladder cancer detection and surveillance? *Eur Urol*. 2005;47(3):323–326.

Lokeshwar VB, Habuchi T, Grossman HB, et al. Bladder tumor markers beyond cytology: International Consensus Panel on bladder tumor markers. *Urology*. 2005;66(6 Suppl 1):35–63.

Lotan Y, Gupta A, Shariat SF, et al. Lymphovascular invasion is independently associated with overall survival, cause-specific survival, and local and distant recurrence in patients with negative lymph nodes at radical cystectomy. *J Clin Oncol*. 2005;23:6533–6539.

Lotan Y, O'Sullivan P, Raman JD, et al. Clinical comparison of noninvasive urine tests for ruling out recurrent urothelial carcinoma. *Urol Oncol*. 2017;35:531.e15–531.e22.

Lu Z, Yeh TK, Tsai M, et al. Paclitaxel-loaded gelatin nanoparticles for intravesical bladder cancer therapy. *Clin Cancer Res*. 2004;10:7677–7684.

Ludwig AT, Moore JM, Luo Y, et al. Tumor necrosis factor-related apoptosis-inducing ligand: a novel mechanism for Bacillus Calmette-Guérin-induced antitumor activity. *Cancer*

Res. 2004;64:3386–3390.

Lutzeyer W, Rubben H, Dahm H. Prognostic parameters in superficial bladder cancer: an analysis of 215 cases. *J Urol*. 1982;127:250.

Mack D, Frick J. Five-year results of a phase II study with low-dose bacille Calmette-Guérin therapy in high risk superficial bladder cancer. *Urology*. 1995;45:958–961.

Madeb R, Golijanin D, Noyes K, et al. Treatment of nonmuscle invading bladder cancer: do physicians in the United States practice evidence based medicine? The use and economic implications of intravesical chemotherapy after transurethral resection of bladder tumors. *Cancer*. 2009;115(12):2660–2670.

Malmstrom PU, Wijkstrom H, Lundholm C. 5-Year follow-up of a randomized prospective study comparing mitomycin C and bacillus Calmette-Guérin in patients with superficial bladder carcinoma. Swedish-Norwegian Bladder Cancer Study Group. *J Urol*. 1999;161:1124–1127.

Malmstrom PU. A randomized comparative dose-ranging study of interferon-alpha and mitomycin-C as an internal control in primary or recurrent superficial transitional cell carcinoma. *BJU Int*. 2001;89:681–686.

Mano R, Shoshany O, Baniel J, et al. Resection of ureteral orifice during transurethral resection of bladder tumor: functional and oncologic implications. *J Urol*. 2012;188:2129–2135.

Mao L, Schoenberg MP, Scicchitano M, et al. Molecular detection of primary bladder cancer by microsatellite analysis. *Science*. 1996;271:659–662.

Martinez-Pineiro JA, Flores N, Isorna S for CUETO (Club Urologico Espanol de Tratamiento Oncologico). Long-term follow-up of a randomized prospective trial comparing a standard 81 mg dose of intravesical bacille Calmette-Guérin with a reduced dose of 27 mg in superficial bladder cancer. *BJU Int*. 2002;89:671–680.

Martinez-Pineiro JA, Solsona E, Flores N, et al. Improving the safety of BCG immunotherapy by dose reduction. *Eur Urol*. 1995;27:13–18.

Masood S, Sriprasad S, Palmer JH. T1G3 bladder cancer—indications for early cystectomy. *Int Urol Nephrol*. 2004;36:41–44.

May F, Treiber V, Hartung R, et al. Significance of random bladder biopsies in superficial bladder cancer. *Eur Urol*. 2003;44:47–50.

Maymi J, Saltsgaver N, O'Donnell MA. *New intravesical sequential chemotherapy for patients with treatment refractory superficial urothelial carcinoma*. [Poster presentation at: Proceedings of the Society of Urologic Oncology] 2004.

Melekos MD, Chionis H, Pantazakos A, et al. Intravesical bacillus Calmette-Guérin immunoprophylaxis of superficial bladder cancer: results of a controlled prospective trial with modified treatment schedule. *J Urol*. 1993;149:744–748.

Mersdorf A, Brauers A, Wolff C, et al. Second TUR for superficial bladder cancer: a must? *J Urol*. 1998;159:143.

Messing EM, Kim K, Wilding G, et al. A randomized prospective phase III trial of difluoromethylornithine (DFMO) vs. placebo (P) in preventing recurrence of completely resected low risk superficial bladder cancer. American Urological Association Annual Meeting 2005. Abstract no. 922. *J Urol*. 2005;173(Suppl):249.

Messing EM, Tangen C, Sahrasrabudhe DM, et al. *A phase III blinded study of immediate post-TURBT instillation of gemcitabine vs saline in patients with newly diagnosed or occasionally recurring low grade non-muscle invading bladder cancer: SWOG S0337 (NCT 0045601)*. [Presented by

Messing EM; May 15] 2017 [AUA 2017 Late-Breaking Abstract].

Michaud DS, Spiegelman D, Clinton SK, et al. Fluid intake and the risk of bladder cancer in men. *N Engl J Med*. 1999;340:1390–1397.

Miladi M, Peyromaure M, Zerbib M. The value of a second transurethral resection in evaluating patients with bladder tumours. *Eur Urol*. 2003;43:241–245.

Millán-Rodríguez F, Chéchile-Toniolo G, Salvador-Bayarri J, et al. Multivariate analysis of the prognostic factors of primary superficial bladder cancer. *J Urol*. 2000;163:73–78.

Miller EB, Eure GR, Schellhammer PF. Upper tract transitional cell carcinoma following treatment of superficial bladder cancer with BCG. *Urology*. 1993;42:26–30.

Moch H, Humphrey PA, Ulbright TM, et al. *WHO classification of tumours of the urinary system and male genital organs*. ed 4. IARC Press: Lyon, France; 2015.

Morales A, Chin JL, Ramsey EW. Mycobacterial cell wall extract for treatment of carcinoma in situ of the bladder. *J Urol*. 2001;166:1633–1637 [discussion 1637–1638].

Morales A, Eidinger D, Bruce AW. Intracavitary bacillus Calmette-Guérin in the treatment of superficial bladder tumors. *J Urol*. 1976;116:180–183.

Morales A, Herr H, Steinberg G, et al. Efficacy and safety of MCNA in patients with nonmuscle invasive bladder cancer at high risk for recurrence and progression after failed treatment with bacillus Calmette-Guérin. *J Urol*. 2015;193:1135–1143.

Morales A, Nickel JA, Wilson JW. Dose-response of bacillus Calmette-Guérin in the treatment of superficial bladder cancer. *J Urol*. 1992;147:1256–1258.

Morales A, Phadke K, Steinhoff G. Intravesical mycobacterial cell wall–DNA complex in the treatment of carcinoma in situ of the bladder after standard intravesical therapy has failed. *J*

Urol. 2009;181(3):1040–1045.

Morris SB, Gordon EM, Shearer RJ, et al. Superficial bladder cancer: for how long should a tumour-free patient have check cystoscopies? *Br J Urol*. 1995;75:195–196.

Moskovitz B, Levin DR. Intravesical irrigation with distilled water during and immediately after transurethral resection and later for superficial bladder cancer. *Eur Urol*. 1987;13:7–9.

Mukherjee N, Svatek RS, Mansour AM. Role of immunotherapy in bacillus Calmette-Guerin-unresponsive non-muscle invasive bladder cancer. *Urol Oncol*. 2018;36(3):103–108.

Mydlo JH, Weinstein R, Shah S, et al. Long-term consequences from bladder perforation and/or violation in the presence of transitional cell carcinoma: results of a small series and a review of the literature. *J Urol*. 1999;161:1128–1132.

Nabi G, Greene D, O'Donnell MO. Suspicious urinary cytology with negative evaluation for malignancy in the diagnostic investigation of haematuria: how to follow up? *J Clin Pathol*. 2004;57(4):365–368.

Nadler RB, Catalona WJ, Hudson MA, et al. Durability of the tumor free response for intravesical BCG therapy. *J Urol*. 1994;152:367–373.

Naito K, Hisazumi H, Uchibayashi T, et al. Integral laser photodynamic treatment of refractory multifocal bladder tumors. *J Urol*. 1991;146:1541–1545.

Naito S, Algaba F, Babjuk M, et al. The Clinical Research Office of the Endourological Society (CROES) multicentre randomised trial of narrow band imaging-assisted transurethral resection of bladder tumour (TURBT) versus conventional white light imaging-assisted turbt in primary non-muscle-invasive bladder cancer patients: trial protocol and 1-year results. *Eur Urol*. 2016;70:506–515.

Naito S, Koga H, Yamaguchi A, et al. Prevention of recurrence with epirubicin and lactobacillus casei after transurethral resection of bladder cancer. *J Urol*. 2008;179:485–490.

Naitoh J, Franklin J, O'Donnell MA, et al. Interferon alpha for the treatment of superficial bladder cancer. Baskin L, Hayward B. *Advances in bladder research*. Plenum: New York; 1999:371–392.

Naselli A, Introini C, Bertolotto F, et al. Narrow band imaging for detecting residual/recurrent cancerous tissue during second transurethral resection of newly diagnosed non-muscle-invasive high-grade bladder cancer. *BJU Int*. 2010;105:208–211.

Naselli A, Introini C, Timossi L, et al. A randomized prospective trial to assess the impact of transurethral resection in narrow band imaging modality on non-muscle-invasive bladder cancer recurrence. *Eur Urol*. 2012;61:908–913.

Nepple KG, Lightfoot AJ, Rosevear HM, et al. Bacillus Calmette-Guérin with or without interferon α-2b and megadose versus recommended daily allowance vitamins during induction and maintenance intravesical treatment of nonmuscle invasive bladder cancer. *J Urol*. 2010;184:1915–1919.

Newling DW, Robinson MR, Smith PH, et al. Tryptophan metabolites, pyridoxine (vitamin B_6), and their influence on the recurrence rate of superficial bladder cancer: results of a prospective, randomized phase III study performed by the EORTC GU Group. *Eur Urol*. 1995;27:110–116.

Nguyen CT, Litt DB, Dolar SE, et al. Prognostic significance of nondiagnostic molecular changes in urine detected by UroVysion fluorescence in situ hybridization during surveillance for bladder cancer. *Urology*. 2009;73(2):347–350.

Nieder AM, Brausi M, Lamm D, et al. Management of stage T1 tumors of the bladder: International Consensus Panel. *Urology*. 2005;66(6 Suppl 1):108–125.

Nieuwenhuijzen JA, Bex A, Horenblas S. Unusual complication after immediate postoperative intravesical mitomycin C instillation. *Eur Urol*. 2003;43(6):711–712.

Nseyo UO, Debord J, Kim H, et al. Sequential whole bladder photodynamic therapy treatments: a preclinical study. *Urol Oncol*. 1997;3:27–30.

Nseyo UO, DeHaven J, Dougherty TJ, et al. Photodynamic therapy (PDT) in the treatment of patients with resistant superficial bladder cancer: a long-term experience. *J Clin Laser Med Surg*. 1998;16:61–68.

O'Donnell MA, Luo Y, Chen X. Role of IL-12 in the induction and potentiation of IFN-gamma in response to bacillus Calmette-Guérin. *J Immunol*. 1999;163:4246–4252.

O'Donnell MA. Advances in the management of superficial bladder cancer. *Semin Oncol*. 2007;34:85–97.

O'Donnell MA. Practical applications of intravesical chemotherapy and immunotherapy in high-risk patients with superficial bladder cancer. *Urol Clin North Am*. 2005;32:121–131.

Oddens J, Brausi M, Sylvester R, et al. Final results of an EORTC-GU cancers group randomized study of maintenance bacillus Calmette-Guérin in intermediate- and high-risk Ta, T1 papillary carcinoma of the urinary bladder: one-third dose versus full dose and 1 year versus 3 years of maintenance. *Eur Urol*. 2013;63:462–472.

Oddens JR, van der Meijden AP, Sylvester R. One immediate postoperative instillation of chemotherapy in low risk Ta, T1 bladder cancer patients. Is it always safe? *Eur Urol*. 2004;46:336–338.

Odisho AY, Berry AB, Ahmad AE, et al. Reflex ImmunoCyt testing for the diagnosis of bladder cancer in patients with atypical urine cytology. *Eur Urol*. 2013;63:936–940.

Oldbring J, Glifberg I, Mikulowski P, et al. Carcinoma of the renal pelvis and ureter following bladder carcinoma: frequency, risk factors and clinicopathological findings. *J Urol*. 1989;141:1311–1313.

Olsen LH, Genster HG. Prolonging follow-up intervals for non-invasive bladder tumors: a randomized controlled trial. *Scand J Urol Nephrol*. 1995;172:33–36.

Olsson CA, Chute R, Rao CN. Immunologic reduction of bladder cancer recurrence rate. *J Urol*. 1974;111:173–176.

Olumi AF, Tsai YC, Nichols PW, et al. Allelic loss of chromosome 17p distinguishes high grade from low-grade transitional cell carcinomas of the bladder. *Cancer Res*. 1990;50:7081–7083.

Onishi T, Sugino Y, Shibahara T, et al. Randomized controlled study of the efficacy and safety of continuous saline bladder irrigation after transurethral resection for the treatment of non-muscle-invasive bladder cancer. *BJU Int*. 2017;119:276–282.

Oosterlinck W, Kurth KH, Schroder F, et al. A prospective European Organization for Research and Treatment of Cancer Genitourinary Group randomized trial comparing transurethral resection followed by a single intravesical instillation of epirubicin or water in single state Ta, T1 papillary carcinoma of the bladder. *J Urol*. 1993;149:749–752.

Orsola A, Palou J, Xavier B, et al. Primary bladder carcinoma in situ: assessment of early BCG response as a prognostic factor. *Eur Urol*. 1998;33:457–463.

Pagano F, Bassi P, Galetti TP, et al. Results of contemporary radical cystectomy for invasive bladder cancer: a clinicopathological study with an emphasis on the inadequacy of tumor, nodes and metastases classification. *J Urol*. 1991;145:45.

Pagano F, Bassi P, Milani C, et al. Low dose BCG regimen in superficial bladder cancer therapy: is it effective? *J Urol*. 1991;146:32–35.

Pagano F, Bassi P, Piazza N, et al. Improving the efficacy of BCG immunotherapy by dose reduction. *Eur Urol*. 1995;27(Suppl 1):19–22.

Palit V, Ashurst HN, Biyani CS, et al. Is using lignocaine gel prior to flexible cystoscopy justified? A randomized prospective study. *Urol Int*. 2003;71:389–392.

Palou J, Farina LA, Villavicencio H, et al. Tumors at the bladder neck may require resection into the prostatic urethra: upper tract urothelial tumor after transurethral resection for bladder tumor. *Eur Urol*. 1992;21:110–114.

Palou J, Laguna P, Millán-Rodríguez F. Control group and maintenance treatment with bacillus Calmette-Guérin for carcinoma in situ and/or high grade bladder tumors. *J Urol*. 2001;165(5):1488–1491.

Palou J, Rodriguez-Rubio F, Huguet J, et al. Multivariate analysis of clinical parameters of synchronous primary superficial bladder cancer and upper urinary tract tumor. *J Urol*. 2005;174(3):859–861.

Palou J, Sylvester RJ, Faba OR, et al. Female gender and carcinoma in situ in the prostatic urethra are prognostic factors for recurrence, progression, and disease-specific mortality in T1G3 bladder cancer patients treated with bacillus Calmette-Guérin. *Eur Urol*. 2012;62:118–125.

Pansadoro V, De Paula F. Intravesical bacillus Calmette-Guérin in the treatment of superficial transitional cell carcinoma of the bladder. *J Urol*. 1987;138:299–301.

Pansadoro V, Emiliozzi P, Defidio L, et al. Bacillus Calmette-Guérin in the treatment of stage T1 grade 3 transitional cell carcinoma of the bladder: long-term results. *J Urol*. 1995;154:2054–2058.

Parmar MK, Freedman LS, Hargreave TB, et al. Prognostic factors for recurrence and follow-up policies in the treatment of superficial bladder cancer: report from the British Medical Research Council subgroup on superficial bladder cancer (Urological Cancer Working Party). *J Urol*. 1989;142:284–288.

Patel AR, Jones JS, Angie S, et al. Office based flexible cystoscopy may be less painful for men allowed to view the procedure. *J Urol*. 2007;177(5):1843–1845.

Patel AR, Jones JS, Babineau D. Impact of real-time visualization of cystoscopy findings on procedural pain in female patients. *J Endourol*. 2008;22(12):2695–2698.

Patel AR, Jones JS, Babineau D. Lidocaine 2% gel versus plain lubricating gel for pain reduction during flexible cystoscopy: a meta-analysis of prospective, randomized, controlled trials. *J Urol*. 2008;179(3):986–990.

Ploeg M, Kiemeney LA, Smits GA, et al. Discrepancy between clinical staging through bimanual palpation and pathological staging after cystectomy. *Urol Oncol*. 2012;30(3):247–251.

Pruthi RS, Baldwin N, Bhalani V, et al. Conservative management of low risk superficial bladder tumors. *J Urol*. 2008;179(1):87–90.

Rao PR, Jones JS. Routine perioperative chemotherapy instillation with initial bladder tumor resection: a reconsideration of economic benefits. *Cancer*. 2009;115:997–1004.

Reading J, Hall RR, Parmar MK. The application of a prognostic factor analysis for Ta,T1 bladder cancer in routine urological practice. *Br J Urol*. 1995;75:604–607.

Richter J, Jiang F, Gorog JP, et al. Marked genetic differences between stage pTa and stage pT1 papillary bladder cancer detected by comparative genomic hybridization. *Cancer Res*. 1997;57:2860–2864.

Riedl CR, Daniltchenko D, Koenig F, et al. Fluorescence endoscopy with 5-aminolevulinic acid reduces early recurrence rate in superficial bladder cancer. *J Urol*. 2001;165:1121–1123.

Rink M, Babjuk M, Catto JW, et al. Aminolevulinate-guided fluorescence cystoscopy in the diagnosis and follow-up of patients with non-muscle-invasive bladder cancer: a critical review of the current literature. *Eur Urol*. 2013;64(4):624–638.

Rintala E, Jauhiainen K, Kaasinen E, et al. Alternating mitomycin C and bacillus Calmette-Guérin instillation prophylaxis for recurrent papillary (stages Ta to T1) superficial bladder cancer: the Finnbladder Group. *J Urol*. 1996;156:56.

Rintala E, Jauhiainen K, Rajala P, et al. Alternating mitomycin C and bacillus Calmette-Guérin instillation therapy for carcinoma in situ of the bladder: the Finnbladder Group. *J Urol*. 1995;154:2050–2053.

Ro JY, Staerkel GA, Ayala AG. Cytologic and histologic features of superficial bladder cancer. *Urol Clin North Am*. 1992;19:435–453.

Robins DJ, Sui W, Matulay JT, et al. Long-term survival outcomes with intravesical nanoparticle albumin-bound Paclitaxel for recurrent non-muscle-invasive bladder cancer after previous Bacillus Calmette-Guerin therapy. *Urology*. 2017;103:149–153.

Rödel C, Dunst J, Grabenbauer GG, et al. Radiotherapy is an effective treatment for high-risk T1-bladder cancer. *Strahlenther Onkol*. 2001;177(2):82–88.

Rodriguez-Rubio F, Sanz G, Garrido S, et al. Patient tolerance during outpatient flexible cystoscopy—a prospective, randomized, double-blind study comparing plain lubrication and lidocaine gel. *Scand J Urol Nephrol*. 2004;38:477–480.

Rosenberg JE, Hoffman-Censits J, Powles T, et al. Atezolizumab in patients with locally advanced and metastatic urothelial carcinoma who have progressed following treatment with platinum-based chemotherapy: a single-arm, multicenter, phase 2 trial. *Lancet*. 2016;387:1909–1920.

Rosevear HM, Lightfoot AJ, Nepple KG, et al. Safety and efficacy of intravesical bacillus Calmette-Guérin plus interferon α-2b therapy for nonmuscle invasive bladder cancer in patients with prosthetic devices. *J Urol*. 2010;184(5):1920–1924.

Rosser CJ, Ross S, Chang M, et al. Multiplex protein signature for the detection of bladder cancer in voided urine samples. *J Urol*. 2013;190:2257–2262.

Roubret M, Seisen T, Comperat E, et al. Prognostic interest in discriminating muscularis mucosa invasion (T1a vs T1b) in nonmuscle invasive bladder carcinoma: French national multicenter study with central pathology review. *J Urol*. 2013;189:2069–2076.

Rozan R, Albuisson E, Donnarieix D, et al. Interstitial iridium-192 for bladder cancer (a multicentric survey of 205 patients). *Int J Radiat Oncol Biol Phys*. 1992;24:469–477.

Sadek S, Soloway MS, Hook S, et al. The value of upper tract cytology after transurethral resection of bladder tumor in patients with bladder transitional cell cancer. *J Urol*. 1999;161:77–80.

Sanchez-Ortiz RF, Huang WC, Mick R. An interval longer than 12 weeks between the diagnosis of muscle invasion and cystectomy is associated with worse outcome in bladder carcinoma. *J Urol*. 2003;169:110–115 [discussion 115].

Sarosdy MF, Schellhammer P, Bokinsky G, et al. Clinical evaluation of a multi-target fluorescent in situ hybridization assay for detection of bladder cancer. *J Urol*. 2002;168:1950–1954.

Sauter G, Mihatsch MJ. Pussycats and baby tigers: non-invasive (pTa) and minimally invasive (pT1) bladder carcinomas are not the same!. *J Pathol*. 1998;185:339–341.

Schellhammer PF, Ladaga LE, Fillion MB. Bacillus Calmette-Guérin for superficial transitional cell carcinoma of the bladder. *J Urol*. 1986;135:261–264.

Schellhammer PF, Ladaga LE, Moriarty RP. Intravesical bacillus Calmette-Guérin for treatment of superficial transitional cell carcinoma of the prostatic urethra in association with carcinoma of the bladder. *J Urol*. 1995;153:53–56.

Schmidbauer J, Witjes F, Schmeller N, et al. Improved detection of urothelial carcinoma in situ with hexaminolevulinate fluorescence cystoscopy. *J Urol*. 2004;171:135–138.

Schoenberg M, Paralta C, Kiemeney LA, et al. A contemporary analysis of superficial bladder cancer monitoring: the Johns Hopkins experience. *J Urol*. 2000;163:152.

Schrag D, Hsieh LJ, Rabbani F, et al. Adherence to surveillance among patients with superficial bladder cancer. *J Natl Cancer Inst*. 2003;95:588–597.

Schrier BP, Hollander MP, van Rhijn BW, et al. Prognosis of muscle-invasive bladder cancer: difference between primary and progressive tumours and implications for therapy. *Eur Urol*. 2004;45(3):292–296.

Schwaibold HE, Treiber U, Kuebler H, et al. Second transurethral resection detects histopathological changes worsening the prognosis in 25% of patients with T1 bladder cancer. *J Urol*. 2000;163:153.

Sekine H, Fukui I, Yamada T. Intravesical mitomycin C and doxorubicin sequential therapy for carcinoma in situ of the bladder: a longer follow-up result. *J Urol*. 1994;151:27–30.

Sfakianos JP, Kim PH, Hakimi AA, et al. The effect of restaging transurethral resection on recurrence and progression rates in patients with non–muscle invasive bladder cancer treated with intravesical bacillus Calmette-Guérin. *J Urol*. 2014;191:341–345.

Shapiro A, Gofrit O, Pode D. The treatment of superficial bladder tumors with IL-2 and BCG. *J Urol*. 2007;177:244.

Shapiro O, Jones K, Wang C, et al. Risk of post-operative intravesical mitomycin C instillation following transurethral bladder tumor resection. *Can J Urol*. 2006;13(6):3317–3320.

Shariat SF, Palapattu GS, Amiel GE, et al. Characteristics and outcomes of patients with carcinoma in situ only at radical cystectomy. *Urology*. 2006;68(3):538–542.

Shen Z, Shen T, Wientjes MG, et al. Intravesical treatments of bladder cancer: review. *Pharm Res*. 2008;25:1500–1510.

Shinka T, Yasunari U, Aoshi H, et al. Occurrence of uroepithelial tumors of the upper urinary tract after the initial diagnosis of bladder cancer. *J Urol*. 1988;140:745–748.

Skacel M, Fahmy M, Brainard JA, et al. Multitarget fluorescence in situ hybridization assay detects transitional cell carcinoma in the majority of patients with bladder cancer and atypical or negative urine cytology. *J Urol*. 2003;169:2101–2105.

Skinner EC, Goldman B, Sakr WA, et al. SWOG S0353: phase ii trial of intravesical gemcitabine in patients with nonmuscle invasive bladder cancer and recurrence after 2 prior courses of intravesical bacillus Calmette-Guérin. *J Urol*. 2013;190(4):1200–1204.

Skolarikos A, Chrisofos M, Ferakis N, et al. Does the management of bladder perforation during transurethral resection of superficial bladder tumors predispose to extravesical tumor recurrence? *J Urol*. 2005;173:1908–1911.

Smith JA Jr, Labasky RF, Cockett AT, et al. Bladder cancer clinical guidelines panel summary report on the management of non–muscle-invasive bladder cancer (stages Ta, T1 and TIS). The American Urological Association. *J Urol*. 1999;162:1697–1701.

Smith JA. Treatment of invasive bladder cancer with a neodymium:YAG laser. *J Urol*. 1986;135:55–57.

Soloway MS, Bruck DS, Kim SS. Expectant management of small, recurrent, noninvasive papillary bladder tumors. *J Urol*. 2003;170:438–441.

Soloway MS, Murphy W, Rao MK, et al. Serial multiple-site biopsies in patients with bladder cancer. *J Urol*. 1978;120:57–59.

Solsona E, Gonzalez M, Fernandez JM, et al. Random trial comparing intravesical chemo-induction with MMC to BCG vs. intravesical BCG in patients with intermediate-high risk superficial bladder cancer: efficacy evaluation of CUETO trial No 93008. *Eur Urol*. 2002;1(Suppl 1):101 [abstract 394].

Solsona E, Iborra I, Ricos JV, et al. Effectiveness of a single immediate mitomycin C instillation in patients with low risk superficial bladder cancer: short and long-term follow up. *J Urol*. 1999;161:1120–1123.

Sousa A, Piñeiro I, Rodríguez S, et al. Recirculant hyperthermic IntraVEsical chemotherapy (HIVEC) in intermediate-high-risk non-muscle-invasive bladder cancer. *Int J Hyperthermia*. 2016;32:374–380.

Sporn MB, Squire RA, Brown CC, et al. 13-*cis*-Retinoic acid: inhibition of bladder carcinogenesis in the rat. *Science*. 1977;195:487–489.

Spruck CH 3rd, Ohneseit PF, Gonzalez-Zulueta M, et al. Two molecular pathways to transitional cell carcinoma of the bladder. *Cancer Res*. 1994;54:744–748.

Stein JP, Lieskovsky G, Cote R, et al. Radical cystectomy in the treatment of invasive bladder cancer: long-term results in 1,054 patients. *J Clin Oncol*. 2001;19:666–675.

Stein JP. Indications for early cystectomy. *Urology*. 2003;62:591–595.

Steinberg G, Bahnson R, Brosman S, et al. Efficacy and safety of valrubicin for the treatment of BCG refractory CIS of the bladder. *J Urol*. 2000;163:761–767.

Steinberg RL, Nepple KG, Velaer KN, et al. Quadruple immunotherapy of Bacillus Calmette-Guérin, interferon, interleukin-2, and granulocyte-macrophage colony-stimulating factor as salvage therapy for non-muscle-invasive bladder cancer. *Urol Oncol*. 2017;35:670.

Steinberg RL, Thomas LJ, O'Donnell MA, et al. Sequential intravesical Gemcitabine and Docetaxel for salvage treatment of non-muscle invasive bladder cancer. *Bladder Cancer*. 2015;1:65–72.

Steineck G, Hagman U, Gerhardsson M, et al. Vitamin A supplements, fried foods, fat and urothelial cancer: a case-referent study in Stockholm in 1985–87. *Int J Cancer*. 1990;45:1006–1011.

Steinmaus CM, Nunez S, Smith AH. Diet and bladder cancer: a meta-analysis of six dietary variables. *Am J Epidemiol*. 2000;151:693–702.

Stenzl A, Burger M, Fradet Y, et al. Hexaminolevulinate guided fluorescence cytoscopy reduces recurrence in patients with nonmuscle invasive bladder cancer. *J Urol*. 2010;184:1907–1914.

Streeper NM, Simons CM, Konety BR, et al. The significance of lymphovascular invasion in transurethral resection of bladder tumour and cystectomy specimens on the survival of patients with urothelial bladder cancer. *BJU Int*. 2009;103(4):475–479.

Stricker P, Pryor K, Nicholson T, et al. BCG plus interferon alpha 2b in patients with superficial bladder cancer. *Urology*. 1996;48:957–962.

Sun CL, Yuan JM, Wang XL, et al. Dietary soy and increased risk of bladder cancer: a prospective cohort study of men in Shanghai, China. *Int J Cancer*. 2004;112:319.

Suzuki T, Takeuchi M, Naiki T, et al. MRI findings of granulomatous prostatitis developing after intravesical Bacillus Calmette-Guérin therapy. *Clin Radiol*. 2013;68(6):595–599.

Sweatman TW, Parker RF, Isreal M. Pharmacologic rationale for (AD-32): a preclinical study. *Cancer Chemother Pharmacol*. 1991;28:1.

Swinn MJ, Walker MM, Harbin LJ, et al. Biopsy of the red patch at cystoscopy: is it worthwhile? *Eur Urol*. 2004;45:471–474.

Sylvester RJ, Oosterlinck W, van der Meijden AP. A single immediate postoperative instillation of chemotherapy decreases the risk of recurrence in patients with stage Ta, T1 bladder cancer: a meta-analysis of published results of randomized clinical trials. *J Urol*. 2004;171:2186–2190.

Sylvester RJ, van der Meijden A, Witjes JA, et al. High-grade Ta urothelial carcinoma and carcinoma in situ of the bladder. *Urology*. 2005;66(6 Suppl 1):90–107.

Sylvester RJ, van der Meijden AP, Lamm DL. Intravesical bacillus Calmette-Guérin reduces the risk of progression in patients with superficial bladder cancer: a meta-analysis of the published results of randomized clinical trials. *J Urol*. 2002;168:1964–1970.

Sylvester RJ, van der Meijden AP, Oosterlinck W, et al. Predicting recurrence and progression in individual patients with stage Ta T1 bladder cancer using EORTC risk tables: a combined analysis of 2596 patients from seven EORTC trials. *Eur Urol*. 2006;49(3):466–475.

Tan WS, Feber A, Sarpong R, et al. Who should be investigated for haematuria? Results of a contemporary prospective observational study of 3556 patients. *Eur Urol*. 2018; 10.1016/j.eururo.2018.03.008 [Epub ahead of print; PubMed PMID] 29653885 [pii: S0302-2838(18)30184-2].

Têtu B, Tiguert R, Harel F, et al. ImmunoCyt/uCyt+ improves the sensitivity of urine cytology in patients followed for urothelial carcinoma. *Mod Pathol*. 2005;18(1):83–89.

Thompson RA, Campbell EW, Kramer HC, et al. Late invasive recurrence despite long-term surveillance for superficial bladder cancer. *J Urol*. 1993;149:1010–1011.

Thrasher JB, Crawford ED. Complications of intravesical chemotherapy. *Urol Clin North Am*. 1992;19:529.

Tilki D, Shariat SF, Lotan Y, et al. Lymphovascular invasion is independently associated with bladder cancer recurrence and survival in patients with final stage T1 disease and negative lymph nodes after radical cystectomy. *BJU Int*. 2013;111(8):1215–1221.

Tissot WD, Diokno AC, Peters KM. A referral center's experience with transitional cell carcinoma misdiagnosed as interstitial cystitis. *J Urol*. 2004;172:478–480.

Tolley DA, Parmar MK, Grigor KM, et al. The effect of intravesical mitomycin C on recurrence of newly diagnosed superficial bladder cancer: a further report with 7 years of follow-up. *J Urol*. 1996;155:1233.

Toma MI, Friedrich MG, Hautmann SH, et al. Comparison of the ImmunoCyt test and urinary cytology with other urine tests in the detection and surveillance of bladder cancer. *World J Urol*. 2004;22(2):145–149.

Torti FM, Shortliffe LD, Williams RD. Alpha-interferon in superficial bladder cancer: a Northern California Oncology Group Study. *J Clin Oncol*. 1988;6:476–483.

Tsivian A, Shtricker A, Sidi AA. Simultaneous transurethral resection of bladder tumor and benign prostatic hyperplasia: hazardous or a safe timesaver? *J Urol*. 2003;170(6 Pt 1):2241–2243.

Uchibayashi T, Koshida K, Kunimi K, et al. Whole bladder wall photodynamic therapy for refractory carcinoma in situ of the bladder. *Br J Cancer*. 1995;71:628.

van der Heijden AG, Kiemeney LA, Gofrit ON, et al. Preliminary European results of local microwave hyperthermia and chemotherapy treatment in intermediate or high risk superficial transitional cell carcinoma of the bladder. *Eur Urol*. 2004;46:65–71.

van der Heijden AG, Moonen PM, Cornel EB, et al. Phase II marker lesion study with intravesical instillation of apaziquone for superficial bladder cancer: toxicity and marker response. *J Urol*. 2006;176:1349–1353.

van der Meijden AP, Brausi M, Zambon V, et al. Intravesical instillation of epirubicin, bacillus Calmette-Guerin and bacillus Calmette-Guerin plus isoniazid for intermediate and high risk Ta, T1 papillary carcinoma of the bladder: a European Organization torfor Research and Treatment of Cancer genito-urinary group randomized phase III trial. *J Urol*. 2001;166:476–481.

van der Meijden AP, Hall RR, Macaluso P, et al. Marker tumour response to the sequential combination of intravesical therapy with mitomycin-C and BCG-RIVM in multiple superficial bladder tumours. *Eur Urol*. 1996;29:199–201.

van der Meijden AP, Oosterlinck W, Brausi M, et al. Significance of bladder biopsies in Ta,T1 bladder tumors: a report from the EORTC Genito-Urinary Tract Cancer Cooperative Group. EORTC-GU Group Superficial Bladder Committee. *Eur Urol*. 1999;35:267–271.

Vianello A, Costantini E, Del Zingaro M, et al. Repeated white-light transurethral resection of the bladder in nonmuscle-invasive urothelial bladder cancers: systematic review and meta-analysis. *J Endourol*. 2011;25:1703–1712.

Virtamo J, Edwards BK, Virtanen M, et al. Effects of supplemental alpha-tocopherol and beta-carotene on urinary tract cancer: incidence and mortality in a controlled trial (Finland). *Cancer Causes Control*. 2000;11:933.

Vogeli TA, Grimm MO, Ackermann R. Prospective study for quality control of TUR of bladder tumors by routine second TUR (ReTUR). *J Urol*. 1998;159:143.

Waldman FM, Carroll PR, Kerschmann R, et al. Centromeric copy number of chromosome 7 is strongly correlated with tumor grade and labeling index in human bladder cancer. *Cancer Res*. 1991;51:3807–3813.

Walther MM. The role of photodynamic therapy in the treatment of recurrent superficial bladder cancer. *Urol Clin North Am*. 2000;27:163–170.

Whitson J, Berry A, Carroll P, et al. A multicolour fluorescence in situ hybridization test predicts recurrence in patients with high-risk superficial bladder tumours undergoing intravesical therapy. *BJU Int*. 2009;104:336–339.

Witjes JA, Caris CT, Mungan NA, et al. Results of a randomized phase III trial of sequential intravesical therapy with mitomycin C and bacillus Calmette-Guérin versus mitomycin alone in patients with superficial bladder cancer. *J Urol*. 1998;160:1668–1672.

Witjes JA, Hendricksen K. Intravesical pharmacotherapy for non–muscle-invasive bladder cancer: a critical analysis of currently available drugs, treatment schedules, and long-term results. *Eur Urol*. 2008;53(1):45–52.

Witjes JA, Moonen PM, van der Heijden AG. Comparison of hexaminolevulinate based flexible and rigid fluorescence cystoscopy with rigid white light cystoscopy in bladder cancer: results of a prospective phase II study. *Eur Urol*.

2005;47(3):319–322.

Wolff EM, Liang G, Jones PA. Mechanisms of disease: genetic and epigenetic alterations that drive bladder cancer. *Nat Clin Pract Urol*. 2005;2(10):502–510.

Wright JL, Hotaling J, Porter MP. Predictors of upper tract urothelial cell carcinoma after primary bladder cancer: a population based analysis. *J Urol*. 2009;181(3):1035–1039.

Xiong Y, Li J, Ma S, et al. A meta-analysis of narrow band imaging for the diagnosis and therapeutic outcome of non-muscle invasive bladder cancer. *PLoS ONE*. 2017;12(2):e0170819.

Yamada Y, Hayashi Y, Kohri K, et al. Random biopsy and recurrence risk in patients with bladder cancer. *Nihon Hinyokika Gakkai Zasshi*. 1996;87:61–66.

Yoder BJ, Skacel M, Hedgepeth R, et al. Reflex UroVysion testing of bladder cancer surveillance patients with equivocal or negative urine cytology: a prospective study with focus on the natural history of anticipatory positive findings. *Am J Clin Pathol*. 2007;127(2):295–301.

Zhao C, Tang K, Yang H, et al. Bipolar versus monopolar transurethral resection of nonmuscle-invasive bladder cancer: a meta-analysis. *J Endourol*. 2016;30(1):5–12.

Zieger K, Wolf H, Olsen PR, et al. Long-term follow-up of noninvasive bladder tumours (stage Ta): recurrence and progression. *BJU Int*. 2000;85:824–828.

Zincke H, Utz DC, Farrow GM. Review of Mayo Clinic experience with carcinoma in situ. *Urology*. 1985;26:39–46.

Zincke H, Utz DC, Taylor WF, et al. Influence of thiotepa and doxorubicin instillation at time of transurethral surgical treatment of bladder cancer on tumor recurrence: a prospective, randomized double blind, controlled trial. *J Urol*. 1983;129:505.

[a] Portions of this chapter are based on or carried forward from previous versions of this text, as authored by J. Stephen Jones, MD, MBA, FACS.

137

Management of Muscle-Invasive and Metastatic Bladder Cancer

Thomas J. Guzzo MD, MPH, John P. Christodouleas MD, MPH, David J. Vaughn MD

Clinical Presentation, Diagnosis, and Evaluation

Bladder cancer has the fifth highest incidence of all malignancies in the United States, with an estimated 81,190 new cases and 17,240 deaths in 2018 (Siegel et al., 2018). Twenty percent to 30% of patients will present with muscle-invasive bladder cancer at the time of initial presentation. Despite aggressive therapy, a significant proportion of patients ultimately will experience recurrence and will die of their disease. Clinical understaging is not uncommon at the time of initial diagnosis with muscle-invasive disease, and therefore a multimodal therapeutic approach is often necessary to improve survival. A multidisciplinary approach is paramount to integrate appropriate therapy to individual patients, including surgery, systemic chemotherapy, and radiation therapy. This chapter reviews the evaluation and treatment of patients with muscle-invasive and metastatic bladder cancer.

Natural History

The majority of patients present with muscle-invasive disease at the time of initial presentation. A smaller subset (approximately 20%) will progress to muscle-invasive disease after an initial diagnosis of non–muscle-invasive bladder cancer. Muscle-invasive bladder cancer is a highly lethal entity and if left untreated will result in mortality within 2 years of diagnosis in 85% of cases (Prout and Marshall, 1956). Additionally, some studies have shown poorer outcomes for patients who progress from non–muscle-invasive disease; however, this may be related to understaging of presumed noninvasive disease or significant progression while undergoing conservative therapy rather than a biologic difference in disease aggressiveness (Guzzo et al., 2009). Bladder cancer death after appropriate local therapy is typically the result of systemic disease; the majority of deaths occur within 2 years of initial treatment. Non–local-regional relapses are reflective of the presence of micrometastatic disease at the time of diagnosis and treatment, and this continues to hamper long-term survival rates for patients with muscle-invasive disease. The significant risk for micrometastatic disease and our current inability to stage and to identify accurately patients with non–organ-confined disease before definitive local therapy continue to hamper pretreatment decisions and argue for a multidisciplinary treatment approach.

Histology

The majority of primary bladder cancers are urothelial carcinomas, representing more than 90% of all bladder tumors. Although squamous cell carcinoma comprises only approximately 5% of all bladder cancers in the Western world, it is more common in parts of the Middle East and Africa secondary to endemic infection with schistosomal parasites, and it accounts for a significant percentage of bladder cancer histology in these regions (el-Mekresh et al., 2009). Of note, the proportion of pure squamous cell bladder cancers in this part of the world does appear to be decreasing likely related to effective anti-bilharzia medications and decreasing prevalence of smoking (Antoni et al., 2017). Squamous cell carcinoma histology in Western countries is more commonly associated with chronic urinary tract inflammation including patients with chronic indwelling catheters. Even rarer, adenocarcinomas represent roughly 2% of bladder cancers and can originate from either the urothelium or the urachus. Patients with bladder exstrophy are classically at an increased risk for bladder adenocarcinoma. Before definitive treatment, it is important to rule out other more common sites of adenocarcinoma such as breast and colorectal sources. Standard treatment regardless of histologic subtype is radical cystectomy; however, timing of neoadjuvant chemotherapy and/or radiation therapy can vary by histologic subtype (Willis et al., 2013). Pure neuroendocrine variants of bladder cancer are relatively rare but highly aggressive, and they typically present at high pathologic stages or with metastatic disease (Mazzucchelli et al., 2009). Neuroendocrine features can also be seen with other histologic variants. Standard treatment for neuroendocrine bladder tumors includes neoadjuvant chemotherapy and radical cystectomy (Siefker-Radtke et al., 2004). Neuroendocrine tumors can be associated with paraneoplastic syndromes including ectopic adrenocorticotropic hormone production, hypercalcemia, and hypophosphatemia. Carcinoid tumors, a type of neuroendocrine tumor, can also originate in the bladder. Large cell neuroendocrine tumors have also been reported and have a similar disease biology to that of small cell tumors (Akamatsu et al., 2008). Other rare histologic entities include rhabdomyosarcoma, leiomyosarcoma, and primary lymphoma.

Variant histologies of urothelial carcinoma also exist, including micropapillary, sarcomatoid, squamous, and glandular differentiation. Micropapillary tumors are aggressive and resemble papillary serous carcinoma of the ovary. There are conflicting reports regarding the responsiveness of micropapillary disease to neoadjuvant chemotherapy (Ghoneim et al., 2011; Kamat et al., 2007; Meeks et al., 2013). There is scant evidence to support treatment guidelines for many variant urothelial histologies; however, many of these subtypes are aggressive, and early definitive therapy should be considered. It is important to recognize variant histology to avoid diagnostic misinterpretations that could delay definitive care.

Clinical Staging

Clinical staging for bladder cancer is the assessment of disease extent before radical cystectomy, whereas pathologic stage is determined by microscopic analysis of radical cystectomy and pelvic lymphadenectomy specimens. Clinical staging for bladder cancer is determined by pathologic analysis of the depth of the invasion of the tumor on the transurethral resection (TUR) specimen, bimanual examination of the patient under anesthesia, liver function tests, chest radiography, and contrast-enhanced cross-sectional imaging of the abdomen and pelvis with upper tract imaging. Clinical and pathologic T and N staging discordance is very common. Contemporary cystectomy series demonstrate pathologic upstaging and downstaging rates to be as high as 50% and 25%, respectively, for patients with clinical T2 stage tumors (Table 137.1) (Svatek et al., 2011).

TABLE 137.1

Incidence of Pathologic Pelvic Node Metastasis (%) at Radical Cystectomy in Selected Contemporary Series (2000–2012)

	NO. OF PATIENTS	P1	P2A	P2	P2B	P3A	P3	P3B	P4A	P4	P4B
Stein et al., 2001	1054	7		18		26		46	42		
Leissner et al., 2004	290	2	11		22	46		40	40		80
Vazina et al., 2004	176	4		16			40			50	
Steven et al., 2007	263	5	14		24	40		33	42		

Ghoneim et al., 2008	2720	2	8		19		39			36	
Tarin et al., 2012	591	6		18				40		60	

TUR is the gold standard method for establishing the diagnosis of muscle-invasive bladder cancer. In addition to pathologic staging, TUR also can provide valuable information on histologic variants that may direct therapeutic decision making. Although data are limited, a complete resection of macroscopic tumor is advisable when it is safe and feasible. Complete resection decreases local tumor burden and may optimize the response to neoadjuvant chemotherapy, or for patients undergoing chemoradiotherapy it may improve the likelihood of successful bladder preservation. Additionally, prospective randomized neoadjuvant chemotherapy trials have clearly demonstrated a significant survival benefit in patients who are pT0 at the time of radical cystectomy. This survival benefit (pT0 status) occurred regardless of whether neoadjuvant chemotherapy was administered, suggesting a potential benefit of aggressive TUR (Grossman et al., 2003b; Lavery et al., 2014). The status of the bladder neck in women and the prostatic urethra in men should also be carefully evaluated at the time of initial resection, as it can affect clinical decision making with regard to neoadjuvant chemotherapy (prostatic stromal invasion), surgical management of the urethra, choice of urinary diversion at the time of radical cystectomy, and clinical target volumes in radiotherapy. Biopsies of the prostatic urethra may provide useful information in advance of radical cystectomy (Lerner and Shen, 2008). Using a resectoscope, a full loop of tissue is taken from the midprostate (or bladder neck in shorter prostates) to the mid- to distal verumontanum and 5 and 7 o'clock adjacent to the verumontanum. This is the site of the highest concentration of prostatic ducts and the area where carcinoma in situ (CIS) is most likely to be found (Sakamoto et al., 1993). The full-thickness prostatic resection allows the pathologist to evaluate the interface between the urethral mucosa, prostatic ducts, and stroma, which allows for accurate staging of the prostatic urethra (Wood et al., 1989). Negative prostatic urethral biopsies are associated with negative apical urethral margins, and it has been suggested that they can replace the need for intraoperative frozen section at the time of radical cystectomy; however, it remains this author's practice to send a full-thickness intraoperative frozen section margin from the urethra in patients who desire a neobladder (Lerner and Shen, 2008). In women, bladder neck biopsy is an accurate surrogate for urethral biopsy when orthotopic urinary diversion is under consideration.

Bimanual examination under anesthesia remains an important aspect of primary tumor assessment. The examination is performed typically by placing the dominant hand on the suprapubic region and one or two fingers from the nondominant hand in the rectum (males) or vagina. Bimanual examination can be performed at the time of initial tumor resection and should be done before and after resection. The bimanual examination should be performed with the bladder drained and without a Foley catheter in place to maximize palpation of the bladder. Findings described originally by Marshall are T2a: nonpalpable; T2b: induration but no three-dimensional mass; T3a: three-dimensional mass that is mobile; T4a: invading adjacent structures such as the prostate, vagina, or rectum; T4b: fixed to pelvic sidewall and not mobile (Marshall, 1952). Bimanual examination is not 100% accurate in predicting final tumor pathology, with an 11% clinical overstaging and a 31% clinical understaging rate reported (Ploeg et al., 2012).

Cross-sectional imaging plays an important adjuvant role to TUR and physical examination in the assessment and staging of the primary bladder tumor in patients with muscle-invasive disease. Abdominal and pelvic cross-sectional imaging are recommended by the National Comprehensive Cancer Network (NCCN) when muscle-invasive disease is suspected before TUR (NCCN guidelines Version 1, 2014). Studies vary widely on the overall sensitivity and specificity of computed tomography (CT) imaging with regard to final pathologic tumor stage at the time of radical cystectomy. Studies using multidetector CT scanners have reported the most favorable results, with sensitivities ranging from 89% to 91% and specificities of 92% to 95% for local staging (Kim et al., 2004; Koplay et al., 2010). The timing of imaging relative to TUR is also important to note. Although it is optimal to obtain cross-sectional imaging before TUR, if imaging is obtained subsequently, it should be delayed approximately 7 days postprocedure to minimize inflammatory artifact, which can be mistaken for T3 disease (Kim et al., 2004). A high suspicion for extravesical disease is warranted when hydronephrosis is noted on cross-sectional imaging. The presence of hydronephrosis on staging CT is associated with an increased risk for extravesical disease (27.8% vs. 17.3%) at the time of cystectomy (Bartsch et al., 2007; Canter et al., 2008). The reported sensitivity and specificity of CT in detecting nodal metastasis ranges from 31% to 50% and 68% to 100%, respectively (Baltaci et al., 2008; Lodde et al., 2010; Picchio et al., 2006).

Magnetic resonance imaging (MRI) is generally considered to be more accurate than CT in detecting local tumor stage; however, reports vary in the literature. Rajesh et al. (2011) reported on 100 consecutive patients who underwent a 1.5-T MRI with gadolinium. The authors reported that the sensitivity and specificity of MRI in differentiating between organ-confined and non–organ-confined disease was 90.5% and 60%, respectively. Other studies have reported staging sensitivity ranging from 68% to 80% and specificity of 90% to 93%. Advancements in MRI technology including 3.0 T magnets, dynamic contrast enhancement, and diffusing weighted imaging have demonstrated improved ability to locally differentiate T-staging of tumors compared with that of CT; however, an inability to improve on the detection of occult lymph node metastasis remains a limitation (Rose and Lotan, 2018; Panebianco et al., 2016). Additionally, MRI has been reported as useful in predicting tumor grade and tumor chemosensitivity (Tuncbilek et al., 2009; Yoshida et al., 2012).

The usefulness of positron emission tomography and CT (PET/CT) in local staging of bladder cancer is limited as a result of the excretion of standard PET (^{18}F-fluorodeoxyglucose) into the urine. Although PET/CT has not proven of superior benefit to that of CT alone for local staging, some studies have demonstrated its superiority with regard to nodal staging. The reported sensitivity and specificity of PET/CT in detecting nodal metastasis ranges from 57% to 81% and 88% to 100%, respectively (Apolo et al., 2010; Drieskens et al., 2005; Kibel et al., 2009; Lodde et al., 2010). Although conventional CT will detect the majority of lymph node metastasis found with PET/CT imaging, Kibel et al. (2009) reported a modest improvement in the detection of nodal metastasis with PET/CT imaging. Novel radiotracers have also been investigated in an attempt to mitigate the limitations of traditional FDG studies. Radiotracers including ^{11}C-choline, ^{11}C-acetate, and ^{11}C-methionine have all been investigated typically with limited improvement over conventional techniques (Rose and Lotan, 2018).

Pathologic Staging

The American Joint Committee on Cancer (AJCC) tumor, node, metastases (TNM) system is the most commonly used method for staging bladder cancer (Table 137.2) and can be used for staging patients clinically and pathologically. Staging follows a stepwise fashion based on depth of tumor penetration. As with other tumors, N and M stages refer to the presence of regional nodal and distant metastasis, respectively. The 8th edition of the AJCC does have some changes worth noting (Paner et al., 2018). Involvement of perivesical lymph nodes are now included in the regional nodal staging. Lymph node metastasis beyond the common iliac vessels is now classified as M1a, given its improved survival relative to patients with non–lymph node metastasis (Galsky et al., 2013). The prognostic value of T2 and T3 substaging has been widely reported. A multicenter series of 565 radical cystectomy patients with pT2, node-negative disease demonstrated improved recurrence-free (73.2% vs. 58.7%) and cancer-specific survival (78.0% vs. 65.1%) for pT2a and pT2b disease, validating this subgrouping (Tilki et al., 2010a). The prognostic usefulness of the pT3 subgrouping was also reported in the same cohort of radical cystectomy patients. Of the 356 pT3N0 patients, pT3b substaging was associated with poorer recurrence-free (60.7% vs. 47.9%) and cancer-specific survival (64.4% vs. 55.0%) at 5 years (Tilki et al., 2010b). The T4a prostate designation requires established stromal invasion, which can occur via the urethra or as a direct extension via the bladder neck or posteriorly into the seminal vesicles or periprostatic ducts. CIS in the prostatic urethra or ducts does not represent upstaging because outcome is determined by the primary bladder cancer stage (Esrig et al., 1996; Pagano et al., 1996). Pathologically, organ-confined bladder cancer is considered to be pT2bN0M0 or less at the time of cystectomy (Soloway et al., 2012).

TABLE 137.2

Tumor Node Metastasis Staging System for Bladder Cancer

PRIMARY TUMOR (T)	
TX	Primary tumor cannot be assessed
T0	No evidence of primary tumor
Ta	Noninvasive papillary carcinoma
Tis	Carcinoma in situ: “flat tumor”
T1	Tumor invades subepithelial connective tissue
T2	Tumor invades muscularis propria
pT2a	Tumor invades superficial muscularis propria (inner half)
pT2b	Tumor invades deep muscularis propria (outer half)
T3	Tumor invades perivesical tissue
pT3a	Microscopically
pT3b	Macroscopically (extravesical mass)
T4	Tumor invades any of the following: prostatic stroma, seminal vesicles, uterus,

	vagina, pelvic wall, abdominal wall		
T4a	Tumor invades prostatic stroma, uterus, vagina		
T4b	Tumor invades pelvic wall, abdominal wall		
REGIONAL LYMPH NODES (N)[a]			
Nx	Lymph nodes cannot be assessed		
N0	No lymph node metastasis		
N1	Single regional lymph node metastasis in the true pelvis (hypogastric, obturator, external iliac, perivesical, or presacral lymph node)		
N2	Multiple regional lymph node metastasis in the true pelvic (hypogastric, obturator, external iliac, or presacral lymph node metastasis)		
N3	Lymph node metastasis to the common iliac lymph nodes		
DISTANT METASTASIS (M)			
M0	No distant metastasis		
M1	Distant metastasis		
ANATOMIC STAGE/PROGNOSTIC GROUPS			
Stage 0a	Ta	N0	M0
Stage 0is	Tis	N0	M0
Stage I	T1	N0	M0
Stage II	T2a	N0	M0
	T2b	N0	M0
Stage III	T3a	N0	M0
	T3b	N0	M0
	T4a	N0	M0
Stage IV	T4b	N0	M0
	Any T	N1-3	M0
	Any T	Any N	M1

[a] Regional lymph nodes include both primary and secondary drainage regions. All other nodes above the aortic bifurcation are considered distant lymph nodes.

Note: cTNM is the clinical classification, and pTNM is the pathologic classification.

From Edge SB, Byrd DR, Compton CC, et al., eds. *AJCC cancer staging manual.* 7th ed. New York, NY: Springer; 2010.

Radical Cystectomy and Pelvic Lymph Node Dissection for Muscle-Invasive Bladder Cancer

For patients with clinical T2–T4a, N0, M0 disease, radical cystectomy and bilateral pelvic lymph node dissection remains the gold standard therapy by which all other treatment modalities should be compared. Although utilization varies with age and comorbidities, approximately 80% of muscle-invasive patients who undergo definitive management have a radical cystectomy (Bekelman et al., 2013). Radical cystectomy provides excellent local control, with pelvic recurrence rates as low as 4% in patients with node-negative disease (Morris et al., 2009). Randomized trial data have demonstrated superior outcomes with neoadjuvant systemic chemotherapy, which will be discussed later in this chapter.

Time from initial diagnosis of muscle invasion to cystectomy likely affects oncologic outcomes, particularly if there is a delay of greater than 12 weeks. Sanchez-Ortiz et al. (2003) initially published this observation in their cohort of 290 cystectomy patients noting a higher proportion of extravesical tumors, nodal metastasis, and poorer survival in patients in which cystectomy was delayed more than 12 weeks. Since this observation was published, multiple studies have demonstrated similar results (Chang et al., 2003; Gore et al., 2009; Lee et al., 2006b). Lee et al. (2006b) reported poorer disease-specific survival (DSS) and overall survival (OS) rates for patients with muscle-invasive disease who underwent radical cystectomy more than 3 months after initial diagnosis. Administrative data sets have also provided similar findings. Of 441 patients who underwent radical cystectomy from 1992 to 2001 in the Surveillance, Epidemiology, and End Results (SEER) database, a delay in surgery of more than 12 weeks and 24 weeks resulted in a twofold increase in disease-specific and overall mortality compared with more timely surgical intervention (Gore et al., 2009). Similar results have been noted in other radical cystectomy cohorts (Ayres et al., 2008; Fahmy et al., 2008; Kulkarni et al., 2009). Although it is difficult to say with certainty, based on retrospective surgical cohorts, exactly how expeditiously surgery should be performed, a significant delay does appear to be detrimental to oncologic outcomes.

In men, radical cystectomy includes excision of the surrounding perivesical soft tissue, prostate, and seminal vesicles, and, in women, it includes the ovaries, uterus with cervix, and anterior vagina. Since the mid-2000s, greater emphasis has been placed on urinary and sexual quality of life following cystectomy. This has led to a greater interest in organ preservation in both men and women. In men, preservation of the neurovascular bundles, some or all of the prostate, and the seminal vesicles have been reported in an attempt to improve postoperative quality of life. The majority of reports are limited to small retrospective cohorts and must be analyzed within the context of such limitations. It is also important for the surgeon to weigh the oncologic risk for organ preservation relative to that of cancer recurrence. For instance, prostate cancer can be present in upward of 23% to 54% of radical cystoprostatectomy specimens, with up to one-third having clinically significant disease (Abdelhady et al., 2007; Pettus et al., 2008). Additionally, the significant incidence of urothelial carcinoma involving the prostate (17% to 75%) noted on complete radical cystoprostatectomy specimens is an obvious oncologic limitation with this technique (Arce et al., 2011; Ayyathurai et al., 2007; Pettus et al., 2008; Revelo et al., 2008; Richards et al., 2010; Tabibi et al., 2011). If prostatic preservation is considered, transurethral sampling of the prostatic urethra and bladder neck is advisable to maximize appropriate patient selection. Other reported preoperative features associated with prostatic urethral involvement include the presence of tumor at the bladder neck (Abdelsalam et al., 2011; Arce et al., 2011; Pettus et al., 2008; Richards et al., 2010), tumor multifocality (Kefer and Campbell, 2008; Nixon et al., 2002), and the presence of CIS (Arce et al., 2011; Kefer and Campbell, 2008; Richards et al., 2010). Functional outcomes after prostate preservation tend to be directly associated with the amount of tissue spared at the time of surgery. Davila et al. (2007) reported on a small number of patients undergoing either apical ($N = 15$) or total prostate-sparing cystectomy ($N = 6$). Using the erectile function domain score of the International Index of Erectile Function (IIEF) questionnaire, the authors reported mild erectile dysfunction in the apical-sparing group. Also using an apical-sparing technique, Wunderlich et al. (2006) reported a 94% daytime and nighttime continence rate, with 87% of patients achieving baseline erectile function following surgery. Posterior sparing (posterior prostate and seminal vesicles) was also reported by several authors with limited numbers of patients. Using this technique, excellent outcomes with regard to continence and erectile function have been reported (Girgin et al., 2006; Spitz et al., 1999). Finally, total prostate sparing has also been described in several series of patients. Nieuwenhuijzen et al. (2008) reported outcomes of 41 patients who underwent total prostate sparing at the time of radical cystectomy, and they noted 95% and 74% daytime and nighttime continence rates, respectively. However, 12 patients did require long-term clean intermittent catheterization because of an inability to empty volitionally. Erectile function was maintained in 78% of patients who were functioning preoperatively. Although organ preservation has the potential to improve overall quality of life, radical cystoprostatectomy remains the gold standard.

Preservation of the uterus, ovaries, and vagina has also been explored in women at the time of radical cystectomy. Although an anterior exenteration has classically been advocated in women at the time of radical cystectomy, urothelial carcinoma rarely involves the gynecologic organs, with an overall incidence of approximately 5% of cases (Chang et al., 2002). Unless there is tumor involvement of the bladder neck, a complete urethrectomy can be omitted at the time of cystectomy, allowing for orthotopic bladder substitution in women. Additionally, carefully selected patients can also forgo removal of the uterus and anterior vagina, which potentially allows for better anatomic support for a neobladder and preserves the autonomous nerves.

Bilateral Pelvic Lymph Node Dissection

A meticulous pelvic lymph node dissection is an essential component of radical cystectomy. It is well established that approximately 25% of patients will have pathologic lymph node metastases at the time of cystectomy (Lerner et al., 1993), and lymph node status is the most powerful surrogate for long-term recurrence-free and OS following radical cystectomy (Poulsen et al., 1998; Stein et al., 2001). Skinner (1982) was first to report the value of a meticulous pelvic lymph node dissection, demonstrating better local control rates, potential for cure, and acceptable morbidity in patients undergoing radical cystectomy. Since that initial report, multiple surgical series have demonstrated the profound impact of nodal involvement at the time of radical cystectomy, with approximately 70% to 80% of patients with lymph node metastasis ultimately experiencing disease recurrence in contrast with approximately 30% of patients with a negative pelvic lymph node dissection (Shariat et al., 2006b; Stamatakis et al., 2012). The extent of lymph node dissection at the time of cystectomy has been shown as an independent predictor of survival and local recurrence, even when chemotherapy status and other pathologic factors are controlled (Herr et al., 2004). Whereas the importance of a lymph node dissection seems undebatable, what actually constitutes an adequate lymph node dissection and its exact therapeutic benefit remains less clear.

Anatomic Extent of Pelvic Lymph Node Dissection and Landing Zones

The primary lymphatic drainage site for bladder cancer includes the internal iliac, external iliac, obturator, and presacral lymph nodes. Secondary drainage sites include higher echelon nodes, including the common iliac, para-aortic, interaortocaval, and paracaval lymph nodes (Abol-Enein et al., 2004; Leissner et al., 2004; Vazina et al., 2004). Although multiple studies have demonstrated that an extended pelvic lymph node dissection offers improved prognostic staging, the exact anatomic extent of dissection remains somewhat controversial. The cranial extent of an adequate lymph node dissection varies across cystectomy series ranging from the crossing of the ureter at the level of the common iliac vessels to as high as above the aortic bifurcation at the level of the inferior mesenteric artery (Abol-Enein et al., 2004; Leissner et al., 2004; Mills et al., 2001; Poulsen et al., 1998).

Multiple surgical series have evaluated the anatomic extent and distribution of nodal metastasis at the time of cystectomy. In Mansoura, Egypt, Abol-Enein et al. (2004) evaluated the extent and distribution of positive lymph nodes in 200 consecutive patients who underwent radical cystectomy at a single institution over a 4-year period. The anatomic extent of the lymph node dissection was the inferior mesenteric artery superiorly in all patients. Twenty-four percent of patients exhibited nodal disease, with a mean number of eight positive lymph nodes. In 22 patients, only a single lymph node was positive, of which 21 were located in the endopelvis. Metastasis outside of the true pelvis was only found in multinodal disease and was associated with involvement of the obturator and/or iliac nodes in all cases. The authors found no evidence of “skip” metastasis in patients with positive nodes. The authors suggested that the obturator and internal iliac nodes represent the sentinel lymphatic drainage areas and that if lymphadenectomy proved to be negative on frozen-section analysis at the time of surgery, a more superior dissection was not warranted. Similarly, the Memorial Sloan Kettering Cancer Center (MSKCC) group has reported on the anatomic extent and spread of lymph node metastasis (Bochner et al., 2004). The authors reported on 144 patients who underwent either a standard or extended pelvic lymph node dissection at the time of radical cystectomy. A standard pelvic lymph node dissection was defined superiorly by the iliac bifurcation and included the external iliac, hypogastric, and obturator lymph node packets. An extended dissection also included the nodal packets to the level of the aortic bifurcation to no more than 2 cm proximal to the bifurcation. The common iliac and presacral nodes were also included in the extended dissection template. As one would expect, the absolute number of positive nodes was significantly higher in the extended lymph node dissection group (22.5 vs. 8). However, there was no staging advantage noted in the extended lymph node group, with both dissections yielding the same percentage of patients with positive lymph nodes (21%). Four percent of patients presented with positive lymph nodes identified within the para-aortic packets, all of whom also showed positive lymph nodes in lower dissection packets. The authors did note four patients with micrometastatic disease to the common iliac vessels only, concluding that this area should be considered part of the standard lymph node dissection.

Although “skip” metastasis appears to be a relatively rare event in bladder cancer, it has been reported in the literature. A prospective multicenter study of 290 patients undergoing radical cystectomy with extended pelvic lymphadenectomy reported nodal metastasis in 27.9% of patients (Leissner et al., 2004). The authors reported lymph node metastasis based on three defined anatomic regions. Level 1 included lymph nodes below the common iliac bifurcation, level 2 included lymph nodes above the common iliac bifurcation but below the aortic bifurcation, and level 3 included lymph nodes to the level of the inferior mesenteric artery. Although no skip lesions were noted above the level of the aortic bifurcation, 6.9% of patients had nodal metastasis in level 2. Tarin et al. (2012) reported their lymph node dissection findings in 591 patients undergoing a radical cystectomy during a 10-year period, of which 19% exhibited positive nodes. The authors reported 6% of patients with skip lesions above the common iliac bifurcation, with no positive nodes in the true pelvis. Finally, Vazina et al. (2004) also reported one patient with lymph node metastases at or above the aortic bifurcation or common iliac region without nodal involvement of more distal sites in their series of 176 radical cystectomy patients.

The anatomic extent of the pelvic lymph node dissection has also been evaluated in multiple series with regard to oncologic outcome. Dhar et al. (2008) reported on two consecutive series of patients from the Cleveland Clinic and the University of Bern, totaling 658 patients who either underwent a limited or an extended pelvic lymph node dissection. The limited node dissection included the pelvic sidewall between the genitofemoral and obturator nerves, and the bifurcation of the iliac vessels to the circumflex iliac vein. The extended dissection extended cephalad to the crossing of the ureters with the common iliac arteries and removal of all tissue along the lateral and medial portion of the internal iliac vessels. The overall proportion of node-positive patients in the extended versus limited cohorts was 26% and 13%, respectively. The 5-year recurrence-free survival of patients with node-positive disease was 7% for limited node dissection and 35% for extended node dissection. The 5-year recurrence-free survival for pT2pN0 cases was 67% and 77% for limited and extended dissections, respectively, and 23% and 57% for pT3N0 cases, respectively. The 5-year recurrence-free survival for pT2pN0-2 cases was 63% and 71%, respectively, for limited and extended lymph node dissections and 19% and 49%, respectively, for pT3pN0-2 patients. This study, in a large cohort of patients, confirms the value of an extended pelvic lymph node dissection with regard to staging accuracy and prognosis.

Based on anatomic mapping studies, it is recommended that a standard pelvic lymph node dissection at the time of radical cystectomy include the lymph node packets from the external iliac lymph vessels up to the level of the common iliac bifurcation cephalad and the genitofemoral nerve laterally to the ureter medially. An extended template dissection should include the tissue extending above the common iliac bifurcation to the aortic bifurcation and presacral region. Finally, with a superextended lymph node dissection, the tissue up to the level of the inferior mesenteric artery should be included (Sanli et al., 2017). The exact anatomic extent of dissection remains debatable; however, clinical recent and ongoing clinical trials will ultimately answer this question. The German Urologic Oncology Group (AUO) prospective, randomized trial comparing limited dissection (obturator, internal and external iliac nodes) with extended dissection (limited plus deep obturator, presacral, paracaval, interaortocaval, and paraaortal nodes) did not demonstrate a 5-year difference in recurrence-free or cancer-specific survival between these two groups; however, the extended arm did demonstrate nonsignificant absolute improvement in these categories (69.3% vs. 62% and 77.5% vs. 66.2%, respectively) (Gschwend et al., 2016). We also await the results of the Southwest Oncology Group (SWOG) S1011 prospective, randomized trial comparing survival in cystectomy patients undergoing extended or standard pelvic lymph node dissection (NCT01224665).

Number of Lymph Nodes Identified at the Time of Cystectomy

Multiple retrospective surgical series have attempted to quantify the minimum number of lymph nodes that constitutes an adequate pelvic lymph node dissection (Bochner et al., 2001; Herr, 2003; Leissner et al., 2000; Stein et al., 2003). Although controversy remains regarding the actual number of nodes that constitutes an adequate dissection, the absolute number of nodes removed has been shown to provide important prognostic information and staging accuracy both in node-positive and node-negative patients.

As one would expect, increasing nodal yield at the time of pelvic lymph node dissection improves the sensitivity of detecting nodal metastasis. Using a multi-institutional cohort, Capitanio et al. (2009) evaluated the probability of finding node-positive disease at the time of cystectomy based on the total number of lymph nodes removed. Of the 731 patients included in this study, 23.8% had positive nodes. Using receiver operating characteristic (ROC) curves, the authors predicted a 75% chance of identifying one or more lymph node metastases if 25 nodes were removed. This probability improved to 90% with 45 nodes and decreased to 50% if 15 to 25 nodes were removed, suggesting a 25-node minimum as a reasonable cutoff to adequately stage and detect lymph node metastasis (Fig. 137.1).

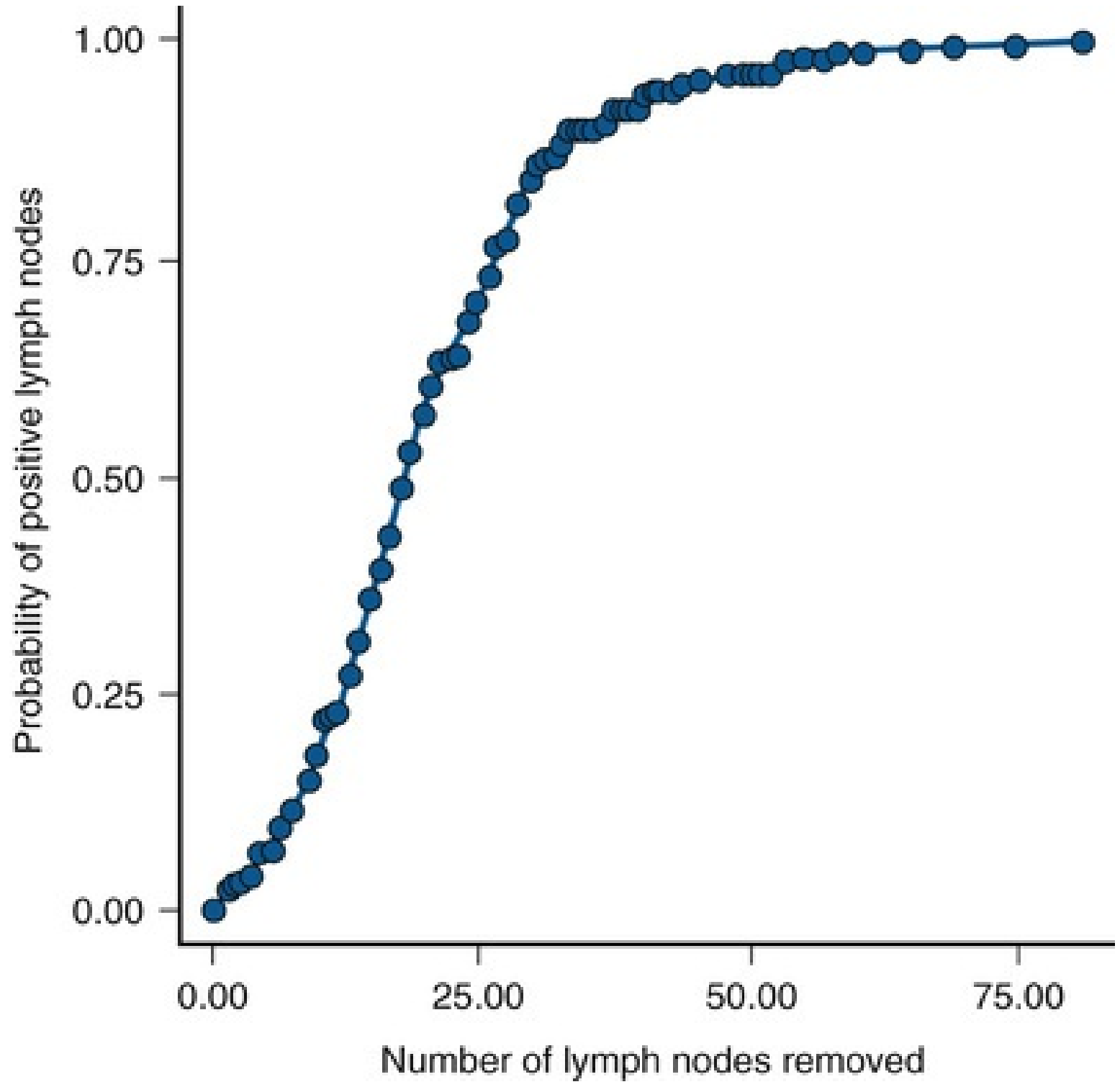

FIG. 137.1 A plot describing the relationship between the number of lymph nodes removed and the probability of detecting lymph node metastasis. (From Capitanio U, Suardi N, Shariat SF, et al. Assessing the minimum number of lymph nodes needed at radical cystectomy in patients with bladder cancer. *BJU Int* 103(10):1359–1362, 2009.)

In addition to staging, lymph node count has been reported to improve therapeutic efficacy; however, prospective data to substantiate such a benefit are currently lacking. Leissner et al. retrospectively analyzed outcomes in 447 cystectomy patients in Mainz, Germany (Leissner et al., 2000). Using a 16-node threshold, there were significant differences in cancer-specific and disease-free survival among patients with 16 or more lymph nodes removed compared with those who had fewer nodes removed. For their survival analysis, a 16-node threshold was used because the correlation between the total number of lymph nodes removed and the percentage of positive nodes was strongest at this count. There is no general consensus in the literature regarding the exact threshold of nodes at which a survival benefit can be predicted, with most studies reporting numbers in the 9 to 16 range (Herr, 2003; Herr et al., 2002; Hollenbeck et al., 2008; Konety et al., 2003; Leissner et al., 2000; May et al., 2011; Stein et al., 2003). Koppie et al. (2006) from the MSKCC group reported a study designed to determine if there is a minimum number of lymph nodes analyzed, above which there is no improvement in survival. The study included 1121 patients who underwent radical cystectomy during a 14-year period. The authors were unable to find a plateau in the dose-response curve with an increasing number of nodes up to 23; however, few patients had more than 24 nodes removed. Limitations of this study include the fact that 13% of patients had no nodes identified on the pathology report, and the percent of patients who underwent an extended node dissection was not reported. The number of lymph nodes identified has also been showed to be consistently associated with risk for pelvic failure, with 10 lymph nodes being the most common threshold in studies of locoregional failure endpoint (Christodouleas et al., 2014; Ku et al., 2014; Novotny et al., 2015).

Although the studies in the last two sections have demonstrated the prognostic and therapeutic value of a thorough pelvic lymph node dissection at the time of radical cystectomy, it must be remembered that they are all either retrospective or nonrandomized reports. There are inherent biases that need to be accounted for when considering the actual value and extent of a pelvic lymph node dissection when one considers it from a nonprospective, nonrandomized approach. Surgical and nonsurgical factors, including anatomic extent of the template and pathologic processing, including the number of packets submitted to pathology, can greatly influence nodal counts (Ather et al., 2008; Bochner et al., 2001; Fang et al., 2010; Kulkarni et al., 2008; Stein et al., 2007a). More definitive studies are currently underway to better address this issue, including randomized controlled trials, with the goal of determining the importance and extent of lymph node dissection at the time of radical cystectomy.

Lymph Node Density and Extracapsular Nodal Extension

Lymph node density refers to the percentage of positive nodes relative to the total number of nodes removed (Kassouf et al., 2008). Studies regarding the impact of lymph node density on prognosis have been mixed. Stein et al. (2003) first described the concept of lymph node density in bladder cancer. In their study of node-positive bladder cancer patients, they identified a lymph node density of 20% to carry prognostic value. Herr (2003) also demonstrated the 20% lymph node density value to confer prognostic value. In their study of 162 patients with node-positive bladder cancer who had a lymph node density of less than 20%, these patients experienced a significantly more favorable 5-year DSS following radical cystectomy. Similarly, Guzzo et al. (2010) reported the outcomes of 85 node-positive patients following radical cystectomy, and they found that lymph node density less than 20% predicted a more favorable response to adjuvant chemotherapy. Conversely, Tarin et al. (2012) could not demonstrate an association between lymph node density compared with that of lymph node status alone in 591 radical cystectomy patients who underwent extended lymphadenectomy. A similar study by Jensen et al. (2012) of 167 radical cystectomy patients echoed these findings. Ku et al. (2015) published a meta-analysis on available lymph node density studies. The authors reported on 14 publications that included more than 3300 patients and found that lymph node density was significantly associated with poorer DSS; however, significant heterogeneity did exist among studies. The current lymph node density studies reported in the literature are retrospective surgical series, and they report varying lymph node counts and templates of dissection, in turn limiting comparisons among studies.

Several small retrospective series have reported the potential prognostic significance of extranodal extension. Fajkovic et al. (2013) evaluated extranodal extension in 748 node-positive bladder cancer cases treated with cystectomy at several centers. A total of 375 (50%) presented with extranodal extension. Using a multivariable model, including pT stage, tumor grade, age, gender, lymphovascular invasion, surgical margin status, lymph node density, total lymph nodes, number of positive nodes, and adjuvant therapy, extranodal extension was significantly associated with both disease recurrence and cancer-specific mortality. Similarly, Seiler et al. (2011) reported an extranodal extension to be an independent predictor of OS and DSS in a smaller cohort ($N = 162$) of node-positive patients.

Intraoperative Decision Making

Grossly Positive Nodes and T4b Disease

For patients with clinically positive lymph nodes, the standard of care is cisplatin-based systemic chemotherapy. Patients who have a radiographic complete or partial response to systemic therapy are candidates for and should be evaluated for cystectomy. Those undergoing cystectomy have been noted to have a complete pathologic response typically in the 14% to 25% range (Meiger et al., 2014; Urakami et al., 2015; Zargar-Shoshtari et al., 2016). Patients who do achieve a complete response appear to have a significant survival advantage with 5-year cancer-specific survival rates of 63% (Meiger et al., 2014). Herr also reported that the overwhelming majority of patients who initially respond to chemotherapy but do not have surgery are destined to recur (Herr, 2001), and therefore consolidative cystectomy should be strongly considered in appropriate surgical candidates who respond to systemic therapy.

If adenopathy is encountered at the time of cystectomy, a frozen section should be taken to confirm metastasis, and an extended lymph node dissection and radical cystectomy should be completed when feasible. Cystectomy is not performed when lymph node metastases are unresectable because of bulk, when there is evidence of extensive periureteral disease, when the bladder is fixed to the pelvic sidewall, or when the tumor is invading the rectosigmoid colon. Not surprisingly, if radical cystectomy is aborted, patient prognosis is poor. The Johns Hopkins group published their outcomes of 35 patients who had an aborted cystectomy because of intraoperative findings of metastatic disease (Guzzo et al., 2008). Sixty percent of patients in the study cohort died from disease progression at a median time of 26 months. Similarly, Yafi et al. (2011) reported outcomes on 31 patients in which cystectomy was aborted for unresectable disease. The 2-year and 5-year OS in this cohort of patients was 41% and 0%, respectively.

Intraoperative Frozen Sections of the Ureter

The incidence of involvement of the distal ureter with tumor on final pathology at the time of radical cystectomy was 6% to 8% (Gakis et al., 2011; Sharma et al., 1970). There is no definitive recommendation for the precise length of the distal ureter that should be removed at the time of surgery. Final ureteral margin status has proven to be an independent predictor of upper tract recurrence following cystectomy (Tran et al., 2008; Volkmer et al., 2009). However, the overall incidence of upper tract recurrence following cystectomy is a relatively rare event ranging from 2% to 8% (Gakis et al., 2011; Giannarini et al., 2010; Schumacher et al., 2006; Tran et al., 2008). There are several risk factors for upper tract recurrence following cystectomy including bladder CIS, distal ureteral involvement with tumor, and high-grade pTa-T1 disease (Volkmer et al., 2009). Upper tract recurrences have been reported to occur most commonly between 2 and 4 years postcystectomy (Meissner et al., 2007; Sanderson et al., 2007; Wagner et al., 2008). Unfortunately, when upper tract recurrences do occur, they are often locally advanced and can be associated with poorer outcomes than de novo upper tract disease (Balaji et al., 1999; Sanderson et al., 2007; Sved et al., 2004). The risk for upper urinary tract recurrence appears to be a stable event with time (Tran et al., 2008).

The role of intraoperative frozen-section analysis of the ureters at the time of cystectomy remains somewhat controversial. Although it would seem intuitive that achieving a negative ureteral margin is necessary, the literature has not always demonstrated improved outcomes with this approach (Lee et al., 2006a; Osman et al., 2007; Schoenberg et al., 1996; Silver et al., 1997). Contemporary studies report frozen-section analysis of the distal ureteral margins to have a 74% to 75% sensitivity, a 98% to 99% specificity, and a positive predictive value of 98% (Gakis et al., 2011; Raj et al., 2006). Whether or not sequential resection for positive frozen ureteral margins confers an absolute benefit remains questionable. An analysis of 1397 cystectomy patients who underwent frozen-section analysis of the distal ureters demonstrated an initial positive margin rate of 12.7% (Tollefson et al., 2010). In those with initial positive margins, 83% were subsequently converted to a negative margin with further resection. Interestingly, those with an initial positive margin but negative final margin still were at higher risk for upper tract recurrence (hazard ratio [HR] = 4.88, 95% confidence interval [CI] 3.02 to 7.90, $P < .001$) compared with those with initial negative margins. This risk was intermediate to that of those with positive final margins (HR, 7.37, 95% CI 4.3 to 16.44, $P < .001$). These findings suggest that patients with ureteral disease at the time of cystectomy experience an increased risk for upper tract recurrence regardless of margin status, but this risk can be at least partially mitigated by achieving a negative margin. Most recently, Moschini et al. (2016) reported their experience with the utility of intraoperative ureteral margins in 1447 patients. In their series, 25% of patients had an intraoperative positive margin that was ultimately converted to a negative margin in 48% of cases. Ureteral margins that were not converted to negative intraoperatively were associated with poorer cancer-specific mortality, but only in patients with negative soft tissue margins and without nodal metastasis. The impact of ureteral skip lesions has also been reported. Investigators from the University of Texas MD Anderson Cancer Center evaluated 660 radical cystectomy patients who had both a distal frozen and final proximal ureteral margin (Hoang et al., 2014). Ureteric skip lesions (negative distal frozen, positive proximal permanent margin) were identified in 4.8% of patients with CIS, which is the most common skip lesion (55.9% of cases). Skip lesions were associated with lower median OS in patients with pT0 or pTa disease.

Given the findings outlined earlier, it appears logical to attempt to clear the distal ureter when feasible at the time of radical cystectomy. When frank tumor is encountered, it should be resected to a negative margin. When CIS only is encountered, maximal resection without compromising ureteral length for urinary diversion is advocated, as it is debatable whether a negative CIS margin reduces upper tract recurrence or is definitively associated with poorer outcome (Lee et al., 2006a; Raj et al., 2006). In patients who are at high risk for an upper tract recurrence, ureteropyeloscopy, when feasible, is the most sensitive means for detecting upper tract recurrences.

Prostatic Urothelial Carcinoma and Management of the Distal Urethra

The absolute risk for urethral recurrence following cystectomy ranges from 4% to 8% in men (Cho et al., 2009; Huguet et al., 2008; Nelles et al., 2008; Nieder et al., 2004; Stein et al., 2005; Varol et al., 2004). The majority of urethral recurrences are symptomatic, but in patients who are deemed at high risk for such events, periodic cytology can be useful for detection of recurrences (Clark et al., 2004; Huguet et al., 2008). Risk factors for urethral recurrence include non–muscle-invasive disease on final pathology and prostatic urethral involvement (Huguet et al., 2008; Stein et al., 2005). The extent of prostatic involvement is also predictive of urethral recurrence. Prostatic stromal invasion is associated with the highest risk (as high as 30%) compared with that of prostatic urethral CIS and ductal or acinar involvement (Hardeman and Soloway, 1990). Urethrectomy should be considered in men with diffuse CIS of the prostatic urethra or ducts or if there is prostatic stromal invasion. Preoperative evaluation of the prostatic urethra via biopsy can be performed to characterize further the risk for urethral recurrence and help dictate intraoperative management of the distal urethra and choice of urinary diversion. The sensitivity and specificity of transurethral prostatic urethral biopsy is moderate, with a relatively low positive predictive value compared with final cystoprostatectomy specimens (Donat et al., 2001). Given the modest value of preoperative urethral biopsy, some experts advocate for urethrectomy only in the setting of a positive apical urethral margin (Donat et al., 2001; Stein et al., 2005). Small low-grade papillary tumors of the urethra can be resected before cystectomy and the urethra retained if there is no other indication for urethrectomy. Of note, several retrospective surgical series have reported a decreased risk for urethral recurrence in patients with orthotopic urinary diversions (Hassan et al., 2004; Nieder et al., 2004; Stein et al., 2005). Whereas some have hypothesized that this decrease may be related to a protective effect of exposing the urethra to urine, it is more likely a result of selection bias.

Managing the Female Urethra

Before female orthotopic bladder substitution became more commonplace, complete removal of the female urethra at the time of radical cystectomy was routine. T4 tumors involving the urethra and/or vagina mandate complete urethrectomy, and these patients should not be offered urethral preservation. Concomitant involvement of the urethra in women with bladder cancer ranges from 2% to 12% (Stein et al., 2007b; Stenzl et al., 1995). Clinical features associated with an increased risk for distal urethral tumor involvement include primary tumor location at the bladder neck, vaginal involvement, or inguinal lymphadenopathy (Maralani et al., 1997; Stein et al., 1995, 1998). Although tumor presence at the bladder neck is significantly associated with urethral involvement, approximately 60% of patients with tumors in this location will not have a tumor in the urethra on final pathology; therefore controversy exists with regard to an absolute need for complete urethrectomy in this setting. Frozen-section analysis of the distal urethra has demonstrated high correlation with final urethral margin and should be performed in all women in which orthotopic bladder substitution is being considered (Akkad et al., 2006; Stein et al., 1998). Isolated urethral recurrence following orthotopic bladder substitution occurs in approximately 1% of cases (Ali-El-Dein et al., 2009; Stein et al., 2009).

Oncologic Outcomes Following Radical Cystectomy

Table 137.3 illustrates the reported oncologic outcomes of large surgical series. Pathologic tumor stage and presence of nodal metastasis are the strongest predictors of recurrence and survival following cystectomy (Frazier et al., 1993; Ghoneim et al., 2008; Hautmann et al., 2006; Madersbacher et al., 2003; Shariat et al., 2006b; Manoharan et al., 2009; Stein et al., 2001). Patients who are pT0 or who have residual noninvasive disease on final pathology have excellent outcomes with 5-year cancer-specific survival rates approaching 90% (Ghoneim et al., 2008; Stein et al., 2001). Patients with pT2 tumors have 5-year DSS rates ranging from 70% to 81%. Pathologic T2 substratification has been shown in multiple studies to confer prognostic value with regard to recurrence-free and DSS (Bastian et al., 2008; Ghoneim et al., 2008; Tilki et al., 2010a). The presence of non–organ-confined disease (>pT2) is a strong predictor of outcome. Pathologic T3 patients fare significantly poorer, with 5-year DSS rates ranging from 40% to 52%. The prognostic value of pT3 substaging has been debated in the literature. Two large multicenter surgical series have reported a prognostic discrimination between pT3a and pT3b, with node-negative patients reporting an improved recurrence-free and DSS advantage in pT3a patients (Sonpavde et al., 2011; Tilki et al., 2010b). However, pT3 substaging has not demonstrated improved stratification in node-positive patients (Quek et al., 2004). Lymph node status appears to be the single greatest predictor of survival. Node-positive disease confers a poor prognosis, with 5-year DSS rates ranging from 21% to 35%. However, long-term survival has been reported in patients with low-volume lymph node metastasis (Bruins et al., 2009; Dhar et al., 2008; Rink et al., 2013; Steven et al., 2007).

TABLE 137.3

Percentage of 5-Year Disease-Specific Survival (DSS) by Pathologic Stage After Radical Cystectomy With and Without Pelvic Lymph Node Metastasis: Selected Series Reporting DSS (2000–2012)

SELECTED SERIES	NO. OF PATIENTS	≤P1	P2A	P2	P2B	P3A	P3	P3B	P4A, B	N NEG	N+
Stein et al., 2001	1054	88		81		68		47	44	78	35
Madersbacher et al., 2003	507	76		74			52		36	—	33
Hautmann et al., 2006	788	90		72			43		28	75	21
Shariat et al., 2006b	888	81		72			44		28	80	35
Ghoneim et al., 2008	2720	82	75		53		40		29	62	27
Manoharan et al., 2009	432	81		70			44		16	72	29

Margin status is also an important predictor of recurrence and survival following radical cystectomy (Dotan et al., 2007; Novara et al., 2010). A multicenter, retrospective study of 4410 radical cystectomy patients reported an overall soft tissue positive margin rate of 6.3% (Novara et al., 2010). A positive soft tissue margin was associated with a significantly increased risk for disease recurrence (HR 1.52, $P < .001$) and cancer-specific mortality (HR 1.51, $P < .001$). Additional variables that were reported to possess prognostic value following radical cystectomy include the presence of lymphovascular invasion

(Herrmann et al., 2008; Lotan et al., 2005; Shariat et al., 2010), molecular markers (Shariat et al., 2014; Youssef et al., 2011), surgical expertise and hospital volume (Konety et al., 2005), body mass index (Bagrodia et al., 2009), and age (Hollenbeck et al., 2004; Nielsen et al., 2007). Despite aggressive surgical therapy, approximately 50% of cystectomy patients will ultimately die of disease. Recurrence of disease often occurs within the first 2 years after surgery, with median recurrence times of 7 to 18 months reported in large series.

Improved and more frequent postoperative imaging has demonstrated more substantial rates of isolated or co-synchronous pelvic failure than historically appreciated. The most important risk factors for pelvic failure are the presence of pT3–4 disease, positive soft-tissue margins, and whether greater than 10 benign or malignant lymph nodes were identified in the lymphadenectomy specimen. These factors have been combined to define three risk groups for pelvic failure: low risk, less than pT3 disease; intermediate risk, pT3–4, negative margins, and greater than 10 lymph nodes identified; high risk, pT3–4 with positive margins or less than 10 lymph nodes identified. This model consistently stratifies pelvic failure risk in geographically and temporally diverse radical cystectomy cohorts, with 5-year pelvic failure rates of approximately 8% for low-risk groups, 19% to 21% for intermediate-risk groups, and 41% to 46% for high-risk groups (Christodouleas et al., 2014; Ku et al., 2014; Novotny et al., 2015).

Neoadjuvant Therapy for Muscle-Invasive Bladder Cancer

Nearly 50% of patients with muscle-invasive bladder cancer treated with cystectomy alone will progress to metastatic disease (Ghoneim et al., 2008; Stein et al., 2001). Clearly, surgery alone is not sufficient therapy in a large number of patients with invasive bladder cancer. Systemic therapy with cisplatin-based chemotherapy has been shown to provide response rates in multiple bladder cancer studies since the mid-1980s (Stenzl et al., 2009; Sternberg et al., 1985). Since the initial reports of its usefulness in muscle-invasive bladder cancer, there have been multiple randomized controlled studies undertaken to define further the effectiveness of neoadjuvant cisplatin-based chemotherapy in advance of cystectomy. Unfortunately, many of these studies have been hampered by inadequate power and a lack of standardization of surgical approaches to demonstrate clearly a survival advantage with neoadjuvant chemotherapy in most of these studies when they are evaluated individually.

There are several arguments for cisplatin-based chemotherapy in the neoadjuvant setting for patients with muscle-invasive bladder cancer. First, systemic chemotherapy is often better tolerated before surgery, rather than after surgery when patients may experience a delay in chemotherapy administration because of complications or debilitation. Second, patients who present with micrometastatic disease will receive therapy in a timelier fashion when their burden of disease is potentially low. Third, neoadjuvant chemotherapy has the potential to downstage bulky and locally advanced tumors, allowing for a higher likelihood for negative surgical margins that are a known predictor of local recurrence following cystectomy. Finally, neoadjuvant chemotherapy allows the clinician to assess each individual's response to therapy. A disadvantage of neoadjuvant chemotherapy is a delay in definitive local therapy for patients who do not respond to chemotherapy and thus experience disease progression.

The European Organization for Research and Treatment of Cancer (EORTC) and the Medical Research Council (MRC) performed the largest neoadjuvant chemotherapy trial in bladder cancer. This study evaluated the benefit of three cycles of neoadjuvant cisplatin, methotrexate, and vinblastine in 976 patients before radiation or cystectomy (International Collaboration of Trialists, 1999). The study was designed to detect an absolute improvement in survival of 10%

with a power of 90% and a type 1 error of 5%. Eighty percent of the 491 patients who were assigned to the chemotherapy arm completed three cycles. The study was performed at 106 centers, and the decision as to whether patients received radiation or cystectomy was at the discretion of the investigators. Chemotherapy-related mortality was reported to be 1%. At the time of the initial analysis, there was a trend noted toward improved survival in the neoadjuvant chemotherapy arm (HR 0.85, 95% CI 0.71 to 1.02; $P = .075$) with a median follow-up of 4 years. This translated into a nonsignificant absolute difference in survival of 5.5% at 3 years with survival rates of 50% for those who did not receive chemotherapy compared with 55.5% for those who did. The results of this trial were updated in 2011, with a median patient follow-up of 8 years (Hall, 2002). The updated survival results were notable for a statistically significant 16% reduction in the risk of death for patients in the chemotherapy arm (HR 0.84, 95% CI 0.72 to 0.99; $P = .37$). The estimated 10-year survival in the chemotherapy arm was 36% compared with 30% in the control arm, translating to a 6% absolute survival benefit (Griffiths et al., 2011). Limitations of the EORTC/MRC trial when compared with current clinical practice include the fact that cisplatin, methotrexate, and vinblastine is not considered a standard of care for muscle-invasive bladder cancer and has not been compared directly to methotrexate, vinblastine, doxorubicin (Adriamycin), and cisplatin (MVAC). Additionally, approximately 40% of patients in both the chemotherapy arm and local therapy arm received radiation and not radical cystectomy.

The intergroup trial (Southwest Oncology Group [SWOG] 8710) randomized 317 patients to three cycles of neoadjuvant MVAC versus cystectomy alone for CT2-T4aN0M0 bladder cancer (Grossman et al., 2003a). Eighty-two percent of patients randomized to chemotherapy ultimately underwent a cystectomy with a mean time to surgery of 115 days. Thirty-eight percent of the chemotherapy patients achieved pT0 status at the time of cystectomy compared with 15% of the controls ($P < .001$). The median OS time in the chemotherapy group was 77 months compared with 46 months in the cystectomy-only group. The 5-year OS rates were 57% and 43% in the chemotherapy and cystectomy-only arms, respectively. However, the survival results failed to reach statistical significance ($P = .06$). Notably, patients who were downstaged to pT0 achieved excellent outcomes, with 80% alive at 5 years compared with 40% of patients with residual disease. A secondary analysis of the SWOG 8710 data compared subgroup outcomes for patients with pure urothelial carcinoma versus mixed histologic subtypes (Scosyrev et al., 2011). The authors reported a survival advantage in the mixed histology subgroup that received neoadjuvant chemotherapy. Given the fact that this was a secondary subgroup analysis, it is difficult to draw definitive conclusions; however, this analysis does suggest that patients with mixed histology should be considered for neoadjuvant chemotherapy. Other randomized trials of neoadjuvant chemotherapy for bladder cancer are summarized in Table 137.4.

TABLE 137.4

Randomized Trials of Neoadjuvant Chemotherapy

STUDY	NO. OF PATIENTS	NEOADJUVANT ARM	CONTROL ARM	STAGE	SURVIVA RATE
EORTC/MRC (International Collaboration of Trialists, 1999)	976	CMV + RC/RT	RC/RT	T2-4aNxM0	10-year OS 36% vs. 30% (*P* = .037)
Nordic I (Malmström et al., 1996)	325	CA + RT + RC	RT + RC	T1-4aNxM0	5-yearr OS 59% vs. 51% (*P* = .1)
Nordic II (Sherif et al., 2002)	317	CM + RC	RC	T2-4aNxM0	5-year OS: 53% vs. 46% (*P* = .24)
SWOG (Grossman et al., 2003a, 2003b)	317	MVAC + RC	RC	T2-4aN0M0	5-year OS: 57% vs. 43% (*P* = .06)
WMURG/ABCSG (Wallace et al., 1991)	255	Cis + RT	RT	T2-4aNxMx	No difference
GUONE (Bassi et al., 1998)	206	MVAC + RC	RC	T2-4aN0M0	5-year OS: 55% vs. 54% (*P* = NS)
Abol-Enein et al., 1997	196	CarboMV + RC	RC	T2NxMx	5-year OS: 62% vs. 42% (*P* = .013)
GISTV (Italian	171	MVEC + RC	RC	T2-	Median OS

Bladder Cancer Study Group), 1996				4N0M0	NR vs. 5.5 year (*P* = NS)
CUETO (Martinez Piñeiro et al., 1995)	122	Cis + RC	RC	T2-4aNx-2M0	6.5-year OS: 35% vs. 37% (*P* = .95)
Daveca 89-02 (Sengelov et al., 2002)	120	CM + RT	RT	T2-4bNx-3M0	5-year OS: 19% vs. 24% (*P* = .98)
Coppin et al., 1996	99	Cis + RT/RC	RT + RC	T2-4bN0-3M0	3-year OS: 47% vs. 33% (*P* = .34)

CA, Cisplatin and doxorubicin; *CarboMV,* carboplatin, methotrexate, and vinblastine; *Cis,* cisplatin; *CM,* cisplatin and methotrexate; *CMV,* cisplatin, methotrexate, and vinblastine; *CUETO,* Spanish Oncology Group; *EORTC/MRC,* European Organization for Research and Treatment of Cancer/Medical Research Council; *GISTV,* Gruppo Italiano per lo Studio dei Tumori della Viscica (Italian Bladder Cancer Study Group); *GUONE,* Gruppo Uro-Oncologico del Nord-Est (North-Eastern Uro-Oncological Group, Italy); *MVAC,* methotrexate, vinblastine, doxorubicin (Adriamycin), and cisplatin; *MVEC,* methotrexate, vinblastine, epirubicin, and cisplatin; *OS,* overall survival; *RC,* radical cystectomy; *RT,* radiation therapy; *SWOG,* Southwest Oncology Group; *WMURG/ABCSG,* West Midlands Urological Research Group/Australian Bladder Cancer Study Group.

Most of the trials reported in the literature have failed to demonstrate a statistically significant survival advantage for those patients who received neoadjuvant chemotherapy. Contributing to these findings are inherent limitations to the trial designs including small sample sizes, varying and sometimes suboptimal chemotherapy protocols, premature closure, and inadequate follow-up (Sylvester and Sternberg, 2000). In an attempt to clarify further the precise benefit of neoadjuvant chemotherapy, several investigators have performed meta-analyses of the current chemotherapy trials. The Advanced Bladder Cancer (ABC) Meta-analysis Collaboration (2005a, b) undertook the largest meta-analysis. This report was an update to the group's previous meta-analysis in 2003, now including the SWOG 8710 trial data for a total of 11 randomized neoadjuvant chemotherapy trials. Individual patient data were analyzed from 3005 patients making up 98% of patients from all known eligible trials. The trials were grouped based on the use of single-agent platinum or platinum-based combination chemotherapy. There was a significant benefit in favor of platinum-based combination chemotherapy with regard to OS (HR 0.86, 95% CI 0.77 to 0.95, $P = .003$). This resulted in an absolute survival benefit of 5%, improving OS from 45% to 50% at 5 years. Disease-free survival data were available on 2846 patients from 10 trials. There was a significant benefit in the platinum-based combination chemotherapy group (HR 0.78, 95% CI 0.71 to 0.86, $P <. 0001$). The 5% survival benefit was consistent across patient subgroups including age, sex, clinical stage, and performance status.

The Cancer Care Ontario Program in Evidence-based Care Practice Guidelines Initiative also reported a neoadjuvant chemotherapy meta-analysis (Winquist et al., 2004). The authors reviewed 16 randomized-controlled trials (3315 patients) and identified 11 (2605 patients) with suitable data. The pooled HR was 0.90 (95% CI 0.78 to 0.96, $P = .02$) in favor of neoadjuvant chemotherapy. When the eight trials using cisplatin-based combination chemotherapy were analyzed, the pooled HR was 0.87 (95% CI 0.78 to 0.96, $P = .006$), consistent with an OS benefit of 6.5% (95% CI 2 to 11).

Based on the randomized trial results and subsequent meta-analyses, cisplatin-based neoadjuvant chemotherapy is associated with an OS advantage of 5% to 6% and a pathologic complete response rate of 30% to 40%. Currently the NCCN guidelines recommend that clinicians strongly consider neoadjuvant cisplatin-based chemotherapy for cT2N0M0 patients and recommend neoadjuvant cisplatin-based chemotherapy for cT3–T4aN0M0 patients. The European Association of Urology guidelines currently recommend neoadjuvant chemotherapy for T2–T4aN0M0 patients and also note that it should always be a cisplatinum-based combination regimen. Despite the evidence supporting neoadjuvant chemotherapy, it continues to be underused. An analysis of 7161 patients with stage III bladder cancer within the National Bladder Cancer Database noted that only 11.6% of patients received perioperative chemotherapy, of which 1.2% were in the neoadjuvant setting (David et al., 2007). SEER-Medicare data have also demonstrated a lack of penetrance of neoadjuvant chemotherapy in the setting of muscle-invasive disease (Porter et al., 2011).

Neoadjuvant radiation was commonly performed in the 1970s and 1980s but fell out of favor after the introduction of cisplatin-based neoadjuvant therapy, which does not complicate surgery or limit surgical options as much as radiation. There have been multiple attempts to study the role of neoadjuvant radiation including at least five small prospective randomized trials (Anderstrom et al., 1983; Blackard and Byar, 1972; Ghoneim et al., 1985; Slack et al., 1977; Smith et al., 1997) but none were able to convincingly demonstrate a benefit.

Adjuvant Therapy for Muscle-Invasive Bladder Cancer

Patients with pT3–T4 or node-positive disease are known to be at high risk for recurrence following cystectomy. Adjuvant chemotherapy has been used in this population in an attempt to treat micrometastatic disease and to improve survival. The rationale for systemic chemotherapy following cystectomy includes the fact that it allows for immediate local treatment with cystectomy and avoids any delay in treatment in patients with chemotherapy-resistant tumors (Sternberg and Sylvester, 2014). The availability of final pathology also allows clinicians to select patients at the highest risk for failure who are most likely to benefit while sparing those who are less likely to progress from the side effects of systemic chemotherapy. Additionally, the role of molecular markers to predict disease aggressiveness and therapeutic response is likely to expand in the future. Cystectomy in this case would provide adequate tissue to direct individualized therapy based on molecular and genomic analysis.

A major limitation of adjuvant chemotherapy is that it is often difficult or impossible for patients to undergo systemic therapy following cystectomy secondary to surgical deconditioning, deteriorating renal function, or perioperative complications (Donat et al., 2009; Hall et al., 1996). For example, in a randomized trial evaluating adjuvant chemotherapy for pT3–4/N+ disease, 25% of patients randomized to the chemotherapy arm did not receive such therapy (Skinner et al., 1991). Adjuvant chemotherapy trials have been hampered by small overall numbers and difficult patient accrual, which has limited the ability to draw definitive conclusions regarding the overall effectiveness of this approach.

Randomized Trials of Adjuvant Chemotherapy

There have been multiple randomized trials set forth to define the role of adjuvant chemotherapy (Table 137.5). Unfortunately, these trials have not provided sufficient evidence to support adjuvant chemotherapy, and this is because of low numbers, difficulty with patient accrual, early termination of the trials, and flawed statistical design. The University of Southern California (USC) group reported the first prospective, randomized trial to demonstrate a survival benefit with adjuvant chemotherapy (Skinner et al., 1991). A total of 91 patients with pT3–4 or N+ disease following cystectomy were randomized to cisplatin-based chemotherapy versus observation. Three-year time to progression was significantly better in the chemotherapy group, with 70% of patients free from disease compared with 46% assigned to observation. Median survival was also significantly improved in the chemotherapy arm (4.3 years vs. 2.4 years; P = .0062). Although this trial did demonstrate an advantage in favor of adjuvant chemotherapy, it has been criticized for several reasons. First, the overall number of patients is small, which limits statistical power. Additionally, chemotherapy regimens were not standardized and included a cisplatin, cyclophosphamide, and doxorubicin (Adriamycin) (CISCA)-like regimen, single-agent cisplatin, and chemotherapy regimens selected by clonal assays. This trial also highlighted the difficulty of administering chemotherapy after cystectomy with 25% of patients who were assigned to receive chemotherapy and who were not receiving therapy.

TABLE 137.5

Adjuvant Chemotherapy Trials Following Cystectomy

INVESTIGATOR	NO. OF PATIENTS	REGIMEN	CHEMO	NO CHEMO	RESULTS/SHO
Logothetis et al., 1988	133	CISCA	62	71	Benefit; not ran
Skinner et al., 1991	91	CAP	47	44	Benefit DFS 4.3 few patients rece
Stockle et al., 1992, 1995	49	MVAC/MVEC	23	26	Benefit DSS (71 months); no che relapse in contro
Studer et al., 1994	77	DDP	40	37	No benefit
Bono et al., 1997	83	CM	48	35	No benefit for N
Freiha et al., 1996	50	CMV	25	25	Benefit TTP (37 early closure, no survival benefit
Otto et al., 2001	108	MVEC	55	53	No benefit
Cognetti et al., 2012	194	GC	102	92	No benefit for N

CAP, Cisplatin, cyclophosphamide, and doxorubicin; *CISCA,* cisplatin, cyclophosphamide, and doxorubicin (Adriamycin); *CM,* cisplatin and methotrexate; *CMV,* cisplatin, methotrexate, and vinblastine; *DDP,* diamminedichloroplatinum (cisplatin); *GC,* gemcitabine and cisplatin; *MVAC,* methotrexate, vinblastine, doxorubicin (Adriamycin), and cisplatin; *MVEC,* methotrexate, vinblastine, epirubicin, and cisplatin; *TTP,* time to progression.

A German trial randomized 49 patients with pT3b–4a and/or N+ disease to receive three cycles of MVAC or MVEC (methotrexate, vinblastine, epirubicin, and cisplatin) (Stockle et al., 1992, 1995). A total of 26 patients were randomized to chemotherapy, and 69% received it. Three-year disease-free survival was significantly improved in the chemotherapy arm (63% vs. 13%, $P = .002$), and based on these results the study stopped early. This study was updated with a total of 83 patients (38 received chemotherapy after the close of the trial based on the interim analysis). Ten-year follow-up data maintained an advantage in the chemotherapy group with regard to progression-free survival (44% vs. 13%, $P = .02$) and DSS (42% vs. 17%, $P = .007$). Although there was a trend toward an OS benefit in the adjuvant chemotherapy arm, this was not statistically significant (27% vs. 17%, $P = .07$). Ultimately, 92% of patients in the observation arm showed evidence of tumor progression compared with 27% who received chemotherapy. Much like the USC trial, this trial has also been widely criticized. Overall, the number of patients is small because of early closure of the trial after interim analysis. Many patients in the observation group were not offered chemotherapy at the time of disease progression and, as one would expect, not all patients randomized to chemotherapy ultimately received such therapy.

Since the mid-2000s, there have been several attempts at large-scale adjuvant chemotherapy trials, most of which have been presented in abstract form. Unfortunately, the majority of these studies have been hampered by poor accrual. The results of an Italian adjuvant chemotherapy, multicenter, randomized phase III trial have been published (Cognetti et al., 2012). This study randomized 194 patients with pT2G3, pT3–4, N0–2 urothelial carcinoma to observation ($N = 92$) versus four cycles of chemotherapy ($N = 102$). The chemotherapy cohort was randomly assigned to one of two regimens; either gemcitabine 1000 mg/m^2 days 1, 8, and 15 and cisplatin 70 mg/m^2 day 2 or the same gemcitabine schedule plus cisplatin 70 mg/m^2 day 15, every 28 days. With a median follow-up of 35 months, the 5-year OS was 48.5% with no difference between the chemotherapy and observation arms ($P = .24$). There was also no statistical difference in disease-free survival in the observation (42.3%) and chemotherapy arms (37.2%). Only 62% of patients received the planned course of chemotherapy, however. The initial study was designed to randomize 610 patients in a 1 : 1 fashion but was closed early because of poor accrual. The smaller sample size resulted in significant underpowering of the study in detecting a significant difference between adjuvant chemotherapy and observation.

The Cancer and Leukemia Group B (CALGB) trial randomized patients following cystectomy with acceptable renal function to either a rapid-cycling regimen of chemotherapy with four cycles of doxorubicin-gemcitabine administered at 14-day intervals with granulocyte colony-stimulating factor (G-CSF) support followed by four cycles of paclitaxel-cisplatin provided at 21-day intervals compared with adjuvant gemcitabine with cisplatin in a 4-week cycle (Bajorin, 2001). The accrual goal in this trial was 800 patients; however, the study was terminated for poor accrual, and ultimately fewer than 100 patients enrolled. Similarly, the EORTC-30994 trial randomized patients with pT3–4 and/or N+ disease with acceptable renal function to either four cycles of either gemcitabine/cisplatin, MVAC, or high-dose intensity (HD) MVAC versus observation. The accrual goal for this trial was 660 patients, but it closed as a result of poor accrual enrolling a total of 278 patients (Sternberg et al., 2001c). The USC/SWOG International trial randomized 114 patients with pT1–2, N0, p53-positive tumors to three cycles of adjuvant MVAC or observation (Stadler et al., 2009). A total of 114 patients were randomized, but further accrual was halted after interim analysis showed no difference in recurrence-free survival. Additionally, 67% of those randomized to MVAC received all three cycles, and 12% received none. The Spanish Oncology Genitourinary Group (SOGUG) 99/01 trial randomized patients with pT3–4 or node-positive disease to four cycles of paclitaxel, gemcitabine, and cisplatin versus observation. At a median follow-up of 51 months, a 5-year OS advantage was noted with chemotherapy (60% vs. 31%, $P < .0009$); however, the trial was stopped prematurely because of poor accrual after 7 years after randomizing 142 patients, which was well below the target of 340.

Similar to the neoadjuvant chemotherapy, the Advanced Bladder Cancer (ABC) Meta-analysis Collaboration evaluated the effect of adjuvant chemotherapy reviewing 11 randomized trials and ultimately including 6 trials with a total of 491 patients (ABC Meta-analysis Collaboration, 2005a, 2005b). The overall HR for survival from this meta-analysis was 0.75 (95% CI 0.60 to 0.96, $P = .019$), suggesting a 25% relative reduction in the risk for death in favor of adjuvant chemotherapy compared with controls. This translated to a 9% absolute survival benefit at 3 years. Despite the positive findings, the authors of the meta-analysis point out that insufficient evidence remains to base treatment decisions reliably. Notably, there were major deficiencies in the trials included in the meta-analysis such as small sample sizes, early closure of trials, limitations in statistical analysis, and differences in the way disease-free survival was defined (Sternberg and Collette, 2006).

Despite the efforts of the trials outlined earlier, the evidence for adjuvant chemotherapy is lacking. An updated meta-analysis including 945 patients noted that adjuvant chemotherapy seems to be most beneficial to patients with node-positive disease; however, this meta-analysis was limited by many of the same issues outlined earlier (Leow et al., 2014). The available evidence suggests that perioperative chemotherapy does confer a survival benefit for bladder cancer patients with stronger evidence available in the neoadjuvant approach. The optimal approach and benefit to systemic chemotherapy in the adjuvant setting remains incompletely defined, and based on the difficulty with patient accrual in past trials it may remain unanswered. Currently the NCCN guidelines favor neoadjuvant chemotherapy instead of adjuvant chemotherapy based on higher-level evidence data; however, the guidelines do suggest considering adjuvant chemotherapy in the setting of pT3–4 or node-positive disease based on the available data. The EAU guidelines currently recommend adjuvant chemotherapy within clinical trials but not as a routine therapeutic option, as randomized trials and meta-analyses have not provided sufficient evidence to support routine use.

Adjuvant Chemoradiation

Multiple studies have demonstrated that patients with locally advanced disease (pT3–4) have high pelvic failure rates (20% to 40% at 5 years) and that perioperative chemotherapy does not significantly improve that risk (Baumann et al., 2013a; Christodouleas et al., 2014). Moreover, after pelvic failure is identified, outcomes are quickly catastrophic with a median survival of approximately 9 months (Baumann et al., 2013a,b). There have been several clinical trials that evaluated the potential benefits of adjuvant radiation. A three-arm randomized trial performed at the National Cancer Institute in Cairo in the 1980s compared adjuvant radiation therapy alone (using two different radiation techniques) versus observation for patients with negative soft-tissue surgical margins but high risk for local failure following radical cystectomy alone (Zaghloul et al., 1992). This study demonstrated a significant improvement in pelvic control and 5-year OS for the two radiation therapy arms. The generalizability of that trial for populations outside Egypt has been questioned because 80% of the patients had squamous cell carcinoma and only 20% urothelial carcinoma, although the outcomes appeared similar regardless of histology. Because of this study, adjuvant radiation was commonly employed in Egypt and other countries where squamous cell carcinoma of the bladder is prevalent. A follow-up randomized phase II study, also performed by the National Cancer Institute in Cairo, compared adjuvant chemotherapy alone (four cycles of gemcitabine and cisplatin [gem/cis]) versus adjuvant sandwich chemoradiation (sequential therapy with two cycles of gem/cis, radiation, and then two additional cycles of gem/cis) (Zaghloul et al., 2018). This small study ($N = 120$) included a majority of urothelial carcinoma patients and demonstrated a significant improvement in 2-year pelvic-failure–free survival favoring the chemoradiation arm (96% vs. 69%, $P < 0.1$) and non–statistically significant higher rates of disease-free (68% vs. 56%, $P = 0.07$) and OS (71% vs. 60%, $P = 0.11$).

Because adjunctive radiation could substantially increase the risk for postoperative small bowel obstruction (Baumann et al., 2015), adoption of adjuvant radiation therapy should proceed cautiously for patients for locally advanced disease. The strongest case for its use can be made for patients with positive soft-tissue surgical margins, but there are several ongoing prospective studies specifically studying its role for patients with pT3–4 primary tumors, less than 10 nodes identified, and N+ disease.

Bladder Preservation

Although radical cystectomy remains the standard of care for patients with muscle-invasive bladder cancer, it is a major operative procedure with significant risk for perioperative morbidity and mortality (Shabsigh et al., 2009). Data from Medicare claims have shown radical cystectomy to have the second highest 30-day readmission rate compared with other urologic and nonurologic procedures (Goodney et al., 2003). The high incidence of perioperative complications, coupled with a classically older patient population with multiple medical comorbidities, has led patients and clinicians to seek alternatives to cystectomy. Bladder preservation is a curative intent paradigm that should be considered in two distinct populations: (1) patients who have high operative risks as a result of comorbidities and frailty and (2) patients who are fit for radical cystectomy but have limited burden of disease, adequate normal bladder urothelial and function, and are motivated to retain their bladder.

The most rigorously studied approach to bladder preservation is trimodality therapy: a maximal safe and ideally visibly complete TUR, chemotherapy, and radiation, but there are other nonradical approaches that a clinician should consider, especially in older, frail patients.

Two basic strategies for trimodal bladder preservation exist: split-course and continuous-course therapy. Split-course therapy is based on the premise of mid-treatment restaging and is only appropriate for patients who are surgically fit and thus eligible for an immediate salvage cystectomy. In a split-course approach, patients are administered induction chemoradiation therapy to approximately 40 Gy, which is followed by restaging with cross-sectional imaging and endoscopic evaluation. If persistent *invasive* disease is noted, radical cystectomy is recommended. Those without persistent invasive disease undergo consolidative chemoradiotherapy to approximately 60 to 64 Gy. As the name implies, continuous-course treatment involves a full course of chemoradiation therapy followed by an endoscopic restaging examination 3 to 4 months after therapy to allow time for an adequate response to therapy. Continuous-course treatment is an appropriate option for both surgically fit and unfit patients. Given the same total dose, continuous-course treatment is more intensive than split-course treatment because continuous-course therapy is completed over a shorter period, which limits the opportunity for both tumor and normal tissue cell repopulation. Regardless of approach, the benefits of concurrent sensitizing chemotherapy during the course of radiation is now well-established. In the largest randomized study of its kind, James et al. demonstrated that mitomycin and 5-fluorouracil (5-FU) given concurrently with radiation was superior to radiation alone with respect to 2-year locoregional disease-free survival (67% vs 48%) without significantly worse late toxicity (James et al., 2012).

Another factor that likely affects the efficacy of trimodality therapy is the quality of the TUR. Studies suggest superior 5- and 10-year OS rates for patients with visibly complete TURs (57% and 39%) compared with those without complete resection (43% and 29%) before trimodal therapy, though these differences are confounded by selection bias. The rates of radical cystectomy for visibly complete resections are lower (11%) compared with incomplete resections (42%) (Efstathiou et al., 2012).

In some patients with severe comorbidities and short life-expectancies, even trimodality bladder preservation may be inappropriately aggressive. In such cases, single-modality therapy can be considered. The outcomes of trimodality and single-modality therapies are described in detail in the following sections.

Trimodal Therapy for Surgically Fit Patients

Trimodality bladder preservation and radical cystectomy with or without perioperative chemotherapy for surgically fit patients have not been compared in randomized trails, so we cannot draw strong conclusions about the relative merits of these very different treatment approaches. Prospective studies suggest that well-selected fit patients have similar long-term cancer control outcomes with trimodality approaches. Appropriate candidates are those with a limited burden of disease and adequate normal bladder urothelial and function and who are motivated to retain their bladder. In general, a patient is considered to have a limited burden of disease if the bladder tumor is unifocal and small (<4 cm in maximal dimension) without frank extravesicular extension on imaging (i.e., not cT3b), does not cause hydronephrosis, and can be gross totally resected by TUR. It has been estimated that 6% to 19% of patients presenting with muscle-invasive bladder cancer meet strict criteria for “limited burden of disease” (Smith et al., 2013). It is also important to consider whether a patient's bladder is worth preserving. If a fit patient has poor baseline bladder function or diffuse CIS that is at risk for generating additional invasive tumors, then the patient's quality of life may be improved by a radical resection. The patient must be motivated to retain his or her bladder because 25% to 30% of patients will ultimately have salvage cystectomy in the long-term as a result of muscle-invasive recurrences (Efstathiou et al., 2012; Sell et al., 1991). It should be noted that there is limited very long-term data (>15 years) on outcomes after trimodality therapy. Given the known very late sequelae of radiation (secondary malignancies in particular), fit patients with long life-expectancies are not ideal candidates for radiation. The major chemoradiation bladder preservation trials for surgically fit patients are summarized in Table 137.6.

TABLE 137.6

Major Prospective Trimodal Bladder Preservation Studies

STUDY	NO. OF PATIENTS	STAGE	CHEMOTHERAPY	RT	CR RATE	SALVAGE CYSTECTOMY RATE
Housset et al., 1993	54	T2–4N0–1Mx	Cisplatin + 5-FU + 4	44 Gy	74%	NA
Shipley et al., 1998	62	T2–4aN0Mx	Cisplatin + 3	64.8 Gy	60%	25.8%

Tunio et al., 2012	200	T2–4N0Mx	Weekly cisplatin	65 Gy	93%	
James et al., 2012	182	T2–4aN0Mx	5-FU, MMC + 2	55 or 64 Gy		11.4%
Gogna et al., 2006	113	T2–4N0Mx	Weekly cisplatin	64 Gy	70%	13%
Kaufman et al., 2009a, 2009b	50	T2–4aN0Mx	Weekly cisplatin + paclitaxel	64.3 Gy	87%	

CR, Complete response; *CSS,* cause-specific survival; *5-FU,* 5-fluorouracil; *MMC,* mitomycin C; *OS,* overall survival.

The Massachusetts General Hospital (MGH) and the Radiation Therapy Oncology Group (RTOG) have developed a split-course approach for surgically fit patients. The RTOG has completed six prospective protocols using the split-course paradigm (total of 468 patients in one phase III and five phase II trials) using slightly different techniques and chemotherapy regimens to evaluate the efficacy of trimodal therapy for muscle-invasive disease. Across these studies, the complete response rate observed at the treatment break was 69%. The 5-year OS and DSS rates were 57% and 71%, respectively. The 10-year OS and DSS rates were 36% and 65%, respectively. Of patients alive at 5 years, 80% had an intact bladder. Overall, 21% of fit patients started on split-course therapy had a salvage cystectomy, 62% of whom had it after the induction phase only because of incomplete response assessment. Two percent had salvage cystectomy resulting from causes other than recurrent tumor, presumably caused by treatment-related complications. Among patients who had a salvage cystectomy, the 5-year OS and DSS were 45% and 60%, respectively, and the 10-year OS and DSS were 18% and 47%, respectively. It is worth noting that more recent North American trimodality trial proposals for surgically fit patients are transitioning away from split-course therapy in favor of continuous-course therapy, likely because of favorable reports from European continuous-course studies, especially BC 2001. In BC 2001, 360 patients (both fit and unfit for surgery) were randomized to continuous-course chemoradiation therapy compared with continuous-course radiation therapy alone. Patients in the chemoradiation cohort received mitomycin followed by 5-FU in conjunction with radiation. At 2 years, the locoregional disease-free survival in the chemoradiation therapy group was 67%. The 5-year OS rate was 48%, and there was no significant increase in toxicity compared with the radiation-only group (James et al., 2012).

Trimodality Therapy for Surgically Unfit Patients

There are no uniformly accepted criteria defining patients who are unfit for radical cystectomy. When considering which patients may not be suitable for radical cystectomy, an important concept to bear in mind is the *therapeutic break-even point.* The therapeutic break-even point reflects the time it would take for a patient to realize the benefits of improved locoregional control (conferred by radical cystectomy) given a short-term increase in treatment-related mortality. If the estimated break-even point for radical cystectomy is longer than the patient's life expectancy, then the short-term risks associated with surgery likely outweigh the potential long-term benefits. Of course, estimating the therapeutic break-even point is a challenge because it requires estimating the marginal short-term mortality costs and long-term mortality benefits of radical cystectomy compared with trimodality therapy, both estimates of which are sensitive to patient factors such as patient frailty (Chappidi et al., 2016) and tumor burden. Tools that provide useful benchmarks for estimating the therapeutic break-even point are under development (Baumann et al., 2018). However, because there is no perfect way to estimate the components of the break-even point algorithm, the best strategy for determining whether a patient is fit for radical cystectomy involves a multidisciplinary evaluation with an emphasis on patient preferences and shared decision making.

The outcomes of surgically unfit patients treated with definitive chemoradiation are surely poorer than those of surgically fit patients. However, estimating outcomes for surgically unfit patients is challenging because very few studies exclusively enroll unfit patients or identify them up front. Because trimodality bladder preservation is rarely employed in the United States, unadjusted results of trimodality therapy from observational national registries likely primarily reflect outcomes of surgically unfit patients. In a study of unadjusted trimodality outcomes of patients with the SEER registry (from 1995 to 2005), 5-year OS and DSS for patients receiving trimodality therapy was approximately 30% and 55%, respectively (Bekelman et al., 2013).

Single-Modality Treatment

Radiation Monotherapy

For clarity of presentation in this section, the term *radiation monotherapy* will also be used to describe studies in which debulking TUR was performed before radiation. The rationale for this terminology is that it is often difficult to ascertain exactly how complete the debulking TUR was that was performed across various series, which likely varies from institution to institution. It should be noted at the outset that two prospective randomized trials and many retrospective studies have firmly established the superiority of radiation when given concurrently with sensitizing systemic therapy. Several sensitizing regimens have been validated, including mitomycin/5-FU, nicotinimide/carbogen, cisplatin/5-FU, and gemcitabine alone, so radiation monotherapy should be reserved only for patients with very poor performance status or severe comorbidities. Indeed, radiation monotherapy should reserve for situations that are quasi-palliative. That said, there is extensive literature establishing the efficacy of radiation monotherapy. Rödel et al. (2002) reported on 126 patients treated with radiation monotherapy. The authors reported 5- and 10-year OS rates of 40% and 19%, respectively, which were inferior to results obtained with a chemoradiation regimen. As with cystectomy series, response to radiation monotherapy is largely dependent on the stage of disease. Local control rates have been reported to be as low as 27% for patients with T3 disease (Pollack and Zagars, 1996). BC 2001 demonstrated more favorable results for radiation monotherapy (2-year disease-free survival of 54% and 5-year OS of 35%); however, improved survival was noted in patients randomized to combined chemoradiation therapy (James et al., 2012). Prognostic factors for local failure after radiation monotherapy are similar to those of radical TUR, including tumor multifocality, presence of hydronephrosis, and higher clinical T stage.

Combined external beam radiation and brachytherapy have also been explored as possible bladder preservation techniques. Using a technique of 30 Gy of external beam radiation followed by 40 Gy of brachytherapy, Nieuwenhuijzen et al. (2005) reported 5- and 10-year OS rates of 62% and 50%, respectively, with 5- and 10-year DSS rates of 73% and 67%, respectively. The local control rate at 5 years was 73%. Survival results were similar to radical cystectomy patients at the same institution during that period; however, this was not a prospective, randomized trial, and therefore definitive conclusions compared with radical cystectomy outcomes are not valid. Additionally, patients with high-grade T1 bladder cancer were also included in this analysis, limiting its generalizability to a population of strictly muscle-invasive patients.

Radical Transurethral Resection

Primary support for radical TUR as a single-modality therapy for patients with T2 disease is largely based on the finding of p0 disease in approximately 10% of patients treated with radical cystectomy alone. A major limitation of radical TUR monotherapy is the significant risk for occult extravesical disease noted in patients with clinical T2 disease. Pathologic T3 and pT4 disease has been noted in cT2 cystectomy specimens in up to 40% and 9% of patients, respectively (Karakiewicz et al., 2006b). Additionally, multiple radical cystectomy series have consistently shown an approximately 25% risk for occult nodal metastasis at the time of surgery (Stein et al., 2001). Therefore, TUR monotherapy in upward of 50% of patients presenting with muscle-invasive bladder cancer would be undertreatment. In highly selected patients, however, several authors have reported reasonable long-term results with this approach.

In a series of 133 patients and a minimum of 15-year follow-up, radical TUR was reported to have a DSS of 82%, 80%, and 77% and progression-free survival of 76%, 65%, and 58% at 5, 10, and 15 years, respectively (Solsona et al., 2010). Patients were excluded from this approach if they presented with tumors greater than 3 cm or hydronephrosis. Patients with CIS at the time of TUR were treated with intravesical therapy. Wide resection of the TUR site was also performed at 3 and 6 months, and the patients underwent intensive endoscopic surveillance every 3 months for 2 years, every 6 months for 3 years, and annually thereafter. Long-term results with TUR monotherapy (≥10 years) have also been reported by the MSKCC group (Herr, 2001). This cohort of 99 patients with muscle-invasive disease all underwent a restaging TUR that demonstrated either no tumor (74%) or residual non–muscle-invasive disease (26%) before enrolling in a bladder-preservation protocol. The 5- and 10-year DSS rates were 82% and 76%, respectively, with actual bladder preservation rates of 67% and 57%, respectively. Patients with cT0 disease at the time of restaging TUR achieved the best long-term responses with a 10-year DSS of 82% compared with 57% for those with residual non–muscle-invasive disease. One-third of the patients ultimately developed muscle-invasive bladder cancer, of which nearly one-half (47%) died of disease. The MD Anderson group has also reported on a smaller cohort of patients treated with TUR monotherapy and a median follow-up of 2.5 years (Leibovici et al., 2007). Criteria for TUR monotherapy in this cohort included no residual tumor at the resection site on repeat TUR, normal examination under anesthesia, normal upper urinary tract evaluation, and no urethral involvement. Of the 327 patients who presented with muscle-invasive bladder cancer during a 6-year period, 35 (11%) met entry criteria and 27 elected for bladder preservation. With a median follow-up of 2.5 years, 44% remained free from disease, whereas 56% experienced a recurrence. Of the 15 patients who had a subsequent recurrence, one presented with node-positive disease. Eight patients ultimately underwent cystectomy, of which five showed extravesical disease on final pathology.

Although specifically selected individuals can achieve a durable response with radical TUR, most patients presenting with muscle-invasive bladder cancer are not appropriate candidates and will not be cured with TUR monotherapy. If a patient is going to elect TUR monotherapy, that patient should be properly informed regarding the risk for recurrent disease and should be appropriately selected based on clinical criteria including a negative restaging TUR, no hydronephrosis, no evidence of adenopathy, tumor size less than 3 cm, and lack of multifocal disease.

Partial Cystectomy

Compared with radical TUR, partial cystectomy offers two distinct advantages. First, a full pelvic lymphadenectomy can be performed that allows for complete staging. Second, the full thickness of bladder wall and associated perivesical fat can be removed. Historically, partial cystectomy was associated with poor outcomes including 5-year OS rates as low as 24% (Kassouf et al., 2006) and high rates of local recurrence and wound recurrences. However, with more stringent selection criteria, partial cystectomy can be associated with acceptable oncologic outcomes.

Ideal candidates for partial cystectomy include those with small, solitary tumors amenable to wide resection with 2-cm margins. Ideally the tumor should be away from the ureteral orifices to avoid reimplantation. It is imperative that the tumor is in a location that allows for complete resection while maintaining adequate functional bladder capacity. Partial cystectomy is also the treatment of choice for urachal adenocarcinoma; however, these lesions are distinct pathologic entities from urothelial carcinoma, and the studies that follow are specific to urothelial carcinoma. The presence of CIS is considered by most to be a contraindication to partial cystectomy, and random bladder biopsies can be performed preoperatively. The MSKCC group has also recommended the routine use of intraoperative frozen sections and proceeding with radical cystectomy if a negative margin cannot be achieved (Holzbeierlein et al., 2004). Using strict selection criteria, long-term oncologic results can approach that of radical cystectomy (Holzbeierlein et al., 2004; Kassouf et al., 2006).

Contemporary series demonstrate non–muscle-invasive recurrences in 12% to 50% of cases, muscle-invasive recurrences in 17% to 57%, and metastatic recurrence in 14% to 52%, respectively (Holzbeierlein et al., 2004; Kassouf et al., 2006; Smaldone et al., 2008). The 5-year OS, recurrence-free survival, and DSS in the same series were 67% to 70%, 39% to 62%, and 84% to 87%, respectively. Bladder intact rates and bladder intact without evidence of disease rates were reported by the MSKCC and the MD Anderson groups as 65% to 74% and 49% to 67%, respectively. Salvage cystectomy may be necessary in up to one-fourth of patients and can be associated with a cure in 75% of cases. It is important to note the presence of late recurrence of muscle-invasive disease in three patients (41, 44, and 138 months) in the MD Anderson experience, highlighting the need for long-term follow-up in such patients. There are risk factors for recurrence after partial cystectomy.

Partial cystectomy has also been reported in combination with neoadjuvant chemoradiation therapy. Koga et al. (2012) reported on 46 patients with muscle-invasive bladder cancer who were treated with this approach. Selection criteria included a solitary tumor composing less than 25% of the total bladder area, no involvement of the bladder neck or trigone, and a complete TUR. Treatment consisted of 40 Gy of external beam radiation concurrently with two cycles of cisplatin (20 mg/day for 5 days). Only three patients (7%) showed residual muscle-invasive disease at the time of partial cystectomy. At a median follow-up of 45 months, the 5-year OS and cancer-specific survival were both 100%. Whereas radical cystectomy remains the gold-standard therapy following neoadjuvant chemotherapy, resection of the primary tumor site with partial cystectomy has been used in partial and complete responders (Herr et al., 1998; Sternberg et al., 2003). Adjuvant chemotherapy has been reported to improve progression-free survival in patients with adverse pathologic features at the time of partial cystectomy (Kassouf et al., 2006); however, absolute numbers are small, warranting further studies to define the role of adjuvant therapy partial cystectomy.

Chemotherapy Monotherapy

The primary role for systemic chemotherapy in the treatment of muscle-invasive bladder cancer has been in the neoadjuvant or adjuvant setting in combination with radical cystectomy. Similar to radiation monotherapy, it is generally accepted that combination chemoradiation therapy is superior to chemotherapy alone. It is well established that an increased proportion of patients who receive neoadjuvant chemotherapy will have p0 disease at the time of cystectomy. Radical cystectomy remains the standard of care in patients who have had a complete response to neoadjuvant therapy; however, patients have refused cystectomy in this setting. The MSKCC group reported outcomes for 63 patients who declined cystectomy after achieving a complete response with neoadjuvant chemotherapy (Herr, 2008). At a minimum of 5 years of follow-up, 64% of patients were alive and 54% exhibited an intact bladder. Thirty-six percent of the cohort ultimately died of bladder cancer, of which the majority relapsed with invasive disease in the bladder. Predictors of prolonged survival with chemotherapy alone in this group included small solitary tumors and low-stage, completely resected tumors. Sternberg et al. (2003) also reported on the use of systemic MVAC and TUR with the intention of bladder preservation in 104 patients. Following completion of chemotherapy, patients underwent a repeat TUR, and 49% were noted to have a complete response. Sixty percent of patients were alive at a median follow-up of 56 months without further therapy. Patients downstaged to pT0 or to non–muscle-invasive disease exhibited superior survival compared with those who had persistent muscle-invasive disease. These data suggest that some patients with low-risk muscle-invasive tumors can be cured with TUR and chemotherapy alone; however, the risk for recurrence in the bladder remains significant, as evidenced by 46% of patients recurring in the bladder at a median time of 5.4 months in the Columbia cT0 series after neoadjuvant chemotherapy.

Prognostic Nomograms for Muscle-Invasive Bladder Cancer

As detailed earlier in this chapter, the TNM staging system provides valuable prognostic information following radical cystectomy. Despite its usefulness, there is often wide variation among patients with regard to absolute risk for recurrence as a result of the heterogeneity of tumor biology and patient characteristics. Better understanding and prediction of disease outcome is important to deliver appropriate adjuvant therapy and to counsel patients with regard to the risk for disease recurrence. The use of standard pathological data to predict outcomes was discussed earlier in this chapter. Nomograms have been developed in an effort to better predict the prognosis in patients with muscle-invasive disease (Bochner et al., 2006; Karakiewicz et al., 2006a; Shariat et al., 2006a). In addition to standard pathological features, molecular markers are now being incorporated into predictive models not only to improve prognostic accuracy, but also to provide the potential to predict response to therapy (Karam et al., 2007; Shariat et al., 2008, 2010; Youssef et al., 2009).

Nomograms incorporating clinical, pathologic, and molecular data have been developed as predictive tools in the muscle-invasive setting (Fig. 137.2). Two consortia have published easy-to-use nomograms for predicting recurrence following radical cystectomy. The International Bladder Cancer Consortium (IBCC) collected data on 9064 patients from 12 centers of excellence (Bochner et al., 2006). Significant variables in the nomogram included age, grade, pathologic stage, histologic subtype, lymph node metastasis, and timing of surgery. The final nomogram was significantly superior to standard prediction models in predicting disease-free survival following cystectomy (95% CI 0.75) compared with TNM stage (95% CI 0.68) or standard pathologic grouping models (95% CI 0.62). The authors modeled several lymph node variables including total number removed, number of positive nodes, and lymph node density, but found binary node status (positive vs. negative) to be the best predictor. The Bladder Cancer Research Consortium (BCRC) has also published a postcystectomy nomogram based on 728 patients from three centers (Karakiewicz et al., 2006a). As opposed to the IBCC nomogram, all patients in the BCRC had urothelial histology. Multivariate predictors of disease recurrence, cancer-specific mortality, and all-cause mortality at 2, 5, and 8 years postcystectomy included pT stage, nodal status, lymphovascular invasion, perioperative chemotherapy administration, and adjuvant radiation therapy. The nomogram improved predictive accuracy in favor of that of the AJCC staging system by 3.2% (0.748 vs. 0.780). Both nomograms have been validated in other patient cohorts (Zaak et al., 2010). More recently, the Cancer of the Bladder Risk Assessment (COBRA) score has been shown to be a relatively straightforward method of predicting mortality after radical cystectomy (Welty et al., 2017). Similar in concept to the CAPRA score for prostate cancer, this nomogram assigns clinical variables including age, tumor stage, and lymph node density a risk score, and it is relatively straightforward and easy to use compared with more complicated nomograms.

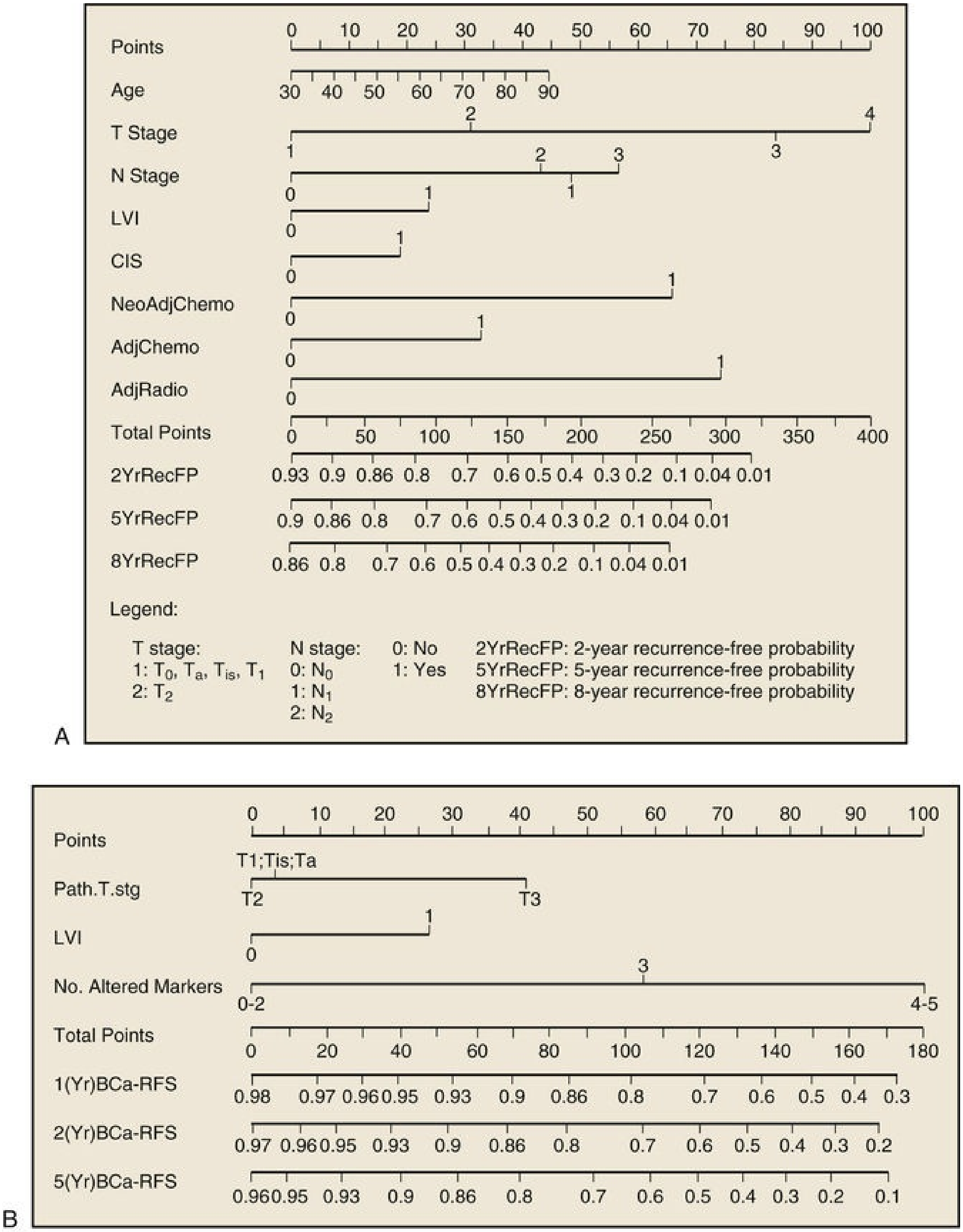

FIG. 137.2 To obtain nomogram-predicted probability of recurrence, locate patient values at each axis. Draw a vertical line to the "Point" axis to determine how many points are attributed for each variable value. Sum the points for all variables. Locate the sum on the *"Total Points"* line. Draw a vertical line toward the *2YrRecFP, 5YrRecFP,* and *8YrRecFP* axes to respectively determine the 2-year recurrence-free probability, 5-year

recurrence-free probability, and 8-year recurrence-free probability. (A) Postoperative nomogram for predicting recurrence after radical cystectomy. (B) Postoperative nomogram for predicting recurrence after radical cystectomy incorporating tissue biomarkers. *CIS,* Carcinoma in situ; *LVI,* lymphovascular invasion, *RFS,* recurrence-free survival. (A, From Karakiewicz PI, Shariat SF, Palapattu GS, et al. Nomogram for predicting disease recurrence after radical cystectomy for transitional cell carcinoma of the bladder. *J Urol* 176(4):1354–1362, 2006; B, from Shariat SF, Karakiewicz PI, Ashfaq R, et al. Multiple biomarkers improve prediction of bladder cancer recurrence and mortality in patients undergoing cystectomy. *Cancer* 112(2):315–325, 2008.)

Although postcystectomy nomograms provided enhanced prognostic value following treatment, precystectomy nomograms may include a greater impact in directing definitive therapy including neoadjuvant chemotherapy decisions. Using the same multicenter cystectomy cohort, Karakiewicz et al. (2006b) evaluated 726 patients and developed a nomogram incorporating age, TUR stage, tumor grade, and the presence of CIS. The multivariate nomogram was 75.7% accurate versus TUR stage (71.4%) in predicting non–organ-confined disease (pT3 or 4). The nomogram was also more accurate (63.1% vs. 61%) in predicting lymph node metastasis on final pathology. Although the overall performance characteristics of this nomogram did not dramatically improve the ability to predict non–organ-confined disease, it does demonstrate the usefulness and future potential of multivariable nomograms in the predictive setting. More recently, Lucca et al. (2016) reported on a preoperative nomogram incorporating the Glasgow prognostic score (a marker of systemic inflammation) with other known preoperative predictors of non–organ-confined disease in a population of patients with clinical N0M0 bladder cancer. Adding the inflammatory biomarker to the nomogram substantially improved its ability to predict non–organ-confined disease in this patient population. A nomogram has also been published to predict response rates to trimodal bladder preservation therapy (Coen et al., 2013). A cohort of 325 patients who underwent bladder preservation at a single institution was used in this evaluation. The final nomogram incorporated clinical T stage, presence of hydronephrosis, completeness of TUR, age, gender, and tumor grade. Using this nomogram, the ROC (receiver operating characteristic) curve was 0.69 for a complete response to therapy and 0.61 for bladder-intact disease-free survival.

Although nomograms appear to improve predictive accuracy over standard pathologic criteria, the addition of molecular markers has the potential to aid diagnostic accuracy further. Molecular markers are important in cell-cycle signaling and angiogenesis pathways, and their expression can be quantified by immunohistochemical staining. Inclusion of single biomarkers into prognostic nomograms is unlikely to significantly enhance the prognostic capability because of the complex tumor heterogeneity and biology. Shariat et al. (2008) studied the use of adding the molecular markers p53, pRB, p21, p27, and cyclin E1 into a nomogram. By adding the molecular markers, the nomogram improved predictive accuracy for recurrence and cancer-specific survival by 10.9% and 8.6%, respectively, for patients with pTa-3N0M0 bladder cancer following radical cystectomy. Shariat et al. (2012) also evaluated p53, p27, p21, and pRB in 272 cystectomy patients and in an external testing cohort of 52 patients with chemotherapy-naïve pT1-2N0M0 urothelial carcinoma. Overall, 80% of patients showed expression of at least one marker. The addition of the number of altered markers increased the accuracy of the base model for disease recurrence and cancer-specific mortality by 15.6% and 14.8%, respectively.

Nomograms, particularly those using novel molecular markers, have demonstrated improved predictive accuracy in favor of standard TNM factors alone. To date, these studies have been performed in retrospective cystectomy and bladder-sparing cohorts and require further validation in the prospective setting. Such nomograms provide the potential to aid clinicians in direct treatment both before definitive treatment (neoadjuvant chemotherapy vs. surgery) and after treatment (adjuvant therapy vs. surveillance).

Management of Metastatic Bladder Cancer

Systemic cisplatin-based combination chemotherapy is the standard of care for patients with metastatic urothelial bladder cancer. First-line systemic regimens include MVAC, HD-MVAC, and gemcitabine/cisplatin (Loehrer et al., 1992; Saxman et al., 1997; Sternberg et al., 1989, 2006b; von der Maase et al., 2005). Although the majority of patients with metastatic disease (40% to 70%) will experience an initial response to chemotherapy, most will ultimately progress with a median survival of 14 months and overall 5-year survival rates of 5% to 20% (Table 137.7) (Bellmunt et al., 2012; Saxman et al., 1997; Sternberg et al., 2006b; von der Maase et al., 2005). Despite the initial effectiveness of systemic cisplatin-based chemotherapy, there are several barriers to optimal delivery of chemotherapy in the bladder cancer population. Renal insufficiency is not uncommon in this population, limiting the use of cisplatin. Additionally, poor performance status, medical comorbidity, and frailty are often preexisting conditions that can limit a patient's ability to tolerate systemic therapy. A working group of medical oncologists has published criteria to define patients who are not cisplatin candidates, including any of the following: a World Health Organization or Eastern Cooperative Oncology Group performance status greater than 2, creatinine clearance less than 60 mL/min, grade 2 or above audiometric hearing loss, grade 2 or above peripheral neuropathy, or a New York Heart Association Class III or higher heart failure (Galsky et al., 2011). When cisplatin therapy is contraindicated, carboplatin has been substituted with the benefit of improved tolerability, but with the cost of decreased efficacy (Bellmunt et al., 1997; Dogliotti et al., 2007; Petrioli et al., 1996). Although carboplatin is a reasonable choice for patients in whom cisplatin is contraindicated, it should not be considered a first-line therapy for cisplatin candidates.

TABLE 137.7

Randomized Trials of Front-Line Chemotherapy for Metastatic Urothelial Cancer

	NO. OF	TREATMENT/CONTROL	RELATIVE	MEDIAN	*P*-

GROUP	PATIENTS	ARM	RISK (%)	SURVIVAL (MONTHS)	VAL
Intergroup (Loehrer et al., 1992)	269	MVAC/Cis	39 vs. 12	12.5 vs. 8.2	.000
MDAH (Logothetis et al., 1990)	110	MVAC/CISCA	65 vs. 46	11.1 vs. 8.3	.000
EORTC (Sternberg et al., 2006b)	263	HD-MVAC/MVAC	72 vs. 58	14.9 vs. 15.1	.041
Lilly (von der Maase et al., 2005)	405	GC/MVAC	49 vs. 46	14.0 vs. 15.2	.66
Greece (Bamias et al., 2004)	220	DC/MVAC	37 vs. 54	9.3 vs. 14.2	.026
EORTC (Bellmunt et al., 2012)	626	GC/PCG	46 vs. 57	12.7 vs. 15.8	.03
Dreicer et al., 2004	85	CaP/MVAC	28 vs. 36	13.8 vs. 15.4	.65

CaP, Carboplatin and paclitaxel; *Cis,* cisplatin; *CISCA,* cisplatin, cyclophosphamide, and doxorubicin (Adriamycin); *DC,* docetaxel and cisplatin; *EORTC,* European Organization for Research and Treatment of Cancer; *GC,* gemcitabine and cisplatin; *HD-MVAC,* high-dose MVAC; *MDAH,* MD Anderson Hospital; *MVAC,* methotrexate, vinblastine, doxorubicin (Adriamycin), and cisplatin; *N,* number of patients; *NR,* not reported; *PCG,* paclitaxel, cisplatin, and gemcitabine.

Poor performance status and the presence of visceral metastasis predict a poor response to chemotherapy for patients with locally advanced or metastatic urothelial carcinoma. The MSKCC group published their data on 203 patients with unresectable or metastatic bladder cancer treated with MVAC (Bajorin et al., 1999). They found a Karnofsky performance status of less than 80% and visceral (lung, liver, bone) metastasis to be independent predictors of poor outcome. Median survival times for patients who had zero, one, or two risk factors were 33, 13.4, and 9.3 months, respectively.

Randomized Trials in Metastatic Bladder Cancer

A phase III Intergroup randomized trial examined the effectiveness of MVAC therapy to that of single-agent cisplatin in patients with metastatic or locally advanced bladder cancer (Loehrer et al., 1992). A total of 269 patients were randomized, and those patients in the MVAC arm were noted to have significantly higher response rates (39% vs. 12%) and OS rates (12.5 vs. 8.2 months). Although superior in efficacy, the MVAC arm was more toxic with regard to leukopenia, mucositis, granulocytopenic fever, and drug-related mortality (3% to 4%). MVAC has also been compared with CISCA in patients with advanced urothelial carcinoma (Logothetis et al., 1990). In this study, 110 patients (86 bladder, 23 upper tract, 1 prostatic urethra) were randomized, with the MVAC regimen demonstrating improved response rates (65% vs. 46%) and OS (11.2 vs. 8.4 weeks) compared with CISCA.

Although most patients with metastatic urothelial carcinoma experience some response (complete or partial) to MVAC, the long-term survival rates are dismal (Bajorin et al., 1999; Saxman et al., 1997). In an effort to improve these results, Sternberg et al. (2001b) investigated whether increasing the dose intensity of MVAC with G-CSF could improve complete response rates and survival. In this study, 263 patients with chemotherapy-naïve metastatic or advanced urothelial carcinoma were randomized to HD-MVAC (MVAC + G-CSF; 2-week cycle) versus standard MVAC (4-week cycle). The HD-MVAC arm did achieve higher complete response rates (21% vs. 9%) and improved progression-free survival (9.1 vs. 8.2 months); however, OS was not significantly different between the two groups. Seven years later, additional follow-up was reported in this same cohort (Sternberg et al., 2006b). In the updated analysis, HD-MVAC was reported to have a statistically significant relative reduction in the risk for progression and death compared with that of MVAC (HR 0.76; 95% CI 0.58 to 0.99; $P = .042$).

Although MVAC has demonstrated efficacy in treating urothelial carcinoma, it has significant toxicity. The toxicity of MVAC led to trials of alternative less-toxic chemotherapy regimens. Most notably, a phase III randomized trial comparing gemcitabine/cisplatin to MVAC was conducted in 405 patients (von der Maase et al., 2000, 2005). There was no difference in response rates (49% vs. 46%), time to progression (7.4 vs. 7.4 months), and OS rates (13.8 vs. 14.8 months) between the two study arms. The updated study analysis confirmed equivalence of the two regimens (HR 1.09, 95% CI 0.88 to 1.34; $P = .66$). The gemcitabine/cisplatin regimen was better tolerated with only 37% of patients in that arm requiring dose modifications compared with 63% in the MVAC arm. Patients in the gemcitabine/cisplatin arm also experienced less grade 3–4 neutropenia, neutropenic fever, neutropenic sepsis, and mucositis. The toxicity-related death rate was also lower in the gemcitabine/cisplatin group (1% vs. 3%). Because of its equivalent efficacy and better tolerability, gemcitabine/cisplatin is the most widely used chemotherapeutic regimen for muscle-invasive and metastatic bladder cancer. The EORTC performed a phase II/III trial comparing gemcitabine/carboplatin versus methotrexate/carboplatin/vinblastine (MCAVI) for patients with metastatic urothelial carcinoma who were deemed "unfit" for cisplatin-based chemotherapy (DeSantis et al., 2012). These patients were considered "unfit" because of impaired renal function or poor performance status. Two hundred thirty eight patients were randomized to gemcitabine/carboplatin or MCAVI. Median OS was not significantly different between the two arms (9.3 months vs. 8.1 months; $P = 0.64$). However, severe toxicity was more common in the MCAVI arm.

Randomized trials have also assessed the usefulness of adding additional drugs to standard chemotherapy regimens (Bellmunt et al., 2000; von der Maase et al., 2006). The largest such trial was a phase III study that compared paclitaxel, gemcitabine, and cisplatin (PGC) to standard gemcitabine/cisplatin in 626 patients with locally advanced or metastatic urothelial cancer (Bellmunt et al., 2012). Overall response rates were significantly higher in the PGC arm (55.5% vs. 43.6%, $P = .0031$); however, there was no significant improvement in OS (15.8 vs. 12.7 months; HR 0.85; 95% CI 0.72 to 1.02, $P = .075$). There was also significantly more grade 3 and 4 neutropenia and thrombocytopenia in the PGC arm. A summary of the major chemotherapy trials for metastatic bladder cancer is presented in Table 137.7.

Second-Line Chemotherapy

There is no clear standard second-line chemotherapy for patients who progress or do not respond to first-line therapy. Patients who fail first-line chemotherapy have a dismal prognosis. Salvage chemotherapy in this setting with conventional agents typically has a suboptimal response rate (Albers et al., 2002; Dreicer et al., 1996; Lorusso et al., 1998; McCaffrey et al., 1997; Vaughn et al., 2002) (Table 137.8).

TABLE 137.8

Salvage Chemotherapy for Metastatic Urothelial Cancer

DRUG	AUTHOR (REFERENCE)	*N*	ELIGIBILITY	RR (%)	MEDIAN PFS (MONTHS)	MEDIAN OS (MONTHS)
Paclitaxel (24-hour)	Dreicer et al., 1996	9	One prior regimen	56	—	—
Paclitaxel (weekly)	Vaughn et al., 2002	31	One prior regimen for advanced disease, prior adjuvant chemotherapy and taxanes allowed	10	2.2	7.2
Docetaxel (every 3 weeks)	McCaffrey et al., 1997	30	One prior cisplatin regimen, prior taxanes not allowed	13	—	9.0
Gemcitabine	Lorusso et al., 1998	35	One prior platinum regimen	22.5	—	5.0
Gemcitabine	Albers et al., 2002	30	One prior cisplatin regimen	11	4.9	8.7
Gemcitabine-paclitaxel	Sternberg et al., 2001a	41	One prior cisplatin regimen including perioperative therapy	60	—	14.4

N, Number of patients; *OS,* overall survival; *PFS,* progression-free survival; *RR,* response rate.

Single-Agent Second-Line Chemotherapy

Multiple novel single agents have been evaluated in patients with advanced bladder cancer, typically with modest response rates of less than 20%.

Vinflunine is a novel antitubulin agent obtained from a vinca alkaloid (Culine et al., 2006). Bellmunt et al. (2009) compared vinflunine plus best supportive care versus best supportive care alone in patients with metastatic urothelial carcinoma previously treated with first-line platinum chemotherapy. Overall, 370 patients were randomized, with a 9% response rate in the vinflunine arm. At the time of initial publication, the results of the study met the 2.3-month improvement in OS (6.9 vs. 4.6 months); however, this did not achieve statistical significance. The authors published updated survival results in 2013, at which time OS had reached statistical significance in favor of the vinflunine arm (HR 0.719; 95% CI 0.570 to 0.906, $P = .0052$) (Bellmunt et al., 2013). Vinflunine is currently approved in Europe as a second-line agent for metastatic bladder cancer.

Paclitaxel has been evaluated in several small phase II studies with modest results. In a study of 31 patients with advanced or progressing urothelial cancer, who had previously been treated with at least one systemic chemotherapy, the patients were treated with a 1-hour weekly infusion of 80 mg/m^2 of paclitaxel. The median number of cycles delivered was three (one cycle = 4 weeks). Ten percent achieved a response, with a median OS time of 7.2 months (Vaughn et al., 2002). Two other phase II trials did not replicate the response rates (5% to 7%) with median survival times in the 6-month range (Joly et al., 2009; Papamichael et al., 1997). Docetaxel has also been used in a similar setting as a second-line agent. This regimen demonstrated modest response rates of 13% and median OS times of 9 months; however, 60% of patients developed myelosuppression requiring a dose reduction (McCaffrey et al., 1997).

Pemetrexed is a multitargeted antifolate agent. Initial phase II trials were promising, using 500 mg/m^2 of pemetrexed intravenously every 21 days and noting complete and partial response rates of 6.4% and 21%, respectively, in 47 patients. The median time to disease progression was 2.9 months, and median survival was 9.6 months (Sweeney et al., 2006). Grade 3 and 4 hematologic events were thrombocytopenia (8.5%, 0%), neutropenia (4.3%, 4.3%), and anemia (2.1%, 2.1%). However, a phase II trial using the same dose of pemetrexed showed less promising results in 13 patients with advanced disease who had previously received chemotherapy. In this cohort, only one (8%) patient had an objective response. Piritrexim is a synthetic antifolate agent that has also been investigated as a second-line agent. In a phase II trial of 27 patients with advanced, previously treated, urothelial carcinoma, piritrexim showed a 7% objective response rate. Toxicity was not insignificant with dose-limiting myelosuppression in 29% (Roth et al., 2002). Lassiter et al. (2008) obtained similar results in 23 previously treated patients in whom no objective responses were observed, and 2 patients had disease stabilization after two to four cycles.

Epothilones are nontaxane tubulin polymerization agents derived from fermentation of the myxobacteria *Sorangium cellulosum*. Ixabepilone is a semisynthetic analogue of natural epothilone B. In a phase II trial involving 45 patients with advanced urothelial carcinoma previously treated with either cisplatin or carboplatin-based chemotherapy, ixabepilone was reported to have an overall response rate of 12% and a median OS of 8 months. Unfortunately, the toxicity profile of this drug was significant, with 27% in the trial experiencing grade 4 toxicity in addition to one treatment-related death (Dreicer et al., 2007). Table 137.9 illustrates published single-agent studies in patients with relapsing or progressive disease following first-line chemotherapy.

TABLE 137.9

Salvage Trials With Single-Agent Chemotherapeutic and Novel Agents for Metastatic Urothelial Cancer

---

AGENT	AUTHOR	*N*	PRIOR	RR (%)	MEDIAN PFS (MONTHS)	MEDIAN OS (MONTHS)
Gemcitabine	Lorusso et al., 1998	35	One prior platinum regimen	23	3.8	5
Gemcitabine	Albers et al., 2002	30	One prior cisplatin regimen	11	4.9	8.7
Paclitaxel	Vaughn et al., 2002	31	One prior regimen for advanced disease, prior adjuvant chemotherapy and taxanes allowed	10	2.2	7.2
Ifosphamide	Witte et al., 1997	56	One prior cytotoxic regimen	20	2.5	5.5
Docetaxel	McCaffrey et al., 1997	30	One prior cisplatin regimen, prior taxanes not allowed	13		9
Nab-Paclitaxel	Ko et al., 2013	48	One prior platinum regimen	32	6	10.8
Abraxane	Sridhar et al., 2011	47	One prior platinum regimen	32	6	10.8
Eribulin	Quinn et al., 2010	40	One prior platinum regimen	38	3.9	9.4
Vinflunine	Culine et al., 2006	51	One prior platinum regimen	18	3.0	6.6
Vinflunine	Bellmunt et al., 2013	370	One prior platinum regimen	28		6.9

Pemetrexed	Sweeney et al., 2006	47	One prior regimen including perioperative therapy within 12 months	27.7	2.9	9.6
Pemetrexed	Galsky et al., 2007	12	One prior regimen	8	—	—
Ixabepilone	Dreicer et al., 2007	42	One prior platinum regimen, prior taxane allowed	11.9	2.7	8.0
Oxaliplatin	Winquist et al., 2005	18	One prior regimen for advanced disease, prior adjuvant chemotherapy >6 months earlier not counted	6	—	—

N, Number of patients; *OS,* overall survival; *PFS,* progression-free survival; *RR,* response rate.

Multiagent Second-Line Chemotherapy

For patients who progress following treatment with gemcitabine/cisplatin, second-line MVAC may be an option for select patients. Han et al. (2008) reported on a small cohort (*N* = 30) of patients who were treated with MVAC after failing initial therapy with gemcitabine/cisplatin. The overall response rate was 30%, and 6.7% of patients achieved a complete response. Patients who previously had a response to gemcitabine/cisplatin had a 44% response rate compared with a 14% response rate in patients who had not responded to initial therapy.

Multiple studies have investigated the effectiveness of paclitaxel and gemcitabine as a second-line agent. The published response rates of these trials vary widely from 0% to 60%, likely reflecting different dosing and administration schedules (Albers et al., 2011; Kanai et al., 2008; Meluch et al., 2001; Sternberg et al., 2001a). The largest of these trials randomized 102 patients to a temporary six-cycle course of paclitaxel and gemcitabine compared with prolonged treatment with gemcitabine/paclitaxel. Although there was no significant difference in OS or progression-free survival between the two groups, the objective response rates were 37.5% and 41.5%, respectively (Albers et al., 2011).

Larotaxel is a next-generation semisynthetic taxane that includes a mechanism of action similar to that of docetaxel and paclitaxel. Larotaxel has been postulated to have advantages beyond other taxanes including activating taxane-resistant tumor cells and the ability to cross the blood-brain barrier (Metzger-Filho et al., 2009; Sessa et al., 2002). In a phase III randomized trial, larotaxel/cisplatin combination therapy was compared with gemcitabine/cisplatin as first-line treatment for locally advanced or metastatic urothelial carcinoma in 337 patients (Sternberg et al., 2013). The trial was closed early as a result of the sponsor's decision to stop clinical development of larotaxel. At the time of analysis, there was no difference in OS between the two study arms, and progression-free survival was poorer with larotaxel/cisplatin (5.6 vs. 7.6 months), suggesting that this regimen does not improve outcomes compared with standard gemcitabine/cisplatin.

There is no general consensus regarding the optimal second-line multiagent therapy for patients with progressing and/or metastatic urothelial carcinoma.

Immune Checkpoint Inhibitor Therapy

Given the suboptimal results of second-line chemotherapy in metastatic urothelial carcinoma, there has been a desperate need for the development of effective novel agents in this disease. As noted earlier, immunotherapy has an established track record in the treatment of non–muscle-invasive bladder cancer. Recently, the development of immune checkpoint inhibitor therapy has been a significant advance in this disease.

Inhibitory immune checkpoint molecules are expressed on the surface of both T cells and tumor cells. Activated T cells express cytotoxic T lymphocyte–associated antigen 4 (CTLA-4), an immune checkpoint molecule that interacts with receptors on the surface of antigen-presenting cells to inhibit T-cell proliferation. Ipilimumab and tremelimumab are monoclonal antibodies that bind to CTLA-4. Programmed cell death-1 (PD-1) is a molecule expressed on activated T cells that binds to PD-L1 to modulate the immune response. Tumor cells may express PD-L1 as a mechanism to neutralize T-cell activation. Atezolizumab, durvalumab, and avelumab are monoclonal antibodies that bind to PD-L1. Pembrolizumab, and nivolumab are monoclonal antibodies that bind to PD-1. These immune checkpoint inhibitors result in an increase in T-cell activation and proliferation, which may result in an antitumor response.

Second-Line Immune Checkpoint Inhibitor Therapy

Immune checkpoint inhibitors have now been studied extensively in metastatic urothelial carcinoma previously treated with platinum-based chemotherapy. Several single-arm trials have investigated PD L1 inhibitors. The IMvigor 210 study is a phase II trial of atezolizumab 1200 mg intravenously every 3 weeks in patients with metastatic urothelial carcinoma with progression after prior platinum-based chemotherapy (Rosenberg et al., 2016). In this trial, 310 eligible patients received treatment. PD-L1 expression on infiltrating immune cells was defined by the percentage of PD L1–positive immune cells into three groups (IC0 <1%; IC1 ≥1% but <5%; IC2/3 ≥5%). The primary analysis demonstrated that compared with a historical chemotherapy control, overall response rate of 10%, atezolizumab resulted in a significantly improved objective response rate in each prespecified immune cell group and all patients (15% [95% CI 11 to 20], $P = 0.0058$). With a median follow-up of 11.7 months, 38 of 45 responders demonstrated ongoing response to therapy. Grade 3-4 treatment-related adverse events occurred in 16% of treated patients. Grade 3-4 immune-mediated adverse events occurred in 5% of treated patients.

In an open-label phase I/II study, 191 patients with previously treated metastatic urothelial carcinoma were treated with durvalumab 10 mg/kg intravenously every 2 weeks (Powles et al., 2017b). The objective response rate was 17.8% (95% CI 12.7% to 24.0%), including 7 complete responses. Responses were observed regardless of expression of PD-L1. Median progression-free survival was 1.5 months, and median OS was 18.2 months. Grade 3–4 treatment-related adverse events occurred in 6.8% of patients.

In the JAVELIN Solid Tumor study, 249 patients previously treated with platinum-based chemotherapy received avelumab 10 mg/kg every 2 weeks (Patel et al., 2018). In 161 patients with at least 6 months of follow-up, the overall response rate was 17% (95% CI 11% to 24%). Grade 3–4 treatment-related adverse events occurred in 8%.

KEYNOTE-012 was an open-label phase Ib basket trial of the anti–PD-1 agent pembrolizumab (Plimack et al., 2018). In the urothelial cohort, 33 patients with tumors that expressed PD-L1 received pembrolizumab 10 mg/kg intravenously every 2 weeks. Fifteen percent of patients experienced grade 3 treatment-related adverse events. In addition, 26% of assessable patients demonstrated objective response including 11% with complete responses.

In CheckMate 275, 270 patients with metastatic urothelial carcinoma previously treated with platinum-based chemotherapy received nivolumab 3 mg/kg intravenously every 2 weeks (Sharma et al., 2017). An objective response rate of 19.6% was demonstrated. Grade 3–4 treatment-related adverse events occurred in 18% of patients.

Based on the promising phase I and II results of immune checkpoint inhibitor therapy, two phase III trials have been conducted in the second-line setting. These trials deserve a more detailed discussion. IMvigor211 is a randomized phase III trial in patients with metastatic urothelial carcinoma who had received two or more previous lines of chemotherapy and had progressed following one or more platinum-containing regimens (for metastatic disease or in a neoadjuvant/adjuvant setting) (Powles et al., 2017a). The investigators randomized 931 patients to receive either atezolizumab ($N = 467$) or investigator's choice of chemotherapy, which could include either dicetaxel, paclitaxrel, or vinflunine ($N = 464$). Patients were stratified into three cohorts based on PD-L1 expression on archival tumor: IC0 (<1%), IC1 (1% to 5%), or IC2–3 (≥5%). The primary endpoint was OS in prespecified populations: IC2–3, IC1–3, intention-to-treat. In the IC2–3 group, OS for the atezolizumab group and for the chemotherapy group was 11.1 months and 10.6 months, respectively; stratified HR 0.87, 95% CI 0.6 to 1.21, $P = 0.41$. Thus, the study did not meet its primary endpoint for efficacy.

KEYNOTE 45 was a phase III randomized trial with a similar study design as IMvigor211 (Bellmunt et al., 2017). Five hundred forty-two patients with advanced urothelial carcinoma that recurred or progressed after platinum-based chemotherapy were randomized to pembrolizumab 200 mg intravenously every 3 weeks or investigator's choice of chemotherapy, again paclitaxel, docetaxel, or vinflunine. This study had coprimary endpoints, OS, and progression-free survival in all patients, and the PD-L1 score (percentage of PD-L1–expressing tumor and infiltrating immune cells) was greater than or equal to 10% among patients with a tumor. The median OS for the entire group was 10.3 months for pembrolizumab versus 7.4 months for chemotherapy, resulting in a HR for death of 0.73; 95% CI 0.59 to 0.91; $P = 0.002$. The median OS among the PD-L1 greater than 10% patients was also superior for pembrolizumab (8 months vs. 5.2 months; $P = 0.005$). There was no significant difference in progression-free survival among either all patients or those in the PD-L1 greater than 10% group. Fewer treatment-related adverse events were noted in the pembrolizumab group compared with the chemotherapy group. On the basis of this trial, pembrolizumab has now received full US Food and Drug Administration (FDA) approval for the treatment of patients with metastatic urothelial carcinoma previously treated with platinum-based chemotherapy.

First-Line Immune Checkpoint Inhibitor Therapy in Cisplatin-Ineligible Patients

The immune checkpoint inhibitors have also been studied in the first-line setting for patients with advanced or metastatic urothelial carcinoma who are cisplatin-ineligible. In IMvigor210, 119 patients received atezolizumab 1200 mg intravenously every 21 days (Balar et al., 2017b). The objective response rate and complete response rate were 23% and 9%, respectively. Median OS was 15.9 months. This compares favorably with what has been previously demonstrated with carboplatin-based chemotherapy.

In KEYNOTE-052, 370 cisplatin-ineligible patients were treated with pembrolizumab 200 mg intravenously every 3 weeks (Balar et al., 2017a). Twenty four percent of patients demonstrated an objective response, and at the time of data cutoff, 83% of these responses were ongoing. This also compares favorably with previously reported carboplatin-based therapy. Based on these two trials, the FDA has approved both atezolizumab and pembrolizumab for first-line treatment of cisplatin-ineligible patients with advanced urothelial carcinoma.

FDA-Approved Agents and Future Directions

The unprecedented activity of the immune checkpoint inhibitors in metastatic urothelial carcinoma has resulted in FDA approval of five agents. The anti-PD-L1 agents atezolizumab, durvalumab, and avelumab received approval in patients with metastatic urothelial cancer previously treated with platinum-based chemotherapy. The anti-PD-1 agents pembrolizumab and nivolumab received approval in patients with metastatic urothelial cancer previously treated with platinum-based chemotherapy. In addition, atezolizumab and pembrolizumab are approved for first-line treatment of patients with metastatic urothelial carcinoma who are not candidates for cisplatin-based chemotherapy regimens.

The continued development of immune checkpoint inhibitor therapy in urothelial carcinoma is clearly warranted. Ongoing trials include combining an immune checkpoint inhibitor with cytotoxic chemotherapy in the first-line setting, evaluation of immune checkpoint inhibitors in the adjuvant setting for postcystectomy high-risk patients, and evaluation in bacille Calmette-Guérin (BCG) refractory non–muscle-invasive bladder cancer.

Targeted Therapy

Vascular Endothelial Growth Factor Inhibitor Therapy

Vascular endothelial growth factor (VEGF) receptors are expressed in urothelial carcinomas (von Hardenberg et al., 2014). It is well established that VEGF recruits circulating endothelial progenitors, which are critical for angiogenesis, which is essential for tumor growth and metastatic spread (Carmeliet and Jain, 2000). VEGF expression in both urine and blood has been shown to correlate with metastatic potential and disease recurrence (Crew et al., 1999; Fauconnet et al., 2009). Bevacizumab is a humanized monoclonal antibody of VEGF. Bevacizumab has been evaluated in patients with advanced urothelial carcinoma. In a phase II trial by the Hossier Oncology Group, 43 chemotherapy-naïve patients with either metastatic or unresectable urothelial carcinoma received bevacizumab in combination with gemcitabine/cisplatin (Hahn et al., 2011). The overall response rate in this cohort was 72% (19% complete, 53% partial). With a median follow-up of 27 months, median progression-free survival was 8.2 months, and median OS was 19.1 months. Of note, grade 3 to 4 hematologic toxicity was not insignificant, with neutropenia in 35%, thrombocytopenia in 12%, anemia in 12%, and neutropenic fever in 2%. Three treatment-related deaths were also reported. The results of a phase III intergroup study that aims to define further the role of bevacizumab in combination with gemcitabine/cisplatin in patients with advanced urothelial carcinoma is forthcoming.

Sunitinib is an oral inhibitor of multiple tyrosine kinases, including VEGF receptors. Sunitinib has demonstrated antitumor activity in human bladder cancer models (Sonpavde et al., 2009; Yoon et al., 2011). Sunitinib was reported as demonstrating a partial response in 8% and disease stabilization in 54% of 37 ciplatin-ineligible patients with advanced urothelial carcinoma (Bellmunt et al., 2011). The median progression-free survival was 5.9 months. Much like bevacizumab, sunitinib has been trialed in combination with gemcitabine/cisplatin, but the side-effect profile was unsatisfactory (Galsky et al., 2013). Sunitinib was also studied in a randomized, phase II trial of maintenance therapy following an initial response to standard chemotherapy compared with placebo (Grivas et al., 2014). The study did not achieve the predefined power as a result of poor accrual and premature closure; however, the maintenance sunitinib arm did not improve 6-month progression-free survival rates (2.9 vs. 2.7 months, respectively). Sorafenib, a similar multikinase inhibitor, has been studied in combination with gemcitabine/cisplatin but did not demonstrate superiority compared with chemotherapy alone (Krege et al., 2014).

Epidermal Growth Factor Receptor Therapy

Epidermal growth factor receptor (EGFR) has demonstrated overexpression in bladder tumors, and the extent of expression has also correlated with stage and grade of tumors (Neal et al., 1990). Cetuximab is a monoclonal antibody to EGFR, and it has been approved for colorectal carcinoma. Cetuximab has been studied in the phase II setting in patients with metastatic urothelial cancer who received previous chemotherapy (Wong et al., 2012). A total of 39 patients were randomized to cetuximab with or without paclitaxel. The single-agent cetuximab arm closed after 9 of 11 patients progressed by 8 weeks. Cetuximab did appear to augment the activity of the paclitaxel arm, with an overall response rate of 28.5% and a median progression-free survival of 115 days. Cetuximab has also been evaluated in combination with gemcitabine/cisplatin in the phase II setting, but did not improve OS (Pea, 2012). The oral tyrosine kinase inhibitor (TKI) gefitinib has produced disappointing results today in urothelial carcinoma trials. In a phase II trial of 31 patients with metastatic urothelial carcinoma, gefitinib was largely ineffective, with a median progression-free survival of 2 months; only two patients survived with no disease progression past 6 months (Petrylak et al., 2010). Gefitinib has also been evaluated in combination with gemcitabine/cisplatin and did not improve response rate compared with that of historical controls (Philips et al., 2009). Gefitinib is also being evaluated as maintenance therapy following systemic chemotherapy; however, the results from such studies have not been reported.

Trastuzumab, an anti–Her-2 monoclonal antibody, has been evaluated in several studies. Human epidermal growth factor receptor 2 (HER2)/neu expression in urothelial cancers is variable and may predict a more aggressive phenotype. In 44 patients with HER2/neu–positive tumors, the overall response rate was 70% when combined with paclitaxel, gemcitabine, and carboplatin (Hussain et al., 2007). A large randomized phase II trial compared gemcitabine/platinum with or without trastuzumab. No difference in progression-free survival, overall response rate, or OS was demonstrated by the addition of trastuzumab (Oudard et al., 2015).

Laptinib is an oral TKI that targets both EGFR and HER2. A phase II trial of lapatinib in 59 patients whose disease progressed on platinum-based chemotherapy demonstrated disease stabilization in 31% of evaluable patients (Wülfing et al., 2009). The median time to disease progression and OS was 8.6

weeks and 17.9 weeks, respectively. The median survival was significantly improved in patients whose tumors expressed EGFR and/or HER2. A recently reported phase III trial randomized 232 patients with HER1- or HER2-positive disease who had received first-line chemotherapy to maintenance lapatinib versus placebo. Unfortunately, this study did not demonstrate benefit of maintenance lapatinib compared with placebo (Powles et al., 2017a).

Fibroblast Growth Factor Receptor Therapy

FGFR3 mutations are commonly seen in low-grade noninvasive papillary bladder cancer. In papillary muscle-invasive bladder cancer, *FGFR3* mutations occur much less frequently. If *FGFR3* mutations are present, these can be targeted using FGFR TKIs. BGJ398 is an FGFR 1 to 3 TKI. In the phase I dose-escalation study of this agent, 3 partial responses were noted in 8 patients with FGFR3-mutated bladder cancer treated at dose levels considered therapeutic (Nogova et al., 2017). Based on these promising results, a phase II study of this agent in FGF3-mutated metastatic urothelial carcinoma has been completed, and the results are forthcoming. Other FGFR-3 TKIs are also under investigation in urothelial cancer.

Key Points

- Optimal treatment of muscle-invasive bladder cancer requires a multidisciplinary approach incorporating urologic oncologists, medical oncologists, and radiation oncologists. Current clinical staging modalities lack the sensitivity and specificity to predict accurately the final disease stage, which is currently a major limitation to pretreatment decision making.
- The gold standard therapy for organ-confined muscle-invasive bladder cancer is radical cystectomy with neoadjuvant cisplatin-based chemotherapy.
- Bladder preservation with chemoradiation therapy has become an increasingly popular option in the muscle-invasive setting and has demonstrated outcomes comparable to those of radical cystectomy in highly selected patients.
- Despite aggressive surgical therapy, approximately 50% of cystectomy

patients will ultimately die of disease.

- Meta-analysis from systemic cisplatin-based neoadjuvant chemotherapy trials has demonstrated a modest but statistically significant survival advantage. The evidence for adjuvant chemotherapy is less robust secondary to inadequately powered trials and methodologic flaws.
- Initial response rates with cisplatin-based chemotherapy in the metastatic setting are favorable; however, durable responses are rare, and outcomes for this patient population are dismal.
- Multiple new second-line chemotherapy trials have been completed or are under way with varying response rates. Newer biologic agents hold promise; however, evidence is currently lacking, and more studies are warranted.

Suggested Readings

Advanced Bladder Cancer (ABC) Meta-analysis Collaboration. Adjuvant chemotherapy in invasive bladder cancer: a systematic review and meta-analysis of individual patient data. *Eur Urol*. 2005;48(2):189–199 [discussion 199–201].

Advanced Bladder Cancer (ABC) Meta-analysis Collaboration. Neoadjuvant chemotherapy in invasive bladder cancer: update of a systematic review and meta-analysis of individual patient data. *Eur Urol*. 2005;48(2):202–205.

Bajorin DF, Dodd PM, Mazumdar M, et al. Long-term survival in metastatic transitional-cell carcinoma and prognostic factors predicting outcome of therapy. *J Clin Oncol*. 1999;17(10):3173–3181.

Bochner BH, Kattan MW, Vora KC. Postoperative nomogram predicting risk of recurrence after radical cystectomy for bladder cancer. *J Clin Oncol*. 2006;24(24):3967–3972.

Grossman HB, Natale RB, Tangen CM, et al. Neoadjuvant chemotherapy plus cystectomy compared with cystectomy alone for locally advanced bladder cancer. *N Engl J Med*. 2003;349(9):859–866.

Herr HW, Faulkner JR, Grossman HB, et al. Surgical factors influence bladder cancer outcomes: a cooperative group report. *J Clin Oncol*. 2004;22(14):2781–2789.

Holzbeierlein JM, Lopez-Corona E, Bochner BH, et al. Partial cystectomy: a contemporary review of the Memorial Sloan-Kettering Cancer Center experience and recommendations for patient selection. *J Urol*. 2004;172:878–881.

Shariat SF, Karakiewicz PI, Palapattu GS, et al. Nomograms provide improved accuracy for predicting survival after radical cystectomy. *Clin Cancer Res*. 2006;12(22):6663–6676.

Stein JP, Lieskovsky G, Cote R, et al. Radical cystectomy in the treatment of invasive bladder cancer: long-term results in 1,054 patients. *J Clin Oncol*. 2001;19(3):666–675.

von der Maase H, Sengelov L, Roberts JT, et al. Long-term survival results of a randomized trial comparing gemcitabine plus cisplatin, with methotrexate, vinblastine, doxorubicin, plus cisplatin in patients with bladder cancer. *J Clin Oncol*. 2005;23(21):4602–4608.

References

Abdelhady M, Abusamra A, Pautler SE, et al. Clinically significant prostate cancer found incidentally in radical cystoprostatectomy specimens. *BJU Int*. 2007;99(2):326–329.

Abdelsalam YM, Mokhtar AA, Kurkar AA, et al. Defining patient selection for prostate-sparing cystectomy in squamous cell carcinoma of the urinary bladder associated with biharziasis: an overview of 236 patients. *Urology*. 2011;78(6):1351–1354.

Abol-Enein H, El Makresh M, El Baz M, et al. Neo-adjuvant chemotherapy in treatment of invasive transitional bladder cancer: a controlled, prospective randomised study. *Br J Urol*. 1997;80(Suppl 2):49.

Abol-Enein H, El-Baz M, Abd El-Hameed MA, et al. Lymph node involvement in patients with bladder cancer treated with radical cystectomy: a patho-anatomical study—a single center experience. *J Urol*. 2004;172:1818–1821.

Advanced Bladder Cancer (ABC) Meta-analysis Collaboration. Adjuvant chemotherapy in invasive bladder cancer: a systematic review and meta-analysis of individual patient data. *Eur Urol*. 2005;48(2):189–199 [discussion 199–201].

Advanced Bladder Cancer (ABC) Meta-analysis Collaboration. Neoadjuvant chemotherapy in invasive bladder cancer: update of a systematic review and meta-analysis of individual patient data advanced bladder cancer. *Eur Urol*. 2005;48(2):202–205.

Akamatsu S, Kanamaru S, Ishihara M, et al. Primary large cell neuroendocrine carcinoma of the urinary bladder. *Int J Urol*. 2008;15(12):1080–1083.

Akkad T, Gozzi C, Deibl M, et al. Tumor recurrence in the remnant urothelium of females undergoing radical cystectomy for transitional cell carcinoma of the bladder: long-term results from a single center. *J Urol*. 2006;175(4):1268–1271.

Albers P, Park SI, Niegisch G, et al. Randomized phase III trial of 2nd line gemcitabine and paclitaxel chemotherapy in patients with advanced bladder cancer: short-term versus prolonged treatment (German Association of Urological Oncology trial AB 20/99). *Ann Oncol*. 2011;22(2):288–294.

Albers P, Siener R, Perabo FG, et al. Gemcitabine monotherapy as 2nd line treatment in cisplatin refractory transitional cell carcinoma—prognostic factors for response and improvement of quality of life. *Onkologie*. 2002;25:47–52.

Ali-El-Dein B. Oncological outcome after radical cystectomy and orthotopic bladder substitution in women. *Eur J Surg Oncol*. 2009;35(3):320–325.

Anderstrom C, Johansson S, Nilsson S, et al. A prospective randomized study of preoperative irradiation with cystectomy or cystectomy alone for invasive bladder cancer. *Eur Urol*. 1983;9(3):142–147.

Antoni S, Ferlay J, Soerjomataram I, et al. Bladder cancer incidence and mortality: a global overview and recent trends. *Eur Urol*. 2017;71(1):96–108.

Apolo AB, Riches J, Schoder H, et al. Clinical value of fluorine-18 2-fluoro-2-deoxy-D-glucose positron emission tomography/computed tomography in bladder cancer. *J Clin Oncol*. 2010;28(25):3972–3978.

Arce J, Gaya JM, Huquet J, et al. Can we identify those patients who will benefit from prostate-sparing surgery? Predictive factors for invasive prostatic involvement by transitional cell carcinoma. *Can J Urol*. 2011;18(1):5529–5536.

Ather MH, Alam Z, Jamshaid A, et al. Separate submission of standard lymphadenectomy in 6 packets versus en bloc lymphadenectomy in bladder cancer. *Urol J*. 2008;5(2):94–

98.

Ayres BE, Gillatt D, Cottrell A, et al. A delay in radical cystectomy of >3 months is not associated with worse clinical outcomes. *BJU Int*. 2008;102(8):1045.

Ayyathurai R, Gomez P, Luongo T, et al. Prostatic involvement by urothelial carcinoma of the bladder: clinicopathological features and outcomes after radical cystectomy. *BJU Int*. 2007;100(5):1021–1025.

Bagrodia A, Grover S, Srivastava A, et al. Impact of body mass index on clinical and cost outcomes after radical cystectomy. *BJU Int*. 2009;104(3):326–330.

Bajorin DF, Dodd PM, Mazumdar M, et al. Long-term survival in metastatic transitional-cell carcinoma and prognostic factors predicting outcome of therapy. *J Clin Oncol*. 1999;17(10):3173–3181.

Bajorin DF. *Phase III study comparing sequential chemotherapy (AG-ITP) to cisplatin and gemcitabine as adjuvant treatment after cystectomy for transitional cell carcinoma of the bladder*. [Available at] http://clinicaltrials.gov/show/NCT00014534; 2001.

Balaji KC, McGuire M, Grotas J, et al. Upper tract recurrences following radical cystectomy: an analysis of prognostic factors, recurrence pattern and stage at presentation. *J Urol*. 1999;162(5):1603–1606.

Balar AV, Castellano D, O'Donnell PH, et al. First-line pembrolizumab in cisplatin-ineligible patients with locally advanced and unresectable or metastatic urothelial cancer (KEYNOTE-052): a multicentre, single-arm, phase 2 study. *Lancet Oncol*. 2017;18(11):1483–1492.

Balar AV, Galsky MD, Rosenberg JE, et al. Atezolizumab as first-line treatment in cisplatin-ineligible patients with locally advanced and metastatic urothelial carcinoma: a single-arm, multicenter, phase 2 trial. *Lancet*. 2017;389(10064):67–76.

Baltaci S, Resorlu B, Yagci C, et al. Computerized tomography for detecting perivesical infiltration and lymph node metastasis in invasive bladder cancer. *Urol Int*. 2008;81(4):399–402.

Bamias A, Aravantinos G, Deliveliotis C. Docetaxel and cisplatin with granulocyte colony-stimulating factor (G-CSF) versus M-VAC with G-CSF in advanced urothelial carcinoma: a multicenter, randomized, phase III study from the Hellenic Cooperative Oncology Group. *J Clin Oncol*. 2004;22:220–228.

Bartsch GC, Kuefer R, Gschwend JE, et al. Hydronephrosis as a prognostic marker in bladder cancer in a cystectomy only series. *Eur Urol*. 2007;51(3):690–697.

Bassi P, Pagano F, Pappagallo G, et al. Neo-adjuvant M-VAC of invasive bladder cancer: the G.U.O.N.E. multicenter phase III trial. *Eur Urol*. 1998;33(Suppl 1):142.

Bastian PJ, Hutterer GC, Shariat SF, et al. Macroscopic, but not microscopic, perivesical fat invasion at radical cystectomy is an adverse predictor of recurrence and survival. *BJU Int*. 2008;101(4):450–454.

Baumann BC, Guzzo TJ, He J, et al. A novel risk stratification to predict local-regional failures in urothelial carcinoma of the bladder after radical cystectomy. *Int J Radiat Oncol Biol Phys*. 2013;85(1):81–88.

Baumann BC, Guzzo TJ, He J, et al. Bladder cancer patterns of pelvic failure: implications for adjuvant radiation therapy. *Int J Radiat Oncol Biol Phys*. 2013;85(2):363–369.

Baumann BC, Noa K, Wileyto EP, et al. Adjuvant radiation therapy for bladder cancer: a dosimetric comparison of techniques. *Med Dosim*. 2015;40(4):372–377.

Baumann BC, Hwang WT, Srinivasan S, et al. A decision-support tool to assist muscle-invasive bladder cancer patients choosing between radical cystectomy and chemotherapy. *J*

Clin Oncol. 2018;36(6 Suppl):505.

Bekelman JE, Handor EA, Guzzo TJ, et al. Radical cystectomy versus bladder-preservation for muscle-invasive urothelial carcinoma: examining confounding and misclassification bias in cancer observational comparative effectiveness research. *Value Health*. 2013;16(4):610–618.

Bellmunt J, Ribas A, Eres N, et al. Carboplatin-based versus cisplatin-based chemotherapy in the treatment of surgically incurable advanced bladder carcinoma. *Cancer*. 1997;80:1966–1972.

Bellmunt J, Guillem V, Paz-Ares L, et al. Phase I-II study of paclitaxel, cisplatin, and gemcitabine in advanced transitional-cell carcinoma of the urothelium. Spanish Oncology Genitourinary Group. *J Clin Oncol*. 2000;18(18):3247–3255.

Bellmunt J, Theodore C, Demkov T, et al. Phase III trial of vinflunine plus best supportive care compared with best supportive care alone after a platinum-containing regimen in patients with advanced transitional cell carcinoma of the urothelial tract. *J Clin Oncol*. 2009;27(27):4454–4461.

Bellmunt J, Gonzalez-Larriba JL, Prior C, et al. Phase II study of sunitinib as first line treatment of urothelial cancer patients ineligible to receive cisplatin-based chemotherapy: baseline interleukin-8 and tumor contrast enhancement as potential predictive factors of activity. *Ann Oncol*. 2011;22(12):2646–2653.

Bellmunt J, von der Maase H, Mead GM, et al. Randomized phase III study comparing paclitaxel/cisplatin/gemcitabine and gemcitabine/cisplatin in patients with locally advanced or metastatic urothelial cancer without prior systemic therapy: EORTC Intergroup Study 30987. *J Clin Oncol*. 2012;30(10):1107–1113.

Bellmunt J, Fougheray R, Rosenberg JE, et al. Long-term survival results of randomized phase III trial of vinflunine plus best supportive care versus best supportive care alone in advanced urothelial carcinoma patients after failure of platinum-based chemotherapy. *Ann Oncol*. 2013;24(6):1466–1472.

Bellmunt J, de Wit R, Vaughn DJ, et al. Pembrolizumab as second-line therapy for advanced urothelial carcinoma. *New Engl J Med*. 2017;376(11):1015–1026.

Blackard CE, Byar DP. Results of a clinical trial of surgery and radiation in stages II and III carcinoma of the bladder. *J Urol*. 1972;108(6):875–878.

Bochner BH, Herr HW, Reuter VE. Impact of separate versus en bloc pelvic lymph node dissection on the number of lymph nodes retrieved in cystectomy specimens. *J Urol*. 2001;166(6):2295–2296.

Bochner BH, Cho D, Herr HW, et al. Prospectively packaged lymph node dissections with radical cystectomy: evaluation of node count variability and node mapping. *J Urol*. 2004;172(4 Pt 1):1286–1290.

Bochner BH, Kattan MW, Vora KC. Postoperative nomogram predicting risk of recurrence after radical cystectomy for bladder cancer. *J Clin Oncol*. 2006;24(24):3967–3972.

Bono AV, Benvenuti C, Gibba A, et al. Adjuvant chemotherapy in locally advanced bladder cancer. Final analysis of a controlled multicentre study. *Acta Urol Ital*. 1997;11(1):5–8.

Bruins HM, Huang GJ, Cai J, et al. Clinical outcomes and recurrence predictors of lymph node positive urothelial cancer after cystectomy. *J Urol*. 2009;182(5):2182–2187.

Canter D, Guzzo TJ, Resnick MJ, et al. Hydronephrosis is an independent predictor of poor clinical outcome in patients treated for muscle-invasive transitional cell carcinoma with radical cystectomy. *Urology*. 2008;72(2):379–383.

Capitanio U, Suardi N, Shariat SF, et al. Assessing the minimum number of lymph nodes needed at radical cystectomy in patients with bladder cancer. *BJU Int*. 2009;103(10):1359–1362.

Carmeliet P, Jain RK. Angiogenesis in cancer and other diseases. *Nature*. 2000;407(6801):249–257.

Chang SS, Cole E, Smith JA Jr, et al. Pathological findings of gynecologic organs obtained at female radical cystectomy. *J Urol*. 2002;168(1):147–149.

Chang SS, Hassan JM, Cookson MS, et al. Delaying radical cystectomy for muscle invasive bladder cancer results in worse pathological stage. *J Urol*. 2003;170(4 Pt 1):1085–1087.

Chappidi MR, Kates M, Patel HD, et al. Frailty as a marker of adverse outcomes in patients with bladder cancer undergoing radical cystectomy. *Urol Oncol*. 2016;34(6):256.e1–256.e6.

Cho KS, Seo JW, Park SJ, et al. The risk factor for urethral recurrence after radical cystectomy in patients with transitional cell carcinoma of the bladder. *Urol Int*. 2009;82(3):306–311.

Christodouleas JP, Baumann BC, He J, et al. Optimizing bladder cancer locoregional failure risk stratification after radical cystectomy using SWOG 8710. *Cancer*. 2014;120(8):1272–1280.

Clark PE, Stein JP, Groshen SB, et al. The management of urethral transitional cell carcinoma after radical cystectomy for invasive bladder cancer. *J Urol*. 2004;172:1342–1347.

Coen JJ, Paly JJ, Niemierko A, et al. Nomograms predicting response to therapy and outcomes after bladder-preserving trimodality therapy for muscle-invasive bladder cancer. *Int J Radiat Oncol Biol Phys*. 2013;86(2):311–316.

Cognetti F, Ruggeri EM, Felici A, et al. Adjuvant chemotherapy with cisplatin and gemcitabine versus chemotherapy at relapse in patients with muscle-invasive bladder cancer submitted to radical cystectomy: an Italian, multicenter, randomized phase III trial. *Ann Oncol*. 2012;23(3):695–700.

Coppin CM, Gospodarowicz MK, James K, et al. Improved local control of invasive bladder cancer by concurrent cisplatin and preoperative or definitive radiation. The National Cancer Institute of Canada Clinical Trials Group. *J Clin Oncol*. 1996;14(11):2901–2907.

Crew JP, O'Brien T, Bicknell R, et al. Urinary vascular endothelial growth factor and its correlation with vascular endothelial growth factor expression and tumour progression. *J Urol*. 1999;161(3):799–804.

Culine S, Theodore C, De Santis M. A phase II study of vinflunine in bladder cancer patients progressing after first-line platinum-containing regimen. *Br J Cancer*. 2006;94(10):1395–1401.

David KA, Milowsky MI, Ritchey J, et al. Low incidence of perioperative chemotherapy for stage III bladder cancer 1998 to 2003: a report from the National Cancer Data Base. *J Urol*. 2007;178(2):451–454.

Davila HH, Weber T, Burday D, et al. Total or partial sparing cystectomy for invasive bladder cancer: long-term implications on erectile function. *BJU Int*. 2007;100(5):1026–1029.

DeSantis M, Bellmunt J, Mead G, et al. Randomized phase II/III trial assessing gemcitabine/carboplatin and methotrexate/carboplatin/vinblastine in patients with advanced urothelial carcinoma who are unfit for cisplatin-based chemotherapy: EORTC study 30986. *J Clin Oncol*. 2012;30:191–199.

Dhar NB, Klein EA, Reuther AM, et al. Outcome after radical cystectomy with limited or extended pelvic lymph node dissection. *J Urol*. 2008;179(3):873–878.

Dogliotti L, Cartenì G, Siena S, et al. Gemcitabine plus cisplatin versus gemcitabine plus carboplatin as first-line chemotherapy in advanced transitional cell carcinoma of the urothelium: results of a randomized phase 2 trial. *Eur Urol*. 2007;52(1):134–141.

Donat SM, Shabsigh A, Savage C, et al. Potential impact of postoperative early complications on the timing of adjuvant chemotherapy in patients undergoing radical cystectomy: a high-volume tertiary cancer center experience. *Eur Urol*. 2009;55(1):177–186.

Donat SM, Wei DC, McGuire MS, et al. The efficacy of transurethral biopsy for predicting the long-term clinical impact of prostatic invasive bladder cancer. *J Urol*. 2001;165(5):1580–1584.

Dotan ZA, Kavanagh K, Yossepowitch O, et al. Positive surgical margins in soft tissue following radical cystectomy for bladder cancer and cancer specific survival. *J Urol*. 2007;178(6):2308–2312 [discussion 2313].

Dreicer R, Gustin DM, See WA, et al. Paclitaxel in advanced urothelial carcinoma: its role in patients with renal insufficiency and as salvage therapy. *J Urol*. 1996;156(5):1606–1608.

Dreicer R, Manola J, Roth BJ, et al. Phase III trial of methotrexate, vinblastine, doxorubicin, and cisplatin versus carboplatin and paclitaxel in patients with advanced carcinoma of the urothelium. *Cancer*. 2004;100(8):1639–1645.

Dreicer R, Li S, Manola J, et al. Phase II trial of epothilone B analog BMS-247550 (ixabepilone) in advanced carcinoma of the urothelium (E3800): a trial of the Eastern Cooperative Oncology Group. *Cancer*. 2007;110:759–763.

Drieskens O, Oven R, Van Poppel H, et al. FDG-PET for preoperative staging of bladder cancer. *Eur J Nucl Med Mol Imaging*. 2005;32(12):1412–1417.

Efstathiou JA, Spiegel DY, Shipley WU, et al. Long-term outcomes of selective bladder preservation by combined-modality therapy for invasive bladder cancer: the MGH experience. *Eur Urol*. 2012;61(4):705–711.

el-Mekresh M, Akl A, Mosbah A, et al. Prediction of survival after radical cystectomy for invasive bladder carcinoma: risk group stratification, nomograms or artificial networks? *J Urol*. 2009;182(2):466–472.

Esrig D, Freeman JA, Elmajian DA, et al. Transitional cell carcinoma involving the prostate with a proposed staging classification for stromal invasion. *J Urol*. 1996;156(3):1071–1076.

Fahmy N, Kassouf W, Jeyaganth S, et al. An analysis of preoperative delays prior to radical cystectomy for bladder cancer in Quebec. *Can Urol Assoc J*. 2008;2(2):102–108.

Fajkovic H, Cha EK, Robinson BD, et al. Extranodal extension is a powerful prognostic factor in bladder cancer patients with lymph node metastasis. *Eur Urol*. 2013;64(5):837–845.

Fang AC, Ahmad AE, Whitson JM, et al. Effect of minimum lymph node policy in radical cystectomy and pelvic lymphadenectomy on lymph node yields, lymph node positivity rates, lymph node density, and survivorship in patients with bladder cancer. *Cancer*. 2010;116(8):1901–1908.

Fauconnet S, Bernardini S, Lascombe I, et al. Expression analysis of VEGF-A and VEGF-B: relationship with clinicopathological parameters in bladder cancer. *Oncol Rep*. 2009;21(6):1495–1504.

Frazier HA, Robertson JE, Dodge RK, et al. The value of pathologic factors in predicting cancer-specific survival among patients treated with radical cystectomy for transitional cell carcinoma of the bladder and prostate. *Cancer*. 1993;71(12):3993–4001.

Freiha F, Reese J, Torti FM. A randomized trial of radical cystectomy versus radical cystectomy plus cisplatin, vinblastine and methotrexate chemotherapy for muscle invasive bladder cancer. *J Urol*. 1996;155(2):495–499.

Gakis G, Schilling D, Perner S, et al. Sequential resection of malignant ureteral margins at radical cystectomy: a critical assessment of the value of frozen section analysis. *World J Urol*. 2011;29(4):451–456.

Galsky MD, Mironov S, Iasonos A, et al. Phase II trial of pemetrexed as second-line therapy in patients with metastatic urothelial carcinoma. *Invest New Drugs*. 2007;25(3):265–270.

Galsky MD, Hahn NM, Rosenberg J, et al. Treatment of patients with metastatic urothelial cancer “unfit” for cisplatin-based chemotherapy. *J Clin Oncol*. 2011;29(17):2432–2438.

Galsky MD, Hahn NM, Powles T, et al. Gemcitabine, cisplatin, and sunitinib for metastatic carcinoma and as preoperative therapy for muscle-invasive bladder cancer. *Clin Gentourin Cancer*. 2013;11(2):175–181.

Ghoneim IA, Miocinovic R, Stephenson AJ, et al. Neoadjuvant systemic therapy or early cystectomy? Single-center analysis of outcomes after therapy for patients with clinically localized micropapillary urothelial carcinoma of the bladder. *Urology*. 2011;77(4):867–870.

Ghoneim MA, Abdel-Latif M, el Mekresh M, et al. Radical cystectomy for carcinoma of the bladder: 2,720 consecutive cases 5 years later. *J Urol*. 2008;180(1):121–127.

Ghoneim MA, Ashamallah AK, Awaad HK, et al. Randomized trial of cystectomy with or without preoperative radiotherapy for carcinoma of the biharzial bladder. *J Urol*. 1985;134(2):266–268.

Giannarini G, Kessler TM, Thoeny HC, et al. Do patients benefit from routine follow-up to detect recurrences after radical cystectomy and ileal orthotopic bladder substitution? *Eur Urol*. 2010;58(4):486–494.

Girgin C, Oder M, Sahin MO, et al. Erection and ejaculation-preserving cystectomy with orthotopic urinary diversion: is it feasible? *J Androl*. 2006;27(2):263–267.

GISTV (Italian Bladder Cancer Study Group). Neoadjuvant treatment for locally advanced bladder cancer: a randomized prospective clinical trial. *J Chemother*. 1996;8:345–346.

Gogna NK, Matthews JH, Turner SL, et al. Efficacy and tolerability of concurrent weekly low dose cisplatin during radiation treatment of localized muscle invasive bladder transitional cell carcinoma: a report of two sequential phase II studies from the Trans Tasman Radiation Oncology Group. *Radiother Oncol*. 2006;81(1):9–17.

Goodney PP, Stukel TA, Lucas FL, et al. Hospital volume, length of stay, and readmission rates in high-risk surgery. *Ann Surg*. 2003;238(2):161–167.

Gore JL, Lai J, Setodji CM, et al. Mortality increases when radical cystectomy is delayed more than 12 weeks: results from a Surveillance, Epidemiology, and End Results-Medicare analysis. *Cancer*. 2009;115(5):988–996.

Griffiths G, Hall R, Sylvester R, et al. International phase III trial assessing neoadjuvant cisplatin, methotrexate, and vinblastine chemotherapy for muscle-invasive bladder cancer: long-term results of the BA06 30894 trial. *J Clin Oncol*. 2011;29(16):2171–2177.

Grivas PD, Daignault S, Tagawa ST, et al. Double-blind, randomized, phase 2 trial of maintenance sunitinib versus placebo after response to chemotherapy in patients with advanced urothelial carcinoma. *Cancer*. 2014;120(5):692–701.

Grossman HB, Natale RB, Tangen CM, et al. Neoadjuvant chemotherapy plus cystectomy compared with cystectomy alone for locally advanced bladder cancer. *N Engl J Med*. 2003;349(9):859–866.

Grossman HB, Natale RB, Tangen CM, et al. Errata for: neoadjuvant chemotherapy plus cystectomy compared with cystectomy alone for locally advanced bladder cancer. *N Engl J Med*. 2003;349(9):1880.

Gschwend JE, Heck MM, Lehmann J, et al. Limited versus extended pelvic lymphadenectomy in patients with bladder cancer undergoing radical cystectomy: survival results from a prospective, randomized trial (LEA AUO AB 25/02). *J Clin Oncol*. 2016;34(15 Suppl):4503.

Guzzo TJ, Magheli A, Bivalacqua TJ, et al. Pathological upstaging during radical cystectomy is associated with worse recurrence-free survival in patients with bacillus Calmette-Guerin-refractory bladder cancer. *Urology*. 2009;74(6):1276–1280.

Guzzo TJ, Resnick MJ, Canter DJ, et al. Impact of adjuvant chemotherapy on patients with lymph node metastasis at the time of radical cystectomy. *Can J Urol*. 2010;17(6):5465–5471.

Guzzo TJ, Rogers CG, Deng CY, et al. Outcomes of patients after aborted radical cystectomy for intraoperative findings of metastatic disease. *BJU Int*. 2008;102(11):1539–1543.

Hahn NM, Stadler WM, Zon RT, et al. Phase II trial of cisplatin, gemcitabine, and bevacizumab as first-line therapy for metastatic urothelial carcinoma: hoosier Oncology Group GU 04-75. *J Clin Oncol*. 2011;29(12):1525–1530.

Hall MC, Swanson DA, Dinney CP. Complications of radical cystectomy: impact of the timing of perioperative chemotherapy. *Urology*. 1996;47(6):826–830.

Hall RR. Updated results of a randomized controlled trial of neoadjuvant cisplatin (C), methotrexate (M) and vinblastine (V) chemotherapy for muscle-invasive bladder cancer.

International Collaboration of Trialists of the MRC Advanced Bladder Cancer Group. *Proc Annu Meet Am Soc Clin Oncol*. 2002;21(1):178a.

Han KS, Joung JY, Kim TS, et al. Methotrexate, vinblastine, doxorubicin and cisplatin combination regimen as salvage chemotherapy for patients with advanced or metastatic transitional cell carcinoma after failure of gemcitabine and cisplatin chemotherapy. *Br J Cancer*. 2008;98(1):86–90.

Hardeman SW, Soloway MS. Urethral recurrence following radical cystectomy. *J Urol*. 1990;144:666–669.

Hassan JM, Cookson MS, Smith JA Jr, et al. Urethral recurrence in patients following orthotopic urinary diversion. *J Urol*. 2004;172:1338–1341.

Hautmann RE, Gschwend JE, de Petriconi RC, et al. Cystectomy for transitional cell carcinoma of the bladder: results of a surgery only series in the neobladder era. *J Urol*. 2006;176:486–492 [discussion 491–492].

Herr HW, Bajorin DF, Scher HI. Neoadjuvant chemotherapy and bladder sparing surgery for invasive bladder cancer: ten-year outcome. *J Clin Oncol*. 1998;16(4):1298–1301.

Herr HW, Bochner BH, Dalbagni G, et al. Impact of the number of lymph nodes retrieved on outcome in patients with muscle invasive bladder cancer. *J Urol*. 2002;167:1295–1298.

Herr HW, Faulkner JR, Grossman HB, et al. Surgical factors influence bladder cancer outcomes: a cooperative group report. *J Clin Oncol*. 2004;22(14):2781–2789.

Herr HW. Transurethral resection of muscle-invasive bladder cancer: 10-year outcome. *J Clin Oncol*. 2001;19(1):89–93.

Herr HW. Superiority of ratio based lymph node staging for bladder cancer. *J Urol*. 2003;169:943–945.

Herr HW. Outcome of patients who refuse cystectomy after receiving neoadjuvant chemotherapy for muscle-invasive bladder cancer. *Eur Urol*. 2008;54(1):126–132.

Herrmann E, Stoter E, van Ophoven A, et al. The prognostic impact of pelvic lymph node metastasis and lymphovascular invasion on bladder cancer. *Int J Urol*. 2008;15(7):607–611.

Hoang AN, Agarwal PK, Walton-Diaz A, et al. Clinical significance of ureteric “skip lesions” at the time of radical cystectomy: the M.D. Anderson experience and literature review. *BJU Int*. 2014;113(5b):E28–E33.

Hollenbeck BK, Miller DC, Taub D, et al. Aggressive treatment for bladder cancer is associated with improved overall survival among patients 80 years old or older. *Urology*. 2004;64(2):292–297.

Hollenbeck BK, Ye Z, Wong SL, et al. Hospital lymph node counts and survival after radical cystectomy. *Cancer*. 2008;112(4):806–812.

Holzbeierlein JM, Lopez-Corona E, Bochner BH, et al. Partial cystectomy: a contemporary review of the Memorial Sloan-Kettering Cancer Center experience and recommendations for patient selection. *J Urol*. 2004;172:878–881.

Housset M, Maulard C, Chretien Y, et al. Combined radiation and chemotherapy for invasive transitional-cell carcinoma of the bladder: a prospective study. *J Clin Oncol*. 1993;11(11):2150–2157.

Huguet J, Monllau V, Sabate S, et al. Diagnosis, risk factors, and outcome of urethral recurrences following radical cystectomy for bladder cancer in 729 male patients. *Eur Urol*. 2008;53(4):785–792.

Hussain MH, MacVicar GR, Petrylak DP, et al. Trastuzumab, paclitaxel, carboplatin, and gemcitabine in advanced human epidermal growth factor receptor-2/neu-positive urothelial carcinoma: results of a multicenter phase II National Cancer Institute trial. *J Clin Oncol*. 2007;25(16):2118–2124.

International Collaboration of Trialists. Neoadjuvant cisplatin, methotrexate, and vinblastine chemotherapy for muscle-invasive bladder cancer: a randomised controlled trial. *Lancet*. 1999;354(9178):533–540.

James ND, Hussain SA, Hall E, et al. Radiotherapy with or without chemotherapy in muscle invasive bladder cancer. *N Engl J Med*. 2012;366:1477–1488.

Jensen JB, Ulhoi BP, Jenson KM. Evaluation of different lymph node (LN) variables as prognostic markers in patients undergoing radical cystectomy and extended LN dissection to the level of the inferior mesenteric artery. *BJU Int*. 2012;109(3):388–393.

Joly F, Houede N, Noal S, et al. Do patients with advanced urothelial carcinoma benefit from weekly paclitaxel chemotherapy? A GETUG phase II study. *Clin Genitourin Cancer*. 2009;7(2):E28–E33.

Kamat AM, Dinney CP, Gee JR, et al. Micropapillary bladder cancer: a review of the University of Texas M.D. Anderson Cancer Center experience with 100 consecutive patients. *Cancer*. 2007;110(1):62–67.

Kanai K, Kikuchi E, Ohigashi T, et al. Gemcitabine and paclitaxel chemotherapy for advanced urothelial carcinoma in patients who have received prior cisplatin-based chemotherapy. *Int J Clin Oncol*. 2008;13(6):510–514.

Karakiewicz PI, Shariat SF, Palapattu GS, et al. Nomogram for predicting disease recurrence after radical cystectomy for transitional cell carcinoma of the bladder. *J Urol*. 2006;176(4):1354–1362.

Karakiewicz PI, Shariat SF, Palapattu GS, et al. Precystectomy nomogram for prediction of advanced bladder cancer stage. *Eur Urol*. 2006;50(6):1254–1260 [discussion 1261–1262].

Karam JA, Lotan Y, Karakiewicz PI, et al. Use of combined apoptosis biomarkers for prediction of bladder cancer recurrence and mortality after radical cystectomy. *Lancet Oncol*. 2007;8:128–136.

Kassouf W, Agarwal PK, Herr HW, et al. Lymph node density is superior to TNM nodal status in predicting disease-specific survival after radical cystectomy for bladder cancer: analysis of pooled data from MDACC and MSKCC. *J Clin Oncol*. 2008;26:121–126.

Kassouf W, Swanson D, Kamat AM, et al. Partial cystectomy for muscle invasive urothelial carcinoma of the bladder: a contemporary review of the M.D. Anderson Cancer Center experience. *J Urol*. 2006;175:2058–2062.

Kaufman DS, Shipley WU, Feldman AS. Bladder cancer. *Lancet*. 2009;374(9685):239–249.

Kaufman DS, Winter KA, Shipley WU, et al. A phase I/II RTOG study (99-06) in patients with muscle-invading bladder cancer of transurethral surgery plus paclitaxel, cisplatin and twice daily irradiation followed by either selective bladder preservation or radical cystectomy and adjuvant chemotherapy. *Urology*. 2009;73:833–837.

Kefer JC, Campbell SC. Current status of prostate-sparing cystectomy. *Urol Oncol*. 2008;26(5):486–493.

Kibel AS, Dehdashti F, Katz MD, et al. Prospective study of [18F] fluorodeoxyglucose positron emission tomography/computed tomography for staging of muscle-invasive bladder carcinoma. *J Clin Oncol*. 2009;27(26):4314–4320.

Kim JK, Park SY, Ahn HJ, et al. Bladder cancer: analysis of multi-detector row helical CT enhancement pattern and accuracy in tumor detection and perivesical staging. *Radiology*. 2004;231(3):725–731.

Ko YJ, Canil CM, Mukherjee SD, et al. Nanoparticle albumin-bound paclitaxel for second-line treatment of metastatic urothelial carcinoma: a single group, multicenter, phase 2 study. *Lancet Oncol*. 2013;14(8):769–776.

Koga JK, Kihara K, Yoshida S, et al. Selective bladder-sparing protocol consisting of induction low-dose chemoradiotherapy plus partial cystectomy with pelvic lymph node dissection against muscle-invasive bladder cancer: oncological outcomes of the initial 46 patients. *BJU Int*. 2012;109(6):860–866.

Konety BR, Dhawan V, Allareddy V, et al. Impact of hospital and surgeon volume on in-hospital mortality from radical cystectomy: data from the health care utilization project. *J Urol*. 2005;173(5):1695–1700.

Konety BR, Joslyn SA, O'Donnell MA. Extent of pelvic lymphadenectomy and its impact on outcome in patients diagnosed with bladder cancer: analysis of data from the Surveillance, Epidemiology and End Results program data base. *J Urol*. 2003;169:946–950.

Koplay M, Kantarci M, Guven F, et al. Diagnostic accuracy of multidetector computed tomography with multiplanar reformatted imaging and virtual cystoscopy in the assessment of bladder tumors after transurethral resection. *J Comput Assist Tomogr*. 2010;34(1):121–126.

Koppie TM, Vickers AJ, Vora K, et al. Standardization of pelvic lymphadenectomy performed at radical cystectomy: can we establish a minimum number of lymph nodes that should be removed? *Cancer*. 2006;107:2368–2374.

Krege S, Rexer H, vom Dorp F, et al. Prospective randomized double-blind multicenter phase II study comparing gemcitabine and cisplatin plus sorafenib chemotherapy with gemcitabine and cisplatin plus placebo in locally advanced and/or metastasized urothelial cancer: SUSE (AUO-AB 31/05). *BJU Int*. 2014;113(3):429–436.

Ku JH, Kang M, Kim HS, et al. Lymph node density as a prognostic variable in node-positive bladder cancer: a meta-analysis. *BMC Cancer*. 2015;2(15):447.

Ku JH, Kim M, Jeong CW, et al. Risk prediction models of locoregional failure after radical cystectomy for urothelial carcinoma: external validation in a cohort of Korean patients. *Int J Radiat Oncol Biol Phys*. 2014;89:1032–1037.

Kulkarni GS, Finelli A, Lockwood G, et al. Effect of healthcare provider characteristics on nodal yield at radical cystectomy. *Urology*. 2008;72:128–132.

Kulkarni GS, Urbach DR, Austin PC, et al. Longer wait times increase overall mortality in patients with bladder cancer. *J Urol*. 2009;182(4):1318–1324.

Lassiter LK, Tummala MK, Hussain MH, et al. Phase II open-label study of oral piritrexim in patients with advanced carcinoma of the urothelium who have experienced failure with standard chemotherapy. *Clin Genitourin Cancer*. 2008;6(1):31–35.

Lavery HJ, Stensland KD, Niegisch G, et al. Pathological T0 following radical cystectomy with or without neoadjuvant chemotherapy: a useful surrogate. *J Urol*. 2014;191(4):898–906.

Lee SE, Byun SS, Hong SK, et al. Significance of cancer involvement at the ureteral margin detected on routine frozen section analysis during radical cystectomy. *Urol Int*. 2006;77(1):13–17.

Lee CT, Madii R, Daignault S, et al. Cystectomy delay more than 3 months from initial bladder cancer diagnosis results in decreased disease specific and overall survival. *J Urol*. 2006;175(4):1262–1267.

Leibovici D, Kassouf W, Pisters LL, et al. Organ preservation for muscle-invasive bladder cancer by transurethral resection. *Urology*. 2007;70(3):473–476.

Leissner J, Hohenfellner R, Thuroff JW, et al. Lymphadenectomy in patients with transitional cell carcinoma of the urinary bladder; significance for staging and prognosis. *BJU Int*. 2000;85(7):817–823.

Leissner J, Ghoneim MA, Abol-Enein H, et al. Extended radical lymphadenectomy in patients with urothelial bladder cancer: results of a prospective multicenter study. *J Urol*. 2004;171(1):139–144.

Leow JJ, Martin-Doyle W, Rajagopal PS, et al. Adjuvant chemotherapy for invasive bladder cancer: a 2013 updated systematic review and meta-analysis of randomized trials. *Eur Urol*. 2014;66(1):42–54.

Lerner SP, Colen J, Shen S. Prostatic biology, histologic patterns and clinical consequences of transitional cell carcinoma. *Curr Opin Urol*. 2008;18:508–512.

Lerner SP, Shen S. Pathologic assessment and clinical significance of prostatic involvement by transitional cell carcinoma and prostate cancer. *Urol Oncol*. 2008;26(5):481–485.

Lerner SP, Skinner DG, Lieskovsky G, et al. The rationale for en bloc pelvic lymph node dissection for bladder cancer patients with nodal metastases: long-term results. *J Urol*. 1993;149:758–764 [discussion 764–765].

Lodde M, Lacombe L, Friede J, et al. Evaluation of fluorodeoxyglucose positron-emission tomography with computed tomography for staging of urothelial carcinoma. *BJU Int*. 2010;106(5):658–663.

Loehrer P, Einhorn LH, Elson PJ, et al. A randomized comparison of cisplatin alone or in combination with methotrexate, vinblastine, and doxorubicin in patients with metastatic urothelial carcinoma: a cooperative group study. *J Clin Oncol*. 1992;10(7):1066–1073.

Logothetis CJ, Johnson DE, Chong C, et al. Adjuvant cyclophosphamide, doxorubicin, and cisplatin chemotherapy for bladder cancer: an update. *J Clin Oncol*. 1988;6(10):1590–1596.

Logothetis CJ, Dexeus F, Finn L, et al. A prospective randomized trial comparing CISCA to M-VAC chemotherapy in advanced metastatic urothelial tumors. *J Clin Oncol*. 1990;8(6):1050–1055.

Lorusso V, Pollera CF, Antimi M, et al. A phase II study of gemcitabine in patients with transitional cell carcinoma of the urinary tract previously treated with platinum. *Eur J Cancer*. 1998;34(8):1208–1212.

Lotan Y, Gupta A, Shariat SF, et al. Lymphovascular invasion is independently associated with overall survival, cause-specific survival, and local and distant recurrence in patients with negative lymph nodes at radical cystectomy. *J Clin Oncol*. 2005;23(27):6533–6539.

Lucca I, Hofbauer SL, Leitner CV, et al. Development of a preoperative nomogram incorporating biomarkers of systemic inflammatory response to predict nonorgan-confined urothelial carcinoma of the bladder at radical cystectomy. *Urology*. 2016;95:132–138.

Madersbacher S, Hochreiter W, Burkhard F, et al. Radical cystectomy for bladder cancer today—a homogeneous series without neoadjuvant therapy. *J Clin Oncol*. 2003;21(4):690–696.

Malmström PU, Rintala E, Wahlqvist R, et al. Five year follow-up of a prospective trial of radical cystectomy and neoadjuvant chemotherapy. *J Urol*. 1996;155(6):1903–1906.

Manoharan M, Ayyathurai R, Soloway MS. Radical cystectomy for urothelial carcinoma of the bladder: an analysis of perioperative and survival outcome. *BJU Int*. 2009;104(9):1227–1232.

Maralani S, Wood DP Jr, Grignon D, et al. Incidence of urethral involvement in female bladder cancer: an anatomic pathologic study. *Urology*. 1997;50(4):537–541.

Marshall VF. The relation of the preoperative estimate to the pathologic demonstration of the extent of vesical neoplasms.

J Urol. 1952;68(4):714–723.

Martinez Piñeiro JA, Gonzalez Martin M, Arocena F. Neoadjuvant cisplatin chemotherapy before radical cystectomy in invasive transitional cell carcinoma of the bladder: prospective randomized phase III study. *J Urol*. 1995;153:964–973.

May M, Herrmann E, Bolenz C, et al. Lymph node density affects cancer-specific survival in patients with lymph node-positive urothelial bladder cancer following radical cystectomy. *Eur Urol*. 2011;59(5):712–718.

Mazzucchelli R, Morichetti D, Lopez-Beltran A, et al. Neuroendocrine tumours of the urinary system and male genital organs: clinical significance. *BJU Int*. 2009;103:1464–1470.

McCaffrey JA, Hilton S, Mazumdar M. Phase II trial of docetaxel in patients with advanced or metastatic transitional cell carcinoma. *J Clin Oncol*. 1997;15(5):1853–1857.

Meeks JJ, Taylor JM, Matsushita K, et al. Pathological response to neoadjuvant chemotherapy for muscle-invasive micropapillary bladder cancer. *BJU Int*. 2013;111(8):E325–E330.

Meiger RP, Mertens LS, van Rhijn BW, et al. Induction chemotherapy followed by surgery in node positive bladder cancer. *Urology*. 2014;83(1):134–139.

Meissner C, Giannarini G, Schumacher MC, et al. The efficiency of excretory urography to detect upper urinary tract tumors after cystectomy for urothelial cancer. *J Urol*. 2007;178(6):2287–2290.

Meluch AA, Greco FA, Burris HA 3rd, et al. Paclitaxel and gemcitabine chemotherapy for advanced transitional cell carcinoma of the urothelial tract: a phase II trial of the Minnie Pearl cancer research network. *J Clin Oncol*. 2001;19(12):3018–3024.

Metzger-Filho O, Moulin C, de Azambuja E, et al. Larotaxel: broadening the road with new taxanes. *Expert Opin Investig Drugs*. 2009;18(8):1183–1189.

Mills RD, Turner WH, Fleischmann A, et al. Pelvic lymph node metastases from bladder cancer: outcome in 83 patients after radical cystectomy and pelvic lymphadenectomy. *J Urol*. 2001;166(1):19–23.

Morris DS, Weizer AZ, Dunn RL, et al. Understanding bladder cancer death: tumor biology versus physician practice. *Cancer*. 2009;115(5):1011–1020.

Moschini M, Gallina A, Freschi M, et al. Effect on postoperative survival of the status of distal ureteral margin: the necessity to achieve negative margins at the time of radical cystectomy. *Urol Oncol*. 2016;34(2):59 [e15–59.e22].

Neal DE, Sharples L, Smith K, et al. The epidermal growth factor receptor and the prognosis of bladder cancer. *Cancer*. 1990;65(7):1619–1625.

Nelles JL, Konety BR, Saigal C, et al. Urethrectomy following cystectomy for bladder cancer in men: practice patterns and impact on survival. *J Urol*. 2008;180(5):1933–1936.

Nieder AM, Sved PD, Gomez P, et al. Urethral recurrence after cystoprostatectomy: implications for urinary diversion and monitoring. *Urology*. 2004;64(5):950–954.

Nielsen ME, Shariat SF, Karakiewicz PI, et al. Advanced age is associated with poorer bladder cancer–specific survival in patients treated with radical cystectomy. *Eur Urol*. 2007;51(3):699–706 [discussion 706–708].

Nieuwenhuijzen JA, Pos F, Moonen LM, et al. Survival after bladder-preservation with brachytherapy versus radical cystectomy; a single institution experience. *Eur Urol*. 2005;48(2):239–245.

Nieuwenhuijzen JA, Meinhardt W, Horenblas S. Clinical outcomes after sexuality preserving cystectomy and neobladder (prostate sparing cystectomy) in 44 patients. *J Urol*. 2008;179:235–238.

Nixon RG, Chang SS, Lafleur BJ, et al. Carcinoma in situ and tumor multifocality predict the risk of prostatic urethral involvement at radical cystectomy in men with transitional cell carcinoma of the bladder. *J Urol*. 2002;167:502–505.

Nogova L, Sequist LV, Perez Garcia JM, et al. Evaluation of BGJ398, a fibroblast growth factor receptor 1-3 kinase inhibitor in patients with advanced solid tumors harboring genetic alterations in fibroblast growth factor receptors: results of a global phase I dose escalation and dose expansion study. *J Clin Oncol*. 2017;35(2):157–165.

Novara G, Svatek RS, Karakiewicz PI, et al. Soft tissue margin status is a powerful predictor of outcomes after radical cystectomy: a multicenter study of more than 4,400 patients. *J Urol*. 2010;183(6):2165–2170.

Novotny V, Froehner M, May M, et al. Risk stratification for locoregional recurrence after radical cystectomy for urothelial carcinoma of the bladder. *World J Urol*. 2015;33(11):1753–1761.

Osman Y, El-Tabey N, Abdel-Latif M, et al. The value of frozen-section analysis of ureteric margins on surgical decision-making in patients undergoing radical cystectomy for bladder cancer. *BJU Int*. 2007;99:81–84.

Otto T, Börgemann C, Krege S, et al. Adjuvant chemotherapy in locally advanced bladder cancer (PT3/PN1-2,M0)—a phase III study. *Eur Urol*. 2001;39(Suppl 5):147.

Oudard S, Culine S, Vano Y, et al. Multicentre randomized phase II trial of gemcitabine + platinum with or without trastuzumab in advanced metastatic urothelial carcinoma expressing Her 2. *Eur J Cancer*. 2015;51(1):45–54.

Pagano F, Bassi P, Ferrante GL, et al. Is stage pT4a (D1) reliable in assessing transitional cell carcinoma involvement of the prostate in patients with a concurrent bladder cancer? A necessary distinction for contiguous or noncontiguous involvement. *J Urol*. 1996;155(1):244–247.

Panebianco V, Barchetti F, de Haas RJ, et al. Improving staging in bladder cancer: the increasing role of multiparametric magnetic resonance imaging. *Eur Urol Focus*. 2016;2(2):113–121.

Paner GP, Stadler WM, Hansel DE, et al. Updates in the eighth edition of the tumor-node-metastasis staging classification for urologic cancers. *Eur Urol*. 2018;73(4):560–569.

Papamichael D, Gallagher CJ, Oliver RT, et al. Phase II study of paclitaxel in pretreated patients with locally advanced/metastatic cancer of the bladder and ureter. *Br J Cancer*. 1997;75(4):606–607.

Patel MR, Ellerton J, Infante JR, et al. Avelumab in metastatic urothelial carcinoma after platinum failure (JAVELIN Solid Tumor): pooled results from two expansion cohorts of an open label, phase 1 trial. *Lancet Oncol*. 2018;19(1):51–64.

Pea G. Randomized phase II trial of gemcitabine/cisplatin (GC) with or without cetuximab CET in patients with advanced urothelial carcinoma. *J Clin Oncol*. 2012;30(Suppl):a4506.

Petrioli R, Frediani B, Manganelli A, et al. Comparison between a cisplatin-containing regimen and a carboplatin-containing regimen for recurrent or metastatic cancer patients: a randomized phase II study. *Cancer*. 1996;77:344–351.

Petrylak DP, Tangen CM, Van Veldhuizen PJ Jr, et al. Results of the Southwest Oncology Group phase II evaluation (study S0031) of ZD1839 for advanced transitional cell carcinoma of the urothelium. *BJU Int*. 2010;105(3):317–321.

Pettus JA, Al-Ahmadie H, Barocas DA, et al. Risk assessment of prostatic pathology in patients undergoing radical cystoprostatectomy. *Eur Urol*. 2008;53(2):370–375.

Philips G, Sanford B, Halabi S, et al. Phase II study of cisplatin

(C), gemcitabine (G) and gefitinib for advanced urothelial carcinoma (UC): analysis of the second cohort of CALGB 90102. *Ann Oncol*. 2009;20(6):1074–1079.

Picchio M, Treiber U, Beer AJ, et al. Value of 11C-choline PET and contrast-enhanced CT for staging of bladder cancer: correlation with histopathologic findings. *J Nucl Med*. 2006;47(6):938–944.

Plimack ER, Bellmunt J, Gupta S, et al. Safety and activity of pembrolizumab in patients with locally advanced or metastatic urothelial cancer (KEYNOTE-012): a non-randomized, open-label, phase 1b study. *Lancet Oncol*. 2018;18(2):212–220.

Ploeg M, Kiemeney LA, Smits GA, et al. Discrepancy between clinical staging through bimanual palpation and pathological staging after cystectomy. *Urol Oncol*. 2012;30(3):247–251.

Pollack A, Zagars GZ. Radiotherapy for stage T3b transitional cell carcinoma of the bladder. *Semin Urol Oncol*. 1996;14(2):86–95.

Porter MP, Kerrigan MC, Donato BM, et al. Patterns of use of systemic chemotherapy for Medicare beneficiaries with urothelial bladder cancer. *Urol Oncol*. 2011;29(3):252–258.

Poulsen AL, Horn T, Steven K. Radical cystectomy: extending the limits of pelvic lymph node dissection improves survival for patients with bladder cancer confined to the bladder wall. *J Urol*. 1998;160(6 Pt 1):2015–2019 [discussion 2020].

Powles T, Huddart RA, Elliott T, et al. Phase III, double-blind, randomized trial that compared maintenance lapatinib versus placebo after first-line chemotherapy in patients with human epidermal growth factor receptor ½-positive metastatic bladder cancer. *J Clin Oncol*. 2017;35(1):48–55.

Powles T, O'Donnell PH, Massard C, et al. Efficacy and safety of durvalumab in locally advanced or metastatic urothelial carcinoma: updated results from phase ½ open-label study.

JAMA Oncol. 2017;3(9):e172411.

Prout GR, Marshall VF. The prognosis with untreated bladder tumors. *Cancer*. 1956;9(3):551–558.

Quek ML, Stein SP, Clark PE, et al. Microscopic and gross extravesical extension in pathological staging of bladder cancer. *J Urol*. 2004;171:640–645.

Quinn DI, Aparicio A, Tsao-Wei DD, et al. Phase II study of eribulin (E7389) in patients with advanced urothelial cancer—final report: a California consortium-led NCI/CTEP-sponsored trial. *J Clin Oncol*. 2010;28(Suppl).

Raj GV, Tal R, Vickers A, et al. Significance of intraoperative ureteral evaluation at radical cystectomy for urothelial cancer. *Cancer*. 2006;107(9):2167–2172.

Rajesh A, Sokhi HK, Fung R, et al. Bladder cancer: evaluation of staging accuracy using dynamic MRI. *Clin Radiol*. 2011;66(12):1140–1145.

Revelo MP, Cookson MS, Chang SS, et al. Incidence and location of prostate and urothelial carcinoma in prostates from cystoprostatectomies: implications for possible apical sparing surgery. *J Urol*. 2008;179:S27–S32.

Richards KA, Parks GE, Badlani GH, et al. Developing selection criteria for prostate-sparing cystectomy: a review of cystoprostatectomy specimens. *Urology*. 2010;75(5):1116–1120.

Rink M, Hansen J, Cha EK, et al. Outcomes and prognostic factors in patients with single lymph node metastasis at time of radical cystectomy. *BJU Int*. 2013;111(1):74–84.

Rödel C, Grabenbauer GG, Kühn R, et al. Combined-modality treatment and selective organ preservation in invasive bladder cancer: long-term results. *J Clin Oncol*. 2002;20(14):3061–3071.

Rose TL, Lotan Y. Advancements in optical techniques and imaging in the diagnosis and management of bladder cancer.

Urol Oncol. 2018;36(3):97–102.

Rosenberg JE, Hoffman-Censits J, Powles T, et al. Atezolizumab in patients with locally advanced and metastatic urothelial carcinoma who have progressed following treatment with platinum-based chemotherapy: a single-arm, multicenter, phase 2 trial. *Lancet*. 2016;387:1909–1920.

Roth BJ, Manola J, Dreicer R, et al. Piritrexim in advanced, refractory carcinoma of the urothelium (E3896): a phase II trial of the Eastern Cooperative Oncology Group. *Invest New Drugs*. 2002;20(4):425–429.

Sakamoto N, Tsuneyoshi M, Naito S, et al. An adequate sampling of the prostate to identify prostatic involvement by urothelial carcinoma in bladder cancer patients. *J Urol*. 1993;149:318–321.

Sanchez-Ortiz RF, Huang WC, Mick R, et al. An interval longer than 12 weeks between the diagnosis of muscle invasion and cystectomy is associated with worse outcome in bladder carcinoma. *J Urol*. 2003;169(1):110–115.

Sanderson KM, Cai J, Miranda G, et al. Upper tract urothelial recurrence following radical cystectomy for transitional cell carcinoma of the bladder: an analysis of 1,069 patients with 10-year followup. *J Urol*. 2007;177(6):2088–2094.

Sanli O, Dobruch J, Knowles MA, et al. Bladder cancer. *Nat Rev Dis Primers*. 2017;13(3):17022.

Saxman SB, Propert KJ, Einhorn LH, et al. Long-term follow-up of a phase III intergroup study of cisplatin alone or in combination with methotrexate, vinblastine, and doxorubicin in patients with metastatic urothelial carcinoma: a cooperative group study. *J Clin Oncol*. 1997;15(7):2564–2569.

Schoenberg MP, Carter HB, Epstein JI. Ureteral frozen section analysis during cystectomy: a reassessment. *J Urol*. 1996;155:1218–1220.

Schumacher MC, Scholz M, Weise ES, et al. Is there an indication for frozen section examination of the ureteral margins during cystectomy for transitional cell carcinoma of the bladder? *J Urol*. 2006;176:2409–2413.

Scosyrev E, Ely BW, Messing EM, et al. Do mixed histological features affect survival benefit from neoadjuvant platinum-based combination chemotherapy in patients with locally advanced bladder cancer? *BJU Int*. 2011;108(5):693–699.

Seiler R, von Guten M, Thalmann GN, et al. Extracapsular extension but not the tumor burden of lymph node metastases is an independent adverse risk factor in lymph node positive bladder cancer. *Histopathology*. 2011;58(4):571–578.

Sell A, Jakobsen A, Nerstrom B, et al. Treatment of advanced bladder cancer category T2 T3 and T4a. A randomized multicenter study of preoperative irradiation and cystectomy versus radical irradiation and early salvage cystectomy for residual tumor. DAVECA protocol 8201. Danish Vesical Cancer Group. *Scan J Urol Nephrol Suppl*. 1991;138:193–201.

Sengelov L, von der Maase H, Lundbeck F, et al. Neoadjuvant chemotherapy with cisplatin and methotrexate in patients with muscle-invasive bladder tumors. *Acta Oncol*. 2002;41(4):447–456.

Sessa C, Cuvier C, Caldiera S, et al. Phase I clinical and pharmacokinetic studies of the taxoid derivative RPR 109881A administered as a 1-hour or a 3-hour infusion in patients with advanced solid tumors. *Ann Oncol*. 2002;13:1140–1150.

Shabsigh A, Korets R, Vora KC, et al. Defining early morbidity of radical cystectomy for patients with bladder cancer using a standardized reporting methodology. *Eur Urol*. 2009;55(1):164–176.

Shariat SF, Chromecki TF, Cha EK, et al. Risk stratification of organ confined bladder cancer after radical cystectomy using cell cycle related biomarkers. *J Urol*. 2012;187(2):457–462.

Shariat SF, Karakiewicz PI, Ashfaq R, et al. Multiple biomarkers improve prediction of bladder cancer recurrence and mortality in patients undergoing cystectomy. *Cancer*. 2008;112(2):315–325.

Shariat SF, Karakiewicz PI, Palapattu GS, et al. Nomograms provide improved accuracy for predicting survival after radical cystectomy. *Clin Cancer Res*. 2006;12(22):6663–6676.

Shariat SF, Karakiewicz PI, Palapattu GS, et al. Outcomes of radical cystectomy for transitional cell carcinoma of the bladder: a contemporary series from the Bladder Cancer Research Consortium. *J Urol*. 2006;176:2414–2422 [discussion 2422].

Shariat SF, Passoni N, Bagrodia A, et al. Prospective evaluation of a preoperative biomarker panel for prediction of upstaging at radical cystectomy. *BJU Int*. 2014;113(1):70–76.

Shariat SF, Svatek RS, Tilki D, et al. International validation of the prognostic value of lymphovascular invasion in patients treated with radical cystectomy. *BJU Int*. 2010;105(10):1402–1412.

Sharma P, Retz M, Siefker-Radtke A, et al. Nivolumab in metastatic urothelial carcinoma after platinum therapy (CheckMate 275: a multicenter, single-arm, phase 2 trial. *Lancet Oncol*. 2017;18:312–322.

Sharma TC, Melamed MR, Whitmore WF Jr. Carcinoma in-situ of the ureter in patients with bladder carcinoma treated by cystectomy. *Cancer*. 1970;26(3):583–587.

Sherif A, Rintala E, Mestad O, et al. Neoadjuvant cisplatin-methotrexate chemotherapy of invasive bladder cancer—Nordic cystectomy trial 2. *Scand J Urol Nephrol*. 2002;36(6):419–425.

Shipley WU, Winter KA, Kaufman DS, et al. Phase III trial of neoadjuvant chemotherapy in patients with invasive bladder cancer treated with selective bladder preservation by combined radiation therapy and chemotherapy: initial results of Radiation Therapy Oncology Group 89-03. *J Clin Oncol*. 1998;16(11):3576–3583.

Siefker-Radtke AO, Dinney CP, Abrahams NA, et al. Evidence supporting preoperative chemotherapy for small cell carcinoma of the bladder: a retrospective review of the M.D. Anderson cancer experience. *J Urol*. 2004;172(2):481–484.

Siegel R, Miller KD, Jemal A. Cancer statistics, 2018. *CA Cancer J Clin*. 2018;68(1):7–30.

Silver DA, Stroumbakis N, Russo P, et al. Ureteral carcinoma in situ at radical cystectomy: does the margin matter? *J Urol*. 1997;158(3 Pt 1):768–771.

Skinner DG, Daniels JR, Russell CA, et al. The role of adjuvant chemotherapy following cystectomy for invasive bladder cancer: a prospective comparative trial. *J Urol*. 1991;145:459–467.

Skinner DG. Management of invasive bladder cancer: a meticulous pelvic node dissection can make a difference. *J Urol*. 1982;128(1):34–36.

Slack NH, Bross ID, Prout GR Jr. Five-year follow up results of a collaborative study of therapies for carcinoma of the bladder. *J Surg Oncol*. 1977;9(4):393–405.

Smaldone MC, Jacobs BL, Smaldone AM, et al. Long-term results of selective partial cystectomy for invasive urothelial bladder carcinoma. *Urology*. 2008;72(3):613–616.

Smith JA Jr, Crawford ED, Paradelo JC, et al. Treatment of advanced bladder cancer with combined preoperative irradiation and radical cystectomy versus radical cystectomy alone: a phase III intergroup study. *J Urol*. 1997;157(3):805–807.

Smith ZL, Christodouleas JP, Keefe SM, et al. Bladder preservation in the treatment of muscle-invasive bladder cancer (MIBC): a review of the literature and a practical approach to therapy. *BJU Int*. 2013;112(1):13–25.

Soloway M, Khoury S. *Bladder cancer*. ed 2. ICUD-EAU; 2012.

Solsona E, Iborra I, Collado A, et al. Feasibility of radical transurethral resection as monotherapy for selected patients with muscle invasive bladder cancer. *J Urol*. 2010;184(2):475–480.

Sonpavde G, Jian W, Lerner SP. Sunitinib malate is active and synergistic with cisplatin against human urothelial carcinoma in a preclinical model. *Urol Oncol*. 2009;27(4):391–399.

Sonpavde G, Khan MM, Svatek RS, et al. Prognostic risk stratification of pathological stage T3N0 bladder cancer after radical cystectomy. *J Urol*. 2011;185(4):1216–1221.

Spitz A, Stein JP, Lieskovsky G, et al. Orthotopic urinary diversion with preservation of erectile and ejaculatory function in men requiring radical cystectomy for nonurothelial malignancy: a new technique. *J Urol*. 1999;161(6):1761–1764.

Sridhar SS, Canil CM, Mukherjee SD, et al. Results of a phase II study of single-agent nab-paclitaxel in platinum-refractory second-line metastatic urothelial carcinoma (UC). *J Clin Oncol*. 2011;29(Suppl 7):241.

Stadler WM, Lerner SP, Groshen S, et al. Randomized trial of p53 targeted adjuvant therapy for patients (pts) with organ-confined node-negative urothelial bladder cancer (UBC). *Proc Annu Meet Am Soc Clin Oncol*. 2009;27(15S):239s.

Stamatakis L, Godoy G, Lerner SP. Innovations in radical cystectomy and pelvic lymph node dissection. *Semin Oncol*. 2012;39(5):573–582.

Stein JP, Cote RJ, Freeman JA, et al. Indications for lower urinary tract reconstruction in women after cystectomy for bladder cancer: a pathological review of female cystectomy specimens. *J Urol*. 1995;154(4):1329–1333.

Stein JP, Esrig D, Freeman JA, et al. Prospective pathologic analysis of female cystectomy specimens: risk factors for orthotopic diversion in women. *Urology*. 1998;51(6):951–955.

Stein JP, Lieskovsky G, Cote R, et al. Radical cystectomy in the treatment of invasive bladder cancer: long-term results in 1,054 patients. *J Clin Oncol*. 2001;19(3):666–675.

Stein JP, Cai J, Groshen S, et al. Risk factors for patients with pelvic lymph node metastases following radical cystectomy with en bloc pelvic lymphadenectomy: concept of lymph node density. *J Urol*. 2003;170(1):35–41.

Stein JP, Clark P, Miranda G, et al. Urethral tumor recurrence following cystectomy and urinary diversion: clinical and pathological characteristics in 768 male patients. *J Urol*. 2005;173(4):1163–1168.

Stein JP, Penson DF, Cai J, et al. Radical cystectomy with extended lymphadenectomy: evaluating separate package versus en bloc submission for node positive bladder cancer. *J Urol*. 2007;177(3):876–881 [discussion 881–882].

Stein JP, Penson DF, Wu SD, et al. Pathological guidelines for orthotopic urinary diversion in women with bladder cancer: a review of the literature. *J Urol*. 2007;178:756–760.

Stein JP, Penson DF, Lee C, et al. Long-term oncological outcomes in women undergoing radical cystectomy and orthotopic diversion for bladder cancer. *J Urol*. 2009;181(5):2052–2058.

Stenzl A, Cowan NC, De Santis M, et al. The updated EAU guidelines on muscle-invasive and metastatic bladder cancer. *Eur Urol*. 2009;55(4):815–825.

Stenzl A, Draxl H, Posch B, et al. The risk of urethral tumors in female bladder cancer: can the urethra be used for orthotopic reconstruction of the lower urinary tract? *J Urol*. 1995;153(3 Pt 2):950–955.

Sternberg CN, Collette L. What has been learned from meta-analyses of neoadjuvant and adjuvant chemotherapy in bladder cancer? *BJU Int*. 2006;98(3):487–489.

Sternberg CN, Sylvester R. Thoughts on a systematic review and meta-analysis of adjuvant chemotherapy in muscle-invasive bladder cancer. *Eur Urol*. 2014;66(1):55–56.

Sternberg CN, Yagoda A, Scher HI, et al. Preliminary results of M-VAC (methotrexate, vinblastine, doxorubicin and cisplatin) for transitional cell carcinoma of the urothelium. *J Urol*. 1985;133(3):403–407.

Sternberg CN, Yagoda A, Scher HI, et al. M-VAC for advanced transitional cell carcinoma of the urothelium: efficacy, and patterns of response and relapse. *Cancer*. 1989;64:2448–2458.

Sternberg CN, Calabrò F, Pizzocaro G, et al. Chemotherapy with an every-2-week regimen of gemcitabine and paclitaxel in patients with transitional cell carcinoma who have received prior cisplatin-based therapy. *Cancer*. 2001;92(12):2993–2998.

Sternberg CN, de Mulder PH, Schornagel JH, et al. Randomized phase III trial of high-dose-intensity methotrexate, vinblastine, doxorubicin, and cisplatin (MVAC) chemotherapy and recombinant human granulocyte colony-stimulating factor versus classic MVAC in advanced urothelial tumors: European Organization for Research and Treatment of Cancer Protocol no. 30924. *J Clin Oncol*. 2001;19(10):2638–2646.

Sternberg CN, Sylvester R, Theodore C, et al. *Comparison of immediate and delayed adjuvant chemotherapy in treating patients who have undergone a radical cystectomy for stage*

III or stage IV transitional cell carcinoma of the bladder urothelium: EORTC 30994. 2001.

Sternberg CN, Pansadoro V, Calabrò F, et al. Can patient selection for bladder preservation be based on response to chemotherapy? *Cancer*. 2003;97(7):1644–1652.

Sternberg CN, de Mulder P, Schornagel JH, et al. Seven year update of an EORTC phase III trial of high dose intensity M-VAC chemotherapy and G-CSF versus classic M-VAC in advanced urothelial tract tumors (EORTC protocol 30924). *Eur J Cancer*. 2006;42(1):50–54.

Sternberg CN, Skoneczna IA, Castellano D, et al. Larotaxel with cisplatin in the first-line treatment of locally advanced/metastatic urothelial tract or bladder cancer: a randomized, active-controlled, phase III trial (CILAB). *Oncology*. 2013;85(4):208–215.

Steven K, Poulsen AL. Radical cystectomy and extended pelvic lymphadenectomy: survival of patients with lymph node metastasis above the bifurcation of the common iliac vessels treated with surgery only. *J Urol*. 2007;178(4 Pt 1):1218–1223 [discussion 1223–1224].

Stockle M, Meyenburg W, Wellek S, et al. Advanced bladder cancer (stages pT3b, pT4a, pN1 and pN2): improved survival after radical cystectomy and 3 adjuvant cycles of chemotherapy: results of a controlled prospective study. *J Urol*. 1992;148:302–307.

Stockle M, Meyenburg W, Wellek S. Adjuvant polychemotherapy of nonorgan-confined bladder cancer after radical cystectomy revisited: long term results of a controlled prospective study and further clinical experience. *J Urol*. 1995;153:47–52.

Studer UE, Bacchi M, Biedermann C. Adjuvant cisplatin chemotherapy following cystectomy for bladder cancer: results of a prospective randomized trial. *J Urol*.

1994;152:81–84.

Svatek RS, Shariat SF, Novara G, et al. Discrepancy between clinical and pathological stage: external validation of the impact on prognosis in an international radical cystectomy cohort. *BJU Int*. 2011;107(6):898–904.

Sved PD, Gomez P, Nieder AM, et al. Upper tract tumour after radical cystectomy for transitional cell carcinoma of the bladder: incidence and risk factors. *BJU Int*. 2004;94(5):785–789.

Sweeney CJ, Roth BJ, Kabbinavar FF, et al. Phase II study of pemetrexed for second-line treatment of transitional cell cancer of the urothelium. *J Clin Oncol*. 2006;24(21):3451–3457.

Sylvester R, Sternberg C. The role of adjuvant combination chemotherapy after cystectomy in locally advanced bladder cancer: what we do not know and why. *Ann Oncol*. 2000;11(7):851–856.

Tabibi A, Simforoosh N, Parvin M, et al. Predictive factors for prostatic involvement by transitional cell carcinoma of the bladder. *Urol J*. 2011;8(1):43–47.

Tarin TV, Power NE, Ehdaie B, et al. Lymph node-positive bladder cancer treated with radical cystectomy and lymphadenectomy: effect of the level of node positivity. *Eur Urol*. 2012;61(5):1025–1030.

Tilki D, Reich O, Karakiewicz PI, et al. Validation of the AJCC TNM substaging of pT2 bladder cancer: deep muscle invasion is associated with significantly worse outcome. *Eur Urol*. 2010;58(1):112–117.

Tilki D, Svatek RS, Karakiewicz PI, et al. pT3 substaging is a prognostic indicator for lymph node negative urothelial carcinoma of the bladder. *J Urol*. 2010;184(2):470–474.

Tollefson MK, Blute ML, Farmer SA, et al. Significance of distal ureteral margin at radical cystectomy for urothelial carcinoma. *J Urol*. 2010;183(1):81–86.

Tran W, Serio AM, Raj GV, et al. Longitudinal risk of upper tract recurrence following radical cystectomy for urothelial cancer and the potential implications for long-term surveillance. *J Urol*. 2008;179(1):96–100.

Tuncbilek N, Kaplan M, Altaner S, et al. Value of dynamic contrast-enhanced MRI and correlation with tumor angiogenesis in bladder cancer. *Am J Roentgenol*. 2009;192:949–955.

Tunio MA, Hashmi A, Qayyum A, et al. Whole pelvis or bladder-only chemoradiation for lymph node-negative invasive bladder cancer: single-institution experience. *Int J Radiat Oncol Biol Phys*. 2012;82(3):e457–e462.

Urakami S, Yuasa T, Yamamoto S, et al. Clinical response to induction chemotherapy predicts improved survival outcome in urothelial carcinoma with clinical lymph nodal metastasis treated by consolidative surgery. *Int J Clin Oncol*. 2015;20(6):1171–1178.

Varol C, Thalmann GN, Burkhard FC, et al. Treatment of urethral recurrence following radical cystectomy and ileal bladder substitution. *J Urol*. 2004;172(3):937–942.

Vaughn DJ, Broome CM, Hussain M, et al. Phase II trial of weekly paclitaxel in patients with previously treated advanced urothelial cancer. *J Clin Oncol*. 2002;20(4):937–940.

Vazina A, Dugi D, Shariat SF, et al. Stage specific lymph node metastasis mapping in radical cystectomy specimens. *J Urol*. 2004;171(5):1830–1834.

Volkmer BG, Schnoeller T, Kuefer R, et al. Upper urinary tract recurrence after radical cystectomy for bladder cancer—who is at risk? *J Urol*. 2009;182(6):2632–2637.

von der Maase H, Hansen SW, Roberts JT, et al. Gemcitabine and cisplatin versus methotrexate, vinblastine, doxorubicin, and cisplatin in advanced or metastatic bladder cancer: results of a large, randomized, multinational, multicenter, phase III study. *J Clin Oncol*. 2000;18(17):3068–3077.

von der Maase H, Sengelov L, Roberts JT, et al. Long-term survival results of a randomized trial comparing gemcitabine plus cisplatin, with methotrexate, vinblastine, doxorubicin, plus cisplatin in patients with bladder cancer. *J Clin Oncol*. 2005;23(21):4602–4608.

von der Maase H, Lehmann J, Gravis G, et al. A phase II trial of pemetrexed plus gemcitabine in locally advanced and/or metastatic transitional cell carcinoma of the urothelium. *Ann Oncol*. 2006;17(10):1533–1538.

von Hardenberg J, Martini T, Knauer A, et al. Expression and predictive value of lymph-specific markers in urothelial carcinoma of the bladder. *Urol Oncol*. 2014;32(1):54.e9–54.e17.

Wagner KR, Schoenberg MP, Bianco FJ Jr, et al. Prospective intermediate follow-up of carcinoma in situ involving the distal ureter at cystectomy: is there a role for ureteroscopy? *J Endourol*. 2008;22(6):1241–1246.

Wallace DM, Raghavan D, Kelly KA, et al. Neo-adjuvant (pre-emptive) cisplatin therapy in invasive transitional cell carcinoma of the bladder. *Br J Urol*. 1991;67:608–615.

Welty CJ, Sanford TH, Wright JL, et al. The cancer of the bladder risk assessment (COBRA) score: estimating mortality after radical cystectomy. *Cancer*. 2017;123(23):4574–4582.

Willis DL, Porten SP, Kamat AM. Should histologic variants alter definitive treatment of bladder cancer? *Curr Opin Urol*. 2013;23(5):435–443.

Winquist E, Kirchner TS, Segal R, et al. Neoadjuvant chemotherapy for transitional cell carcinoma of the bladder: a systematic review and meta-analysis. *J Urol*. 2004;171(2 Pt 1):561–569.

Winquist E, Vokes E, Moore MJ, et al. A phase II study of oxaliplatin in urothelial cancer. *Urol Oncol*. 2005;23(3):150–154.

Witte RS, Elson P, Bono B, et al. Eastern Cooperative Oncology Group phase II trial of ifosfamide in the treatment of previously treated advanced urothelial carcinoma. *J Clin Oncol*. 1997;15(2):589–593.

Wong YN, Litwin S, Vaughn D, et al. Phase II trial of cetuximab with or without paclitaxel in patients with advanced urothelial tract carcinoma. *J Clin Oncol*. 2012;30(28):3545–3551.

Wood DP Jr, Montie JE, Pontes JE, et al. Identification of transitional cell carcinoma of the prostate in bladder cancer patients: a prospective study. *J Urol*. 1989;142(1):83–85.

Wülfing C, Machiels J, Richel D, et al. A single arm, multicenter, open label, phase II study of lapatinib as the second-line treatment of patients with locally advanced or metastatic transitional cell carcinoma. *Cancer*. 2009;115:2881–2890.

Wunderlich H, Wolf M, Reichelt O, et al. Radical cystectomy with ultrasound-guided partial prostatectomy for bladder cancer: a complication-preventing concept. *Urology*. 2006;68(3):554–559.

Yafi FA, Duclos M, Correa JA, et al. Contemporary outcome and management of patients who had an aborted cystectomy due to unresectable bladder cancer. *Urol Oncol*. 2011;29(3):309–313.

Yoon CY, Lee JS, Kim BS, et al. Sunitinib malate synergistically potentiates anti-tumor effect of gemcitabine in human bladder cancer cells. *Korean J Urol*. 2011;52(1):55–63.

Yoshida S, Koga F, Kobayashi S, et al. Role of diffusion-weighted magnetic resonance imaging in predicting sensitivity to chemoradiotherapy in muscle-invasive bladder cancer. *Int J Radiat Oncol Biol Phys*. 2012;83(1):e21–e27.

Youssef RF, Mitra AP, Bartsch G Jr, et al. Molecular targets and targeted therapies in bladder cancer management. *World J Urol*. 2009;27(1):9–20.

Youssef RF, Shariat SF, Kapur P, et al. Expression of cell cycle-related molecular markers in patients treated with radical cystectomy for squamous cell carcinoma of the bladder. *Hum Pathol*. 2011;42(3):347–355.

Zaak D, Burger M, Otto W, et al. Predicting individual outcomes after radical cystectomy: an external validation of current nomograms. *BJU Int*. 2010;106(3):342–348.

Zaghloul MS, Awwad HK, Akoush HH, et al. Postoperative radiotherapy of carcinoma in bilharzial bladder: improved disease free survival through improving local control. *Int J Radiat Oncol Biol Phys*. 1992;23(3):511–517.

Zaghloul MS, Christodouleas JP, Smith A, et al. Adjuvant sandwich chemotherapy plus radiotherapy vs adjuvant chemotherapy alone for locally advanced bladder cancer after radical cystectomy: a randomized phase 2 trial. *JAMA Surg*. 2018;153(1):e174591.

Zargar-Shoshtari K, Zargar H, Lotan Y, et al. A multi-institutional analysis of outcomes of patients with clinically node positive urothelial bladder cancer treated with induction chemotherapy and radical cystectomy. *J Urol*. 2016;195(1):53–59.

Surgical Management of Bladder Cancer

Transurethral, Open, and Robotic

Neema Navai MD, Colin P.N. Dinney MD

According to data available from the American Cancer Society, in 2018 there were expected to be an estimated 81,190 new cases and 17,240 deaths from bladder cancer in the United States (Noone et al., 2018). **This ranks bladder cancer as one of the most common noncutaneous malignancies in the United States.** Without appropriate surgical therapy, the disease can be deadly and can impart significant health care costs. Surgical therapy, whether for non–muscle-invasive or muscle-invasive disease, requires careful attention to technique, oncologic principles, and a firm understanding of disease pathogenesis.

During the initial evaluation, not only does **transurethral resection (TUR) help to establish the pathological diagnosis and the local extent of the disease but should be viewed as a complete oncologic procedure, especially in the setting of low-grade and non–muscle-invasive tumors.** However, in the setting of a muscle-invasive tumor, to achieve adequate local control and to maximize the chance for cure, radical cystectomy with a regional lymph node dissection is necessary.

The history of TUR and surgical removal of the bladder dates to the 1800s. Bardenheuer of Germany is credited with performing the first cystectomy in 1887 in a patient with an advanced tumor of the bladder (Stenzl et al., 2005). Around that same time the first modern endoscope was invented through collaboration between Maximilian Carl-Friedrich Nitze and Joseph Leiter. Nitze, another German urologist, and Leiter, an instrument maker, created a tool that would evolve into the modern instrumentation used today.

The first modern technique for radical cystectomy appeared in 1956 from

Paquin and Marshall. In their early description, radical cystectomy in men began with a perineal exploration and dissection of the rectum from the bladder and prostate under direct visualization. In addition, they favored cutaneous ureterostomies for urinary diversion (Paquin and Marshall, 1956). The initial report by Whitmore and Marshall (1956) of surgical outcomes in 100 patients in that same year demonstrated significant morbidity and 17 (17%) postoperative deaths. Refinements during the years have resulted in substantial improvements in oncologic outcomes and surgical morbidity. A more contemporary analysis of 1142 patients demonstrated only a 0.9% inpatient mortality rate and a 2.7% 90-day mortality rate after radical cystectomy (Shabsigh et al., 2009).

Oncologic outcomes have similarly improved from the 21% to 49% 5-year survival rate reported by Whitmore and Marshall in 1962 to a 59% 5-year survival rate in a study of 507 patients (Madersbacher et al., 2003) and 66% in the largest report to date of 1054 patients treated at the University of Southern California. In addition to improvements in surgical technique, **the administration of neoadjuvant chemotherapy has been demonstrated to improve survival from a median of 46 months to 77 months** (Grossman et al., 2003) **and should be considered in all patients with muscle-invasive tumors who are scheduled to undergo radical cystectomy.** The landscape of systemic therapy for bladder cancer is rapidly changing with the addition of immuno-oncologic therapies for bladder cancer. We anticipate changes to the paradigm of treatment in the coming years, including early stage disease. In addition, further refinements in patient selection and the use of molecular profiling are likely to enter into the decision process in the management of bladder cancer patients. It goes without saying that any clinician managing bladder cancer patients needs to stay diligent and up to date in regard to these developments.

Transurethral Resection of Bladder Tumors

Advances in operative instrumentation have greatly enhanced the ability of urologists to identify, treat, and follow patients with bladder tumors. The approach to a new patient with a bladder tumor mirrors that of any new patient visit, with particular attention paid to those factors most likely to have contributed to the development of bladder cancer. A detailed history and physical examination should be performed. Care should be taken to identify known risk factors including but not limited to tobacco exposure, previous cyclophosphamide chemotherapy, aromatic amines, and phenacetin use. Information regarding surgical implants and valvular heart disease may influence antibiotic prophylaxis and should be obtained and compared with current guidelines. In addition, all patients should be queried regarding either a personal or a family history of bleeding with procedures and the use of anticoagulants, because these questions are relevant in preparation for surgery. We have not observed significant bleeding difficulty in patients who are on aspirin, and it is not our routine to stop aspirin therapy; however, we advise caution in patients taking other anticoagulants (e.g., warfarin, heparin, clopidogrel, ticagrelor, prasugrel) because these pose a higher bleeding risk. The specific timing of discontinuation as it relates to each medication's half-life and the need for bridging should be discussed preoperatively with the appropriate care team.

Physical examination should be thorough and include palpation of abdomen in the suprapubic region noting any palpable mass. A digital rectal examination (DRE) in men can be informative and may aid if there is a suspicion for prostatic involvement. Likewise a bimanual examination in women can elucidate anterior vaginal involvement. Routine laboratory studies should be obtained and include a complete blood count, metabolic panel, coagulation panel, and urinalysis with culture. In the setting of active infection, resection should be delayed until clearance of bacteria with appropriate therapy.

Upper tract imaging should be obtained to complete the diagnostic evaluation and this can include renal ultrasound in conjunction with retrograde pyelogram, computed tomography (CT) urogram (CTU), magnetic resonance imaging (MRI), and rarely intravenous pyelogram. Care should be taken to ensure adequate renal function (glomerular filtration rate

[GFR] > 60 mL/min) if intravenous iodinated contrast is being considered. As an alternative, MRI contrast agents can be administered for GFR greater than 30 mL/min, but these are contraindicated for those less than 30 mL/min. In the case of muscle-invasive tumors, formal staging evaluation should be obtained inclusive of the chest, abdomen, and pelvis.

Patients will routinely have first undergone cystoscopy in the office with a flexible cystoscopy, allowing for visual confirmation of a mucosal tumor and aiding in surgical planning. At the time of diagnostic cystoscopy, care should be taken to note the location and extent of tumor burden.

Although experienced clinicians have been known to predict accurately the stage and grade of tumors on follow-up cystoscopy (Herr et al., 2002), adequate tissue sampling must be obtained at baseline even when a low-grade tumor is suspected. In the setting of tumors overlying a ureteral orifice, clinicians should be prepared to perform additional interventions including ureteroscopy and ureteral stent placement, and they may require the use of fluoroscopy at the time of TUR.

TUR of bladder tumors is performed with the aid of a rigid cystoscope. To ensure adequate maneuverability the patient should be positioned in dorsal lithotomy. Based largely on an extrapolation from a randomized study examining antibiotic prophylaxis for TUR of the prostate in 400 patients, which showed a reduction in postoperative bacteriuria (Wagenlehner et al., 2005), **the American Urologic Association recommends the routine use of antibiotic prophylaxis for patients undergoing TUR of bladder tumors**, and it should be administered within 1 hour of the procedure. **As of July 2016 the US Food and Drug Administration (FDA) changed the label for fluoroquinolone antibiotics. This warning cautioned against the use of this class of antibiotics for conditions such as uncomplicated urinary tract infections, and, although no specific statement was made regarding their use as prophylactic antibiotics, we advise alternate classes of antibiotics be used whenever possible.**

A thorough visual inspection is then performed using the 30-degree lens to examine the urethra in its entirety and then to perform a preliminary evaluation of the bladder mucosa and ureteral orifices. A visual obturator should be used to minimize trauma to the urethra during this phase. After initial inspection, a 70-degree lens should be used to completely evaluate the bladder again with particular attention paid to the bladder neck, dome, and anterior wall. If necessary a more acute lens such as a 120-degree can be used if full visualization is not possible otherwise. The location and extent of tumors should be noted.

Resection can then be performed with either monopolar or bipolar electrocautery. Irrigation fluid can either be sterile water or 1.5% glycine in the case of monopolar electrocautery or 0.9% sodium chloride if bipolar current is used. This has the added benefit of lowering the risk of postoperative electrolyte abnormalities as well as mitigating an obturator reflex if the tumor is overlying the lateral walls of the bladder.

The goal of any resection should be the visual eradication of any tumor burden and the assurance of an adequate depth of resection. Using cutting current, a loop electrode is used to resect the tumor inclusive of muscularis propria (Fig. 138.1). Histologically, bladder tumors frequently exhibit growth beyond the visible edge and, as such, resection should include an approximate 2-cm margin of normal-appearing tissue. Wide resection of tumors ensures completeness whether the tumor has a broad base or a tentacular growth pattern (Fig. 138.2). After resection to visual completion, the bladder should be emptied and a bimanual examination under anesthesia (EUA) performed. Accordingly, any palpable lesion should be noted and staged clinically (cT3b). **In addition, the American Urologic Association and Society of Urology Oncology joint guideline statement recommends enhanced cystoscopic techniques such as narrow band imaging and blue light cystoscopy whenever possible.** These techniques have been shown to increase tumor detection and decrease recurrence rates

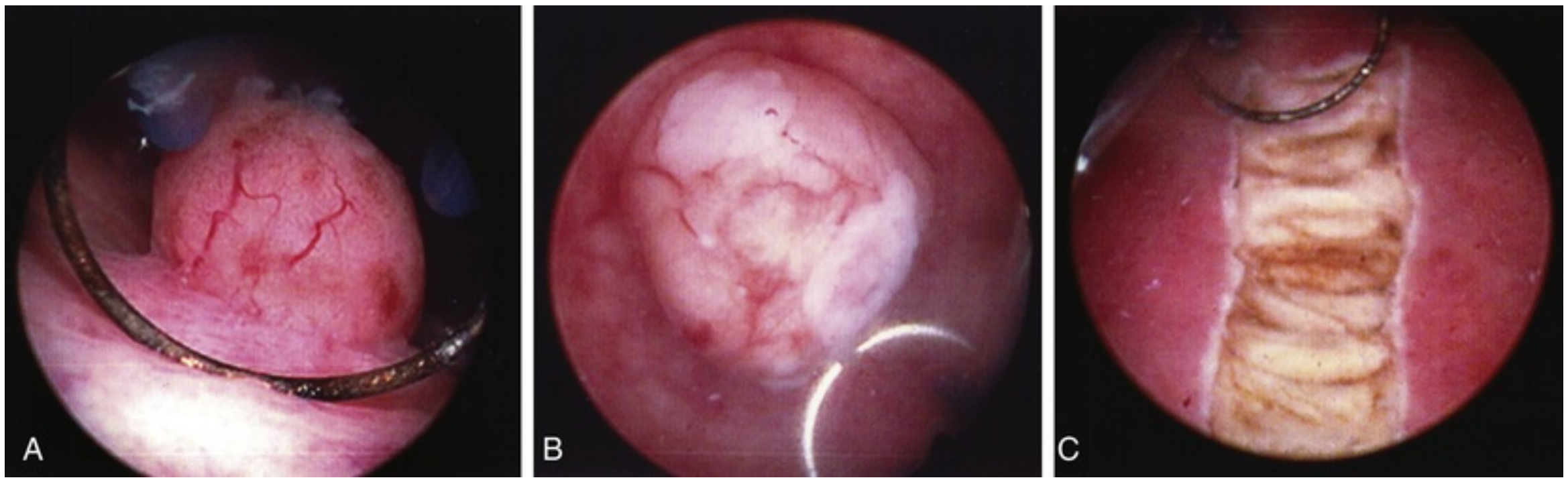

FIG. 138.1 (A) Broad-based papillary lesion. (B**)** Resection of lesion with loop electrocautery. (C) Depth of resection to detrusor muscle.

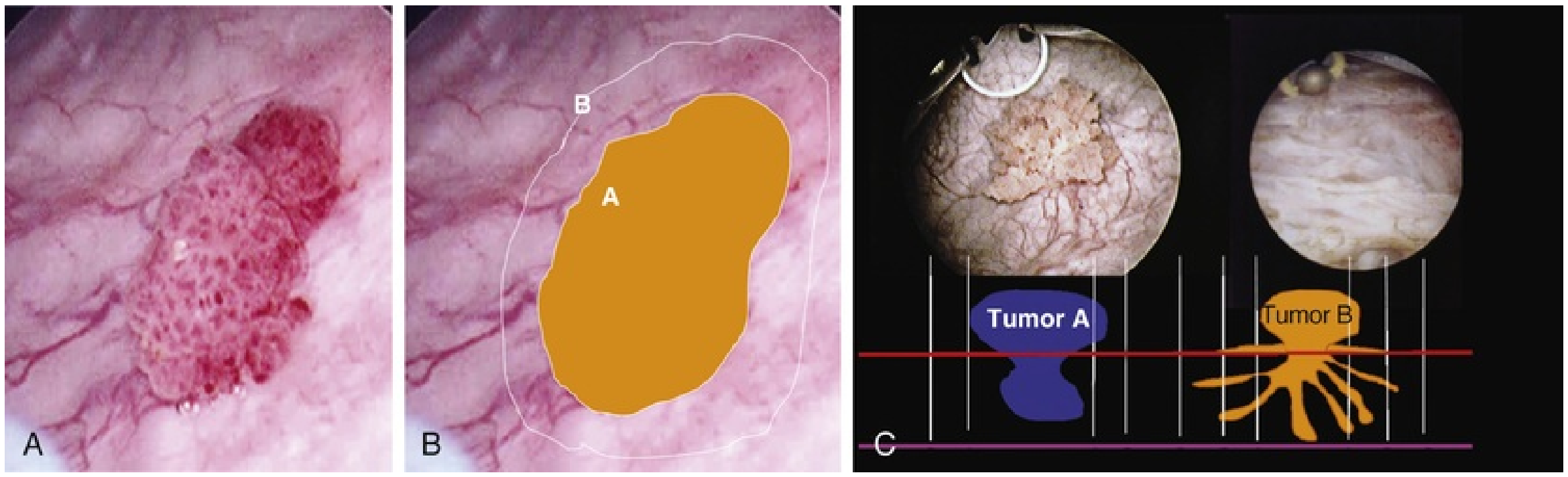

FIG. 138.2 (A) Papillary bladder lesion. (B) Visual boundary of tumor *(A)* and margin of resection to optimize tumor destruction *(B).* (C) Deep invasion of tumor in broad-based and tentacular pattern.

Tumors may pose specific challenges, and a proper understanding of technique helps minimize the risk of complications. When tumors are encountered on the lateral wall, there is the risk of an obturator reflex whereby the cautery current stimulates the obturator nerve, causing the ipsilateral leg to adduct. This can lead to inadvertent deflection of the instrument laterally and can cause perforation. To lessen this risk, we recommend the following techniques. First, minimize distention of the bladder to the minimum needed to perform the resection. Second, check whether available bipolar cautery may mitigate or eliminate the reflex. Last, if the patient is under a general anesthetic, muscle relaxant can be administered, thereby lessening any movement resulting from obturator nerve stimulation.

Tumors overlying a ureteral orifice pose another challenge. In this setting, only pure cutting current should be used, and resection strokes should be as quick as possible to minimize the possibility of cauterizing the ureteral orifice closed. **Data suggest routine stenting is not necessary after ureteral orifice resection.** Mano et al. (2012) found that of 79 patients in whom a ureteral orifice was resected, only 3 (4%) developed hydronephrosis. Although this retrospective study would suggest stenting is not needed in the case of large resections and extensive cautery, we would suggest that stenting may be useful in the short term, although it may not affect ultimate stricture rates. Finally, tumors located at the dome of the bladder may be difficult to resect because of angulation, distance, and concern for intraperitoneal perforation. The challenges are multifactorial and in some cases difficult to overcome. Minimizing bladder distention and suprapubic pressure, either with your nondominant hand or with that of an assistant, can help maneuver the bladder tumor into a location more amenable to resection. A straight ahead loop can also be employed. Care should be observed to avoid prolonged cautery because transmission of heat/energy could potentially occur to adjacent bowel viscera even in the absence of bladder perforation.

Perforation of the bladder may be the natural result of an adequate resection, especially in the setting of advanced tumors (Fig. 138.3). Whereas posterior tumors and those of the dome may result in an intraperitoneal perforation (see Fig. 138.3B), resections elsewhere in the bladder are more likely to result in an extraperitoneal perforation (see Fig. 138.3A). In the event of an extraperitoneal perforation, treatment consists of Foley catheter drainage and observation. However, **large intraperitoneal perforations, although rare, with an incidence of 0.36% in a study of 4144 TURs** (Golan et al., 2010)**, can lead to significant morbidity.** Findings during resection suggestive of an intraperitoneal rupture include loss of bladder distention, visualization of a defect posteriorly or at the dome, and palpable distention of the abdomen. When suspected, confirmation can be obtained with a cystogram at the same setting. In the presence of an intraperitoneal rupture, treatment consists of abdominal exploration, meticulous inspection of the bowel, and repair of the injury with a Foley catheter and abdominal drainage.

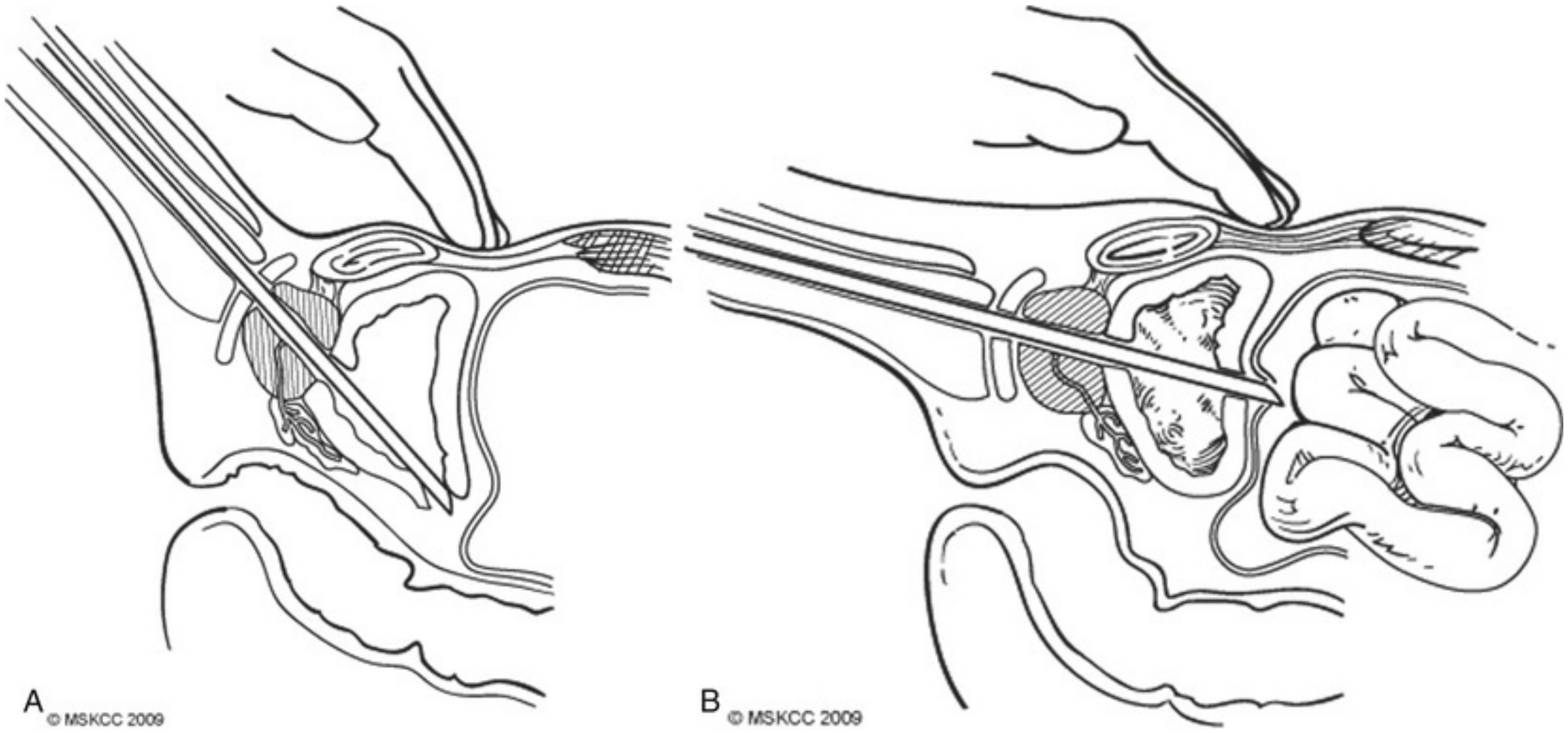

FIG. 138.3 (A) Extraperitoneal bladder rupture during transurethral resection (TUR) of a bladder tumor. (B) Intraperitoneal bladder rupture during TUR of a bladder tumor with subsequent intraperitoneal leakage of irrigant and urine. (A and B, Copyright 2009 Memorial Sloan Kettering Cancer Center.)

Although data would suggest little to no effect on progression rates, adjuvant intravesical chemotherapy has demonstrated efficacy in reducing recurrences (Kurth et al., 1997). A meta-analysis of 18 randomized controlled trials for a pooled cohort of 3103 patients showed that a single dose of intravesical chemotherapy (e.g., mitomycin C, epirubicin) within 24 hours after TUR of non–muscle-invasive bladder tumor resulted in a 13% absolute reduction in tumor recurrence from 50% to 37%, yielding a number needed to treat of 7.2 (Abern et al., 2013). **Further data supporting the use of perioperative chemotherapy are demonstrated by the recently published Southwest Oncology Group (SWOG) trial S0337. Messing et al.** (2018) **conducted a randomized double-blind trial comparing perioperative gemcitabine (2 g in 100 mL of saline) to saline alone (100 mL) immediately after TUR. The treatment was very well tolerated, with no grade 4 or 5 toxicities, and produced an absolute reduction in recurrences of 12% at 4 years (HR 0.66, $P < 0.01$).** Caution should be applied, however, and adjuvant therapy should only be administered in the absence of perforation. In the setting of high-grade non–muscle-invasive disease, bacille Calmette-Guérin therapy remains the most active agent but should not be administered in the immediate postoperative setting. Rather, a waiting period of 2 to 4 weeks should be observed and a lack of gross hematuria confirmed before administration.

Patient Preparation

In advance of surgical therapy for bladder cancer, appropriate preoperative staging and medical evaluation should be performed. **Patients with adequate renal function and an absence of allergy to iodinated contrast can be staged with CT of the chest, abdomen, and pelvis. In instances in which renal function is impaired, MRI can be substituted.** This allows for assessment of distant and regional disease spread and can guide the use of neoadjuvant chemotherapy. Although studies have been conducted examining novel agents for the detection of lymph node metastasis (Birkhäuser et al., 2013) and comparing MRI and CT accuracy (Vargas et al., 2012), CT currently remains the most common modality for staging. A retrospective analysis of 100 patients by Baltaci et al. (2013) demonstrated an accuracy of 72% and 86% for the detection of perivesical invasion and lymph node metastasis, respectively. In a smaller study of 16 patients comparing MRI with CT imaging accuracy in determining final T stage, CT was correct in 63%, overstaged in 31%, and understaged in 6% (Vargas et al., 2012).

After confirmation before surgery of localized disease, patients should undergo routine medical evaluation to maximize health status. Comorbidities such as coronary artery disease, smoking-related lung disease, and peripheral vascular disease will commonly be encountered. After medical optimization, regardless of preferred urinary diversion, enterostomal therapy should be used for stoma marking. Although rare, patients should be made aware of the possibility of an ileal conduit urinary diversion even in the case of a planned continent diversion. **Careful marking of the ostomy site to avoid interference, in a standing and in a seated position, is performed to maximize appliance fit and to minimize stomal irritation.** If stomal therapists are not available, the surgeon should be familiar with marking strategies and should perform these while the patient is awake and wearing typical clothing.

Mechanical bowel preparation was historically used in the hope of mitigated anastomotic leak, abdominal, and wound infections in patients undergoing bowel surgery. However, the results of two large randomized trials in colorectal surgery have brought into question this assumption. **Ren et al.** (2011) **found, in their study of an enhanced recovery pathway following colorectal surgery, that those who did not undergo a bowel preparation, among other modifications, were no more likely to experience a complication (9.4% vs. 9.7%) and had**

similar rates of anastomotic leak. Another large study of 380 patients who underwent colorectal surgery with or without mechanical bowel preparation showed that wound infection rates (prep vs. no prep 6.4% vs. 5.7%), anastomotic leak (prep vs. no prep 3.7% vs. 2.1%), and abdominal abscess (prep vs. no prep 1.1% vs. 1%) were similar (Zmora et al., 2003). Further study in radical cystectomy patients undergoing ileal conduit urinary diversion demonstrated similar findings (Xu et al., 2010). In addition, a study of 40 patients undergoing radical cystectomy with ileal urinary diversion randomized to either 3-day bowel preparation or overnight fasting showed a lower incidence in prolonged ileus (10% vs. 5%) if bowel preparation was not used (Hashad et al., 2012). For this reason **we advise against routine bowel preparation for patients undergoing radical cystectomy with urinary diversion, especially if only ileal segments are to be used.**

To enhance further the return to bowel function, the μ-opioid receptor antagonist alvimopan should be administered 30 to 90 minutes before surgery; it has been studied and it demonstrates a benefit in functional bowel recovery and length of hospitalization. The results of a phase III multicenter trial of alvimopan administered 30 to 90 minutes before bowel resection and twice daily thereafter indicated that those who received this drug exhibited lower rates of postoperative ileus (7.3% vs. 15. 7%) and a time decrease of 6.2 to 5.2 days for a written discharge order to be provided (Ludwig et al., 2008). A phase IV study examining the same drug in radical cystectomy patients demonstrated a 2.63-day reduction in hospital stays, lower rates of total parenteral nutrition for postoperative ileus (10% vs. 25%), and a cost savings of $2340 to $2640 per patient (Kauf et al., 2014).

Although we do not advise on the routine use of oral antibiotic prophylaxis as an adjunct to mechanical bowel preparation, **intravenous antibiotics should be administered within 1 hour of surgical incision**. The choice of antibiotic should be customized to local bacterial susceptibility patterns and should include gram-positive coverage (skin flora) and gram-negative aerobes and anaerobes (distal small bowel and large bowel flora). Generally a broad-spectrum cephalosporin such as cefoxitin will provide adequate coverage. Last, in the absence of significant bleeding, high-risk **patients should undergo both mechanical thromboembolic prophylaxis (pneumatic compression) and pharmacologic prophylaxis before the induction of general or spinal anesthesia.** Extended prophylaxis in the postoperative period has also been shown to decrease thromboembolic events. A prospective study of 703 patients randomized to either 8 days or 28 days of pharmacologic prophylaxis after abdominal or pelvic surgery showed that those treated for 4 weeks had an 82.4% reduction in the incidence of major venous thromboembolism (0.8% vs. 4.6%) without an increase in bleeding complications (Kakkar et al., 2010).

Patient positioning is vital to provide adequate exposure and to minimize the risk of related complications. Male patients should be placed supine with the flexion point of the table at the level of the anterior superior iliac spine (Fig. 138.4A). Flexion to 15 degrees is usually adequate and can be lessened as necessary if there is a history of spinal fusion or lumbar injury. In women, a low lithotomy position with the aid of stirrups or the use of spreader bars provides access to the vagina. In female patients, table flexion is generally not possible. The operative field should be inclusive of the abdomen from the level of the xiphoid to the upper portion of the thighs. The genital organs, including the vagina in women, and the perineum should be prepared as well. A solution containing 10% povidone-iodine is recommended; preparations containing chlorhexidine gluconate should be avoided when used on genital skin.

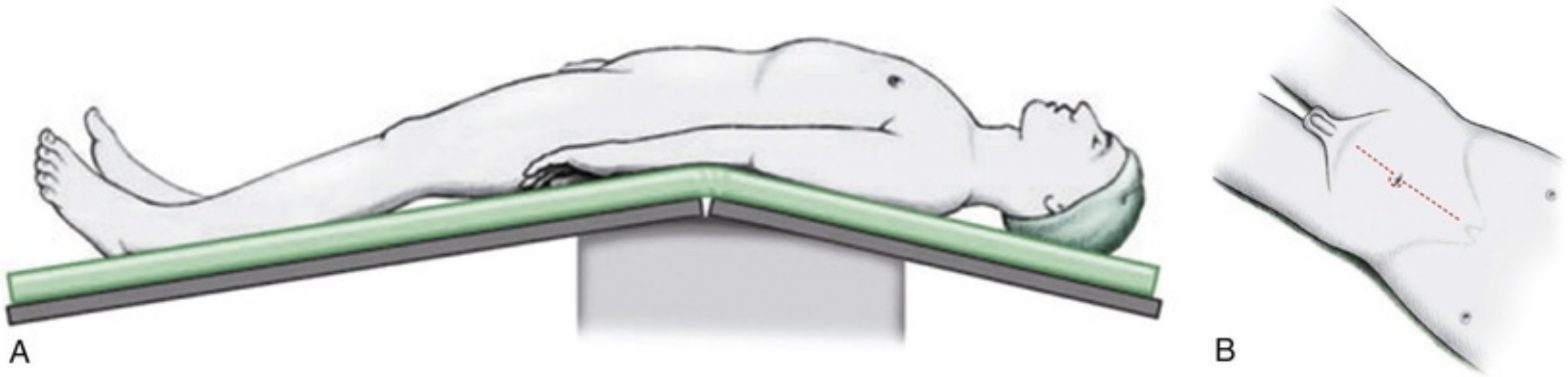

FIG. 138.4 Positioning of the patient in the supine position with the bed flexed to 15 degrees (A). An incision is made in the midline from 2 cm above the umbilicus to just above the level of the pubis (B).

Surgical Technique

A lower midline incision is made sharply extending distally from the level of the symphysis pubis to the umbilicus superiorly. Frequently an infraumbilical incision provides adequate exposure but can be extended cephalad as needed (Fig. 138.4B). Ensuring incision of the abdominal fascia in the midline aids in fascial closure and prevention of inadvertent release of the rectus abdominis from its tendinous insertion at the level of the pubis. Upward retraction of the umbilicus (toward the ceiling) aids in the identification of the linea alba. After the midline is identified, the fascia is divided and the space of Retzius is entered. Blunt dissection is performed to release the bladder from the pelvic sidewall attachments bilaterally. This is carried in a cephalad direction to the level of the vas deferens in men and the round ligament in women. At this point a peritoneotomy is made lateral to either medial umbilical ligament and the urachus is controlled and divided (Fig. 138.5). The peritoneum is incised lateral to the medial umbilical ligaments bilaterally to the level of the internal inguinal rings at which point the vas deferentia in men and the round ligaments in women will be identified and are divided.

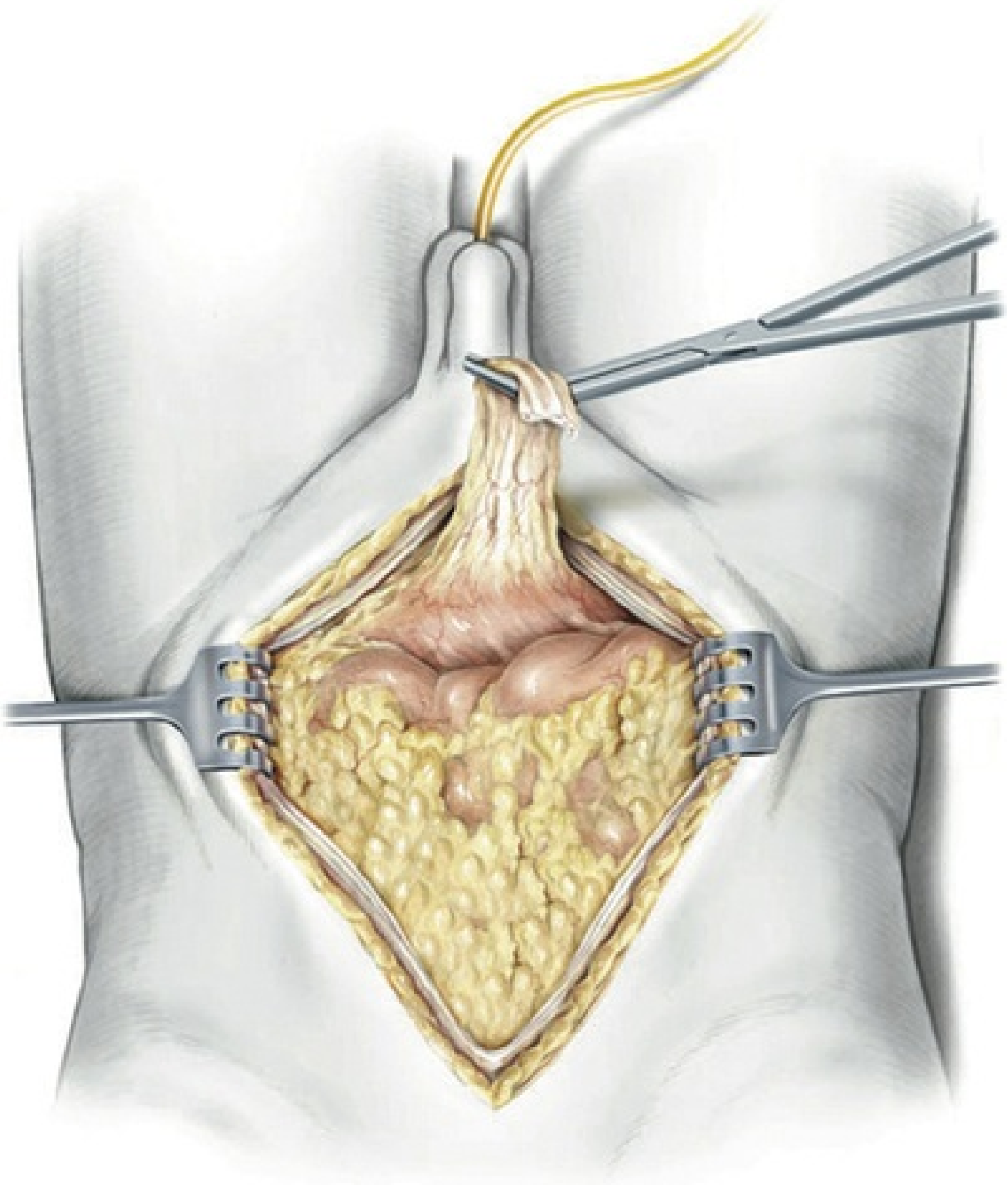

FIG. 138.5 Mobilization and division of the umbilicus.

Attention is then turned to the bowel mobilization to achieve adequate exposure of the great vessels and the ureters. On the right side the white line of Toldt is incised and carried around the cecum where then the posterior peritoneum is incised to allow mobilization of the root of the small bowel mesentery. On the left side the white line of Toldt is likewise incised, and a window is created below the sigmoid colon mesentery to communicate with the right-sided posterior peritoneotomy. This space will later be used to transpose the left ureter to the right lower quadrant for urinary diversion (Fig. 138.6).

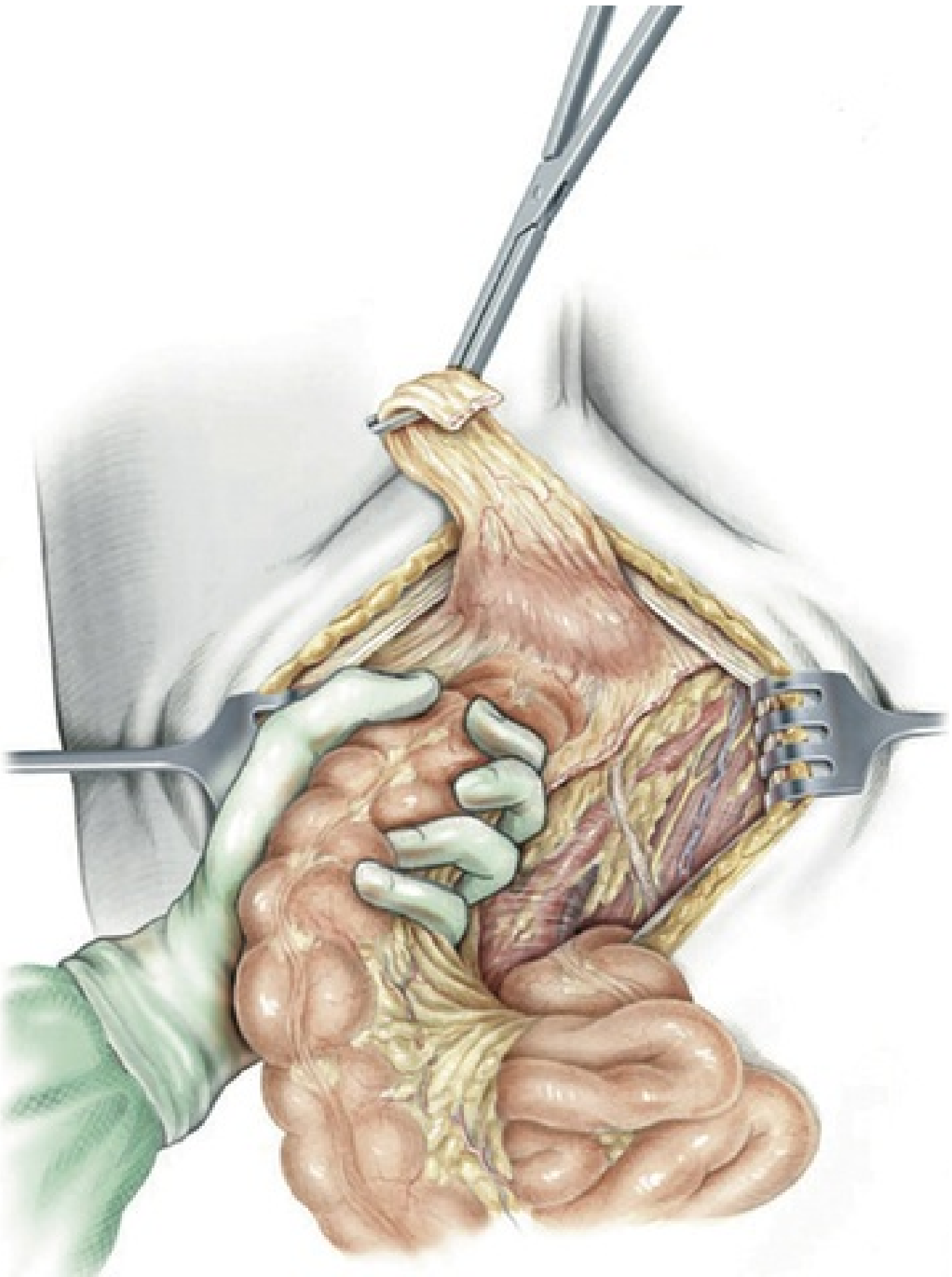

FIG. 138.6 Mobilization of the root of the small bowel mesentery and the left colon.

With the aid of a retractor such as a Bookwalter, exposure is maximized and the bowel retracted cephalad. Communication with the anesthesiologist at this point is vital to ensure that inadvertent compression of the vena cava has not occurred. A moistened laparotomy pad or pads should be placed behind retractor blades to protect the abdominal contents. After adequate exposure is achieved, the bilateral ureters are dissected free from their attachments beginning a few centimeters above where they cross the iliac arteries to the level of the detrusor hiatus. Care should be used to ensure that adequate ureteral adventitia is maintained. The obliterated umbilical artery should be ligated and divided before completing the ureteral dissection; this aids in maximizing ureteral length. The ureter is then controlled with either suture ties or suture ligature and divided.

Although controversial, the distal ureteral margin can be sent for frozen section analysis to evaluate for the presence of urothelial carcinoma. Although **studies have shown a correlation between findings of carcinoma in the**

ureteral margin and subsequent upper tract recurrence (Schumacher et al., 2006), an impact on survival has not been well established (Raj et al., 2006). In addition, the study by Raj et al. (2006) indicated that despite sequential resection to achieve a negative margin in 48 instances of an initial positive ureteral margin, upper tract recurrence was not eliminated. According to surgeon preference, temporary ureteral catheters directed off the surgical field can be used to maintain urinary flow during the remainder of the procedure, or the ureters can be temporarily ligated to avoid spillage of urine into the operative field.

Pelvic Lymphadenectomy

Pelvic lymphadenectomy can be performed at this time or after removal of the bladder specimen according to surgeon preference. **The anatomic boundaries of a standard template dissection consist of the genitofemoral nerves laterally, the internal iliac artery medially, Cooper ligament inferiorly, and the point at which the ureter crosses the common iliac artery superiorly** (Fig. 138.7A). In cases of advanced disease, an extended dissection inclusive of the entire common iliac lymph node packet and the presacral lymph node packet can be obtained (Fig. 138.7B). Although further extension cephalad to include the preaortic packet to the level of the inferior mesenteric artery has been studied in bladder cancer, none have demonstrated any additional staging information beyond a dissection from the common iliac arteries distally (Bochner et al., 2004, Bruins et al., 2014). Care should be taken during lymphadenectomy to avoid injury to the obturator nerve and to ensure control of lymphatics at the caudal and cephalad extremes (Fig. 138.7C) and when complete to confirm that no residual lymphoid tissue remains in the operative field (Fig. 138.7D). Surgical quality as measured by nodal yield has demonstrated a survival benefit in bladder cancer. **Herr et al.** (2004) **found that in patients in whom at least 10 lymph nodes were removed, 5-year survival improved from 44% to 61%.** Later an examination of 1260 patients in the Surveillance, Epidemiology, and End Results data set with lymph node metastatic bladder cancer showed that overall survival improved from a median of 13 months if 1 to 5 nodes were removed to 23 months if 10 or more were removed (Wright et al., 2008).

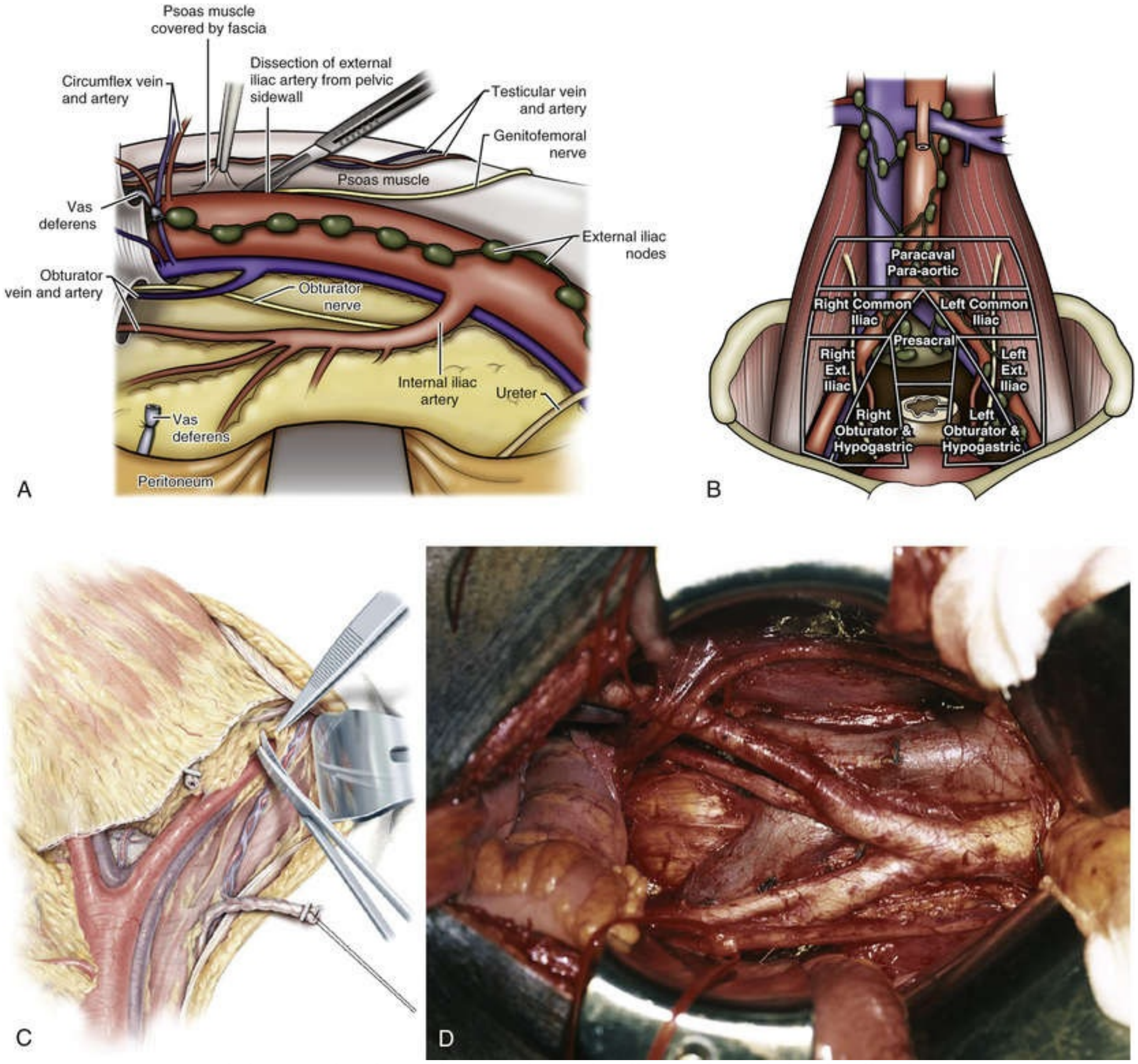
Psoas muscle covered by fascia
Circumflex vein and artery
Dissection of external iliac artery from pelvic sidewall
Testicular vein and artery
Genitofemoral nerve
Psoas muscle
Vas deferens
External iliac nodes
Obturator vein and artery
Obturator nerve
Internal iliac artery
Ureter
Vas deferens
Peritoneum
A
Paracaval Para-aortic
Right Common Iliac
Left Common Iliac
Presacral
Right Ext. Iliac
Left Ext. Iliac
Right Obturator & Hypogastric
Left Obturator & Hypogastric
B
C
D

FIG. 138.7 (A) Standard pelvic lymph node dissection. (B) Distributions of the eight node packets from an extended pelvic and retroperitoneal lymph node dissection. (C) Meticulous pelvic lymph node dissection. (D) Completed extended pelvic lymph node dissection.

Completion of the pelvic lymphadenectomy aids in the exposure and identification of the vascular pedicles to the bladder (Fig. 138.8). Control of the main branches to the bladder, including the superior, middle, and inferior vesical arteries, can be achieved with the aid of a vascular stapler (see Fig. 138.8B), surgical clips (see Fig. 138.8A), or vascular sealing instruments.

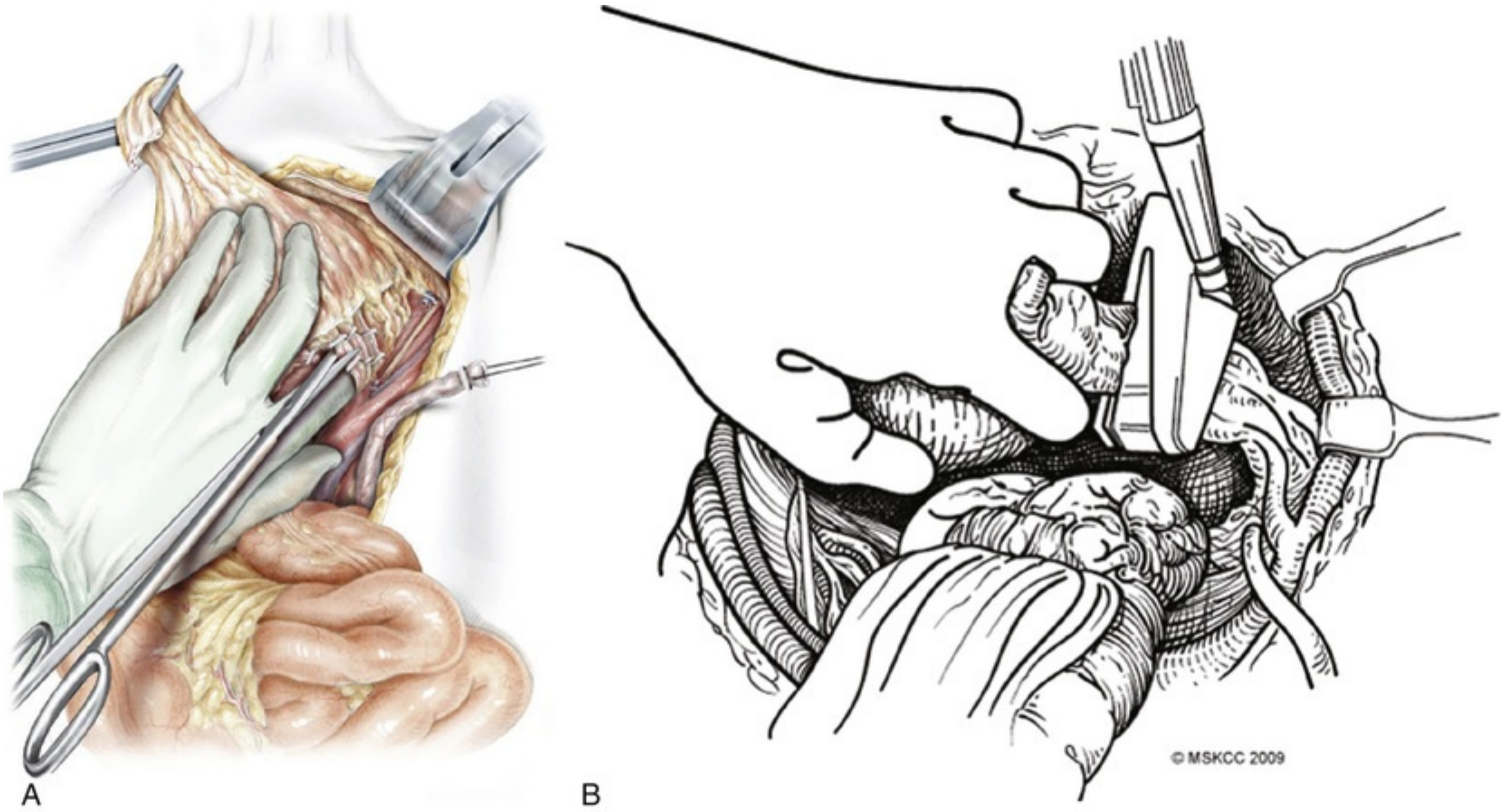

FIG. 138.8 (A) Application of clips to the lateral vascular pedicle of the bladder. (B) Application of an endovascular stapler to the lateral vascular pedicle of the bladder. (B, Copyright 2009 Memorial Sloan Kettering Cancer Center.)

Radical Cystectomy: Male

After the anterior vascular pedicle blood supply is completely ligated, attention is turned to the posterior dissection. The rectal cul-de-sac is identified and the peritoneum is incised where it overlies the seminal vesicles (Fig. 138.9A and B). If there is a large tumor at the base of the bladder, care must be observed to ensure an adequate margin of resection at this point. The rectum is dissected free with either blunt dissection or sharp dissection in the midline and is carried to the level of the prostate, at which point Denonvilliers fascia is encountered and incised. In cases of advanced disease, previous pelvic radiation, or reactive fibrosis from previous resection or intravesical chemotherapy, difficulty in developing this plane may be encountered. In such instances blunt dissection should not be performed, because this may cause inadvertent injury to the rectum. Instead, under direct visualization, sharp dissection should be performed with care taken to maintain rectal integrity. If a rectal injury is encountered, primary repair with or without flap coverage and/or bowel diversion should be performed (Kozminski et al., 1989). After release of the rectum in the midline, dissection is carried laterally and the posterior vesical pedicles are identified (Fig. 138.10A). Similar to the anterior pedicles, they can be controlled with surgical clips, ties, vascular staplers, or sealing instruments (Fig. 138.10B). **Care should be taken, however, if sealing instruments are used: the heat they generate can transmit and may injure the rectum if in close proximity. With a gloved finger, the surgeon should shield the rectum from the tips of such instruments while in use.**

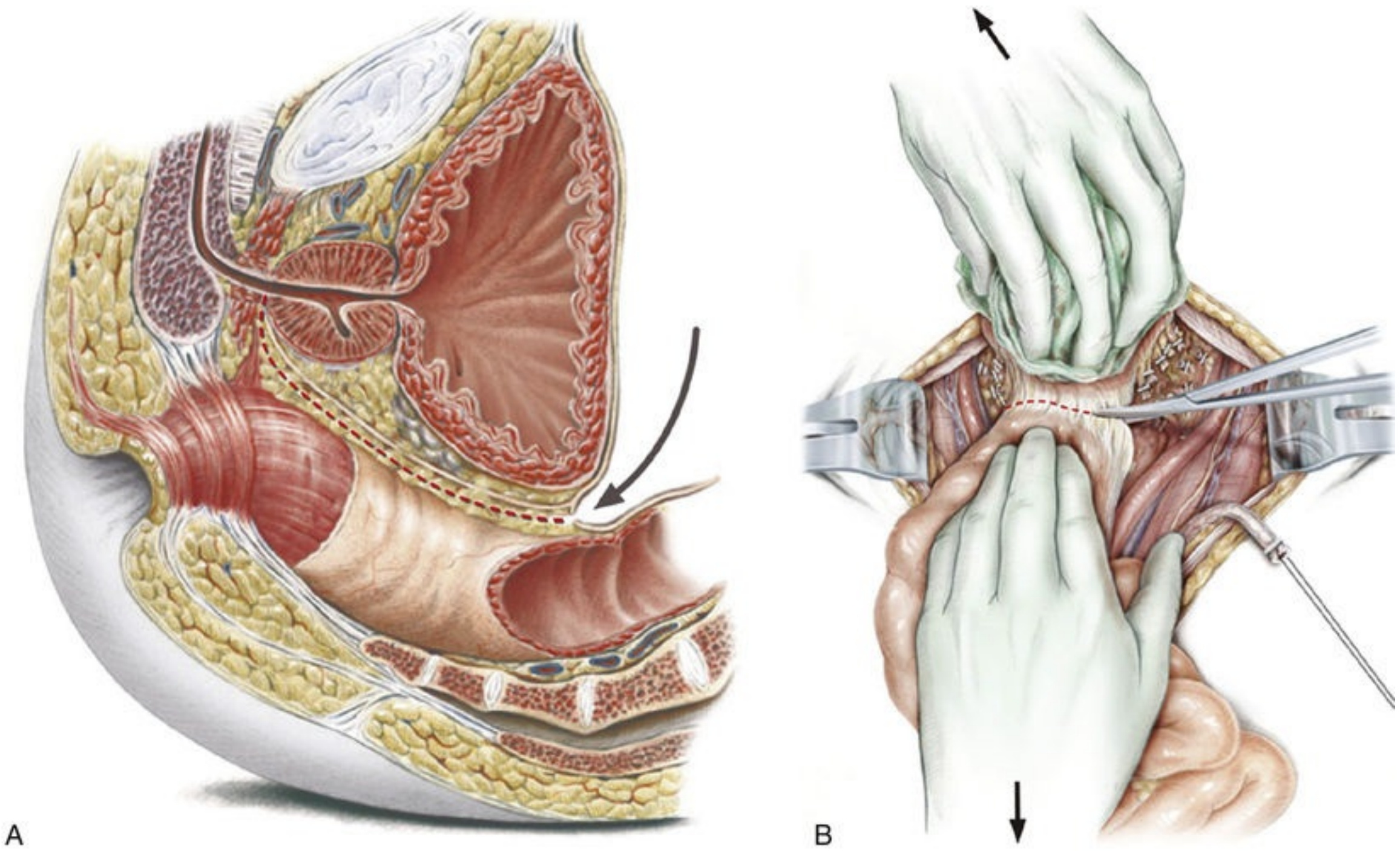

FIG. 138.9 (A) The posterior plane beyond the cul-de-sac, which separates the bladder and prostate from the rectum. (B) Division of the peritoneum overlying the rectum in the cul-de-sac.

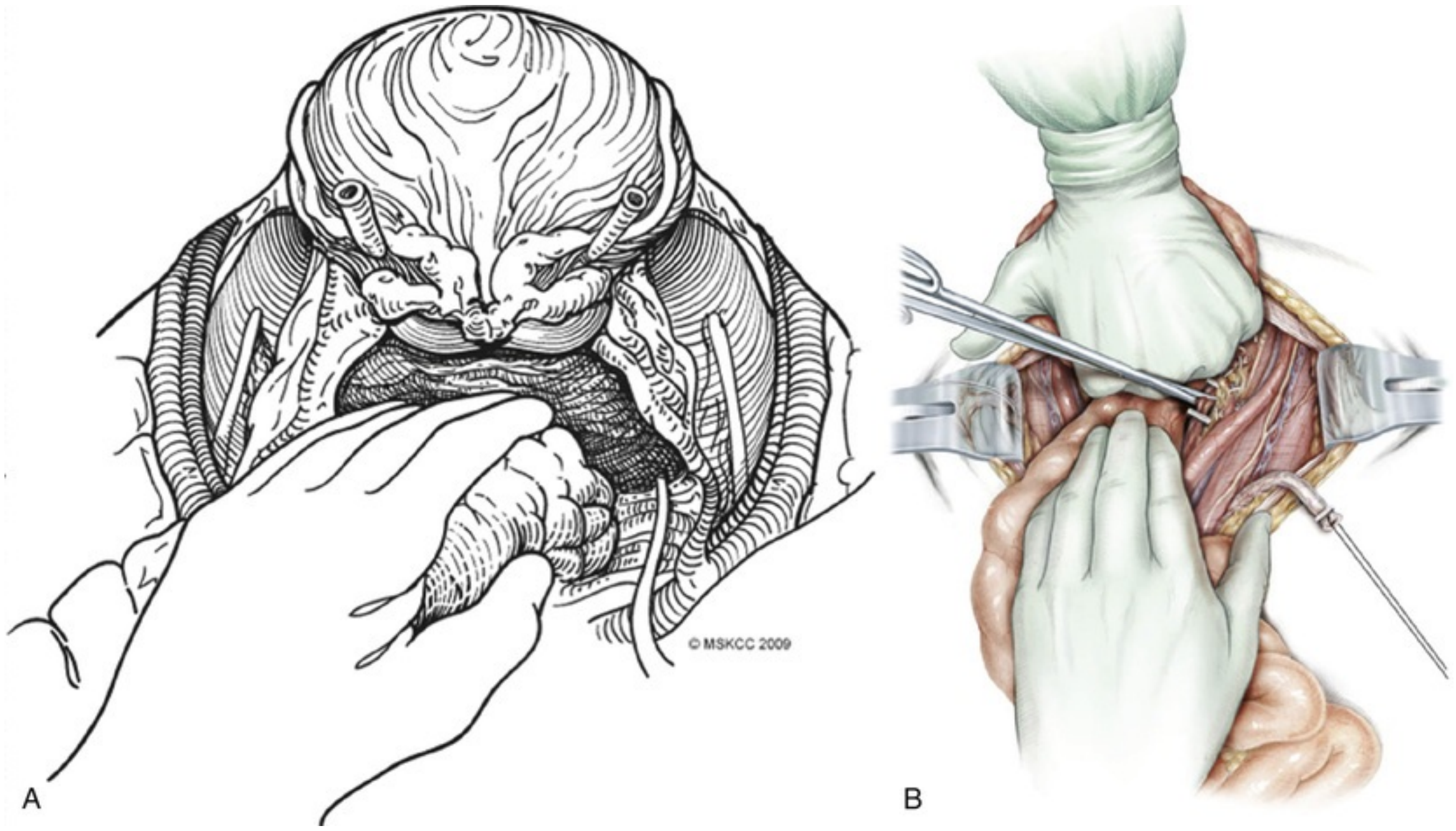

FIG. 138.10 (A) Exposure of the posterior vascular pedicle of the bladder for ligation. (B) Ligation and division of the posterior pedicle. (A, Copyright

2009 Memorial Sloan Kettering Cancer Center.)

After completion of the posterior dissection, the urethra should be palpable, and at this point attention can be turned to the anterior dissection in a fashion similar to a radical prostatectomy. The endopelvic fascia overlying the levator muscles is incised sharply, allowing for identification of the confluence between the urethra and the dorsal venous complex. Ligation and division of the dorsal venous complex (Fig. 138.11) allows for visualization of the anterior urethra, which is then incised.

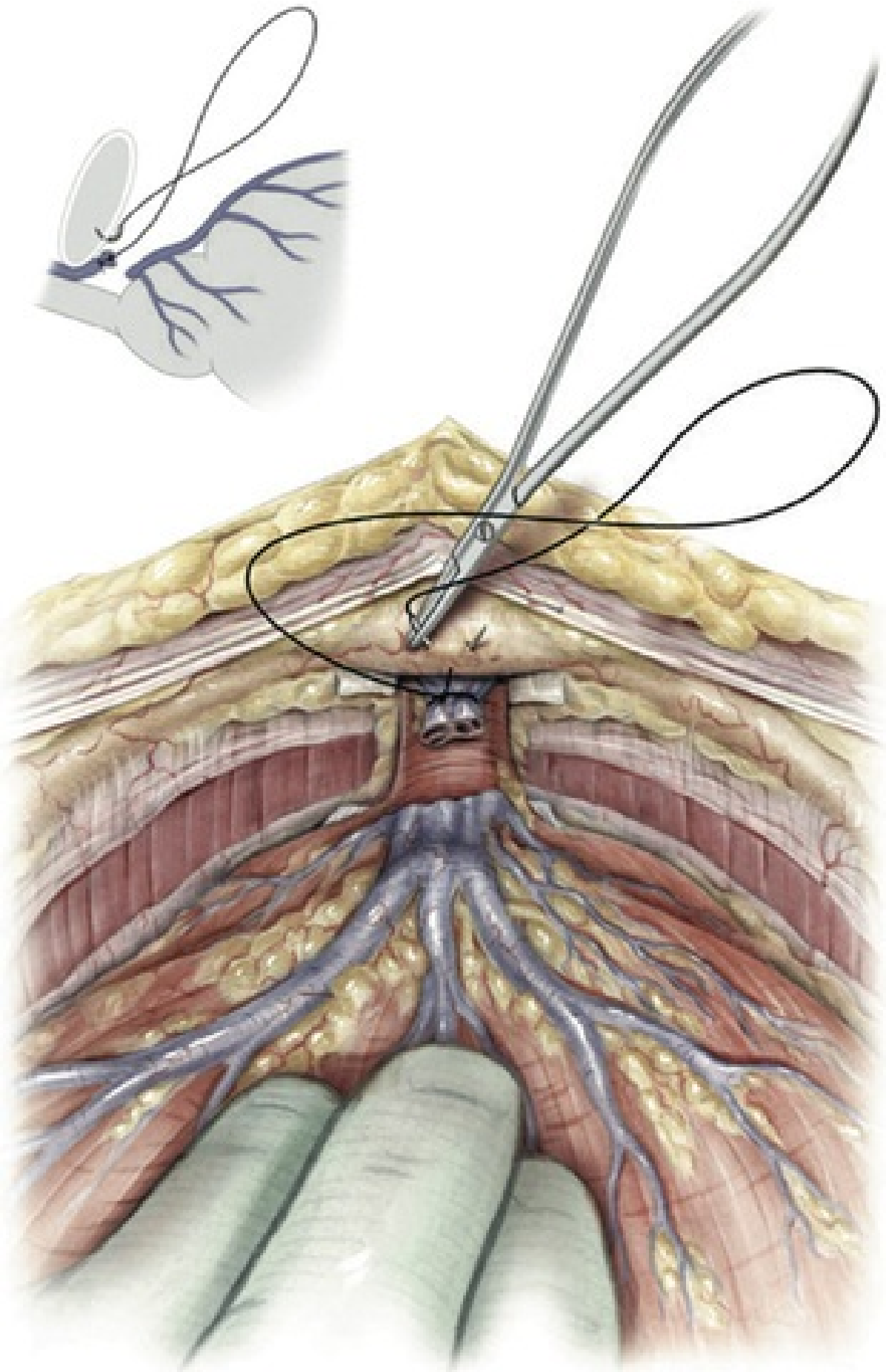

FIG. 138.11 Division of the dorsal venous complex.

If continent ileal neobladder urinary diversion is planned, adequate urethral length must be maintained and a frozen section analysis of the urethral margin performed. In a study of 436 patients who underwent eight cutaneous or orthotopic diversions, urethral recurrence occurred in 7.9% of patients at 5 years and at a median of 1.6 years after radical cystectomy

(Freeman et al., 1996). In addition, the study demonstrated that patients with an orthotopic diversion were at lower risk of urethral recurrence (4% vs. 10%), although the reason is unclear. In another study of 118 male patients after radical cystectomy, no patients with a negative intraoperative urethral frozen section had a urethral recurrence at 10 years of follow-up (Lebret et al., 1998). A large study examining the usefulness of preoperative prostatic urethral biopsy in predicting final urethral margin status demonstrated poor correlation (68%), but very high negative predictive value (100%) if the intraoperative frozen section was negative (Kassouf et al., 2008). We therefore recommend that in the presence of a positive urethral margin, orthotopic neobladder should not be performed and the patient should be made aware of this possibility during preoperative counseling.

The role of preservation of the neurovascular bundles, unlike in radical prostatectomy, remains controversial in radical cystectomy. A technique analogous to radical prostatectomy (Fig. 138.12A and B) can be applied; however, the functional outcomes remain significantly worse. In a report of erectile dysfunction in sexually active men treated with radical cystectomy, Zippe et al. (2004) found in their series of 49 men that only 6 of 16 (38%) who underwent nerve-sparing surgery were naturally potent after surgery, and only 7 of 49 (14%) were potent when including all patients (nerve-sparing and non–nerve-sparing). These results do not differ significantly from reports of men who underwent non–nerve-sparing cystectomy as reported by Asgari et al. (2013). In that study of 81 sexually active men, they found that at 1 year only 9.8% (ileal conduit) to 35% (neobladder) regained function sufficient for vaginal penetration and maintenance of erection until the completion of intercourse (Asgari et al., 2013). Among men who underwent nerve sparing, age, similar to the radical prostatectomy series, is a strong predictor of functional recovery with a drop from 62% potency for men aged 40 to 49 years to 20% for those 70 to 79 years (Schoenberg et al., 1996). In addition, in their report of 101 patients only 5 (5%) suffered a local recurrence; however, caution should be noted as one was a patient with pT2 disease. The risks and benefits of nerve sparing should be judged according to preoperative sexual function and disease burden. **Non-nerve sparing** (Fig. 138.13) **is the preferred choice in advanced disease and in patients with preexisting erectile dysfunction.**

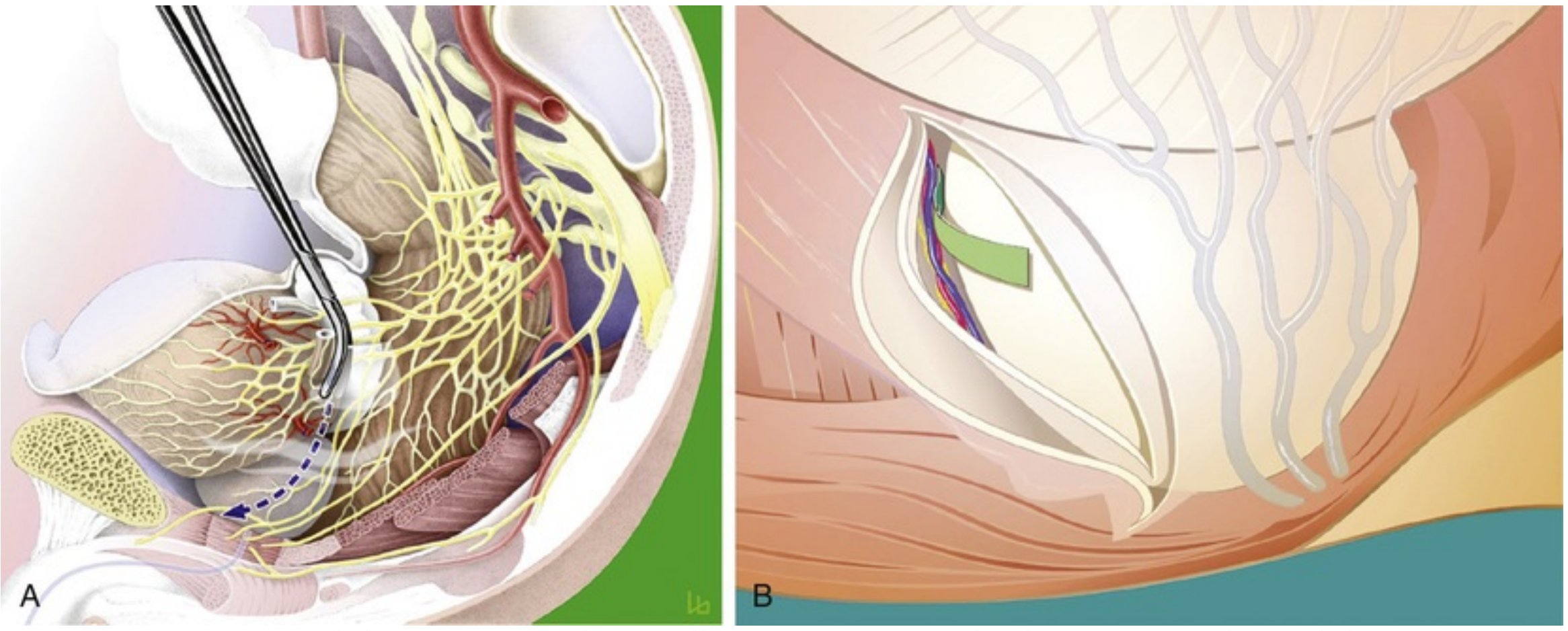

FIG. 138.12 (A) Nerve-sparing radical cystectomy in the male patient. (B) Separation of the plane between the prostatic capsule and the neurovascular bundle.

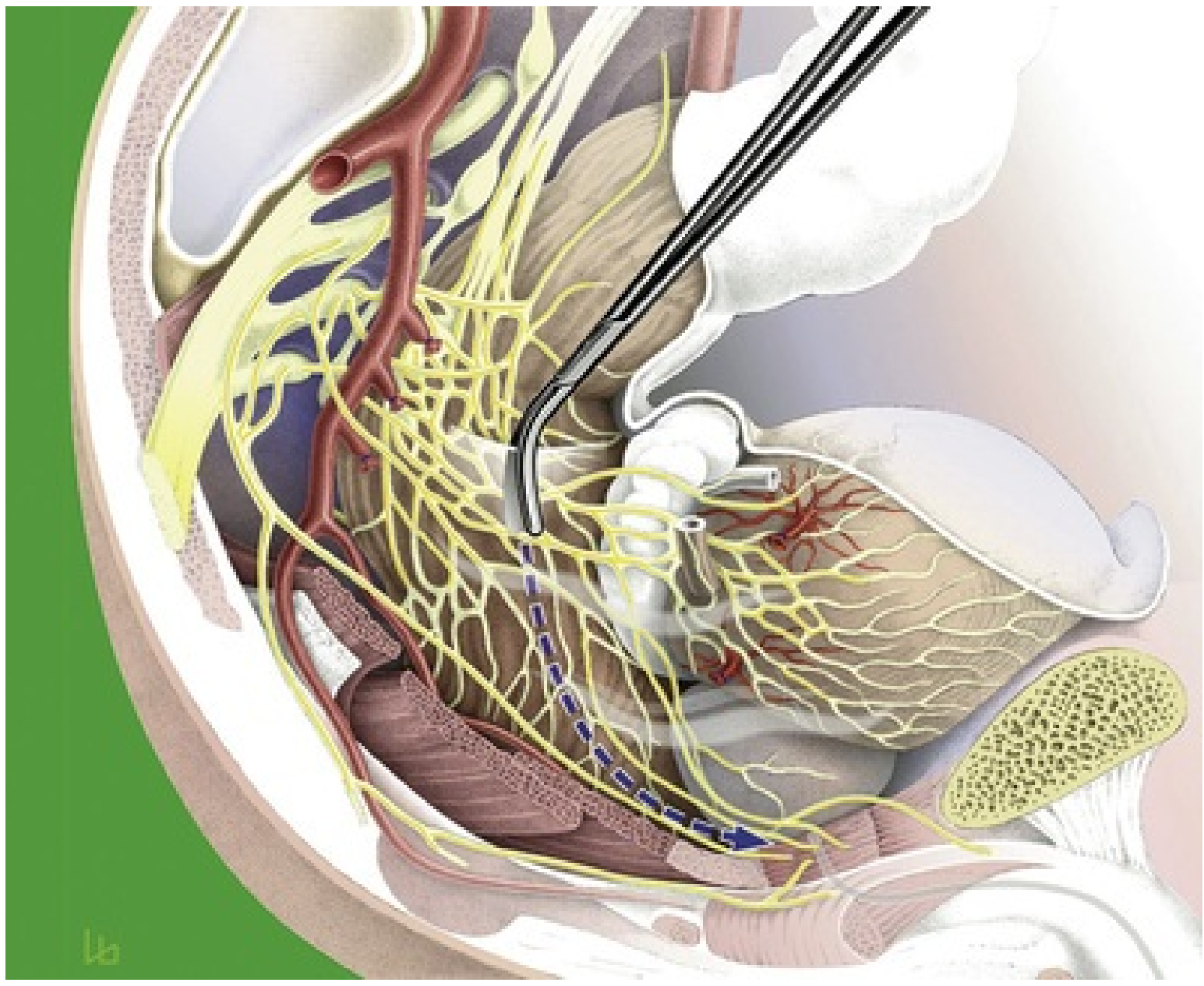

FIG. 138.13 Non–nerve-sparing radical cystectomy in the male.

Additional efforts have been used to improve sexual functional outcomes, including subtotal resection of the prostate. Described techniques include leaving the prostate in its entirety or sparing the prostatic capsule and/or the seminal vesicles. These approaches have largely been studied in the context of orthotopic neobladder urinary diversion. In the setting of nonurothelial cancers, Spitz et al. (1999) showed that erectile and ejaculatory function could be maintained in 3 of

4 patients. In another report, Colombo et al. (2004) showed excellent erectile function outcomes in all of the 27 patients and no instances of local recurrence; however, follow-up was limited to only 32 months. There is, however, concern because of the high rate of occult prostate cancers in radical cystectomy specimens. This has been shown to be as high as 41% in larger series (Revelo et al., 2004). Despite this, in highly selected patients, excellent local control can be maintained. In a study of 100 patients without evidence of prostate cancer preoperatively and negative frozen section at surgery, only 5 (5%) developed local recurrence, although distant metastasis did develop in 31 patients (Vallancien et al., 2002). To achieve such outcomes, however, proper patient selection is paramount. Preoperative evaluation should include DRE, prostate-specific antigen (PSA) testing, transurethral prostatic resection, and intraoperative frozen section analysis. In the setting of PSA or DRE abnormality prostate biopsy should be done in advance of surgery.

Radical Cystectomy: Female

Radical cystectomy in women historically included total anterior pelvic exenteration inclusive of the bladder, urethra, anterior vagina, uterus, and cervix. This allows for adequate resection and is vital in the presence of a positive EUA or if there is concern for anterior vaginal wall invasion (cT4a). Compared with men, women are seen initially with more advanced disease (Kluth et al., 2013; Mitra et al., 2014). In addition, in the study by Kluth et al. (2013) of more than 8000 patients, in multivariable analysis female gender was an independent risk factor for death from disease (hazard ratio [HR] = 1.17 [range 1.05 to 1.31], *P* = 0.005) (Kluth et al., 2013). For this reason, anterior pelvic exenteration remains the gold standard of therapy. As discussed later, however, in patients with low-stage disease (cT1 and cT2) in whom orthotopic neobladder is considered, vaginal and urethral sparing is necessary.

As described earlier, the initial steps for bowel mobilization, anterior bladder mobilization, and ureteral dissection are the same in men and in women with the exception of the gonadal vessels. In female patients the ovarian vessels should be identified during the bowel mobilization and ligated with a 2-0 silk suture distally, and a 2-0 silk suture ligature and a tie proximally, and then divided. Anterior pelvic exenteration begins with identification of the posterior cervical fornix (Fig. 138.14A), and the vaginal cuff is incised at this position (Fig. 138.14B). After gaining entry to the vaginal canal, the surgeon easily can control the lateral and posterior vascular pedicles to the bladder. According to surgeon preference, vascular staplers, sealing devices, or clips are applied, and the specimen can be dissected free inclusive of the uterus, cervix, anterior vaginal cuff, and bladder. The urethral meatus is then incised, either antegrade from the pelvis or externally from the vaginal introitus, and the specimen is removed (Fig. 138.15A and B). Care should be taken to ensure that sufficient vaginal mucosa is maintained above the urethral meatus to allow for closure of the vaginal defect in subsequent steps. Because of the vascular nature of the female pelvis and the sinusoidal nature of the vascular pedicles as they pass over the lateral vaginal wall, care is needed to ensure hemostasis. To complete the vaginal closure with a 2-0 polyglactin 910 suture, often the posterior vaginal wall must be released from the rectum (Fig. 138.15C). The posterior vaginal flap is then closed to the corresponding mucosae of the introitus in a clamshell fashion to maintain vaginal girth at the cost of some vaginal length. **Bothersome drainage of**

peritoneal fluid will result if the vaginal closure is not watertight, and an interrupted closure is preferred. A vaginal packing is then placed with the dual purpose of distending the vagina and providing tamponade to any residual vaginal wall hemorrhage (particularly useful if vaginal sparing is performed; discussed later) and aids in the identification of unrecognized defects in the closure. This packing should be removed 2 days postoperatively.

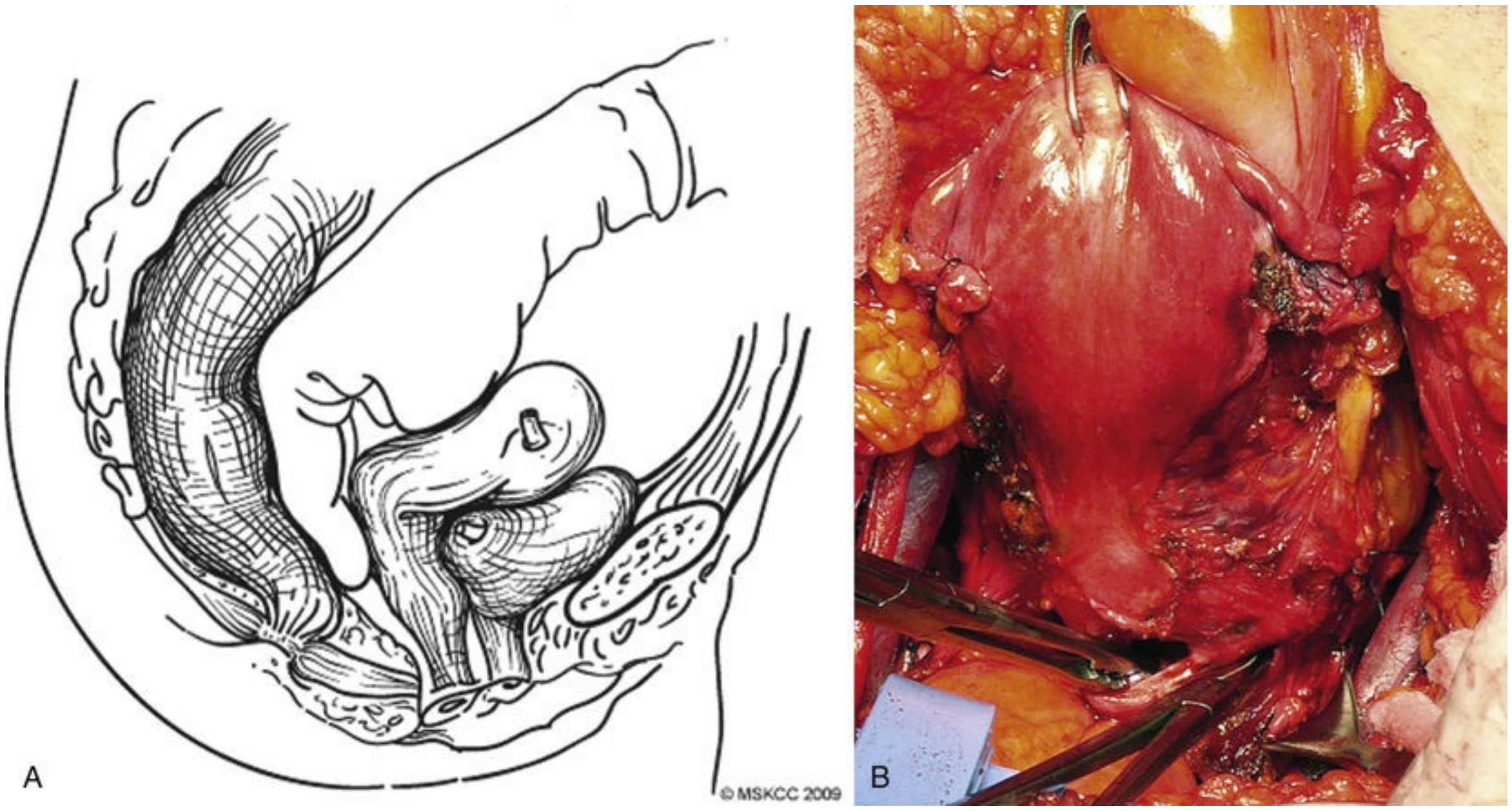

FIG. 138.14 (A) Identification of the vaginal cuff posterior to the cervix. (B) Incision of the posterior vaginal cuff. (A, Copyright 2009 Memorial Sloan Kettering Cancer Center.)

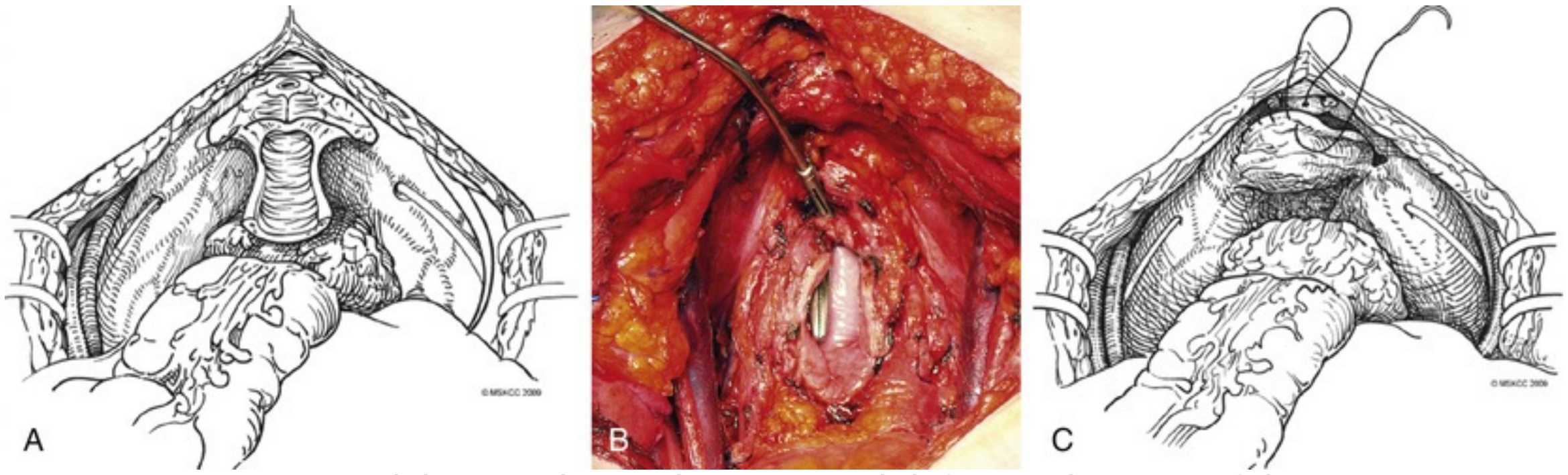

FIG. 138.15 (A) Posterior vaginal wall and defect at the level of the introitus after en bloc removal of the bladder in an anterior pelvic exenteration in the female patient. (B) Intraoperative photograph of the introital defect. (C) Coverage of the introital defect with a flap made from

the posterior vaginal wall.

In the absence of bladder neck involvement and the presence of low-stage disease (≤cT2), orthotopic neobladder can be considered. This necessitates urethral sparing with adequate length proximal to the striated sphincter and anterior vaginal wall sparing to provide support to the neobladder. As described previously, the lateral vascular pedicles are intimate with the lateral wall of the vagina, and to control these vessels properly they must be separated from the vagina before ligation. This can be achieved either after removal of the cervix and uterus at the level of the cervical fornix (Fig. 138.16A) or while they are still in place. A vaginal packing during this step can aid in defining the plane of separation between the bladder and the anterior vaginal wall in the midline. Alternatively an end-to-end anastomosis (EEA) sizer can be introduced into the vagina. This can serve as a vaginal manipulator as well as providing vaginal distention. After development the dissection plane between the posterior bladder and the anterior vagina is extended laterally, separating the lateral vascular pedicles from the lateral vaginal wall. To ensure that an adequate bladder margin is maintained, the vessels should not be divided until the midpoint of the lateral vaginal wall, in the anterior posterior plane, has been reached. This dissection is carried to the level of the bladder neck, which can easily be identified by use of the Foley catheter balloon as a guide. Maintaining the integrity of the striated sphincter, the specimen is removed at this level (Fig. 138.16B), and a frozen section of the urethral margin is sent and managed in the same fashion as in male neobladder candidates. Again, if the urethral margin analysis demonstrated malignancy, orthotopic diversion is contraindicated. The vaginal apex is closed with 2-0 polyglactin 910 sutures and urethral anastomotic sutures placed (see Fig. 138.16BC).

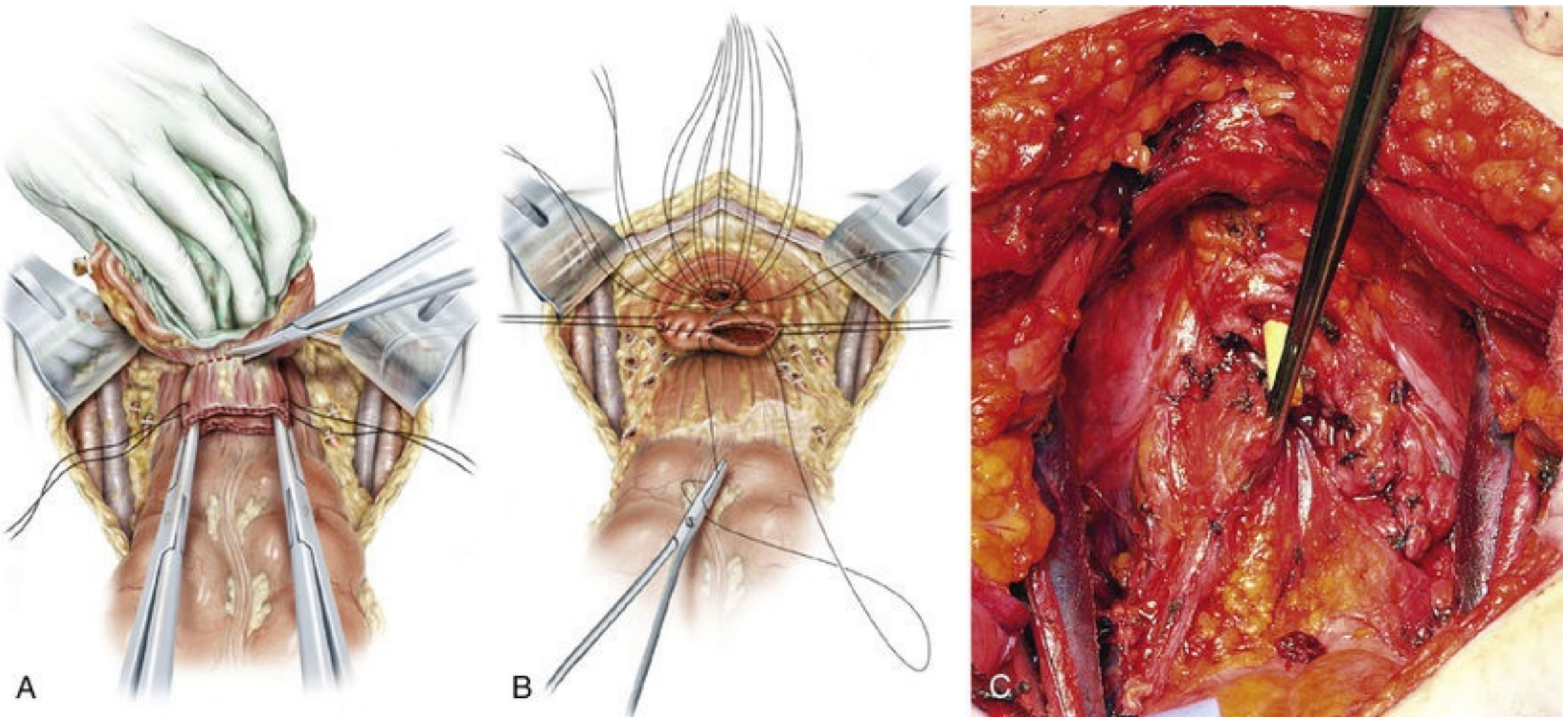

FIG. 138.16 (A) Circumferential division of the vaginal cuff from the attachments to the cervix. (B) Closure of the vaginal cuff and placement of the urethral anastomotic sutures. (C) Intraoperative photograph of the completed repair.

Partial Cystectomy

Consideration for bladder-sparing surgery in the setting of muscle-invasive urothelial carcinoma requires proper patient selection. **For those with solitary lesions of small size and who lack concurrent carcinoma in situ (CIS), results from partial cystectomy are similar to those of radical cystectomy.** In an analysis of 37 such patients treated at the MD Anderson Cancer Center, 9 (24%) developed either a muscle-invasive and/or metastatic recurrence; however, the 5-year overall and the disease-specific survival rates were 67% and 87%, respectively (Kassouf et al., 2006). In a population-based matched cohort study examining partial versus radical cystectomy when matched for surgical quality (number of lymph nodes removed) and clinicopathological features, partial cystectomy was equivalent in terms of overall and cancer-specific survival (Capitanio et al., 2009). Patients initially treated with partial cystectomy can be salvaged with radical cystectomy; however, survival is significantly worse for locally advanced disease at the time of salvage. In patients with organ-confined disease, 5-year survival is 60%, whereas it is only 7% for extravesical disease (Bruins et al., 2012).

In the select patients who are candidates for partial cystectomy, preoperative preparation includes counseling regarding the possibility of radical cystectomy and the discussion of urinary diversion, because it is possible that an adequate margin will not be possible or extravesical disease will be encountered. Partial surgical removal includes pelvic lymphadenectomy, as described earlier, as well as anterior bladder mobilization. Cystotomy is performed in an area away from the tumor. The tumor is then excised, including the underlying bladder wall and perivesical fat with a mucosal margin of 1 to 2 cm and confirmation of resection adequacy with frozen section analysis. If necessary, the ureteral orifice or intramural ureter can be excised and a reimplantation performed. After excision of the tumor the cystotomy is closed with 2-0 polyglactin 910 suture in 2 or 3 layers, and instillation of fluid via a Foley catheter is performed to ensure a watertight closure. Copious warm water irrigation of the surgical field is performed to minimize the possibility of pelvic seeding. A closed suction drain should be placed and the cystotomy closure interrogated with a cystogram on postoperative day 7 before removal of the Foley catheter.

Although rare, primary adenocarcinoma arising from the urachus requires additional resection. These tumors are most commonly confined to the dome of the bladder, although they may grow by direct extension to involve other areas. A circumferential incision around the umbilicus is made and extended toward the pubis. Complete excision includes the umbilicus, the urachus, and the dome of the bladder with a visual margin free from tumor (Fig. 138.17). Again this is confirmed with frozen section analysis, and additional resection may be necessary. Bladder augmentation with the use of an intestinal segment can be performed if bladder capacity is significantly reduced.

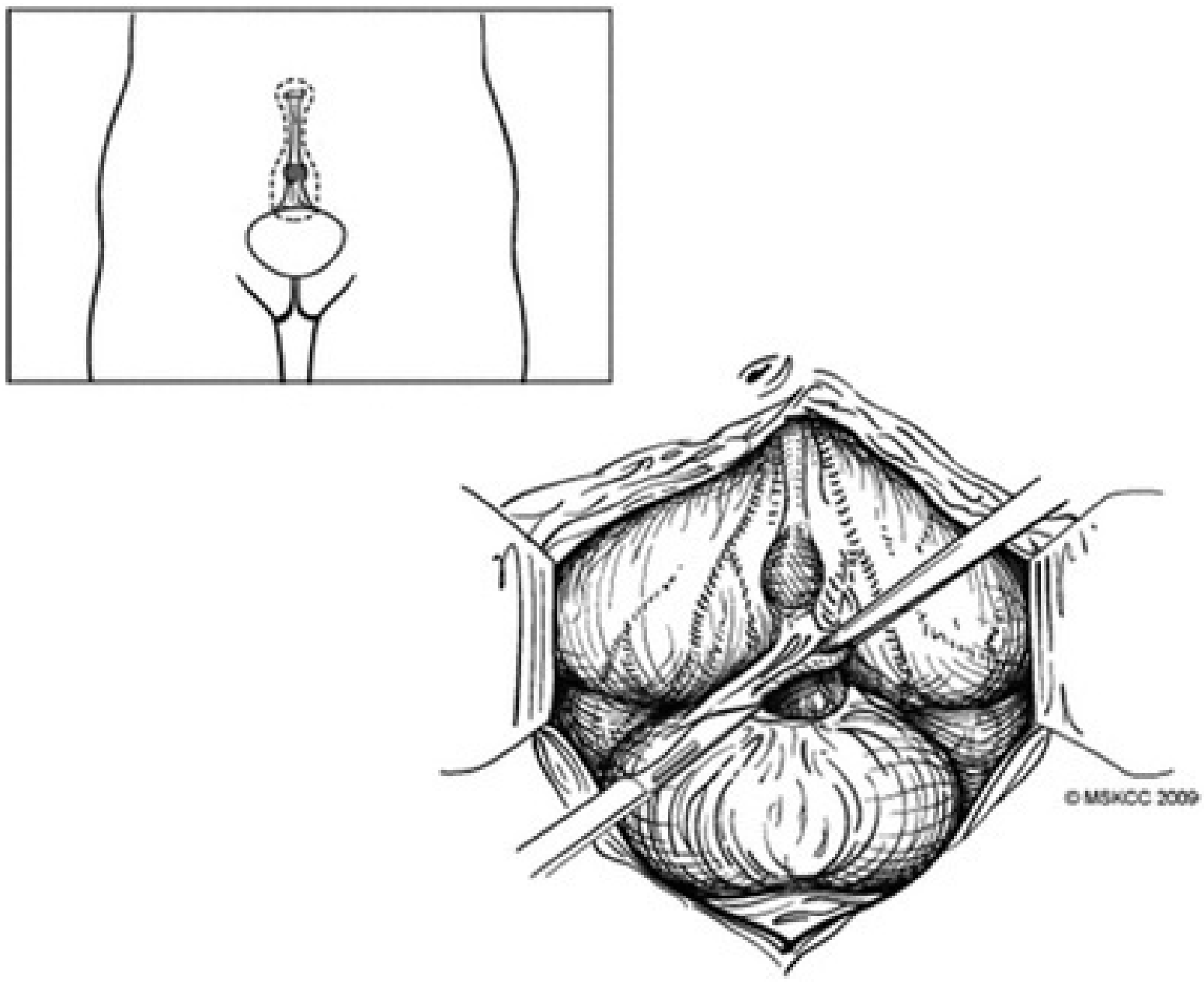

FIG. 138.17 Resection of an adenocarcinoma of the urachus. (Copyright 2009 Memorial Sloan Kettering Cancer Center.)

Robotic Radical Cystectomy

Background

Bladder cancer patients pose a broad array of challenges to clinicians, which are further heightened when the burden of their disease requires radical cystectomy. Whether it be the frequent coexisting medical conditions such as pulmonary and cardiac disease, or the commonly encountered frailty and diminished performance status, bladder cancer patients are rarely straightforward to manage clinically. In addition, given the advanced age at which many patients are seen, they frequently have had prior complicating abdominal surgeries and as a result a thoughtful surgeon must approach surgical decision making carefully.

In light of these myriad challenges, efforts have been implemented to improve patient outcomes. Among these are refinements in the surgical technique, better understanding of proper patient selection, and optimization of perioperative care. As discussed earlier in this chapter, enhanced recovery pathways should be employed whenever possible. A result of these strategies has been a generally shortening of hospitalization and earlier return of bowel function after surgery. What has remained stubbornly high, however, are complications and blood transfusion rates.

Naturally as clinicians search for ever more elusive improvements in patient outcomes, we draw upon experiences in other disease sites. Building on a large collection of data demonstrating advantages for minimally invasive surgery in the areas of complications and blood loss the application of these techniques to bladder cancer care seemed inevitable. The large-scale adoption of laparoscopic and robotic techniques in other urologic disease sites provided a stepping stone. A progression was witnessed in which surgical techniques moved from laparoscopic simple cystectomy, to laparoscopic radical cystectomy with extracorporeal diversion, followed by robotic radical cystectomy and lymphadenectomy (Pruthi et al., 2008) and later intracorporeal urinary diversion (Desai et al., 2014). Despite these advances the universal application of robotic surgery to radical cystectomy has been met with headwinds.

Not unlike the early criticisms of robotic radical prostatectomy, initially the resistance concerned oncologic equipoise, in which a lack of tactile feedback and technical limitations were thought to favor open surgery. **Unlike prostate cancer, for which effective salvage therapy exists, oncologic outcomes in**

bladder cancer are uniquely vulnerable to surgical misadventure. In cases of urinary spillage, inadequacy of the lymphadenectomy, or soft tissue margin positivity, disease recurrence is nearly universally accompanied by death from disease.

In an effort to assuage the concerns of the urologic community, investigators focused their initial studies on pathological outcomes (Davis et al., 2011; Nix et al., 2010). Using a non-inferiority design Nix et al. (2010) conducted a prospective randomized trial in 41 patients comparing nodal yields between open and robotic radical cystectomy and lymphadenectomy. In both arms patients underwent an open urinary diversion. They found no difference in nodal yields (mean 19 vs. 18, robot vs. open, $P = 0.515$). Secondary end points included a demonstration of improved blood loss (mean 273 vs. 564 mL, robot vs. open, $P = 0.0003$), time to first bowel movement (3.2 vs. 4.3 days, robot vs. open, $P = 0.0033$), and decreased morphine equivalents while an inpatient (93.6 vs. 151.6 mg, robot vs. open, $P = 0.0110$) for robotic surgery. However, there was a significant increase in operative times for robotic surgery as well (4.2 vs. 3.5 h, $P \leq 0.0001$).

In the study conducted by Davis et al. (2011) at the MD Anderson Cancer Center, 11 patients underwent a complete robotic extended lymphadenectomy followed by an open, second look, dissection. The purpose of this study was to determine the adequacy of a robotic lymphadenectomy. The median lymph node yield for the robotic technique was 43 (range 19–63) and only a median of 4 (range 0–8) additional lymph nodes resected during the open, second look dissection. In no cases did the additional nodes removed by a second look open dissection result in a pathological stage change (Davis et al., 2011). The results of these studies bolstered the preliminary oncologic efficacy of the robotic technique, leading to larger studies aimed at determining the long-term cancer outcomes and preliminary evidence for a possible benefit to perioperative recovery.

Two notable randomized trials provide some further evidence to support the oncologic efficacy of robotic radical cystectomy but leave questions into the impact on surgical outcomes and complications. Reported as a correspondence in the *New England Journal of Medicine* and in more detail in *European Urology,* Bochner et al. (2014) published results of a single-intuition randomized trial comparing robotic and open radical cystectomy and lymphadenectomy with a primary end point of 90-day complications. The study design employed an open urinary diversion in both arms, which some argue may have had a direct impact on their primary end point. At the mandated interim analysis the study closed as a result of futility after demonstrating a similar grade 2 to 5 (by modified Calvien) complication rate (62% robotic 66% open) (Bochner et al., 2014). The by-randomization and the intention-to-treat analysis demonstrated similar pathological outcomes: no difference in complications, but an improvement in blood loss at the expense of a more costly operation and longer operative times.

The RAZOR trial has provided the highest level of evidence supporting the oncologic efficacy of robotic cystectomy and lymphadenectomy. Published in *The Lancet*, Parekh et al. (2018) showed non-inferiority for robotic cystectomy and lymphadenectomy with a primary end point of 2-year progression-free survival (72.3% vs 71.6%, robot vs. open, $P = 0.001$). Similar to the study by Bochner et al. open urinary diversion was employed in both arms. However, we do not suspect an open urinary diversion should have had any effect on the primary end point of progression-free survival. Consistent with previous study, the RAZOR trial demonstrated lower blood loss, transfusions rates, and shorter hospitalizations for patients treated in the robotic arm.

The role and rationale for minimally invasive bladder cancer surgery nevertheless remain an unsettled question. Although utilization trends for robotic radical cystectomy have not mirrored those seen during the transition to robotic radical prostatectomy (Pak et al., 2017), the demonstration of oncologic equipoise is only likely to further fuel interest in the procedure. Coupled with a stubbornly high rate of complications after radical cystectomy, surgeons naturally will seek tools and techniques to improve patient outcomes. However, **the primary focus must remain on oncologic outcomes, and as a result we do not feel there is compelling evidence to suggest superiority for either robotic or open radical cystectomy.**

Patient Selection

The indications for minimally invasive radical cystectomy are no different from conventional open surgery and follow the same preoperative staging paradigm as described earlier. There are, however, special considerations resulting from the patient position in steep Trendelenburg and the need for pneumoperitoneum. Chief among these are anesthetic concerns as a result of possible increased pulmonary pressures, ventilation mismatch, increased intraocular pressure, and decreased cardiac output (Hsu et al., 2013). These concerns should be discussed and addressed before the day of surgery, and we strongly advise open and thoughtful exchange of information between all team members to ensure patient safety remains paramount.

Specific surgical concerns are more challenging to quantify and characterize. For instance, prospective trials of robotic radical cystectomy have excluded those patients with prior abdominal surgical history. Although rigid criteria such as this may ensure more straightforward access to the peritoneal cavity and easier dissection, we do not feel prior abdominal or pelvic surgery is a strict contraindication. Individual experience will dictate each surgeon's ability to assess and allay such challenges. **However, we would caution against, especially early in the learning curve, the use of robotic technique in patients who have had prior urologic surgeries such as partial cystectomy or ureteral reimplantation. These cases are particularly challenging and may increase the risk of a positive surgical margin in inexperienced hands.**

Another frequently encountered patient selection concern relates to obesity. Not only do larger patients pose positioning challenges but also the increased abdominal weight on the diaphragm while in Trendelenburg position increases the ventilation challenges faced by the anesthesia team. Again, we advise a team approach to the decision making in these cases and open communication during the procedure. **Whenever in doubt, using an open approach or conversion to an open approach after initial robotic access to ensure patient safety is advised.**

Please note that for the purposes of this chapter the robotic technique described will be specific to the Da Vinci Surgical System by Intuitive Surgical. As technologies evolve, the principles herein should provide an framework for adopting the technique to new devices and instrumentation.

Patient Positioning

As with robotic radical prostatectomy, the details of patient positioning for robotic radical cystectomy vary by surgeon preference and case-by-case concerns. A one-size-fits-all approach rarely suffices in surgical planning, and this is even more evident in the radical cystectomy population. Specific concerns relating to prior radiation therapy, increased possibility of rectal or bowel related complications, preservation of sexual and endocrine function, limitations to the range of motion in an extremity and prior prosthetic reservoirs in the operative field represent a short, incomplete list of the challenges that may be faced. As a result of these and other possible challenges, patient positioning and docking strategies should be tailored on a case-by-case basis.

The advances afforded by the Da Vinci Xi system, and specifically the rotating overhead boom, can prove very useful in the bladder cancer population. The Xi system provides easier docking from the side of an operative bed and in some cases eliminates the need for lithotomy positioning. We routinely employ a right-sided docking approach in male and female cases whenever the Xi system is used. In the setting of a male radical cystectomy we generally keep the patient in supine position as well. However, in female cases in which vaginal access is required, or in male patients where rectal complications are more likely (e.g., prior prostatectomy or prostate radiation) maintaining dorsal lithotomy is advised. Even in these circumstances we advise docking the robot from the patient's right because it allows ease of access to the area between the patient's legs should an assistant need to relocate to that area.

When using a robotic system without a rotatable boom (e.g., Da Vinci S, Si, or X system), we still advise that the robot be docked between the legs with the legs in lithotomy position because arm conflicts are bothersome with a side-docking strategy when using these devices.

Another common challenge encountered when performing robotic pelvic surgery is patient migration, or sliding, toward the head. Patient migration may be more pronounced during robotic bladder surgeries, which are among the longest robotic pelvic surgeries performed by urologists. We have devised a useful technique to prevent patient migration through the application of 3M Reston foam. Before the patient is transferred to the operative bed, 3M Reston foam, which has an adhesive side, is adhered to the operative bed such that the area of the operative bed directly under the torso of the patient is covered in a layer of foam. The adhesive prevents the foam from moving relative to the operative bed, and the foam interfaces with the patient skin, passively preventing pressure injury and mitigating patient sliding.

The arms are then tucked at the sides and a chest strap with foam padding is placed approximately at the level of the mid-chest to secure the patient to the bed. If the patient has been placed in supine position, additional straps are placed with foam padding over the legs (Fig. 138.18).

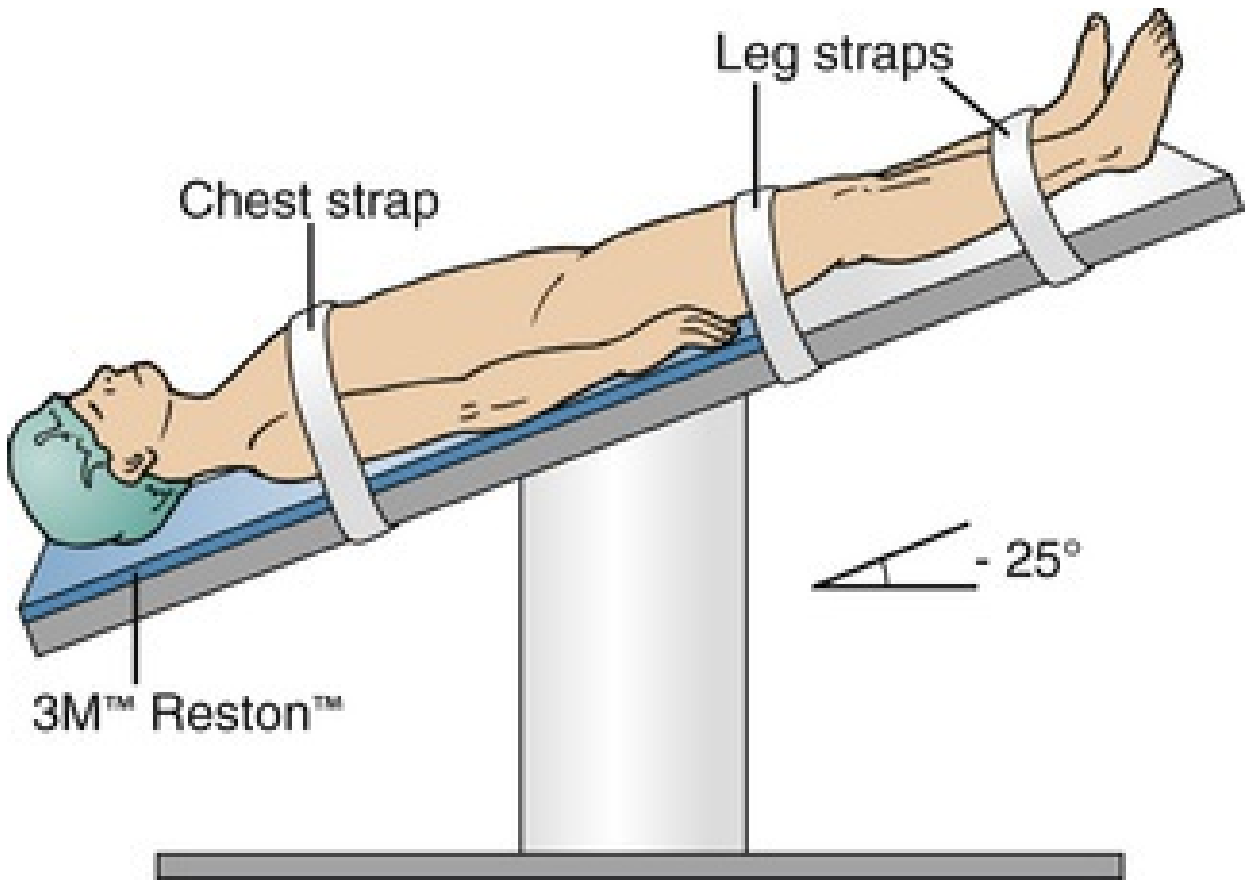

FIG. 138.18 Illustration of patient positioning when docking from the right side is applicable. Note the use of 3M Reston foam under the thorax to prevent patient migration while in Trendelenburg position.

Port and Assistant Placement

Optimal port placement has a profound impact on multiple aspect of the case, most notably the lymphadenectomy and urinary diversion (not discussed in this chapter). Extended lymph node dissections, which are commonplace in bladder cancer surgery, require an analogous transposition of the ports in a cephalad direction as compared with robotic prostate cancer surgery. In addition, if a robotic urinary diversion is to be performed, the right-sided ports benefit from a more cephalad placement. We have found the port placement strategy demonstrated in Fig. 138.19 to be ideal in cases in which an intracorporeal or extracorporeal urinary diversion is planned.

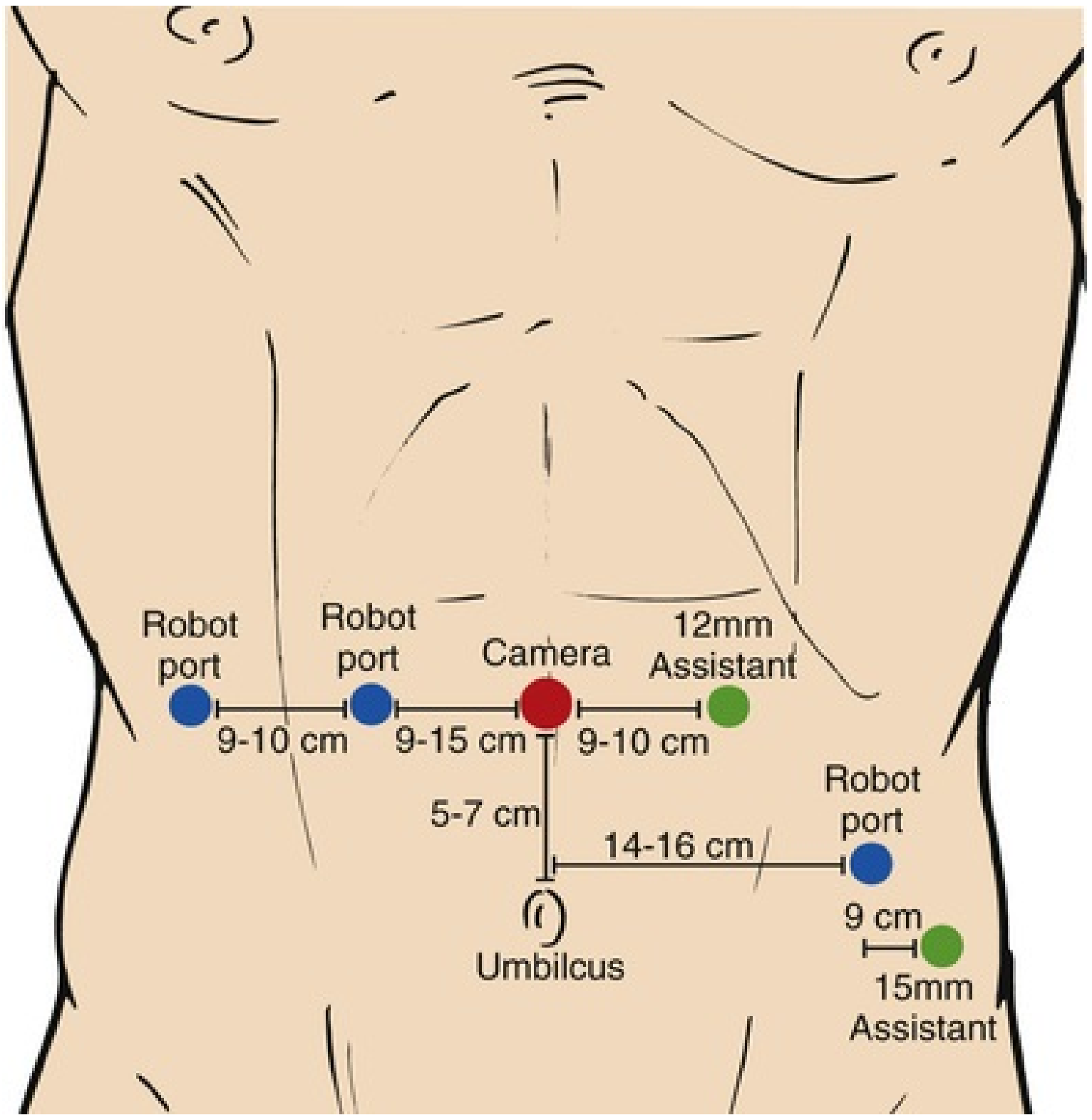

FIG. 138.19 Optimized port placement strategy for robotic radical cystectomy (male and female). Camera placement 5 to 7 cm above the umbilicus with two right-sided robotic ports placed in a level line with the camera spaced 9 to 10 cm apart. A left-sided robotic port placed 14 to 16 cm lateral to the umbilicus and just above the level of the umbilicus. A left-sided 12-mm assistant port is placed 9 to 10 cm lateral to and in level with the camera port. Last, a 15-mm assistant port is placed 9 cm lateral to the left robotic port and just below the level of the umbilicus.

A detailed discussion on the initial access to the peritoneum is not presented here, but our routine has been to insufflate to 15 mm Hg via a Veress needle after a meniscal drop test. We then place a camera port and inspect the abdominal cavity while the patient is still flat to aid in the identification of an inadvertent injury before placing the patient in Trendelenburg and proceeding with the additional port placements.

Key aspects of our port placement strategy included a camera placement, 3 to 4 fingerbreadths (5–7 cm) above the umbilicus and right-sided robotic ports at this level. The right-sided ports are placed in a straight line 9 to 10 cm apart. The high placement of these ports aids in the dissection of the terminal ileum and cecum if a robotic urinary diversion is planned. The left-sided robotic port can be placed closer to the pelvis at a level in line with the umbilicus. The left-sided robotic port is placed farther from the camera (approximately 15 cm) than the right-sided port to provide space for a 12-mm assistant port (can be substituted with a 5-mm port), which is placed between the left robotic port and the camera. Last, a 15-mm assistant port is placed just cephalad to the anterior superior iliac spine. We have found that a 15-mm port at this location provides an excellent angle for stapling the bowel if a robotic urinary diversion is planned and the increased port size allows for large lymph node packets to be removed en bloc. In addition, the 15-mm port provides access for a large Endo Cath bag used to retrieve the bladder specimen. It has also been our routine to place port closure sutures at the site of the 12-mm and 15-mm assistant ports at the time of port placement as opposed to the end of the procedure. We do so with an O polyglactin 910 suture passed with the aid of a Carter-Thomason CloseSure System. The choice of port closure technique is largely surgeon preference and alternative approaches can be employed.

In the technique described here we place a single surgical assistant on the left of the patient and use a four-arm robot configuration with two robotic arms on the right. After port placement and placing the patient in approximately 25-degree Trendelenburg position, the robot is docked. This is done either between the legs or on the right of the patient as described earlier. Insufflation pressure can be reduced according to surgeon preference.

Instrumentation

The choice and location of robotic instruments varies by surgeon preference. A thorough understanding of the grasping strength, intended use, and limitations of the available instruments helps guide an individual surgeon's choice. Table 138.1 provides our current recommendations, but be advised that the robotic systems are rapidly evolving and the instrumentation is likely to change. Familiarizing yourself with the available tools and their specific characteristics allows you to adjust the instruments to your specific needs and preferences. The following principles will help guide these decisions.

TABLE 138.1

Robotic System Recommendations

ARM NUMBER (FROM PATIENT LEFT TO RIGHT)	INSTRUMENT	NOTES
1	Maryland	

	bipolar forceps	
2	Camera	0 degree
3	HotShears (monopolar curved scissors)	
4	Cadiere Forceps	Limited grasping of the bowel with care and under direct vision. (Second Cadiere Forceps in arm 1 during urinary diversion construction)
1 and 3	Large needle driver	Optional Large SutureCut needle driver (particularly useful during continent urinary diversion)

First, we have found the monopolar curved scissors (right medial robotic port) and the Maryland bipolar forceps (left medial robotic port) to be optimal for the majority of our dissection needs. In addition, the Cadier forceps (right lateral robotic port) provides sufficient strength for retraction while limiting the risk of crush injuries when compared with the commonly used ProGrasp (Mucksavage et al., 2011). This may allow for limited and careful manipulation of the bowel. For suturing we favor the use of the large needle drivers, although when performing an intracorporeal neobladder reconstruction the use of a large SutureCut needle driver can improve efficiency. Only in very rare cases have we found the need to use the 30-degree up or down camera lens, and nearly all cases are done with the use of 0-degree lens. This includes lymphadenectomies extending into the low retroperitoneum (e.g., paracaval, para-aortic, and pre-aortic).

Sigmoid Release and Posterior Dissection

There is high variability in the degree of sigmoid attachments to the left pelvic peritoneum as well as within the sigmoid peritoneum. Generally this dissection is best performed by first releasing the sigmoid peritoneal attachments that generate the S-shaped curve to the sigmoid intestine. In doing so the weight of the sigmoid colon then helps auto-retract the large bowel out of the pelvis. As a result, the fourth robotic arm or bedside assistant is available to provide other forms of assistance because retracting the sigmoid colon in cephalad direction is not needed. To accomplish this maneuver we have found that contrary to instinct, whereby most surgeons would retract the sigmoid colon to the right, grasping the sigmoid distal to the S curve and retracting in a cephalad direction provide the best visualization of the sigmoid peritoneal adhesions.

Once the sigmoid curvature is released by incising these peritoneal attachments, the remaining pelvic sidewall and left white line of Toldt dissection is straightforward (Fig. 138.20A–C). Once the white line of Toldt is released as far proximally as possible, the interface of the sigmoid mesentery and the left ureter can be visualized. Incision of the peritoneum just medial to the left ureter prevents violation of the sigmoid mesentery and should maintain the dissection in an avascular plane (Fig. 138.20D–F). Care should be employed to ensure the dissection over the presacral lymph node packet is maintained in this avascular plane and the sigmoid mesentery is not violated. Even small amounts of bleeding in this area quickly obscures visualization. We have found that, if bleeding is encountered during this dissection, it generally indicates dissection into the sigmoid mesentery and the dissection plane should be adjusted. Whenever possible the dissection should be continued until the right common iliac artery is identified (Fig. 138.20F). This will provide ample visualization for the presacral lymphadenectomy and transposition of the left ureter, which is described later. **A helpful visual tool throughout the sigmoid release is that mesenteric fat is a darker yellow than the retroperitoneal or lymphatic fat. Looking for this visual demarcation can significantly aid dissection in the proper tissue planes.**

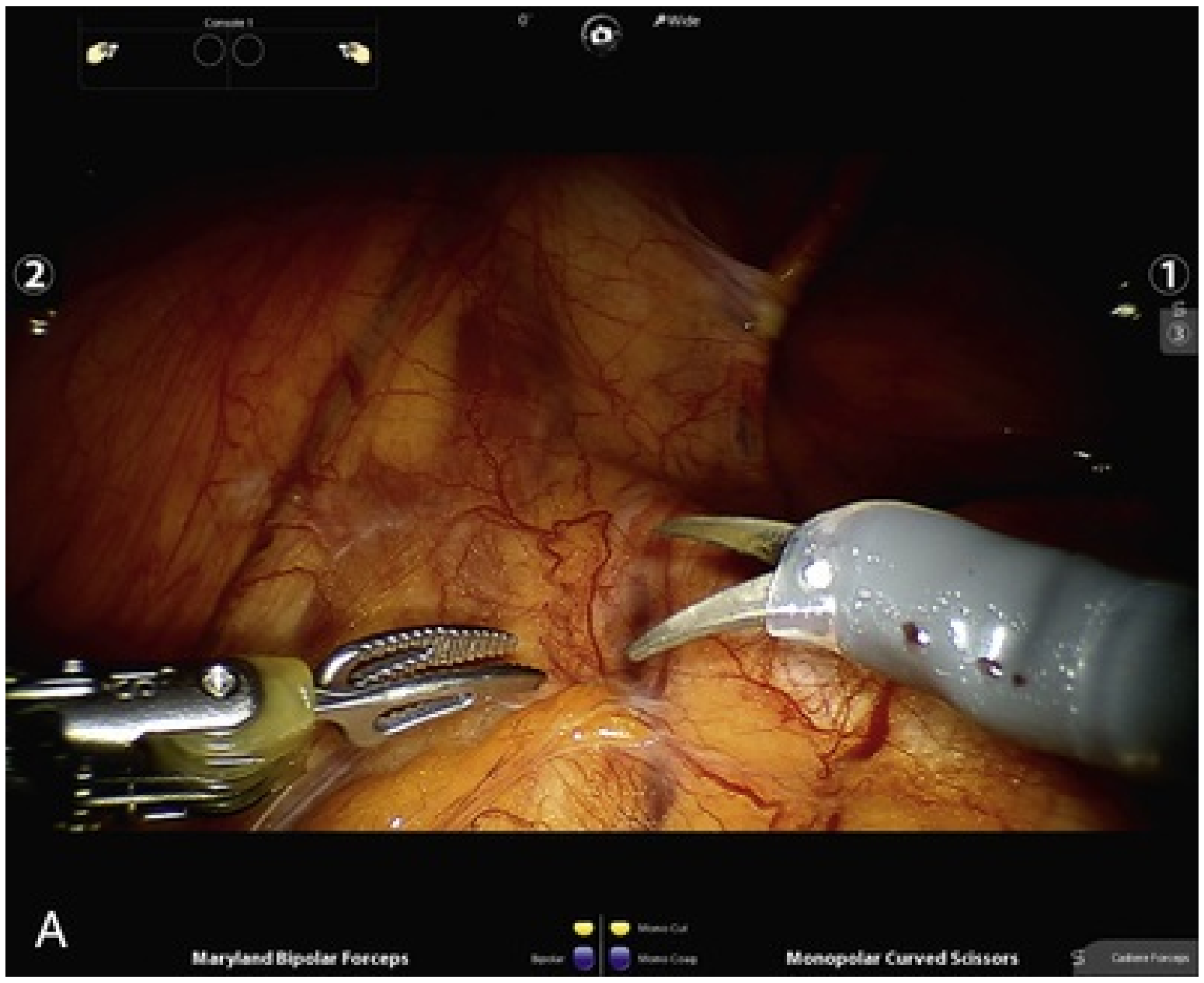

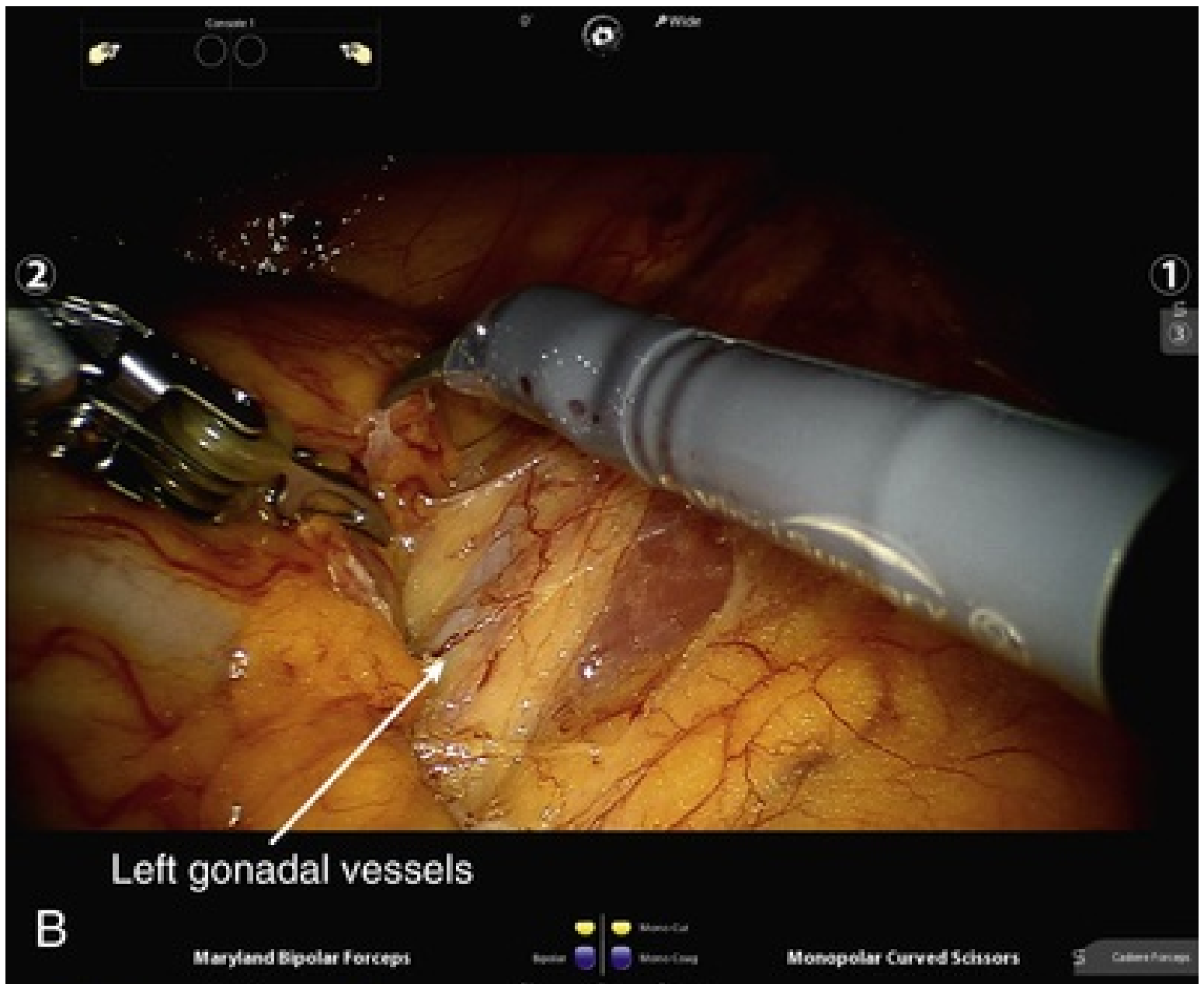
Console 1
0°
Wide
②
①
③
Left gonadal vessels
B
Maryland Bipolar Forceps
Mono Cut
Bipolar
Mono Coag
Monopolar Curved Scissors
Cadiere Forceps

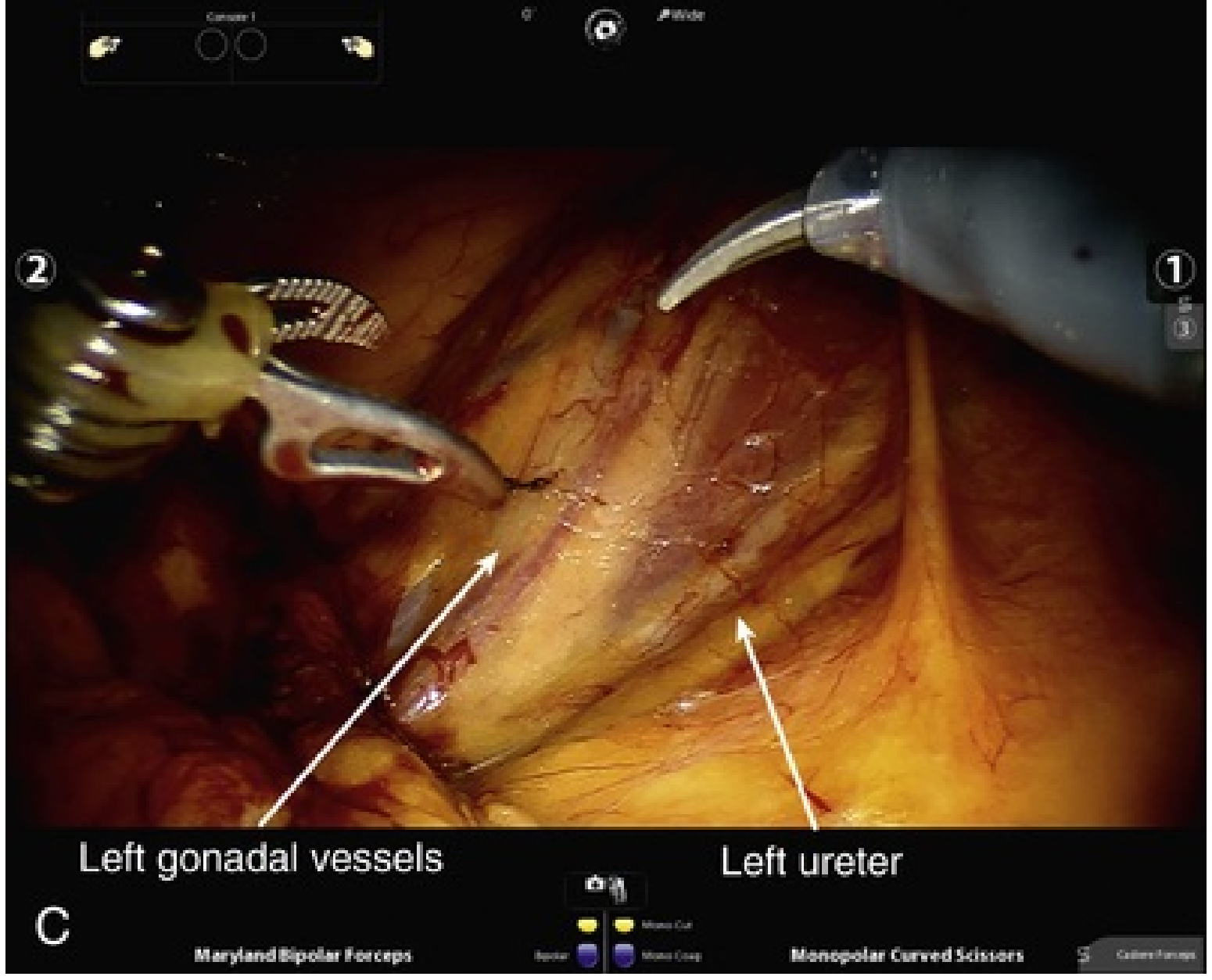
Console 1
0°
Wide
②
①
③
Left gonadal vessels
Left ureter
C
Maryland Bipolar Forceps
Mono Cut
Bipolar
Mono Coag
Monopolar Curved Scissors
Cadiere Forceps

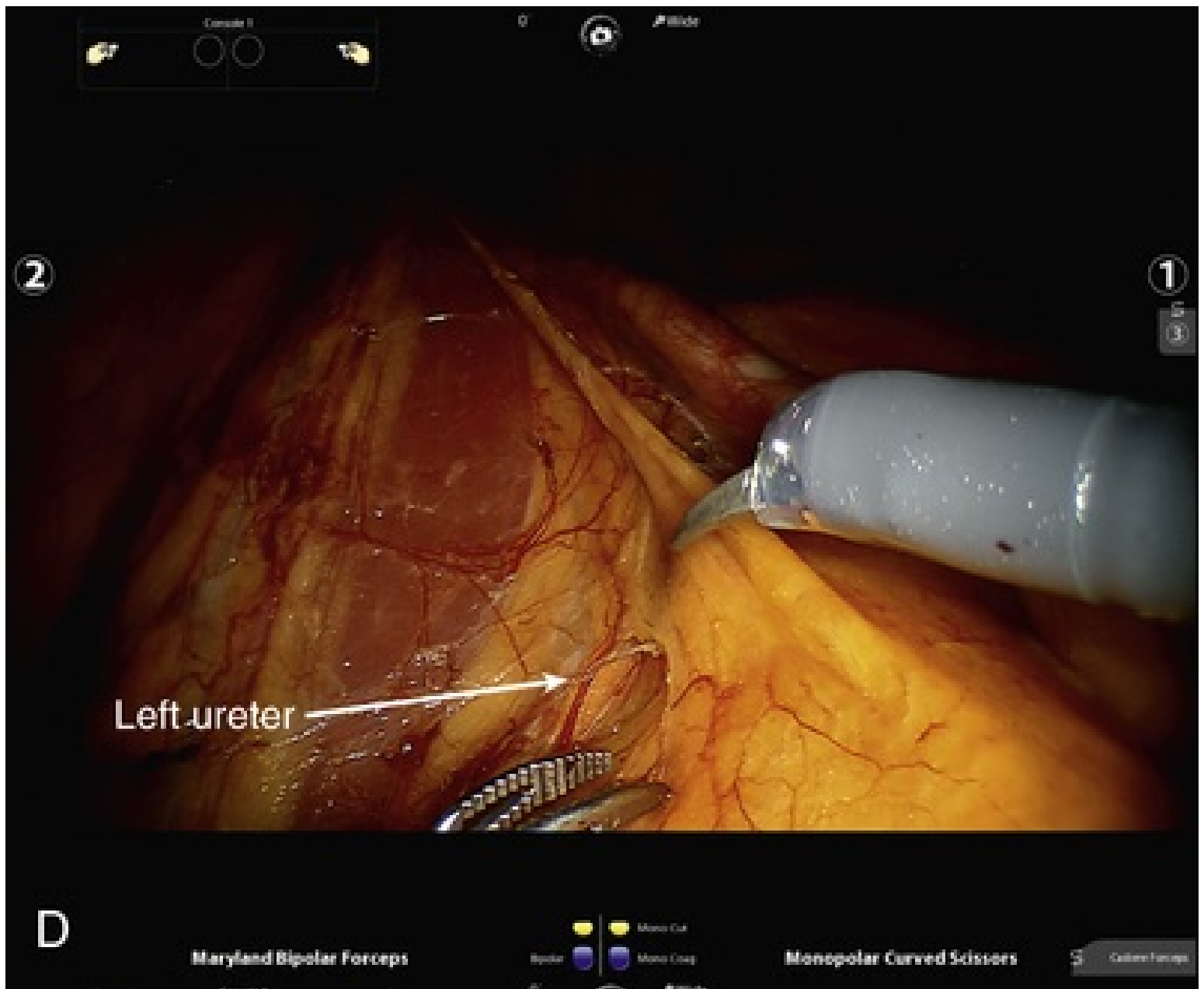
Console 1
0
Wide
②
①
③
Left ureter
Maryland Bipolar Forceps
Mono Cut
Bipolar
Mono Coag
Monopolar Curved Scissors
Cadiere Forceps

D

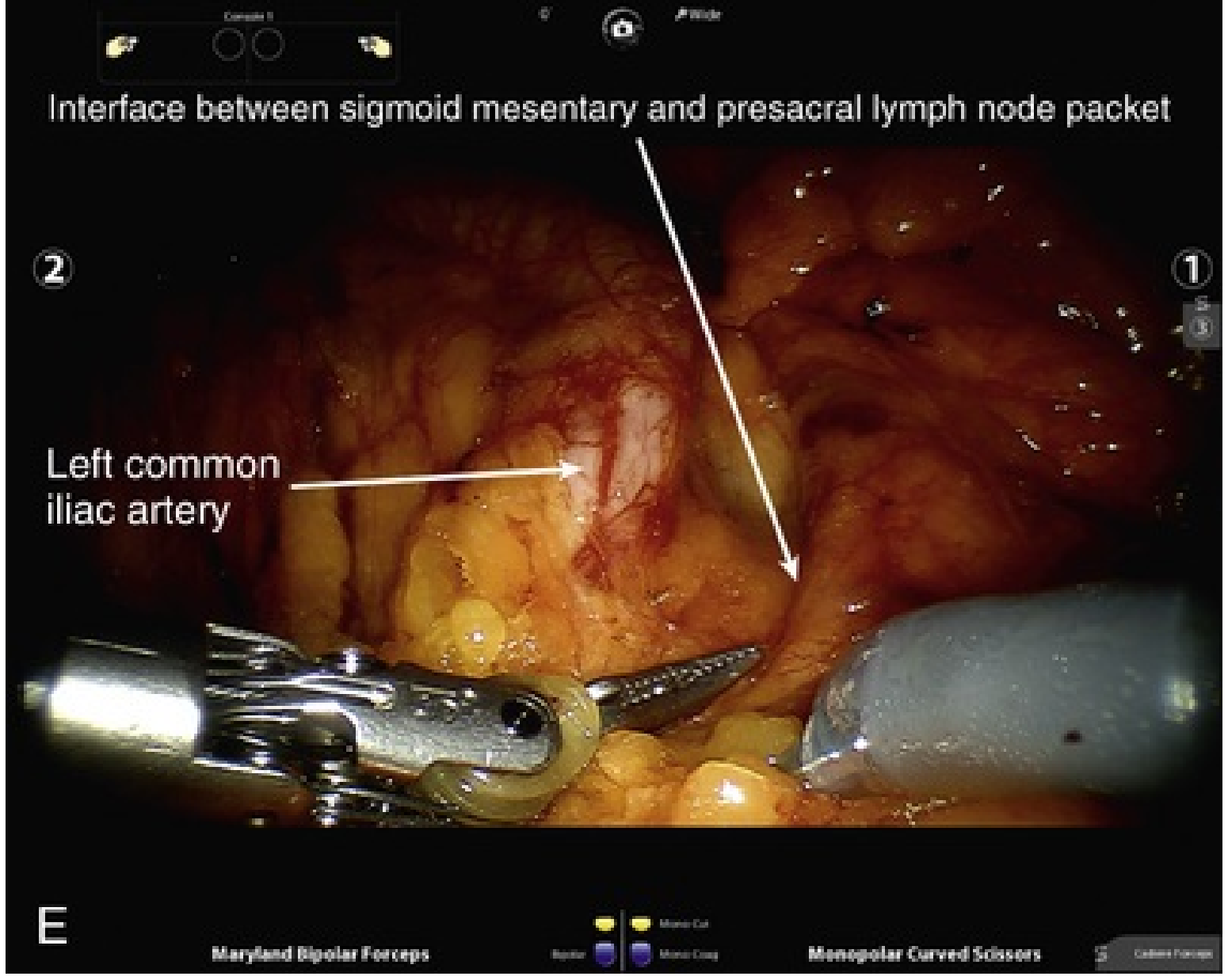
Console 1
0
Wide
Interface between sigmoid mesentary and presacral lymph node packet
②
①
③
Left common iliac artery
Maryland Bipolar Forceps
Mono Cut
Bipolar
Mono Coag
Monopolar Curved Scissors
Cadiere Forceps

E

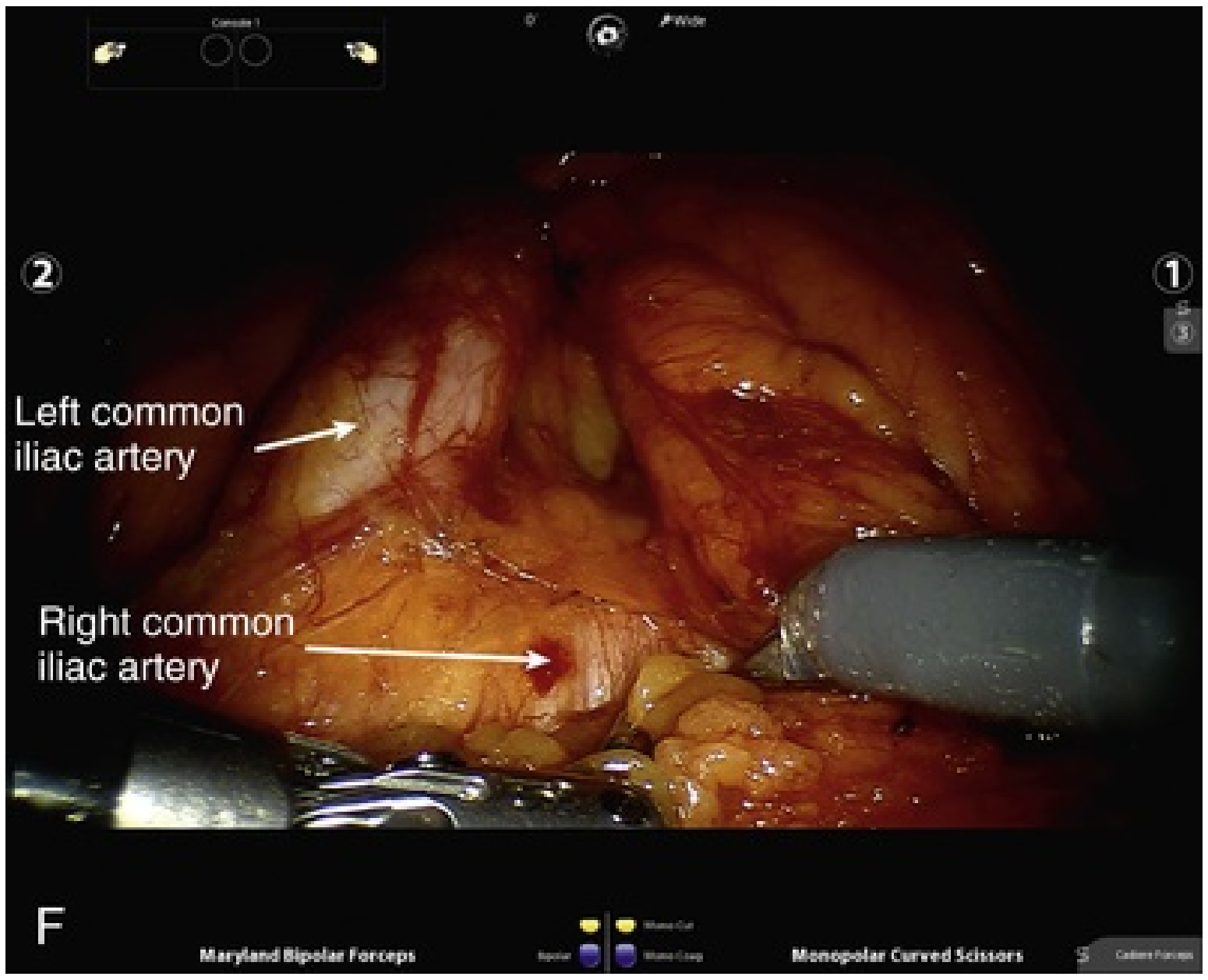
Left common iliac artery
Right common iliac artery
F
Maryland Bipolar Forceps
Monopolar Curved Scissors
2
1

FIG. 138.20 Initial left pelvic dissection including (A) release of the sigmoid colon, (B) identification of the left spermatic cord and (C) ureter and (D) dissection under the sigmoid mesentery. (E) The interface under the sigmoid mesentery is illustrated and the dissection carried to the (F) right common iliac artery.

The male posterior dissection in the cul du sac is shown in Fig. 138.21AB. Similar to a posterior dissection during a robotic prostatectomy, the peritoneum is incised and the dissection carried distally to the prostatic apex. Release of the seminal vesicles is not performed unless a nerve sparing cystoprostectomy is planned.

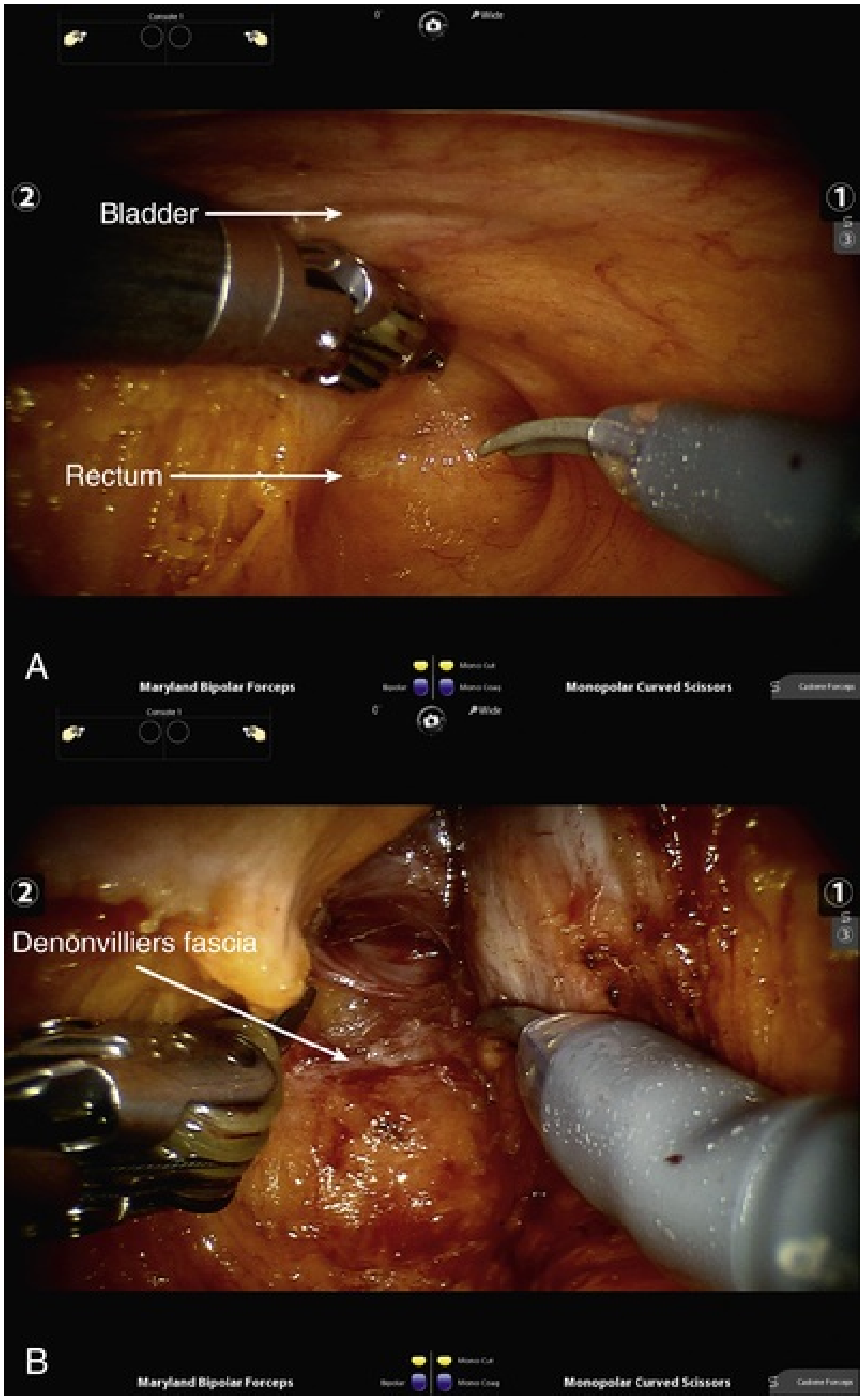
②
①
Bladder
Rectum
A
Maryland Bipolar Forceps
Monopolar Curved Scissors
②
①
Denonvilliers fascia
B
Maryland Bipolar Forceps
Monopolar Curved Scissors

FIG. 138.21 (A) Posterior cul du sac (retrovesical pouch) dissection (male) and (B) carried distally to the level of the apex of the prostate.

Lateral Space of Retzius and Anterior Vascular Pedicle Dissection

After the sigmoid mesenteric release and the posterior dissection (male patients) attention is brought to the lateral dissection. In a female patient in whom a concurrent oophorectomy is planned, the ovarian vessels should be controlled at this point. They will be visualized similarly to the gonadal vessels seen in Fig. 138.20. We advise controlling the ovarian vessels with two clips on the proximal end and one clip on the distal end before transection. Our practice is to use large Weck clips for this purpose.

The approach to the lateral space of Retzius shares commonality with robotic radical prostatectomy. Care should be employed to ensure an adequate amount of perivesical fat is maintained on the bladder. Fig. 138.22A–D demonstrates the stepwise progression of the lateral dissection. The obliterated umbilical artery (medial umbilical ligament) is grasped and retracted medially. Retraction in this manner exposes the peritoneal interface of the bladder and anterior abdominal wall (Fig. 138.22B). Incision of the peritoneum in this plane is carried to the internal inguinal ring, where the vas deferens is controlled in men and the round ligament is controlled in women. Our practice is to control these structures with bipolar cautery, although clips can be used. Care should then be applied to the dissection in the space of Retzius to avoid violation of the perivesical fat medially and the pelvic lymph nodes laterally. The dissection is extended to the endopelvic fascia (Fig. 138.22C) distally and the hypogastric artery posteriorly (Fig. 138.22D). In the case of a male cystectomy the endopelvic fascia is incised in a manner similar to a radical prostatectomy. Variation on the approach to the endopelvic dissection, in accordance to nerve sparing (e.g., high release), can be employed.

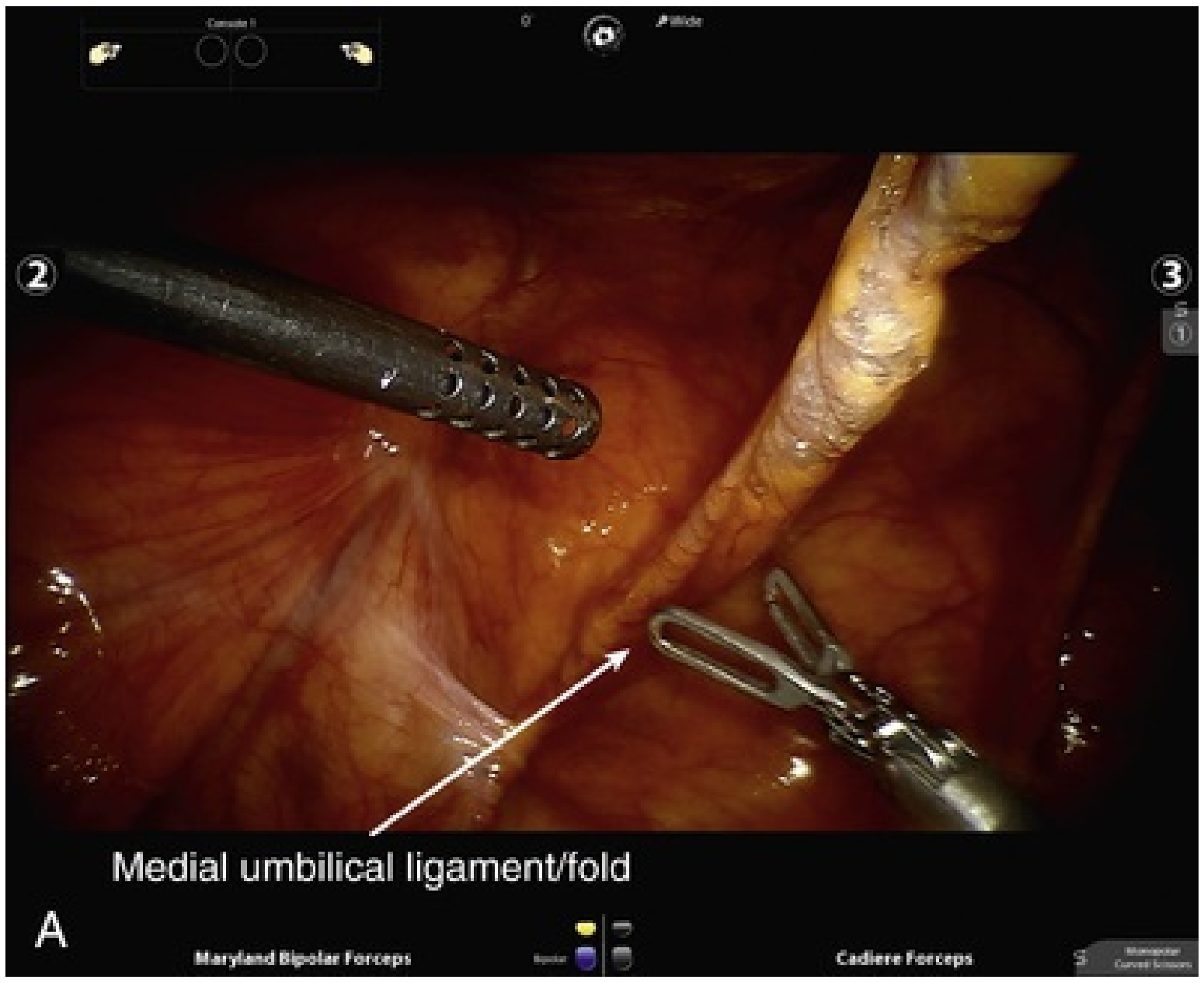

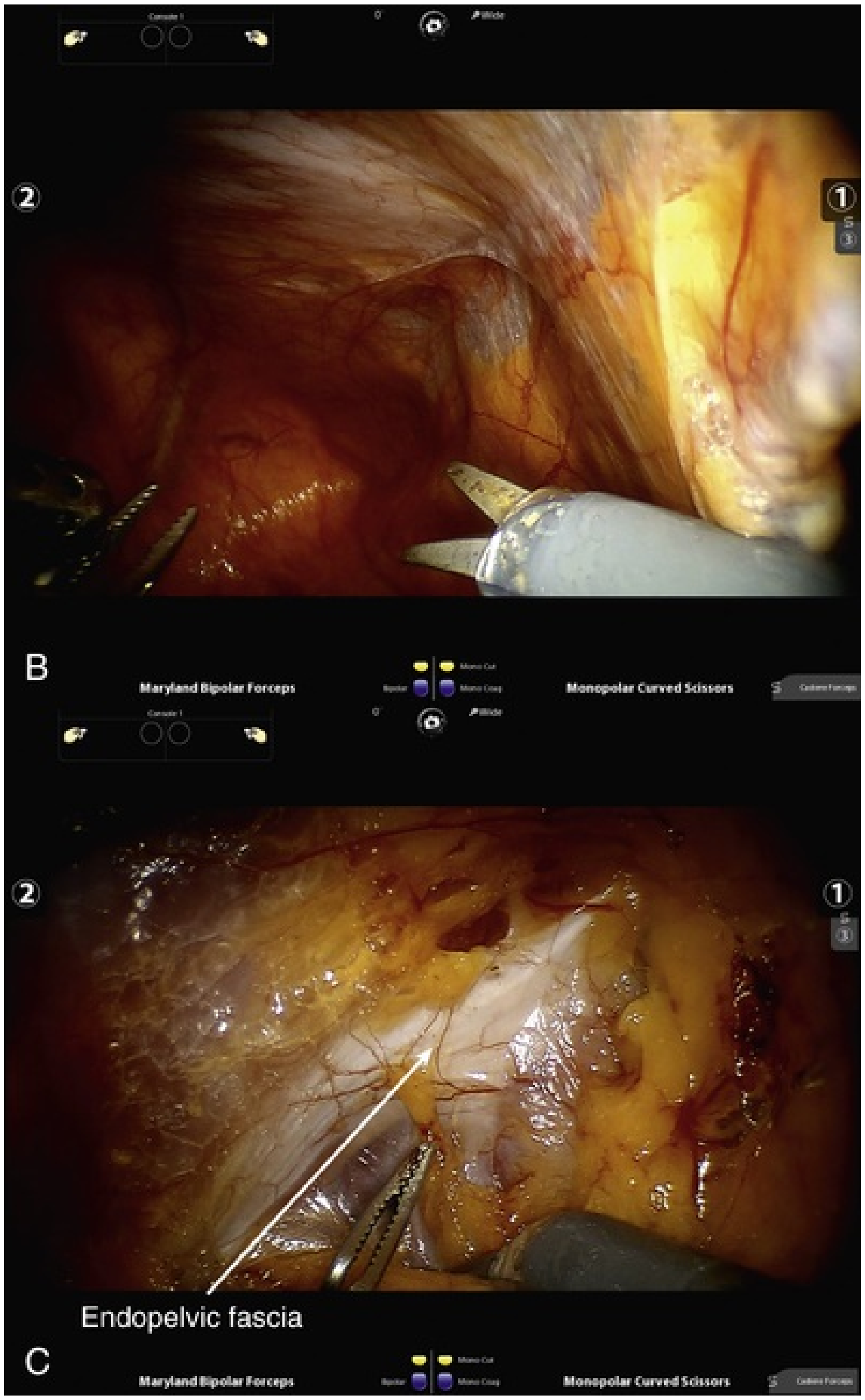
Console 1
0°
Wide
②
①
③
B
Maryland Bipolar Forceps
Mono Cut
Bipolar
Mono Coag
Monopolar Curved Scissors
Cadiere Forceps
Console 1
0°
Wide
②
①
③
Endopelvic fascia
C
Maryland Bipolar Forceps
Mono Cut
Bipolar
Mono Coag
Monopolar Curved Scissors
Cadiere Forceps

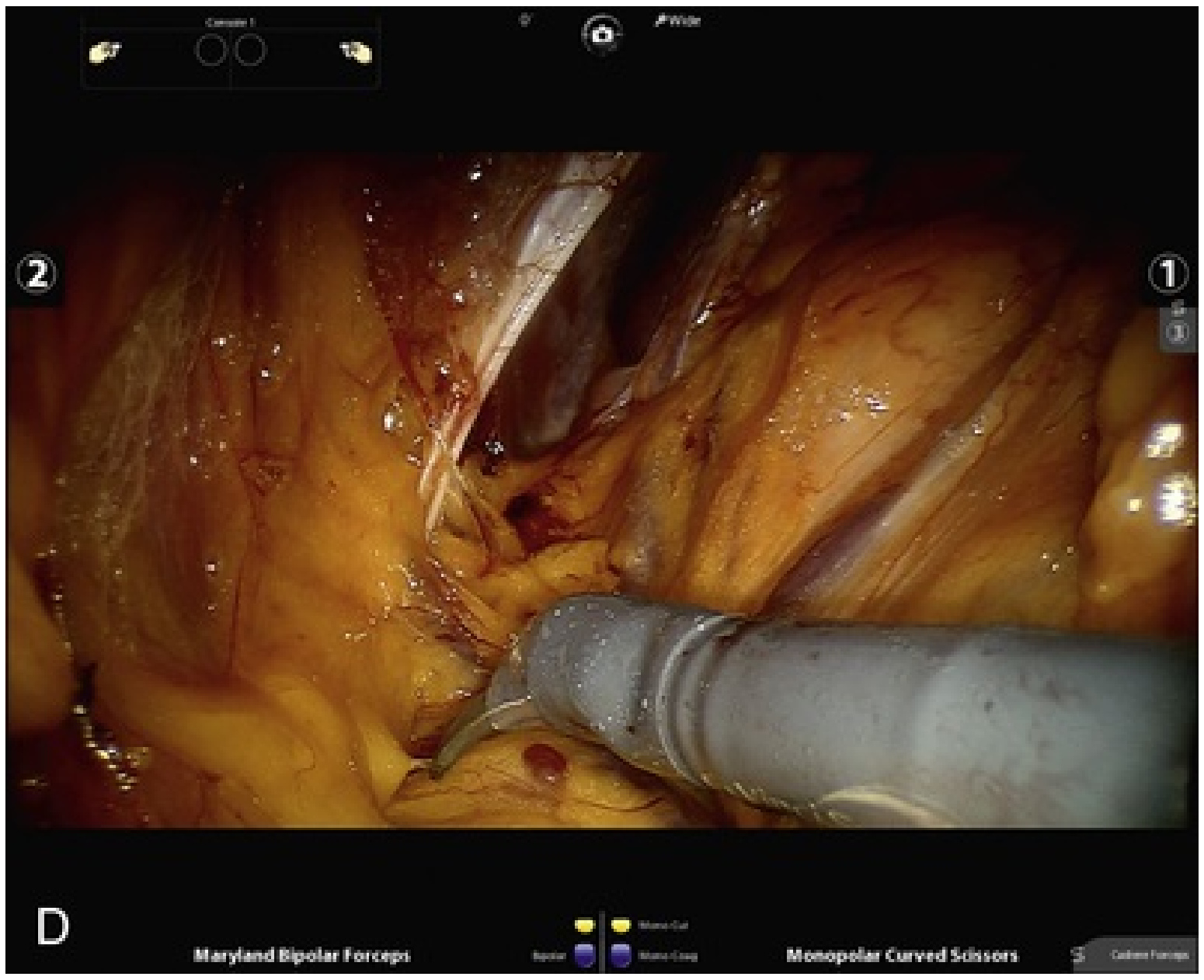

FIG. 138.22 (A) Lateral space of Retzius dissection (left side shown). (B) Tension on the left medial umbilical ligament clearly demarcates the interface between the bladder and the anterior abdominal wall. (C) The dissection is advanced distally to the endopelvic fascia and (D) posteriorly to the hypogastric artery.

Once the space of Retzius is exposed, the anterior vascular pedical of the bladder can be controlled. Although bipolar cautery can be used, we favor Weck clips, which we find provide superior vascular control and avoid heat transmission should nerve sparing be performed. Upward and medial retraction of the obliterated umbilical artery aids in developing the space between the ureter (medially) and the origin of the obliterated umbilical. After retraction is applied, the avascular plane medial to the anterior vascular pedicle comes into view (Fig. 138.23A). The pedicle vessels are then controlled sequentially toward the endopelvic fascia with clips (Fig. 138.23B). Frequently a broad venous branch from the distal hypogastric vein is present just proximal to the endopelvic fascia (Fig. 138.23C) and, once divided, serves as a reliable landmark that a complete anterior vascular pedicle dissection (Fig. 138.23D) has been performed.

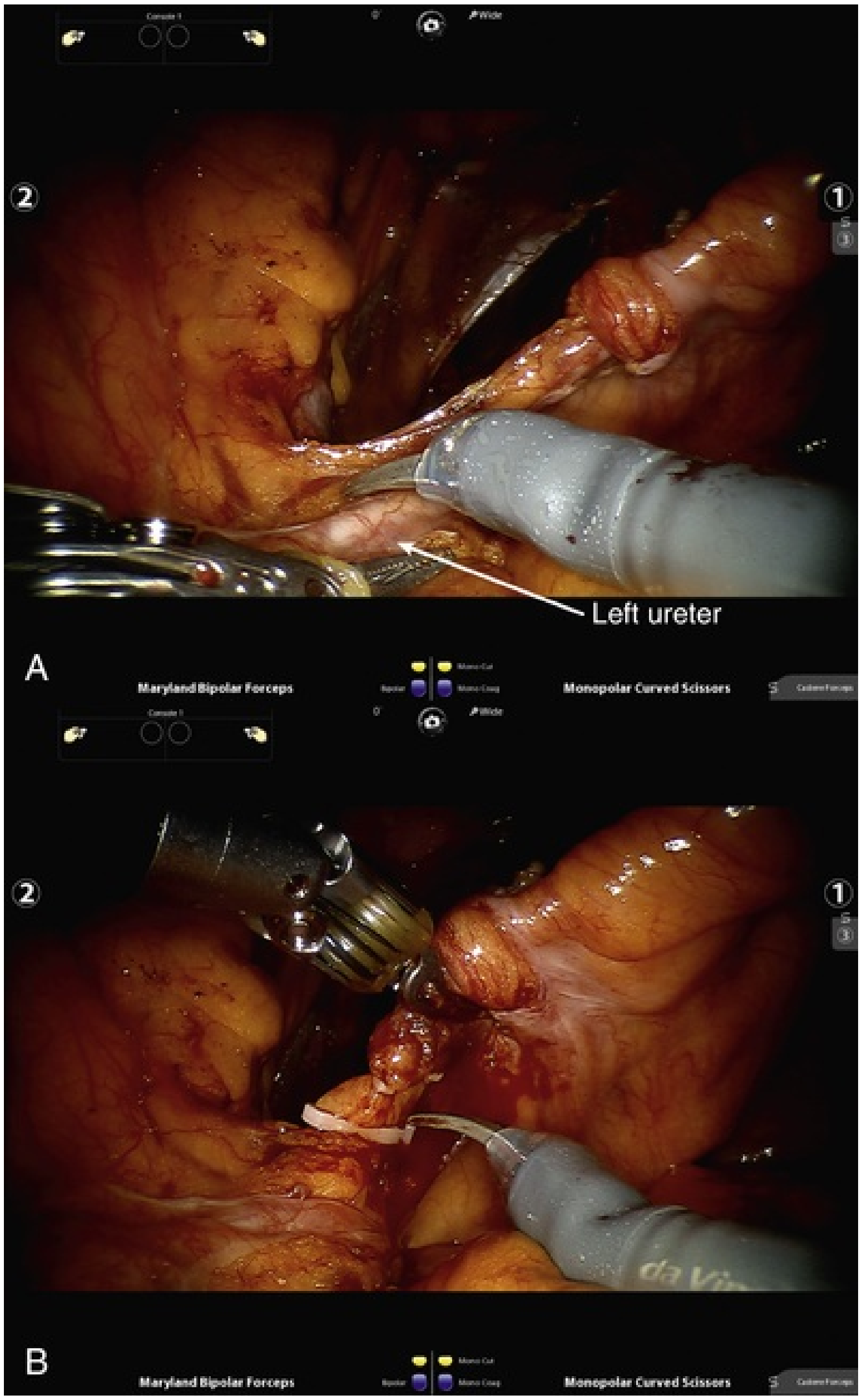
Console 1
Wide
②
①
③
Left ureter
A
Maryland Bipolar Forceps
Mono Cut
Bipolar
Mono Coag
Monopolar Curved Scissors
Cadiere Forceps
Console 1
Wide
②
①
③
da Vin
B
Maryland Bipolar Forceps
Mono Cut
Bipolar
Mono Coag
Monopolar Curved Scissors
Cadiere Forceps

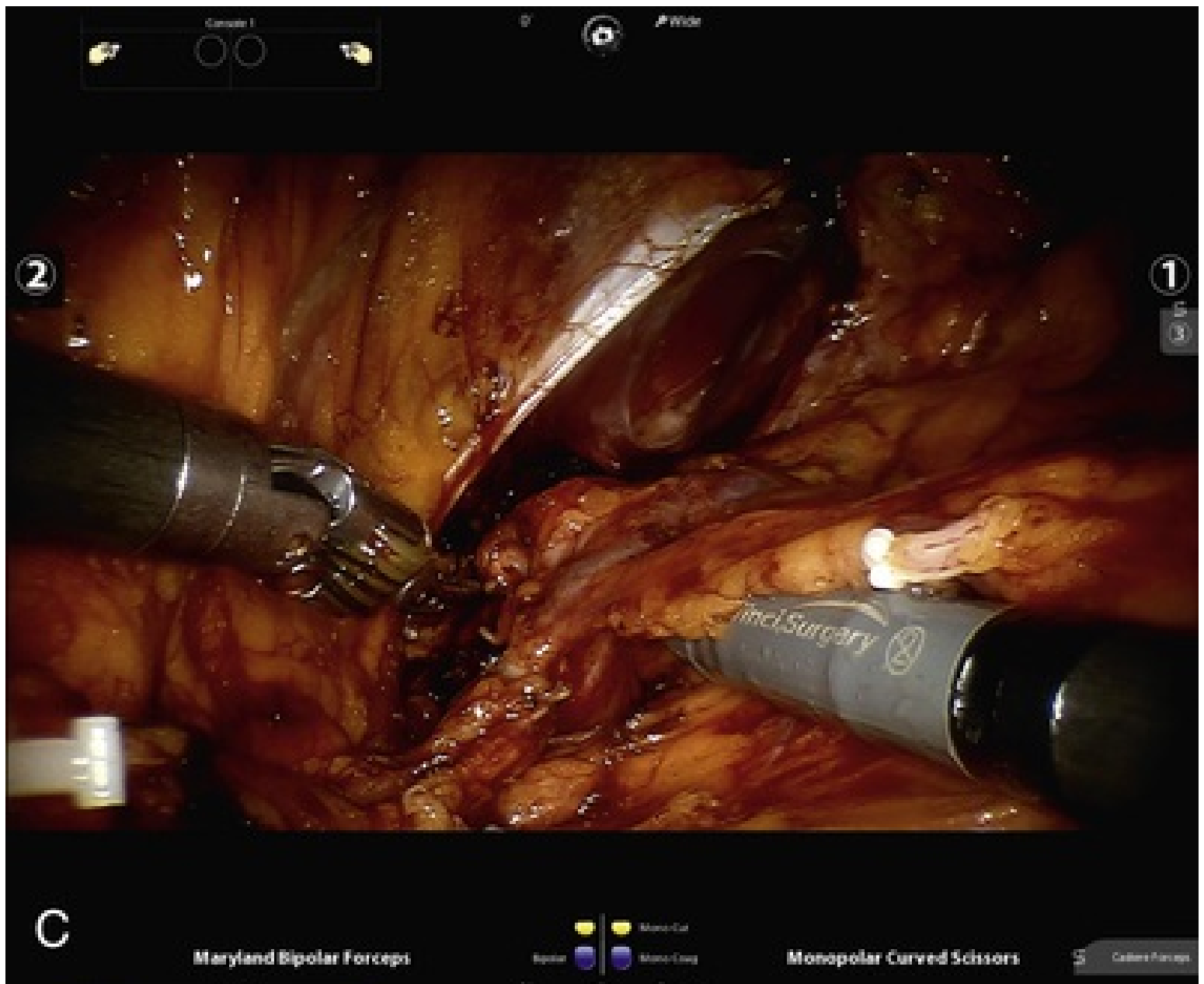
Console 1
0°
Wide
②
①
③
C
Maryland Bipolar Forceps
Bipolar
Mono Cut
Mono Coag
Monopolar Curved Scissors
Cadiere Forceps

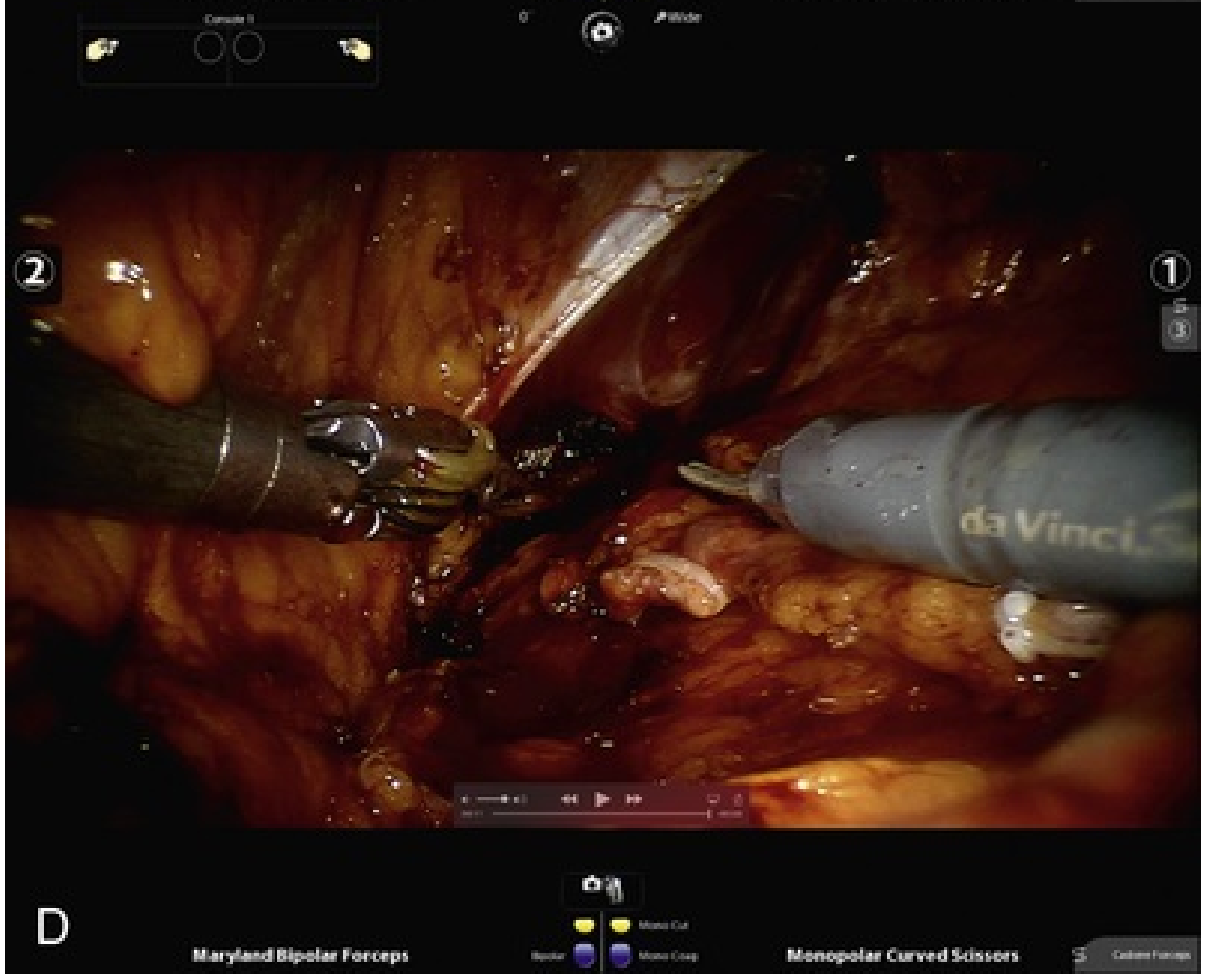
Console 1
0°
Wide
②
①
③
D
Maryland Bipolar Forceps
Bipolar
Mono Cut
Mono Coag
Monopolar Curved Scissors
Cadiere Forceps

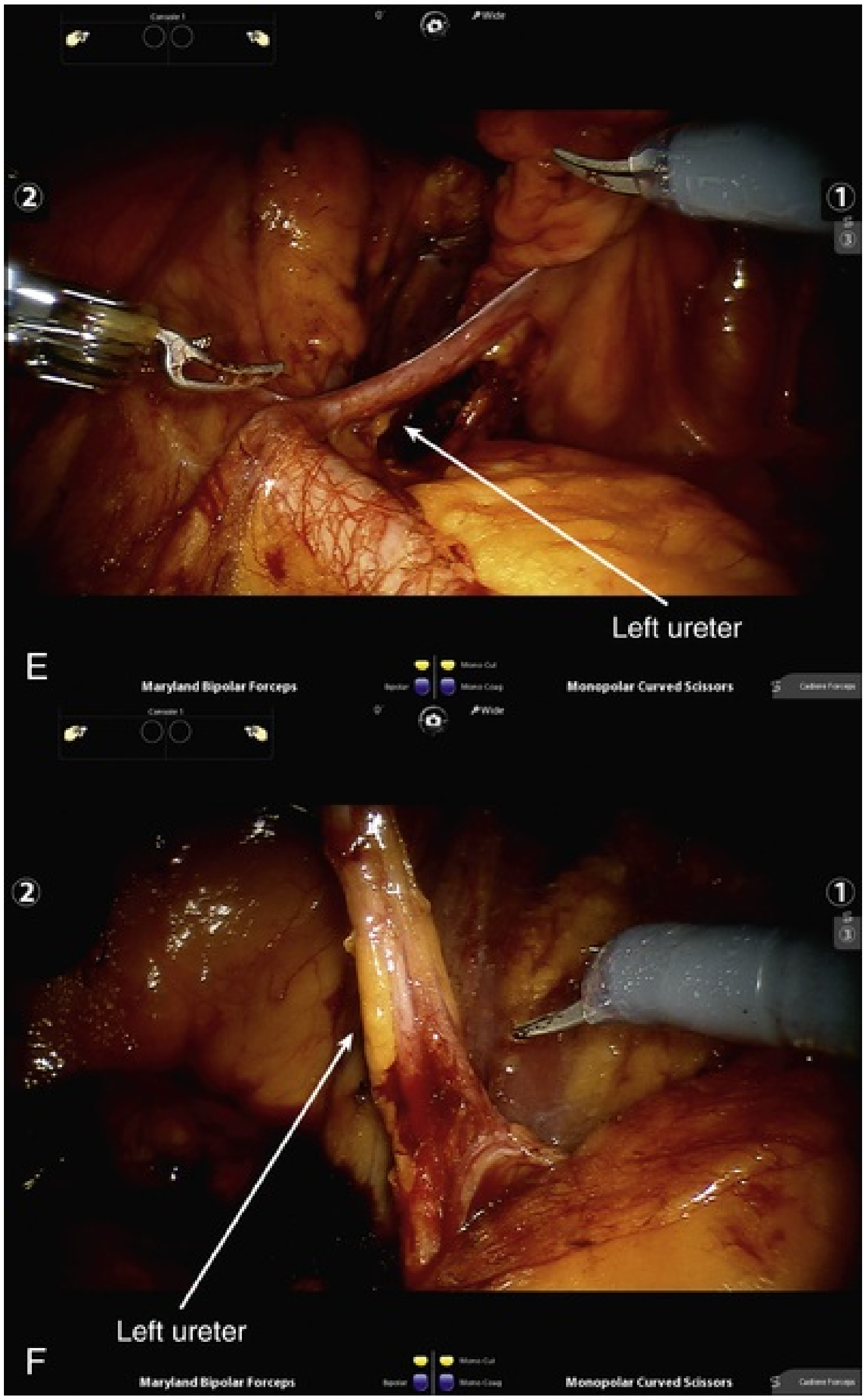
2
1
Left ureter
E
Maryland Bipolar Forceps
Monopolar Curved Scissors
2
1
Left ureter
F
Maryland Bipolar Forceps
Monopolar Curved Scissors

FIG. 138.23 Anterior bladder pedicle dissection. (A) Isolation of the initial portion of the obliterated umbilical artery. (B) Transection of the clipped initial portion of the obliterated umbilical artery. (C) Isolation and (D) control of the distal venous tributaries just proximal to the endopelvic fascia. (E) Left ureter and (F) elevation to aid in dissection.

Mobilization of the ureter is aided by retracting upward on the bladder close to the detrusor hiatus (Fig. 138.23E). This technique will elevate the ureter and should provide access to the tissue plane adhering the ureter to the pelvic vasculature. The ureter can easily be retracted bluntly with the nontraumatic portions of the robotic instruments and bipolar cautery used to control perforating vessels. Care should be taken to never directly grasp the ureter, even with robotic instruments of lower grasping strength.

The mobilization of the ureter continues proximally above the common iliac artery (Fig. 138.23F). Ample periureteral adventitia should always be maintained to mitigate ischemic strictures.

We do not find that vessel loops or other retraction aids are necessary because careful retraction of the ureter is possible by using the smooth, distal surfaces of the robotic instruments in a blunt manner. **In addition, after ureteral mobilization we do not find that it is necessary to control and transect the ureter at the detrusor hiatus at this point in the procedure. Instead we advocate for completion of the lymphadenectomy first while maintaining antegrade flow of urine into the bladder.** Later in the procedure an analogous dissection is performed on the right sided.

Extended Pelvic Lymphadenectomy

Although the pelvic lymphadenectomy can be performed after completion of the radical cystectomy, we feel this unnecessarily necessitates ureteral occlusion for potentially prolonged periods of time. In addition to the potential adverse effects on renal function postoperatively, occlusion of the ureters disadvantages the anesthesia team by withholding a valuable clinical indication of the patients resuscitative status. We have also found no reliable advantage to occlusion-induced dilation the ureters in aiding the ureteral anastomoses. Last, we have found no hindrance to visualization or access to the lymphadenectomy field with the ureters in continuity.

The anatomic landmarks for a complete extended pelvic lymphadenectomy are described earlier and do not differ when performed robotically as compared with open. However, visual clues are interpreted differently because of the differences in the visual angle of the camera as opposed to the overhead view while the surgery is performed via a laparotomy. We provide some technical pointers to ensure a meticulous dissection is performed.

External Iliac Lymphadenectomy

The external iliac lymph nodes frequently extend behind the spermatic cord. Before retraction of the spermatic cord, as seen in Fig. 138.24A, it is unclear where the external iliac lymph node packet ends laterally. Lateral retraction on the spermatic cord (Fig. 138.24B) delineates the lateral border of the lymph node packet and provides an assurance of a complete dissection in this area. Without this lateral retraction maneuver on the spermatic cord, a dissection across this tissue could lead to inadvertent transection of lymph nodes. Release of the lymph node packet laterally is then extended over the top of the artery (Fig. 138.24C,D) and inclusive of the tissue between the external iliac artery and vein. The tissue is then separated from the obturator lymph node packet, in a natural cleavage plan that does not lead to lymph node transection, and carried distally to the inferior epigastric vessels (Fig. 138.24D). Care should be taken to avoid inadvertent injury to the genitofemoral nerve, which has a variable branch point. Many times the femoral branch (parallel to the external iliac artery) and inguinal branches (traveling into the internal inguinal ring) will be recognized and should be released from the lymph node packet as needed. In cases of advanced disease if there is dense adherence of the nerve to the lymph node packet, an en bloc resection may be required. Whenever possible the lymph node packet should be kept as a single specimen (Fig. 138.24E) and placed immediately into a retrieval bag (Fig. 138.24F). The use of a 15-mm assistant port provides ample capacity to remove large lymph node packets, eliminating the need for dissection of the packet into smaller pieces. This aids efficiency but most importantly avoids transection of lymph nodes.

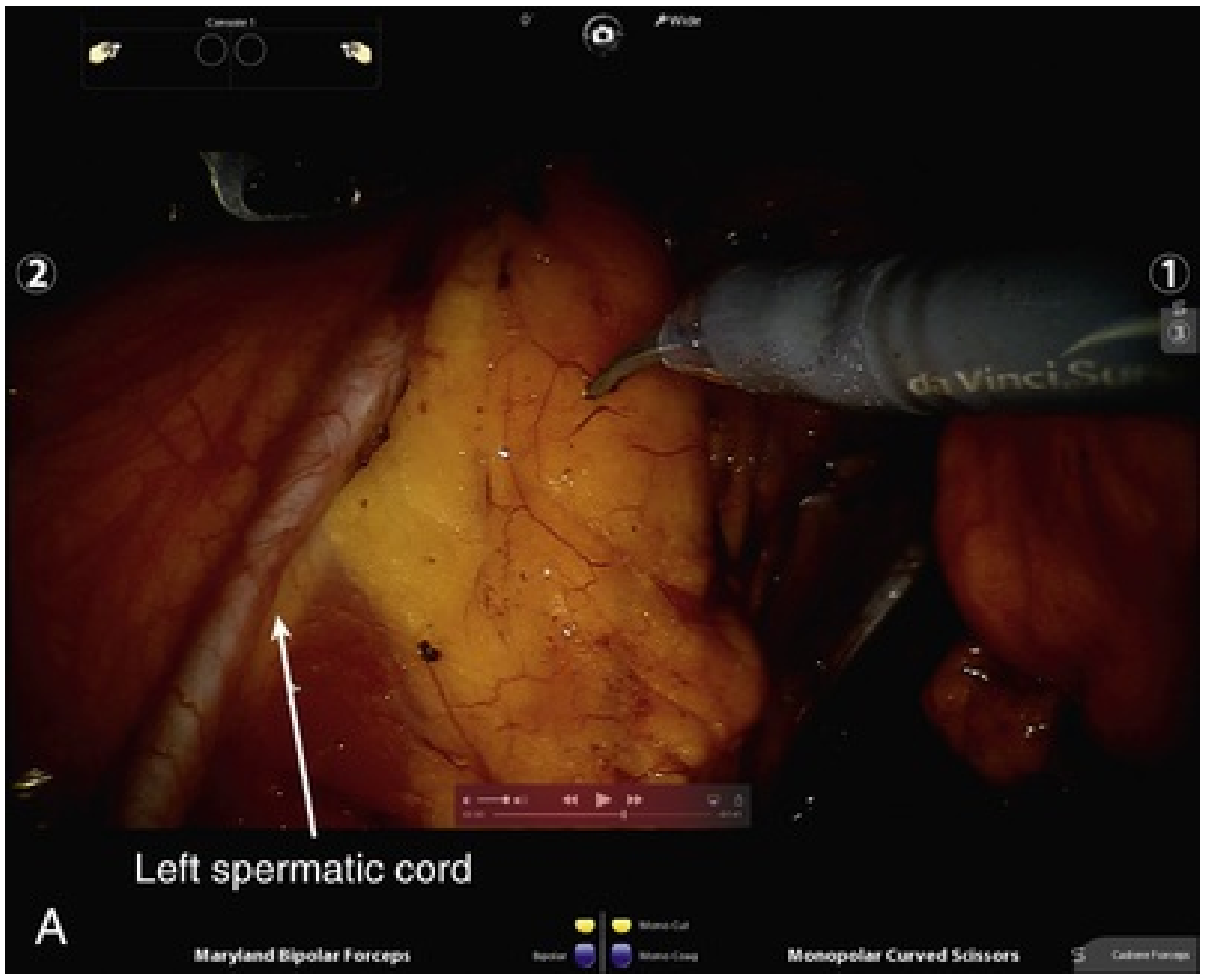

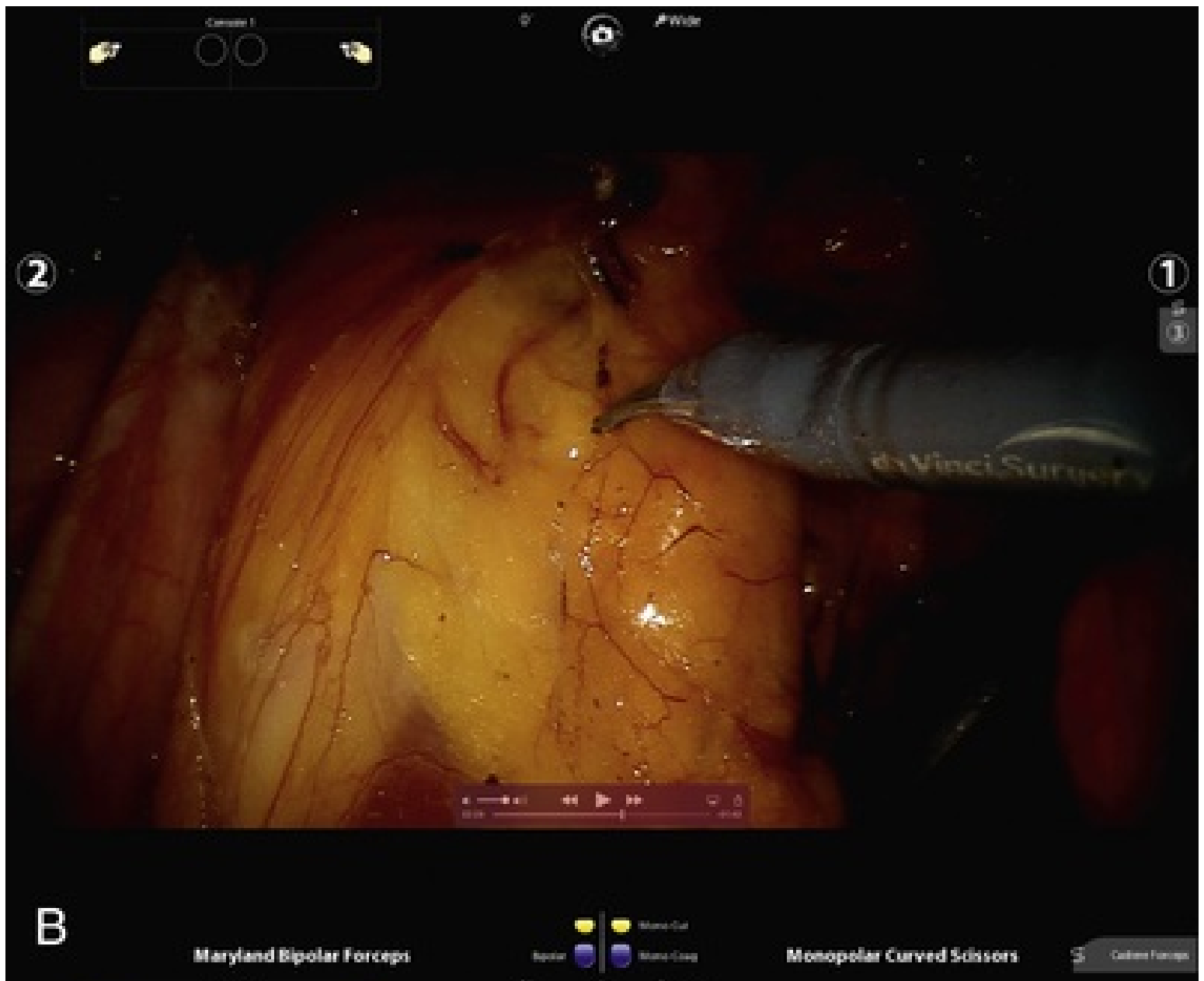
Console 1
0°
Wide
②
①
③
daVinciSurgery
Maryland Bipolar Forceps
Mono Cut
Bipolar
Mono Coag
Monopolar Curved Scissors
Cadiere Forceps

B

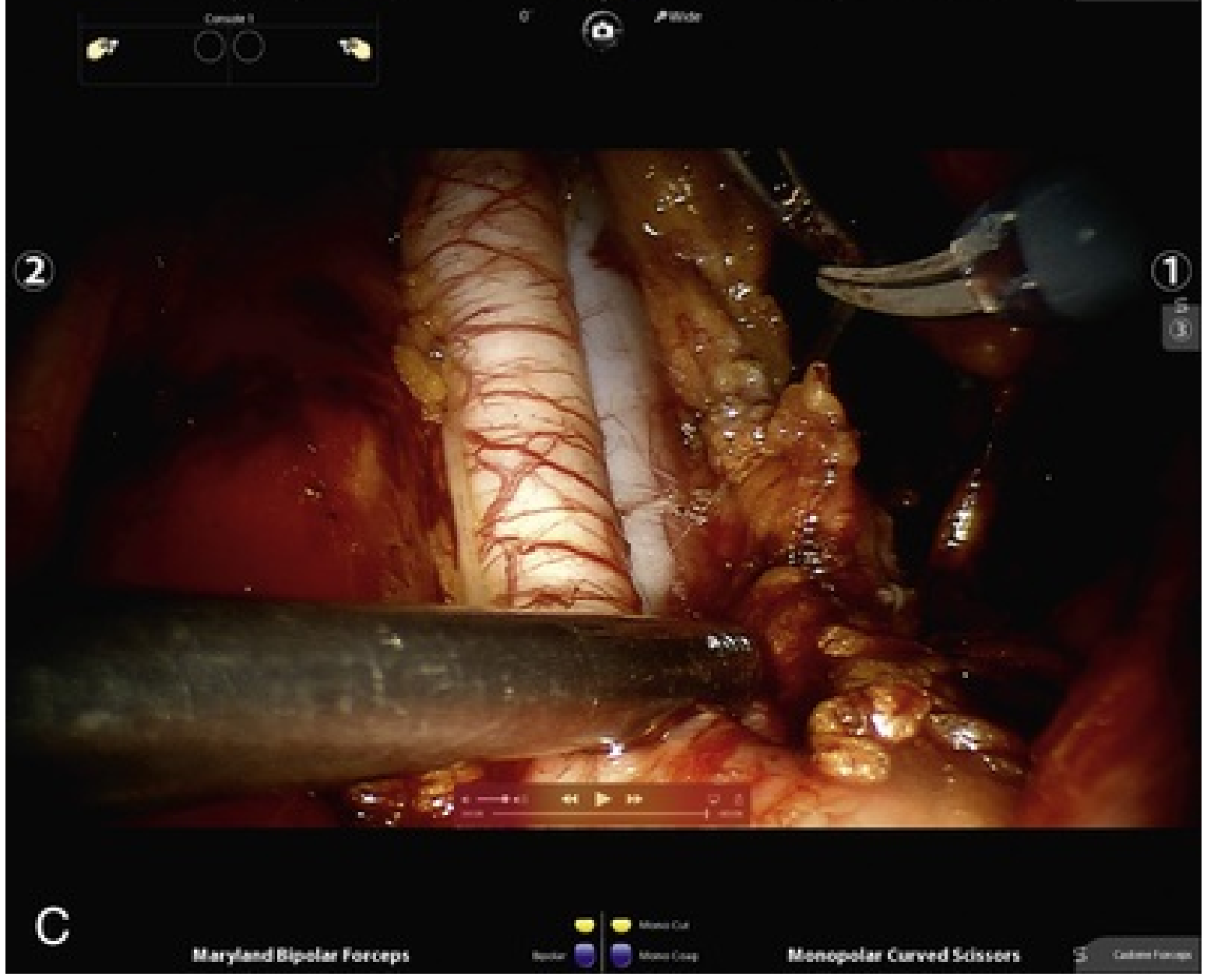
Console 1
0°
Wide
②
①
③
Maryland Bipolar Forceps
Mono Cut
Bipolar
Mono Coag
Monopolar Curved Scissors
Cadiere Forceps

C

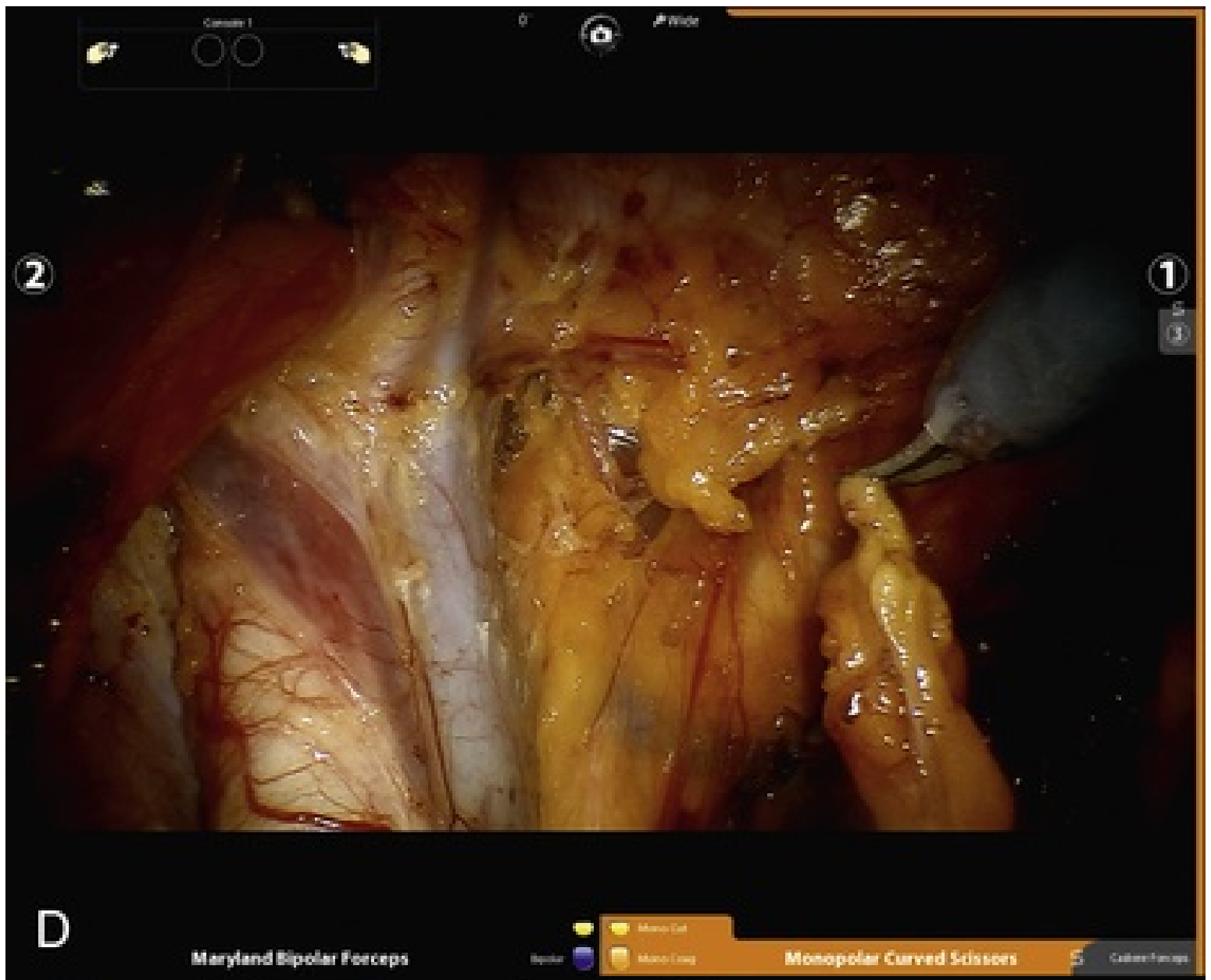
D

Console 1
0°
Wide
②
①
S
③
Maryland Bipolar Forceps
Bipolar
Mono Cut
Mono Coag
Monopolar Curved Scissors
Cadiere Forceps

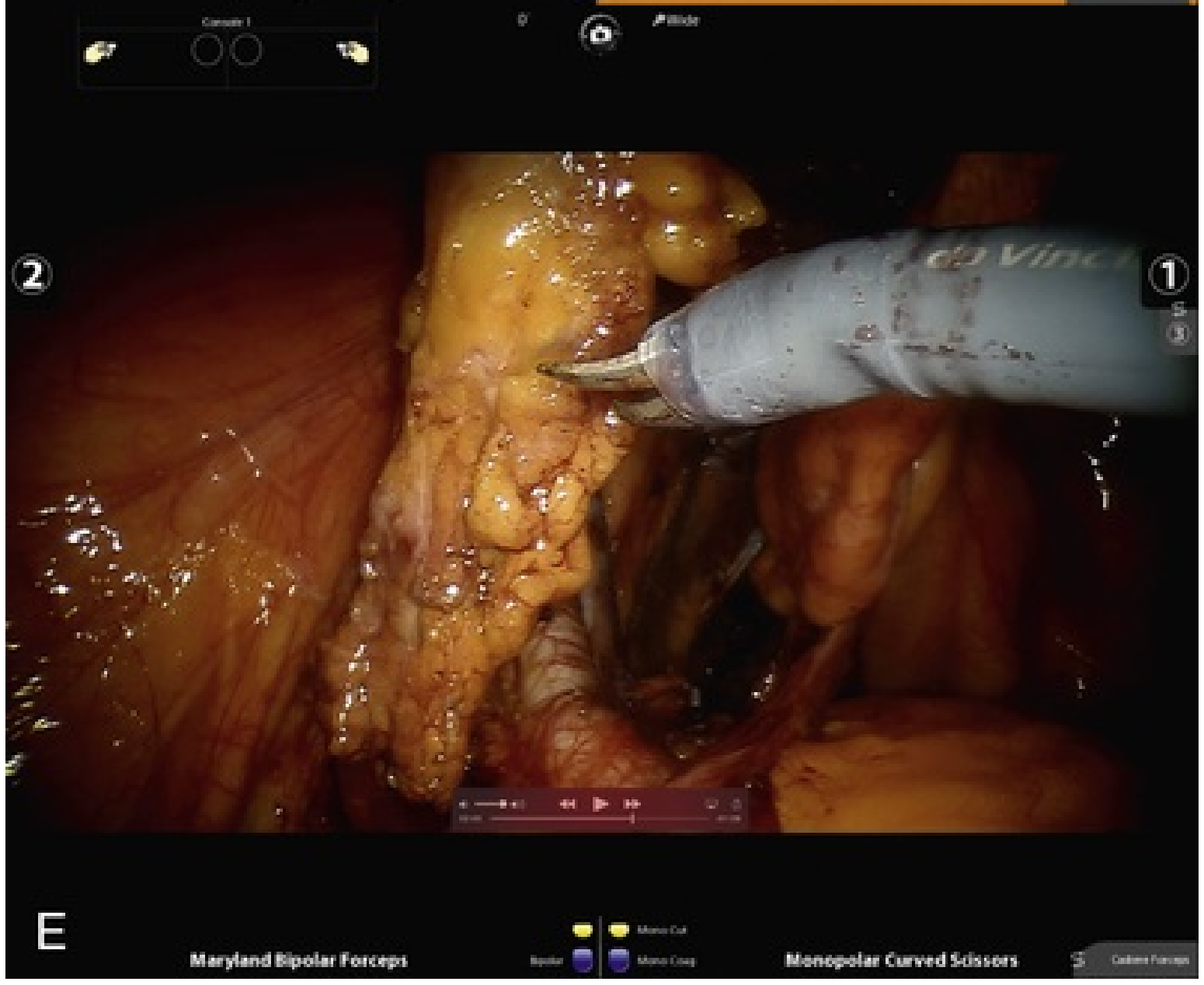
E

Console 1
0°
Wide
②
①
S
③
da Vinci
Maryland Bipolar Forceps
Bipolar
Mono Cut
Mono Coag
Monopolar Curved Scissors
Cadiere Forceps

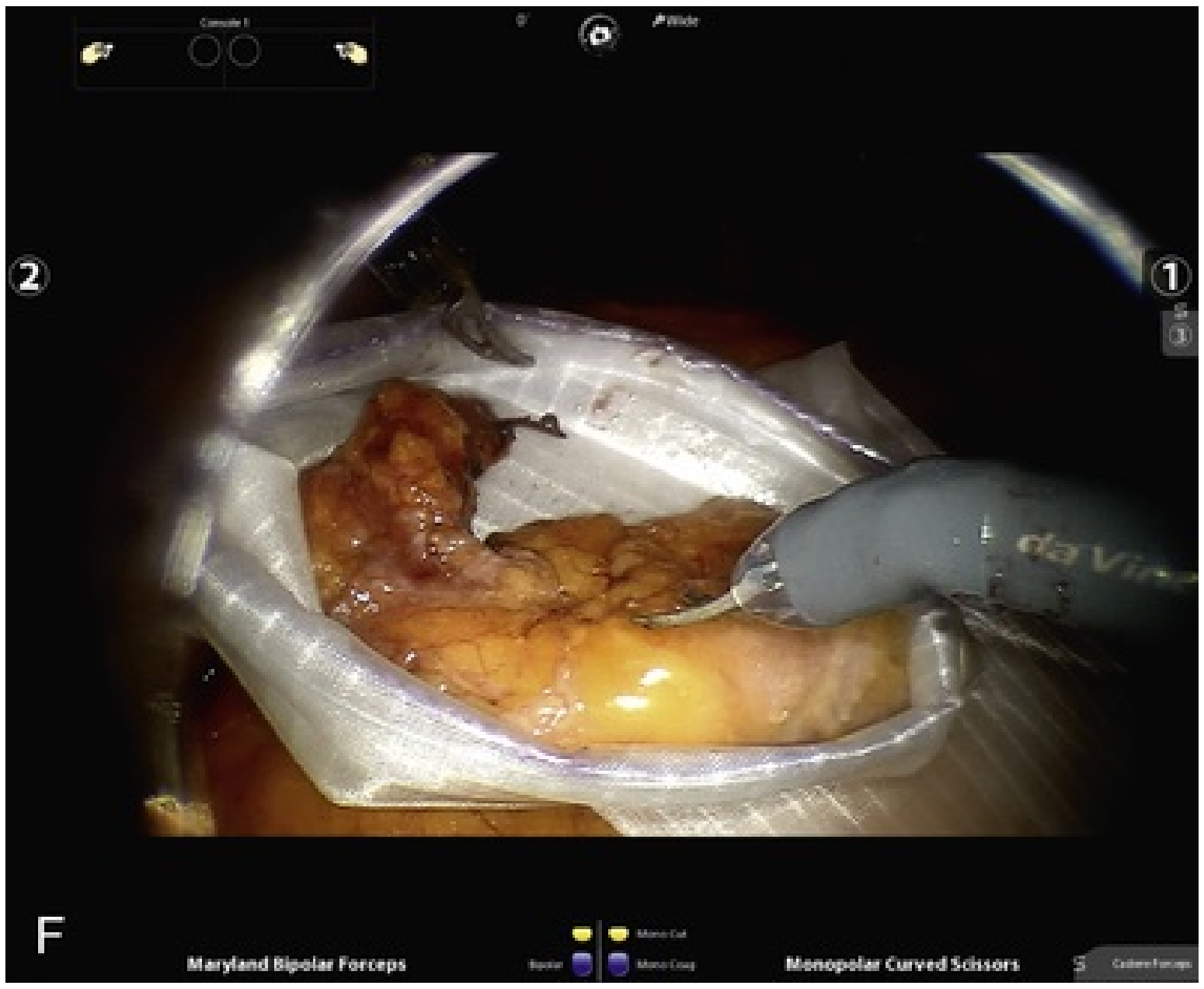

FIG. 138.24 The left external iliac lymphadenectomy is demonstrated. (A) The lymph node packet can be seen extending behind the spermatic cord (B), which is retracted laterally to ensure completeness of the lymph node dissection. (C) The skeletonized external iliac arteries are shown and the (D) interface between the external iliac and obturator lymph node packets is visualized. (E) An en bloc lymph node packet is then (F) placed into a retrieval bag.

Obturator Lymphadenectomy

The obturator lymph node packet can now easily be viewed (Fig. 138.25A). With the aid of gentle retraction by the assistant suction tip (Fig. 138.25B) on the external iliac artery, the lymph node packet can be released from the vein wall. Carefully the packet is released from the lateral pelvic sidewall attachments, and bipolar cautery is used to control lateral perforators. A common misconception is that the obturator nerve serves as the posterior landmark for this dissection; however, to complete this dissection the release of tissue lateral and posterior (toward the patient's back) should extend until the wall of the hypogastric vein is appreciated (Fig. 138.25C). As the packet is released off the hypogastric vein wall, a complete dissection is ensured. Once completed, the obturator fossa should be bare of nodal tissue (Fig. 138.25D). Although this approach may capture a portion of the hypogastric lymph nodes with the obturator specimen, we have found that an attempt to dissect the packet at the level of the obturator nerve laterally frequently leads to nodal transection and as such is ill advised.

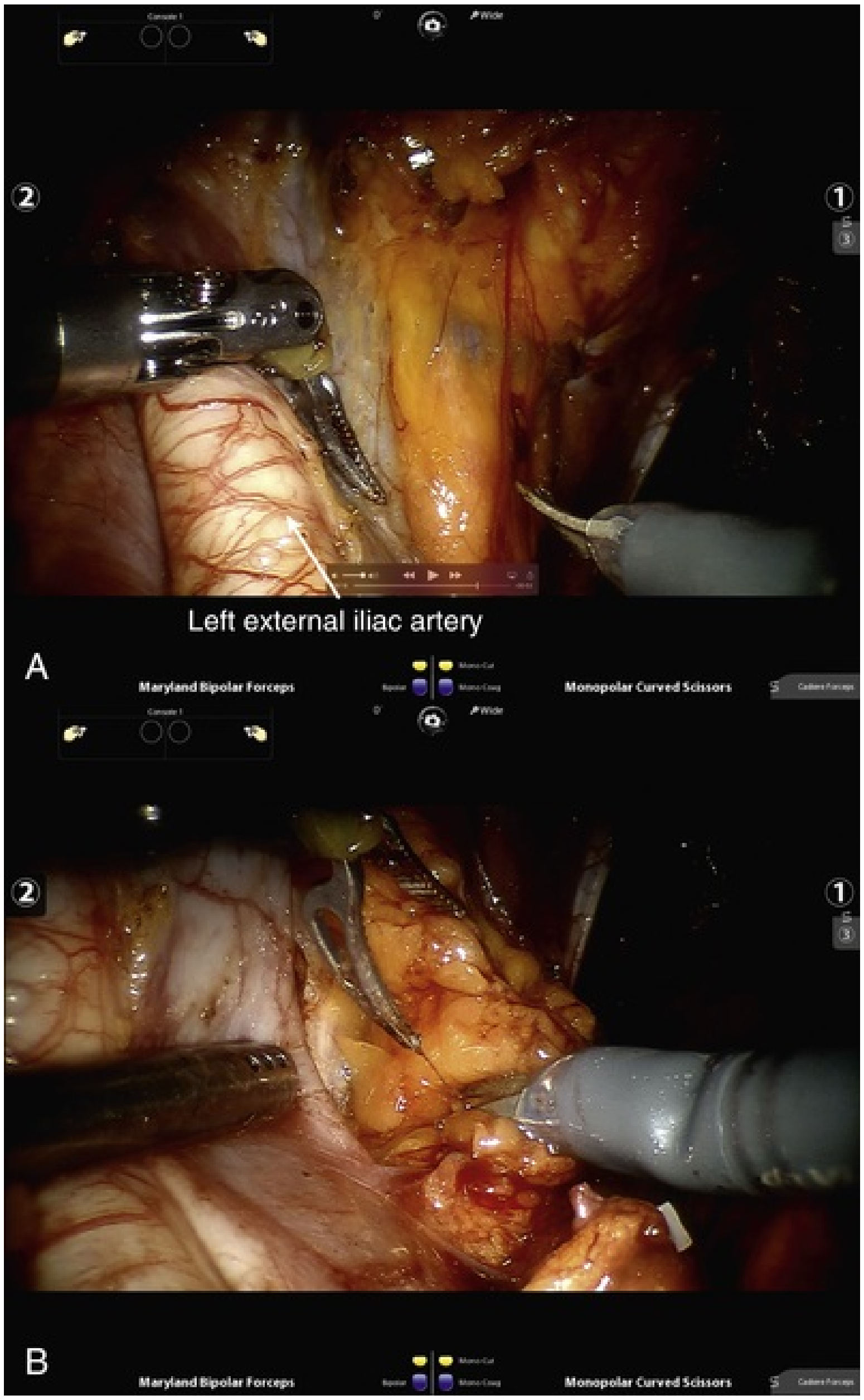
Console 1
0°
Wide
②
①
③
Left external iliac artery
A
Maryland Bipolar Forceps
Bipolar
Mono Cut
Mono Coag
Monopolar Curved Scissors
Cadiere Forceps
Console 1
0°
Wide
②
①
③
B
Maryland Bipolar Forceps
Bipolar
Mono Cut
Mono Coag
Monopolar Curved Scissors
Cadiere Forceps

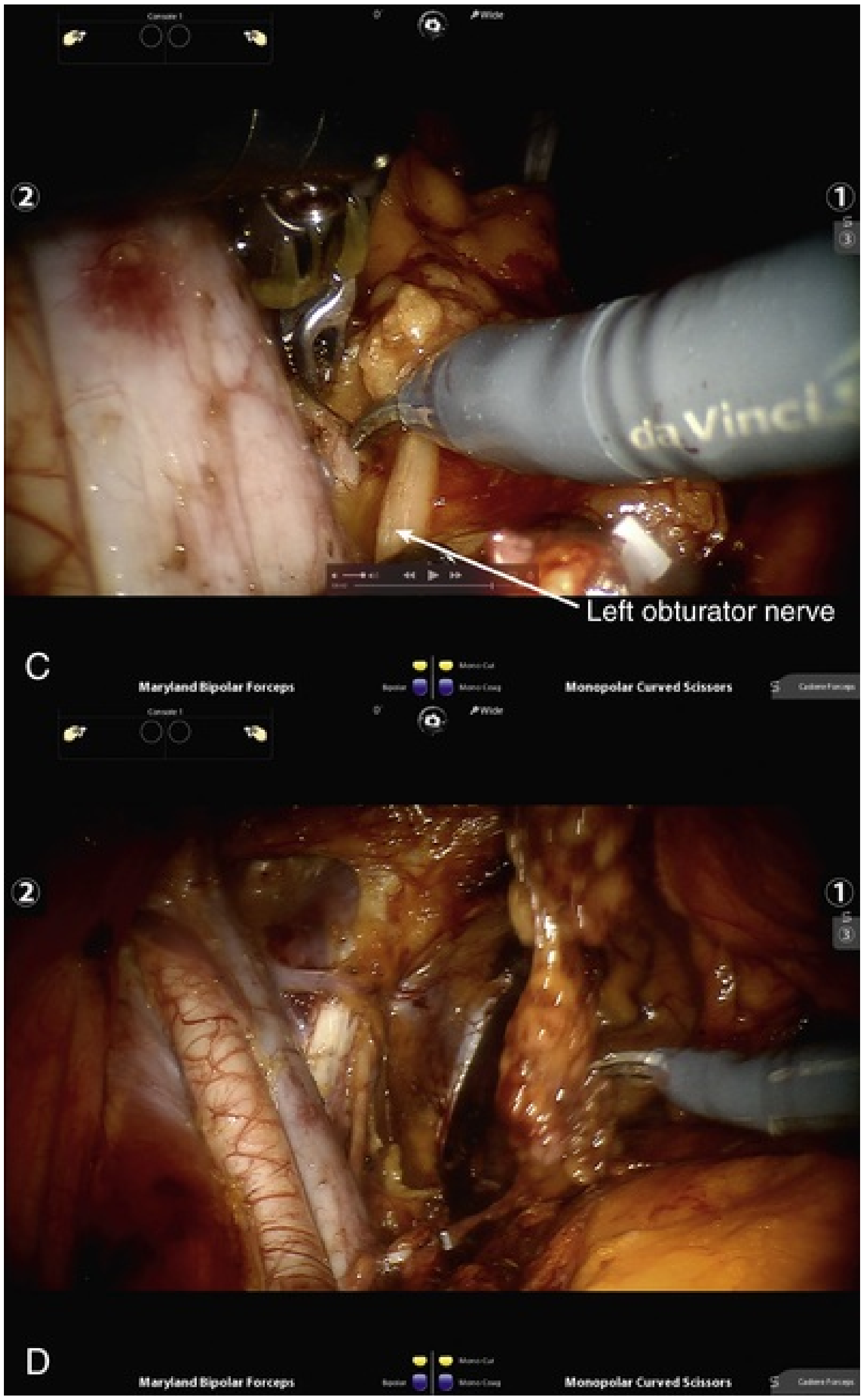
2
1
3
da Vinci
Left obturator nerve
C
Maryland Bipolar Forceps
Monopolar Curved Scissors
2
1
3
D
Maryland Bipolar Forceps
Monopolar Curved Scissors

FIG. 138.25 (A) Initial elevation of the obturator lymph nodes from the external iliac vein and (B) pelvic sidewall. (C) The obturator nerve is demonstrated and the dissection carried posterior and lateral to the nerve. (D) The dissection is complete and the obturator fossa cleared of nodal tissue.

Hypogastric Lymphadenectomy

Attention is then paid to the internal iliac lymph node packet. Deep to the obturator nerve and extending to the lateral pelvic sidewall toward the endopelvic fascia the nodal tissue can be seen (Fig. 138.26A). In a manner analogous to the obturator dissection the nodal tissue is released from the pelvic sidewall (Fig. 138.26B) and released. The hypogastric nodal packet extends posteriorly around the mesorectal fascia, and care must be employed to ensure a complete packet is removed (Fig. 138.26C). Gentle upward retraction aids in the release of this deep portion of the packet, and once completed, the pelvic portion of the lymphadenectomy is complete (Fig. 138.26D).

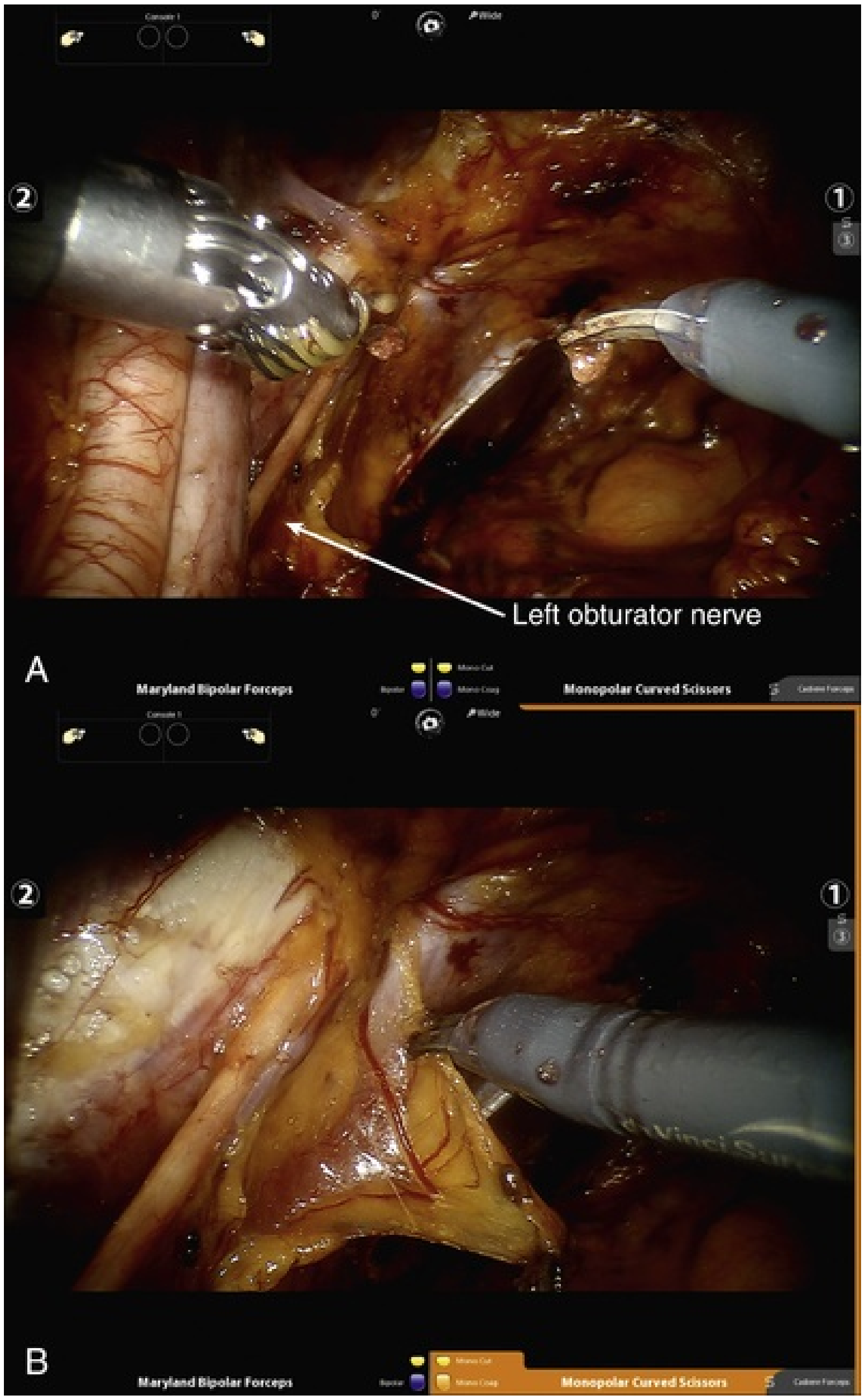
Left obturator nerve
A
Maryland Bipolar Forceps
Monopolar Curved Scissors
B
Maryland Bipolar Forceps
Monopolar Curved Scissors

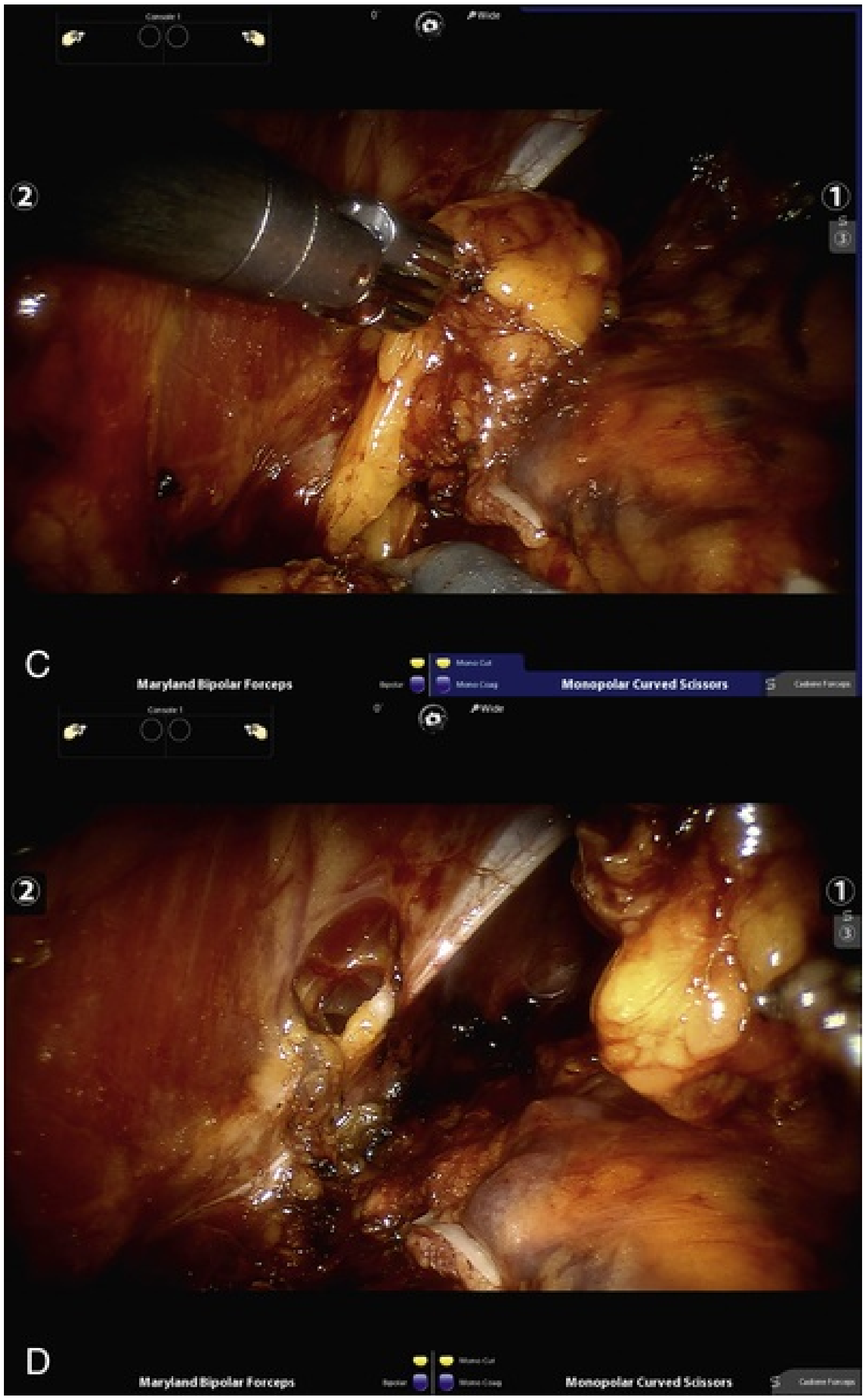
②
①
C
Maryland Bipolar Forceps
Monopolar Curved Scissors
Wide
②
①
D
Maryland Bipolar Forceps
Monopolar Curved Scissors

FIG. 138.26 (A) The hypogastric (internal iliac) lymph node packet is released from the (B) pelvic sidewall distal and posterior to the obturator nerve. (C) The nodal tissue extends posteriorly just lateral to the mesorectal fascia and once released (D) the dissection is complete.

Common Iliac Lymphadenectomy

Following a similar dissection technique to that described earlier, the left common iliac lymph node packet is identified (Fig. 138.27A) and removed. The initial release begins from the lateral border of the common iliac artery (Fig. 138.27B) and progresses posteriorly until the left common iliac vein wall can be seen. The tissue is then released in a lateral direction and excised (Fig. 138.27C). Once complete the left ureter, which had been medially retracted, is seen over the lymphadenectomy bed (Fig. 138.27D). The right-sided common iliac dissection is performed in a similar fashion (not shown).

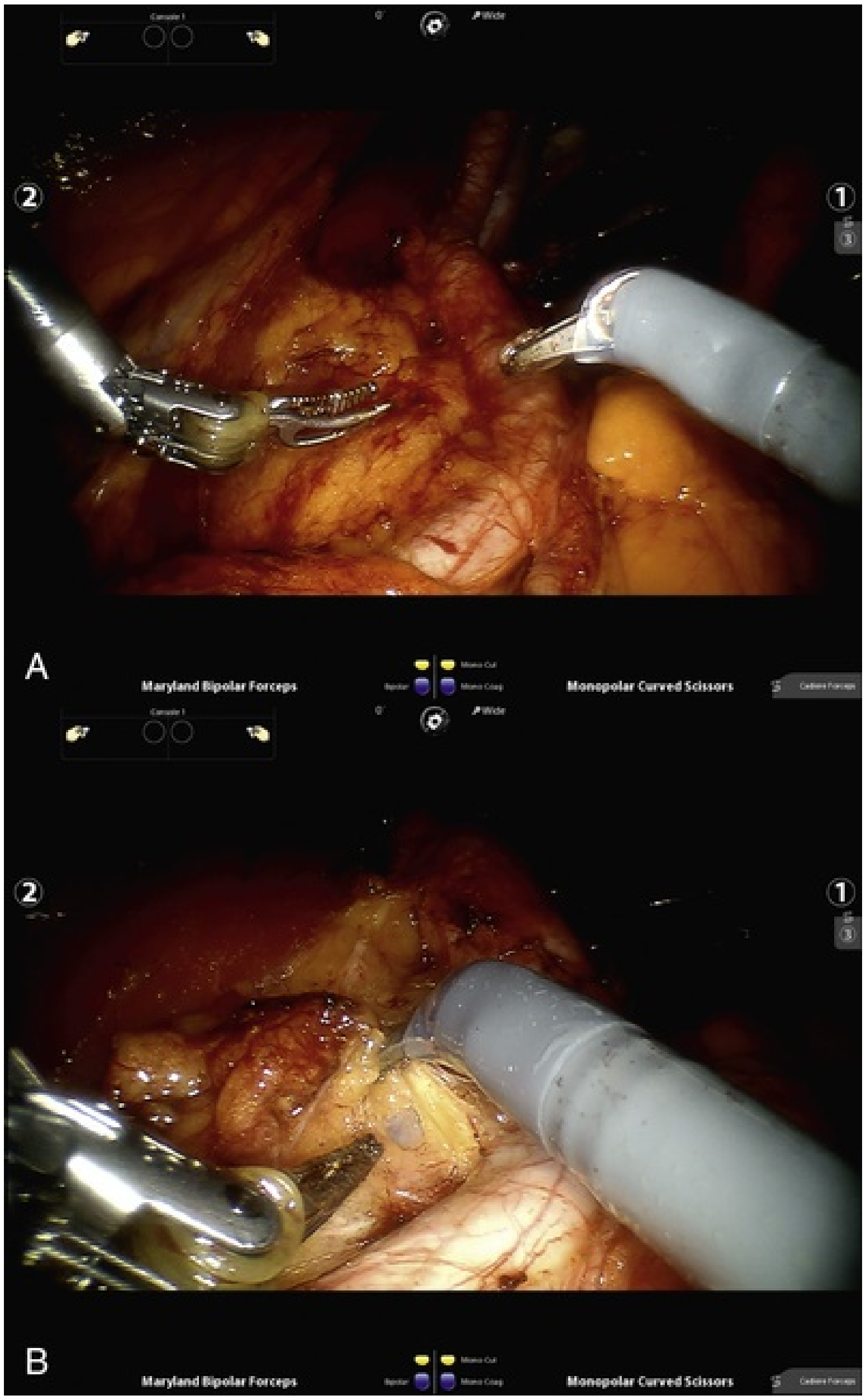
Console 1
Wide
2
1
3
A
Maryland Bipolar Forceps
Mono Cut
Bipolar
Mono Coag
Monopolar Curved Scissors
Cadiere Forceps
B

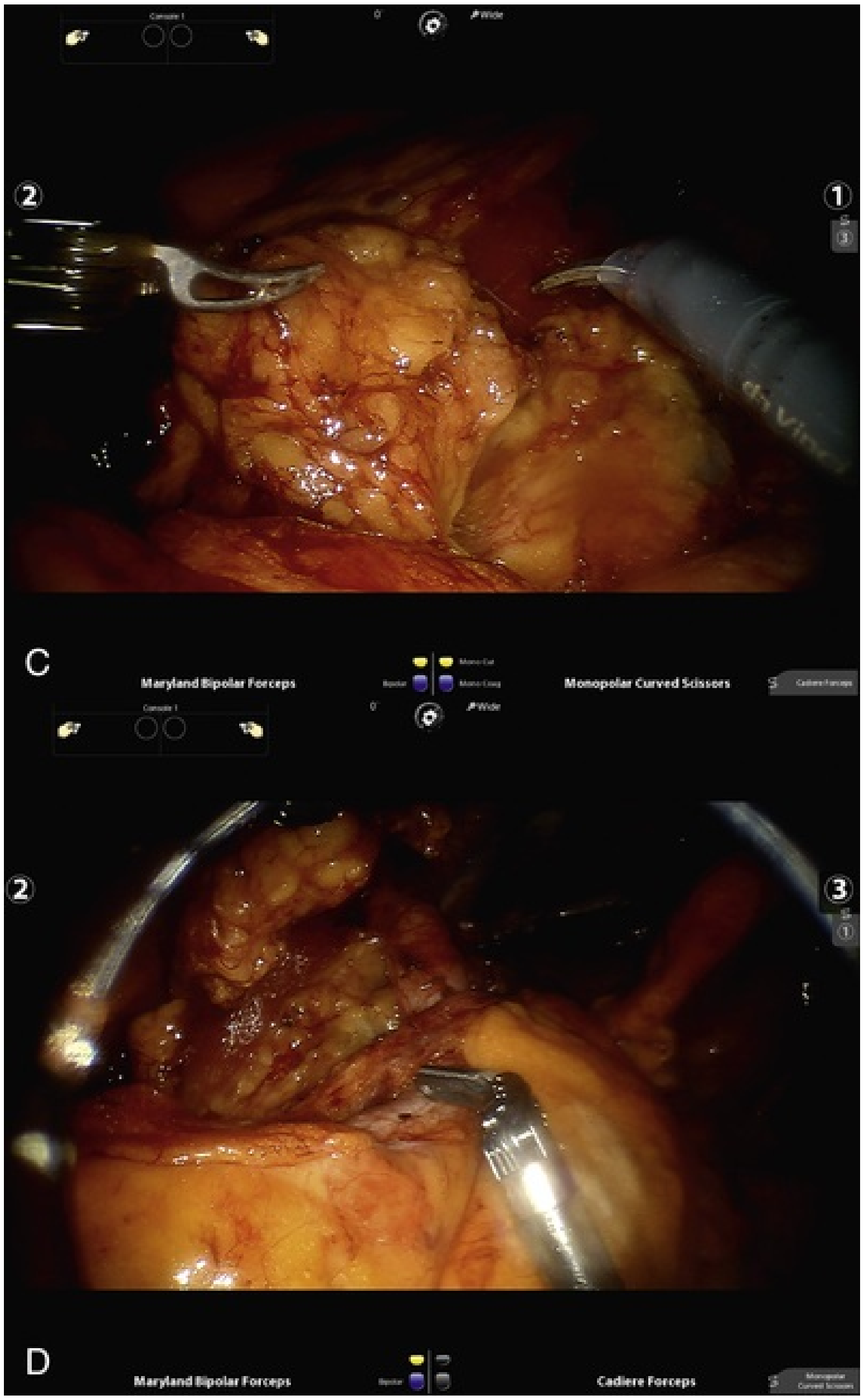
Console 1
Wide
2
1
3
C
Maryland Bipolar Forceps
Bipolar
Mono Cut
Mono Coag
Monopolar Curved Scissors
Cadiere Forceps
Console 1
Wide
2
3
1
D
Maryland Bipolar Forceps
Bipolar
Cadiere Forceps
Monopolar Curved Scissors

FIG. 138.27 (A) The left common iliac lymph nodes are shown and the initial dissection (B) begins with elevation of the nodal packet off the lateral border of the common iliac artery and continues until the left common iliac vein is identified. (C) The nodal packet is elevated and after completion (D) the ureter can be seen over the cleared fossa.

Presacral Lymphadenectomy

The initial dissection posterior to the sigmoid mesentery performed during the early mobilization is now fully appreciated. Having already released the sigmoid mesentery to the right common iliac artery from the left side, the peritoneum overlying the right common iliac artery is thinned (Fig. 138.28A). Once incised, it is easy to gain continuity with the left-sided dissection and gain full visualization of the presacral nodal basin (Fig. 138.28B). Careful dissection with the use of bipolar cautery to control perforating branches allows for complete excision of the presacral lymph node packet (Fig. 138.28C).

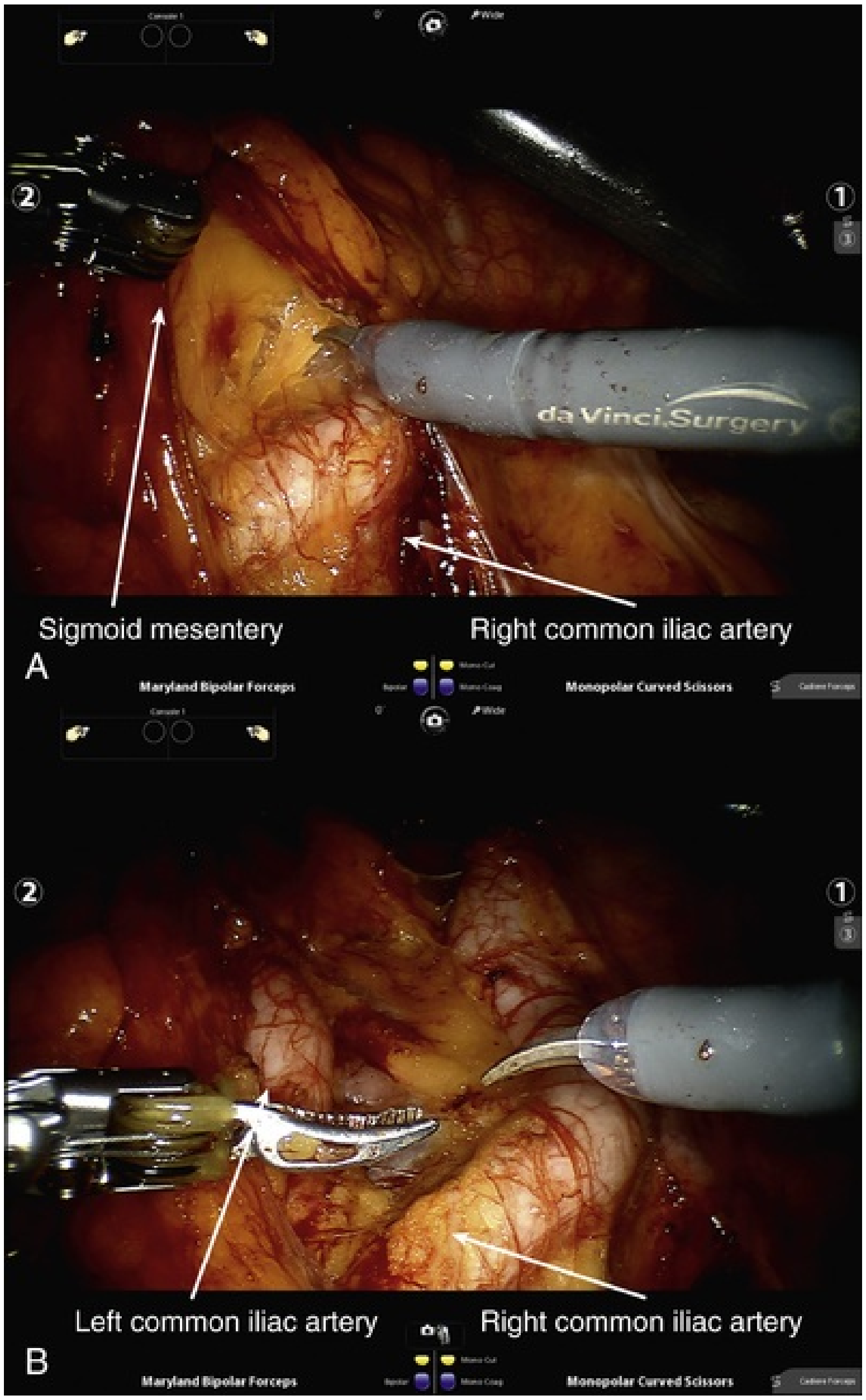
Wide
2
1
da Vinci Surgery
Sigmoid mesentery
Right common iliac artery
A
Maryland Bipolar Forceps
Monopolar Curved Scissors
Wide
2
1
Left common iliac artery
Right common iliac artery
B
Maryland Bipolar Forceps
Monopolar Curved Scissors

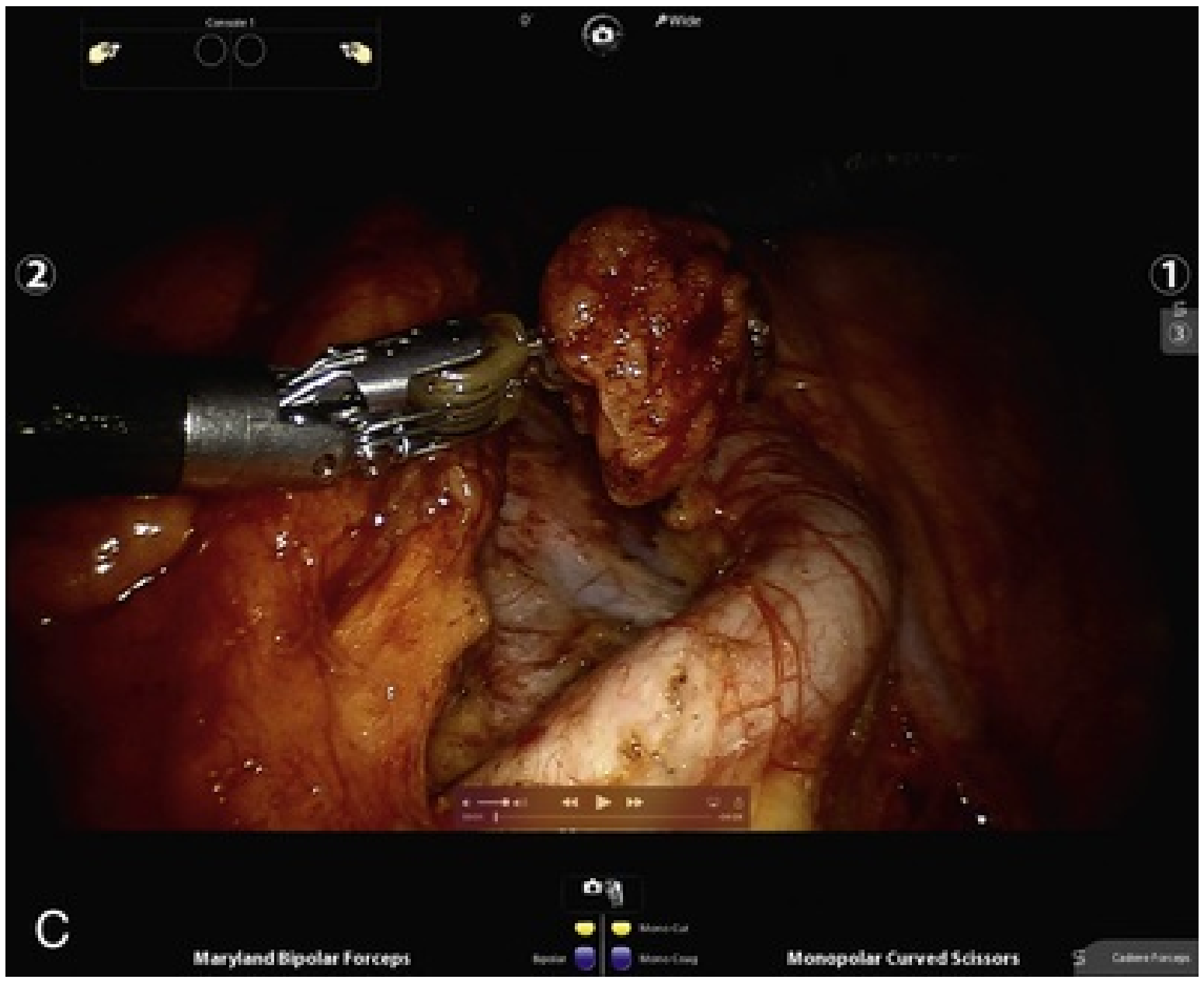

FIG. 138.28 (A) The presacral lymph node packet is identified directly below the sigmoid mesentery (as seen from right to left). (B) With visualization of the aortic bifurcation the nodal packet is carefully elevated (C) off the left common iliac vein and the presacral space.

Oncologic considerations may dictate an alteration to the lymphadenectomy described earlier. For example, the dissection can be extended into the retroperitoneum, or portions of this dissection may be omitted. For example, in non–muscle-invasive disease in which nerve sparing is planned, a presacral dissection may be avoided to mitigate the risk of interrupting the hypogastric plexus proximal to the neurovascular bundles. As discussed earlier in this chapter, the decision regarding the extent of lymphadenectomy is made based on specific cancer characteristics and functional goals.

Ureteral Control and Posterior Pedicle Dissection

After completion of the pelvic lymphadenectomy the ureters are controlled at the detrusor hiatus. If there is oncologic involvement of the trigone, or suspected disease in the intramural ureters, the placement of clips and transection of the ureters can be moved proximally. The placement of clips on the distal right ureter is shown in Figs. 138.29A and B. Adequate space is provided between clips to allow for a ureteral margin to be sent (Fig. 138.29C). Once this has been completed on both sides, the left ureter is transposed to the right lower quadrant under the sigmoid mesentery (Fig. 138.29D). We have not found sutures attached to the ureteral clips, as tethers, to be necessary or helpful. If an adequate release of the sigmoid mesentery has been performed transposition of the left ureter should not be difficult.

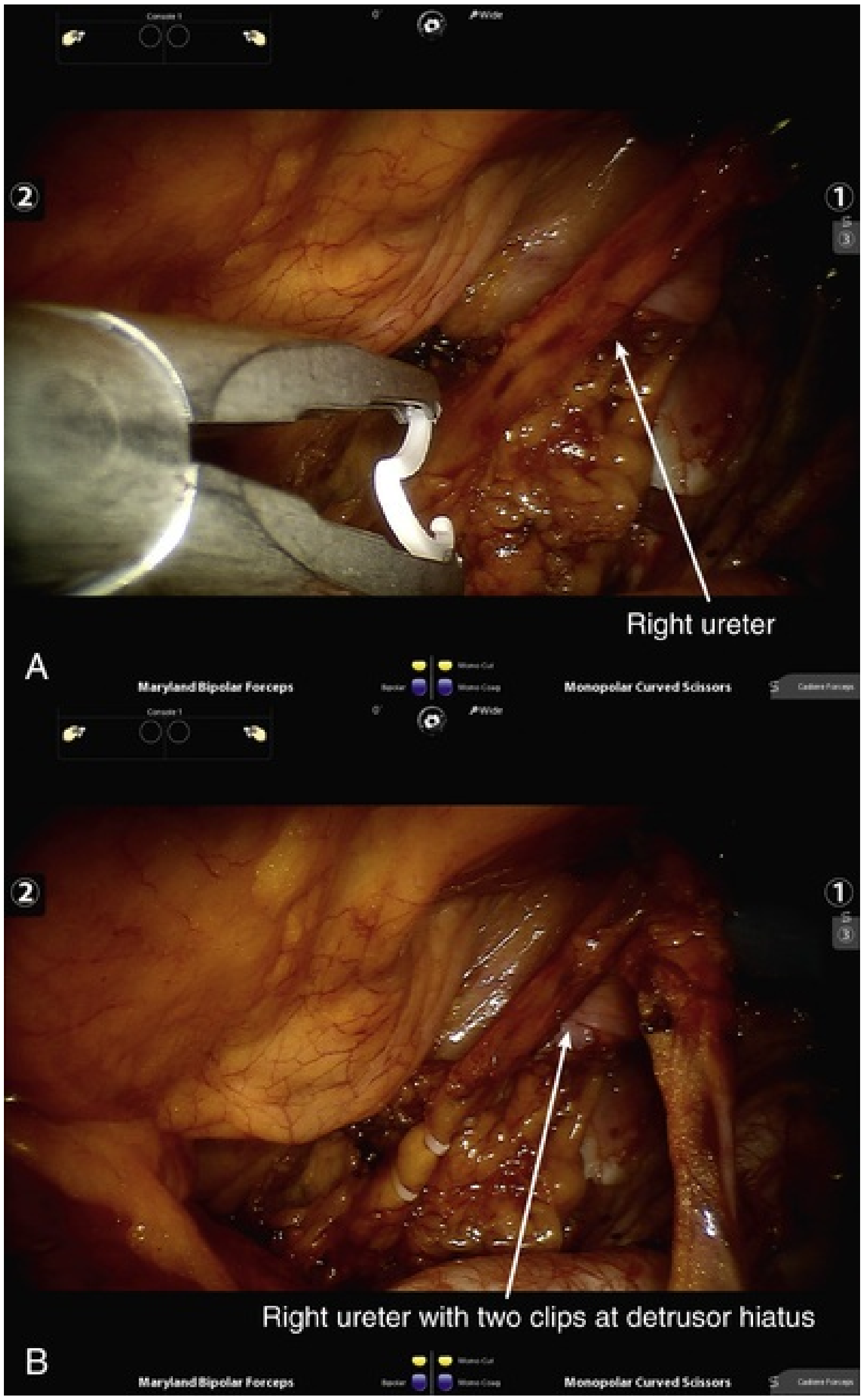
Wide
2
1
3
Right ureter
A
Maryland Bipolar Forceps
Mono Cut
Bipolar
Mono Coag
Monopolar Curved Scissors
Cadiere Forceps
Console 1
Wide
2
1
3
Right ureter with two clips at detrusor hiatus
B
Maryland Bipolar Forceps
Monopolar Curved Scissors

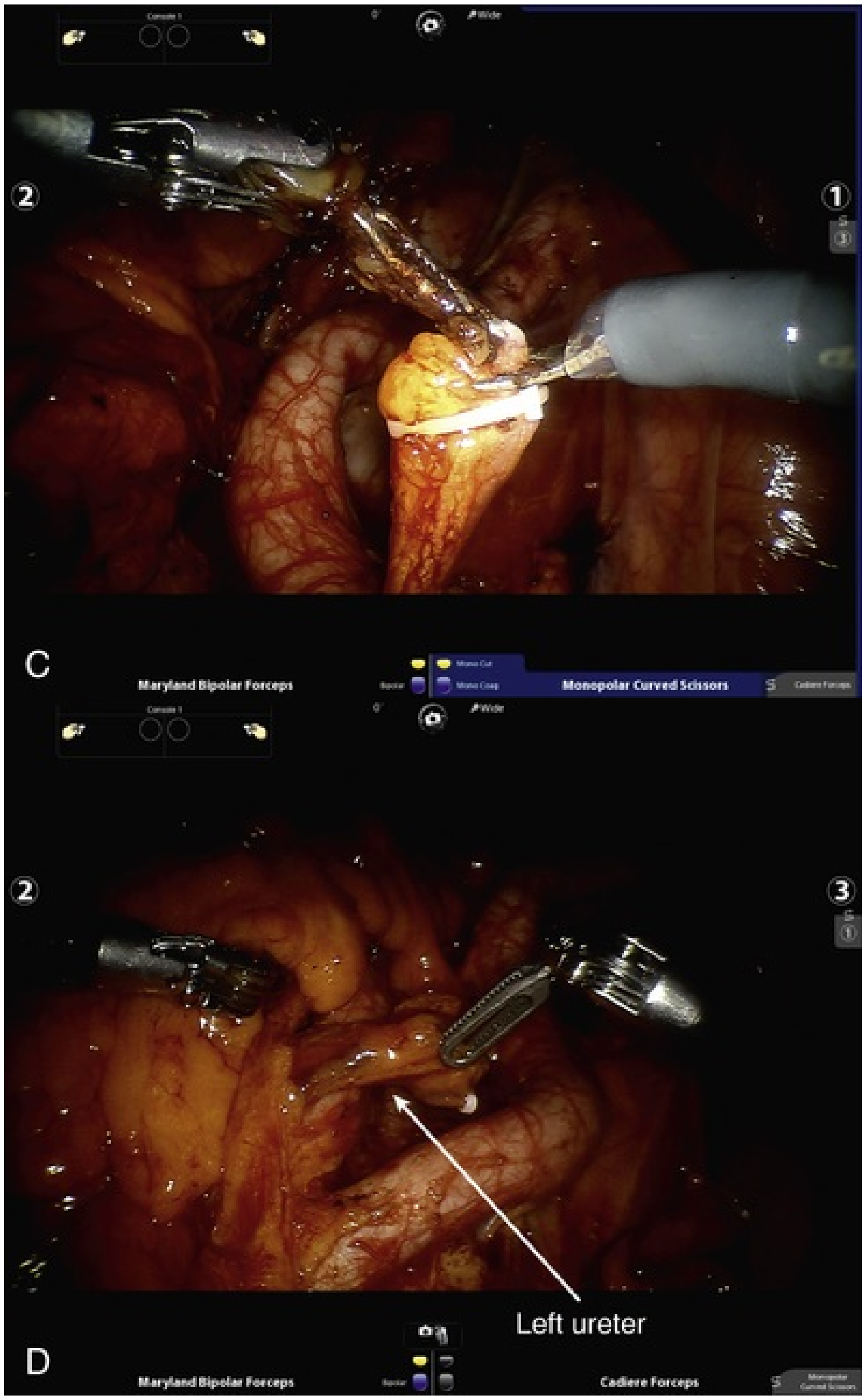
2
1
C
Maryland Bipolar Forceps
Monopolar Curved Scissors
Cadiere Forceps
2
3
Left ureter
D
Maryland Bipolar Forceps
Cadiere Forceps

FIG. 138.29 (A) The right ureter is shown dissected to the detrusor hiatus (B) where it is controlled with clips. (C) After transection a frozen section is sent. (D) The left ureter is transposed under the sigmoid mesentery to the right low quadrant.

After the ureters have been dissected free the posterior vascular pedicle should be controlled before release of the urachus and anterior space of Retzius. This aids in visualization of the posterior tissues. In the case of a male cystoprostatectomy upward retraction of the bladder with the rightmost robotic arm will aid in the dissection (Fig. 138.30A). In this demonstration the vessel sealer is used but can be easily substituted for clips if nerve sparing is desired.

As the dissection is carried toward the genitourinary diaphragm (Fig. 138.30B) the prostatic pedicle is encountered (Fig. 138.30C) and ultimately ends at the prostatic apex (Fig. 138.30D).

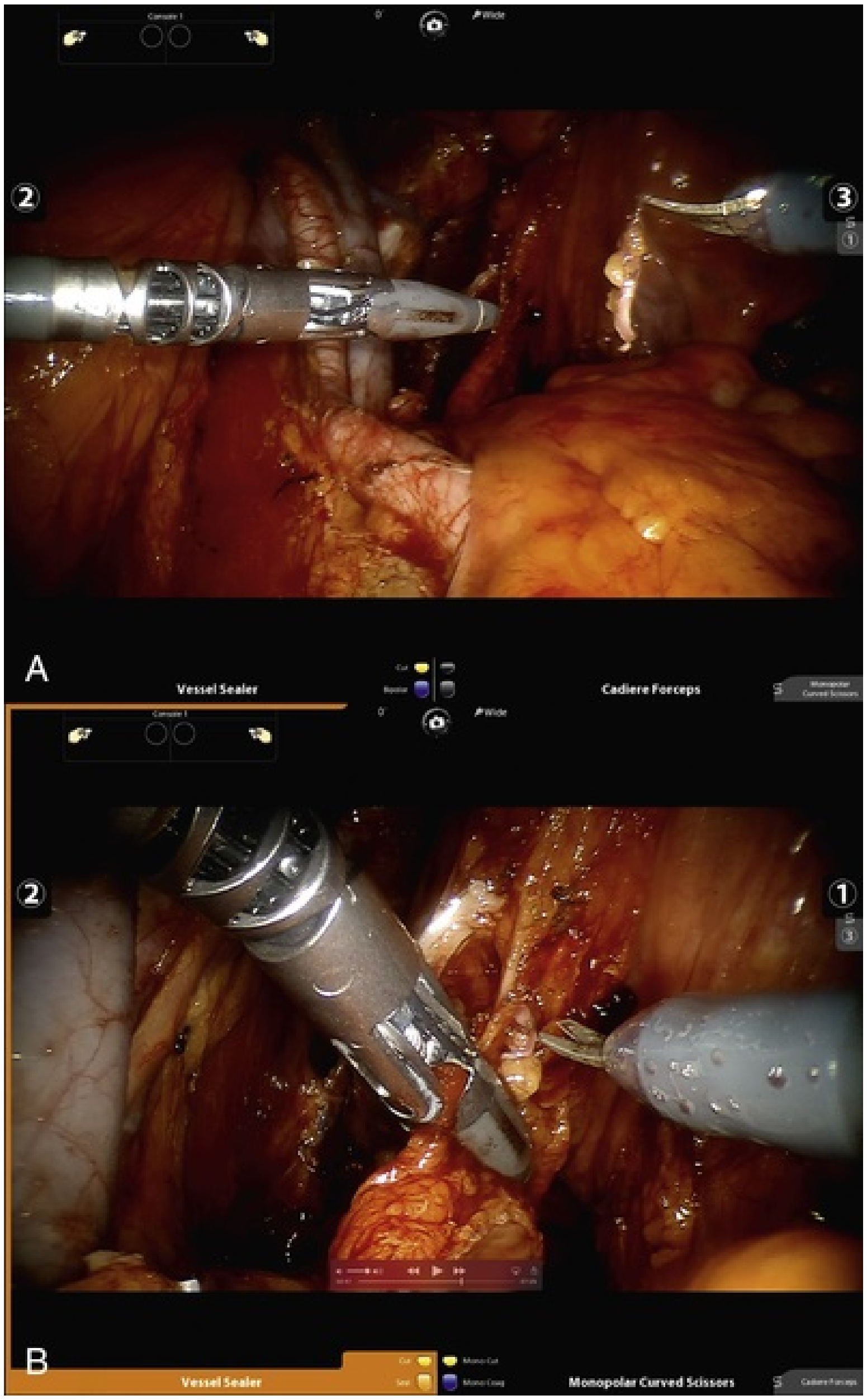
Console 1
Wide
2
3
1
A
Vessel Sealer
Cut
Bipolar
Cadiere Forceps
Monopolar Curved Scissors
Console 1
Wide
2
1
3
B
Vessel Sealer
Cut
Seal
Mono Cut
Mono Coag
Monopolar Curved Scissors
Cadiere Forceps

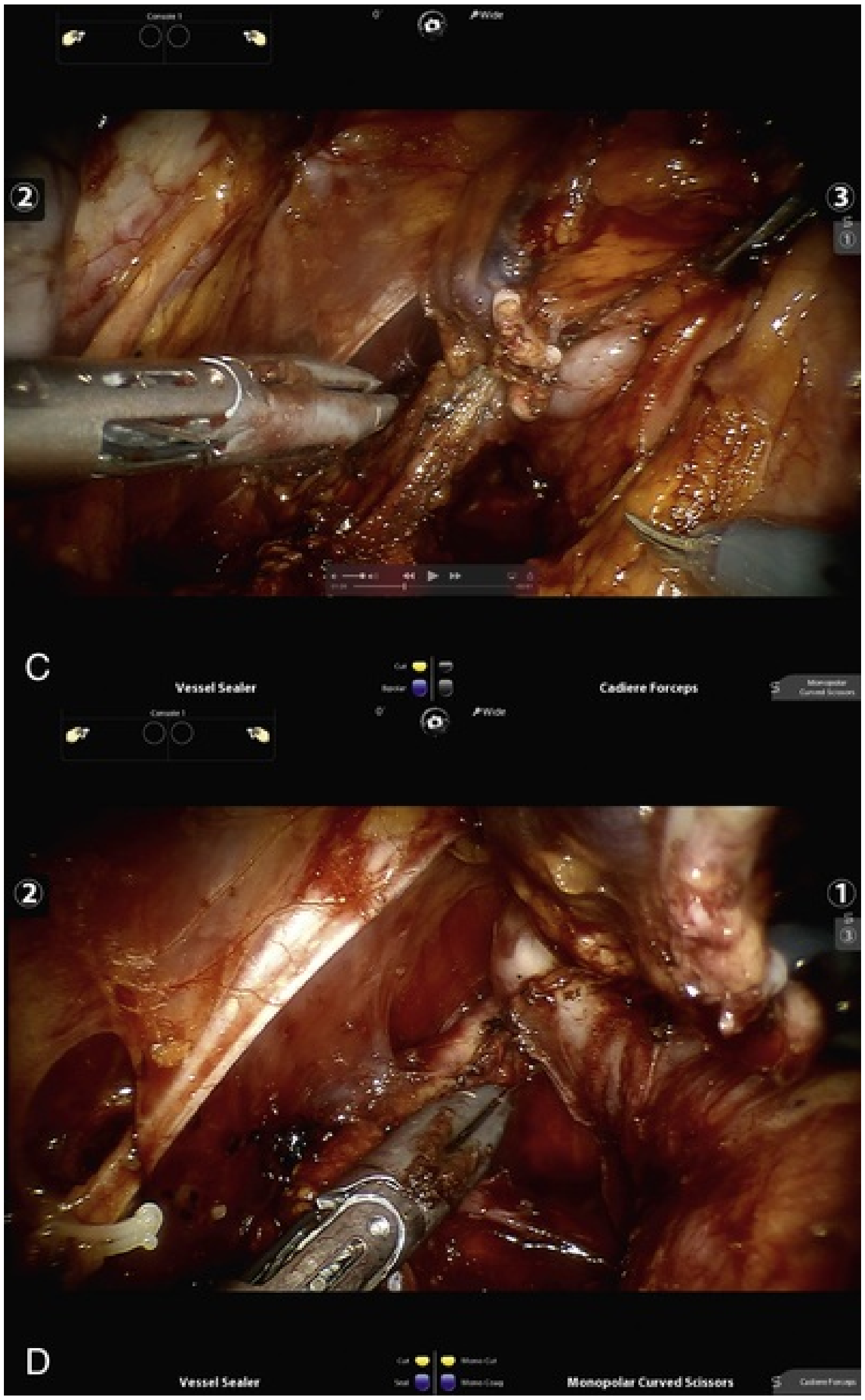
2
3
C
Vessel Sealer
Cadiere Forceps
Wide
2
1
D
Vessel Sealer
Monopolar Curved Scissors

FIG. 138.30 (A) The posterior vascular pedicle of the bladder is visualized by retracting the bladder upward and toward the opposite shoulder. (B) The pedicle is controlled with a vessel sealing device (clips can be substituted) and (C) the prostatic pedicle is identified. (D) The dissection is carried distally to the prostatic apex.

Male Apical Dissection

Male radical cystoprostatectomy can then be completed in a manner similar to radical prostatectomy. We advise releasing the urachal attachments with bipolar cautery and performing an apical prostatic dissection after controlling the dorsal venous complex with a suture ligature. We prefer a 2-O V-loc suture placed in a figure-of-eight fashion and then suspended anteriorly by passing the suture through the synchondrosis of the pubic symphysis (Fig. 138.31A). Once the urethra is isolated (Fig. 138.31B), the Foley catheter should be removed and the urethra controlled proximally and distally and transected. If an orthotopic diversion is planned, a proximal clip should be placed but not a distal urethral clip (Fig. 138.31C). As in an open procedure, a distal urethral margin is sent. A useful technique to aid collection of a urethral margin is to do so by partially transecting the urethra close to the proximal clip (see Fig. 138.31C) then adjusting the urethral transection a few millimeters distally. This then allows a distal margin to be excised (Fig. 138.31D) more easily than attempting to do so after the specimen is fully released.

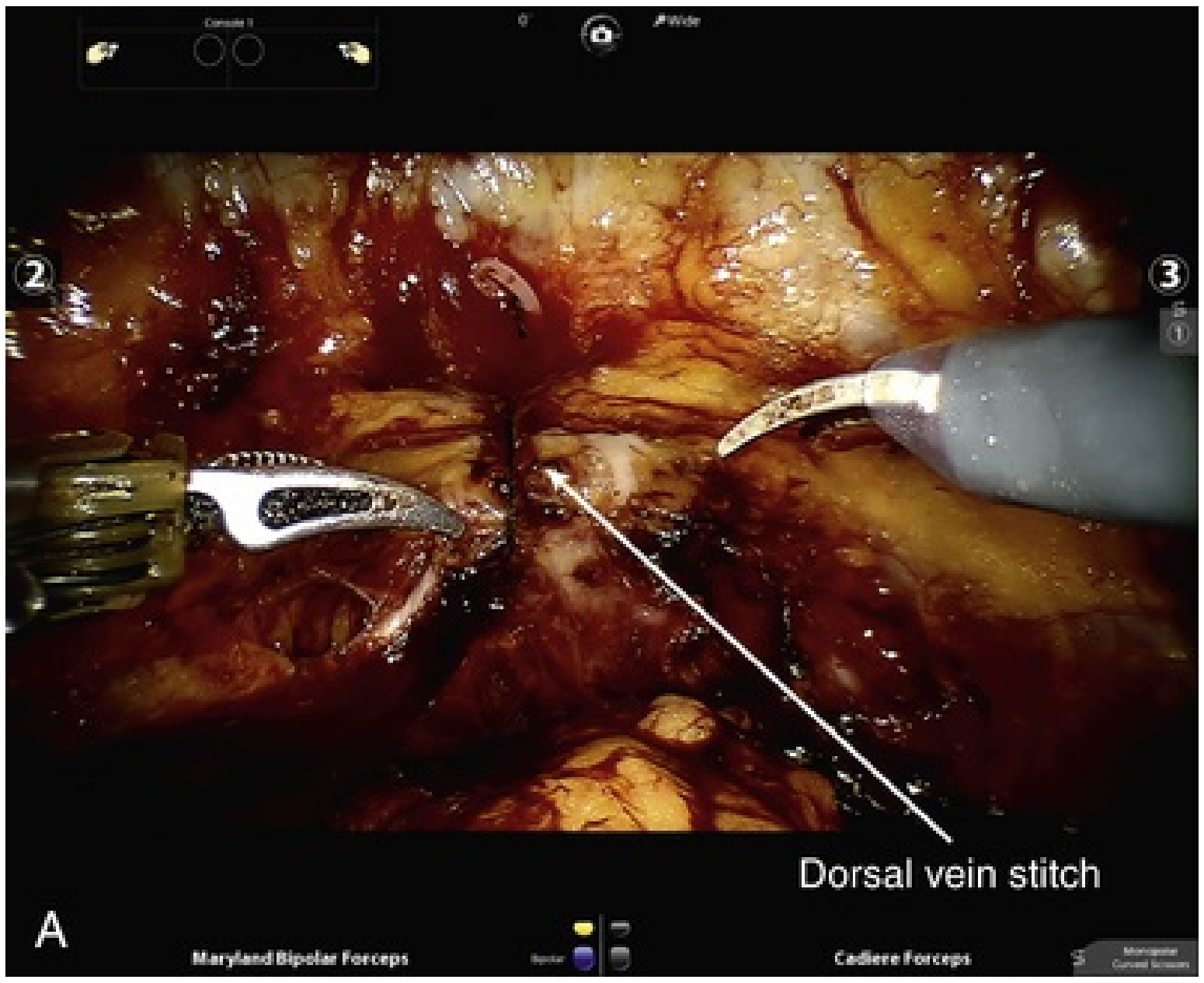
Console 1
0°
Wide
2
3
1
Dorsal vein stitch
A
Maryland Bipolar Forceps
Bipolar
Cadiere Forceps
Monopolar Curved Scissors

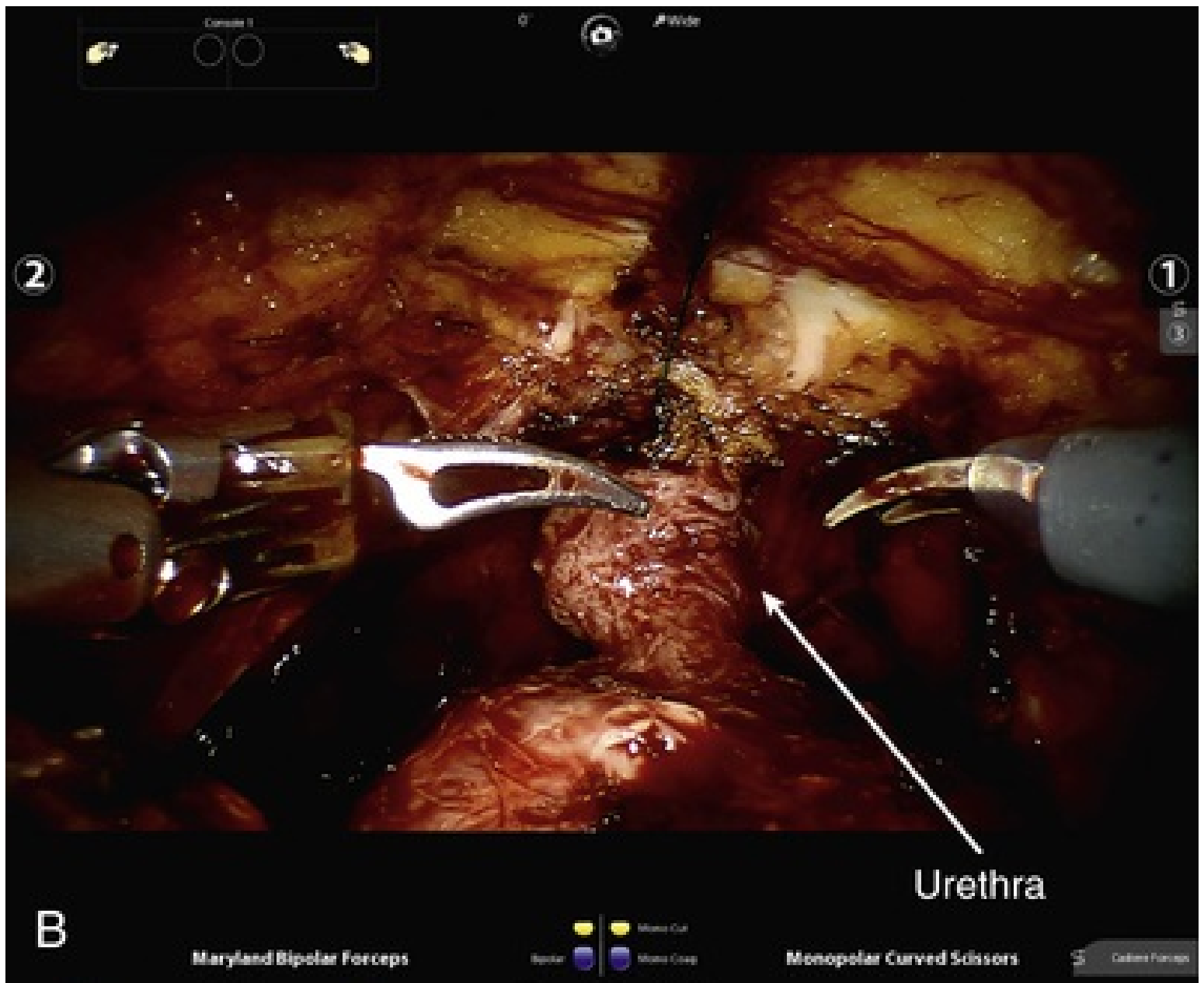
Console 1
0°
Wide
2
1
3
Urethra
B
Maryland Bipolar Forceps
Mono Cut
Bipolar
Mono Coag
Monopolar Curved Scissors
Cadiere Forceps

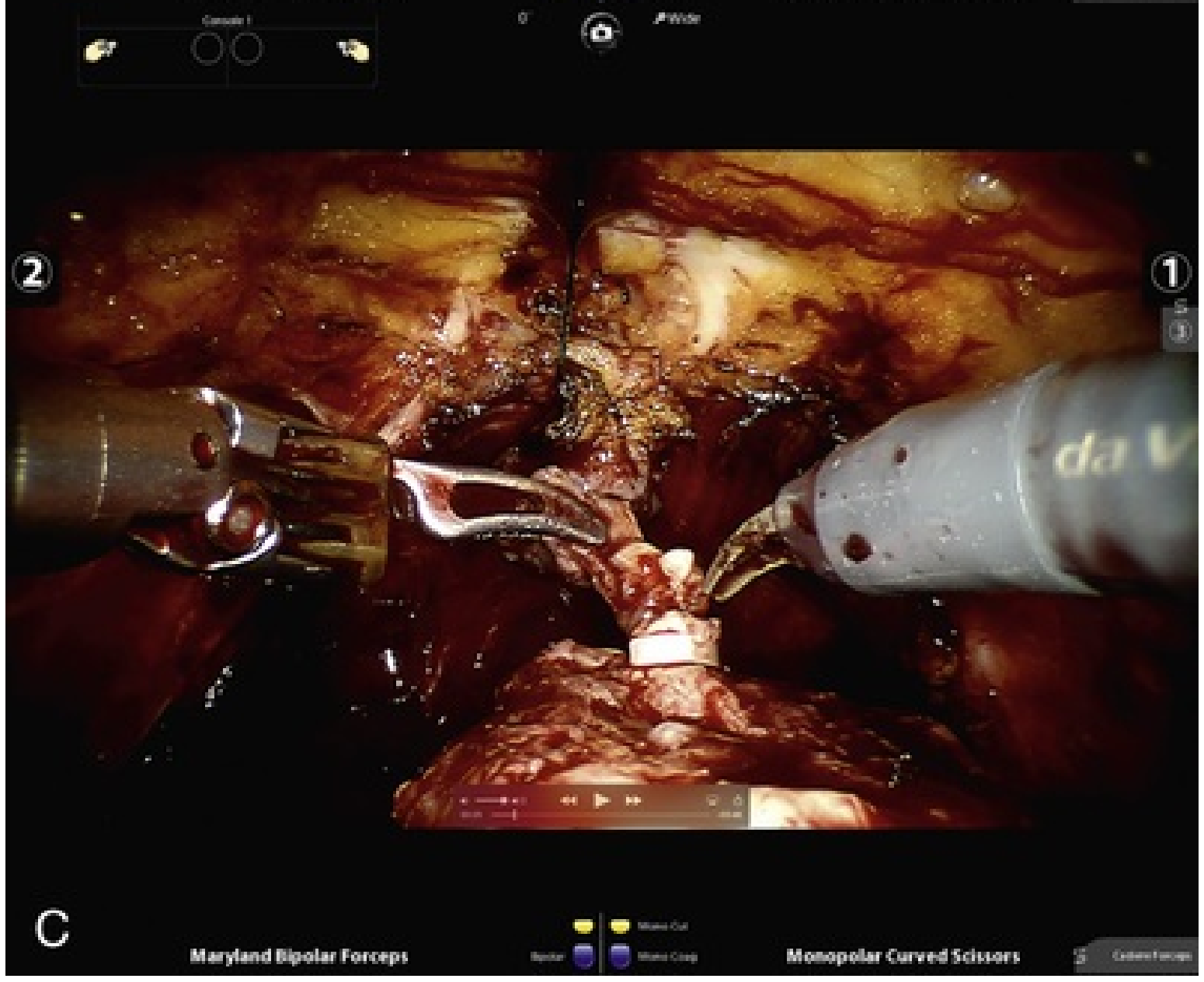
Console 1
0°
Wide
2
1
3
da V
C
Maryland Bipolar Forceps
Mono Cut
Bipolar
Mono Coag
Monopolar Curved Scissors
Cadiere Forceps

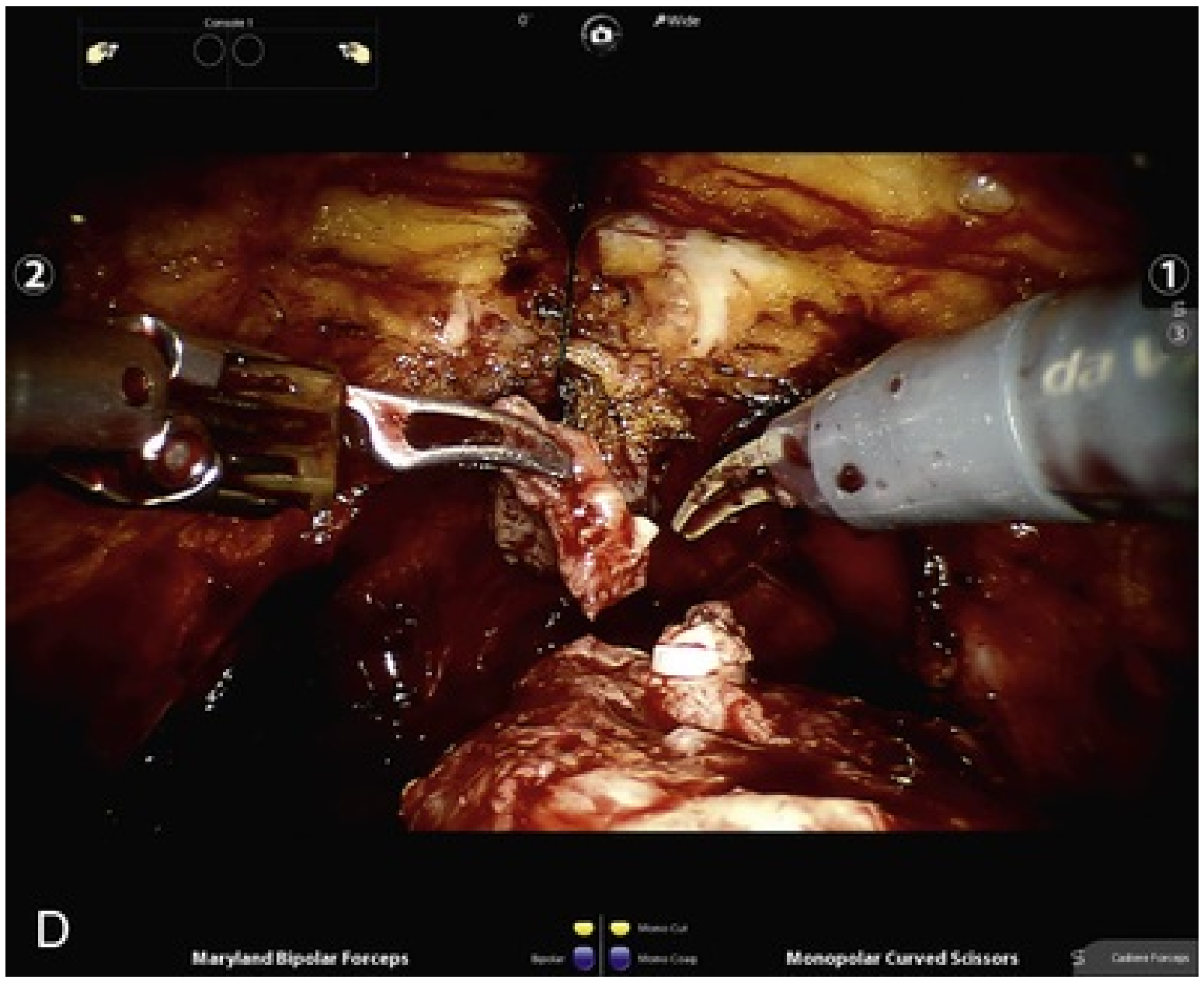

FIG. 138.31 (A) The male dorsal venous complex is controlled and after transection the (B) urethra identified. (C) A proximal clip is placed after the Foley catheter is removed to isolate the bladder contents from the operative field. (D) A urethral margin is isolated during the urethral transection.

Female Radical Cystectomy

As with open surgery, a female radical cystectomy presents unique challenges surgically. A traditional en bloc resection with the uterus and ovaries can be accomplished in the same manner robotically as with an open technique. To aid in the identification of the posterior cervical fornix, or the apex of the vagina if a hysterectomy had been previously performed in the patient, we have found that EEA sizers work very well. These circular sizers can be placed vaginally by the beside assistant and manipulated easily to provide ample countertraction. This provides retraction in the desired direction but also distends the vaginal wall, which can aid in the development of the vaginal sparing plane, described later.

If an en bloc resection of the gynecologic organs and anterior vagina are to be performed after the posterior cervical fornix is opened, the vessel sealer can be used to control the anteriolateral wall of the vagina toward the introitus. Once the dissection reaches the urethral meatus, a useful technique to ensure a complete resection of the urethra and an adequate surrounding vaginal cuff is to detach the Foley catheter from the drainage bag and have the assistant place a clip across the catheter to occlude any urine outflow. The catheter is then passed intracorporally and can be used to retract and visualize the urethral meatus with the robotic instruments.

Vaginal-sparing radical cystectomy can also be performed and is demonstrated in Fig. 138.32. In this example the patient has her uterus in situ. Upward retraction is placed on the bladder with the fourth robotic arm (Fig. 138.32A), and the assistant places an EEA into the vagina, creating countertraction toward the patient's head. The peritoneum is then incised, exposing the anterior vaginal wall (Fig. 138.32B) and the dissection carried toward the introitus in the midline. Commonly this tissue plane is avascular or nearly avascular. The dissection is carried laterally, defining the posterior vascular pedicle in a manner analogous to what is seen during a male case (Fig. 138.32C). The pedicles can be controlled with clips or a vessel sealer (in this example) to the level of the urethral meatus (Fig. 138.32D). At this point if a neobladder is planned, the apical dissection can be completed after release of the urachus and anterior attachments. If urethral sparing is not planned, the vagina can be opened just posterior to the bladder neck and the catheter manipulation described earlier (Figs. 138.32E,F). This technique again ensures a complete urethral and meatal resection.

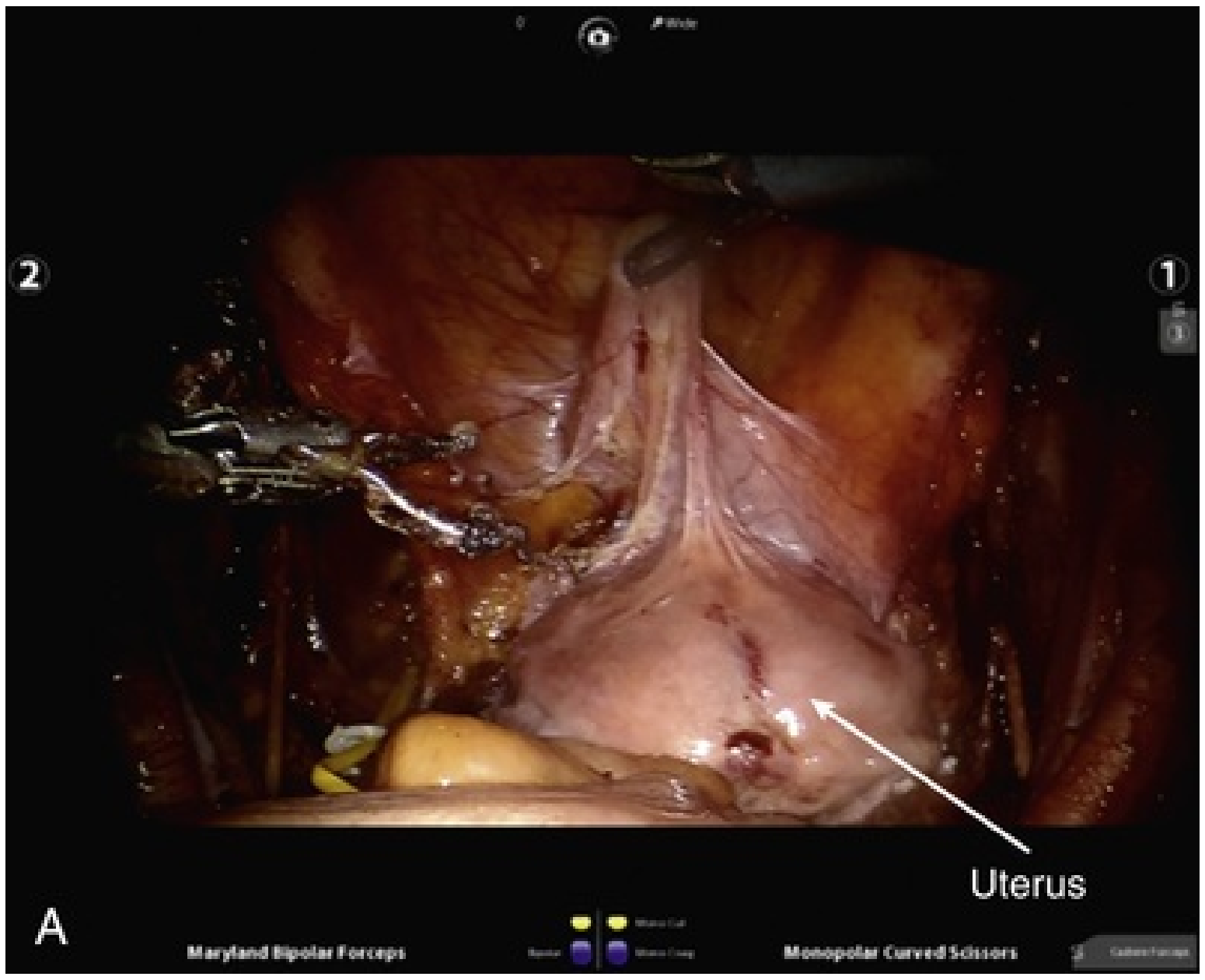

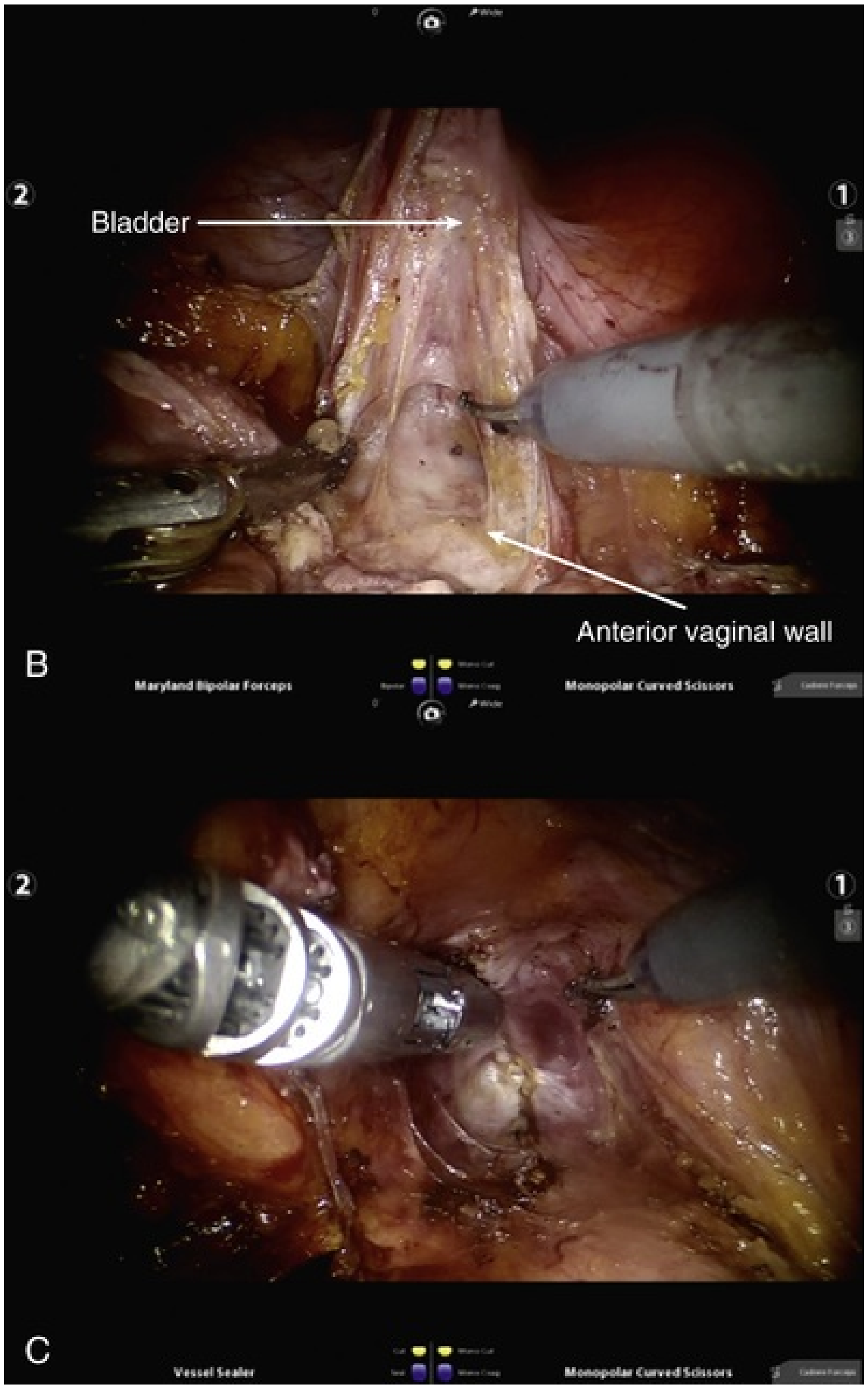
Wide
2
1
3
Bladder
Anterior vaginal wall
B
Maryland Bipolar Forceps
Bipolar
Mono Cut
Mono Coag
Monopolar Curved Scissors
Cadiere Forceps
Wide
2
1
3
C
Vessel Sealer
Cut
Seal
Mono Cut
Mono Coag
Monopolar Curved Scissors
Cadiere Forceps

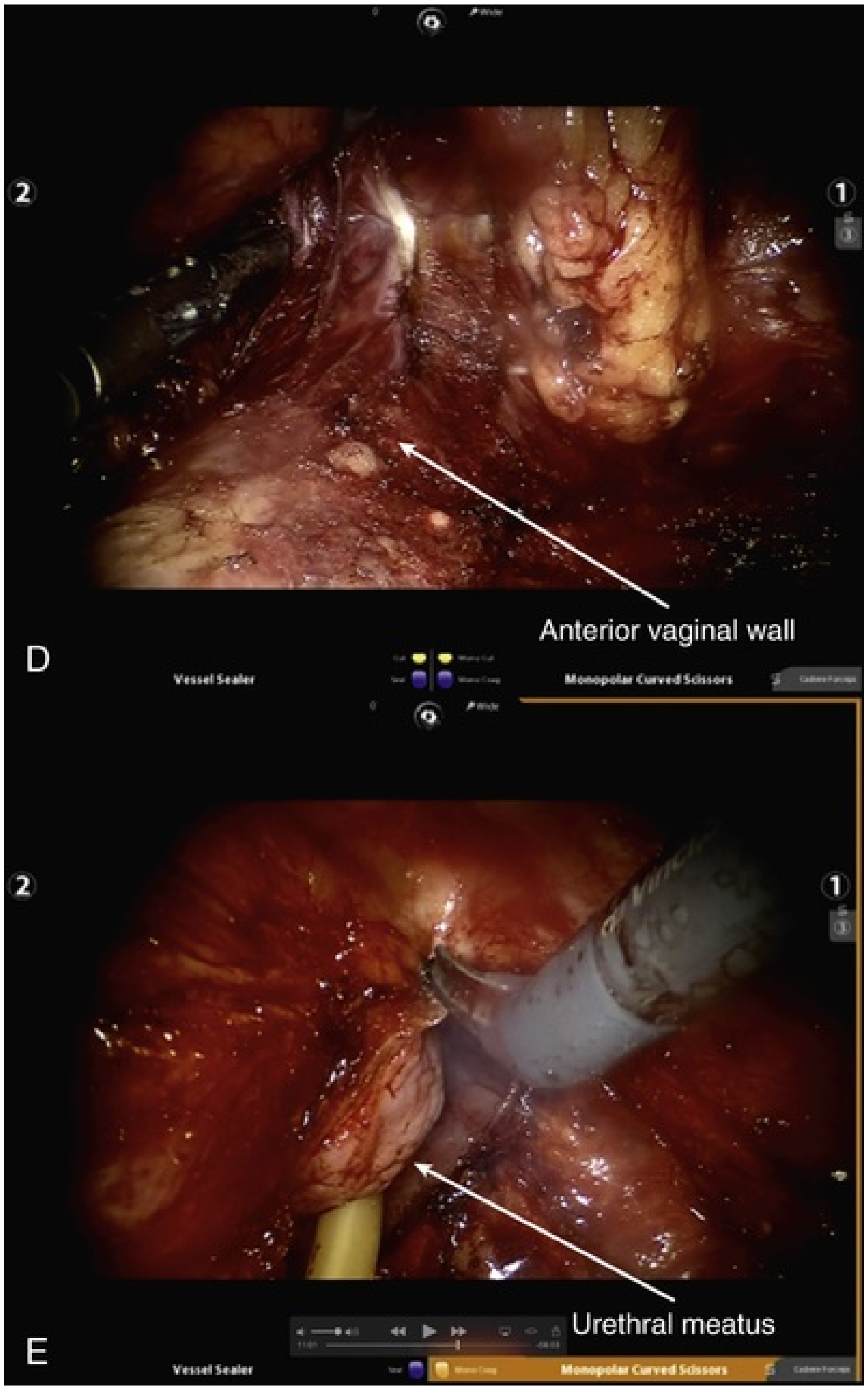
Wide
2
1
Anterior vaginal wall
D
Vessel Sealer
Cut
Seal
Monopolar Curved Scissors
Wide
2
1
Urethral meatus
E
Vessel Sealer
Seal
Monopolar Curved Scissors

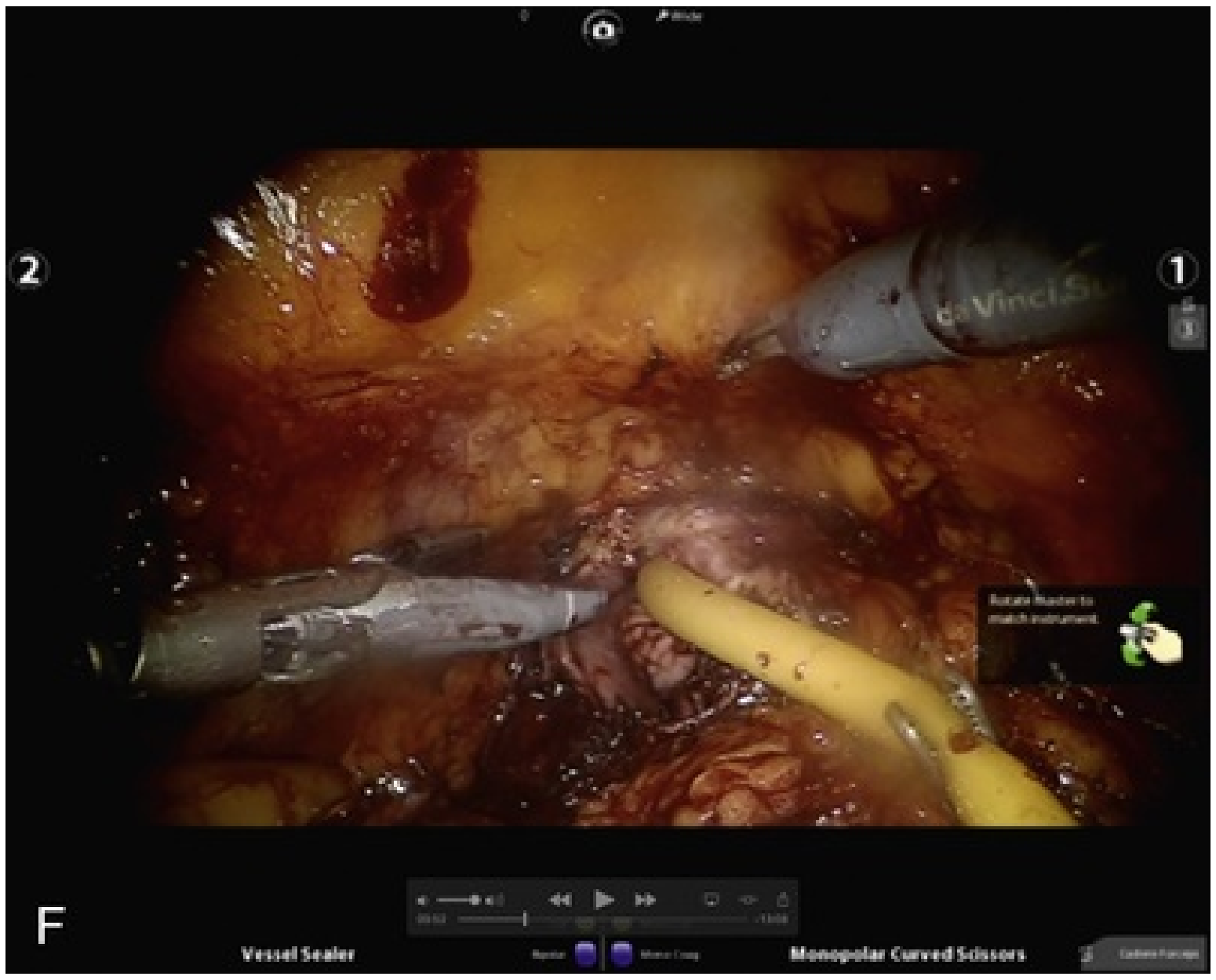

FIG. 138.32 (A) Identification of the vesico-uterine pouch is aided by placement of an end-to-end anastomosis into the vagina by the bedside assistant. (B) The bladder is retracted toward the anterior abdominal wall and the peritoneum incised allowing identification of the anterior vagina. (C) The dissection is then carried forward (distally) to the bladder neck in the midline and the posterior vascular pedicles are isolated laterally. (D) After controlling the posterior vascular pedicles the anterior vagina can be seen in this vaginal sparing example. (E) The vaginal cuff inclusive of the urethral meatus is aided by manipulation of the Foley catheter to ensure (F) a complete excision is performed.

The vaginal defect can be closed according to surgeon preference in a clamshell fashion. We favor a running closure with 2-O V-loc suture; however, alternative approaches include interrupted or figure-of-eight 2-O polyglactin 910 suture. Of paramount concern is achieving excellent apposition of mucosa to mucosa and a watertight closure because peritoneal fistula and prolonged vaginal leakage will result if the closure is not meticulous. We prefer a Premarin or similarly coated vaginal packing be placed and removed on postoperative day 2 to aid in postoperative hemostasis. In the case of an en bloc anterior vaginectomy, frequently the vaginal defect is sufficiently large enough to accommodate specimen extraction. Following oncologic principles, the specimen is immediately placed in a retrieval bag. Extraction is then performed by carefully removing the bag via the vaginal defect while monitoring the tension on the retrieval bag. If at any point the bag fails to progress out or there is concern the vagina or bag may tear, vaginal extraction should be abandoned. Extraction of the cystectomy specimen can then be performed by slightly elongating the midline abdominal port site at the end of the procedure.

Postoperative Care

Radical cystectomy is a complex procedure involving not only the genitourinary but also the gastrointestinal tract because of urinary diversion. In addition to this complexity, patients are frequently elderly and have significant comorbidities. Although major complications are infrequent (13%), any complication remains common (64%) with the most frequent being gastrointestinal (29%) or infectious (25%) (Shabsigh et al., 2009). Postoperative efforts are necessarily directed at minimizing the possibility of complications and maximizing the return of normal physiology. Immediately after surgery, laboratory results including cell count, electrolytes, and renal function are assessed and fluid dynamics are monitored. Frequently patients require initial observation in intensive care or stepdown units. Routine nasogastric suction is not needed; however, it is considered in compromised mentation or known issues with airway protection. As discussed earlier, thromboembolic prophylaxis should be continued in the postoperative setting in the absence of hemorrhage. In addition to pharmacologic measures, early ambulation should be used and pulmonary exercise (incentive spirometry) with deep breathing and coughing should be encouraged.

Delayed return of bowel function frequently prolongs hospitalization after radical cystectomy. Medications such as alvimopan can be used, which has been shown to improve return of bowel function and to shorten hospital stays. Additional postoperative steps to enhance recovery include neostigmine (with telemetry monitoring) to encourage further the return of bowel function, promotility suppositories, stress ulcer prophylaxis, antiemetics, early enteral feeding in the absence of nausea and/or emesis, and avoidance of narcotic pain medication (ketorolac and acetaminophen unless contraindicated) (Djaladat and Daneshmand, 2013).

Key Points

- Bladder cancer is a common cancer associated with high cost and frequent fatality.
- Radical cystectomy offers excellent survival for organ-confined disease.
- TUR is diagnostic and therapeutic, especially for low-grade tumors.

- Perioperative intravesical chemotherapy decreases recurrence rates by 13%.
- A standard template pelvic lymphadenectomy includes the genitofemoral nerves laterally, the internal iliac artery medially, Cooper ligament inferiorly, and the point at which the ureter crosses the common iliac artery superiorly.
- Ureteral margin frozen section aids in predicting upper tract recurrence, but sequential resection to a negative margin may have no impact.
- Nerve-sparing radical cystectomy aids in the preservation of sexual function and is performed in a manner analogous to radical prostatectomy.
- Subtotal prostatic resection can further enhance return of sexual function but should only be offered in select patients in whom the risk of occult prostate cancer is low.
- Vaginal sparing is appropriate in the absence of locally advanced tumors and allows for orthotopic urinary diversion.
- Partial cystectomy can be considered in rare, solitary urothelial tumors without concomitant CIS.
- Urachal adenocarcinomas are treated with en bloc resection of the umbilicus and dome of the bladder.
- Robotic radical cystectomy provides similar oncologic outcomes when compared with open surgery.
- Enhanced recovery protocols can aid in the recovery of normal physiology after radical cystectomy and can shorten hospital stays.

Acknowledgments

The authors acknowledge Drs. John Stein, Kent Berglund, and Harry W. Herr, whose work on the previous version of this chapter was invaluable in the preparation of the current text.

Suggested Readings

Grossman HB, Natale RB, Tangen CM, et al. Neoadjuvant chemotherapy plus cystectomy compared with cystectomy alone for locally advanced bladder cancer. *N Engl J Med*. 2003;349:859–866.

Herr HW. Surgical factors influence bladder cancer outcomes: a cooperative group report. *J Clin Oncol*. 2004;22:2781–2789.

Parekh DJ, Reis IM, Castle EP, et al. Robot-assisted radical cystectomy versus open radical cystectomy in patients with bladder cancer (RAZOR): an open-label, randomised, phase 3, non-inferiority trial. *Lancet*. 2018;391(10139):2525–2536.

Whitmore WF, Marshall VF. Radical surgery for carcinoma of the urinary bladder: one hundred consecutive cases four years later. *Cancer*. 1956;9:596–608.

References

Abern MR, Owusu RA, Anderson MR, et al. Perioperative intravesical chemotherapy in non-muscle-invasive bladder cancer: a systematic review and meta-analysis. *J Natl Compr Canc Netw*. 2013;11:477–484.

Asgari MA, Safarinejad MR, Shakhssalim N, et al. Sexual function after non-nerve-sparing radical cystoprostatectomy: a comparison between ileal conduit urinary diversion and orthotopic ileal neobladder substitution. *Int Braz J Urol*. 2013;39:474–495.

Baltaci S, Resorlu B, Yagci C, et al. Computerized tomography for detecting perivesical infiltration and lymph node metastasis in invasive bladder carcinoma. *Urol Int*. 2013;81:399–402.

Birkhäuser FD, Studer UE, Froehlich JM, et al. Combined ultrasmall superparamagnetic particles of iron oxide—enhanced and diffusion-weighted magnetic resonance imaging facilitates detection of metastases in normal-sized pelvic lymph nodes of patients with bladder and prostate cancer. *Eur Urol*. 2013;64(6):1–8.

Bochner B, Cho D, Herr H, et al. Prospectively packaged lymph node dissections with radical cystectomy: evaluation of node count variability and node mapping. *J Urol*. 2004;172(4 Pt 1):1286–1290.

Bochner BH, Dalbagni G, Sjoberg DD, et al. Comparing open radical cystectomy and robot-assisted laparoscopic radical cystectomy: a randomized clinical trial. *Eur Urol*. 2014;1–9.

Bochner BH, Sjoberg DD, Laudone VP, Memorial Sloan Kettering Cancer Center Bladder Cancer Surgical Trials Group. A randomized trial of robot-assisted laparoscopic radical cystectomy. *N Engl J Med*. 2014;371(4):389–390.

Bruins HM, Skinner EC, Dorin RP, et al. Incidence and location of lymph node metastases in patients undergoing radical cystectomy for clinical non-muscle invasive bladder cancer: results from a prospective lymph node mapping study. *Urol Oncol*. 2014;32:24.e13–24.e19.

Bruins HM, Wopat R, Mitra AP, et al. Long-term outcomes of salvage radical cystectomy for recurrent urothelial carcinoma of the bladder following partial cystectomy. *BJU Int*. 2012;111:E37–E42.

Capitanio U, Isbarn H, Shariat SF, et al. Partial cystectomy does not undermine cancer control in appropriately selected patients with urothelial carcinoma of the bladder: a population-based matched analysis. *Urology*. 2009;74:858–864.

Colombo R, Bertini R, Salonia A, et al. Overall clinical outcomes after nerve and seminal sparing radical cystectomy for the treatment of organ confined bladder cancer. *J Urol*. 2004;171:1819–1822.

Davis JW, Gaston K, Anderson R, et al. Robot assisted extended pelvic lymphadenectomy at radical cystectomy: lymph node yield compared with second look open dissection. *J Urol*. 2011;185(1):79–84.

Desai MM, Gill IS, de Castro Abreu AL, et al. Robotic intracorporeal orthotopic neobladder during radical cystectomy in 132 patients. *J Urol*. 2014;192(6):1734–1740.

Djaladat H, Daneshmand S. Enhanced recovery pathway following radical cystectomy. *Curr Opin Urol*. 2013;24(2):135–139.

Freeman JA, Tarter TA, Esrig D, et al. Urethral recurrence in patients with orthotopic ileal neobladders. *J Urol*. 1996;156:1615–1619.

Golan S, Baniel J, Lask D, et al. Transurethral resection of bladder tumour complicated by perforation requiring open surgical repair—clinical characteristics and oncological outcomes. *BJU Int*. 2010;107:1065–1068.

Grossman HB, Natale RB, Tangen CM, et al. Neoadjuvant chemotherapy plus cystectomy compared with cystectomy alone for locally advanced bladder cancer. *N Engl J Med*. 2003;349:859–866.

Hashad MME, Atta M, Elabbady A, et al. Safety of no bowel preparation before ileal urinary diversion. *BJU Int*. 2012;110:E1109–E1113.

Herr HW, Donat SM, Dalbagni G. Correlation of cystoscopy with histology of recurrent papillary tumors of the bladder. *J Urol*. 2002;168:978–980.

Herr HW. Surgical factors influence bladder cancer outcomes: a cooperative group report. *J Clin Oncol*. 2004;22:2781–2789.

Hsu RL, Kaye AD, Urman RD. Anesthetic challenges in robotic-assisted urologic surgery. *Rev Urol*. 2013;15(4):178–184; 10.3909/riu0589.

Kakkar VV, Balibrea JL, Martinez-Gonzales J, et al. CANBESURE Study Group. Extended prophylaxis with bemiparin for the prevention of venous thromboembolism after abdominal or pelvic surgery for cancer: the CANBESURE randomized study. *J Thromb Haemost*. 2010;8:1223–1229.

Kassouf W, Spiess PE, Brown GA, et al. Prostatic urethral biopsy has limited usefulness in counseling patients regarding final urethral margin status during orthotopic neobladder reconstruction. *J Urol*. 2008;180:164–167.

Kassouf W, Swanson D, Kamat AM, et al. Partial cystectomy for muscle invasive urothelial carcinoma of the bladder: a contemporary review of the M. D. Anderson Cancer Center experience. *J Urol*. 2006;175:2058–2062.

Kauf TL, Svatek RS, Amiel G, et al. Alvimopan, a peripherally acting μ-opioid receptor antagonist, is associated with reduced costs after radical cystectomy: economic analysis of a phase 4 randomized, controlled trial. *J Urol*. 2014;191(6):1721–1727.

Kluth LA, Rieken M, Xylinas E, et al. Gender-specific differences in clinicopathologic outcomes following radical cystectomy: an international multi-institutional study of more than 8000 patients. *Eur Urol*. 2013;66(5):1–7.

Kozminski M, Konnak JW, Grossman HB. Management of rectal injuries during radical cystectomy. *J Urol*. 1989;142:1204–1205.

Kurth K, Tunn U, Ay R, et al. Adjuvant chemotherapy for superficial transitional cell bladder carcinoma: long-term results of a European Organization for Research and Treatment of Cancer randomized trial comparing doxorubicin, ethoglucid and transurethral resection alone. *J Urol*. 1997;158:378–384.

Lebret T, Hervé JM, Barré P, et al. Urethral recurrence of transitional cell carcinoma of the bladder: predictive value of preoperative latero-montanal biopsies and urethral frozen sections during prostatocystectomy. *Eur Urol*. 1998;33:170–174.

Ludwig K, Enker WE, Delaney CP, et al. Gastrointestinal tract recovery in patients undergoing bowel resection: results of a randomized trial of alvimopan and placebo with a standardized accelerated postoperative care pathway. *Arch Surg*. 2008;143:1098–1105.

Madersbacher S, Hochreiter W, Burkhard F, et al. Radical cystectomy for bladder cancer today—a homogeneous series without neoadjuvant therapy. *J Clin Oncol*. 2003;21:690–696.

Mano R, Shoshany O, Baniel J, et al. Resection of ureteral orifice during transurethral resection of bladder tumor: functional and oncologic implications. *J Urol*. 2012;188:2129–2133.

Messing EM, et al. Effect of intravesical instillation of gemcitabine vs saline immediately following resection of suspected low-grade non–muscle-invasive bladder cancer on tumor recurrence. *J Am Med Assoc*. 2018;319:1880–1889.

Mitra AP, Skinner EC, Schuckman AK, et al. Effect of gender on outcomes following radical cystectomy for urothelial carcinoma of the bladder: a critical analysis of 1,994 patients. *Urol Oncol*. 2014;32:52.e1–52.e9.

Mucksavage P, Kerbl DC, Pick DL, et al. Differences in grip forces among various robotic instruments and da Vinci surgical platforms. *J Endourol*. 2011;25(3):523–528.

Nix J, Smith A, Kurpad R, et al. Prospective randomized controlled trial of robotic versus open radical cystectomy for bladder cancer: perioperative and pathologic results. *Eur Urol*. 2010;57(2):196–201.

Noone AM, Howlader N, Krapcho M, et al. *SEER Cancer Statistics Review, 1975-2015*. [eds; National Cancer Institute. Bethesda, MD; (website)] https://seer.cancer.gov/csr/1975_2015/; 2018.

Pak JS, Lee JJ, Bilal K, et al. Utilization trends and short-term outcomes of robotic versus open radical cystectomy for bladder cancer. *Urology*. 2017;103:117–123.

Paquin AJ, Marshall VF. A technique for radical total cystectomy. *Cancer*. 1956;9:585–595.

Parekh DJ, Reis IM, Castle EP, et al. Robot-assisted radical cystectomy versus open radical cystectomy in patients with bladder cancer (RAZOR): an open-label, randomised, phase 3, non-inferiority trial. *Lancet*. 2018;391(10139):2525–2536.

Pruthi RS, Wallen EM. Robotic-assisted laparoscopic radical cystoprostatectomy. *Eur Urol*. 2008;53(2):310–322.

Raj GV, Tal R, Vickers A, et al. Significance of intraoperative ureteral evaluation at radical cystectomy for urothelial cancer. *Cancer*. 2006;107:2167–2172.

Ren L, Zhu D, Wei Y, et al. Enhanced recovery after surgery (ERAS) program attenuates stress and accelerates recovery in patients after radical resection for colorectal cancer: a prospective randomized controlled trial. *World J Surg*. 2011;36:407–414.

Revelo MP, Cookson MS, Chang SS, et al. Incidence and location of prostate and urothelial carcinoma in prostates from cystoprostatectomies: implications for possible apical sparing surgery. *J Urol*. 2004;171:646–651.

Schoenberg MP, Walsh PC, Breazeale DR, et al. Local recurrence and survival following nerve sparing radical cystoprostatectomy for bladder cancer: 10-year followup. *J Urol*. 1996;155:490–494.

Schumacher MC, Scholz M, Weise ES, et al. Is there an indication for frozen section examination of the ureteral margins during cystectomy for transitional cell carcinoma of the bladder? *J Urol*. 2006;176:2409–2413.

Shabsigh A, Korets R, Vora KC, et al. Defining early morbidity of radical cystectomy for patients with bladder cancer using a standardized reporting methodology. *Eur Urol*. 2009;55:164–176.

Spitz A, Stein JP, Lieskovsky G, et al. Orthotopic urinary diversion with preservation of erectile and ejaculatory function in men requiring radical cystectomy for nonurothelial malignancy: a new technique. *J Urol*. 1999;161:1761–1764.

Stenzl A, Nagele U, Kuczyk M, et al. Cystectomy—technical considerations in male and female patients. *EAU Update Ser*. 2005;3:138–146.

Vallancien G, Abou El Fettouh H, Cathelineau X, et al. Cystectomy with prostate sparing for bladder cancer in 100 patients: 10-year experience. *J Urol*. 2002;168:2413–2417.

Vargas HA, Akin O, Schöder H, et al. Prospective evaluation of

MRI, ^{11}C-acetate PET/CT and contrast-enhanced CT for staging of bladder cancer. *Eur J Radiol*. 2012;81:4131–4137.

Wagenlehner FME, Wagenlehner C, Schinzel S, et al. Prospective, randomized, multicentric, open, comparative study on the efficacy of a prophylactic single dose of 500 mg levofloxacin versus 1920 mg trimethoprim/sulfamethoxazole versus a control group in patients undergoing TUR of the prostate. *Eur Urol*. 2005;47:549–556.

Whitmore WF, Marshall VF. Radical surgery for carcinoma of the urinary bladder: one hundred consecutive cases four years later. *Cancer*. 1956;9:596–608.

Whitmore WF, Marshall VF. Radical total cystectomy for cancer of the bladder: 230 consecutive cases five years later. *J Urol*. 1962;87:853–868.

Wright JL, Lin DW, Porter MP. The association between extent of lymphadenectomy and survival among patients with lymph node metastases undergoing radical cystectomy. *Cancer*. 2008;112:2401–2408.

Xu R, Zhao X, Zhong Z, et al. No advantage is gained by preoperative bowel preparation in radical cystectomy and ileal conduit: a randomized controlled trial of 86 patients. *Int Urol Nephrol*. 2010;42:947–950.

Zippe CD, Raina R, Massanyi EZ, et al. Sexual function after male radical cystectomy in a sexually active population. *Urology*. 2004;64:682–685.

Zmora O, Mahajna A, Bar-Zakai B, et al. Colon and rectal surgery without mechanical bowel preparation: a randomized prospective trial. *Ann Surg*. 2003;237:363–367.

139

Use of Intestinal Segments in Urinary Diversion

Anton Wintner MD, Douglas M. Dahl MD, FACS

Reconstructive urologic surgery frequently requires the use of bowel for ureteral substitution, bladder augmentation, or bladder replacement. In rare cases, gastrointestinal segments may also function as urethral or vaginal substitutes. The stomach, jejunum, ileum, and colon all have a role in urinary tract reconstruction. This chapter reviews the surgical anatomy and technical aspects involved in the use of intestinal segments in urologic surgery that pertain to all types of reconstructive procedures and describes the important potential acute and long-term complications of the use of intestinal segments.

Surgical Anatomy

The most frequently used segments of bowel by the urologist are the ileum and colon. The stomach, jejunum, and rectum are also used in reconstructive procedures, although less commonly. Successfully performing surgical mobilization of these structures and reconstructing them for their new function requires a thorough knowledge of the surgical anatomy, vascular supply, and metabolic function of each portion of the intestinal tract.

Stomach

The stomach is a vascular organ that receives its blood supply primarily from the celiac trunk (Fig. 139.1). **Three branches of the celiac axis give rise to the majority of the arterial supply of the stomach.**

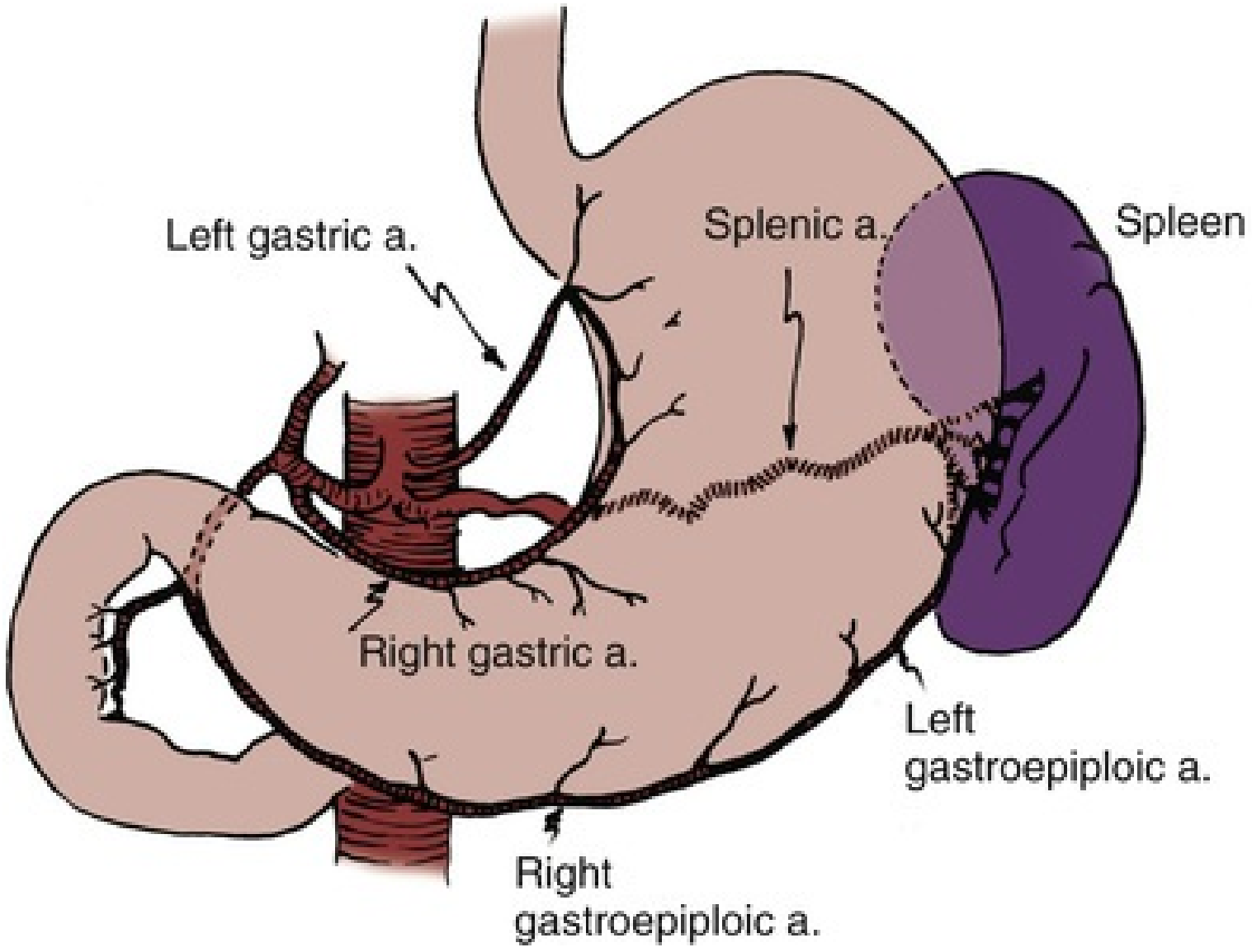

FIG. 139.1 Arterial supply of the stomach. *a,* Artery.

1. The **left gastric (coronary) artery** arises directly from the celiac axis and supplies the lesser curvature.
2. The **hepatic artery,** after arising from the celiac axis, **gives off the right gastric artery,** which also supplies the lesser curve of the stomach, and the **gastroduodenal artery,** which supplies the antrum and duodenum

before giving off the **right gastroepiploic artery.**

3. The **splenic artery** originates from the celiac axis and gives off the **vasa brevia (short gastrics),** which supply the fundus and cardia, and the **left gastroepiploic artery.** The right gastroepiploic artery meets with the left gastroepiploic artery; thus both supply collateral flow to the greater curve of the stomach. **By use of the gastroepiploic vessels, a pedicle of stomach may be mobilized as far as the pelvis.** The pedicle may consist of the entire antrum pylori or a wedge of the fundus.

The blood supply for these segments is based on either the left or right gastroepiploic artery, depending on the portion of stomach used. On occasion, the left gastroepiploic artery is atretic at some point in its course and does not provide an adequate blood supply. Under these circumstances, the right gastroepiploic artery must be used. **When a wedge of fundus is used, it should not include a significant portion of the antrum and should never extend to the pylorus or all the way to the lesser curve of the stomach.** When the blood supply is based on the left gastroepiploic artery, the short gastric vessels that course from the gastroepiploic artery to the stomach are ligated along the greater curvature proximal to the pedicle to the origin of the gastroepiploic artery. The omentum is left attached to the gastroepiploic vessels and helps secure and support them. It may be necessary for proper pedicle mobility to detach the omentum from the colon along the avascular plane located at the point of its attachment to the transverse colon. If an antrectomy is performed, a Billroth I anastomosis reconstitutes gastrointestinal continuity. **The stomach has a thick seromuscular layer that can be easily separated from the mucosa should a submucosal ureteral reimplantation be necessary.**

Small Bowel

The small bowel is about 22 feet long; however, it may vary from 15 to 30 feet in length. Its largest diameter is in the duodenum; the lumen becomes smaller in the more distal portions, reaching its smallest diameter in the ileum, approximately 12 inches from the ileocecal valve. **About two-fifths of the small bowel is jejunum, whereas the distal three-fifths is ileum.**

There is no definite demarcation between the two; however, each possesses several unique properties that allow the surgeon to distinguish one from the other intraoperatively. **The ileum, being more distal in location, has a smaller**

diameter. It has multiple arterial arcades, and the vessels in the arcades are smaller than those in the jejunum. The ileal mesentery is also thicker than the jejunal mesentery. In contrast, the jejunal diameter is larger, the arterial arcades are usually single, and the vessels composing them are larger in diameter.

The arcades anastomose one with another and give off straight vessels, which enter the bowel and form an anastomotic network within the bowel wall. **It has been shown experimentally that up to 15 cm of small bowel can survive laterally to a straight vessel.** Thus, theoretically, the mesentery could be cleared from the small bowel for a length of 15 cm without necrosis of the end. **In general, however, it is unwise to assume that more than 8 cm of small bowel will survive away from a straight vessel.** The arcades receive their blood from the superior mesenteric artery. When segments of jejunum or ileum are isolated, the mesentery should be transected in such a way that the isolated intestinal segment receives its blood supply from an arcade supplied by a palpable artery of substance that courses through the base of the mesenteric pedicle.

Two portions of the small bowel may lie within the confines of the pelvis and, as such, may be exposed to pelvic irradiation and pelvic disease: **the last 2 inches of the terminal ileum,** which is often fixed in the pelvis by ligamentous attachments, **and the 5 feet of small bowel beginning approximately 6 feet from the ligament of Treitz,** the mesentery of which is the longest of the entire small bowel. As such, this portion of the small bowel can descend into the pelvis. **In a postirradiated patient, one should try to avoid use of these two segments of the small intestine in any reconstructive procedure.**

Colon

The large bowel is divided into the cecum, ascending colon, transverse colon, left colon, sigmoid colon, and rectum. Portions of the large bowel are fixed or retroperitoneal, and other segments lie free within the peritoneal cavity. The cecum, on rare occasion, may lie free within the abdominal cavity and therefore may have great mobility. In general, however, it is fixed in the right lower quadrant. Two accessory peritoneal bands bind the cecum and distal ileum to the retroperitoneum and lateral abdominal wall. One band arises from the distal ileum, attaches to the cecum, and is fixed to the retroperitoneum. A second band arises from the cecum and fixes the cecum to the posterior abdominal wall laterally. The remainder of the ascending colon is fixed to the right posterior abdominal wall at the level of the hepatic flexure, at which point the hepatocolic ligament secures this portion of the colon to the liver. The transverse colon lies free within the abdominal cavity and is fixed in the left upper quadrant at the splenic flexure by the phrenocolic ligament. The transverse colon is attached to the stomach by the gastrocolic omentum. The descending colon is fixed to the lateral abdominal wall; however, the sigmoid colon may or may not lie free within the abdominal cavity. The rectosigmoid colon's most cephalad portion is intraperitoneal, and at its distal, more caudad, portions, it becomes retroperitoneal and finally subperitoneal.

The colon receives its blood supply from the superior mesenteric artery, inferior mesenteric artery, and internal iliac arteries (Fig. 139.2). **The major arteries supplying the colon and rectum include the ileocolic, right colic, middle colic, left colic, sigmoid, superior hemorrhoidal, middle hemorrhoidal, and inferior hemorrhoidal arteries.** These arteries anastomose with one another to form the arc of Drummond and allow considerable leeway in mobilizing the colon. The middle colic artery arises from the first portion of the superior mesenteric artery and typically ascends the transverse mesocolon to the right of midline. The right colic artery usually arises just below the middle colic artery from the superior mesenteric artery and courses to the right colon. In some cases, the right colic artery may arise from the ileocolic artery or directly from the middle colic artery. If the right colic artery arises from the ileocolic artery, mobilization of a distal ascending colon segment is more likely to be brought easily into the deep pelvis. On occasion—particularly if the right colic artery originates from the middle colic artery—it is necessary to divide the right colic artery at its origin to mobilize the distal portion of the ascending colon to the pelvis. The ileocolic artery is the terminal portion of the superior mesenteric artery and supplies the last 6 inches of ileum and ascending colon. The left colic artery arises from the inferior mesenteric artery, and then the inferior mesenteric artery gives off four to six sigmoid branches, the last of which becomes the superior hemorrhoidal artery. This anastomoses with the middle hemorrhoidal artery, a branch of the internal iliac artery, which, in turn, anastomoses with the inferior hemorrhoidal artery, the terminal branch of the internal pudendal artery. The middle sacral artery, which originates directly from the aorta, may supply the posterior aspect of the rectum.

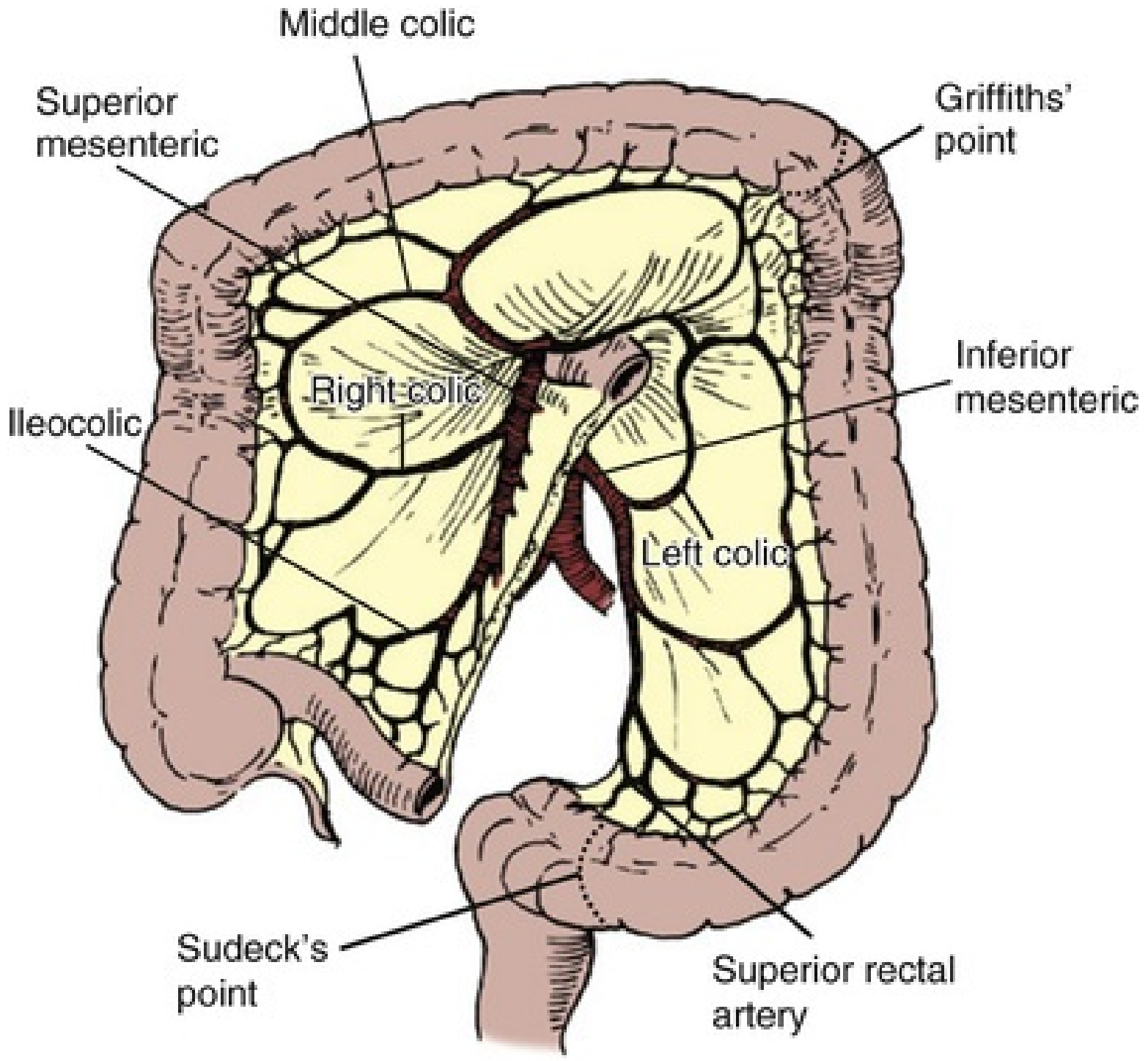

FIG. 139.2 Arterial supply and watershed areas of the small bowel and colon.

Watershed areas are regions of the colon that receive dual blood supply from the most distal branches of two larger arteries. Because of the small diameter of these distal branches, watershed areas are particularly vulnerable to ischemia in the setting of hypotension or thromboembolic event. Within the colon, two main watershed areas need to be considered. **Griffith's point, the collateral communication between the middle colic artery and the ascending left colic artery, is important for perfusion of the splenic flexure and descending colon.** Similarly, **Sudeck's point,** which is located between the junction of the last **sigmoid branch and superior hemorrhoidal artery,** is thought to be a tenuous anastomotic area such that if the colon were transected in this region, the blood supply to the anastomosis may be compromised (Sakorafas et al., 2006). Although anastomoses in these locations usually heal well provided the principles of proper technique are followed, if possible it is wise to select an area for the anastomosis to one side of these points, where the feeding arteries have a larger diameter.

The ascending colon is mobilized first by transecting the cecal and distal ileal fibrous attachments to the lateral abdominal wall and retroperitoneum as described earlier and then by detaching it from the lateral abdominal wall along the avascular line of Toldt. This is a bloodless plane, provided the colonic mesentery is not violated. The transverse colon is mobilized by dividing the gastrocolic omentum (along the avascular plane of its attachment to the colon), the hepatocolic ligament (which may have some small vessels coursing through it), and the phrenocolic ligament. The descending colon is mobilized, much like the right colon, by incision of the avascular line of Toldt lateral to the colon. With these attachments taken down, there is considerable mobility of the colon. Further mobility is gained by isolating a pedicle of the intestinal segment on the basis of one of the major arterial vessels described earlier.

Key Points

- No more than 8 cm of mesentery should be cleared from the end of a small bowel segment to allow for adequate perfusion and minimize the risk for necrosis.
- Two main watershed areas are found in the colon where, if possible, anastomosis should be avoided: Griffith's point near the splenic flexure (middle colic artery and left colic artery) and Sudeck's point near the rectosigmoid junction (most inferior sigmoidal branch and superior rectal artery).

Selecting the Segment of Intestine

The stomach, jejunum, ileum, and colon have unique properties, each of which has special advantages and disadvantages. The selection of the proper intestinal segment should be based on the patient's condition, renal function, history of previous abdominal procedures, and type of diversion or substitution required.

Stomach

The stomach has been used as a replacement for bladder, for augmentation cystoplasty, as a conduit, and for continent diversions (Abdel-Azim and Abdel-Hakim, 2003; Bissada et al., 2004; Castellan et al., 2012; DeFoor et al., 2003). **The advantages of the stomach over other intestinal segments for urinary intestinal diversion are that it is less permeable to urinary solutes, it has a net excretion of chloride and protons rather than a net absorption of them, and it produces less mucus.** Urodynamically, it behaves as other intestinal segments do. When it is used in urinary reconstruction, electrolyte imbalance rarely ensues in patients with normal renal function, although **hypochloremic metabolic alkalosis** has been described. The incidence of bacteriuria has been reported to be as low as 25%, much less than the 60% to 80% incidence reported for ileal and colon segments. However, more recent data suggest that there is no difference in bacteriuria among any of the segments. The urine, which usually has a pH of 6 to 7, does not typically result in an increased incidence of peristomal skin problems. Authors have also noted that in bladder augmentation patients, there is little difference in urinary pH between gastric and ileal augmentations. Serum gastrin levels are usually normal or minimally elevated, depending on what portion of the stomach is used and how much (Adams et al., 1988; Leong, 1978). Experimentally, antral exclusion may result in elevated circulating gastrin levels, leading to intestinal ulcerative problems in the postoperative period (Tiffany et al., 1986).

Rarely, severe ulcerative complications have occurred in cases in which stomach has been used for urinary reconstruction (Reinberg et al., 1992; Tainio et al., 2000)**. Long-term histamine (H_2 receptor) antagonists or proton-pump inhibitors should be considered for these patients.** The antrum should not be used if the fundus is available. If the antrum is used, reconstitution is generally by a Billroth I anastomosis. Complications with Billroth I gastroduodenostomy are well documented.

Early complications of the use of portions of the stomach for reconstruction include gastric retention caused by atony of the stomach or edema of the anastomosis; hemorrhage, most commonly originating from the anastomotic site; hiccups secondary to gastric distention; pancreatitis as a consequence of intraoperative injury; and duodenal leakage. Delayed complications include dumping syndrome, steatorrhea, small stomach syndrome, increased intestinal transit time, bilious vomiting, afferent loop syndrome, hypoproteinemia, and megaloblastic or iron deficiency anemia. Some studies report postoperative bowel obstruction has to be as high as 10% (2 of 21 patients) in adults (Leong, 1978), only a rare complication in pediatric patients (DeFoor et al., 2003; Mingin et al., 1999). Gastroduodenal and gastroureteral leaks have also been reported, occasionally resulting in a fatal outcome (Leong, 1978).

The use of stomach for urinary intestinal diversion may be considered in patients with severe renal dysfunction who would be unable to tolerate metabolic acidosis and those with the potential for short gut syndrome, in whom use of other intestinal segments would result in serious nutritional problems. One advantage of using stomach segments in the patient with severe abdominal adhesions is that the area of the stomach is, in general, adhesion free and easily mobilized.

Other **complications specific to the use of stomach include the hematuria-dysuria syndrome** in approximately 24% of patients (Castellan et al., 2012). Symptoms of hematuria-dysuria syndrome include bladder spasms; suprapubic, penile, or periurethral pain; gross hematuria without infection; skin excoriation; or dysuria without infection (Chadwick Plaire et al., 2000). These symptoms are typically intermittent and self-limiting, and can usually be controlled with H_2 blockers. The etiology is believed to be a result of the production of acid by the gastric segment, however, the symptoms have been seen even with urine acidity in the normal range (Aponte et al., 2015).

Severe metabolic alkalosis associated with respiratory distress has also been seen in some patients' gastric augments or conduits (see the Metabolic Complications section later in this chapter).

Jejunum

The jejunum is usually not used for reconstruction of the urinary system because it may result in severe electrolyte imbalance, most concerningly

hyperkalemia. In general, diseases that would make the ileum inappropriate for use also make the jejunum inappropriate for use. Rarely, it is the only segment available. Under these circumstances, as distal a segment of jejunum as possible should be used to minimize the electrolyte problems.

Ileum and Colon

The ileum and colon are used most often for urinary tract reconstruction and have been used in all types of reconstructive procedures. The ileum is mobile and of small diameter, has a constant blood supply, and serves well for ureteral replacement and the formation of conduits. **Loss of significant portions of the ileum results in nutritional problems because of lack of vitamin B_{12} absorption, diarrhea because of lack of bile salt reabsorption, and fat malabsorption.** On occasion, the mesenteric fat is excessive, making mobility and anastomosis difficult. Also, the mesentery may be so short that it is difficult to mobilize the ileum into the deep pelvis. **Postoperative bowel obstruction occurs in up to 10% of patients who have segments isolated from the ileum for urinary tract reconstruction** (Varkarakis et al., 2007). As many as one-half of the obstructions occur in the early postoperative period (Schwarz and Jeffs, 1975).

The colon requires mobilization from its fixed positions to give it the mobility necessary for use in urinary reconstruction. It has a larger diameter than the ileum and is usually easily mobilized into any area of the abdomen or pelvis. In patients who have received pelvic irradiation, portions of the right, transverse, and descending colon may be used confidently with the knowledge that they have not been exposed to the radiation therapy. Removal of segments of colon from the enteric tract results in fewer nutritional problems than does removal of segments of ileum, provided the ileocecal valve is not violated. Should the ileocecal valve be used, diarrhea, excessive bacterial colonization of the ileum with malabsorption, and fluid and bicarbonate loss may occur. **With colon, the incidence of postoperative bowel obstruction requiring reoperation is 5%, about one-half the incidence of ileum.** Both ileal and colon segments result in the same type of electrolyte imbalance with similar frequencies. **An antireflux ureterointestinal anastomosis by the submucosal tunnel technique is easier to perform with use of the colon.** In general, ileum and colon are comparable and have few differences, which does not argue strongly for the selection of one over the other except under special circumstances.

Key Points

- The use of stomach is associated with ulcerative complications and hematuria-dysuria syndrome, but has the advantage of a net excretion of H^+ and Cl^-.
- The use of jejunum may result in severe electrolyte imbalance, most concerningly hyperkalemia, and should thus be avoided if possible.
- Exclusion of significant portions of the ileum can result in vitamin B_{12} deficiency and decreased bile salt reabsorption.
- There is a lower rate of postoperative bowel obstruction requiring reoperation colon versus ileal urinary diversion.

Preparing the Bowel for Surgery and Postoperative Recovery

Complications that result from bacterial contamination are a major cause of morbidity and mortality in patients undergoing urologic procedures. In experimental animals, it has been shown that an anastomosis with vascular compromise at the anastomotic line, which would normally result in perforation, heals if the bowel has been properly prepared with antibiotics. Additionally, solid feces may place strain on the anastomosis in the early phase of healing and result in ischemia with subsequent perforation and intra-abdominal or wound infection.

In 1981, Bracken et al. reported that infectious complications after radical cystectomy that are the direct result of fecal contamination may occur in 18% to 20% of patients. These include wound infections, peritonitis, intra-abdominal abscesses, wound dehiscence, anastomotic dehiscence, and systemic sepsis. More recent series suggest that current management practices have made a substantial improvement, with perioperative infectious complications of 7% (Månsson et al., 2003; Stein et al., 2004). A series of 359 patients found infectious complications in 11.1% (Berneking et al., 2013).

It has been a long-held tenet of elective intestinal surgery that bowel preparation is beneficial. The bacterial population in the stomach is relatively low, but in the remaining segments of the bowel including the jejunum, ileum, and colon, there are high bacterial counts. Early studies suggested that bowel anastomoses in patients whose intestinal tract had not been prepared before surgery had increased wound infection rates, increased intraperitoneal abscesses, and an anastomotic dehiscence rate greater than in patients who received proper bowel preparation before surgery (Dion et al., 1980; Irwin and Goligher, 1973). Other studies have shown that mechanical preparation resulted in collapsed bowel at the time of surgery, which was shown to reduce the incidence of anastomotic leaks (Christensen and Kronborg, 1981).

Studies have recently begun to question the widely held belief that bowel preparation is mandatory. In meta-analyses of randomized clinical trials of anastomotic leakage during colon and rectal surgery, researchers found that there was no support for the conclusion that mechanical bowel preparation reduces anastomotic leak rates and other complications in elective open colon surgery

(Güenaga et al., 2011). **Several small randomized studies in patients undergoing cystectomy with ileal conduit urinary diversion have shown no difference in infectious complications between the groups of patients who received bowel preparation and those who did not** (Hashad et al., 2012; Xu et al., 2010). Notably, these studies excluded patients with a history of radiotherapy, immunosuppression, antibiotic administration within 1 preparative week, and liver or renal dysfunction.

There are two aspects to bowel preparation: mechanical and antibiotic. Both methods attempt to reduce the complication rate from intestinal surgery. **Mechanical preparation reduces the amount of feces (and therefore the total number of bacteria), whereas antibiotic preparation reduces the bacterial count per gram of feces (concentration).** The bacterial flora in the bowel consists of aerobic organisms, the most common of which are *Escherichia coli* and *Enterococcus faecalis*, and anaerobic organisms, the most common of which are *Bacteroides* species and *Clostridium* species. **The bacterial concentration ranges from 10 to 10^5 organisms per gram of fecal content in the jejunum, 10^5 to 10^7 in the distal ileum, 10^6 to 10^8 in the ascending colon, and 10^{10} to 10^{12} in the descending colon.**

Mechanical Bowel Preparation

Mechanical bowel preparation reduces the total number of bacteria but not their concentration. There is no change in the number of organisms present per gram of fecal content (Nichols et al., 1972). Therefore spilling enteric contents during the procedure may be less likely with the mechanically prepared bowel because there is less of it to spill; however, once spilled, cubic centimeter for cubic centimeter, the inoculum is the same as if the bowel had not been prepared. Some analyses even suggest that there may be an increase in bacterial contamination in patients who have undergone bowel preparation (Fa-Si-Oen et al., 2005), perhaps caused by decreased stool viscosity postprep.

Conventional bowel preparations commonly used in the past tended to exhaust the patient and exacerbate nutritional depletion because they typically required a 3-day preparation period of insufficient calorie intake (Table 139.1). The use of elemental diets has been advocated to clean the colon of feces while not compromising the nutritional status of the patient. Unfortunately, this has not proven useful because the elemental diets do not empty the colon of feces, and they do not reduce the bacterial flora (Arabi et al., 1978). In an attempt to reduce the time required for intestinal preparation and to obviate low-calorie intakes, whole-gut irrigation has been used. Originally, whole-gut irrigation was performed by placement of a nasogastric tube (NGT) into the stomach and infusion of 9 to 12 L of lactated Ringer's solution or normal saline during a several-hour period. These fluids were subsequently replaced with 10% mannitol, which was equally successful in ridding the bowel of its fecal content; however, the mannitol served as a bacterial nutrient and thereby facilitated microbial growth (Hares and Alexander-Williams, 1982). These solutions have largely been replaced by a polyethylene glycol (PEG)–electrolyte solution.

TABLE 139.1

Mechanical Bowel Preparation

PREOPERATIVE		CONVENTIONAL	POLYETHYLENE GLYCOL–ELECTROLYTE SOLUTIONS	
DAY	DIET	CATHARTIC	DIET	POLYETHYLENE GLYCOL
3	Low residue plus supplements		Regular plus supplements	
2	Low residue plus supplements		Low residue plus supplements	
1	Clear liquids	10 oz citrate of magnesia over 2 h at 1 pm	Clear liquids	2–4 L (adults) or 25 mL/kg/h × 2 h (do not exceed 2 L in children)

Whole-gut irrigation may be exhausting to the patient and may, in fact, result in a fluid gain, particularly when either saline or mannitol is used. **Whole-gut irrigation is contraindicated in patients with an unstable cardiovascular system, cirrhosis, severe renal disease, congestive heart failure, or an obstructed bowel.** Whole-gut irrigation has been found to be no more effective than conventional preparations in reducing wound infections and septic complications (Christensen and Kronborg, 1981), even though there is a reduction of aerobic flora compared with conventional preparations (van den Bogaard et al., 1981). **The advantages of whole-gut irrigation are that it gives the patient dietary freedom, there is a short preparation time, and it eliminates an enema. Its disadvantages are that it may result in the patient's exhaustion, it is rather rigorous, and it does result on occasion in fluid**

overload.

The PEG-electrolyte lavage solutions (e.g., GoLYTELY or the more palatable NuLYTELY) are effective lavage agents in preparing the gut. For the adult, 20 to 30 mL/min or approximately 1 to 1.5 L/h for 3 hours is given either orally or through a small-caliber NGT placed into the stomach. If it is taken by mouth, it is better tolerated if the solution is chilled. The administration of PEG lavage is stopped when the rectal effluent is clear and there is no particulate matter in it or when 4 L of fluid has been given. The septic complications with its use are approximately 4%. An inadequate preparation occurs in 5% of the patients using this modality (Wolff et al., 1988). For children, even those younger than 1 year of age, PEG lavage may be used at a rate of 20 to 40 mL/kg/h and given until the rectal effluent is clear and free of particulate matter (Tuggle et al., 1987). Metoclopramide, 10 mg in adults, is often given simultaneously to control nausea.

Oral cathartic bowel preparation is another acceptable strategy for reducing fecal burden before intestinal surgery. Oral solutions of magnesium citrate or sodium phosphate are both effective in cleansing the intestinal tract (Borden et al., 2010). The volume of fluid the patient must consume is substantially lower (148 mL MagCitrate and 45 mL NaPhosphate), and the preparations are typically well tolerated in healthy patients.

Bowel preparation can increase metabolic complications and cause electrolyte disturbances, which could affect surgical care. **Caution must be exercised in elderly and debilitated patients receiving sodium phosphate preparation; the sodium phosphate preparation has been shown to cause significant derangements in potassium, calcium, and phosphorus levels in frail individuals** (Beloosesky et al., 2003)**. Phosphate nephropathy has been recognized as a serious complication of oral sodium phosphate (OSP) bowel preparation** (Markowitz et al., 2005)**. Caution should be used in prescribing OSP to patients with underlying renal insufficiency or those being treated with nephrotoxic medications.** In the United States, OSP was recently changed to prescription only by the US Food and Drug Administration (FDA). **OSP should rarely be used.** The only study in postsurgical complications comparing sodium phosphate with PEG found no significant difference in complication rates (Oliveira et al., 1997). One study suggested that PEG is better tolerated by elderly patients and causes less disruption in potassium and sodium levels (Seinelä et al., 2003). Oral electrolyte solution rehydration may prevent some of the complications of bowel preparation (Tjandra and Tagkalidis, 2004).

A number of studies have questioned the efficacy of mechanical bowel preparation. Some have suggested that a limited mechanical bowel preparation is all that is necessary; others have questioned even the need for a mechanical bowel preparation. In one study, 2 L of PEG plus metoclopramide was compared with the administration of 4 L of PEG solution. There was no difference in surgical complication rate or the extent to which the bowel was clean (Gründel et al., 1997). In another study, when 4 L of PEG was compared with 90 mL of sodium phosphate, there was no significant difference in surgical complication rate (Oliveira et al., 1997). Two meta-analyses have found that there is an increased anastomotic dehiscence rate with preoperative mechanical bowel preparation (Bucher et al., 2005; Wille-Jørgensen et al., 2003). PEG may be the agent responsible for the increased rate of complications, but other preparation strategies have not been adequately analyzed. A meta-analysis of randomized trials comparing mechanical bowel preparation with no bowel prep before elective colorectal surgery found no difference between the groups for anastomotic leakage, abdominal abscess, or wound sepsis (Slim et al., 2009). **No study has adequately addressed the issue of the need for debulking of the intestine before laparoscopic approaches to intestinal surgery.** It is extremely important to note that in these studies, the administration of intravenous antibiotics was crucial in keeping the complication rate low. **Moreover, it is important to note that in these studies there was limited exposure of the intestine because the patients underwent elective bowel resections, unlike urologic procedures in which long segments of the intestine are opened or interposed in a urinary tract that is normally free of fecal contents.**

Antibiotic Bowel Preparation

There has been considerable controversy as to whether the addition of oral antibiotics in elective colon and small bowel surgery reduces mortality and morbidity significantly. **The long-held practice of mechanical and oral antibiotic bowel preparation dates to the 1970s.** In one study, the septic complication rate was reduced from 68% in the control group to 8% in the antibiotic group (Washington et al., 1974). Most series, however, report a lesser incidence of reduction in wound infection, in general from 35% without antibiotics to 9% with their use (Clarke et al., 1977). Others have suggested that the mortality rate drops from 9% to 3% with the use of antibiotics (Baum et al., 1981). It is clear that the use of antibiotics protects vulnerable bowel in that it may allow the tenuous anastomosis to survive.

Other studies, however, have shown that without the use of oral antibiotics in mechanically prepared bowel in elective surgery, the septic complication rate is comparable with that in those studies using antibiotics, and the rate of *Clostridium difficile* colitis is lower without oral antibiotics (Wren et al., 2005). In the presence of a bowel obstruction, however, oral antibiotics are of little value because they do little good in sterilizing the bowel. **The disadvantages of antibiotics may include postoperative increase in the incidence of diarrhea; pseudomembranous enterocolitis; theoretically increased incidence of tumor implantation at the suture line that is not germane to urologic surgery; monilial overgrowth resulting in stomatitis, thrush, and diarrhea; and, with prolonged use, malabsorption of protein, carbohydrate, and fat.** The antibiotics most commonly used for bowel preparation include kanamycin, which is the best single agent; neomycin and erythromycin base; and neomycin and metronidazole (Table 139.2). With an appropriate antibiotic preparation, enteric organisms are reduced to 10^2 per gram of feces (Nichols et al., 1972). **A contemporary randomized trial of patients undergoing elective colonic surgery found the lowest fecal bacterial concentrations when patients had preoperative mechanical bowel preparation, oral neomycin, and supplemental "synbiotic" treatment (to provide benign flora to the intestine).** No difference in clinical infections was seen between patients prepared with or without oral antibiotic bowel preparation (Reddy et al., 2007). A large series of 2475 patients from Michigan **undergoing colon surgery showed lower infection (5.0% vs. 9.7%) and less *C. difficile* colitis (0.5% vs. 1.8%) with mechanical and oral antibiotic bowel preparation** (Kim et al., 2014). Most recently, a retrospective cohort study of 89 patients undergoing left colon and rectal cancer resection demonstrated that **the addition oral antibiotics (neomycin and metronidazole) to mechanical bowel prep (magnesium citrate) decreased the rate of surgical site infection (SSI) from 27% to 8% ($P = 0.03$) versus mechanical bowel prep alone.** In addition, the patients who received an oral antibiotic prep had a decreased rate of organ space infections (0% vs. 18%; $P = 0.004$) and anastomotic leaks (0% vs. 10%; $P = 0.06$). Both groups in the study received perioperative intravenous antibiotics and skin prep with chlorhexidine (Vo et al., 2018)

TABLE 139.2

Antibiotic Bowel Preparation

PREOPERATIVE DAY	**KANAMYCIN**	**NEOMYCIN PLUS ERYTHROMYCIN BASE**	**NEOMYCIN PLUS METRONIDAZOLE**
3	1 g kanamycin orally every 1 h × 4, then 4 times/day	—	—
2	1 g kanamycin orally 4 times/day	—	1 g neomycin 4 times/day plus 750 mg metronidazole 4 times/day
1	1 g kanamycin orally 4 times/day	1 g erythromycin base plus 1 g neomycin at 1 pm, 2 pm, and 11 pm	1 g neomycin 4 times/day plus 750 mg metronidazole 4 times/day

Perioperative intravenous antibiotics appear to be the most important means of preventing infectious complications of intestinal surgery. Systemic antibiotics must be given before the operative event if they are to be effective. Ideally, antibiotics should be given between 1 and 2 hours before the start of surgery (Classen et al., 1992). They appear to be most effective against the anaerobic flora and apparently reduce the complications caused by these organisms (Dion et al., 1980). Perioperative systemic antibiotics, when added to the oral regimen, reduced the septic complication rate from 15% to 20% to 50% that rate in several series (Gottrup et al., 1985; Hares and Alexander-Williams, 1982). Other studies, however, have shown no effect of systemic cephalosporin, for example, in reducing septic complications (Wolff et al., 1988). **If perioperative antibiotics are given, they should be effective against anaerobes because it is complications from these organisms against which perioperative antibiotics appear to be particularly effective.** Third-generation cephalosporins have been advocated as an appropriate systemic antibiotic. Other recent studies support the use of both oral and systemic intravenous antibiotic prophylaxis before intestinal surgery (Kim et al., 2014). It is clear that preoperative antibiotics reduce postoperative complications. Most agree that preoperative intravenous antibiotics are important, and some advocate discontinuing the use of oral antibiotics out of concern for developing *C. difficile* diarrhea (Wren et al., 2005).

It is our preference to perform both a mechanical and an antibiotic bowel preparation. The patient is allowed a normal diet until 1 day preoperatively, at which time a clear liquid diet is begun and magnesium citrate is given as a cathartic. Oral antibiotic bowel preparation with neomycin is also prescribed. Preoperative hydration with a sports beverage is continued until 2 hours before surgery. On the day of surgery, the patient is given intravenous antibiotics 1 hour before the incision as recommended by AUA guidelines.

The AUA guidelines for antibiotic prophylaxis in patients undergoing urinary diversion are summarized in Table 139.3 (Wolf et al., 2008).

TABLE 139.3

AUA Guidelines for Antibiotic Prophylaxis in Patients Undergoing Urologic Surgery Involving Intestine

PROPHYLAXIS RECOMMENDED FOR	PRIMARY CHOICE	ALTERNATIVES
All patients undergoing urologic surgery involving the intestine[a–c]	Second- or third-generation cephalosporin or Aminoglycoside + metronidazole or clindamycin	Ampicillin/sulbactam Ticarcillin/clavulanate Piperacillin/tazobactam Fluoroquinolone

[a] For surgery involving the colon, bowel preparation with oral neomycin plus either erythromycin base or metronidazole can be added to or substituted for systemic agents.

[b] Prophylaxis should be limited to 24 hours after a procedure unless (1) prosthetic material is placed, (2) an external urinary catheter is placed before or at the time of the procedure in patients with certain risk factors, or (3) the patient has documented bacteriuria.

[c] First dose of antibiotics should be given within 60 minutes of surgical incision (or 120 minutes in the case of vancomycin or fluoroquinolones)

Diarrhea and Pseudomembranous Enterocolitis

Bowel preparations may result in diarrhea and pseudomembranous enterocolitis. Pseudomembranous enterocolitis is the more severe form of a spectrum of diarrhea. Clinically, this occurs after a bowel preparation in the postoperative period and is heralded by abdominal pain and diarrhea, usually in the absence of fever or chills. As the symptoms and infection become more severe, systemic toxicity supervenes. **These patients can develop a toxic megacolon, and if this occurs, the mortality may exceed 15% to 20%.** Historically, pseudomembranous enterocolitis was thought to be caused by *Staphylococcus*, but there was, in fact, little evidence to support that organism as the causative agent. It is now clear that ***C. difficile* plays a significant role in the majority of cases.** *C. difficile* elaborates at least two toxins that cause diarrhea and enterocolitis. *C. difficile* does not invade the bowel, and it is not normally a significant inhabitant of the fecal flora. It is held in check by other bacteria that inhibit its growth. Thus antibiotics destroy the bacteria that inhibit the growth of *C. difficile* and thereby allow it to flourish. The toxin produces a diffuse inflammatory response with cream-colored plaque formation, erythema, and edema of the bowel wall. On microscopic examination, the villi appear to be intact, and there is a polymorphonuclear leukocyte infiltrate of the submucosa (Bartlett, 2002).

As the disease progresses, large areas of the bowel are denuded of their mucosa, which may slough. The lesions may involve the colon, in which case it is called *pseudomembranous enterocolitis*, or the small bowel, in which case it is called *pseudomembranous enteritis*, or they may involve both.

The diagnosis may be suspected from symptoms or endoscopy and is confirmed by culture of the organism or identification of its toxin. According to the American Society of Gastroenterology guidelines, only stool from patients with diarrhea should be tested. **Nucleic acid amplification tests (NAATs) for *C. difficile* toxin genes** such as PCR are superior to toxins A + B enzyme immunoassay (EIA) tests because of improved sensitivity and specificity. Repeat testing, and testing for cure are discouraged (Surawicz et al., 2013).

Once the diagnosis has been made, **treatment involves the administration of vancomycin or metronidazole and discontinuance of other antibiotics that the patient is receiving.** Vancomycin or metronidazole is effective in most cases. **Rarely, toxic megacolon supervenes, necessitating subtotal colectomy as a lifesaving procedure** (Chang, 1985). Newer therapy with antibodies to the toxin hold promise in reducing the morbidity of the disease (Lowy et al., 2010). A summary of management recommendations by the American Society of Gastroenterology can be found in Table 139.4 (Surawicz et al., 2013).

TABLE 139.4

C. difficile Severity Scoring System and Summary of Treatments

SEVERITY	CRITERIA	TREATMENT	COMMENT
Mild to	Diarrhea + other	Metronidazole 500 mg PO	If no improvement

moderate	signs or symptoms not meeting criteria for severe or complicated	TID × 10 days; if unable to take, then vancomycin 125 mg PO QID × 10 days	after taking metronidazole for 5–7 days, then switch to vancomycin for 10 days
Severe	Albumin <3g/dL Plus ONE of: WBC >15,000 cells/mm^3 *or* abdominal tenderness	Vancomycin 125 mg PO QID × 10 days	
Severe and complicated	Any of: ICU admission Hypotension Fever >38.5°C Ileus or significant abdominal distention WBC >35,000 or <2000 cells/mm^3 Serum lactate >2.2 mmol/L End organ failure	Vancomycin 500 mg PO QID and metronidazole 500 mg q8h and vancomycin PR (500 mg in 500 mL of saline as enema QID)	Surgical consultation
Recurrent	Within 8 weeks of completion of therapy	Repeat vancomycin or metronidazole pulse regimen	Consider fecal microbiota transplant after three recurrences

Modified from Surawicz CM, Brandt LJ, Binion DG, et al. Guidelines for diagnosis, treatment, and prevention of *Clostridium difficile* infections*. Am J Gastroenterol* 108:478–498; quiz 499, 2013.

Enhanced Recovery After Surgery

Enhanced recovery after surgery (ERAS) protocols (also referred to as “enhanced recovery programs” or “fast-track protocols”) are evidence-based, collaborative perioperative care pathways designed to improve recovery after major surgical procedures. They aim to maintain preoperative organ function and reduce the body's stress response after surgery. ERAS protocols contain preoperative, intraoperative, and postoperative components that include patient counseling, nutritional optimization, standardized analgesic and anesthetic regimens, and early mobilization (Melnyk et al., 2011). Many protocols have also discontinued the use of a bowel prep as standard practice.

ERAS first gained traction in the 1990s in the field of colorectal surgery based on ideas put forth by Henrik Kehlet. Since then, adoption of ERAS protocols has increased as the evidence supporting their use has grown. Meta-analyses of studies of colorectal surgery patients have provided level 1 evidence for reduction of complications (50%) and hospital stay (2.5 days) by application of ERAS pathways (Varadhan et al., 2010). This has led to adoption of modified ERAS protocols in many surgical specialties including gynecologic, thoracic, vascular, pediatric, and orthopedic surgery, and most recently urology.

In urology, the best studied ERAS protocols are in patients undergoing radical cystectomy and urinary diversion. Bowel complications are thought to account for the majority of extended hospital stays in this patient population with postoperative ileus (POI) being the most common complication (Chang et al., 2002). One difference between urology and colorectal surgery is that **radical cystectomy patients are believed to be at higher risk for POI compared with the colectomy population** because of deperitonealization of the pelvis for extended periods during pelvic lymphadenectomy, exposure of the bowel to urine, longer operative times, an older patient population with a higher incidence of comorbid conditions, and a higher smoking rate resulting from the association of smoking with urothelial cancer (Ramirez et al., 2013).

The precise definition of POI varies from study to study, but usually consists of a prolonged inability to tolerate oral intake without evidence of bowel obstruction. Several trials have examined the effect of implementation of ERAS protocols in patients undergoing radical cystectomy. In general, the evidence appears to support implementation of ERAS protocols for well-selected patients, though study results are difficult to compare directly given the variability in protocols and end points between studies (Azhar et al., 2016). In addition, cultural factors, differences in patient expectations, and health-care reimbursement structure can affect end points such as length of stay, time to resumption of regular diet, and patient satisfaction.

Arumainayagam et al. studied the implementation of an ERAS protocol in radical cystectomy patients (Arumainayagam et al., 2008). In this study, 56 consecutive non-ERAS patients were compared with 56 consecutive patients immediately after implementation of an ERAS protocol. Readmission, mortality, and morbidity rates were not significantly different between the groups. The length of stay, however, was reported to be 4 days shorter in the ERAS group (13 vs. 17). Another trial compared 26 consecutive non-ERAS patients to 51 ERAS patients and demonstrated similar findings, with a decreased length of stay in the ERAS group (10.4 days vs. 11.5 days) and no significant increase in complication or readmission rate (Mukhtar et al., 2013).

Shorter length of stay also has been demonstrated with the addition of alvimopan to the ERAS protocol. Alvimopan, a peripherally acting μ-opioid receptor antagonist, accelerates upper and lower gastrointestinal recovery and is indicated after surgeries that include bowel resection (Ludwig et al., 2008). **It acts by binding peripheral μ-opioid receptors in the gastrointestinal tract, preventing the binding of opioids with a subsequent decrease in associated bowel complications including slowed motility. Alvimopan has limited ability to cross the blood-brain barrier, which therefore allows for binding of opioids to μ-opioid receptors in the central nervous system for pain control** (US FDA, 2013).

Lee et al. conducted a randomized double-blind placebo-controlled trial in patients undergoing radical cystectomy and receiving postoperative intravenous patient-controlled opioid analgesics. Patients were randomized to alvimopan (n = 143) or placebo (n = 137). A modified intention-to-treat analysis demonstrated a quicker recovery of bowel function (5.5 vs. 6.8 days), shorter mean length of stay (7.4 vs. 10.1 days), and fewer episodes of postoperative ileus–related morbidity (8.4% vs. 29.1%) in the Alvimopan group (Lee et al., 2014). Alvimopan is only FDA approved for inpatient use only. The standard dosing protocol is 12 mg, 30 minutes to 5 hours before surgery then twice per week beginning the day after surgery until return of bowel function, or up to 7 days (15 total doses) (US FDA, 2013).

Despite these apparent successes, the implementation of ERAS protocols has not universally resulted in quicker return of bowel function and decreased length of stay. Saar et al. (2013) compared 31 consecutive patients on an ERAS pathway to 31 consecutive non-ERAS patients undergoing robotic-assisted laparoscopic radical cystectomy and found significantly decreased opioid use and time to regular diet in the ERAS group, but no difference in the time to bowel movement or length of stay. Similarly, Karl et al. (2014) prospectively randomized 101 consecutive patients to an ERAS (62) or non-ERAS (39) regimen. No significant difference in length of stay or time to bowel movement was noted, though time spent in the ICU appeared to be shorter in the ERAS group by 0.8 days. Interestingly, quality of life parameters as measured by the EORTC (European Organization for the Research and Treatment of Cancer) Quality of Life questionnaire (QLQ-30) did not change significantly between postoperative days 3 and 7 and discharge from hospital in the non-ERAS group, whereas a significant improvement was observed in the ERAS, suggesting that ERAS protocols may improve patient quality of life in the immediate postoperative period.

Several studies looked at the effect of specific components of the ERAS protocol. Pruthi et al. (2010) examined a 7-year experience with an ERAS pathway encompassing 362 consecutive cystectomy patients. Over time, the group altered their ERAS protocol and found the addition of chewing gum and metoclopramide to be beneficial in promoting return of bowel function. Of the 100 most recent patients in the series, 79% were discharged by postoperative day 5.

In a study of 107 patients on an ERAS protocol, Maffezzini et al. (2008) were able to demonstrate early return of flatus (POD 2) and regular diet (POD 4). Interestingly, neither early enteral nutrition nor early reinstitution of a regular diet prevented postoperative protein depletion as assessed by serum levels of total proteins, albumin, and lymphocyte count. This suggests that **even with early enteral nutrition, postoperative nutritional deficiencies are not likely to normalize in the early postoperative period.**

Table 139.5 summarizes the findings from published trials pertaining to the use of ERAS protocols for patients undergoing radical cystectomy, including several not mentioned here (Daneshmand et al., 2014; Dutton et al., 2014).

TABLE 139.5

Summary of Findings from Published Trials Pertaining to the Use of Enhanced Recovery After Surgery (ERAS) Protocols for Radical Cystectomy

STUDY	FINDINGS			
	LENGTH OF STAY	COMPLICATIONS	READMISSIONS	MORTALIT RATES
Arumainayagam	Median time	No significant	No significant	No significar

et al., 2008	significantly shorter for ERAS group by 4 d	difference in total complications between ERAS and control groups (ERAS n = 18; control n = 23)	difference between ERAS and control groups (ERAS n = 3; control n = 5)	difference between ERA and control groups (each group n = 1)
Pruthi et al., 2010	79% discharged on postoperative days 4–5[a]	39%[a]	2%[a]	0.01%[a]
Maffezzini et al., 2008	Not reported	35.3%[a]	Not reported	2.9%[a]
Mukhtar et al., 2013	Median time significantly shorter for ERAS group by 1.1 d	No significant difference between ERAS and control groups (ERAS n = 20; control n = 11)	0% for both groups	3 patients tot across group

Saar et al., 2013	No significant difference between ERAS and control groups (ERAS *M* = 18.0 d; control *M* = 18.1 d)	No significant difference in total complications between ERAS and control groups (ERAS *n* = 12; control *n* = 15)	No significant difference between ERAS and control groups (ERAS = 19.4%; control = 6.4%)	ERAS group = 1

Daneshmand et al., 2014	*M* = 4 d	65%[a]	21%[a]	1%[a]
Dutton et al., 2014	Mean = 9.2 d[a]	Complications rate was 6.6% for Clavien 3 and 43.5% for Clavien 2[a]	13.9%[a]	1.3%[a]
Karl et al., 2014	No significant difference in general LOS between groups; ICU time significantly shorter for ERAS group by 0.8 d	No significant difference in complications between groups	NR	0% in both groups

Lee et al., 2014 (alvimopan vs. placebo)	ERAS group shorter mean LOS (7.4 vs. 10.1 d)	Incidence of opioid consumption and AEs or serious AEs (SAEs) was comparable, except for POI, which was lower in the alvimopan group (AEs: 7% vs. 26%; SAEs: 5% vs. 20%)	30-day all-cause readmissions: alvimopan = 23.8% vs. placebo = 26.9% (NS)	Alvimopan = 3.5% vs. placebo = 2.9% (NS)

[a]No control group

AE, Adverse event; *BM,* bowel movement; *d,* days; *ICU,* intensive care unit; *IV,* intravenous; *LOS,* length of stay; *M,* median; *NG,* nasogastric; *NR,* not reported; *NS,* not significant; *POI,* postoperative ileus; *SAE,* serious adverse event.

Modified from Azhar RA, Bochner B, Catto J, et al. Enhanced recovery after urological surgery: a contemporary systematic review of outcomes, key elements, and research needs. *Eur Urol* 70:176–187, 2016.

The ERAS Society, the main society dedicated to the study of multimodal perioperative care pathways, has published guidelines that include 22 ERAS recommendations for patients undergoing radical cystectomy (Cerantola et al., 2013). Complete discussion of each recommendation is beyond the scope of this chapter, but all 22 recommendations are summarized in Table 139.6.

TABLE 139.6

Enhanced Recovery After Surgery (ERAS) Society Guidelines for Radical Cystectomy

SUMMARY OF EACH ERAS ITEM AND ITS RESPECTIVE LEVEL OF EVIDE RECOMMENDATION DERIVED FROM THE CYSTECTOMY AND THE COL			
ERAS RECOMMENDATION	**SUMMARY**	**SPECIFICS FOR CYSTECTOMY PATIENTS/UNKNOWNS**	**EVIDE CYSTE SURGE**
1. Preoperative counseling and education	Patients should receive routine dedicated preoperative counseling and education.	Surgical details, hospital stay and discharge criteria in oral and written form; stoma education; patient's expectations	NA/low
2. Preoperative medical	Preoperative	Correction of anemia and	NA/mod

optimization	optimization of medical conditions should be recommended. Preoperative nutritional support should be considered, especially for malnourished patients.	comorbidities; nutritional support; smoking cessation and reduction of alcohol intake 4 weeks before surgery; encouraging physical exercise	NA/mod
3. **Oral mechanical bowel preparation**	Preoperative bowel preparation can be safely omitted.	—	Moderat
4. Preoperative carbohydrates loading	Preoperative oral carbohydrate loading should be administered to all nondiabetic patients.	—	NA/low
5. Preoperative fasting	Intake of clear fluids until 2 h before induction of general anesthesia is recommended. Solids are allowed until 6 h before anesthesia.	—	NA/mod
6. Preanasthesia medication	Avoidance of long-acting sedatives.	—	NA/mod
7. Thrombosis prophylaxis	Patients should wear well-fitting compression stockings and receive pharmacologic prophylaxis with LMWH. Extended prophylaxis for 4 weeks should be carried out in patients at risk. Allow a 12-h	Cystectomy patients are considered at risk; prolonged prophylaxis should therefore be administered	NA/high

	interval between injections and epidural manipulation.		
8. Epidural analgesia	Thoracic epidural analgesia is superior to systemic opioids in relieving pain. It should be continued for 72 h.	—	NA/high
9. **Minimally invasive approach**	At most feasible; in trial setting Long-term oncologic results awaited	Laparoscopic/robotic cystectomy is not recommended outside a trial setting until long term results are available.	Low/mo
10. Resection site drainage	Perianastomotic and/or pelvic drain can be safely omitted.	Because of urine leak, drainage might be required in cystectomy patients.	NA/low
11. Antimicrobial prophylaxis and skin preparation	Patient should receive single-dose antimicrobial prophylaxis 1 h before skin incision. Skin preparation with chlorhexidine-alcohol prevents/decreases surgical site infection.	—	NA/high
12. Standard anesthetic protocol	To attenuate the surgical stress response, intraoperative maintenance of adequate hemodynamic control, central and peripheral oxygenation, muscle relaxation, depth of anesthesia, and	—	NA/mod

	appropriate analgesia is recommended.		
13. **Perioperative fluid management**	Fluid balance should be optimized by targeting cardiac output using the esophageal Doppler system or other systems for this purpose and avoiding overhydration. Judicious use of vasopressors is recommended with arterial hypotension.	High-risk patients need close and individualized goal directed fluid management. There are several ways to achieve this and all must be used together with sound clinical judgment.	Low/hig
14. Preventing intraoperative hypothermia	Normal body temperature should be maintained preoperatively and postoperatively.	Especially relevant for cystectomy patients because operative duration is prolonged.	Na/high
15. **Nasogastric intubation**	Postoperative nasogastric intubation should not be used routinely.	Early removal is recommended.	Low/hig
16. **Urinary drainage**	Transurethral catheter can be removed on postoperative day 1 after pelvic surgery in patients with a low risk for urinary retention.	Ureteral stents and transurethral neobladder catheter should be used. The optimal duration of ureteral stenting (at least until POD 5) and transurethral catheterization is unknown.	Very low
17. **Prevention of postoperative ileus**	A multimodal approach to optimize gut function should involve gum chewing and oral magnesium.	—	Moderat
18. **Prevention of PONV**	Multimodal PONV prophylaxis should be adopted in all patients with two risk factors.	Multimodal prophylaxis	Very low risk patie
19. Postoperative	Multimodal	—	NA/high

analgesia	postoperative analgesia should include thoracic epidural analgesia.		
20. Early mobilization	Early mobilization should be encouraged.	2 h out of bed POD 0 6 h out of bed POD 1	NA/low
21. Early oral diet	Early oral nutrition should be started 4 h after surgery.	—	NA/mod
22. Audit	All patients should be audited for protocol compliance and outcomes.	Routine audit of outcomes, cost-effectiveness, compliance, and changes in protocol.	NA/low

Bolded recommendations have been directly studied in urology patients undergoing radical cystectomy.

LMWH, Low–molecular-weight heparin; *Na,* not available; *PONV,* postoperative nausea and vomiting.

Modified from Cerantola Y, Valerio M, Persson B, et al. Guidelines for perioperative care after radical cystectomy for bladder cancer: Enhanced Recovery After Surgery (ERAS®) society recommendations. *Clin Nutr* 32:879–887, 2013.

It is interesting to note that the majority of these recommendations are extrapolated from colorectal surgery literature without any direct evidence from the cystectomy population supporting their use. **Only 7 of the 22 ERAS recommendations, as outlined by the ERAS Society guidelines are backed by direct evidence from urology patients** (Cerantola et al., 2013).

With improved understanding, progress has been made in the perioperative care of colectomy patients, which has translated to improved care for patients undergoing radical cystectomy. It might be tempting to assume that ERAS protocols should be applied to all urinary diversion patients. However, **the use of an ERAS protocol should be carefully considered, especially in patients undergoing surgery for benign conditions.** As noted earlier, the majority of ERAS studies exclude patients with a history of radiotherapy, immunosuppression, or liver or renal dysfunction, making it unclear whether results from these trials are broadly generalizable. Additionally, patients undergoing urinary diversion for benign reasons often do so in the setting of a neurologic condition (such as spinal cord injury), chronic infection, radiation cystitis (with the possibility of concomitant radiation-damaged bowel), or chronic systemic syndrome such as interstitial cystitis (Chong et al., 2014). Many of these patients have decreased bowel motility, poor wound healing, impaired immunity, and other complicating factors.

It is our practice to enroll those patients undergoing radical cystectomy for bladder malignancy in our ERAS protocol (Table 139.7). In contrast, patients undergoing salvage radical cystectomy after trimodality therapy or cystectomy for benign conditions (e.g., radiation cystitis, fistula to the pubic symphysis, neurogenic bladder) are managed more conservatively, given the possible complicating factors outlined earlier. We typically subject these patients to a full mechanical and antibiotic bowel prep, and are slow in advancing their diet until bowel function returns.

TABLE 139.7

Enhanced Recovery After Surgery (ERAS) Radical Cystectomy Pathway

Patient Selection Criteria: cystectomy with orthotopic neobladder or ileal conduit, appropriate home support system **Patient Exclusion Criteria:** neurogenic bladder/bowel, slow gastric emptying, prior significant bowel resection or major bowel surgery (e.g., gastric bypass), autonomic dysfunction, radiation to abdomen, salvage cystectomy	
PREOPERATIVE PERIOD SURGEON CHECKLIST ☐ Book case for OR ☐ **Notify Anesthesia** of ERAS patient ☐ Insurance preapproval for visiting nurse and home IV saline infusion postop, other medications ☐ **Preop visits:** Preoperative anesthesia visit, IV infusion screening, urology nursing visit ☐ **No bowel prep** ☐ Give Rx for preop: **gabapentin (600 mg PO × 1) and acetaminophen (1 g PO × 1)**	**PREOPERATIVE PERIOD PATIENT CHECKLIST** ☐ Hydration and high-carb, high-protein meals 2–3 days before surgery. **Clear liquid diet (>2 L intake)** 1 day before surgery. ☐ Take **24 oz. of Gatorade before midnight** the night before surgery ☐ NPO after midnight ☐ Take **12 oz. of Gatorade 3 hours before surgery** ☐ Report to hospital at least 2 hours before surgery ☐ Take pain medication 2 hours before surgery: **Acetaminophen 1 g PO × 1 dose** **Gabapentin 600 mg PO × 1 dose**
PERIOPERATIVE PERIOD SURGEON AND ANESTHESIA CHECKLIST ☐ **IV antibiotics per AUA**	**POSTANESTHESIA CARE UNIT (PACU) PERIOD CHECKLIST** ☐ **TAP catheters** —max dose 0.1% bupivacaine at 10 cc/h on each side of

guidelines before incision (depending on patient allergies) ❑ **Heparin SC 5000 units** before induction ❑ **Alvimopan 12 mg PO 30–120 min preop**[a] ❑ Knee high **sequential compression boots** ❑ Confirm intake time of Gatorade drink (3 hours before surgery) ❑ Confirm intake time of acetaminophen and gabapentin ❑ Minimize abdominal incision (infraumbilical) **Fluid Management per Anesthesia** ❑ **Goal is continued urine output** ❑ Noninvasive cardiac output monitoring* **Intraop Pain Control** ❑ Eliminate or minimize narcotic use ❑ **Acetaminophen IV 1 g q6h** ❑ **Ketamine prn** for additional pain control **At End of Case** ❑ **Ketorolac IV 30 mg × one dose** for Cr <1.5 (or 15 mg × one dose for Cr 1.5–2.0) ❑ Remove intraop OG/NG tube ❑ **Transversus abdominus plane (TAP) catheter placement by anesthesia service**[b]	incision ❑ **Ketorolac 15 mg IV q6h** × 72 h (exclude patients with Cr >1.5) ❑ **Acetaminophen 1 g IV q6h** × 24 h (POD 0) then PO (POD 1) ❑ **Gabapentin 100 mg PO TID;** discontinue for dizziness, sedation ❑ IV morphine only for significant breakthrough pain ❑ **Titrate IV fluids to urine output ~30 cc/h**
POSTOPERATIVE PERIOD CHECKLIST **Early Mobilization** ❑ Once on general medical floor, sit patient in chair ❑ Ambulate morning of POD 1 ❑ **Ambulate TID or more** often every day ❑ **Physical therapy consult** POD	**DISCHARGE CHECKLIST** **Discharge Criteria** ❑ Adequate pain control ❑ Adequate mobility ❑ Normal chemistries, CBC ❑ ≥1.5 L of PO intake per day ❑ + Bowel movement ❑ Lovenox and drain care teaching complete

1 to work one-on-one with patient and assess discharge needs **Standing Anticoagulation** ☐ **Lovenox 40 mg SC QD** starting POD 1 or heparin SC 5000 units TID if Hct is stable **Early Nutrition** ☐ **Sips of clear liquids on POD 0** (high-carb, high-protein fluids) ☐ **Clear liquids on POD 1** (high-carb, high-protein fluids: Gatorade, Ensure). ☐ **Discontinue continuous IV fluids on POD 1;** bolus 500 cc normal saline as needed for urine output ☐ **Soft to regular diet on POD 2** ☐ TPN if not tolerating PO diet by POD 6	**Home Prescriptions** ☐ **Lovenox 40 mg SC QD** prophylaxis × 28 days ☐ **1L IV normal saline** every other day by visiting nurse × 1 week **Follow-Up** ☐ Urology visit in 1 week ☐ Check in calls QOD by urology nurse ☐ Removal of ureteral stents by surgeon on POD 10–14
Multimodal Antiemetic Regimen ☐ **Ondansetron 4 mg IV standing** ☐ Metoclopramide prn extra agent (age <75) **Bowel Regimen** ☐ **Famotidine 20 mg IV BID** or omeprazole 20 mg PO daily ☐ **Alvimopan 12 mg PO BID POD 1** until BM[a] ☐ **Chewing gum** standing POD 1 until BM ☐ **Bisacodyl PR** on POD 1 and daily until BM **Pain Management: Standing Nonopioid Analgesia** ☐ **Ketorolac 15 mg q6h** × 72 h ☐ **Acetaminophen 1 g q6h** (IV for 24 hr, then transition to PO) ☐ **Gabapentin 100 mg PO TID;** discontinue for dizziness, sedation ☐ **Discontinue TAP catheters on POD 2** if tolerating diet ☐ Transition to PO pain meds by	

POD 2 ☐ Opioid pain management in rare cases (if all else fails) ☐ **PICC line placement** POD 3 (for home IV fluids)	

[a] If available.

[b] Paraincisional fascial catheter used for infusion of bupivacaine for local pain control.

The comprehensive ERAS protocol used at our institution is outlined in Table 139.7. It incorporates many of the evidence-based practices described in this section.

Key Points

- A **mechanical** bowel prep decreases the amount of feces in the intestinal tract and therefore the absolute **bacterial count.**
- An **antibiotic** bowel prep decreases the **concentration** of bacteria per cubic centimeter of feces.
- Decisions about whether or not to administer a mechanical and/or antibiotic bowel prep should take into account the potential risks and benefits for each individual patient.
- Alvimopan is a peripherally acting μ-opioid receptor antagonist that prevents binding of opioids in the intestinal tract. It has limited ability to cross the blood-brain barrier, which allows for binding of opioids to μ-opioid receptors in the central nervous system for pain control.
- Most of the evidence for the use of ERAS protocols in urology is extrapolated from colorectal surgery, however, its use is supported in patients undergoing radical cystectomy and urinary diversion for bladder cancer.
- There are very limited data regarding the use of an ERAS protocol in patients undergoing urinary diversion for benign conditions.

Intestinal Anastomoses

Regardless of the type of anastomosis or the methods used to perform it, certain fundamental principles must be observed to minimize morbidity and mortality from intestinal surgery. **In urologic procedures in which gut is used, the most common cause of mortality and morbidity within the immediate postoperative period relates to complications involving the bowel,** either with the enteroenterostomy or with the segment interposed in the urinary tract. Therefore it cannot be overemphasized that great care must be taken and proper techniques used in handling bowel in urologic procedures. Unfortunately, the portion of the procedure that involves mobilization of the intestine and reanastomosis often follows a rather lengthy extirpative endeavor and is performed when the surgical team is not fresh. Therefore the following principles should be so firmly ingrained in the surgeon that they are performed without the need to recall each one specifically.

Surgical Principles

The first principle of proper technique for intestinal anastomoses is adequate exposure. The intestine should be mobilized sufficiently that the anastomosis may be performed without struggling for exposure. If possible, it is preferable to mobilize the intestine enough to perform the anastomosis on the anterior abdominal wall. The area of the anastomosis should be walled off from the rest of the abdominal cavity with Mikulicz pads. This is important so that any inadvertent enteric spills are not distributed throughout the abdominal cavity. The mesentery must be cleared from the bowel segments to be anastomosed for a suitable distance (usually 0.5 cm) from the intestinal clamps or staple line at the severed ends so that good serosal apposition may be achieved without interposed mesentery. Sufficient serosa must be exposed so that the seromuscular sutures or staples can be placed directly in the serosa without traversing the mesentery.

The second principle of performing a proper anastomosis is to maintain a good blood supply to the severed ends of the bowel. The blood supply may be compromised by construction of an anastomosis under tension, excessive dissection or mobilization of the bowel, excessive use of electrocautery, or tying of the sutures so tightly that the intervening tissue is strangulated. A cut margin of bowel that is pink and bleeds freely suggests that the blood supply has not been compromised; however, hemostasis must be ensured before beginning the anastomosis. The site of transection is selected at a point where the blood supply is adequate to both segments. The mesentery should be transilluminated so that the blood supply may be defined before transection of the bowel segment. In urologic surgery, the location of the transection is elective so that an area may be selected in which excellent arcades supply both sections of the transected segment. The area must be selected with an eye to how deep the mesenteric transection must be for proper segment mobility. After location of the appropriate area where the mesentery is to be transected, it is cleared from the serosa, severed between mosquito clamps, and tied with 4-0 silk sutures. Alternatively, the mesentery may be transected with the LDS stapler (Covidien Surgical, Mansfield, MA), a bipolar cautery device, or ultrasonic shears.

The third principle involves prevention of local spillage of enteric contents. The best way of preventing spills is to operate on properly prepared bowel (i.e., devoid of feces and collapsed). Stripping of the enteric contents between the fingers both cephalad and caudad from the proposed transection site and application of a noncrushing occlusive clamp across the bowel make a spill even less likely. The clamp should prevent enteric contents from exiting the cut ends of the bowel without interference with the mesenteric blood supply. After linen-shod clamps are applied and the area is walled off, Allen clamps are applied to the bowel, and the bowel is transected between the Allen clamps. An anastomotic stapler may be used to transect the bowel at this point in place of Allen clamps (see later). Local spills and local sepsis have an adverse effect on the healing anastomosis, and it is for this reason that noncrushing occlusion clamps and bowel preparation may be useful. If a spill does occur, it should be caught in the Mikulicz pads if the bowel has been properly walled off as described earlier. The isolated segment that is to be used in the reconstructive procedure should be irrigated thoroughly with copious amounts of normal saline. The segment should be walled off. The irrigant is placed in one end of the segment and caught in a kidney basin as it exits the other end. This should be continued until the efflux is clear. This procedure prevents local spills during the ureterointestinal anastomosis and other aspects of reconstruction.

The fourth principle, germane to all intestinal anastomoses, is that **there should be an accurate apposition of serosa to serosa of the two segments of bowel to be anastomosed.** The anastomosis should be watertight and performed without tension. The bowel must be handled gently with the use of noncrushing forceps. The anastomotic line should be inverted and not everted. There is considerable controversy about this issue in that an everted anastomosis has been shown to heal with few complications. It is clear, however, that when marginal conditions occur, an inverted anastomosis is more likely to remain intact than is the everted anastomosis.

The fifth principle is not to tie the sutures so tightly that the tissue is strangulated. Obviously, the sutures must bring the serosa of the two segments firmly together. Nonabsorbable sutures used for the anastomosis result in a stronger anastomotic line in the early healing phase compared with absorbable sutures, but the difference is minimal and probably not particularly significant.

The final principle involves realignment of the mesentery of the two segments of bowel to be joined. These should be parallel to each other; the surgeon should ensure that there is no twist on completion of the anastomosis. Closing the bowel mesentery is classically recommended, though it remains a matter of debate. In bariatric surgery, where this has been most thoroughly studied, some authors suggest a decrease internal hernia rate after mesenteric closure (Steele et al., 2008), and others report an extremely low internal hernia rate without closure of any mesenteric defects (Cho et al., 2006). There is little direct evidence from urinary diversion patients.

Factors that significantly contribute to anastomotic breakdown include poor blood supply, local sepsis induced by fecal spillage, drains placed on an intra-abdominal anastomosis, and anastomosis performed in irradiated bowel. Poor blood supply and local sepsis cause ischemia. Drains placed on the anastomosis increase the likelihood of an anastomotic leak, and an anastomosis performed in irradiated bowel is more likely to result in an anastomotic failure than one performed in nonirradiated tissue. The importance of careful technique and adherence to these principles is emphasized by the fact that in one series of urinary intestinal diversion, **75% of the lethal complications that occurred in the postoperative period were related to the bowel. Eighty percent of these patients had received radiation before the intestinal surgery** (Månsson et al., 1979)**. Prior radiation significantly increases the likelihood of serious complications after radical cystectomy** (Eswara et al., 2012).

Types of Anastomoses

Intestinal anastomoses may be performed with use of sutures or staples. Properly performed, both have similar complication rates (Catena et al., 2004). In selected circumstances, however, one method may have advantages over the other. **Because there is a high rate of stone formation on surgical staples** (Woodhouse and Robertson, 2004)**, absorbable suture should be used for intestinal segments that are exposed to urine,** for example, suturing intestine to renal pelvis or bladder, closing the proximal end of a conduit (Costello and Johnson, 1984), and forming an intestinal pouch for urine. With the advent of minimally invasive cystectomy, stapled neobladders have become an alternative to hand-sewn pouches. One study has reported a stone formation rate comparable to that reported in the literature for completely hand-sewn ileal reservoirs at a mean follow up of 41 months (Ferriero et al., 2015). The long-term durability of these findings is still to be determined.

Enteroenterostomy by a Two-Layer Suture Anastomosis

A 3-0 silk holding suture is placed on the mesenteric border just beneath the Allen clamps traversing both segments to be anastomosed, and a second suture is placed on the antimesenteric border similarly just beneath the Allen clamps (Fig. 139.3). It is important that the mesentery be cleared sufficiently so that these sutures can be placed in the serosa under direct vision. A row of silk sutures is placed 2 mm apart between the two holding sutures. This is accomplished by rotating the two Allen clamps away from each other, thus apposing the serosal surfaces. Sutures must traverse the muscularis but should not traverse the full thickness of the bowel. After all sutures have been placed, each is tied and the tails of all sutures are cut, except those at each end; these are used as holding sutures. The Allen clamps are removed, and hemostasis is achieved, if necessary, with the light application of electrocautery. A 3-0 double-ended chromic intestinal suture is placed in the posterior suture line through all layers and tied to itself. Each end of the suture is then run in a locking fashion away from the midpoint until the mesenteric and antimesenteric borders are approached. As the lateral aspects of the bowel are approached, the suture is converted to a Connell suture (Fig. 139.4), which proceeds onto the anterior bowel wall. The sutures meet anteriorly in the midline and are tied together. The anterior serosa is then apposed with interrupted 3-0 silk sutures. The noncrushing occlusive clamps are removed, and the mesentery is closed with interrupted 3-0 silk sutures. Patency of the anastomosis is ensured by palpating the anastomosis with the thumb and forefinger and feeling an annulus of tissue around the fingers.

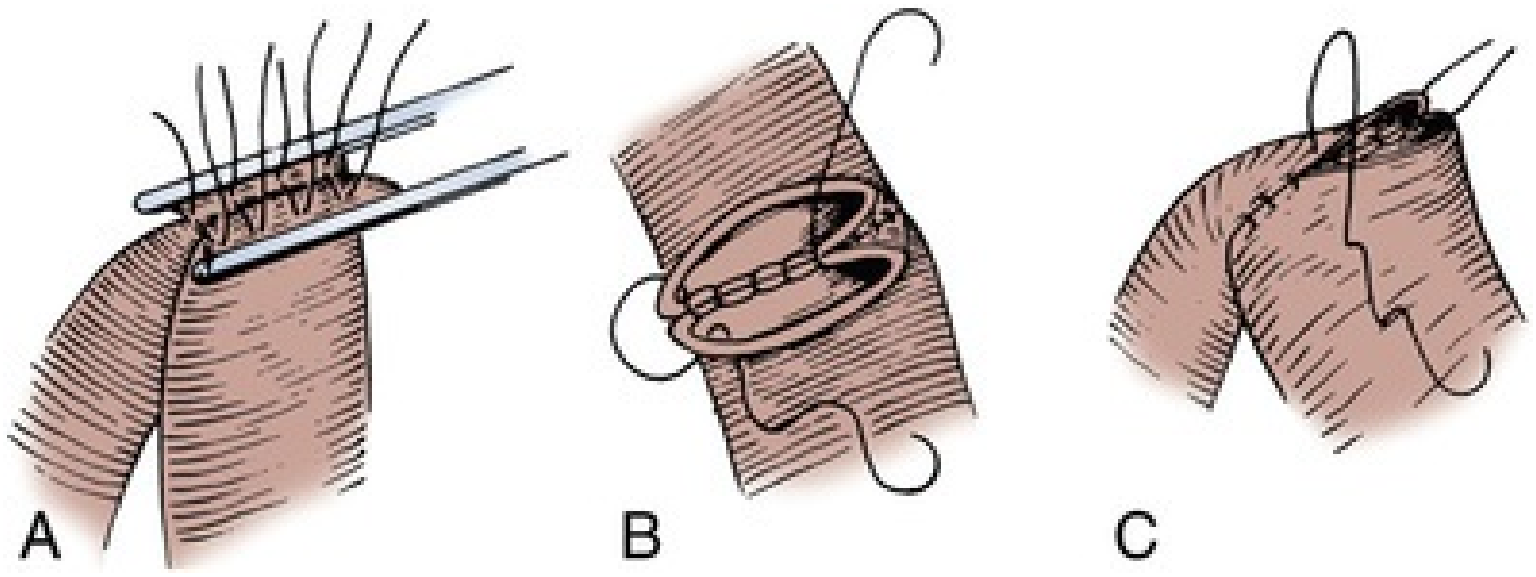

FIG. 139.3 Two-layer suture anastomosis. (A) Two holding sutures of 3-0 silk have been placed at the mesenteric and antimesenteric border, and the posterior wall is approximated with seromuscular sutures of 3-0 silk. (B) A 3-0 intestinal chromic suture is placed through the full thickness of the bowel posteriorly, tied to itself, and run to the lateral borders with a continuous locking suture. At the lateral borders, it is converted to a Connell suture. (C) The Connell suture brings the anterior margins together, inverting the suture line. The anastomosis is completed by placement of horizontal mattress seromuscular sutures of 3-0 silk over the anterior suture line (not depicted).

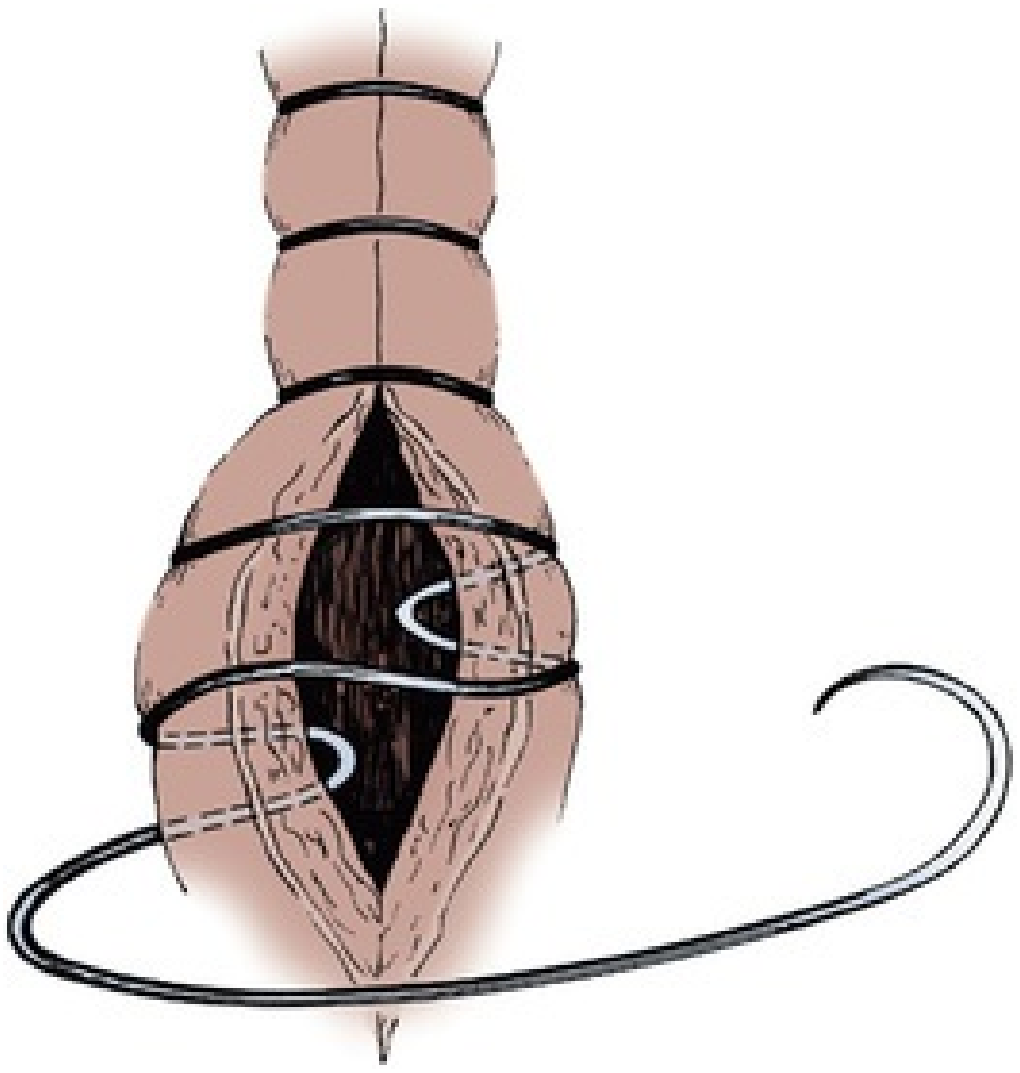

FIG. 139.4 Connell suture. The suture traverses the bowel from serosa to mucosa and then from mucosa to serosa on the same side of the anastomosis. The suture is then placed on the opposite side of the anastomosis “outside in–inside out.” The sequence is repeated until the two segments are approximated.

This anastomotic technique is used when the antrum pylorus is removed and intestinal continuity is restored by a Billroth I procedure. It is also the most secure of all the anastomoses and should be used when one is forced to do an anastomosis under less than ideal circumstances.

Enteroenterostomy by a Single-Layer Suture Anastomosis

The single-layer anastomosis for reapproximating bowel is an excellent technique with a low complication rate, that is, a 0.2% anastomotic leakage rate compared with an 8.4% anastomotic leakage rate for a stapled anastomosis in one large series (Leslie and Steele, 2003).

The mesenteries of the two segments of bowel to be anastomosed are aligned, and a 3-0 silk suture is passed through the seromuscular layers of both segments on the mesenteric side; a second suture is similarly placed on the antimesenteric side. The mesenteric suture is tied, and the antimesenteric suture is left untied. The Allen clamps are removed, and hemostasis is achieved with light electrocautery. The critical point of the anastomosis, where most leaks occur, is at the mesenteric border. Leaking usually occurs because the sutures are placed carelessly or the serosa has not been cleared of mesentery sufficiently that the sutures can be placed through it under direct vision. Because this mesenteric border is the critical area, it is approached first. Two 3-0 silk sutures are placed through the full thickness of the bowel on either side of the mesenteric holding suture. These sutures are placed in such a way as to include more serosa than mucosa, thus causing inversion of the suture line (Fig. 139.5A). Some prefer to use a Gambee stitch at this point, which involves placing the suture through the full thickness of the bowel followed by traversing a small segment of mucosa of each segment of bowel before exiting through the full thickness of the bowel of the other segment (see Fig. 139.5B). The two bowel sutures on the mesenteric border are tied, with care taken to invert the suture line, thus apposing serosa. Then 3-0 silk sutures are placed 2 mm apart, both on the anterior and posterior walls, inverting the suture line, thus apposing the serosa of the two bowel segments to each other. On approaching the antimesenteric holding suture, several sutures are placed before all are tied. A patent anastomosis is confirmed by feeling the annulus with the thumb and forefinger as described earlier.

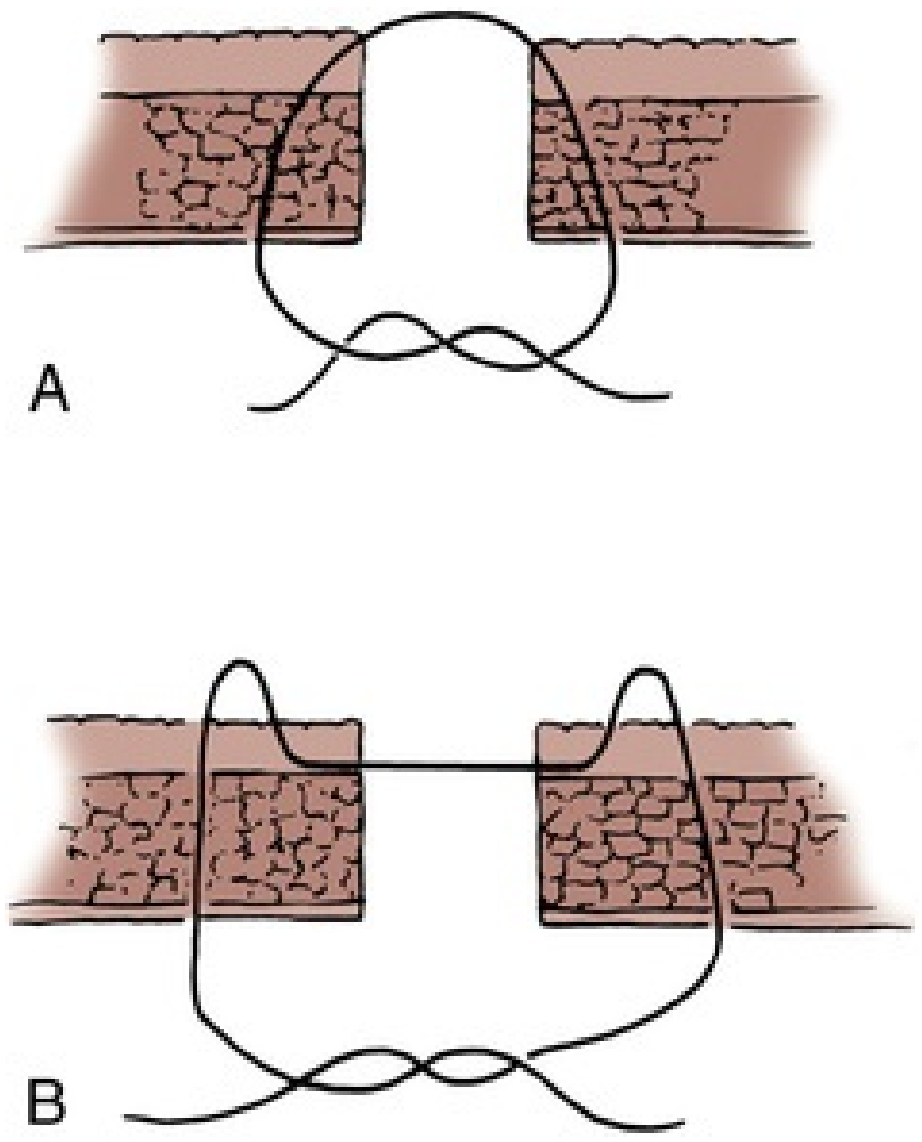

FIG. 139.5 (A) When it is properly placed, the suture through the intestine should include more serosa than mucosa. (B) The Gambee stitch. The suture is placed through the full thickness of the bowel, the mucosa is traversed, and then the mirror image procedure is performed on the segment to be anastomosed.

End-to-Side Ileocolic Sutured Anastomosis

The transected end of the colon is closed in the manner shown in Fig. 139.6. A 3-0 silk suture is placed beneath the Allen clamp on the mesenteric border, and a second suture is placed on the antimesenteric border. These are tied. A 3-0 chromic suture is placed beneath the clamp in a horizontal mattress fashion. Beginning at the mesenteric border, it is tied to itself, and the horizontal mattress suture is placed until the antimesenteric border is reached, at which point the suture is again tied to itself. The clamp is removed, and an over-and-over suture is performed with the same chromic suture through the full thickness of the bowel until returning to the point of origin (i.e., the mesenteric border is approached). At this point, the suture is again tied to itself. The suture line is buried by approximating the serosa on each side with interrupted 3-0 silk sutures placed 2 mm apart. Our preference is to close the end of the colon similarly to the way one closes the proximal end of a conduit. After a 3-0 silk suture is placed through the serosa on the antimesenteric and mesenteric sides, the clamp is removed and a 3-0 chromic suture is placed through all layers at the mesenteric and antimesenteric end. A Connell suture is used—the two chromic sutures meet in the middle and are tied together. Seromuscular sutures of 3-0 silk are placed to appose the serosal margins.

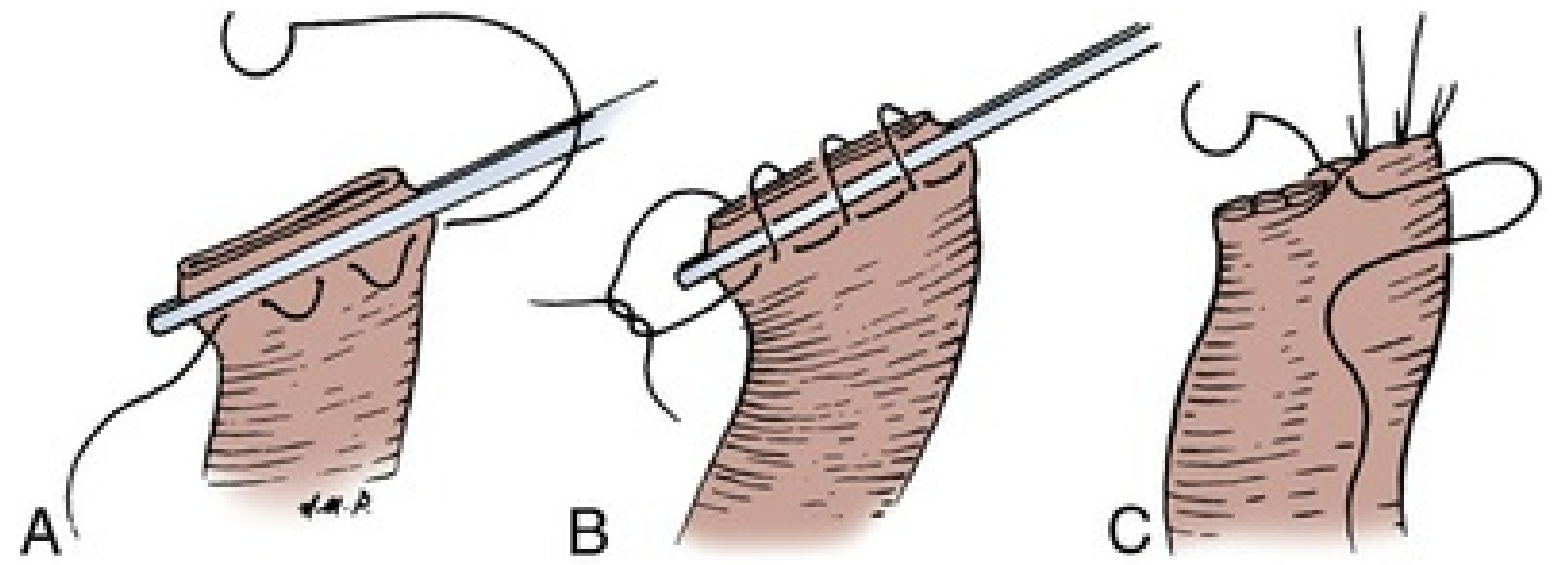

FIG. 139.6 Closure of the proximal end of the intestine. (A) A 3-0 chromic suture is tied to itself at the antimesenteric border and placed beyond the intestinal clamp in a horizontal mattress fashion until the mesenteric border is reached. The suture is then tied to itself at this point. (B) The intestinal clamp is removed, and an over-and-over suture through the full thickness of the bowel returns the chromic suture to its point of origin, where it is again tied to itself. (C) Interrupted horizontal mattress seromuscular sutures of 3-0 silk invert the chromic suture line.

The mesenteries are aligned, and the ileal serosa is sutured with interrupted 3-0 silk sutures to the colonic serosa 2 mm below a taenia (Fig. 139.7). The taenia is incised the length of the diameter of the ileum adjacent to it. As described earlier for the two-layer anastomosis, a 3-0 double-ended intestinal chromic suture is placed through all layers of the colon and ileum in the midpoint of the posterior wall and run in a locking fashion laterally to either side of the incision in the taenia. At the most lateral border, the suture is converted to a Connell suture, and the anterior wall is closed. Seromuscular sutures of 3-0 silk placed from ileum to colon bury the anterior suture line. The mesentery is then reapproximated.

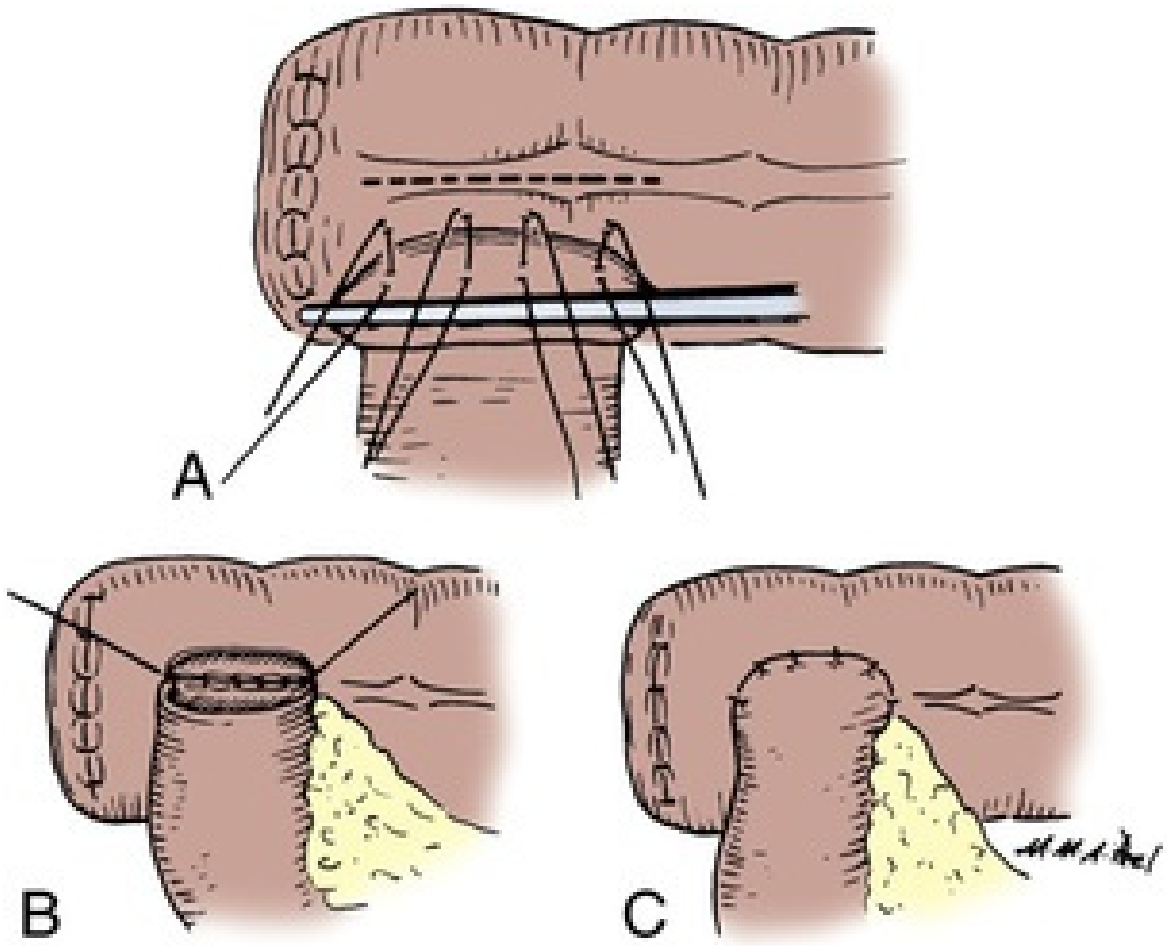

FIG. 139.7 End-to-side anastomosis. (A) The serosa of the ileum is sutured to the serosa of the colon 2 to 3 mm below a taenia. (B) The taenia

is opened for a distance sufficient to accommodate the diameter of the ileum. A 3-0 chromic suture is placed through all layers on the posterior wall, tied to itself, run in a locking fashion to both borders, and converted to a Connell suture laterally, thus completing the inversion anteriorly. (C) The anterior margin of serosa is reapproximated with interrupted horizontal mattress sutures of 3-0 silk.

Ileocolonic End-to-End Sutured Anastomosis With Discrepant Bowel Sizes

A 3-0 silk suture is placed on the mesenteric border of the ileum and colon (Fig. 139.8). A second 3-0 silk suture is placed on the antimesenteric border of the colon immediately beneath the Allen clamp. The other end of the suture is placed on the antimesenteric border of the ileum at a distance proximal to the Allen clamp so that the serosal lengths between the two sutures of both ileal and colon segment are equal. Thus an equal amount of ileal serosa is applied to the length of colonic serosa bordering the severed end of bowel. In the seromuscular layers of ileum and colon, 3-0 silk sutures are placed 2 mm apart, thus apposing the serosa of the ileum to the colon. The Allen clamps are removed. Hemostasis is achieved, and the antimesenteric border of the ileum is incised to the level of the most proximal suture in the ileum. Thus the bowel lumens are now of identical size. With a 3-0 chromic double-ended intestinal suture, the posterior row is run in a locking fashion, laterally converting to a Connell suture, and the anterior row is completed. Seromuscular sutures of 3-0 silk bury the anterior suture line.

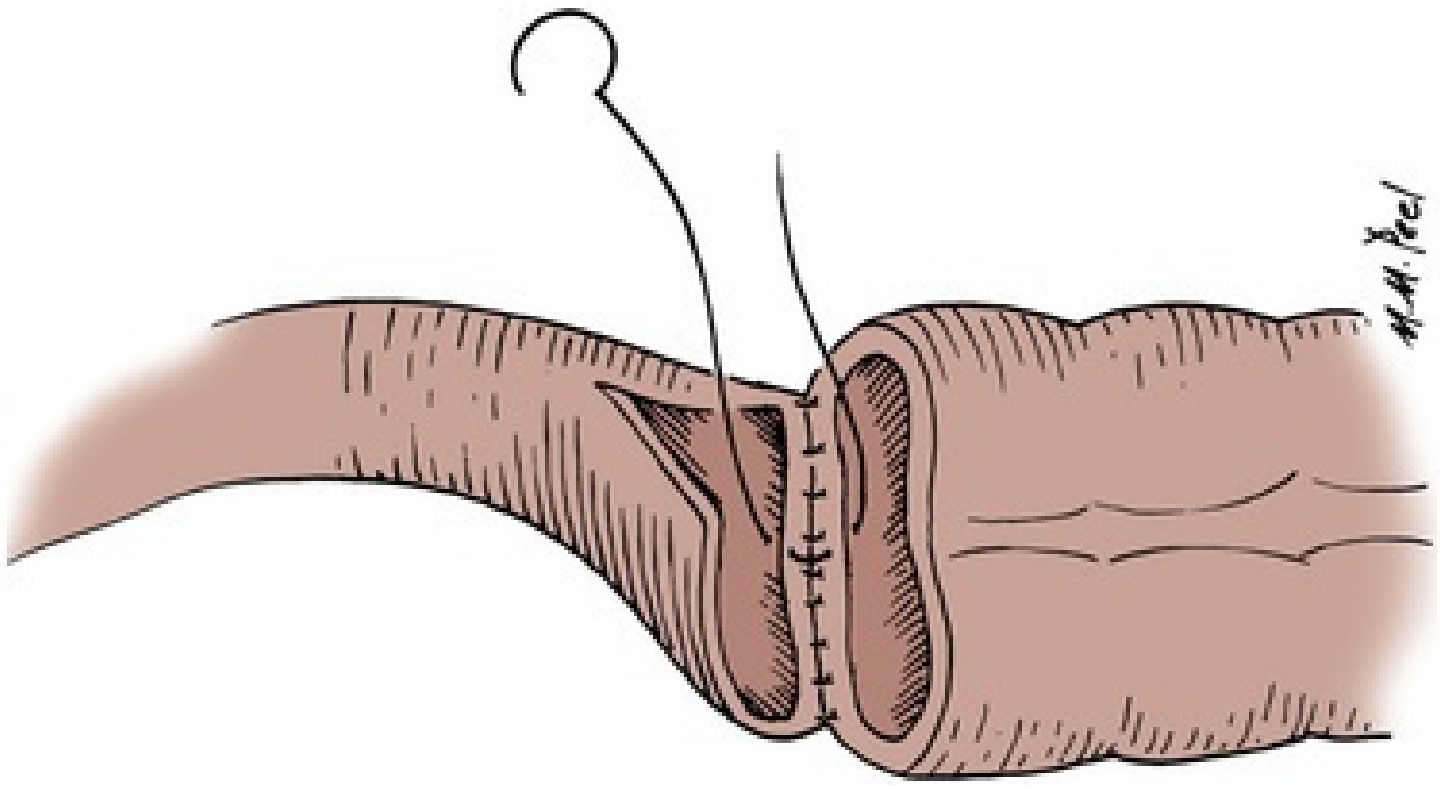

FIG. 139.8 Anastomosis of discrepant-sized bowel. A seromuscular suture of 3-0 silk is placed adjacent to each end of the lumen on the mesenteric side. A second 3-0 silk seromuscular suture is placed adjacent to the lumen on the colon and on the antimesenteric border proximal to the

cut end of the small bowel at a distance sufficient that when the antimesenteric border is incised, the lumens are the same size. Interrupted seromuscular sutures of 3-0 silk are then placed at 2-mm intervals between the two holding sutures. The small bowel is opened on its antimesenteric border until the opening in the small bowel is the same size as the opening in the colon. A 3-0 chromic suture is placed through all layers, tied to itself, and run laterally in a running locking fashion. At the borders, it is converted to a Connell suture, thus inverting the anterior margin. The anastomosis is completed with interrupted horizontal mattress 3-0 silk sutures that bring the seromuscular layers together anteriorly. This is similar to the closure depicted in Fig. 139.3.

Stapled Anastomoses

The theoretical benefits of a stapled anastomosis are that it provides for a better blood supply to the healing margin, there is reduced tissue manipulation, there is minimal edema with uniformity of suture placement, a wider lumen is constructed, there is greater ease and less time involved in performing the anastomosis, and the length of postoperative paralytic ileus is reduced. When they are placed in intestine through which urine traverses, however, stapled anastomoses using nonabsorbable staples frequently cause stone formation and should be avoided (Costello and Johnson, 1984; Woodhouse and Robertson, 2004).

The TA (transverse anastomosis) stapled anastomosis everts the suture line. Because staples close in a B configuration and do not crush the tissue, theoretically they prevent ischemia at the suture line. This may be obvious when a staple line is used to transect the bowel and bleeding continues to occur. The bleeding points may be lightly electrocoagulated or tied off with fine absorbable suture. Stapled bowel anastomoses have been shown to be as efficacious as hand-sewn anastomoses because both have similar complication rates. **They usually require less time to perform when the techniques are properly learned, but for prolonged procedures they save little if any time when the length of time for the whole procedure is taken into account.** In a large prospective, randomized trial in which a two-layer closure was compared with staple closure, it was found that the complication rate was the same, but the time required to complete the stapled anastomosis was 10 minutes less than that for the hand-sewn anastomosis; when the total operative time was compared between the two, it was the same (Didolkar et al., 1986). **A comparison of complications between sutured and stapled anastomoses reveals a leak and**

fistula rate of 2.8% for stapled and 3% for sutured anastomoses (Chassin et al., 1978). The clinically significant leak rate, however, is only 0.9% (Fazio et al., 1985). A 4.5% incidence of stapled anastomotic leakage has been reported during ileal conduit construction (Costello and Johnson, 1984).

Thus the use of staples or sutured anastomosis is at the discretion of the surgeon (MacRae and McLeod, 1998). A stapled anastomosis appears to be superior to a hand-sewn anastomosis in an esophageal-intestinal anastomosis and a low rectal anastomosis. In these two areas, the circular stapler allows a more precise anastomosis than is often possible with hand-sewing techniques. Because these are not problems of urologic surgery, staples are used if that is the preference of the surgeon. The one area in urology in which we believe the stapling device is superior is in the ileocolonic end-to-side anastomosis. With use of the circular stapling device, a widely patent anastomosis can be achieved expeditiously.

Three staple instruments are commonly used in intestinal reconstruction: the linear stapler, the anastomotic stapler, and the circular stapler. The linear stapler places a double or triple row of staggered staples in a straight line. Depending on the cartridge and instrument chosen, various lengths of staple lines and heights of the closed staples may be chosen. The length is selected according to how long one wants the staple line to be. **The height of staple is selected according to the tissue to be stapled.** Vascular and pulmonary tissues require staples with a closed height of 1 mm (open height of 2.0 to 2.5 mm). Most intestinal anastomoses are performed with medium staples, which have a closed height of approximately 1.5 mm (open height of 3.5 mm). On occasion, for thick tissues, large staples are required that have a closed height of 2 mm (open height of 4.8 mm). If there is any doubt in selecting the staple size, the tissue thickness may be measured with a special instrument used for this purpose. In general, **tissues less than 1 mm or more than 3 mm in thickness are not amenable to the use of staples.** Staplers with a variety of staple heights within the same cartridge have recently grown in popularity and should provide more safety in situations with varying tissue thicknesses.

The anastomotic stapler places two linear double rows of staggered staples. When the knife is advanced, the staple line is divided. The height of the staples is also chosen according to the tissue to be transected.

The circular stapler places two concentric, staggered circular staple rows and cuts the tissue within the circle completely from the surrounding tissue. It may be selected in various diameters and with various heights of staples. The diameter and height are selected according to the tissue to be anastomosed. The diameter to be selected is determined by sizing the diameter of the tissue to be stapled. Special sizers are available for this maneuver. In most intestinal anastomoses in urology, the height of the closed staple is 1.5 to 2 mm. The following is a description of various types of stapled anastomoses.

Ileocolonic Anastomosis with the Circular Stapling Device

The mesenteric borders are cleared for a distance of 1.5 cm from the cut end of both the colon and the ileum (Fig. 139.9). Holding sutures of 3-0 silk are placed on the mesenteric and antimesenteric border of the colon. Two other holding sutures are placed on the medial and lateral walls of the colon, midway between the mesenteric and antimesenteric sutures. A purse-string suture of 2-0 polypropylene (Prolene) is placed around the ileum no more than 2 mm from the cut end. It is important to take small bites of mucosa to avoid bunching of tissue. Sutures must be placed evenly to avoid a gap. A purse-string instrument can be used for this step, if preferred. The ileal diameter is determined with sizers so that the correct circular stapler diameter instrument may be chosen—usually 25 mm. A purse-string suture is also placed in a circle, 1 cm in diameter, through which a taenia traverses on the medial aspect of the colon. A stab wound is made in the center of the colonic purse-string suture. The distal anvil of the circular stapler is removed, and the instrument is placed through the open end of the colon with its post passed out the stab wound made in the center of the purse-string on the medial wall of the colon. The purse-string is tied tight. The top anvil is then secured to the post, and the ileum is placed over it. The ileal purse-string is tied.

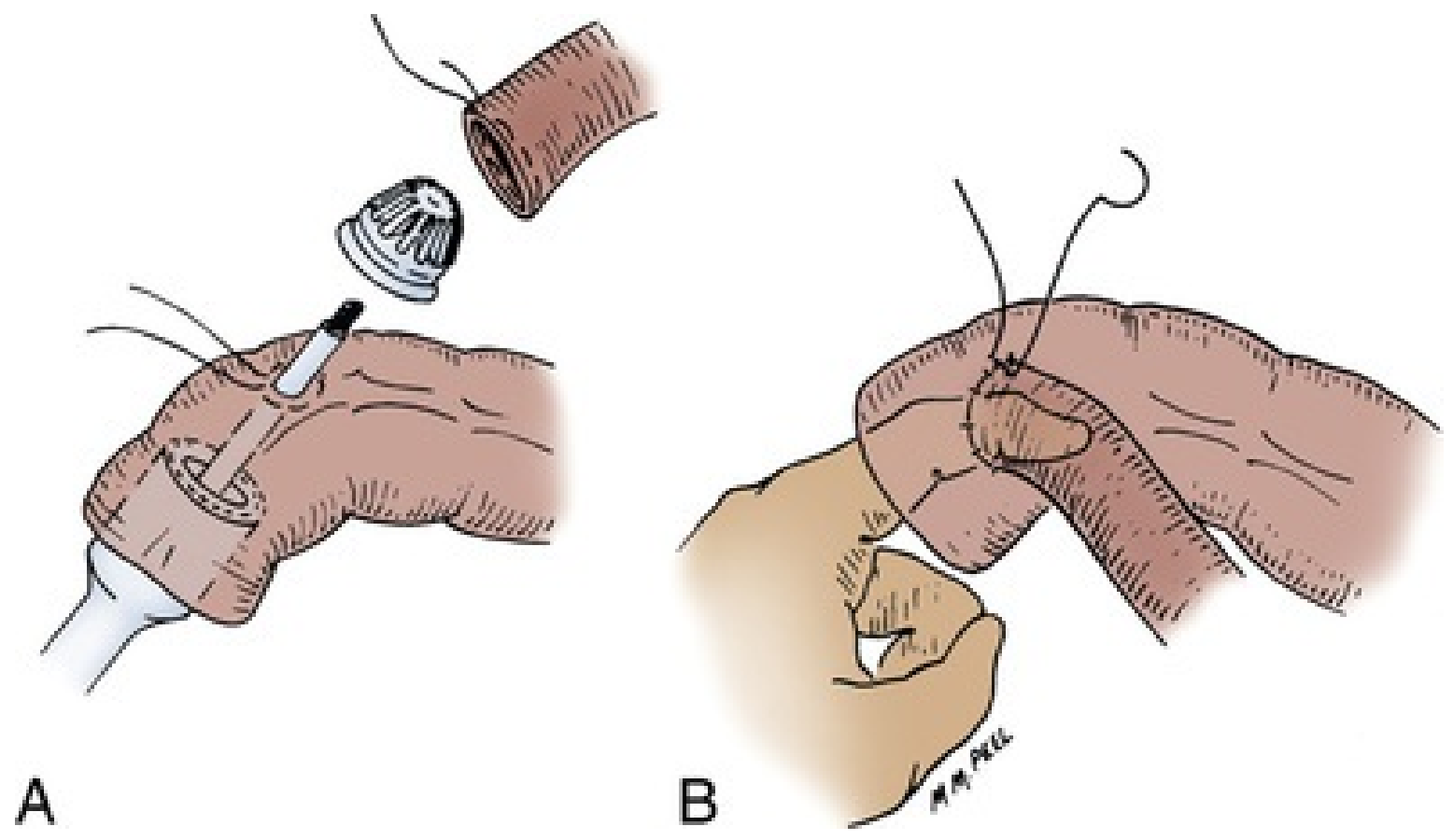

FIG. 139.9 Stapled circular anastomosis. (A) A purse-string suture of 2-0 polypropylene (Prolene) is placed around the circumference of the small bowel, and a second purse-string suture 1 cm in diameter is placed on a medial taenia 5 to 6 cm from the open end of the colon. The anvil is removed. A stab wound is made in the center of the purse-string suture in the colon, and the circular stapler is introduced through the end of the colon, with its post thrust through the stab wound. (B) The anvil is placed on the post and introduced into the end of the small bowel, the purse-string sutures in the small bowel and colon are tied snugly around the post, and the circular stapler is approximated with a gap of 1.5 to 2 mm, with care taken not to include any mesentery in the gap. The anastomosis is completed by placement of interrupted silk sutures around the circumference of the anastomosis.

Care must be taken to align the mesenteries at this point. The instrument is approximated with a staple gap of 1.5 to 2 mm. Care must be taken not to catch fat or mesentery in the gap. The instrument is fired and removed by rotatory movement from the colon. Two doughnuts of tissue should be identified on the instrument, and they should have their complete circumference intact with no gaps. With a finger in the open end of the colon and through the anastomosis, seromuscular sutures of 3-0 silk are placed 3 to 4 mm apart around the circumference of the anastomotic line.

The transected end of the colon may be closed by the suture technique or by the use of staples. If the end is to be closed with sutures, one 3-0 chromic suture is brought out the mesenteric border and another out the antimesenteric border, and both are tied to themselves with the knots on the inside of the bowel. The two sutures are run toward each other with a Connell stitch until they meet, and then they are tied to each other. The suture line is inverted by placement of a second row of 3-0 silk seromuscular sutures. If staples are preferred, the holding sutures are held up and a linear stapler is applied across the open end. Excess tissue is trimmed and the stapler removed. By holding the holding sutures up, one is secure in applying the staple line to the serosa and mucosa circumferentially around the bowel. Some invert the staple line with seromuscular sutures of 3-0 silk. This is not necessary, however. The mesentery between the two segments is now approximated with interrupted 3-0 silk sutures.

Side-to-Side Stapled Anastomosis: Ileal-Ileal or Ileocolonic Anastomosis

The antimesenteric border of the two bowel segments to be joined is approximated with a 3-0 silk suture 5 to 6 cm from the cut ends of the bowel

(Fig. 139.10). A holding suture is placed through both segments of bowel at their cut ends at the midpoint of the antimesenteric borders. Stay sutures are placed at the mesenteric border of each bowel segment, and two other sutures midway between the mesenteric and antimesenteric border on the lateral aspects of the bowel are also placed. The anastomotic stapler is positioned in the lumens of both segments of bowel along the antimesenteric border. The antimesenteric holding suture is pulled up adjacent to the stapler. The anastomotic stapler is locked in place, the staples are fired, and the knife is advanced. The staple lines are inspected for bleeders, which if persistent should be suture-ligated with an absorbable suture. It is important for several 3-0 silk sutures to be placed at the apex of the stapled and cut antimesenteric incision. At this point, slight tension on the anastomotic line can place undue stress on the staple margin and cause a leak. The holding sutures are held up, and a linear stapler is placed across the open end of bowel and fired. Care must be taken so that the staples include the serosa in its entire circumference. Excess bowel tissue is excised flush with the instrument before it is disengaged. The mesentery is then reapproximated. **Because of its simplicity and reliability, this is the most common type of anastomosis used in urology.**

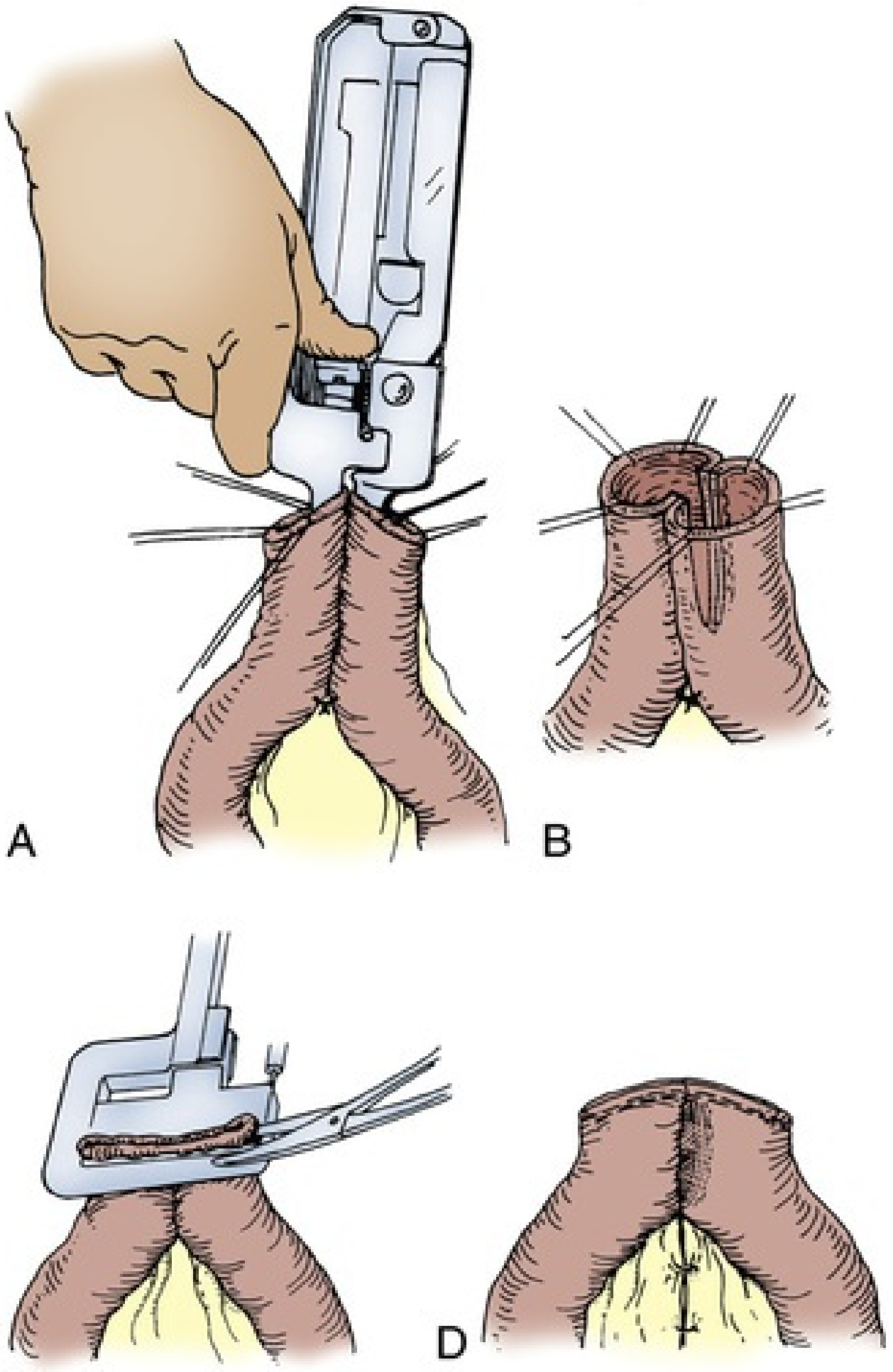

FIG. 139.10 Stapled side-to-side anastomosis. (A) A 3-0 silk suture is placed 5 to 6 cm from the cut ends of the intestine on the antimesenteric borders of both intestinal segments and tied. Holding sutures are placed around the circumference of both intestinal lumens, one suture securing together the antimesenteric borders of both intestinal segments. The linear anastomotic stapler is placed into the lumens, secured and locked in place, and fired. The knife is advanced. (B) The appearance of the intestinal anastomosis after firing of the stapler. (C) The open end of the two intestinal segments is closed with a linear stapler by elevation of the holding sutures while the linear stapler is applied so that the circumferences of the mucosa and serosa are incorporated in the staple margin. (D) The anastomosis is completed by closure of the mesentery with interrupted 3-0 silk sutures.

Laparoscopic and Robotic Anastomoses

Laparoscopic and robotic approaches to cystectomy with urinary diversion and to augmentation cystoplasty are becoming more commonly accepted (Goh et al., 2012; Guillotreau et al., 2009). In these procedures of urinary diversion, a purely laparoscopic or robotic technique is possible for bowel resection with the use of endoscopic stapling devices. Proper placement of the trocars is dependent on the need to mobilize the bowel and the procedure for which the bowel is to be used. Trocar placement for mobilization of the distal ileum is illustrated in Fig. 139.11. The technique primarily involves the use of endoscopic linear cutting and stapling devices, which can be used to divide small bowel and its mesentery (Figs. 139.12 and 139.13). Reanastomosis purely intracorporeally can be accomplished with the same endo-GIA stapler to reconstitute bowel continuity with a side-to-side anastomosis (Gill et al., 2000; Potter et al., 2000). An endoscopic TA stapler may be used to complete the bowel closure.

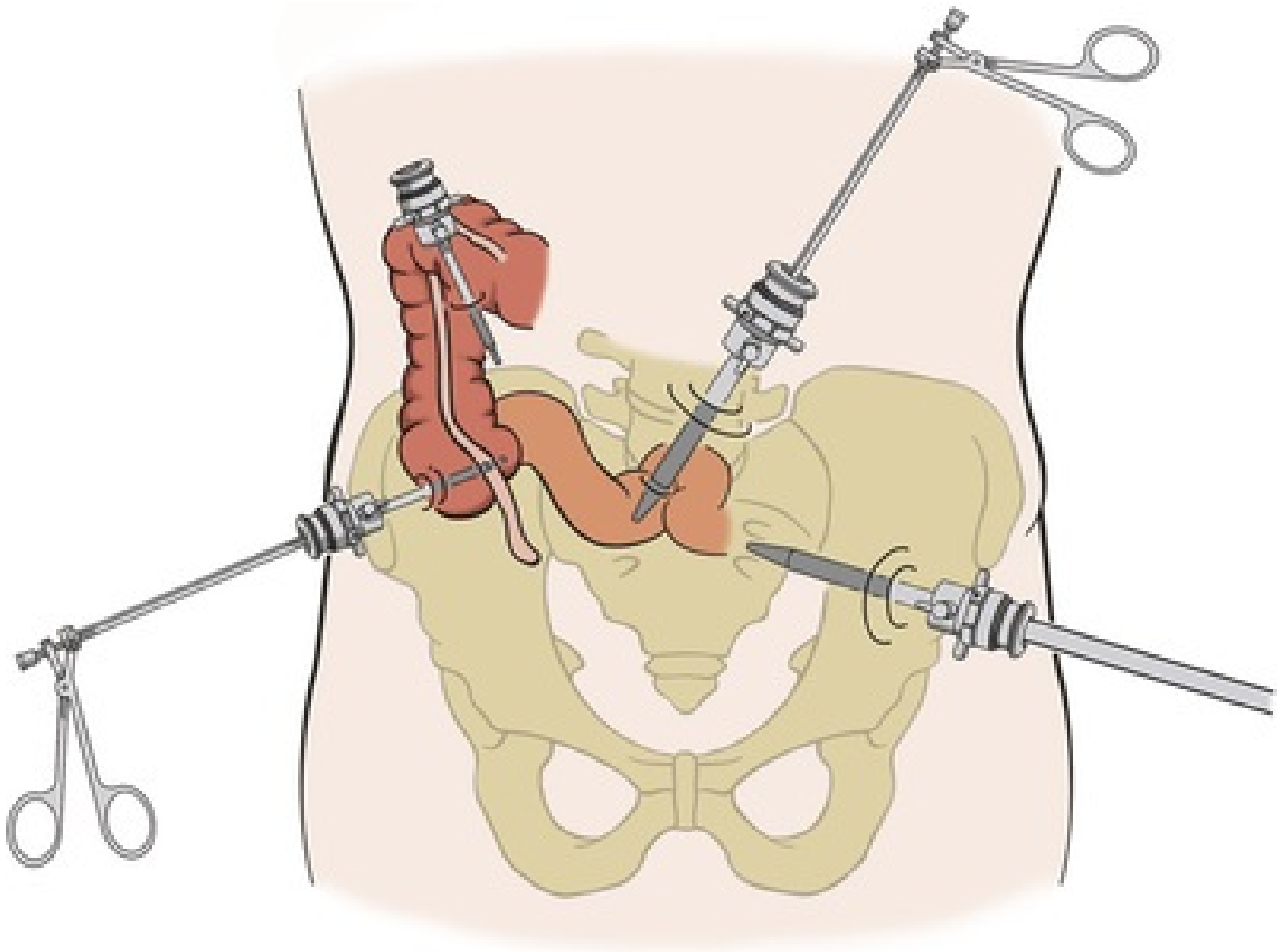

FIG. 139.11 Trocar placement for laparoscopic mobilization of the distal ileum.

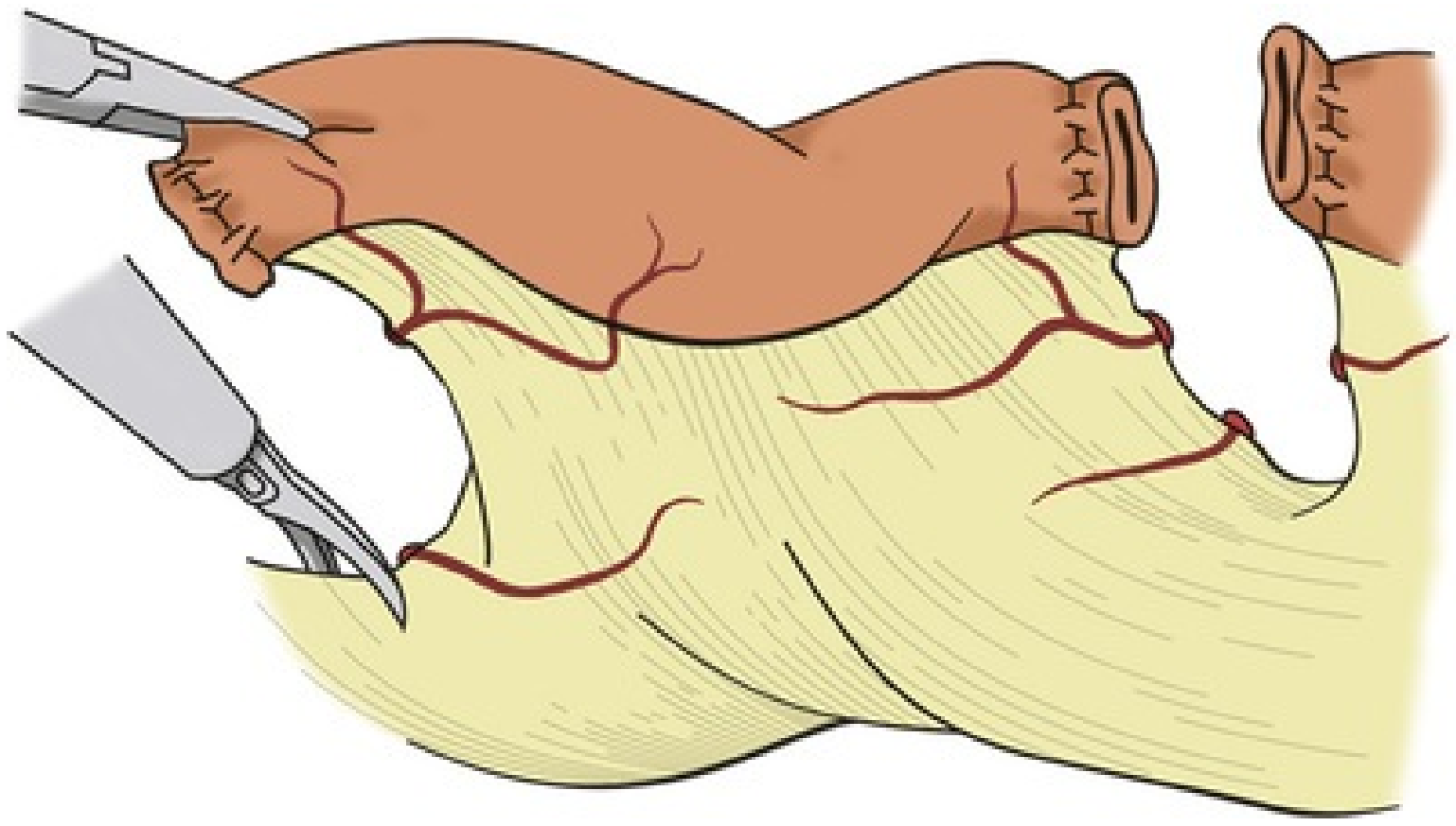

FIG. 139.12 Laparoscopic mobilization of a small bowel segment for use in reconstruction. The visceral peritoneum is divided sharply; then the mesenteric vessels are ligated and divided. Staplers, ultrasonic shears, or bipolar cautery devices may be used to divide the mesenteric vessels.

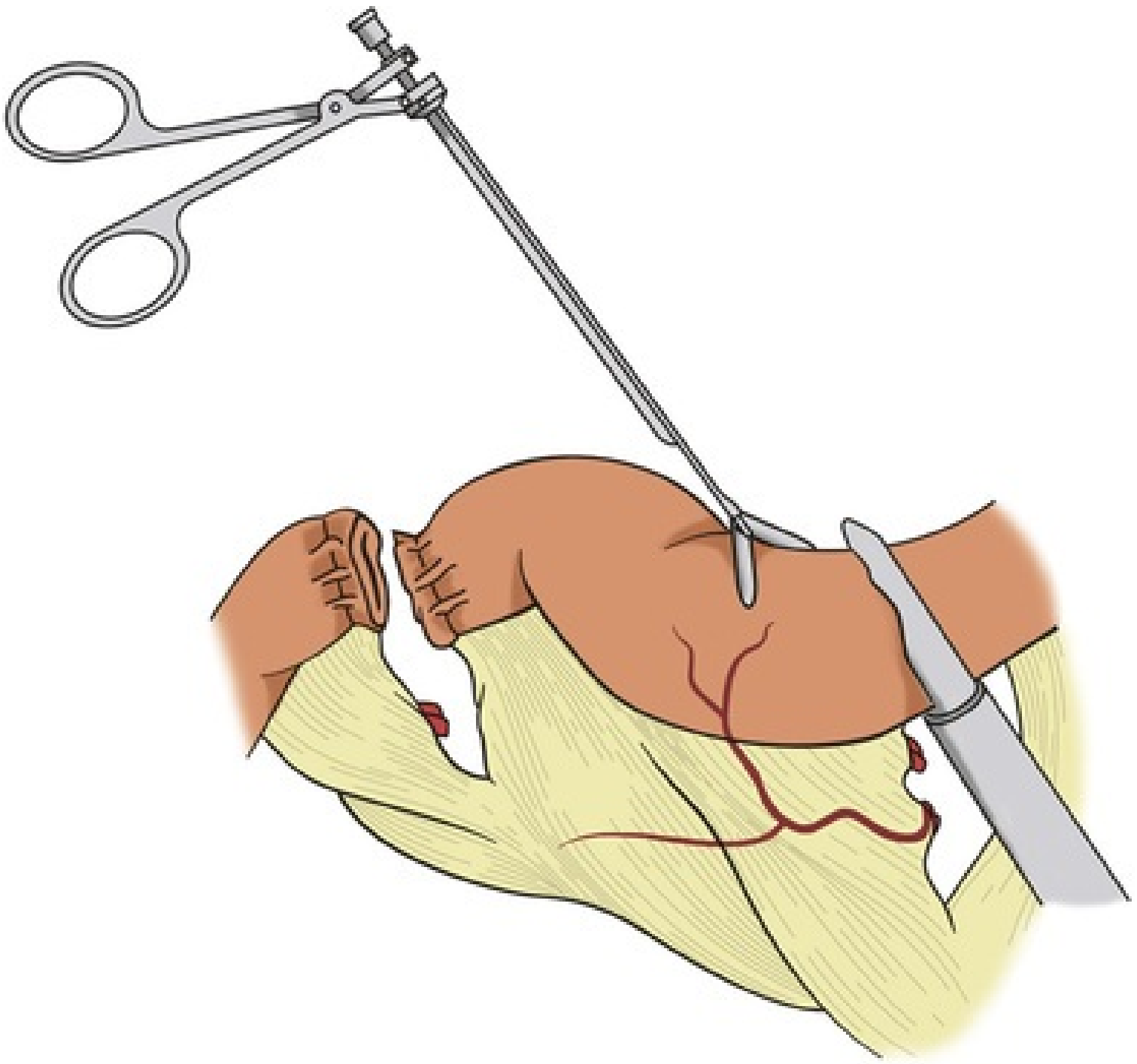

FIG. 139.13 The endoscopic gastrointestinal stapler divides the intestinal segment. The staple line must be excised from the segment intended for use in the urinary reconstruction.

A laparoscopic or robotic ileal conduit can be performed with these techniques as well. In a laparoscopic approach, the ureterointestinal anastomosis is performed with freehand laparoscopic suturing. One of the abdominal trocar sites is used to draw the bowel segment through the abdominal wall for stoma construction.

A completely intracorporeal laparoscopic orthotopic ileal neobladder has been described (Gill et al., 2002). The neobladder is constructed by freehand running suture with use of laparoscopic techniques (Fig. 139.14). The results of laparoscopic bowel anastomoses suggest that these anastomoses are safe (Canin-Endres et al., 1999; Rothenberg, 2002), but no large series that compares open with laparoscopic approaches for bowel anastomosis has been published.

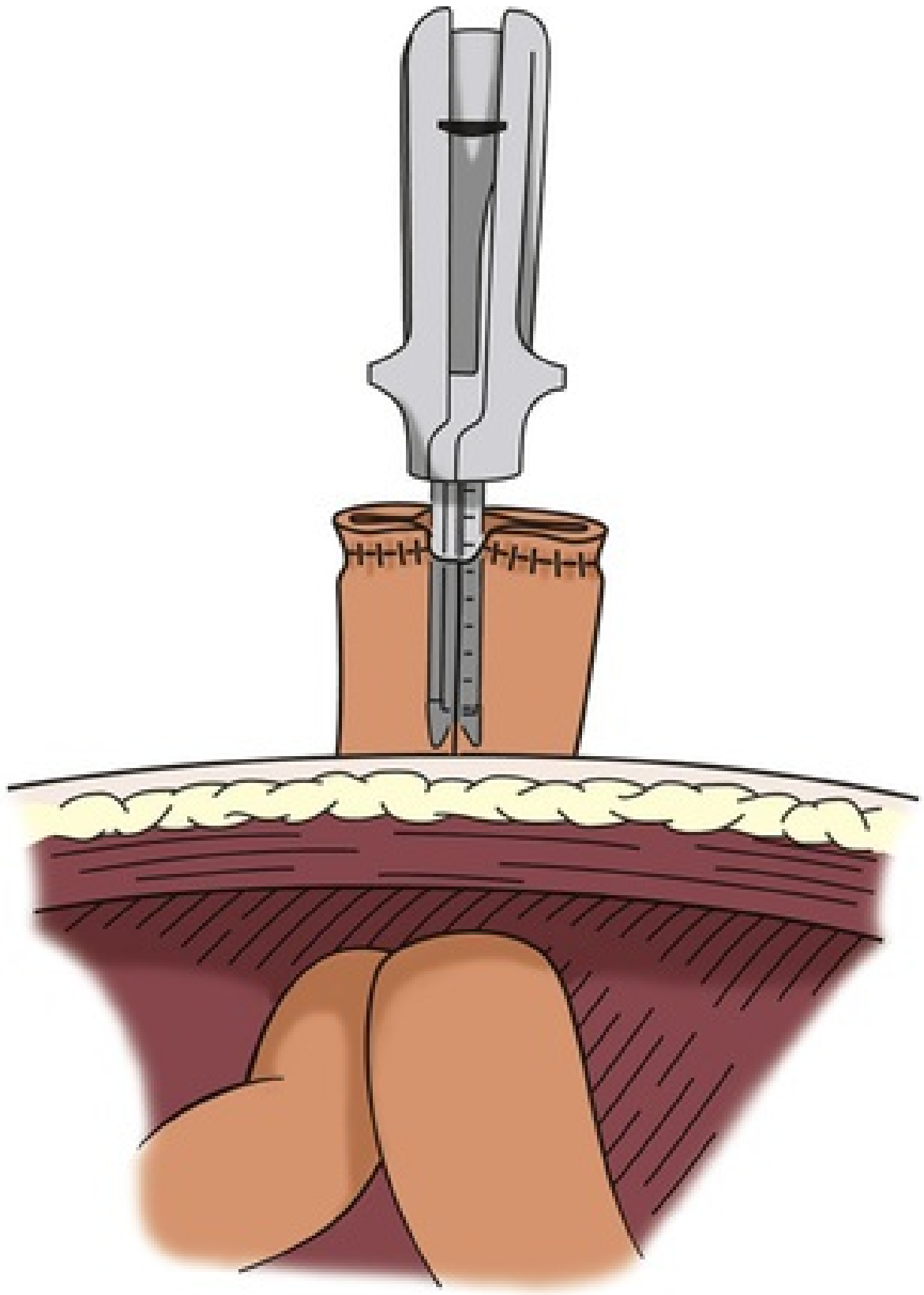

FIG. 139.14 Many urologic procedures in which intestinal segments are used for reconstruction involve extirpative surgery in which a small laparotomy is used for specimen removal. In this case, the small laparotomy is used to deliver the bowel segment outside the abdomen. Any form of anastomosis may be used by this technique, which also reduces the chance of spillage of intestinal contents.

Completely robotic surgical approaches to radical cystectomy with orthotopic neobladder have become increasingly common. A barbed monofilament suture may facilitate suturing of the neobladder (Tyritzis et al., 2012). Approaches using only nonabsorbable staples have also been described (Abreu et al., 2005).

Although intracorporeal neobladder reconstruction is in its infancy, initial perioperative results appear to be comparable to open surgery in well-selected patients (Fahmy et al., 2015).

Other approaches to laparoscopic or robotic intestinal surgery include laparoscopic mobilization of the bowel segment and exteriorization of the segment; the anastomosis of the bowel and ureteral anastomoses are then performed in an open fashion through a small laparotomy incision (Fig. 139.15). This is now the preferred approach for many performing laparoscopic or robotic cystoprostatectomy. **Purely laparoscopic intestinal anastomoses in radical cystectomy are associated with a higher complication rate from intestinal and ureteral anastomotic leaks than an exteriorized approach** (Stephenson and Gill, 2008). In radical cystectomy, a small incision is already required for intact specimen removal. An open approach therefore allows direct tactile assessment of the anastomoses.

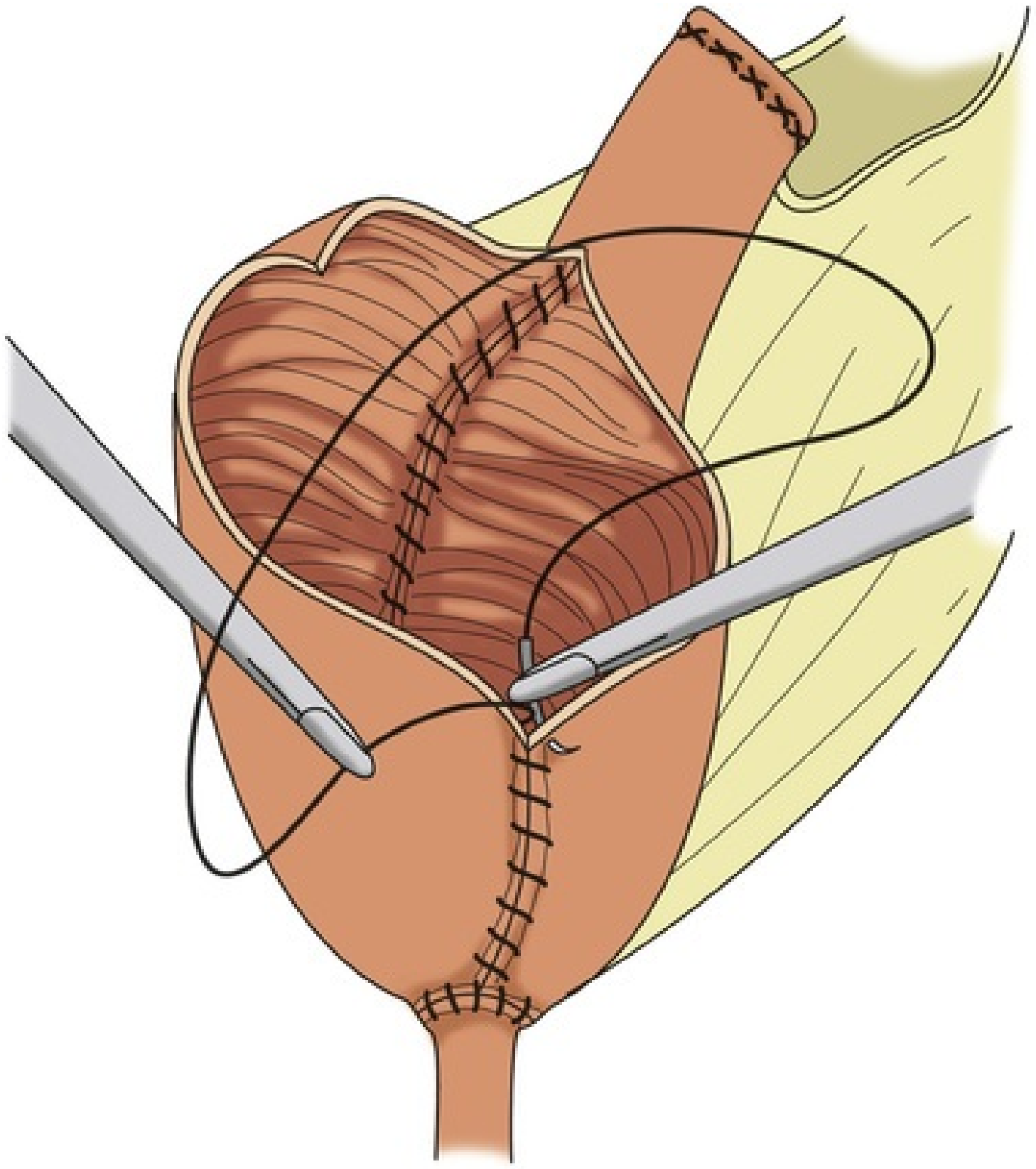

FIG. 139.15 Completely intracorporeal laparoscopic construction of a small intestinal neobladder; 2-0 polyglycolic acid suture is used in a running closure of the pouch.

Compression Anastomoses and the Biofragmentable Ring

There is a long history of experimental work on compression anastomoses. These technologies may facilitate natural orifice and minimally invasive surgery. With the most clinical evidence, the biofragmentable ring has proven safe, effective, and time-efficient. Several studies have shown that these intestinal anastomoses are as safe as hand-sewn or stapled anastomoses (Ghitulescu et al., 2003). Other compression devices have been devised but have not gained in popularity (Kaidar-Person et al., 2008).

Complications of Intestinal Anastomoses

The complications that follow anastomoses include leakage of fecal contents, sepsis, wound infections, abdominal abscesses, hemorrhage, anastomotic stenosis, pseudo-obstruction of the colon (Ogilvie syndrome), and intestinal obstruction. These untoward events increase morbidity and are frequently major contributors to mortality (Hautmann et al., 2010). The complication rates for elective colocolonic and ileocolonic anastomoses performed in prepared bowel with contemporary technique are intestinal leak, 2%; hemorrhage, 1%; and stenosis or obstruction, 4%. These complications require reoperations in 1% of patients and result in death in 0.2% of patients (Jex et al., 1987). The mean time to diagnose an anastomotic leak is 12 days postoperatively; some have occurred even after 30 days (Hyman et al., 2007). Many of the complications of radical cystectomy are attributable to the use of intestinal segments for urinary diversion (Takada et al., 2012).

Fistulas

Fistulas in the postoperative period are of two types: fecal and urinary. **These generally occur within the first several weeks after the operative event.** They frequently result in sepsis and markedly increase morbidity and mortality. Fecal fistulas occur in 4% to 5% of patients (Beckley et al., 1982; Sullivan et al., 1980). **Sepsis is a common complication of these untoward events and carries with it a mortality of 2%** (1 of 47 patients) (Hill and Ransley, 1983). In women undergoing orthotopic neobladder reconstruction after radical cystectomy, the risk for neobladder-vaginal fistula is approximately 11% and usually presents several continuous incontinence episodes several months after surgery (Rapp et al., 2004).

Sepsis and Other Infectious Complications

Wound infections, pelvic abscesses, and wound dehiscences may complicate the immediate postoperative period. Although wound dehiscences and pelvic abscesses are rare complications, wound complications occur with an incidence of 10% (Gilbert et al., 2013). Many of these complications may be averted by walling off the intestine with Mikulicz pads while the anastomosis is being completed; irrigating the intestinal segment to be used in the reconstruction until it is free of any residual enteric contents; being careful to avoid fecal spillage; and washing out the abdominal cavity and incision to dilute any contaminants. The overall septicemia rate after radical cystectomy is currently 3.6%, with a 17% mortality rate (Davies et al., 2009). When assessed for cumulative incidence of infectious complications, nearly 45% of patients after urinary diversion will require treatment (Gilbert et al., 2013).

Bowel Obstruction

The incidence of intestinal obstruction after abdominal procedures for urinary intestinal diversion differs according to whether the stomach, ileum, or colon is used for the diversion. In patients who have had a **segment of stomach or ileum removed for the diversion, there is a 10% incidence of postoperative bowel obstruction requiring treatment.** When the colon is used, the incidence of postoperative obstruction requiring an operation is 5% (Table 139.8). One-half of the bowel obstructions occur in the early postoperative period. In one series, after radical cystectomy and ileal conduit, 15% of the patients had a mild obstruction in the first 6 months that responded to conservative management, whereas 3% required an operation to relieve the obstruction during this period. The occurrence of obstruction after this 6-month period was much less frequent (Sullivan et al., 1980). More recently, a 10.5% incidence of reoperation for bowel obstruction was noted in a large series of radical cystectomy patients (Varkarakis et al., 2007). **Bowel obstruction can be a morbid event; a significant number of patients who develop obstruction after an ileal conduit and require an operation die. The most common cause of the obstruction is adhesions, followed by recurrent cancer.** These two causes account for the great majority of the cases. Volvulus and internal hernia are much more rare, but can occur (Jaffe et al., 1968). Occasionally, severe stenosis or obstruction at the anastomotic suture line can occur. Stenosis is a result of edema, poor technique, or performing the anastomosis on ischemic bowel (Fig. 139.16); obstruction is usually a result of improper technique.

TABLE 139.8

Complications of Urinary Intestinal Diversion[a]

COMPLICATION	TYPE OF DIVERSION	NO. OF PATIENTS (COMPLICATION/TOTAL NO.)	INCIDENCE (%)
Bowel obstruction	Ileal conduit	124/1289	10
	Colon conduit	9/230	4
	Gastric conduit	2/21	10
	Continent diversion	2/250	0.8
Ureteral-intestinal obstruction	Ileal conduit	90/1142	8
	Antireflux colon conduit	25/122	20
	Colon conduit	8/92	9
	Continent diversion	16/461	4
Urine leak	Ileal conduit	23/886	3
	Colon conduit	6/130	5
	Continent diversion		
	Ileum	104/629	17
	Colon	5/123	4
Stomal stenosis, hernia	Ileal conduit	196/806	24
	Colon conduit	45/227	20
	Continent diversion	28/310	9
Renal calculi	Ileal conduit	70/964	7
	Antireflux colon conduit	5/94	5
Pouch calculi	Continent diversion	42/317	13
Acidosis requiring treatment	Ileal conduit	46/296	16
	Antireflux colon conduit	5/94	5
	Gastric conduit	0/21	0

	Continent diversion		
	Ileum	21/263	8
	Colon/colon-ileum	17/63	27
Pyelonephritis	Ileal conduit	132/1142	12
	Antireflux colon conduit	13/96	13
	Continent diversion	15/296	5
Renal deterioration	Ileal conduit	146/808	18
	Antireflux colon conduit	15/103	15

[a] Composite from the literature. Follow-up averages 5 years for ileal conduits, 3 years for colon conduits, 2 years for gastric conduits, and 2 years for continent diversions.

Data is from the following sources, which can be found in this chapter's reference list:

Jaffe et al., 1968; Castro and Ram, 1970; Malek et al., 1971; Smith, 1972; Schmidt et al., 1973; Richie, 1974; Flanigan et al., 1975; Schwarz and Jeffs, 1975; Shapiro et al., 1975; Middleton and Hendren, 1976; Althausen et al., 1978; Elder et al., 1979; Hagen-Cook and Althausen, 1979; Pitts and Muecke, 1979; Sullivan et al., 1980; Beckley et al., 1982; Loening et al., 1982; Adams et al., 1988; Boyd et al., 1989; Madersbacher et al., 2003; Studer et al., 2006; Nieuwenhuijzen et al., 2008.

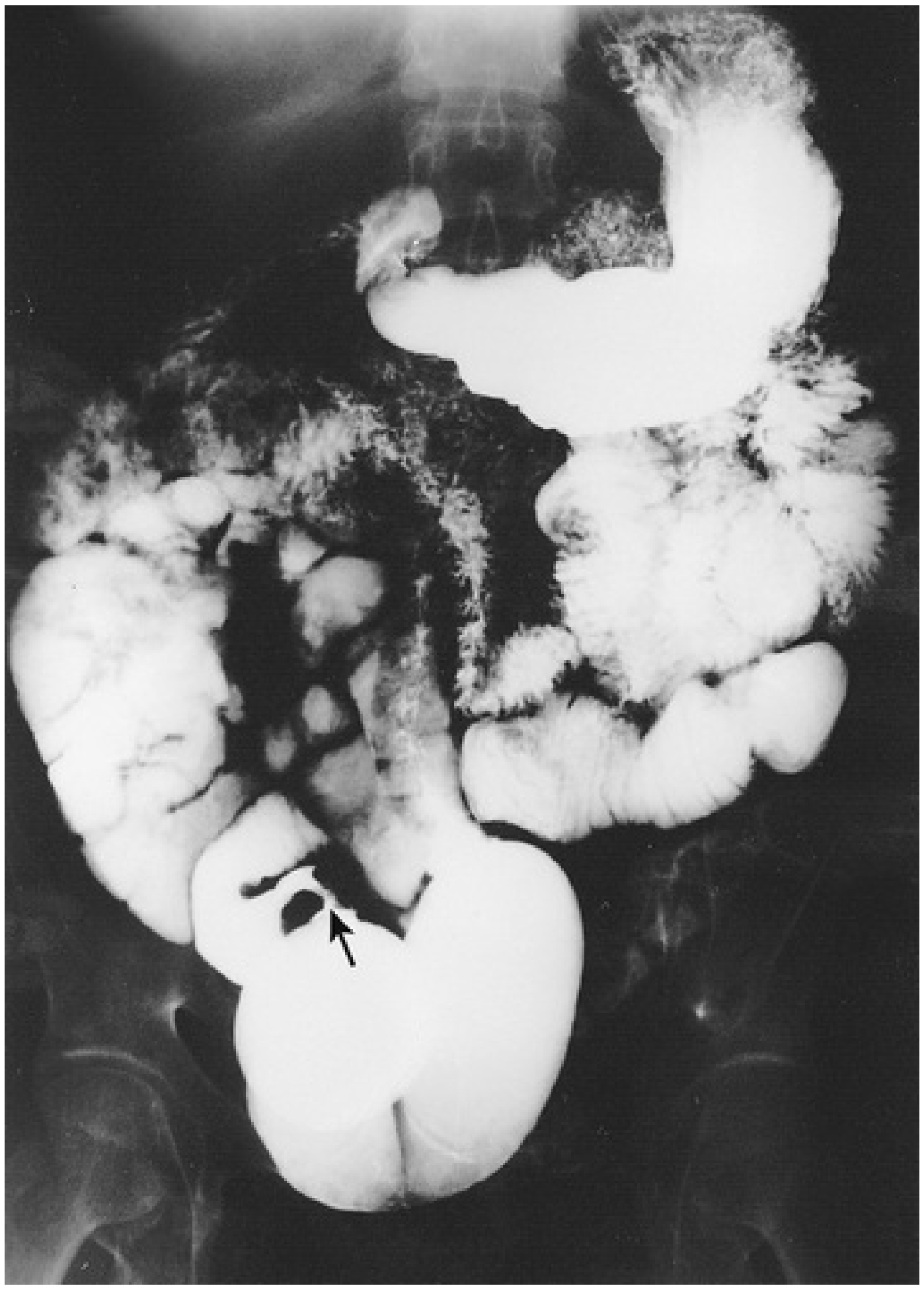

FIG. 139.16 Upper gastrointestinal tract series illustrates a small bowel stricture *(arrow)* at the ileoileostomy after ileal conduit urinary diversion. At the time of the initial ileoileostomy, the anastomotic suture line appeared bluish. At subsequent exploration, a bowel lumen of only 2 mm was found. The serosa at the anastomotic site was fibrotic.

The incidence of postoperative bowel obstruction may be reduced by using nonirradiated bowel, performing the anastomosis on well-vascularized bowel, closing all apertures, reperitonealizing the isolated segment, decompressing the gastrointestinal tract for an adequate time, placing omentum over the anastomosis, and reconstituting the pelvic floor after exenterative surgery. Orthotopic neobladders appear to result in fewer bowel obstructions than ileal conduits or cutaneous reservoirs (Hemelrijck et al., 2013). The isolated segment is reperitonealized by tacking its antimesenteric border to the lateral abdominal sidewall peritoneum. The proximal mesenteric border should be tacked to the posterior parietal peritoneum because failure to obliterate this potential space has resulted in entrapment of bowel, causing bowel obstruction. Placing the sigmoid colon in the area may close the pelvic space left after an anterior exenteration. This effectively prevents small bowel from herniating into the raw pelvis. Omentum may also be mobilized and used to fill any space the sigmoid colon does not fill. In a total exenteration, sufficient sigmoid colon is not available, and the omentum is often not bulky enough to fill the pelvis and thus prevent small bowel from filling the denuded pelvis. This situation is of particular concern in patients who must receive postoperative pelvic irradiation. The bowel may be kept out of the pelvis in these patients by reconstructing the pelvic floor with polyglactin mesh. The mesh is sutured along the posterior pelvic brim to the sacral promontory and presacral fascia and laterally to the adventitia of the iliac vessels. Laterally and anteriorly, it is sewn to the peritoneum two-thirds of the distance between the pubis and umbilicus. The omentum is then brought down, placed over the mesh, and sutured in position. This effectively excludes the bowel from the pelvis for 4 to 6 weeks while postoperative irradiation is being administered (Sener et al., 1989).

Hemorrhage

Hemorrhage is a rare complication of intestinal anastomoses. It is much more likely to occur when stomach is used and a Billroth I anastomosis is constructed. **It is usually caused by failure to secure bleeding at the time of anastomosis or by anastomotic ulcers that develop on the suture line.**

Intestinal Stenosis

Intestinal stenosis occurs at two distinct times: in the immediate postoperative period and during the long term. Intestinal stenosis in the immediate postoperative period is caused by technical mishaps or edema. Edema resolves by continuing the intestinal decompression, whereas technical mishap requires a reoperation. During the long term, it is likely caused by ischemia or perienteric infection. Fig. 139.16 shows an upper gastrointestinal tract series of a severe intestinal stenosis caused by ischemia. At the time of the ileoileostomy, the suture line was blue. Chronic symptoms of partial small bowel obstruction occurred in the postoperative period.

Pseudo-Obstruction

Pseudo-obstruction of the colon, or Ogilvie syndrome, on rare occasion may complicate the early postoperative period. Its cause is not understood. **Pseudo-**

obstruction usually occurs within the first 3 days postoperatively in patients with multiple medical illnesses. The patient develops severe abdominal pain, and a radiograph of the abdomen reveals a dilated cecum. A gentle water-soluble contrast enema eliminates the possibility of a mechanical obstruction. The presence of a rising leukocyte count or a cecum that is increasing in size and exceeds 12 cm in diameter is associated with a 23% risk for rupture (Jain and Vargas, 2012). **Pseudo-obstruction may be treated with neostigmine or endoscopic decompression. Surgical intervention rarely is necessary and should be reserved for patients with ischemia, peritonitis, or refractory cases** (Jain and Vargas, 2012).

Complications of the Isolated Intestinal Segment

Intestinal Stricture

Strictures of intestinal segments are usually late complications primarily occurring in conduits, although they have been described in ileal ureters as well. **The stricture is thought to be a consequence of lymphoid depletion of the intestine exposed to urine.** The lymphoid depletion contributes to persistent infection, which may result in midloop stricture, bacterial seeding of the upper tracts, and renal deterioration (Tapper and Folkman, 1976). Because of the persistent infection and lack of intestinal resistance to the detrimental action of bacteria, submucosal edema with fibrosis and stricture formation occurs. The intestinal segment may also be blocked by encroachment of hypertrophied mesenteric lymph nodes. **Hypertrophied mesenteric lymph nodes, submucosal lymphoid depletion, edema, and fibrosis are commonly found when intestinal segments that have been chronically exposed to urine are examined pathologically.**

Elongation of the Segment

Another complication of the intestinal segment is elongation, occasionally resulting in massive enlargement. When this occurs in conduits or ureteral substitutes, there is usually a distal obstruction. In continent diversions, it may signal failure to catheterize the pouch frequently enough. If allowed to persist, the increased pressure may result in deterioration of renal function. Enlargement and elongation of the intestine may also result in a volvulus of the segment (Fig. 139.17).

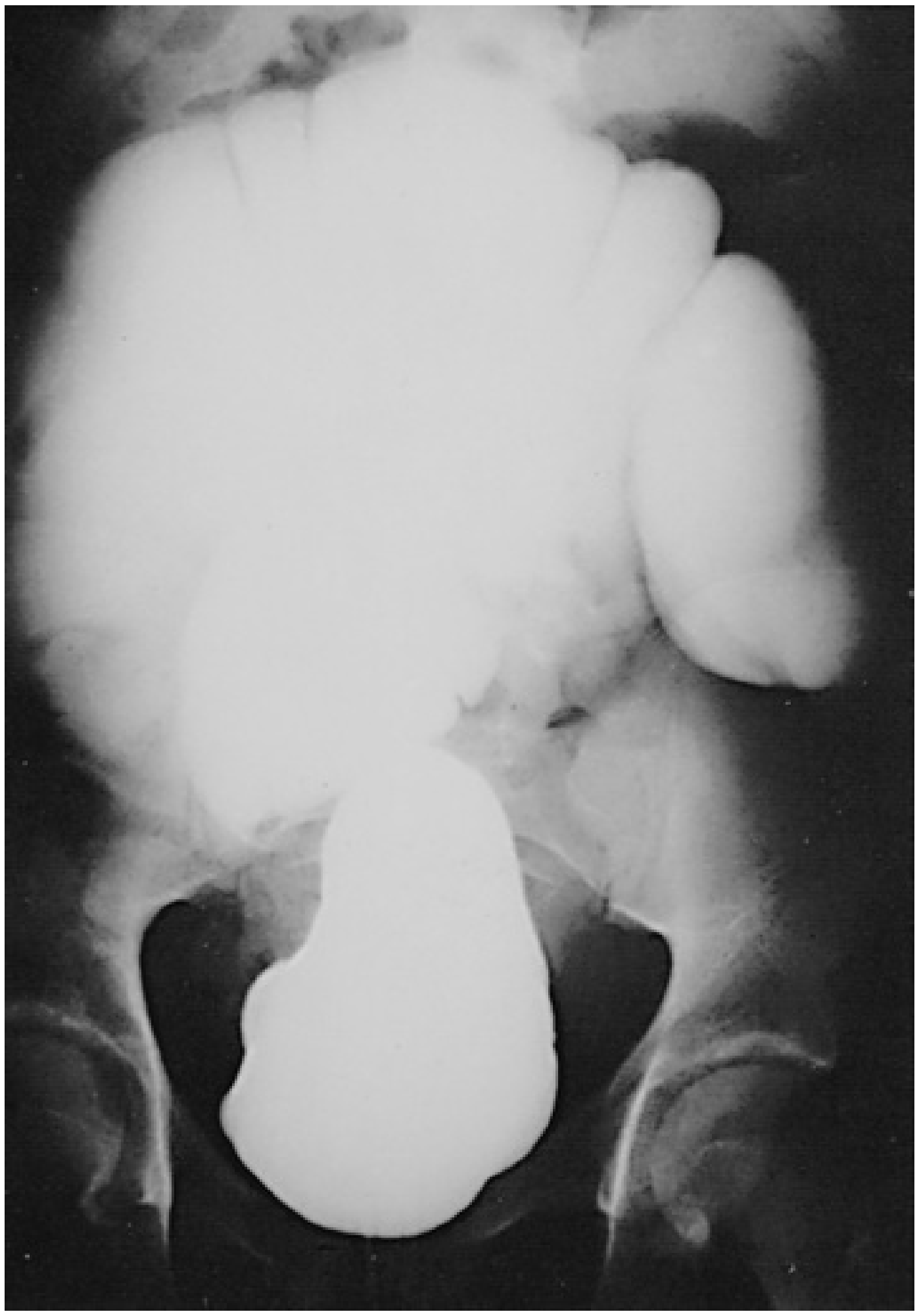

FIG. 139.17 Volvulus of an orthotopic right colon bladder. This segment enlarged markedly because of the patient's lack of adherence to a regimen of frequent intermittent catheterization.

Abdominal Stomas

Two types of stomas may be made on the anterior abdominal wall: those that are flush with the skin and those that protrude. The flush stoma is preferable for the continent type of diversion in which intermittent catheterization is carried out and over which a small dressing is placed. The stoma that protrudes is preferable when a collection device is worn. **A properly protruding stoma worn with an appliance results in a lesser incidence of stomal stenosis and a better appliance fit with fewer peristomal skin problems. There are two types of protruding stomas: the end stoma and the loop end ileostomy. Most complications of stomas are the result of technical errors in their**

construction. Therefore to minimize such complications, specific technical points must be rigidly followed.

The site of the stoma should be selected preoperatively. This is done by marking the stomal site with the patient in the sitting position and in the supine position; care is taken to place it over the rectus muscle at least 5 cm away from the planned incision line. The point chosen should be well away from skin creases, scars, the umbilicus, belt lines, and bone prominences. A site in which radiotherapy has previously injured the area should be avoided. **All stomas should be placed through the belly of the rectus muscle and be located at the peak of the infraumbilical fat roll.** If the stoma is placed lateral to the rectus sheath, a parastomal hernia is likely to occur. The bowel should traverse the abdominal wall perpendicular to the peritoneal lining (i.e., it should come straight out). One should avoid trimming fat or epiploic appendages from around the margin of the stoma, and the appliances should be applied in the operating room.

The stoma should be brought through a circular incision made at the predetermined site. A perfectly circular opening in the skin may be made by placing the finger hole of a Kelly clamp at the desired point and grasping the skin in the center of the hole with a Kocher clamp. Pulling up on the Kocher clamp and pushing the handle of the Kelly clamp against the abdominal wall allows for a small button of skin to be removed with a single pass of the knife. This makes a perfectly circular opening in the skin. However, the tendency to remove too much skin is great, resulting in a circular opening that is too large. To avoid this complication, one should not cut the skin flush with the Kelly clamp but rather immediately beneath the Kocher clamp. The subcutaneous tissue is left intact. This can be spread and does not need to be excised as any fat will fall back adjacent to the bowel and eliminate the dead space. Kocher clamps are placed on the fascia in the incision and pulled medially so that when the fascia and peritoneum are incised, they are incised directly over the skin line and thus do not result in angulation of the gut when the abdominal incision is closed. The fascia is incised in a cruciate manner, and the rectus muscles are spread. The peritoneum is incised. The opening should accommodate two fingers snugly.

Nipple (Rosebud) Stoma

A Babcock clamp is placed through the opening, and the bowel is grasped and brought out for a distance of 5 to 6 cm to make a nipple of about 2 to 3 cm in length (Fig. 139.18). Two 3-0 chromic sutures are placed through the seromuscular layer of the bowel and the peritoneum on the anterior abdominal wall. Alternatively, the serosa may be sutured to the fascia with two 2-0 chromic sutures. The mesentery is aligned in its normal anatomic direction before the serosa is sutured to the peritoneal wall. The ileum is usually curved in a concave manner toward the mesentery. If the curvature is severe, the mesentery may be partially incised 1 cm from the bowel wall (Fig. 139.19). Thus a portion of mesentery is preserved along the entire length of the bowel. This should straighten the curve in the bowel significantly if not completely. Four 3-0 chromic sutures are placed in quadrants through the full thickness of the bowel edge and through the seromuscular layer of the bowel 3 to 4 cm from the cut edge and then through the subcuticular skin layer. Sutures should not traverse the full thickness of the skin but should be placed through the subcuticular and subdermal layers only.

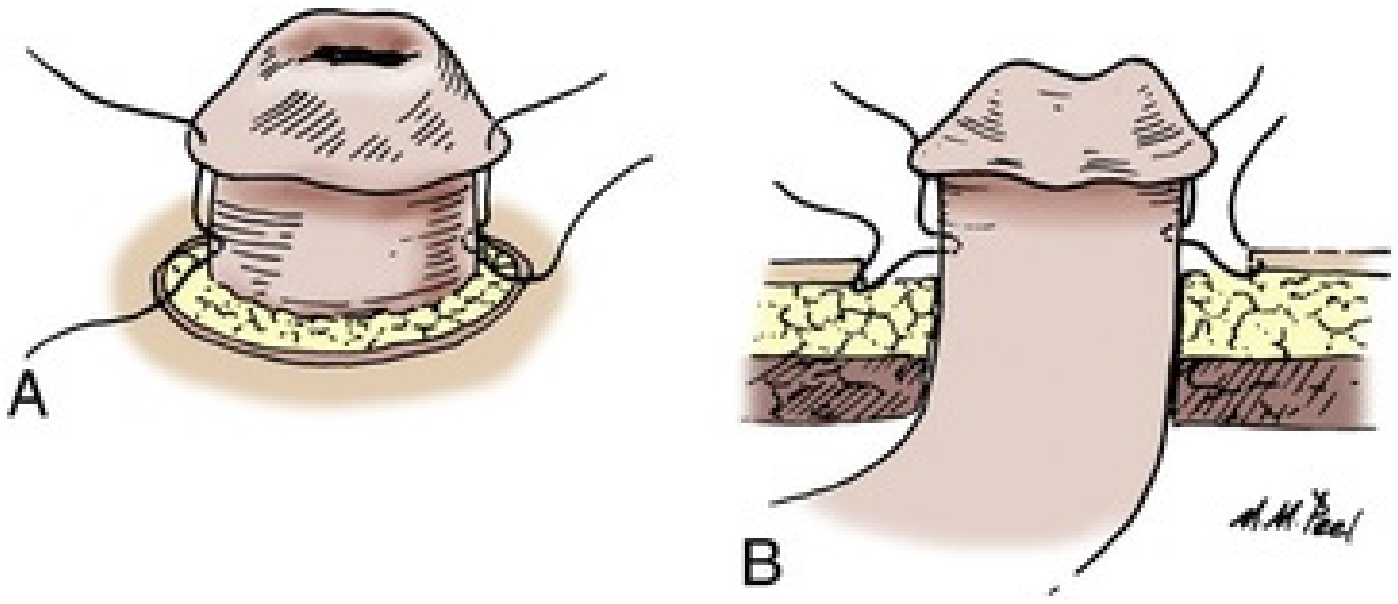

FIG. 139.18 (A and B) Nipple stoma. Five to 6 cm of intestine are brought through the abdominal wall. The serosa is scarified, and quadrant 3-0 chromic sutures are placed through the full thickness of the distal end of the intestine. Each suture is placed in the seromuscular layer 3 cm proximal and then secured to the dermis before it is tied.

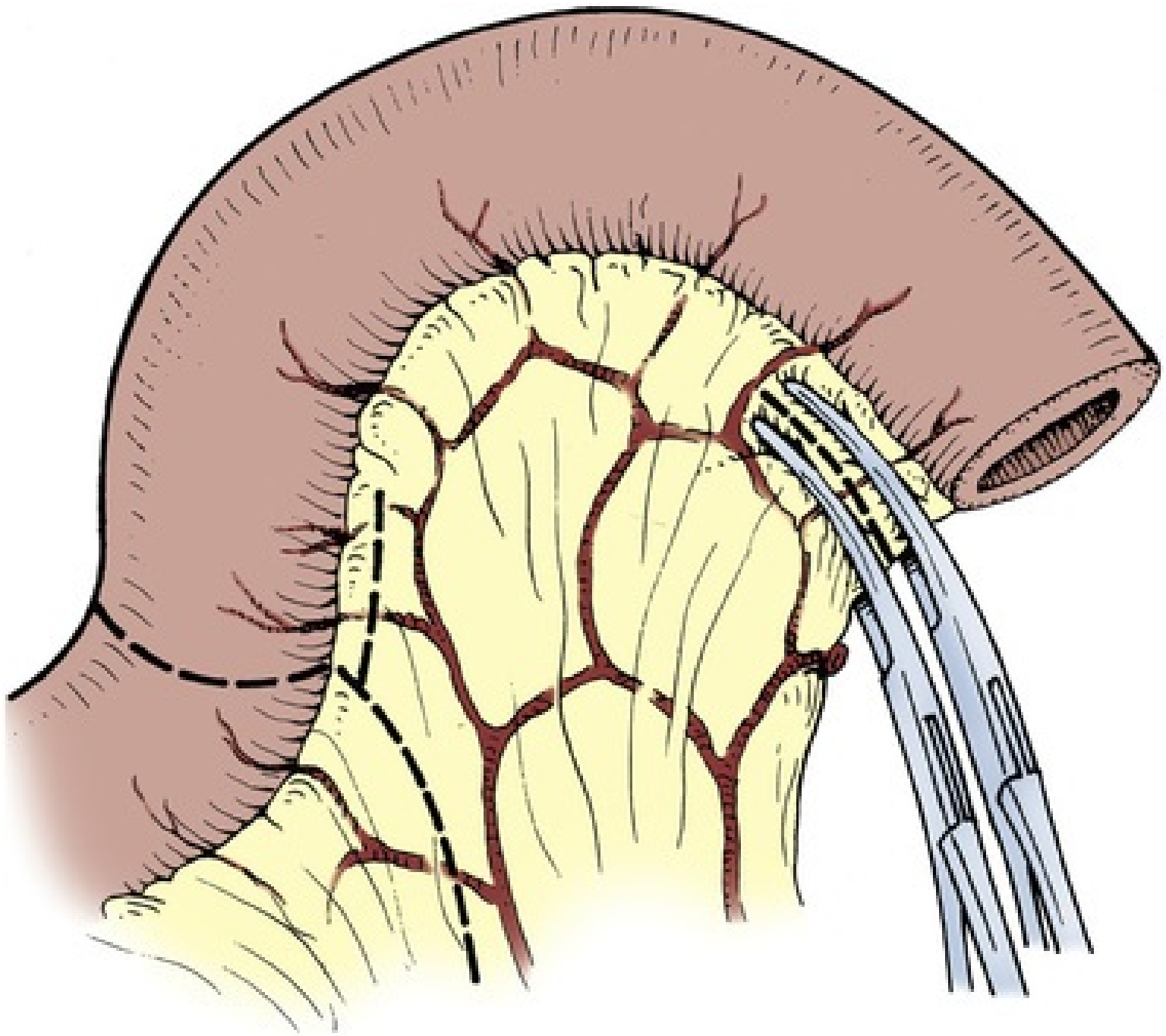

FIG. 139.19 If it is tethered by the mesentery, the bowel may be straightened by incising the mesentery several centimeters away from the serosa and parallel to the bowel.

When the sutures are tied, the bowel is everted and forms a nipple. A more secure nipple may be made by performing multiple myotomies through the seromuscular layer of the bowel above the skin line before construction of the nipple. The myotomies adhere serosa to serosa and reduce the risk for stomal retraction. This is particularly appropriate for patients who are obese.

Flush Stoma

To create a flush stoma, 3-0 chromic sutures are first placed in each quadrant. These should incorporate the full thickness of the bowel and the subdermal layer of skin. Several sutures are placed between the quadrant sutures from bowel to subdermal skin. This constructs a flush stoma that has a 1-mm raised margin.

Loop End Ileostomy

Obese patients have a thick abdominal wall and often a thick, short ileal mesentery. This makes construction of an end ileal stoma extremely difficult. **The loop end ileostomy obviates some of these problems and is usually easier to perform than the ileal end stoma in the patient who is obese** (Fig. 139.20). To construct this type of stoma, the distal end of the ileum is closed as described earlier for closing the proximal end of an intestinal segment, and a loop is brought up through the belly of the rectus muscle and onto the anterior abdominal wall. This avoids bringing the mesenteric border onto the abdominal wall and prevents one side of the ileostomy from being involved with mesentery. A slightly larger skin opening is required than for the end stoma. A 3-cm disk of skin is removed. The subcutaneous tissue is spread, the fascia incised, the rectus spread, and the peritoneum incised as described earlier. The opening should admit two fingers comfortably. The loop may be pulled through the opening in the abdominal wall by passing umbilical tape through a small opening in the mesentery at a distance from the distal end that is sufficient to leave that end in the abdomen when the loop has been pulled through the abdominal wall. By gentle traction on the umbilical tape, the loop is brought onto the abdomen.

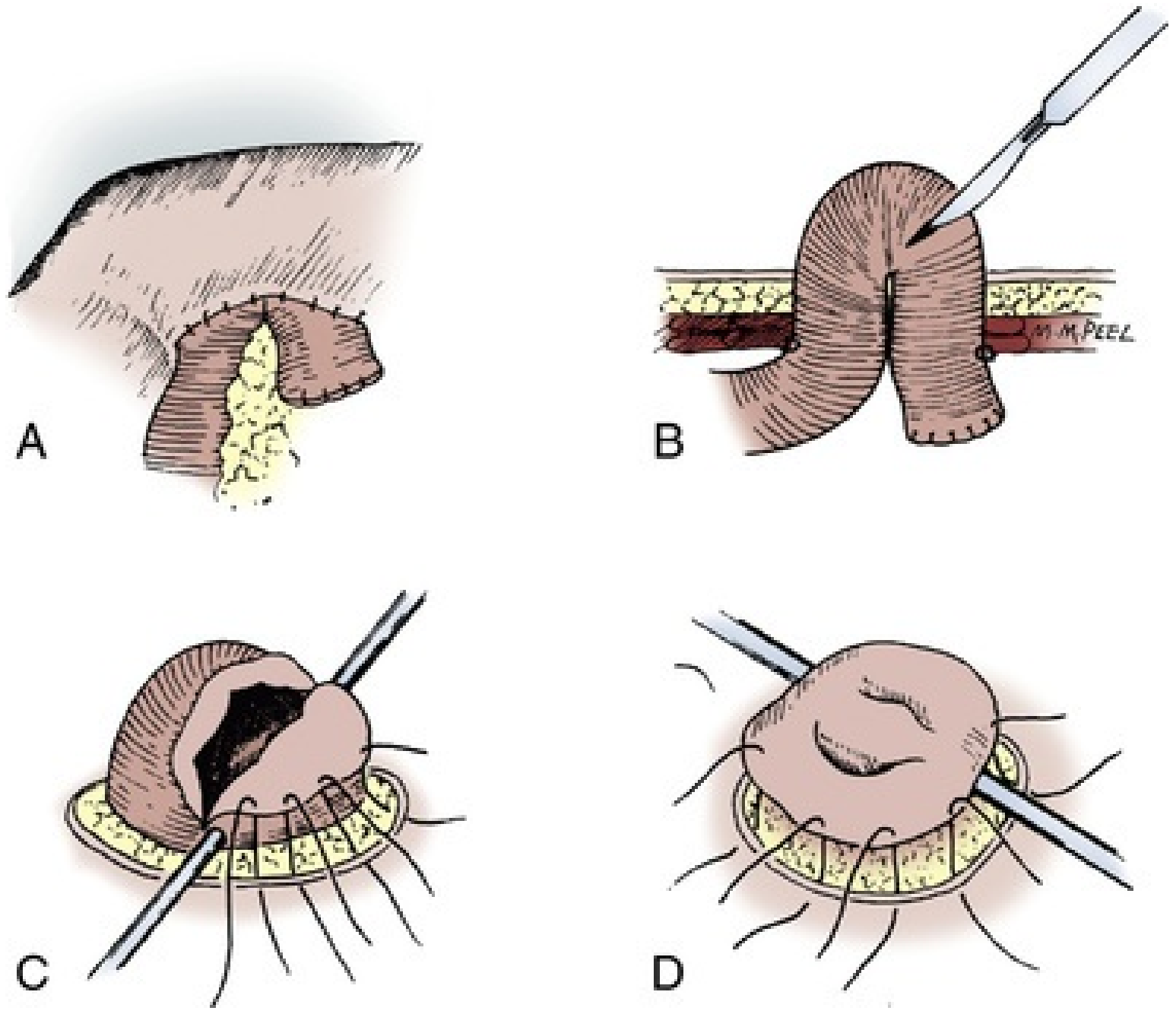

FIG. 139.20 Loop end ileostomy. (A) After the distal end of the loop is closed and the bowel is drawn through the rent in the abdominal wall, the bowel is held in place by a rod passed through the mesentery. The mesentery is realigned, and the peritoneum is sutured to the serosa of the bowel circumferentially. (B) A transverse incision is made in the bowel four-fifths of the loop distance cephalad. (C) The cephalad portion of the stoma is simply sutured to the dermal layer of skin with interrupted 3-0 chromic sutures. (D) On the inferior aspect of the incision, 3-0 chromic sutures are placed through the full thickness of the cut edge, then through the seromuscular layer, and then through the dermis. This everts the caudal portion of the stoma.

The distal portion of the bowel is brought through the opening such that the closed end lies cephalad to the body of the segment. When a sufficient amount of loop protrudes beyond the skin edge, a small rod is placed through the hole in the mesentery at the apex of the loop and holds the bowel on the anterior abdominal wall during suturing. If the rent in the rectus muscle is too large, it may be closed with interrupted 0 chromic sutures from within the abdomen. The serosa is sutured to the peritoneum on the anterior abdominal wall. The bowel wall is opened in a transverse direction at a point four-fifths of the distance cephalad to the most caudal portion of the loop. With 3-0 chromic sutures, the full thickness of the caudal incision in the bowel is sutured back to itself (serosa) and then to the dermis as in the rosebud technique. The cephalad nonfunctional opening is sutured directly to the dermis. The rod is sutured to the skin and left in place for 7 days.

The Turnbull loop stoma results in a lesser incidence of stomal stenosis but a higher incidence of parastomal hernias (Emmott et al., 1985). Overall, the two types of stoma are functionally equivalent over time (Chechile et al., 1992). Stomas for the colon may be constructed in much the same way as end stomas for the ileum. Their suturing, however, is usually more flush than everted.

Complications of Intestinal Stomas

Complications of the abdominal stoma are the single most common problem encountered in the postoperative period after urinary intestinal diversion. Early complications of abdominal stomas include bowel necrosis, bleeding, dermatitis, parastomal hernia, prolapse, obstruction, stomal retraction, and stomal stenosis. At some point, virtually every patient has one of these complications. Many of these complications can be reduced by proper construction of the stoma. If periodic visits to the enterostomal therapist are made, products for skin care are appropriately used, nonirritative stomal adhesives are used, the urine in the collection device is maintained acidic, and properly fitting collection devices are used, most stomal complications can be significantly reduced and many eliminated.

Parastomal skin lesions may be classified as irritative, which are manifested by hypopigmentation, hyperpigmentation, and skin atrophy; erythematous erosive lesions, which appear as macular lesions, scaling of the skin, and loss of the epidermis; and pseudoverrucous, which are wartlike lesions (Borglund et al., 1988).

Stomal stenosis has been reported, on average, in 20% to 24% of patients with ileal conduits and 10% to 20% of patients with colon conduits (see Table 139.8). This incidence has been considerably reduced by better attention to stomal care and better-fitting appliances (Eisenberg et al., 2014). Stomal stenosis is less for loop stomas than for end stomas. Parastomal hernias occur rarely (1% to 4%) with end stomas but are more likely to occur with loop stomas, with reported incidences ranging from 4% to 20%. Incidence of stenosis of catheterizable stomas is high, reaching more than 50% in children (Barqawi et al., 2004). Stoma-related complications appear to be more common in an umbilically placed stoma versus one in the abdominal wall (De Ganck et al., 2002). Others have reported excellent long-term results with few complications in the concealed umbilical stoma (Glassman and Docimo, 2001).

Bleeding, stomal stenosis, and dermatitis can be markedly reduced by attention to parastomal skin care and by the use of a properly fitting appliance around a protruding stoma. The other complications are minimized by proper surgical technique.

Parastomal hernia occurs frequently after ileal loop urinary diversion, with an incidence of 2% to 6.6% (Gilbert et al., 2013). It can be effectively treated with open repair (Franks and Hrebinko, 2001; Ho and Fawcett, 2004). Laparoscopic approaches have also been reported with mixed results. One series reported a 56% failure rate within 6 months of laparoscopic parastomal hernia repair with Gore-Tex mesh (Safadi, 2004). This contrasts with the high success rates reported in other small series (Craft et al., 2008; Kozlowski et al., 2001).

Massive bleeding from the conduit occasionally occurs, usually as a result of varices. There have been several reports of patients who have developed ileal conduit varices generally as a result of hepatic dysfunction and portal hypertension. Treatment by transhepatic portal-systemic shunt and transhepatic angiography and embolization is a relatively minimally invasive technique, and its use is worthwhile in these difficult patients (Medina et al., 1998; Yao et al., 2013).

Key Points

- Principles of surgical technique for a good bowel anastomosis include: (1) obtaining adequate exposure, (2) maintaining good blood supply, (3) minimizing spillage of bowel contents, (4) apposing serosa to serosa, (5) avoiding strangulation of the bowel, and (6) aligning the mesentery of the two segments.

- Intestinal anastomoses may be performed with use of sutures or staples. Properly performed, both have similar complication rates.
- Because of its simplicity and reliability, the stapled side-to-side ileal-ileal anastomosis is the most commonly performed.
- Most complications of stomas are the result of technical errors in their construction and are the most common problem encountered after urinary diversion surgery.
- All stomas should be placed through the belly of the rectus muscle and minimize the risk for parastomal hernia.

Ureterointestinal Anastomoses

The ureter may be anastomosed to the colon or small bowel in a refluxing or nonrefluxing anastomosis. There is considerable controversy as to whether a nonrefluxing or refluxing anastomosis is desirable in urinary tract reconstruction. Regardless of type of diversion, renal failure has been seen in 12.5% of patients over the long term (Gilbert et al., 2013). Deterioration of the upper tracts for ileal and colon conduits has been reported in 10% to 60% of the patients (Koch et al., 1992; Samuel et al., 2006). In one series, 49% of the upper tracts showed changes after conduit diversion, 16% of which had an increase in blood urea nitrogen of 10 mg/dL or more (Schwarz and Jeffs, 1975). **Deterioration of the upper tracts is usually a consequence of lack of ureteral motility, infection, or stones and less commonly caused by obstruction at the ureteral-intestinal anastomosis.** Because bacteriuria occurs in almost all conduits and because the intestine certainly does not inhibit and may, in fact, promote bacterial colonization, many have suggested that a nonrefluxing anastomosis would minimize the incidence of renal deterioration.

Observations based on early studies suggested that a nonrefluxing system in urinary intestinal diversions was desirable. **In a group of patients who had nonrefluxing colon conduits constructed, those whose anastomoses remained nonrefluxing had a lesser incidence of renal deterioration than those in whom the antireflux anastomosis failed.** Follow-up for 9 to 20 years revealed that 79% (22 of 28 patients) of the refluxing renal units deteriorated, whereas only 22% (11 of 51 patients) of the nonrefluxing units deteriorated (Elder et al., 1979; Husmann et al., 1989). Others have reported that in continent diversions, the majority of patients who experience reflux show upper tract dilation and deterioration, whereas few show upper tract deterioration when a nonrefluxing anastomosis is present (Kock et al., 1978). Similar findings have been reported in experimental animals.

If a nonrefluxing ureteral-colonic conduit diversion is constructed, only 7% of the renal units show evidence of pyelonephritic scarring after 3 months. If a refluxing anastomosis is constructed, 83% of the renal units show scarring. One-half of the conduits in both groups have significant bacteriuria (Richie and Skinner, 1975). **Others, however, have not found the same high incidence of renal deterioration associated with ureteral-intestinal reflux.** One group of investigators studying colon conduits noted no difference in the incidence of renal deterioration regardless of whether the colon conduit demonstrated reflux; 17% (5 of 29) of nonrefluxing renal units showed deterioration compared with 18% (5 of 27) of refluxing units (Hill and Ransley, 1983). In another series, only 3 of 135 renal units with refluxing ureteral-intestinal anastomoses that were unobstructed showed evidence of renal deterioration (Shapiro et al., 1975). A more recent study compared refluxing and nonrefluxing ureteral-intestinal anastomoses in 58 patients with conduit diversions; 56 renal units were refluxing, and 60 renal units were nonrefluxing. There was no difference in renal deterioration or in pyelonephritis between the two groups. Ureteral-intestinal stricture formation occurred in 2% of refluxing units as opposed to 13% of nonrefluxing units (Pantuck et al., 2000). A high-capacity, low-pressure reservoir may not require antirefluxing anastomoses (Hohenfellner et al., 2002). Likewise, the complication rate and the potential for renal damage caused by obstruction of a nonrefluxing anastomosis is not justified in patients with low pressure orthotopic bladder substitutes (Studer et al., 1996).

It does not appear that conduit pressures are transmitted to the renal pelvis. The pressure within the renal pelvis in refluxing conduit diversions is not elevated above normal, and it is not dependent on the segment of bowel used (i.e., ileum or colon) (Hayashi et al., 1986; Kamizaki and Cass, 1978; Magnus, 1977). Peristaltic ureteral contractions dampen pressure transmission from intestine to renal pelvis, attesting to the importance of normal ureters. **When bowel is substituted for the ureter, it does not appear that it makes any difference whether there is reflux at the bladder.** The voiding pressure is blunted by the distensible bowel segment. Indeed, in one study of continent diversions in which a segment of ileum formed the pouch to which the ureters were anastomosed, radionuclide voiding cystography failed to detect reflux to the kidneys (Waidelich et al., 1998). Moreover, there is no difference in ileal and colon conduits between those who experience reflux and those who do not in renal function measured 2 to 5 years postoperatively (Månsson et al., 1984). **Also, the successful construction of an antirefluxing anastomosis does not prevent bacterial colonization of the renal pelvis.** In six of eight patients with nonrefluxing enterocystoplasties and one patient with a nonrefluxing colon conduit in whom the absence of reflux was documented by loopogram, percutaneous renal pelvic aspiration revealed positive cultures (Gonzalez and Reinberg, 1987). **One stated advantage of a refluxing anastomosis in patients who have urothelial cancer and are prone to malignant change is that the upper tracts may be observed by periodic introduction of contrast material**

into the conduit. From these studies, it appears that reflux associated with impaired ureteral peristalsis in the presence of bacteriuria or obstruction results in renal deterioration, but it has not been established for either conduit or continent diversions that reflux associated with the normal ureter in the absence of obstruction is detrimental to the adult kidney.

Although many techniques have been described to make the various types of ureterointestinal anastomoses, certain **basic surgical principles are germane to all the anastomoses** regardless of type. **Only as much ureter as needed should be mobilized** so that there is no redundancy or tension on the anastomosis. **Mobilization should not strip the ureter of its periadventitial tissue** because it is in this tissue that the ureter's blood supply courses. The ureter should be cleared of its adventitial tissue only for 2 to 3 mm at its most distal portion where the ureter–intestinal mucosa anastomosis is to be performed. **The ureterointestinal anastomosis must be performed with fine absorbable sutures, which are placed so that a watertight mucosa-to-mucosa apposition is constructed. The bowel should be brought to the ureter and not vice versa** (i.e., the ureter should not be extensively mobilized so that it can be brought into the wound to the bowel lying on the anterior abdominal wall). **At the completion of the anastomosis, the bowel should be fixed to the abdominal cavity, preferably adjacent to the site of the ureterointestinal anastomosis.** If possible, **the anastomosis should be retroperitonealized** or a pedicle flap of peritoneum should be placed over the anastomosis.

In those diversions in which the intestinal stoma is brought to the abdomen and the proximal end of the bowel fixed to the retroperitoneum, there are two places where the bowel may be conveniently fixed to the retroperitoneum without jeopardizing mesenteric blood supply. The most convenient point of fixation is below the root of the small bowel mesentery at the level of the pelvic brim. The ureterointestinal anastomosis may be retroperitonealized at the level of the pelvic brim, thus fixing the bowel segment to the posterior body wall. In situations in which the ureters are short, a more cephalad fixation to the posterior peritoneum may be accomplished by placing the proximal end in the right upper quadrant cephalad to the takeoff of the right colic artery and immediately below the duodenum. This is a relatively avascular area and places the intestine fairly close to the right and left kidneys, thus reducing the length of ureter required to reach the intestinal segment.

Perhaps one of the most difficult complications of ureterointestinal anastomoses to manage is a **stricture. In general, strictures are caused by**

ischemia, a urine leak, radiation, or infection. The incidence of urine leak for all types of ureterointestinal anastomoses is 3% to 5% (see Table 139.8). **This incidence of leak can be reduced nearly to zero if soft Silastic stents are used.** In one series of ureterointestinal anastomoses done at the same institution, the nonstented group had a 2% anastomotic leak and a 4% stricture rate. When non-Silastic rigid stents were used, there was a 10% incidence of stricture. When a soft Silastic stent was used, however, there were no strictures or leaks (Regan and Barrett, 1985). In a similar series in which colon conduits were constructed after gynecologic exenterative operations, the nonstented group had an 18% leak rate and an 18% stricture rate, whereas those who had been stented had a 3% leak rate and an 8% stricture rate (Beddoe et al., 1987). Early postoperative metabolic complications were reduced in a randomized study of stented versus nonstented anastomoses (Mattei et al., 2008). **Thus the evidence indicates that modern soft Silastic stents are effective in reducing the leak rate, subsequent stricture formation, and postoperative complications.** Better technique and better suture materials have also reduced the incidence of stricture in nonrefluxing anastomoses. In a series of nonrefluxing ureterocolonic anastomoses, researchers reported an 8.5% incidence of stricture formation (Stein et al., 1996b).

In constructing a submucosal tunnel in those procedures in which a nonrefluxing anastomosis is made, it is often helpful to inject saline with a 25-gauge needle submucosally to raise the mucosa away from the seromuscular layer. This makes dissection considerably easier (Menon et al., 1982).

General principles of surgical technique, such as those outlined earlier, are common to all ureterointestinal anastomoses. Each type of ureterointestinal anastomosis, however, has specific technical points unique to its construction. Techniques involving ureterocolonic anastomoses are discussed first, followed by ureter–small bowel anastomoses.

Ureterocolonic Anastomoses

Combined Technique of Leadbetter and Clarke

The combined technique of Leadbetter and Clarke establishes a nonrefluxing ureterocolonic anastomosis by using a submucosal tunnel. The technique combines the ureterocolonic anastomosis of Nesbit, which is a refluxing elliptical anastomosis to the intestine, with the tunneled technique of Coffey (Fig. 139.21) (Leadbetter and Clarke, 1954).

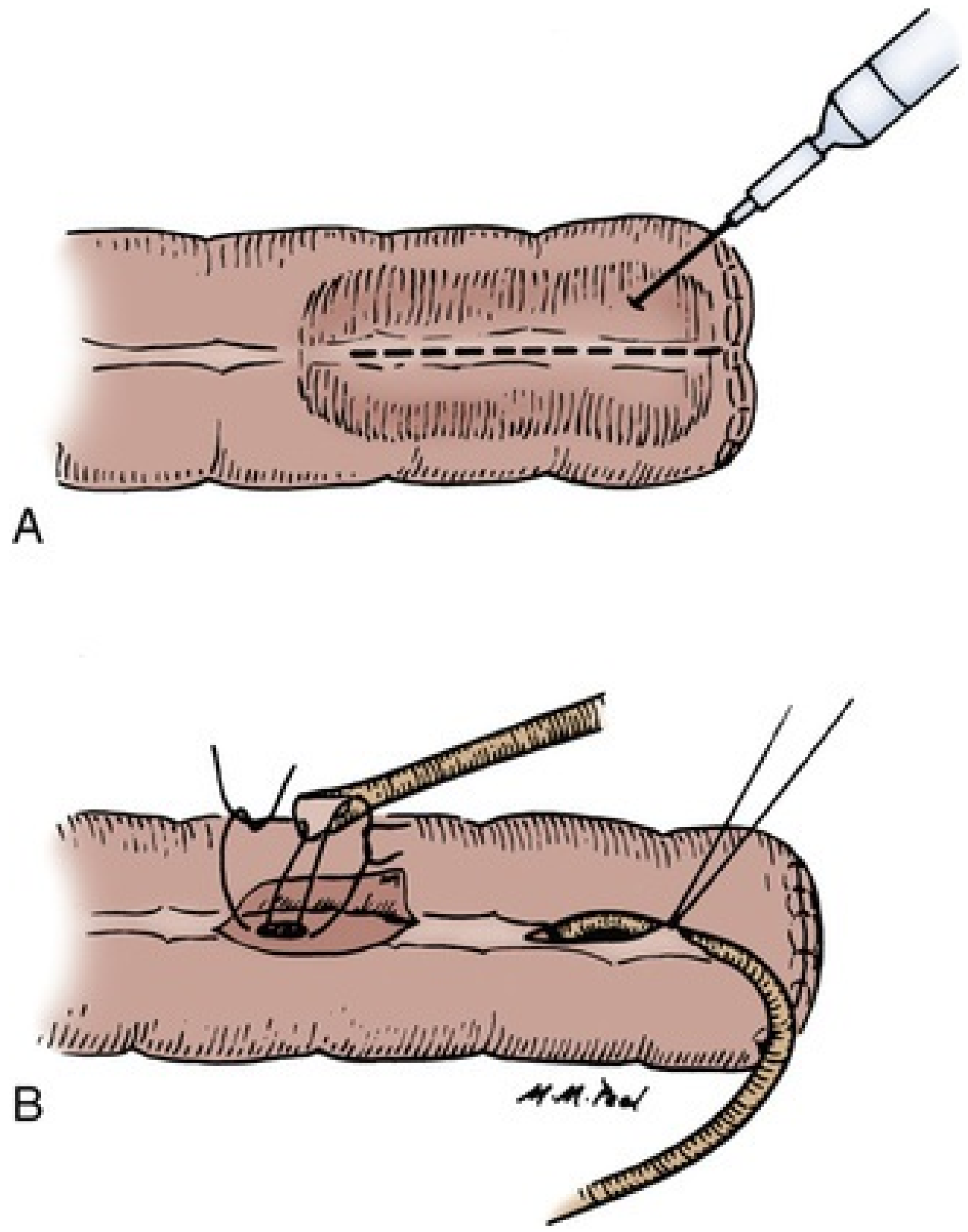

FIG. 139.21 Leadbetter-Clarke ureterointestinal anastomosis. (A) Injection of the submucosal tissues with saline facilitates the dissection. (B) A linear incision is made in the taenia, the taenia is raised, and the mucosa is identified. A small button of mucosa is removed, and the ureter is spatulated and then sutured to the mucosa with 5-0 polydioxanone sutures. The seromuscular layer is sutured over the ureter, with care taken not to compromise or occlude the ureter.

The anterior taenia is incised obliquely for 2.5 to 3 cm as close to the mesenteric border as possible. The mucosa is dissected off the muscularis for the entire length of the incision. At the distal end of the incision in the taenia, the mucosa is picked up with a fine Adson forceps, and a small button is excised. The ureter is spatulated for 5 to 7 mm such that an elliptical anastomosis may be made. The ureter is sewn mucosa to mucosa with 5-0 polydioxanone sutures (PDS) by either interrupted sutures with the knots tied on the outside or a running suture. If the suture line is to be run, it is wise to begin the anastomosis at the apex of the ureter. This suture is tied, and the posterior row is run to the most distal portion of the ureter, which is subsequently tied. A second running suture completes the anterior aspect. The seromuscular layer is then reapproximated loosely over the ureter in such a way as to allow “the ureter [to] lie in the bowel as a hammock without being compressed” (Leadbetter and

Clarke, 1954). The bowel should be fixed to the peritoneum so that there is no tension on the ureters.

The complications reported with this procedure include a leak rate of 2.5%; deterioration of the upper tracts, which varies from 4.3% to 25%; and a stricture rate that varies from 8% to 14% (Table 139.9).

TABLE 139.9

Complications of Ureterointestinal Anastomoses

PROCEDURE	NO. OF PATIENTS	STRICTURE (%)	LEAKAGE (%)	REFLUX (%)
COLON				
Leadbetter-Clarke[a–d]	127	14	3	4
Strickler[e]	28	14	—	—
Pagano[f]	63	7	—	6
SMALL BOWEL				
Bricker[g,h,r,s]	1809	7	4	—
Wallace-Y[h–k,q,s]	129	3	2	—
Nipple[h]	37	8	—	17
Serosal tunnel[l]	10	10	—	0
Le Duc[m–q]	82	18	2	13

[a] Hagen-Cook and Althausen, 1979

[b] Leadbetter and Clarke, 1954

[c] Hill and Ransley, 1983

[d] King, 1987

[e] Jacobs and Young, 1980

[f] Pagano et al., 1984

[g] Clark, 1979

[h] Patil et al., 1976

[i] Clark, 1979

[j] Beckley et al., 1982

[k] Wendel et al., 1969

[l] Starr et al., 1975

[m] Hautmann et al., 1988

[n] Le Duc et al., 1987

[o] Klein et al., 1986

[p] Lockhart and Bejany, 1987

[q] Palascak et al., 2001

[r] Studer et al., 2006

[s] Kouba et al., 2007

The following sources can be found in this chapter's reference list:

Transcolonic Technique of Goodwin

The transcolonic technique of Goodwin establishes a nonrefluxing ureterocolonic anastomosis by construction of a submucosal tunnel (Fig. 139.22). By this technique, the anastomosis is performed from within the bowel (Goodwin, 1953). If it is performed in bowel in continuity with the gastrointestinal tract, a noncrushing occlusive clamp is applied across the bowel cephalad to the desired point of the ureterointestinal anastomosis. This clamp is placed loosely about the bowel so as not to occlude the arterial supply in the mesentery.

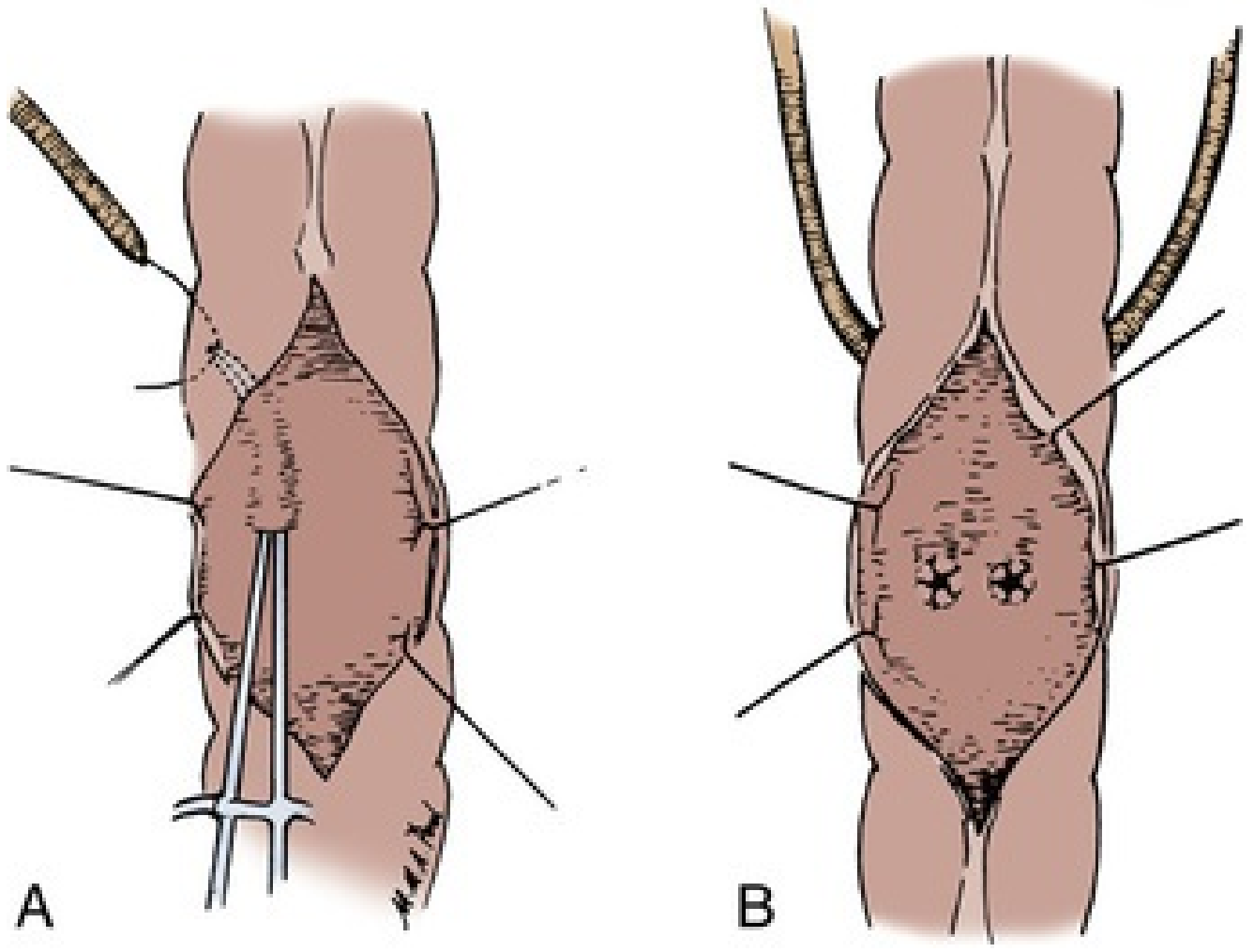

FIG. 139.22 Transcolonic technique of Goodwin. (A) The bowel is opened on its anterior surface; a small rent in the mucosa is made; and with a mosquito hemostat, the mucosa is raised from the submucosa extending laterally. A 3- to 4-cm tunnel is made before the clamp exits the serosal wall. The ureter is grasped and pulled into the submucosal tunnel. (B) Both ureters have been drawn into the bowel through their submucosal tunnels before each is spatulated and circumferentially sutured to the mucosa.

These sutures should also incorporate a portion of the muscularis for security. Where the ureter enters the colonic sidewall adjacent to the mesentery, the adventitia of the ureter is secured to the colonic serosa with interrupted 5-0 polydioxanone sutures.

A vertical incision is made in the bowel anteriorly, and the desired point of entrance of the ureter into the bowel is identified. A 0.5-cm incision is made in the posterior mucosa, and with use of a curved hemostat the mucosa is dissected from the submucosal layer in an oblique fashion coursing from medial to lateral. The hemostat is passed beneath the mucosa for a distance of approximately 3 to 4 cm and then brought through the serosa. A traction suture that has been placed on the ureter is then grasped with the hemostat, and the ureter is brought into the colon. Both ureters should be brought into the bowel before they are sutured to the mucosa. The ureters should lie without tension or angulation. A No. 5 feeding tube is passed through the ureter to be sure that there is no kinking as it passes through the bowel wall. The redundant ureter is excised, and its end is spatulated and sewn with interrupted 5-0 PDS to the mucosa, with care taken to include with the mucosa some muscularis so that the ureter is securely fixed in place. A Silastic stent is placed up both ureters. As the ureters come through the serosa from without the bowel, the adventitia of the ureter is sutured to the serosa of the colon with two 4-0 PDS. The anterior bowel wall is closed in two layers.

The reported results with this technique appear to be satisfactory. However, specific reliable data on the complication rate are not available.

Strickler Technique

The Strickler technique establishes a nonrefluxing ureterocolonic anastomosis by construction of a submucosal tunnel (Fig. 139.23) (Jacobs and Young, 1980; Strickler, 1965). A 1-cm incision is made on the margin of the taenia. The technique originally described removal of a 2-mm button of seromuscular tissue. A 2-cm tunnel is formed laterally beneath the seromuscular layer with a hemostat. The seromuscular layer is incised, with care taken not to tent up the mucosa and inadvertently incise it. The holding suture in the ureter is grasped and drawn throughout the submucosal tunnel. The ureter is spatulated for 0.5 cm. A button of mucosa is removed, and the full thickness of the ureter is sewn to the mucosa of the bowel with either interrupted or running 5-0 PDS. The serosa is reapproximated over the ureter with 4-0 silk sutures. The serosal suture line is perpendicular to the course of the ureter. Where the ureters enter the serosa, they are also fixed with interrupted 4-0 PDS. A lateral peritoneal flap is placed over the anastomosis.

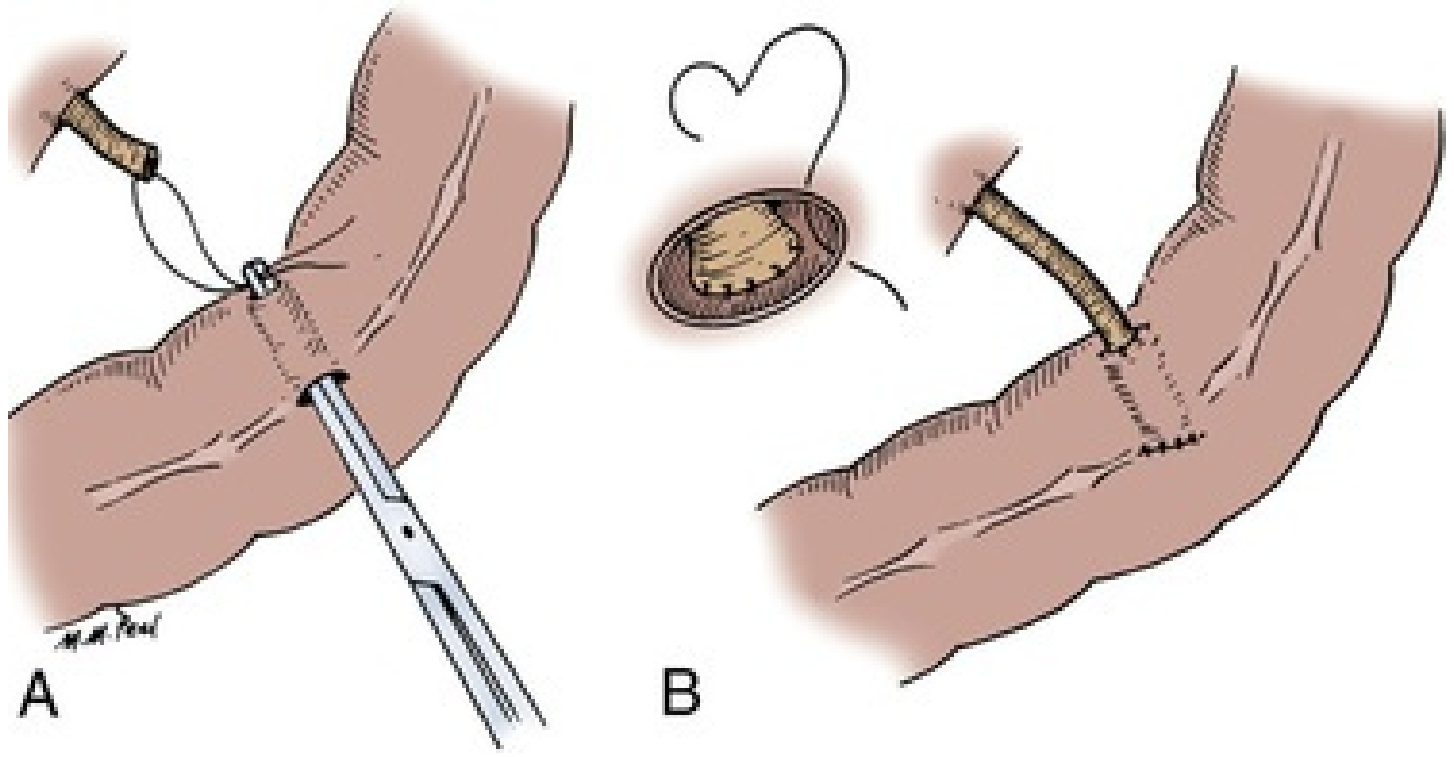

FIG. 139.23 Strickler ureterointestinal anastomosis. (A) A small linear incision is made in the taenia, and the submucosa is dissected from the mucosa laterally. After a distance of 3 to 4 cm has been achieved, a small hole is made in the serosa and the ureter is drawn through. (B) A button of mucosa is excised, and the ureter is spatulated and sutured to the mucosa with 5-0 polydioxanone sutures. The rent in the taenia is closed with interrupted sutures, and an adventitial suture at the ureter's entrance point into the colon secures it to the serosa of the colon.

The advantage of this anastomosis is that because the taeniae do not need to be aligned, one can form the tunnel according to the normal course of the ureter and avoid angulation. This technique reliably prevents reflux but results in a stricture rate of approximately 14% (see Table 139.9).

Pagano Technique

The Pagano technique establishes a nonrefluxing ureterointestinal anastomosis by construction of a submucosal tunnel (Fig. 139.24) (Pagano, 1980). The taenia is incised for a length of 4 to 5 cm, and the seromuscular layer is separated from the mucosa on both sides of the taenia laterally as far as the mesenteric border. The ureter is brought in one end (i.e., the distal end) laterally and laid in the 4- to 5-cm tunnel paralleling the mesenteric border. A button of mucosa is excised, and the ureters are spatulated and sutured to the mucosa with either interrupted or running 5-0 PDS. The seromuscular layer is then closed loosely with silk sutures in the midline. Each suture includes the seromuscular layer of the taenia and the mucosa in the midline.

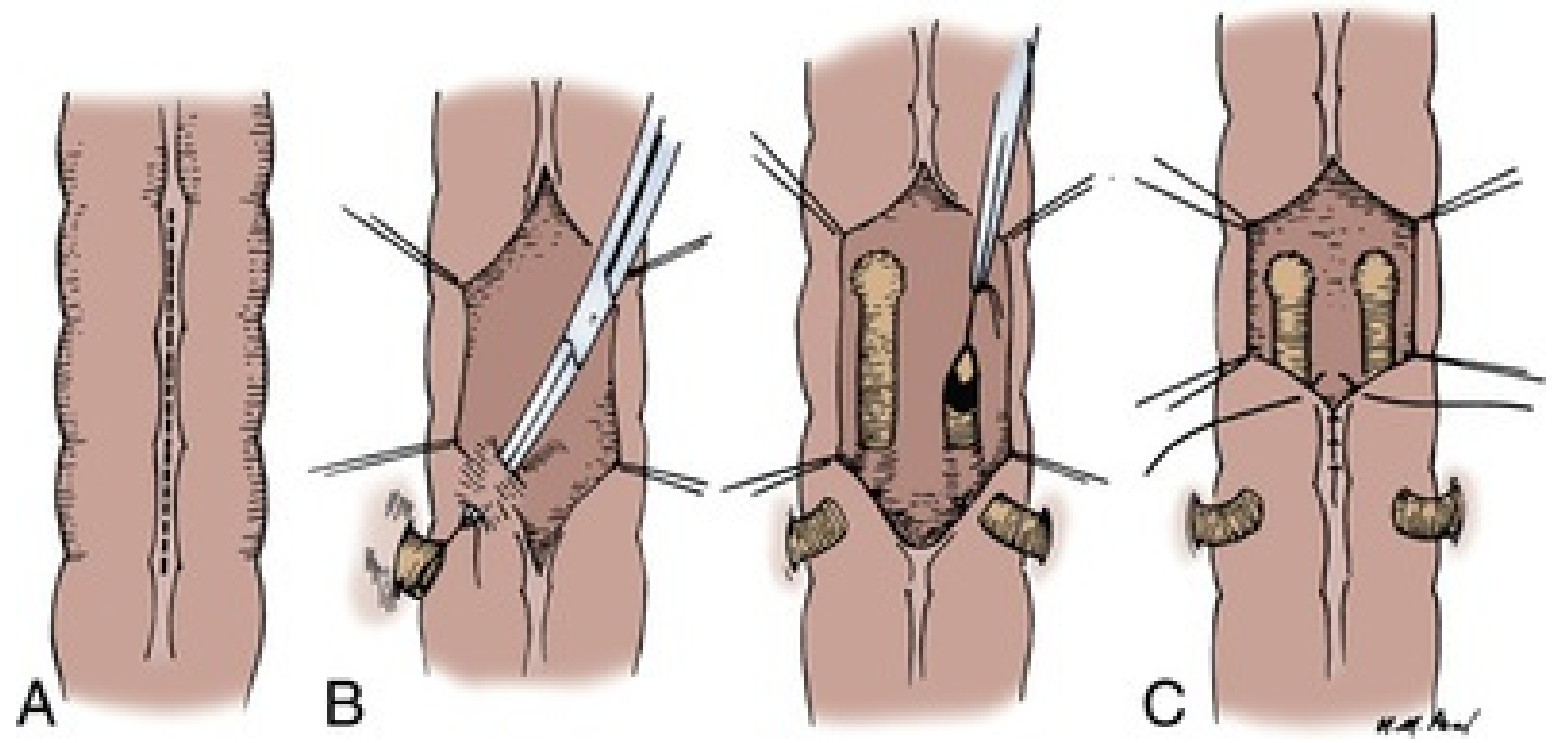

FIG. 139.24 Pagano ureterointestinal anastomosis. (A) A linear incision is made in the taenia between 4 and 5 cm in length. (B) The submucosa is dissected from the mucosa laterally on both sides to the level of the mesentery. The ureters are drawn into the submucosal tunnel distally and sutured to the mucosa with 5-0 polydioxanone sutures proximally. (C) The serosa is reapproximated, with incorporation of the mucosa in the midline.

This technique has a reported low complication rate. The leakage rate is approximately 3%, the stricture rate is 6%, and the reflux rate is approximately 6% (see Table 139.9) (Pagano et al., 1984).

Cordonnier and Nesbit Techniques

The Cordonnier and Nesbit techniques use no tunnel and are direct refluxing anastomoses of the ureter to the colon (Cordonnier, 1950; Nesbit, 1949). They are not desirable for ureterosigmoidostomies. They are performed in much the same way as a Bricker anastomosis would be performed for the small bowel (see later).

Small Bowel Anastomoses

There is a variety of ureter–small bowel anastomoses, which are of two basic types: end to side, and end to end. The end-to-side anastomoses may be constructed in a refluxing or nonrefluxing manner.

Bricker Anastomosis

The Bricker anastomosis is a refluxing end-to-side ureter–small bowel anastomosis that is simple to perform and has a low complication rate (Fig. 139.25) (Bricker, 1950). Although originally described for the small bowel, it may be used in any suitable intestinal segment.

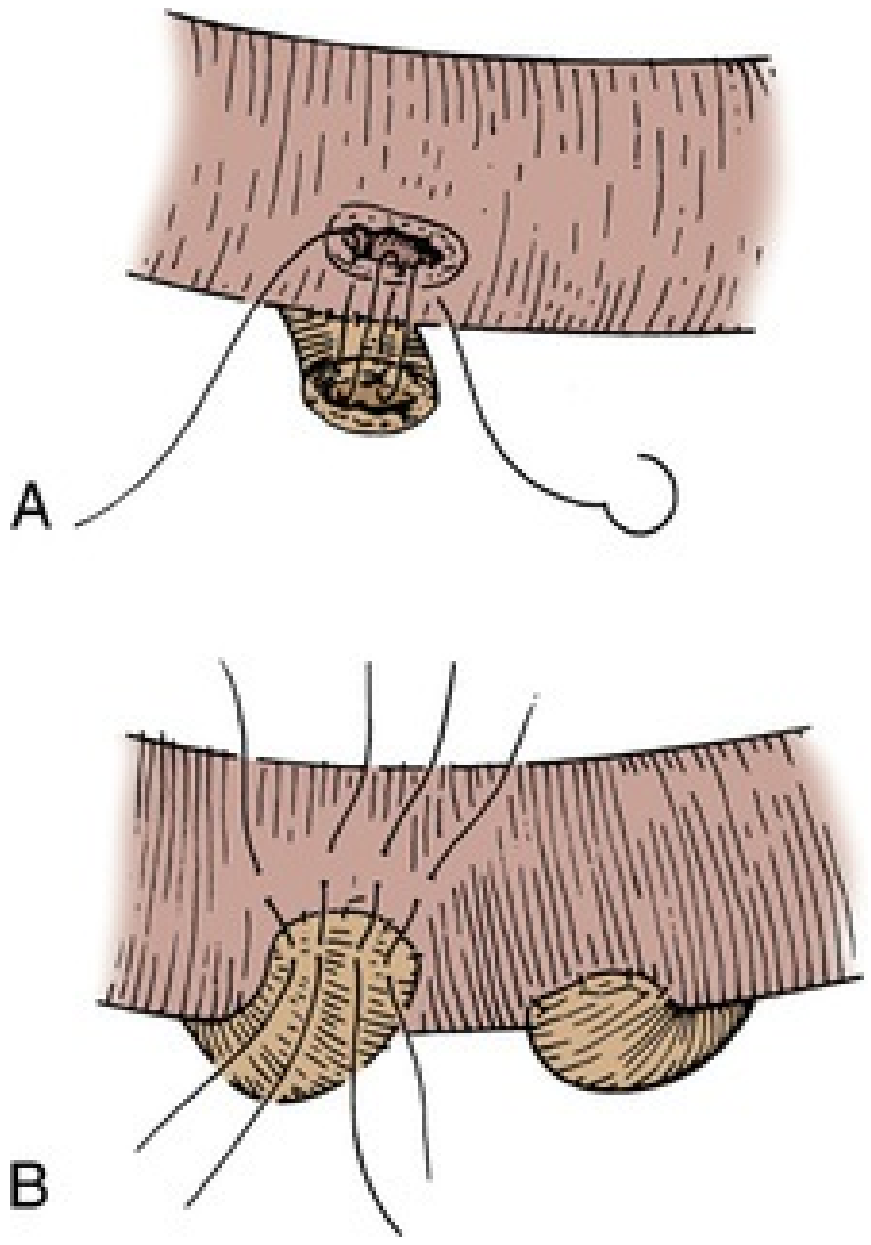

FIG. 139.25 Bricker ureterointestinal anastomosis. (A) The adventitia of the ureter is sutured to the serosa of the bowel. A small full-thickness serosal and mucosal plug is removed. Interrupted 5-0 polydioxanone sutures approximate the ureter to the full thickness of the mucosa and serosa. (B) The anterior layer is completed by interrupted sutures placed through the adventitia of the ureter and the serosa of the small bowel.

In the original description, the adventitia of the ureter was sutured with interrupted silk sutures to the serosa of the bowel. The mucosa and serosa were incised; a small mucosa plug was removed; and with fine absorbable chromic sutures, the full thickness of the ureter was sewn to the mucosa of the bowel. The anterior layer of ureteral adventitia was then sewn with interrupted silk sutures to the serosa of the bowel. A less cumbersome method of performing this anastomosis is to excise a small button of seromuscular tissue and mucosa, spatulate the ureter for 0.5 cm, and suture the full thickness of the ureter to the full thickness of the bowel (i.e., mucosa and seromuscular layer to ureteral wall) with either interrupted or running 5-0 PDS. The anastomosis is stented with a soft Silastic stent.

The stricture rate for this anastomosis varies from 4% to 22% (average of 6%). The leak rate is approximately 3% in the absence of stents (see Table 139.9). Open and robotic approaches have a comparable stricture rate (Anderson et al., 2013).

Wallace Technique

A frequently used anastomotic technique is that of Wallace, in which the end of the intestine is sutured to the end of the ureter (Fig. 139.26) (Albert and Persky, 1971; Wallace, 1970). This is a refluxing anastomosis. The intestinal segment used may be either small bowel or colon. There are three basic types of anastomoses:

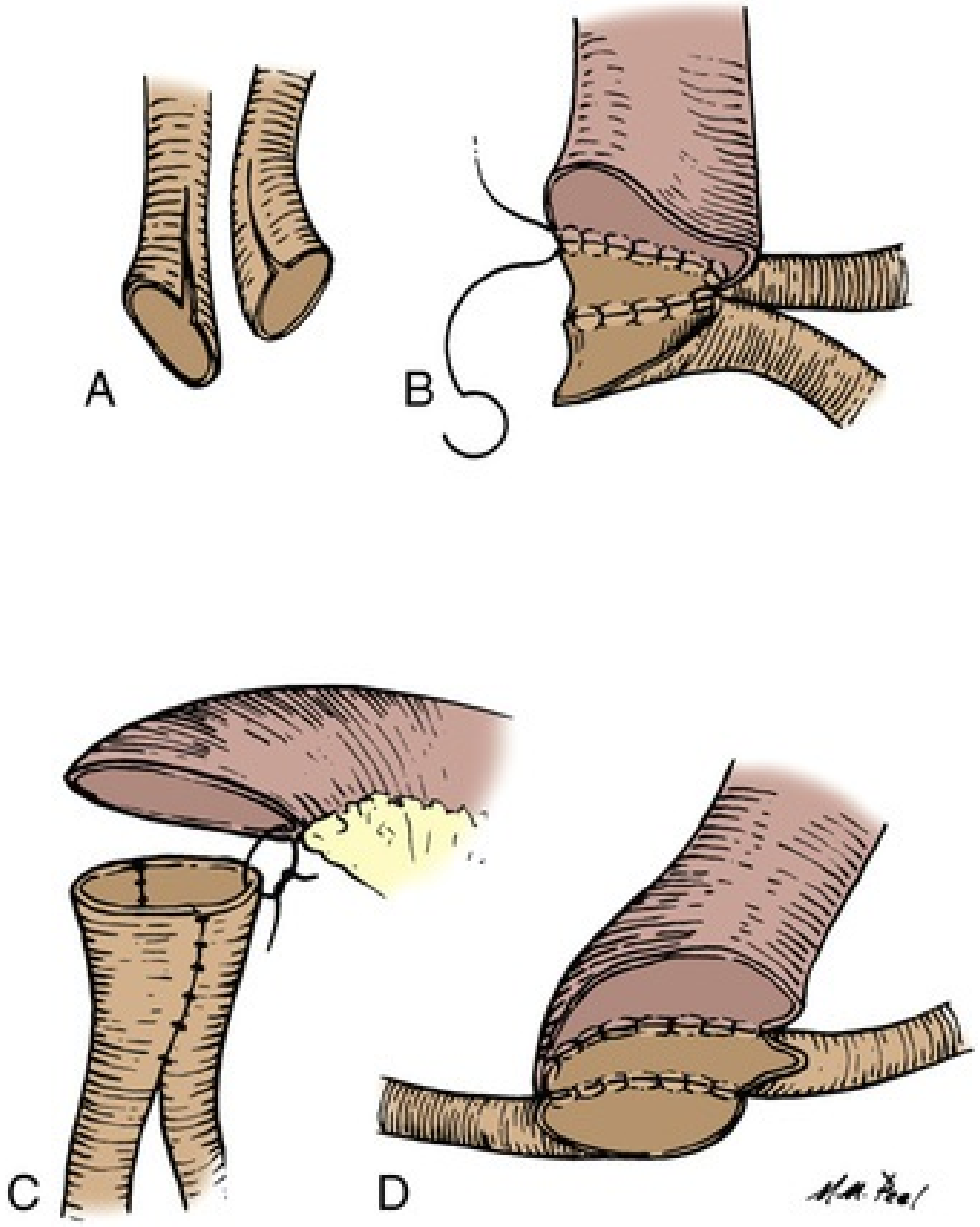

FIG. 139.26 Wallace ureterointestinal anastomosis. (A) Both ureters are spatulated and laid adjacent to each other. (B) The apex of one ureter is sutured to the apex of the other ureter with 5-0 polydioxanone sutures (PDS). The posterior medial walls of both ureters are then sutured together with interrupted or running 5-0 PDS, the knots tied to the outside. The lateral ureteral walls are then sutured to the intestine. (C) A *Y*-type anastomosis is formed by completing the anterior row of the anterior lateral ureteral walls of the ureters as shown in (B) and then suturing the ends of the ureters directly to the intestine. (D) The head-to-tail anastomosis involves suturing the apex of one ureter to the end of the other. The posterior medial walls are sewn together, and then the ends and lateral walls are sewn to the intestine.

1. The end of one ureter is sutured to the end of the other ureter, and this composite anastomosis is sutured to the end of the bowel.

2. A Y anastomosis of the ureters is constructed and sutured to the end of the bowel.
3. A head-to-tail ureteroureteral anastomosis is formed, which is then sutured to the end of the bowel.

The ureters are spatulated for 1.5 to 2 cm, and fine 5-0 PDS are used for each anastomosis.

For the first anastomosis, a fine suture is placed at the apex of each ureter with the knot tied to the outside. The posterior medial ureteral walls are sutured together, and the anterior lateral walls are sutured directly to the bowel with interrupted 5-0 PDS. Where the suture line of the end of the ureters comes to the bowel, a horizontal mattress suture is placed to make the anastomosis watertight. If a Y type of anastomosis is desired, after the posterior ureteral walls have been sutured together as described earlier, the anterior walls of the ureters are sutured together and the end of the composite anastomosis is sutured to the bowel. Again, where the suture lines meet the bowel, a horizontal mattress suture is placed so that the anastomosis is watertight. The head-to-tail anastomosis involves suturing the end of one ureter to the apex of the other. The posterior medial walls of the two ureters are approximated. The anterior lateral walls are sutured to the bowel.

The Wallace anastomosis has the lowest complication rate of any of the ureterointestinal anastomotic techniques. The incidence of stricture formation is approximately 3%, of deterioration of the upper tracts is about 4%, and of leakage is about 2% (see Table 139.9). Historically, the Wallace technique was not recommended for patients who have extensive carcinoma in situ or a high likelihood of recurrent tumor in the ureter out of concern that a recurrence of tumor at the anastomotic line in one ureter would block both ureters. This, however, is exceedingly rare. **A Wallace anastomosis may actually be easier to survey endoscopically** because both ureters can be easily found next to each other at the most proximal portion of the loop. **Additionally, it has a lower rate of obstruction than a Bricker anastomosis** (Kouba et al., 2007).

Tunneled Small Bowel Anastomosis

The tunneled small bowel anastomosis method attempts to establish a nonrefluxing anastomosis by construction of a submucosal tunnel (Fig. 139.27) (Starr et al., 1975). Two 0.5-cm incisions are made in the serosa on the antimesenteric border 2.5 cm apart at right angles to the long axis of the bowel.

The seromuscular layer is then gently separated from the mucosa with a blunt hemostat. The ureter is pulled through one incision, a button of mucosa is removed over the other incision, and the ureter is spatulated and sutured to the mucosa with interrupted 5-0 PDS. The serosa is then closed with interrupted 4-0 silk sutures, and the adventitia of the ureter is sutured at its entrance through the serosa of the bowel to the serosa.

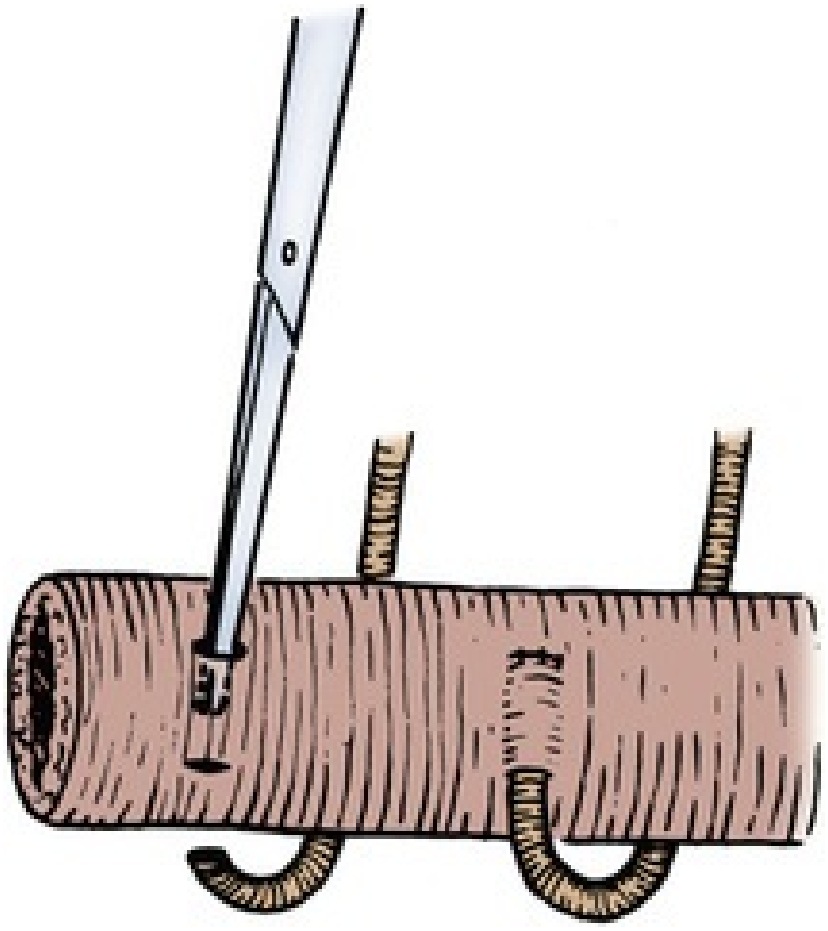

FIG. 139.27 Tunneled small bowel anastomosis. A small transverse incision is made in the small bowel, and a second transverse incision 3 cm lateral to it is also made. The submucosal tunnel is made, a button of mucosa is removed, and the ureter is drawn through the tunnel and sutured directly to the mucosa. The rent in the serosa is closed, and an adventitial ureteral suture is placed and secured to the serosa at the ureter's entrance to the small bowel.

Good results have been reported, but this technique has not been widely used. Therefore long-term follow-up is not available (Osman et al., 2004).

Split-Nipple Technique

The split-nipple technique attempts to establish a nonrefluxing anastomosis by using a nipple mechanism. It may be applied to either the small or large bowel. This technique was described by Griffiths and involves formation of a nipple in the ureter and implantation into the small bowel (Fig. 139.28) (Warwick and Ashken, 1967). A 0.5-cm longitudinal incision in the ureter is made, and the ureteral wall is turned back on itself, constructing a nipple at least twice as long as its width. The cuff is stabilized at the corners with sutures. A button of seromuscular and mucosal tissue is removed, and the ureter is then placed into the bowel such that it protrudes through the mucosa. The adventitia just proximal to the point where the ureter has been sewn to itself is sutured to the full thickness of the bowel wall with interrupted 5-0 PDS. The anastomosis is stented.

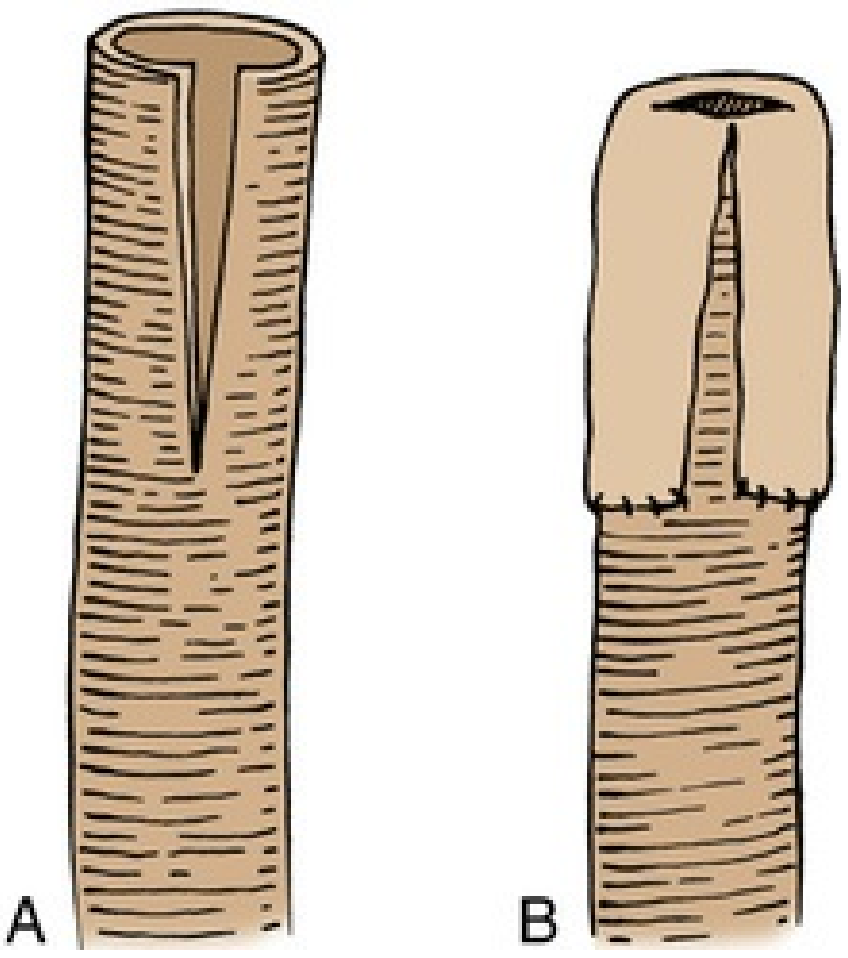

FIG. 139.28 (A and B) Split-nipple technique. The ureter is spatulated and turned back on itself, and the end of the ureter is secured to the adventitia of the ureter with interrupted 5-0 polydioxanone sutures.

In one series, this type of anastomosis prevented reflux in more than 50% of the patients. In subsequent series, approximately 80% of patients had a nonrefluxing anastomosis with an acceptably low incidence of stenosis (see Table 139.9). There is a stricture rate of about 7% (De Carli et al., 1997).

Le Duc Technique

The Le Duc method establishes a nonrefluxing anastomosis by laying the ureter onto the interior of the bowel wall, eventually resulting in a submucosal tunnel when it is re-epithelialized (Fig. 139.29) (Le Duc et al., 1987). This technique has been used to prevent reflux in the ureter–small intestine anastomosis. Excellent exposure is required, and therefore the small bowel needs to be opened along its antimesenteric border for a length of approximately 5 cm. The mucosa is incised for a length of 3 cm beginning 2 cm proximal to the cut edge of the bowel. It is important to begin the mucosal tunnel away from the cut edge of the bowel to allow enough distal bowel for closure without jeopardizing the entrance point of the ureter. The ureter is then brought through the serosa at the most distal portion of the mucosal sulcus, laid in the trough, spatulated, and sutured to the proximal end of the sulcus with interrupted 5-0 PDS using the full thickness of ureteral wall and anchored to the muscularis and mucosal layers of the bowel. The mucosa of the sulcus of the bowel is then sutured to the adventitia of the ureter. The mucosa of the bowel should not be sutured over the ureter but rather to its lateral aspect. The idea is that the mucosa eventually grows over the top of the ureter. Where the ureter enters the small bowel, its adventitia is sutured to the bowel serosa with 4-0 silk sutures. Stents are placed in the ureter, and their passage must be unimpeded to ensure that there is no angulation. The bowel should be fixed to the body wall near the site of the ureteral implantation so that the ureters do not angulate.

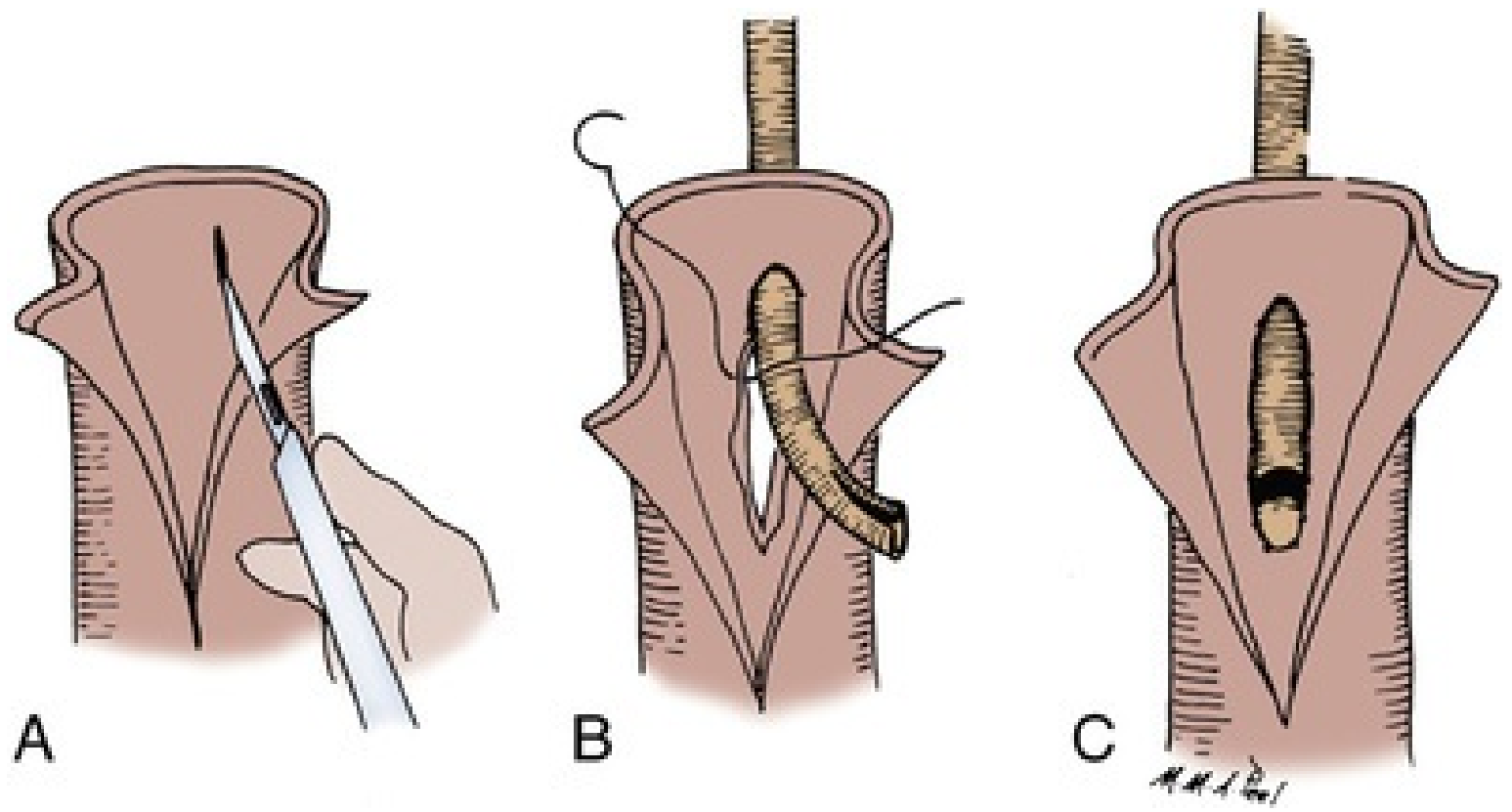

FIG. 139.29 Le Duc ureterointestinal anastomosis. (A) The small bowel is opened for approximately 4 to 5 cm. A longitudinal rent in the mucosa is made, and the mucosa is raised. (B) At the distal end of the mucosal rent, a hole is made in the serosa, and the ureter is then drawn through. The entrance of the ureter through the serosa should be at least 2 cm proximal to the cut end of the bowel to allow sufficient bowel length to close the end. (C) The ureter is spatulated and sutured to the mucosa and muscle layers. The mucosa is not reapproximated over the top of the ureter but rather sutured to the side of it.

The complication rate for this technique is relatively low, although the follow-up is also relatively short. Initial reports suggested that it carried with it an 87% incidence of maintaining an antireflux valve with a 5% incidence of stricture and a 2% incidence of leak (Schwaibold et al., 1998). A modification of the Le Duc technique was prompted by a 15% incidence of stricture when longer follow-up was available. With the modified technique, the stricture rate was 3% with 2.5 years of follow-up. The technique involves construction of a 3-cm mucosal sulcus to the submucosa. The ureter is brought in the proximal sulcus transmurally and anchored to the serosa externally. The ureter is spatulated for 1.5 cm, and only the spatulated portion is sewn to the muscularis of the bowel. The proximal intraluminal ureter is not fixed to the bowel (see Table 139.9).

Hammock Anastomosis

The hammock anastomosis involves conjoining the ureters and implanting them into the small bowel in a nonrefluxing manner. The small bowel is closed at its proximal end, and three 10-cm longitudinal incisions separated by 1 to 2 mm are made through the seromuscular layer to the mucosa. These incisions are cross-hatched by multiple incisions. This serves as a hammock. The ureters are conjoined as in the Wallace technique and sutured to the intestinal mucosa. The ureters are buried by closing the intestinal wall over the top of them with seromuscular sutures of 3-0 polyglycolic acid suture (Hirdes et al., 1988).

With this technique, there is a 6% incidence of ureteroileal stenosis and approximately a 20% incidence of reflux. Follow-up, however, is relatively short.

Ureteral Dipping Technique

Described in 640 patients who underwent continent urinary diversion, the dipping technique is relatively simple to perform and has excellent success (Wishahi et al., 2013). Wishahi et al. form the neobladder, and then make a small opening in the small bowel wall. The ureter is “dipped” approximately 1 cm into the bladder cavity and then secured to the seromuscular portion of the bowel. No mucosal anastomosis is performed. The long-term success of renal preservation reported deserves further investigation.

Ureter–Small Bowel Anastomosis Using Serosal Compression of the Extramural Ureter as an Antireflux Mechanism

Primarily applicable to a continent diversion in which detubularized small bowel is used and an antireflux ureterointestinal anastomosis is desired, ureter–small bowel anastomosis involving serosal compression of the extramural ureter requires two segments of small bowel to be juxtaposed. The ureter is laid between the two small bowel serosal surfaces, which are sutured posterior and anterior to the extramural portion of the ureter. The technique is described in the following sections.

The posterior wall of the extramural tunnel is composed of the two segments of small bowel sutured together with 3-0 silk sutures (Fig. 139.30A and B). The two segments of small bowel are opened along their antimesenteric borders. The ureter is spatulated and sutured to the mucosal-seromuscular layer with 5-0 absorbable sutures. The edges of the opened small bowel are then reapproximated over the anterior ureter with absorbable sutures (see Fig. 139.30C), thus making a serosal tunnel 4 cm in length. When the bowel is distended, it then applies pressure to the extramural ureter, thus preventing reflux (Abol-Enein and Ghoneim, 1994).

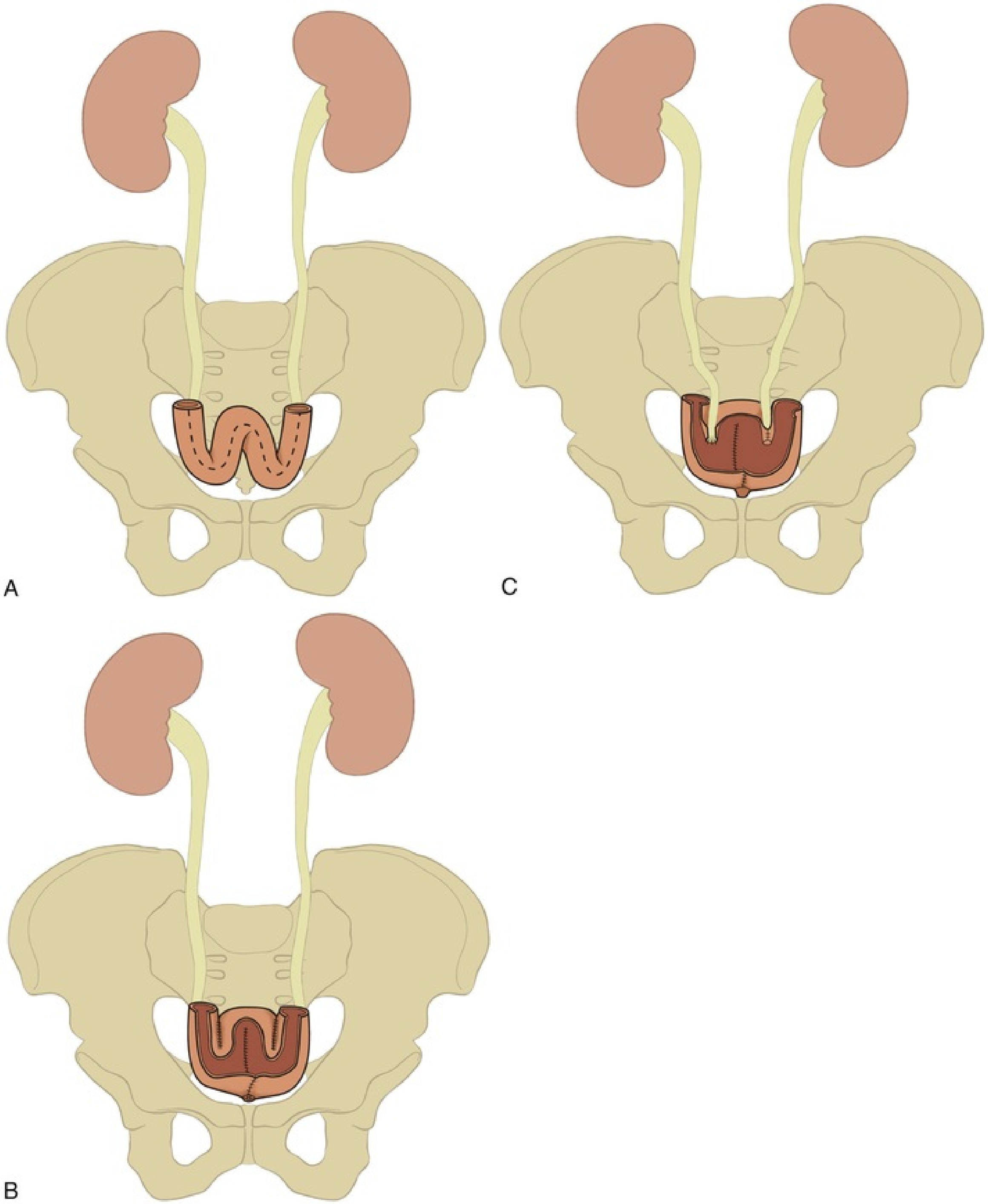

FIG. 139.30 Ureter–small bowel anastomosis. (A) Small bowel aligned so that four serosal surfaces are apposed in preparation for construction of two serosal compression tunnels. Serosal surfaces of the afferent limbs adjacent to the mesentery are sutured together with silk sutures. (B) The serosal surfaces of the afferent limbs adjacent to the mesentery are sutured together with silk sutures. The antimesenteric borders of the apposed bowel segments are opened, thus making a trough. (C) The ureters are laid in the trough and sutured to the seromuscular-mucosal wall

at its distal end (illustrated on the right ureter), and the seromuscular-mucosal layer is closed over the ureter anteriorly (illustrated on the left ureter).

With an average of 3 years of follow-up, the anastomotic stricture rate is 4%, and the rate of failure of the antireflux mechanism is 3% (Abol-Enein and Ghoneim, 2001; Türkölmez et al., 2004).

Intestinal Antireflux Valves

Another technique for preventing reflux into the ureter involves construction of an antireflux mechanism with bowel distal to the ureterointestinal anastomosis. The ureter is sutured by the technique of either Bricker or Wallace (as described earlier) to the end of the bowel, and the bowel is used to make a one-way valve. Unlike with individual ureterointestinal antirefluxing anastomosis, when these valves fail or stenose, both kidneys are affected. Three basic types of antireflux mechanisms commonly used with the bowel are ileocecal intussusception, ileoileal intussusception, and ileal nipple valve placed into colon.

Intussuscepted Ileocecal Valve

The mesentery is cleared from the ileum for a length of 8 cm beginning at the cecum and coursing proximally (Fig. 139.31). At least 5 cm of ileum proximal to the detached mesentery must be intact to ensure intestinal viability. Thus the ileum should not be transected less than 13 cm from the ileocecal junction. A No. 22 catheter is placed through the ileum into the cecum. The ileal serosa is scarified either by multiple cross-incisions with a knife or with the electrocautery unit. The 8-cm segment is intussuscepted over the catheter into the cecum. The intussuscepted ileum is secured to the cecal wall with 3-0 silk sutures placed circumferentially 2 mm apart.

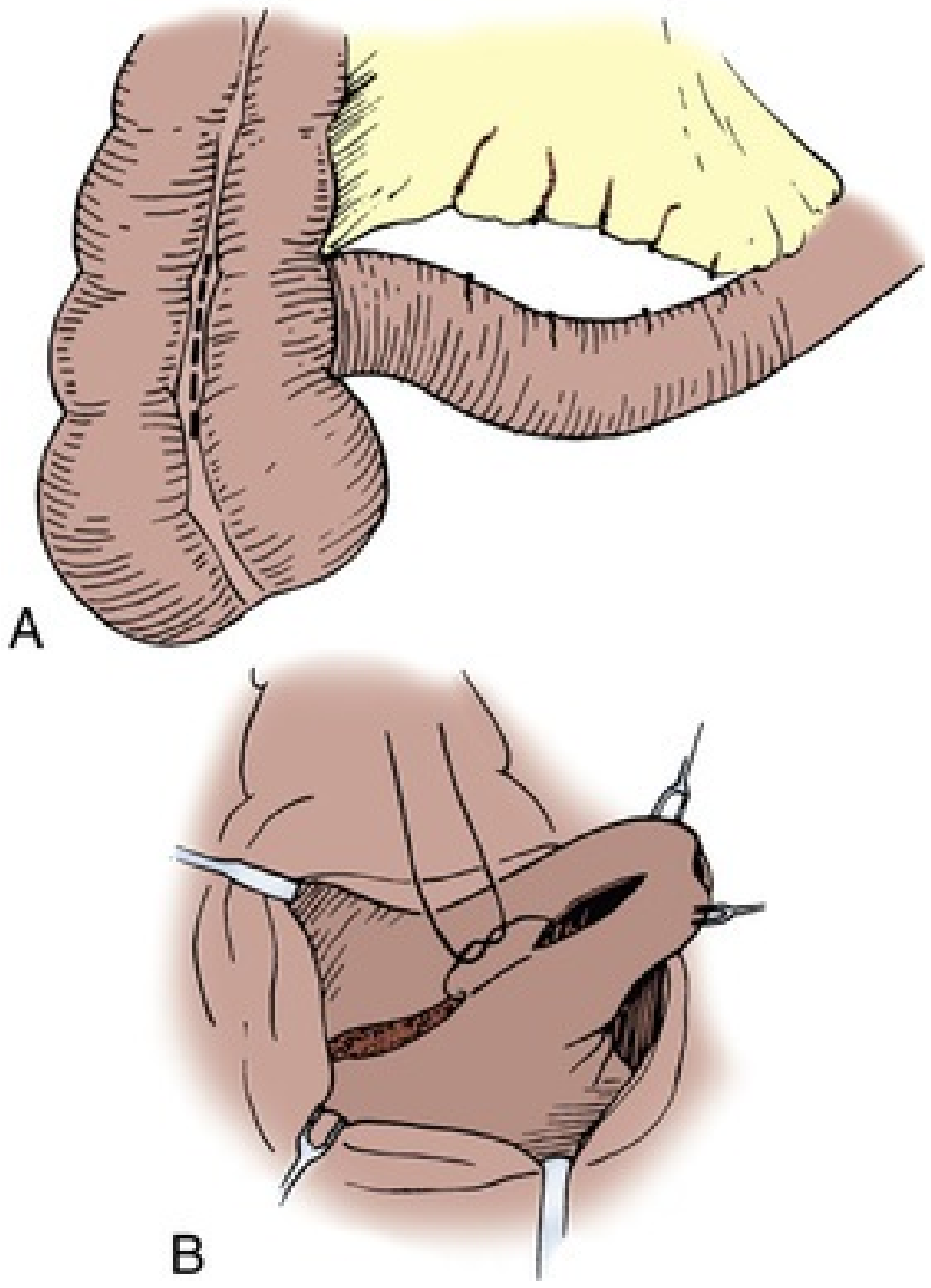

FIG. 139.31 Ileocecal intussusception. (A) An 8-cm segment of ileal mesentery is cleared from the serosa beginning at the ileocecal junction. At least 5 cm of mesentery remains attached to the proximal ileum. An incision is made along a taenia at the level of the ileocecal valve. (B) The ileum is intussuscepted over a 22-Fr catheter into the cecum under direct vision. The mucosa of the intussuscepted segment is incised, and the mucosa of the cecum adjacent to it is also incised. The muscle coats of both segments are sutured together. The serosa of the ileum is secured to the serosa of the cecum with interrupted 3-0 silk sutures placed circumferentially *(not depicted).*

The valve has a moderate tendency to fail because the intussusception has a significant chance of reduction. In one series, the antireflux mechanism remained intact in 55% of the patients during the long term (Hensle and Burbige, 1985). The intussusception may be made more secure by using a modification described by King (1987). The mesentery is cleared as described earlier. The cecum is opened along a taenia, and the ileum is intussuscepted over the catheter under direct vision. Where the intussusception lies adjacent to the cecal wall, mucosa of the intussuscepted ileum and the cecal mucosa adjacent to it are incised down to muscle. The muscles are sewn together with interrupted 3-0 chromic sutures. Long-term follow-up in eight patients reveals maintenance of the antireflux valve in seven with the modified technique (Friedman et al., 1992; King, 1987). The Mainz group advocates stapling the intussuscepted ileum to the ileocecal valve to prevent reduction. In their series, 82% of patients maintained valve competence; however, there was a 20% incidence of stone formation (Wiesner et al., 2006).

Intussuscepted Ileal Valve

The mesentery is cleared from an 8-cm segment of ileal serosa (Fig. 139.32). There must be 5 cm of ileal mesentery proximal and distal to the cleared segment to ensure proper blood supply. The ureters are sewn to the proximal end of ileum. The distal end of ileum is opened along its antimesenteric border to within 2 to 3 cm of the cleared mesentery to provide adequate exposure and direct visualization of the intussuscepted segment. A Babcock clamp is placed into the lumen of the bowel, and a portion of bowel wall is grasped by invaginating it into the clamp with a finger. The ileal segment is intussuscepted by pulling on the Babcock clamp with gentle constant traction. If there is resistance, the mesentery is usually too bulky, and it must be defatted carefully before another attempt to intussuscept the segment. A 5-cm intussuscepted segment should protrude. The gastrointestinal stapler without the knife or the linear stapler, from which the distal five to eight staples have been removed, is used to secure the intussusception in place; three rows with the gastrointestinal stapler or four rows with the linear stapler are placed in quadrants. The staple size should be 4.8 mm. The proximal staples are important in securing the intussusception and preventing its reduction, whereas the distal staples are less effective and more likely to be exposed to urine and thus facilitate stone formation. It is for this reason that the distal staples are removed from the staple cartridge before it is placed in the stapler and before the intussusception is stapled. With the cautery unit, the mucosa of the intussusception is incised along its length. Adjacent to this incision, another is made in the mucosa of the ileum. The muscularis of both is exposed and sewn together with interrupted 3-0 chromic suture. The distal serosa is then sutured proximally to the serosa of the intussuscepted segment circumferentially with 3-0 nonabsorbable sutures. This is meant to secure the intussusception and to prevent its reduction with failure of the antireflux mechanism. The valve is successful in preventing reflux 90% of the time (Kock et al., 1982; Skinner et al., 1989).

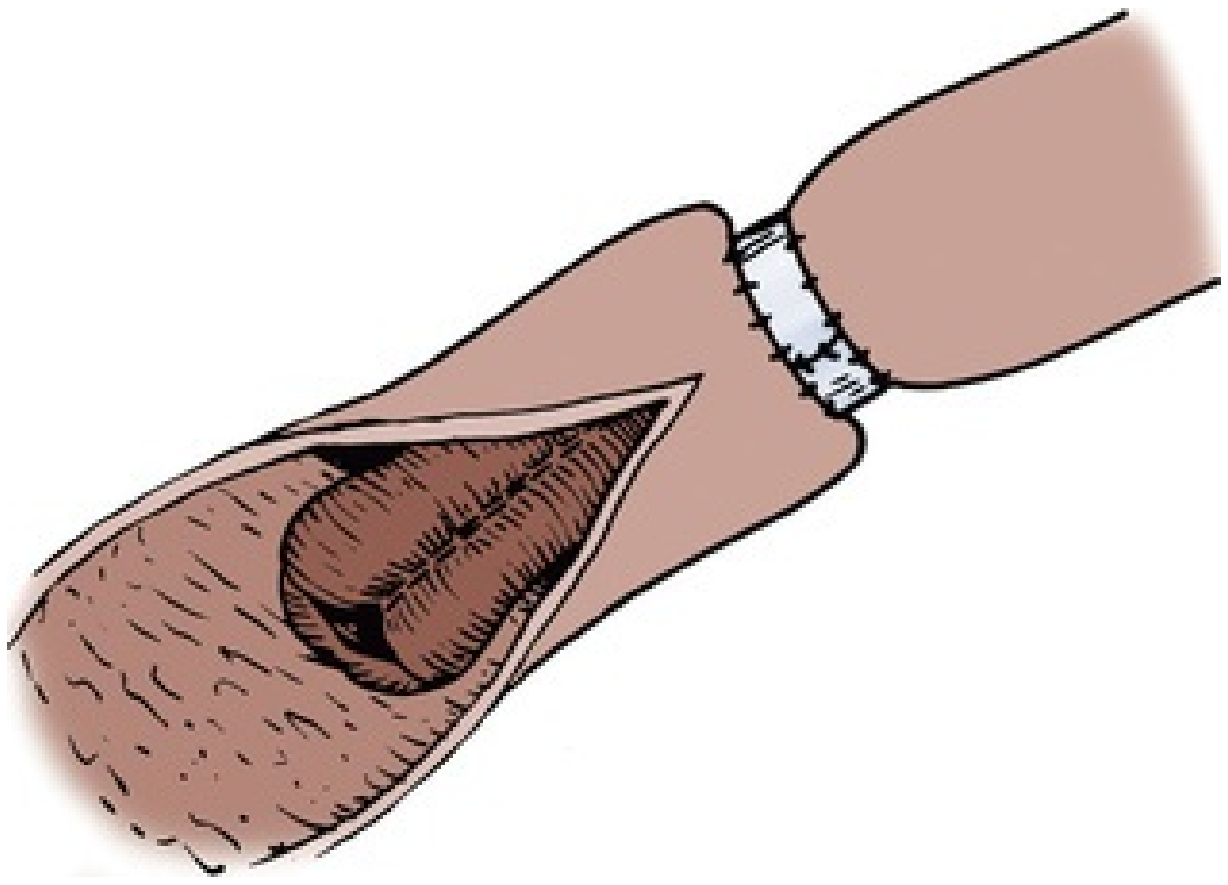

FIG. 139.32 Intussuscepted ileal nipple valve. An 8-cm length of ileal mesentery is cleared from the serosa. The ileum distally is opened within 2 to 3 cm of the rent in the mesentery; a 5-cm length of ileum is intussuscepted and secured by placement of staples in quadrants. The ileal mucosa is incised adjacent to an incision in the intussuscepted segment, and the two muscle coats are sutured together with interrupted 3-0 chromic suture. The serosa of the intussuscepted segment is sutured circumferentially to the base of the ileum, into which the proximal segment is intussuscepted with interrupted silk suture.

Because the intussuscepted nipple valve as an antireflux mechanism has resulted in a 10% complication rate (5% stone formation on the exposed staples, 4% stenosis, and 1% prolapse) (Stein et al., 1996a), modifications have been developed in an attempt to reduce these untoward outcomes. One such modification has been described by the University of Southern California group. An 8- to 10-cm isolated segment of ileum is tapered distally and laid between two segments of small bowel in which their serosal walls adjacent to the mesentery are sutured together. This serves as the posterior support for the isolated segment. The apposed bowel is opened along its antimesenteric border; lateral flaps are constructed adjacent to the segment and closed over its anterior aspect, thus making a serosal trough in which 4 cm of the segment of tapered ileum is positioned (Stein and Skinner, 2003). When the pouch is closed, a nipple valve is constructed. The concept is that as pressure in the pouch increases, the walls of the tapered nipple valve are compressed, thus preventing reflux. The authors call their modification a *T pouch.*

Nipple Valve

The simplest intestinal antireflux valve to make is the nipple valve with use of ileum (Fig. 139.33). The mesentery is cleared from the last 8 cm of the cut end of the ileum. The distal 6 cm of serosa is scarified by multiple cross-striations and then turned back on itself to form a nipple. The nipple should be at least 4 to 4.5 cm in length. The end of the inverted ileum is then sutured to itself with interrupted 4-0 PDS. An incision on the taenia large enough to accommodate the segment is made. A No. 22 catheter is placed through the segment, and its serosa is sutured to the colon serosa circumferentially with interrupted 3-0 silk sutures placed 2 mm apart. The long-term success rate for this type of valve is unknown but is comparable to tunneled anastomoses (Osman et al., 2004).

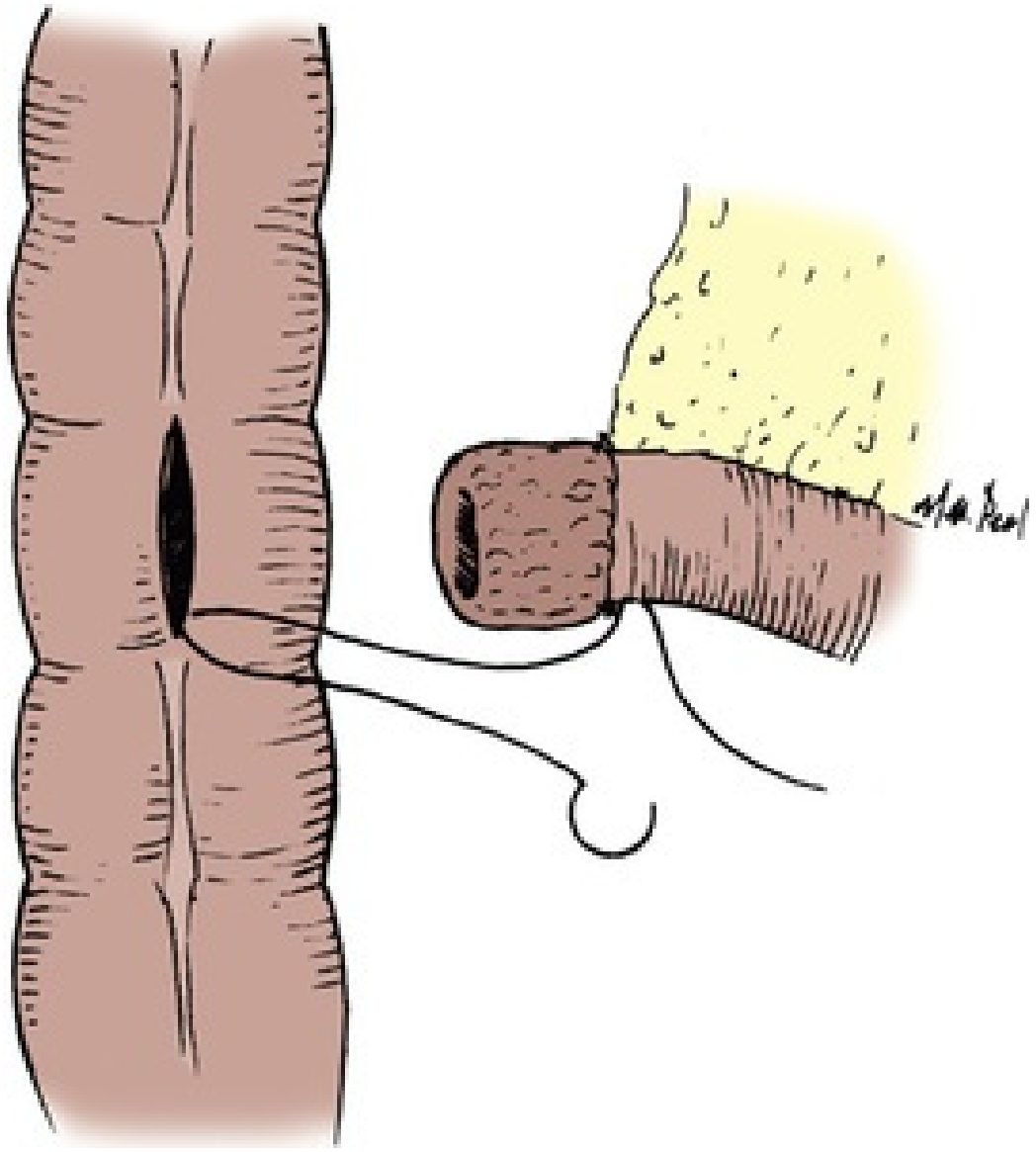

FIG. 139.33 Nipple valve. Approximately 8 cm of mesentery are cleared from the distal end of the ileum, and the serosa is scarified and then turned back on itself to form a nipple of approximately 4 cm in length. The end of the ileum is sutured to itself with interrupted 4-0 polydioxanone sutures (PDS). A rent is made in the colon through a taenia, and the nipple valve is placed through the rent and secured with circumferential interrupted 4-0 PDS through the full thickness of the colon and the seromuscular layer of the ileum.

Complications of Ureterointestinal Anastomoses

The complications that occur with ureterointestinal anastomoses include leakage, stricture, reflux in those anastomoses that were performed to prevent reflux, and pyelonephritis. In a review of the various types of procedures, it appears that of the colonic antirefluxing procedures, the **Pagano technique** offers the lowest incidence of stricture with an acceptable incidence of reflux. With respect to small bowel antireflux procedures, the **Le Duc procedure** and the ureterointestinal serosal apposition procedure seem to offer the lowest incidence of stricture with the highest success rates in preventing reflux. With respect to stricture formation and leakage, it appears the **Wallace technique** has the best results (Kouba et al., 2007).

Urinary Fistula

Urinary fistulas typically occur within the first 7 to 10 days postoperatively with an incidence of 3% to 9% (see Table 139.9) (De Nunzio et al., 2013; Loening et al., 1982)**. The incidence of urinary intestinal leak is markedly reduced by the use of soft Silastic stents** (Mattei et al., 2008). A urinary intestinal leak may cause periureteral fibrosis and scarring with subsequent stricture formation.

Stricture

In general, **the antirefluxing techniques have a higher incidence of stricture.** Patients are at risk for ureterointestinal strictures for the life of the anastomosis and must be observed on a scheduled periodic basis. A stricture has been reported to develop 13 years after the procedure (Shapiro et al., 1975). **Ureteral strictures also occur away from the ureterointestinal anastomosis. This stricture is most common in the left ureter and is usually found as the ureter crosses over the aorta beneath the inferior mesenteric artery.** It has been suggested that this occurs because of overly aggressive stripping of adventitia and angulation of the ureter at the inferior mesenteric artery.

Once a stricture has developed, various techniques may be used to rectify the situation. The most successful is re-exploration, with removal of the stenotic segment and reanastomosis of the ureter to the bowel by one of the aforementioned techniques. A number of studies have compared open surgical correction of ureterointestinal anastomotic strictures with endourologic methods. In general, **open repair has a success rate of approximately 75% at 3 years versus 15% for balloon dilation** with similar follow-up (DiMarco et al., 2001). Open surgical methods may be morbid and difficult procedures. Endourologic procedures using balloon dilation have not proved to be durable, and therefore many surgeons have used either cold knife incisions or laser incisions. **When several series involving use of endourologic methods are combined, there is a 50% to 60% success rate** with 2 years of follow-up. **Strictures occurring in**

less than 1 year from the original procedure, strictures 1.5 cm or longer, and left-sided strictures have less favorable outcomes with endourologic methods (Cornud et al., 1996; Kramolowsky et al., 1987, 1988; Laven et al., 2001; Poulakis et al., 2003). These data must be viewed with caution because longer follow-up usually results in additional recurrences. Metal stents may be considered in a patient with a limited life expectancy, thus avoiding a major open operation; however, such stents should be used with caution in the case of ureteral stricture. In one study utilizing the Resonance metallic ureteral stent (Cook Medical, Bloomington, IN) stricture patency was preserved in only in 8 of 18 cases (44%) at a mean follow-up time of just 2.6 months (Liatsikos et al., 2010). Self-expanding metal alloy stents (Wallstents, Schneider, Zurich, Switzerland) showed more promising results in a small trial of nonmalignant ureterointestinal strictures with successful treatment of 10/10 strictures at a median follow up of 22 months; one patient developed a stone on the stent (Palascak et al., 2001). Additional long-term studies are needed.

Pyelonephritis

Acute pyelonephritis occurs both in the early postoperative period and during the long term. Its incidence is approximately 10% to 20% in patients diverted with ileal conduits and 9% in those diverted with antirefluxing colon conduits (see Table 139.8). **These complications cause considerable morbidity and, in fact, are associated with significant mortality.** In one series of intestinal segments in the urinary tract, 8 of 178 patients died of sepsis (Schmidt et al., 1973). That these complications may result in delayed mortality is indicated by the fact that 2 of 115 children and 3 of 127 adults died of septic complications 5 to 14 years after intestinal diversion (Pitts and Muecke, 1979). **When sepsis is associated with decreasing renal function and uremia, the morbidity and mortality are markedly increased.** Although the mortality rate may be somewhat lower in the current age of antibiotics, the rise of multidrug-resistant organisms poses a significant threat in both the short and long term in patients undergoing urinary diversion.

Table 139.9 summarizes the complications and success rates for the various types of anastomoses. The table is derived from composite reports in the literature in which specific anastomoses were described and from which the data could be accurately analyzed. Because of these two requirements, it is not possible to comment, for example, on the incidences of reflux or leakage among various anastomotic types inclusively. These complications can be minimized by adherence to the principles of ureterointestinal surgery discussed earlier.

Renal Deterioration

The incidence of renal deterioration after conduit urinary intestinal diversion has varied from 10% to 74% (Eisenberg et al., 2014; Gilbert et al., 2013; Madersbacher et al., 2003). This variance is perhaps a result of the fact that many reports include both renal units that were abnormal and those that were normal before diversion. **In analyzing abnormal renal units before diversion and documenting progressive disease, it is difficult to be sure whether the urinary diversion caused the progression or whether progression is caused by the intrinsic abnormality for which the diversion was constructed. When the incidence of renal deterioration is determined by comparing renal units that were normal before diversion and then deteriorated postoperatively, 18% of patients who have ileal conduits show progressive deterioration versus 13% who have nonrefluxing colon conduits** (see Table 139.8). Twenty percent of patients with nonrefluxing continent ileocecal bladders show some evidence of deterioration of the upper tracts when they are observed during the long term (Benchekroun, 1987). This deterioration leads to a 10% incidence of azotemia in children with ileal conduits (Schwarz and Jeffs, 1975) and a 12% (5 of 41 patients) incidence of renal failure in patients with colon conduits constructed for benign disease (Elder et al., 1979). **There is significant and progressive deterioration in renal function in the majority of patients independent of the type of urinary diversion** (Eisenberg et al., 2014).

The incidence rates for both sepsis and renal failure are greater in patients with ureterosigmoidostomy than in those with conduits. Sepsis and renal failure may occur either in the immediate postoperative period or many years later. **The most common cause of death in patients who have had a ureterosigmoidostomy for more than 15 years is acquired renal disease (i.e., sepsis or renal failure).** In this group of patients, approximately 10% to 22% die of these disorders (Zabbo and Kay, 1986), some as late as 27 years after diversion (Mesrobian et al., 1988). **In patients with ileal conduits, about 6% ultimately die of renal failure** (Richie, 1974).

Renal Function Necessary for Urinary Intestinal Diversion

The amount of renal function required to effectively blunt the reabsorption of urinary solutes by the intestinal segment and to prevent serious metabolic side effects depends on the type of urinary intestinal diversion constructed (i.e., the amount of bowel to be used and the length of time the urine is exposed to the intestinal mucosa). Thus **a greater degree of renal function is necessary for retentive (continent) diversions than for short conduit diversions.** In general, patients who have a glomerular filtration rate (GFR) on average above 40 mL/min tolerate a continent diversion reasonably well. Indeed, in one study, two groups of patients were analyzed: those with GFRs around 100 mL/min (range, 91 to 112) and those with GFRs around 55 mL/min (range, 36 to 69). Both seemed to tolerate the metabolic load well with a minimal development of metabolic acidosis. There was a slightly increased incidence of metabolic acidosis in the group with low GFR, as would be expected; however, in this group, distal tubule function was excellently maintained as demonstrated by ammonium chloride loading. This observation points out that GFR is not the sole determining factor that allows the body to manage intestinal diversion. Indeed, GFR is but one factor. Just as important is distal tubule function. This article confirms that when distal tubule function is normal and the GFR is above 40 mL/min, patients do extremely well (Kristjánsson et al., 1997).

There are five components of renal function: renal blood flow, glomerular filtration, tubule transport, concentration and dilution, and glomerular permeability. Aspects of renal function that must be specifically addressed are GFR, best measured by inulin clearance; ability of the tubule to acidify, determined by ammonium chloride loading; concentrating ability, determined by water deprivation; and glomerular permeability, reflected by urine protein concentrations. **In general, patients with normal urine protein content who have a serum creatinine concentration below 2.0 mg/dL do well with intestine interposed in the urinary tract.** Serum cystatin C is a promising serum protein that reflects GFR more accurately than creatinine; however, its usefulness in urinary intestinal diversion has not yet been determined (Herget-Rosenthal et al., 2012; Inker et al., 2012). At a level of serum creatinine below 2 mg/dL, renal blood flow, GFR, tubule transport, and concentrating and diluting ability are relatively well preserved. **In patients whose serum creatinine concentration exceeds 2 mg/dL and who are being considered for retentive diversion or in whom long segments of intestine will be used, a more detailed analysis of renal function is necessary. If the patient can achieve a urine pH of 5.8 or less after an ammonium chloride load, has a urine**

osmolality of 600 mOsm/kg or higher in response to water deprivation, has a GFR that exceeds 35 mL/min, and has minimal protein in the urine, the patient may be considered for a retentive diversion.

Key Points

- Complications that occur with ureterointestinal anastomoses include leakage, stricture, reflux in those anastomoses that were performed to prevent reflux, and pyelonephritis.
- The incidence of urinary intestinal leak is markedly reduced by the use of stents.
- Antirefluxing techniques have a higher incidence of stricture than refluxing anastomotic techniques.
- The Wallace anastomosis has the lowest complication rate of any ureterointestinal anastomotic technique.
- In the long term, there is significant and progressive deterioration in renal function in the majority of patients independent of the type of urinary diversion caused. This deterioration is caused by a lack of ureteral motility, infection, stones, or less commonly a stricture at the anastomotic site.

Urinary Diversion

This section deals with specific types of conduit urinary diversions. Fundamentally, there are two types of conduits: (1) those using the small bowel, which includes the jejunum or ileum and (2) those in which a portion of large bowel is used. Conduits made of stomach have been described but are rarely indicated and may carry with them difficult problems of stomal maintenance. Their construction is not discussed here. Each type of conduit has specific indications and advantages, and for each there are specific complications. Some complications, however, are similar among all types. **The indications for a conduit are the need for urinary diversion: after a cystectomy; because of a diseased bladder; before transplantation in a patient who has a bladder that cannot adequately receive the transplant ureter; and for dysfunctional bladders that result in persistent bleeding, obstructed ureters, poor compliance with upper tract deterioration, and inadequate storage with total urinary incontinence.**

This section describes features that are unique to the construction of the conduit. The complications cited for each conduit also depend on the length of follow-up and the concomitant procedure performed. Orthotopic neobladder construction is discussed in a separate chapter.

Ileal Conduit

In the ileal conduit procedure, a portion of distal ileum is chosen. **It is the simplest type of conduit diversion to perform and is associated with the fewest intraoperative and immediate postoperative complications. It is not advisable to use ileum for a conduit in patients with a short bowel syndrome, in patients with inflammatory small bowel disease, and in those whose ileum has received extensive irradiation, often as a consequence of prior radiation therapy for a pelvic malignant neoplasm.**

Procedure

A segment 10 to 15 cm in length is selected 10 to 15 cm from the ileocecal valve. The cecum and ileal appendage (i.e., that portion of the distal ileum fixed to the retroperitoneum) are mobilized. The ileal mesentery is transilluminated, and a major arcade to the segment selected is identified. With a mosquito clamp, the mesentery immediately beneath the bowel is penetrated, and the bowel is encircled with a vessel loop. An area at the base of the mesentery that is to one side of the feeding vessel is selected, and a second vessel loop is placed through the mesentery. At this juncture, the peritoneum overlying both sides of the mesentery is incised from bowel vessel loop to the base of mesentery vessel loop. With mosquito clamps, the tissue is clamped, severed, and tied with 4-0 silk. A portion of mesentery 2 cm in length is cleared away from the bowel beneath the mesenteric incision. This procedure is repeated at the other end of the selected segment. The base of the mesentery should be as wide as possible and the mesenteric windows not excessive (in general about 5 cm in length) to prevent ischemia of the segment. Allen clamps are placed across the bowel in an angled fashion such that the antimesenteric portion is shorter than the mesenteric portion. (Some prefer to transect the bowel with an anastomotic stapler.) Thus, a triangular piece of bowel is removed and discarded.

The isolated ileal segment is placed caudad, and an ileoileostomy is performed as described earlier (Fig. 139.34). The mesenteric window of the ileoileostomy is closed with interrupted 3-0 silk sutures. The isolated segment is then flushed with copious amounts of saline until the irrigant is clear, at which point the ureters are brought out the retroperitoneum in the right lower quadrant. To accomplish this, the left ureter must be brought over the great vessels and posterior to the sigmoid mesentery to the rent in the posterior peritoneum.

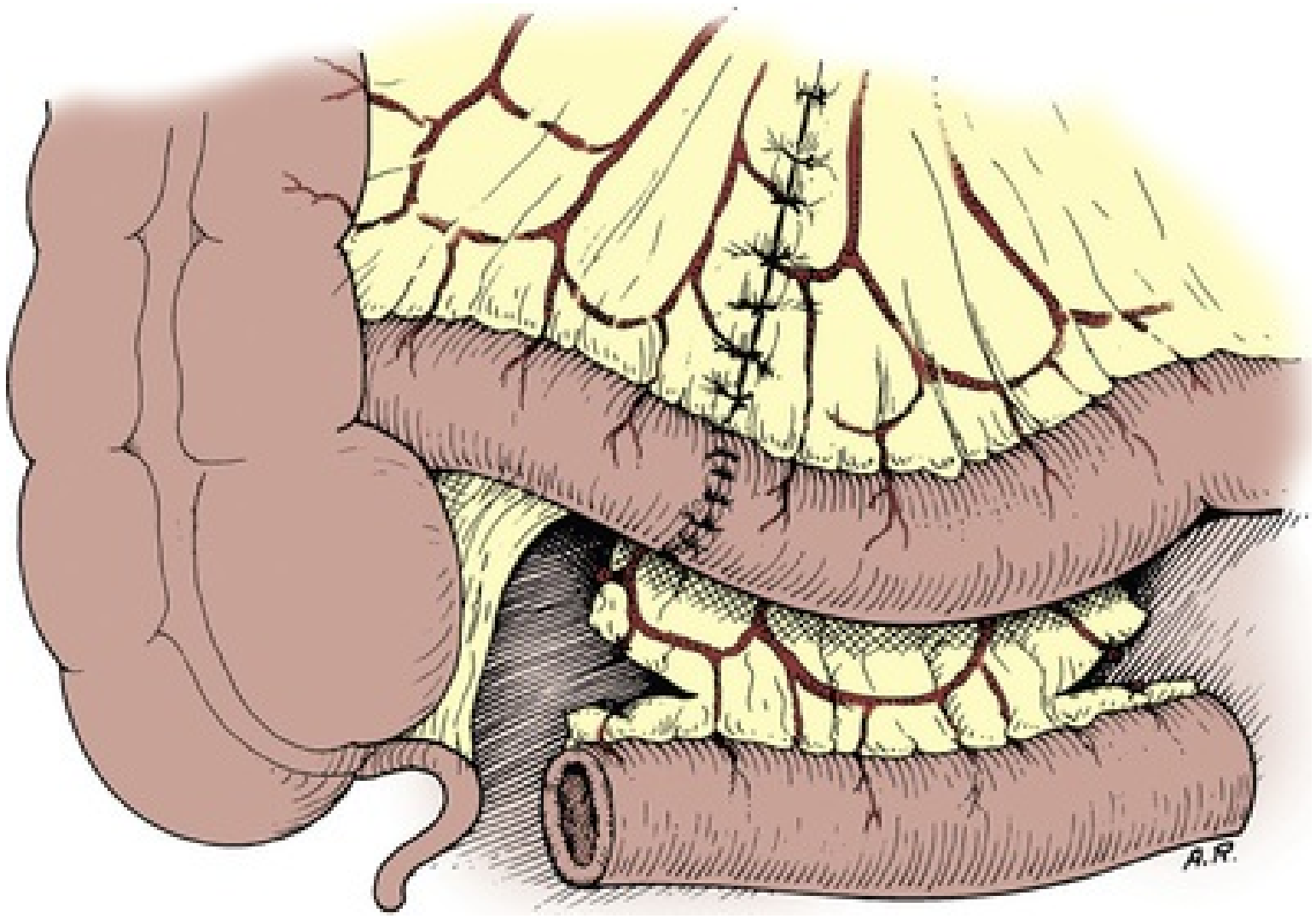

FIG. 139.34 The isolated segment of ileum is placed caudal to the ileoileostomy. An incision on the mesentery of the isolated segment 1 cm

from the bowel wall straightens the end. In general, this is not necessary unless the mesentery is excessively bulky.

The cecum is mobilized cephalad to identify the right ureter. The left ureter may be identified by incising the line of Toldt of the left descending colon (Fig. 139.35). This dissection allows anastomosis of the ileal segment as proximally as needed to the ureter. Indeed, the ileum may be anastomosed directly to the renal pelvis on both sides if necessary (see Fig. 139.35C). After a cystectomy, the ureters are identified caudad to the iliac vessels and may be conveniently traced cephalad similar to the previous description. The ureteroileal anastomoses are performed as described earlier. These anastomoses are stented.

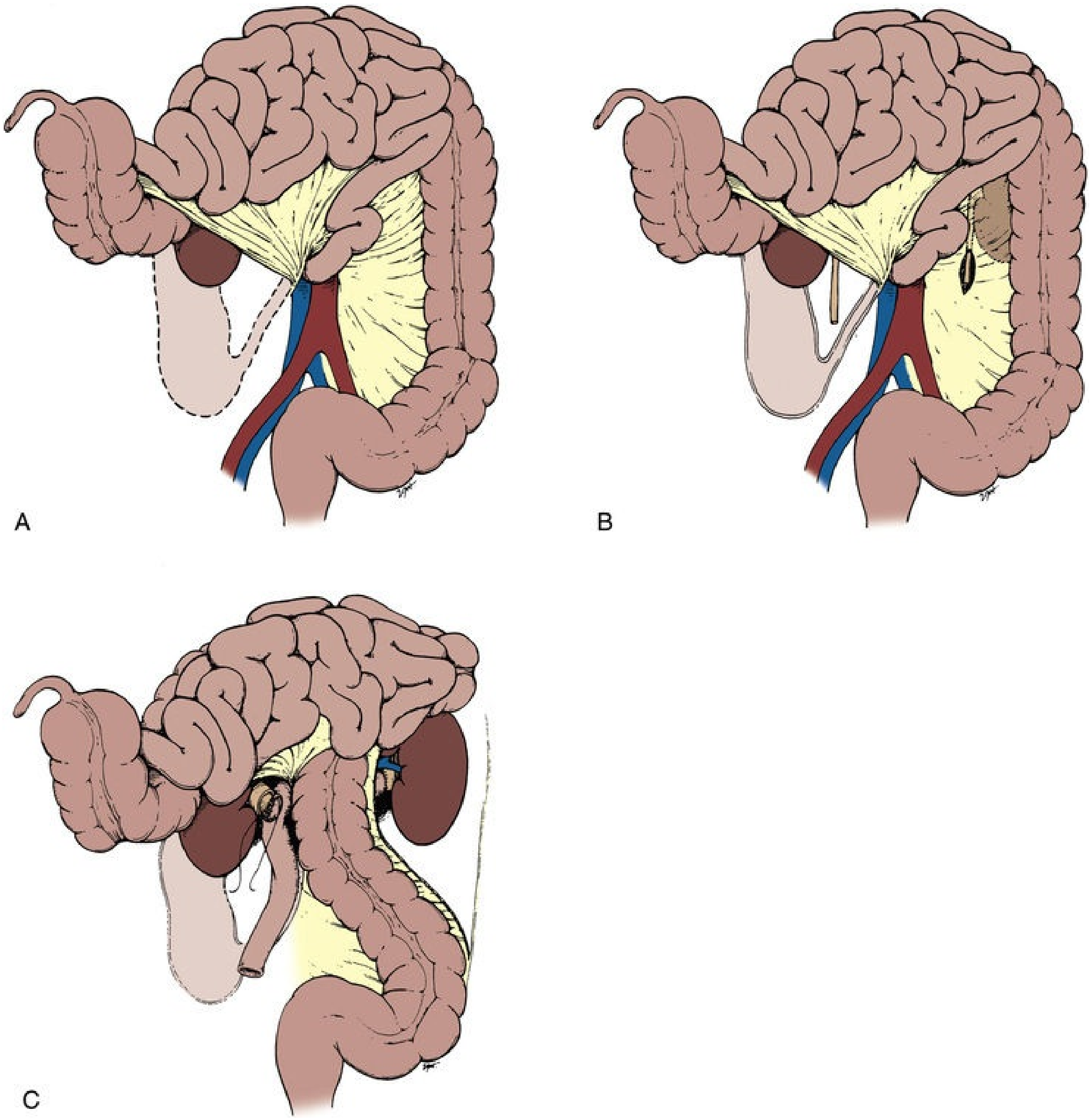

FIG. 139.35 (A) The cecum and root of the mesentery are incised. By blunt dissection, the cecum, ascending colon, and small bowel are mobilized cephalad. (B) The right and left ureters are identified. The left ureter is more easily identified by mobilizing the left colon. (C) The left colon is mobilized by incising the line of Toldt. This degree of mobilization allows anastomosis of the ileal segment to as proximal a position to the ureter as needed. This figure depicts a left renal pelvic and right ureterointestinal anastomosis.

A convenient method of introducing the stent through the loop to the opening in the bowel is illustrated in Fig. 139.36. The base of the conduit is fixed to the retroperitoneum in the right lower quadrant by suturing the posterior peritoneum to the conduit, thus effectively retroperitonealizing the ureterointestinal anastomosis. The stoma is made as described earlier. We prefer to suture the loop segment to the lateral peritoneal wall, thus obviating any chance of herniating small bowel lateral to the conduit. Many prefer to bring the segment directly to the anterior abdominal wall, however, thus allowing bowel to descend caudad on either side of the loop.

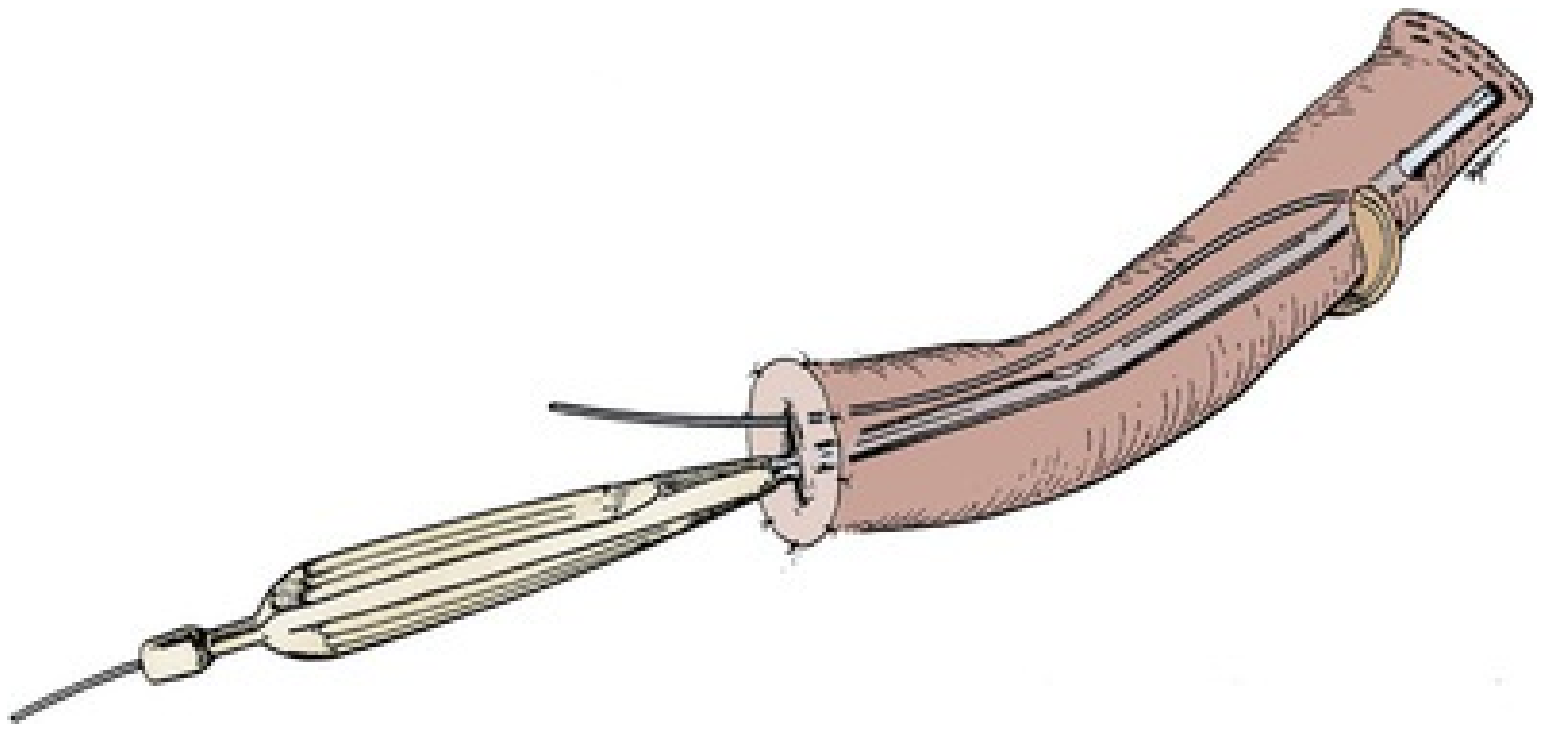

FIG. 139.36 The ureterointestinal anastomoses should be stented with soft Silastic stents. These stents may be conveniently introduced with a Yankauer suction instrument from which the tip has been removed. The suction instrument is introduced by way of the distal end of the segment to the desired location of the ureteral anastomosis. When one cuts down on the Yankauer tip, its end protrudes through the bowel at the desired site. The stent is threaded through the suction instrument, and the instrument is removed.

Robotic and laparoscopic surgical approaches have been described, with similar 90-day complication rates in the hands of experienced robotic surgeons (Ahmed et al., 2014).

Complications

Early and late postoperative complications are listed in Table 139.10. It is difficult to clearly ascribe these complications solely to construction of the conduit because many are reported in patients undergoing a cystectomy as well. These incidences in Table 139.10 are therefore expected to reflect the high end of the spectrum. **Bleeding may occur from either the stoma or the conduit itself. Approximately 10% of patients have stomal bleeding. In 4%, it originates from the loop beneath the fascia** (Delgado and Muecke, 1973). Bleeding that is extremely difficult to manage may be a result of cirrhosis and varices. In this situation, life-threatening bleeding from the conduit may occur. To stop the bleeding, portal decompression may be required. This may involve percutaneous transhepatic portal shunt or transhepatic angiography with embolization (Carrafiello et al., 2007; Lashley et al., 1997; Medina et al., 1998). **Complications not listed include hypertension, renal failure, decreased renal function, and death.** These complications in large part depend on the concomitant procedure performed, the length of follow-up, and the status of the kidneys before diversion. **During the long term (20 years), 7% of patients have renal failure requiring dialysis, and 60% show deterioration of the upper tracts** (Koch et al., 1992)**. Salvage cystectomy is associated with acceptable morbidity, although complication rates are higher than for other cystectomy series. Immediate salvage cystectomies (persistent disease after induction course of chemoradiation) have more cardiovascular/hematologic complications, and delayed salvage cystectomies (those with invasive recurrence after completion course of chemoradiation) have more tissue-healing complications** (Eswara et al., 2012).

TABLE 139.10

Complications: Ileal Conduit[a]

	EARLY	LATE
Urine leak	2% (9/356)	
Bowel leak		
Sepsis	3% (7/230)	3% (4/142)
Acute pyelonephritis	3% (21/700)	18% (133/726)
Wound infection	7% (17/230)	2% (4/178)
Wound dehiscence	3% (11/326)	
Gastrointestinal bleeding	2% (2/90)	
Abscess	2% (3/168)	
Prolonged ileus	6% (14/230)	
Conduit bleeding	2% (3/178)	10% (18/178)
Intestinal obstruction	3% (18/610)	5% (42/878)
Ureteral obstruction	2% (14/610)	6% (56/878)
Parastomal hernia		2% (9/454)
Stomal stenosis		3% (143/486)
Stone formation		7% (59/822)
Excessive conduit length		9% (26/276)
Metabolic acidosis		13% (27/206)
Conduit infarction		2% (2/90)
Volvulus		0.7% (2/268)

Conduit stenosis		3% (11/320)
Conduit-enteric fistula		<1%

[a] Incidence as a percentage of the total number of reported cases from the literature. Numbers in parentheses represent the number of cases from which the percentage is derived.

Also, the complication rate is increased in patients in whom an intestinal segment is used who require renal transplantation (Nguyen et al., 1990).

One should be cautious in identifying duplex ureters. A failure to identify a second ureter on one side results in intraperitoneal urine leak and can cause excessive morbidity (Evans et al., 1994). The duplex ureters may be dealt with by implanting them separately if they are of sufficient caliber, or they may be spatulated, sewn together, and then implanted into the ileal conduit as a single unit (Fig. 139.37).

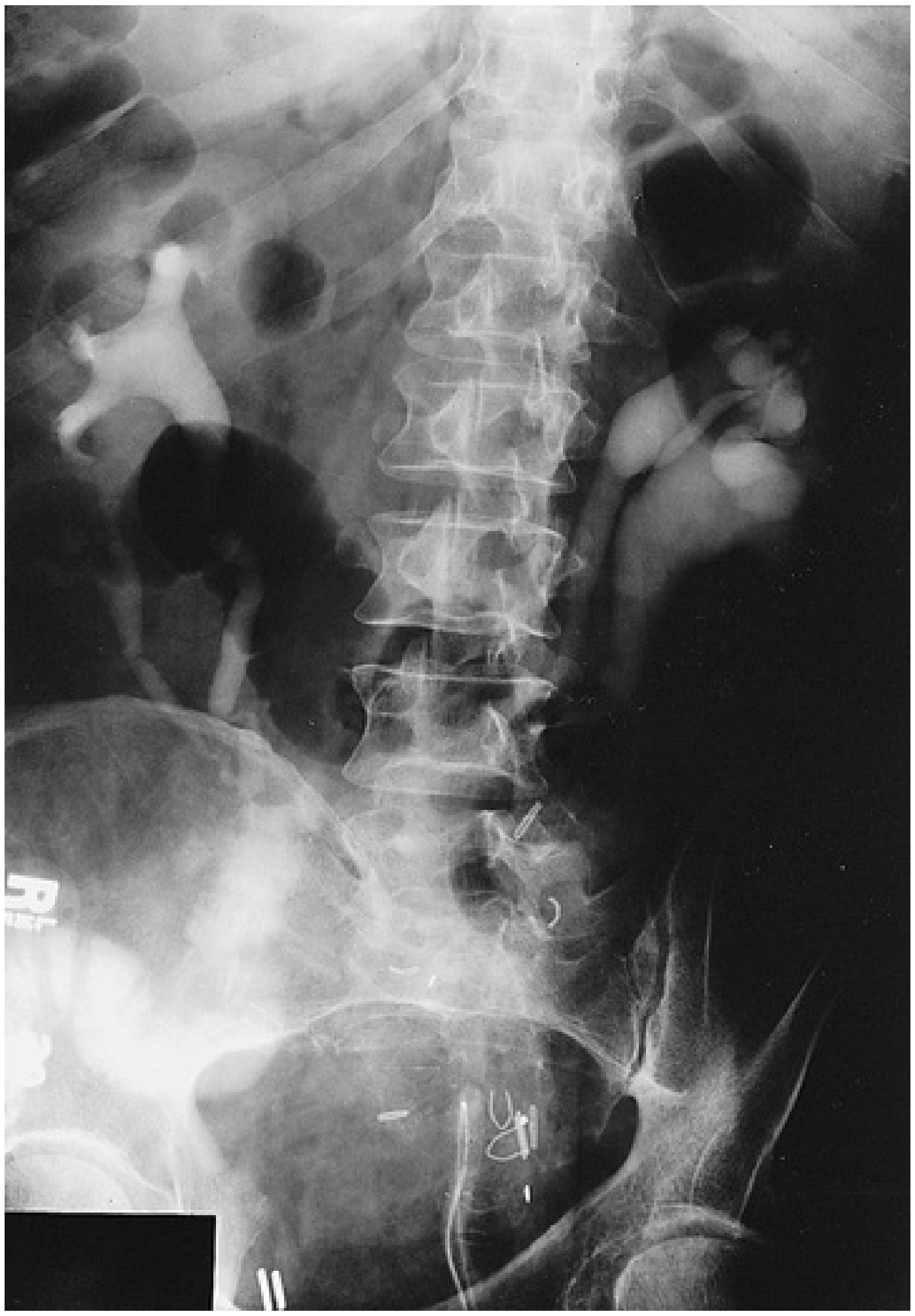

FIG. 139.37 Intravenous urogram 6 days postoperatively in a patient who had bilateral duplex ureters. The ureters on each side were spatulated,

sewn together, and anastomosed to the ileum.

Jejunal Conduit

The jejunum has the largest diameter of the small bowel and the longest mesentery. In general, jejunal conduits have not had a high rate of acceptance because of perceived electrolyte abnormalities. A more recent report of patients, most of whom were observed for more than 5 years, has shown that the bulk of electrolyte problems are minor; only about 4% in that series had severe hyponatremic metabolic acidosis. Renal calculi (12%), parastomal hernia (6%), and pyelonephritis (4%) constituted the majority of the remaining complications (Fontaine et al., 1997). The advantage of using the jejunum is that it avoids irradiated bowel and ureter. It is difficult to make a case for the jejunal conduit except in circumstances in which it is inadvisable to use either colon or ileum. However, this series does point out that when necessary, one can successfully use jejunum as a conduit. This might occur in patients who have extensive irradiation that involves the ileum, those with severe adhesions of the ileum and absence of the large bowel, and those who have an absent colon with inflammatory disease of the distal small bowel. **The contraindications to its use are severe bowel nutritional disorders and the presence of another acceptable segment.**

Procedure

The procedure is similar to that for an ileal conduit. A 10- to 15-cm segment of jejunum is isolated 15 to 25 cm from the ligament of Treitz as described for the ileal conduit. One should typically plan for the stoma to be in the left upper quadrant. The remainder of the technique is as described for the ileal conduit.

Complications

The early and long-term complications are similar to those listed for ileal conduit except that the electrolyte abnormality is a hyperkalemic, hyponatremic metabolic acidosis instead of the hyperchloremic metabolic acidosis of ileal diversion (Table 139.11). The treatment of jejunal syndrome consists of administration of sodium chloride and sodium bicarbonate. Thiazide diuretics may also be used and are helpful in allaying the hyperkalemia (Hasan et al., 1994).

TABLE 139.11

Complications: Jejunal Conduit[a]

	EARLY	LATE
Urine leak	14% (3/21)	
Wound dehiscence	5% (1/21)	
Acute pyelonephritis		10% (2/21)
Gastrointestinal bleeding	4% (1/27)	
Electrolyte abnormalities		27% (17/62)
Stomal stenosis		7% (2/27)
Bowel obstruction		7% (2/27)
Ureteral stricture		12% (5/41)
Enteric fistula	2% (4/140)	

[a] Incidence as a percentage of the total number of reported cases from the literature. Numbers in parentheses represent the number of cases from which the percentage is derived.

Colon Conduit

Three types of colon conduits are commonly used: transverse, sigmoid, and ileocecal. Each has specific indications with advantages and disadvantages.

The transverse colon is used when one wants to be sure that the segment of conduit used has not been irradiated in individuals who have received extensive pelvic irradiation. It is also an excellent segment when an intestinal pyelostomy needs to be performed. The sigmoid conduit is a good choice in patients undergoing a pelvic exenteration who will have a colostomy. Thus no bowel anastomosis needs to be made. It also allows nonrefluxing submucosal reimplantation and provides for an easily placed left-sided stoma when that is desirable.

The use of sigmoid colon is contraindicated with disease of this segment or when the hypogastric arteries have been ligated and the rectum has been left in situ. The latter circumstance may result in sloughing of the rectum or its mucosa because its blood supply of necessity is interrupted. **It is also unwise to use this segment in individuals with extensive pelvic irradiation** because it has probably been included in the radiation fields.

An ileocecal conduit has the advantage of providing a long segment of ileum when long segments of ureter need replacement and the advantage of providing colon for the stoma. It is also used in situations in which free reflux of urine from the conduit to the upper tracts is thought to be undesirable. **Contraindications to the use of transverse, sigmoid, and ileocecal conduits include the presence of inflammatory large bowel disease and severe chronic diarrhea.**

Procedure

Transverse Colon.

The segment may be isolated on the right or middle colic arteries, most commonly the latter (Fig. 139.38). The gastrocolic ligament is taken down, and the omentum is dissected from the portion of colon that is to be isolated. The splenic and hepatic flexures should be mobilized next. The proper length of segment is determined by taking into consideration the desired location of the stoma and the length of available ureters. In general, a length of 15 cm is sufficient. It is important not to isolate a segment that is too short and therefore incapable of reaching the retroperitoneum in such a position that a tension-free ureterocolonic anastomosis may be performed and retroperitonealized. The segment is isolated between bowel clamps, and a two-layer colocolostomy or stapled anastomosis is performed as outlined earlier. The segment is placed caudad to the anastomosis. If a colopyelostomy is to be performed, the segment should be placed cephalad to the bowel anastomosis. The isolated segment is irrigated with copious amounts of saline until the effluent is clear. The proximal end is closed with a running Connell suture of 3-0 chromic and a second layer of Lembert sutures of 3-0 silk. The ureterocolic anastomoses are then performed (see earlier), and the end is anchored to the retroperitoneum close to the midline. The stoma is usually placed in the right upper quadrant but may be placed anywhere in the abdomen if indicated.

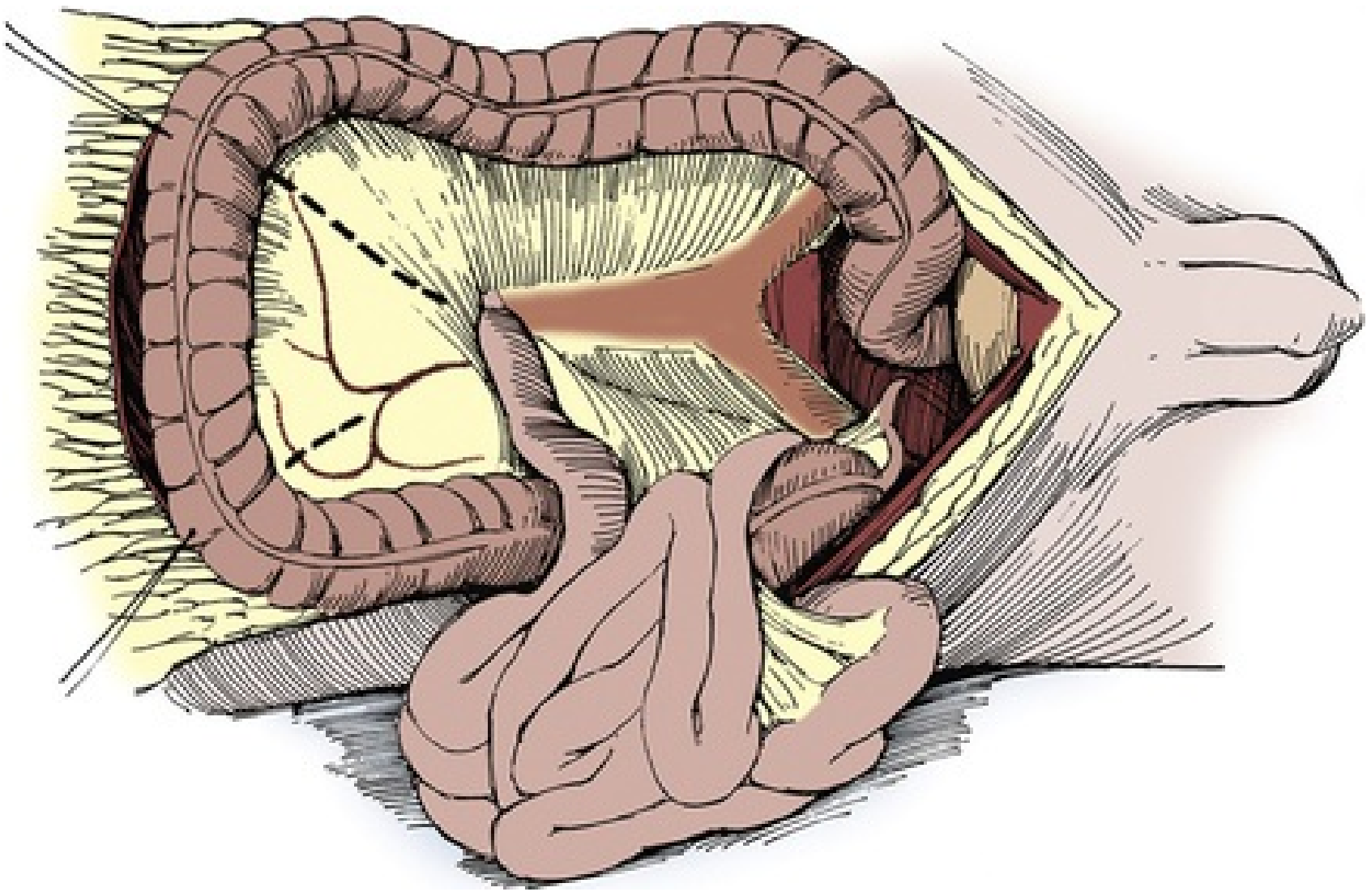

FIG. 139.38 Transverse colon conduit may be based on right colic or middle colic arteries *(depicted).* (From Hinman F Jr. *Atlas of urologic surgery*. Philadelphia, PA: Saunders; 1989.)

Sigmoid Colon.

The sigmoid colon is mobilized by incising its peritoneal attachments and the line of Toldt along the descending colon. The segment is isolated on the sigmoid vessels and placed lateral to the sigmoid colon (Fig. 139.39). The anastomosis of the sigmoid colon and ureterocolic anastomosis are as described for the transverse colon.

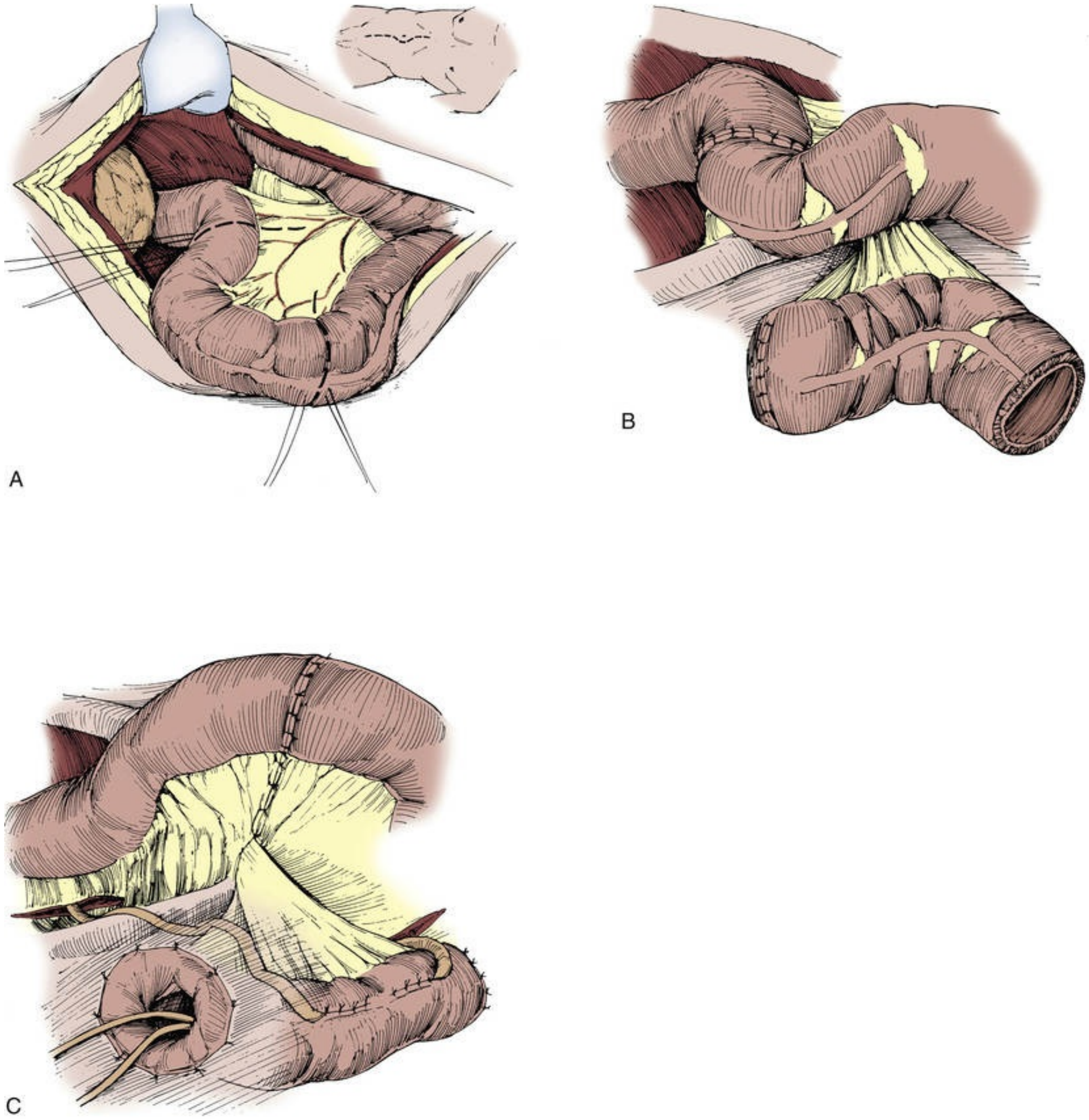

FIG. 139.39 (A) The sigmoid colon is freed of any peritoneal attachments. (B) The segment is isolated and placed laterally. Bowel continuity is restored, and the mesenteric window is closed. (C) The ureters are anastomosed to the colon and stented. (From Hinman F Jr. *Atlas of urologic surgery*. Philadelphia, PA: Saunders; 1989.)

Ileocecal Conduit.

The ileocecal conduit is based on the terminal branches of the superior mesenteric artery (i.e., ileocecal artery). The segment is placed caudad, and an ileum–ascending colon anastomosis is performed as described earlier. The stoma is placed in the right lower quadrant. The ileocecal valve may be reinforced to ensure prevention of reflux. This is described earlier (see Fig. 139.31). For the ureterointestinal anastomoses, also see the earlier description.

Complications

Early and late complications after a transverse colon, sigmoid, or ileocecal conduit are listed in Tables 139.12 to 139.14 (Beckley et al., 1982; Ravi et al., 1994; Schmidt et al., 1985). As is true for the small bowel, complications not listed including death, renal failure, and renal deterioration depend on the concomitant procedure performed and the length of follow-up. It is interesting to note that early reports suggested a lower incidence of renal deterioration with colon conduits, but some recent series suggest that the incidence of these complications is about the same. However, there continue to be proponents of the colon conduit because in the long term the apparent incidence of pyelonephritis is 7.6% and of preservation of the upper tracts is 78% (Stein et al., 1996b).

TABLE 139.12

Complications: Transverse Colon Conduit[a]

	EARLY	LATE
Urine leak	8% (11/137)	8% (2/25)
Acute pyelonephritis		11% (8/75)
Wound infection	5% (5/92)	
Wound dehiscence	7% (8/109)	
Abscess		5% (3/62)
Prolonged ileus	6% (2/30)	
Ureteral stricture	6% (5/84)	17% (37/215)
Bowel obstruction	3% (1/30)	2% (2/109)
Parastomal hernia		4% (5/114)
Stones		11% (11/98)
Enterocutaneous fistula		2% (1/62)
Stomal stenosis		2% (1/62)
Stomal prolapse		11% (6/56)
Metabolic acidosis		12% (3/26)

[a] Incidence as a percentage of the total number of reported cases from the literature. Numbers in parentheses represent the number of cases from which the percentage is derived.

TABLE 139.13

Complications: Sigmoid Conduit[a]

	EARLY	LATE
Urine leak	1% (1/70)	
Wound infection	1% (1/70)	
Wound dehiscence	1% (1/70)	
Acute pyelonephritis		7% (5/70)
Bowel obstruction		6% (4/70)
Ureteral stricture		9% (6/70)
Stones		4% (3/70)
Parastomal hernia		3% (2/70)
Stomal stenosis		3% (2/70)

[a] Incidence as a percentage of the total number of reported cases from the literature. Numbers in parentheses represent the number of cases from which the percentage is derived.

TABLE 139.14

Complications: Ileocecal Conduit[a]

	EARLY	LATE
Urine leak	6% (9/147)	
Bowel leak	3% (5/147)	
Gastrointestinal bleeding	1% (1/147)	
Wound dehiscence	7% (11/147)	
Acute pyelonephritis		14% (20/147)
Bowel obstruction	3% (5/147)	10% (14/147)
Stomal prolapse		16% (24/147)
Parastomal hernia		5% (7/147)
Stomal stenosis		2% (3/147)
Stones		5% (8/147)
Fecal fistula		2% (3/147)

[a] Incidence as a percentage of the total number of reported cases from the literature. Numbers in parentheses represent the number of cases from which the percentage is derived.

Complications of the ileocecal conduit in one reported series occurred in 21% of patients (Matsuura et al., 1991). In this series, complications of the ileal conduit were compared with those of the ileocecal conduit, and there appeared to be no difference in the frequency of early and late postoperative complications.

Early complications included urinary leakage, bowel obstruction, fecal leakage, acute renal failure, fulminant hepatitis, pneumonia, gastrointestinal bleeding, hemorrhage, perforation of ileum, heart failure, and wound dehiscence. Late complications included stomal prolapse, acute pyelonephritis, bowel obstruction, urinary stones, parastomal hernia, incisional hernia, stomal stenosis, and fecal leakage. There was no difference in the incidence of deterioration of the upper tracts with either form of diversion. Of some note is that at high pressures, a large portion of the ileocecal conduits experienced reflux. At low pressures, however, there was minimal or no reflux. Whenever a portion of colon is used for a conduit, chronic diarrhea may be a consequence.

Ileal Vesicostomy

An ileal vesicostomy uses spatulated ileum and a generous transverse cystotomy to decompress the bladder and to allow an appliance to be used on the abdomen. This procedure is particularly well suited to spinal cord injury patients or those with significant neurologic disease. The concept is that patients with a neurogenic bladder have an easier job of caring for themselves with an abdominal stoma. Patients who are particularly good candidates are those with significant detrusor–external sphincter dyssynergia. Those who have detrusor hyperreflexia, particularly women, may have an increased incidence of incontinence. Complications of the procedure include urethral incontinence requiring closure of the urethra in 20% of patients, stomal stenosis, and bladder and renal calculi.

The procedure is performed by spatulating an ileal segment and performing a generous transverse cystotomy. The spatulated ileum is sutured to the bladder with absorbable suture, and the distal segment is brought to the abdominal wall by fashioning a rosebud stoma. This results theoretically in a low-pressure reservoir. Its appeal is that if indicated at a later date, the patient's anatomy can be converted back to normal (Mutchnik et al., 1997; Atan et al., 1999).

Management Common to All Conduits

All anastomoses are stented with Silastic stents. A convenient method for introducing the stents through the conduit and into the ureter is illustrated in Fig. 139.36. They are removed individually on the fourth to sixth postoperative days. If there is no increase in drainage, the Jackson-Pratt closed-suction drain is removed. **All conduits are retroperitonealized,** with the ureterointestinal anastomosis being placed in the retroperitoneum. This may be accomplished by suturing the posterior peritoneum to the serosa of the conduit above the ureterointestinal anastomosis. A drain may then be laid into the retroperitoneum. We prefer to drain the ureterointestinal anastomosis with a Jackson-Pratt or Blake closed-suction drain laid in the retroperitoneum 3 to 4 cm away from the anastomosis. The peritoneal cavity should not be drained.

Key Points

- Salvage cystectomy is associated with acceptable morbidity, although complication rates are higher.
- The ileal conduit is the simplest type of conduit diversion to perform and is associated with the fewest intraoperative and immediate postoperative complications.
- The transverse colon is the least likely segment of colon to be exposed to radiation in individuals who have received extensive pelvic irradiation.
- The sigmoid conduit is a good choice in patients undergoing a pelvic exenteration who will have a colostomy as no bowel anastomosis is required.

Metabolic and Neurochemical Problems of Urinary Intestinal Diversion

Problems that result from interposition of intestine in the urinary tract may be conveniently divided into three areas for the purposes of discussion: metabolic, neuromechanical, and technical-surgical. Metabolic complications are the result of altered solute reabsorption by the intestine of the urine that it contains. Neuromechanical aspects involve configuration of the gut, which affects storage volume and contraction of the intestine that may lead to difficulties in storage. Finally, technical-surgical complications involve aspects of the procedure that result in surgical morbidity; these have been discussed after each section on the technical aspects of urinary intestinal diversion. The following is a discussion of metabolic and neuromechanical problems.

Metabolic Complications

Metabolic complications include electrolyte abnormalities, altered sensorium, abnormal drug metabolism, osteomalacia, growth retardation, persistent and recurrent infections, formation of renal and reservoir calculi, problems ensuing from removal of portions of the gut from the intestinal tract, and development of urothelial or intestinal cancer. Many of these complications are a consequence of altered solute absorption across the intestinal segment. **Factors that influence the amount of solute and type of absorption are the segment of bowel used, the surface area of the bowel, the amount of time the urine is exposed to the bowel, the concentration of solutes in the urine, the renal function, and the pH of the fluid.**

Electrolyte Abnormalities

Serum electrolyte complications and the type of electrolyte abnormalities that occur are different, depending on the segment of bowel used. If stomach is used, hypochloremic metabolic alkalosis may occur. If jejunum is the segment used, hyponatremia, hyperkalemia, and metabolic acidosis occur. If the ileum or colon is used, hyperchloremic metabolic acidosis ensues. Other electrolyte abnormalities that have been described include hypokalemia, hypomagnesemia, hypocalcemia, hyperammonemia, and elevated blood urea nitrogen and creatinine. Specific abnormalities for each segment of intestine are detailed in the following sections and are summarized in Table 139.15.

TABLE 139.15

Syndromes of Electrolyte Disturbances in Patients in Whom Bowel Is Interposed in the Urinary Tract

---

		BLOOD		
SEGMENT	**SYNDROME**	**Na^+**	**K^+**	**Cl^-**
Stomach	Severe metabolic alkalosis	—	↓	↓
Jejunum	Hyperkalemic, hypochloremic metabolic acidosis	↓	↑	↓
Ileum/colon	Hyperchloremic metabolic acidosis	—	↓	↑

When stomach is used, hypochloremic, hypokalemic metabolic alkalosis may ensue. In general, this is not a significant problem unless the patient has concomitant renal failure, in which case there is a significant impairment of bicarbonate excretion or the patient is significantly dehydrated (Kurzrock et al., 1998). The metabolic alkalosis on occasion can be severe and life-threatening (syndrome of severe metabolic alkalosis). This syndrome has been reported in patients with normal renal function. **When it is fully manifested, lethargy, respiratory insufficiency, seizures, and ventricular arrhythmias may occur** (Castellan et al., 2012Gosalbez et al., 1993). These symptoms are usually preceded by vomiting resulting in dehydration. A pronounced hypochloremic, hypokalemic metabolic alkalosis ensues. Patients are usually successfully treated with an H_2 blocker to reduce proton secretion by the gastric segment and rehydration. In life-threatening circumstances, arginine hydrochloride infusion has been used to rapidly restore acid-base balance. On occasion, when H_2 blockers are ineffective, the proton pump blocker omeprazole has been successfully used. Rarely, omeprazole is ineffective, and if the life-threatening metabolic alkalosis persists, the gastric segment must be removed (Castellan et al., 2012).

The role of the serum concentration of gastrin appears pivotal in the syndrome. In the severe cases that have been reported, there is typically an elevated serum gastrin level. **Serum gastrin levels are significantly correlated with systemic bicarbonate concentration in gastrocystoplasty patients;** the greater the gastrin level, the more severe the metabolic alkalosis (Tanrikut and McDougal, 2004). When volume depletion, hypochloremia, and hypokalemia result from vomiting in those who normally have elevated circulating gastrin levels and a persisting long-standing metabolic alkalosis, the patient is at greater risk for development of the syndrome of severe metabolic alkalosis and manifestation of the symptoms outlined earlier. Thus, persistent loss of protons from the gastric-augmented bladder with net addition of bicarbonate to the systemic circulation, alteration of normal homeostatic mechanisms for acute changes in acid-base balance, and impaired ability of even a normal kidney to excrete bicarbonate in the face of hypochloremia, hypokalemia, and increased circulating aldosterone levels (because of the dehydration) create a vicious circle in which normal homeostatic mechanisms are circumvented. Indeed, elevated aldosterone levels have been reported in this syndrome (Gosalbez et al., 1993). Hypokalemia, hypochloremia, and increased aldosterone levels impair the kidney's ability to excrete excess bicarbonate. These perturbations coupled with a continued addition of bicarbonate from the gastric segment produce the extreme electrolyte abnormalities noted in the patients described. In view of the **sigmoid correlation of serum bicarbonate to gastrin levels in patients with gastric segments in the urinary tract, patients at greatest risk for development of the syndrome of severe metabolic alkalosis are those whose serum gastrin concentrations exceed 120 ng/L because on this portion of the**

curve, small additional increments in gastrin concentration result in large increases in serum bicarbonate (Fig. 139.40). On the other hand, patients with serum gastrin concentrations below 100 ng/L can have significant increases in gastrin levels with little change in serum bicarbonate. **Failure to properly empty the diversion with overdistention of the gastric segment would be expected to increase the serum gastrin level because stretch is a stimulus for gastrin release. For those who have either an elevated resting gastrin level in excess of 120 ng/L or impaired renal function, both patient and physician should be made aware of the consequences of dehydration and distention of the segment.**

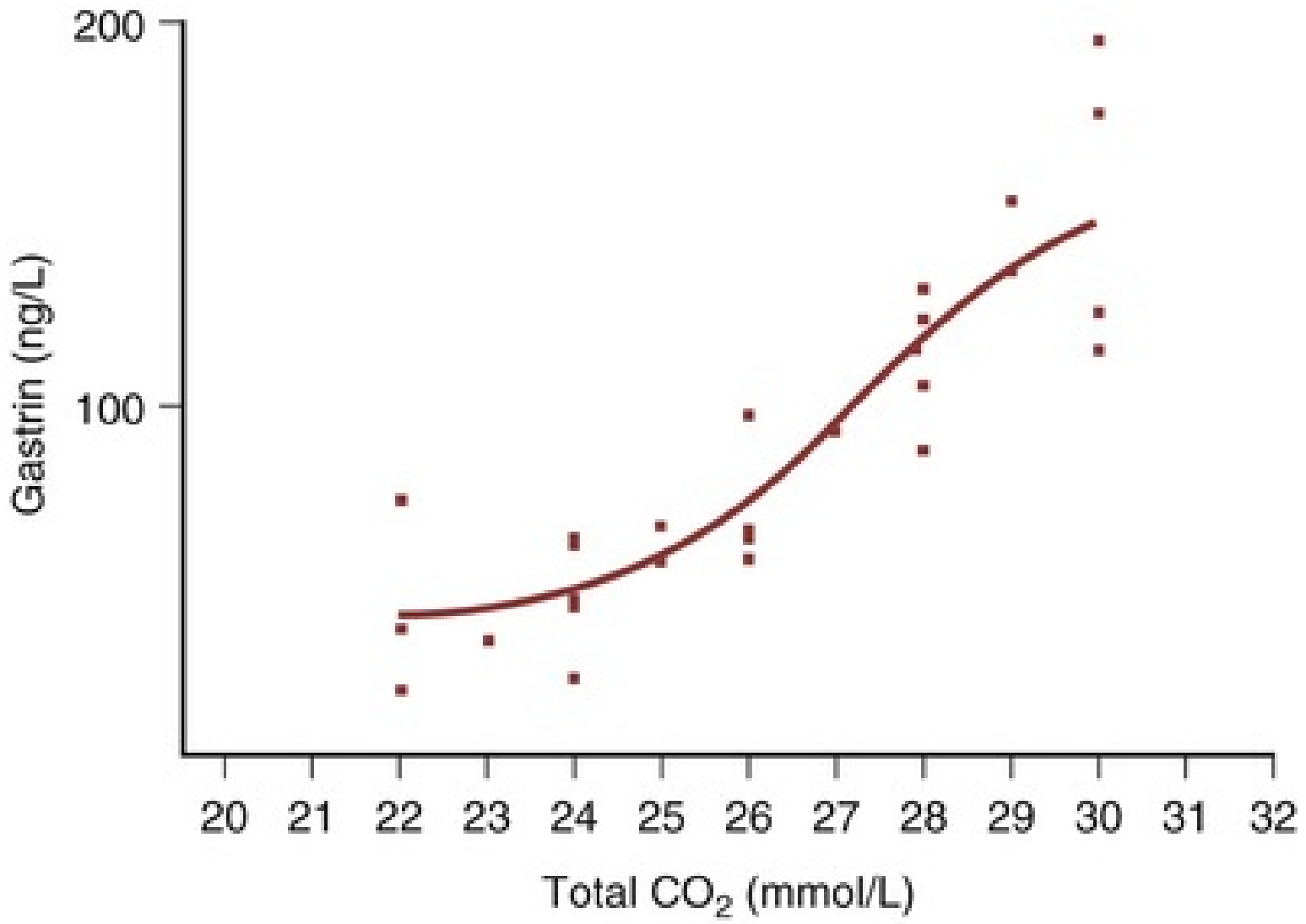

FIG. 139.40 Sigmoid relationship of serum gastrin level to serum bicarbonate. Notice that over the physiologic range of normal gastrin levels, 10 to 120 ng/L, there is little change in serum bicarbonate. However, at levels of serum gastrin in excess of 120 ng/L, small changes in serum gastrin levels result in large changes in serum bicarbonate.

Electrolyte disorders that occur when jejunum is used for urinary intestinal diversion, particularly when proximal jejunum is used, **include hyponatremia, hypochloremia, hyperkalemia, azotemia, and acidosis** (see Table 139.15). These disorders result from an increased secretion of sodium and chloride with an increased reabsorption of potassium and hydrogen ions. This excessive loss of sodium chloride carries with it water, and thus the patient becomes dehydrated. The dehydration results in hypovolemia, which increases renin secretion and thereby aldosterone production (Golimbu and Morales, 1975). Aldosterone production may also be stimulated by hyperkalemia. The high levels of renin-aldosterone facilitate sodium reabsorption by the kidney and potassium loss, which produce a urine low in sodium content and high in potassium. This, when presented to the jejunum, results in a favorable concentration gradient for loss of sodium by the jejunum and increased reabsorption of potassium, thus perpetuating the abnormalities.

These electrolyte abnormalities result in lethargy, nausea, vomiting, dehydration, muscle weakness, and elevated temperature. If the abnormalities are allowed to persist, the patient may become moribund and finally die. **This syndrome may be exacerbated by administration of hyperalimentation solutions.** The mechanism by which hyperalimentation solutions exacerbate this syndrome in patients with jejunal intestine interposed in the urinary tract is unclear (Bonnheim et al., 1984). **The severity of the syndrome depends on the location of the segment of jejunum that is used. The more proximal the segment, the more likely the syndrome is to develop.** Its incidence varies from a low of 25% (Klein et al., 1986) to the majority of patients demonstrating significant abnormalities. Severe abnormalities may occur in as few as 4% when short segments are used (Fontaine et al., 1997). Treatment of the disorder is rehydration with sodium chloride and correction of the acidosis with sodium bicarbonate. Provided that renal function is normal, the hyperkalemia is corrected by renal secretion. On occasion, a diuretic may be helpful to correct the hyperkalemia. After restoration of normal electrolyte balance, long-term therapy involves oral supplements with sodium chloride. A thiazide diuretic has also been useful in selected patients to control hyperkalemia in the long term (Hasan et al., 1994).

The electrolyte abnormality that occurs with the ileum and colon is hyperchloremic metabolic acidosis (see Table 139.10). This acidosis occurs to some degree in most patients who have ileum or colon interposed in the urinary tract but is usually of a minor degree. Its clinical significance when it is of a minor degree is unclear. Hyperchloremic acidosis has been reported with a frequency of 68% of patients (19 of 28 patients; 10 of the 19 cases were severe enough to require treatment) with ileal conduits (Castro and Ram, 1970). In another study, 70% of patients with ileal conduits observed for 4 years or longer had a decreased serum bicarbonate concentration (Malek et al., 1971). A more recent study places the incidence at about 25% (Nieuwenhuijzen et al., 2008) with about 4% requiring hospitalization for correction (Studer et al., 2006). Severe electrolyte disturbances occur to a much lesser degree. It has been reported to be a major problem in 18% of patients (8 of 45) with intestinal cystoplasties (Whitmore and Gittes, 1983), in 10% of patients (17 of 178) with ileal conduits (Schmidt et al., 1973), and in 80% of patients (112 of 141) with ureterosigmoidostomies (Ferris and Odel, 1950).

In continent diversions involving either ileum and cecum or cecum alone, most patients have an elevated serum chloride and depressed serum bicarbonate (Ashken, 1987; McDougal and Koch, 1989). Sixty-five percent of patients with Mainz pouches require alkali therapy to maintain a normal acid-base balance (Thüroff et al., 1986). Early reports of patients with continent diversions made of ileum note a much lower incidence of electrolyte problems, in the range of 10% to 15% (see Table 139.8) (Allen et al., 1985; Boyd et al., 1989). **Symptoms in those in whom the syndrome is severe include easy fatigability, anorexia, weight loss, polydipsia, and lethargy.** Those with ureterosigmoidostomies also have an exacerbation of diarrhea.

These electrolyte abnormalities, if significant and allowed to persist, result in major metabolic abnormalities, to be discussed later. In and of themselves, however, they may be lethal because severe electrolyte abnormalities have contributed to death of patients (Heidler et al., 1979).

The mechanism of hyperchloremic metabolic acidosis is a result of the ionized transport of ammonium. Ammonium substitutes for sodium in the Na^+-H^+ antiport. The exchange of the weak acid NH_4 for a proton is coupled with the exchange of bicarbonate for chloride. **Thus ammonium chloride is absorbed across the lumen into the blood in exchange for carbonic acid (i.e., CO_2 and water).** Ammonium may also gain entry to the blood from bowel lumen through potassium channels (McDougal et al., 1995).

The treatment of hyperchloremic metabolic acidosis involves administration of alkalizing agents or blockers of chloride transport. Alkalinization with oral sodium bicarbonate is effective in restoring normal acid-base balance. Oral administration of bicarbonate may not be tolerated particularly well, however, because it can produce considerable intestinal gas. An effective alternative is sodium citrate and citric acid solution (Bicitra or Shohl's solution) used together; however, many patients do not care for the taste. Potassium citrate, sodium citrate, and citric acid solution (Polycitra) may be used instead if excessive sodium administration is a problem because of cardiac or renal disease and if potassium supplementation is desirable or at least not harmful. In patients in whom persistent hyperchloremic metabolic acidosis occurs and in whom excessive sodium loads are undesirable, chlorpromazine or nicotinic acid may be used to limit the degree of the acidosis. These agents used alone do not correct the acidosis in humans, but they limit its development and thus reduce the need for alkalinizing agents. Chlorpromazine and nicotinic acid inhibit cyclic adenosine monophosphate and thereby impede chloride transport. Chlorpromazine may be given at a dose of 25 mg three times a day. On occasion, as much as 50 mg three times a day may be necessary, but at such doses, side effects are not uncommon. Chlorpromazine should be used with care in adults because there are many untoward side effects including tardive dyskinesia. Nicotinic acid may be given at a dose of 400 mg three or four times a day. The drug should not be used in patients with peptic ulcer disease or significant hepatic insufficiency. Side effects that may be observed include exacerbation of liver dysfunction, exacerbation of peptic ulcer disease, headache, and double vision. Flushing and dermatitis are not uncommon and generally disappear as the patient becomes adapted to the drug.

Hypokalemia and total-body depletion of potassium may occur in patients with urinary intestinal diversion. This is more common in patients with ureterosigmoidostomies than it is in patients who have other types of urinary intestinal diversion (Geist and Ansell, 1961). In one study, patients with ureterocolonic diversions had a 30% reduction in total body potassium, whereas those with ileal conduits had, as a group, no significant alteration in total body potassium; individually, however, some had as much as a 14% reduction in total body potassium (Williams et al., 1967). Patients with continent diversions have also been noted to have a decrease in total body potassium. The patients most susceptible to total body potassium depletion are those with long-standing uncorrected metabolic acidosis (Stein et al., 1998). **The potassium depletion is probably caused by renal potassium wasting as a consequence of renal damage, osmotic diuresis, and gut loss through intestinal secretion.** The last-mentioned (probably quantitatively) plays a relatively minor role. Indeed, it has been shown that ileal segments exposed to high concentrations of potassium in the urine reabsorb some of the potassium, whereas colon is less likely to do so (Koch et al., 1990). Thus **those with ileum interposed in the urinary tract likely blunt the potassium loss by the kidney, whereas those with colon do not, which explains why patients with ureterosigmoidostomies and ureterocolonic diversions are more likely to have total body potassium depletion.** When the depletion is severe, the patient may develop a flaccid paralysis. **In treating these patients, one must remember that if the hypokalemia is associated with severe hyperchloremic metabolic acidosis,**

treatment must involve both replacement of potassium and correction of the acidosis with bicarbonate. If the acidosis is corrected without attention to potassium replacement, severe hypokalemia may occur, marked flaccid paralysis may develop, and significant morbidity may ensue (Koff, 1975).

Because the bowel transports solutes and because its membrane is not particularly watertight, osmolality generally re-equilibrates across the bowel wall. Thus **attempts to deprive a patient of water and determine osmolality as a reflection of renal function are inappropriate because the bowel alters the osmotic content. The bowel also makes the contents more alkaline, and therefore it is impossible to determine the ability of the kidney to acidify simply by measuring urinary pH in patients with urinary intestinal diversion. Finally, because urea and creatinine are reabsorbed by both the ileum and the colon, serum concentrations of urea and creatinine do not necessarily accurately reflect renal function** (Koch and McDougal, 1985; McDougal and Koch, 1986).

Histologic alterations of the intestine may occur over time when urine is chronically exposed to the mucosa. Villous atrophy and the formation of pseudocrypts may occur, particularly in the ileum. These changes are patchy because there is normal ileal mucosa interspersed between these abnormalities. Submucosal inflammatory infiltrates may also be observed. There appear to be fewer changes in the colonic mucosa during the long term. In the colon, a decrease in the size of goblet cells has been described. In time, some transport processes may be altered, with some solutes less actively transported, whereas other processes of solute transport remain active (Philipson et al., 1983). **The ability to establish a hyperchloremic metabolic acidosis, however, appears to be retained by most segments of ileum and colon over time.** In an experimental study, chronic exposure of intestine to urine resulted in a decreased number of transporters, but those that remained were perfectly functional (Grocela and McDougal, 1999).

Altered Sensorium

Alteration of the sensorium may occur as a consequence of magnesium deficiency, drug intoxication, or abnormalities in ammonia metabolism. Patients who develop magnesium deficiency do so either secondary to nutritional depletion or in relation to magnesium wasting by the kidney in much the same way that calcium wasting occurs (see later). Alterations in the sensorium have also occurred because of diabetic hyperglycemia; however, this is not a consequence of the intestinal diversion. In such patients, reabsorption of urinary glucose can result in hyperglycemia without demonstrable glucosuria (Onwubalili, 1982). Perhaps the more common cause of an altered sensorium is altered ammonia metabolism. **Ammoniagenic coma in patients with urinary intestinal diversion has been reported in those with cirrhosis (Silberman, 1958), those with altered liver function without underlying chronic liver disease** (McDermott, 1957), and those with normal hepatic function as determined by serum enzyme activities (Kaufman, 1984; Mounger and Branson, 1972; Perez-Fidalgo et al., 2007). The syndrome is most commonly associated with decreased liver function, however, and even in patients in whom normal liver function has been reported, the crude methods by which it was assessed in these reports have made it impossible to confirm the absence of subtle alterations in liver function. The syndrome is most commonly found in patients with ureterosigmoidostomies but has been reported in those with ileal conduits as well (McDermott, 1957).

The treatment of ammoniagenic coma involves draining the urinary intestinal diversion, either with a rectal tube in patients with ureterosigmoidostomy or with a Foley catheter in those with a continent diversion so that the urine does not remain exposed to the intestine for extended periods. **Neomycin is administered orally to reduce the ammonia load from the enteric tract, and protein consumption is curtailed,** thus limiting the nitrogen load to the patient until serum ammonium levels have returned to normal. In severe circumstances, arginine glutamate, 50 g in 1000 mL of 5% dextrose in water, may be given intravenously. This complexes the ammonia by providing substrate for the formation of glutamine (Silberman, 1958). Lactulose may be given orally or by rectum (Edwards, 1984). This complexes the ammonia in the gut and prevents its absorption. Consult the hospital pharmacist for dosages and schedules of these therapies.

Abnormal Drug Absorption

Drug intoxication has been reported in patients with urinary intestinal diversion. **Drugs more likely to be problematic are those absorbed by the gastrointestinal tract and excreted unchanged by the kidney.** Thus the excreted drug is re-exposed to the intestinal segment, which then reabsorbs it, and toxic serum levels develop. This has been reported with phenytoin (Savarirayan and Dixey, 1969) and with certain antibiotics that are excreted unchanged. Although chemotherapy is usually well tolerated by patients with conduits, methotrexate toxicity has been documented in a patient with an ileal conduit (Bowyer and Davies, 1987).

A more recent study suggests that in patients with normal renal function, both those with and those without continent diversions tolerate chemotherapy well. The authors studied 23 patients with continent diversions and 19 with ileal conduits who received cisplatin, methotrexate, and vinblastine. The authors concluded that there was no difference in toxicity in patients without diversions, those with ileal conduits, and those with continent diversions. Indeed, the patients with continent diversions did not have a Foley catheter placed during the chemotherapy infusion. However, if one looks carefully at the data, it appears that there is in fact an increased toxicity in the continent diversion group, although it did not achieve statistical significance (Srinivas et al., 1998). In patients receiving antimetabolites, it is prudent to carefully monitor the patient for toxic products that are excreted in the urine and capable of intestinal absorption, lest lethal toxic serum levels develop. Moreover, **in patients with continent diversions who are receiving chemotherapy, consideration should be given to draining the pouch while the toxic drugs are being administered.**

Osteomalacia

Osteomalacia or renal rickets occurs when mineralized bone is reduced and the osteoid component becomes excessive. Osteomalacia has been reported in patients with colocystoplasty (Hossain, 1970), ileal ureters (Salahudeen et al., 1984), colon and ileal conduits, and, most commonly, ureterosigmoidostomies (Harrison, 1958). **The cause of osteomalacia may be multifactorial but commonly involves acidosis.** With persistent acidosis, the excess protons are buffered by the bone with release of bone calcium. This results in increased serum calcium and therefore calcium excretion by the kidney to maintain hemostasis. Support for the theory that chronic acidosis is causative in osteomalacia comes from those patients in whom correction of the acidosis results in remineralization of the bone (Richards et al., 1972; Siklos et al., 1980). It has also been shown, however, that major alterations in serum bicarbonate are not necessary for the development of the syndrome (Koch and McDougal, 1988; McDougal et al., 1988). Moreover, some patients with osteomalacia secondary to urinary intestinal diversion do not have bone demineralization corrected with restoration of normal acid-base balance. **These patients have been found to manifest vitamin D resistance that is independent of the acidosis.** It is likely that this resistance is of renal origin. Resistance can be overcome by supplying

1α-hydroxycholecalciferol, a vitamin D metabolite that is much more potent than vitamin D_2. When this substrate is provided in excess amount, remineralization of bone occurs (Perry et al., 1977). Also, it has been shown that reabsorption of urinary solutes may play a role in increasing calcium excretion by the kidney. Sulfate filtered by the kidney inhibits calcium reabsorption and results in both calcium and magnesium loss by the kidney. Thus if the gut increases its sulfate reabsorption and requires the kidney to increase sulfate excretion, this results in hypercalciuria and hypermagnesuria (McDougal and Koch, 1989). Finally, there is some evidence to indicate that the calcium-to-parathormone ratio is altered, suggesting that a resistance to parathormones develops during the long term (Tanrikut and McDougal, 2004). **Osteomalacia in urinary intestinal diversion may be caused by persistent acidosis, vitamin D resistance, and excessive calcium loss by the kidney. It appears that the degree to which each of these contributes to the syndrome may vary from patient to patient.**

It is clear that a number of metabolic problems have been obviated when meticulous attention is paid to correction of the abnormalities prospectively. If a base deficit of more than 2.5 mEq/L is corrected, some investigators have found no evidence of bone mineral density abnormalities (Stein et al., 1998). Indeed, the type of diversion does not seem to make a difference when the acidosis is taken into account and corrected (Kawakita et al., 1996). Others suggest that there is no difference in continent diversions and ileal conduits (Campanello et al., 1996); however, in such selected series, the distribution of acidosis across both groups is typically identical. It is clear that if the groups are large enough and not preselected, there is an increased incidence of acidosis in continent diversion patients. Indeed, if patients are followed long enough, some will develop bone mineral density abnormalities, particularly those who are acidotic over the long term (Incel et al., 2006). The take-home message is that if one pays meticulous attention to correction of the acidosis, bone mineral density abnormalities will probably not become a problem.

In general, patients who develop osteomalacia report lethargy; joint pain, especially in the weight-bearing joints; and proximal myopathy. Analysis of serum chemistries reveals that the calcium concentration is either low or normal. The alkaline phosphatase level is elevated, and the phosphate level is low or normal (Harrison, 1958). The treatment as indicated earlier involves correction of the acidosis and dietary supplementation of calcium. If this does not result in remineralization of the bone, the active form of vitamin D may be administered. If this is not successful, the more active metabolite of vitamin D_3, 1αhydroxycholecalciferol, should be administered.

Growth and Development

Considerable evidence suggests that urinary intestinal diversion has a detrimental effect on growth and development. In a study of 93 myelodysplasia patients observed for 17 to 23 years, significant aberrations in growth were noted when morphometric parameters were analyzed. Anthropometric measurements in those with urinary intestinal diversion showed a decrease in linear growth in all indices measured, with a statistically significant decrease in biacromial span and elbow-hand length (Koch et al., 1992).

Patients with long-term urinary diversions are more susceptible to fractures and to complications after orthopedic procedures. When myelodysplastic patients with ileal conduits were compared with a similar group of patients who retained their bladder and were on intermittent catheterization, the patients with an ileal conduit had an increased number of fractures, and malunions and nonunions after orthopedic procedures (Koch et al., 1992). It was found that more patients with urinary intestinal diversion fell below the tenth percentile than did patients who were treated with intermittent catheterization. There was, in fact, no difference in height and weight between the two groups studied (Koch et al., 1992; McDougal, 1992).

There is also experimental evidence for impaired linear growth in urinary intestinal diversion. Rats with unilateral ureterosigmoidostomies observed long term demonstrated significantly decreased femoral bone length compared with nondiverted controls (Koch and McDougal, 1988). Thus it appears clear that, although obvious alterations in growth and development do not occur in the majority of patients, when carefully studied, patients who have urinary intestinal diversions constructed in childhood and who maintain these diversions for more than 10 years have significant changes in linear growth.

Infection

An increased incidence of bacteriuria, bacteremia, and septic episodes occurs in patients with bowel interposition. A significant number of patients with intestinal cystoplasty develop pyelonephritis, and 13% have septic and major infectious complications (Küss et al., 1970). The episodes are more frequent after colocystoplasty than ileocystoplasty (Küss et al., 1970). In a contemporary series, 4% of patients were admitted to a hospital for sepsis

(Studer et al., 2006). Acute pyelonephritis occurs in 10% to 17% of patients with colon and ileal conduits (Hagen-Cook and Althausen, 1979; Schmidt et al., 1973; Schwarz and Jeffs, 1975). Approximately 4% of patients (8 of 178) with ileal conduits die of sepsis (Schmidt et al., 1973).

Patients with conduits have a high incidence of bacteriuria. **Approximately three-fourths of ileal conduit urine specimens contain bacteria** (Elder et al., 1979; Guinan et al., 1972; Middleton and Hendren, 1976). It is clear that some patients are merely colonized at the distal end of the conduit because the incidence of positive cultures can be markedly diminished by culture of the proximal portion of the loop by a double-catheter technique (Smith, 1972). Many of these patients, however, show no untoward effects and seem to do well with chronic bacteriuria. **Deterioration of the upper tracts is more likely when the culture becomes dominant for *Proteus* or *Pseudomonas.* Thus patients with relatively pure cultures of *Proteus* or *Pseudomonas* should be treated, whereas those with mixed cultures may, in general, be observed, provided they are not symptomatic. Patients with continent diversions also have a significant incidence of bacteriuria and septic episodes** (McDougal, 1986). Indeed, two-thirds of patients with Kock continent diversions have positive cultures (Kock, 1987). The reasons for the increased incidence of bacteriuria and sepsis are unclear, but it is likely that the intestine is incapable of inhibiting bacterial proliferation, in contrast with the urothelium. Thus intestine that normally lives symbiotically with bacteria when interposed in the urinary tract serves as a source for ascending infection and septic complications. Moreover, the intestine may make the urine less bacteriostatic and thereby promote the growth of bacteria. Distention of the intestinal segment may aid in translocation of bacteria across the intestine and into the blood. Studies have shown some changes in intestinal mucosal immunologic bacterial defense mechanisms; however, for the most part they seem to be preserved (Wullt et al., 2004).

Stones

One of the consequences of persistent infection is the development of magnesium ammonium phosphate stones. Indeed, **the great majority of stones formed in patients with urinary intestinal diversions are composed of calcium, magnesium, and ammonium phosphate. Those most susceptible to development of renal calculi are patients who have hyperchloremic metabolic acidosis, preexisting pyelonephritis, and urinary tract infection with a urea-splitting organism** (Dretler, 1973). The incidence of renal stones is

3% to 4% in patients with colon conduits (Althausen et al., 1978; Hagen-Cook and Althausen, 1979) and 10% to 12% in those with ileal conduits (Schmidt et al., 1973). In those with continent cecal reservoirs, there is a 20% incidence of calculi within the reservoir (Ashken, 1987). The stones may be a result of persistent infection with alkalinization of the urine, persistent hypercalciuria for reasons described earlier, and alterations of urinary excretion products by the intestine. A major cause of calculus formation in conduits and pouches is a foreign body such as a staple or nonabsorbable suture, on which concretions form. In intestinal reservoirs, alterations in bowel mucus production may also serve as a nidus for stone formation. Finally, alterations in intestinal mucosa, particularly in the presence of infection or obstruction, may serve as a nidus or, more important, may interfere with emptying and thereby exacerbate infection and stone formation (N'Dow et al., 2004).

Intestinal Motility, Short Bowel, and Nutritional Problems

Many nutritional problems may occur from the loss of significant intestinal absorptive surface resulting from removal of substantial portions of the gut for construction of a urinary intestinal diversion. **In patients with a significant loss of ileum, vitamin B_{12} malabsorption has been reported and results in anemia and neurologic abnormalities.** Vitamin B_{12} deficiency has been shown to occur in 10 of 41 patients who received preoperative radiotherapy before radical cystectomy and ileal ureterostomy (Kinn and Lantz, 1984), and 21% of children who have undergone ileocystoplasty have low serum levels of vitamin B_{12} (Rosenbaum et al., 2008). **Loss of significant portions of ileum also results in malabsorption of bile salts.** Because the ileum is the major site of bile salt reabsorption, the lack of reabsorption allows bile salts entry into the colon, which causes mucosal irritation and diarrhea. Also, loss of the ileum results in the loss of the “ileal break.” The ileal break is a mechanism whereby gut motility is reduced when lipids come in contact with the ileal mucosa so that increased absorption can occur. With the loss of ileum, the lipid does not result in decreased motility and is presented unmetabolized to the colon, which may cause fatty diarrhea.

It has been difficult to demonstrate untoward effects of low serum vitamin B_{12} levels in these patients. The liver stores enough vitamin B_{12} to supply the body's requirement for 3 to 5 years without oral intake. Thus pathologic problems would not be expected to manifest themselves for many years and have rarely been reported. Moreover, low serum levels of vitamin B_{12} do not necessarily correlate with metabolic deficiency. To assess whether or not there is a metabolic impact, it is necessary to measure serum levels of homocysteine and/or methylmalonic acid. Because vitamin B_{12} serves as a coenzyme in the metabolic pathways of homocysteine and methylmalonic acid, their measurement is a sensitive indicator of whether the low vitamin B_{12} level is significant. These measurements have not been done in this group of patients, and thus it is unclear at this time as to the importance of vitamin B_{12} measurements in these patients. Many physicians, however, empirically give parenteral vitamin B_{12} as a precaution to patients who have had intestinal diversions of ileum in place for more than 5 to 7 years.

Loss of the ileocecal valve may have a number of untoward effects. Because of the loss of the valve, reflux of large concentrations of bacteria into the ileum may occur, resulting in small intestinal bacterial overgrowth. This may result in nutritional abnormalities that involve interference with fatty acid reabsorption and bile salt interaction. With the lack of absorption of fats and bile salts, these are presented to the colon and result in diarrhea. Moreover, reflux of bacteria into the small bowel may result in bile salt deficiency. Also, the lack of fat absorption may result in deficiencies of the fat-soluble vitamin A, osteomalacia caused by lack of vitamin D, and complexing of calcium with the fats to form soaps, thus preventing its absorption. The ileocecal valve also serves as a break, and an intact valve prolongs transit time of the small bowel and enhances absorption. Thus its loss may contribute to nutritional abnormalities. Some have advocated reconstruction of the valve mechanism between ileum and colon when the ileocecal segment is used for reconstruction.

Loss of a significant portion of jejunum may result in malabsorption of fat, calcium, and folic acid; however, significant portions of jejunum are rarely used for urologic reconstructive procedures. Loss of the colon may result in diarrhea because of lack of fluid and electrolyte absorption, loss of bicarbonate because of its increased secretion in the ileum and lack of reabsorption, and dehydration because of the loss of fluids.

Of concern when intestinal segments are used in urinary reconstruction is the effect removal of a segment of intestine from the alimentary tract might have on intrinsic bowel function. Indeed, removal of major segments from the alimentary tract may cause nocturnal bowel movements, fecal urgency, fecal incontinence, diarrhea, and nutritional deficiencies (Riddick et al., 2004). A study compared patients with ileal conduits with those who had segments used for clam cystoplasty and, not surprising, found that those with clam cystoplasty had a 40% incidence of significant bowel problems. It is known that there is an association between detrusor instability and irritable bowel, perhaps accounting for the incidence of untoward disorders of bowel function in this series (N'Dow et al., 1998). Thus, there is a need for heightened awareness of bowel dysfunction in patients with detrusor instability in whom bowel segments are to be used. A study of patients who had an ileocystoplasty noted that 7% had significant diarrhea (Blaivas et al., 2005). One should warn patients who will have major portions of the intestinal tract used in the reconstruction that bowel problems may ensue.

Cancer

The incidence of cancer development in patients with ureterosigmoidostomy varies between 6% and 29%, with a mean of 11% (Schipper and Decter, 1981; Stewart et al., 1982; Zabbo and Kay, 1986). In general, there is a 10- to 20-year delay before the cancer manifests. **On histologic examination, the tumors include adenocarcinoma, adenomatous polyps, sarcoma, and transitional cell carcinoma.** Case reports of tumors developing in patients with ileal conduits, colon conduits, bladder augmentations, rectal bladder, neobladders, and ileal ureters have been described (Austen and Kälble, 2004). Anaplastic carcinomas and adenomatous polyps have been reported in patients with ileal conduits. Adenocarcinoma has developed in patients with colon conduits; adenocarcinoma, undifferentiated carcinoma, sarcomas, and transitional cell carcinomas have developed in patients with bladder augmentations with both ileum and colon (Filmer, 1986).

The causative mechanism of development of the carcinoma is not understood. Whether the tumor arises from transitional epithelium or colonic epithelium is unclear. Because most of the tumors are adenocarcinomas, it has been assumed that the tumor arises from the intestinal epithelium. Adenocarcinomas have been shown to arise from transitional cell epithelium exposed to the fecal stream in experimental animals (Aaronson et al., 1987). Furthermore, studies show that the ureters in ureterosigmoidostomy patients have an exceedingly high incidence of dysplasia (Aaronson and Sinclair-Smith, 1984). Moreover, if the transitional epithelium is removed from the enteric tract, adenocarcinomas do not develop. **If the urothelium is left in contact with the intestinal mucosa, however, even though the diversion is defunctionalized and the area is not bathed in urine,**

adenocarcinoma may still develop. This is illustrated by a case report in which a patient who had a ureterosigmoidostomy that was defunctionalized with a conduit subsequently developed cancer 9 months later. The distal ureters at the sigmoid were left in situ. Twenty-two years later, the patient developed cancer at the site of the ureterointestinal anastomosis (Schipper and Decter, 1981). This suggests that **when ureterointestinal anastomoses are defunctionalized, they should be excised rather than merely ligated and left in situ.** Other evidence including cell staining techniques suggests that the colon is the primary organ of origin (Mundy, personal communication, 1991). Whether the urothelium or intestine is the primary site of origin, it seems likely that tumors can arise from both tissues.

The highest incidence of cancer occurs when the transitional epithelium is juxtaposed to the colonic epithelium and both are bathed by feces (Shands et al., 1989). Nitrosamines, known mutagens, are produced in rats with ureterosigmoidostomy (Cohen et al., 1987), but there appears, at least at this juncture, no convincing evidence to support a primary role for them in the genesis of the tumor. An abnormal pattern of colonic mucin secretion has been demonstrated in patients with ureterosigmoidostomy, but its significance is unclear (Iannoni et al., 1986). Induction of specific enzymes associated with carcinoma has also been demonstrated. Ornithine decarboxylase, an enzyme that has been found to be elevated in malignant colonic mucosa, is also elevated in experimental animals with vesicosigmoidostomy (Weber et al., 1988). The role of epidermal growth factor and other growth factors is currently being investigated. Evidence suggests that these may at least play a role in development, if not in induction. At this time, the cause of the genesis of cancer in urinary intestinal diversion is not known.

A recent analysis from Germany looked at 17,758 urinary diversions from 1970 to 2007 and noted 32 secondary malignancies. **Ureterosigmoidostomies (2.6%), cystoplasties (1.6%), and orthotopic (ileo)colonic neobladders (1.3%)** had the highest risk for malignancy. As a result, the authors recommended **regular endoscopic evaluation beginning 5 years postoperatively for these patients,** but not for patients with ileal neobladders (0.05% risk) and ileal conduits (0.02% risk), whose risk was significantly lower. The authors also recommended that patients with catheterizable ileocecal pouches (0.14% risk), should undergo evaluation in the presence of symptoms such as hydronephrosis, chronic urinary infection, and hematuria (Kälble et al., 2011).

Neuromechanical Aspects of Intestinal Segments

Both small bowel and colon contract to propel luminal contents in an aboral direction. The ability to propel luminal contents is a consequence of muscle activity and coordinated nerve activity. Both the small bowel and the colon have an outer longitudinal layer of muscle and an inner circular layer. There is also a muscularis mucosa, which is immediately beneath the mucosa and may extend into the villi. The outer and inner layers of muscle, however, play the major role in peristalsis. In the colon, the outer longitudinal layer of muscle condenses to form three taeniae coli. The bowel receives its parasympathetic innervation from the vagus nerve. It is also innervated by the sympathetic nervous system. The nerves lie between the circular and longitudinal layers of muscle. The enteral nervous system operates autonomously, and therefore one can denervate the intestine and not affect the coordinated contractions. These contractions are termed *activity fronts* and may be stimulated by feeding, or they may be inhibited by exposure of the lumen to various substances (e.g., lipid in the ileum decreases ileal motility). Two aspects of neuromechanical properties are particularly germane to urinary intestinal diversion: volume-pressure relationships and motor activity.

Volume-Pressure Considerations

The volume-pressure relationships depend on the configuration of the bowel. If one splits the bowel segment and turns it back on itself, the volume may be doubled if the ends are not closed (Fig. 139.41). In reconstruction of intestinal segments for the urinary tract, however, one must close the ends. Thus the limit of doubling the volume is never quite reached. Indeed, **the greater the ratio of length to diameter, the greater the volume change when the ends are closed. If the ends are closed when a ratio of diameter to length of 1 : 3.5 is reached, splitting the segment no longer increases the volume. By splitting most segments, one is, in fact, increasing the volume by about 50%. The goal in reconfiguring the bowel is to achieve a spherical storage vessel. This configuration has the most volume for the least surface area.** By increasing the volume, it has been suggested that pressure relationships within the confines of the intestine are reduced. This is based on Laplace's law, which states that for a sphere, the tension of its wall is proportional to the product of the radius and pressure. Thus theoretically, for a given wall tension, the greater the radius, the smaller the generated pressure. This is desirable in an attempt to prevent deterioration of the upper tracts or incontinence. **This relationship (Laplace's law), however, may not be accurately reflected for intestinal segments because they are not perfectly spherical, and the intestinal wall does not conform to Hooke's law,** which states that the force needed to extend or compress a spring by some distance is proportional to that distance. **Rather, the bowel demonstrates viscoelastic properties, which tend to distort the relationship between pressure applied at the wall and tension generated in it.** However, even though the mathematical modeling is complex, it seems desirable to attempt to construct as spheric a container as possible if one is attempting to make a reservoir.

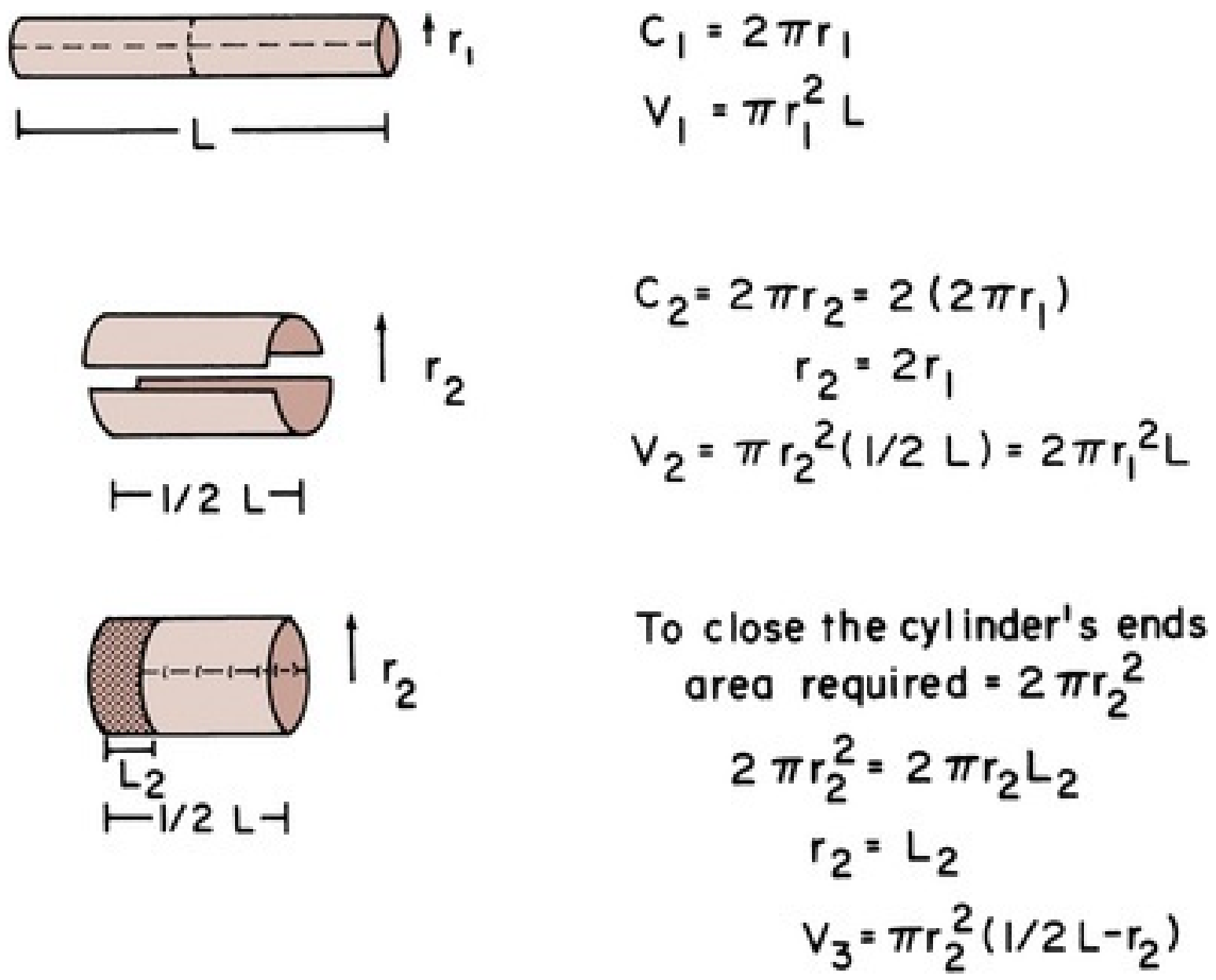
r_1
$C_1 = 2\pi r_1$
$V_1 = \pi r_1^2 L$
L
r_2
$C_2 = 2\pi r_2 = 2(2\pi r_1)$
$r_2 = 2r_1$
$V_2 = \pi r_2^2(1/2\ L) = 2\pi r_1^2 L$
1/2 L
r_2
To close the cylinder's ends
area required = $2\pi r_2^2$
$2\pi r_2^2 = 2\pi r_2 L_2$
$r_2 = L_2$
$V_3 = \pi r_2^2(1/2\ L - r_2)$
L_2
1/2 L

FIG. 139.41 Effect of "detubularization." The bowel is split on its antimesenteric border and divided in two. When the two segments are placed together, the circumference is doubled, thus doubling the volume. Closing the ends of the cylinder requires a reduction in its length equal to the radius of the end. This limits the increase in volume that occurs by reconfiguration.

Over time, the volume capacity of segments increases. This occurs only if they are frequently filled. Their volume decreases with time if they are nonfunctional (Kock et al., 1978). Over time, it can be demonstrated that there is a marked accommodation in volume of pouches made from intestine. For ileal pouches, it has been shown that the capacity increases sevenfold after 1 year

(Berglund et al., 1987). As the reservoirs increase in volume, there is a significant increase in smooth muscle thickness of the bowel wall (Philipson et al., 1983).

Motor Activity

It has been suggested that splitting the bowel on its antimesenteric border discoordinates motor activity and thereby causes a lesser intraluminal pressure. Clearly, the ideal situation is to provide the patient with a spheric vessel that has few or ineffective contractions of its walls. It can be demonstrated in experimental animals that after **the bowel wall has been split on its antimesenteric border and reconfigured, acutely there is a marked interruption of coordinated activity fronts, which over a period of 3 months return to their normal coordinated state** (Concepcion et al., 1988). This has also been demonstrated clinically; initially after reconfiguration of the bowel (detubularization), coordinated activity fronts have been shown to decrease. During extended periods, however, many of the peristaltic waves (activity fronts) reappear and can be readily demonstrated (Fig. 139.42).

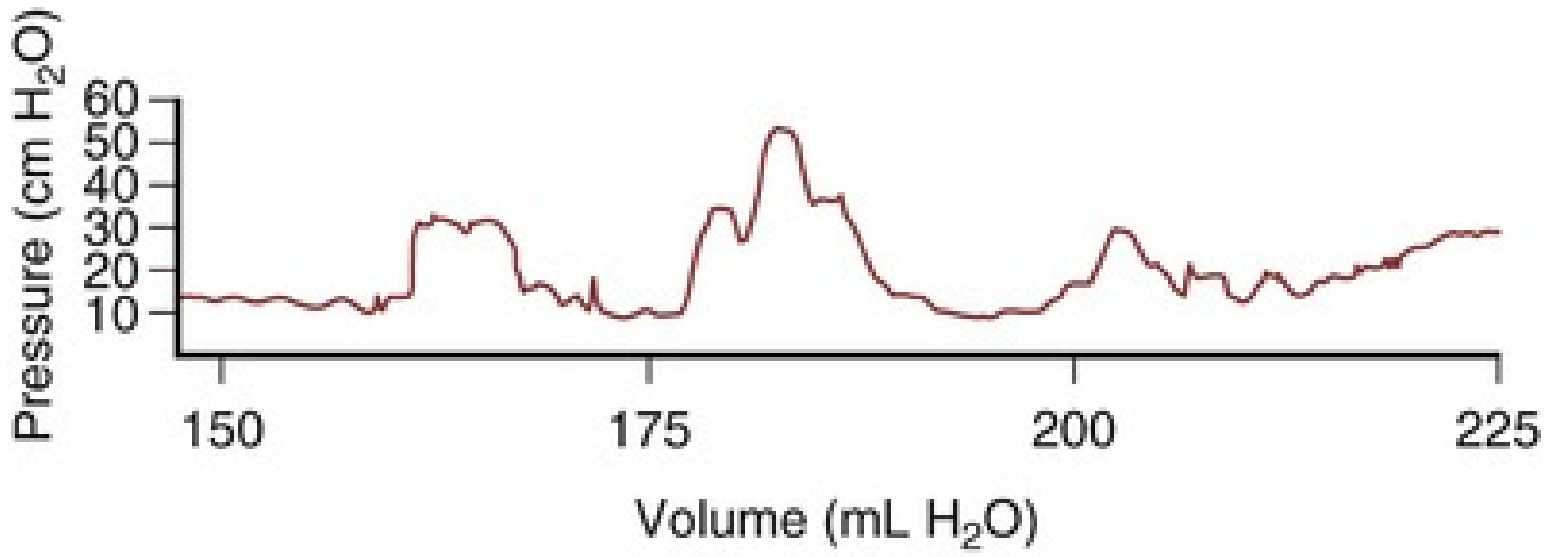

FIG. 139.42 Pressure waves recorded 1 year postoperatively in a patient with a continent diversion constructed from detubularized ileum and right colon. Note that the coordinated pressure waves are of magnitude and frequency similar to those found in a normal colonic or ileal segment.

The literature is contradictory with respect to the effect of detubularization on segments of ileum and colon used to construct storage vessels for continent diversions. Pressure within the lumen of bowel that has both ends closed may be increased by adding volume or reducing the size of the bowel through contractions of its wall. Because the bowel wall is freely permeable to water, the higher osmotic content of urine obligates movement of water into the bowel lumen. Most patients with continent diversions excrete 2 to 4 L/day (McDougal, 1986). In evaluating whether motor activity is the primary determinant of intravesical pressure, one must be cognizant of fluid volume changes. Also, as indicated earlier, early reports of detubularized segments would be expected to differ from later reports when coordinated activity fronts in these segments return.

These facts are often forgotten, and because pressure measurements are used to infer motor activity, rather than its direct measurement as reflected by changes in bowel wall tension, it is not difficult to understand why there are so many contradictions reported in the literature. Detubularization of ileal segments has been reported by some to decrease motor activity at 1 year compared with immediately postoperatively (Berglund et al., 1987), whereas others have noted increased motor activity at 1 year. Involuntary pressure waves occur in 25% of patients with Kock pouches. Maximum intravesical pressures average 41 cm H_2O in these pouches (Chen et al., 1989). Ileum has also been shown to have fewer activity fronts per unit of time than cecum (Berglund et al., 1986). Cecum has been observed to have the same number of activity fronts 1 year postoperatively, but the amplitude of the pressure waves has been observed to decrease over time (Hedlund et al., 1984). Maximum pressures in normal cecum have been shown to range from 18 to 100 cm H_2O (Jakobsen et al., 1987), whereas detubularized cecum has been shown to have pressures that range from 5 to 25 cm H_2O 1 year postoperatively (Hedlund et al., 1984). Others, comparing ileum to cecum, find no difference in pressure generated after 1 year (Hedlund et al., 1984). The Mainz pouch, which uses both ileum and cecum, has an average pressure at capacity of 39 cm H_2O with a maximum pressure of 63 cm H_2O (Thüroff et al., 1987). **Thus, reconfiguring bowel usually increases the volume, but its long-term effect on motor activity and wall tension is unclear at this time. It has been our observation that some patients with orthotopic bladders, after a number of years of spontaneous voiding, require intermittent catheterization. In these patients, the bowel segment has become flaccid, and the ability of the patient to generate intraluminal pressure by the Valsalva maneuver is limited.**

Key Points

- Limited segments of bowel should be used in patients who have an inability to acidify the urine to less than 5.8 and an inability to concentrate greater than 600 mOsm/kg or a GFR less than 35 mL/min.

- Metabolic complications of intestine interposed in the urinary tract include electrolyte abnormalities, altered sensorium, abnormal drug metabolism, osteomalacia, growth retardation, persistent and recurrent urinary tract infection, formation of calculi, short gut, and development of urothelial or intestinal cancers.
- The gastrocystoplasty patients most at risk for development of the syndrome of severe metabolic alkalosis are those with high resting levels of serum gastrin who overdistend their pouches and are dehydrated.
- The electrolyte abnormality that occurs with ileum and colon is a hyperchloremic metabolic acidosis.
- Patients receiving chemotherapy who have intestine interposed in the urinary tract have increased toxic effects of chemotherapeutic agents compared with patients with normal urinary tracts.

Summary

This chapter has addressed complications both independent of and dependent on the specific type of urinary intestinal diversion. Each unique type of diversion has its own set of individual complications. Moreover, the procedure preceding the urinary intestinal diversion also has a set of complications that must be added to those described earlier. It is clear that with current modalities of urinary intestinal diversion, long-term complications significantly contribute to mortality and morbidity. Many patients who have intestinal diversion after an extirpative procedure for cancer, however, die of the cancer rather than of these long-term complications. Those for whom a urinary intestinal diversion has been constructed for benign disease and those who are cured of cancer are most likely to experience long-term morbid complications. The knowledge of the frequency of these complications and the correct performance of preoperative preparation, surgical technique, and postoperative care, as outlined in this chapter, should provide the best chance for the least mortality and morbidity in patients undergoing urinary intestinal diversion.

References

Aaronson IA, Constantinides CG, Sallie LP, et al. Pathogenesis of adenocarcinoma complicating ureterosigmoidostomy. Experimental observations. *Urology*. 1987;29:538–543.

Aaronson IA, Sinclair-Smith CC. Dysplasia of ureteric epithelium: a source of adenocarcinoma in ureterosigmoidostomy? *Z Kinderchir*. 1984;39:364–367.

Abdel-Azim MS, Abdel-Hakim AM. Gastrocystoplasty in patients with an areflexic low compliant bladder. *Eur Urol*. 2003;44:260–265.

Abol-Enein H, Ghoneim MA. A novel uretero-ileal reimplantation technique: the serous lined extramural tunnel. A preliminary report. *J Urol*. 1994;151:1193–1197.

Abol-Enein H, Ghoneim MA. Functional results of orthotopic ileal neobladder with serous-lined extramural ureteral reimplantation: experience with 450 patients. *J Urol*. 2001;165:1427–1432.

Abreu SC, Fonseca GN, Cerqueira JBG, et al. Laparoscopic radical cystectomy with intracorporeally constructed Y-shaped orthotopic ileal neobladder using nonabsorbable titanium staples exclusively. *Urology*. 2005;66:657.

Adams MC, Mitchell ME, Rink RC. Gastrocystoplasty: an alternative solution to the problem of urological reconstruction in the severely compromised patient. *J Urol*. 1988;140:1152–1156.

Ahmed K, Khan SA, Hayn MH, et al. Analysis of intracorporeal compared with extracorporeal urinary diversion after robot-assisted radical cystectomy: results from the International Robotic Cystectomy Consortium. *Eur Urol*. 2014;65:340–347.

Albert DJ, Persky L. Conjoined end-to-end uretero-intestinal anastomosis. *J Urol*. 1971;105:201–204.

Allen TD, Peters PC, Sagalowsky AI, et al. The Camey procedure: preliminary results in 11 patients. *World J Urol*. 1985;3:167–171.

Althausen AF, Hagen-Cook K, Hendren WH 3rd. Non-refluxing colon conduit: experience with 70 cases. *J Urol*. 1978;120:35–39.

Anderson CB, Morgan TM, Kappa S, et al. Ureteroenteric anastomotic strictures after radical cystectomy—does operative approach matter? *J Urol*. 2013;129:541–547.

Aponte HA, Clavijo RA, Quiroz YJ, et al. Gastrocystoplasty and hematuria-dysuria syndrome. what role plays Helicobacter pylori? Case report and literature review. *Urol Case Rep*. 2015;3:70–71.

Arabi Y, Dimock F, Burdon DW, et al. Influence of bowel preparation and antimicrobials on colonic microflora. *Br J Surg*. 1978;65:555–558.

Arumainayagam N, McGrath J, Jefferson KP, et al. Introduction of an enhanced recovery protocol for radical cystectomy. *BJU Int*. 2008;101:698–701.

Ashken MH. *Urinary cecal reservoir. Bladder reconstruction and continent diversion*. Year Book: Chicago, IL; 1987:238–251.

Atan A, Konety BR, Nangia A, et al. Advantages and risks of ileovesicostomy for the management of neuropathic bladder. *Urology*. 1999;54:636–640.

Austen M, Kälble T. Secondary malignancies in different forms of urinary diversion using isolated gut. *J Urol*. 2004;172:831–838.

Azhar RA, Bochner B, Catto J, et al. Enhanced recovery after urological surgery: a contemporary systematic review of outcomes, key elements, and research needs. *Eur Urol*. 2016;70:176–187.

Barqawi A, de Valdenebro M, Furness PD 3rd, et al. Lessons learned from stomal complications in children with cutaneous catheterizable continent stomas. *BJU Int*. 2004;94:1344–1347.

Bartlett JG. Clinical practice. Antibiotic-associated diarrhea. *N Engl J Med*. 2002;346:334–339.

Baum ML, Anish DS, Chalmers TC, et al. A survey of clinical trials of antibiotic prophylaxis in colon surgery: evidence against further use of no-treatment controls. *N Engl J Med*. 1981;305:795–799.

Beckley S, Wajsman Z, Pontes JE, et al. Transverse colon conduit: a method of urinary diversion after pelvic irradiation. *J Urol*. 1982;128:464–468.

Beddoe AM, Boyce JG, Remy JC, et al. Stented versus nonstented transverse colon conduits: a comparative report. *Gynecol Oncol*. 1987;27:305–315.

Beloosesky Y, Grinblat J, Weiss A, et al. Electrolyte disorders following oral sodium phosphate administration for bowel cleansing in elderly patients. *Arch Intern Med*. 2003;163:803–808.

Benchekroun A. The ileocecal continent bladder. King L, Stone AR, Webster GD. *Bladder reconstruction and continent urinary diversion*. Year Book Medical Publishers: Chicago, IL; 1987:224–237.

Berglund B, Kock NG, Myrvold HE. Volume capacity and pressure characteristics of the continent cecal reservoir. *Surg Gynecol Obstet*. 1986;163:42–48.

Berglund B, Kock NG, Norlén L, et al. Volume capacity and pressure characteristics of the continent ileal reservoir used for urinary diversion. *J Urol*. 1987;137:29–34.

Berneking AD, Rosevear HM, Askeland EJ, et al. Morbidity and mortality of octogenarians following open radical cystectomy using a standardized reporting system. *Can J*

Urol. 2013;20:6826–6831.

Bissada NK, Keane T, Caczmarek AT, et al. Experience with coapted gastric tube outlet and composite gastrointestinal reservoir for continent cutaneous urinary diversion. *J Urol*. 2004;171:229–231.

Blaivas JG, Weiss JP, Desai P, et al. Long-term followup of augmentation enterocystoplasty and continent diversion in patients with benign disease. *J Urol*. 2005;173:1631–1634.

Bonnheim DC, Petrelli NJ, Sternberg A, et al. The pathophysiology of the jejunal conduit syndrome and its exacerbation by parenteral hyperalimentation. *J Surg Oncol*. 1984;26:172–175.

Borden ZS, Pickhardt PJ, Kim DH, et al. Bowel preparation for CT colonography: blinded comparison of magnesium citrate and sodium phosphate for catharsis. *Radiology*. 2010;254:138–144.

Borglund E, Nordström G, Nyman CR. Classification of peristomal skin changes in patients with urostomy. *J Am Acad Dermatol*. 1988;19:623–628.

Bowyer GW, Davies TW. Methotrexate toxicity associated with an ileal conduit. *Br J Urol*. 1987;60:592.

Boyd SD, Schiff WM, Skinner DG, et al. Prospective study of metabolic abnormalities in patient with continent Kock pouch urinary diversion. *Urology*. 1989;33:85–88.

Bracken RB, McDonald MW, Johnson DE. Cystectomy for superficial bladder cancer. *Urology*. 1981;18:459–463.

Bricker EM. Bladder substitution after pelvic evisceration. *Surg Clin North Am*. 1950;30:1511–1521.

Bucher P, Gervaz P, Soravia C, et al. Randomized clinical trial of mechanical bowel preparation versus no preparation before elective left-sided colorectal surgery. *Br J Surg*. 2005;92:409–414.

Campanello A, Herlitz H, Lindstedt G, et al. Bone mineral and related biochemical variables in patients with Kock ileal reservoir or Bricker conduit for urinary diversion. *J Urol*. 1996;155:1209–1213.

Canin-Endres J, Salky B, Gattorno F, et al. Laparoscopically assisted intestinal resection in 88 patients with Crohn's disease. *Surg Endosc*. 1999;13:595–599.

Carrafiello G, Laganà D, Giorgianni A, et al. Bleeding from peristomal varices in a cirrhotic patient with ileal conduit: treatment with transjugular intrahepatic portocaval shunt (TIPS). *Emerg Radiol*. 2007;13:341–343.

Castellan M, Gosalbez R, Bar-Yosef Y, et al. Complications after use of gastric segments for lower urinary tract reconstruction. *J Urol*. 2012;187:1823–1827.

Castro JE, Ram MD. Electrolyte imbalance following ileal urinary diversion. *Br J Urol*. 1970;42:29–32.

Catena F, La Donna M, Gagliardi S, et al. Stapled versus hand-sewn anastomoses in emergency intestinal surgery: results of a prospective randomized study. *Surg Today*. 2004;34:123–126.

Cerantola Y, Valerio M, Persson B, et al. Guidelines for perioperative care after radical cystectomy for bladder cancer: Enhanced Recovery After Surgery (ERAS®) Society recommendations. *Clin Nutr*. 2013;32:879–887.

Chadwick Plaire J, Snodgrass WT, Grady RW, et al. Long-term followup of the hematuria-dysuria syndrome. *J Urol*. 2000;164:921–923.

Chang SS, Cookson MS, Baumgartner RG, et al. Analysis of early complications after radical cystectomy: results of a collaborative care pathway. *J Urol*. 2002;167:2012–2016.

Chang T-W. Antibiotic-associated injury to the gut. *Bockus Gastroenterol*. 1985;2583–2592.

Chassin JL, Rifkind KM, Sussman B, et al. The stapled gastrointestinal tract anastomosis: incidence of postoperative complications compared with the sutured anastomosis. *Ann Surg*. 1978;188:689–696.

Chechile G, Klein EA, Bauer L, et al. Functional equivalence of end and loop ileal conduit stomas. *J Urol*. 1992;147:582–586.

Chen KK, Chang LS, Chen MT. Urodynamic and clinical outcome of Kock pouch continent urinary diversion. *J Urol*. 1989;141:94–97.

Cho M, Pinto D, Carrodeguas L, et al. Frequency and management of internal hernias after laparoscopic antecolic antegastric Roux-en-Y gastric bypass without division of the small bowel mesentery or closure of mesenteric defects: review of 1400 consecutive cases. *Surg Obes Relat Dis*. 2006;2:87–91.

Chong JT, Dolat MT, Klausner AP, et al. The role of cystectomy for non-malignant bladder conditions: a review. *Can J Urol*. 2014;21:7433–7441.

Christensen PB, Kronborg O. Whole-gut irrigation versus enema in elective colorectal surgery: a prospective, randomized study. *Dis Colon Rectum*. 1981;24:592–595.

Clark PB. End-to-end ureteroileal anastomoses for ileal conduits. *Br J Urol*. 1979;51:105–109.

Clarke JS, Condon RE, Bartlett JG, et al. Preoperative oral antibiotics reduce septic complications of colon operations: results of prospective, randomized, double-blind clinical study. *Ann Surg*. 1977;186:251–259.

Classen DC, Evans RS, Pestotnik SL, et al. The timing of prophylactic administration of antibiotics and the risk of surgical-wound infection. *N Engl J Med*. 1992;326:281–286.

Cohen MS, Hilz ME, Davis CP, et al. Urinary carcinogen (nitrosamine) production in a rat animal model for ureterosigmoidostomy. *J Urol*. 1987;138:449–452.

Concepcion RS, Koch MO, McDougal S, et al. Detubularised intestinal segments in urinary tract reconstruction: why do they work? *Abstr Am Urol Assoc*. 1988;592.

Cordonnier JJ. Ureterosigmoid anastomosis. *J Urol*. 1950;63:276–285.

Cornud F, Lefebvre JF, Chretien Y, et al. Percutaneous transrenal electro-incision of ureterointestinal anastomotic strictures: long-term results and comparison of fluoroscopic and endoscopic guidance. *J Urol*. 1996;155:1575–1578.

Costello AJ, Johnson DE. Modified autosuture technique for ileal conduit construction in urinary diversion. *Aust N Z J Surg*. 1984;54:477–482.

Craft RO, Huguet KL, McLemore EC, et al. Laparoscopic parastomal hernia repair. *Hernia*. 2008;12:137–140.

Daneshmand S, Ahmadi H, Schuckman AK, et al. Enhanced recovery protocol after radical cystectomy for bladder cancer. *J Urol*. 2014;192:50–55.

Davies BJ, Allareddy V, Konety BR. Effect of postcystectomy infectious complications on cost, length of stay, and mortality. *Urology*. 2009;73:598–602.

De Carli P, Micali S, O'Sullivan D, et al. Ureteral anastomosis in the orthotopic ileal neobladder: comparison of 2 techniques. *J Urol*. 1997;157:469–471.

De Ganck J, Everaert K, Van Laecke E, et al. A high easy-to-treat complication rate is the price for a continent stoma. *BJU Int*. 2002;90:240–243.

De Nunzio C, Cindolo L, Leonardo C, et al. Analysis of radical cystectomy and urinary diversion complications with the Clavien classification system in an Italian real life cohort. *Eur J Surg Oncol*. 2013;39:792–798.

DeFoor W, Minevich E, Reeves D, et al. Gastrocystoplasty: long-term followup. *J Urol*. 2003;170:1647–1650.

Delgado GE, Muecke EC. Evaluation of 80 cases of ileal conduits in children: indication, complication and results. *J Urol*. 1973;109:311–314.

Didolkar MS, Reed WP, Elias EG, et al. A prospective randomized study of sutured versus stapled bowel anastomoses in patients with cancer. *Cancer*. 1986;57:456–460.

DiMarco DS, LeRoy AJ, Thieling S, et al. Long-term results of treatment for ureteroenteric strictures. *Urology*. 2001;58:909–913.

Dion YM, Richards GK, Prentis JJ, et al. The influence of oral versus parenteral preoperative metronidazole on sepsis following colon surgery. *Ann Surg*. 1980;192:221–226.

Dretler SP. The pathogenesis of urinary tract calculi occurring after ileal conduit diversion: I. Clinical Study. II. Conduit Study. III. Prevention. *J Urol*. 1973;109:204–209.

Dutton TJ, Daugherty MO, Mason RG, et al. Implementation of the Exeter enhanced recovery programme for patients undergoing radical cystectomy. *BJU Int*. 2014;113:719–725.

Edwards RH. Hyperammonemic encephalopathy related to ureterosigmoidostomy. *Arch Neurol*. 1984;41:1211–1212.

Eisenberg MS, Thompson RH, Frank I, et al. Long-term renal function outcomes after radical cystectomy. *J Urol*. 2014;191:619–625.

Elder DD, Moisey CU, Rees R. A Long-term follow-up of the colonic conduit operation in children. *BJU Int*. 1979;51:462–465.

Emmott D, Noble MJ, Mebust WK. A comparison of end versus loop stomas for ileal conduit urinary diversion. *J Urol*. 1985;133:588–590.

Eswara JR, Efstathiou JA, Heney NM, et al. Complications and long-term results of salvage cystectomy after failed bladder sparing therapy for muscle invasive bladder cancer. *J Urol*. 2012;187:463–468.

Evans AJ, Manhire AR, Bishop MC. Duplex ureters: a pitfall during ileal conduit urinary diversion. *Br J Urol*.

1994;73:214–215.

Fahmy O, Asri K, Schwentner C, et al. Current status of robotic assisted radical cystectomy with intracorporeal ileal neobladder for bladder cancer. *J Surg Oncol*. 2015;112:427–429.

Fa-Si-Oen PR, Verwaest C, Buitenweg J, et al. Effect of mechanical bowel preparation with polyethyleneglycol on bacterial contamination and wound infection in patients undergoing elective open colon surgery. *Clin Microbiol Infect*. 2005;11:158–160.

Fazio VW, Jagelman DG, Lavery IC, et al. Evaluation of the proximate-ILS circular stapler. A prospective study. *Ann Surg*. 1985;201:108–114.

Ferriero M, Guaglianone S, Papalia R, et al. Risk assessment of stone formation in stapled orthotopic ileal neobladder. *J Urol*. 2015;193:891–896.

Ferris DO, Odel HM. Electrolyte pattern of the blood after bilateral ureterosigmoidostomy. *J Am Med Assoc*. 1950;142:634–641.

Filmer RB. Malignant tumors arising in bladder augmentations and ileal and colon conduits. *Soc Pediatr Urol Newslett*. 1986.

Flanigan RC, Kursh ED, Persky L. Thirteen year experience with ileal loop diversion in children with myelodysplasia. *Am J Surg*. 1975;130:535–538.

Fontaine E, Barthelemy Y, Houlgatte A, et al. Twenty-year experience with jejunal conduits. *Urology*. 1997;50:207–213.

Franks ME, Hrebinko RL Jr. Technique of parastomal hernia repair using synthetic mesh. *Urology*. 2001;57:551–553.

Friedman RM, Flashner SC, King LR. Effectiveness of a handsewn nipple valve for reflux prevention in bladder reconstruction. *J Urol*. 1992;147:441–443.

Geist RW, Ansell JS. Total body potassium in patients after ureteroileostomy. *Surg Gynecol Obstet*. 1961;113:585–590.

Ghitulescu GA, Morin N, Jetty P, et al. Revisiting the biofragmentable anastomotic ring: is it safe in colonic surgery? *Can J Surg*. 2003;46:92–98.

Gilbert SM, Lai J, Saigal CS, et al. Urologic Diseases in America Project. Downstream complications following urinary diversion. *J Urol*. 2013;190:916–922.

Gill IS, Kaouk JH, Meraney AM, et al. Laparoscopic radical cystectomy and continent orthotopic ileal neobladder performed completely intracorporeally: the initial experience. *J Urol*. 2002;168:13–18.

Gill IS, Savage SJ, Senagore AJ, et al. Laparoscopic ileal ureter. *J Urol*. 2000;163:1199–1202.

Glassman DT, Docimo SG. Concealed umbilical stoma: long-term evaluation of stomal stenosis. *J Urol*. 2001;166:1028–1030.

Goh AC, Gill IS, Lee DJ, et al. Robotic intracorporeal orthotopic ileal neobladder: replicating open surgical principles. *Eur Urol*. 2012;62:891–901.

Golimbu M, Morales P. Jejunal conduits: technique and complications. *J Urol*. 1975;113:787–795.

Gonzalez R, Reinberg Y. Localization of bacteriuria in patients with enterocystoplasty and nonrefluxing conduits. *J Urol*. 1987;138:1104–1105.

Goodwin EW. Open, transcolonic ureterointestinal anastomosis: a new approach. *Surg Gynecol Obstet*. 1953;97:295–300.

Gosalbez R Jr, Woodard JR, Broecker BH, et al. Metabolic complications of the use of stomach for urinary reconstruction. *J Urol*. 1993;150:710–712.

Gottrup F, Diederich P, Sørensen K, et al. Prophylaxis with whole gut irrigation and antimicrobials in colorectal surgery. A prospective, randomized double-blind clinical trial. *Am J Surg*. 1985;149:317–322.

Grocela JA, McDougal WS. Ammonium transport in the intestine chronically exposed to urine: is it reduced over time? *Urology*. 1999;54:373–376.

Gründel K, Schwenk W, Böhm B, et al. Improvements in mechanical bowel preparation for elective colorectal surgery. *Dis Colon Rectum*. 1997;40:1348–1352.

Güenaga KF, Matos D, Wille-Jørgensen P. Mechanical bowel preparation for elective colorectal surgery. *Cochrane Database Syst Rev*. 2011;(9) [CD001544].

Guillotreau J, Gamé X, Mouzin M, et al. Radical cystectomy for bladder cancer: morbidity of laparoscopic versus open surgery. *J Urol*. 2009;181:554–559 [discussion 559].

Guinan PD, Moore RH, Neter E, et al. The bacteriology of ileal conduit urine in man. *Surg Gynecol Obstet*. 1972;134:78–82.

Hagen-Cook K, Althausen AF. Early observations on 31 adults with non-refluxing colon conduits. *J Urol*. 1979;121:13–16.

Hares MM, Alexander-Williams J. The effect of bowel preparation on colonic surgery. *World J Surg*. 1982;6:175–181.

Harrison AR. Clinical and metabolic observations on osteomalacia following ureterosigmoidostomy. *Br J Urol*. 1958;30:455–462.

Hasan ST, Coorsh J, Tapson JS. Use of bendrofluazide in the management of recurrent jejunal conduit syndrome. *Br J Urol*. 1994;73:101–102.

Hashad MM, Atta M, Elabbady A, et al. Safety of no bowel preparation before ileal urinary diversion. *BJU Int*. 2012;110:E1109–E1113.

Hautmann RE, de Petriconi RC, Volkmer BG. Lessons learned from 1,000 neobladders: the 90-day complication rate. *J Urol*. 2010;184:990–994 [quiz 1235].

Hautmann RE, Egghart G, Frohneberg D, et al. The ileal neobladder. *J Urol*. 1988;139:39–42.

Hayashi T, Ikai K, Kiriyama T, et al. Percutaneous intrapelvic pressure registration in patients with ureterointestinal urinary diversion. *Urology*. 1986;28:176–178.

Hedlund H, Lindström K, Månsson W. Dynamics of a continent caecal reservoir for urinary diversion. *Br J Urol*. 1984;56:366–372.

Heidler H, Marberger M, Hohenfellner R. The metabolic situation in ureterosigmoidostomy. *Eur Urol*. 1979;5:39–44.

Hemelrijck M, Thorstenson A, Smith P, et al. Risk of in-hospital complications after radical cystectomy for urinary bladder carcinoma: population-based follow-up study of 7608 patients. *BJU Int*. 2013;112:1113–1120.

Hensle TW, Burbige KA. Bladder replacement in children and young adults. *J Urol*. 1985;133:1004–1010.

Herget-Rosenthal S, Metzger J, Albalat A, et al. Proteomic biomarkers for the early detection of acute kidney injury. *Prilozi*. 2012;33:27–48.

Hill JT, Ransley PG. The colonic conduit: a better method of urinary diversion? *Br J Urol*. 1983;55:629–631.

Hirdes WH, Hoekstra I, Vlietstra HP. Hammock anastomosis: a nonrefluxing ureteroileal anastomosis. *J Urol*. 1988;139:517–518.

Ho KMT, Fawcett DP. Parastomal hernia repair using the lateral approach. *BJU Int*. 2004;94:598–602.

Hohenfellner R, Black P, Leissner J, et al. Refluxing ureterointestinal anastomosis for continent cutaneous urinary diversion. *J Urol*. 2002;168:1013–1016 [discussion 1016–1017].

Hossain M. The osteomalacia syndrome after colocystoplasty; a cure with sodium bicarbonate alone. *Br J Urol*. 1970;42:243–245.

Husmann DA, McLorie GA, Churchill BM. Nonrefluxing colonic conduits: a long-term life-table analysis. *J Urol*.

1989;142:1201–1203.

Hyman N, Manchester TL, Osler T, et al. Anastomotic leaks after intestinal anastomosis: it's later than you think. *Ann Surg*. 2007;245:254.

Iannoni C, Marcheggiano A, Pallone F, et al. Abnormal patterns of colorectal mucin secretion after urinary diversion of different types: histochemical and lectin binding studies. *Hum Pathol*. 1986;17:834–840.

Incel N, Incel NA, Uygur MC, et al. Effect of Stanford pouch and ileal conduit urinary diversions on bone mineral density and metabolism. *Int Urol Nephrol*. 2006;38:447–451.

Inker LA, Schmid CH, Tighiouart H, et al. Estimating glomerular filtration rate from serum creatinine and cystatin C. *N Engl J Med*. 2012;367:20–29.

Irwin TT, Goligher JC. Aetiology of disruption of intestinal anastomosis. *Br J Surg*. 1973;60:461–464.

Jacobs JA, Young JD Jr. The Strickler technique of ureterosigmoidostomy. *J Urol*. 1980;124:451–454.

Jaffe BM, Bricker EM, Butcher HR Jr. Surgical complications of ileal segment urinary diversion. *Ann Surg*. 1968;167:367–376.

Jain A, Vargas HD. Advances and challenges in the management of acute colonic pseudo-obstruction (Ogilvie syndrome). *Clin Colon Rectal Surg*. 2012;25:37–45.

Jakobsen H, Steven K, Stigsby B, et al. Pathogenesis of nocturnal urinary incontinence after ileocaecal bladder replacement. Continuous measurement of urethral closure pressure during sleep. *Br J Urol*. 1987;59:148–152.

Jex RK, van Heerden JA, Wolff BG, et al. Gastrointestinal anastomoses. Factors affecting early complications. *Ann Surg*. 1987;206:138–141.

Kaidar-Person O, Rosenthal RJ, Wexner SD, et al. Compression anastomosis: history and clinical considerations. *Am J Surg*.

2008;195:818–826.

Kälble T, Hofmann I, Riedmiller H, et al. Tumor growth in urinary diversion: a multicenter analysis. *Eur Urol*. 2011;60:1081–1086.

Kamizaki H, Cass AS. Conduit and renal pelvic pressures after ileal and colonic urinary diversion in dogs. *Invest Urol*. 1978;16:27–32.

Karl A, Buchner A, Becker A, et al. A new concept for early recovery after surgery for patients undergoing radical cystectomy for bladder cancer: results of a prospective randomized study. *J Urol*. 2014;191:335–340.

Kaufman JJ. Ammoniagenic coma following ureterosigmoidostomy. *J Urol*. 1984;131:743–745.

Kawakita M, Arai Y, Shigeno C, et al. Bone demineralization following urinary intestinal diversion assessed by urinary pyridinium cross-links and dual energy x-ray absorptiometry. *J Urol*. 1996;156:355–359.

Kim EK, Sheetz KH, Bonn J, et al. A statewide colectomy experience: the role of full bowel preparation in preventing surgical site infection. *Ann Surg*. 2014;259:310–314.

King LR. Protection of the upper tracts in undiversion. King LR, Stone AF, Webster GD. *Bladder reconstruction and continent urinary diversion*. Year Book: Chicago, IL; 1987:127–153.

Kinn AC, Lantz B. Vitamin B_{12} deficiency after irradiation for bladder carcinoma. *J Urol*. 1984;131:888–890.

Klein EA, Montie JE, Montague DK, et al. Jejunal conduit urinary diversion. *J Urol*. 1986;135:244–246.

Koch MO, McDougal WS. Determination of renal function following urinary diversion through intestinal segments. *J Urol*. 1985;133:517–520.

Koch MO, McDougal WS. Bone demineralization following ureterosigmoid anastomosis: an experimental study in rats. *J*

Urol. 1988;140:856–859.

Koch MO, Gurevitch E, Hill DE, et al. Urinary solute transport by intestinal segments: a comparative study of ileum and colon in rats. *J Urol*. 1990;143:1275–1279.

Koch MO, McDougal WS, Hall MC, et al. Long-term metabolic effects of urinary diversion: a comparison of myelomeningocele patients managed by clean intermittent catheterization and urinary diversion. *J Urol*. 1992;147:1343–1347.

Kock NG, Nilson AE, Norlen L, et al. Changes in renal parenchyma and the upper urinary tracts following urinary diversion via a continent ileum reservoir. *Scand J Urol Nephrol*. 1978;49:11.

Kock NG, Nilson AE, Nilsson LO, et al. Urinary diversion via a continent ileal reservoir: clinical results in 12 patients. *J Urol*. 1982;128:469–475.

Kock NG. The development of the continent ileal reservoir (Kock pouch) and applications in patients requiring urinary diversion. *Bladder Reconstr Cont Urin Divers*. 1987;269–289.

Koff SA. Mechanism of electrolyte imbalance following urointestinal anastomosis. *Urology*. 1975;5:109–114.

Kouba E, Sands M, Lentz A, et al. A comparison of the Bricker versus Wallace ureteroileal anastomosis in patients undergoing urinary diversion for bladder cancer. *J Urol*. 2007;178:945–948 [discussion 948–949].

Kozlowski PM, Wang PC, Winfield HN. Laparoscopic repair of incisional and parastomal hernias after major genitourinary or abdominal surgery. *J Endourol*. 2001;15:175–179.

Kramolowsky EV, Clayman RV, Weyman PJ. Endourological management of ureteroileal anastomotic strictures: is it effective? *J Urol*. 1987;137:390–394.

Kramolowsky EV, Clayman RV, Weyman PJ. Management of ureterointestinal anastomotic strictures: comparison of open surgical and endourological repair. *J Urol*. 1988;139:1195–1198.

Kristjánsson A, Davidsson T, Månsson W. Metabolic alterations at different levels of renal function following continent urinary diversion through colonic segments. *J Urol*. 1997;157:2099–2103.

Kurzrock EA, Baskin LS, Kogan BA. Gastrocystoplasty: long-term followup. *J Urol*. 1998;160:2182–2186.

Küss R, Bitker M, Camey M, et al. Indications and early and late results of intestino-cystoplasty: a review of 185 cases. *J Urol*. 1970;103:53–63.

Lashley DB, Saxon RR, Fuchs EF, et al. Bleeding ileal conduit stomal varices: diagnosis and management using transjugular transhepatic angiography and embolization. *Urology*. 1997;50:612–614.

Laven BA, O'Connor RC, Steinberg GD, et al. Long-term results of antegrade endoureterotomy using the holmium laser in patients with ureterointestinal strictures. *Urology*. 2001;58:924–929.

Le Duc A, Camey M, Teillac P. An original antireflux ureteroileal implantation technique: long-term followup. *J Urol*. 1987;137:1156–1158.

Leadbetter WF, Clarke BG. Five years' experience with uretero-enterostomy by the "combined" technique. *J Urol*. 1954;73:67–82.

Lee CT, Chang SS, Kamat AM, et al. Alvimopan accelerates gastrointestinal recovery after radical cystectomy: a multicenter randomized placebo-controlled trial. *Eur Urol*. 2014;66:265–272.

Leong CH. Use of the stomach for bladder replacement and urinary diversion. *Ann R Coll Surg Engl*. 1978;60:283–289.

Leslie A, Steele R. The interrupted serosubmucosal anastomosis

—still the gold standard. *Colorectal Dis*. 2003;5:362–366.

Liatsikos E, Kallidonis P, Kyriazis I, et al. Ureteral obstruction: is the full metallic double-pigtail stent the way to go? *Eur Urol*. 2010;57:480–486.

Lockhart JL, Bejany DE. Antireflux ureteroileal reimplantation: an alternative for urinary diversion. *J Urol*. 1987;137:867–870.

Loening SA, Navarre RJ, Narayana AS, et al. Transverse colon conduit urinary diversion. *J Urol*. 1982;127:37–39.

Lowy I, Molrine DC, Leav BA, et al. Treatment with monoclonal antibodies against *Clostridium difficile* toxins. *N Engl J Med*. 2010;362:197–205.

Ludwig K, Enker WE, Delaney CP, et al. Gastrointestinal tract recovery in patients undergoing bowel resection: results of a randomized trial of alvimopan and placebo with a standardized accelerated postoperative care pathway. *Arch Surg*. 2008;143:1098–1105.

MacRae HM, McLeod RS. Handsewn vs. stapled anastomoses in colon and rectal surgery. *Dis Colon Rectum*. 1998;41:180–189.

Madersbacher S, Schmidt J, Eberle JM, et al. Long-term outcome of ileal conduit diversion. *J Urol*. 2003;169:985–990.

Maffezzini M, Campodonico F, Canepa G, et al. Current perioperative management of radical cystectomy with intestinal urinary reconstruction for muscle-invasive bladder cancer and reduction of the incidence of postoperative ileus. *Surg Oncol*. 2008;17:41–48.

Magnus RV. Pressure studies and dynamics of ileal conduits in children. *J Urol*. 1977;118:406–407.

Malek RS, Burke EC, Deweerd JH. Ileal conduit urinary diversion in children. *J Urol*. 1971;105:892–900.

Månsson W, Colleen S, Stigsson L. Four methods of ureterointestinal anastomosis in urinary conduit diversion. A comparative study of early and late complications and the influence of radiotherapy. *Scand J Urol Nephrol*. 1979;13:191–199.

Månsson W, Colleen S, Forsberg L, et al. Renal function after urinary diversion. A study of continent caecal reservoir, ileal conduit and colonic conduit. *Scand J Urol Nephrol*. 1984;18:307–315.

Månsson W, Davidsson T, Könyves J, et al. Continent urinary tract reconstruction—the Lund experience. *BJU Int*. 2003;92:271–276.

Markowitz GS, Stokes MB, Radhakrishnan J, et al. Acute phosphate nephropathy following oral sodium phosphate bowel purgative: an underrecognized cause of chronic renal failure. *J Am Soc Nephrol*. 2005;16:3389–3396.

Matsuura T, Tsujihashi H, Park YC, et al. Assessment of the long-term results of ileocecal conduit urinary diversion. *Urol Int*. 1991;46:154–158.

Mattei A, Birkhaeuser FD, Baermann C, et al. To stent or not to stent perioperatively the ureteroileal anastomosis of ileal orthotopic bladder substitutes and ileal conduits? Results of a prospective randomized trial. *J Urol*. 2008;179:582–586.

McDermott WV. Diversion of urine to the intestines as a factor in ammoniagenic coma. *N Engl J Med*. 1957;256:460–462.

McDougal WS. Bladder reconstruction following cystectomy by uretero-ileo-colourethrostomy. *J Urol*. 1986;135:698–701.

McDougal WS. Metabolic complications of urinary intestinal diversion. *J Urol*. 1992;147:1199–1208.

McDougal WS, Koch MO. Accurate determination of renal function in patients with intestinal urinary diversions. *J Urol*. 1986;135:1175–1178.

McDougal WS, Koch MO. Effect of sulfate on calcium and magnesium homeostasis following urinary diversion. *Kidney*

Int. 1989;35:105–115.

McDougal WS, Koch MO, Shands C 3rd, et al. Bony demineralization following urinary intestinal diversion. *J Urol*. 1988;140:853–855.

McDougal WS, Stampfer DS, Kirley S, et al. Intestinal ammonium transport by ammonium and hydrogen exchange. *J Am Coll Surg*. 1995;181:241–248.

Medina CA, Caridi JG, Wajsman Z. Massive bleeding from ileal conduit peristomal varices: successful treatment with the transjugular intrahepatic portosystemic shunt. *J Urol*. 1998;159:200–201.

Melnyk M, Casey RG, Black P, et al. Enhanced Recovery After Surgery (ERAS) protocols: time to change practice? *Can Urol Assoc J*. 2011;5:342–348.

Menon M, Yu GW, Jeffs RD. Technique for antirefluxing ureterocolonic anastomosis. *J Urol*. 1982;127:236–237.

Mesrobian HG, Kelalis PP, Kramer SA. Long-term followup of 103 patients with bladder exstrophy. *J Urol*. 1988;139:719–722.

Middleton AW Jr, Hendren WH. Ileal conduits in children at the Massachusetts General Hospital from 1955 to 1970. *J Urol*. 1976;115:591–595.

Mingin GC, Stock JA, Hanna MK. Gastrocystoplasty: long-term complications in 22 patients. *J Urol*. 1999;162:1122–1125.

Mounger EJ, Branson AD. Ammonia encephalopathy secondary to ureterosigmoidostomy: a case report. *J Urol*. 1972;108:411–412.

Mukhtar S, Ayres BE, Issa R, et al. Challenging boundaries: an enhanced recovery programme for radical cystectomy. *Ann R Coll Surg Engl*. 2013;95:200–206.

Mutchnik SE, Hinson JL, Nickell KG, et al. Ileovesicostomy as an alternative form of bladder management in tetraplegic patients. *Urology*. 1997;49:353–357.

N'Dow J, Leung HY, Marshall C, et al. Bowel dysfunction after bladder reconstruction. *J Urol*. 1998;159:1470–1474 [discussion 1474–1475].

N'Dow J, Pearson J, Neal D. Mucus production after transposition of intestinal segments into the urinary tract. *World J Urol*. 2004;22:178–185.

Nesbit RM. Ureterosigmoid anastomosis by direct elliptical connection: a preliminary report. *J Urol*. 1949;61:728–734.

Nguyen DH, Reinberg Y, Gonzalez R, et al. Outcome of renal transplantation after urinary diversion and enterocystoplasty: a retrospective, controlled study. *J Urol*. 1990;144:1349–1351.

Nichols RL, Condon RE, Gorbach SL, et al. Efficacy of preoperative antimicrobial preparation of the bowel. *Ann Surg*. 1972;176:227–232.

Nieuwenhuijzen JA, de Vries RR, Bex A, et al. Urinary diversions after cystectomy: the association of clinical factors, complications and functional results of four different diversions. *Eur Urol*. 2008;53:834–842 [discussion 842–844].

Oliveira L, Wexner SD, Daniel N, et al. Mechanical bowel preparation for elective colorectal surgery. *Dis Colon Rectum*. 1997;40:585–591.

Onwubalili JK. Overt diabetes mellitus without glycosuria in a patient with cutaneous ureteroileostomy. *Br Med J*. 1982;284:1836–1837.

Osman Y, Abol-Enein H, Nabeeh A, et al. Long-term results of a prospective randomized study comparing two different antireflux techniques in orthotopic bladder substitution. *Eur Urol*. 2004;45:82–86.

Pagano F, Cosciani-Cunico S, Dal Bianco M, et al. Five years of experience with a modified technique of ureterocolonic

anastomosis. *J Urol*. 1984;132:17–18.
Pagano F. Ureterocolonic anastomosis: description of a technique. *J Urol*. 1980;123:355–356.
Palascak P, Bouchareb M, Zachoval R, et al. Treatment of benign ureterointestinal anastomotic strictures with permanent ureteral Wallstent after Camey and Wallace urinary diversion: long-term follow-up. *J Endourol*. 2001;15:575–580.
Pantuck AJ, Han KR, Perrotti M, et al. Ureteroenteric anastomosis in continent urinary diversion: long-term results and complications of direct versus nonrefluxing techniques. *J Urol*. 2000;163:450–455.
Patil U, Glassberg KI, Waterhouse K. Ileal conduit surgery with nippled ureteroileal anastomoses. *Urology*. 1976;7:594–597.
Perez-Fidalgo JA, Chirivella IG, Günthner S, et al. Hyperammonaemic encephalopathy, possible complication after urinary diversion in radical cystectomy. Review of the literature with regard to a clinical case. *Actas Urol Esp*. 2007;31:394–399.
Perry W, Allen LN, Stamp TC, et al. Vitamin D resistance in osteomalacia after ureterosigmoidostomy. *N Engl J Med*. 1977;297:1110–1112.
Philipson BM, Kock NG, Jagenburg R, et al. Functional and structural studies of ileal reservoirs used for continent urostomy and ileostomy. *Gut*. 1983;24:392–398.
Pitts WR Jr, Muecke EC. A 20-year experience with ileal conduits: the fate of the kidneys. *J Urol*. 1979;122:154–157.
Potter SR, Charambura TC, Adams JB 2nd, et al. Laparoscopic ileal conduit: five-year follow-up. *Urology*. 2000;56:22–25.
Poulakis V, Witzsch U, De Vries R, et al. Cold-knife endoureterotomy for nonmalignant ureterointestinal anastomotic strictures. *Urology*. 2003;61:512–517 [discussion 517].

Pruthi RS, Nielsen M, Smith A, et al. Fast track program in patients undergoing radical cystectomy: results in 362 consecutive patients. *J Am Coll Surg*. 2010;210:93–99.

Ramirez JA, McIntosh AG, Strehlow R, et al. Definition, incidence, risk factors, and prevention of paralytic ileus following radical cystectomy: a systematic review. *Eur Urol*. 2013;64:588–597.

Rapp DE, O'Connor RC, Katz EE, et al. Neobladder-vaginal fistula after cystectomy and orthotopic neobladder construction. *BJU Int*. 2004;94:1092–1095.

Ravi R, Dewan AK, Pandey KK. Transverse colon conduit urinary diversion in patients treated with very high dose pelvic irradiation. *Br J Urol*. 1994;73:51–54.

Reddy BS, Macfie J, Gatt M, et al. Randomized clinical trial of effect of synbiotics, neomycin and mechanical bowel preparation on intestinal barrier function in patients undergoing colectomy. *Br J Surg*. 2007;94:546–554.

Regan JB, Barrett DM. Stented versus nonstented ureteroileal anastomoses: is there a difference with regard to leak and stricture? *J Urol*. 1985;134:1101–1103.

Reinberg Y, Manivel JC, Froemming C, et al. Perforation of the gastric segment of an augmented bladder secondary to peptic ulcer disease. *J Urol*. 1992;148:369–371.

Richards P, Chamberlain MJ, Wrong OM. Treatment of osteomalacia of renal tubular acidosis by sodium bicarbonate alone. *Lancet*. 1972;2:994–997.

Richie JP, Skinner DG. Urinary diversion: the physiological rationale for non-refluxing colonic conduits. *BJU Int*. 1975;47:269–275.

Richie JP. Intestinal loop urinary diversion in children. *J Urol*. 1974;111:687–689.

Riddick ACP, Turner WH, Mills RD. Bowel function after urinary diversion. *World J Urol*. 2004;22:210–214.

Rosenbaum DH, Cain MP, Kaefer M, et al. Ileal enterocystoplasty and B_{12} deficiency in pediatric patients. *J Urol*. 2008;179:1544–1547 [discussion 1547–1548].

Rothenberg SS. Laparoscopic segmental intestinal resection. *Semin Pediatr Surg*. 2002;11:211–216.

Saar M, Ohlmann C-H, Siemer S, et al. Fast-track rehabilitation after robot-assisted laparoscopic cystectomy accelerates postoperative recovery. *BJU Int*. 2013;112:E99–E106.

Safadi B. Laparoscopic repair of parastomal hernias: early results. *Surg Endosc*. 2004;18:676–680.

Sakorafas GH, Zouros E, Peros G. Applied vascular anatomy of the colon and rectum: clinical implications for the surgical oncologist. *Surg Oncol*. 2006;15:243–255.

Salahudeen AK, Elliott RW, Ellis HA. Osteomalacia due to ileal replacement of ureters: report of 2 cases. *J Urol*. 1984;131:335–337.

Samuel JD, Bhatt RI, Montague RJ, et al. The natural history of postoperative renal function in patients undergoing ileal conduit diversion for cancer measured using serial isotopic glomerular filtration rate and 99m technetium-mercaptoacetyltriglycine renography. *J Urol*. 2006;176:2518–2522.

Savarirayan F, Dixey GM. Syncope following ureterosigmoidostomy. *J Urol*. 1969;101:844–845.

Schipper H, Decter A. Carcinoma of the colon arising at ureteral implant sites despite early external diversion: pathogenetic and clinical implications. *Cancer*. 1981;47:2062–2065.

Schmidt JD, Hawtrey CE, Flocks RH, et al. Complications, results and problems of ileal conduit diversions. *J Urol*. 1973;109:210–216.

Schmidt JD, Buchsbaum HJ, Nachtsheim DA. Long-term follow-up, further experience with and modifications of the transverse colon conduit in urinary tract diversion. *BJU Int*.

1985;57:284–288.

Schwaibold H, Friedrich MG, Fernandez S, et al. Improvement of ureteroileal anastomosis in continent urinary diversion with modified Le Duc procedure. *J Urol*. 1998;160:718–720.

Schwarz GR, Jeffs RD. Ileal conduit urinary diversion in children: computer analysis of followup from 2 to 16 years. *J Urol*. 1975;114:285–288.

Seinelä L, Pehkonen E, Laasanen T, et al. Bowel preparation for colonoscopy in very old patients. *Scand J Gastroenterol*. 2003;38:216–220.

Sener SF, Imperato JP, Blum MD, et al. Technique and complications of reconstruction of the pelvic floor with polyglactin mesh. *Surg Gynecol Obstet*. 1989;168:475–480.

Shands C 3rd, McDougal WS, Wright EP. Prevention of cancer at the urothelial enteric anastomotic site. *J Urol*. 1989;141:178–181.

Shapiro SR, Lebowitz R, Colodny AH. Fate of 90 children with ileal conduit urinary diversion a decade later: analysis of complications, pyelography, renal function and bacteriology. *J Urol*. 1975;114:289–295.

Siklos P, Davie M, Jung RT, et al. Osteomalacia in ureterosigmoidostomy: healing by correction of the acidosis. *Br J Urol*. 1980;52:61–62.

Silberman R. Ammonia intoxication following ureterosigmoidostomy in a patient with liver disease. *Lancet*. 1958;2:937–939.

Skinner DG, Lieskovsky G, Boyd S. Continent urinary diversion. *J Urol*. 1989;141:1323–1327.

Slim K, Vicaut E, Launay-Savary M-V, et al. Updated systematic review and meta-analysis of randomized clinical trials on the role of mechanical bowel preparation before colorectal surgery. *Ann Surg*. 2009;249:203–209.

Smith ED. Follow-up studies on 150 ileal conduits in children. *J*

Pediatr Surg. 1972;7:1–10.

Srinivas S, Mahalati K, Freiha FS. Methotrexate tolerance in patients with ileal conduits and continent diversions. *Cancer*. 1998;82:1134–1136.

Starr A, Rose DH, Cooper F. Antireflux ureteroileal anastomoses in humans. *J Urol*. 1975;113:170–174.

Steele KE, Prokopowicz GP, Magnuson T, et al. Laparoscopic antecolic Roux-en-Y gastric bypass with closure of internal defects leads to fewer internal hernias than the retrocolic approach. *Surg Endosc*. 2008;22:2056–2061.

Stein JP, Freeman JA, Esrig D, et al. Complications of the afferent antireflux valve mechanism in the Kock ileal reservoir. *J Urol*. 1996;155:1579–1584.

Stein JP, Skinner DG. The craft of urologic surgery: the T pouch. *Urol Clin North Am*. 2003;30:647–661 [xi].

Stein JP, Dunn MD, Quek ML, et al. The orthotopic T pouch ileal neobladder: experience with 209 patients. *J Urol*. 2004;172:584–587.

Stein R, Fisch M, Stöckle M, et al. Colonic conduit in children: protection of the upper urinary tract 16 years later? *J Urol*. 1996;156:1146–1150.

Stein R, Fisch M, Andreas J, et al. Whole-body potassium and bone mineral density up to 30 years after urinary diversion. *Br J Urol*. 1998;82:798–803.

Stephenson AJ, Gill IS. Laparoscopic radical cystectomy for muscle-invasive bladder cancer: pathological and oncological outcomes. *BJU Int*. 2008;102:1296–1301.

Stewart M, Macrae FA, Williams CB. Neoplasia and ureterosigmoidostomy: a colonoscopy survey. *Br J Surg*. 1982;69:414–416.

Strickler WL. A modification of the combined ureterosigmoidostomy. *J Urol*. 1965;93:370–373.

Studer UE, Burkhard FC, Schumacher M, et al. Twenty years experience with an ileal orthotopic low pressure bladder substitute—lessons to be learned. *J Urol*. 2006;176:161–166.

Studer UE, Danuser H, Thalmann GN, et al. Antireflux nipples or afferent tubular segments in 70 patients with ileal low pressure bladder substitutes: long-term results of a prospective randomized trial. *J Urol*. 1996;156:1913–1917.

Sullivan JW, Grabstald H, Whitmore WF Jr. Complications of ureteroileal conduit with radical cystectomy: review of 336 cases. *J Urol*. 1980;124:797–801.

Surawicz CM, Brandt LJ, Binion DG, et al. Guidelines for diagnosis, treatment, and prevention of *Clostridium difficile* infections. *Am J Gastroenterol*. 2013;108:478–498 [quiz 499].

Tainio H, Kylmälä T, Tammela TL. Ulcer perforation in gastric urinary conduit: never use a gastric segment in the urinary tract if there are other options available. *Urol Int*. 2000;64:101–102 [discussion 103].

Takada N, Abe T, Shinohara N, et al. Peri-operative morbidity and mortality related to radical cystectomy: a multi-institutional retrospective study in Japan. *BJU Int*. 2012;110:756–764.

Tanrikut C, McDougal WS. Acid-base and electrolyte disorders after urinary diversion. *World J Urol*. 2004;22:168–171.

Tapper D, Folkman J. Lymphoid depletion in ileal loops: mechanism and clinical implications. *J Pediatr Surg*. 1976;11:871–880.

Thüroff JW, Alken P, Riedmiller H, et al. The Mainz pouch (mixed augmentation ileum and cecum) for bladder augmentation and continent diversion. *J Urol*. 1986;136:17–26.

Thüroff JW, Alken P, Riedmiller H, et al. The Mainz pouch for augmentation or substitution of the bladder and continent diversion. *Semin Urol*. 1987;5:69–79.

Tiffany P, Vaughan ED Jr, Marion D, et al. Hypergastrinemia following antral gastrocystoplasty. *J Urol*. 1986;136:692–695.

Tjandra JJ, Tagkalidis P. Carbohydrate-electrolyte (E-Lyte®) solution enhances bowel preparation with oral Fleet® Phospho-soda®. *Dis Colon Rectum*. 2004;47:1181–1186.

Tuggle DW, Hoelzer DJ, Tunell WP, et al. The safety and cost-effectiveness of polyethylene glycol electrolyte solution bowel preparation in infants and children. *J Pediatr Surg*. 1987;22:513–515.

Türkölmez K, Baltaci S, Göğüş Ç, et al. Results of the ureteral reimplantation with serous-lined extramural tunnel in orthotopic ileal W-neobladder. *Int J Urol*. 2004;11:368–373.

Tyritzis SI, Hosseini A, Jonsson M, et al. Robot-assisted intracorporeal formation of the ileal neobladder. *J Endourol*. 2012;26:1570–1575.

US Food and Drug Administration. *Entereg Prescribing information*. [Available from:] https://www.accessdata.fda.gov/drugsatfda_docs/label/2013/0 2013.

van den Bogaard AE, Weidema W, Hazen MJ, et al. A bacteriological evaluation of three methods of bowel preparation for elective colorectal surgery. *Antonie Van Leeuwenhoek*. 1981;47:86–88.

Varadhan KK, Neal KR, Dejong CH, et al. The Enhanced Recovery After Surgery (ERAS) pathway for patients undergoing major elective open colorectal surgery: a meta-analysis of randomized controlled trials. *Clin Nutr*. 2010;29:434–440.

Varkarakis IM, Chrisofos M, Antoniou N, et al. Evaluation of findings during re-exploration for obstructive ileus after radical cystectomy and ileal-loop urinary diversion: insight into potential technical improvements. *BJU Int*. 2007;99:893–

897.

Vo E, Massarweh NN, Chai CY, et al. Association of the addition of oral antibiotics to mechanical bowel preparation for left colon and rectal cancer resections with reduction of surgical site infections. *JAMA Surg*. 2018;153:114–121.

Waidelich R, Rink F, Kriegmair M, et al. A study of reflux in patients with an ileal orthotopic bladder. *Br J Urol*. 1998;81:241–246.

Wallace DM. Uretero-ileostomy. *Br J Urol*. 1970;42:529–534.

Warwick RT, Ashken MH. The functional results of partial, subtotal, and total cystoplasty with special reference to ureterocecocystoplasty, selective sphincterotomy and cystocystoplasty. *BJU Int*. 1967;39:3–12.

Washington JA 2nd, Dearing WH, Judd ES, et al. Effect of preoperative antibiotic regimen on development of infection after intestinal surgery: prospective, randomized, double-blind study. *Ann Surg*. 1974;180:567–572.

Weber TR, Westfall SH, Steinhardt GF, et al. Malignancy associated with ureterosigmoidostomy: detection by mucosa ornithine decarboxylase. *J Pediatr Surg*. 1988;23:1091–1094.

Wendel RG, Henning DC, Evans AT. End-to-end ureteroileal anastomosis for iliac conduits: preliminary report. *J Urol*. 1969;102:42–43.

Whitmore WF 3rd, Gittes RF. Reconstruction of the urinary tract by cecal and ileocecal cystoplasty: review of a 15-year experience. *J Urol*. 1983;129:494–498.

Wiesner C, Stein R, Pahernik S, et al. Long-term followup of the intussuscepted ileal nipple and the in situ, submucosally embedded appendix as continence mechanisms of continent urinary diversion with the cutaneous ileocecal pouch (Mainz pouch I). *J Urol*. 2006;176:155–160.

Wille-Jørgensen P, Guenaga KF, Castro AA, et al. Clinical value of preoperative mechanical bowel cleansing in elective colorectal surgery: a systematic review. *Dis Colon Rectum*. 2003;46:1013–1020.

Williams RE, Davenport TJ, Burkinshaw L, et al. Changes in whole body potassium associated with uretero-intestinal anastomoses. *BJU Int*. 1967;39:676–680.

Wishahi MM, Elganzoury H, Elkhouly A, et al. Dipping technique for ureteroileal anastomosis in orthotopic ileal neobladder: 20-year experience in 670 patients—no stenosis with preservation of the upper tract. *ISRN Urol*. 2013;2013:725286.

Wolf JS Jr, Bennett CJ, Dmochowski RR, et al. Best practice policy statement on urologic surgery antimicrobial prophylaxis. *J Urol*. 2008;179:1379–1390.

Wolff BG, Beart RW Jr, Dozois RR, et al. A new bowel preparation for elective colon and rectal surgery. A prospective, randomized clinical trial. *Arch Surg*. 1988;123:895–900.

Woodhouse CRJ, Robertson WG. Urolithiasis in enterocystoplasties. *World J Urol*. 2004;22:215–221.

Wren SM, Ahmed N, Jamal A, et al. Preoperative oral antibiotics in colorectal surgery increase the rate of *Clostridium difficile* colitis. *Arch Surg*. 2005;140:752–756.

Wullt B, Agace W, Mansson W. Bladder, bowel and bugs—bacteriuria in patients with intestinal urinary diversion. *World J Urol*. 2004;22:186–195.

Xu R, Zhao X, Zhong Z, et al. No advantage is gained by preoperative bowel preparation in radical cystectomy and ileal conduit: a randomized controlled trial of 86 patients. *Int Urol Nephrol*. 2010;42:947–950.

Yao D-H, Luo X-F, Zhou B, et al. Ileal conduit stomal variceal bleeding managed by endovascular embolization. *World J Gastroenterol*. 2013;19:8156–8159.

Zabbo A, Kay R. Ureterosigmoidostomy and bladder exstrophy:

a long-term followup. *J Urol*. 1986;136:396–398.

Cutaneous Continent Urinary Diversion

Guarionex Joel DeCastro MD, MPH, James M. McKiernan MD, Mitchell C. Benson MD

General Considerations

Continent urinary diversion is a widely accepted form of urinary reconstruction after cystectomy. Orthotopic urethral anastomotic procedures and continent catheterizable stomal reservoirs have stood the test of time, and both procedures should be considered and offered to all appropriately selected patients. Given the metabolic consequences of continent urinary diversion, which are covered in separate chapters, patient selection is especially important. This chapter focuses on the most common continent cutaneous diversion surgeries associated with the highest success rates. Over the past 40 years the design of the reservoir has not substantially changed. Rather, an evolution has occurred in the techniques used to create antireflux and continence mechanisms to make these diversions more effective and reliable. In addition, attention will be given to the long-term quality-of-life outcomes of continent cutaneous reservoirs, as well as to the newer minimally invasive approaches used to create such reservoirs.

Despite the considerable enthusiasm for continent urinary diversion, those procedures requiring the use of external urinary collecting appliances remain more common. Although continent urinary diversion is certainly appropriate in selected patients, it is technically more challenging and is associated with higher short-term and long-term complication rates than procedures involving external collecting devices, thereby limiting the patient population that can undergo this type of diversion. However, the operating time associated with these more complex procedures has been significantly reduced by the widespread use of absorbable and metal staples in the construction of the reservoirs and limbs. In addition, as experience with continent urinary diversion has increased, complication rates have decreased. As a result, the use of continent diversions has also increased in some centers.

Patient Selection

Because the ability to self-catheterize is essential to the patient undergoing continent diversion, the patient must be assessed for the ability to care for himself or herself. The patient may be at greater ease with an enterostomal therapist to express concerns about forms of urinary diversion, so consultation with such a therapist may be extremely helpful. Certain patients may not be able to comprehend the strict flushing, irrigation, and catheterization regimens that must be followed after continent urinary diversion or may lack the motor skills to independently perform self-care. **Patients with multiple sclerosis, quadriplegic individuals, and very frail or mentally impaired patients will at some point in their lives require family or visiting nurses for basic care and are therefore viewed as poor candidates for any form of continent diversion.** Indeed, these patients may also require assistance with external appliances, but the degree of time and expertise required is much less burdensome on the care provider and the health care system. On the contrary, continent catheterizable diversion requires continuous attention and may limit patient and family options when determining long-term care needs.

Patient Preparation

All patients undergoing anticipated continent urinary diversion should be fully informed and prepared for the possibility that intraoperative findings may lead to the need to perform an ileal conduit diversion. Although this occurrence is rare, it always remains a possibility. Therefore the site for a potential external stoma should be selected with care before the operation. In general, the location must be free from fat creases in the standing and sitting positions, and it should not be close to the umbilicus or prior abdominal scars that may interfere with proper adherence of an external appliance. Here again, the aid of an enterostomal therapist is helpful. In general, the stoma should be brought through the right (or left) lower quadrant of the abdomen on a line extending from the umbilicus to the anterior superior iliac spine. The stoma should be as far lateral from the midline as possible, but the site selected should ensure that the bowel segment comprising the stoma traverses the rectus muscle. Failure to adhere to this rule increases the risk of parastomal hernias. The selected site for the stoma should be marked with an X scratched onto the anterior abdominal wall. Marking the stoma site with ink should be avoided because it may be washed away during the antiseptic preparation of the skin.

The surgeon undertaking continent urinary diversion should be familiar with more than one type of continent urinary diversion technique. Although it is uncommon to have to abandon a given bowel segment for the reservoir, it is not uncommon to have to modify the antireflux or continence mechanism. In these circumstances, it is essential that the surgeon be able to select an alternate form of continent diversion from what was originally intended.

Renal and hepatic function must be reviewed carefully in the patient selected for continent diversion (Mills and Studer, 1999). The reabsorption and recirculation of urinary constituents and other metabolites require that liver function be normal. Renal function should be determined preoperatively, and if borderline, creatinine clearance should be measured. A minimal level of at least 60 mL/min should be documented before the patient is deemed an appropriate candidate for continent diversion. In the case of unilateral or bilateral hydronephrosis, the upper urinary tract(s) should be decompressed with ureteral stenting or percutaneous nephrostomy, with subsequent reevaluation of renal function before consideration for a continent diversion.

Procedures that require the use of the colon should always be preceded by a colonoscopic assessment of the entire large intestine. Performing only a sigmoidoscopy for a procedure that will use only this segment of the large bowel is insufficient because disease proximal to the resected segment may leave the patient with short colon syndrome. The preoperative assessment of the colon is not mandatory but remains prudent if continent urinary diversion using small intestine is planned.

Most patients undergoing radical cystectomy can be admitted to the hospital on the day of surgery. In most institutions a mechanical bowel preparation is employed on the day before surgery, in addition to oral metronidazole (500 mg) the night before. This is still considered standard in any urinary diversion using large bowel. However, in addition to general surgery literature, several nonrandomized urologic studies have called into question the usefulness of preoperative bowel preparation for urinary diversion using small bowel (Large et al., 2012; Raynor et al., 2013). Intraoperative antibiotics (e.g., cefoxitin 1 to 2 g) should be administered within 1 hour of skin incision.

Cystectomy

Although robotic intracorporeal continent cutaneous urinary diversion has been reported by several authors, the majority of such procedures are today performed using an open approach. These require a midline incision, skirting the umbilicus to the side opposite the selected stoma site. The incision for a right colon pouch usually extends from the pubis to a point midway between the umbilicus and the xiphoid. The cranial extent of the incision is governed by the hepatic flexure, which must be divided to obtain sufficient colonic length and to allow for the right colon to easily fold on itself. On some occasions the incision will be extended to the xiphoid. The incision for procedures using only the ileum may only extend to just below the umbilicus, but the length of the incision should be tailored to the patient and will vary. The cystectomy procedure is covered elsewhere in this text, and only those points germane to continent diversion are covered here.

After abdominal exploration, the ureters are isolated, transected, and transposed to an appropriate place for subsequent diversion. The right retroperitoneum is first opened over the iliac artery to expose the right ureter. In the typical circumstance of conduit diversion, the right ureter is transected below the common iliac artery. For all continent diversions, both ureters are transected as low as possible and shortened to the appropriate length once the final anatomy has been determined. The sigmoid colon is freed from its lateral peritoneal attachments by incising along the line of Toldt. A wide tunnel is created by blunt finger dissection ventral to the aorta and common iliac arteries and caudal to the inferior mesenteric artery. This affords left ureteral access to the previously exposed right retroperitoneum. In cases of uroepithelial malignancy, it is prudent to evaluate the margin status of the most distal portion of both ureters using frozen-section analysis. In situations in which substantial ureteral length is removed to obtain negative surgical margins, extension of the afferent limb mechanism may be necessary to allow tension-free ureteral intestinal anastomoses.

All sutures used in the urinary tract should be absorbable. The individual surgeon's preference will dictate the caliber and type of suture material used. In carrying out bowel surgery for continent urinary diversions, stapling is the preferred method for division of the bowel segment as well as for reconstruction of bowel continuity. This technique shortens operative times greatly and affords safe and reliable bowel anastomosis. Suturing is not necessary with the exception of placing two silk Lembert sutures at the apex of side-to-side stapled bowel anastomoses to prevent tension on the staple line. To avoid stone formation on the stapled proximal bowel segments, oversewing the stapled end of the conduit with absorbable material isolates the metal staple line from urinary contact within the lumen.

To construct a nonappendiceal continent urinary diversion stoma, a skin button matching the diameter of the structure to be used in the diversion is resected. Cutaneous tissues are separated down to the level of the anterior rectus fascia, where a circle of similar diameter is excised from this fascia, or alternatively the fascia is incised in a cruciate fashion. In carrying out this maneuver, the surgeon must ensure the fascia and skin are properly aligned to avoid angulation. Rectus muscle fibers are separated bluntly, and an instrument is passed through the posterior fascia and peritoneum. For appendiceal stomas, we initially described and prefer to perform a Y-shaped cutaneous incision that allows for a YV-type plasty incision between the appendiceal limb and the skin (Fig. 140.1). This decreases the likelihood of subsequent stomal stenosis. Alternatively, the appendix lends itself to an umbilical stoma (Bissada, 1993; Gerharz et al., 1997). Favorable results with this appendiceal YV plasty technique to the umbilical site have been reported (Bissada, 1998).

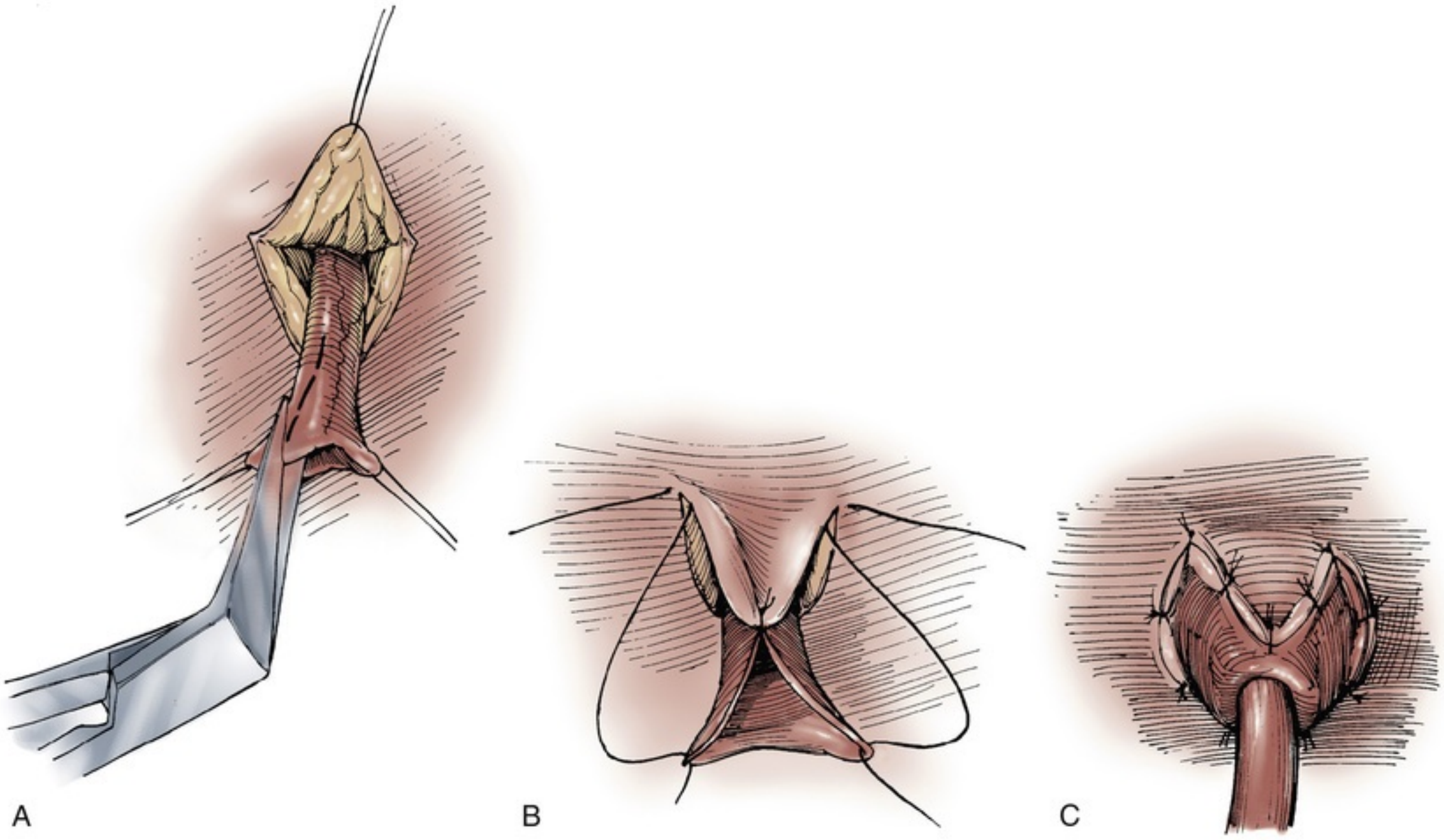

FIG. 140.1 (A to C) A V-flap is incised in the skin, and a similar-length

incision is made on the adjacent appendiceal surface. This is similar to the technique used to mature a cutaneous ureterostomy. For an appendiceal stoma, no eversion is required. (From Hinman F Jr: *Atlas of urologic surgery,* Philadelphia, 1989, Saunders.)

It is standard procedure to use long, single J–type 6- or 7-Fr diverting stents in all continent cutaneous urinary diversions. These stents drain urine externally, ensuring that urine is safely diverted beyond any anastomotic site during the early healing period. They can also be safely manipulated or exchanged if necessary. The distal end hole allows for the passage of a straight wire through the stent, which decreases the likelihood of anastomotic trauma at the time of stent removal.

We advocate the use of closed suction drains in all cases of urinary diversion. Soft silicone Jackson-Pratt closed suction drains are preferred because they have less potential for tissue damage or migration into pouches. The bulb suction should be opened before removal to prevent inadvertent creation of a hernia at the site.

Abdominal closure is performed according to the surgeon's preference. A single-layer closure with No. 2 nylon, Surgilene, or Prolene taken through all layers of fascia and muscle usually provides a rapid and secure abdominal closure in the majority of patients. In obese patients, those with tissues of poor quality, or nutritionally depleted patients, through-and-through stay sutures can also be used. Ureteral stents should always be brought through separate abdominal incisions, sutured to the anterior abdominal wall, and directed into separate drainage bags for monitoring of urine output. Even at this early stage it is important to ensure adequate drainage of the reservoir to prevent pouch rupture should the ureteral stents be displaced. In the case of limited pouch access such as with an appendiceal stoma, a large (approximately 28 Fr) Malecot tube should be placed directly into the reservoir and secured to the skin. The reservoir is sutured to the abdominal wall to prevent urine leakage into the peritoneal cavity when the tube is removed. This maneuver also helps to prevent migration and angulation of the reservoir, which could result in incontinence or catheterization difficulties.

Postoperative Care and Comments

Paralytic ileus is a common complication after urinary diversion procedures. Gastric decompression should be maintained until extubation. This can be achieved in the majority of patients by means of nasogastric intubation. However, a minority of patients may best be managed by formal gastrostomy decompression inserted intraoperatively. These individuals include those with multiple prior abdominal procedures in whom prolonged ileus is more likely. **If the patient is nutritionally depleted preoperatively, hyperalimentation has been suggested to be of value if initiated during the preoperative interval** (Askanazi et al., 1985; Hensle, 1983). A randomized controlled trial demonstrated that in nutritionally *noncompromised* patients, postoperative total parenteral nutrition was associated with increased infectious complications (Roth et al., 2013).

Ureteral stents are usually removed 1 to 2 weeks after surgery. Before manipulation, a urine sample from each stent should be sent for culture and sensitivity testing. Before stent removal, radiographs of the pouch may be obtained to ensure that the pouch is intact. Retrograde ureteral studies can be performed to ensure against ureteral anastomotic leakage. Each stent is injected with contrast agent in a search for extravasation; if none is seen, guide wires are advanced to each kidney, and the stents are removed. If there is any question of extravasation, stents can be advanced over the wires, positioned fluoroscopically, and left in situ for reevaluation after additional healing time. However, the use of ureteral retrograde studies before stent removal is by no means universal, and several retrospective studies have shown it to be of limited value (Pantuck et al., 1997; Touma et al., 2007).

Late malignancy has been reported in all bowel segments exposed to the urinary stream, whether there is a commingling with feces (Austen and Kalble, 2004; Filmer and Spencer, 1990; Shokeir et al., 1995). A study by Gitlin et al. (1999) suggests that the malignancy may develop from the urothelial component and not as a result of urine affecting intestinal mucosa. **As a result, urinary cytology should be performed for all patients undergoing a continent urinary diversion, whether the diversion was performed secondary to a urothelial malignancy. When the ureters are directed into the fecal stream, routine colonoscopy should also be performed. Latency periods as short as 5 years have been reported; therefore all patients**

developing gross or microscopic hematuria should be fully evaluated (Austen and Kalble, 2004; Golomb et al., 1989). If an anastomotic transitional cell cancer is discovered, the patient should be fully evaluated with upper tract imaging and ureteroscopy if possible. Antegrade ureteropyeloscopy can be employed if necessary. For an isolated anastomotic recurrence, distal ureterectomy and reimplantation may be appropriate. If nephroureterectomy is necessary, some patients may require removal of their continent diversion because of resulting renal insufficiency.

Continent Urinary Diversion

Continent, non-orthotopic urinary diversions can be divided into two major categories. First, the variations of ureterosigmoidostomy such as ileocecal sigmoidostomy, rectal bladder, and the sigmoid hemi-Kock operation with proximal colonic intussusception allow for excretion of urine by means of evacuation. Second is the large category of continent diversions requiring clean intermittent catheterization of the constructed pouch for urine drainage at standard intervals.

The concept of refashioning bowel so that it serves as a urinary reservoir rather than a conduit has become universally accepted. This concept is based on original pioneering observations by Goodwin et al. (1958) in the development of the cystoplasty augmentation procedure. The destruction of peristaltic integrity and refashioning of bowel has led to the development of many innovative urinary reservoirs constructed from bowel. Several procedures have been developed to prevent or reduce damage to the upper urinary tract from sepsis or increased pressure from ureteral reflux, and other techniques have evolved to achieve and maintain urinary continence.

Because numerous variants of continent urinary diversion are used worldwide, a complete review of all operative techniques is beyond the scope of this or any chapter. However, many of these procedures are simple modifications of parent operations. In this chapter we describe in detail each of these parent surgeries, as well as their major modifications. The fact that there are many continent urinary diversion procedures reveals an obvious corresponding fact: the “best” continent diversion has yet to be devised. There is no consensus that would indicate that one continent cutaneous diversion is superior to another, but it is becoming apparent that certain procedures are associated with lower early and late complication rates. Points of controversy include (1) which bowel segment is most appropriate for fashioning into a urinary reservoir, (2) the best techniques for achieving urinary continence, and (3) the best method for preventing urinary reflux into the upper tracts. There are now various continence mechanisms that appear reliable. In our experience, procedures using a right colon reservoir with some form of appendiceal continence mechanism are the fastest, most reliable, and easiest to perform.

Again, all continent diversions allow for substantial reabsorption of urinary constituents, which places an increased workload on the kidneys (Mills and

Studer, 1999). Patients with substantial renal impairment should not be considered for any of these procedures. The long-term sequelae of continent urinary diversion commonly involve significant renal damage. Although it has been suggested that the absence of reflux into the upper urinary tracts in catheterizable pouches may reduce the long-term impact of continent diversion procedures on renal function, long-term 15-year data are available, and in some instances, antireflux procedures are associated with a higher risk of obstruction caused by anastomotic stricture (Hohenfellner et al., 2002; Kristjansson et al., 1995). In addition to increased stricture rates, it is not clear whether anti-refluxing mechanisms actually result in improved preservation of the upper tracts (Pantuck et al., 2000; Rink et al., 2010).

The process of patient counseling that we employ refers to ileal conduit diversion as the gold standard against which the newer, more complex operations must be compared. The patient should be advised that continent diversion is, all other considerations being equal, associated with a longer hospital stay, as well as higher complication rates and greater potential for requiring reoperative surgery. Nieuwenhuijzen et al. (2008) reported on 281 consecutive radical cystectomies with urinary diversion using ileal conduit, orthotopic neobladder, or Indiana pouch. There were no significant differences in early complications among the three techniques. The incidence of late complications, including metabolic disturbances and ureteroileal anastomotic strictures, were similar between the two continent diversions but more frequent compared with patients with an ileal conduit. An extensive review from our institution has demonstrated no statistically significant difference in reoperations, mortality, or hospital stay in patients undergoing continent diversion versus conduit diversion by the same three surgeons over a 3-year period (Benson et al., 1992). Analysis of the two patient groups, on the other hand, showed that those selected for continent diversion were significantly younger and four times less likely to have significant concurrent illness. What this review suggests is that, with proper patient selection, continent diversion operations can be safely conducted with results similar to those for conduit diversion. To determine if continent diversion could be safely performed in selected elderly patients, Navon et al. (1995) compared the clinical course of 25 patients over the age of 75 years undergoing a modified Indiana reservoir with results in a cohort of 25 randomly selected patients younger than 75. The mean age of the first group was 78.5 years, and the mean age of the second was 59.3 years. The complication rates between the two groups were acceptably low and surprisingly similar. Navon et al. concluded that age alone should not be a contraindication to continent diversion and that the Indiana reservoir procedure can be successfully performed in elderly patients.

Rectal Bladder Urinary Diversion

Various innovative surgical techniques have been advocated for separating the fecal and urinary streams while still employing the principles of ureterosigmoidostomy. In general, these operations can be discussed together as rectal bladder urinary diversions. In each of these operations the ureters are transplanted into the rectal stump. The proximal sigmoid colon is managed by terminal sigmoid colostomy or, more commonly, by bringing the sigmoid to the perineum, thereby using the anal sphincter to achieve bowel and urinary control. Although these operations are commonly performed globally, they have never been well accepted in the United States. The principal reason is the potential for the calamitous complication of combined urinary and fecal incontinence, presumably occurring as a consequence of damage to the anal sphincter mechanism during the dissection processes (Culp, 1984).

If the urologist selects one of these procedures, the preoperative evaluation should include all of the caveats of ureterosigmoidostomy. Dilated ureters are not acceptable. Patients with extensive pelvic irradiation are not candidates, and neither are those with existing renal insufficiency. Anal sphincteric tone must be judged competent before these operations are selected. **Our preference has been to use a 400- to 500-mL thin mixture of oatmeal and water that the patient is asked to retain for 1 hour in the upright position** (Spirnak and Caldamone, 1986)**. Finally, colonoscopy should be carried out before the procedure to rule out preexisting colorectal disease, and surveillance must be ensured to monitor for subsequent development of colon cancer.** Procedures that separate the fecal and urinary streams but drain both through the rectal sphincter are not described here. Those seeking detailed descriptions of these procedures can find them in prior editions of this chapter. The following is a brief description of more modern surgical procedures that use the intact anal sphincter for urinary and fecal continence. However, the surgical techniques for these procedures are likewise not discussed in this edition.

Folded Rectosigmoid Bladder

A modification of the ureterointestinal anastomosis was described by a group from Mansoura, Egypt (El-Mekresh et al., 1997; Hafez et al., 1995). This procedure creates a folded rectosigmoid bladder with anastomosis of the ureters via serosa-lined tunnels rather than into the taenia coli. This procedure has the advantage of a larger sigmoid reservoir, as well as the prevention of reflux by creating the aforementioned serous-lined tunnel for the anastomosis. This reimplantation technique was first described by Abol-Enein and Ghoneim (1993) and appears to have a lower complication rate than direct taenial implantation (Hafez et al., 1995).

Postoperative Care and Comments.

Patients undergoing this procedure must be closely monitored for the development of hyperchloremic acidosis. This occurs in the majority of patients, and it is wise to initiate a bicarbonate replacement program after the operation. Because hypokalemia is also a feature of ureterosigmoidostomy, replacement of potassium along with bicarbonate may be achieved with oral potassium citrate. Routine nightly insertion of a rectal tube is advocated in the long-term care of the patient. However, many patients will reject this practice as uncomfortable and unappealing. Nighttime urinary drainage should be mandated for any patient who cannot maintain electrolyte homeostasis with oral medication. Bissada et al. (1995) reported that 30 of 61 patients were able to stay dry during the night without awakening. The other 31 required two or more awakenings to remain dry overnight. Hyperchloremic acidosis was reported in 4 of 61 noncompliant patients.

In 1997 El-Mekresh et al. (1997) reported on 64 patients (32 women, 20 men, and 12 children) who underwent their rectosigmoid bladder procedure from 1992 to 1995. Follow-up ranged from 6 to 36 months. Functional results were assessable in 57 patients: 1 died of a postoperative pulmonary embolism, and 6 died from their disease. All patients were continent during the day with 2 to 4 emptyings, and all but 4 remained dry at night with 0 to 2 emptyings. Four children experienced enuresis that responded to 25 mg of imipramine at bedtime. Upper urinary tract function was maintained or improved in 95% of patients. However, 6 renal units (5.3%) developed obstructive hydronephrosis secondary to ureterocolic anastomotic strictures. Two were remedied by antegrade dilation, one was repaired by open revision, and one nonfunctioning renal unit was removed. The fate of the remaining two units was not specified. No patient in this series developed postoperative metabolic acidosis. However, all patients were maintained on prophylactic oral alkalinization.

Obviously, all patients undergoing these procedures have exposure of the urinary tract to fecal flora. Some authors advocate chronic administration of an antibacterial agent to all such patients (Duckett and Gazak, 1983; Spirnak and Caldamone, 1986). Ureteral strictures require reoperative surgery and are experienced in 26% to 35% of patients over time (Duckett and Gazak, 1983; Williams et al., 1969).

Because of the concern for development of rectal cancer anywhere from 5 to 50 years (average, 21 years) after ureterosigmoidostomy (Ambrose, 1983), it is suggested that patients with long-term ureterosigmoidostomy undergo annual colonoscopy (Filmer and Spencer, 1990). Barium enemas are relatively contraindicated because reflux of this material into the kidneys (if the antireflux procedure fails) can be deleterious (Williams, 1984). Additional methods for colon carcinoma screening in this population are the evaluation of stool for blood and the attempted cytologic examination of the mixed urine and feces specimen (Filmer and Spencer, 1990).

Augmented Valved Rectum

Kock et al. (1988) developed the augmented valved rectum technique to be used in locales where stoma appliances were not readily available. This operation is similar to standard ureterosigmoidostomy except that a proximal intussusception of the sigmoid colon confines the urine to a smaller surface area, thus minimizing the problems of electrolyte imbalance. In addition, the rectum is patched with ileum to improve the urodynamic properties of the rectum as a urinary reservoir. Preoperative evaluation is similar to that used in ureterosigmoidostomy. The large bowel should be studied for preexisting disease, and anal sphincteric integrity must be tested before surgery.

Hemi-Kock and T Pouch Procedures with Valved Rectum

In his description of the augmented valved rectum procedure, Kock et al. (1988) described the use of a foreshortened hemi-Kock pouch to be used as a rectal patch when the ureters were too dilated to bring down between the leaves of the intussuscepted sigmoid. Skinner et al. (1989) then modified this procedure by using an entire hemi-Kock segment to augment the rectum after sigmoid intussusception.

After extensive experience with the Kock ileal reservoir, the group at the University of Southern California has attempted to improve on the intussuscepted Kock continence mechanism. The result has been the modification of the T pouch to serve as an ileal anal reservoir (Stein et al., 1999a). The technique consists of the construction of a hemi-Kock or T pouch employing doubly folded, marsupialized ileum and a proximal continence mechanism to prevent pouch-ureteral reflux. This pouch is then anastomosed to the rectum directly as a patch. Contact of urine with the proximal colon can be avoided by the intussusception of the sigmoid colon proximal to the anastomotic site (Fig. 140.2).

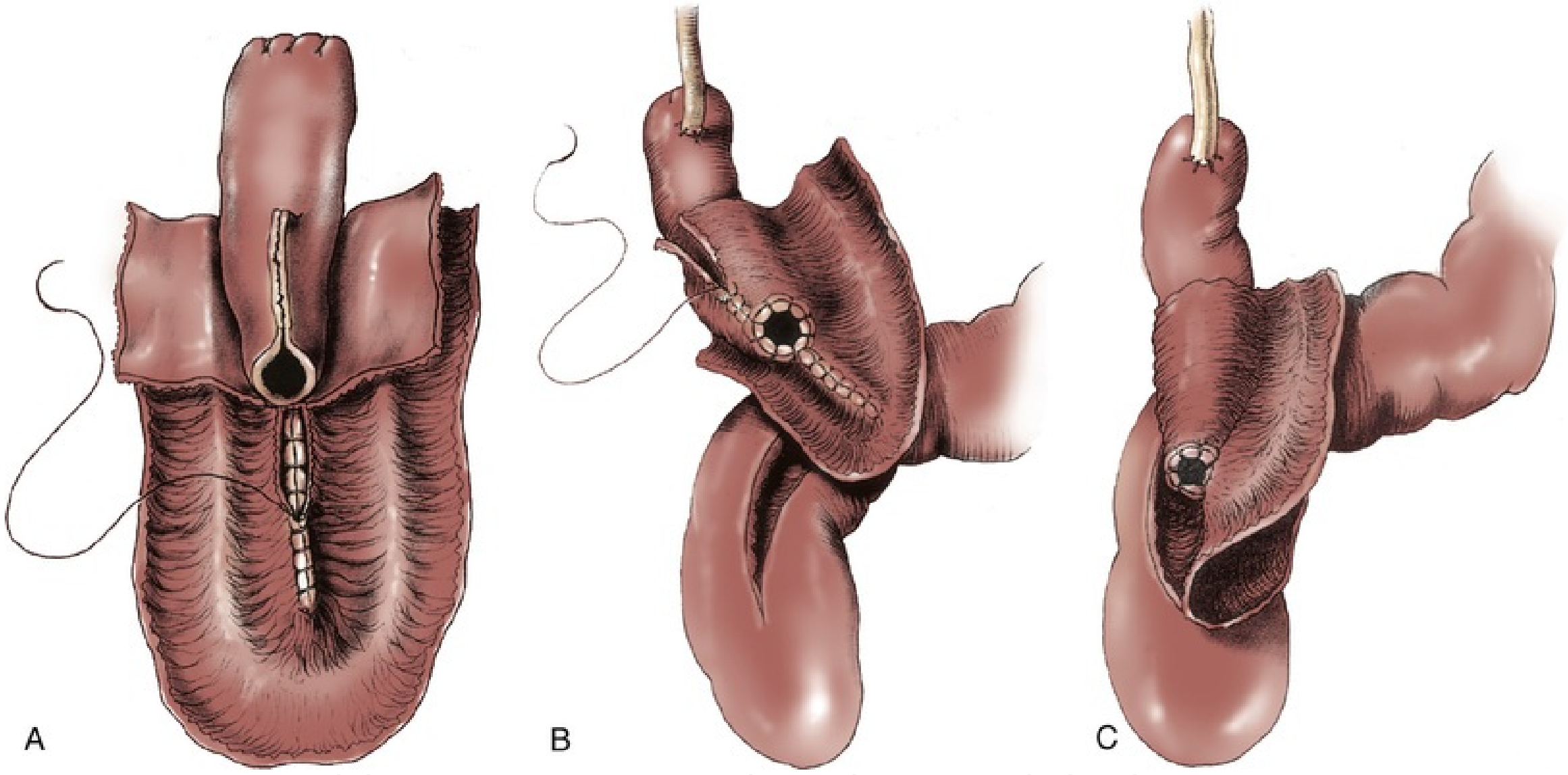

FIG. 140.2 (A) A 30-cm segment of ileum is selected, the first 10 cm for the T implant and the distal 20 cm for the patch. The 20-cm segment is folded into a U and opened as shown. The medial borders are closed with running absorbable sutures. (B) The ostium of the T is secured to the walls of the ileum with interrupted absorbable sutures. The wall of the ileum is closed over the T mechanism with a running absorbable suture. (C) The ureters are anastomosed to the top of the T in the usual end-to-side fashion. The T patch is then secured to the 15-cm proctotomy with a two-layer closure. (From Stein JP, Buscarini M, DeFilippo RE, Skinner DG: Application of the T pouch as an ileo-anal reservoir. *J Urol* 162:2052–2053, 1999b.)

Postoperative Care and Comments.

Postoperative management and complications associated with this operation are very similar to those that may be experienced after any procedure that directs the urinary stream into the rectum. Radiologic studies of the stents can be carried out after the seventh postoperative day. Before stent studies are conducted, a Gastrografin enema may be performed through the rectal tube to ensure that the region of ureterocolonic anastomosis is intact, with follow-up films to ensure prompt drainage of the upper urinary tracts into the rectosigmoid region. The rectal tube may be removed at this point, but some believe that it is advisable to have it reinserted for evening drainage over the forthcoming week. The patient is instructed to empty the colon at intervals of no more than every 2 hours, particularly in the early postoperative period.

When the rectal tube is removed, as in other situations when the urinary tract is diverted to the rectum, the patient must be closely monitored for the development of hyperchloremic acidosis. Because hypokalemic metabolic acidosis often occurs after ureterosigmoidostomy, bicarbonate replacement with oral potassium citrate should begin in the immediate postoperative setting. Long-term care should include nightly insertion of a rectal tube despite the uncomfortable and unappealing nature of the process. In addition, nighttime urinary drainage is necessary in patients who cannot maintain electrolyte homeostasis with oral medication.

The hemi-T procedure with valved rectum has one theoretic advantage over the valved rectum operation: because transitional ureteral epithelium is not in contact with colonic epithelium, there may be a reduced risk of development of colonic malignancy. As in the augmented valved rectum, the proximal colonic intussusception used in this procedure decreases the contact between urine and colonic epithelium, thereby potentially decreasing the risk of hyperchloremic acidosis. Nevertheless, attention should be paid to electrolyte levels after removal of stents and rectal tubes.

Skinner et al. reported on the results of the hemi-Kock procedure in 15 patients from 1987 to 1991 (Simoneau and Skinner, 1995). Four patients had prior bladder exstrophy and were converted to an ileoanal reservoir, and 11 patients underwent the procedure as a form of primary diversion after cystectomy. At the time of the report 10 patients were still alive and could be evaluated. Early postoperative complications occurred in 3 patients (20%): a colocutaneous fistula in 2 patients, urine leak in 1, and deep venous thrombosis in another. Late complications included partial small bowel obstruction in 4 patients (with 2 requiring surgery), urinary retention requiring surgery in 2 patients, and metabolic acidosis in 5 patients. Two of the 11 patients undergoing primary construction never achieved continence; both were older than 68 years. The authors summarized their experience by concluding that the operation is best suited for the younger exstrophy patient and that it is essential to avoid colonic redundancy distal to the reservoir. The use of the T pouch as an ileoanal reservoir has been reported in 1 former exstrophy patient (Stein et al., 1999a), with no reported postoperative complications.

Sigma-Rectum Pouch, Mainz II

A variation of ureterosigmoidostomy was described by Fisch and Hohenfellner in 1991 and updated in 1996 (Fisch et al., 1996). This operation, which they termed the *sigma-rectum* or the *Mainz II pouch*, creates a low-pressure rectosigmoid reservoir of increased capacity. They viewed the simplicity and reproducibility of the operation as two of its major advantages.

Postoperative Care and Comments.

The rectal tube is removed on the third to fifth postoperative day, and the ureteral stents are removed around the eighth day. On the 15th postoperative day the Mainz group performs an intravenous pyelogram to assess the upper tracts and the sigma-rectum pouch construction. Radiography of the pouch is performed on the 17th postoperative day.

The results of the Mainz II pouch were reported by Fisch et al. in 1996. From 1990 to 1993, 73 patients (59 adults and 14 children) underwent the Mainz II pouch procedure. Early complications were encountered in 5 of 73 patients (6.9%). These included single examples of a dislodged ureteral stent, pneumonia, pulmonary embolism, wound dehiscence, and ileus necessitating surgical intervention. There were 8 (11%) late complications that required surgery: ureteral stenosis occurred in 5 patients (6.9%); 1 patient with nephrolithiasis was treated with extracorporeal shockwave lithotripsy; 1 patient with rupture of the anterior suture line required temporary colostomy; and 1 patient experienced perianal bleeding after chemotherapy that required endoscopic coagulation. Six patients had pyelonephritis (8.2%) and were treated with antibiotics. Daytime and nighttime continence rates were reported as 94.5% and 98.6%, respectively. Oral alkalinization to prevent metabolic acidosis was used in 49 of 73 patients (67.1%). Two patients who refused any oral medication developed metabolic acidosis. The Mainz group concluded that the overall complication rate was low and comparable with that of other techniques of continent urinary diversion.

Woodhouse and Christofides (1998) reported on their experience with the Mainz II pouch in 15 primary cystectomy patients and 4 patients with prior standard ureterosigmoidostomy who were incontinent. They reported excellent results: 14 of 15 (93.3%) of the primary patients achieved documented daytime and nighttime urinary control, and the remaining patient refused follow-up but reported continence. The 4 patients undergoing a salvage procedure fared less well. Only 2 patients became continent, and the remaining 2 were found to be in chronic retention. Their failed continence was believed to be secondary to inadequate pouch emptying. Similarly, excellent results have been achieved by Venn and Mundy (1999). They reported full daytime and nighttime urinary continence in 14 of 14 patients and no major postoperative complications.

Bastian et al. (2004) have reported on the health-related quality of life in 83 patients undergoing Mainz II urinary diversion. They found that quality of life was similar to that of age-matched controls except for diarrhea symptoms, with 100% daytime continence.

There appears to be no metabolic advantage to this procedure, because the need for oral alkalinization is similar to that with standard ureterosigmoidostomy. In fact, the only difference between this operation and standard ureterosigmoidostomy is the partial reconfiguration of the rectosigmoid junction. It does appear that the reduced intracolonic pressures that result from the partial reconfiguration increase the sigmoid capacity and result in better daytime and nighttime continence. Whether the increased capacity and lower pressure of this pouch will decrease the incidence of upper tract complications remains to be determined by longer follow-up.

Continent Catheterizing Pouches

Numerous operative techniques have been developed for continent diversion, wherein urine is emptied at intervals by clean intermittent self-catheterization. Many of these operations are described in this chapter, although certain pioneering procedures that used intact bowel—such as those of Gilchrist et al. (1950), Ashken (1987), Mansson et al. (1984; Mansson, 1987), Benchekroun (1987), and others—are not. This is not to discredit the pioneers in the field but simply to allow this chapter to focus on those pouches that incorporate modern principles that attempt to achieve a spheric configuration and disruption of peristalsis.

In continent urinary diversion, the two favorite sites for stomal location are (1) at the umbilicus and (2) in the lower quadrant of the abdomen, through the rectus bulge and below the “bikini line.” This location is often preferred because it affords men and women the opportunity to conceal the stoma. The umbilicus is a preferred location for the individual confined to a wheelchair and has been reported to have a lower incidence of stomal stenosis, especially when an appendiceal stoma is fashioned. The umbilical location is also far easier for the paraplegic individual to catheterize without the need for chair transfer and disrobing. In individuals with a recessed umbilicus, the umbilical location of a stoma is barely perceptible from a normal umbilical dimple. In general, the stoma site is covered with a gauze pad or square bandage to avoid mucous soiling of clothing. Patients undergoing continent urinary diversion to an umbilical location should be advised to wear a medical alert bracelet that informs the examiner of the umbilical stoma.

Before the extension of orthotopic neobladder construction to women, there was some enthusiasm for the orthotopic placement of a catheterizing portal. This procedure has been carried out in certain female patients with success. The construction of a neourethra to the introitus is feasible, provided there is no substantial difficulty in the catheterizing process. However, because it can be difficult to direct a catheter through the “chimney” of an intussuscepted nipple valve, those continent diversions employing nipple valves are not particularly adaptable to orthotopic location, although they have been performed with success in a small number of patients (Olsson, 1987). In contrast, the imbricated and tapered ileal segment leading to an Indiana pouch is relatively easier to catheterize and can be used for orthotopic catheterizing diversion (Rowland et al., 1987). However, it may be difficult to obtain sufficient mesenteric length in some patients. The appendix can also be used as a neourethra, in which case mesenteric length should become less of a problem (Hubner and Pfluger, 1995).

Four general techniques have been employed to create a dependable, catheterizable continence zone. For right colon pouches, appendiceal tunneling procedures are the simplest of all to perform, because they use established surgical techniques already present in the urologic armamentarium. The in situ or transposed appendix is tunneled into the cecal taenia in a fashion similar to ureterocolonic anastomosis. Appendiceal continence mechanisms have been criticized for three general reasons. First, the appendix may be unavailable in some patients because of prior appendectomy. For those individuals, techniques have been developed that allow for the construction of a similar tube fashioned from ileum (Woodhouse and MacNeily, 1994) or from the wall of the right colon (Lampel et al., 1995a). Second, the appendiceal stump may be too short to reach the anterior abdominal wall or umbilicus while sufficient length is still maintained for tunneling. This criticism has been addressed by an operative variation described by Mitchell, in which the appendiceal stump can be lengthened by the inclusion of a tubular portion of proximal cecum (Burns and Mitchell, 1990; Fig. 140.3). This lengthening procedure has the added advantage of allowing for a slightly larger stoma made of cecum that is less prone to stomal stenosis. Appendiceal continence mechanisms share the feature of allowing only small-diameter (14- to 16-Fr) catheters to be used for intermittent catheterization; the large amount of mucus produced by an intestinal reservoir is more easily emptied or irrigated with use of a 20- to 22-Fr catheter. We believe that these criticisms are more theoretical than real and that the appendiceal or pseudoappendiceal continence mechanism remains a very attractive and reliable continence mechanism.

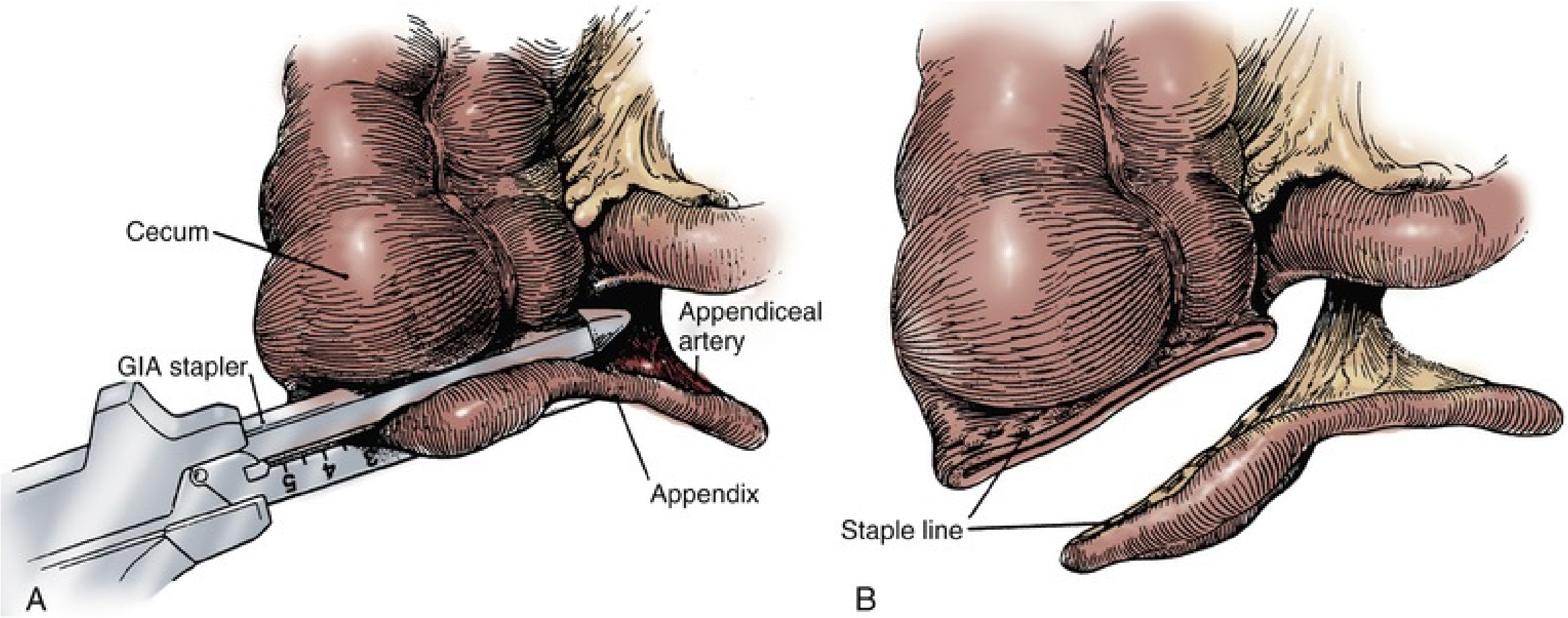

FIG. 140.3 (A) The appendiceal stump is lengthened by the inclusion of a tubular portion of proximal cecum by the application of the gastrointestinal anastomosis (GIA) stapler to the terminal cecum. A window is made in the mesoappendix, and the blade of the GIA stapler is advanced through the window. This maneuver ensures that the blood supply is not inadvertently damaged. (B) The added length is demonstrated. The appendix is rotated and implanted into the taenia; the cecal tube serves as the stoma. (From Burns MW, Mitchell ME: Tips on constructing the Mitrofanoff appendiceal stoma. *Contemp Urol* 2:10–12, 1990.)

The second major type of continence mechanism used in right colon pouches is the tapered and/or imbricated terminal ileum and ileocecal valve. Here again the technique is rather simple, with imbrication or plication of the ileocecal valve region along with tapering of the more proximal ileum in the fashion of a neourethra (Bejany and Politano, 1988; Lockhart, 1987; Rowland et al., 1985). These techniques afford a reliable continence mechanism.

One feature of right colon pouches that has been criticized is the loss of the ileocecal valve. Although this does result in an increased frequency of bowel movements for some patients in the short term, the majority will experience bowel regularity either through intestinal adaptation or with the use of pharmacologic therapy. However, some patients have developed rather striking diarrhea or steatorrhea after the loss of the ileocecal valve. This may be particularly true in pediatric patients in whom there is neurogenic bowel dysfunction (e.g., myelomeningocele).

The third surgical principle in constructing the continence mechanism is the use of the intussuscepted nipple valve or the flap valve, which avoids the need for intussusception. The creation of nipple valves is by far the most technologically demanding of all the continence mechanisms, and it is associated with the highest complication and reoperation rates. There exists a significant learning curve before the surgeon achieves reproducible and dependable results. For this reason, nipple valve construction should probably not be chosen by the surgeon carrying out occasional construction of continent pouches. Furthermore, in the past three decades we have seen the introduction of numerous modifications of the original technique of Kock for construction of a stable nipple valve. The singular reason for all of these modifications is the rather disappointing long-term stability of the nipple valve in some patients. As a result, the group at the University of Southern California has developed the T pouch, which uses a flap valve (Stein et al., 1998). This procedure, which appears much simpler than the intussuscepted nipple valve, has been used to create a continence and an antireflux mechanism. Nipple valve failure from slippage or valve effacement can be anticipated in 10% to 15% of cases even in the hands of the very best and experienced surgeons. In addition to slippage, nipple valves are subject to ischemic atrophy. When this occurs, a new nipple valve must be fashioned from a new bowel segment.

A final feature of stapled nipple valves is the potential for stone formation on exposed staples. This was greatly lessened by the omission of staples at the tip of the intussuscepted nipple valve, as suggested by Skinner et al. (1984). However, more proximal staples occasionally erode into the pouch and serve as a nidus for stone formation. These stones are usually manageable endoscopically with forceps extraction, or else with electrohydraulic or ultrasonic disintegration of the stone with subsequent forceps extraction of the staple. Although exposed staples may serve as a nidus for stone formation, continent urinary diversion results in more urinary excretion of calcium, magnesium, and phosphate as compared with ileal conduit diversion (Terai et al., 1995). Thus all patients undergoing continent diversion are at an increased risk for the formation of reservoir stones.

The fourth major technique for constructing a continence mechanism is the provision of a hydraulic valve, as in the Benchekroun nipple (Benchekroun, 1987). In this procedure a small bowel segment is isolated, with subsequent reversed intussusception that effectively apposes the mucosal surfaces of the segment. Tacking sutures are placed on a portion of the circumference of the intussuscepted segment to stabilize the nipple valve while allowing urine to flow freely between the leaves of apposed ileal mucosa. As the pouch fills, hydraulic pressure closes the leaves, thereby ensuring continence. The premise of this technique is that as the reservoir fills, the pressure within the valve would also increase, resulting in continence. Concerns regarding stomal stenosis, especially in children, and nipple destabilization have resulted in this procedure being largely abandoned (Sanda et al., 1996). As a result, it is not discussed further in this chapter.

General Procedural Methodology

During construction of the pouch, intraoperative testing for pouch integrity should always be performed. The continence mechanism is also tested for ease of catheterization as well as continence after the pouch construction has been completed. The pouch is filled with saline, the continence mechanism catheter is removed, and the pouch is compressed lightly to look for points of leakage as well as to test the continence mechanism for its ability to contain urine. **Thereafter the continence mechanism is catheterized to ensure ease of catheter passage. This is an extremely important and crucial maneuver because the inability to catheterize is a serious complication that will often result in the need for reoperation.** If the surgeon cannot easily catheterize in the operating room, the patient is unlikely to be able to easily catheterize postoperatively. In general, all redundancy should be removed from the continence mechanism. It is often useful to secure the reservoir to the anterior abdominal wall in a manner that prevents the reservoir from migrating. This can prevent the development of a false passage or a kink, thereby facilitating catheterization.

Postoperatively, the larger-bore catheter used for drainage of the pouch should be irrigated at frequent intervals to prevent mucous obstruction. This can be performed at 4-hour intervals by irrigation with 45 to 50 mL of saline. Less frequent intervals of irrigation can be employed when the urine is totally diverted from the kidneys by means of long indwelling stents. It is essential that as soon as possible the patient be taught how to self-irrigate and that he or she understand the required regimen. This not only familiarizes the patients with the catheterization process but also reduces the work burden on the nursing staff and allows for earlier discharge.

If the patient is on a positive nitrogen balance (i.e., eating a regular diet), a contrast study may be performed on the seventh postoperative day to ensure pouch integrity. If no leaks are noted, ureteral stents can be removed. When it has been ascertained that the ureteral anastomoses and pouch are intact, the suction drain is removed. The suprapubic tube (if employed) can also be removed at this time, but we prefer leaving it in place until the patient is confident with self-catheterization. The patient is taught to irrigate the tube traversing the continence mechanism at 4-hour intervals and whenever any episode of intra-abdominal pressure or discomfort is experienced. Once these procedures have been mastered and the patient is tolerating a regular diet, the patient can be discharged, usually at hospital days 6 to 8.

The following represents a summary of common patient questions and everyday solutions:

- *What kind of catheter do I use?* For nipple valves, a straight-ended 22- to 24-Fr tube; for ileocecal plication, a 20- to 22-Fr coudé-tipped catheter; and for appendiceal sphincters, a 14- to 16-Fr coudé-tipped catheter
- *How do I carry my catheter?* If single-use disposable catheters are not obtainable (most medical insurance companies now cover such supplies), a reusable catheter can be placed in a zipper-locked bag that can be placed in a women's purse or a man's coat pocket.
- *How do I clean the stoma before catheterizing in a public facility?* With a topical antiseptic wipe (e.g., with benzalkonium chloride), which can be purchased in individually wrapped packets.
- *How do I lubricate the catheter?* By tearing off the end of an

individual-use foil pack of water-soluble lubricant and inserting the tip of the catheter into the pack. Many catheters are now available in self-lubricating single-use packaging.

- *What do I do with the stoma after catheterizing?* Cover it with a bandage.
- *How do I clean my catheter after draining my pouch?* By rinsing with ordinary tap water through the inside channel and over the outside surface before replacing the catheter in its zipper-locked bag. It remains preferable to use single-use sterile catheters, even though continent reservoirs are chronically colonized.

In the case of ileal pouches, pouch capacity will initially be low (150 mL). Therefore the frequency of catheterization will have to be significantly different in these individuals compared with those with right colon pouches, in which initial comfortable capacities will be in excess of 300 mL. To ensure restful sleep, the smaller-capacity pouches may be managed best with indwelling catheterization during sleeping hours.

General Care

Because all patients with catheterized pouches will have chronic bacteriuria, the problem of antibiotic management should be discussed. **Most authors would suggest that bacteriuria in the absence of symptoms in patients with a urinary diversion does not warrant antibiotic treatment** (Skinner et al., 1987; Suriano et al., 2008). The construction of an effective antireflux mechanism in these pouches may help protect against clinical episodes of pyelonephritis, in contrast to patients with freely refluxing conduits. Obviously, if clinical pyelonephritis does occur, antibiotic treatment should be instituted. Episodes of recurrent pyelonephritis should be evaluated with radiography of the pouch to diagnose failure of the antireflux mechanism, upper tract stone formation, or ureteral stenosis.

A condition termed “pouchitis” has been described that manifests with pain in the region of the pouch along with increased pouch contractility. This condition, although infrequent, may result in temporary failure of the continence mechanism because of the hypercontractility of the bowel segment employed for construction of the pouch. The patient typically has a history of sudden explosive discharge of urine through the continence mechanism (rather than dribbling incontinence), along with discomfort in the region of the pouch. Appropriate antibiotic therapy usually results in resolution of these symptoms. It has been our experience that short courses of antibiotics are not usually successful in treating pouch infections. This may be because of the larger amount of foreign material in the form of mucus and sediment within intestinal pouches as opposed to the bladder. Intestinal crypts may also serve as bacterial sanctuaries. Therefore, whenever a pouch infection is diagnosed, antibiotic therapy should be continued for at least 10 days. Pyelonephritis will, of course, require longer courses of therapy.

Urinary retention is an infrequent but serious occurrence in catheterizable pouches. It is most commonly seen with pouches with continence mechanism consisting of a nipple valve. In these circumstances, when the chimney of the nipple valve is not near the abdominal surface, the catheter may be misdirected into folds of bowel rather than into the nipple valve proper, resulting in urinary retention. **Pouch urinary retention represents a true emergency, and the patient must seek immediate attention so that catheterization and drainage by experienced personnel can be achieved promptly.** The use of a coudé-tipped catheter may be helpful. Rarely, use of a flexible cystoscope will be necessary with passage of a guide wire into the reservoir followed by a Council catheter. After the immediate problem has been resolved by emptying the pouch, a catheter should be left indwelling for 3 to 5 days to allow the edema and trauma to the catheterization portal to resolve. Before discharge, the patient should be observed to successfully self-catheterize on multiple occasions. The appropriate angle of entry is highly variable and individualized. If used, proper use of the angled coudé catheter should be taught to patients until they are comfortable with its use. In fact, we prefer to routinely use coudé catheters with non–nipple valve pouches.

Intraperitoneal rupture of catheterizable pouches has been reported (Kristiansen et al., 1991; Thompson and Kursh, 1992; Watanabe et al., 1994). In general, these episodes are more common in the neurologic patient in whom sensation of pouch fullness may be less distinct (Hensle, personal communication, 1993; Mitchell, personal communication, 1993). Ruptures may also be associated with mild abdominal trauma, such as a fall. In general, these patients require immediate pouch decompression and radiographic pouch studies. For patients with large defects, surgical exploration and pouch repair are required. If the amount of urinary extravasation is small and the patient does not have evidence of peritonitis, catheter drainage and antibiotic administration may suffice in treating an intraperitoneal rupture. Patients managed with this conservative approach require careful monitoring. If there is any sign of progressive peritonitis, surgical exploration and repair are imperative. We have successfully employed this nonoperative approach on patients with ruptured right colon pouches.

Continent Ileal Reservoir (Kock Pouch)

This operation was first reported for use in urinary diversion by Kock et al. in 1982. This report was singularly responsible for the renewed interest in continent diversion procedures at that time. An outgrowth of the Kock procedure for continent ileostomy (Kock, 1971), the Kock pouch combined reasonably dependable techniques for ensuring urinary continence and preventing reflux to the upper urinary tracts (nipple valves) with carefully refashioned bowel that provided a low-pressure urinary reservoir. This procedure and the similarly constructed T pouch are the only catheterizable continent diversions that preserve the ileocecal valve. **Skinner and his coworkers** (Skinner, 1992; Skinner et al., 1989) **have carefully studied and improved the technique over the years while amassing prodigious experience with the operation and its variants. The high complication rate and the technical difficulties involved with constructing this reservoir have resulted in the procedure being abandoned by most individuals.** As a result, this procedure is not discussed further in this edition. Those interested in a more detailed description should refer to our chapter in previous editions of this text. However, the construction of a Kock limb remains an important procedure for use in repairing failed continence or reflux mechanisms and as such is described in more detail. It is Skinner's operative description that is followed closely in this chapter.

Procedure.

A 15- to 20-cm length of ileum is selected for creating the intussuscepted nipple valve. The proximal 10 cm serves as the valve, and the distal 5 to 10 cm serves as the patch (Fig. 140.4A). The distal length is chosen based on the volume lost after resection of the failed mechanism. Only 5 cm is necessary for the patch, but on some occasions the reservoir may require augmentation. The middle 6 to 8 cm of the 10-cm segment is denuded of mesentery by electrocoagulation. An Allis or Babcock clamp is advanced into the ileal terminus, grasping the full thickness of the intussusceptum and inverting the ileum into the pouch (Fig. 140.4B). Using the TA-55 stapler, three rows of 4.8-mm staples are applied to the intussuscepted nipple valve (Fig. 140.4C). The distal six staples from each cartridge are removed before staple application to ensure that the tip of the valve is free of staples. Most authors suggest that the pin of the stapling instrument should always be kept in place so that staple misalignment does not occur. This will result in a pinhole puncture site at the base of the nipple valve that should be oversewn with absorbable suture material to prevent fistula formation after staple application is complete. The nipple valve is then fixed to the back wall of the patch by one of two stapling techniques (Skinner et al., 1984). A small buttonhole may be made in the back wall of the ileal plate so that the anvil of the stapler can be passed through the buttonhole and advanced into the nipple valve before application of the fourth row of staples (Fig. 140.4D). If this is carried out, the buttonhole is oversewn afterward with absorbable material. Alternatively, the anvil of the stapler can be directed between the two leaves of the intussuscipiens and the fourth row of staples used to fix the inner leaf of the nipple valve to the pouch wall (Fig. 140.4E).

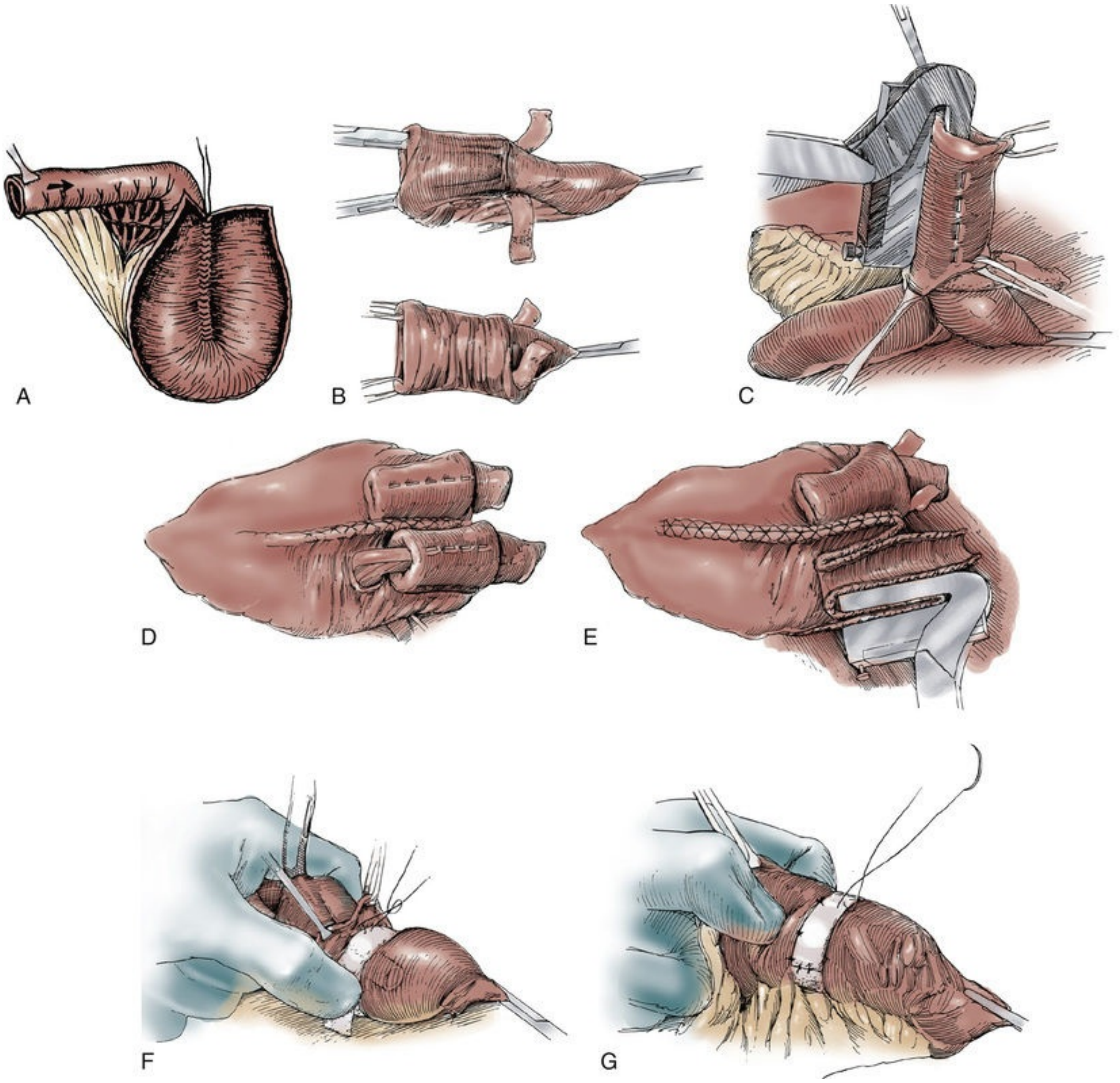

FIG. 140.4 (A) A 15-cm segment of terminal ileum is isolated and opened along its antimesenteric wall. The proximal 10 cm will serve as the continent intussusception and the distal 5 to 10 cm as the patch. The size of the patch will vary according to the size of the excised segment. (B) An Allis or Babcock clamp is advanced into the ileal terminus; the full thickness of the intussuscipiens is grasped, and it is prolapsed into the pouch. (C) Three rows of 4.8-mm staples are applied to the intussuscepted nipple valve using the TA-55 stapler. (D) A small buttonhole is made in the back wall of the ileal plate to allow the anvil of the TA-55 stapler to be passed through and advanced into the nipple valve. A fourth row of staples is applied. The figure shows two valve mechanisms, but in this instance there would be only one. (E), The anvil of the stapler can be directed between the two leaves of the intussuscipiens and the fourth row of staples applied in this manner. Two valve mechanisms are shown, but in this instance there would be only one. (F) A 2.5-cm–wide strip of absorbable mesh is placed through additional windows of Deaver at the base of each nipple valve. The mesh strips are fashioned into collars. (G) The collars are sewn

to the base of the pouch as well as to the ileal terminus with seromuscular sutures. (A, From Ghoneim MA, Lock NG, Lycke G, et al.: An appliance-free, sphincter-controlled bladder substitute. *J Urol* 138:1150–1154, 1987. B to G, From Hinman F Jr: *Atlas of urologic surgery,* Philadelphia, 1989, Saunders.)

Some authors, including Skinner et al. (1989), suggest the use of an absorbable mesh collar to anchor the base of the nipple valve. If a collar is used, a 2.5-cm-wide strip of absorbable mesh is placed through an additional window of Deaver at the base of the nipple valve. The mesh strip is fashioned into a collar and sewn to the base of the patch with seromuscular sutures of absorbable material (Figs. 140.4F and G). The patch is then sewn to the reservoir.

Double T Pouch

As indicated earlier, many surgeons have abandoned the Kock pouch largely because of the technical difficulties of creating the continence and antireflux mechanisms and the high complication rates associated with them. This should not be viewed as a condemnation of the pioneering work of Kock and his associates. Without their initial efforts, many of the procedures described in this chapter would never have come into being. Rather, this represents the natural evolution of surgical techniques.

The group at the University of Southern California modified a technique described by Abol-Enein and Ghoneim (1993, 1994) to create a novel continence mechanism created entirely from ileum (Bochner et al., 1988). Abol-Enein and Ghoneim (1994) described a technique that created an extramural serosal tunnel into which the ureters were implanted. This extramural trough created a pseudotunnel that prevents reflux but in theory is associated with a lower risk of obstruction than the Goodwin et al. (1958), Leadbetter and Leadbetter (1961), or LeDuc et al. (1987) techniques of direct transmural ureteral implantation. Stein et al. (1998) first reported on the use in a neobladder of a tapered ileal segment implanted into a serosal trough as the antireflux mechanism. In 1999 they reported on their adaptation of the technique to the ileal-anal reservoir. Also in 1999 they presented their early experience with a double T pouch as a replacement for the Kock pouch at the meeting of the American Urological Association (Stein et al., 1999a), and they published their findings in 2001 (Stein and Skinner, 2001). Their technique is presented in this section.

Procedure.

A 70-cm segment of terminal ileum is isolated 15 to 20 cm from the ileocecal valve at the line of Treves. The proximal isoperistaltic 10- to 12-cm segment is isolated and will serve as the antireflux mechanism. The distal 12- to 15-cm segment is isolated and rotated in an antiperistaltic fashion and will create the cutaneous continence mechanism (Figs. 140.5A and B). A short 2- to 3-cm mesenteric incision is made to isolate the proximal limb, and a 4-cm incision is made for the distal limb, thereby preserving the major vascular arches. The proximal and distal segments can vary in length, depending on ureteral length and the thickness of the anterior abdominal wall. The middle 44 cm of ileum is folded in a W with each limb measuring 11 cm.

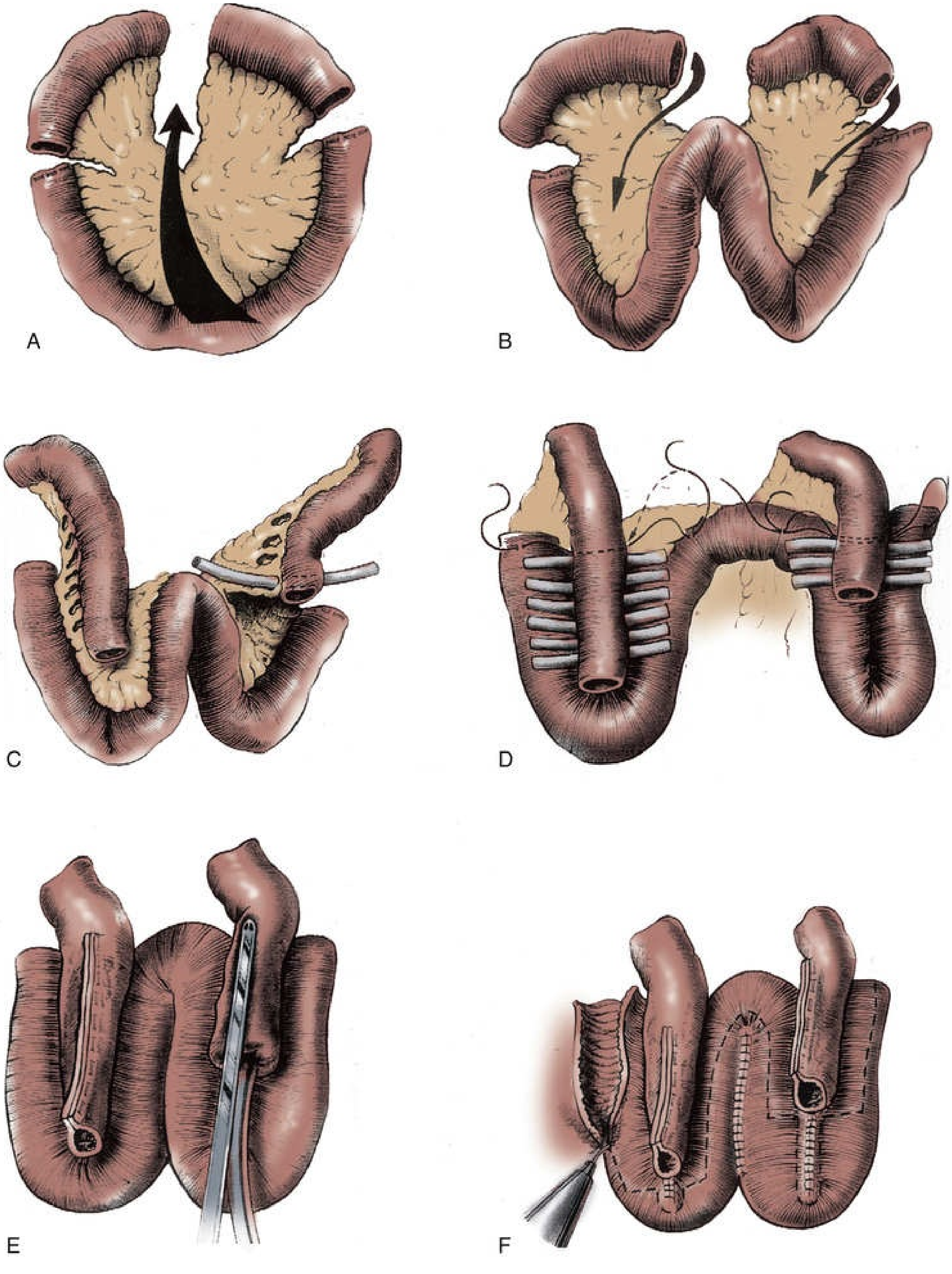
A
B
C
D
E
F

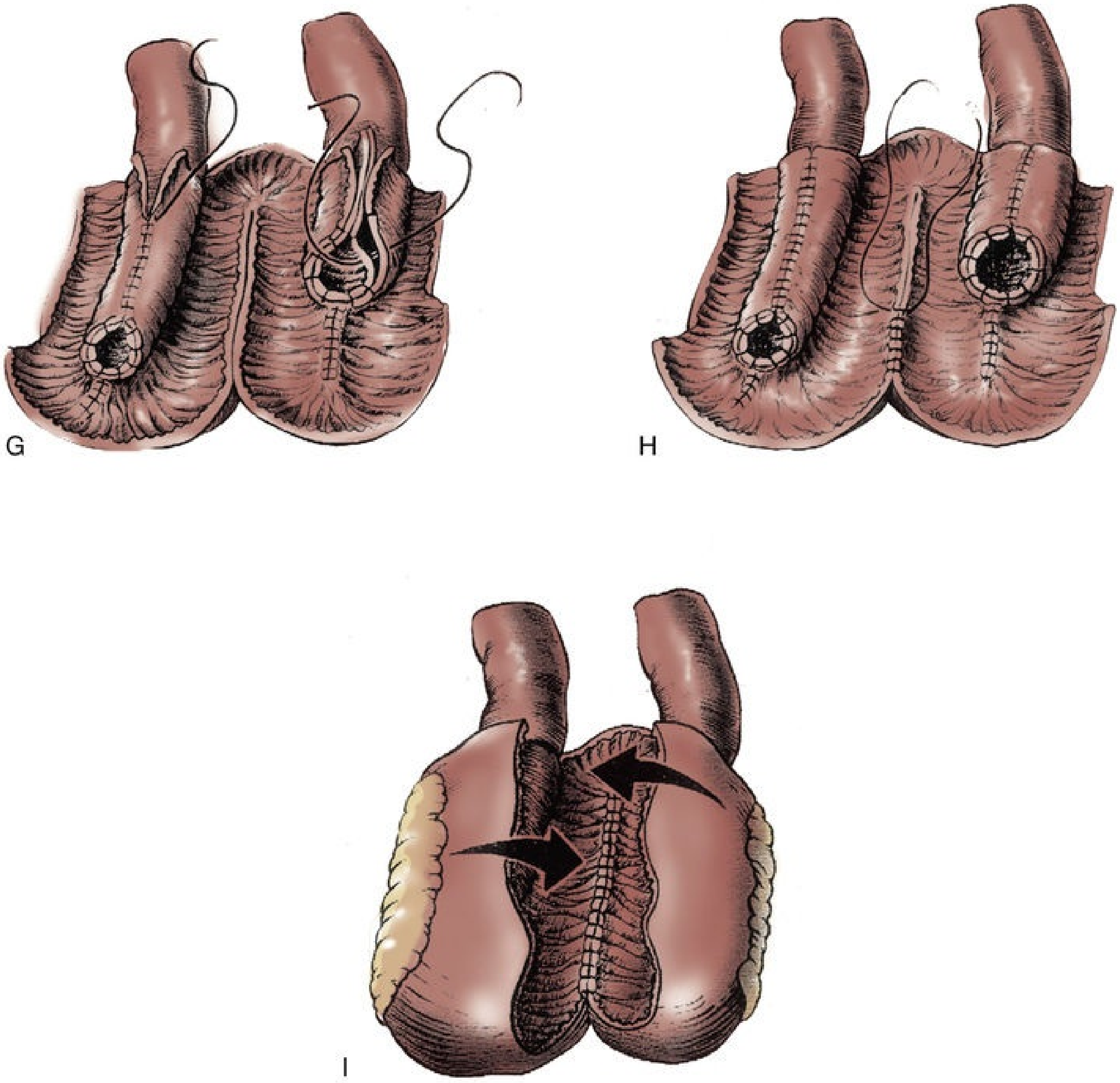

FIG. 140.5 (A) A 70-cm segment of terminal ileum is isolated 15 to 20 cm from the ileocecal valve. (B) A proximal 10-cm segment is isolated and rotated toward what will become the reservoir in an isoperistaltic direction. The distal 12 to 15 cm is rotated toward the reservoir in an antiperistaltic direction. (C) The windows of Deaver are opened to allow the walls of the W reservoir to be apposed behind the valve mechanisms. Penrose drains are passed to guide suture passage. (D) Horizontal mattress sutures of 3-0 silk are passed through each window. The distal continence mechanism is longer than the proximal antireflux mechanism. (E) The proximal and distal mechanisms are tapered with a metal gastrointestinal anastomosis stapler. (F) The bowel is incised along its antimesenteric border where it will overlie the two Ts. Distal to the Ts, the bowel is incised close to the approximated limbs of the reservoir. (G) The ostia of the valves are secured to the bowel wall with interrupted absorbable sutures. The two flaps of ileum are closed over the Ts with running absorbable sutures. (H) The back wall of the reservoir is closed with running absorbable sutures. (I) The lateral walls are folded medially, and the construction is completed with running absorbable

sutures. (From Stein JP, Buscarini M, DeFilippo RE, et al.: Application of the T pouch as an ileo-anal reservoir. *J Urol* 162:2052–2053, 1999.)

The afferent antireflux mechanism is created by opening the windows of Deaver between the vascular arcades along the distal 3 to 4 cm. The efferent continence mechanism is created by opening the proximal 7 to 8 cm of vascular arcades (antiperistaltic) (Fig. 140.5C). One-fourth–inch Penrose drains are then placed in each window of Deaver to facilitate the passage of the 3-0 silk horizontal mattress sutures that are used to approximate the serosa of the corresponding 11-cm limbs of the W (Fig. 140.5D). The 3- to 4-cm anchored portion of the proximal limb is then tapered over a 30-Fr catheter, and the 7- to 8-cm anchored portion of the efferent limb is tapered over a 16-Fr catheter. In both instances, tapering is performed with a gastrointestinal anastomosis (GIA) stapler (the staples will not be in contact with urine). Care must be taken in the efferent limb to create a gradual taper so that the catheter does not hit a false cul-de-sac (Fig. 140.5E). The portions of the 11-cm W limbs not forming the troughs are then sutured together with a running 3-0 polyglycolic acid (PGA) suture. The bowel is now incised along its antimesenteric border in the portion where the serosal trough exists and in proximity to the medial PGA suture lines when beyond the two limbs (Fig. 140.5F). The incised mucosa is then closed in two layers with a running suture of 3-0 PGA. The incised intestinal flaps (antimesenteric incision) are then sutured to each ostium with interrupted sutures of 3-0 PGA, and the two ileal flaps are sutured over each segment with a running suture of 3-0 PGA (Fig. 140.5G). The reservoir is then closed side to side in two layers with 3-0 PGA, thereby completing its construction (Figs. 140.5H and I). The ureters are anastomosed end to side over stents to the proximal limb, which has been closed with a running absorbable Parker-Kerr suture. The efferent limb is then brought to the abdominal wall stoma site, and redundant ileum is resected. The stoma is then matured with the reservoir lying immediately adjacent to the anterior abdominal wall.

Postoperative Care and Comments.

Postoperative care is similar to that for any continent reservoir. Stein et al. (1999b) initially reported on 9 patients, 7 of whom could be evaluated for continence and long-term complications and 2 of whom died of disease during follow-up. All 7 patients achieved immediate continence upon catheter removal. However, 2 patients later became incontinent, with 1 requiring surgical revision. None of the 9 patients experienced an early postoperative complication. One patient developed a reservoir stone 9 months after surgery that was removed endoscopically without sequelae. Pouch capacity was excellent: 400 to 700 mL (average, 500 mL). There was no radiographic evidence of reflux in any patient, and there was no upper tract deterioration. This operative procedure appears to have many advantages over the Kock pouch, and good long-term continence results have been reported. Marino et al. (2002) reported on 18 patients with 1-year follow-up with 100% daytime and nighttime continence and no delayed complications. Seifert et al. (2008) published their results on 19 patients who underwent ileal double T pouch construction between 1998 and 2006. Five patients (26%) had complications related to the diversion, some of which required surgical revision. Three patients (16%), all of whom had a body mass index exceeding 30, developed necrosis of the efferent loop and subsequent cutaneous fistulae. Sixteen (84%) eventually developed daytime and nighttime continence. Although mild acidosis was common in this group, no urinary reflux was detected, and no patients had significant upper tract deterioration or pyelonephritis.

Mainz Pouch I

The catheterizable Mainz pouch has undergone considerable modification over the years (Gerharz et al., 1997; Lampel et al., 1996; Stein et al., 1995; Thüroff et al., 1985, 1988, 2010). **The main impetus for these changes has been the difficulty encountered with the nipple valve mechanism.** The operative technique has now been modified to use the intact ileocecal valve as a means of further stabilizing the intussusception (Thüroff et al., 1988). This procedure is described here without further reference to earlier prototypes.

Procedure.

The catheterizable Mainz pouch varies somewhat from the orthotopic, voiding Mainz pouch. First, a longer segment of bowel is used. A 10- to 15-cm portion of cecum and ascending colon is isolated along with two separate, equally sized limbs of distal ileum and an additional portion of ileum measuring 20 cm (Fig. 140.6A). The entire colon and distal segments of ileum are spatulated, taking care to preserve the ileocecal valve. These three bowel segments are folded in the form of an incomplete W, and their posterior aspects are sutured to one another to form a broad posterior plate (Fig. 140.6B). A portion of the intact proximal ileal terminus is freed of its mesentery for a distance of 6 to 8 cm, and intussusception of the segment is achieved. Two rows of staples are applied on the intussusceptum (Fig. 140.6C). Thereafter, the intussuscipiens is led through the intact ileocecal valve and a third row of staples is applied to stabilize the nipple valve to the ileocecal valve (Fig. 140.6D). Finally, a fourth row of staples is applied inferiorly, securing the inner leaf of the intussusception to the ileal wall (Fig. 140.6E).

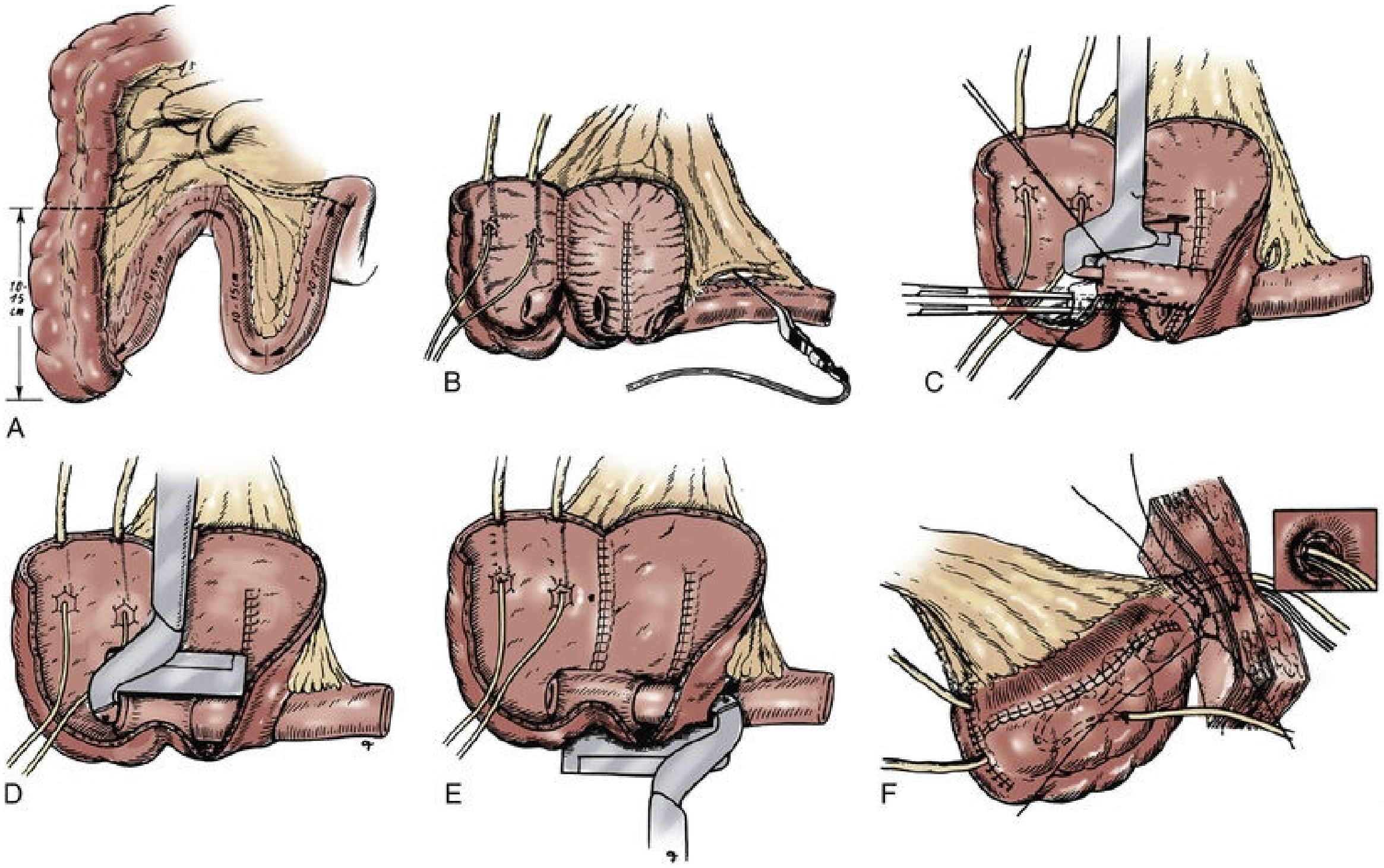

FIG. 140.6 (A) A 10- to 15-cm portion of cecum and ascending colon is isolated along with two separate equal-sized limbs of distal ileum and an additional portion of ileum measuring 20 cm. (B) A portion of the intact proximal ileal terminus is freed of its mesentery for a distance of 6 to 8 cm. (C) The intact ileum is intussuscepted, and two rows of staples are taken on the intussuscipiens. (D) The intussuscipiens is led through the intact ileocecal valve, and a third row of staples is taken to stabilize the nipple valve to the ileocecal valve. (E) A fourth row of staples is taken inferiorly, securing the inner leaf of the intussusception to the ileal wall. (F) A button of skin is removed from the depth of the umbilical funnel, and the ileal terminus is directed through this buttonhole. Excess ileal length is resected and ileum is sutured at the depth of the umbilical funnel. (A, From Thüroff JW, Alken P, Hohenfellner R: The Mainz pouch [mixed augmentation with ileum ‘n’ cecum] for bladder augmentation and continent diversion. In King LR, Stone AR, Webster GD, editors: *Bladder reconstruction and continent urinary diversion,* Chicago, 1987, Year Book, p 252; B to F, From Thüroff JW, Alken P, Riedmiller H, et al.: 100 cases of Mainz pouch: continuing experience and evolution. *J Urol* 140:283–288, 1988.)

Ureterocolonic anastomoses are created at the apex of the reservoir, which is then folded on itself in a side-to-side fashion to complete pouch construction. The entire pouch is rotated cephalad so as to bring the ileal terminus to the region of the umbilicus. A small button of skin is removed from the depth of the umbilical funnel, and the ileal terminus is directed through this buttonhole (Fig. 140.6F). The pouch is secured to the posterior fascia with interrupted absorbable sutures, and the ileal terminus is sewn similarly to anterior fascia. Excess ileal length is resected, and the ileum is sutured at the depth of the umbilical funnel with interrupted absorbable sutures.

Postoperative Care and Comments.

No specific differences in postoperative care or complications associated with the Mainz pouch must be addressed. Initial pouch capacities are higher than with the Kock or T pouch. Final mean capacity averaging more than 600 mL has been reported. Pouch pressures are 23 cm H_2O at half capacity and 31 cm H_2O when the pouch is full. Contraction waves beginning at 50% pouch fullness can be recorded at an amplitude of 12 cm H_2O. Thus this pouch seems to produce a reasonably low-pressure urinary reservoir, although the pressures are not as low as those achieved with the use of small bowel alone.

The 10- and 12-year experiences with the Mainz pouch and the variations created by its developers have been described (Lampel et al., 1996; Stein et al., 1995). From 1983 to 1994, 440 patients underwent a Mainz I operation in two urology departments, Mainz and Wuppertal. Continence mechanisms varied: in 146 patients the appendix was used as the continence mechanism; in 270 patients the intussuscepted nipple was used as the continent stoma; in 14 patients a submucosal, seromuscular bowel flap was used; and in 10 patients a submucosal full-thickness bowel flap was used. The early complication rate was 12% and included mechanical ileus requiring open revision in 9 patients (1.6%), pouch leakage requiring revision in 5 patients (0.9%), wound dehiscence in 4 patients (0.7%), and fatal pulmonary emboli in 4 patients (0.7%).

The late complication rate was 37% and was predominantly attributable to the pouch. Stomal failure requiring open revision occurred in 45 patients (8%) and was directly related to the continence mechanism. Only 2 of 146 patients (1.4%) with an appendiceal continence mechanism were incontinent, but stomal stenosis occurred in 21%. The developers of this procedure were innovative in their attempts to bring the incontinence rate down to an acceptable level. To this end they tried multiple techniques, with variable success: an alloplastic stoma (4 of 4 incontinent), sutured intussusception (8 of 8 incontinent), stapled intussusception (5 of 22, 23% incontinent), and stapled ileocecal intussusception (10 of 204, 4.9% incontinent). The stapled ileocecal intussusception described previously is the current recommendation, and the long-term incontinence rate among the patients undergoing the stapled nipple valves was reduced to 10%. Other late complications included the need for ureteral reimplantation in 28 patients (4.9%), and stomal stenosis in 29 patients with an ileal nipple (11.7%) and in 17 patients with an appendiceal stoma (14.7%).

Calculus formation in the pouch occurred in 38 patients (6.8%), resulting in 36 percutaneous procedures. Despite the loss of the terminal ileum, no significant decrease in serum vitamin B_{12} levels has been reported, and no patient has developed macrocytic anemia or neurologic symptoms. However, 25% of patients are on oral alkalinization to avoid metabolic acidosis.

Since the inception of this procedure, the overall complication rate has been considered high (31%). However, as Stein et al. (1995) **pointed out, 50% of the complications were manageable with percutaneous techniques. In addition, since 1988 the incontinence rate has been only 3.2% and less than 2% in patients with an appendiceal mechanism.**

Gerharz et al. (1997) from Marburg, Germany, reported their single-institution experience with the Mainz I ileocecal pouch. From 1990 to 1996, 202 consecutive patients underwent continent diversion, 96 with a submucosally embedded in situ appendix and 106 with an intussuscepted ileal nipple. All patients had an umbilical stoma. In 172 of 200 patients (86%), no stomal complications occurred. In 17 of 96 patients (18%) with an appendiceal stoma, 23 revisions were performed for stomal stenosis. In contrast, only 13 of 106 patients (12%) with an intussuscepted ileal nipple developed problems with their stoma. However, these patients required more invasive, major procedures for correction, whereas those with an appendiceal stenosis could usually undergo repair with a minor procedure. Three patients with an ileal nipple (3%) developed pouch calculi, whereas none of the patients with an appendiceal continence mechanism developed stones. As a result, Gerharz et al. (1997) concluded that the appendix, when available, should be the intestinal continence mechanism of choice.

We share the enthusiasm for the use of the appendix as a continence mechanism. In our experience this technique has also been reliable and easy to perform. It has been our tendency in constructing right colon pouches involving an appendiceal continence mechanism to use the entire right colon inclusive of the hepatic flexure to form the reservoir, thereby preserving more terminal ileum. This has the theoretic advantage of fewer metabolic complications, but the Mainz group has not reported significant metabolic problems.

The introduction of the more reliable appendiceal continence mechanism has greatly increased the acceptance of the Mainz I procedure. The Mainz group has also developed two new techniques for construction of a Mitrofanoff, or appendiceal, type of tube for use in patients whose appendix is either unsuitable or absent (Lampel and Thüroff, 1998; Lampel et al., 1995a, 1995b). Both techniques use a small-caliber conduit fashioned from the large intestine in the region of the cecum. One technique uses a full-thickness tube lined by mucosa (Fig. 140.7) and the other a seromuscular tube lined by serosa (Fig. 140.8). Both techniques appear to be successful, although the full-thickness tube was associated with a lower complication rate and a higher success rate in the initial report (Lampel et al., 1995b). With longer follow-up, Lampel et al. (1995b) have observed similar success rates with both tubes; 93% of the patients with a seromuscular tube (25 of 27) and 92% of the patients with a bowel wall tube (22 of 24) were continent day and night (Lampel and Thüroff, 1998). The authors believed that either tube was reliable and that each had its own unique advantages and disadvantages. In general, the full-thickness bowel wall tube was more adaptable because of the ability to create a longer tube. However, this came at the expense of a more tenuous blood supply. The decreased distal blood supply may be improved by creating a wider base on the tube. This could, however, make taenial implantation more difficult. The seromuscular tube was equally reliable but could be anastomosed only to the umbilicus, because of the short adit tube. Either tube was believed to be indicated as a continence mechanism in the Mainz I pouch when the appendix was not available or as a continence mechanism for reservoirs created from other large intestinal segments. Either technique could be used as a salvage procedure when another primary continence mechanism had failed.

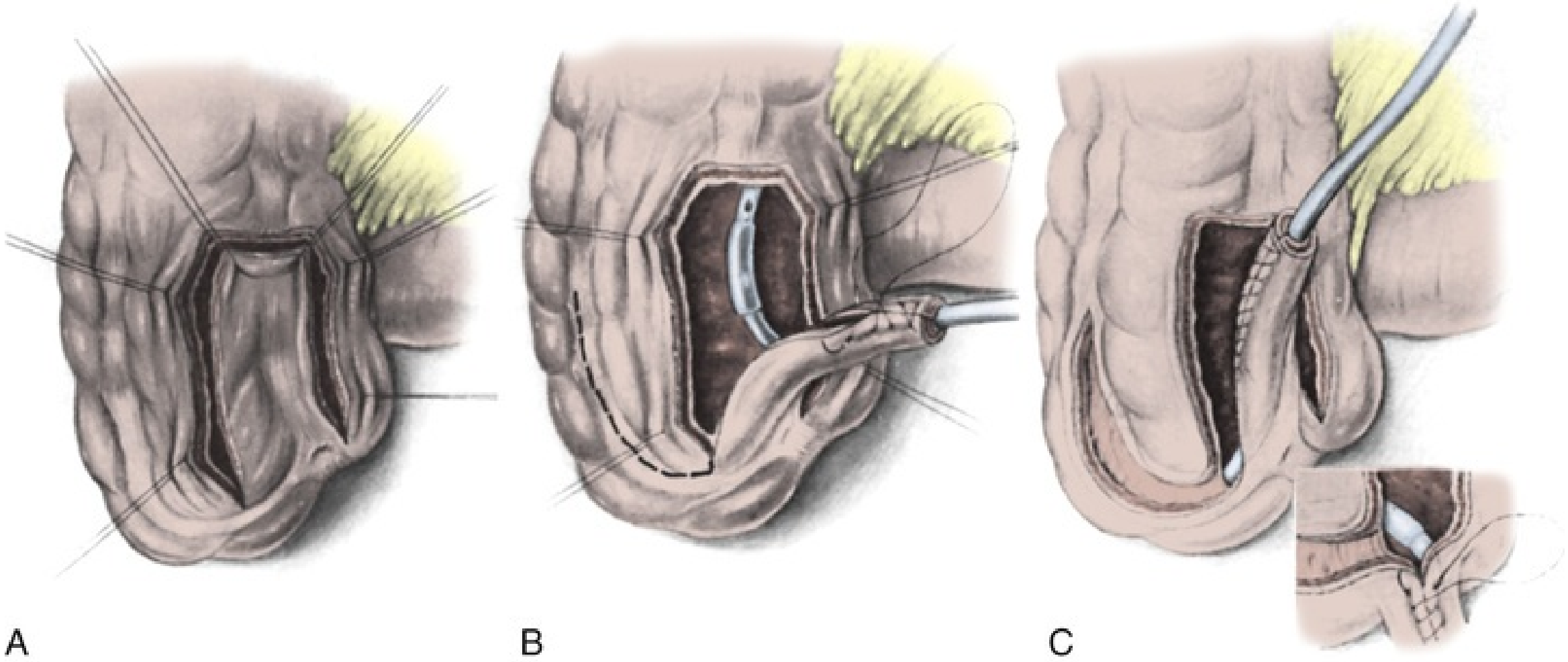

FIG. 140.7 (A to C) A full-thickness tube lined by mucosa is fashioned over an 18-Fr Foley catheter for tunneled reimplantation. The tube is closed with a running 3-0 absorbable suture. For longer tubes, we would advise a wider base to prevent distal ischemia. The continence mechanism is created by placing the tube into the adjacent taenial trough. (From Lampel A, Hohenfellner M, Schultz-Lampel D, Thüroff JW: In-situ tunneled bowel flap tubes: 2 new techniques of a continent outlet for Mainz pouch cutaneous diversion. *J Urol* 153:308–315, 1995.)

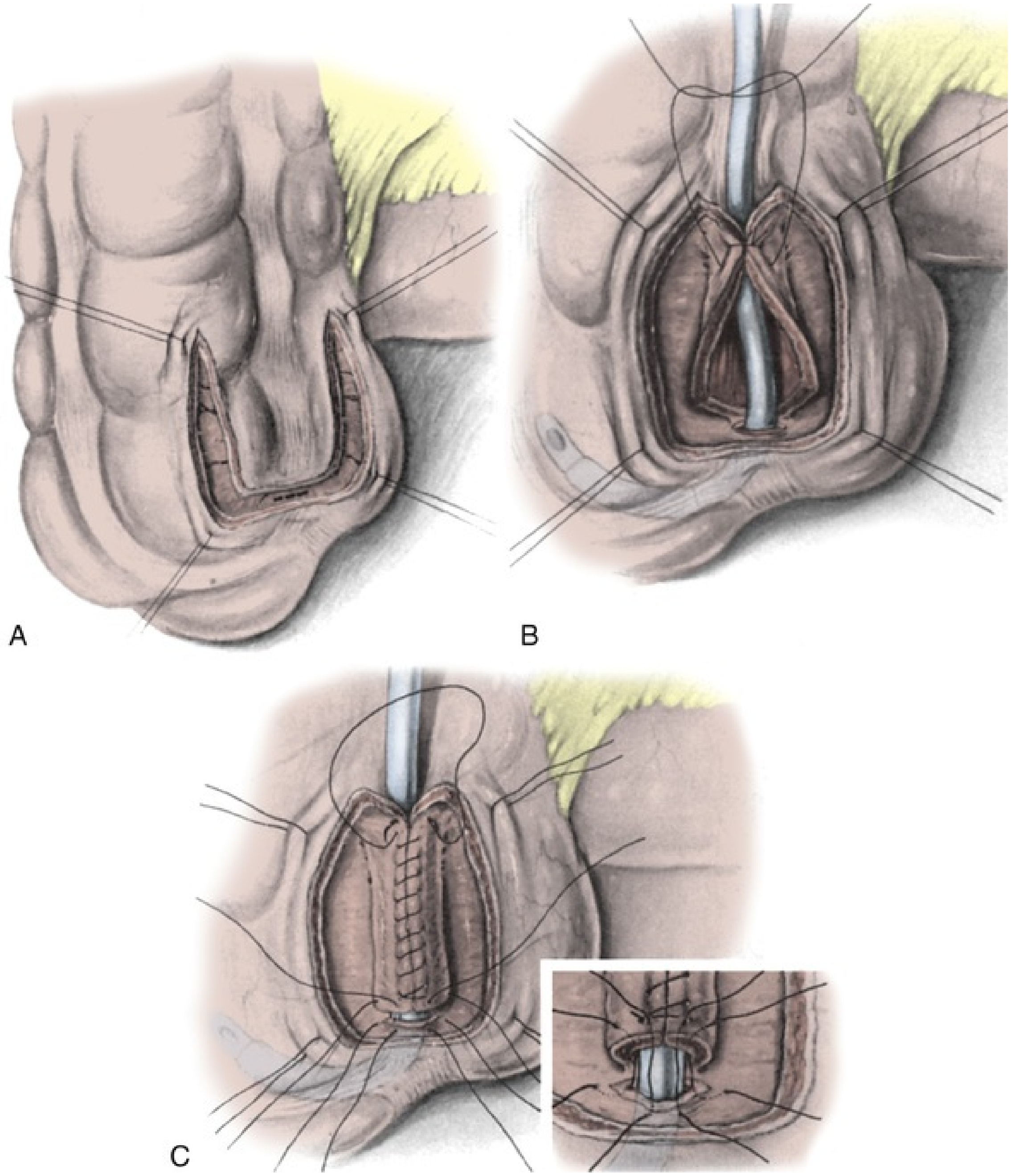

FIG. 140.8 (A to C) A 3- to 5-cm seromuscular tube denuded of mucosa and lined by serosa is fashioned for tunneled reimplantation. The tube is rolled over an 18-Fr Foley catheter. A mucosal window is opened at the base of the U, and the tube sutured to the mucosa with interrupted sutures. (From Lampel A, Hohenfellner M, Schultz-Lampel D, et al.: In situ tunneled bowel flap tubes: 2 new techniques of a continent outlet for Mainz pouch cutaneous diversion. *J Urol* 153:308–315, 1995.)

Another novel Mitrofanoff continence mechanism was described by Montie (1997), who conceived of a procedure in which a 2- to 3-cm segment of terminal ileum is isolated on its blood supply (Fig. 140.9A). The width of the segment was chosen to correspond to the circumference of the tube to be created. Once isolated, the segment is opened near one of its mesenteric junctions to create a longitudinal reconfiguration (Figs. 140.9B and C). The tube is then closed with a running 3-0 absorbable suture (Fig. 140.9D). It can now be used for a Mitrofanoff implant. When longer tubes are necessary, two adjacent segments can be isolated, reconfigured, and joined together (Figs. 140.9E and F). Although the technique was originally described in dogs, Montie (1997) has used it in humans without complication. Montie (1997) reported on a high rate of stomal stenosis in dogs, but this may have been secondary to infrequent catheterizations. Stomal stenosis has not occurred in our limited series of patients. Other groups have used tapered ileum to create a tunneled access into the right colon (Fig. 140.10) (Hampel et al., 1995; Woodhouse and MacNeily, 1994). Using tapered ileum for this purpose has the advantage of a blood supply independent of the reservoir and no length restrictions while having the disadvantage of further limiting intestinal absorptive surface.

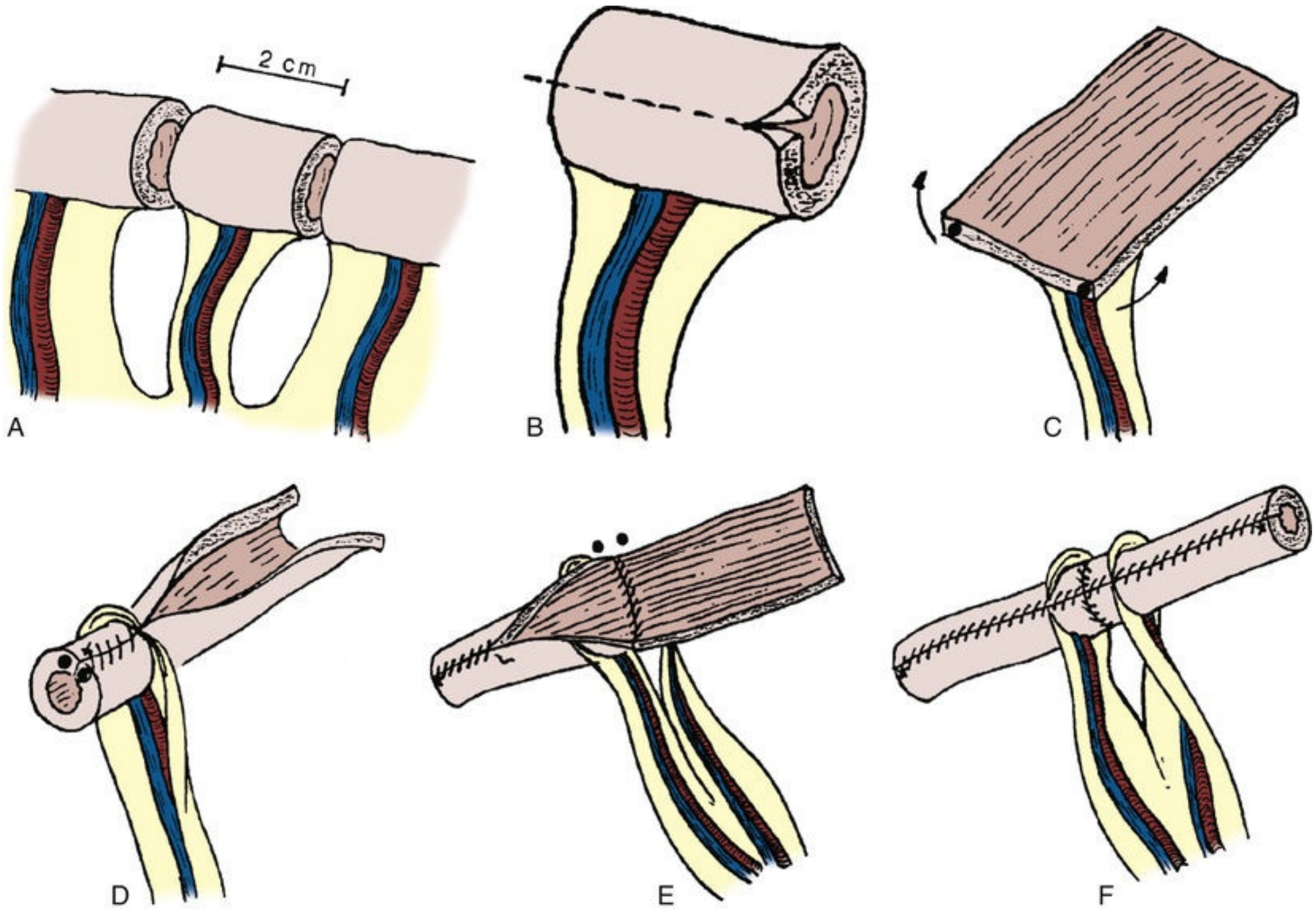

FIG. 140.9 (A) A 2- to 3-cm segment of terminal ileum is isolated on its own blood supply. (B and C) The tubular segment is opened approximately

one-fourth of the way up one side. This results in a well-vascularized rectangular plate. (D) The rectangular tube is now closed over a catheter with a running absorbable suture. (E and F) Two adjacent segments can be joined together to create one long tube. (From Monti PR, Lara RC, Dutra MA, et al.: New techniques for construction of efferent conduits based on the Mitrofanoff principle. *Urology* 49:112–115, 1997.)

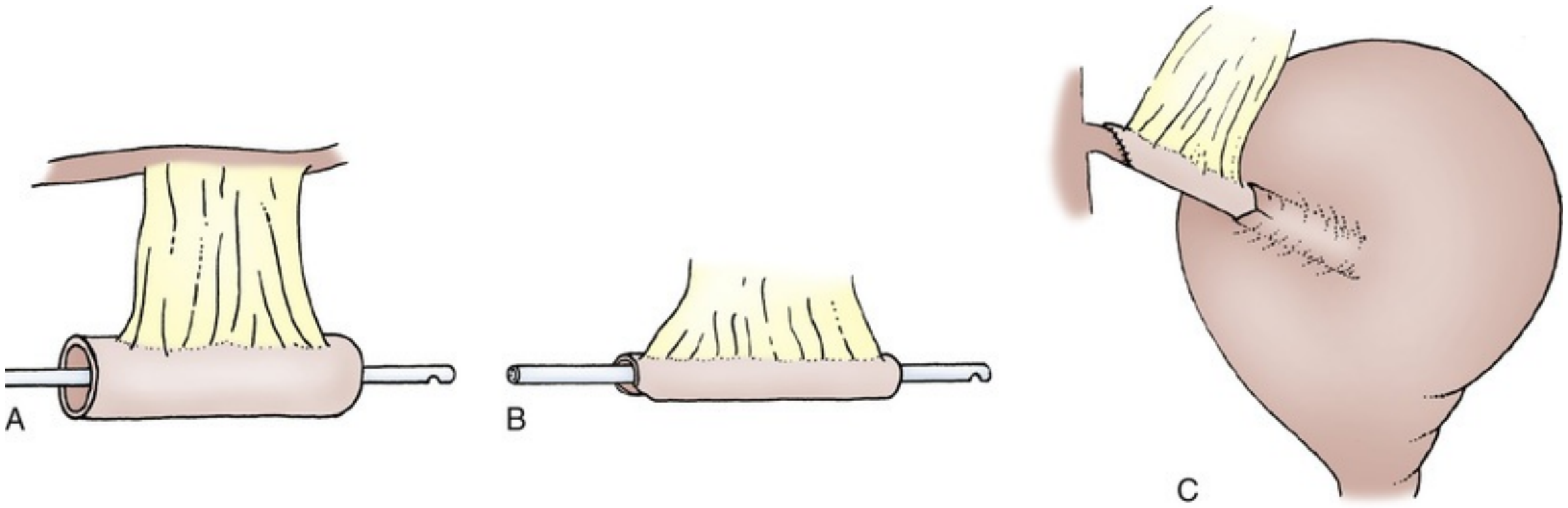

FIG. 140.10 (A to C) Woodhouse tapered ileum. (From Woodhouse CR, MacNeily AE: The Mitrofanoff principle: expanding upon a versatile technique. *Br J Urol* 74:447–453, 1994.)

Wiesner et al. (2007) compared their long-term results in 458 patients who underwent Mainz I pouch construction. The anastomosis was made using a submucosal tunnel in 809 renal-ureteric units and using a serosa-lined extramural tunnel in 74 units. At 17 months postoperatively they found a significantly higher occurrence of anastomotic obstruction in the submucosal tunnel group compared with the extramural group (7.3% vs. 4.1%, respectively). They found a much higher rate of obstruction in patients with previously dilated upper tracts (14%) or with a history of neurogenic bladder (17%). No significant deterioration of the upper tracts was identified.

In another comparison of patients with a Mainz I pouch, Wiesner et al. (2006) reported on 800 patients with almost 8 years of follow-up. Overall continence was approximately 93%. Stomal stenosis occurred in 23.5% of patients with a submucosally embedded in situ appendix, whereas stenosis was reported in 15.3% of patients with an intussuscepted ileal nipple valve. Rates of calculi formation were the reverse: 10.8% incidence in patients with an ileal nipple valve but in only 5.6% of patients with an appendix stoma. Ischemic degeneration of the continence mechanism occurred almost three times more often in the appendiceal group.

Right Colon Pouches With Intussuscepted Terminal Ileum

Additional pouches using nipple valve technology for the continence mechanism include those right colon pouches in which intussusception of the terminal ileum and ileocecal valve is employed. These are variations on the continent cecal reservoir initially described by Mansson (1987) that employ an intact cecal segment. These three pouches are the UCLA pouch (Raz, personal communication, 1989), the Duke pouch (Webster and King, 1987), and Le Bag (Light and Scardino, 1986). These surgeries differ from one another by only a few features, mainly related to the technique employed for stabilizing the nipple valve. Unless the appendix is being used as a continence mechanism, appendectomy should be performed in all cases because an in situ appendix would serve as a nidus for infection and abscess formation.

These operations are described in detail in the prior edition of this text. Since that edition was published, no new modifications to these procedures have been reported, and they are not further described here. The reader is referred to the prior edition of this text for an in-depth description of these operations.

Indiana Pouch

The concept of using the buttressed ileocecal valve as a dependable continence mechanism that can withstand the trauma of intermittent catheterization was first reported by Rowland et al. (1987) **from Indiana University.** This operation, which involved the partial spatulation of the cecal segment and attachment of an ileal patch, represented major contributions to the original ileocecal reservoir as described by Gilchrist et al. (1950), in which the intact bowel reservoir was employed and no attempt was made to strengthen the ileocecal valve. Originally, strengthening the ileocecal valve consisted of making a double row of imbricating sutures to the entire ileal segment (Rowland et al., 1985, 1987). It soon became apparent that this was necessary only in the region of the ileocecal valve. “Neourethral” pressure profiles showed that the continence zone was confined to the region of the reconfigured ileocecal valve (Bejany and Politano, 1988). The remaining “neourethra” could be tapered and brought through an abdominal or perineal stoma. At Indiana University, as well as other institutions, it became clear that the concept of marsupializing only a portion of the ascending colon segment left enough peristaltic integrity in the cecal region to generate pressures sufficiently high to overcome the continence mechanism in some patients. A number of groups contributed to the concept of using the entire right colon or more, marsupializing the entire structure and refashioning it in a Heineke-Mikulicz configuration (Bejany and Politano, 1988; Benson et al., 1988; Lockhart, 1987; Rowland, personal communication, 1989). These variations have been entitled the Florida pouch (Lockhart, 1987) and the University of Miami pouch (Bejany and Politano, 1988). However, they represent relatively minor variations on the theme of the Indiana pouch.

Procedure.

The Indiana pouch in its present form involves isolating a segment of terminal ileum approximately 10 cm in length along with the entire right colon to the junction of the right and middle colic artery blood supplies (Fig. 140.11A). After bowel continuity is reestablished, appendectomy is performed and the appendiceal fat pad obscuring the inferior margin of the ileocecal junction is removed by cautery (Fig. 140.11B). The entire right colon is opened along its antimesenteric border, and ureteral-taenial implants are fashioned (Fig. 140.11C). The ileocecal junction is buttressed according to various reported techniques. With nonabsorbable sutures, interrupted Lembert sutures are taken over a distance of 3 to 4 cm in two rows for the double imbrication of the ileocecal valve as described at Indiana University (Fig. 140.11D). The second row of sutures should attempt to bring the opposite mesenteric edges of ileum together, usually over a 12- to 14-Fr catheter. These two rows of sutures should be placed approximately 8 mm from one another, and the initial suture in each row may be taken in a purse-string fashion around the cecal margin as well. Alternatively, the University of Miami group suggests placing purse-string sutures in the same ileal region (Bejany and Politano, 1988). Finally, the Tampa group suggests placement of apposing Lembert sutures on each side of the terminal ileum (Fig. 140.11E). The remaining ileum can be tapered over the catheter and excess ileum removed with a stapling technique (Fig. 140.11F).

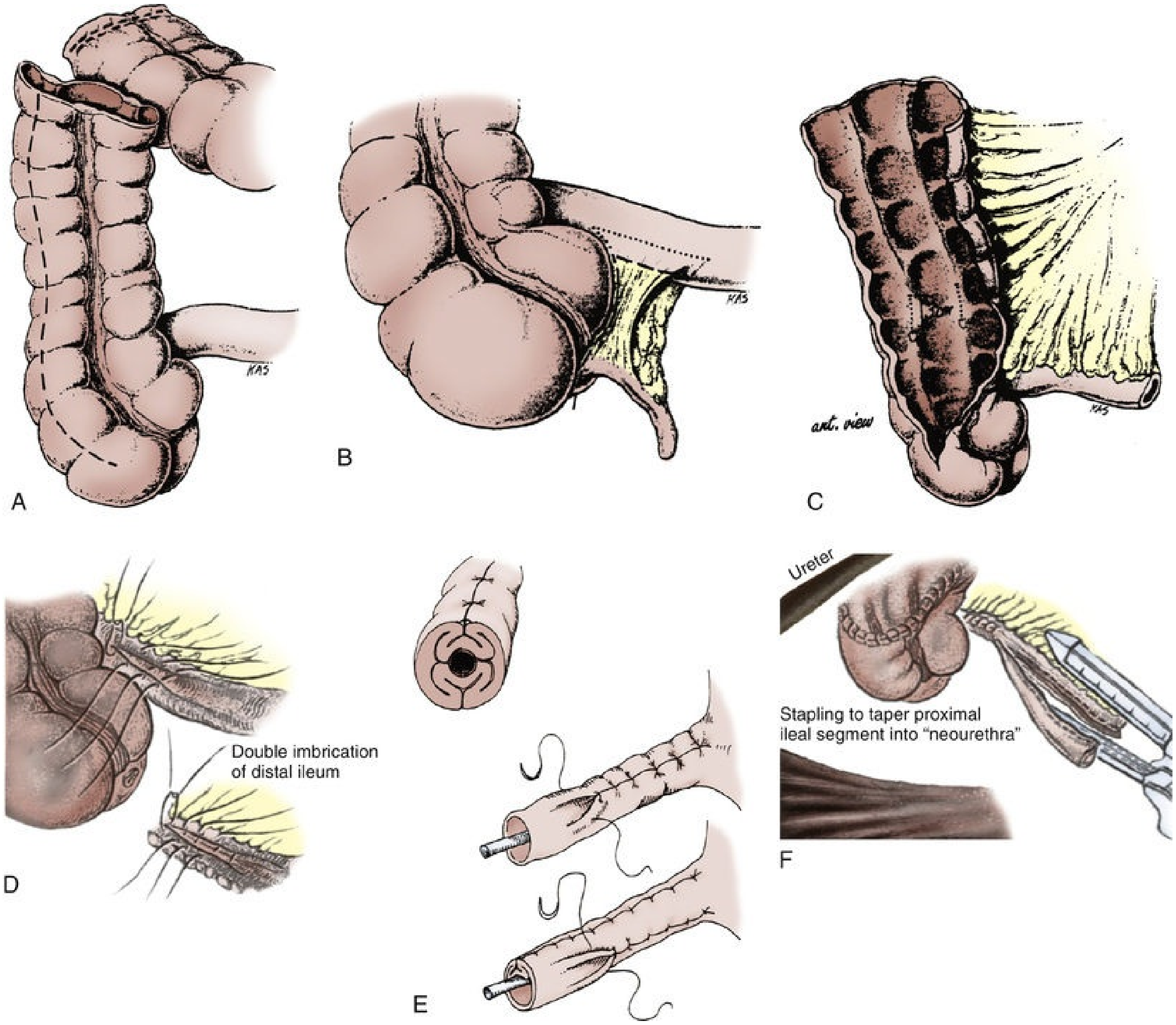

FIG. 140.11 (A) A segment of terminal ileum approximately 10 cm in length along with the entire right colon is isolated. (B) Appendectomy is performed, and the appendiceal fat pad obscuring the inferior margin of the ileocecal junction is removed by cautery. (C) The entire right colon is opened along its antimesenteric border. (D) Interrupted Lembert sutures are taken over a short distance (3 to 4 cm) in two rows for the double imbrication of the ileocecal valve as described at Indiana. (E) Application of apposing Lembert sutures on each side of the terminal ileum. (F) Excess ileum can be tapered by stapling technique. (A to C, From Benson MC, Sawczuk IS, Hensle TW, et al. Modified Indiana University continent diversion. *Curr Surg Tech Urol* 1:1–8, 1988. D and F, From Olsson CA: *Contemp Urol* 62–68, September 1989. E, From Lockhart J: Remodeled right colon: an alternative urinary reservoir. *J Urol* 138:730–734, 1987.)

It is important to carry out the imbrication while the cecal reservoir is still open (Rowland, 1996) so that the gradual closure of the ileocecal valve can be closely observed. The pouch is then closed in a Heineke-Mikulicz configuration with a running absorbable suture. Ureteral stents and a suprapubic tube are taken through a stab wound in the pouch and led through the right lower abdominal quadrant. The pouch is rotated so as to bring the ileal neourethra as close as possible to the selected stoma site. A fingerbreadth-wide skin button is transected along with a similar button from the anterior and posterior fascia. The ileal neourethra is advanced between bundles of the rectus muscle through the stoma and excess ileum is transected. The ileal edges are sewn to skin with interrupted sutures so as to create a flush stoma.

In addition to the differences in the technique of ileocecal valve imbrication, the University of Miami and the Florida pouches differ in the amount of colon used. The entire ascending colon and the right third or half of the transverse colon is isolated along with 10 to 12 cm of ileum. The entire upper extremity of the large bowel is mobilized laterally in the fashion of an inverted U (Fig. 140.12A). The medial limbs of the U are sutured to each other after the bowel has been spatulated (Fig. 140.12B). The bowel plate is then closed side to side (Fig. 140.12C). This inverted-U closure, however, is exactly the same as a Heineke-Mikulicz reconfiguration.

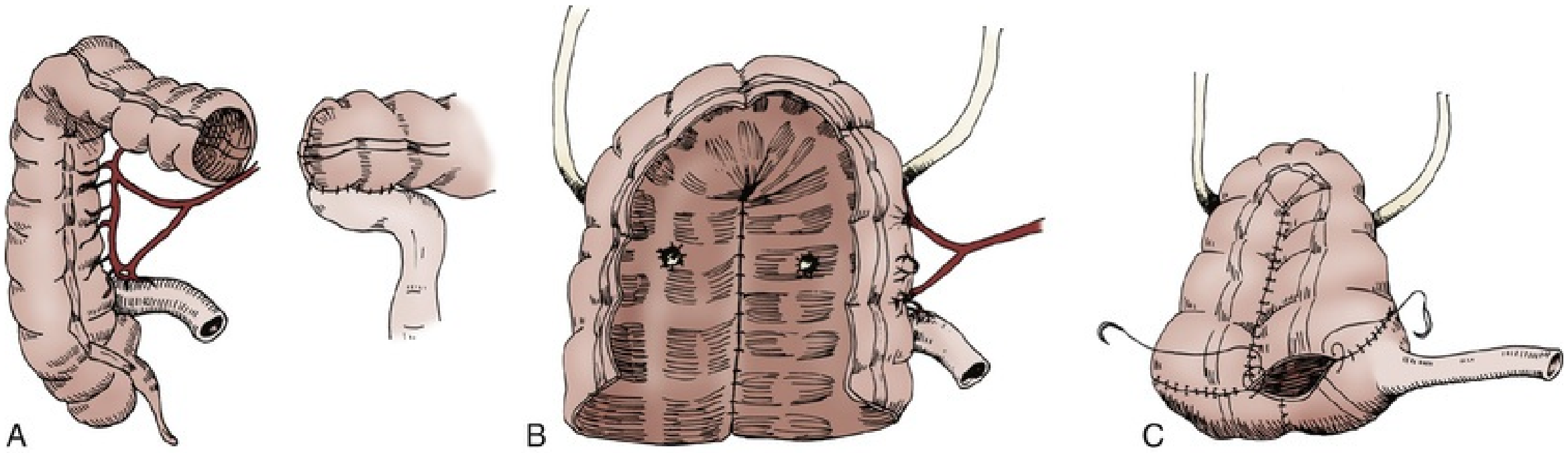

FIG. 140.12 (A) The entire ascending colon and the right third or half of the transverse colon is isolated along with 10 to 12 cm of ileum. (B) The entire upper extremity of the large bowel is mobilized laterally in the fashion of an inverted U. The medial limbs of the U are sutured after the bowel has been spatulated. (C) The bowel plate is then closed side to side. (From Lockhart J: Remodeled right colon: an alternative urinary reservoir. *J Urol* 138:730–734, 1987.)

There have been subsequent modifications to the Indiana reservoir that allow for more rapid construction and a lower complication rate (Rowland, 1996). The modifications incorporate the use of metal staples to create the efferent limb and absorbable staples to fashion the reservoir. The concept of using a metal GIA stapler to fashion the efferent limb was first introduced by Bejany and Politano (1988). Carroll and Presti (1992) reported on the urodynamic features of the stapled and plicated terminal ileum and found that the stapled limb performed equally well and was easier to construct. The use of absorbable staples to create this and other types of reservoirs is described later in the chapter.

Postoperative Care and Comments.

The postoperative care of the patient with an Indiana pouch and its variants is not substantially different from that used in patients with other right colon catheterizable diversions. In early reports, Rowland recommended discharging the patient with the suprapubic tube in place until readmission to the hospital 3 weeks later for tube removal and instruction in self-catheterization. In the current medical climate, which places a premium on outpatient procedures, tube removal and catheterization instruction are now ambulatory procedures at most institutions, including Indiana University (Bihrle, 1997).

Average pouch capacities of 400 to 500 mL have been reported by the Indiana group (Rowland et al., 1987). Combining the partially and totally spatulated bowel procedures, this group reports a reoperation rate of 26%. Overall continence rates of 93% have been achieved. Very elegant urodynamic studies were conducted in Indiana pouch variants by Carroll et al. (1989). They found only 86% of patients totally continent in a small series. However, their pouch capacities exceeded 650 mL, and peak contractions of 47 cm H_2O were recorded at capacity.

The last 81 patients operated on by Rowland underwent construction of a stapled efferent limb, and in the last 20 the reservoir was created with absorbable staples (Rowland, 1996). **The results in this group of patients were extremely favorable. Early pouch-related complications occurred in only 3 patients (3.7%).** Two patients experienced a pouch leak that was managed conservatively, and 1 patient required open revision of the efferent limb because of the difficulty with catheterization. Early complications not directly attributable to the pouch occurred in 7 patients (8.6%). Transient small bowel obstruction was the most common complication, occurring in 4 patients (4.9%). One patient developed a superficial wound infection, and 1 patient developed an abdominal abscess requiring surgery (1.2%). Late complications associated with the reservoir occurred in 23 patients (28.4%). Incontinence occurred in 6 patients (7.4%): in 5 patients it occurred secondary to high pouch pressures, and in the remaining patient it was caused by failure of the efferent limb. One of the former and the latter patient underwent reoperation. Three patients (3.7%) developed stomal stenosis, and 3 had parastomal hernias; all 6 underwent surgery. Pouch stones occurred in 3 patients: 1 underwent open removal, and 2 had endoscopic extraction. Acute pyelonephritis was seen in 4 patients (4.9%). The most common late complication not related to the pouch was small bowel obstruction; this was seen in 6 patients and was managed conservatively in 5. In summary, the early reoperation rate was 2.5% and the late reoperation rate 14.8%. **At 1 year, daytime and nighttime dry intervals of 4 hours or longer were achieved in 98% of patients.** Eighty-four percent of patients stated that they slept through the night without the need to awake for catheterization. Similarly, excellent results in the last 150 patients, 50 with at least 2½-year follow-up, were reported by Bihrle (1997).

The Florida pouch has been performed in 190 patients (Helal et al., 1993; Webster et al., 2003). In 165 patients and 326 ureters, no attempt was made to create a tunneled reimplantation. This approach was adopted because of the high incidence of ureteral obstruction encountered in the first 30 ureters that were tunneled into a Florida pouch (43 patients, 13.3%). In the last 165 patients, 16 of 326 ureters (4.9%) developed primary obstruction and were treated by percutaneous balloon dilation, nephrectomy, or observation. Although no attempt was made to create an antirefluxing anastomosis, only 7.1% of the ureters implanted demonstrated reflux. All patients are being followed conservatively, and no renal deterioration has been demonstrated. In the initial 100 patients, a 7.2% reoperation rate was reported (Lockhart, 1987). Although hyperchloremia was noted in 70% of patients, only 4 patients (including those who had preexisting renal disease) required treatment. Reservoir capacities ranged from 400 to 1200 mL, and maximal reservoir pressures at capacity ranged from 18 to 55 cm H_2O (Lockhart, 1987). The reason why these authors experienced such a high incidence of ureteral obstruction with nontunneled and tunneled ureteral colonic anastomoses is not clear. It is also surprising that only 23 of 326 ureters that were anastomosed end to side had reflux.

The University of Miami group has reported on its results in 75 patients. Early complications occurred in 19 patients (25%). Sixteen patients (21%) experienced late complications. The success rate of the ureterocolonic anastomosis was 90%, and total continence occurred in 98.6% of patients. Average pouch capacities were 750 mL or higher, and end filling pressures of 20 cm H_2O were reported. No patient required alkali therapy.

The Indiana pouch remains one of the most reliable of all catheterizable reservoirs. It is among the easiest to construct, and it has very low rates of short-term and intermediate-term (<2 years) complications (Navon et al., 1995; Rowland and Kropp, 1994). **However, there is evidence that the rate of long-term complications, mainly involving the efferent limb in a modified version of the Indiana Pouch, may be higher** (Holmes et al., 2002).

In our experience, the most common late complication is the development of stones within the pouch. Although most are asymptomatic, they can result in a higher incidence of “pouchitis.” The most common cause is insufficient pouch irrigation resulting in calcification of retained mucus. Pouch stones should not be treated with lithotripsy because it is not feasible to eliminate all fragments. These fragments will serve as a nidus for further stone formation. The best approaches are either a small McBurney incision with direct extraction or a percutaneous approach to the reservoir with placement of the stone(s) into a specimen bag.

Penn Pouch

The Penn pouch was the first continent diversion employing the Mitrofanoff (1980) principle, in which the appendix served as the continence mechanism. As mentioned earlier, this operation enjoys the singular feature of affording a catheterizable continent diversion that can be performed using techniques already present in the urologic armamentarium.

Procedure.

Two techniques of appendiceal continence mechanisms have been reported. Mitrofanoff reported excising the appendix with a button of cecum and reversing it on itself before tunneled reimplantation (Duckett and Snyder, 1986; Mitrofanoff, 1980). Alternatively, Riedmiller et al. (1990) left the appendix attached to the cecum and buried it into the adjacent taenia by rolling it back onto itself. A wide tunnel is created in the taenia extending 5 to 6 cm from the base of the appendix (Fig. 140.13). Windows are created in the mesoappendix between blood vessels. The appendix is folded cephalad into the tunnel, and seromuscular sutures are placed through the mesoappendix windows to complete the tunneling. The tip of the appendix is amputated and brought to the selected stoma site.

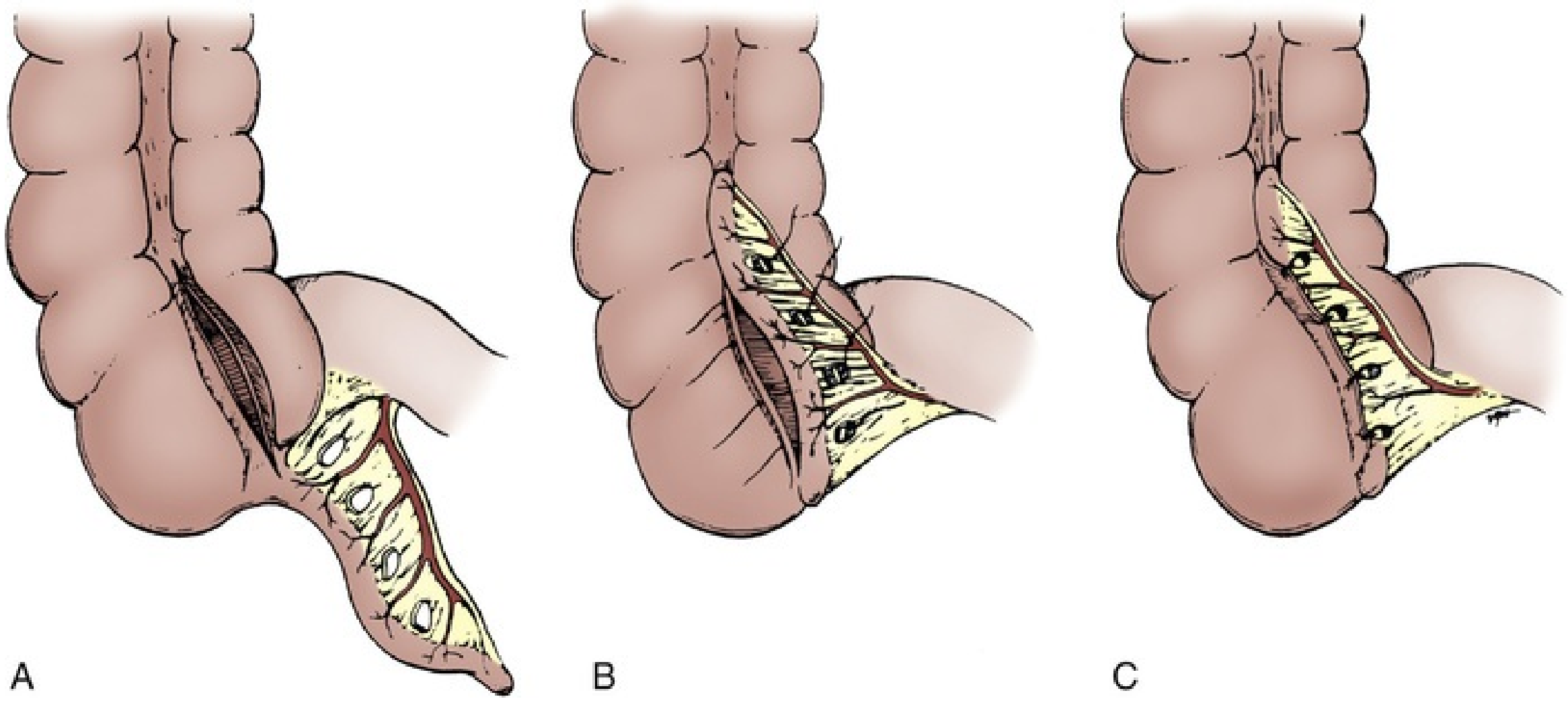

FIG. 140.13 (A) The appendix is left attached to the cecum and buried into the adjacent cecal taenia by rolling it back onto itself. A wide tunnel is created that extends 5 to 6 cm from the base of the appendix. Windows are created in the mesoappendix between blood vessels. The appendix is folded cephalad into the tunnel (B), and seromuscular sutures are placed through the mesoappendix (C).

As described by Duckett and Snyder (1986), an ileocecal pouch is created by isolating a segment of cecum up to the junction of the ileocolic and middle colic blood supplies along with a similar length of terminal ileum. These two structures are marsupialized on the antimesenteric borders and sutured to one another in the form of a neotubularized pouch. The superior margin of the pouch is sutured in a transverse fashion (all sutures being of absorbable material). A button of cecum surrounding the origin of the appendix is circumcised, and the resulting cecal aperture is closed with running absorbable suture. The mesentery of the appendix is dissected carefully from the base of the cecum, thereby preserving its blood supply. The appendix is then reversed on itself so that the cecal button can reach the anterior abdominal wall and the tail of the appendix can be directed to the taenia of the colon (Fig. 140.14). The appendiceal tip is obliquely transected and may be spatulated; then a tunneled appendiceal-taenial implantation is carried out. If additional appendiceal length is required, the variation proposed by Burns and Mitchell (1990) of creating a tube from the base of the cecum can be employed (see Fig. 140.3). Instead of simple removal of the appendix with a button of cecum before preparing it for tunneling, the entire base of the cecum leading to the appendix can be resected in continuity with the appendix by the application of the GIA stapler. We have found it helpful to spatulate the distal tip of the appendix until it accommodates a catheter at least

12 to 14 Fr in diameter.

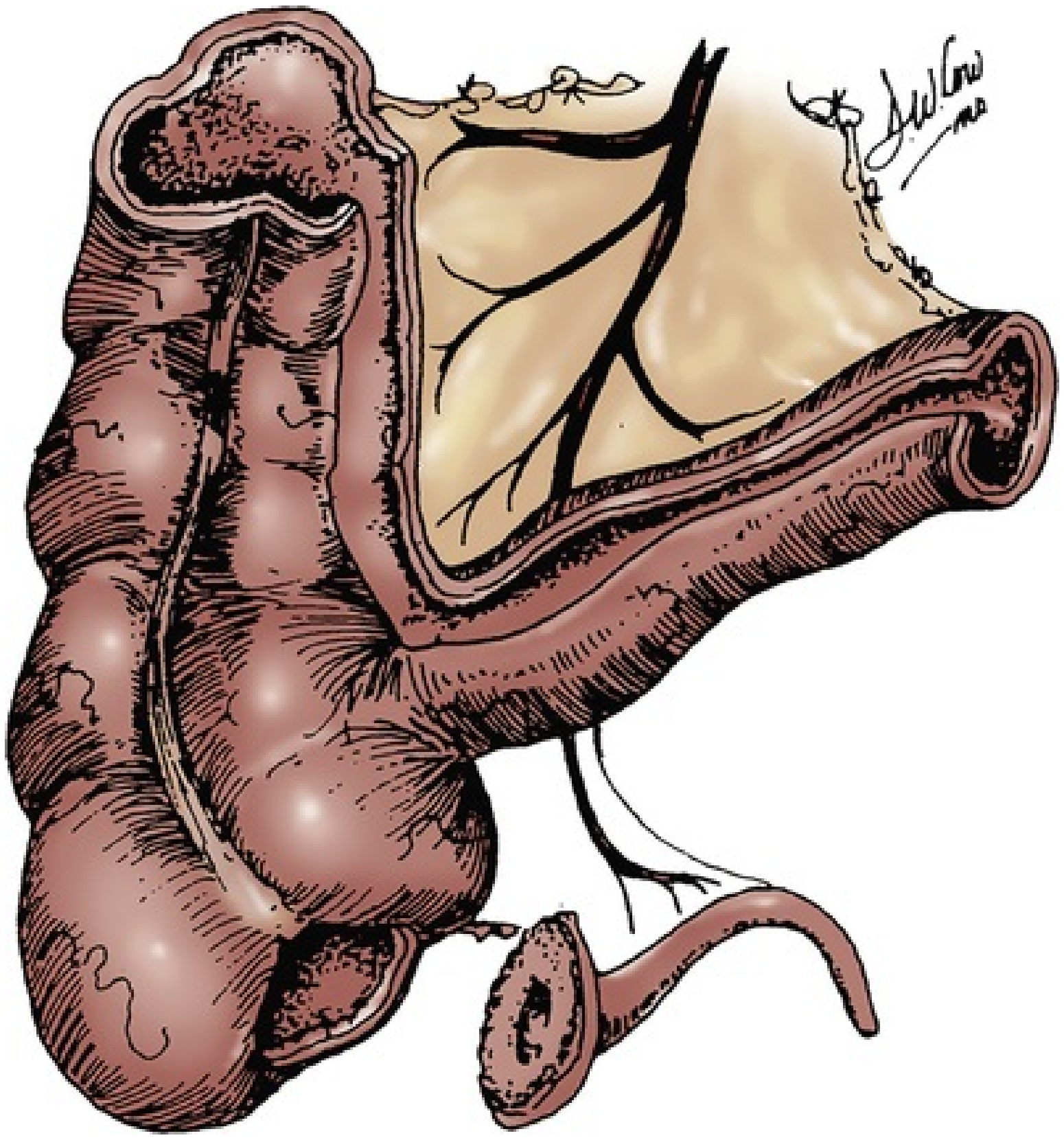

FIG. 140.14 A segment of cecum up to the junction of the ileocolic and middle colic blood supplies along with a similar length of terminal ileum is isolated and marsupialized on the antimesenteric borders. A button of cecum surrounding the origin of the appendix is circumcised. The mesentery of the appendix is dissected carefully from the base of the cecum, preserving its blood supply. (From Duckett JW, Snyder HM 3rd: The Mitrofanoff principle in continent urinary reservoirs. *Semin Urol* 5:55–62, 1987.)

Postoperative Care and Comments.

Although not shown in Duckett's surgical drawings, we suggest that a large-bore suprapubic tube be used to drain the pouch in the early postoperative interval. The size of the catheter admitted by the appendiceal stump is insufficient to allow for the passage of ureteral stents along with the 12- to 14-Fr catheter. In addition, safe irrigation of mucous debris is best managed by a larger-bore catheter.

Many groups have used the Mitrofanoff principle because of the simplicity and reliability of the continence mechanism (Bissada, 1993; Burger et al., 1992; Hampel et al., 1995; Sumfest et al., 1993; Woodhouse and MacNeily, 1994). Woodhouse and MacNeily (1994) reported on a series of 100 patients who underwent surgery from 1985 to 1993. Seven different catheterizable conduits into six different types of reservoir were used. Although these researchers found the Mitrofanoff principle to be versatile and associated with a high success rate (91% continence), the reoperation rate for tube complications was 33%.

Sumfest et al. (1993) affirmed the use of the appendix as the Mitrofanoff segment of choice. They reported a continence rate of 96%. In their hands, late complications included difficulty with catheterization in 10.6% and stomal stenosis in 19.1%.

Urodynamic properties and pouch capacities will be a function of the reservoir constructed. Most often, the appendix is used in situ (Burger et al., 1992), and the right colon, either alone or with associated terminal ileum (Mainz), serves as the reservoir. We have used the in situ appendix with a detubularized right colon reservoir and the native ileocecal valve as an antireflux mechanism (refluxing ureters implanted end to side into terminal ileum). In our hands this has resulted in an excellent success rate with no upper tract problems. The adequacy of the ileocecal valve as an antireflux mechanism was also reported by Alcini et al. (1994). In their series, however, the reservoir was not always detubularized and, as expected, upper tract complications ensued because of high reservoir pressures. This procedure is uniquely capable of affording continent cutaneous diversion to the patient with short ureters because the terminal ileum can be left long enough to reach high into the retroperitoneum.

Gastric Pouches

Pioneering animal experimentation demonstrated the feasibility of employing stomach as a bladder patch or urinary reservoir (Leong, 1978; Rudick et al., 1977; Sinaiko, 1956). **The use of the stomach to create a urinary reservoir has theoretic as well as real advantages** (Adams et al., 1988). **First, electrolyte reabsorption would be greatly diminished by use of this bowel segment in the reservoir. This would potentially make the stomach the selected reservoir for individuals with preexisting metabolic acidosis or renal insufficiency. Hyperchloremic acidosis would not be an anticipated problem; in fact, in addition to presenting a barrier against the absorption of chloride and ammonium, the gastric mucosa secretes chloride ions** (Piser et al., 1987). **Furthermore, in patients in whom shortening of the bowel may**

be expected to lead to some degree of malabsorption, the use of stomach is an attractive alternative. The acid pH of the urine may also reduce the risk of bacterial colonization. Finally, when the entire lower bowel has been irradiated, stomach tissue may provide healthy nonirradiated tissue for use in performing continent diversion. Given these theoretic advantages, a number of groups have initiated trials with gastric pouches and composite reservoirs in pediatric (Adams et al., 1988) and adult (Austin et al., 1997; Lockhart et al., 1993) populations.

Procedure.

A wedge-shaped segment of stomach with maximal width of 7 to 10 cm is fashioned from the greater curvature. Care is taken not to extend the wedge through to the lesser curvature to preserve vagal innervation and normal gastric emptying. The left gastroepiploic artery is preferentially used as the blood supply for the isolated gastric wedge, dividing the short gastric vessels from the more proximal artery up to the gastric fundus. Alternatively, if there is a problem with the left artery, the right gastroepiploic vessel may be employed, dividing the short gastric vessels to the level of the pylorus (Figs. 140.15A and B). The stomach is then closed according to the surgeon's preference. Neither gastroduodenostomy nor gastrojejunostomy is mandatory unless the antrum of the stomach has been used. The isolated wedge is refashioned into nearly a sphere by folding it back on itself and suturing the edges together with running absorbable material. Before pouch closure, one ureter is tunneled into the reservoir according to the surgeon's preferred antireflux technique. Contralaterally, proximal transureteroureterostomy is performed. The contralateral distal ureter is used to create the continence mechanism. The distal ureter is tunneled into the reservoir in a fashion similar to an appendiceal implant. The free portion of the ureter can then be brought to the skin or to the introitus (or urethral stump in males) to serve as a catheterization portal (Fig. 140.15C). Alternatively, the wedge of stomach can be incorporated into a reservoir composed of detubularized ileum (Lockhart et al., 1993). In this procedure, an 11-cm segment of stomach is isolated on the right gastroepiploic blood supply (Fig. 140.16A). A 22-cm segment of ileum is then isolated, opened along its antimesenteric border, and refashioned in a U shape (Fig. 140.16B). The edges of the stomach are then sutured to edges of the ileum with a running absorbable suture of 2-0 PGA. This completes the reservoir. The ureters are tunneled into the stomach, and a Mitrofanoff continence mechanism is created according to the preference of the surgeon. For example, the group from the University of South Florida employs a tapered segment of ileum (Fig. 140.16C).

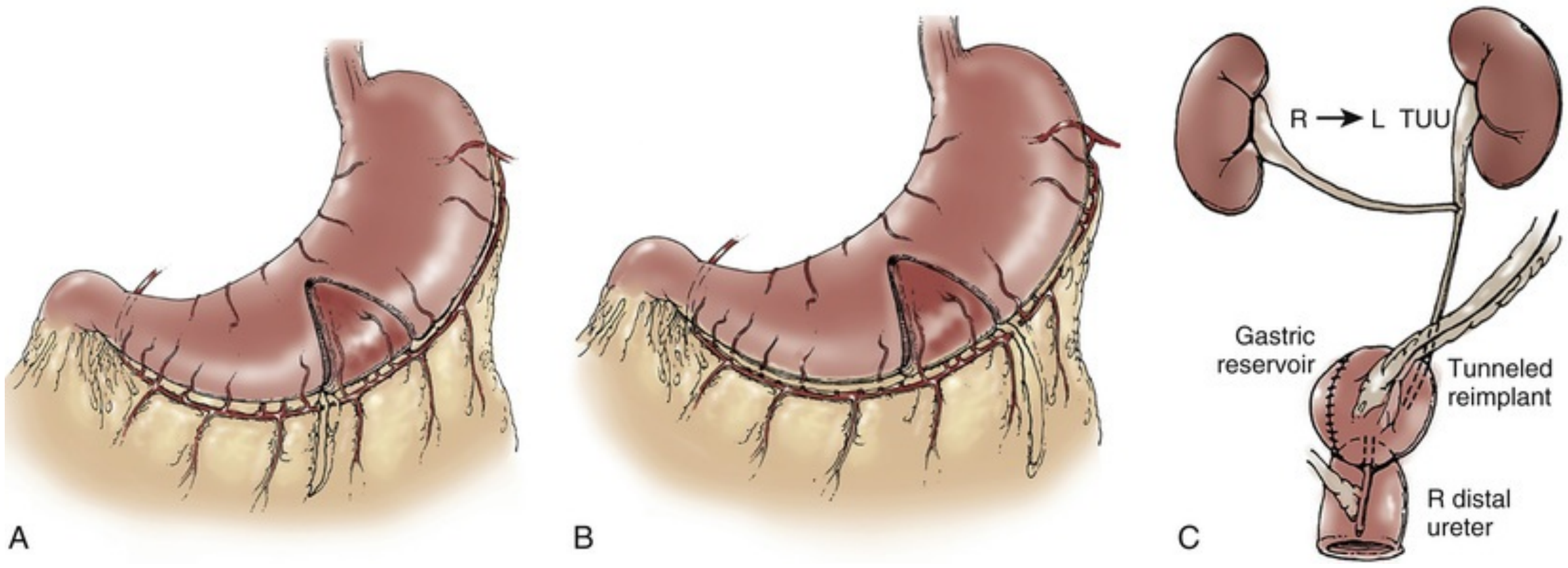

FIG. 140.15 (A and B) A wedge-shaped segment of stomach whose greatest width is 7 to 10 cm is fashioned from the greater curvature. The left gastroepiploic artery is preferentially used as the blood supply for the isolated gastric wedge by dividing the short gastric vessels up to the gastric fundus. Alternatively, if there is a problem with the left artery, the right gastroepiploic vessel may be employed. (C) The isolated wedge is refashioned into nearly a sphere by folding it back on itself and suturing the edges together with running absorbable material. One ureter is tunneled into the reservoir. A proximal transureteroureterostomy is performed. The ipsilateral distal ureter is tunneled into the reservoir with its distal extent brought to the introitus to serve as a catheterization portal. *R → L TUU,* Right-to-left transureteroureterostomy. (From Adams MC, Mitchell ME, Rink RC: Gastrocystoplasty: an alternative solution to the problem of urological reconstruction in the severely compromised patient. *J Urol* 140:1152–1156, 1988.)

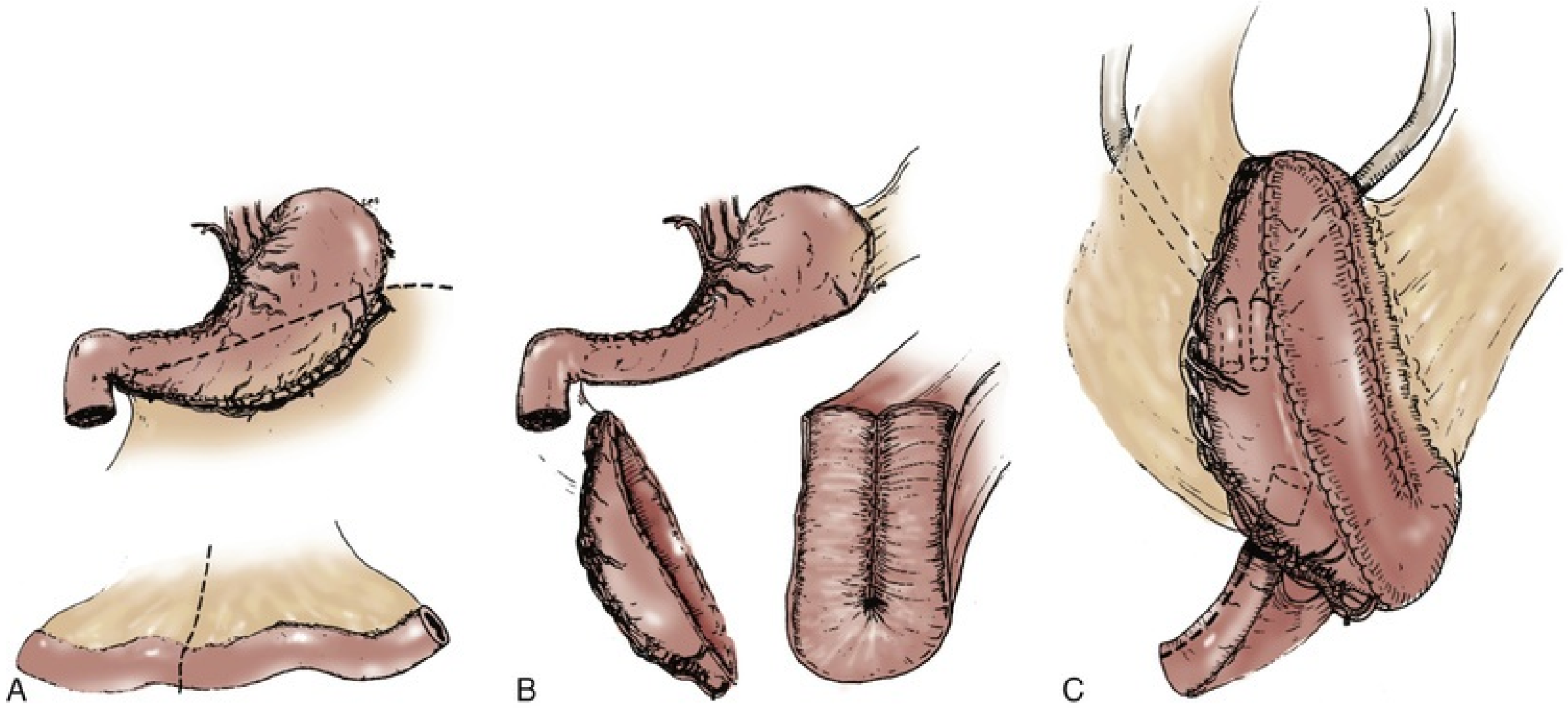

FIG. 140.16 (A) An 11-cm segment of stomach is isolated on the right gastroepiploic blood supply using a GIA-90 stapler. Usually two staplers are required. (B) A 22-cm segment of ileum is then isolated, opened along its antimesenteric border, and refashioned in a U shape. (C) The edges of the stomach are then sutured to edges of the ileum with a running absorbable suture of 2-0 polyglycolic acid. This completes the reservoir. The ureters are tunneled into the stomach, and a Mitrofanoff continence mechanism is created with a tapered segment of ileum. (From Lockhart JL, Davies R, Cox C, et al.: The gastroileal pouch: an alternative continent urinary reservoir for patients with short bowel, acidosis and/or extensive pelvic radiation. *J Urol* 150:46–51, 1993.)

Postoperative Care and Comments.

Adams et al. (1988) reported mean pouch capacities of 245 mL and end filling pressures averaging 35 cm H_2O in a small patient sample. Combining their experience of gastric continent diversion and gastrocystoplasty, they reported minimal mucus production: only 3 of 13 patients required any irrigations, and the majority maintained sterile urine. Urine pH ranged from 4 to 7, but no introital ulceration from acid urine was reported. Three patients had minor elevations of serum gastrin, and none of the continent diversions required reoperation. Leong (1978) used similar concepts in gastric pouch construction and alluded to the creation of a voiding pouch created from stomach as well.

The construction of reservoirs entirely from stomach has not seen widespread acceptance. Rather, there has been greater use of stomach segments either for bladder augmentation or as a portion of a reservoir (composite) either alone or with an in situ catheterizable tube fashioned from a portion of the stomach (Carr and Mitchell, 1996; Gosalbez et al., 1994).

Gosalbez et al. (1994) reported on 15 patients who received a gastric tube as part of a composite gastric patch. Complications associated with the gastric patch and in situ tube included one each of early traumatic perforation of the tube, distal tube stenosis, and mucosal redundancy. Two of these patients required reoperation. Peristomal skin irritation from acid secretion occurred in 2 patients but was not considered severe. This is a more frequent complication in other reports and has resulted in skin breakdown in some instances.

Over a 10-year period from January 1985 to June 1995, Carr and Mitchell (1996) reported on the use of stomach in 12 patients. Seven had urinary reservoirs totally constructed from stomach, whereas 5 had composite reservoirs. They reported continence in all patients but that the continence mechanisms often required revision. Average bladder capacity was 309 mL, and average compliance was 12.9 mL/cm H_2O. When stomach is used as a bladder augment or as a portion of a neobladder, a dysuria and hematuria syndrome has been reported (Nguyen et al., 1993).

Austin et al. (1997) reported on nine adult patients with a mean follow-up of 54 months who underwent construction of a continent composite reservoir that was gastroileal in 7 and gastrocolonic in 2. All 9 patients had either preexisting metabolic acidosis or a short bowel syndrome. All 9 patients achieved electrolyte neutrality, and postoperative serum pH was significantly improved ($P < .01$). Three patients had a short-term serum gastrin elevation; the level returned to normal during follow-up. One patient developed skin ulceration at the stoma site.

The use of stomach has particular appeal in the pediatric population, in which the stomach's unique acid-base properties can be used not only to reconstruct but also to help correct the metabolic problems that are often associated with the need for pediatric urinary reconstruction (Carr and Mitchell, 1996)**. Although experience with use of the stomach remains small, its various unique intrinsic properties as a reservoir suggest that its use will continue in selected clinical situations.**

Quality-of-Life Assessments

Few well-designed, prospectively conducted studies using validated instruments exist to assess quality of life after various forms of urinary diversion and even fewer that include the less common continent cutaneous urinary diversions. Multiple international studies have suggested an improved psychosocial adjustment of the patient undergoing continent urinary and fecal diversion in general compared with those patients with diversions requiring collecting appliances (Bjerre et al., 1995; Filipas et al., 1997; Hart et al., 1999; McGuire et al., 2000; Salter, 1992a, 1992b). Although this may indeed be true, as exemplified by individuals with a conduit who desire conversion to a continent procedure, it is also true that many, if not most patients, adjust well to wearing external appliances. The sense of body image is a remarkably personal and subjective parameter that varies greatly from patient to patient. In general, body image and quality of life after a conduit procedure appear to remain good and may not be significantly different than after continent diversions (Gerharz et al., 2005; Hedgepeth et al., 2010; Somani et al., 2010). However, no randomized prospective trial has ever compared the quality of life after continent cutaneous diversion with that after either orthotopic continent diversion or incontinent urostomy, and there is no definitive conclusion that one form of urinary diversion is superior to any other (Porter and Penson, 2005). Of those studies performed, there appear to be common flaws in the study design and methods used that make any direct comparisons between continent and incontinent diversions difficult (Gerharz et al., 2005).

In general, most quality-of-life studies show similar results between patients undergoing ileal conduit and cutaneous continent diversion, with the latter being associated with improvements in stomal and urinary quality-of-life scores. In one of the few prospective studies to compare quality of life after continent cutaneous and ileal conduit diversion, Hardt et al. (2000) followed patients from the preoperative setting until 1 year after surgery. Using validated instruments tested for reliability, they found life satisfaction improved over time in patients with continent cutaneous diversion, whereas it worsened during the first year after ileal conduit construction. Using the Beck Depression Inventory and Profile of Mood States in adults, Boyd et al. (1987) found that patients choosing ileal conduit diversion had the lowest expectations of their quality of life. Boyd et al. found the highest overall satisfaction among patients undergoing conversion from ileal conduit to Kock cutaneous pouch diversion.

Mansson et al. (2002) found no difference in overall quality of life in men undergoing continent cutaneous diversion when compared with orthotopic neobladder using the Functional Assessment of Cancer Therapy (FACT)–Bladder and Hospital Anxiety and Depression Scale. In specific questions concerning intestinal, urinary, and sexual function, patients with cutaneous reservoirs experienced less difficulty with incontinence and emptied less frequently. Sexual function appeared better in patients undergoing orthotopic bladder substitution, likely because of urethral preservation. Large et al. (2010) used the validated FACT–Vanderbilt Cystectomy Index to compare quality-of-life measures in 92 women who underwent orthotopic neobladder compared with diversion with an Indiana pouch. With a median follow-up of at least 2 years, no significant difference was found in the physical, emotional, functional, or social measures of quality of life included in the instrument.

Variations in Operative Technique

Minimally Invasive Continent Cutaneous Diversion

With improvements in laparoscopic- and robotic-assisted techniques, radical cystectomy is now commonly performed in many centers using these minimally invasive techniques. Many of the centers performing minimally invasive radical cystectomy also perform orthotopic ileal neobladder procedures without converting to open techniques. There is significant literature concerning the potential benefits of this approach, but it is not covered here. In contrast, there are very few reports of continent cutaneous diversions performed using minimally invasive techniques. Given the surgical complexity of these types of diversions, the majority of centers perform continent cutaneous diversions via standard open techniques. Türk et al. (2001) reported on an initial series of five patients who underwent radical cystectomy with bilateral pelvic lymphadenectomy and continent urinary diversion with use of a rectosigmoid pouch performed with an intracorporeal laparoscopic technique. Bilateral stented antireflux ureteral reimplantation was used, and laparotomy was not performed. Operative time was 7.4 hours with minimal blood loss and a mean hospital stay of 10 days. No intraoperative or postoperative complications were encountered. Intermediate-term oncologic and functional outcomes were reportedly similar to those achieved with an open approach (DeGer et al., 2004). Goh et al. (2015) reported on a successful intracorporeal modified Indiana Pouch construction, lasting 3 hours, with no postoperative complications at 1 year. In the largest series available, Desai et al. (2017) reported on a series of 10 patients with at least 1 year of follow-up after intracorporeal Indiana Pouch diversion. Operative time lasted a mean of 3.5 hours (range 3–5 hours), and median hospital stay was 10 days (3–26 days). In terms of GI complications, 2 patients had a prolonged pouch leak managed conservatively. Two patients developed uretero-enteric anastomotic strictures. At 1-year follow-up, one patient had been undiverted because of noncompliance, and the remaining 9 were catheterizing without difficulty.

The complex nature of minimally invasive reconstructive surgery necessary in continent cutaneous diversion has limited these procedures to select centers. In addition, because of the prolonged time for return of postoperative bowel function, the benefits in hospital stay seen in other oncologic surgeries (e.g., laparoscopic nephrectomy) do not seem to exist when urinary diversion is performed.

Conduit Conversion to a Continent Reservoir

The major indication for conversion of a functioning conduit to a continent urinary reservoir is the patient's desire for improved quality of life. Pow-Sang et al. (1992) reported on conversion in 20 patients. Fifteen were converted from an ileal conduit and 1 each from a cecal conduit, ureterosigmoidostomy, cutaneous ureterostomy, sigmoid conduit, and a suprapubic tube. In 14 of the 20 patients the conduit was discarded or used only as a patch to a colonic reservoir. It was observed that renal units that were obstructed preoperatively were associated with a 71% failure rate. Metabolic acidosis was seen in 15 (75%) but was believed to be mild. Pouch-related complications are, in general, a function of the reconstruction selected, and complication rates should not necessarily be higher in this setting. However, patient selection is very important in determining appropriate candidates for conversion.

We prefer to use the conduit in some form whenever possible. This strategy was supported in a report on two patients by Oesterling and Gearhart (1990). The use of an existing bowel segment has the potential to diminish metabolic sequelae and may result in a lower complication rate. The form of continent reconstruction chosen will have to depend on intraoperative findings, and no one procedure is more amenable than another. Before conversion is undertaken, the patient should be fully evaluated for disease recurrence, renal functional status, urinary anatomy, hydronephrosis, intestinal length, and intestinal health.

Pahernik et al. (2004) have described the long-term outcomes of conversion of 39 patients from conduit diversion to Mainz I pouch diversion. With a mean follow-up of 102 months, the most common complications were stomal stenosis and pouch calculi. Long-term continence was achieved in 95% of patients.

Absorbable Stapling Techniques in Continent Urinary Diversion

The principle of bowel detubularization to increase reservoir capacity and diminish the effects of peristalsis is a fundamental principle of all contemporary continent urinary diversions. The process of detubularization and refashioning of the spatulated bowel segment consumes at least 1 hour of operating time and is by far the most time-consuming and tedious aspect of pouch construction. **The use of absorbable staples has substantially reduced the time required to fashion bowel reservoirs and has demonstrated short-term and long-term reliability with respect to reservoir integrity and volume.**

Bonney and Robinson (1990) first demonstrated the potential use of absorbable staplers to substitute for conventional suturing of bowel reservoirs. These authors used a bulky absorbable stapler (Polysorb staples in a TA Premium 55 stapler [US Surgical Corp., Norwalk, CT]) to construct an S-pouch configuration in a canine ileal urinary pouch model. Although the same stapler was used in humans by Bonney and Robinson in 1992 and by Cummings in 1995, its clinical use was never widely adopted because the bulky staple configuration destroyed a significant portion of the bowel diameter, particularly when applied to the small intestine. The fact that up to 20 costly staple cartridges were required to complete the closure of a bowel reservoir further reduced the potential benefits of absorbable pouch construction.

A 75-mm GIA instrument (PolyGIA, US Surgical Corp., Norwalk, CT) that incorporates substantially smaller absorbable staples was made available for clinical use in 1992. The stapler delivers four rows of absorbable polylactic acid and PGA blend copolymer staples, dividing the bowel between the second and third rows. Thus each staple line of the pouch has a double, staggered, stapled closure. This device has enabled both the refashioning and closure of bowel pouches to be performed with fewer staple applications and is strong and watertight. Finally, the width of bowel sacrificed with the new instrument is appreciably less than that with the older staple device. Several investigators have subsequently used the new “absorbable” GIA stapler to construct catheterizable pouches and neobladders (Montie et al., 1994, 1995; Olsson et al., 1993; Olsson and Kirsch, 1995). **However, the absorbable PolyGIA staples must not overlap because this will result in the failure of the staples to lock together. This is in direct contrast to metal staples, which are meant to overlap to create anastomotic integrity.** As a result of the need to prevent overlap of absorbable staples, the reservoir construction procedures must be varied when such staples are used, as described later.

Surgical Techniques

Right Colon Pouch

In 1993 Olsson et al. described a technique using the absorbable GIA staplers to fully detubularize and refashion large bowel. The technique of colon pouch construction described here incorporates the principles of bowel detubularization and refashioning using absorbable staplers in a simple “one-step” process.

The right colon and 10 cm of terminal ileum are mobilized by incising the peritoneum along the white line of Toldt and along the base of the mesentery and are isolated using metal GIA staplers (Fig. 140.17A). After bowel continuity has been restored with standard metal GIA and thoracoabdominal (TA) staplers, the distal staple line of the right colon is excised and the bowel lumen is irrigated to remove residual enteric contents. Using electrocautery, a small opening (2 cm) is created on the antimesenteric border of the cecum to fit the absorbable stapler. The distal open end of the colon is aligned with the cecostomy by folding the right colon on itself, as depicted in Fig. 140.17B. The limbs of the absorbable GIA stapler are inserted into the distal open end and into the cecostomy, and the stapler is fired along the antimesenteric line of the apposed folded bowel (Fig. 140.17C). It is necessary to evert the bowel to continue subsequent staple applications. This may be achieved by placing Babcock clamps on each side of the distal staple line (Fig. 140.17D). A small incision at the junction of each staple line is made to prevent overlap of the absorbable staple rows and to allow for the next staple application. Because of this incision, there is often a short unstapled area at the junction between each application of the stapler, requiring one or two simple figure-of-eight sutures of 2-0 absorbable material at each of these points. The last staple application traverses the apex of the fold of bowel. In adults, three to four applications of the stapling device have been required to construct the right colon pouch, whereas in children two or three staple applications suffice. The appearance of the nearly completed pouch is illustrated in Fig. 140.17E.

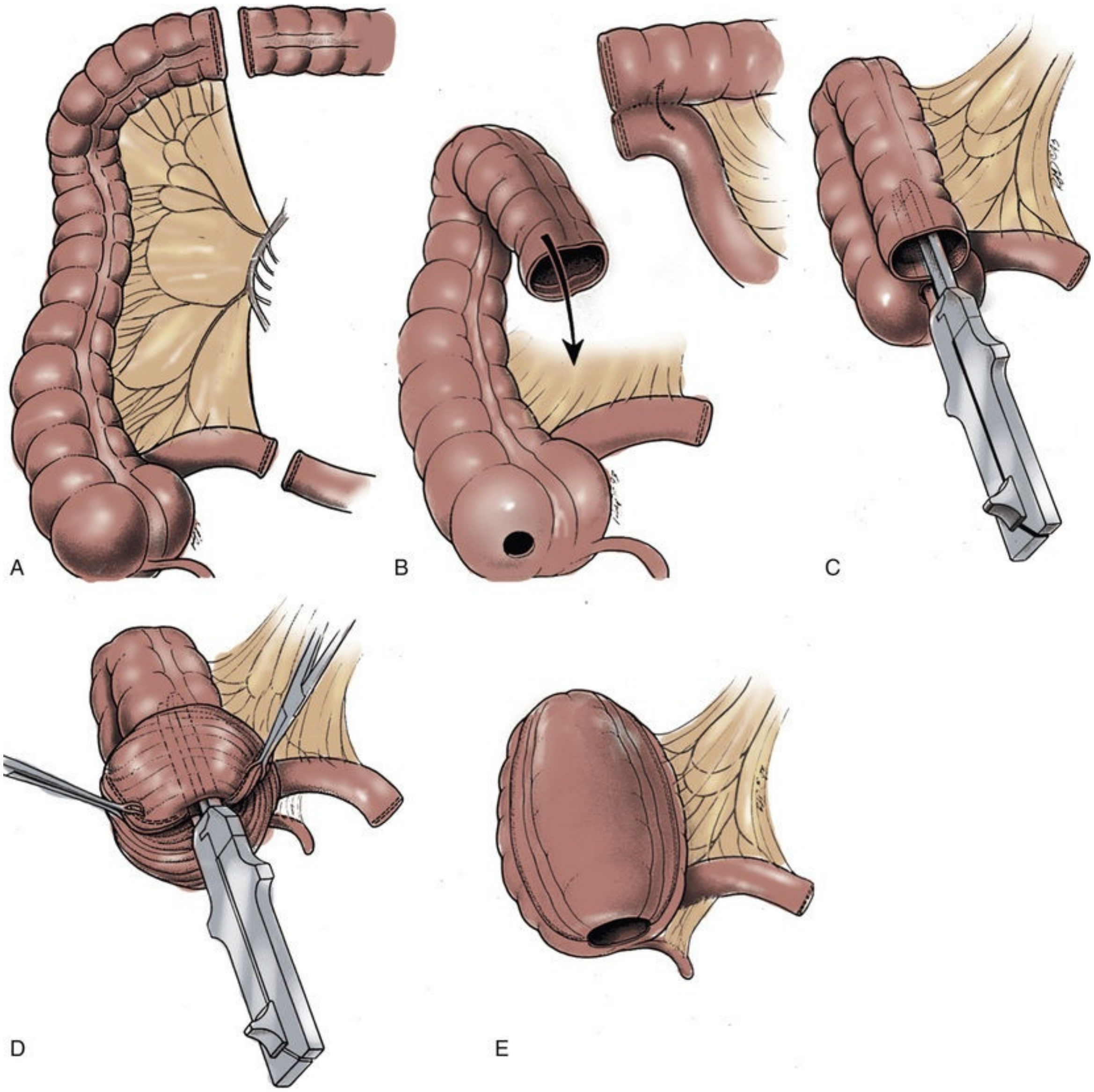

FIG. 140.17 (A) Isolation of colon and blood supply using metal gastrointestinal anastomosis staplers. (B) Opening created in cecum and open end of colon to fit absorbable stapler. Bowel continuity restored between colon and ileum. (C) Stapler activated along antimesenteric line and folded bowel. (D) Inversion of bowel required to continue staple applications. (E) Pouch inversion is complete. (From Olsson CA, Kirsch AJ, Whang MIS: Rapid construction of right colon pouch. *Curr Surg Tech Urol* 6:1–8, 1993.)

Once the generic right pouch has been fashioned, several options exist for ureteral anastomosis and formation of a sphincter mechanism. These maneuvers may be approached through the coalesced distal colon opening and cecostomy, which accesses the interior of the pouch (see Fig. 140.17E). The opening permits appropriate stent placement or inspection of a buttressed ileocecal valve. Any of the Mitrofanoff techniques described in conjunction with the Mainz I procedure can be employed. Likewise, the terminal ileum can be either stapled or plicated to create a continence mechanism. Once construction of a continence mechanism and ureteral anastomoses have been performed, the opening can be closed with a running 2-0 absorbable suture or the application of an absorbable TA stapler of appropriate length.

Continent diversion procedures commonly employ the right colon or the cecum and terminal ileum. The array of right colon pouches that can be facilitated by this technique include all of the reservoirs described previously. Reservoirs using terminal ileum and cecum such as the Penn pouch and the Mainz pouch can also be fashioned in this manner.

Stapled Sigmoid Reservoir

The same stapling maneuvers can be applied to create a reservoir constructed from the sigmoid colon (Olsson and Kirsch, 1995). A portion of the sigmoid and descending colon measuring approximately 35 cm is mobilized by incising the peritoneum along the white line of Toldt. Once mesenteric windows have been created, the segment of colon is isolated using metal GIA staplers (Fig. 140.18A). Restoration of bowel continuity is achieved with GIA, TA, or end-to-end anastomosis (EEA) staple devices.

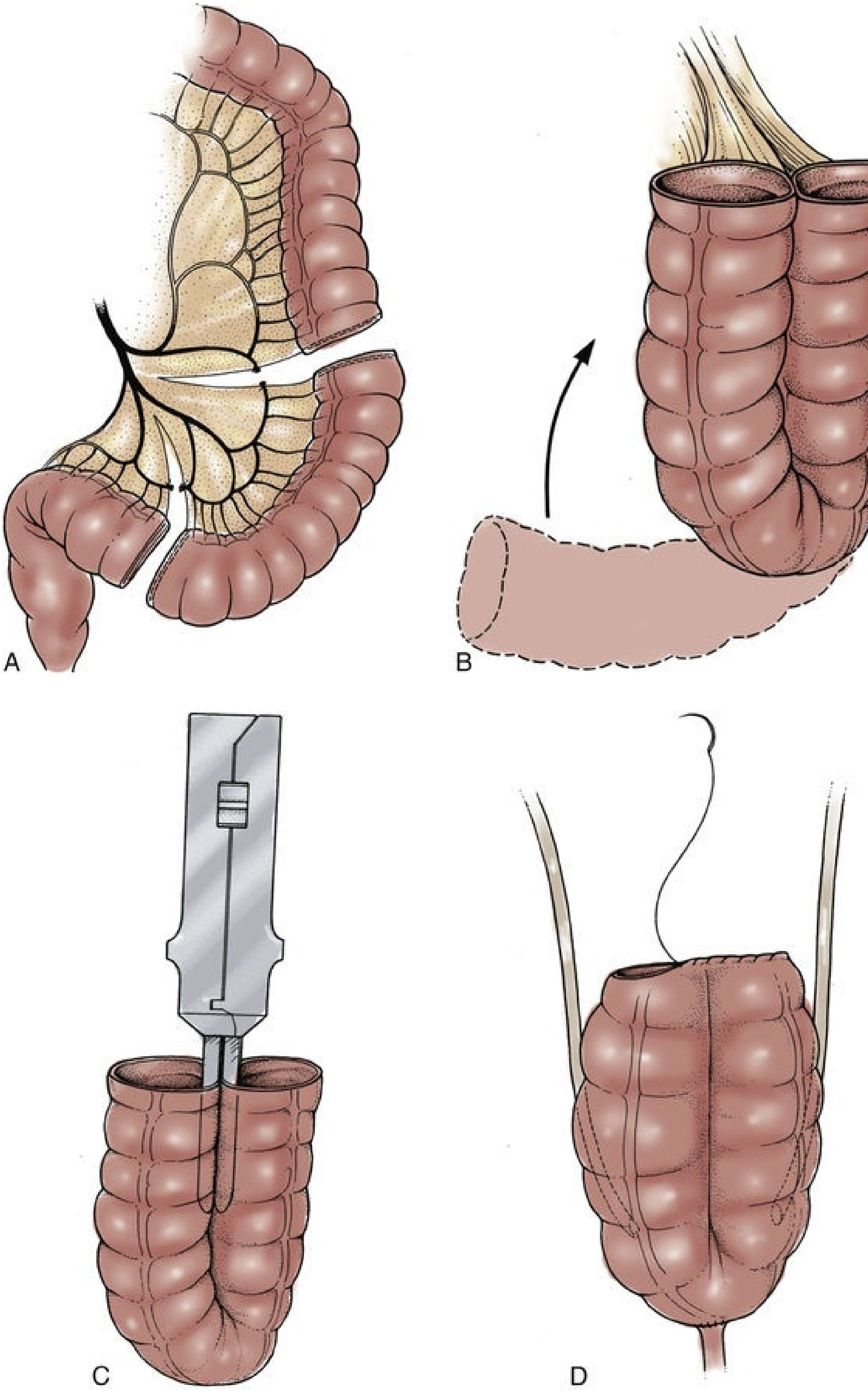
A
B
C
D

FIG. 140.18 (A) Isolation of colon and blood supply using metal gastrointestinal anastomosis staplers. (B) Sigmoid bowel folded in U shape. (C) Stapler fired along antimesenteric border of folded sigmoid. (D) Oversewing of superior open end completes pouch construction. (From Olsson CA, Kirsch AJ, Whang MIS: Rapid construction of right colon pouch. *Curr Surg Tech Urol* 6:1–8, 1993.)

Each of the metal stapled ends of the isolated colon is excised, and the bowel lumen is irrigated. The isolated sigmoid is folded on itself in a U configuration, aligning both open ends (Fig. 140.18B). The absorbable GIA stapler is inserted into the open bowel ends and fired along the antimesenteric line of the folded bowel (Fig. 140.18C). Following the procedure for bowel eversion as described earlier completes the reservoir. Again, usually two or three applications of the stapler are required to complete the pouch, cutting each staple line tip to avoid staple overlap.

After bowel reinversion, ureteral implants into the taenia can be carried out, using the residual colon opening to facilitate stent passage. These stents and a suprapubic tube are led through a separate stab wound in the pouch and brought through a lower abdominal wall stab incision. A continence mechanism employing one of the Mitrofanoff variations is then performed.

W-Stapled Reservoir

Montie et al. (1994) used the absorbable GIA stapler to construct ileal neobladders in patients undergoing cystoprostatectomy. A segment of ileum measuring 50 cm is divided with a standard metal GIA stapler 20 cm from the ileocecal valve. The terminal ends of each limb of the isolated ileal segment are closed with an absorbable TA-55 stapler, and the metal staple line is resected. The bowel is aligned in a W configuration, and an enterotomy is made 10 cm from each end (Fig. 140.19A). To facilitate closure of the enterotomy with a TA instrument (Fig. 140.19, *inset*), the enterotomy must be made midway between the mesentery and antimesenteric border. The absorbable GIA device is inserted through the enterotomy and is activated. This maneuver adjoins the two adjacent bowel segments. The enterotomy may be closed with the absorbable TA-55 instrument or running absorbable suture, completing the distal segment of the W. The middle and proximal segments are constructed similarly (Fig. 140.19B). Montie stresses that the segments of the W must be offset to avoid staple lines that overlap each other. Exceeding a 3- to 6-cm overlap may result in bowel ischemia.

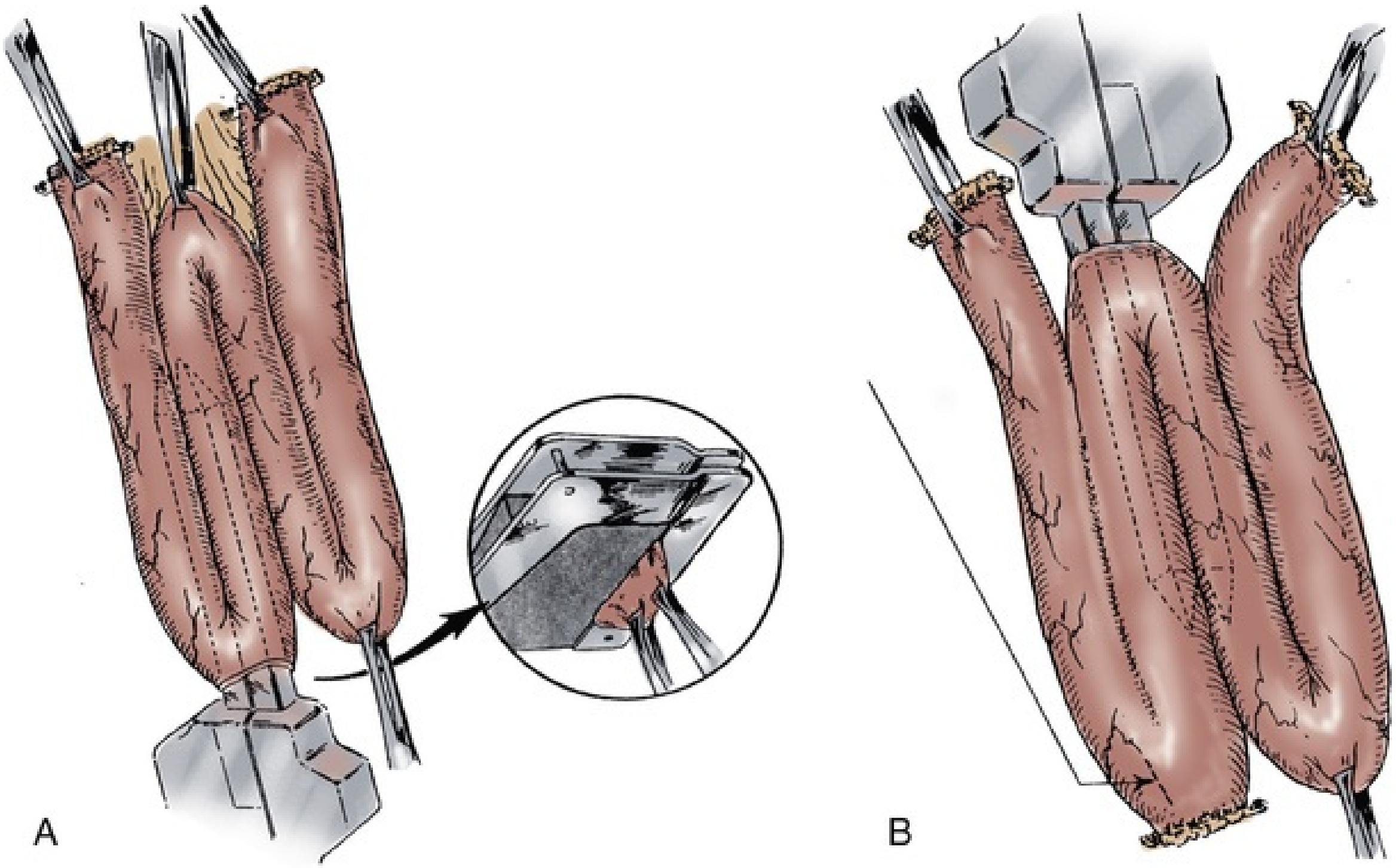

FIG. 140.19 (A) After closure of butt ends of reservoir with TA-55 stapler, enterotomy is made in dependent portion of first limb of W. Absorbable stapler is inserted through enterotomy and fired, creating common lumen between two adjacent limbs. *Arrow* indicates close-up of closure of enterotomy with TA-55 stapler. (B) In the middle limb of W, a stapler is placed through enterotomy at apex, and again, common lumen is created. Staple lines are not directly apposing for their entire distance to avoid ischemia between adjacent staple lines. *Arrow* indicates site of enterotomy where urethroileal anastomosis will be performed. (From Pontes JE: *Genitourinary oncologic pelvic surgery,* New York, 1993, John Wiley.)

Postoperative Care and Comments.

In the first 50 adult patients to undergo our absorbable stapling technique in right colon pouch construction, with at least 7 years of follow-up there have been no complications attributable to absorbable staples. Similar results have been reported by Rowland (1996). In the pediatric population, we have applied the absorbable stapler to continent urinary diversion, as well as to bladder augmentation (Hensle et al., 1995). In the first 18 children observed for up to 3 years, there have been no instances of pouch perforation or inadequate pouch capacity, and only one of the patients has developed a reservoir calculus.

Montie et al. (1994) used absorbable staplers to create W-stapled ileal neobladders in 25 patients. Ileal pouch construction was performed in approximately 20 minutes, and functional aspects were comparable with those of bowel reservoirs constructed by conventional suturing. Urodynamic evaluation at 6 months, however, documented a small-capacity reservoir requiring augmentation enterocystoplasty in 3 of 25 patients (12%). Montie et al. attributed this complication to either the size of the staples or reservoir fibrosis secondary to foreign body reaction. It is conceivable that a similar situation would arise when constructing a W-stapled T pouch.

We have used the absorbable stapler to construct large and small bowel reservoirs. In our experience, colonic pouches appear better suited for construction with the absorbable stapler because of their relatively larger lumen. **The introduction of stapling devices delivering still smaller staples and automatic staple line sealing devices may prevent the problems that occur when ileal pouches are constructed with current technology.**

Summary

In summary, continent urinary diversion is now an accepted part of the urologic surgical armamentarium. A wide array of surgical techniques exist to accomplish the desired goal of creating a continent, stoma-free, nonrefluxing pouch. There is a paucity of long-term quality-of-life studies comparing outcomes between continent cutaneous urinary diversion and ileal conduit urinary diversion. Surgeons contemplating these forms of urinary diversion should familiarize themselves with several of the techniques and the management of the most common complications.

Video 140.1 ▶ shows a bladder reconstruction procedure.

Key Points

- Because the ability to self-catheterize is essential to the patient undergoing continent diversion, the patient must be assessed for the ability to care for himself or herself.
- Patients with multiple sclerosis, quadriplegic individuals, and very frail or mentally impaired patients will at some point in their lives require the care of members of the family or a visiting nurse, and such patients are viewed as poor candidates for any form of continent diversion.
- Renal and hepatic function must be reviewed carefully in the patient selected for continent diversion. The reabsorption and recirculation of urinary constituents and other metabolites require that liver function be normal and that serum creatinine levels be in the normal range and preferably below the level of 1.8 mg/dL.
- When the ureters are directed into the fecal stream, routine colonoscopy should also be performed. There have been isolated reports of malignancy developing earlier, and all patients developing gross or microscopic hematuria should be fully evaluated.
- Many studies from throughout the world have suggested an improved psychosocial adjustment of patient undergoing continent urinary and fecal diversion compared with those patients with diversions requiring collecting appliances.

- Four general techniques have been employed to create a dependable, catheterizable continence zone. For right colon pouches, appendiceal techniques, pseudoappendiceal tubes fashioned from ileum or right colon, and ileocecal valve plication are adaptable. Appendiceal tunneling techniques are the simplest of all to perform in that they use established surgical techniques that are already in the urologic armamentarium.
- The second major type of continence mechanism used in right colon pouches is the tapered and/or imbricated terminal ileum and ileocecal valve. However, some patients have developed rather striking diarrhea and steatorrhea after the loss of the ileocecal valve. This may be particularly true in pediatric patients.
- The third surgical principle used in constructing the continence mechanism is the use of the intussuscepted nipple valve or the flap valve, which avoids the need for intussusception. The creation of nipple valves is the most technologically demanding of all the continence mechanisms and is associated with the highest complication rate.
- The fourth major technique of continence mechanism construction is the provision of a hydraulic valve, as in the Benchekroun nipple. In this procedure, a small bowel segment is isolated and a reversed intussusception is used to appose the surfaces of the small bowel.
- Pouch urinary retention represents a true emergency, and the patient must seek immediate attention so that catheterization and drainage by experienced personnel can be achieved promptly.
- Because all patients with catheterized pouches will have chronic bacteriuria, the problem of antibiotic management should be discussed. Most authors would suggest that bacteriuria in the absence of symptomatology does not warrant antibiotic treatment.
- The concept of using the buttressed ileocecal valve as a dependable continence mechanism that can withstand the trauma of intermittent catheterization was first reported from Indiana University by Rowland and Mitchell (Rowland et al., 1987).
- The Indiana pouch remains one of the most reliable of all catheterizable reservoirs. It is among the easiest to construct, and it has very low short-term and long-term complications.
- The use of absorbable staplers has substantially reduced the time required to fashion bowel reservoirs and has demonstrated short-term and long-term

reliability with respect to reservoir integrity and volume.

- Robotic technology has allowed for an increasing number of continent cutaneous urinary diversions to be achieved in a minimally invasive fashion. However, given the complex nature of these diversions, the benefits over an open approach may be limited.

Suggested Readings

Benson MC, Slawin KM, Wechsler MH, et al. Analysis of continent versus standard urinary diversion. *Br J Urol*. 1992;69:156–162.

Bonney WW, Robinson RA. Absorbable staples in continent ileal urinary pouch. *Urology*. 1990;3:57–62.

Boyd SD, Feinberg SM, Skinner DG, et al. Quality of life survey of urinary diversion patients: comparison of ileal conduits versus continent Kock ileal reservoirs. *J Urol*. 1987;138:1386–1389.

Gerharz EW, Kohl U, Weingartner K, et al. Complications related to different continence mechanisms in ileocecal reservoirs. *J Urol*. 1997;158:1709–1713.

Goodwin WE, Turner RD, Winter CC. Results of ileocystoplasty. *J Urol*. 1958;80:461–466.

Hardt J, Filipas D, Hohenfellner R, et al. Quality of life in patients with bladder carcinoma after cystectomy: first results of a prospective study. *Qual Life Res*. 2000;9:1–12.

McGuire MS, Rimaldi G, Grotas J, et al. The type of urinary diversion after radical cystectomy significantly impacts on the patient's quality of life. *Ann Surg Oncol*. 2000;7:4–8.

Olsson CA, Kirsch AJ, Whang M. Rapid construction of right colon pouch. *Curr Surg Tech Urol*. 1993;6:1–8.

Rowland RG, Mitchell ME, Bihrle R, et al. Indiana continent urinary reservoir. *J Urol*. 1987;137:1136–1139.

Stein JP, Lieskovsky G, Ginsberg DA, et al. The T pouch: an orthotopic ileal neobladder incorporating a serosal lined ileal antireflux technique. *J Urol*. 1998;159:1836–1842.

Stein R, Matani Y, Doi Y, et al. Continent urinary diversion using the Mainz Pouch I technique—ten years later. *J Urol*. 1995;153:251A.

Sumfest JM, Burns MW, Mitchell ME. The Mitrofanoff principle in urinary reconstruction. *J Urol*. 1993;150:1875–1878.

Thüroff JW, Alken P, Riedmiller H, et al. 100 cases of Mainz pouch: continuing experience and evolution. *J Urol*. 1988;140:283–288.

References

Abol-Enein HC, Ghoneim MA. A novel uretero-ileal reimplantation technique: the serous lined extramural tunnel: a preliminary report. *J Urol*. 1994;151:1193–1197.

Abol-Enein HC, Ghoneim MA. Optimization of uretero-intestinal anastomosis in urinary diversion: an experimental study in dogs: III. A new antireflux technique for ureteroileal anastomosis: a serous lined extramural tunnel. *Urol Res*. 1993;21:135–140.

Adams MC, Mitchell ME, Rink RC. Gastrocystoplasty: an alternative solution to the problem of urological reconstruction in the severely compromised patient. *J Urol*. 1988;140:1152–1156.

Alcini E, Racioppi M, D'Addessi A, et al. Refluxes in orthotopic neobladders: can the ileocecal sphincter be considered an adequate antireflux mechanism? *Urology*. 1994;44:38–45.

Ambrose SS. Ureterosigmoidostomy. Glenn JF. *Urologic surgery*. JB Lippincott: Philadelphia; 1983:511–520.

Ashken MH. Urinary cecal reservoir. King LR, Stone AR, Webster GD. *Bladder reconstruction and continent diversion*. Year Book: Chicago; 1987:238.

Askanazi J, Hensle TW, Starker P, et al. Effect of immediate postoperative nutritional support on length of hospitalization. *J Urol*. 1985;134:1032–1036.

Austen M, Kalble T. Secondary malignancies in different forms of urinary diversion using isolated gut. *J Urol*. 2004;172:831–838.

Austin PF, DeLeary G, Homsy YL, et al. Long-term metabolic advantages of a gastrointestinal composite urinary reservoir. *J Urol*. 1997;158:1704–1708.

Bastian PJ, Albers P, Hanitzsch H, et al. Health-related quality-of-life following modified ureterosigmoidostomy (Mainz Pouch II) as continent urinary diversion. *Eur Urol*. 2004;46:591–597.

Bejany DE, Politano VA. Stapled and nonstapled tapered distal ileum for construction of a continent colonic urinary reservoir. *J Urol*. 1988;140:491–494.

Benchekroun A. The ileocecal continent bladder. King LR, Stone AR, Webster GD. *Bladder reconstruction and continent urinary diversion*. Year Book: Chicago; 1987:224–237.

Benson MC, Sawczuk IS, Hensle TW, et al. Modified Indiana University continent diversion. *Curr Surg Tech Urol*. 1988;1:1–8.

Benson MC, Slawin KM, Wechsler MH, et al. Analysis of continent versus standard urinary diversion. *Br J Urol*. 1992;69:156–162.

Bihrle R. The Indiana pouch continent urinary reservoir. *Urol Clin North Am*. 1997;24:773–779.

Bissada NK, Morcos RR, Morgan WM, et al. Ureterosigmoidostomy: is it a viable procedure in the age of continent urinary diversion and bladder substitution? *J Urol*. 1995;153:1429–1431.

Bissada NK. Characteristics of the in-situ appendix as a continent catheterization stoma for continent urinary diversion in adults. *J Urol*. 1993;150:151–152.

Bissada NK. Favorable experience with a simple technique to create a concealed umbilical stoma. *J Urol*. 1998;159:1174–1175.

Bjerre BD, Johansen C, Steven K. Health-related quality of life after cystectomy: bladder substitution compared with ileal conduit diversion: a questionnaire survey. *Br J Urol*. 1995;75:200–205.

Bochner BH, Stein JP, Ginsberg DA, et al. A serous-lined antireflux valve: in vivo fluorourodynamic evaluation of antireflux continence mechanism. *J Urol*. 1988;160:112–115.

Bonney WW, Robinson RA. Absorbable staples in continent ileal urinary pouch. *Urology*. 1990;3:57–62.

Boyd SD, Feinberg SM, Skinner DG, et al. Quality of life survey of urinary diversion patients: comparison of ileal conduits versus continent Kock ileal reservoirs. *J Urol*. 1987;138:1386–1389.

Burger R, Wammack R, Fisch M, et al. The appendix as a continence mechanism. *Eur Urol*. 1992;22:255–262.

Burns MW, Mitchell ME. Tips on constructing the Mitrofanoff appendiceal stoma. *Contemp Urol*. 1990;10–12.

Carr MC, Mitchell ME. Continent gastric pouch. *World J Urol*. 1996;14:112–116.

Carroll PR, Presti JC Jr, McAninch JW, et al. Functional characteristics of the continent ileocecal urinary reservoir: mechanisms of urinary continence. *J Urol*. 1989;142(4):1032–1036.

Carroll PR, Presti JC Jr. Comparison of plicated and stapled continent ileocecal stoma. *Urology*. 1992;40:107–109.

Culp DA. Commentary: Heitz-Boyer-Havelacque procedure: not the procedure of choice. Whitehead ED, Leiter E. *Current operative urology*. ed 2. Harper and Row: Philadelphia; 1984:782–783.

DeGer S, Peters R, Roigas J, et al. Laparoscopic radical cystectomy with continent urinary diversion (rectosigmoid pouch) performed completely intracorporeally: an intermediate functional and oncologic analysis. *Urology*. 2004;64(5):935–939.

Desai MM, Simone G, de Castro Abreu AL, et al. Robotic intracorporeal continent cutaneous diversion. *J Urol*. 2017;198:436–444.

Duckett JW, Gazak JM. Complications of ureterosigmoidostomy. *Urol Clin North Am*. 1983;10:473–481.

Duckett JW, Snyder IIIHM. Use of the Mitrofanoff principle in urinary reconstruction. *Urol Clin North Am*. 1986;13:271–274.

El-Mekresh MM, Hafez AT, Abol-Enein H, et al. Double folded rectosigmoid bladder with a new ureterocolic antireflux technique. *J Urol*. 1997;157:2085–2089.

Filipas D, Egle UT, Budenbender C, et al. Quality of life and health in patients with urinary diversion: a comparison of incontinent versus continent urinary diversion. *Eur Urol*. 1997;32:23–29.

Filmer RB, Spencer JR. Malignancies in bladder augmentations and intestinal conduits. *J Urol*. 1990;143:671–678.

Fisch M, Hohenfellner R. Der sigma rektum pouch: eine modifikation der harnleiterdarm implantation. *Aktuelle Urol*. 1991;22 [Operative Techniken].

Fisch M, Wammack R, Hohenfellner R. The sigma-rectum pouch (Mainz pouch II). *World J Urol*. 1996;14:68–72.

Gerharz EW, Kohl U, Weingartner K, et al. Complications related to different continence mechanisms in ileocecal reservoirs. *J Urol*. 1997;158:1709–1713.

Gerharz EW, Mansson A, Hunt S, et al. Quality of life after cystectomy and urinary diversion: an evidence based analysis. *J Urol*. 2005;174:1729–1736.

Gilchrist RK, Merricks JW, Hamlin HH, et al. Construction of a substitute bladder and urethra. *Surg Gynecol Obstet*. 1950;90:752–760.

Gitlin JS, Wu XR, Sun TT, et al. New concepts of histological changes in experimental augmentation cystoplasty: insights into the development of neoplastic transformation at the enterovesical and gastrovesical anastomosis. *J Urol*.

1999;162:1096–1100.

Goh AC, Aghazadeh MA, Krasnow RE, et al. Robotic intracorporeal continent cutaneous urinary diversion: primary description. *J Endourol*. 2015;29:1217–1220.

Golomb J, Klutke CG, Lewin KJ, et al. Bladder neoplasms associated with augmentation cystoplasty: report of 2 cases and literature review. *J Urol*. 1989;142:377–380.

Goodwin WE, Turner RD, Winter CC. Results of ileocystoplasty. *J Urol*. 1958;80:461–466.

Gosalbez R, Padron OF, Singla AK, et al. The gastric augment single pedicle tube catheterizable stoma: a useful adjunct to reconstruction of the urinary tract. *J Urol*. 1994;152:2005–2007.

Hafez AT, El-Mekresh MM, Abol-Enein H, et al. *Double folded rectosigmoid pouch with a novel ureterocolic reimplantation technique*. [Continent urinary reconstruction, abstract 118, p 151. Presented at: Second International Meeting] 1995 [Jun 28-30; Mainz, Germany].

Hampel N, Hasan ST, Marshall C, et al. Continent urinary diversion using the Mitrofanoff principle. *Br J Urol*. 1995;74:454–459.

Hardt J, Filipas D, Hohenfellner R, et al. Quality of life in patients with bladder carcinoma after cystectomy: first results of a prospective study. *Qual Life Res*. 2000;9:1–12.

Hart S, Skinner EC, Meyerowitz BE, et al. Quality of life after radical cystectomy for bladder cancer in patients with an ileal conduit, or cutaneous or urethral Kock pouch. *J Urol*. 1999;162:77–81.

Hedgepeth RC, Gilbert SM, He C, et al. Body image and bladder cancer specific quality of life in patients with ileal conduit and neobladder urinary diversions. *Urology*. 2010;76:671–675.

Helal M, Pow-Sang J, Sanford E, et al. Direct (non-tunneled) ureterocolonic reimplantation in association with continent reservoirs. *J Urol*. 1993;150:835–837.

Hensle TW, Kirsch AJ, Olsson CA. *Bowel reservoirs created with absorbable staples in a pediatric population*. [Presented at; annual meeting of the American Academy of Pediatrics; 13-15 Oct] 1995 [San Francisco, CA].

Hensle TW. Nutritional support of the surgical patient. *Urol Clin North Am*. 1983;10:109.

Hohenfellner R, Black P, Leissner J, et al. Refluxing ureterointestinal anastomosis for continent cutaneous urinary diversion. *Urology*. 2002;168(3):1013–1067.

Holmes DG, Thrasher JB, Park GY, et al. Long-term complications related to the modified Indiana pouch. *Urology*. 2002;60(4):603–606.

Hubner WA, Pfluger H. Functional replacement of bladder and urethra after cystectomy for bladder cancer in a female patient. *J Urol*. 1995;153:1043–1046.

Kock NG, Ghoneim MA, Lycke KG, et al. Urinary diversion to the augmented and valved rectum: preliminary results with a novel surgical procedure. *J Urol*. 1988;140:1375–1379.

Kock NG, Nilson AE, Nilsson LO, et al. Urinary diversion via a continent ileal reservoir: clinical results in 12 patients. *J Urol*. 1982;128:469.

Kock NG. Ileostomy without external appliance: a survey of 25 patients provided with intestinal reservoir. *Ann Surg*. 1971;173:545.

Kristiansen P, Mansson W, Tyger J. Perforation of continent caecal reservoir for urine twice in one patient. *Scand J Urol Nephrol*. 1991;25:279–281.

Kristjansson A, Bajc M, Wallin L, et al. Renal function up to 16 years after conduit or continent urinary diversion: renal scarring and location of bacteriuria. *Br J Urol*. 1995;76:546–550.

Lampel A, Fisch M, Stein R, et al. Continent diversion with the Mainz pouch. *World J Urol*. 1996;14:85–91.

Lampel A, Hohenfellner M, Schultz-Lampel D, et al. In situ tunneled bowel flap tubes: two new techniques of a continent outlet for Mainz pouch cutaneous diversion. *J Urol*. 1995;153:308–315.

Lampel A, Hohenfellner M, Schultz-Lampel D, et al. Submucosal seromuscular tube and submucosal bowel flap tube: two new stoma techniques for Mainz pouch continent cutaneous urinary diversion. *J Urol*. 1995;153:305A.

Lampel A, Thüroff JW. Bowel-flap tubes for continent urinary diversion. *World J Urol*. 1998;16:235–241.

Large MC, Katz MH, Shikanov S, et al. Orthotopic neobladder versus Indiana pouch in women: a comparison of health related quality of life outcomes. *J Urol*. 2010;183(1):201–206.

Large MC, Kiriluk KJ, DeCastro GJ, et al. The impact of mechanical bowel preparation on postoperative complications for patients undergoing cystectomy and urinary diversion. *J Urol*. 2012;188(5):1801–1805.

Leadbetter GW Jr, Leadbetter WF. Ureteral re-implantation and bladder neck reconstruction: four and one-half years' experience. *J Am Med Assoc*. 1961;175:349.

LeDuc A, Camey M, Teillac P. An original antireflux ureteroileal implantation technique: long-term follow-up. *J Urol*. 1987;137:1156–1158.

Leong CH. Use of stomach for bladder replacement and urinary diversion. *Ann R Coll Surg Engl*. 1978;60:283–289.

Light JK, Scardino PT. Radical cystectomy with preservation of sexual and urinary function: use of the ileocolonic pouch ("Le Bag"). *Urol Clin North Am*. 1986;13:261–270.

Lockhart JL, Davies R, Cox C, et al. The gastroileal pouch: an alternative continent urinary reservoir for patients with short bowel, acidosis and/or extensive pelvic radiation. *J Urol*. 1993;150:46–51.

Lockhart JL. Remodeled right colon: an alternative urinary reservoir. *J Urol*. 1987;138:730–734.

Mansson A, Davidsson T, Hunt S, et al. The quality of life in men after radical cystectomy with a continent cutaneous diversion or orthotopic bladder substitution: is there a difference? *BJU Int*. 2002;90:386–390.

Mansson W, Colleen S, Forsberg L, et al. Renal function after urinary diversion: a study of continent caecal reservoir, ileal conduit, and colonic conduit. *Scand J Urol Nephrol*. 1984;18:307–315.

Mansson W. The continent cecal urinary reservoir. King LR, Stone AR, Webster GD. *Bladder reconstruction and continent urinary diversion*. Year Book: Chicago; 1987:209.

Marino G, Laudi M. Ileal T pouch as a urinary continent cutaneous diversion: clinical and urodynamic evaluation. *BJU Int*. 2002;90:47–50.

McGuire MS, Rimaldi G, Grotas J, et al. The type of urinary diversion after radical cystectomy significantly impacts on the patient's quality of life. *Ann Surg Oncol*. 2000;7:4–8.

Mills RD, Studer UE. Metabolic consequences of continent urinary diversion. *J Urol*. 1999;161:1057–1066.

Mitrofanoff P. Cystostomie continente trans-appendiculaire dans le traitement des vessies neurologiques. *Chir Pediatr*. 1980;21:297–305.

Montie JE, Pontes JE, Parulkar BG, et al. W-stapled ileal neobladder formed entirely with absorbable staples. *J Urol*. 1994;151:1188–1192.

Montie JE, Pontes JE, Powell IJ. Orthotopic ileal neobladder after cystectomy: comparison of hand-sewn vs. absorbable staples for reservoir formation. *J Urol*. 1995;153:305A.

Montie JE. Ileal conduit diversion after radical cystectomy.

Urology. 1997;49:659–662.

Navon JD, Wong AK, Weinberg AC, et al. A comparative study of postoperative complications associated with the modified Indiana pouch in elderly versus younger patients. *J Urol*. 1995;154:1325–1328.

Nguyen DH, Bain MA, Salmonson KL, et al. The syndrome of dysuria and hematuria in pediatric urinary reconstruction with stomach. *J Urol*. 1993;150:707–709.

Nieuwenhuijzen JA, de Vries RR, Bex A, et al. Urinary diversions after cystectomy: the association of clinical factors, complications and functional results of four different diversions. *Eur Urol*. 2008;53(4):834–842.

Oesterling JE, Gearhart JP. Utilization of ileal conduit in construction of continent urinary reservoir. *Urology*. 1990;36:15–19.

Olsson CA, Kirsch AJ, Whang M. Rapid construction of right colon pouch. *Curr Surg Tech Urol*. 1993;6:1–8.

Olsson CA, Kirsch AJ. Stapled sigmoid neo-bladder. *Curr Surg Tech Urol*. 1995;8:1–8.

Olsson CA. Kock continent ileal reservoir for urinary diversion. King LR, Stone AR, Webster GD. *Bladder reconstruction and continent urinary diversion*. Year Book: Chicago; 1987:291–310.

Pahernik S, Stein R, Hohenfellner M, et al. Conversion from colonic or ileal conduit to continent cutaneous urinary diversion. *J Urol*. 2004;171:2293–2297.

Pantuck AJ, Han KR, Perrotti M, et al. Ureteroenteric anastomosis in continent urinary diversion: long-term results and complications of direct versus nonrefluxing techniques. *J Urol*. 2000;163:450–455.

Pantuck AJ, Weiss RE, Cummings KB. Routine stentograms are not necessary before stent removal following radical cystectomy. *J Urol*. 1997;158(3 Pt 1):772–775.

Piser JA, Mitchell ME, Kulb TB, et al. Gastrocystoplasty and colocystoplasty in canines: the metabolic consequences of acute saline and acid loading. *J Urol*. 1987;138:1009.

Porter MP, Penson DF. Health related quality of life after radical cystectomy and urinary diversion for bladder cancer: a systematic review and critical analysis of the literature. *J Urol*. 2005;173(4):1318–1322.

Pow-Sang JM, Helal M, Figueroa E, et al. Conversion from external appliance wearing or internal urinary diversion to a continent urinary reservoir (Florida Pouch I and II): surgical technique, indications and complications. *J Urol*. 1992;147:356–360.

Raynor MC, Lavien G, Nielsen M, et al. Elimination of preoperative mechanical bowel preparation in patients undergoing cystectomy and urinary diversion. *Urol Oncol*. 2013;31(1):32–35.

Riedmiller H, Steinbach F, Thüroff J, et al. *Continent appendix stoma—a modification of the Mainz pouch technique*. [Presented at; the 9th Congress of the European Association of Urology (EAU), Amsterdam, June] 1990.

Rink M, Kluth L, Eichelberg E, et al. Continent catheterizable pouches for urinary diversion. *Eur Urol Suppl*. 2010;9:754–762.

Roth B, Birkhäuser FD, Zehnder P, et al. Parenteral nutrition does not improve postoperative recovery from radical cystectomy: results of a prospective randomised trial. *Eur Urol*. 2013;63(3):475–482.

Rowland RG, Kropp BP. Evolution of the Indiana continent urinary reservoir. *J Urol*. 1994;152:2247–2251.

Rowland RG, Mitchell ME, Bihrle R, et al. Indiana continent urinary reservoir. *J Urol*. 1987;137:1136–1139.

Rowland RG, Mitchell ME, Bihrle R. The cecoileal continent urinary reservoir. *World J Urol*. 1985;3:185–190.

Rowland RG. Present experience with the Indiana pouch. *World J Urol*. 1996;14:92–98.

Rudick J, Schonholz S, Weber HN. The gastric bladder: a continent reservoir for urinary diversion. *Surgery*. 1977;82:1.

Salter MJ. Aspects of sexuality for patients with stomas and continent pouches. *J ET Nurs*. 1992;19:126–130.

Salter MJ. What are the differences in body image between patients with a conventional stoma compared with those who have had a conventional stoma followed by a continent pouch? *J Adv Nurs*. 1992;17:841–848.

Sanda MG, Jeffs RD, Gearhart JP. Evolution of outcomes with the ileal hydraulic valve continent diversion: re-evaluation of the Benchekroun catheterizable stoma. *World J Urol*. 1996;14:108–111.

Seifert HH, Obaje A, Müller-Mattheis V, et al. Clinical and functional results after continent cutaneous urinary diversion with the ileal double-T-pouch. *Urol Int*. 2008;80:8–12.

Shokeir AA, Shamaa M, El-Mekresh MM, et al. Late malignancy in bowel segments exposed to urine without fecal stream. *Urology*. 1995;46:657–661.

Simoneau AR, Skinner DG. Ileo-anal reservoir. *J Urol*. 1995;153:305A.

Sinaiko E. Artificial bladder segment of stomach and study of effect of urine on gastric secretion. *Surg Gynecol Obstet*. 1956;102:433.

Skinner DG, Boyd S, Lieskovsky G. Clinical experience with the Kock continent ileal reservoir for urinary diversion. *J Urol*. 1984;132:1101–1107.

Skinner DG, Lieskovsky G, Boyd S. Continent urinary diversion. *J Urol*. 1989;141:1323–1327.

Skinner DG, Lieskovsky G, Skinner E, et al. Urinary diversion. *Curr Prob Surg*. 1987;24:401–471.

Skinner DG. The Kock pouch for continent urinary reconstruction focusing on the afferent segment and the reservoir. *Scand J Urol Nephrol*. 1992;142:77–78.

Somani BK, MacLennan SJ, N'Dow J. Quality of life with urinary diversion. *Eur Urol Suppl*. 2010;9:763–771.

Spirnak JP, Caldamone AA. Ureterosigmoidostomy. *Urol Clin North Am*. 1986;13:285–294.

Stein JP, Buscarini M, DeFilippo RE, et al. Application of the T pouch as an ileo-anal reservoir. *J Urol*. 1999;162:2052–2053.

Stein JP, Lieskovsky G, Ginsberg DA, et al. The T pouch: an orthotopic ileal neobladder incorporating a serosal lined ileal antireflux technique. *J Urol*. 1998;159:1836–1842.

Stein JP, Lieskovsky G, Skinner DG. The double T pouch: a novel continent cutaneous ileal reservoir. *J Urol*. 1999;161(Suppl 253A):67.

Stein JP, Skinner DG. T-mechanism applied to urinary diversion: the orthotopic T-pouch ileal neobladder and cutaneous double-T-pouch ileal reservoir. *Tech Urol*. 2001;7:209–222.

Stein R, Matani Y, Doi Y, et al. Continent urinary diversion using the Mainz Pouch I technique—ten years later. *J Urol*. 1995;153:251A.

Sumfest JM, Burns MW, Mitchell ME. The Mitrofanoff principle in urinary reconstruction. *J Urol*. 1993;150:1875–1878.

Suriano F, Gallucci M, Flammia GP, et al. Bacteriuria in patients with an orthotopic ileal neobladder: urinary tract infection or asymptomatic bacteriuria? *BJU Int*. 2008;101:1576–1579.

Terai A, Arai Y, Kawakita M, et al. Effect of urinary intestinal diversion urinary risk factors for urolithiasis. *J Urol*. 1995;153:37–41.

Thompson ST, Kursh ED. Delayed spontaneous rupture of an ileocolonic neobladder. *J Urol*. 1992;148:1890–1891.

Thüroff JW, Alken P, Riedmiller H, et al. 100 cases of Mainz pouch: continuing experience and evolution. *J Urol*. 1988;140:283–288.

Thüroff JW, Alken P, Riedmiller H, et al. The Mainz pouch (mixed augmentation ileum ‘n cecum) for bladder augmentation and continent diversion. *World J Urol*. 1985;3:179–184.

Thüroff JW, Riedmiller H, Fisch M, et al. Mainz pouch continent cutaneous diversion. *BJU Int*. 2010;106(11):1830–1854.

Touma N, Spodek J, Kuan J, et al. Confirming routine stentograms after cystectomy is unnecessary. *Can Urol Assoc J*. 2007;1(2):103–105.

Türk I, Deger S, Winkelmann B, et al. Laparoscopic radical cystectomy with continent urinary diversion (rectal sigmoid pouch) performed completely intracorporeally: the initial 5 cases. *J Urol*. 2001;165(6 Pt 1):1863–1866.

Venn SN, Mundy AR. Continent urinary diversion using the Mainz-type ureterosigmoidostomy—a valuable salvage procedure. *Eur Urol*. 1999;36:247–251.

Watanabe K, Kato H, Misawa K, et al. Spontaneous perforation of an ileal neobladder. *Br J Urol*. 1994;73:460–461.

Webster C, Bukkapatnam R, Seigne JD, et al. Continent colonic urinary reservoir (Florida pouch): long-term surgical complications (greater than 11 years). *J Urol*. 2003;169:174–176.

Webster GD, King LR. Further commentary: cecal bladder. King LR, Stone AR, Webster GD. *Bladder reconstruction and continent urinary diversion*. Year Book: Chicago; 1987:206–208.

Wiesner C, Bonfig R, Stein R, et al. Continent cutaneous urinary diversion: long-term follow-up of more than 800 patients with ileocecal reservoirs. *World J Urol*.

2006;24:315–318.

Wiesner C, Pahernik S, Stein R, et al. Long-term follow-up of submucosal tunnel and serosa-lined extramural tunnel ureter implantation in ileocaecal continent cutaneous urinary diversion (Mainz pouch I). *BJU Int*. 2007;100:633–637.

Williams DF, Burkholder GV, Goodwin WE. Ureterosigmoidostomy: a 15-year experience. *J Urol*. 1969;101:168–170.

Williams DF. Commentary: the value of ureterosigmoidostomy. Whithead ED, Leiter E. *Current operative urology*. ed 2. Harper & Row: Philadelphia; 1984:742–744.

Woodhouse CR, Christofides M. Modified ureterosigmoidostomy (Mainz II)—technique and early results. *Br J Urol*. 1998;81:247–252.

Woodhouse CR, MacNeily AE. The Mitrofanoff principle: expanding upon a versatile technique. *Br J Urol*. 1994;74:447–453.

141

Orthotopic Urinary Diversion

Eila C. Skinner MD, Siamak Daneshmand MD

History of Orthotopic Urinary Diversion

Since the early 1900s, innovative surgeons have sought the best method to replace the original bladder when it must be removed because of either benign or malignant disease. The objective of bladder substitution is to allow volitional voiding through the urethra while eliminating the need for a cutaneous urinary stoma or intermittent catheterization.

Ureterosigmoidostomy is the oldest form of urinary diversion. The first reported urinary diversion into a segment of bowel was by Simon in 1852. He attempted a ureterosigmoidostomy in an exstrophy patient by bringing the ureters into the rectum with the use of needles and suture to create a fistula. Although the patient died of sepsis 12 months later, this marked the first reported attempt at some form of urinary diversion (Simon, 1852). Ureterosigmoidostomy continued to be utilized, and the rates of obstruction and ascending pyelonephritis were significantly reduced after introduction of an antireflux tunneled anastomosis of the ureter into the sigmoid colon (Goodwin et al., 1953; Leadbetter, 1951). However, long-term hyperchloremic acidosis, ureteral obstruction and pyelonephritis, and secondary malignant neoplasms arising at the ureteral implantation site were observed (Clarke and Leadbetter, 1955; Wear and Barquin, 1973). **In 1950, Bricker refined and popularized the ileal conduit form of urinary diversion, building on an original description by Zaayer in 1911**. The ileal conduit is a technically simple, reliable form of urinary diversion that continues to be the most common form of urinary diversion performed throughout the world today for patients undergoing cystectomy.

Long-term complications with the Bricker ileal conduit started to come to light in the 1970s. **Late complications such as skin and appliance problems, peristomal hernia, stomal stenosis, pyelonephritis, kidney stones, ureteral obstruction, and renal deterioration became more apparent with longer follow-up** (Amini and Djaladat, 2017; Kouba et al., 2007; Shimko et al., 2011; Sullivan et al., 1980). These clinical sequelae were thought to be related to the high-pressure reflux of infected urine. However, nonrefluxing colon conduits had similar complications (Morales and Golimbu, 1975).

One of the earliest continent cutaneous diversions in humans was described by Gilchrist et al. in 1950 incorporating the ileocecal valve as the continence mechanism and the distal ileum as a catheterizable stoma. However, this innovation attracted little attention at the time. In 1982, Kock et al. subsequently reintroduced the concept of a continent cutaneous diversion with a technique that was originally developed for a continent ileostomy. It incorporated an intussuscepted nipple valve to maintain continence and avoid reflux. In animal experiments and then in humans, **Kock demonstrated the importance of complete detubularization of the bowel segment and the double-folding technique that creates the most spherical shape possible** (Eckman et al., 1964; Kock et al., 1982). These concepts are the cornerstone of current cutaneous and orthotopic reservoirs. After Kock described his results in his initial 12 patients, Skinner began performing this diversion in adults undergoing cystectomy for bladder cancer in 1982 and by 1987 reported on his initial series of 250 patients (Skinner et al., 1987).

The biggest challenge in the development of continent cutaneous diversion has been the design of a reliable, durable, efferent continence mechanism that is easily catheterizable. Many different techniques have been described using large and small bowel and even stomach, with many ingenious continence mechanisms. However, stones, difficulty in catheterizing, peristomal hernia, and the development of stomal leakage are potential problems with all of them, often necessitating later surgical revision (Lieskovsky et al., 1987; Rowland, 1995).

The concept of orthotopic diversion began even before Kock's continent cutaneous diversion. Tizzoni and Poggi were the first to experiment in a dog, transplanting the ureters into an isolated loop of ileum interposed between the ureters and the urethra (Tizzoni and Poggi, 1888). The dog was reportedly continent and subsequently underwent three successful pregnancies before dying 30 months postoperatively. Lemoine is credited with performing the first orthotopic reconstruction in a human subject, converting a patient from a ureterosigmoidostomy to an orthotopic diversion by transposing a segment of sigmoid to the urethral stump (Lemoine, 1913).

In 1979, Camey and Le Duc reported their pioneering clinical experience with orthotopic substitution to the native urethra in male bladder cancer patients. The initial Camey diversion used an intact segment of ileum, resulting in a high-pressure reservoir and unacceptable continence (Lilien and Camey, 1984). Subsequently, the Camey II detubularized reservoir (Camey, 1990); Hautmann W-neobladder (Hautmann et al., 1988); “hemi-Kock” neobladder (Skinner et al., 1991); Studer pouch (Studer et al., 1989); extraserosal-lined ureteral tunnel (Abol-Enein and Ghoneim, 1993); T pouch (Stein et al., 1998b);

Padua pouch (Simone et al., 2018); stomach neobladder (Hauri, 1998); cecal and ileocecal neobladders (Light and Engelmann, 1986; Månsson and Colleen, 1990); and sigmoid reservoir (Reddy and Lange, 1987) have all been described. Many of these now have a large clinical experience with long-term follow-up demonstrating good renal preservation and continence results. Orthotopic diversion quickly surpassed continent cutaneous diversion in popularity for both patients and physicians, because it allows natural voiding, is simpler to construct, and is less likely to require revision surgery at a later date.

Initially these techniques were applied only to male patients because continence in women was believed to be dependent on an intact bladder neck, and there was concern about higher local recurrence with the retained urethra. In the mid 1990s, it was discovered through anatomic dissections and initial clinical experience that women could remain continent with a low-pressure reservoir and preservation of only the urethra itself (Borirakchanyavat et al., 1997; Colleselli et al., 1998; Stein et al., 1994b) and that this was oncologically safe (Stein et al., 1998a, Stenzl et al., 1995b)

The orthotopic neobladder most closely resembles the original bladder in both location and function. This form of lower urinary tract reconstruction avoids the need for an appliance, allows volitional voiding per urethra, seldom requires intermittent catheterization, and avoids the difficulties associated with the efferent continence mechanism of continent cutaneous reservoirs.

Orthotopic diversion rapidly gained popularity during the 1990s and 2000s. Beginning in 1986, the number of orthotopic bladder substitutions performed dramatically increased to more than 75% of cystectomies at some centers, and the number of conduits and continent cutaneous diversions declined. In eight academic centers internationally polled, each with a large cystectomy experience, there was a wide range in the rate of neobladder diversion in recent years, ranging from 6% to 51% (Hautmann et al., 2013, 2015). **However, the rate of orthotopic diversion as reported in the National Bladder Cancer Database has been declining over the past decade in the United States because of unclear reasons** (Fig. 141.1). **In a population-based study in the United States using the Nationwide Inpatient Sample database from 2001 to 2008, only 8% of cystectomy patients underwent continent urinary diversion, a rate that increased only to 20%, even for patients younger than 55 years of age** (Kim et al., 2013). In one high-volume academic center, the rate of neobladder dropped dramatically from 47% to 21% over only a 5-year period from 2000 to 2005 (Lowrance et al., 2009). A more recent study using the

NSQUIP dataset showed the rate of continent diversion decreased from 23% in 2011 to 15% in 2015 (Bachour et al., 2018). In Sweden, the national rate was 14% for all patients from 2003 to 2008 (Hautmann et al., 2013).

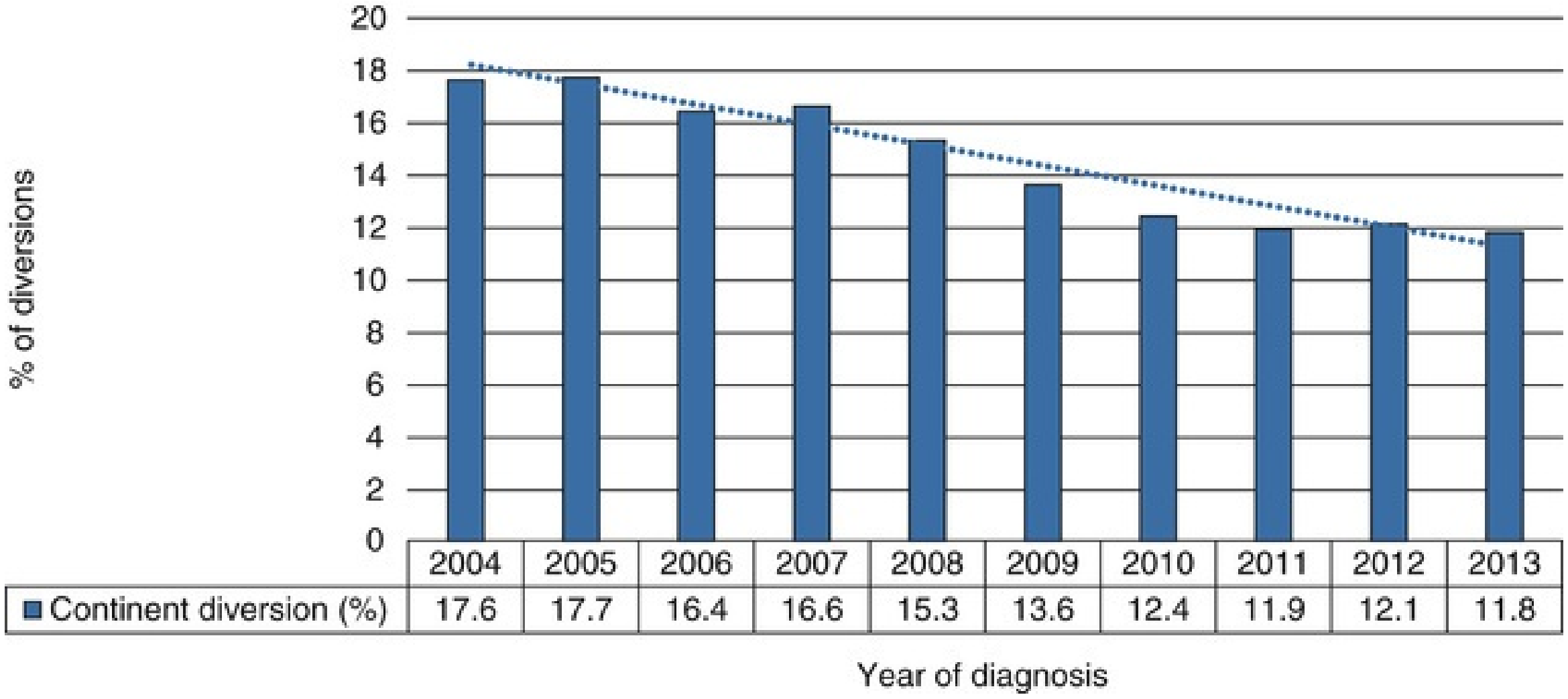

FIG. 141.1 Trend in urinary diversion in the United States from the National Cancer Database (from 27,170 patients diagnosed with primary bladder cancer undergoing radical cystectomy with urinary diversion between 2004 and 2013).

The reasons behind this generally low adoption of continent diversion and the wide variability among centers are complex. Surgeons have pointed out changes in their patient populations, such as increasing age, obesity, comorbidity, and socioeconomic challenges, and the fact that quality-of-life studies to date have not consistently shown an advantage for patients undergoing neobladder reconstruction. Chang et al. (2006) pointed out that trainees in most residency programs are exposed to few if any of these procedures. In addition, many cystectomies in the United States are performed by surgeons who do only a few such cases per year (Barbieri et al., 2007). In the United States, there is also a lack of any economic incentive for the surgeon to learn or perform a potentially more complex operation. Although many surgeons state that their patients chose ileal conduit over continent diversion, in fact, it is not difficult for the surgeon to present the options in a way that convinces the patient to choose the diversion the surgeon wants to do (Skinner, 2011). The adoption of robotic techniques may be further contributing to a move away from continent diversion, especially with a push to perform the entire diversion intracorporeally, because only a few centers have the expertise to do an entirely intracorporeal neobladder.

It is estimated that approximately 80% to 90% of male patients and 75% of female patients undergoing cystectomy are potential candidates for neobladder construction from a purely medical standpoint. In the series from Ulm, Germany, only 16% of the patients undergoing cystectomy had medical contraindications to orthotopic diversion, and another 2% refused (Hautmann et al., 2010). In another study examining the choice of urinary diversion in the context of a standardized preoperative counseling program, only 6% of patients who were eligible for a continent urinary diversion chose to undergo an ileal conduit for personal reasons (Ashley and Daneshmand, 2010). In the PROMETRICS study, the neobladder rate was 28.8% with use of neobladder associated with younger age, males, and fewer comorbidities (Schmid et al., 2015). AUA/SUO and EAU guidelines recommend that patients undergoing cystectomy should be counseled on all three options for urinary diversion (Chang et al., 2017, Witjes et al., 2016). It is incumbent on the surgeon who is counseling patients to understand the selection criteria, basic surgical techniques, and principles of perioperative management. Referral to a surgeon who performs orthotopic diversion is appropriate if the patient is eligible and interested and the treating physician is not experienced with this type of diversion.

Key Points: Historic Evolution of Orthotopic Urinary Diversion

- Urinary diversion has developed along three paths: conduit, continent cutaneous diversion, and most recently orthotopic diversion.
- Long-term complications of ileal and colon conduits include stomal stenosis, peristomal hernia, pyelonephritis, calculus formation, ureteral obstruction, and renal deterioration.
- The major long-term problems with continent cutaneous diversion relate to function of the efferent continence mechanism, and surgical revision is often required.
- The orthotopic neobladder allows for volitional voiding, avoids the need for an appliance, and only requires self-catheterization in a minority of patients.
- 80% to 90% of males and 75% of females undergoing cystectomy are potential candidates for orthotopic reconstruction.

Basic Principles of Continent Orthotopic Urinary Diversion

Three basic principles are common to all orthotopic reconstruction techniques and are key to a successful outcome. First, the patient must have an adequate external sphincter mechanism and nonobstructed urethra. Second, the reservoir must be sufficiently compliant to maintain a low pressure throughout the filling phase. This is best achieved by complete detubularization of the bowel segment and folding it to create a spherical shape. The sphere has the greatest internal volume for a given surface area. The double-folded technique of Kock and S- and W-shaped reservoirs all effectively eliminate the coordinated high-pressure contractions of the bowel wall, allowing the reservoir to maintain low internal pressure throughout the filling phase (Hinman, 1988; Kock et al., 1982).

Finally, the reservoir must have adequate volume to allow for reasonable voiding intervals. In general, this should be at least 300 to 500 mL once the pouch is mature. All bowel segments effectively stretch over time if there is adequate outflow resistance, though ileum stretches more than colon. The standard 44-cm length of ileum formed into a double-folding reservoir by the Kock technique (also used for both the Studer and T-pouch neobladders) has an initial capacity of less than 200 mL but within the first year stretches to hold 500 to 600 mL at low pressure (Studer et al., 2006). Fig. 141.2 shows a computed tomography (CT) scan of a mature spherical pouch at 1 year. A large initial volume is not necessary to ultimately achieve an adequate voiding volume.

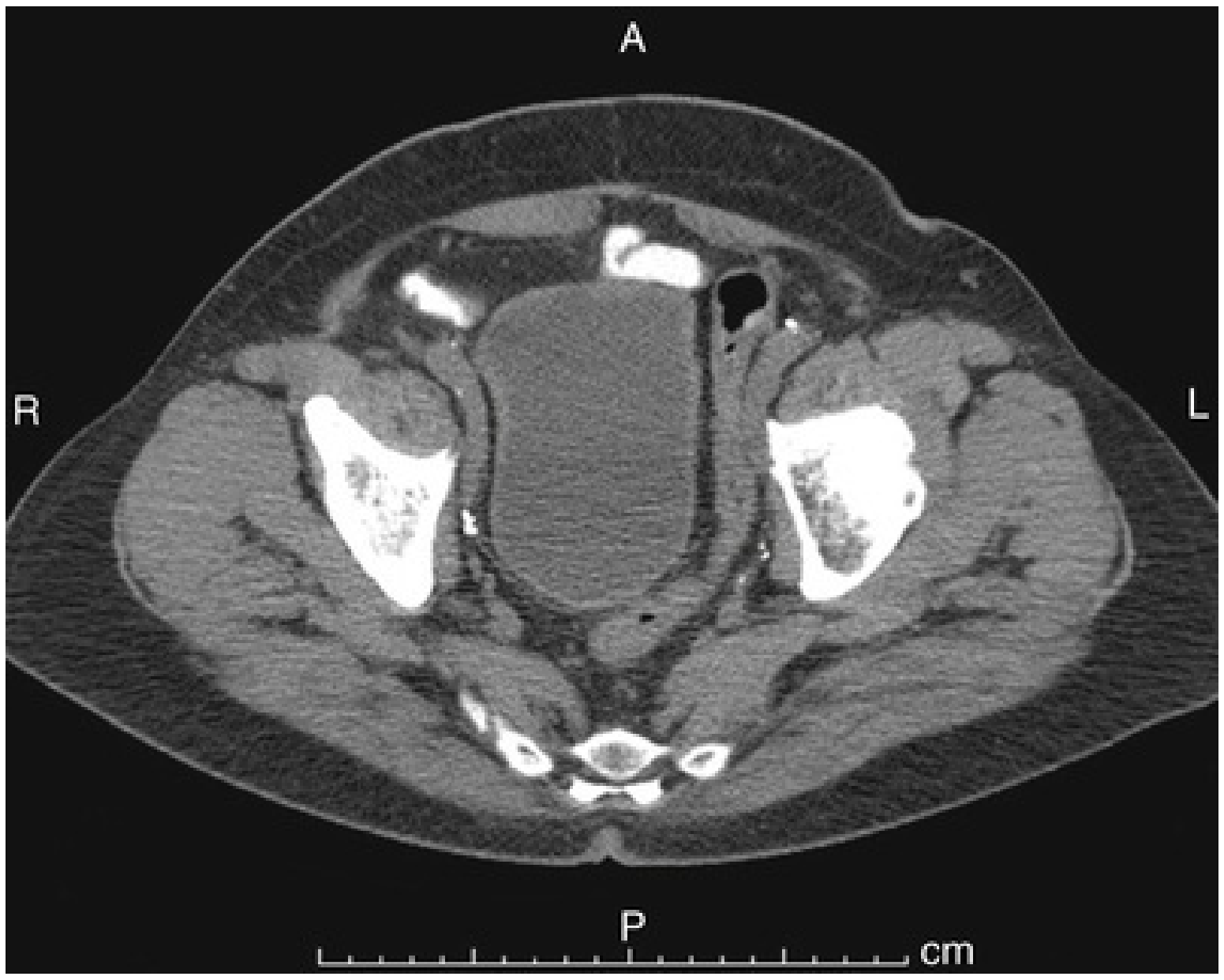

FIG. 141.2 Computed tomography scan of the pelvis after construction of an ileal neobladder (Studer pouch) showing the spheric shape achieved by 1 year.

Key Points: Three Basic Principles of Orthotopic Neobladder Construction

- Patient must have a healthy urethra and adequate external sphincter function to maintain continence.
- The bowel segment used for the reservoir should be completely detubularized and reconstructed into a spherical shape.
- The ultimate storage volume of the mature pouch should be at least 300 to 500 mL at low pressure.

Patient Selection

Nearly all patients who undergo radical cystectomy may be considered at least potential candidates for orthotopic urinary diversion. There are few absolute contraindications. However, a number of factors should be considered in counseling the individual patient as to the best diversion for him or her, and these can be divided into cancer-related factors and patient factors. An algorithm for patient selection is presented in Fig. 141.3.

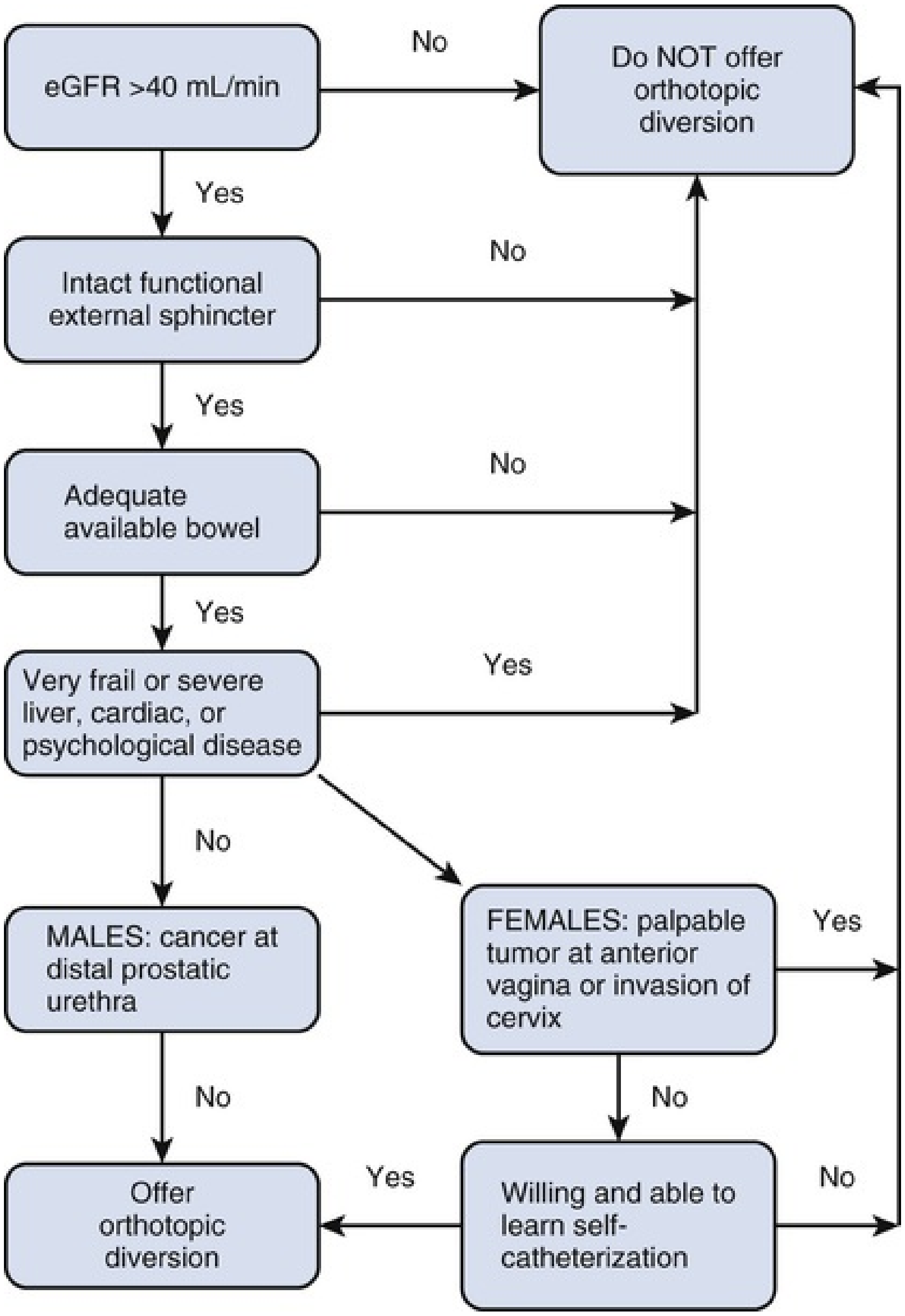
eGFR >40 mL/min
No
Do NOT offer orthotopic diversion
Yes
Intact functional external sphincter
No
Yes
Adequate available bowel
No
Yes
Very frail or severe liver, cardiac, or psychological disease
Yes
No
MALES: cancer at distal prostatic urethra
FEMALES: palpable tumor at anterior vagina or invasion of cervix
Yes
No
No
Offer orthotopic diversion
Yes
Willing and able to learn self-catheterization
No

FIG. 141.3 Algorithm for patient selection.

Oncologic Factors

Risk for Urethral Recurrence in Men

The primary oncologic contraindication for orthotopic diversion is the presence of urothelial carcinoma at the urethral margin on intraoperative frozen-section analysis at the time of cystectomy. In the male patient, involvement of the prostatic urethra is associated with a higher risk for subsequent urethral recurrence (Hardeman and Soloway, 1990; Moschini et al., 2017; Stein et al., 2005; Tobisu et al., 1991). In a pooled analysis of 25 series, Stenzl et al. (1995b) reported a total of 256 anterior urethral tumor recurrences in 3165 patients (8.1%) undergoing cystectomy for bladder cancer.

A retrospective review of 768 men who underwent cystectomy without urethrectomy at the University of Southern California with a 13-year median follow-up found that the overall risks for urethral recurrence were approximately 7% at 5 years and 9% at 10 years. Recurrences appeared at a median of 2 years after cystectomy (range 0.2 to 13 years). The risk was only 5% at 5 years in the 639 patients without prostate tumor involvement compared with 11% in the 129 men with prostate involvement. The extent of prostatic tumor involvement correlated with the risk for subsequent urethral recurrence. Carcinoma in situ (CIS) or mucosal and/or ductal involvement in the prostate carried a 12% 5-year estimated probability of urethral recurrence, compared with 18% for patients with invasion into the stroma. **Prostatic urethral involvement was a significant risk factor for urethral recurrence on multivariate analysis, and presence of CIS in the bladder or tumor multifocality was not** (Stein et al., 2005).

Most patients with prostatic stromal invasion also have positive nodes. Of 1550 males who underwent cystectomy from 1987 to 2008, there were 156 with prostate stromal invasion. All but 59 of these had pathologic node-positive disease, highlighting the importance of neoadjuvant therapy when prostatic stromal invasion is diagnosed preoperatively. The urethral recurrence rate for these 59 patients was 12% overall and only 6% in the 33 men who underwent orthotopic diversion. Thus urethral recurrence is relatively rare, even in those identified at higher risk who are long-term survivors (Djaladat et al., 2013).

Several other investigators have evaluated the presence of CIS in the bladder as a risk factor for urethral recurrence with variable results (Hardeman and

Soloway, 1990; Tobisu et al., 1991). Boorjian et al. (2011) reviewed more than 1500 patients (1230 males) with 13.5-year median follow-up. They found that tumor multifocality was a significant risk factor for urethral recurrence in addition to prostatic urethral involvement but not bladder CIS. Some evidence suggests that orthotopic diversion itself may provide some protection against urethral recurrence. Stein et al. (2005) reported on 397 patients who underwent neobladder diversion compared with 371 who did not. Median follow-up of both groups was long—10 years and 19 years—and patients were excluded if they underwent prophylactic urethrectomy. In patients without prostatic involvement (85% of the neobladder patients vs. 81% of the cutaneous diversion patients), the risk for urethral recurrence at 5 years was 3% versus 8%, respectively. In patients with prostatic stromal invasion, the 5-year risk for recurrence was 11% versus 24% for those with cutaneous diversion. Boorjian et al. (2011) found a similar protective effect of neobladder reconstruction in the Mayo Clinic series of over 1200 male patients with long follow-up. Both studies found that this effect persisted when other pathologic variables were controlled for. A recent meta-analysis of 14 studies including more than 6000 patients confirmed this protective effect, with a hazard ratio of 0.44 (CI 0.24 to 0.79) (Fahmy et al., 2018) for patients with orthotopic diversion. The reason for this observation is unclear, although there has been speculation that continued flow of urine, perhaps with changes in urinary characteristics caused by the interposed bowel, might contribute (Stein et al., 2005).

There is some controversy about the importance of attempting to identify prostatic urethral involvement preoperatively and what to recommend for those patients in whom prostatic involvement is identified. At the time of transurethral resection (TUR) of the primary bladder tumor, the surgeon may perform deep TUR biopsies of the prostate, preferably at the 5-o'clock and 7-o'clock positions lateral to the verumontanum. This should certainly be done if the mucosa of the prostate looks suspicious. Some authors have recommended this as a routine practice, before considering orthotopic diversion (Lerner and Shen, 2008; Sakamoto et al., 1993; Wood et al., 1989). However, others have challenged the reliability of preoperative transurethral prostatic biopsies. In a prospective series of 118 patients, Lebret et al. (1998) compared preoperative TUR biopsy of the prostatic urethra versus intraoperative frozen-section analysis at the time of cystectomy. They found that intraoperative frozen-section analysis was more accurate in predicting urethral recurrence than any preoperative parameter including preoperative prostate biopsy. In another series of 246 men, Donat et al. (2001) also found that preoperative biopsy did not accurately determine prostatic tumor involvement. Forty-three percent of patients with prostatic involvement on final pathology were missed on the TUR biopsy, and 12 of 36 patients with prostatic stromal invasion identified on TUR specimen had no residual prostatic involvement on the final cystectomy specimen. On the other hand, Von Rundstedt et al. (2016) did routine prostate urethral biopsies in 272 men and found that a negative biopsy (74% of the patients) had over 99% correlation with negative frozen section at cystectomy, perhaps obviating the need for the frozen section in that setting. The authors have not routinely recommended repeat TUR solely to rule out prostatic involvement before cystectomy. Other centers have adopted a similar philosophy with comparable clinical outcomes (Hautmann, 2003; Iselin et al., 1997).

In light of this, we have not routinely recommended repeat TUR solely to rule out prostatic involvement before cystectomy. Other centers have adopted a similar philosophy with comparable clinical outcomes (Hautmann, 2003; Iselin et al., 1997).

It has been the authors' practice to counsel patients with documented prostatic mucosal, ductal, or stromal invasion about the increased risk for urethral recurrence if the urethra is left in situ, and to help them weigh that risk against any perceived advantage of an orthotopic diversion. In general, those with prostatic stromal invasion are counseled to undergo neoadjuvant chemotherapy because of the high risk for nodal involvement at cystectomy (Djaladat et al., 2013). In those who are not candidates for neoadjuvant chemotherapy or who have persistent prostatic urethral involvement, at surgery a concomitant urethrectomy and cutaneous form of diversion are recommended. Close surveillance of the urethra is mandatory if a neobladder procedure is performed, with periodic urethral wash cytology and urethroscopy as indicated.

Risk for Urethral Recurrence in Women

In the past, urethrectomy was routinely performed at the time of radical cystectomy in women. With the acceptance of continent neobladder in men, a number of investigators began evaluating the feasibility of preservation of the urethra in women. It had been generally believed that the bladder neck was the primary continence mechanism in women, but initial clinical experience proved that one could achieve excellent continence by dividing the urethra just distal to the bladder neck (Stein et al., 1994b; Tanagho et al., 1966).

Two important pathologic studies were critical to the ultimate decision to offer urethral-preserving cystectomy and neobladder reconstruction to women with urothelial carcinoma. Stein et al. (1995) retrospectively reviewed the pathology from cystectomy specimens in 67 women who underwent cystectomy with urethrectomy for bladder cancer. Seventeen of these women (25%) had involvement of the bladder neck, and 9 of these (13% of the entire group) also had urethral involvement. All female patients with a negative bladder neck also had a negative urethra (no skip lesions), whereas approximately 50% of patients with a bladder neck tumor had concomitant urethral tumor involvement. **Risk factors for urethral involvement in this study included increased grade, stage, and lymph node involvement, but the presence of CIS did not predict urethral involvement. Vaginal wall involvement was a major risk factor for urethral involvement.** Although vaginal wall invasion was a relatively rare event (1%), all of these patients also had bladder neck involvement, and 50% had urethral extension.

Stenzl et al. (1995b) also studied the risk for synchronous or secondary urethral tumors with long-term follow-up in 356 women with bladder cancer of all stages. They found urethral involvement in only 2% of the patients, and it was always associated with bladder neck involvement. No correlation between urethral tumors and other pathologic factors such as CIS or tumor multifocality was found. **Both researchers concluded that the urethra can be safely preserved in selected female cystectomy patients provided that neither preoperative biopsy specimens of the bladder neck nor intraoperative frozen-section specimens of the proximal urethra demonstrate any tumor or severe atypia.** Several other studies confirmed that the most significant risk factor for urethral tumor involvement is tumor at the bladder neck (Chen et al., 1997; Coloby et al., 1994; De Paepe et al., 1990; Maralani et al., 1997).

Stein et al. (1998a) performed a prospective study to confirm the previously established pathologic risk factors in 72 women who had frozen-section analysis of the proximal urethra at cystectomy. Tumor involvement at the bladder neck and proximal urethra was found in 14 (19%) and 5 (7%) cystectomy specimens, respectively. **In all cases, intraoperative frozen section of the proximal urethra was correctly confirmed on final permanent section and accurately identified all patients with urethral involvement.** Stenzl et al. (1998) reported similar results.

Clinical follow-up data from the first 88 women who underwent orthotopic diversion at the University of Southern California showed that no urethral recurrences were observed with a 30-month median follow-up in this group

(Stein et al., 2002). Ali-El-Dein et al. (2004) prospectively evaluated 145 women undergoing cystectomy and orthotopic diversion. Two patients developed urethral recurrence. One had a primary squamous cell cancer of the bladder, and the other had urothelial carcinoma with CIS of the trigone. This series was updated with 180 patients and median follow-up of 57 months, with still only 2 documented urethral recurrences. There were no isolated vaginal wall recurrences. In this series, there was uterine or cervical invasion in only 1% of patients, which was suspected preoperatively in all patients based on imaging (Ali-El-Dein, 2009).

Locally Advanced Tumor Stage

Many urologists are hesitant to perform continent orthotopic diversion in patients with locally extensive disease. This is based on two factors: (1) concern about the possible impact of local recurrence on the neobladder itself and (2) a belief that these patients are doomed to suffer distant recurrence and have a shortened life expectancy and will not benefit from the neobladder.

However, Stein et al. (2001a) reported the clinical outcomes for 1054 patients who underwent radical cystectomy for bladder cancer with a median follow-up of more than 10 years. They observed an overall local pelvic recurrence rate of 7% for the entire group of patients. The risk for pelvic recurrence ranged from 6% with organ-confined, node-negative disease to 13% for patients with extravesical or node-positive disease. Nearly 50% of patients with extravesical tumor extension and 30% of patients with lymph node–positive disease were still alive without evidence of disease 5 years after cystectomy. These results suggest that local recurrence, even for patients demonstrating locally advanced or node-positive disease, is relatively infrequent and that a significant proportion of these patients will be long-term survivors and may benefit from continent diversion.

If local tumor recurrence does develop in patients with an orthotopic diversion, only a minority will have problems arise related to the urinary diversion itself. Hautmann and Simon (1999) evaluated this issue in 43 of 357 men who underwent radical cystectomy and ileal neobladder and developed local recurrence. Most of them (84%) had advanced disease (stage pT3a or higher) on final pathology at the time of cystectomy. A total of 17 patients (43%) had concomitant distant metastasis at the time of diagnosis of the local recurrence. Local recurrence interfered with the upper urinary tract in 24 patients (56%), the neobladder in 10 (23%), and the intestinal tract in 7 (16%); only 1 patient required removal of the neobladder because of an intestinal fistula. The authors concluded that **most patients could anticipate normal neobladder function, even in the presence of locally recurrent disease.** Similarly, Tefilli et al. (1999) found that 1 of 11 patients with orthotopic diversion who developed local recurrence required conversion to an ileal conduit because of invasion of the neobladder.

Based on this experience, the authors do not make decisions about appropriateness of orthotopic diversion based on presence of extravesical extension or positive nodal disease found at surgery. The exception would be a patient with grossly positive margins at the pubic bone or pelvic floor, which is a rare event.

Key Points: Oncologic Factors in Patient Selection

- The presence of CIS, multifocal tumor, or extravesical disease should not preclude orthotopic diversion if frozen section of the urethral margin is negative at surgery.
- The most significant risk factor for urethral tumor recurrence in men after orthotopic diversion is the presence of prostatic stromal invasion on final pathology.
- The most important risk factor in women for urethral tumor involvement is bladder neck or anterior vaginal wall involvement with cancer, best evaluated on bimanual examination under anesthesia.
- Intraoperative frozen-section analysis of the urethral margin accurately identifies urethral involvement in both men and women. Preoperative biopsy of the prostatic urethra or bladder neck is not mandatory.
- Local pelvic recurrence should occur in less than 10% of patients undergoing cystectomy and rarely interferes with the function of the neobladder.

Patient-Related Factors

A number of patient-related factors need to be considered when advising a patient about the best form of urinary diversion. These include the patient's general health and social circumstances, baseline renal function, presence of a healthy urethra and functioning sphincter muscle, manual dexterity, and

previous treatments including pelvic radiation, prostate surgery, or bowel resection. Perhaps equally important is the patient's personal preference and attitudes about the risk for incontinence, potential need to self-catheterize, and management of an external appliance. The relative importance of each of these factors in determining how to counsel an individual patient must be decided on a case-by-case basis. The patient and his or her family must have a realistic understanding of the pros and cons of each type of diversion before making a decision. There is a natural inclination for many patients to opt for an orthotopic reconstruction because it is the most “natural.” On the other hand, physicians may sway the discussion in favor of the simplest, quickest, and most familiar form of diversion for them to perform (Skinner, 2011). Patients must understand that problems can occur with each type of diversion, although the specific types of problems differ. An honest, informed discussion should take place, with the physician carefully explaining the various options along with the short- and long-term risks and benefits of each form of urinary diversion. It may also be helpful to have the patient talk with other patients who have undergone the various forms of urinary reconstruction. In general, patients with poor overall health, the frail elderly, and patients with high surgical risks, difficult social circumstances, or poor cognitive function are generally best managed with an ileal conduit (Daneshmand and Bartsch, 2011).

Age

Many authors have evaluated the success of continent diversion in elderly patients (Clark et al., 2005; Lance et al., 2001; Sogni et al., 2008). Although elderly patients undergoing orthotopic diversion may take longer to regain continence and have a higher rate of mild stress incontinence, ultimately older patients achieve daytime and nighttime continence rates similar to those for younger patients (Elmajian et al., 1996; Steven and Poulsen, 2000). **The clear consensus is that chronologic age alone is not a contraindication for continent diversion and that options should be considered for each patient on the basis of other factors** (Hautmann et al., 2013). Medical comorbidities; renal, cardiac, pulmonary, and cognitive function; and manual dexterity are all important factors that should be considered in the elderly, along with the patient's social support situation. A conduit may be easier for a caregiver to manage than an orthotopic diversion with the risk for incontinence and possible need for catheterization. However, an active, generally healthy, independent elderly patient may certainly be considered a reasonable candidate for orthotopic diversion depending on his or her wishes (Hugen and Daneshmand, 2016; Skinner, 2016).

Renal Function

One of the most important contraindications for continent neobladder reconstruction is compromised renal function. Urinary electrolytes including urea, potassium, and chloride are reabsorbed from the small bowel mucosa with excretion of sodium and bicarbonate, resulting in an increased acid load that must be processed by the kidneys. In patients with compromised renal function, hyperchloremic metabolic acidosis can develop along with worsening dehydration, uremia, nausea, and bone loss. The exact level of acceptable renal function for consideration for continent diversion is somewhat controversial. In one study looking at short-term change in renal function in 168 patients (124 continent diversion vs. 44 ileal conduit), the mean decrease in estimated glomerular filtration rate (eGFR) from before to after surgery in the two groups was 4.1 mL/min and 10.3 mL/min, respectively, at an 18.7-month median follow-up. There was no significant difference in this drop between those with an eGFR of 60 mL/min or higher and those with an eGFR between 40 and 59 mL/min (Winters et al., 2013). On the other hand, in a prospective study of 484 patients undergoing two types of neobladder procedures, preoperative lower eGFR was highly correlated with the risk for subsequent decline in eGFR of more than 10 mL/min by 3 years (Skinner et al., 2015). **As a general rule, a serum creatinine level of less than 1.7 to 2.2 mg/dL (150 to 200 µmol/L) or an eGFR greater than 35 to 40 mL/min/1.72 m^2 is recommended for patients considering continent diversion** (Hautmann, 2003; Hautmann et al., 2013).

However, decision making in an individual patient can at times be less clear-cut. Acute upper tract obstruction caused by the tumor often results in a transient rise in creatinine, which would be expected to improve after cystectomy and should be taken into account when counseling patients. There is no evidence that orthotopic diversion leads to worsening progressive renal dysfunction in patients with normal renal function before surgery compared with patients undergoing ileal conduit diversion (Eisenberg et al., 2014).

Body Habitus

Obesity is not a contraindication for orthotopic diversion, although placing the urethral sutures and working with the thick bowel mesentery may be challenging. **In fact, an obese patient may at times be better served with orthotopic diversion because of the difficulty constructing a functional conduit stoma with a very thick abdominal wall.**

Manual Dexterity and Willingness to Do Self-Catheterization

The need to do occasional or routine self-catheterization is reported in 10% to 20% of men and in up to 30% to 60% of women (see later). In general, it is difficult to predict which patients will require catheterization to empty, and retention can occur many years after the initial surgery. Thus **all patients considered for continent diversion should be willing and able to do self-catheterization. This is particularly important in women, in whom the potential need to do self-catheterization is higher and sometimes technically more difficult than in men.** Nearly all men are able to learn self-catheterization if necessary. Although most patients are hesitant about this potential requirement, it is rare for a patient to decide against an orthotopic diversion because of this once he or she has been educated about it.

Urethral Stricture Disease or External Sphincter Damage

Severe urethral stricture disease in men and women is a contraindication for orthotopic diversion. Poor external sphincter function in a man who is highly motivated to undergo orthotopic diversion may be managed with a concomitant or delayed artificial urinary sphincter device (Simma-Chiang et al., 2012). Similarly, a woman with significant stress incontinence might undergo a concomitant Burch or pubourethral sling procedure, although she is likely to be dependent on intermittent catheterization to drain properly if this is done.

Prior Pelvic Radiation

It is not uncommon for patients to require surgical management of invasive bladder cancer after previous failed radiation therapy or after radiation treatment of a prior pelvic malignancy. Many surgeons are hesitant to offer orthotopic diversion in this setting.

Patients with prior radiation are at increased risk for several complications, even with an ileal conduit diversion. Kim and Steinberg (2001) found an increased risk for surgical complications, especially those that required percutaneous or surgical intervention, in 23 patients undergoing cystectomy and conduit after radiation compared with 23 matched controls. Chang et al. (2004) evaluated outcomes of ileal conduits in 36 patients with prior radiation. They found that ureteroileal complications occurred in 9% of patients by 5 years and concluded that it was not necessary to use transverse colon for diversion in these patients.

The complications and ultimate functional outcome of orthotopic neobladders in patients with prior pelvic radiation have been evaluated by a number of authors. Bochner et al. (1998) described their early experience with salvage surgery and orthotopic bladder substitution after failed radical radiation therapy. A total of 18 patients who had prior radiation therapy (minimum dose, 60 Gy) for bladder or prostate cancer were evaluated. Operative characteristics, postoperative outcomes, and complications (related or unrelated to the urinary diversion) were found to be similar in irradiated and nonirradiated patients. This series was recently updated by Eisenberg et al. (2010) with a total of 48 patients undergoing neobladder reconstruction (32.4% of all patients with the same level of irradiation who underwent salvage cystectomy). Age and higher American Society of Anesthesiologists (ASA) score were associated with more early complications, but not the type of urinary diversion. However, these were clearly a highly selected group of patients who had the least visible damage to the external sphincter and were thought likely to have a good outcome. In spite of this, urinary incontinence was more common than in the larger series of nonirradiated patients.

Nieuwenhuijzen et al. (2004) reported on 27 patients who underwent salvage cystectomy, 9 of whom had an orthotopic diversion. Eight of them achieved complete daytime continence, similar to results expected in nonirradiated patients. Hautmann et al. (2009) also reported on 25 patients (18 males and 7 females) who underwent neobladder construction after high-dose irradiation. This constituted 2.5% of the entire group of neobladder patients, and one-fourth of those who underwent salvage cystectomy at that institution. Early and late outcomes were similar to those in the larger group of nonirradiated patients. Hautmann et al. concluded that indications to be considered for a neobladder in irradiated patients include absence of preoperative incontinence or stricture, no fistula formation, and no severe bowel radiation damage.

It is clear that orthotopic lower urinary tract reconstruction can be safely performed in carefully selected patients with a history of prior full-dose pelvic irradiation. Even selected women with a history of pelvic irradiation may be appropriate candidates for orthotopic reconstruction with good clinical outcomes (Lee et al., 2004; Stein et al., 2002). However, these are challenging procedures that clearly require technical expertise and keen intraoperative judgment. Previous high-dose prostate radiation (external beam or brachytherapy) or a vaginal implant for cervical cancer cause more scarring in the rhabdosphincter area than does external-beam radiation for either bladder cancer or other malignancies. Permanent brachytherapy seeds used for prostate cancer treatment often end up in the levator muscles and urogenital diaphragm and may result in severe scarring around the area of the external sphincter.

Preoperative evaluation including cystoscopy is useful to evaluate the integrity of the mucosa around the area of the sphincter. However, it may not be possible to accurately predict the degree of radiation damage found at surgery, so **careful intraoperative tissue assessment and determination of the condition of the urethra, ureters, and bowel must be performed to make a final decision about the feasibility of orthotopic diversion** (Abbas et al., 2001). These patients should always be counseled preoperatively that the orthotopic diversion may not be possible.

Prior Prostate Surgery or Bowel Resection

Prior abdominal or pelvic surgery may also present challenges for the surgeon performing orthotopic diversion. **Patients who have had a prior radical prostatectomy may have a particularly difficult dissection around the proximal urethra at the prior vesicourethral anastomosis.** Nevertheless, this is often feasible with careful dissection. The location and health of the proximal urethra can be assessed endoscopically both preoperatively and at surgery, and acceptable continence can be obtained in selected patients assuming that they had good continence before cystectomy (Huang et al., 2012; Schuster et al., 2003). Huang et al. (2012) reported on 24 patients who underwent ileal neobladder construction after cystectomy after prior radical prostatectomy (20) or prostatectomy plus adjuvant radiation (4). Nine patients had fair or poor continence before surgery, and 6 of those underwent artificial sphincter placement either at the time of cystectomy or afterward. However, 11 of the 13 men with good preoperative continence, including 1 who had both radical prostatectomy and radiation, regained good continence (0 or 1 pad per day) after neobladder construction. There were no rectal injuries and no anastomotic strictures in this series. One challenge in these surgeries is to identify the prior vesicourethral anastomosis to ensure that the bladder is entirely resected. Flexible cystoscopy at the time of the apical dissection can assist in this regard.

In conclusion, with careful dissection a patient who was continent after the initial radical prostatectomy surgery can be expected to have an acceptable result with a neobladder.

A patient with multiple prior bowel resections may be at risk for developing chronic diarrhea or even short bowel syndrome after an additional 45 to 60 cm of small bowel is resected. In these patients, alternatives to orthotopic diversion such as a sigmoid neobladder might be entertained. In general, prior bowel resections can be managed by carefully dissecting out all of the small bowel, taking down any adhesions before performing the diversion. **It is critical to identify the old bowel anastomosis and, whenever possible, take it down and use that site as one end of the continent reservoir.** This avoids potential devascularization of the bowel segment between the old and new bowel anastomoses.

Key Points: Patient-Related Factors

- Adequate renal function (eGFR >35 or 40 mL/min) is recommended for patients considering continent diversion.
- Older age and obesity are not contraindications to orthotopic diversion.
- Orthotopic diversion can be performed after prior pelvic irradiation or radical prostatectomy in carefully selected male and female patients.
- In patients with prior bowel resection, the prior anastomosis should be taken down and that segment used for the orthotopic diversion rather than choosing a new site, to avoid devascularization of the bowel.

Continence Mechanism in Patients Undergoing Orthotopic Diversion

An understanding of the anatomy of the urethral continence mechanism in men and women is crucial to preserving this function at the time of radical cystectomy. The surgical dissection at the prostatic apex in men and bladder neck in women must be carefully and precisely performed to achieve optimum continence while taking care not to compromise the oncologic effectiveness of the surgery.

In both males and females, the urethral sphincter is made up of both smooth and striated muscles. The striated rhabdosphincter appears to be the most critical for continence and is innervated by the pudendal nerve. Careful neuroanatomic dissections with three-dimensional reconstructions of male and female cadavers have defined the anatomy of the urethral sphincter mechanism (Borirakchanyavat et al., 1997; Colleselli et al., 1998; Stenzl et al., 1997; Strasser and Bartsch, 2000). In the female cadavers, Colleselli et al. (1998) found that the major portion of the striated muscle that makes up the rhabdosphincter is located on the ventral and lateral aspects of the urethra. No clearly defined line could be identified between the transverse smooth muscle cranially and the striated muscle caudally. Rather, a gradual transition was noted in the middle third of the urethra, with intermingling fibers of both types of muscle. Fluorourodynamic studies performed on women who had undergone orthotopic reconstruction after cystectomy also identified the mid-urethra as the primary continence zone (Grossfeld et al., 1996). Branches off the pudendal nerve coursing beneath the levator muscle can be traced to the rhabdosphincter. Delicate fibers from the perineal portion of the pudendal nerve course underneath the urogenital diaphragm, entering the caudal portion of the urethra laterally (Colleselli et al., 1998; Hinata et al., 2012).

In male cadavers, Strasser and Bartsch (2000) described the rhabdosphincter as an independent striated muscle that is not in direct contact with the fibers of the levator ani muscle. These dissections demonstrated that the male sphincter does not form a horizontal muscular ring around the membranous urethra. Rather, the male rhabdosphincter is also “omega-shaped” primarily ventral and lateral to the membranous urethra and prostate. The innervation of the male rhabdosphincter was also found to originate from fine branches that arise off the pudendal nerve. These authors suggested that injury to either the rhabdosphincter or the pudendal innervation may impair the sphincter mechanism in men.

Surgical Techniques for Continence Preservation During Radical Cystectomy

Anterior Apical Dissection in the Male Patient

Attention to anatomic and surgical detail is important to optimize functional and clinical outcomes in patients undergoing cystectomy with planned orthotopic diversion. Minimal manipulation of the tissue around the urethra-corresponding innervation is essential to providing optimal urinary continence (Colleselli et al., 1998; Stein et al., 2001b; Stenzl et al., 1998; Strasser and Bartsch, 2000). Most urologists are familiar with these techniques in male patients from their experience with radical prostatectomy. They may be less familiar with the dissection of the urethra and bladder neck in women.

In a standard cystectomy, the bladder and prostate are completely freed off the rectum and mobilized posteriorly before the urethral dissection. Posterior dissection should not extend distal to the apex of the prostate. If a nerve-sparing approach is planned, the urethra may be divided after the lateral pedicles are taken down to the bladder (anterior branches of the internal iliac vessels). The prostate is then dissected in a retrograde fashion off the rectum and bilateral neurovascular bundles, and the posterior pedicles are divided last.

In either approach, all fibroareolar connections along the anterior bladder wall, prostate, and undersurface of the pubic symphysis are divided. The endopelvic fascia is incised adjacent to the prostate, and the levator muscles are gently swept off the lateral and apical portions of the prostate. The superficial branch of the deep dorsal vein is identified, ligated, and divided. With tension placed posteriorly on the prostate, the puboprostatic ligaments are identified and slightly divided just beneath the pubis and lateral to the deep dorsal venous complex (DVC), which courses between these ligaments. Care should be taken to avoid any extensive dissection in this region. The puboprostatic ligaments need to be incised only enough to allow proper apical dissection of the prostate.

Several methods can be performed to properly control the DVC as discussed in Chapters 155 and 156. We use absorbable suture to avoid the risk for erosion of suture, clips, or staples into the urethral anastomosis. Once the venous complex has been ligated, it is divided close to the apex of the prostate. Any bleeding from the transected venous complex can be controlled with an absorbable suture. **Care should be taken to avoid deep suture bites into the complex or levator muscles, which could injure the continence mechanism.** The DVC suture can then be used to suspend the venous complex anteriorly to the periosteum of the symphysis pubis to reestablish anterior fixation of the DVC, which may enhance continence recovery (Bauer et al., 2011).

The anterior urethra is then incised just beyond the apex of the prostate. Six 2-0 absorbable monofilament or woven polyglycolic acid sutures are placed in the urethra circumferentially under direct vision before complete division of the urethra, carefully incorporating only the wall of the urethra without including the levator muscles. Placing the urethral sutures at this time rather than after the bladder has been removed avoids the retraction of the urethra that makes subsequent accurate placement difficult. The urethral catheter is clamped and divided distally. Two additional sutures are then placed, incorporating the rectourethralis muscle posteriorly and the caudal extent of the Denonvilliers fascia. The posterior urethra is then divided and the specimen removed. The urethral sutures are tagged to identify their location and are placed under a towel until the urethroenteric anastomosis is performed.

Frozen-section analysis of the circumferential distal urethral mucosal margin (prostatic apex) on the cystectomy specimen is performed to exclude tumor involvement. If there is tumor at the prostatic apex, the urethral stump can be excised or a total urethrectomy may be performed at this time to obtain a negative margin, and a cutaneous diversion constructed.

The contribution of prospective nerve-sparing to subsequent continence in male patients is controversial. Retrospective studies suggest continence may be improved if nerve-sparing is attempted, though in all such series it is impossible to control for the impact of selection bias (Turner et al., 1997). However, when oncologically safe it is reasonable to attempt never-sparing in a potent patient when a orthotopic diversion is planned.

Preservation of the Urethra in the Female Patient

When orthotopic diversion is considered in female patients, several technical issues should be noted to optimize the continence mechanism (Stein and Skinner, 2004; Stein et al., 2001b). A standard female cystectomy includes removal of the uterus, cervix, and ovaries (anterior exenteration). However, in selected female patients with clinically lower-stage disease, a number of authors have advocated preservation of the uterus and ovaries (Ali-El-Dein et al., 2013; Chang et al., 2002; Djaladat et al., 2012; Zippe et al., 2005). It appears that preserving the uterus and its supportive ligaments eliminates the risk for vaginal fistula, improves sexual function, and may decrease late urinary retention in women undergoing neobladder reconstruction (see later). If the uterus is preserved, the branches of the internal iliac artery feeding the bladder are taken distal to the takeoff of the uterine artery, and the ureteral stump must be dissected from below the uterine artery. Whether the uterus is removed or not, **whenever possible the bladder is dissected completely off the anterior vaginal wall rather than excising it. However, a deeply invasive tumor on the posterior bladder or trigone may necessitate excision of a portion of the anterior vaginal wall.** This does increase the risk for subsequent pouch-vagina fistula but is not an absolute contraindication to orthotopic reconstruction. **A patient with a significant tumor at the bladder neck or with palpable extension into the vaginal wall is a poor candidate for neobladder and should undergo en bloc urethrectomy and cutaneous diversion.**

In developing the posterior pedicles, if a hysterectomy is planned the posterior vagina is incised at the fornix behind the cervix. If the patient has undergone prior hysterectomy, a sponge stick in the vagina facilitates identification of the vaginal apex. In this case, the vagina is usually not entered. Before dissecting off the bladder, the posterior vascular pedicles coursing around the vagina to the bladder are developed and divided with hemoclips, vascular staples, or a LigaSure (Covidien, Mansfield, MA) or similar device.

There is controversy about the importance of preserving the nerves along the lateral vagina in women. Some authors have suggested that preservation of this tissue may contribute to maintaining continence and avoiding retention in women undergoing orthotopic diversion (Bhatta et al., 2007, Gross et al., 2015; Hautmann, 1997; Stenzl et al., 1995a, 1998; Turner et al., 1997). Others have not made any special effort to preserve the autonomic nerves and have successfully relied on the pudendal innervation of the rhabdosphincter complex for continence (Ali-El-Dein, 2009; Ali-El-Dein et al., 2002; Stein et al., 1997, 2004). This is a difficult question to test, and there are no randomized trials testing this question (Skinner and Comiter, 2015). However, although not absolutely required, it is reasonable to preserve these nerve bundles if possible in women undergoing neobladder reconstruction.

Once the posterior pedicles have been divided, careful dissection of the bladder off of the anterior vaginal wall is performed sharply. Care must be taken to dissect in the proper plane to prevent entry into the posterior bladder and reduce the amount of bleeding in this vessel-rich area. **It is absolutely critical not to compromise the oncologic success of the surgery by inadvertent incision into the bladder.** Dissection is carried caudally to the vesicourethral junction. Tugging on the Foley catheter balloon to position it at the bladder neck assists in identifying this junction.

Once the posterior dissection is completed, the fatty tissue overlying the anterior urethra is swept off the endopelvic fascia and the vesicourethral junction is carefully identified. Again, tugging on the Foley catheter, if necessary with extra water in the balloon, allows the surgeon to visualize the junction between the urethra and bladder. **The endopelvic fascia and periurethral tissue anteriorly should not be disturbed in this process. The proximal urethra in the female extends well above the endopelvic fascia** (Fig. 141.4). Careful sharp dissection is used to free the bladder neck and an initial 0.5 cm of urethra off the vagina. At this point, the specimen is attached only by the urethra itself.

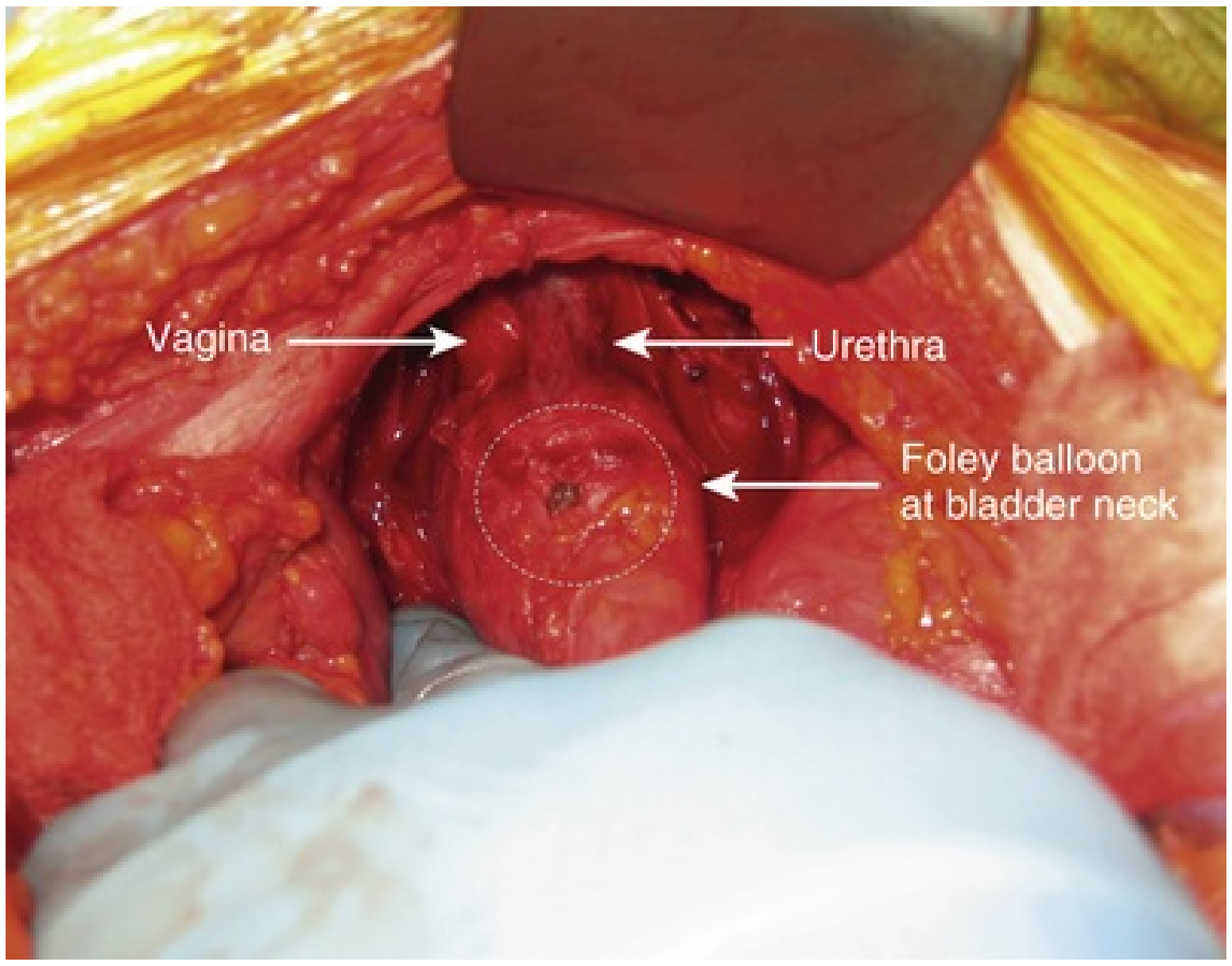

FIG. 141.4 Intraoperative photo of preparation of the female urethra for an orthotopic neobladder. The fatty tissue overlying the anterior urethra is swept off the endopelvic fascia, and the vesicourethral junction is carefully identified by positioning the Foley catheter at the bladder neck (20 cc of water in the catheter balloon can facilitate this). Note that the endopelvic fascia and periurethral tissue anteriorly are not disturbed.

After the site for the incision is marked just distal to the vesicourethral junction, the Foley catheter can be removed and a pedicle clamp placed across the bladder neck, which prevents any tumor spill from the bladder when the urethra is transected. The proximal urethra is sharply divided just distal to the bladder neck. The female urethra does not retract away after division as it does in the male, so sutures can be placed after removal of the bladder. Frozen-section analysis is performed on the urethral margin of the cystectomy specimen to exclude any tumor. Once the decision is made to perform the orthotopic diversion, 8 to 10 individual 2-0 absorbable sutures are placed circumferentially through the urethra, tagged, and set aside.

In the case of a deeply invasive posterior bladder tumor, the anterior vaginal wall may be removed en bloc with the cystectomy specimen by incision along the long axis of the anterolateral vaginal wall. This leaves the anterior vaginal wall attached to the bladder specimen. Again, the Foley catheter balloon facilitates identification of the vesicourethral junction. A rim of anterior vaginal wall must be preserved proximal to the urethra to close the vagina so that the vaginal suture line is not directly abutting the vesicourethral suture line to decrease the risk for subsequent fistula. The vagina may be closed in a clamshell or horizontal manner. Other reconstructions to increase vaginal volume are feasible, but it may be difficult to perform a complex vaginal reconstruction (e.g., a rectus myocutaneous graft) along with a neobladder procedure simply because of a lack of adequate room in the pelvis.

The vagina is then closed at the apex with absorbable suture and then suspended. One may suspend the vagina to the Cooper ligament or to preserved cut ends of the round ligaments to prevent postoperative vaginal prolapse. However, we routinely perform a sacrocolpopexy incorporating a short strip of permanent mesh to fix the vagina to the sacral promontory at a more natural angle without any tension. This may be important to support the neobladder and avoid a possible cause of late voiding difficulty. **Regardless of the form of vaginal reconstruction, a well-vascularized omental pedicle graft should be placed between the reconstructed vagina and the neobladder and secured to the endopelvic fascia at either side of the urethral stump to separate the suture lines and prevent fistula formation between the vaginal and urethral anastomosis, and to help support the pouch posteriorly.** Videos 141.1 and 141.2 show the dissection of the bladder neck and proximal urethra in the female cystectomy.

Key Points: Continence Mechanism and Surgical

Techniques for Continence Preservation

- The striated rhabdosphincter muscle fibers and associated innervation from the pudendal nerve are concentrated in the area anterior and lateral to the proximal urethra in both males and females.
- In male patients, one should obtain careful control of the DVC, and avoidance of deep suture bites into the pelvic floor muscles is critical.
- In female patients, the endopelvic fascia and levator muscles should not be disturbed.

Techniques for Orthotopic Bladder Substitution

Choice of Bowel Segment

A number of different procedures for orthotopic reconstruction incorporating different segments of bowel have been described. There are clearly some physiologic indications to use various segments of intestine, but the surgeon's preference may be even more influential. It has been suggested that **excellent functional and clinical outcomes with voiding can be achieved regardless of the segment of bowel chosen as long as the principles of preservation of the rhabdosphincter as a continence mechanism and construction of an adequate capacity, low-pressure reservoir are maintained** (Lee et al., 2003; Parekh et al., 2000b). Ideally, the surgeon performing orthotopic urinary diversion will be comfortable using a variety of the techniques described later so that he or she can adapt the technique to the needs of the individual patient.

Reservoirs made of detubularized ileum or ileum and colon together appear to have the greatest compliance and lowest likelihood of generating intermittent high-pressure contractions. Hohenfellner et al. (1993) elegantly evaluated the properties of gut smooth muscle layers (circular and longitudinal) of ileal and cecal segments in a canine model. The circular muscle layer of ileum was found to be most distensible, followed by the colonic circular and longitudinal ileal layers. The longitudinal layer of the colonic segment was relatively nondistensible. Studies in humans showed that the urodynamic characteristics of the ileum appear to be superior to those of the colon (Berglund et al., 1987; Chen et al., 2009; Davidsson et al., 1992; Schrier et al., 2005). Stomach and sigmoid colon have been found to have particularly poor compliance and high pressures (Santucci et al., 1999). Schrier et al. (2005) found that neobladders made of ileum had a larger capacity, lower filling pressures, lower maximum capacity pressures, and better compliance. The distal small bowel mesentery also tends to have the greatest mobility and almost always reaches the urethra without much difficulty. In patients with short ureteral length because of malignancy or other pathology of the ureters, an ileal pouch with an afferent limb (such as the Studer) can be extended to reach all the way to the renal pelvis. A final advantage of ileum is the atrophy of the intestinal mucosa as it is exposed to urine over time. This results in decreased mucous production and decreased reabsorption of urinary electrolytes in the mature reservoir. Mucosal atrophy appears to be more reliable in small bowel than in large bowel reservoirs (Mills and Studer, 1999; Norlen and Trasti, 1978). Interestingly, the intestinal epithelial cells also lose their tissue-specific epigenetic profile with time when exposed to urine. De novo methylation of some intestine-specific enhancers occurs with concomitant demethylation of primarily non–intestine-specific transcribed regions (Lay et al. 2014).

The primary disadvantage of using distal ileum lies in the potential loss of absorption of vitamin B_{12}. This segment may also have been unacceptably damaged by prior pelvic radiation or may be unavailable because of multiple prior bowel resections or inflammatory conditions such as Crohn disease. Whenever ileum is available, we preferentially use it for orthotopic diversion.

Bladder replacement using stomach has also been described, although it has not been a popular technique (Hauri, 1998; Lin et al., 2000). The purported advantage of gastric segments is that the gastric mucosa excretes chloride and hydrogen ions, effectively reversing the acidosis of renal insufficiency. The excreted acid from a stomach segment can also reduce the risk for bacterial colonization, and there is less mucous production. However, the disadvantage of using stomach is that compliance is poorer than ileum, and some patients will develop dysuria or hematuria from the excreted acid (Lin et al., 2000). Combining gastric and small or large intestinal segments can counteract some of these side effects and may be ideal from a purely metabolic standpoint (Lockhart et al., 1993). This construction can theoretically be performed in a patient with compromised renal function when continent diversion is contraindicated. It may also provide another option in a patient with prior high-dose pelvic radiation or multiple previous bowel resections. Few urologists have been trained in the surgical anatomy of the stomach, and most who perform a significant number of cystectomies currently rarely, if ever, use this type of diversion.

Isolation of the segment of bowel to be used for the diversion must be performed carefully to preserve blood supply to the pouch and to the bowel anastomosis. If using ileum, one should avoid deep incision into the mesentery at the proximal bowel division to avoid compromising the blood supply to the reservoir. In addition, in patients who have had previous bowel resection, it is important to take down the old anastomosis rather than choosing another site nearby because that could result in a poorly vascularized segment between the new and old bowel anastomoses.

Need to Prevent Reflux

The deleterious effect of vesicoureteral reflux in children is well accepted, especially in the face of infection. In the context of urinary diversion, the importance of reflux was first identified in patients undergoing ureterosigmoidostomy (Clarke and Leadbetter, 1955) and, subsequently, ileal conduit urinary diversion (Middleton and Hendren, 1976). It was previously believed that high-pressure reflux of infected urine may be the cause of upper tract deterioration (Clark et al., 1999; Madersbacher et al., 2002). Age, hypertension, ureteroenteric anastomotic stricture, and pyelonephritis have been reported as independent risk factors for renal function deterioration in different series. Type of urinary diversion, however, does not seem to be a predisposing factor for renal dysfunction (Amini and Djaladat, 2017).

Studies that have compared refluxing versus nonrefluxing urinary diversion have been limited, in general, by short follow-up, patient selection bias, retrospective design, or relatively small patient numbers. Richie et al. (1974) initially showed a protective effect of nonrefluxing anastomoses in a dog model. Kristjánsson et al. (1995a,b) later found no difference in colon conduits with nonrefluxing anastomoses versus ileal conduits with refluxing anastomoses. However, continent diversions with antireflux techniques appeared to result in less upper tract scarring and bacteriuria. Song et al. (2006) and Hautmann et al. (2006) each found no differences in renal function or hydronephrosis in refluxing or nonrefluxing orthotopic neobladders in nonrandomized retrospective studies. These studies were retrospective and nonrandomized and in general included relatively small numbers of patients.

With orthotopic diversion, most patients void by Valsalva maneuver with relaxation of the external sphincter. The resulting increase in pressure in the reservoir should be transmitted equally to the rest of the system, limiting any resulting back pressure even without an antireflux mechanism (Studer et al., 2006; Thoeny et al., 2002). However, free reflux into the upper tracts of the Studer pouch is often visible on cystogram with as little as 300 mL of filling, well within the typical voided volume of these patients. It is likely that there is some low-pressure retrograde flow of urine in these patients at times. In patients who require intermittent catheterization to empty, such reflux could potentially occur at relatively high pressures when the reservoir is full. Finally, although symptomatic infections are uncommon (see later), it is not unusual for these patients to have asymptomatic bacteriuria, especially if they are performing self-catheterization. Steven and Poulsen (2000) reported 34% 3-year and 24% 5-year prevalence rates for bacteriuria in 166 men undergoing orthotopic reconstruction.

Medium- to long-term results with a refluxing type of reservoir such as the Studer pouch suggest that normal renal function and preserved upper tract anatomy are possible in the majority of patients (Minervini et al., 2005; Perimenis et al., 2004; Studer et al., 2006; Thoeny et al., 2002). Thoeny et al. (2002) examined long-term results in 76 patients with a Studer pouch with 5 or more years of follow-up and found preserved renal function and anatomy in 95% of the patients.

It is clear that any mechanism introduced to prevent reflux may also potentially cause upper tract obstruction. Initial experience with the intussuscepted Kock nipple valve showed that it provided reliable protection against reflux and seemed to have few drawbacks. However, as surviving patients were followed up to 10 years and beyond, it became clear that a significant proportion of patients experienced obstruction from stenosis of the afferent nipple valve or extussusception of the afferent nipple valve (Stein et al., 1996). In addition, at least 25% form stones over time (Arai et al., 1993; Ginsberg et al., 1991). Afferent valve obstruction is often clinically silent. Patients who were not followed carefully occasionally developed acute renal failure and bilateral hydroureteronephrosis with significant renal damage, underscoring the need for careful lifetime follow-up in patients with urinary diversion. Similarly, ureteroileal obstruction with the antireflux Camey-Le Duc ureteral implantation technique has been reported to occur in 7% to 29%, compared with less than 3% for a direct ureteroileal anastomosis (Le Duc et al., 1987; Pantuck et al., 2000; Roth et al., 1997; Shaaban et al., 1992).

Abol-Enein and Ghoneim developed a serous-lined ureteral implantation technique with an ileal neobladder and reported their intermediate experiencein 2001 in 450 patients with median follow-up of 38 months. In this large series, 96% of upper tracts remained unchanged or improved; reflux was observed in only 3% of patients. Anastomotic ureteral stricture occurred in 3.8% of patients, an incidence similar to that of most refluxing ureteroileal anastomoses (Abol-Enein et al., 2001; Pantuck et al., 2000; Shah et al., 2015). The T pouch was designed building on this technique to provide protection from reflux while avoiding some of these complications of the Kock nipple valve. This is accomplished by preserving optimum blood supply to the tunneled ileal afferent limb segment while allowing the ureters to be directly implanted into the ileum, allowing for ureters that are dilated or must be divided high (Stein and Skinner, 2006; Stein et al., 1998b). With a 33-month median follow-up, renal function and anatomy were preserved in 90% of patients, with only 2% developing stenosis related to the afferent T limb during this time (Stein et al., 2004). In recent years, the technique has been modified to avoid tapering the afferent limb in an attempt to further limit the development of late stenosis, a complication that increases in frequency with further follow-up.

Shaaban et al. (2006) performed a small prospective randomized clinical trial evaluating whether prevention of reflux is beneficial. They studied 60 patients who all had normal renal function preoperatively and no hydronephrosis. In each patient, one randomly chosen ureter was implanted in an antireflux manner (using an extraserosal tunnel), and the other was implanted directly into a small tubularized chimney on a standard W ileal neobladder. At a 2-year median follow-up, the researchers found more deterioration in the renal units drained with the antireflux technique, which resulted in five cases of documented obstruction, than in those with a direct refluxing anastomosis.

The authors recently completed a larger prospective randomized trial with 484 patients undergoing radical cystectomy randomized to receive either a Studer or T pouch urinary diversion. At 3 years, there were no differences in renal function or urinary tract infections between the two groups. However, the patients with the T pouch were more likely to require diversion-related secondary procedures than those with the Studer construction (Skinner et al., 2015).

As treatment for bladder cancer improves and patients live longer after cystectomy and urinary diversion, they are at further long-term risk for renal deterioration, and reflux prevention may become a more important issue. The question remains whether any benefit in upper tract protection afforded by the antireflux technique outweighs the potential risk for upper tract obstruction from the antireflux technique itself. Further clarification of this question awaits the long-term results of these prospective randomized trials.

Key Points: Choice of Bowel Segment and the Need to Prevent Reflux

- Reservoirs made from ileum or combined ileum and colon appear to have the best physiologic properties for orthotopic diversion.
- Isolation of the segment of bowel to be used for the diversion must be

performed carefully to preserve blood supply to the pouch and bowel anastomosis.

- The addition of an antireflux mechanism does not appear to be necessary for preservation of the upper tracts and prevention of infection, at least in the intermediate term.

General Perioperative Management

Perioperative management of patients undergoing cystectomy and orthotopic diversion is not significantly different than for patients undergoing other types of diversion. Preoperative history should focus on prior abdominal or pelvic surgery or radiation, current voiding patterns and continence, general medical problems and social support, and patient priorities and preferences. If colon may be used for the diversion, a colonoscopy is recommended to rule out polyps or tumors. Preoperative risk stratification using a frailty index and cardiopulmonary exercise testing for high-risk patients should be performed. There is evolving evidence that preoperative optimization of the patient through nutritional and preoperative exercise intervention may improve surgical outcomes (Cui et al., 2017).

There is no consensus on the ideal management of ureteral stents or catheters in patients undergoing orthotopic diversion. Most authors recommend the use of ureteral stents in the early postoperative period (Mattei et al., 2008). We use 8-Fr pediatric feeding tubes or 7-Fr single-J urinary diversion stents and tie them to the urethral catheter so they can be removed at the same time and the patient has fewer external bags to manage. We also use a 24-Fr stiff hematuria catheter, which facilitates routine irrigation of the pouch and is left in for approximately 3 weeks. Other surgeons alternatively use externalized ureteral stents brought through the skin in addition to a separate suprapubic tube, which are drained separately. The latter allow for less urine to pass through the pouch while it is healing and may decrease dependence on attentive nursing. However, this may be cumbersome for patients and could potentially limit their mobility during the immediate postoperative period. A pelvic drain should be placed in every patient. In general, we leave the drain until the pouch has healed because of occasional late leakage if the catheter gets plugged at home.

Postoperative hospitalization in the past averaged approximately 8 to 10 days, primarily because of delayed feeding and postoperative ileus. We have adopted an Early Recovery after Surgery (ERAS) protocol that has allowed routine discharge 3 to 5 days after surgery (Daneshmand et al., 2014). The protocol includes avoiding bowel preparation and nasogastric tubes, decreasing narcotic pain management (including epidural narcotics), instituting early feeding, and using a μ-opioid antagonist that blocks the effects of narcotics on the bowel. Use of the μ-opioid antagonist alvimopan has been associated with a reduction in hospital stay in numerous randomized trials in colorectal surgery and a Phase IV double-blind, placebo-controlled randomized trial of 280 cystectomy patients (Lee et al., 2014; Sultan et al., 2017). Other components vary among programs, and the individual contribution of each component to the overall pathway is less well studied (Karl et al., 2014). Enhanced recovery protocols have now been adopted for radical cystectomy patients in many institutions. No significant differences in overall, minor, or major complications have been observed between the ERAS and control groups. Multiple series have demonstrated the capacity for ERAS protocols to improve outcomes among patients undergoing radical cystectomy through decreased incidence of gastrointestinal complications and decreased length of hospitalization without increased readmissions or overall morbidity (Bazargani et al., 2018; Djaladat et al., 2017; Ramirez et al., 2013). A recent meta-analysis of 13 distinct ERAS studies revealed a lower overall complication rate (especially minor Clavien grades) and faster return of bowel function in the ERAS group (Tyson and Chang, 2016).

Patients are usually seen around postoperative day 10 for follow-up and laboratory evaluation, and drain removal if there is minimal drainage (<100 mL per 24 hours). When patients return 3-weeks postoperatively, the catheter is removed. Routine pouchograms or radiographic studies of the neobladder are not routinely performed unless a significant output from the drain is observed. Patients receive education throughout the perioperative period regarding catheter management, pelvic floor exercises, and proper voiding technique at time of catheter removal.

Surgical Techniques

A large number of modifications of the techniques presented next have been described in a small number of patients, and this is by no means an exhaustive list.

Ileal Reservoirs

Most ileal reservoirs use from 60 to 75 cm of terminal ileum, which is detubularized and folded in a variety of ways to attempt to create a spheric shape. Modifications primarily include variations in the exact folding technique and variations in management of the ureters, with or without an antireflux mechanism. In general, all reservoirs are closed with continuous absorbable sutures. **The use of nonabsorbable suture and metal staples should be avoided because of the potential for stone formation** (Stein et al., 1994b; Suriano et al., 2013). Absorbable staples have been developed, although they tend to be somewhat difficult to use with inconsistent results and thus are not in routine use today (Montie et al., 1996; Olsson et al., 1995).

The two most popular configurations around the world are the Hautmann W-neobladder (and its various modifications) and the Studer pouch neobladder. Both are relatively simple constructions and allow direct ureteroileal anastomosis, which has been shown to have the lowest risk for subsequent stricture. The T pouch and extraserosal tunnel techniques both provide an antireflux mechanism when that is felt to be advantageous (Hugen and Daneshmand, 2016).

Camey II

The Camey II orthotopic substitute (Camey, 1990) is a modification of the original Camey bladder substitute (Lilien and Camey, 1984), which was a simple segment of ileum anastomosed to the ureters and urethra (Fig. 141.5). The modification includes detubularization and folding to eliminate peristaltic activity. A total of 65 cm of ileum is isolated, with an area of the ileum identified to reach to the region of the urethra in a tension-free manner. After the integrity of the bowel is restored, the mesenteric trap is closed and the isolated portion of ileum is opened along the antimesenteric border for the entire length, except the area previously identified for the urethral anastomosis. In this region, the ileal incision is directed toward the mesenteric border. The ileum is then placed in a transverse U orientation. The medial borders of the U are sutured together with a running absorbable suture. A fingertip opening is made in the preselected area for the ileourethral anastomosis, the entire ileal plate is brought down to the pelvis, and the urethral anastomosis is performed. The ureteroileal anastomosis is then performed via the Le Duc technique (Le Duc et al., 1987). The reservoir is completed by folding the ileal plate and suturing with a running absorbable suture. The ends of the U are anchored to the pelvic floor to reduce tension (see Fig. 141.5). A modification of the Camey II has been described by Barre et al. This forms the ileum in a Z configuration and reportedly has the advantages of shorter length requirements, improved reservoir capacity, and potentially improved functional (continence) results (Barre et al., 1996). A modification using gastrointestinal anastomosis (GIA) metal staples for rapid construction has also been described (Muto et al., 2016).

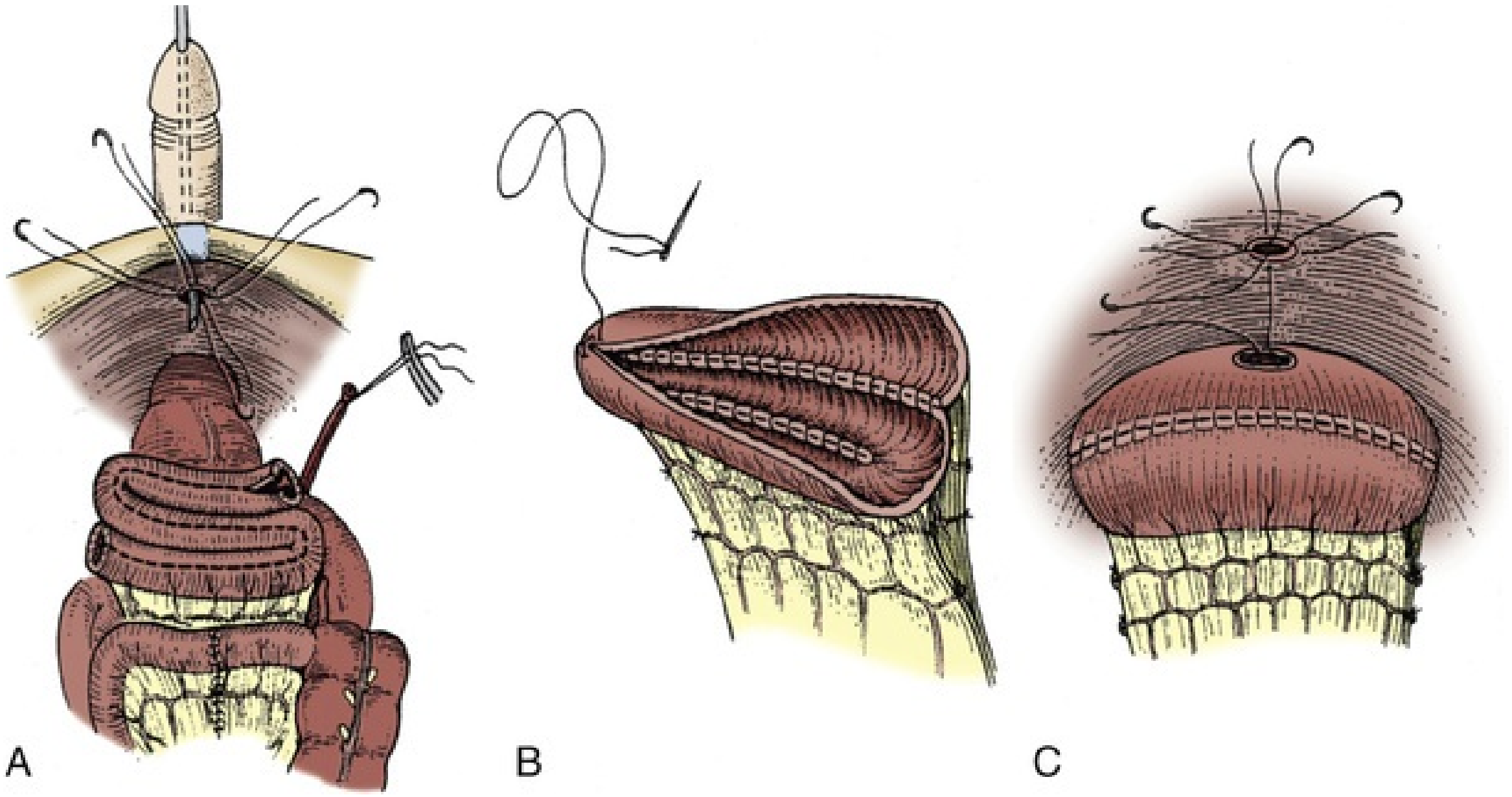

FIG. 141.5 Construction of the modified Camey II neobladder. (A) The ileal loop is folded three times (*Z* shaped) and incised on the antimesenteric border. (B) The reservoir is closed with a running suture to approximate the incised ileum. (C) The urethral anastomosis is performed, and the ureters are implanted using the Le Duc antireflux technique.

Orthotopic Kock Ileal Reservoir (Hemi-Kock)

The Kock ileal reservoir was first used as a continent cutaneous ileal reservoir incorporating intussuscepted nipple valves for both the afferent (antireflux) and efferent (continence) limbs (Kock et al., 1982; Skinner et al., 1984) (Fig. 141.6). This subsequently evolved into an orthotopic form of diversion in which the afferent intussuscepted limb was maintained to prevent urinary reflux (see Fig. 141.6) (Ghoneim et al., 1987; Skinner et al., 1991). Skinner et al. performed more than 500 of these procedures from 1982 to 1995, with excellent continence and a low ureteroileal stricture rate of less than 3% (Skinner et al., 1988; Elmajian et al., 1996). Schreiter and Noll (1989) described an S-shaped modification of the orthotopic Kock ileal reservoir. With long-term follow-up, late complications associated with the afferent intussuscepted antireflux nipple developed in a small but significant number of patients (Stein et al., 1994a, 1996). These included stone formation on exposed staples, stenosis of the afferent nipple ostium thought to be secondary to a compromised blood supply, and extussusception or prolapse of the afferent limb. These complications often occurred more than 10 years after construction of the reservoir and were clinically silent until the patient developed bilateral hydronephrosis or even renal failure (Stein et al., 1996). The technical difficulty of the intussuscepted nipple valve and the associated complications, along with the development of effective alternative techniques, has made this neobladder procedure less commonly used today.

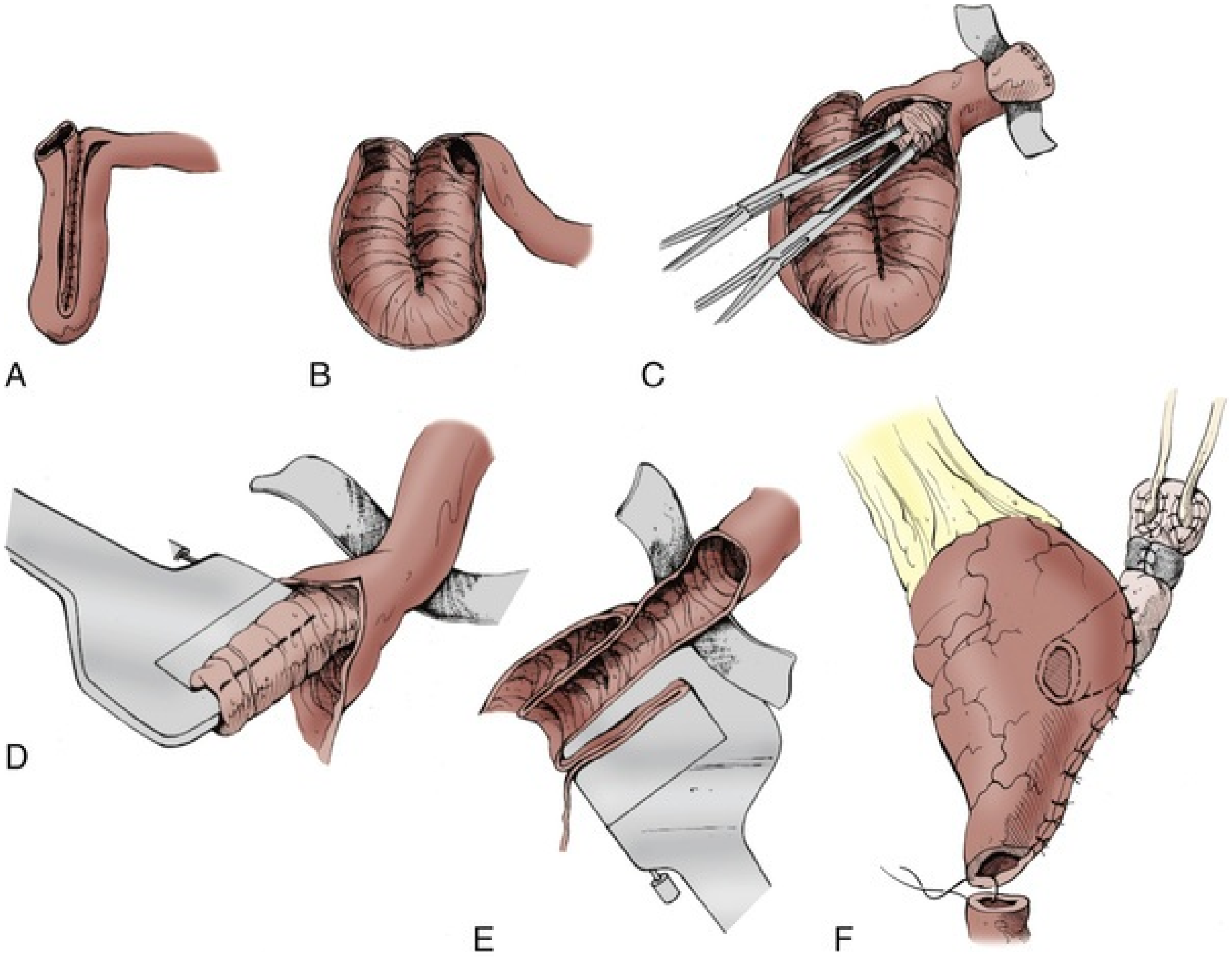

FIG. 141.6 Construction of the Kock ileal reservoir. (A) A total of 61 cm of terminal ileum is isolated. Two 22-cm segments are placed in a *U* configuration and opened adjacent to the mesentery. The more proximal 17-cm segment of ileum will be used to make the afferent intussuscepted nipple valve. (B) The posterior wall of the reservoir is then formed by joining the medial portions of the *U* with a continuous running suture. (C) A 5- to 7-cm antireflux valve is made by removing the mesentery under that

segment and then intussuscepting the afferent limb with the use of Allis forceps clamps. (D) The afferent limb is fixed with two rows of staples placed within the leaves of the valve. (E) The valve is then fixed to the back wall from outside the reservoir with additional surgical staples. (F) After completion of the nipple valve, the reservoir is completed by folding the ileum on itself and closing it, leaving the most dependent end of the suture line open for the urethral anastomosis.

Serous-Lined Extramural Tunnel

Abol-Enein and Ghoneim (1993, 1994) demonstrated that an effective antireflux mechanism could be made by bringing the ureters into a reservoir through extramural serous-lined tunnels. These authors believed that the construction of an extramural serous-lined tunnel provides several advantages. Metallic staples or synthetic materials are not required. The serous-lined tunnel protects the implanted portion of the ureter from exposure to urine so that sound healing without scarring is ensured. Moreover, a relatively short segment of bowel is used, and the procedure is versatile and not technically difficult. The authors updated their excellent results in 450 patients with this technique and demonstrated that the serous-lined extramural tunnel is an effective and durable antireflux technique, with more than 93% of patients having unidirectional, unobstructed urinary flow (Abol-Enein and Ghoneim, 2001).

A 40-cm ileal segment is isolated from the distal ileum and arranged in a W configuration. The antimesenteric border of the isolated intestine is opened, and the edges of the medial flaps are joined with a running absorbable suture. On either side, the serosal surface of the two lateral flaps are joined by a seromuscular continuous suture of silk (3-0). This forms two serous-lined intestinal troughs. Each ureter is laid down in its corresponding trough. A mucosa-to-mucosa anastomosis is performed with the spatulated ureter and the intestinal mucosa at the distal end of the trough. The mucosal edges on each side are then approximated over the reimplanted ureter. The anterior wall of the pouch is then closed in a side-to-side fashion. The suture line of the most dependent portion of the pouch close to the urethral stump is reopened to make a hole that will be anastomosed to the urethra (Fig. 141.7).

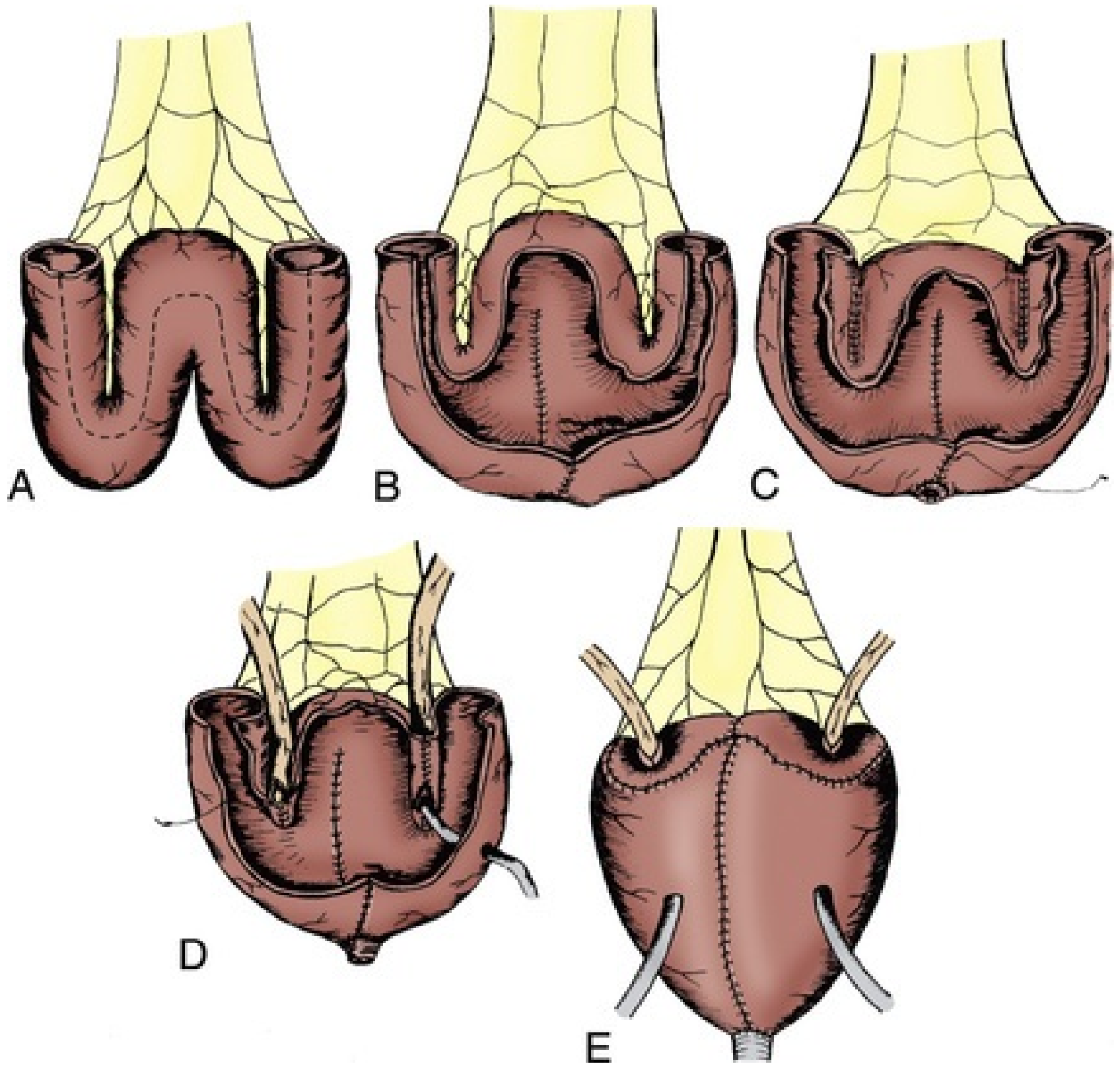

FIG. 141.7 Construction of the serous-lined, extramural ileal neobladder (Ghoneim). (A) A 40-cm segment of ileum is isolated and fashioned into a *W* configuration. (B) The ileum is opened along the antimesenteric border for the entire length. (C) The incised mucosa is joined in the middle with a running suture. The two lateral ileal flaps are joined by a seromuscular continuous suture to make the backing for the serous-lined ureteral tunnels. (D) The spatulated ureters are laid into each trough, anastomosed to the intestinal mucosa, and stented. The tunnel is then closed over the implanted ureter. (E) The anterior wall of the reservoir is formed by folding the ileum side to side. The reservoir is then anastomosed to the urethra.

Others have reported favorable results with this technique (Papadopoulos and Jacobsen, 2001). A modification of this orthotopic substitute with a serous-lined extramural ureteral reimplantation technique was also reported by Kato et al. (2001) with similar results. The primary disadvantage of this technique is the requirement for long ureteral length, inability to accommodate dilated ureters, and a possibly increased risk for ureteral strictures. More than 1600 patients have now undergone the serous-lined antireflux ureteral implantation procedure. Follow-up of 400 patients of minimum 10 years showed preservation of the upper tract in 90% of them (Hautmann et al., 2015).

Ileal Neobladder (Hautmann Pouch)

Hautmann (2010) developed the Hautmann pouch ileal neobladder (Hautmann et al., 2010, 2011). This neobladder is a large-capacity, spheric (W configuration) ileal reservoir that is constructed in an attempt to optimize initial volume and potentially reduce nighttime incontinence. A segment of terminal ileum of approximately 70 cm is selected. The bowel is reconstituted, and the mesenteric trap is closed. The ileal section that reaches the urethra most easily is identified and marked with a traction suture along the antimesenteric border. The isolated bowel segment is then arranged in either an M or W shape and is opened along the antimesenteric border except for a 5-cm section along the traction suture where the incision is curved to make a U-shaped flap.

The four limbs of the M or W are then sutured to one another with a running absorbable suture. A small full-thickness segment of bowel is excised in the site for the urethral anastomosis, which is then performed with the sutures tied from inside the neobladder. Once the ileal neobladder is situated in the pelvis and the urethral sutures are tied, the ureters are implanted from inside the neobladder through a small incision in the ileum at a convenient site. The remaining portion of the anterior wall is then closed with a running absorbable suture (Fig. 141.8).

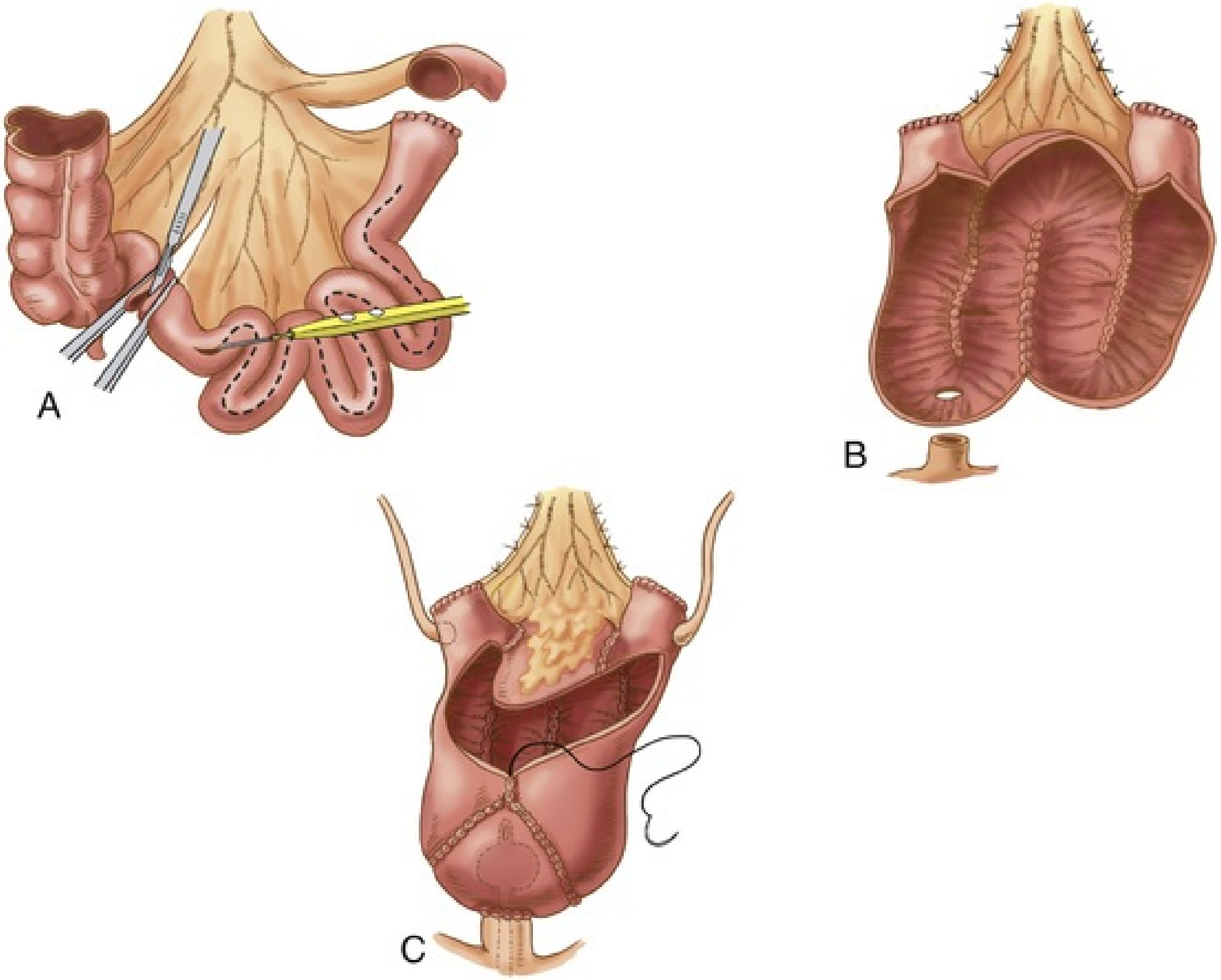

FIG. 141.8 Construction of the modified Hautmann ileal neobladder. (A) A 70-cm portion of terminal ileum is selected. The isolated segment of ileum is incised on the antimesenteric border, leaving approximately 5 cm on each end intact. (B) The ileum is arranged into a *W* configuration with the four limbs sutured to one another. (C) After a buttonhole of ileum is removed on an antimesenteric dependent portion of the ileum, the urethral anastomosis is performed. The ureteral anastomoses are performed by direct implantation, either end-to-side *(as shown)* or directly to the open ends of the two segments, and are stented. The reservoir is then closed in a side-to-side manner.

Initially Hautmann used an antireflux ureteral anastomosis as described by Le Duc et al. (Le Duc et al., 1987). However, ureteroileal strictures were fairly common, and beginning in 1997 he modified this technique and now uses a freely refluxing, open end-to-side anastomosis implanted into short tubularized segments at each end of the W. This resulted in a decrease in the risk for ureteroileal stenosis from 9.5% to 1% (Hautmann, 2001; Hautmann et al., 2006, 2017).

This pouch has a larger initial capacity than the Studer pouch, which may assist in earlier continence. However, it may also result in an increased incidence of late urinary retention and increased electrolyte reabsorption from the pouch.

Sevin et al. (2004) reported a modified Hautmann ileal neobladder in which only 40 cm of ileum is used to reduce these potential issues with acceptable clinical outcomes. The classic configuration of the pouch also could not accommodate short ureters, but in the revised technique shown, one or both ends of the W can be left long to anastomose to one or both shortened ureters (Hollowell et al., 2000).

Studer Pouch

The ileal bladder substitute as initially described by Studer et al. (1989, 1996) used a long, afferent, isoperistaltic, tubular ileal segment. It is believed that the long segment functionally prevents vesicoureteral reflux when the patient voids by Valsalva maneuver. It is straightforward to construct and has become one of the most popular forms of orthotopic diversion in the United States. The advantages of this bladder substitute include simplicity of construction, lack of a requirement for surgical staples, and ability to accommodate short ureters. The reservoir portion uses the optimal double-folded U configuration as originally described by Kock et al. (1989). Studer et al. (2006) reported on 480 of these procedures performed from 1985 to 2005 with excellent long-term results in terms of continence, preservation of renal function, and a ureteroileal stricture rate of less than 3%. The original description used a 20-cm afferent segment, with 40 cm used for the reservoir. In more recent years, Studer et al. (2006) have advocated using a somewhat shorter afferent ileal segment, with similar results. Their group has reported continued excellent functional outcomes with long-term follow-up, with satisfactory urinary continence, the vast majority able to void without self-catheterization, and excellent preservation of renal function up to 20 years. A total of 81 complications were reported in 42 of the 200 patients (21%) 10 years or longer after radical cystectomy, with pyelonephritis being the most frequent cause (Furrer et al., 2016).

The terminal portion of the ileum (54 to 56 cm long) is isolated approximately 15 to 20 cm proximal to the ileocecal valve. The distal mesenteric division is made along the avascular plane between the ileocolic artery and terminal branches of the superior mesenteric artery. The proximal mesenteric division, however, is short and provides a broad vascular blood supply to the reservoir. In addition, a small window of mesentery and 5 cm of small bowel proximal to the overall ileal segment are discarded, ensuring mobility to the pouch and small bowel anastomosis. Bowel anastomosis is performed using staplers.

The pouch is created from 40 to 44 cm of distal ileum with each limb of the U measuring 20 to 22 cm and a proximal 15-cm segment of ileum used as the afferent limb. If ureteral length is short or compromised, a longer afferent ileal segment (proximal ileum) may be used. The proximal end of the isolated afferent ileal segment is closed with absorbable sutures. The isolated ileal segment is opened about 2 cm away from the mesentery, and the incised ileal mucosa is then oversewn with two layers of a running 3-0 polyglycolic acid suture (Fig. 141.9).

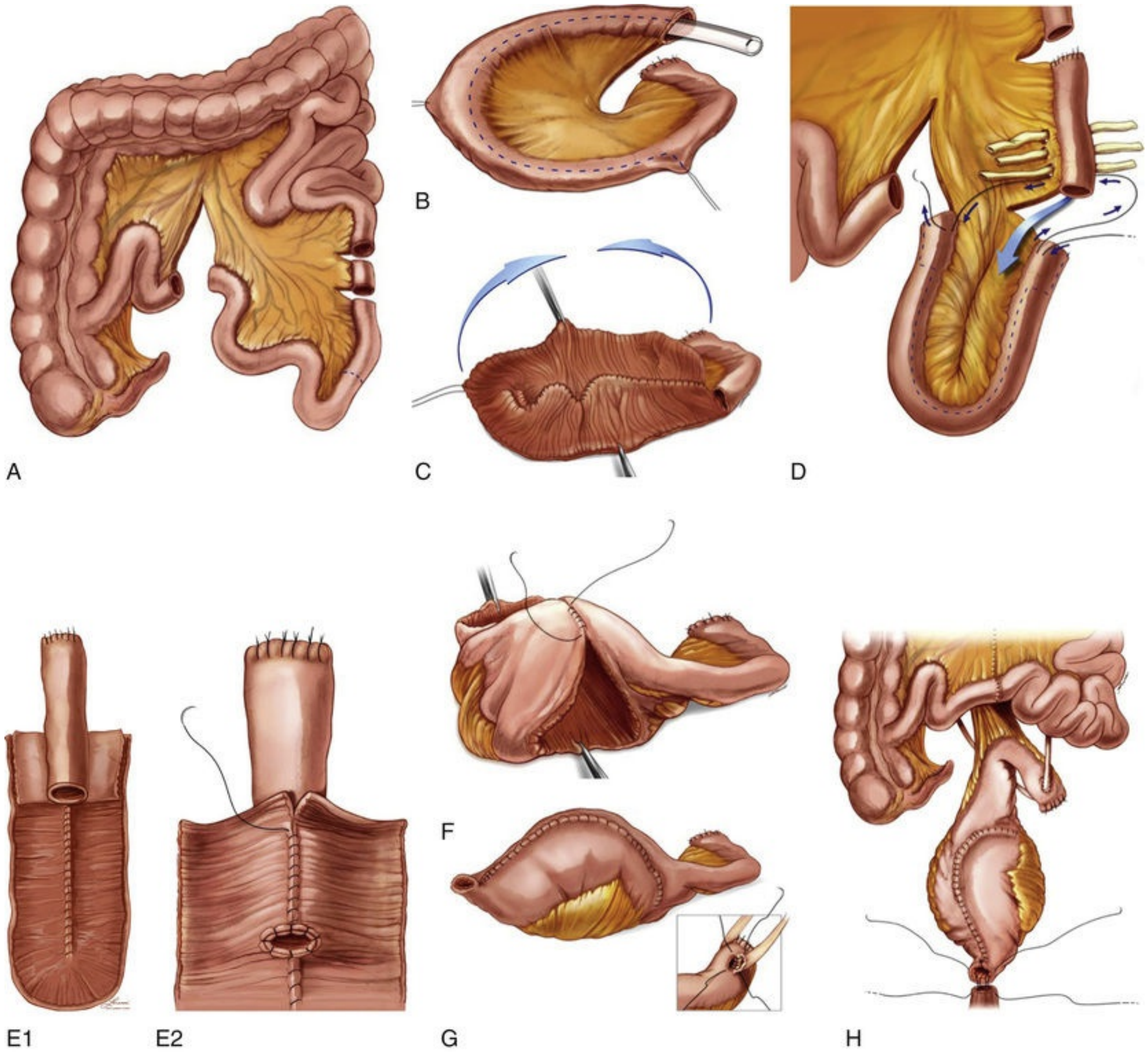

FIG. 141.9 Construction of the modified Studer neobladder (with T pouch modification). (A) Designated segments of terminal ileum for construction of the orthotopic Studer pouch ileal neobladder. Note that the distal mesenteric division is made between the ileocolic and terminal branches of the superior mesenteric artery, which extends into the avascular plane of the mesentery. Two 22-cm lengths make the reservoir and a proximal 10- to 12-cm length for the afferent limb. Proximal to this, a 5-cm segment of

small bowel is discarded to allow mobility to the pouch and small bowel anastomosis and avoid deep incision into the mesentery at that location, which could compromise vascular supply to the pouch. (B) The 44-cm length is opened along the medial mesentery. (C) The two 22-cm segments are joined in a *U* shape and then closed in the opposite direction, sewing each suture line with running 3-0 polyglycolic acid sutures. The reservoir is then folding it in half in the opposite direction to which it was opened. (D) Construction of the antireflux T pouch modification. The afferent limb segment is separated from the reservoir segment. The butt end of the afferent limb is closed. The *dotted line* depicts the incision line on the 44-cm segment to detubularize the portion for the reservoir. The incision is, diverted laterally near the two ends to form the flap for the afferent limb tunnel. The two ends of the reservoir are closed. Mesenteric windows are opened between the vascular arcades adjacent to the serosa of the afferent limb, and a piece of small Penrose drain is placed through each mesenteric window. The serosa of the two limbs of the reservoir is brought together through the windows with interrupted 3-0 silk sutures to fix the backing of the tunneled afferent limb. Multiple sutures are placed through each window to secure the fixation while maintaining good blood supply to the afferent limb. (E1) The afferent limb is fixed in place. (E2) The flaps of the reservoir are closed over the top of the fixed distal afferent limb, and the opening is matured into the reservoir. (F) For either the Studer or T pouch, the reservoir is folded in half, and the anterior wall is closed with a two-layer 3-0 polyglycolic acid running suture. A fingerbreadth opening can be left in the most dependent end of the suture line for the urethral anastomosis, or, alternatively, a separate buttonhole opening can be made in the reservoir. (G) Each ureter is spatulated, and an end-to-side ureteroileal anastomosis is performed using interrupted 4-0 polyglycolic acid sutures and stents placed. (H) The reservoir is anastomosed to the urethra using the previously placed urethral sutures. (Copyright 2012 Laramie Studio. Used with permission.)

T Pouch Modification

In an effort to preserve an antireflux mechanism but avoid the potential long-term complications seen with the Kock nipple valve, and to allow for more flexibility in managing the ureters, Stein and Skinner developed the T pouch with construction of an antirefluxing afferent limb as a modification of Ghoneim and Abol-Enein's serous-lined ureteral tunnel. They reported their results with intermediate follow-up of 209 patients (Stein et al., 2004; Stein and Skinner, 2006). The ileum is divided between the proximal afferent ileal segment and the 44-cm segment, and the antireflux mechanism is created by anchoring the distal 3 to 4 cm of the 15-cm afferent ileal segment into the serosal-lined ileal trough formed by the base of the two adjacent 22-cm ileal segments. Mesenteric windows of Deaver are opened between the vascular arcades on the T limb. A series of 3-0 silk sutures is then used to approximate the serosa of the two adjacent 22-cm ileal segments at the base of the U, with the sutures being passed through the previously opened windows of Deaver to anchor the afferent limb (see Fig. 141.9D, E1, and E2). Initial descriptions of the T pouch included tapering the distal portion of the afferent segment after it had been fixed into the tunnel to decrease its diameter and decrease the risk for reflux. However, these efforts appeared to be associated with occasional late stenosis of the end of the afferent valve. In 2004, the author (E.C.S.) stopped tapering the distal afferent limb with improved results.

When the incision in the U limb of reservoir reaches the level of the afferent ostium, it is extended directly lateral to the antimesenteric border of the ileum and carried upward (cephalad) to the base of the ileal segment. This incision provides wide flaps of ileum that are brought over the afferent ileal segment and sutured in two layers to create the antireflux mechanism in a flap-valve technique. An interrupted mucosa-to-mucosa anastomosis is then performed between the ostium of the afferent ileal limb and the incised intestinal ileal flaps with 3-0 polyglycolic acid sutures (see Fig. 141.9E2). The rest of the neobladder is constructed in the same fashion as the Studer pouch. Ureteral stents are internalized into the pouch and sewn to the indwelling urethral catheter, and no suprapubic tube is used.

Colon and Ileocolic Pouches

Orthotopic neobladders constructed completely of colon are a good option for patients with multiple previous small bowel resections or who have diseased ileum. Colon segments are less distensible than ileal segments and may be more likely to produce higher-pressure waves causing incontinence (Khafagy et al., 2006). As a consequence, initial volume should be larger than for an ileal pouch. Combined colon and ileal segments can mitigate this problem.

Orthotopic Mainz Pouch (Mainz III)

The Mainz (“mixed augmented ileum and zecum”) pouch was initially described as a continent catheterizable reservoir that was subsequently modified into an orthotopic neobladder (Eisenberger et al., 1999; Thuroff et al., 1986). A 10- to 15-cm segment of cecum, in continuity with a 20- to 30-cm segment of ileum, is isolated. An ascending ileocolostomy is performed. The entire segment of bowel is opened along the antimesenteric border, sacrificing the ileocecal valve. The bowel is placed in a W configuration, with the first limb of the W made from cecum and the other limbs made from the ileum. The adjacent three limbs are sutured together with an absorbable suture, forming the posterior plate of the reservoir. At the cephalad portion of the cecum, tunneled ureterocolonic anastomosis is performed. A buttonhole incision is made in the cecum at the base of the reservoir, and a ureterocolonic anastomosis is performed. After this, the reservoir is closed side to side with absorbable suture (Fig. 141.10).

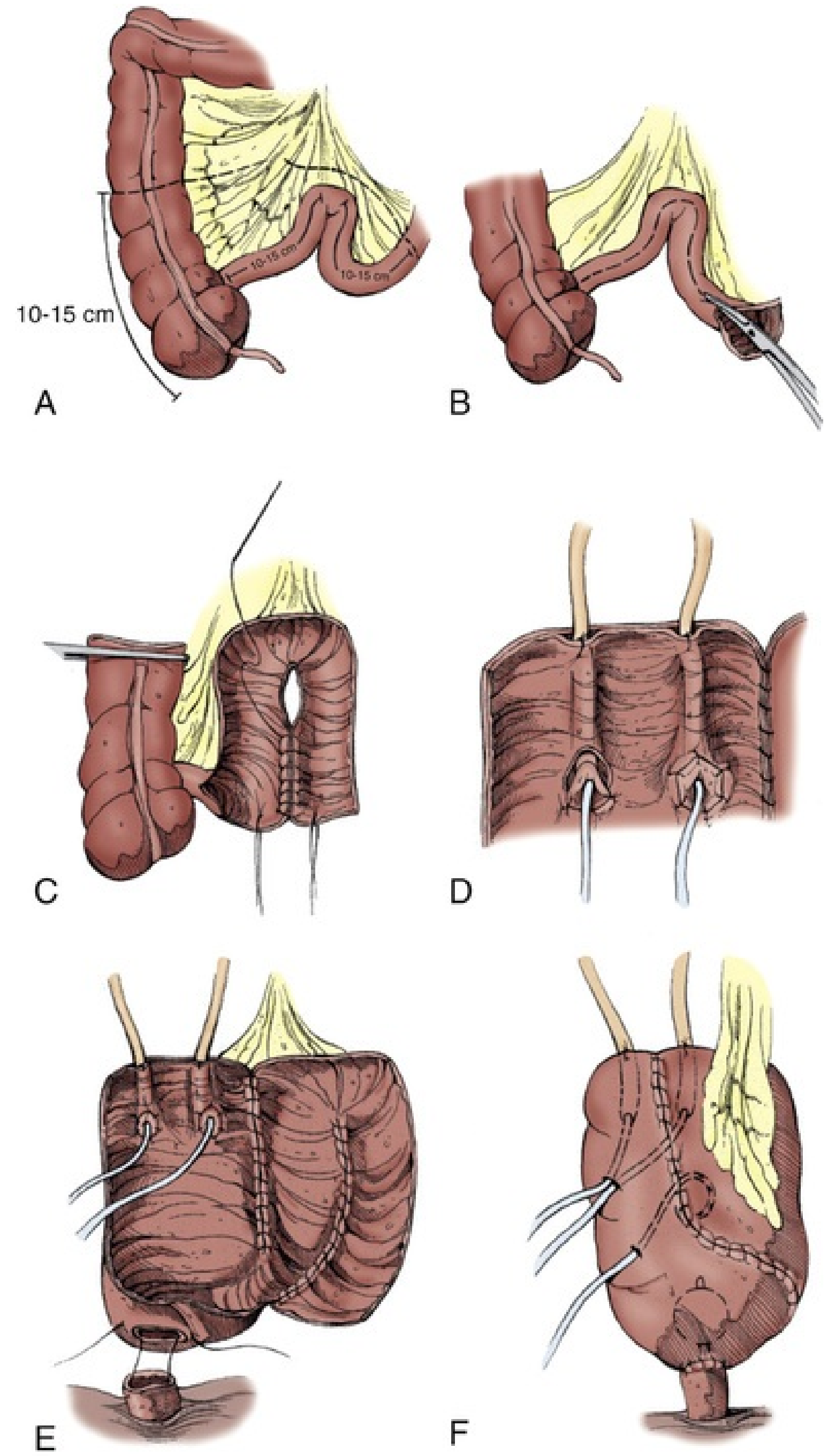

FIG. 141.10 Construction of the Mainz ileocolonic orthotopic reservoir. (A) An isolated 10 to 15 cm of cecum in continuity with 20 to 30 cm of ileum are isolated. (B) The entire bowel segment is opened along the antimesenteric border. An appendectomy is performed. (C) The posterior reservoir is closed by joining the opposing three limbs together with a continuous running suture. (D) An antireflux implantation of the ureters through a submucosal tunnel is performed and stented. (E) A buttonhole incision in the dependent portion of the cecum is made to provide for the urethral anastomosis. (F) The reservoir is closed side to side with a cystostomy tube and the stents exiting.

Right Colon Pouch

An orthotopic substitute using the right colon without ileum has been reported (Goldwasser, 1995; Goldwasser et al., 1986; Månsson and Colleen, 1990; Månsson et al., 2003). The entire right colon and cecum are isolated, and a transverse ileocolonic anastomosis is performed to provide bowel continuity. The ileal stump at the ileocecal valve is closed with a running absorbable suture. The colonic segment is then opened along the anterior taenia, leaving the proximal 2 to 3 inches of cecum intact. An appendectomy is performed, and the ureters are implanted in an antireflux fashion within the reservoir. The colon is then folded in a Heineke-Mikulicz manner and closed with a running absorbable suture. The ureterocolonic anastomosis is then performed.

Sigmoid Pouch

Patients who are candidates for radical cystectomy often have a redundant sigmoid colon, which is readily available for use. The only concern is the potential compromise of the vasculature of the distal colon segment because of interruption of branches of the internal iliac artery during the cystectomy. It is important, therefore, to maintain as much of the vascular supply to both ends of the bowel anastomosis as possible. Some patients will complain of frequent stools or rectal urgency for a period after sigmoid colectomy.

The use of the sigmoid in construction of an orthotopic substitute was initially described by Reddy and Lange (Fig. 141.11). A 35-cm portion of descending colon and sigmoid is isolated and arranged in a U configuration on the basis of the inferior mesenteric artery. The medial taenia of the U is incised down to an area just short of the urethral anastomosis. The incised medial limbs of the U are then brought together with an absorbable suture. Ureteral implantation is performed in a tunnel antireflux fashion. A small button of colon is removed from the most dependent portion of the reservoir, and the urethroenteric anastomosis is performed. The reservoir is then closed side to side (Reddy and Lange, 1987).

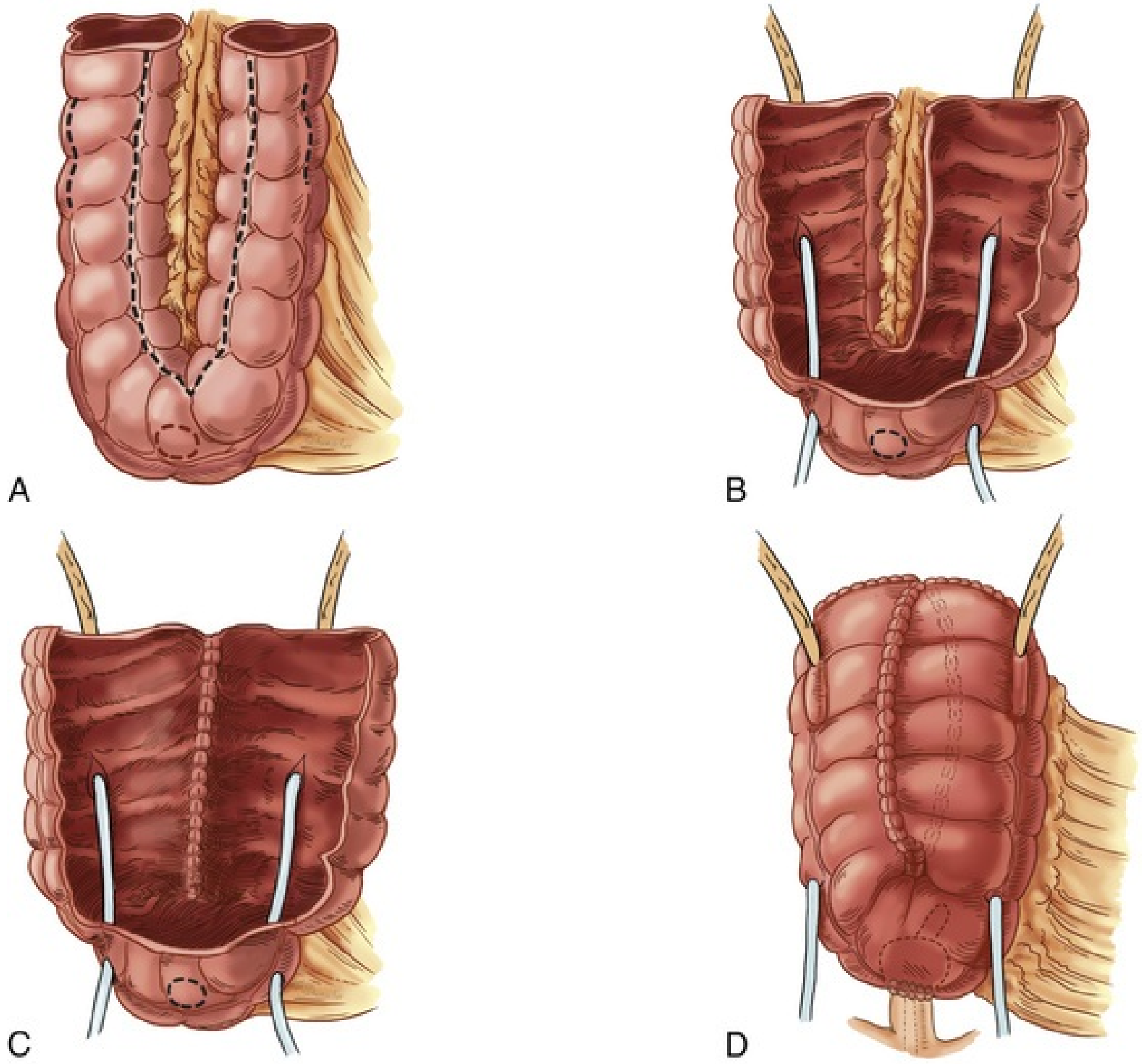

FIG. 141.11 Construction of the sigmoid (Reddy) neobladder. (A) A 35-cm segment of descending and sigmoid colon is isolated and folded into a U shape. (B) The colon is incised along the medial taenia down to a point a few centimeters short of the entire colon. A buttonhole is made in the caudal portion of the colon that is later anastomosed to the urethra. (C) The medial portions of the U are sewn together, and a tunneled ureterocolonic anastomosis is performed. (D) The colonic pouch is closed by folding the reservoir side to side, and it is anastomosed to the urethra.

DaPozzo et al. (1994) reported a modification of this technique in which the entire bowel is detubularized and then folded in a Heineke-Mikulicz fashion to provide a more spheric reservoir.

Padua Pouch (Vesica Ileale Padovana)

The Padua or VIP pouch (“vesica ileale padovana”) uses a detubularized ileal segment for neobladder configuration incorporating two layers of folding and suturing of the posterior plate with subsequent closure of the anterior neobladder wall to create a spherical anatomic bladder. The pouch is constructed from about 42 cm of distal ileum, approximately 20 cm proximal to the ileocecal valve. The optimal point of the selected bowel loop for the urethral anastomosis is identified about 12 to 14 cm proximally to the distal ileal end, after ensuring it reaches the urethral stump without tension. This is usually in the most dependent part of the neobladder. The proximal half of the loop will configure the left base, and the dome of the ileal segments is utilized to tailor the neobladder. Ureters are spatulated and passed through the posterior aspect of the neobladder. Ureteroileal anastomoses are performed according to Le Duc/Camey technique with 4-0 Monocryl interrupted sutures and stented. Finally, the anterior aspect of the neobladder is hand-sewn with two sero-serous running sutures (Fig. 141.12).

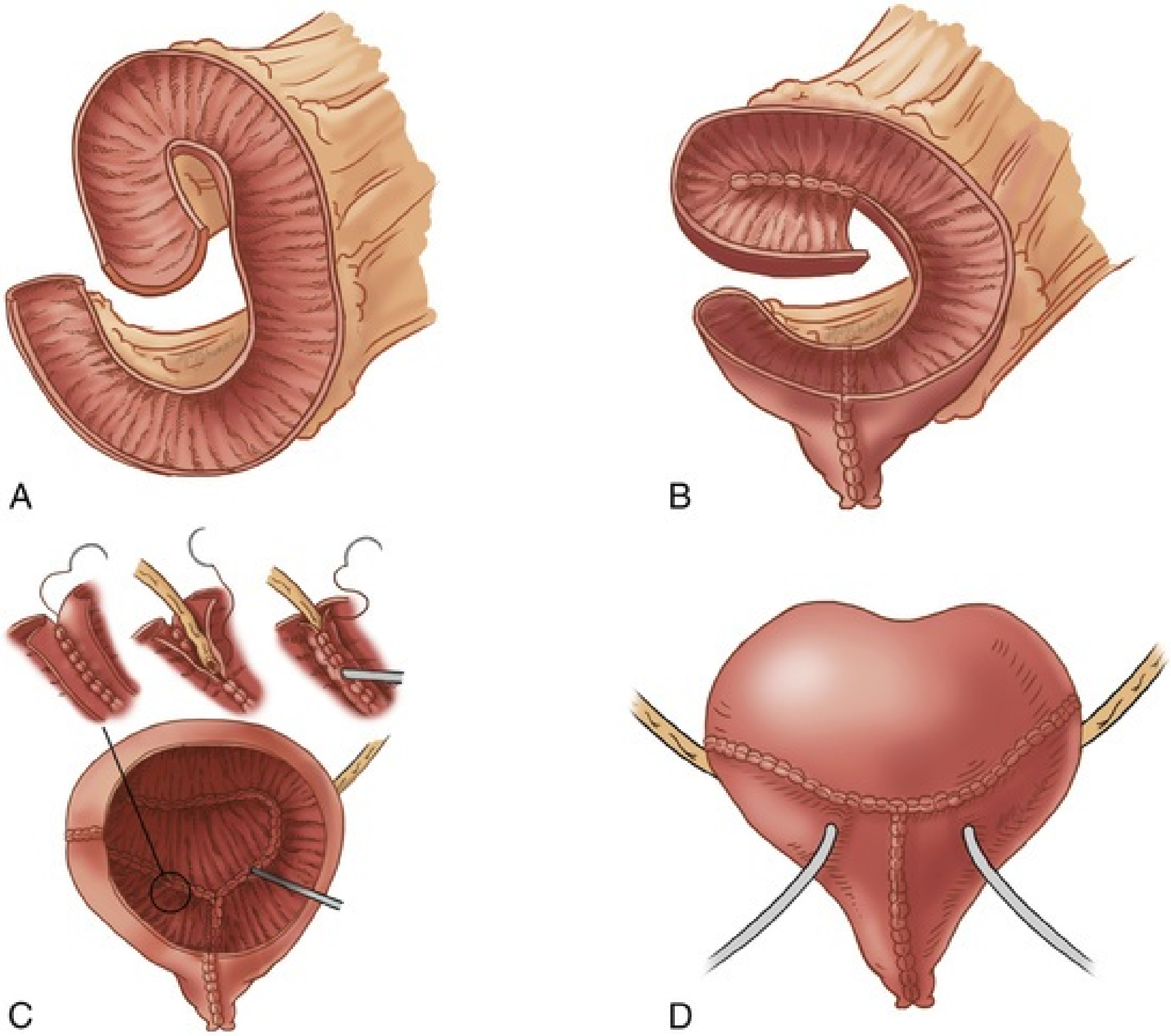

FIG. 141.12 Padua pouch (“vesica ileale padovana”). (A) A 42-cm segment of distal ileum is isolated and opened along its entire length. (B) An opening is made in the most dependent part of the segment for the urethral anastomosis, about 12 to 14 cm from the distal end of the segment. The anterior and posterior walls are sewn to create a funneled

bladder neck. The ileum is formed into a spiral shape *(as shown),* and the back wall is sutured with running absorbable sutures. (C) Before completing the posterior edge, the ureters are spatulated and passed through the posterior aspect of the neobladder and anastomosed according to Le Duc/Camey technique with 4-0 Monocryl interrupted sutures and stented. (D) The anterior aspect of the neobladder is folded together and sewn with two sero-serous running sutures. The ureteral stents are exteriorized.

Simone et al. recently reported their experience performing this technique robotically and completely intracorporeally in 45 patients with excellent functional results (Simone et al., 2018). Overall 30-day complication rates were 44.4%, and 2-year daytime and nighttime continence rates were 73.3% and 55.5%, respectively (Simone et al., 2018).

Use of Minimally Invasive Techniques for Orthotopic Diversion

Over the past 15 years, a number of surgeons have performed cystectomy using laparoscopic or robotic-assisted techniques (Gill et al., 2002; Pruthi and Wallen, 2008; Wang et al., 2008; Yuh et al., 2008). Initial attempts to perform the diversion completely intracorporeally were fraught with difficulty, and the procedure was performed with extracorporeal construction after removal of the bladder through a small midline incision (Haber et al., 2008). This allowed construction of continent diversions, both cutaneous and orthotopic. The Studer ileal neobladder has been the most popular because of ease of mobilization of the segment and simpler bowel anastomosis with a low abdominal incision. In the case of orthotopic neobladders, some authors reestablish the pneumoperitoneum and redock the robot to complete the urethral anastomosis. Others perform the anastomosis in an open fashion (Pruthi and Wallen, 2008).

Postoperative recovery in most series has only been modestly improved compared with open series, with longer operative times but decreased blood loss. Some series have reported reduced ileus and shorter hospital stay (Haber et al., 2008; Huang et al., 2008; Nix et al., 2010; Ng et al., 2010; Wang et al., 2008), but these were generally selected patients. Other unselected large series have shown that postoperative complications were equivalent or even increased compared with open series (Parekh et al., 2013; Raza et al., 2013; Yuh et al., 2012). **A randomized single-institution trial confirmed longer operative time and less blood loss, but no difference in other complications or short-term**

outcomes (Bochner et al., 2015). A multi-institutional prospective randomized noninferiority trial accrued 302 evaluable patients and found longer surgery time, lower blood loss and transfusion rates, and 1 day shorter average length of stay (6 vs. 7 days) for patients undergoing robotic-assisted surgery, with no difference in progression-free survival at 2 years. They also found no difference in major early complications or quality of life between the two arms (Parekh et al., 2018).

With increased robotic proficiency, several centers have gained experience in construction of the neobladder intracorporeally (Dason et al., 2018; Goh et al., 2012, Hussein et al., 2018). This remains a technically difficult procedure, even in the hands of surgeons with extensive robotic experience. The prospect of prolonged operation times and steep learning curves for similar length of stay and higher costs necessitate that these procedures be performed in centers of excellence with highly specialized robotic skills to facilitate superior outcomes. There is a lack of studies with comparable functional, quality-of-life and long-term outcomes of intracorporeal diversion techniques. Robotic cystectomy and urinary diversion are covered extensively in other chapters.

Results and Complications of Orthotopic Urinary Diversion

Early and Late Complications

A complete discussion of the complications of radical cystectomy and diversion is outside the scope of this chapter. These complications could have detrimental effects on health and quality of life, and they may even be life-threatening. Long-term follow-up of patients with urinary diversion is of utmost importance as many diversion-related complications occur years after surgery (Amini and Djaladat, 2017; Ali-El-Dein et al., 2008; Hautmann et al., 2010, 2011; Konety et al., 2006; Quek et al., 2006; Shabsigh et al., 2009). **Early complications include bleeding, thrombotic events, infection, and cardiovascular and pulmonary complications, which are not directly related to the urinary diversion** and do not appear to be different in patients undergoing different types of diversion. Gastrointestinal complications, particularly ileus, are also common after cystectomy and are at least partially related to the need for a bowel anastomosis, which is common to all types of diversion (Bazargani et al., 2018). Similarly, urine leak and ureteral complications are possible with any type of diversion. A number of authors have shown that the overall rate of complications, hospital stay, and reoperation rates are not increased by use of continent diversion compared with ileal conduit diversion (Benson et al., 1992; Gburek et al., 1998; Parekh et al., 2000a).

Urine leaks may be more common in continent diversion than in conduits because of the long suture lines, but with good catheter drainage and properly managed stents and drains, these usually resolve with observation alone as long as a urinoma does not form. **If a patient has an undrained leak, an attempt at percutaneous drainage and/or bilateral nephrostomy tube placement is preferable to open surgical repair.** The latter is extremely difficult during the first few weeks after the initial surgery and is likely to be complicated by enterotomies and a risk for fistula formation. In our experience, less than 5% of patients require some sort of percutaneous drain or nephrostomy tube placement during the early postoperative period to manage these problems.

Both early and late complications may also be influenced by other factors such as prior radiation therapy, diabetes, and other comorbidities. Late complications are also influenced by tumor recurrence and the use of adjuvant or salvage systemic chemotherapy or radiation, and these causes may be difficult to separate out from causes related to the surgery. Late complications not directly related to the diversion include bowel obstruction, ventral hernia, thrombotic events, and cardiovascular problems common to patients in this age group. Hautmann et al. (2011) made the point that most late complications increase with time and are best described using Kaplan-Meier curves rather than as simple percentages. Ventral hernias are quite common and may be in part related to the need for increased abdominal pressure to empty the neobladder. The poor fascial strength associated with advanced age and smoking undoubtedly contributes to this risk as well.

The primary late complications of orthotopic diversion that are directly related to the diversion itself include incontinence, urinary retention, urinary tract infection, ureteroileal or afferent limb obstruction, urethral stricture, upper tract and pouch stones, vaginal fistula, and pouch rupture. Most of these can be managed by endoscopic procedures and rarely require open surgical revision (Amini and Djaladat, 2017; Hautmann et al., 2011; Rowland, 1995).

Although symptomatic urinary infections do occur, asymptomatic colonization of the neobladder with bacteria is also very common, particularly if the patient is on intermittent self-catheterization (Suriano et al., 2008). Incidence of urinary tract infection is comparable between conduit and continent diversions (Al Hussein et al., 2015). Wood et al. (2003) reported on 66 patients undergoing orthotopic refluxing ileal neobladder, 11 of whom (17%) were performing intermittent self-catheterization. Positive urine cultures were found in 39%. Symptomatic urinary tract infections are uncommon after the initial 90-day postoperative period. Hautmann et al. (2011) found a cumulative risk for febrile infections of only 5.7% in 923 patients undergoing ileal neobladder with a 72-month median follow-up. Infections were most common in the first year and occurred in 13.6% of those with poor emptying compared with only 3.4% in those who emptied well (Hautmann et al., 2011; Steven and Poulsen, 2000). Bowel mucosa in contrast with urothelium is not capable of inhibiting bacterial proliferation. Treatment of asymptomatic bacteriuria is likely to simply encourage development of resistant organisms and is often unnecessary. However, patients with symptomatic infection and those with positive cultures for *Proteus* or *Pseudomonas* require treatment because these infections may result in renal function deterioration (McDougal, 1986). **A patient who develops**

a febrile urinary infection or pyelonephritis after the initial few months should be evaluated for possible upper tract obstruction, stones, or incomplete emptying. Daily suppressive antibiotics with nitrofurantoin, sulfa, or methenamine may be helpful in the patient with recurrent symptomatic urinary infections in whom an anatomic cause has been ruled out.

Pouch perforation is rare because outlet resistance is usually low. The risk may be increased in patients who have had previous radiation therapy or are in chronic retention. It is a potentially life-threatening complication when it occurs. Patients with a perforation typically have acute abdominal pain and distention, often with signs of sepsis. A cystogram is usually diagnostic. If the patient is stable, conservative management with catheter drainage with or without percutaneous drains can be considered (Hautmann et al., 2013; Månsson et al., 1997; Singh and Choong, 2004).

The rate of ureteroileal stricture is identical to that in ileal conduit diversion and is influenced by the type of anastomosis. **The direct end-to-side Leadbetter or the combined Wallace anastomoses with interrupted fine absorbable sutures have been shown to have the lowest risk for stricture, approximately 3% to 6%** (Hautmann et al., 2011, 2017; Pantuck et al., 2000)**. Obstruction from an antireflux valve has been seen in both hemi-Kock pouches and in the extraserosal tunneled afferent limb of the T pouch** (Stein et al., 1996, 2004). In a randomized clinical trial comparing refluxing and nonrefluxing ureteroenteric anastomosis, Shaaban et al. (2006) showed that nonrefluxing anastomoses are associated with a significantly higher rate of ureteral obstruction and subsequent renal function deterioration. Stricture usually occurs within a few months of surgery but can occur even after 10 years. Therefore, lifelong observation for ureteral stricture is imperative in patients with urinary diversion. Previous history of abdominal/pelvic irradiation has been postulated to increase the risk for ureteroenteric anastomosis; however, in a recent large series from the University of Southern California, multivariate logistic regression analysis did not show any correlation between ureteroenteric anastomosis stricture and history of perioperative radiation therapy. (Shah et al,. 2015). Surgical technique is the most important determining factor, and ureteroileal anastomosis should be performed using meticulous surgical techniques. Strictures may be clinically silent until the patient develops bilateral hydronephrosis or even renal failure. Diagnosis may be suspected on CT or ultrasonography and can be confirmed on retrograde pyelography or antegrade nephrostogram. **CT scans often will be misinterpreted by radiologists or urologists who are unfamiliar with the anatomy and/or the specific type of neobladder.** The obstructing antireflux segment may be managed by endoscopic incision of the valve mechanism. It can be technically challenging to find the afferent limb in some cases, and special techniques may be necessary to catheterize and incise it (Dunn et al., 2007). Although in selected cases endourologic techniques may be effective, overall success rate is much lower compared with open surgical repair, and the retreatment rate exceeds 50% (Schondorf et al., 2013).

Pouch stones were very commonly seen in the Kock neobladder because of the use of surgical staples to maintain the intussuscepted nipple valve, with the incidence increasing steadily with time (Stein et al., 1996). Stones have been rare in the Studer and Hautmann neobladders, which are made entirely with absorbable suture (Studer et al., 2006; Hautmann et al., 2011). Recently several authors have advocated use of a metal GIA stapler to speed up the construction of an ileal neobladder. In one such series of 50 patients, stones were found in 6% of patients with only a 20-month median follow-up (Barbalat et al., 2012; Fontana et al., 2004). A larger series of more than 600 patients who underwent a stapled form of Camey II found a 4.5% rate of stone formation at 5 years (Muto et al. 2016). It is predictable that the incidence of such stones will increase with more follow-up, and although they can be managed endoscopically this carries significant cost in both money and inconvenience for patients and may lead to further complications (Suriano et al., 2013).

Pouch-vaginal fistula is a unique complication of orthotopic neobladder in women that can be quite difficult to repair. The reported incidence in larger series is 5% to 10%, and the risk is increased if a portion of the anterior vaginal wall is excised along with the cystectomy specimen and in irradiated patients (Ali-El-Dein et al., 2008, 2013; Granberg et al., 2008; Rosenberg et al., 2018). **Prevention methods include vaginal-sparing techniques whenever it is safe from an oncologic standpoint, careful watertight closure of the vaginal cuff when it is opened, and placement of an omental flap** between the vagina and neobladder, secured to the perivaginal tissue on either side of the urethral anastomosis (Stein and Skinner, 2006). In the early postoperative period, any concern about vaginal urinary leakage should be evaluated with a lateral cystogram before removal of the catheter. Fistula should also be ruled out in any woman with persistent significant incontinence after the first few months of recovery. This is most easily done with a careful pelvic examination and with methylene blue instilled into the neobladder if necessary.

Beyond the initial few weeks, a pouch-vaginal fistula is unlikely to heal spontaneously or with catheter drainage or percutaneous nephrostomy tubes alone. Repair may be attempted transvaginally, although reported success varies (Ali-El-Dein and Ashamallah, 2013; Ali-El-Dein et al., 2008; Rosenberg et al., 2018; Rapp et al., 2004; Smith, 2005). Repair may ultimately require transabdominal exploration or even conversion to a cutaneous form of diversion.

Continence

The prevalence and severity of urinary incontinence may be influenced by a number of variables including age and gender of the patients, prior treatments (such as radiation or prostate surgery), surgical techniques, and surgeon experience. In addition, the definitions of continence, the method of data collection (e.g., retrospective chart review, telephone interview, or anonymous validated questionnaire), and the length and diligence of follow-up have varied tremendously among different reports (Clifford et al., 2016; Hautmann et al., 2013; Thuroff et al., 1996). Although there is general consensus that the ideal tool for studying functional outcomes is a validated patient-completed questionnaire, all the tools available today have significant drawbacks. The widely used Bladder Cancer Index (BCI) was developed to be applicable to all types of urinary diversion. It captures urinary leakage but not details such as the severity of incontinence or pad use (Gilbert et al., 2007). Only a few reports have used questionnaires such as these to evaluate neobladder patients (Ahmadi et al., 2013; Clifford et al., 2016; Jentzmik et al., 2012; Stein et al., 2009). **In summary, one should use caution in attempting to compare continence results from different series of patients with orthotopic diversion.** We have summarized results from some of the largest series in Tables 141.1 and 141.2.

TABLE 141.1

Results With Orthotopic Diversion in Series With Predominantly or Only Male Patients

AUTHOR	TYPE OF RESERVOIR	NO. OF PATIENTS	FOLLOW-UP (MONTHS)	MEAN AGE (YEARS)	MORTALITY (%)	C E (
Thuroff et al., 1986	Mainz, ileocecal	61	46	NA	NA	5

Månsson and Colleen, 1990	Right colon	67	70	61	3	4
Studer et al., 1996	Studer, ileum	200	30	64	2	N
Cancrini et al., 1996	Studer, ileum	96	28	60	6	6
Barre et al., 1996	Camey II, ileum	110	32	62	1	N
Elmajian et al., 1996	Kock, ileum	295	42	66	1	7
Kolettis et al., 1996	Ileocecal., Le Bag)	38	14	61	0	8
Hautmann et al., 1999	W, ileum	363	57	63	3	1
Steven and Poulsen, 2000	Kock, ileum	166	32	62	0	1
Hollowell et al., 2000	W, ileum	50	20	62	2	1
Abol-Enein and Ghoneim, 2001	Serous-lined extramural, ileum	450	38	47	0.8	9
Constantinides et al., 2001	Ileal S pouch	52	30	63	3.8	1
Stein et al., 2004	T pouch, ileum	209	33	69	1.4	5
Laguna et al., 2005	Sigmoid	49	38	63	0	N
Ahmadi et al., 2013	Ileum (Studer or T pouch)	179	54	70	NA	N
Clifford et al., 2016	Ileum (Studer or T pouch) (Prospective)	188	>36	67	NA	N
Nayak et al., 2018	Ileum	158		63	NA	N

[a] Complications reported related to urinary diversion; definitions vary by report.

[b] Continence results from validated patient-completed questionnaires.

IC, intermittent catheterization to empty neobladder; *NA,* not available from report.

TABLE 141.2

Results of Orthotopic Diversion in Series Limited to Female Patients

AUTHOR	TYPE OF RESERVOIR	NO. OF PATIENTS	MEAN FOLLOW-UP (MONTHS)	MEAN AGE (YEARS)	MORTALITY (%)	COM
						EAR (%)
Stenzl et al., 2001	Ileum	102	26	59	0	5
Granberg et al., 2008	Ileum (Studer)	59	29	62	0	22
Ali-El-Dein et al., 2008	Ileum, serous-lined extramural tunnel	192	51	54	2	16
Stein et al., 2009	Ileum (Studer or T pouch)	120 (*n* = 56 for continence results)	103	66	2.5	32
Jentzmik et al., 2012	Ileum (Hautmann)	131	56	61	1.7	16
Anderson et al., 2012	NA	49	37	60	NA	NA
Bartsch et al., 2014	Ileum (Studer or T pouch)	56	63	64	NA	NA

[a] Complications reported related to urinary diversion; definitions vary by report.

[b] Continence results from validated patient-completed questionnaires.

IC, Intermittent catheterization to empty neobladder; *NA,* not available from report.

Common observations from series of patients undergoing orthotopic diversion include a gradual period of improvement in daytime continence over the first 6 to 12 months with a slower improvement in nighttime continence, even into the second year. In a pooled analysis of 2238 patients with various forms of orthotopic neobladder, daytime incontinence was reported in an average of only 13% of patients. Risk factors for daytime incontinence included advanced age of the patient (older than 65 years), use of colonic segments, and in some series lack of nerve-sparing techniques (Furrer et al., 2018; Kessler et al., 2004). Other series have identified hysterectomy in women and diabetes as a risk factor for poorer continence results (Ahmadi et al., 2013; Anderson et al., 2012; Steers, 2000). Ahmadi et al. (2013) reported on a group of 263 male patients without prior radiation who were at least 12 months out from a cystectomy and neobladder (Studer or T pouch). They were mailed the validated BCI with some additional questions designed to elucidate the types and degree of wetness of pads and the impact of mucous leak. The response rate was 68%, and 139 of 179 responders used pads at least sometimes, one-half of whom used them both in the day and at night. Forty-seven percent used pads in the day, with one-third of those using a small pad or minipad, and almost one-half found that the pad was usually dry or only slightly wet. Nighttime use was 72%, with most using a medium or heavy pad. Older age and diabetes correlated with poorer outcomes. The degree of incontinence and the urinary function scores on the BCI did not correlate well with the degree of bother from these symptoms, which was generally low (Ahmadi et al., 2013). We recently reported our continence outcomes in a prospective study of 188 male patients using a previously validated pictorial pad usage questionnaire. Daytime continence (defined as no pad use or pads "almost dry") peaked at 92% at 12 to 18 months postoperatively, and nighttime continence peaked at 51% at 18 to 36 months. Age older than 65 and diabetes were associated with poorer daytime continence. Only 10% of the patients reported clean intermittent catheterization at any time point in the postoperative period (Clifford et al., 2016).

Nighttime incontinence remains one of the most bothersome sequelae of neobladders, occurring in up to 50% of patients (see Tables 141.1 and 141.2) (Steers, 2000). Nocturnal incontinence results in part from the absence of neurologic feedback and sphincter detrusor reflex, and decreased sphincter tone and urethral sensitivity at night (Hugonnet et al., 1999). There is also physiologic nocturnal diuresis with an inability to concentrate the urine and a reversal of the normal antidiuretic effect of nighttime dehydration because of secretion of water by the bowel mucosa, which decreases with time (El-Bahnasawy et al., 2000). Instructing the patient to completely empty immediately before bedtime and to awaken two or three times with the assistance of an alarm clock if necessary may significantly reduce nighttime incontinence. We and others have observed that nighttime incontinence may improve as late as 24 months after surgery, and it is not a cause of major disturbance in quality of life for most patients (Elmajian et al., 1996; Granberg et al., 2008). A small study suggested that nightly desmopressin may help to reduce nocturia in patients with neobladders (Goldberg et al., 2014).

In women, preservation of the uterus may significantly affect the functional results of neobladder construction. Anderson et al. (2012) retrospectively reviewed 49 women who underwent cystectomy and neobladder procedures. Of the women, 31% had had a prior hysterectomy, 29% underwent hysterectomy at the time of cystectomy, and 40% had the uterus preserved. Women with the uterus preserved had better daytime continence. Ali-El-Dein et al. (2013) also reported on a small group of women who underwent uterus-sparing cystectomy with excellent short-term results. Studer also reported better functional outcomes in women undergoing preservation of the uterus and attempted nerve sparing (Gross et al., 2015). There is also suggestion that sexual function may be better preserved with this approach (Bhatt et al., 2006; El-Bahnasawy et al., 2011; Zippe et al., 2005).

Stein et al. (2009) previously reported results using the same questionnaire in 56 women. They found that 23% had frequent leakage or no control during the day and 34% during the night, with 61% requiring self-catheterization at least once daily (Stein et al., 2009, Bartsch et al., 2014). These results may more accurately reflect the true patient experience compared with reports from chart reviews.

The evaluation and management of urinary incontinence after orthotopic diversion should be delayed until the neobladder has had time to expand and patients' continence status has plateaued, which may take up to 12 to 18 months (Granberg et al., 2008; Grossfeld et al., 1996; Studer et al., 2006). Physical therapy with biofeedback focused on the pelvic floor muscles may help some patients attain initial continence (Johnson et al., 2017; Parekh et al., 2003). Urodynamic investigation may be indicated to ensure adequate capacity, without pressure waves, especially if colon is used for the neobladder. If reduction in maximal urethral closure or low Valsalva leak pressure is demonstrated, transurethral injection of bulking agents may be considered, but it has had only marginal results in our experience. Alternatively, in men an artificial urinary sphincter or urethral sling can be considered and may provide a more definitive treatment (Simma-Chiang et al., 2012). In women, although injection of urethral bulking agents provides a minimally invasive approach with some positive results (Tchetgen et al., 2000), it is best used for women with minimal symptoms of incontinence, with overall success rates below 50% and with less than optimally durable responses (Wilson et al., 2004). Newer agents that do not absorb over time may have improved results. Pubovaginal sling procedures for incontinence may be more effective than bulking agents in women with incontinence after orthotopic reconstruction; however, most of these patients will subsequently need to perform intermittent catheterization. It is important to note that one should avoid blind passage of needles or sling material into the pelvis in these patients because of a high risk for injury to the pouch or a loop of bowel stuck to the pubic symphysis. Use of infrapubic bone anchors or a prepubic approach may provide the safest surgical options (Quek et al., 2004).

Urinary Retention

Patients with incomplete emptying may have acute retention but more often have recurrent urinary infections or the new onset of overflow incontinence. They may also be discovered on routine follow-up with a palpable suprapubic mass, or distended reservoir or new-onset hydronephrosis on imaging. The development of retention may occur early but is often a late event, so the reported rates are heavily influenced by the length of follow-up of the series. Risk factors for urinary retention in patients with an orthotopic reservoir include the use of excessive intestinal length for the reservoir and the use of prostate-sparing technique (Ji et al., 2010; Steers, 2000; Stein et al., 2004; Steven and Poulsen, 2000). Some authors have suggested that the location of the urethral anastomosis in the neobladder may contribute to retention in men because of folding of the neobladder (Thurairaja and Studer, 2008), but our experience using the end of the suture line for the urethral anastomosis in an ileal neobladder has resulted in a similarly low incidence of retention (Ahmadi et al., 2013; Clifford et al., 2016; Stein et al., 2004). **Actual stricture of the neobladder-urethral anastomosis is rare.** In the series from Ulm with 923 patients and a 72-month median follow-up, such strictures developed in only 11 patients (1.2%) in the absence of tumor recurrence. More distal urethral strictures developed in an additional 8 patients (Hautmann et al., 2011).

Rectal or vaginal examination and cystoscopy should be performed in patients who develop retention to rule out a urethral anastomotic stricture or tumor recurrence. Urinary retention is best managed by intermittent self-catheterization (Steers, 2000), and pharmacologic intervention for patients does not help. Some authors have suggested that many of these patients have a flap of mucosa causing the obstruction that may be incised endoscopically with favorable results (Thurairaja and Studer, 2008). Others have not found this to be a common cause of retention (Simon et al., 2006).

A significant number of patients with orthotopic reservoirs will develop abdominal wall or incisional hernias postoperatively. In the series from Ulm, the estimated risk by Kaplan-Meier analysis was 4% at 5 years and 6% at 10 years (Hautmann et al., 2011). In a prospectively followed patient population, it was as high as 13% at 3 years (Fairey et al., 2013). These fascial defects may reduce the efficiency in completely evacuating the neobladder by reducing the ability to effectively increase intra-abdominal pressure.

In women, the exact cause of retention is still unclear. Some have suggested that posterior prolapse of the pouch may contribute to late retention, and posterior support by means of omental flaps and sacrocolpopexy has been advocated (Ali-El-Dein et al., 2002; Lee et al., 2004; Stein and Skinner, 2004; Stenzl and Höltl, 2003). Ali-El-Dein et al. (2002) elegantly studied the possible causes of chronic retention after radical cystectomy and orthotopic bladder substitution in women. In a series of 136 women undergoing radical cystectomy and orthotopic substitution, 16% were found to be in chronic retention. Video-urodynamics showed that retention appeared to be mechanical in nature; the pouch has fallen back in the wide pelvic cavity, resulting in acute angulation of the posterior pouch–urethral junction. In addition, herniation of the pouch wall through the prolapsed vaginal stump was observed in most patients. Pelvic floor electromyography demonstrated complete pelvic floor silence during voiding, suggesting that urinary retention was not related to a neurogenic cause. The authors suggested that transposition of the omentum behind the reservoir, suturing of the peritoneum on the rectal wall to the vaginal stump, suspension of the vaginal stump by the preserved round ligaments, and suspension of the pouch near the dome to the back of the rectus muscle at cystectomy would help reduce the incidence of chronic retention. We have routinely performed a formal sacrocolpopexy suspension of the vaginal apex to the sacrum, but this alone has not eliminated retention (Bartsch et al., 2014).

Preservation of the uterus and its ligament support structures may significantly reduce the risk for retention in women and should be considered when feasible (Ali-El-Dein et al., 2013; Anderson et al., 2012). Others have suggested that preservation of the neurovascular bundle that runs along the lateral vaginal wall is important in allowing effective relaxation of the urethral sphincter to empty (Gross et al., 2015). None of these theories has yet been addressed with a prospective randomized trial.

Key Points: Continence and Urinary Retention

- Daytime continence develops gradually over 3 to 6 months in most patients and is ultimately achieved in 80% to 90% of both male and female patients.

- Persistent nocturnal incontinence is common, observed in 20% to 50% of patients. Nocturnal continence may continue to improve beyond 12 months from surgery and may improve with timed voiding.
- Factors influencing continence rates include age, intestinal segment used, and application of a prostate-sparing technique.
- Failure to empty or urinary retention has been reported in 4% to 10% of men and 20% to 60% of women.

Follow-Up for Patients With Orthotopic Diversion

There is no consensus on the ideal follow-up regimen for patients with orthotopic diversion. Imaging techniques include intravenous urography (rarely performed today), CT urography, magnetic resonance imaging, and ultrasonography. Physicians in the United States tend to depend more on radiographic imaging, whereas those in Europe often rely more on ultrasound evaluation. Regardless of the type of imaging, the follow-up regimen can be divided into three time segments:

- Early evaluation (first 4 months) to identify early ureteroileal anastomotic strictures caused by technical difficulties or poorly vascularized distal ureters
- Intermediate period (4 months to 3 years) primarily focused on detecting cancer recurrence. This is best managed with CT or other cross-sectional imaging, which also allows evaluation of the upper tracts and reservoir for stones or obstruction. The frequency of the follow-up can be risk-adapted according to the pathologic findings at the time of cystectomy and the risk for subsequent recurrence.
- Long-term follow-up (beyond 3 years) to detect pouch stones, late upper tract obstruction, and urothelial carcinoma arising in the urethra or upper tracts

Our current follow-up scheme is shown in Box 141.1, but others have been described (Thurairaja and Studer, 2008; Yafi et al., 2012). We routinely perform cytology on both voided urine and in selected cases urethral wash in male patients with orthotopic diversion, especially those with CIS in their prostatic urethral pathology. It does require a cytologist with experience in looking at urine specimens from neobladder patients to be adept at evaluating them. Women should be evaluated with bimanual examination and voided cytology, because urethral recurrence, although rare, will not be evident on CT scan. Cystoscopy should be performed in any patient who develops new-onset retention, a change in voiding pattern, or hematuria.

Box 141.1

Suggested Follow-Up Protocol for Bladder Cancer Patients After Cystectomy and Orthotopic Diversion

Every 4 Months First Year, Then Every 6 Months to 3 Years, and Then Annually

Physical examination including pelvic and rectal examination
Serum comprehensive metabolic panel, complete blood count

Annual Visits Only

Urethral wash cytology (if carcinoma in situ on pathology)
Vitamin B_{12} level
Prostate-specific antigen (if prostate cancer on pathology)

Imaging Depending on Cystectomy Pathology

Stage pT3 or N+ or higher: computed tomography (CT) of abdomen and pelvis with intravenous contrast, CT of chest, or chest radiograph at each visit
Stage pT2 or lower: CT abdomen and pelvis with IV contrast and chest radiograph at 4 and 12 months, then annually to 5 years, and then every 2 years thereafter (may replace with ultrasonography after 3 years)

Key Points: Complications From Orthotopic Neobladders and Recommended Follow-Up

- Early morbidity and mortality of cystectomy and orthotopic diversion are not increased compared with ileal conduit.
- Undrained urine leak is best managed using percutaneous drains and bilateral nephrostomy tubes when necessary. Early open surgical revision should be avoided.
- The majority of late urologic complications related to the neobladder can be managed using endoscopic techniques.
- Patients require regular follow-up imaging to identify upper tract obstruction and stones, which may be clinically silent.
- Follow-up should include physical and pelvic examination and urethral cytology to identify urethral recurrence, which occurs in approximately 10% of males and rarely in females.

Quality of Life After Orthotopic Urinary Diversion

During the past several decades, there has been an increasing focus on quality-of-life issues and outcomes in various urologic diseases. This has been aided by the development of new health-related quality-of-life (HRQoL) instruments for use specifically in urology. Urinary diversion is often a life-altering procedure, and quality-of-life issues are becoming increasingly important in selection of the type of urinary diversion. Urinary incontinence and leakage are the most commonly investigated domain among HRQoL in bladder cancer patients.

Initial studies in the 1980s pioneered comparative evaluation regarding quality-of-life issues in patients with different forms of urinary diversion after cystectomy (Månsson et al., 1988). They demonstrated that, in general, patients were satisfied with their diversion and adapted reasonably well socially, physically, and psychologically. This group also demonstrated the importance of how quality-of-life data are collected in terms of the results obtained (Månsson et al., 2004).

A study by Henningsohn et al. showed similar distress levels between orthotopic neobladder patients and matched control populations 1 year after surgery; however, another study showed that nearly one-half of cystectomy patients report general distress (Henningsohn et al., 2002; Palapattu et al., 2004). Most studies point out the importance of body image in patients undergoing urinary diversion.

Hart et al. (1999) reported on a total of 221 patients (25 ileal conduit, 93 cutaneous Kock pouch, and 103 orthotopic neobladder) who completed four self-reported questionnaires including a profile of mood states and adapted versions of the sexual history form, body image dissatisfaction scale, and quality-of-life questionnaire. This study compared self-reports of emotional distress; global quality of life; sexuality; body image dissatisfaction; urinary diversion problems; and problems with social, physical, and functional activities. Regardless of the form of urinary diversion, the majority of patients reported good overall quality of life, little emotional distress, and few problems with social, physical, or functional activities. **After controlling for age, the researchers found no significant differences in any quality-of-life area among the urinary diversion subgroups.** Several studies suggest that patients with a neobladder report better body image compared with patients who have an ileal conduit (Table 141.3). This may reflect not only differences in individuals' perceptions of their body but also cultural values and norms (Shim et al., 2014).

TABLE 141.3

Summary of Comparative Urinary Diversion Health-Related Quality-of-Life Studies Since 2000

REFERENCE	INSTRUMENT	NO. OF PATIENTS	YEAR	POPULATION	FINDINGS
McGuire et al.	SF-36	76	2000	United States	Lower mental QoL scores in IC patients compared with population norm
Fujisawa et al.	SF-36	56	2000	Japan	No differences detected between groups
Hobish et al.	EORTC-QLQ-C30	102	2000	Austria	**Higher QoL scores in NB**

					patients
Hara et al.	SF-36 + informal questionnaire	85	2002	Japan	No differences detected in general HRQoL
Dutta et al.	SF-36 + FACT-G	100	2002	United States	**Marginally higher HRQoL scores detected in NB group**
Protogerou et al.	EORTC-QOL-C30, informal questionnaire	108	2004	Greece	Urinary and sexual function impairments present after cystectomy but no HRQoL differences between groups
Kikuchi et al.	FACT-BL	35	2006	Japan	**Lower body image scores among ileal conduit patients**
Gilbert et al.	BCI	315	2007	United States	Decreased urinary HRQoL among NB group
Saika et al.	EORTC-QLQ-C30	78	2007	Japan	No significant difference between IC and NB
Autorino et al.	SF-36	79	2009	Italy	No difference between IC and NB but physical, emotional,

					and social QoL scores below population norm
Sogni et al.	EORTC-QLQ-C30 + EORTC-QLQ-BLM30	34	2008	Italy	**Global health status higher in NB group but not significant**
Philip et al.	SF-36 + informal questionnaire	52	2009	England	**NB group had significantly better physical functioning**
Somani et al.	EORTC-QLQ-C30 + SWLS	32	2009	England	No HRQoL difference before or after cystectomy
Hedgepeth et al.	BCI	224	2010	United States	No difference between IC and NB groups
Erber et al.	EORTC-QLQ-C30 + EORTC-QLQ-BLM30	58	2012	Germany	**Higher HRQoL scores among NB vs. IC patients**
Gacci et al.	EORTC-QLQ-C30 + EORTC-QLQ-BLM30, FACT-BL	25	2013	Italy	No HRQoL differences among female patients
Metcalfe et al.	FACT-VCI	84	2013	Canada	No HRQoL differences between IC and NB

					groups
Singh et al.	EORTC-QLQ-C30	164	2014	India	**General HRQoL better in NB group compared with IC group**
Huang et al.	BCI	294	2015	China	No difference in long-term HRQoL between IC and NB groups

HRQoL, Health-related quality of life. *IC,* intermittent catheterization to empty neobladder; *NB,* ileal neobladder.

Most of the studies that have evaluated and compared quality-of-life issues in patients undergoing various forms of urinary diversion have been criticized for methodologic problems that limit their conclusions (Gerharz, 2007; Gerharz et al., 2005; Porter et al., 2005)**. Critical analyses of the current quality-of-life literature suggest that there is not enough evidence to conclude that there is a clear quality-of-life advantage for patients undergoing continent diversion** (see Table 141.3). Porter and Penson (2005) performed a systematic review to determine if any differences exist in HRQoL outcomes among different types of urinary diversion after radical cystectomy. Of 378 initial articles, only 15 studies met all of their inclusion criteria. None of the studies were randomized trials, and only one was prospective. **Common limitations included unvalidated HRQoL outcome instruments, use of general HRQoL outcome instruments only, lack of baseline data, cross-sectional analysis, and retrospective study design.** The authors found that the current body of published literature is insufficient for it to be concluded that any form of urinary diversion is superior to another on the basis of HRQoL outcomes. Gerharz came to similar conclusions (Gerharz, 2007; Gerharz et al., 2005).

There have been a number of efforts to develop a new tool that is more specific to patients with muscle-invasive bladder cancer. These include general—or generic—instruments, such as the Medical Outcomes Study Short Forms (SF-36 and SF-12) and EuroQol five-dimension questionnaire (EQ-5D). There are other condition-specific instruments that assess issues associated with urinary diversion, including the Functional Assessment of Cancer Therapy Bladder Cancer subscale (FACT-BL) and the European Organisation for Research and Treatment of Cancer Quality of Life Bladder Module (EORTC QLQ-BLM30) (Gilbert et al. 2007; Leone et al. 2017). These tools have been limited when used for comparing continent versus conduit diversion because of variation in weighting of specific symptoms that only occur with one diversion type (Gellhaus et al., 2017). A 23-item neobladder HRQoL instrument called the IONB-PRO was recently developed to provide more specific information pertaining to issues that arise for patients with neobladders (Siracusano et al., 2014). Each has its advantages and disadvantages, especially when applied to a specific group of patients.

The more recent studies using these condition-specific validated assessment tools are still all cross-sectional and retrospective, and there is still room for methodologic improvements. A recent systematic review favored ileal neobladder in terms of higher quality-of-life scores (Ghosh et al., 2016). Another large meta-analysis of observational HRQoL studies using validated questionnaires identified significantly better quality-of-life outcomes among patients treated with orthotopic neobladders in a subanalysis of studies based on the EORTC QLQ-C30 (Cerruto et al. 2016). Future studies in this area must incorporate prospective data collection, provide longer-term follow-up, and incorporate validated disease-specific HRQoL outcome instruments. With all instruments, the functional outcomes of different diversions and quality of life remain very difficult to assess, and it is extremely difficult to develop a single instrument that allows detailed comparison among different types of diversions.

In summary, there are no clear data showing an overall quality-of-life advantage for patients undergoing neobladder reconstruction, and most patients will clearly adapt to whatever specific challenges their urinary diversion presents to them. Several prospective studies that focus on longitudinal health-related quality-of-life assessment among cystectomy and urinary diversion patients as primary outcomes are currently ongoing. As the results of these studies become available, our understanding of the factors that contribute to and drive health-related quality of life in this patient population should improve. Nevertheless, when presented with the option, most patients will choose orthotopic diversion simply because it seems the most natural and avoids a permanent stoma, and having this option may encourage patients to more readily undergo definitive treatment of their bladder cancer. Patients must, however, have realistic expectations about the risk for incontinence and the possible need for self-catheterization.

Key Points: Quality of Life After Urinary Diversion

- Most quality-of-life studies that have evaluated and compared patients undergoing various forms of urinary diversion have been criticized for methodologic problems that limit their conclusions.
- The current body of published literature is insufficient to conclude that any form of urinary diversion is superior to another on the basis of health-related quality-of-life outcomes, though most studies report better body image with neobladders.

Suggested Readings

Ahmadi H, Skinner EC, Simma-Chiang V, et al. Urinary functional outcome following radical cystoprostatectomy and ileal neobladder reconstruction in male patients. *J Urol*. 2013;189(5):1782–1788.

Anderson CB, Cookson MS, Chang SS, et al. Voiding function in women with orthotopic neobladder urinary diversion. *J Urol*. 2012;188(1):200–204.

Ashley MS, Daneshmand S. Factors influencing the choice of urinary diversion in patients undergoing radical cystectomy. *BJU Int*. 2010;106(5):654–657.

Boorjian SA, Kim SP, Weight CJ, et al. Risk factors and outcomes of urethral recurrence following radical cystectomy. *Eur Urol*. 2011;60(6):1266–1272.

Daneshmand S. *Urinary diversion*. Springer International: Cham, Switzerland; 2017.

Eisenberg MS, Dorin RP, Bartsch G, et al. Early complications of cystectomy after high dose pelvic radiation. *J Urol*. 2010;184(6):2264–2269.

Gerharz EW, Månsson A, Hunt S, et al. Quality of life after cystectomy and urinary diversion: an evidence based analysis. *J Urol*. 2005;174(5):1729–1736.

Granberg CF, Boorjian SA, Crispen PL, et al. Functional and oncological outcomes after orthotopic neobladder reconstruction in women. *BJU Int*. 2008;102(11):1551–1555.

Hautmann RE, Abol-Enein H, Davidsson T, et al. International Consultation on Urologic Disease–European Association of Urology Consultation on Bladder Cancer 2012. *Eur Urol*. 2013;63(1):67–80.

Hautmann RE, de Petriconi RC, Volkmer BG. 25 years of experience with 1000 neobladders: long-term complications.

J Urol. 2011;185(6):2207–2212.

Jentzmik F, Schrader AJ, de Petriconi R, et al. The ileal neobladder in female patients with bladder cancer: long-term clinical, functional, and oncological outcome. *World J Urol*. 2012;30(6):733–739.

Porter MP, Penson DF. Health related quality of life after radical cystectomy and urinary diversion for bladder cancer: a systematic review and critical analysis of the literature. *J Urol*. 2005;173(4):1318–1322.

Steers WD. Voiding dysfunction in the orthotopic neobladder. *World J Urol*. 2000;18(5):330–337.

Stein JP, Cote RJ, Freeman JA, et al. Indications for lower urinary tract reconstruction in women after cystectomy for bladder cancer: a pathological review of female cystectomy specimens. *J Urol*. 1995;154(4):1329–1333.

Stein JP, Lieskovsky G, Ginsberg DA, et al. The T pouch: an orthotopic ileal neobladder incorporating a serosal lined ileal antireflux technique. *J Urol*. 1998;159(6):1836–1842.

Studer UE, Burckard FC, Schumacher M, et al. Twenty years' experience with an ileal orthotopic low pressure bladder substitute—lessons to be learned. *J Urol*. 2006;176(1):161–166.

Yuh BE, Nazmy M, Ruel NH, et al. Standardized analysis of frequency and severity of complications after robot-assisted radical cystectomy. *Eur Urol*. 2012;62(5):806–813.

References

Abbas F, Biyabani SR, Talati J. Orthotopic bladder replacement to the urethra following salvage radical cystoprostatectomy in men with failed radiation therapy. *Tech Urol*. 2001;7:20–26.

Abol-Enein H, Ghoneim MA. Optimization of uretero-intestinal anastomosis in urinary diversion: an experimental study in dogs. III. A new antireflux technique for uretero-ileal anastomosis: a serous-lined extramural tunnel. *Urol Res*. 1993;21:135.

Abol-Enein H, Ghoneim MA. A novel uretero-ileal reimplantation technique: the serous lined extramural tunnel. A preliminary report. *J Urol*. 1994;151:1193.

Abol-Enein H, Ghoneim MA. Functional results of orthotopic ileal neobladder with serous-lined extramural ureteral reimplantation: experience with 450 patients. *J Urol*. 2001;165:1427.

Ahmadi H, Skinner EC, Simma-Chiang V, et al. Urinary functional outcome following radical cystoprostatectomy and ileal neobladder reconstruction in male patients. *J Urol*. 2013;189(5):1782–1788.

Al Hussein Al Awamlh B, Wang LC, Nguyen DP, et al. Is continent cutaneous urinary diversion a suitable alternative to orthotopic bladder substitute and ileal conduit after cystectomy? *BJU Int*. 2015;116(5):805–814.

Ali-El-Dein B. Oncological outcome after radical cystectomy and orthotopic bladder substitution in women. *Eur J Surg Oncol*. 2009;35(3):320–325.

Ali-El-Dein B, Ashamallah A. Vaginal repair of pouch-vaginal fistula after orthotopic bladder substitution in women. *Urology*. 2013;81(1):198–202.

Ali-El-Dein B, Gomha M, Ghoneim MA. Critical evaluation of the problem of chronic urinary retention after orthotopic bladder substitution in women. *J Urol*. 2002;168:587.

Ali-El-Dein B, Abdel-Latif M, Ashamallah A, et al. Local urethral recurrence after radical cystectomy and orthotopic bladder substitution in women: a prospective study. *J Urol*. 2004;171:275.

Ali-El-Dein B, Shaaban AA, Abu-Eideh RH, et al. Surgical complications following radical cystectomy and orthotopic neobladder in women. *J Urol*. 2008;180:206–210.

Ali-El-Dein B, Mosbah A, Osman Y, et al. Preservation of the internal genital organs during radical cystectomy in selected women with bladder cancer: a report on 15 cases with long-term follow-up. *Eur J Surg Oncol*. 2013;39(4):358–364.

Amini E, Djaladat H. Long-term complications of urinary diversion. Daneshmand S. *Urinary diversion*. Springer International: Cham, Switzerland; 2017.

Anderson CB, Cookson MS, Chang SS, et al. Voiding function in women with orthotopic neobladder urinary diversion. *J Urol*. 2012;188(1):200–204.

Arai Y, Kawakita M, Terachi T, et al. Long term follow-up of the Kock pouch and Indiana pouch procedures. *J Urol*. 1993;150:51–55.

Ashley MS, Daneshmand S. Factors influencing the choice of urinary diversion in patients undergoing radical cystectomy. *BJU Int*. 2010;106(5):654–657.

Autorino R, Quarto G, Di Lorenzo G, et al. Health related quality of life after radical cystectomy: comparison of ileal conduit to continent orthotopic neobladder. *Eur J Surg Oncol*. 2009;35(8):858–864.

Bachour K, Faiena I, Salmasi A, et al. Trends in urinary diversion after radical cystectomy for urothelial carcinoma. *World J Urol*. 2018;36(3):409–416.

Barbalat Y, Morales D, Weiss RE. Contemporary use of titanium staples for orthotopic urinary diversion. *Urology*. 2012;80(6):1176–1180.

Barbieri CE, Lee B, Cookson MS, et al. Association of procedure volume with radical cystectomy outcomes in a nationwide database. *J Urol*. 2007;178(4 Pt 1):1418–1421.

Barre PH, Herve JM, Botto H, et al. Update on the Camey II procedure. *World J Urol*. 1996;14(1):27–28.

Bartsch G, Daneshmand S, Skinner EC, et al. Urinary functional outcomes in female neobladder patients. *World J Urol*. 2014;32(1):221–228.

Bauer RM, Herrmann K, Karl A, et al. Real-time MRI of continent and stress incontinent male patients after orthotopic ileal neobladder. *Urol Int*. 2011;87(3):325–329.

Bazargani ST, Djaladat H, Ahmadi H, et al. Gastrointestinal complications following radical cystectomy using enhanced recovery protocol. *Eur Urol Focus*. 2018;4(6):889–894.

Benson MC, Slawin KM, Wechsler MH, et al. Analysis of continent versus standard urinary diversion. *Br J Urol*. 1992;69(2):156–162.

Berglund B, Kock NG, Norlen L, et al. Volume capacity and pressure characteristics of the continent ileal reservoir used for urinary diversion. *J Urol*. 1987;137(1):29–34.

Bhatt A, Nandipati K, Dhar N, et al. Neurovascular preservation in orthotopic cystectomy: impact on female sexual function. *Urology*. 2006;67:742–745.

Bhatta DN, Kessler TM, Mills RD, et al. Nerve-sparing radical cystectomy and orthotopic bladder replacement in female patients. *Eur Urol*. 2007;52(4):1006–1014.

Bochner BH, Figueroa AJ, Skinner EC, et al. Salvage radical cystoprostatectomy and orthotopic urinary diversion following radiation failure. *J Urol*. 1998;160(1):29–33.

Bochner BH, Dalbagni G, Sigberg DD, et al. Comparing open radical cystectomy and robot-assisted laparoscopic radical cystectomy: a randomized clinical trial. *Eur Urol*. 2015;67(6):1042–1050.

Boorjian SA, Kim SP, Weight CJ, et al. Risk factors and outcomes of urethral recurrence following radical cystectomy. *Eur Urol*. 2011;60(6):1266–1272.

Borirakchanyavat S, Aboseif SR, Carroll PR, et al. Continence mechanism of the isolated female urethra: an anatomical study of the intrapelvic somatic nerves. *J Urol*. 1997;158(3 Pt 1):822–826.

Bricker EM. Bladder substitution after pelvic evisceration. *Surg Clin North Am*. 1950;30(5):1511–1521.

Camey M. Detubularized U-shaped cystoplasty (Camey II). *Curr Surg Tech Urol*. 1990;3(1).

Camey M, Le Duc A. L'enterocystoplastie avec cystoprostatectomie totale pour cancer de la vessie. *Ann Urol (Paris)*. 1979;13:114–123.

Cancrini A, DeCarli P, Pompeo V, et al. Lower urinary tract reconstruction following cystectomy: experience and results in 96 patients using the orthotopic ileal bladder substitution of Studer et al. *Eur Urol*. 1996;29(2):204–209.

Cerruto MA, Elia CD, Siracusano S, et al. Systematic review and meta-analysis of non RTCs on health related quality of life after radical cystectomy using validated questionnaires: better results with orthotopic neobladder versus ileal conduit. *Eur J Surg Oncol*. 2016;42(3):343–360.

Chang SS, Cole E, Smith JA Jr, et al. Pathological findings of gynecologic organs obtained at female radical cystectomy. *J Urol*. 2002;168(1):147–149.

Chang SS, Alberts GL, Smith JA Jr, et al. Ileal conduit urinary diversion in patients with previous history of abdominal/pelvic irradiation. *World J Urol*. 2004;22(4):272–276.

Chang SS, Smith JA Jr, Herrell SD, et al. Assessing urinary diversion experience in urologic residency programs—are we adequately training the next generation? *J Urol*. 2006;176(2):691–693.

Chang SS, Bochner BH, Chou R, et al. Treatment of non-metastatic muscle-invasive bladder cancer: AUA/ASCO/ASTRO/SUO Guideline. *J Urol*. 2017;198(3):552–559.

Chen ME, Pisters LL, Malpica A, et al. Risk of urethral, vaginal and cervical involvement in patients undergoing radical cystectomy for bladder cancer: results of a contemporary cystectomy series from M.D. Anderson Cancer Center. *J Urol*. 1997;157:2120.

Chen Z, Lu G, Li X, et al. Better compliance contributes to better nocturnal continence with orthotopic ileal neobladder than ileocolonic neobladder after radical cystectomy for bladder cancer. *Urology*. 2009;73(4):838–843.

Clark PE, Montie JE, Klein EA. Long-term follow up of renal function and upper tract status after ileal conduit urinary diversion. *J Urol*. 1999;161:247A.

Clark PE, Stein JP, Groshen SG, et al. Radical cystectomy in the elderly: comparison of clinical outcomes between younger and older patients. *Cancer*. 2005;104(1):36–43.

Clarke BG, Leadbetter WF. Ureterosigmoidostomy: collective review of results in 2897 cases. *J Urol*. 1955;73(6):999–1008.

Clifford TG, Shah SH, Bazargani ST, et al. Prospective evaluation of continence following radical cystectomy and orthotopic urinary diversion using a validated questionnaire. *J Urol*. 2016;196(6):1685–1691.

Colleselli K, Stenzl A, Eder R, et al. The female urethral sphincter: a morphological and topographical study. *J Urol*. 1998;160(1):49–54.

Coloby PJ, Kakizoe T, Tobisu K, et al. Urethral involvement in female bladder cancer patients: mapping of 47 consecutive cysto-urethrectomy specimens. *J Urol*. 1994;152(5 Pt 1):1438–1442.

Constantinides C, Manousakas T, Chrisofos M, et al. Orthotopic bladder substitution after radical cystectomy: 5 years of experience with a novel personal modification of the ileal s pouch. *J Urol*. 2001;166(2):532–537.

Cui HW, Turney BW, Griffiths J. The preoperative assessment and optimization of patients undergoing major urological surgery. *Curr Urol Rep*. 2017;18(7):54.

Daneshmand S, Bartsch G. Improving selection of appropriate urinary diversion following radical cystectomy for bladder cancer. *Expert Rev Anticancer Ther*. 2011;11(6):941–948.

Daneshmand S, Ahmadi H, Schuckman AK, et al. Enhanced recovery protocol after radical cystectomy for bladder cancer. *J Urol*. 2014;192(1):50–55.

Da Pozzo LF, Colombo R, Pompa P, et al. Detubularized sigmoid colon for bladder replacement after radical cystectomy. *J Urol*. 1994;152(5 Pt 1):1409–1412.

Dason S, Goh AC. Contemporary techniques and outcomes of robotic cystectomy and intracorporeal urinary diversions. *Curr Opin Urol*. 2018;28(2):115–122.

Davidsson TP, Poulsen AL, Hedlund H, et al. A comparative urodynamic study of the ileal and the colonic neobladder. *Scand J Urol Nephrol*. 1992;142:143.

De Paepe ME, André R, Mahadevia P. Urethral involvement in female patients with bladder cancer. A study of 22 cystectomy specimens. *Cancer*. 1990;65(5):1237–1241.

Djaladat H, Bruins HM, Miranda G, et al. Reproductive organ involvement in female patients undergoing radical cystectomy for urothelial bladder cancer. *J Urol*. 2012;188(6):2134–2138.

Djaladat H, Mitra AP, Miranda G, et al. Radical cystectomy and orthotopic urinary diversion in male patients with pT4a urothelial carcinoma: oncological outcomes. *Int J Urol*. 2013;20(12):1229–1233.

Djaladat H, Katebian B, Bazargani ST, et al. 90 Day complication rate in patients undergoing radical cystectomy with enhanced recovery protocol: a prospective cohort study. *World J Urol*. 2017;35(6):907–922.

Donat SM, Wei DC, McGuire MS, et al. The efficacy of transurethral biopsy for predicting the long-term clinical impact of prostatic invasive bladder cancer. *J Urol*. 2001;165(5):1580–1584.

Dunn MD, Kalisvaart M, Stein JP, et al. Endoscopic incision of stenotic afferent antireflux valves in continent urinary diversions: rate of recurrent stenosis and comparison of treatment modalities. *J Urol*. 2007;177:187A.

Dutta SC, Chang SC, Coffey CS, et al. Health related quality of life after radical cystectomy: comparison of ileal conduit with continent orthotopic neobladder. *J Urol*. 2002;168(1):164–167.

Eckman H, Jacobsson B, Kock NG, et al. The functional behavior of different types of intestinal bladder substitutes. *Contrib Soc Int Urol*. 1964;11:213–219.

Eisenberg MS, Dorin RP, Bartsch G, et al. Early complications of cystectomy after high dose pelvic radiation. *J Urol*. 2010;184(6):2264–2269.

Eisenberg MS, Thommpson RH, Frank I, et al. Long-term renal function outcomes after radical cystectomy. *J Urol*. 2014;191(3):619–625.

Eisenberger CF, Schoenberg M, Fitter D, et al. Orthotopic ileocolic neobladder reconstruction following radical cystectomy: history, technique and results of the Johns Hopkins experience, 1986–1998. *Urol Clin North Am*. 1999;26(1):149–156.

El-Bahnasawy MS, Osman Y, Gomha MA, et al. Nocturnal enuresis in men with an orthotopic ileal reservoir: urodynamic evaluation. *J Urol*. 2000;164(1):10–13.

El-Bahnasawy MS, Osman Y, El-Hefnawy A, et al. Radical cystectomy and urinary diversion in women: impact on sexual function. *Scand J Urol Nephrol*. 2011;45(5):332–338.

Elmajian DA, Stein JP, Esrig D, et al. The Kock ileal neobladder: updated experience in 295 male patients. *J Urol*. 1996;156(3):920–925.

Erber B, Schrader M, Miller K, et al. Morbidity and quality of life in bladder cancer patients following cystectomy and urinary diversion: a single-institution comparison of ileal conduit versus orthotopic neobladder. *ISRN Urol*. 2012;2012:342796.

Fairey A, Skinner DG, Groshen S, et al. Effect of Studer pouch versus T-pouch orthotopic ileal bladder substitution on late complications and surgical re-intervention in bladder cancer patients undergoing radical cystectomy: secondary analyses from the USC-STAR randomized trial. *J Urol*. 2013;189(supp4):e579–e580.

Fahmy O, Khairul-Asri MG, Schubert T, et al. Urethral recurrence after radical cystectomy for urothelial carcinoma: a systematic review and meta-analysis. *Urol Oncol*. 2018;36(2):54–59.

Fontana D, Bellina M, Fasolis G, et al. Y-neobladder: an easy, fast, and reliable procedure. *Urology*. 2004;63(4):699–703.

Fujisawa M, Isotani S, Gotoh A, et al. Health-related quality of life with orthotopic neobladder versus ileal conduit according to SF-36 survey. *Urology*. 2000;55(6):862–865.

Furrer MA, Roth B, Kiss B, et al. Patients with an orthotopic low pressure bladder substitute enjoy long-term good function. *J Urol*. 2016;196(4):1172–1180.

Furrer MA, Studer UE, Gross T, et al. Nerve-sparing radical cystectomy has a beneficial impact on urinary continence after orthotopic bladder substitution, which becomes even more apparent over time. *BJU Int*. 2018;121(6):935–944.

Gacci M, Saleh O, Cai T, et al. Quality of life in women undergoing urinary diversion for bladder cancer: results of a multicenter study among long-term disease-free survivors. *Health Qual Life Outcomes*. 2013;11:43.

Gburek BM, Lieber MM, Blute ML. Comparison of Studer ileal neobladder and ileal conduit urinary diversion with respect to perioperative outcome and late complications. *J Urol*. 1998;160(3 Pt 1):721–723.

Gellhaus PT, Cary C, Kaimakliotis HZ, et al. Long term health related quality of life outcomes following radical cystectomy. *Urology*. 2017;106:82–86.

Gerharz EW. Is there any evidence that one continent diversion is any better than any other or than ileal conduit? *Curr Opin Urol*. 2007;17(6):402–407.

Gerharz EW, Månsson A, Hunt S, et al. Quality of life after cystectomy and urinary diversion: an evidence based analysis. *J Urol*. 2005;174(5):1729–1736.

Ghoneim MA, Kock NG, Lycke G, et al. An appliance-free, sphincter-controlled bladder substitute: the urethral Kock pouch. *J Urol*. 1987;138(5):1150–1154.

Ghosh A, Somani BK. Recent trends in postcystectomy health-related quality of life (qol) favors neobladder diversion: systematic review of the literature. *Urology*. 2016;93:22–26.

Gilbert SM, Wood DP, Dunn RL, et al. Measuring health-related quality of life outcomes in bladder cancer patients using the Bladder Cancer Index (BCI). *Cancer*. 2007;109(9):1756–1762.

Gilchrist RK, Merricks JW, Hamlin HH, et al. Construction of a substitute bladder and urethra. *Surg Gynecol Obstet*. 1950;90(6):752–760.

Ginsberg D, Huffman JL, Lieskovsky G, et al. Urinary tract stones: a complication of the Koch pouch continent urinary diversion. *J Urol*. 1991;145(5):956–959.

Gill IS, Kaouk JH, Meraney AM, et al. Laparoscopic radical cystectomy and continent orthotopic ileal neobladder performed completely intracorporeally: the initial experience. *J Urol*. 2002;168(1):13–18.

Goh AC, Gill IS, Lee DJ, et al. Robotic intracorporeal orthotopic neobladder: replicating open surgical principles. *Eur Urol*. 2012;62(5):891–901.

Goldberg H, Baniel J, Mano R, et al. Low-dose oral desmopressin for treatment of nocturia and nocturnal enuresis in patients after radical cystectomy and orthotopic urinary diversion. *BJU Int*. 2014;114(5):727–732.

Goldwasser B. The colonic orthotopic bladder. *Urology*. 1995;45(2):190–192.

Goldwasser B, Barrett DM, Benson RC Jr. Bladder replacement with use of a detubularized right colonic segment: preliminary report of a new technique. *Mayo Clin Proc*. 1986;61(8):615–621.

Goodwin WE, Harris AP, Kaufman JJ, et al. Open, transcolonic ureterointestinal anastomosis: a new approach. *Surg Gynecol Obstet*. 1953;97(3):295–300.

Granberg CF, Boorjian SA, Crispen PL, et al. Functional and oncological outcomes after orthotopic neobladder reconstruction in women. *BJU Int*. 2008;102(11):1551–1555.

Gross T, Meierhans Ruf SD, et al. Orthotopic ileal bladder substitution in women: factors influencing urinary incontinence and hypercontinence. *Eur Urol*. 2015;68(4):664–671.

Grossfeld GD, Stein JP, Bennett J, et al. Lower urinary tract reconstruction in the female using the Kock ileal reservoir with bilateral ureteroileal urethrostomy: update of continence results and fluorourodynamic findings. *Urology*.

1996;48(3):383–388.

Haber GP, Crouzet S, Gill IS. Laparoscopic and robotic assisted radical cystectomy for bladder cancer: a critical analysis. *Eur Urol*. 2008;54(1):54–62.

Hara I, Miyake H, Hara S, et al. Health-related quality of life after radical cystectomy for bladder cancer: a comparison of ileal conduit and orthotopic bladder replacement. *BJU Int*. 2002;89(1):10–13.

Hardeman SW, Soloway MS. Urethral recurrence following radical cystectomy. *J Urol*. 1990;144(3):666–669.

Hart S, Skinner EC, Meyerowitz BE, et al. Quality of life after radical cystectomy for bladder cancer in patients with an ileal conduit, cutaneous or urethral Kock pouch. *J Urol*. 1999;162(1):77–81.

Hauri D. Can gastric pouch as orthotopic bladder replacement be used in adults? *J Urol*. 1998;156(3):931–935.

Hautmann RE. The ileal neobladder to the female urethra. *Urol Clin North Am*. 1997;24(4):827–835.

Hautmann RE. The ileal neobladder. *Atlas Urol Clin North Am*. 2001;9(2):85–108.

Hautmann RE. Urinary diversion: ileal conduit to neobladder. *J Urol*. 2003;169(3):834–842.

Hautmann RE. Surgery illustrated—surgical atlas ileal neobladder. *BJU Int*. 2010;105(7):1024–1035.

Hautmann RE, Abol-Enein H, Davidsson T, et al. International Consultation on Urologic Disease–European Association of Urology Consultation on Bladder Cancer 2012. *Eur Urol*. 2013;63(1):67–80.

Hautmann RE, Abol-Enein H, Lee CT, et al. Urinary diversion: how experts divert. *Urology*. 2015;85(1):233–238.

Hautmann RE, de Petriconi R, Gottfried HW, et al. The ileal neobladder: complications and functional results in 363 patients after 11 years of followup. *J Urol*. 1999;161(2):422–

427.

Hautmann RE, de Petriconi RC, Volkmer BG. Neobladder formation after pelvic irradiation. *World J Urol*. 2009;27(1):57–62.

Hautmann RE, de Petriconi RC, Volkmer BG. Lessons learned from 1000 neobladders: the 90-day complication rate. *J Urol*. 2010;184(3):990–994.

Hautmann RE, de Petriconi RC, Volkmer BG. 25 years of experience with 1000 neobladders: long-term complications. *J Urol*. 2011;185(6):2207–2212.

Hautmann RE, de Petriconi R, Kahlmeyer A, et al. Preoperatively dilated ureters are a specific risk factor for the development of ureterenteric strictures after open radical cystectomy and ileal neobladder. *J Urol*. 2017;198(5):1098–1106.

Hautmann RE, Egghart G, Frohneberg D, et al. The ileal neobladder. *J Urol*. 1988;139(1):39–42.

Hautmann RE, Simon J. Ileal neobladder and local recurrence of bladder cancer: patterns of failure and impact on function in men. *J Urol*. 1999;162(6):1963–1966.

Hautmann S, Chun KH, Currlin E, et al. Refluxing chimney versus nonrefluxing Le Duc ureteroileal anastomosis for orthotopic ileal neobladder: a comparative analysis for patients with bladder cancer. *J Urol*. 2006;175(4):1389–1393 [discussion 1393–1394].

Hedgepeth RC, Gilbert SM, He C, et al. Body image and bladder cancer specific quality of life in patients with ileal conduit and neobladder urinary diversions. *Urology*. 2010;76(3):671–675.

Henningsohn L, Steven K, Kallestrup EB, et al. Distressful symptoms and well-being after radical cystectomy and orthotopic bladder substitution compared with a matched control population. *J Urol*. 2002;168(1):168–174 [discussion

174–175].

Hinata N, Murakami G, Abe S, et al. Detailed histological investigation of the female urethra: application to radical cystectomy. *J Urol*. 2012;187(2):451–456.

Hinman F. Selection of intestinal segments for bladder substitution: physical and physiological characteristics. *J Urol*. 1988;139(3):519–523.

Hobisch A, Tosun K, Kinzl J, et al. Quality of life after cystectomy and orthotopic neobladder versus ileal conduit urinary diversion. *World J Urol*. 2000;18:338.

Hohenfellner M, Bürger R, Schad H, et al. Reservoir characteristics of Mainz pouch studied in animal model. Osmolality of filling solution and effect of oxybutynin. *Urology*. 1993;42(6):741–746.

Hollowell CM, Christiano AP, Steinberg GD. Technique of Hautmann ileal neobladder with chimney modification: interim results in 50 patients. *J Urol*. 2000;163(1):47–50.

Huang J, Lin T, Xu K, et al. Laparoscopic radical cystectomy with orthotopic ileal neobladder: a report of 85 cases. *J Endourol*. 2008;22(5):939–946.

Huang EY, Skinner EC, Boyd SD, et al. Radical cystectomy with orthotopic neobladder reconstruction following prior radical prostatectomy. *World J Urol*. 2012;30(6):741–745.

Huang Y, Pan X, Zhou Q, et al. Quality-of-life outcomes and unmet needs between ileal conduit and orthotopic ileal neobladder after radical cystectomy in a Chinese population: a 2-to-1 matched-pair analysis. *BMC Urol*. 2015;15:117.

Hugen CM, Daneshmand S. Orthotopic urinary diversion in the elderly. *World J Urol*. 2016;34(1):13–18.

Hugonnet CL, Danuser H, Springer JP, et al. Decreased sensitivity in the membranous urethra after orthotopic ileal bladder substitute. *J Urol*. 1999;161(2):418–421.

Hussein AA, May PR, Jing Z, et al. Outcomes of intracorporeal urinary diversion after robotic assisted radical cystectomy: results from the International Robotic Cystectomy Consortium. *J Urol*. 2018;199(5):1302–1311.

Iselin CE, Robertson CN, Webster GD, et al. Does prostate transitional cell carcinoma preclude orthotopic bladder reconstruction after radical cystoprostatectomy for bladder cancer? *J Urol*. 1997;158(6):2123–2126.

Jentzmik F, Schrader AJ, de Petriconi R, et al. The ileal neobladder in female patients with bladder cancer: long-term clinical, functional, and oncological outcome. *World J Urol*. 2012;30(6):733–739.

Ji H, Pan J, Shen W, et al. Identification and management of emptying failure in male patients with orthotopic neobladders after radical cystectomy for bladder cancer. *Urology*. 2010;76(3):644–648.

Johnson EV, Kirages D. Pelvic floor rehabilitation for orthotopic diversion. Daneshmand S. *Urinary diversion*. Springer International: Cham, Switzerland; 2017.

Karl A, Buchner A, Becker A, et al. A new concept for early recovery after surgery in patients undergoing radical cystectomy for bladder cancer—results of a prospective randomized study. *J Urol*. 2014;191(2):335–340.

Kato H, Kiyokawa H, Igawa Y, et al. The serous-lined tunnel principle for urinary reconstruction: a more rational method. *BJU Int*. 2001;87(9):783–788.

Kessler TM, Burkhard FC, Perimenis P, et al. Attempted nerve sparing surgery and age have a significant effect on urinary continence and erectile function after radical cystoprostatectomy and ileal orthotopic bladder substitution. *J Urol*. 2004;172(4 Pt 1):1323–1327.

Khafagy M, Shaheed FA, Moneim TA. Ileocaecal vs ileal neobladder after radical cystectomy in patients with bladder cancer: a comparative study. *BJU Int*. 2006;97(4):799–804.

Kikuchi E, Horiguchi Y, Nakashima J, et al. Assessment of long-term quality of life using the FACT-BL questionnaire in patients with an ileal conduit, continent reservoir, or orthotopic neobladder. *Jpn J Clin Oncol*. 2006;36(11):712–716.

Kim HL, Steinberg GD. Complications of cystectomy in patients with a history of pelvic radiation. *Urology*. 2001;58(4):557–560.

Kim SP, Shah ND, Weight CJ, et al. Population-based trends in urinary diversion among patients undergoing radical cystectomy for bladder cancer. *BJU Int*. 2013;112(4):478–484.

Kock NG, Ghoneim MA, Lycke KG, et al. Replacement of the bladder by the urethral Kock pouch: functional results, urodynamics and radiological features. *J Urol*. 1989;141(5):1111–1116.

Kock NG, Nilson AE, Nilsson LO, et al. Urinary diversion via a continent ileal reservoir: clinical results in 12 patients. *J Urol*. 1982;128(3):469–475.

Kolettis PN, Klein EA, Novick AC, et al. The Le Bag orthotopic urinary diversion. *J Urol*. 1996;156(3):926–930.

Konety BR, Allareddy V, Herr H. Complications after radical cystectomy: analysis of population-based data. *Urology*. 2006;68(1):58–64.

Kouba E, Sands M, Lentz A, et al. Incidence and risk factors of stomal complications in patients undergoing cystectomy with ileal conduit urinary diversion for bladder cancer. *J Urol*. 2007;178(3 Pt 1):950–954.

Kristjánsson A, Bajc M, Wallin L, et al. Renal function up to 16 years after conduit (refluxing or anti-reflux anastomosis) or continent urinary diversion. 2. Renal scarring and location of bacteriuria. *Br J Urol*. 1995;76(5):546–550.

Kristjánsson A, Wallin L, Månsson W. Renal function up to 16 years after conduit (refluxing or anti-reflux anastomosis) or continent urinary diversion. 1. Glomerular filtration rate and patency of uretero-intestinal anastomosis. *Br J Urol*. 1995;76(5):539–545.

Laguna MP, Brenninkmeier M, Belon JA, et al. Long-term functional and urodynamic results of 50 patients receiving a modified sigmoid neobladder created with a short distal segment. *J Urol*. 2005;174(3):963–967.

Lance RS, Dinney CP, Swanson D, et al. Radical cystectomy for invasive bladder cancer in the octogenarian. *Oncol Rep*. 2001;8(4):723–726.

Lay FD, Triche TJ Jr, Tsai YC, et al. Reprogramming of the human intestinal epigenome by surgical tissue transposition. *Genome Res*. 2014;24(4):545–553.

Le Duc A, Camey M, Teillac P. An original antireflux ureteroileal implantation technique: long-term followup. *J Urol*. 1987;137(6):1156–1158.

Leadbetter WF. Consideration of problems incident to performance of ureteroenterostomy: report of technique. *J Urol*. 1951;65:818–830.

Lebret T, Hervé JM, Barré P, et al. Urethral recurrence of transitional cell carcinoma of the bladder. Predictive value of preoperative latero-montanal biopsies and urethral frozen sections during prostatocystectomy. *Eur Urol*. 1998;33(2):170–174.

Lee CT, Chang SS, Kamat AM, et al. Alvimopan accelerates gastrointestinal recovery after radical cystectomy: a multicenter randomized placebo-controlled trial. *Eur Urol*. 2014;66(2):265–272.

Lee CT, Hafez KS, Sheffield JH, et al. Orthotopic bladder substitution in women: nontraditional applications. *J Urol*. 2004;171(4):1585–1588.

Lee KS, Montie JE, Dunn RL, et al. Hautmann and Studer orthotopic neobladders: a contemporary experience. *J Urol*. 2003;169(6):2188–2191.

Leone A, Gilbert SM. Urinary diversion and health-related quality of life. Daneshmand S. *Urinary diversion*. Springer International: Cham, Switzerland; 2017.

Lemoine G. Creation d'une vessie nouvelle par un procédé personnel après cystectomie totale pour cancer. *J Urol Medicale Chir*. 1913;4:367.

Lerner SP, Shen S. Pathologic assessment and clinical significance of prostatic involvement by transitional cell carcinoma and prostate cancer. *Urol Oncol*. 2008;26(5):481–485.

Lieskovsky G, Boyd SD, Skinner DG. Management of late complications of the Kock pouch form of urinary diversion. *J Urol*. 1987;137(6):1146–1150.

Light JK, Engelmann UH. Le Bag: total replacement of the bladder using an ileocolonic pouch. *J Urol*. 1986;136(1):27–31.

Lilien OM, Camey M. 25-year experience with replacement of the human bladder (Camey procedure). *J Urol*. 1984;132(5):886–891.

Lin DW, Santucci RA, Mayo ME, et al. Urodynamic evaluation and long-term results of the orthotopic gastric neobladder in men. *J Urol*. 2000;164(2):356–359.

Lockhart JL, Davies R, Cox C, et al. The gastroileoileal pouch: an alternative continent urinary reservoir for patients with short bowel, acidosis and/or extensive pelvic radiation. *J Urol*. 1993;150(1):46–50.

Lowrance WT, Rumohr JA, Clark PE, et al. Urinary diversion trends at a high volume, single American tertiary care center. *J Urol*. 2009;182(5):2369–2374.

Madersbacher S, Mohrle K, Burkhard F, et al. Long-term voiding pattern of patients with ileal orthotopic bladder substitutes. *J Urol*. 2002;167(5):2052–2057.

Månsson A, Johnson G, Månsson W. Quality of life after cystectomy. Comparison between patients with conduit and those with continent caecal reservoir urinary diversion. *Br J Urol*. 1988;62(3):240–245.

Månsson W, Colleen S. Experience with a detubularized right colonic segment for bladder replacement. *Scand J Urol Nephrol*. 1990;24(1):53–56.

Månsson W, Bakke A, Bergman B, et al. Perforation of continent urinary reservoirs. Scandinavian experience. *Scand J Urol Nephrol*. 1997;31(6):529–532.

Månsson W, Davidsson T, Konyves J, et al. Continent urinary tract reconstruction—the Lund experience. *BJU Int*. 2003;92(3):271–276.

Månsson A, Henningsohn L, Steineck G, et al. Neutral third party versus treating institution for evaluating quality of life after radical cystectomy. *Eur Urol*. 2004;46(2):195–199.

Maralani S, Wood DP Jr, Grignon D, et al. Incidence of urethral involvement in female bladder cancer: an anatomic pathologic study. *Urology*. 1997;50(4):537–541.

Mattei A, Birkhaeuser FD, Baermann C, et al. To stent or not to stent perioperatively the ureteroileal anastomosis of ileal orthotopic bladder substitutes and ileal conduits? Results of a prospective randomized trial. *J Urol*. 2008;179(2):582–586.

McDougal WS. Bladder reconstruction following cystectomy by uretero-ileo-colourethrostomy. *J Urol*. 1986;135(4):698–701.

McGuire MS, Grimaldi G, Grotas J, et al. The type of urinary diversion after radical cystectomy significantly impacts on the patient's quality of life. *Ann Surg Oncol*. 2000;7(1):4–8.

Metcalfe M, Estey E, Jacobsen NE, et al. Association between urinary diversion and quality of life after radical cystectomy. *Can J Urol*. 2013;20(1):6626–6631.

Middleton AN Jr, Hendren WH. Ileal conduit in children at the Massachusetts General Hospital from 1955 to 1970. *J Urol*. 1976;115(5):591–595.

Mills RD, Studer UE. Metabolic consequences of continent urinary diversion. *J Urol*. 1999;161(4):1057–1066.

Minervini A, Boni G, Salinitri G, et al. Evaluation of renal function and upper urinary tract morphology in the ileal orthotopic neobladder with no antireflux mechanism. *J Urol*. 2005;173:144–147.

Morales P, Golimbu M. Colonic urinary diversion: 10 years of experience. *J Urol*. 1975;113(3):302–307.

Moschini M, Soria F, Susani M, et al. Impact of the level of urothelial carcinoma involvement of the prostate on survival after radical cystectomy. *Bladder Cancer*. 2017;3(3):161–169.

Montie JE, Pontes JE, Powell IJ. A comparison of the W-stapled ileal reservoir with hand-sewn reservoirs for orthotopic bladder replacement. *Urology*. 1996;47(4):476–481.

Muto G, Collura D, Simone G, et al. Stapled orthotopic ileal neobladder after radical cystectomy for bladder cancer: functional results and complications over a 20-year period. *Eur J Surg Oncol*. 2016;42(3):412–418.

Nayak AL, Cagiannos I, Lavallée LT, et al. Urinary function following radical cystectomy and orthotopic neobladder urinary reconstruction. *Can Urol Assoc J*. 2018;12(6):181–186.

Ng CK, Kauffman EC, Lee M-M, et al. A comparison of postoperative complications in open versus robotic cystectomy. *Eur Urol*. 2010;57(2):274–281.

Nieuwenhuijzen JA, Horenblas S, Meinhardt W, et al. Salvage cystectomy after failure of interstitial radiotherapy and external beam radiotherapy for bladder cancer. *BJU Int*. 2004;94(6):793–797.

Nix J, Smith A, Kurpad R, et al. Prospective randomized controlled trial of robotic versus open radical cystectomy for bladder cancer: perioperative and pathologic results. *Eur Urol*. 2010;57(2):196–201.

Norlen L, Trasti H. Functional behavior of the continent ileum reservoir for urinary diversion: an experimental and clinical study. *Scand J Urol Nephrol*. 1978;49(Suppl):33–35.

Olsson CA, Hensle TW, Kirsch AJ. Absorbable stapling techniques in bowel reservoirs. *Atlas Urol Clin North Am*. 1995;3(2):69–80.

Palapattu GS, Haisfield-Wolfe ME, Walker JM, et al. Assessment of perioperative psychological distress in patients undergoing radical cystectomy for bladder cancer. *J Urol*. 2004;172(5 Pt 1):1814–1817.

Pantuck AJ, Han KR, Perrotti M, et al. Ureteroenteric anastomosis in continent urinary diversion: long-term results and complications of direct versus nonrefluxing techniques. *J Urol*. 2000;163(2):450–455.

Papadopoulos I, Jacobsen KW. Experiences with the entero-ureteral anastomosis via the extramural serous-lined tunnel: procedure of Abol-Enein. *Urology*. 2001;57(2):234–238.

Parekh DJ, Gilbert WB, Kock MO, et al. Continent urinary reconstruction versus ileal conduit: a contemporary single-institution comparison of perioperative morbidity and mortality. *Urology*. 2000;55(6):852–855.

Parekh DJ, Gilbert WB, Smith JA Jr. Functional lower urinary tract voiding outcomes after cystectomy and orthotopic neobladder. *J Urol*. 2000;163(1):56–58 [discussion 58–59].

Parekh AR, Feng MI, Kirages D, et al. The role of pelvic floor exercises on post-prostatectomy incontinence. *J Urol*. 2003;170(1):130–133.

Parekh DJ, Messer J, Fitzgerald J, et al. Perioperative outcomes and oncologic efficacy from a pilot prospective randomized clinical trial of open versus robotic assisted radical cystectomy. *J Urol*. 2013;189(2):474–479.

Parekh DJ, Reis IM, Castle EP, et al. Robot-assisted radical cystectomy versus open radical cystectomy in patients with bladder cancer (RAZOR): an open-label, randomized, phase 3, non-inferiority trial. *Lancet*. 2018;391(10139):2525–2536.

Perimenis P, Burkhard F, Kessler TM, et al. Ileal orthotopic bladder substitute combined with an afferent tubular segment: long-term upper urinary tract changes and voiding pattern. *Eur Urol*. 2004;46(5):604–609.

Philip J, Manikandan R, Venugopal S, et al. Orthotopic neobladder versus ileal conduit urinary diversion after cystectomy—a quality-of-life based comparison. *Ann R Coll Surg Engl*. 2009;91(7):565–569.

Porter MP, Penson DF. Health related quality of life after radical cystectomy and urinary diversion for bladder cancer: a systematic review and critical analysis of the literature. *J Urol*. 2005;173(4):1318–1322.

Protogerou V, Moschou M, Antoniou N, et al. Modified S-pouch neobladder vs ileal conduit and a matched control population: a quality-of-life survey. *BJU Int*. 2004;94(3):350–354.

Pruthi RS, Wallen EM. Is robotic radical cystectomy an appropriate treatment for bladder cancer? Short-term oncologic and clinical follow-up in 50 consecutive patients. *Urology*. 2008;72(3):617–620 [discussion 620–622].

Quek ML, Ginsberg DA, Wilson S, et al. Pubovaginal slings for stress urinary incontinence following radical cystectomy and orthotopic neobladder reconstruction in women. *J Urol*. 2004;172(1):219–221.

Quek ML, Stein JP, Daneshmand S, et al. A critical analysis of perioperative mortality from radical cystectomy. *J Urol*. 2006;175(3 Pt 1):886–889 [discussion 889–890].

Ramirez JA, McIntosh AG, Strehlow R, et al. Definition, incidence, risk factors, and prevention of paralytic ileus following radical cystectomy: a systematic review. *Eur Urol*. 2013;64(4):588–597.

Rapp DE, O'Connor RC, Katz EE, et al. Neobladder-vaginal fistula after cystectomy and orthotopic neobladder construction. *BJU Int*. 2004;94(7):1092–1095 [discussion 1095].

Raza SJ, Hayn MH, Stegemann AP, et al. Complications after robot-assisted radical cystectomy: results from the International Robotic Cystectomy Consortium. *Eur Urol*. 2013;64(1):52–57.

Reddy PK, Lange PH. Bladder replacement with sigmoid colon after radical cystoprostatectomy. *Urology*. 1987;29(4):368–371.

Richie JP, Skinner DG, Waisman J. The effect of reflux on the development of pyelonephritis in urinary diversion: an experimental study. *J Surg Res*. 1974;16(3):256–261.

Rosenberg S, Miranda G, Ginsberg DA. Neobladder-vaginal fistula: the University of Southern California Experience. *Neurourol Urodyn*. 2018;37(4):1380–1385.

Roth S, van Ahlen H, Semjonow A. Does the success of ureterointestinal implantation in orthotopic bladder substitution depend more on surgeon level of experience or choice of technique? *J Urol*. 1997;157(1):56–60.

Rowland RG. Complications of continent cutaneous reservoirs and neobladders—series using contemporary techniques. *AUA Update Ser*. 1995;XIX(lessons 25):201–215.

Saika T, Arata R, Tsushima T, et al. Health-related quality of life after radical cystectomy for bladder cancer in elderly patients with an ileal conduit, ureterocutaneostomy, or orthotopic urinary reservoir: a comparative questionnaire survey. *Acta Med Okayama*. 2007;61(4):199–203.

Sakamoto N, Tsuneyoshi M, Naito S, et al. An adequate sampling of the prostate to identify prostatic involvement by urothelial carcinoma in bladder cancer patients. *J Urol*. 1993;149(2):318–321.

Santucci RA, Park CH, Mayo ME, et al. Continence and urodynamic parameters of continent urinary reservoirs: comparison of gastric, ileal, ileocolic, right colon and sigmoid segments. *Urology*. 1999;54(2):252–257.

Schmid M, Rink M, Traumann M, et al. Evidence from the “PROspective MulticEnTer RadIcal Cystectomy Series 2011 (PROMETRICS 2011)” study: how are preoperative patient characteristics associated with urinary diversion type after radical cystectomy for bladder cancer? *Ann Surg Oncol*. 2015;22(3):1032–1042.

Schondorf D, Meierhans-Ruf S, Kiss B, et al. Ureteroileal strictures after urinary diversion with an ileal segment—is there a place for endourological treatment at all? *J Urol*. 2013;190(2):585–590.

Schrier BP, Laguna MP, van der Pal F, et al. Comparison of orthotopic ileal neobladder: continence and urodynamic parameters. *Eur Urol*. 2005;47(5):679–685.

Schreiter F, Noll F. Kock pouch and S bladder: two different ways of lower urinary tract reconstruction. *J Urol*. 1989;142(5):1197–1200.

Schuster TG, Marcovich R, Sheffield J, et al. Radical cystectomy for bladder cancer after definitive prostate cancer treatment. *Urology*. 2003;61(2):342–347.

Sevin G, Soyupek S, Armağan A, et al. Ileal orthotopic neobladder (modified Hautmann) via a shorter detubularized ileal segment: experience and results. *BJU Int*. 2004;94(3):355–359.

Shaaban AA, Abdel-Latif M, Mosbahh A, et al. A randomized study comparing an antireflux system with a direct ureteric anastomosis in patients with orthotopic neobladders. *BJU Int*. 2006;97(5):1057–1062.

Shaaban AA, Gaballah MA, el Diasty TA, et al. Urethral controlled bladder substitution: a comparison between the intussuscepted nipple valve and the technique of Le Duc as antireflux procedures. *J Urol*. 1992;148(4):1156–1161.

Shabsigh A, Korets R, Vora KC, et al. Defining early morbidity of radical cystectomy for patients with bladder cancer using a standardized reporting methodology. *Eur Urol*. 2009;55(1):164–174.

Shah SH, Movassaghi K, Skinner D, et al. Ureteroenteric strictures after open radical cystectomy and urinary diversion: the University of Southern California experience. *Urology*. 2015;86(1):87–91.

Shim B, Kim KH, Yoon H, et al. Body image following radical cystectomy and ileal neobladder or conduit in Korean patients. *Korean J Urol*. 2014;55(3):161–166.

Shimko MS, Tollefson MK, Umbreit EC, et al. Long-term complications of conduit urinary diversion. *J Urol*. 2011;185(2):562–567.

Simma-Chiang V, Ginsberg DA, Teruya KK, et al. Outcomes of artificial urinary sphincter placement in men after radical cystectomy and orthotopic urinary diversions for the treatment of stress urinary incontinence: the University of Southern California experience. *Urology*. 2012;69(6):1397–1401.

Simon J. Ectopia vesicae (absence of the anterior walls of the bladder and pubic abdominal parietes); operation for directing the orifices of the ureters into the rectum; temporary success; subsequent death; autopsy. *Lancet*. 1852;2:568.

Simon J, Bartsch G Jr, Kufer R, et al. Neobladder emptying failure in males: incidence, etiology and therapeutic options. *J Urol*. 2006;176(4 Pt 1):1468–1472.

Simone G, Papalia R, Misuraca L, et al. Robotic intracorporeal padua ileal bladder: surgical technique, perioperative, oncologic and functional outcomes. *Eur Urol*. 2018;73(6):934–940.

Singh S, Choong S. Rupture and perforation of urinary reservoirs made from bowel. *World J Urol*. 2004;22(3):222–226.

Singh V, Yadav R, Sinha RJ, et al. Prospective comparison of quality-of-life outcomes between ileal conduit urinary diversion and orthotopic neobladder reconstruction after radical cystectomy: a statistical model. *BJU Int*. 2014;113(5):726–732.

Siracusano S, Niero M, Lonardi C, et al. Development of a questionnaire specifically for patients with Ileal Orthotopic Neobladder (IONB). *Health Qual Life Outcomes*. 2014;12:135.

Skinner DG, Boyd SD, Lieskovsky G. Clinical experience with the Kock continent ileal reservoir for urinary diversion. *J Urol*. 1984;132(6):1101–1107.

Skinner DG, Lieskovsky G, Boyd SD. Continuing experience with the continent ileal reservoir (Kock pouch) as an alternative to cutaneous urinary diversion: an update after 250 cases. *J Urol*. 1987;137(6):1140–1145.

Skinner DG, Lieskovsky G, Boyd SD. Continent urinary diversion. A 5½ year experience. *Ann Surg*. 1988;208(3):337–344.

Skinner DG, Boyd SD, Lieskovsky G, et al. Lower urinary tract reconstruction following cystectomy: experience and results in 126 patients using the Kock ileal reservoir with bilateral ureteroileal urethrostomy. *J Urol*. 1991;146(3):756–760.

Skinner EC. Choosing the right urinary diversion: patient's choice or surgeon's inclination? *Urol Oncol*. 2011;29(5):473–475.

Skinner EC, Fairey AS, Groshen S, et al. Randomized trial of Studer Pouch versus T-pouch orthotopic ileal neobladder in bladder cancer patients. *J Urol*. 2015;194(3):433–440.

Skinner EC, Comiter CV. Editorial: Can we improve on neobladder function in women? *Eur Urol*. 2015;68(4):672–673.

Skinner EC. Treatment of muscle-invasive bladder cancer in older patients. *Am Soc Clin Oncol Educ Book*. 2016;35:e228–e233.

Smith JA Jr. Neobladder-vaginal fistula after cystectomy and orthotopic neobladder construction. *J Urol*. 2005;174:970–971.

Sogni F, Brausi M, Frea B, et al. Morbidity and quality of life in elderly patients receiving ileal conduit or orthotopic neobladder after radical cystectomy for invasive bladder cancer. *Urology*. 2008;71:919–923.

Somani BK, Gimlin D, Fayers P, et al. Quality of life and body image for bladder cancer patients undergoing radical cystectomy and urinary diversion—a prospective cohort study with a systematic review. *Urology*. 2009;74(5):1138–1143.

Song C, Kang T, Hong JH, et al. Changes in the upper urinary tract after radical cystectomy and urinary diversion: a comparison of antirefluxing and refluxing orthotopic bladder substitutes and ileal conduit. *J Urol*. 2006;175(1):185–189 [discussion 189].

Steers WD. Voiding dysfunction in the orthotopic neobladder. *World J Urol*. 2000;18(5):330–337.

Stein JP, Huffman JL, Freeman JA, et al. Stenosis of the afferent antireflux valve in the Kock pouch continent urinary diversion: diagnosis and management. *J Urol*. 1994;151(2):338–340.

Stein JP, Stenzl A, Esrig D, et al. Lower urinary tract reconstruction following cystectomy in women using the Kock ileal reservoir with bilateral ureteroileal urethrostomy: initial clinical experience. *J Urol*. 1994;152(5 Pt 1):1404–1408.

Stein JP, Cote RJ, Freeman JA, et al. Indications for lower urinary tract reconstruction in women after cystectomy for bladder cancer: a pathological review of female cystectomy specimens. *J Urol*. 1995;154(4):1329–1333.

Stein JP, Freeman JA, Esrig D, et al. Complications of the afferent antireflux valve mechanism in the Kock ileal reservoir. *J Urol*. 1996;155(5):1579–1584.

Stein JP, Grossfeld GD, Freeman JA, et al. Orthotopic lower urinary tract reconstruction in women using the Kock ileal neobladder: updated experience in 34 patients. *J Urol*. 1997;158(2):400–405.

Stein JP, Esrig D, Freeman JA, et al. Prospective pathologic analysis of female cystectomy specimens: risk factors for orthotopic diversion in women. *Urology*. 1998;51(6):951–955.

Stein JP, Lieskovsky G, Ginsberg DA, et al. The T pouch: an orthotopic ileal neobladder incorporating a serosal lined ileal antireflux technique. *J Urol*. 1998;159(6):1836–1842.

Stein JP, Lieskovsky G, Cote R, et al. Radical cystectomy in the treatment of invasive bladder cancer: long-term results in 1,054 patients. *J Clin Oncol*. 2001;19(3):666–675.

Stein JP, Quek ML, Skinner DG. Contemporary surgical techniques for continent urinary diversion. *Atlas Urol Clin North Am*. 2001;9(2):147–173.

Stein JP, Ginsberg DA, Skinner DG. Indications and technique of the orthotopic T-pouch ileal neobladder. *Urol Clin North Am*. 2002;29:725–734.

Stein JP, Dunn MD, Quek ML, et al. The orthotopic T pouch ileal neobladder: experience with 209 patients. *J Urol*.

2004;172(2):584–587.

Stein JP, Clark P, Miranda G, et al. Urethral tumor recurrence following cystectomy and urinary diversion: clinical and pathological characteristics in 768 male patients. *J Urol*. 2005;173(4):1163–1168.

Stein JP, Penson DF, Lee C, et al. Long-term oncological outcomes in women undergoing radical cystectomy and orthotopic diversion for bladder cancer. *J Urol*. 2009;181(5):2052–2058.

Stein JP, Skinner DG. Surgical atlas, radical cystectomy. *BJU Int*. 2004;84(1):197–221.

Stein JP, Skinner DG. Surgical atlas: the orthotopic T-pouch ileal neobladder. *BJU Int*. 2006;98(2):469–482.

Stenzl A, Colleselli K, Poisel S, et al. Rationale and technique of nerve sparing radical cystectomy before an orthotopic neobladder procedure in women. *J Urol*. 1995;154(6):2044–2049.

Stenzl A, Draxl H, Posch B, et al. The risk of urethral tumors in female bladder cancer: can the urethra be used for orthotopic reconstruction of the lower urinary tract? *J Urol*. 1995;153(3 Pt 2):950–955.

Stenzl A, Colleselli K, Bartsch G. Update of urethra-sparing approaches in cystectomy in women. *World J Urol*. 1997;15(2):134–138.

Stenzl A, Colleselli K, Poisel S, et al. Anterior exenteration with subsequent ureteroileal urethrostomy in females. Anatomy, risk of urethral recurrence, surgical technique, and results. *Eur Urol*. 1998;33(Suppl 4):18–20.

Stenzl A, Jarolim I, Coloby P, et al. Urethra-sparing cystectomy and orthotopic urinary diversion in women with malignant pelvic tumors. *Cancer*. 2001;92:1864–1871.

Stenzl A, Höltl L. Orthotopic bladder reconstruction in women —what we have learned over the past decade. *Crit Rev Oncol*

Hematol. 2003;47(2):147–154.

Steven K, Poulsen AL. The orthotopic Kock ileal neobladder: functional results, urodynamic features, complications and survival in 166 men. *J Urol*. 2000;164(2):288–295.

Strasser H, Bartsch G. Anatomy and innervation of the rhabdosphincter of the male urethra. *Semin Urol Oncol*. 2000;18(1):2–8.

Studer UE, Ackermann D, Casanova GA, et al. Three years' experience with an ileal low pressure bladder substitute. *Br J Urol*. 1989;63(1):43–52.

Studer UE, Danuser H, Hochreiter W, et al. Summary of 10 years' experience with an ileal low-pressure bladder substitute combined with an afferent tubular isoperistaltic segment. *World J Urol*. 1996;14(1):29–39.

Studer UE, Burckard FC, Schumacher M, et al. Twenty years' experience with an ileal orthotopic low pressure bladder substitute—lessons to be learned. *J Urol*. 2006;176(1):161–166.

Sullivan JW, Grabstald H, Whitmore WF. Complications of ureteroileal conduit with radical cystectomy: review of 336 cases. *J Urol*. 1980;124(6):797–801.

Suriano F, Gallucci M, Flammia GP, et al. Bacteriuria in patients with an orthotopic ileal neobladder: urinary tract infection or asymptomatic bacteriuria? *BJU Int*. 2008;101(12):1576–1579.

Suriano F, Daneshmand S, Buscarini M. The use of nonabsorbable staples for urinary diversion: a step in the wrong direction. *Urol Int*. 2013;90(2):125–129.

Sultan S, Coles B, Dahm P. Alvimopan for recovery of bowel function after radical cystectomy. *Cochrane Database Syst Rev*. 2017;(5) [CD012111].

Tanagho EA, Miller ER, Meyers FH, et al. Observations on the dynamics of the bladder neck. *Br J Urol*. 1966;38(1):72–84.

Tchetgen MB, Sanda MG, Montie JE, et al. Collagen injection for the treatment of incontinence after cystectomy and orthotopic neobladder reconstruction in women. *J Urol*. 2000;163(1):212–214.

Tefilli MV, Gheiler EL, Tiguert R, et al. Urinary diversion–related outcome in patients with pelvic recurrence after radical cystectomy for bladder cancer. *Urology*. 1999;53(5):999–1004.

Thoeny HC, Sonnenschein MJ, Madersbacher S, et al. Is ileal orthotopic bladder substitution with an afferent tubular segment detrimental to the upper urinary tract in the long term? *J Urol*. 2002;168:2030–2034 [discussion 2034].

Thurairaja R, Studer UE. How to avoid intermittent catheterization in men with ileal bladder substitution. *J Urol*. 2008;180(6):2301–2302.

Thuroff JW, Alken P, Riedmiller H, et al. The Mainz pouch (mixed augmentation ileum and cecum) for bladder augmentation and continent diversion. *J Urol*. 1986;136(1):17–26.

Thuroff JW, Mattiasson A, Andersen JT, et al. The standardization of terminology and assessment of functional characteristics of intestinal urinary reservoirs. *Scand J Urol Nephrol*. 1996;30(5):349–356.

Tizzoni G, Poggi A. Die Wiederherstellung der Harnblase: Experimentelle Untersuchungen. *Zentralbl Chir*. 1888;15:921–924.

Tobisu K, Tanaka Y, Mizutani T, et al. Transitional cell carcinoma of the urethra in men following cystectomy for bladder cancer: multivariate analysis for risk factors. *J Urol*. 1991;146(6):1551–1553 [discussion 1553–1534].

Turner WH, Danuser H, Moehrle K, et al. The effect of nerve sparing cystectomy technique on postoperative continence after orthotopic bladder substitution. *J Urol*.

1997;158(6):2118–2122.

Tyson MD, Chang SS. Enhanced recovery pathways versus standard care after cystectomy: a meta-analysis of the effect on perioperative outcomes. *Eur Urol*. 2016;70(6):995–1003.

Von Rundstedt FC, Mata DA, Shen S, et al. Transurethral biopsy of the prostatic urethra is associated with apical margin status at radical cystoprostatectomy. *J Clin Urol*. 2016;9(6):404–408.

Wang GJ, Barocas DA, Raman JD, et al. Robotic vs open radical cystectomy: prospective comparison of perioperative outcomes and pathological measures of early oncological efficacy. *BJU Int*. 2008;101(1):89–93.

Wear JB Jr, Barquin OP. Ureterosigmoidostomy: long-term results. *Urology*. 1973;1(3):192–200.

Wilson S, Quek ML, Ginsberg DA. Transurethral injection of bulking agents for stress urinary incontinence following orthotopic neobladder reconstruction in women. *J Urol*. 2004;172(1):244–246.

Winters B, Cai J, Daneshmand S. Short-term change in renal function in patients undergoing continent versus non-continent urinary diversions. *UroToday Int J*. 2013;6(2).

Witjes JA, Lebret T, Comperat AM, et al. 2016 updated EAU guidelines on muscle-invasive and metastatic bladder cancer. *Eur Urol*. 2016;71(3):462–475.

Wood DP Jr, Bianco FJ Jr, Pontes JE, et al. Incidence and significance of positive urine cultures in patients with an orthotopic neobladder. *J Urol*. 2003;169(6):2196–2199.

Wood DP Jr, Montie JE, Pontes JE, et al. Identification of transitional cell carcinoma of the prostate in bladder cancer patients: a prospective study. *J Urol*. 1989;142(1):83–85.

Yafi FA, Aprikian AG, Fradet Y, et al. Surveillance guidelines based on recurrence patterns after radical cystectomy for bladder cancer: the Canadian Bladder Cancer Network experience. *BJU Int*. 2012;110(9):1317–1323.

Yuh B, Padalino J, Butt ZM, et al. Impact of tumour volume on surgical and pathological outcomes after robot-assisted radical cystectomy. *BJU Int*. 2008;102(7):840–843.

Yuh BE, Nazmy M, Ruel NH, et al. Standardized analysis of frequency and severity of complications after robot-assisted radical cystectomy. *Eur Urol*. 2012;62(5):806–813.

Zaayer EJ. Discussion. Intra-abdominale plastieken. *Ned Tijdschr Geneeskd*. 1911;65:836.

Zippe CD, Nandipati KC, Agarwal A, et al. Female sexual dysfunction after pelvic surgery: the impact of surgical modifications. *BJU Int*. 2005;96(7):959–963.

Minimally Invasive Urinary Diversion

Khurshid A. Guru MD

The frequency of implementing a minimally invasive approach to cystectomy has increased from 26% in 2010 to 39% in 2013 (Bachman et al., 2017). Robot-assisted surgical approach for pelvic urologic oncology has been in practice for more than a decade (Guru et al., 2008; Menon et al., 2003), and the technique for robot-assisted radical cystectomy (RARC) with lymph node dissection has been established (Poch et al., 2013). Oncologic outcomes after RARC and lymph node dissection have proven to be safe and efficacious in early and long-term follow-up (Ahmed et al., 2014; Hellenthal et al., 2011; Raza and Guru, 2015; Parekh et al., 2018). The Roswell Park Comprehensive Cancer Center group has advocated the Quality Cystectomy Score based on star-based criteria to offer quality care to patients undergoing RARC (Hussein et al., 2017c). These quality criteria range from neoadjuvant chemotherapy consultation to adequate lymph node yield and 30-day mortality. **Patients who underwent a minimally invasive approach to cystectomy were more likely to receive neoadjuvant chemotherapy based on the National Cancer Database (NCDB) analysis** (Bachman et al., 2017). Despite validation of oncologic equivalency of RARC based on several randomized controlled trials (Bochner et al., 2015; Khan et al., 2016; Nix et al., 2010; Parekh et al., 2018), the role of intracorporeal urinary diversion (ICUD) has not been investigated.

Laparoscopic approach to urinary diversion has evolved since 1992, and its adoption was hindered by prolonged operative times, limitations of instrument maneuverability used with conventional laparoscopy, and a steep learning curve (Kozminski and Partamian, 1992; Potter et al., 2000; Sanchez de Badajoz et al., 1992). These difficulties led to hybrid procedures, in which extirpation and lymph node dissection were performed by conventional laparoscopy, and diversion was completed using a modified open approach (Haber et al., 2007).

Several perceived advantages of robot-assisted approaches for bladder cancer include less pain, minimal blood loss, and earlier return of bowel function, which ultimately help in quicker return to previous quality of life (Challacombe et al., 2011).

Incorporation of Robot-Assisted Approach

Data from the NCDB during the early learning curve of RARC and incorporation of ICUD (2010–2013) has shown slower adoption of minimally invasive approaches by academic institutions (Bachman et al., 2017). This possibly was related to multiple factors, such as the presence and availability of the surgical robot for cystectomy (longer operative time versus its use for kidney or prostate) and a larger proportion of surgeons with limited training and experience in minimally invasive approach. Based on the NCDB for radical cystectomy, a median hospital volume of 12 cases per year with an average volume of only 2 procedures has been reported (Waingankar et al., 2017). **Despite the slow adoption and early incorporation of this approach, rate of conversion to open was only 4.3% in more than 3000 procedures** (Bachman et al., 2017). This can be interpreted in multiple ways; early adoption of robot-assisted radical prostatectomy could have paved the way for RARC identifying ways to reduce the morbidity of radical cystectomy. The negative impact of this could be suboptimal oncologic procedures during the learning curve and performing urinary diversions that did not meet the standards set by open experts. Attempts to simplify operative steps used in well-established techniques of urinary diversion are believed to lead to a smaller radius pouch and ultimately a geometric low capacity and high-pressure reservoir (Hautmann, 2017).

More than 2750 RARCs have been registered in the International Robotic Cystectomy Consortium (IRCC) database, a quality assurance conglomerate of 50 surgeons at 37 institutions in 13 countries. Based on previous data published in 2013 from the IRCC, only 18% of procedures have been performed with a complete intracorporeal approach (Ahmed et al., 2014). Recent updates from the IRCC in 2018 show that **incorporation of ICUD for the robotic cystectomy–focused group has increased from 9% in 2005 to 97% in 2016 with an annual increase of 11%. This dramatic increase was primarily demonstrated for ileal conduit** (Hussein et al., 2018). This trend has shown an earlier start in Europe than North America. Whether a robot-assisted approach to radical cystectomy encourages surgeons more toward performing ileal conduit diversions, thereby limiting continent urinary diversions, remains unclear. A single-institution study from a high-volume RARC center has shown that surgeon preference may have led to choice of incontinent urinary diversion in only 8% of patients eligible to continent urinary diversion (Hussein et al., 2016a).

Key Points

- Advantages of robot-assisted approach for bladder cancer include less pain, minimal blood loss, and earlier return of bowel function.
- Incorporation of intracorporeal urinary diversion has recently increased (annual increase of 11%).
- Ileal conduit is the most commonly performed diversion with the robot-assisted approach.

Patient Selection

The selection criteria (including high body mass index, locally advanced disease, older age, prior abdominal surgery) have significantly broadened as the learning curve has flattened (Wilson et al., 2015). One of the contraindications for the minimally invasive approach is decreased cardiac and pulmonary compliance because of the inability to tolerate the steep Trendelenburg position, especially with prolonged operative duration during ICUD. This has been addressed with newer technology available in the Xi model of the da Vinci Surgical System and use of the AirSeal, which has allowed surgeons to operate in a less-steep Trendelenburg position. Use of ileum is contraindicated in patients with short bowel, severe inflammatory bowel disease, and postradiation enteritis. Absolute and relative contraindications for neobladder are similar to open surgery. The absolute contraindications include involvement of the urethra distal to the prostate and inadequate renal (serum creatinine >2 mg/dL) and poor hepatic functions (Parekh and Donat, 2007).

Surgeon Choice

The best practices recommended by the Pasadena Consensus Panel (Wilson et al., 2015) **advise surgeons to focus on oncologic outcomes early on in their initial experience.** A stepwise incorporation of intracorporeal ileal conduit (building an experience of more than 30 to 100 procedures) and ultimately incorporating continent urinary diversion to their practice (25% to 50%) is recommended. Once the learning curve has flattened, the **consensus considers adequate overall operation of 4 hours or less (if ileal conduit is performed) and less than 5 hours with neobladders** (Wilson et al., 2015).

Preoperative Care

Enhanced Recovery After Surgery

Multimodal perioperative pathways, especially enhanced recovery after surgery (ERAS), has evolved with more than 20 key components and has been tailored by several cystectomy experts (Collins et al., 2016). Recent modifications include early use of alvimopan, intraoperative goal-oriented fluid optimization, immediate initiation of oral diet, and reduced narcotic use (Wilson et al., 2015). Xu et al. (2015) compared traditional pathway with an enhanced recovery protocol and reported decreased opioid usage per day, incidence of ileus, and hospital stay; however, they reported more pain. **Opioid use for breakthrough pain underwent a radical change from opioid patient-controlled analgesia (PCA) and epidurals to high-dose acetaminophen and/or ketorolac.**

Patients who underwent RARC with ICUD and participated in the ERAS pathway had shorter length of stay and were more likely to receive a neobladder. The ERAS group was associated with significantly lower overall gastrointestinal-related complications and readmission rates at 90 days. Participating in the ERAS pathway and younger age were independently associated with a hospital stay of less than 10 days (Miller et al., 2017; Tan et al., 2017). Pooled meta-analysis of 13 studies with 1493 patients showed that implementation of ERAS protocols after surgery reduced complications and length of stay without affecting overall readmission rates. They concluded that **emphasis on the development of integrated multidisciplinary clinical pathways can improve outcomes and increase patient satisfaction** (Tyson and Chang, 2016). Despite the focus on reducing the length of stay, it is important to understand its impact on patients. In a consecutive study of 484 patients, the team at University of Michigan found that reduced length of stay (less than 5 days) carried a (twofold) increased risk of 90-day major complications (Osawa et al., 2017). **Additional emphasis should be given to care for patients after discharge, especially in areas such as trained nurse visit and home health issues such as hydration, exercise, and ambulation.**

Solids and clear fluids are allowed until 6 and 2 hours, respectively, before induction of anesthesia (Smith et al., 2011). **Mechanical bowel preparation and oral antibiotics preoperatively are no longer recommended.** Bowel preparation can lead to electrolyte imbalance, especially in elderly patients, and may lead to spillage of liquid content during intracorporeal opening of bowel. Several studies have shown no clear benefit of oral mechanical bowel preparation before surgery (Cerantola et al., 2013).

Intermittent pneumatic compression and leg stockings are recommended. **To avoid significant thromboembolic complications, anticoagulant treatment is recommended with low-molecular-weight heparin based on the body weight before and up to 4 weeks after surgery** (Johar et al., 2013; Sun et al., 2015)**. Broad-spectrum intravenous antibiotics are preferably given up at induction and maintained as needed.**

Key Points

- Mechanical bowel preparation *and* oral antibiotics should be avoided.
- Anticoagulant treatment can help avoid significant thromboembolic complications.
- Preoperative broad-spectrum intravenous antibiotics are preferably given up to 1 hour.
- Enrollment in the ERAS pathway helps with reduction in length of stay, complications, and readmissions.

Patient Position and Port Placement

After induction of general endotracheal anesthesia, a nasogastric tube and a Foley urinary catheter are inserted. The patient is placed in lithotomy position with arms adducted and padded. The legs are also abducted and slightly lowered on spreader bars or stirrups. Traditionally the patient has been positioned in steep Trendelenburg position; meanwhile with the da Vinci Xi Surgical System, which integrates table motion with the ability to maneuver the patient position without undocking the robot, has also explored the ability to perform the procedure in lesser steep or even in a flat position. The abdomen is safely insufflated with Veress needle or Hassan technique depending upon the experience and the need (e.g., previous abdominal surgery). A six- to seven-port transperitoneal approach is used and all the ports after the camera port are placed under direct vision in a more cephalad orientation (Fig. 142.1). This **cephalad positioning of the ports helps in small bowel maneuvering during urinary diversion and extended lymph node dissection along the aortic bifurcation.** In the six- to seven-port configuration, the 12-mm camera port (8 mm for the da-Vinci Xi Surgical System) is placed above the umbilicus (midline or slightly to the left of midline). Two robotic ports (8-mm arms) are placed symmetrically at the level of the umbilicus on the left and right side, lateral to the rectus sheath. While performing the neobladder, some expert surgeons use an additional left side port (12–15 mm) above the left 8-mm robotic arm port, and this port is placed just above and medial to this port. The robotic arm just above and medial to the anterior superior iliac spine could be used alternatively (hybrid) with an assistant instrument or by inserting an additional robotic arm inside the 15-mm laparoscopic port for stapling during neobladder creation. A 5-mm (12-mm for neobladder) port is placed between the camera and the right robotic arm port. An extra-short 12-mm port can be inserted in the suprapubic area for bowel re-anastomosis while performing the “marionette” ileal conduit and the “W-neobladder” as performed by the author. This port helps in aligning the bowel during re-anastomosis and can be extended and converted to a Pfannesteil incision for specimen removal.

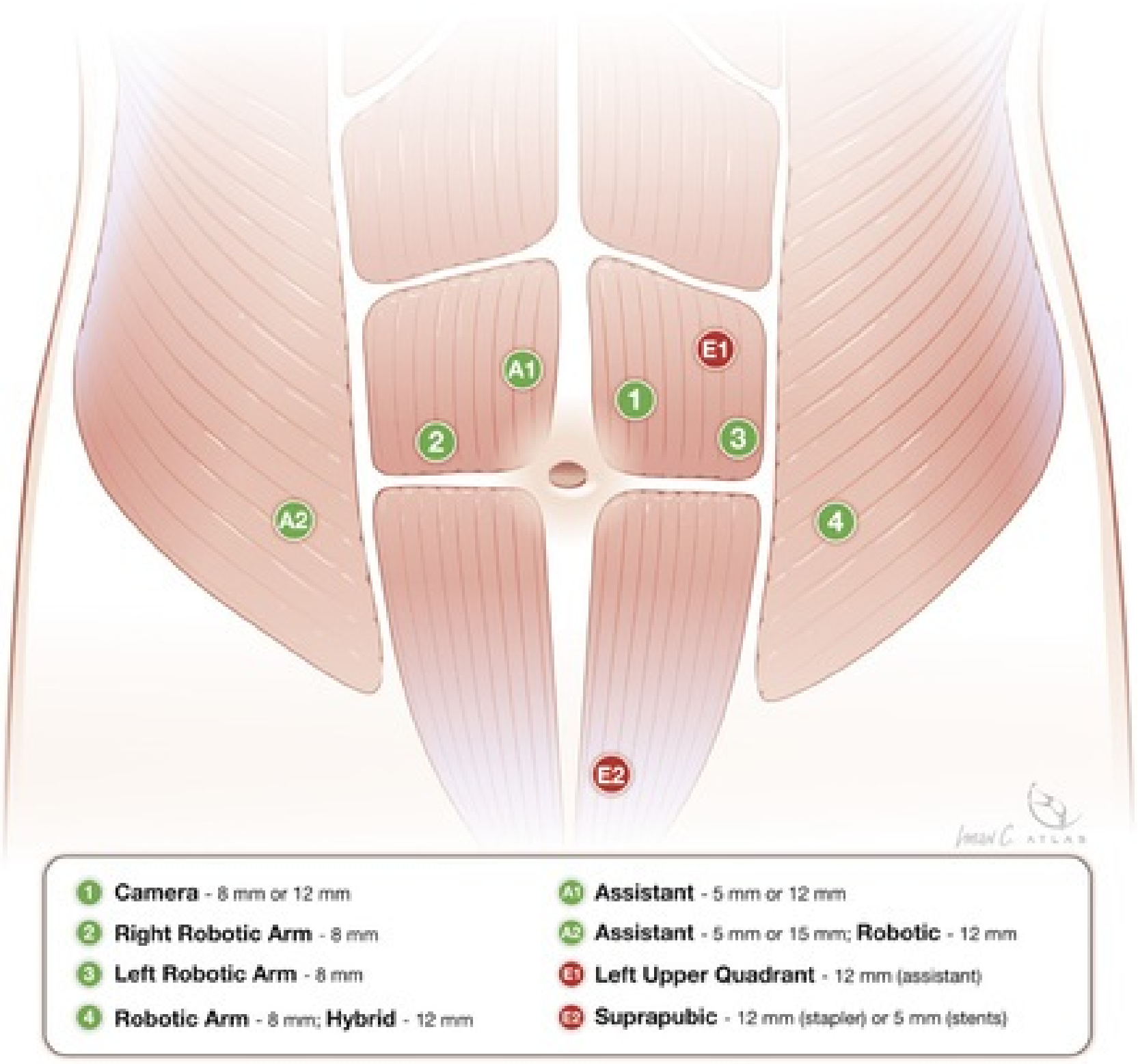

A1
E1
1
2
3
A2
4
E2
1 Camera - 8 mm or 12 mm
2 Right Robotic Arm - 8 mm
3 Left Robotic Arm - 8 mm
4 Robotic Arm - 8 mm; Hybrid - 12 mm
A1 Assistant - 5 mm or 12 mm
A2 Assistant - 5 mm or 15 mm; Robotic - 12 mm
E1 Left Upper Quadrant - 12 mm (assistant)
E2 Suprapubic - 12 mm (stapler) or 5 mm (stents)

FIG. 142.1 Overview of common theme and variation in port placement for intracorporeal urinary diversion.

With use of a stepwise approach, "the technique of spaces" is important in completing extirpation of the bladder and lymph nodes. Dividing the procedure into well-defined steps facilitates teaching and keeps the procedure focused. The four spaces of dissection in men are periureteral, lateral pelvic, anterior rectal, and retropubic spaces (Poch et al., 2013). Extended lymph node dissection is performed up to the aortic bifurcation, which helps with the crossing of the left ureter to the right side for the urinary diversion. Once the bladder and the lymph nodes are placed in the specimen bags, attention is directed toward ICUD. **The entire procedure can be performed with a 0-degree lens.** Occasionally, it is advantageous to use a 30-degree down lens for a deep female pelvis during an extended lymph node and vascular pedicle dissection.

Key Points

- A six- to seven-port transperitoneal approach in a more cephalad position helps in maneuvering small bowel.

- The robotic arm could be used alternatively with an assistant instrument by inserting an additional robotic arm inside 15-mm laparoscopic port.
- A 0-degree lens can be used for the entire procedure.
- Robotic arms can be undocked, and steep Trendelenburg position is reduced for ease of urethra-neobladder anastomosis.

Anatomic Considerations in Men

The radical approach to cystectomy has been modified and nerve sparing is more likely feasible because of the numerous anatomic studies that have focused on nerve preservation and easier operative opportunity because of the 3D view, magnification, and ability to maneuver in a small narrow space with help of a surgical robot (Fig. 142.2). This approach should be used only in patients who have an anatomically safe location of tumor, lower tumor burden, and adequate baseline sexual function, making such patients more amenable to nerve-sparing not only for sexual preservation but also for continence after creation of a neobladder.

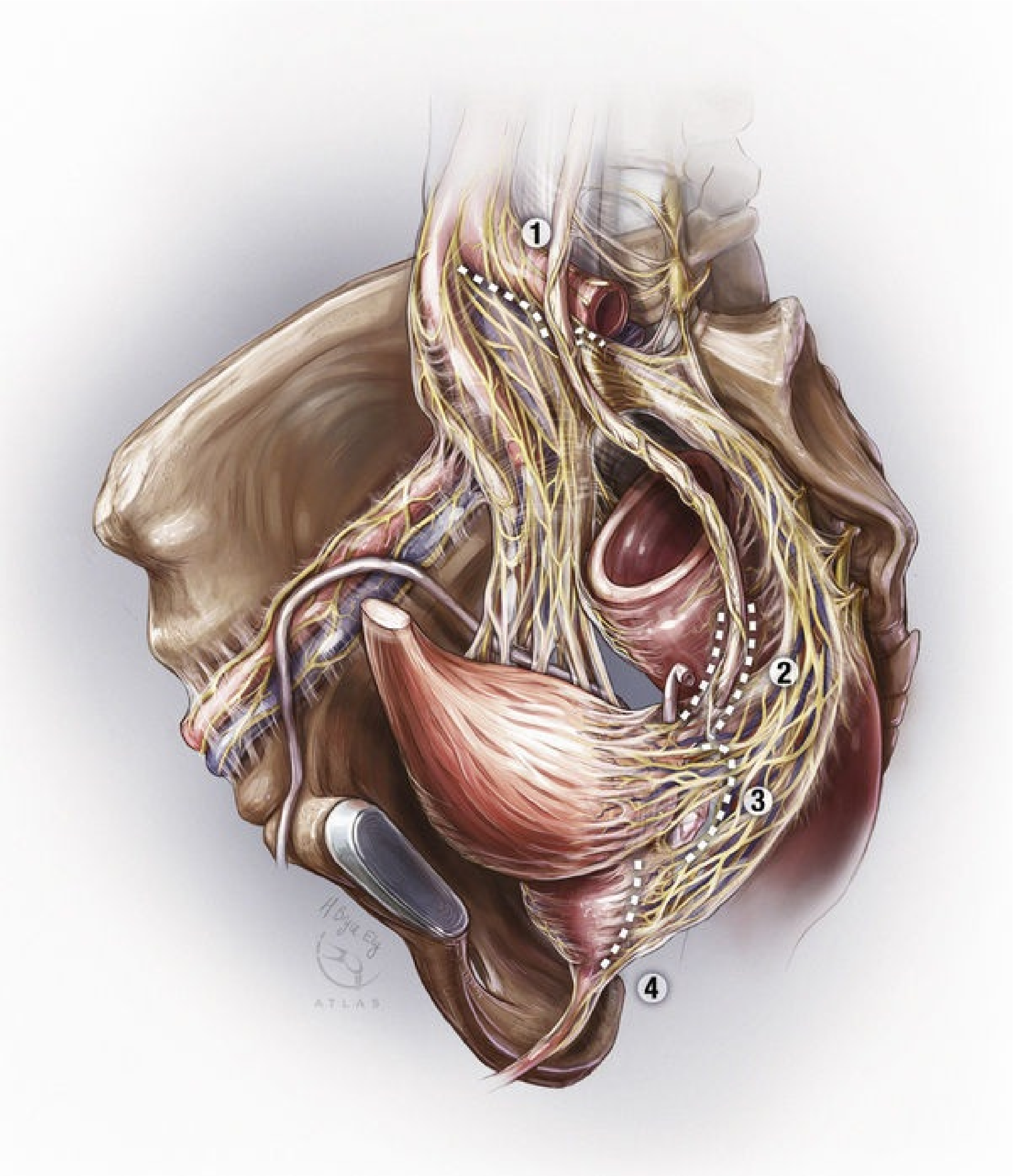

FIG. 142.2 Critical areas of possible nerve damage during nerve-sparing radical cystoprostatectomy in men.

The nerves are at risk at their origin in the medial aspect of the common iliac vessels and the presacral area (1). It is critical to keep in mind the course of the pelvic plexus while performing an extended lymph node dissection because it can risk sexual function and continence (Walz et al., 2016). **The approach to nerve sparing has to also start early on from the high ligation**

of the bladder vascular pedicle (ensuring preservation of the proximal neurovascular complex) to the incision of the peritoneum in the pouch of Douglas overlying the rectovesical space (2). Once the ampullae of the vasa are identified and safely dissected, an athermal approach of the seminal vesicles, while sparing the Denonvillier fascia (where the pelvic plexus is mostly concentrated), should be attempted (Schwalenberg et al., 2010). It is safe to avoid manipulation and sometimes spare the middle to lower part of the seminal vesicles (3). The proximal prostatic pedicles should be controlled close to the prostate, and attempts to perform an intrafascial, traction-free, and athermal nerve preservation should be made. The complete lateral nerve preservation (i.e., Veil of Aphrodite) and its distal extent (4) are difficult to complete without dissecting the apex of the prostate after dropping of the bladder. **Computer-assisted dissection that involved 3D reconstruction of the inferior hypogastric plexus has demonstrated the precise location and distribution of pelvic nerves helping in continence and erectile function** (Alsaid et al., 2009; Takenaka et al., 2005).

Approximately one-third of the cross-sectional external urethral sphincter area has shown to be laterally overlapped by the dorsal venous complex at the prostatic apex (Ganzer et al., 2014). Doppler studies have **shown dorso-cavernous anastomoses play an important role in the cavernous arterial hemodynamics** (Erdogru et al., 2001). Vascular anastomoses have also been found between different arterial supplies (dorsal, the cavernous, and the bulbourethral) of the penis. These arteries, except for bulbo-urethral arteries, have been shown to have function of contractibility based on their muscular walls and accompanying nerves (Diallo et al., 2013). At the site of the external urethral sphincter, cavernosa nerves converge close to the urethra before they penetrate the muscular pelvic floor (Diallo et al., 2013). Anatomic study of 18 adult male cadavers has shown that the external urethral sphincter receives part of innervation through special branches originating from the dorsal nerve of penis after it splits from the pudendal nerve. This study elegantly shows that these branches located as close as 3 mm from the prostatic apex, and 50% had shown only unilateral innervation, emphasizing the need for a meticulous periurethral dissection (Narayan et al., 1995).

Anatomic Considerations in Women

The pelvic splanchnic nerves contain adrenergic and cholinergic fibers and are also responsible for vaginal lubrication and genital swelling during sexual arousal (Trimbos et al., 2001). Therefore damage to these nerves causes decreased flow to the vagina and vulva (Moszkowicz et al., 2011). The inferior hypogastric plexus arises from the hypogastric and pelvic splanchnic nerves and is retroperitoneal in location. It radiates anterolateral to the rectum, passing laterally to the cervix and the vaginal fornix and **extending to the lateral vaginal wall and the base of the bladder, where it is most vulnerable to injury** (Moszkowicz et al., 2011). The cavernous nerves originate along the **lateral edge of the vagina and travel within the vesico-vaginal septum** to pass through the urogenital diaphragm (Baader and Herrmann, 2003).

Advances in studies regarding dissection of the female **urethra have shown that despite removal of bladder neck and cranial third of urethra, urinary continence can still be preserved**. Manipulation of the urethral Foley balloon helps in better defining the bladder neck and the key surrounding landmarks for preservation. Proper posterior dissection and excellent magnified visualization allow for ease in preservation of the periurethral complex and the endopelvic fascia. The majority of striated intrinsic sphincter is situated in the mid- to distal third of the urethra and can be preserved while adhering to safe oncologic practices. In females the nerve branches supplying the urethra course close to the lateral vaginal wall and require preservation of the tissue around the proximal urethra and lateral to the bladder neck (Stenzl et al., 1995). Despite the controversy, the **innervation should be preserved for maintenance of continence. It is preferred that the anterior vaginal wall is preserved in patients with goals of nerve sparing.** I avoid removal of the specimen via the vagina to prevent trauma to the preserved complex and prefer a small Pfannesteil incision in these select situations.

Ileal Conduit

Transfer of Left Ureter and Selection of Bowel

The **left ureter is crossed below the sigmoid mesentery and over the great vessels to the right side.** It is important to identify patients with duplication of the ureter so that they can be implanted separately or together depending upon the caliber of the ureters. If the left ureter is short, the sigmoid colon is retracted with the fourth arm. Occasionally a 30-degree down lens helps to identify and free the proximal left ureter. A 12-cm–long segment of ileum is identified (15–20 cm proximal to the ileocecal valve). **Adequate bowel length on the ileocecal end of the bowel should be left in place to avoid metabolic disturbances and kinking once the conduit is exteriorized and repositioned.** It is also critical to avoid use of redundant segment of ileum to prevent residual urine and subsequent stasis of urine, infections, absorptive and metabolic complications, and subsequent loss of renal function.

Marionette Stitch

A 60-inch 1-0 silk suture using a Keith needle is introduced via the hypogastrium of the anterior abdominal wall and is passed through the distal end of the bowel segment (future stoma) and brought back through the same location on the anterior abdominal wall. The marionette stitch (Fig. 142.3) is held together using a surgical instrument; the **benefit of not tying the marionette stitch is to allow free movement of the bowel segment during the creation of the conduit.** The marionette stitch manipulates the bowel segment to adjust for the limitation of fixed ports and enables mobilization of different areas of the conduit into the surgical field. It is helpful especially in patients with limited distance between physical boundaries of the abdomen/pelvis and the actual operative space. It can be placed farther down in the pelvis to keep the operative field in range of optimal mechanical joint movements of the robotic instruments.

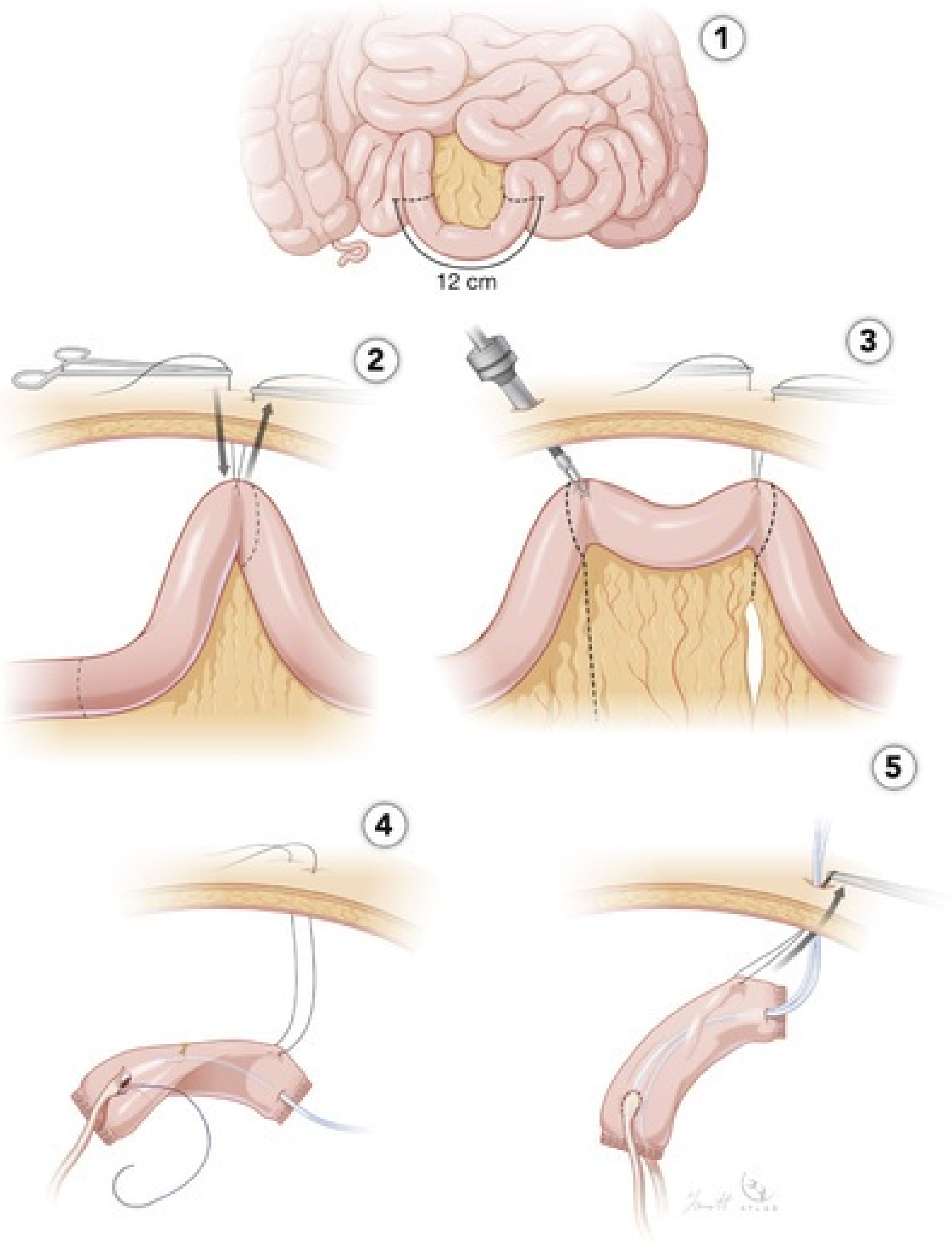

FIG. 142.3 Illustrated schema of key steps in creating the ileal conduit using “marionette” technique. *1,* A 12- to 15-cm ileal segment is harvested approximately 15 cm away from the ileocecal valve. *2,* A 60-inch 1-0 silk suture using a Keith needle is passed through the distal end of the bowel segment and brought back through the same location on the anterior abdominal wall. The marionette stitch is held together using a surgical instrument. *3,* The fourth arm is used to hold the proximal segment of the bowel at stretch opposite to the stoma end held by the marionette stitch. The mesentery is then incised to create 2 mesenteric windows. *4,* Once the marionette is lowered, the ureters are implanted with minimal traction to the proximal end of the ileal conduit. The stent is secured to the conduit by a using 3-0 chromic stitches to prevent accidental dislodgment of the stent. Ureters are anastomosed and the bowel is restored. *5,* The stoma is created.

Isolation of the Bowel Segment and Creation of the Ileal Conduit

The fourth arm is used to hold the proximal segment of the bowel at stretch opposite to the stoma end held by the marionette stitch; meanwhile the hook cautery is used to incise the peritoneum of the bowel mesentery. It is important to keep the appropriate orientation of the bowel and avoid narrowing of the base of the conduit limits (limit mesenteric blood supply). Another alternative is to use a vascular stapler across the mesentery, which makes this process quicker. After the two mesenteric windows are created, a 45-mm Endo GIA stapler is used to divide the bowel proximally and distally. The incised ends are held together using a 0-silk suture to avoid malrotation during anastomosis. The bowel re-anastomosis is not established at this point. **Ileal conduit segment washout has been abandoned because it does not reduce risk of infection and also to avoid spillage during stent manipulation and ureteroileal anastomosis.**

Ureteroileal Anastomosis

The two commonly employed techniques of anastomosis are the Bricker and Wallace. A Bricker anastomosis is a refluxing end-to-side anastomosis and is easy to perform while keeping the two renal units separate. Meanwhile the Wallace technique joins the ends of the two ureters in a Y format, anastomosing a single limb to the proximal portion of the ileal conduit (Rehman et al., 2011).

Two openings are created on either side of the proximal end of the conduit. To avoid risk of strictures, **I avoid the use of electrocautery; instead, I use a cold scissors to create a wide buttonhole enterotomy by removing the serosa in the proximal end of the ileum.** Once the marionette is lowered, the ureter is implanted with minimal traction and stretching of the proximal end of the ileal conduit. Once efflux of clear urine is seen, wide spatulation is carried out, and the fourth arm is used to retract the cut end of the distal ureter**.** I prefer to implant the left ureter first for ease of anastomosis.

A few critical issues should be kept in mind while performing this anastomosis. The key is to place the initial suture in the conduit opening first (outside in) and then into the angle of the incision in the ureter (inside out). The suture on the conduit side should be perpendicular to the proximal staple line of the conduit. This helps to align the ureter and avoids malrotation and back walling of the ureter. This initial suture sets the stage for a proper alignment and placement of the subsequent sutures. It is critical to understand that the position in which the anastomosis is carried out is not the final position in which the proximal end of the conduit will lay. Interrupted sutures can also be run along both sides halfway up to middle of the anastomosis after which the stent is placed. A Van-Velthoven-type, double armed, 4-0 Vicryl sutures approximately 5 cm long can also be used to suture the angle of the spatulation and continued along both sides. After completion of anastomosis of the posterior wall, the ureteral stent is introduced. A metal laparoscopic suction tube is passed into the distal conduit through the 15-mm right assistant port. The metal laparoscopic suction tube is pushed gently across the conduit and positioned at the junction of the conduit and the ureteral anastomosis. **The metal suction tip is held in place by the robotic needle driver to allow passage of stent through it without damaging the anastomosis. This maneuver helps to facilitate threading of the 90-cm, 8.5-Fr, and single-J ureteral stent with a guidewire into the renal pelvis. The guidewire is kept in the stent until it is secured to the conduit by using 3-0 chromic stitches to prevent accidental dislodgment of the stent.** The guidewire is removed only after the suture is placed because it is difficult to identify the stent because of lack of tactile feedback. The distal end of the ureter is excised completely and sent for final histopathology. The author does not routinely perform frozen section of the distal ureter. The ureteroileal anastomosis is then completed. Once the left side is anastomosed, the marionette is manipulated to turn the conduit on the other side, and the right ureteral anastomosis is performed in a similar fashion. The distal ends (external portion) of both ureteral stents are left draining through the 15-mm side port. The exterior portions of the stents should not be clamped to the drape to avoid accidental dislodgment during intracorporeal manipulation of the ileal conduit.

We also have started to preserve a flap of peritoneum while dissecting the right ureter (periureteral space) at the time of RARC and extended lymph node dissection. This peritoneal flap helps in covering the proximal ureteroileal anastomosis and retroperitonealize it to avoid an inflammatory response at the site of the anastomosis (Ahmed et al., 2017).

Restoration of the Bowel

We prefer to re-anastomose the bowel once the two ureters are anastomosed. This helps with ease of conduit manipulation and tailoring the bowel re-anastomosis to avoid kinking or tension. The feasibility of robot-sewn ileoileal anastomosis has been studied. A study of 48 consecutive patients was analyzed, and the operating time was only 23 minutes with no anastomosis leaks. The cost of anastomosis was significantly lower (<1%) in comparison with using staplers and may serve as an alternate approach (Loertzer et al., 2018).

Pre-Stoma Preparation

The robot is left docked and the instruments are removed. The surgeons scrub to create the stoma opening by making a cruciate incision in the anterior fascia and inserting the four stay sutures to anchor the conduit once it is externalized. After completion of four fascial sutures, the robotic arms are reinserted. The pelvis is examined for any bleeding and strings of all specimen bags are brought out via the suprapubic port. A vascular clamp is introduced via the stoma opening under direct vision into the abdominal cavity to grab the marionette stitch and the free ends of the ureteral stents. A Jackson-Pratt drain is introduced via the right assistant port, and the robot is de-docked once the robotic instruments have been removed. A Foley catheter is left as a pelvic drain. **Finally, the distal end of the conduit is brought out gently through the stoma site, ensuring proper orientation once the pneumo-peritoneum is lowered.**

Key Points

- The marionette stitch is not tied but held together using a surgical instrument to allow free movement of the bowel segment.
- Adequate length on the ileocecal end should be preserved to avoid metabolic disturbances and kinking once the conduit is exteriorized.
- We recommend avoiding using thermal approach in creating an enterotomy in ileum at the site of ureteral anastomosis and retroperitonealize the anastomosis.
- The guidewire is removed only after the anchoring suture is placed because it is difficult to identify the stent because of lack of tactile feedback.

Intracorporeal Neobladder

Since the last edition of this chapter, several techniques of intracorporeal neobladder have been developed, evaluated, and incorporated into clinical practice (Table 142.1). The port placement has been explained earlier and incorporates all modifications by various surgeons to accommodate to their techniques (see Fig. 142.1). Instead of describing each technique in detail, the key steps are presented in an easier illustrated format.

TABLE 142.1

Comparison of Configuration and Technical Nuances of Intracorporeal Urinary Diversion

INSTITUTION	CONFIGURATION	LENGTH OF BOWEL SEGMENT (CM) UTILIZED	SUTURE FOR POUCH CREATION	SUTURE FOR URETHRAL-NEOBLADDER ANASTOMOSIS
Karolinska	Modified Studer/Amorphous	50	3-0 V-Loc	2-0 quill
USC	Modified Studer with Rotation/Globular	65	2-0 V-Loc	3-0 Monocryl
University College of London	Pyramid	50	3-0 V-Loc	3-0 V-Loc
Clinique Saint Augustin	Modified Y Shaped	40	NR	NR
Padua	Folded U	42	Stapler	2-0 Monocryl
Roswell Park Comprehensive Cancer Center	Modified W – Hautmann	50	3-0 V-Loc	3-0 V-Loc
University of Florence	Asymmetrical U FloRIN	50	3-0 V-Loc	4-0 Monocryl

NR, Not reported.

Before embarking on an intracorporeal neobladder, the robotic arms are

de-docked from the ports, and the steep Trendelenburg position is reduced to 10 to 15 degrees to facilitate urethra-neobladder anastomosis. This may not be an issue with the da Vinci Xi Surgical System with its integrated operating room table. **The significant difference from the open approach is the performance of early neobladder-urethral anastomosis adopted by majority of institutions as advocated by the Karolinska group.** Several open configurations have been adopted and modified to be performed using a robotic interface.

Modified Studer Neobladder: The Karolinska Institute Technique

Configuration and Setup

The ileum is mobilized to ensure a tension-free anastomosis between the urethra and the future neck of the Neobladder. The orthotopic neobladder is tailored based on the Studer principles, and a U-shaped configuration is measured to ensure up to 25 cm from the ileocecal valve and up to 40 cm proximal to the neobladder-urethral anastomosis (Tyritzis et al., 2013; Fig. 142.4).

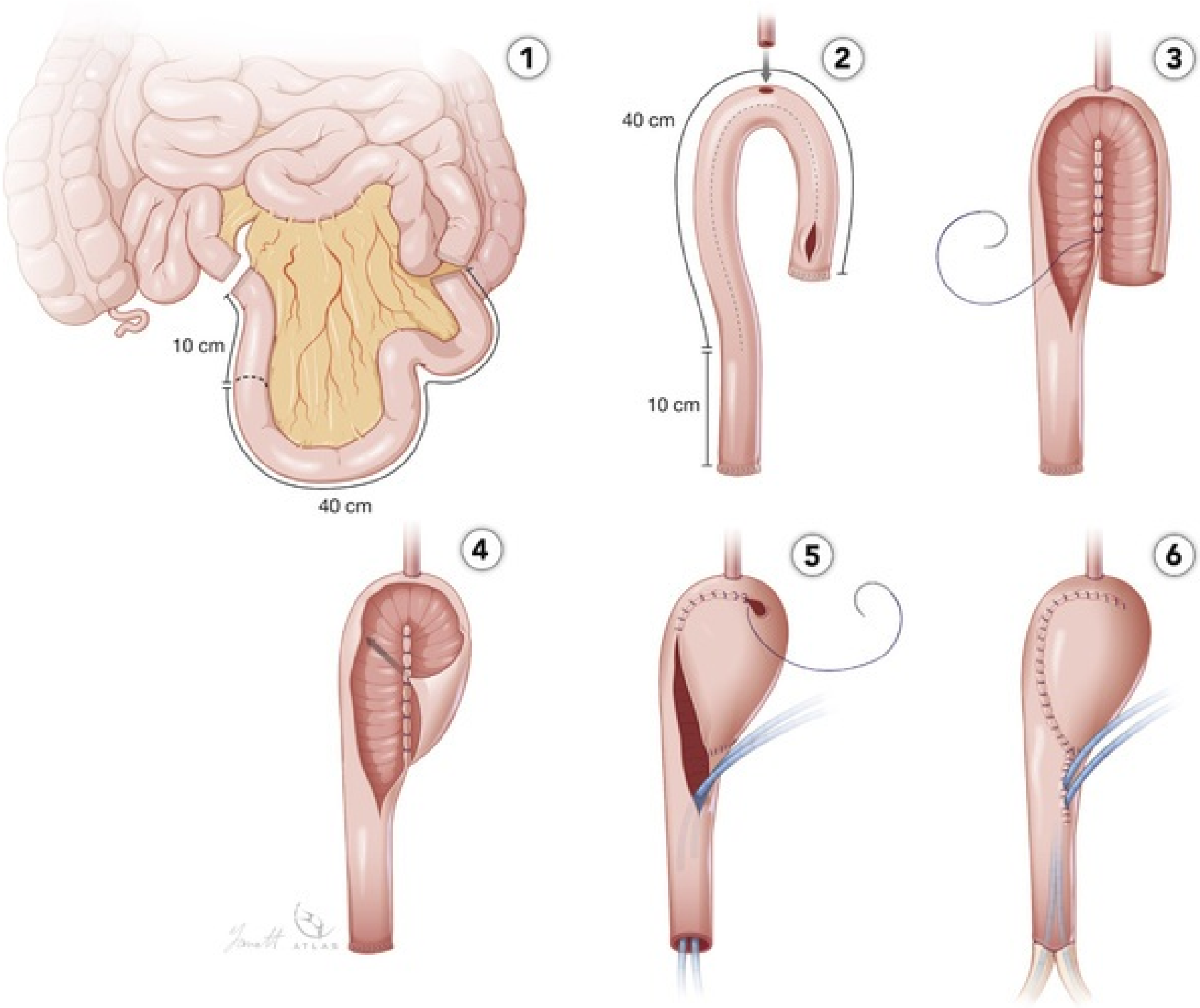

FIG. 142.4 Illustrated schema of key steps in creating the Karolinska modification of the Studer neobladder. *1,* A U-shaped configuration is measured to ensure up to 25 cm from the ileocecal valve and up to 40 cm proximal to the neobladder-urethral anastomosis. *2,* The neobladder-urethral anastomosis is performed by the Van-Velthoven technique with a 4-0 Quill suture. *3,* The posterior plate of the neobladder is closed using absorbable running sutures (2-0 or 3-0 V-Loc). The distal 40 cm of the isolated ileal segment is detubularized along the anti-mesenteric border. A 10-cm proximal isoperistaltic afferent limb is left intact to anastomose the ureters in an end-to-end fashion. *4 and 5,* After the posterior part is sutured, the distal half of the anterior part of the reservoir is also sutured in a similar fashion. *6,* Ureteroileal anastomosis is performed between the ureters and the isoperistaltic afferent limb. The stents can be externalized through the midline just above the pubic symphysis or internalized using double-J stents. The remaining part of the reservoir is then closed.

Neobladder-Urethral Anastomosis

The anastomosis is performed by the Van-Velthoven technique with a 4-0 Quill suture. Some anecdotal experiences have advocated not using the V-Loc suture because of the sharper and larger barbs that may traumatize the neobladder. **In situations in which it is difficult to approximate the bowel to the urethra easily, the neobladder is held in position between two customized Penrose drains rolled around the intestine (urethral end of the future neobladder)**.

Detubularization of Bowel

The distal 40 cm of the isolated ileal segment are detubularized along the antimesenteric border with cold scissors or **inserting a 24-Fr chest tube for ease of identification of most antimesenteric portion.** A 10-cm proximal isoperistaltic afferent limb is left intact to anastomose the ureters on the left side.

Creation of Neobladder

The posterior plate of the neobladder is closed using absorbable running sutures (2-0 or 3-0 V-Loc). After the posterior part is sutured, the distal half of the anterior part of the reservoir is also sutured in a similar fashion. **The anterior part of the reservoir is not sutured completely and is closed toward the end of the procedure.**

Uretero-Neobladder Anastomosis

The left ureter is transposed to the right side by creating a tunnel under the sigmoid mesentery. The Bricker anastomosis is performed between the ureters and the afferent limb. During the Wallace anastomosis, the ureters are spatulated and joined at the posterior walls of the ureters. The stents can be externalized through the midline just above the pubic symphysis or internalized by using double-J stents.

Closure of the Neobladder

The remaining part of the reservoir is closed once ureters are implanted with stents, and the 22 Foley catheter is placed.

Modified Studer Neobladder: The USC Institute of Urology Technique

Configuration and Setup

A total of 65 cm of ileum are used for the modified Studer neobladder technique (44 cm for the pouch, 16 cm for the chimney, and 5 cm are discarded to allow for ease of ileoileal anastomosis without the need for deep mesenteric division) (Fig. 142.5; Chopra et al., 2017). It is critical to identify the most dependent and mobile part of the ileum for tension-free neobladder-urethral anastomosis and is tagged to become the site of the neobladder-urethral anastomosis. Eleven centimeters of bowel are tagged distally toward the ileocecal valve and become the site of bowel division. After the neobladder-urethral anastomosis site is marked, proximally 33 cm are tagged and remaining proximal 16 cm are also tagged to become the future chimney (afferent limb) for the uretero-neobladder anastomosis.

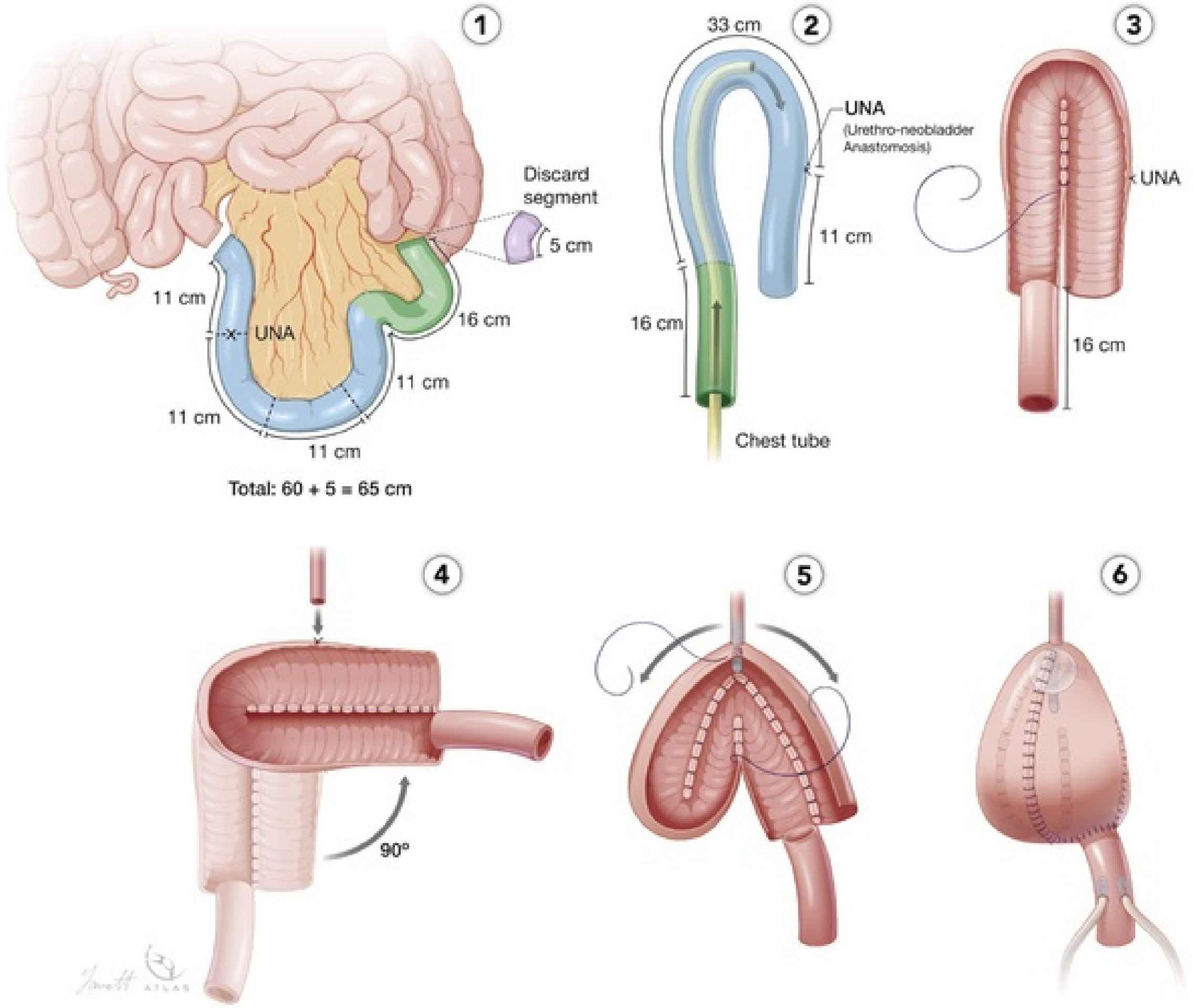
1
Discard segment
5 cm
11 cm
UNA
16 cm
11 cm
11 cm
11 cm
Total: 60 + 5 = 65 cm
33 cm
2
UNA
(Urethro-neobladder Anastomosis)
11 cm
16 cm
Chest tube
3
UNA
16 cm
4
90°
5
6

FIG. 142.5 Illustrated schema of key steps in creating the USC modification of Studer neobladder. *1,* 65 cm of ileum are isolated and used for this technique (44 cm for the pouch, 16 cm for the chimney, and 5 cm

are discarded). It is critical to identify the most dependent and mobile part of the ileum for tension-free urethro-neobladder anastomosis. *2,* 33 cm is tagged for neobladder, and proximal to this, 16 cm are left intact for the future chimney (afferent limb) for ureteroileal anastomosis. *3,* Detubularization is done and the posterior plate is aligned and sutured. *4,* The posterior plate is rotated 90 degrees counterclockwise to align the previously marked urethro-neobladder anastomosis site at the first 11-cm point. *5,* Anastomosis is performed over a 24-Fr hematuria catheter. The lateral walls are aligned and sutured. *6,* The crossed left and the right ureters are spatulated and anastomosed using the Bricker technique with ureteral stents. Once the stents are functional and the catheter is checked, the remaining pouch (anterior suture line) is closed.

Using a 24-Fr chest tube, approximately 44 cm of bowel is incised in its most antimesenteric point, and the staple lines are removed at the ends. The medial edges of the opened ileal segments are aligned by four interrupted sutures and closed using 2-0 V-Loc sutures. The USC group prefer to use the shortest (6 inches) length of barbed suture to increase the efficiency of suturing.

Rotation of Pouch, Neobladder-Urethral Anastomosis, and Cross-Folding of the Pouch

The posterior plate is rotated 90 degrees counterclockwise to align the previously marked neobladder-urethral anastomosis site at the first 11-cm point. A maneuver similar to the “Rocco” stitch is used to assist in suturing the distal posterior Denonvilliers fascia to reduce the tension on the anastomosis. A double-armed Monocryl suture on an RB1 needle is used to perform anastomosis over a 24-Fr hematuria catheter. The remaining pouch is closed using a running 2-0 V-Loc suture.

Uretero-Neobladder Anastomosis

The left ureter is transferred underneath the sigmoid colon. The two ureters are spatulated; double-J stents are placed and anastomosed using the Bricker technique. Once the stents are functional and the position of the catheter is checked, the anterior suture line is closed.

The USC group recommends several surgical maneuvers and tricks to facilitate the procedure and reduce operative time. They include the use of 11 cm premeasured stitch to isolate bowel, color-coded stay sutures for orientation, stay sutures for traction-counter traction, and use of short length of V-Loc suture for sewing the neobladder.

Pyramid Neobladder: The University College London Hospital Technique

Configuration and Setup

This detubularized cross-folded neobladder is based on the technique adapted from Koie (Koie et al., 2006). The pyramid configuration was developed to simplify the creation of the pouch (Fig. 142.6; Tan et al., 2015). A 50-cm segment of bowel is identified with the most dependent part connected to the urethra.

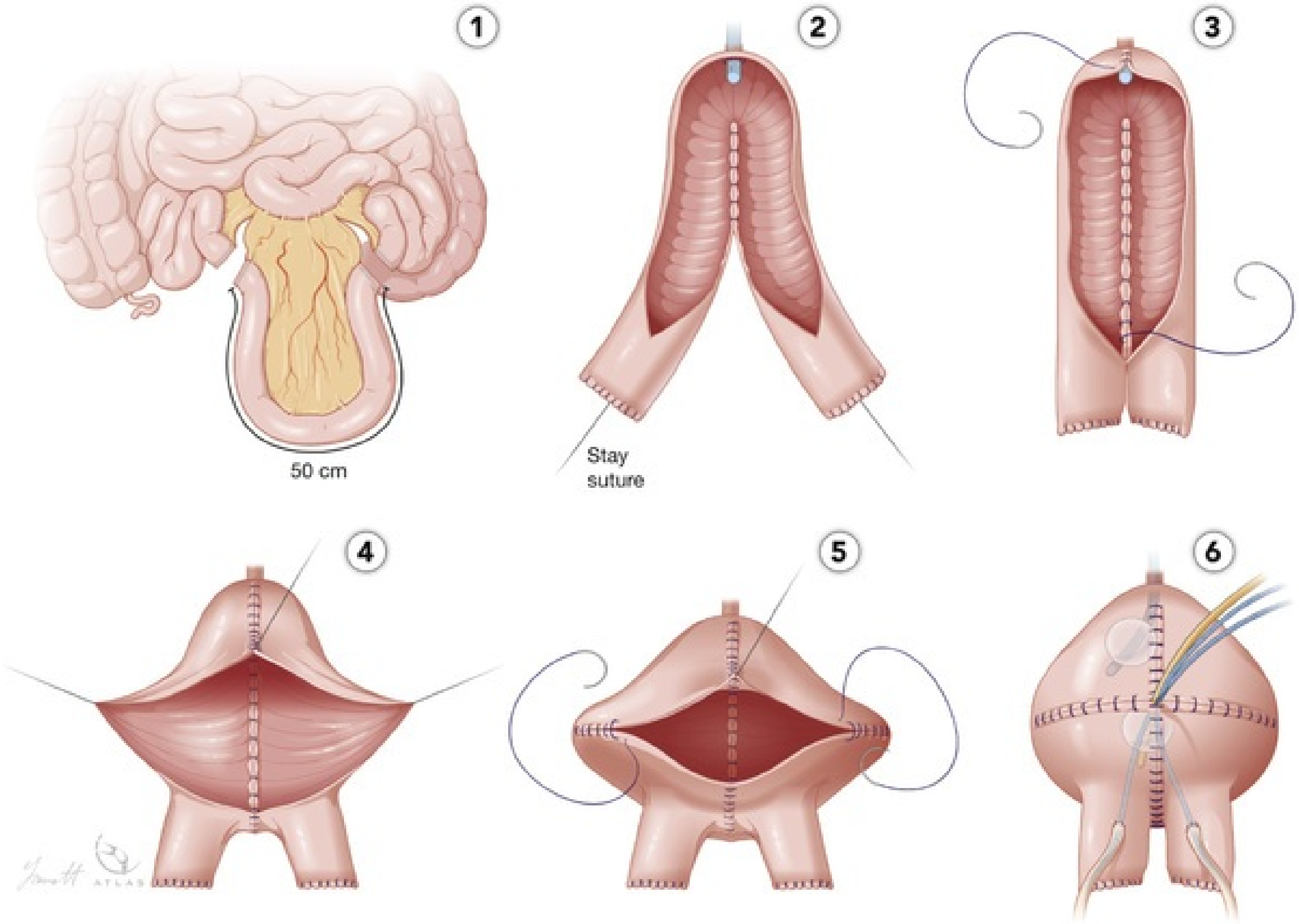

FIG. 142.6 Illustrated schema of key steps in creating the Pyramid neobladder. *1,* A 50-cm segment of bowel is identified and isolated. *2,* The dependent part of ileal segment is detubularized at its antimesenteric boundary followed by two stay sutures, 25 cm from each limb. The most dependent part is connected to the urethra creating the urethro-neobladder anastomosis. *3,* The posterior plate is closed using a 3-0 V-Loc suture. After this the anterior plate is closed up to 10 cm from the pubic symphysis. *4,* Two lateral stay sutures are placed midway along the remaining bowel segment. *5,* At this point the bowel segments are closed from lateral to medial direction in a coronal plane. *6,* The ureters are spatulated and

anastomosed to the short limbs on their respective sides over ureteral stents. The authors externalize the stents and insert a suprapubic tube.

Formation of the Pyramid Neobladder

Once neobladder-urethral anastomosis is completed, the dependent part of ileal segment is detubularized at its antimesenteric boundary followed by placement of two stay sutures 25 cm from each limb. The posterior plate is closed using a 3-0 V-Loc suture. After this, the anterior plate is closed up to 10 cm from the pubic symphysis. Two lateral stay sutures are placed midway along the remaining bowel segment. At this point the bowel segments are closed from lateral to medial direction in a coronal plane.

Uretero-Neobladder Anastomosis

The ureters are spatulated and anastomosed to the short limbs on their respective sides over ureteral stents. The authors externalize the stents and insert a suprapubic tube for irrigation and safety.

Modified Y Neobladder: The Clinique Saint-Augustin Technique

Configuration and Setup

For the modified Y neobladder using the Clinique Saint-Augustin technique, a 40-cm ileal segment is isolated approximately 20 cm from the ileocecal valve (Fig. 142.7; Asimakopoulous et al., 2016). The most dependent part is arranged in a modified Y shape and brought down to the urethra for a tension-free anastomosis. The antimesenteric part is incised and anastomosed to the urethra.

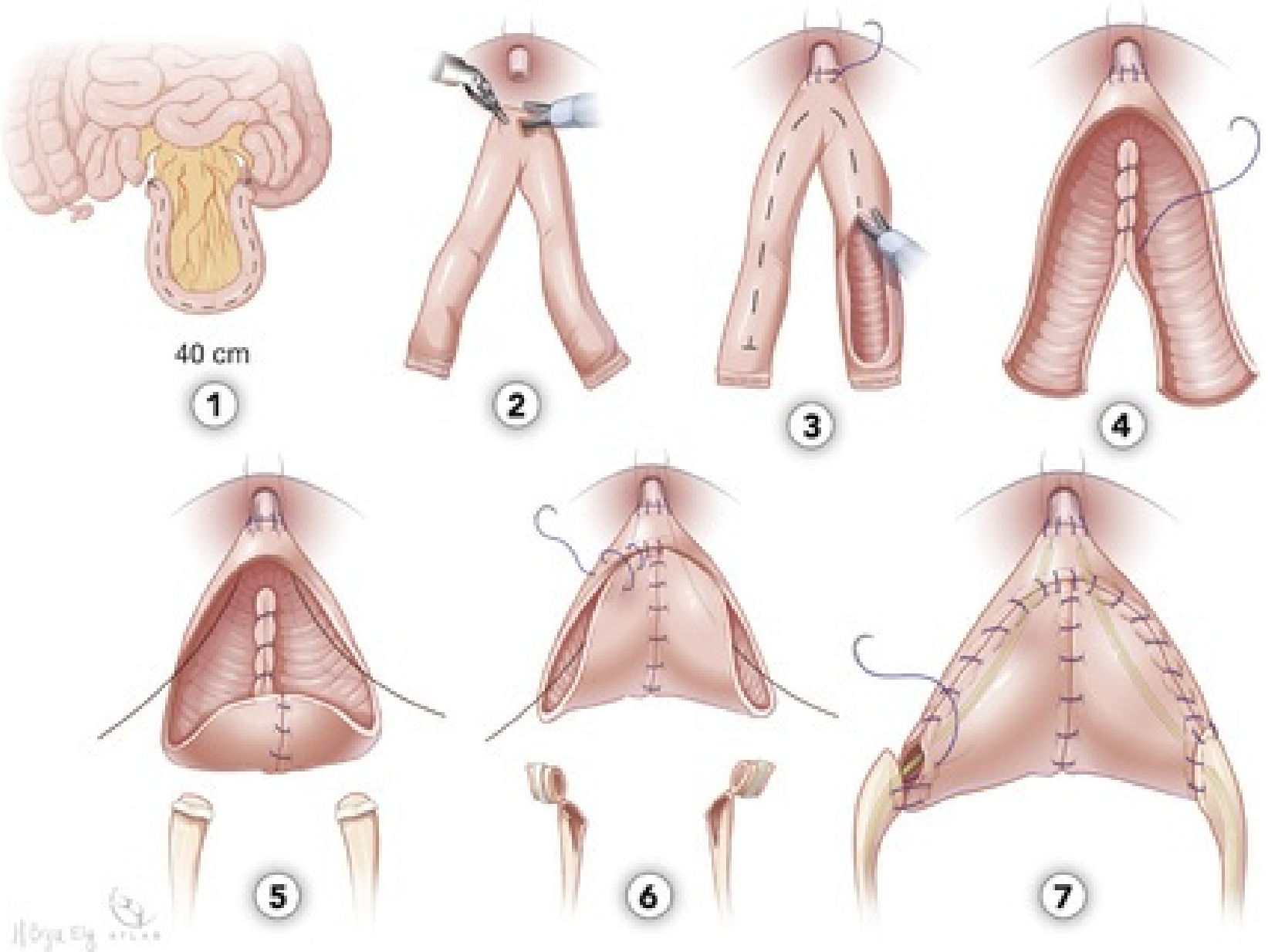

FIG. 142.7 Illustrated schema of key steps in creating the Clinique Saint-Augustin Y neobladder. *1,* A 40-cm ileal segment is isolated approximately 20 cm from the ileocecal valve. *2,* The most dependent part is arranged in a modified Y shape and brought down to the urethra for a tension-free anastomosis. *3,* The antimesenteric border is incised. *4,* The incised ends of the two limbs are connected, and the posterior plate is created. *5 and 6,* Subsequently, the anterior reconstruction of the neobladder is started. The ureters are spatulated and not crossed over. *7,* The ureters are directly anastomosed to the open ends of the neobladder in a refluxing fashion. A 20-Fr Mercier catheter is placed with two hydrophilic guidewires to assist with stent placement. The anterior wall is then closed.

Creation of the Neobladder

The incised ends of the two limbs are connected and the posterior plate is created. Subsequently the anterior reconstruction of the neobladder is performed. A 20-Fr Mercier catheter with two hydrophilic guidewires is placed to assist with stent placement later in the procedure.

Uretero-Neobladder Anastomosis

The ureters are spatulated and directly anastomosed to the open ends of the neobladder in a refluxing fashion in their respective sites. The two single-J stents are placed via the urethra using the Mercier catheter and the preplaced hydrophilic wires.

Padua Neobladder

Configuration and Setup

For the Padua neobladder, approximately 42 cm of ileum is selected at least 20 cm from the ileocecal valve (Fig. 142.8; Simone et al., 2016). The neobladder is isolated with only one stapler load at the proximal end and two stapler loads at the distal end. The isolated bowel is marked approximately 12 to 14 cm proximal to the distal end for the neobladder-urethral anastomosis to ensure a tension-free anastomosis. The proximal half of the separated bowel is used for configuring the left base and the dome of the neobladder.

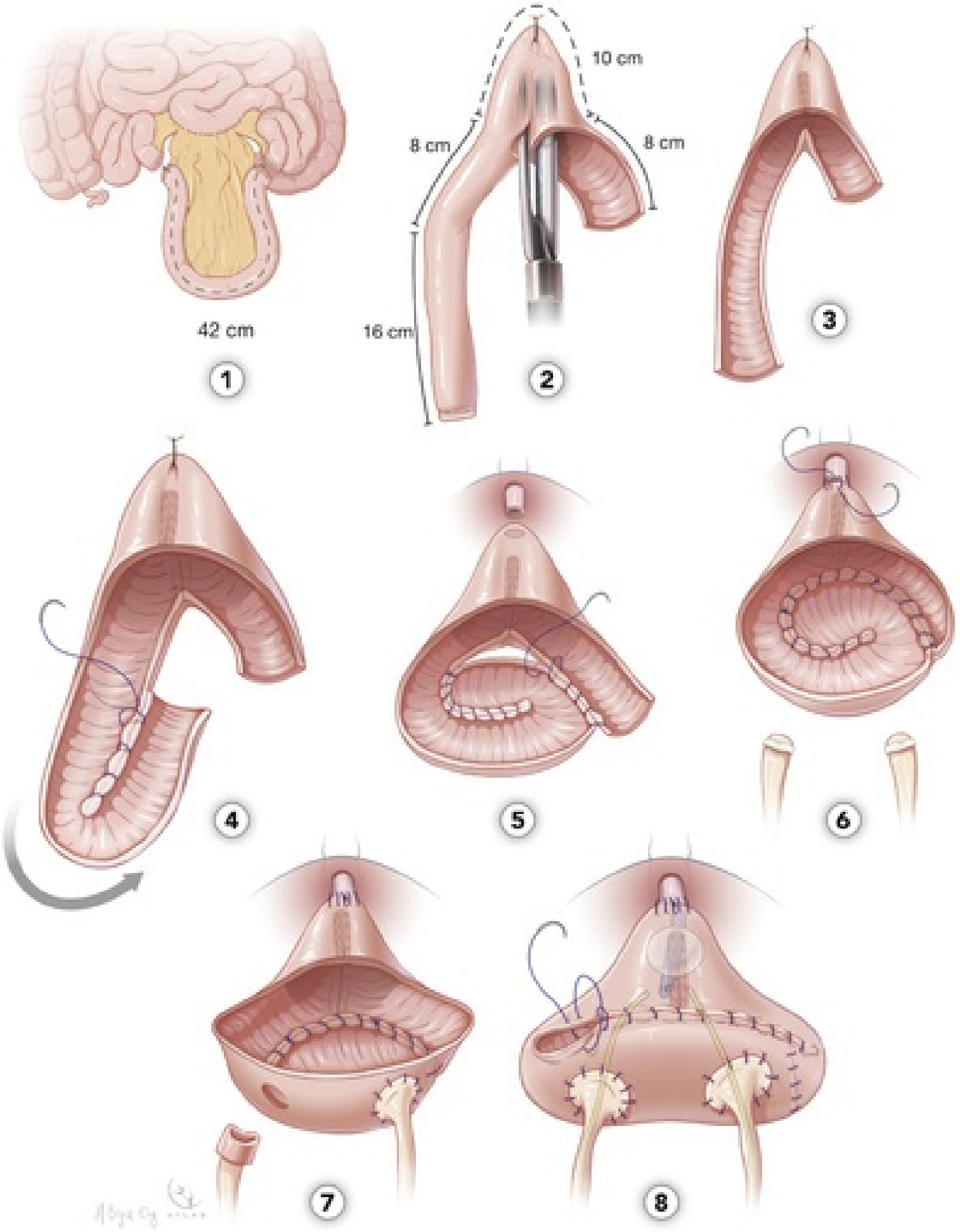

FIG. 142.8 Illustrated schema of key steps in creating the Padua neobladder. *1,* Approximately 42 cm of ileum (8 cm right plate, 10 cm neck configuration, 8 + 16 cm left plate) is folded in U configuration. *2,* The tension-free neobladder neck is identified about 12 to 14 cm proximal to the distal ileum and tagged with a suture. After detubularizing 8 cm of distal

ileum along the anti-mesenteric border, the surgeon introduces a stapler through the inverted U to create the neobladder neck. *3,* The remaining 24 cm of the ileum is subsequently detubularized starting at the proximal ileal edge. *4,* The proximal half of the loop helps in the first folding to configure the left base and the dome of the neobladder. *5,* The second folding helps in configuring the posterior plate of the neobladder. *6,* The 16-cm folded segment and the right plate align to create the posterior plate of the neobladder. The urethroileal anastomosis is performed and a 22-Fr hematuria catheter is inserted. *7,* The ureters are passed through the posterior aspect of the neobladder and spatulated and ureteroileal anastomoses (modified split-nipple technique) are performed. *8,* The anterior wall is closed.

A 10-cm inverted U-neobladder neck is created with a stay suture approximately 8 and 18 cm from the distal ileum. After the 8 cm is detubularized, the bladder neck is created by firing a stapler. The remaining 24 cm are detubularized, the most distal 8 cm is folded, and the edges are joined for creating the future dome of the neobladder. The subsequent fold is used to configure the posterior plate.

Uretero-Neobladder Anastomosis

The ureters are passed through the posterior aspect of the neobladder, spatulated, and the anastomosis is performed according to the modified split-nipple technique. The closure of the anterior plate provides the final shape to the neobladder.

Florin: Florence Robotic Intracorporeal Neobladder

Configuration and Setup

For the Florence robotic intracorporeal neobladder, a 50-cm segment of ileum approximately 20 cm from the ileocecal valve is chosen (Fig. 142.9; Minervini et al., 2018). The neobladder-urethral anastomosis (using a 20 Foley catheter) is used to create an asymmetrical U shape (30 cm distally and 20 cm proximally) between the urethra and the segment of bowel. The ileum segment is entirely detubularized and the posterior plate is reconfigured as an L to create a neo-trigone (widen posterior support of the neobladder). After the completion of the posterior plate, the neobladder neck is reconstructed by suturing the anterior wall of the neobladder (2–5 cm anteriorly and proximal). The posterior plate is folded anteriorly to create two symmetrical segments. The length of the neobladder neck is adjusted based on the capacity of the posterior plate to reach anterior aspect of the anastomosis.

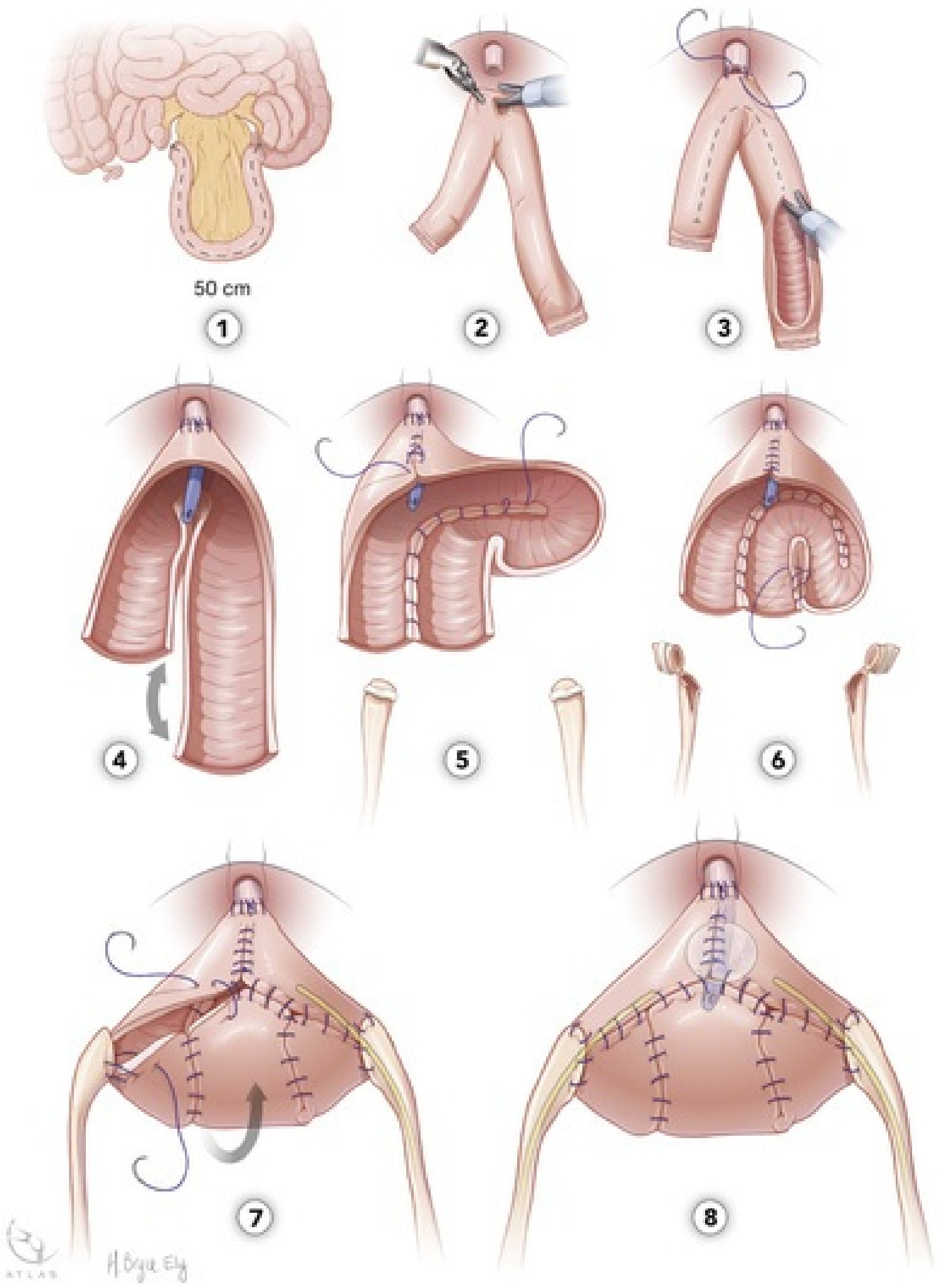

FIG. 142.9 Illustrated schema of key steps in creating the FloRIN neobladder. *1,* A 50-cm segment of ileum approximately 20 cm from the ileocecal valve is chosen. *2,* The neobladder-urethral anastomosis is performed and utilized to create an asymmetrical U shape (30 cm distally and 20 cm proximally). *3,* The ileum segment is entirely detubularized. *4,* The posterior plate is reconfigured as an L to create a neo-trigone. *5,* The neobladder neck is reconstructed by suturing the anterior wall of the neobladder (2–5 cm anteriorly and proximal). *6,* The posterior plate is folded anteriorly to create two symmetrical segments. The distal ends of the ureter are spatulated. *7,* Re-implanted in an antireflux technique on the lateral side of each anterior aspect of the neobladder. *8,* Once the single-J ureteral stents are secured in place, the anterior plate is finally closed in an inverted V-shaped manner.

Uretero-Neobladder Anastomosis

The distal ends of the ureter are spatulated and reimplanted in an antireflux technique on the lateral side of each anterior aspect of the neobladder. Once the single-J ureteral stents are secured in place, the anterior plate is finally closed in an inverted V-shaped manner.

Modified “W” Hautmann Neobladder: The Roswell Park Comprehensive Cancer Center Technique

Configuration and Setup

For the modified “W” Hautmann neobladder, a 45- to 50-cm bowel segment is chosen for the neobladder and divided into right and left troughs (Fig. 142.10; Hussein et al., 2017a). Each trough has a descending and an ascending loop with a chimney. Four stay sutures (Tags A-D) are used to fix the W configuration. The first stay suture (Tag A) should be at the most dependent portion of the right trough. The second stay suture is placed 12 to 15 cm proximal to the first and marks the upper end of the right trough (Tag B). The third suture is placed to create the left trough (Tag C). The fourth stay suture (Tag D) marks the upper end of the left trough.

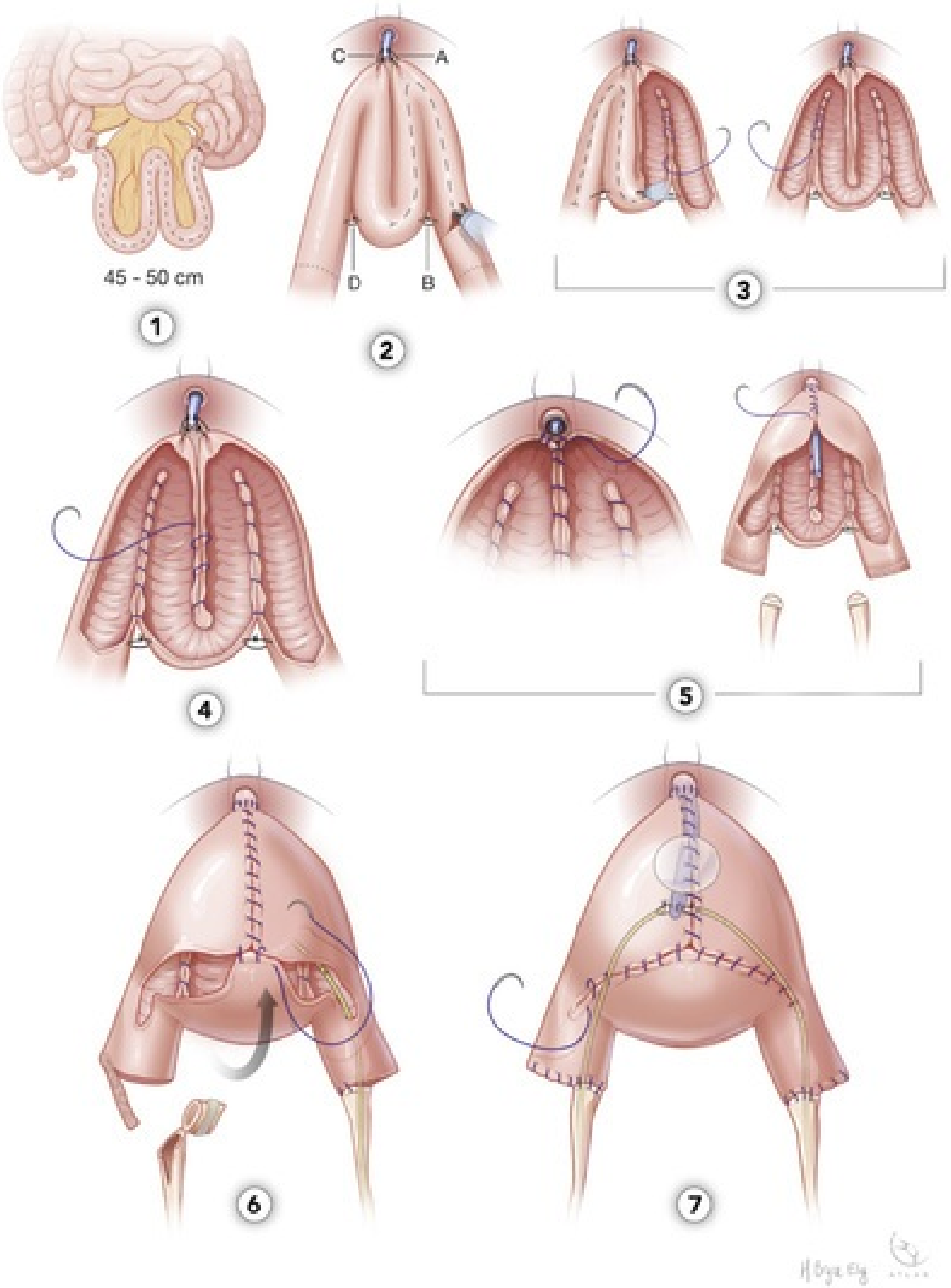

FIG. 142.10 Illustrated schema of key steps in creating the W neobladder. *1,* 45–50 cm of bowel is isolated 12 to 15 cm from the terminal ileum. *2,* The identified bowel is extended into the pelvis and tagged to the tip of the Foley catheter that serves as a marionette (*A* and *C*). Two holding sutures (*B* and *D*) are placed, which complete and stabilize the W configuration of the neobladder. *3,* The right limb is incised along the antimesenteric border, avoiding the afferent limb of the neobladder. Suturing the opposing sides of the incised bowel creates the right trough. Avoid incising both the troughs simultaneously while suturing maintains orientation and spillage of bowel content. *4,* Once both troughs are created, the edges are joined in the middle to develop the posterior plate of the neobladder. *5,* The neobladder urethral anastomosis is completed and the anterior wall closure is started. *6,* The staple lines are excised off the proximal limbs, the ureters are anastomosed directly, and single-J stents/feeding tubes are placed and distally sutured to the Foley catheter. *7,* The final closure of the neobladder is accomplished by completing the inverted T closure of the neobladder.

Creation of the Neobladder

Excluding the 5-cm chimney, the right trough is first detubularized, incised, and sutured to avoid gross spillage of bowel contents and maintain orientation. This can be performed by making an enterotomy cranially then cutting through it (preferably using hot scissors) while exerting traction with bipolar grasper and counter traction using the suction device. The detubularization incision is made a few millimeters away from the mesenteric border to provide a wider bowel surface area when closing the neobladder anteriorly. After detubularization of the right trough, the mesenteric edges of the bowel are sutured together using a series of 3-0 V-Loc suture. Suturing is started caudally and continues cranially while exerting traction on the bowel using the fourth arm. To speed up suturing, the continuous suture line can be tightened at every third throw. The same process is then repeated for the left trough. The right and left troughs are then sutured together to create the posterior plate.

After release of the stay sutures (Tags A and C), the most dependent part of the posterior plate of the neobladder is anastomosed to the posterior urethral plate using a 3-0 V-Loc suture. The anterior part of the anastomosis is then completed over a 22-Fr silicone catheter. Closure of only the lower half of the anterior wall of the neobladder is subsequently performed.

Uretero-Neobladder Anastamosis

The staple line of the right chimney is removed and the opening is sutured (3-0 Vicryl). An enterotomy is made on the anterior aspect of the chimney for an end-to-side ureteroileal anastomosis. The fourth arm is used to steadily retract the cut Hem-o-lock clip end at the distal ureter. The ureter is partially transected and spatulated using robotic scissors for a wide anastomosis. A single-armed 4-0 Vicryl suture (5 cm long) is used to make an anastomosis with interrupted sutures (or double armed for a continuous anastomosis). Either way, the first anchoring stitch should be placed in an “outside-in” manner on the ureter side at the angle of the spatulation. The suture on the neobladder side is placed “inside out.” After placing the first stitch, the fourth arm is manipulated to bring the ureteral end close to the enterotomy before tying the stitch to achieve a tension-free anastomosis. This initial suture ensures proper alignment and placement of the subsequent sutures. Once the first suture is placed, the remaining anastomosis can be completed. Once the posterior wall anastomosis is completed, the ureteral stent/feeding tube is placed. A metal laparoscopic suction tube is gently advanced through the 15-mm assistant port or the urethral 22 coudé hematuria catheter, through open part of the anterior wall of the neobladder. The metal suction tip is held in place by the robotic needle driver to allow passage of stent into the chimney and then into the ureter. An 8.5-Fr, single-J ureteral stent or a pediatric feeding tube with a guidewire is passed through the suction tip and fed into the ureteral opening. Once the stent is pushed all the way, the suction tip is withdrawn while the holding the stent. A single-J stent is preferred to have a sufficient length to fix the stent distally near the neourethra or to the Foley. A 3-0 chromic suture is used to secure the stent to the neobladder to prevent dislodgement, and another stitch can be used to secure the distal end of the single-J stent near the neourethra or to the Foley catheter (to facilitate stent removal later). The anterior half of the uretero-neobladder anastomosis is completed. The anastomosis of the left side is performed in a similar fashion.

The remaining anterior neobladder wall is closed using 3-0 V-Loc suture in a T-shaped manner. The Foley catheter is used for irrigation. A Jackson-Pratt or Blake drain is left in place.

Restoration of the Bowel.

A short suprapubic port is inserted for ease of alignment of bowel re-anastomosis. A 60-mm Endo GIA stapler is inserted through the short 12-mm suprapubic port. A side-to-side anastomosis is performed once both ends of the bowel are aligned along their antimesenteric borders. The open ends of the two anastomosed intestinal segments are stapled by firing an endo GIA stapler horizontally via the right assistant port. A secure stay suture is placed to reduce tension and support the edge of the anti-mesenteric border. The mesentery window is closed using a 3-0 silk suture.

Maneuvers Facilitating Neobladder-Urethral Anastomosis.

A tension-free neobladder urethral anastomosis is critical and is one of the most challenging operative steps during intracorporeal neobladder. This is a key step, especially when the patient is in a steep Trendelenburg position; the amount of stretch that can be used with lack of tactile feedback has to be kept in balance. Various steps have been proposed to facilitate with neobladder-urethral anastomosis. As discussed earlier, preservation of the dorsal venous complex and the length of urethra are critical. The ability to cut the dorsal venous complex without initially suturing helps in releasing and opening the apex for maximal urethral preservation and avoids apical margins (Guru et al., 2009b). Several other key steps include mobilizing the sigmoid colon out of the true pelvis, and occasionally a stay suture is used to keep it temporarily fixed laterally until the neobladder is created.

It is also critical to reduce the steep Trendelenburg position after undocking the robot. The new advances with the da Vinci Xi Surgical Systems with an integrated operating room table make this easier without undocking the surgical robot. Application of perineal pressure at the time of anastomosis with insertion of a Foley catheter to guide the needle toward the urethral opening has already been used consistently during robot-assisted radical prostatectomy. The use of barbed suture, especially the V-Loc, has helped reduce the time and complexity of neobladder creation as well as the urethral anastomosis. Detubularization of the ileal segment, opening, and stretching of the bowel help in adding length to the ileum. The peritoneal covering of the ileum can be also incised, and the mesenteric fat is released to help add length. This should be performed with care because it exposes the mesenteric vessels and can lead to annoying bleeding, which can jeopardize the vascular supply to the neobladder (Almassi et al., 2016). The Karolinska group has used Penrose drains in their early experience for gentle stretching and traction of bowel for ease of anastomosis (Collins et al., 2014).

Robot-Assisted Intracorporeal Continent Cutaneous Diversion

Colon Mobilization, Isolation, and Ileocolic Anastomosis

For robot-assisted intracorporeal continent cutaneous diversion, after cystectomy and lymph node dissection, the right colon is mobilized from the mid-transverse colon to the ileocecal junction (Desai et al., 2017). Two stay sutures (at the cecum and hepatic flexure) are placed to facilitate handling and maintain anatomic orientation. The greater omentum is incised, and the proximal transverse colon is mobilized from the duodenum and retroperitoneal structures. The hepatic flexure is freed from the Gerota fascia by incising the hepatocolic ligament. Dissection continues toward the cecum by incising the white line of Toldt. The terminal ileum is transected 15 cm proximal to the ileocecal junction. Subsequently the transverse colon is transected between the hepatic flexure and the middle colic artery. Ileocolic continuity is restored immediately after this step to avoid malrotation (Fig. 142.11).

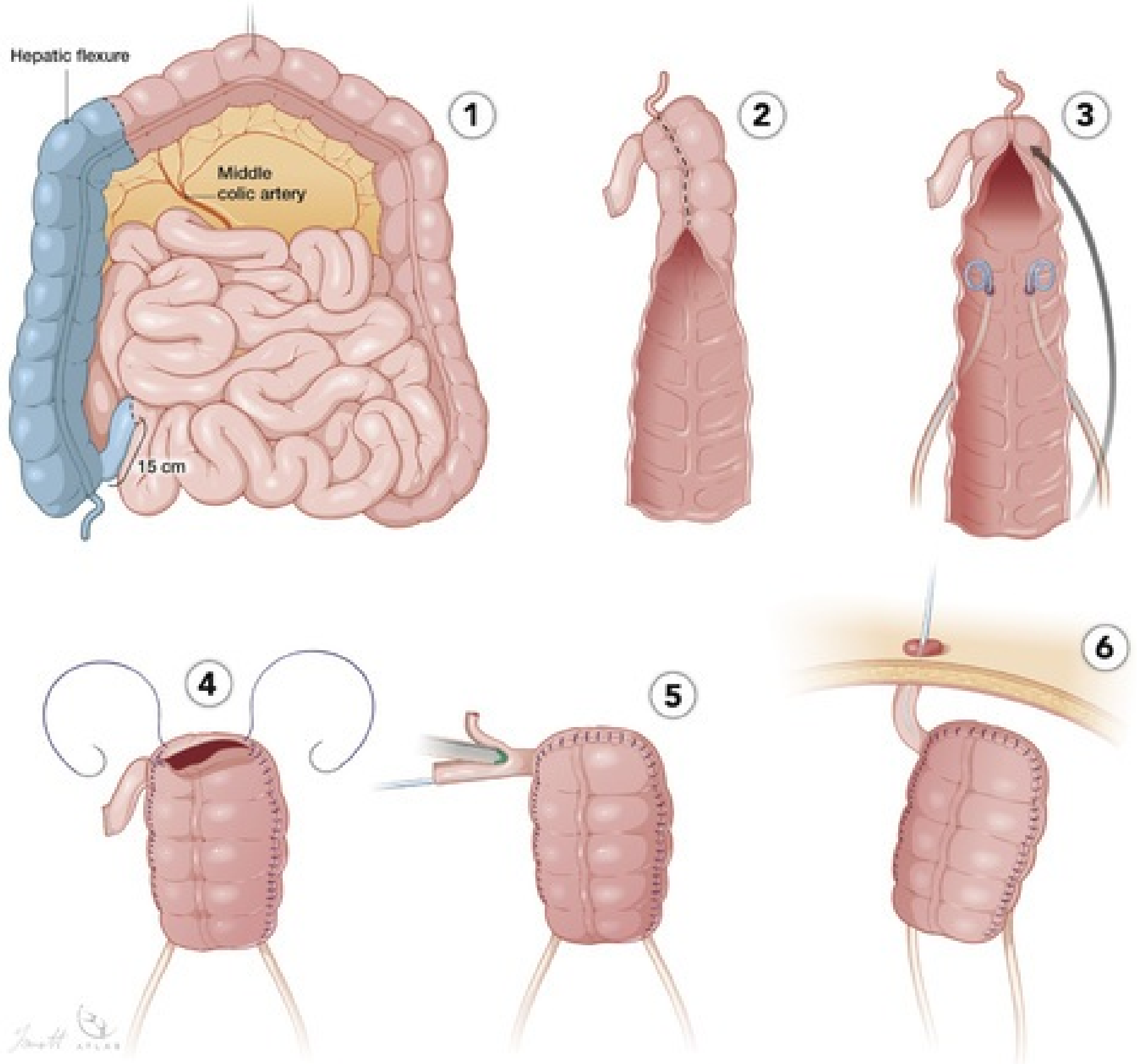

FIG. 142.11 Illustrated schema of key steps in creating the robot-assisted intracorporeal Indiana pouch. *1,* The cecum and ascending colon are isolated by transecting the terminal ileum (15 cm proximal to ileocecal junction) and the transverse colon between the hepatic flexure and the middle colic artery. *2,* The staple line of the colon is excised and the segment is detubularized. *3,* The left ureter is transferred below the sigmoid mesentery. Both ureters are spatulated, delivered through the posterior colonic plate, and anastomosed (double-J stents). *4,* The detubularized colon is folded vertically by connecting the distal end of incised colon with the angle of the ileocecal valve. *5,* A 14-Fr Foley catheter is inserted through the ileum into the colon. The terminal ileum is tapered at the antimesenteric border using staplers. *6,* The edges of the spatulated and tapered ileum are attached to the umbilical skin and fashioned into a stoma.

Creation of the Colonic Pouch

The base of the appendix is resected. The isolated colon pouch is irrigated and cleared with a hematuria catheter through the opening into the cecum. The staple line of the colon is excised and the right colon is detubularized along the anterior tenia coli. The detubularized colon is folded vertically by connecting the distal end of incised colon with spatulated aspect of the ileocecal valve. The posterior suture line is closed first using 2-0 Vicryl and continuous barbed V-Loc.

Uretero-Colonic Anastomosis

The transferred left and the right ureters are spatulated and are delivered through the posterior colonic plate and anastomosed using 4-0 or 5-0 Vicryl sutures. The anastomosis is stented using double-J stents. A 24-Fr Rusch catheter is introduced through the right lateral port as a cecostomy tube and inserted into the pouch through the appendiceal stump. The cecostomy tube is secured with a 2-0 Vicryl purse-string suture into the cecal wall. The anterior suture line is closed in a similar fashion to the posterior.

Tapering of the Ileum and Imbricating the Ileocecal Valve

An Allis clamp is inserted via a 2-cm V-shaped skin flap, and the end of the terminal ileum is exteriorized through the umbilical incision. A 14-Fr Foley catheter is inserted through the ileum into the colon. After proper positioning of the catheter, the ileum is reinserted into the abdomen. The terminal ileum is stretched over the catheter, and the excess antimesenteric portion is excised using serial fires of staplers. The ileocecal valve is reinforced by a series of interrupted 3-0 Vicryl imbricating sutures. The edges of the spatulated and tapered ileum are attached to the umbilical skin to fashion the stoma.

Postoperative Care

Optimizing fluid balance and avoiding overhydration should help manage fluid shifts in this patient population mostly with advanced age. Cochrane meta-analysis revealed no advantage to leaving nasogastric tube after surgery (Nelson et al., 2007). Pelvic drainage is preferred; we use a Blake drain for neobladders and a Foley via the urethra as a drain for ileal conduits (removed on postoperative day 1). Adequate pelvic drainage and stenting of ureters especially at the anastomosis has already been shown to help in bowel recovery and reduce metabolic acidosis. Some authors have shown the feasibility of ureteroileal anastomosis without stents for ileal conduits (Tan et al., 2017). Drains can be removed usually when output is reduced. **The urethral catheter**

in neobladders can be removed approximately 3 to 4 weeks postoperatively once absence of any leak is established on pouchogram. The ureteral stents, if exteriorized to skin, are removed a week after surgery. If the stents are internalized, it is recommended to remove the double-J stents with cystoscopy at 3 to 4 weeks when the neobladder has healed. We have started using pediatric feeding tubes more often and attaching them to the urethral catheter and removing them once the pouchogram is acceptable without the need for cystoscopy. The disadvantage of this method is the loss of attached stents across the anastomosis in case the Foley slips out. Irrigation with saline of the neobladder is recommended every 8 hours to avoid mucus plugging and catheter blockage.

Key Points

- Optimizing fluid balance and avoiding overhydration should help manage fluid shift in this patient population with advanced age.
- Adequate pelvic drainage and stenting of ureters especially at the anastomosis has shown to help in bowel recovery and avoid metabolic abnormalities.
- Irrigation of the neobladder is recommended every 8 hours to avoid mucus plugging and catheter blockage.

Outcomes

ICUD attempts to minimize bowel manipulation and reduce postoperative pain with minimal wound retraction and smaller incisions. **Several factors have facilitated performance of the procedure with an intracorporeal technique. First, RARC and extended PLND technique have been standardized with oncologic results equivalent to standard open techniques. Second, the robot-assisted surgical platform with improving console-based surgical skills have allowed the robotic surgeons to optimize use of this technology.** The advantage of the endo-wrist technology in robot-assisted surgery allows surgeons to use the mechanical wrist for suturing and reconstructive purposes with minimal effort in comparison with conventional laparoscopy. This section addresses various key factors that define the acceptance of ICUD based on operative time, learning curve, complications, functional outcomes, and comparing outcomes of intra- and extracorporeal urinary diversions after RARC.

Operative Time

One of the major limitations of incorporating ICUD has been prolonged operative time (Balaji et al., 2004; Hubert et al., 2006). Operative time for all techniques is presented (ranges between 305 to 420 minutes) in Table 142.1.

Prolonged operative times for radical cystectomy have been associated with higher incidence of complications and perioperative mortality independent of the disease stage or associated comorbidities (Lavallee et al., 2014). Not surprisingly, operative time has been identified as a quality measure for surgical performance for RARC (Hussein et al., 2016a). Patients have multiple confounding factors that contribute to variation in operative time for RARC, including patient demographics and comorbidities, disease stage, procedural complexity, technical modifications, surgeon experience, and hospital volume (Filson et al., 2016).

In a study from IRCC comprising 2134 RARCs, median operative time was 364 minutes (interquartile range [IQR] 300–446). There was a trend toward shorter operative times for RARC, decreasing from a mean of 371 minutes in 2006 to 323 minutes in 2015. The variable most strongly associated with surgical time was the type of diversion, and it resulted in the largest mean difference (ileal conduits were 70 minutes shorter than neobladders) (Hussein et al., 2017b).

Shorter operative times have been demonstrated in older patients with multiple comorbidities. Surgeons are usually concerned of the potential higher anesthetic complications in older and sicker patients. Female patients were also found to have longer operative times (possibly because of performance of hysterectomy and vaginal reconstruction) (Filson et al., 2016). Higher body mass index and prior abdominal surgery add to the complexity of RARC, with more time spent in port placement, careful dissection, and lymph node dissection (Yuh et al., 2009). No significant difference between intracorporeal and extracorporeal approaches to urinary diversion was found. One possible explanation is that the additional time for undocking, patient positioning, and then re-docking for extracorporeal diversion may have reduced the difference between approaches (Hussein et al., 2017b).

High-volume institutions had shorter operative times for radical cystectomy. This may be attributed to the experience of the surgeon and the teams at those institutions (Filson et al., 2016; Hussein et al., 2017b). The cutoff for surgical proficiency for RARC was higher in a study conducted by IRCC than previously reported (22 RARCs) (Hayn et al., 2010). Surgeons who had performed at least 66 RARCs saved an average of 55 minutes of operative time among patients who underwent ileal conduits (Hussein et al., 2017b). This highlights the importance of fellowship training and dedicated cystectomy programs, in which surgeons can increase their RARC volume (Guru et al., 2009a).

Learning Curve

Collins et al. (2014) evaluated the learning curve of intracorporeal neobladders and found that overall operative times and the risk of conversion reduced from 30% to 10% after only 10 consecutive procedures. Reduction in complications was observed in early (70% to 30%) ($P < 0.05$) and late (50% to 0) ($P = 0.01$) categories as the surgeons gained experience with intracorporeal neobladder. The USC group has also shown reduction in operative time by keeping the console surgeon consistent and shown almost a more than 50% reduction (9.3 to 4.7 hours) (Desai et al., 2017). **Mentoring effect was helpful in reducing overall operative time and avoided open conversion during early experience. Conversion of an intracorporeal neobladder to open was associated with an increase in overall length of stay.**

Complications

The majority of the reported complications are attributed to urinary diversion; this part of the procedure is associated with most changes postoperatively. **The possible attributed advantages of a minimally invasive approach are in terms of reduced bowel manipulation, decreased insensible losses, and minimal need for analgesia, which can help reduce the significant morbidity of this procedure.**

The majority of studies reported either modified Dindo-Clavein or the modified Memorial Sloan Kettering classification for complications and reported complications up to 3 months after surgery (Table 142.2). Based on current literature focused on ICUD, overall early (30-day) and late (90-day) complications range from 22% to 63% and 5% to 81%, respectively (see Table 142.2). High-grade complications were observed in up to 37%, and **infections were the most common cause of these complications.** However, it is critical to assess complication beyond 90 days, as the Roswell Park group showed that the majority (two-thirds) of significant complications requiring reoperations occurred after 3 months of surgery (Hussein et al., 2016a)

TABLE 142.2

Comparison of Complication of Intracorporeal Urinary Diversion

INSTITUTION	NUMBERS OF PATIENTS	% OF NB	METHODOLOGY OF COMPLICATION REPORTING	FOLLOW-UP (MONTHS)	EARLY (≤30 DAYS) COMPLICATI (%)
Karolinska USC	132	100	NR	25	47
Ankara Tubingen	101	72	Dindo-Clavien	27	50
Clinique St-Augustine	40	100	Dindo-Clavien	26	30
NCI Rome	45	100	NR	24	58
UCLH	134	25	Modified MSKCC/ Dindo-Clavien	NR	NB 62 IC 52
Florence	18	100	NR	NR	22
RPCCC	100	0	Modified MSKCC	12	63
IRCC	1094	0	NR	11	31

IC, Ileal conduit; *IRCC,* International Robotic Cystectomy Consortium; *MSKCC,* Memorial Sloan Kettering Cancer Center; *NB,* neobladder; *NCI,* National Cancer Institute; *NR,* not reported; *RPCCC,* Roswell Park Comprehensive Cancer Center; *UCLH,* University College London Hospital; *USC,* University of Southern California.

Reoperations After Robot-Assisted Radical Cystectomy

The majority of reoperations for patients who undergo radical cystectomy are related to urinary diversion, especially in the late follow-up period. In my series of more than 400 consecutive procedures, the rate of surgical intervention was 23% after a mean follow-up of 27 months. The mean time to any surgical intervention was 14 months, and 68% of these were performed after 90 days. The reoperation rates were 30% and 46% at 2 and 5 years, respectively.

Neoadjuvant chemotherapy and any high-grade complication after surgery were predictors of surgical intervention after robot-assisted radical cystectomy (Hussein et al., 2016b).

Uretero-Enteric Strictures

Despite meticulous dissection and minimal manipulation, my intracorporeal ileal conduit technique demonstrated higher stricture rates. The prevalence rates were 12%, 16%, and 19% at 1, 3, and 5 years after RARC. Since then, we have abandoned the slitlike enterotomy using the thermal hook and now advocate an athermal, buttonhole enterotomy with removal of the serosa and also retroperitonealize the proximal anastomotic site (Ahmed et al., 2017). The initial experience with robot-assisted revision of ureteroileal strictures showed that open and robot-assisted approaches are comparable in terms of perioperative outcomes (Ahmed et al., 2017; Dangle and Abaza, 2012). Several other surgeons have shown comparable results between the two approaches. Use of indocyanine green dye during robot-assisted ureteral reconstruction has proven to guide accurate identification of the ureter and precise visualization of ureteral strictures (Lee et al., 2015).

Fistula and Bowel Obstruction

In the author's experience the 2-year fistula rate was 3%, and approximately half of the patients were repaired using a robotic interface. Meanwhile, 3% required surgical intervention for bowel obstruction. The rates of intervention for bowel obstruction were 5% and 12% at 2 and 5 years, respectively (Hussein et al., 2016a).

Abdominal Wall–Related Complications

The surgical intervention rate for abdominal wall–related complications was 3% at 2 years. The causes for these interventions included hernias (para-stomal and incisional), adhesions, and wound dehiscence (Hussein et al., 2016a). Twenty percent of parastomal hernias were seen in patients who underwent RARC and ileal conduit after a median time of 13 months after surgery. The rates of developing a parastomal hernia were 9%, 23%, and 32% at 1, 2, and 3 years, respectively. Symptoms only developed in one-third patients, of whom only 15% required surgical intervention. Longer operative times, larger fascial defect (greater or equal to 30 mm), and a lower estimated glomerular filtration rate (poor healing) were significantly associated with the risk of developing parastomal hernia. The Roswell Park group has shown feasibility and durability of robot-assisted parastomal mesh hernioplasty. The operative time was longer (456 minutes vs. 389 minutes) during the initial experience (Hussein et al., 2018).

Functional Outcomes

Continence After Creation of Neobladder.

Radical extirpation of the bladder results in unavoidable consequences resulting from loss of vesicourethral reflex. This leads to a disconnect between the reservoir and the urinary sphincter and deactivation of the spinal reflex, resulting in the inability to have any desire to void. The key events leading to voiding in such scenarios are exposure of urine to sensory mechanism in the posterior urethra, leading to initiation of urethral voiding in patients with intact pudendal nerves. The functional urethro-sphincteric guarding reflexes help activate the contractions of the urinary sphincter and ultimately helps avoid daytime leakage. During the night, especially in deep sleep states, the inactivation of the guarding reflex leaves continence at the mercy of the functional capacity of the urinary reservoir. The ideal surgical maneuvers should focus on adequate detubularization and capacity, leading to compliance and preservation of the urethral sphincter complex (Koraitim et al., 2006).

The factors leading to urinary incontinence after urinary diversion are multifaceted (age, volume and shape of reservoir, functional length of urethra, and nerve supply). It is ideal to evaluate patients' urinary function recovery 6 months to a year after surgery once the neobladder has acquired its maximum capacity (Hautmann, 2003). It is ideal to keep the functional capacity lower than the nocturnal urinary output; use of an alarm at night is recommended until the bladder fullness sensation is recognized (Studer and Zingg, 1997).

Patients also have to understand that up to 25% of men may end up using self-intermittent catheterization for incomplete emptying (Steers, 2000). The intracorporeal neobladders currently published have shown up to 11% patients have a need for self-catheterization (Table 142.3). The range of daytime continence varies from 68% to 100%, and nighttime incontinence has been reported between 55% and 85% (see Table 142.3). Predictive features for favorable continence after open surgery have been found to be good preoperative Eastern Cooperative Oncology Group status, subjective retained sensation of bladder-filling questions (Kretschmer et al., 2017).

TABLE 142.3

Comparison of Continence Outcomes for Intracorporeal Neobladder

INSTITUTION AUTHOR, YEAR	NEOBLADDER (NUMBER OF PATIENTS)	MONTHS	PADS/DAY	DAYTIME CONTINEN (%)
Karolinska institute Tyritzis et al., 2013	Modified Studer (70)	12	0–1	68
Memorial Sisli Hospital, Istanbul/Yildirim Beyazit Unversity. Ankara Sim, 2015	Modified Studer (73)	32	<1	89
UCLH Tan et al., 2015	Pyramid (20)	6	0	95
Clinique St-Augustin, France Asimakopoulos et al., 2016	Modified Y (40)	12	0	100
NCI, Rome Simone et al., 2016	Modified Padua (45)	24	0	73
University of Florence, Italy Minervini et al., 2018	Asymmetrical (U) Florin (18)	2 to 6	NR	78
USC Desai et al., 2014	Globular (73/132)	6	0–1	85
USC/Karolinska Satkunasivam, 2016	Modified Studer (28)	9	0	17 (day and nigh

CIC, Clean intermittent catheterization; *NCI,* National Cancer Institute; *NR,* not reported; *UCLH,* University College London Hospital; *USC,* University of Southern California.

Intracorporeal Versus Extracorporeal Diversion

Based on a previous study by the IRCC (Ahmed et al., 2014), only 8 of 18 institutions had performed ICUD. Readmission rates at 30 days (5% vs. 15%, $P \leq 0.0001$) and 90 days (12% vs. 19%, $P = 0.01$) were lower in the intracorporeal group. Blood transfusions were significantly lower in the intracorporeal group (7% vs. 16%, $P = 0.02$). Gastrointestinal-related complications were significantly lower in the intracorporeal group (10% vs. 23%, $P < 0.001$), supporting the notion of minimal bowel manipulation and open bowel exposure may help in lowering complications and possibly help with early recovery. Mortality at 90 days was lower in the intracorporeal group (1.6% vs. 4.9%, $P = 0.04$) possibly because of patient selection bias and surgeon experience.

A more recent update from IRCC (51% ICUD, $n = 1094$) showed that patients who received ICUD had shorter operative time and required fewer blood transfusions compared with ECUD. Although they experienced more high-grade complications (13% vs. 10%, $P = 0.02$), which decreased over time. On multivariable analysis, the approach to urinary diversion was not significantly associated with high-grade complications or readmissions. Several factors were associated with receiving ICUD in this series; healthier patients (with American Society of Anesthesiologists score less than 3), high-volume institutions, and more recent cystectomy era (2013–2016) compared with earlier experience were all significantly associated with receiving ICUD (Hussein et al., 2018).

Future Directions

After the safe inclusion of RARC and lymph node dissection in our armamentarium, ICUD is now performed worldwide. The incorporation of ICUD should be done in a stepwise fashion from ileal conduits to neobladders. It is vital to understand the anatomic, pathophysiologic, and technical nuances of ICUD to prevent long-term complications and upper tract failure. A permanent place for ICUD in urologic surgery will depend not only on optimal operative times but also on optimization of pathophysiologic functions of neobladder and therefore reduction in morbidity and quicker return of quality of life. These parameters have to be proven in comparison with the standards set with open urinary diversion. No randomized controlled trial (RCT) has investigated whether one approach of urinary diversion is preferred. A randomized controlled study is currently in progress in the UK comparing RARC with ICUD versus open radical cystectomy (iROC), which may answer the question of whether ICUD confers additional benefits or not ("iROC," 2017).

Suggested Readings

Diallo D, Zaitouna M, Alsaid B, et al. What is the origin of the arterial vascularization of the corpora cavernosa? A computer-assisted anatomic dissection study. *J Anat*. 2013;223:489–494.

Hautmann RE. Declining use of orthotopic reconstruction worldwide—what went wrong? *J Urol*. 2017.

Hussein AA, Ahmed YE, Kozlowski JD, et al. Robot-assisted approach to “W”-configuration urinary diversion: a step-by-step technique. *BJU Int*. 2017;120:152–157.

Hussein AA, Hashmi Z, Dibaj S, et al. Reoperations following robot-assisted radical cystectomy: a decade of experience. *J Urol*. 2016;195:1368–1376.

Hussein AA, May PR, Jing Z, et al. Outcomes of intracorporeal urinary diversion after robot-assisted radical cystectomy: results from the international robotic cystectomy consortium. *J Urol*. 2017.

Johar RS, Hayn MH, Stegemann AP, et al. Complications after robot-assisted radical cystectomy: results from the International Robotic Cystectomy Consortium. *Eur Urol*. 2013;64:52–57.

Koraitim MM, Atta MA, Foda MK. Orthotopic bladder substitution in men revisited: identification of continence predictors. *J Urol*. 2006;176:2081–2084.

Studer UE, Zingg EJ. Ileal orthotopic bladder substitutes. What we have learned from 12 years’ experience with 200 patients. *Urol Clin North Am*. 1997;24:781–793.

Takenaka A, Murakami G, Matsubara A, et al. Variation in course of cavernous nerve with special reference to details of topographic relationships near prostatic apex: histologic study using male cadavers. *Urology*. 2005;65:136–142.

Trimbos JB, Maas CP, Deruiter MC, et al. A nerve-sparing radical hysterectomy: guidelines and feasibility in Western patients. *Int J Gynecol Cancer*. 2001;11:180–186.

Walz J, Epstein JI, Ganzer R, et al. A critical analysis of the current knowledge of surgical anatomy of the prostate related to optimisation of cancer control and preservation of continence and erection in candidates for radical prostatectomy: an update. *Eur Urol*. 2016;70:301–311.

Wilson TG, Guru K, Rosen RC, et al. Best practices in robot-assisted radical cystectomy and urinary reconstruction: recommendations of the Pasadena Consensus Panel. *Eur Urol*. 2015;67:363–375.

References

“iROC”. *Trial to compare robotically assisted radical cystectomy with open radical cystectomy (iROC)*. [NIH U.S. National Library of Medicine] https://clinicaltrials.gov/ct2/show/NCT03049410; 2017.

Ahmed K, et al. Analysis of intracorporeal compared with extracorporeal urinary diversion after robot-assisted radical cystectomy: results from the International Robotic Cystectomy Consortium. *Eur Urol*. 2014;65:340–347.

Ahmed YE, et al. Natural history, predictors and management of ureteroenteric strictures after robot assisted radical cystectomy. *J Urol*. 2017;198:567–574.

Almassi N, et al. Management of challenging urethro-ileal anastomosis during robotic assisted radical cystectomy with intracorporeal neobladder formation. *Eur Urol*. 2016;69:704–709.

Alsaid B, et al. Coexistence of adrenergic and cholinergic nerves in the inferior hypogastric plexus: anatomical and immunohistochemical study with 3D reconstruction in human male fetus. *J Anat*. 2009;214:645–654.

Asimakopoulos AD, et al. Nerve sparing, robot-assisted radical cystectomy with intracorporeal bladder substitution in the male. *J Urol*. 2016;196:1549–1557.

Baader B, Herrmann M. Topography of the pelvic autonomic nervous system and its potential impact on surgical intervention in the pelvis. *Clin Anat*. 2003;16:119–130.

Bachman AG, et al. minimally invasive versus open approach for cystectomy: trends in the utilization and demographic or clinical predictors using the National Cancer Database. *Urology*. 2017;103:99–105.

Balaji KC, et al. Feasibility of robot-assisted totally intracorporeal laparoscopic ileal conduit urinary diversion: initial results of a single institutional pilot study. *Urology*. 2004;63:51–55.

Bochner BH, et al. Comparing open radical cystectomy and robot-assisted laparoscopic radical cystectomy: a randomized clinical trial. *Eur Urol*. 2015;67:1042–1050.

Cerantola Y, et al. Guidelines for perioperative care after radical cystectomy for bladder cancer: enhanced Recovery After Surgery (ERAS((R))) society recommendations. *Clin Nutr*. 2013;32:879–887.

Challacombe BJ, et al. The role of laparoscopic and robotic cystectomy in the management of muscle-invasive bladder cancer with special emphasis on cancer control and complications. *Eur Urol*. 2011;60:767–775.

Chopra S, et al. Evolution of robot-assisted orthotopic ileal neobladder formation: a step-by-step update to the University of Southern California (USC) technique. *BJU Int*. 2017;119:185–191.

Collins JW, et al. Robot-assisted radical cystectomy (RARC) with intracorporeal neobladder - what is the effect of the learning curve on outcomes? *BJU Int*. 2014;113:100–107.

Collins JW, et al. Enhanced recovery after robot-assisted radical cystectomy: eau robotic urology section scientific working group consensus view. *Eur Urol*. 2016;70:649–660.

Dangle PP, Abaza R. Robot-assisted repair of ureteroileal anastomosis strictures: initial cases and literature review. *J Endourol*. 2012;26:372–376.

Desai MM, et al. Robotic intracorporeal continent cutaneous diversion. *J Urol*. 2017;198:436–444.

Diallo D, et al. What is the origin of the arterial vascularization of the corpora cavernosa? A computer-assisted anatomic dissection study. *J Anat*. 2013;223:489–494.

Erdogru T, et al. Are normal hemodynamic responses invariably associated with normal penile rigidity and potency? *Int J Impot Res*. 2001;13:10–13 [discussion 14–5].

Filson CP, et al. Determinants of radical cystectomy operative time. *Urol Oncol*. 2016;34(431):e17–e24.

Ganzer R, et al. Is the striated urethral sphincter at risk by standard suture ligation of the dorsal vascular complex in radical prostatectomy? An anatomic study. *Urology*. 2014;84:1453–1458.

Guru KA, et al. A robotic future for bladder cancer? *Lancet Oncol*. 2008;9:184.

Guru KA, et al. The learning curve for robot-assisted radical cystectomy. *JSLS*. 2009;13:509–514.

Guru KA, et al. Apical margins after robot-assisted radical prostatectomy: does technique matter? *J Endourol*. 2009;23:123–127.

Haber GP, et al. Perioperative outcomes with laparoscopic radical cystectomy: “pure laparoscopic” and “open-assisted laparoscopic” approaches. *Urology*. 2007;70:910–915.

Hautmann RE. Urinary diversion: ileal conduit to neobladder. *J Urol*. 2003;169:834–842.

Hautmann RE. Declining use of orthotopic reconstruction worldwide-what went wrong? *J Urol*. 2017.

Hayn MH, et al. The learning curve of robot-assisted radical cystectomy: results from the International Robotic Cystectomy Consortium. *Eur Urol*. 2010;58:197–202.

Hellenthal NJ, et al. Lymphadenectomy at the time of robot-assisted radical cystectomy: results from the International Robotic Cystectomy Consortium. *BJU Int*. 2011;107:642–646.

Hubert J, et al. Initial experience with successful totally robotic laparoscopic cystoprostatectomy and ileal conduit construction in tetraplegic patients: report of two cases. *J Endourol*. 2006;20:139–143.

Hussein AA, et al. Development and validation of a quality assurance score for robot-assisted radical cystectomy: a 10-year analysis. *Urology*. 2016;97:124–129.

Hussein AA, et al. Reoperations following robot-assisted radical cystectomy: a decade of experience. *J Urol*. 2016;195:1368–1376.

Hussein AA, et al. Robot-assisted approach to ‘W’-configuration urinary diversion: a step-by-step technique. *BJU Int*. 2017;120:152–157.

Hussein AA, et al. Development of a patient and institutional-based model for estimation of operative times for robot-assisted radical cystectomy: results from the International Robotic Cystectomy Consortium. *BJU Int*. 2017;120:695–701.

Hussein AA, et al. Outcomes of intracorporeal urinary diversion after robot-assisted radical cystectomy: results from the International Robotic Cystectomy Consortium. *J Urol*. 2017.

Hussein AA, et al. Natural history and predictors of parastomal hernia after robot-assisted radical cystectomy and ileal conduit urinary diversion. *J Urol*. 2018;766–773.

Johar RS, et al. Complications after robot-assisted radical cystectomy: results from the International Robotic Cystectomy Consortium. *Eur Urol*. 2013;64:52–57.

Khan MS, et al. A Single-centre early phase randomised controlled three-arm trial of open, robotic, and laparoscopic radical cystectomy (CORAL). *Eur Urol*. 2016;69:613–621.

Koie T, et al. Experience and functional outcome of modified ileal neobladder in 95 patients. *Int J Urol*. 2006;13:1175–1179.

Koraitim MM, Atta MA, Foda MK. Orthotopic bladder substitution in men revisited: identification of continence predictors. *J Urol*. 2006;176:2081–2084.

Kozminski M, Partamian KO. Case report of laparoscopic ileal loop conduit. *J Endourol*. 1992;6:147–150.

Kretschmer A, et al. Prognostic features for objectively defined urinary continence after radical cystectomy and ileal orthotopic neobladder in a contemporary cohort. *J Urol*. 2017;197:210–215.

Lavallee LT, et al. Peri-operative morbidity associated with radical cystectomy in a multicenter database of community and academic hospitals. *PLoS ONE*. 2014;9 [e111281].

Lee Z, et al. Use of indocyanine green during robot-assisted ureteral reconstructions. *Eur Urol*. 2015;67:291–298.

Loertzer P, et al. Robot-sewn ileoileal anastomosis during robot-assisted cystectomy. *World J Urol*. 2018.

Menon M, et al. Nerve-sparing robot-assisted radical cystoprostatectomy and urinary diversion. *BJU Int*. 2003;92:232–236.

Miller C, et al. Introduction of robot-assisted radical cystectomy within an established enhanced recovery programme. *BJU Int*. 2017;120:265–272.

Minervini A, et al. Florence robotic intracorporeal neobladder (FloRIN): a new reconfiguration strategy developed following the IDEAL guidelines. *BJU Int*. 2018;121:313–317.

Moszkowicz D, et al. Where does pelvic nerve injury occur during rectal surgery for cancer? *Colorectal Dis*. 2011;13:1326–1334.

Narayan P, et al. Neuroanatomy of the external urethral sphincter: implications for urinary continence preservation during radical prostate surgery. *J Urol*. 1995;153:337–341.

Nelson R, Edwards S, Tse B. Prophylactic nasogastric decompression after abdominal surgery. *Cochrane Database Syst Rev*. 2007;(3) [CD004929].

Nix J, et al. Prospective randomized controlled trial of robotic versus open radical cystectomy for bladder cancer:

perioperative and pathologic results. *Eur Urol*. 2010;57:196–201.

Osawa T, et al. Potential implications of shortening length of stay following radical cystectomy in a pre-ERAS population. *Urology*. 2017;102:92–99.

Parekh DJ, Donat SM. Urinary diversion: options, patient selection, and outcomes. *Semin Oncol*. 2007;34:98–109.

Parekh DJ, et al. PNFLBA-18 A prospective, multicenter, randomized trial of open versus robotic radical cystectomy (RAZOR). *J Urol*. 2017;197:e918.

Parekh DJ, Reis IM, Castle EP, et al. Robot-assisted radical cystectomy versus open radical cystectomy in patients with bladder cancer (RAZOR): an open-label, randomised, phase 3, non-inferiority trial. *Lancet*. 2018;391:2525–2536.

Poch MA, et al. Tips and tricks to robot-assisted radical cystectomy and intracorporeal diversion. *Curr Opin Urol*. 2013;23:65–71.

Potter SR, et al. Laparoscopic ileal conduit: five-year follow-up. *Urology*. 2000;56:22–25.

Raza SJ, Guru K. Conventional laparoscopic surgery: more pain, no gain! Editorial comment. *BJU Int*. 2015.

Rehman J, et al. Total intracorporeal robot-assisted laparoscopic ileal conduit (Bricker) urinary diversion: technique and outcomes. *Can J Urol*. 2011;18:5548–5556.

Sanchez de Badajoz E, del Rosal Samaniego JM, Gomez GA. Laparoscopic ileal conduit. *Arch Esp Urol*. 1992;45:761–764.

Schwalenberg T, et al. Neuroanatomy of the male pelvis in respect to radical prostatectomy including three-dimensional visualization. *BJU Int*. 2010;105:21–27.

Simone G, et al. Robotic intracorporeal padua ileal bladder: surgical technique, perioperative, oncologic and functional outcomes. *Eur Urol*. 2016.

Smith I, et al. Perioperative fasting in adults and children:

guidelines from the European Society of Anaesthesiology. *Eur J Anaesthesiol*. 2011;28:556–569.

Steers WD. Voiding dysfunction in the orthotopic neobladder. *World J Urol*. 2000;18:330–337.

Stenzl A, et al. Rationale and technique of nerve sparing radical cystectomy before an orthotopic neobladder procedure in women. *J Urol*. 1995;154:2044–2049.

Studer UE, Zingg EJ. Ileal orthotopic bladder substitutes. What we have learned from 12 years' experience with 200 patients. *Urol Clin North Am*. 1997;24:781–793.

Sun AJ, et al. Venous thromboembolism following radical cystectomy: significant predictors, comparison of different anticoagulants and timing of events. *J Urol*. 2015;193:565–569.

Takenaka A, et al. Variation in course of cavernous nerve with special reference to details of topographic relationships near prostatic apex: histologic study using male cadavers. *Urology*. 2005;65:136–142.

Tan WS, et al. Robot-assisted intracorporeal pyramid neobladder. *BJU Int*. 2015;116:771–779.

Tan WS, et al. Intracorporeal robot-assisted radical cystectomy, together with an enhanced recovery programme, improves postoperative outcomes by aggregating marginal gains. *BJU Int*. 2017.

Trimbos JB, et al. A nerve-sparing radical hysterectomy: guidelines and feasibility in Western patients. *Int J Gynecol Cancer*. 2001;11:180–186.

Tyritzis SI, et al. Oncologic, functional, and complications outcomes of robot-assisted radical cystectomy with totally intracorporeal neobladder diversion. *Eur Urol*. 2013;64:734–741.

Tyson MD, Chang SS. Enhanced recovery pathways versus standard care after cystectomy: a meta-analysis of the effect on perioperative outcomes. *Eur Urol*. 2016;70:995–1003.

Waingankar N, et al. Assessing the relative influence of hospital and surgeon volume on short-term mortality after radical cystectomy. *BJU Int*. 2017;120:239–245.

Walz J, et al. A critical analysis of the current knowledge of surgical anatomy of the prostate related to optimisation of cancer control and preservation of continence and erection in candidates for radical prostatectomy: an update. *Eur Urol*. 2016;70:301–311.

Wilson TG, et al. Best practices in robot-assisted radical cystectomy and urinary reconstruction: recommendations of the Pasadena Consensus Panel. *Eur Urol*. 2015;67:363–375.

Xu W, et al. Postoperative pain management after radical cystectomy: comparing traditional versus enhanced recovery protocol pathway. *J Urol*. 2015;194:1209–1213.

Yuh BE, et al. Impact of previous abdominal surgery on robot-assisted radical cystectomy. *JSLS*. 2009;13:398–405.

PART XV
The Prostate

OUTLINE

143 Development, Molecular Biology, and Physiology of the Prostate
144 Benign Prostatic Hyperplasia Etiology, Pathophysiology, Epidemiology, and Natural History
145 Evaluation and Nonsurgical Management of Benign Prostatic Hyperplasia
146 Minimally Invasive and Endoscopic Management of Benign Prostatic Hyperplasia
147 Simple Prostatectomy Open and Robotic-Assisted Laparoscopic Approaches
148 Epidemiology, Etiology, and Prevention of Prostate Cancer
149 Prostate Cancer Biomarkers
150 Prostate Biopsy Techniques and Imaging
151 Pathology of Prostatic Neoplasia
152 Diagnosis and Staging of Prostate Cancer
153 Active Management Strategies for Localized Prostate Cancer
154 Active Surveillance of Prostate Cancer
155 Open Radical Prostatectomy
156 Laparoscopic and Robotic-Assisted Laparoscopic Radical Prostatectomy and Pelvic Lymphadenectomy
157 Radiation Therapy for Prostate Cancer
158 Focal Therapy for Prostate Cancer
159 Treatment of Locally Advanced Prostate Cancer
160 Management Strategies for Biochemical Recurrence of Prostate Cancer

161 Hormonal Therapy for Prostate Cancer
162 Treatment of Castration-Resistant Prostate Cancer

143

Development, Molecular Biology, and Physiology of the Prostate

Brian Wesley Simons DVM, PhD, Ashley Evan Ross MD, PhD

The focus of this chapter is on the development, anatomy, histology, and physiology of the prostate and seminal vesicles, the male sex accessory glands that contribute to seminal fluid. A general and molecular knowledge regarding the formation and physiologic function of the prostate is becoming increasingly important because reactivation or recapitulation of developmental processes appears to occur during pathological processes such as benign prostatic hyperplasia (BPH) and the development of aggressive prostate cancer (Marker, 2008; Pritchard et al., 2009; Schaeffer et al., 2008). In addition, the physiologic processing of prostate-specific antigen (PSA) and other cellular constituents of the prostate has begun to play increasingly important roles in the development of clinical prostate biomarkers (Loeb and Catalona, 2014; Mikolajczyk et al., 2004; Vickers et al., 2011).

Developmental and Cell Biology

Prostate

Regional Differentiation of the Lower Urinary Tract

The prostate is a derivative of the primitive endoderm (gut tube). Regional differentiation of the primitive gut tube into foregut, midgut, and hindgut is followed by a swelling at the caudal end that creates the cloaca. The *cloaca*, a Latin term meaning “sewer,” receives output from the urinary and intestinal tracts and represents the fully differentiated state in birds, reptiles, amphibians, marsupials, and monotremes. In placental mammals, however, the cloaca divides during embryogenesis to create separate urogenital and digestive outlets. The ventral urinary compartment is called the *primitive urogenital sinus*, which further segments into the urinary bladder at its cranial end and the urethra at its caudal terminus. Differentiation of the pelvic portion of the urogenital sinus is sexually dimorphic and, in males, forms the prostatic and membranous urethra, prostate, and bulbourethral glands.

Prostate Budding

In males, the prostate develops just caudal to the bladder neck via the proliferation of epithelial buds extending out from the urogenital sinus epithelium. Prostate organogenesis occurs in four overlapping stages. Androgen exposure of the urogenital sinus directly or indirectly initiates the first stage, prostate lineage commitment of regions of the urogenital sinus epithelium. In the second stage, solid cords epithelial cords, or prostate buds, form and invade urogenital sinus mesenchyme at stereotyped locations that pattern the future development of distinct prostate lobes in the rodent and, potentially, zones in the human. These regions prepare for epithelial bud invasion by “mesenchymal condensation,” a process in which urogenital sinus mesenchymal cells (cells constituting loose connective tissue that will differentiate into stromal elements) become closely packed together (Thomson, 2008). This condensation occurs in males and females and is therefore androgen *independent*. In contrast, epithelial budding is strictly androgen *dependent* and represents the first events in prostate development that are identifiable at the light microscopic level. Prostate budding requires intricate epithelial-mesenchymal interactions (Fig. 143.1). In humans, prostate budding occurs during the 10th week of gestation. In mice, prostate budding occurs on the 17th day of gestation, 2 days before birth. Androgen exposure is not only *necessary* but also *sufficient* to drive prostatic differentiation and growth in the embryo. This fact, along with the ability to easily manipulate androgen levels in experimental animals, makes the prostate a particularly appealing subject for the study of epithelial cell fate determination (Cunha et al., 1987; Schaeffer et al., 2008). In the third stage of prostate organogenesis, prostate buds elongate and branch to form the mature prostate network, (postnatal days 1 to 14 in mice) as part of a sophisticated branching morphogenesis program (Sugimura et al., 1986). Finally, the ducts canalize, and cytodifferentiation of the epithelium results in mature prostate glands.

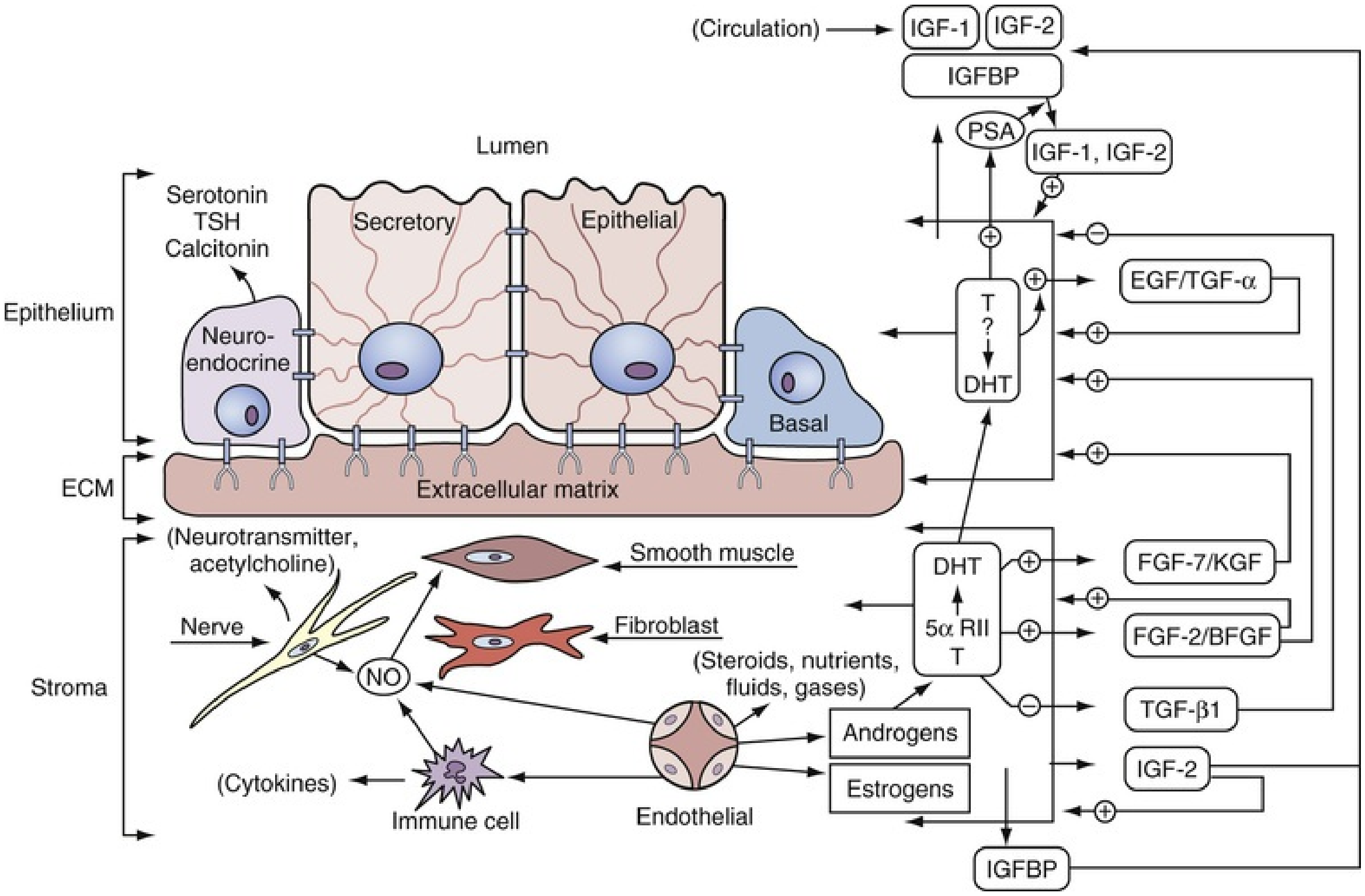
(Circulation)
IGF-1
IGF-2
IGFBP
PSA
IGF-1, IGF-2
Lumen
Serotonin
TSH
Calcitonin
Secretory
Epithelial
Epithelium
Neuro-
endocrine
T
?
DHT
EGF/TGF-α
Basal
ECM
Extracellular matrix
(Neurotransmitter,
acetylcholine)
Smooth muscle
DHT
FGF-7/KGF
Nerve
Fibroblast
5α RII
T
FGF-2/BFGF
Stroma
NO
(Steroids, nutrients,
fluids, gases)
TGF-β1
Androgens
Estrogens
IGF-2
(Cytokines)
Immune cell
Endothelial
IGFBP

FIG. 143.1 Stromal-epithelial interactions. Shown is a schematic of the types of stromal-epithelial interactions in information transfer and regulation within the prostate. Testosterone and growth factors interact on and between stromal and epithelial cells. The production of growth factors is either stimulated or inhibited by androgens. The growth factors can function on the same cell (autocrine) or on distant cells (paracrine). Nitric oxide (NO) is formed from nerve cells, endothelial cells, or macrophages and affects smooth muscle contraction (see text for details). Important features in this schematic are (1) three types of prostate epithelial cells—neuroendocrine, secretory, and basal; (2) five important prostatic stromal

cells—smooth muscle, fibroblast, immune cells, endothelial cells, and nerve cells; (3) testosterone converted to dihydrotestosterone (DHT) by 5α-reductase in the stromal compartment; (4) three sources of NO production in the prostate—nerve, immune cells (e.g., macrophages), and endothelial cells; and (5) stromal-epithelial interactions mediated through various growth factors (see text). *BFGF,* Basic fibroblast growth factor; *ECM,* extracellular matrix; *EGF,* epidermal growth factor; *FGF,* fibroblast growth factor; *IGF,* insulin-like growth factor; *IGFBP,* insulin-like growth factor binding protein; *KGF,* keratinocyte growth factor; *PSA,* prostate-specific antigen; *T,* testosterone; *TGF,* transforming growth factor; *TSH,* thyroid-stimulating hormone.

Cytodifferentiation

Prostate epithelium begins as a homogeneous cell compartment that differentiates (after birth in mice) into distinct basal (adjacent to stroma) and luminal cell types (Wang et al., 2001). Some epithelial cells co-express basal and luminal markers and are called *intermediate cells*. A fourth cell type, the neuroendocrine cell, is present in large numbers before prostate epithelial budding and decreases during embryonic development (Aumuller et al., 2001).

Molecular Features of Prostate Development

Induction of Prostate Budding.

High levels of circulating testosterone in male embryos initiate prostate development. Testosterone is converted to dihydrotestosterone (DHT) in the UGS by 5α-reductase (Berman et al., 1995), which binds to and activates androgen receptor (AR). Exposure to sufficient levels of testosterone at key developmental time points initiates prostate development regardless of genetic sex, suggesting a primary role for androgens in prostate induction. Recombination experiments in mice have shown that prostate lineage commitment and induction of epithelial budding require paracrine signaling from urogenital sinus mesenchyme (UGM) to adjacent urogenital sinus epithelium (UGE), and that intact AR signaling is required in UGM but not UGE for prostate induction (Cunha and Lung, 1978). Thus the action of androgens appears to be indirect, leading to the hypothesis that mesenchymal cells secrete inductive factors in response to androgens called *andromedins* (Tenniswood, 1986; Yan et al., 1992). Although AR signaling is the primary motivating force behind prostate development, it specifies only the timing of events, not their location. The AR signaling machinery is present diffusely throughout the lower genitourinary tract (Berman et al., 1995; Takeda et al., 1985). Prostate epithelial buds form at precise locations through mechanisms that are not understood.

Two main hypotheses have been proposed to describe the mechanism of induction of prostate budding by UGM, the andromedin model and the smooth muscle model (Toivanen and Shen, 2017). In the andromedin model, AR signaling in UGM induces focal expression of signaling factors (andromedins) that induces prostate budding at that spot. The alternative smooth muscle model hypothesizes that andromedin expression is constitutive throughout the UGS, but maturation of smooth muscle between the mesenchyme and epithelium forms a barrier that prevents signal transduction. In this model, AR signaling in the mesenchyme indirectly induces prostate budding by preventing smooth muscle maturation and allowing inductive signals to reach the UGE. Spatial control of bud induction may involve paralogous homeobox *(Hox)* genes, which are transcriptional regulators that govern differential gene expression along the craniocaudal (head to tail) and proximodistal (e.g., shoulder to fingertip) axes in a variety of tissues, including the genitourinary tract (Beck et al., 2000; Kmita and Duboule, 2003). In vertebrates, the paralogous *Hox* genes exist as four similar clusters (clusters A, B, C, and D), each of which resides on a separate chromosome and encodes genes whose chromosomal position from 3′ to 5′ mirrors their expression pattern in the embryo. The paralogous genes are distinct from other, more distantly related transcription factor families that also contain DNA-binding homeobox motifs, such as the NK family, whose members are expressed in a more discrete, organ-specific manner (e.g., see the discussion of Nkx3.1, later). Paralogous *Hox* genes are sequentially numbered from 1 to 13, with the higher numbers in the 5′ position showing the most distal or caudal expression patterns. Accordingly, *Hoxa13, Hoxb13,* and *Hoxd13* are *paralogs* on chromosomes 7, 17, and 2, respectively, and have overlapping expression patterns and functions in distal genitourinary tract development. *Hoxb13* regulatory elements have been characterized that restrict its function to the caudal end of the genitourinary and digestive tracts and can be used to engineer androgen-independent prostatic expression of genes of interest (McMullin et al., 2009). Homozygous mutations in individual *Hox* genes result in subtle changes in prostatic branching patterns (Podlasek et al., 1997) and/or defective epithelial maturation (Economides and Capecchi, 2003). Mutations involving more than one of these genes results in significantly more severe urogenital phenotypes, such as significant prostate hypoplasia in *Hoxd13/Hoxb13* compound mutant mice or failure of separate urinary and gastrointestinal tract outlets to form in *Hoxa13/Hoxd13* compound mutants (Kondo et al., 1997; Warot et al., 1997).

Mesenchymal condensation occurs in males and females, so it is not sufficient to drive prostate development but may be necessary. Condensation of the ventral mesenchymal pad is defective in mice lacking the gene for Noggin (see the section on the transforming growth factor-β [TGF-β] family, later, for further discussion of the roles of Noggin in prostate development), which antagonizes binding of bone morphogenetic protein (BMP) ligands to their receptors (Cook et al., 2007). This observation suggests that BMP signaling enhances mesenchymal condensation, either by direct action on mesenchyme or through regulation of epithelial-derived factors important in this process. Condensed mesenchyme is highly enriched for expression of fibroblast growth factors (FGFs) that are essential for epithelial bud outgrowth. For example, mice with engineered mutations of the mesenchyme-specific growth factor *Fgf10* gene generate small abortive epithelial buds and fail to grow prostates (Donjacour et al., 2003).

Epithelial Budding.

The earliest event seen in the epithelium during prostate development appears to be the upregulation of sex-determining region Y–box 9 (Sox9), an androgen-dependent transcription factor, induced via mesenchymal-dependent FGF signaling (Huang et al., 2012). Sox9 appears to be crucial for the initiation of prostate epithelial lineage. After this, there is increased epithelial expression of the NK homeobox transcription family member Nkx3.1. This transcription factor influences the degree of branching in the mature mouse prostate, where it can also act as a tumor suppressor (Abate-Shen et al., 2008; Bhatia-Gaur et al., 1999; Bieberich et al., 1996).

Mutations in the transcriptional regulator p63 *(TP63)* (Signoretti et al., 2000) or in the AR signaling axis (Cunha et al., 1987) can also abolish prostate induction. TP63 has transcriptional repressor and activator activities that balance differentiation and stem and progenitor cell functions in epithelia (McKeon, 2004). The transcriptional targets of TP63 in prostate epithelial cells (PrECs) remain to be elucidated (Grisanzio and Signoretti, 2008).

Noggin mutations selectively impair budding of the ventral lobes of the prostate, leaving anterior and dorsolateral budding unimpaired (Cook et al., 2007). Overall, however, the process appears to be a very robust one, with evidence of prostate epithelial bud formation persisting in the presence of a variety of genetic mutations that affect future steps in prostate ductal morphogenesis, particularly branching morphogenesis.

Once set in motion, prostate growth and homeostasis continue to require androgens throughout life. This requirement appears to continue to be indirect, through mesenchymal or stromal AR signaling. Epithelial branching morphogenesis occurs through signaling cascades that inhibit further outgrowth along the long axis of an extending epithelial bud while stimulating lateral growth at its tip (Hogan, 1999). Through engineered deletion of genes in transgenic mice, several individual genes and components of classic morphogenetic pathways have been shown to be required for branching morphogenesis. Indeed, morphologic aberrations seen on interruption of a cellular pathway may be the most sensitive measure of a role for that pathway in regulation of prostate growth. Accordingly, a wide variety of genes and pathways have been strongly implicated in prostate branching morphogenesis, only a few of which are covered here. For a more comprehensive perspective, including additional pathways such as those centered around Notch and Forkhead proteins, the reader is referred to recent reviews (Leong and Gao, 2008; Matusik et al., 2008).

Nkx3.1 and Sox9.

Nkx3.1 helps determine the branching pattern of the prostate, as demonstrated by the reduced numbers of duct tips seen in mice with engineered *Nkx3.1* deletion (Bhatia-Gaur et al., 1999). This relatively subtle phenotypic change may be important, however, as indicated by a dramatic decrease in the ability of Nkx3.1-mutant prostates to manufacture mature secretory proteins (Bhatia-Gaur et al., 1999). In addition to its role in the initiation of prostate development, Sox9 appears required for bud growth and branching as well as ductal outgrowth (Thomsen et al., 2008).

Fibroblast Growth Factors.

The FGF family of related secreted peptides promotes growth in recipient cells by binding to cell surface receptors and activating intracellular second-messenger cascades. Epithelial branching morphogenesis, be it in the lung, salivary gland, mammary gland, or prostate, requires such signals to proceed. Of the FGFs, Fgf-7 (keratinocyte growth factor) and Fgf-10 have been studied most extensively in prostate development. Both of these ligands preferentially bind to Fgfr-2 over the three other family members (Fgfr-1, Fgfr-3, and Fgfr-4)

(Thomson, 2001, 2008). Ligand binding activates the intracellular microtubule-associated protein kinase (MAPK) pathway, leading to enhanced activity of growth-promoting transcription factors and increased proliferation.

Fgfr-2 is expressed on developing PrECs, where it can interact with its coreceptor Frs-2α. Fgf-7 and Fgf-10, in contrast, are secreted by prostate mesenchyme. This arrangement, along with androgen-independent growth of prostate organ cultures exposed to these ligands, has led to the proposal that they act as andromedins (Lu et al., 1999; Yan et al., 1992). Accordingly, Fgf-10–deficient mice have almost complete failure of prostate development, and mice lacking Fgfr-2 or Frs-2α demonstrate prostate hypoplasia and decreased epithelial branching (Donjacour et al., 2003).

Wnt Signaling Pathway.

In a variety of organs, Wnt signaling regulates proliferation and differentiation during development. A similar role is seen in prostate development, in which multiple Wnt ligands are expressed during prostate budding (Mehta et al., 2011; Zhang et al., 2006), and canonical Wnt targets such as Lef1 and Axin2 are upregulated in prostate bud epithelium (Kruithof-de Julio et al., 2013; Simons et al., 2012). Deletion of β-catenin, a critical component of canonical Wnt signaling, during prostate development inhibits prostate differentiation and budding (Francis et al., 2013; Mehta et al., 2013; Simons et al., 2012).

Hedgehog Signaling Pathway.

Across a variety of organs, elaboration of secreted hedgehog (Hh) ligands (Sonic hedgehog, Indian hedgehog, and Desert hedgehog) by epithelial cells and reception in adjacent mesenchyme coordinate the activities of the Gli family proteins in regulating hedgehog pathway target genes. In the mesenchyme of developing prostate, several Hh target genes have been identified (Yu et al., 2009), including the cytokine *Cxcl14*, the insulin-like growth factor–binding protein *Igfbp3*, and the delta/notchlike epidermal growth factor–related receptor *Dner*. The roles of these particular genes in prostate development have yet to be ascertained, but, as a whole, Hh pathway target genes have been implicated in placement of prostate epithelial buds and in subsequent ductal branching and outgrowth. In particular, buds form in the absence of the dominant Hh ligand in the prostate (Berman et al., 2004) but are mislocalized in prostates of mice bearing mutations of downstream effectors of the pathway, Gli proteins (Doles et al., 2006). Later in development, Hh ligands enhance epithelial outgrowth and branching (Freestone et al., 2003), which proceed abnormally in prostate organ cultures treated with Hh pathway antagonists (Berman et al., 2004; Freestone et al., 2003; Lamm et al., 2002). In adult animals the pathway may play a role in homeostasis, as indicated in a failure of prostates to regenerate after castration of animals treated with antibodies or small molecules that block Hh signaling (Berman et al., 2004). Taken together, these data indicate a growth-promoting role for the pathway in prostate epithelium, one that may have clinical relevance in pathologic prostate growth (Shaw and Bushman, 2007).

Transforming Growth Factor-β Superfamily.

TGF-β superfamily members include TGF-β, as well as growth and differentiation factors (GDFs) and BMPs. These factors act through transmembrane receptors and the SMAD family of intracellular signal transducing proteins (Schmierer and Hill, 2007). Little is known about GDFs in the prostate, but TGFs and BMPs are likely to play important roles. In organogenesis this superfamily is best known as a mesenchymal mediator of epithelial growth suppression, but (less frequently) they can also stimulate growth and/or be produced by epithelial cells. TGF-β1 inhibits net growth of the prostate but can stimulate growth in certain regions of the gland, particularly in the distal tips of the ventral prostate (Tomlinson et al., 2004a). Although the mechanism for growth promotion by TGF-β1 is unclear, the growth suppressive effect could reasonably relate to its ability to suppress levels of another mesenchymal growth factor, FGF-10 (Tomlinson et al., 2004b) (see FGF section, earlier). A similar mechanism could remain in place in mature males, in whom TGF-β signaling in proximal ducts is believed to help to maintain prostate epithelial stem cells in a quiescent (growth-suppressed) state (Salm et al., 2005). BMP-4 and BMP-7 exert important and highly localized growth-suppressive activities in prostate development that help guide branching morphogenesis and prevent overproduction and disorganized epithelial growth. Like TGF-β, BMPs are most active during epithelial budding and subsequent prostate branching (Grishina et al., 2005; Lamm et al., 2001; Tomlinson et al., 2004a) (embryonic day 17 through postnatal day 5 in the mouse). Activation of BMP signaling suppresses branching morphogenesis, as indicated by experimental addition of exogenous BMP-4 or BMP-7 protein to prostate organ cultures (Grishina et al., 2005; Lamm et al., 2002) or by genetic deletion of the BMP inhibitor Noggin (Cook et al., 2007). BMP inactivation can show the opposite effect, as epithelial overgrowth of prostates with genetic deletion of BMP-7 (Grishina et al., 2005).

Prostate Zonal and Lobar Anatomy.

The rodent prostate is divided into paired anterior, dorsolateral, and ventral lobes. Each empties into the urethra separately at its proximal extreme, with the distal end floating freely in the pelvic cavity. In contrast, the human prostate, like that of most primates and canine species, grows as a single organ encircling the urethra. The individual prostate zones, however, have distinct architectural and molecular features and have a propensity to develop distinct pathologies (Table 143.1). For instance, the transitional zone surrounding the urethra has the propensity to undergo BPH, making males vulnerable to urinary obstruction, whereas the peripheral zone, which contains the majority of the glandular elements of the prostate, is the most common site for prostate cancer. In rodents, the anterior, ventral, and dorsolateral lobes are named for the distinct locations of the urethra from which they originate. Each lobe also has a different branching pattern with a distinctive histologic appearance. These differences, reviewed by Timms (2008), have been likened to different zones of the human prostate histologically (Price, 1963), molecularly (Berquin et al., 2005; Thielen et al., 2007), and in terms of propensity to be affected by disease (the dorsolateral prostate, for instance, is most similar to the human peripheral zone). In mice, mRNA transcripts for spermine-binding protein, probasin, and renin-1 are specific for ventral, dorsolateral, and anterior lobes, respectively (Cook et al., 2007), whereas human zone-specific gene expression has not been as well characterized.

TABLE 143.1

Summary of the Anatomy and Cell Biology of the Prostate Gland

COMPONENTS	PROPERTIES
DEVELOPMENT	
Seminal vesicles	From wolffian ducts through testosterone stimulation
Prostate	From urogenital sinus through dihydrotestosterone stimulation
PROSTATE ZONES	
Anterior fibromuscular	30% of prostate mass, no glandular elements, smooth muscle
Peripheral	Largest zone, 75% of prostate glandular elements, site of carcinomas
Central	25% of prostate glandular elements; surrounds ejaculatory ducts
Transitional	Smallest zone, surrounds upper urethra complex, sphincter
	5% of prostate glandular elements, site of benign prostatic

	hyperplasia
	15%–30% of prostate volume
EPITHELIAL CELLS	
Basal	Small and flattened undifferentiated, nonsecretory cells with a low proliferative index (<1%) that express keratins 5, 14, and 18
Intermediate	Proliferating cell type that has characteristics intermediate between basal and secretory cells, including production of basal and secretory cell keratins
Columnar secretory	Terminally differentiated, nondividing, rich in acid phosphatase and prostate-specific antigen; 20 μm tall, most abundant cell, keratins 5 and 18
Neuroendocrine	Terminally differentiated, nonproliferating cells that express serotonin, chromogranin-A, neuron-specific enolase, and synaptophysin proteins
STROMAL CELLS	
Smooth muscle	Rich in α-actin, myosin, and desmin
Fibroblast	Vimentin rich and associated with fibronectin
Endothelial	Associated with fibronectin; alkaline phosphatase positive
TISSUE MATRIX	
Extracellular matrix	
Basement membrane	Type IV and V collagen meshwork that is laminin rich and supports basal cells, stem cells, transit-amplifying cells, and secretory epithelium
Connective tissue	Type I and type III fibrillar collagen; elastin
Glycosaminoglycans	Sulfates of dermatan, chondroitin, and heparin; hyaluronic acid
Cytomatrix	Tubulin, α-actin, and intermediate filaments of keratin
Nuclear matrix	Dynamic structure of the nucleus that directs the functional organization of DNA into loop domains; contains ribonuclear proteins

Although the gene expression patterns of individual human prostate zones have not been extensively studied, there have been efforts to characterize the zonal distribution of prostate-secreted proteins, in particular of PSA, at least in the adult prostate. For instance, Mikolajczyk et al. (2000a) described BPSA (BPH-related PSA) as a form of unbound PSA that is increased in the transition zone of the prostate. In contrast, the proPSA zymogen (a precursor of PSA) has been found to be preferentially detected in the peripheral zone (Mikolajczyk et al., 2000b).

Key Points: Embryonic Development

- The wolffian ducts develop into the seminal vesicles, epididymis, vas deferens, ampulla, and ejaculatory duct. The developmental growth of this group of glands is stimulated by fetal testosterone and not DHT.
- Through tissue recombination experiments in mice and rats, the developing urogenital sinus mesenchyme and epithelium have been shown to partner in prostate development. That is, the development, growth, and function of the male and female urogenital tract require stromal-epithelial interaction and action of steroid sex hormones. Androgen acts on the mesenchyme to indirectly induce prostate epithelial outgrowth during development and homeostasis in adulthood.

Prostate Cell Types

The prostatic epithelium in the human is composed of two major cellular compartments: epithelial cells and stromal cells (see Table 143.1). The prostate epithelial compartment consists of basal epithelial cells, intermediate cells, neuroendocrine cells, and luminal secretory epithelial cells (De Marzo et al., 1998a). The stromal compartment architecturally serves as structural support and consists predominantly of connective tissue, smooth muscle cells, and fibroblasts. Most prostate cell types have been characterized in vitro (Peehl, 2005).

In most glands with renewing cell populations, there is a steady-state flow of cells from mostly quiescent stem cells to a more rapidly dividing pool of transient proliferating cells. This proliferating population finally reaches terminal differentiation, characterized by metabolically active secretory epithelium. In the prostate, precise cell lineage remains uncertain. Although precise cell lineage analysis is possible in mice, it is unclear if these findings directly translate to human cells. In addition, cytodifferentiation in the embryo during organogenesis may not be maintained by the same cell populations in the adult prostate at homeostasis. Some cells, such as neuroendocrine cells, can be formed from transdifferentiation or by influx of neural crest-derived cells. A hypothetical differentiation scheme for prostate epithelium is presented in Fig. 143.2. As in most multilayered epithelia, stem cells reside in the basal compartment and can give rise to all of the other epithelial cell types, as well as neuroendocrine cells. These include fully differentiated secretory cells that line glandular lumens (luminal cells), neuroendocrine cells that secrete bioactive peptides, and intermediate cells that show phenotypic features that are intermediate between basal cells and luminal cells.

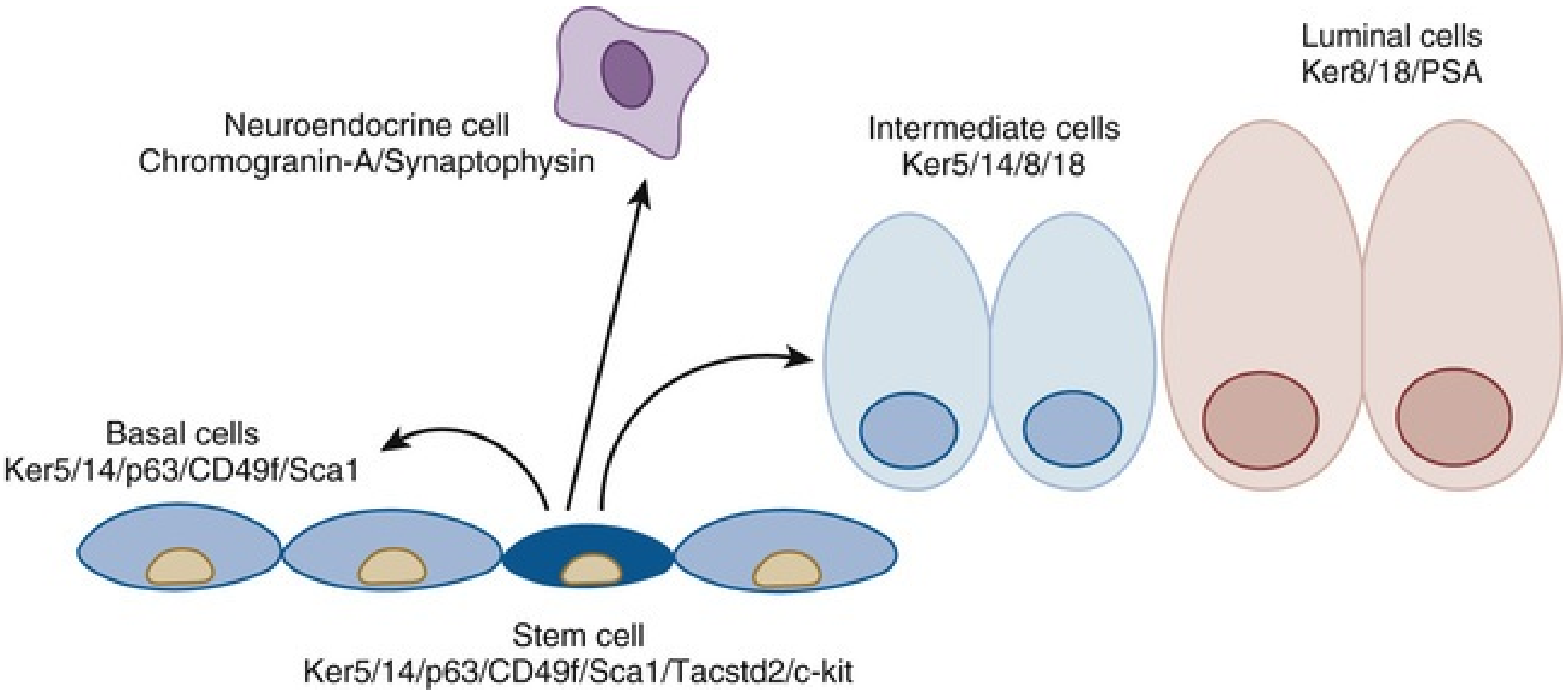

FIG. 143.2 Hypothetical cell differentiation in adult prostate. Basal cells *(medium blue)* express basal cell proteins, including cytokeratin (CK) proteins 5 and 14, p63, CD49f, and Sca1. Stem cells within the basal cell compartment *(dark blue)* express basal cell proteins, as well as Tacstd2 and c-kit. Basal stem cells populate the basal cell compartment *(medium blue)* and eventually intermediate cells *(light blue).* Intermediate cells proliferate and differentiate into quiescent luminal cells *(orange).* Neuroendocrine cells *(purple)* are also believed to derive from epithelial stem cells. Formal lineage tracing has not been performed in all of these cell types; thus the true differentiation pathway remains to be determined. (Modified from Wang Y, Hayward S, Cao M, et al.: Cell differentiation lineage in the prostate. *Differentiation* 68[4–5]:270–279, 2001.)

Luminal Epithelial Cells.

The luminal epithelial cell is the “workhorse” of the prostate gland, responsible for epithelial barrier integrity and production of prostatic secretion. Luminal cells constitute most of the prostate epithelium. These tall (10 to 20 µm) columnar secretory epithelial cells are terminally differentiated and have a low proliferative index (De Marzo et al., 1998a); they are easily distinguished by their morphologic features and abundant secretory granules and enzymes. Secretory cells produce a variety of proteins that characterize prostatic differentiation, including PSA, acid phosphatase, AR, leucine amino peptidase, and 15-lipoxygenase-2 (Bhatia et al., 2003; Shappell et al., 1999). They are also rich in keratin filaments (subtypes 8 and 18) (van Leenders and Schalken, 2003). Secretory cells appear in rows like a picket fence with each cell connected to the next by cell adhesion molecules (CAMs); the apical aspect of these cells projects into the lumen, with the base attached to a basement membrane through integrin receptors (Knox et al., 1994). The nucleus is at the base just below a clear zone (2 to 8 µm) of abundant Golgi apparatus, and the upper cellular periphery is rich in secretory granules and enzymes. The apical plasma membrane facing the lumen possesses microvilli, and secretions move into the open collecting spaces of the acinus. These epithelial cells ring the periphery of the acinus and produce secretions into the acini that drain into ducts connected to the urethra.

Basal Cells.

Basal cells (De Marzo et al., 1998a) are the smallest of epithelial cells. Basal cells express a distinct keratin subtype profile (subtypes 5 and 14) compared with the columnar luminal epithelial cells (subtypes 8 and 18). These cells are typically pyramid shaped with relatively little cytoplasm and condensed chromatin. Basal cells rest on the basement membrane wedged between the bases of adjacent, tall, columnar epithelial cells. The basal cell compartment expresses little or no androgen receptor and is almost devoid of secretory products, such as PSA and prostatic acid phosphatase (PAP) (see Fig. 143.2). Indeed, when mice are castrated after implantation with human prostate primary xenografts and then restimulated with testosterone, the basal cell population is highly overrepresented, consistent with the concept that the human basal compartment also contains prostate epithelial stem cells (Huss et al., 2004).

Prostate Epithelial Stem Cells.

In most glands with renewing cell populations, there is a steady-state flow of cells from mostly quiescent stem cells to a more rapidly dividing pool of transient proliferating cells. This proliferating population finally reaches terminal differentiation, characterized by metabolically active secretory epithelium. In the human prostate, cell lineage has not been rigorously determined but has been inferred from a variety of sources. A hypothetical differentiation scheme for prostate epithelium is presented in Fig. 143.2. In this model, stem cells reside in the basal compartment and appear to give rise to all of the other epithelial cell types, as well as neuroendocrine cells. These include fully differentiated secretory cells that line glandular lumens (luminal cells), neuroendocrine cells that secrete bioactive peptides, and intermediate cells that show phenotypic features that are intermediate between basal cells and luminal cells. Lineage tracing experiments in human prostate suggest bipotential basal stem cells are located at the proximal portion of ducts and can generate the complete spectrum of cell types, whereas human luminal progenitor cells are unipotent and only generate luminal cells (Moad et al., 2017). Studies in mice suggest mouse prostate stem cells follow a different model. In the adult mouse prostate, stem cells are present in luminal and basal compartments and retain the ability to regenerate the full spectrum of cell phenotypes from either compartment (Wang et al., 2009).

These experiments used lineage tracing and in vivo grafting assays to demonstrate critical stem cell characteristics, including the ability of long-lived cells to proliferate indefinitely and to give rise to more differentiated phenotypes. Tsujimura et al. (2002) demonstrated DNA label-retaining PrECs with long-term proliferative potential that were preferentially localized to the proximal segments of prostatic ducts of adult mice. Studies to determine the expression profile that identifies prostate stem cells has found multiple possible candidates including the mouse stem cell antigen Sca1, the basal cell integrin α_6 (Itga6 or CD49f), the tumor-associated calcium signal transducer Tacstd2 (also known as *Trop2*), and the stem cell factor receptor c-kit (Burger et al., 2005; Goldstein et al., 2008; Lawson et al., 2007; Leong and Gao, 2008; Xin et al., 2005). Studies in human prostate cells have additionally identified CD133 and DLK1 as potential stem cell markers (Moad et al., 2017; Vander Griend et al., 2008). Further study of prostate cell differentiation is required to uncover the potential and lineage of prostate cell types and to determine if mouse and human prostate differentiation are similar.

Intermediate Cells.

Intermediate cells are so named because they possess phenotypic characteristics intermediate between basal and luminal cells. Similarities of these cells to prostate cancer cells have marked them as hypothetical substrates for neoplastic transformation (De Marzo et al., 1998b; Verhagen et al., 1992), although their susceptibility to carcinogenesis is unknown. These investigators proposed that intermediate cells fulfill a transient amplifying function, providing a short-term amplification function for the long-term proliferative capabilities of basal stem cells. Intermediate cells produce basal cell keratins (5 and 14) and the secretory cell keratins 8 and 18 (De Marzo et al., 1998b; Schalken and van Leenders, 2003). Uzgare et al. (2004) reported transient amplifying properties of human intermediate cells in culture: a high proliferative fraction with the ability to proliferate for a limited number of generations. Survival of terminally differentiated secretory luminal cells and proliferation of intermediate cells require androgens potentially acting indirectly through the secretion of androgen-regulated growth factors by the stromal compartment (andromedins) (Uzgare et al., 2004).

Neuroendocrine Cells.

Neuroendocrine cells are cells that release hormones in response to neural stimulation. In the prostate, neuroendocrine cells reside among the more abundant secretory epithelial cells in the normal prostate gland as well as in the urothelium of the prostatic urethra (Aumuller et al., 2001). There are two types of neuroendocrine cells: the first is open and possesses specialized microvilli that protrude into the lumen; the second is closed with long dendrite-like processes that extend to nearby epithelial cells and basal cells close to afferent and efferent nerves (Abrahamsson, 1999; diSant-Agnese and deMesy-Jensen, 1984; diSant-Agnese et al., 1985; Vashchenko and Abrahamsson, 2005).

The development of this cell type during prostate organogenesis has not been well characterized, and the source of these cells has been variously proposed to be neural crest or urogenital sinus endoderm (Aumuller et al., 2001; Goldstein et al., 2008). Aumuller et al. (2001) demonstrated that neuroendocrine cells are readily identified in male and female urogenital sinus epithelium before human prostate development, suggesting that these may represent a separate lineage that is independent of prostate epithelium. More recently, Goldstein et al. (2008) showed that neuroendocrine, basal, and secretory luminal cells can originate from a common pluripotent Trop2-expressing prostate epithelial stem cell precursor. Recent lineage tracing studies suggest the majority of neuroendocrine cells in mice and humans are neural crest derived, but the factors that initiate neuroendocrine transdifferentiation of epithelial cells or migration of neural crest cells remain undefined (Szczyrba et al., 2017).

Current evidence suggests that neuroendocrine cells can influence growth, differentiation, and secretory activity of the prostate epithelium through paracrine and autocrine mechanisms (Abrahamsson, 1999; Vashchenko and Abrahamsson, 2005). Neuroendocrine cells bring about their regulatory activity by the secretion of hormonal polypeptides or biogenic amines such as serotonin. High-pressure liquid chromatography measurements have shown that normal human prostatic tissue contains approximately 1400 ng of serotonin per gram of tissue, and this would certainly emphasize the importance of these cells (Davis, 1987). Higgins and Gosling (1989) have studied the structure and intrinsic innervations of the normal human prostate and have observed acetylcholinesterase-containing nerves associated with smooth muscle in the peripheral and the central parts of the prostate. In addition, they have shown that the majority of the acini in the peripheral and central regions possess a rich plexus of autonomic nerves and that vasoactive intestinal peptide-positive nerve fibers are found in relation to the epithelial lining acini in the central and peripheral regions of the gland. Lepor and Kuhar (1984) characterized and studied the location of the muscarinic cholinergic receptor in human prostatic tissue and localized it to the epithelial cells. This is consistent with the neuropharmacology of muscarinic cholinergic agonist, which has a marked effect on increasing prostatic secretion. However, the α_1-adrenergic receptor has its effect in the human prostatic stromal compartment. This is of clinical importance because of the use of selective α_1-adrenergic antagonists to alleviate bladder outlet obstruction secondary to BPH (Lepor, 1993). Recent work has demonstrated three subtypes of the α_1-adrenergic receptor (α_{1A}, α_{1B}, and α_{1D}). Of these, the α_{1A} receptor appears to be linked to smooth muscle contraction of the prostate (Lepor et al., 1993).

Neuroendocrine cells are terminally differentiated (i.e., nonproliferating) and do not express detectable AR, PSA, or Bcl-2. These cells release peptide hormones or prohormones by fusion of intracellular granules with the cell membrane and exocytosis of their contents. In addition to serotonin, neuroendocrine cells produce numerous bioactive macromolecules (major examples include bombesin, neuron-specific enolase, calcitonin gene family members, thyroid-stimulating hormone–like peptide, somatostatin, synaptophysin, and parathyroid hormone–like peptide). Neuroendocrine factors appear likely to influence the growth, differentiation, and secretion of epithelium of the prostate in normal and malignant conditions (Vashchenko and Abrahamsson, 2005).

Key Points: Prostate Epithelial Cell Types

- The prostatic epithelium in the human is composed of two major cell compartments: epithelial cells and stromal cells.

- The epithelial cell types include mature secretory and terminally differentiated cells, neuroendocrine cells, intermediate cells, and basal cells.
- Prostatic stem cells reside in the basal compartment and are enriched in the proximal portions of prostatic ducts.

Stroma and Tissue Matrix

The noncellular stroma and connective tissue of the prostate make up what is termed the *ground substance* and the *extracellular matrix* in what was first suggested by Arcadi (1954) to play an important role in prostate function and disease. The extracellular matrix has long been recognized as one of the important inductive components during normal development of many different types of cells (Cunha, 1976; Bissell et al., 1982; Getzenberg et al., 1990; Hay, 1981; Risbridger et al., 2005). Classic tissue recombination experiments by Cunha et al. (1987) have clearly shown the direct importance of the isolated embryonic mesenchyme to the induction of differentiation of normal prostatic epithelial cells (see earlier discussion).

The epithelial cells rest on the basement lamina or membrane, which is a complex structure containing, in part, collagen types IV and V, glycosaminoglycans, complex polysaccharides, and glycolipids. This layer forms an interface to the stromal compartment that provides structural support for the basal cells and their progeny. It consists of an extracellular matrix, ground substance, and a variety of stromal cells, including the fibroblasts, capillary and lymphatic endothelial cells, smooth muscle cells, neuroendocrine cells, and axons (Taylor and Risbridger, 2008).

The **cytomatrix** (cytoplasmic skeleton) terminates in the center of the cell by direct attachment to the **nuclear matrix.** The prostatic epithelial cell therefore has direct structural linkage via the matrix system from the DNA to the plasma membrane. The cytomatrix then makes direct contact with the basement membrane, extracellular matrix, and ground substance of the stroma. This entire interlocking tissue scaffolding or superstructure is termed the ***tissue matrix*** and may have dynamic properties in ordering and controlling biologic processes as well as in the transport of secretions from the sex accessory tissues (Etienne-Manneville, 2004; Getzenberg et al., 1990; Hallmann et al., 2005; Konety and Getzenberg, 1999; Miner and Yurchenco, 2004).

Understanding the biologic components of the tissue matrix system within sex accessory tissues is paramount to understanding its physiology. The laminin proteins are glycoproteins of the extracellular matrix that mediate attachment of cells to the type IV collagen of the basement membrane (Hallmann et al., 2005; Miner and Yurchenco, 2004; Yurchenco et al., 2004). Laminin is produced by epithelial cells but not by fibroblasts; it is a large molecule (approximately 800 kD) with molecular domains that interact with the type IV collagen of the basement membrane and with integrin-type receptors within the cell surface glycocalyx of the epithelial cell (Aumailley et al., 2005). Laminins are the major anchor filaments in the basement membranes of epithelial cells that stabilize attachment of hemidesmosomes via $\alpha_6\beta_4$ integrin (Brar et al., 2003; Miner and Yurchenco, 2004). **The key functional properties of the laminins are cell adhesion, proliferation, differentiation, growth, and migration.** Laminin surrounds the basement membrane of prostate acinar epithelial cells, capillaries, smooth muscle, and nerve fibers but not lymphatics, lymphocytes, or fibroblasts; the laminin structure and its distribution are disrupted in BPH and higher-grade prostatic interepithelial neoplasia and higher-grade prostate neoplasms (Brar et al., 2003; Miner and Yurchenco, 2004; Sinha et al., 1989).

In summary, the development and maintenance of the prostate occur through androgen-dependent and highly regulated tissue morphogenesis in processes involving epithelial cell differentiation, proliferation, and apoptosis (Cunha et al., 2004)**. Communication through numerous extracellular interactions is directed to the intracellular cytoskeleton and then to the nuclear matrix, which ultimately regulates a variety of transcriptional cell functions that control such critical phenotypic qualities as cell size and shape, cell motility, epithelial cell turnover, proliferation, and differentiation** (Getzenberg et al., 1990; Miner and Yurchenco, 2004; Pienta et al., 1993).

Seminal Vesicles and Their Development

The sex accessory tissues include the epididymis, ampullae, seminal vesicles, prostate, Cowper (bulbourethral) gland, and glands of Littre (urethral or periurethral glands). All of these glands have reproductive roles, but the seminal vesicles work in tandem with the prostate and provide an important counterpoint to its biology and pathologic processes. The seminal vesicles are two saccular glands that pair with the vasa deferentia to form the ejaculatory ducts that empty into the craniodorsal aspects of the prostate. Together with the prostate, the seminal vesicles produce seminal fluid that nurtures, protects, and facilitates sperm transport for mammalian reproduction.

The division of labor between the prostate and seminal vesicles is surprisingly variable among species. At one end of the spectrum is the dog, a species in which seminal vesicles are absent and the prostate must therefore carry out the functions that are divided between the two glands in other species. Most mammals, including humans, rats, and mice, occupy the other end of the spectrum, in which the seminal vesicles produce most of the seminal fluid, with the prostate playing a minor role. In species with both glands, physiologic cooperation between the two glands is also appreciable at the molecular level. For example, the major secretory protein product of the seminal vesicles is semenogelin, a 52-kD protein that acts as a substrate for proteolytic enzymes produced by the prostate, including PSA. Proteolysis of semenogelin yields a variety of peptide byproducts that are believed to serve reproductive and antimicrobial functions in humans (Curry and Atherton, 1990). In mice and rats, seminal vesicle and prostate products cooperate to coagulate the ejaculate into a firm copulatory plug in the vagina during mating. The plug serves as a temporary barrier to further mating by the female, potentially blocking impregnation by competing males.

Seminal vesicles develop from the mesonephric (wolffian) ducts shortly before the onset of prostate development. Seminal vesicle development is strictly dependent on an intact AR signaling pathway, including the ligand testosterone (Wilson et al., 1981). This requirement contrasts to development of the human prostate (see later), which, in addition to an intact AR pathway, requires conversion of testosterone into the more potent 5α-reduced androgen, DHT (Andersson et al., 1991; Mahendroo and Russell, 1999).

Thick smooth muscle layers constitute the muscular stroma of the seminal vesicles, which surrounds a short columnar-to-cuboidal epithelium. The epithelium has distinct basal and luminal layers notable for unusually variable nuclear size and shape, a feature that is also found in prostate cancer (Epstein and Netto, 2007). Another notable feature of the epithelium of the seminal vesicles, the almost invariable appearance of gold intracytoplasmic pigment, is usually absent in prostate cancer and helps to clarify any confusion between the two entities. Seminal vesicle pigment is thought to derive from cellular byproducts of nonviable sperm ingested by the seminal vesicle epithelium (spermatophagy).

The seminal vesicles are extremely resistant to disease. Given their proximity, shared functions, and similar endocrine requirements to the prostate, it is striking that diseases of the seminal vesicles in humans are vanishingly rare.

In contrast, prostate disease, at least in Western cultures, is a nearly universal rite of passage into old age (see subsequent chapters on BPH and prostate cancer). Accordingly, contrasting gene expression between seminal vesicles and the prostate has been used as a strategy to discover the molecular basis of prostate cancer risk (Thompson et al., 2008).

Endocrine Control of Prostate Growth

The prostate, like other sex accessory tissues, is stimulated in its growth, maintenance, and secretory function by the continued presence of certain hormones and growth factors. Foremost among these is testosterone, which is converted within the prostate into the more active androgen DHT. Testosterone is synthesized in the Leydig cells of the testes from pregnenolone by a series of reversible reactions. However, once testosterone is converted by 5α-reductase into DHT or converted by aromatase into estrogens, the process is irreversible: **testosterone can be converted to DHT or estrogens, but estrogens and DHT cannot be converted to testosterone.** Androgens, estrogens, and adrenal steroids are believed to have strong effects on different cells and tissues in the body that can vary with development and age. These vary from embryonic development to puberty and on into adult maintenance and aging. Therefore androgen ablation or androgen treatments have a variety of physiologic effects that merit consideration.

The generalized endocrine physiology of the prostate is depicted in Fig. 143.3. The hypothalamus releases a small 10-residue polypeptide (decapeptide) referred to as *luteinizing hormone–releasing hormone* (LHRH), also called *gonadotropin-releasing hormone* (GnRH). Under the stimulation of LHRH the pituitary releases luteinizing hormone (LH), which is transported to the testes and acts directly on the Leydig cells to stimulate de novo steroid synthesis and release of testosterone, the major serum androgen of the body. Most of the estrogen in the male is derived from peripheral conversion of androgens to estrogens through aromatization. Exogenous estrogens, such as diethylstilbestrol, block androgen action not primarily by direct effects on the prostate but indirectly through blocking pituitary function. The estrogen causes a negative feedback on LH release that reduces the serum signal for testicular testosterone production; therefore estrogen acts as an effective “chemical castration.”

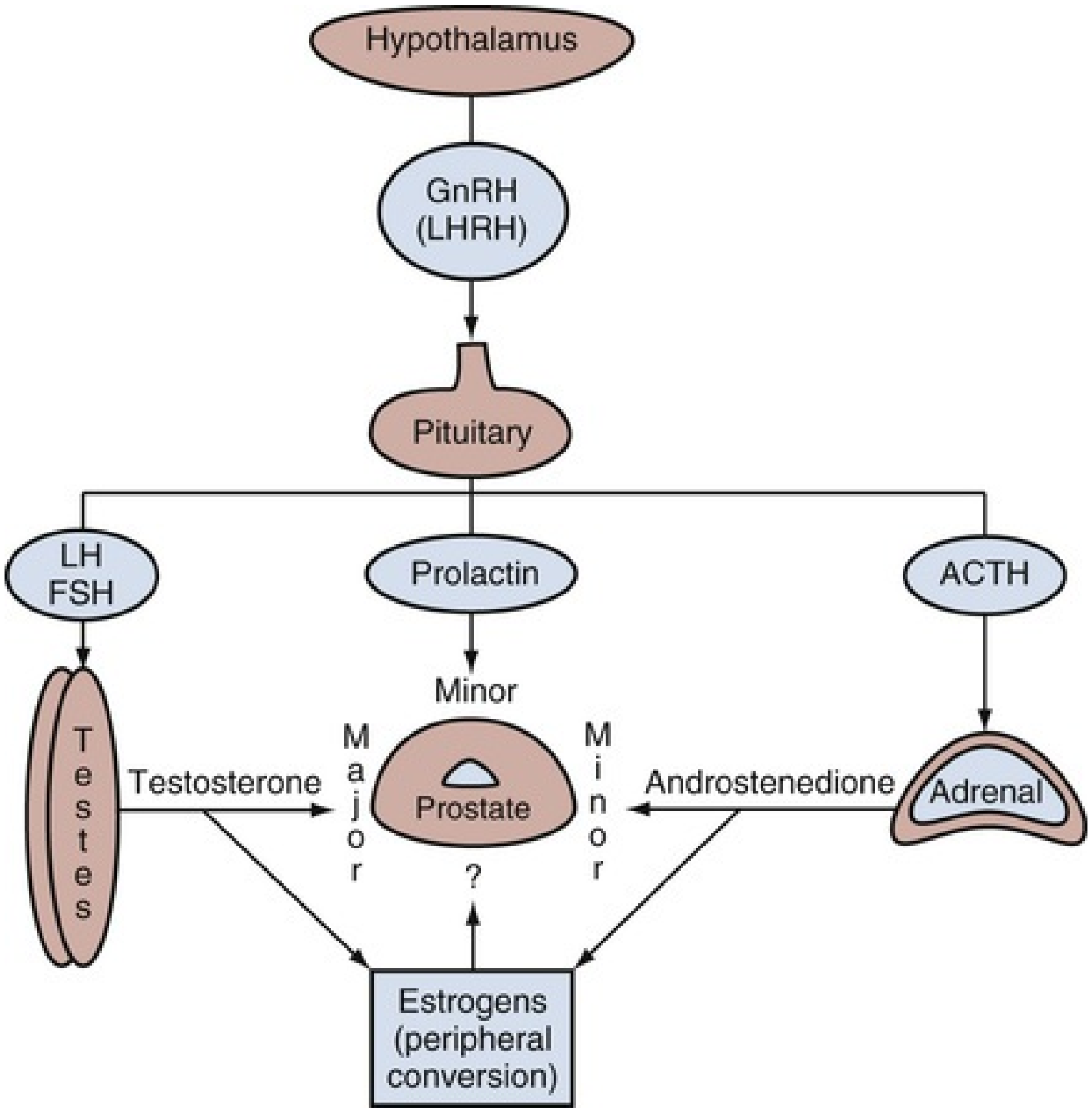
Hypothalamus
GnRH
(LHRH)
Pituitary
LH
FSH
Prolactin
ACTH
Testes
Testosterone
Major
Minor
Prostate
Minor
Androstenedione
Adrenal
?
Estrogens
(peripheral
conversion)

FIG. 143.3 Simplified endocrinology of the prostate. Luteinizing hormone–releasing hormone (LHRH), also known as gonadotropin-releasing hormone (GnRH), stimulates the pituitary to release the gonadotropins luteinizing hormone (LH) and follicle-stimulating hormone (FSH), which stimulate the Leydig cells of the testes to synthesize testosterone. Testosterone is the major serum androgen stimulating prostate growth. Peripheral conversion of testosterone by aromatization forms the estrogens in the male. The adrenal gland is under stimulation by adrenocorticotropic hormone (ACTH) and releases the minor androgens, such as androstenedione, which is also converted peripherally to estrogens. Prolactin has also been shown to have a minor effect in stimulating androgen-induced prostate growth. The prostate can produce its own growth factors (autocrine or paracrine) or respond to circulating growth factors.

Recent studies in prostate cancer biology have revealed that prostate cancer cells are capable of de novo androgen synthesis, leading to renewed interest in steroid 17α-hydroxylase/17,20-lyase blockade (e.g., abiraterone), or direct AR antagonism (e.g., enzalutamide). However, it is doubtful that benign prostatic epithelial cells produce intracrine androgens in clinically significant amounts because castration leads to nearly complete involution of the prostate. In addition, the adrenal secretes a weak androgen, androstenedione. However, this also is not a major influence on prostate physiology because castration leads to almost complete involution of the prostate, meaning that insufficient adrenal androgens are present to stimulate any meaningful growth of the normal prostate. Similar to serum testosterone, androstenedione can undergo aromatization to estrone. Overproduction of androstenedione, such as occurs in certain forms of congenital adrenal hyperplasia, may stimulate prostate growth; however, again, the role of normal circulating adrenal androgens in regulating prostate growth is minor. The presence of a nontesticular minor androgen source has led to the concept of total androgen blockade for the treatment of advanced prostate cancer, whereby an LHRH agonist and a nonsteroidal antiandrogen are combined to eliminate testosterone production and block any residual androgen stimulation of the prostate from the adrenal gland. With the realization that prostate cancer cells can produce intracrine androgens and various constitutively active AR splice isoforms, true androgen blockade requires further addition of drugs of the newer class such as abiraterone and enzalutamide.

Androgen Production by the Testes

Because the testes produce the major serum androgen supporting prostate and sex accessory tissue growth, it is important to briefly review this function. In the normal human male the major circulating serum androgen is testosterone, which is almost exclusively (approximately 95%) of testicular origin. **Under normal physiologic conditions the Leydig cells of the testis are the major source of the testicular androgens.** The Leydig cells are stimulated by the gonadotropins (primarily LH) to synthesize testosterone from acetate and cholesterol. The spermatic vein concentration of testosterone is 40 to 50 µg/dL, approximately 75 times more concentrated than the level detected in the peripheral venous serum (Hammond, 1978), which is approximately 600 ng/dL. Other androgens also leave the testes by the spermatic vein; these include androstanediol, androstenedione (3 µg/dL), dehydroepiandrosterone (DHEA) (7 µg/dL), and DHT (0.4 µg/dL). The concentrations of these androgens are much lower in the spermatic vein than the concentration of testosterone, with all being less than 15% of the concentration of testosterone.

The total testosterone that enters the plasma is referred to as the *testosterone blood production rate* and is 6 to 7 mg/day in the human. Although other steroids, such as androstenedione from the adrenals, can be converted by peripheral metabolism to testosterone, they account for less than 5% of the overall production of plasma testosterone. The plasma half-life of testosterone is only 10 to 20 minutes, which means that a man undergoing bilateral simple orchiectomy is functionally castrated within 1 to 2 hours of surgery. Therefore the most rapid method of androgen suppression for the purposes of immediate relief of spinal cord compression from prostate cancer metastasis is surgical castration.

The average testosterone concentration in the plasma of a man is approximately 611 ng/dL ± 186, with a normal range of 300 to 1000, which is equal to 10.4 to 34.7 nmol/L in SI units (Table 143.2). Serum testosterone level is not remarkably related to age between 25 and 70 years, although it does decline gradually to approximately 500 ng/dL after 70 years of age. It is recognized that plasma concentrations of testosterone can vary widely in an individual on any one day and may reflect episodic and diurnal variations in the production rate.

TABLE 143.2

Average Plasma Levels of Sex Steroids in Healthy Human Males

STEROID (COMMON NAME)	PLASMA CONCENTRATION (ng/dL)	RELATIVE MOLARITY	DAILY BLOOD PRODUCTION RATE (mg/day)	RELA ANDI (RAT
Testosterone	611 ± 186	100	6.6 ± 0.5	100
Dihydrotestosterone	56 ± 20	9	0.3 ± 0.06	181
5α-Androstane-3α,17β-diol (3β-androstanediol)	14 ± 4	2	0.2 ± 0.03	126
5α-Androstane-3β,17β-diol (3β-androstanediol)		<2	<0.3	18
Androstanediol	161 ± 52	26	0.21	
Androsterone	54 ± 32	9	0.28	53
Androstenedione	150 ± 54	25	1.4	39
Dehydroepiandrosterone	501 ± 98	81	29	15
Dehydroepiandrosterone sulfate	135,925 ± 48,000	17,619		<1
Progesterone		30	4.5	
17β-Estradiol	2.5 ± 0.08		0.4	0.75
Estrone		4.6	0.8	0.04

VP, Ventral prostate.

Metabolic androgens such as 17-ketosteroids are then secreted into the urine as water-soluble glucuronide or sulfate conjugates. The total 17-ketosteroid level in the urine in adult men is 4 to 25 mg/24 h and is not an accurate index of testosterone production, because other steroids from the adrenals as well as nonandrogenic steroids can be metabolized to 17-ketosteroids. Only small amounts (25 to 160 μg/day) of testosterone enter the urine without metabolism, and this urinary testosterone represents less than 2% of the daily testosterone production.

Although testosterone is the primary plasma androgen inducing growth of the prostate gland and other sex accessory tissues, it appears to function as a prohormone in that the most active form of the androgen in the prostate is not testosterone but rather DHT (Anderson and Liao, 1968; Bruchovsky and Wilson, 1968; Farnsworth and Brown, 1963; Fig. 143.4). The formation of DHT involves the reduction of the double bond in the A ring of testosterone through the enzymatic action of the enzyme 5α-reductase (Fig. 143.5). There are at least two isoforms of this enzyme (type 1 and type 2). Type 2 5α-reductase expression predominates in human accessory sex tissues and is localized to the fibromuscular stromal compartment (Silver et al., 1994). The type 1 isoform predominates in skin, in prostatic epithelia, and to a lesser extent in prostatic fibromuscular stroma. Inhibition of 5α-reductase by finasteride appears to be largely selective for the type 2 isoform (Habib et al., 1997; Iehle et al., 1995); the newer agent dutasteride inhibits type 1 and type 2 5α-reductase. Both drugs appear to exert similar effects in terms of reduction in prostatic volume and serum PSA concentration, suggesting that the type 2 isoform is the only clinically significant isoform present in the prostate. **DHT concentration in the plasma of normal men is low, 56 ± 20 ng/dL, in comparison to testosterone,** with a concentration 11-fold higher at approximately 611 ng/dL (see Table 143.2). In summary, although DHT is a potent androgen (2 to 10 times as potent as testosterone in many bioassay systems), its low plasma concentration and tight binding to plasma proteins diminishes its direct importance as a circulating androgen affecting prostate and seminal vesicle growth. In contrast, DHT is paramount within the prostate, where it is formed from testosterone. **DHT is the major form of androgen found within the prostate gland (5 ng/g tissue wet weight) and is fivefold higher than testosterone.** In the prostate, DHT binds to ARs and activates the receptors to regulate a variety of cellular processes. In summary, DHT becomes the major androgen regulating the cellular events of growth, differentiation, and secondary functions in the prostate.

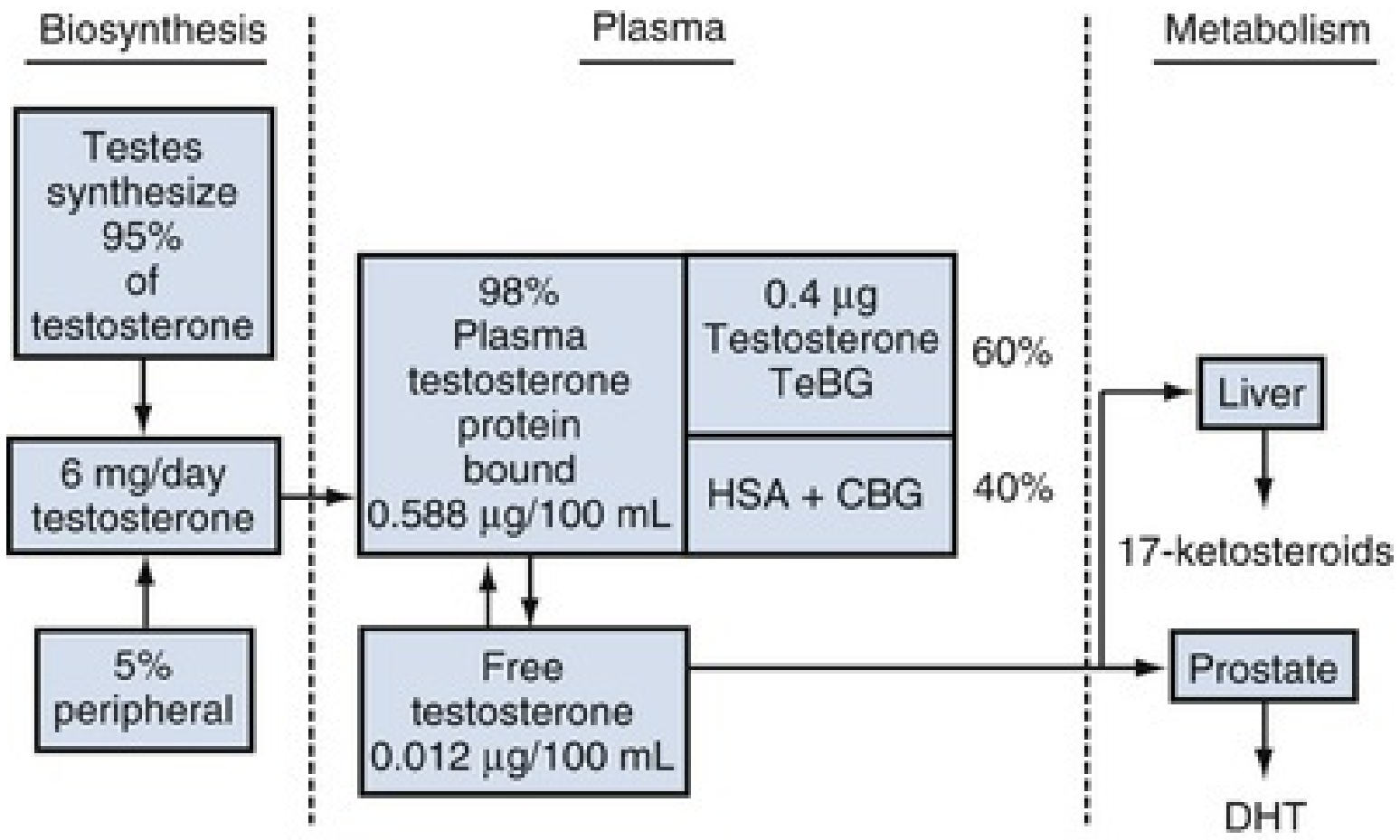
Biosynthesis
Plasma
Metabolism
Testes synthesize 95% of testosterone
6 mg/day testosterone
5% peripheral
98% Plasma testosterone protein bound 0.588 µg/100 mL
0.4 µg Testosterone TeBG
60%
HSA + CBG
40%
Free testosterone 0.012 µg/100 mL
Liver
17-ketosteroids
Prostate
DHT

FIG. 143.4 Quantitative assessment of the testicular biosynthesis, plasma transport, and metabolism of testosterone. Plasma testosterone is bound to sex steroid–binding globulin (SSBG), human serum albumin (HSA), and cortisol-binding globulin (CBG). All numbers are average values for the normal adult male. *DHT,* Dihydrotestosterone; *TeBG,* testosterone-binding globulin.

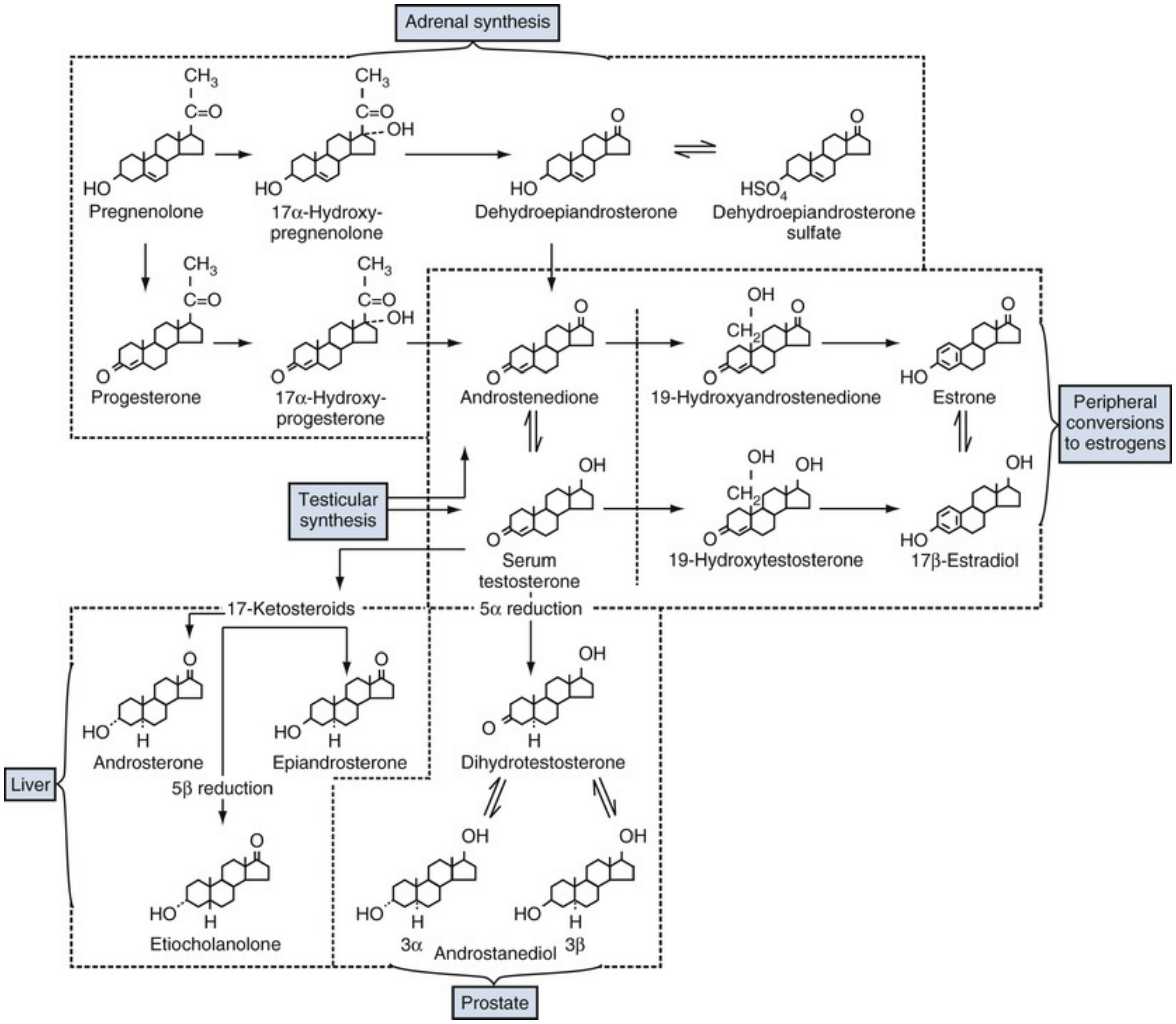
Adrenal synthesis
CH3
C=O
HO
Pregnenolone
CH3
C=O
OH
HO
17α-Hydroxy-pregnenolone
O
HO
Dehydroepiandrosterone
O
HSO4
Dehydroepiandrosterone sulfate
CH3
C=O
O
Progesterone
CH3
C=O
OH
O
17α-Hydroxy-progesterone
O
O
Androstenedione
OH
CH2
O
O
19-Hydroxyandrostenedione
O
HO
Estrone
Peripheral conversions to estrogens
Testicular synthesis
OH
O
Serum testosterone
OH
CH2
OH
O
19-Hydroxytestosterone
OH
HO
17β-Estradiol
17-Ketosteroids
5α reduction
Liver
O
HO
H
Androsterone
O
HO
H
Epiandrosterone
5β reduction
O
HO
H
Etiocholanolone
OH
O
H
Dihydrotestosterone
OH
HO
H
3α
Androstanediol
OH
HO
H
3β
Prostate

FIG. 143.5 Overview of the synthesis and metabolism of testosterone in four main body compartments: adrenal synthesis of androstenedione, peripheral conversion of androgens (androstenedione and testosterone) to estrogens, formation of active androgen (dihydrotestosterone [DHT]) within the prostate, and inactivation in the liver of testosterone to three types of 17-ketosteroids.

The normal adult male plasma levels of some important steroids are summarized in Table 143.2. These values are derived as averages from numerous studies. Individual values can fluctuate with age, time of day, medications, stress, hospitalization, and environmental changes. For this reason, serum measurements of testosterone should be done only in the morning (e.g., 8:00 AM), because late afternoon measurements can drop by as much as 25% by diurnal variation alone (Brambilla et al., 2009).

Adrenal Androgens

There is evidence that overproduction of adrenal steroids can stimulate growth of the prostate gland. For example, in humans, abnormal virilism has been observed in immature males with a hyperfunctioning adrenal cortex. In rodents, overstimulation of the adrenals can also induce limited prostate growth even in the absence of testicular androgens. For example, administration of exogenous adrenocorticotropic hormone to castrated animals does significantly increase the growth of sex accessory glands (Tisell, 1970; Tullner, 1963; Walsh and Gittes, 1970). However, the effect of normal levels of adrenal androgens on the prostate in noncastrated humans and adult male rats does not appear to be significant because adrenalectomy has little effect on prostate size, DNA, or morphologic characteristics of the sex accessory tissue (Mobbs et al., 1973; Oesterling et al., 1986). Furthermore, after castration in animals, with the adrenals intact, the prostate finally diminishes to a very small size (90% reduction in total cell mass). Finally, the small involuted ventral prostate in the castrated rat cannot be significantly reduced further by additional adrenalectomy or hypophysectomy (Kyprianou and Isaacs, 1987). In castrated rats, the DHT level in the prostatic tissue is approximately 20% that in normal intact animals. Adrenalectomy lowers the DHT to undetectable levels without further diminution in prostate growth. This indicates that a threshold level of DHT is required in the prostate to stimulate growth and that the castrate level is below this threshold. Another conclusion is that the human prostate does not restore itself after castration, indicating that adrenal androgens are insufficient to compensate for the loss of testicular function. Quantitative morphometry of the human prostate (Oesterling et al., 1986) also confirms that the adrenal gland has little effect on the epithelial cell size of the normal prostate.

The adrenal steroid DHEA and the conjugate dehydroepiandrosterone sulfate (DHEAS) as well as androstenedione are androgens synthesized from acetate and cholesterol (see Fig. 143.5) that are secreted by the normal human adrenal glands. Essentially all of the DHEA in the male plasma is of adrenal cortex origin, and the production rate in males is 10 to 30 mg/day. **Less than 1% of the total testosterone in the plasma is derived from DHEA** (Horton, 1976; MacDonald, 1976). The prostate and seminal vesicles of the rat and the human prostate can slowly hydrolyze DHEAS to free steroids through prostatic sulfatase enzymatic activity, but the degree of conversion is low; hence DHEAS is not a potent androgen.

A second adrenal androgen is androstenedione, and the plasma concentration in adult men is approximately 150 ± 54 ng/dL (see Table 143.2). The blood production rate of androstenedione in human males is 2 to 6 mg/day, with approximately 20% of the androstenedione being generated by peripheral metabolism of other steroids. **Androstenedione cannot be converted directly to DHT.** An important role for androstenedione in the male may be its peripheral conversion to estrogens through the aromatase reaction (see Fig. 143.5).

The adrenal gland also produces C21 steroids (e.g., progesterone). The plasma production rate at 0.75 mg/day is low, producing a low plasma progesterone concentration of 30 ng/dL. Although progesterone is weakly androgenic, it does not exert a significant effect on the prostate at the low concentrations present in normal male plasma. **In summary, under normal conditions, the adrenals do not support significant growth of prostatic tissue.**

Estrogens in the Male

The estrogen receptors (ERs) are differentially expressed in the prostate. In the mouse, ER-α is expressed early (1 week) in the stroma of the ventral prostate but by 2 weeks is preferentially expressed in the epithelia, and ER-α is absent altogether in the ventral prostate by 4 weeks. In contrast, ER-β exists in the epithelial compartment as the dominant ER by the fourth week. However, knockout mice for ER (both isoforms) are able to form grossly normal prostates, although fertility may be limited in the ER-α group (Couse et al., 2001). Only small amounts of estrogen are produced directly by the testes. In the plasma of young healthy human males, 75% to 90% of the estrogens are derived from the peripheral conversion of androstenedione and testosterone to estrone and estradiol through the aromatase reaction (see Fig. 143.5) (Horton, 1976; MacDonald, 1976). The androgenic C19 steroids (testosterone and androstenedione) are converted to the estrogenic C18 steroids first by removal of the 19-methyl group and then by the formation of an aromatic or phenolic steroid A ring (aromatase reaction), present in estradiol and estrone. Estradiol is formed from testosterone and estrone from androstenedione; these two estrogens are interconvertible. **The daily production of estradiol in the human male is 40 to 50 µg, and only 5 to 10 µg (10% to 25%) can be accounted for by direct testicular secretion** (see Table 143.2).

Androgen-Binding Proteins in the Plasma

Less than 2% of the total testosterone in human plasma is free or unbound; the remaining 98% is bound to several different types of plasma proteins (see Fig. 143.4). The plasma proteins that bind steroids include human serum albumin, sex hormone–binding globulin (denoted SSBG or SHBG), corticosteroid-binding globulin (also named *transcortin*), progesterone-binding globulin, and, to a lesser extent, α_1-acid glycoprotein. Under normal conditions, the total amount of testosterone bound to progesterone-binding globulin and α_1-acid glycoprotein is nominal and is usually ignored. SHBG levels are suppressed by circulating androgens as well as anabolic steroids and may be decreased by diabetes and obesity.

The regulation of the amount of androgen that is free is an important physiologic variable and varies in different species. **The total amount of steroid bound depends on two factors: (1) the *affinity* of the steroid to bind to a specific protein and (2) the *capacity,* which is the maximal potential binding when all of a binding protein is saturated with bound steroid. The capacity is governed by the amount of binding protein in the plasma.** Serum albumin has a relatively low affinity for testosterone, but, given its abundance, it has a high capacity. In contrast, SHBG has a high affinity for binding steroids, but the protein is present in relatively low concentrations; however, the plasma molarity of each binding protein exceeds the plasma molarity for total testosterone concentration. The majority of testosterone bound to plasma protein is associated with SHBG. For example, Vermeulen (1973) has calculated that in the normal human male, 57% of testosterone in the plasma is bound to SHBG and 40% is bound to human serum albumin. Less than 1% is bound to corticosteroid-binding globulin, and only 2% of the total testosterone is free (see Fig. 143.4). The normal plasma free testosterone level is therefore 12.1 ± 3.7 ng/dL or 0.42 nM; this non–protein-bound “free testosterone” is bioavailable to diffuse into the sex accessory tissue and into liver cells for metabolism. In addition, a large percentage of the SHBG is saturated, whereas only a small fraction of the total capacity of corticosteroid-binding globulin and albumin is used under normal conditions. As testosterone levels increase in the plasma, the order of increasing saturation of the plasma proteins proceeds from SHBG to corticosteroid-binding globulin to albumin. Therefore the binding of androgen is a dynamic equilibrium between various serum proteins. Because less than 5% of total testosterone is present in the free form, separate measurement of bound and free testosterone is typically not recommended, and in general only total testosterone is measured.

The total plasma levels of SHBG can be altered by hormone therapy. **Administration of testosterone decreases SHBG levels in the plasma,**

whereas estrogen therapy stimulates SHBG levels (Burton and Westphal, 1972; Forest et al., 1968; Vermeulen et al., 1969). Estrogen also competes with testosterone for binding to SHBG, but estrogen has only one third the binding affinity of testosterone. **Therefore administration of small amounts of estrogen increases the total concentration of SHBG, and this effectively increases the binding of testosterone and thus lowers the free testosterone plasma concentration.**

Because only free testosterone is bioavailable, the binding of testosterone to plasma proteins inhibits net testosterone uptake into the prostate (Lasnitzki and Franklin, 1972). It is apparent that androgenic activity is regulated in part by the extent of binding of an androgen to the steroid-binding proteins in the plasma.

Key Points: Endocrine Control of Prostate Growth

- Free testosterone in the plasma is converted in the prostate by 5α-reductase type 2 into DHT, which is 2 to 10 times more active than testosterone.
- DHT, testosterone, and estrogens are responsible for multiple metabolic actions in the prostate (growth, differentiation, and biologic functions). Free testosterone can be converted to estrogens, but estrogens cannot be converted to testosterone.

Regulation of Prostate Growth by Steroids and Protein Growth Factors

There are multiple levels of prostate growth regulation, which include steroid hormone action, growth factors, and direct cell-cell communication and interactions with the extracellular matrix. These interactive types of growth control are accomplished by several generalized systems, as depicted in the schematic in Fig. 143.6. They include the following:

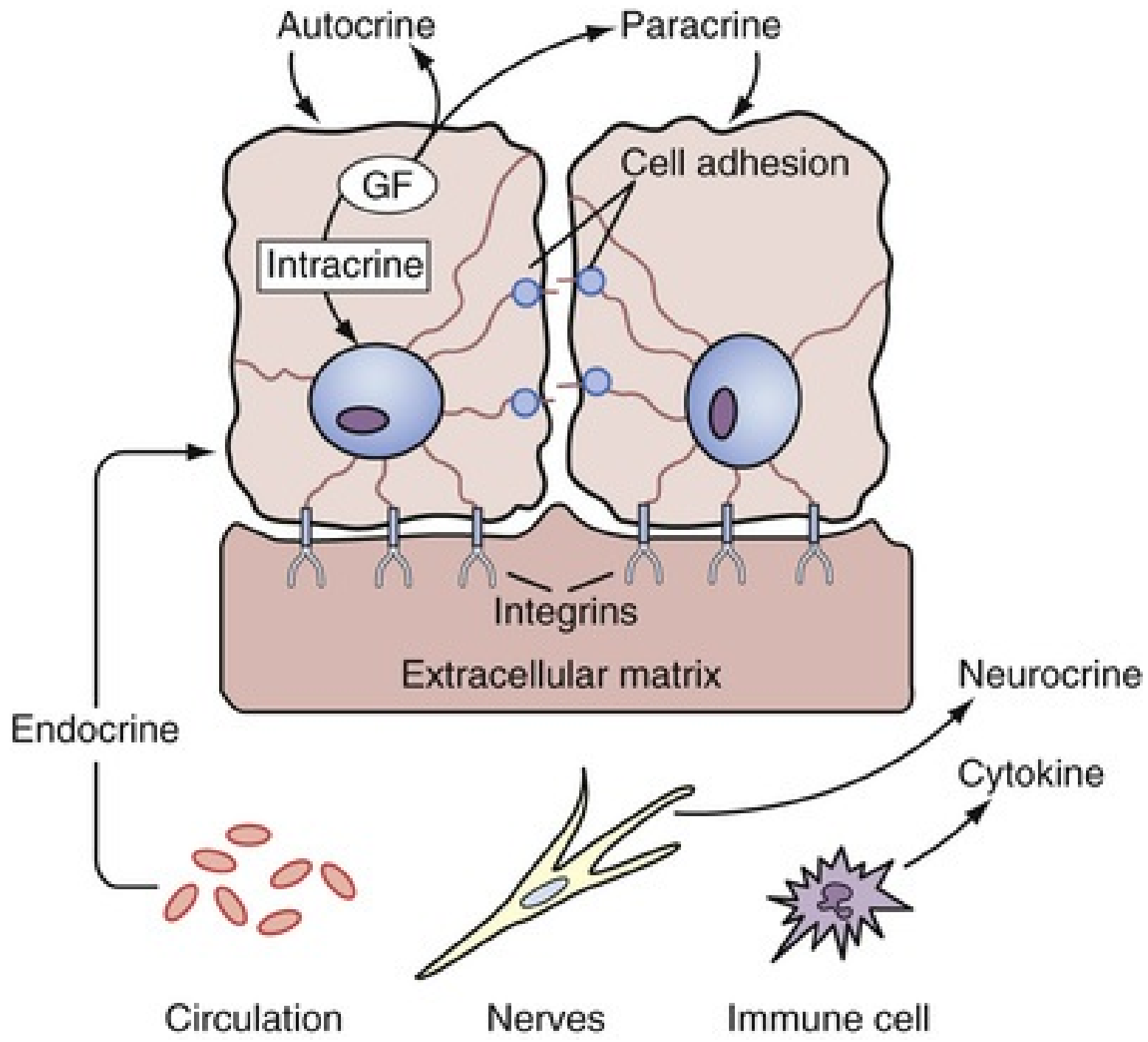
Autocrine
Paracrine
GF
Intracrine
Cell adhesion
Integrins
Extracellular matrix
Endocrine
Neurocrine
Cytokine
Circulation
Nerves
Immune cell

FIG. 143.6 Types of growth control. Endocrine signals are carried through the circulation from distant organs. Paracrine signals are produced in proximity by neighboring cells. Autocrine signals feedback on the same cells from which they are produced. Intracrine signals are a special subset of autocrine signals that never leave the cell but rather act locally within that cell. Cytokines are paracrine-like factors (typically) that are made by immune cells. Neurocrine factors are released by nerves. Cell adhesion molecules directly link neighboring cells, often through association with cognate adhesion molecules. Cells are also bound to the extracellular matrix through interactions with other cell adhesion molecules (e.g., integrins). *GF*, Growth factor.

- *Endocrine factors* or long-range signals arriving at the prostate by serum transport of hormone originating from the secretions of distant organs; endocrine factors include serum steroid hormones such as testosterone and estrogens and serum peptide hormones such as prolactin and gonadotropins
- *Neuroendocrine signals* originating from neural stimulation, such as 5-hydroxytryptamine (serotonin), acetylcholine, and norepinephrine
- *Paracrine factors*, or soluble tissue growth factors that stimulate or inhibit growth, which are elaborated over short ranges between

neighboring cells within the prostatic tissue compartment (FGFs, epidermal growth factor)
- *Autocrine factors,* which are produced and released by a cell and then fed back on the same cell's external membrane receptors to regulate its own growth or function; for example, autocrine motility factor
- *Intracrine factors,* which function like autocrine factors but work inside the cell
- *Extracellular matrix factors,* which are insoluble tissue matrix systems and make direct and coupled contact by being attached through integrins and adhesion molecules of the basal membrane and couple cytoskeleton organization with the extracellular matrix components, which include the glycosaminoglycans, such as heparan sulfate (Getzenberg et al., 1990)
- *Cell-cell interactions* of the epithelial or stromal cells occurring through tight membrane junctions on intramembrane proteins such as the CAMs (e.g., E-cadherin) that couple neighboring cells

Of these seven growth control systems, the first extensively studied on the prostate was the endocrine effect of androgenic steroids, such as testosterone, in the regulation of prostate growth through changes in serum testosterone levels and conversion to DHT. However, androgens alone are not sufficient for full prostate growth. In the past two decades, extensive progress has been made in the understanding of the other systems, particularly the interactive role of growth factors and their receptors. At present, the roles of these receptors in cell signaling to the nucleus and of the structural elements in cellular control involving the tissue matrix are being developed. These mechanisms are reviewed next, starting with androgen action at the cell level beginning with the arrival of testosterone in the serum.

Androgen Action at the Cellular Level

Testosterone in the serum arrives at the prostate bound to albumin and to the steroid-binding globulins. By diffusion, free testosterone enters the prostate cell, where it is then subjected to a variety of steroid metabolic steps that appear to regulate the activity of the steroid hormone and its downstream effectors. A simplified schematic of the temporal sequence of intracellular events is depicted in Fig. 143.7 and includes the following:

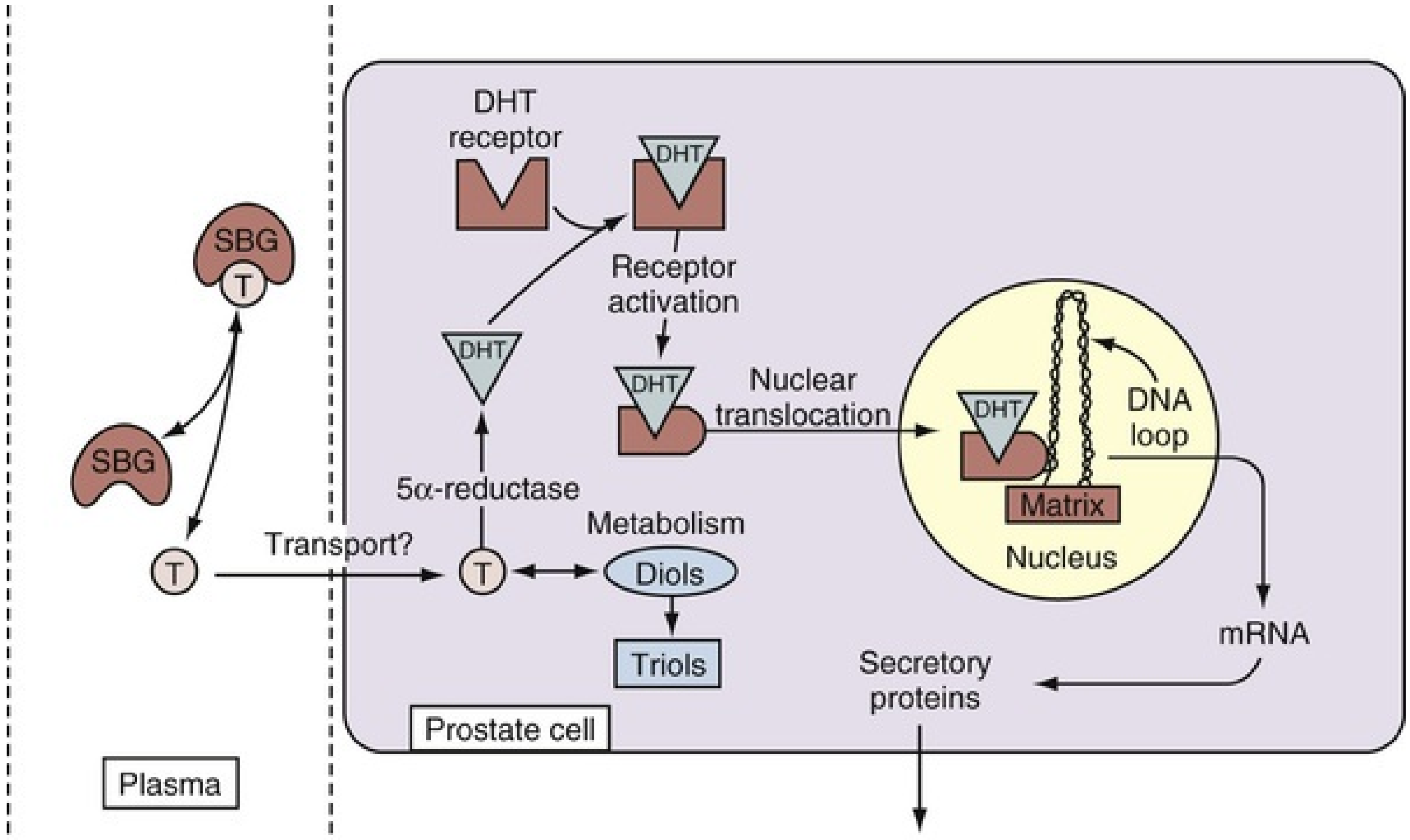
DHT receptor
DHT
Receptor activation
SBG
T
SBG
DHT
DHT
Nuclear translocation
DHT
DNA loop
Matrix
Nucleus
5α-reductase
Metabolism
Transport?
T
T
Diols
Triols
mRNA
Secretory proteins
Prostate cell
Plasma

FIG. 143.7 Simplified schematic of the effects of testosterone in activating transcriptional targets in an epithelial cell. In the plasma, testosterone (T) is bound to serum-binding globulins (SBG), such as testosterone-binding globulin and albumin. Unbound testosterone is transported by passive diffusion into the prostate, where it is enzymatically converted to dihydrotestosterone (DHT) by 5α-reductase (type 2) and further metabolized to diols (3α or 3β) and irreversibly metabolized into the more water-soluble triols (6α or 7α). DHT binds to a cytoplasmic receptor (androgen receptor) that is activated and translocated to the nucleus. There the androgen receptor localizes in matrix acceptor sites and subsequently activates or represses certain target genes by regulating production of their mRNA. The RNA is then transported to the cytoplasm, where it is translated into a variety of proteins (e.g., secretory proteins such as prostate-specific antigen).

- Cellular uptake of testosterone
- Testosterone conversion to DHT by metabolism of 5α-reductase
- DHT or testosterone binding to specific ARs in the cytoplasm
- Dimerization and activation of the steroid receptor by a variety

of post-translational steps, including, for instance, phosphorylation

- Active nuclear transportation of the activated AR in an adenosine triphosphate (ATP)–dependent fashion
- Chromatin remodeling through interaction with coregulatory molecules
- Transactivation or transrepression, through interactions with other coactivators or corepressors, in a histone acetyltransferase–dependent process
- Binding of the activated receptor-coactivator complex to androgen response elements, which are short, specific sequences of DNA recognized specifically by AR dimers
- Gene regulation. The receptor acts as a transcription factor, and when it is bound to the DNA and matrix in proximity to androgen target genes, it increases the RNA polymerase II transcription of the DNA into mRNA. The transcribed message (mRNA) is large and contains introns, exons, and a poly-A tail. The intron portion is excised from the initial RNA species, so only the exon portion is retained in the final message. The trimming and processing of the mRNA are accomplished on the nuclear matrix as it is transported through the nucleus and out through the nuclear pore complex. The stabilized mRNA is transported into the cytoplasmic compartment to be translated at the ribosome into protein, which is then transported to specific cellular sites. Depending on the target gene, some proteins will undergo storage in secretory granules poised for secretion into the lumen on command during the physiologic process of ejaculation.

The epithelial cell is the primary unit in secretion, but specific genes are also activated in the stromal cells, and these events are also regulated by testosterone, estrogens, and growth factors in a similar chain of events. However, not all cells respond in the same manner to androgens or estrogens. For simplicity, these steps are discussed in relation to the epithelial cells. Androgens and estrogens, together and separately, can affect prostate cells through interaction with receptors, and it appears that estrogens may have their primary effect on the stromal cells.

5α-Reductase and Androgen Metabolism Within the Prostate

After the free testosterone in the plasma has entered the prostate cells through diffusion, it is rapidly metabolized to other steroids by a series of prostatic enzymes (Bruchovsky and Dunstan-Adams, 1985; Isaacs and Coffey, 1981; Isaacs et al., 1981, 1983). More than 90% of testosterone is *irreversibly* converted to the main prostatic androgen DHT (Fig. 143.8) through the action of the reduced form of nicotinamide-adenine dinucleotide phosphate (NADP) and the enzyme 5α-reductase located on the endoplasmic reticulum and on the nuclear membrane. The enzyme 5α-reductase reduces the unsaturated bond in testosterone between the 4 and 5 positions to form the 5α-reduced product DHT. The K_m for testosterone is 8.3 nM, and the serum level of testosterone is only in the range of 0.5 to 3.0 nM, indicating that the enzyme cannot be saturated because the testosterone substrate would be less than the K_m value. Bruchovsky and Dunstan-Adams (1985) reported a 10-fold increase in the maximal velocity in the stromal tissue compared with the epithelium. They observed 262 pmol of DHT formed in 30 minutes per milligram of protein from testosterone measured in the stroma and less than 10% of that amount with a maximal velocity of 19 for the epithelium. The stromal K_m was 76 nM, and the epithelial K_m was 13 nM. These differences between stromal and epithelial kinetics were used to deduce the existence of two different isoenzymes of 5α-reductase (Andersson et al., 1991).

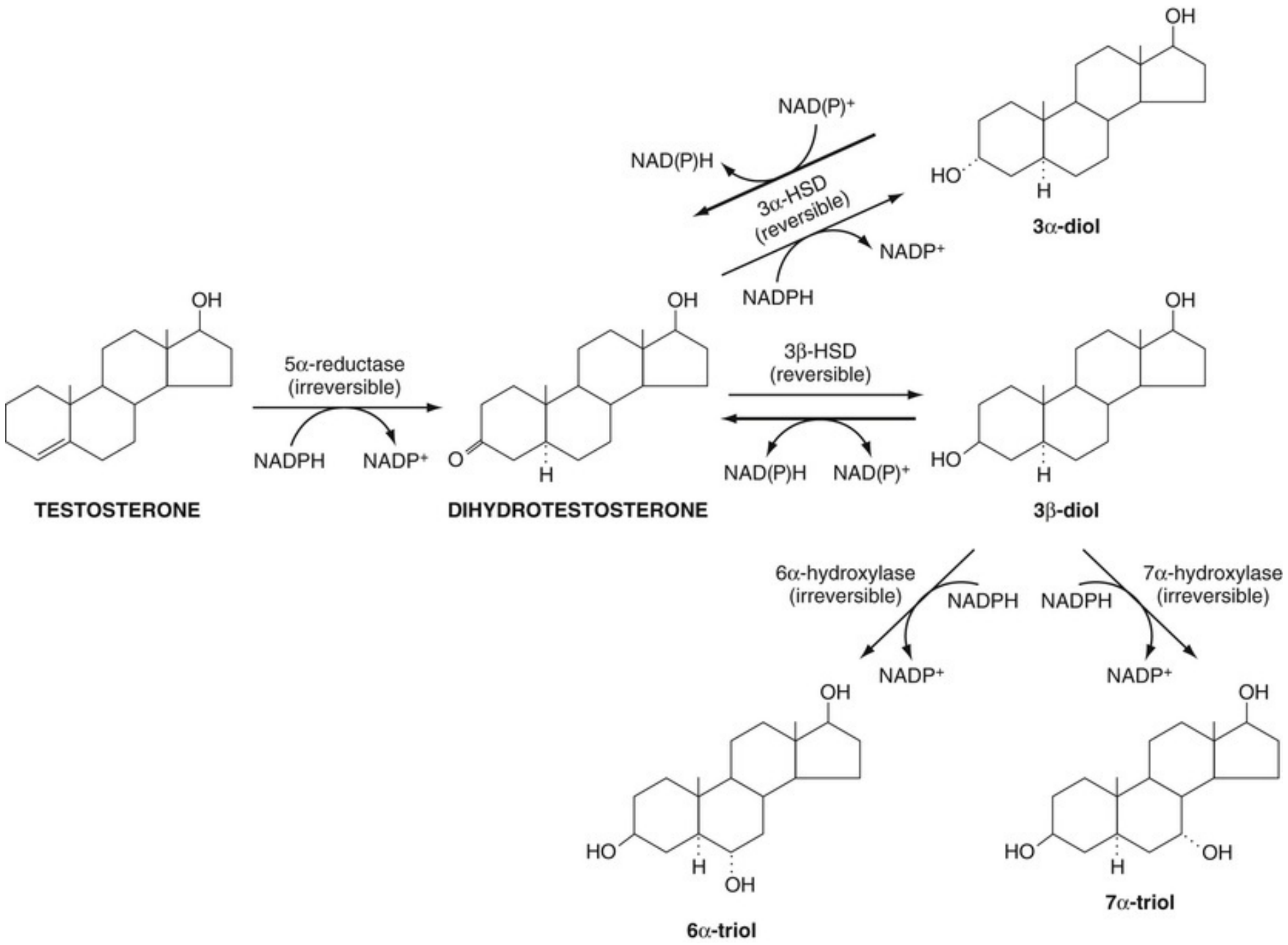
OH
NAD(P)+
NAD(P)H
3α-HSD
(reversible)
NADP+
NADPH
HO
H
3α-diol
OH
OH
5α-reductase
(irreversible)
NADPH
NADP+
O
H
3β-HSD
(reversible)
NAD(P)H
NAD(P)+
OH
HO
H
TESTOSTERONE
DIHYDROTESTOSTERONE
3β-diol
6α-hydroxylase
(irreversible)
NADPH
NADP+
NADPH
7α-hydroxylase
(irreversible)
NADP+
OH
HO
H
OH
6α-triol
OH
HO
H
OH
7α-triol

FIG. 143.8 Metabolic pathways for testosterone within the prostate. Testosterone is irreversibly metabolized by 5α-reductase to dihydrotestosterone (DHT), which is then reversibly converted into 3α-diol and 3β-diol. The 3β-diol is irreversibly inactivated to the more soluble 6α-triol and 7β-triol. *3α-HSD,* 3α-hydroxysteroid dehydrogenase.

In the human, rat, and monkey there are two isozymes of 5α-reductase (Table 143.3). The human and rat 5α-reductase isozymes are composed of 254 to 260 amino acids with a molecular weight of 28 to 29 kD. These enzymes are *N*- and *O*-glycosylated and have a high percentage of hydrophobic amino acids that are distributed throughout the enzyme. The chromosomal localization of the human 5α-reductase isozyme genes has been reported; the type 1 enzyme is at the extreme tip of the short arm of chromosome 5, and the human type 2 gene is on the short arm of chromosome 2. There is a 49% homology between type 1 and 2 enzymes in the human. The properties of these enzymes have been reviewed in detail by Russell and Wilson (1994) and the effects on prostate growth by McConnell (1995). The effect of finasteride on 5α-reductase activity has been reviewed by Rittmaster (1994). The type 1 enzyme is in the skin and in the adult scalp and is believed to be involved in hair formation. It is present to lesser degrees in the prostate epithelium and stroma. This isoform is found in normal levels in men with congenital 5α-reductase deficiency. **The type 2 enzyme is mutated in 5α-reductase deficiency and is the dominant isoform present in the prostate gland.** The type 2 enzyme appears in the basal cells of the epithelium and in the stromal cells but is absent in the secretory epithelial cells. This has raised the possibility that DHT stimulation of epithelial cells is derived from DHT converted within the stromal or basal cells. Silver et al. (1994) have studied the cell type–specific expression of these reductases, as well as their regulation. It appears that the 5α-reductase type 2 in the prostate does not change dramatically in individuals undergoing short-term androgen ablation.

TABLE 143.3

Properties and Distribution of 5α-Reductase Types 1 and 2

	TYPE 1	**TYPE 2**
Chromosome	5p15	2p23
Molecular weight	29,000	28,000
Amino acids	259	254
Exons	4	4
Introns	5	5
Homology	49%	49%
pH optima	Alkaline (6-8.5)	Acidic (5.0)
K_m testosterone (μM)	1.5	0.1–1.0
Ki finasteride (nM)	325	12
Half-life (hr)	20-30	20-30
5α-Reductase deficiency	Normal	Mutated
PROSTATE CELLS		
Human		
Luminal epithelial	±	—
Basal epithelial	—	+
Stromal	±	+
Skin	+	—
Rat		
Prostate cells		
Luminal epithelial	—	—
Basal epithelial	+	—
Stromal	—	+

Berman et al. (1995) have studied the distribution of the two 5α-reductase isozymes in the urogenital tract of the fetal rat. At 17 to 21 days of development the expression of type 1 gene predominated in the epithelial cells; the type 2 gene was limited to the mesenchymal cells. This is true in the testosterone-dependent and DHT-dependent anlagen of the urogenital tract. These investigators observed that androgens could stimulate the expression of the type 2 gene in the urogenital tract but not of the type 1 gene. They suggested that the type 2 5α-reductase gene exhibits positive feedback control in that the product of the enzyme, DHT, can stimulate expression of the gene; however, no evidence for such regulation of either 5α-reductase gene was detected in the fetus.

In summary, 5α-reductase is of great importance because the product DHT is important in the differentiation of the prostate during fetal development and because mutations in 5α-reductase give rise to a rare form of pseudohermaphroditism. In prostate physiology, expression of the 5α-reductase gene is regulated by androgens in the prostate and liver. It is also believed that 5α-reductase is involved in male pattern baldness, acne, and hirsutism as well as in BPH. **The 5α-reductase inhibitors finasteride (type 2 inhibitor) and dutasteride (type 1 and 2 inhibitor) are clinically useful drugs in the treatment of BPH and male pattern baldness when they are given to appropriate patients.**

After DHT is formed from testosterone in the prostate, it is then subjected to a series of reversible metabolic reactions to form 3α-diol (5α-androstane-3α,17β-diol) and 3β-diol (5α-androstane-3β,17β-diol) (see Fig. 143.8). The enzymes that perform this transformation of DHT are 3α- or 3β-hydroxysteroid oxidoreductases. These enzymes use NADP as a cofactor, but in contrast to 5α-reductase they can also use nicotinamide-adenine dinucleotide (NAD). The equilibrium for the metabolism of DHT favors the formation of DHT, that is, the 3-hydroxy group of 3α-diol and 3β-diol is oxidized to the 3-ketone that is present in DHT. It is known that 3α-diol administered to animals is a strong androgen through its rapid conversion to the effective DHT. On the other hand, 3β-diol is not effective as an androgen because it is rapidly and irreversibly converted to the triol form by hydroxylation in the 6α or 7α position (see Fig. 143.8). The triols are dead-end products of testosterone metabolism but are water soluble and inactive as androgens because they cannot re-form DHT. Steroids also can form glucuronide or sulfate conjugates and be secreted in a more soluble form. **In summary, testosterone is irreversibly metabolized to DHT that is in equilibrium with other reduced steroids primarily through oxidation and reduction at the 3 position. The steroids are inactivated by being irreversibly hydroxylated to the inactive triols.**

Androgen Regulation of Stromal-Epithelial Interactions

It is now apparent that there is a dynamic and reciprocal interaction between the functions of epithelial cells and those of stromal cells (Cunha, 1994; Cunha et al., 2003, 2004; Sikes et al., 1995; Steiner, 1993). These crosstalk interactions are mediated through the spatial organization of extracellular matrix elements that form the basement membrane linkage. This linkage presents, filters, and organizes the two-way paracrine signals and the flow of information between those two cellular compartments. For example, fluids, gases, nutrients, hormones, and many growth factors arriving in the prostate through the circulation must first pass through the stromal ground substance, the extracellular matrix, and the basement membrane before reaching the base of the secretory epithelial cells. Early in development, the functions of the epithelial and mesenchymal (stromal) elements vary as to their cell types, compositions, properties, and interactions. It is the integrated system biology of these two tissue elements as well as their dynamics during aging that play a vital role in the prostate's functions as a unit and gland. Indeed, it is the breakdown of these tissue interactions that is one of the hallmarks of the abnormal growth of the prostate that starts very early in life and is initiated at some time just after maximum virilization, at approximately 25 years of age. The prostate is extremely susceptible to permanent early alterations in form and structure as a consequence of genetic, environmental, dietary, or metabolic factors with aging (Risbridger et al., 2005). In fact, it is essential to establish the link between hormonal (androgens and estrogens) changes that occur during the fetal or neonatal period that *imprint* and hence may result in onset of late-life disease. With aging, during a period of 50 to 60 years, this organ slowly progresses through the transition from normal zonal histologic anatomy and function to the early signs of BPH, to prostatic inflammatory atrophy, to prostatic interepithelial neoplasia, and finally to various types of prostatic adenocarcinoma. This concept has been thoroughly documented in several rodent models (Naslund and Coffey, 1986, 1987; Prins et al., 2001; Prins and Birch, 1995; Rajfer and Coffey, 1978, 1979; Risbridger et al., 2005; Singh et al., 1999).

Cell Adhesion Molecules

Cell-cell and extracellular matrix interactions are becoming major targets for understanding how the phenotype of a cell is regulated. Transmembrane receptors on the cell surface extend through the plasma membrane and form a bridge directly connecting the cytoskeleton with proteins and receptors located within the extracellular matrix or on neighboring cells. The CAMs are divided into four major types: (1) integrins, which link the cell to the basement membrane and extracellular matrix components through heterodimer interactions; (2) cadherins, which link the cell to neighboring cells through homotypic polymers; (3) selectins, which link the cell to carbohydrate moieties primarily on the vascular system; and (4) immunoglobulin (Ig) superfamily adhesion molecules. The most extensively studied of these CAMs in the prostate in order of interest have been E-cadherins, which bind PrECs to one another, and CD71, which binds to transferrin, as well as several of the integrin molecules. These bindings have been surveyed in prostate tumor cell lines in vitro (Rokhlin and Cohen, 1995), but more extensive work must be carried out in vivo in the normal developing prostate and in prostate cancer.

The integrins are made up of two covalently linked heterodimers termed *α* and *β subunits.* These integrins externally contact the extracellular matrix receptors of fibronectin, fibrinogens, collagen, and laminin as well as glycosaminoglycans in the proteoglycans of the extracellular matrix. The integrin receptor domains inside the cell compartment are focal points for determining the structure and organization of the cytoskeleton. Approximately eight subunits of α and β can interact in different heterodimers that are tissue specific and can be of several types even on one cell. Different combinations may have varying degrees of binding activity for extracellular matrix components. For example, $\alpha_3\beta_1$ binds to laminin, collagen, and fibronectin and does so by recognizing a triplet of amino acids in those proteins made up of arginine, glycine, and aspartic acid (RGD).

Other types of transmembrane receptors also extend out of the cell to make direct cell-cell contact with the neighboring cell by recognizing similar receptors and forming homodimer bonds. Certain homophilic dimers that require calcium for interactions to form cell-cell bonds with neighboring cells are termed *cadherins.* Four of the cadherin types have been cloned. They contain 723 to 748 amino acids that are composed of a single peptide, an extracellular region with three repeated domains, a hydrophobic transmembrane region, and a long cytoplasmic tail. There is approximately 50% homology across species and between integrins. The cadherins are classified into three subtypes: E-cadherins, found in adult epithelial cells (also earlier termed *uvomorulin*, cell CAM 120/80, ARC-1, or L-CAM); N-cadherins, found in neural tissues of muscle (also termed

A-CAM); and P-cadherins, found primarily in placenta and epithelium (Albelva, 1994). In the prostate cell, for example, E-cadherins extending out of the surface membrane make contact with the neighboring cell and form a homodimer, and the E-cadherin extending inside the cell by passing through the membrane would form as an organizing center that binds a complex of three cytoplasmic proteins termed *catenins* α, β, and γ. This complex is localized to the zonula adherens of the cell and participates in junction formation and stabilization of the cytoskeleton. These interlocking matrix systems interact to form a structural network extending externally from cell-cell contact and the extracellular matrix interactions and then internally to cytoskeleton organization and centrally, terminating by direct contact with the nuclear matrix that forms tissue-specific DNA organization.

The interactions of the nonhistone tissue matrix regulate many aspects of DNA functions involved in growth and differentiation (Boccardo et al., 2003; Getzenberg et al., 1990). The nonhistone proteins such as high-mobility group (HMG) proteins include HMGI/Y (HMGA), which participates in numerous cellular processes, such as regulation of inducible gene transcription, integration of retroviruses into chromosomes, and induction of malignant transformation (Reeves and Beckerbauer, 2003). Through protein-DNA and protein-protein interactions, the members of the HMGA family can influence growth, cell proliferation, differentiation, and cell death; they influence chromosome dynamics by acting as architectural transcription factors affecting several genes that have an impact on tissue structure and organization. This class of genes is often upregulated in cancer (Reeves and Beckerbauer, 2003). These types of tissue matrix interactions are essential to the understanding of stromal-epithelial interactions because they form direct structural linkages and communications between the stroma and the epithelial nuclear DNA. In summary, under the influence of hormones (estrogens and androgens) and diet, it is the regulation of chromatin structure and organization through the histone and nonhistone pathways that replaces and maintains the tissue organization as well as interactions in health and disease.

The discussion, to this point, has concerned primarily insoluble elements in inducing stromal-epithelial interactions, but soluble hormones such as steroids, vitamins, and growth factors are also important (Sikes et al., 1995). The prostate stromal cells contain steroid receptors and respond to androgens and estrogens (see earlier discussion). Androgens and estrogens can alter the formation of collagen (Coffey and Walsh, 1990) and other extracellular matrix components, such as glycosaminoglycans, in the prostate (DeKlerk et al., 1984; DeKlerk and Human, 1985; Horsfall et al., 1994; Kofoed et al., 1990).

In summary, different components of matrix interactions can have either an inhibitory role in negative regulation of normal prostate growth or a positive role in establishing tumor growth. There have been many hypotheses concerning the mechanism of these epithelial-stromal interactions, but they have yet to be fully resolved.

Key Points: Cell Adhesion Molecules

- Transmembrane receptors on the cell surface extend through the plasma membrane and form a bridge directly connecting the cytoskeleton with proteins and receptors located within the extracellular matrix or on neighboring cells.
- The CAMs are divided into four major types: *integrins,* which link the cell to the basement membrane and extracellular matrix components through heterodimer interactions; *cadherins,* which link the cell to neighboring cells through homotypic polymers; *selectins,* which link the cell to carbohydrate moieties primarily on the vascular system; and Ig superfamily adhesion molecules.

Regulation of Prostate Growth at the Molecular Level: Steroid Receptors

In almost all cells in the body, steroids can enter the nucleus, but only a few cells can retain this steroid within the nucleus for any length of time. The cells that retain the steroid have receptors that are steroid specific, which can regulate specific steroid-sensitive genes within the nucleus to alter the expression of certain proteins. The AR's affinity for the nuclear acceptor site to which it binds in the nucleus is probably a compilation of binding to specific sequences on DNA (androgen response elements) as well as tissue-specific binding to coregulatory factors. The uptake and binding of the AR in the nucleus are regulated by the presence of the androgen ligand bound to the receptor, resulting in receptor activation. When androgens are not present, the receptor decreases its affinity for nuclear binding and can easily be removed; indeed, under castrate conditions, receptors may leak back out into the cytoplasm (Husmann et al., 1990). Immunohistochemical techniques indicate that in the presence of androgen the AR localizes primarily to the nucleus.

The prostate and seminal vesicles contain steroid-specific and high-affinity (10^{-9} to 10^{-10} M K_d) saturable (100 to 1000 fmol of receptor per milligram of DNA equivalents of tissue) ARs that were first described by Liao and Fang in 1969. There are 5000 to 20,000 molecules of these receptors per cell, far more than can bind to the androgen response element sites, which are probably fewer than 400. Classic AR function has been characterized as a genomic process, wherein certain transgenes are regulated by the activated AR. More recently, however, attention has been focusing on the nongenomic mechanisms of androgen action (Benten et al., 1997; Jones et al., 2004). Nongenomic androgen action is characterized by extremely rapid changes in cellular physiology, typically measured in seconds or minutes, as opposed to the longer times required for target gene regulation to be translated into protein changes. Whether nongenomic androgen action occurs through the same ARs involved in genomic regulation still remains to be determined. The properties and hormonal regulation of ARs as well as their uses have been reviewed in detail (Black and Paschal, 2004; Gelmann, 2002; McEwan, 2004).

Androgen Receptor

The cloning of the human AR and its expression was a hallmark in the study of the mechanism of androgen action (Chang et al., 1988b; Lubahn et al., 1988). This led to the study of the sequence of the gene and its protein product—and how this is altered in inherited androgen insensitivity syndromes—as well as receptor function (Chang et al., 1995).

The *AR* gene is on the long arm of the X chromosome at position Xq11.2-q12. Because there is only one X chromosome in a male, it is a single-copy gene. The coding sequence on this gene is divided into eight exons that are transcribed and processed into mRNA and then subsequently translated into protein. The total genomic DNA spans a minimum of 80 kilobases (Marcelli et al., 1990) but forms a final message of only 10.6 kilobases, that is, only 17% of the total gene, with an open reading frame of 2757 base pairs. This is similar to the organization of many other steroid receptors that also contain information from eight exons, such as the progesterone and ERs. The AR is a member of the nuclear receptor superfamily, which is a group of ligand-inducible transcription factors. The nuclear receptor superfamily has more than 200 members at present (Escriva et al., 2004). All of these receptors share certain structural features that allow them to regulate gene expression, although the ligands for many of these receptors have yet to be identified (so-called orphan receptors). Such receptors include the glucocorticoid receptor, the retinoic acid receptors (RXR and RAR), the vitamin D receptor, the estrogen and progesterone receptors, the peroxisome proliferator-activated receptor (PPAR-γ), and many orphan receptors. Like other steroid receptors, the AR is divided into three distinct, modular domains: the amino-terminal domain, the DNA-binding domain, and the carboxyl-terminal ligand-binding domain. Despite the similarity in structural organization of all of the nuclear receptors, activation of different receptors results in markedly different cellular responses. Mutational analyses of the human AR have allowed a detailed mapping of a variety of different functions, which are diagrammed schematically in Fig. 143.9.

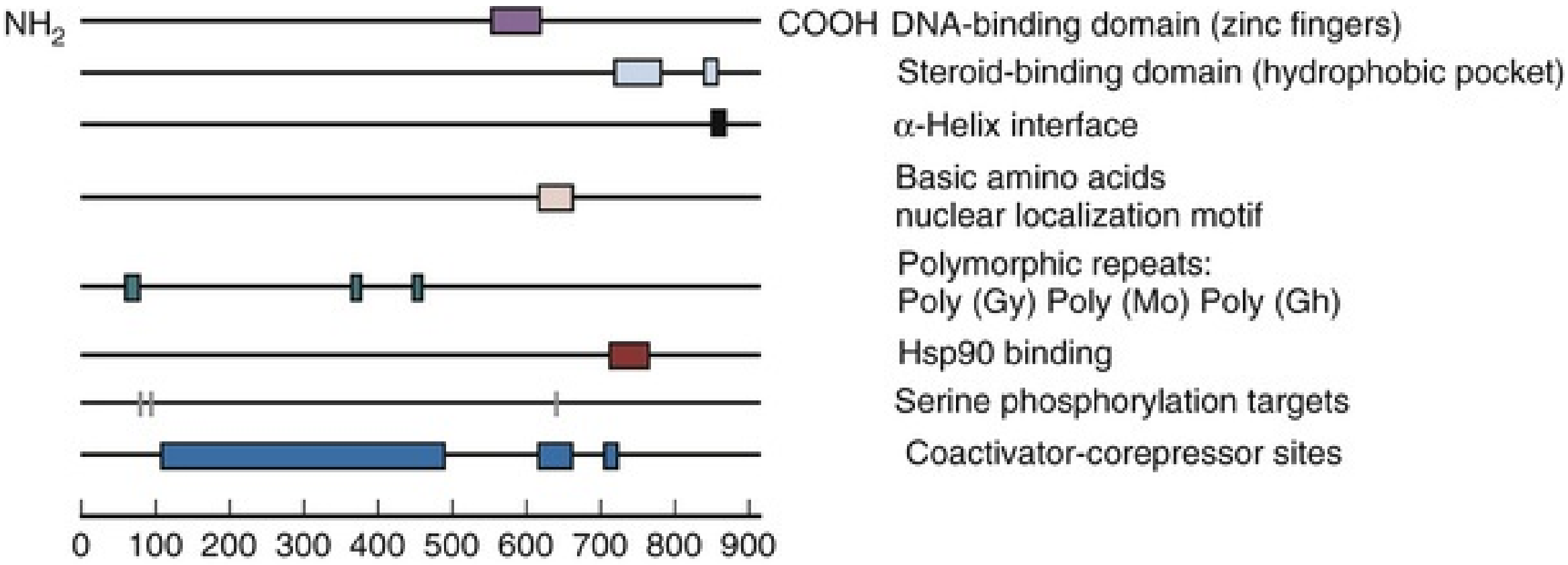
NH_2
COOH
DNA-binding domain (zinc fingers)
Steroid-binding domain (hydrophobic pocket)
α-Helix interface
Basic amino acids
nuclear localization motif
Polymorphic repeats:
Poly (Gy) Poly (Mo) Poly (Gh)
Hsp90 binding
Serine phosphorylation targets
Coactivator-corepressor sites
0
100
200
300
400
500
600
700
800
900

Shown are the coordinates of all known functional elements

FIG. 143.9 Structure of the human androgen receptor protein. The androgen receptor is divided into several functional domains including the DNA-binding domain (consisting of two zinc fingers), a steroid-binding domain (consisting of a hydrophobic pocket), a nuclear localization motif, and several coactivator-corepressor binding sites. There are three polymorphic repeats of glycine, proline, and glutamine, with varying sizes among different populations. The relative positions of the functional elements are shown to scale.

Upstream (5′ direction) of the transcriptional initiation site is the regulatory element of the gene that controls its expression. It is unusual in that it contains the GC box rather than the classic TATA and CCAAT, which are commonly found in promoters of polymerase II–dependent genes. Closer to the initiation site located only 70 base pairs upstream is a 50–base pair purine-rich region that is a *cis*-acting element for AR transcription. There are other *cis*-acting elements, including an AP-1 (which is bound by a heterodimer of c-Fos and c-Jun) and a RARE (retinoic acid response element) as well as a cyclic adenosine monophosphate (cAMP) response element (AR/CRE1). This suggests that the regulation of expression of the *AR* gene may involve cAMP, activation of c-Fos/c-Jun, or retinoids (Faber et al., 1993; Kuiper et al., 1989; Mizokami et al., 1994; Young et al., 1994). Activation of the AR appears to be a function of multiple steps, including initial complex formation with certain chaperonins, binding of ligand, post-translational modifications, dimerization, nuclear localization, and binding of the receptor to certain transcriptional coactivator complexes that remodel chromatin, target the initiation site, and stabilize the RNA polymerase II machinery for repeated rounds of transcription. Each of these features is discussed in the context of known structural features of the receptor as diagrammed in Fig. 143.10.

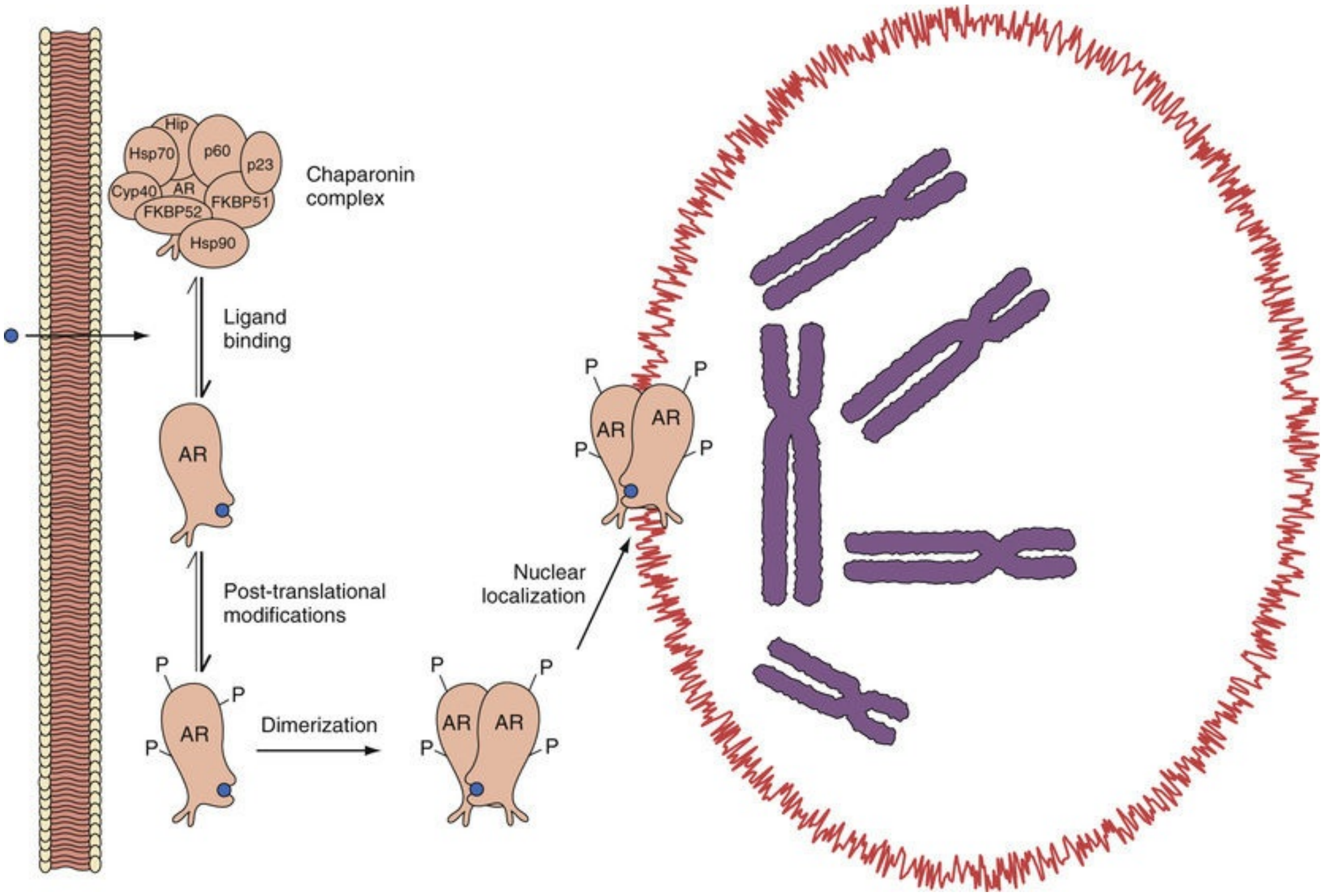
Hip
Hsp70
p60
p23
Cyp40
AR
FKBP52
FKBP51
Hsp90
Chaparonin complex
Ligand binding
AR
Post-translational modifications
P
P
P
AR
Dimerization
P
P
AR
AR
P
P
Nuclear localization
P
P
AR
AR
P
P

FIG. 143.10 Mechanism of androgen receptor (AR) activation by ligand. Androgen enters the cell membrane by passive diffusion and binds the androgen receptor in the cytoplasm. The AR exists in equilibrium with the chaperonin complex, consisting of at least eight different components,

including Hsp90, Hsp70, Hip, p60, p23, FKBP51, FKBP52, and Cyp40. Once activated by binding ligand, post-translational modifications occur, such as phosphorylation. Contemporaneously, dimerization occurs, and the activated modified androgen receptor is translocated to the nucleus by active transport.

Chaperonin Binding.

Immediately after nascent production of the protein in the ribosome, the receptor forms complexes with several other proteins, referred to as *chaperonins*. These chaperonins form an aggregate complex, which is known as the *8S complex*, in reference to the size of the complex on sucrose gradient sedimentation analysis. This chaperonin complex includes at least eight known components (Hsp90, Hsp70, Hip, p60, p23, FKBP51, FKBP52, and Cyp40), which sequester the receptor into an inactive pool (see Fig. 143.10). By analogy to the progesterone receptor, which has had the most detailed scrutiny in regard to the molecular biology of the chaperonin complex (Nair et al., 1996; Pratt and Toft, 1997; Smith, 2000), the AR can dissociate into a monomeric form (4S on sucrose gradient centrifugation) that is in equilibrium with the 8S form, with the preponderant species existing in the chaperonin complex. This larger complex may be particularly favored by virtue of mass action alone, because the heat shock proteins tend to be among the most abundant proteins in the cell. Although the AR is uncomplexed, it is susceptible to various different post-translational processing steps, including phosphorylation or glycosylation. Such interactions may then inhibit reassociation with the chaperonins, leading to ligand-dependent activation, ligand-independent activation, or receptor inactivation with proteasome-mediated degradation. Evidence for such a mechanism includes a PEST sequence similar to one in the vitamin D receptor that is present in the hinge region of all known mammalian ARs, suggesting that it may function in proteasome-mediated AR turnover. Moreover, proteasome inhibition leads to a significant increase in AR isoforms (Sheflin et al., 2000).

DNA-Binding Domain.

Near the end of exon 1 and extending into exon 3 is the coding sequence for the DNA-binding domain. The DNA-binding domain of the AR consists of 72 amino acids rich in cysteine and encoding two zinc finger motifs, which allow specific recognition of certain DNA sequences referred to as *androgen response elements*. Such elements typically consist of a palindromic repeat separated by a three-nucleotide spacer—for example, GG(A/T)ACAnnnTGTTCT (Roche et al., 1992). X-ray crystallography of certain steroid receptors (glucocorticoid receptor and progesterone receptor) has shown that the first zinc finger directs sequence specificity of binding by directly contacting the DNA bases in the major groove; the second zinc finger functions to stabilize the protein-DNA complex by contacting the sugar-phosphate backbone. Although the protein-DNA interaction appears to be largely limited to the zinc finger motifs, sequences in the amino terminus appear to be important in stabilizing these structures because mutations in this region result in a mildly diminished DNA-binding affinity. This DNA-binding domain of the zinc fingers in the steroid receptor molecule is highly conserved. In this region of exon 2 to 3, there is a 79% homology with the progesterone receptor, a 76% homology with the glucocorticoid receptor, and a 56% homology with the ER (Chang et al., 1988a, 1988b). The closest homology of the AR is with the progesterone receptor (Lubahn et al., 1988; Marcelli et al., 1990). Mutations of amino acids in this area of the AR can make the receptor unable to activate androgen-sensitive genes (Govindan, 1990), which is the basis of one of the inherited androgen-insensitivity syndromes—testicular feminization.

The DNA-binding domain binds to its cognate DNA-regulatory site, referred to as a *hormone response element.* Hormone response elements can be divided into different groups on the basis of common structural features for which whole groups of receptors are capable of binding. Class I hormone response elements include the glucocorticoid receptor, the progesterone receptor, and the mineralocorticoid receptor and are characterized by a half-site consensus sequence of TGTTCT. Class II hormone response elements include the ER, whose prototype half-site sequence is TGACC. The hormone response elements to which ARs have been shown to bind belong to the class I subgroup (Tan et al., 1990). A consensus sequence for the androgen response element has been determined by an RNA-binding site selection assay with an AR fusion protein to be GG(A/T)ACAnnnTGTTCT (Roche et al., 1992). Such binding sites are characterized by an inverted palindromic repeat with a dyad axis of symmetry, indicating that the receptors are binding in a head-to-head fashion. However, the androgen response element of the rat probasin promoter has been found to be a direct repeat (Schoenmakers et al., 2000). Surprisingly, x-ray crystallography data reveal that AR dimers bind to direct repeat target sequences in a head-to-head fashion, maintaining the normal orientation of an inverted repeat target sequence (Shaffer et al., 2004). Only the AR has been found to bind to a direct repeat target sequence with an orientation normally expected for an inverted repeat. This difference may represent one way ARs maintain specificity of target gene regulation.

Ligand-Binding Domain.

Ligand-dependent activation is characterized by ligand-receptor dimerization, post-translational modifications (e.g., phosphorylation), nuclear translocation, and subsequent target gene activation (or repression). It is believed that binding of either DHT or testosterone to the ligand-binding domain can facilitate these processes, although the binding affinity for DHT is significantly higher than for testosterone. Binding of the androgen to the carboxyl-terminal ligand-binding domain is required for activation; however, deletion of the ligand-binding domain can lead to a constitutively active AR. In prostate cancer, various splice isoforms have been identified that lead to constitutively active function (Hu et al., 2011). Thus at least part of the interaction with the chaperonin complex involves the carboxyl portion of the receptor (Marcelli et al., 1990). However, small point mutations in the ligand-binding region can lead to significant changes in the characteristics of AR action. For instance, a single-point mutation in the ligand-binding domain of the AR (codon 877, Thr → Ala) identified in the LNCaP cell line of prostate cancer renders it weakly inducible by inappropriate steroids such as progesterone while it retains the ability to be stimulated by androgens. Marcelli et al. (1990) reported that mutations in the AR at amino acid 587 or 794 are inactive in the assay for androgen binding and for transcriptional activation. However, the removal of amino acids from 708 to the carboxyl end at 917 (i.e., the entire ligand-binding domain) leads to the synthesis of a receptor protein that does not bind androgens but is still constitutively active in activating transgenes. As new drugs have become available for prostate cancer androgen axis suppression, resistance to these new agents (e.g., abiraterone and enzalutamide) may involve some of the AR splice isoforms, or potentially even upregulation of other steroid receptors (Sharifi, 2014).

Dimerization.

The identification of the palindromic structure of certain hormone response elements for all steroid receptors led to the proposal that these transcription factors bind to the DNA as a dimer. Subsequent analysis of the receptor-DNA interactions has confirmed this hypothesis, and dimerization is now thought to represent an important step in the regulation of steroid receptor action. A hydrophobic heptad repeat within the ligand-binding domain at codons 859 to 880 is conserved among all steroid receptors and is thought to be necessary for high-affinity dimerization. Removal of these sequences leads to low-affinity dimerization, presumably through the action of the DNA-binding zinc fingers on the palindromic androgen response elements. Abolishment of the DNA-binding domain does not inhibit the strong affinity dimerization present in the ligand-binding domain. The strong dimerization signal appears to be related to a hydrophobic α-helix interface formed by the conserved heptad (Centenera et al., 2008).

Post-Translational Modifications.

Once the AR has been bound to steroid ligand and dissociated from the chaperonin complex, it is susceptible to a variety of post-translational modifications, any one of which may significantly affect the function and turnover of the receptor. For instance, the AR can be acetylated (Fu et al., 2004) or phosphorylated (Goueli et al., 1984). In the rat ventral prostate it has been reported that this occurs through a nuclear cAMP-dependent protein kinase (Kemppainen et al., 1992). Receptor phosphorylation may be an important mechanism in the nuclear translocation of steroid receptors as well as in DNA binding and transcriptional regulation. The stimulation for phosphorylation appears to be optimal with the binding of an androgen agonist, because antagonists such as flutamide appear to favor the dephosphorylated state, suggesting that the phosphorylation status may be associated with the ultimate activity of the receptor (Wang et al., 1999). Serine and tyrosine residues have been found to be phosphorylated in other steroid receptors (Landers and Spelsberg, 1992; Sadar et al., 1999). In addition to phosphorylation by protein kinase A, ARs also appear to stimulate mitogen-activated protein kinases, which may provide a different level of regulation of gene activity because such kinases often modulate other transcription factors, such as Elk-1 (Peterziel et al., 1999). The prostate is a rich source of acid phosphatases, and some have suggested that these enzymes may be active in regulating the phosphotyrosyl residues of the AR, thus playing a role in dephosphorylation and inactivation of ARs (Goldsteyn et al., 1989), although this relationship is certainly not causal.

Nuclear Localization.

After activation by the binding of steroid ligand the AR is transported to the nucleus across the nuclear pore complex by a process involving at least two nuclear localization signals, one for import and one for nuclear export. Evidence for nuclear localization signal-dependent nuclear translocation is well established and can be found in a variety of nuclear proteins, including the SV40 large T antigen. In most cases it consists of a stretch of basic amino acids. The prototype nuclear localization signal from the SV40 large T antigen is PKKKRKV, although various other basic sequences have also been implicated in nuclear localization signaling. The nuclear localization of the AR appears to involve multiple steps, including the binding of the basic amino acid nuclear localization signal to importins α and β, docking of an importin-cargo complex to the nuclear pore, translocation to the nucleus, and Ran-GTP–mediated release of the cargo (Rao et al., 2002).

Two regions of steroid receptors have gained most attention as regulators of receptor trafficking. The first region is the second DNA-binding zinc finger region, together with the flanking hinge region (NL1) consisting of a bipartite signal including flanking leucines and the core signal ^{628}RKLKKLGN (Kemppainen et al., 1992; Poukka et al., 2000; Ylikomi et al., 1992). However, this one putative nuclear signal peptide is not sufficient by itself for high-efficiency translocation, and by analogy to other steroid receptors, additional nuclear localization signals may exist in the steroid-binding domain (Kemppainen et al., 1992). NL1 acts constitutively and participates in rapid nuclear import that is facilitated by importin-α binding (Savory et al., 1999). A number of coregulators of steroid receptor–mediated transactivation interact with regions that encompass NL1 (Jackson et al., 1997; McKenna et al., 1999; Moilanen et al., 1998; Powers et al., 1998). Some of these proteins, such as SNURF and Ubc9, lose their ability to interact with AR when the region overlapping with the bipartite NL1 is destroyed (Moilanen et al., 1998; Poukka et al., 2000). A second signal, NES^{AR}, is located in the ligand-binding domain (Saporita et al., 2003) and is a nuclear export signal that facilitates export of AR when it is not complexed to ligand. Between the NL1 and NES^{AR}, the AR is actively shuttled between the cytoplasm and nucleus, presumably to tightly regulate its intrinsic ability to activate or repress gene expression.

Transcriptional Activation Domains.

Once the AR has achieved active localization into the nucleus, it must find and bind to its target sequences in the genomic DNA. The precise mechanism by which receptor localization occurs to target genes is still unknown; however, there is emerging evidence indicating it is a highly orchestrated process

(O'Malley, 2008). For instance, it is now known that so-called pioneer factors such as FOXA1 are targeted to specific chromosomal sites by epigenetic signaling, and then the ARs bind to these sites to subsequently regulate the target genes (Lupien et al., 2008). Once the AR has properly localized within the target chromatin sites, it must coordinate binding to a number of associated factors referred to as *coactivators* and *corepressors* that subsequently regulate gene expression (Fig. 143.11). A list of recently identified coactivators is provided in Box 143.1. Most of these factors interact promiscuously with many steroid receptors, although more AR-specific factors are routinely being discovered. Because the number of potential coregulators clearly exceeds the capacity for direct interaction by a single receptor, the most likely mechanism is that transcriptional activation by AR involves multiple factors that act in a sequential and a combinatorial manner to reorganize chromatin templates (Pollard and Peterson, 1998). The precise timing and sequence of binding of these factors remain to be elucidated; however, in general, one can break down the processes empirically into chromatin or nucleosomal remodeling (an energy-dependent process), histone acetyltransferase activity, and subsequent recruitment of TATA-binding protein (TBP)–associated factors, all of which promote an increased rate of gene transcription by RNA polymerase II. Under certain conditions, such as binding of an AR antagonist (e.g., flutamide), the histone acetyltransferase activity is actually inhibited and transrepression may occur. Such inhibition of gene expression appears to involve the nuclear corepressor proteins N-CoR and SMRT (Glass and Rosenfeld, 2000). Other proteins may play a similar role, such as the *HBO1* gene (Sharma et al., 2000). Amino-terminal deletions in region 46-408 result in dominant negative suppression of hormone-inducible transgene activation, indicating that the coactivator functions require an interaction within that site and that in the absence of this region the receptor forms dysfunctional complexes in the chromatin (Palvimo et al., 1993).

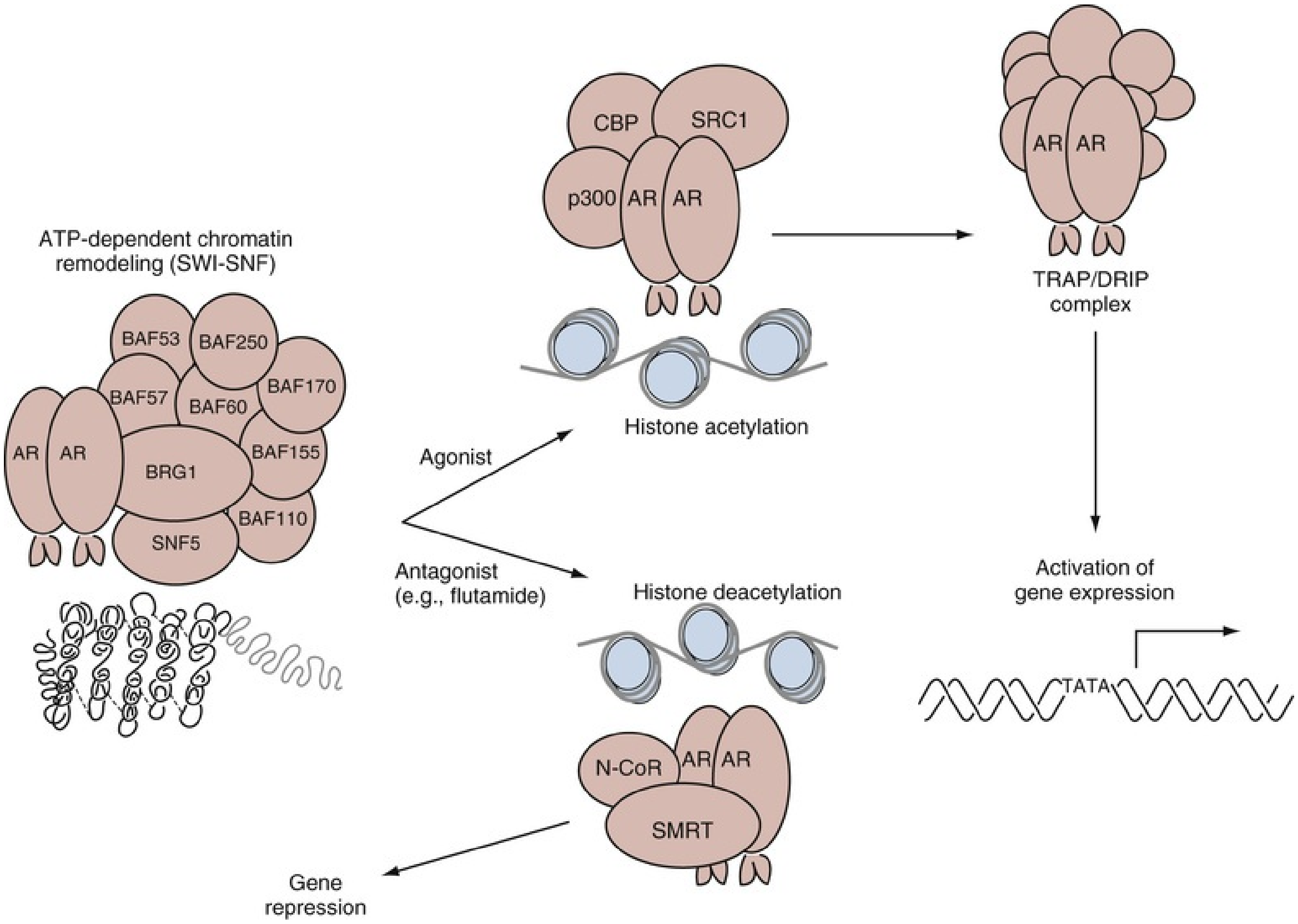
ATP-dependent chromatin remodeling (SWI-SNF)
BAF53
BAF250
BAF57
BAF60
BAF170
AR
AR
BRG1
BAF155
BAF110
SNF5
Agonist
Antagonist (e.g., flutamide)
CBP
SRC1
p300
AR
AR
Histone acetylation
Histone deacetylation
N-CoR
AR
AR
SMRT
Gene repression
AR
AR
TRAP/DRIP complex
Activation of gene expression
TATA

FIG. 143.11 Mechanism of action of the nuclear-activated androgen receptor (AR). Once the androgen receptor has been translocated to the nucleus, it undergoes several steps (many of which may occur contemporaneously): (1) chromatin remodeling in an adenosine triphosphate (ATP)–dependent fashion via the SWI-SNF complex and (2) agonist (i.e., dihydrotestosterone [DHT])-mediated histone acetylation in a process involving multiple transmission factors including p300, CBP, and SRC1. In the case of a certain antagonist, histone deacetylation may be favored, and the activated nuclear receptors complex with repressors of gene expression such as N-CoR and SMRT. (3) The activated androgen receptor complexes then associate with other γ-*trans*-acting factors via the TRAP/DRIP (thyroid receptor-associated protein/D receptor–interacting protein) complex at sites typically upstream of the target gene known as *androgen response elements.* This complex then leads to androgen-regulated activation of gene expression.

Box 143.1

Abbreviated List of Putative Androgen Receptor Coactivators

- ARA24, ARA54, ARA55, ARA70, ARA160
- ART-27, ARIP3
- β-Catenin
- BRCA1, BRCA2
- CARM1, CBP, c-Jun, CDC25B, cyclin E
- FHL2 (specific to androgen receptor)
- GT198
- HBO1
- Ku
- MAGE-11
- OCT-1
- p68 helicase, P160, pp32-Rb
- PCAF, p300, PGC-1, PNRC, P54NRB
- RAC3
- RNF-4
- SNURF
- SRC1, SRC1A, SRC3, SRCAP
- TIF2
- TIP60
- TRAM-1
- TRAP/DRIP/GRIP/NRIP
- UBC9, UBCH7
- ZAC1

The transcription domain of the AR is coded in exon 1, which is the largest of the exons, containing 1607 base pairs. Analysis of this region reveals three homopolymeric repeated regions, including a repeat of approximately 20 glutamines, followed by a space containing 8 repetitive prolines and 23 repetitive glycine units (see Fig. 143.11). The glutamine repeats form a β sheet that helps form a polar zipper, which favors certain protein-protein interactions. Fusion of this type of polymeric glutamine repeat with the DNA-binding domain of GAL4 in yeast results in a GAL4-directed increase in transcriptional activity, demonstrating the importance of this region in promoting transgene activation (Gerber et al., 1994).

Studies demonstrate that these polyglutamine repeats appear to interact directly with the carboxyl terminus of the transcription factor p160 (Irvine et al., 2000). In the normal population this repeat varies over a length of 11 to 31 residues, resulting in a true allelic polymorphism. This means that different people have alleles of variant polyglutamine repeat units. This variation is racially defined, and it has been suggested that this may be related to the differences in the incidence rates of prostate cancer in different ethnic groups. The most common CAG repeat length in Caucasians is a modal value of 21; in African-Americans, it is shorter at 18; and in Asians, it is longer at a mean of 23. The longer the glutamine repeats, the lower the activity of the AR in activating target genes. Patients with X-linked spinal and bulbar muscular atrophy, termed *Kennedy disease,* possess a larger glutamine repeat in the range of 40 to 60. The ARs in Kennedy disease exhibit markedly less transactivation activity (Laspada et al., 1991). Moreover, men with male factor infertility are found to have longer than average polymorphisms of the AR than normal controls (Tut et al., 1997). Genetic studies of inherited diseases of androgen insensitivity and overvirilization as well as changes in the AR mutation associated with prostate cancer and its biologic properties will be of great help in unraveling the role of the human AR in relation to its structure.

Key Points: Androgen Receptor

- The AR, an intracellular steroid-binding protein, is activated by androgens, resulting in genomic and nongenomic actions, which in turn regulate cellular action.
- This regulation is central to prostate development, growth, and homeostasis and occurs in the stromal and epithelial compartments.

Androgen Receptor–Dependent Chromatin Remodeling

Part of the tissue and gene specificity in the recognition of receptors and DNA may depend on the organization of the DNA within the nucleus (Getzenberg et al., 1990). The steroid-receptor complex can interact only with genes that are in regions that are “open” or in the transcriptionally active form. Studies show that these open regions of chromatin (euchromatin) can extend up to 100,000 base pairs in length, or more than 10-fold the size of a typical gene, which usually ranges from 1000 to 10,000 base pairs. It is unknown how such a large range of

DNA is altered in conformation, but it may be through binding to structures such as the nuclear matrix, which can order large loop domains in the region of 60,000 to 120,000 base pairs. Nuclear receptors are thought to interact with chromatin remodeling complexes in an ATP-dependent fashion, in a process directed in part by “pioneer factors” including FOXA1 (Lupien et al., 2008), and this may be among the earliest steps in the ultimate regulation of certain target genes (Glass and Rosenfeld, 2000).

During cell division, chromosomal organization is spatially regulated at each of the critical phases of mitosis (Williams and Fisher, 2003). Epigenetic regulation of chromosome structure and function is highly ordered during cell division, differentiation, and development (Lam et al., 2005; Margueron et al., 2005). In fact, chromosomal proteins are required to maintain such ordered structure for euchromatin, heterochromatin, and centromeric chromatin to sustain normal cell and tissue functions. To achieve such coordinate regulation, the protective packaging of DNA is engineered through an elegant system of tightly wound DNA around an eight-component histone core called a *nucleosome*. This core consists of dimers of H2A, H2B, H3, and H4, whose ability to compact DNA is directly regulated by post-translational modifications. The selective regulation of such post-translational histone modification constitutes a major regulatory mechanism for gene expression and is referred to as the *histone code* (see Fig. 143.11). Histone modifications include acetylation, phosphorylation, ubiquitinylation, and methylation (Cosgrove et al., 2004; Cosgrove and Wolberger, 2005; Downs and Jackson, 2003; He et al., 2003; Lam et al., 2005).

ARs are known to interact with structural components of the chromatin organizing complexes. Such complexes include the multisubunit human SWI-SNF complex, which has been shown to remodel mononucleosome and polynucleosome templates in an ATP-dependent manner (Peterson and Tamkun, 1995). The isolated hSWI-SNF ATPase subunits BRG1 and hBRM also have these activities (Phelan et al., 2000).

The transcriptional activation of nuclear receptors (neuroendocrine cells) requires multiple factors, including SWI-SNF complex, CPB/p300, and steroid receptor coactivator (SRC) family members, which are large and contain numerous subunits, many of which make contact with a variety of nucleosome components and the nuclear matrix (Huang et al., 2003). Such components include BAF53a, BAF57, BAF60, BAF110, BAF155, BAF170, BAF250, BRG1, BRM, and SNF5. Because condensed chromatin renders genes inaccessible for transcription, the combination of a steroid receptor and SWI-SNF complex formation appears to be critical for appropriate nucleosomal remodeling to allow appropriate target genes to be accessible for gene regulation (Huang et al., 2003; Sudarsanam and Winston, 2000). Once the receptor SWI-SNF complex, CPB/p300, and other mediators have successfully “opened” the structure of the chromatin to allow transcriptional regulation, the AR must interact with a distinctly different set of cofactors.

Post-translational histone modification clearly appears to be requisite for chromosome remodeling and optimal gene expression (Ewen, 2000; He et al., 2003). In most models tested the rates of gene transcription actually correlate with the degree of modification of histones through acetylation, phosphorylation, ubiquitinylation, and methylation. In other words, hyperacetylated histone regions correspond to the highest gene-transcriptional regions, whereas the hypoacetylated histone regions correspond to the lowest gene-transcriptional regions (Pazin and Kadonaga, 1997). A number of histone acetyltransferase complexes have been found to be associated with nuclear receptors, including the AR. These complexes include p/CAF, a homolog to the yeast GCN5, which participates in the yeast SAGA complex. This complex includes factors that possess activity but also TBP and a number of TBP-associated factors. The p/CAF protein has been found to be associated with the retinoic acid receptor and may be involved with multiple nuclear receptors. It is also known to bind to other histone acetyltransferase (HAT) proteins, including CBP/p300, which is known to acetylate not only histones but other transcription factors as well. The CBP/p300 complex is an essential coactivator for many genes and may actually serve as a molecular scaffold in stimulating gene transcription (Huang et al., 2003; Marshall et al., 2003; McKenna et al., 1999). Such complexes include the SRC1 coactivator, among others. More recently, the modifiers of the histone code have expanded considerably to include sophisticated enzyme-mediated alterations in the histones H2A, H2B, H3, and H4 by phosphorylation, ubiquitinylation, and methylation, which open the chromatin, allowing the recruitment of important transcription factors that allow normal cell functions (Lam et al., 2005; Margueron et al., 2005).

The list of coactivators associated with nuclear receptors and the AR in particular is extensive and almost certainly incomplete. A short list of factors found to be associated with the receptor at this level of gene regulation is given in Box 143.1. Among the most important factors is SRC1, which has mild HAT activity and seems to be required for optimal stimulation of steroid-dependent transcription. Additional factors include steroid receptor RNA activator (SRA), a structural RNA necessary for the coactivator complex to function optimally (McKenna et al., 1999), and p160 coactivator, which appears to be required for hormone-dependent activation and to directly interact with the polyglutamine repeats found in the amino-terminal transactivation domain (Irvine et al., 2000).

Most genes have a regulatory region immediately upstream of the transcriptional start site. The regulatory region is divided into a core *promoter element* that is present in all genes as well as other upstream elements that serve to regulate the overall gene expression pattern. This promoter element specifies the site to which RNA polymerase II will attach to the DNA and will determine the actual point for the initiation of transcription. The RNA polymerase will copy or transcribe the DNA code into mRNA, a process termed *transcription.* This promoter area starts at −16 nucleotides to +32 upstream from the gene initiation site. This region of −32 to +16 was originally referred to as the *Goldberg-Hogness box* or *TATA box* and has a consensus sequence of TATAAAAG. The RNA polymerase II enzyme binds to this TATA box as one of the initial steps in transcription. Farther upstream from the TATA box is a second gene control element termed generically the *hormone response element*, which has been identified in many genes regulated by steroid hormones and is one of multiple sites where the receptor binds to the DNA. As stated earlier, in androgen-regulated genes, this area is termed the *androgen response element;* in estrogen, the *estrogen response element;* and in glucocorticoid, the *glucocorticoid response element.* This hormone response element area may contain several discrete sequences, but its overall role is to modulate the frequency of transcription initiation vis-à-vis interactions with transcriptional factors. In independent analysis, thyroid hormone receptors were found to be associated with affinity purified proteins, which were found to markedly enhance ligand-dependent cell-free transcription. This complex was referred to as *TRAP*, for thyroid receptor-associated proteins (Fondell et al., 1996). In a similar set of experiments, the same type of complex was isolated for the vitamin D receptor and was called DRIP for D receptor–interacting proteins (Rachez et al., 1998). Subsequent analysis revealed that they shared at least nine proteins, and this activator-recruited cofactor complex (TRAP/DRIP/ARC) is part of a large composite coactivator complex used by a variety of transcription factors for the regulation of certain target genes. Such transcription factors include sterol regulatory element-binding protein (SREBP), nuclear factor-κB (NF-κB), and VP16 (Gu et al., 1999; Ito et al., 1999; Naar et al., 1999; Ryu et al., 1999; Sun et

al., 1998).

In summary, the TATA box tells where RNA polymerase binds and where the initiation of transcription is to start and the hormone response element regulates how frequently it is to be transcribed when it is bound to a hormone receptor. This is accomplished by the presence of certain cofactors in the TRAP/DRIP complex. Because the hormone response element of DNA sequence has been shown to be independent of its position or its orientation, it resembles what has been called the *transcription enhancer element* that has been found in many other types of genes. The hormone response element section can vary in its location upstream from the initiation of the gene from −20 to −6000 for various different types of hormones. With the steroid hormones, it appears to reside about −140 nucleotides upstream from the initiation site. For example, in the glucocorticoid receptor recognition element, the site for glucocorticoid receptor recognition is approximately −140 and contains a sequence of nucleotides of AAAATGGAC. Deletion mapping experiments have indicated that the receptor-binding domain located in the hormone response element is indeed required for receptor binding and is necessary for steroid-mediated control of transcription.

Once the DNA is transcribed into mRNA, a series of adenine units are added to the end (called the *poly-A tail*) and then the mRNA is cut and spliced on small nuclear particles (called *spliceosomes*) located on the nuclear matrix, and this splicing removes the intron portion of the message. The final mRNA is shipped out of the nucleus, believed to occur on the structural components of the nuclear matrix, and passes through the pore complexes of the nucleus and out to the ribosomes where the mRNA is then translated into protein product, a step termed *translation.* The proteins have specific amino acid sequences that instruct the cell where to ship the protein in relation to secretory granules or to the membrane area. The protein can also be modified after translation by the subsequent addition of carbohydrates to become glycoproteins or to be phosphorylated by kinases. Under appropriate signals, such as neurologic control, secretory proteins can then be excreted into the lumen of the prostate. This is a process that occurs when secretory proteins of the prostate and seminal vesicles are formed into the ejaculate. A schematic example of this process is shown in Fig. 143.7, and such a system would include PSA and acid phosphatase as well as many other protein products that are regulated in their synthesis by androgens through receptor interactions.

During embryonic development, the AR appears first in the mesenchyme of the rat ventral prostate and seminal vesicles and a few days later in the epithelial cells, but it is unknown what regulates this timing. **In the development of the seminal vesicles and the wolffian duct, testosterone appears to be the primary androgen in glandular development, and in the ventral prostate that forms from the urogenital sinus the androgen is primarily DHT.** Testosterone and DHT can bind to the AR; however, on a molar basis, DHT is 3 to 10 times more potent. This decrease in potency of testosterone is believed to be caused by the rapid off rates of the testosterone once it is bound so that equilibrium results in less receptor occupancy compared with DHT at similar tissue levels. A report indicates that, in some cases, AR-mediated transcriptional regulation can occur even in the absence of direct interaction of the AR with the specific androgen response elements (Kallio et al., 1995). The report stated that the ARs are able to elicit transrepression and transactivation without interacting directly with the specific DNA elements. This may indicate that the AR can bind to regulatory units within the transcription factors and thus alter their properties even in the absence of direct DNA binding to an androgen response element.

The next part of this discussion is focused on the structure of the nucleus, where the genetic information of the genes, the AR interactions, and the mRNA processing occur and are integrated. This is within a highly ordered structure of the nucleus that is determined by a residual scaffolding framework, called the *nuclear matrix,* which provides three-dimensional organization to the nucleus and the DNA.

Role of the Nuclear Matrix in Androgen Action.

The DNA may be identical in every cell of different tissues in the body, but it appears to be organized in a different three-dimensional array in different cell types. This spatial organization of DNA appears to be determined in part by nuclear architecture and structure dictated by the scaffolding element termed the *nuclear matrix.* Therefore more may be required than just a steroid receptor and a DNA sequence with an androgen response element to determine the high tissue specificity of androgen hormone action. It may require regulation of DNA conformation and three-dimensional structure. There is strong evidence to support the belief that structural components of the nucleus may organize the DNA into different topologic constraints that permit specific steroid receptor interactions themselves. It is also believed that these structural modifications of DNA topology may be an integral part of differentiation. The nuclear matrix has been proposed to be an important structural element in this type of DNA organization (Boccardo et al., 2003; Getzenberg et al., 1990). The matrix facilitates the location of target genes and their conformation and facilitates their cointeraction with steroid receptors. Barrack and Coffey first showed that the nuclear matrix is a major target for androgen and ER binding (Barrack, 1987; Barrack and Coffey, 1980). Because the matrix has been implicated in many important nuclear events, it would provide an ideal target for androgen action. The nuclear matrix has been defined as the dynamic structural subcomponent of the nucleus that directs the functional organization of DNA into loop domains and provides sites for the specific control of nucleic acids (Getzenberg et al., 1990; Nelson et al., 1986). Conceptually, it can be viewed as the nuclear equivalent to the cytomatrix or cytoskeleton. The nuclear matrix contains residual nuclear elements, including the pore complex lamina, the residual nucleolus, and an internal ribonucleoprotein particle network attached to a dynamic fibrous protein mesh (Berezney and Coffey, 1977). The nuclear matrix may be isolated by sequential extractions using nonionic detergent, brief digestion with DNase I, and a hypertonic salt buffer wash. The residual nuclear matrix structures represent only 15% or less of the original total nuclear mass. More than 98% of the DNA, 70% of the RNA, and 90% of the nuclear proteins have been extracted, and the remaining structure is essentially devoid of histones and lipids.

The nuclear matrix has been implicated as an important structural component in a wide variety of biologic functions. There are approximately 50,000 DNA loop domains in a nucleus, each containing about 60 kilobase pairs of DNA, and these loops are attached at their bases to the nuclear matrix (Luke and Coffey, 1994; Pardoll et al., 1980; Vogelstein et al., 1980). This loop organization is maintained during interphase and throughout metaphase (Nelson et al., 1986). Topoisomerase II, an enzyme that modulates DNA twisting and topology, is associated with the nuclear matrix and the mitotic chromosome scaffold. Many studies with a wide variety of systems have demonstrated that active genes are associated with the nuclear matrix, whereas transcriptionally inactive genes are not close to the matrix. This location of active genes on the matrix provides evidence that the matrix plays an important organizing role in differentiation, placing genes in different configuration.

Androgens can activate DNA synthesis and cell replication in target tissues. The nuclear matrix also serves an important role in DNA replication. The matrix contains fixed sites for DNA synthesis (Pardoll et al., 1980) located at the base of the DNA loop. During DNA synthesis the DNA loop domains are reeled down through the attached replicating complex that is fixed on the matrix. Therefore the DNA replication fork, DNA polymerase, and newly replicated DNA have been shown to be associated with the nuclear matrix. It is easy to visualize how hormone action and alteration in the nuclear matrix structures could impinge on the androgen regulation of DNA synthesis and growth in a prostate cell.

The nuclear matrix is also associated with mRNA synthesis during transcription. Ciejek et al. (1982) observed that more than 95% of the unprocessed mRNA precursor for ovalbumin is associated with nuclear matrix of the chick oviduct. When the intron portions of the RNA were spliced out, the mature mRNA was released from the nuclear matrix. This led them to suggest that the nuclear matrix is involved in RNA processing. Marriman and van Venrooij (1985) reported that all RNA cleavage products and RNA processing intermediates are firmly bound to nuclear matrix. Once again, alterations in nuclear matrix structures with steroid receptor interactions could alter important steps in transcription and RNA processing. The nuclear matrix contains the attachment sites for the small nuclear ribonucleoprotein particles that are part of the nuclear spliceosome system central to the nuclear processing of RNA to the final mRNA, which is transported out to the cytoplasm to be translated.

Ahmed and colleagues have carried out an extensive series of studies of the phosphorylation of the nuclear matrix and related proteins in the ventral prostate of the rat after androgen stimulation and withdrawal (Ahmed and Goueli, 1987; Ahmed et al., 1993; Tawfic et al., 1993, 1994). They have shown that the nuclear matrix can be phosphorylated by casein kinase 2 (CK-2). One of the targets of this phosphorylation is nucleolin, which is an abundant nucleolar phosphoprotein involved in the synthesis of ribosomal DNA and exquisitely regulated by androgens (Tawfic et al., 1994). Another important protein in nucleolar function that is required for growth is B23, which is also regulated by CK-2 (Tawfic et al., 1993).

In summary, the nuclear matrix is an important structural modulator of nuclear regulation and is an ideal target for hormonal regulation. Indeed, the nuclear matrix is a major site of steroid hormone receptor binding (Alexander et al., 1987; Barrack, 1987; Barrack and Coffey, 1982; Donnelly et al., 1983; Metzger and Korach, 1990; Luke and Coffey, 1994; Wilson and Colvard, 1984). In the prostate, more than 60% of all nuclear ARs are associated with the nuclear matrix (Barrack and Coffey, 1982). The matrix is also a target for many other types of regulatory interactions, including the nuclear products of oncogenes and viral proteins that can also induce growth regulation similar to hormone-induced growth. For example, the nuclear matrix is reported to be a cellular target for the retrovirus Myc oncogene protein and the polyoma large T antigen. All of these transformation proteins that bind to the nucleus are believed to be early molecular events in carcinogenesis or transformation. Therefore the observation that ARs interact with the matrix has precedence with the matrix as a common target in factors that regulate cell structure and function.

Key Points: Androgen Receptor Structure and Function

- The AR is a ligand-activated transcriptional regulator that, on binding to androgen dissociates from chaperonins, is actively modified by a variety of methods to an active stage, is actively translocated to the nucleus, and associates first with pioneering factors that direct where in the chromatin the receptor will function and then associates with a large number of coactivators and repressors to regulate target gene expression.
- The transport of the AR is reciprocal: it is localized to the nucleus and actively transported out of the nucleus.
- The AR binds to DNA target sequences as a dimer, which can be direct or inverted repeats; however, the receptor always binds with the same orientation.
- The regulation of the AR appears to be one of the most important “gatekeepers” of prostate development and physiology.

Prostatic Secretions and Proteins

Prominent, Nonpeptide Components of Prostatic Secretions

The seminal plasma is formed primarily from the secretions of the sex accessory tissues, which provide a suitable environment for survival and function of spermatozoa. The sex accessory tissues include the epididymis, ampullae, seminal vesicles, prostate, Cowper (bulbourethral) gland, and glands of Littre. **The average volume of the normal human ejaculate is approximately 3 mL, ranging from 2 to 6 mL, and it has two components: spermatozoa and seminal plasma. Spermatozoa, which represent less than 1% of the total ejaculate, are present in the range of 100 million/mL. The major contribution to the volume of seminal plasma (average 3 mL) comes from the seminal vesicles (1.5 to 2 mL), from the prostate (0.5 mL), and from the Cowper gland and glands of Littre (0.1 to 0.2 mL).** During ejaculation the secretions of these glands are released in a sequential manner (Amelar, 1962; Amelar and Hotchkiss, 1965; Tauber and Zaneveld, 1976; Zaneveld and Tauber, 1981). The first fraction of the human ejaculate is rich in sperm and prostatic secretions, such as citric acid. The level of fructose, which represents a major secretory product of the seminal vesicles, is elevated in the later fraction of ejaculate. More recently, seminal albumin was measured in seminal plasma, and the authors demonstrated an association with sperm morphology but not several other semen parameters (Elzanaty et al., 2007). The overall chemical composition of normal human and rodent prostatic secretions and seminal plasma has been widely studied, and the results have been summarized in excellent reviews (Aumuller and Seitz, 1990; Chow et al., 1993; Daniels and Grayhack, 1990; Elzanaty et al., 2007; Gonzalez et al., 1993; Mann and Mann, 1981; Zaneveld and Tauber, 1981). An analysis of expressed prostatic secretions in a small cohort of men revealed that citrate, myo-inositol, and spermine metabolite measurements could potentially differentiate controls from men with prostate cancer (Serkova et al., 2008), with tissue analysis also suggesting that spermine and citrate can distinguish benign from cancerous prostate (Giskeødegård et al., 2013).

In relation to other body fluids the seminal plasma is unusual because of its high concentrations of potassium, zinc, citric acid, fructose, phosphorylcholine, spermine, free amino acids, prostaglandins, and enzymes (most notably acid phosphatase, diamine oxidase, β-glucuronidase, lactate dehydrogenase [LDH], α-amylase, PSA, and seminal proteinase).

Citric Acid

One of the major anions in human seminal plasma is citrate (mean, 376 mg/dL), which is present in the range of 20 mM or 60 mEq/L. This is compared with the chloride ion (155 mg/dL) at 40 mM. Citrate is a potent binder of metal ions, and the seminal plasma concentration of citrate, 20 mM, is comparable with that of the total divalent metals at 13.6 mM (calcium, 7 mM; magnesium, 4.5 mM; zinc, 2.1 mM). Prostatic citrate levels approximate 15.8 mg/mL (Zaneveld and Tauber, 1981), and the values for seminal vesicle citric acid secretions are almost 100-fold less, being only 0.2 mg/mL. Citric acid is formed in the prostate at 100 times higher concentration than is seen in other soft tissues (e.g., prostatic tissue, 30,000 nmol/g; other tissues, range of 150 to 450 nmol/g). **The concentration of citrate in the ejaculate is 500 to 1000 times higher than that in the plasma. Prostatic secretory epithelial cells form citrate from aspartic acid and glucose. The high concentrations within the prostate result partly from the inability of the prostate cell mitochondria to oxidize citrate readily once it is formed; therefore the rate of citrate synthesis far exceeds the rate of citrate oxidation** (Costello and Franklin, 1989, 1994; Kavanagh, 1994).

Fructose

The source of fructose in human seminal plasma is the seminal vesicles (Mann and Mann, 1981). Patients with congenital absence of the seminal vesicles also have an associated absence of fructose in their ejaculates (Phadke et al., 1973). The seminal vesicle secretion contains smaller amounts of other free sugars such as glucose, sorbitol, ribose, and fructose, and these sugars usually amount to less than 10 mg/dL. In comparison, the concentration of the reducing sugar fructose is approximately 300 mg/dL in human seminal secretion, and it has a level of 200 mg/dL in seminal plasma. The fructose of the seminal plasma appears to provide an anaerobic and an aerobic source of energy for the spermatozoa (Mann and Mann, 1981) and has been indirectly linked to forward sperm motility and seminal viscosity (Gonzalez et al., 1993; Fabiani et al., 1995).

Fructose levels are under androgenic regulation, but many factors, such as storage, frequency of ejaculation, blood glucose levels, and nutritional status, can also affect seminal plasma concentration (Mann and Mann, 1981); these considerations may account for the wide variations encountered in different semen samples from the same patient. Furthermore, plasma levels of androgens do not always correlate with seminal plasma fructose levels; therefore these levels are not a reliable index of the androgenic state of the subject. Seminal fructose levels have also been proposed to be under sympathetic control (Kempinas et al., 1995; Lamano-Carvalho et al., 1993).

Polyamines

Polyamines are the most basic (positively charged) small organic molecules in nature. They occur ubiquitously in tissues at high concentrations and are believed to be involved in diverse physiologic processes that share a relationship to cell proliferation and growth. Indeed, polyamines can serve as growth factors for cultured mammalian cells and bacteria and as inhibitors of enzymes, including protein kinases.

The exact role of polyamines at the molecular level still eludes science, but they represent important biologic compounds and are found at high levels in the ejaculate. Polyamines may affect the gating and transport of substances through membrane channels. From a clinical perspective, polyamines (spermidine and spermine) have been investigated as markers of androgen deprivation therapy among men with advanced-stage prostate cancer (Cipolla et al., 1994). Other researchers (Heston, 1991; Kadmon, 1992; Love et al., 1993; Madhubala and Pegg, 1992) have investigated the role of polyamines in the pathophysiology of prostate cancer. The first and rate-limiting step in polyamine synthesis within the prostate is controlled by the enzyme ornithine decarboxylase (ODC). ODC gene expression has been demonstrated to be increased in BPH tissue (Liu et al., 2002). ODC can be inhibited by difluoromethylornithine (DMFO), which in turn inhibits polyamine synthesis. DMFO has been proposed as an agent for chemoprevention of prostate cancer (Kadmon, 1992).

Spermine levels in normal human seminal plasma range from 50 to 350 mg/dL and originate primarily from the prostate gland, which is the richest source of spermine in the body. Spermine $[NH_2–(CH_2)_3–NH–(CH_2)_4–(CH_2)_4–NH–(CH_2)_3–NH_2]$ is a basic aliphatic polyamine and, because of its four positive charges, binds strongly to acidic or negatively charged molecules such as phosphate ions, nucleic acid, and phospholipids. When semen is allowed to stand at room temperature, acid phosphatase enzymatically hydrolyzes seminal phosphorylcholine to form free inorganic phosphate ions, which then interact with the positively charged spermine and precipitate as large, translucent salt crystals of spermine phosphate. Polyamines can also form amide bonds and make their covalent addition to protein carboxylic groups (Williams-Ashman et al., 1975), and this modification may be involved in regulatory function.

There has been much interest in spermine and other related polyamines, such as spermidine and putrescine, because of the rapid and dramatic changes in levels and ratios associated with many types of cells that have been induced into growth. Williams-Ashman et al. (1969, 1972, 1975) have investigated in detail the biosynthesis and regulation of polyamines in the male reproductive tract and have characterized the enzymatic reactions that progress from ornithine to putrescine to spermidine to spermine. Polyamines are oxidized enzymatically by diamine oxidase (present in the seminal plasma) to form highly reactive aldehyde compounds that can be toxic to sperm and bacteria (Le Calvé et al., 1995). The formation of these aldehyde products produces the characteristic odor of semen. It is also possible that these aldehydes or polyamines may, themselves, protect the genitourinary tract from infective agents. Relationships between spermine levels in seminal plasma and sperm count and motility have also been suggested (Fair and Parrish, 1981; Fair et al., 1993; Le Calvé et al., 1995; Stamey et al., 1968). Like citrate, spermine can also be quantified within prostatic tissue by magnetic resonance spectroscopy (van der Graaf et al., 2000).

Phosphorylcholine

Other positively charged amines are at high concentrations in the ejaculate, including choline and phosphorylcholine, which are usually found as components of lipid or as lipotropic factors. The semen of mammals is rich in choline $[(CH_3)_3–N^+–(CH_2)_2–OH]$. In humans, phosphorylcholine predominates, whereas in most other species much higher levels of α-glycerylphosphorylcholine are present, often exceeding 1 g/dL of seminal plasma. Seligman et al. (1975) have demonstrated that phosphorylcholine is a highly specific substrate for PAP, which is also active in seminal plasma. The result of this enzymatic activity is the rapid formation of free choline in the first ejaculate. In contrast, α-glycerylphosphorylcholine is secreted primarily in the epididymis and is not readily hydrolyzed by acid phosphatase. For these reasons, Mann and Mann (1981) have suggested that the level of α-glycerylphosphorylcholine can be used as an index for assessing the contribution of the epididymal secretion to the ejaculate. The secretion from the epididymis is also under androgenic control. The function of these choline compounds is unknown; it appears that they are not metabolized by spermatozoa, nor do they affect the respiration of the sperm (Dawson et al., 1957).

Prostaglandins

The richest sources of prostaglandins in the human are the seminal vesicles (Pourian et al., 1995). Prostaglandins are present in seminal plasma at a total concentration of 100 to 300 µg/mL. Von Euler (1934) proposed the name *prostaglandins* for the active components in seminal plasma in the belief that they originated from the prostate gland, but Eliasson (1959) established that the primary source of prostaglandin is the seminal vesicles, not the prostate; however, the original name has survived. Prostaglandins have a wide distribution in mammalian tissues but at much lower concentrations than in the seminal vesicles (Vane and Botting, 1995).

There are more than 90 different prostaglandins present in the human, with 15 prostaglandins present in human semen, and they are all 20-carbon hydroxy fatty acids with a cyclopentane ring having two side chains; as such, they are derivatives of prostanoic acid. The 15 types of prostaglandins within the prostate are divided into four major groups, designated A, B, E, and F according to the structure of the five-membered cyclopentane ring. Each of these groups is further subdivided according to the position and number of double bonds in the side chain (therefore PGE_3 indicates prostaglandins of E type with three double bonds in the side chain). The E group of prostaglandins is the major component in the male reproductive tract, whereas the F group predominates in the female system. Fuchs and Chantharaski (1976) have summarized the reported levels of human seminal plasma prostaglandins and report the following mean values (µg/mL): PGE_1, 20; PGE_2, 15; $(PGE_1 + PGE_2) - 19\text{-OH}$, 100; $PGA_1 + PGA_2$, 9; $(PGA_1 + PGA_2) - 19\text{-OH}1$, 31; $PGB_1 + PGB_2$, 18; $(PGB_1 + PGB_2) - 19\text{-OH}$, 13; $PGF_{1\alpha}$, 3; and $PGF_{2\alpha}$, 4.

These compounds are potent pharmacologic agents that have been implicated in a variety of biologic events in the male, including erection, ejaculation, and sperm motility and transport, as well as in testicular and penile contractions. In addition, prostaglandins from seminal fluid deposited in the vagina have been reported to affect cervical mucus, vaginal secretion, and sperm transport in the female genital tract. Prostaglandin E has been related to the immunosuppressive effects of seminal plasma mediated through the extracellular organelles, or “prostasomes” (Kelly et al., 1991).

Zinc

The high level of zinc in human seminal plasma (140 µg/mL) appears to originate primarily from secretions of the prostate gland (488 ± 18 µg/mL) (Bedwal and Bahuguna, 1994). The prostate has the highest concentration of zinc (50 mg/100 g dry weight) of any organ. Byar (1974) has reviewed many of the early experiments and concepts related to zinc in the reproductive tract. Zinc levels are elevated or stable in BPH, whereas there is a marked decrease in zinc content associated with prostatic adenocarcinoma. The localization of zinc-65 in the human prostate by radioautography appears to be within the epithelial cells; however, in the lateral prostate of the rat, large quantities of zinc were also associated with the stroma and particularly with the basal membrane and the elastin protein component (Chandler et al., 1977). Oral intake of zinc does not alter zinc levels in prostatic fluid.

Many physiologic roles have been postulated for zinc since the classic studies of Gunn et al. (1956, 1965), who correlated endocrine effects on zinc uptake and concentration in the prostate of the rodent. There are many important zinc-containing metalloenzymes, but the concentration of zinc in the prostate probably exceeds that present in zinc-associated enzymes. Zinc is known to bind many proteins (Sansone et al., 1991). Johnson et al. (1969) characterized zinc-binding proteins in the prostatic secretion of the dog, on hydrolysis, as containing only eight types of amino acids. Heathcote and Washington (1973) described a zinc-binding protein in human BPH that was rich in histidine and alanine. Jonsson et al. (2005) suggested that one possible role of zinc in semen may be to regulate the activity of PSA by binding to semenogelins I and II and fragments thereof. There have been other studies on zinc-binding proteins from the prostate (Fair et al., 1976; Reed and Stitch, 1973), and additional information on these interesting proteins is needed.

An important role for zinc in prostatic secretion has been postulated in the studies of Fair et al. (1976), which suggest the direct role of zinc as a prostatic antibacterial factor. In the study of 36 healthy men free from bacterial prostatic infections, the mean value of zinc in the prostatic secretion was approximately 350 µg/mL, with a wide range of 150 to 1000 µg/mL. In comparison, the prostatic fluid obtained from 61 specimens collected from 15 patients with documented chronic bacterial prostatitis had a reduction of more than 80% and averaged only 50 µg/mL, with a range of 0 to 139 µg/mL. The authors proposed a lower limit of normal at 150 µg/mL. In addition, in vitro studies of free zinc ions at concentrations normally found in prostatic fluid have confirmed the bactericidal activity of zinc against a variety of gram-positive and gram-negative bacteria. However, a considerable portion of the zinc in the prostate appears to be bound to unique proteins, such as metallothionein, and it is not certain how this may alter the biologic properties of zinc (Suzuki et al., 1994, 1995). Yan et al. (2008) reported that assessment of decreased zinc in a normal human PrEC in vitro resulted in increased single-strand DNA breaks (Comet assay) and differential expression of several genes (Affymetrix HG-U133A gene chips) involved in cell cycle progression, apoptosis, transcription, and DNA damage response and repair. Therefore a zinc deficiency may compromise DNA integrity in the prostate. In prostate cancer the ability of prostate cells to accumulate zinc is lost during disease progression and may be in part caused by the genetic and epigenetic alterations produced by zinc depletion.

Prostatic Secretory Proteins

The predominant secretory proteins of the sex accessory tissues have been reviewed (Aumuller and Seitz, 1990; Aumuller et al., 1990; Diamandis and Yousef, 2002; Lilja, 1993a, 1993b; Rittenhouse et al., 1998; Saedi et al., 2001; Yousef and Diamandis, 2002). High-resolution, two-dimensional electrophoresis profiles of the major secretory protein markers from human ejaculate, seminal plasma, and prostatic secretions have been reported (Aumuller and Seitz, 1990; Carter and Resnick, 1982; Dube et al., 1987; Edwards et al., 1981; Rui et al., 1984; Tsai et al., 1984).

With regard to the prostate, several secretory proteins are found in abundance and have clinical significance. These include primarily PSA (human kallikrein 3 [hK3, protein; or *KLK3*, gene]) and human kallikrein 2 (hK2 or *KLK2*), but also prostase/*KLK-L1* (Clements, 2008; Lwaleed et al., 2004; Yousef et al., 1999), PAP, and prostate-specific protein (PSP-94), also called β-microseminoprotein (β-MSP). Table 143.4 lists some characteristics of the major secretory proteins in the sex accessory tissues.

TABLE 143.4

Major Proteins Secreted by the Sex Accessory Tissue

PROTEIN OR GENE IDENTIFICATION	**MOLECULAR WEIGHT (kD)**	**SEMINAL PLASMA (mg/nL)**	**ACTIVITY**
Prostate-specific antigen (PSA) (hK3 [protein] or *KLK3* [gene])	33–36	0.70	Serine protease; arginine esterase
Human kallikrein 2 (hK2 or *KLK2*)	28.4	0.012	In vivo activation of proPSA, arginine esterase
Human kallikrein L1 *(KLK-L1)*	Unknown	Unknown	Serine protease, also in testes, breast, adrenal, uterus, thyroid, and salivary glands
Human kallikrein 11	Approximately 40	0.002–0.037	Serine protease, also in breast, ovary, and prostate
Prostatic acid phosphatase (PAP)	102–106	0.3–1.0	Phosphotyrosyl protein phosphatase
Prostate-specific transglutaminase	17	Unknown	Involved in the formation of stable, functional peptide-bound glutamine and primary amine groups
Semenogelins I and II	50, 63	2 mM[a]	Have chymotrypsin-like activity; inhibit PSA activity in the semen
Prostate-specific membrane antigen (PMSA)	Approximately 120	Unknown	Has a structure identical to glutamate carboxypeptidase II and folate hydrolase I; found in kidney, testis, ovary, brain, salivary gland, small intestine, colon, liver, spleen, breast, and skeletal muscle
Prostate stem cell antigen (PSCA)	Approximately 24	Unknown	A prostate cancer–associated tumor antigen
			Northern blot and in situ data show that PSCA is predominantly prostate specific in normal tissues and is overexpressed in greater than 80% of prostate cancers
Prostate-specific protein (PSP-94), β-microseminoprotein (β-MSP)	10.7–16	0.6–0.9	Also found in epithelial cells of antrum of stomach
Immunoglobulins	160	0.007–0.022	Human IgG

C3 complement	Approximately 178	0.018	An integral part of the complement cascade (C3 activates alternate pathway)
Transferrin	77	0.18	A plasma protein that transports iron through the blood to the liver, spleen, and bone marrow

[a] Only given in mM concentrations.

Table 143.5 illustrates the number of sample, median, and ranges of components of prostatic secretions among normal male reproductive parameters.

TABLE 143.5

Components of Prostatic Secretions

VARIABLES	N	MEDIAN	RANGE
Age (yr)	916	34	20–64
Time of sexual abstinence (days)	916	4.0	1.0–60
Semen volume (mL)	916	4.0	1.0–15
Sperm concentration (×106 mL^{-1})	916	44	0.1–568
Total sperm count (×10^{6} mL^{-1})	916	167	0.4–2400
a (%)	916	14	0–80
b (%)	916	28	0–80
a + *b* (%)	916	50	0–90
c (%)	916	16	0–50
d (%)	916	33	0–100
Total *a* + *b* (×10^{6} per ejaculate)	916	83	0–1200
Normal forms (%)	916	5.0	0–20
Tail defects (%)	916	11	1.0–85
DFI (%)	267	15	3.0–90
HDS (%)	267	7.0	1.0–40
NAG (mU/mL^{-1})	506	6.0	1.0–15
PSA (mg/L^{-1})	900	890	66–3400 or higher
Zinc (mmol/L^{-1})	900	2.0	0–7.0
Fructose (mmol/L^{-1})	900	14	0–39
FSH (IU/L^{-1})	351	5.0	1.0–45
LH (IU/L^{-1})	351	3.0	1.0–13
Testosterone (nmol/L^{-1})	351	13	3.0–31
Inhibin B (ng/L^{-1})	351	150	14–450
SHBG (nmol/L^{-1})	351	26	2.0–88

DFI, DNA fragmentation index; *FSH,* follicle-stimulating hormone; *HDS,* high DNA stainability; *LH,* luteinizing hormone; *NAG, N*-acetylglucosamine; *PSA,* prostate-specific antigen; *SHBG,* sex hormone binding globulin.

From Elzanaty S, Erenpreiss J, Becker C: Seminal plasma albumin: origin and relation to male reproductive parameters. *Andrologia* 39:60–65, 2007.

Prostate-Specific Antigen

PSA is a secreted serine protease, first demonstrated in human prostatic tissue in 1970 (Ablin and Soanes, 1970), found in seminal plasma in 1971 (Hara et al., 1971), purified from prostatic tissue in 1979 (Wang et al., 1979), measured in the serum of men in 1980 (Kuriyama et al., 1980), cloned at the gene level in 1987 (Lundwall and Lilja, 1987), and widely used as a clinical marker of prostate cancer by 1988 (Chan et al., 1987; Oesterling et al., 1988; Seamonds et al., 1986; Stamey et al., 1987).

The discovery of PSA resulted from a search of the ejaculate and prostatic fluid by immunoprecipitation to find specific proteins for forensic use. In 1971 Japanese workers isolated, from the seminal plasma, a protein that was proved to be antigenically specific for semen; they reported its chemical and physical characteristics and termed it γ-*seminoprotein* (Hara et al., 1971). Several years later, in an attempt to develop this protein further as a forensic marker for semen identification, γ-seminoprotein was purified from human seminal plasma. These seminal proteins, initially called γ-seminoproteins, have now been shown by sequence to be the same as PSA.

PSA is a glycoprotein acting as a serine protease of molecular weight 33 kD that contains 7% carbohydrate (Watt et al., 1986) and is found almost exclusively in the epithelial cells of the prostate (Armbruster, 1993; Rittenhouse et al., 1998). It consists of a single polypeptide chain and contains 240 amino acids and an *O*-linked carbohydrate side chain attached to a serine residue (Watt et al., 1986). PSA acts physiologically like a serine protease and an arginine esterase with chymotrypsin-like and trypsin-like activity. The sequence of the protein is similar to that of other kallikreins (Rittenhouse et al., 1998) involved in prostatic cell regulatory mechanisms. Lilja (1985) and Watt et al. (1986) reported that one of the structural proteins of the seminal fluid, semenogelin, causes the ejaculate to clot. Semenogelin is the predominant seminal vesicle–secreted protein and one of the physiologic substrates for PSA. **One possible biologic role of PSA is to lyse the clot in the ejaculate, but it is at present unknown why this clotting and lysing mechanism is important to reproductive physiology.**

The PSA gene *(hKLK3)* is a member of a human tissue kallikrein gene family that includes *hKLK1*, *hKLK2*, *hKLK3*, and *KLK-L1* (Berg et al., 1992; Carbini et al., 1993; Clements, 1994; Lundwall, 1989; McCormack et al., 1995; McMullen et al., 1991; Nelson et al., 1999; Rittenhouse et al., 1998; Yousef and Diamandis, 2003). There are more than 15 different human kallikreins, with expression noted in prostate, breast, ovarian, and testicular cancers (Obiezu and Diamandis, 2005). These genes are located on chromosome 19 (Reigman et al., 1992; Yousef and Diamandis, 2003; Yousef et al., 1999). The ectopic expression of PSA has been reported in smaller concentrations in the tissue of malignant breast tumors (Yu et al., 1994a, 1994b, 1994c), normal breast tissue, breast milk, female serum, and adrenal and renal carcinomas; however, for practical and clinical purposes, PSA is an androgen-dependent and prostate organ-specific (but not a cancer-specific) marker. A limitation of PSA as a tumor marker is demonstrated in the substantial overlap in values between benign and malignant prostate disease (Oesterling et al., 1988; Partin et al., 1990).

Most work regarding the molecular biology and biochemistry of PSA is based on extensive study of purified protein from seminal fluid in which the concentration of PSA is nearly a million-fold higher than that found routinely in serum (McCormack et al., 1995). The concentrations found in seminal plasma range from 0.5 to 5.0 mg/mL, whereas normal serum concentrations in men aged 50 to 80 years without prostatic disease range from 1.0 to 4.0 ng/mL (Catalona et al., 1991).

Prostate-Specific Antigen Derivatives

PreproPSA (261 amino acids) is processed in the endoplasmic reticulum of prostatic epithelial cells, where a 17-peptide leader sequence is cleaved to form proPSA. Seven more peptides are then cleaved from the propeptide to form the active PSA peptide (Rittenhouse et al., 1998). The cleavage of the proPSA inactive (zymogen) precursor of PSA is performed primarily in vivo by hK2 (Lilja, 1985; Rittenhouse et al., 1998; Villoutreix et al., 1994). In addition to its cleavage at the −7 residue, proPSA can also be cleaved at the −2 or −5 residue to produce catalytically inactive PSAs termed *[−2]proPSA* and *[−5]proPSA*. Finally, additional forms of inactive PSA can be formed by internal cleavages at various regions within PSA (presumably occurring in the seminal fluid after PSA is secreted). These cleaved isoforms comprise BPSA.

A small proportion of active PSA diffuses into the circulation, where it is rapidly bound or complexed by covalent attachment to protease inhibitors (most commonly, α_1-antichymotrypsin) (Christensson et al., 1993; Lilja, 1993a; Lilja et al., 1991; McCormack et al., 1995; Partin and Carter, 1996; Polascik et al., 1999; Stenman et al., 1991). Inactive PSA can also enter the bloodstream, where it circulates in an unbound state as free PSA (fPSA).

Depending on the monoclonal antibodies used to measure serum PSA, the amounts of free and complexed PSA, as well as proPSA isoforms, can be detected. This has high clinical usefulness because the various PSA derivatives have associations with benign and cancerous prostatic tissue. In prostate cancer, the loss of gland architecture and basal cells results in a decrease in the luminal processing of proPSA to active PSA (and thus an increase in proPSA) and in addition a decrease in the processing of active PSA to BPSA (thus decreasing the amount of fPSA). Thus increased levels of BPSA in the serum are found in benign disease, whereas proPSA (and particularly [−2]proPSA) and bound PSA are associated with prostate cancer (Balk et al., 2003 and Tosoian and Loeb, 2010).

Human Kallikrein 2

Human kallikrein 2 (hK2 [protein] or *KLK2* [gene]) is a prostate-specific serine protease closely related to PSA (Rittenhouse et al., 1998). hK2 was first demonstrated from a low-stringency hybridization screen of a human liver genomic library in 1992, and the amino acid sequence is predicted to have 80% homology with PSA (hK3, *KLK3*) (Young et al., 1992). The striking homology between these two “prostate-specific” proteins suggested a close physiologic relationship. More recently, recombinant hK2 has been expressed and purified (Kumar et al., 1996; Mikolajczyk et al., 1998). Unlike PSA, hK2 is shown to be trypsin-like with selective cleavage at arginine residues and has a more potent (20,000-fold greater than PSA) protease activity (Mikolajczyk et al., 1998). Monoclonal antibodies to hK2 have been developed and have a low incidence of cross-reacting with PSA (Finlay et al., 1998). As mentioned earlier, physiologically, hK2 cleaves proPSA to generate the enzymatically active form of PSA in the prostate (Kumar et al., 1996). Immunohistochemical studies have shown hK2 to be increased in expression from normal to metastatic, poorly differentiated prostatic epithelium (Darson et al., 1997), and studies of hK2 in the serum of men with prostate cancer have suggested clinical usefulness for early detection of prostate cancer (Partin et al., 1999; Vickers et al., 2010).

Human Kallikrein L1

Attempts to find other novel human kallikrein-like genes on chromosome 19 have identified yet another member of the human kallikrein gene family, *KLK-L1* (Nelson et al., 1999; Yousef et al., 1999). Nelson et al. (1999) constructed a cDNA library enriched through subtraction with the cDNAs from four other normal tissues to yield an expressed sequence tag identifying a gene that they have called *prostase*. The sequence of prostase exhibits features similar to the other members of the kallikrein family. Yousef et al. (1999) also found *KLK-L1* in breast tissue and demonstrated that it is hormonally regulated. Although the clinical usefulness of the members of the kallikrein gene family has not yet been determined, it is under investigation.

Human Kallikrein 11

Human kallikrein 11 (hK11) is a serine protease that shares similarities to human kallikrein 3 (hK3) or PSA with significant homologies at the levels of nucleotide and protein structure (Diamandis and Yousef, 2002). Localization of hK11 in epithelial cells of various organs has been demonstrated immunohistochemically, and hK11 has been further detected in amniotic fluid, milk of lactating women, cerebrospinal fluid, follicular fluid, and breast cancer cytosols. The highest levels of hK11 were observed in prostatic tissue extracts and seminal plasma, in which it was present at 300-fold lower levels than PSA. Elevated serum levels of hK11 were found in 60% of men with prostate cancer; the ratio of hK11 to total PSA was able to reduce the number of biopsies required, and the data were similar to those gleaned from fPSA assays (Diamandis and Yousef, 2002; Nakamura et al., 2003).

Human Kallikrein 14

Human kallikrein 14, a trypsin-like human kallikrein–related peptidase (KLK), has been shown to exert a significant and dose-dependent effect on semen liquefaction (Emami and Diamandis, 2008; Emami et al., 2008). Liquefaction of human semen involves proteolytic degradation of the seminal coagulum and release of motile spermatozoa. Several members of human kallikrein–related peptidases are implicated in semen liquefaction, functioning through highly regulated proteolytic cascades. Among these, *KLK3* (also known as *prostate-specific antigen*) is the main enzyme responsible for processing of the primary components of semen coagulum. *KLK14* recently has been identified as a potential activator of *KLK3* and other KLKs (Emami and Diamandis, 2008; Emami et al., 2008). Borgono et al. (2003) measured seminal plasma levels of *KLK14* by an enzyme-linked immunosorbent immunoassay (ELISA) in 36 human semen samples and found *KLK14* to be 0.6 to 23.6 µg/L (mean 10.8; median 10.7 µg/L). Semenogelin I and semenogelin II are degraded by PSA to form various biologically active peptides involved in semen liquefaction and release of motile spermatozoa. Semenogelins I and II, through chelation with the excess of free zinc, are also directly cleaved by *KLK14*, in the same manner as PSA. In addition, *KLK14* has also been demonstrated to be a potential biomarker for ovarian and breast cancer (Borgono et al., 2003).

Key Points: Secretory Proteins—Kallikreins

- Secreted prostate proteases exert a significant and dose-dependent effect on semen liquefaction.
- Among the most well-studied secreted prostate proteins are hKLK3 (PSA) and a homologous protease, hK2, which functions to cleave PSA.
- PSA and its processed derivative (i.e., BPSA, fPSA, [−2]pro-PSA), as well as hK2, have various associations with benign prostatic tissue and prostate cancer and are currently being used to aid in prostate cancer screening.

Prostate-Specific Transglutaminases

Human prostate-specific transglutaminase 4 belongs to a family of enzymes that irreversibly cross-link peptide-bound glutamine residues through reactions with either lysines or primary amines such as polyamines (Dubbink et al., 1998). Transglutaminases are located throughout the body, but they are highly tissue specific. Dubbink et al. (1998) described a new prostate-specific transglutaminase with 35-kilobase genomic DNA and consisting of 13 exons and 12 introns. The main transcription initiation site is located 52 base pairs upstream of the translational start code. At least one splice variant has been described, and a transglutaminase 4 gene *(TGM4)* promoter was analyzed by sequencing and transfection experiments and found at −1276 to −563. Subsequently, an Sp1 binding site (promoter) required for basal activity of *TGM4* was identified (Dubbink et al., 1999). The *TGM4* promoter was characterized by deletion mapping and mutational analysis. These researchers determined that positions between −113 and −87 were essential for core activity of the promoter. The sequences identified are binding sites for the Sp1 and Sp3 transcription factors; however, their precise role in *TGM4* regulation was not deduced from experiments described (Dubbink et al., 1999). Of importance is the fact that the major gel-forming proteins in semen, semenogelins I and II, are substrates for transglutaminase 4 (Peter et al., 1998). Esposito and Caputo (2005) reviewed the range of substrates for transglutaminases in detail and characterized the molecular basis of transglutaminase-catalyzed reactions and assessed possible physiologic function and pathophysiologic processes resulting from such interactions. The transglutaminase for the prostate is transglutaminase 4; it weighs 77 kD, is androgen regulated, and is found extracellularly. Transglutaminases catalyze the post-translational modification of proteins by formation of polymerized cross-linkages between the γ-carboxamide group of protein-bound glutamine residues and the ε-amino group of protein-bound lysine residues, which results in a stabilized molecular complex. There is evidence to suggest that the biochemical affinity of transglutaminase 4 for acyl-type substrates such as kinesin proteins in protein secretions of the semen may be important for correct extrusion of transglutaminase 4 from the coagulating gland (Esposito and Caputo, 2005).

An et al. (1999) also described cloning of *TGM4* (human prostate-specific transglutaminase) and its promoter in the elements of −1 to −500 and also at −520 to −1400. In addition, this group applied Northern blot hybridization and reverse transcription polymerase chain reaction (RT-PCR) analysis to confirm prostatic specificity and Gleason grade-specific expression by RT-PCR and noted significant downregulation in high Gleason grade as well as in metastatic tissue extracts. From a protein perspective, Birckbichler et al. (2000) revealed by quantitative immunofluorescence that prostate cancer was significantly decreased compared with normal prostate and prostatitis patients, but this is in contrast to what was observed with RT-PCR results (An et al., 1999), in which the higher Gleason grade tumors tended to be significantly decreased. This discrepancy of results must be rectified in larger experiments comparing RT-PCR with protein expression to determine whether this is a technical problem or rather one of translation of transglutaminase 4 mRNA versus protein in the malignant disease process.

Semenogelins I and II.

Semenogelin I and semenogelin II are dominant proteins in human semen coagulum that are degraded by PSA to form various biologically active peptides, which in combination with fibronectin give rise to the gel-like coagulum of newly ejaculated semen (de Lamirande et al., 1997; Lilja, 1985; Malm et al., 1996). The genes encoding semenogelins I and II are located in separate regions 11.5 kilobase pairs apart on chromosome 20. The major biologic function of semenogelin involves **capacitation,** which is defined as a series of changes in cell membranes, enzyme activities, and ion fluxes that sperm undergo as they traverse the female urogenital tract to reach the zona pellucida and fertilize the egg (de Lamirande et al., 1997). It has been demonstrated that biologically active peptides from semenogelin I and semenogelin II proteolysis scavenge superoxide anion and may affect sperm oxidase to serve as natural regulators of sperm capacitation (de Lamirande, 2007; de Lamirande et al., 2001). Semenogelins from the seminal vesicles and zinc ions from the prostate play a significant role in semen aggregation at the time of sperm ejaculation and also in sperm motility by binding to the sperm and then interacting with zinc (de Lamirande, 2007; Yoshida et al., 2008). It is of physiologic and possibly pathophysiologic importance that these major gel-forming proteins in semen, semenogelins I and II, are substrates for transglutaminase 4 (Peter et al., 1998). Both of these proteins originate from the glandular epithelium of the seminal vesicles and are produced in high concentrations; however, in the epididymis, only semenogelin I is expressed. There is evidence by immunohistochemistry that other cell types, including the vas deferens, prostate, and trachea, demonstrate strong signals for semenogelins I and II, and weaker but positive signals were seen in skeletal muscle cells and in the central nervous system (Lundwall et al., 2002).

Prostate-Specific Membrane Antigen.

Reviews of the biochemistry and biology of the prostate-specific membrane antigen (PSMA) in human tissues and prostate cancer surveys describe the differential regulation of the molecule, its enzymatic functions, and its potential as a biomarker for in vivo imaging, targeted therapy, and immunotherapy (Elgamal et al., 2000; Ghosh and Heston, 2004).

The gene encoding PSMA is located on chromosome 11p11-12 and codes for a type II membrane glycoprotein (molecular weight approximately 100,000 Da) with intracellular (1 to 18 amino acids), transmembrane (19 to 43 amino acids), and large extracellular (44 to 750 amino acids) domains (Davis et al., 2005; Ghosh and Heston, 2004; Israeli et al., 1994). The cDNA (2.65 kb GenBank accession number M99487) encoding PSMA was first reported by Israeli and colleagues in 1994 and its deduced amino acid sequence determined (Israeli et al., 1994). It encodes a 750–amino acid protein with a predicted molecular mass of 84 kD (excluding carbohydrates). The hydrophobic amino acids found on amino acid residues 20 to 43 suggested that this protein is a type II integral membrane protein with a small intracellular domain and a large extracellular domain (Fair et al., 1997). The promoter for PSMA has been cloned (Good et al., 1999), and PSMA has been expressed and purified from a baculovirus expression system (Lodge et al., 1999). A portion of the transmembrane domain of this protein (amino acid residues 1250 to 1700) shares 57% homology with the human transferrin receptor mRNA (Mahadevan and Saldanha, 1999). Alternative splicing variants of PSMA (PSM′-PSA′ extracellular domain protein) are under investigation to better understand the clinical significance of this important membrane protein found within the prostate (Ghosh and Heston, 2004; Grauer et al., 1998; Liu et al., 1997; Murphy et al., 1998; Rajasekaran et al., 2005). PSMA has been crystallized and its structure deduced at 3.5-Å resolution. These analyses reveal a homodimer with structural similarity to the transferrin receptor, a receptor for iron-loaded transferrin that lacks protease activity (Davis et al., 2005). However, unlike the transferrin receptor, the protease domain of PSMA (glutamate carboxypeptidase II) contains a binuclear zinc site, catalytic residues, and a proposed substrate-binding arginine patch.

PSMA is strongly expressed in the prostate and is upregulated in prostate cancer and in the neovasculature of other tumors (Chang et al., 1999b, 2001; Silver et al., 1997). In the prostate there are three alternatively spliced variants of PSMA. However, only one of these isoforms (PSM′ located at the 5′ end of PSMA cDNA) is known to be differentially expressed in normal tissue, BPH, and prostate cancer (Elgamal et al., 2000; Rajasekaran et al., 2005). PSMA mRNA expression within prostate cancers is also in the hormone-deprived state, contrary to PSA mRNA, which often demonstrates lower, even absent, expression in the hormone-deprived state (Henttu et al., 1992; Israeli et al., 1994; Rajasekaran et al., 2005; Wright et al., 1995). The association of PSMA with prostate cancer makes it a favorable target for the development of imaging molecules and therapeutics (Chandran et al., 2008; Davis et al., 2005; Lupold and Rodriguez, 2004).

Despite its name, PSMA is also expressed in many nonprostatic tissues, including the kidney, salivary gland, small intestine, and nervous system. PSMA in the central nervous system metabolizes the brain neurotransmitter *N*-acetylaspartyl-glutamate or NAAG (named NAALADase). In the intestine, PSMA is found in the proximal small intestine, where it removes γ-linked glutamates from poly-γ-glutamated folate (folate hydrolase 1), or as a carboxypeptidase, glutamate carboxypeptidase II.

Prostate Stem Cell Antigen.

Reiter et al. (1998) identified prostate stem cell antigen (PSCA), a cell surface antigen that is expressed in the prostate (among other tissues including bladder). The *PSCA* gene encodes a 123–amino acid glycoprotein, with 30% homology to stem cell antigen 2 (Sca-2). Like Sca-2, PSCA is a member of the Thy-1/Ly-6 family and is anchored by a glycosylphosphatidylinositol linkage. **By use of mRNA in situ hybridization, PSCA expression was localized in normal prostate to the basal cell epithelium, the putative stem cell compartment of prostatic epithelium; hence PSCA may be a marker of prostate stem or progenitor cells.** Hara et al. (2002) performed an analysis of PSA, PSMA, and PSCA mRNA level on peripheral blood by RT-PCR in 58 patients with prostate cancer and 71 patients with nonmalignant disorders. The results were 7 of 58 (12.1%) for PSA, 12 of 58 (20.7%) for PSMA, and 8 of 58 (13.8%) for PSCA; zero samples were positive for nonmalignant diseases. A hierarchical summary of prognostic value for the three biomarkers was as follows: PSCA was higher than PSA, which was higher than PSMA for RT-PCR of the 58 patients with prostate cancer. Note that in this group of patients, when the RT-PCR result was positive for PSCA, the patients had a lower disease progression–free survival than with the other two biomarkers. The PSCA expression increased with higher Gleason score and cancer stage as well as with progression to metastasis and may be a useful biomarker for staging of prostate cancer (Hara et al., 2002). Han et al. (2004) performed immunohistochemistry analysis of PSCA by a 246-patient tissue microarray; the results revealed that a PSCA staining intensity of 3.0 correlated with adverse prognostic features including Gleason score of 7.0 ($P = .001$), seminal vesicle invasion ($P = .005$), and capsular involvement ($P = .033$). However, after multivariate analysis, PSCA did not hold up as an independent predictor of PSA recurrence. Zhigang and Wenlv (2004) studied BPH, low-grade prostatic interepithelial neoplasia (LGPIN), high-grade prostatic interepithelial neoplasia (HGPIN), and prostate cancer at the tissue level by immunohistochemistry and at the mRNA level by in situ hybridization. In BPH and LGPIN the staining of PSCA protein and mRNA was weak or negative and less intense and uniform than in HGPIN and prostate cancer. There was moderate to strong PSCA protein as well as mRNA expression in 8 of 11 (72.7%) HGPIN and in 40 of 48 (83.4%) prostate cancer specimens that were examined by immunohistochemistry and in situ hybridization analyses. When the prostate cancer specimens examined by immunohistochemistry and in situ hybridization analyses were compared with BPH (20%) and LGPIN (22.2%) samples, the results were statistically significant ($P < .05$, respectively). The expression level of PSCA increased with high Gleason grade, advanced stage, and progression to androgen independence ($P < .05$, respectively). In addition, in this study, protein immunostaining and in situ hybridization mRNA stain showed a high degree of correlation between PSCA protein and mRNA overexpression in prostate cancer, supporting the potential of PSCA as a prognostic biomarker. Clearly, the value of this protein to the biology of prostate epithelial tissue morphogenesis and also as a new biomarker for diagnosis and treatment of prostate cancer is yet to be realized.

The potential use of PSCA, a membrane surface antigen that is highly expressed in the prostate, as a novel prostate targeting medical device for diagnostics (blood immunoassays or medical imaging) and therapy (vaccines or immunotherapy) is currently being actively studied (Olafsen et al., 2007; Raff et al., 2009). Here is another unique opportunity to use prostate developmental knowledge as a possible tool to manage prostate cancer because of its amplification during carcinogenesis.

Prostatic Acid Phosphatase.

Acid phosphatase activity is more than 200 times more abundant in prostatic tissue than in any other tissue and is the source of the high levels of acid phosphatase in ejaculate. Phosphatase enzymes hydrolyze many types of organic monophosphate esters to yield inorganic phosphate and alcohol. Many phosphatase enzymes exhibit optimal activity in vitro in the acid (pH 4 to 6) or alkaline (pH 8 to 11) ranges and are thus classified broadly as either acid or alkaline phosphatase.

Acid phosphatase activity may be further defined by factors that inhibit its enzymatic activity. For example, erythrocyte acid phosphatase is particularly sensitive to inhibition by 0.5% formaldehyde or copper ions (0.2 mM), whereas PAP activity is far more sensitive to inhibition by fluoride ions (1 mM) or L-tartrate (1 mM).

Osteoclasts are also a rich source of tartrate-insensitive acid phosphatase. Minor elevations in serum acid phosphatase levels can accompany Paget

disease, osteoporosis, nonprostatic bone metastasis, and other conditions of increased bone resorption as well as metastatic prostate cancer. All acid phosphatases hydrolyze a wide range of natural and synthetic phosphomonoesters, and this has provided a wide variety of assay systems and the expression of different units of activity, depending on the assay. These synthetic substrates include, in part, phenylphosphate (Gutman and Gutman, 1938); phenolphthalein phosphate; paranitrophenyl phosphate, also called *Sigma 104;* and thymolphthalein phosphate (Roy et al., 1971). The specificity of these substrates varies with the type and source of acid phosphatase; it appears that thymolphthalein phosphate may be the most specific substrate for assaying serum levels of prostate-specific acid phosphatase, but specific antibodies are now available for immunoassays. Interest in acid phosphatase assays in serum as a measure of prostate cancer metastasis before definitive therapy has decreased with the availability of the more sensitive and specific PSA assay (Burnett et al., 1962).

The natural substrate for PAP may be phosphorylcholine phosphate, which is rapidly hydrolyzed in the semen (Seligman et al., 1951). The biologic functions of this enzyme and its reactions are not known, but it is of interest that PAP can hydrolyze protein tyrosine phosphate esters, natural products of many oncogene protein tyrosine kinases (Li et al., 1984; Lin and Clinton, 1986). By magnetic resonance spectroscopic techniques, it has been shown that the ratio of intracellular choline to citrate levels within the prostate can help differentiate normal from cancerous prostatic tissue (Scheidler et al., 1999). Further clinical testing is required before this finding will influence clinical practice. It is unknown whether acid phosphatase is a regulatory factor in the tyrosyl protein kinase systems that are so essential as signaling mechanisms in growth factor function.

Human PAP is a glycoprotein dimer of molecular weight 102,000 and contains about 7% carbohydrate by weight, composed of 15 residues per mole of neutral sugars (fructose, galactose, and mannose), 6 residues per mole of sialic acid, and 13 residues of *N*-acetylglucosamine (Chu et al., 1977). The protein can be dissociated into two subunits of 50 kD. The activity of the purified human enzyme is 723 U/mg with α-naphthyl phosphate, and the seminal plasma contains 0.3 to 1 g/L or 177 to 760 U/mL. The high enzymatic activity of PAP is not characteristic of accessory tissues in many other species; the level is 1000 times higher per gram of tissue in the human prostate than in the rat prostate. The clinical aspects of PAP were reviewed by Romas and Kwan (Lowe and Trauzzi, 1993; Romas and Kwan, 1993).

Prostate-Specific Protein 94 (β-Microseminoprotein and β-Inhibin).

A major, cysteine-rich, nonglycosylated 16-kD protein that contains 94 amino acids has been found in prostatic secretions and named *prostate-specific protein 94* (PSP-94); it is one of the three predominant proteins secreted in the prostate glands and found in seminal fluids along with PSA and PAP. This protein had previously been designated β-inhibin and also β-MSP (Dube et al., 1987; Ulvsback et al., 1989). Transcripts of mRNA for this protein have also been identified in nongenital tissues (Ulvsback et al., 1989). The human gene for PSP-94 has been mapped to chromosome 10 (q11.2), and there are three glucocorticoid response elements and one estrogen response element in the promoter region of the first intron. Based on these observations the gene is likely regulated by hormones in humans (Nolet et al., 1991; Ochiai et al., 1995) because this also was reported in studies of the rat lateral prostate (Kwong et al., 2000). Also, Valtonen-Andre et al. (2008) demonstrated that in young, healthy males the PSP-94 levels in the serum correlate well with those in the seminal plasma ($r = 0.50$, $P < .001$). An automated immunoassay was performed with an AutoDELFIA 1235 (Wallac) and produced median values of PSP-94 in 205 young men that were 12 mg/L (2.5th to 97.5th percentile, 4.9 to 26 mg/L) in serum and 0.53 g/L (2.5th to 97.5th percentile, 0.13 to 2.0 g/L) or 1.8 mg (2.5th to 97.5th percentile, 0.32 to 6.6 mg) in seminal plasma. These data provide a solid basis for evaluation of this biomarker in healthy men and in those with prostate cancer.

One of the main biologic functions of PSP-94 is the inhibition of follicle-stimulating hormone (Garde et al., 1999). Whereas follicle-stimulating hormone is made by the pituitary gland, the prostate has been shown to be an extrapituitary source of follicle-stimulating hormone. There are follicle-stimulating hormone receptors in the prostate, and it appears that an autocrine or paracrine regulation of this hormone influences prostate epithelial proliferation (Ben-Josef et al., 1999; Porter et al., 2001). Also, Chan et al. (1999) used in situ hybridization to study expression of PSP-94 in human prostates. They found that fetal prostate at 6 to 7 months synthesizes PSA and PAP but not PSP-94, and this observation appears to relate to the development of the prostate gland. Zonal anatomic distribution of PSP-94 in the adult prostate demonstrated that the protein is expressed mostly in the acini of the peripheral zone rather than the central or transitional zones. Anahi Franchi et al. (2008) studied the PSP-94 and its potential interaction with human spermatozoa and its possible role in fertility. Using purified PSP-94, they demonstrated a specific interaction at the sperm surface. Also, using dual-antibody ELISA technology, the authors noted that of 62 patients being assessed for fertility, fertile men had a lower concentration of the protein than subfertile men and suggested that semen quality may be affected by the concentrations of PSP-94. **Another function of PSP-94 may be to interact directly with spermatozoa in a manner that can affect the quality of sperm structure and function.**

In the area of cancer, Chan et al. (1999) found that PSP-94 expression is markedly downregulated with increasing Gleason grade of prostate cancer. Furthermore, Shukeir et al. (2003) demonstrated a significant decrease in growth of the highly metastatic Dunning R3327 subline MatLyLu rat prostate model transfected with parathyroid hormone–related protein by treatment with varying doses of commercial PSP-94 purified from human seminal plasma (0, 0.1, 1.0, and 10 µg/kg/day). Serum levels of parathyroid hormone–related protein and calcium were used to monitor the efficacy of treatment with PSP-94. **Therefore PSP-94 is an effective inhibitor of hormone-independent, late-stage prostate cancer metastasis in this Dunning MatLyLu animal model.** The PSP-94 molecule has not yet been crystallized; however, Joshi and Jyothi (2002), in a computer-simulated molecular model, have predicted its structure and calculated its binding activity and related biologic activity (follicle-stimulating hormone inhibition) and immunogenic properties. Using a three-dimensional structure constructed by nuclear magnetic resonance (NMR), Ghasriani et al. (2006, 2009) have shown the PSP-94 molecule to consist of two distinct domains that form a rather extended structure. The two domains are connected to each other by the peptide backbone, one disulfide bond, and interactions between the amino and carboxyl termini and are oriented to give the molecule a rather extended structure. In addition, Ghasriani et al. (2009) have demonstrated the specific molecular interactions of the PSP-94 with cysteine-rich secretory protein 3 (CRISP-3) by applying multidimensional NMR. The CRISP proteins are ubiquitous among organisms and snake venoms, and they are reported to be calcium ion channel blockers; however, the relevance of these observations of protein-protein interactions to seminal plasma is yet to be determined.

Protein C Inhibitor.

Human semen contains several enzymes and inhibitors of the hemostatic coagulation system (Fernandez and Heeb, 2007; Lwaleed et al., 2004). In human semen, PSA exists as a molecular complex with protein C inhibitor (PCI), and the latter provides some inhibitory consequences for actions of PSA. The predominant structural proteins of coagulated semen are those proteins secreted by the seminal vesicle, including semenogelins I and II and fibronectin, and these proteins remain stable in the seminal vesicle's secretions for up to 20 hours at 37°C but rapidly cleave into small peptides on mixing with the proteases (e.g., PAP, hKLK2 [PSA], hKLK3, hKLK14) of prostatic secretion (Fernandez and Heeb, 2007; Lwaleed et al., 2004). The human PCI gene is located in chromosome 14q32.1 and is a serine protease inhibitor that corresponds to a region containing the genes of related serpins (SERPINA5) (Fernandez and Heeb, 2007; Suzuki et al., 1987, 2007). PCI is a heparin-dependent inhibitor of activated protein C (APC) that is immunologically and functionally identical to a heparin-dependent urokinase inhibitor (plasminogen activator inhibitor type 3). PCI also inhibits several other blood coagulation and fibrinolytic factors (e.g., FXa, FXI, plasma kallikrein) (Espana et al., 2007; Fernandez and Heeb, 2007; Lwaleed et al., 2004; Suzuki et al., 2007). Suzuki et al. (2007) also demonstrated that digestion of human seminal coagula with PSA releases PCI and PSA-PCI complex from the coagula into the soluble phase, suggesting the presence of active PCI within the semen coagula. PCI then forms a “ternary protein complex” with PSA and semenogelin II in the seminal plasma. The binding of semenogelin II to PSA and PCI is influenced by the molecular microenvironment, including pH, ionic strength, heparin, negatively charged dextran sulfate, divalent cations, and particularly by zinc. These observations suggest that binding of PCI to semenogelins in seminal vesicles regulates the PSA-catalyzed degradation of semenogelins in seminal plasma; the complex formation among PCI, PSA, and semenogelins is modulated by several factors in seminal plasma. Espana et al. (2007) determined that PCI is secreted at very high levels in the seminal vesicles in an active form and also occurs in high concentrations in the seminal plasma. The concentration of PCI in 40 seminal plasma samples ranged from 2.2 to 3.7 mM (i.e., about 220 mg/L), and 45% of the seminal PCI was functionally active when assayed immediately after ejaculation. Notably, infertile men had significantly decreased seminal PCI levels (0.6 to 3.2 mM). However, the concentration of PSA in seminal plasma far exceeds the capacity of PCI to inhibit this molecule and hence the biologic role of PCI in seminal plasma. Espana et al. (2007) used purified PCI to assess several functional aspects of PCI, and evidence indicated that PCI is involved in human reproduction at several key steps, including fertilization. Therefore PCI is abundant in the seminal fluid, and it plays a key role in the interaction among semenogelins, PSA, and likely other proteins in semen, resulting in protein-protein interactions critical to semen coagulation and liquefaction. A balance of seminal fluid coagulative proteins, active enzymes, and metabolites is required to effect sperm motility and successful fertilization (Espana et al., 2007; Fernandez and Heeb, 2007; Lwaleed et al., 2004; Suzuki et al., 2007).

Leucine Aminopeptidase.

Aminopeptidases hydrolyze the amino-terminal amino acid from small polypeptides. Leucine aminopeptidases are particularly active against the substrate L-leucyl-glycine, and some of these enzymes are referred to as *arylamidases* because the optimal substrate is L-leucyl-β-naphthylamine. The human prostate is rich in the arylamidase type of leucine aminopeptidase, with a presence in prostatic fluid of 30,000 units/mL.

Leucine aminopeptidase is a product of the epithelial cells of the prostate (Niemi et al., 1963) and is secreted into the lumen of the acini (Kirchheim et al., 1964; Vafa et al., 1993). Rackley et al. (1991) demonstrated that extracts from prostatic carcinoma contained less leucine aminopeptidase activity than did tissue obtained from BPH.

Lactate Dehydrogenase.

The isoenzyme ratios of LDH in human semen may be altered in a patient with prostate cancer (Grayhack et al., 1977; Oliver et al., 1970). LDH (molecular weight 150 kD) is composed of four subunits (each of 35 kD) of only two different types of proteins, denoted M and H. The LDH of muscle has four M units, and that of heart has four H units. Five isoenzymes of LDH can be found in tissues with a four-subunit composition as follows: LDH I, MMMM; LDH II, MMMH; LDH III, MMHH; LDH IV, MHHH; and LDH V, HHHH. The M and H subunits appear to be the same in all tissues, but the amounts of LDH I to V can vary. Denis and Prout (1963) observed increased levels of LDH IV and V in prostate cancer tissue. Several investigators have observed elevated ratios of LDH V/LDH I in human prostate cancer (Elhilali, 1968; Flocks and Schmidt, 1972; Oliver et al., 1970).

Immunoglobulins, C3 Complement, and Transferrin.

There are many reports establishing the presence of Igs in human seminal plasma (Gahankari and Golhar, 1993; Liang et al., 1981). It is possible to measure levels of IgG from 7 to 22 mg/dL and those of IgA from 0 to 6 mg/dL; however, IgM is at low, often undetectable levels (Friberg and Tilley-Friberg, 1976). The complete source of these antibodies is not known, although they are found in expressed prostatic fluid (Grayhack et al., 1979) and may be related to infections (Fowler et al., 1982). They are usually found at lower levels in seminal plasma than in blood, but the possibility of diffusion across the "blood–seminal plasma barrier" has not been eliminated (see discussion by Friberg and Tilley-Friberg, 1976).

Expressed prostatic fluid contains considerable amounts of the C3 component of complement, present at 1.82 mg/dL, and this increases nearly 10-fold in fluid collected from patients with prostatic adenocarcinoma to levels of 16.9 mg/dL (Grayhack and Lee, 1981). Prostatitis has also been shown to be related to C3 in men with chronic prostatitis (Blenk and Hofstetter, 1991). Prostatitis and BPH increase the level only approximately 2-fold. In the same manner, transferrin, an iron-carrying protein, is increased, going from levels of 5.3 mg/dL in normal prostatic fluid to 42.4 mg/dL in prostatic carcinoma (Grayhack and Lee, 1981).

John et al. (2003) conducted a prospective study of the ejaculate of 88 patients with chronic prostatitis by surveying IgG, IgA, and IgM and interleukin-1α, soluble interleukin-2 receptor, and interleukin-6. The control group consisted of 96 normal ejaculates according to the World Health Organization criteria. Ejaculates of patients with chronic prostatitis increased during symptoms and subsided when clinical symptoms decreased. The authors observed that a combination of the humoral immune (IgA and interleukin-6) changes and T-cell–rich infiltrates is suggestive of an autoimmune component of the disease. Alexander et al. (2004) studied a group of patients with chronic granulomatous prostatitis consisting of histologically diffuse nonspecific inflammatory changes that include epithelioid histiocytes and occasional multinucleate giant cells admixed with lymphocytes and plasma cells. They have identified an association between the major histocompatibility locus antigen HLA-DRB2*1501 and granulomatous prostatitis and have suggested the possibility that it may be an autoimmune disease.

Zinc α_2-Glycoprotein.

In the seminal plasma, zinc α_2-glycoprotein (ZAG) is synthesized by PrECs and secreted into seminal fluid (Ding et al., 2007), and it constitutes about 30% of the proteins present in the seminal fluid (Poortmans and Schmid, 1968). The ZAG glycoprotein is found in many body fluids with a molecular mass of 41 kD, and the crystal structure is similar to that of a class I major histocompatibility complex (Burgi and Schmid, 1961; Burgi et al., 1989; Delker et al., 2004; Hassan et al., 2008a, 2008b; Sanchez et al., 1999). In addition, ZAG is assigned to the chromosome 7q22.1 based on fluorescent hybridization karyotyping (Hassan et al., 2008a). The crystal structure of ZAG consists of a large groove analogous to class I major histocompatibility complex peptide-binding grooves, and the structure and environment of the groove reflect its role in immunoregulation and in lipid catabolism (Hassan et al., 2008b; Sanchez et al., 1999). ZAG appears naturally in blood, sweat, **seminal fluid,** breast cyst fluid, cerebrospinal fluid, and urine and is also found in secretory epithelial cells of the liver and the gastrointestinal tract (Hassan et al., 2008a, 2008b; Tada et al., 1991). Biochemically, ZAG stimulates lipid degeneration in adipocytes and appears to be involved in cachexia, a wasting syndrome that can affect people with cancer, acquired immunodeficiency syndrome, and other terminal illnesses (Bing et al., 2004; Hassan et al., 2008b; Hirai et al., 1998; Russell and Tisdale, 2005). The purification and characterization of ZAG from human seminal plasma revealed that it was bound to prolactin-inducible complex (PIP) (Hassan et al., 2008a). With the use of a ZAG tryptic peptide as a standard and a high-flow liquid chromatography–tandem mass spectrometry assay, serum levels in six healthy men were calculated as 3.65 (0.71) mg/L (Bondar et al., 2007). Furthermore, the concentration of ZAG and PIP has been reported to increase dramatically in carcinomas; therefore it has been considered as a good biomarker for prostate, breast, oral, and epidermal carcinomas (Hassan et al., 2008b). Thus **ZAG is a protein regulated by glucocorticoids and has the ability to affect fertilization and lipid mobilization (adipokine).**

Seminal Vesicle Secretory Proteins.

Williams-Ashman (1983) presented a classic review on regulatory features of development and function of the seminal vesicles. The secretory proteins of the seminal vesicles are major proteins and enzymes involved in the rapid clotting of the ejaculate (Cunha et al., 1992). The major clotting protein has been termed *semenogelin* (Lilja and Abrahamsson, 1988). It has been shown to be the seminal vesicle–specific antigen. These clotted proteins from the seminal vesicles serve as substrates for PSA that enzymatically lyse the clot through their protease activity (Aumuller and Seitz, 1990; Lilja, 1985). Beyond the coagulation reaction it is not known what role these seminal vesicle proteins play, but their effects on fertility and uterine sperm motility have been studied in the mouse

(Peitz and Olds-Clarke, 1986). Many of the proteins secreted by the seminal vesicles are under androgen regulation (Hagstrom et al., 1992; Higgins and Hemingway, 1991). More recent work (Harvey et al., 1995) has identified an androgen-regulated protease with elastase-like activity within seminal vesicle secretions. The semenogelins I and II are secreted in abundance by the seminal vesicles. In addition to having coagulum-forming functions and being cleaved by kallikrein-like peptidases to generate biologically active products, the semenogelins are assumed to activate sperm hyaluronidase, affect sperm motility, possess antimicrobial activity, serve as substrates for transglutaminase, and have amyloid properties (de Lamirande, 2007; Hassan et al., 2008b; Jonsson et al., 2006).

In addition, cholesterol and sphingomyelin-rich small, lipid membrane–confined exosome-like vesicles (prostasomes) have been isolated from human semen, and these structures provide an additional source of several hundred proteins that are important to fully understanding the biology of reproduction as well as improving our knowledge of the semen coagulation and liquefaction system (Arienti et al., 1999; Poliakov et al., 2009; Ronquist and Brody, 1985). Prostasomes contain numerous proteins that can affect fertility, promote sperm motility, and stabilize the acrosome reaction (Delves et al., 2007). Sucrose gradient purified prostasomes have been observed by electron microscopy, and their composition has been surveyed after trypsin digestion by liquid chromatography–mass spectroscopy (Poliakov et al., 2009). A diversity of structural and functional proteins involved in fertilization, cell adhesion, apoptosis, immunity, metabolism, signal transduction, transport, angiogenesis, and so on have been identified in prostasomes and have opened a new source of urologic scientific investigation to pursue new biomarkers of disease and elucidate mechanisms of fertility (Delves et al., 2007; Poliakov et al., 2009).

Coagulation and Liquefaction of Semen

Within 5 minutes after ejaculation, human semen coagulates into a semisolid gel. On further standing for a 5- to 20-minute period, the clot spontaneously liquefies to form a viscous liquid (Huggins and Neal, 1942; Mann and Mann, 1981; Tauber and Zaneveld, 1976). Calcium-binding substances, such as sodium citrate and heparin, do not inhibit the coagulation process, nor are prothrombin, fibrinogen, or factor XII required because they are absent in seminal plasma (Mann and Mann, 1981). The seminal clot is formed of fibers 0.15 to 10 nm in width, and its morphologic appearance differs from that of a blood fibrin clot (Huggins and Neal, 1942; Tauber and Zaneveld, 1976; Mann and Mann, 1981). Factors affecting blood coagulation do not regulate semen viscosity (Amelar, 1962). From these observations and others, it appears that the coagulation of human semen is different from that of blood.

Examination of split human ejaculates indicates that the first fraction, originating primarily from the Cowper gland and the prostate, contains the liquefaction factors. The final fraction of the ejaculate, enriched in seminal vesicle secretions, is responsible for the coagulation of the ejaculate (Lilja et al., 1987).

It has long been known that prostatic fluid has a dramatic, fibrinolytic-like activity and that 2 mL of this secretion can liquefy 100 mL of clotted blood in 18 hours at 37°C (Huggins and Neal, 1942; Mann and Mann, 1981). The factors involved in such proteolytic activity in semen have been resolved (Huggins and Neal, 1942; Lilja et al., 1987; Mann and Mann, 1981; Syner et al., 1975; Tauber et al., 1975, 1976; Tauber and Zaneveld, 1976; Zaneveld and Chatterton, 1982). Two types of seminal plasma proteolytic enzymes appear to be major factors in the liquefaction process: plasminogen activators and PSA. Two plasminogen activators have been isolated from seminal plasma; they have molecular weights of 70 and 74 kD and appear to be related to urokinase (Propping et al., 1974). It is believed that the plasminogen activators originate from the prostatic secretions.

The seminal plasma contains a variety of other proteolytic enzymes, including pepsinogen, lysozyme, α-amylase, and hyaluronidase. In addition, human semen inhibits the activity of the proteolytic enzyme trypsin, and this is the result of the presence in the seminal plasma of such proteinase inhibitors as α_1-antitrypsin and α_1-antichymotrypsin. Coagulation and liquefaction vary in different species. For example, the semen of the bull or dog does not coagulate, whereas rodents, such as the rat and guinea pig, ejaculate a firm pellet that does not appear to liquefy (Tauber and Zaneveld, 1976; Tauber et al., 1975, 1976). In rodents the plugs form through the action of an enzyme called *vesiculase*, which comes from the anterior lobe of the prostate and reacts with seminal vesicle secretions. Because of this action, the anterior lobe of the rodent prostate is also called the *coagulating gland*. Vesiculase is not identical to thrombin because it does not coagulate fibrinogen, nor does thrombin clot the secretions of the seminal vesicles. Williams-Ashman et al. (1977) have established that vesiculase has transamidase activity, catalyzing the formation of γ-glutamyl-ε-lysine cross-links in a clottable protein derived from the seminal vesicles. This seminal vesicle protein, which serves as a substrate for vesiculase, is a basic substance with a molecular weight of 17.9 kD; it has been characterized as to its physical properties.

In summary, it appears that seminal plasma coagulation and liquefaction are under enzymatic control, but the biologic purpose of this process has not been resolved. Several key enzymes (e.g., hKLK2 [PSA], hKLK3, hKLK14, PAP) and proteins (e.g., semenogelins, PSP-94, ZAG) of the seminal vesicles and prostate gland are involved in this coagulation and liquefaction system. There have been reports that some infertile men may have impairment of the liquefaction process (Amelar et al., 1977; Anahi Franchi et al., 2008; Bunge, 1970; Bunge and Sherman, 1954; Eliasson, 1973; Jonsson et al., 2006; de Lamirande, 2007; Hassan et al., 2008b; Poliakov et al., 2009).

Key Points: Coagulation and Liquefaction of Semen

- PSA is one of several serine proteases secreted by the prostate in high concentrations into the ejaculate. Although its main function may relate to regulation of semen coagulation, it has proved to be a valuable marker of prostate disease states.
- PCI is abundant in the seminal fluid, and it plays a key role in the interaction among semenogelins, PSA, and likely other proteins in semen, resulting in protein-protein interactions critical to semen coagulation and liquefaction.

Prostatic Secretions and Drug Transport

Aumuller and Seitz (1990) have reviewed the secretory mechanism for the sex accessory tissues. Isaacs (1983) also reviewed the concepts related to the fluid and drug transport properties of the prostate and seminal vesicles and has compared the composition and volume of prostatic secretion under basal stimulation and under neurologic stimulation during ejaculation or pilocarpine stimulation. Isaacs calculated that under neurologic stimulation there is a 205-fold increase in the total potassium, chloride, and sodium output over the basal secretory rate, and he has shown that the prostate is capable of secreting five times its total content of sodium and chloride during this active secretion. These findings show the tremendous transport powers of this system. Smith and Hagopian (1981) have studied the transepithelial voltage changes during prostatic secretion in the dog and have concluded that, although sodium may move passively through the plasma in the prostatic fluid during ejaculation, the movements of potassium and chloride ions involve active transcellular transport. Isaacs et al. (1983) have shown that the androgen-induced secretions can be blocked in the presence of estrogen, although the growth properties and biologic properties of the androgen on the prostate are not markedly altered. This would suggest a direct effect of estrogen in blocking a major transport system in the prostate.

Only a few compounds, including ethanol, iodine, and a few antibiotics, are capable of entering semen by simple diffusion (Reeves, 1982). Drugs entering prostatic secretions have been of interest because of the prevalence of prostatitis and the need for new modalities of chemotherapy. Earlier, Stamey and colleagues had made extensive studies of the ability of chemotherapeutic agents to concentrate in the prostatic fluid of humans and dogs (Hessl and Stamey, 1971; Stamey et al., 1973), and many other investigators have also contributed to this knowledge (Fowler et al., 1982; Madsen et al., 1968, 1976, 1978). Few drugs reach concentrations in the prostatic secretion that approach or surpass their concentrations in blood, but some exceptions are the basic macrolides erythromycin and oleandomycin, sulfonamides, chloramphenicol, tetracycline, clindamycin, trimethoprim, and fluoroquinolones (Reeves, 1982).

In general, these drugs are assumed to pass across the membrane by nonionic diffusion, possibly by lipid solubility, through the membrane; when they reach the more acidic prostatic fluid they are protonated and acquire a more positive charge. Thus the charged drugs become relatively trapped within the prostatic secretions. Several factors are critical, including the pKa of the drug and the pH of the prostatic secretions, as well as the drug binding to proteins in each compartment. Basic drugs would be more positively charged in acidic prostatic fluid than in blood. Slight changes in pH can have large effects on this nonionic diffusion. Samples of prostatic secretions from humans varied widely in pH from 6 to 8, with a mean value of 6.6; however, with prostatic inflammation the pH tended to be 7 or higher (White, 1975). Although prostatic secretions are slightly acidic, the pH of freshly ejaculated human semen is slightly alkaline (pH 7.3 to 7.7); on standing, semen first becomes more alkaline with the loss of carbon dioxide and then later acidic resulting from accumulation of lactic acid. Drugs may be developed in the future that are transported into the prostate as therapeutic agents, as chemoprotectors, or as a route to the semen to regulate fertility; however, more must be learned about the fundamental transport system in and out of the male reproductive tract before such an approach is feasible.

Key Points: Prostatic Secretions and Drug Transport

- Only a few compounds, including ethanol, iodine, and a few antibiotics, are capable of entering the semen by simple diffusion.
- A few exceptions for drugs are the basic macrolides erythromycin and oleandomycin, sulfonamides, chloramphenicol, tetracycline, clindamycin, trimethoprim, and fluoroquinolones. Perhaps these molecules, because of their lipid solubility, are transported by nonionic diffusion.

Suggested Readings

Balk SP, Ko YJ, Bubley GJ. Biology of prostate-specific antigen. *J Clin Oncol*. 2003;21(2):383–391.

Berezney R, Coffey DS. Nuclear matrix: isolation and characterization of a framework structure from rat liver nuclei. *J Cell Biol*. 1977;73:616–637.

Campisi J. Senescent cells, tumor suppression, and organismal aging: good citizens, bad neighbors. *Cell*. 2005;120:513–522.

Clement JA. Reflections on the tissue kallikrein and kallikrein-related peptidase family—from mice to men—what have we learnt in the last two decades? *Biol Chem*. 2008;389:1447–1454.

Cunha GR, Ricke W, Thomson A, et al. Hormonal, cellular, and molecular regulation of normal and neoplastic prostatic development. *J Steroid Biochem Mol Biol*. 2004;92:221–236.

de Lamirande E. Semenogelin, the main protein of the human semen coagulum, regulates sperm function. *Semin Thromb Hemost*. 2007;33:60–68.

De Marzo AM, Nelson WG, Meeker AK, et al. Stem cell features of benign and malignant prostate epithelial cells. *J Urol*. 1998;160:2381–2392.

Diamandis EP, Yousef GM. Human tissue kallikreins: a family of new cancer biomarkers. *Clin Chem*. 2002;48:1198–1205.

Dinant C, Houtsmuller AB, Vermeulen W. Chromatin structure and DNA damage repair. *Epigenetics Chromatin*. 2008;1(1):9.

Hayward SW. Approaches to modeling stromal-epithelial interactions. *J Urol*. 2002;168:1165–1172.

Josson M, Lundwall A, Malm J. The semenogelins: proteins and functions beyond reproduction? *Cell Mol Life Sci*. 2006;63:2886–2888.

Lawson DA, Xin L, et al. Prostate stem cells and prostate cancer. *Cold Spring Harb Symp Quant Biol*. 2005;70:187–196.

Luke MC, Coffey DS. The male sex accessory tissues: structure, androgen action and physiology. Knobil E, Neill JD. *The physiology of reproduction*. 2nd ed. Raven Press: New York; 1994:1435–1487.

Margueron R, Trojer P, Reinberg D. The key to development: interpreting the histone code. *Curr Opin Genet Dev*. 2005;15:163–176.

Matusik RJ, Jin RJ, Sun Q, et al. Prostate epithelial cell fate. *Differentiation*. 2008;76:682–698.

Poliakov A, Spilman M, Dokland T, et al. Structural heterogeneity and protein composition of exosome-like vesicles (prostasomes) in human semen. *Prostate*. 2009;69:159–167.

Pollard KJ, Peterson CL. Chromatin remodeling: a marriage between two families? *Bioessays*. 1998;20:771–780.

Schaeffer EM, Marchionni L, et al. Androgen-induced programs for prostate epithelial growth and invasion arise in embryogenesis and are reactivated in cancer. *Oncogene*. 2008;27(57):7180–7191.

Thomson AA. Mesenchymal mechanisms in prostate organogenesis. *Differentiation*. 2008;76(6):587–598.

References

Abate-Shen C, Shen MM, Gelmann E. Integrating differentiation and cancer: the Nkx3.1 homeobox gene in prostate organogenesis and carcinogenesis. *Differentiation*. 2008;76(6):717–727.

Ablin RJ, Soanes WA, Bronson P, et al. Precipitating antigens of the normal human prostate. *J Reprod Fertil*. 1970;22(3):573–574.

Abrahamsson PA. Neuroendocrine cells in tumour growth of the prostate. *Endocr Relat Cancer*. 1999;6(4):503–519.

Ahmed K, Goueli SA. Androgen regulation of prostatic protein phosphokinases and protein phosphorylation. *Biochem Actions Horm*. 1987;14:237–291.

Ahmed K, Yenice S, Davis A, et al. Association of casein kinase 2 with nuclear chromatin in relation to androgenic regulation of rat prostate. *Proc Natl Acad Sci USA*. 1993;90(10):4426–4430.

Albelva S. *Role of cell adhesion molecules in tumor progression and metastatic*. Academic Press: London; 1994:71–84.

Alexander RB, Greene GL, Barrack ER. Estrogen receptors in the nuclear matrix: direct demonstration using monoclonal antireceptor antibody. *Endocrinology*. 1987;120(5):1851–1857.

Alexander RB, Propert KJ, Schaeffer AJ, et al. Ciprofloxacin or tamsulosin in men with chronic prostatitis/chronic pelvic pain syndrome: a randomized, double-blind trial. *Ann Intern Med*. 2004;141(8):581–589.

Amelar RD, Dubin L, Gordon J, et al. Male infertility practice and Orthodox Jewish law. *Urology*. 1977;10(2):177–180.

Amelar RD, Hotchkiss RS. The split ejaculate: its use in the management of male infertility. *Fertil Steril*. 1965;16:46–60.

Amelar RD. Coagulation, liquefaction and viscosity of human semen. *J Urol*. 1962;87:187–190.

An G, Meka CS, Bright SP, et al. Human prostate-specific transglutaminase gene: promoter cloning, tissue-specific expression, and down-regulation in metastatic prostate cancer. *Urology*. 1999;54(6):1105–1111.

Anahi Franchi N, Avendano C, Molina RI, et al. Beta-microseminoprotein in human spermatozoa and its potential role in male fertility. *Reproduction*. 2008;136(2):157–166.

Anderson KM, Liao S. Selective retention of dihydrotestosterone by prostatic nuclei. *Nature*. 1968;219(151):277–279.

Andersson S, Berman DM, Jenkins EP, et al. Deletion of steroid 5 alpha-reductase 2 gene in male pseudohermaphroditism. *Nature*. 1991;354(6349):159–161.

Arcadi JA. Role of the ground substance in atrophy of normal and malignant prostatic tissue following estrogen administration and orchiectomy. *J Clin Endocrinol Metab*. 1954;14(10):1113–1125.

Arienti G, Saccardi C, Carlini E, et al. Distribution of lipid and protein in human semen fractions. *Clin Chim Acta*. 1999;289(1–2):111–120.

Armbruster DA. Prostate-specific antigen: biochemistry, analytical methods, and clinical application. *Clin Chem*. 1993;39(2):181–195.

Aumailley M, Bruckner-Tuderman L, Carter WG, et al. A simplified laminin nomenclature. *Matrix Biol*. 2005;24(5):326–332.

Aumuller G, Leonhardt M, Renneberg H, et al. Semiquantitative morphology of human prostatic development and regional distribution of prostatic neuroendocrine cells. *Prostate*. 2001;46(2):108–115.

Aumuller G, Seitz J, Lilja H, et al. Species- and organ-specificity of secretory proteins derived from human prostate and seminal vesicles. *Prostate*. 1990;17(1):31–40.

Aumuller G, Seitz J. Protein secretion and secretory processes in male accessory sex glands. *Int Rev Cytol*. 1990;121:127–231.

Balk SP, Ko YJ, Bubley GJ. Biology of prostate-specific antigen. *J Clin Oncol*. 2003;21(2):383–391.

Barrack ER, Coffey DS. Biological properties of the nuclear matrix: steroid hormone binding. *Recent Prog Horm Res*. 1982;38:133–195.

Barrack ER, Coffey DS. The specific binding of estrogens and androgens to the nuclear matrix of sex hormone responsive tissues. *J Biol Chem*. 1980;255(15):7265–7275.

Barrack ER. Steroid hormone receptor localization in the nuclear matrix: interaction with acceptor sites. *J Steroid Biochem*. 1987;27(1–3):115–121.

Beck F, Tata F, Chawengsaksophak K. Homeobox genes and gut development. *Bioessays*. 2000;22(5):431–441.

Bedwal RS, Bahuguna A. Zinc, copper and selenium in reproduction. *Experientia*. 1994;50(7):626–640.

Ben-Josef E, Yang SY, Ji TH, et al. Hormone-refractory prostate cancer cells express functional follicle-stimulating hormone receptor (FSHR). *J Urol*. 1999;161(3):970–976.

Benten WP, Lieberherr M, Sekeris CE, et al. Testosterone induces Ca^{2+} influx via non-genomic surface receptors in activated T cells. *FEBS Lett*. 1997;407(2):211–214.

Berezney R, Coffey DS. Nuclear matrix: isolation and characterization of a framework structure from rat liver nuclei. *J Cell Biol*. 1977;73(3):616–637.

Berg T, Bradshaw RA, Carretero OA, et al. A common nomenclature for members of the tissue (glandular) kallikrein gene families. *Agents Actions Suppl*. 1992;38(Pt 1):19–25.

Berman DM, Desai N, Wang X, et al. Roles for hedgehog signaling in androgen production and prostate ductal morphogenesis. *Dev Biol*. 2004;267(2):387–398.

Berman DM, Tian H, Russell DW. Expression and regulation of steroid 5 alpha-reductase in the urogenital tract of the fetal rat. *Mol Endocrinol*. 1995;9(11):1561–1570.

Berquin IM, Min Y, Wu R, et al. Expression signature of the mouse prostate. *J Biol Chem*. 2005;280(43):36442–36451.

Bhatia B, Maldonado CJ, Tang S, et al. Subcellular localization and tumor-suppressive functions of 15-lipoxygenase 2 (15-LOX2) and its splice variants. *J Biol Chem*. 2003;278(27):25091–25100.

Bhatia-Gaur R, Donjacour AA, Sciavolini PJ, et al. Roles for Nkx3.1 in prostate development and cancer. *Genes Dev*. 1999;13(8):966–977.

Bieberich CJ, Fujita K, He WW, et al. Prostate-specific and androgen-dependent expression of a novel homeobox gene. *J Biol Chem*. 1996;271(50):31779–31782.

Bing C, Bao Y, Jenkins J, et al. Zinc-alpha2-glycoprotein, a lipid mobilizing factor, is expressed in adipocytes and is up-regulated in mice with cancer cachexia. *Proc Natl Acad Sci USA*. 2004;101(8):2500–2505.

Birckbichler PJ, Bonner RB, Hurst RE, et al. Loss of tissue transglutaminase as a biomarker for prostate adenocarcinoma. *Cancer*. 2000;89(2):412–423.

Bissell MJ, Hall HG, Parry G. How does the extracellular matrix direct gene expression? *J Theor Biol*. 1982;99(1):31–68.

Black BE, Paschal BM. Intranuclear organization and function of the androgen receptor. *Trends Endocrinol Metab*.

2004;15(9):411–417.

Blenk H, Hofstetter A. Complement C3, coeruloplasmin and PMN-elastase in the ejaculate in chronic prostato-adnexitis and their diagnostic value. *Infection*. 1991;19(Suppl 3):S138–S140.

Boccardo F, Rubagotti A, Carmignani G, et al. Nuclear matrix proteins changes in cancerous prostate tissues and their prognostic value in clinically localized prostate cancer. *Prostate*. 2003;55(4):259–264.

Bondar OP, Barnidge DR, Klee EW, et al. LC-MS/MS quantification of Zn-alpha2 glycoprotein: a potential serum biomarker for prostate cancer. *Clin Chem*. 2007;53(4):673–678.

Borgono CA, Grass L, Soosapillai A, et al. Human kallikrein 14: a new potential biomarker for ovarian and breast cancer. *Cancer Res*. 2003;63(24):9032–9041.

Brambilla DJ, Matsumoto AM, Araujo AB, et al. The effect of diurnal variation on clinical measurement of serum testosterone and other sex hormone levels in men. *J Clin Endocrinol Metab*. 2009;94(3):907–913.

Brar PK, Dalkin BL, Weyer C, et al. Laminin alpha-1, alpha-3, and alpha-5 chain expression in human prepubertal benign prostate glands and adult benign and malignant prostate glands. *Prostate*. 2003;55(1):65–70.

Bruchovsky N, Dunstan-Adams E. Regulation of 5α-reductase activity in stroma and epithelium of human prostate. Bruchovsky N, Chapdelaine A, Neumann F. *Regulation of androgen action*. Congressdruck R. Bruckner: Berlin; 1985:31–34.

Bruchovsky N, Wilson JD. The conversion of testosterone to 5-alpha-androstan-17-beta-ol-3-one by rat prostate in vivo and in vitro. *J Biol Chem*. 1968;243(8):2012–2021.

Bunge RG, Sherman JK. Liquefaction of human semen by alpha-amylase. *Fertil Steril*. 1954;5(4):353–356.

Bunge RG. Some observations on the male ejaculate. *Fertil Steril*. 1970;21(9):639–644.

Burger PE, Xiong X, Coetzee S, et al. Sca-1 expression identifies stem cells in the proximal region of prostatic ducts with high capacity to reconstitute prostatic tissue. *Proc Natl Acad Sci USA*. 2005;102(20):7180–7185.

Burgi W, Schmid K. Preparation and properties of Zn-alpha 2-glycoprotein of normal human plasma. *J Biol Chem*. 1961;236:1066–1074.

Burgi W, Simonen S, Baudner S, et al. Unusually high concentrations of Zn alpha 2-glycoprotein and the lack of alpha 2HS-glycoprotein in human ejaculates. *Clin Chem*. 1989;35(8):1649–1650.

Burnett AL, Chan DW, Brendler CB, et al. The value of serum enzymatic acid phosphatase in the staging of localized prostate cancer. *J Urol*. 1962;148(6):1832–1834.

Burton RM, Westphal U. Steroid hormone-binding proteins in blood plasma. *Metabolism*. 1972;21(3):253–276.

Byar DP. *Zinc in male sex accessory organs: distribution and hormonal response*. Academic Press: New York; 1974:161–171.

Carbini LA, Scicli AG, Carretero OA. The molecular biology of the kallikrein-kinin system: III. The human kallikrein gene family and kallikrein substrate. *J Hypertens*. 1993;11(9):893–898.

Carter DB, Resnick MI. High resolution analysis of human prostatic fluid by two-dimensional electrophoresis. *Prostate*. 1982;3(1):27–33.

Catalona WJ, Smith DS, Ratliff TL, et al. Measurement of prostate-specific antigen in serum as a screening test for prostate cancer. *N Engl J Med*. 1991;324(17):1156–1161.

Centenera MM, Harris JM, Tilley WD, et al. The contribution of different androgen receptor domains to receptor dimerization and signaling. *Mol Endocrinol*. 2008;22(11):2373–2382.

Chan DW, Bruzek DJ, et al. Prostate-specific antigen as a marker for prostatic cancer: a monoclonal and a polyclonal immunoassay compared. *Clin Chem*. 1987;33(10):1916–1920.

Chan PS, Chan LW, Xuan JW, et al. In situ hybridization study of PSP94 (prostatic secretory protein of 94 amino acids) expression in human prostates. *Prostate*. 1999;41(2):99–109.

Chandler JA, Timms BG, Morton MS. Subcellular distribution of zinc in rat prostate studied by x-ray microanalysis: I. Normal prostate. *Histochem J*. 1977;9(1):103–120.

Chandran SS, Banerjee SR, Mease RC, et al. Characterization of a targeted nanoparticle functionalized with a urea-based inhibitor of prostate-specific membrane antigen (PSMA). *Cancer Biol Ther*. 2008;7(6):974–982.

Chang C, Saltzman A, Yeh S, et al. Androgen receptor: an overview. *Crit Rev Eukaryot Gene Expr*. 1995;5(2):97–125.

Chang CS, Kokontis J, Liao ST. Molecular cloning of human and rat complementary DNA encoding androgen receptors. *Science*. 1988;240(4850):324–326.

Chang CS, Kokontis J, Liao ST. Structural analysis of complementary DNA and amino acid sequences of human and rat androgen receptors. *Proc Natl Acad Sci USA*. 1988;85(19):7211–7215.

Chang SS, Reuter VE, Heston WD, et al. Five different anti–prostate-specific membrane antigen (PSMA) antibodies confirm PSMA expression in tumor-associated neovasculature. *Cancer Res*. 1999;59(13):3192–3198.

Chang SS, Reuter VE, Heston WD, et al. Metastatic renal cell carcinoma neovasculature expresses prostate-specific membrane antigen. *Urology*. 2001;57(4):801–805.

Chow PH, Chan CW, Cheng YL. Contents of fructose, citric acid, acid phosphatase, proteins and electrolytes in secretions of the accessory sex glands of the male golden hamster. *Int J Androl*. 1993;16(1):41–45.

Christensson A, Bjork T, Nilsson O. Serum prostate specific antigen complexed to alpha 1-antichymotrypsin as an indicator of prostate cancer. *J Urol*. 1993;150(1):100–105.

Chu TM, Wang MC, Kuciel R, et al. Enzyme markers in human prostatic carcinoma. *Cancer Treat Rep*. 1977;61(2):193–200.

Ciejek EM, Nordstrom JL, Tsai MJ, et al. Ribonucleic acid precursors are associated with the chick oviduct nuclear matrix. *Biochemistry*. 1982;21:4945–4953.

Cipolla B, Guille F, Mouinoux JP, et al. Erythrocyte polyamines and prognosis in stage D2 prostatic carcinoma patients. *J Urol*. 1994;151(3):629–633.

Clements JA. Reflections on the tissue kallikrein and kallikrein-related peptidase family—from mice to men—what have we learnt in the last two decades? *Biol Chem*. 2008;389(12):1447–1454.

Clements JA. The human kallikrein gene family: a diversity of expression and function. *Mol Cell Endocrinol*. 1994;99(1):C1–C6.

Coffey DS, Walsh PC. Clinical and experimental studies of benign prostatic hyperplasia. *Urol Clin North Am*. 1990;17(3):461–475.

Cook C, Vezina CM, Allgeier SH, et al. Noggin is required for normal lobe patterning and ductal budding in the mouse prostate. *Dev Biol*. 2007;312(1):217–230.

Cosgrove MS, Boeke JD, Wolberger C. Regulated nucleosome mobility and the histone code. *Nat Struct Mol Biol*. 2004;11(11):1037–1043.

Cosgrove MS, Wolberger C. How does the histone code work? *Biochem Cell Biol*. 2005;83(4):468–476.

Costello LC, Franklin RB. Effect of prolactin on the prostate. *Prostate*. 1994;24(3):162–166.

Costello LC, Franklin RB. Prostate epithelial cells utilize glucose and aspartate as the carbon sources for net citrate production. *Prostate*. 1989;15(4):335–342.

Couse JE, Mahato D, Eddy DM, et al. Molecular mechanism of estrogen action in the male: insights from the estrogen receptor null mice. *Reprod Fertil Dev*. 2001;13(4):211–219.

Cunha GR, Alarid ET, Turner T, et al. Normal and abnormal development of the male urogenital tract: role of androgens, mesenchymal-epithelial interactions, and growth factors. *J Androl*. 1992;13(6):465–475.

Cunha GR, Donjacour AA, Cooke PS, et al. The endocrinology and developmental biology of the prostate. *Endocr Rev*. 1987;8(3):338–362.

Cunha GR, Hayward SW, Wang YZ, et al. Role of the stromal microenvironment in carcinogenesis of the prostate. *Int J Cancer*. 2003;107(1):1–10.

Cunha GR, Lung B. The possible influence of temporal factors in androgenic responsiveness of urogenital tissue recombinants from wild-type and androgen-insensitive (Tfm) mice. *J Exp Zool*. 1978;205(2):181–193.

Cunha GR, Ricke W, Thomson A, et al. Hormonal, cellular, and molecular regulation of normal and neoplastic prostatic development. *J Steroid Biochem Mol Biol*. 2004;92(4):221–236.

Cunha GR. Epithelial-stromal interactions in development of the urogenital tract. *Int Rev Cytol*. 1976;47:137–194.

Cunha GR. Role of mesenchymal-epithelial interactions in normal and abnormal development of the mammary gland and prostate. *Cancer*. 1994;74(3 Suppl):1030–1044.

Curry PT, Atherton RW. Seminal vesicles: development, secretory products, and fertility. *Arch Androl*.

1990;25(2):107–113.

Daniels GF Jr, Grayhack JT. Physiology of prostatic secretions. *Sci Found Urol*. 1990;3:351–358.

Darson MF, Pacelli A, Roche P, et al. Human glandular kallikrein 2 (hK2) expression in prostatic intraepithelial neoplasia and adenocarcinoma: a novel prostate cancer marker. *Urology*. 1997;49(6):857–862.

Davis MI, Bennett MJ, Thomas LM, et al. Crystal structure of prostate-specific membrane antigen, a tumor marker and peptidase. *Proc Natl Acad Sci USA*. 2005;102(17):5981–5986.

Davis NS. Determination of serotonin and 5-hydroxyindoleacetic acid in guinea pig and human prostate using HPLC. *Prostate*. 1987;11(4):353–360.

Dawson RM, Mann T, White AG. Glycerylphosphorylcholine and phosphorylcholine in semen, and their relation to choline. *Biochem J*. 1957;65(4):627–634.

de Lamirande E, Leclerc P, Gagnon C. Capacitation as a regulatory event that primes spermatozoa for the acrosome reaction and fertilization. *Mol Hum Reprod*. 1997;3(3):175–194.

de Lamirande E, Yoshida K, Yoshida TM, et al. Semenogelin, the main protein of semen coagulum, inhibits human sperm capacitation by interfering with the superoxide anion generated during this process. *J Androl*. 2001;22(4):672–679.

de Lamirande E. Semenogelin, the main protein of the human semen coagulum, regulates sperm function. *Semin Thromb Hemost*. 2007;33(1):60–68.

De Marzo AM, Meeker AK, Epstein JI, et al. Prostate stem cell compartments: expression of the cell cycle inhibitor p27Kip1 in normal, hyperplastic, and neoplastic cells. *Am J Pathol*. 1998;153(3):911–919.

De Marzo AM, Nelson WG, Meeker AK, et al. Stem cell features of benign and malignant prostate epithelial cells. *J Urol*. 1998;160(6 Pt 2):2381–2392.

DeKlerk DP, Human HJ. Fluctuations of prostatic glycosaminoglycans during fetal and pubertal growth. *Prostate*. 1985;6:169–175.

DeKlerk DP, Lee D, Human HJ. Glycosaminoglycans in human prostate cancer. *J Urol*. 1984;131:1008–1012.

Delker SL, West AP Jr, McDermott L, et al. Crystallographic studies of ligand binding by Zn-alpha2-glycoprotein. *J Struct Biol*. 2004;148(2):205–213.

Delves GH, Stewart AB, Cooper AJ, et al. Prostasomes, angiogenesis, and tissue factor. *Semin Thromb Hemost*. 2007;33(1):75–79.

Denis LJ, Prout GR Jr. Lactic dehydrogenase in prostatic cancer. *Invest Urol*. 1963;96:101–111.

Diamandis EP, Yousef GM. Human tissue kallikreins: a family of new cancer biomarkers. *Clin Chem*. 2002;48(8):1198–1205.

Ding Z, Qu F, Guo W, et al. Identification of sperm forward motility-related proteins in human seminal plasma. *Mol Reprod Dev*. 2007;74(9):1124–1131.

diSant-Agnese PA, deMesy-Jensen KL, Churukien CJ, et al. Human prostatic endocrine-paracrine (APUD) cells: distribution analysis for the comparison of serotonin and neuron-specific amylase immunoreactivity in silver stains. *Arch Pathol Lab Med*. 1985;109:607–612.

diSant-Agnese PA, deMesy-Jensen KL. Endocrine-paracrine cells of the prostate and prostatic urethra: an ultrastructural study. *Hum Pathol*. 1984;15:1034–1041.

Doles J, Cook C, Shi X, et al. Functional compensation in hedgehog signaling during mouse prostate development. *Dev Biol*. 2006;295(1):13–25.

Donjacour AA, Thomson AA, Cunha GR. FGF-10 plays an essential role in the growth of the fetal prostate. *Dev Biol*. 2003;261(1):39–54.

Donnelly BJ, Lakey WH, et al. Estrogen receptor in human benign prostatic hyperplasia. *J Urol*. 1983;130(1):183–187.

Downs JA, Jackson SP. Cancer: protective packaging for DNA. *Nature*. 2003;424(6950):732–734.

Dubbink HJ, Cleutjens KB, van der Korput HA, et al. An Sp1 binding site is essential for basal activity of the human prostate-specific transglutaminase gene (TGM4) promoter. *Gene*. 1999;240(2):261–267.

Dubbink HJ, de Waal L, van Haperen R, et al. The human prostate-specific transglutaminase gene (TGM4): genomic organization, tissue-specific expression, and promoter characterization. *Genomics*. 1998;51(3):434–444.

Dube JY, Frenette G, Paquin R, et al. Isolation from human seminal plasma of an abundant 16-kDa protein originating from the prostate, its identification with a 94-residue peptide originally described as beta-inhibin. *J Androl*. 1987;8(3):182–189.

Economides KD, Capecchi MR. *Hoxb13* is required for normal differentiation and secretory function of the ventral prostate. *Development*. 2003;130(10):2061–2069.

Edwards JJ, Tollaksen SL, Anderson NG. Proteins of human semen. I. Two-dimensional mapping of human seminal fluid. *Clin Chem*. 1981;27(8):1335–1340.

Elgamal AA, Holmes EH, Su SL, et al. Prostate-specific membrane antigen (PSMA): current benefits and future value. *Semin Surg Oncol*. 2000;18(1):10–16.

Elhilali MM. Lactate dehydrogenase isoenzymes in hyperplasia and carcinoma of the prostate: a clinical study. *J Urol*. 1968;98:686–692.

Eliasson R. *Parameters of male infertility*. Harper & Row: New York; 1973:39–51.

Eliasson R. Studies on prostaglandin: occurrence, formation and biological actions. *Acta Physiol Scand*. 1959;46(Suppl 158):1–73.

Elzanaty S, Erenpreiss J, Malm J, et al. Seminal plasma albumin: origin and relation to the male reproductive parameters. *Andrologia*. 2007;39(2):60–65.

Emami N, Deperthes D, Malm J, et al. Major role of human KLK14 in seminal clot liquefaction. *J Biol Chem*. 2008;283(28):19561–19569.

Emami N, Diamandis EP. Human kallikrein–related peptidase 14 (KLK14) is a new activator component of the KLK proteolytic cascade: possible function in seminal plasma and skin. *J Biol Chem*. 2008;283(6):3031–3041.

Epstein JI, Netto G. *Prostate biopsy interpretation*. Lippincott Williams & Wilkins: Philadelphia; 2007.

Escriva H, Bertrand S, Laudet V. The evolution of the nuclear receptor superfamily. *Essays Biochem*. 2004;40:11–26.

Espana F, Navarro S, Medina P, et al. The role of protein C inhibitor in human reproduction. *Semin Thromb Hemost*. 2007;33(1):41–45.

Esposito C, Caputo I. Mammalian transglutaminases: identification of substrates as a key to physiological function and physiopathological relevance. *FEBS J*. 2005;272(3):615–631.

Etienne-Manneville S. Actin and microtubules in cell motility: which one is in control? *Traffic*. 2004;5(7):470–477.

Ewen ME. Where the cell cycle and histones meet. *Genes Dev*. 2000;14(18):2265–2270.

Faber PW, van Rooij HC, Schipper HJ, et al. Two different, overlapping pathways of transcription initiation are active on the TATA—less human androgen receptor promoter: the role of Sp1. *J Biol Chem*. 1993;268(13):9296–9301.

Fabiani R, Johansson L, Lundkvist O, et al. Prolongation and improvement of prostasome promotive effect on sperm forward motility. *Eur J Obstet Gynecol Reprod Biol*. 1995;58(2):191–198.

Fair WR, Couch J, Wehner N. Prostatic antibacterial factor: identity and significance. *Urology*. 1976;7(2):169–177.

Fair WR, Couch J, Wehner N. The purification and assay of the prostatic antibacterial factor (PAF). *Biochem Med*. 1993;8(2):329–339.

Fair WR, Israeli RS, Heston WD. Prostate-specific membrane antigen. *Prostate*. 1997;32(2):140–148.

Fair WR, Parrish RF. Antibacterial substances in prostatic fluid. *Prog Clin Biol Res*. 1981;75A:247–264.

Farnsworth WE, Brown JR. Testosterone metabolism in the prostate. *Natl Cancer Inst Monogr*. 1963;12:323–329.

Fernandez JA, Heeb MJ. Role of protein C inhibitor and tissue factor in fertilization. *Semin Thromb Hemost*. 2007;33(1):13–20.

Finlay JA, Evans CL, Day JR, et al. Development of monoclonal antibodies specific for human glandular kallikrein (hK2): development of a dual antibody immunoassay for hK2 with negligible prostate-specific antigen cross-reactivity. *Urology*. 1998;51(5):804–809.

Flocks RH, Schmidt JD. Lactate dehydrogenase isoenzyme patterns of prostatic cancer and hyperplasia. *J Surg Oncol*. 1972;4(2):161–167.

Fondell JD, Brunel F, Histake K, et al. Unliganded thyroid hormone receptor alpha can target TATA-binding protein for transcriptional repression. *Mol Cell Biol*. 1996;16(1):281–287.

Forest MG, Rivarola MA, Migeon CJ. Percentage binding of testosterone, androstenedione and dehydroisoandrosterone in human plasma. *Steroids*. 1968;12(3):323–343.

Fowler JE Jr, Kaiser DL, et al. Immunologic response of the prostate to bacteriuria and bacterial prostatitis. I. Immunoglobulin concentrations in prostatic fluid. *J Urol*. 1982;128(1):158–164.

Francis JC, Thomsen MK, Taketo MM, et al. Beta-catenin is required for prostate development and cooperates with Pten loss to drive invasive carcinoma. *PLoS Genet*. 2013;9:e1003180.

Freestone SH, Marker P, Grace OC, et al. Sonic hedgehog regulates prostatic growth and epithelial differentiation. *Dev Biol*. 2003;264(2):352–362.

Friberg J, Tilley-Friberg I. Antibodies in human seminal fluid. Hafez ESE. *Human semen and fertility regulation in men*. Mosby: St. Louis; 1976:258–264.

Fu M, Rao M, Wu K, et al. The androgen receptor acetylation site regulates cAMP and AKT but not ERK-induced activity. *J Biol Chem*. 2004;279(28):29436–29449.

Fuchs AR, Chantharaski U. Prostaglandins and male fertility. Hafez ESE. *Human semen and fertility regulation in men*. Mosby: St. Louis; 1976:187–197.

Gahankari DR, Golhar KB. An evaluation of serum and tissue bound immunoglobulins in prostatic diseases. *J Postgrad Med*. 1993;39(2):63–67.

Garde SV, Basrur VS, Li L, et al. Prostate secretory protein (PSP94) suppresses the growth of androgen-independent prostate cancer cell line (PC3) and xenografts by inducing apoptosis. *Prostate*. 1999;38(2):118–125.

Gelmann EP. Molecular biology of the androgen receptor. *J Clin Oncol*. 2002;20(13):3001–3015.

Gerber HP, Seipel K, Georgiev O, et al. Transcriptional activation modulated by homopolymeric glutamine and proline stretches. *Science*. 1994;263(5148):808–811.

Getzenberg RH, Pienta KJ, Coffey PS, et al. The tissue matrix: cell dynamics and hormone action. *Endocr Rev*.

1990;11(3):399–417.

Ghasriani H, Fernlund P, Udby L, et al. A model of the complex between human beta-microseminoprotein and CRISP-3 based on NMR data. *Biochem Biophys Res Commun*. 2009;378(2):235–239.

Ghasriani H, Teilum K, Johnson Y, et al. Solution structures of human and porcine beta-microseminoprotein. *J Mol Biol*. 2006;362(3):502–515.

Ghosh A, Heston WD. Tumor target prostate specific membrane antigen (PSMA) and its regulation in prostate cancer. *J Cell Biochem*. 2004;91(3):528–539.

Giskeødegård GF, Bertilsson H, Selnæs KM. Spermine and citrate as metabolic biomarkers for assessing prostate cancer aggressiveness. *PLoS One*. 2013;8(4):e62375.

Glass CK, Rosenfeld MG. The coregulator exchange in transcriptional functions of nuclear receptors. *Genes Dev*. 2000;14(2):121–141.

Goldstein AS, Lawson DA, Cheng D, et al. Trop2 identifies a subpopulation of murine and human prostate basal cells with stem cell characteristics. *Proc Natl Acad Sci USA*. 2008;105(52):20882–20887.

Goldsteyn ME, Hsieh JT, von Eschenbah AC. Phosphorylation status of the nuclear cytosolic androgen receptors in the rat ventral prostate. *Prostate*. 1989;14:91–101.

Gonzalez GF, Kortebani G, Mazzolli AB. Hyperviscosity and hypofunction of the seminal vesicles. *Arch Androl*. 1993;30:63–88.

Good D, Schwarzenberger P, Eastham JA, et al. Cloning and characterization of the prostate-specific membrane antigen promoter. *J Cell Biochem*. 1999;74(3):395–405.

Goueli SA, Holtzman JL, Ahmed K. Phosphorylation of the androgen receptor by a nuclear cAMP-independent protein kinase. *Biochem Biophys Res Commun*. 1984;123(2):778–

784.

Govindan MV. Specific region in hormone binding domain is essential for hormone binding and trans-activation by human androgen receptor. *Mol Endocrinol*. 1990;4(3):417–427.

Grauer LS, Lawler KD, Marignac JL, et al. Identification, purification, and subcellular localization of prostate-specific membrane antigen PSM′ protein in the LNCaP prostatic carcinoma cell line. *Cancer Res*. 1998;58(21):4787–4789.

Grayhack JT, Lee C. Evaluation of prostatic fluid in prostatic pathology. *Prog Clin Biol Res*. 1981;75A:231–246.

Grayhack JT, Wendel EF, Oliver L, et al. Analysis of specific proteins in prostatic fluid for detecting prostatic malignancy. *J Urol*. 1979;121(3):295–299.

Grayhack JT, Wendel EF, Lee C, et al. Lactate dehydrogenase isoenzymes in human prostatic fluid: an aid in recognition of malignancy? *J Urol*. 1977;118(1 Pt 2):204–208.

Grisanzio C, Signoretti S. p63 in prostate biology and pathology. *J Cell Biochem*. 2008;103(5):1354–1368.

Grishina IB, Kim SY, Ferrara C, et al. BMP7 inhibits branching morphogenesis in the prostate gland and interferes with Notch signaling. *Dev Biol*. 2005;288(2):334–347.

Gu W, Malik S, Ito M, et al. A novel human SRB/MED-containing cofactor complex, SMCC, involved in transcription regulation. *Mol Cell*. 1999;3(1):97–108.

Gunn SA, Gould TC, Anderson WA. The effect of growth hormone and prolactin preparations on the control by interstitial cell-stimulating hormone of uptake of 65-Zn by the rat dorsolateral prostate. *J Endocrinol*. 1965;32:205–214.

Gunn SA, Gould TC. The relative importance of androgen and estrogen in the selective uptake of Zn65 by the dorsolateral prostate of the rat. *Endocrinology*. 1956;58(4):443–452.

Gutman AB, Gutman EB. An acid phosphatase occurring in serum of patients with metastasizing carcinoma of the

prostate gland. *J Clin Invest*. 1938;17:473–478.
Habib FK, Ross M, Tate R, et al. Differential effect of finasteride on the tissue androgen concentrations in benign prostatic hyperplasia. *Clin Endocrinol (Oxf)*. 1997;46(2):137–144.
Hagstrom J, Harvey S, et al. Androgens are necessary for the establishment of secretory protein expression in the guinea pig seminal vesicle epithelium. *Biol Reprod*. 1992;47(5):768–775.
Hallmann R, Horn N, Selg M, et al. Expression and function of laminins in the embryonic and mature vasculature. *Physiol Rev*. 2005;85(3):979–1000.
Hammond GL. Endogenous steroid levels in the human prostate from birth to old age: a comparison of normal and diseased tissues. *J Endocrinol*. 1978;78(1):7–19.
Han KR, Seligson DB, Liu X, et al. Prostate stem cell antigen expression is associated with Gleason score, seminal vesicle invasion and capsular invasion in prostate cancer. *J Urol*. 2004;171(3):1117–1121.
Hara M, Koyanagi Y, Inoue T, et al. Some physico-chemical characteristics of “-seminoprotein,” an antigenic component specific for human seminal plasma. Forensic immunological study of body fluids and secretion. VII. *Nihon Hoigaku Zasshi*. 1971;25(4):322–324 [in Japanese].
Hara N, Kasahara T, Kawasaki T, et al. Reverse transcription-polymerase chain reaction detection of prostate-specific antigen, prostate-specific membrane antigen, and prostate stem cell antigen in one milliliter of peripheral blood: value for the staging of prostate cancer. *Clin Cancer Res*. 2002;8(6):1794–1799.
Harvey S, Vrabel A, Smith S, et al. Androgen regulation of an elastase-like protease activity in the seminal vesicle. *Biol Reprod*. 1995;52(5):1059–1065.

Hassan MI, Kumar V, Singh TP, et al. Purification and characterization of zinc alpha2-glycoprotein-prolactin inducible protein complex from human seminal plasma. *J Sep Sci*. 2008;31(12):2318–2324.

Hassan MI, Waheed A, Yadav S, et al. Zinc alpha 2-glycoprotein: a multidisciplinary protein. *Mol Cancer Res*. 2008;6(6):892–906.

Hay ED. *The cell biology of the extracellular matrix*. Plenum Press: New York; 1981.

He S, Bauman D, Davis JS, et al. Facile synthesis of site-specifically acetylated and methylated histone proteins: reagents for evaluation of the histone code hypothesis. *Proc Natl Acad Sci USA*. 2003;100(21):12033–12038.

Heathcote JG, Washington RJ. Analysis of the zinc-binding protein derived from the human benign hypertrophic prostate. *J Endocrinol*. 1973;58:421–423.

Henttu P, Liao SS, Vihko P. Androgens up-regulate the human prostate-specific antigen messenger ribonucleic acid (mRNA), but down-regulate the prostatic acid phosphatase mRNA in the LNCaP cell line. *Endocrinology*. 1992;130(2):766–772.

Hessl JM, Stamey TA. The passage of tetracyclines across epithelial membranes with special reference to prostatic epithelium. *J Urol*. 1971;106(2):253–256.

Heston WD. Prostatic polyamines and polyamine targeting as a new approach to therapy of prostatic cancer. *Cancer Surv*. 1991;11:217–238.

Higgins JR, Gosling JA. Studies on the structure and intrinsic innervation of the normal human prostate. *Prostate*. 1989;(Suppl 2):5–16.

Higgins SJ, Hemingway AL. Effects of androgens on the transcription of secretory protein genes in rat seminal vesicle. *Mol Cell Endocrinol*. 1991;76(1–3):55–61.

Hirai K, Hussey HJ, Barber MD, et al. Biological evaluation of a lipid-mobilizing factor isolated from the urine of cancer patients. *Cancer Res*. 1998;58(11):2359–2365.

Hogan BL. Morphogenesis. *Cell*. 1999;96(2):225–233.

Horsfall DJ, Mayne K, Skinner JM, et al. Glycosaminoglycans of guinea pig prostate fibromuscular stroma: influence of estrogen and androgen on levels and location of chondroitin sulfate. *Prostate*. 1994;25(6):320–332.

Horton RJ. Androgen hormones and prehormones in young and elderly men. Grayhack JT, Wilson JD, Scherbenske MJ. *Benign prostatic hyperplasia. Proceedings of a workshop sponsored by the Kidney Disease and Urology Program of the NIAMDD*. U.S. Government Printing Office: Washington (DC); 1976:183–188.

Hu R, Isaacs WB, Luo J. A snapshot of the expression signature of androgen receptor splicing variants and their distinctive transcriptional activities. *Prostate*. 2011;71(15):1656–1667.

Huang Z, Hurley PJ, Simons BW, et al. Sox9 is required for prostate development and prostate cancer initiation. *Oncotarget*. 2012;3(6):651–663.

Huang ZQ, Li J, Sachs LM, et al. A role for cofactor-cofactor and cofactor-histone interactions in targeting p300, SWI/SNF and mediator for transcription. *EMBO J*. 2003;22(9):2146–2155.

Huggins C, Neal W. Proteolytic enzymes and citrate in prostatic fluid. *J Exp Med*. 1942;7:527–541.

Husmann DA, Wilson CM, McPhaul MJ, et al. Antipeptide antibodies to two distinct regions of the androgen receptor localize the receptor protein to the nuclei of target cells in the rat and human prostate. *Endocrinology*. 1990;126(5):2359–2368.

Huss WJ, Gray DR, Werdin ES, et al. Evidence of pluripotent human prostate stem cells in a human prostate primary xenograft model. *Prostate*. 2004;60(2):77–90.

Iehle C, Delos S, Guirio O, et al. Human prostatic steroid 5 alpha-reductase isoforms—a comparative study of selective inhibitors. *J Steroid Biochem Mol Biol*. 1995;54(5–6):273–279.

Irvine RA, Ma H, Yu MC, et al. Inhibition of p160-mediated coactivation with increasing androgen receptor polyglutamine length. *Hum Mol Genet*. 2000;9(2):267–274.

Isaacs JT, Barrack ER, Isaacs ER, et al. The relationship of cellular structure and function: the matrix system. *Prog Clin Biol Res*. 1981;75A:1–24.

Isaacs JT, Brendler CB, Walsh PC. Changes in the metabolism of dihydrotestosterone in the hyperplastic human prostate. *J Clin Endocrinol Metab*. 1983;56(1):139–146.

Isaacs JT, Coffey DS. Changes in dihydrotestosterone metabolism associated with the development of canine benign prostatic hyperplasia. *Endocrinology*. 1981;108(2):445–453.

Isaacs JT. Prostatic structure and function in relation to the etiology of prostatic cancer. *Prostate*. 1983;4(4):351–366.

Israeli RS, Powell CT, Corr JG, et al. Expression of the prostate-specific membrane antigen. *Cancer Res*. 1994;54(7):1807–1811.

Ito M, Yuan CX, Malik S, et al. Identity between TRAP and SMCC complexes indicates novel pathways for the function of nuclear receptors and diverse mammalian activators. *Mol Cell*. 1999;3(3):361–370.

Jackson TA, Richer JK, Bain DL, et al. The partial agonist activity of antagonist-occupied steroid receptors is controlled by a novel hinge domain-binding coactivator L7/SPA and the corepressors N-CoR or SMRT. *Mol Endocrinol*. 1997;11(6):693–705.

John H, Maake C, Barghorn A, et al. Immunological alterations in the ejaculate of chronic prostatitis patients: clues for autoimmunity. *Andrologia*. 2003;35(5):294–299.

Johnson L, Wikstrom S, Nylander G. The vehicle for zinc in the prostatic secretion of dogs. *Scand J Urol Nephrol*. 1969;3(1):9–11.

Jones RD, English KM, Jones TH, et al. Testosterone-induced coronary vasodilatation occurs via a non-genomic mechanism: evidence of a direct calcium antagonism action. *Clin Sci*. 2004;107(2):149–158.

Jonsson M, Linse S, Frohm B, et al. Semenogelins I and II bind zinc and regulate the activity of prostate-specific antigen. *Biochem J*. 2005;387(Pt 2):447–453.

Jonsson M, Lundwall A, Maim J. The semenogelins: proteins with functions beyond reproduction? *Cell Mol Life Sci*. 2006;63(24):2886–2888.

Joshi RR, Jyothi S. Ab initio structure of human seminal plasma prostatic inhibin gives significant insight into its biological functions. *J Mol Model*. 2002;8(2):50–57.

Kadmon D. Chemoprevention in prostate cancer: the role of difluoromethylornithine (DFMO). *J Cell Biochem Suppl*. 1992;16H:122–127.

Kallio PJ, Poukka H, Moilanen A, et al. Androgen receptor-mediated transcriptional regulation in the absence of direct interaction with a specific DNA element. *Mol Endocrinol*. 1995;9(8):1017–1028.

Kavanagh JP. Isocitric and citric acid in human prostatic and seminal fluid: implications for prostatic metabolism and secretion. *Prostate*. 1994;24(3):139–142.

Kelly RW, Holland P, Skibinski G, et al. Extracellular organelles (prostasomes) are immunosuppressive components of human semen. *Clin Exp Immunol*. 1991;86(3):550–556.

Kempinas WG, Petenusci SO, Rosa e Silva AA, et al. The hypophyseal-testicular axis and sex accessory glands following chemical sympathectomy with guanethidine of pre-pubertal to mature rats. *Andrologia*. 1995;27(2):121–125.

Kemppainen JA, Lane MV, Sar M, et al. Androgen receptor phosphorylation, turnover, nuclear transport, and transcriptional activation: specificity for steroids and antihormones. *J Biol Chem*. 1992;267(2):968–974.

Kirchheim D, Gyoerkey F, Brandes D, et al. Histochemistry of the normal, hyperplastic, and neoplastic human prostate gland. *Invest Urol*. 1964;12:403–421.

Kmita M, Duboule D. Organizing axes in time and space; 25 years of colinear tinkering. *Science*. 2003;301(5631):331–333.

Knox JD, Cress AE, Clark V, et al. Differential expression of extracellular matrix molecules and the alpha 6-integrins in the normal and neoplastic prostate. *Am J Pathol*. 1994;145(1):167–174.

Kofoed JA, Tumilasci OR, Curbelo HM, et al. Effects of castration and androgens upon prostatic proteoglycans in rats. *Prostate*. 1990;16(2):93–102.

Kondo T, Zakany J, Innis JW, et al. Of fingers, toes and penises. *Nature*. 1997;390(6655):29.

Konety BR, Getzenberg RH. Nuclear structural proteins as biomarkers of cancer. *J Cell Biochem Suppl*. 1999;32–33:183–191.

Kruithof-de Julio M, Shibata M, Desai N, et al. Canonical Wnt signaling regulates Nkx3.1 expression and luminal epithelial differentiation during prostate organogenesis. *Dev Dyn*. 2013;242:1160–1171.

Kuiper GG, Faber PW, van Rooij HC, et al. Structural organization of the human androgen receptor gene. *J Mol Endocrinol*. 1989;2(3):R1–R4.

Kumar A, Goel AS, Hill TM, et al. Expression of human glandular kallikrein, hK2, in mammalian cells. *Cancer Res*.

1996;56(23):5397–5402.

Kuriyama M, Wang MC, Papsidero LD, et al. Quantitation of prostatic specific antigen serum by a sensitive enzyme immunoassay. *Cancer Res*. 1980;40:4658–4662.

Kwong J, Xuan JW, Chan PS, et al. A comparative study of hormonal regulation of three secretory proteins (prostatic secretory protein-PSP94, probasin, and seminal vesicle secretion II) in rat lateral prostate. *Endocrinology*. 2000;141(12):4543–4551.

Kyprianou N, Isaacs JT. Significance of measurable androgen levels in the rat following castration. *Prostate*. 1987;10:313–324.

Lam AL, Pazin DE, Sullivan BA. Control of gene expression and assembly of chromosomal subdomains by chromatin regulators with antagonistic functions. *Chromosoma*. 2005;114(4):242–251.

Lamano-Carvalho TL, Favaretto AL, Petenusci SO, et al. Prepubertal development of rat prostate and seminal vesicle following chemical sympathectomy with guanethidine. *Braz J Med Biol Res*. 1993;26(6):639–646.

Lamm ML, Catbagan WS, Laciak W, et al. Sonic hedgehog activates mesenchymal Gli1 expression during prostate ductal bud formation. *Dev Biol*. 2002;249(2):349–366.

Lamm ML, Podlasek CA, Barnett DH, et al. Mesenchymal factor bone morphogenetic protein 4 restricts ductal budding and branching morphogenesis in the developing prostate. *Dev Biol*. 2001;232(2):301–314.

Landers JP, Spelsberg TC. New concepts in steroid hormone action: transcription factors, proto-oncogenes, and the cascade model for steroid regulation of gene expression. *Crit Rev Eukaryot Gene Expr*. 1992;2(1):19–63.

Lasnitzki I, Franklin HR. The influence of serum on uptake, conversion and action of testosterone in rat prostate glands in organ culture. *J Endocrinol*. 1972;54(2):333–342.

Laspada A, Wilson E, Lubahn DB, et al. Androgen receptor gene mutation in X linked spinal and bulbar muscular atrophy. *Nature*. 1991;352:77–79.

Lawson DA, Xin L, Lukacs RU, et al. Isolation and functional characterization of murine prostate stem cells. *Proc Natl Acad Sci USA*. 2007;104(1):181–186.

Le Calvé M, Segalen J, Quernee D, et al. Diamine oxidase activity and biochemical markers in human seminal plasma. *Hum Reprod*. 1995;10:1141–1144.

Leong KG, Gao WQ. The Notch pathway in prostate development and cancer. *Differentiation*. 2008;76(6):699–716.

Lepor H, Kuhar MJ. Characterization and localization of the muscarinic cholinergic receptor in human prostatic tissue. *J Urol*. 1984;132(2):397–402.

Lepor H, Tang R, Shapiro E. The alpha-adrenoceptor subtype mediating the tension of human prostatic smooth muscle. *Prostate*. 1993;22(4):301–307.

Lepor H. Medical management of benign prostatic hyperplasia. *Urology*. 1993;42:483–501.

Li HC, Chernoff J, Chen LB, et al. A phosphotyrosyl-protein phosphatase activity associated with acid phosphatase from human prostate gland. *Eur J Biochem*. 1984;138(1):45–51.

Liang ZG, Kamada M, Mitsudo SM, et al. Immunoglobulin-Fc binding factor in human male reproductive organs. *Andrologia*. 1981;23(6):435–437.

Liao S, Fang S. Receptor-proteins for androgens and the mode of action of androgens on gene transcription in ventral prostate. *Vitm Horm*. 1969;27:17–90.

Lilja H, Abrahamsson PA. Three predominant proteins secreted by the human prostate gland. *Prostate*. 1988;12(1):29–38.

Lilja H, Christensson A, Dahlen U, et al. Prostate-specific antigen in serum occurs predominantly in complex with alpha-1-antichymotrypsin. *Clin Chem*. 1991;37(9):1618–1625.

Lilja H, Oldbring J, Rannevik G, et al. Seminal vesicle–secreted proteins and their reactions during gelation and liquefaction of human semen. *J Clin Invest*. 1987;80(2):281–285.

Lilja H. A kallikrein-like serine protease in prostatic fluid cleaves the predominant seminal vesicle protein. *J Clin Invest*. 1985;76(5):1899–1903.

Lilja H. Significance of different molecular forms of serum PSA: the free, noncomplexed form of PSA versus that complexed to alpha 1-antichymotrypsin. *Urol Clin North Am*. 1993;20(4):681–686.

Lilja H. Structure, function, and regulation of the enzyme activity of prostate-specific antigen. *World J Urol*. 1993;11(4):188–191.

Lin MF, Clinton GM. Human prostatic acid phosphatase has phosphotyrosyl protein phosphatase activity. *Biochem J*. 1986;235(2):351–357.

Liu AY, Nelson PS, van den Engh G, et al. Human prostate epithelial cell-type cDNA libraries and prostate expression patterns. *Prostate*. 2002;50(2):92–103.

Liu H, Moy P, Kim S, et al. Monoclonal antibodies to the extracellular domain of prostate-specific membrane antigen also react with tumor vascular endothelium. *Cancer Res*. 1997;57(17):3629–3634.

Lodge PA, Childs RA, et al. Expression and purification of prostate-specific membrane antigen in the baculovirus expression system and recognition by prostate-specific membrane antigen-specific T cells. *J Immunother*. 1999;22(4):346–355.

Loeb S, Catalona WJ. The Prostate Health Index: a new test for the detection of prostate cancer. *Ther Adv Urol*.

2014;6(2):74–77.

Love RR, Carbone PP, Verma AK, et al. Randomized phase I chemoprevention dose-seeking study of alpha-difluoromethylornithine. *J Natl Cancer Inst*. 1993;85(9):732–737.

Lowe FC, Trauzzi SJ. Prostatic acid phosphatase in 1993: its limited clinical utility. *Urol Clin North Am*. 1993;20(4):589–595.

Lu W, Luo Y, Kan M, et al. Fibroblast growth factor-10: a second candidate stromal to epithelial cell andromedin in prostate. *J Biol Chem*. 1999;274(18):12827–12834.

Lubahn DB, Joseph DR, Sullivan PM, et al. Cloning of human androgen receptor complementary DNA and localization to the X chromosome. *Science*. 1988;240(4850):327–330.

Luke MC, Coffey DS. The male sex accessory tissues: structure, androgen action and physiology. Knobil E, Neill JD. *The physiology of reproduction*. 2nd ed. Raven: New York; 1994:1435–1487.

Lundwall A, Bjartell A, Olsson AY, et al. Semenogelin I and II, the predominant human seminal plasma proteins, are also expressed in non-genital tissues. *Mol Hum Reprod*. 2002;8(9):805–810.

Lundwall A, Lilja H. Molecular cloning of human prostate specific antigen cDNA. *FEBS Lett*. 1987;214(2):317–322.

Lundwall A. Characterization of the gene for prostate-specific antigen, a human glandular kallikrein. *Biochem Biophys Res Commun*. 1989;161(3):1151–1159.

Lupien M, Eeckhoute J, Meyer CA, et al. FoxA1 translates epigenetic signatures into enhancer-driven lineage-specific transcription. *Cell*. 2008;132(6):958–970.

Lupold SE, Rodriguez R. Disulfide-constrained peptides that bind to the extracellular portion of the prostate-specific membrane antigen. *Mol Cancer Ther*. 2004;3(5):597–603.

Lwaleed BA, Greenfield R, Stewart A, et al. Seminal clotting and fibrinolytic balance: a possible physiological role in the male reproductive system. *Thromb Haemost*. 2004;92(4):752–766.

MacDonald PC. Origin of estrogen in men. Grayhack JT, Wilson JD, Scherbenske MJ. *Benign prostatic hyperplasia. Proceedings of a workshop sponsored by the Kidney Disease and Urology Program of the NIAMDD*. U.S. Government Printing Office: Washington (DC); 1976:191–192.

Madhubala R, Pegg AE. Inhibition of ornithine decarboxylase and S-adenosylmethionine decarboxylase synthesis by antisense oligodeoxynucleotides. *Mol Cell Biochem*. 1992;118(2):191–195.

Madsen PO, Baumueller A, Hoyme U. Experimental models for determination of antimicrobials in prostatic tissue, interstitial fluid and secretion. *Scand J Infect Dis Suppl*. 1978;14:145–150.

Madsen PO, Kjaer B, Baumueller A, et al. Antimicrobial agents in prostatic fluid and tissue. *Infection*. 1976;4(Suppl 2):154–156.

Madsen PO, Wolf H, Barquin OP, et al. The nitrofurantoin concentration in prostatic fluid of humans and dogs. *J Urol*. 1968;100(1):54–56.

Mahadevan D, Saldanha JW. The extracellular regions of PSMA and the transferrin receptor contain an aminopeptidase domain: implications for drug design. *Protein Sci*. 1999;8(11):2546–2549.

Mahendroo MS, Russell DW. Male and female isoenzymes of steroid 5alpha-reductase. *Rev Reprod*. 1999;4(3):179–183.

Malm J, Hellman J, Magnusson H, et al. Isolation and characterization of the major gel proteins in human semen, semenogelin I and semenogelin II. *Eur J Biochem*. 1996;238(1):48–53.

Mann T, Mann CL. *Male reproductive function and semen*. Springer-Verlag: New York; 1981.

Marcelli M, Tilley WD, Wilson CM, et al. Definition of the human androgen receptor gene structure permits the identification of mutations that cause androgen resistance: premature termination of the receptor protein at amino acid residue 588 causes complete androgen resistance. *Mol Endocrinol*. 1990;4(8):1105–1116.

Margueron R, Trojer P, Reinberg D. The key to development: interpreting the histone code? *Curr Opin Genet Dev*. 2005;15(2):163–176.

Marker PC. Does prostate cancer co-opt the developmental program? *Differentiation*. 2008;76(6):736–744.

Marriman EC, van Venrooij WJ. *The nuclear matrix and RNA processing: use of human antibodies*. Alan R. Liss: New York; 1985:315–319.

Marshall TW, Link KA, Petre-Draviam CD, et al. Differential requirement of SWI/SNF for androgen receptor activity. *J Biol Chem*. 2003;278(33):30605–30613.

Matusik RJ, Jin RJ, Sun Q, et al. Prostate epithelial cell fate. *Differentiation*. 2008;76(6):682–698.

McConnell JD. Prostatic growth: new insights into hormonal regulation. *Br J Urol*. 1995;76(Suppl 1):5–10.

McCormack RT, Rittenhouse HG, Finlay JA, et al. Molecular forms of prostate-specific antigen and the human kallikrein gene family: a new era. *Urology*. 1995;45(5):729–744.

McEwan IJ. Molecular mechanisms of androgen receptor-mediated gene regulation: structure-function analysis of the AF-1 domain. *Endocr Relat Cancer*. 2004;11(2):281–293.

McKenna NJ, Lanz RB, O'Malley BW. Nuclear receptor coregulators: cellular and molecular biology. *Endocr Rev*. 1999;20(3):321–344.

McKeon F. p63 and the epithelial stem cell: more than status quo? *Genes Dev*. 2004;18(5):465–469.

McMullen BA, Fujikawa K, Davie EW. Location of the disulfide bonds in human plasma prekallikrein: the presence of four novel apple domains in the amino-terminal portion of the molecule. *Biochemistry*. 1991;30(8):2050–2056.

McMullin RP, Mutton LN, Bieberich CJ. Hoxb13 regulatory elements mediate transgene expression during prostate organogenesis and carcinogenesis. *Dev Dyn*. 2009;238(3):664–672.

Mehta V, Schmitz CT, Keil KP, et al. Beta-catenin (CTNNB1) induces Bmp expression in urogenital sinus epithelium and participates in prostatic bud initiation and patterning. *Dev Biol*. 2013;376:125–135.

Mehta V, Abler LL, Keil KP, et al. Atlas of Wnt and R-spondin gene expression in the developing male mouse lower urogenital tract. *Dev Dyn*. 2011;240:2548–2560.

Metzger DA, Korach KS. Cell-free interaction of the estrogen receptor with mouse uterine nuclear matrix: evidence of saturability, specificity, and resistance to KCl extraction. *Endocrinology*. 1990;126(4):2190–2195.

Mikolajczyk SD, Catalona WJ, Evans CL, et al. Proenzyme forms of prostate-specific antigen in serum improve the detection of prostate cancer. *Clin Chem*. 2004;50(6):1017–1025.

Mikolajczyk SD, Millar LS, Wang TJ, et al. A precursor form of prostate-specific antigen is more highly elevated in prostate cancer compared with benign transition zone prostate tissue. *Cancer Res*. 2000;60(3):756–759.

Mikolajczyk SD, Millar LS, Wang TJ, et al. BPSA, a specific molecular form of free prostate-specific antigen, is found predominantly in the transition zone of patients with nodular benign prostatic hyperplasia. *Urology*. 2000;55(1):41–45.

Mikolajczyk SD, Millar LS, Kumar A, et al. Human glandular kallikrein, hK2, shows arginine-restricted specificity and forms complexes with plasma protease inhibitors. *Prostate*. 1998;34(1):44–50.

Miner JH, Yurchenco PD. Laminin functions in tissue morphogenesis. *Annu Rev Cell Dev Biol*. 2004;20:255–284.

Mizokami A, Yeh SY, Chang C. Identification of 3′,5′-cyclic adenosine monophosphate response element and other *cis*-acting elements in the human androgen receptor gene promoter. *Mol Endocrinol*. 1994;8(1):77–88.

Moad M, Hannezo E, Buczacki SJ, et al. Multipotent basal stem cells, maintained in localized proximal niches, support directed long-ranging epithelial flows in human prostates. *Cell Rep*. 2017;20:1609–1622.

Mobbs BG, Johnson IE, Connolly JG, et al. Influence of the adrenal gland on prostatic activity in adult rats. *J Endocrinol*. 1973;59(2):335–344.

Moilanen AM, Poukka H, Karvonen U, et al. Identification of a novel RING finger protein as a coregulator in steroid receptor–mediated gene transcription. *Mol Cell Biol*. 1998;18(9):5128–5139.

Murphy GP, Elgamal AA, Su SL, et al. Current evaluation of the tissue localization and diagnostic utility of prostate specific membrane antigen. *Cancer*. 1998;83(11):2259–2269.

Naar AM, Beaurang PA, Zhou S, et al. Composite co-activator ARC mediates chromatin-directed transcriptional activation. *Nature*. 1999;398(6730):828–832.

Nair SC, Toran EJ, Rimerman RA, et al. A pathway of multi-chaperone interactions common to diverse regulatory proteins: estrogen receptor, Fes tyrosine kinase, heat shock transcription factor Hsf1, and the aryl hydrocarbon receptor. *Cell Stress Chaperones*. 1996;1(4):237–250.

Nakamura T, Scorilas A, Stephan C, et al. The usefulness of serum human kallikrein 11 for discriminating between prostate cancer and benign prostatic hyperplasia. *Cancer Res*. 2003;63(19):6543–6546.

Naslund MJ, Coffey DS. *Benign prostatic hyperplasia. U.S. Department of Health and Human Services, NIH publication 2(87–2881)*. National Institutes of Health: Bethesda (MD); 1987:73–83.

Naslund MJ, Coffey DS. The differential effects of neonatal androgen, estrogen and progesterone on adult rat prostate growth. *J Urol*. 1986;136(5):1136–1140.

Nelson PS, Gan L, Ferguson C, et al. Molecular cloning and characterization of prostase, an androgen-regulated serine protease with prostate-restricted expression. *Proc Natl Acad Sci USA*. 1999;96(6):3114–3119.

Nelson WG, Pienta KJ, Barrack ER, et al. The role of the nuclear matrix in the organization and function of DNA. *Annu Rev Biophys Chem*. 1986;15:457–475.

Niemi M, Harkonen M, Larmi TK, et al. Enzymic histochemistry of human prostate: localization of oxidative enzymes, esterase, and aminopeptidase in the normal and hyperplastic human prostate. *Arch Pathol*. 1963;75:528–537.

Nolet S, St-Louis D, Mbikay M, et al. Rapid evolution of prostatic protein PSP94 suggested by sequence divergence between rhesus monkey and human cDNAs. *Genomics*. 1991;9(4):775–777.

O'Malley B. The year in basic science: nuclear receptors and coregulators. *Mol Endocrinol*. 2008;22(12):2751–2758.

Obiezu CV, Diamandis EP. Human tissue kallikrein gene family: applications in cancer. *Cancer Lett*. 2005;224(1):1–22.

Ochiai Y, Inazawa J, Ueyama H, et al. Human gene for beta-microseminoprotein: its promoter structure and chromosomal localization. *J Biochem*. 1995;117(2):346–352.

Oesterling JE, Chan DW, Epstein JI, et al. Prostate specific antigen in the preoperative and postoperative evaluation of localized prostatic cancer treated with radical prostatectomy. *J Urol*. 1988;139(4):766–772.

Oesterling JE, Epstein JI, Walsh PC, et al. The inability of adrenal androgens to stimulate the adult human prostate: an autopsy evaluation of men with hypogonadotropic hypogonadism and panhypopituitarism. *J Urol*. 1986;136(5):1030–1034.

Olafsen T, Gu Z, Sherman MA, et al. Targeting, imaging, and therapy using a humanized antiprostate stem cell antigen (PSCA) antibody. *J Immunother*. 2007;30(4):396–405.

Oliver JA, el-Hilali MM, Belitsky P, et al. LDH isoenzymes in benign and malignant prostate tissue: the LDH V-I ratio as an index of malignancy. *Cancer*. 1970;25(4):863–866.

Palvimo JJ, Kallio PJ, Ikonen T, et al. Dominant negative regulation of *trans*-activation by the rat androgen receptor: roles of the *N*-terminal domain and heterodimer formation. *Mol Endocrinol*. 1993;7(11):1399–1407.

Pardoll DM, Vogelstein B, Coffey DS. A fixed site of DNA replication in eucaryotic cells. *Cell*. 1980;19(2):527–536.

Partin AW, Carter HB, Chan DW, et al. Prostate specific antigen in the staging of localized prostate cancer: influence of tumor differentiation, tumor volume and benign hyperplasia. *J Urol*. 1990;143(4):747–752.

Partin AW, Carter HB. The use of prostate-specific antigen and free/total prostate-specific antigen in the diagnosis of localized prostate cancer. *Urol Clin North Am*. 1996;23(4):531–540.

Partin AW, Catalona WJ, Finlay JA, et al. Use of human glandular kallikrein 2 for the detection of prostate cancer: preliminary analysis. *Urology*. 1999;54(5):839–845.

Pazin MJ, Kadonaga JT. SWI2/SNF2 and related proteins: ATP-driven motors that disrupt protein-DNA interactions? *Cell*.

1997;88(6):737–740.

Peehl DM. Primary cell cultures as models of prostate cancer development. *Endocr Relat Cancer*. 2005;12(1):19–47.

Peitz B, Olds-Clarke P. Effects of seminal vesicle removal on fertility and uterine sperm motility in the house mouse. *Biol Reprod*. 1986;35(3):608–617.

Peter A, Lilja H, Lundwall A, et al. Semenogelin I and semenogelin II, the major gel-forming proteins in human semen, are substrates for transglutaminase. *Eur J Biochem*. 1998;252(2):216–221.

Peterson CL, Tamkun JW. The SWI-SNF complex: a chromatin remodeling machine? *Trends Biochem Sci*. 1995;20(4):143–146.

Peterziel H, Mink S, Schonert A, et al. Rapid signalling by androgen receptor in prostate cancer cells. *Oncogene*. 1999;18(46):6322–6329.

Phadke AM, Samant NR, Deval SD, et al. Significance of seminal fructose studies in male infertility. *Fertil Steril*. 1973;24(11):894–903.

Phelan ML, Schnitzler GR, Kingston RE. Octamer transfer and creation of stably remodeled nucleosomes by human SWI-SNF and its isolated ATPases. *Mol Cell Biol*. 2000;20(17):6380–6389.

Pienta KJ, Murphy BC, et al. The tissue matrix and the regulation of gene expression in cancer cell. *Adv Mol Cell Biol*. 1993;7:131–156.

Podlasek CA, Duboule D, Bushman W, et al. Male accessory sex organ morphogenesis is altered by loss of function of *Hoxd-13*. *Dev Dyn*. 1997;208(4):454–465.

Polascik TJ, Oesterling JE, Partin AW. Prostate specific antigen: a decade of discovery—what we have learned and where we are going. *J Urol*. 1999;162(2):293–306.

Poliakov A, Spilman M, Dokland T, et al. Structural heterogeneity and protein composition of exosome-like vesicles (prostasomes) in human semen. *Prostate*. 2009;69(2):159–167.

Pollard KJ, Peterson CL. Chromatin remodeling: a marriage between two families? *Bioessays*. 1998;20(9):771–780.

Poortmans JR, Schmid K. The level of Zn-alpha 2-glycoprotein in normal human body fluids and kidney extract. *J Lab Clin Med*. 1968;71(5):807–811.

Porter AT, Ben-Josef E. Humoral mechanisms in prostate cancer: a role for FSH. *Urol Oncol*. 2001;6(4):131–138.

Poukka H, Karvonen U, Yoshikawa N, et al. The RING finger protein SNURF modulates nuclear trafficking of the androgen receptor. *J Cell Sci*. 2000;113(Pt 17):2991–3001.

Pourian MR, Kvist U, Bjorndahl L, et al. Rapid and slow hydroxylators of seminal E prostaglandins among men in barren unions. *Andrologia*. 1995;27(2):71–79.

Powers CA, Mathur M, Raaka BM, et al. TLS (translocated-in-liposarcoma) is a high-affinity interactor for steroid, thyroid hormone, and retinoid receptors. *Mol Endocrinol*. 1998;12(1):4–18.

Pratt WB, Toft DO. Steroid receptor interactions with heat shock protein and immunophilin chaperones. *Endocr Rev*. 1997;18(3):306–360.

Price D. Comparative aspects of development and structure in the prostate. *Natl Cancer Inst Monogr*. 1963;12:1–27.

Prins GS, Birch L, Course JF, et al. Estrogen imprinting of the developing prostate gland is mediated through stromal estrogen receptor alpha: studies with alphaERKO and betaERKO mice. *Cancer Res*. 2001;61(16):6089–6097.

Prins GS, Birch L. The developmental pattern of androgen receptor expression in rat prostate lobes is altered after neonatal exposure to estrogen. *Endocrinology*. 1995;136(3):1303–1314.

Pritchard C, Mecham B, Dumpit R, et al. Conserved gene expression programs integrate mammalian prostate development and tumorigenesis. *Cancer Res*. 2009;69(5):1739–1747.

Propping D, Tauber PF, Zaneveld LJD, et al. Purification and characterization of two plasminogen activators from human seminal plasma. *Fed Proc*. 1974;33:289–293.

Rachez C, Suldan Z, Ward J, et al. A novel protein complex that interacts with the vitamin D_3 receptor in a ligand-dependent manner and enhances VDR transactivation in a cell-free system. *Genes Dev*. 1998;12(12):1787–1800.

Rackley RR, Yang B, Pretlow TG, et al. Differences in the leucine aminopeptidase activity in extracts from human prostatic carcinoma and benign prostatic hyperplasia. *Cancer*. 1991;68(3):587–593.

Raff AB, Gray A, Kast WM. Prostate stem cell antigen: a prospective therapeutic and diagnostic target. *Cancer Lett*. 2009;277(2):126–132.

Rajasekaran AK, Anilkumar G, Christiansen JJ. Is prostate-specific membrane antigen a multifunctional protein? *Am J Physiol Cell Physiol*. 2005;288(5):C975–C981.

Rajfer J, Coffey DS. Effects of neonatal steroids on male sex tissues. *Invest Urol*. 1979;17(1):3–8.

Rajfer J, Coffey DS. Sex steroid imprinting of the immature prostate: long-term effects. *Invest Urol*. 1978;16(3):186–190.

Rao MA, Cheng H, Quayle AN. RanBPM, a nuclear protein that interacts with and regulates transcriptional activity of androgen receptor and glucocorticoid receptor. *J Biol Chem*. 2002;277(50):48020–48027.

Reed MJ, Stitch SR. The uptake of testosterone and zinc in vitro by the human benign hypertrophic prostate. *J Endocrinol*. 1973;58(3):405–419.

Reeves DS. Pharmacology of the prostate. Chisholm GD, Williams DI. *Scientific foundations of urology*. 2nd ed. William Heinemann: London; 1982:514–520.

Reeves R, Beckerbauer LM. HMGA proteins as therapeutic drug targets. *Prog Cell Cycle Res*. 2003;5:279–286.

Reigman PH, Vliestra RJ, van der Korput J, et al. Characterization of the human kallikrein locus. *Genomics*. 1992;14:6–11.

Reiter RE, Gu Z, Watabe T, et al. Prostate stem cell antigen: a cell surface marker overexpressed in prostate cancer. *Proc Natl Acad Sci USA*. 1998;95(4):1735–1740.

Risbridger GP, Almahbobi GA, Taylor RA. Early prostate development and its association with late-life prostate disease. *Cell Tissue Res*. 2005;322(1):173–181.

Rittenhouse HG, Finlay JA, Micolajcyk SD. Human kallikrein 2 (hK2) and prostate-specific antigen (PSA): two closely related, but distinct, kallikreins in the prostate. *Crit Rev Clin Lab Sci*. 1998;35(4):275–368.

Rittmaster RS. Finasteride. *N Engl J Med*. 1994;330(2):120–125.

Roche PJ, Hoare SA, Parker MG. A consensus DNA-binding site for the androgen receptor. *Mol Endocrinol*. 1992;6(12):2229–2235.

Rokhlin OW, Cohen MB. Expression of cellular adhesion molecules on human prostate tumor cell lines. *Prostate*. 1995;26(4):205–212.

Romas NA, Kwan DJ. Prostatic acid phosphatase: biomolecular features and assays for serum determination. *Urol Clin North Am*. 1993;20(4):581–588.

Ronquist G, Brody I. The prostasome: its secretion and function in man. *Biochim Biophys Acta*. 1985;822(2):203–218.

Roy AV, Brower ME, Hayden JE. Sodium thymolphthalein monophosphate: a new acid phosphatase substrate with greater specificity for the prostatic enzyme in serum. *Clin*

Chem. 1971;17(11):1093–1102.

Rui H, Mevag B, Purvis K. Two-dimensional electrophoresis of proteins in various fractions of the human split ejaculate. *Int J Androl*. 1984;7(6):509–520.

Russell DW, Wilson JD. Steroid 5 alpha-reductase: two genes/two enzymes. *Annu Rev Biochem*. 1994;63:25–61.

Russell ST, Tisdale MJ. The role of glucocorticoids in the induction of zinc-alpha2-glycoprotein expression in adipose tissue in cancer cachexia. *Br J Cancer*. 2005;92(5):876–881.

Ryu S, Zhou S, Ladurner AG. The transcriptional cofactor complex CRSP is required for activity of the enhancer-binding protein Sp1. *Nature*. 1999;397(6718):446–450.

Sadar MD, Hussain M, Bruchovsky N. Prostate cancer: molecular biology of early progression to androgen independence. *Endocr Relat Cancer*. 1999;6(4):487–502.

Saedi MS, Zhu Z, Marker K, et al. Human kallikrein 2 (hK2), but not prostate-specific antigen (PSA), rapidly complexes with protease inhibitor 6 (PI-6) released from prostate carcinoma cells. *Int J Cancer*. 2001;94(4):558–563.

Salm SN, Burger PE, Coetzee S, et al. TGF-β maintains dormancy of prostatic stem cells in the proximal region of ducts. *J Cell Biol*. 2005;170(1):81–90.

Sanchez LM, Chirino AJ, et al. Crystal structure of human ZAG, a fat-depleting factor related to MHC molecules. *Science*. 1999;283(5409):1914–1919.

Sansone G, Martino M, Bjorkman PJ. Binding of free and protein-associated zinc to rat spermatozoa. *Comp Biochem Physiol C*. 1991;99(1–2):113–117.

Saporita AJ, Zhang Q, Navai N, et al. Identification and characterization of a ligand-regulated nuclear export signal in androgen receptor. *J Biol Chem*. 2003;278(43):41998–42005.

Savory JG, Hsu B, Laquian IR, et al. Discrimination between NL1- and NL2-mediated nuclear localization of the glucocorticoid receptor. *Mol Cell Biol*. 1999;19(2):1025–1037.

Schaeffer EM, Marchionni L, Huang Z, et al. Androgen-induced programs for prostate epithelial growth and invasion arise in embryogenesis and are reactivated in cancer. *Oncogene*. 2008;27(57):7180–7191.

Schalken JA, van Leenders G. Cellular and molecular biology of the prostate: stem cell biology. *Urology*. 2003;62(5 Suppl 1):11–20.

Scheidler J, Hricak H, Vigneron DB, et al. Prostate cancer: localization with three-dimensional proton MR spectroscopic imaging—clinicopathologic study. *Radiology*. 1999;213(2):473–480.

Schmierer B, Hill CS. TGFbeta-SMAD signal transduction: molecular specificity and functional flexibility. *Nat Rev Mol Cell Biol*. 2007;8(12):970–982.

Schoenmakers E, Verrijdt G, Peeters B, et al. Differences in DNA binding characteristics of the androgen and glucocorticoid receptors can determine hormone-specific responses. *J Biol Chem*. 2000;275(16):12290–12297.

Seamonds B, Yang N, Anderson K, et al. Evaluation of prostate-specific antigen and prostatic acid phosphatase as prostate cancer markers. *Urology*. 1986;28(6):472–479.

Seligman AM, Chauncey HH, Nachlas MM, et al. The colorimetric determination of phosphatases in human serum. *J Biol Chem*. 1951;190(1):7–15.

Seligman AM, Sternberger NJ, Paul BD, et al. Design of spindle poisons activated specifically by prostatic acid phosphatase (PAP) and new methods for PAP cytochemistry. *Cancer Chemother Rep*. 1975;59(1):233–242.

Serkova NJ, Gamito EJ, Jones RH, et al. The metabolites citrate, myo-inositol, and spermine are potential age-independent markers of prostate cancer in human expressed prostatic secretions. *Prostate*. 2008;68(6):620–628.

Shaffer PL, Jivan A, Dollins DE, et al. Structural basis of androgen receptor binding to selective androgen response elements. *Proc Natl Acad Sci USA*. 2004;101(14):4758–4763.

Shappell SB, Boeglin WE, Olson SJ, et al. 15-lipoxygenase-2 (15-LOX-2) is expressed in benign prostatic epithelium and reduced in prostate adenocarcinoma. *Am J Pathol*. 1999;155(1):235–245.

Sharifi N. Steroid receptors aplenty in prostate cancer. *N Engl J Med*. 2014;370(10):970–971.

Sharma M, Zarnegar M, Li X, et al. Androgen receptor interacts with a novel MYST protein, HBO1. *J Biol Chem*. 2000;275(45):35200–35208.

Shaw A, Bushman W. Hedgehog signaling in the prostate. *J Urol*. 2007;177(3):832–838.

Sheflin L, Keegan B, Zhang W, et al. Inhibiting proteasomes in human HepG2 and LNCaP cells increases endogenous androgen receptor levels. *Biochem Biophys Res Commun*. 2000;276(1):144–150.

Shukeir N, Arakelian A, Khadim S, et al. Prostate secretory protein PSP-94 decreases tumor growth and hypercalcemia of malignancy in a syngenic in vivo model of prostate cancer. *Cancer Res*. 2003;63(9):2072–2078.

Signoretti S, Waltregny D, Dilks J, et al. p63 is a prostate basal cell marker and is required for prostate development. *Am J Pathol*. 2000;157(6):1769–1775.

Sikes RA, Kao C, Chung LW. Autocrine and paracrine mediators for prostate growth in cancer progression. *Adv Urol*. 1995;8:21–60.

Silver DA, Pellicer I, Fair WR, et al. Prostate-specific membrane antigen expression in normal and malignant human tissues. *Clin Cancer Res*. 1997;3(1):81–85.

Silver RI, Wiley EL, Thigpen AE, et al. Cell type specific expression of steroid 5 alpha-reductase 2. *J Urol*. 1994;152(2 Pt 1):438–442.

Simons BW, Hurley PJ, Huang Z, et al. Wnt signaling though beta-catenin is required for prostate lineage specification. *Dev Biol*. 2012;371:246–255.

Singh J, Zhu Q, Handelsman DJ. Stereological evaluation of mouse prostate development. *J Androl*. 1999;20(2):251–258.

Sinha AA, Gleason DF, Wilson MJ, et al. Immunohistochemical localization of laminin in the basement membranes of normal, hyperplastic, and neoplastic human prostate. *Prostate*. 1989;15(4):299–313.

Smith DF. Chaperones in progesterone receptor complexes. *Semin Cell Dev Biol*. 2000;11(1):45–52.

Smith ER, Hagopian M. Uptake and secretion of carcinogenic chemicals by the dog and rat prostate. *Prog Clin Biol Res*. 1981;75B:131–163.

Stamey TA, Bushby SR, Bragonie J. The concentration of trimethoprim in prostatic fluid: nonionic diffusion or active transport? *J Infect Dis*. 1973;128(Suppl):686–692.

Stamey TA, Fair WR, Timothy MM, et al. Antibacterial nature of prostatic fluid. *Nature*. 1968;218(140):444–447.

Stamey TA, Yang N, Hay AR, et al. Prostate-specific antigen as a serum marker for adenocarcinoma of the prostate. *N Engl J Med*. 1987;317(15):909–916.

Steiner MS. Growth factors in urology. *Urology*. 1993;42:99–110.

Stenman UH, Leinonen J, Alfthan H, et al. A complex antigen and alpha 1-antichymotrypsin is the major form of prostate-specific antigen in serum of patients with prostate cancer: assay of the complex improves clinical sensitivity for cancer. *Cancer Res*. 1991;51:222–226.

Sudarsanam P, Winston F. The Swi/Snf family nucleosome-remodeling complexes and transcriptional control. *Trends*

Genet. 2000;16(8):345–351.

Sugimura Y, Cunha GR, Donjacour AA, et al. Morphogenesis of ductal networks in the mouse prostate. *Biol Reprod*. 1986;34(5):961–971.

Sun X, Zhang Y, Cho H, et al. NAT, a human complex containing Srb polypeptides that functions as a negative regulator of activated transcription. *Mol Cell*. 1998;2(2):213–222.

Suzuki K, Deyashiki Y, Nishioka J, et al. Characterization of a cDNA for human protein C inhibitor: a new member of the plasma serine protease inhibitor superfamily. *J Biol Chem*. 1987;262(2):611–616.

Suzuki K, Kise H, Nishioka J, et al. The interaction among protein C inhibitor, prostate-specific antigen, and the semenogelin system. *Semin Thromb Hemost*. 2007;33(1):46–52.

Suzuki T, Nakajima K, Yamamoto A, et al. Metallothionein binding zinc inhibits nuclear chromatin decondensation of human spermatozoa. *Andrologia*. 1995;27(3):161–164.

Suzuki T, Suzuki K, et al. Metallothionein in human seminal plasma. *Int J Urol*. 1994;1(4):345–348.

Syner FN, Moghissi KS, Yanez J. Isolation of a factor from normal human semen that accelerates dissolution of abnormally liquefying semen. *Fertil Steril*. 1975;26(11):1064–1069.

Szczyrba J, Niesen A, Wagner M, et al. Neuroendocrine cells of the prostate derive from the neural crest. *J Biol Chem*. 2017;292:2021–2031.

Tada T, Ohkubo I, Niwa M, et al. Immunohistochemical localization of Zn-alpha 2-glycoprotein in normal human tissues. *J Histochem Cytochem*. 1991;39(9):1221–1226.

Takeda H, Mizuno T, Lasnitzki I. Autoradiographic studies of androgen-binding sites in the rat urogenital sinus and postnatal prostate. *J Endocrinol*. 1985;104(1):87–92.

Tan JA, Marschkek B, et al. *Androgen receptor stimulated transcriptional activation mediated by GRE/PRE–like sequences within the prostatein C3 subunit gene*. [Paper presented at: 72nd Annual Endocrine Society Meeting] 1990 [Atlanta, GA].

Tauber PF, Zaneveld LJ, Propping D, et al. Components of human split ejaculates. I. Spermatozoa, fructose, immunoglobulins, albumin, lactoferrin, transferrin and other plasma proteins. *J Reprod Fertil*. 1975;43(2):249–267.

Tauber PF, Zaneveld LJ, Propping D, et al. Components of human split ejaculates. II. Enzymes and proteinase inhibitors. *J Reprod Fertil*. 1976;46(1):165–171.

Tauber PF, Zaneveld LJ. Coagulation and liquefaction of human semen. Hafez ES. *Human semen and fertility regulation in men*. Mosby: St. Louis; 1976.

Tawfic S, Goueli SA, Ahmed K, et al. Androgenic regulation of phosphorylation and stability of nucleolar protein nucleolin in rat ventral prostate. *Prostate*. 1994;24(2):101–106.

Tawfic S, Goueli SA, Olson MO, et al. Androgenic regulation of the expression and phosphorylation of prostatic nucleolar protein B23. *Cell Mol Biol Res*. 1993;39(1):43–51.

Taylor RA, Risbridger GP. Prostatic tumor stroma: a key player in cancer progression. *Curr Cancer Drug Targets*. 2008;8(6):490–497.

Tenniswood M. Role of epithelial-stromal interactions in control of gene expression in the prostate: an hypothesis. *Prostate*. 1986;9(4):375–385.

Thielen JL, Volzing KG, Collier LS, et al. Markers of prostate region-specific epithelial identity define anatomical locations in the mouse prostate that are molecularly similar to human prostate cancers. *Differentiation*. 2007;75(1):49–61.

Thompson M, Lapointe J, Choi YL, et al. Identification of candidate prostate cancer genes through comparative expression-profiling of seminal vesicle. *Prostate*. 2008;68(11):1248–1256.

Thomsen MK, Butler CM, Shen MM, et al. Sox9 is required for prostate development. *Dev Biol*. 2008;316(2):302–311.

Thomson AA. Mesenchymal mechanisms in prostate organogenesis. *Differentiation*. 2008;76(6):587–598.

Thomson AA. Role of androgens and fibroblast growth factors in prostatic development. *Reproduction*. 2001;121(2):187–195.

Timms BG. Prostate development: a historical perspective. *Differentiation*. 2008;76(6):565–577.

Tisell LE. Effect of cortisone on the growth of the ventral prostate, the dorsolateral prostate, the coagulating glands and the seminal vesicles in castrated adrenalectomized and castrated non-adrenalectomized rats. *Acta Endocrinol (Copenh)*. 1970;64(4):637–655.

Toivanen R, Shen MM. Prostate organogenesis: tissue induction, hormonal regulation and cell type specification. *Development*. 2017;144:1382–1398.

Tomlinson DC, Freestone SH, Grace OC, et al. Differential effects of transforming growth factor-beta1 on cellular proliferation in the developing prostate. *Endocrinology*. 2004;145(9):4292–4300.

Tomlinson DC, Grindley JC, Thomson AA. Regulation of Fgf10 gene expression in the prostate: identification of transforming growth factor-beta1 and promoter elements. *Endocrinology*. 2004;145(4):1988–1995.

Tosoian J, Loeb S. PSA and beyond: the past, present, and future of investigative biomarkers for prostate cancer. *Scientific World Journal*. 2010;10:1919–1931.

Tsai YC, Harrison HH, Lee C, et al. Systematic characterization of human prostatic fluid proteins with two-dimensional electrophoresis. *Clin Chem*. 1984;30(12 Pt 1):2026–2030.

Tsujimura A, Koikawa Y, Saim S, et al. Proximal location of mouse prostate epithelial stem cells: a model of prostatic homeostasis. *J Cell Biol*. 2002;157(7):1257–1265.

Tullner WW. Hormonal factors in the adrenal-dependent growth of the rat ventral prostate. *Natl Cancer Inst Monogr*. 1963;12:211–223.

Tut TG, Ghadessy FJ, Trifiro MA, et al. Long polyglutamine tracts in the androgen receptor are associated with reduced trans-activation, impaired sperm production, and male infertility. *J Clin Endocrinol Metab*. 1997;82(11):3777–3782.

Ulvsback M, Lindstrom C, Weiber H, et al. Molecular cloning of a small prostate protein, known as beta-microsemenoprotein, PSP94 or beta-inhibin, and demonstration of transcripts in non-genital tissues. *Biochem Biophys Res Commun*. 1989;164(3):1310–1315.

Uzgare AR, Xu Y, Isaacs JT. In vitro culturing and characteristics of transit amplifying epithelial cells from human prostate tissue. *J Cell Biochem*. 2004;91(1):196–205.

Vafa AZ, Grover PK, Pretlow TG, et al. Study of activities of arginase, hexosaminidase, and leucine aminopeptidase in prostate fluid. *Urology*. 1993;42(2):138–143.

Valtonen-Andre C, Savblom C, et al. Beta-microseminoprotein in serum correlates with the levels in seminal plasma of young, healthy males. *J Androl*. 2008;29(3):330–337.

van der Graaf M, Schipper RG, Oosterhof GO, et al. Proton MR spectroscopy of prostatic tissue focused on the detection of spermine, a possible biomarker of malignant behavior in prostate cancer. *MAGMA*. 2000;10(3):153–159.

van Leenders GJ, Schalken JA. Epithelial cell differentiation in the human prostate epithelium: implications for the pathogenesis and therapy of prostate cancer. *Crit Rev Oncol Hematol*. 2003;46(Suppl):S3–S10.

Vander Griend DJ, Karthaus WL, Dalrymple S, et al. The role of CD133 in normal human prostate stem cells and malignant cancer-initiating cells. *Cancer Res*. 2008;68(23):9703–9711.

Vane JR, Botting RM. Pharmacodynamic profile of prostacyclin. *Am J Cardiol*. 1995;75(3):3A–10A.

Vashchenko N, Abrahamsson PA. Neuroendocrine differentiation in prostate cancer: implications for new treatment modalities. *Eur Urol*. 2005;47(2):147–155.

Verhagen AP, Ramaekers FC, Aalders TW, et al. Colocalization of basal and luminal cell-type cytokeratins in human prostate cancer. *Cancer Res*. 1992;52(22):6182–6187.

Vermeulen A, Vrdonck L, Van der Straeten M, et al. Capacity of the TeBG in human plasma and influence of specific binding of testosterone on its metabolic clearance rate. *J Clin Endocrinol Metab*. 1969;29:1470–1480.

Vermeulen A. The physical state of testosterone in plasma. Academic Press: New York; 1973:157–170. James VH, Serio M, Maratini L. *The endocrine function of the human testes*. vol 1.

Vickers AJ, Cronin AM, Roobol MJ, et al. A four-kallikrein panel predicts prostate cancer in men with recent screening: data from the European Randomized Study of Screening for Prostate Cancer, Rotterdam. *Clin Cancer Res*. 2010;16(12):3232–3239.

Vickers AJ, Gupta A, Savage CJ, et al. A panel of kallikrein marker predicts prostate cancer in a large, population based cohort followed for 15 years without screening. *Cancer Epidemiol Biomarkers Prev*. 2011;20(2):255–261.

Villoutreix BO, Getzoff ED, Griffin HJ. A structural model for the prostate disease marker, human prostate-specific antigen. *Protein Sci*. 1994;3(11):2033–2044.

Vogelstein B, Pardoll DM, Coffey DS. Supercoiled loops and eucaryotic DNA replication. *Cell*. 1980;22(1 Pt 1):79–85.

Von Euler US. Zur Kenntnis der pharmakologischen Wirkungen von Natirsekreten und Extrackten mannkicher accessorischer Geschlechtsdrusen. *Arch Pathol Pharmakol*. 1934;175:78–84.

Walsh PC, Gittes RF. Inhibition of extratesticular stimuli to prostatic growth in the castrate rat by antiandrogens. *Endocrinology*. 1970;87(3):624–627.

Wang LG, Liu SM, Kreis W, et al. Phosphorylation/dephosphorylation of androgen receptor as a determinant of androgen agonistic or antagonistic activity. *Biochem Biophys Res Commun*. 1999;259(1):21–28.

Wang MC, Valenzuela LA, Murphy GP, et al. Purification of a human prostate specific antigen. *Invest Urol*. 1979;17(2):159–163.

Wang X, Kruithof-de Julio M, Economides KD, et al. A luminal epithelial stem cell that is a cell of origin for prostate cancer. *Nature*. 2009;461:495–500.

Wang Y, Hayward S, Cao M, et al. Cell differentiation lineage in the prostate. *Differentiation*. 2001;68(4–5):270–279.

Warot X, Fromental-Ramain C, Fraulob V, et al. Gene dosage-dependent effects of the Hoxa-13 and Hoxd-13 mutations on morphogenesis of the terminal parts of the digestive and urogenital tracts. *Development*. 1997;124(23):4781–4791.

Watt KW, Lee PJ, M'Timkulu T, et al. Human prostate-specific antigen: structural and functional similarity with serine proteases. *Proc Natl Acad Sci USA*. 1986;83(10):3166–3170.

White MA. Change in pH of expressed prostatic secretion during the course of prostatitis. *Proc R Soc Med*. 1975;68(8):511–513.

Williams RR, Fisher AG. Chromosomes, positions please!. *Nat Cell Biol*. 2003;5(5):388–390.

Williams-Ashman HG, Corti A, Sheth AR, et al. Formation and functions of aliphatic polyamines in the prostate and its secretions. Goland M. *Normal and abnormal growth of the* *prostates*. Charles C. Thomas: Springfield (IL); 1975:222–239.

Williams-Ashman HG, Janne J, et al. New aspects of polyamine biosynthesis in eukaryotic organisms. *Adv Enzyme Regul*. 1972;10:225–245.

Williams-Ashman HG, Pegg AE, Lockwood DH, et al. Mechanisms and regulation of polyamine and putrescine biosynthesis in male genital glands and other tissues of mammals. *Adv Enzyme Regul*. 1969;7:291–323.

Williams-Ashman HG, Wilson J, Beil RE, et al. Transglutaminase reactions associated with the rat semen clotting system: modulation by macromolecular polyanions. *Biochem Biophys Res Commun*. 1977;79(4):1192–1198.

Williams-Ashman HG. Regulatory features of seminal vesicle development and function. *Curr Top Cell Regul*. 1983;22:201–275.

Wilson EM, Colvard DS. Factors that influence the interaction of androgen receptors with nuclei and nuclear matrix. *Ann N Y Acad Sci*. 1984;438:85–100.

Wilson JD, Griffin JE, George FW, et al. The role of gonadal steroids in sexual differentiation. *Recent Prog Horm Res*. 1981;37:1–39.

Wright GL, Haley C, Beckett ML, et al. Expression of prostatic-specific membrane antigen in normal, benign, and malignant prostate tissues. *Urol Oncol*. 1995;1:18–28.

Xin L, Lawson DA, Witte ON. The Sca-1 cell surface marker enriches for a prostate-regenerating cell subpopulation that can initiate prostate tumorigenesis. *Proc Natl Acad Sci USA*. 2005;102(19):6942–6947.

Yan G, Fukabori Y, Nikolaropoulous S, et al. Heparin-binding keratinocyte growth factor is a candidate stromal-to-epithelial-cell andromedin. *Mol Endocrinol*. 1992;6(12):2123–2128.

Yan M, Song Y, Wong CP, et al. Zinc deficiency alters DNA damage response genes in normal human prostate epithelial cells. *J Nutr*. 2008;138(4):667–673.

Ylikomi T, Bocquel MT, Berry M, et al. Cooperation of proto-signals for nuclear accumulation of estrogen and progesterone receptors. *EMBO J*. 1992;11(10):3681–3694.

Yoshida K, Kawano N, Yoshilke M, et al. Physiological roles of semenogelin I and zinc in sperm motility and semen coagulation on ejaculation in humans. *Mol Hum Reprod*. 2008;14(3):151–156.

Young CY, Andrews PE, Montgomery BT, et al. Tissue-specific and hormonal regulation of human prostate-specific glandular kallikrein. *Biochemistry*. 1992;31(3):818–824.

Young CY, Murtha PE, Andrews PE, et al. Antagonism of androgen action in prostate tumor cells by retinoic acid. *Prostate*. 1994;25(1):39–45.

Yousef GM, Diamandis EP. An overview of the kallikrein gene families in humans and other species: emerging candidate tumour markers. *Clin Biochem*. 2003;36(6):443–452.

Yousef GM, Diamandis EP. Expanded human tissue kallikrein family—a novel panel of cancer biomarkers. *Tumour Biol*. 2002;23(3):185–192.

Yousef GM, Obiezu CV, Luo LY, et al. Prostase/KLK-L1 is a new member of the human kallikrein gene family, is expressed in prostate and breast tissues, and is hormonally regulated. *Cancer Res*. 1999;59(17):4252–4256.

Yu H, Diamandis EP, Levesque M, et al. Ectopic production of prostate specific antigen by a breast tumor metastatic to the ovary. *J Clin Lab Anal*. 1994;8(4):251–253.

Yu H, Diamandis EP, Sutherland DJ. Immunoreactive prostate-specific antigen levels in female and male breast tumors and its association with steroid hormone receptors and patient age. *Clin Biochem*. 1994;27(2):75–79.

Yu H, Diamandis EP, Sutherland DJ, et al. Induction of prostate specific antigen production by steroids and tamoxifen in breast cancer cell lines. *Breast Cancer Res Treat*. 1994;32(3):291–300.

Yu M, Gipp J, Won Yoon J, et al. Sonic hedgehog–responsive genes in the fetal prostate. *J Biol Chem*. 2009;284(9):5620–5629.

Yurchenco PD, Amenta PS, Patton BL, et al. Basement membrane assembly, stability and activities observed through a developmental lens. *Matrix Biol*. 2004;22(7):521–538.

Zaneveld LJ, Chatterton RT. *Biochemistry of mammalian reproduction*. J Wiley & Sons: New York; 1982.

Zaneveld LJ, Tauber PF. Contributions of prostatic fluid components to the ejaculate. *Prog Clin Biol Res*. 1981;75A:265–277.

Zhang TJ, Hoffman BG, Ruiz de Algara T, et al. SAGE reveals expression of Wnt signaling pathway members during mouse prostate development. *Gene Expr Patterns*. 2006;6:310–324.

Zhigang Z, Wenlv S. Prostate stem cell antigen (PSCA) expression in human prostate cancer tissues and its potential role in prostate carcinogenesis and progression of prostate cancer. *World J Surg Oncol*. 2004;2(1):13.

Benign Prostatic Hyperplasia

Etiology, Pathophysiology, Epidemiology, and Natural History

Claus G. Roehrborn MD, Douglas William Strand PhD

Benign prostatic hyperplasia (BPH) is a pathologic process that is one but certainly not the only cause of lower urinary tract symptoms (LUTS) in aging men—also described as *male LUTS*. Despite intense research efforts in the past five decades to elucidate the underlying etiology of prostatic growth in older men, cause-and-effect relationships have not been established. For example, androgens are necessary, but not sufficient to drive BPH**. Previously held notions that the clinical symptoms of male LUTS (in the past erroneously called *prostatism*) are simply caused by a mass-related increase in urethral resistance are too simplistic.** It is now clear that **a significant portion of male LUTS is caused by age-related detrusor dysfunction and other conditions such as polyuria, sleep disorders, and a variety of systemic medical conditions unrelated to the prostate-bladder unit.**

Historically, voiding symptoms have been related to obstruction of the bladder outlet (Chapple et al., 2008). The traditional association in men is with the prostate, the so-called symptoms of *prostatism*. However, it is well recognized that voiding symptoms poorly correlate with underlying pathophysiology (de la Rosette et al., 1998). Similar symptoms can also be produced by any other form of obstruction, such as a urethral stricture or, conversely, by poor function of the lower urinary tract in circumstances in which there is impaired detrusor contractility. This has led to the recognition that, although LUTS may commonly be related to bladder outlet obstruction (BOO) as a result of benign prostatic obstruction (BPO), which is often associated with benign prostatic enlargement resulting from the histologic condition of BPH, this is not invariably the case.

For example, women also commonly present with voiding symptoms (Irwin et al., 2006). Lepor has shown that age-matched community-dwelling men and women have similar levels of symptom frequency and severity (Lepor and Machi, 1993). Failure to empty can be related either to an outlet obstruction or to detrusor underactivity of the bladder or to a combination of both. Postmicturition symptoms, such as postvoid dribbling, occur in both sexes, but most often in men, in whom these symptoms are highly common, very troublesome, and cause significant interference with quality of life (Reynard et al., 1996). Storage symptoms are currently largely encompassed by the term *overactive bladder (OAB) syndrome*, which is defined as urgency, frequency, nocturia, and urgency incontinence, and which is believed to be correlated with an underlying detrusor overactivity (Abrams et al., 2003). These symptoms tend to be more bothersome than voiding symptoms, especially if they are associated with incontinence. Storage symptoms in both sexes are commonly associated with urinary infections or, more rarely, with other conditions, such as bladder stones, carcinoma, or carcinoma *in situ* in the bladder.

This understanding can be shown as partially overlapping populations (Fig. 144.1). Although many men older than 40 years of age will develop histologic hyperplasia (i.e., BPH), not all will have bothersome LUTS. Of these, some will and others will not develop measurable enlargement of the prostate that may be referred to as *benign prostatic enlargement*, or *BPE*. It is common for men to have BPE without having LUTS and vice versa. BOO may also be present with or without LUTS and with or without BPE, and in some cases, BOO exists in men with BPH (e.g., stricture) (Roehrborn, 2008).

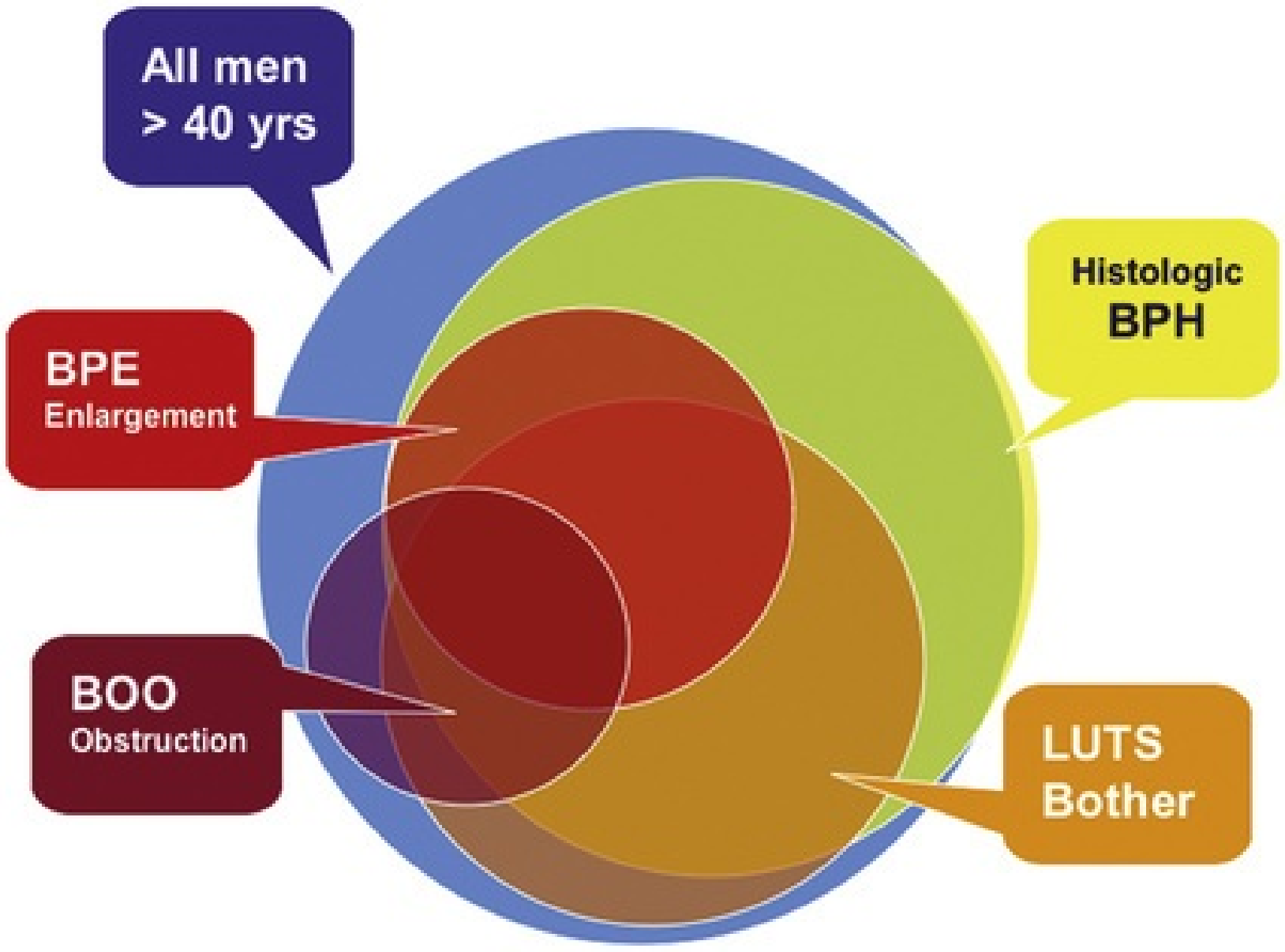

FIG. 144.1 Diagram showing the relationship between histologic hyperplasia of the prostate *(BPH),* lower urinary tract symptoms *(LUTS),* benign prostate enlargement *(BPE),* and bladder outlet obstruction *(BOO).* The size of the circles does not represent actual proportions but rather illustrates the partial overlap between the different disease definitions. (From Roehrborn CG. Pathology of benign prostatic hyperplasia. *Int J Impot Res* 20[Suppl 3]:S11–S18, 2008.)

Undoubtedly, the constellation of cellular pathologies that give rise to the symptoms of LUTS is far more complex than we currently realize. Only by unraveling these complexities, however, will we be able to design alternative strategies to treat successfully and possibly prevent the adverse impact of BPH on lower urinary tract function.

Etiology of Benign Prostatic Hyperplasia

Histopathologically, BPH is characterized by an increased number of epithelial and stromal cells in the periurethral area of the prostate and thus is correctly referred to as *hyperplasia* and not *hypertrophy*, as is often found in the older literature. The observation of new epithelial gland formation is normally seen only in fetal development and gives rise to the concept of embryonic reawakening of the stroma cell's inductive potential (Cunha et al., 1983; Isaacs, 2008). The precise molecular etiology of this hyperplastic process is uncertain. **The observed increase in cell number may be caused by epithelial and stromal proliferation or impaired programmed cell death leading to cellular accumulation.** Androgens, estrogens, stromal-epithelial interactions, growth factors, and neurotransmitters may play a role, either singly or in combination, in the etiology of the hyperplastic process.

Hyperplasia

In a given organ, the number of cells, and thus the volume of the organ, is dependent on the equilibrium between cell proliferation and cell death (Isaacs and Coffey, 1989). An organ can enlarge not only by an increase in cell proliferation but also by a decrease in cell death. **Although androgens and growth factors stimulate cell proliferation in experimental models, the relative role of cell proliferation in human BPH is questioned because there is no clear evidence of an active proliferative process.** Although it is possible that the early phases of BPH are associated with a rapid proliferation of cells, the established disease appears to be maintained in the presence of an equal or reduced rate of cell replication. Increased expression of antiapoptotic pathway genes (e.g., *bcl-2*) supports this hypothesis (Colombel et al., 1998; Kyprianou et al., 1996). **Androgens not only are required for normal cell proliferation and differentiation in the prostate but also actively inhibit cell death** (Isaacs, 1984). In dogs, experimental BPH can be produced by androgens combined with estradiol (Berry et al., 1986a; DeKlerk et al., 1979; Juniewicz et al., 1994; Walsh and Wilson, 1976). Despite a significant increase in gland size, there is actually a reduction in the rate of DNA synthesis compared with untreated controls (Barrack and Berry, 1987), indicating that androgens and estrogens both inhibit the rate of cell death. Neural signaling pathways, especially α-adrenergic pathways, may also play a role in balancing cell death and cell proliferation (Anglin et al., 2002).

Hyperplasia results in a remodeling of the normal prostatic architecture (Untergasser et al., 2005). Epithelial budding from preexisting ducts and the appearance of mesenchymal nodules characterize early stages of the process, but the tissue phenotype of patients with established disease is highly variable (Strand et al., 2017). This phenotypic heterogeneity has likely confounded a precise understanding of the molecular pathogenesis of hyperplasia.

Branching morphogenesis is a developmental process regulated by stromal-epithelial interactions in the fetal prostate (Yu and Bushman, 2013). Castration in an adult mouse results in involution of distal branches; testosterone replacement works through stromal androgen receptor (AR) to induce glandular regeneration (Sugimura et al., 1986a,b).

BPH may be viewed as a stem cell disease (Isaacs, 2008), but the precise identity of these cells has proven elusive. In transgenic mice, lineage tracing using promoters that label basal or luminal epithelia with fluorescent proteins has shown that stem cells within both lineages are capable of contributing to prostate regrowth after inducing forms of stress such as castration, inflammation, obesity, or luminal anoikis (Kwon et al., 2014a, 2016; Toivanen et al., 2016; Wang et al., 2009). In the adult human prostate, quantitative clonal mapping revealed that multipotent basal stem cells in the proximal niche are mainly responsible for replenishing the loss of apoptotic luminal epithelia (Moad et al., 2017).

Presumably, dormant stem cells in the normal prostate rarely divide, but when they do, they give rise to a second type of transiently proliferating cell capable of undergoing DNA synthesis and proliferation, thus maintaining the number of cells in the prostate. When the proliferating cells mature through a process of terminal differentiation, they have a finite life span before undergoing programmed cell death. In this paradigm, **the aging process induces a block in this maturation process so that the progression to terminally differentiated cells is reduced, reducing the overall rate of cell death.** Indirect evidence for this hypothesis comes from the observation that secretion, one parameter of epithelial cell differentiation, decreases with age, suggesting that the number of differentiated cells capable of secretory activity may be decreasing (Isaacs and Coffey, 1989). In humans, PSA expression in luminal epithelia decreases with increasing prostate volume (Zhang et al., 2016). A survey of human BPH specimens for a marker of cellular senescence (senescence-associated βgalactosidase [SA-beta-gal]) demonstrated a higher portion of senescent epithelial cells in men with large prostates, suggesting that an accumulation of these cells may play a role in the development of prostate enlargement (Choi et al., 2000). More recent studies support the hypothesis that impaired cell senescence may play a significant role in the etiology of BPH (Castro et al., 2003).

Hormones may exert their influence over the stem cell population not only with advancing age but also during embryonic and neonatal development (Naslund and Coffey, 1986). The size of the prostate may be defined by the absolute number of potential stem cells present in the gland, which in turn may be dictated at the time of embryonic development. Studies in animal models have suggested that **early imprinting of prostatic tissue by postnatal androgen surges is critical to subsequent hormonally induced prostatic growth.** As with the hormonal regulation of adult prostatic tissues, sex steroid hormones may exert their imprinting effect directly or indirectly through a complex series of signaling pathways (Lee and Peehl, 2004).

The Role of Androgens

Although androgens do not cause BPH, the development of BPH requires the presence of testicular androgens during prostate development, puberty, and aging (Marcelli and Cunningham, 1999; McConnell, 1995). Patients who are castrated before puberty or who are affected by a variety of genetic diseases that impair androgen action or production do not develop BPH. It is also known that prostatic levels of dihydrotestosterone (DHT) and the AR remain high with aging despite the fact that peripheral levels of testosterone are decreasing. Moreover, androgen withdrawal leads to partial involution of established BPH (Isaacs, 2008; Peters and Walsh, 1987).

Assuming normal ranges, there is no clear relationship between the concentration of circulating androgens and prostate size in aging men. In the Olmsted County cohort (median age 60.9) serum bioavailable testosterone levels were found to decline with increasing age, and the estradiol/bioavailable testosterone ratio increased (Roberts et al., 2004). Bioavailable testosterone correlated negatively and estradiol/bioavailable testosterone ratio positively with prostate volume, but this association was much less apparent after age adjustment. Baseline data from a large BPH medical therapy study confirmed the absence of a relationship among serum testosterone, serum PSA, and prostate volume (Marberger et al., 2006) (Table 144.1). On the other hand, in a 20-year follow-up study, Parsons et al showed that higher baseline serum dihydrotestosterone levels were associated with an increased risk for BPH. The odds ratios (OR) for the second, third, and fourth quartiles of dihydrotestosterone were 1.83 (95% CI, 0.96 to 3.47), 1.50 (0.79 to 2.85), and 2.75 (1.46 to 5.19), respectively (p trend = 0.02). A higher testosterone-to-dihydrotestosterone ratio, however, was associated with a 42% decreased risk for BPH (Parsons et al., 2010; Trifiro et al., 2010).

TABLE 144.1

Absence of Significant Relationship Among Serum Testosterone, Serum PSA, and Prostate Volume

BASELINE TESTOSTERONE CATEGORY (Ng/Ml)[a]	NO. OF INDIVIDUALS (*N* = 4254)	AGE (YEARS)	PSA (Ng/Ml − 1)	PROSTATE VOLUME (ML)	BMI (Kg/M^2)	BAS SFI SCO
≥300	3092	66.5	4.0	54	27.0	6.8
275–300	291	65.3	3.8	56	28.2	6.6
250–275	269	66.2	3.9	55	28.1	6.4
225–250	225	65.3	4.0	57	29.0	7.2
200–225	143	64.8	3.9	56	30.1	5.9
175–200	115	66.5	4.0	56	29.5	6.8
150–175	67	66.2	3.6	56	29.5	5.8
<150	52	68.7	4.0	61	31.0	5.6

[a] For nanomoles per liter, divide by 28.8.

BMI, Body mass index; *PSA,* prostate-specific antigen; *SFI,* Sexual Function Inventory.

Modified from Marberger M, Roehrborn CG, Marks LS, et al. Relationship among serum testosterone, sexual function, and response to treatment in men receiving dutasteride for benign prostatic hyperplasia. *J Clin Endocrinol Metab* 91(4):1323–1328, 2006.

In the brain, skeletal muscle, and seminiferous epithelium, testosterone directly stimulates androgen-dependent processes. **In the prostate, however, the nuclear membrane bound enzyme steroid 5α-reductase converts the hormone testosterone into DHT, the principal androgen in this tissue (see Fig. 144.1)** (McConnell, 1995). Ninety percent of total prostatic androgen is in the form of DHT, principally derived from testicular androgens. Adrenal androgens may constitute 10% of total prostatic androgen, although the importance of this stored hormone source in the etiology of BPH is negligible.

Inside the cell, both testosterone and DHT bind to the same high-affinity androgen receptor protein (Chatterjee, 2003). DHT is a more potent androgen than testosterone because of its higher affinity for the AR. Moreover, the DHT-receptor complex may be more stable than the testosterone-receptor complex. The hormone receptor then binds to specific DNA-binding sites in the nucleus, which results in increased transcription of androgen-dependent genes and ultimately stimulation of protein synthesis (Andriole et al., 2004). Conversely, androgen withdrawal from androgen-sensitive tissue results in a decrease in protein synthesis and tissue involution. **Besides inactivation of key androgen-dependent genes (e.g., prostate-specific antigen [PSA]), androgen withdrawal leads to the activation of specific genes involved in programmed cell death** (Kyprianou and Isaacs, 1989; Martikainen et al., 1990). Despite the importance of androgens in normal prostatic development and secretory physiology, there is no evidence that either testosterone or DHT serves as the direct mitogen for growth of the prostate in older men. Indeed, neither hormone is mitogenic to cultured prostatic epithelial cells (McKeehan et al., 1984). In the rat ventral prostate, differential gene expression experiments failed to demonstrate direct activation of mitogenic pathways (Wang et al., 1997). However, many proinflammatory cytokines as well as growth factors and their receptors are regulated by androgens (see later). Thus, the action of testosterone and DHT in the prostate is mediated indirectly through autocrine and paracrine pathways.

Androgen Receptors

The prostate, unlike other androgen-dependent organs, maintains its ability to respond to androgens throughout life. In the penis, AR expression decreases to negligible rates at the completion of puberty (Roehrborn et al., 1987; Takane et al., 1991a,b). Thus, despite high circulating levels of androgen, the adult penis loses its ability for androgen-dependent growth. If the penis maintained high levels of AR throughout life, presumably the organ would grow until the time of death. In contrast, AR levels in the prostate remain high throughout aging (Barrack et al., 1983; Rennie et al., 1988). In fact, there is evidence to suggest that nuclear AR levels may be higher in hyperplastic tissue than in normal controls. Age-related increases in estrogen, as well as other factors, may increase AR expression in the aging prostate, leading to further growth (or to a decrease in cell death), despite decreasing levels of androgen in the peripheral circulation and “normal” levels of DHT in the prostate.

The potential roles of AR mutations, polymorphisms, or other alterations in the pathogenesis of BPH are unclear (Chatterjee, 2003). A polymorphism in the number of CAG repeats (short vs. control) in the *AR* gene has been associated with larger prostate size and an increased risk for surgery (Giovannucci et al., 1999a,b). However, another study from the Netherlands showed no relationship between the number of CAG repeats and BPH (Bousema et al., 2000). The later study also found no relationship between BPH and vitamin D receptor polymorphisms, although one Japanese study suggested an association (Habuchi et al., 2000b). A more recent study of US men showed a positive correlation between short CAG repeats and prostate volume, but a study of Finnish men found that short CAG repeats were significantly less common in men with BPH compared with control subjects (Mononen et al., 2002). Given the significant variation in reported findings, if short CAG repeats play a role in BPH pathogenesis, it is likely to be minor (Hoke and McWilliams, 2008).

Dihydrotestosterone and Steroid 5α-Reductase

Intraprostatic DHT concentrations are maintained but not elevated in BPH. Initial studies of resected prostatic tissue suggested that prostatic DHT levels were higher in the hyperplastic gland than in normal control tissues. However, the controls used for these early studies were largely accident victims. Ongoing metabolism of DHT after death lowers the level of this androgen in cadaveric tissues. This was clearly shown in a study by Walsh et al. (1983) in which prostatic surgical specimens from men without BPH were used as the control. These investigators demonstrated that DHT levels are the same in hyperplastic glands as in normal glands. However, the aging prostate maintains a high level of DHT and a high level of AR; thus, the mechanism for androgen-dependent cell growth is maintained. There is little question that androgens have at least a permissive role in the development of the disease process.

Two steroid 5α-reductase enzymes have been discovered, each encoded by a separate gene (Russell and Wilson, 1994). Type 1 5α-reductase, the predominant enzyme in extraprostatic tissues, such as skin and liver, is normally expressed in the 5α-reductase deficiency syndrome and is inhibited by dutasteride, but not substantially by finasteride. Type 2 5α-reductase is the predominant prostatic 5α-reductase, although it is also expressed in extraprostatic tissues. Mutations in the type 2 enzyme are responsible for the clinical phenotype observed in the 5α-reductase deficiency syndrome. It is exquisitely sensitive to inhibition by finasteride and dutasteride (Carson and

Rittmaster, 2003). Clearly, **the type 2 enzyme is critical to normal development of the prostate and hyperplastic growth later in life.** The role of type 1 5α-reductase in normal, and abnormal prostate growth remains to be defined. There is growing evidence to suggest that the type 1 isoenzyme may play a more important role in prostate cancer compared with BPH, as increased levels of mRNA expression, protein, and functional enzymes have been demonstrated in prostate cancer (Thomas et al., 2008). Given that finasteride produces prostate size reduction identical to that with dual type1/type 2 inhibitors and roughly equivalent to that with castration, it is unlikely that type 1–derived DHT is critical to hyperplastic growth.

Immunohistochemical studies with type 2 5α-reductase–specific antibodies show primarily stromal cell localization of the enzyme (Silver et al., 1994; Thigpen et al., 1993). Epithelial cells uniformly lack type 2 protein, and some basal epithelial cells stain positively. Type 1 5α-reductase protein could not be detected in BPH or prostate cancer using initially available antibodies, although trace levels of type 1 messenger RNA (mRNA) have been seen in normal prostates, BPH, and cancer (Shirakawa et al., 2004). A study with a selective type 1 antibody demonstrated positive staining in only 7% of BPH cases (Thomas et al., 2003). In the same study, type 1 enzymatic activity was found in only 2 of 29 BPH specimens.

These data demonstrate that the **stromal cell plays a central role in androgen-dependent prostatic growth and that the type 2 5α-reductase enzyme within the stromal cell is the key androgenic amplification step.** Thus, a paracrine model for androgen action in the gland (Fig. 144.2) is evident. In addition, it is possible that **circulating DHT produced in the skin and liver may act on prostate epithelial cells in a true endocrine fashion** (McConnell, 1995). If dual type 1/type 2 5α-reductase inhibition has clinical utility over selective type 2 inhibitors, it is likely to be caused by inhibition of peripherally produced DHT.

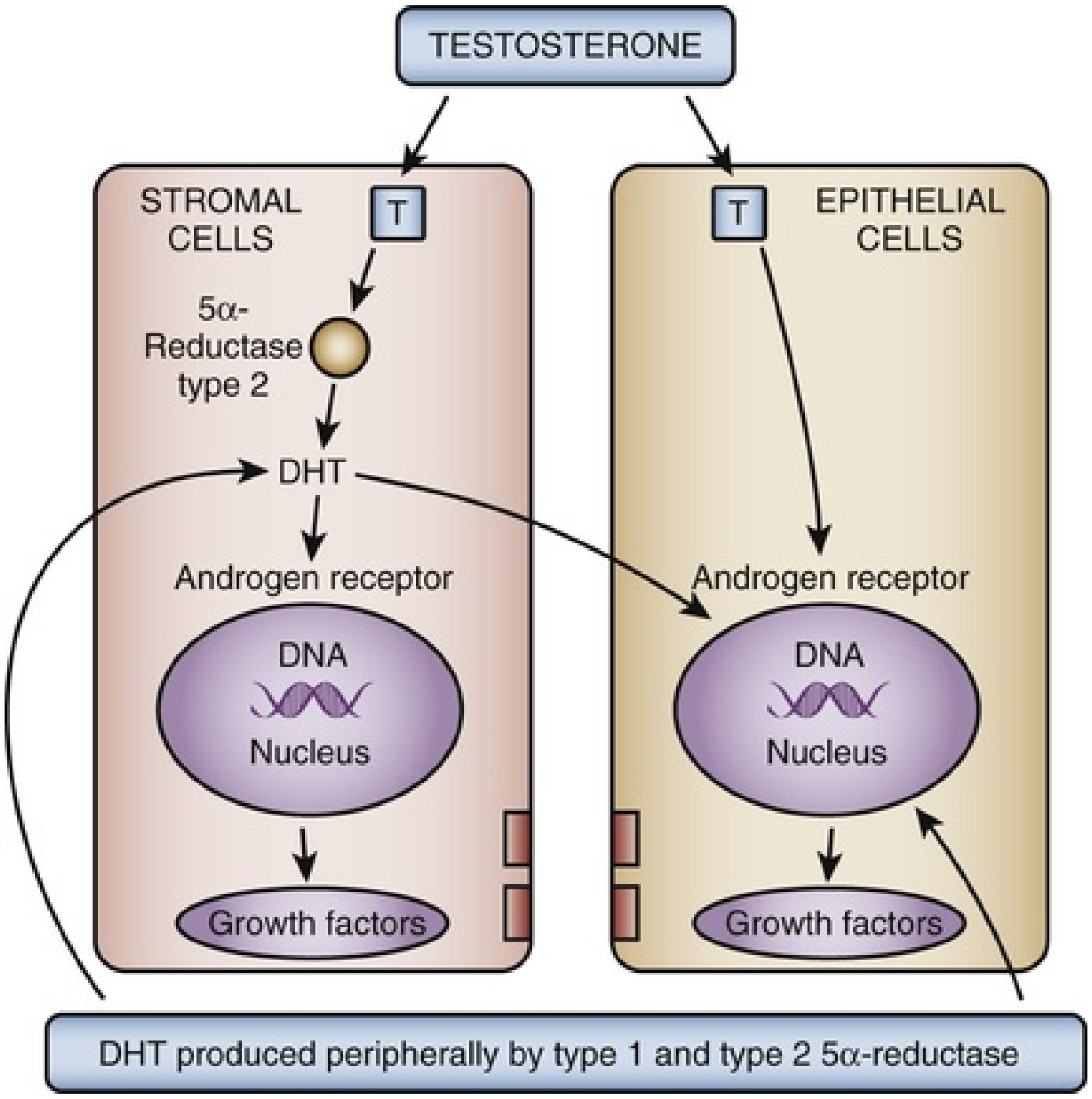
TESTOSTERONE
STROMAL CELLS
T
5α-Reductase type 2
DHT
Androgen receptor
DNA
Nucleus
Growth factors
EPITHELIAL CELLS
T
Androgen receptor
DNA
Nucleus
Growth factors
DHT produced peripherally by type 1 and type 2 5α-reductase

FIG. 144.2 Testosterone *(T)* diffuses into the prostate epithelial and stromal cell. Testosterone can interact directly with the androgen (steroid) receptors bound to the promoter region of androgen-regulated genes. In the stromal cell, a majority of testosterone is converted into dihydrotestosterone (DHT)—a much more potent androgen—which can act in an autocrine fashion in the stromal cell or in a paracrine fashion by diffusing into epithelial cells in close proximity. DHT produced peripherally, primarily in the skin and liver, can diffuse into the prostate from the circulation and act in a true endocrine fashion. In some cases, the basal cell in the prostate may serve as a DHT production site, similar to the stromal cell. Autocrine and paracrine growth factors may also be involved in androgen-dependent processes within the prostate. (From Roehrborn CG. Pathology of benign prostatic hyperplasia. *Int J Impot Res* 20[Suppl 3]:S11–S18, 2008.)

Immunohistochemical studies in open enucleated BPH specimens show considerable intraprostatic and interprostatic 5α-reductase enzyme expression, making studies of its distribution based on single or one-time biopsy material very difficult (Sherwood et al., 2003). Because it is the only medical treatment available for reducing prostate volume, defining the resistance to 5ARI treatment is an important scientific question although complex. Clinically, 5ARI resistance may be defined as failure to significantly improve LUTS, but this is unlikely to be caused by failure of the drug to reduce intraprostatic DHT levels (personal observation). More likely, clinical failure is caused by (1) a lack a luminal epithelial atrophy focally within glandular nodules resulting in persistent anatomic obstruction, or (2) widespread stromal hyperplasia (Strand et al., 2017).

Several mechanisms have been proposed for mediating the resistance of luminal epithelia to 5ARI treatment. Austin et al. (2016a,b) showed in human tissue and cell lines that NF-κB is increased in BPH and could induce expression of androgen-independent AR variant expression. Wang et al. (2017) demonstrated that SRD5A2 can be epigenetically silenced in a subset of BPH patients, resulting in a switch to estrogenic pathways for survival. Interestingly, both of these mechanisms are linked to inflammation, and inflammation is also correlated with 5ARI resistance in clinical trials (Nickel et al., 2008). However, these pathways are still correlative and have yet to be proven responsible for 5ARI resistance in vivo. A clinical definition of resistance should include volumetric (prostate volume unchanged), histologic (lack of glandular atrophy), and biochemical (decreased DHT) criteria.

Polymorphisms in the type 2 5α-reductase enzyme (SRD5A2) have been reported, but their linkage to BPH is uncertain. The *SRD5A2* gene on chromosome 2p23 frequently encompasses A49T and V89L substitutions and a TA dinucleotide repeat polymorphism. The *89L* allele has been associated with lower enzyme activity, whereas the *49T* allele has been associated with higher activity. Longer TA repeats are associated with mRNA instability and thus decreased enzyme activity. The number of *L* alleles, but not testosterone alleles or TA repeats, in one study correlated significantly with the presence of BPH (Salam et al., 2005). In the Olmsted County population, consistent associations between SRD5A2 genotypes and BPH were not demonstrated, although there was a weak correlation between V89L polymorphisms and prostate volume (Roberts et al., 2005).

Androgen withdrawal may partially exert its effect on the prostate through vascular effects (Buttyan et al., 2000). Castration induces acute and drastic vasoconstriction of blood vessels in the rat prostate (Hayek et al., 1999). This effect does not appear to be mediated through vascular endothelial growth factor (VEGF) (Burchardt et al., 2000). There is indirect evidence to suggest that abnormalities in the prostatic vascular system produced by other disease states (e.g., diabetes) may be a risk factor of BPH (Parsons, 2007; Parsons et al., 2006).

The Role of Estrogens

There is animal model evidence to suggest that estrogens play a role in the pathogenesis of BPH; the role of estrogens in the development of human BPH, however, is less clear. In the dog, where estrogens act synergistically with androgens to produce experimental BPH, estrogen appears to be involved in induction of the AR (Moore et al., 1979). Estrogen may, in fact, "sensitize" the aging dog prostate to the effects of androgen (Barrack and Berry, 1987). The canine prostate contains an abundance of high-affinity estrogen receptor. In the dog, estrogen treatment stimulates the stroma, causing an increase in the total amount of collagen (Berry et al., 1986a, 1986b). There are at least two forms of the estrogen receptor. Estrogen receptor α is expressed by prostate stromal cells, and estrogen receptor β is expressed by prostate epithelial cells (Prins et al., 1998). The estrogenic response of the prostate is determined by the type of estrogen receptor present within the prostatic cells. Experiments in knockout mice suggest a "constraining influence" of estrogens on the prostate (Krege et al., 1998). In vitro studies suggest that upregulation of estrogen receptor α in cultured prostate stromal cells is also associated with upregulation of fibroblast growth factor 2 (FGF-2), FGF-7, and other growth factors; the addition of androgens downregulated the estrogen receptor and various stroma-derived growth factors (Smith et al., 2000, 2002).

Different actions may be mediated by stromal ERα and epithelial ERβ (Prins and Korach, 2008). Evidence also indicates that estrogen action mediated through the separate receptors may contribute to the etiology and progression of multiple prostate diseased states (Table 144.2). These findings provide new avenues and alternative approaches for the treatment of prostate diseases, including prostate cancer, with novel therapies directed at estrogen receptors or estrogen metabolism. Because the two types of estrogen receptors may play distinct and perhaps opposing roles in many diseases of the prostate including cancer progression, it is possible that receptor-specific agonists and antagonists may prove beneficial in therapeutic strategies in future clinical trials. A recent randomized, placebo-controlled study using an ERβ agonist in men with male LUTS failed, however, to show any effect on symptoms, serum PSA, prostate size, and urodynamic parameters (Roehrborn et al., 2015).

TABLE 144.2

Comparison of ER-α and ER-β Expression and Activities in the

	ER-α	ER-β
Localization	Stromal	Epithelial
Proliferation	Epithelial squamous metaplasia	Antiproliferative
	Stromal proliferation	
Differentiation	Epithelial dysplasia	Prodifferentiation
Immune response		Anti-inflammatory
		Antioxidant
Expression	Dysregulated in prostate cancer	Dysregulated in prostate cancer
	Silenced in early cancers	↓ Organ-confined disease
	Re-emergence with progression	↑ In metastatic prostate cancer

ER, Estrogen receptor.

From Prins GS, Korach KS. The role of estrogens and estrogen receptors in normal prostate growth and disease. *Steroids* 73(3):233–244, 2008.

Serum estrogen levels increase in men with age, absolutely or relative to testosterone levels. There is also suggestive evidence that intraprostatic levels of estrogen are increased in men with BPH. Patients with larger volumes of BPH tend to have higher levels of estradiol in the peripheral circulation (Partin et al., 1991). In the Olmsted County cohort, in men with above median levels of bioavailable testosterone, serum estradiol level correlated positively with prostate volume, even after adjusting for age (Roberts et al., 2004). Data on obesity, serum testosterone, estradiol, and prostate volume are conflicting (Zucchetto et al., 2005). Although there are relatively low concentrations of classical high-affinity estrogen receptors in human BPH (Farnsworth, 1996; Sciarra and Toscano, 2000), there may be a sufficient amount for biologic activity.

From experimental studies with aromatase inhibitors, it appears that decreases in intraprostatic estrogen in animal models may lead to reduction in drug-induced stromal hyperplasia (Farnsworth, 1996, 1999). At present, however, the role of estrogens in human BPH is not as firmly established as the role of androgens. Species variation and cause-and-effect relationships are problematic.

There are high levels of progesterone receptor in the normal and hyperplastic prostate. However, the role of the progesterone receptor in normal prostatic physiology and in BPH remains to be defined.

Regulation of Programmed Cell Death

Programmed cell death (apoptosis) is a physiologic mechanism crucial to the maintenance of normal glandular homeostasis (Kerr and Searle, 1973). Cellular condensation and fragmentation precede phagocytosis and degradation, during which the apoptotic cell is phagocytosed by neighboring cells and degraded by lysosomal enzymes. Apoptosis occurs without activation of the immune system but requires both RNA and protein synthesis (Lee, 1981). In the rat prostate, active cell death occurs naturally in the proximal segment of the prostatic ductal system in the presence of normal concentrations of plasma testosterone (Lee et al., 1990). Androgens (presumably testosterone and DHT) appear to suppress programmed cell death elsewhere in the gland. **Following castration, active cell death is increased in the luminal epithelial population and in the distal region of each duct.** Tenniswood suggested that there is regional control over androgen action and epithelial response, with androgens providing a modulating influence over the local production of growth regulatory factors that varies in different parts of the gland (Tenniswood, 1986). Members of the transforming growth factor β (TGF-β) family are likely candidates for this regulatory step (Martikainen et al., 1990).

In the rat prostate, at least 25 different genes are induced after castration (Montpetit et al., 1986). Normal glandular homeostasis requires a balance between growth inhibitors and mitogens, which respectively restrain or induce cell proliferation but also prevent or modulate cell death. Abnormal hyperplastic growth patterns, such as BPH, might be induced by local growth factor or growth factor receptor abnormalities, leading to increased proliferation or decreased levels of programmed cell death.

Stromal-Epithelial Interaction

There is abundant experimental evidence to demonstrate that **prostatic stromal and epithelial cells maintain a sophisticated paracrine type of communication.** The growth of canine prostate epithelium can be regulated by cellular interaction with the basement membrane and stromal cells. Isaacs and Coffey used a marker of canine prostatic epithelial cell function to demonstrate that epithelial cells grown on plastic quickly lose their ability to secrete this protein (Isaacs and Coffey, 1989). In addition, the cells begin to grow rapidly and change their cytoskeletal staining pattern. In contrast, if the cells are grown on prostatic collagen, they maintain their normal secretory capacity and cytoskeletal staining pattern and do not grow rapidly. This is strong evidence that

one class of stromal cell excretory protein (i.e., extracellular matrix) partially regulates epithelial cell differentiation. Thus, BPH may be caused by a defect in a stromal component that normally inhibits cell proliferation, resulting in loss of a normal "braking" mechanism for proliferation. This abnormality could act in an autocrine fashion to lead to proliferation of stromal cells as well.

Further evidence of the importance of stromal-epithelial interactions in the prostate comes from the elegant developmental studies of Cunha, which demonstrate the importance of embryonic prostatic mesenchyme in dictating differentiation of the urogenital sinus epithelium (Cunha et al., 1980, 1983, 2003; Cunha and Donjacour, 1987; Cunha, 1994). **The process of new gland formation in the hyperplastic prostate suggests a "reawakening" of embryonic processes in which the underlying prostatic stroma induces epithelial cell development (McNeal, 1990).** Many of the prostatic stromal-epithelial interactions observed during normal development and in BPH may be mediated by soluble growth factors or by the extracellular matrix (ECM), which itself has growth factor–like properties. This model is even more intriguing, given the cellular localization of 5α-reductase (and thus DHT production) in the prostate stromal cell (Silver et al., 1994).

The complexity of the stromal-ECM-epithelial relationship is revealed in studies of CXC motif chemokines such as CXCL1, CXCL5, CXCL6, and CXCL12. These chemokines are predominantly expressed by the microenvironment, but are capable of stimulating proliferation of both stroma and epithelia in vitro. Furthermore, these chemokines and others such as interleukin (IL)-8 are capable of converting fibroblasts to myofibroblasts (Schauer et al., 2008). Myofibroblasts are associated with increased collagen deposition and fibrosis, potentially contributing to lower urinary tract dysfunction (Rodriguez-Nieves and Macoska, 2013).

As described in many other organs, there is a putative stem cell niche in the prostate that is composed of a set of poorly defined stromal and epithelial cell types. Several signaling pathways including Hedgehog (Karhadkar et al., 2004; Wang et al., 2003), Notch (Wang et al., 2004; Wu et al., 2011), WNT (Murillo-Garzon and Kypta, 2017), and TGFβ (Salm et al., 2012) are implicated in the autocrine/paracrine maintenance of the stem cell niche. As our understanding of stromal-epithelial cell relationships in the prostate increases, it is possible that therapies may be designed to induce regression of established BPH by modulating these autocrine/paracrine mechanisms.

Growth Factors

Growth factors are small peptide molecules that stimulate, or in some cases inhibit, cell division and differentiation processes (Lee and Peehl, 2004; Steiner, 1995). Cells that respond to growth factors have on their surface receptors specific for that growth factor that in turn are linked to a variety of transmembrane and intracellular signaling mechanisms. **Interactions between growth factors and steroid hormones may alter the balance of cell proliferation versus cell death to produce BPH** (Fig. 144.3). Story et al. (1989) were first to demonstrate that extracts of BPH stimulate cellular growth. This putative prostatic growth factor was subsequently found on sequence analysis to be basic fibroblastic growth factor (bFGF). Subsequently, a variety of growth factors have been characterized in normal, hyperplastic, and neoplastic prostatic tissue. In addition to bFGF (FGF-2), acidic FGF (FGF-1), Int-2 (FGF-3), keratinocyte growth factor (KGF, FGF-7), transforming growth factor (TGF-β), and epidermal growth factor (EGF) have been implicated in prostate growth. TGF-β is a potent inhibitor of proliferation in normal epithelial cells in a variety of tissues. In models of prostatic cancer, there is evidence that malignant cells have escaped the growth inhibitory effect of TGF-β (McKeehan and Adams, 1988). Similar mechanisms may be operational in BPH (Salm et al., 2000), leading to the accumulation of epithelial cells (Kundu et al., 2000). Growth factors may also be important in modulating the phenotype of the prostate smooth muscle cell (Peehl and Sellers, 1998).

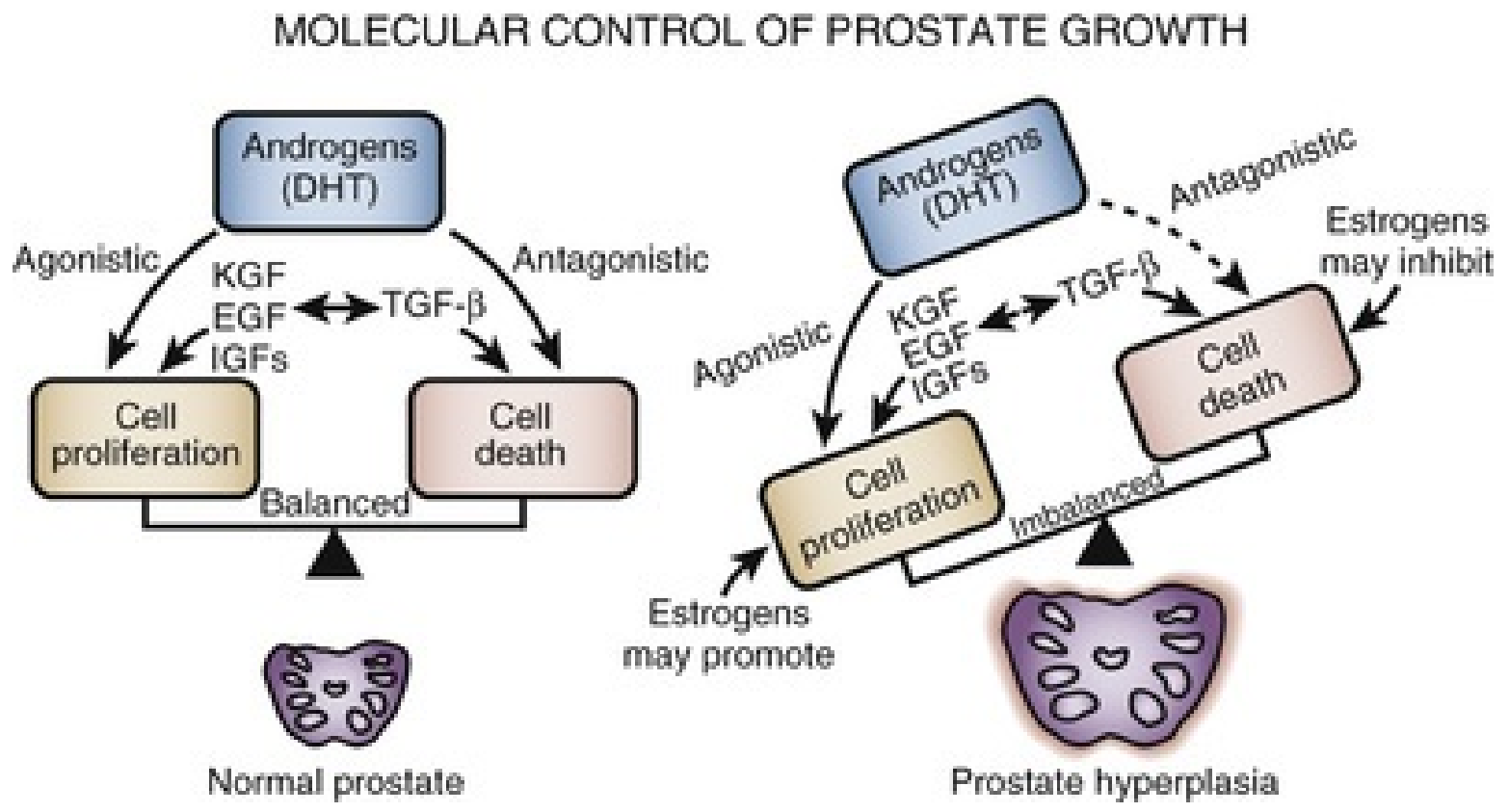
MOLECULAR CONTROL OF PROSTATE GROWTH
Androgens (DHT)
Agonistic
Antagonistic
KGF
EGF
IGFs
TGF-β
Cell proliferation
Cell death
Balanced
Normal prostate
Androgens (DHT)
Antagonistic
Estrogens may inhibit
Agonistic
KGF
EGF
IGFs
TGF-β
Cell death
Cell proliferation
Imbalanced
Estrogens may promote
Prostate hyperplasia

FIG. 144.3 Prostate hyperplasia is most likely due to an imbalance between cell proliferation and cell death. Androgens play a necessary but probably permissive role. Growth factors are more likely to be sites of primary defects.

There is mounting evidence of interdependence between growth factors, growth factor receptors, and the steroid hormone milieu of the prostate (Lee and Peehl, 2004; Rennie et al., 1988). Although data on the absolute level of growth factor and growth factor receptors in hyperplastic as opposed to normal tissue are conflicting, it is likely that growth factors play some role in the pathogenesis of BPH. However, further research is necessary to establish the role of growth factors in a disease process in which cellular proliferation is not obvious.

If cellular proliferation is a component of the BPH process, it appears that growth stimulatory factors such as the FGF-1, -2, -7, and -17 families; VEGF; and insulin-like growth factor (IGF) may play a role, with DHT augmenting or modulating the growth factor effects. In contrast, TGF-β, which is known to inhibit epithelial cell proliferation, may normally exert a restraining influence over epithelial proliferation that is lost or downregulated in BPH (Cohen et al., 2000; Lee and Peehl, 2004; Peehl et al., 1995; Sporn and Roberts, 1990; Wilding et al., 1989). TGF-β_1 is a potent mitogen for fibroblasts and other mesenchymal cells but is also an important inhibitor of epithelial cell proliferation (Roberts and Sporn, 1993). TGF-β_1 also regulates ECM synthesis and degradation and can induce cells to undergo apoptosis. In addition, TGF-β upregulates the production of basic fibroblast growth factor (bFGF-2), which is known to be an autocrine growth factor for prostate stromal cells (Story et al., 1993), and at least on one prostate smooth muscle cell line (PSMC1), TGF-β1 functions as an autocrine mitogen (Salm et al., 2000). Thus, upregulation of TGF-β1 (which is expressed in prostate stromal cells) during BPH would favor expansion of the stromal compartment.

Indirect evidence to support this view comes from studies of reconstituted mouse prostate (Yang et al., 1997). Interestingly, the observation that TGF-β1 may regulate smooth muscle contractile protein expression suggests that TGF-β isoforms may be physiologic regulators of prostatic smooth muscle function (Orlandi et al., 1994). Cohen et al. (2000) found that stromal cells isolated from BPH specimens exhibited a blunted TGF-β growth inhibition relative to normal stromal cells and that the blunted response appeared to be caused by a reduction in TGF-β–mediated increase in IGF-binding protein 3 (IGFBP-3) expression. TGF- β may stimulate the overexpression of versican (chondroitin sulfate proteoglycan 2) in the ECM through inhibition of key metalloproteases (ADAMTS lineage) that normally degrade versican, leading to accumulation in the ECM (Cross et al., 2006). An increased risk for BPH was described in patients with a codon 10 polymorphism in TGF-β (Li et al., 2004).

The first evidence of increased FGF-2 levels in BPH came from the studies of Begun et al. (1995), who demonstrated a twofold to threefold elevation of FGF-2 in BPH compared with histologically normal glands. Further studies have demonstrated that both FGF-2 and FGF-7 are overexpressed in BPH tissues (Ropiquet et al., 1999). The major target of FGF-2 is thought to be the stroma itself (autocrine), although transgenic mice overexpressing FGF-2 develop glandular epithelial hyperplasia (Konno-Takahashi et al., 2004). KGF, a member of the FGF family (FGF-7), is produced in prostatic stromal cells (Yan et al., 1992). However, cell surface receptors for stroma-derived KGF are expressed exclusively in epithelial cells. As a result, **FGF-7 (or a homolog) is the leading candidate for the factor mediating the stromal cell–based hormonal regulation of the prostatic epithelium.** There is direct evidence that FGF-7 plays this role in the androgen-dependent mesenchymal-epithelial interactions involved in development of the seminal vesicle (Alarid et al., 1994). Abnormalities in stromal FGF-7 production or epithelial FGF-7 receptor could promote epithelial cell proliferation. Indirect evidence supporting this hypothesis comes from a study of transgenic mice overexpressing FGF-7 that develop atypical prostatic hyperplasia (Kitsberg and Leder, 1996). McKeehan's laboratory demonstrated that FGF-10, a homolog of FGF-7, is expressed at high levels in the rat prostate, specifically in stromal cells of smooth muscle origin (Lu et al., 1999; Nakano et al., 1999). FGF-10 expression is increased by androgens and may have a mitogenic effect on prostate epithelium. Other studies suggest that cells expressing FGF-7 are localized in the stroma immediately adjacent to the epithelium, suggesting that the epithelial cells may induce FGF-7 expression. The paracrine factor most likely responsible for this effect is cytokine interleukin (IL)-1a (Giri and Ittmann, 2000; Lee and Peehl, 2004).

Some investigators have speculated that local hypoxia in the prostate (perhaps from atherosclerosis or other vascular events) is the initial event that induces FGF production (Lee and Peehl, 2004). Further growth of BPH nodules could impede blood flow, leading to further hypoxia (Parsons and Kashefi, 2008; Parsons et al., 2008). Hypoxia leads to upregulation of hypoxia inducible factor 1, which in turn increases the secretion of FGF-2 and FGF-7 from stromal cells.

Other growth factors implicated in BPH include FGF-17 (Polnaszek et al., 2004), FGF-10, and VEGF (Walsh et al., 2002). It remains difficult to ascertain which of the growth factors and growth factor receptors are key mediators of the BPH disease process and which are bystanders.

Insulin-like growth factors, binding proteins, and receptors also appear to be important modulators of prostatic growth, at least as it relates to cell growth in culture (Lee and Peehl, 2004; Peehl et al., 1995). A transgenic mouse model with overexpression of IGF-1 demonstrated prostate gland enlargement (Konno-Takahashi et al., 2003). Studies of BPH tissue demonstrate a higher concentration of IGF-2 in the periurethral area than in the peripheral zone (Monti et al., 2001). A study of Chinese men demonstrated a significant correlation between circulating IGF-1 and IGFBP-3 level and BPH (Dahle et al., 2002), but a study of the Olmsted County cohort failed to demonstrate any relationship between serum IGF-1 and prostate volume (Roberts et al., 2003).

Other Signaling Pathways

Sympathetic signaling pathways are important in the pathophysiology of LUTS, as is evident from the use of drugs interfering with the adrenergic nervous system such as α-adrenergic receptor blockers, which are highly effective for the treatment of LUTS (American Urological Association Practice Guidelines Committee, 2003). In addition, there is increasing evidence that sympathetic pathways may be important in the pathogenesis of the hyperplastic growth process (McVary et al., 1994, 2005). Alpha blockade, in some model systems, can induce apoptosis (Anglin et al., 2002). α-Adrenergic pathways can also modulate the smooth muscle cell phenotype in the prostate (Lin et al., 2000). All components of the renin-angiotensin system (RAS) are present in prostatic tissue and may be activated in BPH (Dinh et al., 2001, 2002; Fabiani et al., 2001). Either with or without sympathetic modulation, local RAS pathways may contribute to cell proliferation and smooth muscle contraction.

The early growth response gene 1 *(EGR-1)* transcription regulation pathway was found to be active in a BPH cell line (Mora et al., 2005). Also of interest is the finding that α_2-macroglobulin, a large protein that binds PSA and many growth factors, is very highly expressed in human prostate and is upregulated in BPH (Lin et al., 2005). Trapping and inactivation of inhibitory molecules could promote growth pathways.

The Potential Role of Inflammatory Pathways and Cytokines in Benign Prostatic Hyperplasia

An additional source of growth factors in human BPH tissue may be the inflammatory cell infiltrates seen in many men with BPH. In the 1990s, descriptive studies suggested a link between inflammation and BPH-related growth. Theyer et al. (1992) reported extensive infiltration of human BPH tissues by activated T cells. Peripheral blood and tumor-infiltrating T cells are known to express VEGF, a potent epithelial mitogen (Blotnick et al., 1994; Freeman et al., 1995). T cells are known to produce and secrete a variety of other growth factors, including HB-EGF and bFGF/FGF-2. Thus, T cells present in the local prostate environment were thought to be capable of secreting potent epithelial and stromal mitogens that promote stromal and glandular hyperplasia.

In the past 5 years, specific inflammatory mediator pathways have been studied in detail to elucidate the potential role of these pathways in BPH pathogenesis. A large number of cytokines and their receptors are seen in BPH tissue (Konig et al., 2004). Specifically, significant levels of IL-2, IL-4, IL-7, IL-17, interferon γ (IFN-γ), and their relevant receptors are found in BPH tissue (Kramer et al., 2002; Steiner et al., 2003a,b). IL-2, IL-7, and IFN-γ stimulate the proliferation of prostatic stromal cells in vitro. Prostatic epithelial cell senescence results in increased expression of IL-8, which can promote proliferation of nonsenescent epithelial and stromal cells (Castro et al., 2004). Macrophage inhibitory cytokine 1 is expressed in normal prostate tissue but significantly downregulated in BPH (Kakehi et al., 2004; Taoka et al., 2004). Chronic inflammation in BPH is also associated with focal upregulation of cyclooxygenase 2 (COX-2) in the glandular epithelium (Wang et al., 2004). To establish potential cause-and-effect relationships between prostatic inflammation and stromal-epithelial hyperplasia, mouse models of autoimmune and bacterial prostatitis have been developed. The POET (prostate ovalbumin expressing transgenic) autoimmune mouse model displays infiltration of lymphocytes, macrophages and neutrophils, which is accompanied by epithelial/stromal thickening and epithelial stem cell expansion (Wang et al., 2015). Bacteria-induced prostate inflammation in mice can also drive epithelial turnover (Kwon et al., 2014b). Correlative evidence in human prostate also demonstrates an expansion of epithelial progenitor cells near sites of inflammation (Liu et al., 2016).

To date, however, no firm cause-and-effect relationships have been established between prostatic inflammation and related cytokine pathways and stromal-epithelial hyperplasia.

Recent work from an Italian laboratory suggests that the metabolic syndrome may be a clinical determinant of a higher risk for prostatic inflammation and thus for male LUTS and BPH, and that androgen receptor activation by testosterone (in a rabbit model) and DHT may have a protective effect on prostatic inflammation (Vignozzi et al., 2012a,b; Gacci et al., 2013). Conditional knockout of the androgen receptor in adult mouse prostate epithelia results in increased secretion of proinflammatory cytokines and immune infiltration (Zhang et al., 2016). In the human, hypogonadism is associated with inflammation (Sorrentino et al., 2011). This work, if confirmed, effectively establishes a link between the role of androgenic steroids and prostatic inflammation in the pathophysiology of male LUTS and BPH.

Kramer et al. (2007) published recent reviews of BPH as a potentially autoimmune disease, and Fig. 144.4 illustrates the immunologic key features of chronic inflammation in BPH and the present interpretation of these changes in the development and progression of BPH. A summary of clinical observations regarding the role of inflammation in clinical BPH suggested it as a therapeutic target (Gandaglia et al., 2013). A more thorough characterization of the immune/inflammatory environment in BPH is needed to identify therapeutic targets.

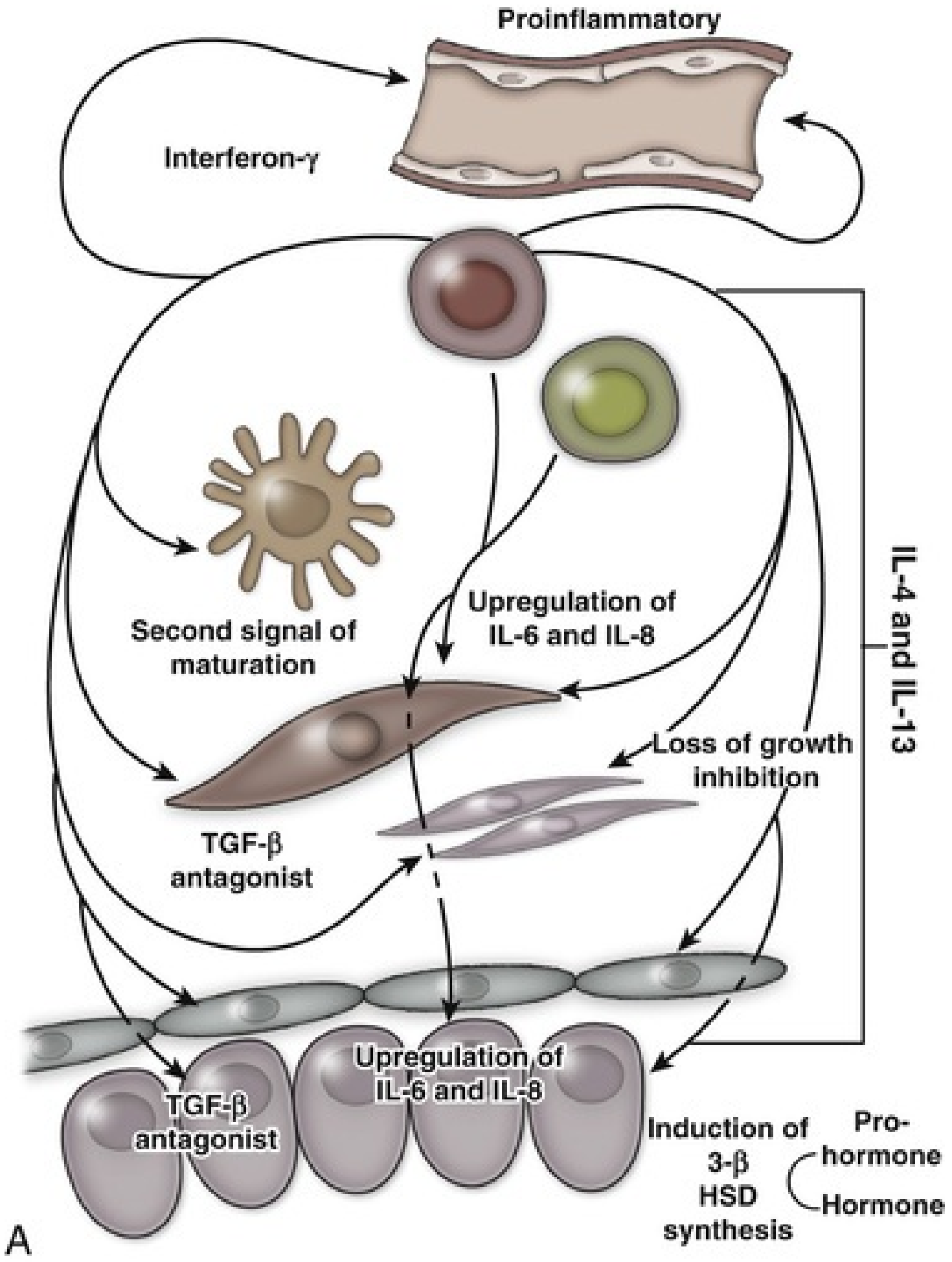
Proinflammatory
Interferon-γ
IL-4 and IL-13
Second signal of maturation
Upregulation of IL-6 and IL-8
Loss of growth inhibition
TGF-β antagonist
Upregulation of IL-6 and IL-8
TGF-β antagonist
Induction of 3-β HSD synthesis
Pro-hormone
Hormone
A

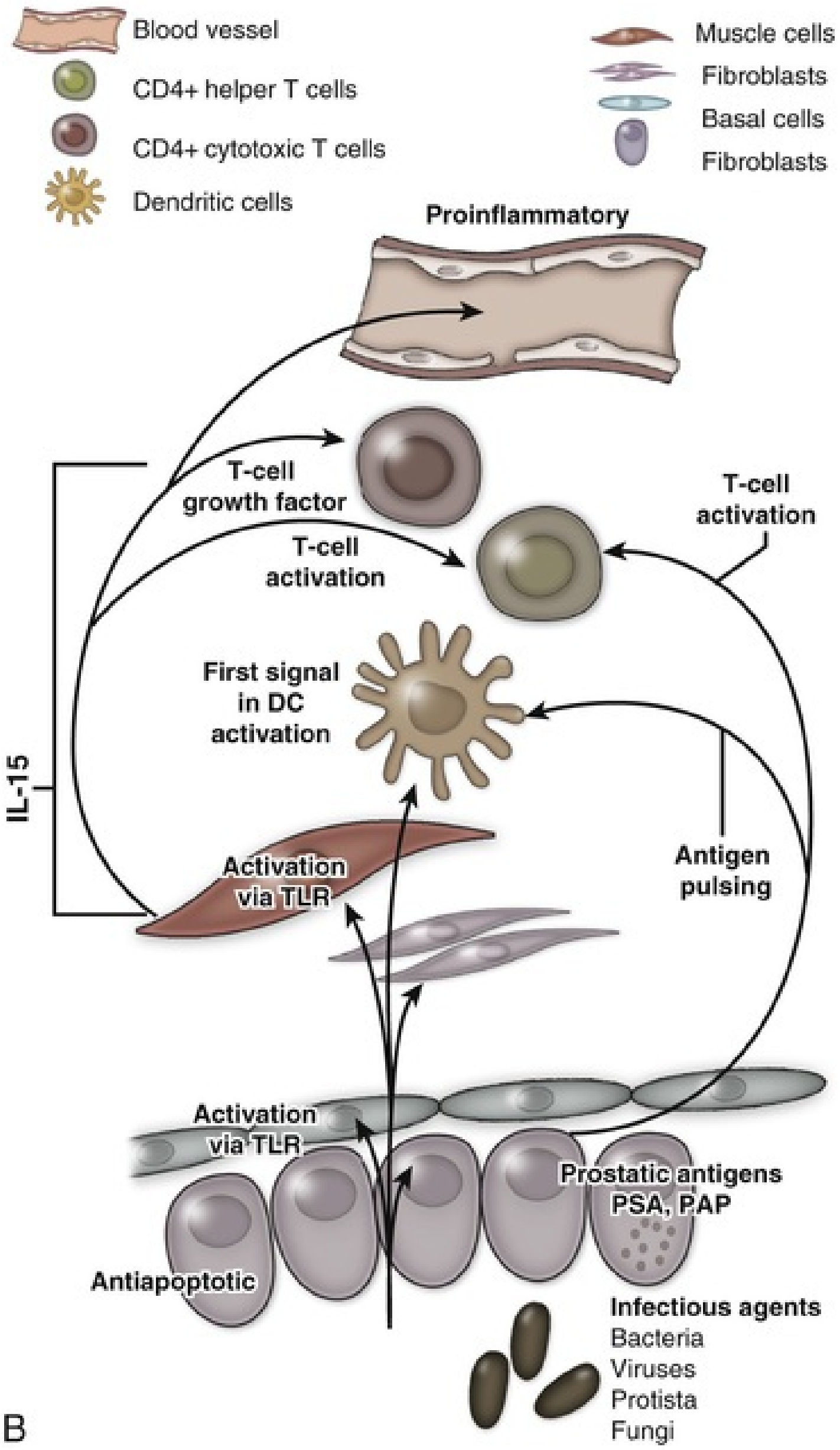

Blood vessel
CD4+ helper T cells
CD4+ cytotoxic T cells
Dendritic cells
Muscle cells
Fibroblasts
Basal cells
Fibroblasts
Proinflammatory
T-cell growth factor
T-cell activation
T-cell activation
First signal in DC activation
IL-15
Antigen pulsing
Activation via TLR
Activation via TLR
Prostatic antigens PSA, PAP
Antiapoptotic
Infectious agents
Bacteria
Viruses
Protista
Fungi
B

FIG. 144.4 (A) Tissue effect of T cell–derived proinflammatory cytokines on the pathogenesis and progression of immune inflammation and stromal growth in the aging prostate. (B) Role of smooth muscle cells in maintenance and propagation of immune infiltration in the aging prostate. *PAP,* Prostatic acid phosphatase; *PSA,* prostate-specific antigen; *TLR,* toll-like receptor. (From Kramer G, Mitteregger D, Marberger M. Is benign prostatic hyperplasia [BPH] an immune inflammatory disease? *Eur Urol* 51[5]:1202–1216, 2007.)

Genetic and Familial Factors

There is substantial evidence that **BPH has an inheritable genetic component.**

Sanda et al. conducted a retrospective case-control analysis of surgically treated BPH patients and control subjects at Johns Hopkins (Partin and Coffey, 1994; Sanda et al., 1994). The BPH patients were men whose resected prostate weights were in the highest quartile (greater than 37 g) and whose age at prostatectomy were in the lowest quartile. **The hazard-function ratio for surgically-treated BPH among first-degree male relatives of the BPH cases compared with the first-degree male relatives of the controls was 4.2 (95% confidence interval [CI], 1.7 to 10.2), demonstrating a very strong relationship** (Table 144.3). The results did not appear to be caused by differences in health-seeking behavior between the two groups. A segregation analysis showed that the results were most consistent with an **autosomal dominant inheritance pattern.** Utilizing this model, **approximately 50% of men undergoing prostatectomy for BPH before 60 years of age could be attributable to an inheritable form of disease.** In contrast, **only about 9% of men undergoing prostatectomy for BPH after 60 years of age would be predicted to have a familial risk.** In addition, monozygotic twins demonstrate a higher concordance rate of BPH than dizygotic twins (Partin and Coffey, 1994).

TABLE 144.3

Family History of Early-Onset Benign Prostatic Hyperplasia (BPH) Increases Risk for Clinically-Significant BPH

BPH (%)[a] RELATIVES	FREQUENCY OF CLINICAL BPH		AGE-ADJUSTED RISK		SIGNI
	CASE RELATIVES	CONTROL RELATIVES	ODDS RATIO (UNADJUSTED)[b]	RELATIVE RISK FOR CLINICAL BPH[c]	CHI-SQUA
All first-degree male relatives	28.3	8.6	4.2 (1.7–10.2)	4.4 (1.9–9.9)	13.36
Fathers of proband	33.3	13.2	3.3 (1.1–10.2)	3.5 (1.3–9.5)	5.94
Brothers of proband	24.2	3.9	8.0 (1.6–40.5)	6.1 (1.3–29.7)	6.85

[a] Percent of informative male relatives with history of prostatectomy (open or transurethral) for BPH (60 case relatives and 105 control relatives).

[b] Chi-square analysis of proportions; Taylor 95% confidence intervals in parentheses.

[c] Cox proportional hazards survival model. Censored outcome—prostatectomy. Time variable—age at death or current age. Values in parentheses indicate 95% confidence intervals.

BPH, Benign prostatic hyperplasia.

From Sanda MG, Beaty TH, Stutzman RE, et al. Genetic susceptibility of benign prostatic hyperplasia. *J Urol* 152(1):115–119, 1994.

In a community-based cohort study of more than 2000 men, Roberts et al. (1995) found an elevated risk for moderate to severe urologic symptoms in men with a family history of an enlarged prostate and a family history of BPH compared with those with no history. Analysis of the subjects who participated in the US finasteride clinical trial identified 69 men who had three or more family members with BPH, including the proband (Sanda et al., 1997). Regression analysis demonstrated that **familial BPH was characterized by large prostate size, with a mean prostate volume of 82.7 mL in men with hereditary BPH compared with 55.5 mL in men with sporadic BPH.** Serum androgen levels and the response to 5α-reductase inhibition were similar in familial and sporadic BPH. A more recent familial aggregation study in the finasteride database confirmed that a strong family history of early onset and large prostate volume is more likely to be associated with inheritance of risk than symptom severity or other factors (Pearson et al., 2003).

These studies clearly demonstrate the presence of a familial form of BPH and suggest the presence of a gene contributing to the pathogenesis of the disease. The studies of Meikle et al. (1997) also support a genetic basis for BPH. Preliminary studies demonstrate evidence of DNA mutations (White et al., 1990), DNA hypomethylation (Bedford and van Helden, 1987), abnormalities of nuclear matrix protein expression (Partin et al., 1993), miscellaneous genetic polymorphisms (Habuchi et al., 2000a; Konishi et al., 1997; Werely et al., 1996), and abnormal expression of the Wilms' tumor gene (WT-1) (Dong et al., 1997) in human BPH. By analyzing 14 SNPs associated with prostate cancer, genetic variants in 2q31 and 5p15 were found to be associated with aggressive BPH in a Chinese population (Qi et al., 2013). However, the specific gene or genes involved in familial BPH or that contribute to the risk for significant prostatic enlargement in sporadic disease remain to be elucidated.

Other Etiologic Factors

Androgens and soluble growth factors are clearly not the only important factors for the development of BPH. All mammalian prostates studied have testosterone, DHT, and AR as well as most of the known growth factor signaling pathways; however, only dogs and humans develop BPH. Interestingly, another glandular organ that remains androgen responsive throughout life, the seminal vesicle, does not develop hyperplasia. Obviously, other mechanisms or cofactors must be present in these two unique species making them susceptible to the disease. Nonandrogenic substances from the testis, perhaps transmitted through the vas deferens or deferential blood vessels, for example, may play some role (Dalton et al., 1990). Rats with intact testes treated with exogenous androgen demonstrate a greater degree of prostatic growth than castrated rats treated with androgen. Sutkowski et al. (1993) demonstrated that human spermatocele fluid is mitogenic to both human prostatic epithelial and stromal cells in culture. Similar results were seen in castrated versus testes-intact dogs treated with exogenous androgen and exogenous testosterone and estradiol combination (Juniewicz et al., 1994). In addition to increases in prostate weight, the incidence of histologic BPH was significantly higher in the dogs with intact testes. Grayhack et al. (1998) identified a putative substance that may be a candidate for such a factor.

Prolactin has long been speculated to play a role in BPH because of the known effects of this hormone on prostate cells in vitro. Transgenic mice overexpressing the prolactin gene develop significant enlargement of the prostate (Wennbo et al., 1997). However, despite the documented presence of prolactin receptors in the human prostate and low circulating levels of the hormone, the role of prolactin in human prostate disease is unclear.

Molecular profiling, fingerprinting, microarrays, and high-throughput screening tools have uncovered new genes, as well as known genes not previously associated with BPH. Preliminary findings from the Getzenberg laboratory (Minnery and Getzenberg, 2005; Prakash et al., 2002; Sakamoto et al., 2004; Shah et al., 2004) and other groups (Dhanasekaran et al., 2005; Fromont et al., 2004; Henry et al., 2017; Lin-Tsai et al., 2014) suggest that new markers for BPH and new therapeutic targets will be forthcoming in the next few years.

Although there are many mouse models with prostate hyperplasia because of the differences in mouse and human prostate anatomy (Ittmann, 2018) and a poor understanding of the molecular drivers of BPH pathogenesis, there has yet to be developed a mouse model of human BPH. Although a mouse model may never fully recapitulate every aspect of the human disease, greater efforts to model specific aspects of human BPH are needed.

Pathophysiology

The pathophysiology of BPH is complex (Fig. 144.5). **Prostatic hyperplasia increases urethral resistance, resulting in compensatory changes in bladder function.** However, the elevated detrusor pressure required to maintain urinary flow in the presence of increased outflow resistance occurs at the expense of normal bladder storage function. **Obstruction-induced changes in detrusor function, compounded by age-related changes in both bladder and nervous system function, lead to urinary frequency, urgency, and nocturia, the most bothersome BPH-related complaints.** Thus, an understanding of BPH pathophysiology requires detailed insight into obstruction-induced bladder dysfunction.

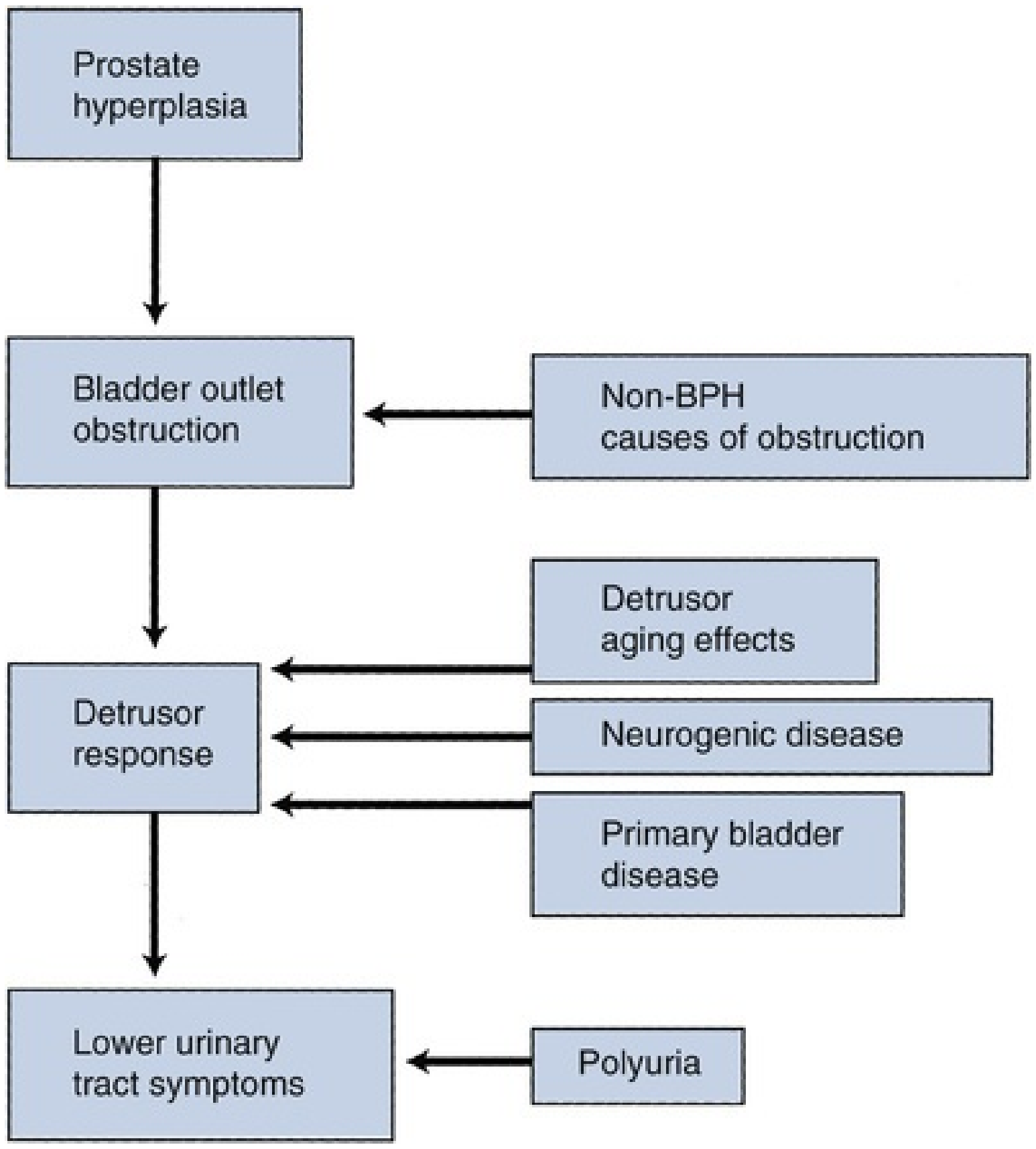
Prostate hyperplasia
Bladder outlet obstruction
Non-BPH causes of obstruction
Detrusor aging effects
Detrusor response
Neurogenic disease
Primary bladder disease
Lower urinary tract symptoms
Polyuria

FIG. 144.5 The pathophysiology of benign prostatic hyperplasia *(BPH)* involves complex interactions among urethral obstruction, detrusor function and dysfunction, and urine production.

Pathology

Anatomic Features

McNeal demonstrated that **BPH first develops in the periurethral *transition zone* of the prostate** (McNeal, 1978) (Fig. 144.6). The transition zone consists of two separate glands immediately external to the preprostatic sphincter. The main ducts of the transition zone arise on the lateral aspects of the urethral wall at the point of urethral angulation near the verumontanum. Proximal to the origin of the transition zone ducts are the glands of the *periurethral zone* that are confined within the preprostatic sphincter and course parallel to the axis of the urethra. All BPH nodules develop either in the transition zone or in the periurethral region (McNeal, 1978, 1990). Although early transition zone nodules appear to occur either within or immediately adjacent to the preprostatic sphincter, as the disease progresses and the number of small nodules increases, they can be found in almost any portion of the transition or periurethral zone. However, **the transition zone also enlarges with age, unrelated to the development of nodules.**

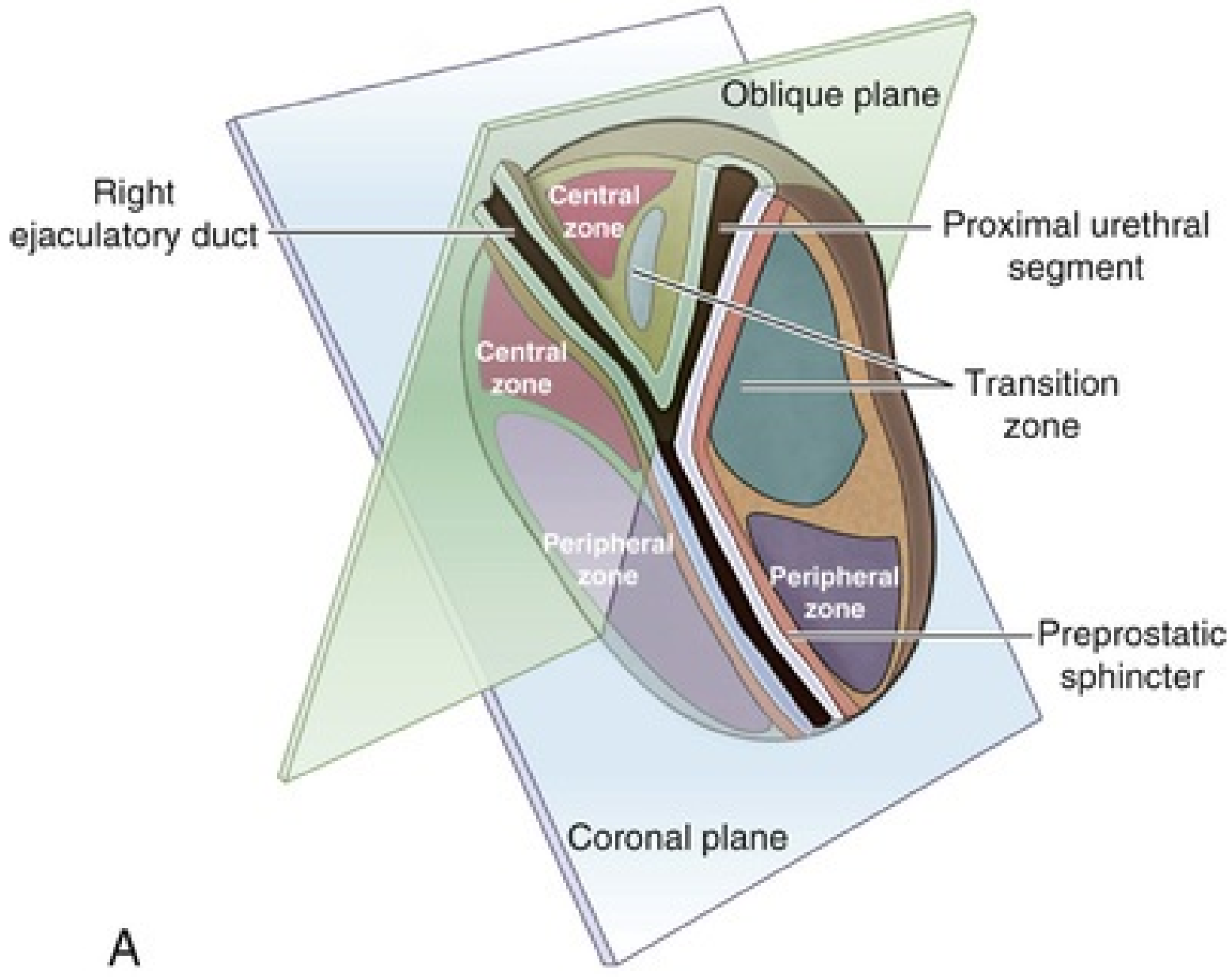
Oblique plane
Right ejaculatory duct
Central zone
Proximal urethral segment
Central zone
Transition zone
Peripheral zone
Peripheral zone
Preprostatic sphincter
Coronal plane
A

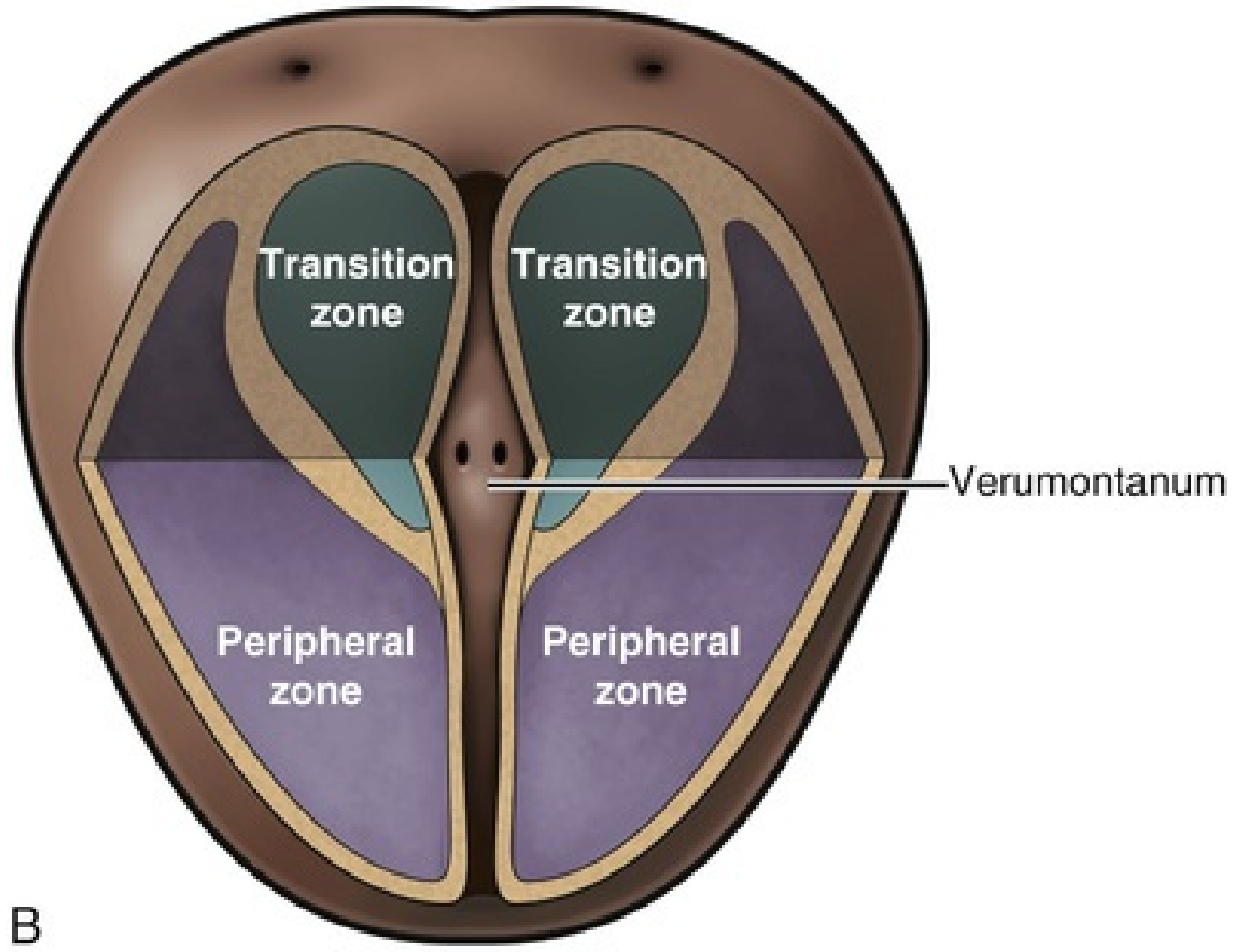

FIG. 144.6 Zonal anatomy of the prostate as first described by McNeal (1978). Sagittal (A) and coronal (B) sections of the prostate showing peripheral zone, transition zone, central zone, the verumontanum, the proximal urethral segment, and preprostatic sphincter and ejaculatory duct. (From Roehrborn CG. Pathology of benign prostatic hyperplasia. *Int J Impot Res* 20[Suppl 3]:S11–S18, 2008.)

One of the unique features of the human prostate is **the presence of the prostatic capsule, which plays an important role in the development of LUTS** (Caine and Schuger, 1987). In the dog, the only other species known to develop naturally occurring BPH, symptoms of bladder outlet obstruction and urinary symptoms rarely develop because the canine prostate lacks a capsule. Presumably the capsule transmits the "pressure" of tissue expansion to the urethra and leads to an increase in urethral resistance. Thus, the clinical symptoms of BPH in humans may be caused by not only age-related increases in prostatic size but also the unique anatomic structure of the human gland. **Clinical evidence of the importance of the capsule can be found in series that clearly document that incision of the prostatic capsule (transurethral incision of the prostate) results in a significant improvement in outflow obstruction, despite the fact that the volume of the prostate remains the same.**

The size of the prostate does not correlate with the degree of obstruction. Thus, other factors such as dynamic urethral resistance, the prostatic capsule, and anatomic pleomorphism are more important in the production of clinical symptoms than the absolute size of the gland. In some cases, predominant growth of periurethral nodules at the bladder neck gives rise to the "middle lobe"

(Fig. 144.7). The middle lobe must be of periurethral origin because there is no transition zone tissue in this area. It is not clear whether middle lobe growth occurs at random in men with BPH or whether there is an underlying genetic susceptibility to this pattern of enlargement.

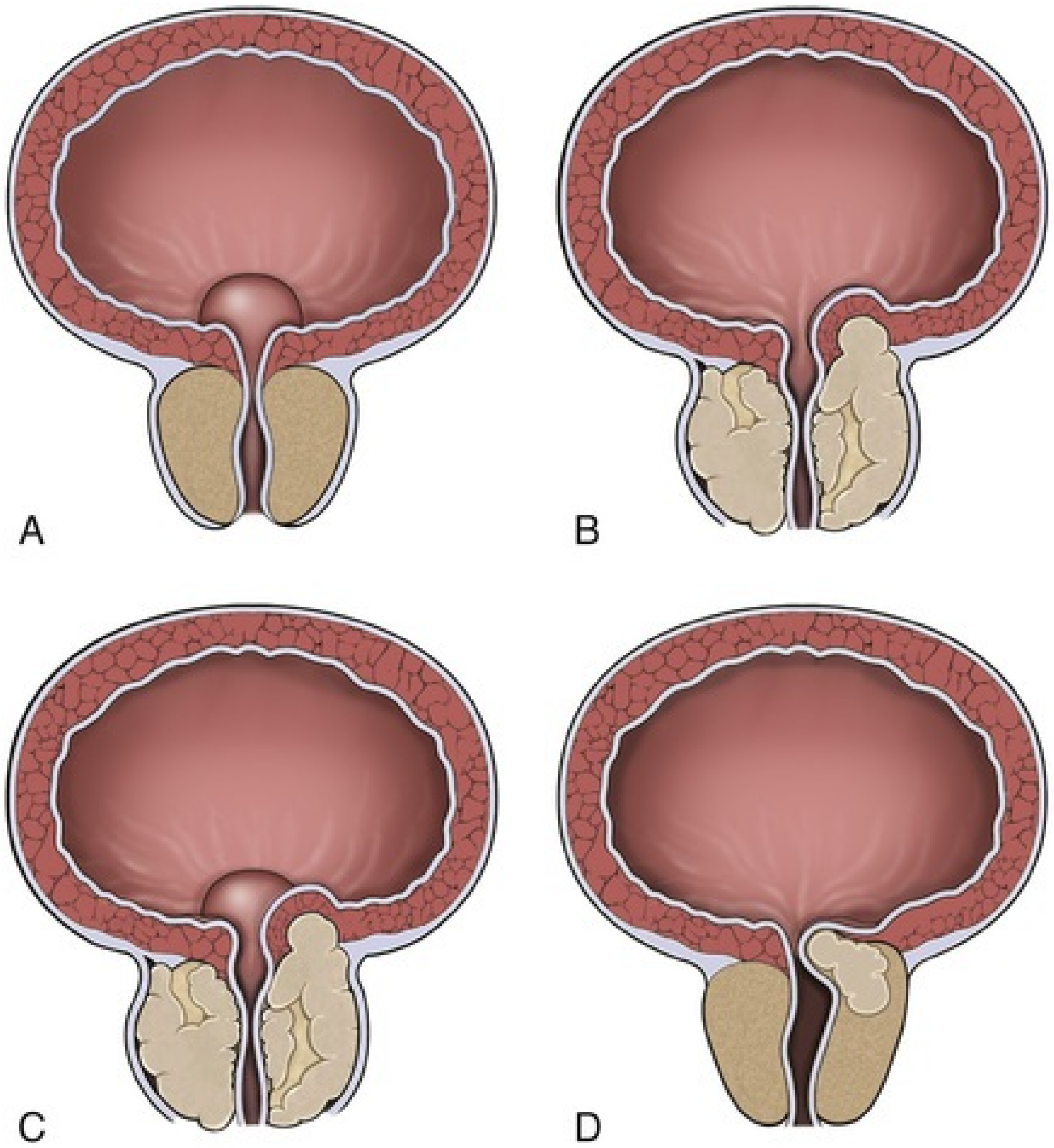

FIG. 144.7 Diagrams of hyperplastic prostatic tissue obstructing the prostatic urethra, forming "lobes." (A) Isolated middle lobe enlargement. (B) Isolated lateral lobe enlargement. (C) Lateral and middle lobe enlargement. (D) Posterior commissural hyperplasia *(median bar).* (After Randall [1931], from Roehrborn CG. Pathology of benign prostatic hyperplasia. *Int J Impot Res*20[Suppl 3]:S11–S18, 2008.)

Histologic Features

BPH is a hyperplastic and not a hypertrophic process (i.e., there is a net increase in the number of cells and not in the size of the cells). Histologic studies document an increase in cell number (McNeal, 1990). In addition, thymidine uptake studies in the dog clearly indicate an increase in DNA synthesis in experimentally induced BPH (Barrack and Berry, 1987). The term *benign prostatic hypertrophy* is pathologically incorrect.

McNeal's studies demonstrate that the majority of **early periurethral nodules are purely stromal in character** (McNeal, 1990). These small stromal nodules resemble embryonic mesenchyme with an abundance of pale ground substance and minimal collagen. It is unclear whether these early stromal nodules contain mainly fibroblast-like cells or whether differentiation toward a smooth muscle cell type is occurring. In contrast, **the earliest transition zone nodules represent proliferation of glandular tissue** that may be associated with an actual reduction in the relative amount of stroma (Fig. 144.8). The minimal stroma seen initially consists primarily of mature smooth muscle, not unlike that of the uninvolved transition zone tissue. These **glandular nodules are apparently derived from newly formed small duct branches** that bud off from existing ducts, leading to a totally new ductal system within the nodule. This type of **new gland formation is quite rare** outside embryonic development. This proliferative process leads to a tight packing of glands within a given area and an increase in the height of the lining epithelium. There appears to be hypertrophy of individual epithelial cells as well. Again, the observed increase in transition zone volume with age appears to be related not only to an increased number of nodules but also to an increase in the overall size of the zone.

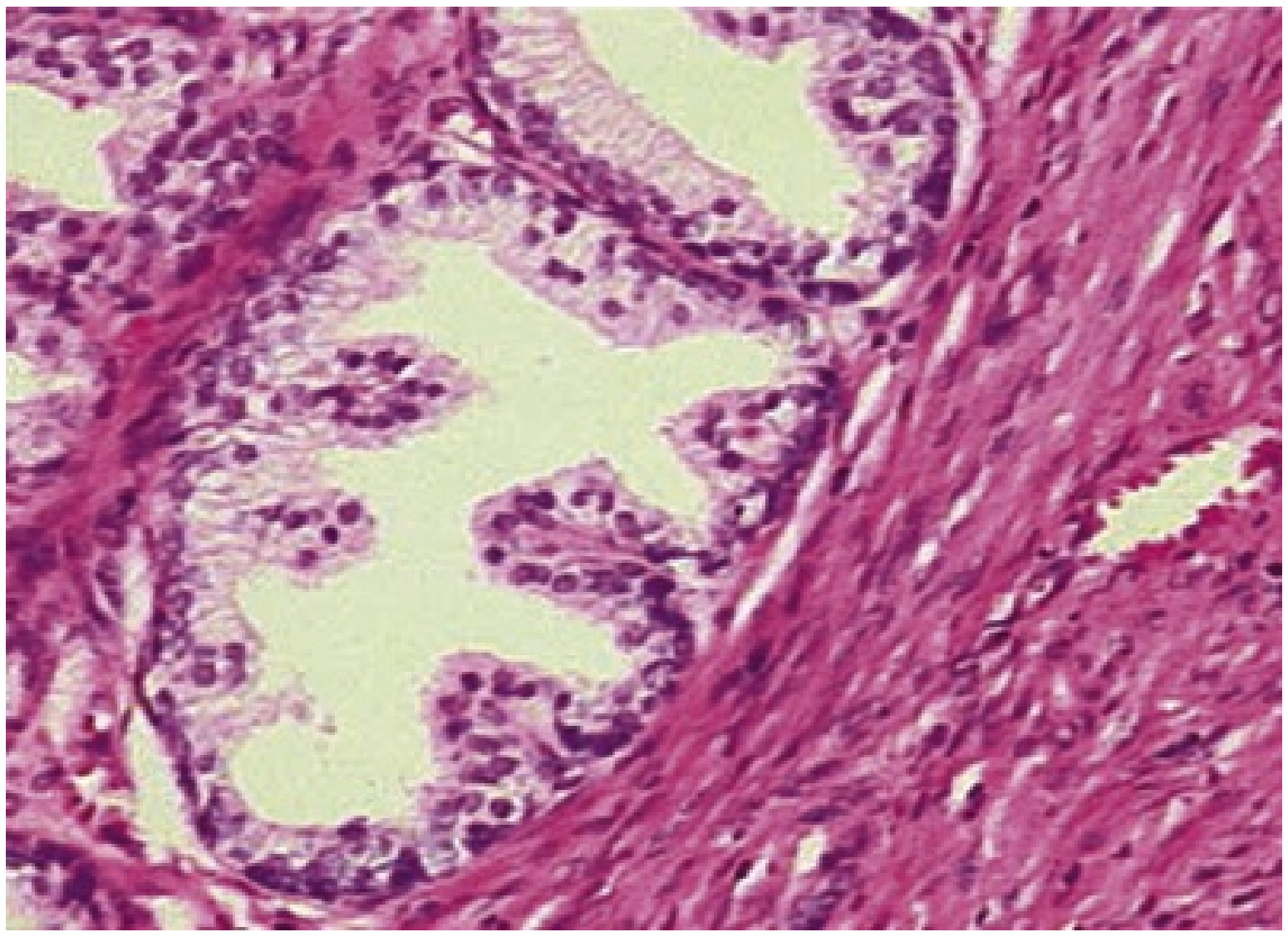

FIG. 144.8 Stromoglandular hyperplasia of the prostate showing glandular *(upper left)* and stromal *(lower right)* tissue (hematoxylin and eosin stain). (From Roehrborn CG. Pathology of benign prostatic

hyperplasia. *Int J Impot Res* 20[Suppl 3]:S11–8, 2008.)

During the first 20 years of BPH development, the disease may be predominantly characterized by an increased number of nodules, and the subsequent growth of each new nodule is generally slow. Then a second phase of evolution occurs in which there is a significant increase in large nodules. In the first phase, the glandular nodules tend to be larger than the stromal nodules. In the second phase, when the size of individual nodules is increasing, the size of glandular nodules clearly predominates (Price et al., 1990).

There is significant pleomorphism in stromal-epithelial ratios in resected tissue specimens, which is largely ignored in molecular studies of BPH. Studies from primarily **small resected glands demonstrate a predominance of fibromuscular stroma** (Shapiro et al., 1992). Larger glands, predominantly those removed by enucleation, demonstrate primarily epithelial nodules (Franks, 1976). However, an increase in stromal-epithelial ratios does not necessarily indicate that this is a “stromal disease”; stromal proliferation may well be caused by “epithelial disease.” A cellular composition and inferred cellular origin for each phenotype has yet to be described (Strand et al., 2017). **This is primarily caused by the lack of proper normal controls in BPH research, where a benchmark of cellular composition and molecular signatures is needed.**

Importance of Prostatic Smooth Muscle

Regardless of the exact proportion of epithelial to stromal cells in the hyperplastic prostate, there is no question that **prostatic smooth muscle represents a significant volume of the gland** (Shapiro et al., 1992) (Fig. 144.9). Although the smooth muscle cells in the prostate have not been extensively characterized, presumably their contractile properties are similar to those seen in other smooth muscle organs. The spatial arrangement of smooth muscle cells in the prostate is not optimal for force generation; however, there is no question that **both passive and active forces in prostatic tissue play a major role in the pathophysiology of BPH.** The factors that determine passive tone in the prostate remain to be elucidated. The series elastic elements in the stromal and epithelial cells and (most important) the ECM contribute to passive tissue force, independent of active smooth muscle contraction. However, **stimulation of the adrenergic nervous system clearly results in a dynamic increase in prostatic urethral resistance. Blockade of this stimulation by α-receptor blockers clearly diminishes this response.** However, α-blockade does not decrease passive tension in the prostate, which may be an equal determinant of urethral resistance.

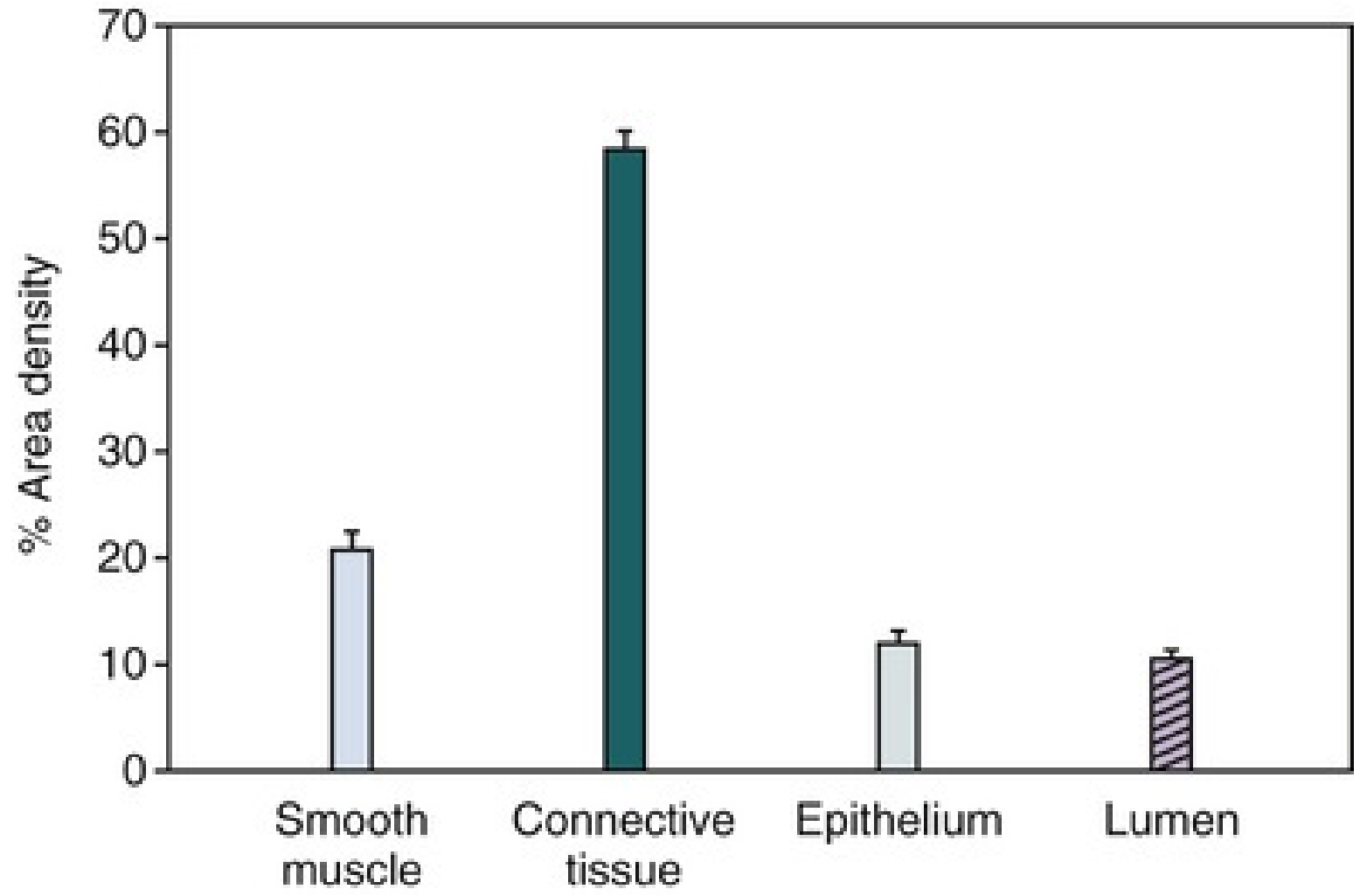

FIG. 144.9 Prostate sections obtained from men with symptomatic benign prostatic hyperplasia were analyzed by double immunoenzymatic staining and quantitative image analysis. The percent area density of smooth muscle and connective tissue is significantly greater than glandular epithelium and glandular lumen area density (mean ± SEM). (From Shapiro E, Becich MJ, Hartanto V, Lepor H. The relative proportion of stromal and epithelial hyperplasia is related to the development of symptomatic benign prostate hyperplasia. *J Urol* 147(5):1293–1297, 1992.)

Several additional observations on the prostatic stromal/smooth muscle cell are important. It is generally assumed that the stromal cells are resistant to the effects of androgen withdrawal. In short-term studies, androgen ablation appears to affect primarily the epithelial cell population. In general, however, stromal cells have much slower turnover rates than epithelial cells. If the effect of androgen ablation is primarily to increase cell death rates, a decrease in stromal cell numbers may not be appreciated until 1 year or more of therapy. Thus, further study is required to determine whether the stromal cell is really resistant to androgen withdrawal. Likewise, it cannot be assumed that hormonal therapy has no effect on the stroma even if stromal cell volumes are not decreased. In a variety of smooth muscle cell systems (e.g., vascular and myometrial), contractile proteins, neuroreceptors, and ECM proteins are regulated by a variety of hormones and growth factors. In vitro, androgens have been shown to modulate the effects of α agonists on prostate smooth muscle cells (Smith et al., 2000). Thus, a given therapy may affect stromal cell function without decreasing the absolute number or volume of cells.

Studies of human tissue samples by Lin et al. (2000) have clearly shown that the smooth muscle cells from men with BPH have a significant downregulation of smooth muscle myosin heavy chain and a significant upregulation of nonmuscle myosin heavy chain. This myosin expression pattern is typical of dedifferentiated smooth muscle and indicates either proliferation or loss of normal modulation pathways.

Active smooth muscle tone in the human prostate is regulated by the adrenergic nervous system (Roehrborn and Schwinn, 2004). The α_1-adrenoreceptor nomenclature has been standardized to reconcile differences in nomenclature based on pharmacologic and molecular studies (Hieble et al., 1995). **Receptor binding studies clearly demonstrate that the α_{1A} is the most abundant adrenoreceptor subtype present in the human prostate** (Lepor et al., 1993a,b; Price et al., 1993)**. Moreover, the α_{1A} adrenoreceptor clearly mediates active tension in human prostatic smooth muscle.** It is still unclear whether other factors may regulate smooth muscle contraction. Endothelin and endothelin receptors have been reported in human prostate (Imajo et al., 1997; Kobayashi et al., 1994a,b; Walden et al., 1998). However, the physiologic role of this potent contractile agent in prostate smooth muscle function remains to be defined. Various components of the kallikrein-kinin system (e.g., bradykinin) may play a role in the regulation of both smooth muscle proliferation and contraction in the prostate (Srinivasan et al., 2004; Walden et al., 1999).

The presence of type 4 and type 5 phosphodiesterase isoenzymes in the prostate and the detrusor muscle of the bladder implies that phosphodiesterase inhibitors may be appropriate candidate therapies for BPH-related LUTS (Uckert et al., 2001, 2008, 2009). In fact, placebo-controlled trials have verified a beneficial effect of commercially available drugs for the treatment of erectile dysfunction (ED) in men with LUTS and BPH (McVary et al., 2007; Roehrborn et al., 2008; Stief et al., 2008).

The role of adrenergic stimulation in the prostate may exceed simple smooth muscle contraction. Adrenergic neurotransmitters are known to regulate expression of contractile protein genes in cardiac myocytes (Kariya et al., 1993) and to be involved in the development of cardiac hypertrophy (Matsui et al., 1994). Interestingly, evidence suggests that testosterone may regulate the expression of adrenergic receptors, at least in the kidney (Gong et al., 1995). It is possible that adrenergic neurotransmitters may play a role in prostatic smooth muscle cell *regulation* and contraction (Smith et al., 2000). α-Adrenergic blockade in patients with documented BPH leads to a significant downregulation of normal contractile protein gene expression, specifically smooth muscle myosin heavy chain.

Autonomic nervous system overactivity may contribute to LUTS in men with BPH. McVary et al. (2005) demonstrated that autonomic nervous system activity, as measured by a standard set of physiologic tests, plasma, and urinary catecholamines, correlates positively with symptom score and other BPH measures. Serum norepinephrine increase after tilt predicted prostate size (transition zone).

The Bladder's Response to Obstruction

Current evidence suggests that the bladder's response to obstruction is largely an adaptive one. However, it is also clear that many lower tract symptoms in men with BPH or prostate enlargement are related to obstruction-induced changes in bladder function rather than to outflow obstruction directly. Approximately one-third of men continue to have significant voiding dysfunction and mostly storage symptoms after surgical relief of obstruction (Abrams et al., 1979). Obstruction-induced changes in the bladder are of two basic types. First, the **changes that lead to *detrusor instability* or decreased *compliance* are clinically associated with symptoms of frequency and urgency.** Second, the **changes associated with decreased *detrusor contractility* are associated with further deterioration in the force of the urinary stream, hesitancy, intermittency, increased residual urine,** and (in a minority of cases) detrusor failure. Acute urinary retention (AUR) should not be viewed as an inevitable result of this process. Many patients presenting with AUR have more than adequate detrusor function, with evidence of a precipitating event leading to the obstruction.

Much of our knowledge of the detrusor's response to obstruction is based on experimental animal studies. Limited information is available on the natural history of the human bladder's response to obstruction. Gosling et al. demonstrated that **the major endoscopic detrusor change, trabeculation, is caused by an increase in detrusor collagen** (Gosling and Dixon, 1980; Gosling et al., 1986). Severe trabeculation is associated with significant residual urine (Barry et al., 1993), suggesting that incomplete emptying may be caused by increased collagen rather than impaired muscle function. Severe trabeculation, however, is seen in fairly advanced disease. In experimental animal models, **the initial response of the detrusor to obstruction is the development of smooth**

muscle hypertrophy (Levin et al., 1995, 2000). It is likely that this **increase in muscle mass, although an adaptive response to increased intravesical pressure and maintained flow, is associated with significant intracellular and extracellular changes in the smooth muscle cell that lead to detrusor instability and in some cases impaired contractility.** Obstruction also induces changes in smooth muscle cell contractile protein expression, impaired energy production (mitochondrial dysfunction), calcium signaling abnormalities, and impaired cell-to-cell communication (Levin et al., 1995, 2000). The study of bladder trabeculation in the epidemiology of BPH and bladder outlet obstruction suffers from a universal definition and a widely accepted grading system of trabeculation. A recent attempt to create such a grading system demonstrated acceptable correlation with urodynamic parameters (Cho et al., 2013).

There is considerable evidence that the response of the detrusor smooth muscle cell to stress (increased load related to outlet obstruction) is not as adaptive as the response of skeletal muscle to stress. In the latter case, a relatively normal repertoire of contractile protein genes are upregulated, and an increased number of normally organized contractile units assemble in the muscle cell. In the detrusor smooth muscle cell, load-induced hypertrophy leads to a change in myosin heavy chain isoform expression (Cher et al., 1996; Lin and McConnell, 1994) and to a significant alteration in the expression of a variety of thin filament–associated proteins (Mannikarottu et al., 2005a,b, 2006). Taken together, these observations strongly suggest that smooth muscle cells revert to a secretory phenotype in response to obstruction-induced hypertrophy. One consequence of this phenotypic switch is increased ECM production. The detrusor smooth muscle cell is a key contributor to the complex of symptoms associated with prostatic obstruction. Additional research in this area is required (Christ and Liebert, 2005).

In experimental animal models, unrelieved obstruction is associated with the development of significant increases in detrusor ECM (collagen) (Levin et al., 1995, 2000). This also appears to be the case in the human, although cause-and-effect relationships have not been established (Gosling et al., 1986). In addition to obstruction-induced changes in the smooth muscle cell and ECM of the bladder, there is increasing evidence **that obstruction may modulate neural-detrusor responses** as well (Clemow et al., 1998, 2000; Steers et al., 1990, 1999). Altered neural control of micturition has been noted in aging rats, including reduced bladder contractility, impaired central processing, and altered sensation (Chai et al., 2000).

Fusco et al proposed after conducting an exhaustive review of the literature a three-stage model of bladder wall remodeling involving an initial hypertrophy phase, a subsequent compensation phase, and a later decompensation involving urothelium, suburothelium, detrusor smooth muscle cells, detrusor extracellular matrix, and bladder nerves. Cyclic stretch, increased hydrostatic and cyclic hydrodynamic pressure, and hypoxia are stimuli capable of modulating multiple signaling pathways involved in this remodeling process (Fusco et al., 2018).

A late response of the bladder to longstanding obstruction may be detrusor underactivity or underactive bladder, representing an end-stage condition with limited therapeutic options and found with increasing prevalence in elderly men and women (Osman and Chapple, 2018; Osman et al., 2018).

Independent of obstruction, aging produces some of the same changes in bladder function, histology, and cellular function (Nordling, 2002). There is suggestive evidence from animal models that atherosclerosis and the resultant chronic bladder ischemia or hypoxia induced by other mechanisms (e.g., increased bladder wall tension) may contribute to bladder pathology (Azadzoi, 2003; Azadzoi et al., 1999, 2003, 2008; Tarcan et al., 1998).

Key Points

- Androgens are necessary for maintenance but not growth of the prostate and are anti-inflammatory.
- Inflammation is correlated with prostatic enlargement, but its causal role is unclear.
- Intrapatient and interpatient anatomic pleomorphism confounds a cell type–specific molecular understanding of BPH and possibly contributes to therapeutic resistance.
- Animal models do not fully recapitulate human BPH because of anatomic differences, and there is a poor mechanistic understanding of the human disease.
- A heritable form of BPH exists, but precise mutations are unidentified.
- A mechanistic understanding of the secondary effects of prostatic obstruction on bladder contractile and neuromodulatory functions could improve clinical outcomes in patients with BPH/LUTS.

Epidemiology and Natural History

Definitions

The study of epidemiology determines the distribution and determinants of diseases in man. From this evolve the components of descriptive epidemiology, which is the description of disease incidence, mortality, and prevalence by person, place and time, and analytical epidemiology, which is the search for determinants of disease risk that may serve to increase prospects for prevention. Epidemiologists assess and compare rates of diseases within one population stratified by sex, age, and other demographic and socioeconomic parameters, and among populations of different culture, ethnicity, lifestyle, and diet.

The following definitions of rates are important to understand:

- Incidence: number of diseased people per 100,000 population per year
- Prevalence: number of existing cases per 100,000 population at a distinct target date
- Mortality: number of deaths per 100,000 population per year
- Fatality: number of deaths per number of diseased

Although the incidence rate (rate of people developing the condition in 1 year) is of preeminent interest for highly fatal conditions (those with a high fatality and mortality rate), the prevalence rate (number of men having the condition at a given point in time) is of greater interest for conditions such as BPH, which are rather benign in their course.

There is no globally accepted epidemiologic definition of BPH, and thus, prevalence and incidence rates must be viewed in the context of the definitions chosen by the investigator reporting the data (Barry, 1990). The prevalence of BPH thus can be calculated based on histologic criteria (autopsy prevalence) or clinical criteria (clinical prevalence). Because clinical definitions vary widely, it is easier to compare the autopsy or histologic prevalence of BPH. Despite the low mortality and fatality rates for BPH in modern series, a review of these data is interesting and revealing from a historical point of view.

Lastly, descriptive epidemiologic studies can be divided into *cross-sectional* (population stratified by baseline parameters is assessed one single time to determine if and how certain measures change depending on the parameter of interest) and *longitudinal* (population is assessed at baseline and at regular intervals to study the changes in parameters of interest stratified by age or other demographic criteria). It is obviously easier to perform cross-sectional studies because of the cost and logistical difficulties involved with longitudinal follow-up of a cohort over time. The majority of studies addressing LUTS and clinical BPH are cross-sectional in nature and are discussed later. Further, there are by definition no longitudinal autopsy studies of any condition, and histologically based longitudinal studies are exceedingly difficult to carry out because of the need for repetitive tissue procurement.

Descriptive Epidemiologic Studies

Histologic or Autopsy Prevalence

The definition of BPH is the presence of stromo-glandular hyperplasia on a surgical specimen or in the case of autopsy series in whole prostates removed after death from men not dying from prostate conditions. The 1984 landmark study by Berry et al. summarized the data from five studies demonstrating that no men younger than 30 years of age had evidence of BPH and that the prevalence rose with each age group, peaking at 88% in men in their 80s. Fig. 144.10 demonstrates the age-stratified prevalence based on several rigorously performed autopsy studies in the United States, the United Kingdom, Austria, Norway, Denmark, China, Japan, and India. The prevalence increases rapidly in the fourth decade of life, reaching nearly 100% in the ninth decade. It is striking that the age-specific autopsy prevalence is remarkably similar in all populations studied regardless of ethnic and geographic origin (Berry et al., 1984; Carter and Coffey, 1990; Franks, 1953; Harbitz and Haugen, 1972; Haugen and Harbitz, 1972; Karube, 1961; Holund, 1980; Moore, 1943; Pradhan and Chandra, 1975; Swyer, 1944).

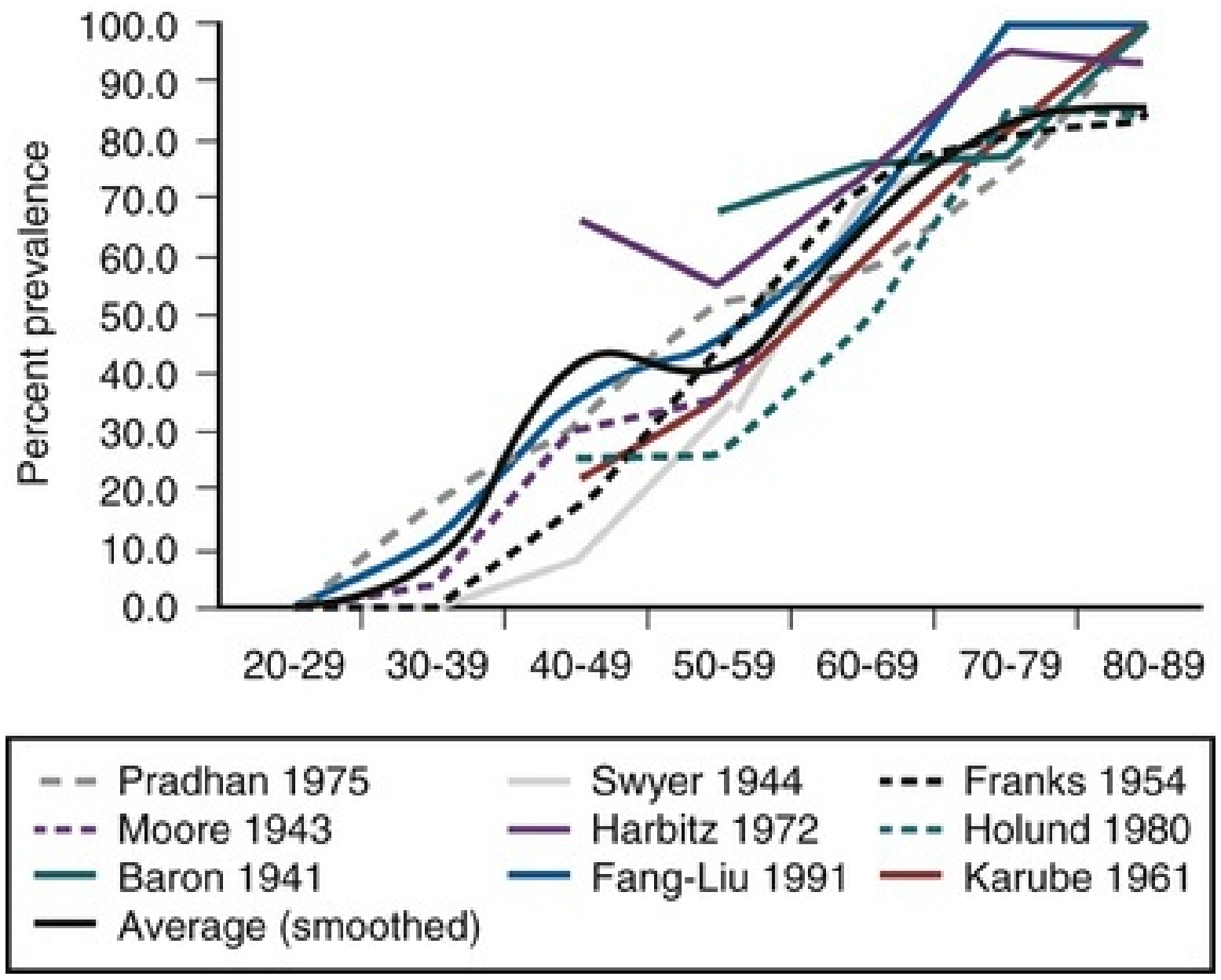

FIG. 144.10 Age-stratified autopsy prevalence of histologic benign prostatic hyperplasia from different series and (smoothed) average. (Data from Moore RA. Benign hypertrophy of the prostate. A morphological study. *J Urol* 50[6]:680–710, 1943; Swyer GI. Post-natal growth changes in the human prostate. *J Anat* 78[Pt 4]:130–145, 1994; Franks LM. Benign nodular hyperplasia of the prostate; a review. *Ann R Coll Surg Engl* 14[2]:92–106, 1953; Karube K. Study of latent carcinoma of the prostate in the Japanese based on necropsy material. *Tohoku J Exp Med* 74:265–285, 1961; Harbitz TB, Haugen OA. Histology of the prostate in elderly men. A study in an autopsy series. *Acta Pathol Microbiol Scand A* 80[6]:756–768, 1972; Haugen OA, Harbitz TB. Prostatic weight in elderly men. An analysis in an autopsy series. *Acta Pathol Microbiol Scand A* 80[6]:769–777, 1972; Pradhan BK, Chandra K. Morphogenesis of nodular hyperplasia—prostate. *J Urol* 113[2]:210–213, 1975; Holund B. Latent prostatic cancer in a consecutive autopsy series. *Scand J Urol Nephrol* 14[1]:29–35, 1980; Berry SJ, Coffey DS, Walsh PC, Ewing LL. The development of human benign prostatic hyperplasia with age. *J Urol* 132[3]:474–479, 1984; Carter HB, Coffey DS. The prostate: an increasing medical problem. *Prostate* 16[1]:39–48, 1990.)

Cross-Sectional Studies of Clinical Prevalence

Descriptive epidemiology relies on the presence of a single universally accepted definition of “disease.” The definitions of BPH, however, have undergone several changes in the past decade, and at present, no single criterion can be applied. In the past, the term *prostatism* was used, incorrectly referring to the prostate as the sole source of the typical LUTS found in aging men. Paul Abrams coined the term *LUTS* to replace the old and inappropriate term *prostatism*

(Chapple et al., 2008). When evaluating elderly men, one can therefore stratify them by the level of LUTS into mildly, moderately, and severely symptomatic according to a standardized symptom severity and frequency questionnaire (Barry et al., 1992a). It is important to recognize that BPH is only one potential cause for LUTS, which also may be caused by bladder, urethral, neurogenic, and as of now unknown causes. Patients can also be classified based on the degree of prostatic enlargement as measured by digital rectal examination (DRE), transrectal ultrasonography (TRUS), or magnetic resonance imaging (MRI), and lastly by the presence and degree of bladder outlet obstruction as measured by flow rate recordings or invasive pressure-flow studies**.** The diagram in Fig. 144.1 illustrates the difficulties in using different disease definitions. Of all men older than 40 years of age, a certain proportion will develop histologic hyperplasia of the prostate (i.e., BPH). Of these, some but not all will develop LUTS, and others may have LUTS caused by reasons other than BPH (e.g., overactive bladder or other bladder- and detrusor-related conditions, urethral stricture, stones, inflammation). Prostate enlargement occurs in some but again not all men with histologic BPH and LUTS, and some men with enlarged glands may not have any symptoms. Lastly, urodynamically proven obstruction may be present in men who have either one, several, or all of histologic BPH, LUTS, enlarged glands, and others yet may have obstruction without having evidence of BPH (e.g., urethral stricture, prostate cancer, primary bladder neck sclerosis). In addition to the mere enumeration of symptoms by frequency of occurrence, the bother associated with the symptoms, interference with activities of daily living, and the impact the symptoms have on quality of life are important distinguishing characteristics.

Accordingly, when studying the prevalence of “clinical BPH” (admittedly an imprecise term describing the constellation of LUTS, bother, interference, quality-of-life impact, with or without enlargement, obstruction), disease definitions may be applied that take either one or several of these items into consideration. For the subsequent discussion, it is important to recognize that very few if any clear cutoff points have been established that allow differentiation among disease states. For example, one might argue that a prostate volume more than 30 mL constitutes “clinical BPH,” but others might argue for a higher or lower cutoff point. Similar observations apply to symptom severity above or below a certain threshold, degrees of obstruction, and so on. Thus, rather than describing truly the prevalence of “a disease” in populations, one can describe the distribution of certain attributes of such disease in different populations stratified by age. Fig. 144.11 illustrates the different estimates of prevalence of “disease” when different definitions are applied ranging from autopsy prevalence to a combination of clinical threshold parameters and insurance examination data (Berry et al., 1984; Bosch et al., 1995; Chute et al., 1993; Garraway et al., 1991; Gu et al., 1994; Guess, 1995; Jolleys et al., 1994; Moon et al., 1995; Overland et al., 2001).

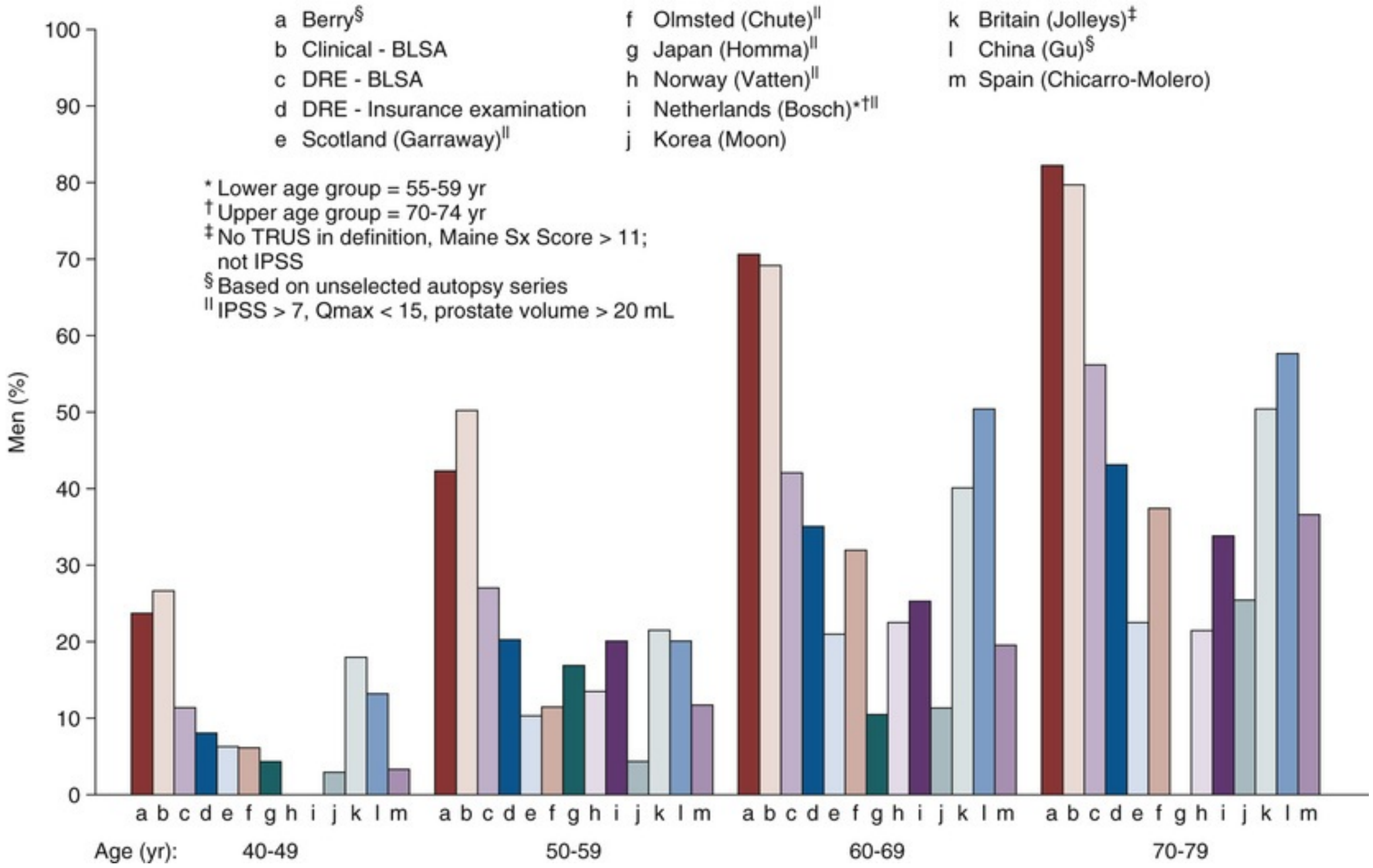

FIG. 144.11 Prevalence of disease using autopsy series, clinical diagnosis, low maximum flow rate, palpable prostatic enlargement by digital rectal examination *(DRE),* and community-based studies. *BLSA,* Baltimore Longitudinal Study of Aging; *IPSS, I*nternational Prostate Symptom Score; *TRUS,* transrectal ultrasonography. (Data from Berry SJ, Coffey DS, Walsh PC, Ewing LL. The development of human benign prostatic hyperplasia with age. *J Urol* 132[3]:474–479, 1984; Garraway WM, Collins GN, Lee RJ. High prevalence of benign prostatic hypertrophy in the community. *Lancet* 338[8765]:469–471, 1991; Chute CG, Panser LA, Girman CJ, et al. The prevalence of prostatism: a population-based survey of urinary symptoms. *J Urol* 150[1]:85–89, 1993; Gu FL, Xia TL, Kong XT. Preliminary study of the frequency of benign prostatic hyperplasia and prostatic cancer in China. *Urology* 44[5]:688–691, 1994; Jolleys JV, Donovan JL, Nanchahal K, et al. Urinary symptoms in the community: how bothersome are they? *Br J Urol* 74[5]:551–555, 1994; Bosch JL, Hop WC, Kirkels WJ, Schroder FH. The International Prostate Symptom Score in a community-based sample of men between 55 and 74 years of age:

prevalence and correlation of symptoms with age, prostate volume, flow rate and residual urine volume. *Br J Urol* 75[5]:622–630, 1995a; Moon H, Moon W, Seo K. High prevalence of prostatism and benign prostatic hyperplasia in Korean men. *J Urol* 155[Suppl]:631A, 1995; Overland GB, Vatten L, Rhodes T, et al. Lower urinary tract symptoms, prostate volume and uroflow in Norwegian community men. *Eur Urol* 39[1]:36–41, 2001.)

Symptom Severity and Frequency

From a pragmatic point of view, studies of symptom severity and frequency are of greatest importance in a disease, which is rarely fatal and is characterized by its effect on quality of life. The development, validation, and translation with cultural and linguistic validation of the standardized, self-administered seven-item AUA Symptom Index (AUASI; also known as the International Prostate Symptom Score [IPSS]) has been a pivotal event in the clinical research of LUTS and BPH (Barry et al., 1992a, 1992b; O'Leary et al., 1992). With the total score running from 0 to 35 points, patients scoring 0 to 7 points are classified as mildly symptomatic, those scoring from 8 to 19 points as moderately symptomatic, and those scoring 20 to 35 points as severely symptomatic. The instrument is an integral part of virtually every epidemiologic study and treatment studies in the field, and the availability of validated translations in many common languages allows cross-cultural comparisons of unprecedented scope. Socioeconomic factors do not seem to influence responses to the questionnaire (Moon et al., 1994), and fundamentally similar responses are obtained when the questionnaire is self-administered, read to the patient, mailed in or administered in some other way (Barry et al., 1995a), or readministered in a scrambled format (Barnboym et al., 1999). However, there is no question that subtle differences in comprehension of the translated questionnaire, and different perception of the symptoms, willingness to admit to the symptoms, acceptance of symptoms as a natural sign of aging, and other factors are at least partially the cause for cross-cultural differences in symptom severity reported in the literature. Fig. 144.12 shows the prevalence of at least moderate to severe symptoms stratified by decade of life as reported in 11 cross-sectional population-based studies from around the world (Bosch et al., 1995; Chute et al., 1993; Garraway et al., 1991; Hunter et al., 1994, 1996; Moon et al., 1995; Norman et al., 1994; Overland et al., 2001; Sagnier et al., 1996;Tsukamoto et al., 1995). A very large international investigation of LUTS in Asian men was undertaken by Homma et al. (1997) in which 7588 men from Japan, China, Taiwan, Korea, the Philippines, Thailand, Singapore, Pakistan, India, and Australia were queried. The finding of 18%, 29%, 40%, and 56% of men in their 40s, 50s, 60s, and 70s having moderate to severe symptoms is in line with the other studies reported both from Asia and from Europe and North America. In addition to the major community-based studies listed, other studies have been published with similar findings, but often done under less stringent conditions (Nacey et al., 1995; Tay et al., 1996). Despite the significantly different proportion of men admitting to moderate to severe symptoms, a clear trend toward an increase in symptom severity and frequency with advancing age is noticeable in all reported studies.

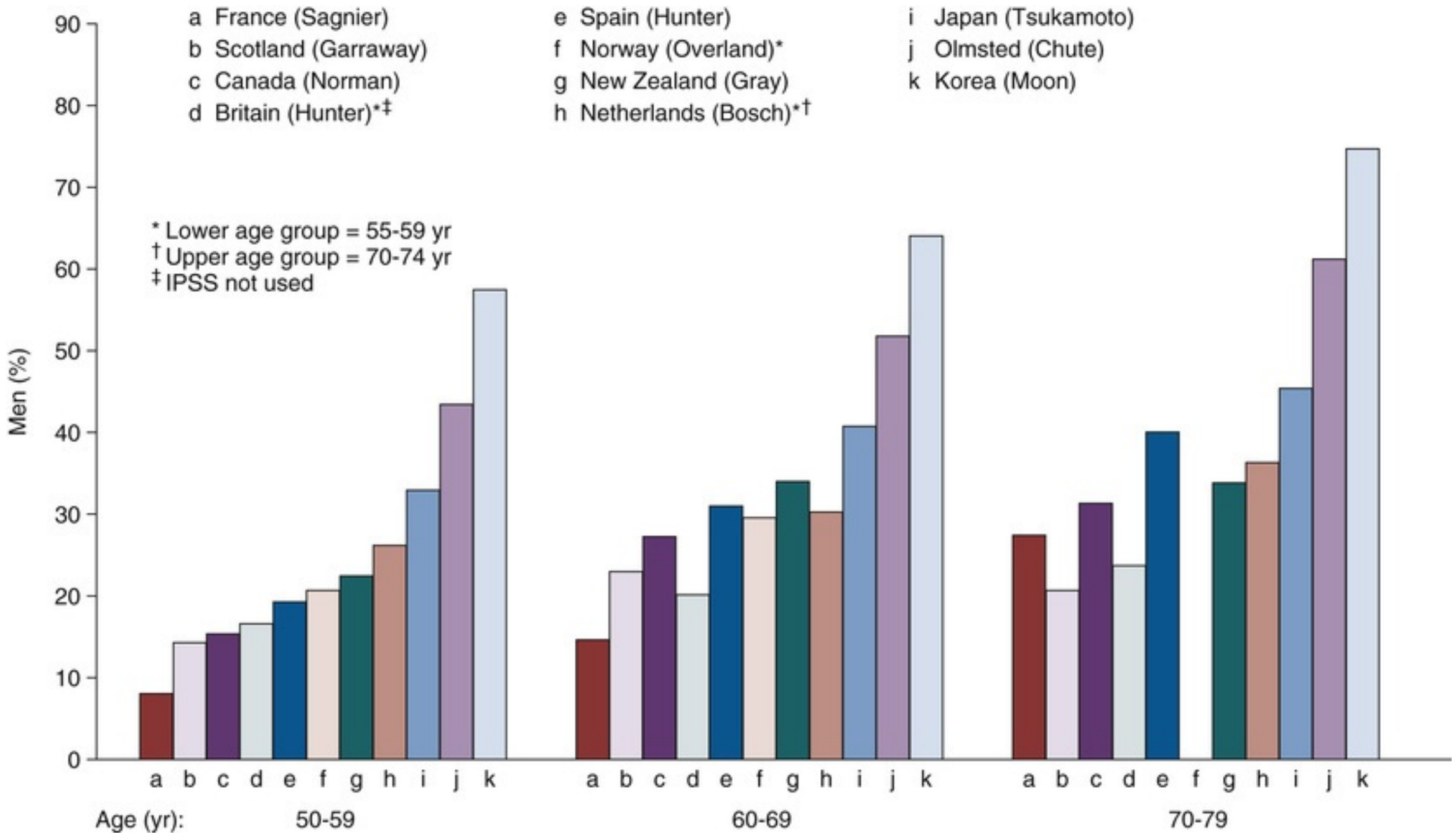

FIG. 144.12 Prevalence of at least moderate to severe symptoms stratified by decade of life as reported in cross-sectional population-based studies from around the world. (Data from Garraway WM, Collins GN, Lee RJ. High prevalence of benign prostatic hypertrophy in the community. *Lancet* 338[8765]:469–471, 1991; Chute CG, Panser LA, Girman CJ, et al. The prevalence of prostatism: a population-based survey of urinary symptoms. *J Urol* 150[1]:85–89, 1993; Hunter DJ, McKee CM, Black NA, Sanderson CF. Urinary symptoms: prevalence and severity in British men aged 55 and over. *J Epidemiol Community Health* 48[6]:569–575, 1994; Norman RW, Nickel JC, Fish D, Pickett SN. “Prostate-related symptoms” in Canadian men 50 years of age or older: prevalence and relationships among symptoms. *Br J Urol* 74[5]:542–550, 1994; Bosch JL, Hop WC, Kirkels WJ, Schroder FH. The International Prostate Symptom Score in a community-based sample of men between 55 and 74 years of age:

prevalence and correlation of symptoms with age, prostate volume, flow rate and residual urine volume. *Br J Urol* 75[5]:622–630, 1995a; Moon H, Moon W, Seo K. High prevalence of prostatism and benign prostatic hyperplasia in Korean men. *J Urol* 155[Suppl]:631A, 1995; Tsukamoto T, Kumamoto Y, Masumori N, et al. Prevalence of prostatism in Japanese men in a community-based study with comparison to a similar American study. *J Urol* 154[2 Pt 1]:391–395, 1995; Hunter DJ, Berra-Unamuno A, Martin-Gordo A. Prevalence of urinary symptoms and other urological conditions in Spanish men 50 years old or older. *J Urol* 155[6]:1965–1970, 1996; Sagnier PP, Girman CJ, Garraway M, et al. International comparison of the community prevalence of symptoms of prostatism in four countries. *Eur Urol* 29[1]:15–20, 1996. Homma Y, Kawabe K, Tsukamoto T, et al. Epidemiologic survey of lower urinary tract symptoms in Asia and Australia using the international prostate symptom score. *Int J Urol* 4[1]:40–46, 1997; Overland GB, Vatten L, Rhodes T, et al. Lower urinary tract symptoms, prostate volume and uroflow in Norwegian community men. *Eur Urol* 39[1]:36–41, 2001.)

Bother, Interference, and Health-Related Quality of Life

Bother and interference with activities of daily living caused by LUTS are equally if not more important than the enumeration of symptom frequency and severity alone (Garraway et al., 1993; Roberts et al., 1994b). Embarrassment resulting from symptoms has been found to be an important determinant in seeking medical care (Roberts et al., 1994b). LUTS and clinical BPH affect overall quality of life as measured with the Medical Outcomes Trust Short-Form (SF-36) only marginally (Hunter et al., 1995). Accordingly, several instruments were developed and validated to assess bother, interference, and the disease-specific quality of life and sexual function (Barry et al., 1995b; Donovan et al., 1996; Epstein et al., 1992; Hansen et al., 1995; Lukacs et al., 1995; O'Leary et al., 1995).

These instruments have not been as widely applied to cross-sectional descriptive epidemiologic studies as compared with the IPSS. However, as observed for symptom severity and frequency, both bother and interference scores increase with advancing age, and disease-specific health-related quality of life (HRQoL) measures are significantly poorer in men with higher symptom frequency and severity ratings in population-based studies done in Olmsted County, US; Forth Valley, Scotland; France; and a small fishing village in Japan (Shimamaki-Mura) (Girman et al., 1998).

A recent multi-institutional study funded by the National Institute of Diabetes and Digestive and Kidney Diseases (NIDDK) under the umbrella name LURN

(Symptoms of Lower Urinary Tract Dysfunction Research Network) has published their initial findings. Among other findings, a high incidence of urinary incontinence in men presenting with LUTS was observed, casting doubt on the IPSS as the single best tool to assess LUTS in men as it has no question specific to stress or urge incontinence (Griffith et al., 2018; Helfand et al., 2018; Yang et al., 2016).

Prostate Size

Prostate size can be estimated by DRE, although the reliability across observers is in general considered poor (Roehrborn et al., 1997). A recent analysis of the PLCO trial verified the significant errors associated with the DRE-assessed prostate size (Pinsky et al., 2006). In addition, DRE tends to underestimate true prostate size as determined by TRUS or other imaging modalities. The magnitude of the underestimation increases with increasing prostate size from 25% up to 50% or more (Roehrborn et al., 1997). For the purpose of epidemiologic studies, TRUS and MRI measurements are preferred, although MRI measurements are somewhat expensive when attempting cross-sectional examinations of populations. TRUS volume measurements using the prolate ellipsoid volume formula are the most widely accepted measure of prostate volume with reasonable statistical performance characteristics, particularly when performed by a single or several well-trained examiners (Sech et al., 2001). Three-dimensional TRUS appears to provide even more accurate measurements, although such technology is not available in urologists' offices for the most part (Giubilei et al., 2005).

In general, in all cross-sectional studies prostate volume as assessed by TRUS has been found to increase slowly but steadily with advancing age. The slight differences in the absolute volume measures, and the different slopes of increase with advancing age may be caused by differences in the population examined as follows (Fig. 144.13).

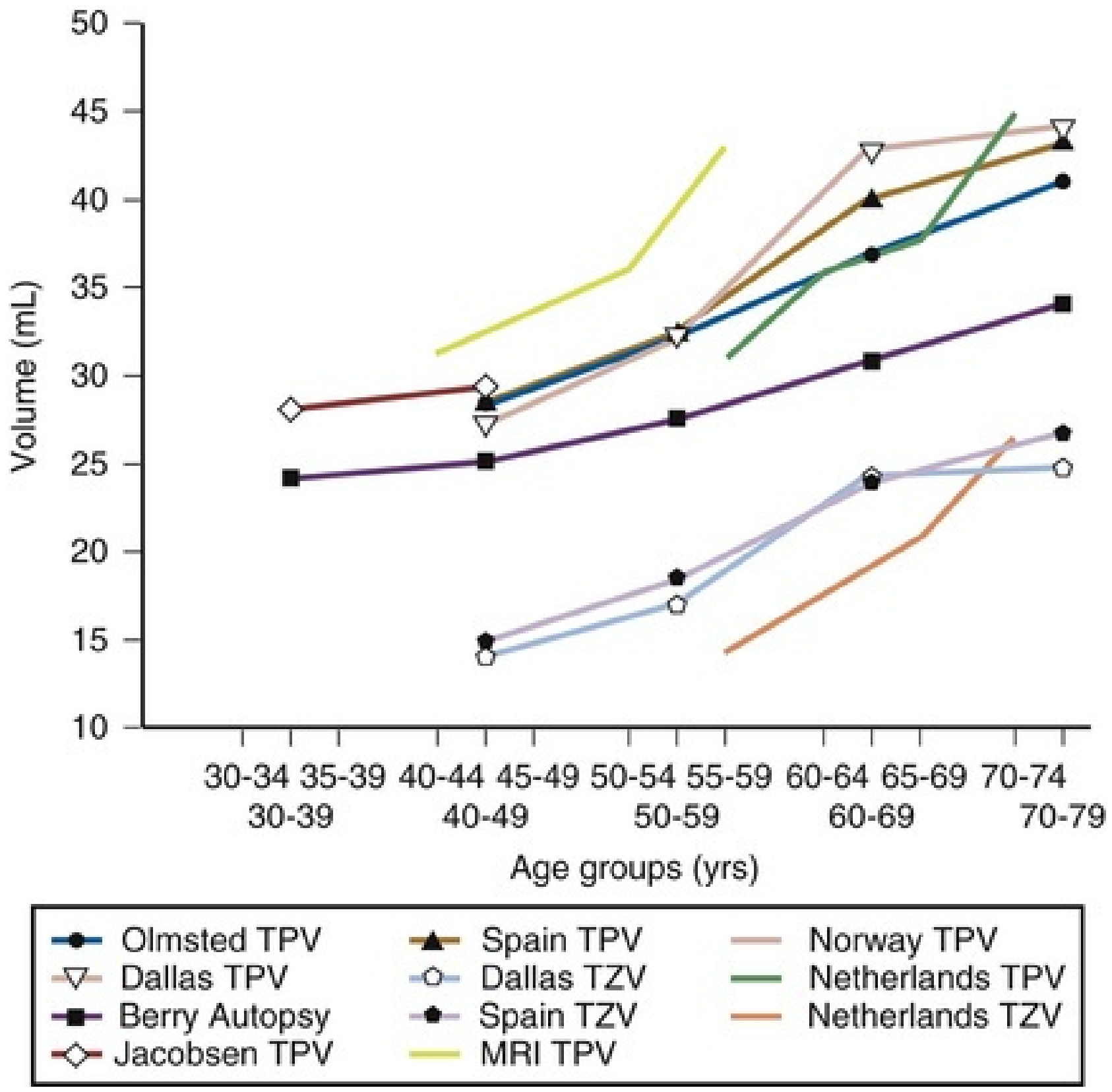

FIG. 144.13 Mean estimates for total prostatic volume *(TPV)* and transitional zone volume *(TZV)* based on one autopsy series (Berry et al, 1984), one series of baseline MRI measurements in men with alopecia (Roehrborn et al, 2000b), and cross-sectional population-based studies (Torp-Pedersen et al, 1988; Oesterling et al, 1993; Bosch et al, 1994; Benaim et al, 1998; Chicharro-Molero et al, 1998; Overland et al, 2001).

A cohort of 344 men between 40 and 60 years of age with no evidence of BPH enrolled in an alopecia study had baseline endorectal coil MRI measurements done (Roehrborn et al., 2000c). Mean TPV increased from 31.3, 33.7, 36.1 to 43.1 mL in increments of 5 years. MRI tends to yield prostate volume measurements approximately 10% larger compared with TRUS. A series of 100 men 40 to 80 years of age without BPH or LUTS underwent TRUS measurements of TPV and TZV. TPV increased from 22.1, 29.1, 41.5 to 43.2 mL by decade, and TZV from 7.2, 9.9, 19.0 to 19.6 mL (Benaim et al., 1998). A cross-sectional study of 611 Norwegian men from 55 to 70 years of age exhibited increases in TPV from 26.5, 31.0 to 32.0 mL in increments of 5 years (Overland et al., 2001), and Jakobsen examined patients between 30 and 50 years of age by TRUS, the mean TPV being 23.9 and 25.7 mL per decade of life (Jakobsen et al., 1988). TPV and TZV were assessed in 1104 men older than 40 years of age in a Spanish cross-sectional study, yielding increases from 23.4 to

41.9 mL for TPV and from 7.9 to 21.9 mL for TZV (Chicharro-Molero et al., 1998). Finally, the baseline data from the Olmsted County Study of Urinary Symptoms in Men provided data on men from 40 to 79 years of age (Oesterling et al., 1993).

Overall, TPV increases in these cross-sectional studies from approximately 25 mL for men in their 30s to 35 to 45 mL for men in their 70s, and TZV increases from 15 mL to 25 mL for similarly aged men. The similarities between the TPV and TZV measurements done in the different studies are striking, particularly when considering the different measurement methods used (see Fig. 144.13).

Measures of Obstruction

Subvesical obstruction can only be measured by invasive pressure-flow studies, and nonintubated free flow rates provide at best an indirect measure for the probability of obstruction being present (Abrams, 1995). Unfortunately, no large-scale cross-sectional studies have been done employing pressure-flow studies because of the invasive and costly nature of the test, and it is unlikely that significant datasets will ever become available.

It is commonly accepted that a maximum flow rate of less than 10 mL/sec indicates a high probability of obstruction, and a flow rate of greater than 15 mL/sec indicates a low probability, with the 10- to 15-mL/sec range presenting an intermediate range. The utility of this categorization is reduced by several observations. First, the maximum flow rate is somewhat dependent of the voided volume (Girman et al., 1993). This has prompted some to propose a nomogram to correct for this phenomenon; however, at present no single nomogram is accepted universally (Beck and Gaudin, 1969; Drach and Steinbronn, 1986; Haylen et al., 1989; Scott and McIlhaney, 1961; Siroky et al., 1979, 1980; Susset et al., 1973; von Garrelts, 1956, 1957, 1958). A high degree of diurnal variability (Golomb et al., 1992) and within subject day-to-day variability (Barry et al., 1995c) further reduces the utility of flow rate recording in defining disease.

Aging men and women experience a decrease in the maximum urinary flow rate, which is nearly linear in nature. In the Olmsted County Study, the median flow rate decreased from 20.3 mL/sec for men 40 to 44 years of age to 11.3 mL/sec for men 75 to 79 years of age (Girman et al., 1993), and similar declines have been reported from other cross-sectional studies. When applying combined thresholds such as at least moderate symptoms of greater than 7 points on the IPSS **and** a maximum flow rate of less than 15 mL/sec, in the Olmsted County study, 17% of men in their 50s, 27% of men in their 60s, and 35% of men in their 70s would fall into such category (Jacobsen et al., 1995), versus 14.4%, 28.6%, and 38.7% of men in the respective age groups in the Spanish population-based study (Chicharro-Molero et al., 1998).

Analytical Epidemiologic Studies

Analytical epidemiologic studies address the search for determinant of a disease. Inasmuch as a clear disease definition is lacking, such search could attempt to find determinants for LUTS, prostate growth, and/or bladder outlet obstruction, consistent with the previously outlined concepts. The presence of functioning testes at time of puberty (hormonal factor) as a required permissive element has long been established and accepted (McConnell, 1991), and age has been shown to be the most critical determinant of all aspects of this complex entity. Numerous other demographic and environmental factors have been suggested as risk factors or contributors to the disease process.

Religion

The case-control study by Morrison (1978), the cohort study by Lytton et al. (1968), and the Normative Aging Study by Glynn et al. (1985) all revealed Jewish religion to be associated with a higher prostatectomy rate (2.2 to 2.6 fold increase). The fact, however, that Jewish religion is not associated with an increase in the *diagnosis* of BPH, allows the speculation that Jewish patients are more likely to see a physician or to be offered surgical therapy.

Socioeconomic Factors

Araki et al. (1983) found higher rates of BPH in higher-income groups. In contrast, Glynn et al. (1985) reported higher rates of surgery in lower-income groups. One might argue that higher-income groups might have better access to health care, and lower-income groups might submit more readily to the suggestion of a surgical procedure. Education and socioeconomic status do not influence responses to the IPSS (Badia et al., 2001; Moon et al., 1994), but they do appear to influence both expectations from treatment for BPH and perception of improvement, with patients in higher-income strata requiring a larger drop in symptom scores after treatment to perceive subjectively similar levels of improvement (Padley et al., 1997). This finding suggests at least some impact of socioeconomic factors if not in the growth of the prostate or measures of obstruction, but likely in the perception of symptoms. Data from the Olmsted

County study suggest a relationship between care-seeking behavior and physician visit and retirement status. Bivariate analysis suggested significant associations between a propensity to seek care for physical reasons and retirement (OR 2.0; 95% CI, 1.1 to 2.6), age of 65 years or more (OR 1.9; 95% CI, 1.5 to 2.4), incomplete high school education (OR, 1.6; 95% CI, 1.1 to 2.2), and annual income of less than $25,000 (OR, 1.4; 95% CI, 1.1 to 1.9). Multivariable logistic regression analysis demonstrated that retired men were more likely to have a high propensity to seek care (OR, 1.7; 95% CI, 1.2 to 2.4), with the other variables no longer being significant (Roberts et al., 1997a).

Recently our understanding of the impact of some socioeconomic factors on LUTS and BPH had deepened with the help of two studies, the EPIC and EpiLUTS, and the Boston Area Community Health (BACH) studies (Kaplan et al., 2009; Rosen et al., 2008) (Table 144.4). It is likely that the longitudinally designed BACH study with a balanced enrollment of men and women stratified by age and race/ethnicity will contribute in the future significantly to our understanding of LUTS in both men and women. A symptom-based cluster analysis was performed in both cohorts and, remarkably, similar clusters of symptoms were identified, allowing for an in-depth analysis of their association with comorbidities and other factors (Rosen et al., 2008). In the BACH study, decreasing household income and increasing difficulties in paying for health care were associated with increasingly more severe symptom clusters (Hall et al., 2009).

TABLE 144.4

Overview of the EpiLUTS and BACH Studies

EPILUTS	BACH
DESCRIPTION	
Cross-sectional, population-representative, Internet-based survey conducted in the United States, the United Kingdom, and Sweden in 30,000 (US, 20,000; UK, 7500; Sweden, 2500) men and women aged 40–99 years (mean age, 56.6 years)	Population-based epidemiologic survey among 5503 randomly selected adults residing in Boston aged 30–79 years in three race/ethnic groups (2301 men, 3202 women; 1767 black, 1877 Hispanic, 1859 white respondents)
LUTS PREVALENCE	

1 LUTS at least sometimes: 72.3% (men), 76.3% (women) 1 LUTS at least often: 79.99% (men), 52.5% (women)	LUTS (AUASI ≥8): 18.7% (men), 18.6% (women); increased with age (10.5% for 30–39 years to 25.5% for 70–79 years), no difference by race/ethnicity (16.2%–19.3%)
BOTHER	
Rates of bother were lower for LUTS classified as at least “sometimes” than those classified as at least “often” However, leaking urine during sexual activity, which was reported infrequently, was highly bothersome (82.1% men; 87.2% women), whereas terminal dribble, which was reported frequently, was less bothersome (40.6% men; 40.2% women)	Mean bother scores were higher in those with LUTS (vs. no LUTS) and for women vs. men
TREATMENT SEEKING	
Treatment seeking was low but most common in those in the voiding + storage + postmicturition subgroup: 29.1% men, 27.5% women; prescription medication use was also highest in this subgroup (17.6% and 10.4%, respectively)	Prescription medication use for urinary symptoms was low even among those with AUASI ≥8, at 9.8% (men) and 2.1% (women)
COMORBIDITIES	
Comorbid conditions were most common in the voiding + storage + postmicturition subgroup with significant associations for LUTS with arthritis, asthma, chronic anxiety, depression, diabetes (men only), heart disease, irritable bowel syndrome, neurologic conditions, recurrent UTI, and sleep disorders; childhood nocturnal enuresis was significantly associated with most LUTS subgroups	LUTS (AUASI ≥8) was associated with heart disease, diabetes (men only), and depression

AUASI, American Urological Association Symptom Index; *LUTS,* lower urinary tract symptoms; *UTI,* urinary tract infection.

From Kaplan SA, Roehrborn CG, Chapple CR et al. Implications of recent epidemiology studies for the clinical management of lower urinary tract symptoms. *BJU Int* 103(Suppl 3):48–57, 2009.

Egan et al. found no evidence in the NHANES study that rural/urban status was not associated with significantly increased adjusted odds of either recognized or unrecognized LUTS/BPH (Egan et al., 2015).

Sexual Activity and Vasectomy

Ekman suggested that the increase in the fibromuscular stroma is a result of sexual activity (Ekman, 1989), and many authors since then have attempted to find relevant associations. Morrison reported a 49% reduction in risk for prostatectomy in widowed versus single men (Morrison, 1992). Similar association could not be verified by other authors. Cross-sectional data from the Olmsted County study suggest that the frequency of ejaculation has no effect on LUTS, peak urinary flow rates, or prostate volume; the apparent protective association appears to be an artifact caused by the confounding effects of age (Jacobsen et al., 2003). The decrease in sexual ability and frequency of sexual activity with advancing age, exactly when the prevalence of BPH increases, in fact might suggest a reverse relationship, namely a causative effect of BPH on sexual function (Altwein and Keuler, 1992).

Recent evidence suggests a strong correlation between the severity of LUTS and impairment of sexual function, that is, ED and ejaculatory disturbances (Boyle et al., 2003; Chung et al., 2003; Rosen et al., 2003). Cross-sectional questionnaire-based data from various countries suggest that ED and ejaculatory disturbances increase with advancing age, but also within each decade of life with increasing LUTS symptom severity (Fig. 144.14). Although these correlations do not necessarily imply a causative mechanism, it is possible that similar pathophysiologic events underlie the development of both problems in the aging male, the most obvious being ischemia in both the genital and lower urinary tract organs (McVary, 2005). A logistic regression analysis of the EpiLUTS data documented as well a strong relationship between various domains of sexual and ejaculatory dysfunction and LUTS (Wein et al., 2009) (Table 144.5).

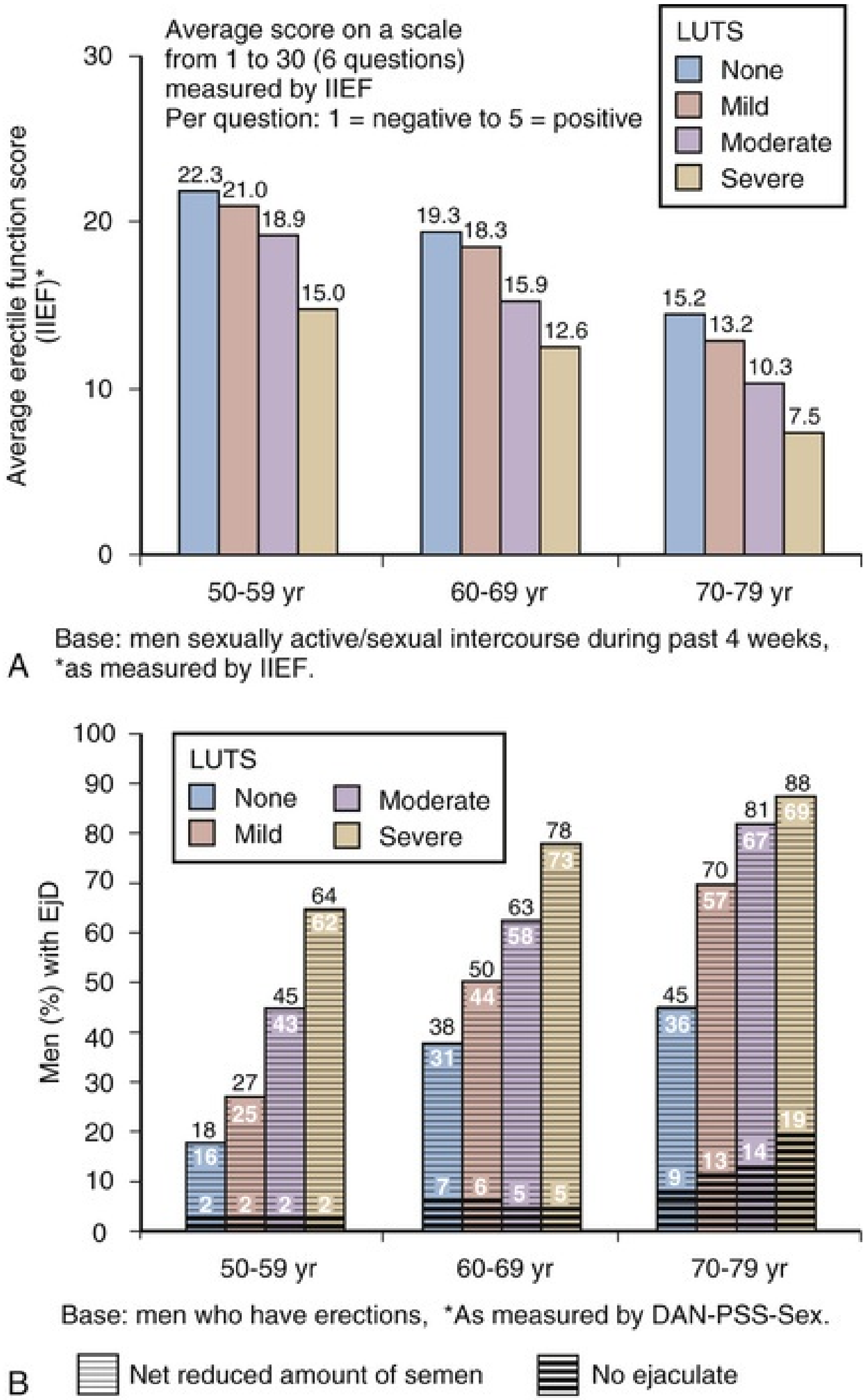

FIG. 144.14 Erectile function (A) decreases and ejaculatory disturbances (B) increase with advancing age, but within each decade of life they also decrease and increase, respectively, with increasing severity in lower urinary tract symptoms (LUTS). *DAN-PSS,* Danish Prostatic Symptom Score; *IIEF,* International Index of Erectile Function. (From Rosen R, Altwein J, Boyle P, et al. Lower urinary tract symptoms and male sexual dysfunction: the multinational survey of the aging male [MSAM-7]. *Eur Urol* 44[6]:637–649, 2003.)

TABLE 144.5

Logistic Regression of Decreased Sexual Enjoyment and Activity and Predictors of Erectile Dysfunction, Ejaculatory Dysfunction, and Premature Ejaculation

COVARIATES	DECREASED SEXUAL ENJOYMENT	SEXUAL ACTIVITY	ED (IIEF-EF <21)	EJD	PE
DEMOGRAPHIC			+[b]	+[b]	−[b]
Age					
BMI					
Hispanic vs. white					
Black vs. white					
Asian vs. white					
Other vs. white		+[a]			
Sweden vs. US			−[b]		
UK vs. US					
LUTS					
Weak stream	+[b]	+[b]	+[b]		
Split stream	+[a]		+[b]		
Intermittency					+[a]
Hesitancy					
Straining					
Terminal dribble					+[a]
Perceived frequency	+[a]	+[a]			
Nocturia					
Urgency					
Urgency with fear of leaking	+[a]		+[a]	+[a]	
Urgency incontinence					
SUI (laugh/cough)	−[a]				
SUI (physical activity)					
Leak for no reason		+[a]			
Other leaking					
Nocturnal enuresis					
Leak during sex	+[b]	+[b]	+[a]	+[a]	
Incomplete emptying	+[b]	+[a]			+[a]

Postmicturition incontinence					
Dysuria	+[a]	+[b]	+[a]		
Bladder area pain	+[b]				+[a]
Pain during sex	+[b]	+[b]			
COMORBID CONDITIONS					
Heart disease		+[b]			
Hypertension			+[b]		
Diabetes			+[b]		
Prostate cancer	+[b]	+[b]		+[b]	
Bladder cancer	+[b]	+[b]			
Prostatitis	+[b]	+[a]			-[bc]
Depression			+[b]	+[b]	
Neurologic conditions					
Concordance index	0.86	0.86	0.77	0.73	0.62

[a] *P* < .01

[b] *P* < .001.

[c] Not having a history of prostatitis is associated with premature ejaculation.

−, negative values for point estimates; +, positive values for point estimates; *BMI,* body mass index; *ED,* erectile dysfunction; *EjD,* ejaculatory dysfunction; *LUTS,* lower urinary tract symptoms; *PE,* premature ejaculation; *SUI,* stress urinary incontinence.

From Wein AJ, Coyne KS, Tubaro A, et al. The impact of lower urinary tract symptoms on male sexual health: EpiLUTS. *BJU Int* 103(Suppl 3):33–41, 2009.

Sidney analyzed the Kaiser Permanente Database and initially found a RR (Risk Ratio) of 1.2 for the diagnosis of BPH among men who had a vasectomy (Sidney, 1987). However, after 5 years of follow-up, the RR was 0.97 and not significant. There does not appear to be a relationship between vasectomy and BPH development or prostate size (Jakobsen et al., 1988), and in the Massachusetts Male Aging Study, Meigs et al. (2001) did not find that vasectomy increased the risk for being diagnosed with BPH.

Alcohol and Liver Cirrhosis

Alcohol may effect the level of plasma testosterone by affecting the production as well as the clearance of testosterone (Chopra et al., 1973). Despite this hypothetical reason for a lower incidence of BPH, inverse relationships have been described. Both Morrison (1992) and Sidney (1991a) reported by multivariate analysis an adjusted RR of 0.49 and age-adjusted RR of 0.75, respectively, for the risk of having surgery for BPH when taking in more than three glasses of alcohol per day. However, one might argue that the poorer health in heavy drinkers might bias physician against surgery. Glynn et al. (1985) in fact found no increased risk for either the clinical diagnosis or surgical rates. A recent analysis of the prostate cancer prevention trial (PCPT) showed as well an inverse relationship between a diagnosis of BPH and alcohol intake, that is, a somewhat protective effect (Kristal et al., 2008). A meta-analysis of alcohol intake, BPH, and LUTS demonstrated that consumption of alcohol decreases the likelihood of BPH in all six strata, but not LUTS. Compared with no alcohol, an alcohol intake of greater than or equal to 36 g/day was associated with a 35% decreased likelihood of BPH (OR 0.65) (Rees, 2009).

Of five studies examining the relationship between liver cirrhosis and BPH based on autopsy material, four found a lower prevalence of BPH in men with cirrhosis (Bennett et al., 1950; Frea et al., 1987; Robson, 1966; Stumpf and Wilens, 1953), and one study (admittedly with some design flaws) found a higher prevalence (Wu, 1942). Because most cirrhosis cases are alcohol-induced, the separation of the effects of alcohol versus cirrhosis is virtually impossible.

On the other hand, nonalcoholic fatty liver disease (NAFLD) which is part of the metabolic syndrome, is associated with BPH in men and with overactive bladder in women (Uzun et al., 2013).

Hypertension

The sympathetic nervous system plays via alpha adrenergic fibers and receptors an important role in both hypertension and the symptoms of BPH. However, because both hypertension and LUTS/BPH increase with advancing age, it is difficult to prove a causal relationship between these two conditions (Boyle and Napalkov, 1995). The previously cited studies by Glynn et al. (1985) and Sidney et al. (1991) did not find an association. In a small-clinic cohort study with methodologic flaws, Pressler et al. (1997) reported an increase in the incidence of hypertension from 15%, to 18% and 31% for men with mild, moderate, and severe symptoms. Autonomic hyperactivity has been implicated in the development of both LUTS and ED in the aging male, but conclusive clinical data are lacking (McVary et al., 2005). In the EpiLUTS study, both heart disease and hypertension were associated with more severe LUTS symptom constellations (Coyne et al., 2009). Further studies are needed to better understand the common underlying pathophysiologic mechanisms and a potential cause-and-effect relationship.

Smoking

Smoking cigarettes appears to increase both testosterone and estrogen levels because of the nicotine level, and thus should have a positive and inductive effect on the development of BPH. However, because severe smoking causes other health problems, surgery rates are probably a poor indicator for a possible correlation because physicians are biased against surgery in heavy smokers. Seitter and Barrett-Connor (1992) indeed found no correlation between smoking and prostatectomy rates, and Glynn et al. (1985) failed to identify a correlation between smoking and the clinical diagnosis of BPH. Sidney et al. (1991a) followed 16,000 men over 15 years and found a negative correlation between being a smoker at baseline and subsequent risk for prostatectomy. Daniell (1993b) examined the records of 345 patients who underwent prostatectomy and found smaller gland volumes in smokers and a lower age-adjusted prevalence of never-smokers compared with a control group. Roberts et al. (1994a) examined this issue in the Olmsted County Study and later in a Japanese population (Roberts et al., 1997b). In Olmsted County, only 16% of the more than 2000 men were current smokers, which appears low but understandable considering the population mix in Rochester, Minnesota. A biphasic association was found, with light to moderate smokers being less likely to have moderate to severe LUTS, and heavy smokers being at least the same risk as never smokers.

A recent update from the Olmsted County Study suggests that smoking is associated with decreased urinary flow rates and moderate to severe symptoms, but not with enlarged prostate volume or increasing serum PSA (Rule et al., 2005). This is in contrast with earlier studies suggesting a relationship between smoking and prostate size (Kupeli et al., 1997). In EpiLUTS, ex-smokers had an increased risk for having more severe symptom constellations and never smokers a decreased risk, and the risk for current smokers was not a factor (Coyne et al., 2009).

Recent evidence from the Olmsted County Study verified the absence of a meaningful clinical association between current smoking and urinary retention (Sarma et al., 2009), and in the BACH study, no correlation between smoking and LUTS was observed (Maserejian et al., 2012).

In an exhaustive meta-analysis, Xu et al. (2016) found no significant association between cigarette smoking and BPH risk, either for ex-smokers or for current smokers.

Any relationships between current or past smoking and LUTS/BPH are likely to be weak and of limited clinical significance.

Physical Activity, Diet, Obesity, Body Mass Index, and the Metabolic Syndrome

Chyou et al. (1993) examined 33 food items in relationship to prostatectomy rates, and found only beef intake significantly associated. Araki et al. (1983) reported increased clinical diagnosis of BPH in men with higher milk consumption and lower consumption of green and yellow vegetables. **Overall, there is no convincing evidence for any individual diet factor to play a major role in the development of LUTS/BPH.**

The relationships between LUTS/BPH and obesity, body mass index (BMI), and the metabolic syndrome have recently been of great interest (Gupta et al., 2006; Hammarsten and Hogstedt, 1999, 2001; Hammarsten et al., 1998 Kasturi et al., 2006; Rohrmann et al., 2005). Metabolic syndrome is a clinical constellation of metabolic abnormalities, including obesity, glucose intolerance, dyslipidemia, and hypertension, that increases the risk for cardiovascular disease and results primarily from modifiable risk factors, particularly physical inactivity and dietary practices endemic to Westernized societies (Haffner and Taegtmeyer, 2003). **There are plausible biologic considerations: adipose tissue is the main source of aromatization of testosterone to estrogen, and men with lower BMIs have higher serum testosterone levels** (Eldrup et al., 1987).

BMI was negatively associated with surgically treated BPH in the Kaiser Permanente cohort study (Sidney et al., 1991a) and with a clinical diagnosis of BPH in the Normative Aging Study (Glynn et al., 1985). In contrast, in a study of 68 men, the average prostate weight increased both with age and with increasing obesity together with an increase in serum estradiol levels (Soygur et al., 1996). Daniell (1993a) also found larger adenoma in more obese men undergoing prostatectomy. Both latter studies report a positive correlation between obesity and prostate size, but none between obesity and symptom severity. Several caveats must be mentioned: DRE is less likely to yield a diagnosis of BPH and prostate enlargement in very obese patients because of anatomic obstacles, and patients with high BMIs may be biased against surgical interventions.

Men 40 to 75 years of age who were participants in the Health Professionals Follow-up Study and who were without prior diagnosis of cancer or prostatectomy provided data on weight, height, and waist and hip circumferences. After adjustment for age, smoking, and BMI, abdominal obesity was related to prostatectomy (OR, 2.38) and with frequent urinary symptoms among those without prostatectomy (OR, 2.00). BMI, hip circumference, and waist-to-hip ratio were not associated with BPH independently of waist circumference. **These results suggest that abdominal obesity in men may increase the frequency and severity of urinary obstructive symptoms and may increase the likelihood that such obese men will undergo a prostatectomy** (Giovannucci et al., 1994).

Hammarsten examined 250 patients with LUTS and found NIDDM, hypertension, height, obesity, high insulin, and low HDL cholesterol levels to be risk factors for the development of BPH. They suggest a causal relationship between high insulin levels and the development of BPH, and hypothesize increased sympathetic nerve activity in men with BPH (Hammarsten and Hogstedt, 1999). In a hospital-based case-control study, overweight was modestly inversely related to BPH. The hypothesis of reduced testosterone levels in obese individuals may explain the different BPH risk and needs to be tested (Zucchetto et al., 2005). Parsons (2007) performed a comprehensive literature review and found that factors that potentially increase the risk for BPH and LUTS include obesity and diabetes, and factors that potentially decrease the risk include increased physical activity and moderate alcohol consumption (Table 144.6). Parsons and Kashefi (2008) also performed a comprehensive literature review and found that eight studies (*n* = 35,675) were eligible for a pooled analyses to study the effect of physical activity levels stratified into light, moderate, and vigorous categories, with a sedentary category for reference. Compared with the sedentary group, the pooled ORs for BPH or LUTS were 0.70, 0.74, and 0.74 for men engaging in light, moderate, and heavy physical activity, respectively. Physical activity thus appears to reduce the risks for BPH and LUTS. Similar findings of increased likelihood of LUTS with increasing BMI and decreasing likelihood with greater physical activity were also reported from the EpiLUTS study (Coyne et al., 2009).

TABLE 144.6

Cohort Studies of Modifiable Risk Factor Associated With Decreased or Increased Risk for LUTS and/or BPH

DECREASED RISK FOR BPH AND LUTS			
STUDY	**OUTCOME MEASURE (RISK FACTOR)**	**REFERENCE CATEGORY**	**OR (95% CI)**
Health Professionals Follow-up Study	Clinical BPH:		

	Alcohol intake 30.1–50 g/day Walking ≥2 h/week	Alcohol intake 0 g/day	0.59 (0.51–0.70)
		Walking 0 h/week	0.73 (0.63–0.84)
Massachusetts Male Aging Study	Clinical BPH (physical activity 862 kcal/day or greater)	Physical activity 140 kcal/day or less	0.50 (0.3–0.9)
PLCO	Clinical BPH (alcohol intake 60 g/day or greater)	Alcohol intake <5 g/day	0.60 (0.5–0.7)
	TURP likelihood (alcohol intake ≥60 g/day)	Alcohol intake <5 g/day	0.40 (0.3–0.7)
	Nocturia (alcohol intake ≥60 g/day)	Alcohol intake <5 g/day	0.80 (0.7–1.0)
NHANES III	LUTS:		
	Alcohol intake ≥1 drink/day	Never	0.59 (0.36–0.97)
	Physical activity >6 times/week	Physical activity 0 times/week	0.49 (0.29–0.84)
INCREASED RISK OF BPH AND LUTS			
STUDY	**OUTCOME MEASURE (RISK FACTOR)**	**REFERENCE CATEGORY**	**OR (95% CI)**
BLSA	LUTS:		
	Diabetes	No diabetes	2.80 (1.10–7.10)
	Fasting glucose >110 ng/dL	Fasting glucose ≤110 ng/dL	2.60 (1.01–6.70)
	Prostate ≥40 mL:		
	BMI >35 mg/kg^2	BMI <25 kg/m^2	3.52 (1.45–8.56)
	Diabetes	No diabetes	2.25 (1.25–4.11)
	Fasting glucose >110 ng/dL	Fasting glucose ≤110 ng/dL	2.98 (1.70–5.23)

Flint Men's Health Study	LUTS:		
	Diabetes	No diabetes	1.95 (1.49–2.57)
	Hypertension	No hypertension	1.29 (1.04–1.61)
Health Professionals Follow-up Study	BPH surgery (waist circumference >109 cm)	Waist circumference <89 cm	2.38 (1.42–3.99)
	LUTS (waist circumference >109 cm)	Waist circumference <89 cm	2.00 (1.47–2.72)
Hunt-2	LUTS:		
	BMI 40 mg/kg^2 or less	BMI <25	1.79 (0.90–3.56)
	Diabetes	No diabetes	1.25 (1.04–1.49)
	Waist/hip ratio 0.94 or less	Waist/hip ratio 0.85 or less	1.32 (1.15–1.50)
NHANES III	LUTS:		
	Diabetes	No diabetes	1.67 (0.72–3.86)
	Hypertension	No hypertension	1.76 (1.20–2.59)
	Increase in BMI between age 25 y + highest BMI ever	No increase	1.90 (0.89–4.05)
	Waist circumference >102 cm	Waist circumference <94 cm	1.48 (0.87–2.54)

BMI, Body mass index; *BPH,* benign prostatic hyperplasia; *CI,* confidence interval; *h,* hours; *LUTS,* lower urinary tract symptoms; *OR,* odds ratio; *TURP,* transurethral resection of the prostate.

From Parsons JK. Modifiable risk factors for benign prostatic hyperplasia and lower urinary tract symptoms: new approaches to old problems. *J Urol* 178(2):395–401, 2007.

The evidence at present suggests a positive relationship among lack of physical activity, obesity, BMI, and other measures of the metabolic syndrome and both LUTS and BPH (including prostate volume), and increased physical activity appears to have a protective effect.

Medications

Very limited information is available. **Cold medications containing α-sympathomimetic drugs exacerbate LUTS by the expected effect on the smooth muscles of the bladder outlet. Recently a careful analysis of the data from the Olmsted County Study demonstrated that daily use of antidepressants, antihistamines, or bronchodilators is associated with a 2- to 3-point increase in the IPSS compared with age-matched nonusers, and daily use of antidepressants is associated with a decrease in the age-adjusted flow rate** (Su et al., 1996).

Correlations Among Parameters

As noted, all relevant parameters such as symptom severity and frequency, bother, interference, disease-specific HRQoL, maximum flow rate, and prostate volume tend to worsen with advancing age. However, reported correlations between these parameters and urodynamic pressure-flow studies are in general weak with some exceptions. Strong correlations exist as one might expect between subjective measures such as symptom severity and frequency (IPSS), bother, disease-specific HRQoL, and interference scores (Barry et al., 1995c; Girman et al., 1999) (Fig. 144.15).

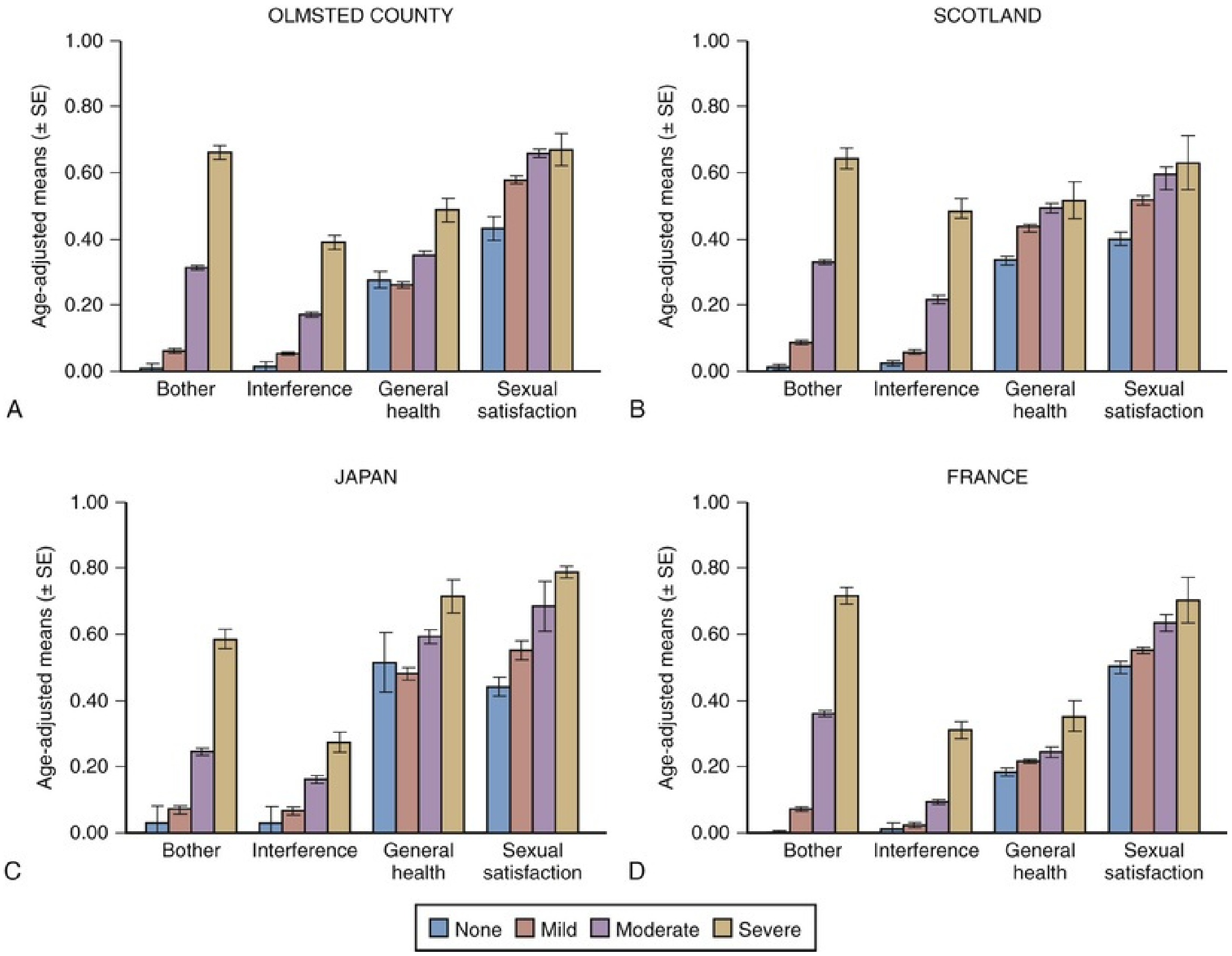

FIG. 144.15 (A–D) Age-adjusted means of disease-specific health-related quality-of-life measures after transformation to a 0 to 1 scale stratified by levels of symptom severity and frequency (International Prostate Symptom Score). (From Girman CJ, Jacobsen SJ, Tsukamoto T, et al. Health-related quality of life associated with lower urinary tract symptoms in four countries. *Urology* 51[3]:428–436, 1998.)

Weak numerical correlations can arise artifactually, regardless of whether true physiologic relationships exist (Girman et al., 1998). Correlations are further affected by intraindividual variability of measured parameters, day-to-day variability, measurement errors associated with the technique or equipment, or the natural history of the condition itself (Barry et al., 1995c; Bruskewitz et al., 1982; Diokno et al., 1992; Sagnier et al., 1996).

It is furthermore crucial to consider the population utilized to evaluate correlations. A correlation is easier identified if patients exhibiting the full spectrum of the parameters of interest are included. In most LUTS/BPH studies, however, patients are excluded based on thresholds imposed, making it more difficult for a significant correlation to emerge. There are many examples in clinical medicine in which weak numerical correlations exist, but strong clinical relationships are well-accepted (Wilson and Cleary, 1995).

The absence of meaningful baseline correlations for symptoms, flow rate, and prostate volume in a tightly controlled population of men with LUTS and BPH enrolled in a BPH treatment study is shown in Table 144.7.

TABLE 144.7

Correlation Table Among Baseline Parameters in a BPH Treatment Study of 2800 Men Older Than Age 50 Years, an IPSS >12, Peak Flow Rate (Qmax) <15 mL/sec, Serum PSA between 1.5 and 10 ng/mL, and TPV >30 mL (TZV Not Specified)[a]

	PSA	QMAX	IPSS	TPV	TZV
Age	0.092	−0.078	−0.069	0.152	0.154
	<0.0001	<0.0001	<0.0001	<0.0001	<0.0001
PSA		−0.031	−0.016	0.384	0.352
		0.111	0.423	<0.0001	<0.0001
Qmax			−0.117	−0.059	−0.047
			<0.0001	<0.001	<0.05
IPSS				0.020	0.005
				0.293	0.761
TPV					0.775
					<0.0001

[a] Note the lack of strong correlations except for age and serum PSA versus volume among parameters.

BPH, Benign prostatic hyperplasia; *IPSS,* International Prostate Symptom Score; *PSA,* prostate-specific antigen; *TPV,* total prostate volume; *TZV,* transition zone volume.

An example of how restriction of the full range of parameters affects correlations is shown in Fig. 144.16. Volunteers without known prostatic diseases were asked to fill in an AUA symptom score (AUASS) and perform a flow rate. When all data are considered, a clear relationship exists with the maximum flow rate decreasing with increasing symptom severity ($r = 0.4$; $P < 0.05$). However, when only considering those patients typically seen in a BPH study, namely with a score above 10 points and a maximum flow rate between 5 and 15 mL/sec, the correlation within that cohort exhibiting a limited range of observation on both scales is very weak ($r = 0.08$; n.s.), and the regression line becomes flat (see Fig. 144.16).

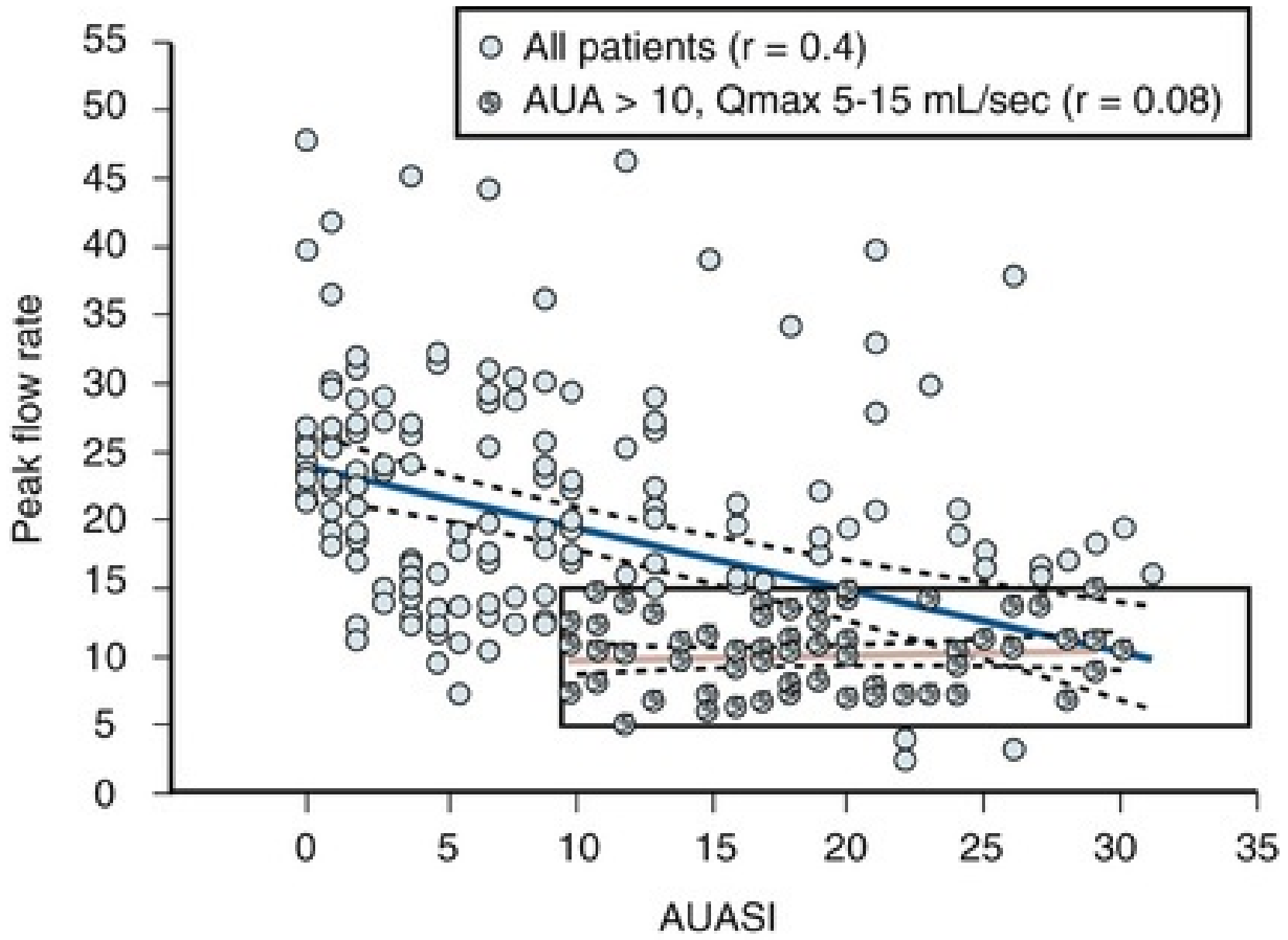

FIG. 144.16 Correlation and regression (95% confidence interval) between symptom score and maximum flow rate in volunteers ($r = 0.4$; $P < .05$). When only those volunteers are considered with a symptom score above 10 points and a flow rate between 5 and 15 mL/sec (◉), the correlation is virtually absent ($r = 0.08$; NS) as indicated by a flat regression line *(black). AUASI,* American Urological Association Symptom Index.

The correlations observed among symptoms, flow rate, and prostate volume in true community-based population studies without artificially imposed entry criteria are consequently somewhat higher than those seen in BPH clinic or trial populations. In the Olmsted County Study, after adjusting for age, the odds of moderate to severe symptoms were 3.5 times greater for men with prostatic enlargement (more than 50 mL) than for men with smaller prostates, and the odds were similarly increased (2.4-fold) for men not achieving a peak urinary flow rate of 10 mL/sec (Girman et al., 1995). Men with enlarged prostates were about twice as likely to have bother caused by symptoms (OR 2.4) or activity interference (OR 1.8) relative to men with smaller prostates (Girman et al., 1999). In a similar study from the Netherlands, Bosch et al. (1995) reported numerically weak but statistically significant correlations between the IPSS and total prostate volume ($r = 0.19$, $P < 0.001$), peak flow rate ($r = -0.18$, $P < 0.001$), and postvoid residual urine volume ($r = 0.25$, $P < 0.001$).

Although weak correlations between prostate volume and symptoms and flow rate have been accepted, recent attention has focused on correlations between the transition zone of the prostate and physiologic measures. A stronger correlation between transition zone and symptoms ($r = 0.48$, $P = 0.03$) and peak urine flow ($r = -0.34$, $P = 0.05$) was reported first by Kaplan et al. (1995), who also showed a significant correlation between transition zone index (TZV/TPV) and symptoms ($r = 0.75$), peak urine flow ($r = -0.71$), and—somewhat unexpectedly—detrusor pressure at peak urine flow ($r = 0.43$). These data were generated from a relatively small cohort of 61 men with BPH. Invasive pressure-flow studies are not performed in community-based studies, and thus comparative data from population-based studies cannot be reviewed. However, the finding of a relationship between measures of obstruction and prostate volume is rare, with most authors denying such a relationship in series of BPH clinic or trial patients (Bosch et al., 1995; d'Ancona et al., 1998; Ezz el Din et al., 1996; Homma et al., 1998; Kuo, 1999; Steele et al., 2000; Witjes et al., 1997; Yalla et al., 1995). Data from the Olmsted County Study suggest no stronger correlation between symptoms and peak flow rate with transition zone volume ($r = 0.17$, $P = 0.001$ and $r = -0.20$, $P<0.001$, respectively) than with total volume ($r = 0.16$, $P < 0.001$ and $r = -0.16$, $P < 0.001$, respectively). The transition zone index weakly correlated with AUA symptom index ($r = 0.08$, $P = 0.103$) and peak urinary flow rate ($r = -0.08$, $P = 0.0823$) (Corica et al., 1999). In a large BPH treatment trial, correlations between transition zone and other measures were no better than the correlations between total prostate volume and those same measures.

The correlation between serum PSA and prostate volume, both total and transition zone, has been described in greater detail (Roehrborn et al., 1999a). Although the individual variability is significant, precluding an accurate prediction of prostate volume by serum PSA in individual patients, there is a strong log linear relationship between these parameters that can be shown in both population-based and clinical studies (Hedelin et al., 2005; Hochberg et al., 2000; Morote et al., 2000). The relationship is further influenced by patients' age, with older patients having a greater increase in prostate volume per unit of serum PSA (Fig. 144.17). In Asian men, similar relationships exist, however, in general both prostate volume and serum PSA tend to be smaller/lower (see Fig. 144.17B) (Gupta et al., 2005). Relationships between other PSA-derived parameters have recently been examined, and certain subforms of PSA (BPSA) has been shown to be stronger related to BPH compared with total serum PSA (Canto et al., 2004).

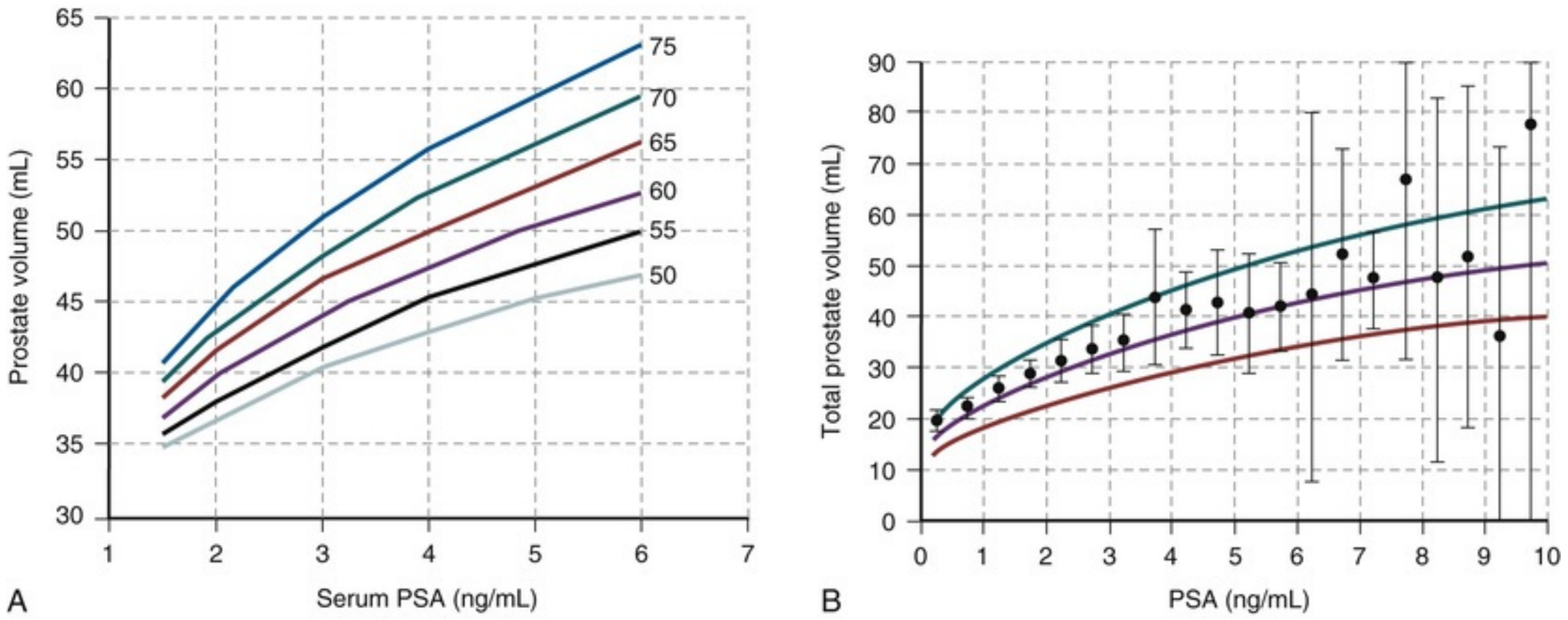

FIG. 144.17 Prediction of prostate volume based on serum prostate-specific antigen *(PSA)* stratified by age in white men (A) and in Japanese men (B). (A, From Roehrborn CG, Boyle P, Gould AL, Waldstreicher J. Serum prostate-specific antigen as a predictor of prostate volume in men with benign prostatic hyperplasia. *Urology* 53[3]:581–589, 1999c. B, From Gupta A, Aragaki C, Gotoh M, et al. Relationship between prostate specific antigen and indexes of prostate volume in Japanese men. *J Urol* 173[2]:503–506, 2005.)

With the exception of age, correlations between various measures of LUTS and BPH are modest in community-based population studies and weak in BPH clinic and trial populations. The relationship between serum PSA and prostate volume is moderate and influenced by age and race and ethnic origin. Neither symptoms nor flow rate nor prostate volume measures can predict presence and degree of obstruction reliably.

Natural History of Untreated Benign Prostatic Hyperplasia

The natural history of a disease process refers to the prognosis of the disease over time. In other words, the measurement of changes in parameters of interest and the incidence rates of significant outcomes constitute what is commonly referred to as the “natural history” of a disease. It is important for clinicians to gain as good an understanding as possible of the natural history of any illness, because the benefits and risks associated with any therapeutic interventions should always be balanced with the risks involved in just watching the disease (i.e., the natural history). In fact, the degree to which natural history must be studied depends on the seriousness of the disease and the risks involved with the therapeutic intervention. For example, it proves to be crucial to understand the natural history of abdominal aortic aneurysms and how their prognosis is determined by their size to adequately counsel patients regarding surgical interventions, which have considerable risks in themselves.

Clinical Parameters and Outcomes of Interest

Table 144.8 lists the beneficial and harmful changes in measurable parameters and outcomes, which are of interest in both the natural history and treatment of LUTS and BPH. They may be divided further into direct or biologic and indirect or proxy outcomes (Eddy, 1990, 1992). The biologic or direct outcomes are those that are immediately noticeable by the patients (e.g., symptom changes, infections, death), and the indirect or proxy outcomes are not directly noticeable, but may predict future changes in direct outcomes (e.g., changes in pressure flow parameters may predict episode of retention). The parameters and outcomes are dichotomous (yes or no, e.g., retention or no retention), categorical (grades of severity, e.g., grades of obstruction measured by pressure-flow studies), or continuous (scales of severity, e.g., symptom score, maximum flow rate). Accordingly, the most common ways to measure such outcomes are probabilities or rates of occurrences for dichotomous or categorical outcomes, and measures of central tendency (mean or median) and variability (standard deviation [SD] or standard error [SE] or confidence intervals [CIs]) for outcomes measured by continuous scales.

TABLE 144.8

Beneficial and Adverse Changes in Parameters and Outcomes

BENEFICIAL CHANGES		**HARMFUL CHANGES**	
Probability of symptom improvement	D	D	Probability of symptom worsening
Magnitude of symptom improvement	D	Co	Magnitude of symptom worsening
Magnitude of bother improvement	D	Co	Magnitude of bother worsening
Magnitude of quality of life improvement	D	Co	Magnitude of quality of life worsening
Flow rate improvement	I	Co	Flow rate worsening
Residual urine volume reduction	I	Co	Residual urine volume increase
Prostate size reduction	I	Co	Prostate size increase
Pressure flow parameter improvement	I	Co	Pressure-flow parameter worsening
		Ca	
	D	D or	Urinary incontinence

		Ca	
	D	D or Ca	Erectile dysfunction
	D	D	Acute urinary retention
	D	D	Need for treatment/surgery
	D	D or Ca	Hematuria
	D	D	Urinary tract infection
	D	D	Bladder stones
	D	D	Bladder diverticula
	D	D or Ca	Detrusor failure
	D	D or Ca	Upper tract obstruction/deterioration
	D	Co	Azotemia/renal failure
	D	D	Death

Left center column: *D,* Direct/biologic; *I,* Indirect/proxy outcome.

Right center column: *D,* Dichotomous; *Ca,* Categorical; *Co,* Continuous outcome.

Methods of Studying Natural History of Benign Prostatic Hyperplasia

The natural history of BPH can theoretically be evaluated by studies of a variety of designs:

Longitudinal studies of untreated cohorts of men diagnosed with LUTS and clinical BPH by any definition *(watchful waiting cohorts).*

- Studies of the behavior of men diagnosed with LUTS and BPH and enrolled in controlled studies of LUTS and BPH *(control groups)* and receiving one of the following:
  - *no treatment* (compared with active intervention)
  - *placebo* treatment (compared with medical treatment)
  - *sham* treatment (compared with device or surgical treatment)

Longitudinal studies of unselected (i.e., undiagnosed) men living in the community who are less likely to progress and request or require therapy *(longitudinal population-based studies).*

There are problems associated with either of the approaches. Concerning the *watchful waiting cohorts,* the first question to be resolved is whether or not it is ethical (or feasible) to enroll symptomatic men in such a study, even if the disease studied is not fatal. Secondly, the very fact that the patients had initial and presumably subsequent contact with health care providers in the course of the study will bias them, leading to changes in outcome parameters of interest presumably different from those observed in an age-matched cohort of men who were similar in all parameters at baseline but did not choose to participate (a cohort one might call in analogy to genetic language “wild type”). Further, many diagnosed men will in the course of such natural history study become more and more symptomatic and desire and receive treatment, making them ineligible to further participate in the study, thus reducing the number of men available for analyses. Lastly, a very important bias is introduced by the fact that patients in such cohorts are selected based on thresholds imposed by inclusion and exclusion criteria. In general, patients are selected to participate who are more symptomatic (i.e., those with higher symptom scores and lower maximum flow rates). By the principle of trial conduct, patients then repeat the symptom and flow rate assessment during follow-up (or after treatment). However, the same inclusion/exclusion criteria are not applied to the follow-up measurements, which leads to a unilateral regression to the mean, suggesting (falsely) an improvement in the parameter of interest.

To determine the effect that the stringency of pretrial screening has on the outcome of placebo treatment, a cohort of 145 volunteers were invited to fill in the IPSS and perform a flow rate recording twice within 1 month without receiving any therapy or instructions whatsoever (Sech et al., 1998). Although many patients experienced either an increase or a decrease in both parameters, the mean values did not change significantly (IPSS 12.1 vs. 11.7 points, peak flow rate 17.7 vs. 17.4 mL/sec; not significant). However, when typical BPH trial conditions were applied and only those patients considered for analyses who had an IPSS above (>7, >10, >15) and a flow rate below a certain threshold (<15, <12, <10 mL/sec), a unilateral regression to the mean took place, by which the more symptomatic volunteers (i.e., patients) experienced still considerable natural variability on the second assessment, but the net effect was toward “improvement” (i.e., lower scores and higher flow rates). For example, when only considering patients with IPSS greater than 10 points, the mean difference between the first and second assessment was between 19.9 versus 18.8 points, or –1.1 (*P* < 0.05). Similarly, when only patients with a peak flow rate less than 12 mL/sec were considered, the mean difference between the first and second assessment was 9.3 versus 10.9 mL/sec, or +1.6 mL/sec (*P* < 0.01) (Table 144.9).

TABLE 144.9

Mean ± Standard Deviation (SD) and Range for American Urological Association Symptom Index for Test No. 1 and Test No. 2, Mean Difference Between the Two Tests, and the 95% Confidence Interval (CI) for the Difference, for All Subjects and for Subjects Censored Based on Test No. 1 >7 Points, >10 Points, and >15 Points

SELECTION		MEAN ± SD	RANGE	MEAN DIFFERENCE 95% CI	T-TEST	*N*
All subjects	No. 1	12.1 ± 8.8	0–32	−0.39	0.133	145
	No. 2	11.7 ± 9.0	0–32	−1.1 to 0.29		
>7 at No. 1	No. 1	17.8 ± 6.5	9–32	−0.97	0.035[a]	88
	No. 2	16.8 ± 7.7	0–32	−2.0 to 0.08		
>10 at No. 1	No. 1	19.9 ± 5.6	11–32	−1.1	0.036[a]	70
	No. 2	18.9 ± 6.9	0–32	−2.2 to 0.1		
>15 at No. 1	No. 1	22.0 ± 4.6	16–32	−1.4	0.026[a]	54
	No. 2	20.6 ± 6.6	0–32	−2.8 to 0.01		

[a] Statistical comparison between test No. 1 and No. 2 by T-test.

Note the reduction in the number of patients available for follow-up because of censoring that affects the power of the statistical test.

From Sech SM, Montoya JD, Bernier PA, et al. The so-called “placebo effect” in benign prostatic hyperplasia treatment trials represents partially a conditional regression to the mean induced by censoring. *Urology* 51(2):242–250, 1998.

This experiment clearly illustrates that a unilateral regression to the mean induced and controlled by the stringency of the inclusion criteria can result in a significant “improvement” in any parameter for which a threshold is set at the baseline screening. Such purely mathematical effect is likely at work in many if not all studies in which the outcome parameters are measured using a numerical scale of some sort, and where baseline screening criteria are applied.

Control groups of men being randomized to receive no treatment, placebo, or sham treatment, while being compared with a matched group of men receiving active therapeutic interventions also suffer from a variety of biases. As the *watchful waiting cohorts*, they have initial and constant contact with health care providers, they know from the design of the study that they are randomized to the perceived less effective or ineffective arm, and thus they may have a lower threshold than community-dwelling men to cross over to active therapy. On the other hand, because of a sense of obligation, they may elect to be followed until the trial is over and then choose an active treatment. They are also subject to regression to the mean bias discussed earlier, because they were subjected to inclusion/exclusion criteria.

***Longitudinal population-based studies*, although difficult and expensive to conduct, are likely the best vehicle to understand the natural history of the disease.** The regression to the mean bias does not apply, as the participants are not selected based on inclusion and exclusion thresholds. Because no formal diagnosis is established, the natural history may take place unencumbered by preconceived notions about symptoms, endpoints of trials, and anything else leading to a bias in a watchful waiting cohort of diagnosed and thus labeled men or in a control group of diagnosed men. One must realize, however, that the very need to monitor the natural history (i.e., the need to ask questions, perform tests and intervention) conflicts with the notion of “natural history,” and thus some biases are likely to be unavoidable, even in the most ideal setting.

Watchful Waiting Studies

In the past, some investigators have attempted to conservatively follow cohorts of men diagnosed with LUTS and/or BPH *(watchful waiting cohort)*, but the few published reports are of limited scientific rigor and informational value, and they have significant shortcomings. Inclusion and exclusion criteria are poorly defined, follow-up and compliance are poor, assessment instruments are either not defined or insufficient, and patient accounting is incomplete. The studies provide answers regarding the probability of symptom changes and the magnitude of flow rate changes.

Five such studies were reported between 1919 and 1988, with a total

enrollment of 456 patients and a follow-up ranging from 3 to 6 years (Ball et al., 1981; Birkhoff et al., 1976; Clarke, 1919; Craigen et al., 1969; Kadow et al., 1988). A change in symptom status was reported for all 456 patients, and none of the studies utilized a quantitative symptom severity scale. Data on urinary flow rate and residual urine were available for 223 and 197 patients, respectively. The peak urinary flow rate deteriorated in 66% and improved in 20%. Residual urine increased (35%), decreased (37%), and remained unchanged (28%) in about the same number of all patients. The mean change in peak flow rate (in those patients for whom data are available) was +2.2 mL/sec (from a mean of 9.0 to 11.2) or 24%, and the mean change in residual urine was +37 mL (from a mean of 115 to 152) or 32%. Data on symptom improvement were reported as a dichotomous outcome (improved versus not improved). **The mean probability for any improvement in symptom severity in these studies is 42.5% (90% CI 30.8 to 54.8) as calculated by meta-analytical methods** (Eddy and Hasselblad, 1992).

Wasson et al. (1995) **chose a superior approach, namely to follow a *no-treatment control group* of men diagnosed with LUTS and BPH. A total of 556 men with moderate symptoms and a Madsen-Iversen symptom score between 10 and 20 points (0- to 27-point scale) were randomized to either undergo transurethral resection of the prostate (TURP) or be watched conservatively.** There were 47 treatment failures (defined as death, recurrent infection, residual urine volume over 350 mL, development of bladder calculus, incontinence, symptom score of 24 or higher, or doubling of serum creatinine from baseline) in the watchful waiting arm ($N = 276$) versus 23 in the surgery arm ($N = 280$) over a 3-year follow-up (relative risk 0.48; 95% CI, 0.3 to 0.77). Sixty-five men (24%) assigned to watchful waiting underwent surgery during follow-up, 20 of them for treatment failure. The majority of these men were classified as more bothered at baseline, and about 40% of patients in this category experienced an improvement in the degree of bother from urinary difficulties, a proportion strikingly similar to the overall estimate of 42.5% from the natural history studies. At 3 years of follow-up, the patients randomized to watchful waiting who did not fail or cross over to surgery had a small but noticeable improvement in nearly all outcomes measured, including a +0.4 mL/sec increase in the maximum flow rate. In 1998, a 60-month update was reported providing data on 966 patient-years of follow-up on the TURP and 990 patient-years on the watchful waiting patients (Flanigan et al., 1998). The treatment failure rates were 21% for the watchful waiting group and 10% for the

TURP group, and all outcomes were better for the TURP treated patients (Table 144.10). During follow-up, 76 watchful waiting patients (27%) crossed over to TURP; the 5-year Kaplan Meier estimate of the crossover rate was 36%; and twice as many patients crossed over electively as compared with post-treatment failure protocol–dictated crossover. **The most significant factor predicting elective crossover was high baseline bother caused by urinary symptoms** (Fig. 144.18). When separately analyzed, the patients' crossing over from watchful waiting to TURP had fewer improvements in outcome parameters compared with those randomized to TURP initially (Table 144.11). In many instances, the differences between the groups were statistically and clinically significant. A reduction in symptom score by –11 points (high baseline symptom group) and an improvement in maximum flow rate by 8.7 mL/sec (low baseline flow rate group) after TURP is expected; however, the improvements were only –8 points and +4.7 mL/sec in men undergoing TURP after an unsuccessful trial of watchful waiting. **This allows the speculation that during the period of watchful waiting before crossover, some irreversible damage might have occurred preventing symptom and flow rate improvements to the same level as observed in those men initially treated by TURP.**

TABLE 144.10

Extended Follow-up Treatment Outcomes by Intention to Treat in the Veterans Affairs Cooperative Study Comparing Watchful Waiting With TURP

OUTCOME	**TURP (*N* = 280)**[b]	**WATCHFUL WAITING (*N* = 276)**[b]	**RELATIVE RISK**[c]	***P*-VALUE**
Treatment failure	28	58	0.476	.0004
Death	16	12	1.311	.562
Urinary retention	1	9	0.110	.011
High residual	5	19	0.259	.003
Azotemia[a]	3	2	1.479	1.000
Bladder stones	0	1		.496
Incontinence	4	8	0.493	.259
High symptom score	1	13	0.076	.0008
Lost to follow-	16	18	0.876	.726

up				
Withdrawal of consent	57	36	1.561	.023
Prostate cancer	24	11	2.151	.035

[a] Azotemia defined as doubling of baseline creatinine value or greater than 3.0 mg/dL.

[b] High symptom score defined as 21 or greater on two consecutive measurements or 24 or greater on one measurement.

[c] Relative risk of TURP to watchful waiting.

TURP, Transuretheral resection of the prostate.

From Flanigan RC, Reda DJ, Wasson JH, et al. 5-Year outcome of surgical resection and watchful waiting for men with moderately symptomatic benign prostatic hyperplasia: a Department of Veterans Affairs cooperative study. *J Urol* 160(1):12–16; discussion 16–17, 1998.

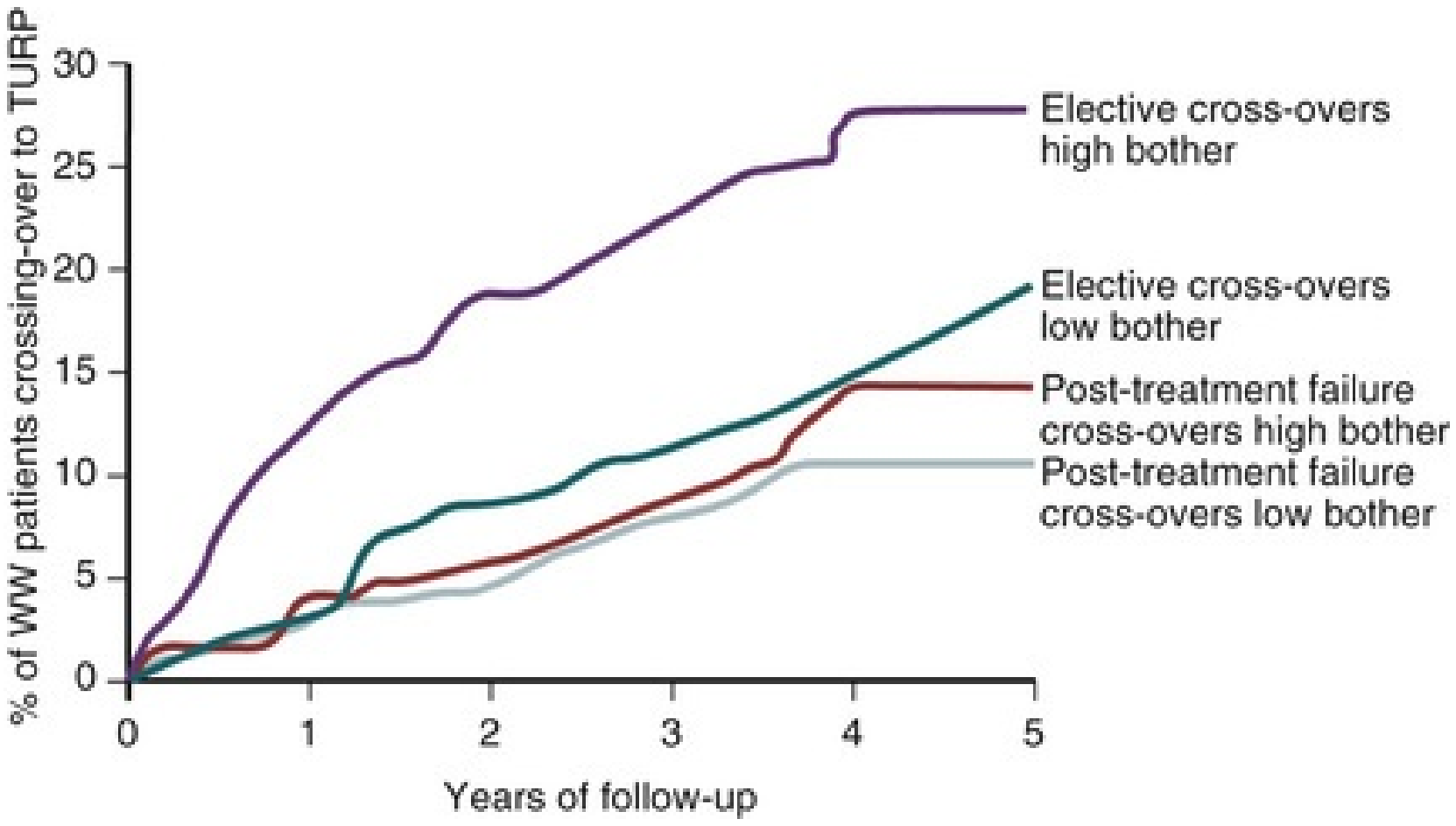

FIG. 144.18 Percent of patients crossing over from watchful waiting *(WW)* to transurethral resection of the prostate *(TURP)* by baseline bother scores and elective versus post-treatment failure protocol dictated. (From Flanigan RC, Reda DJ, Wasson JH, et al. 5-Year outcome of surgical resection and watchful waiting for men with moderately symptomatic benign prostatic hyperplasia: a Department of Veterans Affairs cooperative study. *J Urol* 160[1]:12–16; discussion 16–17, 1998.)

TABLE 144.11

Changes from Baseline to 60 Months of Follow-up for Patients Initially Randomized to TURP (1), Randomized and Remaining on Watchful Waiting (2), and Randomized to Watchful Waiting but Crossing Over to TURP at Some Point During Follow-up (3)

	GROUP	HIGH BASELINE	LOW BASELINE
Symptom score	1	−11.0[ab]	−7.7[ab]
	3	−8.0[c]	−6.2[c]
	2	−5.8	−2.2
Maximum flow rate	1	4.6[b]	8.7[ab]
	3	2.9[c]	4.7[c]
	2	−2.2	2.2
Residual urine	1	−100[ab]	−19
	3	−81[c]	−24
	2	−50	−7
Bother score	1	−34.9[b]	−14.7[b]
	3	−42.3[c]	−7.2
	2	−10.7	1.6

[a] *P* value group 1 vs. group 3.

[b] *P* value group 1 vs. group 2.

[c] *P* value group 3 vs. group 2.

From Flanigan RC, Reda DJ, Wasson JH, et al. 5-Year outcome of surgical resection and watchful waiting for men with moderately symptomatic benign prostatic hyperplasia: a Department of Veterans Affairs cooperative study. *J Urol* 160(1):12–16; discussion 16–17, 1998.

Djavan et al. (2004) followed a group of 397 men presenting to a urology clinic with mild LUTS, defined as scoring less than 8 points on the IPSS. These men were followed for 4 years beginning with a watchful waiting protocol and were reevaluated every 3 months for 48 months total time. The cumulative incidence of clinical progression, defined as worsening of the IPSS with migration from mild to moderate (IPSS 8 to 18 points) or severe symptoms (IPSS 19 to 35 points) was assessed. The likelihood of migrating or transitioning from one health state to another was 6%, 13%, 15%, 24%, 28%, and 31% at 6, 12, 18, 24, 36, and 48 months, respectively.

Placebo and Sham Control Groups in Randomized Trials

Data from *control groups treated with placebo or sham* and compared with matched groups of patients treated with medications or devices are available to address many of the parameters and outcomes of interest.

Placebo Control Groups.

For the Guidelines for the Diagnosis and Treatment of BPH published by the Agency for Health Care Policy and Research in 1994, data on 1417

patients treated in 45 placebo arms of placebo-controlled trials were analyzed (McConnell et al., 1994). Table 144.12 **allows a direct comparison between the watchful waiting studies discussed earlier and these placebo groups, both summarized by meta-analytical techniques.** For none of the examined parameters, a significant difference between the two treatment modalities can be identified. However, several points deserve discussion. As opposed to the longer-term follow-up in the watchful waiting studies, the placebo studies are part of short- to mid-term medical treatment trials ranging from 3 days to 52 weeks in duration (mean 13 weeks). In all of these studies, the patients are blinded as to the treatment arm, and thus have in most cases at least a 50 : 50 (or better in case of 2 : 1 or 3 : 1 randomization) chance of receiving active drug. Dropping out of such studies because of failure does not have the same ramification as in watchful waiting studies, where the patients willingly assumed a conservative treatment approach knowing that it might fail (i.e., they might fail and go on to active treatments). In contrast, in some placebo-controlled studies a promise (either tacit or openly) is made stating that after the conclusion of the trial, the patient would be eligible for either "free" active treatment or would be "moved up" on the surgical waiting list (this phenomenon is unique to those studies conducted in the United Kingdom). The inactive preparation given should theoretically add to the placebo effect and thus improve the outcome above those noted for watchful waiting studies. The probability for a patient to experience improvement, however, is estimated to be about 40% in the uncontrolled watchful waiting studies, the randomized watchful waiting versus TURP study, and the combined placebo arms. The changes in peak flow rate and residual urine are similar, and similarly small, for these three groups as well. **It becomes evident that 40% of patients report some improvement, and the minimal fluctuation of peak flow rate and residual urine represent the "placebo effect" background against which the more substantial changes in these parameters achieved by active treatment modalities must be seen.**

TABLE 144.12

Comparison of Outcomes After Watchful Waiting and Placebo Treatment

OUTCOME	WATCHFUL WAITING	PLACEBO
Total number of patients	456	1417

Probability for flow rate increase	19.7%	35.8%
Probability for no change in flow rate	14.2%	41.1%
Probability for flow rate decrease	66.1%	23.1%
Mean pre- and post-treatment flow rate (mL/sec)	9.0–11.2	9.1–9.7
Difference (mL/sec) and percent change	+2.2/+24.4%	+0.6%/+6.6%
Probability for decrease in residual urine	35.0%	38.0%
Probability for residual urine to remain unchanged	28.0%	26.1%
Probability for increase in residual urine	37.0%	35.9%
Mean pre- and post-treatment residual urine (mL)	115–152	87–76
Difference (mL) and percent change	+37/+32.2%	−11%/−12.6%
Probability for symptom improvement	41.7%	41.7%
Probability for symptoms to remain unchanged	25.8%	53.5%
Probability for symptom worsening	32.4%	4.7%
Mean probability for symptom improvement[a]	41.7%	41.7%
90% CI for symptoms improvement[a]	30.8–54.8%	26.3%–65.1%

[a] Calculated by confidence profile method using hierarchical Bayes (Eddy and Hasselblad, 1992).

CI, Confidence interval.

Modified from McConnell, JD, Barry MJ, Bruskewitz RC. Benign prostatic hyperplasia: diagnosis and treatment. Agency for Health Care Policy and Research. *Clin Pract Guidel Quick Ref Guide Clin* (8):1–17, 1994.

Sham Control Arms of Device Treatment Trials for BPH.

In recent years, a multitude of minimally invasive device treatments for BPH have been developed and tested in randomized, sham-controlled, open, single-, or even double-blind trials. Although the majority of these trials compare various types of heat treatments (transrectal or transurethral hyperthermia or thermotherapy) with a sham treatment, one investigator compared balloon dilation with “sham” cystoscopy alone in a randomized, double-blind trial involving 33 men with BPH (Lepor et al., 1992b).

The outcomes of the balloon dilation versus cystoscopy trial, one multicenter trial using transrectal or transurethral hyperthermia in comparison with a sham control (Abbou et al., 1994), and five transurethral microwave thermotherapy (TUMT) trials and their respective sham control arms can be used for analyses (Bdesha et al., 1994; Blute et al., 1993; de la Rosette et al., 1994; Ogden et al., 1993). Although the mean pretreatment severity score differs from trial to trial, the mean improvements in symptom severity in the sham groups ranged from 5.2% to 15.6% (on a 100% scale), and the active thermotherapy treated patients had improvements ranging from 27.0% to 37.8%, or in most cases twice the improvement as the sham control. The multicenter hyperthermia trial represents the exception, in that the actively treated cohort has an improvement similar to the sham control, which is well within the range of the other sham control trials. The changes in peak urinary flow rate follow a similar pattern. With few exceptions, the changes in peak flow rate are either very modest improvements or deteriorations (0.5, 0.6, –0.2, –1.0 mL/sec), and the active treatment arms report substantial improvements, with the exception of the hyperthermia trial.

Placebo/Sham Effect and Baseline Symptom Severity.

An area of considerable interest is the question to what degree the placebo/sham effect depends on the baseline status of the patients. This could pertain to baseline symptom severity, baseline bother, quality of life, baseline flow rate, and all other imaginable parameters. Although few investigators have thus far reported data stratified by baseline parameters, results from a multicenter, placebo-controlled, 12-month α-blocker trial (terazosin) can be analyzed (Roehrborn, 1996). Although the active drug-treated cohort has almost twice the improvement within each stratum, the placebo-treated patients had improvements ranging from 1.4 points (4.6%) to 7.5 points (21.4%) in order of increasing baseline severity score. The placebo improvements for the placebo cohort overall was 3.3 points (10.6%).

A similar increase in the placebo effect with increasing baseline symptom severity has been reported for patients treated with finasteride in the phase III trials (Gormley et al., 1992). It might be speculated that the baseline symptom severity may also affect the sham effect seen in device trials. **This phenomenon might be caused by increased expectations in patients with more severe baseline symptoms or simply caused by a regression to the mean.**

Natural History and Disease Progression in Long-Term Placebo Arms.

The distinction between changes in parameters and rates of outcomes observed in *placebo and sham control groups* versus the *longitudinal population-based studies* becomes blurred when the placebo control is carried out over a period long enough to allow natural history changes to

take place and confound the situation.

The Proscar Long Term Efficacy and Safety Study (PLESS) followed a cohort of over 3000 men with moderate symptoms and enlarged prostate glands randomized to treatment with finasteride 5 mg daily versus placebo over 4 years (McConnell et al., 1998). In most control arms, both placebo and sham, the combined placebo effect interfering with the natural history of the disease is maintained for the entire duration of the study. In this 4-year trial, however, both the mean symptom score and mean maximum flow rate slowly drifted back to baseline after a typical initial placebo response (McConnell et al., 1998). The changes occurring in measurable parameters after the initial placebo effect has taken place thus can be considered to represent the natural history of the disease. The rates of outcomes such as AUR or surgery, and changes in prostate volume, which are less or not at all susceptible to the placebo effect, are also valid measures of the natural history of the disease.

The almost 1500 men in the placebo arm of this trial allowed for a detailed analysis of the placebo response and the subsequent natural history stratified by baseline parameters. It had been shown that in men with BPH, there is a relatively strong correlation between prostate volume and serum PSA. In the PLESS, only 10% of patients underwent baseline and yearly volume measurements by endorectal coil MRI. Based on the assumption that serum PSA would be a good proxy parameter for prostate volume, the analysis was initially performed for serum PSA and based on all 1500 men treated with placebo.

When stratifying the population by serum PSA into tertiles or thirds of patients with PSA levels from 0 to 1.3, 1.4 to 3.2, and 3.3 to 10 ng/mL, three distinctly different patterns regarding symptom score and maximum flow rate changes emerge (Fig. 144.19) (Roehrborn et al., 1999a). Although the initial placebo response in the lowest PSA tertile for both symptom and flow rate was maintained over the entire 4 years of follow-up, the middle tertile experienced a slow deterioration of symptoms back to baseline, and in essence the natural history and progression of disease negated any flow rate gains. In the highest PSA tertile, the symptom score increased steadily over time after an initial placebo response by –1.5 points. Over the subsequent years, the score increased by 0.5 points per year, bringing it back to the original baseline level at the end of the study. The initial response in terms of flow rate improvement was completely negated by the progression/natural history after 2 years, and at the end of the study, this group of patients registered a net worsening of the flow rate by a mean of –1.0 mL/sec (see Fig. 144.19B). Similar results regarding changes in symptom and maximum flow rate over time were obtained when the 150 patients for whom prostate volume measurements were available were divided into tertiles (14 to 41 mL, 42 to 57 mL, 58 to 150 mL). The PLESS also assessed periodically bother caused by urinary symptoms, disease-specific quality of life, aspects of sexual function, and overall sense of well-being. Surprisingly, serum PSA at baseline also predicts after an initial placebo response the rate of deterioration of bother, quality of life, and certain aspects of sexual function (Bruskewitz et al., 1999) (Fig. 144.20).

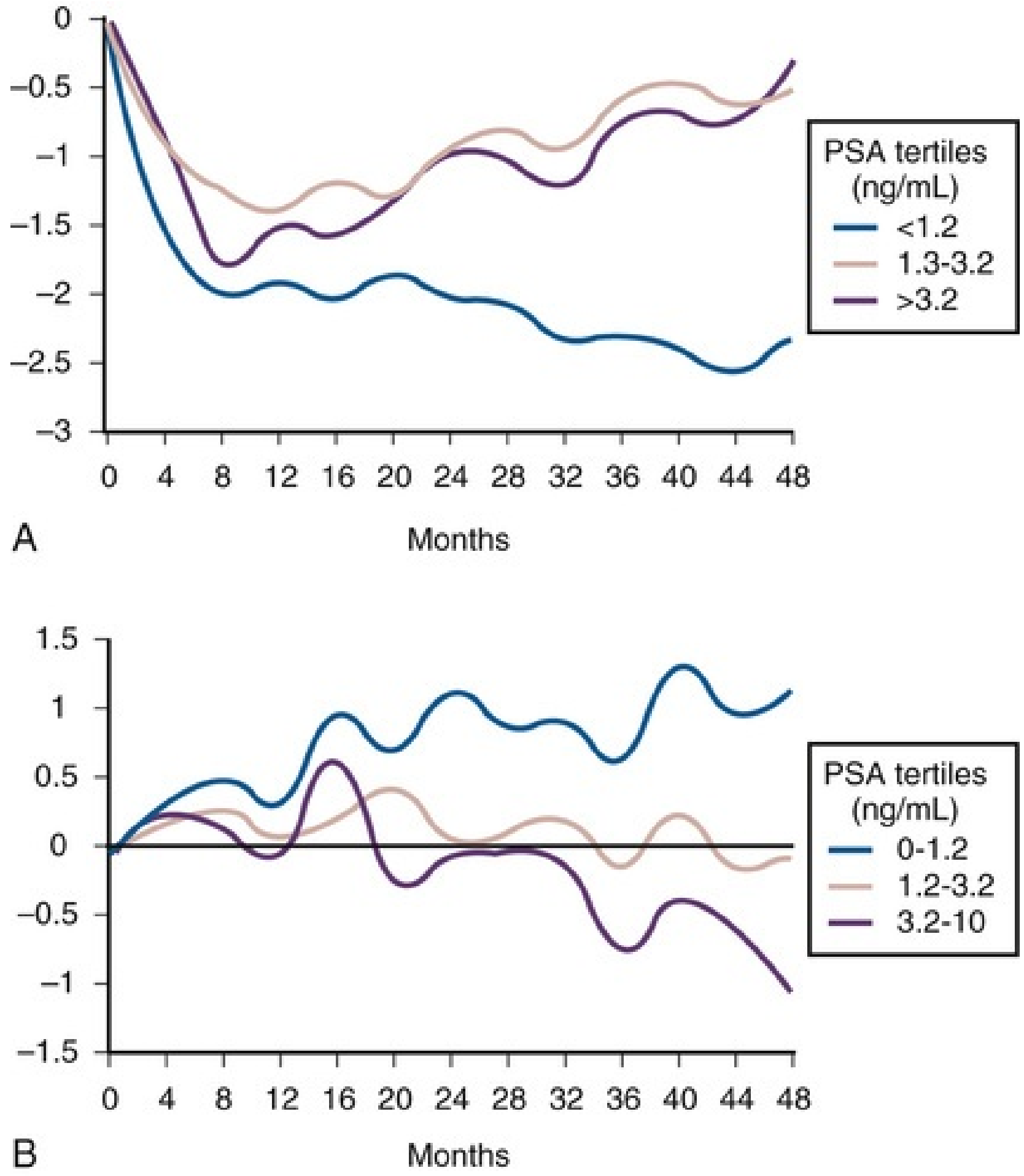

FIG. 144.19 Mean changes for symptom (A) and peak flow rate (B) in placebo-treated patients in Proscar Long-Term Efficacy and Safety Study stratified by baseline serum prostate-specific antigen *(PSA)* levels. (From Roehrborn CG, Boyle P, Gould AL, Waldstreicher J. Serum prostate-specific antigen is a reliable surrogate for prostate volume. *Urology* 53[3]:581–589, 1999c.)

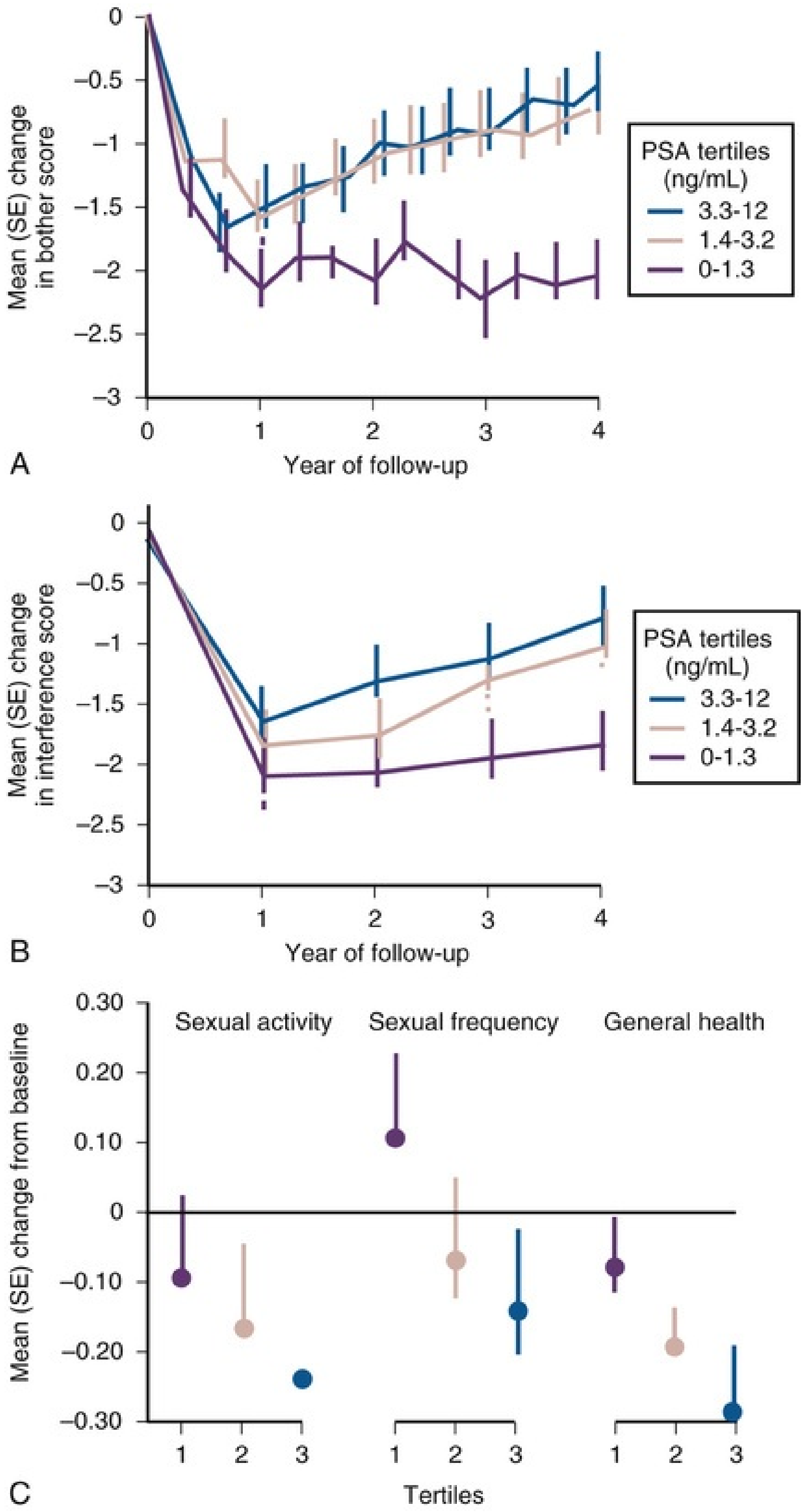

FIG. 144.20 Mean changes for bother (A), interference with activities of daily living (B), and for sexual activity, frequency, and perception of general health (C) in placebo-treated patients in Proscar Long-Term Efficacy and Safety Study stratified by baseline serum prostate-specific antigen *(PSA)*

levels. *SE,* Standard error. (From Bruskewitz R, Girman CJ, Fowler J, et al. Effect of finasteride on bother and other health-related quality of life aspects associated with benign prostatic hyperplasia. PLESS Study Group. Proscar Long-term Efficacy and Safety Study. *Urology* 54[4]:670–678, 1999.)

The Medical Therapy of Prostatic Symptoms (MTOPS) study followed 3045 men treated with either placebo versus doxazosin versus finasteride versus combination therapy for 4 to 5 years and was designed as a progression study (Bautista et al., 2003; McConnell et al., 2003). The composite endpoint captured either a worsening of greater than or equal to 4 points on the IPSS verified twice within 4 weeks, AUR, socially unacceptable incontinence, recurrent urinary tract infection (UTI), or renal insufficiency caused by BPH (Table 144.13). The greater than or equal to 4 points worsening was chosen to reflect a clinically meaningful worsening of LUTS symptomatology. Despite an overall numerical improvement in the IPSS by –4.9 points in the placebo group (intention to treat cohort), about 14% of placebo-treated patients experienced a verified worsening by greater than or equal to 4 points over the course of the study for an incidence of 3.6/100 patient-years (see Table 144.13).

TABLE 144.13

Clinical Progression of BPH in Placebo-Treated Patients in MTOPS

EVENT	RATE OVER DURATION OF STUDY	CUMULATIVE NUMBERS OF EVENTS AT 4 YEARS	CUMULATIVE INCIDENCE (95% CI) AT 4 YEARS
Clinical progression overall	4.5	122	17 (14–20)
≥4 points IPSS increase	3.6	97	14 (11–17)
Acute urinary retention	0.6	18	2 (1–4)
Socially unacceptable incontinence	0.3	6	<1 (0–1)
Urinary tract infections	0.1	1	<1 (0–1)
Renal insufficiency	0.0	0	0

caused by BPH			
Invasive therapy caused by BPH	1.3	37	5 (3–7)

BPH, Benign prostatic hyperplasia; *CI,* confidence interval; *MTOPS,* Medical Therapy of Prostatic Symptoms.

From McConnell J, Roehrborn CG, Bautista OM, et al. The long-term effects of doxazosin, finasteride and the combination on the clinical progression of benign prostatic hyperplasia. *N Engl J Med* 349(25):2385–2396, 2003.

Recently, two separate post-hoc analyses of the prostate cancer prevention trial REDUCE were published shedding light on the natural history of the interrelationship between prostate size and development of LUTS (Simon et al., 2016). Among men treated with placebo during the REDUCE study, those with a prostate size of 40 to 80 mL had a 67% higher risk (hazard risk 1.67, 95% CI, 1.23 to 2.26, $P = 0.001$) for developing incident LUTS compared with men who had a prostate size of 40 mL or smaller. The second analysis focused on the urinary flow rate parameters and showed in univariable analysis when peak flow was categorized as 15 mL/sec or greater, 10 to 14.9 mL/sec, and less than 10 mL/sec, flow rates of 10 to 14.9 mL/sec and less than 10 mL/sec were associated with a significantly increased risk for incident LUTS (hazard ratio [HR] 1.39, $P = 0.011$ and 1.67, $P<0.001$, respectively) (Simon et al., 2017).

The placebo control groups of large studies such as the PLESS and the MOTPS allow the study of natural history and disease progression in a cohort selected for moderate symptoms and other evidence of disease (in contrast with a population-based study) on the background of the initial placebo responses. In the MTOPS, approximately 14% of placebo-treated patients experienced a greater than or equal to 4-point worsening in the IPSS over 4 years of follow-up. REDUCE as a prostate cancer prevention trial does not suffer from the placebo effect and demonstrated prostate size and peak urinary flow rate to predict future development and diagnosis of LUTS.

Relationship Between Placebo/Sham Effect and Perception of Improvement.

Barry et al. reported an important observation by assessing the relationship between changes in the AUA symptom index and patients' global rating of improvement in over 1200 men treated in a medical treatment trial for BPH

(Barry et al., 1995d). **They noted that a mean decrease in AUA symptom index of 3.1 points was associated with a slight improvement; however, this relationship was strictly dependent of the baseline AUA symptom index. For patients to perceive a slight, moderate, or marked improvement, increasing drops in AUA symptom index were required with increasing baseline symptom severity.** For patients starting with a lower versus higher baseline score, the drop had to be –7.4 versus –15.3 points, respectively, to perceive a marked improvement; –4.0 versus –8.7, respectively, for a moderate improvement; –1.9 versus –6.1, respectively, for a slight improvement; –0.2 versus –2.0, respectively, for no improvement; and +3.3 versus +1.2, respectively, for worsening.

Longitudinal Population-Based Studies.

Diokno et al. (1992) **provided estimates of the prevalence, incidence, and remission of LUTS in 803 community-dwelling men 60 years of age or older.** The annual incidence of prostate surgery was 2.6% and 3.3% during years 1 and 2 of follow-up, respectively. The prevalence of at least one symptom was 35%, with annual incidence rates of 16.4% and 16.1% during years 1 and 2 of follow-up, respectively. Remission was also noted in that 22.9% of those having severe symptoms at baseline were asymptomatic at follow-up. Table 144.14 details the changes in symptom severity from one survey to the next. **The tendency for fluctuation and spontaneous remission of symptoms and the regression to the mean become evident from an analysis of these data.**

TABLE 144.14

Changes in Status of Symptom Severity From One Survey to the Next[a]

SEVERITY	YEAR	NO. PATIENTS	SEVERITY IN FOLLOWING YEAR (%)			
			NONE	MILD	MODERATE	SEVERE
None	Baseline	293	83.6	12.3	2.7	1.4
	Year 1	223	83.9	9.0	2.2	4.9
Mild	Baseline	88	18.2	55.7	11.4	14.8
	Year 1	84	33.3	52.4	8.3	6.0
Moderate	Baseline	38	7.9	31.6	26.3	34.2
	Year 1	27	3.7	33.3	22.2	40.7
Severe	Baseline	35	22.9	17.1	11.4	48.6
	Year 1	31	9.7	22.6	12.9	54.8

---

[a] Patients who underwent prostatectomy in the preceding year were excluded from the next survey.

Modified from Diokno AC, Brown MB, Goldstein N, Herzog AR. Epidemiology of bladder emptying symptoms in elderly men. *J Urol* 148(6):1817–1821, 1992.

Garraway et al. conducted a study of LUTS in four villages in the Forth Valley in Scotland in men 40 to 79 years of age defining BPH as a prostate volume of over 20 mL by TRUS, a maximum flow rate of less than 15 mL/sec, and applying a lower threshold to the symptom severity (Garraway et al., 1993; Guess et al., 1993; Tsang and Garraway, 1993). By this definition, the prevalence of BPH increased at baseline from 14% in men in their 40s to 43% in men in their 60s, and about one-half of men reported interference with activities of daily living caused by LUTS and BPH. One-year and 3-year follow-up data have been reported (Lee et al., 1996). **From baseline to 3 years, the proportion of men with moderate symptoms increased from 34% to 45%, and significant increases in symptom level occurred for 8 of 12 symptoms queried and for the AUASI (increase from 6.37 to 7.88 from baseline to year 3, $P<0.0001$)** (Lee et al., 1996)**. Parallel to symptom frequency and severity, bothersomeness of symptoms increased over time (Fig. 144.21), and the proportion of men reporting interference with two or more activities increased from 26% to 41%, with three or more activities from 18% to 27%, and with four or more activities from 15% to 18%. This study clearly demonstrated LUTS and BPH being a progressive disease, albeit with a very flat slope of progression.**

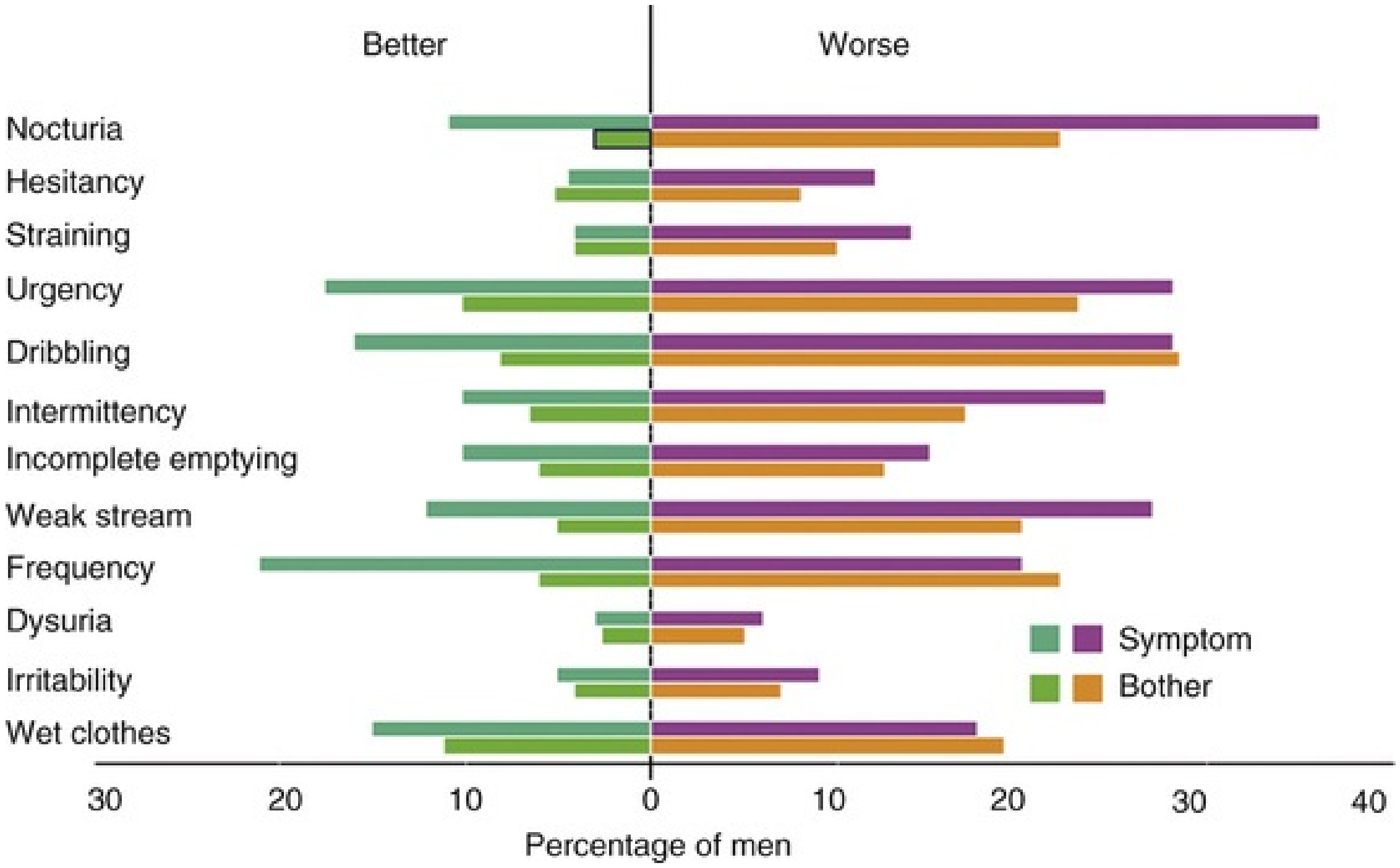

FIG. 144.21 Changes in urinary symptoms and bothersomeness status between baseline and 3 years in a Scottish population-based study. (From Lee AJ, Russell EB, Garraway WM, Prescott RJ. Three-year follow-up of a community-based cohort of men with untreated benign prostatic hyperplasia. *Eur Urol* 30[1]:11–17, 1996.)

The most informative natural history study to date is the Olmsted County Study of Urinary Symptoms and Health Status among Men, which has given us much information about prevalence and severity of urinary symptoms, bother, worry and embarrassment, quality of life caused by symptoms, and the relationship between symptoms and other parameters such as flow rates, prostate volume, and PSA (Girman et al., 1994, 1995; Guess et al., 1995; Jacobsen et al., 2003; Oesterling et al., 1993; Rule et al., 2005; Sarma et al., 2003).

With continued follow-up of this cohort, data have emerged regarding the longitudinal changes in symptoms and flow rate over time in this population-based study. Of 904 men reporting none to mild symptoms (AUASI 0 to 7 points) at baseline, 118 reported moderate to severe symptoms (AUASI >7 points) at 18 months, and 196 at 42 months of follow-up (Girman et al., 1995). However, 47 men who had developed moderate to severe symptoms at 18 months had none to mild symptoms at 42 months. At 42 months of follow-up, an average increase in the IPSS of 0.18 points (95% CI, 0.13 to 0.24) per year of follow-up was recorded. **The average annual symptom score slope and**

variability in slope increased with patient age at baseline from a mean of 0.05 +/– 1.06 (standard deviation) per year among men in the 40s to 0.44 +/– 1.35 per year for men in the 60s, and decreased to 0.14 +/– 1.42 per year for men in the 70s (Jacobsen et al., 1996)**. More recently, 92-month data showed an annual change of 0.34 points/year, with 31% of all men reporting at least a 3-point increase. The greatest annualized increase was observed in men in their 60s with 0.6 points/year** (Rhodes et al., 2000).

The Boston Area Community Health Survey enrolled 5502 participants 30 to 79 years of age with black, Hispanic, or white race/ethnicity (Piccolo et al., 2014). At 5-year follow-up interviews in 4144 participants, symptom progression, defined as an increase in AUASI by greater than 3 points, was reported by 21% to 33% of participants, and regression (decrease ≥3) was reported by 30% to 44% of participants, most commonly women and Hispanics. Age and higher BMI were associated with progression ($P<0.01$), but not regression (Maserejian et al., 2014) (Table 144.15).

TABLE 144.15

Change in LUTS Severity Classification: Age Adjusted Percentage of Men and Women With LUTS Severity at Follow-up by LUTS Severity at Baseline

BASELINE (PREVALENCE)	FOLLOW-UP IN MEN				BASELINE (PREVALENCE)	FOL
	NONE	MILD	MODERATE	SEVERE		NON
None (18.1)	26.8	69.9	2.8	0.5	None (13.7)	38.9
Mild (62.7)	12.2	77.0	10.3	0.5	Mild (67.4)	11.8
Moderate (18.4)	7.0	41.3	47.5	4.2	Moderate (17.0)	4.4
Severe (0.8)	0.8	1.0	36.7	61.5	Severe (1.9)	0

From Maserejian NN, Chen S, Chiu GR, et al. Treatment status and progression or regression of lower urinary tract symptoms among adults in a general population sample. *J Urol* 191(1):107–113, 2014.

Peak flow rate measurements in a subset of about 500 men from the Olmsted County Study showed a median peak urinary flow rate slope decrease of –2.1% per year (25th percentile –4.0, 75th percentile –0.6). Peak urinary flow rate declined more rapidly with decreasing baseline rate, and increasing baseline age, prostate volume and symptom severity (all P = 0.001). When the variables were simultaneously adjusted for each other, a rapid decline (negative slope 4.5% or greater per year) was more likely in

men 70 years of age or older and those with a rate less than 10 mL/sec at baseline compared with those 40 to 49 years of age and those with a rate of 15 mL/sec or greater, respectively. Prostate volume and symptom severity were not statistically significant predictors of a rapid decline in peak urinary flow rate when variables were considered simultaneously (Roberts et al., 2000).

Based on TRUS, the growth of the prostate in these men 40 to 79 years of age was estimated to be about 0.6 mL per year or 6 mL per decade of life. However, prostate growth followed an exponential growth pattern, with a slope estimate of 0.4 mL/year for men 40 to 59 years of age at baseline and of 1.2 mL/year for those 60 to 79 years of age at baseline (Rhodes et al., 1995, 1999). An updated analysis revealed a median growth rate of about 1.9%/year independent of age and symptoms. However, a higher baseline serum PSA and larger prostate volume predicted greater annualized volume increases.

Complications of Benign Prostatic Hyperplasia

Many of the complications of progressive BPH are rare, and much of the knowledge comes from studies of men presenting with such complications for treatment, that is, cases, rather than observing cohorts of men for the development of complications.

Mortality

Between 1950 and 1954, 17 of 24 countries reported mortality rates of greater than 10 per 100,000, and between 1985 and 1989 data were available for 61 countries, only one reporting a greater than 10/100,000 mortality rate (Boyle et al., 1996). **If the mortality rates from 1950 were applied to 1990, 13,681 fewer deaths occurred in the United States alone than expected, a major but unheralded health care achievement.**

Bladder Stones

In a large autopsy study, the prevalence of bladder stones was 8 times higher in men with a histologic diagnosis of BPH (3.4%) compared with controls (0.4%), but no increased incidence of ureteral or kidney stones was found (Grosse, 1990). In a study comparing watchful waiting and TURP in men with moderate symptoms, only 1 of 276 patients assigned to watchful waiting developed a bladder stone at 3-year follow-up (Wasson et al., 1995). The self-reported rate of a bladder stone in a cross-sectional study in 2002 Spanish men was 0.7% (Hunter et al., 1996).

In clinical practice, the risk for bladder stone development is small, and screening is only indicated if clinical circumstances warrant it (e.g., hematuria, stuttering of urination).

Bladder Decompensation

When endoscopically evaluating the bladder in men with BPH, urologists search for a progression from normal mucosa to advancing trabeculation,

development of cellules, and diverticula, with ultimate detrusor muscle failure in mind. However, when the process starts, it is unclear whether it really is related to BPH and obstruction and when an intervention is necessary to prevent decompensation with resultant inability to void.

Biopsies from trabeculated, obstructed bladders show dense connective tissue deposition, a finding similar to that seen in experimentally obstructed animals (Chapple et al., 1991; Gosling and Dixon, 1980; Levin et al., 1990, 2000). However, bladder fibrosis is seen in both sexes with advancing age and may be a normal consequence of aging (Lepor et al., 1992b).

The critical question is whether or not delayed intervention might lead to progressive irreversible loss of bladder function and misses a window for cure. There is no direct evidence for this from longitudinal population or clinic patient studies. However, in the VA Cooperative study comparing watchful waiting with TURP, the patients who crossed over from the conservative arm to TURP later in the trial did not have as significant an improvement in symptoms and flow rate compared with those who underwent TURP at the beginning after randomization (Flanigan et al., 1998).

The topic continues to be of interest, and a recent literature review emphasized the absence of high-quality data and the importance of the “design of longitudinal, prospective randomised studies evaluating early pharmacological/surgical treatments versus deferred interventions to better identify the clinical profile of patients who could best benefit from early intervention and the ideal type and time of it” (Presicce et al., 2018).

Urinary Incontinence

Incontinence is one of the most feared complications from surgical intervention for BPH. Although it may be the result of BPH secondary to overdistension of the bladder (overflow incontinence) or to detrusor instability estimated to affect up to one-half or more of all obstructed patients (urge incontinence) (McConnell, 1994), it also is associated with aging, and in a community study an incidence of incontinence of 24% and 49%, respectively, in men and women older than 50 years of age was reported (Roberts et al., 1998). In the VA Cooperative study, a 4% incidence of incontinence in both the surgical and conservative treatment arms was reported (Wasson et al., 1995). The self-reported rate of incontinence in a cross-sectional study in 2002 Spanish men was 6.1% (Hunter et al., 1996). In the MTOPS, the rate of socially unacceptable incontinence was 0.3/100 patient-year (McConnell et al., 2003).

Urinary Tract Infections

In older surgical series, UTIs constitute the main indication for surgical intervention in about 12% (Holtgrewe et al., 1989; Mebust et al., 1989). **Although one might intuitively assume that increased amounts of residual urine would predispose to the development of UTI, clear evidence is lacking.** Hunter quoted a rate of 5.2% self-reported episodes of UTI in a cross-sectional survey of 2002 men in Madrid, Spain (Hunter et al., 1996). The best data to date come from the MTOPS study, where the incidence of UTIs in the placebo-treated patients was only 0.1/100 patient-years (McConnell et al., 2003).

Upper Urinary Tract Deterioration and Azotemia

The Agency for Health Care Policy and Research BPH guidelines reported a mean of 13.6% (range from 0.3% to 30%) of patients presenting for TURP with evidence of renal failure based on predominantly older studies (McConnell et al., 1994). Patients in renal failure have an increased risk for complications after TURP compared with those with normal renal function (25% vs. 17%) (Holtgrewe et al., 1989; Mebust et al., 1989), and the mortality rate increases up to sixfold (Holtgrewe and Valk, 1962; Melchior et al., 1974a, 1974b). In the large database of patients who had upper tract imaging before surgery, 7.6% of 6102 patients in 25 series had evidence of hydronephrosis, of whom one-third had renal insufficiency (McConnell et al., 1994).

The term *silent obstruction* or *silent prostatism* has been used to describe the constellation of asymptomatic patients who eventually develop renal failure resulting from bladder outlet obstruction, a case both rare and important (Mukamel et al., 1979). In the VA Cooperative study, only 3 of 280 surgically treated patients and 1 of 276 patients in the watchful waiting arm developed renal azotemia, defined as a doubling of serum creatinine from baseline (Wasson et al., 1995). In none of the cohort or population-based studies have cases of renal failure been reported clearly attributable to BPH. However, the self-reported rate of an episode of renal failure in a cross-sectional study in 2002 Spanish men was 2.4% (Hunter et al., 1996).

In the MTOPS, there was no single case of renal insufficiency caused by BPH in more than 3000 men followed for over 4 years (McConnell et al., 2003). One has to be, however, careful not to overinterpret these findings. Participants in the MTOPS were screened at baseline, and one might argue that some at higher risk for developing renal failure were excluded from participation.

Hematuria

It has always been recognized that patients with BPH might develop gross hematuria and form clots with no other cause being identifiable. Recent evidence suggests that in patients predisposed to hematuria, microvessel density is higher compared with controls. Some renewed interest in the issue of BPH-related hematuria stems from the observation that finasteride appears to be a reasonable first-line therapy apparently influencing the expression of VEGF (DiPaola et al., 2001). The self-reported rate of hematuria in a cross-sectional study in 2002 Spanish men was 2.5% (Hunter et al., 1996). Precise population estimates and incidence rates are not available, and the clinical management is dictated by the circumstances.

Acute Urinary Retention

AUR is for several reasons one of the most significant complications or long-term outcomes resulting from BPH. It has in the past represented an immediate indication for surgery. Between 25% and 30% of men who underwent TURP had AUR as their main indication in older series (Holtgrewe et al., 1989; Mebust et al., 1989)**, and today most patients failing to void after an attempt of catheter removal still undergo surgery. For this reason alone, AUR is both an important and feared event from an economical perspective and from the viewpoint of the patient.** For the patient, it presents itself by the inability to urinate with increasing pain, eventually a visit to the emergency room, catheterization, follow-up visits to physicians, an attempt at catheter removal, and either recovery of spontaneous voiding or surgery, both a painful and time-consuming process. In older literature, the risk for recurrent AUR was cited as being 56% to 64% within 1 week of the first episode and 76% to 83% in men with diagnosed BPH (Breum et al., 1982; Hastie et al., 1990; Klarskov et al., 1987).

The etiology of AUR is poorly understood, and obstructive, myogenic, and neurogenic causes all may play a role (Kaplan et al., 2008)**. Prostate infection, bladder overdistension** (Powell et al., 1980)**, excessive fluid intake,**

alcohol consumption, sexual activity, debility, and bed rest have all been mentioned (Stimson and Fihn, 1990)**. Prostatic infarction has been suggested as being an underlying event causing AUR** (Graversen et al., 1989). Spiro et al. (1974) found evidence for infarction in 85% of prostates removed for AUR versus 3% in prostates of men having surgery for symptoms only. In contrast, there was no evidence of infarction in six prostatectomy specimens removed from men who had surgery for AUR (Jacobsen et al., 1997). Anjum found fundamentally similar rates of infarction in 35 men each in AUR versus no AUR (1.9% vs. 3.0%) (Anjum et al., 1998).

From a clinical and prognostic point of view, spontaneous AUR should be separated from precipitated AUR, although this is by no means consistently done in the literature. Precipitated AUR refers to the inability to urinate after a triggering event such as non–prostate-related surgery; catheterization; anesthesia; ingestion of medications with α-sympathomimetic or anticholinergic effects or antihistamines; or others. All other AUR episodes are classified as spontaneous (Roehrborn et al., 2000b). The importance of differentiating the two types of AUR becomes clear when evaluating the ultimate outcomes of patients. After spontaneous AUR, 15% of patients had another episode of spontaneous AUR, and a total of 75% underwent surgery, and after precipitated AUR, only 9% had an episode of spontaneous AUR, and 26% underwent spontaneous surgery (Roehrborn et al., 2000a).

Descriptive Epidemiology (*Table 144.16*)

Older estimates of occurrence of AUR range from 4 to 15 to as high as 130 per 1000 person-years (calculated by Jacobsen et al., 1997) based on studies (by Ball et al., 1981; Birkhoff et al., 1976; Craigen et al., 1969), which leads to 10-year cumulative incidence rates ranging from 4% to 73%. The self-reported rate of AUR in a cross-sectional study in 2002 Spanish men was 5.1% (Hunter et al., 1996).

TABLE 144.16

Descriptive Studies on the Incidence of Acute Urinary Retention

FIRST AUTHOR/YEAR	DESCRIPTION OF COHORT	CASES	COHORT	YEARS OF FOLLOW-UP	PERCENT OVERALL	P

Ball, 1981	Watchful waiting study	2	107	5	1.9	0.
Craigen, 1969	Watchful waiting study					
Birkhoff, 1976	Watchful waiting study	10	26	3	39	13
Wasson, 1995	TURP vs. watchful waiting VA Cooperative Study	8	276	3	2.8	0.
Hunter, 1996	Self-reported prior events in Spanish men	102	2002	?	5.1	
Barry, 1997	Prostatectomy candidates	40	500	4	8	2.
Meigs, 2001	Physicians Health Study, self-reported	82	6100	3	1.3	
Jacobsen, 1997	Community cohort 40–49 years of age	57	2115	4		
Roehrborn, 1999	Placebo group of PLESS	99	1376	4	7.2	1.
Andersen, 1997	Placebo groups of 2-year BPH studies	57	2109	2	2.7	1.

BPH, Benign prostatic hyperplasia; *CI,* confidence interval; *IR,* incidence rate; *PLESS,* Proscar Long-Term Efficacy and Safety Study; *TURP,* transurethral resection of the prostate.

More recent data from carefully controlled studies in better defined populations shed additional light on the incidence rates in community-dwelling men and clinical BPH populations. AUR occurred in the VA Cooperative study over 3 years in 1 man after TURP and in 8 of 276 men in the watchful waiting arm for an incidence rate of 9.6/1000 person-years (Wasson et al., 1995). Barry et al. (1997) reported outcomes of 500 men diagnosed by urologists with BPH, who were candidates for prostatectomy by established criteria but elected to be followed conservatively. In 1574 person-years, 40 episodes of AUR occurred at a constant rate throughout the 4 years of follow-up for an incidence rate of 25/1000 person-years.

During 15,851 person-years of follow-up in the Physicians Health Study, 82 men reported an episode of AUR for an incidence rate of 4.5/1000 person-years

(95% CI, 3.1 to 6.2) (Meigs et al., 1999). Of the 2115 men 40-79 years of age in the Olmsted County Study, 57 had a first episode of AUR during 8344 person-years of follow-p (incidence 6.8/1000 person-years, 95% CI, 5.2 to 8.9) (Jacobsen et al., 1997).

The first excellent data from men diagnosed with BPH stem from the PLESS (McConnell et al., 1998)**. In the PLESS, 1376 placebo-treated men with enlarged prostates and moderate symptoms had complete follow-up over 4 years, of which 99 experienced an episode of AUR for a calculated incidence rate of 1.8/100 person-years. Boyle** (1998) **meta-analyzed the placebo treatment groups from three 2-year studies with a similar patient population. Of 2109 patients, 57 experienced AUR over the 2 years with a constant hazard for an incidence rate of 14/1,000 person-years. In the MTOPS placebo group, the incidence rate was 0.6/100 patient-years for a cumulative incidence of 2%.**

Analytical Epidemiology

Age.

Several well-controlled studies provided considerable insights into the risk factors for AUR. Perhaps the most significant of these risk factors is age. Studies from European countries and the United States demonstrate a nearly linear increase in the age-specific incidence of AUR for men ranging from 40 to over 80 years of age (Cathcart et al., 2006; Jacobsen et al., 1997; Meigs et al., 1999; Verhamme et al., 2005) (Fig. 144.22).

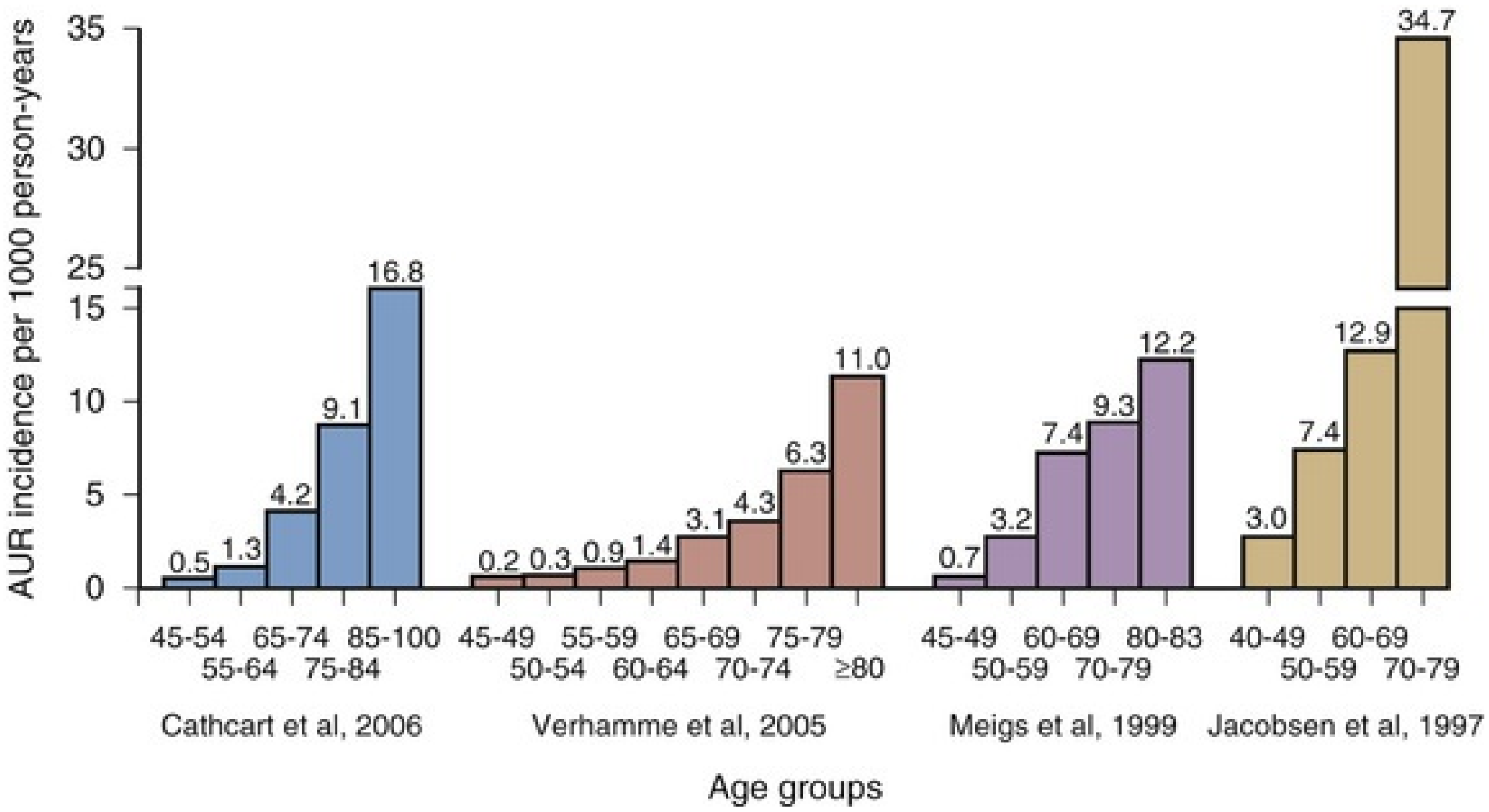

FIG. 144.22 Increase in incidence of acute urinary retention *(AUR)* with age in four large studies. (From Kaplan SA, Wein AJ, Staskin DR, et al. Urinary retention and post-void residual urine in men: separating truth from tradition. *J Urol* 180[1]:47–54, 2008.)

LUTS.

Increased symptom severity was associated with increased risk for AUR in several large population-based or cohort studies (Table 144.17). In the Physician's Health Study in men with mild symptoms, the incidence of AUR increased from 0.4/1000 person-years for those 45 to 49 years of age to 7.9/1000 person-years for those 70 to 83 years of age. In men with a symptom score of 8 to 35, rates increased from 3.3/1000 person-years for those 45 to 49 years of age to 11.3/1000 person-years for those 70 to 83 years of age. Men with a clinical diagnosis of BPH and a symptom score of 8 or greater had the highest rates (age-adjusted incidence 13.7/1000 person-years). All seven LUTS comprising the American Urological Association (AUA) symptom index individually predicted AUR. The sensation of incomplete bladder emptying, having to void again after less than 2 hours, and a weak urinary stream were the best independent symptom predictors. Use of medications with adrenergic or anticholinergic side effects also predicted AUR (Meigs et al., 1999).

TABLE 144.17

Incidence of AUR by Patient Age and AUASI Score in Two Population-Based Studies

AGE GROUP	NO. AUR EVENTS/1000 MEN-YEARS (95% CI)	
	HEALTH PROFESSIONALS FOLLOW-UP STUDY[a]	OLMSTED COUNTY STUDY OF URINARY SYMPTOMS AND HEALTH STATUS AMONG MEN[b]
AUASI ≤7:		
40–49		2.6 (0.8–6.0)
45–49	0.4 (0.02–1.8)	
50–59	1.2 (0.4–2.6)	1.7 (0.3–4.8)
60–69	3.6 (1.9–6.1)	5.4 (2.0–11.6)
70–79		9.3 (3.4–20.3)
70–83	7.9 (4.1–13.5)	
AUASI >7:		
40–49		3.0 (0.4–10.8)
45–49	3.3 (0.2–14.4)	
50–59	10.0 (5.4–16.8)	7.4 (2.7–16.1)
60–69	14.1 (9.4–20.2)	12.9 (6.2–23.8)
70–79		34.7 (20.2–55.5)
70–83	11.3 (6.4–18.3)	

[a] Total of 82 AUR episodes in 6100 men with a crude incidence of 5.2/1000 patient-years (95% CI 4.1–6.4) in 15,851 patient-years of follow-up.

[b] Total of 57 AUR episodes in 2115 men with an overall incidence of 6.8/1000 patient-years (95% CI 5.2–8.9) in 8344 patient-years of follow-up.

AUASI, American Urological Association Symptom Index; *AUR,* acute urinary retention; *CI,* confidence interval.

From Kaplan SA, Wein AJ, Staskin DR, et al. Urinary retention and post-void residual urine in men: separating truth from tradition. *J Urol* 180(1):47–54, 2008.

The Olmsted County Study analyses focused on age, symptom severity, maximum flow rate, and prostate volume (Jacobsen et al., 1997). **Incidence rates per 1000 person-years increased from 2.6 to 9.3 for men in their 40s to 70s if they had mild symptoms and from 3.0 to 34.7 if they had more than mild symptoms.**

Urodynamic Parameters.

The relative risk increased for older men, men with moderate to severe symptoms (3.2×), those with a flow rate less than 12 mL/sec (3.9×), and those with a prostate volume greater than 30 mL by TRUS (3.0×), all compared with a baseline risk for 1.0× for the corresponding groups (Fig. 144.23). The highest relative risk by proportional hazard models exists for men

60 to 69 years of age with more than mild symptoms and a flow rate less than 12 mL/sec (10.3×), and for men 70 to 79 years of age, except if they had mild symptoms and a flow rate greater than 12 mL/sec. All other stratification of men older than 70 years of age had a RR ranging from 12.9× to 14.8× (all compared with men 40 to 49 years of age with mild symptoms and a flow rate greater than 12 mL/sec for which the base risk is 1.0×).

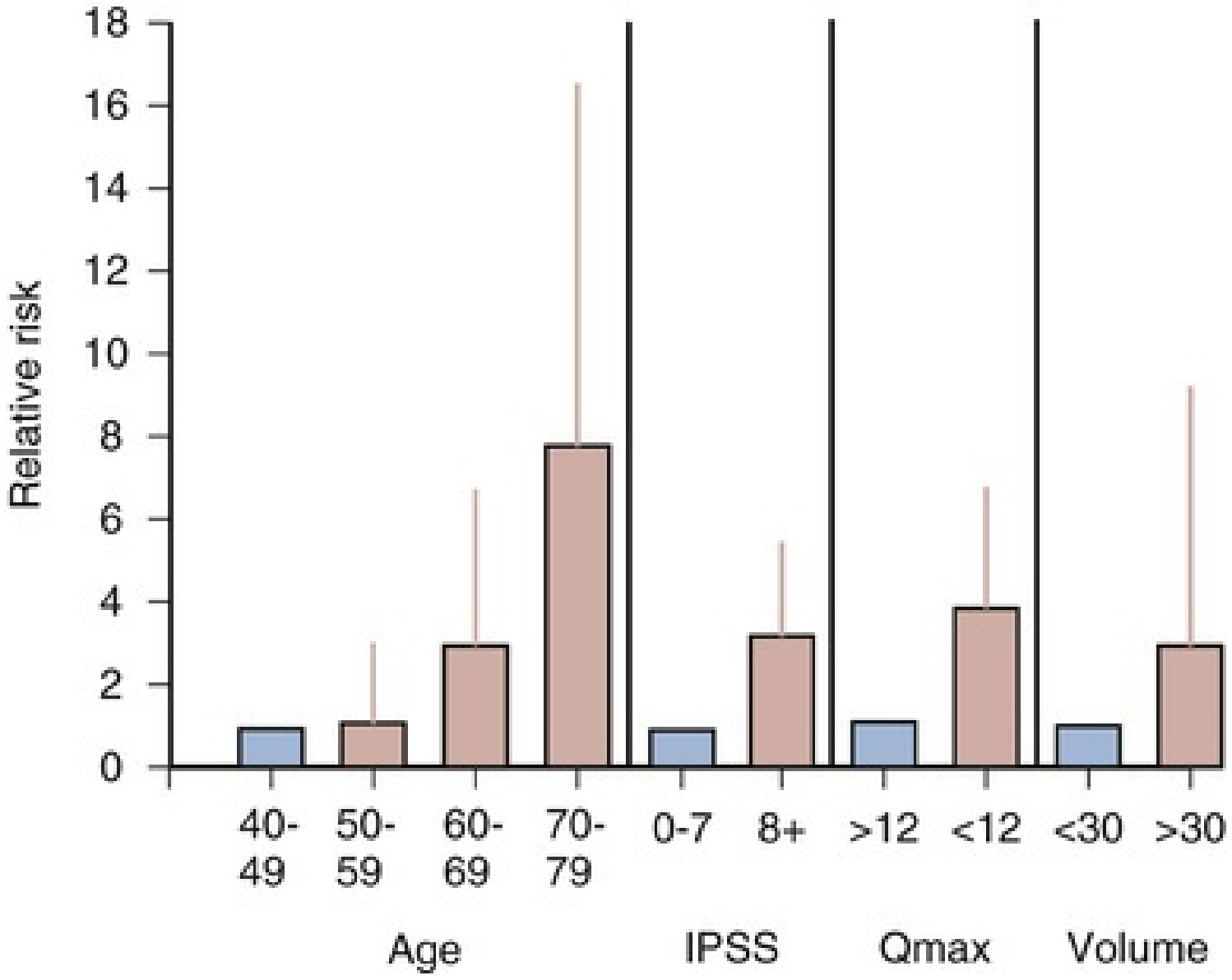

FIG. 144.23 Relative risk of acute urinary retention in Olmsted County Study of Urinary Symptoms and Health Status Among Men by age, symptom severity, peak flow rate, and prostate volume. The shaded column represents the baseline and a relative risk of 1.0; the vertical line represents the 95% confidence interval. *IPSS,* International Prostate Symptom Score. (Data from Jacobsen SJ, Jacobson DJ, Girman CJ, et al. Natural history of prostatism: risk factors for acute urinary retention. *J Urol* 158[2]:481–487, 1997.)

Prostate Volume and Serum PSA.

Although age in community-dwelling men is an important risk factor, in a BPH trial population of men who already are diagnosed with BPH, other factors can be analyzed. In the placebo groups of three 2-year studies (Marberger et al., 2000) and a 4-year study (PLESS) prostate volume, serum PSA, and symptom severity all were predictors of AUR episodes (Kaplan et al., 2000; McConnell et al., 1998; Roehrborn et al., 2000a).

The incidence increased from 5.6% to 7.7% in men with a serum PSA less

than 1.4 ng/mL from mild to severe symptoms, and from 7.8% to 10.2% for those with a serum PSA greater than 1.4 ng/mL over 4 years in the PLESS (Kaplan et al., 2000). In the 2-year studies, the rate of AUR was eightfold higher in those with a serum PSA greater than 1.4 ng/mL (0.4 vs. 3.9%) and threefold higher if the prostate volume was greater than 40 mL (1.6 vs. 4.2%) (Marberger et al., 2000; Roehrborn, 2001). **A detailed analysis showed a near linear increase in risk for AUR with increasing thresholds of serum PSA (**Fig. 144.24**) in the PLESS, an observation that applies to both spontaneous and precipitated AUR** (Roehrborn et al., 1999b)**. The risk for both types of AUR increases with increasing serum PSA and prostate volume stratified by tertiles (Fig. 144.25).** Similar observations were made in the MTOPS, where the risk for AUR increased with increasing prostate volume and increasing baseline serum PSA (Fig. 144.26), **and in the 2-year phase III studies comparing dutasteride with placebo** (Roehrborn et al., 2002)**. An analysis of more than 100 possible outcome predictors alone or in combination revealed a combination of serum PSA, urinating more than every 2 hours, symptom problem index, maximum urinary flow rate, and hesitancy as being only slightly superior to PSA alone in predicting AUR episodes** (Roehrborn et al., 2001).

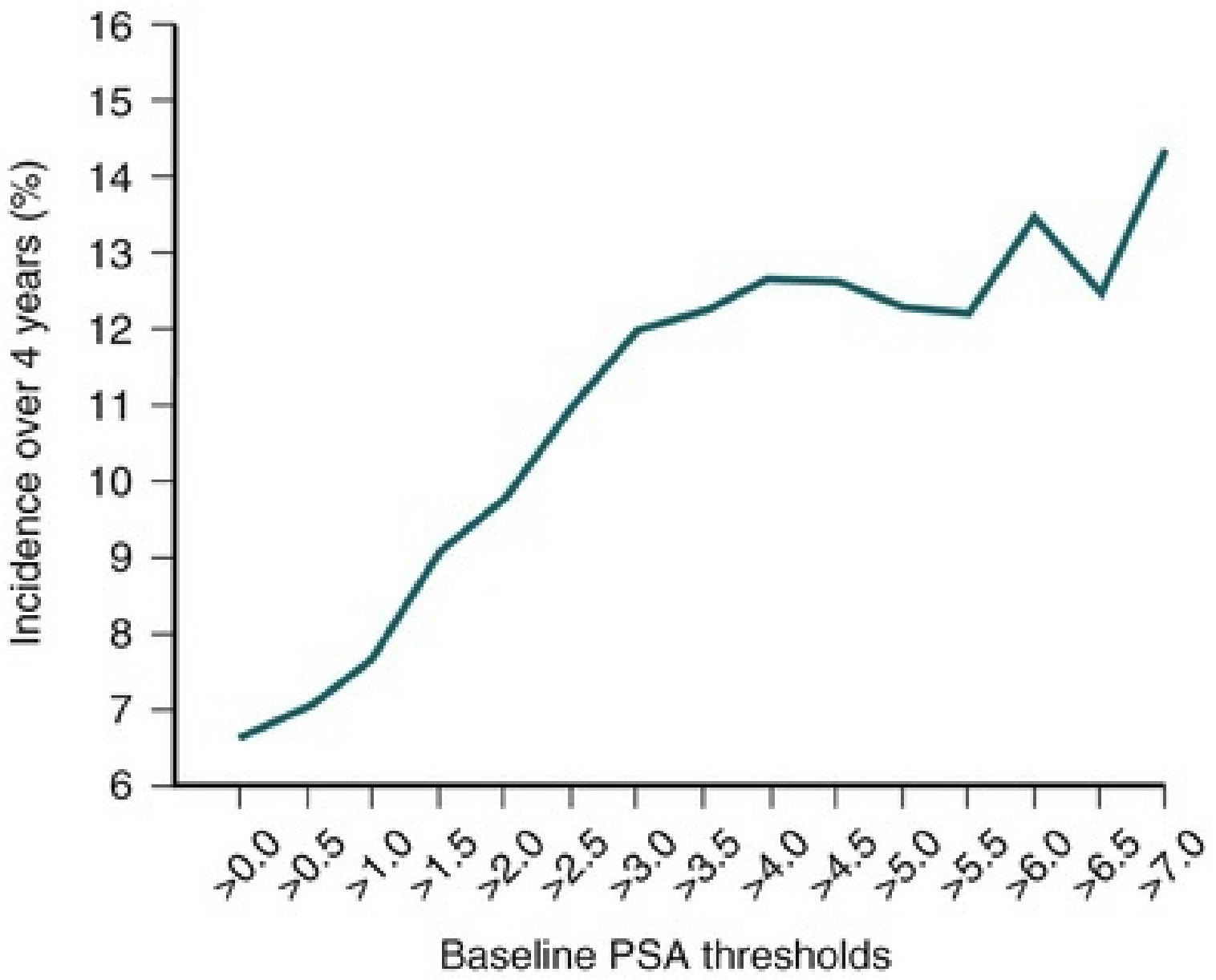

FIG. 144.24 Incidence of spontaneous or precipitated acute urinary retention in the Proscar Long-Term Efficacy and Safety Study over 4 years stratified by increasing thresholds of serum prostate-specific antigen *(PSA)* at baseline. (From Roehrborn CG, McConnell JD, Lieber M, et al. Serum

prostate-specific antigen concentration is a powerful predictor of acute urinary retention and need for surgery in men with clinical benign prostatic hyperplasia. PLESS Study Group. *Urology* 53[3]:473–480, 1999.)

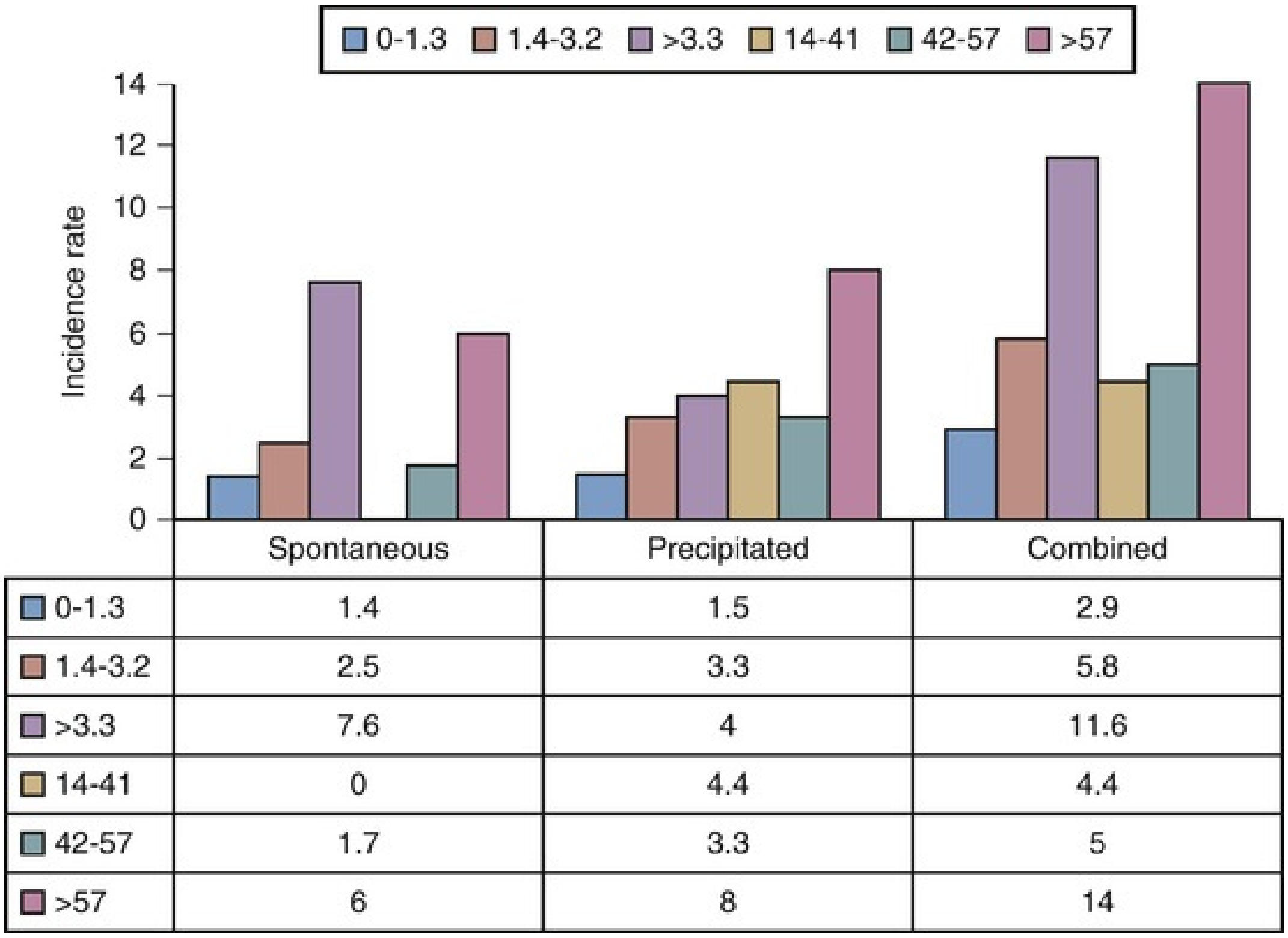

	Spontaneous	Precipitated	Combined
🟦 0-1.3	1.4	1.5	2.9
🟫 1.4-3.2	2.5	3.3	5.8
🟪 >3.3	7.6	4	11.6
🟨 14-41	0	4.4	4.4
🟩 42-57	1.7	3.3	5
🟥 >57	6	8	14

FIG. 144.25 Spontaneous, precipitated, or combined acute urinary retention incidence over 4 years in the Proscar Long-Term Efficacy and Safety Study stratified by tertiles of serum prostate-specific antigen or prostate volume at baseline. (From Roehrborn CG, McConnell JD, Lieber M, et al. Serum prostate-specific antigen concentration is a powerful predictor of acute urinary retention and need for surgery in men with clinical benign prostatic hyperplasia. PLESS Study Group. *Urology* 53[3]:473–480, 1999.)

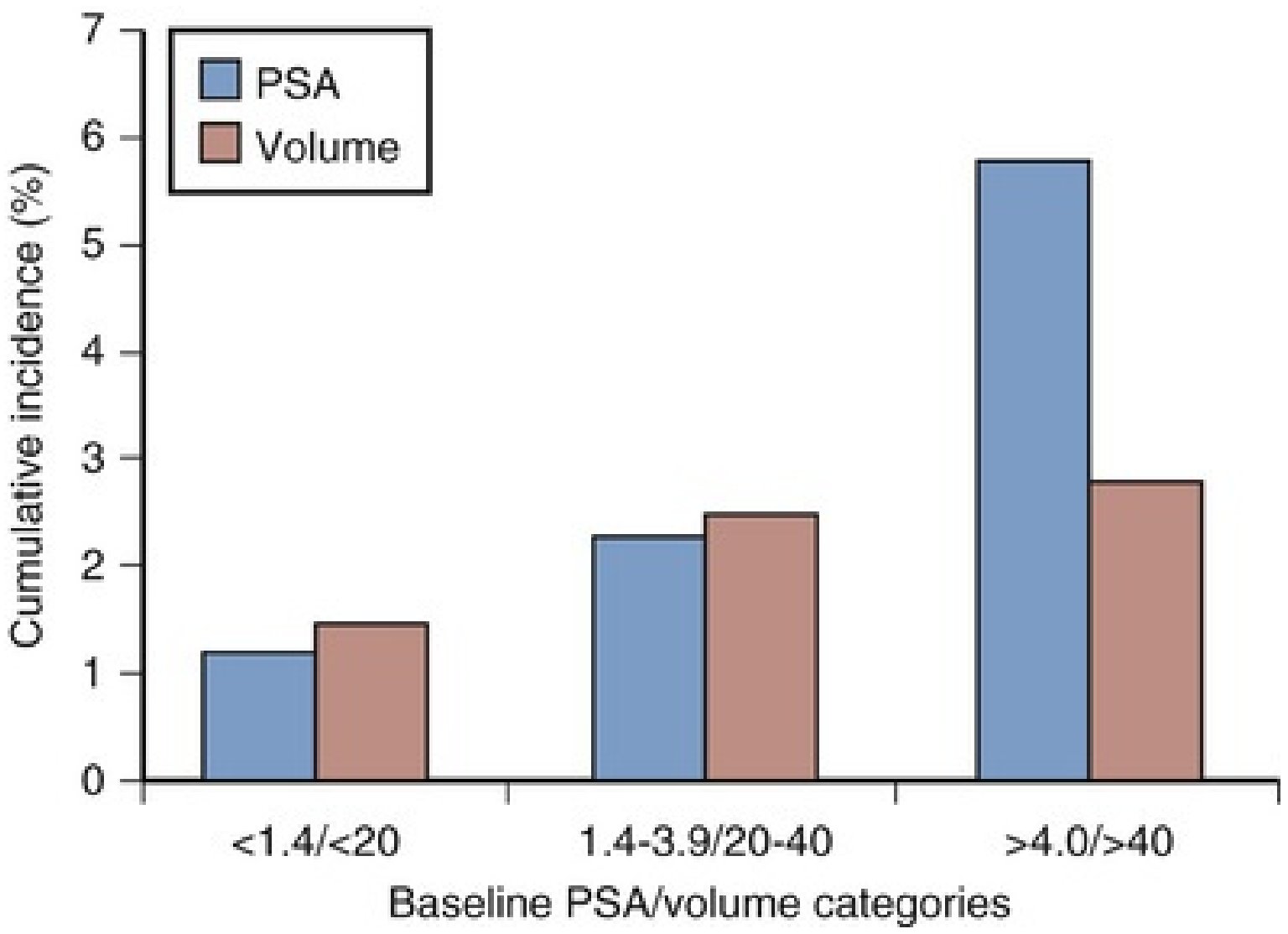

FIG. 144.26 Cumulative incidence of acute urinary retention in placebo-treated patients in the Medical Therapy of Prostatic Symptoms study stratified by baseline prostate volume *(yellow)* and baseline serum prostate-specific antigen *(PSA) (orange).* (From Roehrborn CG, McConnell JD, Lieber M, et al. Serum prostate-specific antigen concentration is a powerful predictor of acute urinary retention and need for surgery in men with clinical benign prostatic hyperplasia. PLESS Study Group. *Urology* 53[3]:473–480, 1999.)

Surgery for Benign Prostatic Hyperplasia

Both surgery and AUR represent distinct endpoints in the disease progression of BPH. There are, however, distinct differences. AUR is an outcome mandating management, and surgery is one of the commonly employed management styles. AUR is probably one of the clearer indications for surgery, leaving the treating physician little choice in a patient who failed a trial without catheter (TWOC). However, most patients undergo surgery for symptoms, not for AUR (Holtgrewe et al., 1989)**. Depending on local practice pattern, AUR accounts for 5% to over 30% of the indications for surgery. AUR can be compared with a bone fracture. It is impossible for the physician in his or her interaction with the patient to increase or decrease the probability for this outcome to occur. Furthermore, once it has occurred, no interaction or consultation can undo it. In contrast, it is easy to see how patients can be influenced in their decision to undergo surgery by the consultation with the physician. The interaction style, the quoted probabilities of beneficial and harmful outcomes to occur, and many other factors cause considerable variability in the incidence rates of prostate-related surgery, an observation that caused the AHCPR to develop guidelines for the treatment of BPH** (Wennberg et al., 1988). This situation is similar to myocardial infarction (MI) and coronary artery bypass grafting (CABG). The analytical epidemiology of MI is well understood, and risk factors are characterized. Not all MIs result in CABG, and in fact CABG is frequently performed for other indications than a recent MI. Consequently, there is abundant literature focusing on the geographic variation in the usage of CABG. **From this brief discussion, it becomes clear that surgery for BPH is a softer endpoint from an epidemiologic point of view than AUR, and data on rates of prostatectomy need to be interpreted in light of variation in its use, from provider to provider, region to region, health care plan to health care plan, and over time.**

Of all prostate surgeries, TURP and laser ablation of the prostate are still clearly the most common procedures and the best studied ones. Cross-sectional descriptive data on incidence rates are available from the Medicare database. Although in 1962 TURP constituted over 50% of all major surgeries performed by American urologists, this number dropped to 38% by 1986 (Holtgrewe et al., 1989; Mebust et al., 1989). Although the number of TURPs performed on

Medicare patients declined from an all-time peak of 258,000 in 1987 to 168,000 in 1993 (a reduction of 34%), it remains second only to cataract surgery on the list of Medicare's most costly surgical procedures. A 20% sample of Medicare beneficiaries was examined to further specify rates of TURP in the United States. In 1990, the rates of TURP (including all indications) were approximately 25, 19, and 13 per 1000 for men older than 75, 70 to 74, and 65 to 69 years of age, respectively. The 30-day mortality rate after TURP for the treatment of BPH decreased from 1.20% in 1984 to 0.77% in 1990 (Lu-Yao et al., 1994). **Compared with 1984 to 1990, age-adjusted rates of TURP for BPH during 1991 to 1997 declined further by approximately 50% for white men (14.6 to 6.72/1000) and 40% for black men (11.8 to 6.58/1000)** (Wasson et al., 2000). Medicare databases are only relevant to those men older than 65 years of age who are enrolled in Medicare, and therefore are less interesting from a longitudinal epidemiologic point of view.

Older series on the natural history of BPH such as the one reported by Craigen et al. projected somewhat unrealistic estimates of 35% incidence of prostatectomy at 1 year and 45% at 7 years (Craigen et al., 1969). Diokno reported an annual incidence rate of 2.6% and 3.3% for years 1 and 2 in his cohort of men followed longitudinally (Diokno et al., 1992). Frequency, hesitancy, straining, and an interrupted stream were all associated with increased risk.

The first study of substantial quality reporting on incidence rates and risk factors of prostate surgery was the Baltimore Longitudinal Study of Aging (BLSA) (Arrighi et al., 1990, 1991; Guess et al., 1990). More than 1000 men were followed for 30 years with yearly symptom assessments, questionnaires, and examinations. **Age, incomplete emptying, change in size, and force of stream were all independently associated with the risk for prostate surgery, as was a reportedly enlarged prostate by DRE.** Of 464 men without risk factors, only 3% required surgery during follow-up. For men with one risk factor, the cumulative incidence was 9%, with two risk factors 16%, and with three risk factors even 37%. In a similar study, namely the VA Normative Aging Study, nocturia and hesitancy emerged as independent predictors of surgery in 1868 men 49 to 68 years of age followed for more than 20 years (Hindley et al., 2001). Age and five LUTS (dysuria, incontinence, trouble initiating flow, nocturia, and slow stream) were associated with the risk for surgery in 16,219 men older than 40 years of age enrolled in the Kaiser Permanente Health Plan in California, of whom 1027 men underwent prostatectomy over 12 years of follow-up (Sidney et al., 1991a,b).

In the VA Cooperative trial comparing surgery with watchful waiting, 65 of 276 (24%) patients assigned to watchful waiting crossed over to surgery within 3 years of follow-up, of which 20 met predefined endpoints (azotemia, high residuals, incontinence, or high symptom scores). High baseline bother score was a strong predictor of requiring surgery (Wasson et al., 1995).

The probability of undergoing surgery over 4 years increased from 10% in men diagnosed with BPH who had mild symptoms to 24% in those with moderate symptoms and 39% in those with severe symptoms at baseline, as reported in a natural history and observation study (Barry et al., 1997).

The Olmsted County Study and the placebo-treated patients from the PLESS provide additional insight into the risk factors for undergoing prostate surgery in either community-dwelling men or men enrolled in a BPH treatment trial.

In the Olmsted County study during more than 10,000 person-years of follow-up, 167 men were treated, yielding an overall incidence of 16.0/1000 person-years. There was a strong age-related increase in risk for any treatment from 3.3/1000 person-years for men 40 to 49 years of age to more than 30/1000 person-years for those 70 years of age or older. Men with moderate to severe symptoms, depressed peak urinary flow rates (< 12 mL/sec), enlarged prostate (>30 mL), or elevated serum PSA (≥1.4 ng/mL) had about four times the risk for BPH treatment than those who did not. After adjustment for all measures simultaneously, an enlarged prostate (HR 2.3, 95% CI, 1.1 to 4.7), depressed peak flow rate (HR 2.7, 95% CI, 1.4 to 5.3), and moderate to severe symptoms (HR 5.3, 95% CI, 2.5 to 11.1) at baseline each independently predicted subsequent treatment. Overall nearly 1 in 4 men received treatment in the eighth decade of life. **These data suggest that men with moderate to severe LUTS, impaired flow rate, or enlarged prostate are more likely to undergo treatment, with increases in risk for similar magnitude to those associated with adverse outcomes such as AUR** (Jacobsen et al., 1999).

Over 1500 patients with moderate LUTS and enlarged prostate glands were followed in the PLESS on placebo for 4 years. Of these, 10% or 2.5% per year underwent surgery for BPH (McConnell et al., 1998). Although the hazard of undergoing surgery was linear (i.e., it remained constant throughout the duration of the study), it was different when patients were stratified by either prostate volume or serum PSA in tertiles at the beginning of the study (Fig. 144.27). **Similar to the incidence of AUR, the rates of surgery increased from 6.2% to 14.6% for patients in the lowest to the highest PSA tertile, and from 6.7%**

to 14.0% from the lowest to the highest prostate volume tertile. In the MTOPS, the incidence of invasive therapy for BPH in the placebo group increased equally nearly linearly when stratifying by baseline serum PSA or prostate volume (Fig. 144.28) (McConnell et al., 2003).

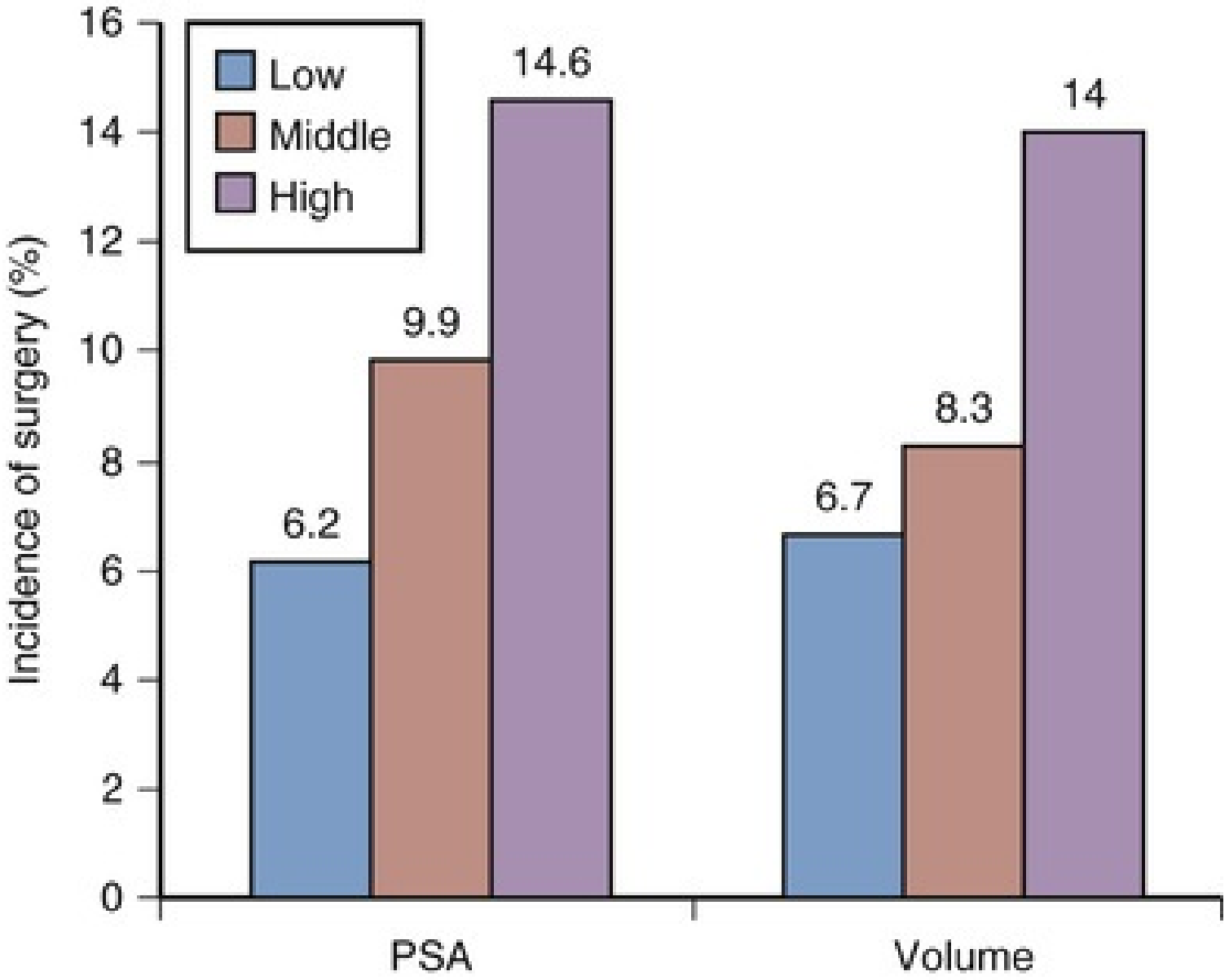

FIG. 144.27 Incidence of surgery stratified by tertiles of serum prostate-specific antigen *(PSA)* and prostate volume in placebo-treated patients in the Proscar Long-Term Efficacy and Safety Study. (From Roehrborn CG, McConnell JD, Lieber M, et al. Serum prostate-specific antigen concentration is a powerful predictor of acute urinary retention and need for surgery in men with clinical benign prostatic hyperplasia. PLESS Study Group. *Urology* 53[3]:473–480, 1999.)

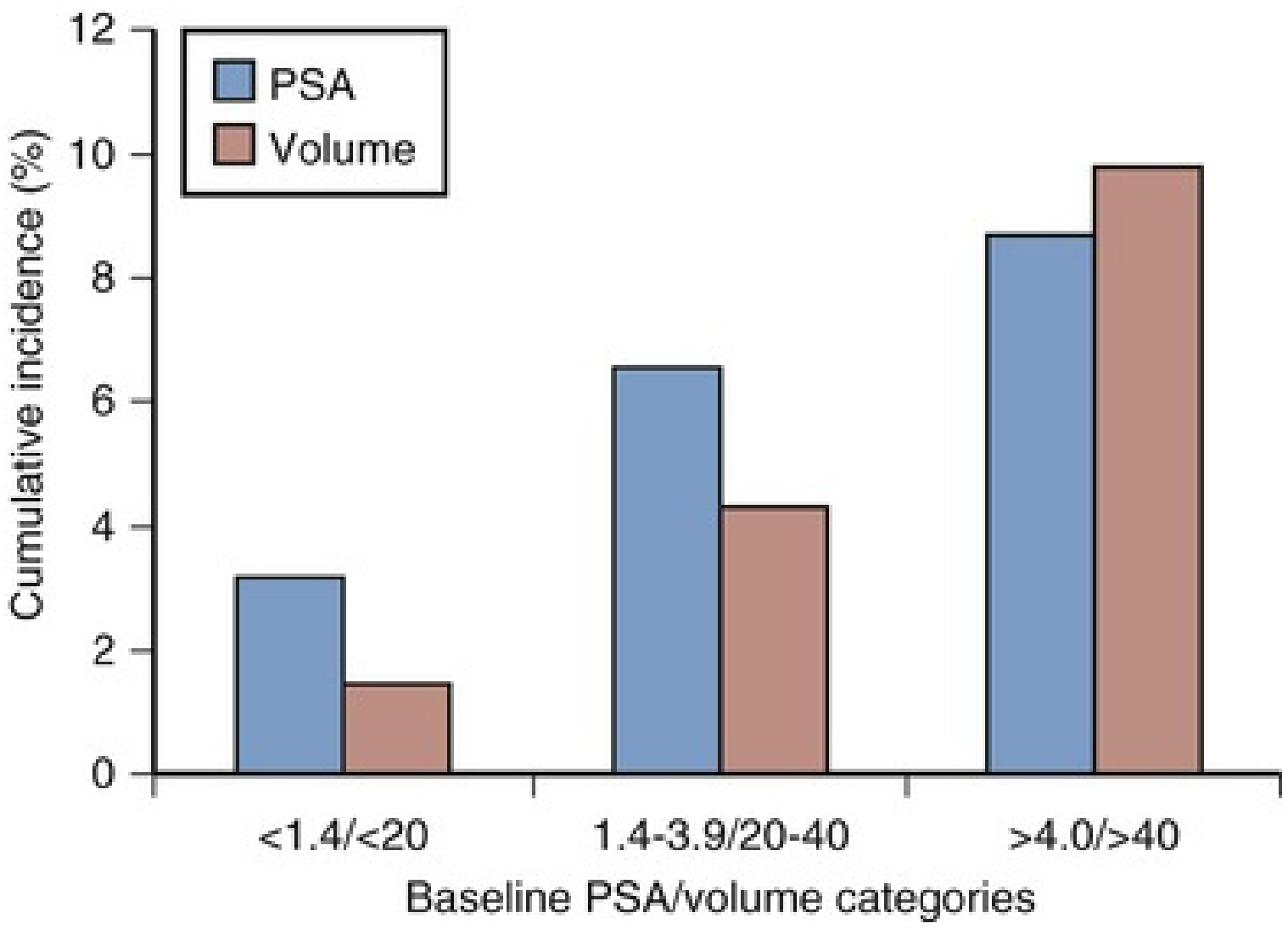

FIG. 144.28 Cumulative incidence of invasive therapy (surgery) for benign prostatic hyperplasia in placebo-treated patients in the Medical Therapy of Prostatic Symptoms study stratified by baseline prostate volume *(red)* and baseline serum prostate-specific antigen (PSA) *(blue).* (From Roehrborn CG, McConnell JD, Lieber M, et al. Serum prostate-specific antigen concentration is a powerful predictor of acute urinary retention and need for surgery in men with clinical benign prostatic hyperplasia. PLESS Study Group. *Urology* 53[3]:473–480, 1999.)

Key Points

- The autopsy prevalence of BPH increases linearly starting at 40 years of age and is remarkably similar across cultures and ethnicities.
- Cross-sectional studies suggest increases in LUTS severity, frequency, bother, and quality-of-life impairment with age that are fundamentally similar in all societies studied.
- Analytical studies have failed to reveal significant risk factors for the development of BPH and LUTS.
- The natural history of BPH in individual patients is highly variable measured primarily by prostate volume growth
- Interindividual variability is also noted in secondary physiologic measures such as urinary flow and residual urine, and the development of complication and the risk for urinary retention and the need for surgery
- There are certain baseline factors allowing an assessment of risk for volume

growth, progression and risk for complications.

Suggested Readings

Abrams P. Objective evaluation of bladder outlet obstruction [review]. *Br J Urol*. 1995;76(Suppl 1):11–15.

Abrams P, Cardozo L, Fall M, et al. The standardisation of terminology in lower urinary tract function: report from the standardisation sub-committee of the International Continence Society. *Urology*. 2003;61(1):37–49.

Abrams PH, Farrar DJ, Turner-Warwick RT, et al. The results of prostatectomy: a symptomatic and urodynamic analysis of 152 patients. *J Urol*. 1979;121(5):640–642.

American Urological Association Practice Guidelines Committee. AUA guideline on management of benign prostatic hyperplasia. Chapter 1: diagnosis and treatment recommendations. *J Urol*. 2003;170(2 Pt 1):530–547.

Andriole G, Bruchovsky N, Chung LW, et al. Dihydrotestosterone and the prostate: the scientific rationale for 5alpha-reductase inhibitors in the treatment of benign prostatic hyperplasia. *J Urol*. 2004;172(4 Pt 1):1399–1403.

Arrighi HM, Guess HA, Metter EJ, et al. Symptoms and signs of prostatism as risk factors for prostatectomy. *Prostate*. 1990;16(3):253–261.

Arrighi HM, Metter EJ, Guess HA, et al. Natural history of benign prostatic hyperplasia and risk of prostatectomy. *Urology*. 1991;38(1 Suppl):4–8.

Barry MJ, Cockett AT, Holtgrewe HL, et al. Relationship of symptoms of prostatism to commonly used physiological and anatomical measures of the severity of benign prostatic hyperplasia. *J Urol*. 1993;150(2 Pt 1):351–358.

Barry MJ, Fowler FJ Jr, O'Leary MP, et al. The American Urological Association symptom index for benign prostatic hyperplasia. The Measurement Committee of the American

Urological Association. *J Urol*. 1992;148(5):1549–1557 [discussion 1564].

Barry MJ, Williford WO, Chang Y, et al. Benign prostatic hyperplasia specific health status measures in clinical research: how much change in the American Urological Association symptom index and the benign prostatic hyperplasia impact index is perceptible to patients? [see comments]. *J Urol*. 1995;154(5):1770–1774.

Berry SJ, Coffey DS, Walsh PC, et al. The development of human benign prostatic hyperplasia with age. *J Urol*. 1984;132(3):474–479.

Berry SJ, Coffey DS, Strandberg JD, et al. Effect of age, castration, and testosterone replacement on the development and restoration of canine benign prostatic hyperplasia. *Prostate*. 1986;9(3):295–302.

Berry SJ, Coffey DS, Ewing LL. Effects of aging on prostate growth in beagles. *Am J Physiol*. 1986;250(6 Pt 2):R1039–R1046.

Boyle P, Maisonneuve P, Steg A. Decrease in mortality from benign prostatic hyperplasia: a major unheralded health triumph [see comments]. *J Urol*. 1996;155(1):176–180.

Boyle P, Robertson C, Mazzetta C, et al. The association between lower urinary tract symptoms and erectile dysfunction in four centres: the UrEpik study. *BJU Int*. 2003;92(7):719–725.

Bruskewitz RC, Iversen P, Madsen PO. Value of postvoid residual urine determination in evaluation of prostatism. *Urology*. 1982;20(6):602–604.

Chapple CR, Wein AJ, Abrams P, et al. Lower urinary tract symptoms revisited: a broader clinical perspective. *Eur Urol*. 2008;54(3):563–569.

Cunha GR. Role of mesenchymal-epithelial interactions in normal and abnormal development of the mammary gland

and prostate [review]. *Cancer*. 1994;74(3):1030–1044.

Cunha GR, Chung LW, Shannon JM, et al. Hormone-induced morphogenesis and growth: role of mesenchymal-epithelial interactions. *Recent Prog Horm Res*. 1983;39:559–598.

Flanigan RC, Reda DJ, Wasson JH, et al. 5-Year outcome of surgical resection and watchful waiting for men with moderately symptomatic benign prostatic hyperplasia: a Department of Veterans Affairs cooperative study. *J Urol*. 1998;160(1):12–16 [discussion 16–17].

Garraway WM, Armstrong C, Auld S, et al. Follow-up of a cohort of men with untreated benign prostatic hyperplasia. *Eur Urol*. 1993;24(3):313–318.

Girman CJ. Natural history and epidemiology of benign prostatic hyperplasia: relationship among urologic measures. *Urology*. 1998;51(Suppl 4A):8–12.

Girman CJ, Epstein RS, Jacobsen SJ, et al. Natural history of prostatism: impact of urinary symptoms on quality of life in 2115 randomly selected community men. *Urology*. 1994;44(6):825–831.

Girman CJ, Jacobsen SJ, Guess HA, et al. Natural history of prostatism: relationship among symptoms, prostate volume and peak urinary flow rate. *J Urol*. 1995;153(5):1510–1515.

Girman CJ, Jacobsen SJ, Tsukamoto T, et al. Health-related quality of life associated with lower urinary tract symptoms in four countries. *Urology*. 1998;51(3):428–436.

Glynn RJ, Campion EW, Bouchard GR, et al. The development of benign prostatic hyperplasia among volunteers in the normative aging study. *Am J Epidemiol*. 1985;121(1):78–90.

Gormley GJ, Stoner E, Bruskewitz RC, et al. The effect of finasteride in men with benign prostatic hyperplasia. The Finasteride Study Group [see comments]. *N Engl J Med*. 1992;327(17):1185–1191.

Gosling JA, Dixon JS. Structure of trabeculated detrusor smooth muscle in cases of prostatic hypertrophy. *Urol Int*. 1980;35(5):351–355.

Gosling JA, Gilpin SA, Dixon JS, et al. Decrease in the autonomic innervation of human detrusor muscle in outflow obstruction. *J Urol*. 1986;136(2):501–504.

Holtgrewe HL, Mebust WK, Dowd JB, et al. Transurethral prostatectomy: practice aspects of the dominant operation in American urology. *J Urol*. 1989;141(2):248–253.

Irwin DE, Milsom I, Hunskaar S, et al. Population-based survey of urinary incontinence, overactive bladder, and other lower urinary tract symptoms in five countries: results of the EPIC study. *Eur Urol*. 2006;50(6):1306–1314 [discussion 1314–1315].

Isaacs JT. Prostate stem cells and benign prostatic hyperplasia. *Prostate*. 2008;68(9):1025–1034.

Jacobsen SJ, Jacobson DJ, Rohe DE, et al. Frequency of sexual activity and prostatic health: fact or fairy tale? *Urology*. 2003;61(2):348–353.

Kaplan SA, Wein AJ, Staskin DR, et al. Urinary retention and post-void residual urine in men: separating truth from tradition. *J Urol*. 2008;180(1):47–54.

Kramer G, Mitteregger D, Marberger M. Is benign prostatic hyperplasia (BPH) an immune inflammatory disease? *Eur Urol*. 2007;51(5):1202–1216.

Kyprianou N, Tu H, Jacobs SC. Apoptotic versus proliferative activities in human benign prostatic hyperplasia. *Hum Pathol*. 1996;27(7):668–675.

Lepor H, Tang R, Shapiro E. The alpha-adrenoceptor subtype mediating the tension of human prostatic smooth muscle. *Prostate*. 1993;22(4):301–307.

Lu-Yao GL, Barry MJ, Chang CH, et al. Transurethral resection of the prostate among Medicare beneficiaries in the United States: time trends and outcomes. Prostate Patient Outcomes

Research Team (PORT). *Urology*. 1994;44(5):692–698 [discussion 698–699].

Marberger M, Roehrborn CG, Marks LS, et al. Relationship among serum testosterone, sexual function, and response to treatment in men receiving dutasteride for benign prostatic hyperplasia. *J Clin Endocrinol Metab*. 2006;91(4):1323–1328.

McConnell JD, Barry MJ, Bruskewitz RC. Benign prostatic hyperplasia: diagnosis and treatment. Agency for Health Care Policy and Research. *Clin Pract Guidel Quick Ref Guide Clin*. 1994;8:1–17.

McConnell JD, Bruskewitz R, Walsh P, et al. The effect of finasteride on the risk of acute urinary retention and the need for surgical treatment among men with benign prostatic hyperplasia. Finasteride Long-Term Efficacy and Safety Study Group. *N Engl J Med*. 1998;338(9):557–563.

McConnell JD, Roehrborn C, Bautista OM, et al. The long-term effects of doxazosin, finasteride and the combination on the clinical progression of benign prostatic hyperplasia. *N Engl J Med*. 2003;349(25):2385–2396.

McNeal J. Pathology of benign prostatic hyperplasia: insight into etiology [review]. *Urol Clin North Am*. 1990;17(3):477–486.

McVary KT. Erectile dysfunction and lower urinary tract symptoms secondary to BPH. *Eur Urol*. 2005;47(6):838–845.

Mebust WK, Holtgrewe HL, Cockett AT, et al. Transurethral prostatectomy: immediate and postoperative complications: a cooperative study of 13 participating institutions evaluating 3,885 patients. *J Urol*. 1989;141(2):243–247.

Nordling J. The aging bladder—a significant but underestimated role in the development of lower urinary tract symptoms. *Exp Gerontol*. 2002;37(8–9):991–999.

Oishi K, Boyle P, Barry M, et al. Epidemiology and natural history of benign prostatic hyperplasia. *4th International consultation on benign prostatic hyperplasia*. Plymbridge Distributors Ltd: Plymouth (UK); 1988:23–59.

Parsons JK. Modifiable risk factors for benign prostatic hyperplasia and lower urinary tract symptoms: new approaches to old problems. *J Urol*. 2007;178(2):395–401.

Partin AW, Oesterling JE, Epstein JI, et al. Influence of age and endocrine factors on the volume of benign prostatic hyperplasia. *J Urol*. 1991;145(2):405–409.

Partin AW, Page WF, Lee BR, et al. Concordance rates for benign prostatic disease among twins suggest hereditary influence. *Urology*. 1994;44(5):646–650.

Roehrborn CG, Lange JL, George FW, et al. Changes in amount and intracellular distribution of androgen receptor in human foreskin as a function of age. *J Clin Invest*. 1987;79(1):44–47.

Roehrborn CG, Boyle P, Bergner D, et al. Serum prostate-specific antigen and prostate volume predict long-term changes in symptoms and flow rate: results of a four-year, randomized trial comparing finasteride versus placebo. PLESS Study Group. *Urology*. 1999;54(4):662–669.

Roehrborn CG, Boyle P, Gould AL, et al. Serum prostate-specific antigen as a predictor of prostate volume in men with benign prostatic hyperplasia. *Urology*. 1999;53(3):581–589.

Roehrborn CG, Bruskewitz R, Nickel GC, et al. Urinary retention in patients with BPH treated with finasteride or placebo over 4 years: characterization of patients and ultimate outcomes. The PLESS Study Group. *Eur Urol*. 2000;37(5):528–536.

Roehrborn CG, McConnell JD, Lieber M, et al. Serum prostate-specific antigen concentration is a powerful predictor of acute urinary retention and need for surgery in men with clinical benign prostatic hyperplasia. PLESS Study Group. *Urology*.

1999;53(3):473–480.

Roehrborn CG, Schwinn DA. Alpha1-adrenergic receptors and their inhibitors in lower urinary tract symptoms and benign prostatic hyperplasia. *J Urol*. 2004;171(3):1029–1035.

Rosen R, Altwein J, Boyle P, et al. Lower urinary tract symptoms and male sexual dysfunction: the multinational survey of the aging male (MSAM-7). *Eur Urol*. 2003;44(6):637–649.

Rosen RC, Coyne KS, Henry D, et al. Beyond the cluster: methodological and clinical implications in the Boston Area Community Health survey and EPIC studies. *BJU Int*. 2008;101(10):1274–1278.

Russell DW, Wilson JD. Steroid 5 alpha-reductase: two genes/two enzymes. *Annu Rev Biochem*. 1994;63:25–61.

Sagnier PP, Girman CJ, Garraway M, et al. International comparison of the community prevalence of symptoms of prostatism in four countries. *Eur Urol*. 1996;29(1):15–20.

Sech SM, Montoya JD, Bernier PA, et al. The so-called “placebo effect” in benign prostatic hyperplasia treatment trials represents partially a conditional regression to the mean induced by censoring. *Urology*. 1998;51(2):242–250.

Sherwood JB, McConnell JD, Vazquez DJ, et al. Heterogeneity of 5 alpha-reductase gene expression in benign prostatic hyperplasia. *J Urol*. 2003;169(2):575–579.

Steers WD, Ciambotti J, Erdman S, et al. Morphological plasticity in efferent pathways to the urinary bladder of the rat following urethral obstruction. *J Neurosci*. 1990;10(6):1943–1951.

Walsh PC, Hutchins GM, Ewing LL. Tissue content of dihydrotestosterone in human prostatic hyperplasia is not supernormal. *J Clin Invest*. 1983;72(5):1772–1777.

Walsh PC, Wilson JD. The induction of prostatic hypertrophy in the dog with androstanediol. *J Clin Invest*. 1976;57(4):1093–

1097.

Wang W, Bergh A, Damber JE. Chronic inflammation in benign prostate hyperplasia is associated with focal upregulation of cyclooxygenase-2, Bcl-2, and cell proliferation in the glandular epithelium. *Prostate*. 2004;61(1):60–72.

Wang Z, Tufts R, Haleem R, et al. Genes regulated by androgen in the rat ventral prostate. *Proc Natl Acad Sci USA*. 1997;94(24):12999–13004.

Wasson JH, Bubolz TA, Lu-Yao GL, et al. Transurethral resection of the prostate among Medicare beneficiaries: 1984 to 1997. For the Patient Outcomes Research Team for Prostatic Diseases. *J Urol*. 2000;164(4):1212–1215.

Wasson JH, Reda DJ, Bruskewitz RC, et al. A comparison of transurethral surgery with watchful waiting for moderate symptoms of benign prostatic hyperplasia. The Veterans Affairs Cooperative Study Group on Transurethral Resection of the Prostate. *N Engl J Med*. 1995;332(2):75–79.

Wein AJ, Coyne KS, Tubaro A, et al. The impact of lower urinary tract symptoms on male sexual health: EpiLUTS. *BJU Int*. 2009;103(Suppl 3):33–41.

Wennberg JE, Mulley AG Jr, Hanley D, et al. An assessment of prostatectomy for benign urinary tract obstruction: geographic variations and the evaluation of medical care outcomes. *JAMA*. 1988;259(20):3027–3030.

Yang G, Timme TL, Park SH, et al. Transforming growth factor beta 1 transduced mouse prostate reconstitutions: II. Induction of apoptosis by doxazosin. *Prostate*. 1997;33(3):157–163.

Zucchetto A, Tavani A, Dal Maso L, et al. History of weight and obesity through life and risk of benign prostatic hyperplasia. *Int J Obes (Lond)*. 2005;29(7):798–803.

References

Abbou CC, Colombel M, Payan C, et al. The efficacy of microwave induced hyperthermia in the treatment of BPH: the Paris Public Hospitals' experience. Kurth KH, Newling DWW. *Benign prostatic hyperplasia. recent progress in clinical research and practice*. Wiley-Liss: New York, NY; 1994:449–454.

Abrams P. Objective evaluation of bladder outlet obstruction. [Review]. *Br J Urol*. 1995;76(Suppl 1):11–15.

Abrams P, Cardozo L, Fall M, et al. The standardisation of terminology in lower urinary tract function: report from the standardisation sub-committee of the International Continence Society. *Urology*. 2003;61(1):37–49.

Abrams PH, Farrar DJ, Turner-Warwick RT, et al. The results of prostatectomy: a symptomatic and urodynamic analysis of 152 patients. *J Urol*. 1979;121(5):640–642.

Alarid ET, Rubin JS, Young P, et al. Keratinocyte growth factor functions in epithelial induction during seminal vesicle development. *Proc Natl Acad Sci USA*. 1994;91(3):1074–1078.

Altwein JE, Keuler FU. Benign prostatic hyperplasia and erectile dysfunction: a review. *Urol Int*. 1992;48(1):53–57.

American Urological Association Practice Guidelines Committee. AUA guideline on management of benign prostatic hyperplasia. Chapter 1: diagnosis and treatment recommendations. *J Urol*. 2003;170(2 Pt 1):530–547.

Andersen JT, Nickel JC, Marshall VR, et al. Finasteride significantly reduces acute urinary retention and need for surgery in patients with symptomatic benign prostatic hyperplasia. *Urology*. 1997;49(6):839–845.

Andriole G, Bruchovsky N, Chung LW, et al.

Dihydrotestosterone and the prostate: the scientific rationale for 5alpha-reductase inhibitors in the treatment of benign prostatic hyperplasia. *J Urol*. 2004;172(4 Pt 1):1399–1403.

Anglin IE, Glassman DT, Kyprianou N. Induction of prostate apoptosis by alpha1-adrenoceptor antagonists: mechanistic significance of the quinazoline component. *Prostate Cancer Prostatic Dis*. 2002;5(2):88–95.

Anjum I, Ahmed M, Azzopardi A, et al. Prostatic infarction/infection in acute urinary retention secondary to benign prostatic hyperplasia. *J Urol*. 1998;160(3 Pt 1):792–793.

Araki H, Watanabe H, Mishina T, et al. High-risk group for benign prostatic hypertrophy. *Prostate*. 1983;4(3):253–264.

Arrighi HM, Guess HA, Metter EJ, et al. Symptoms and signs of prostatism as risk factors for prostatectomy. *Prostate*. 1990;16(3):253–261.

Arrighi HM, Metter EJ, Guess HA, et al. Natural history of benign prostatic hyperplasia and risk of prostatectomy. *Urology*. 1991;38(1 Suppl):4–8.

Austin DC, Strand DW, Love HL, et al. NF-kappaB and androgen receptor variant 7 induce expression of SRD5A isoforms and confer 5ARI resistance. *Prostate*. 2016;76(11):1004–1018.

Austin DC, Strand DW, Love HL, et al. NF-kappaB and androgen receptor variant expression correlate with human BPH progression. *Prostate*. 2016;76(5):491–511.

Azadzoi KM. Effect of chronic ischemia on bladder structure and function. *Adv Exp Med Biol*. 2003;539(Pt A):271–280.

Azadzoi KM, Tarcan T, Kozlowski R, et al. Overactivity and structural changes in the chronically ischemic bladder. *J Urol*. 1999;162(5):1768–1778.

Azadzoi KM, Babayan RK, Kozlowski R, et al. Chronic ischemia increases prostatic smooth muscle contraction in the rabbit. *J Urol*. 2003;170(2 Pt 1):659–663.

Azadzoi KM, Radisavljevic ZM, Siroky MB. Effects of ischemia on tachykinin-containing nerves and neurokinin receptors in the rabbit bladder. *Urology*. 2008;71(5):979–983.

Badia X, Rodriguez F, Carballido J, et al. Influence of sociodemographic and health status variables on the American Urological Association symptom scores in patients with lower urinary tract symptoms. *Urology*. 2001;57(1):71–77.

Ball AJ, Feneley RC, Abrams PH. The natural history of untreated prostatism. *Br J Urol*. 1981;53(6):613–616.

Barnboym E, Ahrens A, Roehrborn CG. Effect of scrambling on the short-term reliability of the American Urological Association Symptom Index. *Urology*. 1999;53(3):568–573.

Barrack ER, Berry SJ. DNA synthesis in the canine prostate: effects of androgen and estrogen treatment. *Prostate*. 1987;10(1):45–56.

Barrack ER, Bujnovszky P, Walsh PC. Subcellular distribution of androgen receptors in human normal, benign hyperplastic, and malignant prostatic tissues: characterization of nuclear salt-resistant receptors. *Cancer Res*. 1983;43(3):1107–1116.

Barry MJ. Epidemiology and natural history of benign prostatic hyperplasia. *Urol Clin North Am*. 1990;17(3):495–507.

Barry MJ, Fowler FJ Jr, O'Leary MP, et al. The American Urological Association symptom index for benign prostatic hyperplasia. The Measurement Committee of the American Urological Association. *J Urol*. 1992;148(5):1549–1557 [discussion 1564].

Barry MJ, Fowler FJ Jr, O'Leary MP, et al. Correlation of the American Urological Association symptom index with self-administered versions of the Madsen-Iversen, Boyarsky and Maine Medical Assessment Program symptom indexes. Measurement Committee of the American Urological

Association. *J Urol*. 1992;148(5):1558–1563 [discussion 1564].

Barry MJ, Cockett AT, Holtgrewe HL, et al. Relationship of symptoms of prostatism to commonly used physiological and anatomical measures of the severity of benign prostatic hyperplasia. *J Urol*. 1993;150(2 Pt 1):351–358.

Barry MJ, Fowler FJ, Chang Y, et al. The American Urological Association symptom index: does mode of administration affect its psychometric properties? *J Urol*. 1995;154(3):1056–1059.

Barry MJ, Fowler FJ Jr, O'Leary MP, et al. Measuring disease-specific health status in men with benign prostatic hyperplasia. Measurement Committee of The American Urological Association. *Med Care*. 1995;33(4 Suppl):AS145–AS155.

Barry MJ, Girman CJ, O'Leary MP, et al. Using repeated measures of symptom score, uroflowmetry and prostate specific antigen in the clinical management of prostate disease. Benign Prostatic Hyperplasia Treatment Outcomes Study Group. *J Urol*. 1995;153(1):99–103.

Barry MJ, Williford WO, Chang Y, et al. Benign prostatic hyperplasia specific health status measures in clinical research: how much change in the American Urological Association symptom index and the benign prostatic hyperplasia impact index is perceptible to patients? [see comments]. *J Urol*. 1995;154(5):1770–1774.

Barry MJ, Fowler FJ Jr, Bin L, et al. A nationwide survey of practicing urologists: current management of benign prostatic hyperplasia and clinically localized prostate cancer. *J Urol*. 1997;158(2):488–491 [discussion 492].

Barry MJ, Fowler FJ Jr, Bin L, et al. The natural history of patients with benign prostatic hyperplasia as diagnosed by North American urologists. *J Urol*. 1997;157(1):10–14

[discussion 14–15].

Bautista OM, Kusek JW, Nyberg LM, et al. Study design of the Medical Therapy of Prostatic Symptoms (MTOPS) trial. *Control Clin Trials*. 2003;24(2):224–243.

Bdesha AS, Bunce CJ, Snell ME, et al. A sham controlled trial of transurethral microwave therapy with subsequent treatment of the control group. *J Urol*. 1994;152(2 Pt 1):453–458.

Beck AD, Gaudin HJ. The measurement and significance of the urinary flow rate. *Aust N Z J Surg*. 1969;39(1):99–102.

Bedford MT, van Helden PD. Hypomethylation of DNA in pathological conditions of the human prostate. *Cancer Res*. 1987;47(20):5274–5276.

Begun FP, Story MT, Hopp KA, et al. Regional concentration of basic fibroblast growth factor in normal and benign hyperplastic human prostates. *J Urol*. 1995;153(3 Pt 1):839–843.

Benaim EA, Montoya JD, Saboorian MH, et al. Characterization of prostate size, PSA and endocrine profiles in patients with spinal cord injuries. *Prostate Cancer Prostatic Dis*. 1998;1(5):250–255.

Bennett HS, Baggenstoss AH, Butt HR. The testis, breast and prostate of men who die of cirrhosis of the liver. *Am J Clin Pathol*. 1950;20(9):814–828.

Berry SJ, Coffey DS, Walsh PC, et al. The development of human benign prostatic hyperplasia with age. *J Urol*. 1984;132(3):474–479.

Berry SJ, Coffey DS, Strandberg JD, et al. Effect of age, castration, and testosterone replacement on the development and restoration of canine benign prostatic hyperplasia. *Prostate*. 1986;9(3):295–302.

Berry SJ, Coffey DS, Ewing LL. Effects of aging on prostate growth in beagles. *Am J Physiol*. 1986;250(6 Pt 2):R1039–R1046.

Birkhoff JD, Wiederhorn AR, Hamilton ML, et al. Natural history of benign prostatic hypertrophy and acute urinary retention. *Urology*. 1976;7(1):48–52.

Blotnick S, Peoples GE, Freeman MR, et al. T lymphocytes synthesize and export heparin-binding epidermal growth factor-like growth factor and basic fibroblast growth factor, mitogens for vascular cells and fibroblasts: differential production and release by CD4+ and CD8+ T cells. *Proc Natl Acad Sci USA*. 1994;91(8):2890–2894.

Blute ML, Tomera KM, Hellerstein DK, et al. Transurethral microwave thermotherapy for management of benign prostatic hyperplasia: results of the United States Prostatron Cooperative Study. *J Urol*. 1993;150(5 Pt 2):1591–1596.

Bosch JL, Hop WC, Niemer AQ, et al. Parameters of prostate volume and shape in a community based population of men 55 to 74 years old. *J Urol*. 1994;152(5 Pt 1):1501–1505.

Bosch JL, Hop WC, Kirkels WJ, et al. The International Prostate Symptom Score in a community-based sample of men between 55 and 74 years of age: prevalence and correlation of symptoms with age, prostate volume, flow rate and residual urine volume. *Br J Urol*. 1995;75(5):622–630.

Bosch JL, Hop WC, Kirkels WJ, et al. Natural history of benign prostatic hyperplasia: appropriate case definition and estimation of its prevalence in the community. *Urology*. 1995;46(3 SupplA):34–40.

Bosch JL, Kranse R, van Mastrigt R, et al. Reasons for the weak correlation between prostate volume and urethral resistance parameters in patients with prostatism. *J Urol*. 1995;153(3 Pt 1):689–693.

Bousema JT, Bussemakers MJ, van Houwelingen KP, et al. Polymorphisms in the vitamin D receptor gene and the androgen receptor gene and the risk of benign prostatic hyperplasia. *Eur Urol*. 2000;37(2):234–238.

Boyle P. Some remarks on the epidemiology of acute urinary retention. *Arch Ital Urol Androl*. 1998;70(2):77–82.

Boyle P, Maisonneuve P, Steg A. Decrease in mortality from benign prostatic hyperplasia: a major unheralded health triumph [see comments]. *J Urol*. 1996;155(1):176–180.

Boyle P, Napalkov P. The epidemiology of benign prostatic hyperplasia and observations on concomitant hypertension. *Scand J Urol Nephrol Suppl*. 1995;168:7–12.

Boyle P, Robertson C, Mazzetta C, et al. The association between lower urinary tract symptoms and erectile dysfunction in four centres: the UrEpik study. *BJU Int*. 2003;92(7):719–725.

Breum L, Klarskov P, Munck LK, et al. Significance of acute urinary retention due to intravesical obstruction. *Scand J Urol Nephrol*. 1982;16(1):21–24.

Bruskewitz R, Girman CJ, Fowler J, et al. Effect of finasteride on bother and other health-related quality of life aspects associated with benign prostatic hyperplasia. PLESS Study Group. Proscar Long-term Efficacy and Safety Study. *Urology*. 1999;54(4):670–678.

Bruskewitz RC, Iversen P, Madsen PO. Value of postvoid residual urine determination in evaluation of prostatism. *Urology*. 1982;20(6):602–604.

Burchardt M, Burchardt T, Chen MW, et al. Vascular endothelial growth factor-A expression in the rat ventral prostate gland and the early effects of castration. *Prostate*. 2000;43(3):184–194.

Buttyan R, Ghafar MA, Shabsigh A. The effects of androgen deprivation on the prostate gland: cell death mediated by vascular regression. *Curr Opin Urol*. 2000;10(5):415–420.

Caine M, Schuger L. *The "capsule" in benign prostatic hypertrophy*. [NIH Publication No. 87-2881 Rockville, MD: US Department of Health and Human Services] 1987:221.

Canto EI, Singh H, Shariat SF, et al. Serum BPSA outperforms both total PSA and free PSA as a predictor of prostatic enlargement in men without prostate cancer. *Urology*. 2004;63(5):905–910 [discussion 910–901].

Carson C 3rd, Rittmaster R. The role of dihydrotestosterone in benign prostatic hyperplasia. *Urology*. 2003;61(4 Suppl 1):2–7.

Carter HB, Coffey DS. The prostate: an increasing medical problem. *Prostate*. 1990;16(1):39–48.

Castro P, Giri D, Lamb D, et al. Cellular senescence in the pathogenesis of benign prostatic hyperplasia. *Prostate*. 2003;55(1):30–38.

Castro P, Xia C, Gomez L, et al. Interleukin-8 expression is increased in senescent prostatic epithelial cells and promotes the development of benign prostatic hyperplasia. *Prostate*. 2004;60(2):153–159.

Cathcart P, van der Meulen J, Armitage J, et al. Incidence of primary and recurrent acute urinary retention between 1998 and 2003 in England. *J Urol*. 2006;176(1):200–204 [discussion 204].

Chai TC, Andersson KE, Tuttle JB, et al. Altered neural control of micturition in the aged F344 rat. *Urol Res*. 2000;28(5):348–354.

Chapple CR, Crowe R, Gilpin SA, et al. The innervation of the human prostate gland—the changes associated with benign enlargement. *J Urol*. 1991;146(6):1637–1644.

Chapple CR, Wein AJ, Abrams P, et al. Lower urinary tract symptoms revisited: a broader clinical perspective. *Eur Urol*. 2008;54(3):563–569.

Chatterjee B. The role of the androgen receptor in the development of prostatic hyperplasia and prostate cancer. *Mol Cell Biochem*. 2003;253(1–2):89–101.

Cher ML, Abernathy BB, McConnell JD, et al. Smooth-muscle myosin heavy-chain isoform expression in bladder-outlet obstruction. *World J Urol*. 1996;14(5):295–300.

Chicharro-Molero JA, Burgos-Rodriguez R, Sanchez-Cruz JJ, et al. Prevalence of benign prostatic hyperplasia in Spanish men 40 years old or older. *J Urol*. 1998;159(3):878–882.

Cho SY, Bae J, Yoo C, et al. Establishment of a grading system for bladder trabeculation. *Urology*. 2013;81(3):503–507.

Choi J, Shendrik I, Peacocke M, et al. Expression of senescence-associated beta-galactosidase in enlarged prostates from men with benign prostatic hyperplasia. *Urology*. 2000;56(1):160–166.

Chopra IJ, Tulchinsky D, Greenway FL. Estrogen-androgen imbalance in hepatic cirrhosis. Studies in 13 male patients. *Ann Intern Med*. 1973;79(2):198–203.

Christ GJ, Liebert M. Proceedings of the Baltimore smooth muscle meeting: identifying research frontiers and priorities for the lower urinary tract. *J Urol*. 2005;173(4):1406–1409.

Chung W, Nehra A, Jacobsen S, et al. Epidemiologic evidence evaluating lower urinary tract symptoms (LUTS) and sexual dysfunction in the Olmsted County Study of Urinary Tract Symptoms and Health Status Among Men. *J Urol*. 2003;169(4):323A.

Chute CG, Panser LA, Girman CJ, et al. The prevalence of prostatism: a population-based survey of urinary symptoms. *J Urol*. 1993;150(1):85–89.

Chyou PH, Nomura AM, Stemmermann GN, et al. A prospective study of alcohol, diet, and other lifestyle factors in relation to obstructive uropathy. *Prostate*. 1993;22(3):253–264.

Clarke R. *The prostate and the endocrines*. 1919:254–271.

Clemow DB, Steers WD, McCarty R, et al. Altered regulation of bladder nerve growth factor and neurally mediated hyperactive voiding. *Am J Physiol*. 1998;275(4 Pt 2):R1279–

R1286.

Clemow DB, Steers WD, Tuttle JB. Stretch-activated signaling of nerve growth factor secretion in bladder and vascular smooth muscle cells from hypertensive and hyperactive rats. *J Cell Physiol*. 2000;183(3):289–300.

Cohen P, Nunn SE, Peehl DM. Transforming growth factor-beta induces growth inhibition and IGF-binding protein-3 production in prostatic stromal cells: abnormalities in cells cultured from benign prostatic hyperplasia tissues. *J Endocrinol*. 2000;164(2):215–223.

Colombel M, Vacherot F, Diez SG, et al. Zonal variation of apoptosis and proliferation in the normal prostate and in benign prostatic hyperplasia. *Br J Urol*. 1998;82(3):380–385.

Corica FA, Jacobsen SJ, King BF, et al. Prostatic central zone volume, lower urinary tract symptom severity and peak urinary flow rates in community dwelling men. *J Urol*. 1999;161(3):831–834.

Coyne KS, Kaplan SA, Chapple CR, et al. Risk factors and comorbid conditions associated with lower urinary tract symptoms: EpiLUTS. *BJU Int*. 2009;103(Suppl 3):24–32.

Craigen AA, Hickling JB, Saunders CR, et al. Natural history of prostatic obstruction. A prospective survey. *J R Coll Gen Pract*. 1969;18(87):226–232.

Cross NA, Reid SV, Harvey AJ, et al. Opposing actions of TGFbeta1 and FGF2 on growth, differentiation and extracellular matrix accumulation in prostatic stromal cells. *Growth Factors*. 2006;24(4):233–241.

Cunha GR. Role of mesenchymal-epithelial interactions in normal and abnormal development of the mammary gland and prostate [review]. *Cancer*. 1994;74(3):1030–1044.

Cunha R, Donjacour A. Stromal-epithelial interactions in normal and abnormal prostatic development. *Prog Clin Biol Res*. 1987;239:251–272.

Cunha GR, Chung LW, Shannon JM, et al. Stromal-epithelial interactions in sex differentiation. *Biol Reprod*. 1980;22(1):19–42.

Cunha GR, Chung LW, Shannon JM, et al. Hormone-induced morphogenesis and growth: role of mesenchymal-epithelial interactions. *Recent Prog Horm Res*. 1983;39:559–598.

Cunha GR, Hayward SW, Wang YZ, et al. Role of the stromal microenvironment in carcinogenesis of the prostate. *Int J Cancer*. 2003;107(1):1–10.

d'Ancona FC, Francisca EA, Hendriks JC, et al. The predictive value of baseline variables in the treatment of benign prostatic hyperplasia using high-energy transurethral microwave thermotherapy. *Br J Urol*. 1998;82(6):808–813.

Dahle SE, Chokkalingam AP, Gao YT, et al. Body size and serum levels of insulin and leptin in relation to the risk of benign prostatic hyperplasia. *J Urol*. 2002;168(2):599–604.

Dalton DP, Lee C, Huprikar S, et al. Non-androgenic role of testis in enhancing ventral prostate growth in rats. *Prostate*. 1990;16(3):225–233.

Daniell HW. Larger prostatic adenomas in obese men with no associated increase in obstructive uropathy. *J Urol*. 1993;149(2):315–317.

Daniell HW. More stage A prostatic cancers, less surgery for benign hypertrophy in smokers. *J Urol*. 1993;149(1):68–72.

de la Rosette JJ, de Wildt MJ, Alivizatos G, et al. Transurethral microwave thermotherapy (TUMT) in benign prostatic hyperplasia: placebo versus TUMT. *Urology*. 1994;44(1):58–63.

de la Rosette JJ, Witjes WP, Schafer W, et al. Relationships between lower urinary tract symptoms and bladder outlet obstruction: results from the ICS-BPH study. *Neurourol Urodyn*. 1998;17(2):99–108.

DeKlerk DP, Coffey DS, Ewing LL, et al. Comparison of spontaneous and experimentally induced canine prostatic hyperplasia. *J Clin Invest*. 1979;64(3):842–849.

Dhanasekaran SM, Dash A, Yu J, et al. Molecular profiling of human prostate tissues: insights into gene expression patterns of prostate development during puberty. *FASEB J*. 2005;19(2):243–245.

Dinh DT, Frauman AG, Sourial M, et al. Identification, distribution, and expression of angiotensin II receptors in the normal human prostate and benign prostatic hyperplasia. *Endocrinology*. 2001;142(3):1349–1356.

Dinh DT, Frauman AG, Somers GR, et al. Evidence for activation of the renin-angiotensin system in the human prostate: increased angiotensin II and reduced AT(1) receptor expression in benign prostatic hyperplasia. *J Pathol*. 2002;196(2):213–219.

Diokno AC, Brown MB, Goldstein N, et al. Epidemiology of bladder emptying symptoms in elderly men. *J Urol*. 1992;148(6):1817–1821.

DiPaola RS, Kumar P, Hait WN, et al. State-of-the-art prostate cancer treatment and research. A report from the Cancer Institute of New Jersey. *N J Med*. 2001;98(2):23–33.

Djavan B, Fong YK, Harik M, et al. Longitudinal study of men with mild symptoms of bladder outlet obstruction treated with watchful waiting for four years. *Urology*. 2004;64(6):1144–1148.

Dong G, Rajah R, Vu T, et al. Decreased expression of Wilms' tumor gene WT-1 and elevated expression of insulin growth factor-II (IGF-II) and type 1 IGF receptor genes in prostatic stromal cells from patients with benign prostatic hyperplasia. *J Clin Endocrinol Metab*. 1997;82(7):2198–2203.

Donovan JL, Abrams P, Peters TJ, et al. The ICS-'BPH' Study: the psychometric validity and reliability of the ICSmale questionnaire. *Br J Urol*. 1996;77(4):554–562 8777617.

Drach GW, Steinbronn DV. Clinical evaluation of patients with prostatic obstruction: correlation of flow rates with voided, residual or total bladder volume. *J Urol*. 1986;135(4):737–740.

Eddy DM. Comparing benefits and harms: the balance sheet. *JAMA*. 1990;263(18):2493 [2498, 2501 passim].

Eddy DM. Clinical decision making: from theory to practice. Applying cost-effectiveness analysis. The inside story. *JAMA*. 1992;268(18):2575–2582.

Eddy DM, Hasselblad V. FAST*PRO *software for meta-analysis by the confidence profile method*. Academic Press: Boston, MA; 1992.

Egan KB, Suh M, Rosen RC, et al. Rural vs. urban disparities in association with lower urinary tract symptoms and benign prostatic hyperplasia in ageing men, NHANES 2001-2008. *Int J Clin Pract*. 2015;69(11):1316–1325.

Ekman P. BPH epidemiology and risk factors. *Prostate Suppl*. 1989;2:23–31.

Eldrup E, Lindholm J, Winkel P. Plasma sex hormones and ischemic heart disease. *Clin Biochem*. 1987;20(2):105–112.

Epstein RS, Deverka PA, Chute CG, et al. Validation of a new quality of life questionnaire for benign prostatic hyperplasia. *J Clin Epidemiol*. 1992;45(12):1431–1445.

Ezz el Din K, Kiemeney LA, de Wildt MJ, et al. Correlation between uroflowmetry, prostate volume, postvoid residue, and lower urinary tract symptoms as measured by the International Prostate Symptom Score. *Urology*. 1996;48(3):393–397.

Fabiani ME, Sourial M, Thomas WG, et al. Angiotensin II enhances noradrenaline release from sympathetic nerves of the rat prostate via a novel angiotensin receptor: implications for the pathophysiology of benign prostatic hyperplasia. *J Endocrinol*. 2001;171(1):97–108.

Farnsworth WE. Roles of estrogen and SHBG in prostate physiology. *Prostate*. 1996;28(1):17–23.

Farnsworth WE. Estrogen in the etiopathogenesis of BPH. *Prostate*. 1999;41(4):263–274.

Flanigan RC, Reda DJ, Wasson JH, et al. 5-Year outcome of surgical resection and watchful waiting for men with moderately symptomatic benign prostatic hyperplasia: a Department of Veterans Affairs cooperative study. *J Urol*. 1998;160(1):12–16 [discussion 16–17].

Franks LM. Benign nodular hyperplasia of the prostate; a review. *Ann R Coll Surg Engl*. 1953;14(2):92–106.

Franks LM. *Benign prostatic hyperplasia: gross and microscopic anatomy*. [US Department of Health, Education, and Welfare NIH Publication No. 76-1113-63] 1976.

Frea B, Annoscia S, Stanta G, et al. Correlation between liver cirrhosis and benign prostatic hyperplasia: a morphological study. *Urol Res*. 1987;15(5):311–314.

Freeman MR, Schneck FX, Gagnon ML, et al. Peripheral blood T lymphocytes and lymphocytes infiltrating human cancers express vascular endothelial growth factor: a potential role for T cells in angiogenesis. *Cancer Res*. 1995;55(18):4140–4145.

Fromont G, Chene L, Latil A, et al. Molecular profiling of benign prostatic hyperplasia using a large scale real-time reverse transcriptase-polymerase chain reaction approach. *J Urol*. 2004;172(4 Pt 1):1382–1385.

Fusco F, Creta M, De Nunzio C, et al. Progressive bladder remodeling due to bladder outlet obstruction: a systematic review of morphological and molecular evidences in humans. *BMC Urol*. 2018;18(1):15.

Gacci M, Vignozzi L, Sebastianelli A, et al. Metabolic syndrome and lower urinary tract symptoms: the role of inflammation. *Prostate Cancer Prostatic Dis*.

2013;16(1):101–106.

Gandaglia G, Briganti A, Gontero P, et al. The role of chronic prostatic inflammation in the pathogenesis and progression of benign prostatic hyperplasia (BPH). *BJU Int*. 2013;112(4):432–441.

Garraway WM, Collins GN, Lee RJ. High prevalence of benign prostatic hypertrophy in the community. *Lancet*. 1991;338(8765):469–471.

Garraway WM, Russell EB, Lee RJ, et al. Impact of previously unrecognized benign prostatic hyperplasia on the daily activities of middle-aged and elderly men. *Br J Gen Pract*. 1993;43(373):318–321.

Giovannucci E, Rimm EB, Chute CG, et al. Obesity and benign prostatic hyperplasia. *Am J Epidemiol*. 1994;140(11):989–1002.

Giovannucci E, Platz EA, Stampfer MJ, et al. The CAG repeat within the androgen receptor gene and benign prostatic hyperplasia. *Urology*. 1999;53(1):121–125.

Giovannucci E, Stampfer MJ, Chan A, et al. CAG repeat within the androgen receptor gene and incidence of surgery for benign prostatic hyperplasia in US physicians. *Prostate*. 1999;39(2):130–134.

Giri D, Ittmann M. Interleukin-1alpha is a paracrine inducer of FGF7, a key epithelial growth factor in benign prostatic hyperplasia. *Am J Pathol*. 2000;157(1):249–255.

Girman CJ, Panser LA, Chute CG, et al. Natural history of prostatism: urinary flow rates in a community-based study. *J Urol*. 1993;150(3):887–892.

Girman CJ, Epstein RS, Jacobsen SJ, et al. Natural history of prostatism: impact of urinary symptoms on quality of life in 2115 randomly selected community men. *Urology*. 1994;44(6):825–831.

Girman CJ, Jacobsen SJ, Guess HA, et al. Natural history of prostatism: relationship among symptoms, prostate volume and peak urinary flow rate. *J Urol*. 1995;153(5):1510–1515.

Girman CJ, Jacobsen SJ, Tsukamoto T, et al. Health-related quality of life associated with lower urinary tract symptoms in four countries. *Urology*. 1998;51(3):428–436.

Girman CJ, Jacobsen SJ, Rhodes T, et al. Association of health-related quality of life and benign prostatic enlargement. *Eur Urol*. 1999;35(4):277–284.

Giubilei G, Ponchietti R, Biscioni S, et al. Accuracy of prostate volume measurements using transrectal multiplanar three-dimensional sonography. *Int J Urol*. 2005;12(10):936–938.

Glynn RJ, Campion EW, Bouchard GR, et al. The development of benign prostatic hyperplasia among volunteers in the normative aging study. *Am J Epidemiol*. 1985;121(1):78–90.

Golomb J, Lindner A, Siegel Y, et al. Variability and circadian changes in home uroflowmetry in patients with benign prostatic hyperplasia compared to normal controls. *J Urol*. 1992;147(4):1044–1047.

Gong G, Johnson ML, Pettinger WA. Testosterone regulation of renal alpha 2B-adrenergic receptor mRNA levels. *Hypertension*. 1995;25(3):350–355.

Gormley GJ, Stoner E, Bruskewitz RC, et al. The effect of finasteride in men with benign prostatic hyperplasia. The Finasteride Study Group [see comments]. *N Engl J Med*. 1992;327(17):1185–1191.

Gosling JA, Dixon JS. Structure of trabeculated detrusor smooth muscle in cases of prostatic hypertrophy. *Urol Int*. 1980;35(5):351–355.

Gosling JA, Gilpin SA, Dixon JS, et al. Decrease in the autonomic innervation of human detrusor muscle in outflow obstruction. *J Urol*. 1986;136(2):501–504.

Graversen PH, Gasser TC, Wasson JH, et al. Controversies about indications for transurethral resection of the prostate. *J*

Urol. 1989;141(3):475–481.

Grayhack JT, Sensibar JA, Ilio KY, et al. Synergistic action of steroids and spermatocele fluid on in vitro proliferation of prostate stroma. *J Urol*. 1998;159(6):2202–2209.

Griffith JW, Messersmith EE, Gillespie BW, et al. Reasons for seeking clinical care for lower urinary tract symptoms: a mixed methods study. *J Urol*. 2018;199(2):528–535.

Grosse H. Frequency, localization and associated disorders in urinary calculi. Analysis of 1671 autopsies in urolithiasis]. *Z Urol Nephrol*. 1990;83(9):469–474.

Gu FL, Xia TL, Kong XT. Preliminary study of the frequency of benign prostatic hyperplasia and prostatic cancer in China. *Urology*. 1994;44(5):688–691.

Guess HA. Epidemiology and natural history of benign prostatic hyperplasia. *Urol Clin North Am*. 1995;22(2):247–261.

Guess HA, Arrighi HM, Metter EJ, et al. Cumulative prevalence of prostatism matches the autopsy prevalence of benign prostatic hyperplasia. *Prostate*. 1990;17(3):241–246.

Guess HA, Chute CG, Garraway WM, et al. Similar levels of urological symptoms have similar impact on Scottish and American men—although Scots report less symptoms. *J Urol*. 1993;150(5 Pt 2):1701–1705.

Guess HA, Jacobsen SJ, Girman CJ, et al. The role of community-based longitudinal studies in evaluating treatment effects. Example: benign prostatic hyperplasia. *Med Care*. 1995;33(4 Suppl):AS26–AS35.

Gupta A, Aragaki C, Gotoh M, et al. Relationship between prostate specific antigen and indexes of prostate volume in Japanese men. *J Urol*. 2005;173(2):503–506.

Gupta A, Gupta S, Pavuk M, et al. Anthropometric and metabolic factors and risk of benign prostatic hyperplasia: a prospective cohort study of Air Force veterans. *Urology*. 2006;68(6):1198–1205.

Habuchi T, Liqing Z, Suzuki T, et al. Increased risk of prostate cancer and benign prostatic hyperplasia associated with a CYP17 gene polymorphism with a gene dosage effect. *Cancer Res*. 2000;60(20):5710–5713.

Habuchi T, Suzuki T, Sasaki R, et al. Association of vitamin D receptor gene polymorphism with prostate cancer and benign prostatic hyperplasia in a Japanese population. *Cancer Res*. 2000;60(2):305–308.

Haffner S, Taegtmeyer H. Epidemic obesity and the metabolic syndrome. *Circulation*. 2003;108(13):1541–1545.

Hall SA, Link CL, Tennstedt SL, et al. Urological symptom clusters and health-related quality-of-life: results from the Boston Area Community Health Survey. *BJU Int*. 2009;103(11):1502–1508.

Hammarsten J, Hogstedt B, Holthuis N, et al. Components of the metabolic syndrome—risk factors for the development of benign prostatic hyperplasia. *Prostate Cancer Prostatic Dis*. 1998;1(3):157–162.

Hammarsten J, Hogstedt B. Clinical, anthropometric, metabolic and insulin profile of men with fast annual growth rates of benign prostatic hyperplasia. *Blood Press*. 1999;8(1):29–36.

Hammarsten J, Hogstedt B. Hyperinsulinaemia as a risk factor for developing benign prostatic hyperplasia. *Eur Urol*. 2001;39(2):151–158.

Hansen BJ, Flyger H, Brasso K, et al. Validation of the self-administered Danish Prostatic Symptom Score (DAN-PSS-1) system for use in benign prostatic hyperplasia. *Br J Urol*. 1995;76(4):451–458.

Harbitz TB, Haugen OA. Histology of the prostate in elderly men. A study in an autopsy series. *Acta Pathol Microbiol Scand [A]*. 1972;80(6):756–768.

Hastie KJ, Dickinson AJ, Ahmad R, et al. Acute retention of urine: is trial without catheter justified? *J R Coll Surg Edinb*.

1990;35(4):225–227.

Haugen OA, Harbitz TB. Prostatic weight in elderly men. An analysis in an autopsy series. *Acta Pathol Microbiol Scand [A]*. 1972;80(6):769–777.

Hayek OR, Shabsigh A, Kaplan SA, et al. Castration induces acute vasoconstriction of blood vessels in the rat prostate concomitant with a reduction of prostatic nitric oxide synthase activity. *J Urol*. 1999;162(4):1527–1531.

Haylen BT, Ashby D, Sutherst JR, et al. Maximum and average urine flow rates in normal male and female populations—the Liverpool nomograms. *Br J Urol*. 1989;64(1):30–38.

Hedelin H, Johansson N, Stroberg P. Relationship between benign prostatic hyperplasia and lower urinary tract symptoms and correlation between prostate volume and serum prostate-specific antigen in clinical routine. *Scand J Urol Nephrol*. 2005;39(2):154–159.

Helfand BT, Smith AR, Lai HH, et al. Prevalence and characteristics of urinary incontinence in a treatment seeking male prospective cohort: results from the LURN study. *J Urol*. 2018;200(2):397–404.

Henry G, Malewska A, Mauck R, et al. Molecular pathogenesis of human prostate basal cell hyperplasia. *Prostate*. 2017;77(13):1344–1355.

Hieble JP, Bylund DB, Clarke DE, et al. International Union of Pharmacology. X Recommendation for nomenclature of alpha 1-adrenoceptors: consensus update. *Pharmacol Rev*. 1995;47(2):267–270.

Hindley RG, Mostafid AH, Brierly RD, et al. The 2-year symptomatic and urodynamic results of a prospective randomized trial of interstitial radiofrequency therapy vs transurethral resection of the prostate. *BJU Int*. 2001;88(3):217–220.

Hochberg DA, Armenakas NA, Fracchia JA. Relationship of prostate-specific antigen and prostate volume in patients with biopsy proven benign prostatic hyperplasia. *Prostate*. 2000;45(4):315–319.

Hoke GP, McWilliams GW. Epidemiology of benign prostatic hyperplasia and comorbidities in racial and ethnic minority populations. *Am J Med*. 2008;121(8 Suppl 2):S3–S10.

Holtgrewe HL, Mebust WK, Dowd JB, et al. Transurethral prostatectomy: practice aspects of the dominant operation in American urology. *J Urol*. 1989;141(2):248–253.

Holtgrewe HL, Valk WL. Factors influencing the mortality and morbidity of transurethral prostatectomy: a study of 2,015 cases. *J Urol*. 1962;87:450–459.

Holund B. Latent prostatic cancer in a consecutive autopsy series. *Scand J Urol Nephrol*. 1980;14(1):29–35.

Homma Y, Kawabe K, Tsukamoto T, et al. Epidemiologic survey of lower urinary tract symptoms in Asia and Australia using the international prostate symptom score. *Int J Urol*. 1997;4(1):40–46.

Homma Y, Gotoh M, Takei M, et al. Predictability of conventional tests for the assessment of bladder outlet obstruction in benign prostatic hyperplasia. *Int J Urol*. 1998;5(1):61–66.

Hunter DJ, McKee CM, Black NA, et al. Urinary symptoms: prevalence and severity in British men aged 55 and over. *J Epidemiol Community Health*. 1994;48(6):569–575.

Hunter DJ, McKee M, Black NA, et al. Health status and quality of life of British men with lower urinary tract symptoms: results from the SF-36. *Urology*. 1995;45(6):962–971.

Hunter DJ, Berra-Unamuno A, Martin-Gordo A. Prevalence of urinary symptoms and other urological conditions in Spanish men 50 years old or older. *J Urol*. 1996;155(6):1965–1970.

Imajo C, Walden PD, Shapiro E, et al. Evaluation of the effect of endothelin-1 and characterization of the selective endothelin a receptor antagonist PD155080 in the prostate. *J Urol*. 1997;158(1):253–257.

Irwin DE, Milsom I, Hunskaar S, et al. Population-based survey of urinary incontinence, overactive bladder, and other lower urinary tract symptoms in five countries: results of the EPIC study. *Eur Urol*. 2006;50(6):1306–1314 [discussion 1314–1315].

Isaacs JT. Common characteristics of human and canine benign prostatic hyperplasia. *Prog Clin Biol Res*. 1984;145:217–234 6201876 [Review].

Isaacs JT. Prostate stem cells and benign prostatic hyperplasia. *Prostate*. 2008;68(9):1025–1034.

Isaacs JT, Coffey DS. Etiology and disease process of benign prostatic hyperplasia. *Prostate Suppl*. 1989;2:33–50.

Ittmann M. Anatomy and histology of the human and murine prostate. *Cold Spring Harb Perspect Med*. 2018;8(5).

Jacobsen SJ, Girman CJ, Guess HA, et al. New diagnostic and treatment guidelines for benign prostatic hyperplasia. Potential impact in the United States. *Arch Intern Med*. 1995;155(5):477–481.

Jacobsen SJ, Girman CJ, Guess HA, et al. Natural history of prostatism: longitudinal changes in voiding symptoms in community dwelling men. *J Urol*. 1996;155(2):595–600.

Jacobsen SJ, Jacobson DJ, Girman CJ, et al. Natural history of prostatism: risk factors for acute urinary retention. *J Urol*. 1997;158(2):481–487.

Jacobsen SJ, Jacobson DJ, Girman CJ, et al. Treatment for benign prostatic hyperplasia among community dwelling men: the Olmsted County study of urinary symptoms and health status. *J Urol*. 1999;162(4):1301–1306.

Jacobsen SJ, Jacobson DJ, Rohe DE, et al. Frequency of sexual activity and prostatic health: fact or fairy tale? *Urology*.

2003;61(2):348–353.

Jakobsen H, Torp-Pedersen S, Juul N. Ultrasonic evaluation of age-related human prostatic growth and development of benign prostatic hyperplasia. *Scand J Urol Nephrol Suppl*. 1988;107:26–31.

Jolleys JV, Donovan JL, Nanchahal K, et al. Urinary symptoms in the community: how bothersome are they? *Br J Urol*. 1994;74(5):551–555.

Juniewicz PE, Berry SJ, Coffey DS, et al. The requirement of the testis in establishing the sensitivity of the canine prostate to develop benign prostatic hyperplasia. *J Urol*. 1994;152(3):996–1001.

Kadow C, Feneley RC, Abrams PH. Prostatectomy or conservative management in the treatment of benign prostatic hypertrophy? *Br J Urol*. 1988;61(5):432–434.

Kakehi Y, Segawa T, Wu XX, et al. Down-regulation of macrophage inhibitory cytokine-1/prostate derived factor in benign prostatic hyperplasia. *Prostate*. 2004;59(4):351–356.

Kaplan SA, Te AE, Pressler LB, et al. Transition zone index as a method of assessing benign prostatic hyperplasia: correlation with symptoms, urine flow and detrusor pressure. *J Urol*. 1995;154(5):1764–1769.

Kaplan S, Garvin D, Gilhooly P, et al. Impact of baseline symptom severity on future risk of benign prostatic hyperplasia–related outcomes and long-term response to finasteride. The PLESS Study Group. *Urology*. 2000;56(4):610–616.

Kaplan SA, Wein AJ, Staskin DR, et al. Urinary retention and post-void residual urine in men: separating truth from tradition. *J Urol*. 2008;180(1):47–54.

Kaplan SA, Roehrborn CG, Chapple CR, et al. Implications of recent epidemiology studies for the clinical management of lower urinary tract symptoms. *BJU Int*. 2009;103(Suppl

3):48–57.

Karhadkar SS, Bova GS, Abdallah N, et al. Hedgehog signalling in prostate regeneration, neoplasia and metastasis. *Nature*. 2004;431(7009):707–712.

Kariya K, Farrance IK, Simpson PC. Transcriptional enhancer factor-1 in cardiac myocytes interacts with an alpha 1-adrenergic- and beta-protein kinase C-inducible element in the rat beta-myosin heavy chain promoter. *J Biol Chem*. 1993;268(35):26658–26662.

Karube K. Study of latent carcinoma of the prostate in the Japanese based on necropsy material. *Tohoku J Exp Med*. 1961;74:265–285.

Kasturi S, Russell S, McVary KT. Metabolic syndrome and lower urinary tract symptoms secondary to benign prostatic hyperplasia. *Curr Urol Rep*. 2006;7(4):288–292.

Kerr JF, Searle J. Deletion of cells by apoptosis during castration-induced involution of the rat prostate. *Virchows Arch B Cell Pathol*. 1973;13(2):87–102.

Kitsberg DI, Leder P. Keratinocyte growth factor induces mammary and prostatic hyperplasia and mammary adenocarcinoma in transgenic mice. *Oncogene*. 1996;13(12):2507–2515.

Klarskov P, Andersen JT, Asmussen CF, et al. Acute urinary retention in women: a prospective study of 18 consecutive cases. *Scand J Urol Nephrol*. 1987;21(1):29–31.

Kobayashi S, Tang R, Wang B, et al. Binding and functional properties of endothelin receptor subtypes in the human prostate. *Mol Pharmacol*. 1994;45(2):306–311.

Kobayashi S, Tang R, Wang B, et al. Localization of endothelin receptors in the human prostate. *J Urol*. 1994;151(3):763–766.

Konig JE, Senge T, Allhoff EP, et al. Analysis of the inflammatory network in benign prostate hyperplasia and prostate cancer. *Prostate*. 2004;58(2):121–129.

Konishi N, Hiasa Y, Matsuda H, et al. Genetic variations in human benign prostatic hyperplasia detected by restriction landmark genomic scanning. *J Urol*. 1997;157(4):1499–1503.

Konno-Takahashi N, Takeuchi T, Shimizu T, et al. Engineered IGF-I expression induces glandular enlargement in the murine prostate. *J Endocrinol*. 2003;177(3):389–398.

Konno-Takahashi N, Takeuchi T, Nishimatsu H, et al. Engineered FGF-2 expression induces glandular epithelial hyperplasia in the murine prostatic dorsal lobe. *Eur Urol*. 2004;46(1):126–132.

Kramer G, Steiner GE, Handisurya A, et al. Increased expression of lymphocyte-derived cytokines in benign hyperplastic prostate tissue, identification of the producing cell types, and effect of differentially expressed cytokines on stromal cell proliferation. *Prostate*. 2002;52(1):43–58.

Kramer G, Mitteregger D, Marberger M. Is benign prostatic hyperplasia (BPH) an immune inflammatory disease? *Eur Urol*. 2007;51(5):1202–1216.

Krege JH, Hodgin JB, Couse JF, et al. Generation and reproductive phenotypes of mice lacking estrogen receptor beta. *Proc Natl Acad Sci USA*. 1998;95(26):15677–15682.

Kristal AR, Arnold KB, Schenk JM, et al. Dietary patterns, supplement use, and the risk of symptomatic benign prostatic hyperplasia: results from the prostate cancer prevention trial. *Am J Epidemiol*. 2008;167(8):925–934.

Kundu SD, Kim IY, Yang T, et al. Absence of proximal duct apoptosis in the ventral prostate of transgenic mice carrying the C3(1)-TGF-beta type II dominant negative receptor. *Prostate*. 2000;43(2):118–124.

Kuo HC. Clinical prostate score for diagnosis of bladder outlet obstruction by prostate measurements and uroflowmetry. *Urology*. 1999;54(1):90–96.

Kupeli B, Soygur T, Aydos K, et al. The role of cigarette smoking in prostatic enlargement. *Br J Urol*. 1997;80(2):201–204.

Kwon OJ, Valdez JM, Zhang L, et al. Increased Notch signalling inhibits anoikis and stimulates proliferation of prostate luminal epithelial cells. *Nat Commun*. 2014;5:4416.

Kwon OJ, Zhang L, Ittmann MM, et al. Prostatic inflammation enhances basal-to-luminal differentiation and accelerates initiation of prostate cancer with a basal cell origin. *Proc Natl Acad Sci USA*. 2014;111(5):E592–E600.

Kwon OJ, Zhang B, Zhang L, et al. High fat diet promotes prostatic basal-to-luminal differentiation and accelerates initiation of prostate epithelial hyperplasia originated from basal cells. *Stem Cell Res*. 2016;16(3):682–691.

Kyprianou N, Isaacs JT. Expression of transforming growth factor-beta in the rat ventral prostate during castration-induced programmed cell death. *Mol Endocrinol*. 1989;3(10):1515–1522.

Kyprianou N, Tu H, Jacobs SC. Apoptotic versus proliferative activities in human benign prostatic hyperplasia. *Hum Pathol*. 1996;27(7):668–675.

Lee AJ, Russell EB, Garraway WM, et al. Three-year follow-up of a community-based cohort of men with untreated benign prostatic hyperplasia. *Eur Urol*. 1996;30(1):11–17.

Lee C. Physiology of castration-induced regression in rat prostate. *Prog Clin Biol Res*. 1981;75A:145–159.

Lee C, Sensibar JA, Dudek SM, et al. Prostatic ductal system in rats: regional variation in morphological and functional activities. *Biol Reprod*. 1990;43(6):1079–1086.

Lee KL, Peehl DM. Molecular and cellular pathogenesis of benign prostatic hyperplasia. *J Urol*. 2004;172(5 Pt 1):1784–1791.

Lepor H, Machi G. Comparison of AUA symptom index in unselected males and females between fifty-five and seventy-nine years of age. *Urology*. 1993;42(1):36–40 [discussion 40–31].

Lepor H, Sypherd D, Machi G, et al. Randomized double-blind study comparing the effectiveness of balloon dilation of the prostate and cystoscopy for the treatment of symptomatic benign prostatic hyperplasia. *J Urol*. 1992;147(3):639–642 [discussion 642–634].

Lepor H, Tang R, Meretyk S, et al. Alpha 1 adrenoceptor subtypes in the human prostate. *J Urol*. 1993;149(3):640–642.

Lepor H, Tang R, Shapiro E. The alpha-adrenoceptor subtype mediating the tension of human prostatic smooth muscle. *Prostate*. 1993;22(4):301–307.

Levin RM, Longhurst PA, Monson FC, et al. Effect of bladder outlet obstruction on the morphology, physiology, and pharmacology of the bladder. *Prostate Suppl*. 1990;3:9–26.

Levin RM, Monson FC, Haugaard N, et al. Genetic and cellular characteristics of bladder outlet obstruction. *Urol Clin North Am*. 1995;22(2):263–283.

Levin RM, Haugaard N, O'Connor L, et al. Obstructive response of human bladder to BPH vs. rabbit bladder response to partial outlet obstruction: a direct comparison. *Neurourol Urodyn*. 2000;19(5):609–629.

Li Z, Habuchi T, Tsuchiya N, et al. Increased risk of prostate cancer and benign prostatic hyperplasia associated with transforming growth factor-beta 1 gene polymorphism at codon 10. *Carcinogenesis*. 2004;25(2):237–240.

Lin VK, McConnell JD. Effects of obstruction on bladder contractile proteins. *Prog Clin Biol Res*. 1994;386:263–269.

Lin VK, Wang D, Lee IL, et al. Myosin heavy chain gene expression in normal and hyperplastic human prostate tissue. *Prostate*. 2000;44(3):193–203.

Lin VK, Wang SY, Boetticher NC, et al. Alpha(2) macroglobulin, a PSA binding protein, is expressed in human prostate stroma. *Prostate*. 2005;63(3):299–308.

Lin-Tsai O, Clark PE, Miller NL, et al. Surgical intervention for symptomatic benign prostatic hyperplasia is correlated with expression of the AP-1 transcription factor network. *Prostate*. 2014;74(6):669–679.

Liu X, Grogan TR, Hieronymus H, et al. Low CD38 Identifies progenitor-like inflammation-associated luminal cells that can initiate human prostate cancer and predict poor outcome. *Cell Rep*. 2016;17(10):2596–2606.

Lu W, Luo Y, Kan M, et al. Fibroblast growth factor-10. A second candidate stromal to epithelial cell andromedin in prostate. *J Biol Chem*. 1999;274(18):12827–12834.

Lu-Yao GL, Barry MJ, Chang CH, et al. Transurethral resection of the prostate among Medicare beneficiaries in the United States: time trends and outcomes. Prostate Patient Outcomes Research Team (PORT). *Urology*. 1994;44(5):692–698 [discussion 698–699].

Lukacs B, Leplege A, MacCarthy C, et al. Construction and validation of a BPH specific health related quality of life scale including evaluation of sexuality. *Proc Am Urol Assoc*. 1995;153(Suppl):320A.

Lytton B, Emery JM, Harvard BM. The incidence of benign prostatic obstruction. *J Urol*. 1968;99(5):639–645.

Mannikarottu AS, Changolkar AK, Disanto ME, et al. Over expression of smooth muscle thin filament associated proteins in the bladder wall of diabetics. *J Urol*. 2005;174(1):360–364.

Mannikarottu AS, Hypolite JA, Zderic SA, et al. Regional alterations in the expression of smooth muscle myosin isoforms in response to partial bladder outlet obstruction. *J Urol*. 2005;173(1):302–308.

Mannikarottu AS, Disanto ME, Zderic SA, et al. Altered expression of thin filament-associated proteins in hypertrophied urinary bladder smooth muscle. *Neurourol Urodyn*. 2006;25(1):78–88.

Marberger MJ, Andersen JT, Nickel JC, et al. Prostate volume and serum prostate-specific antigen as predictors of acute urinary retention. Combined experience from three large multinational placebo-controlled trials. *Eur Urol*. 2000;38(5):563–568.

Marberger M, Roehrborn CG, Marks LS, et al. Relationship among serum testosterone, sexual function, and response to treatment in men receiving dutasteride for benign prostatic hyperplasia. *J Clin Endocrinol Metab*. 2006;91(4):1323–1328.

Marcelli M, Cunningham GR. Hormonal signaling in prostatic hyperplasia and neoplasia. *J Clin Endocrinol Metab*. 1999;84(10):3463–3468.

Martikainen P, Kyprianou N, Isaacs JT. Effect of transforming growth factor-beta 1 on proliferation and death of rat prostatic cells. *Endocrinology*. 1990;127(6):2963–2968.

Maserejian NN, Kupelian V, Miyasato G, et al. Are physical activity, smoking and alcohol consumption associated with lower urinary tract symptoms in men or women? Results from a population based observational study. *J Urol*. 2012;188(2):490–495.

Maserejian NN, Chen S, Chiu GR, et al. Treatment status and progression or regression of lower urinary tract symptoms among adults in a general population sample. *J Urol*. 2014;191(1):107–113.

Matsui H, Makino N, Yano K, et al. Modulation of adrenergic receptors during regression of cardiac hypertrophy. *J Hypertens*. 1994;12(12):1353–1357.

McConnell JD. The pathophysiology of benign prostatic hyperplasia. *J Androl*. 1991;12(6):356–363.

McConnell JD. Why pressure-flow studies should be optional and not mandatory studies for evaluating men with benign prostatic hyperplasia. *Urology*. 1994;44(2):156–158.

McConnell JD. Prostatic growth: new insights into hormonal regulation. *Br J Urol*. 1995;76(Suppl 1):5–10.

McConnell JD, Barry MJ, Bruskewitz RC. Benign prostatic hyperplasia: diagnosis and treatment. Agency for Health Care Policy and Research. *Clin Pract Guidel Quick Ref Guide Clin*. 1994;8:1–17.

McConnell JD, Bruskewitz R, Walsh P, et al. The effect of finasteride on the risk of acute urinary retention and the need for surgical treatment among men with benign prostatic hyperplasia. Finasteride Long-Term Efficacy and Safety Study Group. *N Engl J Med*. 1998;338(9):557–563.

McConnell JD, Roehrborn CG, Bautista OM, Medical Therapy of Prostatic Symptoms (MTOPS) Research Group, et al. The long-term effect of doxazosin, finasteride, and combination therapy on the clinical progression of benign prostatic hyperplasia. *N Engl J Med*. 2003;349(25):2387–2398.

McKeehan WL, Adams PS, Rosser MP. Direct mitogenic effects of insulin, epidermal growth factor, glucocorticoid, cholera toxin, unknown pituitary factors and possibly prolactin, but not androgen, on normal rat prostate epithelial cells in serum-free, primary cell culture. *Cancer Res*. 1984;44(5):1998–2010.

McKeehan WL, Adams PS. Heparin-binding growth factor/prostatropin attenuates inhibition of rat prostate tumor epithelial cell growth by transforming growth factor type beta. *In Vitro Cell Dev Biol*. 1988;24(3):243–246.

McNeal J. Pathology of benign prostatic hyperplasia: insight into etiology [review]. *Urol Clin North Am*. 1990;17(3):477–486.

McNeal JE. Origin and evolution of benign prostatic enlargement. *Invest Urol*. 1978;15(4):340–345.

McVary KT. Erectile dysfunction and lower urinary tract symptoms secondary to BPH. *Eur Urol*. 2005;47(6):838–845.

McVary KT, Razzaq A, Lee C, et al. Growth of the rat prostate gland is facilitated by the autonomic nervous system. *Biol Reprod*. 1994;51(1):99–107.

McVary KT, Rademaker A, Lloyd GL, et al. Autonomic nervous system overactivity in men with lower urinary tract symptoms secondary to benign prostatic hyperplasia. *J Urol*. 2005;174(4 Pt 1):1327–1433.

McVary KT, Monnig W, Camps JL Jr, et al. Sildenafil citrate improves erectile function and urinary symptoms in men with erectile dysfunction and lower urinary tract symptoms associated with benign prostatic hyperplasia: a randomized, double-blind trial. *J Urol*. 2007;177(3):1071–1077.

Mebust WK, Holtgrewe HL, Cockett AT, et al. Transurethral prostatectomy: immediate and postoperative complications: a cooperative study of 13 participating institutions evaluating 3,885 patients. *J Urol*. 1989;141(2):243–247.

Meigs JB, Barry MJ, Giovannucci E, et al. Incidence rates and risk factors for acute urinary retention: the health professionals followup study. *J Urol*. 1999;162(2):376–382.

Meigs JB, Mohr B, Barry MJ, et al. Risk factors for clinical benign prostatic hyperplasia in a community-based population of healthy aging men. *J Clin Epidemiol*. 2001;54(9):935–944.

Meikle AW, Stephenson RA, Lewis CM, et al. Age, genetic, and nongenetic factors influencing variation in serum sex steroids and zonal volumes of the prostate and benign prostatic hyperplasia in twins. *Prostate*. 1997;33(2):105–111 9316651.

Melchior J, Valk WL, Foret JD, et al. Transurethral prostatectomy in the azotemic patient. *J Urol*.

1974;112(5):643–646.

Melchior J, Valk WL, Foret JD, et al. Transurethral prostatectomy: computerized analysis of 2,223 consecutive cases. *J Urol*. 1974;112(5):634–642.

Minnery CH, Getzenberg RH. Benign prostatic hyperplasia cell line viability and modulation of jm-27 by doxazosin and Ibuprofen. *J Urol*. 2005;174(1):375–379.

Moad M, Hannezo E, Buczacki SJ, et al. Multipotent basal stem cells, maintained in localized proximal niches, support directed long-ranging epithelial flows in human prostates. *Cell Rep*. 2017;20(7):1609–1622.

Mononen N, Ikonen T, Autio V, et al. Androgen receptor CAG polymorphism and prostate cancer risk. *Hum Genet*. 2002;111(2):166–171.

Monti S, Di Silverio F, Iraci R, et al. Regional variations of insulin-like growth factor I (IGF-I), IGF-II, and receptor type I in benign prostatic hyperplasia tissue and their correlation with intraprostatic androgens. *J Clin Endocrinol Metab*. 2001;86(4):1700–1706.

Montpetit ML, Lawless KR, Tenniswood M. Androgen-repressed messages in the rat ventral prostate. *Prostate*. 1986;8(1):25–36.

Moon TD, Brannan W, Stone NN, et al. Effect of age, educational status, ethnicity and geographic location on prostate symptom scores. *J Urol*. 1994;152(5 Pt 1):1498–1500.

Moon H, Moon W, Seo K. High prevalence of prostatism and benign prostatic hyperplasia in Korean men. *J Urol*. 1995;155(Suppl):631A.

Moore RA. Benign hypertrophy of the prostate. A morphological study. *J Urol*. 1943;50(6):680–710.

Moore RJ, Gazak JM, Quebbeman JF, et al. Concentration of dihydrotestosterone and 3 alpha-androstanediol in naturally occurring and androgen-induced prostatic hyperplasia in the dog. *J Clin Invest*. 1979;64(4):1003–1010.

Mora GR, Olivier KR, Mitchell RF Jr, et al. Regulation of expression of the early growth response gene-1 (EGR-1) in malignant and benign cells of the prostate. *Prostate*. 2005;63(2):198–207.

Morote J, Encabo G, Lopez M, et al. Prediction of prostate volume based on total and free serum prostate-specific antigen: is it reliable? *Eur Urol*. 2000;38(1):91–95.

Morrison AS. Prostatic hypertrophy in greater Boston. *J Chronic Dis*. 1978;31(5):357–362.

Morrison AS. Risk factors for surgery for prostatic hypertrophy. *Am J Epidemiol*. 1992;135(9):974–980.

Mukamel E, Nissenkorn I, Boner G, et al. Occult progressive renal damage in the elderly male due to benign prostatic hypertrophy. *J Am Geriatr Soc*. 1979;27(9):403–406.

Murillo-Garzon V, Kypta R. WNT signalling in prostate cancer. *Nat Rev Urol*. 2017;14(11):683–696.

Nacey JN, Morum P, Delahunt B. Analysis of the prevalence of voiding symptoms in Maori, Pacific Island, and Caucasian New Zealand men. *Urology*. 1995;46(4):506–511.

Nakano K, Fukabori Y, Itoh N, et al. Androgen-stimulated human prostate epithelial growth mediated by stromal-derived fibroblast growth factor-10. *Endocr J*. 1999;46(3):405–413.

Naslund MJ, Coffey DS. The differential effects of neonatal androgen, estrogen and progesterone on adult rat prostate growth. *J Urol*. 1986;136(5):1136–1140.

Nickel JC, Roehrborn CG, O'Leary MP, et al. The relationship between prostate inflammation and lower urinary tract symptoms: examination of baseline data from the REDUCE trial. *Eur Urol*. 2008;54(6):1379–1384.

Nordling J. The aging bladder—a significant but underestimated role in the development of lower urinary tract symptoms. *Exp Gerontol*. 2002;37(8–9):991–999.

Norman RW, Nickel JC, Fish D, et al. “Prostate-related symptoms” in Canadian men 50 years of age or older: prevalence and relationships among symptoms. *Br J Urol*. 1994;74(5):542–550.

O'Leary MP, Barry MJ, Fowler FJ Jr. Hard measures of subjective outcomes: validating symptom indexes in urology. *J Urol*. 1992;148(5):1546–1548 [discussion 1564].

O'Leary MP, Fowler FJ, Lenderking WR, et al. A brief male sexual function inventory for urology. *Urology*. 1995;46(5):697–706.

Oesterling JE, Jacobsen SJ, Chute CG, et al. Serum prostate-specific antigen in a community-based population of healthy men. Establishment of age-specific reference ranges. *JAMA*. 1993;270(7):860–864.

Ogden CW, Reddy P, Johnson H, et al. Sham versus transurethral microwave thermotherapy in patients with symptoms of benign prostatic bladder outflow obstruction. *Lancet*. 1993;341(8836):14–17.

Orlandi A, Ropraz P, Gabbiani G. Proliferative activity and alpha-smooth muscle actin expression in cultured rat aortic smooth muscle cells are differently modulated by transforming growth factor-beta 1 and heparin. *Exp Cell Res*. 1994;214(2):528–536.

Osman NI, Chapple CR. Are There pharmacotherapeutic options for underactive bladder? *Eur Urol Focus*. 2018;4(1):6–7.

Osman NI, Esperto F, Chapple CR. Detrusor underactivity and the underactive bladder: a systematic review of preclinical and clinical studies. *Eur Urol*. 2018;74(5):633–643.

Overland GB, Vatten L, Rhodes T, et al. Lower urinary tract symptoms, prostate volume and uroflow in Norwegian community men. *Eur Urol*. 2001;39(1):36–41.

Padley R, Olson P, Oesterling J, et al. Education and socioeconomic status influence patterns of response to therapy with the alpha adrenergic receptor blocker terazosin and placebo in men with clinical benign prostatic hyperplasia (BPH). *J Urol*. 1997;157(Suppl):312A.

Parsons JK. Modifiable risk factors for benign prostatic hyperplasia and lower urinary tract symptoms: new approaches to old problems. *J Urol*. 2007;178(2):395–401.

Parsons JK, Kashefi C. Physical activity, benign prostatic hyperplasia, and lower urinary tract symptoms. *Eur Urol*. 2008;53(6):1228–1235.

Parsons JK, Bergstrom J, Barrett-Connor E. Lipids, lipoproteins and the risk of benign prostatic hyperplasia in community-dwelling men. *BJU Int*. 2008;101(3):313–318.

Parsons JK, Carter HB, Partin AW, et al. Metabolic factors associated with benign prostatic hyperplasia. *J Clin Endocrinol Metab*. 2006;91(7):2562–2568.

Parsons JK, Palazzi-Churas K, Bergstrom J, et al. Prospective study of serum dihydrotestosterone and subsequent risk of benign prostatic hyperplasia in community dwelling men: the Rancho Bernardo Study. *J Urol*. 2010;184(3):1040–1044.

Partin AW, Coffey DS. Benign and malignant prostatic neoplasms: human studies. *Recent Prog Horm Res*. 1994;49:293–331.

Partin AW, Oesterling JE, Epstein JI, et al. Influence of age and endocrine factors on the volume of benign prostatic hyperplasia. *J Urol*. 1991;145(2):405–409.

Partin AW, Getzenberg RH, CarMichael MJ, et al. Nuclear matrix protein patterns in human benign prostatic hyperplasia and prostate cancer. *Cancer Res*. 1993;53(4):744–746.

Pearson JD, Lei HH, Beaty TH, et al. Familial aggregation of bothersome benign prostatic hyperplasia symptoms. *Urology*.

2003;61(4):781–785.

Peehl DM, Cohen P, Rosenfeld RG. The insulin-like growth factor system in the prostate. *World J Urol*. 1995;13(5):306–311.

Peehl DM, Sellers RG. Basic FGF, EGF, and PDGF modify TGFbeta-induction of smooth muscle cell phenotype in human prostatic stromal cells. *Prostate*. 1998;35(2):125–134.

Peters CA, Walsh PC. The effect of nafarelin acetate, a luteinizing-hormone-releasing hormone agonist, on benign prostatic hyperplasia. *N Engl J Med*. 1987;317(10):599–604.

Piccolo RS, Araujo AB, Pearce N, et al. Cohort profile: the Boston Area Community Health (BACH) survey. *Int J Epidemiol*. 2014;43(1):42–51.

Pinsky PF, Kramer BS, Crawford ED, et al. Prostate volume and prostate-specific antigen levels in men enrolled in a large screening trial. *Urology*. 2006;68(2):352–356.

Polnaszek N, Kwabi-Addo B, Wang J, et al. FGF17 is an autocrine prostatic epithelial growth factor and is upregulated in benign prostatic hyperplasia. *Prostate*. 2004;60(1):18–24.

Powell PH, Smith PJ, Feneley RC. The identification of patients at risk from acute retention. *Br J Urol*. 1980;52(6):520–522.

Pradhan BK, Chandra K. Morphogenesis of nodular hyperplasia—prostate. *J Urol*. 1975;113(2):210–213.

Prakash K, Pirozzi G, Elashoff M, et al. Symptomatic and asymptomatic benign prostatic hyperplasia: molecular differentiation by using microarrays. *Proc Natl Acad Sci USA*. 2002;99(11):7598–7603.

Presicce F, De Nunzio C, Tubaro A. Clinical implications for the early treatment of benign prostatic enlargement (BPE): a systematic review. *Curr Urol Rep*. 2018;19(9):70.

Pressler L, Santarosa R, Te A, et al. The incidence of hypertension (HTN) in a population of men with benign prostatic hyperplasia (BPH): analysis based on the AUA symptom score and race. *J Urol*. 1997;157:371A.

Price H, McNeal JE, Stamey TA. Evolving patterns of tissue composition in benign prostatic hyperplasia as a function of specimen size. *Hum Pathol*. 1990;21(6):578–585.

Price DT, Schwinn DA, Lomasney JW, et al. Identification, quantification, and localization of mRNA for three distinct alpha 1 adrenergic receptor subtypes in human prostate. *J Urol*. 1993;150(2 Pt 1):546–551.

Prins GS, Korach KS. The role of estrogens and estrogen receptors in normal prostate growth and disease. *Steroids*. 2008;73(3):233–244.

Prins GS, Marmer M, Woodham C, et al. Estrogen receptor-beta messenger ribonucleic acid ontogeny in the prostate of normal and neonatally estrogenized rats. *Endocrinology*. 1998;139(3):874–883.

Qi J, Tian L, Chen Z, et al. Genetic variants in 2q31 and 5p15 are associated with aggressive benign prostatic hyperplasia in a Chinese population. *Prostate*. 2013;73(11):1182–1190.

Rees J. Alcohol consumption decreases risk of BPH. *Practitioner*. 2009;253(1724):5 [3].

Rennie PS, Bruchovsky N, Goldenberg SL. Relationship of androgen receptors to the growth and regression of the prostate. *Am J Clin Oncol*. 1988;11(Suppl 2):S13–S17.

Reynard JM, Lim C, Peters TJ, et al. The significance of terminal dribbling in men with lower urinary tract symptoms. *Br J Urol*. 1996;77(5):705–710.

Rhodes T, Girman C, Jacobson D, et al. Longitudinal prostate volume in a community-based sample: 7-year followup in the Olmsted County Study of Urinary Symptoms and Health Status among Men. *J Urol*. 2000;163(4):249.

Rhodes T, Girman CJ, Jacobsen SJ, et al. Longitudinal measures of prostate volume in a community-based sample: 3.5 year followup in the Olmsted County study of health status and

Urinary symptoms among men. *J Urol*. 1995;153:301A.

Rhodes T, Girman CJ, Jacobsen SJ, et al. Longitudinal prostate growth rates during 5 years in randomly selected community men 40 to 79 years old. *J Urol*. 1999;161(4):1174–1179.

Roberts AB, Sporn MB. Physiological actions and clinical applications of transforming growth factor-beta (TGF-beta). *Growth Factors*. 1993;8(1):1–9.

Roberts RO, Jacobsen SJ, Jacobson DJ, et al. Longitudinal changes in peak urinary flow rates in a community based cohort. *J Urol*. 2000;163(1):107–113.

Roberts RO, Jacobsen SJ, Rhodes T, et al. Cigarette smoking and prostatism: a biphasic association? *Urology*. 1994;43(6):797–801.

Roberts RO, Rhodes T, Panser LA, et al. Natural history of prostatism: worry and embarrassment from urinary symptoms and health care-seeking behavior. *Urology*. 1994;43(5):621–628.

Roberts RO, Rhodes T, Panser LA, et al. Association between family history of benign prostatic hyperplasia and urinary symptoms: results of a population-based study. *Am J Epidemiol*. 1995;142(9):965–973.

Roberts RO, Rhodes T, Girman CJ, et al. The decision to seek care. Factors associated with the propensity to seek care in a community-based cohort of men. *Arch Fam Med*. 1997;6(3):218–222.

Roberts RO, Tsukamoto T, Kumamoto Y, et al. Association between cigarette smoking and prostatism in a Japanese community. *Prostate*. 1997;30(3):154–159.

Roberts RO, Jacobsen SJ, Rhodes T, et al. Urinary incontinence in a community-based cohort: prevalence and healthcare-seeking. *J Am Geriatr Soc*. 1998;46(4):467–472.

Roberts RO, Jacobson DJ, Girman CJ, et al. Insulin-like growth factor I, insulin-like growth factor binding protein 3, and urologic measures of benign prostatic hyperplasia. *Am J Epidemiol*. 2003;157(9):784–791.

Roberts RO, Jacobson DJ, Rhodes T, et al. Serum sex hormones and measures of benign prostatic hyperplasia. *Prostate*. 2004;61(2):124–131.

Roberts RO, Bergstralh EJ, Farmer SA, et al. Polymorphisms in the 5alpha reductase type 2 gene and urologic measures of BPH. *Prostate*. 2005;62(4):380–387.

Robson MC. Cirrhosis and prostatic neoplasms. *Geriatrics*. 1966;21(12):150–154.

Rodriguez-Nieves JA, Macoska JA. Prostatic fibrosis, lower urinary tract symptoms, and BPH. *Nat Rev Urol*. 2013;10(9):546–550.

Roehrborn CG. The placebo effect in the treatment of benign prostatic hyperplasia. Kirby RS, McConnell JD, Fitzpatrick JM, et al. *Textbook of benign prostatic hyperplasia*. Isis Medical Media, Ltd: Oxford, England; 1996.

Roehrborn CG. The epidemiology of acute urinary retention in benign prostatic hyperplasia. *Rev Urol*. 2001;3(4):187–192.

Roehrborn CG. Pathology of benign prostatic hyperplasia. *Int J Impot Res*. 2008;20(Suppl 3):S11–S18.

Roehrborn CG, Schwinn DA. Alpha1-adrenergic receptors and their inhibitors in lower urinary tract symptoms and benign prostatic hyperplasia. *J Urol*. 2004;171(3):1029–1035.

Roehrborn CG, Lange JL, George FW, et al. Changes in amount and intracellular distribution of androgen receptor in human foreskin as a function of age. *J Clin Invest*. 1987;79(1):44–47.

Roehrborn CG, Girman CJ, Rhodes T, et al. Correlation between prostate size estimated by digital rectal examination and measured by transrectal ultrasound. *Urology*. 1997;49(4):548–557.

Roehrborn CG, Boyle P, Bergner D, et al. Serum prostate-specific antigen and prostate volume predict long-term changes in symptoms and flow rate: results of a four-year, randomized trial comparing finasteride versus placebo. PLESS Study Group. *Urology*. 1999;54(4):662–669.

Roehrborn CG, McConnell JD, Lieber M, et al. Serum prostate-specific antigen concentration is a powerful predictor of acute urinary retention and need for surgery in men with clinical benign prostatic hyperplasia. PLESS Study Group. *Urology*. 1999;53(3):473–480.

Roehrborn CG, Bruskewitz R, Nickel GC, et al. Urinary retention in patients with BPH treated with finasteride or placebo over 4 years: characterization of patients and ultimate outcomes. The PLESS Study Group. *Eur Urol*. 2000;37(5):528–536.

Roehrborn CG, Dolte KS, Ross KS, et al. Incidence and risk reduction of long-term outcomes: a comparison of benign prostatic hyperplasia with several other disease areas. *Urology*. 2000;56(1):9–18.

Roehrborn C, Fuh V, Ruane P, et al. The relationship between total and free PSA, prostate volume and age in men age 40–60 with no clinical diagnosis of benign prostatic hyperplasia necessitating therapy. *J Urol*. 2000;163(Suppl):252A.

Roehrborn CG, Malice M, Cook TJ, et al. Clinical predictors of spontaneous acute urinary retention in men with LUTS and clinical BPH: a comprehensive analysis of the pooled placebo groups of several large clinical trials. *Urology*. 2001;58(2):210–216.

Roehrborn CG, Boyle P, Nickel JC, et al. Efficacy and safety of a dual inhibitor of 5-alpha-reductase types 1 and 2 (dutasteride) in men with benign prostatic hyperplasia. *Urology*. 2002;60(3):434–441.

Roehrborn CG, McVary KT, Elion-Mboussa A, et al. Tadalafil administered once daily for lower urinary tract symptoms secondary to benign prostatic hyperplasia: a dose finding study. *J Urol*. 2008;180(4):1228–1234.

Roehrborn CG, Spann ME, Myers SL, et al. Estrogen receptor beta agonist LY500307 fails to improve symptoms in men with enlarged prostate secondary to benign prostatic hypertrophy. *Prostate Cancer Prostatic Dis*. 2015;18(1):43–48.

Rohrmann S, Smit E, Giovannucci E, et al. Association between markers of the metabolic syndrome and lower urinary tract symptoms in the Third National Health and Nutrition Examination Survey (NHANES III). *Int J Obes (Lond)*. 2005;29(3):310–316.

Ropiquet F, Giri D, Lamb DJ, et al. FGF7 and FGF2 are increased in benign prostatic hyperplasia and are associated with increased proliferation. *J Urol*. 1999;162(2):595–599.

Rosen R, Altwein J, Boyle P, et al. Lower urinary tract symptoms and male sexual dysfunction: the multinational survey of the aging male (MSAM-7). *Eur Urol*. 2003;44(6):637–649.

Rosen RC, Coyne KS, Henry D, et al. Beyond the cluster: methodological and clinical implications in the Boston Area Community Health survey and EPIC studies. *BJU Int*. 2008;101(10):1274–1278.

Rule AD, Jacobson DJ, Roberts RO, et al. The association between benign prostatic hyperplasia and chronic kidney disease in community-dwelling men. *Kidney Int*. 2005;67(6):2376–2382.

Russell DW, Wilson JD. Steroid 5 alpha-reductase: two genes/two enzymes. *Annu Rev Biochem*. 1994;63:25–61.

Sagnier PP, Girman CJ, Garraway M, et al. International comparison of the community prevalence of symptoms of prostatism in four countries. *Eur Urol*. 1996;29(1):15–20.

Sakamoto S, Yokoyama M, Zhang X, et al. Increased expression of CYR61, an extracellular matrix signaling protein, in human benign prostatic hyperplasia and its regulation by lysophosphatidic acid. *Endocrinology*. 2004;145(6):2929–2940.

Salam MT, Ursin G, Skinner EC, et al. Associations between polymorphisms in the steroid 5-alpha reductase type II (SRD5A2) gene and benign prostatic hyperplasia and prostate cancer. *Urol Oncol*. 2005;23(4):246–253.

Salm S, Burger PE, Wilson EL. TGF-beta and stem cell factor regulate cell proliferation in the proximal stem cell niche. *Prostate*. 2012;72(9):998–1005.

Salm SN, Koikawa Y, Ogilvie V, et al. Transforming growth factor-beta is an autocrine mitogen for a novel androgen-responsive murine prostatic smooth muscle cell line, PSMC1. *J Cell Physiol*. 2000;185(3):416–424.

Sanda MG, Beaty TH, Stutzman RE, et al. Genetic susceptibility of benign prostatic hyperplasia. *J Urol*. 1994;152(1):115–119.

Sanda MG, Doehring CB, Binkowitz B, et al. Clinical and biological characteristics of familial benign prostatic hyperplasia. *J Urol*. 1997;157(3):876–879.

Sarma AV, Jacobson DJ, St Sauver JL, et al. Smoking and acute urinary retention: the Olmsted County study of urinary symptoms and health status among men. *Prostate*. 2009;69(7):699–705.

Sarma AV, Wei JT, Jacobson DJ, et al. Comparison of lower urinary tract symptom severity and associated bother between community-dwelling black and white men: the Olmsted County Study of Urinary Symptoms and Health Status and the Flint Men's Health Study. *Urology*. 2003;61(6):1086–1091.

Schauer IG, Ressler SJ, Tuxhorn JA, et al. Elevated epithelial expression of interleukin-8 correlates with myofibroblast reactive stroma in benign prostatic hyperplasia. *Urology*. 2008;72(1):205–213.

Sciarra F, Toscano V. Role of estrogens in human benign prostatic hyperplasia. *Arch Androl*. 2000;44(3):213–220.

Scott R, McIlhaney JS. Voiding rates in normal adults. *J Urol*. 1961;85:980–982.

Sech S, Montoya J, Girman CJ, et al. Interexaminer reliability of transrectal ultrasound for estimating prostate volume. *J Urol*. 2001;166(1):125–129.

Sech SM, Montoya JD, Bernier PA, et al. The so-called "placebo effect" in benign prostatic hyperplasia treatment trials represents partially a conditional regression to the mean induced by censoring. *Urology*. 1998;51(2):242–250.

Seitter WR, Barrett-Connor E. Cigarette smoking, obesity, and benign prostatic hypertrophy: a prospective population-based study. *Am J Epidemiol*. 1992;135(5):500–503.

Shah US, Arlotti J, Dhir R, et al. Androgen regulation of JM-27 is associated with the diseased prostate. *J Androl*. 2004;25(4):618–624.

Shapiro E, Becich MJ, Hartanto V, et al. The relative proportion of stromal and epithelial hyperplasia is related to the development of symptomatic benign prostate hyperplasia. *J Urol*. 1992;147(5):1293–1297.

Sherwood JB, McConnell JD, Vazquez DJ, et al. Heterogeneity of 5 alpha-reductase gene expression in benign prostatic hyperplasia. *J Urol*. 2003;169(2):575–579.

Shirakawa T, Okada H, Acharya B, et al. Messenger RNA levels and enzyme activities of 5 alpha-reductase types 1 and 2 in human benign prostatic hyperplasia (BPH) tissue. *Prostate*. 2004;58(1):33–40.

Sidney S. Vasectomy and the risk of prostatic cancer and benign prostatic hypertrophy. *J Urol*. 1987;138(4):795–797.

Sidney S, Quesenberry C Jr, Sadler MC, et al. Risk factors for surgically treated benign prostatic hyperplasia in a prepaid health care plan. *Urology*. 1991;38(1 Suppl):13–19.

Sidney S, Quesenberry CP Jr, Sadler MC, et al. Incidence of surgically treated benign prostatic hypertrophy and of prostate cancer among blacks and whites in a prepaid health care plan. *Am J Epidemiol*. 1991;134(8):825–829.

Silver RI, Wiley EL, Davis DL, et al. Expression and regulation of steroid 5 alpha-reductase 2 in prostate disease. *J Urol*. 1994;152(2 Pt 1):433–437.

Simon RM, Howard LE, Moreira DM, et al. Does peak urine flow rate predict the development of incident lower urinary tract symptoms in men with mild to no current symptoms? Results from REDUCE. *J Urol*. 2017;198(3):650–656.

Simon RM, Howard LE, Moreira DM, et al. Does prostate size predict the development of incident lower urinary tract symptoms in men with mild to no current symptoms? Results from the REDUCE Trial. *Eur Urol*. 2016;69(5):885–891.

Siroky MB, Olsson CA, Krane RJ. The flow rate nomogram: I Development. *J Urol*. 1979;122(5):665–668.

Siroky MB, Olsson CA, Krane RJ. The flow rate nomogram: II Clinical correlation. *J Urol*. 1980;123(2):208–210.

Smith P, Rhodes NP, Ke Y, et al. Modulating effect of estrogen and testosterone on prostatic stromal cell phenotype differentiation induced by noradrenaline and doxazosin. *Prostate*. 2000;44(2):111–117.

Smith P, Rhodes NP, Ke Y, et al. Upregulation of estrogen and androgen receptors modulate expression of FGF-2 and FGF-7 in human, cultured, prostatic stromal cells exposed to high concentrations of estradiol. *Prostate Cancer Prostatic Dis*. 2002;5(2):105–110.

Sorrentino C, Musiani P, Pompa P, et al. Androgen deprivation boosts prostatic infiltration of cytotoxic and regulatory T lymphocytes and has no effect on disease-free survival in prostate cancer patients. *Clin Cancer Res*. 2011;17(6):1571–1581.

Soygur T, Kupeli B, Aydos K, et al. Effect of obesity on prostatic hyperplasia: its relation to sex steroid levels. *Int Urol Nephrol*. 1996;28(1):55–59.

Spiro LH, Labay G, Orkin LA. Prostatic infarction. Role in acute urinary retention. *Urology*. 1974;3(3):345–347.

Sporn MB, Roberts AB. TGF-beta: problems and prospects. *Cell Regul*. 1990;1(12):875–882.

Srinivasan D, Kosaka AH, Daniels DV, et al. Pharmacological and functional characterization of bradykinin B2 receptor in human prostate. *Eur J Pharmacol*. 2004;504(3):155–167.

Steele GS, Sullivan MP, Sleep DJ, et al. Combination of symptom score, flow rate and prostate volume for predicting bladder outflow obstruction in men with lower urinary tract symptoms. *J Urol*. 2000;164(2):344–348.

Steers WD, Ciambotti J, Erdman S, et al. Morphological plasticity in efferent pathways to the urinary bladder of the rat following urethral obstruction. *J Neurosci*. 1990;10(6):1943–1951.

Steers WD, Clemow DB, Persson K, et al. The spontaneously hypertensive rat: insight into the pathogenesis of irritative symptoms in benign prostatic hyperplasia and young anxious males. *Exp Physiol*. 1999;84(1):137–147.

Steiner MS. Review of peptide growth factors in benign prostatic hyperplasia and urological malignancy. *J Urol*. 1995;153(4):1085–1096.

Steiner GE, Newman ME, Paikl D, et al. Expression and function of pro-inflammatory interleukin IL-17 and IL-17 receptor in normal, benign hyperplastic, and malignant prostate. *Prostate*. 2003;56(3):171–182.

Steiner GE, Stix U, Handisurya A, et al. Cytokine expression pattern in benign prostatic hyperplasia infiltrating T cells and impact of lymphocytic infiltration on cytokine mRNA profile in prostatic tissue. *Lab Invest*. 2003;83(8):1131–1146.

Stief CG, Porst H, Neuser D, et al. A randomised, placebo-controlled study to assess the efficacy of twice-daily vardenafil in the treatment of lower urinary tract symptoms secondary to benign prostatic hyperplasia. *Eur Urol*. 2008;53(6):1236–1244.

Stimson JB, Fihn SD. Benign prostatic hyperplasia and its treatment. *J Gen Intern Med*. 1990;5(2):153–165.

Story MT, Hopp KA, Meier DA, et al. Influence of transforming growth factor beta 1 and other growth factors on basic fibroblast growth factor level and proliferation of cultured human prostate-derived fibroblasts. *Prostate*. 1993;22(3):183–197.

Story MT, Livingston B, Baeten L, et al. Cultured human prostate-derived fibroblasts produce a factor that stimulates their growth with properties indistinguishable from basic fibroblast growth factor. *Prostate*. 1989;15(4):355–365.

Strand DW, Costa DN, Francis F, et al. Targeting phenotypic heterogeneity in benign prostatic hyperplasia. *Differentiation*. 2017;96:49–61.

Stumpf HH, Wilens SL. Inhibitory effects of portal cirrhosis of liver on prostatic enlargement. *AMA Arch Intern Med*. 1953;91(3):304–309.

Su L, Guess HA, Girman CJ, et al. Adverse effects of medications on urinary symptoms and flow rate: a community-based study. *J Clin Epidemiol*. 1996;49(4):483–487.

Sugimura Y, Cunha GR, Bigsby RM. Androgenic induction of DNA synthesis in prostatic glands induced in the urothelium of testicular feminized (Tfm/Y) mice. *Prostate*. 1986;9(3):217–225.

Sugimura Y, Cunha GR, Donjacour AA. Morphological and histological study of castration-induced degeneration and androgen-induced regeneration in the mouse prostate. *Biol Reprod*. 1986;34(5):973–983.

Susset JG, Picker P, Kretz M, et al. Critical evaluation of uroflowmeters and analysis of normal curves. *J Urol*. 1973;109(5):874–878.

Sutkowski DM, Kasjanski RZ, Sensibar JA, et al. Effect of spermatocele fluid on growth of human prostatic cells in culture. *J Androl*. 1993;14(4):233–239.

Swyer GI. Post-natal growth changes in the human prostate. *J Anat*. 1944;78(Pt 4):130–145.

Takane KK, Husmann DA, McPhaul MJ, et al. Androgen receptor levels in the rat penis are controlled differently in distinctive cell types. *Endocrinology*. 1991;128(5):2234–2238.

Takane KK, Wilson JD, McPhaul MJ. Decreased levels of the androgen receptor in the mature rat phallus are associated with decreased levels of androgen receptor messenger ribonucleic acid. *Endocrinology*. 1991;129(2):1093–1100.

Taoka R, Tsukuda F, Ishikawa M, et al. Association of prostatic inflammation with down-regulation of macrophage inhibitory cytokine-1 gene in symptomatic benign prostatic hyperplasia. *J Urol*. 2004;171(6 Pt 1):2330–2335.

Tarcan T, Azadzoi KM, Siroky MB, et al. Age-related erectile and voiding dysfunction: the role of arterial insufficiency. *Br J Urol*. 1998;82(Suppl 1):26–33.

Tay KP, Chin CM, Lim PH, et al. Prostate screening—the Singapore experience. *Int J Urol*. 1996;3(2):102–107.

Tenniswood M. Role of epithelial-stromal interactions in the control of gene expression in the prostate: an hypothesis. *Prostate*. 1986;9(4):375–385.

Theyer G, Kramer G, Assmann I, et al. Phenotypic characterization of infiltrating leukocytes in benign prostatic hyperplasia. *Lab Invest*. 1992;66(1):96–107.

Thigpen AE, Silver RI, Guileyardo JM, et al. Tissue distribution and ontogeny of steroid 5 alpha-reductase isozyme expression. *J Clin Invest*. 1993;92(2):903–910.

Thomas LN, Douglas RC, Lazier CB, et al. Type 1 and type 2 5alpha-reductase expression in the development and progression of prostate cancer. *Eur Urol*. 2008;53(2):244–252.

Thomas LN, Douglas RC, Vessey JP, et al. 5alpha-reductase type 1 immunostaining is enhanced in some prostate cancers compared with benign prostatic hyperplasia epithelium. *J Urol*. 2003;170(5):2019–2025.

Toivanen R, Mohan A, Shen MM. Basal progenitors contribute to repair of the prostate epithelium following induced luminal anoikis. *Stem Cell Reports*. 2016;6(5):660–667.

Torp-Pedersen ST, Littrup PJ, Lee F, et al. Early prostate cancer: diagnostic costs of screening transrectal US and digital rectal examination. *Radiology*. 1988;169(2):351–354 3140290.

Trifiro MD, Parsons JK, Palazzi-Churas K, et al. Serum sex hormones and the 20-year risk of lower urinary tract symptoms in community-dwelling older men. *BJU Int*. 2010;105(11):1554–1559.

Tsang KK, Garraway WM. Impact of benign prostatic hyperplasia on general well-being of men. *Prostate*. 1993;23(1):1–7.

Tsukamoto T, Kumamoto Y, Masumori N, et al. Prevalence of prostatism in Japanese men in a community-based study with comparison to a similar American study. *J Urol*. 1995;154(2 Pt 1):391–395.

Uckert S, Kuthe A, Stief CG, et al. Phosphodiesterase isoenzymes as pharmacological targets in the treatment of male erectile dysfunction. *World J Urol*. 2001;19(1):14–22.

Uckert S, Sormes M, Kedia G, et al. Effects of phosphodiesterase inhibitors on tension induced by norepinephrine and accumulation of cyclic nucleotides in isolated human prostatic tissue. *Urology*. 2008;71(3):526–530.

Uckert S, Sigl K, Waldkirch ES, et al. [Significance of phosphodiesterase isoenzymes in the control of human detrusor smooth muscle function: an immunohistochemical and functional study.]. *Urologe A*. 2009;48(7):764–769.

Untergasser G, Madersbacher S, Berger P. Benign prostatic hyperplasia: age-related tissue-remodeling. *Exp Gerontol*. 2005;40(3):121–128.

Uzun H, Oğullar S, Ünal H, et al. Non-alcoholic fatty liver disease is associated with benign prostate hyperplasia in men and with overactive bladder in women. *Scand J Urol*. 2013;47(6):497–502.

Verhamme KM, Dieleman JP, van Wijk MA, et al. Low incidence of acute urinary retention in the general male population: the triumph project. *Eur Urol*. 2005;47(4):494–498.

Vignozzi L, Cellai I, Santi R, et al. Antiinflammatory effect of androgen receptor activation in human benign prostatic hyperplasia cells. *J Endocrinol*. 2012;214(1):31–43.

Vignozzi L, Morelli A, Sarchielli E, et al. Testosterone protects from metabolic syndrome–associated prostate inflammation: an experimental study in rabbit. *J Endocrinol*. 2012;212(1):71–84.

von Garrelts B. Analysis of micturition. A new method of recording the voiding of the bladder. *Acta Chir Scand*. 1956;112(3–4):326–340.

von Garrelts B. Micturition in the normal male. *Acta Chir Scand*. 1957;114(3):197–210.

von Garrelts B. Micturition in disorders of the prostate and posterior urethra. *Acta Chir Scand*. 1958;115(3):227–241.

Walden PD, Ittmann M, Monaco ME, et al. Endothelin-1 production and agonist activities in cultured prostate-derived cells: implications for regulation of endothelin bioactivity and bioavailability in prostatic hyperplasia. *Prostate*. 1998;34(4):241–250.

Walden PD, Lefkowitz GK, Ittmann M, et al. Mitogenic activation of human prostate-derived fibromuscular stromal cells by bradykinin. *Br J Pharmacol*. 1999;127(1):220–226.

Walsh K, Sriprasad S, Hopster D, et al. Distribution of vascular endothelial growth factor (VEGF) in prostate disease. *Prostate Cancer Prostatic Dis*. 2002;5(2):119–122.

Walsh PC, Hutchins GM, Ewing LL. Tissue content of dihydrotestosterone in human prostatic hyperplasia is not supernormal. *J Clin Invest*. 1983;72(5):1772–1777.

Walsh PC, Wilson JD. The induction of prostatic hypertrophy in the dog with androstanediol. *J Clin Invest*. 1976;57(4):1093–1097.

Wang BE, Shou J, Ross S, et al. Inhibition of epithelial ductal branching in the prostate by sonic hedgehog is indirectly mediated by stromal cells. *J Biol Chem*. 2003;278(20):18506–18513.

Wang HH, Wang L, Jerde TJ, et al. Characterization of autoimmune inflammation induced prostate stem cell expansion. *Prostate*. 2015;75(14):1620–1631.

Wang W, Bergh A, Damber JE. Chronic inflammation in benign prostate hyperplasia is associated with focal upregulation of cyclooxygenase-2, Bcl-2, and cell proliferation in the glandular epithelium. *Prostate*. 2004;61(1):60–72.

Wang X, Kruithof-de Julio M, Economides KD, et al. A luminal epithelial stem cell that is a cell of origin for prostate cancer. *Nature*. 2009;461(7263):495–500.

Wang XD, Shou J, Wong P, et al. Notch1-expressing cells are indispensable for prostatic branching morphogenesis during development and re-growth following castration and androgen replacement. *J Biol Chem*. 2004;279(23):24733–24744.

Wang Z, Hu L, Salari K, et al. Androgenic to oestrogenic switch in the human adult prostate gland is regulated by epigenetic silencing of steroid 5alpha-reductase 2. *J Pathol*. 2017;243(4):457–467.

Wang Z, Tufts R, Haleem R, et al. Genes regulated by androgen in the rat ventral prostate. *Proc Natl Acad Sci USA*. 1997;94(24):12999–13004.

Wasson JH, Bubolz TA, Lu-Yao GL, et al. Transurethral resection of the prostate among medicare beneficiaries: 1984 to 1997. For the Patient Outcomes Research Team for Prostatic Diseases. *J Urol*. 2000;164(4):1212–1215.

Wasson JH, Reda DJ, Bruskewitz RC, et al. A comparison of transurethral surgery with watchful waiting for moderate symptoms of benign prostatic hyperplasia. The Veterans Affairs Cooperative Study Group on Transurethral Resection of the Prostate. *N Engl J Med*. 1995;332(2):75–79.

Wein AJ, Coyne KS, Tubaro A, et al. The impact of lower urinary tract symptoms on male sexual health: EpiLUTS. *BJU Int*. 2009;103(Suppl 3):33–41.

Wennberg JE, Mulley AG Jr, Hanley D, et al. An assessment of prostatectomy for benign urinary tract obstruction: geographic variations and the evaluation of medical care outcomes. *JAMA*. 1988;259(20):3027–3030.

Wennbo H, Kindblom J, Isaksson OG, et al. Transgenic mice overexpressing the prolactin gene develop dramatic enlargement of the prostate gland. *Endocrinology*. 1997;138(10):4410–4415.

Werely CJ, Heyns CF, Van Velden DJ, et al. DNA fingerprint detection of somatic mutations in benign prostatic hyperplasia and prostatic adenocarcinoma. *Genes*

Chromosomes Cancer. 1996;17(1):31–36.

White JJ, Neuwirth H, Miller CD, et al. DNA alterations in prostatic adenocarcinoma and benign prostatic hyperplasia: detection by DNA fingerprint analyses. *Mutat Res*. 1990;237(1):37–43.

Wilding G, Zugmeier G, Knabbe C, et al. Differential effects of transforming growth factor beta on human prostate cancer cells in vitro. *Mol Cell Endocrinol*. 1989;62(1):79–87.

Wilson IB, Cleary PD. Linking clinical variables with health-related quality of life. A conceptual model of patient outcomes. *JAMA*. 1995;273(1):59–65.

Witjes WP, Aarnink RG, Ezz-el-Din K, et al. The correlation between prostate volume, transition zone volume, transition zone index and clinical and urodynamic investigations in patients with lower urinary tract symptoms. *Br J Urol*. 1997;80(1):84–90.

Wu S. Anatomic changes in the prostate of patients with cirrhosis of the liver. *Arch Pathol*. 1942;34:735–741.

Wu X, Xu K, Zhang L, et al. Differentiation of the ductal epithelium and smooth muscle in the prostate gland are regulated by the Notch/PTEN-dependent mechanism. *Dev Biol*. 2011;356(2):337–349.

Xu H, Fu S, Chen Y, et al. Smoking habits and benign prostatic hyperplasia: a systematic review and meta-analysis of observational studies. *Medicine (Baltimore)*. 2016;95(32):e4565.

Yalla SV, Sullivan MP, Lecamwasam HS, et al. Correlation of American Urological Association symptom index with obstructive and nonobstructive prostatism. *J Urol*. 1995;153(3 Pt 1):674–679 [discussion 679–680].

Yan G, Fukabori Y, Nikolaropoulos S, et al. Heparin-binding keratinocyte growth factor is a candidate stromal-to-epithelial-cell andromedin. *Mol Endocrinol*.

1992;6(12):2123–2128.

Yang CC, Weinfurt KP, Merion RM, et al. Symptoms of lower urinary tract dysfunction research network. *J Urol*. 2016;196(1):146–152.

Yang G, Timme TL, Park SH, et al. Transforming growth factor beta 1 transduced mouse prostate reconstitutions: II. Induction of apoptosis by doxazosin. *Prostate*. 1997;33(3):157–163.

Yu M, Bushman W. Differential stage-dependent regulation of prostatic epithelial morphogenesis by Hedgehog signaling. *Dev Biol*. 2013;380(1):87–98.

Zhang B, Kwon OJ, Henry G, et al. Non-cell-autonomous regulation of prostate epithelial homeostasis by androgen receptor. *Mol Cell*. 2016;63(6):976–989.

Zucchetto A, Tavani A, Dal Maso L, et al. History of weight and obesity through life and risk of benign prostatic hyperplasia. *Int J Obes (Lond)*. 2005;29(7):798–803.

145

Evaluation and Nonsurgical Management of Benign Prostatic Hyperplasia

---

Paolo Capogrosso MD, Andrea Salonia MD, PhD, Francesco Montorsi MD, FRCS (Hon)

The term **benign prostatic hyperplasia (BPH)** has been historically used to define a disease characterized by symptoms of urinary dysfunction as a consequence of an obstacle to micturition caused by an enlarged prostate. During recent decades, the acronym **LUTS (i.e., lower urinary tract symptoms)** has been introduced as an umbrella term to define a complex of symptoms involving dysfunction of both the storage phase and the voiding phase of micturition, and BPH has been referred to a histologic diagnosis characterized by the proliferation of smooth muscle and epithelial cells within the prostatic transition zone (Abrams 1994; Abrams et al., 1982; Chapple et al., 2008).

LUTS are considered as a clinical manifestation with a multifactorial pathophysiology arising from different conditions, including bladder outlet obstruction (BOO) possibly caused by benign prostatic obstruction (BPO), associated with benign prostatic enlargement (BPE), and potentially resulting from the histologic condition of BPH (Abrams et al., 2002). However, LUTS may also be the expression of nonprostatic conditions, such as bladder dysfunction (e.g., detrusor overactivity [DO] or detrusor underactivity [DUA]), urethral strictures, or urinary tract infections (UTIs) (Chapple et al., 2008). In addition, nonurologic conditions involving hormonal, metabolic, and cardiovascular processes (Chapple et al., 2008; Gacci et al., 2016a) and neurologic diseases (Panicker et al., 2015) can be responsible for LUTS as a whole.

It is clear that patients bothered by LUTS and seeking first medical help cannot be regarded as affected only by BOO caused by BPH until a more comprehensive assessment of their condition has been undertaken. Therefore, as currently outlined by a number of international clinical guidelines (Gratzke et al., 2015; McVary et al., 2011), a physician should follow a diagnostic algorithm aimed to assess LUTS severity and identify the pathogenesis, which would further drive therapeutic management.

In this chapter, we discuss patient workup in men seeking first medical help because of LUTS, focusing on the clinical management of those bothered by LUTS caused by BOO associated with BPE resulting from BPH.

Diagnostic Evaluation

LUTS are a complex of symptoms bothering up to 51.3% of men (Irwin et al., 2006) with a detrimental impact on health-related quality of life (QoL) (Kupelian et al., 2006), and a consequent relevant social and economic burden. **The proper diagnostic assessment of men complaining of LUTS represents a major issue in the everyday clinical practice of both general physicians and urologists.**

The diagnostic workup of every patient with LUTS should aim at evaluating the severity of symptoms and their impact on a patient's QoL, and the proper assessment of the underlying conditions, which is essential for correct therapeutic management.

A basic diagnostic evaluation, including medical history, physical examination, and urinalysis, is often crucial to exclude most—if not all—nonprostatic causes of LUTS. Additional diagnostic tests could be further required to better clarify the diagnosis, improve disease severity estimation, and predict the response to treatment. The American Urological Association (AUA) BPH guidelines were last updated in 2010 (McVary et al., 2011). The full version is available at: http://www.auanet.org/guidelines/benign-prostatic-hyperplasia-(2010-reviewed-and-validity-confirmed-2014); the European Association of Urology (EAU) has more recently updated its guidelines regarding the clinical evaluation and treatment of nonneurogenic male LUTS (Gratzke et al., 2015; Oelke et al., 2013). The full version is available at: https://uroweb.org/wp-content/uploads/EAU-Guidelines-Management-of-no n-neurogenic-male-LUTS-2016.pdf.

Medical History

Both internationally published guidelines and expert consensus panels emphasize the importance of a comprehensive medical history as a first step in the evaluation of patients with LUTS (Gratzke et al., 2015; McVary et al., 2011). **The main goal of the baseline interview of any patient is to identify potential causes of LUTS so as to further address the diagnostic and therapeutic decision-making process with a more patient-tailored approach.**

Patients should be comprehensively evaluated in terms of comorbidities, with a specific focus on those medical conditions potentially associated with LUTS, including diabetes (either diabetes mellitus or diabetes insipidus), renal diseases, heart failure, sleep apnea, and neurologic diseases (e.g., Parkinson's disease, multiple sclerosis, cerebrovascular disease, spinal cord injury, or prolapsed intervertebral disc impinging on the spinal cord) (Gratzke et al., 2015). A history of conditions affecting the lower urinary tract and the occurrence of gross hematuria should be investigated as well, along with the history of any previous surgical intervention involving the prostate, bladder, or urethra. It is recommended to assess any medication potentially worsening storage symptoms, such as loop diuretics and β-blockers (Lewandowski et al., 2013; Ruby et al., 2010), and also anticholinergic drugs, which may significantly impair bladder contractility.

In addition, emotional and psychological factors and lifestyle habits should be assessed: the association between food and fluid intake and LUTS severity has recently been reviewed, showing a negative impact of increased fluid and caffeine intake on storage symptoms (Bradley et al., 2017). Similarly, a bidirectional association between LUTS and emotional distress has been reported (Coyne et al., 2009).

As a final task, physicians should reassure the patient regarding the lack of an association between LUTS and prostate cancer (PCa) risk (Gratzke et al., 2015).

Symptom Assessment

LUTS can be ascribed to the macrocategories of voiding and storage phase impairment: the former includes weak urinary stream, sensation of incomplete urination, hesitancy, straining, prolonged micturition, and dribbling; the latter includes frequency, urgency, urge incontinence, and nocturia (Abrams 1994; Chapple et al., 2008). Voiding symptoms in men are frequently related to BOO, although they cannot always be ascribed to BPE/BPH (Abrams et al., 2002; Chapple et al., 2008). Likewise, storage symptoms, which have been recently largely encompassed by the term *overactive bladder (OAB) syndrome*, also can be associated with an obstacle to micturition eventually caused by BPE/BPH (Chapple et al., 2008; Drake 2014).

The quantification of symptom severity and the assessment of how a given level of symptoms may affect each man's QoL (degree of associated bothersome) provides valuable information in terms of the severity of disease, response to therapy, and risk for disease progression.

Patient-reported outcomes, through the use of internationally validated questionnaires, are currently considered the gold standard to assess disease severity in the primary setting (Gratzke et al., 2015; McVary et al., 2011). Barry et al. (1992) developed and validated the American Urological Association Symptom Index (AUASI) for BPH. The AUASI includes seven questions investigating frequency, nocturia, weak urinary stream, hesitancy, intermittence, incomplete emptying, and urgency: a score of 0 to 5 points can be assigned to each question, producing a total symptom score ranging from 0 to 35. According to the final score, symptoms can be classified as mild (0 to 7), moderate (8 to 19), or severe (20 to 35). This seven-question set is internally consistent and reliable, correlates strongly with patients' global ratings of their urinary difficulties, and is sensitive to treatment response. In 1993, the World Health of Organization adapted the AUASI to create the International Prostate Symptom Score (IPSS), which is based on the original seven questions combined with one more question devoted to assessing the degree to which patients find their symptoms bothersome (bother score) (Cockett et al., 1994). **The IPSS is currently considered the international standard tool to investigate LUTS severity.**

Recently a further segregation of the IPSS into storage (three questions) and voiding (four questions) subscales was suggested to provide a more reliable measure of storage and voiding dysfunctions, although these subscales have not been validated yet.

Despite the accuracy of both the AUASI and the IPSS in assessing LUTS severity, these tools are not intended to be used for a clinical diagnosis of BOO (Gratzke et al., 2015; McVary et al., 2011). Indeed LUTS severity has been poorly correlated with the underlying pathophysiology (McVary et al., 2011; Gratzke et al., 2015). D'Silva et al. (2014) reviewed available evidence for the diagnostic accuracy of questionnaires widely used to diagnose BOO, using urodynamic multichannel studies as a reference standard. They reported a likelihood ratio 95% confidence interval (CI) of 1.1 to 2.0 for patients with an IPSS above 20 and 0.67 to 1.00 for patients with an IPSS below 20. Their findings confirmed the poor diagnostic accuracy of the IPSS as a single instrument to identify patients with BOO.

Beside the IPSS, other tools have been developed and validated to investigate LUTS severity and treatment outcomes. To this specific aim, an AUA committee developed the BPH Impact Index (BII), assessing the impact of BPH symptoms on patients' health and functioning (Barry et al., 1995). The BII is a four-question tool dealing with urinary symptoms concerning physical discomfort, concern for individual health, how bothersome symptoms are, and whether the symptoms are interfering with usual activities. The International Consultation on Incontinence Modular Questionnaire—male LUTS (ICIQ-MLUTS) was derived from the International Continence Society (ICS) male questionnaire, and allows evaluation of the degree of bother associated with a specific symptom, using a 0 to 10 linear analog scale (Abrams et al., 2006a). Similarly, the Danish Prostate Symptom Score (DAN-PSS) showed good correlation with LUTS severity, and is sensitive to symptom changes after therapy (Pannek et al., 1998). However, compared with the IPSS, the DAN-PSS does not correlate with obstruction (Pannek et al., 1998). In addition, given the high prevalence of storage symptoms affecting also the female counterpart (Irwin et al., 2006), specific tools—such as the Overactive Bladder Symptom Score (OABSS) (Homma et al., 2006) and the Overactive Bladder Questionnaire (OAB-q)—have been specifically developed to assess storage symptoms and their impact on QoL (Coyne et al., 2002). Both tools could be useful for a comprehensive estimation of the degree of symptom-associated bother for patients with a prevalent storage component.

Finally, evidence of a strong link between LUTS/BPH and sexual dysfunction (Rosen et al., 2003) supports the investigation of sexual issues, which may negatively affect a patient's QoL and deserve further attention (Gratzke et al., 2015).

Physical Examination

Physical examination is an important step in the basic workup of every patient complaining of LUTS, and should not be neglected (Gratzke et al., 2015; McVary et al., 2011). Physicians should accurately assess the male pelvis, mostly to identify disorders potentially associated with LUTS. To this aim, the suprapubic area must be inspected to exclude an overdistended, palpable, or percussable bladder. Moreover, the penis deserves to be carefully evaluated to exclude any stricture of the external meatus, potentially responsible for BOO, as well as the presence of a phimosis or of malignant lesions of the penile skin/foreskin. The ventral side of the penis should be palpated to search for palpable urethral masses as an indirect sign of strictures. Similarly, the presence of urethral discharges should be taken into consideration as a sign of urethritis. The scrotum and the testicles should always be examined to look for signs of orchiepididymitis. Moreover, the evaluation of testicular size along with other secondary male sex characteristics (e.g., body hair, pattern of hair loss) may be useful to detect a low testosterone level, which could be associated with central obesity and metabolic alterations suggestive of metabolic syndrome. Indeed, the association between metabolic alterations and BPE has been widely demonstrated (Gacci et al., 2015); as such, LUTS patients with elevated BMI and signs suggestive for metabolic syndrome may benefit from lifestyle changing involving dietary interventions (Gratzke et al., 2015). In addition, the motor/sensory functions of the perineum and the lower limb should be assessed to rule out neurologic alterations.

As the last step of the physical assessment, a digital rectal examination (DRE) should be performed. **DRE has a double aim: (1) to obtain a baseline estimation of prostate volume (PV), which is a useful parameter throughout the clinical decision-making process; and (2) to exclude the presence of palpable nodules or any increased consistency that may signal the presence of PCa.**

The sensitivity of DRE in detecting PCa is low, with historical series showing PCa detection rates on biopsy as low as 40% to 50% in the era before prostate-specific antigen (PSA) testing among patients with positive DRE findings (Chodak et al., 1989). More recently, positive predictive values of abnormal DRE findings have been reported, ranging from 6% to 33% (Bozeman et al., 2005). However, in the European Randomized Study of Screening for Prostate Cancer (ERSPC), DRE was found to be useful in combination with PSA testing to decrease overdiagnosis of cancer (Gosselaar et al., 2008).

The PV tends to be underestimated by DRE, because of impalpable areas on the bilateral prostate (Roehrborn 1998), especially for PV greater than 30 mL. However, Bosch et al. (2004) reported a positive predictive value of 69.2% for a 30-mL cutoff level and 99.8% for a 50-mL cutoff level; similarly, a positive predictive value of 94.1% for PV less than 30 mL has been associated with the presence of a flat/normal prostate on DRE (Yamamoto et al., 2017). In this context, although PV does not correlate with LUTS severity or with the degree of obstruction (Roehrborn et al., 1986; Simonsen et al., 1987), the 30- and 50-mL cutoffs could be useful to predict treatment response and the risk for disease progression (Roehrborn et al., 2001).

Finally, anal sphincter tone should be assessed while a DRE is being performed: a flaccid or spastic sphincter may be a sign of neurologic disorders (Gratzke et al., 2015; McVary et al., 2011).

Frequency-Volume Charts and Bladder Diaries

The assessment of the storage component of LUTS should rely on the use of urinary diaries, providing the caregiver with an objective estimation of the patient's urinary behavior.

The ICS has defined three types of urinary diaries (Abrams et al., 2002), based on recorded parameters:

- Micturition charts, recording the time of each micturition for at least 24 hours
- Frequency-volume charts (FVCs), recording the voided volume and the time of each micturition during day and night hours for 24 hours
- Bladder diaries, recording the time of micturition, voided volume, and additional information such as fluid intake, incontinence episodes, degree of incontinence, pad usage, and degree of urgency

With these tools, it is possible to estimate the so-called *24-hour voiding frequency*, the fraction of urine production during the night (nocturnal polyuria index), and the mean voided volume.

International clinical guidelines advise that FVCs (or their derived forms) should be used during the basic evaluation of patients with prevalent storage LUTS or nocturia (Abrams et al., 2013; Gratzke et al., 2015; McVary et al., 2011). FVCs are considered as a mainstay for the assessment of nocturia (Cornu et al., 2012). Nocturia has been defined as “the complaint that an individual has to wake at night one or more times to void” (Abrams et al., 2002), and belongs to the storage component of LUTS. FVCs are regarded as more accurate than recall-based measures, such as the IPSS questionnaire, in terms of nocturia diagnosis (Yap et al., 2007) and to characterize its underlying mechanism (Weiss et al., 2012). However, there is a substantial heterogeneity concerning the content, format, and the duration of urinary diaries in the literature; moreover, a bladder training effect has been associated with the use of FVCs, thus leading to biased measurements (Vaughan et al., 2014). In this context, instructing patients not to change their routines and teaching them how to complete the FVCs might reduce these types of measurement error. As a main issue of controversy, the exact duration of the assessment should be carefully selected, given the reported evidence of reduced adherence associated with a prolonged assessment (7 days), and an increase in the reliability of measures caused by a higher number of recording days (Bright et al., 2011). In a systematic review aimed at identifying the proper duration of an FVC assessment, Yap et al. (2007) recommended the use of FVCs with a duration of 3 days or more. Bright et al. (2014) conducted a phase II prospective study aimed at validating urinary diaries according to the psychometric validation protocol of the ICS: they assessed the optimal diary duration by comparing a 4-day diary with diaries of shorter durations, and concluded that 3 days should be considered as a reference duration.

Laboratory Tests

Laboratory tests are used both as part of the basic patient's evaluation and as secondary investigations in selected clinical contexts (Gratzke et al., 2015; McVary et al., 2011).

Urinalysis

The use of a dipstick test and/or the microscopic evaluation of urine samples is suggested in all patients complaining of LUTS as a part of the baseline evaluation (Gratzke et al., 2015; McVary et al., 2011). This costless and readily available tool could provide the physician with useful information to help the differential diagnosis and to prompt secondary diagnostic tests, when needed.

The presence of pyuria and a positive nitrite test on urinalysis suggest an underlying urinary tract infection (UTI), which could be responsible for reported patient symptoms. However, in a prospective study assessing the accuracy of dipstick urinalysis and microscopic pyuria in detecting UTI among patients presenting for painless LUTS, sensitivities of only 56%, 10%, and 56% for 10^5 cfu/mL leukocyte esterase, the presence of nitrites, and microscopic pyuria, respectively, were reported (Khasriya et al., 2010).

Moreover, the presence of gross hematuria should prompt the physician to exclude the presence of bladder cancer; likewise, proteinuria, glucosuria, and ketonuria detected by urinalysis could be considered a sign of diabetes mellitus, potentially correlated with LUTS.

Urine cytology should always be requested in men with severe storage symptoms and dysuria, especially if they have a smoking history.

Prospective controlled trials assessing the clinical benefit of urinalysis for the basic evaluation of patients with LUTS are currently lacking. However, the general expert consensus is that the benefits of such a readily available diagnostic test outweigh the costs.

Prostate-Specific Antigen

The value of PSA testing among patients presenting for LUTS is multiple: assess the risk and eventually rule out the presence of PCa; estimate PV; and predict BPH-related outcomes.

BPH and PCa are two distinct conditions that may often overlap: autopsy studies provided evidence for the coexistence of PCa and BPH in 83% of cases (Bostwick et al., 1992). Moreover, in a large European population-based study including 3 million men, a significant association between LUTS and the risk for subsequent diagnosis of PCa was reported, with hazard ratios (HRs) ranging from 2.2 to 4.5 (Ørsted et al., 2011). However, these results could have been affected by a detection bias related to a higher frequency of medical assessments for men complaining of LUTS compared with controls, which could result in a greater likelihood of testing and diagnosis of PCa. Indeed, in a prospective study assessing the association between LUTS and PCa in 1922 men, those treated for LUTS were more likely to undergo prostate biopsy (HR, 2.4; 95% CI, 1.7 to 3.3), thus resulting in an increased PCa diagnosis rate for men younger than 65 years of age (Weight et al., 2013). Moreover, in the placebo arm of the Prostate Cancer Prevention Trial (PCPT), there was no association between LUTS and PCa (Schenk et al., 2011).

Outlet obstruction is likely a late event in the natural history of PCa, infrequently occurring in the modern era (Bhindi et al., 2017). Serum PSA trends over time (PSA velocity), measurement of free versus complexed PSA, PSA density, and new markers such as PCA3 and p2PSA (Lazzeri et al., 2013) may help to improve PSA testing specificity in men with BPH. In this context, the benefits and risks of PSA testing always should be discussed with every patient, considering the possibility of false-positive and false-negative results and the complications possibly associated with prostatic biopsy. **Current international clinical guidelines suggest measurement of PSA if a diagnosis of PCa will change LUTS management,** excluding, for instance, those men with a life expectancy of less than 10 years (Gratzke et al., 2015; McVary et al., 2011).

Data from pooled analysis of placebo-controlled trials showed that the PSA test has an area under the curve of 0.76 to 0.78 for various PV thresholds (30 mL, 40 mL, 50 mL) (Bohnen et al., 2007). Moreover, a PSA level of more than 1.6 ng/mL, more than 2.0 ng/mL, and more than 2.3 ng/mL was associated with a sensitivity of 70% and a specificity of 65% to 70% in terms of detection of PV greater than 40 mL for patients in their 50s, 60s, and 70s, respectively (Bohnen et al., 2007). Comparable accuracy in the estimation of PV was reported for free PSA (Kayikci et al., 2012). Both PSA forms were found to predict transrectal ultrasound (TRUS)-measured PV to within ±20% in more than 90% of cases (Morote et al., 2000).

PSA level is also a predictor of BPH-related outcomes. In a large randomized trial, PSA level correctly predicted changes in terms of LUTS, QoL, and maximum urinary flow rate (Qmax) (Roehrborn et al., 1999). Moreover, baseline PSA level was found to be a consistent predictor of acute urinary retention (AUR) and BPH-related surgery in the placebo arm of large long-term randomized controlled studies (McConnell et al., 2003; Roehrborn et al., 2008a). In addition, a positive predictive value of 68% for the diagnosis of BOO has been reported to be associated with total PSA levels (Lim et al., 2006).

Finally, caution should be paid in patients treated with 5α-reductase inhibitors (5ARIs), given that serum PSA level is reduced by 40% to 50% after 12 months of treatment (Guess et al., 1993). Failure to establish a baseline (pretreatment) PSA level may complicate the interpretation of future PSA assessments.

Renal Function Assessment

The assessment of renal function based on serum creatinine level or estimated glomerular filtration rate is not routinely suggested in patients with LUTS (Gratzke et al., 2015; McVary et al., 2011)**. As a whole, AUA guidelines no longer recommend a routine renal function assessment, but EAU guidelines suggest assessment of serum creatinine level if renal impairment is suspected on the basis of medical history or when surgical treatment is considered.**

An elevated serum creatinine level was found in 11% of patients presenting for LUTS (Gerber et al., 1997). In a more recent series, 161 of 2741 LUTS patients (5.9%) received a diagnosis of chronic kidney disease (Hong et al., 2010). In addition, in the Medical Therapy of Prostatic Symptoms (MTOPS) trial, less than 1% of men with LUTS experienced kidney failure over a period of 4 years (McConnell et al., 2003). Decreased peak flow rate (Qmax) along with a history of hypertension and/or diabetes was associated with chronic kidney disease in men with LUTS (Hong et al., 2010). Similarly, Qmax significantly correlated with estimated glomerular filtration rate in middle-aged men with moderate-to-severe LUTS, whereas PV, postvoid residual (PVR) volume, and IPSS did not (Lee et al., 2013). Patients with renal insufficiency have been found to have increased risk for complications after BPH surgery (Mebust et al., 1989).

Instrumental Investigations

Instrumental diagnostic modalities have emerged as potential useful tools to better characterize the causes of LUTS. However, although some of these tests are considered part of the basic routine assessment of male LUTS, others should be suggested only in specific cases, with the specific aim to help the physician to choose the right treatment and to allow a correct differential diagnosis between BPE and other conditions (Gratzke et al., 2015; McVary et al., 2011).

Postvoid Residual Volume

PVR volume is defined as the volume (mL) of urine left in the bladder at the end of micturition. Currently, there is no standardized definition for a normal PVR volume. **In clinical practice, a PVR volume of less than 30 mL is usually considered nonsignificant, whereas PVR volume persistently greater than 50 mL could be regarded as important** (Asimakopoulos et al., 2016). Significant chronic PVR volume has been widely defined as a volume more than 300 mL (Asimakopoulos et al., 2016).

Of clinical relevance, there is a large within-subject variability in the PVR volume assessment: a wide volume variation was reported in 66% of cases when three measurements were done on the same day (Birch et al., 1988).

In 2014, the ICS Urodynamics Committee established a guideline for the correct assessment of PVR volume (Asimakopoulos et al., 2016) stating that (level of evidence 3):

- The interval between voiding and PVR volume measurement should be of short duration.
- Although transurethral catheterization is considered the gold standard to assess PVR volume, it could be associated with patient discomfort and the risk for UTIs and urinary tract trauma.
- **The ultrasound bladder volume measurement should be**

> **used to assess PVR volume and can be performed with either a real-time transabdominal ultrasound scanner or a portable bladder scanner.**

The presence of an abnormal PVR volume is not highly correlated with BOO. Indeed, an abnormal PVR volume could be the consequence of either BOO or DUA. In this context, the diagnostic accuracy of PVR volume measurement has a positive predictive value of 63% and a negative predictive value of 52% to detect BOO (Oelke et al., 2007). At the same time, a PVR volume of 200 to 300 mL may indicate DUA and predict a less favorable response to LUTS treatment according to expert opinion (Asimakopoulos et al., 2016).

In two large randomized controlled trials (RCTs), a high PVR volume was significantly associated with the risk for LUTS deterioration: a PVR volume of more than 39 mL and more than 93 mL was associated with a 4-point or more increase of the IPSS in the MTOPS trial and in the Alfuzosin Long-Term Efficacy and Safety Study (ALTESS), respectively (McConnell et al., 2003; Roehrborn et al., 2008a). Conversely, PVR volume did not correlate with the need for BPH-related surgery.

The association between PVR volume and AUR has also been assessed. Mochtar et al. (2006), for instance, failed to find an association between AUR and PVR volume (either above or below 300 mL) in men treated with α-blockers or watchful waiting (WW). However, a PVR volume of at least 500 mL was previously associated with a 3.6 times higher risk for AUR recurrence (Klarskov et al., 1987). Moreover, in a 10-year longitudinal study including 1068 men with BOO, PVR volume was not a predictor of AUR (Thomas et al., 2005a). Conversely, findings from the MTOPS trial showed that the increase of PVR volume over time correlated with increased risk for AUR in the placebo group (Roehrborn 2008).

Large or persistent PVR volume has also been associated with UTI in males at risk (e.g., children, patients with neurologic alterations or diabetes). Conversely, this association was not demonstrated in adults without risk factors for UTIs (Asimakopoulos et al., 2016).

In conclusion, **PVR volume assessment is suggested both during basic workup and during the follow-up of patients with LUTS. Men with significant PVR volume should be monitored closely if they elect to have nonsurgical therapy** (Gratzke et al., 2015; McVary et al., 2011).

Uroflowmetry

Uroflow measurement is a basic noninvasive urodynamic test providing an objective and quantitative indication of the integration of bladder function and outlet. It is based on the electronic recording of the free urinary flow rate throughout the course of micturition. The main parameters provided by uroflowmetry are Qmax (or peak urinary flow rate [PFR]), voided volume, and flow pattern (Fig. 145.1). Average flow rate is considered less accurate than Qmax to detect BOO (McConnell et al., 1994).

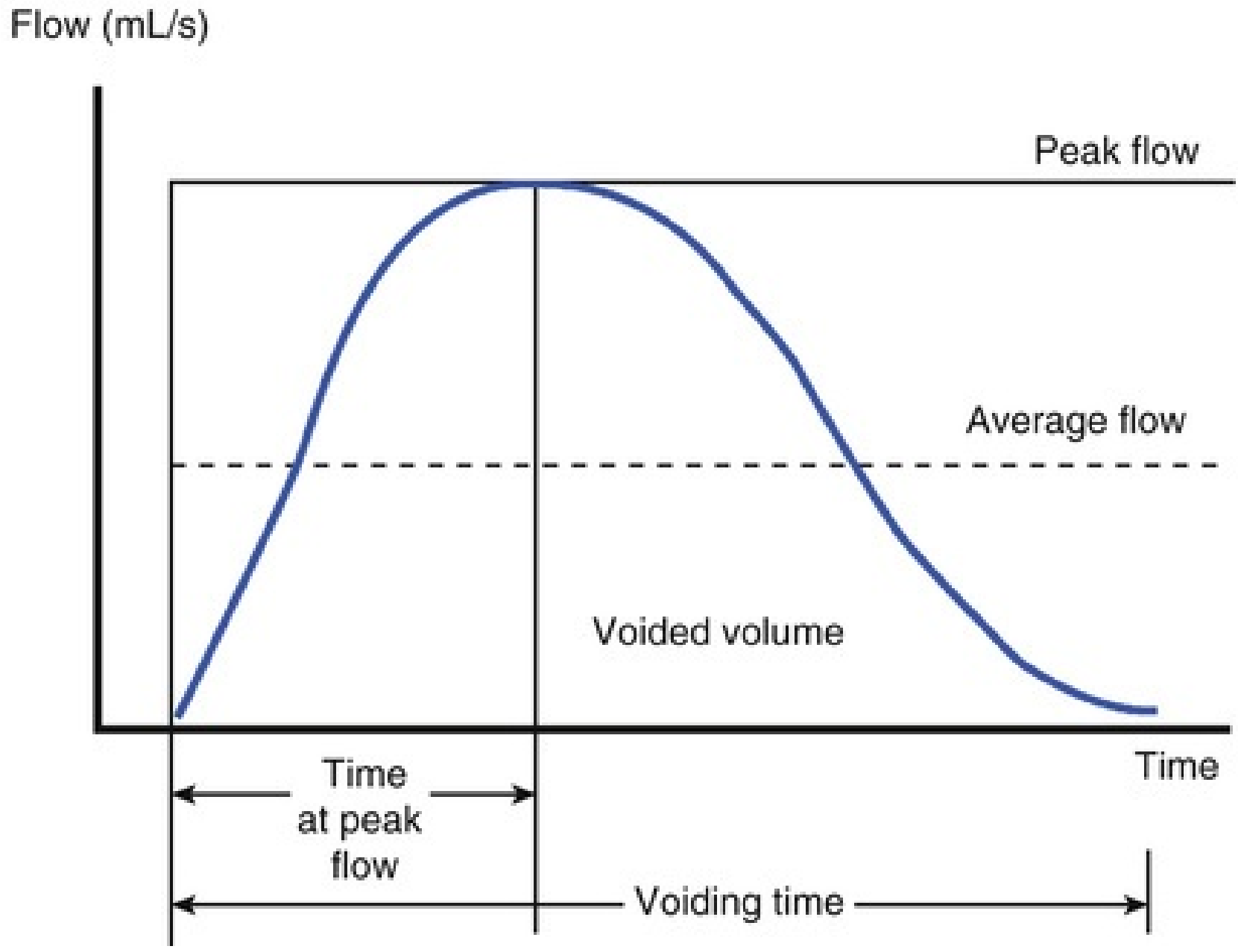

FIG. 145.1 Uroflometry graph; the peak flow rate *(PFR),* the flow pattern, and the voided volume are the main parameters of the test.

There is substantial within-subject variation in terms of uroflowmetry results among measurements taken either on the same day or on consecutive days (Jørgensen et al., 1992; Kranse and van Mastrigt, 2003). Single free-flow measurements tend to underestimate achievable Qmax levels (Reynard et al., 1996). Indeed, Qmax is greatly influenced by the voided volume: flow rate measurements are inaccurate if the voided volume is less than 125 to 150 mL (Gratzke et al., 2015; McConnell et al., 1994; McVary et al., 2011). Moreover, there is evidence of possible changes in the uroflow parameters associated with different voiding positions (Choudhury et al., 2010; Yamanishi et al., 1999). According to ICS recently published good urodynamic practices and terms

(Rosier et al., 2017), patients should be allowed to undergo uroflowmetry in their own preferred position. Furthermore, given the correlation between uroflow parameters and patient cooperation and emotion, uroflowmetry findings should be clinically interpreted if the voiding per se has been representative according to the patient's opinion (Rosier et al., 2017). Repetition of the test is suggested to increase the reliability of the results, especially for voided volumes below 150 mL (Gratzke et al., 2015; McVary et al., 2011; Rosier et al., 2017).

The role of uroflowmetry in the diagnosis of BOO has been widely investigated, and is limited by its inability to distinguish between a low flow rate caused by BOO, DUA (which is present in 9% to 48% of men undergoing urodynamic evaluation for non-neurogenic LUTS) (Osman et al., 2014), or both. To date, several studies specifically assessed the accuracy of uroflowmetry for BOO detection. The results differed considerably according to the threshold values applied. In the largest published series, including 1271 men recruited at 12 centers, a Qmax threshold value of 10 mL/s had a 70% specificity, a positive predictive value of 70%, and a sensitivity of 47% for detection of BOO. Increase of the threshold to 15 mL/s was associated with a specificity of 38% and a sensitivity of 82% (Reynard et al., 1998). The EAU Male LUTS Guidelines Panel performed a systematic review of published studies assessing the accuracy of noninvasive tests in 2580 men with suspected BOO. They showed that a 10 mL/s cutoff threshold value to define BOO was associated with a positive predictive value of 74.3% and a negative predictive value of 68% (Malde et al., 2017). The panel confirmed that uroflowmetry alone is unsuitable to detect and properly quantify BOO (Gratzke et al., 2015; Malde et al., 2017).

According to expert opinion, a PFR cutoff of 15 mL/s could be used to define outlet obstruction in clinical practice (McConnell et al., 1994)**. However, a PFR of less than 15 mL/s does not differentiate between obstruction and bladder decompensation.**

International clinical guidelines consider uroflowmetry as on optional test in the assessment of patients with LUTS, although its use is recommended before any active treatment (Gratzke et al., 2015; McVary et al., 2011).

Finally, uroflowmetry is considered a valuable test for monitoring treatment outcomes and correlating symptoms with objective findings.

Urodynamics

The term *urodynamics* refers to a diagnostic test allowing the assessment of lower urinary tract function via the measurement of relevant physiologic parameters (Rosier et al., 2017). Invasive urodynamic testing involves the use of catheters or transducers inserted into the bladder and/or other body cavities, whereas noninvasive urodynamic tests are performed without the use of catheters (e.g., uroflowmetry, PVR volume, penile compression–release test, penile cuff).

The invasive urodynamic test is the gold standard for the assessment of LUTS pathophysiology and it is used to identify DO, DUA, low bladder compliance, and BOO. The examination is characterized by two distinct evaluations investigating the storage and voiding phase of micturition: the filling cystometry and the pressure-flow study (PFS).

The term *videourodynamics* refers to the use of synchronous radiographic imaging and filling the bladder with contrast medium while cystometry and a PFS are performed. This test allows one to obtain additional anatomic information by showing the presence of eventual alteration of the bladder profile (diverticula, trabeculation), of vesicoureteral reflux, or of alterations of the pelvic floor activity. No clear recommendation is currently provided regarding the use of videourodynamics (Abrams et al., 2013; Gratzke et al., 2015).

Filling Cystometry

Cystometry allows the assessment of the storage phase. It is characterized by a continuous fluid filling of the bladder through a transurethral catheter, with a concomitant measurement of intravesical and abdominal pressure and the display of the detrusor pressure (Rosier et al., 2017). Patients are instructed before the test on how to report sensations: during the filling phase, parameters such as first sensation of filling, first desire to void, and strong desire to void are recorded. **In patients with LUTS suggestive of BOO, the main goal of this test is the detection of involuntary detrusor contractions, which may identify DO** (Gratzke et al., 2015). In a study assessing DO in a cohort of 1418 patients with suspected BPH, up to 60.9% of them showed DO on filling cystometry. Age and obstruction degree were significantly associated with DO (Thomas et al., 2005b).

The diagnosis of DO could be useful to identify patients who may benefit from the use of anticholinergic drugs either alone or in combination with other treatments.

Pressure-Flow Study

The PFS allows assessment of the voiding phase. It is defined as the measurement of the intravesical and abdominal pressure while uroflowmetry is performed with a transurethral catheter in place (Rosier et al., 2017). The findings of this test are depicted in a plot of the flow rate on the *x*-axis and the synchronous detrusor pressure on the *y*-axis. **The joint evaluation of detrusor pressure and flow rate allows the diagnosis of either BOO (characterized by impaired flow rate along with an increased detrusor pressure) or DUA (characterized by the impairment of both flow rate and detrusor pressure)**.

The prevalence of DUA in men with LUTS ranges between 9% and 48% (Osman et al., 2014). The presence of DUA was associated with long-term symptomatic failure and decreased flow rates after BPH surgery in a large cohort of 1068 men followed up for a mean of 13 years after treatment (Thomas et al., 2005a). Moreover, the bladder contractility index (obtained after PFS) was reported neither to improve after surgery nor to decrease over time in patients conservatively managed for BOO/BPH (Al-Hayek et al., 2004), suggesting that detrusor contractility is not influenced by active treatment and the duration of BOO.

No RCTs specifically compared the accuracy of noninvasive tests (e.g., uroflowmetry and PVR volume) with PFS in predicting treatment outcomes in patients with BOO. However, a similar randomized trial was ongoing in the United Kingdom at the time this chapter was written.

As invasive diagnostic modalities, both the European and the American guideline panels do not routinely suggest the use of urodynamic tests to assess men with LUTS (Gratzke et al., 2015; McVary et al., 2011). However, **PFS is suggested before invasive treatments in some specific scenarios:**

- **Patients with previously unsuccessful invasive treatments for LUTS**
- **Patients who cannot void more than 150 mL**
- **Patients with PVR volume greater than 300 mL**
- **Patients older than 80 years of age with predominantly voiding LUTS**
- **Patients younger than 50 years of age with predominantly voiding LUTS**

Moreover, the AUA consensus panel stated that PFS may be performed in patients with a Qmax greater than 10 mL/s before surgical treatment is considered (Abrams et al., 2013).

Finally, urodynamic tests should be considered for men with suspected underlying neurologic conditions or with a history of pelvic surgery.

Imaging

The role of imaging in the management of LUTS is mainly restricted to candidates for surgery and only in selected cases before medical treatment. Novel ultrasound parameters assessing the morphology of the bladder and the prostate are currently under evaluation in terms of BOO diagnosis.

Upper-Tract Imaging

The routine assessment of the upper tract with ultrasonography is not recommended in patients with LUTS (Gratzke et al., 2015; McVary et al., 2011). Indeed, the presence of kidney abnormalities in patients with LUTS has been infrequently reported. In a population of 6102 patients evaluated in 25 studies by intravenous urography before prostate surgery, only 7.6% were found to have hydronephrosis (McConnell et al., 1994). Similarly, Koch et al. (1996) reported a 2.5% prevalence of hydronephrosis in 665 patients with BPH, along with 11.7% of patients with renal cysts and 0.18% of patients with renal cell carcinoma. According to these findings, **imaging assessment of the upper tract is currently suggested for patients with LUTS combined with an elevated serum creatinine level or large PVR volumes. Likewise, patients with a history of hematuria, UTI, urolithiasis, or prior urinary tract surgery should also be assessed with abdominal ultrasonography** (Andrews et al., 2002; Gratzke et al., 2015).

Intravenous urography is no longer used in this clinical setting.

Prostate and Bladder Imaging

Imaging of the prostate is usually performed through suprapubic ultrasonography or TRUS. TRUS imaging is considered the method of choice to define PV, which can be a valuable parameter driving the choice of treatment and serving as a predictor of treatment outcomes.

Candidates for treatment with 5ARIs should be evaluated for PV, as treatment outcomes have been related to the baseline gland volume (McConnell et al., 2003; Roehrborn et al., 2010). The PV estimated by TRUS imaging was a predictor of BPH progression and invasive treatment in the MTOPS trial (McConnell et al., 2003). Similarly, data from the placebo arm of the ALTESS showed that men with a PV greater than 49 mL had a 3.2% risk for AUR compared with those with a PV of 49 mL or less (Roehrborn, 2008). Likewise, the Olmsted County study found an increased risk for AUR with increasing prostate size in a cohort of 2115 men (Jacobsen et al., 1997).

In a retrospective study of 521 patients, the sensitivity and specificity of PV in the detection of BOO were 49% and 32%, respectively, for a cutoff of 40 mL (Eckhardt et al., 2001). These results confirmed previous evidence of a weak correlation between PV and BOO (Rosier et al., 1995).

Ultrasound-based estimation of PV (either suprapubic or TR) should be routinely performed before any BPH surgery so as to help the physician in choosing the most appropriate technique (Gratzke et al., 2015; McVary et al., 2011). Moreover, the detection of a third prostate lobe protruding into the bladder could guide the choice of treatment in patients scheduled for minimally invasive approaches (Gratzke et al., 2015).

Intravesical prostatic protrusion (IPP) is defined as the distance from the tip of the protruding prostate to the base at the circumference of the bladder, and can be assessed by suprapubic ultrasound imaging in the sagittal plane. According to the theory that a greater IPP would cause a greater restriction of the proximal urethra, this parameter has been used as a noninvasive tool for the diagnosis of BOO (Gratzke et al., 2015). The IPP can differ according to the bladder volume, and should be estimated with a volume of 100 to 200 mL of urine in the bladder (Yuen et al., 2002). In a cohort of 2115 men with LUTS, a high IPP grade (>10 mm) was associated with a higher probability of medical treatment over time (Lieber et al., 2009); moreover, in a meta-analysis including patients from five studies, the median sensitivity and specificity of IPP for the detection of BOO were 67.8% and 74.8%, respectively, with a positive predictive value of 73.8% and a negative predictive value of 69.3% for a cutoff of 10 mm (Malde et al., 2017). Similarly, IPP showed good overall accuracy in predicting the outcome of a trial without catheter (TWOC) after AUR (Mariappan et al., 2007). However, **given the wide variability in the threshold values used and in terms of the method of assessment, there is currently no clear recommendation for using IPP as a noninvasive alternative to PFS to diagnose BOO.**

The ultrasound assessment of the bladder provides two additional parameters that are useful for the detection of BOO. As BOO leads to hypertrophy of the bladder wall, the bladder wall thickness (BWT) is defined as the entire diameter of the bladder wall measured from the hyperechogenic mucosa and hyperechogenic adventitia, whereas the detrusor wall thickness (DWT) is defined as the distance between the hypoechogenic detrusor sandwiched between the hyperechogenic mucosa and hyperechogenic adventitia (Arnolds et al., 2009). The accuracy of both measures in detecting BOO is higher than that of Qmax, PVR volume, PV, or symptom severity (Malde et al., 2017). Furthermore, pooled data analysis showed a median sensitivity of 82.7% and a median specificity of 92.6% for a BWT threshold of 2 mm (Malde et al., 2017). However, **because of the multifactorial nature of bladder wall hypertrophy and the lack of well-designed studies assessing the accuracy of these measures, a recommendation for the use of BWT/DWT for the diagnosis of BOO cannot be currently made.**

Recently, the ultrasound-estimated bladder weight (UEBW)—calculated using a specific ultrasound instrument as the product of bladder surface area (BWT) and bladder muscle-specific gravity—has been suggested to provide a more reliable measure of bladder wall hypertrophy; indeed BWT is greatly influenced by bladder filling volume. Currently, only two studies have evaluated the accuracy of UEBW, using different threshold values and showing wide variation in the results (Malde et al., 2017).

Cystourethrogram

The voiding cystourethrogram provides both morphologic and functional information allowing the detection of bladder wall diverticula, vesicoureteral reflux, and urethral strictures. **The use of cystourethrogram is suggested as an additional diagnostic test when urethral strictures or bladder abnormalities are suspected** (Gratzke et al., 2015).

Cystourethroscopy

In the context of LUTS assessment, cystourethroscopy can provide information regarding the morphology of the prostate and bladder neck, and the detection of detrusor trabeculation at the level of the bladder wall or the presence of diverticula. However, **cystourethroscopy is neither useful for the diagnosis of BOO nor to determine the need for treatment.**

A poor correlation between BOO and cystourethroscopy findings has been widely reported. The largest and updated series on this topic assessed 492 men with voiding complaints who underwent urodynamic investigations and flexible cystourethroscopy (Ezz El Din et al., 1996). The authors categorized the degree of bladder trabeculations found on endoscopy as 0 for none, 1 for slight to moderate, 2 for severe, and 3 for severe with (pseudo)diverticula. A significant correlation between BOO severity and the degree of bladder trabeculation was observed. However, up to 15% of patients with BOO showed a normal bladder wall, and up to 8% had severe trabeculation and no evidence of BOO.

Clinical guidelines suggest the use of cystourethroscopy in the case of reported gross hematuria, history of bladder cancer, history of recurrent UTIs or urethral injury (to rule out urethral stenosis), or in the case of previous surgery of the prostate or urethra.

Moreover, cystourethroscopy could help physicians in choosing the proper surgical treatment: the presence of a prostatic middle lobe is an important parameter to assess when one is considering the use of microwave therapy or needle ablation (Gratzke et al., 2015; McVary et al., 2011). Similarly, in young patients with small PV and predominantly obstructive LUTS, the presence of bladder neck contracture should be excluded before surgery.

Other Noninvasive Tests

Noninvasive modalities for the diagnosis of BOO associated with BPH have been developed as an alternative to invasive urodynamic tests. The external condom catheter test and the penile cuff test (PCT) allow the measurement of detrusor pressure without the use of a urethral catheter, by assessing the equal urine pressure along the urethra (in the penile cuff) or at the external meatus (using an external condom catheter). In the PCT, the pressure needed to stop the flow of urine represents the bladder isovolumetric pressure, and is detected by a cuff placed around the penis (Griffiths et al., 2002). Pooled data analysis of seven studies investigating the diagnostic accuracy of the PCT showed a median sensitivity of 88% and a specificity of 70% in detecting BOO (Malde et al., 2017). A single study evaluated the accuracy of the external condom method, showing that BOO could be detected in up to 73% of patients with this method (Pel et al. 2002).

Among other imaging modalities, the use of Doppler ultrasound imaging was proposed to measure the reduction in detrusor blood flow associated with detrusor hypertrophy and BOO. Color Doppler ultrasound imaging allows the identification of arterial blood flow within the bladder wall and the calculation of the detrusor resistive index (RI) as the average of the RIs measured from three different sites in the bladder wall (Belenky et al., 2003); a positive predictive value of 95% and a negative predictive value of 57% have been reported in detecting BOO, with an RI greater than 0.05 (Belenky et al., 2003).

Near-infrared spectroscopy (NIRS) is based on the use of the infrared spectrum to monitor changes in the concentration of chromophores (oxyhemoglobin and deoxyhemoglobin) as a consequence of changes in detrusor oxygenation and hemodynamics, which usually occur with BOO during both the storage phase and voiding phase of the bladder. A mathematical algorithm has been developed for the assessment of BOO using NIRS parameters (Stothers et al., 2010), with data showing an 80% concordance rate with PFS (Macnab et al., 2008). Pooled data analysis from five studies showed a high diagnostic accuracy, with a median sensitivity of 85.7% and a specificity of 87.5% (Malde et al., 2017).

In 2017, the EAU guidelines expert consensus panel on the evaluation and treatment of LUTS provided a detailed analysis of the accuracy of noninvasive tests for BOO (Malde et al., 2017): the panel reported the highest accuracy for PCT, DWT, UEBW, and NIRS among all noninvasive modalities. However, because of the heterogeneity in the definition of BOO and the relatively small number of studies assessing each method, **the use of noninvasive tests for the diagnosis of BOO in patients with LUTS is currently not recommended as an alternative to PFS by the EAU.**

Practical Flowchart for the Evaluation of Patients With Lower Urinary Tract Symptoms

The EAU and AUA expert guidelines consensus panels have developed a practical algorithm to guide the physician in the management and evaluation of patients presenting with LUTS (Fig. 145.2).

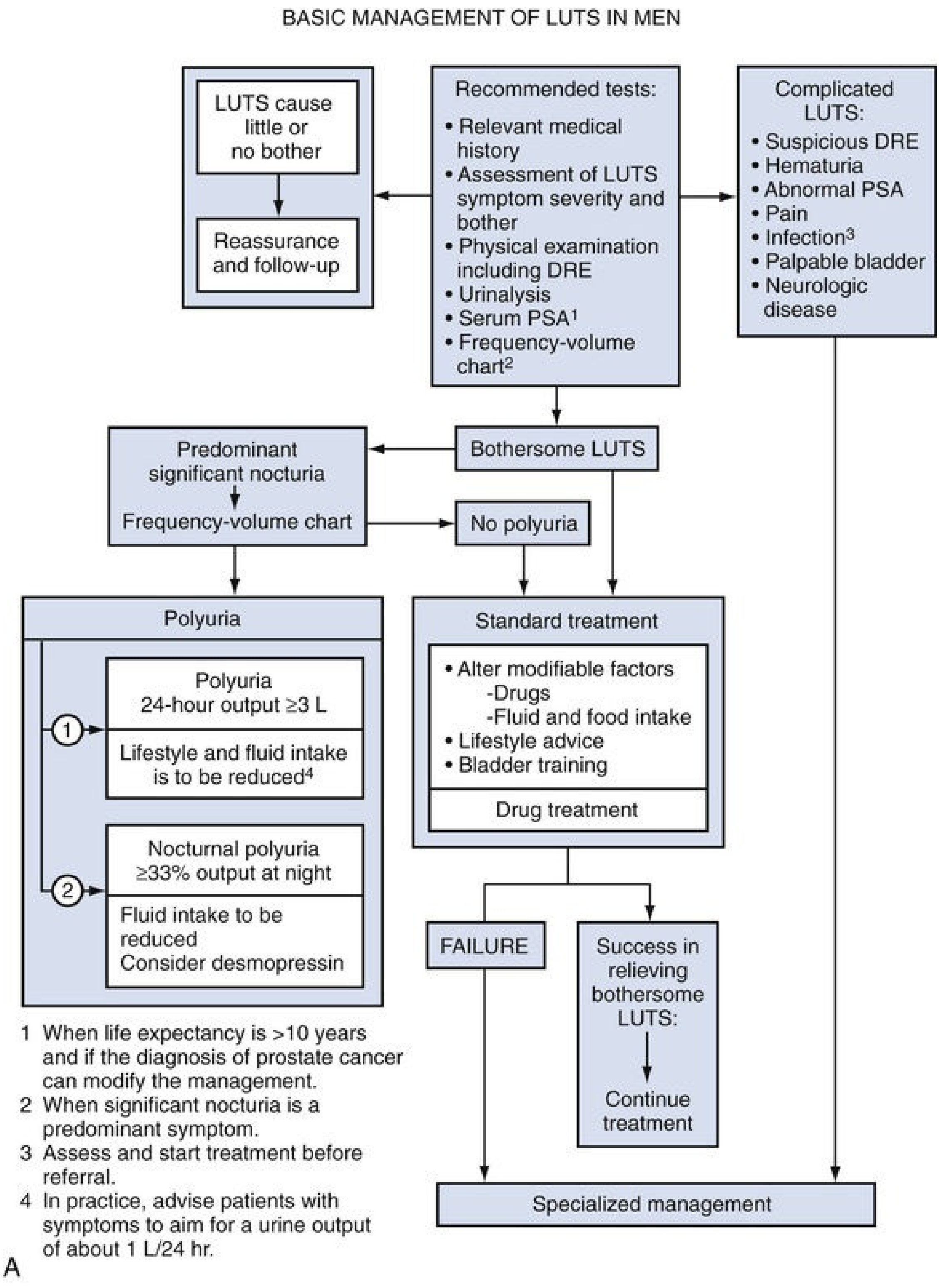
BASIC MANAGEMENT OF LUTS IN MEN

LUTS cause little or no bother
Reassurance and follow-up
Recommended tests:
• Relevant medical history
• Assessment of LUTS symptom severity and bother
• Physical examination including DRE
• Urinalysis
• Serum PSA1
• Frequency-volume chart2
Complicated LUTS:
• Suspicious DRE
• Hematuria
• Abnormal PSA
• Pain
• Infection3
• Palpable bladder
• Neurologic disease
Bothersome LUTS
Predominant significant nocturia
Frequency-volume chart
No polyuria
Polyuria
1
Polyuria 24-hour output ≥3 L
Lifestyle and fluid intake is to be reduced4
2
Nocturnal polyuria ≥33% output at night
Fluid intake to be reduced
Consider desmopressin
Standard treatment
• Alter modifiable factors
-Drugs
-Fluid and food intake
• Lifestyle advice
• Bladder training
Drug treatment
FAILURE
Success in relieving bothersome LUTS:
Continue treatment
Specialized management
A

1 When life expectancy is >10 years and if the diagnosis of prostate cancer can modify the management.
2 When significant nocturia is a predominant symptom.
3 Assess and start treatment before referral.
4 In practice, advise patients with symptoms to aim for a urine output of about 1 L/24 hr.

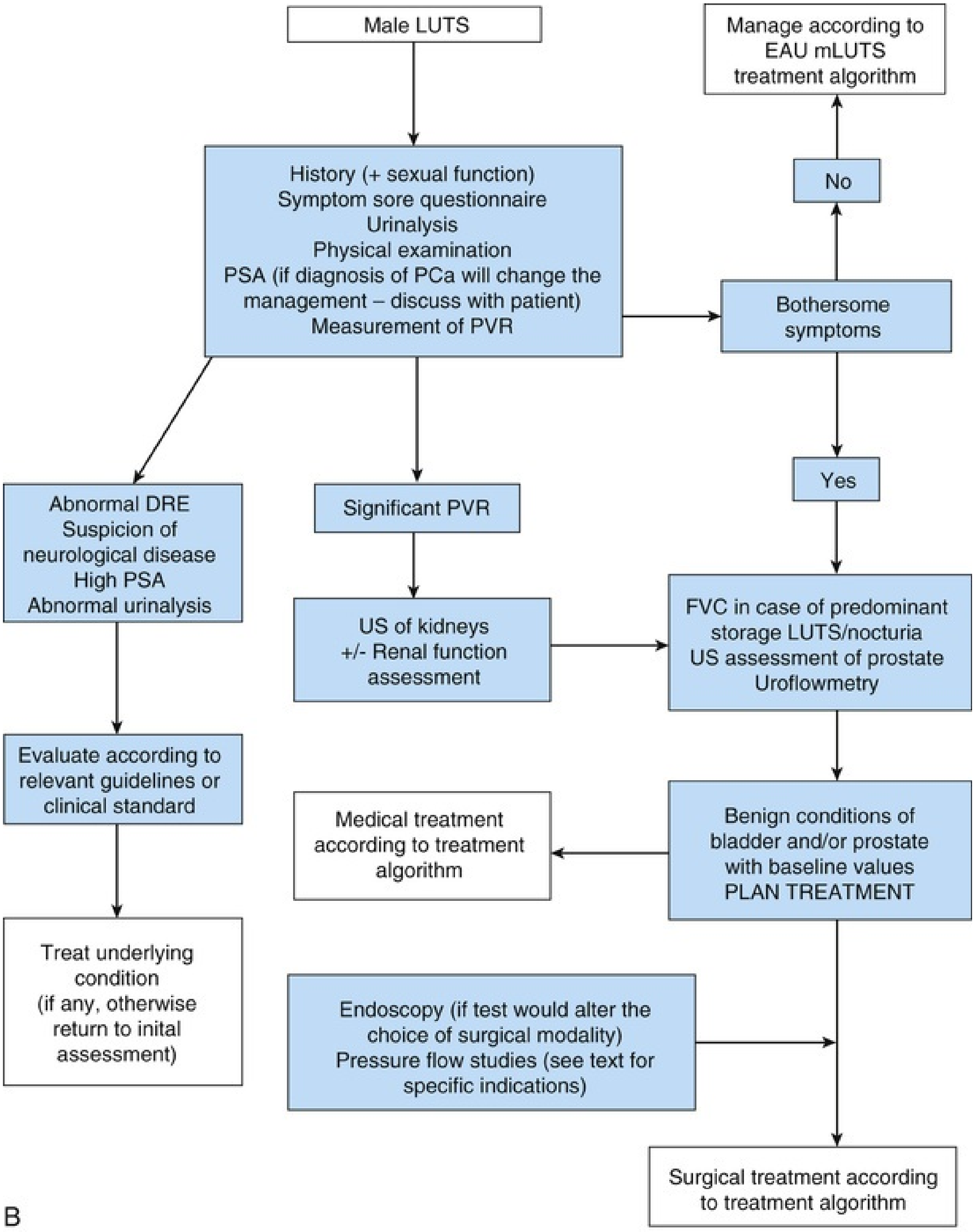
Male LUTS
Manage according to EAU mLUTS treatment algorithm
History (+ sexual function)
Symptom sore questionnaire
Urinalysis
Physical examination
PSA (if diagnosis of PCa will change the management – discuss with patient)
Measurement of PVR
No
Bothersome symptoms
Yes
Abnormal DRE
Suspicion of neurological disease
High PSA
Abnormal urinalysis
Significant PVR
US of kidneys +/- Renal function assessment
FVC in case of predominant storage LUTS/nocturia
US assessment of prostate
Uroflowmetry
Evaluate according to relevant guidelines or clinical standard
Medical treatment according to treatment algorithm
Benign conditions of bladder and/or prostate with baseline values
PLAN TREATMENT
Treat underlying condition (if any, otherwise return to inital assessment)
Endoscopy (if test would alter the choice of surgical modality)
Pressure flow studies (see text for specific indications)
Surgical treatment according to treatment algorithm
B

FIG. 145.2 (A) International consensus guideline (2009) algorithm for management of lower urinary tract symptoms *(LUTS):* basic management. (B) Assessment algorithm for LUTS in men 40 years of age or older according to the European Urological Association consensus panel on LUTS treatment. *DRE,* Digital rectal examination; *FVC,* frequency–volume chart; *PCa,* prostate cancer; *PSA,* prostate-specific antigen; *PVR,* postvoid residual; *US,* ultrasound. (A, From Abrams P, Chapple C, Khoury S, et al.

Evaluation and treatment of lower urinary tract symptoms in older men. *J Urol* 189[1 Suppl]:S93–S101, 2013. B, From Gravas S, Bach T, Drake M, et al. EAU Guidelines on Management of non-neurogenic male LUTS, incl. benign prostatic obstruction [BPO]. Retrieved from: https://uroweb.org/wp-content/uploads/EAU-Guidelines-Management-of-non-neurogenic-male-LUTS-2016.pdf.)

According to the EAU guidelines, as a baseline assessment, the physician should collect a comprehensive medical history and examine the severity of symptoms and their impact on QoL by using dedicated tools; moreover, physical examination with DRE to estimate PV and exclude a locally advanced PCa should be conducted. Furthermore, urinalysis helps identify conditions other than BPH as a potential underlying cause of LUTS, and the assessment of PVR volume is a valuable noninvasive method to assess the risk for disease progression and to prompt further diagnostic evaluations if needed. Finally, a PSA test should be regarded as a basic diagnostic tool for patients with a life expectancy longer than 10 years, for whom the diagnosis of PCa would change the management.

According to the results of the baseline assessment, patients should undergo no further evaluation and treatment in the case of low-severity symptoms and normal findings from all performed tests, or should undergo additional investigations to help make the correct treatment choice. In this context, FVCs are useful for patients with predominantly storage phase LUTS; ultrasound assessment of the bladder and the prostate along with an uroflowmetry test is suggested when the severity of the symptoms requires either medical or surgical treatment. Moreover, upper urinary tract imaging and renal function evaluation should be considered for patients with elevated PVR volumes. Finally, although invasive urodynamic tests are the gold standard for the detection of BOO, they should be used in specific clinical scenarios suggestive of DO or DUA or after previous unsuccessful invasive treatments whenever surgical treatment is considered.

A comparable practical flowchart has been proposed by the AUA consensus panel, discriminating between a basic evaluation, possibly done by the general physician and based on the aforementioned baseline assessment tools, and specialized management performed by the urologist, with additional investigations for patients in whom non-BPH conditions are suspected and/or for those highly bothered by symptoms.

Key Points

- Assessing symptom severity is the first step in the workup of patients with LUTS.
- The PSA test should be considered for patients with a life expectancy longer than 10 years.
- Ultrasound imaging and uroflowmetry should be performed for patients with moderate to severe symptoms.
- Invasive urodynamic tests should be considered if bladder motility alterations (e.g., DO, DUA) are suspected.

Management of Lower Urinary Tract Symptoms Caused by Benign Prostatic Enlargement

The therapeutic management of patients with LUTS is driven by the patient's clinical characteristics, findings of the baseline diagnostic assessment, and patient preferences (McVary et al., 2011; Oelke et al., 2013). Overall, two different therapeutic approaches could be adopted: a conservative approach or active management (involving either medical or surgical treatment).

Conservative Management

Both the AUA and EAU expert consensus panels suggest that patients with mild-to-moderate noncomplicated LUTS who are minimally bothered by their symptoms should be offered conservative management (McVary et al., 2011; Oelke et al., 2013) (Fig. 145.3; see Fig. 145.2). Complicating factors may be detected throughout the diagnostic assessment process and include the following:

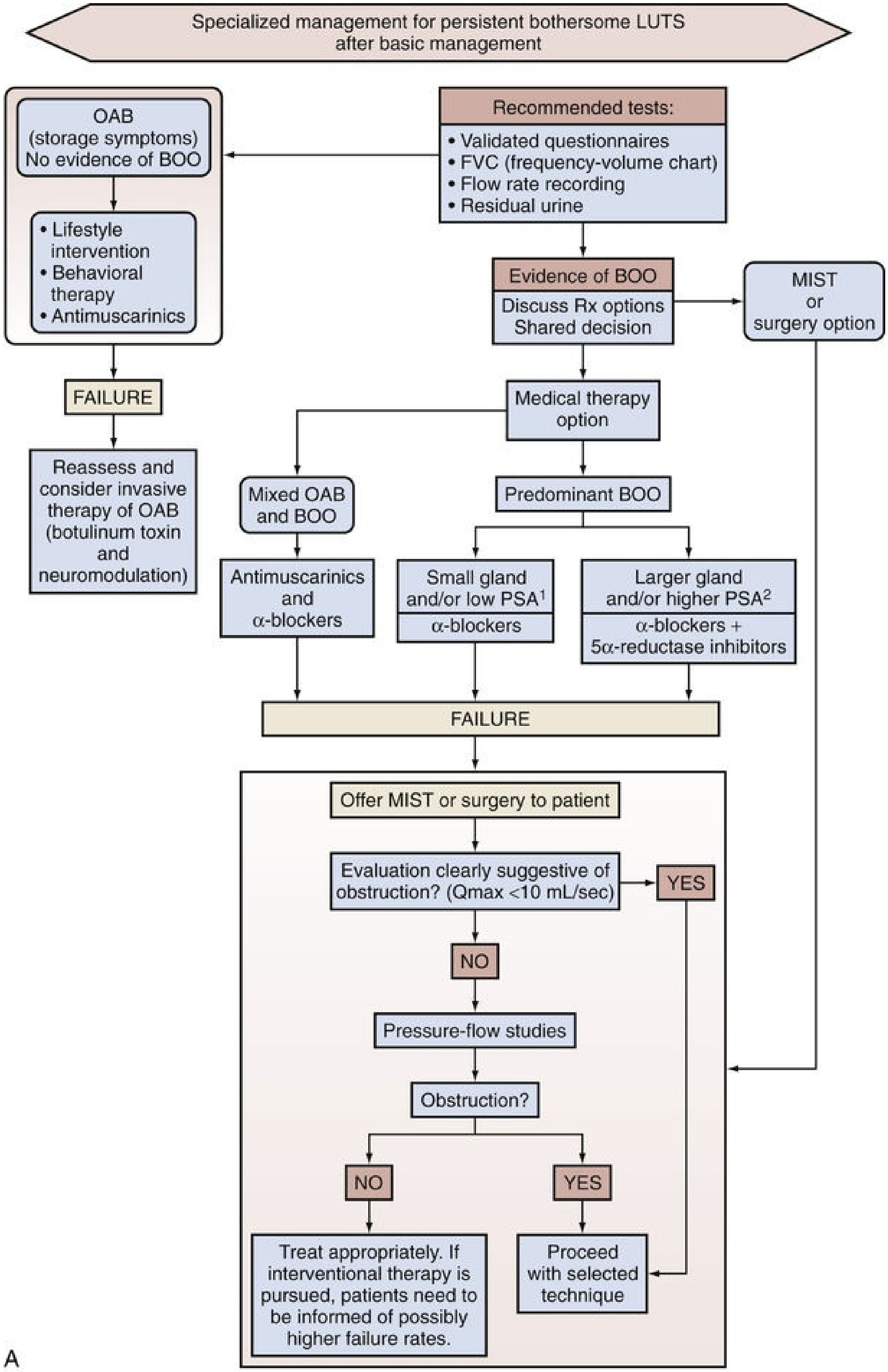
Specialized management for persistent bothersome LUTS after basic management
OAB (storage symptoms) No evidence of BOO
• Lifestyle intervention
• Behavioral therapy
• Antimuscarinics
FAILURE
Reassess and consider invasive therapy of OAB (botulinum toxin and neuromodulation)
Recommended tests:
• Validated questionnaires
• FVC (frequency-volume chart)
• Flow rate recording
• Residual urine
Evidence of BOO
Discuss Rx options Shared decision
MIST or surgery option
Medical therapy option
Mixed OAB and BOO
Predominant BOO
Antimuscarinics and α-blockers
Small gland and/or low PSA1
α-blockers
Larger gland and/or higher PSA2
α-blockers + 5α-reductase inhibitors
FAILURE
Offer MIST or surgery to patient
Evaluation clearly suggestive of obstruction? (Qmax <10 mL/sec)
YES
NO
Pressure-flow studies
Obstruction?
NO
YES
Treat appropriately. If interventional therapy is pursued, patients need to be informed of possibly higher failure rates.
Proceed with selected technique
A

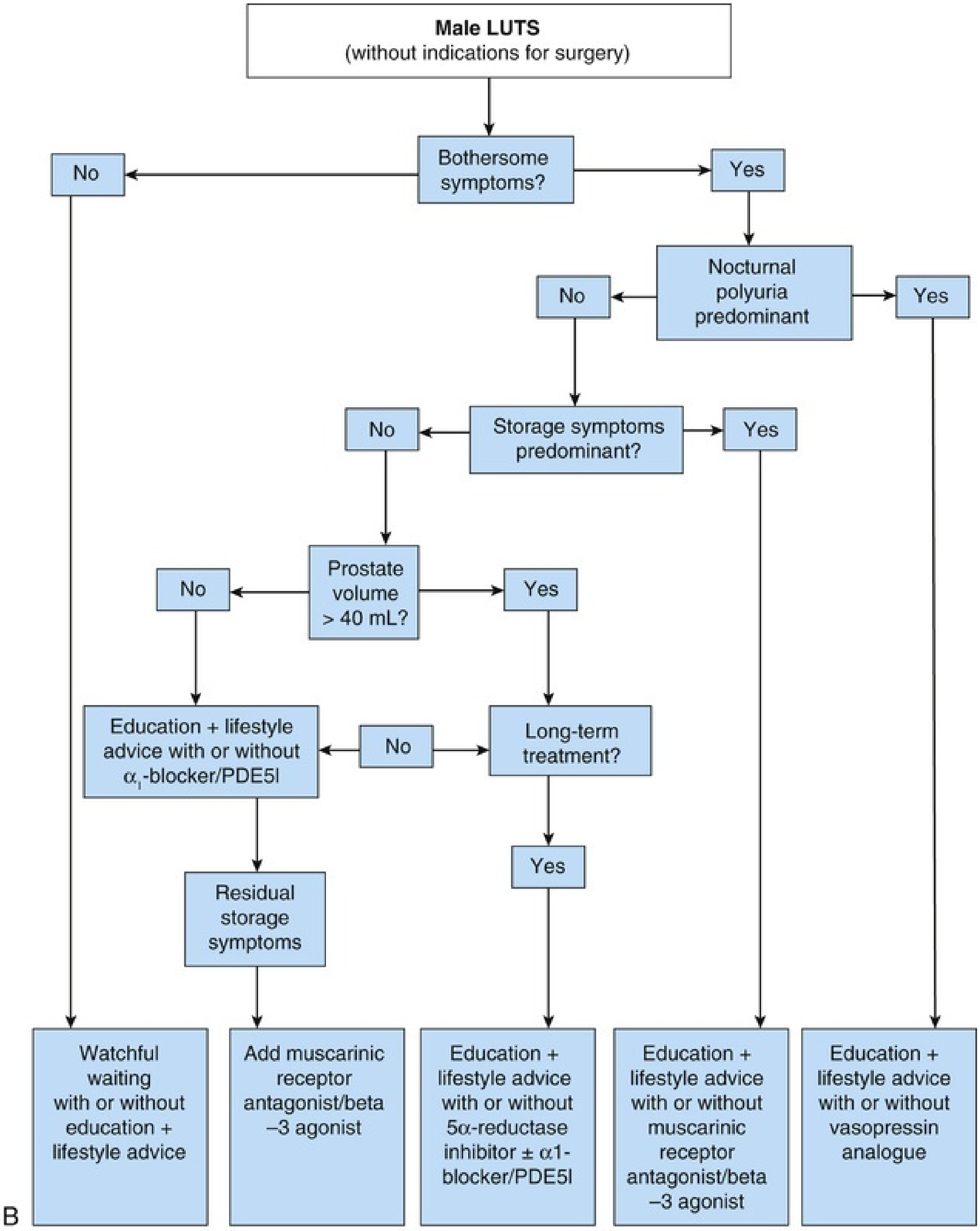
Male LUTS
(without indications for surgery)
Bothersome symptoms?
No
Yes
Nocturnal polyuria predominant
No
Yes
Storage symptoms predominant?
No
Yes
Prostate volume > 40 mL?
No
Yes
Education + lifestyle advice with or without α1-blocker/PDE5I
No
Long-term treatment?
Yes
Residual storage symptoms
Watchful waiting with or without education + lifestyle advice
Add muscarinic receptor antagonist/beta –3 agonist
Education + lifestyle advice with or without 5α-reductase inhibitor ± α1-blocker/PDE5I
Education + lifestyle advice with or without muscarinic receptor antagonist/beta –3 agonist
Education + lifestyle advice with or without vasopressin analogue
B

FIG. 145.3 (A) International consensus guideline (2009) algorithm for management of lower urinary tract symptoms *(LUTS):* specialized management. 1, Prostate-specific antigen (PSA) level below 1.5 ng/mL; 2, PSA level above 1.5 ng/mL. (B) Treatment algorithm for male LUTS using medical and/or conservative treatment options. *BOO,* bladder outlet obstruction; *MIST,* minimally invasive surgical treatment; *OAB,* overactive bladder; *PDE5I,* phosphodiesterase type 5 inhibitors; *Rx,* treatment. (A, From Abrams P, Chapple C, Khoury S, et al. Evaluation and treatment of lower urinary tract symptoms in older men. *J Urol* 181[4]:1779–1787, 2009; (B) From Gravas S, Bach T, Drake M, et al. Management of Non-neurogenic male LUTS, incl. benign prostatic obstruction [BPO]. Retrieved from: https://uroweb.org/wp-content/uploads/EAU-Guidelines-Management-of-non-neurogenic-male-LUTS-2016.pdf.)

- Gross hematuria
- UTIs
- Elevated PSA level
- Elevated PVR volume
- Neurologic diseases

The conservative management is based on a WW approach.

Watchful Waiting

WW is based on reassurance and education of the patient, lifestyle interventions, and periodic monitoring of the disease (Oelke et al., 2013).

The rationale behind WW is based on the evidence that a number of patients with LUTS suggestive of BPH are affected by an indolent, nonprogressive disease that does not require active treatment.

The progression of BPH is defined as the deterioration of clinical variables, such as symptoms and PFR, the occurrence of AUR, or the need for surgical treatment. Data from longitudinal community-based studies show that unfavorable outcomes such as AUR and BPH-related surgery are relatively uncommon throughout the natural history of BPH patients, reporting a cumulative incidence of 1% to 2.7% for AUR and 3% for surgery (Jacobsen et al., 1997, 1999; Meigs et al., 1999). In a more recent 15-year longitudinal study, 50% of included patients showed stable symptom scores over the time frame investigated (Fukuta et al., 2012). Similarly, data from the placebo arms of large RCTs assessing the outcomes of medical treatment for BPH showed an incidence of AUR and the need for BPH surgery ranging between 2% and 10% at long-term follow-up (Bruskewitz et al., 1999; McConnell et al., 2003; Roehrborn, 2006).

In an RCT, Wasson et al. (1995) compared the outcomes of 280 patients treated with transurethral resection of the prostate and 276 patients managed with WW. All patients were given simple instructions to avoid coffee, alcohol, and medications potentially worsening their symptoms; surgery was associated with more favorable outcomes in terms of symptom relief, uroflowmetry parameters, and clinical failure rate (defined as the occurrence of any of death, AUR, elevated PVR volume, bladder stones, incontinence, renal failure, and elevated symptom score). However, only 17% of patients experienced treatment failure in the WW group, mainly because of elevated PVR volume or symptom score. Moreover, 24% of WW patients crossed over to surgical treatment during follow-up; those with higher baseline bother score showed a higher risk for crossing over to surgery. In the updated 5-year follow-up study, in the WW group only 1.5% patients experienced AUR and only 1% of patients experienced kidney failure (Flanigan et al., 1998). Of note, patients managed with WW reported reduced urinary symptom scores and a decreased symptom-associated bother at 5-year follow-up.

The impact of a “self-management” approach based on lifestyle and dietary modification, as an integral part of WW, was assessed in RCTs in the past two decades. Specific standards for a self-management approach were defined in a consensus meeting (Brown et al., 2004) and consisted of three small-group sessions of standardized urinary education and lifestyle advice. Brown et al. (2007) evaluated the effectiveness of this approach as a first-line intervention for men with uncomplicated LUTS and mild-to-moderate symptoms in a teaching hospital and a district general hospital in London. A total of 140 men were randomized to either standard care (i.e., simple monitoring of the disease) or a self-management program. The rate of treatment failure and the symptom score at follow-up were significantly lower for the self-management group compared with the control group. Similarly, a multicenter RCT showed that a rigorously structured behavioral program could significantly reduce LUTS severity and decrease symptoms such as nocturia, urgency, and frequency as compared with standard care alone (Yap and Emberton, 2010).

If patients choose WW as the preferred management, they should be followed up yearly to detect any progression in terms of symptoms or the occurrence of complications, which should prompt a more aggressive treatment approach (Abrams et al., 2013; McVary et al., 2011).

Lifestyle and Dietary Modifications

The main components of WW and self-management programs for men with

LUTS are as follows (Yap et al., 2009):

Education and Reassurance

- Discuss the causes of LUTS, including normal prostate and bladder function.
- Discuss the natural history of BPH and LUTS, including the expected future symptoms.
- Reassure the patient that no evidence of detectable PCa has been found.

Fluid Management

- Advise a daily fluid intake of 1500 to 2000 mL (minor adjustments may be made for climate and activity).
- Avoid inadequate or excessive fluid intake on the basis of an FVC.
- Advise fluid restriction when symptoms are most inconvenient (e.g., during long journeys or when out in public).
- Advise evening fluid restriction for nocturia (no fluid for 2 hours before retiring).

Caffeine and Alcohol

- Avoid caffeine by replacing caffeine with alternatives (e.g., decaffeinated or caffeine-free drinks).
- Avoid alcohol in the evening if nocturia is bothersome.
- Replace large-volume alcoholic drinks (e.g., pint of beer) with small-volume alcoholic drinks (e.g., wine or spirits).

Concurrent Medication

- Adjust the time when medication with an effect on the urinary system is taken to reduce LUTS at times of greatest inconvenience (e.g., during long journeys and when out in public).
- Replace antihypertensive diuretics with suitable alternatives with fewer urinary effects (via the patient's general practitioner).

Types of Toileting and Bladder Retraining

- Advise men to double-void (spending extra time on the toilet to try to empty the bladder completely).
- Advise urethral milking for men with postmicturition dribbling.
- Advise bladder retraining. With use of distraction techniques (predetermined mind exercise, perineal pressure, or pelvic floor exercises), aim to increase the minimum time between voids to 3 hours (daytime) and/or the minimum voided volume to between 200

and 400 mL (daytime). The urge to void should be suppressed for 1 minute, then 5 minutes, then 10 minutes, and so on, increasing on a weekly basis. Use FVCs to monitor progress.

Miscellaneous

- Avoid constipation in men with LUTS.

Regarding dietary advice, a recent systematic review of 111 studies assessing the role of diet, fluids, and tobacco on LUTS confirmed a significant association between increased fluid, tea, and caffeine intake with storage symptoms; moreover, a lower alcohol intake was associated with decreased diagnosis of BPH and LUTS (Bradley et al., 2017).

Key Points

- Conservative management is the preferred approach for patients with mild symptoms and without complicating factors.
- WW is based on patient education, lifestyle interventions, and disease monitoring.
- Lifestyle modifications include proper daily fluid intake, tea, caffeine and alcohol avoidance/restriction, and concurrent medication adjustment.
- Patients should be followed up yearly to detect worsening of symptoms or the occurrence of complications.

Medical Therapy

Medical therapy plays a major role in the management of patients with LUTS. **The current drug armamentarium includes α-adrenergic blockers (α_1-blockers), 5ARIs, antimuscarinic drugs, phosphodiesterase type 5 inhibitors (PDE5Is), β_3-agonists, and numerous plant extracts.** Of note, different combinations of medical compounds play a relevant role in the management of LUTS.

Impact and Trends of Medical Therapy Use for Lower Urinary Tract Symptoms

Surgical treatment was the mainstay of treatment for patients with BPH-related

LUTS until the 1990s. Afterward, the use of medical therapies significantly increased (Sarma et al., 2005), along with a reduction of the absolute number of prostatectomies, which decreased from 250,000 in 1987 to 116,000 in 1996 to 88,000 in 2000 and has stabilized since then, according to a survey of the US Medicare database (Wasson et al., 2000). Similar reductions in numbers of transurethral resections of the prostate have been reported in Europe as well.

The preference of patients for medical treatments compared with surgery has been widely demonstrated in several population-based studies (Emberton, 2010; Kaplan and Naslund, 2006; Piercy et al., 1999; Watson et al., 2004).

Beside patient preferences, studies assessing treatment choices among urologists confirmed the prevailing role of medical therapy over surgery (Emberton, 2010). In the PROBE study, including patients from five European countries, 63% of urologists reported prescribing drug therapy to more than 70% of patients, with α_1-blockers being the most frequently prescribed drug (Emberton et al., 2008). Similar data were reported by a US survey investigating treatment preferences of 1087 urologists and 177 primary care physicians, showing that medical therapy was the treatment most commonly suggested by both categories (Seftel et al., 2007).

Clinical Indications

Medical therapy is the first-line treatment for patients bothered by LUTS without imperative indications for surgery, such as the occurrence of AUR, recurrent UTIs, renal insufficiency, bladder stones, and recurrent gross hematuria (McVary et al., 2011; Oelke et al., 2013).

Drug therapy should be tailored to the patient's symptoms (see Fig. 145.3). In a patient with predominantly voiding symptoms, α_1-blockers, 5ARIs and PDE5Is may be all valid treatment options. Several factors, including symptom severity, PV, PVR volume, and patient preferences, should be considered so as to make the proper treatment choice.

Patients suffering from predominant storage symptoms may require therapy with muscarinic receptor antagonists or β_3-agonists. Moreover, different therapeutic strategies should be considered for patients who complain of nocturnal polyuria, defined as nocturnal output exceeding 20% of 24-hour urine output in younger patients or 33% of urine output in men older than 65 years of age as assessed with FVCs (Abrams et al., 2002). In this case, patient education, lifestyle changes, and the optional use of desmopressin have to be considered according to the guidelines for the treatment of nocturia (Sakalis et al., 2017).

The physician should always discuss with the patient the benefits and risks of all available drugs before deciding on a specific treatment.

The outcomes and specific indications of each class of drugs will be discussed throughout this chapter.

Assessment of Response to Medical Treatment: Outcome Measures

The assessment of response to medical treatments is based on the evaluation of quantitative parameters, allowing the physician to objectify the effectiveness of a drug and the possible need to modify the therapy.

The goals of LUTS medical treatment may include relieving symptoms, decreasing BOO, improving bladder emptying, ameliorating DO, reversing renal insufficiency, and preventing disease progression, defined as symptom deterioration and/or the occurrence of complications requiring surgical treatment.

The clinical end points to be evaluated in patients receiving medical treatment for LUTS include symptom severity, BOO, and detrusor function.

Symptoms

Changes in patients' symptoms, as assessed with validated tools such as the AUASI or the IPSS, are considered the gold standard to quantify the impact of therapeutic interventions on LUTS (Barry et al., 1992).

Each treatment can be assessed in terms of the probability and magnitude of symptom relief and the magnitude of bother reduction; the relief on symptom scales can be expressed either as an absolute value or as a percentage change value.

Barry et al. (1995) investigated the clinical significant changes in the AUASI score. Absolute score changes after treatment were compared with five global ratings of symptom relief. **The mean changes in the AUASI score for patients rating their symptoms as markedly, moderately or slightly relieved, unchanged, or worse were −8.8, −5.1, −3.0, −0.7, and +2.7, respectively.** According to these data, **a minimum of a 3-point change in terms of the symptom score appears perceptible to patients.** Of note, because of the nature of tools such as the IPSS and the AUASI, the perceived relief for each increasing point in the total score may differ according to the baseline condition (Barry et al., 1995). Indeed, patients with a higher IPSS, identifying “severe symptoms,” would need a smaller change in their score to perceive a clinically significant relief of symptoms compared with patients who had a lower baseline score suggestive of “mild symptoms.” Therefore, assessment of the percentage score reduction is generally considered more reliable, and has been applied in several clinical trials.

Bladder Outlet Obstruction

The increased resistance in the urine outflow has been associated with profound changes in the bladder ultrastructure and metabolism, with direct implication for bladder function (Levin et al., 2000). For this reason, relief or resolution of BOO is considered an important goal in the treatment of patients with LUTS.

PFSs are the gold standard for the assessment and quantification of BOO; however, as an invasive test, this modality is not suggested for the evaluation of treatment outcomes in clinical practice. Moreover, there is evidence suggesting a lack of correlation between PFS results and treatment efficacy; indeed, parameters such as the bladder contractility index did not prove to be significantly changed after active treatment (Al-Hayek et al., 2004). Nonetheless, the use of invasive urodynamic tests is recommended in clinical trials investigating the effect of a therapeutic intervention in patients with BOO.

As a surrogate for urodynamic parameters, **several studies used uroflowmetry parameters to compare the efficacy of different LUTS treatments;** of those, PFR (Qmax) is considered an indirect measure of BOO (McConnell et al., 1994; Oelke et al., 2007) and is sensitive to treatment modifications. Percentage change rather than absolute change in PFR should be used to evaluate treatment efficacy: relatively small absolute changes in PFR (i.e., 4 to 6 mL/s) correspond to a relatively high percentage change for patients with low baseline PFRs, whereas large absolute changes (i.e., 12 to 17 mL/s) correspond to a relatively low percentage change for patients with a high baseline PFR.

Bladder Emptying

PVR volume is considered an indirect sign of incomplete evacuation and bladder voiding dysfunction, although it does not allow one to differentiate between DUA and BOO (Oelke et al., 2007). While baseline PVR volumes may be predictive of treatment outcomes and complications (Asimakopoulos et al., 2016; Roehrborn 2008), data on post-treatment PVR volumes reported in randomized trials could be misleading; indeed, patients with relevant baseline PVR volumes are usually excluded from these studies, thus undermining the relevance of most clinical trials in the real-life setting. Therefore, there is no standardization in terms of evaluation and meaning of PVR volume changes after LUTS treatment.

Detrusor Overactivity

An urodynamic profile characterized by involuntary detrusor contractions during the filling phase suggests DO, which may be spontaneous or provoked (Abrams, 2003). Morphologic and neurologic alterations of the bladder wall may occur in individuals with BOO, with DO patterns in up to 83% of men with severe BOO (Drake et al., 2017; Thomas et al., 2004). However, longitudinal data failed to demonstrate significant changes in terms of detrusor contractility after active treatment of BOO (Thomas et al., 2005a). Of clinical relevance, urodynamically demonstrated DO is not invariably associated with OAB syndrome (Abrams, 2003). Therefore, although the magnitude of storage symptom relief is useful in the evaluation of treatment efficacy, DO assessment is not considered a standard outcome measure.

Interpreting the Literature: Bias Associated With Trials on Medical Treatment of Lower Urinary Tract Symptoms

Randomized, placebo-controlled, double-blind trials are the best study design to assess the impact of any medical therapy in terms of effectiveness and safety in LUTS/BPH. Caveats still remain across the published literature on this topic.

- There is an important placebo effect in LUTS outcome measures (Nickel, 1998); indeed, both subjective outcomes, such as symptom scale scores, and more objective measures, including uroflowmetry parameters, have been shown to improve from the baseline, even in the placebo arm of RCTs. Therefore, **ideally a 4-week placebo run-in period before initiation of treatment**

should be included in any trial design; this would allow the incorporation of a baseline placebo effect before any comparison is made.

- Sample size is an important issue to be considered in any clinical trial; studies including an insufficient number of patients according to the assessed outcome may not be able to detect a significant difference between treatment groups. Similarly, if the population included is too large, small differences in outcome measurements may be statistically significant, although the real clinical benefit perceived by the patients is not different between treatments. **Therefore, the sample size of clinical trials should be properly determined immediately during the early planning phase of the study.**
- **Inclusion and exclusion criteria of any trial have to be taken into account in the interpretation of the efficacy and tolerability outcomes of a given therapy;** indeed, a specific drug may have a different impact according to patients’ baseline characteristics.
- Data on adverse events (AEs) also should be interpreted with caution. Indeed, AEs can be spontaneously reported by patients, or the patients could be requested to choose from a list of possible AEs; the latter method of assessment could result in a higher rate of reported AEs. Moreover, **most trials are designed to assess the efficacy of a certain drug and could be underpowered to detect a difference in terms of treatment tolerability.**
- **Trial duration has to be taken into account in the interpretation of both the safety and the efficacy of a specific treatment;** indeed, drugs may lose effect over longer periods, and AEs could be detected only after a consistent period of treatment.

Therapy With α_1-Adrenergic Blockers

α_1-Blockers are usually considered as the first-line treatment of LUTS in men

(McVary et al., 2011; Oelke et al., 2013).

Rationale

Adrenergic receptors (ARs) are divided in two macrocategories: α-ARs and β-ARs. Furthermore, a total of nine AR subtypes have been identified: α_{1a}, α_{1b}, α_{1d}, α_{2a}, α_{2b}, α_{2c}, β_1, β_2, β_3 (Fig. 145.4). Each receptor subtype has a distinct molecular structure, pharmacology, and distribution within human tissues; the **α_1-AR subfamily plays a major role in the pathophysiology of LUTS and is the target of α_1-blockers.**

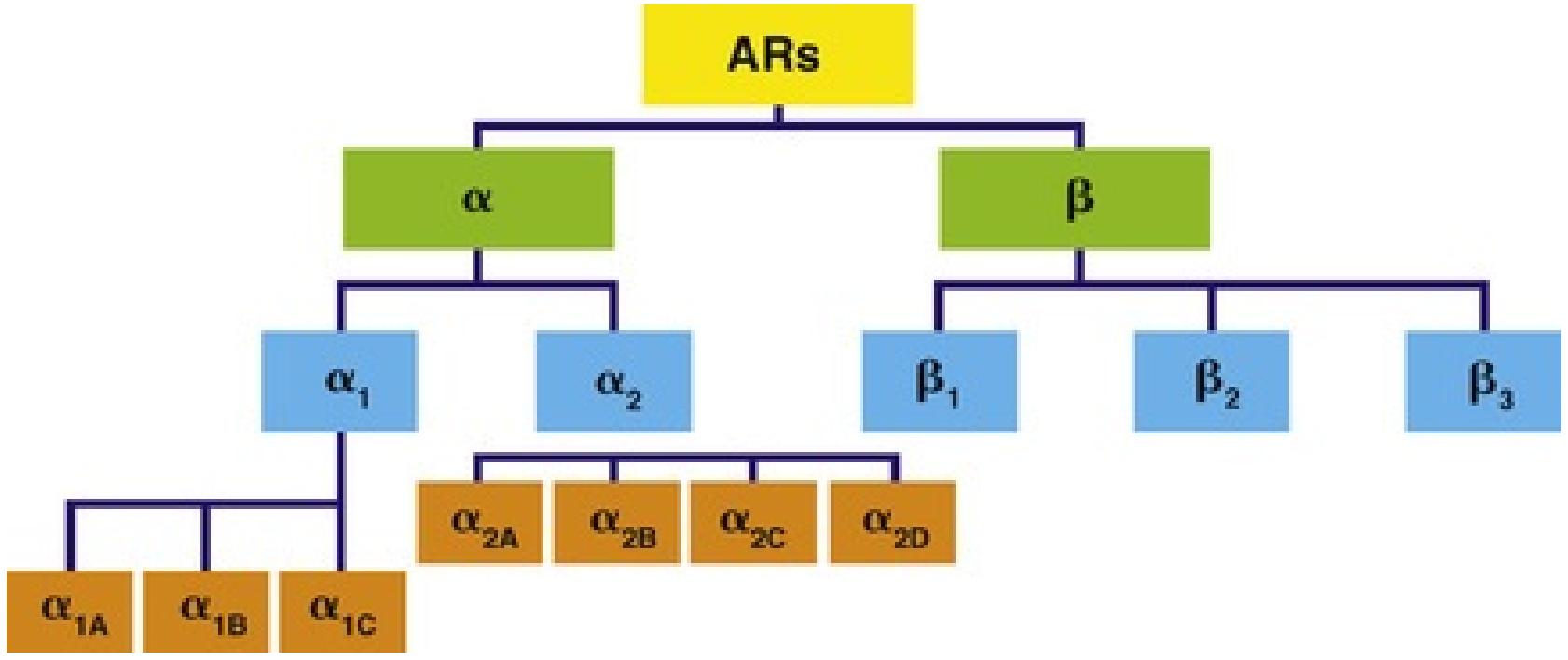

FIG. 145.4 Adrenergic receptor (AR) macrocategories and subtypes.

The distribution of α_1-ARs in human tissues is wide: α_{1a}-ARs are mainly expressed in the liver, followed by the heart and the central nervous system; conversely, α_{1b}-ARs are mainly expressed in blood vessels, spleen, and kidney, and α_{1d}-ARs are highly expressed in the cerebral cortex and the aorta (Price et al., 1994). Overall, smooth muscle contraction is largely mediated by α_1-ARs both in the prostate and urethra (Andersson and Gratzke 2007; Kobayashi et al., 1994; Walden et al., 1999); of the α_1-AR population, the α_{1a} subtype accounts for 70% within the prostate (Andersson, 2002) (Fig. 145.5). Moriyama et al. (1999) analyzed the expression of α_1-AR messenger RNA in BPH and non-BPH prostate tissues, showing that subtypes α_{1a}, α_{1b}, and α_{1d} account for 85%, 14%, and 1% of total expression in BPH prostate tissue compared with 63%, 6%, and 31% in non-BPH prostate tissue, respectively. A similar predominance of α_{1a}-ARs was found at the level of the urethral tissue, including bladder neck and prostatic urethra (Andersson, 2002). Furthermore, α_1-ARs have also been described at the level of the glandular epithelium of the prostate (Walden et al., 1999).

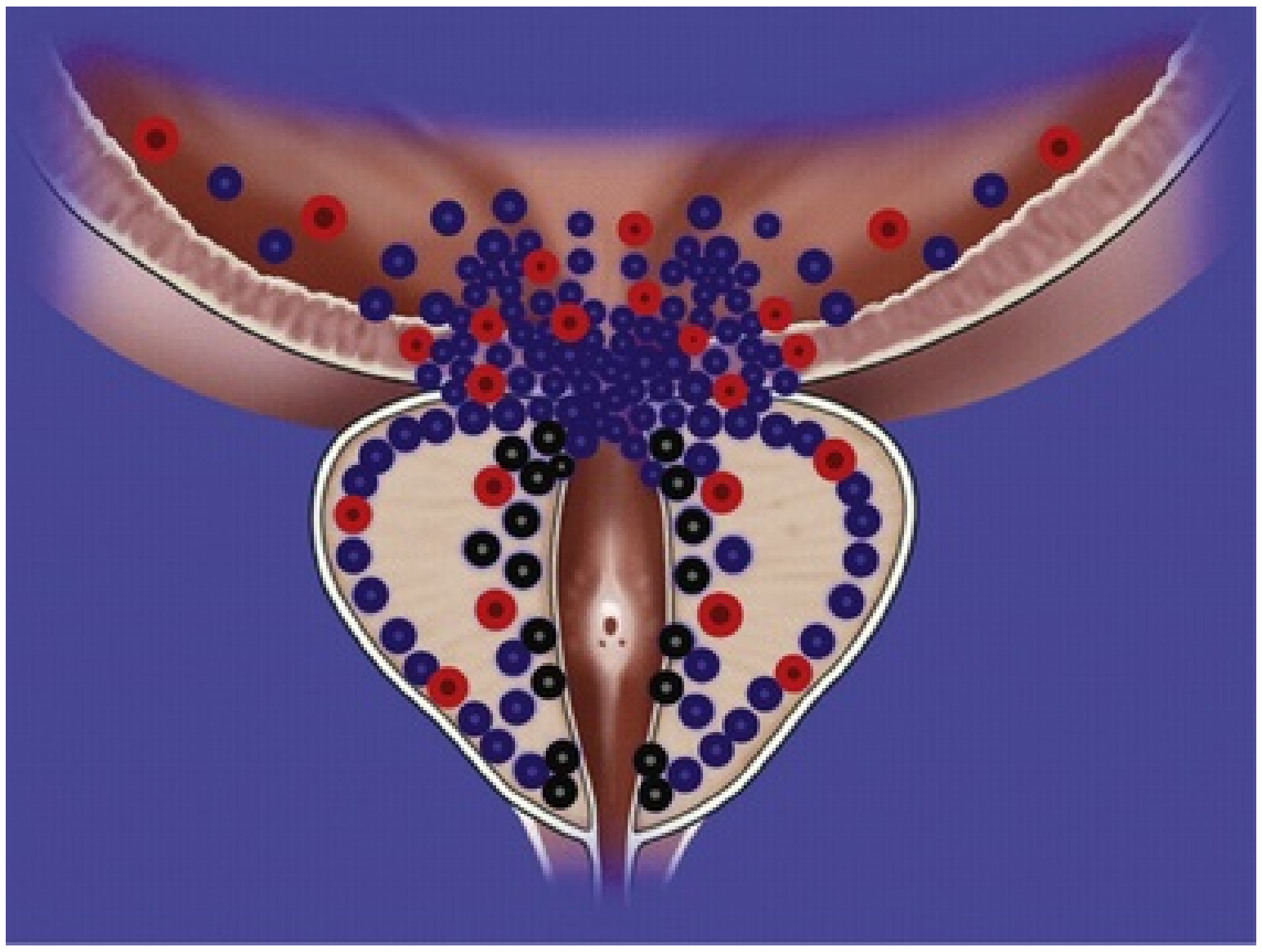

FIG. 145.5 Distribution of α_1-adrenergic receptors at the level of the prostate and bladder neck. The red dots represent α1d receptors, the blue dots represent α1a receptors, and the black dots represent α1b receptors.

Noradrenaline-mediated contraction of the smooth muscle via the binding with α_1-ARs (mainly α_{1a} subtype) at the level of the bladder neck, the proximal urethra, and the prostate is responsible for the dynamic component of BOO in patients with BPH; therefore, **the blockade of α_1-ARs leads to the relaxation of smooth muscle tissue at both sites, with a decrease of the sympathetic baseline muscle tone and the consequent relief of symptoms** (Gup et al., 1989; Lepor et al., 1988). Moreover, α_1-blockers may impact also on the static component of the obstruction; indeed, a suppression of prostate cell proliferation has been observed with α_1-blocker treatment, although it seems to be unrelated to α_1-AR blockade (Chon et al., 1999); whether this effect has a therapeutic significance remains to be established.

Besides the prostate and urethra, α_1-ARs have been detected in the bladder at different sites, including the detrusor muscle, nerve endings, intramural ganglia, urothelium, and interstitial cells (Andersson and Gratzke, 2007). At a subtype level, α_{1d}-ARs are twice as abundant as α_{1a}-ARs in the human detrusor (Malloy et al., 1998). **The effect of α_1-blockers on bladder detrusor function has not**

yet been clarified. Indeed, controversial findings have been reported regarding a possible different pattern of expression of receptor subtypes between obstructed and nonobstructed detrusors (Hampel et al., 2002; Nomiya and Yamaguchi, 2003); likewise, data on the effect of phenylephrine on detrusor contractility are not conclusive (Bouchelouche et al., 2005). A potential beneficial effect of α_1-blockers in treating DO has been supported by the evidence of increased perfusion of the bladder associated with AR blockade; indeed, decreased bladder blood flow is a contributing factor in the pathogenesis of LUTS and OAB syndrome (Andersson et al., 2017).

Chen et al. (2005) showed that mice in which α_{1d}-AR expression had been knocked out had larger bladder capacity and voided volumes compared with controls, thus supporting a facilitating role of α_{1d}-ARs in the voiding reflex. In this context, α_1-ARs may exert inhibitory control on the frequency of voiding through the regulation of afferent processing in the spinal cord (Yoshiyama et al., 2000). Ishihama et al. (2006) showed that α_{1d}-ARs are expressed in the bladder urothelium and that their inhibition affects the voiding reflex through an afferent nerve decrease. Therefore, α_{1d}-ARs seem to play an important role in bladder function regulation both at the level of the urothelium and in afferent nerve pathways. In this context, α_1-blockers with a specific affinity for α_{1d}-ARs have been found to increase bladder volume at the first desire to void and bladder volume at the maximum desire to void, with a reduction of DO (Ishizuka et al., 2013). Further research is needed to draw a final conclusion regarding the role of α_{1d}-ARs in terms of LUTS pathogenesis and the related effect of α_{1d}-AR blockade.

Classification of α_1-Blockers

Two macrocategories of α_1-blockers have been developed over the past three decades, with different affinity for α-ARs and the related effects on the lower urinary tract (Table 145.1).

TABLE 145.1

Classification of α-Adrenergic Blockers and Recommended Doses

CLASS OF α-BLOCKERS	AVAILABLE FORMULATION	RECOMMENDED DAILY DOSE	RECOMMENDED ADMINISTRATION[a]

NONSELECTIVE			
Phenoxybenzamine	10-mg capsule	10 mg bid	No longer indicated for LUTS treatment
SELECTIVE			
Prazosin	0.5[c]-, 1-, 2[d]-, 5[d]-mg capsule	2 mg bid	No longer indicated for LUTS treatment
Indoramin	20-mg capsule	20 mg bid	No longer indicated for LUTS treatment
Terazosin	1[d]-, 2-, 5-, 10[d]-mg capsule	5 or 10 mg qd	Initial dose is 1 mg at bedtime. The dose should be titrated up to 5 or 10 mg.
Doxazosin IR	1-, 2-, 4-mg capsule	2–8 mg qd	Initial dose is 2 mg at bedtime. The dose should be titrated up to 4 or 8 mg.
Doxazosin SR	4-, 8-mg capsule	4 or 8 mg qd	Initial dose is 4 mg after breakfast, eventually increased to 8 mg.
UROSELECTIVE			
Alfuzosin ER[b]	10-mg capsule	10 mg qd	Initial dose is 10 mg with the same meal each day.
Tamsulosin	0.4-, 0.8[d]-mg capsule	0.4–0.8 mg qd	Initial dose is 0.4 mg with the same meal each day.
Silodosin	4-, 8-mg capsule	8 mg qd	Initial dose is 8 mg with the same meal each day.
Naftopidil	25-, 50-mg capsule	25–75 mg/day	Marketed only in Asian countries

[a] As for patient information leaflet.

[b] Alfuzosin is considered a uroselective agent on the basis of the efficacy profile characterized by a preferential effect on the urogenital system.

[c] Marketed only in Europe.

[d] Marketed only in the United States.

αABs, α-Adrenergic blockers; *bid,* twice a day; *ER,* extended release; *qd,* once a day; *IR,* immediate release; *LUTS,* lower urinary tract symptoms; *SR,* sustained release; *tid,* three times a day.

Nonselective α_1-Blockers

Caine et al. (1978) conducted a placebo-controlled double-blind trial to test the efficacy of the novel compound phenoxybenzamine as a symptomatic treatment of BPO; they showed a significant improvement in uroflowmetry parameters and significant relief of patients' symptoms. These results were attributed to the inhibitor effect of phenoxybenzamine on the α-ARs previously isolated at the level of the prostate and the proximal urethra (Caine et al., 1975). **However, because of the nonselectivity of the molecule, blocking both α_1 and α_2 receptor subtypes, serious cardiovascular AEs were observed, and the drug was no longer used to treat LUTS/BPH.**

Selective α_1-Blockers

The discovery of the predominance of the α_1 receptor subtype at the level of the lower urinary tract stimulated the search for molecules with selective affinity for this subtype. **Prazosin was the first selective α_1-AR antagonist investigated for LUTS treatment** (Hedlund et al., 1983); in placebo-controlled studies, prazosin resulted in a significant increase in urinary flow rates (Chapple et al., 1992; Kirby et al., 1987) and was better tolerated than phenoxybenzamine. However, because of its short serum elimination half-life, prazosin requires administration at least twice daily. Afterward, doxazosin and terazosin were developed as selective α_1-AR antagonists with a longer half-life, allowing a more user-friendly once-daily administration (Gillenwater et al., 1995; Lepor et al., 1992), although both drugs were associated with significant treatment-emergent AEs caused by smooth muscle relaxation at the level of the vascular district.

Therefore, to maintain efficacy and reduce the incidence of AEs, α_1-blockers selective for the prostatic and urethral tissue were then developed (Andersson, 1998); **tamsulosin, alfuzosin, silodosin, and naftopidil are defined as uroselective drugs and have a higher affinity for the α_{1a} and α_{1d} receptor subtypes than for the α_{1b} subtype.**

Review of the Literature on Currently Approved α_1-Blockers for the Treatment of Lower Urinary Tract Symptoms

Several RCTs investigated the efficacy and tolerability of α_1-blockers for the

treatment of LUTS; pooled analyses have provided level 1a evidence for each compound.

The effect and tolerance of α_1-blockers are dose dependent; therefore, randomized trials have been conducted with different designs so as to provide data on dose-dependent efficacy and tolerability (titration to fixed-dose design) and data on the threshold dose for the maximal achievable response in clinical practice (titration to response or to maximal dose design).

The trials investigating both the safety and efficacy of the nonselective α_1-blockers phenoxybenzamine (Abrams et al., 1982; Caine et al., 1978), prazosin (Chapple et al., 1992; Hedlund et al., 1983; Kirby et al., 1987), and indoramin (Chow et al., 1990; Iacovou and Dunn, 1987) are not discussed in this chapter because all of the aforementioned compounds are no longer used for the medical treatment of BPH.

The results of the most significant RCTs and comparative studies on terazosin, doxazosin, extended-release (ER) alfuzosin, tamsulosin, silodosin, and naftopidil are summarized and discussed next.

Terazosin

Several RCTs have demonstrated the efficacy of terazosin in patients with LUTS related to BPE (Table 145.2).

TABLE 145.2

Randomized Placebo-Controlled Trials Evaluating the Efficacy and Tolerability of Terazosin

	DRUG	PATIENTS	LENGTH OF TREATMENT	SYMPTOMS (MEAN CHANGE FROM BASELINE [SD]; PERCENTAGE CHANGE [P[a]])	
Lepor et al., 1992	Terazosin 2 mg Terazosin 5 mg	*N* = 285 50–75 years of age with symptomatic	12 weeks	Boyarsky total 2 mg: –3.3 (0.4); –33 (0.09) 5 mg: –3.6 (0.4);	

	Terazosin 10 mg Placebo	BPH (score ≥1 point for at least two obstructive symptoms on the Boyarsky symptom scale)		–33 (0.042) 10 mg: –4.5 (0.5); –45 (<0.001) placebo: –2.3 (0.5); –24	
Brawer et al., 1993	Terazosin titrated up to 10 mg Placebo	*N* = 160 >45 years of age with symptomatic BPH (score ≥1 point for at least two obstructive symptoms on the Boyarsky symptom scale)	24 weeks	Boyarsky total 10 mg: –4.6 (0.4); –42 (<0.05) Placebo: –1.1 (0.4); –10	
Elhilali et	Terazosin	*N* = 164	24 weeks	10 mg: –3.4; –31	

al., 1996	titrated up to 10 mg Placebo	50–80 years of age with symptomatic BPH (score ≥1 point on at least two obstructive symptoms on the Boyarsky symptom scale)		(0.05) Placebo: –1.6; –15	
Lepor et al., 1996	Terazosin titrated up to 10 mg Placebo	*N* = 610 50–75 years of age with symptomatic BPH (IPSS ≥8)	52 weeks	IPSS total 10 mg: –6.1; -38 (<0.001) Placebo: –2.6; -16	
Roehrborn et al., 1996	Terazosin titrated up to 10 mg Placebo	*N* = 2084 ≥55 years of age with symptomatic BPH (IPSS ≥13)	52 weeks	IPSS total 10 mg: –7.6 (0.21); –38 (<0.001) Placebo: –3.7 (0.22); –18	

[a] Compared with placebo.

[b] The three most common adverse events are reported if available.

[c] Estimates are significantly different as compared with placebo.

BPH, Benign prostatic hyperplasia; *IPSS,* International Prostatic Symptom Score; *SD,* standard deviation.

Lepor et al. (1992) published the first phase III multicenter trial, with 285 patients with LUTS suggestive of BOO randomized to receive placebo or 2 mg, 5 mg, or 10 mg terazosin once daily for a 12-week treatment period. **The results showed a 22.4% reduction in symptom score (Boyarsky symptom scale) in favor of the treatment group. Moreover, patients treated with terazosin had a significant increase in PFRs and mean urinary flow rates. Both effects were dose dependent, with better results with 10 mg terazosin. Overall, AEs were minor and reversible in all four terazosin-treated groups.** In this context, higher but not statistically significant incidences of asthenia, flu syndrome, and dizziness were observed for the terazosin-treated groups compared with the placebo group. Conversely, a significantly greater incidence of postural hypotension was reported in the 5-mg terazosin group compared with the placebo group. The incidence of syncope for all terazosin-treated patients was less than 0.5%.

The two longest and largest trials (including 68% of patients enrolled in all published RCTs assessing the effect of terazosin vs. placebo) provided significant findings on the effect and safety of terazosin. In the four-arm study of Lepor et al. (1996), 305 men randomized to receive terazosin were compared with 305 men randomized to receive placebo. Patients were included if they had a PFR of less than 15 mL but more than 4 mL and a PVR volume less than 300 mL. A terazosin dose titration was applied, with 80% of patients receiving the maximum dose of 10 mg by the end of the study. AUASI scores significantly decreased by 6.1 points in the terazosin group at the 1-year assessment. Similarly, the mean increase in PFR was significant after 12 months for terazosin compared with placebo (2.7 vs. 1.4 mL/s). **Dizziness and asthenia were the most commonly reported AEs in the terazosin group (26% and 14%, respectively)**; postural hypotension was reported in 8% of patients in the terazosin group versus 1% of patients in the placebo group ($P < 0.001$).

Roehrborn et al. (1996) reported the results of the 1-year multicenter Hytrin Community Assessment Trial (HYCAT), which enrolled 2084 men with an

AUASI score of 13 or greater and a PFR of less than 15 mL/s. Patients were randomized to receive placebo or terazosin; the dose was titrated from 1 mg to 5 mg or 10 mg according to the clinical response. **The symptom score decreased by 37.8% in the terazosin group and by 18.4% in the placebo group (*P* < 0.001)** (Fig. 145.6); **similarly treatment with terazosin significantly improved urinary flow parameters. Of note, 19.7% of patients discontinued use of terazosin because of AEs.** Dizziness was the most frequent AE (11.7% of cases).

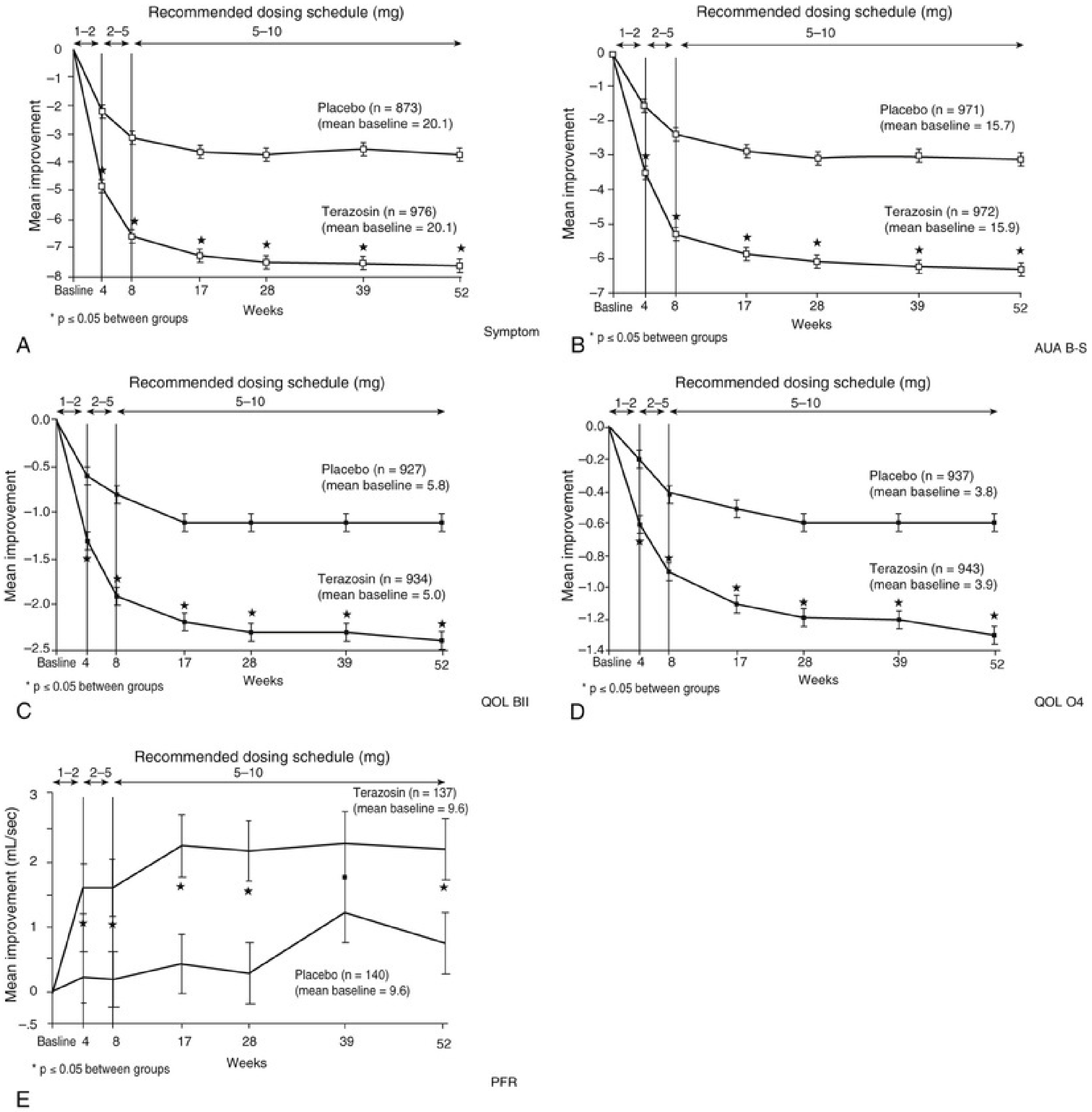

FIG. 145.6 Time course of reductions in (A) AUA Symptom Score, (B) AUA Bothersome Score, (C) BPH Impact Index *(BII)*, (D) quality-of-life

score (QoL), and (E) peak urinary flow rate for placebo and terazosin treatment groups. A lowering of the score represents clinical improvement. (From: Roehrborn CG, Oesterling JE, Auerbach S, et al. The Hytrin Community Assessment Trial study: a one-year study of terazosin versus placebo in the treatment of men with symptomatic benign prostatic hyperplasia. HYCAT Investigator Group. *Urology*. 47[2]:159–168, 1996. Figure 2, p. 163.)

Evidence from basic science has shown that terazosin induces prostate epithelial and stromal apoptosis (Chon et al., 1999). This effect is related to the quinazoline structure of the drug rather than the antagonist effect on α-ARs; however, **terazosin was not shown to reduce PV when compared with placebo** (Lepor et al., 1996).

Regarding the effect of terazosin on BOO, as assessed with urodynamic tests, a recent meta-analysis including both randomized and observational trials showed a decrease of 6.69 (95% CI, –11.35 to –2.04) in the BOO index (BOOI) associated with terazosin treatment (Fusco et al. 2016), suggesting a clinically significant impact of terazosin on BOO.

Wilt et al. (2002a) systematically reviewed the findings of 10 randomized trials on terazosin versus placebo. The analyses confirmed the efficacy of terazosin in terms of symptom relief and urinary flow rate increase, with some evidence in favor of a 10-mg dose; overall, AEs were associated with a twofold to fourfold increase in the rate of treatment discontinuation. In this context, terazosin **dose titration is recommended to minimize the risk for first-dose hypotension and syncope. Patients should be counseled to start treatment with 1 mg terazosin taken at bedtime, further increasing up to 5 or 10 mg** (see Table 145.1). Kirby (1998) examined mean blood pressure changes according to whether patients were normotensive or hypertensive at baseline. Overall, in normotensive men, small clinically insignificant decreases in blood pressure were noted; untreated hypertensive men had larger and clinically significant decreases in blood pressure; medically controlled hypertensive patients did not show a significant change in blood pressure, whereas poorly controlled individuals showed significantly lowered blood pressure after terazosin treatment.

Doxazosin

Multicenter, randomized, placebo-controlled trials assessed the efficacy and tolerability of doxazosin in men with LUTS/BPH (Table 145.3). In a 16-week, double-blind, multicenter trial, 100 patients were randomized to receive doxazosin or placebo (Fawzy et al., 1995). All patients had symptomatic BPH with an AUASI score of 10 or greater, PFR of 5 to 15 mL/s, and PVR volume of 125 to 500 mL; dose titration was applied to 2, 4, or 8 mg once daily (88% of patients reached the 8-mg dose). **The symptom score decreased significantly by 39% in the treatment group compared with 17% in the placebo group ($P < 0.001$); similarly, PFR increased by a mean of 2.9 mL/s with doxazosin compared with 0.7 mL/s with placebo. All patients were normotensive at enrollment, and hypotension was reported by 8% of patients.** The incidences of dizziness, fatigue, headache, somnolence, and nausea were 20%, 8%, 8%, 6%, and 8%, respectively. Withdrawal because of treatment-emergent AEs occurred in 14% of patients in the doxazosin group and in 2.1% of patients in the placebo group. Gillenwater et al. (1995) reported data from a larger multicenter RCT including 248 hypertensive patients randomized to 16-week therapy with doxazosin or placebo. Efficacy and safety were investigated for 2, 4, 8, and 12 mg doxazosin doses, with titration to a fixed-dose approach. **The results showed a significant reduction of symptom severity only for doxazosin at doses of 4 and 8 mg over placebo, although the small number of patients in each dosing group may be responsible for the lack of significance compared with placebo for the other doses.** The average PFR increased from 2.3 to 3.6 mL/s in the 4-, 8-, and 12-mg doxazosin groups, compared with 0.1 mL/s in the placebo group ($P < 0.01$); this increase was significant, even after only 1 week of therapy. The overall treatment-related incidences of dizziness and fatigue were 15% and 10%, respectively. **Standing and sitting blood pressure significantly decreased for the 4-, 8-, and 12-mg doxazosi**n **groups compared with placebo, with a maximum average decrease in systolic blood pressure of 17.4 mm Hg in the standing position. These data confirmed the significant impact of doxazosin on blood pressure, at least in hypertensive men.** Other trials showed lower overall mean decrease in sitting and standing blood pressure for normotensive men treated with doxazosin (Fawzy et al., 1995; Kirby et al., 1998; Lepor et al., 1997). In a pooled analysis of 10 placebo-controlled trials with doxazosin, MacDonald et al. (2004) showed that the relative risk for postural hypotension with doxazosin was 2.72 (95% CI, 1.21 to 6.15) compared with placebo, considering both hypertensive and normotensive patients. The overall incidences of dizziness, asthenia, and postural hypotension were 11%, 6%, and 2% with doxazosin compared with 7%, 3%, and less than 1% with placebo, respectively.

TABLE 145.3

Randomized Placebo-Controlled Trials Evaluating the Efficacy and Tolerability of Doxazosin

	DRUG	PATIENTS	LENGTH OF TREATMENT	SYMPTOMS (MEAN INCREASE FROM BASELINE [SD]; PERCENTAGE CHANGE [P[a]])
Chapple et al., 1994	Doxazosin 4 mg Placebo	*N* = 135 Symptomatic patients with urodynamically confirmed BOO (PFR <15 mL/s)	14 weeks	NR
Fawzy et al., 1995	Doxazosin titrated 1 to 8 mg Placebo	*N* = 100 >45 years of age, with symptomatic BPH (IPSS ≥10; PFR 5–15 mL/s)	17 weeks	IPSS total 1–8 mg: –5.7; –39 (<0.001) Placebo: –2.5; –17
Gillenwater et al., 1995	Doxazosin 2 mg Doxazosin 4 mg Doxazosin 8 mg Doxazosin 12 mg	*N* = 248 ≥45 years of age with mild to moderate HT and symptomatic BPH (PFR 5–15 mL/s; PVR	16 weeks	Modified Boyarsky total 2 mg: –2.8; –10 (NS) 4 mg: –5.0; –17 (<0.01) 8 mg: –4.2; –14 (<0.05)

	Placebo	<200 mL; daytime voids ≥4, nocturia ≥2)		12 mg: –3.6; –12 (NS) Placebo: –2.5; –9
Andersen et al., 2000	Doxazosin titrated from 1 to 8 mg Doxazosin GITS 4–8 mg Placebo	*N* = 795 50–80 years of age with symptomatic BPH (IPSS ≥12; PFR 5–15 mL/s)	17 weeks	IPSS total 1–8 mg: –8.4 (0.3); –47 (<0.001) GITS: –8.0 (0.3); –45 (<0.001) Placebo –6.0 (0.4); –33
Kirby et al., 2003	Doxazosin titrated from 1 to 8 mg Placebo	*N* = 545 50–80 years of age with symptomatic BPH (IPSS ≥12; PFR 5–15 mL/s)	54 weeks	IPSS total 1–8 mg: –8.3 (0.4); –49 (<0.05) Placebo: –5.7 (0.4); –33
McConnell et al., 2003	Doxazosin titrated from 1 to 8 mg Placebo	*N* = 1,493 ≥50 years of age with symptomatic BPH (IPSS ≥8; PFR 4–15 mL/s)	Mean follow-up 234 weeks	IPSS total: 1–8 mg: –6.6; –39 (<0.001) Placebo –4.9; –29

[a] Compared with placebo.

[b] The three most common adverse events are reported if available.

[c] Estimates are significantly different as compared with placebo.

AEs, Adverse events; *BPH,* benign prostatic hyperplasia; *GITS,* gastrointestinal therapeutic system; *IPSS,* International Prostate Symptom Score; *NR,* not reported; *NS,* not significant; *PFR,* peak flow rate; *PVR,* postvoid residual volume; *SD,* standard deviation.

Both the 1-year Prospective European Doxazosin and Combination Therapy (PREDICT) trial (Kirby et al., 2003) and the 4-year MTOPS trial (McConnell et al., 2003) provided evidence of the maintenance of symptom score decrease and PFR increase with doxazosin therapy at long term-follow up. **Findings from the MTOPS trial showed that doxazosin alone reduced the risk for clinical progression of BPH by 39% as compared with placebo ($P < 0.001$)** (McConnell et al., 2003).

In a recent meta-analysis assessing the effect of α_1-blocker treatment on urodynamic parameters, a significant effect of doxazosin on BOO was observed, with a decrease of 19.4 points of the BOOI (Fusco et al., 2016).

A gastrointestinal therapeutic system (GITS) sustained-release (SR) formulation of doxazosin was developed as a controlled-release formulation to enhance the pharmacologic profile of the drug (Chung et al., 1999); the GITS formulation had a lower maximum plasma concentration of doxazosin and a minimum concentration sustained for a longer period compared with the standard formulation (Chung et al., 1999). Two randomized, double-blind, parallel-group multicenter studies compared the efficacy of GITS therapy (starting dose of 4 mg, then uptitrated to 8 mg to reach clinical efficacy) versus standard doxazosin (from 1 mg up to 8 mg) (Andersen et al., 2000; Gratzke and Kirby 2000); the combined analysis of both trials confirmed the overall comparable efficacy of both formulations (Kirby et al., 2001). Of all patients randomized to receive GITS therapy, 42.6% continued to use the 4-mg formulation; moreover, AE incidence was lower in the GITS group compared with the standard doxazosin group (16.1% vs. 25.3%, respectively). Similarly, treatment withdrawal caused by AEs was lower in the GITS group (3.3% vs. 4.8%, respectively). Overall, the **doxazosin GITS therapy showed a pattern of earlier onset of symptom relief and increase in flow rates compared with the doxazosin standard formulation; this finding was related to the possibility to start the therapy at a higher dose (4 mg), with no need for dose titration for the SR formulation** (Kirby et al., 2001)**. Doxazosin SR is recommended at the initial dose of 4 mg taken at breakfast** (see Table 145.1).

As for terazosin, the quinazoline structure of doxazosin was associated with cell apoptosis in vitro. The mean apoptotic index in the epithelial and stromal prostate components was shown to increase from 1.9% and 1.0% to 6% and 12%, respectively, after 3 months of doxazosin treatment (Kyprianou et al., 1998). Ilio et al. (2001) suggested that this effect might be caused by the autocrine production of transforming growth factor β_1 stimulated by doxazosin. However, as for terazosin, **no significant changes in PV have been reported after treatment with doxazosin compared with placebo** (McConnell et al., 2003).

Alfuzosin

Alfuzosin was launched as a uroselective α_1-blocker. Although the compound does not have in vitro selectivity for any of the α_1-AR subtypes, alfuzosin shows clinical uroselectivity, which is related to a preferential effect of the drug on the urogenital system. Indeed, in isolated human tissues, alfuzosin showed a high selectivity ratio toward prostate tissue over vascular tissue (Mottet et al., 2003). Moreover, alfuzosin has poor diffusion in the central nervous system (CNS) (Rouquier et al., 1994). **This pharmacokinetic profile is reflected in a high efficacy for relieving LUTS, along with a lower rate of cardiovascular AEs (postural hypotension, syncope, vertigo, and dizziness) or CNS AEs (somnolence, asthenia)** (Table 145.4).

TABLE 145.4

Randomized Placebo-Controlled Trials Evaluating the Efficacy and Tolerability of Alfuzosin

	SYMPTOMS (MEAN INCREASE

	DRUG	PATIENTS	LENGTH OF TREATMENT	FROM BASELINE [SD]; PERCENTAGE CHANGE [P[a]])
Jardin et al., 1991	Alfuzosin IR 7.5–10 mg Placebo	*N* = 518 45–81 years of age with symptomatic BPH (Boyarsky score ≥6)	26 weeks	Boyarsky total 7.5–10 mg: –4; –42 (0.0004) Placebo: –3; –32
Martorana et al., 1997	Alfuzosin IR 7.5 mg Placebo	*N* = 94 47.80 years of age with symptomatic BPH (Boyarsky score ≥6; PFR 5–12 mL/s)	4 weeks	Boyarsky total 7.5 mg: –2–7; –25 (NS) Placebo: –2.5; –24
Buzelin et al., 1997a	Alfuzosin SR 10 mg Placebo	*N* = 390 >45 years of age with symptomatic BPH (daytime micturitions ≥8 or nocturia ≥2; PFR 5–15 mL/s; PVR <150 mL)	12 weeks	IPSS total 10 mg: –5.0; –31 (0.007) Placebo: –3.4; –18
van Kerrebroeck et al., 2000	Alfuzosin qd 10 mg Alfuzosin 7.5 mg	*N* = 447 >50 years of age with symptomatic	12 weeks	IPSS total 10 mg: –6.9; –40 (0.002) 7.5 mg: –6.4; –

	Placebo	BPH (IPSS ≥13; PFR 5–12 mL/s; PVR >350 mL)		38 (0.02) Placebo –4.9; –28	
Roehrborn et al., 2001	Alfuzosin qd 10 mg Alfuzosin qd 15 mg Placebo	*N* = 536 ≥50 years of age with symptomatic BPH (IPSS ≥13; PFR 5–12 mL/s; PVR >350 mL; QoL score ≥3)	12 weeks	IPSS total 10 mg: –3.6 (4.8); –20 (0.001) 15 mg: –3.4 (5.7); –19 (0.004) Placebo –1.6 (5.8); –9	

[a] Compared with placebo.

[b] The three most common adverse events are reported if available.

AEs, Adverse events; *BPH,* benign prostatic hyperplasia; *IR,* intermediate release; *IPSS,* International Prostate Symptom Score; *NR,* not reported; *NS,* not significant; *PFR,* peak flow rate; *PVR,* postvoid residual volume; *qd,* once a day; *SD,* standard deviation; *SR,* sustained release; *tid,* three times a day.

Alfuzosin was initially tested in a 2.5-mg immediate-release (IR) formulation administered three times daily; Jardin et al. (1991) assessed the efficacy of IR alfuzosin in an RCT with 518 symptomatic men with BPH, showing significant relief of both storage and voiding symptoms (formerly defined obstructive and irritative symptoms) in the treatment group. The overall incidence of AEs was comparable between groups. Afterward, a novel SR formulation of 5 mg, allowing administration twice daily, was tested in a placebo-controlled trial (Buzelin et al., 1997a). After 12 weeks, there was a reduction of 31% versus 18% in the IPSS in the alfuzosin group and the placebo group, respectively ($P = 0.007$); moreover, patients treated with SR alfuzosin showed a mean increase in PFR of 2.4 mL/s compared with 1.1 mL/s in the placebo group. As for the IR formulation, the rate of treatment-emergent AEs was low and comparable with that for placebo, with rates of vascular-related events of 3.1% and 3.6% in the alfuzosin group and the placebo group, respectively.

To improve the convenience of dosing, a 10-mg once-daily formulation was developed; van Kerrebroeck et al. (2000) compared the efficacy and safety of once-daily alfuzosin with IR alfuzosin and placebo in 447 patients. Both alfuzosin groups showed a comparable significant decrease in terms of IPSS compared with placebo (10 mg once daily, –6.9; 2.5 mg three times daily, –6.4; placebo, –4.9; $P = 0.005$). Similarly, the mean increase in PFR was comparable between alfuzosin-treated groups and significantly superior to that resulting from use of placebo. The incidence of vasodilatory AEs was lower with the once-daily formulation compared with the IR formulation (6.3% vs. 9.4%, respectively), and no first-day effect on blood pressure was reported with the 10-mg dosing in both normotensive and hypertensive patients. The clinical benefits of alfuzosin once daily was maintained in the 9-month open-label extension. These results were further confirmed in the ALFUS trial, which assessed the efficacy of 10 mg once-daily alfuzosin versus placebo in a double-blind fashion (Roehrborn, 2001).

Overall, these findings showed 10 mg once-daily alfuzosin is an effective and safe compound with no need for dose titration. Alfuzosin should be taken after the same meal each day (see Table 145.1).

In a meta-analysis comparing the results of eight RCTs (see Table 145.4), alfuzosin was highly effective in relieving symptoms and improving uroflowmetry parameters, with good efficacy maintained up to 3 years of treatment (MacDonald and Wilt, 2005); dizziness was the most frequently reported AE, ranging in incidence from 1.7% to 11.8%, whereas other vasodilatory effects, including hypotension, syncope, and somnolence, occurred in less than 2% of participants. Moreover, in a systematic review of studies assessing urodynamic findings, treatment with alfuzosin was associated with a mean BOOI change of –14.88 (95% CI, –26.68 to –3.08) (Fusco et al., 2016).

Tamsulosin

Tamsulosin is a uroselective α_1-blocker with higher affinity for the α_{1a} and α_{1d} receptor subtypes (Noble et al., 1997). In vitro pharmacokinetic studies showed that the selectivity of tamsulosin for the α_{1d} subtype is marginally greater than that for the α_{1a} subtype, but 10-fold greater for α_{1a} than for α_{1b}. In a rat model of BPH, Kojima et al. (2011) demonstrated that the administration of tamsulosin led to a dose-dependent increased expression of α_{1a} and α_{1d} receptors in prostatic tissue, thus confirming the uroselectivity of the drug. This profile confers tamsulosin with excellent efficacy along with good tolerability.

The efficacy and safety of tamsulosin were investigated in five RCTs (Table 145.5) (Abrams et al., 1995, 1997; Chapple et al., 1996; Lepor 1998a; Narayan and Tewari, 1998).

TABLE 145.5

Randomized Placebo-Controlled Trials Evaluating the Efficacy and Tolerability of Tamsulosin

	DRUG	PATIENTS	LENGTH OF TREATMENT	SYMPTOMS (MEAN INCREASE FROM BASELINE [SE]; PERCENTAGE CHANGE [P[a]])
Abrams et al., 1995	Tamsulosin 0.4 mg Placebo	*N* = 296 ≥45 years of age with symptomatic BPH (Boyarsky score >6; PFR 4–12 mL/s)	14 weeks	Boyarsky total 0.4 mg: –2.4 (0.2); –36 (0.002) Placebo: –2.2 (0.3); –24
Abrams et al.,	Tamsulosin 0.2 mg	*N* = 126 50–85 years	7 weeks	Boyarsky total 0.2 mg: –3.4; –

1997	Tamsulosin 0.4 mg Tamsulosin 0.6 mg Placebo	of age with symptomatic BPH (PFR <15 mL/s)		20 (NS) 0.4 mg: –4.1; –29 (NS) 0.6 mg: –4.4; –28 (NS) Placebo: –2,9; –18	
Chapple et al., 1996	Tamsulosin 0.4 mg Placebo	*N* = 575 ≥45 years of age with symptomatic BPH (Boyarsky score >6; PFR 4–12 mL/s)	14 weeks	Boyarsky total 0.4 mg: –3.3 (3.1); –35 (0.002) Placebo: –2.4 (3.2); –26	
Lepor, 1998a	Tamsulosin 0.4 mg Tamsulosin 0.8 mg Placebo	*N* = 756 ≥45 years of age with symptomatic BPH (IPSS ≥13; PFR 4–15 mL/s)	17 weeks	IPSS total 0.4 mg: –9.3 (6.3); –41 (<0.001) 0.8 mg: –9.6 (6.2); –48 (<0.001) Placebo: –5.5 (6.3); –28	
Narayan and	Tamsulosin 0.4 mg	*N* = 735 ≥45 years of	17 weeks	IPSS total 0.4 mg: –5.1	

Tewari, 1998	Tamsulosin 0.8 mg Placebo	age with symptomatic BPH		(6.4); –27 (0.01) –5.8 (6.4); –30 (0.01) –3.6 (5.7); –19	

[a] Compared with placebo.

[b] The three most common adverse events are reported if available.

[c] Estimates are significantly different as compared with placebo.

AEs, adverse events; *BPH,* benign prostatic hyperplasia; *IPSS,* International Prostate Symptom Score; *NR,* not reported; *NS,* not significant; *PFR,* peak flow rate; *SE,* standard error.

In a phase III multicenter trial, 756 patients with BPH were randomized to receive either tamsulosin (0.4 vs. 0.8 mg/day) or placebo for 13 weeks (Lepor 1998a); the mean change in the AUASI score was –8.3 in the 0.4-mg group versus –5.5 in the placebo group ($P<0.001$), and the tamsulosin dose of 0.8 mg was associated with a mean decrease of 9.6 points, which was significantly greater than with both placebo and the 0.4-mg dose ($P < 0.02$) (Fig. 145.7). Moreover, both treatment groups showed a significant higher mean increase of the PFR than the placebo group (0.4 mg, 1.75 mL/s; 0.8 mg, 1.78 mL/s; placebo, 0.5 mL/s). Rhinitis, dizziness, and abnormal ejaculation were reported in 5%, 3%, and 6% of patients, respectively, with the tamsulosin dose of 0.4 mg, and in 6%, 9%, and 18% of patients, respectively, with the tamsulosin dose of 0.8 mg. Of clinical relevance, **PFR increased within 4 to 8 hours after a single 0.4-mg dose, and symptom relief was evident after 1 week of treatment.** Overall, AE incidence was comparable after treatment with the 0.4-mg dose and placebo, but was greater for the 0.8-mg dose. Mean changes in systolic and diastolic blood pressure did not differ between placebo and tamsulosin in both hypertensive and normotensive patients. The open-label extension of the same trial confirmed these results in terms of efficacy and safety after 40 weeks of treatment (Lepor, 1998b).

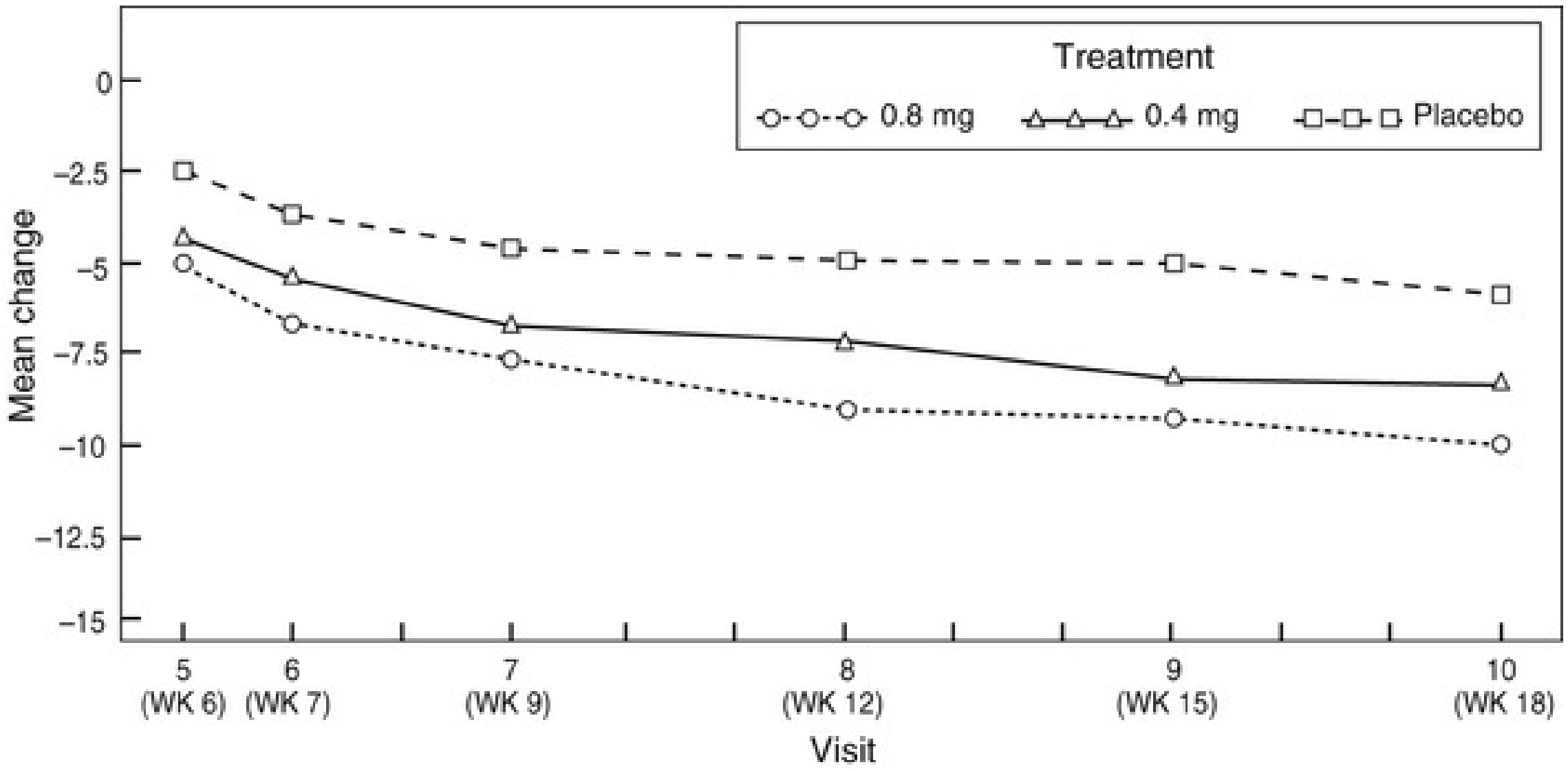

FIG. 145.7 Mean change from the baseline in the total American Urological Association Symptom Score by visit. Changes from the baseline were apparent for all three treatment groups as early as 1 week after the initiation of double-blind therapy. Near-maximal responses were obtained by visit 8, approximately 8 weeks after the initiation of double-blind therapy. (From: Lepor H. Phase III multicenter placebo-controlled study of tamsulosin in benign prostatic hyperplasia. Tamsulosin Investigator Group. *Urology* 51[6]:892–900, 1998a. Figure 1A, p. 896.)

Narayan and Tewari (1998) reported similar results investigating the effect of 0.4 and 0.8 mg tamsulosin versus placebo in 735 patients in a double-blind fashion. After 13 weeks of therapy, both treatment groups showed a significant reduction of symptom scores and significant increase of urinary flow rates compared with the placebo group; the results were comparable between active doses, although the study lacked statistical power to detect a significant difference between the two treatment groups. The incidences of asthenia, dizziness, rhinitis, and abnormal ejaculation were 2%, 5%, 3%, and 11%, respectively, after treatment with 0.4 mg tamsulosin, with a higher incidence of rhinitis and abnormal ejaculation in the 0.8-mg group. No significant changes in systolic blood pressure were reported.

Wilt et al. performed a meta-analysis of RCTs assessing the efficacy of tamsulosin versus placebo and showed a percentage reduction in symptom score ranging from 20% to 48% and a mean change in PFR ranging from 1.2 to 4 mL/s after tamsulosin therapy (Wilt et al., 2003). Symptomatic relief **was slightly greater with 0.8 mg tamsulosin compared with 0.4 mg tamsulosin; however, notwithstanding that tamsulosin was generally well tolerated, the rates of AEs and treatment withdrawal were dose dependent, and therefore 0.4 mg tamsulosin emerged as the formulation of choice for LUTS treatment. Tamsulosin is recommended at the dose of 0.4 mg taken after the same meal each day** (see Table 145.1).

Overall, tamsulosin has been shown to relieve both voiding and storage symptoms. In a prospective trial involving 160 patients with nocturia, tamsulosin significantly improved QoL by reducing the nocturnal frequency, as assessed with FVCs (Yoshida et al., 2010). Moreover, a recent study assessing the effect of tamsulosin on specific symptoms by a cluster analysis showed that nocturia was significantly reduced by tamsulosin, with the strongest impact on QoL improvement along with weak stream (Aikawa et al., 2015). These results are supported by preclinical findings showing that the administration of tamsulosin is associated with an increased bladder blood flow and the amelioration of bladder overactivity in a rat model (Okutsu et al., 2011).

Finally, in a pooled analysis including five studies assessing the urodynamic effects of tamsulosin in patients with BOO, the compound showed a significant mean change of –14.27 points (95% CI, –23.30 to –5.23 points) in the BOOI (Fusco et al., 2016).

Silodosin

As a uroselective α_1-blocker, silodosin has demonstrated the highest selectivity for the α_{1a}-AR subtype, with 583-fold and 56-fold higher binding affinity compared with the α_{1b} and α_{1d} subtypes, respectively (Moriyama et al., 1997; Shibata et al., 1995).

Four prospective RCTs were conducted to evaluate the superiority of silodosin over placebo and the noninferiority of silodosin compared with tamsulosin in men with LUTS/BPH (inclusion criteria of moderate-to severe LUTS, PV greater than 20 mL, PFR less than 15 mL/s) (Table 145.6) (Chapple et al., 2011; Kawabe et al., 2006; Marks et al., 2009a). The pooled analysis of the American registration trials showed a change of IPSS of –6.4 for patients randomized to receive 8 mg silodosin compared with –3.5 for those randomized to receive placebo after 12 weeks of treatment ($P < 0.0001$) (Marks et al., 2009a). PFR increased by 2.6 mL/s in the silodosin group and by 1.5 mL/s in the placebo group ($P < 0.0001$). The drug showed a rapid onset time, with significant symptom relief as early as 3 to 4 days after treatment along with a PFR increase greater than with placebo 2 to 6 hours after the initial dose. The most commonly reported AE was anejaculation (28.1%), although only 2.8% of patients discontinued use of silodosin because of this symptom. The three-arm European registration trial (Chapple et al., 2011) confirmed the good efficacy of 8 mg silodosin as compared with placebo and the noninferiority compared with 0.4 mg tamsulosin (Fig. 145.8). Moreover, in the open-label extension studies of both trials, the efficacy and safety of the drug were investigated up to 9 months (Marks et al., 2009b; Osman et al., 2015); the results showed further relief of both storage and voiding symptoms at the long-term assessment; again, anejaculation was the most commonly reported AE, followed by dizziness, whereas orthostatic hypotension was rarely observed. **Silodosin is recommended at the daily dose of 8 mg taken with a meal** (see Table 145.1).

TABLE 145.6

Randomized Placebo-Controlled Trials Evaluating the Efficacy and Tolerability of Silodosin

	DRUG	PATIENTS	LENGTH OF TREATMENTS	SYMPTOMS (MEAN INCREASE FROM BASELINE [SD]; PERCENTAGE CHANGE [P[a]])	

Kawabe et al., 2006	Silodosin 8 mg Placebo	*N* = 126 ≥50 years of age with symptomatic BPH (IPSS ≥8, QoL score ≥3, PV ≥20 mL, PFR <15 mL/s, PVR <100 mL)	12 weeks	IPSS total 8 mg: –8.3 (6.4); (<0.006) Placebo: –5.3 (7.4);
Marks et al., 2009a	Silodosin 8 mg Placebo	*N* = 923 ≥50 years of age with symptomatic BPH (IPSS ≥13, PFR 4–15 mL/s, PVR <250 mL)	12 weeks	IPSS total 8 mg: –6.4 (6.6); (<0.0001) Placebo: –3.5 (5.8)
Chapple et al., 2011	Silodosin 8 mg Placebo	*N* = 1228 ≥50 years of age with symptomatic BPH (IPSS	12 weeks	IPSS total 8 mg: –7.0; (<0.0001) Placebo: –4.7

		≥13, PFR 4–15 mL/s, PVR <250 mL)			

[a]Compared with placebo.

[b]The three most common adverse events are reported if available.

[c]Estimates are significantly different as compared with placebo.

BPH, Benign prostatic hyperplasia; *IPSS,* International Prostate Symptom Score; *NS,* not significant; *PFR,* peak flow rate; *PV,* prostate volume; *PVR,* postvoid residual volume; *QoL,* quality of life; *SD,* standard deviation.

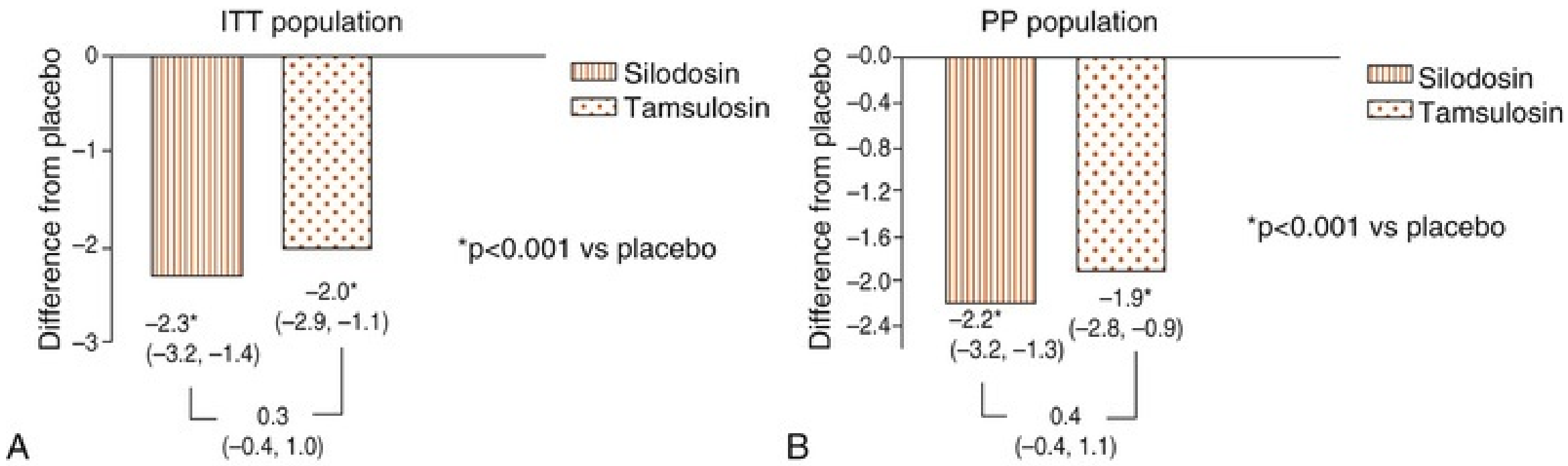

FIG. 145.8 (A and B) Differences from placebo in the total International Prostate Symptom Score. *ITT,* Intention to treat; *PP,* per protocol. (From: Chapple CR, Montorsi F, Tammela TL, et al. Silodosin therapy for lower urinary tract symptoms in men with suspected benign prostatic hyperplasia: results of an international, randomized, double-blind, placebo- and active-controlled clinical trial performed in Europe. *Eur Urol* 59[3]:342–352, 2011. Figure 2, p. 347.)

Two recent meta-analyses provided results of pooled data from the phase III clinical trials on silodosin (Ding et al., 2013; Novara et al., 2013). **Ding et al. (2013) reported a mean change in terms of IPPS storage symptoms score (–0.85; 95% CI, –1.11 to –0.59), IPPS voiding symptoms score (–1.81; 95% CI, –2.21 to –1.42), and QoL score (–0.42; 95% CI, –0.71 to –0.13) that was significantly greater with silodosin than with placebo, with no differences between silodosin and 0.4 mg tamsulosin.** Novara et al. (2013) confirmed these findings. Silodosin demonstrated minimal effects on the cardiovascular system, without any meaningful prolongation of the QT interval and or change of blood pressure. Both meta-analyses confirmed that anejaculation was more likely observed after silodosin treatment compared with either placebo or tamsulosin treatment. In this regard, various reports have well established that anejaculation is linked to silodosin affinity for α_{1a}-ARs (Tatemichi et al., 2012). However, post hoc analysis of phase III studies showed that the odds of achieving a reduction of at least 3 points in the total IPSS and an increase of 3 mL/s for PFR were 1.75 times higher among patients experiencing anejaculation as compared with those who were not (Roehrborn et al., 2011). The discontinuation rates associated with anejaculation were only 1.6% to 2.9% in the phase III trials.

The high selectivity of silodosin for the α_{1a}-AR subtype has also been associated with improvement of urodynamic parameters; indeed, silodosin showed a high mean decrease in terms of BOOI (–30.45; 95% CI, –40.46 to –29.45) (Fusco et al., 2016). Of note, these findings suggest that the perceived overall clinical benefit of this therapy is associated with the main decrease in the detrusor pressure at Qmax as a consequence of the reduction in the magnitude of BOO.

Naftopidil

Naftopidil is the only compound developed with a distinct selectivity for the α_{1d}-AR subtype; preclinical studies showed a threefold higher selectivity for α_{1d}-AR compared with α_{1a}-AR (Ishihama et al., 2006). To date, the drug has been investigated in clinical trials conducted in Japan, but none of these trials were placebo controlled (Table 145.7). Naftopidil was compared with low-dose (0.2 mg/day) tamsulosin in six trials; Ikemoto et al. conducted a randomized crossover study comparing the effect of 8 weeks of therapy with naftopidil at 25 to 50 mg/day followed by therapy with 0.2 mg tamsulosin versus 8 weeks of tamsulosin therapy followed by naftopidil therapy (Ikemoto et al., 2003). There was a significant reduction in terms of total IPSS and QoL score and a significant improvement in urinary flow parameters in both treatment groups without intergroup differences. The noninferiority of naftopidil compared with low-dose tamsulosin was further confirmed in other studies (Gotoh et al., 2005; Momose et al., 2007; Nishino et al., 2006; Ukimura et al., 2008). Naftopidil was found to relieve storage symptoms (e.g., frequency, urgency, and nocturia) with a higher magnitude than low-dose tamsulosin (Nishino et al., 2006; Ukimura et al., 2008). Randomized trials comparing naftopidil with silodosin showed superiority of the latter in terms of IPSS reduction and QoL improvement without differences in terms of uroflowmetry parameters (Shirakawa et al., 2013; Yamaguchi et al., 2013). Moreover, urodynamic data showed an overall change in the BOOI of –16.47 after treatment with naftopidil (Fusco et al., 2016).

TABLE 145.7

Randomized Trials Evaluating the Efficacy and Tolerability of Naftopidil vs. Active Control

	DRUG	PATIENTS	LENGTH OF TREATMENTS	SYMPTOMS (MEAN CHANGE FROM BASELINE [SD]; PERCENTAGE CHANGE [P[a]])
Ikemoto et al., 2003	Naftopidil titrated from 25 to 50 mg Tamsulosin 0.2 mg Crossover study	*N* = 96 Symptomatic BPH patients (IPSS ≥8; PFR <12 mL/s)	8 weeks per drug	IPSS total 50 mg: –6.1 (1.3); NS
Yokoyama et al., 2006	Naftopidil 25 mg Naftopidil 75 mg	*N* = 153 50–80 years of age with symptomatic BPH (PV >20 mL; IPSS ≥8; QoL score >2)	4 weeks	IPSS total 25 mg: –4.5; (NS) 75 mg: –4.6
Yamaguchi et al., 2013	Naftopidil 75 mg Silodosin 8 mg	*N* = 97 Symptomatic BPH patients (IPSS ≥8)	12 weeks	IPSS total: 75 mg: –5.7; (NS) Silodosin: –7.1
Shirakawa	Naftopidil	*N* = 121	8 weeks	IPSS total

et al., 2013	50 mg Silodosin 4 mg twice daily	Symptomatic BPH patients (IPSS ≥8; QoL score ≥3; PFR <12 mL/s; PV ≥20 mL)		50 mg: –7,2 (2.9); (0.004) Silodosin: –2.7 (4.9)

[a] Compared with active control.

[b] The three most common adverse events are reported if available.

AEs, Adverse events; *BPH,* benign prostatic hyperplasia; *IPSS,* International Prostate Symptom Score; *NR,* not reported; *NS,* not significant; *PFR,* peak flow rate; *PV,* prostate volume; *QoL,* quality of life; *SD,* standard deviation.

There are different available doses of naftopidil. One study compared a high dose (75 mg) with a low dose (25 mg), showing comparable efficacy in terms of symptom relief, but better results in terms of PFR changes with the higher dose (Yokoyama et al., 2006). However, when the data were stratified for symptom severity, 75-mg naftopidil achieved better results in terms of voiding symptoms in patients with moderate symptoms at the baseline; no significant differences in terms of AEs were observed between the two groups. Recently, evening dosing of naftopidil at 75 mg showed better results in terms of nocturia QoL index compared with morning dosing (Tanaka et al., 2015).

Overall, naftopidil has a good safety profile, with dizziness and hypotension being the most commonly reported AEs. Garimella et al. (2009) conducted a meta-analysis of the available trials assessing the efficacy of naftopidil. The authors concluded that because of the small number of studies and the lack of placebo-controlled trials, a strong conclusion on the efficacy of naftopidil could not be drawn. Moreover, the studies comparing naftopidil with tamsulosin used a low-dose formulation of the latter, which is not currently used in Western countries. Finally, treatment in all studies lasted from 4 to 16 weeks, thus being too short to provide an adequate assessment regarding the safety profile of naftopidil.

Comparison of α-Adrenergic Blockers

Solid evidence for a comparison between available α_1-blockers can be retrieved only from findings of randomized active-controlled trials comparing the effect and tolerability of two different compounds (Table

145.8). The existing discrepancies in study design, patient inclusion criteria, and the modality of recording AEs make the results of single placebo-controlled trials difficult to compare.

TABLE 145.8

Randomized Trials Comparing Different α-Adrenergic Blockers

	DRUG	PATIENTS	LENGTH OF TREATMENT	SYMPTOMS (MEAN CHANGE FROM BASELINE [SD]; PERCENTAGE CHANGE [P])
Kaplan et al., 1995	Terazosin 5 mg Doxazosin 4 mg	*N* = 74 >50 years of age with symptomatic BPH (IPSS >12)	52 weeks	Boyarsky total: Terazosin: –4.6; –38 (NS) Doxazosin: –4.9; –42
Na et al., 1998	Terazosin 2 mg Tamsulosin 0.2 mg	*N* = 212 46–83 years of age with symptomatic BPH (IPSS >13)	4 weeks	IPSS total Terazosin: –8.5; –39 (<0.05) Tamsulosin: –9.7; –45
Kirby, 2003	Doxazosin GITS titrated from 4 to 8 mg Tamsulosin titrated	*N* = 42 50–80 years of age with symptomatic BPH (IPSS ≥12; PFR 5–15 mL/s)	8 weeks	IPSS total Doxazosin: –8.0 (0.5); –50 (0.01) Tamsulosin: –6.4 (0.5); –40

	from 0.4 to 0.8 mg Crossover study				
de Reijke and Klarskov, 2004	Doxazosin titrated from 1 to 8 mg Alfuzosin titrated from 5 to 10 mg	*N* = 210 49–80 years of age with symptomatic BPH (IPSS ≥12; PFR 5–15 mL/s)	16 weeks	IPSS total Doxazosin: –9.2 (0.6); –48 (<0.05) Alfuzosin: –7.4 (0.6); –41	
Buzelin et al., 1997b	Alfuzosin 2.5 mg tid Tamsulosin 0.4 mg	*N* = 256 Patients with symptomatic BPH	12 weeks	Boyarsky total Alfuzosin: +39% (NS) Tamsulosin: +40%	
Yu et al., 2011	Silodosin 4 mg bid Tamsulosin 0.2 mg	*N* = 209 ≥40 years of age with symptomatic BPH (IPSS ≥13; PFR <15 mL/s; PVR <250 mL)	12 weeks	IPSS total Silodosin: –7.2 (5.2); (NS) Tamsulosin: –10 (5.1)	
Chapple et al., 2011	Silodosin 8 mg Tamsulosin 0.4 mg	*N* = 1228 ≥50 years of age with symptomatic	12 weeks	IPSS total Silodosin: –7.0; (NS) Tamsulosin: –6.7	

		BPH (IPSS ≥13, PFR 4–15 mL/s, PVR <250 mL)			

[a] The three most common adverse events are reported if available.

[b] Estimates are significantly different between treatment arms.

AEs, Adverse events; *bid,* twice a day; *BPH,* benign prostatic hyperplasia; *GITS,* gastrointestinal therapeutic system; *IPSS,* International Prostate Symptom Score; *NS,* not significant; *PFR,* peak flow rate; *PVR,* postvoid residual volume; *SD,* standard deviation; *tid,* three times a day.

Among nonuroselective α_1-blockers, terazosin and doxazosin have shown a good efficacy profile in terms of both symptom relief and uroflowmetry parameter improvement; both drugs need dose titration to avoid the risk for vascular-related AEs associated with first dosing (see Table 145.1).

Kaplan et al. (1995) compared the effect of 4-mg doxazosin versus 5-mg terazosin in a fixed-dose randomized trial with no significant differences in terms of symptom relief and PFR increase at a mean follow-up of 42 weeks. Likewise, the drugs did not differ in terms of tolerability.

The GITS formulation of doxazosin (4 to 8 mg) was compared with tamsulosin (0.4 to 0.8 mg) in a crossover study (Kirby, 2003); doxazosin therapy resulted a greater reduction in total IPSS than tamsulosin, but no difference was observed in terms of PFR. Both drugs were well tolerated; hypotension was reported by 8.3% of patients in the doxazosin group and 0.4% of patients in the tamsulosin group, although the difference was not significant between groups.

There are no active-controlled trials comparing the alfuzosin once-daily formulation with other α_1-blockers; in a randomized trial with doxazosin versus alfuzosin, dose titration was applied in both treatment groups, and the mean daily treatment dose was 6.1 mg in the doxazosin group and 8.8 mg in the alfuzosin group (de Reijke and Klarskov, 2004). At the end of treatment (16 weeks), patients treated with doxazosin showed a mean percentage symptomatic change of 48% versus 41% in the alfuzosin group ($P < 0.05$). Moreover, no significant differences were observed in terms of reported AEs, although 14.3% of patients discontinued therapy because of AEs in the doxazosin group compared with 6.7% in the alfuzosin group.

Buzelin et al. compared 7.5-mg alfuzosin with 0.4-mg tamsulosin in an active-controlled trial. No differences were observed in terms of both efficacy and tolerability between the drugs, but patients treated with tamsulosin reported a higher rate of retrograde ejaculation. **Both tamsulosin and alfuzosin are uroselective compounds that do not require dose titration and are currently recommended for use at a daily dose of 0.4 mg and 10 mg, respectively** (see Table 145.1). Data from placebo-controlled trials supported comparable efficacy, although alfuzosin was associated with a higher rate of vasodilatory AEs, especially in the elderly and in patients with cardiovascular disease. Conversely, anejaculation was more frequently reported after tamsulosin intake.

Data from two meta-analyses of RCTs comparing silodosin with tamsulosin showed that silodosin was significantly superior to 0.2 mg tamsulosin in terms of total IPSS, voiding symptoms subscore, and QoL; however, no difference was found between silodosin and 0.4 mg tamsulosin (Ding et al., 2013; Novara et al., 2014). Moreover, the two drugs showed comparable rates of AEs and of treatment withdrawal, although the likelihood of reporting anejaculation was significantly higher with silodosin compared with tamsulosin, regardless of the dose used.

Few evidences comparing naftopidil with other α_1-blockers have been published to date, hampering to draw solid conclusions. Overall these data should be interpreted with caution given that the available trials have been conducted only in Asiatic populations and there is large heterogeneity concerning study design and patient selection (Garimella et al., 2009).

Most studies investigating the clinical efficacy profile of α_1-blockers focused on outcomes such as symptom scores and free uroflowmetry parameters; however, urodynamic outcome measures, such as the BOOI, are useful to evaluate the effect of medical therapy on BOO. Fusco et al. (2016) reported the results of a meta-analysis dedicated to urodynamic outcomes after therapy with α_1-blockers; the analysis included a total of 656 patients from 10 observational studies and 7 RCTs. Although a direct comparison of the different compounds was not reported, they performed a subanalysis of data according to each drug investigated, showing a greater decrease of mean BOOI for silodosin as compared with doxazosin, terazosin, alfuzosin, naftopidil, and tamsulosin.

Safety Profile of α_1-Blockers in Specific Patient

Populations

All available α_1-blockers demonstrated an overall good safety profile; however, small differences in terms of AE incidence can be detected among the drugs as a result of their specific α_1-AR subtype selectivity and the different pharmacokinetics profiles.

Treatment-emergent AEs associated with α_1-blockers are caused by the effect of every drug on the vascular tissue, CNS, and urogenital system. Overall, dizziness, asthenia, hypotension, and anejaculation are the most commonly reported AEs according to RCTs.

Hemodynamic Side Effects

Data from RCTs assessing the safety profile of a single α_1-blocker showed a greater incidence of vascular AEs for the nonuroselective compounds terazosin and doxazosin compared with alfuzosin, tamsulosin, and silodosin. **The observed difference in terms of cardiovascular tolerability was related to the higher affinity of nonuroselective compounds for the α_{1b}-AR subtype, which is widely present at the level of vascular tissues. The inhibition of this receptor can lead to a decrease in either systolic or diastolic blood pressure, and to a number of associated events, such as dizziness, asthenia, headache, palpitations, and syncope.**

De Mey et al. (1998) reported data from a direct comparative study using the orthostatic stress test as the most appropriate method to assess the magnitude for interference of drugs with blood pressure. The authors compared 0.4 mg tamsulosin with terazosin titrated from 1 to 5 mg in 50 normotensive men. Terazosin caused significantly more episodes of symptomatic hypotension (defined as a decrease in systolic blood pressure of ≥20 mm Hg with related symptoms) than tamsulosin (36% vs. 4%; $P = 0.01$) (Fig. 145.9). The risk for orthostatic hypotension is considered particularly prominent on initiation of treatment (“first-dose hypotension”); for this reason, dose titration has been advised for both terazosin and doxazosin.

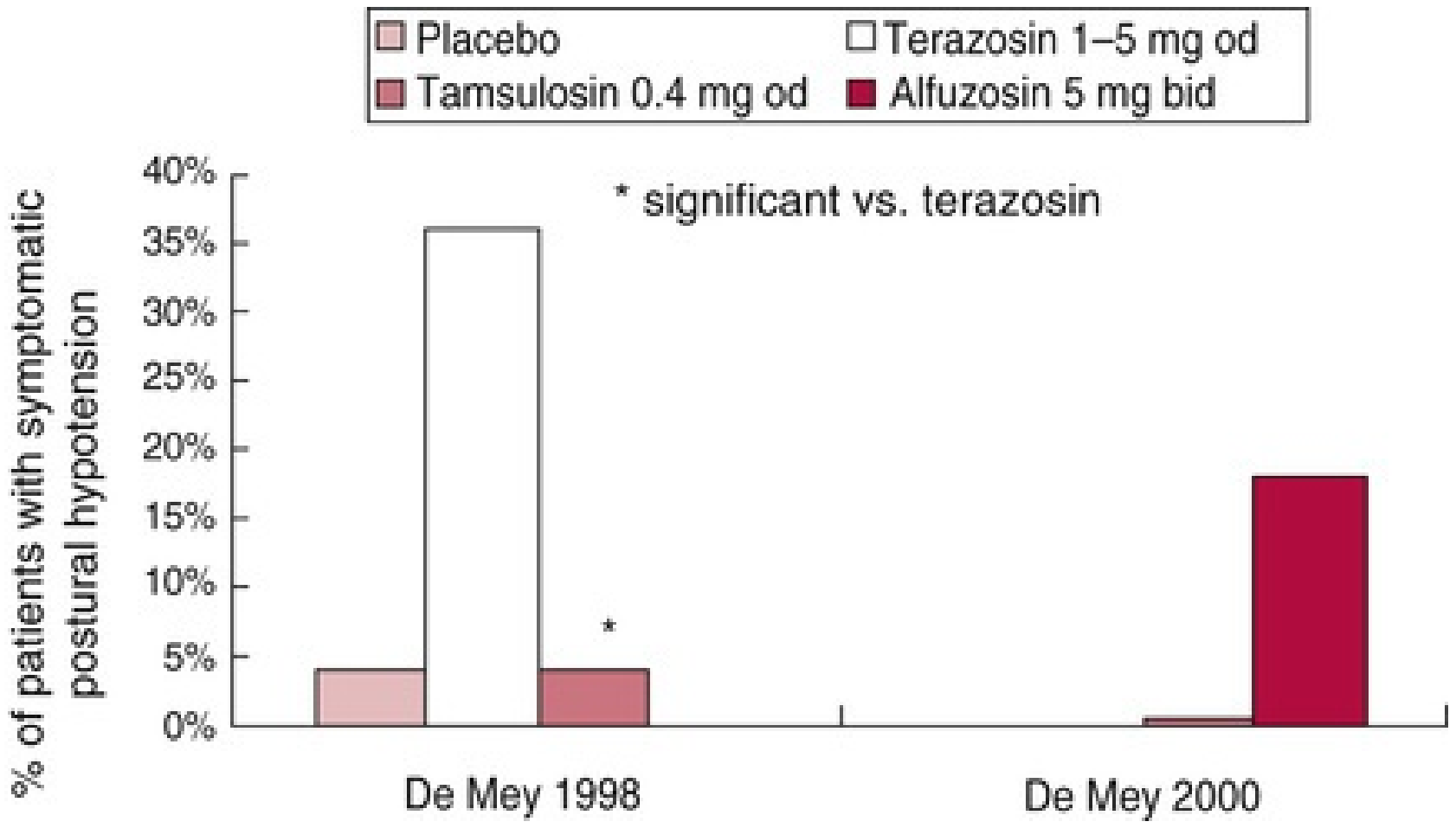

FIG. 145.9 Percentage of patients with symptomatic postural hypotension during orthostatic stress testing in direct comparative studies with 0.4 mg tamsulosin versus terazosin titrated from 1 to 5 mg and 0.4 mg tamsulosin versus 5 mg alfuzosin twice daily. Positive symptomatic postural stress test findings: decrease in systolic blood pressure of 20 mm Hg or more on standing accompanied by symptoms (e.g., dizziness, lightheadedness, and/or syncope). (From: Milani S, Djavan B. Lower urinary tract symptoms suggestive of benign prostatic hyperplasia: latest update on alpha-adrenoceptor antagonists. *BJU Int* 95[Suppl 4]:29–36, 2005. Figure 6, p. 32.)

Indirect comparison of data from placebo-controlled studies showed a higher incidence of dizziness associated with doxazosin and terazosin as compared with both tamsulosin and alfuzosin. The former drugs caused dizziness in 0% to 20% of participants compared with 0% to 8% of participants (corrected for placebo) observed with tamsulosin and alfuzosin (Milani and Djavan, 2005). Dizziness and asthenia have been also reported as the major cause of treatment withdrawal (Roehrborn and Siegel, 1996; Roehrborn et al., 1996). **Of note, commonly reported AEs such as dizziness and asthenia are not exclusively related to the hemodynamic changes associated with the peripheral blockade of α_1-ARs, and are also related to an effect exerted on the CNS.** The pharmacokinetic profile associated with a different speed of onset of blood pressure lowering and the ability of the drug to enter the CNS have been both suggested to play a role in determining the risk for dizziness and asthenia associated with α_1-blockers (Andersson and Gratzke, 2007).

Among uroselective compounds, alfuzosin showed a slightly greater impact on the cardiovascular system compared with tamsulosin; in a direct-comparison randomized trial, 2.5 mg alfuzosin three times daily significantly decreased both supine and standing blood pressure compared with the baseline, whereas 0.4 mg tamsulosin did not (Buzelin et al., 1997b). Similarly, orthostatic stress tests showed that 0.4 mg tamsulosin favored less symptomatic orthostatic hypotension compared with 5 mg alfuzosin twice daily among patients 60 years of age or older (De Mey, 2000) (see Fig. 145.9).

Meta-analyses of RCTs showed that 8 mg silodosin is not associated with a significantly higher risk for hypotension or other vascular AEs compared with placebo (Ding et al., 2013; Novara et al., 2013); similarly no differences were reported in comparison with tamsulosin.

α-Blocker Therapy in Patients With Cardiovascular Diseases

α_1-Blockers were initially developed for the treatment of arterial hypertension, with doxazosin and terazosin originally approved for this indication. Data from RCTs showed that the effect of both drugs on blood pressure is relevant only for patients with hypertension at the baseline (Fawzy et al., 1995; Kirby et al., 1998; Lepor et al., 1997). However, these data have to be interpreted with caution given the heterogeneity among studies in defining a clinically significant hypotensive episode and regarding the method of blood pressure measurement. The Antihypertensive and Lipid-Lowering Treatment to Prevent Heart Attack Trial (ALLHAT) included 24,335 men with hypertension and at least one other coronary risk factor (ALLHAT Collaborative Research Group, 2000). Patients were randomized to receive chlorthalidone, doxazosin, amlodipine, or lisinopril; the finding of a significant increased risk for congestive heart failure in the doxazosin group relative to the chlorthalidone group was the rationale to discontinue the investigation of doxazosin in the antihypertensive trial; data analysis did not show a significant increase of congestive heart failure incidence between doxazosin and the other antihypertensive agents. This trial raised concern on the safety of the use of doxazosin among patients with cardiovascular disease. However, no major cardiovascular AEs have been reported in RCTs assessing the effect of doxazosin for LUTS treatment.

Of clinical relevance, concomitant medications in patients with LUTS and cardiovascular disease should be taken into account when patients are being counseled for treatment. Alfuzosin, for instance, has been associated with an increased risk for cardiovascular AEs among patients with concomitant antihypertensive or vasodilating medications (Lukacs et al., 1996, 2000). Conversely, tamsulosin did not show a significant interaction with different antihypertensive agents (e.g., β-blockers, calcium antagonists, angiotensin-converting enzyme inhibitors) (Lowe, 1997); similarly, in a pooled analysis including almost 20,000 patients from two RCTs, the tolerability of tamsulosin did not differ for patients with hypertension or other cardiovascular diseases (Michel et al., 1998). Likewise, silodosin did not show differences in terms of cardiovascular AEs between patients treated with concomitant antihypertensive medications and normotensive men (Novara et al., 2014).

Overall, α_1-blockers should be carefully administered in patients taking antihypertensive medications. The concomitant use of α_1-blockers with other α-blocker compounds is not recommended.

α_1-Blockers in the Elderly

The tolerability profile of α_1-blockers appears more relevant in the elderly population; **AEs such as dizziness and orthostatic hypotension may lead to falls, fractures, and institutionalization in older patients.** Indeed, older patients have a less dynamic adaptation to orthostatic stress and a reduced vascular compliance as they tend to rely more on the homeostatic contribution of ancillary vasoconstriction (Milani and Djavan, 2005).

The nonuroselective compounds terazosin and doxazosin could be less tolerated by elderly men, although pooled analyses of multicenter RCTs of terazosin (Wilt et al., 2002a) and doxazosin (Kaplan and D'Alisera, 1998) did not show any age-dependent incidence of AEs. However, it should be noted that most of those trials included highly selected patients.

Among uroselective compounds, open-label studies showed that alfuzosin was associated with more cardiovascular AEs in patients older than 75 years of age (Lukacs et al., 1996, 2000). In the Osteoporotic Fractures in Men study, including 5,872 men 65 years of age or older, Parsons et al. (2009) reported that the risk for falls was significantly associated with moderate to severe LUTS, suggesting a negative influence of LUTS medications. Similarly, in a recent population-based cohort study including 147,084 men 66 years of age or older and prescribed alfuzosin, tamsulosin, or silodosin, the risk for falling and of sustaining fractures was significantly higher compared with that in a matched-control unexposed cohort (Welk et al., 2015).

Bird et al. (2013) looked at the US health care claims data for men 40 to 85 years of age who were first prescribed tamsulosin or a 5ARI and who developed hypotension requiring hospital admission. They observed an increased rate of severe hypotension with tamsulosin treatment (42.4 events per 10,000 person-years) versus 5ARI treatment (31.3 events per 10,000 person-years). This was particularly significant within the first 8 weeks of new drug use. Therefore, **physicians should warn patients regarding a risk for first-dose hypotension with α_1-blockers**.

In a subanalysis of individual patient data from registration trials of silodosin, the prevalences of dizziness and orthostatic hypotension were similar between patients younger than 65 years of age and patients older than 65 years of age (Novara et al., 2015). Similarly, in a study including patients older than 65 years of age taking antihypertensive medications and firstly prescribed silodosin, Choi et al. (2017) did not find evidence of changes in blood pressure associated with treatment.

α_1-Blockers and Sexual Function

There is a proved link between sexual dysfunction and LUTS (Rosen et al., 2003); in this context, the impact of α_1-blockers on sexual function has been comprehensively investigated (Gacci et al., 2011, 2014). **Positive effects of α_1-blockers on erectile function have been variably observed and ascribed to the beneficial effect of these drugs in terms of LUTS relief and QoL improvement** (Gacci et al., 2011; Van Dijk et al., 2006); moreover, there is evidence showing that α-AR inhibition within cavernosal tissue may lead to smooth muscle relaxation and to a consequent enhancement of the erection (Goldstein 2000). Data from RCTs showed a comparable incidence of erectile dysfunction between α_1-blockers and placebo (MacDonald and Wilt, 2005; MacDonald et al., 2004; Wilt et al., 2002a). In a meta-analysis conducted by the AUA, the overall incidence of erectile dysfunction associated with α_1-blocker therapy was 3% to 5% (AUA Practice Guidelines Committee, 2003). Similarly, pooled data analysis showed no significant impact of these drugs on sexual desire (Van Dijk et al., 2006).

Ejaculation disorders also have been associated with α_1-blocker therapy (Gacci et al., 2014); smooth muscle inhibition at the level of the bladder neck was originally considered the main reason for retrograde ejaculation; furthermore, a direct effect of α_1-blockers on seminal vesicles leading to anejaculation has also been proposed (Andersson and Gratzke, 2007). Moreover, data on tamsulosin also suggested a central effect on the control of ejaculation mediated by binding to the D_2-like and 5-HT_{1A} receptors (Giuliano, 2006). Overall, **the nonselective compounds doxazosin and terazosin did not show a detrimental effect on ejaculation in RCTs.**

Tamsulosin at 0.8 mg has been associated with an 18% incidence of anejaculation (Wilt et al., 2003). However, silodosin showed an even higher incidence of ejaculation disorders when compared with tamsulosin in a multicenter trial (14% vs. 2%) (Chapple et al., 2011). These findings were confirmed by a meta-analysis **including data from 10 randomized trials, showing that the odds of reporting ejaculation disorders was significantly higher for silodosin (odds ratio, 32.5; $P < 0.001$) than for tamsulosin (odds ratio, 8.57; $P = 0.006$)** (Gacci et al., 2014). Moreover, in a real-life study, Capogrosso et al. showed that almost 70% of patients reported either anejaculation or hypospermia after treatment with silodosin, with a concomitant orgasmic function impairment in 17% of the patients (Capogrosso et al., 2015). Younger patients showed higher rates of a concomitant impairment of ejaculation and orgasmic function (Capogrosso et al., 2015).

Other Complications Associated with α-Blocker Therapy

Intraoperative floppy iris syndrome (IFIS) was firstly reported after the intake of tamsulosin (Chang and Campbell, 2005); **the syndrome occurs during cataract surgery, and is characterized by a floppy iris that flutters and billows in response to normal intraoperative fluid movement, a prolapse of iris tissue toward surgical incisions, and a progressive intraoperative miosis despite standard preoperative pupil dilation.** This triad of symptoms is not always present, and most patients show only one or two signs. The occurrence of IFIS has been associated with the blockade of the α_{1a}-AR subtype at the level of the iris dilator muscle, although the exact pathophysiology is still under debate. IFIS has also been reported several years after drug use discontinuation (Nguyen et al., 2007); in this context, it was suggested that the pharmacologic inhibition of iris smooth muscle can lead to muscle atrophy in the long term. Indeed, structural changes of iris tissue have been observed in patients taking α_1-blockers (Santaella et al., 2010).

The incidence of IFIS differs among different drugs: a rate of 30% to 88% has been reported for patients treated with tamsulosin, compared with 15% to 70%

for alfuzosin, 2% to 45% for doxazosin, and 19% for naftopidil (Oelke et al., 2014). No significant data have been reported regarding the occurrence of IFIS among patients treated with silodosin, although this issue has not been specifically investigated. A meta-analysis assessing the risk for IFIS among individuals taking α_1-blockers confirmed the higher incidence of this syndrome after therapy with tamsulosin as compared with the other compounds (Chatziralli et al., 2011). **Discontinuation of the use of drug before cataract surgery does not significantly reduce the risk for IFIS. Therefore, cataract surgeons should ask about either current or previous use of α_1-blockers and be prepared to manage the complications. Similarly, the prescribing physician should counsel patients regarding the need to report the use of α_1-blockers to the ophthalmologist.**

Summary

Efficacy and safety profiles of α_1-blockers in men with LUTS have been largely described in multicenter RCTs. Published data showed a significant reduction of symptom scores and improvement of uroflowmetry parameters associated with α_1-blockers therapy, along with an excellent safety profile. Asthenia, dizziness, anejaculation, and orthostatic hypotension are the main treatment-emergent AEs. Moreover, longitudinal trials have provided evidence for the long-term efficacy and safety of these drugs.

Few studies directly compared the different α_1-blockers, thus hampering the ability to draw a conclusion in terms of superiority of one drug over the others concerning efficacy. However, there is a major distinction between nonuroselective and uroselective drugs depicting a different safety profile: the latest released uroselective drugs tamsulosin and silodosin showed a lower risk for vascular AEs compared with the nonuroselective drugs doxazosin and terazosin. On the other hand, the uroselective compounds are associated with a higher risk for ejaculatory disorders.

International clinical guidelines suggest α_1-blockers as the first-line treatment in patients with bothersome moderate to severe LUTS. Patients should be counseled before treatment regarding the risk for sexual and vascular side effects associated with this therapy. It is advised to monitor blood pressure during the first week of treatment.

Androgen Manipulation

Hormonal therapy for BPH has been clinically investigated since the 1970s and still has an important role in the therapeutic armamentarium for patients with LUTS caused by BPE.

Rationale for Androgen Manipulation

Prostate tissue is androgen dependent, and both testosterone and dihydrotestosterone (DHT) play a key role in the development of BPH (Coffey and Walsh 1990; Shapiro 1990). The potent male sex hormone DHT is a metabolite of testosterone and is synthesized by two isoenzymes: type 1 and type 2 5α-reductase. Of these, the type 2 isoenzyme is mainly expressed at the level of the prostate and genital tissues; the type 1 isoenzyme is present in several organs other than the prostate, such as the liver and the skin.

Through binding with androgen receptors, both DHT and testosterone act as chemical messengers for the process of prostate growth and cellular function. Although the two hormones are capable of binding androgen receptors, DHT tends to dissociate more slowly and is intrinsically more potent than testosterone at the prostate level (Andriole et al., 2004).

Castration and pharmacologic agents suppressing testosterone and DHT synthesis or action are able to reduce PV in men with BPH (McConnell 1990). Reducing PV is thought to decrease the static component of BOO in BPH patients. However, the first limitation of the androgen suppression hypothesis is that LUTS pathophysiology is not entirely dependent on prostate size.

Classification of Pharmacologic Agents

Surgical castration was reported to be effective in reducing the volume of an enlarged prostate in the 1890s (White, 1895; Cabot, 1896). Scott and Wade (1969) were first to report the effect of medical castration as a treatment of LUTS associated with BPE. They investigated the effect of a progestational antiandrogen (cyproterone acetate) on prostate tissue; the drug was able to induce prostate atrophy by suppressing steroid synthesis at the level of the testes, without suppressing luteinizing hormone. Furthermore, other nonsteroidal drugs (e.g., flutamide, bicalutamide) blocking the binding of testosterone and DHT to the androgen receptor were investigated for the treatment of BPH (Caine et al., 1975; Eri and Tveter, 1993). Similarly, a regression of prostatic enlargement was clinically observed with gonadotropin-releasing hormone (GnRH) analogues (Schroeder et al., 1986), but all of these compounds were associated with AEs related to the alteration of the hypothalamic-pituitary-gonadal (HPG) axis and of the overall hormonal milieu. Conversely, 5ARIs are able to block the conversion of testosterone to DHT in prostatic stroma cells by inhibiting the enzyme 5α-reductase, without a significant interaction with the HPG axis. The pharmacologic strategies of androgen suppression that have been investigated for LUTS and BPH in the past three decades are summarized in Table 145.9.

TABLE 145.9

Androgen Manipulation: Classification of Pharmacologic Agents and Dosages

DRUGS	DOSAGE	REFERENCE
GONADOTROPIN-RELEASING HORMONE ANALOGUES		
Leuprolide	3.75 mg IM monthly	Schroeder et al., 1986
		Keane et al., 1988
		Eri and Tveter, 1993
Nafarelin acetate	400 mg SC qd	Peters and Walsh, 1987
Cetrorelix	1 mg SC qd ± loading dose	Lepor et al., 1997
	Three dosage regimens	Debruyne et al., 2008
PROGESTATIONAL AGENTS		
17α-Hydroxycortisone	200 mg IM weekly	Meiraz et al., 1977
Megestrol	250 mg PO tid	Donkervoort et al., 1975
	40 mg PO tid	Geller et al., 1979
ANTIANDROGENS		
Flutamide	100 mg tid	Caine et al., 1975
	250 mg tid	Stone, 1989
Oxandrolone	200 mg IM weekly	Ostri et al., 1989
Bicalutamide	50 mg qd	Eri and Tveter, 1993
Zanoterone	100–800 mg qd	Berger et al., 1995
Chlormadinone acetate	50 mg qd	Fujimoto et al., 2013
		Warnings and important notices
5α-REDUCTASE INHIBITORS		

Finasteride	5 mg qd. Treatment is recommended for at least 6 months	• PSA levels decrease by approximately 50% • Finasteride is not indicated for PCa prevention because of an observed increased risk for high-risk disease • Patients should be warned regarding risk for sexual dysfunction and depression
Dutasteride	0.5 mg qd. Treatment is recommended for at least 6 months	• PSA levels decrease by approximately 50% • Dutasteride is not indicated for PCa prevention because of an observed increased risk for high-risk disease • Patients should be warned regarding risk for sexual dysfunction and depression

IM, Intramuscularly; *PCa,* prostate cancer; *PO,* per os; *qd,* once a day; *SC,* subcutaneously; *tid,* three times a day.

Interpreting the Literature on Androgen Manipulation

Because the maximal PV reduction is achieved within 6 months after initiation of androgen suppression (Gormley et al., 1992; Peters and Walsh, 1987), **the outcomes of RCTs should be considered reliable only for time points at or after 6 months from the beginning of treatment.** Moreover, several data showed that patients with larger PV are likely to achieve the greatest therapeutic benefit (McConnell et al., 1998, Tacklind et al., 2010). **In this context, most of the published RCTs enrolled men with larger prostates, and therefore the reported results may not be representative of the overall population of patients with BPH.**

Treatment-emergent AEs after 5ARI therapy may have been overlooked and underestimated in trials that were not designed to assess specific drug-related side effects as primary or secondary end points. Indeed, the U.S. Food and Drug Administration (FDA) reviewed the safety profile of 5ARIs in 2011 given the new emerging evidence supporting a risk for depressive symptoms and sexual dysfunction associated with these drugs. Similarly, results concerning the metabolic and cardiovascular safety of these drugs should be interpreted with caution given the heterogeneity in the interpretation and recording of AEs among different studies.

Review of the Literature

Several nonrandomized studies evaluated the effects of androgen manipulation on the outcomes of patients with BPH**; the 5ARIs finasteride and dutasteride currently represent the paradigm for androgen suppression in the treatment of BPH.** This section considers the multicenter RCTs investigating the efficacy and safety profile of finasteride and dutasteride.

Finasteride

Finasteride is a selective inhibitor of the type 2, 5α-reductase isozyme (Vermeulen et al., 1989) and is responsible for decreasing intraprostatic DHT levels without reaching a castration level because of the remaining activity of the type 1 5α-reductase isozyme converting serum testosterone to DHT at the level of the skin and liver (Thigpen et al., 1993).

The results of the most relevant RCTs assessing the efficacy and safety of finasteride are summarized in Table 145.10. In the first multicenter, randomized, double-blind, placebo-controlled trial (the North American Finasteride Trial), Gormley et al. (1992) evaluated the effect of either 1 mg or 5 mg finasteride given once daily for 12 months in 895 patients with BPH (Gormley et al., 1992). Patients were selected on the basis of symptoms and urinary flow parameters (Qmax <15 mL/s). Mean PV at the baseline was approximately 60 mL. Data showed significant symptomatic relief in men treated with 5 mg finasteride as compared with placebo, with a maximal decrease of 2.7 points on the Boyarsky scale after 12 months; similarly, urinary flow rate increased in both active treatment groups compared with the placebo group, with a larger effect observed for the 5-mg group (mean PFR increase, 1.6 mL/s). **The authors observed a progressive decrease in PV in both finasteride groups; after 12 months of treatment, the mean reduction in PV from the baseline was 19% in men treated with 5 mg finasteride**. The changes in PV were not directly related to the magnitude of the clinical response to finasteride, suggesting that the efficacy of finasteride may not be mediated exclusively by reduction of PV. At the same time, a significant reduction in serum PSA level was reported starting after 3 months of treatment. The median decrease in serum PSA level was 50% from the baseline in the 5-mg group. **The drug was overall well tolerated: the most frequently observed AEs in the 5-mg group were decreased libido (4.7%) and ejaculatory disorders (4.4%)**. In the 1-mg treatment group, 5% of patients reported impotence, which was significantly higher than with placebo.

TABLE 145.10

Placebo-Controlled Trials Assessing Finasteride for Treatment of Benign Prostatic Hyperplasia

	DRUG	PATIENTS	LENGTH OF TREATMENT	SYMPTOMS (MEAN CHANGE FROM BASELINE; PERCENTAGE CHANGE [P[a]])
Gormley et al., 1992	Finasteride 1 mg Finasteride 5 mg Placebo	*N* = 895 40–83 years of age with symptomatic BPH (PFR <15 mL/s)	12 months	Boyarsky total 1 mg: –9% (NS) 5 mg: –21% (<0.05) Placebo: –2%
Andersen et al., 1995	Finasteride 5 mg Placebo	*N* = 707 <80 years of age with symptomatic BPH (PFR 5–15 mL/s, PVR ≤150 mL)	24 months	Boyarsky total 5 mg: –2.0; (<0.01) Placebo: +0.2
Marberger, 1998	Finasteride 5 mg	*N* = 3270 50–75 years	24 months	Boyarsky total 5 mg: –3.1;

	Placebo	of age with symptomatic BPH (PFR 5–15 mL/s; PSA <10 ng/mL)		(<0.01) Placebo: –1.5	
McConnell et al., 1998	Finasteride 5 mg Placebo	*N* = 3040 Symptomatic BPH patients (PFR <15 mL/s; PSA <10 ng/mL)	48 months	IPSS total 5 mg: –1.6; (<0.001) Placebo: –1.0	

[a] Compared with placebo.

[b] The three most common adverse events are reported if available.

[c] Estimates are significantly different between treatment arms.

BPH, Benign prostatic hyperplasia; *IPSS,* International Prostate Symptom Score; *NS,* not significant; *PFR,* peak flow rate; *PSA,* prostate-specific antigen; *PVR,* postvoid residual volume.

To evaluate the effect of finasteride in terms of disease progression, Andersen et al. (1995) conducted a 2-year multicenter RCT. A total of 707 patients with LUTS associated with prostate enlargement on DRE (mean volume at the baseline, 40 mL) were randomized to receive 5 mg finasteride or placebo. The authors observed a reduction in symptom score in both groups. However, the placebo effect disappeared after 8 months, and patients had returned to baseline values at the 24-month assessment. Conversely, the symptom scores steadily decreased in the finasteride group, reaching a mean decrease of 2 points at the end of the study period. Likewise, a 1.5 mL/s mean increase in PFR was observed in the finasteride group, and PV decreased by 17.9% after 12 months of treatment and was maintained after 24 months, along with a 52% reduction in PSA value. **Fewer patients in the finasteride group as compared with the placebo group developed urinary retention or needed prostate surgery.** The overall rate of AEs was similar between the groups, although a higher rate of sexual dysfunctions was observed in the finasteride group than in the placebo group (19% vs. 10%).

In the open-label extension of the North American and International Finasteride trial, Stoner (1994) reported the results after 3 years of treatment. A total of 297 patients treated with 5 mg finasteride completed the 3-year trial. After 36 months of treatment, 42% of patients showed a decrease in PV of 30% or more. The effects on symptom score and urinary flow parameters were also maintained after 3 years of treatment, with most changes observed between 12 and 18 months after the beginning of treatment. Sexual dysfunction (erectile dysfunction, decreased libido, and ejaculation disorders) was reported by 10.8% of patients in the finasteride group and 5.2% in the placebo group. These results were further confirmed in a 5-year open-label extension trial on the same population (Hudson et al., 1999).

The Proscar Long-Term Efficacy and Safety Study (PLESS) represented, at the time, the longest-duration multicenter RCT ever reported in terms of BPH medical therapy (McConnell et al., 1998). The study enrolled 3040 men with a mean PV of 55 mL and moderate to severe symptoms treated with finasteride or placebo and followed up for 4 years. The effects on urinary flow rate and PV were comparable with those in the previously published trials. Of note, the authors assessed the rate of occurrence of AUR and surgery for BPH: patients treated with finasteride showed a 51% reduction in the risk for either AUR or surgery compared with patients given placebo. The cumulative incidence of AUR after 4 years was 7% in the finasteride group and 3% in the placebo group (57% risk reduction). The cumulative risk rates for undergoing BPH-related surgery were 10% in the placebo group and 5% in the finasteride group (55% risk reduction). In men with PV greater than 55 mL, the risk reduction for AUR and/or surgical intervention after finasteride treatment was 70%. Men with significantly enlarged prostates should be advised about the risk for urinary retention and the beneficial effects of finasteride therapy. Finasteride is recommended at the daily dose of 5 mg with or without a meal (see Table 145.9); patients should be informed that although early improvement could be seen, treatment for at least 6 months may be necessary to perceive a beneficial effect.

In a meta-analysis including 19 placebo-controlled trials of finasteride, Tacklind et al. (2010) confirmed moderate relief of symptoms after 1 year of treatment with finasteride and a significant decrease in the risk for disease progression and AUR. Moreover, the results showed that patients with a prostate larger than 40 mL appeared to benefit the most from treatment.

The PCPT showed that **finasteride reduced the incidence of diagnosed PCa** (vs. placebo), although an increased incidence of high-grade disease was observed, possibly because of a volume change effect (Thompson et al., 2003).

Finasteride has been demonstrated to significantly decrease serum PSA levels by approximately 50%; in terms of PCa detection, results from PCPT demonstrated that treatment with finasteride significantly increases the sensitivity of the PSA test in predicting PCa (Thompson et al., 2006).

Finally, the effect of finasteride in preventing gross hematuria secondary to BPH has also been investigated: in an RCT, gross refractory hematuria recurred within 1 year in 63% of men randomized to receive placebo and in 14% of men randomized to receive finasteride (Foley et al., 2000).

Dutasteride

Dutasteride is a dual inhibitor of 5α-reductase types 1 and 2. Because of the inhibition of both isozymes, dutasteride leads to a greater decrease of serum DHT levels compared with finasteride (Clark et al., 2004). Table 145.11 details RCTs assessing the efficacy and safety profile of dutasteride as compared with placebo.

TABLE 145.11

Placebo-Controlled Trials Assessing Dutasteride for Treatment of Benign Prostatic Hyperplasia

DRUG	PATIENTS	LENGTH OF	SYMPTOMS (MEAN CHANGE FROM

			TREATMENT	**BASELINE [SD]; PERCENTAGE CHANGE [P[a]])**
Roehrborn et al., 2002	Dutasteride 0.5 mg Placebo	*N* = 4325 ≥50 years of age with symptomatic BPH (IPSS ≥12, PFR ≤15 mL/s; PV ≥30 mL; PSA 1.5–10 ng/mL)	24 months	IPSS total 0.5 mg: –4.5 (6.6): (<0.001) Placebo: –2.3 (6.8)
Clark et al., 2004	Dutasteride 0.5 mg Placebo	*N* = 132 ≥50 years of age with symptomatic BPH (IPSS ≥8, PFR ≤15 mL/s; PV ≥30 mL)	6 months	NR
Tsukamoto et al., 2009	Dutasteride 0.5 mg Placebo	*N* = 253 ≥50 years of age with symptomatic BPH (IPSS ≥8, PFR ≤15 mL/s; PV ≥30 mL)	12 months	IPSS total 0.5 mg: –5.3; (<0.05) Placebo: –3.7
Na et al.,	Dutasteride	*N* = 253	6 months	IPSS total

2012	0.5 mg Placebo	Symptomatic BPH patients (IPSS ≥12, PFR 5–15 mL/s; PV ≥30 mL)		0.5 mg: –4.9 (4.8); (NS) Placebo: –4.1 (5.4) Placebo: –1.0

[a] Compared with placebo.

[b] The three most common adverse events are reported if available.

[c] Estimates are significantly different between treatment arms.

BPH, Benign prostatic hyperplasia; *IPSS,* International Prostate Symptom Score; *NR,* not reported; *NS,* not significant; *PFR,* peak flow rate; *PV,* prostate volume; *PVR,* postvoid residual volume.

Roehrborn et al. (2002) performed a multicenter RCT that enrolled 4325 men treated with either dutasteride at 0.5 mg daily or placebo for 24 months. Patients were included if they had moderate to severe symptoms, a PFR of 15 mL/s or less, and a PV of 30 mL or more. There was a 90.2% decrease in serum DHT level among patients who received dutasteride. At the end of study treatment, the mean reduction in the symptom score from the baseline was 4.5 after dutasteride treatment and 2.3 with placebo ($P < 0.001$) (Fig. 145.10); moreover, PFR increased by 2.2 mL/s on average, and PV was reduced by a mean of 25.7% after 24 months in the active treatment group. The risk reduction for AUR and BPH surgery was 57% and 48%, respectively, with dutasteride ($P < 0.001$; Fig. 145.11). Overall, dutasteride was well tolerated; **the most frequent AEs were erectile dysfunction and decreased libido, observed in 6% and 3.7% of patients, respectively, after 1 year of treatment; however, these rates significantly dropped after 2 years of treatment.** These results were further confirmed in other smaller randomized trials (Clark et al., 2004; Na et al., 2012; Tsukamoto et al., 2009) (see Table 145.11).

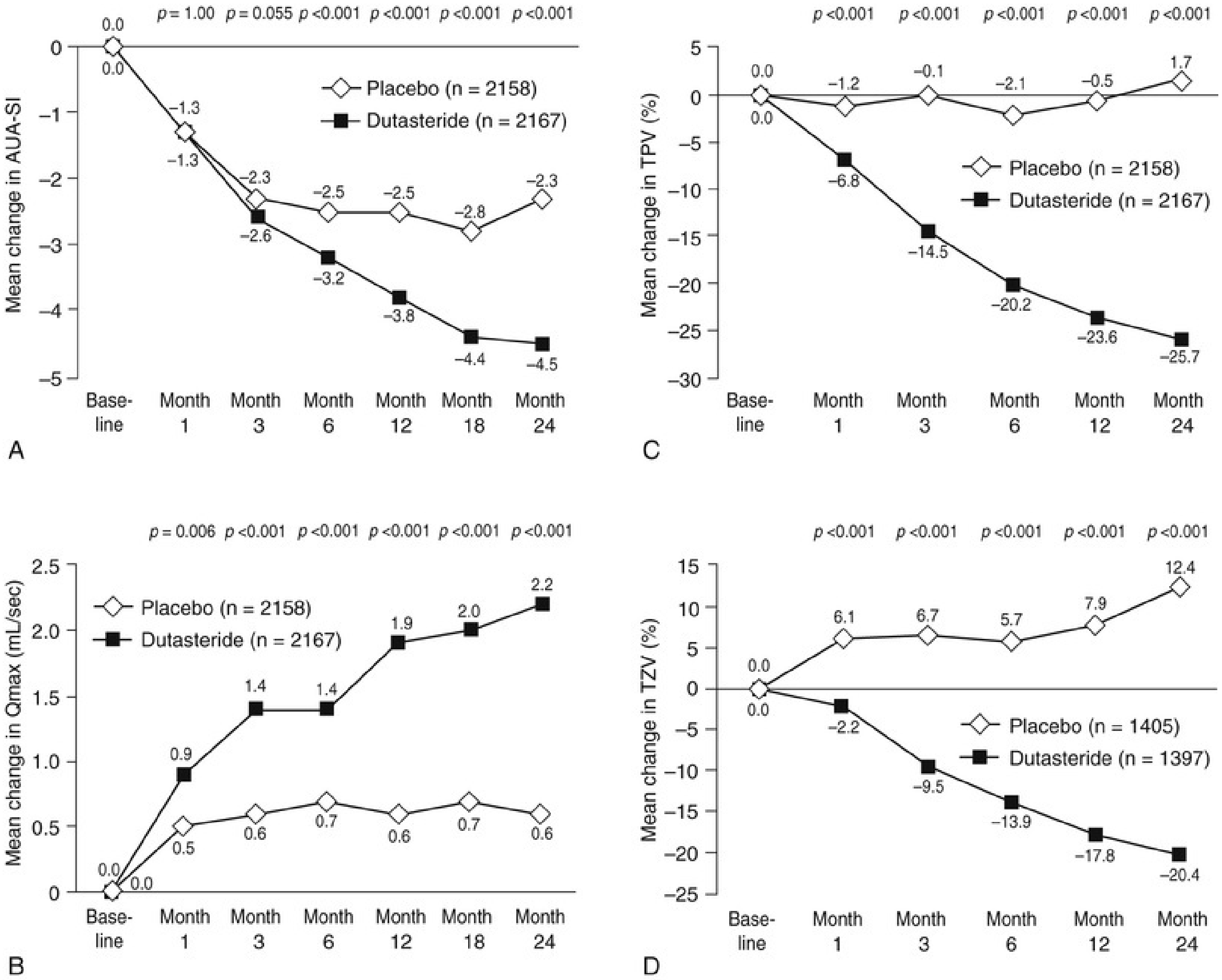

FIG. 145.10 Mean changes from the baseline for placebo-treated and dutasteride-treated patients. (a) AUA Symptom Index, (b) Qmax, (c) total prostate volume (TPV), and (d) transition zone volume (TZV). Patient numbers shown are at the baseline. (From Roehrborn CG, Boyle P, Nickel JC, et al. Efficacy and safety of a dual inhibitor of 5-alpha-reductase types 1 and 2 (dutasteride) in men with benign prostatic hyperplasia. *Urology* 60[3]:434–441, 2002. Figure 2, p. 437.)

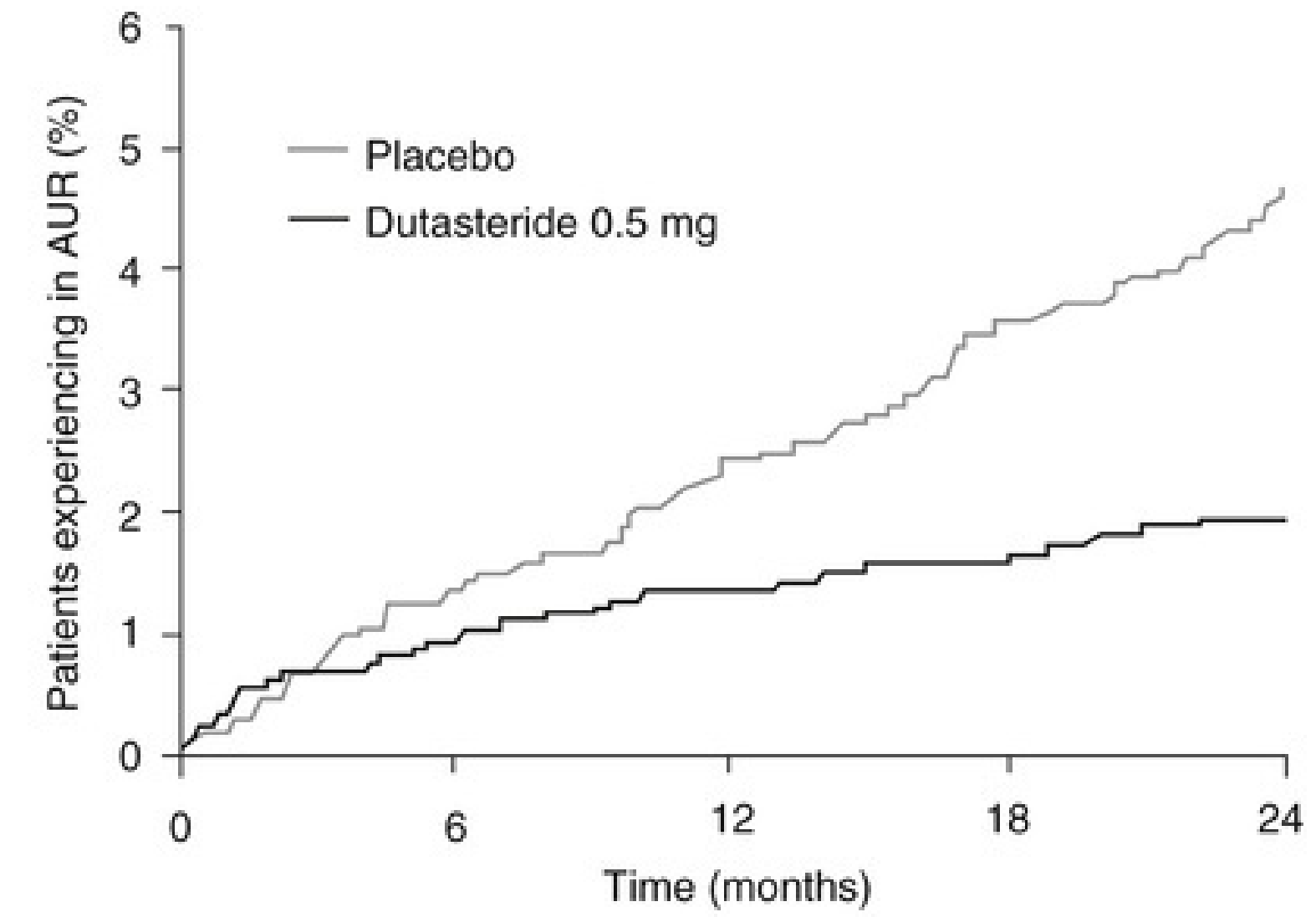

Placebo group

No. of events, cumulative	28	49	70	90
No. at risk	2158	2039	1919	1793

Dutasteride group

No. of events, cumulative	19	27	31	39
No. at risk	2167	2052	1928	1827

A

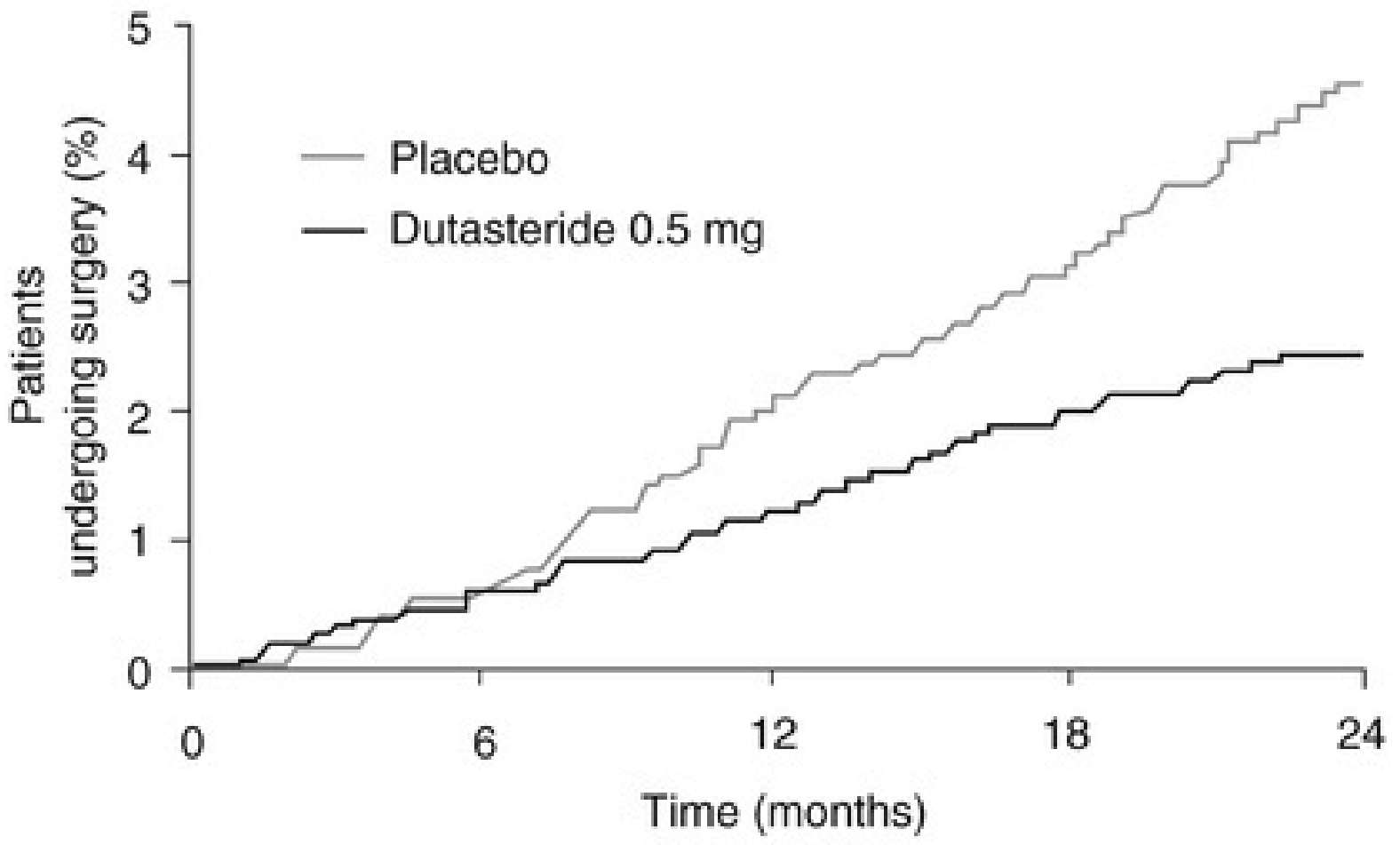

Placebo group

No. of events, cumulative	13	40	59	89
No. at risk	2158	2057	1944	1823

Dutasteride group

No. of events, cumulative	12	25	39	47
No. at risk	2167	2064	1944	1846

B

FIG. 145.11 Kaplan-Meier estimates for the first episode of (A) acute urinary retention and (B) BPH-related surgical intervention according to the treatment arms. (From Roehrborn CG, Boyle P, Nickel JC, et al. Efficacy and safety of a dual inhibitor of 5-alpha-reductase types 1 and 2 (dutasteride) in men with benign prostatic hyperplasia. *Urology* 60[3]:434–441, 2002. Figure 3, p. 438.)

Debruyne et al. (2004) reported the results of a 4-year open-label extension of a multicenter trial comparing dutasteride and placebo. Patients treated with dutasteride during the randomized trial continued the therapy for another 24 months; conversely, those previously randomized to receive placebo were switched to dutasteride for 2 years. There was further relief of symptoms and improvement of uroflow parameters at 48 months. Patients who received dutasteride throughout the entire 4-year treatment period did not show a significant further reduction in PV from 24 to 48 months. AUR and BPH surgery were rarely observed from month 24 to month 48. A decrease in the incidence of sexual AEs in the last 2 years of treatment was also observed.

A recent meta-analysis including RCTs assessing the effect of dutasteride versus placebo for the treatment of BPH confirmed the efficacy of the drug in relieving urinary symptoms and improving uroflow parameters, with a mean symptom score reduction of 1.78 and a PFR increase of 1.27 mL/s; moreover, pooled analyses showed a mean reduction in PV of 17.40 mL (Park and Choi, 2014). **Dutasteride is recommended at the daily dose of 0.5 mg with or without a meal; a long-term treatment (at least 6 months) is usually needed to observe a clinical benefit** (see Table 145.9).

Data comparing finasteride and dutasteride were reported in only two studies (Clark et al., 2004; Nickel et al., 2011). In the larger trial, Nickel et al. (2011) compared data from 813 patients treated with dutasteride with data from 817 patients receiving finasteride in a randomized, double-blind fashion. **After 1 year of treatment, there was no difference in terms of symptom relief and PFR increase between patients treated with dutasteride and patients treated with finasteride; similarly, the reduction of PV was comparable between the groups.** Both drugs were well tolerated, without significant differences in the incidence of AEs. These results confirmed the findings of a previous trial (Clark et al., 2004).

In the REDUCE trial, Andriole et al. (2010) investigated the effect of dutasteride versus placebo in preventing PCa in a population of patients with

BPH and a previous negative prostate biopsy result. **There was a 23% relative reduction in the risk for PCa within 4 years of treatment with dutasteride. However, a small increase in the number of cancers with a Gleason score of 8 or more was observed in the treatment arm.** Therefore, in December 2010 the FDA Oncologic Drugs Advisory Committee voted against the use of dutasteride for reducing the risk for PCa, and the manufacturer has withdrawn the application.

As for finasteride, a 50% reduction in the PSA level has to be expected with dutasteride treatment; in this context, data from the REDUCE trial showed that treatment with dutasteride can improve the accuracy of PSA testing in predicting biopsy outcomes (Vickers and Sjoberg, 2015).

Zanoterone

Zanoterone is a steroidal competitive androgen receptor antagonist (Juniewicz et al., 1993). Previously investigated androgen receptor antagonists, in the context of BPH treatment, have shown several drawbacks associated with interference with the HPG axis.

Zanoterone was investigated in a multicenter RCT including 463 patients receiving either placebo or 100-, 200-, 400- or 800-mg zanoterone for 6 months (Berger et al., 1995). There was a significant mean increase in PFR only in the 200-mg group (1.7 mL/s; $P = 0.02$). No significant difference was observed between any treatment dose and placebo in terms of symptom score reduction and PV reduction. Moreover, there was a significant increase in estradiol and testosterone serum concentrations; similarly, a higher incidence of AEs such as breast pain and gynecomastia were observed in the zanoterone group as compared with the placebo group. Overall, the observed minimal efficacy and the greater than expected frequency of AEs led to early trial discontinuation and precluded further development of this drug for treatment of LUTS/BPH.

Flutamide

Flutamide is a nonsteroidal antiandrogen that inhibits the binding of testosterone and DHT to the androgen receptor. In the first double-blind placebo-controlled study, 30 patients with symptomatic BPH were randomized to receive flutamide at 300 mg/day versus placebo (Caine et al., 1975). There was no significant difference in terms of symptom relief, PV changes, and urinary flow parameter improvement between flutamide and placebo. In a multicenter, randomized, double-blind trial, flutamide at 250 mg three times a day for 6 months was compared with placebo (Stone, 1989). The study included patients with obstructive BPH according to uroflowmetry measurements. Of 84 patients included, 58 (69%) were evaluable at 12 weeks and 12 (14%) were evaluable at 24 weeks on double-blind treatment. The small sample size at 24 weeks precluded any meaningful conclusions. **The between-group comparisons of mean changes from the baseline in the investigated outcomes were not statistically significant at any time point.** The incidences of breast tenderness and diarrhea after flutamide treatment were 53% and 11%, respectively. In a further multicenter randomized trial including 372 patients, the authors tested different doses of flutamide (125 mg twice daily; 250 mg once daily; 250 mg twice daily; 250 mg three times daily) versus placebo. There was a dose-dependent decrease of PV, with a maximum of –24% after 6 months. No significant difference between placebo and flutamide was observed in terms of any other efficacy outcome. From 25% to 39% of patients in the flutamide groups discontinued treatment because of diarrhea or breast tenderness.

Cetrorelix

Cetrorelix is a GnRH antagonist allowing a submaximal, noncastrating blockade of testosterone and DHT. The advantage of cetrorelix, as compared with other GnRH agonists, is the ability to titrate the level of androgen suppression. This would be clinically relevant if different levels of androgen suppression mediate prostate size reduction and AEs (hot flashes, decreased libido, impotence). In an open-label phase I/II study, 13 patients with symptomatic BPH were treated with subcutaneous injection of cetrorelix administered at 5 mg for the first 2 days (loading dose) and at 1 mg/day for 2 months (Comaru-Schally et al., 1998). At the end of treatment, IPSSs decreased by a mean of 11.7 points. Symptom scores continued to decrease after treatment discontinuation, reaching a 61% mean decrease at the end of the follow-up period (18 months). Mean PV decreased by 27% after 2 months of treatment; however, PV slightly increased after treatment discontinuation. Total testosterone level reached castration levels after the loading dose, but during maintenance treatment was inhibited by only 64% to 74%. Up to 77% of men reported decreased libido and nocturnal penile tumescence at the end of treatment. Debruyne et al. (2008) tested three regimens of cetrorelix in a double-blind, placebo-controlled, randomized trial. In this study, 140 patients with BPH were randomized to receive subcutaneous injections of cetrorelix at 5 mg per week for 4 weeks versus 10 mg every 2 weeks for 2 weeks versus 10 mg per week for 4 weeks versus placebo. In all treatment groups, the IPSS rapidly decreased, with a peak effect of –5.4 to –5.9 points; 4 months after the end of the treatment, the reduction in the symptom score was significantly higher in all treatment groups compared with the placebo group. Similarly, urinary flow parameters showed a significant and persistent improvement after cetrorelix treatment compared with placebo. A significant and persistent decrease in PV from the baseline was observed only in the group receiving 10 mg cetrorelix. Moreover, the authors did not report any clinically significant change in sexual function. These results, showing a rapid onset of relief of symptoms lasting well beyond the end of treatment, suggested the possibility of an intermittent dosage regimen to treat patients with BPH. In a subsequent randomized placebo-controlled trial investigating an SR intramuscular formulation of cetrorelix, symptom relief lasted up to 6 months after 2 weeks of treatment (Debruyne et al., 2010).

The primary disadvantages of cetrorelix was the requirement for an injection and the cost; if further data prove that a single-injection therapy provides a desirable clinical response (e.g., over 6 months) with minimal side effects, there may be a role for this antagonist in the treatment of LUTS/BPH.

Chlormadinone Acetate

Chlormadinone acetate (CMA) is a steroid antiandrogen that inhibits the uptake of testosterone by epithelial cells and the binding of DHT to the androgen receptor within the cell. Treatment with CMA has been shown to reduce testosterone levels by approximately 90% (Fujimoto et al., 2013). In a multicenter, noncontrolled, prospective study, 115 patients with symptomatic BPH were treated with 25 mg CMA twice daily or 50 mg once daily for a total of 16 weeks and were followed up to 48 weeks (Fujimoto et al., 2013). There was significant reduction in IPSS starting 8 weeks after treatment and lasting until the end of follow-up. The mean PFR increased to a maximum of 1.96 mL/s at week 16 and remained elevated until week 48. Similarly, a 25% decrease in PV was observed after 16 weeks of treatment. A significant deterioration of erectile function was observed at the end of treatment.

Aromatase Inhibitors

Preclinical data have demonstrated a role for estrogens in the pathogenesis of BPH. Their binding to estrogen receptors, at the level of stromal cells, may influence proliferation and differentiation. The role of prostatic mesenchyme (stroma) in the development of BPH is supported by the observation of Cunha et al. (1980) in a mouse embryonic animal model. Moreover, treatment of male dogs with both androgens and estrogens led to earlier and more extensive BPH (Coffey and Walsh, 1990); indeed, estrogens can also greatly enhance the ability of androgens to induce BPH, as shown in other preclinical studies (Walsh and Wilson, 1976; DeKlerk et al., 1979).

Aromatase inhibitors are able to block the conversion of testosterone to estrogens in tissues by inhibiting the enzyme aromatase.

Atamestane is a highly selective aromatase inhibitor that lowers both serum and intraprostatic levels of estradiol and estrone (el Etreby et al., 1991). In a multicenter RCT, 160 patients with symptomatic BPH were treated with 40 mg (Gingell et al., 1995). There was a significant decrease in serum estrogen levels and a 15% decrease in PV. **However, there was no relief of symptoms or improvement of urinary flow parameters. Moreover, a dose-dependent increase in peripheral androgen concentration was observed, and this may be the reason for the lack of efficacy of the drug.** However, in a randomized trial including 88 hypogonadal men, treatment with the aromatase inhibitor anastrozole did not result in significant relief of symptoms, despite the low level of serum testosterone (Burnett-Bowie et al., 2009).

Selective Estrogen and Androgen Receptor Modulators

Therapeutic selective estrogen receptor modulators (SERMs) have been used for PCa prevention and for the amelioration of side effects associated with androgen ablation therapy in patients with advanced disease. They act by modulating the activity of the estrogen receptor, exerting an enhancing or inhibitory effect according to the different receptor types (Ellem and Risbridger, 2007). This modulation can translate into an antiproliferative and proapoptotic effect. Tamoxifen, raloxifene, and toremifene have been found to inhibit the proliferation of both prostatic epithelial cells and prostatic stromal cells in vitro (Glienke et al., 2004; Nomura et al., 2009). Moreover, tamoxifen significantly reduced PV by 28.5% in a randomized trial in dogs (Gonzalez et al., 2009). Trials assessing the effect of SERMs for the treatment of BPH in humans are limited. Tamoxifen was tested in 10 patients before they underwent BPH surgery, showing a reduced level of nuclear androgen receptors on the analysis of prostate specimens after surgery (Albert et al., 1984). In a population of patients with metastatic PCa, the use of SERMs was shown to ameliorate AEs associated with antiandrogen therapy, thus reducing the risk for fracture and improving the lipid profile (Smith et al., 2008). For these reasons, SERMs may play a role in the future for the treatment of BPH as a potential adjuvant to antiandrogen therapies.

Selective androgen receptor modulators (SARMs) exert a tissue-selective effect; they act as partial antagonists on the prostate and as full agonists at the level of the muscle tissue and pituitary gland, thus inducing a suppression of prostate growth while maintaining a positive effect peripherally (Negro-Vilar, 1999). In vivo studies on rat models have shown a dose-dependent decrease in PV associated with SARM treatment, without significant changes in serum testosterone and gonadotropin hormone concentrations (Gao et al., 2004; Nejishima et al., 2012). Further trials are needed to test the effect of SARMs in patients with BPH.

Tolerability and Safety of Androgen Manipulation Therapy for Benign Prostatic Hyperplasia

Pooled analyses of RCTs have demonstrated an overall good safety profile of 5ARIs (Park et al., 2014; Tacklind et al., 2010). Apart from sexual side effects, finasteride showed no significant difference in the overall incidence of AEs or serious AEs when compared with placebo (Tacklind et al., 2010); similarly the rate of patients stopping therapy because of AEs was not higher in the finasteride group than in the placebo group (Tacklind et al., 2010). In the long-term PLESS, after 4 years of treatment the rate of patients withdrawing therapy for AEs was 34% in the finasteride group and 42% in the placebo group (McConnell et al., 1998). Similarly, pooled data from RCTs of dutasteride did not show a significant higher incidence of AEs other than sexual dysfunction after treatment with dutasteride or placebo (Park et al., 2014). The large 4-year randomized REDUCE trial showed no difference in terms of AE rates between dutasteride and placebo (Andriole et al., 2010). **However, data from more recent studies have raised questions regarding the safety of 5ARIs because of controversial findings on the risk for treatment-emergent insulin resistance and diabetes, cardiovascular disease, and depression.**

Preclinical data showed that the dual inhibition of 5α-reductases promoted by dutasteride was associated with impaired insulin sensitivity in peripheral tissues and with increased body fat in an animal model (Upreti et al., 2014). Similarly, other animal studies have suggested an increased risk for nonalcoholic fatty liver disease associated with 5ARI treatment (Livingstone et al., 2015). These data are in line with findings demonstrating an increased risk for type 2 diabetes mellitus in men with lower testosterone levels (Corona et al., 2006). **However, the association between diabetes and 5ARI therapy in patients with BPH has not been confirmed in clinical studies.** Data from the REDUCE trial did not show an increased risk for diabetes in the dutasteride treatment group (Wu et al., 2011). Similarly, in a population-based study including 1298 patients with diagnosed BPH, the use of 5ARIs was not associated with the occurrence of type 2 diabetes in a 5-year period (3.5% vs. 5.3% with 5ARIs vs. control group). Moreover, patients younger than 65 years of age treated with 5ARIs showed lower risk for developing diabetes compared with same-age controls (Lee et al., 2016). Similarly, long-term data from the PCPT did not show any difference in the cumulative incidence of diabetes among patients treated with finasteride versus placebo (Unger et al., 2016).

Given the important role of androgens in the metabolism of bone and muscle, treatment with 5ARIs, affecting the serum level of DHT, may have an influence at these two levels; a population-based study including 1352 men with osteoporosis compared with 5387 controls reported a 1.5-fold increase of osteoporosis diagnosis among patients treated with finasteride (Lin et al., 2015). However, these findings were not corroborated by data from RCTs; **the bone mineral density of patients receiving finasteride for 4 years was not significantly different as from that of patients receiving placebo** (Matsumoto et al., 2002)**. Similar results were reported with dutasteride** (Amory et al., 2008). Moreover, a recent randomized trial evaluating the effect of testosterone therapy in patients treated with dutasteride versus placebo showed no difference in the effect of testosterone on fat-free mass and muscle strength, suggesting that the suppression of DHT does not affect the anabolic effect of testosterone on muscle (Bhasin et al., 2012).

The link between low testosterone level and the risk for cardiovascular events has raised concerns regarding a possible association between 5ARIs and cardiovascular diseases. Andriole et al. (2010) reported a higher incidence of cardiac failure among patients treated with dutasteride versus placebo in the REDUCE trial. Conversely, long-term results of the PCPT did not show a higher cumulative incidence of cardiovascular events among patients treated with finasteride (Unger et al., 2016). **In a recent population-based study including 36,311 men treated with dutasteride and 36,311 men treated with finasteride, there was no difference in the risk for heart failure and acute myocardial infarction between the two groups** (Skeldon et al., 2017); these results were corroborated by a nation-based study comparing 1486 men treated with 5ARIs with 9995 controls, showing that the active treatment was not associated with an increased risk for cardiovascular disease (Hsieh et al., 2015).

In 2011, the FDA added depression as a potential side effect in the product monograph of 5ARIs because of postmarketing studies reporting a higher risk for depression and suicide associated with finasteride use. Data from PCPT reported a 10% higher risk for depression associated with finasteride compared with placebo (Unger et al., 2016). Similar findings were reported in a cross-sectional study investigating the link between depressive symptoms and 5ARIs (Pietrzyk et al., 2015). This association may be related to the role of testosterone and DHT in the modulation of neuroendocrine stress response and in the production of neuroactive steroids. A recent population-based study including 93,197 men showed that the use of 5ARIs was not associated with an increased risk for suicide, whereas there was a significantly higher risk for depression (HR, 1.94; 95% CI, 1.73 to 2.16) and self-harm for men treated with 5ARIs (Welk et al., 2017). **Patients should be properly counseled regarding the risk for depressive symptoms associated with 5ARI treatment.**

5α-Reductase Inhibitors and Sexual Dysfunction

Both finasteride and dutasteride have been associated with the risk for sexual side effects, including erectile dysfunction, decreased libido, and ejaculation disorders. The biologic reasons behind this association are not fully clarified; the decrease of serum DHT level has been associated with decreasing levels of nitric oxide and nitric oxide synthase in the corpus cavernosum (Pinsky et al., 2011). Moreover, structural changes at the level of the cavernosal tissue have been observed after therapy with 5ARIs (Oztekin et al., 2012). In a 2-year RCT, the erectile dysfunction rate among patients treated with finasteride was

15.8% compared with 6.3% for patients receiving placebo (Nickel et al., 1996). Data from the large PLESS showed a higher rate of patients reporting decreased libido and decreased ejaculate volume in the finasteride group as compared with the placebo group after 1 year of treatment (McConnell et al., 1998). Similarly, data from a placebo-controlled trial showed a 7.3% incidence of erectile dysfunction after dutasteride treatment, along with a 4.2% of patients complaining of decreased libido and 2.2% of patients complaining of ejaculation disorders (Roehrborn et al., 2002). Comparable data on dutasteride were also reported in the REDUCE trial (Andriole et al., 2010).

Two recently published meta-analyses reported pooled results of randomized trials assessing sexual side effects after treatment with 5ARIs (Corona et al., 2017; Liu et al., 2016). Liu et al. (2016) pooled data from nine studies investigating the safety of 5ARIs in patients with BPH. The authors reported a relative risk of 1.55 (95% CI, 1.48 to 4.42) for erectile dysfunction and 1.69 (95% CI, 1.03 to 2.79) for decreased libido for patients treated with 5ARIs compared with placebo; no differences were found when data from patients treated with finasteride or dutasteride were compared. These results were further confirmed in a second meta-analysis (Corona et al., 2017). Moreover, a pooled data analysis looking at ejaculation disorders associated with LUTS therapies confirmed a significantly higher risk for ejaculation disorders after 5ARI treatment than after placebo treatment (Gacci et al., 2014).

Controversial findings have been reported regarding the time of onset and duration of sexual dysfunction associated with 5ARI therapy. Long-term data from the PCPT showed that the effect of finasteride on sexual function decreased over time (Moinpour et al., 2007). Similarly, in PLESS the rate of reported sexual side effects was no longer significant after 2 to 4 years of treatment (Wessells et al., 2003). Conversely, data from a meta-analysis of randomized trials showed a higher risk for sexual dysfunction among patients treated with 5ARIs for more than 1 year as compared with those treated for less than 1 year (Liu et al., 2016). Similarly, preclinical studies have shown an incomplete restoration of erectile function after discontinuation of dutasteride treatment (Oztekin et al., 2012).

Therefore, patients should be properly counseled regarding the possibility of experiencing erectile dysfunction, decreased libido, or ejaculation disorders after therapy with 5ARIs.

Summary

Multicenter RCTs have demonstrated the efficacy of finasteride and dutasteride for the treatment of patients with BPH. Therapy with finasteride has been associated with a roughly 20% reduction of PV along with modest relief of urinary symptoms and modest improvement of urinary flow parameters as compared with placebo. Of note, long-term data have shown a 51% reduction in the risk for either AUR or surgery for patients treated with finasteride. Comparable results have been reported in RCTs assessing the efficacy of dutasteride versus placebo. Both finasteride and dutasteride have a higher efficacy in patients with larger PV; long-term (≥6 months) treatment is required to observe a significant reduction of PV and a benefit in terms of symptom relief.

Safety profile data of 5ARIs demonstrated a higher risk for sexual dysfunction and depressive symptoms associated with both finasteride and dutasteride, although the overall incidence of AEs is generally low. Currently, there are no solid data to support a higher risk for diabetes mellitus or cardiovascular diseases associated with 5ARIs.

In the REDUCE trial and PCPT, a reduction in PCa incidence was observed after therapy with 5ARIs. However, caused by a concomitant small increase in the detection of high-grade tumors, neither finasteride nor dutasteride are indicated for PCa prevention.

Antiandrogens have also been investigated for treatment of LUTS/BPH. Current studies failed to demonstrate clinically significant efficacy of these drugs in patients with LUTS. The equivocal efficacy and problematic toxicity of antiandrogens have limited the enthusiasm for marketing these drugs for the treatment of LUTS/BPH. The role of GnRH antagonists requires further assessment. International clinical guidelines suggest therapy with 5ARIs for patients with an enlarged prostate (>40 mL) and moderate to severe symptoms.

Muscarinic Receptor Antagonists

Muscarinic receptor antagonists are used for the treatment of patients with BOO presenting with predominant and/or bothering storage LUTS. From 11% to 16% of men in Europe and North America complain of storage symptoms (Irwin et al., 2006; Stewart et al., 2003), and a non-negligible portion of them may suffer from concomitant BOO. Antimuscarinics (or anticholinergic compounds) are considered the mainstay of treatment for patients with OAB; their use in selected patients with LUTS has increased in the past two decades.

Rationale and Indication for Patients With Benign Prostatic Hyperplasia

The detrusor muscle receives parasympathetic innervation from cholinergic fibers responsible for the stimulation of muscarinic receptors at the peripheral level. Muscarinic receptors are responsible for involuntary detrusor contractions and are involved in the determination of the sensory threshold of the bladder (Chess-Williams et al., 2001). Of the five muscarinic receptor subtypes (M_1 to M_5), M_2 and M_3 receptors are predominant at the bladder level; the inhibition of these receptors through antimuscarinic drugs reduces involuntary bladder contractions and alters the contraction threshold, thus resulting in decreased urgency and increased bladder capacity (Chapple et al., 2002). There is an increasing body of evidence showing that antimuscarinics act mainly on bladder sensory pathways rather than motor pathways (Andersson, 2011); moreover, their effect might also be induced or modulated through the bladder urothelium or by the CNS (Kono et al., 2006).

Muscarinic receptor antagonists are mainly used for the treatment of patients with OAB syndrome; however, both the European and the American international clinical guidelines support the use of these compounds to treat patients with BOO mainly presenting with storage LUTS (McVary et al., 2011; Oelke et al., 2013). Of note, antimuscarinic therapy should be carefully administered in this subset of patients, given the associated higher risk for urinary retention and the risk for an increased PVR volume.

The following muscarinic receptor antagonists are licensed for treatment of storage symptoms: darifenacin hydrobromide (darifenacin), fesoterodine fumarate (fesoterodine), oxybutynin hydrochloride (oxybutynin), propiverine hydrochloride (propiverine), solifenacin succinate (solifenacin), tolterodine tartrate (tolterodine), and trospium chloride. Table 145.12 reports recommended dose and administration for each compound.

TABLE 145.12

Antimuscarinic Drugs for the Treatment of Lower Urinary Tract Symptoms

DRUG	AVAILABLE FORMULATION	RECOMMENDED DAILY DOSE
Darifenacin ER	7.5-, 15-mg capsule	1 × day
Fesoterodine ER	4-, 8-mg capsule	1 × day
Oxybutynin ER	5-, 10-, 15-mg[b] capsule	1 × day (up to 20 mg/day)
Oxybutynin IR	2.5-, 5-mg[a] capsule	3-4 × day (max 20 mg/day)
Propiverine ER (no US)	30-mg capsule	1 × day
Propiverine (no US)	15-mg capsule	2–3 × day
Solifenacin	5-, 10-mg capsule	1 × day
Tolterodine IR	1-, 2-mg capsule	2 × day
Tolterodine ER	2-mg[b], 4-mg capsule	1 × day 1 × day
Trospium IR	20-mg capsule	2 × day
Trospium ER	60-mg capsule	1 × day

[a] Marketed only in Europe.

[b] Marketed only in the United States.

ER, Extended release; *IR,* immediate release;

Efficacy

The efficacy of antimuscarinic monotherapy for storage symptoms in patients with BOO associated with BPH has been investigated in a few trials (Table 145.13). In a small open-label prospective study, Kaplan et al. (2005) reported data from 43 patients with symptomatic BPH who received α1-blocker therapy for at least 1 month without efficacy. All patients were treated with 4 mg tolterodine ER formulation daily for 6 months. There was a significant decrease of the 24-hour micturition frequency (from 9.8 to 6.3 voids) and of the nocturia episodes (from 4.1 to 2.9); moreover, overall symptoms were relieved significantly after 1 month of treatment, and there was a significant increase in

PFR and PVR volume. Of note, no episodes of AUR were reported. In the first large RCT assessing the effect of antimuscarinic therapy for patients with proven BOO, Abrams et al. (2006b) randomized men with evidence of BOO and DO on urodynamic tests to receive tolterodine at 2 mg twice daily versus placebo for 12 weeks. Patients with a PVR volume greater than 40% of the maximum cystometric capacity and a history of urinary retention during the preceding 12 months were excluded. **Treatment with tolterodine was associated with a significant reduction of BOOI compared with placebo; significant differences in terms of the volume to the first detrusor contraction (+59 mL; 95% CI, 19 to 100 mL) and in the maximum cystometric capacity (+67 mL; 95% CI, 35 to 103 mL) favoring tolterodine over placebo ($P < 0.003$) were also observed.** The authors reported a 25-mL mean significant PVR volume increase after tolterodine therapy; however, the overall AE rate was not significantly different compared with placebo, and only three episodes of urinary retention were recorded in the tolterodine group. Less enthusiastic results in terms of efficacy were reported in a larger trial of 879 men with OAB and BOO symptoms randomized to receive tolterodine ER formulation at 4 mg/day, tamsulosin at 0.4 mg/day, tolterodine in combination with tamsulosin, or placebo for a total of 12 weeks (Kaplan et al., 2006). As a primary end point, the authors looked at patients who perceived treatment benefit at the end of treatment; **patients treated with tolterodine as a monotherapy did not report any significant improvement in terms of measures of urgency or significant reduction of IPSS compared with patients who received placebo. Only one patient reported AUR in the tolterodine group, although it must be noted that men with PVR volume greater than 200 mL and PFR less than 5 mL/s were excluded from the study.** Conversely, in another small, randomized study, propiverine as a monotherapy was found to reduce frequency and urgency episodes in patients with BOO (Yokoyama et al., 2009).

TABLE 145.13

Randomized Trials Investigating Antimuscarinic Drugs in Patients With Benign Prostatic Hyperplasia

	DRUG	PATIENTS	LENGTH OF	SYMPTOMS

			TREATMENT	
Saito et al., 1999	Tamsulosin Tamsulosin + propiverine	*N* = 134 Patients with detrusor overactivity	4 weeks	Greater reduction in daytime (44.7% vs. 29.6%) and nighttime frequency (44.4% vs. 33.5%) with tamsulosin + propiverine vs. tamsulosin alone
Athanasopoulos et al., 2003	Tamsulosin 0.4 mg Tamsulosin + tolterodine 2 mg bid	*N* = 50 Patients with urodynamically proven BOO and detrusor instability	12 weeks	Statistically significant reduction in quality of life score from the baseline only in patients treated with tamsulosin + tolterodine ($P<0.0003$)
Lee et al., 2005	Doxazosin 4 mg Doxazosin 4 mg + propiverine 20 mg	*N* = 211 ≥50 years of age with OAB symptoms and urodynamically proven BOO (mean PVR <31 mL)	8 weeks	Change in daytime frequency: Doxazosin + Propiverine –1.9; (P = 0.004) Doxazosin: –0.9 Change in nocturia episodes: Doxazosin + propiverine:

				–0.7; (*P* = 0.1) Doxazosin: –0.6
Abrams et al., 2006	Tolterodine 2 mg bid Placebo	*N* = 222 ≥40 years of age with urodynamically proven BOO and detrusor overactivity	12 weeks	NR
Kaplan et al., 2006	Tolterodine 4 mg ER Tamsulosin 0.4 mg Tolterodine + tamsulosin Placebo	*N* = 172 ≥40 years of age with IPSS ≥12, ≥8 micturitions/24 h, ≥3 urgency episodes/24 h, PVR <200 mL	12 weeks	Patients reporting treatment benefit: Tolterodine: 65.1% (vs. tamsulosin *P* = 0.2); (vs. placebo *P* = 0.6) Tolterodine + tamsulosin: 80%; (*P* = 0.03 vs. tolterodine) Tamsulosin: 70.5% Placebo: 61.7%
Yokoyama et al., 2009	Propiverine 20 mg Naftopidil 50 mg Propiverine + naftopidil	*N* = 66 ≥50 years of age with IPSS ≥8, ≥8 micturitions/24 h, >1 urgency episode/24 h	4 weeks	Change in 24-h voiding frequency: Propiverine –2.0; (intergroup *P* = 0.7) Naftopidil:

				–1.4 Propiverine + naftopidil: -2.0

AUR, Acute urinary retention; *bid,* twice a day; *BOO,* bladder outlet obstruction; *BOOI,* bladder outlet obstruction index; *BPH,* benign prostatic hyperplasia; *ER,* extended release; *IPSS,* International Prostate Symptom Score; *NR,* not reported; *NS,* not significant; *OAB,* overactive bladder; *PFR,* peak flow rate; *PVR,* postvoid residual volume.

Novara et al. (2006) performed a meta-analysis of four RCTs investigating antimuscarinics in men with BPH. Their results showed that monotherapy was not associated with reduction in the total IPSS; no significant changes in PFR were observed (0.1 mL/s; 95% CI, 0.6 to 0.7 mL/s). The PVR volume increased by 11.6 mL (95% CI, 4.5 to 18.6 mL), although AUR rates were not significant. **Overall, the efficacy of antimuscarinics alone in patients with BOO/BPH is controversial, although storage symptom relief has been demonstrated.**

In a study aimed at identifying patients who may have greater benefit from treatment with antimuscarinic drugs, those with higher IPSS storage symptom subscores and higher PFR had a higher chance of therapeutic success (Liao et al., 2013). Similarly, in a post hoc analysis of an RCT, patients with a baseline PSA level below 1.3 ng/mL showed a significant reduction in IPSS storage scores, daytime frequency, and frequency-urgency sum with tolterodine alone compared with placebo (Roehrborn et al., 2006), suggesting a possible greater benefit of antimuscarinic monotherapy in patients with OAB symptoms and small PV.

Tolerability and Safety Profile

Muscarinic receptors are expressed in several tissues, including the brain, heart, gut, salivary glands, and tear ducts. For this reason, **the use of antimuscarinic drugs may lead to treatment-related side effects, including dry mouth (≤16%), constipation (≤4%), nasopharyngitis (≤3%), dizziness (≤5%), and CNS side effects (cognitive dysfunction or delirium)** (Oelke et al., 2013). Both receptor selectivity and the specific molecular structure, influencing the diffusion of the drug into the brain, are responsible for the different tolerability profiles among antimuscarinics.

Oxybutynin was the first compound marketed for the treatment of OAB, but there was poor adherence for the IR formulation, with early discontinuation in a large number of patients (Rovner and Wein, 2002). Tolterodine ER formulation showed better tolerability. In a large multicenter RCT, dry mouth was the only AE more significantly reported in the tolterodine group than in the placebo group (23% vs. 8%) (Van Kerrebroeck et al., 2001). Similarly, in a four-arm trial comparing tolterodine ER formulation versus tamsulosin monotherapy versus combination therapy versus placebo in patients with BPH, the most frequently reported AEs were dry mouth (7%) and constipation (6%) (Kaplan et al., 2006). Of note, the side effects of the combination therapy of antimuscarinics with α_1-blockers or 5ARIs are those expected with each individual drug (Athanasopoulos et al., 2011).

Both solifenacin and fesoterodine have shown a higher rate of reported dry mouth and constipation compared with tolterodine ER formulation (Novara et al., 2008).

The risk for CNS side effects is of particular concern for vulnerable patients such as elderly men and those with CNS disorders. Because of greater diffusion through the blood-brain barrier, oxybutynin has shown a higher risk for CNS impairment compared with the other compounds (Kay and Ebinger, 2008). **The use of antimuscarinics with CNS activity should be avoided in patients with cognitive impairment** (Athanasopoulos et al., 2011).

Data from trials assessing the safety of antimuscarinics in patients with BOO showed a minimal effect in terms of PVR volume increase; tolterodine alone showed a 5.2-mL mean PVR volume increase in patients with BOO (Kaplan et al., 2006); moreover, the incidence of AUR among patients treated with antimuscarinics was not significantly higher than that among patients who received placebo (Athanasopoulos et al., 2011). In line with these findings, a preclinical study has demonstrated that the effect of antimuscarinic drugs on detrusor muscle contractions is unlikely to aggravate voiding difficulties in the presence of BOO (Füllhase et al., 2010). **However, all trials assessing the safety of antimuscarinics to treat storage symptoms associated with BOO included men with a PVR volume below 200 mL. Therefore, this treatment should be considered safe for patients presenting with a low PVR volume.**

Summary

Muscarinic receptor antagonists are the mainstay of treatment for patients with OAB syndrome. Few trials have assessed the efficacy and safety of

antimuscarinic therapy in patients with BOO related to BPH and presenting with prevalent storage symptoms. The results showed that antimuscarinics can be safely administered in patients with low PVR volume and no history of AUR. However, controversial findings have been reported regarding the efficacy of monotherapy with an antimuscarinic drug in patients with BPH. A few studies showed a benefit in reducing storage symptoms in men with lower gland volume.

International clinical guidelines suggest the use of antimuscarinic therapy in patients with moderate to severe LUTS who mainly complain of bladder storage symptoms and present with a baseline PVR volume lower than 200 mL (McVary et al., 2011; Oelke et al., 2013).

β3-Agonist (Mirabegron)

The β_3 subtype is the predominant form of β-ARs in the bladder (Yamaguchi and Chapple, 2007); **the stimulation of the β_3-AR is responsible for an increase in bladder capacity without a significant change in micturition pressure, PVR volume, and voiding contraction** (Leon et al., 2008). Mirabegron is the first β_3-agonist internationally approved for the treatment of storage symptoms.

Indication, Efficacy, and Safety Profile

Mirabegron acts as a β_3-AR agonist at the level of the bladder, inducing detrusor smooth muscle relaxation and contributing to urine storage (Aizawa et al., 2012). Phase III randomized trials provided evidence of the efficacy of mirabegron for the treatment of patients with OAB syndrome (Chapple et al., 2013; Khullar et al., 2013). Few data are currently available regarding the safety and efficacy of mirabegron in the selected population of patients with BOO associated with BPH.

Nitti et al. (2013) conducted a phase II randomized trial aimed at evaluating urodynamic parameters in 200 men with LUTS and BOO treated with mirabegron at 50 or 100 mg daily versus placebo. At the end of the 12-week therapy, mean values of PFR and detrusor pressure at Qmax were not significantly different across groups; moreover, the number of patients for whom the BOOI score category shifted (from equivocal to obstructed) decreased in the treatment arms at the end of treatment. However, a dose-dependent increase in PVR volume of about 30 mL was observed in the 100-mg group. Patients treated with mirabegron showed a significant decrease in the mean number of micturitions per day (–1.37) and urgency episodes per day (–1.60) compared with patients who received placebo; conversely, no significant difference was observed in terms of changes of IPSS voiding and storage scores between the placebo group and the mirabegron-treated groups. **These results support the urodynamic safety of mirabegron in patients affected by BOO and suggest a role in the treatment of storage symptoms in this setting.** Recent evidence suggests that mirabegron might exert an effect also at the level of the urethra (Alexandre et al., 2016). Preclinical data showed that mirabegron was able to induce relaxation of the urethral smooth muscle in an animal model. This effect was mediated by binding to the β_3-AR at the urethral level and by a selective block of the α_{1a}-ARs and α_{1d}-ARs. A similar effect on the prostatic smooth muscle was also reported by another group (Calmasini et al., 2015).

Compared with antimuscarinics, mirabegron is expected to have a better tolerability profile; indeed, given the different receptor target of this drug, side effects such as constipation, dry mouth, and neurologic impairments are uncommonly observed with mirabegron. Similarly, the inhibition of the β_3-AR at the level of the bladder does not appear to be associated with impairment of the voiding phase (Nitti et al., 2013). In a recent review of data from three 12-week trials of mirabegron versus placebo and two noninferiority trials comparing mirabegron with solifenacin and tolterodine, Tubaro et al. (2017) analyzed the safety and tolerability of mirabegron. A total of 37% of patients included in these trials had a history of BPH. Overall, the rate of AEs was not significantly different compared with placebo treatment (46.1% vs. 45.2%); the rate of dry mouth was significantly higher for patients treated with solifenacin (6.7%) and tolterodine (8%) compared with mirabegron (3.3% to 3.5%), whereas no difference was observed for constipation. The most commonly reported AEs in the mirabegron group were nasopharyngitis (5.9% to 3.3%), headache (2.4% to 3.1%), and hypertension (10% to 12%), although the latter was reported at a comparable rate in patients in the placebo group. Similarly, pooled data from 12-week phase III trials showed that mirabegron was associated with only a ≤1 mm Hg increase in blood pressure as compared with placebo (Rosa et al., 2016). **However, because of previous evidence showing a significant increase of systolic blood pressure among healthy volunteers** (Malik et al., 2012)**, mirabegron is not recommended for patients with uncontrolled hypertension.** Only three cases of AUR were reported, and PVR volume did not significantly change compared with placebo treatment.

International clinical guidelines suggest the use of mirabegron as an option for the treatment of patients with moderate to severe LUTS and prevalent storage symptoms (Abrams et al., 2013; Oelke et al., 2013)**. The recommended starting dose is 25 mg daily with or without food, which may be further increased to 50 mg.**

Phosphodiesterase Type 5 Inhibitors

Erectile dysfunction and LUTS are strongly correlated (Gacci et al., 2011); PDE5Is demonstrated a beneficial effect in both conditions in several randomized trials (Gacci et al., 2012a). It has been proposed that PDE5Is may act by reducing inflammation and increasing oxygenation at the level of the prostatic tissue, thus normalizing the structural anatomy and physiologic activity of the prostate (Morelli et al., 2013; Vignozzi et al., 2013).

Rationale and Efficacy of Phosphodiesterase Type 5 Inhibitors in Patients With Lower Urinary Tract Symptoms

The enzyme PDE5 is expressed throughout the entire lower urinary tract (Fibbi et al., 2010). The biologic mechanisms associated with its inhibition have not been completely clarified, although there are several theories supporting a role for PDE5Is in the treatment of male LUTS (Fig. 145.12):

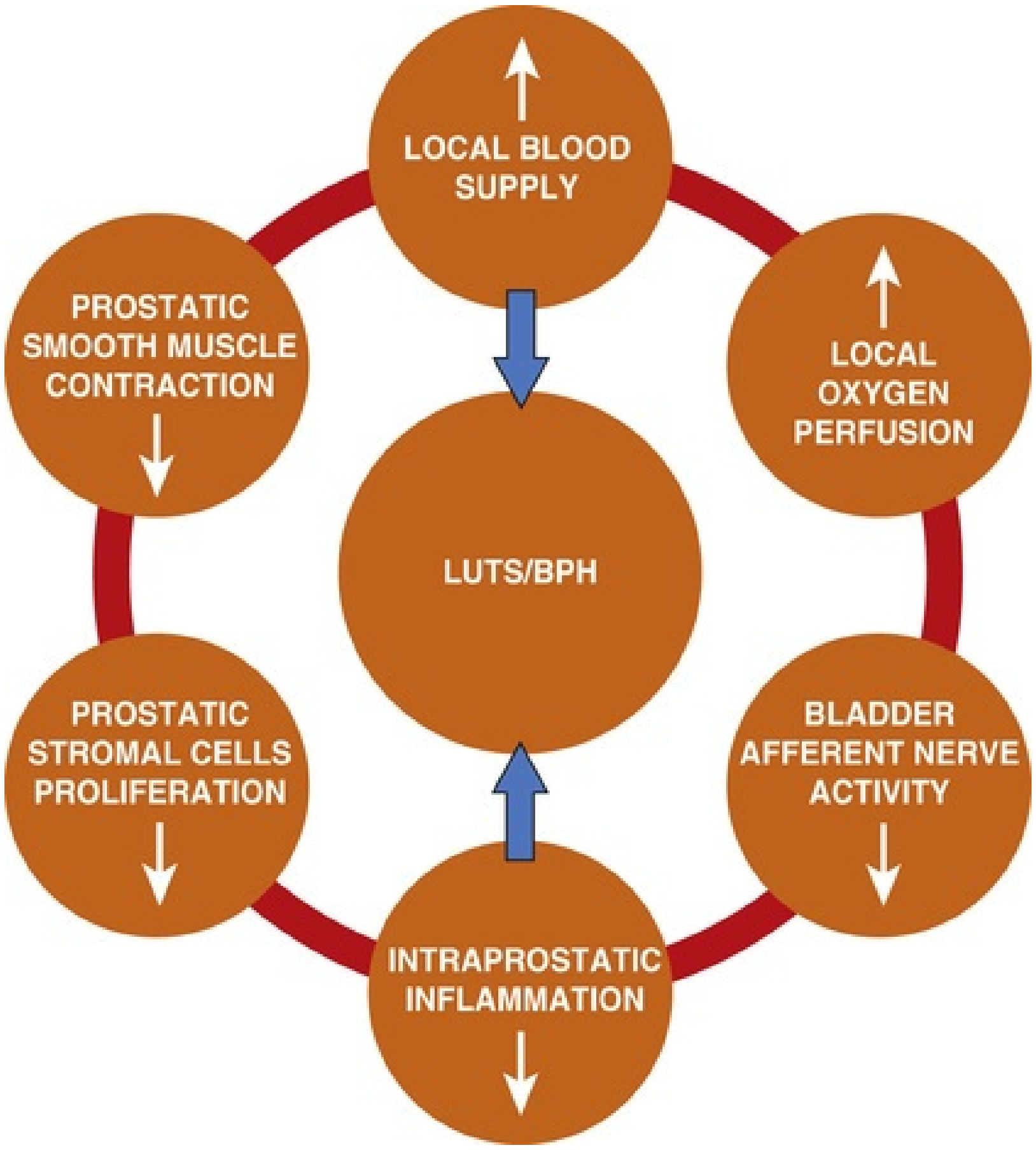
↑ LOCAL BLOOD SUPPLY
↑ LOCAL OXYGEN PERFUSION
BLADDER AFFERENT NERVE ACTIVITY ↓
INTRAPROSTATIC INFLAMMATION ↓
PROSTATIC STROMAL CELLS PROLIFERATION ↓
PROSTATIC SMOOTH MUSCLE CONTRACTION ↓
LUTS/BPH

FIG. 145.12 Effects of phosphodiesterase type 5 inhibitors on the lower urinary tract.

- **The inhibition of PDE5 at the level of the endothelial and smooth muscle cells of blood vessels can lead to increased oxygenation of both the bladder and the prostate** (Morelli et al., 2010). Both vardenafil and tadalafil were demonstrated to improve bladder and prostate oxygenation in a rat model (Morelli et al., 2009, 2011).
- **PDE5Is can relax the prostate and bladder neck smooth muscle** (Angulo et al., 2012; Kedia et al., 2009). This effect is associated with an increase in nitric oxide signaling from nerve fibers close to the muscle fibers. In rat models of partial urethral obstruction, the administration of vardenafil and tadalafil improved the urodynamic profile (Kawai et al., 2016; Morelli et al., 2009).
- PDE5 is greatly expressed at the level of prostatic stroma; **in human prostatic tissue preparations, vardenafil showed an antiproliferative effect** mediated by the cyclic GMP/protein kinase G pathway (Fibbi et al., 2010; Morelli et al., 2009). Moreover, PDE5Is inhibited fibroblast-myofibroblast transdifferentiation in human prostatic cells (Zenzmaier et al., 2010) and reversed stromal remodeling (Zenzmaier et al., 2012).
- **In rat models, PDE5Is decreased the activity of afferent nerves in the lower urinary tract, with a hypothesized consequent decrease in terms of perception of bladder filling and urgency** (Caremel et al., 2010). This effect is mediated by the nitric oxide/cyclic GMP pathway, and vardenafil resulted in significant improvement in urodynamic parameters in patients with neurogenic bladder secondary to spinal cord injury (Gacci et al., 2007).
- Metabolic syndrome has a proven role in BPH pathophysiology; in a rabbit model with metabolic syndrome–associated prostate alterations, tadalafil was able to **reduce prostate inflammation** (Morelli et al., 2013)**, suggesting that PDE5Is may attenuate the negative effect of metabolic alterations on prostatic tissue.**

The effects of PDE5I therapy in patients with LUTS have been evaluated in several RCTs (Table 145.14) and in trials comparing α_1-blockers with PDE5Is; moreover, several meta-analyses provided further evidence regarding the use of PDE5Is in the treatment of LUTS (see Table 145.14). The first evidence of a PDE5I-associated relief of LUTS came from a study including 112 men treated with sildenafil for erectile dysfunction (Sairam et al., 2002); IPSS data showed an unexpected relief of symptoms with sildenafil treatment.

TABLE 145.14

Randomized Trials Investigating Phosphodiesterase Type 5 Inhibitors in Patients With Lower Urinary Tract Symptoms

	DRUG	PATIENTS	LENGTH OF TREATMENT	SYMPTOMS [IPSS TOTAL: WEIGHTED DIFFERENCE BETWEEN DRUGS (95% CI)]	PE RA [W DI BE DR CI)
PLACEBO-CONTROLLED TRIALS					
McVary et al., 2007a	Sildenafil 100 mg daily Placebo	*N* = 323	12 weeks	Sildenafil vs. placebo –3.9 (–5.3, –2.4)	Sil pla +0.
Stief et al., 2008	Vardenafil 10 mg bid Placebo	*N* = 215 Mean IPSS 16.8	8 weeks	Vardenafil vs. placebo –2.2 (–5.1, +0.7)	Va pla +0. +3.
McVary et al., 2007b	Tadalafil dose escalation 5-20 mg	*N* = 251 Mean IPSS	12 weeks	Tadalafil vs. placebo –2.5 (.3.8, –1.1)	Ta pla + 0 +2.

	daily Placebo	17.9			
Roehrborn et al., 2008b	Tadalafil 2.5 mg daily Tadalafil 5 mg daily Tadalafil 10 mg daily Tadalafil 20 mg daily Placebo	*N* = 886 Mean IPSS 17.2	12 weeks	2.5 mg vs. placebo –1.2(–3.6, +1.2) 5 mg vs. placebo –2.3 (–4.7 –0.1) 10 mg vs. placebo –2.2 (–4.5, +0.1) 20 mg vs. placebo –3.7 (–5.5, –1.8)	Me cha bas 2.5 (0.3 5 m (0.3 10 (0.3 20 (0.3 Pla (0.4
Porst et al., 2009	Tadalafil 2.5 mg daily Tadalafil 5 mg daily Tadalafil 10 mg daily Tadalafil 20 mg daily Placebo	*N* = 491 Mean IPSS 16.1	12 weeks	Mean (SE) change from baseline 2.5 mg: –3.6 (0.8) 5 mg: –4.2 (0.8) 10 mg –4.7 (0.8) 20 mg –4.7 (0.8) Placebo: –2.1 (0.8)	2.5 pla -0.1 5 m pla +0. +2. 10 pla -0.1 20 pla +0. +2.
Porst et al., 2011	Tadalafil 5 mg daily Placebo	*N* = 300 Mean IPSS 16.8	12 weeks	Tadalafil v. placebo –1.4 (–3.9, +1.1)	Tad pla -0.6
Oelke et al., 2012	Tadalafil 5 mg daily	*N* = 511	12 weeks	Tadalafil vs. placebo	Me cha

	Tamsulosin 0.4 mg Placebo	Mean IPSS 17.2		–2.1 (–3.3, –0.8) Tamsulosin vs. placebo –1.5 (–2.8, –0–2)	bas pla Tad (5. Tan +2. (0. Pla (4.

META-ANALYSIS OF RCTS			
	No. of patients	IPSS (mean difference vs, placebo)	PF (me
Liu et al., 2011	2,119	2.6[a]	0.21
Gacci et al., 2012	3,214	2.8[a] 1.8[b]	0.0 1.5
Yan et al., 2014	515	4.2[a]	1.4[a]
Dong et al., 2013	2,913	2.3[a]	0.6[a]
Dahm et al., 2017	1,010	Mean change from baseline Sildenafil vs. alfuzosin –2.2 vs. –3.2 (NS) Sildenafil vs. tamsulosin –4.0 vs. –5.4 (NS) Tadalafil 5 mg vs. tamsulosin –5.6 vs. –5.9 (NS) Tadalafil 10–20 mg vs. alfuzosin Range –1.3 to –6.3 vs. range –5.2 to –9.5 (favored alfuzosin)	–

[a] Significant reduction versus placebo.

[b] Significant reduction versus α-blocker monotherapy when in combination with an α-blocker.

[c] The three most common adverse events are reported if available.

BPH, Benign prostatic hyperplasia; *CI,* confidence interval; *IPSS,* International Prostate Symptom Score; *NR,* not reported; *NS,* not significant; *PFR,* peak flow rate; *RCTs,* randomized controlled trials.

Modified from Gacci M, Corona G, Salvi M, et al. A systematic review and meta-analysis on the use of phosphodiesterase 5 inhibitors alone or in combination with α-blockers for lower urinary tract symptoms due to benign prostatic hyperplasia. *Eur Urol* 61(5):994–1003, 2012a; Gacci M, Andersson KE, Chapple C, et al. Latest evidence on the use of phosphodiesterase type 5 inhibitors for the treatment of lower urinary tract symptoms secondary to benign prostatic hyperplasia. *Eur Urol* 70(1):124–133, 2016b.

In an RCT, 189 men with both erectile dysfunction and LUTS (defined as IPSS ≥12) received 50 mg sildenafil once daily for 2 weeks, further increased to 100 mg for a total of 12 weeks of treatment (McVary et al., 2007a); **the IPSS decreased by a mean of 6.32 points from the baseline after sildenafil therapy as compared with a decrease of 1.93 points in the placebo group ($P < 0.0001$).** Men with severe LUTS showed the higher benefit from treatment (–8.6 points compared with –2.4 points in the less severely symptomatic men). No differences were reported in terms of changes in urinary flow parameters between groups. The same authors performed a second RCT, which included 281 men with LUTS/BPH treated either with placebo or with 5 mg tadalafil once daily for 6 weeks, followed by a dose escalation to 20 mg for an additional 6 weeks (McVary et al., 2007b). At the end of treatment, the IPSS decreased by 3.8 points in the tadalafil group compared with 1.7 points in the placebo group. They also observed a significantly greater decrease of the IPSS QoL score and the BII. **Men in the tadalafil group were more likely to show a 3-point or greater decrease in the IPSS by 12 weeks than those in the placebo group (60.9% vs. 42.7%).** As for the sildenafil trial, changes in the uroflowmetry parameters were not significant on assessment at 12 weeks. Overall, AEs commonly associated with tadalafil treatment were observed, with 2.2% of patients reporting dyspepsia, back pain, and headache.

Likewise, the effect of vardenafil on LUTS was assessed in an RCT including men with an IPSS of 12 or greater treated with 10 mg vardenafil twice daily or placebo (Stief et al., 2008). **The IPSS significantly decreased after 8 weeks of treatment, with a greater decrease in the vardenafil group (–5.9 vs. –3.6; $P = 0.001$)**; the decrease was significant for both the storage subscore and the voiding subscore. Headache, dyspepsia, and flushing were the most commonly observed AEs, reported by 13%, 7.4%, and 6.5% of patients, respectively.

Because of its longer half-life and convenient 5-mg daily dose, **tadalafil has been the most widely assessed PDE5I in patients with LUTS,** resulting in it being the only drug currently licensed as an on-label treatment for male LUTS. Roehrborn et al. (2008b) performed a dose-finding trial that enrolled 1058 men with LUTS who were randomly allocated to receive either placebo or tadalafil at 2.5, 5, 10, or 20 mg once daily for 12 weeks. All tadalafil doses resulted in a significant decrease of the IPSS as compared with placebo, with a clear dose-response effect (Fig. 145.13). Moreover, all doses were well tolerated, although the rate of patients reporting at least one AE increased with increasing doses; overall, the 5-mg dose provided the best risk-benefit profile. The efficacy of tadalafil therapy in patients with LUTS was confirmed in other well-conducted RCTs (Egerdie et al., 2012; Oelke et al., 2012; Porst et al., 2009, 2011) and by three meta-analyses (Brock et al., 2013; Porst et al., 2013a, 2013b). Overall, 5 mg tadalafil once daily has been shown to reduce both the total IPSS and the QoL score by 6 and 1 points compared with 3.6 and 0.7 points for placebo ($P >$ 0.001) (Hatzimouratidis, 2014). There was no significant differences in the magnitude of the effect among patients with and without erectile dysfunction at the baseline, thus suggesting that drug efficacy is not related to an indirect effect involving psychological benefit associated with erectile function improvement (Brock et al., 2013).

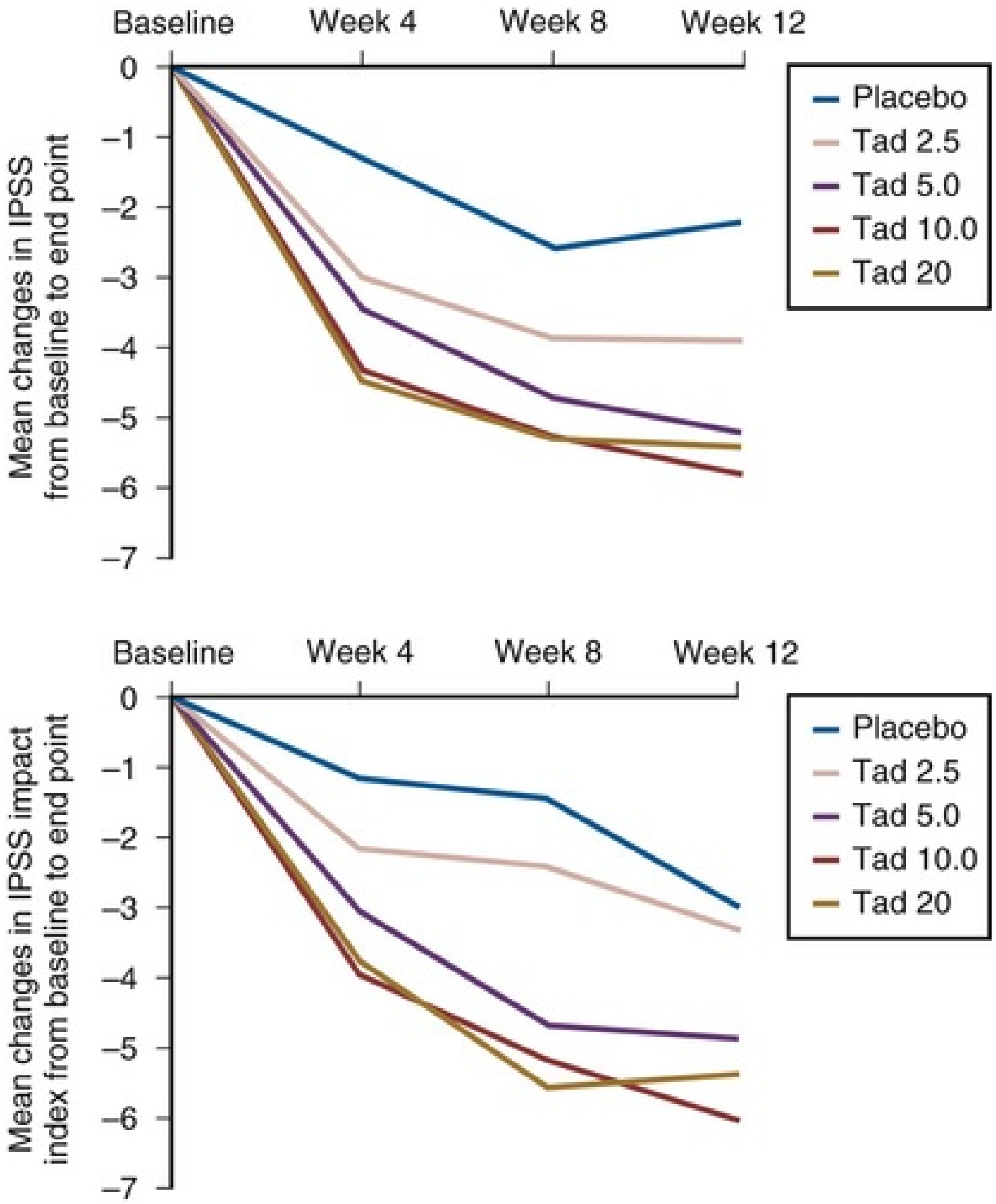

FIG. 145.13 Response of lower urinary tract symptoms to tadalafil. Mean change in International Prostate Symptom Score (IPSS) and Benign Prostatic Hyperplasia Impact Index after treatment with placebo or tadalafil

(Tad) at 2.5, 5, 10, and 20 mg/day. (From Roehrborn CG, McVary KT, Elion-Mboussa A, et al. Tadalafil administered once daily for lower urinary tract symptoms secondary to benign prostatic hyperplasia: a dose finding study. *J Urol* 180[4]:1228–1234, 2008b.)

Urodynamic studies, and meta-analyses of RCTs did not report a significant impact of tadalafil in terms of urodynamic and uroflowmetry parameters (Dmochowski et al., 2010; Dong et al., 2013).

Gacci et al. (2016b) summarized data from eight systematic reviews and meta-analyses concerning the use of PDE5Is in men with BPH and from nine studies reporting post hoc pooled data analyses of patients with LUTS treated with 5 mg tadalafil versus placebo. Their findings confirmed the efficacy of PDE5Is in terms of IPSS reduction, without significant effects on uroflow parameters; moreover, they showed that PDE5Is are overall well tolerated. Pooled data on 5 mg tadalafil compared with placebo showed clinically significant relief of urinary symptoms and reduction of nocturnal voiding frequency.

Dahm et al. (2017) recently reviewed the results of trials comparing tadalafil alone with α_1-blockers for the treatment of LUTS. In four 3-month trials comparing tadalafil with tamsulosin, both drugs caused a similar reduction of mean total IPSS and QoL score. Similarly, in two trials comparing tadalafil with alfuzosin, both drugs caused a significant IPSS reduction, although the mean change from baseline was greater in the alfuzosin group (4.1 vs. 7.2).

Similar results emerged from pooled data analyses of trials comparing sildenafil with alfuzosin, doxazosin, or tamsulosin (Dahm et al., 2017).

International clinical guidelines currently suggest PDE5Is as an alternative therapy for men with moderate to severe LUTS, with or without associated erectile dysfunction (Abrams et al., 2013; Oelke et al., 2013)**. Tadalafil is currently the only officially licensed PDE5I for the treatment of male LUTS. The recommended dose is 5 mg taken at approximately the same time every day with or without food.**

Combination Therapy for Lower Urinary Tract Symptoms

α-Adrenergic Blockers and 5α-Reductase Inhibitors

To date, five RCTs have assessed the efficacy of combination therapy of α_1-blockers and 5ARIs for LUTS (Debruyne et al., 1998; Kirby et al., 2003; Lepor et al., 1996; McConnell et al., 2003; Roehrborn et al., 2008a). **Of those, only the MTOPS study and the Combination of Avodart and Tamsulosin (CombAT) study reported results at follow-up longer than 1 year.**

In the Veterans Affairs Cooperative Study, Lepor et al. (1996) evaluated 1229 men with symptomatic BPH, a PFR below 15 mL/s and a PVR volume lower than 300 mL who had been randomized to receive placebo, finasteride, terazosin (titrated from 1 to 10 mg), or a combination of both active compounds for 52 weeks. There was a greater significant reduction of the AUASI scores in the terazosin group (6.1 points) and the combination therapy group (6.2 points) compared with the finasteride group (3.2 points) and the placebo group (2.6 points) (Fig. 145.14A). Similarly, changes in PFR were significant only for the terazosin and the combination therapy groups (see Fig. 145.14B). PV decreased by approximately 20% in the finasteride and combination therapy groups. The authors concluded that the combination therapy was not more effective than terazosin alone in treating patients with LUTS/BPH. Of note, the mean PV in all treated arms was lower than 40 mL.

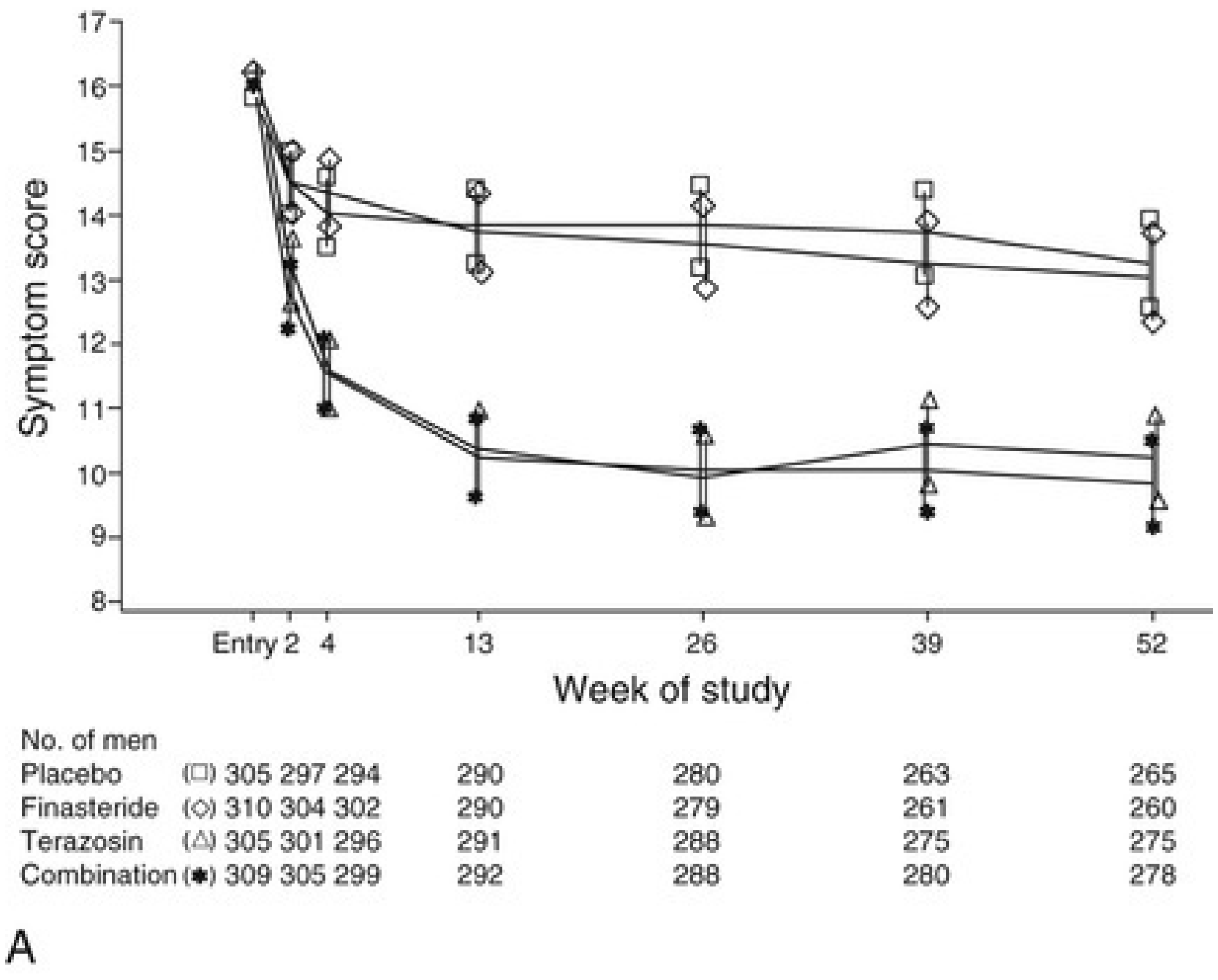

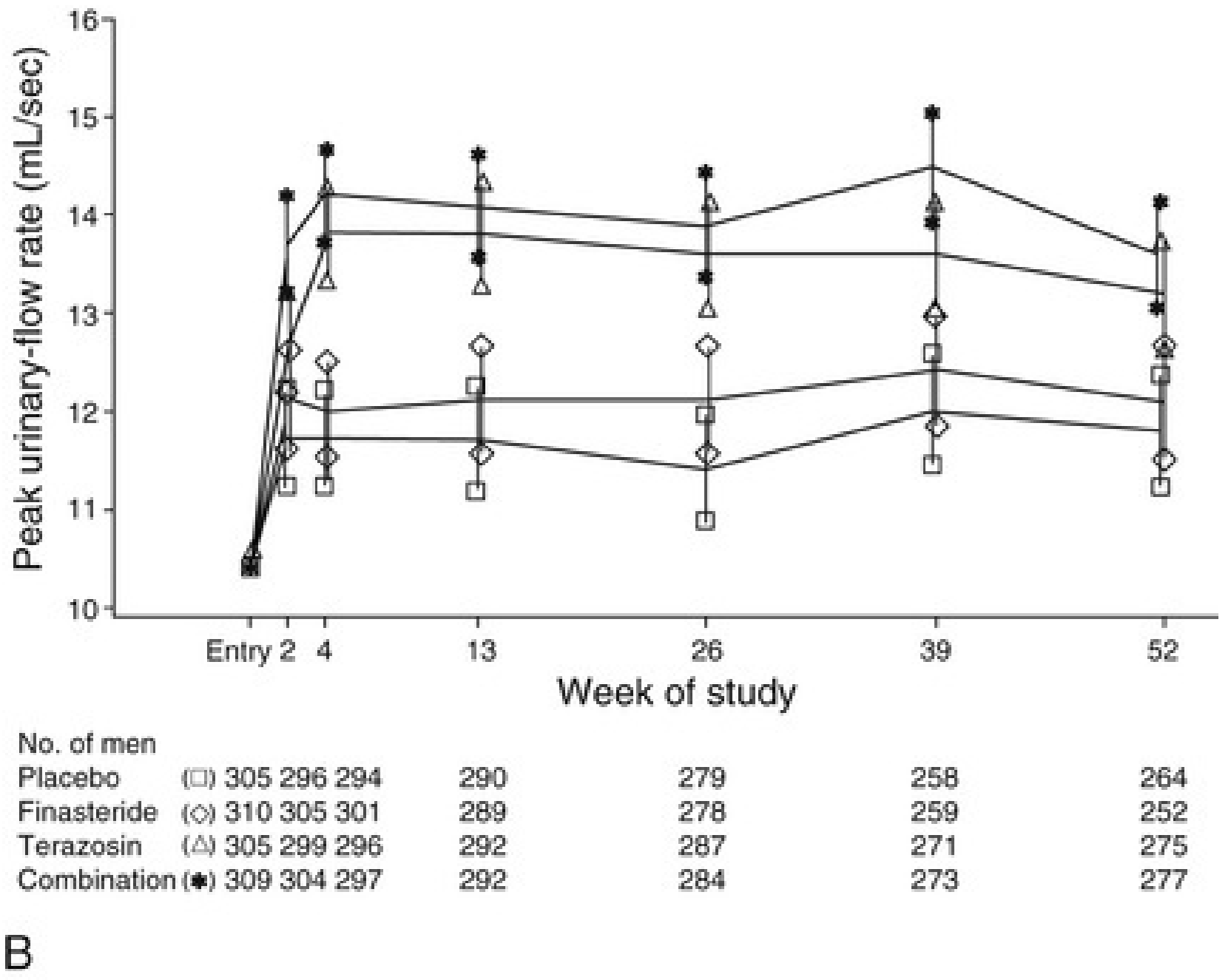

FIG. 145.14 (A) AUA Symptom Scores in men with BPH, according to treatment group. Scores are expressed as adjusted means and the 95% confidence interval *(CI).* The results of primary pairwise comparisons are as follows: finasteride and terazosin, $P < 0.001$; finasteride and combination therapy, $P < 0.001$; and terazosin and combination therapy, $P = 1.00$. The results of secondary pairwise treatment comparisons are as follows: finasteride and placebo, $P = 0.63$; terazosin and placebo, $P < 0.001$; and combination therapy and placebo, $P < 0.001$. (B) Peak urinary flow rates in men with BPH, according to treatment group. Rates are expressed as adjusted means and the 95% CI. The results of primary pairwise comparisons are as follows: finasteride and terazosin, $P < 0.001$; finasteride and combination therapy, $P < 0.001$; and terazosin and combination therapy, $P= 0.15$. The results of secondary pairwise treatment comparisons are as follows: finasteride and placebo, $P= 0.07$; terazosin and placebo, $P < 0.001$; and combination therapy and placebo, $P < 0.001$. (From Lepor H, Williford WO, Barry MJ, et al. The efficacy of terazosin, finasteride, or both in benign prostatic hyperplasia. Veterans Affairs Cooperative Studies Benign Prostatic Hyperplasia Study Group. *N Engl J Med*;335[8]:533–539, 1996. Figure 1, p. 536; Figure 2, p. 537.)

The Alfuzosin, Finasteride and Combination study enrolled 1051 patients from several centers in Europe (Debruyne et al., 1998). Patients were randomized to receive 5 mg alfuzosin twice daily, 5 mg finasteride, or combination therapy for 6 months. Both patients treated with alfuzosin alone and patients treated with combination therapy showed significantly greater IPSS decreases as compared with those treated with finasteride alone. The rates of patients with at least a 50% IPSS decrease were 43%, 42%, and 33% in the alfuzosin, combination therapy, and finasteride groups, respectively.

Similar findings were also reported by the Prospective European Doxazosin and Combination Therapy (PREDICT) study, which enrolled 1095 patients randomized to receive either doxazosin (titrated from 4 to 8 mg), 5 mg finasteride, placebo, or combination therapy (Kirby et al., 2003). The doxazosin and the combination therapy groups both showed a significantly greater change of the IPSS from the baseline compared with the placebo and finasteride groups. Similar results were reported regarding PFR changes among different groups.

Medical Therapy of Prostatic Symptoms Trial

The previously discussed studies did not show an advantage of either 5ARIs or combination therapy in relieving symptoms and improving uroflowmetry parameters as compared with the first-line α_1-blocker treatment. However, all of them were designed to assess treatment outcomes after only 6 to 12 months of therapy. The MTOPS trial is a multicenter RCT aimed at assessing the outcomes of both monotherapy with doxazosin or finasteride and combination therapy over a period of no less than 4 years (McConnell et al., 2003). The primary aim of the MTOPS trial was to assess the risk for clinical progression, defined as occurrence of the following:

- 4-point or greater increase from baseline of the AUASI score
- AUR
- Recurrent UTIs (defined as two or more episodes within 1 year or urosepsis)
- Self-reported urinary incontinence
- Renal insufficiency (defined as an increase in serum creatinine level of at least 1.5 mg/dL or a 50% relative increase from the baseline)

Regarding the inclusion criteria, there were no restrictions related to PV, thus leading to the enrollment of patients with a wide difference in gland volumes. A total of 3047 men were enrolled and were randomized to receive 5 mg finasteride and placebo, doxazosin (titrated from 1 to 8 mg) and placebo, a combination of doxazosin plus finasteride, or two placebo drugs.

Four years after therapy had begun, the cumulative incidence of clinical progression was 17% in the placebo group, 10% in the doxazosin group, 10% in the finasteride group, and 5% in the combination therapy group (Fig. 145.15 and Table 145.15). **Both doxazosin and finasteride were significantly more effective than placebo in reducing the risk for clinical progression; moreover, combination therapy was even more effective than monotherapy.** The number of events per year was reduced by 39%, 34%, and 66% for doxazosin, finasteride, and combination therapy, respectively, compared with placebo. The authors showed that after both placebo and doxazosin treatment, the risk for clinical progression increased with increasing baseline PSA level and PV. **With regard to the specific events, the risk for AUR was significantly lower than with placebo only for the combination therapy and finasteride groups** (Fig. 145.16). Similarly, the authors looked at the occurrence of invasive therapy for BPH (open, endoscopic, or minimally invasive surgery) and estimated the cumulative incidence over time in the four groups. **Compared with placebo, both finasteride and combination therapy reduced the risk for receiving invasive therapy by 64% and 67%, respectively (*P* < 0.001)** (see Fig. 145.16). **Conversely, a similar result was not observed in the doxazosin group.**

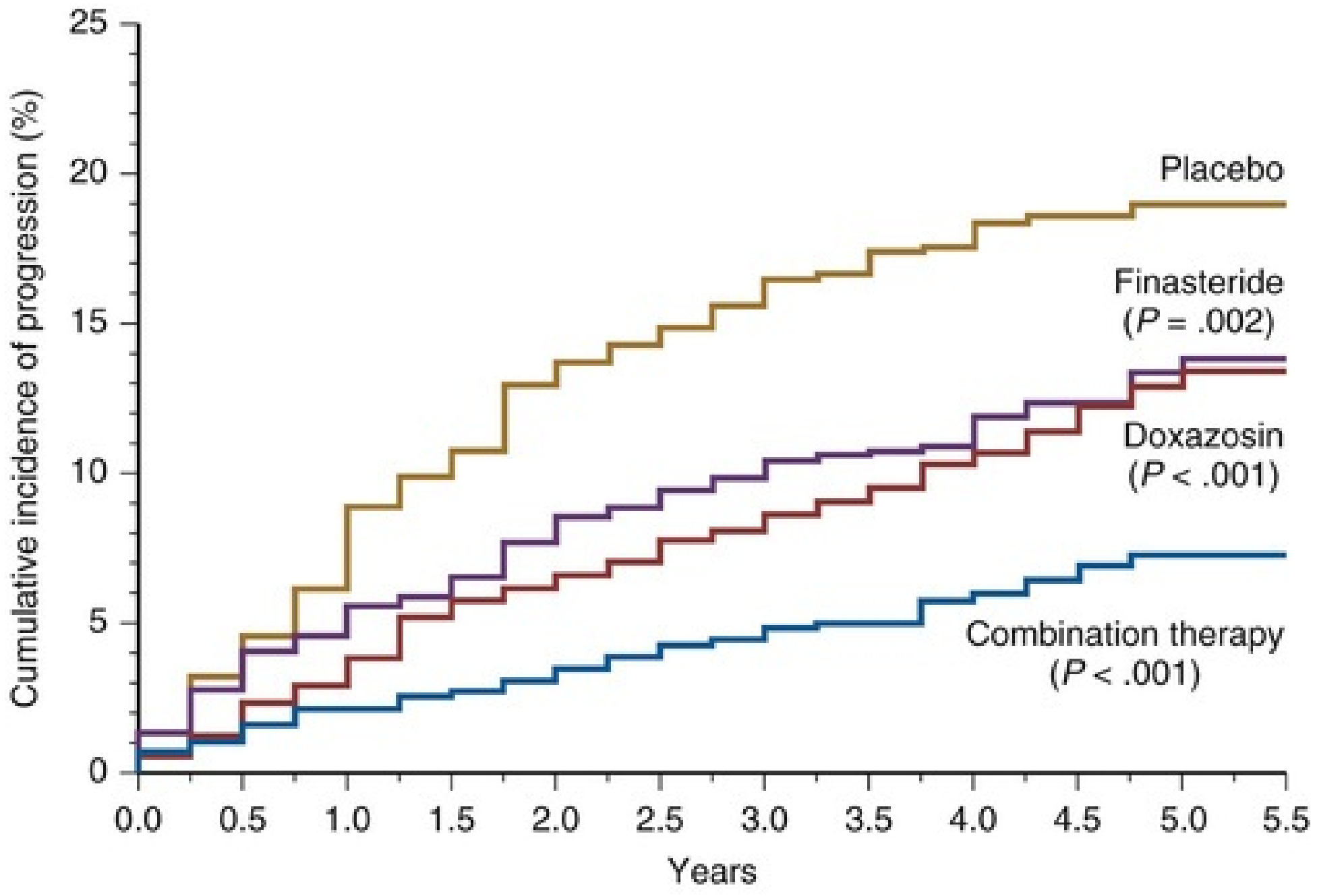

No. at risk												
Placebo	737	712	670	631	612	588	575	555	492	337	218	84
Doxazosin	756	735	715	698	675	660	641	627	565	387	259	98
Finasteride	768	737	699	675	659	634	617	599	530	379	257	105
Combination therapy	786	762	747	733	726	715	697	683	599	426	280	112

FIG. 145.15 Cumulative incidence of progression in the Medical Therapy

of Prostatic Symptoms (MTOPS) trial. (From McConnell JD, Roehrborn CG, Bautista OM, et al. The long-term effect of doxazosin, finasteride, and combination therapy on the clinical progression of benign prostatic hyperplasia. *N Engl J Med* 349[25]:2387–2398, 2003.)

TABLE 145.15

Clinical Progression of Benign Prostatic Hyperplasia and Reduction in Risk in the Medical Therapy of Prostatic Symptoms (MTOPS) Trial

EVENT	PLACEBO (*N* = 737)	DOXAZOSIN (*N* = 756)		FINASTERIDE (*N* = 768)		COMBIN 786)	
	Rate/100 person-years	Rate/100 person-years	Risk reduction (95% CI)	Rate/100 person-years	Risk reduction (95% CI)	Rate/100 person-years	
Clinical progression of benign prostatic hyperplasia	4.5	2.7	39 (20–53)	2.9	34 (14–50)	1.5	
≥4-point increase in AUA symptom score	3.6	1.9	45 (25–60)	2.5	30 (6–48)	1.3	
Retention	0.6	0.4	35 (-31 to 67)	0.2	68 (21–87)	0.1	
Incontinence	0.3	0.3	-32 (-227 to 46)	0.3	-9 (-183 to 57)	0.1	
Urinary tract infection or urosepsis	0.1	0.1	Insufficient data	0.0	Insufficient data	<0.1	
Invasive therapy resulting from benign prostatic hyperplasia	1.3	1.3	3 (-48 to 37)	0.5	64 (34–80)	0.4	

AUA, American Urological Association; *CI,* confidence interval.

Modified from McConnell JD, Roehrborn CG, Bautista OM, et al. The long-term effect of doxazosin, finasteride, and combination therapy on the clinical progression of benign prostatic hyperplasia. *N Engl J Med* 349(25):2387-98, 2003.

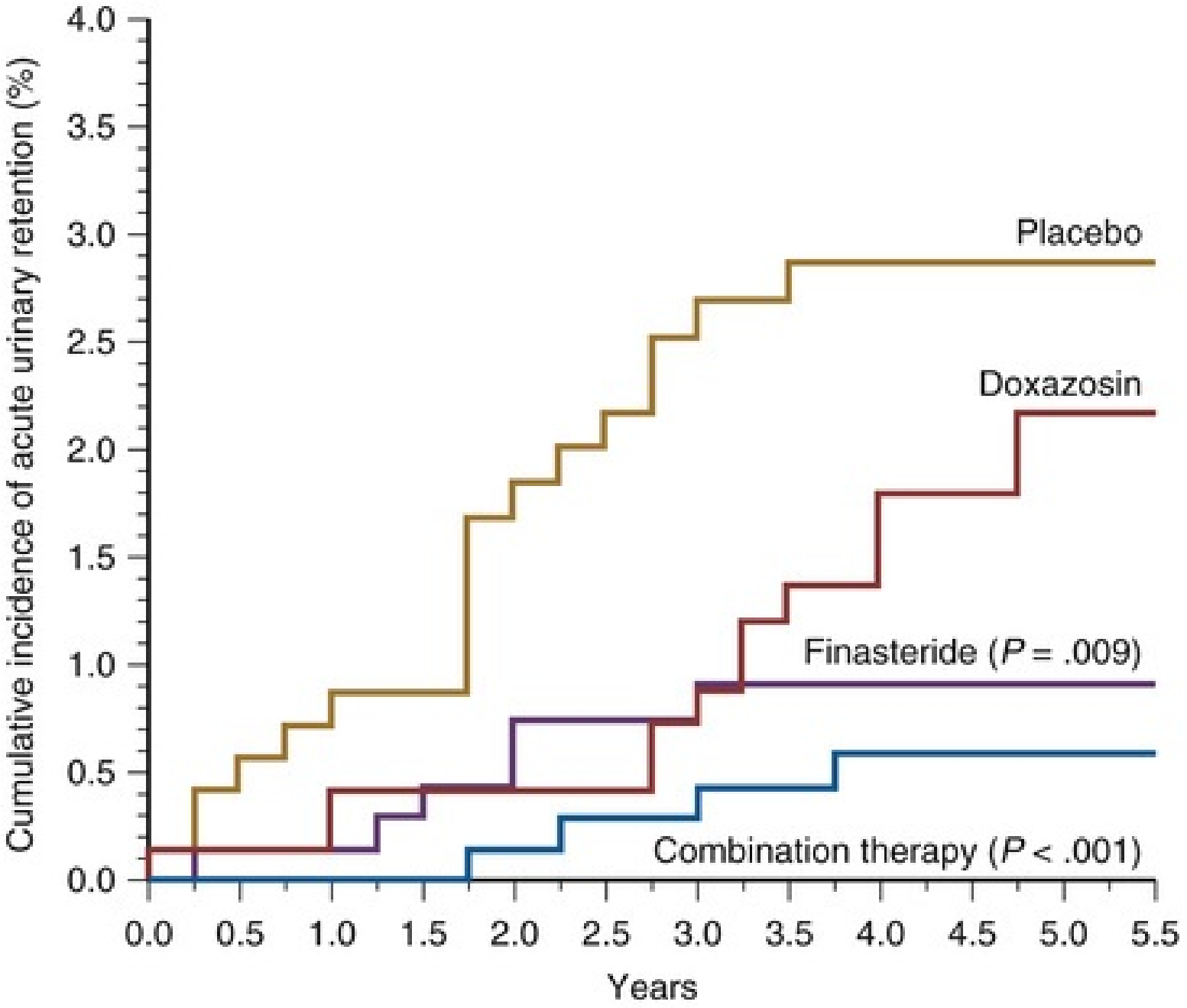

No. at risk

Placebo	737	712	670	631	612	588	575	555	492	337	218	84
Doxazosin	756	735	715	698	675	660	641	627	565	387	259	98
Finasteride	768	737	699	675	659	634	617	599	530	379	257	105
Combination therapy	786	762	747	733	726	715	697	683	599	426	280	112

A

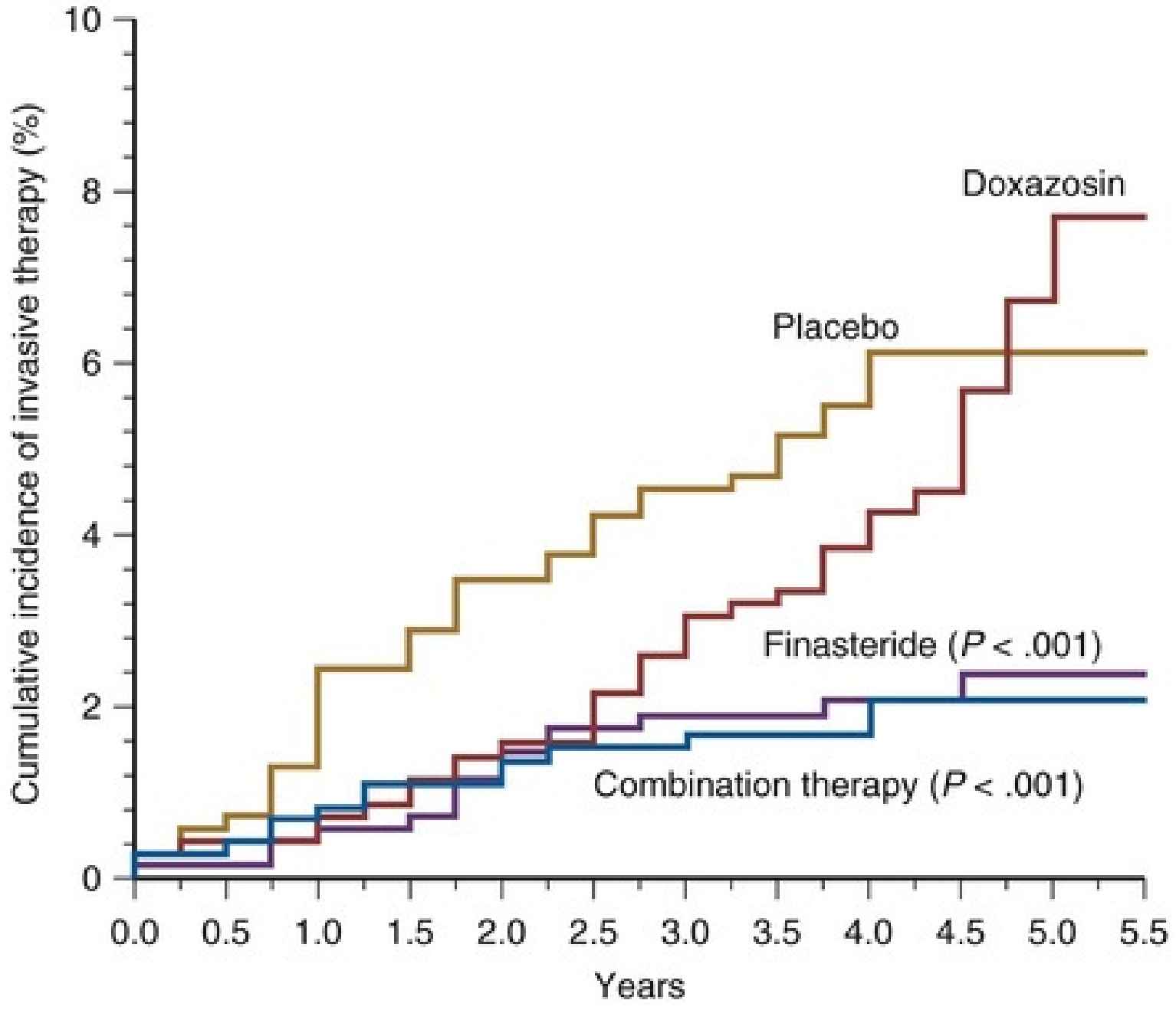

No. at risk

Placebo	737	720	698	670	656	643	632	616	543	373	247	96
Doxazosin	756	736	728	712	691	675	660	642	584	399	272	105
Finasteride	768	744	724	706	689	670	655	640	562	401	274	110
Combination therapy	786	764	753	727	717	701	687	675	588	420	278	102

B

FIG. 145.16 Cumulative incidence of (A) acute urinary retention and (B) invasive therapy for benign prostatic hyperplasia in the Medical Therapy of Prostatic Symptoms (MTOPS) trial. (From McConnell JD, Roehrborn CG, Bautista OM, et al. The long-term effect of doxazosin, finasteride, and combination therapy on the clinical progression of benign prostatic hyperplasia. *N Engl J Med* 349[25]:2387–2398, 2003.)

Secondary outcomes were changes over time of AUASI score, PFR, total PSA level, and PV; **a reduction of the AUASI score was observed over time in all active treatment groups compared with placebo, with a greater reduction found in the combination therapy group compared with the doxazosin group (7.4 vs. 6.6) and the finasteride group (7.4 vs. 5.6). Similarly, PFR increased in all groups.**

The number needed to treat to prevent clinical progression in the overall population was 8.4 for the combination therapy group but 13.7 and 15 for the doxazosin group and the finasteride group, respectively. **In the combination therapy group, these numbers dropped to 4.7 and 4.9 when patients with a baseline PSA level greater than 4.0 ng/mL and a PV greater than 40 mL were considered, suggesting that this strategy is an economically stronger option in patients at higher risk for progression.**

In terms of tolerability, **the overall rate of AEs was significantly higher in the combination therapy group as compared with both the placebo group and the monotherapy groups. However, the rates of each individual side effect were similar to those observed in the monotherapy groups.** In a recent re-evaluation of safety data from the MTOPS study, the rates of both sexual function–related AEs and other AEs appeared to be higher throughout the first year of treatment and decreased thereafter (Kaplan et al., 2016).

Combination of Avodart and Tamsulosin Study

The 4-year CombAT trial was designed with the primary aim of investigating whether the combination of dutasteride and tamsulosin was more effective than monotherapy in reducing the risk for AUR and BPH-related surgery (Roehrborn et al., 2008a). The inclusion criteria for the CombAT study were somewhat different from those of the MTOPS trial. Indeed, **to assess the effect of combination therapy on patients at high risk for BPH clinical progression, only men with a PV of 30 mL or greater and a serum PSA level of 1.5 ng/mL or greater were included.** As for the MTOPS trial, patients were 50 years or older and had an IPSS of 12 or greater and a PFR of 5 to 15 mL/s. Patients were randomized to receive either 0.5 mg dutasteride once daily plus placebo, or 0.4 mg tamsulosin once daily plus placebo or tamsulosin plus dutasteride for 4 years. As secondary outcomes, the risk for BPH clinical progression (as defined in the MTOPS trial), changes in IPSS, PFR, or PV; and the rate of AEs were recorded. A total of 4844 men were initially randomized, and 66% of them reached the end of treatment at 48 months. **There was a greater risk reduction for AUR and BPH related–surgery both for men treated with the combination therapy and for men treated with dutasteride monotherapy compared with men treated with tamsulosin monotherapy** (Table 145.16). Treatment with both drugs reduced the risk for AUR by 65.8% as compared with treatment with tamsulosin alone. The risk for AUR in the tamsulosin arm started to be significantly higher from 8 months afterward (Fig. 145.17). The risk for BPH surgery was reduced by 67.6% in the combination therapy group compared with the tamsulosin group (*P* < 0.001).

TABLE 145.16

Clinical Progression of Benign Prostatic Hyperplasia and Reduction in Risk in the Combination of Avodart and Tamsulosin (CombAT) Trial

	COMBINATION (*N* = 1610)	**DUTASTERIDE (*N* = 1623)**	**TAMSULOSIN (*N* = 1611)**	
	INCIDENCE (95% CI)	**INCIDENCE (95% CI)**	**INCIDENCE (95% CI)**	**COMBINATION VS. DUTASTERIDE**
BPH clinical progression events				
Symptom deterioration by IPSS ≥4 points	8.6% (7.3–10.0%)	13.1% (11.4–14.7%)	14.2% (12.5–15.9%)	35.2% (19.7, 47.7) p<0.001
BPH-related AUR	1.6% (1.0–2.2%)	2.3% (1.6–3.0%)	5.1% (4.0–6.2%)	29.7% (–16.1, 57.4) p=0.17
BPH-related urinary	3.0% (2.2–3.9%)	3.7% (2.8–4.6%)	4.0% (3.1–5.0%)	16% (–22.5, 42.4)

incontinence				p=0.3
Recurrent BPH-related UTI or urosepsis	0.2% (0.0–0.4%)	0.3% (0.0–0.6%)	0.3% (0.0–0.6%)	39.1% (–155.0, 85.4) p=0.4
BPH-related renal insufficiency	<0.1% (0.0–0.2%)	0.1% (0.0–0.3%)	0.4% (0.1–0.8%)	48.9% (–464.5, 95.4) p=0.5
BPH-related surgery	2.4% (1.6–3.1%)	3.5% (2.6–4.3%)	7.8% (6.5–9.1%)	31.1% (–4.0, 54.4) p=0.07
AUR	2.2% (1.5–3.0%)	2.7% (1.9–3.5%)	6.8% (5.5–8.0%)	18.3% (–27.0, 47.4) p=0.3

AUR, Acute urinary retention; *BPH,* benign prostatic hyperplasia; *CI,* confidence interval; *IPSS,* International Prostate Symptom Score; *UTI,* urinary tract infection.

Modified from: Roehrborn CG, Siami P, Barkin J, et al. The effects of combination therapy with dutasteride and tamsulosin on clinical outcomes in men with symptomatic benign prostatic hyperplasia: 4-year results from the CombAT study. *Eur Urol* 57(1):123-31, 2010.

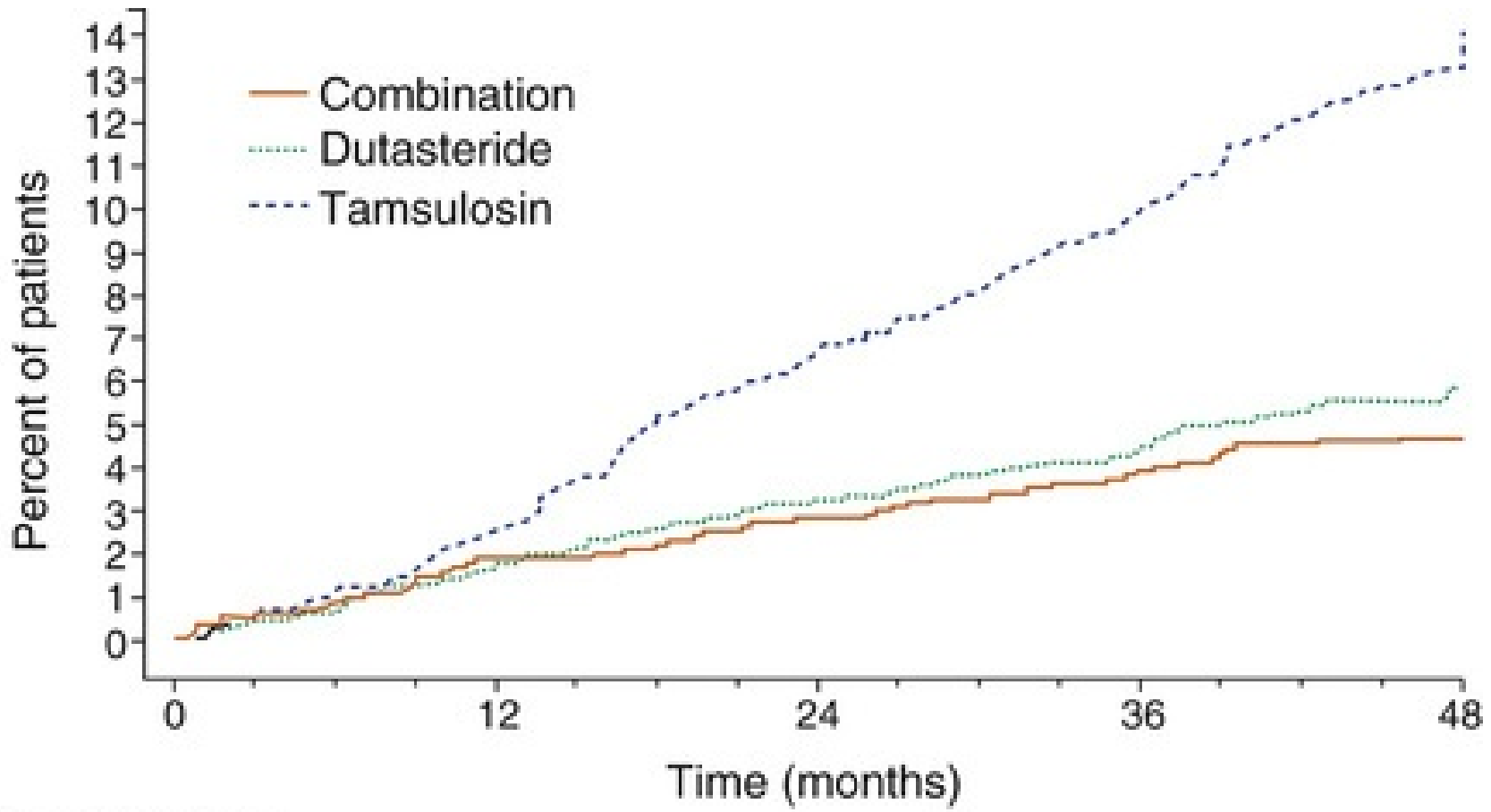

Combination				
Cumulative no. of events	29	43	58	67
No. at risk	1610	1457	1347	1274
Dutasteride				
Cumulative no. of events	27	49	65	84
No. at risk	1623	1484	1365	1277
Tamsulosin				
Cumulative no. of events	40	102	146	191
No. at risk	1611	1464	1307	1176

FIG. 145.17 Kaplan-Meier estimates of the time to the first episode of acute urinary retention or benign prostatic hyperplasia–related prostatic

surgery. (From: Roehrborn CG, Siami P, Barkin J, et al. The effects of combination therapy with dutasteride and tamsulosin on clinical outcomes in men with symptomatic benign prostatic hyperplasia: 4-year results from the CombAT study. *Eur Urol* 57[1]:123–131, 2010. Figure 3, p. 126.)

Combination therapy was superior than both monotherapies in reducing the risk for BPH clinical progression. In terms of symptom relief, patients in the combination therapy group reported a significant 7.3-point reduction of the IPSS after 4 years compared with reductions of 4.9 and 6.4 points for the tamsulosin and dutasteride groups, respectively ($P < 0.001$). These data confirmed the superiority also of dutasteride monotherapy over tamsulosin in terms of symptom relief at long-term follow-up; similar results were observed for PFR, thus suggesting that dutasteride could be more effective than tamsulosin at long-term follow-up. Further analyses showed that combination therapy was more effective than tamsulosin therapy alone in reducing both voiding and storage subscores (Montorsi et al., 2011).

Men with a baseline gland volume of 40 mL or greater showed the greater reduction in terms of the risk for AUR and BPH-related surgery both with combination therapy and with dutasteride monotherapy compared with tamsulosin monotherapy.

In terms of safety, the occurrence of AEs was higher in the combination therapy group relative to the monotherapy groups. However, withdrawal rates caused by drug-related AEs were comparable between the groups.

Overall, both the MTOPS trial and the CombAT trial support the therapeutic advantage of the combination of 5ARIs and α_1-blockers to treat patients with moderate to severe LUTS at high risk for BPH clinical progression (PV ≥ 30 to 40 mL and PSA level ≥1.5 ng/mL) as now suggested by international guidelines (Abrams et al., 2013; Oelke et al., 2013). The two drugs can be safely administered once daily at the usual dose recommended for monotherapy.

According to the results of the Symptoms Management After Reducing Therapy (SMART) trial, use of α_1-blockers may be discontinued after 6 months of successful combination therapy without symptom deterioration being expected (Barkin et al., 2003).

α-Adrenergic Blockers and Anticholinergic Receptor Blockers

Combination therapy with antimuscarinics and α_1-blockers in patients with BPH has been evaluated in several trials (Table 145.17). Kaplan et al. (2006) performed a multicenter RCT that enrolled 879 patients with an IPSS greater than 12 and significant storage symptoms reported over the previous 3 months (Kaplan et al., 2006). Patients were treated with tolterodine ER formulation at 4 mg/day, tamsulosin at 0.4 mg/day, tolterodine in combination with tamsulosin, or placebo for a total of 12 weeks. **The primary end point of the study was patients' perception of treatment benefit at the end of the treatment course as measured with a single-item question (the Perception of Treatment Benefit question). The rate of patients reporting a treatment benefit was significantly higher in the combination therapy group (80%) compared with the placebo group. The findings were neither comparable for the tolterodine-alone group or for the tamsulosin-alone group.** Moreover, patients in the combination therapy group showed a significant reduction in urgency episodes, daily and nightly number of micturitions, and total IPSS and QoL scores (Fig. 145.18). Urinary flow and PVR volume did not differ among the groups. Only two patients (0.4%) treated with tamsulosin plus tolterodine reported an episode of AUR.

TABLE 145.17

Randomized Controlled Trials Comparing Combination Therapy or Add-on Therapy Involving α-Blockers and Antimuscarinic Drugs

	DRUG	PATIENTS	LENGTH OF TREATMENT	SYMPTOMS
COMBINATION THERAPY				
Lee et al. (2005)	Doxazosin 4 mg Doxazosin 4 mg + propiverine 20 mg	N = 211 ≥50 years of age with OAB symptoms and urodynamically proven BOO (mean PVR	8 weeks	Change in daytime frequency: Doxazosin + propiverine: –1.9 (P = 0.004)

		<31 mL)		Doxazosin: –0.9 Change in nocturia episodes: Doxazosin + propiverine: –0.7 (*P* = 0.1) Doxazosin: –0.6
Kaplan et al. (2006b)	Tolterodine 4 mg Tamsulosin 0.4 mg Tolterodine 4 mg + tamsulosin 0.4 mg Placebo	*N* = 172 ≥40 years of age with IPSS ≥12, ≥8 voids/24 h, ≥3 urgency episodes/24 h, PVR <200 mL	12 weeks	IPSS total (mean change from baseline) Tolterodine: 6.8 (NS vs. placebo) Tamsulosin + tolterodine: 8.0 (significant vs. placebo) Tamsulosin: 7.8 (Significant vs. placebo) Placebo 6.2
van Kerrebroeck et al. (2013)	TOCAS 0.4 mg TOCAS + solifenacin 6 mg TOCAS + solifenacin 9 mg Placebo	*N* = 1,334 IPSS ≥13, PFR 4–12 mL/s, ≥2 urgency episodes/24 h, ≥ 8 voids/24 h	12 weeks	Total IPSS (mean change from baseline) TOCAS: –6.2 6 mg solifenacin + TOCAS: –7.0 (significant vs. placebo) 9 mg

				solifenacin + TOCAS: –6.5 (significant vs. placebo) Placebo: –5.4
Matsukawa et al. (2017)	Silodosin 8 mg Silodosin 8 mg + propiverine 20 mg	*N* = 120 Age ≥50 years, IPSS ≥8, OABSS ≥3, urgency episodes ≥1/week, PFR <15 mL/s, PVR <150 mL	1 year	OABSS (mean change from baseline) Silodosin: –2.4 Silodosin + propiverine: –3.4 (*P* = 0.04)
ADD-ON THERAPY				
	Drug	Patients	Length of treatment	Symptoms
MacDiarmid et al. (2008)	Tamsulosin 0.4 mg + placebo Tamsulosin 0.4 + oxybutynin 10 mg	*N* = 409 after ≥4 weeks' tamsulosin therapy Age >45 years, IPSS >13, IPSS storage subset score >8, PFR >8 mL/s, PVR <150 mL	12 weeks	Total IPSS (mean change from baseline) Tamsulosin + placebo: +5.2 Tamsulosin + oxybutynin: +6.9; (significant vs. tamsulosin)
Kaplan et al. (2009)	Tamsulosin 0.4 mg + placebo Tamsulosin 0.4 +	*N* = 397 after ≥4 weeks' tamsulosin therapy Age >45 years,	16 weeks	Total IPSS (mean change from baseline) Tamsulosin

	solifenacin 5 mg	IPSS >13, >8 voids/24 h, PFR >5 mL/s, PVR <100 mL		+ placebo: +4.9 Tamsulosin + solifenacin: +5.4 (NS)
Chapple et al. (2009)	Any α-blocker + placebo Any α-blocker + tolterodine 4 mg	*N* = 652 after ≥4 weeks' α-blocker therapy Age >45 years, >8 voids/24 n, >1 urgency episodes/24 h, PVR <200 mL	12 weeks	IPSS storage subscale (mean change from baseline) α–blocker + placebo: –2.1 α–blocker + tolterodine: –2.6 (*P* = 0.03)
Kaplan et al. (2012)	Any α-blocker + placebo Any α-blocker + fesoterodine 4 mg	*N* = 943 men after ≥6 weeks' α-blocker therapy >8 voids/24 h, >1 urgency episodes/24 h, PVR <200 mL		IPSS storage subscale (mean change from baseline) Any α–blocker + placebo: –2.1 Any α–blocker + fesoterodine: –2.4 (NS vs. placebo)

AUR, Acute urinary retention; *BPH,* benign prostatic hyperplasia; *BOO,* bladder outlet obstruction; *h,* hours; *IPSS,* International Prostate Symptom Score; *NR,* not reported; *NS,* not significant; *OAB,* overactive bladder; *OABSS,* Overactive Bladder Symptom Score; *PFR,* peak flow rate; *PVR,* postvoid residual volume; *TOCAS,* tamsulosin oral controlled-absorption system formulation.

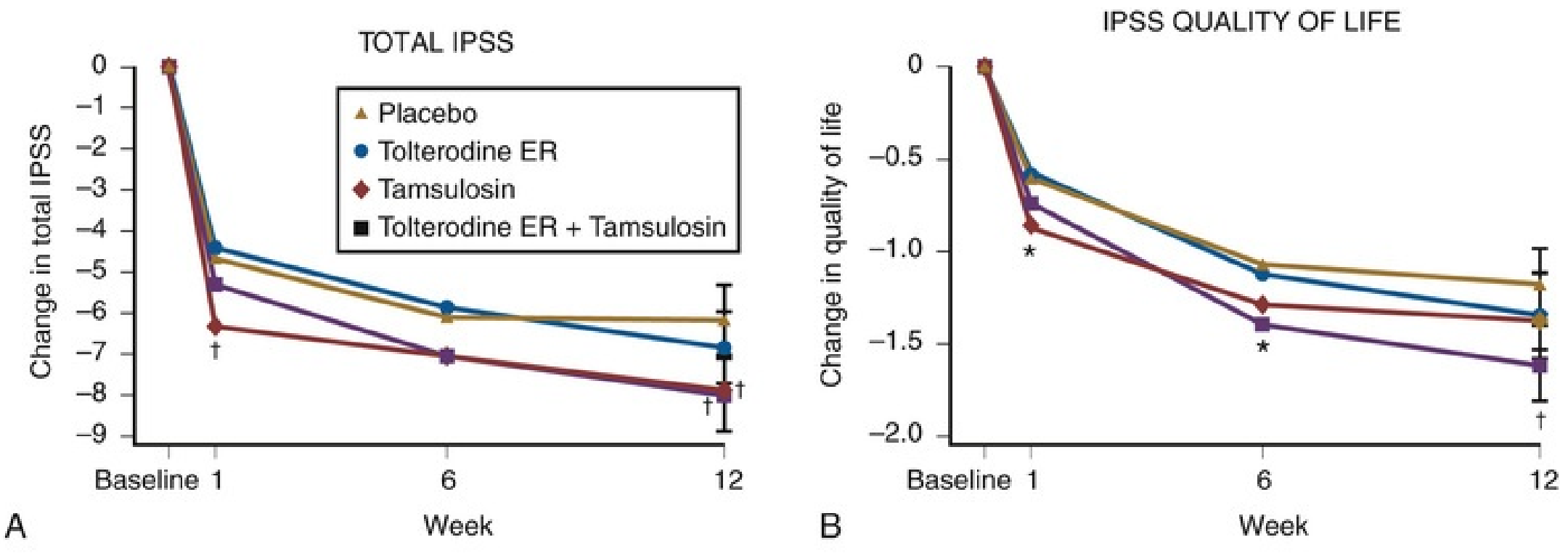

No. of patients								
Placebo	215	208	213	213	215	210	213	213
Tolterodine ER	210	203	206	206	210	206	206	206
Tamsulosin	209	196	197	197	206	198	198	198
Tolterodine ER + Tamsulosin	217	200	203	203	217	204	205	205

Values are adjusted means (i.e., least-squares means).
*$P < .05$.
†$P < .01$ vs. placebo.

FIG. 145.18 (A and B) Response of lower urinary tract symptoms to tolterodine, tamsulosin, or combination therapy versus placebo. *ER,* Extended release; *IPSS,* International Prostate Symptom Score. (From Kaplan SA, Roehrborn CG, Rovner ES, et al. Tolterodine and tamsulosin for treatment of men with lower urinary tract symptoms and overactive bladder: a randomized controlled trial. *JAMA* 296[19]:2319–2328, 2006.)

In a previous multicenter randomized trial, 198 patients with urodynamically proven BOO and OAB symptoms were treated with 4 mg doxazosin once daily versus 20 mg propiverine combined with 4 mg doxazosin daily for 8 weeks (Lee et al., 2005). The combination therapy group showed more favorable outcomes in terms of urinary frequency reduction, average micturition volume, and IPSS (see Table 145.17). There was a significant increase in PVR volume (20.7 mL) with the combined therapies, without any case of AUR. The overall rate of AEs was higher for patients receiving both drugs, although discontinuation because of AEs was not different between the groups.

The combination therapy of propiverine plus naftopidil was compared with monotherapy with either naftopidil or propiverine for 4 weeks in a randomized study with men reporting symptomatic BPH and storage symptoms (Yokoyama et al., 2009). There was a significant reduction in terms of IPSS and urinary frequency episodes in the group of patients receiving both compounds (see Table 145.13). More recently Matsukawa et al. (2017) reported the results of a randomized trial comparing the efficacy of the combination of silodosin and propiverine compared with silodosin alone in 120 patients with BPH and storage symptoms. Patients in the combination therapy group showed a significantly greater reduction in the OABSS and urgency score after 1 year of treatment. Moreover, the presence of DO disappeared in 54.5% of patients after combination therapy as compared with 34.2% of patients after monotherapy.

The effect of sequential combined therapies has been investigated as an approach that better mirrors what is likely to happen in real-life clinical practice; according to this therapeutic paradigm, only patients not responding to α_1-blockers may deserve treatment with an antimuscarinic in addition to the first drug. MacDiarmid et al. (2008) performed a multicenter double-blind study that enrolled 420 men with symptomatic BPH and IPSS storage subscore of 8 or greater treated with a 4-week course of tamsulosin without benefit. Patients were randomized to receive tamsulosin plus oxybutynin once daily or tamsulosin plus placebo for 12 weeks. Patients receiving the combination treatment showed a significantly greater reduction in all symptom scores, without any difference in terms of PFR and PVR volume (see Table 145.17). Chapple et al. (2009) reported findings of a double-blind trial including men complaining of frequency, urgency, and at least one moderate issue reported with the Patient Perception of Bladder Condition (PPBC) despite taking a stable α_1-blocker dose for at least 1 month. Patients were thus randomized to receive a 4-mg tolterodine ER formulation once daily or placebo in addition to the same α_1-blocker for 12 weeks. There was a reduction in the number of 24-hour micturition and urgency episodes and nocturnal urgency episodes in the tolterodine group compared with the placebo group. Moreover, in a double-blind trial that tested solifenacin add-on therapy in patients with residual OAB symptoms after tamsulosin therapy, a significant reduction in terms of urgency episodes was observed for the combination therapy group compared with the placebo plus tamsulosin group (Kaplan et al., 2009).

Finally, the results of the phase II (SATURN) and phase III (NEPTUNE) trials assessing the effect of a novel drug formulation combining solifenacin with an oral controlled-absorption system (OCAS) formulation of tamsulosin were recently reported (Drake et al., 2015; Van Kerrebroeck et al., 2013a, 2013b). A total of 1334 patients with IPSS of 13 or greater, two or more urgency episodes daily, and eight or more micturition episodes per day were randomized to receive a single tablet of 6 or 9 mg solifenacin plus OCAS tamsulosin, monotherapy with OCAS tamsulosin, or placebo for 12 weeks. The combination treatment led to a significant reduction of both storage and voiding symptom scores and QoL scores as compared with placebo; moreover, patients with moderate to severe LUTS receiving solifenacin plus tamsulosin showed greater reductions of storage symptom and QoL scores as compared with patients receiving tamsulosin alone. The open-label extension trial (52 weeks) confirmed the efficacy of the new single tablet formulation and a good safety profile, with only 0.7% of patients reporting an episode of AUR. Of note, as in the other trials assessing the effect of antimuscarinics in BPH patients, only men with low (<150 mL) baseline PVR volume were included in the study.

Overall, the combination of antimuscarinics and α_1-blockers appears safe and effective in patients with persisting storage symptoms after first-line treatment with α_1-blockers. Dose adjustment is not required when adding antimuscarinic drugs to α_1-blockers therapy. However, the profile of patients who would benefit more from a combination treatment has not yet been clarified.

α-Adrenergic Blockers and β_3-Agonists

The advantage of combining mirabegron with α_1-blockers to treat LUTS/BPH was recently assessed in a few studies (Ichihara et al., 2015; Matsuo et al., 2016; Wada et al., 2016). In a prospective trial with patients older than 65 years of age with persistent LUTS and OAB symptoms after a course of therapy with an α_1-blocker for more than 12 weeks, the effect of 3-month add-on therapy with mirabegron was evaluated with use of the OABSS and the IPSS (Matsuo et al., 2016). There was a significant reduction of OABSS (from 6 to 4.4), total IPSS (from 15.1 to 11.8), and IPSS QoL score (from 4.2 to 3.4) at the end of treatment, and a PFR increase (4 mL/s) without a significant PVR volume modification was also observed. Similar findings were reported, even in a small prospective study evaluating the combination of mirabegron and tamsulosin in 26 men with persisting OAB symptoms after α_1-blocker monotherapy (Wada et al., 2016). Patients were assessed with PFS at the baseline and after the combination therapy, with no significant changes of the bladder contractility index being shown.

Ichihara et al. (2015) performed the only randomized trial investigating the effect of a combination of mirabegron and tamsulosin. The study enrolled 94 patients with LUTS most likely secondary to BPH and persistent OAB symptoms after a therapy course of at least 8 weeks with 0.2 mg tamsulosin. Patients were randomized to receive either 0.2 mg tamsulosin once daily alone or tamsulosin plus 50 mg mirabegron daily for 8 weeks. There was a significant reduction of the total OABSS during the treatment period, which was greater for the combination therapy group compared with the monotherapy group (–2.21 vs. –0.87; $P = 0.01$). Moreover, patients treated with mirabegron plus tamsulosin showed a greater reduction of IPSS storage subscore (–2.03 vs. –0.42), daytime frequency (–0.76 vs. –0.05), and IPSS QoL score (–0.76 vs. –0.05). In terms of safety, a significant PVR volume increase was observed in the combination therapy group, but only one patient reported urinary retention.

Overall these data suggest that mirabegron can be safely added to a treatment with α_1-blockers in patients with persisting storage symptoms. Dose adjustment is not required because mirabegron has no interactions with α_1-blockers. Further data are needed to confirm the benefit of this combination therapy.

α-Adrenergic Blockers and Phosphodiesterase Type 5 Inhibitors

Therapy with PDE5Is alone was demonstrated to significantly relieve LUTS compared with placebo. In this context, the effect of a combination therapy of PDE5Is and α_1-blockers has been assessed (Table 145.18). Kaplan et al. (2007) performed a randomized trial including 62 patients with previously untreated LUTS and erectile dysfunction treated with either alfuzosin, sildenafil, or the combination of both for 12 weeks. At the end of the treatment course, the **IPSS was significantly reduced in both groups, but the magnitude of the reduction was greater for the combination therapy group (–24.1%) than for either the alfuzosin group (–15.6%) or the sildenafil group (–16.9%). A significant increase in PFR and decrease in PVR volume was observed after alfuzosin and combination therapy, whereas uroflowmetry parameters did not change after sildenafil monotherapy.** The combination therapy was well tolerated, with no hypotension or syncope events during the 3 months of treatment. Conversely, in a trial randomizing 60 patients with LUTS to receive an 8-week course of sildenafil therapy alone, tamsulosin therapy alone or the combination of the two, IPSS reduction was not significantly different between the combination therapy group and the tamsulosin monotherapy group (Tuncel et al., 2010).

TABLE 145.18

Randomized Trials Assessing Combination Therapy of Phosphodiesterase Type 5 Inhibitors and α-Blockers

	DRUG	PATIENTS	LENGTH OF TREATMENT	SYMPTOMS (IPSS TOTAL: WEIGHTED DIFFERENCE BETWEEN DRUGS [95% CI])	PEAK RATE (WEI DIFF BETW DRUG CI])
Kaplan et al., 2007	Alfuzosin 10 mg Sildenafil 25 mg daily Alfuzosin + sildenafil	*N* = 37 Mean IPSS 17.3	12 weeks	α-Blocker alone vs. combination therapy: –1.1 (–3.5 to 1.3)	α-Blocker combinati therapy: 1 2.6)
Bechara et al., 2008	Tamsulosin 0.4 mg Tadalafil 20 mg daily Tamsulosin + tadalafil	*N* = 27 Mean IPSS 19.4	12 weeks	α-Blocker alone vs. combination therapy: –2.5 (–5.7 to 0.7)	α-Blocker combinati therapy: 3.6)
Liguori et al., 2009	Alfuzosin 10 mg Tadalafil 20 mg daily Alfuzosin + tadalafil	*N* = 39 Mean IPSS 15	12 weeks	α-Blocker alone vs. combination therapy: –1.5 (–3.7 to 0.7)	α-Blocker combinati therapy: 1 3.2)
Tuncel et al., 2010	Tamsulosin 0.4 mg Sildenafil 25 mg 4/week Tamsulosin + sildenafil	*N* = 40 Mean IPSS 15.4	8 weeks	α-Blocker alone vs. combination therapy: 0.0 (–1.8 to 1.8)	α-Blocker combinati therapy: 5.9)
Gacci et al., 2012b	Tamsulosin 0.4 mg Vardenafil	*N* = 59 Mean IPSS	12 weeks	α-Blocker alone vs. combination therapy: –3.8 (–4.3	α-Blocker combinati therapy: 1

	10 mg daily Tamsulosin + vardenafil	19.6		to –3.2)	1.9)

[a] The most common adverse events are reported if available.

IPSS, International Prostate Symptom Score; *NR,* not reported; *NS,* not significant; *PFR,* peak flow rate.

In a randomized, double-blind, crossover study, 30 men with at least a 6-month history of LUTS were randomized to receive tamsulosin versus tamsulosin plus 20 mg tadalafil daily for 45 days and then switched to the other treatment modality for a further 45 days (Bechara et al., 2008). The IPSS and IPSS QoL score did decrease with both treatments, but did with combination of the drugs (–9.2 vs. –6.7; –2.5 vs. –1.8; $P < 0.05$). Similar findings were reported in a trial investigating the efficacy of the combination of 20-mg tadalafil once daily and 10-mg alfuzosin (Liguori et al., 2009). A greater increase of PFR was found in patients who received combination therapy (+29.6%) compared with patients who received either alfuzosin monotherapy (+21.7%) or tadalafil monotherapy (+9.5%).

The effect of PDE5I therapy in addition to previous α_1-blocker therapy was investigated in a randomized trial that enrolled 60 men with persistent storage LUTS after 2 weeks of therapy with tamsulosin (Gacci et al., 2012b). Patients were randomized to receive tamsulosin plus placebo versus a combination of tamsulosin and 10 mg vardenafil once daily for 12 weeks. There was a between-group significant difference in PFR (placebo, +0.07 mL/s, vardenafil, +2.56 mL/s; $P = 0.03$); average urinary flow rate (placebo, –0.15 mL/s, vardenafil, +1.02 mL/s; $P = 0.03$), and IPSS storage subscore (placebo, –1.67, vardenafil, –3.11; $P = 0.03$). Vardenafil was well tolerated with no treatment discontinuation because of AEs.

In a comparable trial, the addition of 5 mg tadalafil once daily was investigated in patients with persisting LUTS despite therapy with silodosin for at least 1 month (Yoshida et al., 2017); the add-on therapy promoted a greater reduction in all symptom scores and a greater increase in PFR.

Gacci et al. (2012a) performed a meta-analysis of randomized trials comparing combination therapy with PDE5Is and α_1-blockers with α_1-blockers alone. Overall, a combination of the two drugs led to a mean reduction of the IPSS of 1.8 (95% CI, –3.7 to – 0.0) and a mean increase of PFR of 1.5 mL/s

(95% CI, 0.9 to 2.2 mL/s). The rates of AEs were 6.8% and 5.1% in the combination therapy group and the α_1-blocker alone group, respectively. The most commonly reported AEs were flushing, gastroesophageal reflux, headache, and dyspepsia.

Finally, the effect of a single fixed-dose compound combining either 0.2 or 0.4 mg tamsulosin with 5 mg tadalafil compared with tadalafil alone was investigated (Kim et al., 2017) in a double-blind, active-controlled trial for 12 weeks. The findings showed that the 0.4 mg tamsulosin/5 mg tadalafil combination was superior to tadalafil alone in terms of LUTS relief (IPSS change, –9.46 vs. –8.14; $P = 0.03$).

Although currently available data on combination therapy with PDE5Is and α_1-blockers are encouraging, further data concerning safety and cost-effectiveness of this treatment are needed to prove a clinical benefit in LUTS patients.

Given that both drugs are vasodilators, the FDA and the European Medicines Agency (EMA) do not recommend the combination of tadalafil with α_1-blockers because of a significant risk for hypotension. However, this risk is lower with uroselective α_1-blockers. As such, PDE5Is should be carefully administered to patients receiving α_1-blocker therapy. In patients who are stable with α_1-blocker therapy, PDE5I therapy should be initiated at the lowest recommended starting dose. Similarly, in those men already taking an optimized dose of PDE5Is, α_1-blockers therapy should be initiated at the lowest dose.

Phytotherapy

The use of plants and plant products for a therapeutic purpose, defined as phytotherapy, gained a significant role in the treatment of patients with BPH over the past two decades (Fourcade et al., 2008; Smith et al., 2015). The current role of phytotherapy in the management of BPH is discussed in the following sections.

Composition of Phytotherapy Extracts

Phytotherapeutic agents are composed of extracts derived from the roots, seeds, bark or fruits of plants (Table 145.19). Plant extracts contain a variety of chemical compounds, including phytosterols, plant oils, fatty acids, and phytoestrogens (Table 145.20). Several strategies have been reported regarding extraction from the source, with differences in terms of method, time, temperature, pressure, and solvents used; therefore, **the exact composition of each agent is unique, and there is a huge discrepancy in terms of quantitative and qualitative composition of the extracts obtained from the same plant.** This issue has a direct reflection on the beneficial effects of the compound.

TABLE 145.19

Origin of Plant Extracts

SPECIES	COMMON NAME
Serenoa repens, Sabal serrulata	Saw palmetto berry, American dwarf palm
Hypoxis rooperi	South African star grass
Pygeum africanum	African plum tree
Urtica dioica	Stinging nettle
Secale cereale	Rye pollen
Cucurbita pepo	Pumpkin seed
Opuntia	Cactus flower
Pinus	Pine flower
Picea	Spruce

TABLE 145.20

Components of Plant Extracts

Phytosterols	β-Sitosterol δ5-Sterol δ7-Sterol Stigmasterol Campesterol
Phytoestrogens	Coumestrol Genistein (isoflavone) Flavonoids Free fatty acids Esterified fatty acids
Terpenoids	Lectins Polysaccharides Aliphatic alcohols Plant oils

Although single plant preparations are available, many companies manufacture combination products (two or more plant extracts) in an attempt to provide enhanced efficacy, improve marketability, and provide a unique product that can be registered.

Mechanism of Action

The biologic activity of phytotherapeutic agents has been extensively assessed in both in vitro and animal studies; however, a full understanding of the mechanisms of action of these compounds is still lacking.

Two agents have been mainly investigated in preclinical studies: the extract of the American dwarf palm (saw palmetto, *Serenoa repens*) and the extract from the bark of the African plum tree *(Pygeum africanum)*. Several mechanisms of action have been proposed for these agents (Table 145.21); among them, the anti-inflammatory effect, 5α-reductase inhibition, and the apoptotic and antiproliferative effect caused by growth factor alteration have received the greatest attention (Buck 2004).

TABLE 145.21

Suggested Mechanisms of Actions of Plant Extracts[a]

Inhibition of 5α-reductase

Anti-inflammatory action
Interference with growth factors
Antiandrogenic effects
Estrogenic effects
Inhibition of aromatase
Decrease of sex hormone–binding globulin
Alteration of cholesterol metabolism
Action on α-adrenergic receptors
Free-radical scavenging
Alteration of lipid peroxidation
Modulation of prolactin-induced prostatic growth
Protection of bladder and detrusor function
Placebo effect

[a] The most investigated mechanisms are highlighted in bold.

The anti-inflammatory effect of plant extracts is caused by the inhibition of cyclooxygenases and lipoxygenases in the eicosanoid cascade. Prostaglandins and leukotrienes are generated via cyclooxygenases and lipoxygenases and play a key role in the inflammation response, which, in turn, is associated with BPH pathogenesis. Flavone, a phytoestrogen commonly found in plants and herbs, is a strong inhibitor of cyclooxygenase (Alcaraz and Ferrandiz 1987; Mower et al., 1984). In vitro studies showed that the lipidosterolic extract of *Serenoa repens* was able to inhibit the production of leukotrienes by neutrophils in human tissues (Paubert-Braquet et al., 1997). The acid lipophilic fraction of the compound was deemed responsible for this effect. Similarly, inhibition of phospholipase A_2 activity, along with a consequent reduction of prostaglandin synthesis, has also been observed with *Serenoa repens* in vitro (Plosker and Brogden, 1996).

The antiandrogenic action of *Serenoa repens* has been associated with the following (Buck, 2004):

- Inhibition of 5α-reductase isoenzymes I and II
- Inhibition of DHT binding to the cytosolic androgen receptor
- Inhibition of nuclear estrogen receptors in prostatic tissue

- Modulation of prolactin-induced prostatic growth by receptor signal transduction

The inhibition of 5α-reductases is associated with the presence of free fatty acids in the extract (Rhodes et al., 1993). However, this effect has been observed mainly in vitro and has not been confirmed in studies conducted on human prostatic samples (Weisser et al., 1996). Of note, in a large multicenter trial comparing *Serenoa repens* with finasteride, no effect on PSA levels was observed for *Serenoa repens*–treated patients, and only a 6% PV reduction was found (Carraro et al., 1996).

In a study evaluating the effect of *Serenoa repens* on castrated rats receiving estrogen and testosterone therapy, Paubert-Braquet et al. (1996) suggested an active role of the plant extract in reducing the increase in prostate weight associated with hormone treatment. Similar results were observed in a hyperprolactinaemic rat model (Van Coppenolle et al., 2000).

The apoptotic and antiproliferative effects of plant extract have been demonstrated in vitro. *Serenoa repens* decreased the proliferative index in BPH human prostate tissue (Vacherot et al., 2000). Moreover, in vitro studies with *Pygeum africanum* demonstrated an inhibitory effect on both basic fibroblast growth factor– and estrogen growth factor–induced human and rat prostate fibroblast proliferation (Paubert-Braquet et al., 1994; Yablonsky et al., 1997). Similarly, *Serenoa repens* has also showed inhibition of basic fibroblast growth factor– and estrogen growth factor–induced proliferation of human BPH prostate cells retrieved from biopsy specimens (Paubert-Braquet et al., 1998). Finally, in a study conducted on two different BPH cell lines, the lipidosterolic extract of *Serenoa repens* was able to alter the expression of genes involved in both proliferation and apoptosis (Sirab et al., 2013).

Despite the considerable amount of preclinical data, there is no certainty regarding the link between the biologic mechanisms observed in vitro and in animal studies and the clinical effects of phytotherapeutic agents.

Current Role of Phytotherapy in the Treatment of Patients With Lower Urinary Tract Symptoms

Wide population-based studies assessed the rate of prescriptions of phytotherapeutic agents in recent decades. For example, Fourcade et al. (2008) reported the management profile of patients medically treated for BPH in four

European countries. **Phytotherapy was the second most commonly prescribed therapy (23.5%), after α$_1$-blockers (62.5%).** The rate of prescriptions of phytotherapeutic agents differed among countries, reaching a rate of 49.6% in France. This is mainly caused by the differences in the commercialization policy of these products across countries. Patients who were prescribed phytotherapy showed an overall lower IPSS compared with those who were prescribed other drugs. Moreover, in a small percentage of cases (1.25% of overall prescriptions), phytotherapy was prescribed in combination with α$_1$-blockers. These data were further confirmed in a study involving a larger population of European patients evaluated from 2004 to 2008 (Cornu et al., 2010). The authors observed a huge variation in the rate of phytotherapy prescriptions for LUTS treatment, ranging from 0% to 40% of the overall BPH medical prescriptions across countries. Similarly, the use of phytotherapy in the United States has escalated; although the data may be outdated, it was estimated that more than $1 billion is spent per year in the United States alone for these products (Lowe and Fagelman, 1999).

International clinical guidelines do not include a specific recommendation regarding the use of phytotherapy in the treatment of patients with LUTS (McVary et al., 2011; Oelke et al., 2013)**. This is because the significant heterogeneity among commercialized products hampers the possibility to draw reliable conclusions on the efficacy of each different agent.**

Serenoa Repens (Saw Palmetto Berry)

The extract of the berry of the American dwarf palm (saw palmetto), *Serenoa repens* (also known as *Serenoa serrulata*), is the most popular and widely studied phytotherapeutic agent for the treatment of LUTS.

There is a wide heterogeneity across studies in terms of the methods of extraction and solvents used for herbal preparations. In a study comparing different marketed *Serenoa repens* extracts according to their free fatty acid content, Habib and Wyllie (2004) observed substantial heterogeneity among the products investigated (Fig. 145.19A). Similarly, Booker et al. (2014) analyzed 57 samples of *Serenoa repens* obtained from retail outlets in several countries and reported that the content of free fatty acids declared on the package differed by 9.9% to 460.4% from the actual amount measured. Given that free fatty acids are considered the main biologic active component of the herbal preparation, these results suggest a possible discrepancy in the efficacy between marketed compounds. Indeed, in a study assessing the biologic activity of different batches of seven different *Serenoa repens* extracts, Scaglione et al. (2008) observed a considerable variation in the inhibition of 5α-reductases among different extracts and batches of the same extract (Fig. 145.19B).

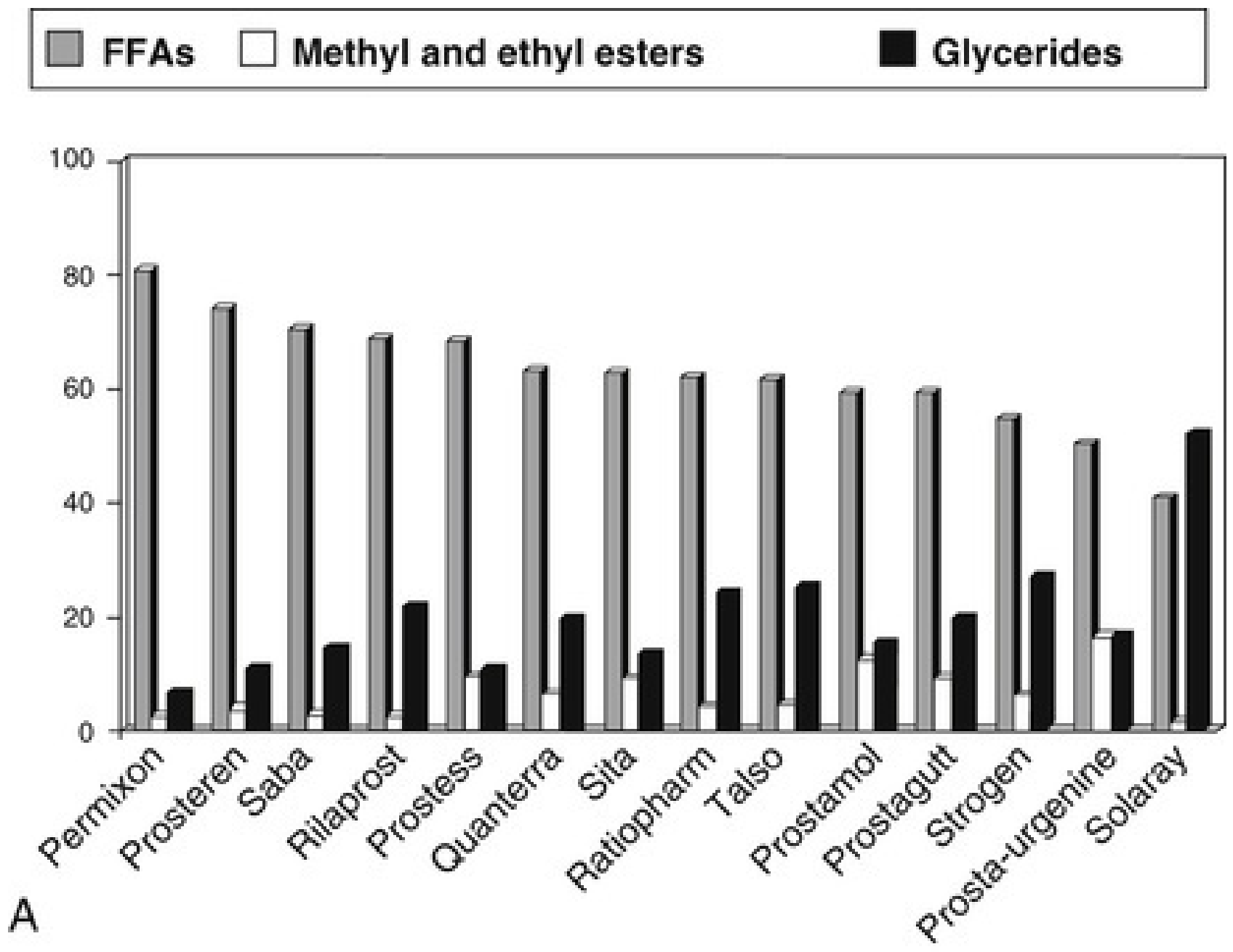

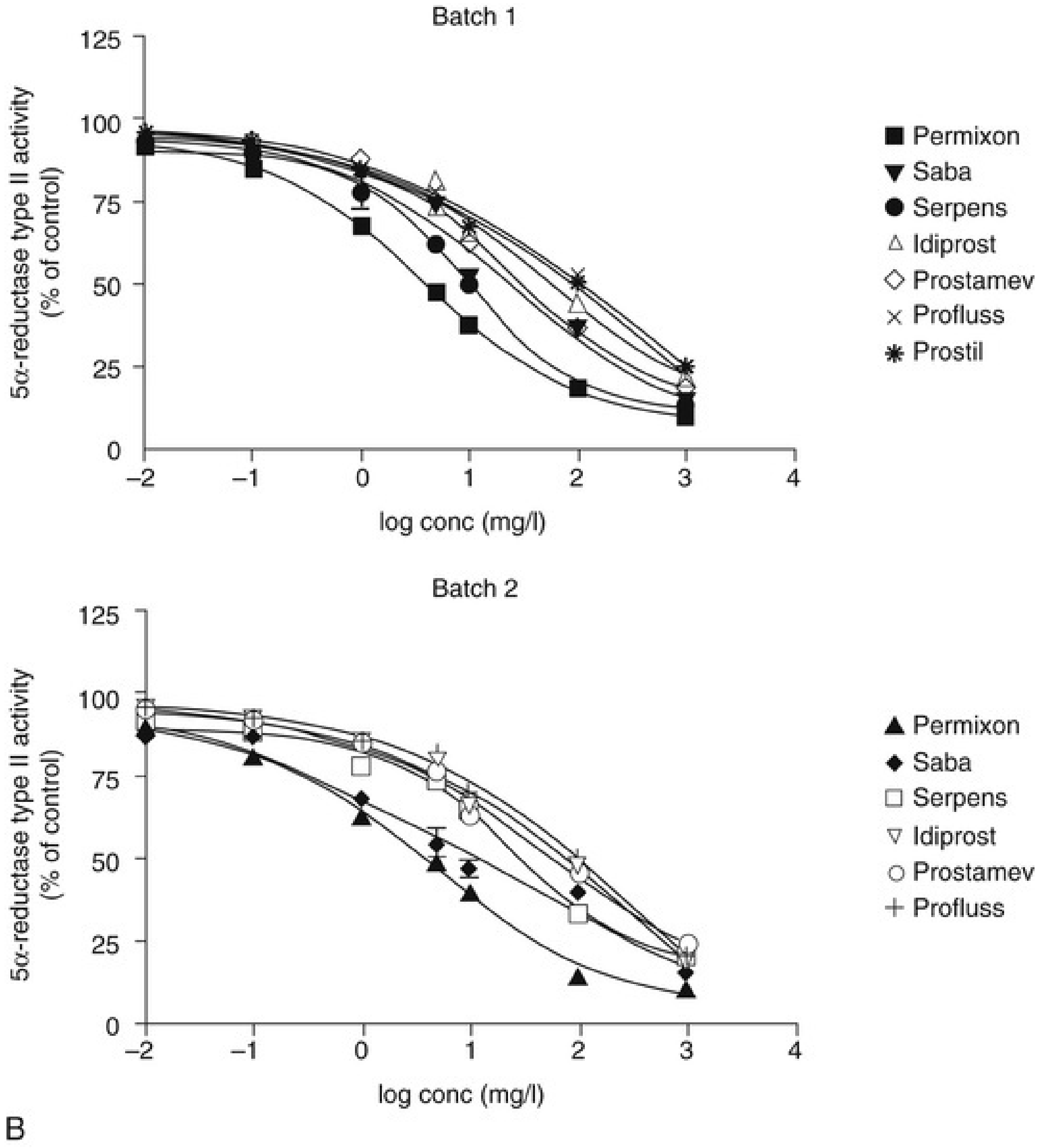

FIG. 145.19 (A) Visual representation of the content of 14 brands of *Serenoa repens* as determined by analysis. (B) Inhibition of 5α-reductase type 2. Enzyme activity is expressed as a percentage of the control (the conversion of 1 μM testosterone in the absence of inhibitors is defined as 100% activity). *FFAs,* Free fatty acids. (A, From Habib FK, Wyllie MG. Not all brands are created equal: a comparison of selected components of different brands of Serenoa repens extract. *Prostate Cancer Prostatic Dis* 7(3):195–200, 2004. Figure 2, p. 198. B, From Scaglione F, Lucini V, Pannacci M, et al. Comparison of the potency of different brands of Serenoa repens extract on 5alpha-reductase types I and II in prostatic co-cultured epithelial and fibroblast cells. *Pharmacology*82[4]:270–275, 2008. Figure 2, p. 273.)

Most of the trials assessing the clinical efficacy of *Serenoa repens* have been conducted with hexane, ethanolic, and supercritical CO_2 extracts (all commercially available in Europe), whereas in some studies the type of extract is not specified. The results of placebo-controlled RCTs on *Serenoa repens* are reported in Table 145.22.

TABLE 145.22

Randomized Placebo-Controlled Trials Investigating the Effect of *Serenoa Repens* for Treatment of Lower Urinary Tract Symptoms

---

	DRUG	NUMBER OF PATIENTS	LENGTH OF TREATMENT	SYMPTOMS (MEAN CHANGE FROM BASELINE; [P])	PEAK FLOW RATE, ML/ (MEAN CHANGE FROM BASELINE; [P])
Mandressi et al., 1983	Permixon 320 mg Placebo	60	1 month	Nocturnal voids Permixon: –2.06 Placebo: –0.96	NR
Emili et al., 1983	Permixon 320 mg Placebo	30	2 months	Nocturnal voids at study end Permixon: 1.67 Placebo: 2.33	Mean value at study end Permixon 13.7 Placebo: 9.4
Boccafoschi and Annoscia, 1983	Permixon 320 mg Placebo	22	2 months	Nocturnal voids at study end Permixon: 1.67 Placebo: 2.33	Mean value at study end Permixon 13.7 Placebo: 12.2
Champault et al., 1984	Permixon 320 mg Placebo	110	1 month	Nocturnal voids at study end Permixon: 1.69	Mean value at study end Permixon 8.1

				Placebo: 2.72 (<0.001)	Placebo: 5.2 (<0.001)
Tasca et al., 1985	Permixon 320 mg Placebo	30	2 months	Nocturnal voids at study end Permixon: 0.9 Placebo: 1.9	Mean value at study end Permixon 16.2 Placebo: 11.8
Cukier et al., 1985	Permixon 320 mg Placebo	22	2 months	Nocturnal voids at study end Permixon: 2.2 Placebo: 2.9	NR
Reece-Smith et al., 1986	Permixon 320 mg Placebo	10	2 months	Nocturnal voids at study end Permixon: 1.8 Placebo: 1.9	NR
Descotes et al., 1995	Permixon 320 mg Placebo	215	2 months	Nocturnal voids Permixon: –0.7 Placebo: –0.3	Mean value at study end Permixon 15.3 Placebo: 13.5
Gerber et al., 2001	S. repens 320 mg Placebo	85	6 months	IPSS total *S. repens:* –4.4; (NS) Placebo: –2.2	*S. repens*. +1.0; (NS) Placebo: +1.4
Willetts et al., 2003	*S. repens* 320 mg Placebo	100	3 months	IPSS total: *S. repens:* –2.01 Placebo:	*S. repens*. +1.5 Placebo: +4.4 (0.09)

				– 5.23 (0.1)	
Bent et al., 2006	*S. repens* 320 mg Placebo	225	12 months	IPSS total *S. repens:* –0.6; (NS) Placebo: –0.7	*S. repens* +0.4; (NS) Placebo: –0.01
Barry et al., 2011	*S. repens* 320–960 mg Placebo	369	18 months	IPSS total *S. repens:* –2.2; (NS) Placebo: –2.9	*S. repens* –0.2; (NS) Placebo: –0.8

IPSS, International Prostate Symptom Score; *NR,* not reported; *NS,* not significant.

In the first meta-analysis reporting data from 18 randomized trials comparing *Serenoa repens* with placebo ($N = 14$), finasteride ($N = 3$), or two different formulations of the drug ($N = 1$), a positive effect of *Serenoa repens* on LUTS relief was observed (Wilt et al., 1998). Therapy in the studies included lasted from 4 to 48 weeks. The authors found a significant change in mean symptom scores (–1.41 points), nocturia episodes (–0.76), and PFR (+1.93 mL/s) for patients treated with *Serenoa repens* compared with placebo. Moreover, *Serenoa repens* was not inferior to finasteride in terms of symptom score reduction and PFR increase. AEs were mild and infrequent and equally reported, even in the placebo group.

These results were not confirmed in the updated versions of the review (MacDonald et al., 2012; Tacklind et al., 2009, 2012); indeed, the trials included in the first meta-analysis by Wilt et al. (1998) were mostly underpowered, dealing with short-term treatment courses and used different outcomes and symptom scale scores. Tacklind et al. (2009) published an update including nine new trials involving a total of 2053 patients. *Serenoa repens* was not superior to placebo in terms of symptom score reduction, PFR increase, and PV reduction. Of note, in one trial assessing differences between *Serenoa repens* and finasteride (Carraro et al., 1996) and in two trials comparing *Serenoa repens* and tamsulosin, the plant extract was not inferior to the active control in terms of symptom score reduction and PFR increase (Debruyne et al., 2002; Hizli and Uygur 2007).

In the last review updates (MacDonald et al., 2012; Tacklind et al., 2012), two high-quality long-term trials were included (Barry et al., 2011; Bent et al., 2006). In the first trial, 225 men with moderate to severe symptoms were randomized to receive either 160 mg *Serenoa repens* twice daily (supercritical CO_2 extract) or placebo for 1 year (Bent et al., 2006). In the second multicenter trial, 369 men were randomized to receive a dose escalation of *Serenoa repens* up to 960 mg/day (ethanolic extract) or placebo for 72 weeks (Barry et al., 2011). Both trials used the validated AUASI (IPSS) to assess symptoms, and reported no difference between groups at the end of treatment. Likewise, PFR and PV modifications that occurred after active treatment were comparable to those that occurred with placebo.

Overall, these results suggest that *Serenoa repens* therapy does not relieve LUTS or increase PFR compared with placebo in men with BPH, even at double or triple the usual dose. However, it has been recognized that these results could have been affected by the heterogeneity of the extracts used in the different trials, therefore not being applicable to all marketed products.

In this context, the hexane extract of *Serenoa repens* (commercially known as Permixon) has been shown to have higher biologic activity along with the lowest variability from batch to batch in terms of free fatty acid content (Habib and Wyllie 2004; Scaglione et al., 2008), possibly suggesting a higher efficacy of this specific extract. Novara et al. (2016) reported the results of a meta-analysis including only RCTs assessing the efficacy of Permixon. Overall, seven trials compared Permixon with placebo, two trials compared Permixon plus tamsulosin with placebo and tamsulosin alone, and one trial compared Permixon with finasteride. The results of the meta-analysis showed that Permixon was more effective than placebo in reducing the number of nocturnal voids (–0.31) and increasing PFR (+3.37 mL/s). Moreover, Permixon was not inferior to tamsulosin monotherapy and short-term finasteride therapy in reducing IPSS and increasing PFR. Permixon's safety profile was favorable: there were no differences in reported AEs and rates of drug withdrawal compared with placebo.

Recently, the combination of silodosin and Permixon was investigated, showing higher rates of patients reporting clinically meaningful reduction of the IPSS as compared with silodosin monotherapy (Boeri et al., 2017).

In 2015, the EMA recognized the hexane extract of *Serenoa repens* (Permixon) as a well-established medicinal product according to the results of randomized trials showing a good efficacy and tolerability profile.

***Serenoa repens* has shown only mild gastrointestinal side effects reported, especially when taken on an empty stomach. It is advised to take *Serenoa repens* with food at the daily dose of 320 mg.** Few cases of suspected interactions with anticoagulants (warfarin) have been reported. As such, a warning has been included in the product monograph.

Conversely, the ethanolic and supercritical CO_2 extracts currently lack significant data to support their clinical efficacy.

Pygeum Africanum (African Plum)

The extract from the bark of the African plum tree, *Pygeum africanum*, has been used for the treatment of LUTS in Europe since 1969. The biologic activity of this plant extract is not completely clear yet; however, besides the previously discussed mechanisms, data from animal models have demonstrated a modulation of bladder contractility associated with the administration of *Pygeum africanum* (Levin et al., 1996).

In the first review of open-label and comparative studies assessing the effect and safety of *Pygeum africanum* to treat LUTS, an overall positive effect of the plant extract in terms of symptom relief and PFR increase was reported (Andro and Riffaud, 1995). However, the review included only results from uncontrolled studies, and a quantitative meta-analysis was not performed. Wilt et al. (2002b) conducted a subsequent meta-analysis including 18 randomized trials involving 1562 patients. Among the trials included, 11 compared *Pygeum africanum* with placebo, whereas other plant extracts were used as active control groups in the other trials. Most trials were short-term, with an 8-week mean length; the most commonly used formulation of *Pygeum africanum* was a standardized extract at a dose of 100 to 200 mg daily. Pooled analyses of five double-blind trials showed that men treated with *Pygeum africanum* were more than twice as likely to be rated by their physicians as having overall relief of symptoms compared with those who received placebo (65% vs. 30%; relative risk, 2.1). The lack of standardized tools to measure symptom relief was the main limitation of these findings. Likewise, the authors reported a significant increase in PFR of 23% in the *Pygeum africanum* group. In terms of safety, most of the reported AEs were mild in nature and comparable in terms of frequency with those in the placebo group.

Overall, *Pygeum africanum* has been shown to be more effective than placebo in treating men with LUTS, although the benefit appears modest

and is only reported at short-term follow-up.

Hypoxis Rooperi (South African Star Grass)

β-Sitosterol is a phytopharmacologic extract containing a mixture of phytosterols and is commonly derived from South African star grass, *Hypoxis rooperi*. The biologic activity of β-sitosterol has been related to an anti-inflammatory effect (inhibition of prostaglandin metabolism) (Lowe and Ku, 1996).

The two main preparations of β-sitosterol have been marketed with the names Harzol (containing 50% of a nonglucosidic β-sitosterol form) and Azuprostat (containing β-sitosterol from *Hypoxis rooperi* and from *Pinus* [pine] and *Picea* [spruce]). Both compounds have been evaluated in RCTs, with overall good efficacy being shown (Berges et al., 1995; Klippel et al., 1997).

Wilt et al. (1999) reported pooled analysis of four placebo-controlled studies assessing the safety and efficacy of β-sitosterols in men with LUTS. Two studies used Azuprostat, one study used Harzol, and one study used a preparation of 100% β-sitosterol (WA184). Overall, therapy courses ranged from 4 to 26 weeks. The pooled analysis showed relief of urinary symptoms (4.9-point reduction in IPSS) and increase of PFR (+3.91 mL/s) that were significantly greater than with placebo. The PVR volume reduction was 28.6 mL with β-sitosterol. AEs were mild and comparable in frequency to those observed with placebo.

Overall, this evidence suggests that preparations with β-sitosterols are effective in relieving symptoms and increasing flow rates at short-term assessment; however, the large reported effect, which is even greater than the effects observed with other proper pharmacologic compounds, raises concern regarding the reliability of these data.

Other Plant Extracts and Lycopene

Other plant extracts, including extracts of *Urtica dioica*, *Cucurbita pepo*, *Opuntia*, and *Secale cereale* (see Table 145.19), have been scantly and not homogeneously analyzed in a clinical setting.

Cernilton is a compound prepared from the pollen of rye *(Secale cereale)*, and its efficacy has been assessed in four randomized trials. Wilt et al. (2000) reported pooled analyses of data from these trials. Overall, two trials were placebo-controlled trials, and the other two used a different plant extract as an active control. The results showed that Cernilton was superior to placebo in terms of self-reported relief of overall symptoms (relative risk, 2.4) and nocturia (relative risk, 2.05). Conversely, there was no difference in terms of PFR and average flow changes from baseline between patients treated with Cernilton and those receiving placebo. All studies were short-term (maximum 24 weeks), and the overall quality was deemed to be poor.

In conclusion, although Cernilton seems to provide modest relief of symptoms, its efficacy in treating patients with LUTS remains questionable.

Besides plant extracts, there is a considerable amount of data assessing the effect of dietary antioxidants on prostatic diseases; among them, lycopene and selenium have shown controversial results in terms of LUTS relief (Holton et al., 2016; Kristal et al., 2008).

Lycopene is a nonprovitamin A carotenoid with potent antioxidant and anti-inflammatory activity that has been found to modulate cell growth in the prostate through inhibition of 5α-reductase and IL-6 signaling (Holzapfel et al., 2013). Similarly, selenium exerts epigenetic and antioxidant effects that may play a role in prostate growth and inflammation (Vinceti et al., 2014). A combination of lycopene and selenium with *Serenoa repens* (Ser-Ly-Se; commercially known as Profluss) has been proposed with the aim to improve the efficacy of the latter in the treatment of patients with LUTS. Preclinical data showed that Ser-Ly-Se was more effective than *Serenoa repens* alone in decreasing the prostate inflammatory response, decreasing growth factor expression, and improving histologic features (Bonvissuto et al., 2011). Similarly, in a rat model treated with testosterone, the administration of Ser-Ly-Se inhibited prostate growth by 83% (Altavilla et al., 2011).

In a randomized, double-blind, multicenter study, 225 patients were treated with either Ser-Ly-Se, tamsulosin, or a combination of both drugs (Morgia et al., 2014). The results showed that the combination of tamsulosin plus Ser-Ly-Se was superior to each drug alone in terms of symptom relief and PFR increase after 12 months of treatment, thus suggesting a possible role of combining an α_1-blocker with a plant extract administered together with two potent antioxidants for the treatment of patients with moderate LUTS.

Summary

The use of phytotherapy for the treatment of LUTS has greatly increased worldwide over the past two decades; however, randomized clinical trials have reported inconclusive results on the efficacy of phytotherapeutic

agents in terms of symptom relief and uroflow parameter improvement. Large and long-term trials did not report any difference between phytotherapy and placebo.

There is a huge variability in the biologic activity of each marketed compound as a consequence of the lack of a standard extraction method, thus making comparison difficult between data. For these reasons, both European and American guidelines do not provide specific recommendations for the use of phytotherapy in treating patients with LUTS related to BPH.

***Serenoa repens* is the most widely investigated phytotherapeutic agent for the treatment of LUTS and is recommended at a daily dose of 320 mg taken with food.**

Prognosis of Patients Receiving Medical Treatment for Lower Urinary Tract Symptoms

Longitudinal population-based studies provided data showing that BPH is a progressive disease (Roehrborn, 2008). The Olmsted study, including 2115 men 40 to 79 years of age followed up for 12 years, showed an average IPSS increase of 0.18 points per year, a decrease in PFR of 2% per year, and a prostate growth rate of 1.9% per year (Fitzpatrick, 2006). As a progressive disease, BPH may lead to serious events other than symptom deterioration, including AUR, hypoactive detrusor activity, and eventually hydronephrosis.

Medical therapy has been demonstrated to reduce the risk for BPH progression and to avoid the need for BPH surgery. In this context, long-term RCTs allowed the identification of patients at higher risk for progression who may gain greater benefit from treatment.

In the MTOPS study, the cumulative incidence of disease progression in the placebo group (identified as symptom deterioration in most cases) was 17% over a 4-year period (McConnell et al., 2003). Patients receiving treatment with a single agent (either doxazosin or finasteride) showed a risk reduction in BPH progression of 34% to 39%, further increasing to 66% for those treated with a double agent; of note, the risk for AUR and BPH-related surgery was significantly reduced only by finasteride treatment. Similar findings were observed in the CombAT trial (Roehrborn et al., 2008a) and in the ALTESS (Roehrborn, 2006). According to the results of these trials, baseline characteristics associated with a higher risk for BPH clinical progression were higher PSA values, larger prostates, and greater PVR volumes; these factors should be carefully considered when patients are being counseled for LUTS treatment.

Recent post hoc analyses from another large prospective trial including patients treated with either dutasteride or placebo (REDUCE trial) provided further evidence on the risk for BPH progression (Simon et al., 2016). The REDUCE trial included more than 3000 men with mild to no symptoms at the baseline (IPSS <8); Simon et al. (2016) looked at the risk for developing LUTS (defined as IPSS >14) in a subgroup of mild-asymptomatic patients treated with placebo. They showed that those with a prostate size of 40 to 80 mL had a higher risk for further developing LUTS (HR, 1.67) as compared with those with a PV of 40 mL or lower. Similarly, a lower PFR at baseline was associated with a higher risk for developing LUTS in the same subgroup of patients. Data from the CONDUCT study, assessing the efficacy of a fixed-dose combination of dutasteride and tamsulosin as compared with a WW approach, suggested that the degree of bother associated with LUTS at the baseline (BII) could be a better indicator of whether or not a patient will benefit from medical treatment (Rosa et al., 2016). Indeed, the superiority of combination therapy over WW in terms of IPSS reduction at 2 years was observed only in patients with higher BII scores at baseline.

The dynamic changes of baseline variables are also considered as a predictor of disease progression: symptom worsening and PVR volume changes over time have been associated with a higher risk for AUR in long-term RCTs (Roehrborn, 2008). For instance, in the placebo arms of the MTOPS trial, patients who did not develop AUR showed a stable PVR volume throughout the period investigated.

Medical treatment of LUTS should be tailored to the patient's baseline characteristics, and the effect of therapy should be properly monitored over time. International clinical guidelines suggest properly following up patients receiving medical treatment for LUTS/BPH: patients treated with either α_1-blockers or 5ARIs should be assessed after 4 to 12 weeks to check the initial response to therapy (for α_1-blockers) and the occurrence of AEs. Patients should be reassessed after 6 months and annually thereafter to monitor changes in symptoms, uroflowmetry parameters, and PVR volume. Moreover, serum PSA level should be carefully monitored in patients treated with 5ARIs with a life expectancy greater than 10 years (Oelke et al., 2013).

Key Points

- α_1-Blockers are the first-line treatment for patients with moderate to severe LUTS.
- The uroselective α_1-blockers tamsulosin, silodosin, and alfuzosin showed the best tolerability profile.
- 5ARIs are effective in reducing the risk for disease progression and the need

for invasive treatment.

- Patients with predominant storage symptoms may benefit from combination therapy with antimuscarinic drugs.
- PDE5Is are effective in relieving LUTS, either alone or in combination with α_1-blockers.
- There is no consensus on the efficacy of phytotherapy for LUTS treatment, although encouraging results have been published for the hexane extract of *Serenoa repens* and for the combination of *Serenoa repens* with lycopene and selenium.

Acute Urinary Retention

AUR is defined as a sudden and painful inability to void voluntarily (Emberton and Anson, 1999)**; it is a severe complication of BPH and is a major public health issue.** Two distinct forms of AUR can be distinguished in clinical practice: *spontaneous AUR*, as a consequence of the natural history of progressive BPH, and *precipitated AUR*, developing after a precipitating event other than BPH, such as surgical procedures with general or locoregional anaesthesia, UTIs, bladder overdistension, or medications with anticholinergic or sympathomimetic agents (McNeil, 2006).

Data from longitudinal population studies provided information on the incidence and risk factors associated with spontaneous AUR (Oelke et al., 2015). Older age, severe LUTS, low PFR, high PVR volume, large PV, and high serum PSA level are all recognized predictors of AUR (Jacobsen et al., 1997). The overall incidence of AUR in the general male population has been reported to be between 2.2 and 8.5 events per 1000 person-years (Table 145.23). In a large population study including 165,527 adult men from the United Kingdom, the incidence of AUR was reported to be as high as 3.1 per 1000 person-years, with about 65% of cases being spontaneous AUR (Cathcart et al., 2006). In the Olmsted County study, including a large US male population 50 years of age or older, up to 8.5 events per 1000 person-years were reported (Roberts et al., 2005).

TABLE 145.23

Incidence of AUR in the General Population and Among Men With LUTS

STUDY	COUNTRY	POPULATION	INCIDENCE	
			GENERAL POPULATION (RATE PER 1000 PERSON-YEARS [95% CI])	MEN WITH LUTS (RATE PER 1000 PERSON-YEARS [95% CI])
Verhamme et al., 2005	Netherlands	56,958 men ≥45 years of age with no history of	2.2 (2.0–2.4)	35.9 (30.5–42.0)

		AUR		
Cathcart et al., 2006	United Kingdom	165,527 men	3.1	NR
Meigs et al., 1999	United States	6100 men 45–83 years of age without prostatectomy for BPH or AUR	4.5 (3.1–6.2)	NR
Roberts et al., 2005	United States	2115 men 40–79 years of age	8.5[a] (6.4–11.2)	18.3[b] (11.3–28.0)

[a] *N,* 1193; men 50 years of age or older.

[b] *N,* 238: selected cohort of men with characteristics meeting selection criteria for the Medical Therapy of Prostatic Symptoms study.

AUR, Acute urinary retention; *BPH,* benign prostatic hyperplasia; *CI,* confidence interval; *LUTS,* lower urinary tract symptoms.

Modified from Oelke M, Speakman MJ, Desgrandchamps F, Mamoulakis C. Acute urinary retention rates in the general male population and in adult men with lower urinary tract symptoms participating in pharmacotherapy trials: a literature review. *Urology* 86(4):654–665, 2015.

The incidence of AUR is even higher in populations of patients complaining of LUTS. In a retrospective Dutch study, 35.9 episodes of AUR per 1000 person-years among patients with LUTS were reported (Verhamme et al., 2005) (Fig. 145.20). Similarly, in a subcohort of the Olmsted County study including men with symptomatic BPH, the incidence of AUR was up to 18.3 per 1000 person-years (Roberts et al., 2005). Recently, in a Californian study investigating the temporal trend in the rate of patients presenting to the emergency department for AUR associated with BPH, Groves et al. (2013) reported an increase in the incidence of AUR from 4 per 1000 visits in 2007 to 5.23 per 1000 visits in 2010. These findings may be the consequence of either an increasing number of older men with advanced BPH or a larger proportion of patients receiving inappropriate treatment for LUTS in the primary care setting.

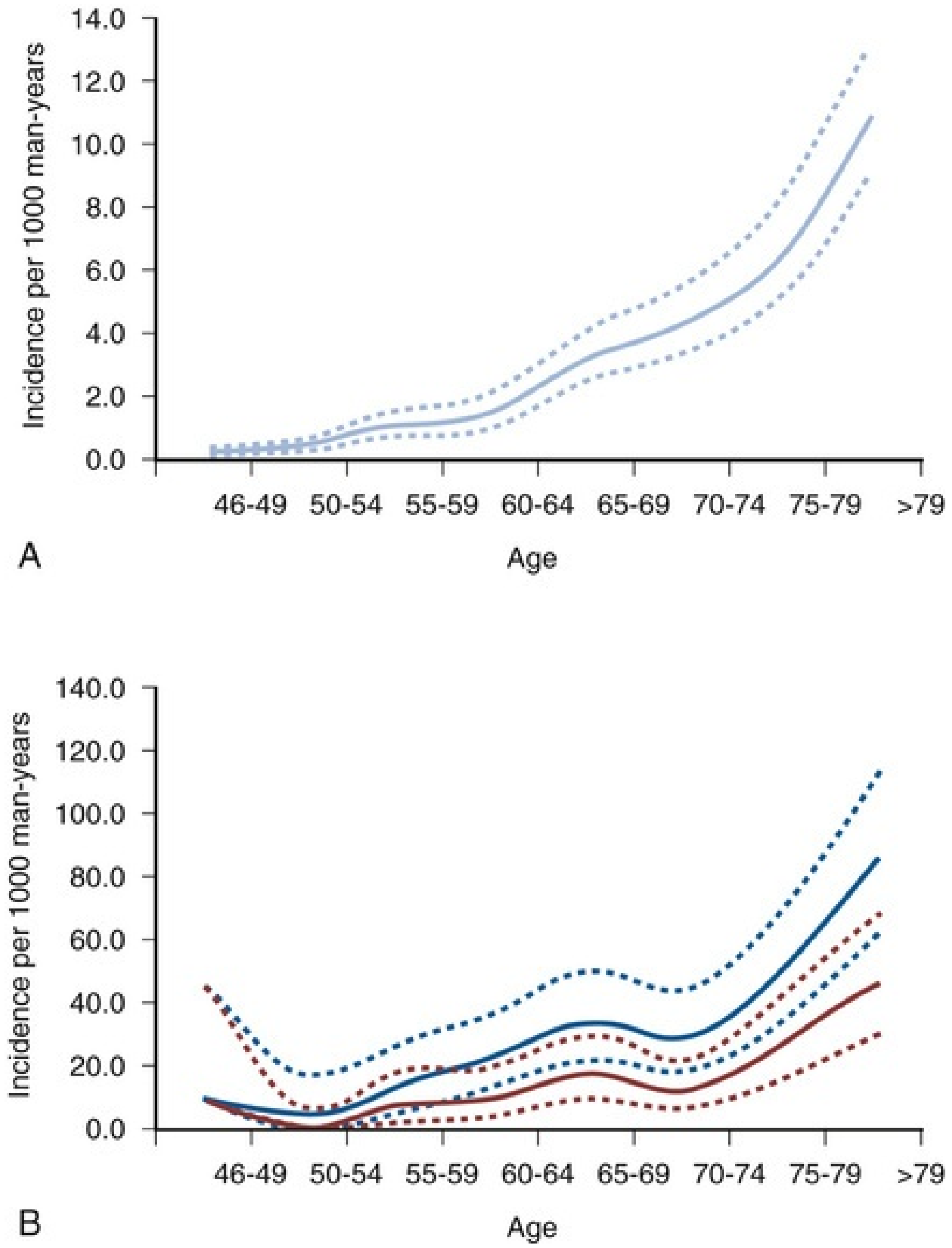

FIG. 145.20 Incidence of acute urinary retention in the general population of Dutch men (A) and in the population with lower urinary tract symptoms and benign prostatic hyperplasia (B). (From Verhamme KM, Dieleman JP, van Wijk MA, et al. Low incidence of acute urinary retention in the general male population: the triumph project. *Eur Urol* 47[4]:494–498, 2005.)

Management of Acute Urinary Retention

The initial management of AUR consists of immediate bladder decompression by catheterization. After catheterization, patients could undergo either immediate surgery or a TWOC. The advantage of immediate surgery relies on the early resolution of BOO, enabling spontaneous voiding and protecting both the bladder and the upper urinary tract from injury. However, emergency surgery has been associated with increased morbidity, thus shifting the paradigm of treatment toward a more conservative strategy (Fitzpatrick et al., 2012; Manikandan et al., 2004). The TWOC is based on the removal of the catheter after a few days from its placement, which allows the patient to return to normal voiding in about 60% of cases (Fitzpatrick et al., 2012; McNeil, 2006). There is substantial heterogeneity in the type and duration of catheterization and in the use of concurrent medical therapies. In a multi-institution study collecting data from 6074 patients treated worldwide for a first episode of AUR in the 2004 to 2008 period, TWOC was the treatment of choice in 78% of cases (Fitzpatrick et al., 2012). The duration of catheterization ranged from 3 to 8 days (median 5 days), and the success rate of TWOC was 61%. Moreover, among patients in whom TWOC failed, 43.5% underwent a second attempt, which was successful in 29.5% of cases, whereas a third attempt had a success rate of 26.4%. These data suggest that up to three TWOCs may be attempted before patients are counseled for more invasive treatments. **However, a high rate of patients with a successful TWOC will experience a subsequent AUR episode, with 80% of them failing to void within 6 months** (Cathcart et al., 2006). At this point, pressure-flow studies and surgery are indicated.

Advanced age, severe LUTS, and large volume drained at catheterization (≥1 L) are all factors associated with a higher risk for TWOC failure; similarly, failure is more likely in a patient with an episode of spontaneous AUR than in a patient experiencing AUR secondary to trigger events (Fitzpatrick et al., 2012; Yoon et al., 2015).

In a recent systematic review assessing the outcomes of TWOC, Yoon et al. (2015) underlined the substantial heterogeneity in terms of the duration of catheterization applied in clinical practice, with no study providing convincing data supporting a higher probability of success associated with either a short or a long catheterization time. In a small trial, the effect of clean intermittent self-catheterization was compared with a conventional TWOC after indwelling catheterization, showing higher success rates for patients undergoing intermittent catheterization (56% vs. 25%); however, this trial was not randomized, and patients managed with self-catheterization were younger and had a smaller prostate (Ko et al., 2012).

The dynamic component of obstruction, characterized by an increase sympathetic tone inducing the contraction of the smooth muscle fibers of the bladder neck, has been deemed to be partially responsible for urinary retention. For this reason, α_1-blockers have been widely used to increase the probability of a successful TWOC (Emberton et al 2008). In the Alfuzosin in Acute Urinary Retention study, patients who underwent emergency catheterization were blindly randomized to receive 10 mg alfuzosin once daily or placebo for 3 days; the results showed that α_1-blockers treatment was associated with a significantly higher success rate compared with placebo treatment (61.9% vs. 47.9%; $P = 0.01$) (McNeill et al., 2005). In a meta-analysis of eight RCTs assessing the benefit of using α_1-blockers before TWOC, Fisher et al. (2014) confirmed that the rate of successful TWOC was significantly higher with α_1-blockers compared with placebo (relative risk, 1.55; 95% CI, 1.36 to 1.76). Likewise, AUR recurrence was lower among patients treated with α_1-blockers. The duration of α_1-blockers therapy ranged from 1 to 3 days in seven of eight trials; the optimal duration of treatment has not been investigated yet.

Medical Therapy in the Prevention of Acute Urinary Retention

Long-term randomized trials of α_1-blockers and 5ARIs provided data on the effect of medical therapy for the prevention of AUR in patients with BPH.

Among α_1-blockers, data are available for alfuzosin, doxazosin, and tamsulosin therapy. In a post hoc analysis of the 2-year ALTESS, randomizing patients to receive 10 mg alfuzosin daily or placebo, the authors looked at the overall clinical progression of BPH defined as the occurrence of AUR, surgery, or symptom deterioration (Roehrborn, 2006). The **results showed that alfuzosin was not able to reduce the risk for AUR as compared with placebo (2.1% vs. 1.8%; $P = 0.8$).**

In the 4-year MTOPS trial, randomizing patients to receive doxazosin, finasteride, a combination of doxazosin and finasteride, or placebo, the cumulative incidence of AUR was compared among groups (McConnell et al., 2003); **AUR incidence did not differ between the placebo group (0.6 per 100 person-years) and the doxazosin group (0.4 per 100 person-years; $P = 0.2$), although patients treated with α_1-blockers showed an increased time to event compared with the placebo group.**

In the CombAT study, tamsulosin intake was associated with a 4-year AUR incidence of 6.8% (95% CI, 5.5% to 8%) (Roehrborn et al., 2010); the lack of a placebo arm did not allow a conclusion to be drawn regarding the benefit of tamsulosin in preventing AUR. **However, patients receiving both tamsulosin and dutasteride showed a risk reduction for AUR of 67.6% and 18.3% compared with tamsulosin and dutasteride alone, respectively, suggesting that treatment with 5ARIs plays a major role in preventing AUR over time.**

Key Points

- AUR is a common complication of BPH progression.
- A TWOC is the preferred management after initial decompression by bladder catheterization.
- The use of α_1-blockers is recommended to increase the odds of a successful TWOC.
- Dutasteride and finasteride have been shown to significantly decrease the risk for AUR in patients with moderate to severe LUTS.

Future Directions in Medical Treatment of Benign Prostatic Hyperplasia

Despite the efficacy of currently available treatments for LUTS, there are still a nonnegligible number of patients who do not benefit from medical therapy, thus deserving surgery. Surgical treatment is still considered the most effective and long-lasting treatment modality for BPH (McVary et al., 2011; Oelke et al., 2013).

Improvements in the knowledge of lower urinary tract physiology may lead to the development of new drugs aimed at further improving the effectiveness of medical treatment of LUTS/BPH. The active role played by the bladder urothelium and the interstitial cells in the physiopathology of LUTS is currently under investigation. Likewise, the transient receptor potential (TRP) channel family, cannabinoid receptors, purinergic receptors, and vitamin D_3 receptors have been considered as potential targets of newly developed drugs for LUTS management (Soler et al., 2013) (Fig. 145.21).

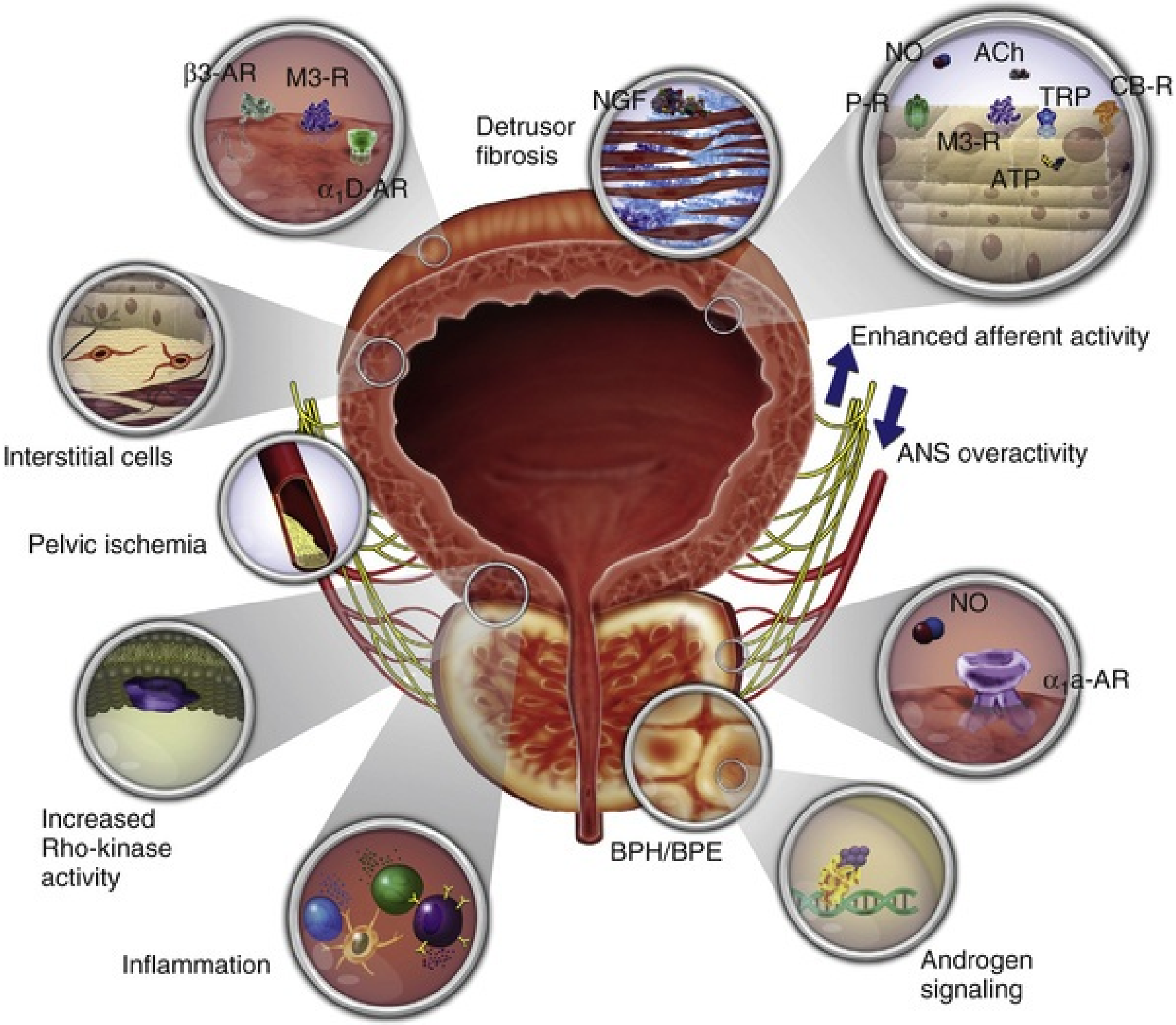
β3-AR
M3-R
α_1D-AR
Detrusor fibrosis
NGF
NO
ACh
P-R
TRP
CB-R
M3-R
ATP
Enhanced afferent activity
ANS overactivity
Interstitial cells
Pelvic ischemia
NO
α_1a-AR
Increased Rho-kinase activity
BPH/BPE
Inflammation
Androgen signaling

FIG. 145.21 Pathophysiologic mechanisms and targets for future nonsurgical therapy. (From Soler R, Andersson KE, Chancellor MB, et al. Future direction in pharmacotherapy for non-neurogenic male lower urinary tract symptoms. *Eur Urol* 64[4]:610–621, 2013.)

The effect of the vitamin D_3 receptor agonist elocalcitol has been investigated in vitro (Adorini et al., 2007; Morelli et al., 2007), with decreases in stromal prostate cell proliferation and interference with the androgen receptor signaling being observed. However, in a phase II RCT, treatment with elocalcitol failed to show an advantage over placebo in terms of PFR increase and symptom relief (Colli et al., 2006). Nonetheless, this drug remains currently under investigation (Digesu et al., 2012).

In an animal model, an orally active antagonist of the TRPV1 receptor, which belongs to the vanilloid TRP subfamily, was found to counteract bladder hyperactivity induced by cystitis (Charrua et al., 2009). Similarly, rats treated with a selective antagonist of TRPV4 showed a decreased voiding frequency and an increased voided volume (Everaerts et al., 2010). However, the effects of these compounds have not yet been investigated in humans.

The use of cannabinoids for the treatment of LUTS has been investigated in the setting of patients with multiple sclerosis. In a multicenter trial that enrolled 630 patients, the oral administration of a cannabis extract led to a significant reduction of incontinence episodes of 38% compared with 18% in the placebo group (Freeman et al., 2006).

Endothelin 1 was shown to be overexpressed in detrusor muscle of obstructed rabbits and to be responsible for detrusor contraction. The oral antagonist of endothelin-converting enzyme, which is responsible for endothelin 1 production, showed promising results in terms of inhibition of nonvoiding contractions in a hyperactive bladder animal model (Schröder et al., 2004).

Anti-inflammatory drugs have been also investigated as potential therapies for LUTS. Flavocoxid, a dual inhibitor of cyclooxygenase 2 and 5-lipoxygenase, reduced PV in a rat model via the enhancement of the proapoptotic proteins Bax and caspase 9 (Altavilla et al., 2012). Similarly, the combination of rofecoxib and finasteride led to a greater reduction in IPSS and greater PFR increase as compared with finasteride alone in a clinical setting (Di Silverio et al., 2005).

Other compounds, including Rho kinase inhibitors and purinergic receptor blockers, have shown promising results in preclinical studies, thus deserving further investigation (Füllhase et al., 2014). Finally, the effect of intraprostatic drug injection therapy to treat BPH has been investigated. In this context, NX-1207 is a new therapeutic protein with proapoptotic properties that has been tested in a phase II trial and showed a significant reduction of gland volume (Soler et al., 2013). Similarly, PRX302 is a PSA-activated channel-forming toxin that is able to decrease PV. The drug was tested in 33 patients with BPH, showing promising results in terms of IPSS reduction (Williams et al., 2007). Lastly, onabotulinumtoxinA, a form of botulinum neurotoxin, has been tested as an intraprostatic injected agent in a placebo-controlled trial, showing a significant reduction of IPSS and increase of PFR, along with a significant PV reduction (Marberger et al., 2013). All of these drugs deserve further clinical investigations before any implementation in the treatment algorithm for patients with LUTS.

References

Abrams P. New words for old: lower urinary tract symptoms for “prostatism”. *BMJ*. 1994;308(6934):929–930.

Abrams P. Describing bladder storage function: overactive bladder syndrome and detrusor overactivity. *Urology*. 2003;62(5 Suppl 2):28–37.

Abrams PH, Shah PJ, Stone R, et al. Bladder outflow obstruction treated with phenoxybenzamine. *Br J Urol*. 1982;54(5):527–530.

Abrams P, Schulman CC, Vaage S. Tamsulosin, a selective alpha 1c-adrenoceptor antagonist: a randomized, controlled trial in patients with benign prostatic “obstruction” (symptomatic BPH). The European Tamsulosin Study Group. *Br J Urol*. 1995;76(3):325–336.

Abrams P, Speakman M, Stott M, et al. A dose-ranging study of the efficacy and safety of tamsulosin, the first prostate-selective alpha 1A-adrenoceptor antagonist, in patients with benign prostatic obstruction (symptomatic benign prostatic hyperplasia). *Br J Urol*. 1997;80(4):587–596.

Abrams P, Cardozo L, Fall M, et al. The standardisation of terminology of lower urinary tract function: report from the Standardisation Sub-committee of the International Continence Society. *Neurourol Urodyn*. 2002;21(2):167–178.

Abrams P, Avery K, Gardener N, et al. The international consultation on incontinence modular questionnaire. *J Urol*. 2006;175(3 Pt 1):1063–1066.

Abrams P, Kaplan S, De Koning Gans HJ, et al. Safety and tolerability of tolterodine for the treatment of overactive bladder in men with bladder outlet obstruction. *J Urol*. 2006;175(3 Pt 1):999–1004.

Abrams P, Chapple C, Khoury S, et al. Evaluation and treatment of lower urinary tract symptoms in older men. *J Urol*. 2013;189(1 Suppl)):S93–S101.

Adorini L, Penna G, Amuchastegui S, et al. Inhibition of prostate growth and inflammation by the vitamin D receptor agonist BXL-628 (elocalcitol). *J Steroid Biochem Mol Biol*. 2007;103(3–5):689–693.

Aikawa K, Kataoka M, Ogawa S, et al. Elucidation of the pattern of the onset of male lower urinary tract symptoms using cluster analysis: efficacy of tamsulosin in each symptom group. *Urology*. 2015;86(2):349–353.

Aizawa N, Homma Y, Igawa Y. Effects of mirabegron, a novel β_3-adrenoceptor agonist, on primary bladder afferent activity and bladder microcontractions in rats compared with the effects of oxybutynin. *Eur Urol*. 2012;62(6):1165–1173.

Albert JD, Geller J, Liu JD, et al. Tamoxifen decreases progesterone and nuclear androgen receptors in the human prostate. *J Steroid Biochem*. 1984;21(6):659–662.

Alcaraz MJ, Ferrandiz ML. Modification of arachidonic metabolism by flavonoids. *J Ethnopharmacol*. 1987;21(3):209–229.

Alexandre EC, Kiguti LR, Calmasini FB, et al. Mirabegron relaxes urethral smooth muscle by a dual mechanism involving β_3-adrenoceptor activation and α_1-adrenoceptor blockade. *Br J Pharmacol*. 2016;173(3):415–428.

Al-Hayek S, Thomas A, Abrams P. Natural history of detrusor contractility—minimum ten-year urodynamic follow-up in men with bladder outlet obstruction and those with detrusor. *Scand J Urol Nephrol Suppl*. 2004;215:101–108.

Altavilla D, Bitto A, Polito F, et al. The combination of Serenoa repens, selenium and lycopene is more effective than serenoa repens alone to prevent hormone dependent prostatic growth. *J Urol*. 2011;186(4):1524–1529.

Altavilla D, Minutoli L, Polito F, et al. Effects of flavocoxid, a dual inhibitor of COX and 5-lipoxygenase enzymes, on benign prostatic hyperplasia. *Br J Pharmacol*. 2012;167(1):95–108.

American Urological Association Practice Guidelines Committee. AUA guideline on management of benign prostatic hyperplasia (2003). Chapter 1: diagnosis and treatment recommendations. *J Urol*. 2003;170:530–547.

Amory JK, Anawalt BD, Matsumoto AM, et al. The effect of 5alpha-reductase inhibition with dutasteride and finasteride on bone mineral density, serum lipoproteins, hemoglobin, prostate specific antigen and sexual function in healthy young men. *J Urol*. 2008;179(6):2333–2338.

Andersen JT, Ekman P, Wolf H, et al. Can finasteride reverse the progress of benign prostatic hyperplasia? A two-year placebo-controlled study. The Scandinavian BPH Study Group. *Urology*. 1995;46(5):631–637.

Andersen M, Dahlstrand C, Høye K. Double-blind trial of the efficacy and tolerability of doxazosin in the gastrointestinal therapeutic system, doxazosin standard, and placebo in patients with benign prostatic hyperplasia. *Eur Urol*. 2000;38(4):400–409.

Andersson KE, Gratzke C. Pharmacology of alpha$_1$-adrenoceptor antagonists in the lower urinary tract and central nervous system. *Nat Clin Pract Urol*. 2007;4(7):368–378.

Andersson KE, Boedtkjer DB, Forman A. The link between vascular dysfunction, bladder ischemia, and aging bladder dysfunction. *Ther Adv Urol*. 2017;9(1):11–27.

Andersson KE. The concept of uroselectivity. *Eur Urol*. 1998;33(Suppl 2):7–11.

Andersson KE. Alpha-adrenoceptors and benign prostatic hyperplasia: basic principles for treatment with alpha-adrenoceptor antagonists. *World J Urol*. 2002;19(6):390–396.

Andersson KE. Antimuscarinic mechanisms and the overactive detrusor: an update. *Eur Urol*. 2011;59(3):377–386.

Andrews SJ, Brooks PT, Hanbury DC, et al. Ultrasonography and abdominal radiography versus intravenous urography in investigation of urinary tract infection in men: prospective incident cohort study. *BMJ*. 2002;324(7335):454–456.

Andriole G, Bruchovsky N, Chung LW, et al. Dihydrotestosterone and the prostate: the scientific rationale for 5alpha-reductase inhibitors in the treatment of benign prostatic hyperplasia. *J Urol*. 2004;172(4 Pt 1):1399–1403.

Andriole GL, Bostwick DG, Brawley OW, et al. Effect of dutasteride on the risk of prostate cancer. *N Engl J Med*. 2010;362(13):1192–1202.

Andro M, Riffaud J. Pygeum africanum extract for the treatment of patients with benign prostatic hyperplasia: a review of 25 years of published experience. *Curr Ther Res*. 1995;56(8):796–817.

Angulo J, Cuevas P, Fernández A, et al. Tadalafil enhances the inhibitory effects of tamsulosin on neurogenic contractions of human prostate and bladder neck. *J Sex Med*. 2012;9(9):2293–2306.

Arnolds M, Oelke M. Positioning invasive versus noninvasive urodynamics in the assessment of bladder outlet obstruction. *Curr Opin Urol*. 2009;19(1):55–62.

Asimakopoulos AD, De Nunzio C, Kocjancic E, et al. Measurement of post-void residual urine. *Neurourol Urodyn*. 2016;35(1):55–57.

Athanasopoulos A, Gyftopoulos K, Giannitsas K, et al. Combination treatment with an alpha-blocker plus an anticholinergic for bladder outlet obstruction: a prospective, randomized, controlled study. *J Urol*. 2003;169(6):2253–2256.

Athanasopoulos A, Chapple C, Fowler C, et al. The role of antimuscarinics in the management of men with symptoms of overactive bladder associated with concomitant bladder outlet obstruction: an update. *Eur Urol*. 2011;60(1):94–105.

Barkin J, Guimarães M, Jacobi G, et al. Alpha-blocker therapy can be withdrawn in the majority of men following initial combination therapy with the dual 5alpha-reductase inhibitor dutasteride. *Eur Urol*. 2003;44(4):461–466.

Barry MJ, Fowler FJ Jr, O'Leary MP, et al. The American Urological Association Symptom Index for benign prostatic hyperplasia. The Measurement Committee of the American Urological Association. *J Urol*. 1992;148(5):1549–1557.

Barry MJ, Fowler FJ Jr, O'Leary MP, et al. Measuring disease-specific health status in men with benign prostatic hyperplasia. Measurement Committee of The American Urological Association. *Med Care*. 1995;33(4 Suppl):AS145–AS155.

Barry MJ, Meleth S, Lee JY, et al. Complementary, Alternative Medicine for Urological Symptoms Study G: effect of increasing doses of saw palmetto extract on lower urinary tract symptoms: a randomized trial. *JAMA*. 2011;306(12):1344–1351.

Bechara A, Romano S, Casabé A, et al. Comparative efficacy assessment of tamsulosin vs. tamsulosin plus tadalafil in the treatment of LUTS/BPH. Pilot study. *J Sex Med*. 2008;5(9):2170–2178.

Belenky A, Abarbanel Y, Cohen M, et al. Detrusor resistive index evaluated by Doppler ultrasonography as a potential indicator of bladder outlet obstruction. *Urology*. 2003;62(4):647–650.

Bent S, Kane C, Shinohara K, et al. Saw palmetto for benign prostatic hyperplasia. *N Engl J Med*. 2006;354(6):557–566.

Berger BM, Naadimuthu A, Boddy A, et al. The effect of zanoterone, a steroidal androgen receptor antagonist, in men with benign prostatic hyperplasia. The Zanoterone Study

Group. *J Urol*. 1995;154(3):1060–1064.

Berges RR, Windeler J, Trampisch HJ, et al. Randomised, placebo-controlled, double-blind clinical trial of beta-sitosterol in patients with benign prostatic hyperplasia. Beta-sitosterol Study Group. *Lancet*. 1995;345(8964):1529–1532.

Bhasin S, Travison TG, Storer TW, et al. Effect of testosterone supplementation with and without a dual 5α-reductase inhibitor on fat-free mass in men with suppressed testosterone production: a randomized controlled trial. *JAMA*. 2012;307(9):931–939.

Bhindi A, Bhindi B, Kulkarni GS, et al. Modern-day prostate cancer is not meaningfully associated with lower urinary tract symptoms: analysis of a propensity score-matched cohort. *Can Urol Assoc J*. 2017;11(1–2):41–46.

Birch NC, Hurst G, Doyle PT. Serial residual volumes in men with prostatic hypertrophy. *Br J Urol*. 1988;62(6):571–575.

Bird ST, Delaney JA, Brophy JM, et al. Tamsulosin treatment for benign prostatic hyperplasia and risk of severe hypotension in men aged 40–85 years in the United States: risk window analyses using between and within patient methodology. *BMJ*. 2013;347:f6320.

Boccafoschi C, Annoscia S. Confronto fra estratto di Serenoa repens e placebo mediate prova clinica controllata in pazienti con adenomatosi prostatica. *Urologia*. 1983;50:1257–1268.

Boeri L, Capogrosso P, Ventimiglia E, et al. Clinically meaningful improvements in LUTS/BPH severity in men treated with silodosin plus hexanic extract of serenoa repens or silodosin alone. *Sci Rep*. 2017;7(1):15179.

Bohnen AM, Groeneveld FP, Bosch JL. Serum prostate-specific antigen as a predictor of prostate volume in the community: the Krimpen study. *Eur Urol*. 2007;51(6):1645–1652 [discussion 1652–1653].

Bonvissuto G, Minutoli L, Morgia G, et al. Effect of Serenoa repens, lycopene, and selenium on proinflammatory phenotype activation: an in vitro and in vivo comparison study. *Urology*. 2011;77(1):248.e9–248.e16.

Booker A, Suter A, Krnjic A, et al. A phytochemical comparison of saw palmetto products using gas chromatography and (1) H nuclear magnetic resonance spectroscopy metabolomic profiling. *J Pharm Pharmacol*. 2014;66(6):811–822.

Bosch JL, Bohnen AM, Groeneveld FP. Validity of digital rectal examination and serum prostate specific antigen in the estimation of prostate volume in community-based men aged 50 to 78 years: the Krimpen Study. *Eur Urol*. 2004;46(6):753–759.

Bostwick DG, Cooner WH, Denis L, et al. The association of benign prostatic hyperplasia and cancer of the prostate. *Cancer*. 1992;70(1 Suppl):291–301.

Bouchelouche K, Andersen L, Alvarez S, et al. Increased contractile response to phenylephrine in detrusor of patients with bladder outlet obstruction: effect of the alpha1A and alpha1D-adrenergic receptor antagonist tamsulosin. *J Urol*. 2005;173(2):657–661.

Bozeman CB, Carver BS, Caldito G, et al. Prostate cancer in patients with an abnormal digital rectal examination and serum prostate-specific antigen less than 4.0 ng/mL. *Urology*. 2005;66(4):803–807.

Bradley CS, Erickson BA, Messersmith EE, et al. Evidence for the impact of diet, fluid intake, caffeine, alcohol and tobacco on lower urinary tract symptoms: a systematic review. *J Urol*. 2017;198(5):1010–1020.

Brawer MK, Adams G, Epstein H. Terazosin in the treatment of benign prostatic hyperplasia. Terazosin Benign Prostatic Hyperplasia Study Group. *Arch Fam Med*. 1993;2(9):929–935.

Bright E, Cotterill N, Drake M, et al. Developing and validating the International Consultation on Incontinence Questionnaire bladder diary. *Eur Urol*. 2014;66(2):294–300.

Bright E, Drake MJ, Abrams P. Urinary diaries: evidence for the development and validation of diary content, format, and duration. *Neurourol Urodyn*. 2011;30(3):348–352.

Brock G, Broderick G, Roehrborn CG, et al. Tadalafil once daily in the treatment of lower urinary tract symptoms (LUTS) suggestive of benign prostatic hyperplasia (BPH) in men without erectile dysfunction. *BJU Int*. 2013;112(7):990–997.

Brown CT, van der Meulen J, Mundy AR, et al. Defining the components of a self-management programme for men with uncomplicated lower urinary tract symptoms: a consensus approach. *Eur Urol*. 2004;46(2):254–262.

Brown CT, Yap T, Cromwell DA, et al. Self management for men with lower urinary tract symptoms: randomised controlled trial. *BMJ*. 2007;334(7583):25.

Bruskewitz R, Girman CJ, Fowler J, et al. Effect of finasteride on bother and other health-related quality of life aspects associated with benign prostatic hyperplasia. PLESS Study Group. Proscar Long-term Efficacy and Safety Study. *Urology*. 1999;54(4):670–678.

Buck AC. Is there a scientific basis for the therapeutic effects of serenoa repens in benign prostatic hyperplasia? Mechanisms of action. *J Urol*. 2004;172(5 Pt 1):1792–1799.

Burnett-Bowie SA, Roupenian KC, Dere ME, et al. Effects of aromatase inhibition in hypogonadal older men: a randomized, double-blind, placebo-controlled trial. *Clin Endocrinol (Oxf)*. 2009;70(1):116–123.

Buzelin JM, Roth S, Geffriaud-Ricouard C, et al. Efficacy and safety of sustained-release alfuzosin 5 mg in patients with benign prostatic hyperplasia. ALGEBI Study Group. *Eur*

Urol. 1997;31(2):190–198.

Buzelin JM, Fonteyne E, Kontturi M, et al. Comparison of tamsulosin with alfuzosin in the treatment of patients with lower urinary tract symptoms suggestive of bladder outlet obstruction (symptomatic benign prostatic hyperplasia). The European Tamsulosin Study Group. *Br J Urol*. 1997;80(4):597–605.

Cabot AT. The question of castration for enlarged prostate. *Ann Surg*. 1896;24(3):265–309.

Caine M, Perlberg S, Gordon R. The treatment of benign prostatic hypertrophy with flutamide (SCH: 13521): a placebo-controlled study. *J Urol*. 1975;114(4):564–568.

Caine M, Perlberg S, Meretyk S. A placebo-controlled double-blind study of the effect of phenoxybenzamine in benign prostatic obstruction. *Br J Urol*. 1978;50(7):551–554.

Calmasini FB, Candido TZ, Alexandre EC, et al. The beta-3 adrenoceptor agonist, mirabegron relaxes isolated prostate from human and rabbit: new therapeutic indication? *Prostate*. 2015;75(4):440–447.

Capogrosso P, Serino A, Ventimiglia E. Effects of silodosin on sexual function—realistic picture from the everyday clinical practice. *Andrology*. 2015;3(6):1076–1081.

Caremel R, Oger-Roussel S, Behr-Roussel D, et al. Nitric oxide/cyclic guanosine monophosphate signalling mediates an inhibitory action on sensory pathways of the micturition reflex in the rat. *Eur Urol*. 2010;58(4):616–625.

Carraro JC, Raynaud JP, Koch G, et al. Comparison of phytotherapy (Permixon) with finasteride in the treatment of benign prostate hyperplasia: a randomized international study of 1,098 patients. *Prostate*. 1996;29(4):231–240 [discussion 241–242].

Cathcart P, van der Meulen J, Armitage J, et al. Incidence of primary and recurrent acute urinary retention between 1998 and 2003 in England. *J Urol*. 2006;176(1):200–204 [discussion 204].

Champault G, Patel JC, Bonnard AM. A double-blind trial of an extract of the plant Serenoa repens in benign prostatic hyperplasia. *Br J Clin Pharmacol*. 1984;18(3):461–462.

Chang DF, Campbell JR. Intraoperative floppy iris syndrome associated with tamsulosin. *J Cataract Refract Surg*. 2005;31(4):664–673.

Chapple CR, Stott M, Abrams PH, et al. A 12-week placebo-controlled double-blind study of prazosin in the treatment of prostatic obstruction due to benign prostatic hyperplasia. *Br J Urol*. 1992;70(3):285–294.

Chapple CR, Carter P, Christmas TJ, et al. A three month double-blind study of doxazosin as treatment for benign prostatic bladder outlet obstruction. *Br J Urol*. 1994;74(1):50–56.

Chapple CR, Wyndaele JJ, Nordling J, et al. Tamsulosin, the first prostate-selective alpha 1A-adrenoceptor antagonist. A meta-analysis of two randomized, placebo-controlled, multicentre studies in patients with benign prostatic obstruction (symptomatic BPH). European Tamsulosin Study Group. *Eur Urol*. 1996;29(2):155–167.

Chapple CR, Yamanishi T, Chess-Williams R. Muscarinic receptor subtypes and management of the overactive bladder. *Urology*. 2002;60(5 Suppl 1):82–88 [discussion 88–89].

Chapple CR, Wein AJ, Abrams P, et al. Lower urinary tract symptoms revisited: a broader clinical perspective. *Eur Urol*. 2008;54(3):563–569.

Chapple C, Herschorn S, Abrams P, et al. Tolterodine treatment improves storage symptoms suggestive of overactive bladder in men treated with alpha-blockers. *Eur Urol*. 2009;56(3):534–541.

Chapple CR, Montorsi F, Tammela TL, et al. Silodosin therapy for lower urinary tract symptoms in men with suspected benign prostatic hyperplasia: results of an international, randomized, double-blind, placebo- and active-controlled clinical trial performed in Europe. *Eur Urol*. 2011;59(3):342–352.

Chapple CR, Kaplan SA, Mitcheson D, et al. Randomized double-blind, active-controlled phase 3 study to assess 12-month safety and efficacy of mirabegron, a β(3)-adrenoceptor agonist, in overactive bladder. *Eur Urol*. 2013;63(2):296–305.

Charrua A, Cruz CD, Narayanan S, et al. GRC-6211, a new oral specific TRPV1 antagonist, decreases bladder overactivity and noxious bladder input in cystitis animal models. *J Urol*. 2009;181(1):379–386.

Chatziralli IP, Sergentanis TN. Risk factors for intraoperative floppy iris syndrome: a meta-analysis. *Ophthalmology*. 2011;118(4):730–735.

Chen Q, Takahashi S, Zhong S, et al. Function of the lower urinary tract in mice lacking alpha1d-adrenoceptor. *J Urol*. 2005;174(1):370–374.

Chess-Williams R, Chapple CR, Yamanishi T, et al. The minor population of M3-receptors mediate contraction of human detrusor muscle in vitro. *J Auton Pharmacol*. 2001;21(5–6):243–248.

Chodak GW, Keller P, Schoenberg HW. Assessment of screening for prostate cancer using the digital rectal examination. *J Urol*. 1989;141(5):1136–1138.

Choi WS, Cho MC, Lee JW. Efficacy and safety of silodosin in the treatment of lower urinary tract symptoms in elderly men taking antihypertensive medications. *Prostate Int*. 2017;5(3):113–118.

Chon JK, Borkowski A, Partin AW, et al. Alpha 1-adrenoceptor antagonists terazosin and doxazosin induce prostate apoptosis without affecting cell proliferation in patients with benign prostatic hyperplasia. *J Urol*. 1999;161(6):2002–2008.

Choudhury S, Agarwal MM, Mandal AK, et al. Which voiding position is associated with lowest flow rates in healthy adult men? Role of natural voiding position. *Neurourol Urodyn*. 2010;29(3):413–417.

Chow W, Hahn D, Sandhu D. Multicentre controlled trial of indoramin in the symptomatic relief of benign prostatic hypertrophy. *Br J Urol*. 1990;65(1):36–38.

Chung M, Vashi V, Puente J, et al. Clinical pharmacokinetics of doxazosin in a controlled-release gastrointestinal therapeutic system (GITS) formulation. *Br J Clin Pharmacol*. 1999;48(5):678–687.

Clark RV, Hermann DJ, Cunningham GR, et al. Marked suppression of dihydrotestosterone in men with benign prostatic hyperplasia by dutasteride, a dual 5alpha-reductase inhibitor. *J Clin Endocrinol Metab*. 2004;89(5):2179–2184.

Cockett A, Aso Y, Denis L. Prostate symptom score and quality of life assessment. Cockett ATK, Khoury S, Aso Y, et al. *Proceedings of the second international consultation on benign prostatic hyperplasia (BPH); 27-30 June 1993*. Scientific Communication International: Paris; Channel Island, Jersey; 1994:553–555.

Coffey DS, Walsh PC. Clinical and experimental studies of benign prostatic hyperplasia. *Urol Clin North Am*. 1990;17(3):461–475.

Colli E, Rigatti P, Montorsi F, et al. BXL628, a novel vitamin D3 analog arrests prostate growth in patients with benign prostatic hyperplasia: a randomized clinical trial. *Eur Urol*. 2006;49(1):82–86.

Cornu JN, Cussenot O, Haab F, et al. A widespread population study of actual medical management of lower urinary tract symptoms related to benign prostatic hyperplasia across

Europe and beyond official clinical guidelines. *Eur Urol*. 2010;58(3):450–456.

Cornu JN, Abrams P, Chapple CR, et al. A contemporary assessment of nocturia: definition, epidemiology, pathophysiology, and management—a systematic review and meta-analysis. *Eur Urol*. 2012;62(5):877–890.

Corona G, Mannucci E, Petrone L, et al. Association of hypogonadism and type II diabetes in men attending an outpatient erectile dysfunction clinic. *Int J Impot Res*. 2006;18(2):190–197.

Corona G, Tirabassi G, Santi D, et al. Sexual dysfunction in subjects treated with inhibitors of 5α-reductase for benign prostatic hyperplasia: a comprehensive review and meta-analysis. *Andrology*. 2017;5(4):671–678.

Coyne K, Revicki D, Hunt T, et al. Psychometric validation of an overactive bladder symptom and health-related quality of life questionnaire: the OAB-q. *Qual Life Res*. 2002;11(6):563–574.

Coyne KS, Wein AJ, Tubaro A, et al. The burden of lower urinary tract symptoms: evaluating the effect of LUTS on health-related quality of life, anxiety and depression: EpiLUTS. *BJU Int*. 2009;103(Suppl 3):4–11.

Cukier J, Ducassou J, Le Guillou M, et al. Permixon versus placebo; resultats d'une ‘etude multicentrique. *Comptes Rend Therapeut Pharmacol Clin*. 1985;4:15–21.

Cunha GR, Lung B, Reese B. Glandular epithelial induction by embryonic mesenchyme in adult bladder epithelium of BALB/c mice. *Invest Urol*. 1980;17(4):302–304.

Dahm P, Brasure M, MacDonald R, et al. Comparative effectiveness of newer medications for lower urinary tract symptoms attributed to benign prostatic hyperplasia: a systematic review and meta-analysis. *Eur Urol*. 2017;71(4):570–581.

de Mey C, Michel MC, McEwen J, et al. A double-blind comparison of terazosin and tamsulosin on their differential effects on ambulatory blood pressure and nocturnal orthostatic stress testing. *Eur Urol*. 1998;33(5):481–488.

De Mey C. Alpha1-blocker therapy for lower urinary tract symptoms suggestive of benign prostatic obstruction: what are the relevant differences in randomised controlled trials? *Eur Urol*. 2000;38(Suppl 1):25–39.

de Reijke TM, Klarskov P. Comparative efficacy of two alpha-adrenoreceptor antagonists, doxazosin and alfuzosin, in patients with lower urinary tract symptoms from benign prostatic enlargement. *BJU Int*. 2004;93(6):757–762.

Debruyne FM, Jardin A, Colloi D, et al. Sustained-release alfuzosin, finasteride and the combination of both in the treatment of benign prostatic hyperplasia. European ALFIN Study Group. *Eur Urol*. 1998;34(3):169–175.

Debruyne F, Koch G, Boyle P, et al. Comparison of a phytotherapeutic agent (Permixon) with an alpha-blocker (Tamsulosin) in the treatment of benign prostatic hyperplasia: a 1-year randomized international study. *Eur Urol*. 2002;41(5):497–506.

Debruyne F, Barkin J, van Erps P, et al. Efficacy and safety of long-term treatment with the dual 5 alpha-reductase inhibitor dutasteride in men with symptomatic benign prostatic hyperplasia. *Eur Urol*. 2004;46(4):488–494.

Debruyne F, Gres AA, Arustamov DL. Placebo-controlled dose-ranging phase 2 study of subcutaneously administered LHRH antagonist cetrorelix in patients with symptomatic benign prostatic hyperplasia. *Eur Urol*. 2008;54(1):170–177.

Debruyne F, Tzvetkov M, Altarac S, et al. Dose-ranging study of the luteinizing hormone-releasing hormone receptor antagonist cetrorelix pamoate in the treatment of patients with symptomatic benign prostatic hyperplasia. *Urology*.

2010;76(4):927–933.

DeKlerk DP, Coffey DS, Ewing LL, et al. Comparison of spontaneous and experimentally induced canine prostatic hyperplasia. *J Clin Invest*. 1979;64(3):842–849.

Descotes JL, Rambeaud JJ, Deschaseaux P, et al. Placebo-controlled evaluation of the efficacy and tolerability of Permixon® in benign prostatic hyperplasia after exclusion of placebo responders. *Clin Drug Investig*. 1995;9(5):291–297.

Di Silverio F, Bosman C, Salvatori M, et al. Combination therapy with rofecoxib and finasteride in the treatment of men with lower urinary tract symptoms (LUTS) and benign prostatic hyperplasia (BPH). *Eur Urol*. 2005;47(1):72–78 [discussion 78–79].

Digesu GA, Verdi E, Cardozo L, et al. Phase IIb, multicenter, double-blind, randomized, placebo-controlled, parallel-group study to determine effects of elocalcitol in women with overactive bladder and idiopathic detrusor overactivity. *Urology*. 2012;80(1):48–54.

Ding H, Du W, Hou ZZ, et al. Silodosin is effective for treatment of LUTS in men with BPH: a systematic review. *Asian J Androl*. 2013;15(1):121–128.

Dmochowski R, Roehrborn C, Klise S, et al. Urodynamic effects of once daily tadalafil in men with lower urinary tract symptoms secondary to clinical benign prostatic hyperplasia: a randomized, placebo controlled 12-week clinical trial. *J Urol*. 2010;183(3):1092–1097.

Dong Y, Hao L, Shi Z, et al. Efficacy and safety of tadalafil monotherapy for lower urinary tract symptoms secondary to benign prostatic hyperplasia: a meta-analysis. *Urol Int*. 2013;91(1):10–18.

Donkervoort T, Zinner NR, Sterling AM, et al. Megestrol acetate in treatment of benign prostatic hypertrophy. *Urology*. 1975;6(5):580–587.

Drake MJ, Chapple C, Sokol R, et al. Long-term safety and efficacy of single-tablet combinations of solifenacin and tamsulosin oral controlled absorption system in men with storage and voiding lower urinary tract symptoms: results from the NEPTUNE Study and NEPTUNE II open-label extension. *Eur Urol*. 2015;67(2):262–270.

Drake MJ, Kanai A, Bijos DA, et al. The potential role of unregulated autonomous bladder micromotions in urinary storage and voiding dysfunction; overactive bladder and detrusor underactivity. *BJU Int*. 2017;119(1):22–29.

Drake MJ. Do we need a new definition of the overactive bladder syndrome? ICI-RS 2013. *Neurourol Urodyn*. 2014;33(5):622–624.

D'Silva KA, Dahm P, Wong CL. Does this man with lower urinary tract symptoms have bladder outlet obstruction?: the Rational Clinical Examination: a systematic review. *JAMA*. 2014;312(5):535–542.

Eckhardt MD, van Venrooij GE, Boon TA. Symptoms, prostate volume, and urodynamic findings in elderly male volunteers without and with LUTS and in patients with LUTS suggestive of benign prostatic hyperplasia. *Urology*. 2001;58(6):966–971.

Egerdie RB, Auerbach S, Roehrborn CG, et al. Tadalafil 2.5 or 5 mg administered once daily for 12 weeks in men with both erectile dysfunction and signs and symptoms of benign prostatic hyperplasia: results of a randomized, placebo-controlled, double-blind study. *J Sex Med*. 2012;9(1):271–281.

el Etreby MF, Nishino Y, Habenicht UF, et al. Atamestane, a new aromatase inhibitor for the management of benign prostatic hyperplasia. *J Androl*. 1991;12(6):403–414.

Elhilali MM, Ramsey EW, Barkin J, et al. A multicenter, randomized, double-blind, placebo-controlled study to evaluate the safety and efficacy of terazosin in the treatment of benign prostatic hyperplasia. *Urology*. 1996;47(3):335–342.

Ellem SJ, Risbridger GP. Treating prostate cancer: a rationale for targeting local oestrogens. *Nat Rev Cancer*. 2007;7(8):621–627.

Emberton M, Anson K. Acute urinary retention in men: an age old problem. *BMJ*. 1999;318(7188):921–925.

Emberton M, Marberger M, de la Rosette J. Understanding patient and physician perceptions of benign prostatic hyperplasia in Europe: the Prostate Research on Behaviour and Education (PROBE) Survey. *Int J Clin Pract*. 2008;62(1):18–26.

Emberton M. Medical treatment of benign prostatic hyperplasia: physician and patient preferences and satisfaction. *Int J Clin Pract*. 2010;64(10):1425–1435.

Emili E, Lo Cigno M, Petrone U. Risultati clinici su un nuovo farmaco nella terapia dell ’ ipertofi a della prostate (Permixon). *Urologia*. 1983;50(5):1042–1048.

Eri L, Tveter K. A prospective placebo-controlled study of the antiandrogen Casodex as treatment for patients with benign prostatic hyperplasia. *J Urol*. 1993;150:90–94.

Everaerts W, Zhen X, Ghosh D, et al. Inhibition of the cation channel TRPV4 improves bladder function in mice and rats with cyclophosphamide-induced cystitis. *Proc Natl Acad Sci USA*. 2010;107(44):19084–19089.

Ezz el Din KE, de Wildt MJ, Rosier PF, et al. The correlation between urodynamic and cystoscopic findings in elderly men with voiding complaints. *J Urol*. 1996;155(3):1018–1022.

Fawzy A, Braun K, Lewis GP, et al. Doxazosin in the treatment of benign prostatic hyperplasia in normotensive patients: a multicenter study. *J Urol*. 1995;154(1):105–109.

Fibbi B, Morelli A, Vignozzi L, et al. Characterization of phosphodiesterase type 5 expression and functional activity in the human male lower urinary tract. *J Sex Med*. 2010;7(1 Pt 1):59–69.

Fisher E, Subramonian K, Omar MI. The role of alpha blockers prior to removal of urethral catheter for acute urinary retention in men. *Cochrane Database Syst Rev*. 2014;(6) [CD006744].

Fitzpatrick JM. The natural history of benign prostatic hyperplasia. *BJU Int*. 2006;97(Suppl 2):3–6.

Fitzpatrick JM, Desgrandchamps F, Adjali K, et al. Management of acute urinary retention: a worldwide survey of 6074 men with benign prostatic hyperplasia. *BJU Int*. 2012;109(1):88–95.

Flanigan RC, Reda DJ, Wasson JH, et al. 5-year outcome of surgical resection and watchful waiting for men with moderately symptomatic benign prostatic hyperplasia: a Department of Veterans Affairs cooperative study. *J Urol*. 1998;160(1):12–16 [discussion 16–17].

Foley SJ, Soloman LZ, Wedderburn AW, et al. A prospective study of the natural history of hematuria associated with benign prostatic hyperplasia and the effect of finasteride. *J Urol*. 2000;163(2):496–498.

Fourcade RO, Théret N, Taïeb C. Profile and management of patients treated for the first time for lower urinary tract symptoms/benign prostatic hyperplasia in four European countries. *BJU Int*. 2008;101(9):1111–1118.

Freeman RM, Adekanmi O, Waterfield MR, et al. The effect of cannabis on urge incontinence in patients with multiple sclerosis: a multicentre, randomised placebo-controlled trial (CAMS-LUTS). *Int Urogynecol J Pelvic Floor Dysfunct*. 2006;17(6):636–641.

Fujimoto K, Hirao Y, Ohashi Y, et al. The effects of chlormadinone acetate on lower urinary tract symptoms and erectile functions of patients with benign prostatic hyperplasia: a prospective multicenter clinical study. *Adv Urol*. 2013;2013:584678.

Fukuta F, Masumori N, Mori M, et al. Natural history of lower urinary tract symptoms in Japanese men from a 15-year longitudinal community-based study. *BJU Int*. 2012;110(7):1023–1029.

Füllhase C, Soler R, Gratzke C. New strategies in treating male lower urinary tract symptoms. *Curr Opin Urol*. 2014;24(1):29–35.

Füllhase C, Soler R, Gratzke C, et al. Urodynamic evaluation of fesoterodine metabolite, doxazosin and their combination in a rat model of partial urethral obstruction. *BJU Int*. 2010;106(2):287–293.

Fusco F, Palmieri A, Ficarra V, et al. α_1-Blockers improve benign prostatic obstruction in men with lower urinary tract symptoms: a systematic review and meta-analysis of urodynamic studies. *Eur Urol*. 2016;69(6):1091–1101.

Gacci M, Del Popolo G, Macchiarella A, et al. Vardenafil improves urodynamic parameters in men with spinal cord injury: results from a single dose, pilot study. *J Urol*. 2007;178(5):2040–2043.

Gacci M, Eardley I, Giuliano F, et al. Critical analysis of the relationship between sexual dysfunctions and lower urinary tract symptoms due to benign prostatic hyperplasia. *Eur Urol*. 2011;60(4):809–825.

Gacci M, Corona G, Salvi M, et al. A systematic review and meta-analysis on the use of phosphodiesterase 5 inhibitors alone or in combination with α-blockers for lower urinary tract symptoms due to benign prostatic hyperplasia. *Eur Urol*. 2012;61(5):994–1003.

Gacci M, Vittori G, Tosi N, et al. A randomized, placebo-controlled study to assess safety and efficacy of vardenafil

10 mg and tamsulosin 0.4 mg vs. tamsulosin 0.4 mg alone in the treatment of lower urinary tract symptoms secondary to benign prostatic hyperplasia. *J Sex Med*. 2012;9(6):1624–1633.

Gacci M, Ficarra V, Sebastianelli A, et al. Impact of medical treatments for male lower urinary tract symptoms due to benign prostatic hyperplasia on ejaculatory function: a systematic review and meta-analysis. *J Sex Med*. 2014;11(6):1554–1566.

Gacci M, Corona G, Vignozzi L, et al. Metabolic syndrome and benign prostatic enlargement: a systematic review and meta-analysis. *BJU Int*. 2015;115(1):24–31.

Gacci M, Corona G, Sebastianelli A, et al. Male lower urinary tract symptoms and cardiovascular events: a systematic review and meta-analysis. *Eur Urol*. 2016;70(5):788–796.

Gacci M, Andersson KE, Chapple C, et al. Latest evidence on the use of phosphodiesterase type 5 inhibitors for the treatment of lower urinary tract symptoms secondary to benign prostatic hyperplasia. *Eur Urol*. 2016;70(1):124–133.

Gao W, Kearbey JD, Nair VA, et al. Comparison of the pharmacological effects of a novel selective androgen receptor modulator, the 5alpha-reductase inhibitor finasteride, and the antiandrogen hydroxyflutamide in intact rats: new approach for benign prostate hyperplasia. *Endocrinology*. 2004;145(12):5420–5428.

Garimella PS, Fink HA, Macdonald R, et al. Naftopidil for the treatment of lower urinary tract symptoms compatible with benign prostatic hyperplasia. *Cochrane Database Syst Rev*. 2009;(4) [CD007360].

Geller J, Nelson CG, Albert JD, et al. Effect of megestrol acetate on uroflow rates in patients with benign prostatic hypertrophy: double-blind study. *Urology*. 1979;14(5):467–474.

Gerber GS, Goldfischer ER, Karrison TG, et al. Serum creatinine measurements in men with lower urinary tract symptoms secondary to benign prostatic hyperplasia. *Urology*. 1997;49(5):697–702.

Gerber GS, Kuznetsov D, Johnson BC, et al. Randomized, double-blind, placebo-controlled trial of saw palmetto in men with lower urinary tract symptoms. *Urology*. 2001;58:960–964.

Gillenwater JY, Conn RL, Chrysant SG, et al. Doxazosin for the treatment of benign prostatic hyperplasia in patients with mild to moderate essential hypertension: a double-blind, placebo-controlled, dose-response multicenter study. *J Urol*. 1995;154(1):110–115.

Gingell JC, Knonagel H, Kurth KH, et al. Placebo controlled double-blind study to test the efficacy of the aromatase inhibitor atamestane in patients with benign prostatic hyperplasia not requiring operation. The Schering 90.062 Study Group. *J Urol*. 1995;154(2 Pt 1):399–401.

Giuliano F. Impact of medical treatments for benign prostatic hyperplasia on sexual function. *BJU Int*. 2006;97(Suppl 2):34–38.

Glienke W, Dolgova Y, Müller I, et al. Induction of apoptosis in human prostate stromal cells by 4-hydroxytamoxifen: an alternative therapy for benign prostate hyperplasia. *World J Urol*. 2004;22(6):452–456.

Goldstein I. Oral phentolamine: an alpha-1, alpha-2 adrenergic antagonist for the treatment of erectile dysfunction. *Int J Impot Res*. 2000;12(Suppl 1):S75–S80.

Gonzalez G, Guendulain C, Maffrand C, et al. Comparison of the effect of the aromatase inhibitor, anastrazole, to the antioestrogen, tamoxifen citrate, on canine prostate and semen. *Reprod Domest Anim*. 2009;44(Suppl 2):316–319.

Gormley GJ, Stoner E, Bruskewitz RC, et al. The effect of finasteride in men with benign prostatic hyperplasia. The Finasteride Study Group. *N Engl J Med*. 1992;327(17):1185–1191.

Gosselaar C, Roobol MJ, Roemeling S, et al. The role of the digital rectal examination in subsequent screening visits in the European randomized study of screening for prostate cancer (ERSPC), Rotterdam. *Eur Urol*. 2008;54(3):581–588.

Gotoh M, Kamihira O, Kinukawa T, et al. Comparison of tamsulosin and naftopidil for efficacy and safety in the treatment of benign prostatic hyperplasia: a randomized controlled trial. *BJU Int*. 2005;96(4):581–586.

Gratzke P, Kirby RS. Doxazosin GITS versus regular doxazosin in benign prostatic hyperplasia. Restoring urine flow and sexual function more easily. *MMW Fortschr Med*. 2000;142(26–27):40.

Gratzke C, Bachmann A, Descazeaud A, et al. EAU guidelines on the assessment of non-neurogenic male lower urinary tract symptoms including benign prostatic obstruction. *Eur Urol*. 2015;67(6):1099–1109.

Griffiths CJ, Rix D, MacDonald AM, et al. Noninvasive measurement of bladder pressure by controlled inflation of a penile cuff. *J Urol*. 2002;167(3):1344–1347.

Groves HK, Chang D, Palazzi K, et al. The incidence of acute urinary retention secondary to BPH is increasing among California men. *Prostate Cancer Prostatic Dis*. 2013;16(3):260–265.

Guess HA, Heyse JF, Gormley GJ. The effect of finasteride on prostate-specific antigen in men with benign prostatic hyperplasia. *Prostate*. 1993;22(1):31–37.

Gup DI, Shapiro E, Baumann M, et al. Contractile properties of human prostate adenomas and the development of infravesical obstruction. *Prostate*. 1989;15(2):105–114.

Habib FK, Wyllie MG. Not all brands are created equal: a comparison of selected components of different brands of *Serenoa repens* extract. *Prostate Cancer Prostatic Dis*. 2004;7(3):195–200.

Hampel C, Dolber PC, Smith MP, et al. Modulation of bladder alpha1-adrenergic receptor subtype expression by bladder outlet obstruction. *J Urol*. 2002;167(3):1513–1521.

Hatzimouratidis K. A review of the use of tadalafil in the treatment of benign prostatic hyperplasia in men with and without erectile dysfunction. *Ther Adv Urol*. 2014;6(4):135–147.

Hedlund H, Andersson KE, Ek A. Effects of prazosin in patients with benign prostatic obstruction. *J Urol*. 1983;130(2):275–278.

Hizli F, Uygur MC. A prospective study of the efficacy of Serenoa repens, tamsulosin, and Serenoa repens plus tamsulosin treatment for patients with benign prostate hyperplasia. *Int Urol Nephrol*. 2007;39(3):879–886.

Holton KF, Marshall LM, Shannon J, et al. Dietary antioxidants and longitudinal changes in lower urinary tract symptoms in elderly men: the Osteoporotic Fractures in Men Study. *Eur Urol Focus*. 2016;2(3):310–318.

Holzapfel NP, Holzapfel BM, Champ S, et al. The potential role of lycopene for the prevention and therapy of prostate cancer: from molecular mechanisms to clinical evidence. *Int J Mol Sci*. 2013;14(7):14620–14646.

Homma Y, Yoshida M, Seki N, et al. Symptom assessment tool for overactive bladder syndrome—overactive bladder symptom score. *Urology*. 2006;68:318–323.

Hong SK, Lee ST, Jeong SJ, et al. Chronic kidney disease among men with lower urinary tract symptoms due to benign prostatic hyperplasia. *BJU Int*. 2010;105(10):1424–1428.

Hsieh TF, Yang YW, Lee SS, et al. Use of 5-alpha-reductase inhibitors did not increase the risk of cardiovascular diseases in patients with benign prostate hyperplasia: a five-year follow-up study. *PLoS ONE*. 2015;10(3):e0119694.

Hudson PB, Boake R, Trachtenberg J, et al. Efficacy of finasteride is maintained in patients with benign prostatic hyperplasia treated for 5 years. The North American Finasteride Study Group. *Urology*. 1999;53(4):690–695.

Iacovou JW, Dunn M. Indoramin—an effective new drug in the management of bladder outflow obstruction. *Br J Urol*. 1987;60(6):526–528.

Ichihara K, Masumori N, Fukuta F, et al. A randomized controlled study of the efficacy of tamsulosin monotherapy and its combination with mirabegron for overactive bladder induced by benign prostatic obstruction. *J Urol*. 2015;193(3):921–926.

Ikemoto I, Kiyota H, Ohishi Y, et al. Usefulness of tamsulosin hydrochloride and naftopidil in patients with urinary disturbances caused by benign prostatic hyperplasia: a comparative, randomized, two-drug crossover study. *Int J Urol*. 2003;10(11):587–594.

Ilio KY, Park II, Pins MR, et al. Apoptotic activity of doxazosin on prostate stroma in vitro is mediated through an autocrine expression of TGF-beta1. *Prostate*. 2001;48(3):131–135.

Irwin E, Milsom I, Hunskaar S, et al. Population-based survey of urinary incontinence, overactive bladder, and other lower urinary tract symptoms in five countries: results of the EPIC Study. *Eur Urol*. 2006;50:1306–1315.

Ishihama H, Momota Y, Yanase H, et al. Activation of alpha1D adrenergic receptors in the rat urothelium facilitates the micturition reflex. *J Urol*. 2006;175(1):358–364.

Ishizuka O, Imamura T, Kurizaki Y, et al. Male lower urinary tract symptoms and α1D-adrenoceptors. *Int J Urol*. 2013;20(1):73–78.

Jacobsen SJ, Jacobson DJ, Girman CJ, et al. Natural history of prostatism: risk factors for acute urinary retention. *J Urol*. 1997;158(2):481–487.

Jacobsen SJ, Jacobson DJ, Girman CJ, et al. Treatment for benign prostatic hyperplasia among community dwelling men: the Olmsted County study of urinary symptoms and health status. *J Urol*. 1999;162(4):1301–1306.

Jardin A, Bensadoun H, Delauche-Cavallier MC, et al. Alfuzosin for treatment of benign prostatic hypertrophy. The BPH-ALF Group. *Lancet*. 1991;337(8755):1457–1461.

Jørgensen JB, Jensen KM, Mogensen P. Age-related variation in urinary flow variables and flow curve patterns in elderly males. *Br J Urol*. 1992;69(3):265–271.

Juniewicz PE, Hoekstra SJ, Lemp BM, et al. Effect of combination treatment with zanoterone (WIN 49596), a steroidal androgen receptor antagonist, and finasteride (MK-906), a steroidal 5 alpha-reductase inhibitor, on the prostate and testes of beagle dogs. *Endocrinology*. 1993;133(2):904–913.

Kaplan SA, D'Alisera PM. Tolerability of alpha-blockade with doxazosin as a therapeutic option for symptomatic benign prostatic hyperplasia in the elderly patient: a pooled analysis of seven double-blind, placebo-controlled studies. *J Gerontol A Biol Sci Med Sci*. 1998;53(3):M201–M206.

Kaplan S, Naslund M. Public, patient, and professional attitudes toward the diagnosis and treatment of enlarged prostate: a landmark national US survey. *Int J Clin Pract*. 2006;60(10):1157–1165.

Kaplan SA, Soldo KA, Olsson CA, et al. Terazosin and doxazosin in normotensive men with symptomatic prostatism: a pilot study to determine the effect of dosing regimen on efficacy and safety. *Eur Urol*. 1995;28(3):223–228.

Kaplan SA, Walmsley K, Te AE. Tolterodine extended release attenuates lower urinary tract symptoms in men with benign prostatic hyperplasia. *J Urol*. 2005;174(6):2273–2275.

Kaplan SA, Roehrborn CG, Rovner ES, et al. Tolterodine and tamsulosin for treatment of men with lower urinary tract symptoms and overactive bladder: a randomized controlled trial. *JAMA*. 2006;296(19):2319–2328.

Kaplan SA, Gonzalez RR, Te AE. Combination of alfuzosin and sildenafil is superior to monotherapy in treating lower urinary tract symptoms and erectile dysfunction. *Eur Urol*. 2007;51(6):1717–1723.

Kaplan SA, McCammon K, Fincher R, et al. Safety and tolerability of solifenacin add-on therapy to alpha-blocker treated men with residual urgency and frequency. *J Urol*. 2009;182(6):2825–2830.

Kaplan SA, Roehrborn CG, Gong J, et al. Add-on fesoterodine for residual storage symptoms suggestive of overactive bladder in men receiving α-blocker treatment for lower urinary tract symptoms. *BJU Int*. 2012;109(12):1831–1840.

Kaplan SA, Lee JY, Meehan AG, et al. Time course of incident adverse experiences associated with doxazosin, finasteride and combination therapy in men with benign prostatic hyperplasia: the MTOPS trial. *J Urol*. 2016;195(6):1825–1829.

Kawabe K, Yoshida M, Homma Y. Silodosin, a new alpha1A-adrenoceptor-selective antagonist for treating benign prostatic hyperplasia: results of a phase III randomized, placebo-controlled, double-blind study in Japanese men. *BJU Int*. 2006;98(5):1019–1024.

Kawai Y, Oka M, Yoshinaga R, et al. Effects of the phosphodiesterase 5 inhibitor Tadalafil on bladder function in a rat model of partial bladder outlet obstruction. *Neurourol Urodyn*. 2016;35(4):444–449.

Kay GG, Ebinger U. Preserving cognitive function for patients with overactive bladder: evidence for a differential effect with darifenacin. *Int J Clin Pract*. 2008;62(11):1792–1800.

Kayikci A, Cam K, Kacagan C, et al. Free prostate-specific antigen is a better tool than total prostate-specific antigen at predicting prostate volume in patients with lower urinary tract symptoms. *Urology*. 2012;80(5):1088–1092.

Keane PF, Timoney AG, Kiely E, et al. Response of the benign hypertrophied prostate to treatment with an LHRH analogue. *Br J Urol*. 1988;62(2):163–165.

Kedia GT, Uckert S, Kedia M, et al. Effects of phosphodiesterase inhibitors on contraction induced by endothelin-1 of isolated human prostatic tissue. *Urology*. 2009;73(6):1397–1401.

Khasriya R, Khan S, Lunawat R, et al. The inadequacy of urinary dipstick and microscopy as surrogate markers of urinary tract infection in urological outpatients with lower urinary tract symptoms without acute frequency and dysuria. *J Urol*. 2010;183(5):1843–1847.

Khullar V, Amarenco G, Angulo JC, et al. Efficacy and tolerability of mirabegron, a β(3)-adrenoceptor agonist, in patients with overactive bladder: results from a randomised European-Australian phase 3 trial. *Eur Urol*. 2013;63(2):283–295.

Kim SW, Park NC, Lee SW, et al. Efficacy and safety of a fixed-dose combination therapy of tamsulosin and tadalafil for patients with lower urinary tract symptoms and erectile dysfunction: results of a randomized, double-blinded, active-controlled trial. *J Sex Med*. 2017;14(8):1018–1027.

Kirby RS. A randomized, double-blind crossover study of tamsulosin and controlled-release doxazosin in patients with benign prostatic hyperplasia. *BJU Int*. 2003;91(1):41–44.

Kirby RS, Coppinger SW, Corcoran MO, et al. Prazosin in the treatment of prostatic obstruction. A placebo-controlled study.

Br J Urol. 1987;60(2):136–142.

Kirby RS. Terazosin in benign prostatic hyperplasia: effects on blood pressure in normotensive and hypertensive men. *Br J Urol*. 1998;82(3):373–379.

Kirby RS, Andersen M, Gratzke P, et al. A combined analysis of double-blind trials of the efficacy and tolerability of doxazosin-gastrointestinal therapeutic system, doxazosin standard and placebo in patients with benign prostatic hyperplasia. *BJU Int*. 2001;87(3):192–200.

Kirby RS, Chapple CR, Sethia K, et al. Morning vs evening dosing with doxazosin in benign prostatic hyperplasia: efficacy and safety. *Prostate Cancer Prostatic Dis*. 1998;1(3):163–171.

Kirby RS, Roehrborn C, Boyle P, et al. Efficacy and tolerability of doxazosin and finasteride, alone or in combination, in treatment of symptomatic benign prostatic hyperplasia: the Prospective European Doxazosin and Combination Therapy (PREDICT) trial. *Urology*. 2003;61(1):119–126.

Klarskov P, Andersen JT, Asmussen CF, et al. Symptoms and signs predictive of the voiding pattern after acute urinary retention in men. *Scand J Urol Nephrol*. 1987;21(1):23–28.

Klippel KF, Hiltl DM, Schipp B. A multicentric, placebo-controlled, double-blind clinical trial of beta-sitosterol (phytosterol) for the treatment of benign prostatic hyperplasia. German BPH-Phyto Study group. *Br J Urol*. 1997;80(3):427–432.

Ko YH, Kim JW, Kang SG, et al. The efficacy of in-and-out catheterization as a way of trial without catheterization strategy for treatment of acute urinary retention induced by benign prostate hyperplasia: variables predicting success outcome. *Neurourol Urodyn*. 2012;31(4):460–464.

Kobayashi S, Tang R, Wang B, et al. Localization of endothelin receptors in the human prostate. *J Urol*. 1994;151(3):763–

766.

Koch WF, Ezz el Din K, de Wildt MJ, et al. The outcome of renal ultrasound in the assessment of 556 consecutive patients with benign prostatic hyperplasia. *J Urol*. 1996;155(1):186–189.

Kojima Y, Sasaki S, Kubota Y, et al. Up-regulation of α1a and α1d-adrenoceptors in the prostate by administration of subtype selective α1-adrenoceptor antagonist tamsulosin in patients with benign prostatic hyperplasia. *J Urol*. 2011;186(4):1530–1536.

Kono M, Nakamura Y, Ishiura Y, et al. Central muscarinic receptor subtypes regulating voiding in rats. *J Urol*. 2006;175(1):353–357.

Kranse R, van Mastrigt R. Causes for variability in repeated pressure-flow measurements. *Urology*. 2003;61(5):930–934.

Kristal AR, Arnold KB, Schenk JM, et al. Dietary patterns, supplement use, and the risk of symptomatic benign prostatic hyperplasia: results from the prostate cancer prevention trial. *Am J Epidemiol*. 2008;167(8):925–934.

Kupelian V, Wei JT, O'Leary MP, et al. Prevalence of lower urinary tract symptoms and effect on quality of life in a racially and ethnically diverse random sample: the Boston Area Community Health (BACH) Survey. *Arch Intern Med*. 2006;166(21):2381–2387.

Kyprianou N, Litvak JP, Borkowski A, et al. Induction of prostate apoptosis by doxazosin in benign prostatic hyperplasia. *J Urol*. 1998;159(6):1810–1815.

Lazzeri M, Haese A, de la Taille A, et al. Serum isoform [-2]proPSA derivatives significantly improve prediction of prostate cancer at initial biopsy in a total PSA range of 2–10 ng/ml: a multicentric European study. *Eur Urol*. 2013;63(6):986–994.

Lee JH, Kwon H, Park YW, et al. Relationship of estimated glomerular filtration rate with lower urinary tract symptoms/benign prostatic hyperplasia measures in middle-aged men with moderate to severe lower urinary tract symptoms. *Urology*. 2013;82(6):1381–1385.

Lee KS, Choo MS, Kim DY, et al. Combination treatment with propiverine hydrochloride plus doxazosin controlled release gastrointestinal therapeutic system formulation for overactive bladder and coexisting benign prostatic obstruction: a prospective, randomized, controlled multicenter study. *J Urol*. 2005;174(4 Pt 1):1334–1338.

Lee SS, Yang YW, Tsai TH, et al. 5-alpha-reductase inhibitors and the risk of diabetes mellitus: a nationwide population-based study. *Prostate*. 2016;76(1):41–47.

Leon LA, Hoffman BE, Gardner SDJ, et al. Effects of the beta 3-adrenergic receptor agonist disodium 5-[(2R)-2-[[(2R)-2-(3-chlorophenyl)-2-hydroxyethyl]amino]propyl]-1,3-benzodioxole-2,2-dicarboxylate (CL-316243) on bladder micturition reflex in spontaneously hypertensive rats. *J Pharmacol Exp Ther*. 2008;326(1):178–185.

Lepor H. Phase III multicenter placebo-controlled study of tamsulosin in benign prostatic hyperplasia. Tamsulosin Investigator Group. *Urology*. 1998;51(6):892–900.

Lepor H. Long-term evaluation of tamsulosin in benign prostatic hyperplasia: placebo-controlled, double-blind extension of phase III trial. Tamsulosin Investigator Group. *Urology*. 1998;51(6):901–906.

Lepor H, Gup DI, Baumann M, et al. Laboratory assessment of terazosin and alpha-1 blockade in prostatic hyperplasia. *Urology*. 1988;32(6 Suppl):21–26.

Lepor H, Auerbach S, Puras-Baez A, et al. A randomized, placebo-controlled multicenter study of the efficacy and safety of terazosin in the treatment of benign prostatic hyperplasia. *J Urol*. 1992;148(5):1467–1474.

Lepor H, Williford WO, Barry MJ, et al. The efficacy of terazosin, finasteride, or both in benign prostatic hyperplasia. Veterans Affairs Cooperative Studies Benign Prostatic Hyperplasia Study Group. *N Engl J Med*. 1996;335(8):533–539.

Lepor H, Kaplan SA, Klimberg I, et al. Doxazosin for benign prostatic hyperplasia: long-term efficacy and safety in hypertensive and normotensive patients. The Multicenter Study Group. *J Urol*. 1997;157(2):525–530.

Levin RM, Haugaard N, O'Connor L, et al. Obstructive response of human bladder to BPH vs. rabbit bladder response to partial outlet obstruction: a direct comparison. *Neurourol Urodyn*. 2000;19(5):609–629.

Levin RM, Riffaud JP, Bellamy F, et al. Effects of Tadenan pretreatment on bladder physiology and biochemistry following partial outlet obstruction. *J Urol*. 1996;156(6):2084–2088.

Lewandowski J, Sinski M, Symonides B, et al. Beneficial influence of carvedilol on urologic indices in patients with hypertension and benign prostatic hyperplasia: results of a randomized, crossover study. *Urology*. 2013;82(3):660–665.

Liao CH, Kuo YC, Kuo HC. Predictors of successful first-line antimuscarinic monotherapy in men with enlarged prostate and predominant storage symptoms. *Urology*. 2013;81(5):1030–1033.

Lieber MM, Jacobson DJ, McGree ME, et al. Intravesical prostatic protrusion in men in Olmsted County, Minnesota. *J Urol*. 2009;182(6):2819–2824.

Liguori G, Trombetta C, De Giorgi G, et al. Efficacy and safety of combined oral therapy with tadalafil and alfuzosin: an integrated approach to the management of patients with lower urinary tract symptoms and erectile dysfunction. Preliminary report. *J Sex Med*. 2009;6(2):544–552.

Lim KB, Ho H, Foo KT, et al. Comparison of intravesical prostatic protrusion, prostate volume and serum prostatic-specific antigen in the evaluation of bladder outlet obstruction. *Int J Urol*. 2006;13(12):1509–1513.

Lin WL, Hsieh YW, Lin CL, et al. A population-based nested case-control study: the use of 5-alpha-reductase inhibitors and the increased risk of osteoporosis diagnosis in patients with benign prostate hyperplasia. *Clin Endocrinol (Oxf)*. 2015;82(4):503–508.

Liu L, Zheng S, Han P, et al. Phosphodiesterase-5 inhibitors for lower urinary tract symptoms secondary to benign prostatic hyperplasia: a systematic review and meta-analysis. *Urology*. 2011;77(1):123–129.

Liu L, Zhao S, Li F, et al. Effect of 5α-reductase inhibitors on sexual function: a meta-analysis and systematic review of randomized controlled trials. *J Sex Med*. 2016;13(9):1297–1310.

Livingstone DE, Barat P, Di Rollo EM, et al. 5α-Reductase type 1 deficiency or inhibition predisposes to insulin resistance, hepatic steatosis, and liver fibrosis in rodents. *Diabetes*. 2015;64(2):447–458.

Lowe FC. Coadministration of tamsulosin and three antihypertensive agents in patients with benign prostatic hyperplasia: pharmacodynamic effect. *Clin Ther*. 1997;19(4):730–742.

Lowe FC, Ku JC. Phytotherapy in treatment of benign prostatic hyperplasia: a critical review. *Urology*. 1996;48(1):12–20.

Lowe FC, Fagelman E. Phytotherapy in the treatment of benign prostatic hyperplasia: an update. *Urology*. 1999;53(4):671–678.

Lukacs B, Blondin P, MacCarthy C, et al. Safety profile of 3 months’ therapy with alfuzosin in 13,389 patients suffering from benign prostatic hypertrophy. *Eur Urol*. 1996;29(1):29–

35.

Lukacs B, Grange JC, Comet D. One-year follow-up of 2829 patients with moderate to severe lower urinary tract symptoms treated with alfuzosin in general practice according to IPSS and a health-related quality-of-life questionnaire. BPM Group in General Practice. *Urology*. 2000;55(4):540–546.

MacDiarmid SA, Peters KM, Chen A, et al. Efficacy and safety of extended-release oxybutynin in combination with tamsulosin for treatment of lower urinary tract symptoms in men: randomized, double-blind, placebo-controlled study. *Mayo Clin Proc*. 2008;83(9):1002–1010.

MacDonald R, Wilt TJ, Howe RW. Doxazosin for treating lower urinary tract symptoms compatible with benign prostatic obstruction: a systematic review of efficacy and adverse effects. *BJU Int*. 2004;94(9):1263–1270.

MacDonald R, Wilt TJ. Alfuzosin for treatment of lower urinary tract symptoms compatible with benign prostatic hyperplasia: a systematic review of efficacy and adverse effects. *Urology*. 2005;66(4):780–788.

MacDonald R, Tacklind JW, Rutks I, et al. Serenoa repens monotherapy for benign prostatic hyperplasia (BPH): an updated Cochrane systematic review. *BJU Int*. 2012;109(12):1756–1761.

Macnab AJ, Stothers L. Near-infrared spectroscopy: validation of bladder-outlet obstruction assessment using non-invasive parameters. *Can J Urol*. 2008;15(5):4241–4248.

Malde S, Nambiar AK, Umbach R. Systematic review of the performance of noninvasive tests in diagnosing bladder outlet obstruction in men with lower urinary tract symptoms. *Eur Urol*. 2017;71(3):391–402.

Malik M, van Gelderen EM, Lee JH, et al. Proarrhythmic safety of repeat doses of mirabegron in healthy subjects: a randomized, double-blind, placebo-, and active-controlled thorough QT study. *Clin Pharmacol Ther*. 2012;92(6):696–706.

Malloy BJ, Price DT, Price RR, et al. Alpha1-adrenergic receptor subtypes in human detrusor. *J Urol*. 1998;160(3 Pt 1):937–943.

Mandressi S, Tarallo U, Maggioni A, et al. Terapia medica dell'adenoma prostatico: confronto della efficacia dell'estratto di *Serenoa Repens* (Permixon®) versus l'estratto di Pigeum Africanum e placebo. Valutazione in doppio cieco. *Urologia*. 1983;50:752–758.

Manikandan R, Srirangam SJ, O'Reilly PH, et al. Management of acute urinary retention secondary to benign prostatic hyperplasia in the UK: a national survey. *BJU Int*. 2004;93(1):84–88.

Marberger MJ. Long-term effects of finasteride in patients with benign prostatic hyperplasia: a double-blind, placebo-controlled, multicenter study. PROWESS Study Group. *Urology*. 1998;51(5):677–686.

Marberger M, Chartier-Kastler E, Egerdie B, et al. A randomized double-blind placebo-controlled phase 2 dose-ranging study of onabotulinumtoxinA in men with benign prostatic hyperplasia. *Eur Urol*. 2013;63(3):496–503.

Mariappan P, Brown DJ, McNeill AS. Intravesical prostatic protrusion is better than prostate volume in predicting the outcome of trial without catheter in white men presenting with acute urinary retention: a prospective clinical study. *J Urol*. 2007;178(2):573–577.

Marks LS, Gittelman MC, Hill LA, et al. Rapid efficacy of the highly selective alpha1A-adrenoceptor antagonist silodosin in men with signs and symptoms of benign prostatic hyperplasia: pooled results of 2 phase 3 studies. *J Urol*. 2009;181(6):2634–2640.

Marks LS, Gittelman MC, Hill LA, et al. Silodosin in the treatment of the signs and symptoms of benign prostatic hyperplasia: a 9-month, open-label extension study. *Urology*. 2009;74(6):1318–1322.

Martorana G, Giberti C, Di Silverio F, et al. Effects of short-term treatment with the alpha 1-blocker alfuzosin on urodynamic pressure/flow parameters in patients with benign prostatic hyperplasia. *Eur Urol*. 1997;32(1):47–53.

Matsukawa Y, Takai S, Funahashi Y, et al. Long-term efficacy of a combination therapy with an anticholinergic agent and an α1-blocker for patients with benign prostatic enlargement complaining both voiding and overactive bladder symptoms: a randomized, prospective, comparative trial using a urodynamic study. *Neurourol Urodyn*. 2017;36(3):748–754.

Matsumoto AM, Tenover L, McClung M, et al. The long-term effect of specific type II 5alpha-reductase inhibition with finasteride on bone mineral density in men: results of a 4-year placebo controlled trial. *J Urol*. 2002;167(5):2105–2108.

Matsuo T, Miyata Y, Kakoki K, et al. The efficacy of mirabegron additional therapy for lower urinary tract symptoms after treatment with α1-adrenergic receptor blocker monotherapy: prospective analysis of elderly men. *BMC Urol*. 2016;16(1):45.

McConnell JD. Medical management of benign prostatic hyperplasia with androgen suppression. *Prostate Suppl*. 1990;17(Suppl 3):49–59.

McConnell JD, Barry MJ, Bruskewitz RC. Benign prostatic hyperplasia: diagnosis and treatment. Agency for Health Care Policy and Research. *Clin Pract Guidel Quick Ref Guide Clin*. 1994;8:1–17.

McConnell JD, Bruskewitz R, Walsh P, et al. The effect of finasteride on the risk of acute urinary retention and the need for surgical treatment among men with benign prostatic hyperplasia. Finasteride Long-Term Efficacy and Safety Study Group. *N Engl J Med*. 1998;338(9):557–563.

McConnell JD, Roehrborn CG, Bautista OM, et al. The long-term effect of doxazosin, finasteride, and combination therapy on the clinical progression of benign prostatic hyperplasia. *N Engl J Med*. 2003;349(25):2387–2398.

McNeill SA. Spontaneous versus precipitated AUR: the same? *World J Urol*. 2006;24(4):354–359.

McNeill SA, Hargreave TB, Roehrborn CG, et al. Alfuzosin 10 mg once daily in the management of acute urinary retention: results of a double-blind placebo-controlled study. *Urology*. 2005;65(1):83–89 [discussion 89–90].

McVary KT, Monnig W, Camps JL Jr, et al. Sildenafil citrate improves erectile function and urinary symptoms in men with erectile dysfunction and lower urinary tract symptoms associated with benign prostatic hyperplasia: a randomized, double-blind trial. *J Urol*. 2007;177(3):1071–1077.

McVary KT, Roehrborn CG, Kaminetsky JC, et al. Tadalafil relieves lower urinary tract symptoms secondary to benign prostatic hyperplasia. *J Urol*. 2007;177(4):1401–1407.

McVary KT, Roehrborn CG, Avins AL, et al. Update on AUA guideline on the management of benign prostatic hyperplasia. *J Urol*. 2011;185(5):1793–1803.

Mebust WK, Holtgrewe HL, Cockett AT, et al. Transurethral prostatectomy: immediate and postoperative complications. A cooperative study of 13 participating institutions evaluating 3,885 patients. *J Urol*. 1989;141(2):243–247.

Meigs JB, Barry MJ, Giovannucci E, et al. Incidence rates and risk factors for acute urinary retention: the health professionals followup study. *J Urol*. 1999;162(2):376–382.

Meiraz D, Margolin Y, Lev-Ran A, et al. Treatment of benign prostatic hyperplasia with hydroxyprogesterone-caproate: placebo-controlled study. *Urology*. 1977;9(2):144–148.

Michel MC, Mehlburger L, Bressel HU, et al. Tamsulosin treatment of 19,365 patients with lower urinary tract symptoms: does co-morbidity alter tolerability? *J Urol*. 1998;160(3 Pt 1):784–791.

Milani S, Djavan B. Lower urinary tract symptoms suggestive of benign prostatic hyperplasia: latest update on alpha-adrenoceptor antagonists. *BJU Int*. 2005;95(Suppl 4):29–36.

Mochtar CA, Kiemeney LA, van Riemsdijk MM, et al. Post-void residual urine volume is not a good predictor of the need for invasive therapy among patients with benign prostatic hyperplasia. *J Urol*. 2006;175(1):213–216.

Moinpour CM, Darke AK, Donaldson GW, et al. Longitudinal analysis of sexual function reported by men in the Prostate Cancer Prevention Trial. *J Natl Cancer Inst*. 2007;99(13):1025–1035.

Momose H, Hosokawa Y, Kishino T, et al. Crossover comparison study on the therapeutic effects of tamsulosin hydrochloride and naftopidil in lower urinary tract symptoms associated with benign prostatic hyperplasia. *Drugs Today (Barc)*. 2007;43(SupplA):1–10.

Montorsi F, Roehrborn C, Garcia-Penit J, et al. The effects of dutasteride or tamsulosin alone and in combination on storage and voiding symptoms in men with lower urinary tract symptoms (LUTS) and benign prostatic hyperplasia (BPH): 4-year data from the Combination of Avodart and Tamsulosin (CombAT) study. *BJU Int*. 2011;107(9):1426–1431.

Morelli A, Comeglio P, Filippi S, et al. Mechanism of action of phosphodiesterase type 5 inhibition in metabolic syndrome-associated prostate alterations: an experimental study in the rabbit. *Prostate*. 2013;73(4):428–441.

Morelli A, Filippi S, Comeglio P, et al. Acute vardenafil administration improves bladder oxygenation in spontaneously hypertensive rats. *J Sex Med*. 2010;7(1 Pt

1):107–120.

Morelli A, Filippi S, Sandner P, et al. Vardenafil modulates bladder contractility through cGMP-mediated inhibition of RhoA/Rho kinase signaling pathway in spontaneously hypertensive rats. *J Sex Med*. 2009;6(6):1594–1608.

Morelli A, Sarchielli E, Comeglio P, et al. Phosphodiesterase type 5 expression in human and rat lower urinary tract tissues and the effect of tadalafil on prostate gland oxygenation in spontaneously hypertensive rats. *J Sex Med*. 2011;8(10):2746–2760.

Morelli A, Vignozzi L, Filippi S, et al. BXL-628, a vitamin D receptor agonist effective in benign prostatic hyperplasia treatment, prevents RhoA activation and inhibits RhoA/Rho kinase signaling in rat and human bladder. *Prostate*. 2007;67(3):234–247.

Morgia G, Russo GI, Voce S, et al. Serenoa repens, lycopene and selenium versus tamsulosin for the treatment of LUTS/BPH. An Italian multicenter double-blinded randomized study between single or combination therapy (PROCOMB trial). *Prostate*. 2014;74(15):1471–1480.

Moriyama N, Akiyama K, Murata S, et al. KMD-3213, a novel alpha1A-adrenoceptor antagonist, potently inhibits the functional alpha1-adrenoceptor in human prostate. *Eur J Pharmacol*. 1997;331(1):39–42.

Moriyama N, Yamaguchi T, Takeuchi T, et al. Semiquantitative evaluation of alpha1A-adrenoceptor subtype mRNA in human hypertrophied and non-hypertrophied prostates: regional comparison. *Life Sci*. 1999;64(3):201–210.

Morote J, Encabo G, López M, et al. Prediction of prostate volume based on total and free serum prostate-specific antigen: is it reliable? *Eur Urol*. 2000;38(1):91–95.

Mottet N, Bressolle F, Delmas V, et al. Prostatic tissual distribution of alfuzosin in patients with benign prostatic hyperplasia following repeated oral administration. *Eur Urol*. 2003;44(1):101–105.

Mower RL, Landolfi R, Steiner M. Inhibition in vitro of platelet aggregation and arachidonic acid metabolism by flavone. *Biochem Pharmacol*. 1984;33(3):357–363.

Na YJ, Guo YL, Gu FL. Clinical comparison of selective and non-selective alpha 1A-adrenoceptor antagonists for bladder outlet obstruction associated with benign prostatic hyperplasia: studies on tamsulosin and terazosin in Chinese patients. The Chinese Tamsulosin Study Group. *J Med*. 1998;29(5–6):289–304.

Na Y, Ye Z, Zhang S. Efficacy and safety of dutasteride in Chinese adults with symptomatic benign prostatic hyperplasia: a randomized, double-blind, parallel-group, placebo-controlled study with an open-label extension. *Clin Drug Investig*. 2012;32(1):29–39.

Narayan P, Tewari A. A second phase III multicenter placebo controlled study of 2 dosages of modified release tamsulosin in patients with symptoms of benign prostatic hyperplasia. United States 93-01 Study Group. *J Urol*. 1998;160(5):1701–1706.

Negro-Vilar A. Selective androgen receptor modulators (SARMs): a novel approach to androgen therapy for the new millennium. *J Clin Endocrinol Metab*. 1999;84(10):3459–3462.

Nejishima H, Yamamoto N, Suzuki M, et al. Anti-androgenic effects of S-40542, a novel non-steroidal selective androgen receptor modulator (SARM) for the treatment of benign prostatic hyperplasia. *Prostate*. 2012;72(14):1580–1587.

Nguyen DQ, Sebastian RT, Kyle G. Surgeon's experiences of the intraoperative floppy iris syndrome in the United Kingdom. *Eye (Lond)*. 2007;21(3):443–444.

Nickel JC, Fradet Y, Boake RC, et al. Efficacy and safety of finasteride therapy for benign prostatic hyperplasia: results of a 2-year randomized controlled trial (the PROSPECT study). PROscar Safety Plus Efficacy Canadian Two year Study. *CMAJ*. 1996;155(9):1251–1259.

Nickel JC, Gilling P, Tammela TL, et al. Comparison of dutasteride and finasteride for treating benign prostatic hyperplasia: the Enlarged Prostate International Comparator Study (EPICS). *BJU Int*. 2011;108(3):388–394.

Nickel JC. Placebo therapy of benign prostatic hyperplasia: a 25-month study. Canadian PROSPECT Study Group. *Br J Urol*. 1998;81(3):383–387.

Nishino Y, Masue T, Miwa K, et al. Comparison of two alpha1-adrenoceptor antagonists, naftopidil and tamsulosin hydrochloride, in the treatment of lower urinary tract symptoms with benign prostatic hyperplasia: a randomized crossover study. *BJU Int*. 2006;97(4):747–751.

Nitti VW, Rosenberg S, Mitcheson DH, et al. Urodynamics and safety of the β_3-adrenoceptor agonist mirabegron in males with lower urinary tract symptoms and bladder outlet obstruction. *J Urol*. 2013;190(4):1320–1327.

Noble AJ, Chess-Williams R, et al. The effects of tamsulosin, a high affinity antagonist at functional alpha 1A- and alpha 1D-adrenoceptor subtypes. *Br J Pharmacol*. 1997;120(2):231–238.

Nomiya M, Yamaguchi O. A quantitative analysis of mRNA expression of alpha 1 and beta-adrenoceptor subtypes and their functional roles in human normal and obstructed bladders. *J Urol*. 2003;170(2 Pt 1):649–653.

Nomura H, Kawashima H, Masaki S, et al. Effect of selective estrogen receptor modulators on cell proliferation and estrogen receptor activities in normal human prostate stromal and epithelial cells. *Prostate Cancer Prostatic Dis*. 2009;12(4):375–381.

Novara G, Galfano A, Ficarra V, et al. Anticholinergic drugs in patients with bladder outlet obstruction and lower urinary tract symptoms: a systematic review. *Eur Urol*. 2006;50(4):675–683.

Novara G, Galfano A, Secco S, et al. A systematic review and meta-analysis of randomized controlled trials with antimuscarinic drugs for overactive bladder. *Eur Urol*. 2008;54(4):740–763.

Novara G, Tubaro A, Sanseverino R, et al. Systematic review and meta-analysis of randomized controlled trials evaluating silodosin in the treatment of non-neurogenic male lower urinary tract symptoms suggestive of benign prostatic enlargement. *World J Urol*. 2013;31(4):997–1008.

Novara G, Chapple CR, Montorsi F. A pooled analysis of individual patient data from registrational trials of silodosin in the treatment of non-neurogenic male lower urinary tract symptoms (LUTS) suggestive of benign prostatic hyperplasia (BPH). *BJU Int*. 2014;114(3):427–433.

Novara G, Chapple CR, Montorsi F. Individual patient data from registrational trials of silodosin in the treatment of non-neurogenic male lower urinary tract symptoms (LUTS) associated with benign prostatic hyperplasia (BPH): subgroup analyses of efficacy and safety data. *BJU Int*. 2015;115(5):802–814.

Novara G, Giannarini G, Alcaraz A, et al. Efficacy and safety of hexanic lipidosterolic extract of Serenoa repens (Permixon) in the treatment of lower urinary tract symptoms due to benign prostatic hyperplasia: systematic review and meta-analysis of randomized controlled trials. *Eur Urol Focus*. 2016;2(5):553–561.

Oelke M, Höfner K, Jonas U, et al. Diagnostic accuracy of noninvasive tests to evaluate bladder outlet obstruction in men: detrusor wall thickness, uroflowmetry, postvoid residual urine, and prostate volume. *Eur Urol*. 2007;52(3):827–834.

Oelke M, Giuliano F, Mirone V, et al. Monotherapy with tadalafil or tamsulosin similarly improved lower urinary tract symptoms suggestive of benign prostatic hyperplasia in an international, randomised, parallel, placebo-controlled clinical trial. *Eur Urol*. 2012;61(5):917–925.

Oelke M, Bachmann A, Descazeaud A, et al. EAU guidelines on the treatment and follow-up of non-neurogenic male lower urinary tract symptoms including benign prostatic obstruction. *Eur Urol*. 2013;64(1):118–140.

Oelke M, Gericke A, Michel MC. Cardiovascular and ocular safety of α_1-adrenoceptor antagonists in the treatment of male lower urinary tract symptoms. *Expert Opin Drug Saf*. 2014;13(9):1187–1197.

Oelke M, Speakman MJ, Desgrandchamps F, et al. Acute urinary retention rates in the general male population and in adult men with lower urinary tract symptoms participating in pharmacotherapy trials: a literature review. *Urology*. 2015;86(4):654–665.

Okutsu H, Matsumoto S, Ohtake A, et al. Effect of tamsulosin on bladder blood flow and bladder function in a rat model of bladder over distention/emptying induced bladder overactivity. *J Urol*. 2011;186(6):2470–2477.

Ørsted DD, Bojesen SE, Nielsen SF, et al. Association of clinical benign prostate hyperplasia with prostate cancer incidence and mortality revisited: a nationwide cohort study of 3,009,258 men. *Eur Urol*. 2011;60(4):691–698.

Osman NI, Chapple CR, Abrams P, et al. Detrusor underactivity and the underactive bladder: a new clinical entity? A review of current terminology, definitions, epidemiology, aetiology, and diagnosis. *Eur Urol*. 2014;65(2):389–398.

Osman NI, Chapple CR, Tammela TL, et al. Open-label, 9-month extension study investigating the uro-selective alpha-blocker silodosin in men with LUTS associated with BPH. *World J Urol*. 2015;33(5):697–706.

Ostri P, Swartz R, Meyhoff HH, et al. Antiandrogenic treatment of benign prostatic hyperplasia: a placebo controlled trial. *Urol Res*. 1989;17(1):29–33.

Oztekin CV, Gur S, Abdulkadir NA, et al. Incomplete recovery of erectile function in rat after discontinuation of dual 5-alpha reductase inhibitor therapy. *J Sex Med*. 2012;9(7):1773–1781.

Panicker JN, Fowler CJ, Kessler TM. Lower urinary tract dysfunction in the neurological patient: clinical assessment and management. *Lancet Neurol*. 2015;14(7):720–732.

Pannek J, Berges RR, Haupt G, et al. Value of the Danish Prostate Symptom Score compared to the AUA symptom score and pressure/flow studies in the preoperative evaluation of men with symptomatic benign prostatic hyperplasia. *Neurourol Urodyn*. 1998;17(1):9–18.

Park T, Choi JY. Efficacy and safety of dutasteride for the treatment of symptomatic benign prostatic hyperplasia (BPH): a systematic review and meta-analysis. *World J Urol*. 2014;32(4):1093–1105.

Parsons JK, Mougey J, Lambert L, et al. Lower urinary tract symptoms increase the risk of falls in older men. *BJU Int*. 2009;104(1):63–68.

Paubert-Braquet M, Cave A, Hocquemiller R, et al. Effect of *Pygeum africanum* extract on A23187-stimulated production of lipoxygenase metabolites from human polymorphonuclear cells. *J Lipid Mediat Cell Signal*. 1994;9(3):285–290.

Paubert-Braquet M, Mencia Huerta JM, Cousse H, et al. Effect of the lipidic lipidosterolic extract of *Serenoa repens* (Permixon) on the ionophore A23187-stimulated production of leukotriene B4 (LTB4) from human polymorphonuclear neutrophils. *Prostaglandins Leukot Essent Fatty Acids*. 1997;57(3):299–304.

Paubert-Braquet M, Cousse H, Raynaud JP, et al. Effect of the lipidosterolic extract of *Serenoa repens* (Permixon) and its major components on basic fibroblast growth factor–induced proliferation of cultures of human prostate biopsies. *Eur Urol*. 1998;33(3):340–347.

Paubert-Braquet M1, Richardson FO, Servent-Saez N, et al. Effect of *Serenoa repens* extract (Permixon) on estradiol/testosterone-induced experimental prostate enlargement in the rat. *Pharmacol Res*. 1996;34(3–4):171–179.

Pel JJ, Bosch JL, Blom JH, et al. Development of a non-invasive strategy to classify bladder outlet obstruction in male patients with LUTS. *Neurourol Urodyn*. 2002;21(2):117–125.

Peters CA, Walsh PC. The effect of nafarelin acetate, a luteinizing-hormone-releasing hormone agonist, on benign prostatic hyperplasia. *N Engl J Med*. 1987;317(10):599–604.

Piercy GB, Deber R, Trachtenberg J, et al. Impact of a shared decision-making program on patients with benign prostatic hyperplasia. *Urology*. 1999;53(5):913–920.

Pietrzyk B, Olszanecka-Glinianowicz M, Owczarek A, et al. Depressive symptoms in patients diagnosed with benign prostatic hyperplasia. *Int Urol Nephrol*. 2015;47(3):431–440.

Pinsky MR, Gur S, Tracey AJ, et al. The effects of chronic 5-alpha-reductase inhibitor (dutasteride) treatment on rat erectile function. *J Sex Med*. 2011;8(11):3066–3074.

Plosker GL, Brogden RN. *Serenoa repen*s (Permixon). A review of its pharmacology and therapeutic efficacy in benign prostatic hyperplasia. *Drugs Aging*. 1996;9(5):379–395.

Porst H, McVary KT, Montorsi F, et al. Effects of once-daily tadalafil on erectile function in men with erectile dysfunction and signs and symptoms of benign prostatic hyperplasia. *Eur Urol*. 2009;56(4):727–735.

Porst H, Kim ED, Casabé AR, et al. Efficacy and safety of tadalafil once daily in the treatment of men with lower urinary tract symptoms suggestive of benign prostatic hyperplasia: results of an international randomized, double-blind, placebo-controlled trial. *Eur Urol*. 2011;60(5):1105–1113.

Porst H, Oelke M, Goldfischer ER, et al. Efficacy and safety of tadalafil 5 mg once daily for lower urinary tract symptoms suggestive of benign prostatic hyperplasia: subgroup analyses of pooled data from 4 multinational, randomized, placebo-controlled clinical studies. *Urology*. 2013;82(3):667–673.

Porst H, Roehrborn CG, Secrest RJ, et al. Effects of tadalafil on lower urinary tract symptoms secondary to benign prostatic hyperplasia and on erectile dysfunction in sexually active men with both conditions: analyses of pooled data from four randomized, placebo-controlled tadalafil clinical studies. *J Sex Med*. 2013;10(8):2044–2052.

Price DT, Lefkowitz RJ, Caron MG, et al. Localization of mRNA for three distinct alpha 1-adrenergic receptor subtypes in human tissues: implications for human alpha-adrenergic physiology. *Mol Pharmacol*. 1994;45(2):171–175.

Reece Smith H, Memon A, Smart CJ, et al. The value of Permixon in benign prostatic hypertrophy. *Br J Urol*. 1986;58(1):36–40.

Reynard JM, Peters TJ, Lim C, et al. The value of multiple free-flow studies in men with lower urinary tract symptoms. *Br J Urol*. 1996;77(6):813–818.

Reynard JM, Yang Q, Donovan JL. The ICS-“BPH” Study: uroflowmetry, lower urinary tract symptoms and bladder outlet obstruction. *Br J Urol*. 1998;82(5):619–623.

Rhodes L, Primka RL, Berman C, et al. Comparison of finasteride (Proscar), a 5 alpha reductase inhibitor, and various commercial plant extracts in in vitro and in vivo 5 alpha reductase inhibition. *Prostate*. 1993;22(1):43–51.

Roberts RO, Lieber MM, Jacobson DJ, et al. Limitations of using outcomes in the placebo arm of a clinical trial of benign prostatic hyperplasia to quantify those in the community. *Mayo Clin Proc*. 2005;80(6):759–764.

Roehrborn CG. Accurate determination of prostate size via digital rectal examination and transrectal ultrasound. *Urology*. 1998;51(4A Suppl):19–22.

Roehrborn CG. Efficacy and safety of once-daily alfuzosin in the treatment of lower urinary tract symptoms and clinical benign prostatic hyperplasia: a randomized, placebo-controlled trial. *Urology*. 2001;58(6):953–959.

Roehrborn CG. Alfuzosin 10 mg once daily prevents overall clinical progression of benign prostatic hyperplasia but not acute urinary retention: results of a 2-year placebo-controlled study. *BJU Int*. 2006;97(4):734–741.

Roehrborn CG. BPH progression: concept and key learning from MTOPS, ALTESS, COMBAT, and ALF-ONE. *BJU Int*. 2008;101(Suppl 3):17–21.

Roehrborn CG, Siegel RL. Safety and efficacy of doxazosin in benign prostatic hyperplasia: a pooled analysis of three double-blind, placebo-controlled studies. *Urology*. 1996;48(3):406–415.

Roehrborn CG, Chinn HK, Fulgham PF, et al. The role of transabdominal ultrasound in the preoperative evaluation of patients with benign prostatic hypertrophy. *J Urol*. 1986;135(6):1190–1193.

Roehrborn CG, Oesterling JE, Auerbach S, et al. The Hytrin Community Assessment Trial study: a one-year study of terazosin versus placebo in the treatment of men with symptomatic benign prostatic hyperplasia. HYCAT Investigator Group. *Urology*. 1996;47(2):159–168.

Roehrborn CG, Boyle P, Bergner D, et al. Serum prostate-specific antigen and prostate volume predict long-term changes in symptoms and flow rate: results of a four-year, randomized trial comparing finasteride versus placebo. PLESS Study Group. *Urology*. 1999;54(4):662–669.

Roehrborn CG, Malice M, Cook TJ, et al. Clinical predictors of spontaneous acute urinary retention in men with LUTS and clinical BPH: a comprehensive analysis of the pooled placebo groups of several large clinical trials. *Urology*. 2001;58(2):210–216.

Roehrborn CG, Boyle P, Nickel JC, et al. Efficacy and safety of a dual inhibitor of 5-alpha-reductase types 1 and 2 (dutasteride) in men with benign prostatic hyperplasia. *Urology*. 2002;60(3):434–441.

Roehrborn CG, Abrams P, Rovner ES, et al. Efficacy and tolerability of tolterodine extended-release in men with overactive bladder and urgency urinary incontinence. *BJU Int*. 2006;97(5):1003–1006.

Roehrborn C, Siami P, Barkin J, et al. The effects of dutasteride, tamsulosin and combination therapy on lower urinary tract symptoms in men with benign prostatic hyperplasia and prostatic enlargement: 2-year results from the CombAT study. *J Urol*. 2008;179(2):616–621.

Roehrborn CG, McVary KT, Elion-Mboussa A, et al. Tadalafil administered once daily for lower urinary tract symptoms secondary to benign prostatic hyperplasia: a dose finding study. *J Urol*. 2008;180(4):1228–1234.

Roehrborn CG, Siami P, Barkin J, et al. The effects of combination therapy with dutasteride and tamsulosin on clinical outcomes in men with symptomatic benign prostatic hyperplasia: 4-year results from the CombAT study. *Eur Urol*. 2010;57(1):123–131.

Roehrborn CG, Kaplan SA, Lepor H, et al. Symptomatic and urodynamic responses in patients with reduced or no seminal emission during silodosin treatment for LUTS and BPH.

Prostate Cancer Prostatic Dis. 2011;14(2):143–148.

Rosa GM, Ferrero S, Nitti VW, et al. Cardiovascular safety of β_3-adrenoceptor agonists for the treatment of patients with overactive bladder syndrome. *Eur Urol*. 2016;69(2):311–323.

Rosen R, Altwein J, Boyle P, et al. Lower urinary tract symptoms and male sexual dysfunction: the multinational survey of the aging male (MSAM-7). *Eur Urol*. 2003;44(6):637–649.

Rosier PF, de la Rosette JJ, Wijkstra H, et al. Is detrusor instability in elderly males related to the grade of obstruction? *Neurourol Urodyn*. 1995;14(6):625–633.

Rosier PFWM, Schaefer W, Lose G, et al. International Continence Society Good Urodynamic Practices and Terms 2016: urodynamics, uroflowmetry, cystometry, and pressure-flow study. *Neurourol Urodyn*. 2017;36(5):1243–1260.

Rouquier L, Claustre Y, Benavides J. Alpha 1-adrenoceptor antagonists differentially control serotonin release in the hippocampus and striatum: a microdialysis study. *Eur J Pharmacol*. 1994;261(1–2):59–64.

Rovner ES, Wein AJ. Once-daily, extended-release formulations of antimuscarinic agents in the treatment of overactive bladder: a review. *Eur Urol*. 2002;41(1):6–14.

Ruby CM, Hanlon JT, Boudreau RM, et al. The effect of medication use on urinary incontinence in community-dwelling elderly women. *J Am Geriatr Soc*. 2010;58(9):1715–1720.

Sairam K, Kulinskaya E, McNicholas TA, et al. Sildenafil influences lower urinary tract symptoms. *BJU Int*. 2002;90(9):836–839.

Saito H, Yamada T, Oshima H, et al. A comparative study of the efficacy and safety of tamsulosin hydrochloride alone and combination of propiverine hydrochloride and tamsulosin hydrochloride in the benign prostatic hypertrophy with pollakisuria and/or urinary incontinence. *Jap J Urol Surg*. 1999;12:525–536.

Sakalis VI, Karavitakis M, Bedretdinova D, et al. Medical treatment of nocturia in men with lower urinary tract symptoms: systematic review by the European Association of Urology Guidelines Panel for Male Lower Urinary Tract Symptoms. *Eur Urol*. 2017;72(5):757–769.

Santaella RM, Destafeno JJ, Stinnett SS, et al. The effect of alpha1-adrenergic receptor antagonist tamsulosin (Flomax) on iris dilator smooth muscle anatomy. *Ophthalmology*. 2010;117(9):1743–1749.

Sarma AV, Jacobson DJ, McGree ME, et al. A population based study of incidence and treatment of benign prostatic hyperplasia among residents of Olmsted County, Minnesota: 1987 to 1997. *J Urol*. 2005;173(6):2048–2053.

Scaglione F, Lucini V, Pannacci M, et al. Comparison of the potency of different brands of Serenoa repens extract on 5alpha-reductase types I and II in prostatic co-cultured epithelial and fibroblast cells. *Pharmacology*. 2008;82(4):270–275.

Schenk JM, Kristal AR, Arnold KB, et al. Association of symptomatic benign prostatic hyperplasia and prostate cancer: results from the prostate cancer prevention trial. *Am J Epidemiol*. 2011;173(12):1419–1428.

Schröder A, Tajimi M, Matsumoto H, et al. Protective effect of an oral endothelin converting enzyme inhibitor on rat detrusor function after outlet obstruction. *J Urol*. 2004;172(3):1171–1174.

Schroeder FH, Westerhof M, Bosch RJ, et al. Benign prostatic hyperplasia treated by castration or the LH-RH analogue buserelin: a report on 6 cases. *Eur Urol*. 1986;12(5):318–321.

Scott WW, Wade JC. Medical treatment of benign nodular prostatic hyperplasia with cyproterone acetate. *J Urol*.

1969;101(1):81–85.

Seftel A, Rosen R, Kuritzky L. Physician perceptions of sexual dysfunction related to benign prostatic hyperplasia (BPH) symptoms and sexual side effects related to BPH medications. *Int J Impot Res*. 2007;19(4):386–392.

Shapiro E. Embryologic development of the prostate. Insights into the etiology and treatment of benign prostatic hyperplasia. *Urol Clin North Am*. 1990;17(3):487–493.

Shibata K, Foglar R, Horie K, et al. KMD-3213, a novel, potent, alpha 1a-adrenoceptor-selective antagonist: characterization using recombinant human alpha 1-adrenoceptors and native tissues. *Mol Pharmacol*. 1995;48(2):250–258.

Shirakawa T, Haraguchi T, Shigemura K, et al. Silodosin versus naftopidil in Japanese patients with lower urinary tract symptoms associated with benign prostatic hyperplasia: a randomized multicenter study. *Int J Urol*. 2013;20(9):903–910.

Simon RM, Howard LE, Moreira DM, et al. Does prostate size predict the development of incident lower urinary tract symptoms in men with mild to no current symptoms? Results from the REDUCE Trial. *Eur Urol*. 2016;69(5):885–891.

Simonsen O, Moller-Madsen B, Dorflinger T, et al. The significance of age on symptoms and urodynamic and cystoscopic findings in benign prostatic hypertrophy. *Urol Res*. 1987;15(6):355–358.

Sirab N, Robert G, Fasolo V, et al. Lipidosterolic extract of serenoa repens modulates the expression of inflammation related-genes in benign prostatic hyperplasia epithelial and stromal cells. *Int J Mol Sci*. 2013;14(7):14301–14320.

Skeldon SC, Macdonald EM, Law MR, et al. The cardiovascular safety of dutasteride. *J Urol*. 2017;197(5):1309–1314.

Smith MR, Malkowicz SB, Chu F, et al. Toremifene improves lipid profiles in men receiving androgen-deprivation therapy for prostate cancer: interim analysis of a multicenter phase III study. *J Clin Oncol*. 2008;26(11):1824–1829.

Smith T, Lynch M, Johnson J, et al. Herbal dietary supplement sales in US increase 6.8% in 2014. *HerbalGram*. 2015;107:7.

Soler R, Andersson KE, Chancellor MB, et al. Future direction in pharmacotherapy for non-neurogenic male lower urinary tract symptoms. *Eur Urol*. 2013;64(4):610–621.

Stewart WF, Van Rooyen JB, Cundiff GW, et al. Prevalence and burden of overactive bladder in the United States. *World J Urol*. 2003;20(6):327–336.

Stief CG, Porst H, Neuser D, et al. A randomised, placebo-controlled study to assess the efficacy of twice-daily vardenafil in the treatment of lower urinary tract symptoms secondary to benign prostatic hyperplasia. *Eur Urol*. 2008;53(6):1236–1244.

Stone NN. Flutamide in treatment of benign prostatic hypertrophy. *Urology*. 1989;34(4 Suppl):64–68.

Stoner E. Three-year safety and efficacy data on the use of finasteride in the treatment of benign prostatic hyperplasia. *Urology*. 1994;43(3):284–292.

Stothers L, Guevara R, Macnab A. Classification of male lower urinary tract symptoms using mathematical modelling and a regression tree algorithm of noninvasive near-infrared spectroscopy parameters. *Eur Urol*. 2010;57(2):327–332.

Tacklind J, MacDonald R, Rutks I, et al. *Serenoa repens* for benign prostatic hyperplasia. *Cochrane Database Syst Rev*. 2009;(2) [CD001423].

Tacklind J, Fink HA, Macdonald R, et al. Finasteride for benign prostatic hyperplasia. *Cochrane Database Syst Rev*. 2010;(10) [CD006015].

Tacklind J, Macdonald R, Rutks I, et al. Serenoa repens for benign prostatic hyperplasia. *Cochrane Database Syst Rev*.

2012;(12) [CD001423].
Tanaka T, Kuratsukuri K, Yoshimura R, et al. Efficacy of naftopidil for nocturia in male patients with lower urinary tract symptoms: comparison of morning and evening dosing. *Int J Urol*. 2015;22(3):317–321.
Tasca A, Barulli M, Cavazzana A, et al. Trattamento della sintomatologia ostruttiva da adenoma prostatico con estratto di Serenoa repens. Studio clinic in doppio cieco. *Minerva Urol Nefrol*. 1985;37:87–91.
Tatemichi S, Kobayashi K, Yokoi R, et al. Comparison of the effects of four α_1-adrenoceptor antagonists on ejaculatory function in rats. *Urology*. 2012;80(2):486.e9–486.e16.
Thigpen AE, Silver RI, Guileyardo JM, et al. Tissue distribution and ontogeny of steroid 5 alpha-reductase isozyme expression. *J Clin Invest*. 1993;92(2):903–910.
Thomas AW, Cannon A, Bartlett E, et al. The natural history of lower urinary tract dysfunction in men: the influence of detrusor underactivity on the outcome after transurethral resection of the prostate with a minimum 10-year urodynamic follow-up. *BJU Int*. 2004;93(6):745–750.
Thomas AW, Cannon A, Bartlett E, et al. The natural history of lower urinary tract dysfunction in men: minimum 10-year urodynamic followup of transurethral resection of prostate for bladder outlet obstruction. *J Urol*. 2005;174(5):1887–1891.
Thomas AW, Cannon A, Bartlett E, et al. The natural history of lower urinary tract dysfunction in men: minimum 10-year urodynamic follow-up of untreated bladder outlet obstruction. *BJU Int*. 2005;96(9):1301–1306.
Thompson I, Goodman P, Tangen C, et al. The influence of finasteride on the development of prostate cancer. *N Engl J Med*. 2003;349(3):215–224.
Thompson IM, Chi C, Ankerst DP, et al. Effect of finasteride on the sensitivity of PSA for detecting prostate cancer. *J Natl*

Cancer Inst. 2006;98(16):1128–1133.

Tsukamoto T, Endo Y, Narita M. Efficacy and safety of dutasteride in Japanese men with benign prostatic hyperplasia. *Int J Urol*. 2009;16(9):745–755.

Tubaro A, Batista JE, Nitti VW, et al. Efficacy and safety of daily mirabegron 50 mg in male patients with overactive bladder: a critical analysis of five phase III studies. *Ther Adv Urol*. 2017;9(6):137–154.

Tuncel A, Nalcacioglu V, Ener K, et al. Sildenafil citrate and tamsulosin combination is not superior to monotherapy in treating lower urinary tract symptoms and erectile dysfunction. *World J Urol*. 2010;28(1):17–22.

Ukimura O, Kanazawa M, Fujihara A, et al. Naftopidil versus tamsulosin hydrochloride for lower urinary tract symptoms associated with benign prostatic hyperplasia with special reference to the storage symptom: a prospective randomized controlled study. *Int J Urol*. 2008;15(12):1049–1054.

Unger JM, Till C, Thompson IM Jr, et al. Long-term consequences of finasteride vs placebo in the Prostate Cancer Prevention Trial. *J Natl Cancer Inst*. 2016;108(12).

Upreti R, Hughes KA, Livingstone DE, et al. 5α-reductase type 1 modulates insulin sensitivity in men. *J Clin Endocrinol Metab*. 2014;99(8):E1397–E1406.

Vacherot F, Azzouz M, Gil-Diez-De-Medina S, et al. Induction of apoptosis and inhibition of cell proliferation by the lipido-sterolic extract of *Serenoa repens* (LSESr, Permixon in benign prostatic hyperplasia. *Prostate*. 2000;45(3):259–266.

Van Coppenolle F, Le Bourhis X, Carpentier F, et al. Pharmacological effects of the lipidosterolic extract of *Serenoa repens* (Permixon) on rat prostate hyperplasia induced by hyperprolactinemia: comparison with finasteride. *Prostate*. 2000;43(1):49–58.

van Dijk MM, de la Rosette JJ, Michel MC. Effects of alpha(1)-

adrenoceptor antagonists on male sexual function. *Drugs*. 2006;66(3):287–301.

van Kerrebroeck P, Jardin A, Laval KU, et al. Efficacy and safety of a new prolonged release formulation of alfuzosin 10 mg once daily versus alfuzosin 2.5 mg thrice daily and placebo in patients with symptomatic benign prostatic hyperplasia. ALFORTI Study Group. *Eur Urol*. 2000;37(3):306–313.

van Kerrebroeck P, Kreder K, Jonas U, et al. Tolterodine once-daily: superior efficacy and tolerability in the treatment of the overactive bladder. *Urology*. 2001;57(3):414–421.

van Kerrebroeck P, Haab F, Angulo JC, et al. Efficacy and safety of solifenacin plus tamsulosin OCAS in men with voiding and storage lower urinary tract symptoms: results from a phase 2, dose-finding study (SATURN). *Eur Urol*. 2013;64(3):398–407.

van Kerrebroeck P, Chapple C, Drogendijk T, et al. Combination therapy with solifenacin and tamsulosin oral controlled absorption system in a single tablet for lower urinary tract symptoms in men: efficacy and safety results from the randomised controlled NEPTUNE trial. *Eur Urol*. 2013;64(6):1003–1012.

Vaughan CP, Johnson TM 2nd, Goode PS, et al. Military exposure and urinary incontinence among American men. *J Urol*. 2014;191(1):125–129.

Verhamme KM, Dieleman JP, van Wijk MA, et al. Low incidence of acute urinary retention in the general male population: the triumph project. *Eur Urol*. 2005;47(4):494–498.

Vermeulen A, Giagulli VA, De Schepper P, et al. Hormonal effects of an orally active 4-azasteroid inhibitor of 5 alpha-reductase in humans. *Prostate*. 1989;14(1):45–53.

Vickers AJ, Sjoberg DD. Decision analysis of dutasteride use for patients with negative prostate biopsy. *Urology*. 2015;85(2):337–341.

Vignozzi L, Gacci M, Cellai I, et al. PDE5 inhibitors blunt inflammation in human BPH: a potential mechanism of action for PDE5 inhibitors in LUTS. *Prostate*. 2013;73(13):1391–1402.

Vinceti M, Dennert G, Crespi CM, et al. Selenium for preventing cancer. *Cochrane Database Syst Rev*. 2014;(3) [CD005195].

Wada N, Iuchi H, Kita M, et al. Urodynamic efficacy and safety of mirabegron add-on treatment with tamsulosin for Japanese male patients with overactive bladder. *Low Urin Tract Symptoms*. 2016;8(3):171–176.

Walden PD, Gerardi C, Lepor H. Localization and expression of the alpha1A-1, alpha1B and alpha1D-adrenoceptors in hyperplastic and non-hyperplastic human prostate. *J Urol*. 1999;161(2):635–640.

Walsh PC, Wilson JD. The induction of prostatic hypertrophy in the dog with androstanediol. *J Clin Invest*. 1976;57(4):1093–1097.

Wasson JH, Bubolz TA, Lu-Yao GL, et al. Transurethral resection of the prostate among medicare beneficiaries: 1984 to 1997. For the Patient Outcomes Research Team for Prostatic Diseases. *J Urol*. 2000;164(4):1212–1215.

Wasson JH, Reda DJ, Bruskewitz RC, et al. A comparison of transurethral surgery with watchful waiting for moderate symptoms of benign prostatic hyperplasia. The Veterans Affairs Cooperative Study Group on Transurethral Resection of the Prostate. *N Engl J Med*. 1995;332(2):75–79.

Watson V, Ryan M, Brown CT. Eliciting preferences for drug treatment of lower urinary tract symptoms associated with benign prostatic hyperplasia. *J Urol*. 2004;172(6 Pt 1):2321–2325.

Weight CJ, Kim SP, Jacobson DJ, et al. The effect of benign lower urinary tract symptoms on subsequent prostate cancer testing and diagnosis. *Eur Urol*. 2013;63(6):1021–1027.

Weiss JP, Ruud Bosch JL, Drake M, et al. Nocturia think tank: focus on nocturnal polyuria: ICI-RS 2011. *Neurourol Urodyn*. 2012;31(3):330–339.

Weisser H, Tunn S, Behnke B, et al. Effects of the Sabal serrulata extract IDS 89 and its subfractions on 5 alpha-reductase activity in human benign prostatic hyperplasia. *Prostate*. 1996;28(5):300–306.

Welk B, McArthur E, Fraser LA. The risk of fall and fracture with the initiation of a prostate-selective α antagonist: a population based cohort study. *BMJ*. 2015;26(351):h5398.

Welk B, McArthur E, Ordon M, et al. Association of suicidality and depression with 5α-reductase inhibitors. *JAMA Intern Med*. 2017;177(5):683–691.

Wessells H, Roy J, Bannow J, et al. Incidence and severity of sexual adverse experiences in finasteride and placebo-treated men with benign prostatic hyperplasia. *Urology*. 2003;61(3):579–584.

White JW. The results of double castration in hypertrophy of the prostate. *Ann Surg*. 1895;22(1):1–80.

Willetts KE, Clements MS, Champion S, et al. Serenoa repens extract for benign prostate hyperplasia: a randomized controlled trial. *BJU Int*. 2003;92:267–270.

Williams SA, Merchant RF, Garrett-Mayer E, et al. A prostate-specific antigen-activated channel-forming toxin as therapy for prostatic disease. *J Natl Cancer Inst*. 2007;99(5):376–385.

Wilt TJ, Ishani A, Stark G, et al. Saw palmetto extracts for treatment of benign prostatic hyperplasia: a systematic review. *JAMA*. 1998;280(18):1604–1609.

Wilt T, Mac Donald R, Ishani A, et al. Cernilton for benign prostatic hyperplasia. *Cochrane Database Syst Rev*. 2000;(2)

[CD001042].

Wilt TJ, Howe RW, Rutks IR, et al. Terazosin for benign prostatic hyperplasia. *Cochrane Database Syst Rev*. 2002;(4) [CD003851].

Wilt TJ, Ishani A, Mac Donald R, et al. Pygeum africanum for benign prostatic hyperplasia. *Cochrane Database Syst Rev*. 2002;(1) [CD001044].

Wilt TJ, Mac Donald R, Rutks I. Tamsulosin for benign prostatic hyperplasia. *Cochrane Database Syst Rev*. 2003;(1) [CD002081].

Wilt TJ, MacDonald R, Ishani A. Beta-sitosterol for the treatment of benign prostatic hyperplasia: a systematic review. *BJU Int*. 1999;83(9):976–983.

Wu C, Moreira DM, Gerber L, et al. Diabetes and prostate cancer risk in the REDUCE trial. *Prostate Cancer Prostatic Dis*. 2011;14(4):326–331.

Yablonsky F, Nicolas V, Riffaud JP, et al. Antiproliferative effect of *Pygeum africanum* extract on rat prostatic fibroblasts. *J Urol*. 1997;157(6):2381–2387.

Yamaguchi K, Aoki Y, Yoshikawa T, et al. Silodosin versus naftopidil for the treatment of benign prostatic hyperplasia: a multicenter randomized trial. *Int J Urol*. 2013;20(12):1234–1238.

Yamaguchi O, Chapple CR. Beta3-adrenoceptors in urinary bladder. *Neurourol Urodyn*. 2007;26(6):752–756.

Yamamoto T, Fukuta F, Masumori N. Does digital rectal examination predict prostate volume greater than 30 mL? *Int J Urol*. 2017;24(5):373–376.

Yamanishi T, Yasuda K, Sakakibara R, et al. Variation in urinary flow according to voiding position in normal males. *Neurourol Urodyn*. 1999;18(6):553–557.

Yan H, Zong H, Cui Y, et al. The efficacy of PDE5 inhibitors alone or in combination with alpha-blockers for the treatment of erectile dysfunction and lower urinary tract symptoms due to benign prostatic hyperplasia: a systematic review and meta-analysis. *J Sex Med*. 2014;11(6):1539–1545.

Yap TL, Cromwell DC, Emberton M. A systematic review of the reliability of frequency-volume charts in urological research and its implications for the optimum chart duration. *BJU Int*. 2007;99:9–16.

Yap TL, Brown C, Cromwell DA, et al. The impact of self-management of lower urinary tract symptoms on frequency-volume chart measures. *BJU Int*. 2009;104(8):1104–1108.

Yap T, Emberton M. Behaviour modification and benign prostatic hyperplasia: replacement for medications. *Curr Opin Urol*. 2010;20(1):20–27.

Yokoyama T, Kumon H, Nasu Y, et al. Comparison of 25 and 75 mg/day naftopidil for lower urinary tract symptoms associated with benign prostatic hyperplasia: a prospective, randomized controlled study. *Int J Urol*. 2006;13(7):932–938.

Yokoyama T, Uematsu K, Watanabe T, et al. Naftopidil and propiverine hydrochloride for treatment of male lower urinary tract symptoms suggestive of benign prostatic hyperplasia and concomitant overactive bladder: a prospective randomized controlled study. *Scand J Urol Nephrol*. 2009;43(4):307–314.

Yoon PD, Chalasani V, Woo HH. Systematic review and meta-analysis on management of acute urinary retention. *Prostate Cancer Prostatic Dis*. 2015;18(4):297–302.

Yoshida M, Inadome A, Masunaga K, et al. Effectiveness of tamsulosin hydrochloride and its mechanism in improving nocturia associated with lower urinary tract symptoms/benign prostatic hyperplasia. *Neurourol Urodyn*. 2010;29(7):1276–1281.

Yoshida T, Kinoshita H, Shimada S, et al. Comparison of silodosin monotherapy vs silodosin with tadalafil add-on therapy in patients with benign prostatic hyperplasia. *Urology*. 2017;106:153–159.

Yoshiyama M, Yamamoto T, de Groat WC. Role of spinal alpha(1)-adrenergic mechanisms in the control of lower urinary tract in the rat. *Brain Res*. 2000;882(1–2):36–44.

Yu HJ, Lin AT, Yang SS, et al. Non-inferiority of silodosin to tamsulosin in treating patients with lower urinary tract symptoms (LUTS) associated with benign prostatic hyperplasia (BPH). *BJU Int*. 2011;108(11):1843–1848.

Yuen JS, Ngiap JT, Cheng CW, et al. Effects of bladder volume on transabdominal ultrasound measurements of intravesical prostatic protrusion and volume. *Int J Urol*. 2002;9(4):225–229.

Zenzmaier C, Sampson N, Pernkopf D, et al. Attenuated proliferation and trans-differentiation of prostatic stromal cells indicate suitability of phosphodiesterase type 5 inhibitors for prevention and treatment of benign prostatic hyperplasia. *Endocrinology*. 2010;151(8):3975–3984.

Zenzmaier C, Kern J, Sampson N, et al. Phosphodiesterase type 5 inhibition reverts prostate fibroblast-to-myofibroblast trans-differentiation. *Endocrinology*. 2012;153(11):5546–5555.

[No authors listed]. Major cardiovascular events in hypertensive patients randomized to doxazosin vs chlorthalidone: the antihypertensive and lipid-lowering treatment to prevent heart attack trial (ALLHAT). ALLHAT Collaborative Research Group. *JAMA*. 2000;283(15):1967–1975.

Minimally Invasive and Endoscopic Management of Benign Prostatic Hyperplasia

Sevann Helo MD, R. Charles Welliver Jr, MD, Kevin T. McVary MD, FACS

Introduction

Urinary obstruction because of benign prostatic disease has probably been recognized to some degree since the earliest days of medicine. One of the earliest descriptions of benign prostatic hyperplasia (BPH) was described by Morgagni in the eighteenth century (Morgagni, 1760). Early treatments for BPH centered on open procedures utilizing both suprapubic and perineal approaches. These surgeries were prone to profound hemorrhage and led to unacceptable mortality and morbidity. The arrival of transurethral resection of the prostate (TURP) offered another option between watchful waiting and open prostatectomy (OP). However, with the rudimentary equipment at that time and an incomplete understanding of the postoperative physiology, this procedure continued to have an elevated morbidity and even mortality.

With the introduction of medical management in the 1990s, we began to see a decrease in the need for surgery to treat lower urinary tract symptoms related to BPH (LUTS/BPH). Medical management provided a lower-risk treatment option for patients over the previously unchallenged surgical treatments yet at a cost of lower benefit in urologic outcomes and the need for ongoing and often indefinite therapy. However, despite the strides made in optimizing medical management, many patients still need or request additional treatment in the form of surgical procedures.

The ever-expanding endoscopic options for LUTS/BPH include many minimally invasive surgical treatments (MISTs), allowing the practitioner to further parse the continuum between surgical approaches and medical management. Subsequently, the urologist witnessed an explosion in procedures available for the treatment of LUTS/BPH. These new technologies are often embraced with excitement; however, many do not live up to these initial expectations that were often based on small series of patients followed for a short duration.

As the pressure to accept a new technology grows with increasing marketplace competition, the urologist must be careful to embrace each new technology until the results have been thoroughly vetted. Often when new technologies or techniques are compared with the classic, monopolar TURP, outdated data are quoted that do not reflect contemporary TURP results. Additionally, there is a considerable placebo effect inherent to all LUTS/BPH treatments, and in nonrigorous study design such as an uncontrolled single series cohort, any inherent placebo or sham effect will be credited to the new technology.

In this chapter, we discuss the many endoscopic treatment options available to the patient and urologist for the treatment of LUTS/BPH. Special attention will be paid to inimitable advantages or disadvantages of these techniques/technologies with differences in patient outcomes highlighted. TURP held a unique position as the only endoscopic treatment for many decades, and the depth and variety of literature surrounding the procedure are impressive. This treatment is still clearly considered the gold standard, and almost any new technology inherently ends up compared with TURP in a randomized controlled trial (RCT) setting or by historical data.

Epidemiology and Marketshare

Marketshare

The rate of surgical treatment of LUTS/BPH has steadily decreased with the advent of medical therapy in the 1980s, only to be accelerated by the publication of the Veterans Affairs Cooperative Study and Medical Therapy of Prostatic Symptoms study (Bautista et al., 2003, Lepor et al., 1996). Analysis of hospital claims data of Medicare beneficiaries demonstrates a peak in the number of TURP procedures in 1987 (Lu-Yao et al., 1994; Wasson et al., 2000), with a 5% decrease per year seen between 1999 and 2005. Despite this decrease between 1999 and 2005, there was a 44% overall increase in surgical treatment of LUTS/BPH (all treatment options) mostly brought on by a **529% increase in thermotherapy or LASER treatment** (Yu et al., 2008).

The most recent installment of this series (Malaeb et al., 2012) showed an overall peak in surgical treatment for LUTS/BPH in 2005, with a subsequent 19.8% decrease until the end of the study in 2008. Throughout the entire study period, TURP continued to decrease, even with the introduction of the bipolar resection system. Thermotherapy and LASER therapy also had an overall decrease between 2005 and 2008, although LASER vaporization was the only treatment option to experience an increase since 2005. Review of case logs of surgeons undergoing certification or recertification reveals an increase in the number of LASER procedures from 11% to 44% between 2004 and 2010. The differential between LASER procedures and standard TURP was fairly equal from 2008 to 2010 (44% to 46% to 54% to 56%, respectively), as there was an increase in the number and proportion of urologists performing LASER procedures (Lowrance et al., 2013).

Another study utilizing the New York Statewide Planning and Research Cooperation System database showed a similar trend with LASER usage, which increased from 6.4% to 44.5% between 2000 and 2011, and TURP usage decreased from 72.2% to 48.3% (Chughtai et al., 2015). Additionally, the authors noted that Medicaid patients were less likely to undergo LASER surgery than those with private insurance (odds ratio [OR] 0.58), and that mid- to high-volume institutions were more likely to use LASER treatment than low-volume centers (OR 2.26). The socioeconomic factors affecting LASER usage and adoption are further illustrated by an analysis of payer data in Florida looking at both inpatient and ambulatory surgery discharges for LASER prostatectomy or TURP. Socioeconomic areas were characterized by lowest, medium, and highest terciles after being identified by zip code. A better socioeconomic environment correlated with offering LASER prostatectomy and with a more rapid adoption of the technique (Schroeck et al., 2013).

Epidemiology of Surgical Treatment for Benign Prostatic Hyperplasia

The prevalence of both LUTS/BPH and histologic BPH increases with age. **The Baltimore Longitudinal Study examined 1057 men and found that “prostatism” or BPH voiding dysfunction increased progressively from 26% in the fifth decade of life to 79% in the eighth decade of life** (Guess et al., 1990)**. Prevalence of symptoms related to an enlarged prostate increased from 26% of men 40 to 49 years of age to 46% of men older than 70 years of age in the Olmstead County Study** (Chute et al., 1993).

The prevalence of the histologic evidence of BPH follows a similar correlation with age. In the study from Berry et al. (1984), men in their eighth decade (82%) were more likely to have histologic evidence than men in their fourth decade (8%). The autopsy study by Robson (1964) found a prevalence of histologically confirmed BPH in prostates with gross enlargement of 14%, 37%, and 39% of men 50 to 59, 60 to 69, and older than 70 years of age, respectively.

Increasing Age

The risk for surgery related to BPH was noted to be considerably greater for an 80-year-old man than for a 40-year-old man in the Veterans Administration Normative Aging Study, which was carried out prospectively from 1961 to 1982 (Glynn et al., 1985). The retrospective New Haven Hospital Study (Lytton et al., 1968) also found an increasing incidence of surgery for BPH increasing through the eighth decade. Although intuitively, the advent of medical therapy may delay the need for surgical intervention of LUTS/BPH, a review of medical and surgical therapy in France between 2004 and 2008 revealed a slight decrease in mean age of patients treated for LUTS/BPH with medical or surgical therapy (Lukacs et al., 2013). The mean age of patients who received medical treatment decreased from 69.7 to 68.04 years and was associated with a 24% increase in use of medical therapy. Although the mean age of patients who underwent surgical treatment also decreased, from 71.5 to 69.0 years, the total number of surgical procedures decreased by 10% during the same period.

Effects of Medications for Benign Prostatic Hyperplasia

The successes of medical therapy for LUTS/BPH have led to the previously decreased rates of surgical management of BPH. **Subsequently, patients are now older at the time of surgical intervention than they were in previous years** (Vela-Navarrete et al., 2005) **and frequently have an increase in medical comorbidities** (Choi et al., 2012).

An interesting retrospective review of a single Canadian institution further highlighted changes in patients undergoing intervention for LUTS/BPH (Izard and Nickel, 2011). Patients who underwent TURP in 1988, 1998, and 2008 were compared with regard to preoperative use of BPH medications, indications for surgery, postoperative complications, and preoperative BPH-related events. Although TURP decreased by 60% between 1988 and 1998, an increase was noted in the percentage of total clinic patients undergoing TURP between 1998 and 2008. The indication for surgery of “failure of medical management” increased from essentially zero in 1988 to 36% in 1998 and to 87% in 2008. **Troublingly, adverse preoperative BPH-related events like acute urinary retention and hydronephrosis were more common in 2008 than in 1988. Additionally, postoperative complications and patients discharged with a catheter were more common in 2008 than in 1988**. This highlights the change in the type of patient who undergoes surgery and that medical therapy may be leading to a decompensated bladder and urinary tract. This is consistent with the findings of Flanigan et al. (1998), who found that patients who underwent immediate TURP had a more significant improvement in peak flow rates and symptom scores than men who underwent an extended period of watchful waiting. It appears that there is a consequence to the delay in effective treatment for many men. However, baseline characteristics of men who have significant deterioration in voiding without treatment have not been defined.

Prostate Size

Despite on overall lack of correlation between prostate size and bladder outlet obstruction (BOO), a correlation does seem to exist between prostate volume and the decision for surgical intervention. Although the data come from a period before medical treatment, Berry et al. (1984) did find a correlation between prostate size and the decision for surgical intervention. More contemporary data on the correlation between prostate size and need for surgery is sure to be skewed by multiple factors. The now common use of 5α-reductase inhibitors (5ARIs) will decrease both prostate size and the risk for surgery (McConnell et al., 1998; Roehrborn et al., 2002), suggesting that smaller glands are less likely to need treatment.

However, drawing any further conclusion about increased prostate size leading to surgery may have been contaminated because of the use of the other class of BPH treatments. Although not altering prostate gland size, α-blockers allowed for the relief of symptoms while their overall prostate growth continued unchecked. Patients who failed medical therapy and proceeded to surgery would thus have larger glands. This fact contaminates the concept that larger glands would lead to more surgical intervention as the common use of these medications "induced" a selection bias.

Key Points

- The incorporation of medical management and new technologies has changed which treatment options are selected for the treatment of LUTS/BPH.
- **LASER-based treatments are increasingly used, although multiple factors have affected acceptance.**
- Multiple factors have changed the usual patient that advances to surgical management of BPH in the preceding decades. Increasingly these are more challenging clinical scenarios.

Workup

The evaluation of LUTS/BPH should always include a detailed medical history and focused physical examination, which should include a brief neurologic screen, abdominal examination, and genitourinary examination including digital rectal examination (DRE). Urinalysis is another recommended test to screen for hematuria and urinary tract infection (UTI). According to American Urologic Association BPH guidelines, men with a predominant symptom of nocturia should complete a frequency-volume chart (voiding diary) to evaluate for nocturnal polyuria (American Urological Association, 2011; McVary et al., 2011). An algorithm for the basic and more detailed workup can be seen in Figs. 146.1 and 146.2. The specific goals for the patient should be clearly defined from both the standpoint of the patient and the treating physician. If the symptoms are not significantly bothersome or if the patient does not want treatment, no further evaluation is recommended.

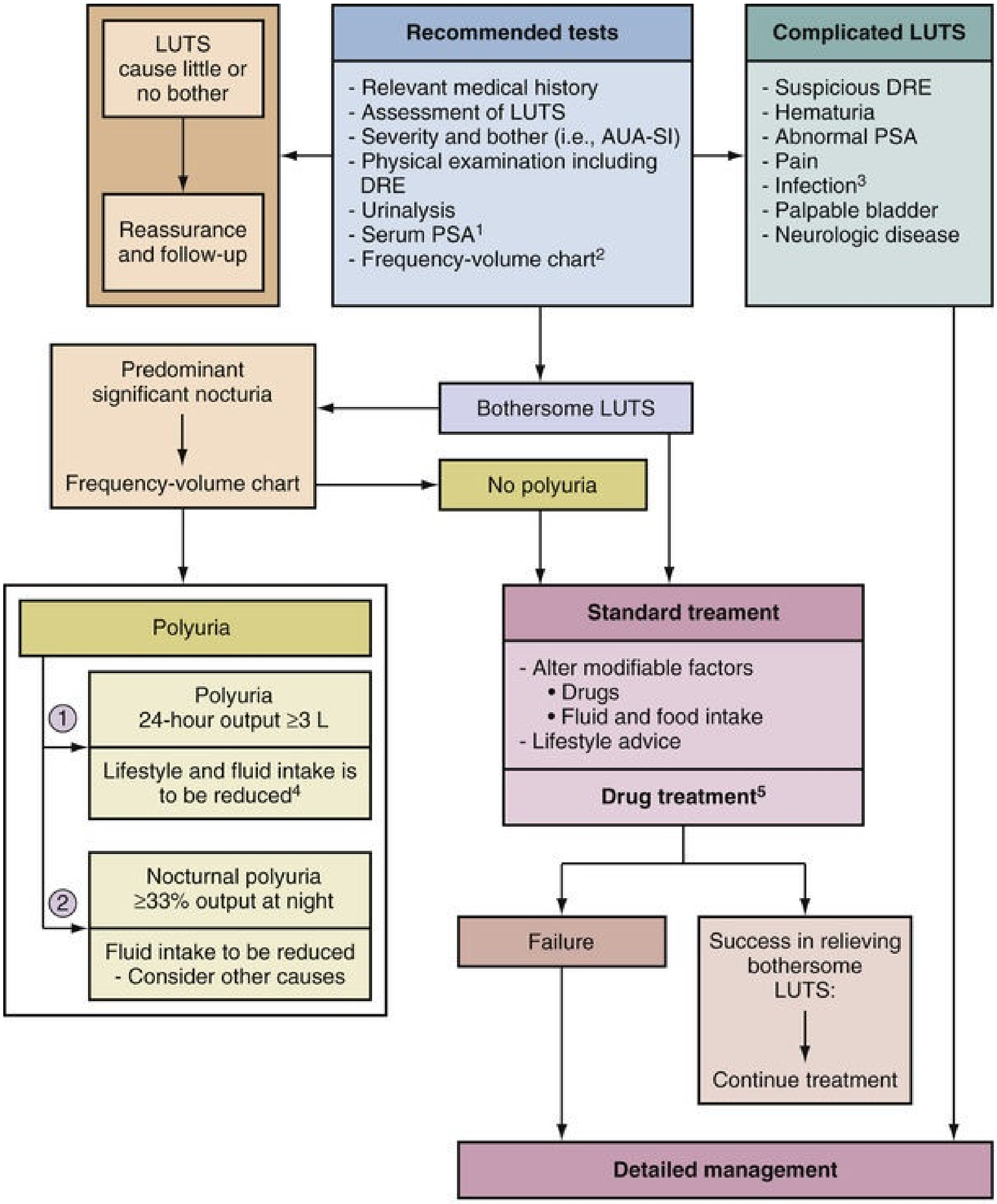
LUTS cause little or no bother
Reassurance and follow-up
Recommended tests
- Relevant medical history
- Assessment of LUTS
- Severity and bother (i.e., AUA-SI)
- Physical examination including DRE
- Urinalysis
- Serum PSA1
- Frequency-volume chart2
Complicated LUTS
- Suspicious DRE
- Hematuria
- Abnormal PSA
- Pain
- Infection3
- Palpable bladder
- Neurologic disease
Predominant significant nocturia
Frequency-volume chart
Bothersome LUTS
No polyuria
Polyuria
①
Polyuria 24-hour output ≥3 L
Lifestyle and fluid intake is to be reduced4
②
Nocturnal polyuria ≥33% output at night
Fluid intake to be reduced - Consider other causes
Standard treament
- Alter modifiable factors
• Drugs
• Fluid and food intake
- Lifestyle advice
Drug treatment5
Failure
Success in relieving bothersome LUTS:
Continue treatment
Detailed management

[1] When life expectancy is >10 years and if the diagnosis of prostate cancer can modify the management. For the *AUA PSA best practice statement: 2009 update,* see www.auanet.org.

[2] When significant nocturia is a predominant symptom.

[3] Assess and start treatment before referral.

[4] In practice, advise patients with symptoms to aim for a urine output of about 1 L/24 hr.

[5] See Figure 105-2.

FIG. 146.1 Basic management of lower urinary tract symptoms *(LUTS)* in men. *AUA-SI,* American Urological Association Symptom Index; *DRE,* digital rectal examination; *PSA,* prostate-specific antigen. (Modified from McVary KT, Roehrborn CG, Avins AL, et al. Update on AUA guideline on the management of benign prostatic hyperplasia. *J Urol* 185(5):1793–1803, 2011.)

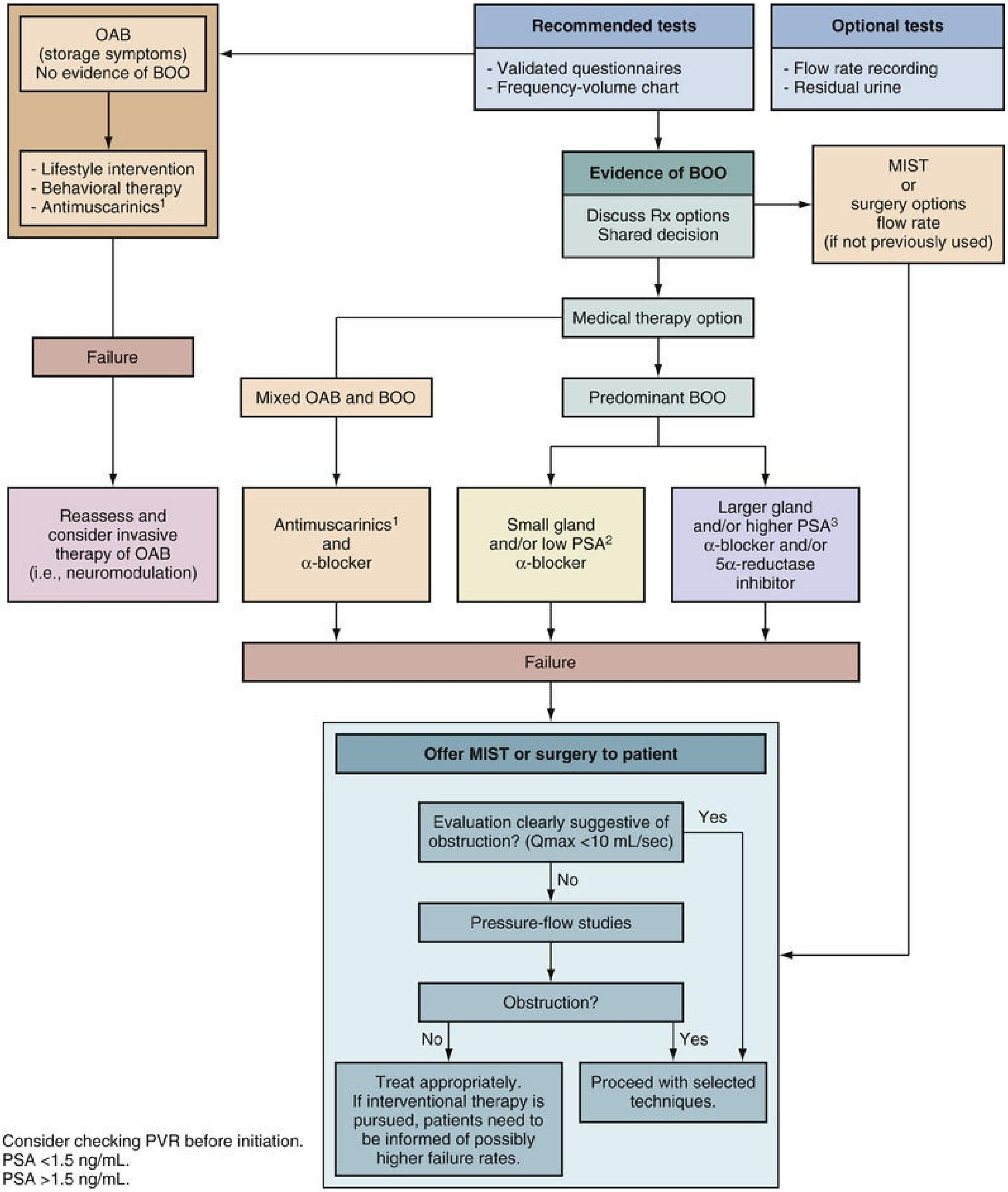
Recommended tests
- Validated questionnaires
- Frequency-volume chart
Optional tests
- Flow rate recording
- Residual urine
OAB
(storage symptoms)
No evidence of BOO
- Lifestyle intervention
- Behavioral therapy
- Antimuscarinics¹
Evidence of BOO
Discuss Rx options
Shared decision
MIST
or
surgery options
flow rate
(if not previously used)
Medical therapy option
Failure
Mixed OAB and BOO
Predominant BOO
Reassess and
consider invasive
therapy of OAB
(i.e., neuromodulation)
Antimuscarinics¹
and
α-blocker
Small gland
and/or low PSA²
α-blocker
Larger gland
and/or higher PSA³
α-blocker and/or
5α-reductase
inhibitor
Failure
Offer MIST or surgery to patient
Evaluation clearly suggestive of
obstruction? (Qmax <10 mL/sec)
Yes
No
Pressure-flow studies
Obstruction?
No
Yes
Treat appropriately.
If interventional therapy is
pursued, patients need to
be informed of possibly
higher failure rates.
Proceed with selected
techniques.

[1] Consider checking PVR before initiation.

[2] PSA <1.5 ng/mL.

[3] PSA >1.5 ng/mL.

FIG. 146.2 Detailed management for persistent, bothersome lower urinary tract symptoms (LUTS) after basic management. *BOO,* Bladder outlet obstruction; *MIST,* minimally invasive surgical treatment; *OAB,* overactive bladder; *PSA,* prostate-specific antigen; *PVR,* postvoid residual; *Rx,* treatment. (Modified from McVary KT, Roehrborn CG, Avins AL, et al. Update on AUA guideline on the management of benign prostatic hyperplasia. *J Urol* 185(5):1793–1803, 2011.)

Validated questionnaires should be utilized to measure subjective outcomes for BPH and LUTS by documenting response to medical or surgical therapies. The AUA Symptom Score (AUA-SS), also known as the International Prostate Symptom Score (IPSS), is the most commonly used and should be obtained at each visit. An AUA-SS of 0 to 7 is considered mildly symptomatic, 8 to 19 is moderately symptomatic, and 20 to 35 is severely symptomatic. Flow rate and postvoid residual (PVR) are additional metrics that can supplement the history and physical examination. Cystoscopy should not be routinely performed unless it is being done to work up hematuria or evaluate whether the patient is a candidate for surgical therapy that is dependent on anatomic configuration. Per the AUA BPH guidelines (American Urological Association, 2011; McVary et al., 2011), urodynamics are considered optional and best suited for patients who demonstrate LUTS in which the diagnosis of BOO is unclear. Detrusor overactivity or detrusor underactivity is not a contraindication for surgical intervention of LUTS/BPH but must be evaluated in the context of the clinical situation and the patient appropriately counseled. Before surgical intervention, clinicians should consider assessment of prostate size and shape via abdominal or transrectal ultrasonography (TRUS), cystoscopy, or cross-sectional imaging (i.e., magnetic resonance imaging [MRI]/computed tomography [CT]).

Screening of men for prostate cancer has become a more controversial topic in recent years. The AUA BPH guidelines recommend the consideration of screening appropriately aged men with a life expectancy of greater than 10 years presenting with LUTS. **The most recent guidelines for the detection of prostate cancer recognized that the greatest benefit for prostate-specific antigen (PSA) screening is for men between 55 and 69 years of age** (Carter et al., 2013). This screening should include DRE and serum PSA if the patient so elects after an informed discussion. If the PSA is elevated, prostate biopsy should be performed before proceeding with surgical therapy. Clinicians should also be aware of the effect of different surgical therapies on PSA, as this may influence prostate cancer screening in the future. Although serum PSA has chiefly been used as a screening tool for prostate cancer, it may also be used as a surrogate for prostate volume, which can be a critical factor in the choice of BPH therapy. For this reason, we endorse its utility.

The goals for treatment should be used to guide the clinical evaluation. During the evaluation, the patient's voiding pattern should be assessed along with any medical conditions or medications that may affect voiding symptoms. The role of BPH in their overall voiding pattern should be assessed, particularly with respect to the possible benefits of any treatment. The necessity for treatment along with the probability of success of any treatment should be factored in and weighed against the risk associated with treatment. Finally, the physician's assessment along with the rationale should be explained to the patient using terms that the patient is able to understand.

Defining Outcomes

Response Rates

Subjective

Although verified questionnaire data have become customary in the reporting of symptoms, other data can be more open to interpretation. How severely a patient defines his or her dysuria or hematuria after a procedure can affect how he or she is included into what is often a binary scoring system defining the absolute presence or absence of a symptom. Clinicians should be aware of the effect of sham surgery on objective measures when comparing outcomes of BPH surgery arms. A systematic review of the literature has demonstrated a 27% improvement in AUA-SS and a 14% improvement in maximum urinary flow rate (Qmax) at 3 months after a sham endoscopic procedure (Welliver et al., 2015).

Objective

Although hopefully the most reproducible of results across studies, objective data are also dependent on accurate reporting and thus can be affected by many confounding variables. The most frequent confounders noted are the reporting of changes in patients with long-term follow-up. These data are prone to contamination from multiple sources including patients lost to follow-up and patients who are nonresponders and received additional treatment. Rarely are intent-to-treat analyses reported in series, and, in reality, the endpoints reported are generally those patients who are treatment “responders” who continued to return for future appointments.

Need for Secondary Procedures

The issues surrounding reporting of secondary procedures have been well delineated in previous versions of the AUA BPH guidelines. In summary, the defined metrics for re-intervention are generally rendered by the treating physician. These are difficult to classify as treatment may be triggered by subjective complaints, objective findings, or a combination of the two. **These thresholds can vary by patient or treating physician, and both same- study**

and cross-study reproducibility and reliability are challenging. Additionally, patients involved in trials may be more closely followed and carefully scrutinized causing both the patient and physician to change the threshold (in either direction) at which they may customarily initiate treatment. **Although treatment failures are clearly an important endpoint as they can lead to an increased overall cost in health care, the current literature can make these issues difficult to interpret clearly**.

Comparisons to Other Treatments

Comparing surgical procedures to each other and to medical management in an equitable way can be challenging. In particular, when comparing studies with an intervention (which by the nature of the intervention usually do not have a placebo) with those that use a placebo lead-in (common in medication studies), the former treatment will take full credit for the placebo effect and the true intervention effect, and the latter only for the true intervention effect. Although for the patient these outcomes may feel the same, the comparisons are inherently flawed.

When accepting any new procedure into the armamentarium of the urologist, studies generally begin with a small number of patients from a narrowly defined cohort. If success is seen there, then larger cohorts with more broad inclusion criteria follow. Frequently, these findings are compared with historical improvements and morbidities seen in early TURP data. These comparisons are somewhat unfair as they compare a current technology to a historical and often inferior data set. Studies making broad conclusions based on comparisons to historical controls should be viewed with skepticism.

If a technology truly appears successful, it moves on to the eventual RCT comparing the new technology to another treatment approach. Although the comparative effectiveness trial is a high bar to pass, caution must still be taken when interpreting these results. For instance, the comparison to TURP assumes that the surgeons performing the comparative technique are sufficiently trained and can produce predictable results.

Table 146.1**outlines expected complication rates based on the differing technologies.**Table 146.2**outlines expected outcomes in voiding parameters and is drawn only from RCTs. In constructing tables comparing the outcomes and complications, the inequalities of good, high level of evidence data comes to the forefront.** Many technologies have meta-analyses of large

RCT trials, and other included data were dependent on large case series. This is merely a sign of the available studies conducted. Although any comparison across technologies and time periods may be considered unequal, the authors attempted to use data from meta-analysis and RCTs filling in data from large series only when necessary.

TABLE 146.1

Expected Complication Rates after Endoscopic Benign Prostatic Hyperplasia Procedures

	M-TURP	B-TURP	TUNA	TUMT	HoLEP	PVP	TUVP	TUIP
Transient urinary retention	4.3–6.8[a]	3.3–3.7[b]	23[c]	10–24[d]	2.7–5.9[e]	5.2–9.9[e]	2–9.8[f]	4.9–11.3[g]
UTI	4.1–6.2[a]	2.6–8.4[c]	4[c]	15–20[h]	0.9–2.7[e]	4.2–12[e]	0[f]	IE
Bladder neck contracture	2–3.2[a]	0.5[b]	IE	0[d]	1.2–1.5[e]	1.1–5[e]	0.5–1[f]	IE
Urethral stricture	3.4–4.1[a]	0.5–4.7[i]	0.5[c]	0–2[h]	1.9–4.4[e]	1–6.3[e]	1.9–3.3[f]	2.9–8.8[g]
Incontinence	0.6–1.5[a]	0–1[i]	IE	IE	0.9–1.1[e]	0–0.4[e]	0–2[f]	0.3–1.8[g]
Blood transfusion	2–4.4[a]	1.5–2.3[i]	Very rare	0[d]	0–1[e]	0[e]	0–0.5[f]	1.1[j]
Clot retention	4.9–7.2[a]	2.7–7.9[i]	IE	1[d]	0[k]	0[k]	0–0.5[f]	IE
Postoperative hematuria	3.5–15.7[a]	1[b]	6–28[c]	1–26[d]	0[k]	0.7[k]	0[f]	4.3[l]
Dysuria	0.8[a]	0[b]	8–14[c]	14[d]	1.2[k]	8.5–13.9[e]	2.9[f]	IE
Urgency	2.2[a]	0.2[b]	10[c]	IE	5.6[k]	0[k]	0[f]	IE
Storage symptoms	IE	IE	IE	18–31[d]	IE	IE	21[f]	IE
Reoperation for non-BPE cause	1.1[a]	0.2[b]	0[c]	IE	1.9–2.8[e]	IE	5.4[f]	9.6–18.4[g]
Reoperation for BPE	0.5[a]	0.2[b]	19[c]	4[d]	0[k]	0.7–5.6[e]	2.4[f]	IE
Capsular perforation	0.1[a]	0[b]	IE	IE	0.2[k]	0[k]	0[f]	IE
Conversion to TURP	n/a	0[b]	n/a	n/a	0[k]	3.5[k]	0[f]	IE
TUR syndrome	0.8–2.5[a]	0[b]	0[c]	0[d]	0[k]	0[k]	0[f]	IE

Bladder mucosal injury	0[a]	0[b]	0[c]	IE	3.3[k]	0[k]	0[f]	IE

[a] Meta-analysis of RCTs (Ahyai et al., 2010; Mayer et al., 2012; Omar et al., 2014).

[b] Meta-analysis of RCTs (Ahyai et al., 2010; Omar et al., 2014).

[c] Meta-analysis of systematic review (Bouza et al., 2006).

[d] Meta-analysis of RCTs (Hoffman et al., 2012).

[e] Meta-analysis of RCTs with data from systematic review (Ahyai et al., 2010; Kuntz, 2006).

[f] Meta-analysis of RCTs (Hammadeh and Philp, 2003; Poulakis et al., 2004; Ahyai et al., 2010).

[g] Meta-analysis of RCTs with some data supplemented by large case series (Lourenco et al., 2010; Orandi, 1985).

[h] Review article (Floratos et al., 2001).

[i] Meta-analysis of RCTs with some data from systematic review (Ahyai et al., 2010; Omar et al., 2014; Issa, 2008).

[j] Meta-analysis of RCTs (Lourenco et al., 2010).

[k] Meta-analysis of RCTs (Ahyai et al., 2010).

[l] Large case series (Orandi, 1985).

BPE, Benign prostatic enlargement; *B-TURP,* bipolar transurethral resection of the prostate; *HoLEP,* holmium laser enucleation of the prostate; *IE,* insufficient evidence; *M-TURP,* monopolar transurethral resection of the prostate; *n/a,* not applicable; *PVP,* photoselective vaporization of the prostate; *RCT,* randomized controlled trial; *TUIP,* transurethral incision of the prostate; *TUMT,* transurethral microwave therapy; *TUNA,* transurethral needle ablation of the prostate; *TUR,* transurethral resection; *TUVP,* transurethral vaporization of the prostate; *UTI,* urinary tract infection.

Data courtesy of Dr. Jean-Nicholas Cornu.

TABLE 146.2

Expected Change in Objective Measures at 12 Months (Mean Change ± Standard Deviation)

	M-TURP	B-TURP	HoLEP	PVP (120 W)
Decrease in AUA symptom score	71% ± 11	71% ± 10	79% ± 11	67% ± 9
Decrease in prostate volume	46% ± 19	46% ± 5	59% ± 14	44% ± 12
Decrease in PVR	77% ± 19	83% ± 14	85% ± 13	84% ± 14
Increase in Qmax (mL/sec)	12.1 ± 6	13.3 ± 4	17.1 ± 4	12.5 ± 2

AUA, American Urological Association; *B-TURP,* bipolar transurethral resection of the prostate; *HoLEP,* holmium laser enucleation of the prostate; *M-TURP,* monopolar transurethral resection of the prostate; *PVP,* photoselective vaporization of the prostate; *PVR,* postvoid residual.

Data courtesy of Dr. Jean-Nicholas Cornu.

Presurgical Factors

Indications for Treatment

The most common indications for TURP have shifted considerably in the past few decades. Although this previously was voiding symptoms without formal subjective or objective quantification, we now recognize that the indication is more likely to be moderate to severe voiding symptoms attributed to BPH that are refractory to medical therapy. Questionnaires and objective data (e.g., uroflow, urodynamics/pressure flow) augment the history and physical examination before making the decision for surgical management of this condition.

Acute urinary retention (AUR) can often be indicative of an end-stage bladder. Although the presence of painful urinary retention at a low volume (<500 mL) may be considered a potentially positive sign for a nonatonic bladder, definitive assessment of bladder function can only be made definitively by pressure-flow studies. Taube and Gajraj reported on the amount of urine retained at time of catheter placement for AUR as a predictor of later successful void trial without surgical intervention (Taube and Gajraj, 1989). Of the 34 men who retained less than 900 mL, 15 were able to void, compared with only 2 of 29 men who retained greater than 900 mL of urine. In a patient who went into AUR triggered by medication ingestion such as α-agonists or anticholinergics, it is reasonable to initially place a catheter and allow time for the medication to leave the system with subsequent supervised decatheterization. In a patient with AUR caused by an inciting event such as postoperative or acute bacterial prostatitis, a similar plan can be utilized allowing the exacerbating incident to be treated or run its course. In the community-based Olmstead County Study (Jacobsen et al., 1997), 57 of the 2115 men studied developed AUR. One-half of these episodes of AUR were related to surgical procedures, and ultimately only 8 of these 57 patients required TURP within 6 months of the incident. The addition of an α-blocker during a spontaneous episode of AUR leading to catheterization is commonly used and has been shown to increase the percentage of patients subsequently passing a voiding trial from 47.9% to 61.9% ($P = .012$) when compared with placebo (McNeill et al., 2005).

Recurrent and robust gross hematuria is a legitimate indication for treatment of the prostate once other causes (e.g., infection, carcinoma, trauma) have been excluded. This may be done as either a scheduled case in the recurrent patient or done in the acute setting in a patient presenting for clot retention or continued hemorrhage despite more conservative management options (Borth and Nickel, 2006). The use of 5ARIs may also be of use in a patient with repeated episodes that are not serious enough to require surgical intervention (Foley et al., 2000).

The findings of **bladder calculi, bladder diverticula,** and other signs of end-stage bladder decompensation are also possible indications for surgical intervention provided medical management has been previously attempted. **Recurrent urinary tract infections** resulting from an elevated PVR urine is also an indication for considering intervention after bacterial prostatitis (both acute and chronic) has been excluded as a possible source of these infections. A bladder diverticulum is not an absolute indication for surgery; however, surgical intervention may be warranted if the diverticulum is associated with recurrent UTI or progressive bladder deterioration. Although classically an indication for surgical treatment of BPH, the most recent AUA BPH guidelines state that bladder calculi themselves should be treated when diagnosed, and a trial with medical management may be considered once the calculi have been removed.

Bilateral hydronephrosis with renal functional impairment requires relief of the obstruction with the paramount goal to preserve the upper tracts and renal function. With catheterization and relief of obstruction, a postoperative diuresis may ensue. If the level of obstruction is confirmed at the bladder outlet, the treating physician should only proceed to definitive care after the patient's general medical condition has been optimized and any sequelae of the obstruction (e.g., impaired renal function, edema) have been fully evaluated or have returned to baseline status. In the case of bilateral hydronephrosis (or elevated serum creatinine) unrelieved by catheter placement, additional studies should be considered. In patients with long-standing BOO leading to a hypertonic and thickened bladder, the ureters could be obstructed at the level of the bladder, and ureteral stenting may be required. As routine screening for upper tract dilation is not currently recommended in patients with BPH, the urologist should continue to consider its presence in these settings. Sarmina and Resnick (1989) documented previously unrecognized renal failure in 3.7% of the 909 men treated for BPH between 1980 and 1986. They estimated that greater than 5% of men with unrelieved BOO related to BPH would have chronic renal insufficiency and concluded that risk would be higher in those with a history of enuresis, UTI, urinary retention, and a history of symptoms for more than 1 year.

An elevated or increasing PVR has been postulated as a possible indication for surgical intervention. However, the urologist should remember that there can be significant variability in this value when assessed over time (Bruskewitz et al., 1982). The above, “classic” indications for BPH treatment are still relevant, and under these circumstances, it is reasonable to forego a trial of medical or conservative therapy and proceed directly to surgical intervention. However, patients should generally be trialed on medical management before proceeding to surgical intervention. Once patients have “failed” medical management, they should be considered for surgical therapy to relieve obstruction and improve LUTS and overall quality of life (QoL). Surgery is considered for patients with moderate to severe symptoms (AUA-SS >8) and who have failed appropriate medical management (McVary et al., 2011).

Although the validated AUA-SS is an important questionnaire for the urologist when evaluating a patient with LUTS, it does not completely replace a careful history as it is not diagnostic of LUTS/BPH. The symptom characteristics that the patient reports should carefully be defined both through the use of an AUA-SS and history; surgery should be used carefully in patients with predominant storage symptoms unless these symptoms are thought to be a result of problems emptying the bladder.

OP was the mainstay of treatment for LUTS/BPH for decades and is still an excellent treatment option. Although covered in detail elsewhere in this text, this treatment is useful in men with very large glands, which still may be a challenge for endoscopic treatment and for men who need treatment for large or multiple concomitant bladder calculi or diverticula.

Antibiotic Coverage

Antibiotic coverage for surgery should be carefully considered for each patient with reference to the AUA Best Practice Statement (Wolf et al., 2008). The minimum coverage would include either the use of a fluoroquinolone or trimethoprim/sulfamethoxazole. However, if the patient has an indwelling catheter (urethral or suprapubic), then extended coverage should be considered.

Sepsis is still an occasional occurrence after TURP, and antibiotics should be carefully selected. One European series with 857 patients had a bacteremia/septic shock rate of 2.3% (Vivien et al., 1998). Risk factors for bacteremia/sepsis included preoperative bacteruria and surgery longer than 70 minutes. The center where the surgery was performed was noted to also be a risk factor, implying that surgeon factors such as antibiotic choice or technique may be a factor.

The practice of extended antimicrobials is supported by the frequency with which patients with indwelling catheters have a positive (and often polymicrobial) urine culture (Warren et al., 1982). The spectrum of these organisms is variable with factors like local patient population, facility specifics, and previous antimicrobial treatment all affecting the latent organisms. Additionally, patients with long-term catheters are often exposed to antimicrobials, and they may have an increased risk for resistance (Bjork et al., 1984).

Histologic Specimen

In an era before PSA screening, prostate cancer was frequently diagnosed by the examination of the pathologic specimen obtained during TURP. With the increase in many treatment options that do not procure a specimen, there is some concern that we may be missing clinically significant cancers. The advent of common PSA screening was shown to decrease incidentally found cancer from 12.9% to 8.0% in one series (Mai et al., 2000). In a series looking at a 13-year period around the time of incorporation of PSA screening, Tombal et al. (1999) found a decrease in all T1 cancers from 23% to 7% of specimens from BPH treatments, with a greater effect on T1b disease (decrease from 15 to 2%). Patients with incidentally found prostate cancer during TURP were more likely to have organ-confined disease and lower Gleason scores than men detected by prostate biopsy (Helfand et al., 2009). A study from Meeks et al. (2013) concluded that in men with a PSA less than 4 ng/mL, the risk for finding a clinically significant cancer would occur in only 1 of 382 TURPs, making up a total of 390 such cancers detected nationally in a 3-year period. In a pool of 60,000 LASER vaporizations, 163 clinically significant cancers would be missed. Taken in concert, these studies report that in men who have undergone adequate PSA screening, relatively few clinically significant prostate cancers will be missed by using a technology that does not obtain a pathologic specimen.

Matching Treatment with Patient

Multiple patient factors may lead the urologist to recommend a particular treatment option for a patient as each treatment has its own inherent risk, benefit, and safety profile. Some patient factors to consider are prostate size, previous surgical intervention, history of urinary retention, inability to stop ongoing anticoagulation, surgeon experience, and, of course, patient preference. Factors more specific to the surgeon would include surgeon experience with different treatments and their availability at that institution. Historically, the urologist used a DRE or cystoscopy to estimate prostate size. DRE has been found to overestimate small glands and underestimate large ones, even in the setting of an experienced gray-haired endoscopic savant. During cystoscopy, each centimeter above the normal 2.5-cm prostate length would roughly equate with an additional 10 g of additional prostate weight. Although these may give the treating physician a general idea of prostate size, these types of assessments have been shown to be inaccurate. **If gland size may lead the urologist to choose between two different treatment techniques, the patient may be well served by undergoing an office TRUS to precisely assess prostate size before deciding on the surgical intervention.** Most urologists have an algorithm wherein they use prostate volume to dictate their recommendation for surgical intervention, with a very large gland leading the urologist to a bipolar TURP or OP and a smaller gland leading toward LASER or photoselective vaporization (PVP). However, more and more data are being generated showing efficacy of LASER methods in larger glands as is discussed in the PVP (LASER TURP) section of text. The authors of this chapter prefer the use of LASER TURP for glands less than 100 cc, with bipolar TURP for glands between 100 to 150 cc and simple prostatectomy (open or robotic) for glands larger than 150 cc. Regardless of the specific cutoffs used for each technology, it is a wise urologist who adheres to the AUA BPH guidelines suggestion that the choice of approach should be based on the patient's individual characteristics, including anatomy, the surgeon's experience, and discussion of the potential benefit and risks for complications (American Urological Association, 2011; McVary et al., 2011).

Additional factors that may also lead toward the use of conventional loop resection over LASER treatment may be the presence of a median lobe or a ring of intravesical prostate. The use of a loop in this situation may be preferable as it allows a less experienced surgeon the option to reach out and “pull” the protruding prostate away from the bladder wall during resection.

With increasing age and comorbidity, patients may now frequently be on anticoagulation when the urologist recommends surgical therapy. The inability of these patients to come off of their anticoagulation may lead the urologist to a difficult decision with regard to treatment options. Patients who are unable to cease anticoagulation for surgery may frequently be counseled that a treatment like LASER TURP may limit their surgical risk as this technique appears to have improvements over TURP in terms of bleeding risk.

Key Points

- Patients should generally be trialed on medical management before proceeding to surgical intervention. Patients failing medical management may be considered for surgical therapy.
- Perioperative antibiotic coverage should not be neglected as serious adverse outcomes still occur.
- Both patient and physician factors should be considered when selecting the appropriate surgical treatment for patients.

Specific Technologies

Non-LASER Options

Monopolar Transurethral Resection of the Prostate

TURP involves an endoscopic approach via the patient's urethra to surgically remove the inner portion (primarily the transition zone) of the prostate that encircles the urethra. An electrified wire loop is used to remove the portion of the prostate between the bladder neck and the verumontanum to a depth of the surgical capsule. The current is carried from the cutting loop through the tissue (and patient) to the return electrode in the grounding pad. Although still considered the gold standard for BPH treatment, the morbidity associated with the procedure has led to the development of many endoscopic alternatives to the classic monopolar transurethral resection of the prostate (M-TURP).

The original M-TURP requires the use of a non-ionic irrigant (glycine, sorbitol) to carry the current through the cutting loop into the tissue (and through the patient) to the grounding pad electrode. Unfortunately, these non-ionic solutions are hypo-osmolar and can be problematic when absorbed through open prostate sinuses into the systemic circulation, leading to acute dilutional hyponatremia (TUR syndrome). The migration of monopolar to bipolar energy has produced a considerable improvement in the safety profile of TURP. The use of iso-osmolar saline in bipolar TURP has reduced the incidence of TUR syndrome.

Technique (from Preoperative Area to Recovery Room)

Preoperative.

TURP is generally performed under general or spinal anesthesia. Traditionally, TURP was accomplished with the patient under spinal anesthesia so the anesthesiologist could monitor for signs of TUR syndrome caused by hyponatremia. However, this practice has become less commonplace for this indication, but the method remains useful. After adequate anesthesia has been initiated, the patient is positioned and secured in the dorsal lithotomy position and padded appropriately to prevent positioning injury, with special attention paid to the patient's legs. **The patient's buttocks should be placed near the table edge so that the table does not impede the full course of the scope. If**

not positioned far enough down the table, the anterior portions of the prostate may be difficult to reach, particularly in patients with fixed pelvic anatomy from previous pelvic injury, orthopedic history, radiation, or trauma. Adequate antibiotic coverage should be given as detailed earlier in this chapter. A quick abdominal examination will provide a baseline for any subsequent intraoperative examination should a perforation occur during the case leading to prevesical irrigant accumulation. Shaving of the genitals and perineum is not required, and any variety of standard skin preparations may be used on the lower abdomen, genitalia, and perineum. If required, a grounding pad should be placed on the leg outside of the surgically prepped area and a pad placed on the contralateral leg to any previous joint replacement surgeries. Use of the O'Conor type rectal shield provides ready, sterile access to the rectum in case the prostate needs to be lifted anteriorly for resection. Irrigating fluid should be maintained at body temperature and placed at the lowest height relative to the patient to provide adequate visualization. **Fluid level may be raised during the case if visualization becomes obscured by bleeding.**

Intraoperative.

Before the resectoscope is inserted, it should be assembled to make certain all elements are appropriately fitted and in working order. The use of a video camera mounted to the lens is largely standard at this point as few urologists prefer to place their eye directly to the lens. Some urologists prefer an instrument that permits a continuous flow of irrigating fluid. This can be done in either a passive mechanism into the cystoscopic drape or with the aid of a machine that allows for active removal of fluid from the bladder.

The plan for resection can be varied by any number of patient factors, and in general the best approach is the one best practiced and understood by the urologist. Despite the multiplicity of approaches, some generalizations are proposed later in this chapter with the consideration that the surgeon should always take an organized and systematic approach.

Before beginning to resect, the bladder should be inspected for any bladder pathology (e.g., tumor, diverticula). The presence of an unsuspected bladder tumor may necessitate a change in plan with resection of the bladder tumor at that time and return for TURP in the future once pathologic staging is complete. **The bladder neck, trigone, and position of the ureteral orifices, verumontanum, and external sphincter should be noted, and their relationship to the prostatic adenoma confirmed.** If the surgeon has difficulty identifying the ureteral orifices, indigo carmine may be given intravenously by the anesthesiologist with the efflux seen coming from the orifices a few minutes later. The type of irrigant used is based on the type of resection planned but generally is either normal saline (for bipolar resections) and glycine or water (for monopolar resection). **In situations in which the cutting element does not seem to be functioning, there is a general algorithm to check: Check the connection to the scope and generator; inspect the irrigating fluid to verify that it is commensurate with the generator technology being used; and, if a monopolar technology is being used, check that the patient is properly grounded.** The opening of the procedure should start with resection of any impediment to movement of the irrigating fluid. The presence of a middle lobe should lead the surgeon to start the resection there. The numerical choice of current is also dependent on the surgeon's preference, but mixed currents generally provide great hemostasis with less cutting ability. Once a median lobe has been removed, the lateral lobes of the prostate may then be tackled by the resectionist.

When resecting the lateral lobes, some surgeons prefer to resect the floor of the prostatic urethra initially (between the 5 o'clock and 7 o'clock positions), and others use a modification of the Nesbit “encirclement” approach (Fig. 146.3) (Nesbit, 1943). In the Nesbit approach, resection is initiated at the 11-o'clock to 9-o'clock and 1-o'clock to 3-o'clock positions. The resection exposes but does not resect the bladder neck fibers and carries the resection proximally to the base of the verumontanum and avoiding any injury to the external sphincter (Greene, 1979; Thompson, 1975).

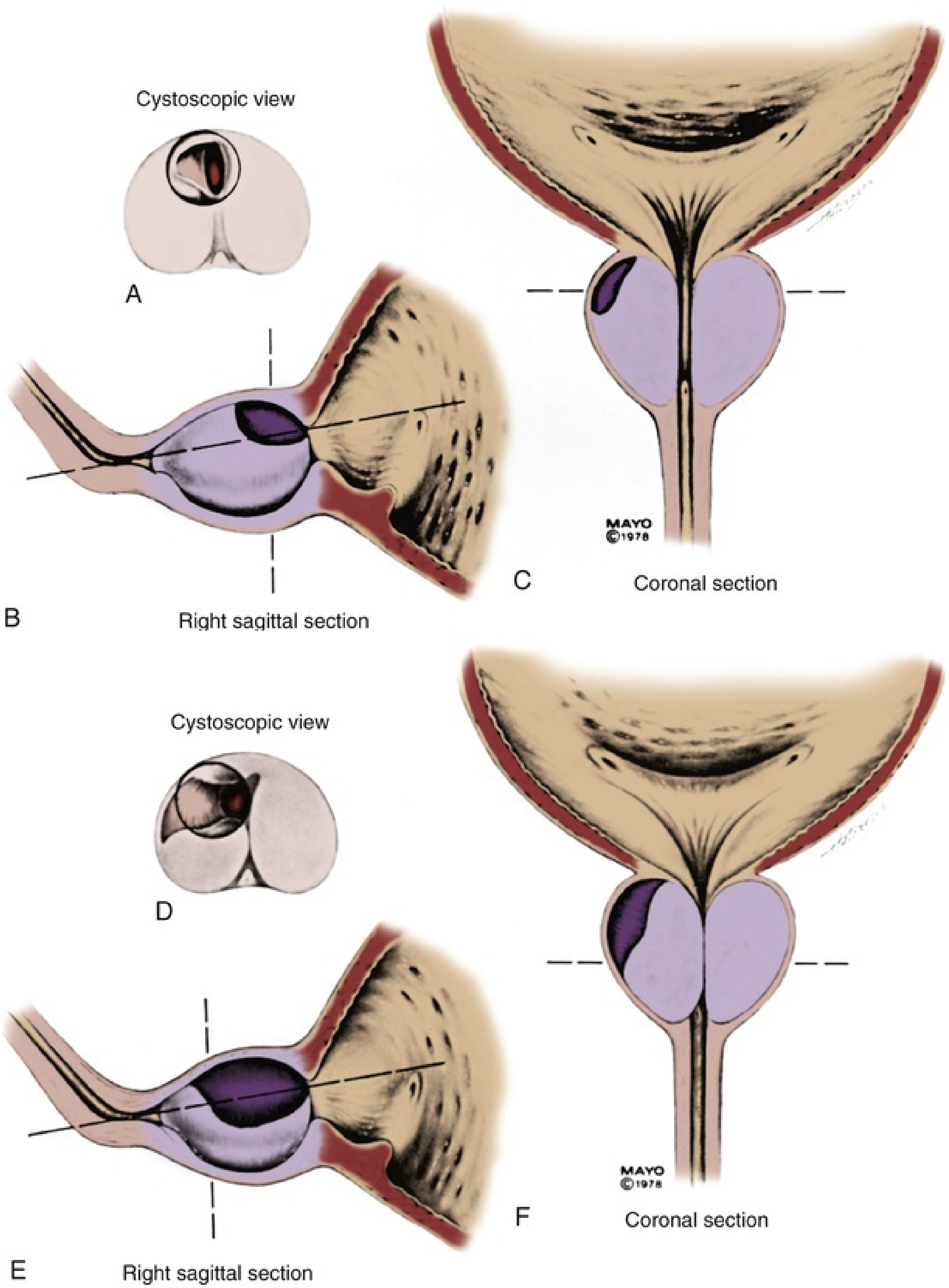
Cystoscopic view
A
B
Right sagittal section
MAYO
©1978
C
Coronal section
Cystoscopic view
D
E
Right sagittal section
MAYO
©1978
F
Coronal section

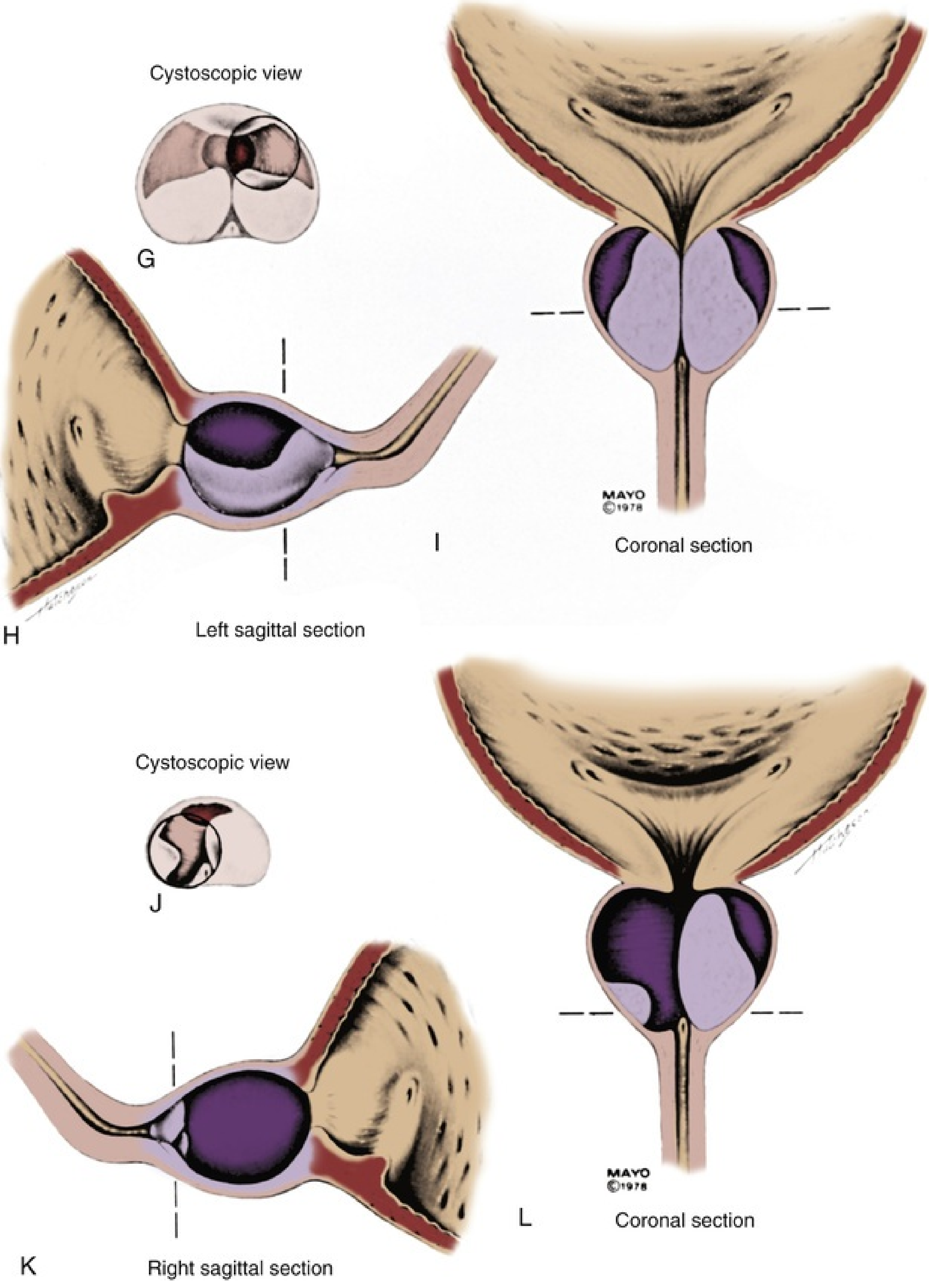
Cystoscopic view
G
H
Left sagittal section
MAYO ©1978
I
Coronal section
Cystoscopic view
J
K
Right sagittal section
MAYO ©1978
L
Coronal section

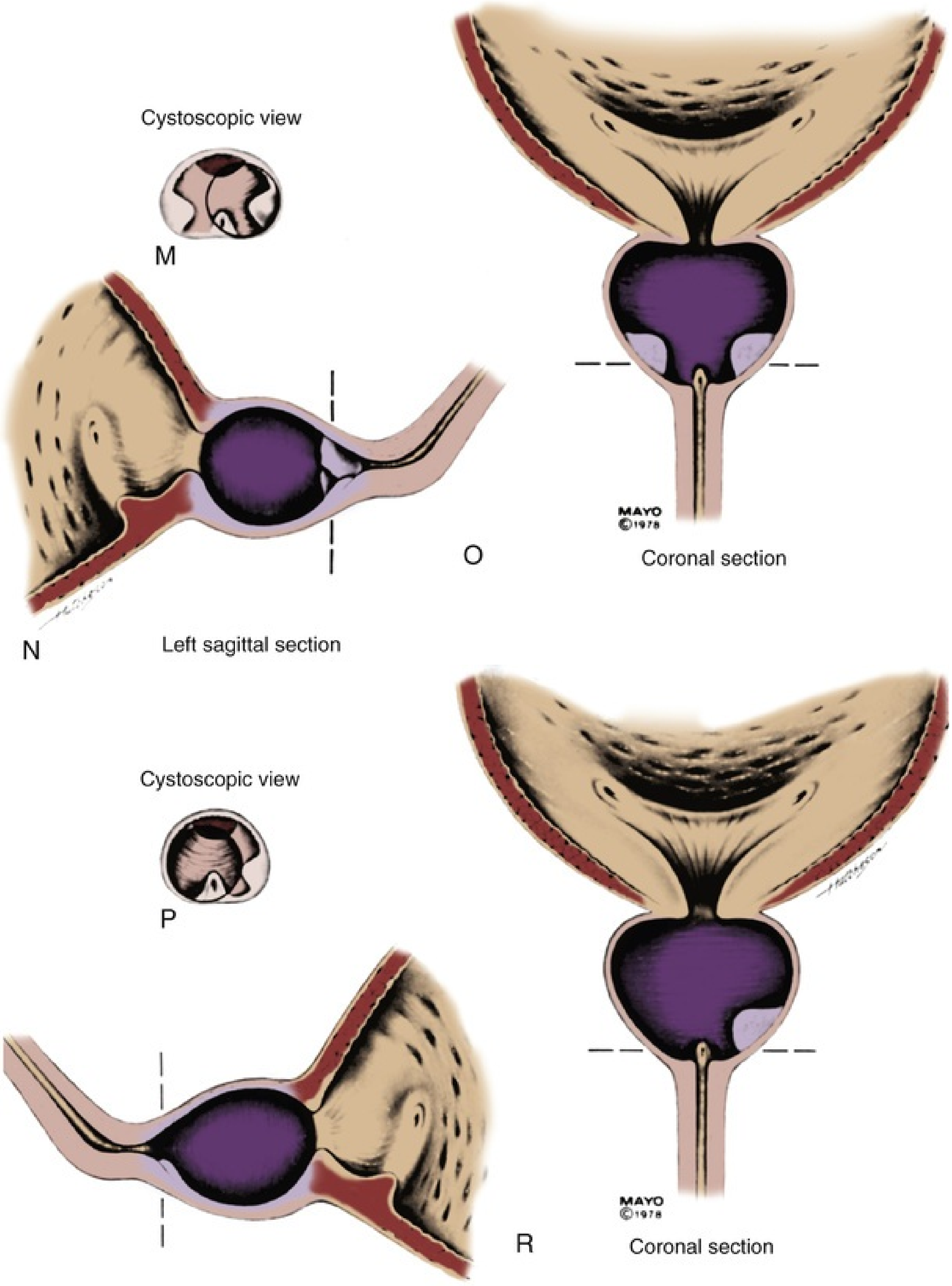
Cystoscopic view
M
N
Left sagittal section
MAYO
©1978
O
Coronal section
Cystoscopic view
P
Q
Right sagittal section
MAYO
©1978
R
Coronal section

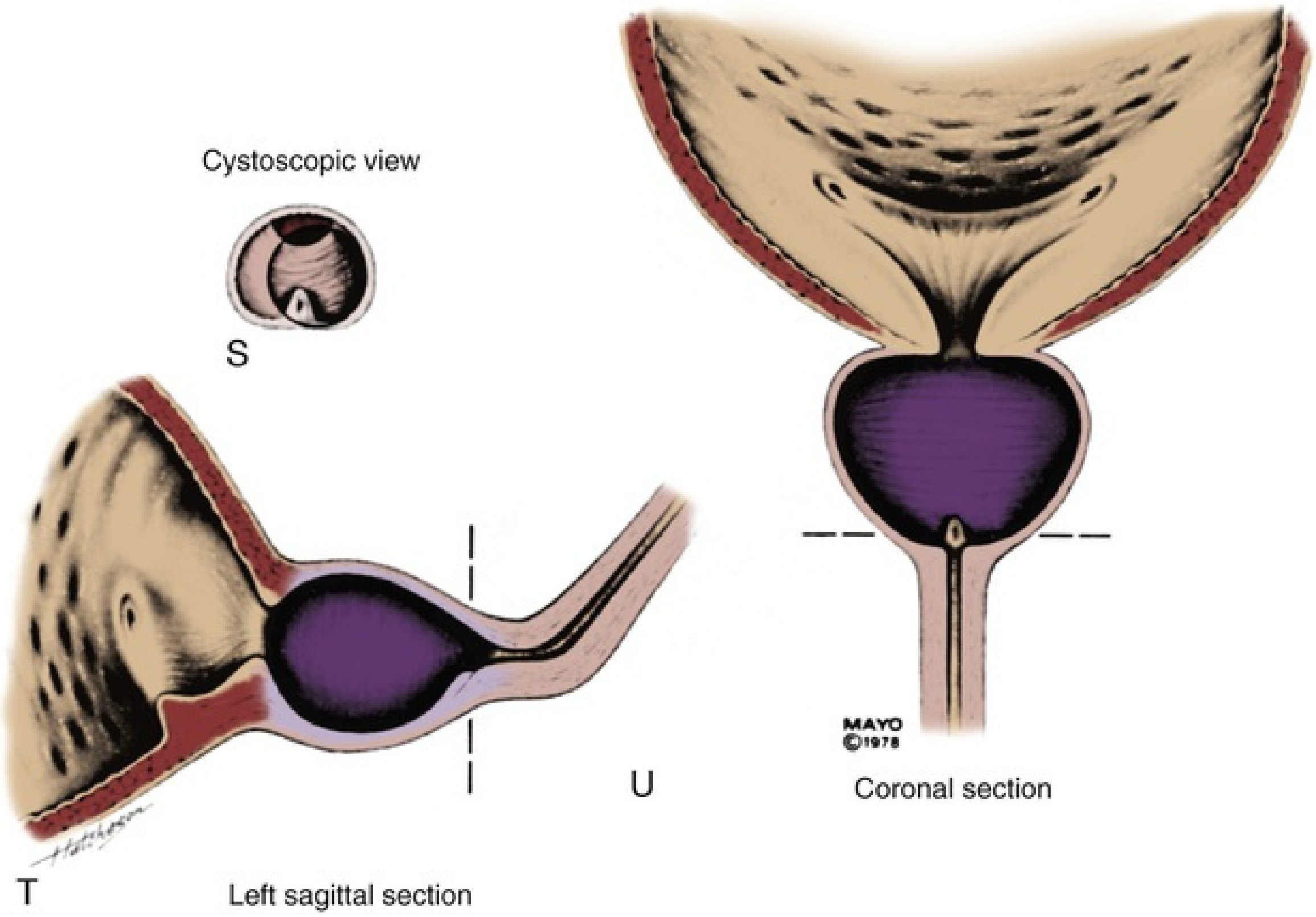

FIG. 146.3 Approach to transurethral resection of the prostate by starting the resection anteriorly. (A to C) First stage of resection of the prostate. The resection is begun at the 12 o'clock position, and the tissue at the bladder neck and the adjacent adenoma are resected in quadrants. (D) The midportion of the gland is resected starting at the 12 o'clock position and carried down to the 9 o'clock position. (E and F) Sagittal and coronal sections are shown. (G) The resection is now begun at the 12 o'clock position, and the left side of the patient's gland in the midfossa is resected down to the 3 o'clock position. (H and I) Sagittal and coronal sections are shown. (J) The midportion of the gland is resected farther down from the 9 o'clock position to the 6 o'clock position. (K and L) Sagittal views. (M to O) The tissue remaining at the apex is now resected. Resection is initiated next to the verumontanum and carried toward the 12 o'clock position. (P to R) Residual tissue is carefully cleared on the patient's right side. (S to U) The remaining residual tissue is cleared from the patient's left side, leaving an unobstructed view from the verumontanum through the bladder neck into the bladder. (©1978, the Mayo Foundation.)

Surgeons starting with the prostatic floor generally start by resecting a "channel" at either the 5 o'clock or 7 o'clock position and resecting down to the surgical capsule of the prostate (Fig. 146.4). By finding the surgical capsule early in the procedure, the depth of the resection is set. The channel is then widened (usually laterally) and then carried up the lateral walls toward the anterior aspect of the prostate following the surgical capsule as the depth of resection. The resectionist may note that the lateral lobes will begin to “fall” into the fossa as they are resected, making subsequent resection easier. Ultimately, the area between the 5 o'clock and 7 o'clock positions is then resected at the final stages of the procedure to smooth out the prostatic floor and finish the procedure without undermining the bladder neck during multiple movement of the scope.

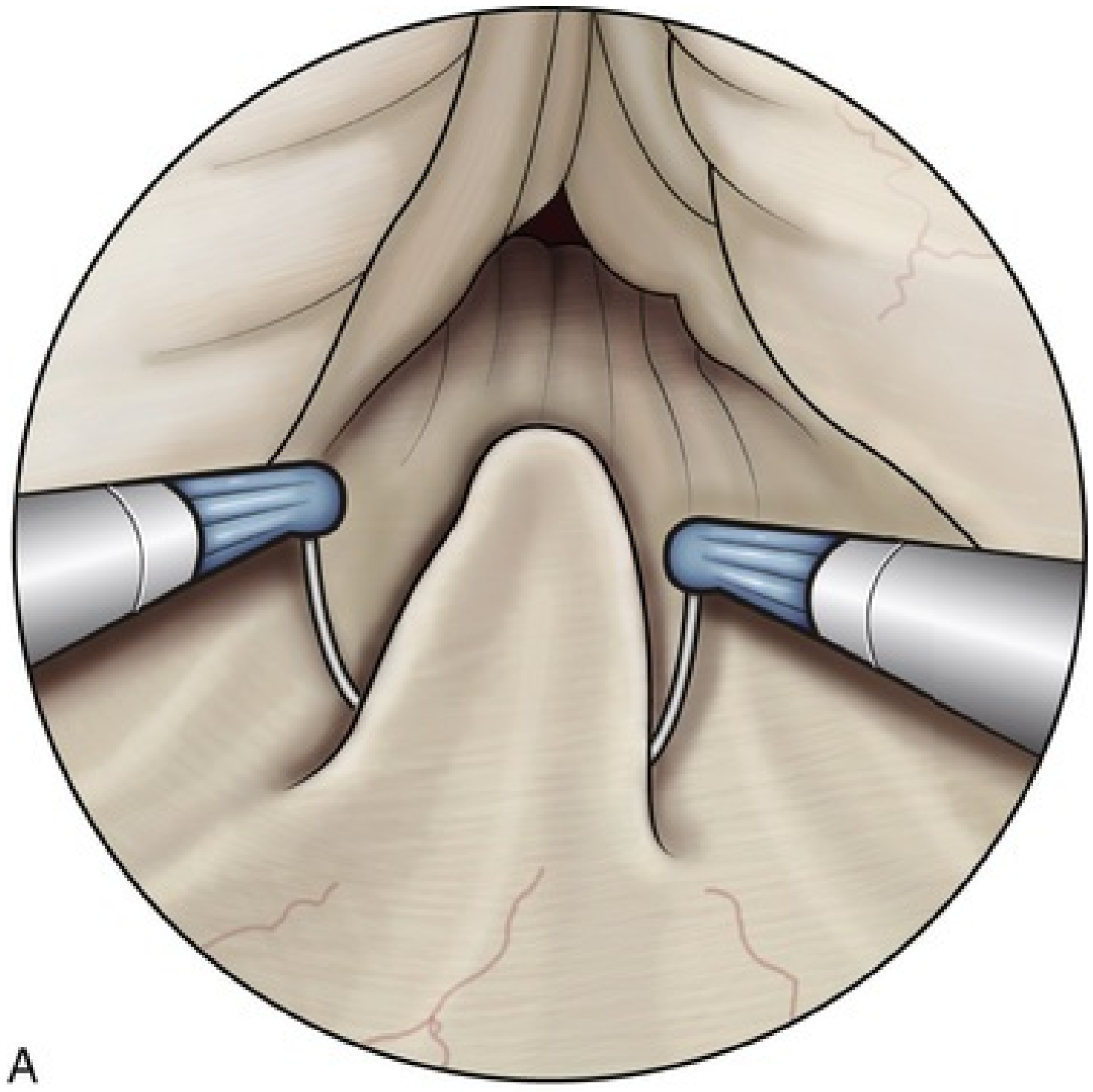

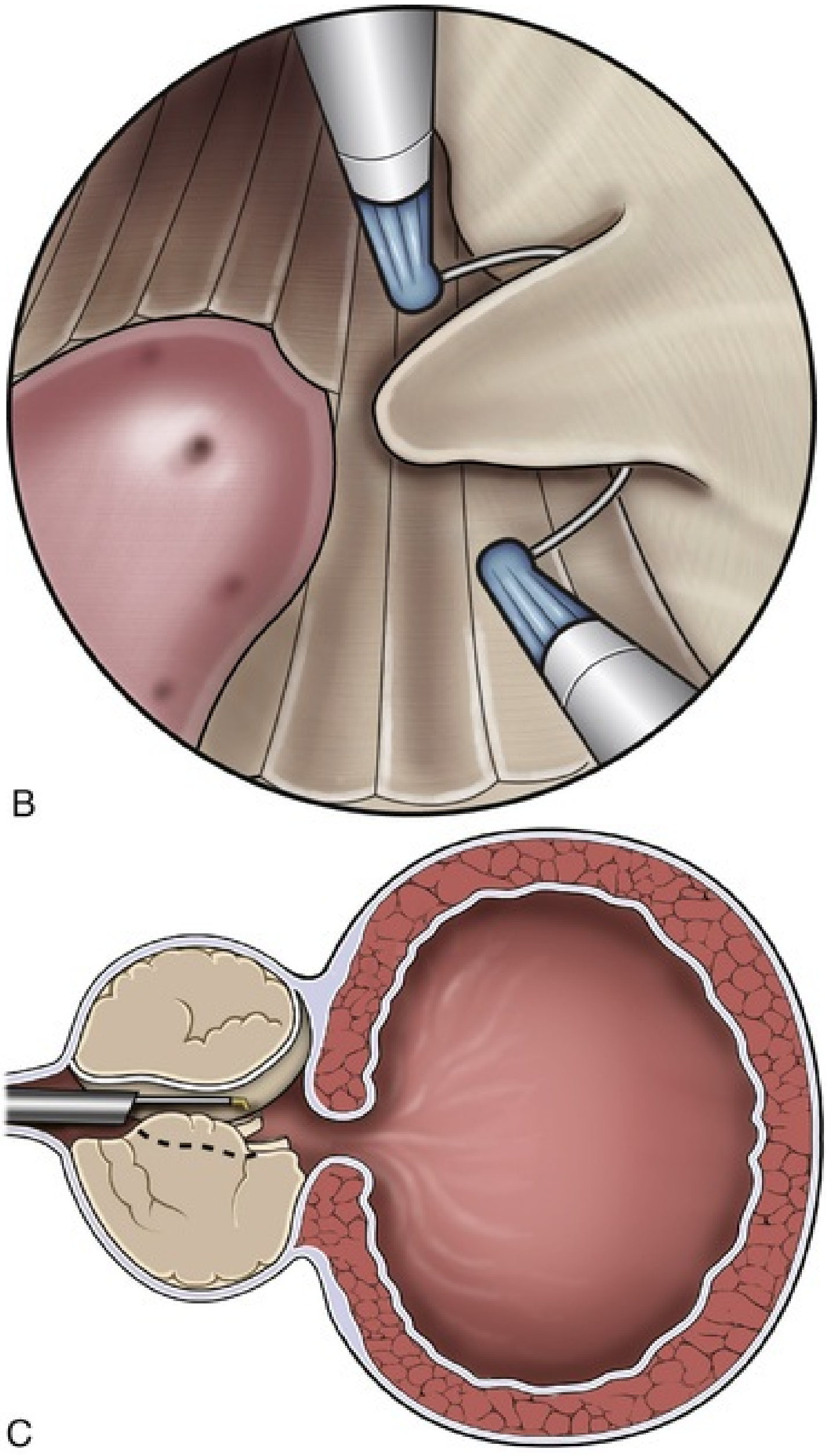
B
C

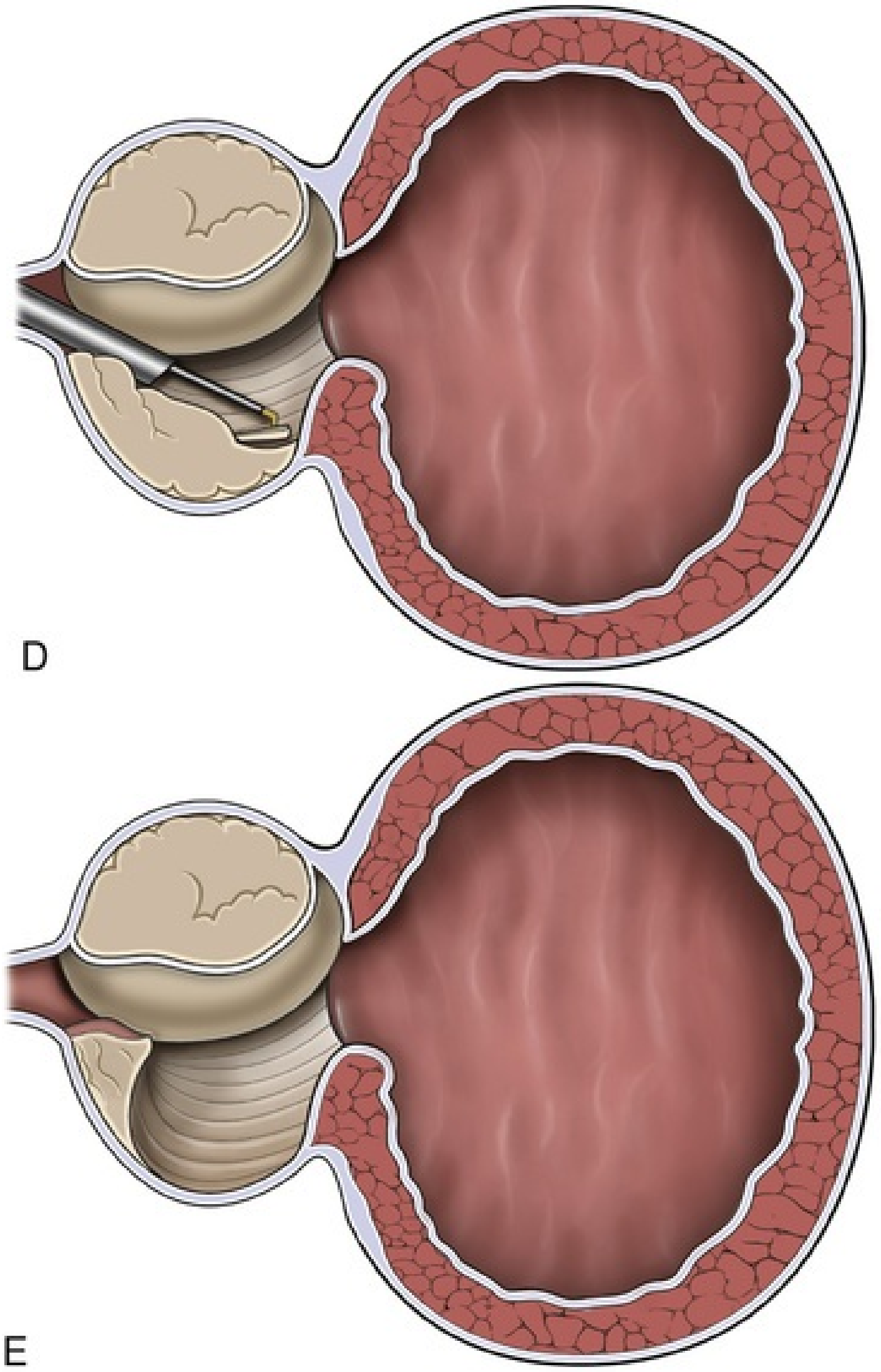

FIG. 146.4 Approach to transurethral resection of the prostate starting with the prostate floor. (A) View from resectoscope with an electrosurgical loop resecting prostate floor. (B) Resecting a lateral lobe. (C) Sagittal view of resection of the prostate floor. (D) Continuing resection down to the capsule. (E) Completed resection of this section of prostate, leaving some residual apical tissue to avoid injury to the external sphincter. (Modified from May F, Hartung R. Surgical atlas: transurethral resection of the prostate. *BJU Int* 98(4):921–934, 2006.)

In either resection schema, the initial stages of the resection should involve long, smooth tissue cuts. The produced prostate chips should be long and "canoe-like" in appearance with a length equivalent to the extended resection loop. A synchronized, rocking motion with the resectoscope allows the resectionist to follow the prostate shape and achieve the desired chip shape and resection. One should avoid cutting chips of insufficient length or thickness as this is inefficient and may lead to an irregular resection bed that hides bleeding areas. As the resection progresses, the surgeon may need more deliberate pressure on the resectoscope to reach more lateral and anterior aspects of the prostate. In surgeons utilizing the O'Conor shield, digital elevation of the prostate may aid in resection. Generally, aggressive resection of the anterior and apex of the prostate are postponed until the end of the procedure. The anterior aspect of the prostate fossa has the least depth of adenoma and is easily perforated. Additionally, the sphincter has a slight tilt with the anterior portion of the sphincter being the most proximal in the urethra. Although emptying the bladder may allow this anterior portion to become more visible to the surgeon and aid in resection, adequate fluid should be kept in the bladder to avoid inadvertent bladder perforation with the loop extended.

Overresection (including capsular perforation) in any area before the major portion of the adenoma has been removed may expose large venous sinuses. Exposing these sinuses will predispose to bleeding and fluid extravasation/absorption and compromise the resection and patient outcome. **The prostate apex is best resected at the end of the procedure in a bloodless field, where resection can be done precisely to avoid injury to the external sphincter.** A finger placed in the rectum via the O'Conor shield may also aid in resection at the apex. A limited amount of residual tissue may be left near the verumontanum as it is certainly preferable to repeat the procedure than to make the patient incontinent with an overzealous resection near the apex.

Hemostasis should be maintained throughout the procedure. Arterial bleeding is characterized by its bright red color and persistence, even with irrigation running over the area of hemorrhage. Additionally, this type of bleeding will persist during filling and drainage of the bladder. Arterial bleeding should always be controlled, and precise fulguration is paramount. If vision is obscured, the cutting loop may be advanced to place the loop on an area of bleeding with the fulguration current and then used to control the arterial end. “Ricochet” or “bounce” bleeding from the opposite wall or a cryptic bleeding site that requires further, deeper resection should also be kept in mind (Greene and Holcomb, 1979). Identifying bleeding at the bladder neck (particularly anteriorly) can be facilitated by nearly emptying the bladder.

Venous bleeding can be more vexing and generally appears darker in color than arterial bleeding. Venous bleeding will often disappear with a full bladder as it applies pressure to the prostatic fossa. Identifying venous sinuses may be difficult because of the lack of persistent bleeding with rapid irrigation influx, and controlling of the bleeding with fulguration may be even more challenging. Once again, the cutting loop may be used to temporarily tamponade any bleeding with precise fulguration. If the venous bleeding cannot be completely controlled (as is frequently the case), a catheter may be inserted and the balloon overinflated and pulled to traction for tamponade of venous bleeding.

Before the operation is terminated, all tissue must be removed from the bladder with careful attention paid to make sure prostatic chips have not fallen into any bladder diverticulae that may exist. An Ellik or Toomey syringe may help facilitate removal of any tissue. The prostatic fossa should be examined again as one of the final steps with control of any arterial bleeding. A large-bore catheter should be carefully placed into the bladder with the use of a wire catheter guide if required. The amount of fluid placed in the balloon should be tailored to the volume of resected tissue to avoid the catheter balloon falling into the excavated prostatic fossa. In our practice, the Foley catheter is generally placed to traction for a short time with release of traction based on residual hematuria. The use of continuous bladder irrigation (CBI) is not compulsory but can be used if the irrigant is not clear at the end of the case.

Placement of a three-way catheter at the end of the case does not commit the patient to CBI as the inflow port can always be obstructed with a catheter plug. If CBI is elected, skilled nursing is preferable as an unrecognized obstruction to the outflow tract can lead to bladder distension and a worsening of bleeding. Intermittent irrigation may also be used but requires extra attention to the inflow/outflow patterns.

Postoperative Care.

Most patients undergoing TURP have an uneventful postoperative course (Mebust, 1993). The diet can quickly be advanced in the postoperative period, and the patient may ambulate on the day of surgery if there is a mild degree of hematuria. When ordering postoperative fluids, one should remember that even an uncomplicated resection has fluid absorption between 800 mL and 1000 mL (Oester and Madsen, 1969). Patients with persistent complaints of bladder spasms or rectal discomfort should prompt the clinician to examine the catheter to make sure it is not obstructed.

In the absence of significant capsular perforation or persistent bleeding, the catheter can be removed in 24 to 48 hours. If minor bleeding persists beyond this timeframe, the patient may be discharged to home with the catheter in place with close outpatient follow-up. Although a wide variety of practice patterns exist, patients may be discharged to home with or without the catheter, and we generally discharge patients on postoperative day 1. The use of narcotics for pain control is almost never necessary, and they should be avoided at discharge.

The use of stool softeners in the postoperative period (extending out 1 month from surgery) is likely beneficial as passage of hard, impacted stool may precipitate bleeding. **Patients should avoid activities that place excessive or uneven pressure on the perineum (e.g., horse riding, use of a riding lawnmower) for 4 to 6 weeks to avoid inciting any postoperative bleeding while the freshly resected prosthetic bed re-epithelializes.** Epithelialization of the prostate bed occurs by migration and proliferation of transitional cells for the resected margins. This usually requires a few weeks, and patients will frequently report dysuria during this time. **The long-term use of phenazopyridine is discouraged but may help patients overcome this dysuria in the immediate postoperative period.** Patients should be warned that this medication may make bodily fluids appear red-orange in color and can stain contact lenses. To alleviate patient anxiety when this occurs, patients should be warned that they will frequently pass tissue or eschar with some minor, delayed bleeding 1 to 4 weeks from the time of the procedure. It is our practice to have the patient refrain from any sexual activity as concern arises about precipitous bleeding, even though this is clearly a matter of expert opinion.

Patients with long-standing obstruction (particularly those with urgency and frequency preoperatively) will often experience a continuation or exacerbation of these symptoms in the postoperative period. If proper bladder emptying can be verified, an anticholinergic or beta-3 agonist medication during this time may help the patient feel more comfortable. It is our practice to warn those men with preoperatively documented detrusor overactivity that patience will be required in the months after surgery to see if this will resolve. Such caution goes a long way in assuring patients to adopt a strong coping mechanism rather than a polypharmacy approach.

Outcomes.

Although morbidity data for men after TURP is commonly cited in a negative fashion, these data should not detract from the large number of men who benefit from the procedure. The number of patients who judge their voiding symptoms to be “better” or “much better” depends partly on the initial severity of symptoms and duration of follow-up but is generally

above 75% and can be as high as 93% (Bruskewitz et al., 1986; Fowler et al., 1988; Lepor and Rigaud, 1990). The review by the Agency for Health Care Policy and Research (McConnell et al., 1994) indicated an overall symptomatic improvement of 88% for TURP. These data review indicated that surgical procedures in general (OP, TURP, TUIP) produced about an 80% improvement in symptom scores compared with 30% to 40% range for placebo and nonsurgical therapies.

The large, multicenter Veterans Administration study was conducted before the common use of medical treatment for BPH and compared TURP and watchful waiting (Wasson et al., 1995). TURP was considerably more effective than watchful waiting in improving symptoms and avoiding treatment failure. More substantial benefit was noted in men with severe urinary symptoms as men with substantial bother had a 91% chance of improvement compared with 62% in those with less significant bother.

Considerable and durable changes in AUASS, QoL score, Qmax, and many other voiding and lifestyle metrics have been observed with TURP. Masumori et al. (2010) showed the procedure's symptomatic durability in their analysis of patients available at 12 years after TURP. Although patients started out with an overall fairly low AUA-SS (16.7), they improved by 75% at 3 months postprocedure. The difference was less pronounced (40% decrease compared with baseline) but still statistically significant at 12 years. QoL scores followed a similar pattern, with a 67% decrease at 3 months compared with baseline, which was still significant but less pronounced (52%) at 12 years. The patients with confirmed BOO by pressure-flow study performed better than those without this finding. Patients with urodynamic study (UDS) findings of detrusor overactivity or underactivity did not differentiate themselves with regard to change in AUA-SS compared with the rest of the cohort. Analysis 7 years after M-TURP found an improvement in Qmax of 106% at 1 year, with a 28% improvement at 7 years (Nielsen et al., 1989). Of the 44 patients still able to be evaluated at 7 years, 16% required repeat resection.

Recent data on M-TURP generally needs to be drawn from the procedure as the control group in RCTs. In general, marked reductions in AUA-SS and QoL scores are seen with significant improvements in Qmax and UDS parameters. An increase in Qmax from 125% to 175% and a reduction in AUA-SS of 75% are frequently seen. Additionally, rarely does a competing technology have a lower risk for BPH-specific retreatment.

In RCTs examining comparison of TURP to other treatments for

LUTS/BPH, TURP is generally at least equivalent if not superior in terms of outcomes focusing on improvements in voiding, with most other treatment options having better safety and adverse-event profiles.

TURP in the Anticoagulated Patient.

A controlled study by Dotan et al. (2002) looked at patients undergoing bridging with low-molecular-weight heparin and early resumption of warfarin after stopping warfarin 5 days preoperatively. The average change in hemoglobin was not statistically different, and although the study group did more frequently require transfusion, this difference was also not significant.

Chakravarti and MacDermott (1998) utilized a different strategy with patients in which they only underwent a 2-day cessation of warfarin before surgery with intravenous heparin substitution during cessation. Of the 11 patients studied, they had a modest decrease in hemoglobin (1.6 g/dL) with surgery, with 3 patients readmitted within 30 days for bleeding issues.

In a multicenter study of 612 patients, 33% were on blood thinners before surgery (55 on warfarin, 74 on clopidrogel, and 62 on aspirin) (Descazeaud et al., 2011). All patients discontinued warfarin and clopidrogel for surgery, with most patients getting bridged until surgery with some form of heparin. Only three patients continued their aspirin through surgery, with the majority of those stopping aspirin also getting a heparin bridge. **Follow-up at 3 months demonstrated that anticoagulated patients had a higher rate of transfusion (1.9% vs. 1.0%, *P* = .026), bladder clots (13% vs 4.7%, *P* < .001) and thromboembolic events (2.4% vs. 0.7%, *P* = .02). Follow-up studies have found differing results** (Raj et al., 2011; Taylor et al., 2011).

A dose-escalating, randomized, double-blind, placebo-controlled trial on a heparinoid medication showed a dose-dependent increase in blood loss when given during the time of TURP. Bleeding was so significant at the highest dose that the study was stopped prematurely (ten Cate et al., 1987).

Aspirin has also been studied in the perioperative period. A well-designed prospective, randomized, double-blind, placebo-controlled study looked at patients randomized to 150 mg of aspirin or placebo for 10 days before TURP. With no difference in intraoperative blood loss, the aspirin group had a significantly higher postoperative blood loss. Although there was no statistical difference in transfusion requirements, more units of blood were used in the group on aspirin (Nielsen et al., 2000). Two older, controlled studies concluded there was no difference in blood loss for patients continuing aspirin therapy through surgery (Ala-Opas and Grönlund, 1996; Thurston and Briant, 1993).

In summation, the risk associated with TURP in the anticoagulated patient is significant, and authors have postulated that LASER options may be preferable in patients who are unable to come off of anticoagulation for surgery (Descazeaud et al., 2009).

Complications.

Despite decades of use, M-TURP still has a considerable intraoperative complication rate. Although the overall complication rate has improved, there is **still at least a 3% chance of intraoperative complication** (Ahyai et al., 2010) **primarily from hemorrhage leading to transfusion.** However, with other MISTs requiring more frequent reoperation, the perioperative and late complication rates of M-TURP continue to make it a viable option in the correctly chosen patient. The overall morbidity of TURP continues to approach 20% when studies include blood loss requiring transfusion, infections, strictures, sexual dysfunction, urinary incontinence, urinary retention, and the development of TUR syndrome (Borboroglu et al., 1999; Mebust et al., 1989).

Intraoperative and Perioperative Problems.

There is always the possibility of absorption of the irrigating fluid into the patient's systemic circulation during resection of prostatic tissue, and **TUR syndrome does still occur**. Much of our current understanding of the etiology of TUR syndrome starts with work from the 1950s (Hagstrom, 1955; Harrison et al., 1956). **The prostatic venous system has a pressure of approximately 10 mm Hg, and fluid at a pressure exceeding this will lead to fluid absorption when these vessels are exposed during resection.** The absorption of the hypo-osmolar irrigating fluid leads to an acute dilutional hyponatremia with resulting neurologic changes (confusion, nausea, vomiting, visual changes, hypertension, tachypnea, and bradycardia). Now with the use of isotonic, iso-osmolar irrigating solution and the bipolar electroresection system, this risk has theoretically been eliminated. **TUR syndrome was seen in 2% of cases in the AUA cooperative study** (Mebust et al., 1989)**. Larger glands (greater than 45 g) and longer resections (greater than 90 minutes) were risk factors.** The recent meta-analysis of RCTs found a lower incidence, with only 0.8% of patients suffering from TUR syndrome (Ahyai et al., 2010). Although most authors agree that TUR syndrome is caused by dilutional hyponatremia, there have been alternate etiologies proposed. Hoekstra et al. (1983) and Ryder et al.

(1984) noted elevated serum ammonia levels after glycine irrigant resections. Excessive glycine absorption led to liberation of ammonia from metabolic pathways leading to immediate or delayed encaphalopathic symptoms.

Several steps can be taken to prevent this complication. Use of a bipolar resection method should certainly be considered. **The height of the irrigating fluid above the patient should be carefully chosen.Madsen and Naber** (1973)**demonstrated that the ideal height of the fluid was 60 cm above the patient. From their work, this appears to be the minimal height to maintain good vision but also not lead to excessive systemic fluid absorption.** Increasing the height 10 cm above this leads to increased pressure in the prostatic fossa and a greater than twofold increase in systemic fluid absorption. Diagnosis of this condition is made by assessment of neurologic status and comparison to laboratory values. Serum sodium should be obtained in long, large resections postoperatively (or intraoperatively if concern exists). A serum sodium of less than 120 mEq/L indicates a significant dilution and may lead to coma or seizures. Transient visual disturbances or blindness indicate central nervous system (CNS) toxicity and are obviously very distressing to all the parties involved.

If profound CNS symptoms are noted, judicious administration of hypertonic saline should be instituted, and formulas exist to help guide this resuscitation as overly rapid correction of hyponatremia may lead to a demyelinating lesion of the brain (central pontine myelinolysis).

In either resection approach, the scope may need to make multiple trips across the prostatovesical junction leading to trigone undermining. If during initial resection the dorsal aspect of this junction becomes overly resected, these trips may become more challenging as the scope is forced to move “uphill” and increase the detachment of the trigone from the posterior prostate base.

Ureteral injury is an uncommon complication. Identification of the ureteral orifices should be attempted before resecting. The 70-degree lens and intravenous injection of an agent that colors the urine (methylene blue, indigo carmine) may be of aid in identifying the ureteral orifices. If still unable to identify them because of a high bladder neck or large median lobe, resection should begin in the midline, taking down the median lobe as described earlier. After this is accomplished, the ureteral orifices may become more apparent to the resectionist without the mass effect of the median lobe obscuring the view.

Hemorrhage in the resected area is a common complication both during and after TURP. Every effort should be made to achieve hemostasis during the operation to prevent the need for a return to the operating room. The risk associated with transfusion in patients undergoing TURP is low but still occurs, and patients should be counseled appropriately. Ideally, hemorrhaging areas are controlled as the procedure is ongoing. **Arterial bleeding should generally be fulgurated during the procedure, although the resectionist may continue to resect arterial bleeding until the capsule is exposed and fulgurate a bleeding vessel at this level. This practice should be engaged in carefully but is reasonable**. Venous bleeding is classically more difficult to control. Fulguration of open venous sinuses should be attempted, but this may be ineffective, even in the most trained hands. In these cases, balloon tamponade may be most effective. Once arterial bleeding has been controlled, a large balloon (30 mL) Foley catheter may be placed with 50 to 60 mL of water placed in the balloon. The catheter may then be put to traction for a short time to see if this relieves bleeding. In certain cases, it may be prudent to continue traction overnight. The Veterans Affairs Cooperative Study of 3885 patients found a **transfusion rate of 2.5%** (Mebust et al., 1989). Other early data reported high transfusion rates with over 20% of patients receiving transfusion (Doll et al., 1992), and more **recent data from an analysis of RCTs found that 4.4% of patients would require transfusion** (Mayer et al., 2012).

Perforation may occur at many places during the resection; the prostatovesical junction, prostatic capsule, or the bladder itself are all possibilities. The electroresection itself or overdistension of a thinned area of the prostatic capsule may lead to frank perforation with visual evidence often being subtle. The glistening fat of the periprostatic or perivesical spaces is usually a telltale sign of perforation. In unclear cases, cystography (with drainage films) may be used to assess the degree of perforation and the drainage pattern. **Extravasation related to prostatic resection is almost always extraperitoneal.** If bladder perforation occurs near the dome, then cystography should be considered to rule out an intraperitoneal rupture, which would require open closure. Extraperitoneal rupture caused by resection with limited extravasation can almost always be managed with extended catheter drainage and careful observation. In cases of extraperitoneal rupture occurring with extensive extravasation, percutaneous or open drainage may be required.

Persistent penile erection may develop at any point during the case and may drastically limit the mobility of the resectoscope. Detumescence may occur spontaneously without active management. In cases in which this does not occur, detumescence may be encouraged with pharmacologic agents such as phenylephrine (Lue et al., 1986). Anesthesia should be alerted to injection of this vasoactive substance as overly judicious use may lead to systemic cardiovascular changes. Considerable attempts should be made with vasoactive substances, but if these all fail, perineal urethrostomy can be used to gain access in a dire situation.

Postoperative.

Original estimates of **bladder neck contracture** were 2% (Greene and Holcomb, 1979). Subsequent data have shown this to be a fairly consistent 2% (Ahyai et al., 2010), although a large range was found in this study (2% to 21%). This complication is thought to result from overresection of the tissue at the bladder neck paired with injudicious fulguration of this area. Undermining of the trigone may create a flap that then heals as a membrane. Patients with this complication customarily report excellent flow rates in the immediate postoperative period that slowly decrease in the coming weeks, months, or years. This course will be well exaggerated over the usual progression of BPH-type symptoms of a weakening stream. The average interval of development was approximately 6 months from the time of the surgery but have ranged from 3 weeks to 10 years (Greene and Holcomb, 1979). If serial flow rates are available during this time, the results will predictably get worse as the contracture develops. **Prompt office cystoscopy should be performed to verify the diagnosis.** Gentle dilation in the office with sounds or a dilating balloon may be attempted. If dilation does not prevail, then evaluation in the operating room with endoscopic incision may be required. If the bladder opening appears completely obliterated, intravenous administration of methylene blue and use of suprapubic pressure may help identify a jet of blue urine to lead the urologist toward the opening (usually located anteriorly). An open-ended ureteral catheter may be placed into the narrowed opening and guide incision of the constricted ring. Incision may be made with a Collins knife or optical urethrotome until the ring springs open. Incisions are generally made aggressively in the patient with a bladder neck contracture after TURP as the sphincter is still anatomically far away; this is in contrast with anastomotic contractures after radical prostatectomy as these contractures sit very close to the sphincter. Once the band has been opened wide enough to accept the cystoscope, additional resection should be avoided as it may exacerbate the healing reaction and cause a re-stenosis. Intractable bladder neck contractures may require an open VY-plasty to solve the problem.

The incidence of **urethral stricture** after TURP has a large variation in reported incidence. Mayer et al. (2012) found that this occurred in 4.1% of cases in the 34 analyzed RCTs, although the severity and necessary treatments were not outlined. The etiology of urethral stricture is thought to be caused by resectoscope trauma, catheter usage, or bacterial infection in the postoperative period. The surgeon should be careful to select an appropriately sized resectoscope sheath to prevent any unneeded trauma. Interesting data from Emmett et al. (1957)showed that only 62% of men who underwent urethral calibration had a urethral meatus and fossa navicularis of 28 F or greater. **Calibration and gentle dilation of the meatus along with careful visual inspection of the urethra on insertion of the cystoscope may help in preventing trauma that may lead to stricture.** The resectoscope should always be well lubricated. The role of a urethral catheter leading to stricture formation is supported by a comparison of patients with suprapubic versus urethral catheters, wherein the former had a lower incidence of stricture formation (Hammarsten and Lindqvist, 1992).

The internal sphincter predominates as a continence mechanism in men. During the course of a normal resection, this sphincteric mechanism is resected or rendered incompetent. (Rolnick and Arnheim, 1949). Without exception, the surgeon must **preserve the external sphincter mechanism,** or the patient will have total or stress urinary incontinence (SUI). This injury may be caused by errant resection or excessive fulguration around the striated muscle fibers. The verumontanum is an invaluable landmark and should be preserved not only as a landmark during the ongoing resection, but also for any future identification during cystouretheroscopy. Resections that are terminated proximal or adjacent to the verumontanum are unlikely to have a significant injury to the external sphincter. However, the extent of the complex smooth and striated muscle fibers that make up the external sphincter are not always clearly demarcated. The anterior portion of these muscular fibers is the least substantial, and the sphincter lies on a tilt with the dorsal portion being the most proximal and thus most likely to extend into the resection. The poor understanding of the complexities of the external sphincter is most evident when one considers the extent of incision during an external sphincterotomy. This purposeful act often requires considerable depth and length, and highlights our poor understanding of post-TURP incontinence. Nonetheless, caution in overresection of the distal portions of the prostate should be exercised. Even in contemporary studies, this is a continued problem. **The study byAhyai et al.** (2010)**found a 0.6% incidence of**

SUI, with some studies reporting up to 5%. However, this is often a transient issue and rarely requires additional intervention.

Significant hemorrhage in the immediate postoperative period is most often caused by incompletely controlled hemostasis during surgery, and minor hemorrhage requiring minimal irrigation is fairly common with a wide variability in occurrence between practitioners (Mayer et al., 2012). **Some delayed postoperative bleeding is frequently noted around 1 to 4 weeks postoperatively and is frequently accompanied by some sloughed tissue or eschar.** Outside of this period, the likelihood of bleeding decreases as the time from surgery lengthens. Limited bleeding may occur for many weeks after the initial resection, but it is usually limited and transient in nature. This customarily responds to curtailing physical activity and increasing fluid intake.

Postoperative urinary retention after any BOO procedure is a common finding. Variability is different based on surgical technique and procedure type. Prolonged catheterization is generally a result of persistent bleeding or surgeon preference. In major case series, this ranges between 6.5% and 7.1% of cases and does not appear to have changed over time (Mayer et al., 2012).

The **need for retreatment** may arise from one of many reasons. **Incomplete resection (likely at the apex or anteriorly), poor patient selection, diagnostic error, and intraoperative technical errors are all possible causes.** The need for retreatment may be caused by urethral stricture, bladder neck contracture, regrowth of BPH, or residual BPH left at the previous surgery. In the meta-analysis of RCTs, Ahyai et al. (2010) found a rate of 0.5% re-intervention for BPH type symptoms with another 0.1% requiring secondary treatment resulting from other causes (e.g., bladder neck contracture, urethral stricture). The need for surgical revision does appear to increase with increasing gland size, and preoperative retention also is a risk factor (Reich et al., 2008).

Urinary storage symptoms are a common finding after any BOO procedure wherein the urethral epithelium is disrupted. The raw prostatic fossa takes time to re-epithelialize, and the patient will likely frequently experience symptoms of **urgency** or **dysuria** during this time. Although wide ranges of reporting are seen for both urgency (0% to 38%) and dysuria (0% to 22%), the physician can expect an average of 2.2% and 0.8%, respectively (Ahyai et al., 2010).

Ejaculatory problems are a significant concern as the bladder neck is resected as part of the procedure. In the TURP arm of randomized series compared with holmium enucleation, the TURP groups had a new incidence of retrograde ejaculation of 62% and 78% (Briganti et al., 2006; Wilson et al.,

2006).

Multiple large series have reported on the effects of TURP with regard to a **change in erection quality.** In a trial of 644 men, 30% noted an improvement in erections after the procedure, and only 20% noted worsening function. The percentage of men engaging in sexual activity before and after surgery was essentially identical (Muntener et al., 2007). Another series showed that a capsular perforation during surgery had a relative risk of 1.12 in postoperative erectile dysfunction (ED) (Poulakis et al., 2006), and other studies did not find an increase in risk (Jaidane et al., 2010). **In a comparative study of patients undergoing either TURP or transurethral resection of bladder tumor (TURBT), the baseline voiding and erectile function in the TURBT group was statistically far superior. However, after prostate resection, the TURP group displayed significant improvements in almost all International Index of Erectile Function-15 (IIEF-15) subdomains with an impressive improvement in erectile function (improving from 7.18 to 20.74). After TURP, the groups were no longer statistically different with regard to voiding and sexual function** (Jaidane et al., 2010).

Conclusion.

Although most men improved in overall QoL and the important symptom and urodynamic outcomes with M-TURP, the morbidity and adverse events are such that multiple different and generally less invasive treatment options have been developed. Although many of these technologies do not achieve the same efficacy as TURP, they are associated with less risk or fulfill a particular treatment niche.

Bipolar Transurethral Resection of the Prostate

Concept.

Bipolar transurethral resection of the prostate (B-TURP) utilizes a specialized resecting loop that incorporates both the active and the return portions of the circuit on the same electrode. Consequently, the current does not need to run through the patient to a return electrode (in the form of a grounding pad), and current is kept at the site of the resection. This innovation in design has also allowed for the resection to take place in ionic irrigating solution and has eliminated most of the risk for TUR syndrome.

True bipolar systems meet the criteria set by the International Electrosurgical

Commission, which requires both active and return poles to be attached in a single system. Frequently a dual-loop design is used wherein both loops are in close proximity to each other at the end of the cutting electrode. In this design, the electrical energy is able to connect between the loops and supply the resecting energy there. Another form of bipolar technology is the PlasmaKinetic (PK) system (Olympus, Tokyo, Japan) wherein energy is initially transmitted from the loop into the surrounding saline. This B-TURP technology is commonly used in the United States, and the mechanism is described in detail here. The saline is vaporized into gas around the loop with additional energy from the loop then converting the gas to plasma. The excited sodium ions of the plasma give this technology the characteristic orange glow. Once created, the plasma molecules are now able to be excited for use in resection. Although this seems like a dynamic and explosive process, it actually allows tissue resection at lower temperatures with a lower voltage. In practice, this allows for a more simultaneous cutting of tissue with sealing of vessels leading to the overall improved hemostasis recognized in studies.

Although the PK loop and scope look almost identical to the conventional monopolar systems, the loop is made of platinum-iridium instead of the standard tungsten loop. This specialized loop is able to withstand the electrical and thermal stresses that come with plasma usage (Issa, 2008).

When using the coagulation setting in this system, a different process takes place. Plasma is not created, and the input energy from the generator is used to increase the tissue temperature and seals the vessels in the prostate. The depth of energy transmission is not as important as previously seen with the monopolar system. Additionally, the lower voltage and temperature used in a plasma system minimizes tissue charring and may lead to a decrease in unnecessary tissue coagulation and a subsequent decrease in storage symptoms.

Technique.

B-TURP has an almost identical technique to the M-TURP with regard to approach to the resection. However, the resectionist may note that the bipolar technology allows for quicker resections as bleeding vessels are less likely to be encountered as the simultaneous cutting and sealing of vessels decreases time spent controlling hemorrhagic areas. The previous generator with the PK system would often have trouble overcoming the additional energy needed to ignite the plasma. The newer SuperPulse generator has increased capacity and has made this less of an issue. However, the resectionist may still note a drag on the loop as it first comes in contact with the tissue.

Outcomes

Single-Cohort Studies.

With the B-TURP's similarity to its monopolar predecessor, comparative trials quickly arose. Compared with other treatment systems, relatively few single-cohort studies of bipolar TURP are available in the literature. One of the large early studies reported excellent results with the PK system (Falsaperla et al., 2007). With a relatively short mean catheterization time of 1.3 days, the authors found a mean increase in Qmax of 190% at 12 months from the procedure. The AUA-SS decreased by an average of 79%. Complications were relatively infrequent, with acute urinary retention, urethral strictures, bladder neck contracture, and urinary incontinence recorded in only 1.57%, 2.57%, 1.28%, and 0.77% of patients, respectively. A smaller study published around the same time had equally impressive results and included a high percentage (49%) of patients who had urinary retention (Ho et al., 2006). Patients had improvements in mean Qmax (6.5 to 18.3 mL/sec) and AUA-SS (22.6 to 6.5) at 1 year. Plateaus in these improvements were noted at around 3 months.

Comparative Studies.

In the excellent review of the bipolar technology by Issa, a 10-year Medline review of outcomes of both M-TURP and B-TURP was conducted for the years 1997 to 2007 (Issa, 2008). **He found similar efficacy in regard to AUA-SS, QoL score, Qmax, and residual urine.** Multiple comparisons of bipolar and monopolar technology have been published by a European consortium (Mamoulakis et al., 2012). Utilizing the Autocon II 400 ESU system (Karl Storz, Tuttlingen, Germany), they were able to conduct an RCT comparing monopolar versus bipolar techniques. This generator has a touch-screen system that allows for selection of either a monopolar or bipolar current. Although the study states it is double-blind, they report that surgeons could not be blinded at procedure, and only the assessors were blinded to treatment selected. Additionally, resection technique, power settings, irrigant, and anesthesia type were not standardized across treatment centers. **Improvements were pronounced in both groups, with no difference in voiding outcomes at 6 weeks. The only significant difference over the short follow-up in this study was the decrease in serum sodium, although there was no statistical difference in occurrence of TUR**

syndrome, mostly because of the low incidence of the event overall. Widespread application of these findings may be difficult as this is a rarely used platform, and this is the only RCT utilizing this technology.

In the more commonly studied PlasmaKinetic technology, Patankar et al. (2006) reported that at 3-week follow-up robust changes in AUA-SS and Qmax were noted in both groups with no statistical difference. Differences in blood loss and time with catheter favored the bipolar group, with postoperative complications like hematuria, clot retention, and blood transfusion appearing to be more common in M-TURP patients.

A meta-analysis of RCTs found similar results with no difference in regard to AUA-SS, QoL score, Qmax, or change in PVR (Ahyai et al., 2010)**, and another meta-analysis of RCTs looking at flow rates at 12 months found a slight (0.72 mL/sec) weighted mean increase in flow rates for B-TURP** (Mamoulakis et al., 2009). This finding is not clinically significant and was mostly bolstered by the large difference in a highly weighted study.

Omar et al. (2014) published a large meta-analysis and systematic review in which they examined 949 abstracts and found 24 trials acceptable for inclusion in the review. **No statistically significant differences were found in terms of AUA-SS or QoL score between groups. The analysis of Qmax revealed improvements that were more significant in the bipolar group at 3, 6, and 12 months but were once again skewed by a few largely weighted studies.** The meta-analysis could not show homogeneity among studies, and the result was not clinically significant. **A second meta-analysis evaluating outcomes only at 12 months found that bipolar devices demonstrated no significant difference in AUA-SS or prostate volume reductions compared with M-TURP. However, B-TURP seemed associated with a better Qmax and a lower PVR** (Cornu et al., 2015).

Complications.

Issa (2008) also reviewed complications from 1997 to 2007. **The overall rate of adverse events was lower with B-TURP (15.5% vs. 28.6%, $P < .001$) compared with M-TURP**. This was mostly fueled by lower rates of bleeding, transfusion, time with catheter, CBI need, hyponatremia, and TUR syndrome differences. Although the overall rates of complications were statistically significant, these individual subgroups consistently favored bipolar TURP with only occasional statistical significance.

Intraoperative and Perioperative.

Although the most exciting innovation with the bipolar technology is the **ability to perform the resection in an ionic iso-osmolar solution,** other possible improvements in outcomes may be related to this advancement in technology. A well-recognized complication of the M-TURP is the bleeding risk, which may lead to repeat irrigations and prolonged catheterization. The energy profile of the bipolar system has a “cut and seal” effect on vessels that should improve hemostasis and lead to decreased bleeding complications and transfusion rates (Issa, 2008).

In the meta-analysis of patients undergoing bipolar TURP, no patient suffered from **TUR syndrome. The authors concluded that by treating 50 patients with B-TURP, one case of TUR syndrome could be prevented** (Mamoulakis et al., 2009).

The hemostasis achieved during bipolar resection has allowed for reductions in many bleeding measures. A relative risk of 0.53 for **blood transfusion** and 0.48 for **clot retention** with bipolar resection was found compared with monopolar resection, with 2.3% and 2.7% of patients having these complications, respectively, in the bipolar cohort (Omar et al., 2014). The improved hemostasis and absent risk for TUR syndrome allows the urologist a longer resection time and the ability to treat larger glands. Improved visualization may also lead to a decrease in **capsular perforations** and **operative time** (Erturhan et al., 2007). Bipolar resection is also associated with a decrease in overall immediate reoperation rate (OR = 0.43) (Cornu et al., 2015).

Postoperative.

There are many different types of bipolar systems, all utilizing different mechanisms. The TURis systems (Olympus, Tokyo, Japan) were originally mistakenly labeled as bipolar systems (Issa, 2008). In reality, the return electrode in these systems was the outer resectoscope sheath. This could potentially predispose the patient's entire urethra and penis to the return energy. Ho et al. (2006) reported a 6.3% **urethral stricture** rate during procedures utilizing the TURis system. The review by Issa (2008) found an overall risk for urethral stricture of 4.7%, which was higher than the TURP group (2.7%, P = NS), and other authors did not find this difference (Michielsen and Coomans, 2010). The meta-analysis from Cornu et al. (2014) found that there was no difference between M-TURP and B-TURP for the incidence of urethral stricture or **SUI.**

Other late complications like **bladder neck contracture** and need for

retreatment of BPH do not appear to be much different from those found with conventional M-TURP (Ahyai et al., 2010). Overall reoperation rates at 1 year were low in both M-TURP and B-TURP groups and were not statistically different (Cornu et al., 2015).

Again, the improved hemostatic properties of the bipolar technology were evident during postoperative care as patients were more likely to have reduced **catheter and hospital times** (de Sio et al., 2006; Singh et al., 2005).

Conclusion.

Results for the bipolar resection system are encouraging, and this technology will likely replace M-TURP as the gold standard for treatment of BPH in the coming years. Although clinical outcomes are roughly equivalent, the improved hemostasis of the procedure and use of isotonic irrigating solution allows for longer and safer resections. Although different systems utilize different approaches to meet the bipolar standards, finding differences among systems with regard to outcomes is challenging at this point.

Prostatic Urethral Lift

Introduction.

The prostatic urethral lift (PUL), marketed under the name UroLift (NeoTract, Inc., Pleasanton, CA), was developed in 2004 as a treatment option for BPH that works by **altering prostatic anatomy without ablating tissue. These permanent transprostatic implants take the form of sutures that are delivered by a handheld device through a cystoscope to mechanically open the prostatic urethra by compressing the prostate parenchyma** (Fig. 146.5). The sutures have “T-shaped” bars on the ends of the suture and are spring-loaded and placed so that the bars are set with one outside the prostate and the other within the prostatic urethra lumen. The suture is placed on tension and once activated pulls the lumen of the prostatic urethra toward the capsule, opening the prostatic urethral lumen. The PUL is used to treat the lateral lobes of the prostate and is thus not appropriate for patients with a median lobe. Roehrborn et al. (2013) demonstrated with cystoscopy that the implant does not encrust, and epithelializes within 12 months. Histopathologic analysis of tissue obtained after PUL demonstrates a benign response to the implant (Woo et al., 2011) and no changes in PSA (Woo et al., 2012).

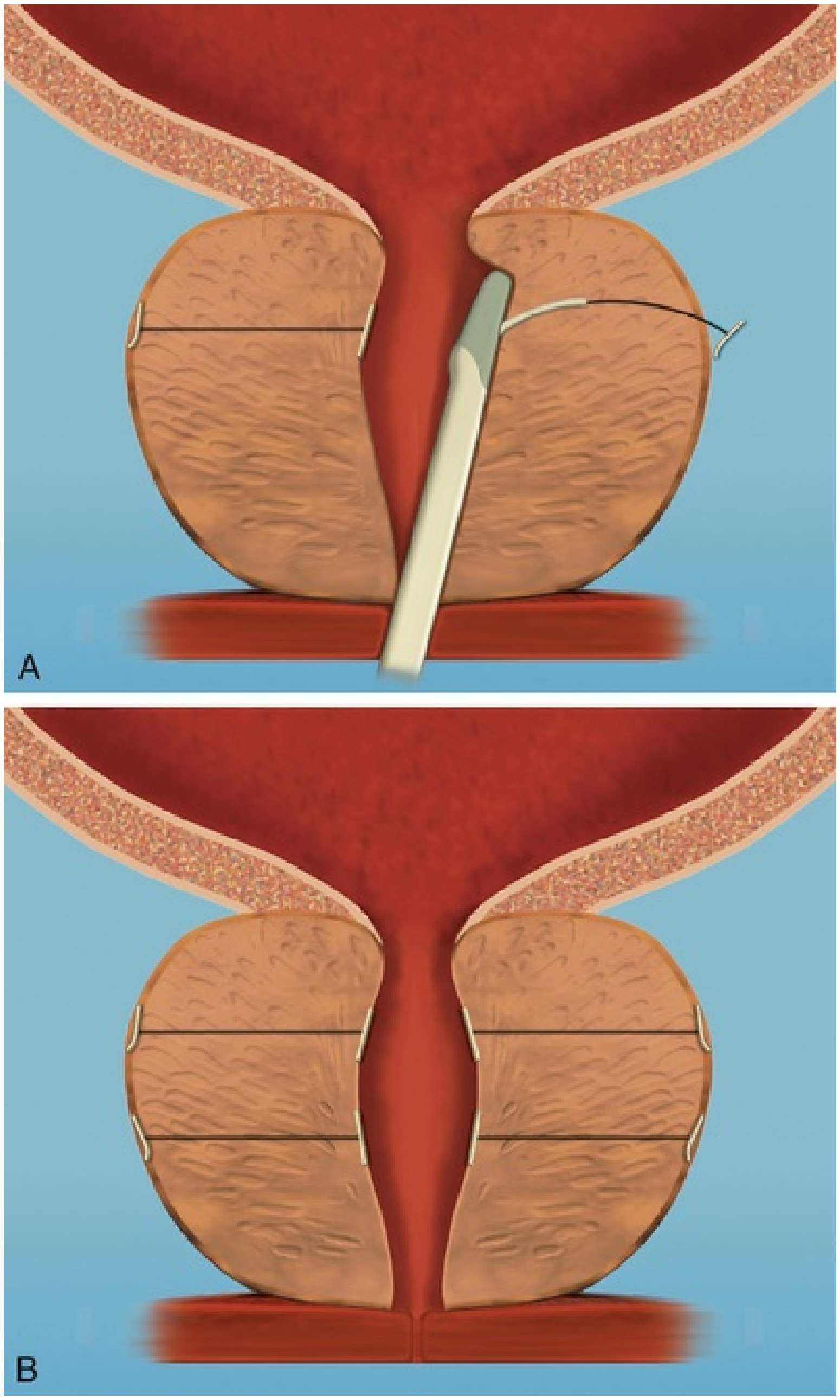

FIG. 146.5 (A and B) Placement of Urolift devices. (Courtesy of NeoTract, Inc.)

The particular advantages of this technology include low rates of local symptoms along with minimization of impact on sexual factors like ED and ejaculatory problems. As the procedure is nonablative and the urethral mucosa largely stays intact, there should be a minimization of dysuria and other storage symptoms along with more severe complications like bladder neck contracture and postoperative incontinence. Roehrborn et al. (2016) reported that the majority of adverse events were transient, mild to moderate in severity, and occurred primarily in the immediate postoperative period. As the implants are placed anterolaterally in the prostate, injury to the neurovascular bundles or dorsal venous complex should not occur (Fig. 146.6). Preservation of the bladder neck maintains ejaculatory function, making it an option for men desiring a minimally invasive treatment that will not affect sexual function. Verifying the absence of an obstructing middle lobe or median bar is mandatory for the use of PUL as is the need to restrict treatment to those prostates less than 80 g. Because of these size restrictions, the clinician should verify the absence of the middle lobe with either cystoscopy or prostate ultrasonography before committing the patient to this procedure. Similarly, the requirement of verifying the proper prostate volume can be accomplished by cystoscopy, TRUS, or abdominal ultrasonography as detailed earlier.

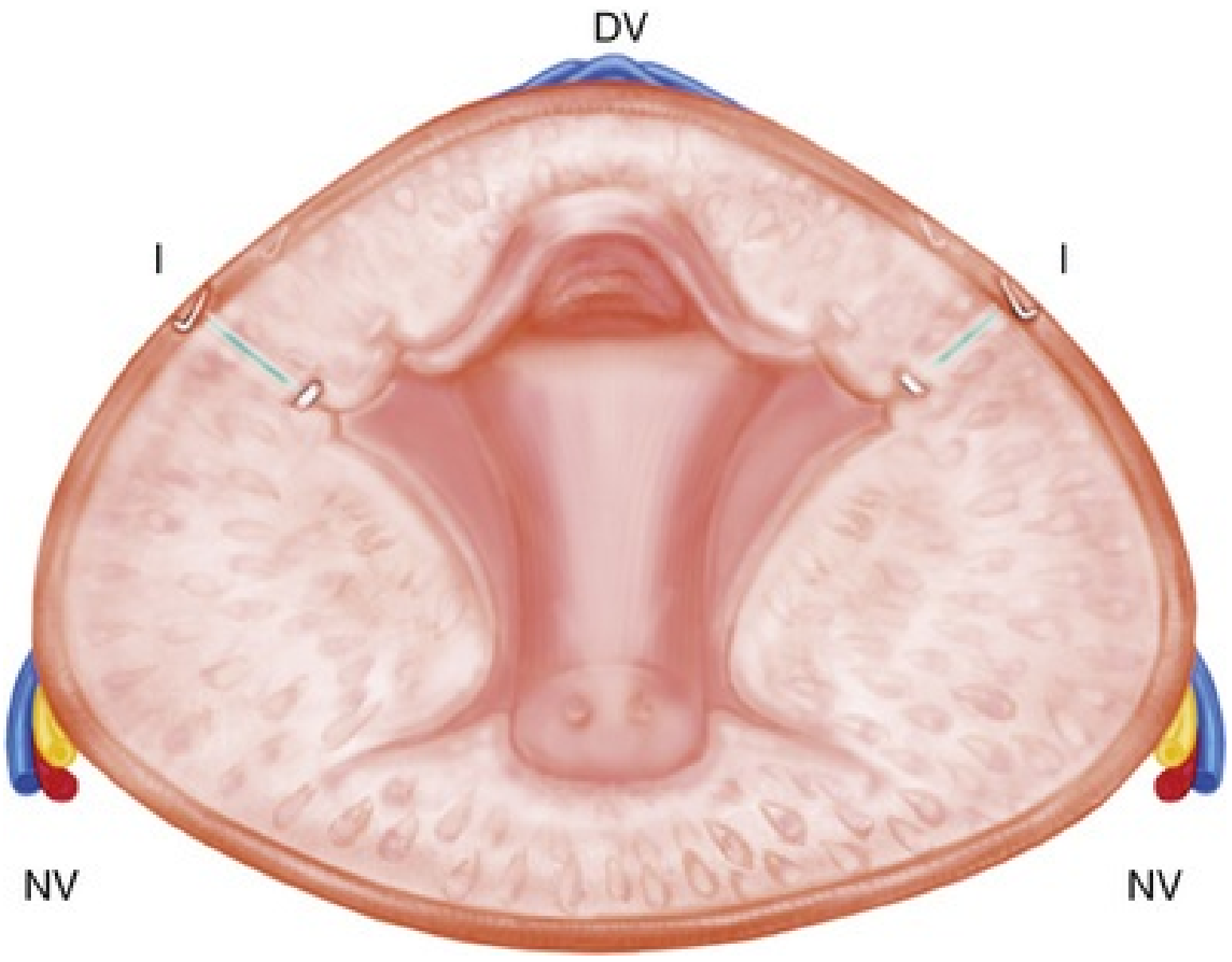

FIG. 146.6 Placement of implants *(I)* in the anterolateral position in the prostate between the dorsal veins *(DV)* and neurovascular bundles *(NV).* (Courtesy NeoTract, Inc.)

The procedure is done through a rigid cystoscope sheath and can generally be performed in the office setting with only local anesthesia. Overall, the procedure is well tolerated with minor and self-limited postoperative adverse events.

Outcomes

Single-Cohort Studies.

Following a proof-of-concept clinical study (Woo et al., 2011), a multicenter study of 64 subjects at five Australian sites led to approval with European and Australian regulatory bodies (Chin et al., 2012, Woo et al., 2012). This was followed by a prospective RCT of 206 men, 140 in the PUL arm and 66 in the sham arm, which is also known as the Luminal Improvement Following Prostatic Tissue Approximation for the Treatment of LUTS secondary to BPH (LIFT) study (Roehrborn et al., 2013). Subjects were unblinded at 3 months, with 80% of the subjects in the sham group enrolling in a crossover study (Cantwell et al., 2014; Rukstalis et al., 2016). The mean procedure time was 66 minutes, and in the North American arm 99% of the procedures were completed under local anesthesia. Patients in the PUL arm experienced an improvement in AUA-SS from 22 at baseline to 11.5 at 12 months ($P < .0001$) (Roehrborn et al., 2013) and 14.47 at 60 months ($P < .0001$) (Roehrborn et al., 2017). Maximum flow rate in the PUL arm improved by 4.0 mL/sec at 12 months ($P < .0001$) and 3.21 mL/sec at 60 months ($P < 0.0001$) when compared with baseline (Roehrborn et al., 2013, 2017).

Comparative Studies.

Gratzke et al. (2017) recently published a prospective, randomized, controlled, nonblinded study of 80 patients who underwent PUL or TURP. Inclusion criteria included men with an AUA-SS greater than 12, Qmax less than or equal to 15 mL/sec, and prostate volume less than or equal to 60 g. TURP was superior to PUL in terms of improving IPSS and Qmax at 1 and 2 years. Retreatment rates were 13.6% for the PUL and 5.7% for the TURP arms at 2 years. This study had many limitations, including: (1) an unclear risk for bias for many reported domains, (2) imprecise outcome measures with wide confidence intervals, and (3) sparse data in many areas. In this comparison of TURP versus PUL, the evidence revealed that there was a lower proportion of individuals in the PUL group who responded to treatment at long-term follow up (>12 months) as measured by the IPSS reduction goal of greater than or equal to 30%. Additionally, the % responders based on the IPSS had a relative effect (95% CI) RR of 0.81 (0.65 to 1.00) (PUL vs. TURP), an anticipated absolute effects (95% CI) of 73.4% (58.9 to 90.6) for PUL and 90.6% for TURP, or a difference of 17.2% fewer for PUL versus TURP (31.7 fewer to 0 fewer). Similarly, when comparing the mean change in IPSS, it was noted that the mean difference between PUL and TURP was 6.1 points lower for PUL (2.2 higher to 10 higher), supporting the notion that the long-term improvement in overall IPSS scores was greater with TURP compared with PUL. Although PUL is clearly a MIST, the comparable impact on IPSS QoL was not different from TURP as the mean change in IPSS-QoL from baseline through long-term follow up (>12 months) was similar with PUL compared with TURP. Importantly, it was noted that the need for reoperation was 13.7% (2.9 to 63.4) for PUL and only 5.7% for TURP (RR 2.4 [0.5 to 11.1]).

Erectile function was preserved in both arms as assessed by SHIM, and ejaculatory function was superior for the PUL group, with 100% of patients in the PUL group reporting preserved function compared with only 34% in the TURP group at 2 years.

One of the purported advantages of PUL includes the preservation of sexual function. McVary et al. (2014a) demonstrated that the sexual function of men with normal or moderate ED at baseline was unaffected, and those with severe ED actually reported modest improvement. **There was no evidence of de novo ejaculatory dysfunction or ED over the course of the study.** Ejaculatory bother improved by 40% at 1 year ($P < .001$), and intensity of ejaculation and amount of ejaculate improved by 23% and 22%, respectively ($P < .001$). This larger studied verified the findings previously published in initial testing (Woo et al., 2012).

Overall, patients must be warned that PUL is a relatively new intervention for LUTS/BPH, thus the long-term durability is uncertain, though long-term uncontrolled data are available. Durability was reported in the most recent 5-year data (Roehrborn et al., 2017). Surgical retreatment rates for PUL are concerning as noted in Roerborn et al., 2017. These retreatment rates were 5% at year 1, 10.7% at year 3, 13.6% at year 4, and 13.6% at year 5. When closely evaluating the original 140 participants randomized to PUL were followed for 5 years. Results showed PUL demonstrated modest durability. This modest durability is different from that concluded in the original article concerning 5-year data, as on closer inspection 6 patients received a second PUL procedure, 13 went on to a TURP procedure or its laser equivalent, 15 went on to BPH/LUTS medical therapy, and 13 had PUL implants removed (primarily for encrustation). Thus the retreatment rate, additional procedure rate, and need for return to medication combine to an overall “failure” of approximately 33.6%. (Roehrborn et al., 2017).

Complications.

A meta-analysis by Perera et al. (2015) demonstrated that procedure-related adverse events were more common in the PUL group, with the most common being dysuria (25% to 53%), hematuria (16% to 75%), and pelvic pain (3.7% to 19.3%). There were no reports of bleeding requiring transfusion, or new-onset SUI. One-third of PUL subjects (32%) required catheterization for failed voiding trial for an average catheter time of 0.9 day. During the LIFT study, 2% of implants were suboptimally placed and had to be removed because of exposure of the stainless steel urethral endpiece (Roerhborn et al., 2017).

Conclusion.

The utility of PUL depends on whether it is being evaluated as a substitute for medical or surgical therapy. It is not suited for men with a gland larger than 80 g as the LIFT study excluded men with a gland larger than 80 g. **PUL is contraindicated in men with a median lobe, which is why providers should perform cystoscopy before evaluating urethral anatomy.** It does offer advantages over currently available minimally invasive surgical options for the treatment of BPH, namely preservation of sexual function. Despite 5-year data supporting its modest durability, younger men should be counseled about the likelihood that they will require surgical treatment in the future with progression of their BPH. PUL may, however, be well suited for men who are unwilling to submit to daily medical therapy.

Convective Radiofrequency Water Vapor Thermal Therapy

Introduction.

Convective radiofrequency (RF) water vapor thermal therapy, marketed as Rezūm (NxThera, Inc., Maple Grove, MN), utilizes *convective* rather than *conductive* energy to ablate prostatic tissue. Rezūm utilizes RF power to generate thermal therapy in the form of water vapor, which is injected transurethrally into the transition zone of the prostate. The water vapor is injected at 103°C for 9 seconds at a pressure slightly above interstitial pressure, facilitating the dispersion of water vapor through the cellular interstices via convective energy. As the water vapor comes into contact with prostatic tissue, it condenses from steam to a liquid, releasing 540 calories of energy per gram onto the exterior cell membrane of the tissue, which causes cell death and tissue necrosis in a spherical ablative lesion of 1.5 to 2.0 cm, which has been confirmed by MRI and pathologic studies (Bhowmick et al., 2004, Dixon et al., 2015a,b; Hahn and Özişik, 2012, Mynderse et al., 2015).

Unlike *conductive* energy, which is used in transurethral needle ablation (TUNA) and transurethral microwave thermotherapy (TUMT), *convective* energy requires the application of lower energy levels for a shorter duration to induce tissue necrosis (Bhowmick et al., 2004). Water vapor therapy only uses 4 kJ per procedure to produce cell necrosis compared with TUNA (20 kJ), TUMT (86 kJ), and other laser ablative technologies (250 kJ). An additional advantage of water vapor therapy over other minimally invasive technologies include its ability to respect the natural collagen barriers that compartmentalize the prostate, limiting its effect to the hyperplastic tissue of the transitional zone and precluding thermal effects outside of the desired treatment area. Lastly, water vapor therapy preserves ejaculatory function, unlike transurethral vaporization of the prostate (TUVP) and TURP.

Technique.

The Rezūm system is composed of a generator with a handheld delivery device that includes a transurethral rigid cystoscope and an 18-gauge retractable needle with 12 vapor-emitting holes located at the tip of the delivery device (Fig. 146.7). It utilizes saline irrigation solution to enhance visualization and cool the surface of the urethra. The vapor needle penetrates the prostate at a fixed length of 10.25 mm and is deployed at the 3 o'clock and 9 o'clock positions starting 1 cm distal to the bladder neck, leaving approximately 1 cm between injection sites to create contiguous overlapping thermal lesions distally until the proximal edge of the verumontanum (Fig. 146.8). The procedure can also be modified for patients with a median lobe, giving it an advantage over other minimally invasive procedures. It was developed as a minimally invasive procedure intended for the outpatient setting. Water vapor thermal therapy can be performed with oral sedation, conscious sedation, or a regional prostate block.



FIG. 146.7 Convective water vapor ablation is a transurethral radiofrequency thermal therapy used to treat LUTS/BPH using a handheld device and a central generator unit (Rezūm system). The Rezūm system delivers radiofrequency-generated thermal therapy in the form of water vapor, directly to the extra prostate tissue.

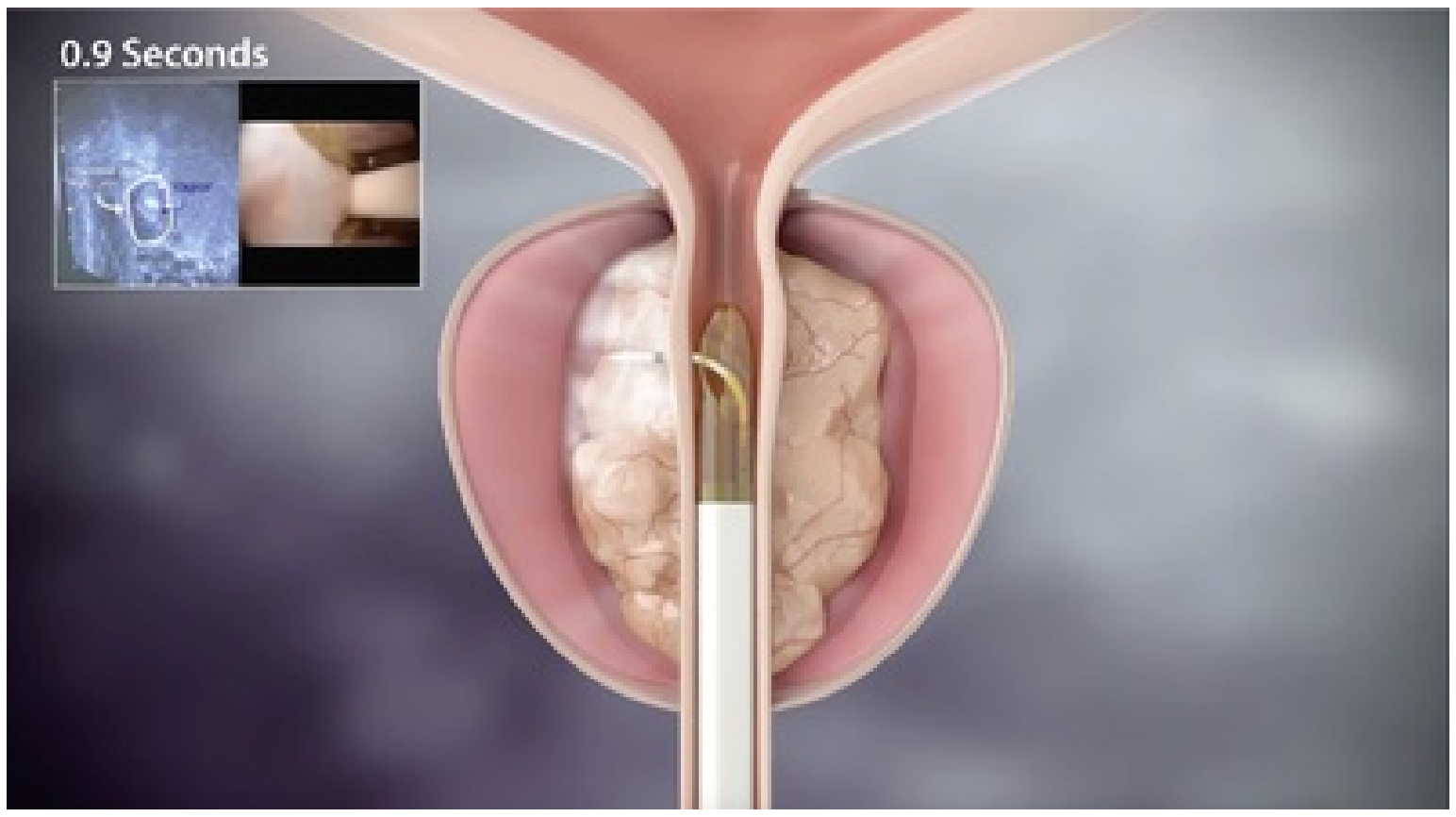

FIG. 146.8 *Inset (left),* The treated prostate using the convective water vapor device with the vapor delivery needle deployed in sequence. *Inset (right),* Transurethral delivery using a vapor delivery needle shown within the transition zone. Water vapor is delivered in a predetermined amount in 9 seconds. (Courtesy of NxThera, Inc.)

Outcomes

Single-Cohort Studies.

In the first-in-man study reported by Dixon et al. (2015a), researchers analyzed histopathologic specimens of 7 patients treated with water vapor thermal therapy followed by suprapubic prostatectomy. Tissue staining of the extirpated adenomas demonstrated nonviable tissue from the steam injection, thrombosed vasculature, and general preservation of the prostatic urethral epithelium. The excised tissue did not show carbonization or heat fixation effects, and no thermal effects were observed outside of the prostate. A second cohort of 15 patients underwent water vapor thermal therapy followed by gadolinium-enhanced MRI 1 week after surgery. MRI confirmed treatment defects in the transition zone, with the largest defect volume of 35.1 cm^3 and no thermal effects observed in the peripheral zone.

A subsequent prospective, nonrandomized single-arm pilot study of 65 patients by Dixon et al. (2015b) demonstrated the safety and efficacy of water vapor thermal therapy in men with moderate to severe LUTS. Patients were evaluated at 1 week, 1 month, 3 months, 6 months, and 12 months post-treatment. The mean baseline was IPSS 21.6, QoL score 4.3, Qmax 7.9 mL/sec, and PVR 92.4 mL. Subjects demonstrated a sustained statistically significant improvement in IPSS, Qmax, and QoL at all time points out to 12 months. A total of 36 patients were catheterized immediately after the procedure or before discharge, with an average catheterization time of 5.6 days. An additional 11 patients were catheterized after release for an average catheter time of 4.3 days. IIEF scores did not change significantly from 1 to 12 months, and although PSA level initially increased at 1 week and 1 month, PSA returned to baseline values by 3 months. A total of 125 AEs were reported by 45 patients, the most common being urinary retention (33.8%), dysuria (21.5%), urinary urgency (20%), UTI (20%), hematuria (13.8%), and poor stream (13.8%).

Comparative Studies.

The largest reported study to date includes a randomized controlled trial of 197 men who underwent either water vapor thermal therapy (136 subjects) or sham procedure (61 subjects), with 53 patients from the sham group crossing over to the treatment group after 3 months. Inclusion criteria included prostate volume less than 80 g and PVR less than 250 mL; men who had urinary retention were excluded. The most recent 2-year data confirmed long-term efficacy with a 51% reduction in IPSS, 4.2 mL/sec improvement in Qmax, and 50% improvement in QoL at 24 months (Roehrborn et al., 2017). Patients who underwent treatment of a median lobe showed similar improvement in IPSS and Qmax as those without a median lobe who underwent water vapor therapy (McVary et al., 2016a). Although there were initial changes in PSA (fivefold increase at 1 week), PSA returned to baseline by 3 months (Mynderse et al., 2015).

Sexual function was assessed using IIEF and Male Sexual Health Questionnaire-Ejaculatory Dysfunction (MSHQ-EjD) scores. No changes were noted in the treatment group at 3 months, and ejaculatory bother improved by 31% at 12 and 24 months (McVary et al., 2016b; Roehrborn et al., 2017). No de novo ED was reported in the treatment group, although six (4.4%) men reported decreased ejaculatory volume, and four men (2.9%) reported anejaculation. Authors stipulated that this may have occurred if the initial treatment was delivered too proximal to the bladder neck. For all subjects, the retreatment rate was 3.7% at 24 months (Roehrborn et al., 2017).

Complications.

The majority of patients who underwent treatment with water vapor thermal therapy did not report any adverse events. Of those patients who did report an adverse event, events were typically mild to moderate in severity and resolved within 3 weeks. Of the 189 subjects who underwent water vapor thermal therapy, four patients experienced a procedure-related serious adverse event, one developed de novo extended urinary retention, one experienced a bladder neck contracture and bladder stone at 6 months, one developed urosepsis after cystoscopy performed in the follow-up period, and one developed nausea and vomiting caused by alprazolam requiring overnight hospitalization for observation. The most common nonserious procedure-related adverse events included dysuria, hematuria, urinary frequency and urgency, hematospermia, and urinary tract infection (McVary et al 2016a; Roehrborn et al., 2017).

Conclusion.

Convective water thermal therapy ablation of the prostate for the treatment of LUTS/BPH utilizes new technology to provide durable efficacy evident at 2 years of follow-up. It offers the ability to target hyperplastic prostatic tissue within the transition zone, while avoiding delivery of high energy outside of the desired treatment area. Patients will benefit from improvement in clinical symptoms as measured by IIEF, Qmax, and QoL scores, including patients with a median lobe. Water vapor thermal therapy should be used cautiously in patients with a gland greater than 80 g and in men who have urinary retention. **Water vapor thermal ablation therapy boasts a favorable safety profile and a low retreatment rate, and it can be used in the office or outpatient setting using minimal anesthesia, making it an attractive option for both providers and**

patients, particularly those concerned with preserving sexual function.

Key Points

- PUL is an option for patients with LUTS/BPH provided prostate volume is less than 80 g and the clinician has verified the absence of a middle lobe.
- Patients electing PUL or water vapor thermal ablation therapy should be warned that long-term durability is uncertain, though long-term uncontrolled data are available.
- In appropriate patients, PUL and water vapor thermal ablation therapy are less likely to affect erection and ejaculation than conventional therapies.

Transurethral Vaporization of the Prostate

Introduction and Concept.

Prostate vaporization was first reported by Kaplan and Te in 1995 and is contemporary with many of the other MISTs in this regard. **However, this technique used the same set of equipment as TURP at that time with the exchange of the resecting loop for an element with a larger surface area.** Strategically, these modifications allowed for a broader contact area over which the current was delivered to the prostate tissue and did not involve tissue resection. These changes allowed for the use of a higher energy that led to controlled tissue vaporization with simultaneous underlying tissue coagulation and ideally improved hemostasis during treatment. **These modifications to the conventional TURP provided the urologist with an improved visual field in which to work and did not require the capital involved with the purchase of new equipment seen with other TURP alternatives at that time.**

The power distribution along the electrode provides the advantages of TUVP. As the leading edge of the electrode makes first contact with the virgin tissue (low electrical resistance), a high volume of energy is delivered, and tissue vaporization occurs. The lagging edge of the electrode interacts with tissue that has already been desiccated to some degree giving it a higher resistance to the supplied energy. Overall, this leads to a combination of tissue vaporization at the leading edge with the lagging portion of the electrode then providing almost instantaneous tissue coagulation. This was verified by a two-staged in vivo study wherein the cutting current was found to cause vaporization with minimal tissue necrosis. When the obtained TURP samples were excised using coagulating current, coagulative necrosis predominated in samples (Juma, 1996).

A variety of different electrodes were used initially, including the VaporTrode (Fig. 146.9), formerly ACMI, now part of Olympus), which is a grooved roller electrode and is the most studied of the monopolar options. Additional options included a fluted and spiked variety (Figs. 146.10 and 146.11) Each of these options provided an irregular edge for tissue contact wherein electrical charge would accumulate (Narayan et al., 1996). Although all were conceptually different working elements, these were easily fitted to existing equipment with fairly similar results.



FIG. 146.9 VaporTrode electrode. (Courtesy of Olympus, Inc.)



FIG. 146.10 Fluted electrode. (Courtesy of Olympus, Inc.)



FIG. 146.11 Spiked electrode. (Courtesy of Olympus, Inc.)

The technology was updated in the late 1990s and is now customarily done with bipolar current allowing the use of isosmotic solution as irrigant. The use of bipolar current concentrated the current at the end of the instrument as described in the Bipolar Transurethral Resection of the Prostate section earlier in this chapter. Initial bipolar vaporizations were done with the Gyrus Axipolaire (now part of Olympus), a nonrotating element composed of an 80/20 platinum/iridium alloy that was separated from the stainless-steel return electrode by a ceramic insulator. This operated by forming a vapor pocket at the tip of the device that had a high temperature. When this pocket was brought into contact with the prostate, tissue vaporization would occur, but the electrical circuit would be completed with the low-impedance saline allowing the active electrode to arc to the return electrode. Current was not required to pass through the patient, and deeper tissue heating would not occur.

Currently, Olympus markets the updated variation of the bipolar technology that utilizes PlasmaKinetic technology. The PlasmaButton electrode (Fig. 146.12) utilizes a half-spherical shape that provides a large surface area for current accumulation. Plasma is generated in a similar fashion to that described in the Bipolar Transurethral Resection of the Prostate section. However, because of the large surface area of the working element, tissue contact is almost always required to create the orange “corona.”



FIG. 146.12 PlasmaButton electrode. (Courtesy of Olympus, Inc.)

Unlike other TURP alternatives, general or regional anesthesia is generally required. As all tissue is vaporized, no pathologic specimen is available for examination.

Technique

Preoperative.

The procedure is generally done under general or regional anesthesia. Once this has been established, the patient should be carefully placed into the dorsal lithotomy position with all pressure points carefully padded. Adequate antibiotic coverage should be given and a standard skin preparation should be used. A grounding pad will be required for a monopolar approach but is unnecessary if a bipolar technology is used. Appropriate irrigating fluid should be maintained at body temperature and placed at a height that allows adequate visualization without compromising patient safety.

Intraoperative.

As described byKaplan and Te (1995)**, the operative technique is similar to a standard TURP. Standard transurethral resection equipment is used.** The major difference is the use of a specially designed electrode for vaporization and replaces the standard loop TURP electrode. This technique was originally described with the VaporTrode and required a non-ionic solution as it was a monopolar technology. The VaporTrode is a spherical electrode on a transverse-oriented axis that will roll as it is drawn along tissue. This allows continuous contact with tissue. The Olympus PlasmaButton electrode has replaced this in many urologists' armamentarium as this technology allows the procedure to be done with normal saline irrigation. The PlasmaButton electrode has a half-moon shape that provides a large surface area for contact with tissue without the moving parts of the VaporTrode.

As always, the scope and moving pieces should be examined and checked before being placed into use. An obturator is usually used to place the resectoscope sheath. The bladder should once again be examined for any pathology before beginning; the location of the ureteral orifices and verumontanum should also be identified.

Although alternate strategies certainly exist, the initial technique will be described here. **The "cutting" current is used for vaporization with the "fulguration" current leading to tissue coagulation.** Common monopolar power settings are 200 W to 240 W for cutting current and 60 W for coagulation. The bipolar technology uses settings of 280 W and 140 W.

In this technique, the surgeon begins by vaporizing the middle lobe from the bladder neck to the verumontanum (between the 5 o'clock and 7 o'clock positions). This will open a large channel for fluid irrigation and continued visualization. The vaporization is accomplished with overlapping sweeps of the electrode that can simultaneously deepen and widen the channel. The depth of the treatment remains the same as visualization of the white fibers of the surgical capsule marking the desired depth of vaporization.

Once a sufficient channel has been opened for irrigation flow, the lateral lobes are then vaporized starting at the 1 o'clock position to the 5 o'clock position moving in a clockwise fashion. The urologist should encounter minimal bleeding with this technique with any hemorrhagic area controlled at the time of identification. Similar to the TURP loop, the electrode can be used to place pressure on the bleeding area with “spot treatment” using the coagulation setting. The coagulation setting utilizes a lower energy setting and will coagulate tissue with minimal further vaporization.

After the left lobe is completed, the right lobe may be vaporized starting at the 11 o'clock position and moving counterclockwise down to the 7 o'clock position. This will complete all but the anterior area of the vaporization. The volume of irrigant in the bladder will often change the surgeon's perspective on the magnitude of the cavity in the prostatic fossa as a full bladder will naturally pull the prostatic fossa open. When vaporizing the anterior portions of the prostate, one may find that this is easier with a bladder at a lower overall volume as the anterior aspects fall into the surgeon's view.

Vaporization of tissue around the prostatic apex can be a problem during the procedure with concerns of energy advancing beyond visualization leading to sphincteric injury. The risk for sphincteric injury must be balanced against the risk for symptom recurrence with avoidance of sphincteric injury being paramount. Because of these difficulties and fear of unrecognized vaporization depth, one group described a hybrid technique of resection of apex tissue with fulguration of the resected bed afterward. Although economically less sound because of the use of two electrodes, this is a possible approach (Tefekli et al., 2005).

Once hemostasis has been achieved, the scope can be removed and a Foley catheter is placed. The catheter should be irrigated, and the return of clear to light pink irrigation fluid should be confirmed before terminating the procedure.

Postoperative.

Patients can expect the catheter to be removed within the first 24 hours, and we commonly remove this the morning of the day after surgery as long as there is minimal bleeding and no unforeseen intraoperative complication. Patients should be able to void shortly thereafter. Some authors have performed the procedure as a same-day discharge procedure because of the improved hemostasis (Eaton and Francis, 2002). Convalescence should be fairly rapid, but trauma or pressure to the perineum should be avoided with similar instructions as for patients undergoing TURP. An eschar or other solid tissue mass may be passed around 7 to 14 days after the operation.

Outcomes.

Outcomes for both monopolar and bipolar studies will be presented in the following sections and marked accordingly. **Overall, initial results of monopolar TUVP were similar to those for TURP with a decrease in some adverse events. Long-term durability came into question, and enthusiasm for TUVP waned in the late 1990s to early 2000s. The update to bipolar technology renewed some interest in the technique, and although long-term durability is untested, it is a promising improvement.** However, in almost all studies, maximum prostate volume is limited to 70 to 80 g, making application of the technology to large glands unknown.

Animal/In Vitro Studies.

In a canine model, Perlmutter et al. (1995) examined the grooved rolling cylinder (Richard Wolf Medical, Vernon Hills, IL) and provided some basic understanding of coagulation depth and peripheral heating. They found that multiple passes in the same area did increase the depth of the coagulated zone (78% deeper than a single pass). Temperatures at the neurovascular bundle and rectal wall were unchanged by the procedure, and a 2°C rise was noted at a distance of 6 to 7 mm from the fossa cavity. The prostate capsule measurements were 5 mm from the edge of the vaporization margin, and a 4.3°C increase was noted there. Wattage was noted to increase both coagulation depth and width when applied to the canine liver during the same study. In general, coagulated tissue was not seen deeper than 2 to 3 mm from the prostatic fossa cavity. The largest change in temperature was noted in the irrigating fluid, which the authors concluded acted as a heat sink during the procedure.

Benjamin et al. (1997) defined chronic histopathologic changes in the prostate after vaporization. Throughout the healing process, no extension of the initial 2-mm necrotic area occurred. Re-epithelialization of the fossa was ongoing by week 3, with epithelial stratification at 5 weeks postoperatively.

Single-Cohort Studies.

Kaplan and Te (1995)reported on their first 25 patients treated with VaporTrode. Initial results were encouraging, with significant changes in

AUA-SS (17.8 to 4.2) and Qmax (7.4 to 17.3 mL/sec) at 3 months. Improvements in these values were seen at 1 week, and the catheter was removed at a mean of 14.6 hours from the end of surgery. Although all 14 patients who had erections preoperatively had retrograde ejaculation after the procedure, the lower cost associated with a shortened hospital stay encouraged more study. Te and Kaplan (1998) reported on their first 114 patients in 1998 and now had data out to 18 months in some patients. AUA-SS and Qmax changes were durable to at least 12 months. No patients required transfusion, and a mean hemoglobin decrease of 1.7 g/dL was reported. A high percentage of patients (89%) had their catheter removed within 24 hours, and although there was no increase in ED incidence, 84% of patients reported retrograde ejaculation. Other early adapters reported similar results (Narayan et al., 1996).

Studies naturally evolved into RCTs comparing TUVP to TURP, until Botto et al. (2001) reported on the use of bipolar vaporization. A Gyrus system (now part of Olympus) was the first to utilize bipolar vaporization, and the electrode had a riverboat wheel–type configuration. At 3 months, 42 patients reported a decrease in mean AUA-SS from 19 to 9 and an increase in mean maximum flow from 7.9 to 19.7 mL/sec. Urethral stricture occurred in two patients, and four patients reported dysuria. Bladder irrigation was required in one patient for up to 3 days, but no transfusions and an overall low risk for bleeding were reported.

Dincel et al. (2004) reported on 20 patients who had a vaporization using the PlasmaKinetic Tissue Management System (Olympus, Tokyo, Japan) using an older electrode. Improvements in AUA-SS (72%), QoL score (61%), and Qmax (111%) were noted. Prostate volume and PSA both decreased by a little over 50%, confirming significant tissue removal with the procedure. By measuring size and operating room time, they were able to calculate an average of 2.8 minutes for each gram of prostate vaporized.

Reich et al. (2010) reported on the contemporary mushroom-shaped PlasmaButton electrode (Olympus). No major intraoperative or postoperative complications were noted in this initial report. No clinical signs of fluid absorption were noted, and in the 12 patients for whom breath ethanol technique (Cummings et al., 1995) was used, no patient demonstrated an increase in ethanol concentration, implying minimal fluid absorption. Thirteen percent of patients continued platelet inhibitors throughout the procedure. Decrease in hemoglobin was minimal (1.1 g/dL), and no transfusions were needed, although 53% of patients needed postoperative irrigation, and one patient continued on the catheter for 8 days because of hemorrhage. Improvements in AUA-SS (61%), Qmax (174%), and PVR (77%) were all significant. One patient needed to be converted to TURP because of bleeding. This patient had a large gland (>100 g) and was in the first 5 patients treated in the study.

The single-center “Zurich Experience” described the results of this technology on 83 consecutive patients (Kranzbuhler et al., 2013). Each patient had a preoperative mean Qmax of over 10 mL/sec, which is atypical for LUTS/BPH treatment studies. This increased nonsignificantly to 14 mL/sec directly after catheter removal. After 6 weeks, all functional outcomes (AUA-SS, QoL, PVR) improved significantly when compared with baseline values, with further improvements compared with the 6-week values at 6 months for AUA-SS and QoL. The PSA reduced by an average of 60% at 12 months. In one patient with a large prostate (110 mL) a conversion to bipolar TURP was necessary because of obscured visualization by bleeding. Many patients (31%) were on antiplatelet medications during the treatment.

Comparative Studies

Monopolar Studies.

Hammadeh and Philp (2003) analyzed six early RCTs of monopolar vaporization and resection with 1 year of follow-up. **They were able to analyze over 200 patients in each group and found essentially identical changes in AUA-SS (–73% in both groups) and Qmax (216% in TUVP, 191% in TURP) between the different techniques.** Complication profiles were similar, although this was better studied by Poulakis et al. (2004). This study included patients anywhere within the first year of follow-up and compared occurrence of complication rates. **The authors found that TUVP had an improved profile compared with TURP with respect to operative duration, catheterization time, hospital stay, blood transfusion, and clot retention. Reintervention for LUTS/BPH and postoperative urinary retention was less likely to occur in the TURP group.**

Of these six early trials with 1-year follow-up, the study by Gallucci et al. (1998) included only patients who were obstructed on preoperative UDS. **At 3 months postprocedure, 92.5% of the TURP group was unobstructed by UDS standards, with 88.6% of the TUVP group unobstructed.** A small percentage of the TUVP group (1.4%) was still obstructed on UDS and underwent TURP, and no patient in the TURP cohort obstructed on follow-up UDS. Similar changes were noted in AUA-SS, Qmax, PdetQmax, and PVR between groups. However, a surprising 18.6% of the TUVP group had transient SUI, with 5.7%

of the total cohort having true SUI at 12 months after surgery. This surprising presence of incontinence was attributed to a possible unseen depth of coagulation near the apex that was unanticipated by the surgeon.

Although TUR syndrome was still a possibility because of the use of hypo-osmolar fluid, a study using ethanol-labeled glycine as the irrigant showed that vaporization led to less (672 mL) fluid absorption than resection (1347 mL, $P < .005$). This was thought to be caused by the sealing effect of vaporization techniques on the prostate sinuses and vessels.

Another of these six early trials followed patients to a total of 5 years after randomization to M-TURP or TUVP (Hammadeh et al., 2003). A total of 53 of the original 104 patients were analyzed. Both groups had statistically improved AUA-SS, QoL, PVR, and Qmax compared with their respective preoperative values. Although there was no statistical difference between groups at 5 years, trends toward an advantage with TUVP could be seen.

An RCT with 10-year results of patients undergoing TURP, contact LASER, and electrovaporization was published in 2010 (Hoekstra et al., 2010). Although 91% of patients could be accounted for, only 44% of the original 150 patients were available for analysis. Only TURP had a statistically significant improvement still at 10 years with regard to maximum flow rate and PSA. Although the TURP and contact LASER groups had prostate volumes roughly equal to the prostate volume at study start, the vaporization group was noted to have an increase at the 10-year mark compared with the baseline value (43 g from 28 g, $P < .05$). Although failure rates were not statistically different, TURP had a failure rate roughly one-half that of vaporization and contact LASER.

Bipolar Studies.

Multiple studies compared the newly utilized bipolar vaporization technology to M-TURP in RCTs. Reports on the PlasmaKinetic technology at 12 months (Karaman et al., 2005) and then at 36 months (Kaya et al., 2007) found a decrease in operating room and catheterization time, and although no patients in the bipolar group required transfusion, two TURP patients did. **AUA-SS improvement was statistically better in the vaporization group, although the TURP group had an uncharacteristically modest change in AUA-SS (only 45% reduction).** Although the early results seemed to favor bipolar vaporization, the 36-month results were less complementary. Although a bias related to follow-up could certainly be a factor in this change with only 40.5% of TURP patients and 65.8% of TUVP patients analyzed, results were heavily in favor of TURP. **At 3 years, TURP had improved AUA-SS (–74%) and Qmax (263%) compared with TUVP (–64% and 140%, respectively).** Three patients in the vaporization group required retreatment for BPH (one in the TURP group) and were overall less satisfied with treatment (48% vs. 60%). Differences in ED and retrograde ejaculation rates were not significant.

The higher rate of complications with more clinical efficacy was also noted by the higher recatheterization rate in the bipolar group (30% vs. 5%), with clot evacuation (19% vs. 0%) more often needed in the TURP group (Dunsmuir et al., 2003). Change in hematocrit was greater, and more irrigation was required in the M-TURP group in the results of Hon et al. (2006). Although no difference in systemically absorbed fluid was noted, four M-TURP patients required transfusion compared with no-vaporization patients.

Use of the TURis vaporization system seemed to further improve the results when compared with M-TURP. The single-center report from Geavlete et al. (2010) found that the PlasmaButton system led to better improvement in AUA-SS, QoL, and Qmax, with less significant hematuria, transfusion, and clot retention compared with M-TURP at 6 months. In their report at 18 months, they also included a B-TURP group (Geavlete et al., 2011). The bipolar vaporization group fared better than either TURP group with regard to capsular perforation, operating room time, and catheterization time. Outcomes such as postoperative AUA-SS, QoL, and Qmax were equivalent among all groups at the 18-month point, with all groups improved compared with baseline.

In a study of 55 Canadian patients randomized to either Olympus Plasma Button or Biolitec EVOLVE Diode laser vaporization (Biolitec Company, Jena, Germany), there were **similarities in safety and efficacy** (Skinner et al., 2017). However, costs were noted to be lower in the bipolar vaporization group along with shorter vaporization times.

Complications

Intraoperative and Perioperative.

It appears that the simultaneous vaporizing and coagulating properties of these vaporization technologies decrease the risk for intraoperative bleeding. Although there is **less blood loss** (Küpeli et al., 2001), the overall low risk for **transfusion** in most RCTs makes a statistical difference difficult to achieve, although a range of 0% to 2% was seen in a systematic analysis of RCTs (Ahyai et al., 2010). Other intraoperative complications like **capsular perforation** or **conversion to**

TURP are also rare, with conversions to TURP for bleeding seeming to occur more frequently in larger glands (Kranzbuhler et al., 2013).

Postoperative.

The largest postoperative risk associated with TUVP is the **need for retreatment** for LUTS and risk for unplanned **postoperative recatheterization.** The meta-analysis by Ahyai et al. found that 8.2% of patients required recatheterization after TUVP, which was among the highest rates of the analyzed techniques (Ahyai et al., 2010). The increased hemostasis achieved intraoperatively appears to lead to a decreased postoperative risk for **clot retention** (Geavlete et al., 2010), although 13% of TUVP patients in the series from Skinner et al. (2017) had clot retention, with 10% of the cohort requiring hospital readmission.

The inability to accurately judge the depth of energy dispersion led many early adapters to be concerned about inadvertent coagulation, particularly around the apex. Although not statistically significant, the slight increase in **incontinence** compared with TURP seen in the review by Hammadeh and Philp (2003) may be a product of the energy dispersion. Although still not rigorously studied, the increased risk for new **ED** (12% vs 5%) when compared with TURP also increased the concern of unwanted depth of coagulation. The risk for postoperative dysuria also appears to be more common in TUVP (Ahyai et al., 2010).

As described in the B-TURP section, the TURis/TUVis system uses the outer resectoscope sheath as the return electrode. In a study looking at the use of this system, a small series of calamitous complications were noted. In three consecutive patients, a patient had **bladder necrosis** leading to severe storage symptoms, and two patients had complete **urethral necrosis** with resulting urethrocutaneous fistula (Robert et al., 2012). We would recommend our preference for use of the PK system as opposed to the TURis/TUVis system.

Conclusion.

Prostate electrovaporization continues to be a viable option for treatment of LUTS/BPH. Although initially a very popular option for treatment of LUTS/BPH, widespread acceptance was likely tempered by questions about durability with a concern about dysuria and retreatment rates when used by itself. The excellent hemostasis of the procedure leads to excellent intraoperative visualization and is currently most commonly used as an adjunct to TURP for improved hemostasis after resection is complete. Although a significant innovation in its time, it appears that LASER vaporization is likely to supplant this as the preferred form of prostate vaporization for most providers.

Transurethral Microwave Therapy

Introduction and Concept.

The objective of TUMT is to locally thermoablate prostate tissue while maintaining normal temperatures in the surrounding, nontargeted tissue. This concept uses a specialized urethral catheter with an antenna that generates radially emitted electromagnetic (EM) waves. These EM waves are in the frequency of 915 to 1296 MHz and penetrate tissue to induce changes that produce localized heat. Treatments that achieve a temperature less than 44°C are designated *hyperthermia,* those that achieve a temperature greater than 44.5°C are designated as *thermotherapy,* and those that achieve a temperature greater than 65°C are designated as *themoablative* (Perlmutter et al., 1993).

Prostate parenchyma destruction occurs once a crucial "**thermal dose**" has been reached. This occurs as part of the multiplicative product of the temperature and exposure duration. Therefore, the critical values are the temperature achieved in the gland (not necessarily the same as the temperature generated by the machine) and the period over which that temperature is able to be maintained.

Optimally, the thermal dose should be confined to the prostate gland with minimal to no heating of the nontargeted, surrounding tissues such as the external urethral sphincter, bladder neck, and rectum. Collateral damage to these tissues will induce complications and may limit the treatment effect by inducing automatic shutdowns in the machine. Additionally, this misplaced heat may cause significant patient discomfort and inability to tolerate the procedure in the office setting.

The potential advantages of microwave technology include the convenience of an in-office procedure with rapid patient convalescence and minimal anesthesia requirements. It is likely the least operator dependent of the treatments for BPH with an easy learning curve.

Although patient selection is crucial to achieving results, there are particular factors that need to be examined when considering TUMT. Patient factors such as prostate volume, gland configuration, and the patient's ability to undergo a transurethral treatment under local anesthesia must all be carefully considered.

Prostates with marked middle lobe configurations may distort catheter positioning as the middle lobe will go largely untreated and project the microwave in unintended and unsafe locations. Prostate volumes at the extremes (<25 or >80 g) may impede uniform heating and lead to suboptimal results. Those smaller prostates may lead to unsafe heating of extraprostatic locations inducing complications such as sphincter injury. Importantly, patients with pacemakers, defibrillators, and pelvic/penile prosthesis should be excluded from treatment as these devices may undergo significant electrical or mechanical damage from TUMT systems. Results in patients who have undergone previous invasive BPH treatments may have unexpected transmission of the microwaves with dire results.

Significant differences exist among microwave treatment system designs. These include differences affecting antenna design, the heating pattern generated, and the treatment protocol; these should be carefully considered when choosing microwave treatment for patients. TUMT was pioneered using the Prostatron microwave system (Technomed International, France), and this design has been considerably investigated. The original design was later advanced to a "high-energy" (HE-TUMT) platform that inventors hoped would enhance the treatment effect. It appears that the antenna design dictates the heating pattern more than the frequency of wave energy used (Bolmsjö et al., 1996). Currently, the primarily utilized systems available are the CoreTherm (Prostalund, Lund, Sweden), Prolieve (Boston Scientific, Boston, MA), Prostatron (Urologix, Minneapolis, MN), TherMatrix (American Medical Systems, Minnetonka, MN), and Cooled ThermoTherapy (Urologix, Minneapolis, MN) (Fig. 146.13).

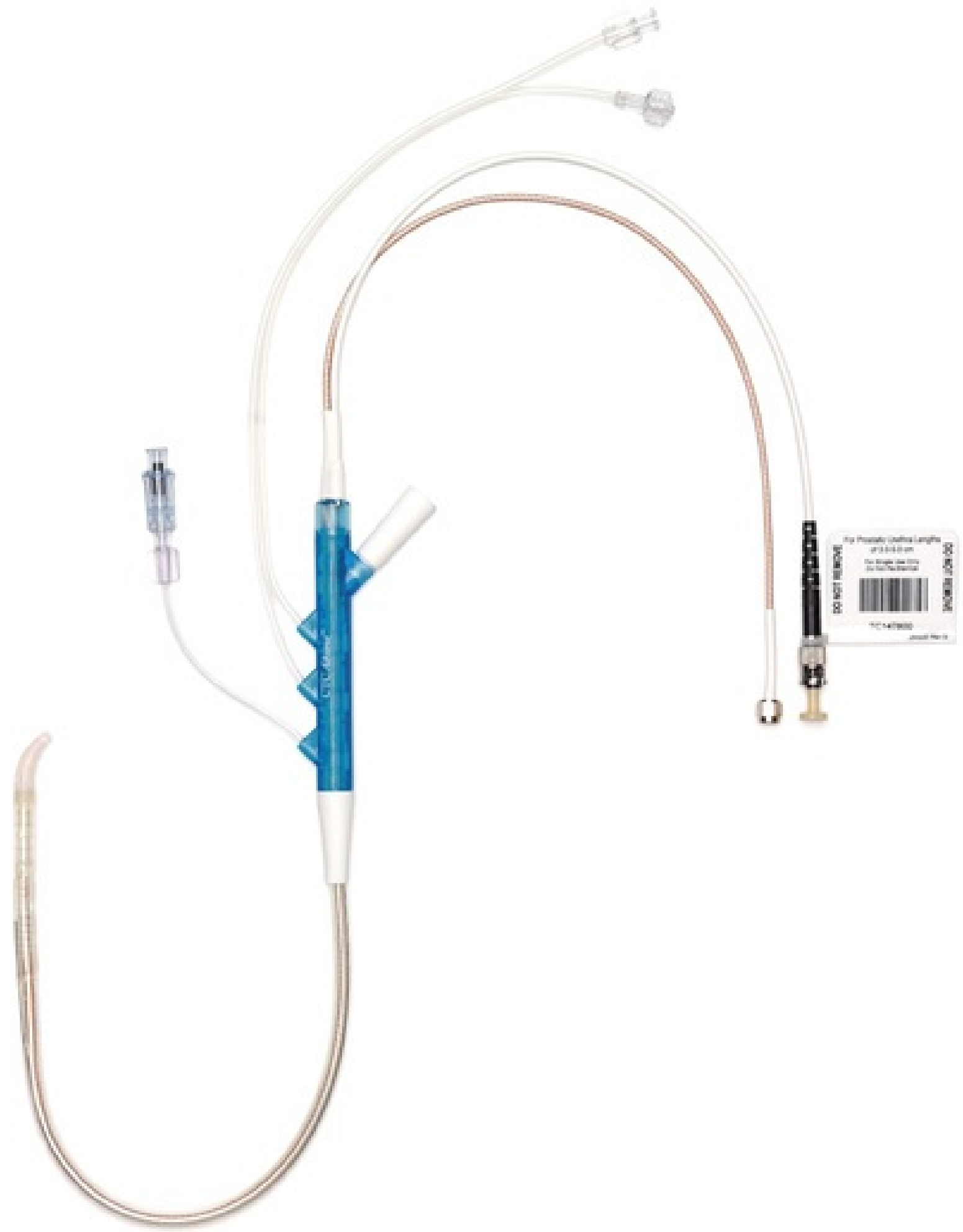

FIG. 146.13 Cooled ThermoTherapy transurethral microwave therapy catheter. (Courtesy of Urologix, Inc.)

The various TUMT platforms generate intraprostatic temperatures of 45°C to 70°C. The early systems supplied heat ranges from 42°C to 44°C and had rather disappointing results. As devices became more advanced, the intraprostatic treatment temperatures increased. The HE-TUMT nomenclature is applied to the more advanced devices at the higher end of this thermal range. Much of the advancement to using higher temperatures was precipitated by the ability of catheter cooling that would reduce urethral temperatures during use and reduce intraprocedural patient discomfort.

In these protocols, the energy was slowly increased to allow the patient to gradually adjust to the rising temperature. **When heat is applied to the prostatic parenchyma, there is a natural response with vasodilation of local vessels to physiologically dissipate the heat. Although it makes the procedure more tolerable, this slow increase of energy increased procedure**

times and decreased efficacy. The use of “heat shock” or high-intensity TUMT has been utilized to decrease this compensatory vasodilation. In this variation, the heat is delivered quickly so that the prostate vessels undergo thrombosis with improved heat entrapment in the prostate and decreased procedure times. This process is supported by the fact that prostates with a more significant vessel density are less likely to respond well to treatment in general (d'Ancona et al., 1999a).

Mechanism of Action.

The mechanism by which TUMT causes the reduction in LUTS/BPH is **not completely understood**. Multiple theories exist and are not mutually exclusive. These theories focus on altering prostate innervation or morphologic tissue changes in the prostate.

Nerve Degeneration/Sensory Changes.

The first of these theories appears to rest on the **dynamic concept of prostatic obstruction** wherein the tone of the smooth muscle of the prostate causes obstruction. This has been studied by investigators by examining tissue after TUMT wherein a biopsy was obtained. Ten patients underwent OP after TUMT with specimens evaluated using histologic immunohistochemical stains. The urethra was well preserved, and compared with controls, the specimens were found to have “disrupted” nerve fibers with axons rarely being found. The authors suggested that thermal damage to the adrenergic fibers essentially induced a “long-term α-blockade” (Perachino et al., 1993). This theory has few adherents.

The denervation may also be specifically targeted to the smooth muscle fibers of the prostate. A carefully controlled study using a prostate chip taken at the beginning of the case was stained using a nonspecific neuromarker protein gene product in both a control group of 10 patients and 10 patients who underwent TUMT 1 week before. Stained fibers were seen in all layers of the control biopsies. Almost all of the study group biopsies had nerve fibers in the lamina propria and epithelial layer. However, all but one study group specimen showed an almost complete absence of nerve fibers in the smooth muscle layer. The TUMT-treated patient without the smooth muscle nerve fiber changes had a small prostate (20 g). The findings of a preferential smooth muscle destruction of muscle fibers were noted even without a large degree of necrosis in the specimen (Brehmer et al., 2000).

Although this study noted changes in only some nerve fibers, there is still the possibility of a later-onset denervation of the other fiber groups. Animal studies looking at heat treatment of dog sciatic nerves found almost no histologic changes immediately after a heat treatment similar in duration and temperature to TUMT. However, segmental demyelination and axon loss was noted 3 weeks later, with changes persisting out to 1 year (Vujaskovic et al., 1994).

A more specific look at the subgroup of nerve fiber destruction in TUMT was completed by a group binding assay specific for the α_1 receptor. Twenty-five patients were included. Ten of these patients received TUMT before the cold-bunch biopsy and then subsequent TURP. Five patients had TUMT then retropubic prostatectomy. The control group underwent TURP (*n* = 10). **A statistically significant difference in the mean α_1-adrenergic receptor density was found between the control group (96.4 fmol/mg) and the TUMT-treated group (71.3 fmol/mg).** The receptors in all groups continued to have a similar dissociation constant (ability to bind their ligand) (Bdesha et al., 1996).

In an interesting study using electrical stimulation to examine the prostatic urethra in 13 patients before and after TUMT, the large majority of patients had improvements in symptoms, with the most favorable effect noted in storage symptoms (nocturia primarily). The decrease in urinary urge effectively was parallel to the increase in sensory threshold. The authors have postulated that the decreasing prostatic urethral sensation may lead to decreased input in the urethra-detrusor excitatory reflexes with an overall improvement in perception of voiding symptoms (Brehmer and Nilsson, 2000).

Morphology Changes.

When heat is applied to a specific portion of the prostate to a sufficient temperature and duration, an **area of necrosis is created**. This area of necrosis eventually contracts to form a scar and reduces overall prostate volume.

In a study looking at heat gradients in the prostate and histologic effects, patients underwent TUMT, followed by surgical tissue retrieval at varying later times. During the microwave procedure, temperature mapping was performed at multiple prostatic sites using fiberoptic thermosensors. Microwave treatments resulted in peak prostate temperature of 80°C with penetration of heat deep into the prostate parenchyma. Histologic changes were related to temperatures in the prostate. Mean temperatures increased rapidly with radial distance from the urethra to a maximum of 54°C at a distance of 0.5 cm from the urethra. As temperature increased beyond this distance from the urethra, temperature decreased exponentially but remained above 45°C at a distance of 1.6 cm radially. Pathologic findings were similar in all specimens with sharply circumscribed intraprostatic hemorrhagic necrosis at sites where 60 minutes of a minimum of 45°C was elicited by treatment. The borders of the areas of necrosis and the viable tissue were sharply demarcated. The mean range of this border was 0.5 to 2.5 cm from the urethra with a mean distance of 1.6 cm. They also noted, but poorly explained, an area of devitalized but noninflammatory tissue between the necrotic and normal areas (Larson et al., 1996).

A similar study explained this area between necrotic and normal tissue. Patients exposed to TUMT had an area of necrosis in a discrete area 20 to 25 mm from the urethra in the prostatic tissue. Within the area surrounding the necrosis, widespread apoptosis was noted (Brehmer, 1997). The root cause of the apoptosis could not be elicited in this study, but other work has shown that cell death results from apoptosis then necrosis based on an increasing heat load applied to the tissue (Harmon et al., 1990). Cultured prostatic stromal cells exposed to moderate hyperthermia of only 47°C for 1 hour confirmed the possibility of heat-induced apoptosis as 76% of cells were apoptotic. Cells also did undergo necrosis (14% of the sample), which further solidifies that there is a “thermal load” at which cells preferentially die of necrosis or apoptosis (Brehmer and Svensson, 2000).

The reduction in prostate volume appears to be related to the energy platform used as the LE protocol decreased by only 14%, and HE protocols decreased by 25% (Devonec et al., 1993).

Technique

Preoperative.

The benefit of a MIST selection is the ability to **perform the procedure in the office generally under just local anesthesia.** As always, the patient's ability to tolerate the procedure should be considered. Overnight admission is not needed, and patients are generally sent home directly after recovering from the procedure.

Cystoscopy is required before TUMT as the **presence of a median lobe is an exclusion criterion.** The median lobe would not be treated during the procedure, and its presence may also direct the catheter away from the midline altering the treatment. The prostatic length must be measured during the cystoscopy. A prostatic length of less than 25 mm is not suggestive of an enlarged prostate and will make the procedure technically challenging and perhaps unsafe. Prostate size should be between 30 and 100 g for TUMT.

Contraindications to the procedure include implanted pacemakers, defibrillators, inflatable penile prostheses, artificial urinary sphincters, and metal implants in the pelvis (e.g., a total hip replacement). Patients with urethral strictures should also be excluded from treatment as the catheter may be difficult to both place and verify correct position. Patients with a previous invasive BPH treatment should also be excluded as this is an untested group, and there may be unexpected projection of microwaves into aberrant locations. Comorbid conditions like peripheral arterial disease with claudication, prostate cancer, bladder cancer, and underlying neurologic disorders should also lead the patient and surgeon to choose a different treatment method.

Intraoperative and Perioperative.

The specialized catheter is inserted per urethra and advanced into position. The anterior wall of the rectum is monitored by the placed rectal thermometer probe. The preset program can then be started with an automated program running for the duration of the procedure and monitoring urethral and rectal temperatures. The balloon of the catheter remains in the bladder keeping the catheter in place while the EM waves are emitted into the transition zone of the prostate (Fig. 146.14).

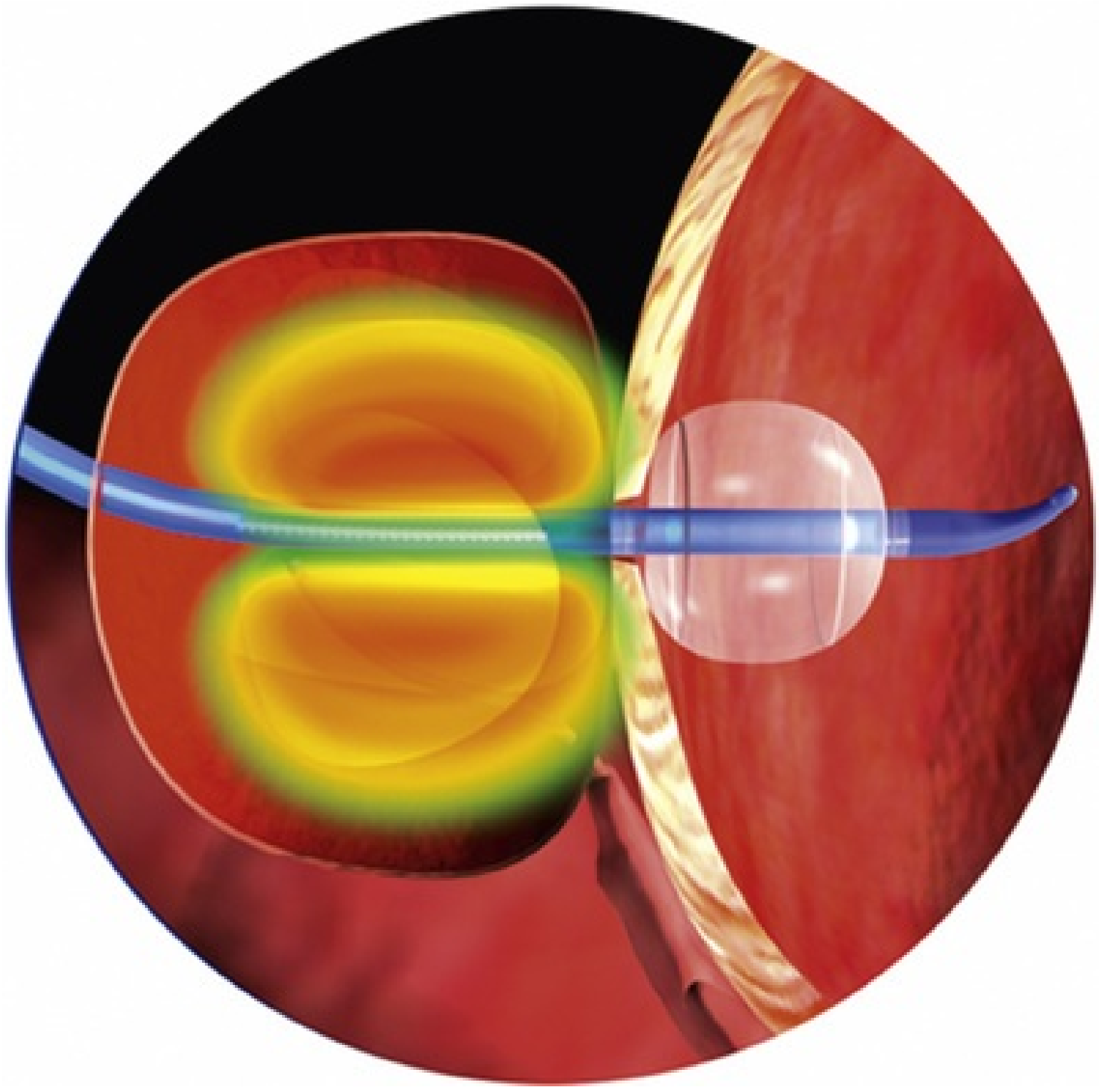

FIG. 146.14 Transurethral microwave therapy catheter treating the transition zone of the prostate. (Courtesy of Kevin T. McVary.)

One role that the surgeon plays in this procedure is to provide occasional "vocal" anesthesia to the patient in the form of calming the patient and providing reassurance to an awake patient. Continuous monitoring of patient comfort is critical. Unexpected discomfort may imply misplacement of the catheter. Significant injuries have occurred when such advice is not heeded.

Postoperative.

A benefit of TUMT is the benign postoperative course. **Perioperative complications are unlikely,** and patients do not require hospital admission. Patients may return home directly from the procedure, and convalescence is rapid.

Postoperative catheterization for a period of days is almost certain with previous generations of TUMT but is becoming less common. Higher-energy platforms have led to an overall lower rate of the standard transient postoperative urinary retention, but patients should be carefully counseled about this risk.

Outcomes.

Thermal or microwave therapy continues to be a treatment for BPH because of its relative ease of use and ability to be done as an office-based procedure. Because of the many different technology platforms, trials are difficult to group into larger analyses. **In general, the studies available are very heterogeneous and are frequently single-cohort and noncomparative trials having short-term follow-up, which should be judged carefully and individually**. An obvious lesson learned from these trials is that higher-power systems have superior results compared with their lower-powered predecessors.

Predicting Outcomes.

Initial work published on predicting outcomes of TUMT focused on the Prostatron 2.5 platform. This work defined early cutoff points to help guide the urologist in the care of patients after TUMT (d'Ancona et al., 1999a). **Outcomes were evaluated at 6 months, limiting the long-term scope of the study, but good response was independently predicted by preprocedural variables like younger age at treatment, larger prostate volume, and higher grade of BOO.** The energy used on the prostate during the procedure was also predictive of response but has less utility as it is post priori. Because PSA is a surrogate for prostate volume, pretreatment PSA was also found to be helpful in predicting outcomes in some studies (Djavan et al., 2000) but not in others (Laguna et al., 2002).

The ability to predict outcomes based on initial AUA-SS has been more difficult, and in one controlled study the proportion of patients achieving an AUA-SS of less than 9 (mild symptoms) was similar among patients in both the moderate and severe symptoms groups. Of the patients in the moderate symptoms group, 50% migrated to the mild group with many patients staying in the moderate group (38%) and some worsening to the severe group (12%). Of those already in the severe group by pretreatment AUA-SS, 14% continued to have severe symptoms, and many patients improved to the moderate (36%) and mild (49%) groups (Larson et al., 1998).

As many urologists may prefer this treatment in patients at higher risk for surgery, the utility in higher-risk patients has also been studied. In a study of a HE-TUMT device, the treatment was equally efficacious in high (3 to 4) or low (1 to 2) ASA scores (d'Ancona et al., 1999b), with no differences in post-treatment catheterization or ability to tolerate the procedure.

Single-Cohort Studies.

Despite the ease of use and relatively low complication rates, the major concern with TUMT is reduced overall LUTS improvement compared with other treatment options and the lack of durability. One vexing study using an older, low-energy (LE) machine (Prostatron 2.0) demonstrated initial significant improvement in patient level of satisfaction with treatment (Hallin and Berlin, 1998). **However, over the 4-year period there was a progressive, marked decrease in the number of satisfied patients from 62% at 1 year to only 23% at 4 years.** The initial improvements in symptoms and increase in flow rates were followed by reversal of these findings at 4-year follow-up. Additionally, **two-thirds of the patients in the study received additional BPH treatment within the 4 years they were followed.** These concerns were further justified when studies showed a cumulative risk for subsequent TURP retreatment of 40.5% at 5-year follow-up and a percent cumulative risk for any retreatment (including α-blockers) of 57% (Keijzers et al., 1998). Another LE-TUMT protocol confirmed high retreatment rates, with 35% of patients requiring additional treatment within 3 years (Daehlin and Frugard, 1999).

Studies of early, LE systems looking at changes in both subjective and objective measures of improvement have found varying results. **Almost all of the LE studies showed an improvement in subjective symptom scores but often without changes in objective measurements like maximum flow, residual urine, or UDS features like peak detrusor pressures.** With the upgrade to HE devices, changes in objective metrics became more common. Although more energy is used, the HE protocols are still well tolerated under local anesthesia (Eliasson and Wagrell, 2000). When heat shock protocols are used, the shorter duration of treatment also leads to an increased initial pain score but a similar post-treatment pain score (Francisca et al., 2000).

Using an HE-TUMT device (Targis), a group of investigators demonstrated significant improvement in AUA-SS, QoL score, Qmax, and PVR that was durable at 24 months (Thalmann et al., 1999). UDS was routinely performed in patients, and improvements in mean detrusor opening pressure and detrusor pressure at maximum flow were also significantly improved 6 months after treatment. A cavity in the prostatic fossa (similar to those seen in patients after TURP) was noted in 77% of patients, and TRUS demonstrated a decrease in prostate volume from 57.6 g to 42.4 g. Despite these positive results, 13% of patients required retreatment.

In one of the most recent TUMT studies, the findings of many previous studies were reiterated (Mynderse et al., 2011). The Cooled ThermoCath catheter with a Targis system was used under a 30-minute heat shock protocol. The percentage of patients requiring any sort of postoperative catheterization (50%) was less than previous TUMT studies, and only 3% of patients required catheterization for more than 7 days. **At the final follow-up at 5 years post-treatment, a 43% improvement in AUA-SS and 39% increase in Qmax was noted. Unfortunately, 29% of patients required additional BPH related treatment with 9% of the overall cohort requiring surgical treatment.**

When summarizing symptomatic improvement with HE-TUMT, **patients will have a 60% reduction in symptom scores noted at 3-month follow-up**. This tends to become slightly better at the 6- and 12-month points. There is no significant difference between HE-TUMT devices in reduction of symptoms. **At 3 years, symptom improvements worsen to only 45% improvement, but retreatment is seen in close to 20% of patients** (Floratos et al., 2001)**. The aggregated changes in Qmax represent a 50% improvement seen at 3 months and stable at 12 months** (Gravas et al., 2003) **with studies rarely reporting a post-treatment Qmax greater than 15 cm/sec.**

Patients who had urinary retention represent a more challenging BPH group to treat. In one of the first HE-TUMT studies on men with AUR, 94% of men were able to spontaneously void at 4 weeks after treatment (Djavan et al., 1999a). Although no pressure-flow studies were obtained, this group likely represents a cohort with functional detrusor muscle. Contrary to this, a study that included chronic urinary retention patients, the 1-year failure rate was 25%, and mean catheterization time was 38 days (Floratos et al., 2000). In a study of surgically high-risk patients in acute urinary retention, 87% were able to void spontaneously (3 months postprocedure), with 7.3% experiencing repeat urinary retention within 2 years (Berger et al., 2003).

Comparative Studies

TUMT vs Sham.

Many sham-controlled studies have been performed involving TUMT. This is likely caused by the low morbidity of producing a sham equivalent arm as minimal anesthesia is required. These sham studies are interesting as they highlight the placebo effect present in BPH treatment.

The placebo effect of a sham study is most notably highlighted in Nawrocki et al. (1997). In this study, patients were randomized to one of three groups—TUMT, simulated TUMT, and observation—with 6-month follow-up. The simulated TUMT group underwent a process identical to TUMT, except the generator ran a simulated program that included machine noise, screen readouts, and heat emission by a pad placed under a blanket. No statistical changes were noted in objective measures like pressure-flow outcomes or urodynamic variables. **Surprisingly, there was a statistically significant decrease in AUA-SS for both the TUMT group (19 to 9.5) and the simulated TUMT group (17.5 to 9.5). The untreated group did not note this change (AUA-SS changed from 18 to 17).** These results are interesting in that they highlight the perceived benefits of TUMT (in terms of reported AUA-SS changes seen in both the TUMT and simulated TUMT group) but showed no objective changes in any of the groups. Interestingly, just performing a sham treatment reduced AUA-SS in a significant fashion.

Other prospective sham studies (without untreated groups) did show improvements in peak flow to complement the decrease in AUA-SS. Studies of the Targis thermoablation system (Larson et al., 1998) and Dornier Urowave system (Roehrborn et al., 1998a) both exhibited this response with overall similar findings. The Dornier Urowave system provided decreases in the AUA-SS for both the treatment and sham groups. The treatment group AUA-SS decreased from 23.6 to 12.7 at 6 months, with a decrease of 23.8 to 18.0 in the sham group. Although both study groups had a significant decrease, the change in the treatment group was statistically superior. Peak flow improved in the treated group (7.7 to 10.7 mL/s) and untreated group (8.1 to 9.8 mL/s), with the treated group being statistically superior.

The study of the Targis system had a similar pattern of findings. Both the treatment and sham groups had statistically significant improvements in AUA-SS from a mean of 20.8 to 10.5 in the treatment group with a lesser but still significant decrease in the sham group (21.3 to 14.3). Flow rates improved from 7.8 to 11.8 mL/sec in the treated group, with a less impressive increase in the sham group (7.8 to 9.8 mL/s) (Larson et al., 1998).

TUMT vs α-blocker.

Some authors have stated that TUMT should stand on the continuum of BPH treatment in between medical management and more aggressive treatments like TURP and OP (Djavan et al., 1998a)**. The underlying precept of this view is that the single, low-risk procedure could remove the hassle and cost of years of medical treatment.** Although patients undergoing TUMT do have a frequent need for additional BPH retreatment, the results are not far different from those failing medical management. In an investigation of retreatment in patients using α-blockers, results were assessed at 3 years with failure rates of 27% (tamsulosin), 37% (alfuzosin), and 49% (terazosin) noted (de la Rosette et al., 2002).

One RCT has compared TUMT with α-blocker (terazosin). Mean AUA-SS and Qmax were improved for both groups, with TUMT having a more pronounced effect at both 6 and 12 months. The TUMT had a 35% improvement in AUASS compared with α-blockers and a 22% improvement in Qmax. The terazosin group had a sevenfold higher actuarial treatment failure rate (Djavan et al., 2001). However, the definition of failure was qualitatively different between groups, and this should be interpreted cautiously.

TUMT vs TURP.

Concerns about the durability of TUMT are common despite the improvement seen in uncontrolled studies and sham comparisons; many studies had higher than acceptable retreatment rates, with patients often failing TUMT only months after surgery. As always, comparison to the “gold standard” treatment is necessary before any treatment is considered standard practice. Although changes in the energy delivered by the system improved many patient outcomes, comparison to TURP further highlighted the weaknesses of the TUMT intervention.

A randomized trial using the HE-TUMT Prostatron 2.5 system included 6 months of follow-up (Ahmed et al., 1997). The primary endpoints for the study included AUA-SS, maximum flow, residual urine, detrusor pressure at maximum flow, and prostate volume. All outcomes in the TURP group were improved. **The TURP group was improved in all outcomes, and in the TUMT cohort, only the AUASS was improved with multiple other factors worsening. Generally, the adverse events were higher with TURP, but the TUMT group had a prolonged postoperative retention.**

Contemporary studies of the same machine had very different results. At 1 year of follow-up, there was a decrease of 78% in the TURP in the Madsen-Iversen symptom index with a decrease in the TUMT group also noted (68%). Maximum flow rate improved by 100% (TURP) and 69% (TUMT), and both groups had relief of bladder outlet symptoms by urodynamic parameters. Although the effects in the TURP group were pronounced in all accounts, they were not statistically different from the TUMT group. Groups were equivalent on need for retreatment, but the TURP group needed more frequent returns to the operating room for coagulation (3 vs. 0 patients). The TUMT group had a longer duration of catheterization, with one patient requiring 35 days. Correspondingly, the TUMT group had an increased risk for postoperative UTI, with one patient requiring readmission to the hospital for infection. Additionally, postoperative irritative symptoms were more common in the TUMT group (29% vs. 14%) (d'Ancona et al., 1997).

A similar randomized study with longer follow-up (median 33 months) displayed improvements in the TUMT group with respect to urinary flow (improved 64%) and AUA-SS reduction (–60%), although these paled in comparison with those in the TURP group (+214% in Qmax and –85% in AUA-SS). With a longer follow-up, the retreatment rates in this study should be carefully examined. A retreatment of 19.8% in the TUMT group and 12.9% in the TURP group were not statistically different (*P* = .28), but the reasons for retreatment appeared to be caused by different etiologies. In the TUMT group, 10 of the 14 patients underwent additional BPH treatment (TURP, LASER prostatectomy, TUNA, α-blockers), whereas only 1 of the 8 patients in the TURP group required this type of retreatment (α-blockers). Although these did not have different statistical needs for additional treatment of any kind, it would appear that more patients in the TUMT group needed retreatment for residual BPH (Floratos et al., 2001).

More recently a multicenter, randomized trial released 5-year follow-up results to complement the previously released results at 1 and 3 years. At the initial 12-month follow-up, they concluded there was no statistical difference between treatments in Qmax, detrusor pressure, and prostate volume, but the change in each of these was more pronounced in the TURP patients. A longer postprocedural catheter time (14 days vs. 3 days) was seen in the TUMT group. **Adverse events were graded according to severity, with the TUMT group undergoing more mild-moderate events (often characterized as "expected") and the TURP group having more "serious" events (i.e., clot retention requiring readmission)** (Wagrell et al., 2002). The 5-year data (66% of the original patients available) showed that 16% of the TUMT group was considered a treatment failure, with only 6% of the TURP group being considered a failure of treatment (Mattiasson et al., 2007).

In studies using UDS to classify the obstruction, TURP proved superior. A comparison at 30 months of HE-TUMT to TURP found that one-third of the TUMT patients remained "obstructed" on UDS, and only 14% of the TURP group maintained this UDS classification of "obstructed" (d'Ancona et al., 1998).

A recent Cochrane review of TUMT analyzed the 6 trials comparing TUMT and TURP. **The pooled mean AUASS of TURP decreased by 77%, with a 65% reduction seen in TUMT. The pooled mean peak urinary flow increased by 119% with TURP and 77% with TUMT, with a weighted mean difference favoring TURP by 5.08 mL/sec** (Hoffman et al., 2012).

In a study comparing QoL outcomes between TURP and TUMT results, a 41-question assessment was completed before and after surgery. Metrics of overall well-being, urinary symptoms, sexual function, daily activities, social activities, and psychological well-being were assessed. Both treatment modalities had a significantly positive effect on aspects of life, with perception of activities of daily living along with perception of urinary difficulties improving. Although both treatments were efficacious in improving quality measures, TURP did have a greater impact than TUMT in the 147 patients examined (Francisca et al., 2000).

Complications

Intraoperative and Perioperative.

Much of the argument for the use of TUMT over TURP in the treatment of BPH is the **decreased complication rate, particularly in the perioperative period.** Higher rates of early retreatment for procedural complications are seen for TURP compared with TUMT. Unfortunately, most TUMT trials do not have a comprehensive review of adverse events. This leads to a potential bias as those reporting may have had lower than average complication rates.

In almost all cases, patients are **able to tolerate the procedure** in an office setting. Patients reporting a sensation of local, perineal warmth or an urge to urinate are common but do not limit the ability to complete treatment. Although some may advocate sedatives or analgesics for every patient, a randomized comparison proved that topical anesthesia alone was sufficient (Djavan et al., 1998b).

With careful monitoring and correct placement of the catheter and rectal temperature probe, **injury to surrounding structures** should not occur. Errant reports of severe complications like penile necrosis and urethral fistulae have been seen in the FDA registry but are likely caused by improper catheter placement or poor monitoring of the patient during the procedure (Walmsley and Kaplan, 2004).

Postoperative.

Contrary to the perioperative profile described earlier, the long-term complication rates generally favor TURP. Retreatment rates for BPH are significantly higher for TUMT than for TURP. Retreatment rates have been discussed at length earlier and will not be further elaborated on here.

Complications like postprocedural **hematuria leading to transfusion** are rare after TUMT. **Urethral stricture** and **bladder neck stenosis** are occasional complications, with a cumulative risk of about 2% (Floratos et al., 2001). **Transient incontinence** is seen in about 2% of cases, with permanent incontinence being extremely rare.

Post-treatment convalesce is fairly rapid, with a mean recovery at home of 5 days and 55% of patients spending less than 3 days at home (Ramsey et al., 1997).

Prolonged catheterization times and **acute urinary retention** with the early generations of TUMT were the rule and not the exception. Almost all studies demonstrated an increased catheter duration compared with TURP, and catheterization durations of up to 1 to 2 weeks are not unusual (de la Rosette et al., 1997).

In an effort to reduce the catheterization times and postprocedural symptoms, attempts were made to use biodegradable urethral stents (Dahlstrand et al., 1997), temporary urethral stents (Djavan et al., 1999b), and periprocedural α-blockade (Djavan et al., 1999c). α-Blockade reduced postoperative retention from 12% in TUMT alone to 2% in TUMT with periprocedural α-blockade. In a prospective comparison of α-blockers and urethral stents, stents were more effective at 2 weeks, reduced symptom scores, and improved flow rates. No patient with a urethral stent was in retention 1 week after TUMT (compared with 11% of patients with TUMT alone), but 11% of patients with a urethral stent needed early removal because of clot formation or stent migration (Djavan et al., 1999d).

Coinciding with prolonged catheterization, **urinary tract infection** in the post-TUMT patient is a common finding. Reports of incidence are sporadic, but numbers as high as 13.5% (Dahlstrand et al., 1995) have been published, with most large studies reporting an incidence in the low- to mid- single-digit percentages.

With HE protocols, the **effects on sexual function** have been more pronounced. Although not rigorously studied with validated questionnaire data from preprocedural and postprocedural periods, few reports have high rates of sexual dysfunction. Most studies had no incidence of **ED,** although these data should not be frequently quoted. One report found only 5% of patients with new ED (Kirby et al., 1993), and 55% of patients still graded sex as "very satisfying" (Francisca et al., 1999). In the TURP cohort of this comparative study, only 21% of the TURP group gave the "very satisfying" answer.

Reports of **ejaculatory dysfunction** after TUMT follow a similar pattern but have also not been rigorously studied. Most have reported low event numbers, with many reporting no change at all. A fairly high (44%) incidence was reported in one study, which stands out against otherwise benign reports (de la Rosette et al., 1996). A study dedicated to sexual outcomes found that 74% of the patients had antegrade ejaculation after the procedure (Francisca et al., 1999).

In the Cochrane review of TUMT versus TURP, TUMT was associated with a decreased risk for retrograde ejaculation, stricture treatment, hematuria, blood transfusion, and TUR syndrome. TUMT did have an increased risk for dysuria, urinary retention, and BPH symptom retreatment (Hoffman et al., 2012).

Conclusion.

TUMT is a technology that is used to apply heat to the prostate, and its mechanism of action is still in debate decades later. Although a technically easier procedure than many of its counterparts, it carries a **potentially prohibitive need for retreatment** because of persistent LUTS/BPH. Although it does have a favorable overall complication profile compared with TURP, the risk for eventually requiring retreatment needs to be weighed carefully when considering TUMT for a patient. One should note that any long-term durability and measure of voiding symptoms after TUMT suffers from selection bias as it only includes patients who were responders and did not advance to other treatments.

Overall, the summation of the large volume of literature on TUMT does support the place of TUMT in the continuum of treatment for BPH although in a lower-efficacy/low-risk location. The patient generally will experience an improvement in symptoms that is not as pronounced for more invasive procedures with a low risk for adverse events. The use of this technology as a replacement for medical therapy is reasonable. How the influx of newer office-based MISTs changes the use of TUMT in the future is still yet to be seen.

Transurethral Needle Ablation of the Prostate

Introduction and Concept.

The TUNA system is composed of an RF generator, a disposable urethral endoscopic catheter that attaches to a reusable catheter handle, and an optics system. The treatment concept and design was originally FDA approved in 1996 and was significantly updated in 2003. The procedure was first performed in 1993 (Schulman et al., 1993).

The specialized urethral endoscopic catheter is used for this procedure and is attached to a reusable control handle. This rigid catheter is placed into the urethra and advanced into the prostate under direct vision as this device utilizes an embedded lens that is at either zero or 15 degrees based on surgeon preference. Once in position, needles are deployed from the end of the catheter into the prostatic parenchyma. The needles deploy at an acute angle to each other and at a right angle to the longitudinal axis of the catheter. The needles have a variable length that can be adjusted to different prostate widths and sizes. The urethra is protected from heat energy because of PTFE/nylon sheaths that extend to cover the proximal portions of the treatment needles. The urethra is untreated and not denuded, so the patient should theoretically have minimal local symptoms. The protective sheaths also have a thermocouple that monitors the temperature at the edge of the sheath. The needles and shield are adjusted by controls on the catheter handle (Figs. 146.15 and 146.16).

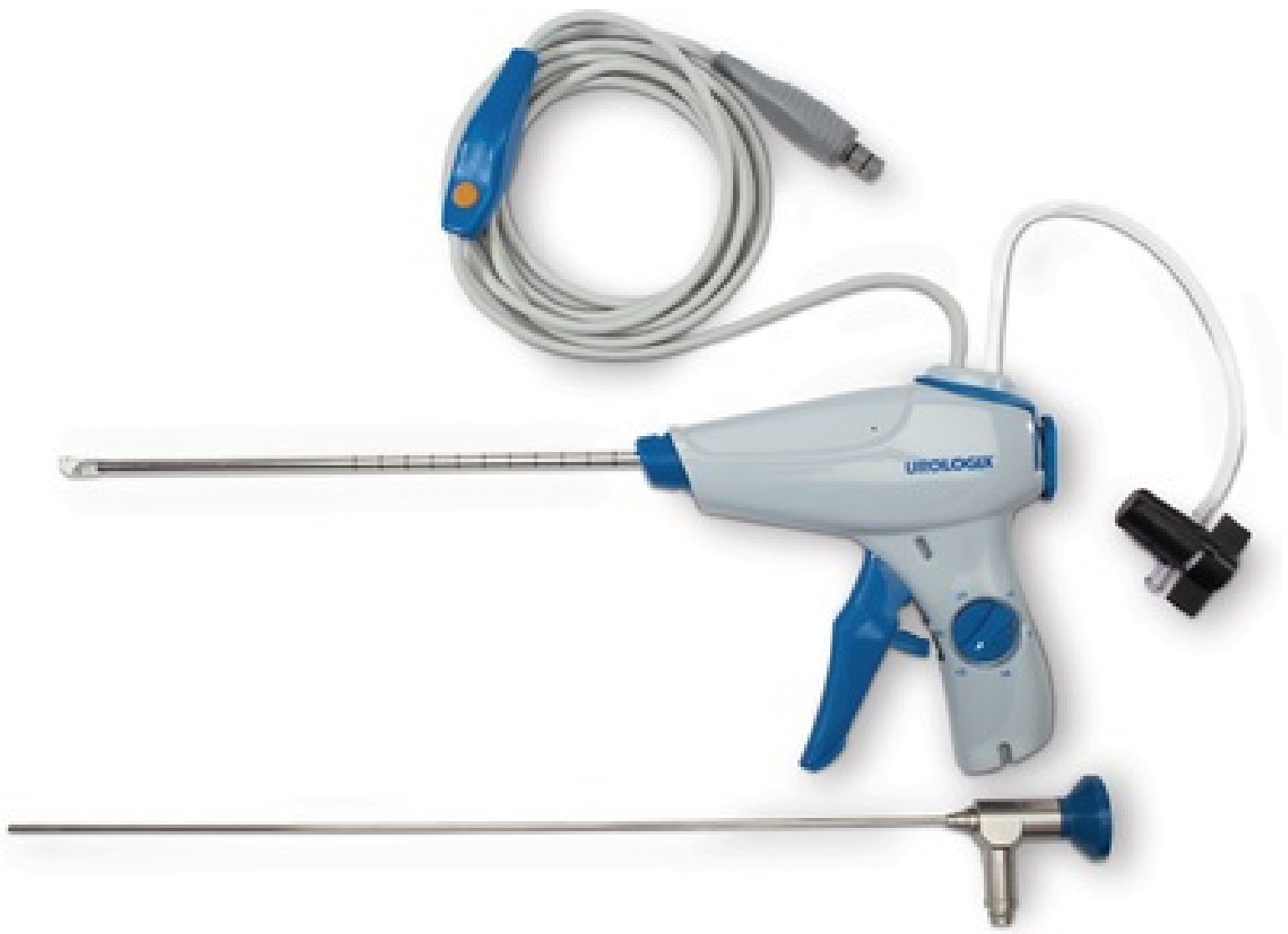

FIG. 146.15 Transurethral needle ablation handpiece. (Courtesy of Urologix, Inc.)

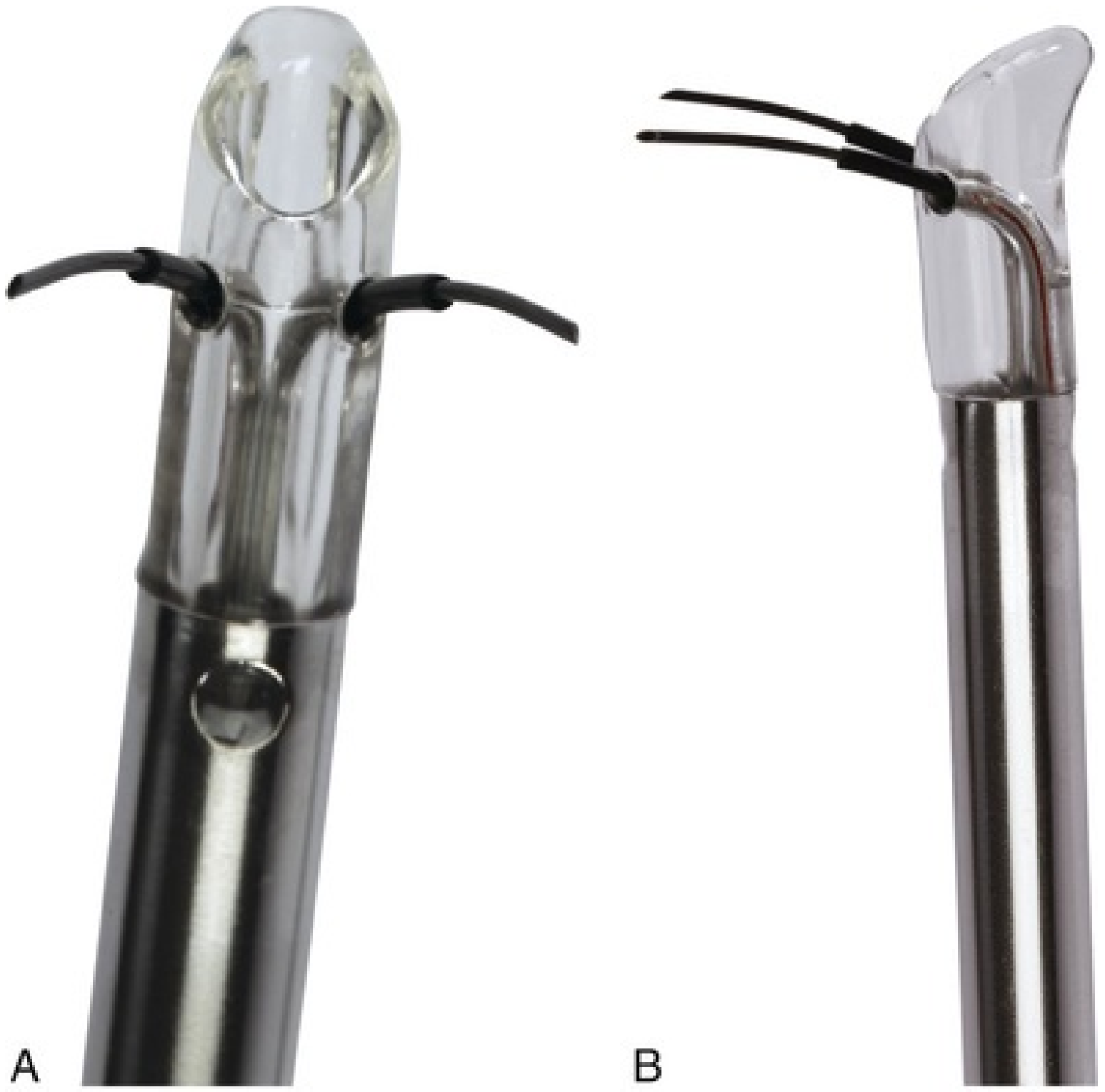

FIG. 146.16 (A and B) Deployed transurethral needle ablation needles. (Courtesy of Urologix, Inc.)

As with ultrasonography, the lower the frequency generated, the greater the depth of tissue penetration of the RF energy (or sound waves in the case of ultrasonography). **The LE monopolar RF has excellent tissue penetration. The RF flows into the prostate parenchyma and interacts with the water molecules in the cells. This interaction creates localized heat around the needles.** The heat energy has a fairly low dissipation into unwanted tissue as the temperature decreases when the distance from the needles increases (temperature decreases by a factor of 1/radius^4). **When an adequate amount of heat is applied to the tissue, a spheroidal area of coagulative necrosis is created, which later undergoes cavitation.** This cavitation should lead to an overall size decrease in the prostate, although there is some thought that the treatment area actually later becomes scar tissue and does not lead to a significant decrease in prostate size. Retrograde ejaculation should be minimized as the bladder neck is unaffected.

The original systems were reactive to change in tissue impedance, and the platform redesign called the Precision Plus (now marketed by Urologix, Minneapolis, MN) introduced a system in 2003 that **measures both temperature and impedance.** In the older, entirely impedance-based system, the generator delivers energy while the impedance of the tissue between the needles is monitored as if part of a completed circuit. The impedance increases as the tissue between the needles desiccates and is destroyed. Once the impedance reaches a certain level, the treatment in this area is complete as the tissue is desiccated and no longer able to conduct current. The level of output energy delivered was operator dependent, and the rate and amount of energy delivered were vital to creating a successful lesion. If too little energy was delivered, the lesion would be small and incomplete. If the energy was delivered too quickly, tissue would desiccate too rapidly with an inadequate total thermal load (a product of delivered energy and time), and the treatment would be less effective. The size of the created lesions is proportional to the area of tissue in contact with the needle and the quantity of energy delivered. In an MRI study looking at changes in prostate volume, the mean area of necrosis was 7.56 cc (constituting 11.28% of total prostate volume) (Huidobro et al., 2009).

The modern system is more straightforward. In this system, the needles have thermocouple electrodes at the tips that are able to monitor the temperature of the target tissue while the overall tissue impedance is also monitored. Currently the only device available in the United States is marketed by Urologix.

Technique

Preoperative.

TUNA is indicated in men with bothersome LUTS who are refractory to medications with prostate sizes up to 80 g. Sterile urine should be verified before the procedure. TUNA is not recommended in patients with metallic pelvic prostheses. Additionally, a defibrillator or a pacemaker may receive EM interference from the procedure, and they should be considered a contraindication.

A benefit of TUNA is that the procedure can be done under local anesthesia. This can be done safely in the office setting without postoperative admission, although a 23-hour admission is not uncommon after the procedure. The procedures should be done with a minimum of viscous urethral lidocaine, but oral or intravenous sedation may also be of benefit to the anxious patient. There is significant variation in the degree of anesthesia given by providers of this type of care (Bouza et al., 2006).

A **preprocedural TRUS** is performed to gauge the prostatic size, anatomy, and prostate width. Cystoscopy is also performed routinely to rule out any bladder pathology and verify the distance from the bladder neck to the verumontanum.

The **prostate length and width are of particular importance** as the length will determine the number of levels at which needle deployment will be required. Prostates of 3 cm or less are treated at two different zone levels. A length of 3 to 4 cm will require three levels of treatment, with prostates larger than 4 cm requiring four zones of treatment. The length into the prostate that the needles are deployed is based on the prostate width.

Intraoperative.

The patient is positioned in the dorsal lithotomy position on a table. A grounding pad is applied to the patient's back in the lumbar area or over the sacrum. The anesthesia of choice is then given. The viscous lidocaine is given per meatus with a penile clamp left in place to keep the lidocaine in the urethra for 10 minutes. If a periprostatic block is elected, then this is done similar to the block for a prostate biopsy.

The specialized cystoscope is placed per urethra under direct vision. The needles are deployed using controls at the catheter handle base and can be rotated 180 degrees to engage the prostate lobes based on these controls. The length of the Teflon shield on the needles should be adjusted so that the prostatic urothelium is spared from any treatment effects (usually 4 to 6 mm). The scope often needs to be pressed into the lobe for the needles to “grab” and keep the catheter from being pushed away from the lobe as the needles are advanced. Needles are deployed directly laterally into the lobes (at 8/10 o'clock position and 2/4 o'clock position).

Once deployed, the needles are placed through the urethral mucosa into the prostatic parenchyma. Once the ideal needle location is verified and the Teflon sheaths have been advanced to protect the urothelium, the generator is activated. Thermocouples monitor the urethral and needle-tip temperature. The energy is slowly increased until the tissue temperature is reached. The needle tips are employed to be more than 6 mm from the prostatic capsule to ensure no damage to structures outside the capsule. The needle tips are then heated to at least 100°C. It takes only 20 to 30 seconds to reach the treatment temperature, and once it has been achieved the area is treated for 2 to 3 minutes. The delivered energy is adjusted by the software to maintain the temperature.

The needles treat a discrete area around and between the tips creating an area of coagulative necrosis. To treat the entire gland, multiple planes in each gland must be treated. **The number of zones and planes required for treatment is dependent on prostate size and shape** (Fig. 146.17). Generally, the needles are first deployed in a plane 1 cm below the bladder neck into the parenchyma, with subsequent placements at 1-cm intervals in the prostate and the last placement 1 cm proximal to the verumontanum. The length that the needle is deployed into the prostate parenchyma is calculated by the software program based on the dimensions of the prostate including the width and other measurements from the preprocedural TRUS.

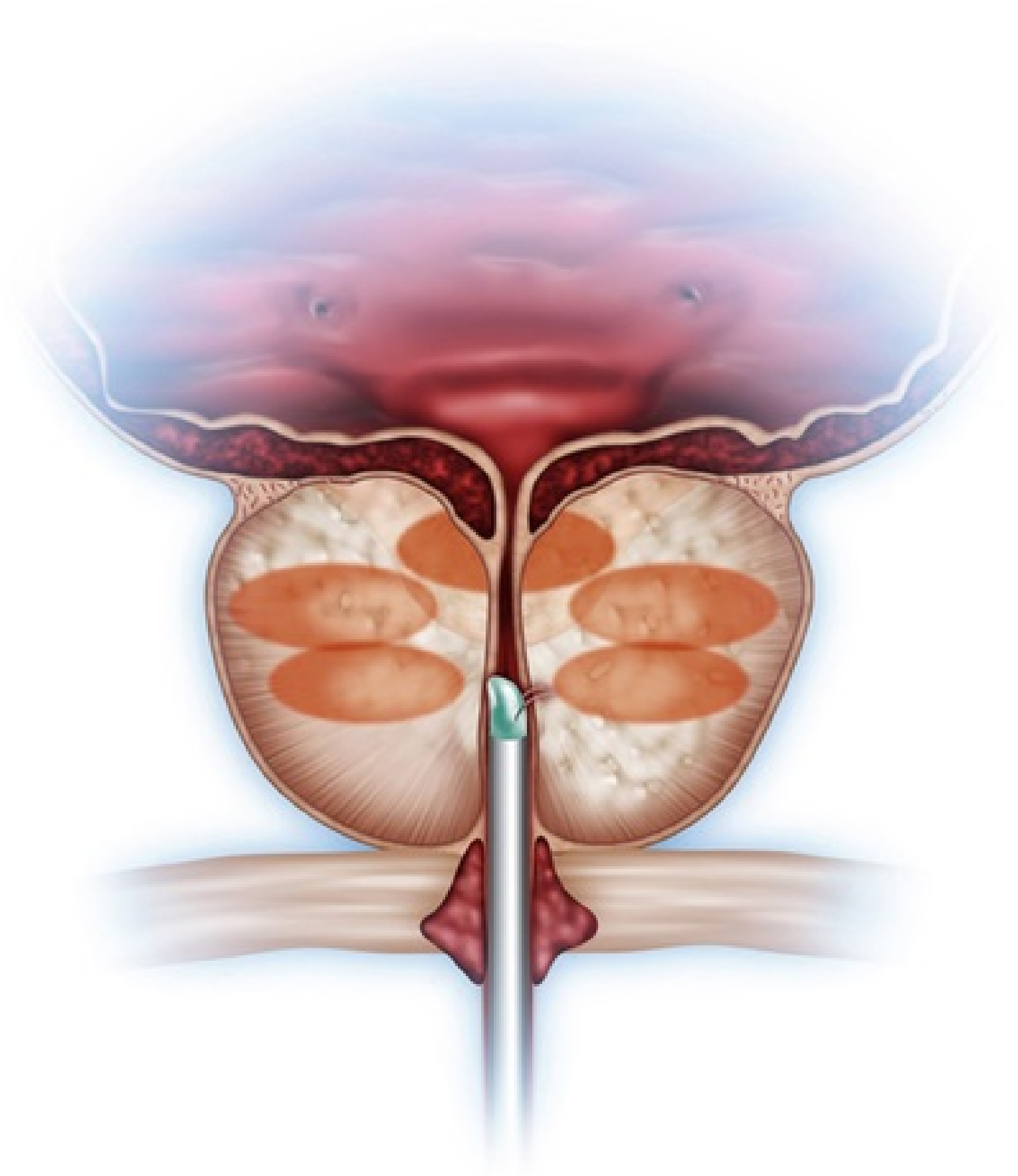

FIG. 146.17 The treated prostate in transurethral needle ablation. (Courtesy of Kevin T. McVary.)

During treatment, temperatures near the needle tips will rise to 115°C within 20 seconds of generator activation. Temperatures are then maintained at this level for 2 to 3 minutes. This temperature and duration should cause the desired local tissue necrosis. The tissue temperature should be monitored throughout the procedure along with the urethral temperature. **The machine is automatically**

equipped to shut down if the urethral temperature increases to a potentially harmful level. Treatment is complete once all of the predetermined areas of the prostate have been treated.

Postoperative.

Patients are able to return home after the procedure, and convalescence is rapid. A few days of irritative symptoms are normal and likely minimized because of the minimal effacement of the urethral mucosa. If a urinary catheter is placed, it is maintained between 1 and 3 days based on surgeon preference. Antibiotics can be used for up to 2 weeks, and NSAIDs are continued for 10 days. The empiric antibiotic treatment is to avoid bacterial proliferation forming an abscess in the cavitated necrosis of the post-TUNA prostate (Barmoshe et al., 2006). Most patients are able to return to work in 2 to 3 days.

Outcomes.

Although TUNA does show improvements in both subjective and objective measures of voiding, the results are less impressive than those found in TURP. **Studies utilizing UDS frequently show that patients do not migrate from an obstructed classification.** A prohibitive need for retreatment also attenuates enthusiasm. Comparisons to TURP are found in the literature, but no such comparisons of TUNA to medical treatment exist. Although it may have an overall lower rate of efficacy, the treatment is relatively safe with few if any major adverse events.

Single-Cohort Studies.

There is a consensus that TUNA treatment provides improvements in both subjective and objective measure of voiding at least in short-term studies. However, there are a **surprising lack of long-term data** published, with only a handful of reports on patients further than 2 years from procedure.

Rosario et al. (1997) completed a comprehensive study primarily utilizing an early generation of TUNA devices. A total of 71 patients who were all found to be obstructed on pressure-flow studies were enrolled. Patients completed a 5-day voiding diary before the procedure and before each visit. Analysis completed at 12 months found a variety of positive results. **Significant improvement was seen in multiple subjective outcomes including AUA-SS (21.9 to 10.6), QoL score (4.8 to 2.2), number of daytime voids (8.7 to 5.6), and number of nighttime voids (2.7 to 1.7).** At 1 year, 45 of the original 71 patients underwent repeat UDS. A statistical, but clinically questionable, decrease in PdetQmax was noted (97 to 82 cmH_2O). None of the patients were able to move into the "unobstructed" portion of the Abrams-Griffiths nomogram, and 78% remained "obstructed." No significant change in prostate volume or PSA was noted. Only 54% of patients were "completely satisfied" with the treatment. A total of 22 (30.1%) went on to additional treatment with TURP.

The study by Steele and Sleep (1997) reported a more impressive decrease at 2 years in PdetQmax (92.4 to 58.9 cmH_2O). Maximum flow increased from 6.6 to 11.2, and AUA-SS decreased from 22.4 to 9.5. A total of 6 patients from the initial 47 patients required TURP during the study period. They attempted to determine any preprocedural values that predicted failure but were unable to find any significant correlations.

In one of the larger noncomparative studies, Roehrborn et al. (1998b) studied 130 patients prospectively. Improvements were once again seen in AUA-SS (23.7 to 11.9) and Qmax (8.7 to 14.6 mL/s). **Surprisingly, 13.1% of patients reported an improvement in AUA-SS with either a decrease or no change in their peak urinary flow. Conversely, 4.8% of patients noted an increase in Qmax without an improvement in AUA-SS.** Treatment duration was quick (mean 37.4 minutes), and although no patient required general anesthesia to complete the procedure, 22% reported some degree of pain. Most patients (59.2%) were able to void after the procedure. Of those who required catheterization, the mean duration was 3.1 days, although one patient required a catheter for 35 days.

In one of the few studies with data beyond 2 years, Zlotta et al. (2003) enrolled 188 patients into a multicenter study. At 5 years postprocedure, 121 patients were still available for analysis, with another 10 patients reaching 4 years. **Significant improvements were seen in Qmax (40.7%), AUA-SS (–58.4%), QoL score (–55.1%), and PVR (–31.8%). Patients had a fairly large prostate at baseline with a mean size of 53.9 g, and, again, no appreciable change in volume was noted with the procedure.** Additionally, the PSA did not have any significant change with treatment. Of the 176 patients (2 deaths, 10 lost to follow-up) remaining at final analysis, 23.3% required some form of retreatment. Of the total cohort, 6.4% received additional medical treatment, 3.7% underwent a second TUNA, and 11.1% underwent unspecified surgery.

In studies looking at TUNA use in patients with AUR, results were surprisingly positive. A total of 20 patients were included, and inclusion criteria included good detrusor function on UDS. All patients had also failed a trial of void after their initial catheterization. Although all patients remained obstructed by the Schafer coefficient after the procedure, 17 of the 20 were able to spontaneously void. Five patients still progressed to receiving TURP for symptoms (Millard et al., 1996).

In their review, Bouza et al. (2006) analyzed the available data and found that **TUNA could reliably reduce symptom scores and QoL values by 50% to 60% compared with preprocedural values.** They concluded this improvement was maintained over time with a downward trend noted after 3 years. **In objective parameters, improvements were more modest but still statistically significant. A 30% to 35% improvement over baseline values was noted in objective measures like Qmax, with even poorer outcomes on measures obtained from UDS.** Of studies assessing patients with acute or chronic AUR, 70% of patients could spontaneously void within the first few weeks of the procedure.

Comparative Studies.

Very few studies comparing TUNA to other treatments exist, and of these comparative studies a minority have been done in a randomized fashion. Although most studies report the standard subjective and objective measure of voiding, complications are irregularly reported. Follow-up beyond 3 years is rare in any type of study, and conclusions on long-term durability of this procedure should be made with caution.

TUNA vs. other MISTs.

In a nonrandomized treatment protocol comparing patients selecting TUNA, TUMT, or high-intensity focused ultrasonography (HIFU) for treatment of BPH, discouraging results were found with regard to MIST treatments (Ohigashi et al., 2007). Although statistical decreases were seen in all three MIST treatments with regard to AUA-SS at 6 months after treatment, with HIFU (52%) performing better than TUNA (45%) or TUMT (38%), all three treatments no longer had statistically significant improvements at 24 months. Although a large number of patients were lost to follow-up, retreatment rates were surprisingly high, with 34% of TUMT, 36% of TUNA and 58% of HIFU patients requiring retreatment by 3 years. At 5 years, retreatment ranged from 54% to 68% for the groups. In an interesting analysis, they found that an initial Qmax of less than 10 mL/sec and an AUA-SS greater than 19 were risk factors for retreatment. This is suggestive that patients with more severe metrics of BOO may be better suited with a different form of treatment. Although data was only accumulated for 3 months post-treatment in this nonrandomized trial, Arai et al. (2000) found that patients undergoing TUNA were more likely to rate their satisfaction with the procedure higher than those having TUMT.

A few studies have compared TUNA to TUVP (Schatzl et al., 1997, 2000; Minardi et al., 2004). The analysis of these outcomes reports that TUVP has a higher risk for adverse events with more significant improvements in subjective and objective voiding outcomes (Bouza et al., 2006).

TUNA vs TURP.

TUNA was rigorously compared with TURP in an RCT that had data reported at multiple time points. The first installment occurred at 1 year postrandomization and showed that **both procedures were efficacious but with superiority in the TURP cohort** (Bruskewitz et al., 1998). A significant decrease was seen in AUA-SS in both arms at 1 year, with TURP (64% decrease) having a statistical advantage compared with TUNA (55% decrease). Measured prostate volume actually increased in the TUNA group (+2.4%), and the TURP group had a 17% reduction ($P = .014$). Peak urinary flow also underwent a more significant improvement in the TURP group (147.6%) compared with the TUNA group (72.4%), although both groups improved compared with their respective baseline. Longer hospital stay was noted in the TURP group as all patients in the TUNA group went home the day of the procedure.

The second installment focused more primarily on UDS changes noted between the treatment arms (Roehrborn et al., 1999). **Changes in the Abrams-Griffiths number and detrusor pressure at peak flow were superior in the TURP group.** When comparing UDS changes to symptom improvements, they were not able to predict which preprocedural UDS findings could predict postprocedural subjective success.

The final publication from this series occurred after 5 years post-treatment (Hill et al., 2004). Cautious conclusions should be taken from these results as at least one-half of the initial cohort did not provide data at the 5-year mark, and in some categories only 20% of the initial cohort was analyzed. Both treatments were found to be effective in treating BPH, but TURP was superior in almost all metrics. AUA-SS improvements were more profound from years 1 to 4 for TURP. Peak flow was better at all analyzed time points in the TURP group compared with TUNA. TUNA did have less adverse events but a higher need for retreatment (13.8%) compared with 1.8% in TURP group.

Another RCT by Cimentepe et al. (2003) had overall results that were more favorable to TUNA but still not exceeding TURP. The authors reported no postoperative complications in the TUNA group other than a 7% risk for retreatment over 18 months.

The meta-analysis of RCTs (Bouza et al., 2006) **concluded that TUNA and TURP were fairly equivalent in results at 3 months, with TURP providing superior results after that point.** Results for symptom score were improved by a factor of 1.3 at 1 year and 1.49 at 3 years. QoL score had less of a disparity, with a factor difference in results of 1.14 at 1 year and 1.34 at 3 years. **Maximum flow of the TURP group was at least double the improvement seen in the TUNA group throughout the entire analysis.**

Complications.

The excellent systematic review and meta-analysis by Bouza et al. (2006) analyzed the total complication rates of both open and comparative trials. **They found that TUNA had a much higher rate of secondary procedures (OR 7.4) compared with TURP but was safer with a lower rate of complications (OR 0.14).** They noted that differences were particularly notable in risk for sexual disorders and postoperative bleeding.

Intraoperative and Perioperative.

In the study by Steele and Sleep (1997), a mild postprocedural **hematuria** was seen in all 47 patients. At 1 month postprocedure, 8% continued to have some degree of **irritative voiding symptoms. Pain during the procedure** is a fairly common finding, with 22% of patients reporting in one series (Roehrborn et al., 1998b).

Postoperative.

In the comprehensive study by Rosario et al. (1997), patients were routinely sent home with catheters after initial problems with postprocedure retention. Likely as a result of this, they had a high rate of **UTI** (14%). Only 5.8% of patients reported **sexual dysfunction,** although the rigor to which this was investigated in the individual trials is suspect**. Dysuria** was noted in 7% of patients in the review, and other studies reported this as high as 25% (Ramon et al., 1997).

Perineal pain both during and after the procedure is a common finding, with 50% of patients in one study having pain lasting 1 to 2 weeks and 23% using pain medications for control of this pain (Daehlin et al., 2002).

From the comparative trials, Bruskewitz et al. (1998) noted a 12.7% incidence of **ED** in the TURP group, with no TUNA patients reporting ED. A **decrease in ejaculation** was noted in the TURP group 54% of the time, and only 13% of TUNA patients noted the same complaint. At final analysis of this cohort, 41% of the TURP group reported **retrograde ejaculation,** with no TUNA patients reporting this (Hill et al., 2004). **Prolonged catheterization** is unlikely as 90% to 95% of patients have been shown to be catheter free within 1 week of treatment (Chapple et al., 1999).

Conclusion.

The role of TUNA in the continuum of BPH treatments is difficult to ascertain because there is insufficient evidence and a lack of high-quality studies with significant long-term data. Although TUNA statistically improves symptoms, QoL, and urinary flow rates, the results are not as impressive as other treatment options for LUTS/BPH. The reduction in prostate volume is negligible as the cavitated areas are putatively replaced with scar leading to minimal significant change in overall prostate volume. Although a large initial volume of research was generated, there is a paucity of recent publications. Likely this technology is headed toward a minimal role as more durable and impressive options continue to evolve. Although overall the procedure is very safe, it is an overall less attractive as other MIST options.

Transurethral Incision of the Prostate

Introduction and Concept.

A dynamic role of peripheral condensation of the prostatic stroma acting as a capsule leading to BPH/LUTS has been proposed (Hutch and Rambo, 1970; Ohnishi, 1986). The alleviation of symptoms seen in patients with BPH treated with α-blockade also supports this capsular contraction or prostatic hypertonicity leading to symptoms. Clearly, capsular constriction could further exacerbate the symptoms derived from an already hyperplastic prostate.

The practice of incising the prostate or bladder neck to relieve voiding symptoms has been verified as early as reports dating back to the 1800s. In their review, Hedlund and Ek (1985) credit Guthrie in 1834 with the first disruption of the bladder neck as a treatment.

Transurethral incision of the prostate (TUIP) is an operative approach to disrupt the prostatic capsule to alleviate voiding symptoms. This procedure can be considered in men with small prostate glands (<30 g), although surgeons have tried this in larger glands. **Generally, a unilateral or bilateral incision is made through the bladder neck and can be extended all the way distally to the verumontanum. This incision is usually made posterolaterally (in the region of the 5 o'clock and 7 o'clock positions).**

The ideal patient for this procedure is a young man with a small prostate who is concerned about either a loss of ejaculation or future fertility. This procedure has a lower risk for retrograde ejaculation than other BPH treatment options, particularly if only done unilaterally. However, if retrograde ejaculation is truly being avoided, authors have avoided bladder neck and complete capsular incision (Orandi, 1987).

Technique.

The most critical part of the preoperative care for a TUIP is **correct patient selection.** Patients with large glands or significant symptoms are unlikely to achieve significant benefit and will likely require additional treatment. Many studies exclude patients with a median lobe from the procedure, and this should be considered as a potential contraindication. However, other authors have found that the presence of a median lobe is not a contraindication and opine that with incision of the prostate, the median lobe will often become atrophic (Orandi, 1985).

The technique itself is fairly simple and technically straightforward. A cold knife, hot knife, resectoscope with a thin loop, or even end-firing holmium LASER can be used to complete the procedure. The incision should be started distal the ureteral orifice. Incision is carried through the bladder neck, into the prostate with the incision ending proximal to the verumontanum. The depth of incision should visualize the surgical capsule at a minimum, but more aggressive surgeons may prefer to see periprostatic fat as they incise through the capsule. Hemostasis should be achieved, but significant bleeding should not be encountered (Fig. 146.18).

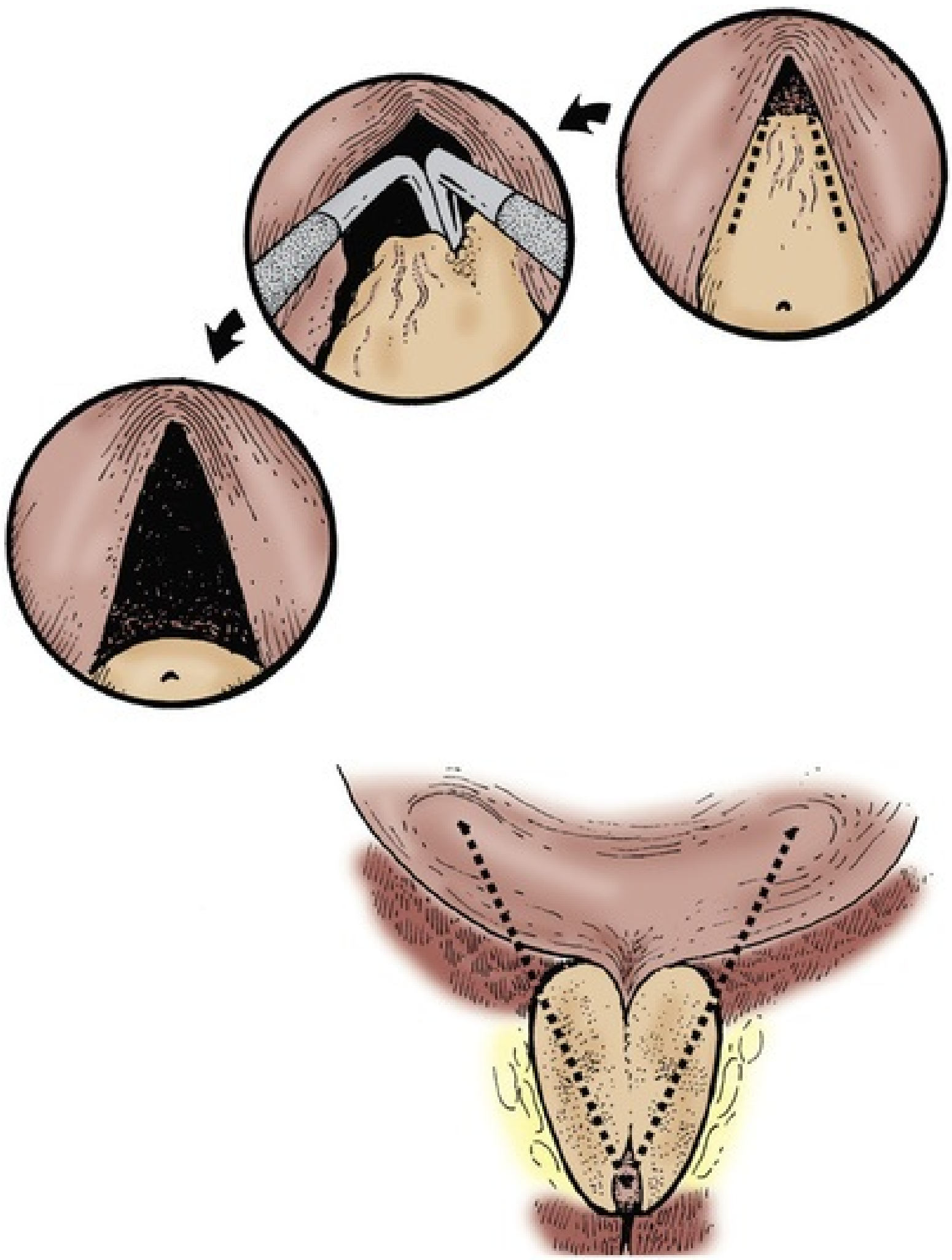

FIG. 146.18 Transurethral incision of the prostate. The incision is started at the ureteral orifice and carried through the bladder neck up to the verumontanum. This procedure is done bilaterally. (From Mebust WK. A review of TURP complications and the National Cooperative Study. Lesson 24, volume 8. *AUA Update Series* 1989:189–190.)

The patient can have the catheter removed and can be discharged to home quickly after surgery (the day of surgery or next day). Convalescence should be rapid with little to no postoperative irritative symptoms.

Outcomes

Single-Cohort Studies.

Compared with other BPH treatments, TUIP has generated less significant and rigorous research. Only a few large series exist, and they are primarily focused on few authors. In a rigorous study by Sirls et al. (1993), a small group of patients were evaluated with both subjective and objective measures to evaluate the procedure. UDS were routinely performed along with interviews and questionnaire data in 41 patients. Data was only reported if patients were followed for a minimum of 12 months. Significant changes were seen in mean peak urinary flow (increased from 10 to 15 mL/sec) and Madsen-Iversen symptom scores (decreased from 12.5 to 6.9). The mean detrusor pressure at maximum flow decreased (from 85 to 44 cm of water), which was statistically significant, but left many patients remaining in the obstructed (29%) or equivocal (43%) classification by the Abrams-Griffiths nomogram. Additional subjective information was obtained by interview. Although no objective questionnaire was used to evaluate sexual function, only 11% of patients reported new retrograde ejaculation. Additionally, only 67% of patients reported being overall satisfied with the procedure.

In the large series published by Orandi (1990), 646 cases over a 15-year period were assessed. Although not randomized, many patients during that time underwent TURP, and some matching of results was attempted.

Comparative Studies

TUIP vs TURP.

The trials comparing TUIP and TURP are of generally poor methodological quality with nonuniformity making any large meta-analysis prohibitive. Specifics on randomization are most notably missing. Additionally, they sample a fairly homogeneous group of patients with small prostates.

In a randomized study of 85 subjects by Jahnson et al. (1998), the authors evaluated patient prostate volume primarily with DRE (TRUS in some circumstances). In those evaluated by TRUS, the average prostate volume was less than 27 g in both groups. The authors concluded that operative time was longer in TURP compared with TUIP; furthermore, TURP subjects experienced a greater estimated blood loss (EBL) but larger improvement in postoperative Qmax. Ten patients in the TUIP group required reoperation compared with only three in the TURP group ($P = .039$).

Another randomized study by Tkocz and Prajsner (2002) only included patients with a prostate volume less than 30 g by TRUS. The age range of patients included was 51 to 78 years, and assessment was made at 24 months. Although both groups had statistical improvements in AUASS, Pdet at Qmax, and Qmax, there was no significant difference between groups in these metrics.

Retrograde ejaculation was seen in only 12% of the TUIP group, compared with 32% of the TURP group, although it was unclear if this was statistically different.

Soonawalla and Pardanani (1992) published the largest randomized series, which excluded patients with glands larger than 30 g. Although patients were randomized to either TURP (*n* = 110) or TUIP (*n* = 110), the TUIP group did have a small volume of prostate resected for histopathologic examination. A surprising number of patients (38 of 110) having a TURP received a blood transfusion. Peak flow rates were increased in both the TURP (157%) and TUIP (145%) groups.

Lourenco et al. (2010)**published a fairly recent analysis of randomized trials involving TUIP. The authors concluded that the available randomized trials were of "poor to moderate quality," and in many comparisons only a few trials could be included because the trial did not report methods or results comprehensively enough. TURP had a more significant improvement in flow rates, and a conclusion on changes in symptom scores could not be drawn from the data.**

Complications

Intraoperative and Perioperative.

Hemorrhage should be controlled quickly, although significant bleeding and transfusion are rare. In cases in which **capsular perforation** occurs (either intentionally as part of the procedure or caused by an overly zealous incision), this can generally be treated with prolonged postoperative catheterization. In the series by Orandi (1985), 11% of patients had temporary **urinary retention** after TUIP. Significant hemorrhage was rare, with only 0.9% of patients requiring **transfusion.** The previously discussed analysis of RCTs (Lourenco et al., 2010) more confidently reported morbidity data. A higher rate of **blood transfusion** was found in TURP but was fueled by two studies, with abnormally high rates of 35% (Soonawalla and Pardanani, 1992) and 80% (Nielsen, 1988).

Postoperative.

Retrograde ejaculation is less likely with TUIP than with other forms of BPH treatment. Reported rates of retrograde ejaculation range from 0% to 37% but are likely toward the lower end of this range. The incidence of this complication is less likely with one incision (Turner-Warwick, 1979), but other reports came to the conclusion that two incisions did not increase the risk (Hedlund and Ek, 1985). When compared with TURP, TUIP had a lower risk for retrograde ejaculation (RR 0.54, *P* < .001) but a higher risk for reoperation (RR 2.40, *P* < .01). The risk for **ED** with either treatment was not different. Additionally, they found no difference between treatments with respect to urinary retention, urinary infection, stricture, or incontinence (Lourenco et al., 2010). In the Orandi series (1987), 2.9% of patients developed urethral stricture, and 9.6% required repeat prostatic surgery. In fewer than 1% of cases were complications of incontinence or bladder neck contracture encountered.

Summary.

TUIP offers reasonable results in correctly selected patients. It does appear to have a lower risk for retrograde ejaculation compared with other treatment options, particularly TURP. The operation is of short duration, and a minimal hospital stay is required. This treatment should be discouraged in a patient with a larger prostate gland but may be of benefit in patients who are particularly concerned about retrograde ejaculation.

Key Points

- M-TURP is still an important treatment for LUTS/BPH but will continue to progress to B-TURP because of multiple improvements in its safety profile.
- MIST treatments like TUNA and TUMT have been plagued by a high need for retreatment and likely fill a role between medical management and more invasive and effective treatments for LUTS/BPH.
- TUIP is a reasonable treatment option in the carefully selected patient.

LASER Treatments

LASER treatment of BPH has been an increasing choice for urologists and patients. Over the past decade, LASER technology has become more refined, leading to improved treatments and outcomes. The acronym LASER stands for “light amplification by stimulated emission radiation.” **LASER prostate treatments rely on the prostate interacting with the light energy and converting it to local thermal energy.** The volume of tissue that is heated by the LASER depends on multiple variables, including light scatter, reflection, and most importantly absorption.

Initial LASER technologies relied on tissue coagulation with eventual abandonment in favor of LASERs with a preference for vaporization. The temperature that the tissue is heated to determines whether the tissue is vaporized or coagulated. Below the vaporization temperature, the tissue proteins are denatured, leading to coagulative necrosis with delayed tissue death and sloughing. Vaporization occurs when the tissue is heated above the vaporization (boiling) temperature, which leads to intracellular water vaporization and quick tissue destruction.

The amount of tissue that heats beyond a target temperature during LASER treatment of the prostate is based on characteristics of the LASER and tissue. LASER characteristics include the irradiation time and power along with delivery characteristics such as power intensity, beam angle, and spread. Tissue variables such as carbonization and light scatter affect tissue heating also and the response to the applied energy. An appeal of the LASER technologies is the ability to allow for ambulatory or outpatient surgery or mimic a more invasive treatment option with a minimally invasive approach (e.g., holmium enucleation replacing OP).

There are several characteristics of LASERs that we will discuss briefly. The wavelength of the LASER is the distance between the sinusoidal waves of the LASER energy and is measured in nanometers. Energy of a LASER is measured in Joules and is the amount of work or heat that the LASER produces. The LASER power is measure in Watts and is the amount of energy that the LASER produces in a certain amount of time.

LASER Safety.

The incorporation of LASER energy into the operating room has allowed for many new techniques for the treatment of BPH along with multiple other urologic and nonurologic indications. The ability to destroy tissue is important for prostate treatment but when used errantly can lead to unintended consequences such as injury of the patient or operating room personnel. In particular, the human eye is at the highest risk for accidental exposure because of the lack of a protective layer (like the epidermis for most of the body).

The portion of the eye that is injured depends on the wavelength used. For LASERs with a larger wavelength like the holmium or thulium, the cornea is at greatest risk. The potassium-titnyl-phosphate (KTP), lithium-triborate (LBO), and neodinium:yttrium-aluminum-garnet (Nd:YAG) LASERs are particularly dangerous as this wavelength is focused on the retina. The lens of the eye focuses this energy on the retina causing an increased intensity of up to a factor of 100,000 (Donnell, 2014).

The regulation of the operating environment is standardized by the Occupational Safety and Health Administration (OSHA). **LASERs are classified by their inherent wavelength, maximum output power, and risk for damaging the eye or skin.** All of the LASERs used by urologists are class 4 LASERs (the highest classification) and can cause permanent eye damage from a variety of exposures including indirect beam contact.

The safe use of LASERs in surgery should be done as part of a “**culture of safety.**” Appropriate OSHA-approved signage should be displayed outside the room so that personnel entering the room are aware of the use of LASERs. Appropriate LASER-rated protective eyewear should be worn by all persons in the operating room (including the patient) and should be accessible to those entering the room. Any windows or other portals for LASER light to leave the operating room should be appropriately blocked to prevent the escape of LASER light.

The LASER technician or surgeon should review the LASER before each case to inspect for any visible signs of damage, and all LASER operators should have received appropriate training. Your institution likely has a LASER safety officer who can be consulted with any questions regarding LASER usage or safety.

Holmium and Prostate Enucleation

Introduction and Concept.

The Ho:YAG LASER emits light at 2140 nm but has a pulsed instead of continuous energy emission. This wavelength is strongly absorbed by water (and water-rich tissues) and has an absorption length of 0.4 mm with excellent hemostatic properties (Kuntz, 2006). The light is easily transmitted along flexible quartz fibers and creates a high-energy density that leads to vaporization with a superficial coagulation zone. The dissipated heat from the tissue-fiber interaction is dissipated over a short distance (2 to 3 mm) and causes coagulation of small- to medium-sized vessels.

Although this LASER has many uses in urology, it is generally now used to precisely incise tissue when used for BPH treatment. Historically, the holmium LASER was used also for ablative procedure (HoLAP), but its hemostatic properties were found wanting when compared with other contemporary LASER technologies. **Primarily it is now used to enucleate the prostate in a procedure named the holmium LASER enucleation of the prostate (HoLEP).** This procedure allows the surgeon to follow anatomic planes to enucleate entire lobes of the prostate. Generally, these lobes are then pushed into the prostate with subsequent morcellation.

Holmium resection of the prostate (HoLRP) was the precursor procedure to HoLEP. In HoLRP, large sections of the prostate were cut away and pushed into the bladder for later retrieval. **However, with the incorporation of morcellation, the pieces resected could be larger (now entire lobes), and the HoLRP fell out of favor for the more efficient HoLEP**.

LASER enucleation represents the endoscopic response to open simple prostatectomy and is the most technically advanced LASER prostate surgery. Many reviews and meta-analyses of the HoLEP make this the most rigorously analyzed LASER technique (Gravas et al., 2011).

Although a treatment with excellent results, a difficult and exaggerated learning curve has consistently been seen in adapters of this technique. Although the enucleation of lobes is not without possible complication, the morcellator requirement can lead to significant injury to the urinary bladder with catastrophic complications (e.g., bladder fibrosis, cystectomy, and need for urinary diversion).

Technique

Preoperative.

This technique is probably not necessary for small glands (with many alternatives available) and may be better suited for patients with a larger gland that would previously have received an OP.

Although crossmatching of blood may not be necessary as a routine precaution for this procedure, the urologist may be well headed to consider a preoperative crossmatch for blood transfusion. Antibiotics should be administered as described earlier for TURP. HoLEP generally is done in a hospital (or outpatient surgery center) under regional or general anesthesia. Patients should be counseled that an overnight stay is expected with catheter removal the next day.

Intraoperative.

The HoLRP and current HoLEP technology both utilize the Ho:YAG LASER generator. This technology uses an end-firing 550-micron fiber delivered through a continuous-flow LASER resectoscope (usually 26 Fr in size). The LASER resectoscope has a modification in which the inner sheath contains a fiber guide to stabilize and prevent fiber movement while in use. A 6-Fr open-ended catheter may also be used as a fiber guide when placed through the sheath. An offset lens of 30 degrees is used along with normal saline irrigation (▶Video 146.1).

The HoLEP technique was initially described by the group from New Zealand led by Gilling (Fraundorfer and Gilling, 1998). The use of the morcellator modified the technique from the HoLRP to the HoLEP. Initially, the size of the pieces that could be removed from the prostate was limited to a size that was small enough to be retrieved through the modified resectoscope. With the addition of morcellation, larger pieces were able to be fragmented and removed, making enucleation possible. These whole prostate lobes were moved into the bladder after enucleation with morcellation then commencing after the entire enucleation was complete.

An 80-W or 100-W generator is used. The power settings are generally 2.0 J at 50 Hz, giving the surgeon a total of 100 W. **The procedure begins with a bladder neck incision at the 5 o'clock and 7 o'clock positions.** These incisions are carried down to the surgical capsule, which is identified by its reflective fibers running longitudinally. This is an important distinction as the landmark will mark the depth for the remainder of the procedure. **The incisions are lengthened distally until just proximal to the verumontanum.** Incisions are widened laterally by following the surgical capsule to undermine the lateral lobes. This allows for improved visualization with a larger channel of irrigation influx to the bladder and sets up later steps in the case.

A transversely oriented incision is made between the distal aspects of the previously extended bladder neck incisions. This begins the undermining of the median lobe in a retrograde fashion. **The surgical capsule is followed as the median lobe is lifted off the capsule.** The beak of the scope may be used to retract the median lobe to improve visualization. This step is complete once the median lobe has been enucleated and advanced into the bladder. Care should be taken to not undermine the bladder during the latter portion of this step.

The incisions made at the distal aspects of the lateral lobes are now developed to enucleate the lateral lobes. These incisions are developed laterally up the walls once again following the surgical capsule. Initially, this is done circumferentially at the apex of the prostate and then carried proximally toward the bladder neck, separating the adenoma from the capsule. An incision at the 12 o'clock position is then made down to the capsule. The surgical capsule is then followed from both the inferior and 12 o'clock position until the entire lobe is free and can be moved into the bladder. The procedure is repeated on the other side, and hemostasis is achieved using a defocused LASER beam to coagulate any bleeding.

Morcellation is then used to remove the large adenoma pieces from the bladder as the morcellator digests these large pieces down to more manageable strips of tissue. A dedicated scope or nephroscope with a 5-mm working channel is used. The morcellator itself has two blades within a long hollow inner lumen. The bladder is distended to keep the bladder wall away from the morcellator's moving pieces. A foot-operated variable suction is applied to the morcellator to draw the adenoma pieces toward the morcellator. Once the pieces are engaged, the morcellator's guillotine action slices off fragments of tissue. These smaller fragments are able to be suctioned through the lumen of the morcellator. A unique complication of the morcellator is bladder injury, and the operator should be careful to stop suctioning if the blade engages the bladder mucosa. Small, residual fragments may be removed with the flow of irrigation through a resectoscope sheath or with a large-bore syringe.

An alternate technique of lobe fragmentation or “mushroom” technique involves leaving the lobes attached at a stalk and then resecting the lobes down into pieces suitable to come through the resectoscope (Hochreiter et al., 2002). A urethral catheter is then carefully placed after all of the fragments have been removed. Of course, this technique allows for preservation of the tissue for histologic examination, and the morcellated pieces should be sent to the pathologist for examination. Additional hybrid holmium resection/enucleation techniques have been described that improve the learning curve and have decreased complication rates compared with traditional HoLEP (Helfand et al., 2010).

Postoperative.

A minimum of an overnight hospital stay is generally accepted, and patients can expect to be discharged on the first postoperative day. In the absence of a definitive capsular perforation, the catheter can be removed first thing in the morning. If a large perforation has occurred, the catheter should be left for a few days and then removed at the clinic without further repercussions.

Although most bladder injuries during morcellation are superficial and require no additional treatment, large extraperitoneal or intraperitoneal bladder injuries may require exploration and closure. Unless there is a large degree of extravasation of irrigant from an extraperitoneal injury, these can generally be managed conservatively with extended catheterization.

Outcomes

Single-Cohort Series.

Large series of patients appeared quickly, and one of the early adapters reported on 552 patients retrospectively in 2005. **Elzayat et al.** (2005a)**found a 200% increase in Qmax to complement a 75% improvement in AUA-SS at 1 year.** A short mean catheterization (1.4 days) and hospital stay (1.5 days) was also observed. **The authors quickly reported on successful treatment of large glands customarily removing over 100 g at surgery** (Moody and Lingeman, 2001)**. The ability to handle such large glands quickly made this a unique endoscopic treatment, as most other technologies did not include gland sizes larger than 70 to 80 g in studies.** Studies looking at patients in AUR displayed the effectiveness of the treatment. In a study of patients with a mean volume of 670 mL of urine drained at initial catheter placement, only 1.75% of patients were unable to void after surgery (Elzayat et al., 2005b). In another study on patients with urinary retention, all patients were able to void after surgery (Peterson et al., 2005).

Longer-term data continued to be encouraging. In a review of 118 cases by Elzayat and Elhilali (2007), objective data were only available on 26 patients at 6 years, but mean flow increased from 6.3 to 16.2 mL/sec and mean AUA-SS decreased from 17.3 to 5.6 ($P < .0001$ for both). They observed that 8% of their first 50 cases required retreatment with only 1.5% of the later 68 patients requiring retreatment, hinting that a significant learning curve may be expected. Enucleated tissue weight and total energy used were increased in the latter group, possibly explaining the lower retreatment needs.

Krambeck et al. (2010a) reported on their data from 1065 HoLEP patients. Although they had a mean follow-up of 287 days, (range 6 to 3571 days), they observed an increasing maximum flow and decreasing AUASS when stratifying patients by time from procedure. This further solidified the long-term efficacy of the procedure.

The popularity of the HoLEP has been hampered by concerns about a steep learning curve. This was evident in the analysis of the first 125 patients undergoing the procedure by a self-taught surgeon (Placer et al., 2009). **In skilled hands, the HoLEP can treat glands over 175 g with a reported outcome equivalent to OP with a low morbidity** (Krambeck et al., 2010b)**, but it has been estimated that a self-taught trainee must perform at least 20 procedures on moderate-sized glands before being able to reliably reproduce quality results** (El-Hakim and Elhilali, 2002).

An advantage of the HoLEP technique is that it appears that prostate size does not influence efficacy in a surgeon with experience in this technique. When researchers broke down prostate size into three groups with increasing size, they found that although mean resected tissue weight increased among groups, the groups all had immediate and profound changes in AUASS, flow rate, and residual volume. Complication rates were roughly equivalent, with only a slight increase in bleeding noted with increasing prostate size (Kuntz et al., 2004a).

Comparative Series

HoLEP vs. TURP.

A large RCT looking at HoLEP versus M-TURP was initially composed of 200 urodynamically obstructed patients who were randomized to HoLEP or M-TURP. Prostate volumes were measured by TRUS to be approximately 50 g in both groups, and patients had high PVRs (>200 mL) in both groups. Follow-up was available out to 36 months; results were published in two reports.

The authors reported a significantly decreased change in hemoglobin (1.3 vs. 1.8 g/dL), catheterization time (27.6 vs. 43.4 hours), and hospital stay (53.3 vs. 85.8 hours) in an initial report (Kuntz et al., 2004b). Operative time was longer in the HoLEP group (94.6 vs. 73.8 minutes). Peak flow rates improved from 4.9 to 23.1 mL/sec in the HoLEP group, with the TURP group improving from 5.9 to 25.5 mL/sec at 12 months without differences seen between groups. Residual volume in the HoLEP group was superior compared with the TURP group (4.8 vs. 16.7 mL at 6 months and 5.3 vs. 26.6 mL at 12 months), although with such low volumes this is likely not clinically significant. AUA-SS were in the low 20s in both groups preoperatively to 4.3 (HoLEP) and 5.5 (TURP) at 1 month.

At 36 months, PVR continued to be significantly lower in the HoLEP group (202 mL vs. 8.4 mL). The statistical difference between AUASS was no longer present, but both groups had a very low score (2.7 in HoLEP, 3.3 in TURP). Flow rates were not different between groups and were greater than 27 mL/sec in both groups (Ahyai et al., 2007). Other RCTs have verified the increased operative time with decreased catheterization and hospital time (Montorsi et al., 2004; Tan et al., 2003).

The longest randomized data comparing HoLEP to TURP come from Gilling et al. (2012) and includes 7-year follow-up of 31 of the initial 61 subjects. Data from the initial operation was reviewed and is in agreement with the increased operating room time and prostate tissue weight removal. Catheterization (17.7 vs. 44.9 hours) and hospital time (27.6 vs. 49.9 hours) were once again lower for HoLEP versus TURP. They concluded that HoLEP is at least equivalent to TURP with regard to durability. In their data, three of the TURP patients required additional intervention for BPH (compared with none in the HoLEP group).

Multiple meta-analyses have been performed looking at RCTs of HoLEP versus TURP Lourenco et al. found increased rates of Qmax for HoLEP compared with TURP (weighted mean difference of 1.48 mL/sec) (Lourenco et al., 2008). Symptom scores trended toward an advantage for HoLEP but did not quite meet statistical significance. Lourenco et al. and another meta-analysis (Tan et al., 2007) found shorter catheter and hospital times. With different RCTs included in their reviews, the analysis of flow rates did not meet statistical significance in the latter review.

The most convincing data for HoLEP utility was published in the meta-analysis of RCTs by Ahyai et al. (Ahyai et al. 2010). **The authors concluded that operating room time was indeed increased, but because of the large weight of adenoma removed in studies, HoLEP and TURP have similar time efficiency (weight of adenoma removed/operating room time).** Catheter time was also found to be shorter in the HoLEP group. **Most interestingly, statistical superiority in support of HoLEP was seen with regard to change in AUASS and Qmax. The authors concluded that HoLEP was the only endoscopic procedure that has shown superiority compared with TURP.** For longer-term data, Cornu et al. (2015) analyzed results after 3 to 8 years postprocedure. Although data could only be reliably drawn from the two studies in the analysis, results still appear to favor HoLEP.

HoLEP vs. Open Prostatectomy.

HoLEP is effective in treating BPH, particularly in large glands, and has fared well in two randomized trials comparing HoLEP versus OP. Naspro et al. (2006) randomized 80 consecutive patients with a prostate size greater than 70 g to HoLEP (mean prostate size 113 g) or OP (mean prostate size 124 g). The authors reported a decrease in time to catheter removal (4.1 vs. 1.5 days), length of stay

(5.4 vs. 2.7 days), and risk for blood transfusion (7 vs. 2 patients) for subjects in the HoLEP group. Subjects in the OP group had a shorter mean operative time (72 vs. 58 minutes) and greater amount of adenoma removed (87.9 vs. 59.3 g).

Patients underwent repeat urodynamic assessment at 12 months, with uroflow and AUA-SS assessment out to 24 months. Comparable urodynamic improvements were seen in both groups. Qmax improved significantly in both groups, from a baseline of 7.8 and 8.32 mL/sec to 19.19 and 20.11 mL/sec at 24 months, for the HoLEP and OP groups, respectively. **Between groups, there was no statistical difference in voiding rates at any time.** Both groups also experienced a statistically significant improvement in AUASS from 20.11 and 21.60 to 7.9 and 8.1 at 24 months for the HoLEP and OP groups, respectively. **There was no statistical difference at any time point in AUASS between groups.**

Five-year data from Kuntz et al. (2008) demonstrates excellent durability in improvements in AUASS, Qmax, and PVR in their study of 120 subjects with large prostate glands (>100 g) who were randomized to HoLEP or OP. AUASS improved by nearly 19 points in both groups at 1 year, and was sustained out to 5 years. Although operative time was longer in the HoLEP group, no patients required a blood transfusion (compared with 13% in the OP group), length of stay was shorter, and catheterization time was shorter. **At 5 years, both HoLEP and OP groups experienced significant improvements in AUASS, Qmax, and PVR, with no differences observed between groups.** Bladder neck contractures and urethral strictures were noted in both groups, but there was no statistical difference in likelihood of a delayed complication or required intervention for complication.

HoLEP in the Anticoagulated Patient.

The data regarding the use of HoLEP in the setting of anticoagulation are based entirely on small retrospective cohorts of subjects on a variety of anticoagulation or antiplatelet therapy. Data regarding the continued use of oral anticoagulation or antiplatelet therapy at the time of surgery are sparse, as the majority of the literature has focused on patients who discontinued their medication in the perioperative period. The largest series available was recently published by El Tayeb et al. (2016), which compared 116 patients on anticoagulation or antiplatelet therapy to 1558 control patients. They reported longer length of stay (27.8 vs. 24 hours), duration of continuous bladder irrigation (15 vs. 13.5 hours), and increased risk for reoperation rate (1.9 vs. 0.7%). Further subgroup analysis also revealed an increased risk for blood transfusion for patients in whom anticoagulation could not be stopped at the time of surgery (6.7 vs. 2.32%).

Several other retrospective reviews have demonstrated similar findings. There does not appear to be an increased risk for longer operative or morcellation time (Bishop et al., 2013, El Tayeb et al., 2016). Blood transfusion rate, length of stay, and time to successful void trial do appear to be increased in patients on anticoagulation, although there are conflicting data among these heterogeneous reports (Bishop et al., 2013; Neuville et al., 2018; Tyson and Lerner, 2009). Patients should be counseled appropriately about these risks, yet surgical outcomes appear to be similar to men not on anticoagulation. Lastly, the literature regarding newer direct oral anticoagulants and HoLEP is limited, so further studies are needed before drawing any conclusions regarding these newer agents.

Complications

Intraoperative and Perioperative.

Although the use of the morcellator has led to decreased operative times compared with HoLRP (Gilling et al., 1998), it does enable a unique complication in that **morcellator-mediated bladder injury can occur.** Although these injuries are generally superficial, the possibility of deeper and more significant injury is certainly possible as the morcellator engages tissue indiscriminately. Keeping a reasonable volume of irrigant in the bladder and a bloodless field may help visualization and reduce this risk. Reported ranges of these injuries vary widely, with one study reporting an 18.2% occurrence (Montorsi et al., 2004).

Another unique complication is the possibility of **incomplete evacuation of the adenoma** leading to postponed morcellation. This is generally caused by a malfunction of the morcellating device or poor hemostasis leading to obscured vision.

During either enucleation or morcellation, there is the possibility of **injury to the ureteral orifice.** This outcome was only examined in a few series. One report found a 2.1% chance of occurrence (Shah et al., 2007), and another series found that of the four of these injuries that occurred, three were in the group with the largest prostates (>80 g) (Kuntz et al., 2004a).

Capsular perforation generally occurs as the resection is carried along in the plane between the prostate adenoma and the surgical capsule. Although carrying into the adenoma in this area will cause bleeding, an error to the other side will lead to capsular perforation. Many authors classify these perforations into categories including “threatened,” “covered,” or “free” and use the degree of perforation to guide management. Generally, authors have managed complete or “free” capsular perforation with prolonged catheterization (a few days) with no change in management for other types of perforation. This complication has been reported as high as 9.6% (Shah et al., 2007), with another large review placing this complication lower at 1.5% (Kuo et al., 2003).

The overall risk for **hemorrhage** during HoLEP is fairly minimal. A defocused holmium LASER beam can be used to control most bleeding, and conversion to another form of transurethral intervention is a rare to never event. It does appear that the risk for bleeding increases with increasing gland size, although the correlation was fairly weak (Kuntz et al., 2004a).

Bleeding is also well controlled by the hemostatic properties of the holmium LASER. Some series have reported a **transfusion rate** as high as 1.7% after HoLEP (Shah et al., 2007), but data incorporated into the meta-analysis of Lourenco et al. (2008) found that HoLEP had a decreased relative risk for transfusion compared with TURP (RR = 0.27).

Postoperative.

Urinary urgency and other storage symptoms are a common finding after HoLEP and are thought to be caused by the high amount of LASER energy applied to the capsule during enucleation (Shah et al., 2007). In attempts to grade the severity of these symptoms, Larner et al. (2003) found that most patients characterized the symptoms as mild (defined as causing minimal bother).

Transient urinary incontinence occurs with some frequency but generally resolves with time. In the study by Shah et al. (2007), 10.7% of patients reported initial incontinence, with only 0.7% of the cohort maintaining this complaint permanently. A similar pattern was seen in another large study, in which 4.2% initially reported stress-type incontinence, but only 0.5% had this complaint at the last visit before publication (Elzayat et al., 2005a). This may be avoided by careful incision at the 12 o'clock position with care to not incise distal to the verumontanum. The depth and length of the required incision may be mistaken by a more novice surgeon (Shah et al., 2007).

The incidence of **bladder neck contracture** is 0% to 3.2% (Shah et al., 2007) and appears to occur more likely in smaller prostates (Kuo et al., 2003). The surgeon may consider a prophylactic bladder neck incision in patients they deem at a higher risk for this complication.

Urethral stricture is a common finding, with studies reporting an incidence as high as 7% (Seki et al., 2003) and a later meta-analysis finding a rate of 4.4% (Ahyai et al., 2010). The large-diameter instruments used during the procedure may predispose to this occurrence. Although the location of the stricture was not frequently reported, one group found this to occur more frequently at the meatus (Seki et al., 2003).

Retrograde ejaculation is a common finding after HoLEP, with two randomized trials finding incidence rates of 75% and 78% (Briganti et al., 2006; Wilson et al., 2006). However, one of these trials found that changes in IIEF domains were minimal (Briganti et al., 2006).

Conclusion.

HoLEP is an interesting treatment option overall. Although there are concerns about an exaggerated learning curve, results are comparable if not superior to TURP. Patients have significantly decreased catheterization and hospital times. Although the time in the operating room is increased compared with TURP, many studies show equivalent efficiencies in tissue removal, offsetting the increased operating room time. Additionally, it appears that reintervention rates for BPH may be lower. Complication profiles show HoLEP, with a lower rate of transfusion and similar rates of bladder neck contracture and urethral stricture to TURP.

Prostate Ablation and Vaporization

Concept and Introduction.

The KTP and LBO labeled LASERs are a derivative of the Nd:YAG. The 1064-nm wavelength Nd:YAG LASER beam is passed through a KTP or LBO crystal that doubles the frequency of the light along with decreasing the wavelength to the desired 532 nm. **This wavelength is selectively absorbed by hemoglobin, which acts as an intravascular target for the light energy.** The improved energy density compared with the Nd:YAG LASER led to preferential vaporization, with the hemoglobin absorption improving hemostasis as a thin (0.2-mm) layer of coagulation would be created outside the area of vaporization. The LASER energy freely moves through irrigating fluid without a loss of power.

The original KTP LASER (Greenlight PVP, Boston Scientific Corp., Marlborough, MA) used a 532-nm wavelength and was available in 80-W and 100-W settings. The LBO LASER (Greenlight HPS and XPS, Boston Scientific Corp.) also uses a 532-nm wavelength like the KTP. This LASER offered higher energy setting with an available 120-W (HPS) and 180-W (XPS) setting. This 180-W setting allows for more efficacy in vaporization and coagulation over the 120-W platform (Malek et al., 2011). The 180-W fiber (MoXy Fiber) also has improvements with a built-in dedicated water cooling system for the fiber with automatic safety system that protects the fiber from overheating.

Although the Nd:YAG was originally thought to be the ideal LASER fiber for treatment of BPH (Anson et al., 1993)**, the large amount of prostate sloughing that occurred after visual LASER ablation of the prostate (VLAP) caused by extreme depth of LASER penetration was later found to be undesirable.** The delayed bulk prostate sloughing would often lead patients to suffer from intermittent voiding and urinary retention postoperatively. The failure to sufficiently vaporize tissue was evident in an in vivo canine study (Kabalin et al., 1995).

The VLAP generally utilized a longer-wavelength LASER than the currently used KTP/LBO but is technically similar to the current technique. As the power of the LASER improved, the term *ablation* gradually migrated to *vaporization* because of the immediate removal of tissue visualized during surgery as opposed to the delayed sloughing of tissue seen when called *ablation*. An early canine study comparing the Nd:YAG to the KTP LASER displayed the advantages of a

LASER system that favored vaporization over ablation/coagulation. In this small study, **KTP had significant increases in defect size in the prostates leaving a thin but effective layer of coagulated tissue** (Kuntzman et al., 1996)**. Unsurprisingly, as the power of the LASER has been increased, there have been corresponding improvements in the tissue vaporization** (Kang et al., 2008; Malek et al., 2011; Rieken et al., 2013).

The advantage of the current PVP technology is the combined vaporization and coagulation. Although tissue volume is decreased by the vaporization, coagulation leads to almost instantaneous hemostasis, with closure of venous sinuses reducing absorption of irrigation fluid.

Technique

Preoperative.

A standard preoperative workup should be completed for PVP. Routine cystoscopy is not necessary unless there is particular concern of the patient or physician. Concurrent infection should be ruled out and treated before the operation. Many physicians advocate the use of TRUS to determine prostate size and anatomy. TRUS findings may help the physician to determine if a different surgical approach or technique would be preferable based on the prostatic size or shape. The knowledge of gland size also allows the physician to know the rough estimate of operative time to allow appropriate operating room scheduling.

Patients taking anticoagulation can be managed in many ways before this procedure. It is our preference to allow patients who are already on low-dose aspirin to continue this medication through the operative period with a strong preference for holding stronger aspirin products or other antiplatelet medications. However, we prefer that patients on anticoagulants (e.g., warfarin, apixaban) hold these medications for surgery with the decision on the need for bridging left to the managing physician.

Intraoperative.

The PVP fiber is a 600-micron side-firing probe with the energy produced by the fiber at a 70-degree angle from the longitudinal axis. **Vaporization occurs by sweeping the fiber along the prostate parenchyma, sequentially vaporizing layers of the prostate from the inside out.** Vaporization of the prostate parenchyma is complete when the capsule fibers are visible. **The distance between the LASER fiber and prostate tissue (working distance) is**

important for many reasons and is often difficult to control for the vaporization novice. A distance too close to the tissue will lead to possible “contact vaporization” with resulting damage to the LASER fiber. A distance too far will lead to inefficient energy use with more tissue coagulation (and a subsequent increase in postoperative storage symptoms). If in tight quarters, like at the beginning of the case when the lateral lobes may still be in contact, lower power should be used. Tissue buildup on the fiber should be avoided as this leads to fiber degradation and possibly leading to shortened fiber life and further inefficiencies.

Management of the bladder neck is an important part of the procedure and is generally the first step. We prefer to use a lower-power setting (80 W) in this area. **The ureteral orifices should clearly be identified before beginning treatment of the bladder neck. A single midline incision of the prostate or two incisions at 5 o'clock and 7 o'clock allow for the bladder neck to open. The posterior bladder neck is then vaporized until level with the trigone of the bladder.** After this is complete, the LASER fiber should be pointed in a medial or lateral direction as this allows for visualization of the vaporization that is often lost when working with the fiber pointed posteriorly (toward the rectum). Any potential injury to the ureteral orifices should be minimized by orienting the LASER beam laterally and not pointing in the direction of the ipsilateral or contralateral ureteral orifice. Aggressive coagulation at the bladder neck should be avoided, and we customarily do not vaporize the anterior portion of the prostate in this area to leave a strip of intact urothelium to prevent circumferential vaporization and possible bladder neck contracture. In patients concerned about retrograde ejaculation, incision of the bladder neck fibers can be avoided.

The posterior aspect of the prostate is generally more challenging with PVP compared with TURP as the angle of the PVP fiber does not allow for treatment of tissue directly in line with laser fiber. This can become a more significant problem, particularly in very large prostates where a high bladder neck dominates the visual field. When vaporizing this posterior prostate tissue, we recommend applying LASER energy once again in a horizontal fashion and vaporizing away “layers” of this posterior tissue, carefully working into deeper portions of the prostate parenchyma and not directing LASER energy in a posterior direction (i.e., toward the rectum).

Movement of the fiber into position for vaporization should be done preferentially with a minimization of cystoscopic motion. **A continuous, even**

motion of the sweeping action of the fiber is vital to minimize large and irregular crater formation in the prostate. Bleeding in a recessed portion of the prostate has the potential to be a significant problem as the vessels are unable to be visualized. **The angle of sweep and time to complete the sweep arc are important factors for optimizing outcomes.** If the angle is changed too rapidly, insufficient energy will be transferred, leading to poor vaporization. However, if the LASER beam is left on tissue for too long of a time (slow sweep), a crater will be formed as the energy accumulates in one area. The sweep angle that the fiber is turned at is also an important factor. Research from an in vitro study found that most efficient vaporization occurred when the angle was between 15 and 30 degrees with the depth of coagulation minimized at 30 degrees of sweep (Ko et al., 2012). A frequent rule dictated to the novice vaporizer is to sweep over 30 degrees in 1 to 2 seconds (Welliver et al., 2017).

Bleeding is more frequently seen at that prostate apex, median lobe, and bladder neck, particularly at the posterolateral aspects, where the blood supply of the prostate enters. If bleeding is not severe, the LASER treatment may proceed with focus on the areas directly adjacent to the bleeding area as this may allow for control of the feeding vessels. If pulsatile, arterial bleeding is recognized, the coagulation mode on the LASER may be used. This should once again be used on the area around the bleeding along with the bleeding area itself. If bleeding cannot be controlled, a bugbee electrode may be placed through the working bridge. This allows for the placement of pressure on the vessel to stop continued bleeding (improving visualization) and then controlled coagulation. The surgeon should keep in mind that the irrigating fluid will likely have to be changed to something non-ionic. If all else fails, a larger sheath and possibly the resecting loop should be inserted to help control bleeding. Such need is markedly infrequent in experienced hands.

When vaporization is complete and hemostasis is verified, the bladder should be examined one more time to ensure there is no erroneous LASER damage. A catheter should then be placed, and irrigation of the bladder should verify clear (or nearly clear) irrigant.

Throughout the procedure, the surgeon should be aware of inefficient vaporization. Large bubbles should be visible coming from the tissue throughout vaporization as an indication of efficient energy use. When this is not seen, the LASER energy is being used inefficiently and most likely is causing coagulative necrosis or charring of the tissue. When the tissue is charred, the subsequent vaporization will be more challenging, leading to excessive energy usage. Unnecessary coagulative necrosis should be avoided as this will lead to more pronounced postoperative dysuria and possible passing of tissue per urethra.

Postoperative.

In almost all cases, the catheter can be removed the day of or the day after surgery. Bleeding should be minimal in the postoperative period, although patients will customarily pass some tissue with minimal bleeding 7 to 10 days from the surgery date. In cases of minor but continued bleeding, patients can be encouraged to increase fluid intake with careful outpatient follow-up. It is our custom to discharge patients home the day of surgery, with them removing the catheter the next day at home after the postoperative swelling of the prostate has significantly decreased.

Dysuria in the postoperative period can be exacerbated by technical inefficiency during the procedure, especially if tissue is being coagulated more than vaporized. The degree of dysuria is correlated with the volume of coagulated tissue (Choi et al., 2008). Patient characteristics that may lead to a risk for dysuria include a large median lobe, previous prostatitis, dense or fibrous prostate tissue, or previous treatments that change prostate tissue characteristics (TUNA, TUMT). **Generally, a sterile pyuria should be noted and can be treated with NSAIDs or a short course of a steroid taper if severe**. Although dysuria can be a common finding in these patients, the physician should always consider re-evaluation for an unexpected complication like a tissue flap or retained fiber fragment. Even in the best vaporizations, a layer of coagulated tissue will remain that could potentially lead to a subacute prostatitis and an increased risk for UTI. If a true infection is suspected because of either a prolonged dysuria or positive urinalysis/culture, culture-directed antibiotic therapy should be initiated, and culture should be considered after completed therapy.

Outcomes.

Rapid acceptance provided a considerable number of early studies looking at the outcomes of the lower-energy LASER fibers. As the manufacturer continues to update the LASER power over time, long-term results have become more difficult to incorporate into practice as a new power level is available frequently when research from the previous generation is being released. **Overall, the PVP technology has been viewed to have a forgiving learning curve with a**

favorable safety profile.

Single-Cohort Studies.

Hai and Malek (2003) published the first pilot study looking at the use of the 80-W KTP LASER. Ten patients were treated and then followed for 1 year. Significant improvements in AUA-SS, QoL score, Qmax, and PVR were noted initially with durability to 1 year. This was quickly followed by the multicenter trial study of 145 patients (Te et al., 2004). Once again, **improvements 12 months after the procedure were noted in AUA-SS (–82%), QoL score (–77%), Qmax (190%), and PVR (–78%).**

The change in urodynamic parameters even with the 80-W LASER was encouraging. In urodynamically obstructed patients who underwent PVP, a decrease in Schafer obstruction grade from 3.6 to 1.1 was noted at 12 months ($P < .0001$) with a decrease in PdetQmax from 75.0 to 36.6 cmH_2O (Hamann et al., 2008). The authors also found that the mean number of nighttime voids (3.5 to 1.2) and daytime voids (7.2 to 5.7) decreased with treatment.

Data became available on the 500 patients treated with the 80-W fiber in 2008 (Ruszat et al., 2008)**. With a mean follow-up of 30.6 months, the results of patients with 3 years of follow-up showed a mean AUA-SS of 8.0, QoL of 1.3, and a Qmax of 18.4 mL/sec.** In patients with 5 years of data (only 5.4% of the cohort), there was no appreciable difference in these numbers compared with the data at 3 years. The retreatment rate of the cohort was 6.8%, with a rate of urethral strictures of 3.6% and 4.4% for bladder neck contracture. Dysuria and bladder neck contractures were more common in smaller glands, but larger glands did not lead to a higher risk for retreatment. In another study evaluating the use of the 80-W LASER in large prostates, reintervention because of residual adenoma was 23% in the larger-gland (>80 g) group compared with only 10.4% ($P = .09$) in the group with glands less than 80 g (Pfitzenmaier et al., 2008).

As the improved hemostatic qualities of the LASER were recognized, challenging patients populations were tested. Patients requiring anticoagulation were able to be safely treated (Sandhu et al., 2005). Although many of the other endoscopic treatments were not rigorously tested on large glands, the improved visualization during vaporization allowed many early adapters to attempt treatment of large glands (>80 g). The International GreenLight Users (IGLU) group compiled some of the early data on 120-W LASER treatment of patients both with large glands and undergoing anticoagulation (Woo et al., 2008). For all the studied patients, there were improvements in Qmax, PVR, AUA-SS, and prostate volume compared with baseline. **The use of anticoagulants did not significantly increase complications. Large glands did not alter outcomes beyond the expected larger change in prostate volume.** A reduction of 52.5% was seen in larger glands compared with 42.3% in glands less than 80 g (*P* < .001).

Retrospectively reviewed 3-year results of the 120-W HPS reported durability and indicators of response (Cho et al., 2012). Preoperative AUA-SS was 21.7, which nadired to 11.5 at 6 months but was not statistically higher at 3 years (13.4). Maximum flow followed a similar pattern, improving to 15.7 mL/sec from 8.7 mL/sec at 6 months, with a value of 13.9 mL/sec at 3 years. Predictors of response were reported as AUA-SS greater than 19, with even higher scores being more likely to respond. Patients customarily underwent UDS, and the BOO index (BOOI) and bladder contractility index were predictors of a favorable outcome. Operative time and energy used during the procedure were interestingly not predictive.

Reoperation rates specifically for residual LUTS/BPH for the 180-W XPS system have proven to be better than previous generations although are **likely affected by the energy density (kJ/cc of prostate tissue) used during surgery.** In the longest study to date, with a mean follow-up of 57 months on 84 patients, an overall reoperation rate of 4.8% was noted, although **only 2.4% of the overall cohort had another surgery specifically for residual BPH.** The authors used a robust mean energy density of 5.3 kJ/cc. IPSS scores decreased from a preoperative average of 19.9 to 3.9 at 12 months increasing to 5.9 at the final visit for patients included (Calves et al., 2017).

In a multicenter study of 440 patients stratifying surgical outcome by four different energy densities (<3 kJ/cc, 3 to 5 kJ/cc, 5 to 7 kJ/cc and >7 kJ/cc), there were no statistical differences with regard to intraoperative or postoperative complications among groups. However, **all of the cases for retreatment of residual BPH occurred when less than 5 kJ/CC were used and principally occurred if less than 3 kJ/cc were used** (Valdivieso et al., 2016). Not surprisingly, a larger PSA decrease was noted with an increasing use of energy density with the greater than 7 kJ/cc group, noting a median decrease of 83%. Interestingly, the less than 3 kj/CC group had larger prostates, had a higher preoperative IPSS score and were more likely to come to surgery with a catheter in place.

Comparative Studies.

In the first RCT comparing 80-W PVP to TURP, Bouchier-Hayes et al. (2006) compared the results of trainees who had performed between 35 and 325 TURPs but had done at most 5 LASER prostatectomies. They exhibited comparable improvements in Qmax (149% for TURP, 167% for PVP) and AUA-SS (roughly 50% decreases in both groups). **This study exhibited the relative ease of performing the procedure and went on to conclude that PVP was 22% cheaper than TURP, primarily because of the shorter hospital stay**. Another RCT comparing the 80-W PVP and TURP focused on patients with glands larger than 70 g (Horasanli et al., 2008). Operating time favored TURP, and time in the hospital and time with a catheter favored PVP. Differences in the final AUA-SS, Qmax, and PVR favored TURP within the follow-up period. Blood transfusion was more common in the TURP group, and the PVP group had an increased risk for postoperative retention and need for reintervention (17.9% in the first year). The summary of these results demonstrated the excellent safety profile but decreased efficacy of the lower-energy PVP (especially in larger glands).

In an RCT of the 120-W HPS to TURP, Al-Ansari et al. (2010) found dramatic improvements in Qmax, AUA-SS, and PVR in both groups out to 36 months. **TURP did outperform in many metrics (Qmax, AUA-SS, PVR, mean PSA, mean prostate volume), although the differences were not statistically significant.** Although intraoperative complications were significantly fewer in PVP, a strikingly high 93% experienced dysuria or urge, and 11% required retreatment for residual adenoma (compared with only 1.8% of the TURP group, $P = .001$). Mean catheterization and mean hospital stay did favor PVP. Another RCT looking at the HPS versus TURP was completed the following year (Capitán et al., 2011). Once again, similar improvements were seen in Qmax, AUA-SS, and QoL, but these improvements appeared to nadir more rapidly in the PVP group. Interestingly, the authors stratified the AUA-SS questionnaire by symptom type and did not find an increase in storage symptoms for the PVP group. Intraoperative, early, and late complications did not differ between groups.

In their review of both 80-W and 120-W RCTs, Thangasamy et al. (2012) consistently found that catheterization and hospital stays were shorter in patients undergoing PVP by 1.91 and 2.13 days, respectively. Operative times were shorter in the TURP cohort by almost 20 minutes, with PVP having a risk ratio of 0.16 for blood transfusion compared with TURP. Other complications were not statistically different. In this review of 80-W and 120-W RCTs, six of the nine studies found no differences in functional outcomes. The one study that favored PVP was an 80-W study that never appeared to reach final publication with the two studies favoring TURP both specifically looked at patients with large prostates (>70 g) and had a LASER power of 80 W. In the analysis of 120-W PVP, Cornu et al. (2015) found a decrease in catheter time (mean 23 hours) and length of stay in hospital (mean 1.84 days).

Few studies have reliably compared the new XPS and previous HPS system. In a nonrandomized series of consecutive patients, Ben-Zvi et al. (2013) found that mean operating time and mean lasing time were decreased in the XPS group with comparable energy delivery. **The significantly different reductions in PSA (54% in HPS vs. 79% in XPS, *P* < .01) show that the XPS surely has a higher efficiency of tissue vaporization, although notable clinical parameters (AUA-SS, QoL, Qmax, PVR) were not different between groups.** Postoperative retention was higher in the HPS group (16% vs. 6%).

Since the last publication of this book, results from the landmark GOLIATH study have been released. This industry-sponsored study was a noninferiority trial comparing 180-W PVP to TURP at nine European centers with papers published with 6-, 12-, and 24-month data (Bachman et al., 2014, 2015; Thomas et al., 2016). The primary study outcome was IPSS at 6 months, with secondary outcomes including Qmax, freedom from complication, PVR, prostate volume, PSA, length of catheterization, length of hospitalization, convalescence time, and a variety of patient-reported measures. Individual cites had the option to choose monopolar or bipolar TURP at their discretion if patients were randomized to TURP.

A total of 281 patients underwent randomization. At the 6-month review, there were no statistical or clinically significant differences between groups with regard to IPSS, Qmax, or PVR (Bachman et al., 2014). A treatment-related adverse event was seen in 54% of PVP patients and 48% of TURP patients (*P* = .3). Self-reported incontinence was observed in 12% of PVP patients and 5% of TURP patients at 6 months with similar values between groups at 12 months (3%). No patient needed more than medical therapy to manage their incontinence. Storage urinary symptoms were similar between groups at the 6-month evaluation.

A large percentage of the cohort (89% of patients) were still in the study protocol at the 24- month visit (Thomas et al., 2016). **No differences were noted between the complication free rate and Qmax between groups. Final IPSS was 6.9 in the PVP group and 5.9 in the TURP group. Although this difference was statistically significant, it did not meet the predetermined**

IPSS difference of 3 for inferiority and is almost certainly not clinically significant. No differences were noted in PVR, prostate volume, PSA, or questionnaire data evaluating overactive bladder symptoms or erectile function.

Use of Photoselective Vaporization in Anticoagulated Patients.

A total of 116 men were included (36 on warfarin, 9 on clopidogrel, and 71 on aspirin), and all continued on their medications through the perioperative period while undergoing 80-W PVP (Ruszat et al., 2007). These groups were compared with 92 controls who were not on anticoagulants/antiplatelet medications. The control group was younger and had a lower ASA class. The average INR was 2.0 (range 1.3 to 2.9), with 14 of the 36 patients on warfarin having an INR of 2 or less. No patients required transfusion, but patients in the study group did have an increased hospital time (3.8 vs. 2.8 days) and were more likely to have CBI for 24 hours (17% vs. 5%). In particular, patients with an INR greater than 2 required CBI postoperatively. Other studies have shown the same risk for transfusion in a group of patients on mixed forms of anticoagulants or antiplatelet medications (Sandhu et al., 2005).

An uncontrolled study reporting on 43 patients continuing warfarin during surgery showed no patient requiring transfusion; two patients required prolonged catheterization subsequent to bleeding, but 70% of patients discharged to home within 24 hours of surgery (Woo and Hossack, 2011). A Cochrane review that compared LASER treatment methods with TURP found an overall reduced risk for transfusion with LASER prostatectomy (Hoffman et al., 2004).

Complications

Intraoperative and Perioperative.

Overall, the safety profile of PVP technology is excellent. **TUR syndrome** is not reported in any series as normal saline is used as irrigation. **Blood transfusion** is exceedingly rare, and patients on anticoagulation do not appear to be at a significantly increased risk. PVP had a lower risk (OR, 0.10) for perioperative blood transfusion when compared with M-TURP (Cornu et al., 2015).

Capsular perforation has been reported with PVP with ranges from 0.2% to 1% of cases (Rieken et al., 2010). Surgeons may find visualization of the capsule more difficult with the PVP, particularly early in the learning curve. Maintaining a proper sweeping motion and serially removing tissue in a circumferential fashion will avoid irregularities in vaporization depth and avoid perforation. In cases in which capsular perforation occurs, increased bleeding is generally noted, and conversion to TURP is more common (Bachmann et al., 2014, 2015).

Although rates are largely unreported, **ureteral orifice injury** can occur from errant LASER energy. The ureteral orifices should be identified before beginning the vaporization, and being careful not to extend the fiber into the bladder when vaporizing the bladder neck should minimize the possibility of this occurring.

Postoperative.

Postoperative dysuria and storage symptoms are not uncommon after PVP. In large series examining these outcomes, the adverse events were usually self-limiting and resolving spontaneously within 3 months. Anti-inflammatories, antibiotics, or even a short course of steroids may help the unhappy patient. The reported ranges of these symptoms range from 0% to 25.7% and are generally higher than data reported from TURP studies (Naspro et al., 2009), although this was not demonstrated in the GOLIATH study (Bachman EU 2014). As stated earlier, the inefficient use of LASER energy should be minimized to decrease unwanted outcomes. In a small series of patients, Matoka and Averch (2007) found that preoperative finasteride use and lower preoperative AUA-SS were predictors of postoperative irritative symptoms.

Infectious complications may be more common after PVP because of the necrotic tissue that occurs with coagulation. **Epididymitis** has been reported in 5% to 7% of patients, with **UTI** reported in 1% to 20% of patients (Chughtai and Te, 2011). Treatment of these conditions may be more challenging because of the presence of the necrotic tissue and its ability to harbor and feed bacteria. The treating physician should consider longer courses of antibiotics in these patients.

As the sheath used for PVP is generally smaller than those customarily used for TURP, the risk for **urethral stricture** should be lower. The surgeon should minimize movements of the sheath with a preference for LASER fiber movement to further lower this risk. Only 2.8% of patients had urethral stricture, and a relative risk of 0.65 was calculated compared with TURP (Thangasamy et al., 2012). A more recent meta-analysis did not verify this finding as comparable rates of stricture (and **bladder neck contracture**) were found between 120-W PVP and M-TURP (Cornu et al., 2015).

Reoperation rates specifically for residual adenoma vary significantly based on study and LASER power used. In their summary of PVP technology, Gravas et al. (2011) compared the reoperation rates of 80-W KTP with TURP at different time frames. The rates were 18% versus 0% after 6 months, 10% versus

3.4% after 12 months, and 6.7% versus 3.9% after 24 months for PVP and TURP, respectively. Other authors have found rates of 7.7% (Hai, 2009) and 6.8% (Ruszat et al., 2008) at 5 years, although both studies had high attrition rates. In an analysis of only 120-W studies, a slight increase in need for reoperation for residual BPH was found, but the authors commented on an overall small sample size (Cornu et al., 2015).

The 24-month 180-W GOLIATH data had three PVP patients (2% of PVP cohort) requiring reoperation for residual adenoma (Thomas et al., 2016), with only 2.4% in the 57-month series from Calves et al. (2017). **The increased energy density able to be delivered by the 180-W system may help mitigate this risk, with need for BPH-specific reoperations** (1.7% at 24 months) seen only in lower-energy densities shown in the series by Valdivieso et al. (2016).

Changes in **erectile function** in patients undergoing PVP are still being more clearly elucidated, but early results are encouraging. In 105 men undergoing PVP who completed SHIM scores preoperatively and 12 months after surgery, there was clearly no worsening of erectile function. In those men who were catheter free before surgery, statistically insignificant improvements were seen in erectile function (Kavoussi and Hermans, 2008). Mild but statistically significant improvements were noted in all IIEF-15 subdomains in a similarly structured trial of 45 men (Paick et al., 2007).

Conclusion.

Early LASER techniques focused on coagulation, with more contemporary techniques using LASER power to vaporize large portions of the prostate in an essentially bloodless field. **Although coagulation is still part of the LASER vernacular, a de-emphasis on broad coagulation has championed less postoperative irritative symptoms with a preference for LASER technology that chiefly leads to prostate vaporization.**

The early and lower-power PVP technology appears to have been less efficient against larger prostate glands with long operative times and cautionary retreatment rates. As the LASER energy has improved, both durability and operative times have improved. The excellent hemostasis and vaporization of the PVP technology have allowed for the treatment of many challenging patients, such as those on anticoagulation, who have not been attempted with many other endoscopic treatments of BPH.

Thulium

Concept and Introduction.

The thulium (Tm:YAG) LASER is a continuous wave of 2013-nm energy and has recently been introduced for the treatment of BPH. With a similar wavelength to the holmium LASER, this undergoes absorption in the irrigant but without the intermittent nature of holmium. The continuous energy emission has been suggested to lead to a cleaner incision, and with a slightly shorter wavelength than holmium, absorption by tissue is theoretically more pronounced and efficient (Chung and Te, 2009). However, such claims are putative until scientific proof is offered.

As the emitted wavelength reaches closer to the ideal in soft tissue, theoretically there will be a decrease in scattered thermal damage (Schomacker et al., 1991), which may lead to decreased scarring and stricture formation. However, in an animal model there was a wider thermal damage zone than predicted, and it was similar to that seen with holmium (Fried and Murray 2005).

Technique.

Like other LASER technologies, thulium may be used to either vaporize or incise tissue, although early clinical use has been to incise tissue to enucleate the transition zone of the prostate. This technology has introduced a new technique wherein the prostatic lobes are “peeled like a tangerine” off the prostatic capsule (Xia, 2009). The anatomy followed during prostate enucleation with thulium is similar to that done during HoLEP. The procedure is essentially analogous to HoLEP including morcellator use when the surgeon selects this option.

Some authors have utilized a resection-type technique wherein multiple incisions are made in the prostate parenchyma down to the capsule. Smaller sections of prostate are then liberated from the capsule leading to small prostate chips that can be irrigated through the resectoscope sheath. This eliminates the need for using the often troubling morcellator.

Catheter drainage is maintained at least overnight and can customarily be removed once hematuria has resolved (usually 1 to 3 days postoperatively). Patients can generally be discharged to home the same day as catheter removal.

Outcomes

Single-Cohort Series.

In an early retrospective review on the technology, 56 patients were reviewed (Szlauer et al., 2009). Maximum flow at day of discharge was improved from 8.1

mL/sec to 19.3 mL/sec, with a decrease in average residual urine to 57 mL from 151 mL. At a median follow-up of 9 months, PSA was reduced by 56% and the AUASS decreased from 19.8 to 8.6. The authors pointed out a slightly lower acquisition cost for thulium compared with holmium. They did estimate that 56% to 70% of the tissue was removed by their “vaporesection” approach compared with 30% to 85% for HoLEP.

Bach et al. reviewed patients who underwent enucleation and morcellation (“vapoenucleation”) with at least 12 months of follow-up (Bach et al., 2010). At 12 months, maximum urinary flow rate improved from 3.5 to 23.3 mL/sec (range of 6.6 to 47.9 mL/sec). AUASS decreased from 18.4 to 6.8, with an improvement in QoL score from 4.6 to 1.5. Patients who had a preoperative TRUS volume greater than 60 g were not more likely to have improvements in voiding parameters.

In a study looking exclusively at patients with prostate volumes greater than 75 g, with 70% having a volume greater than 100 g, the AUA-SS decreased from 21.1 to 3.9, with a 248% increase in maximum flow. Mean prostate volume assessed by TRUS decreased from 108 to 13.8 g. PSA also decreased substantially from 9.53 to 0.93 ng/dL, and IIEF score improved by 1 point with treatment (Iacono et al., 2012).

Taken as a whole, the improvements seen with these thulium-based removals of the transition zone are largely equivalent to those seen with HoLEP.

Comparative Series

Thulium Resection vs. TURP.

In a randomized trial of 100 patients undergoing standard M-TURP versus thulium resection, thulium treatment was superior with regard to catheterization time, hospital stay, and perioperative hemoglobin change, although operative time was similar between groups (Xia et al., 2008). Both groups demonstrated a similar improvement in IPSS and detrusor pressure at Qmax at 12 months. Late-term complications were also similar within groups, with retrograde ejaculation being the most common. Changes in symptom scores and urodynamics were comparable between groups.

In a report published by Yang et al. (2013), 158 patients were evenly randomized to receive either B-TURP or thulium enucleation. Operative time was 18 minutes longer in the thulium group, but significant decreases were noted in catheterization and hospital days with thulium resection. AUA-SS, QoL score, Qmax, and PVR had similar outcomes between groups, even out to 18 months.

Tang et al. (2014) performed a systematic literature review and meta-analysis of studies comparing TURP and thulium resection. Both randomized and nonrandomized trials were included along with both monopolar and bipolar TURP. They found a statistically significant longer operative time in the thulium group, although the clinical significance of the 9-minute weighted mean difference is likely inconsequential. Neither technique displayed consistent superiority with regard to AUA-SS, QoL score, PVR, or Qmax. The authors were also able to analyze complication rates and demonstrated decreased odds of receiving transfusion with thulium resection (OR 0.28, $P = .04$). Complications they deemed as “local” including need for re-catheterization, incontinence (stress or urge), UTI, and retrograde ejaculation did not have significant differences between treatment options. Thulium did seem to display lower odds of developing urethral stricture (OR 0.29, $P = .007$).

Thulium Enucleation vs. HoLEP.

Zhang et al. (2012) published a randomized comparison of thulium and holmium enucleation. A total of 133 consecutive patients were randomized to a similar enucleation technique with the different fibers at a single center. **Thulium required a longer operation time by approximately 10 minutes, with similar outcomes regarding postoperative AUA-SS, Qmax, and PVR**. PSA reductions were more modest than in most other enucleation studies (30% in the HoLEP group and 43% in the thulium group) but were not statistically different when compared. Complications were sparsely reported, but there was no appreciable difference in catheterization times.

Netsch et al. (2017) recently published the data of their randomized trial comparing thulium (48 patients) and holmium (46 patients) laser enucleation of the prostate. Preoperative prostate volume (median 80 g), Qmax (median 10.7 mL/sec), and IPSS (median 20) were similar between groups. Enucleation time was significantly longer in the HoLEP group (40 min) compared with the thulium group (27.03 min), although overall operative time was similar (60 min). The authors attributed this to the faster enucleation of the continuous wave mode of the thulium:YAG laser, which also yields a more shallow depth of coagulation (2 mm) compared with the holmium:YAG laser (4 mm). Patients in both groups achieved statistically significant improvements in IPSS, QoL, Qmax, and PVR, with no differences observed between groups. No difference in intraoperative complications were observed between groups, although the incidence of acute postoperative urinary retention was higher after HoLEP compared with thulium (15.2% vs. 2.1%).

Complications

Intraoperative and Perioperative.

The learning curve associated with resection of the prostate has not been adequately studied, but it is safe to assume that it will be similar to HoLEP. Most studies either did not report, or did not have any intraoperative complications. In a study using the morcellator for evacuation of prostate lobes after enucleation, no patients suffered from incomplete morcellation or ureteric orifice injuries, but 1.3% had bladder wall injuries resulting from the morcellator (Iacono et al., 2012), which is similar to the results reported by Netsch et al. (2017).

Postoperative.

Bach et al. (2010) analyzed early complications and defined rates of symptomatic UTI (6.8%), bleeding (5.6%), and immediate retreatment for residual BPH (2.2%). Blood transfusion was required in 2.2% of patients. Mild storage symptoms were observed frequently (27%), but most resolved within 1 month of surgery. They found with a cutoff prostate size of 60 cc, there was no difference in rates of complications based on prostate size.

In one of the first thulium enucleation studies published, a prohibitively high reoperation rate of 10.7% was seen in the relatively short follow-up period (Szlauer et al., 2009)**. The most common was need for reoperation for residual prostate hyperplasia and was attributed primarily to the learning curve associated with the procedure as all of these occurred within the first 20 cases.** The authors used a technique wherein the prostate is resected off the capsule in small pieces (“vaporesection,” not true enucleation) and commented that they felt the learning curve for this technique would be shorter than that for HoLEP.

In their series of large prostates (all >75g) undergoing thulium resection, 2.7% of patients required early recatheterization after surgery. Continued postoperative hematuria resulted in 2.7% of patients requiring blood transfusion. Transient urge incontinence was noted in 6.7% of patients, but all of these had resolved at 1-year follow-up. UTI was reported in 12.8% (Iacono et al., 2012).

Long-term complications appear to be comparable to other minimally invasive surgical techniques. Gross et al. (2017) reported that in their retrospective data of 500 consecutive thulium vapoenucleation cases, the rate of bladder neck contracture or urethral stricture was 3.1%, and the total retreatment rate was 8.4% at 5 years.

Conclusion.

Initial results from this new LASER technology are encouraging. It appears that there is potentially an improvement in tissue removal rate compared with other technologies because of the combined vaporization/incision that occurs with this technology. Theoretically it may have advantages compared with holmium enucleation with regard to tissue interaction, but certainly more populated and longer studies are required to evaluate this newcomer.

Key Points

- LASER treatments are the fastest-growing option in treatment of LUTS/BPH but should be used as part of a “culture of safety” in the operating room.
- HoLEP is a very effective treatment option with excellent results that are often comparable to those historically seen with OP. There is a significant learning curve associated with the procedure, and catastrophic complications (mostly caused by the morcellator) have been observed.
- PVP is a growing and very safe treatment option for BPH/LUTS. Results in patients on anticoagulation have been encouraging.
- Thulium is the newest addition to the LASER family and has some theoretical advantages, although scientific data are lacking.

Failed, Failing, and Future Directions

Prostate Stents

Concept

The concept of placing a stent into the prostate for relief of infravesical obstruction has a long track record. Stents can be classified into many categories including temporary or permanent, epithelializing, or nonepithelializing. Generally, the temporary varieties are used to combat the edema that accompanies many of the minimally invasive treatments options and are removed when the edema has resolved. **Although previously used on a wide variety of patients, permanent stents have largely been relegated to use in older men with medical comorbidities that severely restrict their treatment options because of the inability to tolerate any level of anesthesia.**

The mechanism of action of these prostatic stents is straightforward. The stent provides a rigid framework that, once in place in the prostatic fossa, pushes outward to open the prostatic lumen. In the epithelializing version, the stent is incorporated into the urethra as the urothelium grows into the stent, which should prevent encrustation or migration. Although commonly used for treatment of the enlarged prostate, other indications wherein stents have been used in the urethra include the treatment of detrusor-sphincter dyssynergia (Chancellor et al., 1999; Chartier-Kastler et al., 2000; Gajewski et al., 2000), postbrachytherapy obstruction (Konety et al., 2000), and complications of radical prostatectomy (Meulen et al., 1991).

The no longer produced UroLume (previously from American Medical Systems, Minnetonka, MN) was an epithelializing permanent stent composed of alloy wire in a woven shape that can expand to 42 Fr within the prostatic urethra. It came in varying lengths with a stent as short as 1.5 cm. As a result of issues with this stent (i.e., incomplete epithelialization leading to encrustation, stent migration), second-generation stents were developed including the Memokath (Pnn Medical, Kvistgaard, Denmark). These spiral stents expanded when flushed with hot water, with a portion of them securing at the prostatic apex.

Data

Initial clinical trials in the United States and Europe demonstrated efficacy in treatment of LUTS/BPH. In a study by Oesterling et al. (1994), patients were grouped into those with urinary retention and those without retention. In the nonretention group, 80 of the 95 patients were able to be evaluated at 12 months, and 52 had data available at 24 months. The Madsen symptom score decreased from a modest 14 to 5.9 and 5.4 at 12 and 24 months, respectively. The maximum urinary flow increased from 9.1 to 13.0 and 13.1 mL/sec respectively. In the retention group, a mean Madsen symptom score of 6.1 was noted at 12 months. This group had a Qmax of 11.7 mL/sec at 1-year post-treatment.

The European equivalent of this study examined 135 healthy men of whom roughly one-third had retention (Guazzoni et al., 1994). In the nonretention group, the Madsen score decreased from 14.1 to 6.4 at 12 months, with an increase in Qmax from 9.3 to 15.7 mL/sec. In the retention group, the mean symptom score was 4.5 after stent placement, and the Qmax was 13.1 mL/sec.

Masood et al. (2004) reported on 62 men with a follow-up of 12 years. A total of 47% of the stents were removed for a variety of reasons including malpositioning, migration, and patient satisfaction. Most (62%) of these removals occurred within the first 2 years after stent placement. The authors cautioned the use of careful case selection and surgeon experience.

In a review of results on the UroLume, of 176 men who could be identified as depending on catheterization before stent placement, 84% were able to void spontaneously after stent placement (Armitage et al., 2007).

Perry et al. (2002) reported on the use of a Memokath stent in 211 men who were unfit for surgery, with a reduction in AUA-SS of 59.6% at 3 months and almost no change in the next 7 years. The authors interestingly observed that these frail older men were more likely to die with their stent in situ (38%) than to require removal (23%).

A similar study on 144 men considered unsuitable for surgery over 17 years found that 79% of men who were in urinary retention could void spontaneously after stent placement. Stent failure was defined as removal, replacement, or reposition of the stent, with 38% of stents that were placed defined as a failure (Sethi et al., 2017).

Conclusion

Although originally a popular procedure for men who were unfit for surgery, the clinical application broadened but eventually was abandoned, except as a palliative procedure or in patients who are unable to tolerate any other procedure because of medical comorbidities. **The high failure and removal rates, with a**

sometimes challenging removal, were overall prohibitive, especially compared with many other suitable options.

Temporary Implantable Nitinol Device

Concept

The Temporary Implantable Nitinol Device (TIND) (Medi-Tate, Or Akiva, Israel) was developed to provide immediate relief from LUTS without the side effects of a permanent urethral implant. The device is composed of elongated struts and an anchoring leaflet, entirely composed of nitinol, which is a biocompatible superelastic shape-memory alloy widely used in medical devices. The total length of the device is 50 mm, and its outer diameter is 33 mm, allowing the device to cover the entire length of the prostatic urethra from bladder neck to a point just proximal to the external urinary sphincter. It is preloaded on a dedicated delivery system and is deployed in a folded configuration through a standard rigid cystoscope under light intravenous sedation. The device is then manipulated under direct visualization so that the anchoring leaflet slides into the 6 o'clock position distal to the bladder neck.

Once in place, the struts of the TIND expand and exert longitudinal pressure on the obstructing portion of the prostatic urethra and the bladder neck at the 12 o'clock, 5 o'clock, and 7 o'clock positions. The radial force exerted by the struts of the nitinol device is intended to cause ischemia, necrosis, and scarring of the prostatic urethra to “reshape” the prostatic urethra allowing urine to flow freely. On postoperative day 5, the TIND is retrieved in an outpatient setting using a standard 22-Fr cystoscope. As the device is retracted into the cystoscope sheath under visualization, it theoretically leaves the new channels in place.

Data

Initial proof-of-concept studies were performed using a retrievable PTFE-covered nitinol stent in a canine model by Crisostomo et al. (2007). Stent deployment under fluoroscopic guidance was successful in 7 of the 8 subjects and failed in 1 because of a narrow urethral lumen. Complete stent migration was seen in 2 animals at 1 month. Histologic analysis at 1 month revealed chronic inflammatory cell infiltrates, prostate glandular atrophy, periurethral fibrosis, and dilation of the prostatic urethra.

Porpiglia et al. (2015) published the first human results in their single-arm, prospective study of 32 patients with LUTS who underwent TIND implantation at the University of Turin between May 2010 and July 2013. Only patients with a prostate volume less than 60 g were included. All implants were placed under light sedation using a rigid cystoscope and were removed 5 days later in the outpatient setting. Patient underwent follow-up with IPSS, QoL, and uroflowmetry assessments out to 12 months.

Mean baseline prostate volume was 29.5 g, median IPSS 19, and QoL index 3. At 12 months mean Qmax increased from 7.6 to 11.9 mL/sec ($P < .01$), median IPSS improved from 19 to 9 ($P = .18$), and QoL index improved from 3 to 1 ($P = .45$) compared with baseline. Four patients (12.5%) presented with complications in the early postoperative period (<30 days); no late complications were reported. Complications included infection (6.2%), urinary retention (3.1%), and urinary incontinence 1 day after surgery (3.1%). One of the patients who developed an infection presented with a 2-cm prostatic abscess and was treated with medical therapy. In the patient who presented with urinary incontinence, cystoscopy revealed the distal portion of the device distal to the external sphincter, suggesting displacement of the device. The patient's urinary incontinence resolved on TIND removal. No patients underwent adjunctive surgical treatments during the follow-up period.

Verdict

Although the concept of a TIND is interesting, and preliminary studies have demonstrated its feasibility in a small cohort of patients, long-term safety and efficacy data are needed before drawing any concrete conclusions about this technology. Whether TIND permanently restructures the anatomy of the prostatic urethra remains to be proven.

Aquablation (Aquabeam)

Concept

This TRUS-guided technology utilizes a nonthermal high-velocity saline water jet stream to ablate prostate tissue. A real-time TRUS probe defines the treatment area, and a robotically guided transurethral system then quickly hydrodissects the target area. Hydrodissection times range over a few minutes and are only minimally affected by prostate size. As the treatment carefully carves out the transitional zone without possible thermal or anatomic injury to the bladder neck, external sphincter, or periprostatic nerves, the effect on continence, erections, and antegrade ejaculation should be minimized.

The AquaBeam system is manufactured by PROCEPT BioRobotics (Redwood Shores, CA) and includes a console/pump, a robotically controlled handpiece, and a TRUS probe (Fig. 146.19). The 24-Fr handpiece with integrated cystoscopy is inserted transurethrally into position and then locked into place via a bedrail-mounted articulating arm. After the biplanar TRUS probe is inserted, the surgeon plans the treatment zone. **The angle of resection is first selected followed by visualization of the prostate in the sagittal view to conform the treatment zone to the shape of the adenoma. The treatment zone is adjusted to exclude the bladder neck and external sphincter and focus on the adenoma.** Foot pedal activation by the surgeon initiates the treatment by guiding the high-velocity saline waterjet proximal to distal in a sweeping fashion through the prostate, with changes in the waterjet velocity regulating the depth of ablation of targeted prostate parenchyma. The treatment can be monitored by the ultrasound images and cystoscopic view. Hemostasis after the procedure can be achieved either with resectoscope or with a Foley catheter on traction.

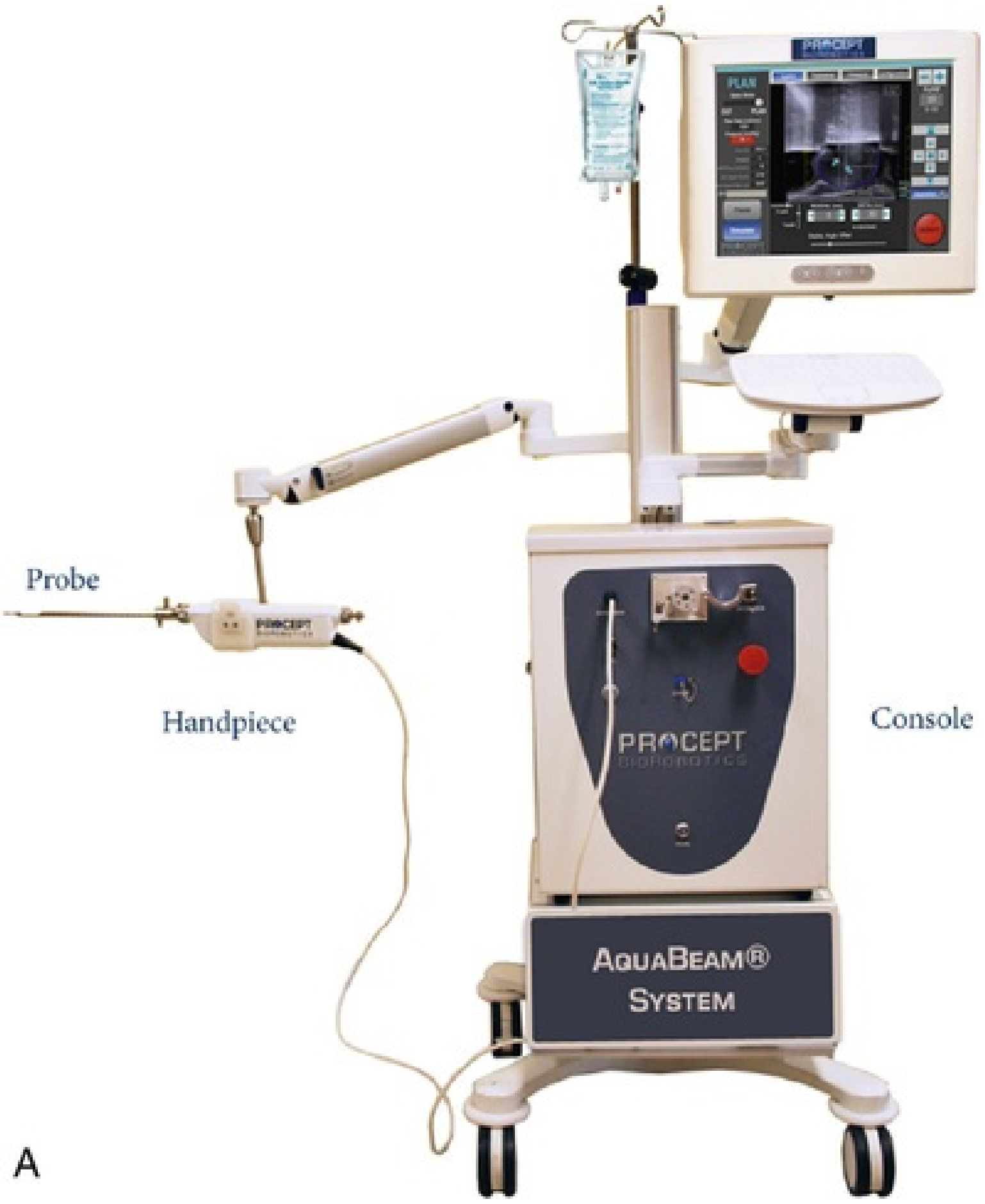
Probe
Handpiece
Console
PROCEPT BIOROBOTICS
AquaBeam® System
A

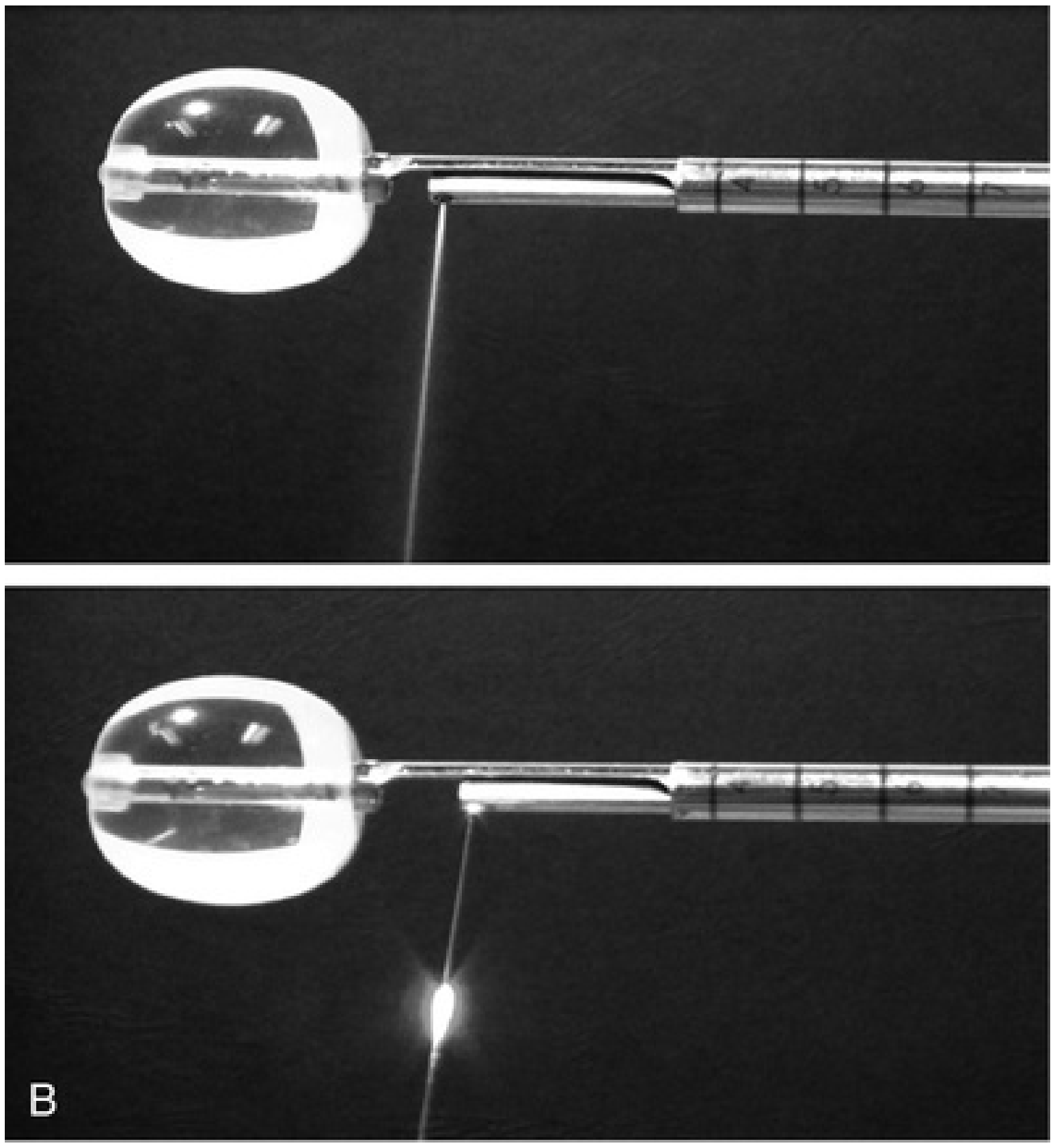

FIG. 146.19 (A) The AquaBeam system console, pump and articulating arm with Handpiece. (B) High-velocity waterjet for prostate ablation. (Courtesy of PROCEPT BioRobotics.)

Data

The first publication on aquablation was a prospective single-center nonrandomized study in men with moderate to severe LUTS/BPH (Gilling et al., 2016). An international, blinded, multicenter randomized controlled trial comparing aquablation to TURP quickly followed (Gilling et al., 2017). A total of 181 patients completed the 6-month follow-up. Improvements in IPSS for aquablation (22.9 to 5.9) and TURP (22.2 to 6.8) were both significant without a statistical difference between treatment modalities. **Change in IPSS was more pronounced, with aquablation for the 50- to 80-g prostate size subgroup ($P = .0099$).**

Operative times were similar between treatment options, with a much lower resection time for aquablation (4 vs. 27 minutes, $P < .0001$). Outcomes relating to ejaculation were better for patients undergoing aquablation (likely related to the sparing of the bladder neck with treatment), with other individual safety measures statistically similar between groups.

Verdict

With this new application of robotics, the transition zone can be precisely defined for treatment, which should ideally minimize undertreatment of the prostate adenoma. The procedure does require general anesthesia, making it difficult to characterize as a MIST but may demonstrate improvements over conventional BPH treatments like TURP.

Prostate Embolization

Concept

Despite the first reported case of prostatic arterial embolization (PAE) by DeMeritt et al. (2000), PAE did not gain more widespread use until recently. Access is generally gained at one of the femoral arteries, and pelvic angiography is performed to evaluate the iliac tree and prostatic arteries. **Once the catheter has been advanced into the prostatic arteries, an embolizing agent (e.g., alcohol, microspheres) is then infused through the catheter until stasis is seen in the prostatic vessels.** Access can be gained through one or both femoral vessels to perform unilateral or bilateral PAE, although it appears that bilateral procedures incur better results (Bilhim et al., 2013).

As seen commonly with embolization of blood-rich organs (e.g., kidney), a postembolization syndrome of pain and fever is customary. The incidence of post-PAE syndrome reported in the literature varies from 0% to 22%, the symptoms of which some authors argue may be mitigated by expectant medical management (Antunes et al., 2013, Gao et al., 2014, Grosso et al., 2015, Rampoldi et al., 2017). As tissue is not directly removed or ablated in PAE, theoretically local symptoms should be minimized; however, gaining the access to the femoral vessels may lead to local problems at that area including pseudoaneurysm or bleeding (Stone and Campbell, 2012). Additionally, intravascular contrast agents are used, making a contrast allergy a contraindication. The angiography needed during this procedure also exposes the patient to a significant amount of radiation exposure.

Possible technical problems include the inability to access the prostatic arteries because of tortuosity, vessel atherosclerosis, or aberrant pelvic arterial anatomy. In the study by Bilhim et al. (2012), the prostatic artery was found to arise from five different arterial trunks, with the most common site being the internal pudendal artery (34%). In 43% of the cases, there were two prostatic arteries on one side, with anastomoses to adjacent arteries also commonly found.

Data

Single-Cohort Studies.

Although the body of evidence regarding PAE is growing, the literature is primarily based on small cohort series concentrated in a handful of centers. It is important to note that there have only been two randomized trials published to date, both comparing PAE to TURP. Pisco et al. (2011) were first to report on a small series of patients who underwent PAE prospectively. They noted statistically significant improvements in AUA-SS (6.5 points, *P* = .005) at a mean follow-up of 7.9 months. Peak urinary flow only increased by 3.85 mL/sec (*P* = .015), and PSA and prostate volume decreased by 26% and 27%, respectively. The procedure was unable to be completed in 6.7% of patients, and 28.6% of patients met criteria for clinical failure. There was one major complication, an ischemic area of the bladder wall that required surgical intervention. Mean procedure time was 85 minutes (range 25 to 135 minutes), with patients undergoing a **mean fluoroscopy exposure time of 35 minutes** (range 15 to 45 minutes) (Pisco et al., 2011). Later studies have reported a mean fluoroscopy time ranging from 18 to 85.9 minutes, which in part, may be caused by the learning curve associated with the procedure (Kuang et al., 2017).

Antunes et al. (2013) included urodynamic data in their cohort of 11 patients who presented with urinary retention, with a prostate volume between 30 and 90 g. In this study, 10 of the 11 patients were catheter-free at a minimum follow-up of 12 months (mean follow up 22.3 months), and mean AUA-SS score at 12 months was 2.8 (range 1 to 7). UDS performed before and after treatment showed a decrease in detrusor pressure at Qmax from a mean of 85.7 to 51.5 cm H_2O. All patients had a BOOI greater than 40 before PAE. Post-PAE, only 30% of patients were clearly unobstructed (BOOI <20), 40% in the equivocal range (BOOI 20 to 40), and 30% demonstrated persistent obstruction (BOOI >40). Almost all patients reported mild, transitory pelvic pain, with three patients having minor rectal bleeding. One patient had an a focal area of hypoperfusion of the bladder wall on MRI at 1 month, which normalized on MRI at 90 days and 2 years.

Bilhim et al. (2013) investigated the effect of unilateral versus bilateral PAE in a single-center cohort study of 122 consecutive patients. A comparison of 103 patients who underwent bilateral PAE and 19 who underwent unilateral PAE revealed no statistically significant differences in change in prostate volume, PSA, IPSS, QoL, Qmax, PVR, or IIEF. A significant proportion of patients in both groups required medical therapy for persistent LUTS after PAE, 52% and 77.8% of patients in the bilateral and unilateral PAE groups, respectively. In addition, 20% of patients who underwent bilateral PAE went on to require prostatic surgery, compared with 11.1% of patients in the unilateral PAE group.

Pisco et al. (2013) published the largest series to date in their prospective nonrandomized single-cohort study of 255 patients with moderate to severe LUTS. PAE was technically successful (defined as bilateral arterial occlusion) in 250 patients (97.9%) and deemed clinically successful (defined as >25% reduction in IPSS and improvement in QoL by 1 point or QoL ≤3) in 72% at 18, 24, 30, and 36 months based on Kaplan-Meier curves. Clinical failure had no direct correlation with the reduction in prostate volume, although it appeared that failures were more common if only unilateral embolization occurred. At 6 months, patients saw a statistically significant improvement in IPSS, QoL, Qmax, and PVR. Prostate volume initially decreased from 83.5 g to 66.6 g at 6 months, but increased to 90.9 g at 24 months. Similarly, PSA initially decreased from 5.68 to 4.3 at 6 months, only to increase to 6.1 at 24 months. Both prostate volume and PSA at 24 months are based on available follow-up data for less than 15 patients, making these results difficult to interpret.

At 3 months, the mean AUA-SS was reduced by 54%, with a reduction in QoL score of 49%. Over the same period, maximum flow improved by 35%, prostate volume decreased by 18%, and IIEF score improved by 10.6%. In those patients with data at 1 year after the procedure, the absolute scores were not appreciably different from those at 3 months. It is important to note that despite the improvement in AUA-SS, on average, patients still had moderate LUTS at 6 months (mean AUA-SS was 11.5). Furthermore, the authors noted that there was no relationship between reduction in prostatic volume and clinical outcome, highlighting the disconnect of taking a prostatocentric approach.

Others have argued the utility of PAE it the treatment of larger prostate glands, which would traditionally be considered candidates for simple prostatectomy. In a single-center prospective study of 88 patients with a prostate volume greater than 80 g, with a mean prostate volume of 129.3 g, prostate size decreased to 71.2 g at 1 year. Patients also saw an improvement in IPSS (23.98 to 10.4) and Qmax (7.28 to 16.89 mL/sec). Wang et al. (2015) also looked at larger glands between 90 and 252 g (mean prostate volume 135 g), noting a similar improvement in IPSS from 18.3 to 2.7 at 3 months. Qmax also improved from

7.1 to 15.2 mL/sec at 3 months. Unfortunately, longer follow-up data were not available, making it difficult to extrapolate these results. Other authors who have also looked at prostate glands greater than 80 g with at least 18 months of follow-up have touted a clinical improvement rate ranging from 77.8% to 91.7% (Li et al., 2015; Pisco et al., 2016; Wang et al., 2015).

Comparative Studies.

In the first prospective randomized trial of 114 patients, Gao et al. (2014) compared PAE to bipolar TURP in men with a prostate volume between 20 and 100 g. The authors described clinical failure as persistent severe LUTS (decrease in IPSS of ≤25%, IPSS ≥18, decrease of QoL score by ≤1, and QoL score ≥4) and/or Qmax increase less than 2.5 mL and Qmax slower than 7 mL/sec. Despite using these generous criteria, they classified 9.4% of patients who underwent PAE as a clinical failure, compared with only 3.9% in the TURP group. Furthermore, patients in the TURP group showed greater degrees of improvement in IPSS, QoL, Qmax, and PVR at 1 and 3 months, a difference that was no longer evident at 12 and 24 months. The TURP group also saw greater reductions in PSA and prostate volume at all time points measured when compared with the PAE group. Patient in the PAE group were more likely to experience an adverse event or complication, primarily related to acute urinary retention, post-PAE syndrome, or treatment failure. The overall complication rate was 52.6% in the PAE group versus 29.8% in the TURP group. Although the authors noted that both urologists who performed TURP had several years of experience, qualifying this with a statement that before this study, both had “performed at least six bipolar TURP procedures,” this calls into question whether they were sufficiently experienced in TURP.

Carnevale et al. (2016) published the only other prospective randomized trial comparing 30 patients who underwent monopolar TURP versus PAE with a minimum of 1 year follow-up. Notably, mean procedure time was significantly longer in the PAE group compared with the TURP group, and times were 144.8 minutes and 61.7 minutes, respectively. This large discrepancy occurred despite the fact that prostate volume was similar between groups, TURP 56.6 g versus PAE 63.0 g. Although both groups experienced a statistically significant improvement in IPSS, at 12 months IPSS in the TURP group was 6.1 compared with 12.8 in the PAE group. Similarly, Qmax improved from 9.7 to 27.1 mL/sec, and the PAE group saw a modest improvement from 7.0 to 10.1 mL/sec, which is arguably clinically insignificant. In addition to the adverse events that has previously been described by others, they also reported an incident of asymptomatic transient pubic bone ischemia seen on MRI at 3 months.

Patients must be warned of the potential side effects/adverse events associated with PAE before its use, including the increased risk for need for reoperation, acute urinary retention requiring recatheterization, transfusion, urinary incontinence, rectal bleeding, hematospermia, pubic bone ischemia, hematuria, clot retention, alterations in ejaculate volume, postembolization syndrome, and severe pelvic pain. As intravenous contrast is used for the angiography portions, a contrast allergy is a contraindication for this procedure. Minimal local prostatic symptoms are generally seen; however, a generalized postembolization syndrome may ensue that includes fever or perineal pain. The more customary postprocedural voiding symptoms, however, are traded for possible complications of vascular access, including pseudoaneurysm and retroperitoneal bleeding.

Verdict

A technically challenging, and highly variable, pelvic anatomy may limit the widespread acceptance of this technology, with only expert interventionists performing the procedure. Completed studies have largely been nonrigorously performed, and application of the generated data makes it difficult to predict the role of prostate embolization in the treatment of LUTS/BPH. The many problems with these embolization reports include (1) reliance on imaging-based reduction in prostate volume, (2) naïve prostato-centric concepts of BPH, (3) lack of control patients, (4) unconventional definition of clinical improvement, (5) uniform failure to account for a placebo effect, thus leading one to assume that the improvement in LUTS or other outcomes were PAE related (intervention effect remains unknown), and (6) ignoring LUTS as the motivating complaint and the ultimate arbitrator of success.

Prostatic Injections

Concept

References to intraprostatic injection for management of prostate disease date back more than 100 years (Plante et al., 2004). The ease of application and overall low start-up costs make this an attractive option. **An injectable is**

commonly administered via a transperineal or transurethral approach into the prostatic parenchyma, with the injected substance theoretically causing localized changes to reduce prostate volume.

Although a wide variety of solutions have been tried in animal models, reported agents used in human studies include acid mixtures (Talwar and Pande, 1966), pepsin/iodine concoctions (Payr, 1936), ethanol, botulinum toxin A (BONT-A), and new agents with novel mechanisms of action.

Data

PRX302.

PRX302 is a novel injectable protein that is derived from the *Aeromonas hydrophilia* and manufactured by Sophiris Bio Inc. (La Jolla, California). **This pro-toxin that has been genetically modified to be activated by PSA (instead of its native furin), making it active only in the prostate. After being injected into the prostate parenchyma, the protein is cleaved by PSA, which activates the protein to oligomerize and form a transmembrane pore leading to cell death.**

The most recent publication on the medication is from 2013 and enrolled 92 men in a randomized double-blind phase IIb trial. A considerable placebo effect was noted as men were followed out to 1 year. Although improvements were noted above placebo at earlier time points, there was no statistical difference in IPSS at 1 year despite utilizing a P value of less than 0.1 for determining statistical differences between the treatment and control groups. No changes in sexual function were noted, and adverse events like pain with injection and voiding symptoms were mild. Interestingly, antibodies to PRX302 were noted in 73% of patients (Elhilali et al., 2013).

Further clinical trials are necessary before this medication could be considered a standard of care. Although imaginative in its approach, the lack of recent publication may be telling, although apparently ongoing trials are recruiting including a trial utilizing PRX302 as a focal treatment for prostate cancer.

Anhydrous Ethanol.

Anhydrous ethanol treatments of the prostate for LUTS/BPH have been primarily studied in non-US markets. Investigative trials are underway in the United States to allow ethanol to formally gain FDA approval for use in the prostate (Plante et al., 2007). **Although the mechanism of action with human**

prostate cells is not entirely delineated, it is likely that there are pro-apoptotic mechanisms that are induced (Plante et al., 2013). Other possible mechanisms include hemorrhagic coagulation necrosis caused by vessel thrombosis and occlusion (Goya et al., 1999).

In a study of 35 patients with a mean follow-up of 50 months (range 47 to 56 months), initial significant changes were noted in AUA-SS (–75%), Qmax (+247%), and prostate volume (–30%) at 3 months (Sakr et al., 2009). At 4-year follow-up, 25 of the initial 35 patients had data for reporting with improvements compared with preinjection of 55% in AUA-SS, 187% in Qmax, and 5.2% in prostate volume. Nine patients (26% of the initial cohort) required some form of retreatment (TURP, reinjection, or medical therapy) during the study period. In a study with a long follow-up but high attrition rate, 23% of patients required alternative treatment (El-Husseiny et al., 2011).

In 36 patients followed to 1 year after treatment, AUA-SS (46% reduction) and QoL scores (48% reduction) were significantly decreased at the last visit. Maximum flow improved throughout the study period, with improvements significant at 3 months (78%), 6 months (137%), and 12 months (154%). Reports on potential nonresponders and patients needing retreatment were not included, and it was unclear if these were consecutive patients (Magno et al., 2008).

In a phase I/II trial evaluating varying doses of ethanol injection, the most common reported adverse events were hematuria (42%), irritative voiding symptoms (39%), pain/discomfort (28%), and transient urinary retention (22%) when using absolute reporting (Plante et al., 2007). However, when stratified to AUA guidelines, these percentages were 0%, 2.7%, 5.4%, and 16.2%, respectively. Patients were randomized to a low, medium, or high dose adjusted for prostate size and had a roughly 50% decrease in AUA-SS and QoL scores across doses. Injection was done transurethrally, with the average procedure lasting 25 minutes. Moderate or severe pain during the procedure was reported by 6.7% and 12.2% of patients, respectively.

Botulinum Toxin.

BONT-A is produced by *Clostridium botulinum* with an already established use in urology for the care of patients with neurogenic voiding dysfunction. Although the exact mechanism to improve voiding when injected into the prostate is not completely understood, this exotoxin may have influence over both the static and dynamic components of BPH (Chuang et al., 2006a). In a placebo-controlled animal study, male rats 1 week after BONT-A injection were noted to have an increase in apoptotic cells with decreases in proliferative cells and the α_{1A} receptor. No significant change was noted in the presence of the androgen receptor. In rats sacrificed 2 weeks after injection, these effects were less notable (Chuang et al., 2006b). This was validated an earlier study wherein BONT-A injection lead to a generalized apoptotic atrophy of the rat prostate thought to be caused by denervation (Doggweiler et al., 1998). In an interestingly designed study, Silva et al. (2009) concluded that BONT-A induced prostate atrophy in the rat that may be the result of sympathetic nerve impairment, with the data indirectly suggesting that sympathetic neural drive played a role in prostate size regulation.

Lin et al. (2007) studied two doses of BONT-A (100 U and 200 U) on prostatic contractile function and structural changes and established a dose response. The higher dose produced a more pronounced atrophic change in the smooth muscles cells of the dog prostate. Under electrostimulation, prostate urethral pressure response was statistically lower in only the 200-U group.

A placebo-controlled trial in humans found a 65% reduction in AUA-SS at 2 months after injection. PSA was reduced by 51%, and prostate volume was reduced by 68% compared with baseline, corroborating the findings of induced cell atrophy seen in animal studies (Maria et al., 2003). Of the 15 patients receiving BONT-A injection, 13 noted improvements in voiding. No patients in the placebo group experienced benefits from saline injection. Four control group patients later received BONT-A, with 17 patients having longer follow-up data. Reductions in AUA-SS, serum PSA, Qmax, and prostate volume appeared durable at 1 year.

In a cohort of 60 patients with a prostate volume of more than 60 g with unsatisfactory response to combination medical therapy, 30 were randomized to BONT-A injection (Kuo and Liu, 2009). Although injection did reduce prostate volume and improve AUA-SS and QoL scores, the long-term therapeutic benefits were minimal compared with the control group. At 6 and 12 months after injection, only the QoL score in the study group was statistically different from the group continuing combination therapy. At the end of the study, three patients in the treatment group and two patients in the control group progressed to TURP for relief of LUTS. Surprisingly, despite not receiving any placebo drug or sham procedure, the control group had statistically significant improvements in AUA-SS, QoL score, and prostate volume at 6 and 12 months.

A phase II dose-ranging placebo-controlled RCT was published in 2013

(Marberger et al., 2013). Significant improvements from baseline values were found in AUA-SS, Qmax, and prostate volume at 12 weeks in all groups (including normal saline placebo). No significant differences were found between the doses of BONT-A and placebo. Adverse events were comparable across study groups.

A multicenter, double blind, sham-controlled study verified these results and included 315 patients (McVary et al., 2014b). Although decreases in AUA-SS were seen in both the BONT-A (–6.3) and placebo (–5.6) groups, there was no difference between BONT-A and placebo. **Authors concluded that although the treatments were well tolerated, no increased efficacy was seen with BONT-A over saline injection.**

Verdict

The simplicity of delivery for prostate injections makes it theoretically an attractive option for a MIST for LUTS/BPH. A significant placebo effect is frequently noted, with medication effects often not outpacing the improvements over vehicle or placebo.

Conclusion

Although OP and M-TURP had high complication rates, they did provide an excellent treatment to the age-old problem of LUTS/BPH. Many new suitors have been introduced to the market to achieve maximum results with a more acceptable safety profile, but each new technology led us to previously unconsidered complications and new paradigms to consider. The trainee and even veteran urologist should be conscious to carefully examine the results of each new treatment as new studies frequently attempt to mislead or overstate their results by not including a rigorous design or adequately controlling for a placebo/sham effect.

The gold standard operation for any patient is the one that meets his or her needs and expectations while still being safe. This decision for which technique is ideal should include a careful consideration of patient factors, but the surgeon's familiarity and ability to safely perform the selected procedure should also be a factor.

Suggested Readings

Ahyai SA, Gilling P, Kaplan SA, et al. Meta-analysis of functional outcomes and complications following transurethral procedures for lower urinary tract symptoms resulting from benign prostatic enlargement. *Eur Urol*. 2010;58(3):384–397.

Cornu JN, Ahyai S, Bachmann A, et al. A systematic review and meta-analysis of functional outcomes and complications following transurethral procedures for lower urinary tract symptoms resulting from benign prostatic obstruction: an update. *Eur Urol*. 2015;67(6):1066–1096.

Issa MM. Technological advances in transurethral resection of the prostate: bipolar versus monopolar TURP. *J Endourol*. 2008;22(8):1587–1595.

McVary KT, Roehrborn CG, Avins AL, et al. Update on AUA guideline on the management of benign prostatic hyperplasia. *J Urol*. 2011;185(5):1793–1803.

Mebust WK, Holtgrewe HL, Cockett AT, et al. Transurethral prostatectomy: immediate and postoperative complications. A cooperative study of 13 participating institutions evaluating 3,885 patients. *J Urol*. 1989;141(2):243–247.

Thomas JA, Tubaro A, Barber N, et al. A multicenter randomized noninferiority trial comparing GreenLight-XPS laser vaporization of the prostate and transurethral resection of the prostate for the treatment of benign prostatic obstruction: two-yr outcomes of the GOLIATH study. *Eur Urol*. 2016;69(1):94–102.

Welliver C, Kottwitz M, Feustel P, et al. Clinically and statistically significant changes seen in sham surgery arms of randomized, controlled benign prostatic hyperplasia surgery trials. *J Urol*. 2015;194(6):1682–1687.

References

Ahmed M, Bell T, Lawrence WT, et al. Transurethral microwave thermotherapy (Prostatron version 2.5) compared with transurethral resection of the prostate for the treatment of benign prostatic hyperplasia: a randomized, controlled, parallel study. *Br J Urol*. 1997;79(2):181–185.

Ahyai SA, Lehrich K, Kuntz RM. Holmium laser enucleation versus transurethral resection of the prostate: 3-year follow-up results of a randomized clinical trial. *Eur Urol*. 2007;52(5):1456–1463.

Ahyai SA, Gilling P, Kaplan SA, et al. Meta-analysis of functional outcomes and complications following transurethral procedures for lower urinary tract symptoms resulting from benign prostatic enlargement. *Eur Urol*. 2010;58(3):384–397.

Al-Ansari A, Younes N, Sampige VP, et al. GreenLight HPS 120-W laser vaporization versus transurethral resection of the prostate for treatment of benign prostatic hyperplasia: a randomized clinical trial with midterm follow-up. *Eur Urol*. 2010;58(3):349–355.

Ala-Opas MY, Grönlund SS. Blood loss in long-term aspirin users undergoing transurethral prostatectomy. *Scand J Urol Nephrol*. 1996;30(3):203–206.

American Urological Association. *New clinical guideline on BPH outlines diagnostic workup protocol*. http://auanet.mediaroom.com/2011-02-03-NEW-CLINICAL-GUIDELINE-ON-BPH-OUTLINES-DIAGNOSTIC-WORKUP-PROTOCOL; 2011.

Anson KM, Watson GM, Shah TK, et al. Laser prostatectomy: our initial experience of a technique in evolution. *J Endourol*. 1993;7(4):333–336.

Antunes AA, Carnevale FC, da Motta Leal Filho JM, et al. Clinical, laboratorial, and urodynamic findings of prostatic artery embolization for the treatment of urinary retention related to benign prostatic hyperplasia. A prospective single-center pilot study. *Cardiovasc Intervent Radiol*. 2013;36(4):978–986.

Arai Y, Aoki Y, Okubo K, et al. Impact of interventional therapy for benign prostatic hyperplasia on quality of life and sexual function: a prospective study. *J Urol*. 2000;164(4):1206–1211.

Armitage JN, Cathcart PJ, Rashidian A, et al. Epithelializing stent for benign prostatic hyperplasia: a systematic review of the literature. *J Urol*. 2007;177(5):1619–1624.

Bach T, Netsch C, Haecker A, et al. Thulium:YAG laser enucleation (VapoEnucleation) of the prostate: safety and durability during intermediate-term follow-up. *World J Urol*. 2010;28(1):39–43.

Bachmann A, Tubaro A, Barber N, et al. 180-W XPS GreenLight Laser vaporisation versus transurethral resection of the prostate for the treatment of benign prostatic obstruction: 6-month safety and efficacy results of a European multicentre randomised trial—the GOLIATH study. *Eur Urol*. 2014;65(5):931–942.

Bachmann A, Tubaro A, Barber N, et al. A European multicenter randomized noninferiority trial comparing 180 WGreenLight XPS laser vaporization and transurethral resection of the prostate for the treatment of benign prostatic obstruction: 12-month results of the GOLIATH study. *J Urol*. 2015;193(2):570–578.

Barmoshe S, Zlotta AR. How do I treat and follow my TUNA patients. *World J Urol*. 2006;24(4):397–404.

Bautista OM, Kusek JW, Nyberg LM, et al. Study design of the Medical Therapy of Prostatic Symptoms (MTOPS) trial.

Control Clin Trials. 2003;24(2):224–243.

Bdesha AS, Schachter M, Sever P, et al. Radioligand-binding analysis of human prostatic alpha-1 adrenoreceptor density following transurethral microwave therapy. *Br J Urol*. 1996;78(6):886–892.

Benjamin DS, Oberg KC, Saukel GW, et al. Histopathologic evaluation of the canine prostate following electrovaporization. *J Urol*. 1997;157(3):1144–1148.

Ben-Zvi T, Hueber PA, Liberman D, et al. GreenLight XPS 180W vs HPS 120W laser therapy for benign prostate hyperplasia: a prospective comparative analysis after 200 cases in a single-center study. *Urology*. 2013;81(4):853–858.

Berger AP, Niescher M, Spranger R, et al. Transurethral microwave thermotherapy (TUMT) with the Targis System: a single-centre study on 78 patients with acute urinary retention and poor general health. *Eur Urol*. 2003;43(2):176–180.

Berry SJ, Coffey DS, Walsh PC, et al. The development of human benign prostatic hyperplasia with age. *J Urol*. 1984;132(3):474–479.

Bhowmick P, Coad J, Bhowmick S, et al. In vitro assessment of the efficacy of thermal therapy in human benign prostatic hyperplasia. *Int J Hyperthermia*. 2004;20(4):421–439.

Bilhim T, Pisco JM, Rio Tinto H, et al. Prostatic arterial supply: anatomic and imaging findings relevant for selective arterial embolization. *J Vasc Interv Radiol*. 2012;23(11):1403–1415.

Bilhim T, Pisco J, Rio Tinto H, et al. Unilateral versus bilateral prostatic arterial embolization for lower urinary tract symptoms in patients with prostate enlargement. *Cardiovasc Intervent Radiol*. 2013;36(2):403–411.

Bishop CV, Liddell H, Ischia J, et al. Holmium laser enucleation of the prostate: comparison of immediate postoperative outcomes in patients with and without antithrombotic therapy. *Curr Urol*. 2013;7(1):28–33.

Bjork DT, Pelletier LL, Tight RR. Urinary tract infections with antibiotic resistant organisms in catheterized nursing home patients. *Infect Control*. 1984;5(4):173–176.

Bolmsjö M, Wagrell L, Hallin A, et al. The heat is on—but how? A comparison of TUMT devices. *Br J Urol*. 1996;78(4):564–572.

Borboroglu PG, Kane CJ, Ward JF, et al. Immediate and postoperative complications of transurethral prostatectomy in the 1990s. *J Urol*. 1999;162(4):1307–1310.

Borth CS, Nickel JC. Management of spontaneous prostate related bleeding. *AUA Update Ser*. 2006;25:Lesson 1.

Botto H, Lebret T, Barré P, et al. Electrovaporization of the prostate with the Gyrus device. *J Endourol*. 2001;15(3):313–316.

Bouchier-Hayes DM, Anderson P, Van Appledorn S, et al. KTP laser versus transurethral resection: early results of a randomized trial. *J Endourol*. 2006;20(8):580–585.

Bouza C, López T, Magro A, et al. Systematic review and meta-analysis of transurethral needle ablation in symptomatic benign prostatic hyperplasia. *BMC Urol*. 2006;6:14.

Brehmer M. Morphological changes in prostatic adenomas after transurethral microwave thermotherapy. *Br J Urol*. 1997;80(1):123–127.

Brehmer M, Nilsson BY. Elevation of sensory thresholds in the prostatic urethra after microwave thermotherapy. *BJU Int*. 2000;86(4):427–431.

Brehmer M, Svensson I. Heat-induced apoptosis in human prostatic stromal cells. *BJU Int*. 2000;85(4):535–541.

Brehmer M, Hilliges M, Kinn AC. Denervation of periurethral prostatic tissue by transurethral microwave thermotherapy. *Scand J Urol Nephrol*. 2000;34(1):42–45.

Briganti A, Naspro R, Gallina A, et al. Impact on sexual function of holmium laser enucleation versus transurethral resection of the prostate: results of a prospective, 2-center, randomized trial. *J Urol*. 2006;175(5):1817–1821.

Bruskewitz RC, Iversen P, Madsen PO. Value of postvoid residual urine determination in evaluation of prostatism. *Urology*. 1982;20(6):602–604.

Bruskewitz RC, Larsen EH, Madsen PO. Dørflinger T. 3-year followup of urinary symptoms after transurethral resection of the prostate. *J Urol*. 1986;136(3):613–615.

Bruskewitz R, Issa MM, Roehrborn CG, et al. A prospective, randomized 1-year clinical trial comparing transurethral needle ablation to transurethral resection of the prostate for the treatment of symptomatic benign prostatic hyperplasia. *J Urol*. 1998;159(5):1588–1593 [discussion 1593–1594].

Calves J, Thoulouzan M, Perrouin-Verbe MA, et al. Long-term patient-reported clinical outcomes and reoperation rate after photovaporization with the XPS-180W GreenLight laser. *Eur Urol Focus*. 2017 [pii: S2405-S4569(17)30243–2. [Epub ahead of print].

Cantwell AL, Bogache WK, Richardson SF, et al. Multicentre prospective crossover study of the “prostatic urethral lift” for the treatment of lower urinary tract symptoms secondary to benign prostatic hyperplasia. *BJU Int*. 2014;113(4):615–622.

Capitán C, Blazquez C, Martin MD, et al. GreenLight HPS 120-W laser vaporization versus transurethral resection of the prostate for the treatment of lower urinary tract symptoms due to benign prostatic hyperplasia: a randomized clinical trial with 2-year follow-up. *Eur Urol*. 2011;60(4):734–739.

Carnevale FC, Iscaife A, Yoshinaga EM, et al. Transurethral resection of the prostate (TURP) versus original and PErFecTED Prostate Artery Embolization (PAE) due to benign prostatic hyperplasia (BPH): preliminary results of a single center, prospective, urodynamic-controlled analysis. *Cardiovasc Intervent Radiol*. 2016;39(1):44–52.

Carter HB, Albertsen PC, Barry MJ, et al. Early detection of prostate cancer: AUA Guideline. *J Urol*. 2013;190(2):419–426.

Chakravarti A, MacDermott S. Transurethral resection of the prostate in the anticoagulated patient. *Br J Urol*. 1998;81(4):520–522.

Chancellor MB, Bennett C, Simoneau AR, et al. Sphincteric stent versus external sphincterotomy in spinal cord injured men: prospective randomized multicenter trial. *J Urol*. 1999;161(6):1893–1898.

Chapple CR, Issa MM, Woo H. Transurethral needle ablation (TUNA). A critical review of radiofrequency thermal therapy in the management of benign prostatic hyperplasia. *Eur Urol*. 1999;35(2):119–128.

Chartier-Kastler EJ, Thomas L, Bussel B, et al. A urethral stent for the treatment of detrusor-striated sphincter dyssynergia. *BJU Int*. 2000;86(1):52–57.

Chin PT, Bolton DM, Jack G, et al. Prostatic urethral lift: two-year results after treatment for lower urinary tract symptoms secondary to benign prostatic hyperplasia. *Urology*. 2012;79(1):5–11.

Cho SY, Park S, Jeong MY, et al. 120W GreenLight High Performance System laser for benign prostate hyperplasia: 68 patients with 3-year follow-up and analysis of predictors of response. *Urology*. 2012;80(2):396–401.

Choi B, Tabatabaei S, Bachmann A, et al. GreenLight HPS 120-W laser for benign prostatic hyperplasia: comparative complications and technical recommendations. *Eur Urol Supp*. 2008;7(4):384–392.

Choi SY, Kim TH, Myung SC, et al. Impact of changing trends in medical therapy on surgery for benign prostatic hyperplasia over two decades. *Korean J Urol*. 2012;53(1):23–28.

Chuang YC, Chiang PH, Yoshimura N, et al. Sustained beneficial effects of intraprostatic botulinum toxin type A on lower urinary tract symptoms and quality of life in men with benign prostatic hyperplasia. *BJU Int*. 2006;98(5):1033–1037 [discussion 1337].

Chuang YC, Huang CC, Kang HY, et al. Novel action of botulinum toxin on the stromal and epithelial components of the prostate gland. *J Urol*. 2006;175(3 Pt 1):1158–1163.

Chughtai B, Te A. Photoselective vaporization of the prostate for treating benign prostatic hyperplasia. *Expert Rev Med Devices*. 2011;8(5):591–595.

Chughtai BI, Simma-Chiang V, Lee R, et al. Trends and utilization of laser prostatectomy in ambulatory surgical procedures for the treatment of benign prostatic hyperplasia in New York State (2000-2011). *J Endourol*. 2015;29(6):700–706.

Chung DE, Te AE. New techniques for laser prostatectomy: an update. *Ther Adv Urol*. 2009;1(2):85–97.

Chute CG, Panser LA, Girman CJ, et al. The prevalence of prostatism: a population-based survey of urinary symptoms. *J Urol*. 1993;150(1):85–89.

Cimentepe E, Unsal A, Saglam R. Randomized clinical trial comparing transurethral needle ablation with transurethral resection of the prostate for the treatment of benign prostatic hyperplasia: results at 18 months. *J Endourol*. 2003;17(2):103–107.

Cornu JN, Ahyai S, Bachmann A, et al. A systematic review and meta-analysis of functional outcomes and complications following transurethral procedures for lower urinary tract symptoms resulting from benign prostatic obstruction: an update. *Eur Urol*. 2015;67(6):1066–1096.

Crisostomo V, Song HY, Maynar M, et al. Evaluation of the effects of temporary covered nitinol stent placement in the prostatic urethra: short-term study in the canine model. *Cardiovasc Intervent Radiol*. 2007;30(4):731–737.

Cummings JM, Parra RO, Boullier JA, et al. Evaluation of fluid absorption during laser prostatectomy by breath ethanol techniques. *J Urol*. 1995;154(6):2080–2082.

Daehlin L, Frugard J. Three-year follow-up after transurethral microwave thermotherapy (TUMT) for benign prostatic hyperplasia using the PRIMUS U + R device. *Scand J Urol Nephrol*. 1999;33(4):217–221.

Daehlin L, Gustavsen A, Nilsen AH, et al. Transurethral needle ablation for treatment of lower urinary tract symptoms associated with benign prostatic hyperplasia: outcome after 1 year. *J Endourol*. 2002;16(2):111–115.

Dahlstrand C, Waldén M, Geirsson G, et al. Transurethral microwave thermotherapy versus transurethral resection for symptomatic benign prostatic obstruction: a prospective randomized study with a 2-year follow-up. *Br J Urol*. 1995;76(5):614–618.

Dahlstrand C, Grundtman S, Pettersson S. High-energy transurethral microwave thermotherapy for large severely obstructing prostates and the use of biodegradable stents to avoid catheterization after treatment. *Br J Urol*. 1997;79(6):907–909.

d'Ancona FC, Francisca EA, Witjes WP, et al. High energy thermotherapy versus transurethral resection in the treatment of benign prostatic hyperplasia: results of a prospective randomized study with 1 year of followup. *J Urol*. 1997;158(1):120–125.

d'Ancona FC, Francisca EA, Witjes WP, et al. Transurethral resection of the prostate vs high-energy thermotherapy of the prostate in patients with benign prostatic hyperplasia: long-term results. *Br J Urol*. 1998;81(2):259–264.

d'Ancona FC, Albers YH, Kiemeney LA, et al. Can histopathology predict treatment outcome following high-energy transurethral microwave thermotherapy of the prostate? Results of a biopsy study. *Prostate*. 1999;40(1):28–36.

d'Ancona FC, van der Bij AK, Francisca EA, et al. Results of high-energy transurethral microwave thermotherapy in patients categorized according to the American Society of Anesthesiologists operative risk classification. *Urology*. 1999;53(2):322–328.

de la Rosette JJ, de Wildt MJ, Hofner K, et al. High energy thermotherapy in the treatment of benign prostatic hyperplasia: results of the European Benign Prostatic Hyperplasia Study Group. *J Urol*. 1996;156(1):97–101 [discussion 101–102].

de la Rosette JJ, D'Ancona FC, Debruyne FM. Current status of thermotherapy of the prostate. *J Urol*. 1997;157(2):430–438.

de la Rosette JJ, Kortmann BB, Rossi C, et al. Long-term risk of re-treatment of patients using alpha-blockers for lower urinary tract symptoms. *J Urol*. 2002;167(4):1734–1739.

de Sio M, Autorino R, Quarto G, et al. Gyrus bipolar versus standard monopolar transurethral resection of the prostate: a randomized prospective trial. *Urology*. 2006;67(1):69–72.

DeMeritt JS, Elmasri FF, Esposito MP, et al. Relief of benign prostatic hyperplasia-related bladder outlet obstruction after transarterial polyvinyl alcohol prostate embolization. *J Vasc Interv Radiol*. 2000;11(6):767–770.

Descazeaud A, Robert G, Azzousi AR, et al. Laser treatment of benign prostatic hyperplasia in patients on oral anticoagulant therapy: a review. *BJU Int*. 2009;103(9):1162–1165.

Descazeaud A, Robert G, Lebdai S, et al. Impact of oral anticoagulation on morbidity of transurethral resection of the prostate. *World J Urol*. 2011;29(2):211–216.

Devonec M, Ogden C, Perrin P, et al. Clinical response to transurethral microwave thermotherapy is thermal dose dependent. *Eur Urol*. 1993;23(2):267–274.

Dincel C, Samli MM, Guler C, et al. Plasma kinetic vaporization of the prostate: clinical evaluation of a new technique. *J Endourol*. 2004;18(3):293–298.

Dixon C, Cedano ER, Pacik D, et al. Efficacy and safety of Rezūm system water vapor treatment for lower urinary tract symptoms secondary to benign prostatic hyperplasia. *Urology*. 2015;86(5):1042–1047.

Dixon CM, Rijo Cedano E, Mynderse LA, et al. Transurethral convective water vapor as a treatment for lower urinary tract symptomatology due to benign prostatic hyperplasia using the Rezum system: evaluation of acute ablative capabilities in the human prostate. *Res Rep Urol*. 2015;7:13–18.

Djavan B, Larson TR, Blute ML, et al. Transurethral microwave thermotherapy: what role should it play versus medical management in the treatment of benign prostatic hyperplasia? *Urology*. 1998;52(6):935–947.

Djavan B, Seitz C, Ghawidel K, et al. High-energy transurethral microwave thermotherapy in patients with acute urinary retention due to benign prostatic hyperplasia. *Urology*. 1999;54(1):18–22.

Djavan B, Shariat S, Schäfer B, et al. Tolerability of high energy transurethral microwave thermotherapy with topical urethral anesthesia: results of a prospective, randomized, single-blinded clinical trial. *J Urol*. 1998;160(3 Pt 1):772–776.

Djavan B, Fakhari M, Shariat S, et al. A novel intraurethral prostatic bridge catheter for prevention of temporary prostatic obstruction following high energy transurethral microwave thermotherapy in patients with benign prostatic hyperplasia. *J Urol*. 1999;161(1):144–151.

Djavan B, Shariat S, Fakhari M, et al. Neoadjuvant and adjuvant alpha-blockade improves early results of high-energy transurethral microwave thermotherapy for lower urinary tract symptoms of benign prostatic hyperplasia: a randomized, prospective clinical trial. *Urology*. 1999;53(2):251–259.

Djavan B, Ghawidel K, Basharkhah A, et al. Temporary intraurethral prostatic bridge-catheter compared with neoadjuvant and adjuvant alpha-blockade to improve early results of high-energy transurethral microwave thermotherapy. *Urology*. 1999;54(1):73–80.

Djavan B, Bursa B, Basharkhah A, et al. Pretreatment prostate-specific antigen as an outcome predictor of targeted transurethral microwave thermotherapy. *Urology*. 2000;55(1):51–57.

Djavan B, Seitz C, Roehrborn CG, et al. Targeted transurethral microwave thermotherapy versus alpha-blockade in benign prostatic hyperplasia: outcomes at 18 months. *Urology*. 2001;57(1):66–70.

Doggweiler R, Zermann DH, Ishigooka M, et al. Botox-induced prostatic involution. *Prostate*. 1998;37(1):44–50.

Doll HA, Black NA, McPherson K, et al. Mortality, morbidity and complications following transurethral resection of the prostate for benign prostatic hypertrophy. *J Urol*. 1992;147(6):1566–1573.

Donnell RF. Laser safety and clinical application in Urology. *AUA Update Ser*. 2014;32 [Lesson 39].

Dotan ZA, Mor Y, Leibovitch I, et al. The efficacy and safety of perioperative low molecular weight heparin substitution in patients on chronic oral anticoagulant therapy undergoing transurethral prostatectomy for bladder outlet obstruction. *J Urol*. 2002;168(2):610–613 [discussion 614].

Dunsmuir WD, McFarlane JP, Tan A, et al. Gyrus bipolar electrovaporization vs transurethral resection of the prostate: a randomized prospective single-blind trial with 1 y follow-up. *Prostate Cancer Prostatic Dis*. 2003;6(2):182–186.

Eaton AC, Francis RN. The provision of transurethral prostatectomy on a day-case basis using bipolar plasma kinetic technology. *BJU Int*. 2002;89(6):534–537.

El Tayeb MM, Jacob JM, Bhojani N, et al. Holmium laser enucleation of the prostate in patients requiring anticoagulation. *J Endourol*. 2016;30(7):805–809.

El-Hakim A, Elhilali MM. Holmium laser enucleation of the prostate can be taught: the first learning experience. *BJU Int*. 2002;90(9):863–869.

Elhilali MM, Pommerville P, Yocum RC, et al. Prospective, randomized, double-blind, vehicle controlled, multicenter phase IIb clinical trial of the pore forming protein PRX302 for targeted treatment of symptomatic benign prostatic hyperplasia. *J Urol*. 2013;189(4):1421–1426.

El-Husseiny T, Buchholz N. Transurethral ethanol ablation of the prostate for symptomatic benign prostatic hyperplasia: long-term follow-up. *J Endourol*. 2011;25(3):477–480.

Eliasson T, Wagrell L. New technologies for the surgical management of symptomatic benign prostatic enlargement: tolerability and morbidity of high energy transurethral microwave thermotherapy. *Curr Opin Urol*. 2000;10(1):15–17.

Elzayat EA, Habib EI, Elhilali MM. Holmium laser enucleation of the prostate: a size-independent new “gold standard. *Urology*. 2005;66(5 Suppl):108–113.

Elzayat EA, Habib EI, Elhilali MM. Holmium laser enucleation of prostate for patients in urinary retention. *Urology*. 2005;66(4):789–793.

Elzayat EA, Elhilali MM. Holmium laser enucleation of the prostate (HoLEP): long-term results, reoperation rate, and possible impact of the learning curve. *Eur Urol*. 2007;52(5):1465–1471.

Emmett JL, Kirchheim D, Greene LF. Prevention of postoperative stricture from transurethral resection by preliminary internal urethrotomy: report of experience with 447 cases. *J Urol*. 1957;78(4):456–465.

Erturhan S, Erbagci A, Seckiner I, et al. Plasmakinetic resection of the prostate versus standard transurethral resection of the prostate: a prospective randomized trial with 1-year follow-up. *Prostate Cancer Prostatic Dis*. 2007;10(1):97–100.

Falsaperla M, Cindolo L, Saita A, et al. Transurethral resection of prostate: technical progress by bipolar Gyrus plasma-kinetic tissue management system. *Minerva Urol Nefrol*. 2007;59(2):125–129.

Flanigan RC, Reda DJ, Wasson JH, et al. 5-year outcome of surgical resection and watchful waiting for men with moderately symptomatic benign prostatic hyperplasia: a Department of Veterans Affairs cooperative study. *J Urol*. 1998;160(1):12–16 [discussion 16–17].

Floratos DL, Sonke GS, Francisca EA, et al. High energy transurethral microwave thermotherapy for the treatment of patients in urinary retention. *J Urol*. 2000;163(5):1457–1460.

Floratos DL, Kiemeney LA, Rossi C, et al. Long-term followup of randomized transurethral microwave thermotherapy versus transurethral prostatic resection study. *J Urol*. 2001;165(5):1533–1538.

Foley SJ, Soloman LZ, Wedderburn AW, et al. A prospective study of the natural history of hematuria associated with benign prostatic hyperplasia and the effect of finasteride. *J Urol*. 2000;163(2):496–498.

Fowler FJ Jr, Wennberg JE, Timothy RP, et al. Symptom status and quality of life following prostatectomy. *JAMA*. 1988;259(20):3018–3022.

Francisca EA, d'Ancona FC, Meuleman EJ, et al. Sexual function following high energy microwave thermotherapy:

results of a randomized controlled study comparing transurethral microwave thermotherapy to transurethral prostatic resection. *J Urol*. 1999;161(2):486–490.

Francisca EA, Kortmann BB, Floratos DL, et al. Tolerability of 3.5 versus 2.5 high-energy transurethral microwave thermotherapy. *Eur Urol*. 2000;38(1):59–63.

Fraundorfer MR, Gilling PJ. Holmium:YAG laser enucleation of the prostate combined with mechanical morcellation: preliminary results. *Eur Urol*. 1998;33(1):69–72.

Fried NM, Murray KE. High-power thulium fiber laser ablation of urinary tissues at 1.94 microm. *J Endourol*. 2005;19(1):25–31.

Gajewski JB, Chancellor MB, Ackman CF, et al. Removal of UroLume endoprosthesis: experience of the North American Study Group for detrusor-sphincter dyssynergia application. *J Urol*. 2000;163(3):773–776.

Gallucci M, Puppo P, Perachino M, et al. Transurethral electrovaporization of the prostate vs. transurethral resection. Results of a multicentric, randomized clinical study on 150 patients. *Eur Urol*. 1998;33(4):359–364.

Gao YA, Huang Y, Zhang R, et al. Benign prostatic hyperplasia: prostatic arterial embolization versus transurethral resection of the prostate—a prospective, randomized, and controlled clinical trial. *Radiology*. 2014;270(3):920–928.

Geavlete B, Multescu R, Dragutescu M, et al. Transurethral resection (TUR) in saline plasma vaporization of the prostate vs standard TUR of the prostate: “the better choice” in benign prostatic hyperplasia? *BJU Int*. 2010;106(11):1695–1699.

Geavlete B, Georgescu D, Multescu R, et al. Bipolar plasma vaporization vs monopolar and bipolar TURP—a prospective, randomized, long-term comparison. *Urology*. 2011;78(4):930–935.

Gilling P, Anderson P, Tan A. Aquablation of the prostate for symptomatic benign prostatic hyperplasia: 1-year results. *J Urol*. 2017;197(6):1565–1572.

Gilling PJ, Kennett K, Das AK, et al. Holmium laser enucleation of the prostate (HoLEP) combined with transurethral tissue morcellation: an update on the early clinical experience. *J Endourol*. 1998;12(5):457–459.

Gilling PJ, Wilson LC, King CJ, et al. Long-term results of a randomized trial comparing holmium laser enucleation of the prostate and transurethral resection of the prostate: results at 7 years. *BJU Int*. 2012;109(3):408–411.

Gilling P, Reuther R, Kahokehr A, et al. Aquablation—image-guided robot-assisted waterjet ablation of the prostate: initial clinical experience. *BJU Int*. 2016;117(6):923–929.

Glynn RJ, Campion EW, Bouchard GR, et al. The development of benign prostatic hyperplasia among volunteers in the Normative Aging Study. *Am J Epidemiol*. 1985;121(1):78–90.

Goya N, Ishikawa N, Ito F, et al. Ethanol injection therapy of the prostate for benign prostatic hyperplasia: preliminary report on application of a new technique. *J Urol*. 1999;162(2):383–386.

Gratzke C, Barber N, Speakman MJ, et al. Prostatic urethral lift vs transurethral resection of the prostate: 2-year results of the BPH6 prospective, multicentre, randomized study. *BJU Int*. 2017;119(5):767–775.

Gravas S, Laguna MP, De La Rosette JJ. Application of external microwave thermotherapy in urology: past, present, and future. *J Endourol*. 2003;17(8):659–666.

Gravas S, Bachmann A, Reich O, et al. Critical review of lasers in benign prostatic hyperplasia (BPH). *BJU Int*. 2011;107(7):1030–1043.

Greene LF. Transurethral prostatic resection. Greene LF, Segura JW. *Transurethral surgery*. WB Saunders: Philadelphia, PA;

1979:108.

Greene LF, Holcomb GR. Transurethral resection in special situations. Greene LF, Segura JW. *Transurethral surgery*. WB Saunders: Philadelphia, PA; 1979:214.

Gross AJ, Orywal AK, Becker B, et al. Five-year outcomes of thulium vapoenucleation of the prostate for symptomatic benign prostatic obstruction. *World J Urol*. 2017;35(10):1585–1593.

Grosso M, Balderi A, Arno M, et al. Prostatic artery embolization in benign prostatic hyperplasia: preliminary results in 13 patients. *Radiol Med*. 2015;120(4):361–368.

Guazzoni G, Montorsi F, Coulange C, et al. A modified prostatic UroLume Wallstent for healthy patients with symptomatic benign prostatic hyperplasia: a European Multicenter Study. *Urology*. 1994;44(3):364–370.

Guess HA, Arrighi HM, Metter EJ, et al. Cumulative prevalence of prostatism matches the autopsy prevalence of benign prostatic hyperplasia. *Prostate*. 1990;17(3):241–246.

Hagstrom RS. Studies on fluid absorption during transurethral prostatic resection. *J Urol*. 1955;73(5):852–859.

Hahn DW, Özişik MN. Heat conduction fundamentals (chapter 1). *Heat conduction*. 3rd ed. John Wiley & Sons: Hoboken, NJ; 2012:1–39.

Hai MA, Malek RS. Photoselective vaporization of the prostate: initial experience with a new 80 W KTP laser for the treatment of benign prostatic hyperplasia. *J Endourol*. 2003;17(2):93–96.

Hai MA. Photoselective vaporization of prostate: five-year outcomes of entire clinic patient population. *Urology*. 2009;73(4):807–810.

Hallin A, Berlin T. Transurethral microwave thermotherapy for benign prostatic hyperplasia: clinical outcome after 4 years. *J Urol*. 1998;159(2):459–464.

Hamann MF, Naumann CM, Seif C, et al. Functional outcome following photoselective vaporisation of the prostate (PVP): urodynamic findings within 12 months follow-up. *Eur Urol*. 2008;54(4):902–907.

Hammadeh MY, Philp T. Transurethral electrovaporization of the prostate (TUVP) is effective, safe and durable. *Prostate Cancer Prostatic Dis*. 2003;6(2):121–126.

Hammadeh MY, Madaan S, Hines J, et al. 5-year outcome of a prospective randomized trial to compare transurethral electrovaporization of the prostate and standard transurethral resection. *Urology*. 2003;61(6):1166–1171.

Hammarsten J, Lindqvist K. Suprapubic catheter following transurethral resection of the prostate: a way to decrease the number of urethral strictures and improve the outcome of operations. *J Urol*. 1992;147(3):648–651 [discussion 651–652].

Harmon BV, Corder AM, Collins RJ, et al. Cell death induced in a murine mastocytoma by 42–47 degrees C heating in vitro: evidence that the form of death changes from apoptosis to necrosis above a critical heat load. *Int J Radiat Biol*. 1990;58(5):845–858.

Harrison RH 3rd, Boren JS, Robison JR. Dilutional hyponatremic shock: another concept of the transurethral prostatic resection reaction. *J Urol*. 1956;75(1):95–110.

Hedlund H, Ek A. Ejaculation and sexual function after endoscopic bladder neck incision. *Br J Urol*. 1985;57(2):164–167.

Helfand BT, Mongiu AK, Kan D, et al. Outcomes of radical prostatectomy for patients with clinical stage T1a and T1b disease. *BJU Int*. 2009;104(3):304–309.

Helfand BT, Manvar AM, Auffenberg GB, et al. Holmium laser ablation and enucleation of the prostate: a pilot study of the hybrid technique. *Can J Urol*. 2010;17(3):5190–5194.

Hill B, Belville W, Bruskewitz R, et al. Transurethral needle ablation versus transurethral resection of the prostate for the treatment of symptomatic benign prostatic hyperplasia: 5-year results of a prospective, randomized, multicenter clinical trial. *J Urol*. 2004;171(6 Pt 1):2336–2340.

Ho H, Yip SK, Cheng CW, et al. Bipolar transurethral resection of prostate in saline: preliminary report on clinical efficacy and safety at 1 year. *J Endourol*. 2006;20(4):244–246 [discussion 246–247].

Hochreiter WW, Thalmann GN, Burkhard FC, et al. Holmium laser enucleation of the prostate combined with electrocautery resection: the mushroom technique. *J Urol*. 2002;168(4 Pt 1):1470–1474.

Hoekstra PT, Kahnoski R, McCamish MA, et al. Transurethral prostatic resection syndrome–a new perspective: encephalopathy with associated hyperammonemia. *J Urol*. 1983;130(4):704–707.

Hoekstra RJ, Van Melick HH, Kok ET, et al. A 10-year follow-up after transurethral resection of the prostate, contact laser prostatectomy and electrovaporization in men with benign prostatic hyperplasia; long-term results of a randomized controlled trial. *BJU Int*. 2010;106(6):822–826.

Hoffman RM, MacDonald R, Wilt TJ. Laser prostatectomy for benign prostatic obstruction. *Cochrane Database Syst Rev*. 2004;(1) [CD001987].

Hoffman RM, Monga M, Elliott SP, et al. Microwave thermotherapy for benign prostatic hyperplasia. *Cochrane Database Syst Rev*. 2012;(9) [CD004135].

Hon NH, Brathwaite D, Hussain Z, et al. A prospective, randomized trial comparing conventional transurethral prostate resection with PlasmaKinetic vaporization of the prostate: physiological changes, early complications and long-term followup. *J Urol*. 2006;176(1):205–209.

Horasanli K, Silay MS, Altay B, et al. Photoselective potassium titanyl phosphate (KTP) laser vaporization versus transurethral resection of the prostate for prostates larger than 70 mL: a short-term prospective randomized trial. *Urology*. 2008;71(2):247–251.

Huidobro C, Larson B, Mynderse S, et al. Characterizing Prostiva RF treatments of the prostate for BPH with gadolinium-enhanced MRI. *ScientificWorldJournal*. 2009;9:10–16.

Hutch JA, Rambo OS Jr. A study of the anatomy of the prostate, prostatic urethra and the urinary sphincter system. *J Urol*. 1970;104(3):443–452.

Iacono F, Prezioso D, Di Lauro G, et al. Efficacy and safety profile of a novel technique, ThuLEP (thulium laser enucleation of the prostate) for the treatment of benign prostate hypertrophy. Our experience on 148 patients. *BMC Surg*. 2012;12(Suppl 1):S21.

Issa MM. Technological advances in transurethral resection of the prostate: bipolar versus monopolar TURP. *J Endourol*. 2008;22(8):1587–1595.

Izard J, Nickel JC. Impact of medical therapy on transurethral resection of the prostate: two decades of change. *BJU Int*. 2011;108(1):89–93.

Jacobsen SJ, Jacobson DJ, Girman CJ, et al. Natural history of prostatism: risk factors for acute urinary retention. *J Urol*. 1997;158(2):481–487.

Jahnson S, Dalén M, Gustavsson G, et al. Transurethral incision versus resection of the prostate for small to medium benign prostatic hyperplasia. *Br J Urol*. 1998;81(2):276–281.

Jaidane M, Arfa NB, Hmida W, et al. Effect of transurethral resection of the prostate on erectile function: a prospective comparative study. *Int J Impot Res*. 2010;22(2):146–151.

Juma S. Transurethral fulguration of the prostate with the roller ball. *Urology*. 1996;47(1):53–58.

Kabalin JN, Gong M, Issa MM, et al. Insight into mechanism of neodymium: yttrium-aluminum-garnet laser prostatectomy utilizing the high-power contact-free beam technique. *Urology*. 1995;45(3):421–426.

Kang HW, Jebens D, Malek RS, et al. Laser vaporization of bovine prostate: a quantitative comparison of potassium-titanyl-phosphate and lithium triborate lasers. *J Urol*. 2008;180(6):2675–2680.

Kaplan SA, Te AE. Transurethral electrovaporization of the prostate: a novel method for treating men with benign prostatic hyperplasia. *Urology*. 1995;45(4):566–572.

Karaman MI, Kaya C, Ozturk M, et al. Comparison of transurethral vaporization using PlasmaKinetic energy and transurethral resection of prostate: 1-year follow-up. *J Endourol*. 2005;19(6):734–737.

Kavoussi PK, Hermans MR. Maintenance of erectile function after photoselective vaporization of the prostate for obstructive benign prostatic hyperplasia. *J Sex Med*. 2008;5(11):2669–2671.

Kaya C, Ilktac A, Gokmen E, et al. The long-term results of transurethral vaporization of the prostate using plasmakinetic energy. *BJU Int*. 2007;99(4):845–848.

Keijzers GB, Francisca EA, D'Ancona FC, et al. Long-term results of lower energy transurethral microwave thermotherapy. *J Urol*. 1998;159(6):1966–1972 [discussion 1972–1973].

Kirby RS, Williams G, Witherow R, et al. The prostatron transurethral microwave device in the treatment of bladder outflow obstruction due to benign prostatic hyperplasia. *Br J Urol*. 1993;72(2):190–194.

Ko WJ, Choi BB, Kang HW, et al. Defining optimal laser-fiber sweeping angle for effective tissue vaporization using 180 W

532 nm lithium triborate laser. *J Endourol*. 2012;26(4):313–317.

Konety BR, Phelan MW, O'Donnell WF, et al. Urolume stent placement for the treatment of postbrachytherapy bladder outlet obstruction. *Urology*. 2000;55(5):721–724.

Krambeck AE, Handa SE, Lingeman JE. Experience with more than 1,000 holmium laser prostate enucleations for benign prostatic hyperplasia. *J Urol*. 2010;183(3):1105–1109.

Krambeck AE, Handa SE, Lingeman JE. Holmium laser enucleation of the prostate for prostates larger than 175 grams. *J Endourol*. 2010;24(3):433–437.

Kranzbuhler B, Wettstein MS, Fankhauser CD, et al. Pure bipolar plasma vaporization of the prostate: the Zurich experience. *J Endourol*. 2013;27(10):1261–1266.

Kuang M, Vu A, Athreya S. A systematic review of prostatic artery embolization in the treatment of symptomatic benign prostatic hyperplasia. *Cardiovasc Intervent Radiol*. 2017;40(5):655–663.

Kuntz RM, Lehrich K, Ahyai S. Does perioperative outcome of transurethral holmium laser enucleation of the prostate depend on prostate size? *J Endourol*. 2004;18(2):183–188.

Kuntz RM, Ahyai S, Lehrich K, et al. Transurethral holmium laser enucleation of the prostate versus transurethral electrocautery resection of the prostate: a randomized prospective trial in 200 patients. *J Urol*. 2004;172(3):1012–1016.

Kuntz RM. Current role of lasers in the treatment of benign prostatic hyperplasia (BPH). *Eur Urol*. 2006;49(6):961–969.

Kuntz RM, Lehrich K, Ahyai SA. Holmium laser enucleation of the prostate versus open prostatectomy for prostates greater than 100 grams: 5-year follow-up results of a randomised clinical trial. *Eur Urol*. 2008;53(1):160–166.

Kuntzman RS, Malek RS, Barrett DM, et al. Potassium-titanyl-phosphate laser vaporization of the prostate: a comparative functional and pathologic study in canines. *Urology*. 1996;48(4):575–583.

Kuo HC, Liu HT. Therapeutic effects of add-on botulinum toxin A on patients with large benign prostatic hyperplasia and unsatisfactory response to combined medical therapy. *Scand J Urol Nephrol*. 2009;43(3):206–211.

Kuo RL, Paterson RF, Siqueira TM Jr, et al. Holmium laser enucleation of the prostate: morbidity in a series of 206 patients. *Urology*. 2003;62(1):59–63.

Küpeli S, Yilmaz E, Soygür T, et al. Randomized study of transurethral resection of the prostate and combined transurethral resection and vaporization of the prostate as a therapeutic alternative in men with benign prostatic hyperplasia. *J Endourol*. 2001;15(3):317–321.

Laguna MP, Kiemeney LA, Debruyne FM, et al. Baseline prostatic specific antigen does not predict the outcome of high energy transurethral microwave thermotherapy. *J Urol*. 2002;167(4):1727–1730.

Larner TR, Agarwal D, Costello AJ. Day-case holmium laser enucleation of the prostate for gland volumes of < 60 mL: early experience. *BJU Int*. 2003;91(1):61–64.

Larson TR, Bostwick DG, Corica A. Temperature-correlated histopathologic changes following microwave thermoablation of obstructive tissue in patients with benign prostatic hyperplasia. *Urology*. 1996;47(4):463–469.

Larson TR, Blute ML, Bruskewitz RC, et al. A high-efficiency microwave thermoablation system for the treatment of benign prostatic hyperplasia: results of a randomized, sham-controlled, prospective, double-blind, multicenter clinical trial. *Urology*. 1998;51(5):731–742.

Lepor H, Rigaud G. The efficacy of transurethral resection of the prostate in men with moderate symptoms of prostatism. *J*

Urol. 1990;143(3):533–537.

Lepor H, Williford WO, Barry MJ, et al. Veterans Affairs Cooperative Studies Benign Prostatic Hyperplasia Study Group: The efficacy of terazosin, finasteride, or both in benign prostatic hyperplasia. *N Engl J Med*. 1996;335(8):533–539.

Li Q, Duan F, Wang MQ, et al. Prostatic arterial embolization with small sized particles for the treatment of lower urinary tract symptoms due to large benign prostatic hyperplasia: preliminary results. *Chin Med J*. 2015;128(15):2072–2077.

Lin AT, Yang AH, Chen KK. Effects of botulinum toxin A on the contractile function of dog prostate. *Eur Urol*. 2007;52(2):582–589.

Lourenco T, Pickard R, Vale L, et al. Minimally invasive treatments for benign prostatic enlargement: systematic review of randomised controlled trials. *BMJ*. 2008;337:a1662.

Lourenco T, Shaw M, Fraser C, et al. The clinical effectiveness of transurethral incision of the prostate: a systematic review of randomised controlled trials. *World J Urol*. 2010;28(1):23–32.

Lowrance WT, Southwick A, Maschino AC, et al. Contemporary practice patterns of endoscopic surgical management for benign prostatic hyperplasia among urologists in the United States. *J Urol*. 2013;189(5):1811–1816.

Lue TF, Hellstrom WJ, McAninch JW, et al. Priapism: a refined approach to diagnosis and treatment. *J Urol*. 1986;136(1):104–108.

Lukacs B, Cornu JN, Aout M, et al. Management of lower urinary tract symptoms related to benign prostatic hyperplasia in real-life practice in france: a comprehensive population study. *Eur Urol*. 2013;64(3):493–501.

Lu-Yao GL, Barry MJ, Chang CH, et al. Transurethral resection of the prostate among Medicare beneficiaries in the United States: time trends and outcomes. Prostate Patient Outcomes Research Team (PORT). *Urology*. 1994;44(5):692–698 [discussion 698–699].

Lytton B, Emery JM, Harvard BM. The incidence of benign prostatic obstruction. *J Urol*. 1968;99(5):639–645.

Madsen PO, Naber KG. The importance of the pressure in the prostatic fossa and absorption of irrigating fluid during transurethral resection of the prostate. *J Urol*. 1973;109(3):446–452.

Magno C, Mucciardi G, Gali A, et al. Transurethral ethanol ablation of the prostate (TEAP): an effective minimally invasive treatment alternative to traditional surgery for symptomatic benign prostatic hyperplasia (BPH) in high-risk comorbidity patients. *Int Urol Nephrol*. 2008;40(4):941–946.

Mai KT, Isotalo PA, Green J, et al. Incidental prostatic adenocarcinomas and putative premalignant lesions in TURP specimens collected before and after the introduction of prostrate-specific antigen screening. *Arch Pathol Lab Med*. 2000;124(10):1454–1456.

Malaeb BS, Yu X, McBean AM, et al. National trends in surgical therapy for benign prostatic hyperplasia in the United States (2000–2008). *Urology*. 2012;79(5):1111–1116.

Malek RS, Kang HW, Peng YS, et al. Photoselective vaporization prostatectomy: experience with a novel 180 W 532 nm lithium triborate laser and fiber delivery system in living dogs. *J Urol*. 2011;185(2):712–718.

Mamoulakis C, Ubbink DT, de la Rosette JJ. Bipolar versus monopolar transurethral resection of the prostate: a systematic review and meta-analysis of randomized controlled trials. *Eur Urol*. 2009;56(5):798–809.

Mamoulakis C, Skolarikos A, Schulze M, et al. Results from an international multicentre double-blind randomized controlled trial on the perioperative efficacy and safety of bipolar vs monopolar transurethral resection of the prostate. *BJU Int*. 2012;109(2):240–248.

Marberger M, Chartier-Kastler E, Egerdie B, et al. A randomized double-blind placebo-controlled phase 2 dose-ranging study of onabotulinumtoxinA in men with benign prostatic hyperplasia. *Eur Urol*. 2013;63(3):496–503.

Maria G, Brisinda G, Civello IM, et al. Relief by botulinum toxin of voiding dysfunction due to benign prostatic hyperplasia: results of a randomized, placebo-controlled study. *Urology*. 2003;62(2):259–264 [discussion 264–265].

Masood S, Djaladat H, Kouriefs C, et al. The 12-year outcome analysis of an endourethral wallstent for treating benign prostatic hyperplasia. *BJU Int*. 2004;94(9):1271–1274.

Masumori N, Furuya R, Tanaka Y, et al. The 12-year symptomatic outcome of transurethral resection of the prostate for patients with lower urinary tract symptoms suggestive of benign prostatic obstruction compared to the urodynamic findings before surgery. *BJU Int*. 2010;105(10):1429–1433.

Matoka DJ, Averch TD. Predictability of irritative voiding symptoms following photoselective laser vaporization of the prostate. *Can J Urol*. 2007;14(5):3710–3714.

Mattiasson A, Wagrell L, Schelin S, et al. Five-year follow-up of feedback microwave thermotherapy versus TURP for clinical BPH: a prospective randomized multicenter study. *Urology*. 2007;69:91–96 [discussion 96–97].

Mayer EK, Kroeze SG, Chopra S, et al. Examining the “gold standard”: a comparative critical analysis of three consecutive decades of monopolar transurethral resection of the prostate (TURP) outcomes. *BJU Int*. 2012;110(11):1595–1601.

McConnell JD, Barry MJ, Bruskewitz RC, et al. Benign prostatic hyperplasia: diagnosis and treatment. *Clin Pract Guidel Quick Ref Guide Clin*. 1994;8:1–17.

McConnell JD, Bruskewitz R, Walsh P, et al. The effect of finasteride on the risk of acute urinary retention and the need for surgical treatment among men with benign prostatic hyperplasia. Finasteride Long-Term Efficacy and Safety Study Group. *N Engl J Med*. 1998;338(9):557–563.

McNeill SA, Hargreave TB, Roehrborn CG. Alfaur study group. Alfuzosin 10 mg once daily in the management of acute urinary retention: results of a double-blind placebo-controlled study. *Urology*. 2005;65(1):83–89 [discussion 89–90].

McVary KT, Roehrborn CG, Avins AL, et al. Update on AUA guideline on the management of benign prostatic hyperplasia. *J Urol*. 2011;185(5):1793–1803.

McVary KT, Gange SN, Shore ND, et al. Treatment of LUTS secondary to BPH while preserving sexual function: randomized controlled study of prostatic urethral lift. *J Sex Med*. 2014;11(1):279–287.

McVary KT, Roehrborn CG, Chartier-Kastler E, et al. A multicenter, randomized, double-blind, placebo controlled study of onabotulinumtoxinA 200 U to treat lower urinary tract symptoms in men with benign prostatic hyperplasia. *J Urol*. 2014;192(1):150–156.

McVary KT, Gange SN, Gittelman MC, et al. Minimally invasive prostate convective water vapor energy ablation: a multicenter, randomized, controlled study for the treatment of lower urinary tract symptoms secondary to benign prostatic hyperplasia. *J Urol*. 2016;195(5):1529–1538.

McVary KT, Gange SN, Gittelman MC, et al. Erectile and ejaculatory function preserved with convective water vapor energy treatment of lower urinary tract symptoms secondary to benign prostatic hyperplasia: randomized controlled study. *J Sex Med*. 2016;13(6):924–933.

Mebust WK, Holtgrewe HL, Cockett AT, et al. Transurethral prostatectomy: immediate and postoperative complications. A cooperative study of 13 participating institutions evaluating 3,885 patients. *J Urol*. 1989;141(2):243–247.

Mebust WK. Transurethral resection of the prostate and transurethral incision of the prostate. Lepor H, Lawson RK. *Prostate disease*. WB Saunders: Philadelphia, PA; 1993:150–163.

Meeks JJ, Maschino AC, McVary KT, et al. Clinically significant prostate cancer is rarely missed by ablative procedures of the prostate in men with prostate specific antigen less than 4 ng/ml. *J Urol*. 2013;189(1):111–115.

Meulen T, Zambon JV, Janknegt RA. Treatment of anastomotic strictures and urinary incontinence after radical prostatectomy with UroLume Wallstent and AMS 800 artificial sphincter. *J Endourol*. 1991;13(7):517–520.

Michielsen DP, Coomans D. Urethral strictures and bipolar transurethral resection in saline of the prostate: fact or fiction? *J Endourol*. 2010;24(8):1333–1337.

Millard RJ, Harewood LM, Tamaddon K. A study of the efficacy and safety of transurethral needle ablation (TUNA) treatment for benign prostatic hyperplasia. *Neurourol Urodyn*. 1996;15(6):619–629.

Minardi D, Galosi AB, Yehia M, et al. Transurethral resection versus minimally invasive treatments of benign prostatic hyperplasia: results of treatments. Our experience. *Arch Ital Urol Androl*. 2004;76(1):11–18.

Montorsi F, Naspro R, Salonia A, et al. Holmium laser enucleation versus transurethral resection of the prostate: results from a 2-center, prospective, randomized trial in patients with obstructive benign prostatic hyperplasia. *J Urol*. 2004;172(5 Pt 1):1926–1929.

Moody JA, Lingeman JE. Holmium laser enucleation for prostate adenoma greater than 100 gm. comparison to open prostatectomy. *J Urol*. 2001;165(2):459–462.

Morgagni GB. *The seats and causes of disease investigated by anatomy, book 3*. Johnson & Paine: London; 1760:460.

Muntener M, Aellig S, Kuettel R, et al. Sexual function after transurethral resection of the prostate (TURP): results of an independent prospective multicentre assessment of outcome. *Eur Urol*. 2007;52(2):510–515.

Mynderse LA, Roehrborn CG, Partin AW, et al. Results of a 5-year multicenter trial of a new generation cooled high energy transurethral microwave thermal therapy catheter for benign prostatic hyperplasia. *J Urol*. 2011;185(5):1804–1810.

Mynderse LA, Hanson D, Robb RA, et al. Rezūm system water vapor treatment for lower urinary tract symptoms/benign prostatic hyperplasia: validation of convective thermal energy transfer and characterization with magnetic resonance imaging and 3-dimensional renderings. *Urology*. 2015;86(1):122–127.

Narayan P, Tewari A, Garzotto M, et al. Transurethral VaporTrode electrovaporization of the prostate: physical principles, technique, and results. *Urology*. 1996;47(4):505–510.

Naspro R, Suardi N, Salonia A, et al. Holmium laser enucleation of the prostate versus open prostatectomy for prostates >70 g: 24-month follow-up. *Eur Urol*. 2006;50(3):563–568.

Naspro R, Bachmann A, Gilling P, et al. A review of the recent evidence (2006-2008) for 532-nm photoselective laser vaporisation and holmium laser enucleation of the prostate. *Eur Urol*. 2009;55:1345–1357.

Nawrocki JD, Bell TJ, Lawrence WT, et al. A randomized controlled trial of transurethral microwave thermotherapy. *Br J Urol*. 1997;79(3):389–393.

Nesbit RM. *Transurethral prostatectomy*. Charles C Thomas: Springfield, IL; 1943.

Netsch C, Becker B, Tiburtius C, et al. A prospective, randomized trial comparing thulium vapoenucleation with holmium laser enucleation of the prostate for the treatment of symptomatic benign prostatic obstruction: perioperative safety and efficacy. *World J Urol*. 2017;35(12):1913–1921.

Neuville P, Codas R, Ravier E, et al. Anticoagulation impact on bleeding risk during HoLEP: monocentric study of 156 patients]. *Prog Urol*. 2018;28(2):128–134.

Nielsen HO. Transurethral prostatotomy versus transurethral prostatectomy in benign prostatic hypertrophy. A prospective randomised study. *Br J Urol*. 1988;61(5):435–438.

Nielsen KT, Christensen MM, Madsen PO, et al. Symptom analysis and uroflowmetry 7 years after transurethral resection of the prostate. *J Urol*. 1989;142(5):1251–1253.

Nielsen JD, Holm-Nielsen A, Jespersen J, et al. The effect of low-dose acetylsalicylic acid on bleeding after transurethral prostatectomy—a prospective, randomized, double-blind, placebo-controlled study. *Scand J Urol Nephrol*. 2000;34(3):194–198.

Oester A, Madsen PO. Determination of absorption of irrigating fluid during transurethral resection of the prostate by means of radioisotopes. *J Urol*. 1969;102(6):714–719.

Oesterling JE, Kaplan SA, Epstein HB, et al. The North American experience with the UroLume endoprosthesis as a treatment for benign prostatic hyperplasia: long-term results. The North American UroLume Study Group. *Urology*. 1994;44(3):353–362.

Ohigashi T, Nakamura K, Nakashima J, et al. Long-term results of three different minimally invasive therapies for lower urinary tract symptoms due to benign prostatic hyperplasia: comparison at a single institute. *Int J Urol*. 2007;14(4):326–

330.

Ohnishi K. [A study of the physical properties of the prostate (second report)–the relationships between dysuria and the strength of the surgical capsule in benign prostatic hypertrophy]. *Nihon Hinyokika Gakkai Zasshi*. 1986;77(9):1388–1399.

Omar MI, Lam TB, Alexander CE, et al. Systematic review and meta-analysis of the clinical effectiveness of bipolar compared with monopolar transurethral resection of the prostate (TURP). *BJU Int*. 2014;113(1):24–35.

Orandi A. Transurethral incision of prostate (TUIP): 646 cases in 15 years–a chronological appraisal. *Br J Urol*. 1985;57(6):703–707.

Orandi A. Transurethral incision of prostate compared with transurethral resection of prostate in 132 matching cases. *J Urol*. 1987;138(4):810–815.

Orandi A. Transurethral resection versus transurethral incision of the prostate. *Urol Clin North Am*. 1990;17(3):601–612.

Paick JS, Um JM, Kim SW, et al. Influence of high-power potassium-titanyl-phosphate photoselective vaporization of the prostate on erectile function: a short-term follow-up study. *J Sex Med*. 2007;4(6):1701–1707.

Patankar S, Jamkar A, Dobhada S, et al. PlasmaKinetic Superpulse transurethral resection versus conventional transurethral resection of prostate. *J Endourol*. 2006;20(3):215–219.

Payr E. Presjod (Pregl's solution) in treatment of inoperable prostatic hypertrophy. *Munch Med Wochenschr*. 1936;83:381.

Perachino M, Bozzo W, Puppo P, et al. Does transurethral thermotherapy induce a long-term alpha blockade? An immunohistochemical study. *Eur Urol*. 1993;23(2):299–301.

Perera M, Roberts MJ, Doi SA, et al. Prostatic urethral lift improves urinary symptoms and flow while preserving sexual function for men with benign prostatic hyperplasia: a systematic review and meta-analysis. *Eur Urol*. 2015;67(4):704–713.

Perlmutter AP, Verdi J, Watson GM. Prostatic heat treatments for urinary outflow obstruction. *J Urol*. 1993;150(5 Pt 2):1603–1606.

Perlmutter AP, Muschter R, Razvi HA. Electrosurgical vaporization of the prostate in the canine model. *Urology*. 1995;46(4):518–523.

Perry MJ, Roodhouse AJ, Gidlow AB, et al. Thermo-expandable intraprostatic stents in bladder outlet obstruction: an 8-year study. *BJU Int*. 2002;90(3):216–223.

Peterson MD, Matlaga BR, Kim SC, et al. Holmium laser enucleation of the prostate for men with urinary retention. *J Urol*. 2005;174(3):998–1001 [discussion 1001].

Pfitzenmaier J, Gilfrich C, Pritsch M, et al. Vaporization of prostates of > or =80 mL using a potassium-titanyl-phosphate laser: midterm-results and comparison with prostates of <80 mL. *BJU Int*. 2008;102(3):322–327.

Pisco J, Bilhim T, Pinheiro LC, et al. Prostate embolization as an alternative to open surgery in patients with large prostate and moderate to severe lower urinary tract symptoms. *J Vasc Interv Radiol*. 2016;27(5):700–708.

Pisco JM, Pinheiro LC, Bilhim T, et al. Prostatic arterial embolization to treat benign prostatic hyperplasia. *J Vasc Interv Radiol*. 2011;22(1):11–19 [quiz 20].

Pisco JM, Rio Tinto H, Campos Pinheiro L, et al. Embolisation of prostatic arteries as treatment of moderate to severe lower urinary symptoms (LUTS) secondary to benign hyperplasia: results of short- and mid-term follow-up. *Eur Radiol*. 2013;23(9):2561–2572.

Placer J, Gelabert-Mas A, Vallmanya F, et al. Holmium laser enucleation of prostate: outcome and complications of self-taught learning curve. *Urology*. 2009;73(5):1042–1048.

Plante MK, Folsom JB, Zvara P. Prostatic tissue ablation by injection: a literature review. *J Urol*. 2004;172(1):20–26.

Plante MK, Marks LS, Anderson R, et al. Phase I/II examination of transurethral ethanol ablation of the prostate for the treatment of symptomatic benign prostatic hyperplasia. *J Urol*. 2007;177(3):1030–1035 [discussion 1035].

Plante MK, Arscott WT, Folsom JB, et al. Ethanol promotes cytotoxic effects of tumor necrosis factor-related apoptosis-inducing ligand through induction of reactive oxygen species in prostate cancer cells. *Prostate Cancer Prostatic Dis*. 2013;16(1):16–22.

Porpiglia F, Fiori C, Bertolo R, et al. Temporary implantable nitinol device (TIND): a novel, minimally invasive treatment for relief of lower urinary tract symptoms (LUTS) related to benign prostatic hyperplasia (BPH): feasibility, safety and functional results at 1 year of follow-up. *BJU Int*. 2015;116(2):278–287.

Poulakis V, Dahm P, Witzsch U, et al. Transurethral electrovaporization vs transurethral resection for symptomatic prostatic obstruction: a meta-analysis. *BJU Int*. 2004;94(1):89–95.

Poulakis V, Ferakis N, Witzsch U, et al. Erectile dysfunction after transurethral prostatectomy for lower urinary tract symptoms: results from a center with over 500 patients. *Asian J Androl*. 2006;8(1):69–74.

Raj MD, McDonald C, Brooks AJ, et al. Stopping anticoagulation before TURP does not appear to increase perioperative cardiovascular complications. *Urology*. 2011;78(6):1380–1384.

Ramon J, Lynch TH, Eardley I, et al. Transurethral needle ablation of the prostate for the treatment of benign prostatic hyperplasia: a collaborative multicentre study. *Br J Urol*. 1997;80(1):128–134 [discussion 134–135].

Rampoldi A, Barbosa F, Secco S, et al. Prostatic artery embolization as an alternative to indwelling bladder catheterization to manage benign prostatic hyperplasia in poor surgical candidates. *Cardiovasc Intervent Radiol*. 2017;40(4):530–536.

Ramsey EW, Miller PD, Parsons K. A novel transurethral microwave thermal ablation system to treat benign prostatic hyperplasia: results of a prospective multicenter clinical trial. *J Urol*. 1997;158(1):112–118 [discussion 118–119].

Reich O, Gratzke C, Bachmann A, et al. Morbidity, mortality and early outcome of transurethral resection of the prostate: a prospective multicenter evaluation of 10,654 patients. *J Urol*. 2008;180(1):246–249.

Reich O, Schlenker B, Gratzke C, et al. Plasma vaporisation of the prostate: initial clinical results. *Eur Urol*. 2010;57(4):693–697.

Rieken M, Ebinger Mundorff N, Bonkat G, et al. Complications of laser prostatectomy: a review of recent data. *World J Urol*. 2010;28(1):53–62.

Rieken M, Bonkat G, Muller G, et al. The effect of increased maximum power output on perioperative and early postoperative outcome in photoselective vaporization of the prostate. *Lasers Surg Med*. 2013;45(1):28–33.

Robert G, Descazeaud A, Delongchamps NB, et al. Transurethral plasma vaporization of the prostate: 3-month functional outcome and complications. *BJU Int*. 2012;110(4):555–560.

Robson MC. The incidence of benign prostatic hyperplasia and prostatic carcinoma in cirrhosis of the liver. *J Urol*. 1964;92:307–310.

Roehrborn CG, Preminger G, Newhall P, et al. Microwave thermotherapy for benign prostatic hyperplasia with the Dornier Urowave: results of a randomized, double-blind, multicenter, sham-controlled trial. *Urology*. 1998;51(1):19–28.

Roehrborn CG, Issa MM, Bruskewitz RC, et al. Transurethral needle ablation for benign prostatic hyperplasia: 12-month results of a prospective, multicenter U.S. study. *Urology*. 1998;51(3):415–421.

Roehrborn CG, Burkhard FC, Bruskewitz RC, et al. The effects of transurethral needle ablation and resection of the prostate on pressure flow urodynamic parameters: analysis of the United States randomized study. *J Urol*. 1999;162(1):92–97.

Roehrborn CG, Boyle P, Nickel JC, et al. Efficacy and safety of a dual inhibitor of 5-alpha-reductase types 1 and 2 (dutasteride) in men with benign prostatic hyperplasia. *Urology*. 2002;60(3):434–441.

Roehrborn CG, Gange SN, Shore ND, et al. The prostatic urethral lift for the treatment of lower urinary tract symptoms associated with prostate enlargement due to benign prostatic hyperplasia: the L.I.F.T. Study. *J Urol*. 2013;190(6):2161–2167.

Roehrborn CG, Gange SN, Gittelman MC, et al. Convective radiofrequency water vapor thermal therapy with Rezum system: durable two-year results of randomized controlled and prospective crossover studies for treatment of lower urinary tract symptoms due to benign prostatic hyperplasia. *J Urol*. 2017;197(6):1507–1516.

Rolnick HC, Arnheim FK. An anatomic study of the external urethral sphincter in relation to prostatic surgery. *J Urol*. 1949;61(3):591–603.

Rosario DJ, Woo H, Potts KL, et al. Safety and efficacy of transurethral needle ablation of the prostate for symptomatic outlet obstruction. *Br J Urol*. 1997;80(4):579–586.

Rukstalis D, Rashid P, Bogache WK, et al. 24-month durability after crossover to the prostatic urethral lift from randomised, blinded sham. *BJU Int*. 2016;118(Suppl 3):14–22.

Ruszat R, Wyler S, Forster T, et al. Safety and effectiveness of photoselective vaporization of the prostate (PVP) in patients on ongoing oral anticoagulation. *Eur Urol*. 2007;51(4):1031–1038 [discussion 1038–1041].

Ruszat R, Seitz M, Wyler SF, et al. GreenLight laser vaporization of the prostate: single-center experience and long-term results after 500 procedures. *Eur Urol*. 2008;54(4):893–901.

Ryder KW, Olson JF, Kahnoski RJ, et al. Hyperammonemia after transurethral resection of the prostate: a report of 2 cases. *J Urol*. 1984;132(5):995–997.

Sakr M, Eid A, Shoukry M, et al. Transurethral ethanol injection therapy of benign prostatic hyperplasia: four-year follow-up. *Int J Urol*. 2009;16(2):196–201.

Sandhu JS, Ng CK, Gonzalez RR, et al. Photoselective laser vaporization prostatectomy in men receiving anticoagulants. *J Endourol*. 2005;19(10):1196–1198.

Sarmina I, Resnick MI. Obstructive uropathy in patients with benign prostatic hyperplasia. *J Urol*. 1989;141(4):866–869.

Schatzl G, Madersbacher S, Lang T, et al. The early postoperative morbidity of transurethral resection of the prostate and of 4 minimally invasive treatment alternatives. *J Urol*. 1997;158(1):105–110 [discussion 110–111].

Schatzl G, Madersbacher S, Djavan B, et al. Two-year results of transurethral resection of the prostate versus four “less invasive” treatment options. *Eur Urol*. 2000;37(6):695–701.

Schomacker KT, Domankevitz Y, Flotte TJ, et al. Co:MgF2 laser ablation of tissue: effect of wavelength on ablation threshold and thermal damage. *Lasers Surg Med*. 1991;11(2):141–151.

Schroeck FR, Hollingsworth JM, Hollenbeck BK, et al. Differential adoption of laser prostatectomy for treatment of benign prostatic hyperplasia. *Urology*. 2013;81(6):1177–1182.

Schulman CC, Zlotta AR, Rasor JS, et al. Transurethral needle ablation (TUNA): safety, feasibility, and tolerance of a new office procedure for treatment of benign prostatic hyperplasia. *Eur Urol*. 1993;24(3):415–423.

Seki N, Mochida O, Kinukawa N, et al. Holmium laser enucleation for prostatic adenoma: analysis of learning curve over the course of 70 consecutive cases. *J Urol*. 2003;170(5):1847–1850.

Sethi K, Bozin M, Jabane T, et al. Thermo-expandable prostatic stents for bladder outlet obstruction in the frail and elderly population: an underutilized procedure? *Investig Clin Urol*. 2017;58(6):447–452.

Shah HN, Mahajan AP, Hegde SS, et al. Peri-operative complications of holmium laser enucleation of the prostate: experience in the first 280 patients, and a review of literature. *BJU Int*. 2007;100(1):94–101.

Silva J, Pinto R, Carvallho T, et al. Mechanisms of prostate atrophy after glandular botulinum neurotoxin type a injection: an experimental study in the rat. *Eur Urol*. 2009;56(1):134–140.

Singh H, Desai MR, Shrivastav P, et al. Bipolar versus monopolar transurethral resection of prostate: randomized controlled study. *J Endourol*. 2005;19(3):333–338.

Sirls LT, Ganabathi K, Zimmern PE, et al. Transurethral incision of the prostate: an objective and subjective evaluation of long-term efficacy. *J Urol*. 1993;150(5 Pt 2):1615–1621.

Skinner TAA, Leslie RJ, Steele SS, et al. Randomized, controlled trial of laser vs bipolar plasma vaporization treatment of benign prostatic hyperplasia. *Can Urol Assoc J*.

2017;11(6):194–198.

Soonawalla PF, Pardanani DS. Transurethral incision versus transurethral resection of the prostate. A subjective and objective analysis. *Br J Urol*. 1992;70(2):174–177.

Steele GS, Sleep DJ. Transurethral needle ablation of the prostate: a urodynamic based study with 2-year followup. *J Urol*. 1997;158(5):1834–1838.

Stone PA, Campbell JE. Complications related to femoral artery access for transcatheter procedures. *Vasc Endovascular Surg*. 2012;46(8):617–623.

Szlauer R, Gotschl R, Razmaria A, et al. Endoscopic vaporesection of the prostate using the continuous-wave 2-microm thulium laser: outcome and demonstration of the surgical technique. *Eur Urol*. 2009;55(2):368–375.

Talwar GL, Pande SK. Injection treatment of enlarged prostate. *Br J Surg*. 1966;53(5):421–427.

Tan AH, Gilling PJ, Kennett KM, et al. A randomized trial comparing holmium laser enucleation of the prostate with transurethral resection of the prostate for the treatment of bladder outlet obstruction secondary to benign prostatic hyperplasia in large glands (40 to 200 grams). *J Urol*. 2003;170(4 Pt 1):1270–1274.

Tan A, Liao C, Mo Z, et al. Meta-analysis of holmium laser enucleation versus transurethral resection of the prostate for symptomatic prostatic obstruction. *Br J Surg*. 2007;94(10):1201–1208.

Tang K, Xu Z, Xia D, et al. Early outcomes of thulium laser versus transurethral resection of the prostate for managing benign prostatic hyperplasia: a systematic review and meta-analysis of comparative studies. *J Endourol*. 2014;28(1):65–72.

Taube M, Gajraj H. Trial without catheter following acute retention of urine. *Br J Urol*. 1989;63(2):180–182.

Taylor K, Filgate R, Guo DY, et al. A retrospective study to assess the morbidity associated with transurethral prostatectomy in patients on antiplatelet or anticoagulant drugs. *BJU Int*. 2011;108(Suppl 2):45–50.

Te AE, Kaplan SA. Transurethral electrovaporization of the prostate. *Mayo Clin Proc*. 1998;73(7):691–695.

Te AE, Malloy TR, Stein BS, et al. Photoselective vaporization of the prostate for the treatment of benign prostatic hyperplasia: 12-month results from the first United States multicenter prospective trial. *J Urol*. 2004;172(4 Pt 1):1404–1408.

Tefekli A, Muslumanoglu AY, Baykal M, et al. A hybrid technique using bipolar energy in transurethral prostate surgery: a prospective, randomized comparison. *J Urol*. 2005;174(4 Pt 1):1339–1343.

ten Cate H, Henny CP, ten Cate JW, et al. Randomized double-blind, placebo controlled safety study of a low molecular weight heparinoid in patients undergoing transurethral resection of the prostate. *Thromb Haemost*. 1987;57(1):92–96.

Thalmann GN, Graber SF, Bitton A, et al. Transurethral thermotherapy for benign prostatic hyperplasia significantly decreases infravesical obstruction: results in 134 patients after 1 year. *J Urol*. 1999;162(2):387–393.

Thangasamy IA, Chalasani V, Bachmann A, et al. Photoselective vaporisation of the prostate using 80-W and 120-W laser versus transurethral resection of the prostate for benign prostatic hyperplasia: a systematic review with meta-analysis from 2002 to 2012. *Eur Urol*. 2012;62(2):315–323.

Thomas JA, Tubaro A, Barber N, et al. A multicenter randomized noninferiority trial comparing GreenLight-XPS laser vaporization of the prostate and transurethral resection of the prostate for the treatment of benign prostatic obstruction: two-yr outcomes of the GOLIATH Study. *Eur Urol*. 2016;69(1):94–102.

Thompson IM. Transurethral surgery. Glenn JF. *Urologic surgery*. 2nd ed. Harper & Row: Hagerstown, MD; 1975:470.

Thurston AV, Briant SL. Aspirin and post-prostatectomy haemorrhage. *Br J Urol*. 1993;71(5):574–576.

Tkocz M, Prajsner A. Comparison of long-term results of transurethral incision of the prostate with transurethral resection of the prostate, in patients with benign prostatic hypertrophy. *Neurourol Urodyn*. 2002;21(2):112–116.

Tombal B, De Visccher L, Cosyns JP, et al. Assessing the risk of unsuspected prostate cancer in patients with benign prostatic hypertrophy: a 13-year retrospective study of the incidence and natural history of T1a-T1b prostate cancers. *BJU Int*. 1999;84(9):1015–1020.

Turner-Warwick R. A urodynamic review of bladder outlet obstruction in the male and its clinical implications. *Urol Clin North Am*. 1979;6(1):171–192.

Tyson MD, Lerner LB. Safety of holmium laser enucleation of the prostate in anticoagulated patients. *J Endourol*. 2009;23(8):1343–1346.

Valdivieso R, Meyer CP, Hueber PA, et al. Assessment of energy density usage during 180W lithium triborate laser photoselective vaporization of the prostate for benign prostatic hyperplasia. Is there an optimum amount of kilo-Joules per gram of prostate? *BJU Int*. 2016;118(4):633–640.

Vela-Navarrete R, Gonzalez-Enguita C, Garcia-Cardoso JV, et al. The impact of medical therapy on surgery for benign prostatic hyperplasia: a study comparing changes in a decade (1992–2002). *BJU Int*. 2005;96(7):1045–1048.

Vivien A, Lazard T, Rauss A, et al. Infection after transurethral resection of the prostate: variation among centers and correlation with a long-lasting surgical procedure.

Association pour la Recherche en Anesthesie-Reanimation. *Eur Urol*. 1998;33(4):365–369.

Vujaskovic Z, McChesney Gillette S, Powers BE, et al. Effects of intraoperative hyperthermia on canine sciatic nerve: histopathologic and morphometric studies. *Int J Hyperthermia*. 1994;10(6):845–855.

Wagrell L, Schelin S, Nordling J, et al. Feedback microwave thermotherapy versus TURP for clinical BPH—a randomized controlled multicenter study. *Urology*. 2002;60(2):292–299.

Walmsley K, Kaplan SA. Transurethral microwave thermotherapy for benign prostate hyperplasia: separating truth from marketing hype. *J Urol*. 2004;172(4 Pt 1):1249–1255.

Wang M, Guo L, Duan F, et al. Prostatic arterial embolization for the treatment of lower urinary tract symptoms as a result of large benign prostatic hyperplasia: a prospective single-center investigation. *Int J Urol*. 2015;22:766–772.

Warren JW, Tenney JH, Hoopes JM, et al. A prospective microbiologic study of bacteriuria in patients with chronic indwelling urethral catheters. *J Infect Dis*. 1982;146(6):719–723.

Wasson JH, Reda DJ, Bruskewitz RC, et al. A comparison of transurethral surgery with watchful waiting for moderate symptoms of benign prostatic hyperplasia. The Veterans Affairs Cooperative Study Group on Transurethral Resection of the Prostate. *N Engl J Med*. 1995;332(2):75–97.

Wasson JH, Bubolz TA, Lu-Yao GL, et al. Transurethral resection of the prostate among medicare beneficiaries: 1984 to 1997. For the Patient Outcomes Research Team for Prostatic Diseases. *J Urol*. 2000;164(4):1212–1215.

Welliver C, Kottwitz M, Feustel P, et al. Clinically and statistically significant changes seen in sham surgery arms of randomized, controlled benign prostatic hyperplasia surgery trials. *J Urol*. 2015;194(6):1682–1687.

Welliver C, Helo S, McVary KT. Technique considerations and complication management in transurethral resection of the prostate and photoselective vaporization of the prostate. *Transl Androl Urol*. 2017;6(4):695–703.

Wilson LC, Gilling PJ, Williams A, et al. A randomised trial comparing holmium laser enucleation versus transurethral resection in the treatment of prostates larger than 40 grams: results at 2 years. *Eur Urol*. 2006;50(3):569–573.

Wolf JS Jr, Bennett CJ, Dmochowski RR, et al. Best practice policy statement on urologic surgery antimicrobial prophylaxis. *J Urol*. 2008;179(4):1379–1390.

Woo HH, Hossack TA. Photoselective vaporization of the prostate with the 120-W lithium triborate laser in men taking coumadin. *Urology*. 2011;78(1):142–145.

Woo H, Reich O, Bachmann A, et al. Outcome of GreenLight HPS 120-W laser therapy in specific patient populations: those in retention, on anticoagulants, and with large prostates (≥80 ml). *Eur Urol Supp*. 2008;7(4):378–383.

Woo HH, Bolton DM, Laborde E, et al. Preservation of sexual function with the prostatic urethral lift: a novel treatment for lower urinary tract symptoms secondary to benign prostatic hyperplasia. *J Sex Med*. 2012;9(2):568–575.

Woo HH, Chin PT, McNicholas TA, et al. Safety and feasibility of the prostatic urethral lift: a novel, minimally invasive treatment for lower urinary tract symptoms (LUTS) secondary to benign prostatic hyperplasia (BPH). *BJU Int*. 2011;108(1):82–88.

Xia SJ, Zhuo J, Sun XW, et al. Thulium laser versus standard transurethral resection of the prostate: a randomized prospective trial. *Eur Urol*. 2008;53(2):382–389.

Xia SJ. Two-micron (thulium) laser resection of the prostate-tangerine technique: a new method for BPH treatment. *Asian*

J Androl. 2009;11(3):277–281.

Yang Z, Wang X, Liu T. Thulium laser enucleation versus plasmakinetic resection of the prostate: a randomized prospective trial with 18-month follow-up. *Urology*. 2013;81(2):396–400.

Yu X, Elliott SP, Wilt TJ, et al. Practice patterns in benign prostatic hyperplasia surgical therapy: the dramatic increase in minimally invasive technologies. *J Urol*. 2008;180(1):241–245 [discussion 245].

Zhang F, Shao Q, Herrmann TR, et al. Thulium laser versus holmium laser transurethral enucleation of the prostate: 18-month follow-up data of a single center. *Urology*. 2012;79(4):869–874.

Zlotta AR, Giannakopoulos X, Maehlum O, et al. Long-term evaluation of transurethral needle ablation of the prostate (TUNA) for treatment of symptomatic benign prostatic hyperplasia: clinical outcome up to five years from three centers. *Eur Urol*. 2003;44(1):89–93.

147

Simple Prostatectomy

Open and Robotic-Assisted Laparoscopic Approaches

Misop Han MD, MS, Alan W. Partin MD, PhD

The treatment options for bladder outlet obstruction resulting from benign prostatic hyperplasia have greatly expanded over the past three decades with the development of improved medical and minimally invasive surgical therapies. Newer minimally invasive procedures include visual laser ablation of the prostate (Cowles et al., 1995), transurethral electrovaporization of the prostate (Kaplan et al., 1996), transurethral needle ablation (Campo et al., 1997; Schulman et al. 1993), transurethral microwave thermotherapy (Ogden et al., 1993), interstitial laser coagulation (Muschter and Hofstetter, 1995), bipolar transurethral resection of the prostate (bipolar TURP) (Botto et al., 2001; Eaton and Francis, 2002), and transurethral incision of the prostate (Cornford et al., 1997). However, these approaches are usually reserved for men with moderate symptoms and a small- to medium-sized (up to 75 g) prostate gland (Reich et al., 2006). For larger prostate glands, open simple prostatectomy has been frequently performed, although it is usually associated with a longer hospital stay and a larger blood loss (McVary et al., 2011). Lately, holmium laser enucleation of the prostate (HoLEP) with the holmium:yttrium-aluminum-garnet (Ho:YAG) laser has been performed as a minimally invasive alternative to open surgery (Comat et al., 2017; Gilling et al., 1998). However, the learning curve with HoLEP is considered steep (Robert et al., 2016). Most recently, as urologists have gained experience in minimally invasive therapy, a simple prostatectomy has been performed more frequently using a robotic-assisted laparoscopic approach (Holden and Parsons, 2016; Sotelo et al., 2008). **This chapter describes simple prostatectomy technique using an open and robotic-assisted laparoscopic**

approach.

For patients with acute urinary retention, persistent or recurrent urinary tract infections (UTIs), severe hemorrhage from the prostate, bladder calculi, severe symptoms unresponsive to medical therapy, and/or renal insufficiency as a result of chronic bladder outlet obstruction, TURP or simple prostatectomy is indicated. **When compared with TURP, simple prostatectomy offers the advantages of a lower retreatment rate and more complete removal of the prostatic adenoma under direct vision and avoids the risk for dilutional hyponatremia (the TUR syndrome) that occurs in approximately 2% of patients undergoing traditional monopolar TURP** (Roos et al., 1989). Several contemporary series have demonstrated objective improvement in urinary symptoms after simple prostatectomy (Lucca et al., 2015; Varkarakis et al., 2004). **The disadvantages of open simple prostatectomy, compared with those of TURP, include the potential for perioperative hemorrhage, the need for a lower midline incision, and a resultant longer hospitalization and convalescence period. However, robotic-assisted laparoscopic simple prostatectomy results in a significantly decreased risk for perioperative hemorrhage and transfusion** (Holden and Parsons, 2016).

Open simple prostatectomy can be performed by either the retropubic or the suprapubic approach. **In retropubic prostatectomy, the enucleation of the hyperplastic prostatic adenoma is achieved through a direct incision of the anterior prostatic pseudocapsule.** This approach to open simple prostatectomy was popularized by Terrence Millin (Millin, 1945). **The advantages of this procedure over the suprapubic approach are (1) excellent anatomic exposure of the prostate, (2) direct visualization of the prostatic adenoma during enucleation to ensure complete removal, (3) precise transection of the urethra distally to preserve urinary continence, (4) clear and immediate visualization of the prostatic fossa after enucleation to control bleeding, and (5) minimal to no surgical trauma to the urinary bladder. The disadvantage of the retropubic approach, as compared with the suprapubic prostatectomy, is that direct access to the bladder is not achieved.** This may be important when one considers excising a concomitant bladder diverticulum or removing bladder calculi. The suprapubic approach also may be the preferred method when the obstructive prostatic enlargement includes a large intravesical median lobe.

Suprapubic prostatectomy, or transvesical prostatectomy, consists of the enucleation of the hyperplastic prostatic adenoma through an

extraperitoneal incision of the lower anterior bladder wall. This approach to open prostatectomy was first performed by Eugene Fuller in New York in 1894; it was later popularized by Peter Freyer in London, United Kingdom, who described the procedure in 1900 and later reported the results of his first 1000 patients in 1912 (Freyer, 1900, 1912). The major advantage of this suprapubic procedure over the retropubic approach is that it allows direct visualization of the bladder neck and bladder mucosa. **As a result, this operation is ideally suited for patients with (1) a large median lobe protruding into the bladder, (2) a clinically significant bladder diverticulum, or (3) large bladder calculi. The disadvantage, compared with the retropubic approach, is that direct visualization of the apical prostatic adenoma is reduced. Furthermore, hemostasis may be more difficult because of inadequate visualization of the entire prostatic fossa after enucleation.**

Since the performance of the initial laparoscopic radical prostatectomy in 1997 (Schuessler et al., 1997) and the introduction of the da Vinci Surgical System (Intuitive Surgical, Sunnyvale, CA) in 2000, the minimally invasive approach, especially the robotic approach, for radical prostatectomy has gained wide popularity. As urologic surgeons gain more experience with robotic instruments, the robotic-assisted laparoscopic simple prostatectomy has gained acceptance (Holden and Parsons 2016; Sotelo et al., 2008). **The major advantages of the robotic-assisted laparoscopic simple prostatectomy approach over the open approaches are excellent hemostasis, negligible need for transfusion, shorter hospital stay, and better visualization because of pneumoperitoneum and magnification.** This approach also can manage a large median lobe, bladder diverticulum, or large bladder stones. **The disadvantages of robotic-assisted laparoscopic simple prostatectomy, compared with the open approaches, include the need for a general anesthesia and a longer operative time, especially in the initial experience** (Matei et al., 2012)**. Therefore, robotic-assisted laparoscopic simple prostatectomy should be considered by urologic surgeons who have extensive experience in robotic surgery, especially in robotic-assisted laparoscopic radical prostatectomy.**

Indications for Simple Prostatectomy

The indications for prostatectomy, by either an open or robotic-assisted laparoscopic approach or transurethral resection, include (1) acute urinary retention; (2) recurrent or persistent UTIs; (3) significant symptoms from bladder outlet obstruction not responsive to medical therapy; (4) recurrent gross hematuria of prostatic origin; (5) pathophysiologic changes of the kidneys, ureters, or bladder secondary to prostatic obstruction; and (6) bladder calculi secondary to obstruction.

Simple prostatectomy should be considered when the obstructive tissue is estimated to weigh more than 75 g. If sizable bladder diverticula justify removal, suprapubic or robotic prostatectomy and diverticulectomy should be performed concurrently. If the prostatectomy is performed without the diverticulectomy, incomplete emptying of the bladder diverticulum and subsequent, persistent infection may occur. Large bladder calculi that are not amenable to easy transurethral fragmentation also may be removed during the procedure. Simple prostatectomy should be considered when a patient presents with ankylosis of the hip or other orthopedic conditions that prevent proper positioning for TURP. Also, it may be wise to perform a simple prostatectomy in men with recurrent or complex urethral conditions, such as urethral stricture or previous hypospadias repair, to avoid the urethral trauma associated with TURP. Finally, the association of an inguinal hernia with an enlarged prostate suggests a simple procedure, because the hernia may be repaired by the same lower abdominal incision (Brunocilla et al., 2005; Schlegel and Walsh, 1987) **or laparoscopically/robotically** (Do et al., 2011; Nakamura et al., 2011)**.**

Contraindications to simple prostatectomy include a small fibrous gland, the presence of significant prostate cancer, and previous pelvic surgery that may obliterate access to the prostate gland.

Preoperative Evaluation

In deciding whether to perform a simple prostatectomy for symptomatic obstruction resulting from benign prostatic hyperplasia, it may be necessary to consider the upper and lower urinary tracts. Usually the patient will have already completed the International Prostate Symptom Score (IPSS) questionnaire and had a peak urinary flow rate determination. The postvoid residual urine volume also may have been verified with abdominal ultrasonography. **A cystoscopic examination is not indicated in the routine evaluation of a patient with obstructive voiding symptoms**. **However, cystoscopy should be performed in men with hematuria, suspected urethral stricture, and bladder calculus or diverticulum.** It also can be helpful in confirming the presence of a large median lobe or in assessing the length of the prostatic urethra.

Before performing a simple prostatectomy, the presence of significant prostate cancer should be determined. All men should undergo a digital rectal examination and have a serum prostate-specific antigen determination. If the digital rectal examination detects induration or nodularity, or the serum prostate-specific antigen level is elevated, a biopsy of the prostate gland should be performed. **Men participating in an active surveillance program for a very low-risk prostate cancer may consider a simple prostatectomy for symptomatic obstruction if they clearly understand the potential risks and benefits of the surgery. The upper urinary tracts should be evaluated preoperatively in men with known renal disease, abnormal renal function, recurrent UTI, or hematuria.**

Before surgery, the patient should undergo a complete medical evaluation consisting of a detailed history, thorough physical examination, and appropriate laboratory assessment.

Men in urinary retention should have an evaluation of renal function. If the serum creatinine value is elevated, surgery should be delayed until this parameter stabilizes. Urinalysis is performed to rule out a UTI, and a urine specimen should be sent for culture and sensitivity if an infection is suspected. If an infection is present, appropriate antimicrobial therapy must be instituted before surgery to prevent urinary sepsis (Serretta et al., 2002).

Historically, 3% to 10% of men undergoing an open simple prostatectomy will require 1 or more units of blood in the perioperative period (Serretta et al., 2002; Varkarakis et al., 2004; Zargooshi, 2007). Thus **it may be prudent to have 1 or**

2 units of blood available intraoperatively for an open approach. For a robotic-assisted laparoscopic simple prostatectomy approach, type and screen is sufficient.

Finally, the patient must be informed of the benefits and risks associated with simple prostatectomy and written informed consent obtained. The benefit to be achieved is improved urination. **Potential risks include urinary incontinence, erectile dysfunction, retrograde ejaculation, UTI, injury to adjacent structures, bladder neck contracture, urethral stricture, and the need for a blood transfusion. Other potential untoward effects include deep vein thrombosis and pulmonary embolus. For a robotic or laparoscopic approach, open conversion also should be listed as a rare, yet potential, risk.**

Operating Day Preparation

The patient is placed on a clear liquid diet for 1 day before the procedure and self-administers an oral bowel preparation the day before the surgery. He is kept without oral intake after midnight and self-administers a Fleet enema the morning of surgery. The type of anesthesia to be used and the risks associated with it are discussed and finalized with the patient and his family in conjunction with the anesthesiologist. One dose of a second-generation cephalosporin is administered before making the incision. Sequential compression devices in the lower extremities are used to minimize the risk for deep vein thrombosis.

Surgical Technique

Anesthesia

The preferred anesthesia is general endotracheal anesthesia. Spinal or epidural anesthesia may be used only in an open approach when there is a medical or anatomic contraindication to general anesthesia or when the patient simply prefers regional anesthesia.

Open Simple Prostatectomy (Retropubic and Suprapubic Approach)

Proper Positioning of the Patient

Once anesthesia has been induced, the patient is positioned on the operating table in the supine position. If a cystoscopic examination is to be performed, the patient is prepared and draped in the usual manner for a transurethral diagnostic procedure. Flexible cystoscopy, in this situation, will obviate major repositioning of the patient. After the cystoscopy the table is placed in a mild Trendelenburg position without extension.

Incision and Development of the Space of Retzius

The suprapubic area is shaved, prepared, and draped in the usual sterile manner. A 22-Fr urethral catheter with a 30-mL balloon is passed into the bladder and connected to a sterile closed drainage system, and the balloon is inflated with 30 mL of saline. A lower midline incision from the umbilicus to the pubic symphysis is made. It is deepened through the subcutaneous tissue. **The linea alba is incised, allowing the rectus abdominis muscles to be separated in the midline. The transversalis fascia is incised sharply to expose the space of Retzius.** At the superior aspect of the wound, the posterior rectus abdominis fascia is incised above the semicircular line to the level of the umbilicus, and the peritoneum is mobilized cephalad starting at the pubic symphysis and swept anterolaterally. The pelvis is inspected for any abnormalities, and the inguinal area is examined for hernias. If a hernia is identified, it can be repaired using the preperitoneal approach (Schlegel and Walsh, 1987). A self-retaining Balfour retractor is placed in the incision and widened.

Retropubic Simple Prostatectomy

Exposure of the Prostate

A well-padded, malleable blade is connected to the Balfour retractor and used to displace the bladder posteriorly and superiorly. The anterior surface of the bladder and prostate are exposed. With the use of DeBakey forceps and Metzenbaum scissors, the preprostatic adipose tissue is gently removed to expose the superficial branch of the dorsal vein complex and the puboprostatic ligaments (Fig. 147.1).

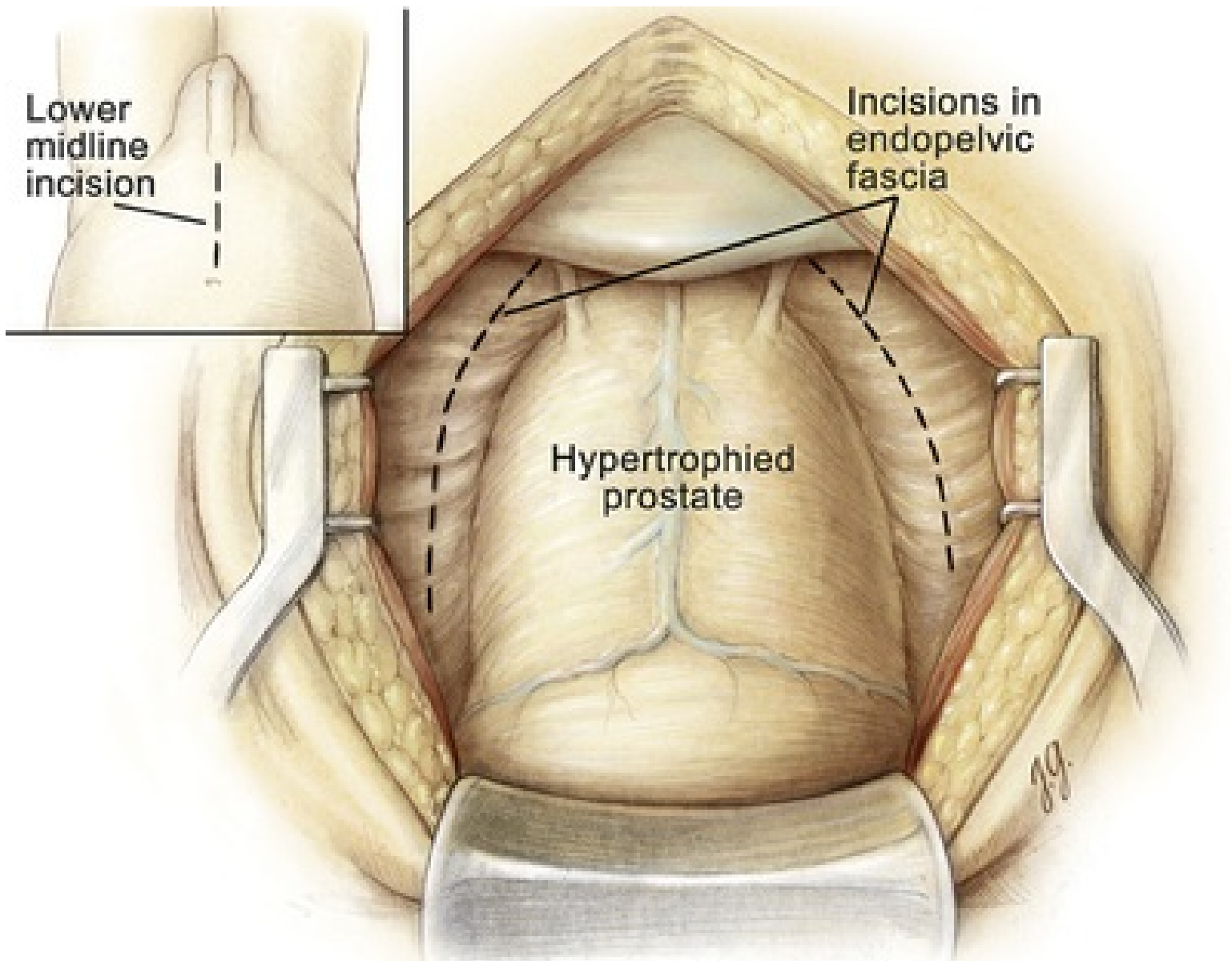

FIG. 147.1 Retropubic simple prostatectomy. The space of Retzius has been opened, and the periprostatic adipose tissue has been dissected free from the superficial branch of the dorsal vein complex. The endopelvic fascia is incised bilaterally *(dotted lines)*, and the puboprostatic ligaments are transected bilaterally. (© Brady Urological Institute.)

Hemostatic Maneuvers

Before proceeding with enucleation of the prostatic adenoma, it is important to achieve complete control of the dorsal vein complex and the lateral pedicles at the bladder neck (the main arterial blood supply to the prostate gland) (Walsh and Oesterling, 1990). To accomplish this task, the endopelvic fascia is incised laterally, and the puboprostatic ligaments are partially transected, similar to the maneuver in an anatomic radical retropubic prostatectomy (Reiner and Walsh, 1979). In patients with marked prostatic enlargement, this maneuver can be easier because the enlarged prostate gland protrudes out from beneath the pubic symphysis. A 3-0 Monocryl suture on a ⅝-inch circle-tapered needle is passed in the avascular plane between the urethra and the dorsal vein complex at the apex of the prostate and tied (Fig. 147.2A). The superficial branch of the dorsal vein at the bladder should be coagulated or ligated.

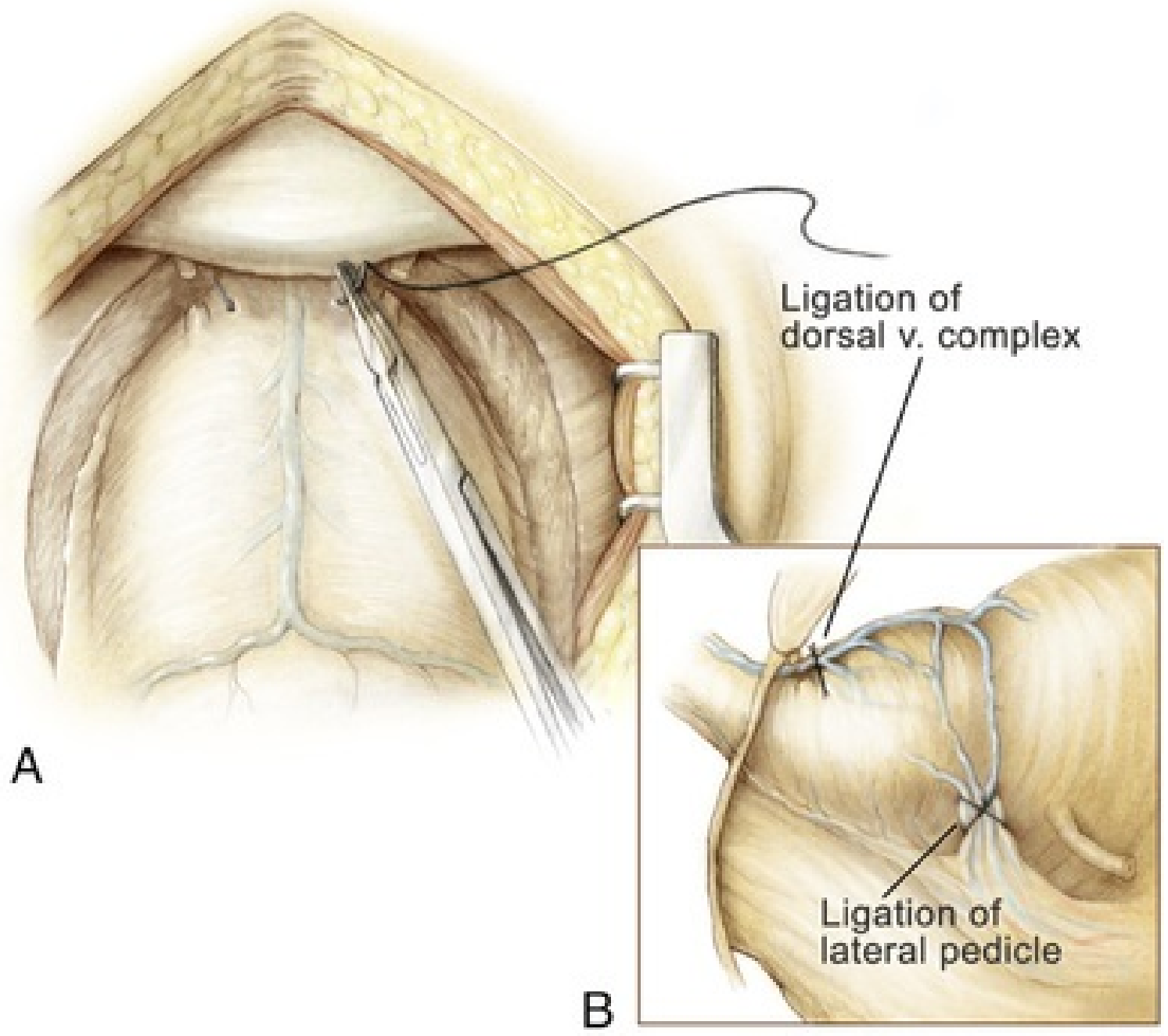

FIG. 147.2 Retropubic simple prostatectomy. (A) A 2-0 chromic suture on a ⅝-inch circle-tapered needle is passed in the avascular plane between the urethra and the dorsal vein complex at the apex of the prostate. A tie is grasped and tied around the dorsal vein complex. (B) With 2-0 chromic suture material on a CTX needle, a figure-of-eight suture is placed through the prostatovesicular junction just above the level of the seminal vesicles to control the main arterial blood supply to the prostate gland. When placing this suture, care must be taken to avoid entrapment of the neurovascular bundles located posteriorly and slightly laterally. (© Brady Urological Institute.)

At this point, attention is focused on securing the lateral pedicles at the prostatovesical junction. The 30-mL balloon of the catheter is used to identify the junction between the bladder and the prostate. The balloon is then deflated, and 2-0 chromic suture material on a large CTX needle is used to place a figure-of-eight suture deep into the prostatovesical junction at the level where the seminal vesicles approach the prostate gland bilaterally (see Fig. 147.2B). With this maneuver, the main arterial blood supply to the prostate adenoma is controlled. Having secured the dorsal vein complex earlier, the major sources of hemorrhage for this operation have been eliminated.

Enucleation of the Adenoma

With a sponge stick on the bladder neck to depress the bladder posteriorly, a No. 15 blade on a long handle is used to make a transverse capsulotomy in the prostate 1.5 to 2.0 cm distal to the bladder neck (Fig. 147.3). The superficial branch of the dorsal vein complex is transected as the transverse capsulotomy is made. It does not bleed because hemostasis of the dorsal vein complex has previously been controlled both proximally and distally. The incision is deepened to the level of the adenoma and extended sufficiently lateral in each direction to permit complete enucleation. A pair of Metzenbaum scissors is used to dissect the overlying prostatic pseudocapsule from the underlying prostatic adenoma. Once a well-defined plane is sufficiently developed, the index finger can be inserted between the prostatic adenoma and the pseudocapsule to further develop the plane laterally and posteriorly (Fig. 147.4). A pair of Metzenbaum scissors is then used to incise the anterior commissure from the bladder neck to the apex, separating the lateral lobes of the prostate anteriorly. The posterior prostatic urethra is exposed, and the index finger is inserted down to the verumontanum. The mucosa of the urethra overlying the left lateral lobe is divided sharply at the level of the apex under direct vision without injury to the external urinary sphincter. With the aid of a Babcock clamp, the left lateral lobe is removed safely. This maneuver is then repeated for the right lateral lobe. If a median lobe is present, the overlying mucosa is incised at the level of the bladder neck, and this lobe is removed (Fig. 147.5). In this manner, the entire prostatic adenoma is removed with preservation of a strip of posterior prostatic urethra. Because the capsulotomy was a transverse rather than longitudinal incision, there is little risk that the incision will be inadvertently extended into the sphincteric mechanism during the enucleation process, which would compromise subsequent urinary continence.

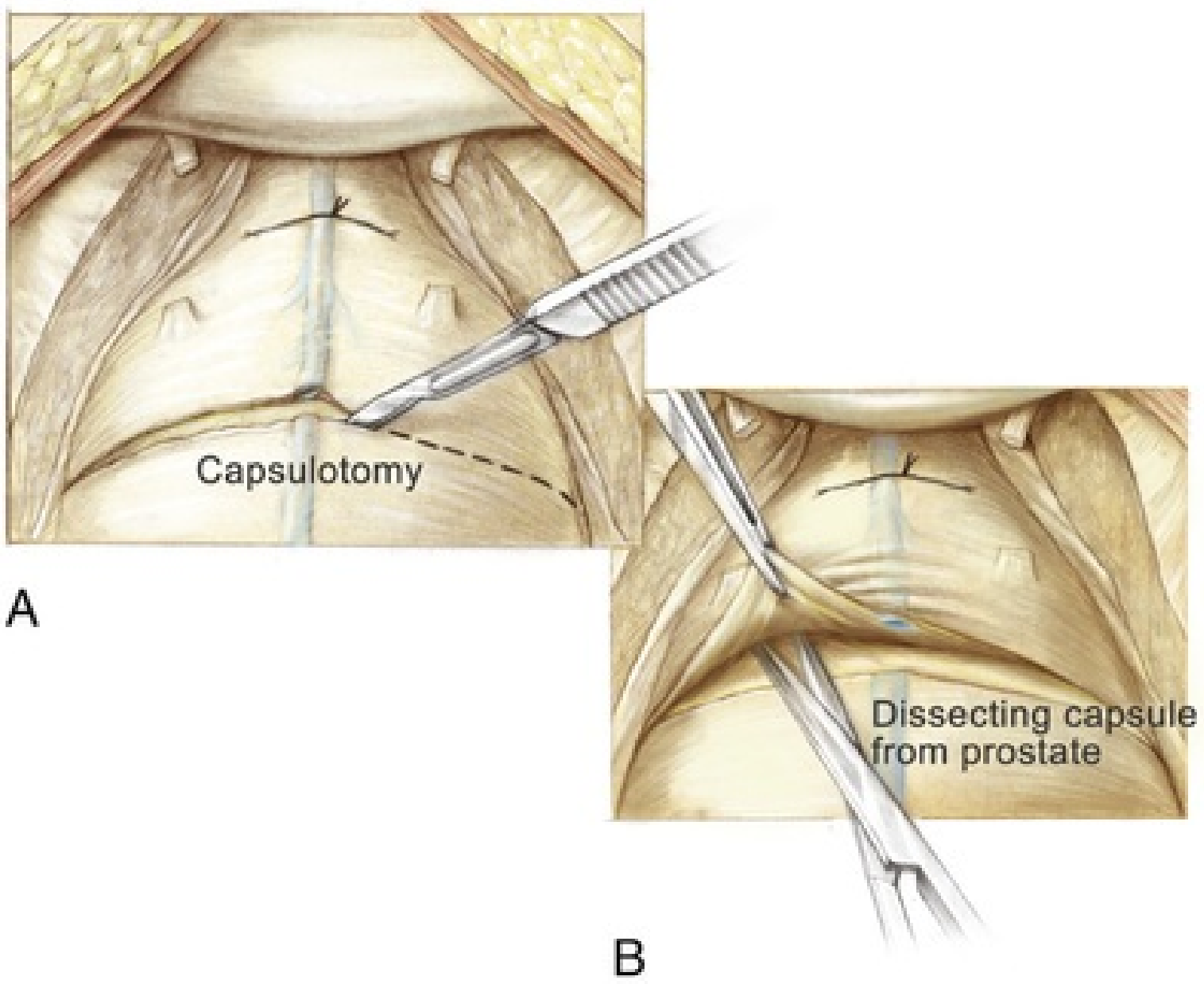
Capsulotomy
A
Dissecting capsule from prostate
B

FIG. 147.3 Retropubic simple prostatectomy. (A) With the superficial branch of the dorsal vein complex secured proximally and distally, a No. 15 blade on a long handle is used to make the transverse capsulotomy. (B) Metzenbaum scissors are used to develop the plane anteriorly between the prostatic adenoma and the prostatic pseudocapsule. (© Brady Urological Institute.)

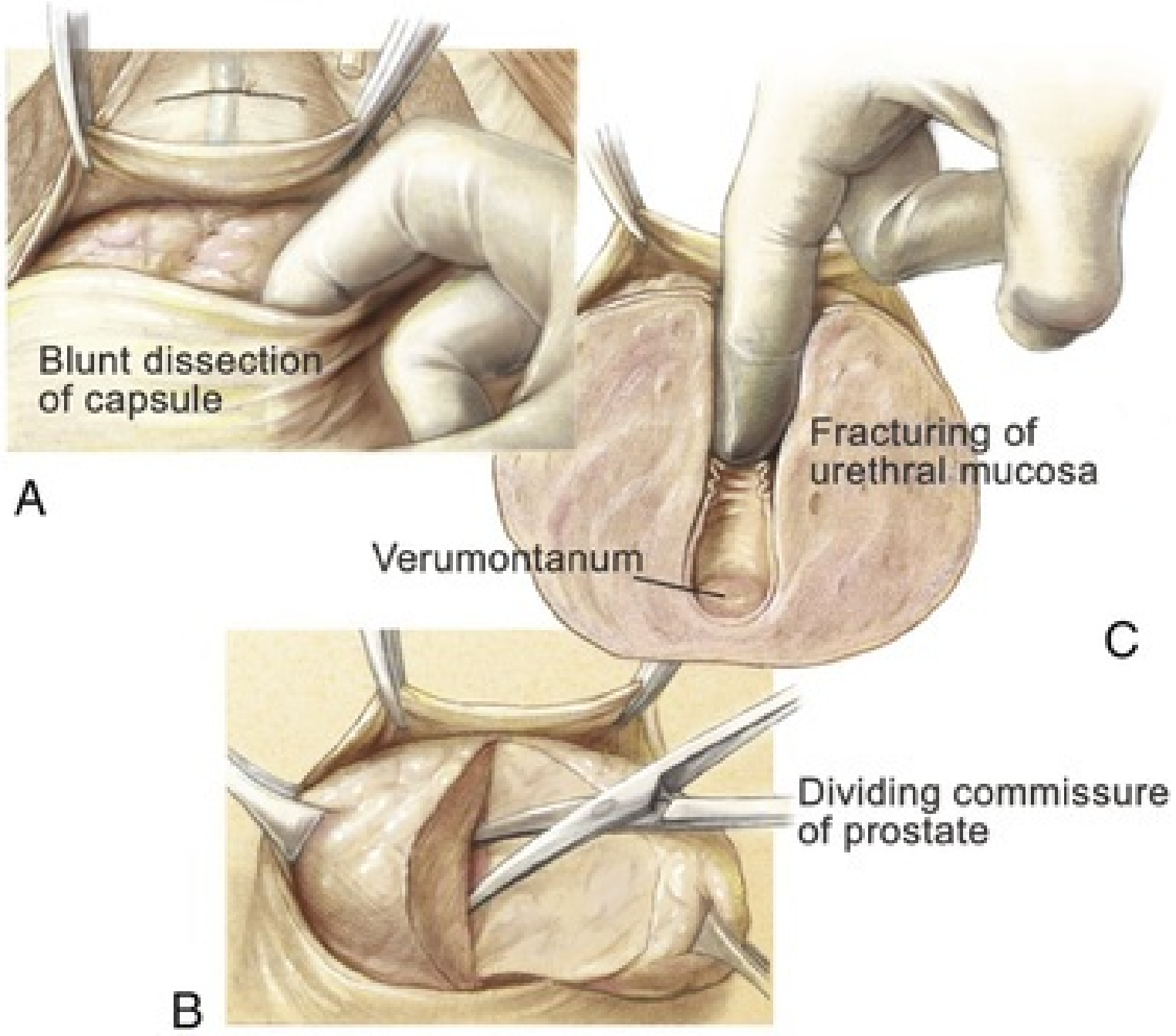
Blunt dissection of capsule
A
Fracturing of urethral mucosa
Verumontanum
C
Dividing commissure of prostate
B

FIG. 147.4 Retropubic simple prostatectomy. (A) With blunt dissection with the index finger, the prostatic adenoma is dissected free laterally and

posteriorly. (B) Metzenbaum scissors are used to divide the anterior commissure to visualize the posterior urethra and verumontanum. (C) The index finger is then used to fracture the urethral mucosa at the level of the verumontanum. With this last maneuver, extreme care is taken not to injure the external sphincteric mechanism. (© Brady Urological Institute.)

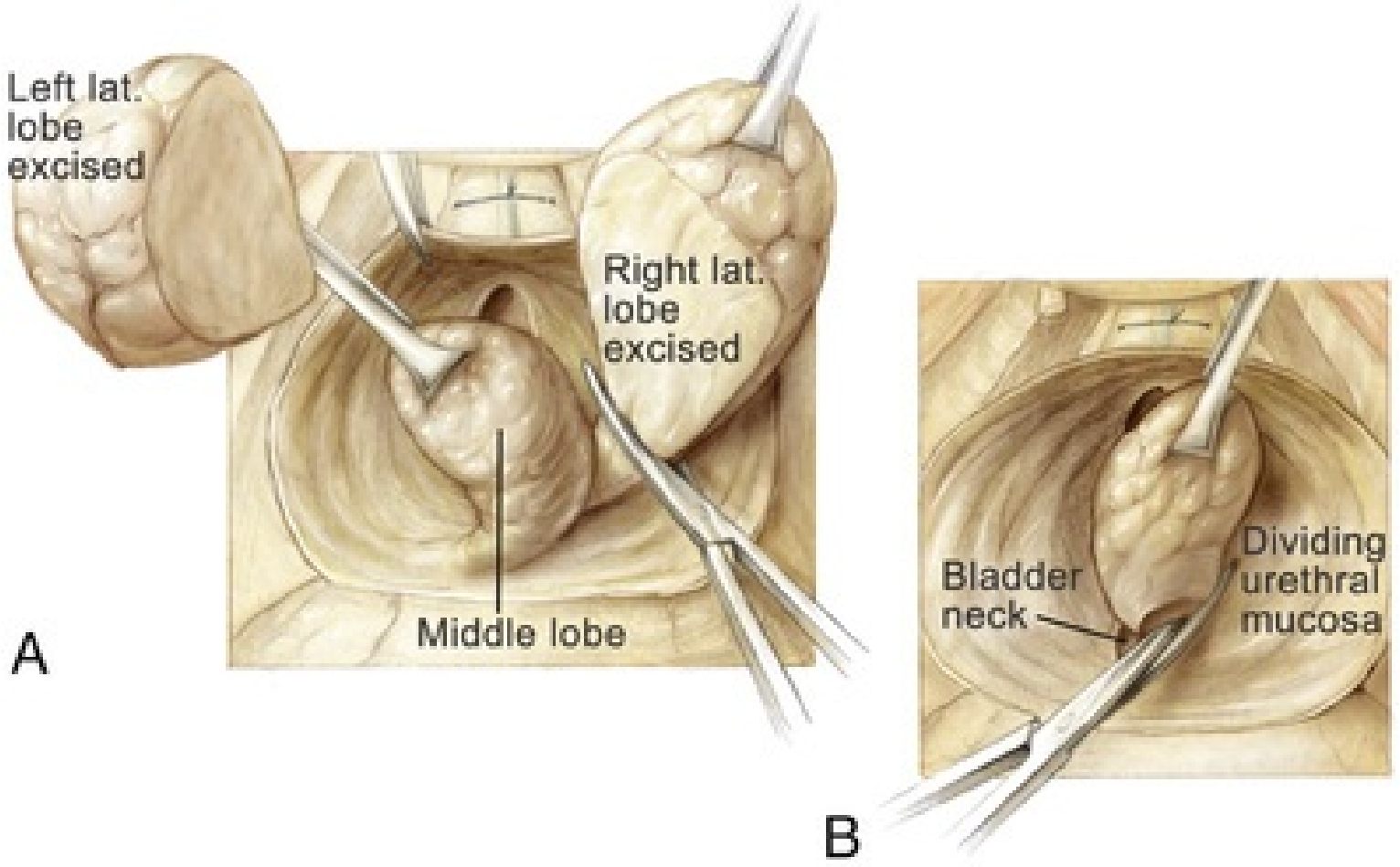

FIG. 147.5 Retropubic simple prostatectomy. (A) After removal of the left lateral lobe of the prostate, the right lateral lobe is excised with the aid of a tenaculum and Metzenbaum scissors. (B) Finally, the median lobe is removed under direct vision. (© Brady Urological Institute.)

The prostatic fossa is carefully inspected to ensure that all of the adenoma has been removed and that hemostasis is complete. **If hemorrhage is persistent, 4-0 chromic suture material can be used to place a figure-of-eight suture in the bladder neck at the 5- o'clock and 7-o'clock positions, as in suprapubic prostatectomy** (Fig. 147.6)**. When placing these sutures, it is necessary to visualize the ureteric orifices so that they are not incorporated.** Indigo carmine dye may be given intravenously to aid in the visualization of the ureteric orifices if necessary. If the bladder neck appears obstructive at the completion of the operation, it may be appropriate to perform a wedge resection at the 6-o'clock position and advance the bladder mucosa into the prostatic fossa.

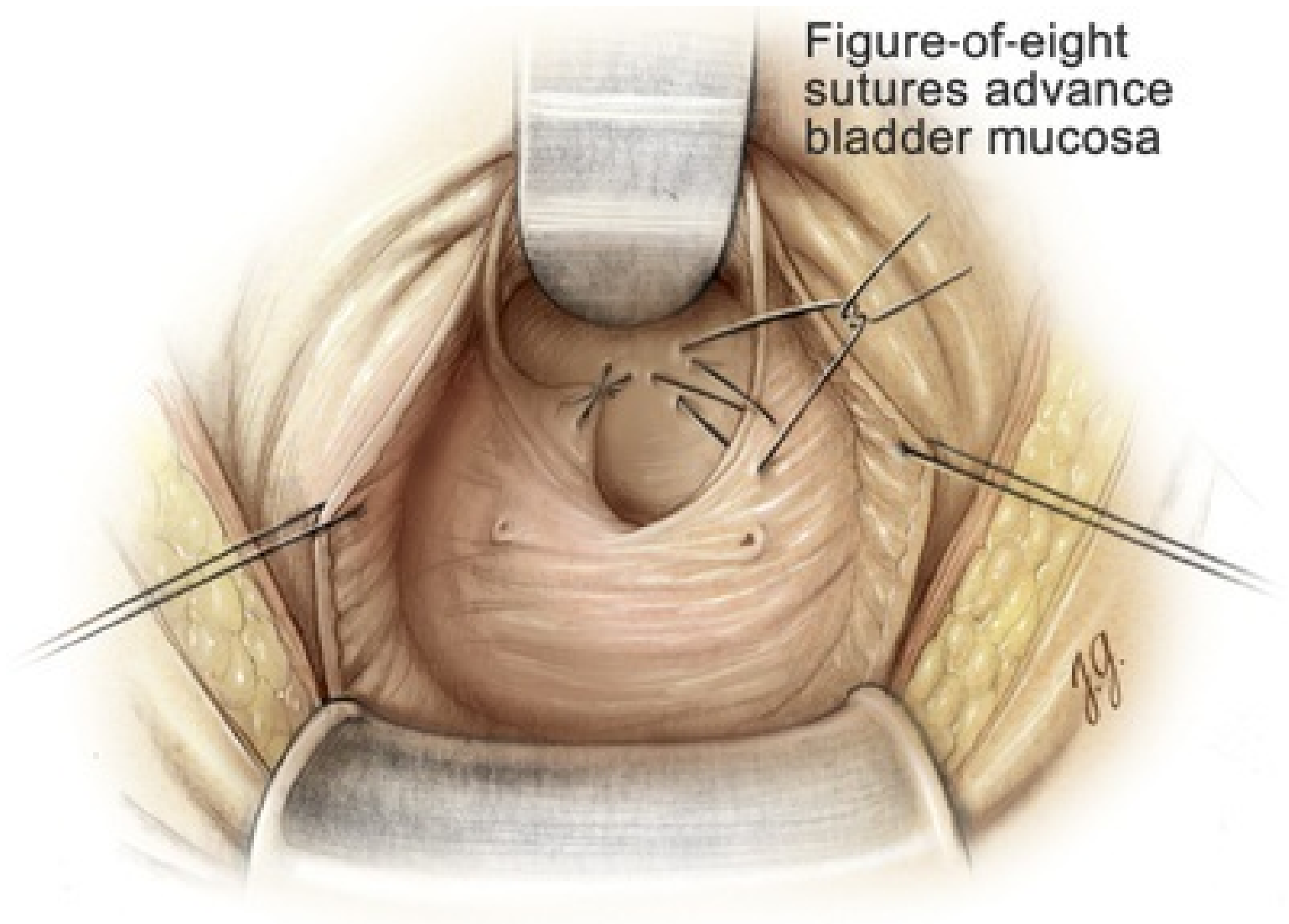

FIG. 147.6 Hemostatic maneuver during open simple prostatectomy. After enucleation of the entire prostatic adenoma, a 0-chromic suture is used to place two figure-of-eight sutures to advance bladder mucosa into the prostatic fossa at the 5-o'clock and 7-o'clock positions at the prostatovesicular junction to ensure control of the main arterial blood supply to the prostate. (© Brady Urological Institute.)

Suprapubic Simple Prostatectomy

Exposure of the Prostate

The anterior bladder wall is identified, and two 3-0 Vicryl stitches are placed on each side of the midline below the peritoneal reflection. A vertical cystotomy is made with electrocautery. With use of a pair of Metzenbaum scissors, a cystotomy is then extended cephalad and caudally to within 1 cm of the bladder neck. Several pairs of stay sutures are placed using 3-0 Vicryl on each side of the midline to facilitate exposure (Fig. 147.7). A figure-of-eight suture using 3-0 Vicryl is placed and tied at the most caudal position of the cystotomy to prevent further extension of the cystotomy incision during blunt finger dissection of the adenoma. Alternatively, a transverse bladder incision can be used. After inspecting the bladder, a well-padded, malleable blade is placed in the bladder, connected to the Balfour retractor, and used to retract the bladder cephalad. The bladder neck and prostate gland now can be visualized. A narrow Deaver retractor can be placed over the bladder neck and used to further expose the trigone. Indigo carmine dye may be given intravenously to aid in visualization of the ureteric orifices if necessary.

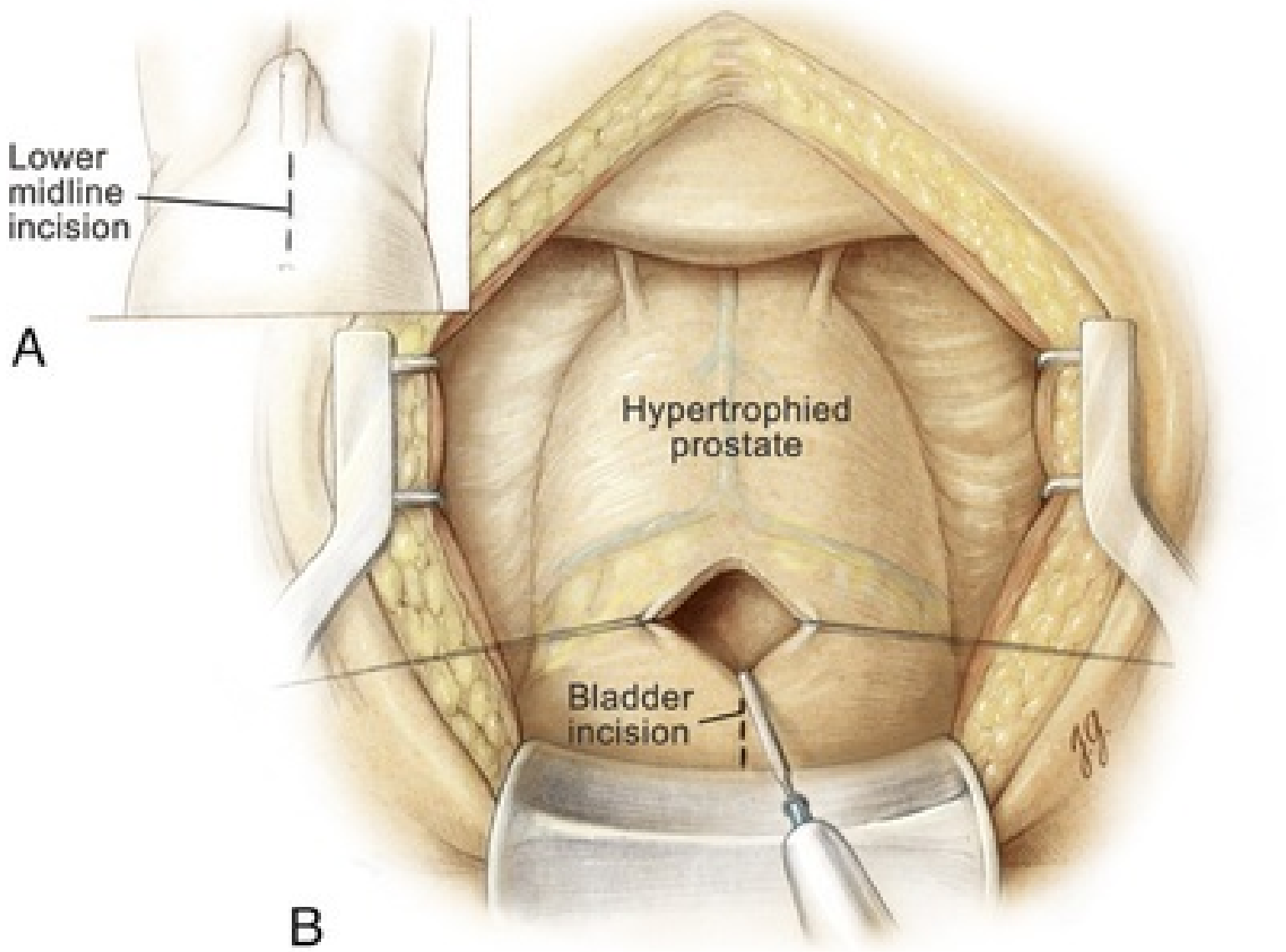

FIG. 147.7 Suprapubic simple prostatectomy. (A) A lower midline incision is made from the umbilicus to the pubic symphysis. (B) After developing the prevesical space, a small, longitudinal cystotomy is made with electrocautery. (© Brady Urological Institute.)

Enucleation of the Adenoma

Electrocautery is used to create a circular incision in the bladder mucosa distal to the trigone (Fig. 147.8). Care is taken not to injure the ureteric orifices. With use of a pair of Metzenbaum scissors, the plane between the prostatic adenoma and prostatic pseudocapsule is developed at the 6-o'clock position (Fig. 147.9). Once a well-established plane is created posteriorly, the prostatic adenoma is dissected circumferentially and inferiorly toward the apex, using blunt dissection (Fig. 147.10). At the apex, the prostatic urethra is transected using a pinch action of the two fingertips and avoiding excessive traction so as not to avulse the urethra and injure the sphincteric mechanism. At this point, the prostatic adenoma, either as one unit or separate lobes, can be removed from the prostatic fossa.

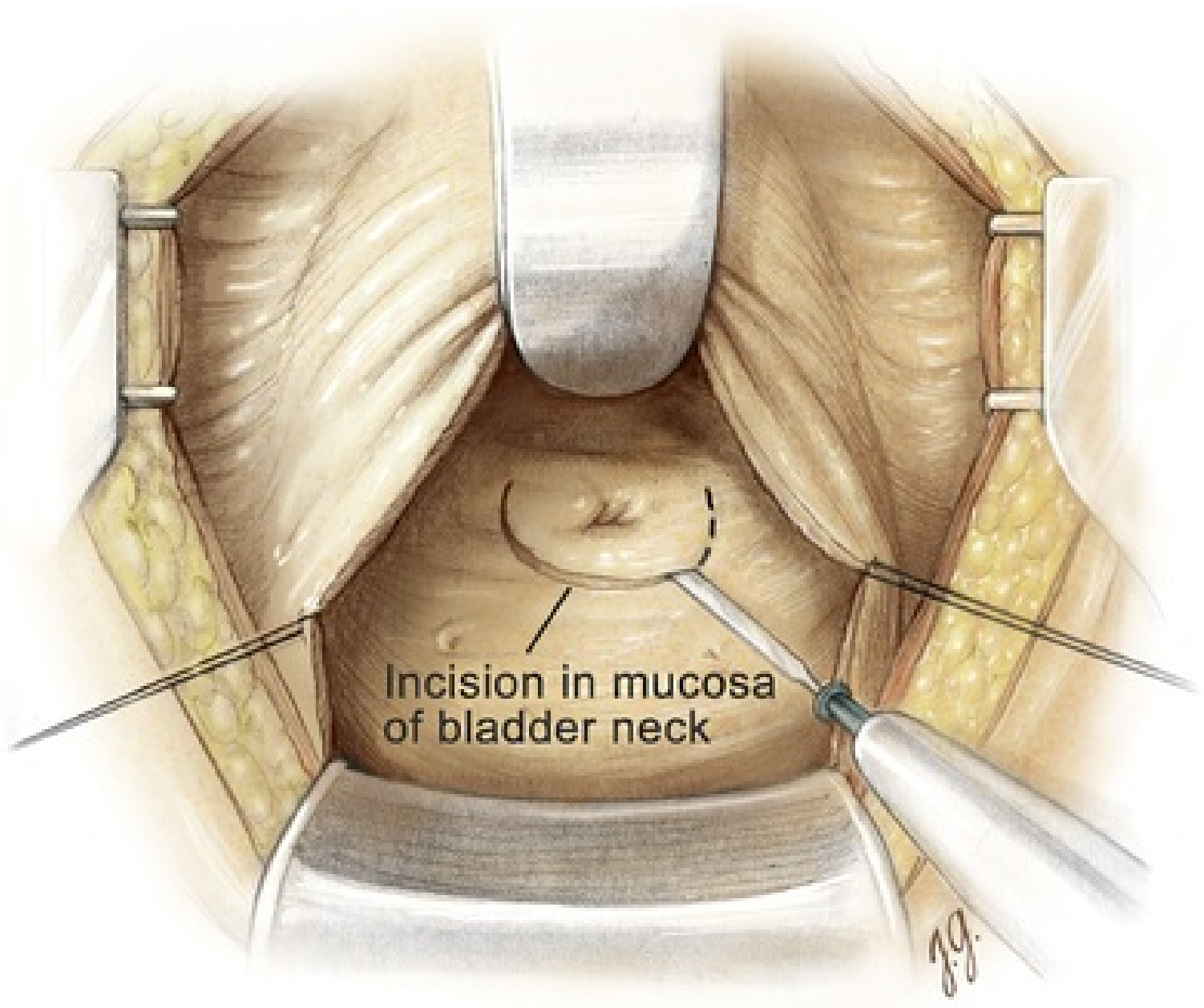
Incision in mucosa
of bladder neck

FIG. 147.8 Suprapubic simple prostatectomy. With adequate exposure of the bladder neck, a circular incision in the bladder mucosa is made distal to the trigone, using electrocautery. (© Brady Urological Institute.)

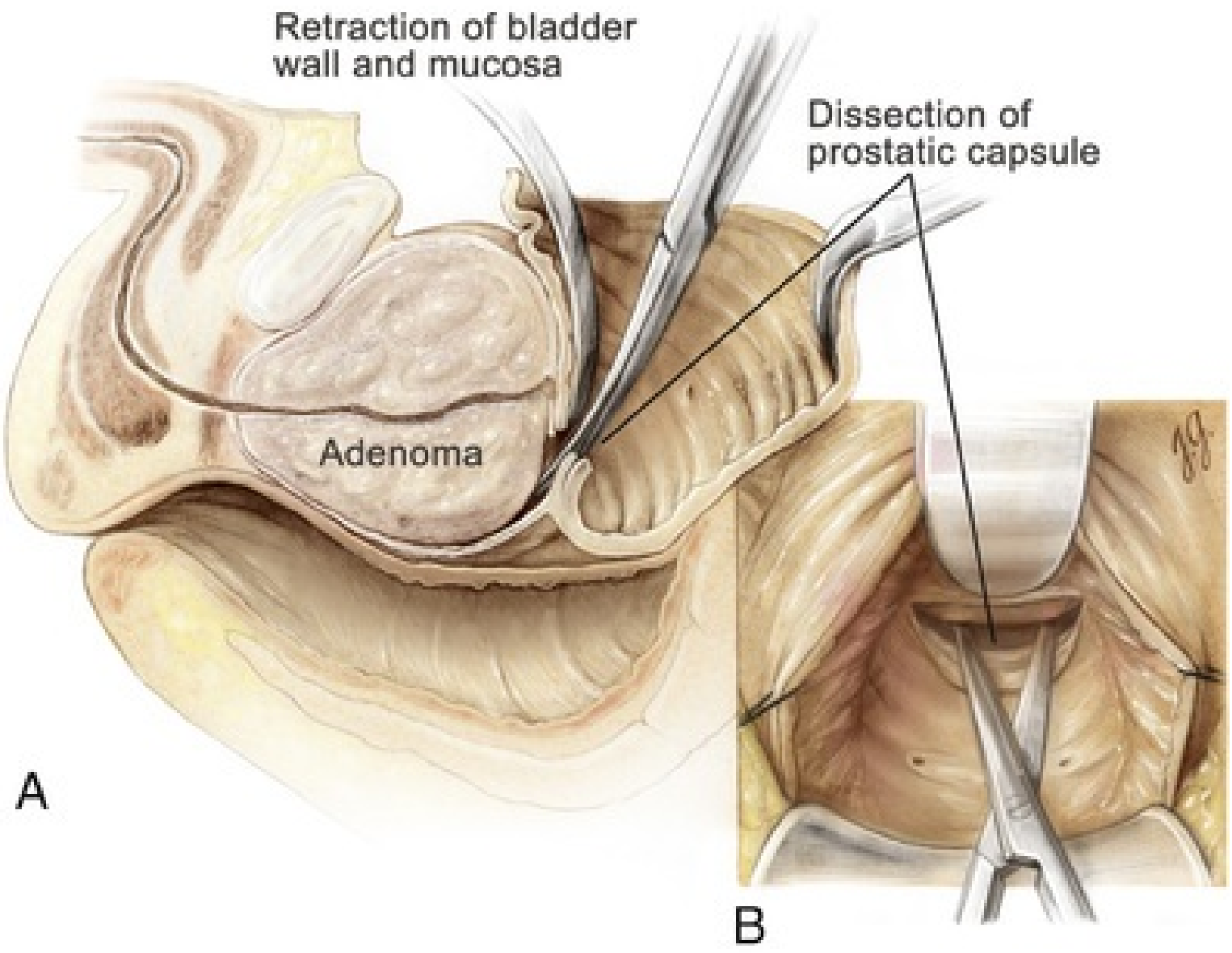
Retraction of bladder
wall and mucosa
Dissection of
prostatic capsule
Adenoma
A
B

FIG. 147.9 Suprapubic simple prostatectomy. (A) Starting at the bladder neck posteriorly, Metzenbaum scissors are used to develop the plane between the prostatic adenoma and the prostatic pseudocapsule *(lateral view).* (B) Anterior view of the same maneuver. (© Brady Urological Institute.)

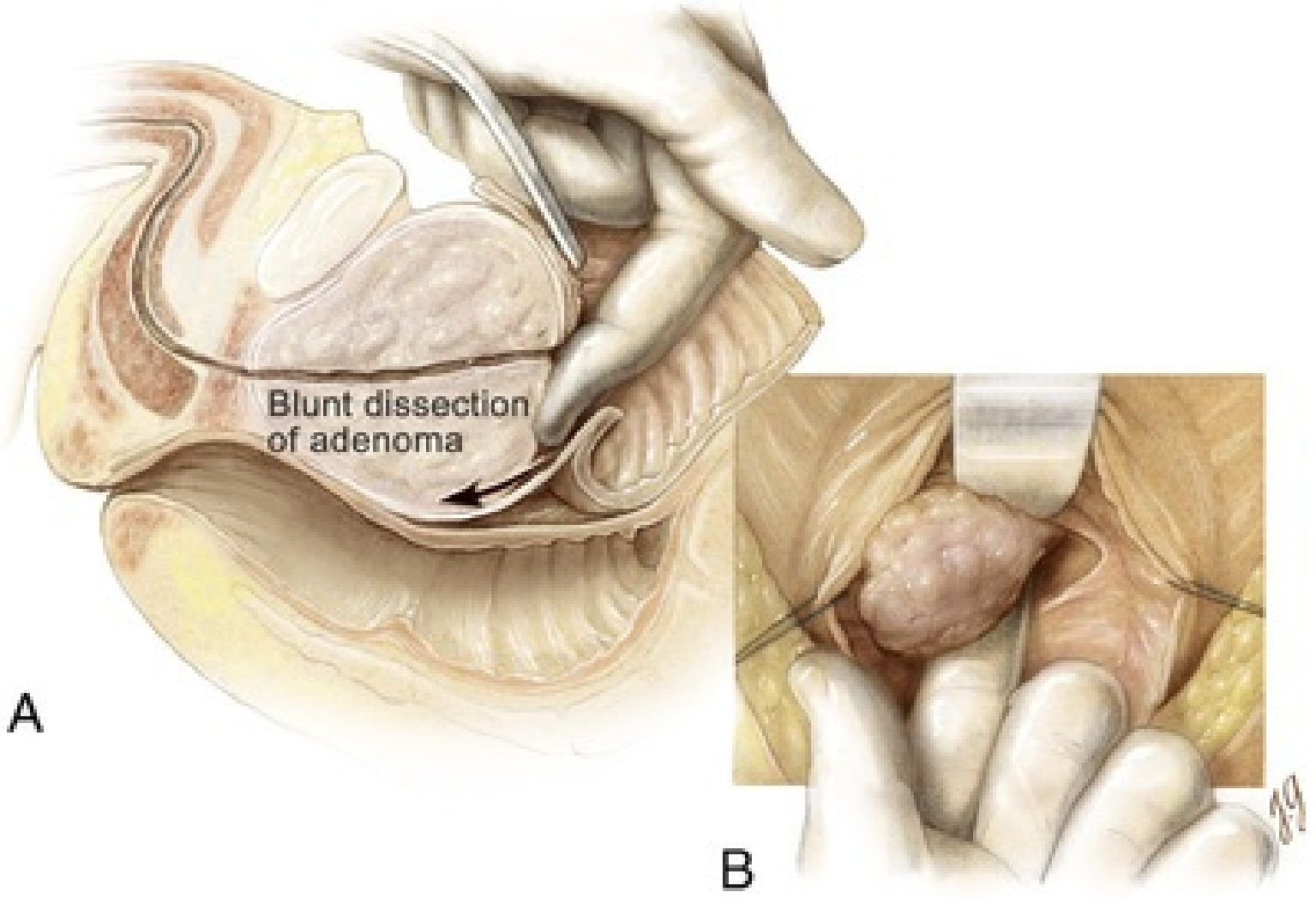

FIG. 147.10 Suprapubic simple prostatectomy. (A) Using the index finger, the prostatic adenoma is enucleated from the prostatic fossa *(lateral view).* (B) Anterior view of the same maneuver. With extremely large prostate glands, the left, right, and median lobes should be removed separately. (© Brady Urological Institute.)

Hemostatic Maneuvers

After enucleation of the adenoma, the prostatic fossa is inspected for residual tissue. If found, these nodules are removed by sharp or blunt dissection. The prostatic fossa also must be examined for discrete bleeding sites that frequently can be controlled with electrocautery or 4-0 chromic suture ligatures. In addition, a 0-chromic suture is used to place two figure-of-eight sutures to advance the bladder mucosa into the prostatic fossa at the 5-o'clock and 7-o'clock positions at the prostatovesical junction to ensure control of the main arterial blood supply to the prostate (see Fig. 147.6). With this maneuver, hemostasis is usually complete.

If hemorrhage remains pronounced despite the hemostatic sutures, a size 2 nylon purse-string suture can be placed around the vesical neck, brought out through the skin, and tied firmly, as described by Malament (1965). This maneuver closes the bladder neck and tamponades the prostatic fossa. The nylon suture is removed by cutting it at the skin and applying gentle traction on postoperative day 2 or 3. Plicating sutures can be placed transversely in the posterior prostatic pseudocapsule to prevent further bleeding, as described by O'Conor (1982).

Closure

After inspecting for complete adenoma removal and hemostasis, a 22-Fr, three-way Foley catheter with a 30-mL balloon is inserted through the anterior urethra and prostatic fossa into the bladder. Alternatively, a 22-Fr, two-way Foley catheter with a 30-mL balloon and a 20- to 24-Fr Malecot suprapubic tube are placed into the dome of the bladder. The suprapubic tube exits the bladder via a separate stab incision at the lateral aspect of the dome, avoiding the peritoneal cavity (Fig. 147.11). The suprapubic tube is secured with a 4-0 chromic purse-string suture.

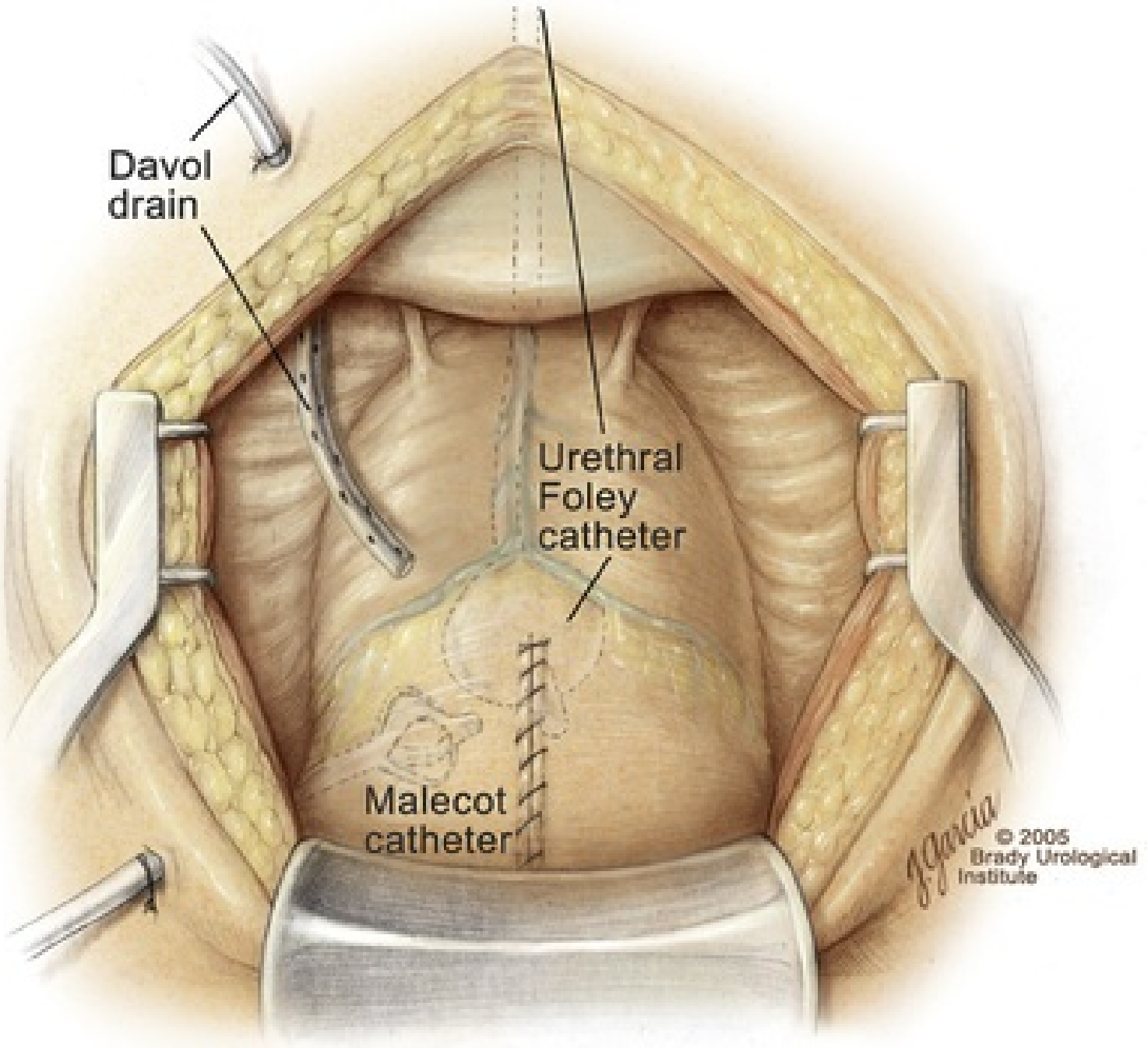

FIG. 147.11 Closure during suprapubic simple prostatectomy. After placement of a urethral catheter and a Malecot suprapubic tube, the cystotomy is closed in two layers using a running 2-0 Vicryl suture, enforced by tying multiple interrupted 3-0 Vicryl stay sutures. A closed Davol suction drain is placed on one side of the bladder and exits via a separate stab incision. (© Brady Urological Institute.)

In the suprapubic approach, with the urethral catheter in place, the prostatic pseudocapsule is closed (see Fig. 147.11) using 2-0 absorbable sutures. In the retropubic approach, the cystotomy incision is closed in two layers using 2-0 absorbable sutures (Fig. 147.12).

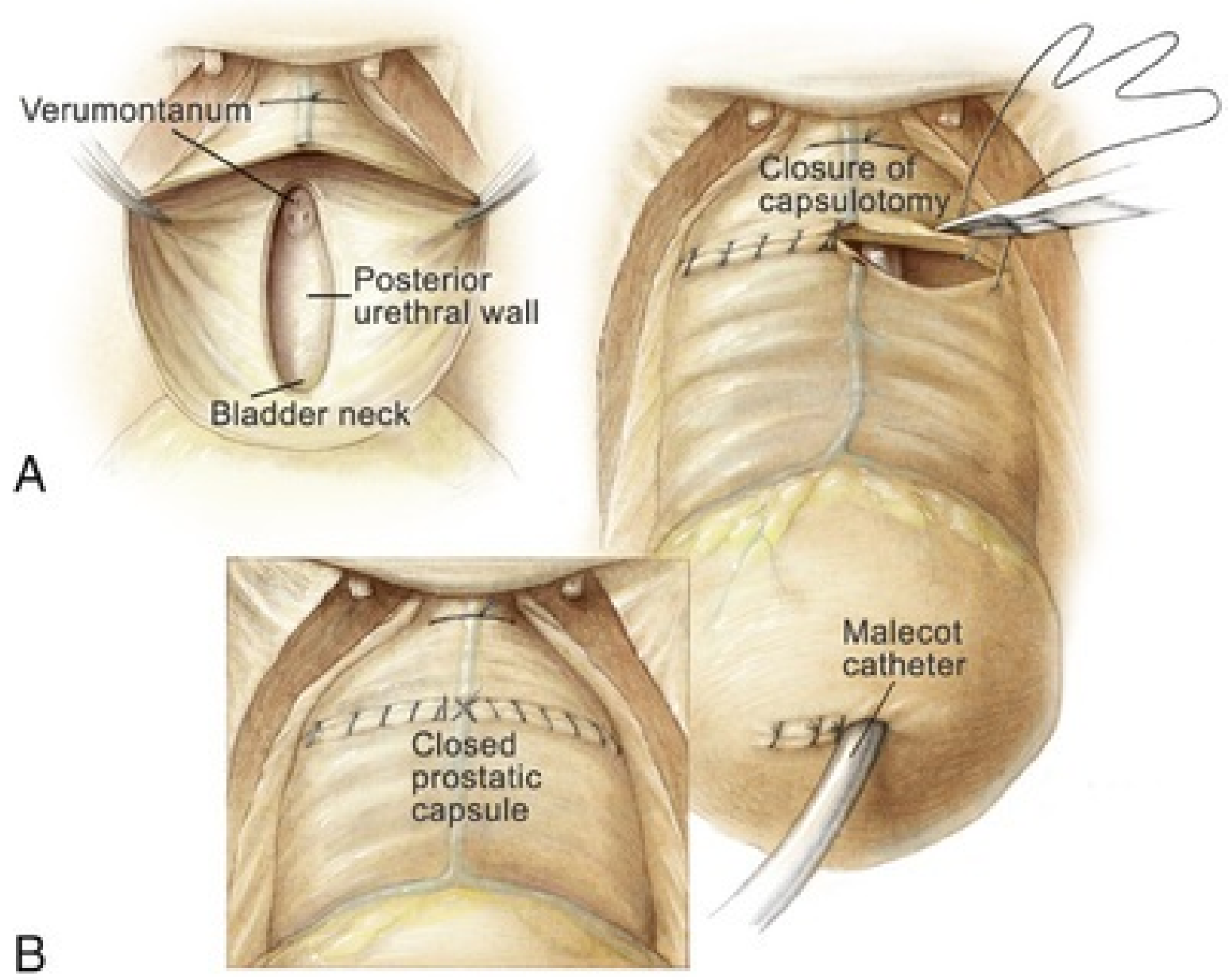

FIG. 147.12 Closure during retropubic simple prostatectomy. (A) View of the prostatic fossa and posterior urethra after enucleation of all the prostatic adenoma. Note that the verumontanum and a strip of posterior urethra remain intact. (B) After placement of a urethral catheter and, if needed, a Malecot suprapubic tube, the transverse capsulotomy is closed with two running 2-0 chromic sutures. The two sutures are tied first to themselves and then to each other across the midline to create a watertight closure of the prostatic pseudocapsule. (© Brady Urological Institute.)

Fifty milliliters of water is then placed in the balloon to ensure the Foley catheter balloon remains in the bladder and does not retract into the prostatic fossa. The bladder is then irrigated with saline to ensure continued hemostasis and test the closure for leakage. A small closed-suction drain is placed via a separate stab incision lateral to the prostate and bladder on one side to prevent hematoma and urinoma formation. The pelvis is irrigated with copious amounts of normal saline solution, and the rectus fascia is reapproximated with a size 1 polydioxanone (PDS) suture on a needle in a running fashion. The skin is closed with skin staples or 4-0 absorbable suture. The drain is secured to the abdominal wall, and the urethral catheter is secured to the lower extremity.

Postoperative Management

In the recovery area, the outputs from the pelvic drain and urethral catheter are monitored. In addition, it is routine to verify the hematocrit. If significant hemorrhage is noted, the urethral catheter may be placed on traction so that the balloon containing 50 mL of saline can compress the bladder neck and prostatic fossa. Constant and reliable traction can be maintained by securing the catheter to the abdomen. In addition, continuous bladder irrigation can be initiated to prevent clot formation. For most patients these measures are adequate and effective. However, if excessive bleeding persists after these measures, the urethral catheter can be removed in the operating suite and a cystoscopic inspection of the prostatic fossa and bladder neck can be performed to identify and fulgurate discrete bleeding sites. If marked hemorrhage continues to persist, re-exploration should be strongly considered.

On the evening of the day of surgery, the patient is asked to perform the dorsiflexion and plantarflexion exercises while awake and perform pulmonary exercises. Effective pain management consists of intravenous opioids by a patient-controlled analgesic pump.

On the first postoperative day, the patient is started on a gradually advancing diet and asked to ambulate four times per day. Pulmonary exercises are continued. If the hematuria is resolved, continuous bladder irrigation can be discontinued with a urethral catheter (and suprapubic tube, if present) placed for gravity drainage. Also, the balloon in the urethral catheter is partially deflated to 30 mL of saline, and residual clots are removed by irrigation.

On the second postoperative day, if urine is clear and both a suprapubic tube and a urethral catheter were placed intraoperatively, the urethral catheter may be removed, and the suprapubic tube is clamped to allow a voiding trial. The patient is encouraged to ambulate and continue pulmonary exercises. When the patient tolerates a regular diet, oral analgesics can be given and parenteral opioids discontinued. Appropriate discharge instructions are reviewed with the patient at this time in preparation for discharge on the second day after surgery. The pelvic drain is removed if the drainage is low. Pathologic examination of the enucleated prostatic adenoma should be performed.

On discharge from the hospital, the patient is encouraged to gradually increase his activity. If the patient has a clamped suprapubic tube and voids well with a minimal postvoid residual urine volume, the suprapubic tube is then removed in the clinic 1 week after surgery. If only the urethral catheter was used without a suprapubic tube, it is removed in the clinic 1 week after surgery. The patient should be able to resume full activity 3 to 4 weeks postoperatively with outpatient visits at 6 weeks and 3 months.

Robotic-Assisted Laparoscopic Simple Prostatectomy (Video 147.1)

Proper Positioning of the Patient

Positioning of the patient for this procedure is same as that for robotic-assisted laparoscopic radical prostatectomy. After general endotracheal anesthesia has been induced, the patient is positioned in the supine position on the operating table. Both arms are padded and tucked to the side. The legs are placed in the low lithotomy position in a spreader bar. The patient is secured to the operative table at the level of the shoulders with heavy cloth tape. The lower abdomen is shaved, prepared, and draped in the usual sterile manner. A 16-Fr urethral catheter is passed into the bladder and connected to a sterile closed drainage system. The balloon is inflated with 10 mL of saline. The operative table is placed in the maximum Trendelenburg position.

Abdominal Access, Insufflation, and Trocar Placement

The transperitoneal approach is favored over the extraperitoneal approach because of the greater working space in the setting of a massively enlarged prostatic adenoma. Intraperitoneal access is obtained with a Veress needle through an umbilical puncture site. After adequate insufflation at 15 mm Hg, the peritoneal cavity is entered through a vertical supraumbilical incision using a 12-mm bladeless trocar followed by confirmation of the proper placement with a robotic camera. Alternatively, the initial entrance can be achieved using the Visiport device and 0-degree lens and camera. Adhesions are lysed laparoscopically, if present. One additional 12-mm trocar is placed on the right side, then three 8-mm robotic trocars are placed bilaterally (two on the left, one on the right), and then one additional 5-mm trocar is placed on the right side, all under direct vision. The da Vinci Robotic System is then docked. Typically, three robotic instruments are used (fenestrated bipolar forceps and ProGrasp forceps on the left side and monopolar scissors on the right side).

Development of the Space of Retzius

The anterior peritoneum is taken down lateral to the medial umbilical ligaments to displace the bladder posteriorly. Applying posterior and cephalad traction on the urachus, the space of Retzius is developed using both blunt and sharp dissection. Periprostatic adipose tissue is then removed. Endopelvic fascia is taken down carefully to expose the prostatic contour. Control of the deep dorsal vein complex or prostatic lateral pedicles is not necessary.

Bladder Neck Incision

The anterior bladder neck is divided transversely using monopolar scissors until the urinary catheter is visualized. After identifying the catheter, it is grasped by an assistant or the fourth robotic arm with ProGrasp forceps and pulled anteriorly before widening the bladder neck incision. **To better visualize the intravesical component of the prostate and the trigone, the bladder neck incision in this approach should be wider and more cephalad compared with the narrow incision at the vesicoprostatic junction in a typical robotic-assisted laparoscopic radical prostatectomy.** When a large median lobe is encountered, it is lifted anteriorly by the assistant or the ProGrasp forceps. Bilateral ureteric orifices are identified to avoid inadvertent injury.

Enucleation of the Adenoma

Electrocautery of the robotic monopolar scissors is used to create a circular incision in the bladder mucosa distal to the trigone. Care is taken not to injure the ureteric orifices. With the use of monopolar scissors, the subcapsular plane between the prostatic adenoma and prostatic pseudocapsule is developed initially at the 6-o'clock position to prevent inadvertent injury to ureteral orifices. **While developing the plane between the prostatic adenoma and pseudocapsule, it is crucial to have an experienced assistant or the robotic fourth arm with forceps to optimize the visualization of the dissection plane and provide traction. Compared with the open simple prostatectomy approach, the dissection plane should be better visualized at all times during this procedure.** Once a well-established plane is created posteriorly, the prostatic adenoma is dissected circumferentially and inferiorly toward the apex, using both blunt dissection and limited electrocautery. At the apex, the prostatic urethra is transected while avoiding excessive traction. At this point, the prostatic adenoma, either as one unit or separate lobes, can be removed from the prostatic fossa and set aside.

Hemostasis and Vesicourethral Anastomosis

The prostatic fossa is carefully inspected, and hemostasis is achieved by limited electrocautery or suture ligatures. The vesicourethral anastomosis is performed continuously with 2-0 barbed sutures in a single-knot method (Van Velthoven et al., 2003). A 20-Fr, two-way Foley catheter is inserted. A watertight closure is confirmed using normal saline irrigation by Foley catheter. A closed-suction pelvic drain is placed through the lateral 8-mm robotic trocar site and secured to the skin.

Adenoma Extraction and Closure

Hemostasis is reconfirmed with lower insufflation pressure (<10 mm Hg). The prostatic adenoma is placed inside of the entrapment bag and extracted through extension of the supraumbilical trocar site. The rectus abdominis fascial defect of the extraction incision is closed using No. 1 PDS in a figure-of-eight fashion. The skin edges are reapproximated using 4-0 Biosyn subcuticular suture.

Postoperative Management

Postoperative management after robotic-assisted laparoscopic simple prostatectomy is similar to that after open simple prostatectomy. However, continuous bladder irrigation and blood transfusion are less frequently used after robotic-assisted laparoscopic simple prostatectomy.

On discharge from the hospital, the patient is encouraged to gradually increase his activity. A Foley catheter is removed in the clinic 1 week after surgery.

Complications of Simple Prostatectomy

The overall rate of morbidity and mortality associated with simple prostatectomy is extremely low. Historically, excessive hemorrhage had been a major concern. But with modern surgical techniques, blood loss is now minimal and the need for a blood transfusion is uncommon (Zargooshi, 2007). In retropubic simple prostatectomy, controlling the dorsal vein complex distal to the apex of the prostate and ligating the lateral pedicles to the prostate at the prostatovesical junction markedly reduces venous and arterial bleeding, respectively. Nevertheless, it may still be prudent to have 1 to 2 units of autologous blood available at the time of open simple prostatectomy. **In laparoscopic simple prostatectomy with or without robotic assistance, pneumoperitoneum significantly decreases the perioperative hemorrhage and almost eliminates the need for blood transfusion.**

Urinary extravasation can be of concern in the immediate postoperative period; this most likely results from incomplete closure of the prostatic capsulotomy in retropubic simple prostatectomy or the cystotomy in suprapubic simple prostatectomy and robotic-assisted laparoscopic simple prostatectomy. This usually resolves spontaneously with continued catheter drainage. The drain should be left in place until urinary extravasation ceases.

After a simple prostatectomy, urgency and urgency incontinence may be present for several weeks to several months, depending on the preoperative bladder status. If the condition is severe, the patient may be given an anticholinergic agent such as oxybutynin (Ditropan). Stress incontinence and total incontinence are rare. With precise enucleation of the prostatic adenoma, risk for injury to the external sphincter mechanism is minimal. If stress incontinence does result after the procedure, the patient may benefit from transurethral collagen injections for a mild condition or an artificial urinary external sphincter when the situation is more severe.

Late urologic complications are not common. Acute cystitis rarely occurs as long as the patient voids to completion. Acute epididymitis can occur occasionally if infected urine refluxes into the ejaculatory ducts.

Erectile dysfunction occurs in 3% to 5% of patients undergoing a simple prostatectomy; it is more common in older men than in younger men. Retrograde ejaculation occurs in 80% to 90% of patients after surgery. Also, 2% to 5% of patients develop bladder neck contracture 6 to 12 weeks after open simple prostatectomy (Tubaro et al., 2001; Varkarakis et al., 2004). If bladder neck contracture develops, initial management should be dilation with urethral sounds or a direct vision incision of the bladder neck using a Collings knife to create a 22-Fr opening.

The most common nonurologic adverse effects include deep vein thrombosis, pulmonary embolus, myocardial infarction, and a cerebrovascular event. The incidence of any one of these complications is less than 1%, and the overall mortality rate resulting from this operation should approach zero (Varkarakis et al., 2004).

Summary

Simple prostatectomy, whether performed by an open retropubic or suprapubic approach or a robotic-assisted laparoscopic approach, is an excellent treatment option for (1) men with symptomatic bladder outlet obstruction as a result of benign prostatic hyperplasia causing a markedly enlarged prostate gland, (2) individuals with a concomitant bladder condition, such as a bladder diverticulum or large bladder calculi, and (3) patients who cannot be placed in the dorsal lithotomy position for TURP. With improved surgical technique, these procedures can be routinely performed in a precise manner with minimal hemorrhage. Efficacy, in terms of durable improvement in symptom score and peak urinary flow rate, is superior to other treatment options available for the obstructing prostate gland, including TURP. Meanwhile, complications are minimal, and the length of hospitalization has been markedly reduced. For most patients, the length of hospital stay is 2 days or less. Thus, for the properly selected individual, a simple prostatectomy is a highly effective and well-tolerated operation.

Key Points

- Simple prostatectomy should be considered when the obstructive tissue is estimated to weigh more than 75 g or sizable bladder diverticuli or calculi exist.
- Before performing a simple prostatectomy, the presence of significant prostate cancer should be determined.
- Potential risks of simple prostatectomy include urinary incontinence, erectile dysfunction, retrograde ejaculation, UTI, bladder neck contracture, urethral stricture, deep vein thrombosis, pulmonary embolus, and the need for blood transfusion.
- Advantages of simple prostatectomy over TURP are a lower retreatment rate, more complete removal of the prostatic adenoma under direct vision, and no risk for TUR syndrome.
- Disadvantages of open simple prostatectomy over TURP are a lower midline incision, longer hospitalization, and increased potential for

perioperative hemorrhage.

- Compared with open simple prostatectomy, robotic-assisted laparoscopic simple prostatectomy can be performed with smaller incisions with shorter hospital stay and decreased risk for perioperative hemorrhage and blood transfusion.
- Two approaches to open simple prostatectomy are retropubic and suprapubic.
- Compared with the retropubic approach, suprapubic prostatectomy is ideal for men with a large median lobe, clinically significant bladder diverticulum, or large bladder calculi.

Suggested Readings

Roos NP, Wennberg JE, Malenka DJ, et al. Mortality and reoperation after open and transurethral resection of the prostate for benign prostatic hyperplasia. *N Engl J Med*. 1989;320(17):1120–1124.

Sotelo R, Clavijo R, Carmona O, et al. Robotic simple prostatectomy. *J Urol*. 2008;179(2):513–515.

References

Botto H, Lebret T, Barre P, et al. Electrovaporization of the prostate with the gyrus device. *J Endourol*. 2001;15(3):313–316.

Brunocilla E, Vece E, Lupo S, et al. Preperitoneal prosthetic mesh hernioplasty for the simultaneous repair of inguinal hernia during prostatic surgery: experience with 172 patients. *Urol Int*. 2005;75(1):38–42.

Campo B, Bergamaschi F, Corrada P, et al. Transurethral needle ablation (TUNA) of the prostate: a clinical and urodynamic evaluation. *Urology*. 1997;49(6):847–850.

Comat V, Marquette T, Sutter W, et al. Day-case holmium laser enucleation of the prostate: prospective evaluation of 90 consecutive cases. *J Endourol*. 2017;31(10):1056–1061.

Cornford PA, Biyani CS, Brough SJ, et al. Daycase transurethral incision of the prostate using the holmium: YAG laser: initial experience. *Br J Urol*. 1997;79(3):383–384.

Cowles RS 3rd, Kabalin JN, Childs S, et al. A prospective randomized comparison of transurethral resection to visual laser ablation of the prostate for the treatment of benign prostatic hyperplasia. *Urology*. 1995;46(2):155–160.

Do M, Liatsikos EN, Kallidonis P, et al. Hernia repair during endoscopic extraperitoneal radical prostatectomy: outcome after 93 cases. *J Endourol*. 2011;25(4):625–629.

Eaton AC, Francis RN. The provision of transurethral prostatectomy on a day-case basis using bipolar plasma kinetic technology. *BJU Int*. 2002;89(6):534–537.

Freyer P. A new method of performing prostatectomy. *Lancet*. 1900;1:774.

Freyer P. One thousand cases of total enucleation of the prostate for radical cure of enlargement of that organ. *Br Med J*.

1912;2(2701):868–870.

Gilling PJ, Kennett K, Das AK, et al. Holmium laser enucleation of the prostate (HoLEP) combined with transurethral tissue morcellation: an update on the early clinical experience. *J Endourol*. 1998;12(5):457–459.

Holden M, Parsons JK. Robotic-assisted simple prostatectomy: an overview. *Urol Clin North Am*. 2016;43(3):385–391.

Kaplan SA, Santarosa RP, Te AE. Transurethral electrovaporization of the prostate: one-year experience. *Urology*. 1996;48(6):876–881.

Lucca I, Shariat SF, Hofbauer SL, et al. Outcomes of minimally invasive simple prostatectomy for benign prostatic hyperplasia: a systematic review and meta-analysis. *World J Urol*. 2015;33(4):563–570.

Malament M. Maximal hemostasis in suprapubic prostatectomy. *Surg Gynecol Obstet*. 1965;120:1307–1312.

Matei DV, Brescia A, Mazzoleni F, et al. Robot-assisted simple prostatectomy (RASP): does it make sense? *BJU Int*. 2012;110(11 Pt C):E972–E979.

McVary KT, Roehrborn CG, Avins AL, et al. Update on AUA guideline on the management of benign prostatic hyperplasia. *J Urol*. 2011;185(5):1793–1803.

Millin T. Retropubic prostatectomy; a new extravesical technique; report of 20 cases. *Lancet*. 1945;2(6380):693–696.

Muschter R, Hofstetter A. Technique and results of interstitial laser coagulation. *World J Urol*. 1995;13(2):109–114.

Nakamura LY, Nunez RN, Castle EP, et al. Different approaches to an inguinal hernia repair during a simultaneous robot-assisted radical prostatectomy. *J Endourol*. 2011;25(4):621–624.

O'Conor VJ Jr. An aid for hemostasis in open prostatectomy: capsular plication. *J Urol*. 1982;127(3):448.

Ogden CW, Reddy P, Johnson H, et al. Sham versus transurethral microwave thermotherapy in patients with symptoms of benign prostatic bladder outflow obstruction. *Lancet*. 1993;341(8836):14–17.

Reich O, Gratzke C, Stief CG. Techniques and long-term results of surgical procedures for BPH. *Eur Urol*. 2006;49(6):970–978 [discussion 978].

Reiner WG, Walsh PC. An anatomical approach to the surgical management of the dorsal vein and Santorini's plexus during radical retropubic surgery. *J Urol*. 1979;121(2):198–200.

Robert G, Cornu JN, Fourmarier M, et al. Multicentre prospective evaluation of the learning curve of holmium laser enucleation of the prostate (HoLEP). *BJU Int*. 2016;117(3):495–499.

Roos NP, Wennberg JE, Malenka DJ, et al. Mortality and reoperation after open and transurethral resection of the prostate for benign prostatic hyperplasia. *N Engl J Med*. 1989;320(17):1120–1124.

Schlegel PN, Walsh PC. Simultaneous preperitoneal hernia repair during radical pelvic surgery. *J Urol*. 1987;137(6):1180–1183.

Schuessler WW, Schulam PG, Clayman RV, et al. Laparoscopic radical prostatectomy: initial short-term experience. *Urology*. 1997;50(6):854–857.

Schulman CC, Zlotta AR, Rasor JS, et al. Transurethral needle ablation (TUNA): safety, feasibility, and tolerance of a new office procedure for treatment of benign prostatic hyperplasia. *Eur Urol*. 1993;24(3):415–423.

Serretta V, Morgia G, Fondacaro L, et al. Open prostatectomy for benign prostatic enlargement in southern Europe in the late 1990s: a contemporary series of 1800 interventions. *Urology*. 2002;60(4):623–627.

Sotelo R, Clavijo R, Carmona O, et al. Robotic simple prostatectomy. *J Urol*. 2008;179(2):513–515.

Tubaro A, Carter S, Hind A, et al. A prospective study of the safety and efficacy of suprapubic transvesical prostatectomy in patients with benign prostatic hyperplasia. *J Urol*. 2001;166(1):172–176.

Van Velthoven RF, Ahlering TE, Peltier A, et al. Technique for laparoscopic running urethrovesical anastomosis: the single knot method. *Urology*. 2003;61(4):699–702.

Varkarakis I, Kyriakakis Z, Delis A, et al. Long-term results of open transvesical prostatectomy from a contemporary series of patients. *Urology*. 2004;64(2):306–310.

Walsh PC, Oesterling JE. Improved hemostasis during simple retropubic prostatectomy. *J Urol*. 1990;143(6):1203–1204.

Zargooshi J. Open prostatectomy for benign prostate hyperplasia: short-term outcome in 3000 consecutive patients. *Prostate Cancer Prostatic Dis*. 2007;10(4):374–377.

Epidemiology, Etiology, and Prevention of Prostate Cancer

Andrew J. Stephenson MD, MBA, FRCSC, FACS, Robert Abouassaly MD, MS, Eric A. Klein MD

Epidemiology

Incidence and Mortality Trends

Incidence

Prostate cancer has been the most common noncutaneous malignancy in US men since 1984, now accounting for 19% of all such cancers (Fig. 148.1) (American Cancer Society, 2017)**. Among men alive today, it is estimated that approximately 1 in 8 (12.9%) will be diagnosed with prostate cancer, and 1 in 40 (2.5%) will die from this disease** (American Cancer Society, 2017)**. Prostate cancer incidence varies by race/ethnicity, with African-Americans experiencing a 73% higher incidence rate than whites (Table 148.1)** (Siegel et al., 2014). Incidence rates for prostate cancer have changed substantially over the past 25 years. The incidence rate rose by approximately 2% per year from 1975 to the late 1980s, related in part to the incidental detection of prostate cancer associated with the use of TURP for benign prostatic hyperplasia (Potosky et al., 1990). The incidence of prostate cancer rose dramatically from 1989 to 1992 after the introduction of the prostate-specific antigen (PSA) screening test (with approval from the U.S. Food and Drug Administration [FDA] for early diagnosis in 1992), declined sharply from 1992 to 1995, and generally decreased from 2000 to 2013, with a marked drop between 2011 and 2012 (see Fig. 148.1), reflecting changes in screening practices (American Cancer Society, 2017; Jemal et al., 2015). **The precipitous fall in incidence between 1992 and 1995 has been attributed to the “cull effect” of identifying previously unknown cancers in the population by the use of PSA, followed by a return to baseline incidence rates** (Stephenson et al., 1996). For 2019, an estimated 174,650 new cases of prostate cancer will be diagnosed in the United States, and the age-adjusted incidence rate is 109.2 per 100,000 men per year (American Cancer Society, 2017).

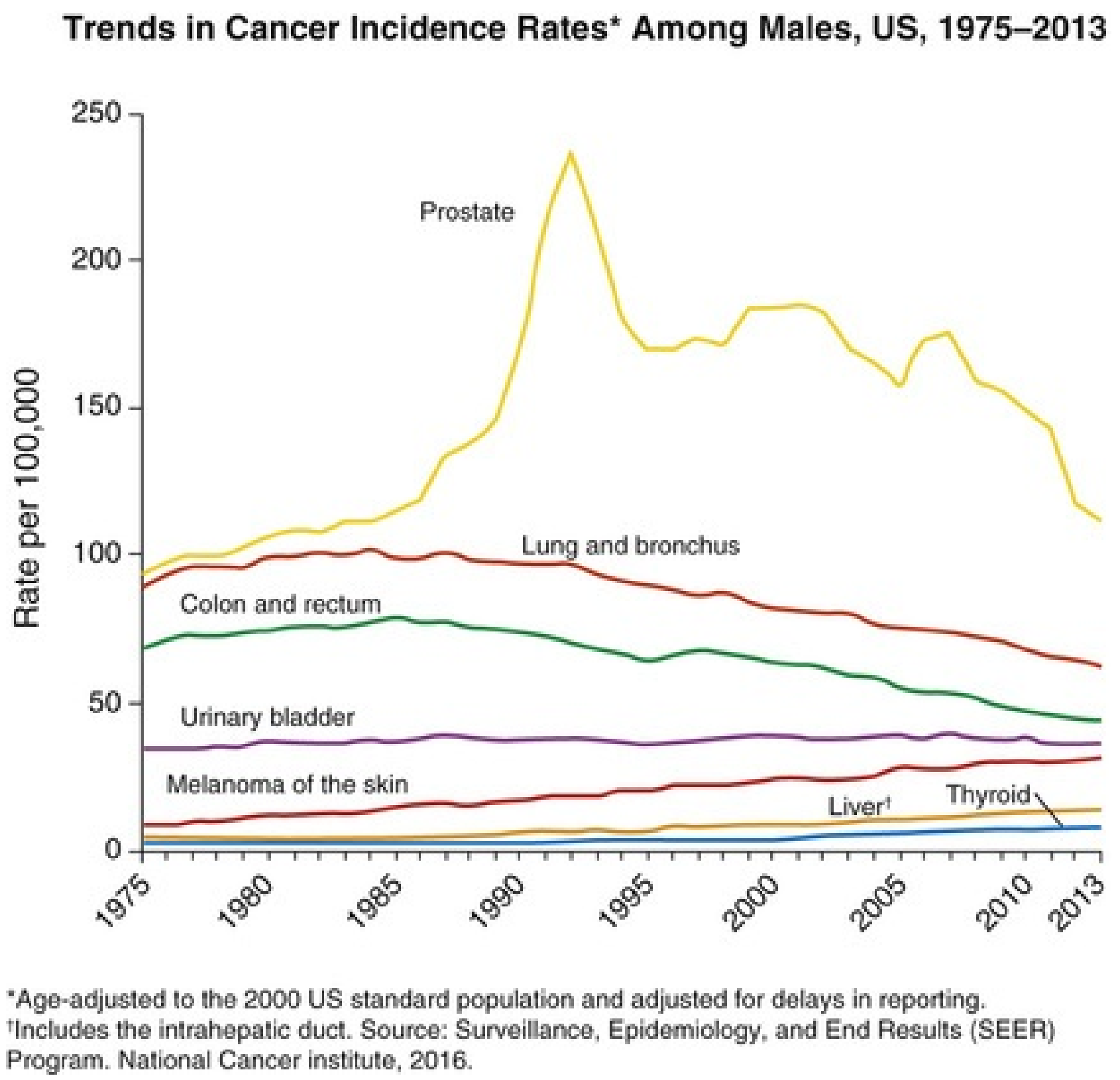

Trends in Cancer Incidence Rates* Among Males, US, 1975–2013

*Age-adjusted to the 2000 US standard population and adjusted for delays in reporting.
†Includes the intrahepatic duct. Source: Surveillance, Epidemiology, and End Results (SEER) Program. National Cancer institute, 2016.

FIG. 148.1 Data from Trends in Cancer Incidence Rates for Men, United States, 1975–2013.

TABLE 148.1

Prostate Cancer Incidence and Mortality by Race/Ethnicity, US, 2009–2013

	INCIDENCE[a]	MORTALITY[a]
White	114.8	18.7
African-American	198.4	42.8
Hispanic/Latino	104.9	16.5
Asian-American and Pacific Islander	63.5	8.8
American Indian and Alaska Native	85.1	19.4

[a] Per 100,000, age adjusted to the 2000 US standard population.

Data from American Cancer Society, 2017. Cancer facts and figures 2017. Available at: https://www.cancer.org/research/cancer-facts-statistics/all-cancer-facts-figures/cancer-facts-figures-2017.html.

Mortality

Prostate cancer mortality rates in the United States rose slowly between 1973 and 1990 (Fig. 148.2). This may have resulted from a gradual increase in the number of biologically lethal cancers or a decreasing use or effectiveness of therapy during this interval. In the early 1990s, an abrupt rise in mortality was observed. This increase was likely caused by an increase in attribution bias occurring when the National Center for Health Statistics made a change from manual to automated methods for assignment of cause of death (Feuer et al., 1999). **Subsequent to 1991, the peak mortality year, steady declines in prostate cancer mortality were reported in both Caucasians and African-Americans at an average rate of 4.1% per year. The magnitude of this decline is nearly 2.5 times larger than the increase in mortality seen as a result of attribution bias, so it seems likely that the observed declines since 1991 are real and clinically significant** (Stephenson et al., 2005). Prostate cancer is the third-leading cause of cancer death in the United States, accounting for 8% of all such events. In 2019, an estimated 31,620 men will die from prostate cancer in the United States, for an approximate annual rate of 19.2 per 100,000 population, representing a 48% decrease from the 1991 peak (American Cancer Society, 2017). **Furthermore, the mortality rate for prostate cancer in Caucasians in the United States has declined to a level lower than that observed before the introduction of PSA-based screening in 1987** (Tarone et al., 2000). As the natural history of progressive prostate cancer is protracted relative to other common solid malignancies, it is associated with the fewest expected years of life lost, estimated at 5.9 and 1.8 years for clinically detected and screen-detected cancers, respectively (Liu et al., 2013; Friman et al., 1989). **Prostate cancer was the leading single cause of death (35%) among those diagnosed with this disease between 1973 and 2008 in the U.S. Surveillance, Epidemiology, and End Results (SEER) program, but these men were still more likely to die from other causes** (Epstein et al., 2012).

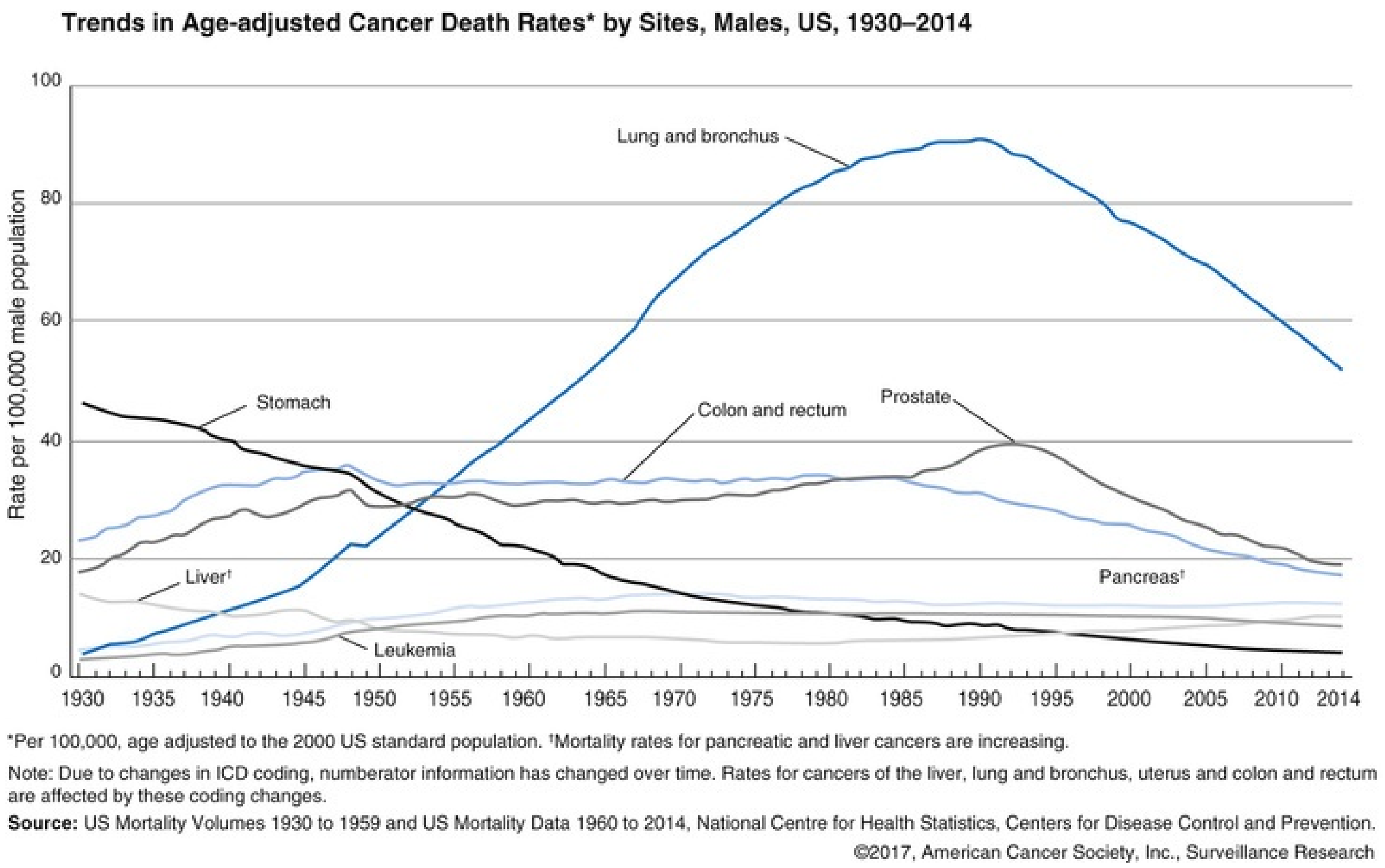

*Per 100,000, age adjusted to the 2000 US standard population. †Mortality rates for pancreatic and liver cancers are increasing.

Note: Due to changes in ICD coding, numberator information has changed over time. Rates for cancers of the liver, lung and bronchus, uterus and colon and rectum are affected by these coding changes.

Source: US Mortality Volumes 1930 to 1959 and US Mortality Data 1960 to 2014, National Centre for Health Statistics, Centers for Disease Control and Prevention.

©2017, American Cancer Society, Inc., Surveillance Research

FIG. 148.2 Data from Trends in Cancer Death Rates for Men, United States, 1930–2014. (American Cancer Society, 2017).

The observed decline in mortality since 1991 may be a result of (1) early detection and stage migration from PSA screening, (2) increased utilization and effectiveness of curative treatments, (3) changes in the attribution of cause of death, (4) improvements in therapy for advanced disease, or (5) increased risk for death from secondary causes among men receiving prostate cancer therapy (Tarone et al., 2000). The initial decline in mortality appears to have occurred too soon after the introduction of the PSA test to be attributable to screening (Etzioni et al., 1999). One hypothesis is that it is the result of the more aggressive treatment of prostate cancer that began in the 1980s (Walsh, 2000). Indeed, the vast majority of men diagnosed with prostate cancer since 1986 have received curative-intent therapy at rates that are double that observed before 1986 (Etzioni et al., 2008; Welch and Albertsen, 2009). Using mathematical models under some assumptions, it is estimated that up to one-third of the observed decline in mortality may be caused by changes in treatment approaches to prostate cancer (i.e., increased use of surgery and radiation), whereas the remainder is thought to be caused by other interventions, such as prostate-specific antigen screening and advances in the treatment of recurrent and progressive disease (Etzioni et al., 2012).

Racial Differences

African-Americans and Jamaicans of African descent have the highest incidence of prostate cancer in the world, although incidence rates have been decreasing at a similar rate to Caucasians, at least in part resulting from a recent decrease in PSA testing (American Cancer Society, 2017; Houston et al., 2018)**. Although African-Americans have experienced a greater decline in mortality than Caucasians since the early 1990s, their death rates are still 2.3 times higher.**

Many biologic, environmental, and social hypotheses have been advanced to explain these differences, ranging from postulated differences in genetic predisposition; differences in mechanisms of tumor initiation, promotion, and/or progression; higher-fat diets, higher serum testosterone (T) levels, or higher body mass index (BMI); structural, financial, educational, and cultural barriers to screening, early detection, and aggressive therapy; and physician bias. Models of prostate cancer natural history in African-Americans suggest that their observed incidence patterns implicate higher incidence of preclinical disease and higher risk for metastatic progression (Tsodikov et al., 2017a). **Additionally, differences in treatment patterns by race have consistently shown that African-Americans at every stage get less aggressive therapy regardless of age, marital status, tumor risk, and comorbidities status compared with Caucasians, even within equal-access health care systems** (Gross et al., 2008; Hoffman et al., 2003; Klabunde et al., 1998; Moses et al., 2016; Nambudiri et al., 2012; Presley et al., 2013; Shavers et al., 2004). Among men 67 to 84 years of age in the SEER-Medicare dataset, the racial disparity between African-Americans and Caucasians was highest (OR 0.57, 95% CI, 0.48 to 0.68) among those most likely to benefit (life expectancy greater than 10 years, Gleason 7 to 10, or clinical stage T2b to T2c (Presley et al., 2013). **However, prostate cancer mortality among African-Americans and Caucasians is similar in equal-access health care systems** (Graham-Steed et al., 2013)**. There are currently no data that clearly indicate if any of these hypotheses account for observed differences in incidence or mortality, and it seems likely that the source of the disparity is multifactorial, although recent molecular data indicate biologic differences are at least in part responsible** (see the Etiology and Molecular Genetics section later in this chapter).

The incidence of prostate cancer in other ethnic groups is lower than that of Caucasians and African-Americans (see Table 148.1). Interestingly, men of Asian descent living in the United States have a lower incidence compared with white Americans, but their risk is higher than that of men of similar backgrounds living in Asia (Haenszel et al., 1968; Yu et al., 1991). Likewise, Japanese immigrants have an incidence more comparable to men of similar ancestry born in the United States than to those living in Japan (Shimizu et al., 1991). Conversely, US-born blacks have a lower incidence of prostate cancer than sub-Saharan African-born blacks (Moses et al., 2016). These data implicate external factors (dietary, lifestyle, environmental) in the development of prostate cancer.

Global Incidence and Mortality

Prostate cancer is the second most common cancer and the fifth leading cause of cancer deaths worldwide, with an estimated 1.1 million new cases and 300,000 deaths in 2012 (World, 2014)**. By 2030, these rates are anticipated to increase to 1,700,000 and 499,000 as a result of global population growth and increased life expectancy. Prostate cancer incidence rates vary by 25-fold worldwide, primarily resulting from differences in screening practices, although the westernization of lifestyle has also been suggested as a possible explanation** (Hsing et al., 2000)**. The highest incidence rates are in Australia and New Zealand (111.6 per 100,000), northern and western Europe, and North America, and the lowest are in Asia and Northern Africa** (World, 2014). Incidence rates increased dramatically in the 1990s in many of the highest-resource countries as PSA testing became available. Although incidence rates have leveled off in some of these countries, they continue to uniformly increase in countries transitioning toward higher levels of human development (Zhou et al., 2016). Prostate cancer mortality rates varied 10-fold with the highest age-adjusted rates per 100,000 men in the Caribbean (26.3), Sub-Saharan Africa (18.3 to 19.3), and South America (16.2), and the lowest rates in Asia (3.1) (Center et al., 2012). Mortality rates have been decreasing since the 1990s in some of the highest-resource countries, such as the United States (–4.3%), Canada (–3.1%), Western Europe (–2.3 to –4%), Australia (–2.3%), and New Zealand (–2.8%), likely as a result of improved treatment and/or PSA screening (Collin et al., 2008). However, increasing prostate cancer mortality was seen among nations of central and eastern Europe, Asia, and Africa. Prostate cancer is the most common cancer among Sub-Saharan Africans, with a mortality rate more than 5 times higher than in African-Americans (Gronberg et al., 2003; Rebbeck et al., 2013). In general, there appears to be a positive correlation between the human development index (HDI, composite index composed of life expectancy, education, gross national income per capita, health, and living standard) and prostate cancer incidence rates. However, there is a negative correlation between the HDI and standardized mortality rates (Khazaei et al., 2016). **Using data from population-based cancer registries, the CONCORD study found that age-standardized 5-year survival rates vary greatly, ranging from greater than or equal to 80% in the United States, Australia, and Canada to less than 40% in Denmark, Poland, and Algeria, suggesting local influences on detection and therapy** (Coleman et al., 2008).

Age at Diagnosis

Prostate cancer is rarely diagnosed in men younger than 50 years of age, accounting for only 2% of all cases (Jani et al., 2008)**, however, this is highly correlated with age at first screening** (Godtman et al., 2016)**. Before the PSA era, the median age at diagnosis was 70, falling to 67 over the past decade, with 63% diagnosed after 65 years of age** (Ries et al., 2008). Patients with familial prostate cancer, or germline mutations increasing susceptibility to prostate cancer (e.g., *BRCA2* mutation), tend to be diagnosed at an earlier age compared with men with sporadic prostate cancer (Brandt et al., 2009; Gleicher et al., 2016; Plonis et al., 2015). The incidence rate in 2005 relative to 1986 (the year before PSA was commercially available) was 0.56 in men ≥ 80 years of age, 1.09 in those 70 to 79 years, 1.91 in those 60 to 69 years, 3.64 in those 50 to 59 years, and 7.23 in men younger than 50 years of age (Welch and Albertsen, 2009). **This reflects a shift in diagnosis to an increasingly younger population after the introduction of PSA, with important implications for deciding on the need for and type of therapy.** Although age-specific incidence rates decline after 70 years of age, the risk for prostate cancer death increases throughout life. **The average age of death from prostate cancer is 77 years of age and has remained stable over the past three decades** (Epstein et al., 2012)**, however, men with familial prostate cancer, on average, die at an earlier age than men without a family history of prostate cancer** (Brandt et al., 2009).

Stage at Diagnosis

In addition to changes in incidence and mortality over the past several decades, there has been a substantial shift to more favorable stage at presentation of newly diagnosed disease. **This clinical stage migration is largely if not**

exclusively accounted for by PSA screening (Catalona et al., 1993; Mettlin et al., 1993)**. Since the introduction of PSA testing, 81% of newly diagnosed men have localized disease, whereas the incidence of metastatic disease has decreased by 75%** (Newcomer et al., 1997). Nonpalpable cancers (AJCC clinical stage T1c) now account for 60-75% of newly diagnosed disease (Gallina et al., 2008). Clinical stage migration has also been associated with improvements in 5-year disease-specific survival, which is 99.2% overall and 28% for men with advanced disease (Siegel et al., 2014).

The use of PSA has also resulted in a substantial downward pathologic stage migration as evidenced by an increase in the proportion of patients with organ-confined disease (Catalona et al., 1993; Jhaveri et al., 1999) **and a decrease in the proportion with seminal vesicle involvement** (Gallina et al., 2008). Since 1995, however, a slowing in this trend has been observed, suggesting a diminishing effect of PSA screening on pathologic stage migration (Dong et al., 2007).

Effect of Screening on Incidence and Mortality

The use of PSA as a screening test has had the greatest impact on the incidence and potentially mortality of prostate cancer worldwide. Since the introduction of the PSA test, lifetime risk for prostate cancer in the United States has nearly doubled from 7.8% to 12.9%, and the risk for dying from this disease has decreased from 3% to 2.5% (American Cancer Society, 2017). In the **Prostate Cancer Prevention Trial (PCPT),** 14% of men in the placebo arm were diagnosed by annual PSA screening within 7 years of enrollment (Thompson et al., 2003), suggesting that lifetime risk for regular screening may approach 20% (Boyle et al., 2009).

Recently, the results of two large randomized trials assessing the effect of PSA screening on prostate cancer mortality were published. The U.S. Prostate, Lung, Colorectal, and Ovarian (PLCO) cancer screening trial reported on 76,685 US men 55 to 74 years of age randomized between annual screening or usual care (Andriole et al., 2012). **Through 15 years of follow-up, there was no difference in prostate cancer mortality between the groups (47.8 vs. 46.0 deaths per 100,000 person-years in the screening and control groups, respectively; HR 1.03; 95% CI, 0.87 to 1.23)** (Pinsky et al., 2017)**. The trial has been criticized for high rates of contamination, with an estimated 90% of patients in the control arm having received at least one PSA before or during the trial** (Shoag et al., 2016). Thus, the trial did not fairly compare annual screening versus none and has been more accurately described as a comparison of organized screening versus opportunistic screening. **A recent reanalysis of the PLCO trial comparing those screened versus those not screened (rather than on an intent-to screen basis) suggested a 25% to 30% reduction in prostate-cancer–specific mortality in those screened** (Tsodikov et al., 2017a). The European Randomized Study of Screening for Prostate Cancer (ERSPC) included 162,243 men between 55 and 69 years of age randomized between PSA screening every 4 years or no screening (Schröder et al., 2014). **After a median follow-up of 13 years, men in the screening arm had a 57% (95% CI, 51 to 62) increased incidence of prostate cancer compared with controls and a 21% (95% CI, 9 to 31) relative reduction in death from prostate cancer (4.3 vs. 5.4 cancer deaths per 10,000 person-years). Models based on these two trials estimate a reduction in prostate cancer mortality of 37% to 43% under annual screening with 100% attendance and biopsy compliance and no contamination** (de Koning et al., 2018).

Soon after publication of the PLCO and ERSPC, the U.S. Preventive Services Task Force (USPSTF) in 2012 recommended against routine PSA screening in healthy men regardless of age, race, or family history. It gave PSA a grade D recommendation, meaning that there was a moderate-to-high certainty that the service has no net benefit or that the harms outweigh the benefits (Moyer et al., 2012). The early impact of these recommendations on clinical practice, and the epidemiology of the disease, have been examined in several publications (Lee et al., 2017). Data from self-reported PSA screening demonstrated an up to 55% relative reduction in prostate cancer screening across all age groups, whereas data from electronic medical records and administrative claims showed modest to no reductions in screening in men younger than 70 years of age. Studies have also demonstrated up to 40% relative reductions in prostate biopsies and a 16% reduction in the number of prostatectomies performed per urologist (Halpern et al., 2017). Further, data from the SEER and the National Cancer Database suggest a nearly 30% decrease in the incidence of prostate cancer in the years after the USPSTF recommendations (Barocas et al., 2015; Jemal et al., 2015), with observed decreases in low-, intermediate-, and high-risk disease (Herget et al., 2016). Modeling studies suggest that if screening for prostate cancer were abandoned entirely, there would be an estimated 46% to 57% increase in metastatic cases at presentation, leading to as much as a 20% increase in prostate cancer deaths. However, it is too early to determine the actual impact of changes in USPSTF recommendations on prostate cancer incidence and mortality. **In April 2017, the USPSTF partially reversed its course and submitted new draft recommendations, giving a grade of C to prostate cancer screening in men 55 to 69 years of age (offered for selected patients), but keeping the grade of D for men 70 years of age and older (discouraging its use). In doing so, the task force acknowledged the limitations of the PLCO with respect to PSA contamination in the nonscreened arm, the marked mortality reduction in those screened in the ERSPC, and the growing adoption of active surveillance in men with low-risk disease leading to less overtreatment of PSA-detected nonlethal cancers.** How the new recommendations will affect prostate cancer incidence and mortality remains to be determined.

Risk Factors

Considerable evidence suggests that **both genetics and environment play a role in the origin and evolution of prostate cancer.** Traditional and molecular epidemiology and newer genome-based techniques have identified a number of potential risk factors associated with the development of prostate cancer.

Familial and Germline Genetic Influences

Epidemiologic and molecular evidence suggests that prostate cancer has as strong familial component as demonstrated by epidemiologic studies and germline genetic analysis. The inherited risk for prostate cancer has been estimated to be as high as 60% (Hjelmborg et al., 2014). It is believed that between 5% and 10% of prostate cancer cases are primarily caused by high-risk inherited genetic factors or prostate cancer susceptibility genes (PDQ Cancer Genetics Editorial Board, 2002). A family history of a brother or father with prostate cancer increases the risk for prostate cancer, and the risk is inversely related to age at diagnosis of the relative. **Generally, relative risk increases according to the number of affected family members, their degree of relatedness, and the age at which they were affected** (Table 148.2) (Zeegers et al., 2003).

TABLE 148.2

Family History and Risk for Prostate Cancer

FAMILY HISTORY	RELATIVE RISK	95% CONFIDENCE INTERVAL
Father affected at any age	2.35	2.02–2.72
Brother(s) affected at any age	3.14	2.37–4.15
One affected first-degree relative diagnosed at any age	2.48	2.25–2.74
Affected first-degree relatives diagnosed <65 years	2.87	2.21–3.74
Affected first-degree relatives diagnosed ≥65 years	1.92	1.49–2.47
Second-degree relatives diagnosed at any age	2.52	0.99–6.46
Two or more affected first-degree relatives	4.39	2.61–7.39

diagnosed at any age		

Data from Kiciński M, Vangronsveld J, Nawrot TS. An epidemiological reappraisal of the familial aggregation of prostate cancer: a meta-analysis. *PloS One* 6(10):e27130, 2011.

Various research methods have been employed to identify genetic variation associated with prostate cancer. Linkage studies identified possible loci on several chromosomes, but with the exceptions of *BRCA1*, *BRCA2*, and *HOXB13*, most have not been consistently replicated by subsequent studies (Eeles et al., 2014). This suggests that the hereditary etiology of prostate cancer has a significant polygenetic inheritance. With advances in genomic technology utilizing databases of millions of common single-nucleotide polymorphisms (SNPs), genome-wide association studies (GWAS) have further identified candidate loci associated with prostate cancer. **Using this technique, several prostate cancer susceptibility loci, confirmed in more than one study, have been identified on chromosomes 3, 5, 6, 7, 8, 9, 11, 15, 16, 17, 19, and 22** (PDQ Cancer Genetics Editorial Board, 2002)**. Genetic variants identified from GWAS do not pose a clinically significant effect on their own, but the risk is cumulative and increases with increasing number of risk alleles present in an individual.** One approach to this challenge is to combine multiple risk alleles into a predictive model, as risk increases with the number of specific alleles carried. **A polygenic risk score composed of the full complement of risk SNPs has been proposed, and is estimated to account for a 2.9-fold increased risk for prostate cancer among men in the top 10% risk group, and a 5.7-fold risk increase among men in the top 1% risk group, compared with the population average risk** (Al Olama et al., 2014).

To date, however, GWAS findings are estimated to account for only 33% to 50% of heritable prostate cancer risk (Gudmundsson et al., 2012). Ongoing research is continuing to uncover the remaining portion of genetic risk, including the discovery of rarer alleles with higher ORs for risk. **The performance of predictive models based on germline alleles and thus their clinical utility may improve with the incorporation of these rarer variants that confer higher risk.** Several such variants, with a minor allele frequencies approximately 1%, have recently been described for prostate cancer. A recurrent mutation in the coding region of the *HOXB13* gene (i.e., *G84E* pathogenic variant), which maps to an area of interest at 17q21-22 identified by GWAS, was present in 1.34% of cases compared with only 0.28% of controls and was significantly more common in men with early-onset, familial prostate cancer (3.1%) than in those with late-onset, sporadic disease (0.6%) (Ewing et al., 2012;

Witte et al., 2013). This mutation increases overall risk for disease almost 5 times, and more than 8 times in men younger than 55 years of age or with a family history (Witte et al., 2013). Lifetime risk for prostate cancer among *G84E* carriers is estimated between 33% to 60% (MacInnis et al., 2013). Although the exact mechanism with which *HOXB13* contributes to the pathogenesis remains unknown, it has been shown to play a role in prostate cancer development and interacts with the androgen receptor (AR) (PDQ Cancer Genetics Editorial Board, 2002). However, the implications of the *HOXB13 G84E* pathogenic variant for genetic counseling is currently unclear.

Several studies have suggested a familial coaggregation of prostate cancer with breast cancer (Goldgar et al., 1994; Thiessen, 1974; Tulinius et al., 1992), and there is clear evidence that both *BRCA1* and *BRCA2* carriers are at increased risk for prostate cancer, especially early-onset disease. *BRCA1* has been estimated to increase risk by 1.8- to 3.5-fold and *BRCA2* from 4.6- to 8.6-fold in men younger than 65 years of age (reviewed in Castro and Eeeles, 2012). ***BRCA*-associated cancers, especially for *BRCA2*, are also more likely to present with higher-grade, locally advanced, and metastatic disease and have poorer cancer-specific and metastasis-free survival after prostatectomy** (Castro et al., 2015)**. One recent study found that early-stage *BRCA2*-associated prostate cancers are characterized by de novo aberration in genes usually associated with metastatic disease** (Taylor et al., 2017)**.**

Using germline information to predict the risk for developing prostate cancer for individuals or on a population basis has yet to be realized because of low penetrance of relevant alleles in the general population; cost; lack of ability of most alleles (*BRCA* being a notable exception) to predict for disease that is biologically significant; and lack of evidence that targeted prevention strategies or early intervention will have a meaningful impact on outcome (Fig. 148.3). That being said, multigene tests for variants associated with prostate cancer susceptibility are currently available and increasingly being used clinically, and centers are studying the utility of germline testing and counseling in these patients. A recent consensus conference established guidelines for their use (Giri et al., 2018).

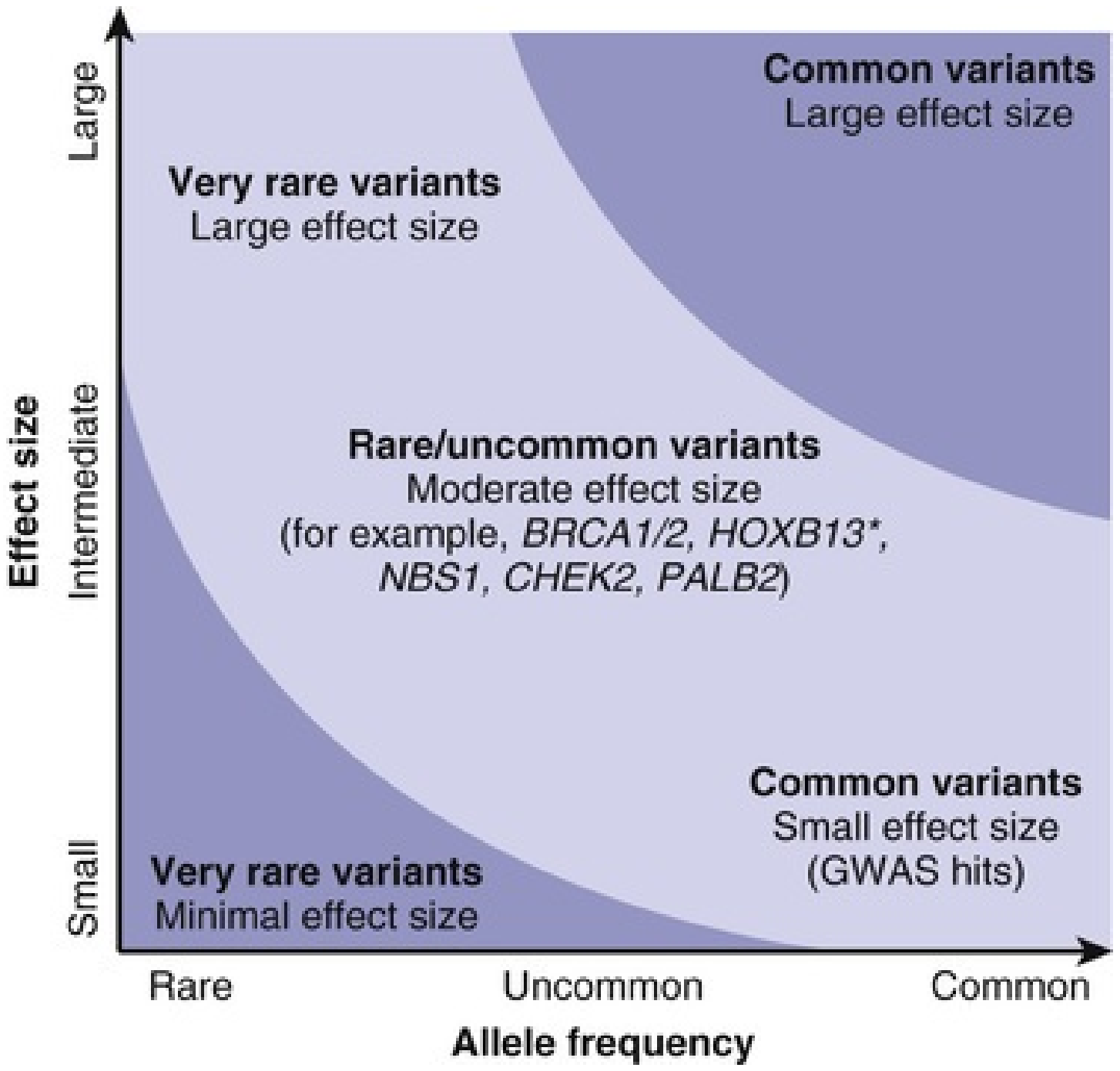
Effect size
Large
Intermediate
Small
Common variants
Large effect size
Very rare variants
Large effect size
Rare/uncommon variants
Moderate effect size
(for example, *BRCA1/2, HOXB13**,
NBS1, CHEK2, PALB2)
Common variants
Small effect size
(GWAS hits)
Very rare variants
Minimal effect size
Rare
Uncommon
Common
Allele frequency

FIG. 148.3 Germline influences on susceptibility to prostate cancer. The genetic architecture of prostate cancer illustrates that susceptibility is highly likely to be caused by a mixed model of common and rare genetic variants. (Reproduced with permission from Eeles R, Goh C, Castro E, et al. The genetic epidemiology of prostate cancer and its clinical implications. *Nat Rev Urol* 11[1]:18–31, 2014.)

Inflammation and Infection

Infections cause about 16% of all cancers worldwide (de Martel et al., 2012). **Chronic inflammation leading to cellular hyperproliferation to replace damaged tissue contributes to the development of infection-associated cancers of the colon, esophagus, stomach, bladder, and liver** (Coussens and Werb, 2002; De Marzo et al., 2007)**. Accumulating evidence suggests that a similar process may underlie the development of prostate cancer, and although no specific infectious agent has been identified, inflammation resulting from infection, dietary intake, or other causes likely contributes to development and progression of early-stage disease. Attempts have been made to establish an epidemiologic link between inflammation on prostate biopsy and the subsequent development of prostate cancer, however, these studies are susceptible to detection bias. In one study that circumvents this problem, men initially enrolled in the PCPT who had negative end-of-study biopsies and who were subsequently enrolled in the Selenium and Vitamin E**

Cancer Prevention Trial (SELECT) were monitored for prostate cancer development. The study found that inflammation on negative biopsy was associated with the later development of prostate cancer (Platz et al., 2017)**.**

Inflammatory infiltrates and the histologic lesion called proliferative inflammatory atrophy (PIA) are frequent in clinical prostate specimens (De Marzo et al., 1999). PIA is a spectrum of lesions characterized by epithelial atrophy, low apoptotic index, and an increased proliferative index, usually associated with inflammatory infiltrates (Putzi and De Marzo, 2000). PIA appears to be a regenerative lesion appearing as a consequence of infection or cell trauma resulting from oxidant damage, hypoxia, infection, or autoimmunity, and its hyperproliferative state may lead to cancer. PIA is often found adjacent to high-grade prostatic intraepithelial neoplasia (HGPIN) or early cancer (Putzi and De Marzo, 2000), and there is an identifiable genetic pathway between PIA, HGPIN, and cancer (Nakayama et al., 2003; Nelson et al., 2003; Shah et al., 2001).

Genetic alterations in genes that regulate the inflammatory response and mediate DNA repair, and histologic observations in prostate cancer strongly suggest that compromised cellular defenses against inflammatory oxidants may initiate and/or perpetuate prostatic carcinogenesis (Klein and Silverman, 2008). Although the exact mechanisms remain unclear, one hypothesis is that reactive oxygen species (ROS) and reactive nitrogen species released by immune cells cause direct DNA damage and genetic instability in an environment where epithelial cell proliferations stimulated by immune cells is occurring (Fig. 148.4) (Sfanos et al., 2018). Another potential mechanism relates to the recruitment of epigenetic machinery to sites of DNA damage resulting from the oxidative stress, including DNA methyltransferases, chromatin remodelers, and repressor complexes (O'Hagan et al., 2008, 2011). Recently, in vitro studies of prostate epithelial cells exposed to oxidative stress and AR signaling were found to develop *TMPRSS2-ERG* gene fusions (Mani et al., 2016). Inflammation may also contribute to carcinogenesis through stimulating the development of intermediate cells, which are suspected target cells for prostate carcinogenesis (van Leenders et al., 2003).

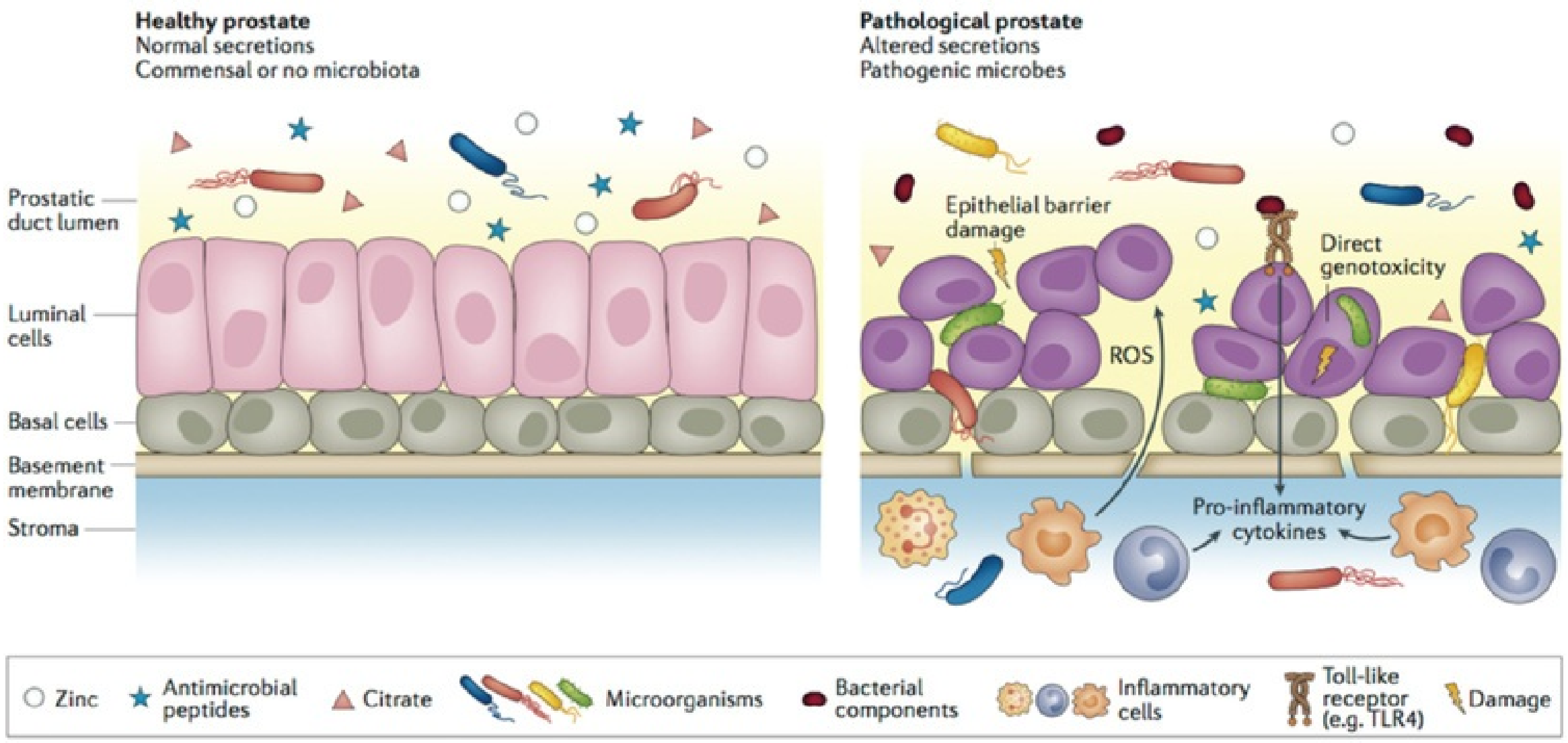
Healthy prostate
Normal secretions
Commensal or no microbiota
Pathological prostate
Altered secretions
Pathogenic microbes
Prostatic duct lumen
Luminal cells
Basal cells
Basement membrane
Stroma
Epithelial barrier damage
Direct genotoxicity
ROS
Pro-inflammatory cytokines
Zinc
Antimicrobial peptides
Citrate
Microorganisms
Bacterial components
Inflammatory cells
Toll-like receptor (e.g. TLR4)
Damage

FIG. 148.4 Effects of inflammation on early events in prostate cancer. (Reproduced from Sfanos KS, Yegnasubramanian S, Nelson WG, De Marzo AM. The inflammatory microenvironment and microbiome in prostate cancer development. *Nat Rev Urol* 15[1]:11–24, 2018.)

There has been much interest and effort in trying to isolate and identify an infectious agent or agents that cause prostate cancer. **However, recent studies assessing the association between infection and prostate cancer have shown mixed results.** In the Health Professionals Follow-up Study (HPFS) (Sutcliffe et al., 2006), a prospective study of 51,529 American male health professionals 40 to 75 years of age, no association was found between a self-reported history of gonorrhea or syphilis and prostate cancer, although the incidence of sexually transmitted infection (STI) was very low in this population. In addition, no overall correlation between prostate cancer and clinical prostatitis was found. Similarly in this cohort, no associations were observed between *Chlamydia trachomatis*, human papillomavirus (HPV)-16, HPV-18, and HPV-33 antibody seropositivity and prostate cancer (Sutcliffe et al., 2007b). To date, no single microorganism (bacterial, viral, or other) has emerged as the driver of inflammation associated with prostate cancer or as a significant contributor to prostate carcinogenesis. Evidence supports the theory that multiple different microorganism species lead to prostate inflammation. One study that sequenced microbial DNA in prostatectomy samples from men with prostate cancer found DNA from multiple different bacterial species (Sfanos et al., 2008). The authors concluded that microorganisms are present in focal regions of the prostate, perhaps in those associated with foci of acute or chronic inflammation. The discovery of the urinary microbiome, with multiple diverse microorganisms, suggests that prostates are exposed to multiple types of bacteria that elicit prostatic inflammation, contributing to the inflammatory microenvironment associated with prostate cancer. Studies characterizing the microbiota in urine from adult men found common genera, including *Corynebacterium, Streptococcus, Veillonella, Prevotella, Anaerococcus, Propionibacterium, Finegoldia, Staphylococcus, and Lactobacillus* (Dong et al., 2011; Fouts et al., 2012; Nelson et al., 2010). Whether susceptibility to prostatic infection, chronic inflammation, or the development of prostate cancer is determined by the composition of the urinary flora has not yet been determined. **At present, no infectious agent has been proven to cause prostate cancer.**

Molecular Epidemiology

Molecular epidemiologic approaches have identified many biomarkers of exposure measured in blood or tissue and evaluated them in relation to incidence or mortality. These biomarkers capture aspects of diet, environmental exposures, and hormonal and other factors for which concentrations are partly genetically determined. A brief survey of major molecular epidemiologic studies relating to prostate cancer is presented.

Androgens

Androgens influence the development, maturation, and maintenance of the prostate, affecting both proliferation and differentiation of the luminal epithelium. Exposure of the prostate to androgens at key developmental times plays an important role in prostate carcinogenesis. Androgens are also important in the maintenance of established cancers, as supported by clinical experience where the majority of prostate cancers initially respond to androgen deprivation, by the central role of AR biology in castrate-resistant disease, and by results of the PCPT and the Reduction by Dutasteride of Prostate Cancer Events (REDUCE) trial, which demonstrated that inhibition of the conversion of T to the more potent dihydrotestosterone (DHT) by a 5α-reductase inhibitor reduces the incidence of prostate cancer by 25% to 30% (Andriole et al., 2010; Thompson et al., 2003, 2013). Establishing the precise effect of androgens on risk is complicated by the complex biology of the androgen axis: (1) androgen levels are affected by both synthesis and metabolism, which are each controlled by multiple genes; (2) the biologic effects of androgen are exerted at the cellular level by its interaction with the AR; and (3) intraprostatic and serum levels of specific androgens may differ. **Polymorphisms in both synthetic and metabolic genes, including AR** (Balic et al., 2002)**, the type 2 5α-reductase isoenzyme** (Li et al., 2013; Makridakis and Reichardt, 2004), **and genes involved in T biosynthesis** (Chang et al., 2002), **have been reported to affect risk. A meta-analysis of 47 published studies with 13,346 cases and 15,172 controls concluded that men with shorter CAG repeats in the AR were at higher risk for prostate cancer, with an OR of 1.21 (95% CI, 1.10 to 1.34), with the effect most evident in Caucasians and Asians** (Sun and Lee, 2013). Polymorphisms in both the type 1 and type 2 5α-reductase genes have been shown to affect both circulating and intraprostatic androgen levels (Lévesque et al., 2014).

High serum androgens have long been hypothesized to be a risk factor for prostate cancer. However, studies examining this association have been inconsistent, with only some studies finding an association between specific hormones and prostate cancer risk. **A pooled analysis of 18 prospective studies assessing this association using data from 3886 men with prostate cancer and 6438 control subjects** (Endogenous Hormones and Prostate Cancer Collaborative Group, 2008) **failed to detect an association between the risk for prostate cancer and serum concentrations of T, calculated free T, DHT, DHEA, androstenedione, androstanediol glucuronide, estradiol, or calculated free estradiol.** The only positive finding was a modest inverse association between risk and serum concentration of sex-hormone–binding globulin. **The results suggest that one-time measurements of serum sex hormones in adulthood are not a good measure of prostate cancer risk.** No studies have reported on intraprostatic androgen levels as a measure of risk in unaffected men.

Estrogens

Estrogens have both direct and indirect effects on prostatic growth and development and likely play a role in prostate cancer initiation and progression. Traditionally, estrogens have been considered protective against prostate cancer and have been used as a treatment for advanced disease. This treatment effect is primarily through a negative feedback on the hypothalamo-pituitary-gonadal axis, and also through a direct inhibitory effect of estrogens on prostate epithelial cell growth. **However, there is increasing direct evidence**

that estrogens may act as procarcinogens in the prostate. In a seminal study, isolated prostate progenitor cells from normal human prostate that were grown in three-dimensional culture to form prostatospheres expressed estrogen receptor (ER)α, ERβ, and estrogen-responsive G protein–coupled receptor 30 messenger RNA (mRNA) and protein, and grew in response to exogenous estradiol (Hu et al., 2011). When cocultured with rat urogenital sinus mesenchyme and grown in a renal subscapular model, subsequent exposure to T and estradiol resulted in the sequential induction of epithelial hyperplasia, PIN, and locally invasive prostate cancer from the human progenitor cells, providing direct evidence that these cells are estrogen sensitive and that estradiol is a carcinogen for human prostate epithelium. Proposed underlying mechanisms for this effect include epigenetic modifications (especially in utero), genotoxicity, induction of hyperprolactinemia, proinflammatory changes, and prostatic ER-mediated changes (Nelles et al., 2011). In a rat model, a significant increase in prostate cancer incidence was seen when estrogen was given in conjunction with T compared with rats given T alone (90% to 100% vs. 35% to 40%) (Bosland, 2013). The bulk of reported evidence relates to ER-mediated effects (Prins and Korach, 2008). ERα expression, present in stromal and basal cells, is silenced in early prostate cancers, and re-emerges with disease progression. ERα knockout mice have resistance to the development of prostate cancer when given the combination of T and estrogen, suggesting a role for ERα in prostate cancer induction (Ricke et al., 2008). Prostate epithelial ERβ is also thought to play an important role in cancer initiation, with loss of ERβ potentially contributing to disease progression in organ-confined disease (Prins and Korach, 2008). The re-emergence of ERβ expression in metastatic prostate cancer suggests a potential role in progression to castrate-resistant disease.

At a more macro level, age-related prostatic disease parallels increases in serum estrogens, and there is a low incidence of prostate cancer in cultures with diets rich in phytoestrogens (Denis et al., 1999). As for androgens, serum levels of estrogen do not correlate with prostate cancer risk (reviewed in Nelles et al., 2011), though it is clear that that estradiol can be produced from T by intraprostatic aromatase (Ellem et al., 2004), and its potential biologic effects may not be evident from serum levels. **Interestingly, an aromatase knockout mouse model demonstrated a lower risk for prostate cancer compared with wild-type mice after exposure to T and estrogen; the results suggest that intraprostatic estrogen production is important in prostate cancer development** (Ricke et al., 2008). Similar to effects seen for androgen metabolism genes, polymorphisms in two estrogen metabolism genes, *CYP1B1* and *CYP19*, have been observed to increase risk for prostate cancer in a cohort of French men (Cussenot et al., 2007), and polymorphisms in *CYP19A1* and *UGT1A1* were associated with increased risk in the PCPT (Tang et al., 2011).

Insulin-like Growth Factor Axis

Insulin-like growth factors (IGF) are peptide hormones that play an essential role in metabolism and body growth and exert influence on fundamental cellular processes including proliferation, migration, and differentiation. The IGF axis consists of two ligands (IGFI and IGFII), two receptors (type I IGFR-IR and IGF-II/M6P-R), and six binding proteins (numbered IGFBP-1 to -6), the latter of which modulate IGF bioavailability (Biernacka et al., 2012). IGFs may also bind the insulin receptor, and it and the IGF receptors share many downstream targets, making the interaction of these molecules complex.

IGFs promote proliferation and inhibit apoptosis in normal prostate and tumor cells in vitro (Uzoh et al., 2011)**. The IGFBPs can influence prostate growth independent of IGF.** In particular, IGFBP-2 stimulates proliferation, and IGFBP-3 promotes apoptosis and may mediate growth inhibition by 1,25-dihydroxyvitamin D (Chatterjee at al, 2004; Ingermann et al., 2010). IGFBP-3 can be cleaved by PSA, reducing its proapoptotic activity (Koistinen et al., 2002). In cell lines, IGF-1 can bind and activate the AR in the absence of androgen and promote androgen-independent growth (Krueckl et al., 2004).

Results of epidemiologic studies linking the IGF axis to risk have shown mostly null results, although the data suggests a potential effect on cancer progression rather than initiation (reviewed in Uzoh et al., 2011). For example, in the PLCO, there was no association of the IGF axis with risk for developing prostate cancer, but a suggestion that the ratio of IGF-1:IGFBP-3 in obese men was predictive of disease aggressiveness (Weiss et al., 2007).

Leptin

Leptin, a peptide hormone produced by adipocytes, contributes to the control of body weight by appetite suppression and modulating energy utilization (Friedman, 2002). Obese men become leptin resistant and exhibit elevated plasma leptin (Chu et al., 2001). **Epidemiologic studies assessing the association between circulating leptin concentrations with prostate cancer**

have yielded mixed results (Chung and Leibel, 2006). A meta-analysis concluded that a germline variant allele in the *LEP* gene is associated with a 1.2 to 1.3 times increased risk (He and Xu, 2013). **There is evidence that leptin plays a role in the development of advanced disease** (Ribeiro et al., 2006), by growth stimulation of the androgen-independent prostate cancer cell lines DU145 and PC-3 (Deo et al., 2008; Hoda et al., 2012; Somasundar et al., 2004) inducing expression of vascular endothelial growth factor, transforming growth factor β_1, and basic fibroblastic growth factor, and stimulation of cell migration via upregulation of αvβ3 integrin and intracellular signal transduction (Huang et al., 2011). Recent evidence supports another mechanism of prostate cellular migration induced by leptin through its influence on estrogen metabolism and increased expression of ERα and a decrease in ERβ (Habib et al., 2015). A variant allele in the gene for leptin receptor, *LEPR,* was found to be the strongest predictor among five candidate genes for fatal prostate cancer in a Swedish population-based study (Lin et al., 2011).

Vitamin D, Vitamin D Receptor, and Calcium

Vitamin D (1,25 dihydroxyvitamin D_3) is an essential vitamin that is a part of the steroid hormone superfamily. Human sources include both dietary intake and sunlight exposure, which converts inactive to active vitamin D in the skin. **Interest in vitamin D as a determinant of prostate cancer risk comes from epidemiologic observations** (Schwartz, 2013)**: (1) men living in Northern latitudes with less exposure to sunlight-derived ultraviolet exposure have a higher mortality rate from prostate cancer; (2) prostate cancer occurs more frequently in older men, in whom vitamin D deficiency is more common both because of less ultraviolet exposure and age-related declines in the hydroxylases responsible for synthesis of active vitamin D; (3) African-Americans, whose skin melanin blocks ultraviolet radiation and inhibits activation of vitamin D, have the highest worldwide incidence and mortality rates; (4) dietary intake of dairy products rich in calcium, which depresses serum levels of vitamin D, is associated with a higher risk for prostate cancer; and (5) Native Japanese, whose diet is rich in vitamin D derived from fish, have a low incidence of prostate cancer. In addition, prostate cancer cells express vitamin D receptor (VDR), and many studies have demonstrated significant biologic effects of vitamin D including inducing cell cycle arrest and inhibiting invasion, cell migration, metastasis,**

angiogenesis, and inflammation.

Like other steroidal regulators of prostate growth (i.e., androgens and estrogens), normal prostate epithelial cells can synthesize vitamin D, which, in turn, can inhibit their growth (Barreto et al., 2000). The enzyme that converts the prohormone 25-hydroxyvitamin D (25-OHD) to the most active form of 1,25 hydroxyvitamin D (1,25-OHD), is diminished in prostate cancer, leading to a potential loss of autocrine-regulated growth inhibition (Whitlatach et al., 2002). VDR, which binds to 1,25-OHD from serum-derived (diet, sunlight, and paracrine sources) and autocrine sources, is also widely expressed by normal prostate epithelium (Krill et al., 2001). VDR polymorphisms have been associated with prostate cancer risk in some meta-analyses (Yin et al., 2009), but not in others (Shui et al., 2015; Wang et al., 2016). Studies of plasma vitamin D levels and prostate cancer risk are mixed, with most showing no or a weak association (reviewed in Schwartz, 2013). However, there appears to be an association of vitamin D levels and adverse pathology in men undergoing radical prostatectomy (Nyame et al., 2016), as well as risk for lethal prostate cancer, as illustrated by findings in the Health Professional Follow-up Study and the Malmo Diet and Cancer Study (Brändstedt et al., 2016; Shui et al., 2012). However similar associations were not observed in an analysis of the National Cancer Institute Breast and Prostate Cancer Cohort Consortium (Shui et al., 2012).

A meta-analysis of 45 observational studies found null results for dairy, milk, calcium, or vitamin intake and risk for prostate cancer (Huncharek et al., 2008). However, other studies found that the associations between calcium and vitamin D intake and aggressive prostate cancer varied by race, with African-Americans most susceptible to the effects of these micronutrients (Batai et al., 2017; Nelson et al., 2016).

Other Influences

Sexual Activity/Sexually Transmitted Diseases.

Sexual activity has been hypothesized to expose the prostate to infectious agents that may increase the risk for cancer by direct infection with a carcinogenic organism (akin to HPV and cervical cancer) or by initiating an inflammatory response that has known downstream carcinogenic effects. A sexually transmitted etiology for prostate cancer was first proposed in 1950s based on an observed increased prevalence in uncircumcised men (Ravich and

Ravich, 1951). A seminal meta-analysis, published in 2002, suggested an elevated risk for prostate cancer among men with a history of STI (especially for syphilis), increasing frequency of sexual activity, and a higher number of sexual partners (Dennis and Dawson, 2002), however, subsequent case-control and cohort studies have not always confirmed these observations (reviewed in Sutcliffe, 2010). **Prospective studies that have included measurement of serologic markers of STI have generally reported null findings.** For example, in the PLCO, although a borderline increased risk for prostate cancer for a history of any STI was observed, null results were reported for serum levels of antibodies to *Chlamydia trachomatis*, HPV-16 and -18, HSV-2, CMV, and HHV-8 (Huang et al., 2008). A prospective cohort study of more than 68,000 men in California reported that those with a history of prostatitis or longer duration of prostatitis symptoms had an increased risk for prostate cancer compared with men with no history (RR 1.30) or shorter duration of symptoms (Cheng et al., 2010). However, this risk disappeared in those screened for cancer, and a history of STIs was not associated with risk. More recent work has identified two nontraditional infectious agents, the protozoan *Trichomonas vaginalis* and the skin bacterium *Propionibacterium acnes* as potential causes of prostatic infection and inflammation that are associated with increased risk for prostate cancer (Shinohara et al., 2013; Sutcliffe, 2010).

Studies have also suggested a protective association between prostate cancer and frequency of ejaculation, with RR ranging from 0.66 to 0.89 (Giles et al., 2003; Leitzmann et al., 2004). In the Giles study, the protective effect was seen in men who reported more than 5 ejaculations/week in their twenties; the large prospective cohort study by Leitzmann (2004) demonstrated a protective effect for men reporting 21 or more ejaculations/month in their twenties and forties, in the previous year, and as a lifetime average. Another study, examining the association between sexual activity and the risk for prostate cancer diagnosed before 60 years of age, found differing effects at different ages. Frequent overall sexual activity in men in their twenties increased the risk for prostate cancer, but appeared to be protective against the disease in men in their fifties (Dimitropoulou et al., 2009). The biologic basis for this effect is not known.

Vasectomy.

A relationship between vasectomy and prostate cancer risk was initially suggested in a case-control study published in 1988 (Honda et al., 1988) and seemingly confirmed a few years later with the report of a relative risk of 1.6

based on two large cohort studies (Giovannucci et al., 1993a,b). Not all subsequent studies have been confirmatory (reviewed in Köhler et al., 2009), and the positive studies are limited by potential confounders including differences in vasectomy rates between cases and controls and detection bias resulting from a higher likelihood that someone undergoing vasectomy will see a urologist for screening. **A recent systematic review and meta-analysis that took into account risk for bias among 16 cohort studies, 33 case-control studies, and 4 cross-sectional studies found no association between vasectomy and high-grade, advanced-stage, or fatal prostate cancer. There was a weak association between vasectomy and any prostate cancer that was closer to the null with increasingly robust study design** (Bhindi et al., 2017)**. Thus at present, the weight of evidence does not support an increased risk for prostate cancer in men who have undergone vasectomy.**

Smoking.

Cigarette smoking may be a risk factor for prostate cancer because it is a source of cadmium exposure, increases circulating androgen levels, and causes significant cellular oxidative stress. **Meta-analyses have not consistently found an association between smoking and the incidence of prostate cancer, but have demonstrated increased prostate cancer mortality among current smokers** (Huncharek et al., 2010; Ordonez-Mena et al., 2016)**. Some studies have suggested an association with higher grade and more advanced stage at diagnosis** (Byrne et al., 2010; Tang et al., 2017)**, and there is some evidence that current smokers are at higher risk for biochemical recurrence and metastasis than nonsmokers across all treatment modalities, even when intensity of screening is accounted for** (Kenfield et al., 2011; Moreira et al., 2014).

Diet.

Descriptive epidemiologic studies of migrants, geographic variations, and temporal studies suggest that dietary factors may contribute to prostate cancer development (Bostwick et al., 2004). The incidence of latent prostate cancers is similar around the world, but the incidence of clinically manifest cancers differs, with Asians having the lowest rates of clinical disease (Center et al., 2012). **Thus, the most convincing evidence for the role of the diet and other environmental factors in modulating prostate cancer risk comes from migration studies showing an increased incidence of prostate cancer in first-**

generation immigrants to the United States from Japan and China (Muir et al., 1991; Shimizu et al., 1991). These observations suggest that diet may play a role in tumor progression, allowing latent cancers to become clinically evident. A strong positive correlation exists between prostate cancer incidence and the corresponding rates of several other diet-related cancers, including breast and colon (Bostwick et al., 2004). However, the prospective epidemiologic evidence linking diet to prostate cancer risk is largely inconsistent, which was verified in a recent umbrella review in which only 21% of the examined meta-analyses gave nominally statistically significant findings (Markozannes et al., 2016). Most meta-analyses yield effect sizes between 0.95 and 1.05, raising the question of whether the observed risk estimates represent true magnitude of association, or are caused by chance or bias.

Epidemiologic studies have also suggested a moderate to strong association between total and specific fats and the risk for developing prostate cancer (Chan et al., 2005). **However, results from large prospective studies showed no association between dietary fat intake and prostate cancer risk** (Crowe et al., 2008; Park et al., 2007; Wallström et al., 2007). A meta-analysis of observational studies demonstrated only a weak association between higher intake of total fat and risk for prostate cancer (RR 1.2) (Dennis et al., 2004). Observations on the association of dietary fat and risk may have alternative explanations. Diets high in meat that are sources of fat are also usually low in vegetables that contain nutrients that may protect against prostate cancer. Meats and dairy products also contain other constituents, such as zinc and calcium, that may affect prostate cancer risk. Furthermore, some have implicated the cooking process in the association between red meat intake and the risk for prostate cancer. Cooking these meats at high temperatures creates both heterocyclic aromatic amine and polycyclic aromatic hydrocarbon carcinogens (Knize et al., 1997; Lijinsky and Shubik, 1964). The best studied of these carcinogens for prostate cancer is 2-amino-1-methyl-6-phenylimidazopyridine (PhIP). In rat models, PhIP ingestion causes PIA and prostate cancer (Shirai et al., 1997). It is thought to cause prostate epithelial cell damage and elicit inflammatory responses leading to DNA damage/mutations (Nakai et al., 2007). Other mechanisms by which diet is thought to contribute to prostate carcinogenesis includes DNA and histone methylation as well as histone acetylation (Labbe et al., 2015).

The nutritional complexity of the typical Western diet, the association of healthier dietary habits with healthier lifestyle choices (physical activity and smoking avoidance), and the potential interaction of specific nutrients with

genetic variability among individuals are significant limitations to understanding how diet influences risk. Masko et al. (2013) summarized the state of preclinical and clinical evidence that specific dietary components may exert on prostate cancer risk and progression. Recent revelations about the role of intratumoral androgen in driving castrate-resistant prostate cancer have increased focus on cholesterol as a risk factor (Sharifi, 2013). Intracellular cholesterol may be carcinogenic by being a proximate steroidal precursor to both T and DHT, and by enhancing *Akt* signaling (Lee et al., 2012). Recent molecular work has demonstrated that ABCA1, the major cellular cholesterol efflux transporter, is preferentially downregulated by promoter hypermethylation in intermediate- to high-grade prostate cancers and that its expression levels are inversely correlated with Gleason grade (Lee et al., 2012). Further, lethal prostate cancers have been shown to rely on de novo cholesterol synthesis, rather than transcellular uptake (Stopsack et al., 2017). **Coupled with epidemiologic evidence that lower levels of serum cholesterol and use of cholesterol-lowering agents (statins) reduce the risk for aggressive and advanced-stage disease, loss of cholesterol homeostasis may be a contributor to prostate cancer risk and progression** (Platz et al., 2006, 2009).

Obesity.

Obesity as measured by BMI has been suggested to be a risk factor for prostate cancer because of its common occurrence in middle-aged men and clear links to colon and breast cancer risk (Giovannucci, 1995; Madigan et al., 1998). White fat in mammals serves not only as an important energy reservoir, but also as an endocrine organ, with secretion of cytokines and agents with cytokine-like activity (TNFα, IL-1β, IL-6, IL-8, IL-10, TGFβ) and their soluble receptors (Trayhurn and Wood, 2004). Treatment of obesity through reduction in fat intake and increased exercise has been shown to reduce oxidative stress, suggesting that lifestyle modification could be important in reducing the risk for prostate cancer (Roberts et al., 2002).

Current evidence has failed to show a clear link between obesity and overall prostate cancer incidence (Yang et al., 2016)**. A meta-analysis of 27 cohorts found a modest, nonsignificant 1.03 (95% CI, 1.00 to 1.07) per 5 kg/m^2 increase in BMI relative risk for prostate cancer** (Renehan et al., 2008). However, several studies have suggested an association between obesity and an increased risk for high-grade disease and prostate cancer death (De Nunzio et al., 2013; Perez-Cornago et al., 2017). The association between obesity and high-grade disease was also observed in the PCPT, a study in which all men underwent biopsy, making it unlikely that detection bias is solely responsible for this finding (Gong et al., 2006). Potential explanations for the latter observation include the association of obesity with higher serum estradiol, insulin, free IGF-1, and leptin levels, and lower free T and adiponectin levels, which have also been associated with more aggressive prostate cancer (Buschemeyer and Freedland, 2007). Moreover, studies have found genes involved in chromatin regulation, RNA processing, and cellular disassembly enriched in tumor tissue of overweight and obese prostate cancer patients when compared with healthy-weight patients, suggesting that obesity may promote tumor progression in part by influencing the epigenetic state of prostate cancer (Ebot et al., 2017).

Obesity has also been shown to be associated with higher rates of biochemical failure after surgery or external-beam radiotherapy and a 15% to 20% increase per 5 kg/m^2 increase in BMI in prostate specific-cancer mortality (Masko et al., 2013). These observations likely reflect higher-grade and more locally advanced disease at presentation, technical challenges in surgery and radiotherapy in obese men, and more aggressive biology driven by adipocyte-derived biologic factors. This complex interplay and the specific molecular mechanisms that may underlie the biologic effects of obesity are illustrated in Fig. 148.5.

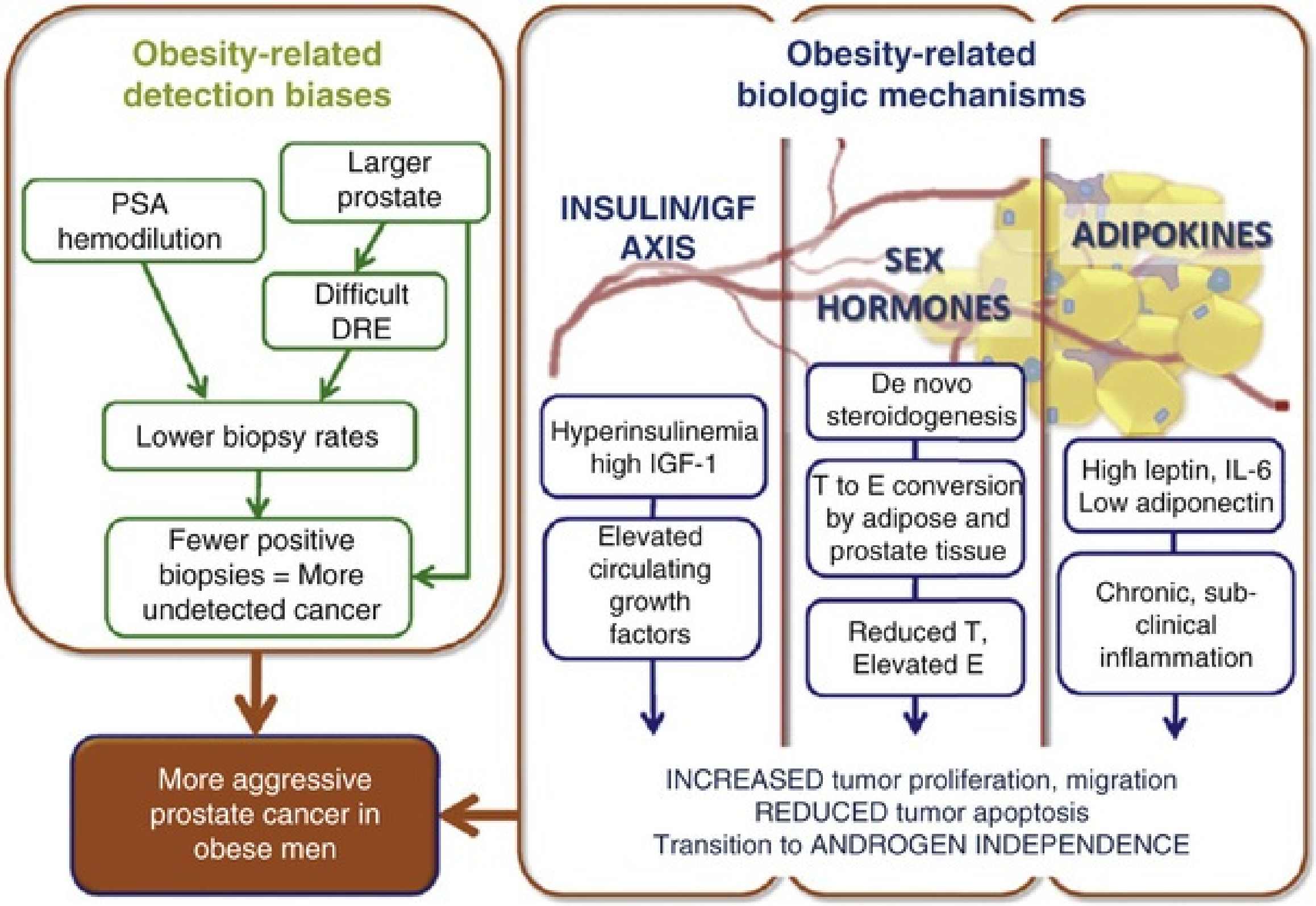
Obesity-related detection biases
PSA hemodilution
Larger prostate
Difficult DRE
Lower biopsy rates
Fewer positive biopsies = More undetected cancer
More aggressive prostate cancer in obese men
Obesity-related biologic mechanisms
INSULIN/IGF AXIS
SEX HORMONES
ADIPOKINES
Hyperinsulinemia high IGF-1
Elevated circulating growth factors
De novo steroidogenesis
T to E conversion by adipose and prostate tissue
Reduced T, Elevated E
High leptin, IL-6 Low adiponectin
Chronic, sub-clinical inflammation
INCREASED tumor proliferation, migration
REDUCED tumor apoptosis
Transition to ANDROGEN INDEPENDENCE

FIG. 148.5 The complex interplay between detection bias and biology in obese men. (Reproduced with permission from Allott EH, Masko EM, Freedland SJ. Obesity and prostate cancer: weighing the evidence. *Eur Urol* 63[5]:800–809, 2013.)

Alcohol Consumption.

Alcohol consumption and risk for prostate cancer is of interest because of its association with other cancers, its effect on estrogen and T, and the high content of polyphenolic compounds with antioxidant activity in red wine. Epidemiologic studies including both case-control and cohort designs have reported mixed results, with some suggesting increased risk, some null, and some suggesting a protective effect of alcohol use (reviewed in McGregor et al., 2013.). A recent meta-analysis found a significant dose-response relationship between level of alcohol intake and risk for prostate cancer, with studies free from misclassification errors producing the highest risk estimates for drinkers versus abstainers in adjusted models (RR 1.22, $P < 0.05$) (Zhao et al., 2016).

Etiology and Molecular Genetics

Prostate cancer exists in two forms: a histologic only or clinically occult form, which can be identified in approximately 30% of men older than 50 years of age and 60% to 70% of men older than 80 years of age, and a clinically evident form, which affects approximately 1 in 6 US men. Latent prostate cancer is believed to have a similar prevalence worldwide and among all ethnicities, whereas the incidence of clinical prostate cancer varies dramatically among and within different countries. For this reason, an understanding of prostate cancer etiology must encompass the steps leading to both the *initiation* of histologic cancer and *progression* to clinically evident disease. The exact molecular relationship between latent and clinical cancers is not known, and it is likely that the progression from the former to the latter is a biologic continuum with overlap in the associated molecular events. **Recent molecular evidence suggests that some low- and high-grade cancers share a common origin, where the tumors share a common precursor and subsequently undergo branched evolution with the accumulation of additional genomic alterations in high-grade disease; further, there is clear evidence that some low-grade (Gleason pattern 3) tumors can appear histologically indolent while containing molecular features of high-grade disease** (Sowalsky et al., 2017). Gene fusions, mutations, downregulation by promoter methylation, changes in gene expression, and protein modification have all been implicated in progression of prostate cancer.

The Influence of Androgens

As discussed earlier, androgens play an important role in prostate carcinogenesis. **The primary androgen of the prostate is DHT, irreversibly catalyzed from T by 5α-reductase.** DHT binds to intracytoplasmic AR with much greater affinity than T, dissociates more slowly than T, enhances translocation of the steroid-receptor complex into the nucleus, upregulates AR synthesis and reduces AR turnover, and activates androgen-responsive genes (Steers, 2001; Swerdloff et al., 2017). Type 1 5α-reductase is expressed primarily in the skin and liver and to lesser extent in prostate, and the type-2 enzyme is expressed predominantly in prostate epithelium and other genital tissues (Andriole et al., 2004a).

Functional type 2 5α-reductase is a prerequisite for normal development

of the prostate and external genitalia in males, and insufficient exposure of the prostate to DHT appears to protect against the development of prostate cancer. Males with inherited 5α-reductase deficiency have miniscule prostatic tissue, and biopsies demonstrate stroma but no epithelium (Zhu and Imperato-McGinley, 2009). **In addition to the lack of enzyme activity, a lack of T may also protect against the development of prostate cancer, as evidenced by the atrophic prostates seen in men after surgical castration** (Wilson and Roehrborn, 1999)**. Nonetheless, there is evidence that even hypogonadal adults can develop prostate cancer** (Morgentaler and Rhoden, 2006) **and that their cancers may be driven by growth pathways that are independent of androgens** (although they may still act through the AR, which is known to exhibit ligand promiscuity).

The preponderance of currently available data suggest that there is no evidence that circulating levels of androgens, including DHT, affect prostate cancer risk because of local regulatory mechanisms that tightly control intracellular androgen homeostasis (Swerdloff et al., 2017). In the placebo arm of REDUCE, there was no association of serum T or DHT levels with risk for prostate cancer or Gleason grade (Muller et al., 2012). Cancer detection was similar among men with low compared with normal baseline T levels, and higher T levels at baseline were associated with higher prostate cancer detection only if men had low baseline T (<10 nmol/L) (OR 1.23; 95% CI, 1.06 to 1.43; $P = 0.006$). For men with normal baseline T (≥10 nmol/L), higher T levels at baseline were unrelated to prostate cancer risk (Fig. 148.6A). A placebo-controlled trial of daily DHT gel supplementation given over 24 months in 114 healthy, eugonadal men older than 50 years of age demonstrated only minor and clinically insignificant changes to serum PSA and prostate volume; there were no cases of prostate cancer diagnosed in either group (Idan et al., 2010). A longitudinal, observational community-based cohort study of more than 3600 men reported no association of circuiting T or DHT levels and prostate cancer risk over a 9-year observation period (Chan et al., 2017). A large case-control study from Sweden that included all newly diagnosed prostate cancer cases between 2009 and 2012 found that use of T replacement therapy had no effect on the risk for being diagnosed with prostate cancer (Loeb et al., 2017). In another double-blind, randomized, placebo-controlled study, exogenous DHT administration had no impact on PSA or intraprostatic androgen levels, and no effect on expression of androgen-regulated genes measured on tissue biopsy (Page et al., 2011). **In summary, these studies suggest that intraprostatic**

levels of androgen are determined locally within the prostate, more likely affected by genetic and metabolic factors than serum concentrations.

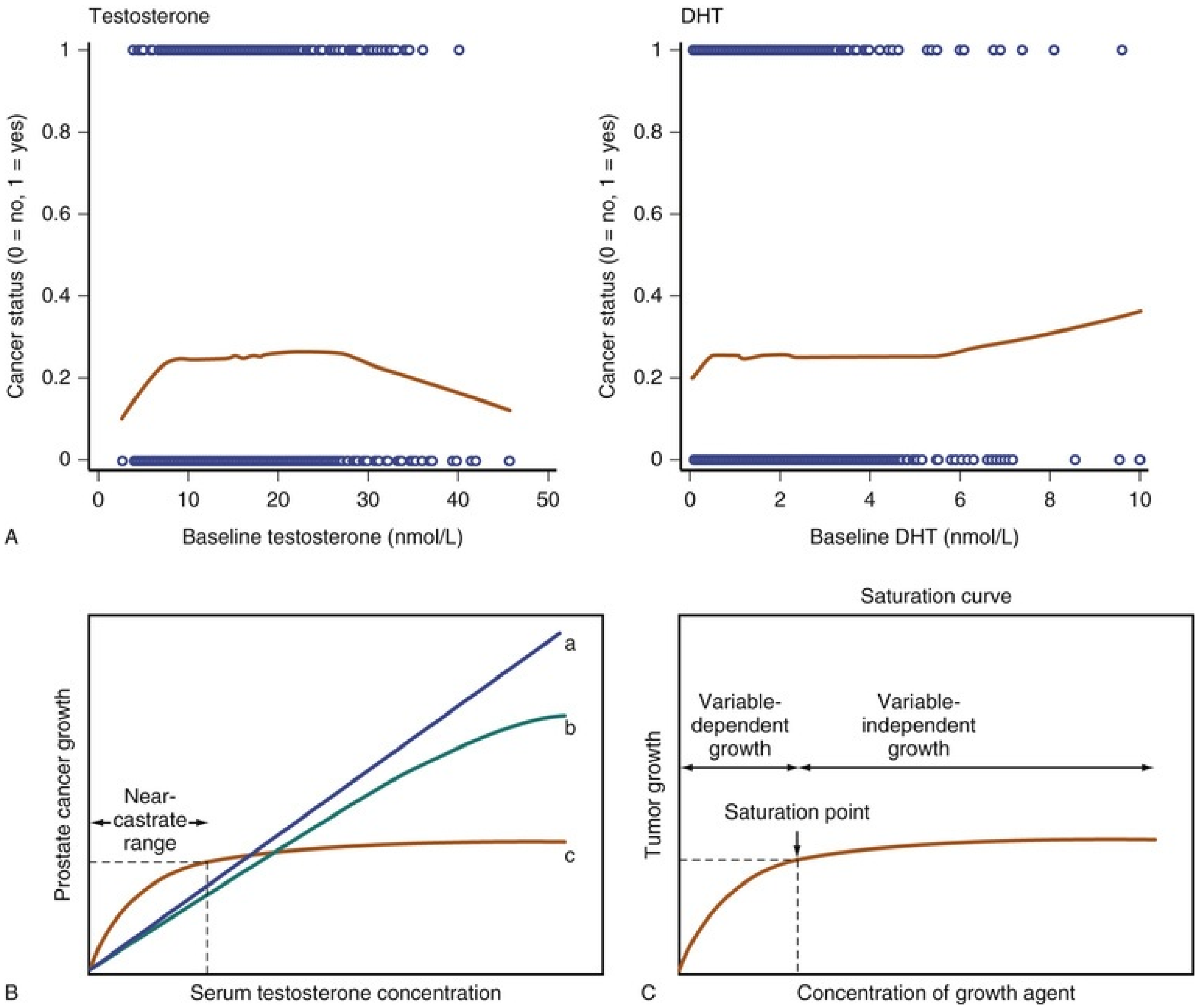

FIG. 148.6 Testosterone and prostate cancer risk in the REDUCE trial. (A) Locally weighted scatterplot smoothing of serum levels of testosterone and dihydrotestosterone *(DHT)* at baseline and final cancer status after considering all biopsies during 4 years of the REDUCE trial. The overlapping circles on the top and bottom of the chart represent each individual case. The left portion of the curve for testosterone mimics that proposed in the saturation model for the effect of androgen on prostate cancer risk (see text). (B) The saturation hypothesis of testosterone and prostate cancer risk. *(a)* The traditional model of testosterone *(t)*-dependent prostate cancer *(pca)* growth suggested that greater serum t concentrations would lead to some degree of greater pca growth *(curves a, b)*. The saturation model *(curve c)* describes a steep t-dependent curve at t concentrations at or below the near-castrate range, with a plateau representing little or no further growth above this concentration. *(b)* the relationship between t and pca appears to follow a saturation curve, present in many biologic systems, in which growth corresponds with

concentration of a key nutrient until a concentration is reached in which an excess of the nutrient is achieved. This type of curve is seen with hormones acting via binding to specific receptors, which have a finite number of binding sites. Once full binding is achieved (saturation) (C), further increases in concentration of the hormone (or other nutrient) produce no further growth. (A, Reproduced with permission from Muller RL, Gerber L, Moreira DM, et al. Serum testosterone and dihydrotestosterone and prostate cancer risk in the placebo arm of the Reduction by Dutasteride of Prostate Cancer Events trial. *Eur Urol* 62[5]:757–764, 2012. B, C, Reproduced with permission from Morgentaler A, Traish AM. Shifting the paradigm of testosterone and prostate cancer: the saturation model and the limits of androgen-dependent growth. *Eur Urol* 55[2]:310–320, 2009.)

These observations also suggest a saturation point for T exposure as a risk factor for prostate cancer, such that further increases in T have no effect on risk. The saturation model hypothesis states that changes in serum or tissue T concentrations below the point of maximal androgen-AR binding will elicit substantial changes in prostate epithelial and cancer growth, but that once maximal binding is reached the presence of additional androgen produces little further effect (Morgantaler and Traish, 2009) (see Fig. 148.6B). This model is supported by animal studies showing that intraprostatic androgen levels and prostate mass in castrated rats are extremely sensitive to serum T around near-castrate levels, but plateau above this level (Wright et al., 1999), and similar findings in intact rats showing that normal prostate growth plateaus with increasing doses of exogenous T (Banerjee et al., 1994), and by numerous clinical observations in humans (reviewed by Morgantaler and Traish, 2009).

In summary, exposure of the prostate to androgens before or at puberty seems to be prerequisite for later development of prostate cancer, but beyond a certain level of exposure in adulthood the risk is not linear as measured by serum androgen levels.

Stem Cells

Stem cells are required for the maintenance of high cell turnover tissues, where cells continually need to be replaced, and, like most epithelial organs, the prostate contains stem cells capable of multilineage differentiation. **The existence of prostatic stem cells was initially suggested by studies in mice demonstrating the ability of prostate epithelium to regress and regenerate with repeated cycles of castration and androgen replacement** (Bui and Reiter, 1998,1999; Isaacs and Coffey, 1989; Tsujimura et al., 2002)**. The ability of**

these cells to resist androgen deprivation suggest they may be the source of castration-resistant disease. Supportive evidence includes (1) organogenesis experiments demonstrating multipotent basal progenitors that generate basal, luminal, and neuroendocrine progeny, and unipotent luminal progenitors that only generate luminal progeny; (2) the existence of bipotential basal progenitors that undergo asymmetric cell divisions to generate luminal and basal daughter cells during regeneration; and (3) stem-cell–enriched cell populations that can produce three-dimensional structures with basal cells and fully differentiated luminal cells in nude mice (Shibata and Shen, 2015). Several molecular markers (including *Sca1*, *Trop2*, and *DLK1*) are now recognized to reliably identify stem cells and have facilitated their study.

The epithelial cell layer of the prostate, from which adenocarcinomas arise, contains four distinct cell types: basal, secretory luminal, neuroendocrine (NE), and transit-amplifying (TA) cells that have distinct morphology and molecular phenotypes (Prajapati et al., 2013)**. Various genetic events in these cells can result in tumor formation from any of these cell types** (Maitland and Collins, 2008).

Stem cells compose about 1% of the basal cell population, based on specific marker expression and growth characteristics (Collins et al., 2001). In a set of remarkable experiments, Moad et al. (2017) demonstrated that **multipotent basal stem cells reside in a protected niche adjacent to the urethra and populate the epithelium along the entire length of the glandular ducts by means of a cohesive cell migration stream, reaching distally to glandular acini (Fig. 148.7). The data suggest that adult prostatic epithelium is maintained by these stem cells located in the most proximal region of the main ducts, giving rise to bipotent basal progenitors that produce luminal cells only later in the stream, where the microenvironment induces luminal differentiation.** The authors also speculated that **the arrangement of prostate epithelium into discrete long-ranging flows feeding distal ducts in a monoclonal fashion could account for field cancerization and give rise to multifocal tumors sharing clonality.** Interestingly, there is evidence that stem cells contain TRMPSS2:ERG fusions that are thought be one of the earliest events in prostate cancer initiation (Polson et al., 2013). Stem cell biology makes them attractive targets for both prevention and therapy.

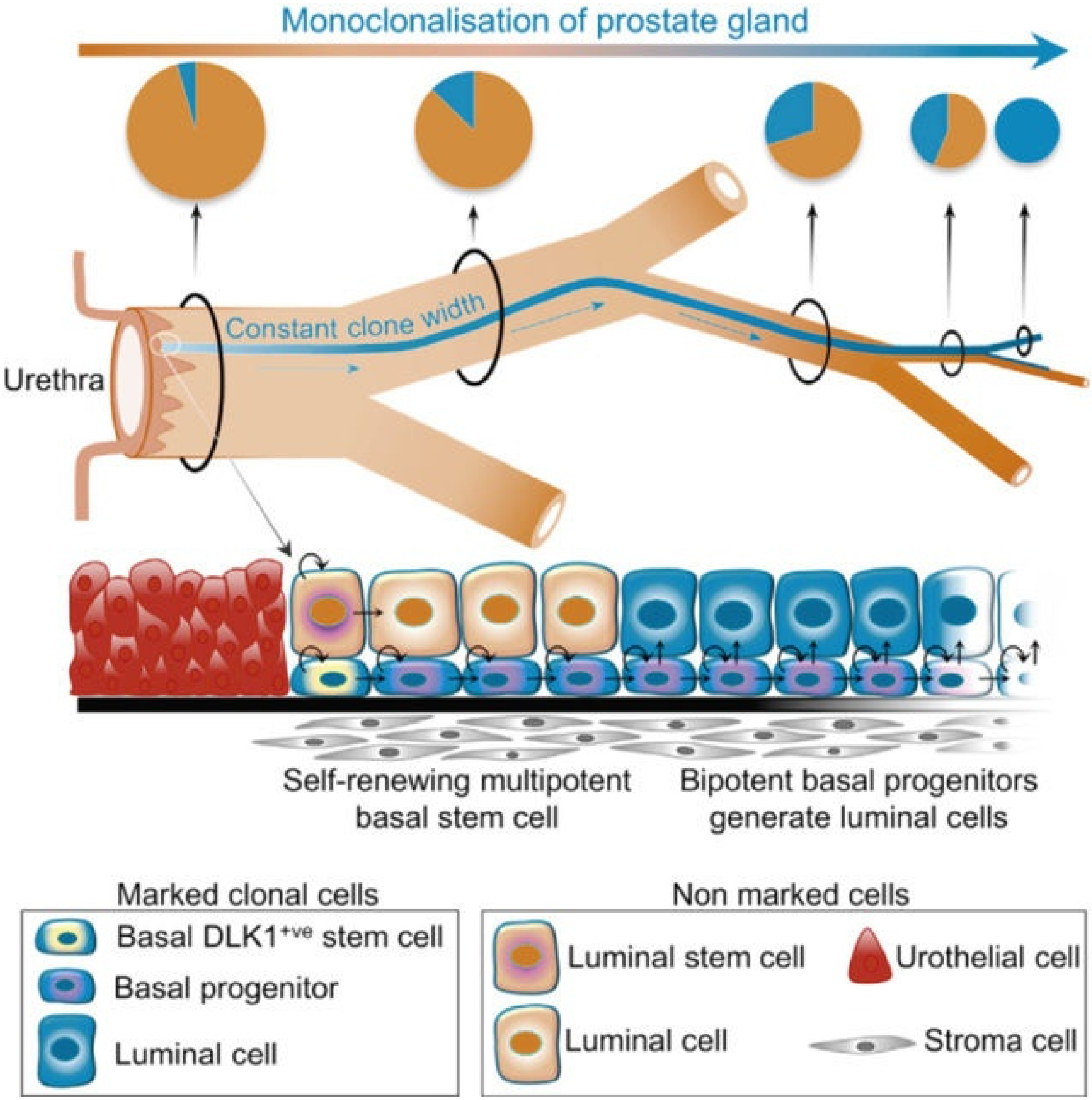
Monoclonalisation of prostate gland
Urethra
Constant clone width
Self-renewing multipotent basal stem cell
Bipotent basal progenitors generate luminal cells
Marked clonal cells
Basal DLK1+ve stem cell
Basal progenitor
Luminal cell
Non marked cells
Luminal stem cell
Urothelial cell
Luminal cell
Stroma cell

FIG. 148.7 Stem cell origin and population of prostatic acini. Multipotent stem cells reside in a protected niche adjacent to the urethra and populate the epithelium along the entire length of the glandular ducts by means of a cohesive cell migration stream. This leads to a clonal repopulation of apoptotic luminal epithelial cells. (Reproduced with permission from Moad M, Hannezo E, Buczacki SJ, et al. Multipotent basal stem cells, maintained in localized proximal niches, support directed long-ranging epithelial flows in human prostates. *Cell Rep* 20[7]:1609–1622, 2017.)

Somatic Genetic Changes Associated With Tumor Initiation and Progression

Substantial evidence exists that prostate cancer arises and progresses by genetic alterations that activate oncogenes and inactivate tumor suppressors. These changes result most commonly from epigenetic and structural genomic changes, including gene fusions, mutations, somatic copy number alterations, and chromosomal rearrangements. Unlike many metabolic diseases, the incidence of point and missense mutations resulting in altered proteins are rare in prostate cancer, estimated to occur in only about 1% of primary tumors (Taylor et al., 2010). **A plethora of reports using next-generation sequencing, microarray data, and functional studies has led to an emerging comprehensive understanding of the temporal genomic events that occur in prostate cancer development and progression to the lethal phenotype of metastatic castrate-resistant disease** (Barbieri and Tomlins, 2014; Barbieri et al., 2012) (Fig. 148.8). A comprehensive analysis of primary tumors by The Cancer Genome Atlas (TCGA) has yielded additional insight into the molecular taxonomy of early-stage disease (Cancer Genome Atlas Research Network, 2015).

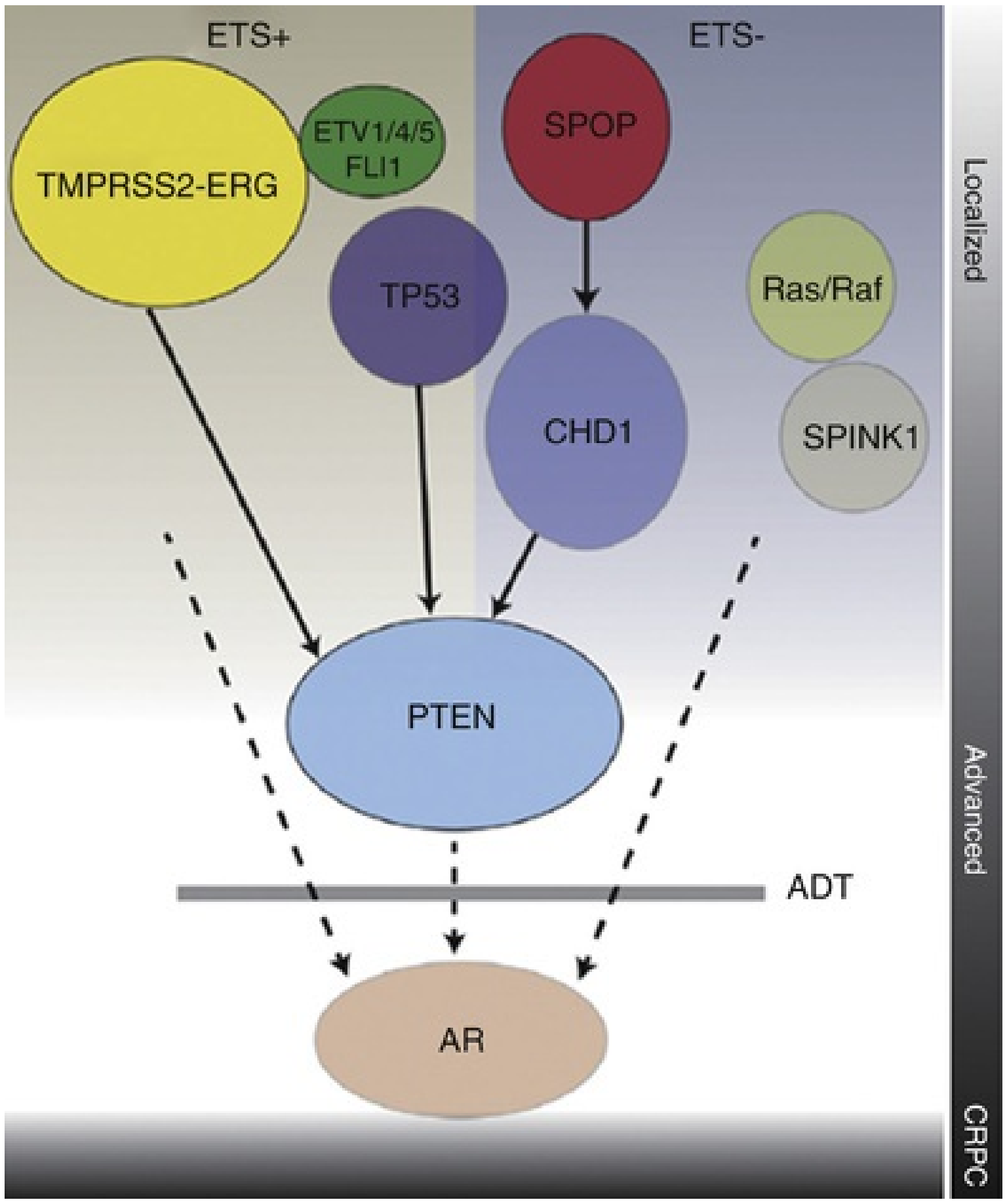

FIG. 148.8 Molecular classification of prostate cancer. Genomic lesions in the time line of prostate cancer. Genes with common genomic lesions (including mutation, rearrangement, or copy number alteration) are shown. *Solid arrows* designate a temporal relationship between events; presumptive “early” lesions are at the top, with “later” lesions below. Tumors with ETS fusions (ETS+) are shown on the *left;* ETS– tumors are shown on the *right*. *ADT,* androgen deprivation therapy; *CRPC,* castration-resistant prostate cancer. (Reproduced with permission from Barbieri CE, Tomlins SA. The prostate cancer genome: perspectives and potential. *Urol Oncol* 32[1]:53.e15–53.e22, 2014.)

The Cancer Genome Atlas and Its Findings

The TCGA is the most comprehensive study of early-stage prostate cancer published to date. In this study, 333 tumors were subjected to whole-exome sequencing for detecting somatic mutations, array-based methods for profiling somatic copy-number alterations and DNA methylation, and messenger RNA (mRNA) sequencing. In addition, a subset of tumors underwent microRNA (miRNA) sequencing and reverse-phase protein array (RPPA), and a small number of paired normal and tumor samples were subjected to whole-genome sequencing. **The results allowed molecular classification of 74% of the tumors studied into seven families based on distinct molecular features: gene fusions involving (1) *ERG*, (2) *ETV1*, (3) *ETV4*, or (4) *FLI1*, or mutations in (5) *SPOP*, (6) *FOXA1*, or (7) *IDH1* (Fig. 148.9). The results confirmed prior studies identifying the most frequent genomic alterations in prostate cancer as fusions of androgen-regulated promoters with ERG and other ETS-family transcription factors, accounting for 53% of the cases. In addition to these common gene fusions, the study confirmed a preponderance of *PTEN* deletions in *ERG* fusion–positive cases** (Taylor et al., 2010) **and that tumors with *SPOP* mutations (accounting for about 10% of cases) are mutually exclusive of tumors defined by *ETS* rearrangements.** In this study, 26% of the tumors could not be classified into one of these seven families. New observations from TCGA included (1) identification of a subset of cases defined by *SPOP*-mutant/*CHD1*-deletions with marked DNA methylation, homogeneous gene expression patterns, and overexpression of *SPINK1*; (2) similar mRNA expression levels, copy-number alterations, and methylation profiles in tumors defined by *SPOP* or *FOXA1* mutations; and (3) a new and distinct subtype defined by mutations in *IDH1*. **Another recently reported study of 1577 cases obtained from radical prostatectomy specimens using a genome-wide expression array confirmed that ERG and ETS-family gene fusions define about one-half of primary prostate cancers, with another 8% defined by *SPOP* mutation** (Tomlins et al., 2015). In this study, the proportions of each molecular subtype were similar across eight independent prostatectomy cohorts from the United States and Europe, suggesting that these molecular subtypes are universal. *ERG*-positive tumors were more common in European Americans and associated with lower Gleason scores and pretreatment PSAs. **The molecular subtypes were not predictive of biochemical recurrence, metastasis, or death caused by prostate cancer after prostatectomy, suggesting that the molecular events that define these families are more important for tumor initiation and local growth rather than progression.**

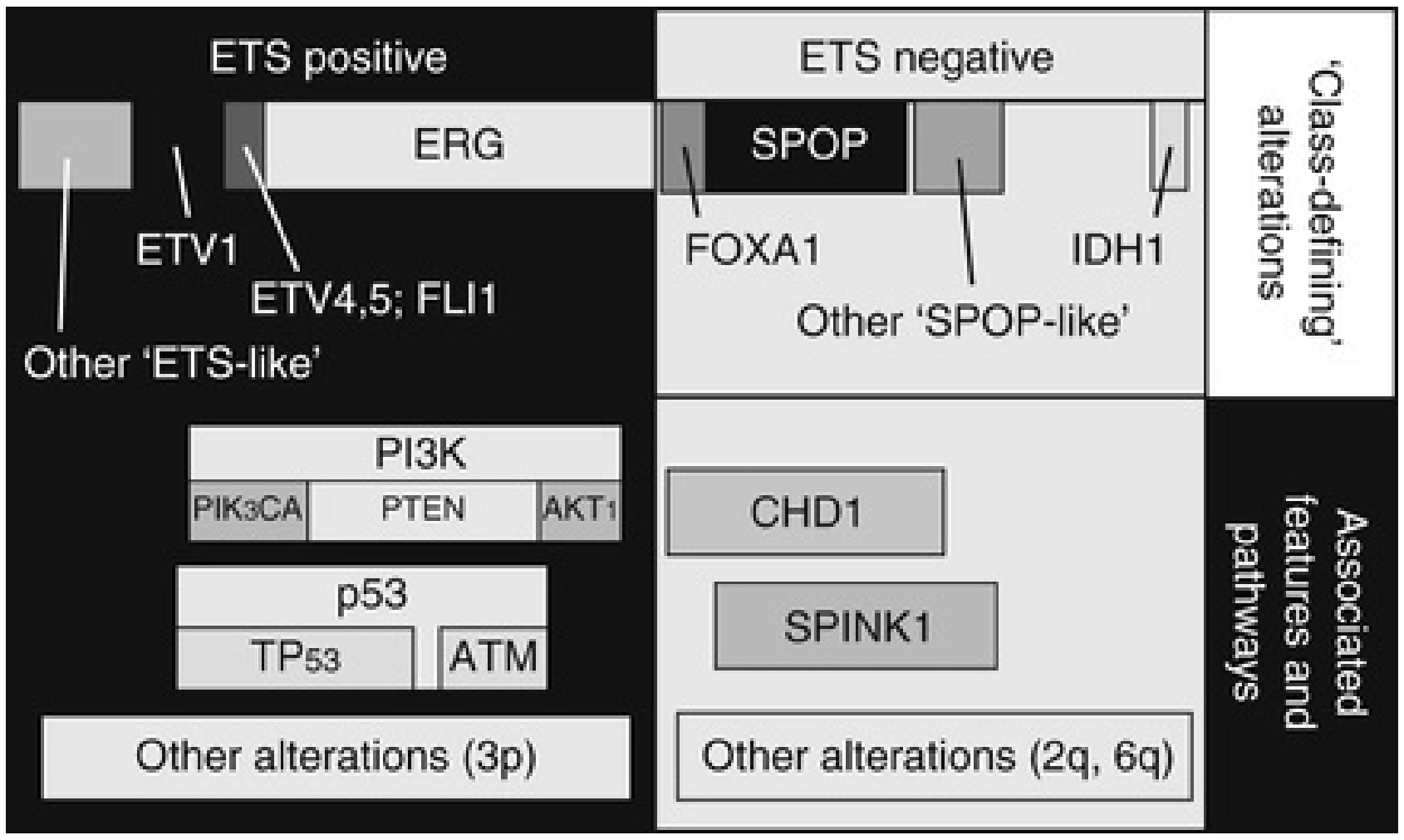
ETS positive
ETS negative
'Class-defining' alterations
ERG
ETV1
ETV4,5; FLI1
Other 'ETS-like'
SPOP
FOXA1
IDH1
Other 'SPOP-like'
PI3K
PIK3CA
PTEN
AKT1
p53
TP53
ATM
Other alterations (3p)
CHD1
SPINK1
Other alterations (2q, 6q)
Associated features and pathways

FIG. 148.9 The molecular taxonomy of prostate cancer as defined by The Tissue Cancer Genome Atlas *(TCGA).* Prostate cancer can be classified into those with rearrangements in ETS family transcription factors (e.g., ERG, ETV1, ETV4, and FLI1) and those negative for ETS factors. ETS-negative PCas show recurrent mutations in *SPOP, FOXA1,* and *IDH1.* Alterations in PI3K and p53 signaling are common in ETS-positive cancers, whereas deletions of CHD1 and overexpression of SPINK1 are specific to ETS-negative cancers. *CHD1,* Chromodomain Helicase DNA Binding Protein 1; *FLI1,* Friend Leukemia Virus Integration 1; *FOXA1,* forkhead box A1; *IDH1,* isocitrate dehydrogenase-1; *PCa,* prostate cancer; *PI3K,* phosphatidylinositide 3-kinase; *PTEN,* Phosphatase and Tensin Homolog. (Reproduced with permission from Kaffenberger SD, Barbieri CE. Molecular subtyping of prostate cancer. *Curr Opin Urol* 26[3]:213–218, 2016.)

Tumors Defined by Gene Fusions

Gene fusions resulting from chromosomal translocations are the most common genetic alteration in human cancers (Futreal et al., 2001) **Recurrent genomic rearrangements in prostate cancer result in the fusion of the 5′ untranslated end of *TMPRSS2* (an androgen-responsive, prostate-specific, transmembrane serine protease gene) to members of the *ETS* family of oncogenic transcription factors** (Tomlins et al., 2005)**. Other important gene fusions involving the *RAF1* kinase family and *SPINK1* have been described, highlighting the fundamental importance of this genetic mechanism in the genesis of prostate cancers** (Rubin et al., 2011) **(Fig. 148.6B).**

ETS Family Gene Fusions

The most common fusion identified in localized prostate cancer involves *TMPRSS2* or other promoters (*SLC45A3* and *NDRG*) fused to *ERG* (ETS-related gene) in 50% to 60% of patients (Cancer Genome Atlas Research Network, 2015; Kumar-Sinha et al., 2008; Rubin et al., 2011). While TMPRSS2-ERG fusions account for 90% of gene fusions seen in prostate cancer, fusions involving other members of the *ETS* family (*ETV1*, ETV4, and *FLI1*) also occur. Both *TMPRSS2* and *SLC45A3* are androgen responsive such that fusion of either of these genes to a growth-promoting gene of the normally androgen-indifferent *ETS* family brings a powerful signal for cellular growth under androgen control. **These fusions are not observed in benign prostate tissue, but are present in prostate stem cells, HGPIN, and early-stage, low-grade prostate cancer, suggesting they are an early and seminal event in prostate tumorigenesis** (Polson et al., 2013; Rubin et al., 2011). Recent data from animal models suggest that defects in the *PTEN/PI3K/Akt* pathway in the presence of *TRMPSS2:ERG* fusions drive early tumor progression, the former stimulating proliferation and the latter cell migration that together may result in a more aggressive phenotype (Carver et al., 2009). **However, there are mixed data on whether the presence of *TMPRSS2:ERG* fusions affect prognosis** (reviewed in Rubin et al., 2011); ERG rearrangement has been observed to be associated with a higher risk for death caused by prostate cancer in two cohorts of men managed by watchful waiting after tumor detection on TURP (Attard et al., 2008; Demichelis et al., 2007), but, as noted earlier, a large study of radical prostatectomy specimens using whole-genome expression analysis found no prognostic value for any molecular subtype (Tomlins et al., 2015). One reason for the discrepancy between studies may relate to epigenetic phenomena. TCGA noted distinct methylation patterns in *ERG*-positive tumors: about two-thirds of all *ETS* fusion–positive tumors had only moderate DNA methylation, and the remaining one-third was characterized by hypermethylation that was almost exclusively associated with *ERG* fusions and distinct from the methylation patterns of *ETV1*-positive and *ETV4*-positive tumors. Furthermore, *ETS*-positive tumors are enriched for *PTEN* deletions, *TP53* alterations, *PI3K* pathway alterations, and specific amplifications in chromosome 3p. The molecular diversity within the *ETS*-positive molecular subset suggests the existence of multiple subfamilies that at present confounds the use of this classification to predict clinical outcomes (Kaffenberger and Barbieri, 2016).

However, **the high specificity of *TPMRSS2:ERG* fusions for cancer makes it an attractive target for other clinical uses.** Fusion transcripts can be detected in the urine, and clinical evidence suggests that when combined with an assay for PCA3, detection of ETS fusions can improve the detection of cancer in screened populations over PSA alone (Tomlins et al., 2011). Some data suggest that quantification of *TPMRSS2:ERG* fusion in urine can predict both tumor volume and tumor aggressiveness, perhaps making it useful for selecting appropriate candidates for active surveillance (Lin et al., 2013). It has been observed that not all tumor foci within a prostate harbor *ETS* fusions, so that a positive urine for *TRMPSS2:ERG* fusion in the face of a negative biopsy would suggest that cancer was missed because of a sampling error, and that additional evaluation with MRI or repeat biopsy is indicated. The presence of gene fusions that occur only in cancer also makes them targets for novel therapies.

Other Gene Fusions

As noted, **prostate cancers also are rarely observed to contain fusions involving *SPINK1* and *RAF* kinases.** *SPINK1* fusions occur in about 10% to 15% of cancers, exclusively in ETS fusion–negative tumors, and in cell lines seem to drive tumor invasion (Tomlins et al., 2008). Fusions involving *RAF* kinases are even rarer and also define another ETS fusion–negative phenotype that is associated with aggressive cancers (Palanisamy et al., 2010). **Both examples likely represent alternative growth pathways for ETS fusion–negative tumors and may represent distinct phenotypes (see Figs. 148.8 and 148.9).**

Tumors Defined by Mutations *(SPOP, FOXA1, IDH1)*

Tumors with mutations in *SPOP* (Speckle-type POZ protein, which mediates ubiquitination leading to the degradation of target proteins) occur in about 10% of primary prostate cancers and define a distinct subclass that lacks *ETS* family gene fusions (Cancer Genome Atlas Research Network, 2015). SPOP mutations have been identified in HGPIN adjacent to adenocarcinoma, suggesting they occur early in tumorigenesis (Jung et al., 2016). **Functional analysis indicates that intact *SPOP* helps mediate DNA double-strand break repair, and consequently mutations in this gene lead to genomic instability, promoting tumor growth** (Boysen et al., 2015) **(Fig. 148.10).** In vitro data show that *SPOP*-mutant tumors may be more sensitive to

DNA-damaging therapeutic agents (such as PARP inhibitors), suggesting that a *SPOP* mutation may be a biomarker for predicting response to these agents. *SPOP*-mutant tumors are also characterized by deletions of *CHD1* (which codes for a chromatin-remodeling enzyme) and frequently by overexpression of *SPINK1* (Serine peptidase inhibitor, Kazal type 1). **Tumors overexpressing *SPINK1* are associated with higher Gleason scores and occur more frequently in African-Americans** (Tomlins et al., 2015).

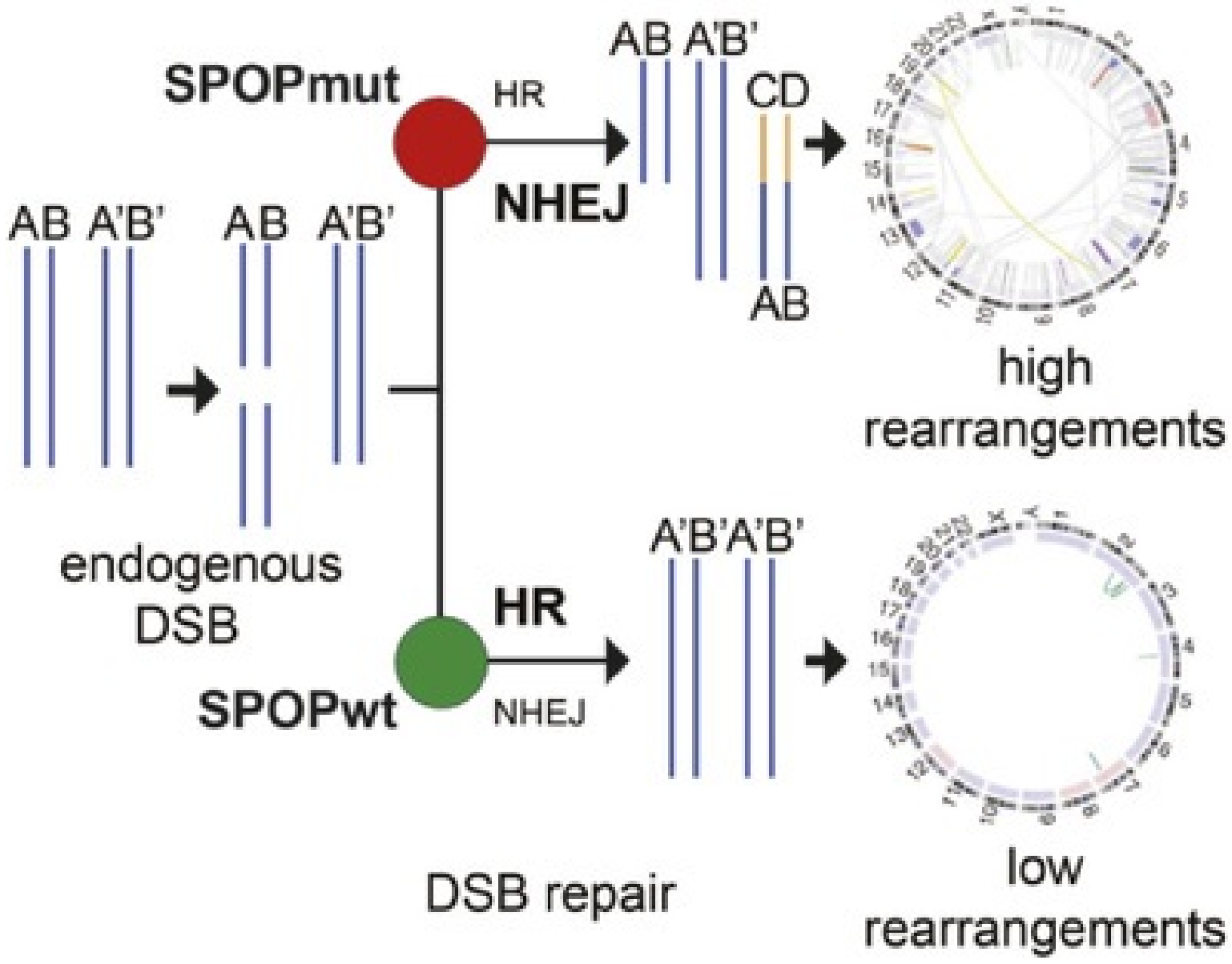

FIG. 148.10 Proposed model of the effects of *SPOP* mutation on genome instability. In prostate epithelial cells, wild-type *SPOP* promotes error-free homologous recombination *(HR)* and maintains genome stability. *SPOP* mutation impairs HR repair and promotes error prone nonhomologous end joining *(NHEJ)* leading to increased genomic instability. (Reproduced with permission from Boysen G, Barbieri CE, Prandi D, et al. SPOP mutation leads to genomic instability in prostate cancer. *Elife* 4:e09207, 2015.)

Tumors with mutations in *FOXA1* (a transcription factor of the AR) occur in about 3% of primary prostate cancers, and as noted earlier, share many molecular features with *SPOP*-mutant tumors, including mRNA, SCNAs, and methylation profiles. *SPOP*-mutant and *FOXA1*-mutant tumors have the highest levels of AR transcriptional activity seen in TCGA. Paradoxically, *FOXA1* stimulates cell proliferation in an AR-dependent manner, but also serves as a tumor suppressor independent of AR (Jin et al., 2013).

A small number of primary prostate cancers (about 1%) are characterized by mutations in *IDH1* (isocitrate dehydrogenase-1), also seen in gliomas and acute myeloid leukemia, albeit with mutations distinct from those seen in nonprostate cancers. **Mutations in *IDH1* result in pan-genomic hypermethylation. IDH1-associated tumors are associated with early age of onset,** and few copy number or other genomic alterations.

Epigenetic Changes

Epigenetic events affect gene expression without altering the actual sequence of DNA. Known mechanisms include DNA hypermethylation and hypomethylation, chromatin remodeling, and microRNA (miRNA) and long-noncoding RNA (lncRNA) regulation, all of which are important in prostate cancer.

DNA hypermethylation generally causes gene silencing and is the most well-characterized epigenetic alteration in prostate cancer, affecting more than 50 genes across a diverse number of basic cellular processes including hormone response (*ERαA*, *ERβ*, and *RARβ)*, signal transduction (*EDNRB* and *SFRP1*), cell cycle control (*CyclinD2* and *14-3-3σ*), DNA repair (*GSTpi*, *GPX3*, and *GSTM1*), inflammatory response genes (*PTGS/COX2*), tumor suppressor genes (*APC*, *RASSF1α*, *DKK3*, *p16INK4α*, *E-cadherin*, and *p57WAF1*), tumor invasiveness (*CD44*), and apoptosis (Li et al., 2005; Jerónimo et al., 2011). DNA hypomethylation, which usually affects areas of the genome distinct from hypermethylated regions, causes activation of oncogenes and leads to genetic instability, and has been reported for genes associated with tumor progression (*CAGE*, *HPSE*, and *PLAU*) (Li et al., 2005). **Promoter methylation of some genes is influenced by diet and age, and is frequently seen in HGPIN and morphologically normal prostate tissue, suggesting that these events are drivers early in the development of prostate cancer and suggest the outgrowth of tumor clones originating from clonal benign and PIN tissue** (Brocks et al., 2014; Massie et al., 2017). Both hypomethylation and hypermethylation define a field cancerization effect in normal prostate tissue, as revealed by methylation microarray analysis of tumor-associated and nontumor-associated normal prostatic tissue (Yang et al., 2013a). This observation is consistent with the outgrowth of tumor clones originating from stem cells and clonal benign and PIN tissue. Clinical studies have shown that quantitative methylation analysis of the *GSTP1*, *APC*, *PTGS2*, *RASSF1α*, *MDR1*, *p16*, and *MGMT* genes can improve sensitivity and specificity for the diagnosis of cancer (Dobosy et al., 2007). **These observations have clinical utility, as demonstrated by a study that showed that the methylation status of *GSTP1*,**

***APC*, and *RASSF1a* on prostate needle biopsy can be used to predict the likelihood of cancer on subsequent biopsy with a negative predictive value of 90%** (Stewart et al., 2013)**.**

TCGA defined four distinct subtypes of DNA methylation in primary prostate cancers. About one-third of *ERG*-positive tumors were hypermethylated, with about twice the number of hypermethylated loci as the other subtypes (Fig. 148.11), with methylation patterns distinct from *ETV1*-positive and *ETV4*-positive tumors. The results suggest that tumors characterized by *ETS*-family fusions can be further subdivided by epigenetic changes into two subclasses that carry distinct biologic behavior. *SPOP*- and *FOXA1*-mutant tumors had homogeneous epigenetic profiles, similar to *ETV1*-positive and *ETV4*-positive tumors. As noted earlier, *IDH1*-mutant tumors had the highest levels of hypermethylation.

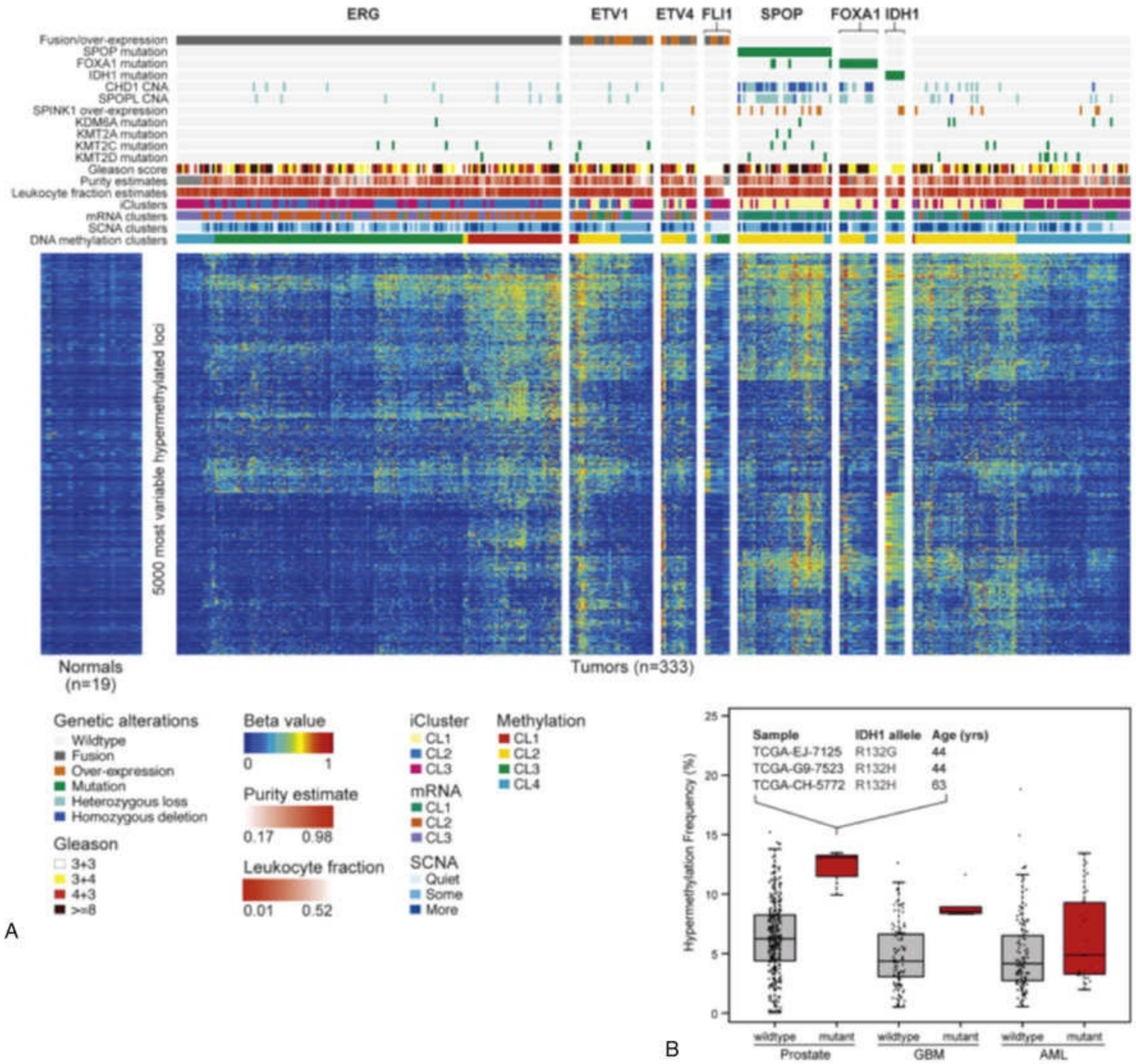

FIG. 148.11 Distinct hypermethylation patterns in prostate cancer across molecular subtypes. (A) Primary prostate cancers show diverse methylation changes compared with normal prostate samples *(left).* ERG-positive tumors had a high diversity of methylation changes, with a distinct subgroup (cluster 1) nearly unique to this group. *SPOP* and *FOXA1* mutant tumors also exhibited global hypermethylation. (B) *IDH1*-mutant prostate cancers, which are associated with younger age, are among the most hypermethylated tumors, similar to that seen in gliomas and acute myeloid leukemia. (Reproduced with permission from Cancer Genome Atlas Research Network. The molecular taxonomy of primary prostate cancer. *Cell* 163[4]:1011–1025, 2015.)

Chromatin remodeling and histone post-translational modifications are also important epigenetic mechanisms of gene deregulation in prostate cancer. A number of histone-modifying enzymes have been reported to be altered, the best characterized of which is the histone methyltransferase polycomb protein *EZH2*. *EZH2* overexpression is correlated with promoter hypermethylation leading to gene silencing and is associated with higher proliferation rates and disease recurrence (van Leenders et al., 2007). Other histone modifiers, including histone deacetylators (HDACs), are upregulated in prostate cancer and are targets for both prevention and therapy using agents that can inhibit or reverse their effects. Histone acetylation also appears important in regulating AR function (Jerónimo et al., 2011).

Newly discovered forms of noncoding RNA species, including miRNA and lncRNA, affect post-transcriptional gene expression. miRNAs are typically 18 to 25 nucleotides long and act by binding to and thereby silencing messenger RNAs (mRNAs) that have complementary sequences (Malik and Feng, 2016). lncRNAs are species of more than 200 nucleotides that regulate gene expression by a variety of mechanisms. While numerous miRNAs have been demonstrated to affect the cell cycle, intracellular signaling, DNA repair, and adhesion/migration in prostate cancer, their main effects seem to be on suppression of apoptosis and AR regulation (Catto et al., 2011). **lncRNAs are emerging as molecules with fundamental biologic and clinical importance in prostate cancer:** PCA3 is a lncRNA that can be detected in urine after a DRE and has clinical utility both in cancer detection and deciding on the need for subsequent biopsy after an initial negative biopsy (Marks et al., 2007). Prostate cancer–associated ncRNA Transcript 1 (PCAT1) is upregulated in early-stage prostate cancer and represses the DNA repair gene *BRCA2*, leading to a functional deficiency in homologous recombination and resulting in sensitivity to PARP inhibitors and radiation. PCAT1 also promotes prostate cell proliferation through the upregulation of *c-MYC*. (Prensner et al., 2014a,b). Expression levels of the lncRNA *SChLAP1* have been shown to be associated with metastasis and prostate-cancer–specific mortality after radical prostatectomy (Prensner et al., 2013). PRNCR1 (prostate cancer noncoding RNA 1) lncRNA has been isolated from the “gene desert” region of 8q24 (the germline susceptibility locus most repeatedly identified in GWAS) is overexpressed in PIN and cancer, and causes ligand-independent activation of the AR (Chung et al., 2011; Yang et al., 2013b).

There is a complex interplay between the described epigenetic mechanisms in prostate cancer. For example, several miRNAs are known to be regulated through promoter methylation or hypomethylation, and some miRNAs control the expression of histone-modifying enzymes. At another level of complexity, both miRNAs and EZH2 independently interact with the *ETS*-gene fusion axis

(Jerónimo et al., 2011).

Androgen Receptor

As discussed earlier, germline polymorphisms of the AR are linked epidemiologically to prostate cancer risk. **The role of AR is well established in the progression of castrate-resistant disease, which is characterized by AR point mutations and amplification, alternative splice mechanisms, and ligand promiscuity, which makes the AR constitutively active, exquisitely sensitive to low levels of intratumoral androgen, or both** (Scher and Sawyers, 2005)**. While these lesions are absent in early-stage disease, dysregulation of the AR signaling axis may occur earlier in disease progression,** involving activating mutations in *FOX1A* and amplification of *NCOA2* that increase androgen-dependent proliferation (Barbieri and Tomlins, 2014). Whole-genome analysis has demonstrated that rearrangement break points are more common near AR binding sites, suggesting AR-mediated transcription brings together distant genomic loci and predisposes to genomic rearrangements (Berger et al., 2011). **TCGA found that AR transcriptional activity is present in all primary tumors, but with activity that varies according to molecular subtype, with variable activity in ETS-positive tumors and highest activity in SPOP-positive and FOXA1-positive tumors** (Cancer Genome Atlas Research Network, 2015)**. TCGA also found that several AR splice variants, including AR-V7, can be detected at low levels in primary tumors.** Androgen signaling promotes corecruitment of AR and topoisomerase II beta (TOP2B) to sites of *TMPRSS2-ERG* genomic break points, triggering DNA double-strand breaks and resulting in de novo production of *TMPRSS2-ERG* fusion transcripts (Haffner et al., 2010). **These observations suggest that AR-mediated transcriptional activity acts as an early driver of genomic rearrangements in prostate cancer, and reinforces AR-mediated transcription as a critical signaling pathway in both primary and advanced disease** (Barbieri and Tomlins, 2014).

DNA Repair Defects and Other Alterations

Defects in DNA repair pathways were found in 19% of primary tumors in TCGA, including mutations in *BRCA2, CDK12, ATM, FANCD2,* and *RAD51C* (Cancer Genome Atlas Research Network, 2015). These mutations may serve as markers of therapies that target DNA repair, recently shown to be active in men with somatic *BRCA* mutations in castrate-resistant disease (Mateo et al., 2015). Alterations in the *PI3K/mTOR* pathway were also frequent, with 17% of tumors containing *PTEN* alterations and rare activation of *PIK3CA, PIK3CB, AKT1,* and *MTOR*, and of several small GTPases including *HRAS* and *BRAF*. These alterations also serve as potential therapeutic targets.

Differences Between African-Americans and Caucasians

As noted earlier, African-American men have the highest worldwide incidence of and mortality caused by prostate cancer. While the underlying reason for this is unknown, it is likely multifactorial (including diet, social determinants, and access to care), and recent molecular genetic data suggest that it is explained in part by differences in tumor biology (Faisal et al., 2016) (Fig. 148.12). **Multiple studies have observed (1) fewer *ERG*-positive tumors; (2) more frequent overexpression of *SPINK1*; (3) more frequent *ERG-/ETS-/SPINK1*-negative tumors; and (4) fewer *PTEN* mutations in African-American men than in European-American men** (Faisal et al., 2016; Khani et al., 2014, Tomlins et al., 2015). One additional study demonstrated differential expression of six molecular markers (including ERG) in primary tumors from prostatectomy specimens between African-Americans and European-Americans that predicted for adverse pathology (Yamoah et al., 2015). The emerging data suggest measurable biologic differences in the pathogenesis of prostate cancer in these men, and efforts are ongoing to understand whether they have clinically meaningful implications for screening and treatment.

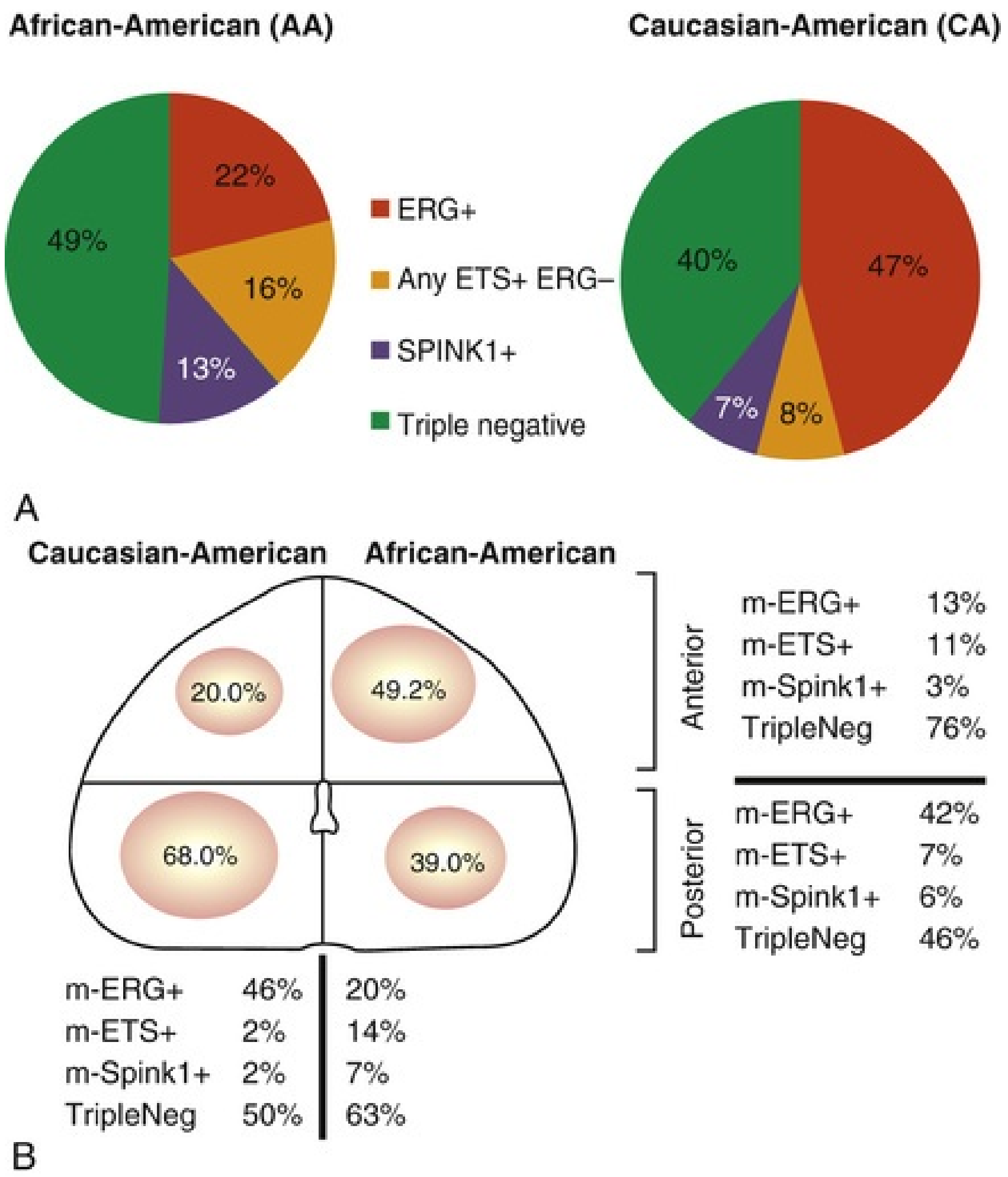

FIG. 148.12 Molecular and spatial differences in prostate cancers from African-American and Caucasian-American men. (A) Distribution of genomic alterations by race; (B) tumor location by race with associated genomic changes. (Reproduced with permission from Faisal FA, Sundi D,, Tosoian JJ, et al. Racial variations in prostate cancer molecular subtypes and androgen receptor signaling reflect anatomic tumor location. *Eur Urol* 70[1]:14–17, 2016.)

An Integrated Model of Prostate Cancer Tumorigenesis

A comprehensive, integrated model of the genetic and environmental events that underlie the genesis and progression of prostate cancer from germline susceptibility to castrate-resistant metastatic disease is now emerging (see Figs. 148.8 and 148.9). Early events in genetically susceptible men include environmental insults such as diet and infection that result in inflammatory insults to DNA integrity in prostate epithelium. Early genetic events that fuel the progression of precursor lesions to early cancers include *ETS* fusion or mutations in *SPOP, FOXA1, or IDH1* in *ETS*-negative tumors. Alterations in DNA repair pathways and mutations in classical tumor suppressors follow, leading to inactivation of the *PI3K/PTEN/Akt* pathway and disease progression, culminating in the multifaceted dysregulation of AR function and signaling that leads to lethal disease. In TCGA, relative to metastatic disease, primary prostate cancers had a lower burden of copy-number alterations and mutations, and the distribution of molecular subtypes was similar, with the notable exception that IDH1-mutant tumors seem limited to primary cancers (Cancer Genome Atlas Research Network, 2015). Similar to the overall burden of genomic alterations, many genes and pathways have increased alteration rates in metastatic disease, especially the DNA repair pathways. Amplification and mutations of AR, commonly seen in metastatic disease, were absent in primary tumors. While many gaps in understanding this process still exist, we are on the threshold of having a detailed molecular map with temporal sequencing that will allow advances in the most important clinical challenges facing the field—improved identification of those at risk for disease development who will be the best candidates for chemoprevention; improved identification of those with indolent tumors who can avoid or delay initial therapy; biologic measures of disease progression that identify those who need therapy; and targeted molecular therapy for those with progressive disease.

Chemoprevention

Rationale

The ubiquity and mortality of prostate cancer make it an attractive target for chemoprevention, defined as the use of natural or synthetic agents that reverse, suppress, or prevent the carcinogenic process, thereby preventing the development of clinically evident cancer. **The goal of chemoprevention is to decrease the incidence of a given cancer, simultaneously reducing both treatment-related side effects and mortality. Primary chemoprevention targets the general population of healthy individuals at risk to prevent the development of prostate cancer. Secondary prevention strategies target individuals with premalignant lesions with the goal of preventing progression to frank cancer. Tertiary prevention aims to prevent the development of a second primary cancer in an affected individual.** Numerous epidemiologic observations suggest associations between dietary and lifestyle factors and the risk for developing prostate cancer. **The clinical rationale for chemoprevention is based on the fact that the risk factors for prostate cancer (age, ethnicity, and family history) are not modifiable (with the exception of PSA screening); the biologic rationale is that premalignant changes appear as long as 20 to 30 years before the appearance of cancer** (Nelson et al., 2003; Umar et al., 2012)**, providing an opportunity to intervene before a malignancy is established using lifestyle changes (dietary alterations, smoking cessation, exercise) or by chemoprevention.** The challenge of chemoprevention is finding an effective intervention that has acceptable toxicity, and identifying a population of individuals at sufficiently increased risk for developing prostate cancer for which chemoprevention is appropriate and cost-effective (see Fig. 148.10).

An effective primary prevention strategy would spare many men the burden of diagnosis and cure and further reduce overdiagnosis and overtreatment associated with screening, augmenting recent gains in the use of more accurate of screening tests than PSA and the growing use of active surveillance. When combined with aggressive early detection and treatment, chemoprevention also has the potential to reduce the mortality from prostate cancer. Several large, controlled, randomized trials that tested the ability of various agents to prevent prostate cancer have been reported in recent years.

Pharmacologic Agents

5α-Reductase Inhibitors

Prostate Cancer Prevention Trial

The PCPT was the first large-scale primary chemoprevention trial in men at risk for prostate cancer (Thompson et al., 2003). The study randomized 18,882 men 55 years of age and older with a normal DRE and a PSA less than or equal to 3.0 ng/mL to finasteride 5 mg or placebo daily for 7 years. **The rationale for finasteride (a selective type 2 5α-reductase inhibitor [5ARI]) as a chemopreventive agent was based on the absence of prostate cancer in men with congenital deficiency of 5α-reductase (the enzyme that converts T to DHT) and the critical role of androgens in the development of prostate cancer.** Biopsy was recommended at the end of study for all participants or “for cause” if men had a PSA level greater than or equal to 4 ng/mL (adjusted for the effect of finasteride) or an abnormal DRE. The primary end point was the prevalence of prostate cancer during the 7 years of the study. Ultimately, 9060 (48%) participants were evaluable for the primary end point.

The main finding of PCPT was a 25% (95% CI, 19 to 31) reduction in the period prevalence of prostate cancer in men taking finasteride (18.4%) compared with placebo (24.4%). The relative benefit of finasteride versus placebo in reducing the risk for prostate cancer was apparent across all groups as defined by age, ethnicity, family history of prostate cancer, and PSA at study entry, with HRs between 0.66 and 0.81. The risk reduction in the finasteride arm was seen in both clinically apparent tumors (those diagnosed “for cause” because of an elevated PSA or abnormal DRE) and end-of-study biopsies (men with PSA <4.0 ng/mL and normal DRE at study termination). **However, a significant increase in the prevalence biopsy Gleason score 7 to 10 cancers was observed in men receiving finasteride (280 [37%]) compared with placebo (237 [22%]), particularly for biopsy Gleason score 8 to 10 cancers (90 [12%] in the finasteride arm vs. 53 [5%] in the placebo arm).**

A number of relevant observations can be made about the results of the trial. Most surprising was the 24.4% prevalence of prostate cancer in the placebo arm, four times higher than the 6% assumed for the trial design. This discrepancy can be explained by the fact that the 6% assumption was based on SEER incidence estimates, which are derived from clinically evident cases and not on the prevalence in men undergoing biopsy with PSA less than 4 ng/mL and normal DRE. The incidence of clinically evident cancers detected “for cause” by elevations in PSA or abnormal PSA was 7.2% at 7 years, similar to the cancer incidence in the screening arms of the ERSPC (8.2%) and PLCO (7.4%) (Andriole et al., 2009; Schröder et al., 2009). **Another observation was a marked effect of finasteride on the prevalence of biopsy Gleason score 2 to 6 tumors, no effect on the prevalence of biopsy Gleason score 7 tumors, and an increase in the prevalence of biopsy Gleason score 8 to 10 tumors**. The higher incidence of biopsy Gleason score 8 to 10 tumors was restricted to those men undergoing “for cause” biopsy, though this is partly explained by the low prevalence of these high-grade cancers in men with PSA less than 4.0 ng/mL and normal DRE (20 of 3652 in the finasteride arm vs. 8 of 3820 in the placebo arm).

Secondary analyses of PCPT have demonstrated an overall improved sensitivity of DRE, and a higher accuracy of PSA for the diagnosis of prostate cancer in the finasteride arm (Thompson et al., 2006, 2007b)**. Finasteride-treated glands were also 28% smaller on average compared with those in the placebo arm, and data suggest that having a smaller prostate enhances the detection of cancer, and proportionately more diagnosed cancers are high-grade** (Kulkarni et al., 2006). These effects of finasteride on the detection of prostate cancer should bias PCPT in favor of the placebo arm and lead to a greater detection of all grades of prostate cancer with finasteride, further strengthening the results of the trial.

There are two areas of continued debate over the results of the PCPT. The first is that critics argue that finasteride prevents insignificant cancers and does little to prevent “potentially lethal” cancers. This criticism is based on the fact that the incidence of cancers in the control arm (24.4%) was significantly higher than a man's lifetime risk for developing prostate cancer (18%) and four times higher than the cancer incidence in screening trials over a similar period. Finasteride also reduced the prevalence of low-grade cancers and did not appear to reduce the risk for high-grade cancers. **However, in a secondary analysis of 93.4% of biopsy specimens that were subject to central pathology review, the rate of insignificant cancers (as defined by the Epstein criteria)** (Epstein et al., 1994) **among the biopsy Gleason 2 to 6 cancers detected in the finasteride (38%) and placebo arms (36%) was not significantly different** (Lucia et al., 2008).

The second question still under debate is whether finasteride induces the development of high-grade or aggressive cancers. Androgen-deprivation therapy is known to change the appearance of prostatic epithelium in a way that could bias interpretation (Civantos et al., 1996). Thus, the apparent increase in high-grade cancers in men treated with finasteride may be an artifact of these morphologic changes. However, when this was examined in PCPT, **there appeared to be no morphologic effect of finasteride on prostate cancer grading when specimens were reviewed by a panel of expert pathologists blinded to the treatment arm** (Lucia et al., 2008). Another potential explanation for the observed increase in high-grade tumors in the finasteride group is ascertainment bias. As stated earlier, finasteride has been shown to increase the sensitivity of PSA and DRE, and decrease prostate volume by 28%, leading to a higher probability of finding the high-grade component of cancer (among men with Gleason 7 to 10 cancer) on biopsy. **Indeed, the rate of upgrading from biopsy Gleason score 2 to 6 to pathologic Gleason score 7 to 10 among men treated by radical prostatectomy was higher in the placebo arm compared with the finasteride arm** (Lucia et al., 2008).

If finasteride induces high-grade cancers, one would expect a higher proportion of cancers with adverse features by biopsy criteria or at radical prostatectomy in the finasteride arm. **Among Gleason 7 to 10 cancers, use of finasteride was associated with more favorable features of tumor extent on biopsy specimens compared with placebo, including percent of positive cores (34% vs. 38%, *P* = 0.016), aggregate linear tumor length (7.6 vs. 9.2 mm, *P* = 0.13), bilaterality (23% vs. 31%, *P* = 0.046), and perineural invasion (14% vs. 20%, *P* = 0.07)** (Lucia et al., 2007, 2008). Among the 528 men who were treated by radical prostatectomy, no significant difference in the rate of extraprostatic extension, seminal vesicle invasion, or lymph node metastasis was observed between the two arms, and there were fewer pathologic Gleason 7 to 10 cancers among men treated with finasteride versus placebo (89 vs. 105).

In a secondary analysis of PCPT that adjusted for the effects of finasteride on the detection of prostate cancer, the adjusted prostate cancer rates were estimated to be 21.1% for the placebo group and 14.7% in the finasteride group, a 30% risk reduction for all cancers (HR 0.70; 95% CI, 0.64 to 0.76) and a nonstatistically significant 14% increase in high-grade cancer (Redman et al., 2008)**. Accounting for the increased probability of upgrading to pathologic Gleason 7 to 10 cancer at radical prostatectomy among men with biopsy Gleason 2 to 6 cancers in the placebo arm, the investigators estimated the rate of true high-grade cancer to be 6% in the finasteride arm and 8.2% in the placebo arm, representing a 27% relative**

risk reduction in the rate of true high-grade cancers in men treated with finasteride (HR 0.73; 95% CI, 0.56 to 0.96). Using different methodology in an independent analysis, Pinsky et al. (2008) concurred that the rate of true high-grade disease may have been lower in the finasteride group compared with the placebo group.

In a long-term follow-up study of all 18,880 men enrolled in the PCPT, some of whom had survival information out to 18 years, no significant differences between treatment groups was observed for overall survival at 15 years (78% vs. 78.2%; unadjusted HR 1.02; 95% CI, 0.97 to 1.08; *P* = 0.5) or among 2401 men with prostate cancer at 10 years (79.3% vs. 79.5%; adjusted HR 1.01; 95% CI, 0.85 to 1.2; *P* = 0.9) (Thompson et al., 2013) **(Fig. 148.13). The absence of important survival differences between treatment arms (and among those with cancer) suggest that the apparent higher incidence of higher-grade cancers in men treated with finasteride does affect survival.** While finasteride did not appear to reduce overall mortality, it was associated with a 43% reduction in the risk for low-grade cancers. Using survival data from the PLCO trial to project prostate cancer mortality from incidence patterns, Pinsky et al. (2013) estimated that use of a 5ARI had no impact on prostate cancer mortality based on the PCPT data using unadjusted (HR 1.02; 95% CI, 0.9 to 1.2) and adjusted analyses (HR 0.9; 95% CI, 0.8 to 1.1) for the effects of 5ARIs on cancer detection. Several other cohort studies have shown no effect on prostate cancer–specific or overall mortality in men taking 5ARIs (Azoulay et al., 2015; Wallner et al., 2016). Together, these studies suggest the apparent increase in high-grade cancers with the use of 5ARIs does not translate into impacts on survival or mortality from prostate cancer or other causes.

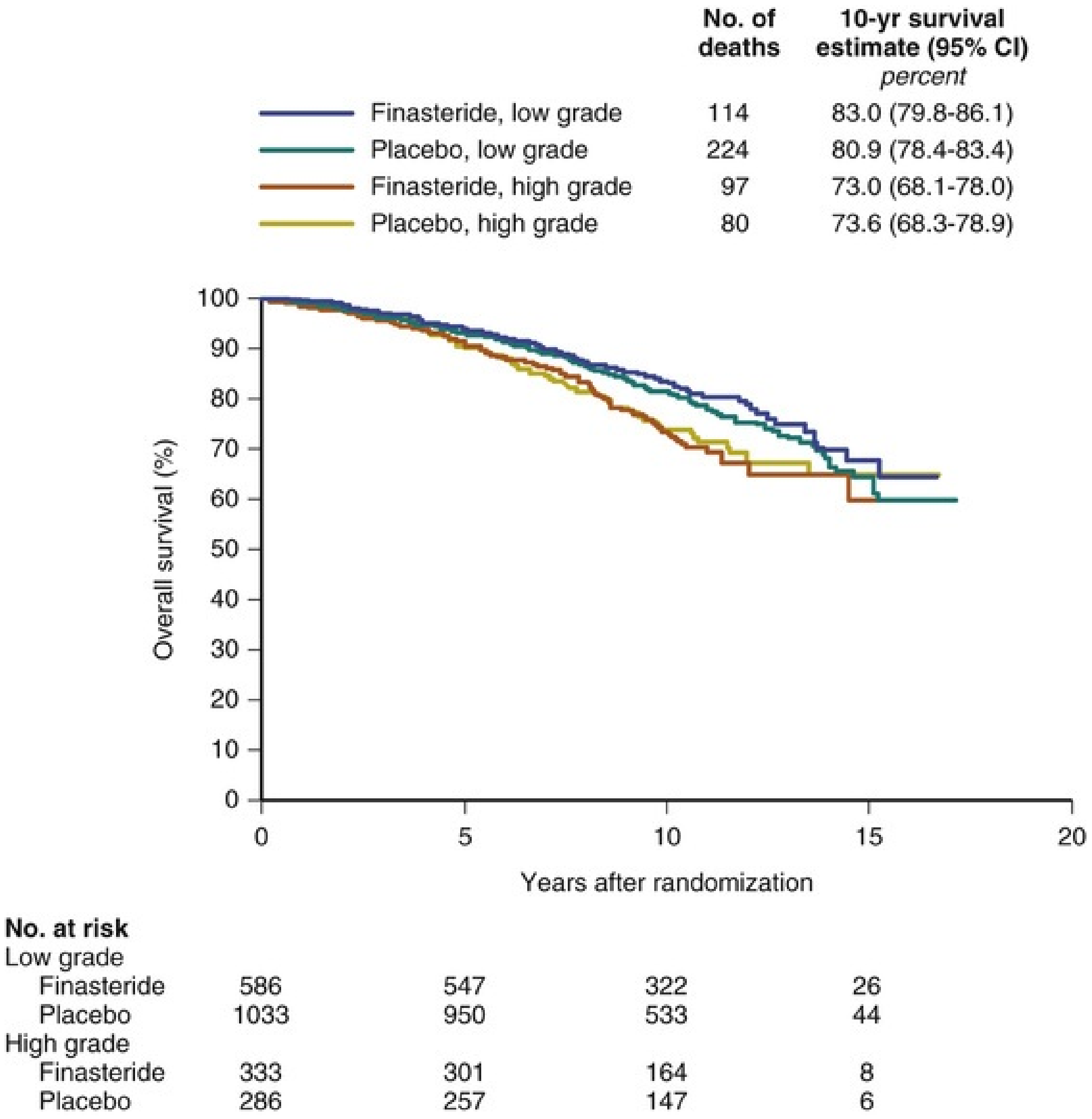

FIG. 148.13 Overall survival of men with prostate cancer, according to cancer grade, in the Prostate Cancer Prevention Trial. (From Thompson IM, Goodman PJ, Tangen CM, et al. Long-term survival of participants in the Prostate Cancer Prevention Trial. *N Engl J Med* 369(7):603–610, 2013; Figure 3.)

In addition to the prevention of prostate cancer, 5ARIs have other benefits which need to be considered. As mentioned earlier, finasteride improves the sensitivity of PSA and DRE for prostate cancer detection (Thompson et al., 2006, 2007b). Furthermore, finasteride reduced the risk for prostatitis, acute urinary retention, and the need for surgical intervention. On the other hand, adverse effects more common with finasteride than placebo include impaired sexual or erectile function and endocrine effects. Pooled data from randomized trials indicate absolute differences of 2% (95% CI, 1 to 2) for gynecomastia, 3%

(95% CI, 1 to 6) for decreased libido, 4% (95% CI, 1 to 8) for erectile dysfunction, and 4% (95% CI, 8 to 17) for reduced volume of ejaculate (Moinpour et al., 2007). Sexual dysfunction was also assessed in the PCPT participants during the 7-year trial period using the Sexual Activity Scale. Compared with baseline scores, over the course of 7 years finasteride was associated with a slight increase in sexual dysfunction relative to placebo. **A 20-year follow-up study showed that men in the finasteride arm experienced fewer Medicare claims for BPH-related symptoms, a slight increase in claims related to depression, and no differences compared with placebo for ischemic and thrombotic events (acute myocardial infarction, ischemic heart disease, thrombosis), endocrine events (diabetes, diabetes with sequelae, hypercholesterolemia, obesity, osteoporosis, fractures, any bone event), sexual dysfunction, or dementia** (Unger et al., 2016)**. These data, along with the long-term survival data, suggest that long-term finasteride use is safe.**

Reduction by Dutasteride of Prostate Cancer Events Trial

The REDUCE trial is another large-scale, randomized, placebo-controlled primary chemoprevention trial using a different 5ARI called dutasteride, which is an inhibitor of both type 1 and type 2 isoforms of 5α-reductase. Dutasteride has been shown to reduce the risk for prostate cancer in men treated for lower urinary tract symptoms related to BPH compared with placebo (Andriole et al., 2004b). Eligibility for the REDUCE trial included men with a prior negative prostate biopsy (6 to 12 cores) within 6 months of enrollment who were 50 to 75 years of age and had a baseline PSA 2.5 to 10 ng/mL and a prostate volume less than or equal to 80 cc. The primary end point of the REDUCE trial was the prevalence of cancer on study-mandated 10-core prostate biopsies performed at 2 and 4 years after randomization.

The REDUCE trial accrued 8231 men, of which 6726 (82.6%) underwent at least one biopsy and 1516 (22.5%) were diagnosed with prostate cancer. **Dutasteride reduced the risk for prostate cancer over 4 years by 23% (858 in the placebo arm vs. 659 in the dutasteride arm, $P < 0.001$) and showed similar reductions in years 1 to 2 and years 3 to 4** (Andriole et al., 2010). There was no significant difference between groups in terms of cancer reduction on protocol-independent (“for-cause”) biopsies (17% in both arms). As with finasteride in the PCPT, the benefit of dutasteride in prostate cancer risk versus placebo was apparent across all subgroups, including age, family history, and PSA level at study entry (relative risk reduction 22% to 32%). While there was no difference in the detection of Gleason 7 to 10 cancers throughout the study ($P = 0.8$), including Gleason 8 to 10 cancers (29 in dutasteride arm vs. 19 in the placebo arm, $P = 0.15$), there was an increased risk for Gleason 8 to 10 cancers during years 3 to 4 of the study (1 in placebo vs. 12 in dutasteride, $P = 0.003$), although no additional Gleason 8 to 10 cancers were seen 2 years off-study among 2751 men assessed (Grubb et al., 2013). There were no deaths from prostate cancer reported during the study, and there were no significant differences between treatment arms among detected cancers in terms of percentage or number of positive cores or tumor volume, even among Gleason 7 to 10 cancers. The rate of HGPIN was also significantly lower among men receiving dutasteride (3.8% vs. 4.9%, $P = 0.04$). Dutasteride also demonstrated beneficial effects on BPH outcomes (acute urinary retention and BPH-related surgery) and was generally well tolerated (15% drug-related adverse events in the placebo arm vs. 22% in the dutasteride arm). Dutasteride also appeared to have beneficial effects on PSA as a marker of prostate cancer (Marberger et al., 2012).

Summary: PCPT and REDUCE

The PCPT and REDUCE trials confirm the consistency of effect of 5ARIs at reducing the risk for prostate cancer, with a similar magnitude of risk reduction across all subgroups. The fact that the results of the REDUCE trial were congruent with those of the PCPT in the magnitude of risk reduction, benefits on BPH end points, and minimal toxicity suggest that 5ARIs represent an effective primary prevention strategy. In 2010, the Oncology Drug Advisory Committee of the FDA convened to assess the evidence in support of 5ARI as chemoprevention agents for prostate cancer. As part of its review, all biopsy specimens from the PCPT and the REDUCE trial that showed prostate cancer were subject to central pathology review and regraded using the modified Gleason scale. **The FDA reassessment showed a significant increase in Gleason 8 to 10 cancers across both trials (relative risk 1.7; 95% CI, 1.2 to 2.3), suggesting that one additional man would be diagnosed with high-grade prostate cancer to avert 3 to 4 low-grade cancers for every 150 to 200 men treated with a 5ARI** (Theoret et al., 2011). The committee believed that the post-hoc exploratory analyses of the PCPT and REDUCE trials did not provide convincing evidence that the increased incidence of high-grade cancer observed in both trials can be dismissed. **The FDA concluded that 5ARIs did not have a favorable risk-benefit profile for the chemoprevention of prostate cancer.** Despite multiple analyses suggesting that detection bias accounted, at least in part, for the observed increase in the rate of high-grade tumors with 5ARIs, concern regarding this risk has all but eliminated the use of 5ARIs for prostate cancer prevention in common urologic practice. Several cost-utility analyses have, however, suggested that chemoprevention with a 5ARI may be cost-effective in populations at high risk (Kattan et al., 2011; Svatek et al., 2008, 2011), and, as noted earlier, long-term follow-up of the PCPT and several cohort studies have demonstrated no impact on long-term mortality in men taking 5ARIs.

Toremifene Citrate

Toremifene citrate is a modulator of the ER and is FDA-approved for the treatment of breast cancer. In vitro studies in prostate cancer have shown that low-dose toremifene selectively inhibits ER-α, which serves as a mediator of growth-stimulatory signal transduction and has a direct antiproliferative effect through ER-β. **A randomized trial in 1467 men with HGPIN failed to show a reduction in prostate cancer incidence at 3 years among those receiving toremifene citrate 20 mg daily vs. placebo, even among select high-risk groups** (Taneja et al., 2013).

Other Pharmacologic Agents

Interest in metformin as a chemopreventive agent is based on epidemiologic evidence showing a link between obesity, metabolic syndrome, and high circulating insulin levels with the development of various cancers. **Epidemiologic studies on the risk for prostate cancer in men using metformin have been mixed, with some showing no effect and others suggesting a benefit** (Chen et al., 2017; Häggström et al., 2017). Statins are widely used cholesterol-lowering drugs and are hypothesized to play a role in the prevention of cancer by inhibiting inflammation, angiogenesis, altering steroid-hormone biosynthesis or metabolism, cell cycle regulation, or promoting apoptosis in tumor cells (Murtola et al., 2008). **A recent meta-analysis of 27 observational studies concluded that satin use reduces the overall risk for**

prostate cancer by about 7% and the risk for higher grade or advanced cancer by 20% (Bansal et al., 2012)**. Neither metformin or statins have been tested in controlled intervention trials for their potential ability to reduce prostate cancer risk.**

Vitamins and Micronutrients

Selenium and Vitamin E

The Selenium and Vitamin E Cancer Prevention Trial

The SELECT was a randomized, placebo-controlled, population-based primary chemoprevention trial designed to test the efficacy of selenium and vitamin E alone and in combination in the prevention of prostate cancer (Lippman et al., 2005). The rationale for using selenium was based on a secondary analysis of the Nutritional Prevention of Cancer Trial of oral selenized yeast for nonmelanoma skin cancer in which men randomized to selenium versus placebo had a 65% reduction in prostate cancer incidence over a mean follow-up of 4.5 years (Clark et al., 1996). The rationale for vitamin E was based on the Alpha-Tocopherol, Beta-Carotene Cancer Prevention Trial (ATBC) for lung cancer incidence and mortality in which male smokers were randomized to α-tocopherol (50 mg daily) and beta-carotene (20 mg daily) alone or in combination versus placebo (ATBC Prevention Study Group, 1994). On secondary analysis, the ATBC trial found a statistically significant 32% reduction in prostate cancer incidence in those receiving α-tocopherol (Albanes et al., 1995).

The SELECT randomized 35,533 men to four treatment arms (selenium + placebo, vitamin E + placebo, selenium + vitamin E, and placebo + placebo) (Lippman et al., 2009). Eligibility criteria included age 50 years and older for African-Americans, age 55 years and older for Caucasians, a DRE not suspicious for cancer, serum PSA less than or equal to 4 ng/mL, and normal blood pressure. The primary end point was biopsy-confirmed prostate cancer, although the indications for biopsy were not dictated by protocol. **Although the study duration was planned for 12 years, the study was closed after an interim analysis at 7 years because the data convincingly demonstrated no effect on the risk for prostate cancer by either agent alone or in combination, and no chance of a beneficial effect of the hypothesized magnitude with continued supplementation** (Lippman et al., 2009)**. Hazard ratios for prostate cancer were 1.13 (99% CI, 0.95 to 1.13) for vitamin E, 1.04 (99% CI, 0.87 to 1.24) for selenium, and 1.05 (99% CI, 0.88 to 1.25) for selenium and vitamin E. A follow-up study that included an additional 54,464 person-years showed that dietary supplementation with vitamin E**

actually increased the risk for prostate cancer (HR 1.17, 95% CI, 1.004 to 1.36, *P* = 0.008) (Klein et al., 2011) **(Fig. 148.14).**

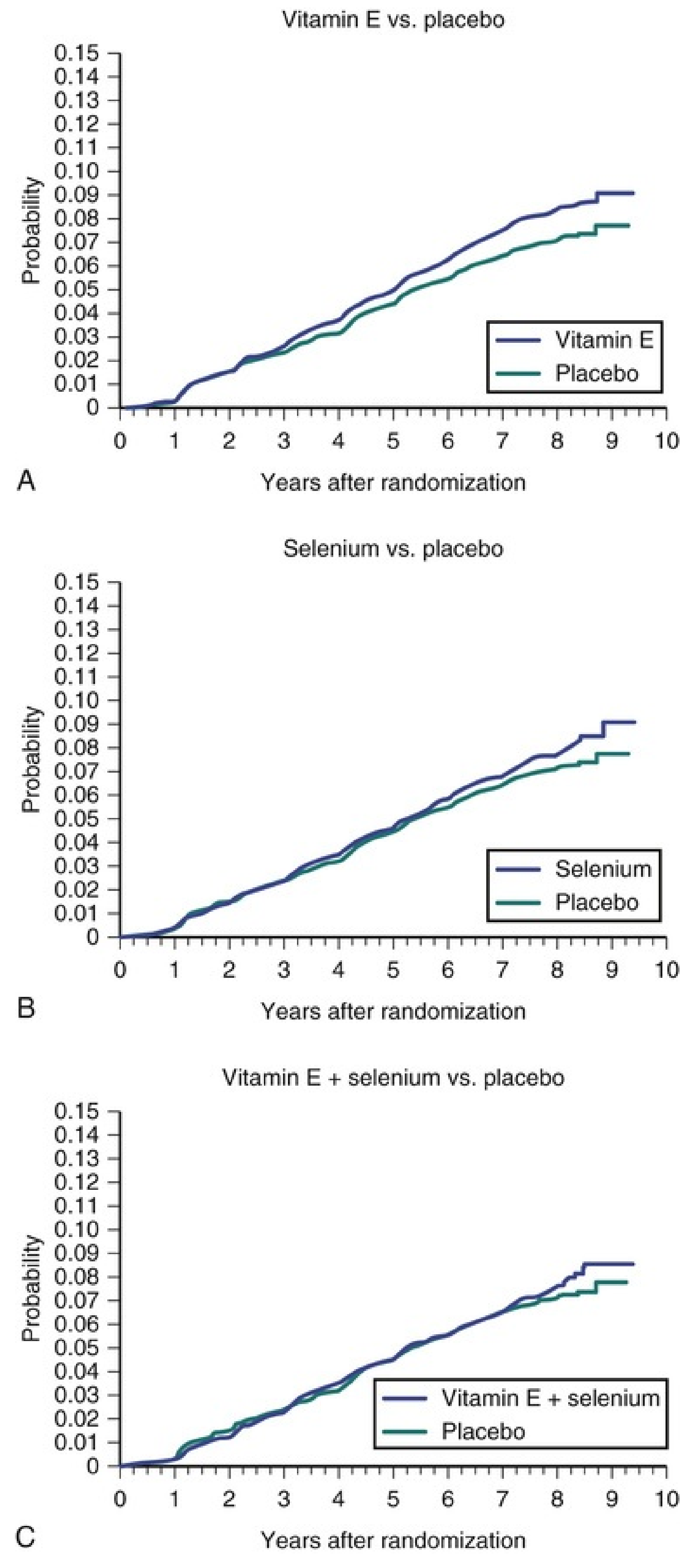
Vitamin E vs. placebo
Probability
0.15
0.14
0.13
0.12
0.11
0.10
0.09
0.08
0.07
0.06
0.05
0.04
0.03
0.02
0.01
0
Vitamin E
Placebo
0
1
2
3
4
5
6
7
8
9
10
A
Years after randomization
Selenium vs. placebo
Probability
Selenium
Placebo
B
Years after randomization
Vitamin E + selenium vs. placebo
Probability
Vitamin E + selenium
Placebo
C
Years after randomization

FIG. 148.14 Cumulative incidence of prostate cancer detection over time by intervention group in the Selection and Vitamin E Cancer Prevention Trial (SELECT). Those taking vitamin E alone had a 17% increased risk of prostate cancer compared with placebo (HR = 1.17; 99% CI, 1.004 to 1.36, *P* = .008); rates of prostate cancer in the selenium alone arm and selenium plus vitamin E arm were not different from placebo (HR = 1.09; 99% CI, 0.93 to 1.27; *P* = .18 and HR = 1.05; 99% CI, 0.89 to 1.22, *P* = .46, respectively). (Data from Klein EA, Thompson IM Jr, Tangen CM, et al. Vitamin E and the risk of prostate cancer: the Selenium and Vitamin E Cancer Prevention Trial (SELECT). *JAMA* 306(14):1549–1556, 2011; Figure 2.)

The absence of a beneficial effect of these micronutrients on prostate cancer risk was also observed in other randomized trials (Algotar et al., 2013; Gaziano et al., 2009). Two randomized trials have evaluated the effect of selenium, vitamin E, and/or soy on the risk for prostate cancer among men with evidence of HGPIN on prior biopsy. The Southwest Oncology Group 9917 randomized 423 men with HGPIN to selenium 200 mcg/day versus placebo and found no difference in the 3-year risk for prostate cancer (36% vs. 37%, *P* = 0.7), although men with the lowest baseline plasma selenium levels experienced a nonstatistically significant risk reduction (Marshall et al., 2011). A similar trial from the National Cancer Institute of Canada randomized 303 men with HGPIN to daily soy (40 g), vitamin E (800 U), and selenium (200 mcg) versus placebo and found no significant reduction in prostate cancer risk at 3 years (HR 1.03, 95% CI, 0.7 to 1.6; *P* = 0.9) (Fleshner et al., 2011).

Together, these results suggest that neither selenium nor vitamin E should be used in the hope of preventing prostate or other cancers. The 17% increased prostate cancer risk associated with vitamin E in the SELECT demonstrates the potential for seemingly innocuous yet biologically active substances to cause harm. The reasons why these trials failed to confirm the presumed cancer-preventive activity of micronutrients are uncertain. A possible explanation is that men in earlier trials were relatively deficient of these micronutrients compared with those enrolled in the more recent trials. **Thus, micronutrients may have cancer-preventive activity in deficient individuals but have no benefit (and potentially harm) in those who are nutritionally replete.**

Conclusion

It is clear that the process of prostate carcinogenesis is complex. The interplay of constitutional, behavioral, and molecular and environmental factors against the backdrop of various processes occurring during aging interact to set in motion a series of events that ultimately manifest through the diagnosis of prostate cancer. Complicating the understanding of this process are various confounds associated with the diagnosis of the disease in clinical trials, in the general population, and in epidemiologic studies.

Despite promising outcomes from clinical trials of 5ARIs for chemoprevention of prostate cancer, their relatively low use/enthusiasm by prostate cancer specialists and primary care practitioners despite endorsement by professional societies and subsequent failure to gain regulatory approval by government agencies highlights the challenges of developing new agents and approaches to chemoprevention. The FDA poses a substantial obstacle because of intense scrutiny over toxicity, as was seen with 5ARIs. As seen with the SELECT, the promise of micronutrients as chemopreventive agents have fallen well short of expectations, and may potentially be harmful. Future directions will require genetic and molecular approaches for identifying at-risk patients and appropriate targets for chemoprevention.

Key Points: Epidemiology

- In the United States, prostate cancer is the most common visceral malignancy in men and the third leading cause of cancer-related deaths.
- Prostate cancer mortality has declined since 1991 and for Caucasians is now lower than before PSA was introduced.
- Worldwide, prostate cancer incidence and mortality rates vary significantly among countries and regions but are highest in African-American and Jamaican men.
- PSA has induced a significant downward migration in age and both clinical and pathologic stage at diagnosis.
- PSA screening reduces prostate cancer mortality, however, the absolute effect is small relative to the number needed to screen and treat to cure a

single individual.

Key Points: Familial and Germline Genetic Influences

- Both genetics and environment are important in the origin and evolution of prostate cancer.
- Genome-wide association studies have identified multiple chromosomal loci and variant alleles in germline DNA that confer risk for developing prostate cancer.
- Because the predictive value of single loci is small, models with multiple risk loci or less common alleles with greater risk are needed for individual risk prediction.
- *HOXB13* and *BRCA* are two genes that substantially increase individual risk. *BRCA*-related tumors present with more aggressive clinical features.

Key Points: Inflammation and Infection

- Chronic inflammation leading to cellular hyperproliferation to replace damaged tissue appears to contribute to the development of prostate cancer.
- Both genetic and histologic observations suggest that compromised cellular defenses against inflammatory oxidants are important in prostate cancer initiation and promotion.
- Inflammation may be triggered by diet, infection, estrogens, or other environmental agents.
- Histologic evidence of inflammation, as manifested by PIA, is common in prostate cancer and may represent a key pathobiologic process in its development.

Key Points: Molecular Epidemiology

- Androgen exposure of the prostate plays an important but incompletely defined role in prostate carcinogenesis.

- Long-term absence of androgen exposure protects against cancer, but a dose-response relationship between androgen levels and prostate cancer risk has not been established.
- Polymorphisms in genes encoding for the androgen receptor and various enzymes related to androgen metabolism may be important determinants of prostate cancer risk.
- Vitamin D and its interaction with its receptor modulate risk and disease aggressiveness.
- Smoking increases the risk for disease recurrence and death caused by prostate cancer.
- Obesity is associated with lower PSA, increases the risk for developing high-grade disease, and is associated with higher treatment failure rates and mortality.

Key Points: Etiology and Molecular Genetics

- The primary androgen of the prostate is dihydrotestosterone (DHT). Exposure to DHT is a prerequisite for developing prostate cancer.
- Stem cells are precursors with multilineage differentiation potential that populate epithelium of prostatic acini and are the origin of clonal epithelial expansion.
- Primary prostate cancer has a distinct molecular taxonomy characterized by seven distinct subtypes, including four defined by gene fusions and three by mutations.
- Variations in gene methylation profiles further distinguish the molecular subtypes of prostate cancer.
- The AR plays a central role in prostate cancer development and progression.
- There are distinct biologic differences in the genomics of prostate cancers of African-American and European-American men.

Key Points: Prevention

- The goal of primary chemoprevention is to decrease the incidence of a given cancer, simultaneously reducing both treatment-related side effects and mortality.

- Effective chemoprevention requires the use of nontoxic agents that inhibit specific molecular steps in the carcinogenic pathway.
- Prostate cancer is an attractive target for primary prevention because of its incidence, prevalence, treatment-related morbidity, and mortality.
- The Prostate Cancer Prevention Trial demonstrated that finasteride reduces the period prevalence of prostate cancer by 25%, with no effect on overall mortality.
- The SELECT demonstrated that neither vitamin E nor selenium prevent prostate cancer, and that use of vitamin E was associated with an increased risk for prostate cancer.

References

Al Olama AA, Kote-Jarai Z, Berndt SI, et al. A meta-analysis of 87,040 individuals identifies 23 new susceptibility loci for prostate cancer. *Nat Genet*. 2014;46(10):1103–1139.

Albanes D, Heinonen OP, Huttunen JK, et al. Effects of alpha-tocopherol and beta-carotene supplements on cancer incidence in the Alpha-Tocopherol Beta-Carotene Cancer Prevention Study. *Am J Clin Nutr*. 1995;62(6 Suppl):1427S–1430S.

Algotar AM, Stratton MS, Ahmann FR, et al. Phase 3 clinical trial investigating the effect of selenium supplementation in men at high-risk for prostate cancer. *Prostate*. 2013;73(3):328–335.

Alpha-Tocopherol, Beta Carotene Cancer Prevention Study Group. The effect of vitamin E and beta carotene on the incidence of lung cancer and other cancers in male smokers. *N Engl J Med*. 1994;330(15):1029–1035.

American Cancer Society. *Cancer facts and figures 2017*. [Available at] https://www.cancer.org/research/cancer-facts-statistics/all-cancer-facts-figures/cancer-facts-figures-2017.html; 2017.

Andriole G, Bruchovsky N, Chung LW, et al. Dihydrotestosterone and the prostate: the scientific rationale for 5alpha-reductase inhibitors in the treatment of benign prostatic hyperplasia. *J Urol*. 2004;172(4 Pt 1):1399–1403.

Andriole GL, Roehrborn C, Schulman C, et al. Effect of dutasteride on the detection of prostate cancer in men with benign prostatic hyperplasia. *Urology*. 2004;64(3):537–541 [discussion 542–543].

Andriole GL, Grubb RL 3rd, Buys SS, et al. Mortality results from a randomized prostate-cancer screening trial. *N Engl J*

Med. 2009;360(13):1310–1319.

Andriole G, Bostwick DG, Brawley OW, et al. Effect of dutasteride on the risk of prostate cancer. *N Engl J Med*. 2010;362(13):1192–1202.

Andriole GL, Crawford ED, Grubb RL 3rd, et al. Prostate cancer screening in the randomized Prostate, Lung, Colorectal, and Ovarian Cancer Screening Trial: mortality results after 13 years of follow-up. *J Natl Cancer Inst*. 2012;104(2):125–132.

Attard G, Clark J, Ambroisine L, et al. Duplication of the fusion of TMPRSS2 to ERG sequences identifies fatal human prostate cancer. *Oncogene*. 2008;27(3):253–263.

Azoulay L, Eberg M, Benayoun S, et al. 5α-Reductase inhibitors and the risk of cancer-related mortality in men with prostate cancer. *JAMA Oncol*. 2015;1(3):314–320.

Balic I, Graham ST, Troyer DA, et al. Androgen receptor length polymorphism associated with prostate cancer risk in Hispanic men. *J Urol*. 2002;168(5):2245–2248.

Banerjee PP, Banerjee S, Dorsey R, et al. Age- and lobe-specific responses of the brown Norway rat prostate to androgen. *Biol Reprod*. 1994;51(4):675–684.

Bansal D, Undela K, D'Cruz S, et al. Statin use and risk of prostate cancer: a meta-analysis of observational studies. *PLoS ONE*. 2012;7(10):e46691.

Barbieri CE, Demichelis F, Rubin MA. Molecular genetics of prostate cancer: emerging appreciation of genetic complexity. *Histopathology*. 2012;60(1):187–198.

Barbieri CE, Tomlins SA. The prostate cancer genome: perspectives and potential. *Urol Oncol*. 2014;32(1):53.e15–53.e22.

Barocas DA, Mallin K, Graves AJ, et al. Effect of the USPSTF grade D recommendation against screening for prostate cancer on incident prostate cancer diagnoses in the United

States. *J Urol*. 2015;194(6):1587–1593.

Barreto AM, Schwartz GG, Woodruff R, et al. 25-Hydroxyvitamin D3, the prohormonal form of 1,25-dihydroxyvitamin D3, inhibits the proliferation of primary prostatic epithelial cells. *Cancer Epidemiol Biomarkers Prev*. 2000;9(3):265–270.

Batai K, Murphy AB, Ruden M, et al. Race and BMI modify associations of calcium and vitamin D intake with prostate cancer. *BMC Cancer*. 2017;17(1):64.

Berger MF, Lawrence MS, Demichelis F, et al. The genomic complexity of primary human prostate cancer. *Nature*. 2011;470(7333):214–220.

Bhindi B, Wallis CJD, Nayan M, et al. The association between vasectomy and prostate cancer: a systematic review and meta-analysis. *JAMA Intern Med*. 2017;177(9):1273–1286.

Biernacka KM, Perks CM, Holly JM. Role of the IGF axis in prostate cancer. *Minerva Endocrinol*. 2012;37(2):173–185.

Bosland MC. A perspective on the role of estrogen in hormone-induced prostate carcinogenesis. *Cancer Lett*. 2013;334(1):28–33.

Bostwick DG, Burke HB, Djakiew D, et al. Human prostate cancer risk factors. *Cancer*. 2004;101(10 Suppl):2371–2490.

Boyle P, Brawley OW. Prostate cancer: current evidence weighs against population screening. *CA Cancer J Clin*. 2009;59(4):220–224.

Boysen G, Barbieri CE, Prandi D, et al. SPOP mutation leads to genomic instability in prostate cancer. *Elife*. 2015;4:e09207.

Brändstedt J, Almquist M, Manjer J, et al. Vitamin D, PTH, and calcium in relation to survival following prostate cancer. *Cancer Causes Control*. 2016;27(5):669–677.

Brandt A, Bermejo JL, Sundquist J, et al. Age at diagnosis and age at death in familial prostate cancer. *Oncologist*. 2009;14(12):1209–1217.

Brocks Y, Assenov S, Minner O, et al. Intratumor DNA methylation heterogeneity reflects clonal evolution in aggressive prostate cancer. *Cell Rep*. 2014;8(3):798–806.

Bui M, Reiter RE. Stem cell genes in androgen-independent prostate cancer. *Cancer Metastasis Rev*. 1998–1999;17(4):391–399.

Buschemeyer WC 3rd, Freedland SJ. Obesity and prostate cancer: epidemiology and clinical implications. *Eur Urol*. 2007;52(2):331–343.

Byrne MM, Davila EP, Zhao W, et al. Cancer screening behaviors among smokers and nonsmokers. *Cancer Epidemiol*. 2010;34(5):611–617.

Cancer Genome Atlas Research Network. The molecular taxonomy of primary prostate cancer. *Cell*. 2015;163(4):1011–1025.

Carver BS, Tran J, Gopalan A, et al. Aberrant ERG expression cooperates with loss of PTEN to promote cancer progression in the prostate. *Nat Genet*. 2009;41(5):619–624.

Castro E, Eeles R. The role of BRCA1 and BRCA2 in prostate cancer. *Asian J Androl*. 2012;14(3):409–414.

Castro E, Goh C, Leongamornlert D, et al. Effect of BRCA mutations on metastatic relapse and cause-specific survival after radical treatment for localised prostate cancer. *Eur Urol*. 2015;68(2):186–193.

Catalona WJ, Smith DS, Ratliff TL, et al. Detection of organ-confined prostate cancer is increased through prostate-specific antigen-based screening. *JAMA*. 1993;270(8):948–954.

Catto JWF, Alcaraz A, Bjartell AS, et al. MicroRNA in prostate, bladder, and kidney cancer: a systematic review. *Eur Urol*. 2011;59(5):671–681.

Center MM, Jemal A, Lortet-Tieulent J, et al. International variation in prostate cancer incidence and mortality rates. *Eur*

Urol. 2012;61(6):1079–1092.

Chan JM, Gann PH, Giovannucci EL. Role of diet in prostate cancer development and progression. *J Clin Oncol*. 2005;23(32):8152–8160.

Chan YX, Alfonso H, Chubb SA, et al. Higher dihydrotestosterone is associated with the incidence of lung cancer in older men. *Horm Cancer*. 2017;8(2):119–126.

Chang BL, Zheng SL, Hawkins GA, et al. Joint effect of HSD3B1 and HSD3B2 genes is associated with hereditary and sporadic prostate cancer susceptibility. *Cancer Res*. 2002;62(6):1784–1789.

Chatterjee S, Park ES, Soloff MS. Proliferation of DU145 prostate cancer cells is inhibited by suppressing insulin-like growth factor binding protein-2. *Int J Urol*. 2004;11(10):876–884.

Chen CB, Eurich DT, Majumdar SR, et al. Metformin and the risk of prostate cancer across racial/ethnic groups: a population-based cohort study. *Prostate Cancer Prostatic Dis*. 2017;20(1):122–126.

Cheng I, Witte JS, Jacobsen SJ, et al. Prostatitis, sexually transmitted diseases, and prostate cancer: the California Men's Health Study. *PLoS ONE*. 2010;5(1):e8736.

Chu NF, Spiegelman D, Yu J, et al. Plasma leptin concentrations and fouryear weight gain among US men. *Int J Obes Relat Metab Disord*. 2001;25(3):346–353.

Chung WK, Leibel RL. The links between obesity, leptin, and prostate cancer. *Cancer J*. 2006;12(3):178–181.

Chung S, Nakagawa H, Uemura M, et al. Association of a novel long non-coding RNA in 8q24 with prostate cancer susceptibility. *Cancer Sci*. 2011;102(1):245–252.

Civantos F, Soloway MS, Pinto JE. Histopathological effects of androgen deprivation in prostatic cancer. *Semin Urol Oncol*. 1996;14(2 Suppl 2):22–31.

Clark LC, Combs GF Jr, Turnbull BW, et al. Effects of selenium supplementation for cancer prevention in patients with carcinoma of the skin. A randomized controlled trial. Nutritional Prevention of Cancer Study Group. *JAMA*. 1996;276(24):1957–1963 [Erratum in JAMA 277(19):1520, 1997].

Coleman MP, Quaresma M, Berrino F, et al. Cancer survival in five continents: a worldwide population-based study (CONCORD). *Lancet Oncol*. 2008;9(8):730–756.

Collin SM, Martin RM, Metcalfe C, et al. Prostate-cancer mortality in the USA and UK in 1975-2004: an ecological study. *Lancet Oncol*. 2008;9(5):445–452.

Collins AT, Habib FK, Maitland NJ, et al. Identification and isolation of human prostate epithelial stem cells based on α1β2-integrin expression. *J Cell Sci*. 2001;114(Pt 21):3865–3872.

Coussens LM, Werb Z. Inflammation and cancer. *Nature*. 2002;420(6917):860–867.

Crowe FL, Key TJ, Appleby PN, et al. Dietary fat intake and risk of prostate cancer in the European prospective investigation into cancer and nutrition. *Am J Clin Nutr*. 2008;87(5):1405–1413.

Culp MB, Soerjomataram I, Efstathiou JA, et al. Recent global patterns in prostate cancer incidence and mortality rates. *Eur Urol*. 2019 [Epub ahead of print].

Cussenot O, Azzouzi AR, Nicolaiew N, et al. Combination of polymorphisms from genes related to estrogen metabolism and risk of prostate cancers: the hidden face of estrogens. *J Clin Oncol*. 2007;25(24):3596–3602.

de Koning HJ, Gulati R, Moss SM, et al. The efficacy of prostate-specific antigen screening: impact of key components in the ERSPC and PLCO trials. *Cancer*. 2018;124(6):1197–1206.

de Martel C, Ferlay J, Franceschi S, et al. Global burden of cancers attributable to infections in 2008: a review and synthetic analysis. *Lancet Oncol*. 2012;13(6):607–615.

De Marzo AM, Marchi VL, Epstein JI, et al. Proliferative inflammatory atrophy of the prostate: implications for prostatic carcinogenesis. *Am J Pathol*. 1999;155(6):1985–1992.

De Marzo AM, Platz EA, Sutcliffe S, et al. Inflammation in prostate carcinogenesis. *Nat Rev Cancer*. 2007;7(4):256–269.

De Nunzio C, Albisinni S, Freedland SJ, et al. Abdominal obesity as risk factor for prostate cancer diagnosis and high grade disease: a prospective multicenter italian cohort study. *Urol Oncol*. 2013;31(7):997–1002.

Demichelis F, Fall K, Perner S, et al. TMPRSS2:ERG gene fusion associated with lethal prostate cancer in a watchful waiting cohort. *Oncogene*. 2007;26(31):4596–4599.

Denis L, Morton MS, Griffiths K. Diet and its preventive role in prostatic disease. *Eur Urol*. 1999;35(5–6):377–387.

Dennis LK, Dawson DV. Meta-analysis of measures of sexual activity and prostate cancer. *Epidemiology*. 2002;13(1):72–79.

Dennis LK, Snetselaar LG, Smith BJ, et al. Problems with the assessment of dietary fat in prostate cancer studies. *Am J Epidemiol*. 2004;160(5):436–444.

Deo DD, Rao AP, Bose SS, et al. Differential effects of leptin on the invasive potential of androgen-dependent and -independent prostate carcinoma cells. *J Biomed Biotechnol*. 2008;2008:163902.

Dimitropoulou P, Lophatananon A, Easton D, et al. Sexual activity and prostate cancer risk in men diagnosed at a younger age. *BJU Int*. 2009;103(2):178–185.

Dobosy JR, Roberts JL, Fu VX, et al. The expanding role of epigenetics in the development, diagnosis and treatment of prostate cancer and benign prostatic hyperplasia. *J Urol*. 2007;177(3):822–831.

Dong F, Reuther AM, Magi-Galluzzi C, et al. Pathologic stage migration has slowed in the late PSA era. *Urology*. 2007;70(5):839–842.

Dong Q, Nelson DE, Toh E, et al. The microbial communities in male first catch urine are highly similar to those in paired urethral swab specimens. *PLoS ONE*. 2011;6(5):e19709.

Ebot EM, Gerke T, Labbe DP, et al. Gene expression profiling of prostate tissue identifies chromatin regulation as a potential link between obesity and lethal prostate cancer. *Cancer*. 2017;123(21):4130–4138.

Eeles R, Goh C, Castro E, et al. The genetic epidemiology of prostate cancer and its clinical implications. *Nat Rev Urol*. 2014;11(1):18–31.

Ellem SJ, Schmitt JF, Pedersen JS, et al. Local aromatase expression in human prostate is altered in malignancy. *J Clin Endocrinol Metab*. 2004;89(5):2431–2441.

Endogenous Hormones and Prostate Cancer Collaborative Group, Roddam AW, Allen NE, et al. Endogenous sex hormones and prostate cancer: a collaborative analysis of 18 prospective studies. *J Natl Cancer Inst*. 2008;100(3):170–183.

Epstein JI, Walsh PC, Carmichael M, et al. Pathologic and clinical findings to predict tumor extent of nonpalpable (stage T1c) prostate cancer. *JAMA*. 1994;271(5):368–374.

Epstein MM, Edgren G, Rider JR, et al. Temporal trends in cause of death among Swedish and US men with prostate cancer. *J Natl Cancer Inst*. 2012;104(17):1335–1342.

Etzioni R, Legler JM, Feuer EJ, et al. Cancer surveillance series: interpreting trends in prostate cancer—part III: quantifying the link between population prostate-specific antigen testing and recent declines in prostate cancer mortality. *J Natl Cancer Inst*. 1999;91(12):1033–1039.

Etzioni R, Tsodikov A, Mariotto A, et al. Quantifying the role of PSA screening in the US prostate cancer mortality decline. *Cancer Causes Control*. 2008;19(2):175–181.

Etzioni R, Gulati R, Tsodikov A, et al. The prostate cancer conundrum revisited: treatment changes and prostate cancer mortality declines. *Cancer*. 2012;118(23):5955–5963.

Ewing CM, Ray AM, Lange EM, et al. Germline mutations in HOXB13 and prostate-cancer risk. *N Engl J Med*. 2012;366(2):141–149.

Faisal FA, Sundi D, Tosoian JJ, et al. Racial variations in prostate cancer molecular subtypes and androgen receptor signaling reflect anatomic tumor location. *Eur Urol*. 2016;70(1):14–17.

Feuer EJ, Merrill RM, Hankey BF. Cancer surveillance series: interpreting trends in prostate cancer—part II: cause of death misclassification and the recent rise and fall in prostate cancer mortality. *J Natl Cancer Inst*. 1999;91(12):1025–1032.

Fleshner NE, Kapusta L, Donnelly B, et al. Progression from high-grade prostatic intraepithelial neoplasia to cancer: a randomized trial of combination vitamin-E, soy, and selenium. *J Clin Oncol*. 2011;29(17):2386–2390.

Fouts DE, Pieper R, Szpakowski S, et al. Integrated next-generation sequencing of 16S rDNA and metaproteomics differentiate the healthy urine microbiome from asymptomatic bacteriuria in neuropathic bladder associated with spinal cord injury. *J Transl Med*. 2012;10:174.

Friedman JM. The function of leptin in nutrition, weight, and physiology. *Nutr Rev*. 2002;60(10 Pt 2):S1–S14.

Friman PC, Finney JW, Leibowitz JM. Years of potential life lost: evaluating premature cancer death in men. *J Community Health*. 1989;14(2):101–106.

Futreal PA, Kasprzyk A, Birney E, et al. Cancer and genomics.

Nature. 2001;409(6822):850–852.

Gallina A, Chun FK, Suardi N, et al. Comparison of stage migration patterns between Europe and the USA: an analysis of 11 350 men treated with radical prostatectomy for prostate cancer. *BJU Int*. 2008;101(12):1513–1518.

Gaziano JM, Glynn RJ, Christen WG, et al. Vitamins E and C in the prevention of prostate and total cancer in men: the Physicians’ Health Study II randomized controlled trial. *JAMA*. 2009;301(1):52–62.

Giles GG, Severi G, English DR, et al. Sexual factors and prostate cancer. *BJU Int*. 2003;92(3):211–216.

Giovannucci E. Insulin and colon cancer. *Cancer Causes Control*. 1995;6(2):164–179.

Giovannucci E, Ascherio A, Rimm EB, et al. A prospective cohort study of vasectomy and prostate cancer in US men. *JAMA*. 1993;269(7):873–877.

Giovannucci E, Tosteson TD, Speizer FE, et al. A retrospective cohort study of vasectomy and prostate cancer in US men. *JAMA*. 1993;269(7):878–882.

Giri VN, Knudsen KE, Kelly WK, et al. Role of genetic testing for inherited prostate cancer risk: philadelphia Prostate Cancer Consensus Conference 2017. *J Clin Oncol*. 2018;36(4):414–424.

Gleicher S, Kauffman EC, Kotula L, et al. Implications of high rates of metastatic prostate cancer in BRCA2 mutation carriers. *Prostate*. 2016;76(13):1135–1145.

Godtman RA, Carlsson S, Holmberg E, et al. The effect of start and stop age at screening on the risk of being diagnosed with prostate cancer. *J Urol*. 2016;195(5):1390–1396.

Goldgar DE, Easton DF, Cannon-Albright LA, et al. Systematic population-based assessment of cancer risk in first-degree relatives of cancer probands. *J Natl Cancer Inst*. 1994;86(21):1600–1608.

Gong Z, Neuhouser ML, Goodman PJ, et al. Obesity, diabetes, and risk of prostate cancer: results from the Prostate Cancer Prevention Trial. *Cancer Epidemiol Biomarkers Prev*. 2006;15(10):1977–1983.

Graham-Steed T, Uchio E, Wells CK, et al. “Race” and prostate cancer mortality in equal-access healthcare systems. *Am J Med*. 2013;126(12):1084–1088.

Gronberg H. Prostate cancer epidemiology. *Lancet*. 2003;361:859–864.

Gross CP, Smith BD, Wolf E, et al. Racial disparities in cancer therapy: did the gap narrow between 1992 and 2002? *Cancer*. 2008;112(4):900–908.

Grubb RL, Andriole GL, Somerville MC, et al. The REDUCE Follow-Up Study: low rate of new prostate cancer diagnoses observed during a 2-year, observational, followup study of men who participated in the REDUCE trial. *J Urol*. 2013;189(3):871–877.

Gudmundsson J, Sulem P, Gudbjartsson DF, et al. A study based on whole-genome sequencing yields a rare variant at 8q24 associated with prostate cancer. *Nat Genet*. 2012;44(12):1326–1329.

Habib CN, Al-Abd AM, Tolba MF, et al. Leptin influences estrogen metabolism and accelerates prostate cell proliferation. *Life Sci*. 2015;121:10–15.

Haenszel W, Kurihara M. Studies of Japanese migrants. I Mortality from cancer and other diseases among Japanese in the United States. *J Natl Cancer Inst*. 1968;40(1):43–68.

Haffner MC, Aryee MJ, Toubaji A, et al. Androgen-induced TOP2B- mediated double-strand breaks and prostate cancer gene rearrangements. *Nat Genet*. 2010;42(8):668–675.

Häggström C, Van Hemelrijck M, Zethelius B, et al. Prospective study of Type 2 diabetes mellitus, anti-diabetic drugs and risk of prostate cancer. *Int J Cancer*. 2017;140(3):611–617.

Halpern JA, Shoag JE, Artis AS, et al. National trends in prostate biopsy and radical prostatectomy volumes following the US preventive services task force guidelines against prostate-specific antigen screening. *JAMA Surg*. 2017;152(2):192–198.

He J, Xu G. LEP gene variant is associated with prostate cancer but not with colorectal cancer. *Tumour Biol*. 2013;34(5):3131–3136.

Herget KA, Patel DP, Hanson HA, et al. Recent decline in prostate cancer incidence in the united states, by age, stage, and Gleason score. *Cancer Med*. 2016;5(1):136–141.

Hjelmborg JB, Scheike T, Holst K, et al. The heritability of prostate cancer in the Nordic Twin Study of Cancer. *Cancer Epidemiol Biomarkers Prev*. 2014;23(11):2303–2310.

Hoda MR, Theil G, Mohammed N, et al. The adipocyte-derived hormone leptin has proliferative actions on androgen-resistant prostate cancer cells linking obesity to advanced stages of prostate cancer. *J Oncol*. 2012;2012:280386.

Hoffman RM, Harlan LC, Klabunde CN, et al. Racial differences in initial treatment for clinically localized prostate cancer. Results from the Prostate Cancer Outcomes Study. *J Gen Intern Med*. 2003;18(10):845–853.

Honda GD, Bernstein L, Ross RK, et al. Vasectomy, cigarette smoking, and age at first sexual intercourse as risk factors for prostate cancer in middle-aged men. *Br J Cancer*. 1988;57(3):326–331.

Houston KA, King J, Li J, et al. Trends in prostate cancer incidence rates and prevalence of prostate specific antigen screening by socioeconomic status and regions in the United States, 2004 to 2013. *J Urol*. 2018;199(3):676–682.

Hsing AW, Tsao L, Devesa SS. International trends and patterns of prostate cancer incidence and mortality. *Int J Cancer*. 2000;85(1):60–67.

Hu WY, Shi GB, Lam HM, et al. Estrogen-initiated transformation of prostate epithelium derived from normal human prostate stem-progenitor cells. *Endocrinology*. 2011;152(6):2150–2163.

Huang WY, Hayes R, Pfeiffer R, et al. Sexually transmissible infections and prostate cancer risk. *Cancer Epidemiol Biomarkers Prev*. 2008;17(9):2374–2381.

Huang CY, Yu HS, Lai TY, et al. Leptin increases motility and integrin up-regulation in human prostate cancer cells. *J Cell Physiol*. 2011;226(5):1274–1282.

Huncharek M, Muscat J, Kupelnick B. Dairy products, dietary calcium and vitamin D intake as risk factors for prostate cancer: a meta-analysis of 26,769 cases from 45 observational studies. *Nutr Cancer*. 2008;60(4):421–441.

Huncharek M, Haddock KS, Reid R, et al. Smoking as a risk factor for prostate cancer: a meta-analysis of 24 prospective cohort studies. *Am J Public Health*. 2010;100(4):693–701.

Idan A, Griffiths KA, Harwood DT, et al. Long-term effects of dihydrotestosterone treatment on prostate growth in healthy, middle-aged men without prostate disease: a randomized, placebo-controlled trial. *Ann Intern Med*. 2010;153(10):621–632.

Ingermann AR, Yang YF, Han J, et al. Identification of a novel cell death receptor mediating IGFBP-3-induced anti-tumor effects in breast and prostate cancer. *J Biol Chem*. 2010;285(39):30233–30246.

Isaacs JT, Coffey DS. Etiology and disease process of benign prostatic hyperplasia. *Prostate Suppl*. 1989;2:33–50.

Jani AB, Johnstone PA, Liauw SL, et al. Age and grade trends in prostate cancer (1974-2003): a Surveillance, Epidemiology, and End Results Registry analysis. *Am J Clin Oncol*. 2008;31(4):375–378.

Jemal A, Fedewa SA, Ma J, et al. Prostate cancer incidence and

PSA testing patterns in relation to USPSTF screening recommendations. *JAMA*. 2015;314(19):2054–2061.

Jerónimo C, Bastian PJ, Bjartell A, et al. Epigenetics in prostate cancer: biologic and clinical relevance. *Eur Urol*. 2011;60(4):753–766.

Jhaveri FM, Klein EA, Kupelian PA, et al. Declining rates of extracapsular extension after radical prostatectomy: evidence for continued stage migration. *J Clin Oncol*. 1999;17(10):3167–3172.

Jin HJ, Zhao JC, Ogden I, et al. Androgen receptor-independent function of FoxA1 in prostate cancer metastasis. *Cancer Res*. 2013;73(12):3725–3736.

Jung SH, Shin S, Kim MS, et al. Genetic progression of high grade prostatic intraepithelial neoplasia to prostate cancer. *Eur Urol*. 2016;69(5):823–830.

Kaffenberger SD, Barbieri CE. Molecular subtyping of prostate cancer. *Curr Opin Urol*. 2016;26(3):213–218.

Kattan MW, Earnshaw SR, McDade CL, et al. Cost effectiveness of chemoprevention for prostate cancer with dutasteride in a high-risk population based on results from the REDUCE clinical trial. *Appl Health Econ Health Policy*. 2011;9(5):305–315.

Kenfield SA, Stampfer MJ, Chan JM, et al. Smoking and prostate cancer survival and recurrence. *JAMA*. 2011;305(24):2548–2555.

Khani F, Mosquera JM, Park K, et al. Evidence for molecular differences in prostate cancer between African American and Caucasian men. *Clin Cancer Res*. 2014;20(18):4925–4934.

Khazaei S, Rezaeian S, Ayubi E, et al. Global prostate cancer incidence and mortality rates according to the human development index. *Asian Pac J Cancer Prev*. 2016;17(8):3793–3796.

Klabunde CN, Potosky AL, Harlan LC, et al. Trends and black/white differences in treatment for nonmetastatic prostate cancer. *Med Care*. 1998;36(9):1337–1348.

Klein EA, Silverman R. Inflammation, infection, and prostate cancer. *Curr Opin Urol*. 2008;18(3):315–319.

Klein EA, Thompson IM Jr, Tangen CM, et al. Vitamin E and the risk of prostate cancer: the Selenium and Vitamin E Cancer Prevention Trial (SELECT). *JAMA*. 2011;306(14):1549–1556.

Knize MG, Salmon CP, Mehta SS, et al. Analysis of cooked muscle meats for heterocyclic aromatic amine carcinogens. *Mutat Res*. 1997;376(1–2):129–134.

Köhler TS, Fazili AA, Brannigan RE. Putative health risks associated with vasectomy. *Urol Clin North Am*. 2009;36(3):337–345.

Koistinen H, Paju A, Koistinen R, et al. Prostate-specific antigen and other prostate-derived proteases cleave IGFBP-3, but prostate cancer is not associated with proteolytically cleaved circulating IGFBP-3. *Prostate*. 2002;50(2):112–118.

Krill D, DeFlavia P, Dhir R, et al. Expression patterns of vitamin D receptor in human prostate. *J Cell Biochem*. 2001;82(4):566–572.

Krueckl SL, Sikes RA, Edlund NM, et al. Increased insulin-like growth factor I receptor expression and signaling are components of androgen-independent progression in a lineage-derived prostate cancer progression model. *Cancer Res*. 2004;64(23):8620–8629.

Kulkarni GS, Al-Azab R, Lockwood G, et al. Evidence for a biopsy derived grade artifact among larger prostate glands. *J Urol*. 2006;175(2):505–509.

Kumar-Sinha C, Tomlins SA, Chinnaiyan AM. Recurrent gene fusions in prostate cancer. *Nat Rev Cancer*. 2008;8(7):497–511.

Labbe DP, Zadra G, Ebot EM, et al. Role of diet in prostate cancer: the epigenetic link. *Oncogene*. 2015;34(36):4683–4691.

Lee D, Das Gupta J, Gaughan C, et al. In-depth investigation of archival and prospectively collected samples reveals no evidence for XMRV infection in prostate cancer. *PLoS ONE*. 2012;7(9):e44954.

Lee DJ, Mallin K, Graves AJ, et al. Recent changes in prostate cancer screening practices and epidemiology. *J Urol*. 2017;198(6):1230–1240.

Leitzmann MF, Platz EA, Stampfer MJ, et al. Ejaculation frequency and subsequent risk of prostate cancer. *JAMA*. 2004;291(13):1578–1586.

Lévesque É, Laverdière I, Lacombe L, et al. Importance of 5α-reductase gene polymorphisms on circulating and intraprostatic androgens in prostate cancer. *Clin Cancer Res*. 2014;20(3):576–584.

Li LC, Carroll PR, Dahiya R. Epigenetic changes in prostate cancer: implication for diagnosis and treatment. *J Natl Cancer Inst*. 2005;97(2):103–115.

Li Q, Zhu Y, He J, et al. Steroid 5-alpha-reductase type 2 (SRD5A2) V89L and A49T polymorphisms and sporadic prostate cancer risk: a meta-analysis. *Mol Biol Rep*. 2013;40(5):3597–3608.

Lijinsky W, Shubik P. Benzo(a)pyrene and other polynuclear hydrocarbons in charcoal-broiled meat. *Science*. 1964;145(3627):53–55.

Lin DW, FitzGerald LM, Fu R, et al. Genetic variants in the LEPR, CRY1, RNASEL, IL4, and ARVCF genes are prognostic markers of prostate cancer-specific mortality. *Cancer Epidemiol Biomarkers Prev*. 2011;20(9):1928–1936.

Lin DW, Newcomb LF, Brown EC, et al. Urinary TMPRSS2:ERG and PCA3 in an active surveillance cohort: results from a baseline analysis in the Canary Prostate Active

Surveillance Study. *Clin Cancer Res*. 2013;19(9):2442–2450.

Lippman SM, Goodman PJ, Klein EA, et al. Designing the Selenium and Vitamin E Cancer Prevention Trial (SELECT). *J Natl Cancer Inst*. 2005;97(2):94–102.

Lippman SM, Klein EA, Goodman PJ, et al. Effect of selenium and vitamin E on risk of prostate cancer and other cancers: the Selenium and Vitamin E Cancer Prevention Trial (SELECT). *JAMA*. 2009;301(1):39–51.

Liu PH, Wang JD, Keating NL. Expected years of life lost for six potentially preventable cancers in the United States. *Prev Med*. 2013;56(5):309–313.

Loeb S, Folkvaljon Y, Damber JE, et al. Testosterone replacement therapy and risk of favorable and aggressive prostate cancer. *J Clin Oncol*. 2017;35(13):1430–1436.

Lucia MS, Epstein JI, Goodman PJ, et al. Finasteride and high-grade prostate cancer in the Prostate Cancer Prevention Trial. *J Natl Cancer Inst*. 2007;99(18):1375–1383.

Lucia MS, Darke AK, Goodman PJ, et al. Pathologic characteristics of cancers detected in the Prostate Cancer Prevention Trial: implications for prostate cancer detection and chemoprevention. *Cancer Prev Res (Phila)*. 2008;1(3):167–173.

MacInnis RJ, Severi G, Baglietto L, et al. Population-based estimate of prostate cancer risk for carriers of the HOXB13 missense mutation G84E. *PLoS ONE*. 2013;8(2):e54727.

Madigan MP, Troisi R, Potischman N, et al. Serum hormone levels in relation to reproductive and lifestyle factors in postmenopausal women (United States). *Cancer Causes Control*. 1998;9(2):199–207.

Maitland NJ, Collins AT. Prostate cancer stem cells: a new target for therapy. *J Clin Oncol*. 2008;26(17):2862–2870.

Makridakis NM, Reichardt JK. Molecular epidemiology of androgen-metabolic loci in prostate cancer: predisposition and progression. *J Urol*. 2004;171(2 Pt 2):S25–S28 [discussion S28–S29].

Malik B, Feng FY. Long noncoding RNAs in prostate cancer: overview and clinical implications. *Asian J Androl*. 2016;18(4):568–574.

Mani RS, Amin MA, Li X, et al. Inflammation-induced oxidative stress mediates gene fusion formation in prostate cancer. *Cell Rep*. 2016;17(10):2620–2631.

Marberger M, Freedland SJ, Andriole GL, et al. Usefulness of prostate-specific antigen (PSA) rise as a marker of prostate cancer in men treated with dutasteride: lessons from the REDUCE study. *BJU Int*. 2012;109(8):1162–1169.

Markozannes G, Tzoulaki I, Karli D, et al. Diet, body size, physical activity and risk of prostate cancer: an umbrella review of the evidence. *Eur J Cancer*. 2016;69:61–69.

Marks LS, Fradet Y, Deras IL, et al. PCA3 molecular urine assay for prostate cancer in men undergoing repeat biopsy. *Urology*. 2007;69(3):532–535.

Marshall JR, Tangen CM, Sakr WA, et al. Phase III trial of selenium to prevent prostate cancer in men with high-grade prostatic intraepithelial neoplasia: SWOG S9917. *Cancer Prev Res (Phila)*. 2011;4(11):1761–1769.

Masko EM, Allott EH, Freedland SJ. The relationship between nutrition and prostate cancer: is more always better? *Eur Urol*. 2013;63(5):810–820.

Massie CE, Mills IG, Lynch AG. The importance of DNA methylation in prostate cancer development. *J Steroid Biochem Mol Biol*. 2017;166:1–15.

Mateo J, Carreira S, Sandhu S, et al. DNA-repair defects and olaparib in metastatic prostate cancer. *N Engl J Med*. 2015;373(18):1697–1708.

McGregor SE, Courneya KS, Kopciuk KA, et al. Case-control study of lifetime alcohol intake and prostate cancer risk.

Cancer Causes Control. 2013;24(3):451–461.

Mettlin C, Murphy GP, Lee F, et al. Characteristics of prostate cancers detected in a multimodality early detection program. The Investigators of the American Cancer Society-National Prostate Cancer Detection Project. *Cancer*. 1993;72(5):1701–1708.

Moad M, Hannezo E, Buczacki SJ, et al. Multipotent basal stem cells, maintained in localized proximal niches, support directed long-ranging epithelial flows in human prostates. *Cell Rep*. 2017;20(7):1609–1622.

Moinpour CM, Darke AK, Donaldson GW, et al. Longitudinal analysis of sexual function reported by men in the Prostate Cancer Prevention Trial. *J Natl Cancer Inst*. 2007;99(13):1025–1035.

Moreira DM, Aronson WJ, Terris MK, et al. Cigarette smoking is associated with an increased risk of biochemical disease recurrence, metastasis, castration-resistant prostate cancer, and mortality after radical prostatectomy: results from the SEARCH database. *Cancer*. 2014;120(2):197–204.

Morgentaler A, Rhoden EL. Prevalence of prostate cancer among hypogonadal men with prostate-specific antigen of 4.0 ng/ml or less. *Urology*. 2006;68(6):1263–1267.

Morgentaler A, Traish AM. Shifting the paradigm of testosterone and prostate cancer: the saturation model and the limits of androgen-dependent growth. *Eur Urol*. 2009;55:310–332.

Moses KA, Orom H, Brasel A, et al. Racial/ethnic differences in the relative risk of receipt of specific treatment among men with prostate cancer. *Urol Oncol*. 2016;34(9):415.e7–415.e12.

Moyer VA, U.S. Preventive Services Task Force. Screening for prostate cancer: US Preventive Services Task Force recommendation statement. *Ann Intern Med*.

2012;157(2):120–134.

Muir CS, Nectoux J, Staszewski J. The epidemiology of prostatic cancer. Geographical distribution and time-trends. *Acta Oncol*. 1991;30(2):133–140.

Muller RL, Gerber L, Moreira DM, et al. Serum testosterone and dihydrotestosterone and prostate cancer risk in the placebo arm of the Reduction by Dutasteride of Prostate Cancer Events trial. *Eur Urol*. 2012;62(5):757–764.

Murtola TJ, Visakorpi T, Lahtela J, et al. Statins and prostate cancer prevention: where we are now, and future directions. *Nat Clin Pract Urol*. 2008;5(7):376–387.

Nakai Y, Nelson WG, De Marzo AM. The dietary charred meat carcinogen 2-amino-1-methyl-6-phenylimidazo[4,5-b]pyridine acts as both a tumor initiator and promoter in the rat ventral prostate. *Cancer Res*. 2007;67(3):1378–1384.

Nakayama M, Bennett CJ, Hicks JL, et al. Hypermethylation of the human glutathione S-transferase-π gene (GSTP1) CpG island is present in a subset of proliferative inflammatory atrophy lesions but not in normal or hyperplastic epithelium of the prostate: a detailed study using laser-capture microdissection. *Am J Pathol*. 2003;163(3):923–933.

Nambudiri VE, Landrum MB, Lamont EB, et al. Understanding variation in primary prostate cancer treatment within the Veterans Health Administration. *Urology*. 2012;79(3):537–545.

Nelles JL, Hu WY, Prins GS. Estrogen action and prostate cancer. *Expert Rev Endocrinol Metab*. 2011;6(3):437–451.

Nelson WG, De Marzo AM, Isaacs WB. Prostate cancer. *N Engl J Med*. 2003;349(4):366–381.

Nelson DE, Van Der Pol B, Dong Q, et al. Characteristic male urine microbiomes associate with asymptomatic sexually transmitted infection. *PLoS ONE*. 2010;5(11):e14116.

Nelson SM, Batai K, Ahaghotu C, et al. Association between serum 25-hydroxy-vitamin D and aggressive prostate cancer in African American men. *Nutrients*. 2016;9(1).

Newcomer LM, Stanford JL, Blumenstein BA, et al. Temporal trends in rates of prostate cancer: declining incidence of advanced stage disease, 1974 to 1994. *J Urol*. 1997;158(4):1427–1430.

Nyame YA, Murphy AB, Bowen DK, et al. Associations between serum vitamin D and adverse pathology in men undergoing radical prostatectomy. *J Clin Oncol*. 2016;34(12):1345–1349.

O'Hagan HM, Mohammad HP, Baylin SB. Double strand breaks can initiate gene silencing and SIRT1-dependent onset of DNA methylation in an exogenous promoter CpG island. *PLoS Genet*. 2008;4(8):e1000155.

O'Hagan HM, Wang W, Sen S, et al. Oxidative damage targets complexes containing DNA methyltransferases, SIRT1, and polycomb members to promoter CpG islands. *Cancer Cell*. 2011;20(5):606–619.

Ordonez-Mena JM, Schottker B, Mons U, et al. Quantification of the smoking-associated cancer risk with rate advancement periods: Meta-analysis of individual participant data from cohorts of the CHANCES consortium. *BMC Med*. 2016;14:62.

Page ST, Lin DW, Mostaghel EA, et al. Dihydrotestosterone administration does not increase intraprostatic androgen concentrations or alter prostate androgen action in healthy men: a randomizedcontrolled trial. *J Clin Endocrinol Metab*. 2011;96(2):430–437.

Palanisamy N, Ateeq B, Kalyana-Sundaram S, et al. Rearrangements of the RAF kinase pathway in prostate cancer, gastric cancer and melanoma. *Nat Med*. 2010;16(7):793–798.

Park SY, Murphy SP, Wilkens LR, et al. Fat and meat intake and prostate cancer risk: the multiethnic cohort study. *Int J Cancer*. 2007;121(6):1339–1345.

PDQ Cancer Genetics Editorial Board. Genetics of prostate cancer (PDQ®): health professional version. *PDQ cancer information summaries*. National Cancer Institute (US): Bethesda, MD; 2002 [Available at] https://www.ncbi.nlm.nih.gov/books/NBK82221/ [2002].

Perez-Cornago A, Appleby PN, Pischon T, et al. Tall height and obesity are associated with an increased risk of aggressive prostate cancer: results from the EPIC cohort study. *BMC Med*. 2017;15(1):115.

Pinsky P, Parnes H, Ford L. Estimating rates of true high-grade disease in the Prostate Cancer Prevention Trial. *Cancer Prev Res (Phila)*. 2008;1(3):182–186.

Pinsky P, Black A, Grubb R, et al. Projecting prostate cancer mortality in the PCPT and REDUCE chemoprevention trials. *Cancer*. 2013;119(3):593–601.

Pinsky PF, Prorok PC, Yu K, et al. Extended mortality results for prostate cancer screening in the PLCO trial with median follow-up of 15 years. *Cancer*. 2017;123(4):592–599.

Platz EA, Leitzmann MF, Visvanathan K, et al. Statin drugs and risk of advanced prostate cancer. *J Natl Cancer Inst*. 2006;98(24):1819–1825.

Platz EA, Till C, Goodman PJ, et al. Men with low serum cholesterol have a lower risk of high-grade prostate cancer in the placebo arm of the Prostate Cancer Prevention Trial. *Cancer Epidemiol Biomarkers Prev*. 2009;18(11):2807–2813.

Platz EA, Kulac I, Barber JR, et al. A prospective study of chronic inflammation in benign prostate tissue and risk of prostate cancer: linked PCPT and SELECT cohorts. *Cancer Epidemiol Biomarkers Prev*. 2017;26(10):1549–1557.

Plonis J, Nakazawa-Miklasevica M, Malevskis A, et al. Survival rates of familial and sporadic prostate cancer patients. *Exp*

Oncol. 2015;37(2):154–155.

Polson ES, Lewis JL, Celik H, et al. Monoallelic expression of TMPRSS2/ERG in prostate cancer stem cells. *Nat Commun*. 2013;4:1623.

Potosky AL, Kessler L, Gridley G, et al. Rise in prostatic cancer incidence associated with increased use of transurethral resection. *J Natl Cancer Inst*. 1990;82(20):1624–1628.

Prajapati A, Gupta S, Mistry B, et al. Prostate stem cells in the development of benign prostate hyperplasia and prostate cancer: emerging role and concepts. *Biomed Res Int*. 2013;2013:107954.

Prensner JR, Iyer MK, Sahu A, et al. The long noncoding RNA SChLAP1 promotes aggressive prostate cancer and antagonizes the SWI/SNF complex. *Nat Genet*. 2013;45(11):1392–1398.

Prensner JR, Chen W, Iyer MK, et al. PCAT-1, a long noncoding RNA, regulates BRCA2 and controls homologous recombination in cancer. *Cancer Res*. 2014;74(6):1651–1660.

Prensner JR, Chen W, Han S, et al. The long non-coding RNA PCAT-1 promotes prostate cancer cell proliferation through cMyc. *Neoplasia*. 2014;16(11):900–908.

Presley CJ, Raldow AC, Cramer LD, et al. A new approach to understanding racial disparities in prostate cancer treatment. *J Geriatr Oncol*. 2013;4(1):1–8.

Prins GS, Korach KS. The role of estrogens and estrogen receptors in normal prostate growth and disease. *Steroids*. 2008;73(3):233–244.

Putzi MJ, De Marzo AM. Morphologic transitions between proliferative inflammatory atrophy and high-grade prostatic intraepithelial neoplasia. *Urology*. 2000;56(5):828–832.

Ravich A, Ravich RA. Prophylaxis of cancer of the prostate, penis, and cervix by circumcision. *N Y State J Med*. 1951;51(12):1519–1520.

Rebbeck TR, Devesa SS, Chang BL, et al. Global patterns of prostate cancer incidence, aggressiveness, and mortality in men of African descent. *Prostate Cancer*. 2013;2013:560857.

Redman MW, Tangen CM, Goodman PJ, et al. Finasteride does not increase the risk of high-grade prostate cancer: a bias-adjusted modeling approach. *Cancer Prev Res (Phila)*. 2008;1(3):174–181.

Renehan AG, Tyson M, Egger M, et al. Body-mass index and incidence of cancer: a systematic review and meta-analysis of prospective observational studies. *Lancet*. 2008;371(9612):569–578.

Ribeiro R, Lopes C, Medeiros R. The link between obesity and prostate cancer: the leptin pathway and therapeutic perspectives. [See comment]. *Prostate Cancer Prostatic Dis*. 2006;9(1):19–24.

Ricke WA, McPherson SJ, Bianco JJ, et al. Prostatic hormonal carcinogenesis is mediated by in situ estrogen production and estrogen receptor α signaling. *FASEB J*. 2008;22(5):1512–1520.

Ries LAG, Melbert D, Krapcho M, et al. *SEER cancer statistics review, 1975–2005*. National Cancer Institute: Bethesda, MD; 2008 [Available at] https://seer.cancer.gov/archive/csr/1975_2005/.

Roberts CK, Vaziri ND, Barnard RJ. Effect of diet and exercise intervention on blood pressure, insulin, oxidative stress, and nitric oxide availability. *Circulation*. 2002;106(20):2530–2532.

Rubin MA, Maher CA, Chinnaiyan AM. Common gene rearrangements in prostate cancer. *J Clin Oncol*. 2011;29(27):3659–3668.

Scher HI, Sawyers CL. Biology of progressive, castration-resistant prostate cancer: directed therapies targeting the androgen-receptor signaling axis. *J Clin Oncol*.

2005;23(32):8253–8261.

Schröder FH, Hugosson J, Roobol MJ, et al. Screening and prostate-cancer mortality in a randomized European study. *N Engl J Med*. 2009;360(13):1320–1328.

Schröder FH, Hugosson J, Roobol MJ, et al. Screening and prostate cancer mortality: results of the European Randomised Study of Screening for Prostate Cancer (ERSPC) at 13 years of follow-up. *Lancet*. 2014;384(9959):2027–2035.

Schwartz GG. Vitamin D, sunlight, and the epidemiology of prostate cancer. *Anticancer Agents Med Chem*. 2013;13(1):45–57.

Sfanos KS, Sauvageot J, Fedor HL, et al. A molecular analysis of prokaryotic and viral DNA sequences in prostate tissue from patients with prostate cancer indicates the presence of multiple and diverse microorganisms. *Prostate*. 2008;68(3):306–320.

Sfanos KS, Yegnasubramanian S, Nelson WG, et al. The inflammatory microenvironment and microbiome in prostate cancer development. *Nat Rev Urol*. 2018;15(1):11–24.

Shah R, Mucci NR, Amin A, et al. Postatrophic hyperplasia of the prostate gland: neoplastic precursor or innocent bystander? *Am J Pathol*. 2001;158(5):1767–1773.

Sharifi N. Mechanisms of androgen receptor activation in castration-resistant prostate cancer. *Endocrinology*. 2013;154(11):4010–4017.

Shavers VL, Brown ML, Potosky AL, et al. Race/ethnicity and the receipt of watchful waiting for the initial management of prostate cancer. *J Gen Intern Med*. 2004;19(2):146–155.

Shibata M, Shen MM. Stem cells in genetically-engineered mouse models of prostate cancer. *Endocr Relat Cancer*. 2015;22(6):T199–T208.

Shimizu H, Ross RK, Bernstein L, et al. Cancers of the prostate and breast among Japanese and white immigrants in Los Angeles county. *Br J Cancer*. 1991;63(6):963–966.

Shinohara DB, Vaghasia AM, Yu SH, et al. A mouse model of chronic prostatic inflammation using a human prostate cancer-derived isolate of Propionibacterium acnes. *Prostate*. 2013;73(9):1007–1015.

Shirai T, Sano M, Tamano S, et al. The prostate: a target for carcinogenicity of 2-amino-1-methyl-6-phenylimidazo[4,5-b]pyridine (PhIP) derived from cooked foods. *Cancer Res*. 1997;57(2):195–198.

Shoag JE, Mittal S, Hu JC. Reevaluating PSA testing rates in the PLCO trial. *N Engl J Med*. 2016;374(18):1795–1796.

Shui IM, Mucci LA, Kraft P, et al. Vitamin D-related genetic variation, plasma vitamin D, and risk of lethal prostate cancer: a prospective nested case-control study. *J Natl Cancer Inst*. 2012;104(9):690–699.

Shui IM, Mondul AM, Lindström S, Breast and Prostate Cancer Cohort Consortium Group, et al. Circulating vitamin D, vitamin D-related genetic variation, and risk of fatal prostate cancer in the National Cancer Institute Breast and Prostate Cancer Cohort Consortium. *Cancer*. 2015;121(12):1949–1956.

Siegel R, Ma J, Zou Z, et al. Cancer statistics, 2014. *CA Cancer J Clin*. 2014;64(1):9–29.

Somasundar P, Frankenberry KA, Skinner H, et al. Prostate cancer cell proliferation is influenced by leptin. *J Surg Res*. 2004;118(1):71–82.

Sowalsky AG, Kissick HT, Gerrin SJ, et al. Gleason score 7 prostate cancers emerge through branched evolution of clonal Gleason pattern 3 and 4. *Clin Cancer Res*. 2017;23(14):3823–3833.

Steers WD. 5alpha-reductase activity in the prostate. *Urology*. 2001;58(6 Suppl 1):17–24.

Stephenson RA, Smart CR, Mineau GP, et al. The fall in incidence of prostate carcinoma. On the down side of a prostate specific antigen induced peak in incidence—data from the Utah cancer registry. *Cancer*. 1996;77(7):1342–1348.

Stephenson RA. Prostate cancer overdiagnosis and overtreatment. Analysis of US mortality and SEER incidence. Trends in the PSA and pre-PSA eras. Klein EA. *Management of prostate cancer*. Humana Press: Totowa (NJ); 2005:3–13.

Stewart GD, Van Neste L, Delvenne P, et al. Clinical utility of an epigenetic assay to detect occult prostate cancer in histopathologically negative biopsies: results of the MATLOC study. *J Urol*. 2013;189(3):1110–1116.

Stopsack KH, Gerke TA, Andren O, et al. Cholesterol uptake and regulation in high-grade and lethal prostate cancers. *Carcinogenesis*. 2017;38(8):806–811.

Sun JH, Lee SA. Association between CAG repeat polymorphisms and the risk of prostate cancer: a meta-analysis by race, study design and the number of (CAG)n repeat polymorphisms. *Int J Mol Med*. 2013;32(5):1195–1203.

Sutcliffe S, Giovannucci E, De Marzo AM, et al. Gonorrhea, syphilis, clinical prostatitis, and the risk of prostate cancer. *Cancer Epidemiol Biomarkers Prev*. 2006;15(11):2160–2166.

Sutcliffe S, Giovannucci E, Leitzmann MF, et al. A prospective cohort study of red wine consumption and risk of prostate cancer. *Int J Cancer*. 2007;120(7):1529–1535.

Sutcliffe S. Sexually transmitted infections and risk of prostate cancer: review of historical and emerging hypotheses. *Future Oncol*. 2010;6(8):1289–1311.

Svatek RS, Lee JJ, Roehrborn CG, et al. Cost-effectiveness of prostate cancer chemoprevention: a quality of life-years analysis. *Cancer*. 2008;112(5):1058–1065.

Svatek RS, Lotan Y. Cost utility of prostate cancer chemoprevention with dutasteride in men with an elevated prostate specific antigen. *Cancer Prev Res (Phila)*. 2011;4(2):277–283.

Swerdloff RS, Dudley RE, Page ST, et al. Dihydrotestosterone: biochemistry, physiology, and clinical implications of elevated blood levels. *Endocr Rev*. 2017;38(3):220–254.

Taneja SS, Morton R, Barnette G, et al. Prostate cancer diagnosis among men with isolated high-grade intraepithelial neoplasia enrolled onto a 3-year prospective phase III clinical trial of oral toremifene. *J Clin Oncol*. 2013;31(5):523–529.

Tang L, Yao S, Till C, et al. Repeat polymorphisms in estrogen metabolism genes and prostate cancer risk: results from the Prostate Cancer Prevention Trial. *Carcinogenesis*. 2011;32(10):1500–1506.

Tang B, Han CT, Gan HL, et al. Smoking increased the risk of prostate cancer with grade group ≥ 4 and intraductal carcinoma in a prospective biopsy cohort. *Prostate*. 2017;77(9):984–989.

Tarone RE, Chu KC, Brawley OW. Implications of stage-specific survival rates in assessing recent declines in prostate cancer mortality rates. *Epidemiology*. 2000;11(2):167–170.

Taylor BS, Schultz N, Hieronymus H, et al. Integrative genomic profiling of human prostate cancer. *Cancer Cell*. 2010;18(1):11–22.

Taylor RA, Fraser M, Livingstone J, et al. Germline BRCA2 mutations drive prostate cancers with distinct evolutionary trajectories. *Nat Commun*. 2017;8:13671.

Theoret MR, Ning YM, Zhang JJ, et al. The risks and benefits of 5α-reductase inhibitors for prostate-cancer prevention. *N Engl J Med*. 2011;365(2):97–99.

Thiessen EU. Concerning a familial association between breast cancer and both prostatic and uterine malignancies. *Cancer*.

1974;34(4):1102–1107.

Thompson IM, Goodman PJ, Tangen CM, et al. The influence of finasteride on the development of prostate cancer. *N Engl J Med*. 2003;349(3):215–224.

Thompson IM, Chi C, Ankerst DP, et al. Effect of finasteride on the sensitivity of PSA for detecting prostate cancer. *J Natl Cancer Inst*. 2006;98(16):1128–1133.

Thompson IM, Tangen CM, Goodman PJ, et al. Finasteride improves the sensitivity of digital rectal examination for prostate cancer detection. *J Urol*. 2007;177(5):1749–1752.

Thompson IM, Goodman PJ, Tangen CM, et al. Long-term survival of participants in the Prostate Cancer Prevention Trial. *N Engl J Med*. 2013;369(7):603–610.

Tomlins SA, Rhodes DR, Perner S, et al. Recurrent fusion of TMPRSS2 and ETS transcription factor genes in prostate cancer. *Science*. 2005;310(5748):644–648.

Tomlins SA, Rhodes DR, Yu J, et al. The role of SPINK1 in ETS rearrangement-negative prostate cancers. *Cancer Cell*. 2008;13(6):519–528.

Tomlins SA, Aubin SM, Siddiqui J, et al. Urine TMPRSS2:ERG fusion transcript stratifies prostate cancer risk in men with elevated serum PSA. *Sci Transl Med*. 2011;3(94):94ra72.

Tomlins SA, Alshalalfa M, Davicioni E, et al. Characterization of 1577 primary prostate cancers reveals novel biological and clinicopathologic insights into molecular subtypes. *Eur Urol*. 2015;68(4):555–567.

Trayhurn P, Wood IS. Adipokines: inflammation and the pleiotropic role of white adipose tissue. *Br J Nutr*. 2004;923:347–355.

Tsodikov A, Gulati R, de Carvalho TM, et al. Is prostate cancer different in black men? answers from 3 natural history models. *Cancer*. 2017;123(12):2312–2319.

Tsujimura A, Koikawa Y, Salm S, et al. Proximal location of mouse prostate epithelial stem cells: a model of prostatic homeostasis. *J Cell Biol*. 2002;157(7):1257–1265.

Tulinius H, Egilsson V, Olafsdóttir GH, et al. Risk of prostate, ovarian, and endometrial cancer among relatives of women with breast cancer. *BMJ*. 1992;305(6858):855–857.

Umar A, Dunn BK, Greenwald P. Future directions in cancer prevention. *Nat Rev Cancer*. 2012;12(12):835–848.

Unger JM, Till C, Thompson IM Jr, et al. Long-term consequences of finasteride vs placebo in the prostate cancer prevention trial. *J Natl Cancer Inst*. 2016;108(12) [djw168].

Uzoh CC, Holly JM, Biernacka KM, et al. Insulin-like growth factor-binding protein-2 promotes prostate cancer cell growth via IGF-dependent or -independent mechanisms and reduces the efficacy of docetaxel. *Br J Cancer*. 2011;104(10):1587–1593.

van Leenders GJ, Gage WR, Hicks JL, et al. Intermediate cells in human prostate epithelium are enriched in proliferative inflammatory atrophy. *Am J Pathol*. 2003;162(5):1529–1537.

van Leenders GJ, Dukers D, Hessels D, et al. Polycomb-group oncogenes EZH2, BMI1, and RING1 are overexpressed in prostate cancer with adverse pathologic and clinical features. *Eur Urol*. 2007;52(2):455–463.

Wallner LP, DiBello JR, Li BH, et al. 5-Alpha reductase inhibitors and the risk of prostate cancer mortality in men treated for benign prostatic hyperplasia. *Mayo Clin Proc*. 2016;91(12):1717–1726.

Wallström P, Bjartell A, Gullberg B, et al. A prospective study on dietary fat and incidence of prostate cancer (Malmo, Sweden). *Cancer Causes Control*. 2007;18(10):1107–1121.

Walsh PC. Cancer surveillance series: interpreting trends in prostate cancer—part I: evidence of the effects of screening in recent prostate cancer incidence, mortality, and survival rates. *J Urol*. 2000;163(1):364–365.

Wang K, Wu G, Li J, et al. Role of vitamin D receptor gene Cdx2 and Apa1 polymorphisms in prostate cancer susceptibility: a meta-analysis. *BMC Cancer*. 2016;16(1):674.

Weiss JM, Huang WY, Rinaldi S, et al. IGF-1 and IGFBP-3: risk of prostate cancer among men in the Prostate, Lung, Colorectal and Ovarian Cancer Screening Trial. *Int J Cancer*. 2007;121(10):2267–2273.

Welch HG, Albertsen PC. Prostate cancer diagnosis and treatment after the introduction of prostate-specific antigen screening: 1986-2005. *J Natl Cancer Inst*. 2009;101(19):1325–1329.

Whitlatch LW, Young MV, Schwartz GG, et al. 25-Hydroxyvitamin D-1α-hydroxylase activity is diminished in human prostate cancer cells and is enhanced by gene transfer. *J Steroid Biochem Mol Biol*. 2002;81(2):135–140.

Wilson JD, Roehrborn C. Long-term consequences of castration in men: lessons from the Skoptzy and the eunuchs of the Chinese and Ottoman courts. *J Clin Endocrinol Metab*. 1999;84(12):4324–4331.

Witte JS, Mefford J, Plummer SJ, et al. HOXB13 mutation and prostate cancer: studies of siblings and aggressive disease. *Cancer Epidemiol Biomarkers Prev*. 2013;22(4):675–680.

Wright AS, Douglas RC, Thomas LN. Androgen-induced regrowth in the castrated rat ventral prostate: role of 5alpha-reductase. *Endocrinology*. 1999;140(10):4509–4515.

Yamoah K, Johnson MH, Choeurng V, et al. Novel biomarker signature that may predict aggressive disease in African American men with prostate cancer. *J Clin Oncol*. 2015;33(25):2789–2796.

Yang B, Bhusari S, Kueck J, et al. Methylation profiling defines an extensive field defect in histologically normal prostate tissues associated with prostate cancer. *Neoplasia*.

2013;15(4):399–408.

Yang L, Lin C, Jin C, et al. lncRNA-dependent mechanisms of androgen-receptor-regulated gene activation programs. *Nature*. 2013;500(7464):598–602.

Yang L, Drake BF, Colditz GA. Obesity and other cancers. *J Clin Oncol*. 2016;34(35):4231–4237.

Yin M, Wei S, Wei Q. Vitamin D receptor genetic polymorphisms and prostate cancer risk: a meta-analysis of 36 published studies. *Int J Clin Exp Med*. 2009;2(2):159–175.

Yu H, Harris RE, Gao YT, et al. Comparative epidemiology of cancers of the colon, rectum, prostate and breast in Shanghai, China versus the United States. *Int J Epidemiol*. 1991;20(1):76–81.

Zeegers MP, Jellema A, Ostrer H. Empiric risk of prostate carcinoma for relatives of patients with prostate carcinoma: a meta-analysis. *Cancer*. 2003;97(8):1894–1903.

Zhao J, Stockwell T, Roemer A, et al. Is alcohol consumption a risk factor for prostate cancer? A systematic review and meta-analysis. *BMC Cancer*. 2016;16(1):845.

Zhou CK, Check DP, Lortet-Tieulent J, et al. Prostate cancer incidence in 43 populations worldwide: an analysis of time trends overall and by age group. *Int J Cancer*. 2016;138(6):1388–1400.

Zhu YS, Imperato-McGinley JL. 5alpha-reductase isozymes and androgen actions in the prostate. *Ann N Y Acad Sci*. 2009;1155:43–56.

149

Prostate Cancer Biomarkers

Simpa S. Salami MD, MPH, Ganesh S. Palapattu MD, Alan W. Partin MD, PhD, Todd M. Morgan MD

The development and implementation of prostate cancer biomarkers have continued to expand rapidly over the past decade. In an era in which early detection based on prostate-specific antigen (PSA) has been under fire from the United States Preventative Services Task force, new markers to aid in biopsy decision have become available in the clinic. Furthermore, attention has turned from detection of any cancer to a focus on detecting clinically significant disease, often interpreted as Gleason score ≥7 cancer. In addition, biomarkers that can aid in distinguishing aggressive from indolent disease for men who have cancer continue to be sought after, and a number of these are now clinically available. However, substantial limitations exist for all of the currently available markers, and it is critical to understand the strengths and potential weaknesses for each of these before using them for clinical decision making.

Prostate cancer is one of the few malignancies with a serum-based, clinically informative biomarker. **Since its discovery in 1979 until clinical application in the late 1980s through 1990s, the PSA has evolved into an invaluable tool for detecting, staging, and monitoring prostate cancer in men.** The widespread use of PSA screening led to a dramatic increase in prostate cancer diagnoses in the mid-1990s, and the subsequent drop in prostate cancer deaths is at least partially attributable to the adoption of population-based PSA screening. **Whereas the majority of prostate cancers in the 1980s and early 1990s commonly arose through finding an abnormal digital rectal examination (DRE) or elevated PSA, or both, today most prostate cancer arises as clinically nonpalpable (stage T1c) disease with PSA levels between 2.5 and 10 ng/mL.** Widespread application of PSA screening and the long natural history of prostate cancer have also resulted in a stage migration to nonpalpable, clinically localized (stage T1c) disease to go along with the parallel reduction in mortality (Diamandis et al., 2000; Lilja, 1997; McCormack et al., 1995; Polascik et al., 1999; Pound et al., 1997, 1999; Rittenhouse et al., 1998; Stephenson and Stanford, 1997).

Although PSA screening has improved survival, however, outcomes are not the same for all PSA-detected disease (Diamandis et al., 2000; Gretzer et al., 2002; Yousef and Diamandis, 2001). Indeed the most common cause of mortality for *all* men with prostate cancer is heart disease. This is not to downplay the influence of prostate cancer on the mortality of the nearly 30,000 men who die from it annually in the United States but rather to highlight the critical need for reliable tools that allow for identification of harmful cancers.

Although PSA is the most well-known prostate cancer tumor marker, it is organ specific and not cancer specific. **There is significant overlap in serum PSA levels among men with cancer and those with benign disease. Thus even substantially elevated serum PSA levels may be due to inflammation or benign prostatic hyperplasia (BPH) rather than malignancy** (Catalona et al., 1991; Oesterling et al., 1988; Partin et al., 1990). To this end, application of PSA derivatives such as PSA density, PSA velocity, age-adjusted values, and, more recently, molecular derivatives may be used to improve clinical decisions compared with using PSA in isolation.

There are three main domains in which clinically localized prostate cancer biomarkers are needed: (1) early detection, (2) newly diagnosed prostate cancer, and (3) post-treatment. By identifying men at greatest risk of harboring harmful disease, improved early detection biomarkers could markedly reduce the group of men subjected to prostate biopsy. The cohort of men who possess an elevated PSA after an initial negative biopsy represents a particularly challenging group. After a diagnosis of prostate cancer has been made, balancing the risks and benefits of active surveillance with primary therapy as the initial management strategy is a central question. Knowledge regarding biologic behavior could drastically improve the decision-making process for a patient contemplating curative intent therapy (e.g., radical prostatectomy or radiation) or active surveillance. Finally, post-treatment biomarkers hold promise for improving our ability to make decisions regarding adjuvant or salvage therapies in men at high risk of developing metastatic disease.

Several molecular approaches have been undertaken in pursuit of finding the optimal prostate cancer biomarker. An overview of basic cellular processes starts first with a DNA sequence **(gene)** that is transcribed to mRNA **(transcript)** and then translated to a **protein** that can then carry out specific cellular functions (e.g., catalyze biochemical reactions leading to the formation of products such as

metabolites). A guiding principle of prostate cancer biomarker development is that prostate cancer cells, a priori, are different in some molecular way than their benign counterparts. Further, another important observation is that aggressive prostate cancer cells are similarly different in comparison with their more indolent counterparts. The identification and quantification of these molecular differences in tissues and bodily fluids form the basis of prostate cancer biomarker discovery.

Advances in molecular oncology and breakthroughs in laboratory techniques have exponentially expanded our repertoire of innovative tools for the discovery of novel ways of predicting the future. In this chapter, we discuss the process and phases of biomarker development, paying particular attention to scientific rationale and clinical application of blood-, urine-, and tissue-based biomarkers.

Biomarker Development

Although there are many groups now developing methods for early detection of prostate cancer, the early detection research network (EDRN) has developed a particularly robust infrastructure for biomarker development. The EDRN is a National Cancer Institute (NCI) funded program set forth with the objective to identify, develop, and validate promising biomarkers and technologies for the early detection of cancer (Clements, 1989; Schedlich et al., 1987; Srivastava, 2014; Srivastava et al., 2001). As suggested by its name, it is actually a network of academic centers working in collaboration with industry, public health groups, informatics centers, and patient advocates. The structure of the network consists of five scientific components.

The first of these are the biomarker development laboratories (BDLs), which is responsible for discovery of novel biomarkers and technologies. They identify biomarkers and participate in the early phases of validation. The biomarker reference laboratories (BRLs) facilitate the development and validation of assays that measure these new biomarkers. Without such efforts, assays results may be difficult to reproduce when deployed at a different site. The BRLs also assist in developing a more robust and efficient clinical assay. The third scientific component are the clinical epidemiological validation centers (CEVCs). These are large clinical practices with infrastructure to procure ample clinical samples and to lead clinical trials. They are responsible for procuring samples for the BDLs. The fourth component of the network is the data management and coordinating center (DMCC). This component is the spine of the network in the sense that they provide all the logistical and statistical support for all phases of development. Importantly, this EDRN component is responsible for creating a reliable, secure, and practical means by which data may be collected for network studies. The fifth and final component is the informatics center responsible for developing software for information management. As the EDRN experience grew, experts in oncology, clinical trials, biostatistics, and informatics came together and refined what is considered best practice for the development of new biomarkers (Lilja, 1997; Pepe et al., 2001; Rittenhouse et al., 1998; Young et al., 1995).

Similar to the phases of drug development, biomarker development has been broken down into a number of sequential phases. Conceptually, progression of a biomarker through each of the five phases of development indicates increasing strength of evidence in favor of its clinical application. Phase 1 consists of biomarker discovery. Although this may occur at any laboratory, the BDLs are intended to be factories of discovery along the lines of genomics, proteomics, glycomics, and metabolomics. The objective of this phase is to identify potential biomarkers and prioritize each for validation. The typical outcome of phase 1 development is a novel biomarker with some measure of test sensitivity and specificity in a subset of cancer and control subjects. In this way, a preclinical assay is moved forward into phase 2.

Phase 2 has the objective of more reliably measuring the sensitivity and specificity of the new biomarker in its ability to differentiate case status from control. Here the BRL often participates to optimize the clinical assay and assess the reproducibility of the assay in preparation for a clinical trial. It would not be unusual to see comparisons of biomarkers measured in tissue samples compared with levels from less invasive approaches such as voided urine or serum. The clinical samples deployed at this stage tend to be more representative of the target population and, as a result, biomarkers may fail at this phase if they were initially developed on an overly selected set of tissues.

In phase 3, investigators examine the ability of new biomarkers to detect preclinical disease and evaluate how much lead time is provided by the biomarker relative to clinical presentation. The criteria necessary for “a positive test” are defined in this phase. Robust studies examining the impact of covariates on biomarker expression and measurement will take place. Given the growing number of biomarkers, it would not be uncommon to see algorithms developed during this phase to support the use of panels of biomarkers as opposed to a single biomarker. The tissue repositories used for this phase are typically retrospective cohort studies in which clinical samples have been procured prospectively over time with careful annotation of clinical end points and risk factors. These subjects are usually identified before cancer is diagnosed, sometimes years in advance of diagnosis. Having completed phase 3, a new biomarker would possess a validated clinical assay and strong evidence of ability to differentiate case from control according to its clinical indication, conducted on a fairly robust sample of subjects. An understanding of factors that may affect measurement and expression of the biomarker is established, and plans are made for a prospective validation trial, that is, phase 4.

In phase 4, indications for applying a new biomarker are clearly defined according to the labeling. Potential subjects are identified for eligibility, consented, and enrolled with careful annotation of all demographic, disease, risk factors, and cancer end points. The goal of phase 4 is to quantify the performance characteristics of a biomarker in the target population of interest. This is typically done by examination of sensitivity, specificity, positive, and negative predictive values (NPVs). Secondarily, this phase also examines characteristics of cancers diagnosed using the biomarker; considers implementation feasibility and costs; and considers potential impact on overall mortality.

Unlike drug studies, in which randomized clinical trials are conducted as validation of treatment effect, biomarkers are rarely tested with such trials given the large sample sizes, long durations, and prohibitive costs (Andriole et al., 2009; Lundwall and Lilja, 1987; Schröder et al., 2009). Fortunately, robust clinical validation design specifically for biomarker discovery (prospective randomized open label, blinded end point study design, or PRoBE) has been proposed by Pepe et al. (Kumar et al., 1997; Lövgren et al., 1997; Pepe et al., 2008; Takayama et al., 1997). Use of the PRoBE design is intended to overcome spectrum bias, in which there is differential selection of cases and controls. In addition, this approach overcomes ascertainment bias, defined as inclination for differential levels of the biomarker to undergo diagnostic testing, because all subjects receive the same testing. A common strategy has been to develop prospective registries to be used for validation studies by blinding samples, which are stored at the National Cancer Institute. In this way, validation studies can be performed using large cohorts for a series of biomarkers as long as sample size is sufficient.

The ultimate objective for new biomarkers is to reduce the burden of cancer. This takes place in phase 5, cancer control studies. With deployment over time, biomarkers are expected to efficiently identify cancers earlier in the disease course, leading to greater construct validity. To achieve a successful outcome in phase 5 requires reduction in cancer mortality that can be attributed to the biomarker use without prohibitive costs or overdiagnosis. This lofty goal has been achieved by few biomarkers.

Inherently, the cost necessary to take a biomarker from phase 1 through phase 5 is often in excess of millions of dollars. A common strategy applied by the EDRN is to partner with multiple institutions and industry to fund work along the different phases with a common goal of moving biomarkers into clinical practice that are likely to improve the health of a population. It is worth pointing out that the EDRN's approach is not the only means by which biomarkers may be developed but the outline here developed by the EDRN scientists provides a rigorous framework for doing so.

Assessment of Biomarker Performance

In the previous section, we have discussed study designs as applied by the EDRN in the development and validation of biomarkers. In this section, we briefly discuss common ways by which biomarker performance may be assessed. Typically, this will be conducted using the clinical grade assay in the intended population along the indicated clinical indications. Perhaps the most common means for assessing validity is calculations of sensitivity, specificity, and accuracy. Sensitivity is defined as the proportion of individuals with the disease who have a positive biomarker test, whereas specificity is defined as the proportion of individuals without the disease who will have a negative test. Accuracy is then the sum of true positives and true negatives divided by the total population. Sensitivity and specificity are graphically summarized using the receiver operating characteristics (ROC) curve. This approach plots sensitivity on the vertical axis and 1- specificity on the horizontal axis. In doing so, the area under the curve (AUC) is a measure of the accuracy of the test. An AUC of 1 signifies an ideal test, whereas AUCs approaching 0.5 indicate a poorly performing test.

Despite widespread use, sensitivity and specificity are not intuitive to interpret in a clinical setting; therefore positive and negative predictive values are often used instead. These are calculated based on sensitivity and specificity as well as the prevalence of the disease. The definition of positive predictive value is the probability that a positive test indicates presence of cancer. Similarly, negative predictive value is the probability that the patient does not have cancer when the biomarker test is negative. In many ways, these measures are more relevant to clinical practice, and there is an increasing tendency to use these as the end point for biomarker validation trials.

In prostate cancer early detection, it is useful to think in terms of pretest and post-test probability. When new biomarkers are introduced, the natural question becomes, “How much does this add to what we already know in terms of risk prediction?” The likelihood ratio (LR) is useful in this regard because the test indicates how much a new biomarker raises or lowers the pre-biopsy probability of disease. A positive LR is calculated as the probability of a positive test in those with cancer divided by the probability of that test result in disease-free individuals. Similarly, a negative LR is calculated as the probability of a negative test result among healthy men divided by the probability of the same result among those with prostate cancer. Likelihood ratios greater than 1 indicate that the test results increases the likelihood that patient has cancer, whereas likelihood ratios less than 1 decrease the probability of the condition. In the literature, likelihood ratios greater than 5 or less than 0.2 are regarded as meaningful shifts in pretest probability.

Prostate biomarkers today are proliferating at a greater rate thanks to the many innovations in high throughput methods (Prensner et al., 2012; Takayama et al., 2001). As such, understanding the status of biomarkers with result with regard to the US Food and Drug Administration (FDA) and other approvals is helpful (Ablin et al., 1970; Füzéry et al., 2013; Kuriyama et al., 1980; Oesterling et al., 1988; Seamonds et al., 1986; Sensabaugh, 1978; Stamey et al., 1987).

FDA approval is considered to be the final end point in the development process because that indicates governmental approval for a specific indication and provides for biomarker validity and safety. Such processes are not undertaken lightly and often cost millions of dollars. Currently FDA-approved biomarkers include PSA, percent-free PSA, PHI, and PCA3. However, the FDA does not actively regulate so-called laboratory-developed tests (LDTs) that are performed in a central Clinical Laboratory Improvement Amendments (CLIA)-certified laboratory. CLIA laboratory standards established by the Centers for Medicare and Medicaid Services exist to ensure quality laboratory testing but not necessarily biomarker validity nor safety. The CLIA program examines performance characteristics of the tests with regard to laboratory precision, analytical sensitivity and specificity, reporting ranges, reference ranges, and criteria for the test systems. A CLIA-certified LDT can be offered commercially for use in the clinic, but rigorous clinical validation may or may not have taken place.

Blood-Based Biomarkers

Prostate-Specific Antigen (PSA or hK3)

Initially developed as a biomarker for monitoring prostate cancer patients after treatment, PSA continues to be a lightning rod for controversy in the setting of prostate cancer screening. Given its unique prominence, a clear understanding of PSA is needed to lay the foundation for other potential prostate cancer biomarkers. **Also known as hK3 (human kallikrein 3), PSA is a member of the kallikrein gene family** (Fig. 149.1). Originally, only three genes of this family of genes were identified: the pancreatic/renal kallikrein *(hKLK1)*, human kallikrein 2 *(hKLK2)*, and PSA *(hKLK3)* genes (Diamandis et al., 2000; Lilja, 1997; McCormack et al., 1995; Rittenhouse et al., 1998; Yu et al., 1994; Yu et al., 1994a, 1994b). Since the identification of 12 other kallikrein genes, this family of proteases now consists of 15 members and is described with a distinct nomenclature (Diamandis et al., 2000; Monne et al., 1994; Yousef and Diamandis, 2001). These proteins are all serine proteases and are located on the long arm of chromosome 19 within the region spanning q13.2-q13.4. These serine proteases have similar amino acid sequences, with hK1 expressing 60% and hK2 expressing 78% homology with PSA (Clements, 1989; Schedlich et al., 1987; Yu and Diamandis, 1995). hK2 and hK3 (PSA) are released in zymogen form from the prostatic epithelium and are found in seminal fluid as well as serum. Because they share structural homology, they can form complexes with endogenous protease inhibitors such as α_2-macroglobulin (A2M) and α_1-antichymotrypsin (ACT) (Levesque et al., 1995; Lilja, 1997; Rittenhouse et al., 1998; Young et al., 1995).

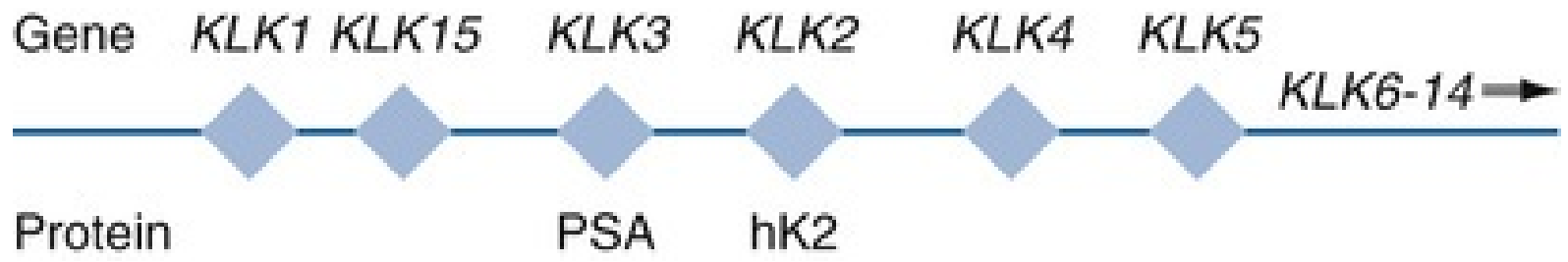

FIG. 149.1 Human kallikrein gene map. Map of the human kallikrein locus and corresponding proteins as described by Yousef and Diamandis (2001).

To understand PSA and its related derivative biomarkers, it is important to understand how PSA is processed. **PSA begins as a zymogen, termed pre-pro-PSA, that contains a 17–amino acid leader sequence** (Lundwall and Lilja, 1987; Oesterling et al., 1988; Partin et al., 1990). **Cleavage of pre-pro-PSA results in an inactive 244-amino acid proenzyme termed proPSA. Finally, cleavage of a leader amino acid sequence of proPSA by hK2 produces the active form of PSA** (Kumar et al., 1997; Lövgren et al., 1997; Magklara et al., 2000; Meng et al., 2002; Takayama et al., 1997).

PSA was first identified and purified in the late 1970s, but widespread use in clinical urology did not occur for another decade (Ablin et al., 1970; Christensson et al., 1990; Kuriyama et al., 1980; McCormack et al., 1995; Oesterling et al., 1988; Otto et al., 1998; Seamonds et al., 1986; Sensabaugh, 1978; Stamey et al., 1987). Although ectopic expression of PSA has been reported in smaller concentrations in the tissue of malignant breast tumors (Partin et al., 2003; Yu et al., 1994a, 1994b) normal breast tissue (Christensson et al., 1990; Monne et al., 1994; Zhang et al., 2000), breast milk (Lilja et al., 1991; Végvári et al., 2010; Yu and Diamandis, 1995), and adrenal and renal carcinomas (Levesque et al., 1995; McCormack et al., 1995; Sensabaugh, 1978), **PSA is highly organ specific because it is produced primarily by prostatic luminal epithelial cells.**

The function of this androgen-regulated protease is to liquefy semen through its action on the gel-forming proteins semenogelin and fibronectin within the semen after ejaculation (Goldfarb et al., 1986; Lilja, 1985; Lilja and Weiber, 1984; McGee and Herr, 1988). In serum**, PSA circulates in bound (complexed, cPSA) and unbound forms (free, fPSA)** (Fig. 149.2). **Three proteins that are known to bind to PSA in the blood are ACT, α_2-macroglobulin (A2M), and α_1-protease inhibitor (API)** (Christensson et al., 1990; McCormack et al., 1995; Otto et al., 1998; Vieira et al., 1994). Binding of free PSA to ACT inactivates the protease, but the complex PSA-ACT remains immunodetectable (Meng et al., 2002; Partin et al., 2003).

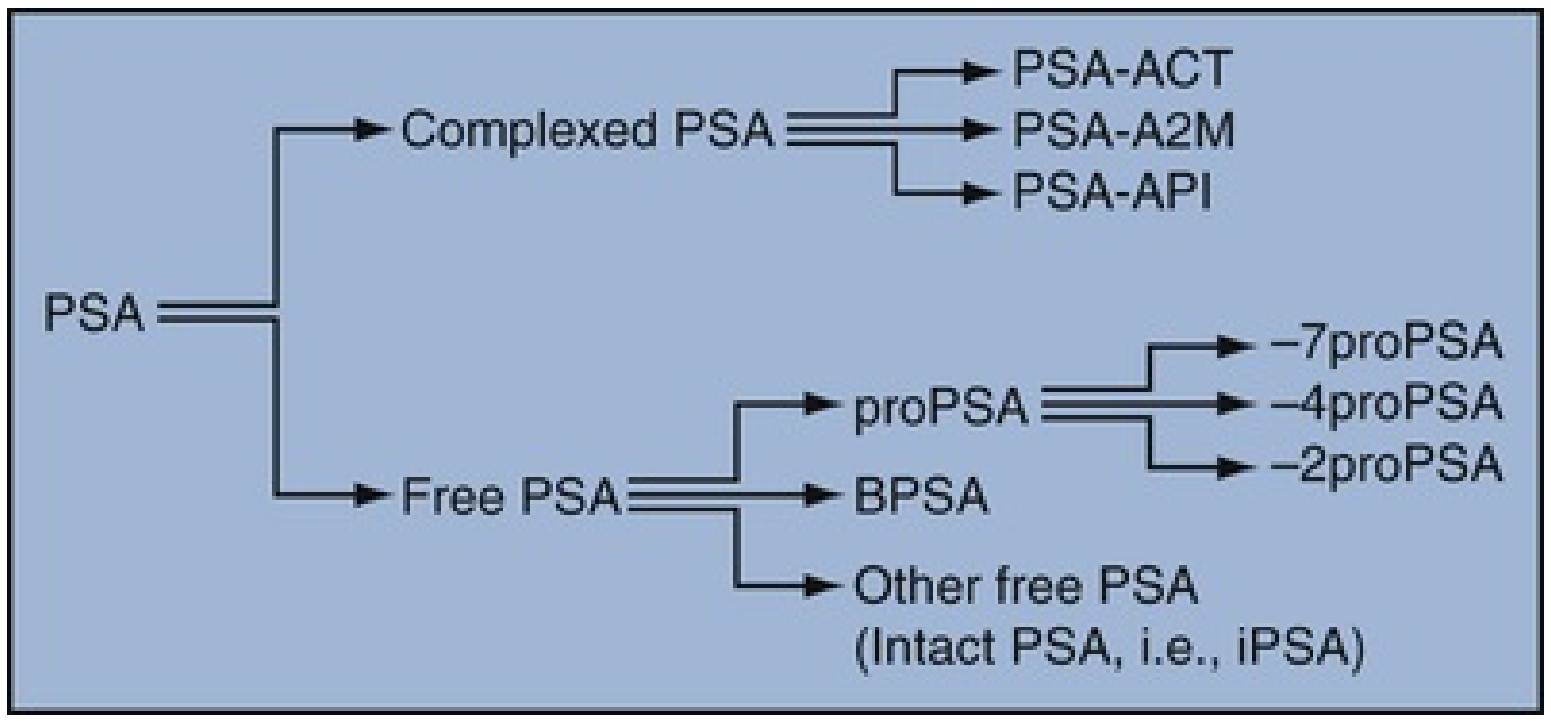

FIG. 149.2 Molecular forms of prostate-specific antigen (PSA). Molecular derivatives of PSA include free PSA, such as proPSA (and the various clipped forms), BPSA (benign PSA), and other free PSA forms such as intact, inactivated PSA. Complexed PSA includes free PSA that is bound to proteases such as ACT (α_1-antichymotrypsin), API (α_1-protease inhibitor), and A2M (α_2-macroglobulin).

The majority (approximately 70%) of PSA in serum is protein bound, most to ACT in an irreversible fashion. Only 5% to 10% of PSA is bound to A2M and 1% to 2% to API. Binding of PSA to A2M still allows some proteolytic activity but renders the PSA-A2M complex undetectable by most current assays because all PSA epitope sites become masked (Fig. 149.3) (Carter et al., 1992; Christensson et al., 1990; Oesterling et al., 1993; Zhang et al., 2000). PSA-ACT and PSA-API are detected by PSA assays, as is fPSA.

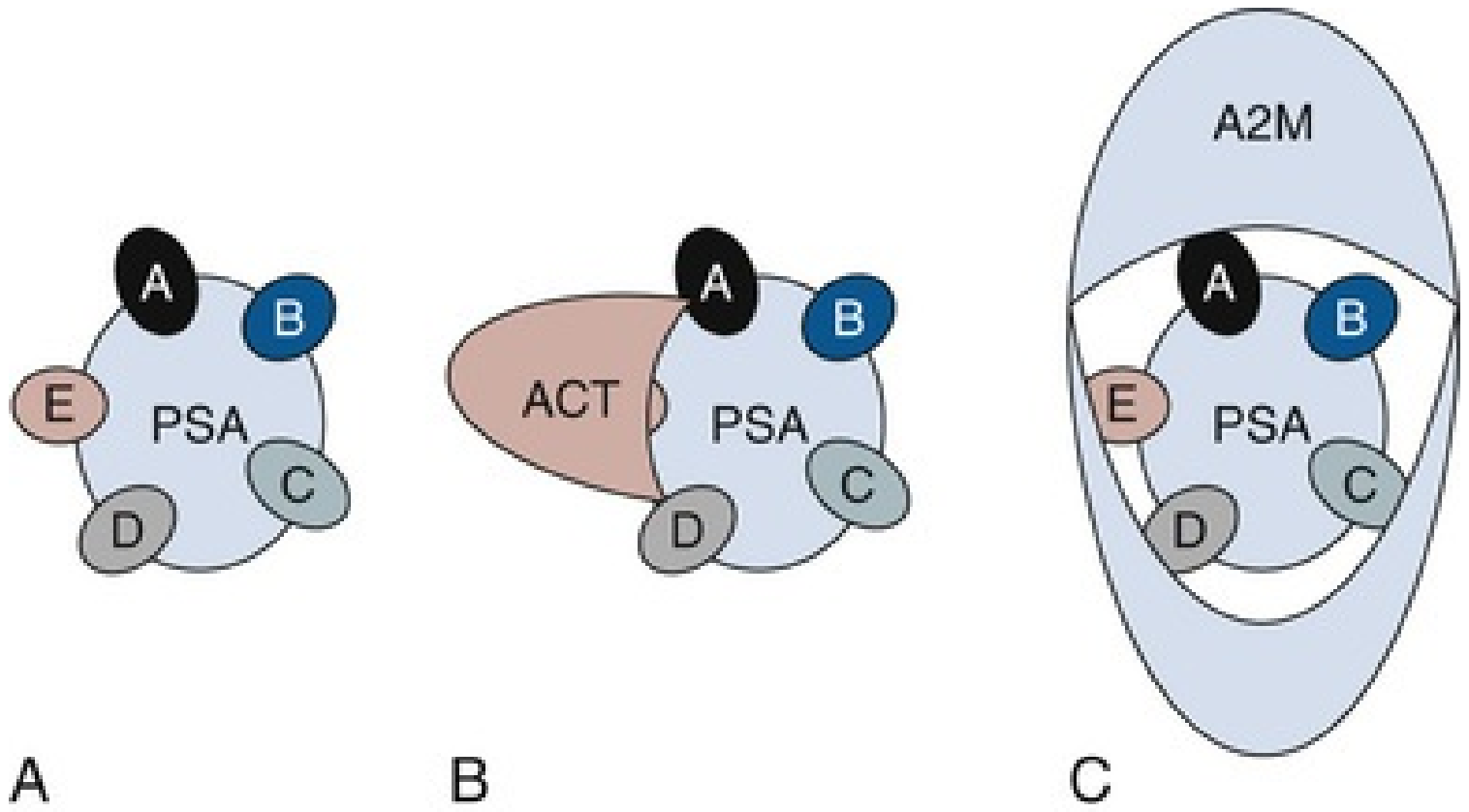

FIG. 149.3 Prostate-specific antigen (PSA)–binding proteases. (A) Free PSA with *A* to *E* representing immunoreactive epitopes of free PSA. (B) α_1-Antichymotrypsin (ACT) blocks the E epitope during binding. (C) α_2-Macroglobulin (A2M) blocks all immunoreactive sites on PSA, making this derivative difficult to measure in serum.

PSA expression is strongly androgen dependent (Henttu et al., 1992; Ohwaki et al., 2010). Immunohistochemical detection of PSA within the prostate is characterized by bimodal peaks between birth and 6 months of age and after 10 years, correlating directly with testosterone levels (Goldfarb et al., 1986; Stamey et al., 1987). Serum PSA becomes detectable at puberty with increases in luteinizing hormone and testosterone (Stamey et al., 1987; Vieira et al., 1994). **In the absence of prostate cancer, serum PSA levels vary with age, race, and prostate volume. Importantly, on a per-cell basis, PSA expression is similar**

between benign and malignant prostate cells (Armitage et al., 1988; Dalton, 1989; Meng et al., 2002; Nadler et al., 1995).

Elevated serum PSA levels are probably a product of disruption of cellular architecture within the prostate gland (Mejak et al., 2013; Stamey et al., 1987). The loss of the barrier afforded by the basal layer and basement membranes within the normal gland is a likely site for the egress of PSA into the circulation. This can occur in the setting of prostate disease (BPH, prostatitis, prostate cancer) and with prostate manipulation (prostate massage, prostate biopsy) (Ercole et al., 1987; Morote Robles et al., 1988; Stamey et al., 1987; Wang et al., 1981). Prostatic inflammation (acute and chronic) and urinary retention can cause PSA elevations to variable degrees (Armitage et al., 1988; Dalton, 1989; Etzioni et al., 2005; Marks et al., 2006; Nadler et al., 1995; Thompson et al., 2003). **Prostatic trauma, such as occurs after prostatic biopsy, can result in a temporary spike in serum PSA that persists for 4 or more weeks before returning to baseline values** (Kaplan et al., 2012; Thompson et al., 2006; Yuan et al., 1992).

Most studies of the effect of ejaculation on serum PSA have shown no significant change in PSA (Kirkali et al., 1995; McCormack et al., 1995; Woodrum et al., 1998), although in men 50 years of age and older ejaculation can lead to a very transient increase in PSA (Catalona et al., 1998; Herschman et al., 1997; Partin et al., 1998; Tchetgen et al., 1996). However, PSA appears to return to baseline within 24 hours (Rajaei et al., 2013). Men with a new PSA elevation should be asked about sexual activity within 24 hours of PSA testing and, if so, should be asked to abstain before a repeat blood draw. Long-distance cycling is another potential cause of false PSA elevation, with PSA levels increasing by approximately 10% after bicycle rides exceeding 55 kilometers (Mejak et al., 2013).

Although these factors can cause small-scale changes in PSA levels**, the presence of prostate disease (prostate cancer, BPH, and prostatitis) is certainly the most important factor affecting serum PSA** (Ercole et al., 1987; Morote Robles et al., 1988; Wang et al., 1981), **and it is primarily the impact of BPH and prostatitis on PSA levels that confounds the accuracy of PSA in the screening setting.** Prostate-directed treatment (for BPH and cancer) can lower serum PSA by decreasing the volume of prostatic epithelium available for PSA production and by decreasing the amount of PSA produced per cell. **5α-reductase inhibitors (5ARI) such as finasteride and dutasteride have been shown to lower PSA levels by roughly 50% after 12 months of treatment**

(Guess et al., 1993). **This has resulted in the so-called “doubling rule,” whereby PSA levels are multiplied by a factor of 2 in men undergoing 5ARI therapy to guide decisions regarding prostate cancer risk. However, using a multiple of 2 may overestimate PSA values in the first 6 months of treatment and underestimate PSA levels after several years of treatment** (Etzioni et al., 2005; Marks et al., 2006; Thompson et al., 2003). In addition, compelling data from the Prostate Cancer Prevention Trial (PCPT) and other sources suggest that 5ARI therapy substantially improves the performance characteristics of PSA in the screening setting with an AUC of 0.76 (finasteride) versus 0.68 (placebo) (Kaplan et al., 2012; Thompson et al., 2006). Interpretation of PSA values should always take into account the presence of prostate disease, previous diagnostic procedures, and prostate-directed treatments.

In men without BPH, the rate of change in PSA is 0.04 ng/mL per year, compared with 0.07 to 0.27 ng/mL per year in men with BPH who are between the ages of 60 and 85 years (Carter et al., 1992; Oesterling et al., 1993; Yuan et al., 1992). PSA velocity has long held interest as a potential predictor of prostate cancer in the early detection setting and as a marker of higher-risk disease in patients on active surveillance. There are now substantial data showing that PSA velocity is of minimal, if any, use for prostate cancer screening, including in patients at higher baseline risk of developing prostate cancer (Mikropoulos et al., 2018; Vickers et al., 2014). As such, **PSA velocity should not be used as a trigger for biopsy.** In the active surveillance setting, there are now more recent data that PSA kinetics can improve prediction of reclassification over time, although the clinical utility of this metric still remains to be determined (Cooperberg et al., 2018). PSA density, which is total PSA divided by prostate volume, is another PSA-derived metric and provides substantially more predictive information than PSA velocity. Proposed cutoffs for biopsy in the early detection setting have ranged from 0.08 ng/mL^2 to 0.15 ng/mL^2 (Aminsharifi et al., 2018; Nordström et al., 2018). Nordstrom et al. (2018) reported that PSA density cutoffs of 0.10 ng/mL^2 and 0.15 ng/mL^2 would lead to detection of 77% and 49% of Gleason score ≥7 tumors, respectively, in a population-based cohort with PSA of at least 3 ng/mL. **In the multicenter Prostate Cancer Active Surveillance Study, PSA density is a key predictor of adverse reclassification on surveillance biopsy** (Newcomb et al., 2016)**.**

Free Prostate-Specific Antigen

Although the majority of serum PSA is found complexed to the proteases (primarily ACT), 5% to 45% of PSA exists as enzymatically inactive fPSA (Table 149.1; McCormack et al., 1995; Woodrum et al., 1998)**. PSA produced from malignant cells appears to more frequently escape proteolytic processing, resulting in a greater fraction of serum PSA complexed to ACT and a lower percentage of total PSA that is free compared with men without prostate cancer** (Catalona et al., 1997; Christensson et al., 1993; Leinonen et al., 1993; Lilja, 1993; Stenman et al., 1994). This principle led to the development of fPSA testing as a means to improve the accuracy of PSA as a prostate cancer screening biomarker, and the FDA has approved its use in men with a serum total PSA level of 4 to 10 ng/mL and a negative DRE (Catalona et al., 1998; Partin et al., 1998).

TABLE 149.1

Molecular Derivatives of Prostate-Specific Antigen

PSA Type	% In Serum
Complexed PSA	60–95
PSA-ACT	60–90
PSA-API	1–5
PSA-A2M	10–20
Free PSA	5–45

ACT, α_1-antichymotrypsin; *API,* α_1-protease inhibitor; *A2M,* α_2-macroglobulin; *PSA,* prostate-specific antigen.

A number of studies have evaluated %fPSA cut points to determine potential thresholds that optimize the performance of this tool. Christensson et al. (1993) measured free and total PSA fractions in men with and without prostate cancer and found that a free/total PSA cutoff of 0.18 (18% fPSA) significantly improved the ability to distinguish between subjects with and without cancer compared with use of total PSA alone. As many as 20% to 65% of unnecessary biopsies may be avoided when using %fPSA cutoff values ranging between 14% and 28% while maintaining sensitivity rates from 70% to 95% within the tPSA range of 4 to 10 ng/mL (Catalona et al., 1998; Partin et al., 1998; Polascik et al., 1999; Pound et al., 1997; 1999; Stephenson and Stanford, 1997; Veltri and Miller, 1999; Vessella et al., 2000). In a prospective, multi-institutional study of men aged 50 to 75 years with PSA levels between 4 and 10 ng/mL and palpably benign prostate glands, a %fPSA cutoff of 25% detected 95% of cancers (sensitivity) while avoiding 20% of unnecessary biopsies (specificity) (Catalona et al., 1998; Gretzer et al., 2002). This resulted in an AUC for %fPSA that was significantly higher than that of total PSA (0.72 vs. 0.53).

Although there remains no single, established %fPSA threshold, proposed cut points generally range from 15% to 25%. The National Comprehensive Cancer Network Prostate Cancer Early Detection Guidelines incorporate %fPSA as an option to help with decision making before biopsy and recommend a threshold of 10% (Carroll and Mohler, 2018). However, an important recent development has been the increasing availability and usage of predictive tools that incorporate multiple clinical variables such as total PSA, %fPSA, and DRE findings (Hernandez et al., 2009; Pepe et al., 2001; Zaytoun et al., 2011). **In particular, the updated calculator based on results of the prostate cancer prevention trial (PCPT) provide a calibrated estimate of prostate cancer risk that can facilitate shared clinical decision making (Fig. 149.4;** Andriole et al., 2009; Ankerst et al., 2012; Schröder et al., 2009). fPSA decreases in a similar fashion as total PSA in the setting of 5ARI therapy; thus the percentage of fPSA is not altered significantly by these medications (Keetch et al., 1997; Pannek et al., 1998).

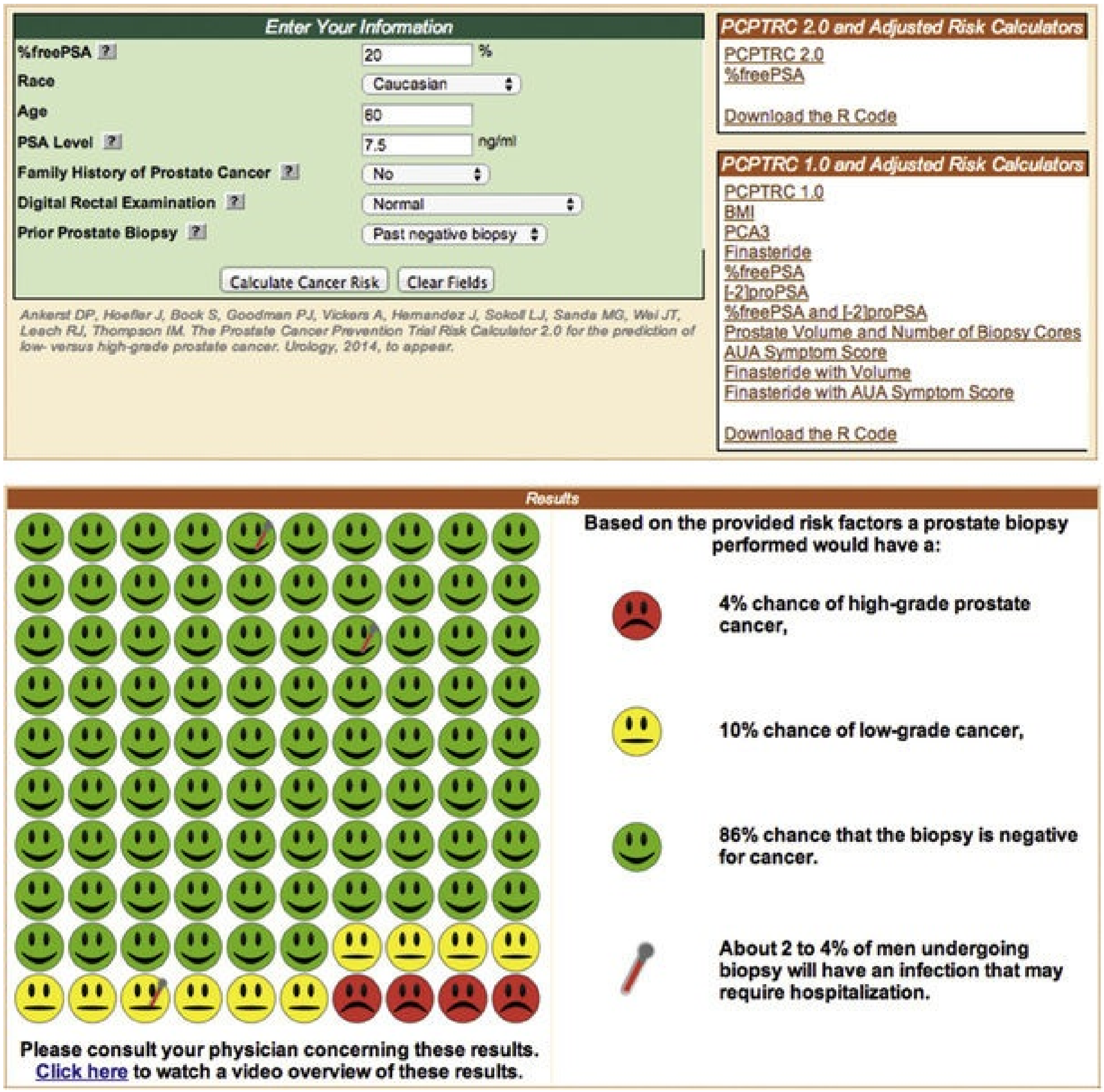
Enter Your Information
PCPTRC 2.0 and Adjusted Risk Calculators
PCPTRC 2.0
%freePSA
Download the R Code
PCPTRC 1.0 and Adjusted Risk Calculators
PCPTRC 1.0
BMI
PCA3
Finasteride
%freePSA
[-2]proPSA
%freePSA and [-2]proPSA
Prostate Volume and Number of Biopsy Cores
AUA Symptom Score
Finasteride with Volume
Finasteride with AUA Symptom Score
Download the R Code
Calculate Cancer Risk
Clear Fields
Results

%freePSA: 20 %

Race: Caucasian

Age: 60

PSA Level: 7.5 ng/ml

Family History of Prostate Cancer: No

Digital Rectal Examination: Normal

Prior Prostate Biopsy: Past negative biopsy

Ankerst DP, Hoefler J, Bock S, Goodman PJ, Vickers A, Hernandez J, Sokoll LJ, Sanda MG, Wei JT, Leach RJ, Thompson IM. The Prostate Cancer Prevention Trial Risk Calculator 2.0 for the prediction of low- versus high-grade prostate cancer. Urology, 2014, to appear.

Based on the provided risk factors a prostate biopsy performed would have a:

4% chance of high-grade prostate cancer,

10% chance of low-grade cancer,

86% chance that the biopsy is negative for cancer.

About 2 to 4% of men undergoing biopsy will have an infection that may require hospitalization.

Please consult your physician concerning these results.
Click here to watch a video overview of these results.

FIG. 149.4 Web-based calculation of prostate-cancer risk using the PCPT risk calculator operationalized by the University of Texas Health Science Center at San Antonio (**http://deb.uthscsa.edu/UROR iskCalc/Pages/calcs.jsp**). Distinct nomograms using different patient factors and biomarkers are available, and the output for the most commonly used nomograms gives the risk of high-risk cancer and any prostate cancer using a pictorial interface.

In addition to contributing to detection, fPSA may provide prognostic information. Serial measurement of %fPSA within archival serum has shown significant differences in aggressive and nonaggressive prostate cancers (Carter et al., 1997). This study suggested that the longitudinal measurement of %fPSA changes may not only aid in detection but also contribute information regarding disease behavior. A number of studies have reported on the correlation between

%fPSA and pathological outcomes, showing some correlation between low %fPSA and aggressive pathological features (Aus et al., 2003; Masieri et al., 2012; Morote et al., 2000; Shariat et al., 2006). In addition, Shariat et al. (2006) reported an independent association between lower %fPSA and biochemical recurrence in 402 men who underwent radical prostatectomy for clinically localized disease.

Perhaps the clinical setting in which %fPSA is most often used is in patients with an elevated PSA and a prior negative prostate biopsy (Djavan et al., 2000; Hayek et al., 1999; Stephan et al., 1997). Stephan et al. (1997) reported a 5% cancer underdiagnosis rate when using a %fPSA value of 21% to trigger rebiopsy, and Catalona et al. (1997) reported that a threshold of 28% detected 95% of cancers and avoided 12% of repeat biopsies. More recent European data reported an AUC of 0.73 for %fPSA in a repeat biopsy population, exceeding that of PSA and PCA3 (Auprich et al., 2012). At a threshold of 18%, %fPSA demonstrated a sensitivity of 85% and specificity of 41%. However, the AUC for %fPSA was only 0.52 in another European repeat biopsy cohort, suggesting a need for other biomarkers in this setting (Scattoni et al., 2013).

Free Prostate-Specific Antigen Isoforms

fPSA in serum comprises three isoforms: proPSA, BPH-associated PSA (BPSA), and intact fPSA (Jansen et al., 2009; Mikolajczyk et al., 2002). These three isoforms exist in approximately equal concentrations in serum, and each has shown promise as a prostate cancer biomarker. As discussed earlier, PSA originates with a 17–amino acid chain that is cleaved to yield a precursor inactive form of PSA termed proPSA (Kumar et al., 1997; Mikolajczyk et al., 1997, 2000, 2001; Peter et al., 2001; Zhang et al., 1995). As depicted in Fig. 149.5, **the precursor form of PSA contains a 7–amino acid proleader peptide, in addition to the 237 constituent amino acids of mature PSA, and is termed proPSA or [−7]proPSA.** This leader amino acid chain is cleaved by hK2, resulting in the active form of PSA. Incomplete removal of the 7–amino acid leader chain has led to the identification of various other truncated or clipped forms of proPSA. These include proPSAs with 2–, 4–, and 5–leader amino acids ([–2]pPSA, [–4]pPSA, and [–5]pPSA), and all are primarily expressed in the peripheral zone of the prostate. **With cellular disruption, these enzymatically inactive forms circulate as fPSA and may constitute the majority of the circulating fPSA in patients with prostate cancer** (Mikolajczyk et al., 1997; Fig. 149.6).

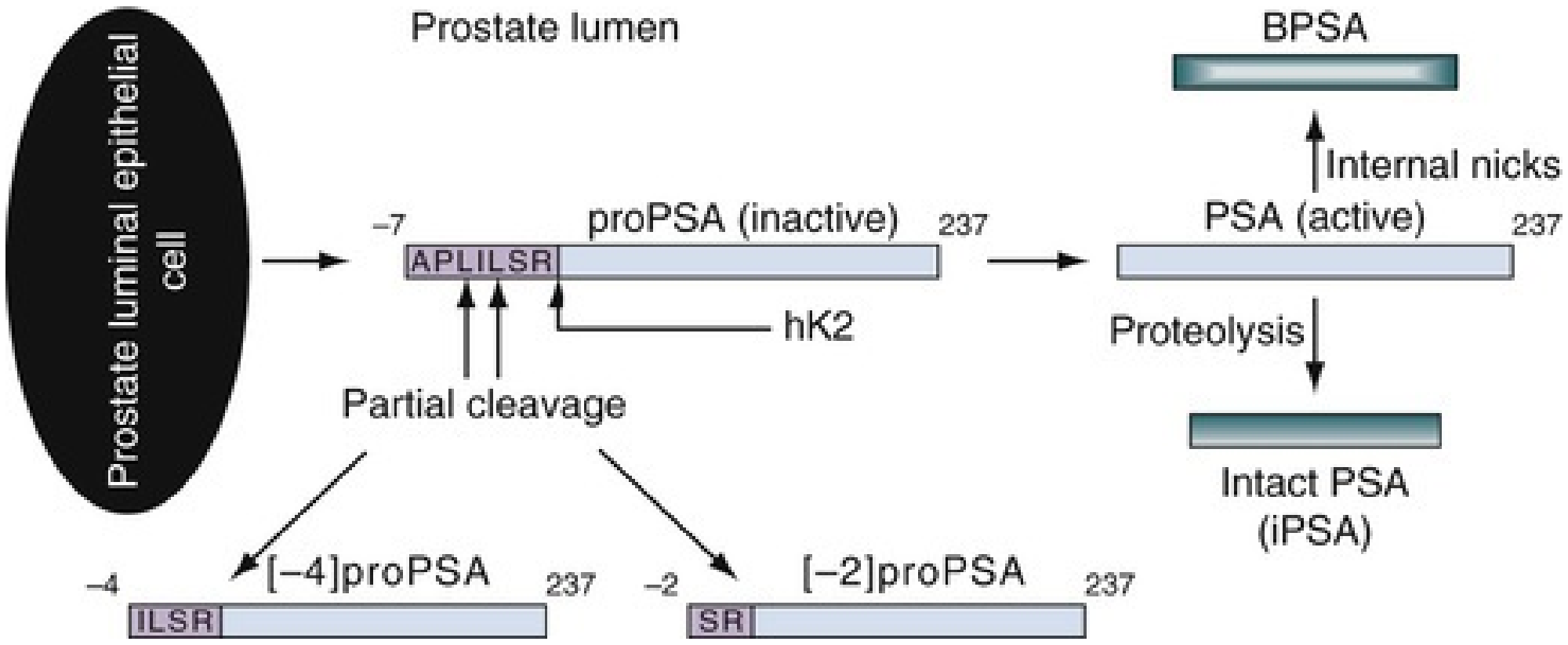
Prostate luminal epithelial cell
Prostate lumen
−7
proPSA (inactive)
237
APLILSR
hK2
Partial cleavage
−4
[−4]proPSA
237
ILSR
−2
[−2]proPSA
237
SR
BPSA
Internal nicks
PSA (active)
237
Proteolysis
Intact PSA
(iPSA)

FIG. 149.5 Differential cleavage and activation of pro–prostate-specific antigen (PSA). ProPSA is released from the prostate epithelial cell with a 7–amino acid leader sequence. hK2 cleaves the amino acid leader to activate PSA. Active PSA undergoes proteolysis to yield inactive PSA (iPSA) and may also undergo internal degradation to form benign PSA (BPSA). Partial cleavage of the 7–amino acid leader sequence yields inactive forms of proPSA (i.e., [–2]pPSA or [–4]pPSA).

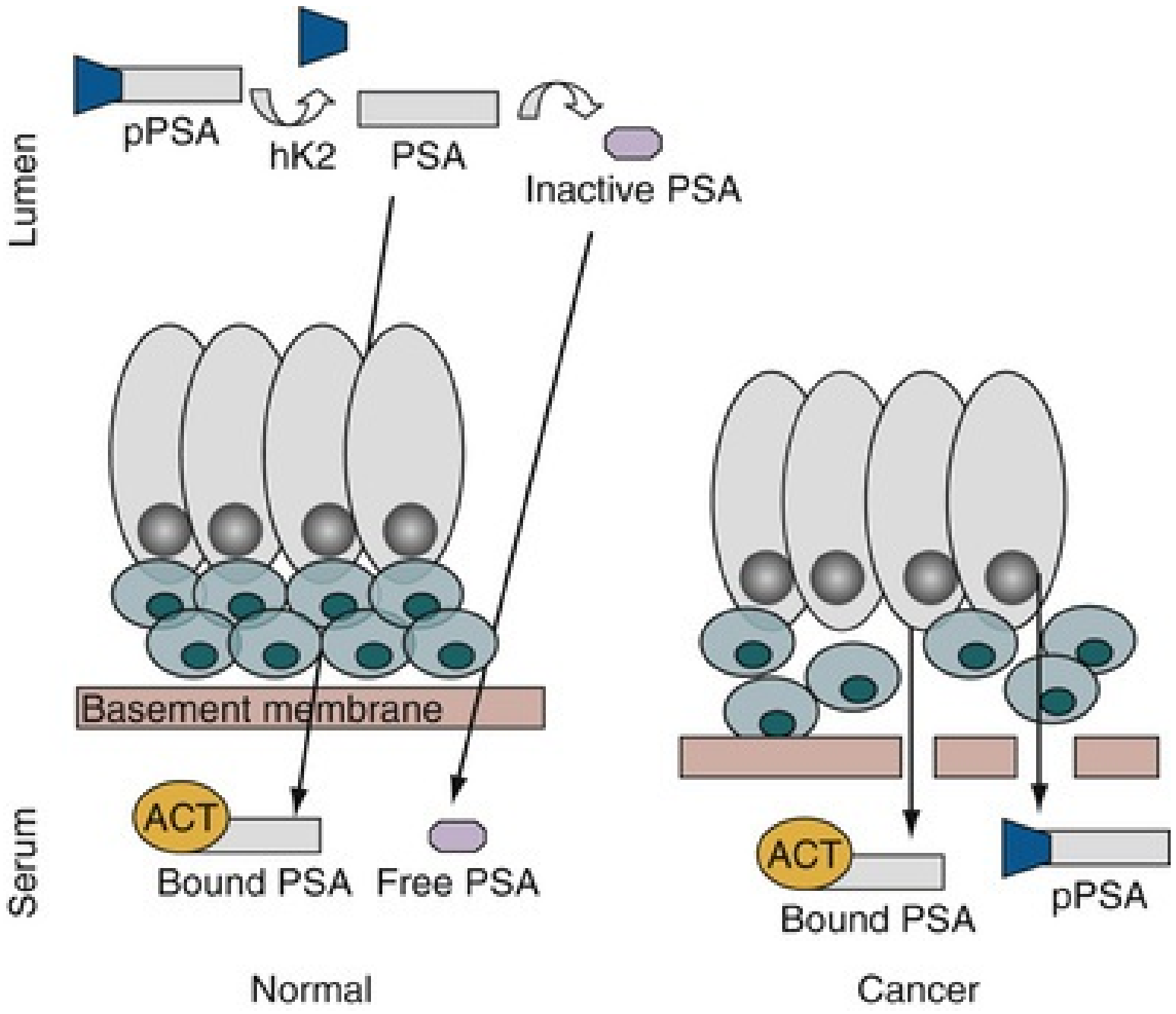
Lumen
pPSA
hK2
PSA
Inactive PSA
Basement membrane
Serum
ACT
Bound PSA
Free PSA
ACT
Bound PSA
pPSA
Normal
Cancer

FIG. 149.6 Prostate-specific antigen (PSA) synthesis in normal versus cancer tissue. ProPSA is secreted into the lumen, where the 7–amino acid leader sequence is cleaved by hK2 to yield active PSA. Some of the active PSA diffuses into the serum, where it is bound to proteases such as α_1-antichymotrypsin (ACT). The luminal active PSA undergoes proteolysis, and the resulting inactive PSA (iPSA) may also enter the circulation to circulate in the unbound or free state. In prostate cancer, loss of the tissue

architecture may permit a relative increase in bound PSA and proPSA in serum.

Reports by Mikolajczyk et al. (2000, 2001) have revealed significantly elevated levels of these truncated forms of proPSA in prostate cancer tissue. In particular, the [−2]proPSA isoform, cleaved between leucine 5 and serine 6 of the propeptide, has shown increasing promise as a serum prostate cancer biomarker (Lazzeri et al., 2012; 2013; Le et al., 2010). Although the underlying biology behind the increased levels of [−2]proPSA in prostate cancer remains unclear, it may be that the decreased PSA processing in prostate cancer results in a relative increase in proPSA and its cleaved forms, especially [–2]proPSA. In addition, Makarov et al. (2009) have proposed that proPSA production may be driven by benign tissue adjacent to malignant prostatic epithelium.

From a clinical standpoint, [−2]proPSA has been extensively validated in the screening setting, before either initial biopsy or repeat biopsy (Guazzoni et al., 2011; Lazzeri et al., 2012, 2013; Le et al., 2010; Loeb et al., 2015, 2017). Lazzeri et al. (2013) reported on a prospective European cohort of 646 patients with total PSA between 2 and 10 ng/mL who were undergoing initial prostate biopsy. The %[−2]proPSA was a strong independent predictor of prostate cancer at biopsy in a model that included free and total PSA, and the AUC for %[−2]proPSA was 0.67. The %[−2]proPSA was also a strong predictor of Gleason score ≥7 prostate cancer in this study. In the United States, a prospective National Cancer Institute (NCI) EDRN validation study demonstrated excellent performance characteristics for %[−2]proPSA (Sokoll et al., 2010). Including %[−2]proPSA in the base model consisting of free and total PSA significantly improved the predictive accuracy, and %[−2]PSA outperformed PSA and %fPSA in predicting the presence of prostate cancer at the time of biopsy in patients with a serum total PSA of 2 to 10 ng/mL. In addition, %[−2]proPSA was closely correlated with increasing Gleason score.

The levels of [−2]proPSA have been incorporated into a formula that also includes free and total PSA and is called the Prostate Health Index (PHI) (Lazzeri et al., 2013). PHI is FDA approved in men aged 50 years and older with total PSA 4 to 10 ng/mL and negative DRE. The accuracy of PHI for predicting clinically significant prostate cancer in the early detection setting is consistently better than PSA or %fPSA, and adding PHI to existing risk calculators such as PCPT significantly improves their performance (Loeb et al., 2015, 2017; Tosoian et al., 2017). PHI is also strongly associated with reclassification in men on active surveillance (Hirama et al., 2014; Tosoian et al., 2012). This test is discussed in more detail in Chapter 152.

Another isoform of fPSA, referred to as benign PSA or BPSA, is identical to mature PSA except for internal cleavages between Lys 182 and Lys 145 (Mikolajczyk et al., 2002). Its expression is generally limited to transition zone tissue, and it is highly expressed in the setting of BPH (Canto et al., 2004; Mikolajczyk et al., 2000; Wang et al., 2000). BPSA is closely related to prostate volume and does not appear to have any prognostic capacity in terms of distinguishing potentially indolent from aggressive disease (de Vries et al., 2005; Naya et al., 2004). Although serum BPSA alone is unlikely to differentiate between hyperplasia and cancer, in combination with assays for [−2]proPSA, it may allow additional discrimination (Rhodes et al., 2012; Stephan et al., 2009).

So-called “intact PSA” comprises an additional fPSA subset that has been identified as a predictive serum biomarker (Hori et al., 2013; Nurmikko et al., 2000; Steuber et al., 2007a). Preliminary studies have demonstrated that the ratio of intact to free PSA may improve the accuracy of prostate cancer detection (Nurmikko et al., 2000, 2001; Steuber et al., 2002). However, some studies of intact PSA include proPSA in their intact PSA assay, making it difficult to determine the predictive value of intact PSA alone (Peltola et al., 2011). This parameter has primarily been used as part of a multi-kallikrein panel, which is discussed later in this chapter (Vickers et al., 2008).

Prostate-Specific Membrane Antigen

The glycoprotein prostate-specific membrane antigen (PSMA) has been evaluated for a number of years as a potential serum, urine, and/or tissue biomarker of prostate cancer. A folate hydrolase, PSMA is found embedded within the cell membrane of all prostatic epithelial cells. It is a type II transmembrane protein with an extracellular C-terminus that exists as a dimer and binds glutamate and glutamate-like structures (Fair et al., 1997; Israeli et al., 1997). The gene for PSMA has been cloned, fully sequenced, and localized to the short arm of chromosome 11 (11p11-p12). Although PSMA is predominantly expressed in the secretory acinar epithelium of the prostate gland, it has been isolated in other tissues, including in the central nervous system (astrocytes and Schwann cells) and intestine (jejunal brush border).

Of interest for diagnosis (Douglas et al., 1997), prognosis (Perner et al., 2007), and imaging (Ristau et al., 2013) is the discovery of elevated expression of this protein in tissue from prostate cancer compared with normal prostate tissue

(Chang et al., 1999; Elgamal et al., 2000; Minner et al., 2011; Silver et al., 1997). There is also evidence that increased tissue expression of PSMA may confer a worse prognosis in patients undergoing radical prostatectomy (Minner et al., 2011; Perner et al., 2007).

Currently, PSMA has its greatest use in targeted imaging and theranostics (Barrett et al., 2013; Milowsky et al., 2007; Osborne et al., 2013; Tagawa et al., 2013). In particular, ^{68}Gallium prostate-specific membrane antigen positron emission tomography (^{68}Ga-PSMA PET) has become an increasingly used diagnostic tool in the setting of biochemical recurrence after primary therapy. A meta-analysis of 15 studies found 69% of patients with detectable disease, leading to increases in use of radiotherapy and salvage lymphadenectomy along with concomitant decreased use of systemic therapy (Han et al., 2018). Another meta-analysis reported 40% of patients with positive ^{68}Ga-PSMA PET scans at the time of primary staging and 76% positive at the time of biochemical recurrence (Perera et al., 2016). Specificity of this modality approaches 97%, and even at PSA levels as low as 0 to 0.2, 42% of patients in this report were found to have positive scans.

Human Kallikrein 2

Human kallikrein peptidase 2 (hK2) shares many important properties with PSA and has demonstrated potential as another prostate cancer tumor marker (Becker et al., 2000; Darson et al., 1997; Kumar et al., 1997; Lövgren et al., 1999; Rittenhouse et al., 1998; Young et al., 1992). **Among many similarities, hK2 and PSA share 80% amino acid homology** (see Fig. 149.1)**, exhibit similar specificity for prostate tissue, and are hormonally regulated by androgens.** As discussed earlier, one of the key functions of hK2 is to activate the zymogen (proPSA) to the active PSA through cleavage of the amino acid presequence (see Fig. 149.6).

Critical to its utility as a biomarker, hK2 expression varies independent of PSA expression, in tissue and serum (Tremblay et al., 1997). For example, **in benign epithelium, PSA is intensely expressed compared with minimal immunoreactivity of hK2** (Darson et al., 1999; Tremblay et al., 1997)**. In contrast, in cancerous tissue hK2 is expressed more intensely.** Furthermore, tissue expression of hK2 appears to correlate with more aggressive pathological features, including Gleason grade (Darson et al., 1997, 1999; Tremblay et al., 1997).

A number of studies have shown an association between serum hK2 levels and the presence of prostate cancer, suggesting that it may be used in conjunction with PSA to improve the selection of patients for prostate needle biopsy (Becker et al., 2000; Nam et al., 2000; Vickers et al., 2007). Furthermore, men with low-grade disease have lower concentrations of serum hK2 than men with more aggressive cancer (Darson et al., 1999). Data from a multicenter study demonstrated a statistically significant difference between men with biopsies positive for cancer, looking at hK2 alone and in combination with fPSA/tPSA (Kwiatkowski et al., 1998). Combining fPSA and hK2, Partin et al. (1999) demonstrated an increased cancer detection rate within the tPSA range of 2 to 10 ng/mL. Serum hK2 may also offer prognostic information: studies show correlations with aggressive pathological features as well as biochemical recurrence (Haese et al., 2001; Steuber et al., 2007b).

Currently, hK2 used clinically as one of the components of the 4Kscore, a multi-kallikrein panel reported by Vickers et al. (2008). Early reports used a large cohort of men from the Goteborg arm of the European Randomized Study of Screening for Prostate Cancer (ERSPC) to combine, within a statistical model, four kallikrein forms (total PSA, fPSA, intact PSA, and hK2) to accurately predict the presence of prostate cancer in men with a PSA of at least 3.0 ng/mL (AUC 0.84). These findings were then validated in a separate ERSPC cohort (Rotterdam arm) in which it was suggested that use of the multi-kallikrein panel could avoid 513/1000 biopsies with only 54/177 missed low-grade cancers and 12/100 missed high-grade cancers (Vickers et al., 2010). In addition, of 392 men in this arm who underwent radical prostatectomy between 1994 and 2004, the four kallikrein markers were independently associated with pathologically aggressive disease features and improved the accuracy of the base model (AUC 0.81 to 0.84) (Carlsson et al., 2013).

Although the statistical model has not been the same in all studies, there have been multiple studies validating the performance of this assay. In a US-based study of 1012 men undergoing prostate biopsy, the 4Kscore would decrease biopsy rates by 30% to 58% while missing 1.3% to 4.7% of Gleason score ≥7 tumors, depending on the threshold used (Parekh et al., 2013). A meta-analysis using individual patient data has demonstrated the value of all four components of the kallikrein panel, and this same data analyzed across multiple different patient subgroups showed a mean increase in AUC of 0.11 when the 4Kscore was added to a base clinical model (Vickers et al., 2018a,b).

Circulating Tumor Cells and Circulating Tumor DNA

Circulating tumor cells (CTCs) have long been touted as potential prognostic biomarkers and treatment response indicators. The excitement in this area of research goes back more than 20 years, when investigators demonstrated the ability to detect PSA mRNA in the blood of men with advanced prostate cancer (Katz et al., 1994). Subsequent CTC research in prostate cancer has used a wide range of methods, capitalizing on features such as size, surface marker expression, and cellular plasticity that differentiate CTCs from circulating mononuclear cells in the blood (Danila et al., 2011; Pantel and Alix-Panabières, 2010; Yu et al., 2011). Typically, CTCs are defined as being $CD45^-$ and positive for an epithelial marker such as epithelial cell adhesion molecule (EpCAM) and/or cytokeratin. Although the development of CTCs as a prostate cancer biomarker has been relatively slow to evolve, there has been substantial recent progress in this field with a movement toward an increasing number of clinical assays.

Currently, there is only one FDA-approved methodology for identifying CTCs: CellSearch (Veridex, Warren, NJ). The CellSearch system uses antibodies against EpCAM for CTC capture and then stains with antibodies against CD45 (negative) and cytokeratins 8, 18, and 19 (positive) to identify individual CTCs. With this system, a CTC count of 5 or more cells per 7.5 mL of blood at any time during the course of the disease has been associated with a poor prognosis in prostate, breast, and colorectal cancers (Cohen et al., 2008; Cristofanilli et al., 2004; de Bono et al., 2008; Shaffer et al., 2007). In a study of 422 patients with metastatic prostate cancer, using the CellSearch platform the investigators demonstrated that there was a difference between baseline numbers of cells and those seen 2 to 5 weeks post-treatment (Fig. 149.7). For example, 57% of the patients had greater than 5 cells per 7.5 mL of blood before treatment, and 39% had greater than 5 cells per 7.5 mL after treatment (Shaffer et al., 2007). Similar studies have lent further support to the potential use of CTCs as a response indicator, with conversion from unfavorable to favorable CTC counts (<5 CTCs) frequently occurring in men with advanced prostate cancer receiving hormonal agents or chemotherapy (Danila et al., 2010; de Bono et al., 2008; Reid et al., 2010). Further data demonstrating that CTC response independently predicts survival in these settings are needed before CTCs can be used as an efficacy-response surrogate marker (Scher et al., 2009, 2013).

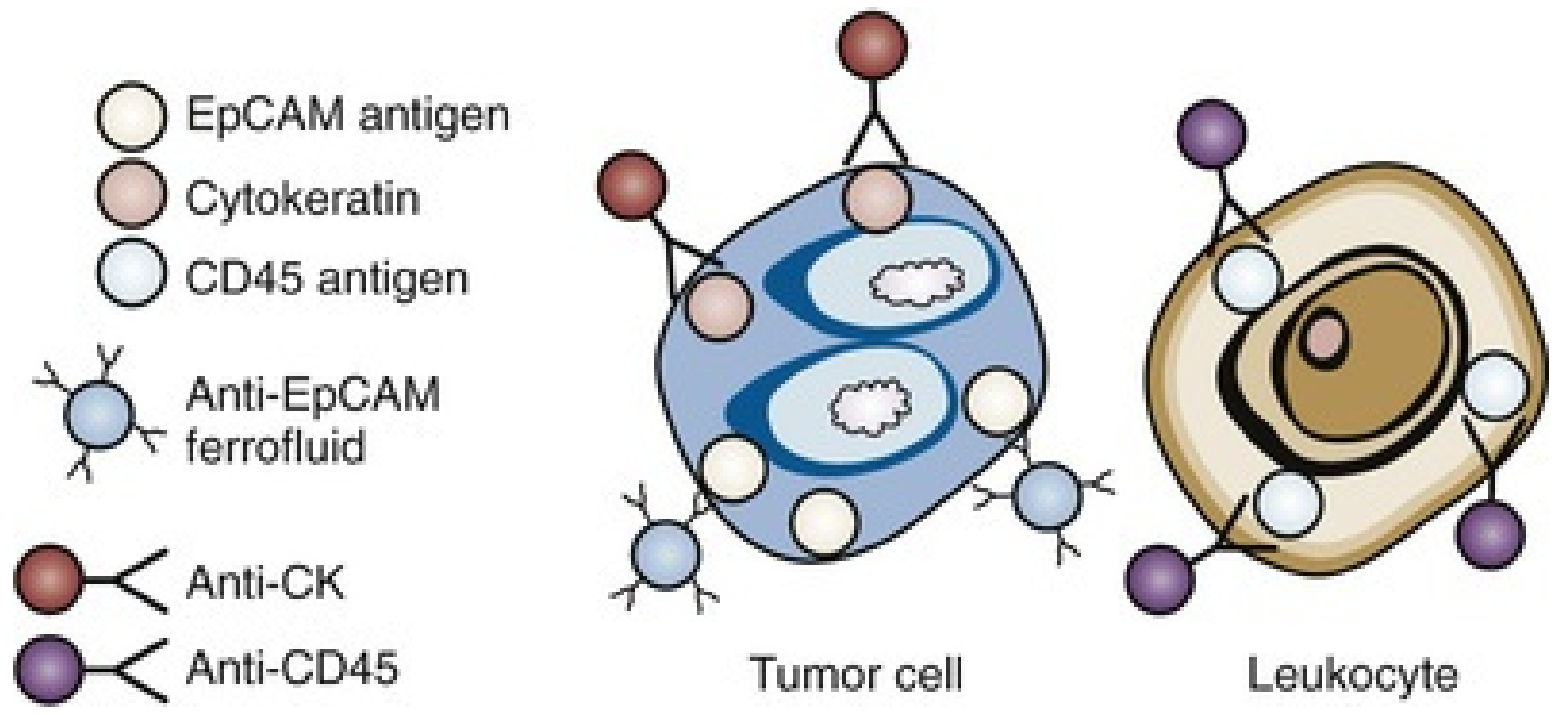

FIG. 149.7 CellSearch CTC: Circulating Tumor Cell (Veridex) cell enumeration system. *CD45,* CD stands for "*cluster of differentiation,*" which was originally called *leukocyte common antigen; CK,* cytokeratin; *EpCAM,* epithelial cell adhesion molecule. The anti-EpCAM ferrofluid captures the cells, and they are then validated with cytokeratin-positive and CD45-negative staining.

A number of other platforms for CTC detection have been developed, and this continues to be an area of rapid growth in the biomarker space. Investigators at Harvard Medical School developed a microfluidic system known as the "CTC-Chip," which has garnered a great deal of attention (Nagrath et al., 2007). This system has a high level of sensitivity, able to detect a single EpCAM-positive cell among 1 billion blood cells, and the capture efficiency has been further improved with an updated device (Nagrath et al., 2007; Stott et al., 2010).

Going forward, the use of CTCs as a biomarker will likely revolve less around simple enumeration and more around the specific molecular alterations that can be identified—either within the cells or from cell-free nucleic acids—providing a real-time "liquid biopsy" in men with prostate cancer (Danila et al., 2011, 2014; Dawson et al., 2013). **In 2014 a seminal study published in the *New England Journal of Medicine* demonstrated that detection of the androgen-receptor splice variant 7 (AR-V7) in CTCs predicts resistance to abiraterone and enzalutamide in metastatic castration-resistant prostate cancer** (Antonarakis et al., 2014). These results were subsequently validated in a larger study, which also demonstrated that outcomes were best for patients without CTCs, intermediate for patients with AR-V7–negative CTCs, and worst for patients with AR-V7–positive CTCs (Antonarakis et al., 2017). **Similar findings were demonstrated using another commercially available platform based on digital imaging, which found that patients with nuclear expression of AR-V7 in CTCs responded better to taxane therapy than abiraterone or enzalutamide** (Scher et al., 2016).

Instead of capturing cells in circulation to evaluate gene expression, cell-free

DNA can be analyzed to detect and characterize circulating tumor DNA (ctDNA). The goal of these approaches is generally to profile a tumor's somatic alterations, which can then potentially be used for early detection or to inform prognosis and/or treatment in patients with known cancer. For example, the recently described CancerSEEK test combines ctDNA analysis with additional circulating markers in a single early detection assay covering multiple cancer types (Cohen et al., 2018). In advanced disease, ctDNA can inform the timing and mechanism of therapeutic resistance and potentially be used to guide subsequent treatment decisions (Goodall et al., 2017).

Urine-Based Biomarkers

PCA3

Given the ease of collecting urine specimens and the known shedding of prostate cells, urine has long held promise as a potential biomarker source in prostate cancer (Truong et al., 2013). It was not until relatively recently, however, that urinary biomarkers of prostate cancer have come into clinical use. The first of these, prostate cancer antigen 3 (PCA3), was initially described by Bussemakers et al. (1999), who used differential display and Northern blot analysis to compare normal and prostate cancer tissue. They were able to identify a prostate cancer–specific gene on chromosome 9q21-22 that, although it does not encode a protein, is one of the most sensitive and specific prostate cancer biomarkers. Although its function remains unknown, multiple studies have demonstrated that PCA3 is a long noncoding RNA (lncRNA) that is not expressed outside of the prostate, and PCA3 levels in malignant tissue generally far exceed levels in benign tissue (de Kok et al., 2002; Popa et al., 2007). **Early studies used reverse transcription polymerase chain reaction (RT-PCR) assays to detect PCA3 in urine and showed improved performance characteristics for PCA3 over PSA in diagnosing prostate cancer** (Hessels et al., 2003; van Gils et al., 2007).

More recently, a transcription-mediated amplification assay was developed, offering improved sensitivity and quantitation relative to standard RT-PCR (Groskopf et al., 2006). **This has become the commercial assay (Progensa, Hologic Inc.), which is CE marked and FDA approved (2012) to assist with decisions in the setting of a prior negative prostate needle biopsy.** To enhance the sensitivity of PCA3 detection, urine samples are collected after an “attentive” digital rectal examination (Fig. 149.8). This involves three firm strokes on each lobe of the prostate toward the median sulcus, and the first 20 to 30 mL of voided urine should be collected within 1 hour (Sokoll et al., 2008). The commercial PCA3 score is reported as the ratio of urine PCA3 mRNA/urine PSA mRNA × 1,000, thus normalizing PCA3 expression to PSA expression.

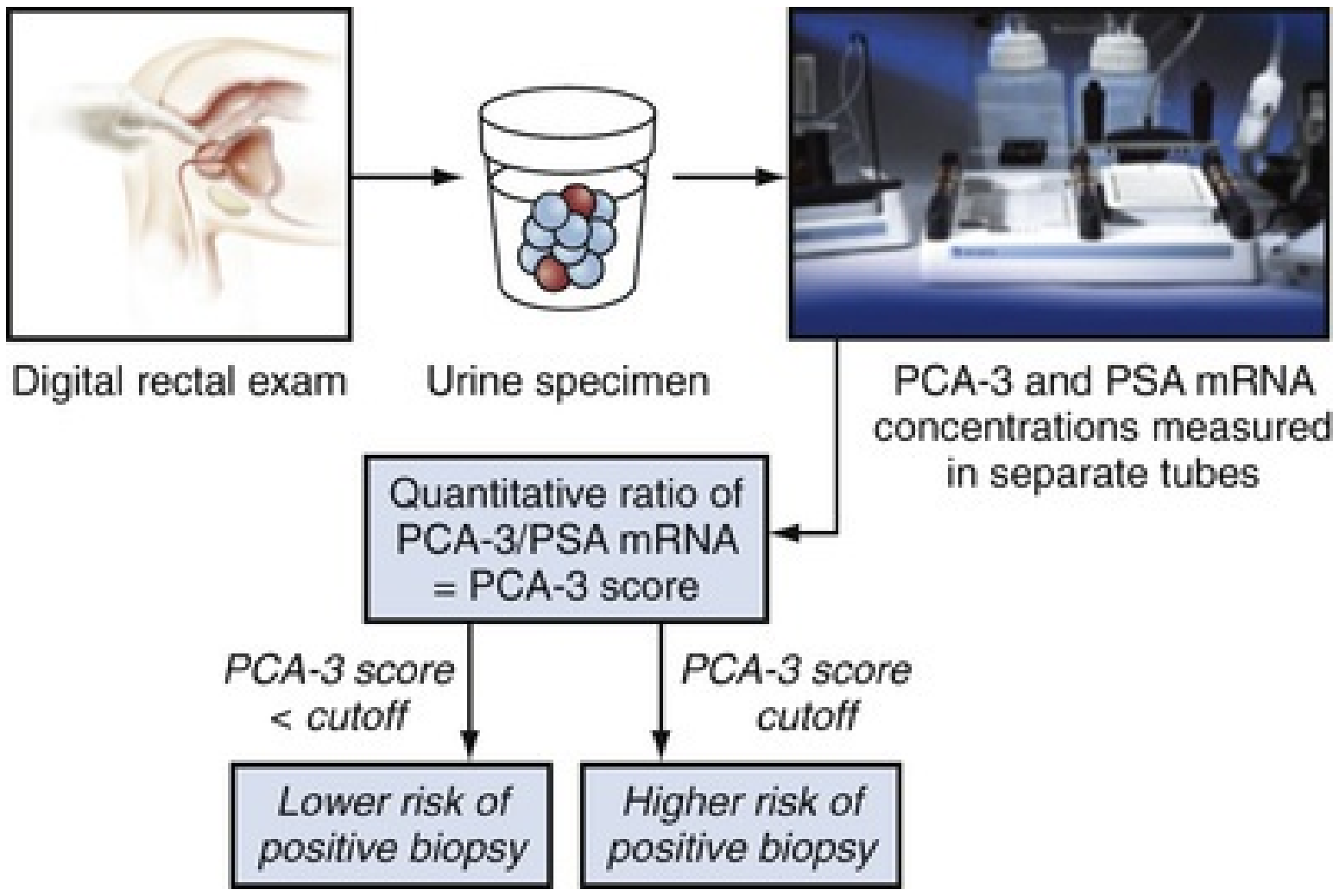
Digital rectal exam
Urine specimen
PCA-3 and PSA mRNA concentrations measured in separate tubes
Quantitative ratio of PCA-3/PSA mRNA = PCA-3 score
PCA-3 score < cutoff
PCA-3 score cutoff
Lower risk of positive biopsy
Higher risk of positive biopsy

FIG. 149.8 PCA3 assay protocol. After "attentive" digital rectal exam, urine is collected. RT-PCR determines the mRNA levels for PCA3 and PSA. The ratio between PCA3/PSA determines the PCA3 score. Prostate cancer risk level suggests need for biopsy. (From Groskopf J, Aubin SM, Deras IL, et al.: APTIMA PCA3 molecular urine test: development of a method to aid in the diagnosis of prostate cancer. *Clin Chem* 52:1089–1095, 2006.)

Numerous clinical studies have now been performed to evaluate the utility of urine PCA3 to serve as a prostate cancer biomarker, and all have shown that PCA3 scores are closely correlated with the likelihood of a positive biopsy (Alshalalfa et al., 2017; Deras et al., 2008; Hessels et al., 2003; Roobol et al., 2010b; van Gils et al., 2008). Deras et al. (2008) reported that men with a PCA3 below 5 had a 14% positive biopsy rate, compared with a 70% positive biopsy rate in men with PCA3 above 100. However, in another study, patients with PCA3 above 100 had only a 52% positive biopsy rate (Roobol et al., 2010a). Unlike PSA, PCA3 levels are independent of prostate size (Haese et al., 2008).

One of the critical challenges in using PCA3—or any biomarker reported as a continuous score rather than just "positive/negative"—is establishing appropriate cutoffs. Given that PCA3 scores represent a continuum of risk, different thresholds will lead to differences in sensitivity and specificity of the assay. Multiple cutoffs have been proposed, most commonly 10, 25, and 35 (Crawford et al., 2012; Haese et al., 2008). Haese et al. (2008) reported on a cutoff of 35, with positive biopsies in 39% of those above versus 22% in those below the threshold. In a comparative effectiveness review commissioned by the US Agency for Healthcare Quality and Research, Bradley et al. (2013) showed that a threshold of 25 results in a sensitivity of 74% and specificity of 57% (false-positive rate of 43%). **It is this lower threshold of 25 that was used in the**

FDA approval. However, different thresholds may be required for different patient populations of clinical scenarios. For example, using a PCA3 score of less than 20 in men with repeat prostate biopsy, Wei et al. (2014) reported a negative predictive value of 88%, and a sensitivity and specificity of 76% and 52%, respectively. However, in men being seen for an initial prostate biopsy using a PCA3 score of more than 60, Wei et al. reported a positive predictive value of 80% and a sensitivity and specificity of 42% and 91%, respectively (Wei et al., 2014).

There are increasing reports on the use of PCA3 in the initial screening setting of patients without a prior biopsy. Roobol et al. (2010b) reported on a cohort of 721 men, the majority of whom had not previously undergone a biopsy and showed that PCA3 (AUC 0.64) outperformed PSA (AUC 0.58) in predicting cancer on subsequent biopsy. In a prospective, community-based evaluation of PCA3 in 1962 men before any prostate biopsy, prostate cancer was detected in 61% of men with a PCA3 of at least 35 and 32% with a PCA3 below 35 (Crawford et al., 2012). The AUC for PCA3 was 0.71 compared with an AUC of 0.57 for PSA. Another study of 3073 men undergoing initial biopsy demonstrated that PCA3 was an independent predictor of any prostate cancer and high-grade prostate cancer after controlling for additional clinical variables (Chevli et al., 2014). Although PCA3 performed better than PSA for the detection of any cancer (AUC 0.70 vs. 0.60), they performed similarly for the detection of high-grade cancer (AUC 0.68 vs. 0.68).

To improve the predictive accuracy of PCA3, a number of nomograms have been developed that incorporate PCA3 along with other known clinical predictors to identify men most likely to have a positive prostate biopsy. For example, Chun et al. (2009) showed that PCA3 improves the accuracy of a base clinical model (AUC 0.73 vs. 0.68) and proposed a final model that incorporated a PCA3 cutoff of 17. Similarly, Ankerst et al. (2008) reported on an updated version of the Prostate Cancer Prevention Trial (PCPT) nomogram that includes PCA3 as a continuous variable. The final model outperformed the base PCPT model (0.70 vs. 0.65) and has been operationalized on the web (as in Fig. 149.4). Another nomogram incorporating PCA3 and clinical variables was developed by Elshafei et al. (2015) for predicting prostate cancer and high-grade prostate cancer in an initial biopsy setting with C-indices of 0.74 and 0.77, respectively, compared with 0.70 and 0.75, respectively, without PCA3. Given the available data, the comparative effectiveness review by Bradley et al. (2013) concluded that PCA3 appears to be superior to total PSA in diagnosing prostate cancer, but that further evidence is needed and there is not yet evidence that use of PCA3 leads to better health outcomes.

Gene Fusions

With the landmark discovery of the presence of gene fusions in prostate cancer by Tomlins et al. (2005), considerable work has been performed to determine their potential utility as prostate cancer biomarkers. **In particular, fusions of the 5′untranslated region of the androgen-regulated gene transmembrane protease, serine 2 (TMPRSS2) with v-ets erythroblastosis virus E26 oncogene homolog (ERG) or ets variant 1 (ETV1) were found to be nearly 100% specific for prostate cancer and present in at least 50% of PSA-screened prostate cancers. ERG and ETV1 are members of the erythroblastosis virus E26 transformation-specific (ETS) transcription factor family, and TMPRSS2:ERG fusions represent about 90% of all ETS gene fusions** (Tomlins et al., 2009; Young et al., 2012).

Although tissue-based detection of the fusion using either chromosomal analysis (i.e., fluorescence in situ hybridization) or immunohistochemical staining for ERG has shown some utility, this biomarker appears to have its greatest potential as a urine-based assay (Hessels et al., 2007; Laxman et al., 2006, 2008). A feasibility study that examined urine samples post-DRE confirmed that the *TMPRSS2:ERG* fusion can indeed be detected in the urine and may aid in the decision to proceed with a prostate biopsy (Laxman et al., 2008). Like PCA3, TMPRSSS2:ERG levels are normalized to urine PSA mRNA expression. Tomlins et al. (2011) reported on the development and use of a clinical grade assay based on transcription-mediated amplification (similar to the PCA3 assay) in 1312 men before prostate biopsy. TMPRSS2:ERG outperformed serum PSA for predicting the presence of prostate cancer with an AUC of 0.65 to 0.71 versus 0.59 to 0.61. In addition, in a subset of men who underwent prostatectomy, higher urine TMPRSS2:ERG score was associated with increased tumor volume, higher-grade disease, and non–organ-confined cancer.

Moving toward the concept that single biomarkers will probably not answer the important clinical questions in prostate cancer alone, many investigators have begun to multiplex markers, resulting in additive value. Specifically, given that TMPRSS2:ERG is found in only half of all prostate cancer foci (approximately 75% of men with cancer), its greatest utility will be in combination with other biomarkers. It has been evaluated closely in concert with

PCA3, and the two biomarkers together appear to provide improved performance over either one alone (Hessels et al., 2007; Laxman et al., 2008; Salami et al., 2013; Tomlins et al., 2016). In the 1312 patient cohort reported by Tomlins et al. (2011), combining TMPRSS2:ERG and PCA3 scores with the PCPT nomogram resulted in an AUC for predicting cancer of 075 to 0.79. TMPRSS2:ERG + PCA3 score groups were also shown to correlate with features of disease aggressiveness such as Gleason grade, although data in this area continue to be mixed (Gopalan et al., 2009; Leyten et al., 2014).

Three other large studies have reported on the combination of TMPRSS2:ERG and PCA3 for predicting the presence of prostate cancer (Sanda et al., 2017). Cornu et al. (2013) showed that PCA3 and TMPRSS2:ERG were independent predictors of prostate cancer in a multivariable model that also included other clinical parameters. Leyten et al. (2014) reported on the prospective use of the combined assay in 497 patients at 6 centers in Europe. The combination of PCA3 and TMPRSS2:ERG increased the performance of the European Randomized Study of Screening for Prostate Cancer (ERSPC) risk calculator from an AUC of 0.80 to 0.84. In addition, the sensitivity of PCA3 increased from 68% to 76% when TMPRSS2:ERG was added. More recently, Sanda et al. (2017) reported that combined testing of urinary T2:ERG and PCA3 at thresholds that preserved 95% sensitivity for detecting aggressive prostate cancer improved specificity from 18% to 39% in the training cohort and from 17% to 33% in the validation cohort. Further, 42% of unnecessary prostate biopsies would have been avoided using the combined urine assay, with the greatest potential benefit in younger men. Currently, the combined test is commercially available as The Mi-Prostate Score (MiPS, University of Michigan Health System), combining serum PSA, urine PCA3, and urine TMPRSS2:ERG to provide a quantitative risk estimate of the likelihood of detecting prostate cancer on prostate biopsy as well as the probability of detecting high-grade cancer (Tomlins et al., 2016). This test may also have a role in the management of patients on active surveillance for prostate cancer, because it has been correlated with features of tumor aggressiveness in a prospective active surveillance cohort (Lin et al., 2013).

Other Urine Biomarkers

Recently, Van Neste et al. (2016) reported that HOXC6 and DLX1 mRNA levels in urine in combination with clinical factors improved the detection of high-grade prostate cancer with overall AUC of 0.86 and 0.90 in the training and validation cohorts, respectively. The authors performed a decision curve analysis, which revealed a strong net benefit with the best reduction in unnecessary biopsies compared with other clinical decision-making tools, such as the PCPT risk calculator and the PCA3 assay. This assay is now commercially available as the SelectMDx test.

Annexin A3

Another potential urine-based prostate cancer biomarker is annexin A3, which is inversely related to the presence of prostate cancer. This protein is part of a family of calcium and phospholipid binding proteins that have been shown to be altered in cancer (Köllermann et al., 2008; Wozny et al., 2007). Evaluating annexin A3 concentrations in post-DRE urine before prostate needle biopsy, Schostak et al. (2009) evaluated the potential clinical utility of urine-based annexin A3, either as a stand-alone biomarker or together with PSA. In a blinded study that consisted of training and evaluation sets of 243 and 264 men, respectively, these investigators showed that annexin A3 added to the ability of PSA to predict a positive needle biopsy with a combined AUC of 0.81. Using a multiplex approach, Cao et al. (2011) reported on the combination of urine annexin A3, PCA3, TMPRSS2:ERG, and sarcosine to help identify patients with prostate cancer. The multi-marker model demonstrated a high level of predictive accuracy with an AUC of 0.84 in patients with PSA 4 to 10 ng/mL and an AUC of 0.86 across all patients in their cohort.

miRNA

Based upon the realization that a majority of the DNA in the genome does not encode protein sequences, the utility of these sequences in the regulation of gene expression has been under intense investigation. Among the most important components of this regulation are microRNAs (miRNAs). These are small (approximately 19–22 nucleotide) noncoding, single-strand RNAs involved in the regulation of mRNA. They have been detected in a wide range of biologic fluid and are being explored as potential biomarkers in across a variety of malignancies. Given their potential mechanistic role, they may provide diagnostic and prognostic information. In prostate cancer, miR-141 has shown promise in a number of studies in terms of its association not only with prostate cancer but potentially also with disease aggressiveness (Bryant et al., 2012;

Mitchell et al., 2008). In addition, Casanovas-Salas et al. (2014) recently reported that urine miR-187 is an independent predictor of prostate cancer at needle biopsy. Although these findings must be expanded to larger populations of individuals, this remains a promising family of potential markers.

Tissue-Based Biomarkers

α-Methylacyl Coenzyme A Racemase

α-methylacyl coenzyme A racemase *(AMACR)* gene, located on chromosome 5, is upregulated in prostate cancer tissues (Luo et al., 2002; Rubin et al., 2002). *AMACR* functions as an enzyme responsible for the beta-oxidation of branched-chain fatty acids obtained in diets consisting of beef and dairy products. Luo et al. (2002) demonstrated that 88% of prostate cancer cases and untreated metastasis and hormone-refractory prostate cancers were strongly positive for *AMACR*. Immunohistochemical studies by Rubin et al. (2002) have shown that *AMACR* expression in biopsy tissue may provide 97% sensitivity and 100% specificity for prostate cancer detection. Furthermore, in combination with other markers, such as TP63, that aid in identifying basal cells absent in prostate cancer, measurement of *AMACR* has potential for the development of molecular probes to aid in the detection of prostate cancer. As a result, *AMACR* immunostaining is sometimes performed on prostate needle biopsies to confirm the presence of cancer. *AMACR* may also have some prognostic utility: decreased staining levels are associated with an increased risk of disease progression (Rubin et al., 2005). Although other roles for *AMACR* as a biomarker have shown some promise—for example, as a urinary assay for prostate cancer detection—the performance of serum and urine tests has not been sufficient to warrant clinical use to date.

Epigenetic Modifications

Changes in gene expression may occur as a result of alterations in DNA, and epigenetic changes are those not caused by alterations in DNA sequence. These epigenetic modifications include changes in DNA methylation and histone acetylation status. Segments within the gene promoter that are composed of GC-rich regions are termed CpG islands. **Alterations in the methylation status of these regions may affect gene expression and have been shown to play a role in carcinogenesis** (Jones and Baylin, 2002). Furthermore, cumulative effects of environmental exposures, such as diet and stress throughout life, may affect DNA methylation status and thus contribute to the risk of cancer development (Li et al., 2004). **The products of a number of hypermethylated genes have**

been implicated in prostate cancer development, including glutathione-*S*-transferase π *(GSTP1)*, adenomatous polyposis coli *(APC)*, retinoic acid receptors beta 2 *(RARβ2)*, and RAS association domain family protein isoform A *(RASSF1A)* (Mahapatra et al., 2012)**.**

GSTP1 belongs to a family of detoxifying enzymes that are involved in metabolic reduction of electrophilic carcinogens and was the first tissue methylation-biomarker to be discovered. Li et al. (2004) noted that the *GSTP1* gene was unmethylated in all normal human tissues and BPH but was hypermethylated in all 20 prostate cancer specimens analyzed. Harden et al. (2003a,b) used PCR to detect hypermethylated *GSTP1* in prostate biopsy specimens, and *GSTP1* methylation was detected in 11 of 15 (73% sensitivity) prostate cancer cases and in none of 14 (100% specificity) benign controls. Quantitation of *GSTP1* hypermethylation accurately detected CaP even in small, limited tissue samples. Elevated levels of *GSTP1* CpG hypermethylation have been detected in tissues from precancerous lesions (atypia and prostatic intraepithelial neoplasia [PIN]) and within ejaculates, urine, and plasma from men with prostate cancer (Bastian et al., 2005; Nakayama et al., 2003). Cairns et al. (2001) have demonstrated the presence of elevated *GSTP1* hypermethylation in up to 79% of prostate cancer specimens. *GSTP1* methylation appears to occur early in prostate carcinogenesis, and methylation levels may correlate with features of tumor aggressiveness (Jerónimo et al., 2001; Zhou et al., 2004). In a recent meta-analysis, *GSTP1* promoter hypermethylation was shown to have a sensitivity of 82% and specificity of 95% for distinguishing malignant from normal prostate tissue (Van Neste et al., 2012).

In addition to *GSTP1*, hypermethylation of other genes has also been noted to occur in close to 100% of prostate cancers (Mahapatra et al., 2012). *APC* is a tumor suppressor involved in apoptosis and cell migration, and mutation of *APC* is often an early event in the colon carcinogenesis. In a retrospective analysis assessing patients with newly diagnosed prostate cancer, *APC* methylation was associated with an independent 50% increase in the likelihood of death from prostate cancer (Richiardi et al., 2009). *RASSF1*, a gene involved in cell cycle regulation, and *RARβ2*, a nuclear transcriptional regulator, are other key genes methylated in a large proportion of prostate cancers and shown to distinguish benign from malignant prostate in a number of studies (Van Neste et al., 2012; Zon et al., 2009).

Perhaps the most clinically relevant aspect of these methylation changes is the discovery that they are frequently detectable in normal tissue adjacent to tumors but not in normal tissue well away from the primary tumor (Richiardi et al., 2013). Thus these changes may be useful indicators of the field effect that has long been known to exist: the presence of molecular changes in histologically normal tissue bordering a tumor. In patients with a prior negative biopsy, the identification of these molecular changes in the original biopsy tissue may suggest an increased likelihood of occult prostate cancer. Trock et al. (2012) showed that methylation of *APC* in histologically negative prostate biopsies predicted the presence of prostate cancer in 86 men undergoing repeat biopsy, with a negative predictive value (NPV) of 0.96 and sensitivity of 0.95. Using a quantitative commercial methylation assay (ConfirmMDx, MDxHealth, Inc.) that assesses methylation of *GSTP1*, *APC*, and *RASSF1*, Stewart et al. (2013) showed an NPV of 0.90 and sensitivity of 0.68. In this retrospective study, methylation status was an independent predictor of the presence of prostate cancer on repeat biopsy. Similarly, in a multi-institutional analysis of 350 subjects, Partin et al. (2014) demonstrated that the epigenetic assay assessing methylation of *GSTP1*, *APC*, and *RASSF1* resulted in an NPV of 88% (95% CI 85–91) in patients undergoing repeat prostate biopsy. In a recent analysis of 211 African-American men undergoing repeat prostate biopsy, ConfirmMDx was shown to have a sensitivity and specificity of 74.1% and 60.0%, respectively, for prostate cancer detection and 78% and 53%, respectively, for Gleason score ≥ 7 disease (Waterhouse et al., 2018). The NPVs for detection of all prostate cancer and Gleason score ≥ 7 disease were 78.8% and 94.2%, respectively. These findings suggest accurate identification of at-risk patients based on the “halo effect” of aberrant methylation.

Genomic Expression Profiles

For more than a decade, a great deal of attention has been devoted to discovering large sets of genes that, when evaluated together as a single biomarker assay, perform better than any individual gene on its own. Relatively recent advances in genomics have facilitated the evaluation of gene expression in formalin-fixed paraffin-embedded (FFPE) tissue, meaning prostate-archived prostate specimens can be interrogated for expression of gene profiles that are associated with aggressive disease features. Gene expression profiling has been explored in numerous settings, resulting in genomic classifiers for response to chemotherapy in breast and colorectal cancers (Del Rio et al., 2007; Iwao-Koizumi et al., 2005; Sparano et al., 2018).

A number of LDTs using genomic expression profiling for risk stratification in men with prostate cancer are now being developed and commercialized. This includes Prolaris (Myriad Genetics, Inc.), Oncotype Dx Prostate (Genomic Health, Inc.), and Decipher (GenomeDx Biosciences, Inc). The Prolaris test assesses 31 cell cycle progression (CCP) genes and 15 housekeeping genes, and a number of studies have demonstrated an association between this gene signature and the risk of progression and death from prostate cancer (Cuzick et al., 2011, 2012). Cuzick et al. (2012) reported that, in a conservatively managed cohort, Prolaris score was an independent predictor of prostate cancer specific death. In men who underwent subsequent prostatectomy, Bishoff et al. (2014) retrospectively assessed the performance of this assay on prostate needle biopsies and demonstrated that Prolaris score was an independent predictor of biochemical recurrence and metastasis. Recently, Cooperberg et al. (2013) incorporated the Prolaris score with the CAPRA score and reported improved performance for predicting biochemical recurrence after radical prostatectomy. Similarly, Prolaris score has been shown to predict outcomes in men undergoing external beam radiation therapy for prostate cancer, including prostate cancer–specific mortality (Freedland et al., 2013).

The Oncotype Dx Prostate classifier uses 12 cancer-related genes in 4 biologic pathways and 5 housekeeping genes to predict the likelihood of aggressive pathological features at the time of prostatectomy (Knezevic et al., 2013). This is defined as primary Gleason pattern 4 or pT3 disease at prostatectomy. Like Prolaris, Oncotype Dx is primarily intended to help with management decisions in patients with newly diagnosed prostate cancer regarding active surveillance or primary treatment and has been extensively validated for its clinical outcome (Cullen et al., 2015; Eure et al., 2017; Klein et al., 2014).

Last, the Decipher assay is a 22-marker genomic classifier initially developed for use in the post-prostatectomy setting (Erho et al., 2013). In men with high-risk disease and those with biochemical recurrence, the genomic classifier was demonstrated to be independently associated with the development of metastatic disease and prostate cancer–specific mortality (Karnes et al., 2013, 2018; Ross et al., 2014; Spratt et al., 2018). In a recent meta-analysis, Spratt et al. (2017) classified patients by Decipher as low-, intermediate-, and high-risk categories with 10-year cumulative incidence of metastases after radical prostatectomy of 5.5%, 15.0%, and 26.7% ($P < .001$), respectively. In this post-prostatectomy setting, Decipher may be used to guide decision making regarding adjuvant or salvage radiation therapy and retrospective data that patients with higher Decipher scores (≥0.4) may benefit from postoperative radiation (Dalela et al., 2017; Den et al., 2015; Gore et al., 2017). Building on these findings and using the GenomeDx Decipher database, Zhao et al. developed a 24-gene biomarker signature, PORTOS (Post-Operative Radiation Therapy Outcomes Score) to predict response to adjuvant radiation therapy. Decipher is now also available for clinical use in patients with newly diagnosed prostate cancer to potentially assist with initial management decisions, based on more recent biopsy data (Nguyen et al., 2017).

Although these tissue-based prognostic biomarker tests are increasingly used in the evaluation of patients with early stage prostate cancer to assess tumor aggressiveness, recent studies suggest that these assays may not be robust to tumor multifocality and heterogeneity. For example, Wei et al. (2017) observed discordant RNA expression profiles across distinct foci of prostate cancer obtained from the same patient. A more recent analysis of grade-discordant multifocal prostate cancer demonstrated that derived Prolaris, Oncotype Dx, and Decipher scores of low-grade prostate cancers do not predict the concomitant presence of an unsampled high-grade cancer from the same patient (Hovelson et al., 2018). Although there is likely a role for these tissue-based prognostic biomarkers in the management of prostate cancer, almost all of the published data have been from retrospective studies. The Genomics in Michigan ImpactiNg Observation or Radiation study is an ongoing prospective randomized trial assessing the impact of Decipher on decision making and outcomes after prostatectomy for men at high risk of local recurrence (NCT02783950).

Inherited Genetic Markers

Up to 40% to 50% of prostate cancer risk may be related to familial and hereditary factors (Lichtenstein et al., 2000). Familial prostate cancer is a broad term that encompasses 15% to 20% of cases and can include those patients with a strong family history of prostate cancer but no detectable genetic mutations (Giri and Beebe-Dimmer, 2016). Having a relative with prostate cancer increases risk of developing the disease by two- to fourfold (Goldgar et al., 1994; Liss et al., 2015). Single nucleotide polymorphisms (SNPs) are common genetic variants that may or may not have a functional role but are associated with an increased risk of prostate cancer and likely factor into many of these familial cases. Men possessing more than four prostate cancer–related SNPs have a 4.5-fold increase in risk of developing prostate cancer, and this risk increases to 10-fold for men with a family history of prostate cancer (Zheng et al., 2008). An example of SNPs being brought into practice is the STHLM3 biomarker test. This assay incorporates the four kallikreins that are part of the 4Kscore along with 232 risk SNPs and relevant clinical variables to form a composite prostate cancer early detection assay with an AUC of 0.74 for detecting Gleason score ≥7 prostate cancers (Eklund et al., 2018; Grönberg et al., 2015).

A number of genes have been implicated in heritable prostate cancer, most of which have important roles in the DNA damage repair machinery. These include *BRCA1*, *BRCA2*, *CHEK2*, *ATM*, and *PALB2*, along with mismatch repair mutations responsible for Lynch syndrome (*MLH1*, *MSH2*, *MSH6*, and *PMS2*). *BRCA1* and *BRCA2* are critical proteins in the process of homologous recombination, and pathogenic mutations in these genes have long been known to increase the risk of breast and ovarian cancers in women (Yoshida and Miki, 2004). More recently, *BRCA1* and *BRCA2* mutations in men have been associated with a significant increase in the risk of prostate cancer, and **men with pathogenic *BRCA2* mutations are diagnosed at a younger age, have higher Gleason grade tumors, and have a shorter median survival time than men with sporadic prostate cancers** (Mitra et al., 2008; Tryggvadóttir et al., 2007). For men under age 65 years, *BRCA1* carriers who have a 1.8-fold increased risk of prostate cancer and *BRCA2* carriers a 4.5-fold increased risk of prostate cancer compared with noncarriers (Thompson et al., 2002). Across all ages, Kote-Jarai et al. (2011) report an **estimated 8.6-fold increased risk of prostate cancer in *BRCA2*-positive men**. Although Lynch syndrome is well known to be associated with colorectal, liver, skin, and upper urinary tract cancers, **men with Lynch syndrome are also at an increased risk of developing prostate cancer.** A study of 821 male Lynch syndrome carriers reported a 10-fold increase in relative risk of prostate cancer for *MSH2* carriers (Barrow et al., 2013).

Other key genes include *ATM* and *CHEK2*, involved in double-strand DNA break repair, as well as the homeobox protein HOXB13, and all of these may be used as a potential marker of prostate cancer risk. The Hale et al. (2014) pooled analysis of five studies shows that *CHEK2* carriers have a prostate cancer odds ratio of 1.98 and 3.39 in unselected and familial cases, respectively. The *HOXB13 G84E* variant was identified as a key prostate cancer risk gene through familial linkage studies, and the relative risk for prostate cancer increases in mutation carriers by 4.5-fold (Ewing et al., 2012; Huang and Cai, 2014). There is no evidence that *HOXB13* increases the risk of aggressive cancers, however.

Next generation sequencing (NGS)–based testing is clinically available for

single genes such as for *BRCA1* or *BRCA2*, but multi-gene panel testing has become more common in the absence of a known familial mutation. For prostate cancer, these panels typically include *BRCA1*, *BRCA2*, *ATM*, *CHEK2*, *MLH1*, *MSH2*, *TP53*, and *EPCAM*, among others specific to the individual commercial platform. Importantly, although many of the genes included in these panels have a clear association with prostate cancer risk, others carry a still unknown clinical significance with poorly defined cancer risk. National Comprehensive Cancer Network (NCCN) recommendations focus on *BRCA* testing at this point (Hall et al., 2014). Identification of *BRCA* mutations—or potentially these other mutations causing increased prostate cancer risk—could have important implications for early detection and management of patients at high risk of developing prostate cancer (Bancroft et al., 2014).

Summary

Early detection when cancer remains confined to the prostate not only improves cure rates but also decreases mortality from this disease. Although the discovery and application of PSA have revolutionized current prostate cancer detection and management, stage migration and changes in the natural history of this cancer have outrun the currently maximized application of this tumor marker. Application of various PSA derivatives, although improving sensitivity, risks impairing specificity. The discovery of molecular derivatives of PSA, PCA3, new kallikrein markers, and gene rearrangements are leading to significant improvements in the efficiency of prostate cancer detection.

Innovations and new understanding in the field of molecular oncology have provided a host of potential prostate cancer tumor markers. Because prostate cancer has been shown to be a heterogeneous disease, application of a panel of markers will probably ultimately provide added sensitivity and specificity for detection of the disease. Identification of hypermethylated regions, such as for *GSTP1*, as well as tissue-based genomic classifiers may substantially improve the diagnostic and prognostic potential of prostate needle biopsies. Development of these markers from research into clinically applicable tools will require clear demonstration of clinical validity and clinical utility, showing that these new assays have a real impact in the clinical care of men with prostate cancer.

Key Points

- PSMA has been identified in the central nervous system, intestine, and prostate and now serves as an important target for advanced molecular imaging.
- PSA is a member of the human kallikrein gene family. PSA and human kallikrein-2 have been used in prostate cancer detection.
- Ectopic expression of PSA occurs in breast tissue, adrenal, and renal carcinomas.
- PSA is organ specific, not disease specific; its half-life is 2 to 3 days.
- 5α-reductase inhibitors reduce serum PSA by 50%.
- Prostate cancer cells make less PSA than normal prostate tissue, gram for

gram. PSA expression is strongly influenced by androgens. Ejaculation can lead to a false increase in PSA.

- Seventy percent of serum PSA is bound to three proteins: α_2-macroglobulin, α_1-protease inhibitor, and α_1-antichymotrypsin. Patients with prostate cancer have a higher fraction of circulating PSA bound to these proteins, that is, they have a lower free PSA.
- When PSA is released from the cell, a portion of an attached amino acid chain is cleaved, leaving a smaller amino acid chain attached, which inactivates its biologic activity. This molecule is termed proPSA. When this amino acid chain is cleaved from proPSA, PSA becomes active as a serum protease. ProPSA may be used to diagnose prostate cancer.
- PCA3 is a urine-based marker used in the diagnosis of prostate cancer. It can be combined with detection of the TMPRSS2:ERG gene fusion to improve diagnostic accuracy.
- Circulating tumor cells and circulating tumor DNA are promising sources of biomarkers, particularly in advanced prostate cancer.
- Tissue-based gene expression signatures are commercially available and can be performed on small amounts of formalin-fixed paraffin-embedded tissue and may provide additional prognostic information beyond Gleason score and other clinical parameters.
- Prostate cancer susceptibility genes have been located on a number of chromosomes increase the risk of developing prostate cancer.
- Key inherited genes with moderate penetrance that increase the risk of aggressive prostate cancer are *BRCA1*, *BRCA2*, and *ATM*. These are all DNA damage repair genes.

Suggested Readings

Bancroft EK, Page EC, Castro E, et al. Targeted prostate cancer screening in BRCA1 and BRCA2 mutation carriers: results from the initial screening round of the IMPACT Study. *Eur Urol*. 2014;66:489–499.

Byrne JC, Downes MR, O'Donoghue N, et al. 2D-DIGE as a strategy to identify serum markers for the progression of prostate cancer. *J Proteome Res*. 2009;8(2):942–957.

de Bono JS, Scher HI, Montgomery RB, et al. Circulating tumor cells predict survival benefit from treatment in metastatic castration-resistant prostate cancer. *Clin Cancer Res*. 2008;14(19):6302–6309 [Erratum in: Clin Cancer Res. 2009;15(4):1506].

Chevli KK, Duff M, Walter P, et al. Urinary PCA3 as a predictor of prostate cancer in a cohort of 3,073 men undergoing initial prostate biopsy. *J Urol*. 2014;191:1743–1748.

Cucchiara V, Cooperberg MR, Dall'Era M, et al. Genomic markers in prostate cancer decision making. *Eur Urol*. 2018;73:572–582.

Ewing CM, Ray AM, Lange EM, et al. Germline mutations in HOXB13 and prostate-cancer risk. *N Engl J Med*. 2012;366(2):141–149.

Hu R, Dunn TA, Wei S, et al. Ligand-independent androgen receptor variants derived from splicing of cryptic exons signify hormone-refractory prostate cancer. *Cancer Res*. 2009;69(1):16–22.

Karnes RJ, Bergstralh EJ, Davicioni E, et al. Validation of a genomic classifier that predicts metastasis following radical prostatectomy in an at risk patient population. *J Urol*. 2013;190(6):2047–2053.

Lazzeri M, Haese A, de la Taille A, et al. Serum isoform [-2]proPSA derivatives significantly improve prediction of prostate cancer at initial biopsy in a total PSA range of 2-10 ng/ml: a multicentric European study. *Eur Urol*. 2013;63(6):986–994.

Polascik TJ, Oesterling JE, Partin AW. Prostate specific antigen: a decade of discovery—what we have learned and where we are going. *J Urol*. 1999;162:293–306.

Roobol MJ, Schröder FH, van Leeuwen P, et al. Performance of the prostate cancer antigen 3 (PCA3) gene and prostate-specific antigen in prescreened men: exploring the value of PCA3 for a first-line diagnostic test. *Eur Urol*. 2010;58(4):475–481.

Sokoll LJ, Wang Y, Feng Z, et al. [-2]Proenzyme prostate specific antigen for prostate cancer detection: a National Cancer Institute early detection research network validation study. *J Urol*. 2008;180:539–543.

Tomlins SA, Rhodes DR, Perner S, et al. Recurrent fusion of TMPRSS2 and ETS transcription factor genes in prostate cancer. *Science*. 2005;310(5748):644–648.

Vickers A, Cronin A, Roobol M, et al. Reducing unnecessary biopsy during prostate cancer screening using a four-kallikrein panel: an independent replication. *J Clin Oncol*. 2010;28(15):2493–2498.

References

Ablin RJ, Soanes WA, Bronson P, et al. Precipitating antigens of the normal human prostate. *J Reprod Fertil*. 1970;22:573–574.

Alshalalfa M, Verhaegh GW, Gibb EA, et al. Low PCA3 expression is a marker of poor differentiation in localized prostate tumors: exploratory analysis from 12,076 patients. *Oncotarget*. 2017;8:50804–50813.

Aminsharifi A, Howard L, Wu Y, et al. Prostate specific antigen density as a predictor of clinically significant prostate cancer when the prostate specific antigen is in the diagnostic gray zone: defining the optimum cutoff point stratified by race and body mass index. *J Urol*. 2018;200:758–766.

Andriole GL, Crawford ED, Grubb RL, et al. Mortality results from a randomized prostate-cancer screening trial. *N Engl J Med*. 2009;360:1310–1319.

Ankerst DP, Groskopf J, Day JR, et al. Predicting prostate cancer risk through incorporation of prostate cancer gene 3. *J Urol*. 2008;180:1303–1308 [discussion 1308].

Ankerst DP, Koniarski T, Liang Y, et al. Updating risk prediction tools: a case study in prostate cancer. *Biom J*. 2012;54:127–142.

Antonarakis ES, Lu C, Luber B, et al. Clinical significance of androgen receptor splice variant-7 mRNA detection in circulating tumor cells of men with metastatic castration-resistant prostate cancer treated with first- and second-line abiraterone and enzalutamide. *J Clin Oncol*. 2017;35(19):2149–2156.

Antonarakis ES, Lu C, Wang H, et al. AR-V7 and resistance to enzalutamide and abiraterone in prostate cancer. *N Engl J Med*. 2014;371:1028–1038.

Armitage TG, Cooper EH, Newling DW, et al. The value of the measurement of serum prostate specific antigen in patients with benign prostatic hyperplasia and untreated prostate cancer. *Br J Urol*. 1988;62:584–589.

Auprich M, Augustin H, Budäus L, et al. A comparative performance analysis of total prostate-specific antigen, percentage free prostate-specific antigen, prostate-specific antigen velocity and urinary prostate cancer gene 3 in the first, second and third repeat prostate biopsy. *BJU Int*. 2012;109:1627–1635.

Aus G, Becker C, Lilja H, et al. Free-to-total prostate-specific antigen ratio as a predictor of non-organ-confined prostate cancer (stage pT3). *Scand J Urol Nephrol*. 2003;37:466–470.

Bancroft EK, Page EC, Castro E, et al. Targeted prostate cancer screening in BRCA1 and BRCA2 mutation carriers: results from the initial screening round of the IMPACT Study. *Eur Urol*. 2014;66:489–499.

Barrett JA, Coleman RE, Goldsmith SJ, et al. First-in-man evaluation of 2 high-affinity PSMA-avid small molecules for imaging prostate cancer. *J Nucl Med*. 2013;54:380–387.

Barrow PJ, Ingham S, O'Hara C, et al. The spectrum of urological malignancy in Lynch syndrome. *Fam Cancer*. 2013;12:57–63.

Bastian PJ, Ellinger J, Wellmann A, et al. Diagnostic and prognostic information in prostate cancer with the help of a small set of hypermethylated gene loci. *Clin Cancer Res*. 2005;11:4097–4106.

Becker C, Piironen T, Kiviniemi J, et al. Sensitive and specific immunodetection of human glandular kallikrein 2 in serum. *Clin Chem*. 2000;46:198–206.

Becker C, Piironen T, Pettersson K, et al. Discrimination of men with prostate cancer from those with benign disease by measurements of human glandular kallikrein 2 (HK2) in serum. *J Urol*. 2000;163:311–316.

Bishoff JT, Freedland SJ, Gerber L, et al. Prognostic utility of the cell cycle progression score generated from biopsy in men treated with prostatectomy. *J Urol*. 2014;192:409–414.

Bradley LA, Palomaki GE, Gutman S, et al. Comparative effectiveness review: prostate cancer antigen 3 testing for the diagnosis and management of prostate cancer. *J Urol*. 2013;190:389–398.

Bryant RJ, Pawlowski T, Catto JWF, et al. Changes in circulating microRNA levels associated with prostate cancer. *Br J Cancer*. 2012;106:768–774.

Bussemakers MJ, van Bokhoven A, Verhaegh GW, et al. DD3: a new prostate-specific gene, highly overexpressed in prostate cancer. *Cancer Res*. 1999;59:5975–5979.

Cairns P, Esteller M, Herman JG, et al. Molecular detection of prostate cancer in urine by GSTP1 hypermethylation. *Clin Cancer Res*. 2001;7:2727–2730.

Canto EI, Singh H, Shariat SF, et al. Serum BPSA outperforms both total PSA and free PSA as a predictor of prostatic enlargement in men without prostate cancer. *Urology*. 2004;63:905–910 [discussion 910–1].

Cao D-L, Ye D-W, Zhang H-L, et al. A multiplex model of combining gene-based, protein-based, and metabolite-based with positive and negative markers in urine for the early diagnosis of prostate cancer. *Prostate*. 2011;71:700–710.

Carlsson S, Maschino A, Schröder F, et al. Predictive value of four kallikrein markers for pathologically insignificant compared with aggressive prostate cancer in radical prostatectomy specimens: results from the European Randomized Study of Screening for Prostate Cancer section Rotterdam. *Eur Urol*. 2013;64:693–699.

Carroll PH, Mohler JL. NCCN guidelines updates: prostate cancer and prostate cancer early detection. *J Natl Compr*

Canc Netw. 2018;16:620–623.

Carter HB, Pearson JD, Metter EJ, et al. Longitudinal evaluation of prostate-specific antigen levels in men with and without prostate disease. *J Am Med Assoc*. 1992;267:2215–2220.

Carter HB, Partin AW, Luderer AA, et al. Percentage of free prostate-specific antigen in sera predicts aggressiveness of prostate cancer a decade before diagnosis. *Urology*. 1997;49:379–384.

Casanova-Salas I, Rubio-Briones J, Calatrava A, et al. Identification of miR-187 and miR-182 as biomarkers of early diagnosis and prognosis in patients with prostate cancer treated with radical prostatectomy. *J Urol*. 2014;192(1):252–259.

Catalona WJ, Beiser JA, Smith DS. Serum free prostate specific antigen and prostate specific antigen density measurements for predicting cancer in men with prior negative prostatic biopsies. *J Urol*. 1997;158:2162–2167.

Catalona WJ, Partin AW, Slawin KM, et al. Use of the percentage of free prostate-specific antigen to enhance differentiation of prostate cancer from benign prostatic disease: a prospective multicenter clinical trial. *J Am Med Assoc*. 1998;279:1542–1547.

Catalona WJ, Smith DS, Ratliff TL, et al. Measurement of prostate-specific antigen in serum as a screening test for prostate cancer. *N Engl J Med*. 1991;324:1156–1161.

Chang SS, O'Keefe DS, Bacich DJ, et al. Prostate-specific membrane antigen is produced in tumor-associated neovasculature. *Clin Cancer Res*. 1999;5:2674–2681.

Chevli KK, Duff M, Walter P, et al. Urinary PCA3 as a predictor of prostate cancer in a cohort of 3,073 men undergoing initial prostate biopsy. *J Urol*. 2014;191:1743–1748.

Christensson A, Björk T, Nilsson O, et al. Serum prostate specific antigen complexed to alpha 1-antichymotrypsin as an indicator of prostate cancer. *J Urol*. 1993;150:100–105.

Christensson A, Laurell CB, Lilja H. Enzymatic activity of prostate-specific antigen and its reactions with extracellular serine proteinase inhibitors. *Eur J Biochem*. 1990;194:755–763.

Chun FK, la Taille de A, van Poppel H, et al. Prostate cancer gene 3 (PCA3): development and internal validation of a novel biopsy nomogram. *Eur Urol*. 2009;56:659–667.

Clements JA. The glandular kallikrein family of enzymes: tissue-specific expression and hormonal regulation. *Endocr Rev*. 1989;10:393–419.

Cohen JD, Li L, Wang Y, et al. Detection and localization of surgically resectable cancers with a multi-analyte blood test. *Science*. 2018;1 [eaar3247].

Cohen SJ, Punt CJA, Iannotti N, et al. Relationship of circulating tumor cells to tumor response, progression-free survival, and overall survival in patients with metastatic colorectal cancer. *J Clin Oncol*. 2008;26:3213–3221.

Cooperberg MR, Brooks JD, Faino AV, et al. Refined analysis of prostate-specific antigen kinetics to predict prostate cancer active surveillance outcomes. *Eur Urol*. 2018;74:211–217.

Cooperberg MR, Simko JP, Cowan JE, et al. Validation of a cell-cycle progression gene panel to improve risk stratification in a contemporary prostatectomy cohort. *J Clin Oncol*. 2013;31:1428–1434.

Cornu J-N, Cancel-Tassin G, Egrot C, et al. Urine TMPRSS2:ERG fusion transcript integrated with PCA3 score, genotyping, and biological features are correlated to the results of prostatic biopsies in men at risk of prostate cancer. *Prostate*. 2013;73:242–249.

Crawford ED, Rove KO, Trabulsi EJ, et al. Diagnostic performance of PCA3 to detect prostate cancer in men with increased prostate specific antigen: a prospective study of 1,962 cases. *J Urol*. 2012;188:1726–1731.

Cristofanilli M, Budd G, Ellis M, et al. Circulating tumor cells, disease progression, and survival in metastatic breast cancer. *N Engl J Med*. 2004;351:781–791.

Cullen J, Rosner IL, Brand TC, et al. A biopsy-based 17-gene genomic prostate score predicts recurrence after radical prostatectomy and adverse surgical pathology in a racially diverse population of men with clinically low- and intermediate-risk prostate cancer. *Eur Urol*. 2015;68:123–131.

Cuzick J, Berney DM, Fisher G, et al. Prognostic value of a cell cycle progression signature for prostate cancer death in a conservatively managed needle biopsy cohort. *Br J Cancer*. 2012;106:1095–1099.

Cuzick J, Swanson GP, Fisher G, et al. Prognostic value of an RNA expression signature derived from cell cycle proliferation genes in patients with prostate cancer: a retrospective study. *Lancet Oncol*. 2011;12:245–255.

Dalela D, Santiago-Jiménez M, Yousefi K, et al. Genomic classifier augments the role of pathological features in identifying optimal candidates for adjuvant radiation therapy in patients with prostate cancer: development and internal validation of a multivariable prognostic model. *J Clin Oncol*. 2017;35:1982–1990.

Dalton DL. Elevated serum prostate-specific antigen due to acute bacterial prostatitis. *URL*. 1989;33:465.

Danila DC, Anand A, Schultz N, et al. Analytic and clinical validation of a prostate cancer-enhanced messenger RNA detection assay in whole blood as a prognostic biomarker for survival. *Eur Urol*. 2014;65(6):1191–1197.

Danila DC, Anand A, Sung CC, et al. TMPRSS2-ERG status in circulating tumor cells as a predictive biomarker of sensitivity in castration-resistant prostate cancer patients treated with abiraterone acetate. *Eur Urol*. 2011;60:897–904.

Danila DC, Fleisher M, Scher HI. Circulating tumor cells as biomarkers in prostate cancer. *Clin Cancer Res*. 2011;17:3903–3912.

Danila DC, Morris MJ, de Bono JS, et al. Phase II multicenter study of abiraterone acetate plus prednisone therapy in patients with docetaxel-treated castration-resistant prostate cancer. *J Clin Oncol*. 2010;28:1496–1501.

Darson MF, Pacelli A, Roche P, et al. Human glandular kallikrein 2 expression in prostate adenocarcinoma and lymph node metastases. *URL*. 1999;53:939–944.

Darson MF, Pacelli A, Roche P, et al. Human glandular kallikrein 2 (hK2) expression in prostatic intraepithelial neoplasia and adenocarcinoma: a novel prostate cancer marker. *URL*. 1997;49:857–862.

Dawson S-J, Tsui DWY, Murtaza M, et al. Analysis of circulating tumor DNA to monitor metastatic breast cancer. *N Engl J Med*. 2013;368:1199–1209.

de Bono JS, Scher HI, Montgomery RB, et al. Circulating tumor cells predict survival benefit from treatment in metastatic castration-resistant prostate cancer. *Clin Cancer Res*. 2008;14:6302–6309.

de Kok JB, Verhaegh GW, Roelofs RW, et al. DD3(PCA3), a very sensitive and specific marker to detect prostate tumors. *Cancer Res*. 2002;62:2695–2698.

de Vries SH, Raaijmakers R, Blijenberg BG, et al. Additional use of [-2] precursor prostate-specific antigen and ‘benign’ PSA at diagnosis in screen-detected prostate cancer. *Urology*. 2005;65:926–930.

Del Rio M, Molina F, Bascoul-Mollevi C, et al. Gene expression signature in advanced colorectal cancer patients select drugs and response for the use of leucovorin, fluorouracil, and irinotecan. *J Clin Oncol*. 2007;25:773–780.

Den RB, Yousefi K, Trabulsi EJ, et al. Genomic classifier identifies men with adverse pathology after radical prostatectomy who benefit from adjuvant radiation therapy. *J Clin Oncol*. 2015;33:944–951.

Deras IL, Aubin SMJ, Blase A, et al. PCA3: a molecular urine assay for predicting prostate biopsy outcome. *J Urol*. 2008;179:1587–1592.

Diamandis EP, Yousef GM, Luo LY, et al. The new human kallikrein gene family: implications in carcinogenesis. *Trends Endocrinol Metab*. 2000;11:54–60.

Djavan B, Zlotta A, Remzi M, et al. Optimal predictors of prostate cancer on repeat prostate biopsy: a prospective study of 1,051 men. *J Urol*. 2000;163:1144–1148 [discussion 1148–9].

Douglas TH, Morgan TO, McLeod DG, et al. Comparison of serum prostate specific membrane antigen, prostate specific antigen, and free prostate specific antigen levels in radical prostatectomy patients. *Cancer*. 1997;80:107–114.

Eklund M, Nordström T, Aly M, et al. The Stockholm-3 (STHLM3) Model can improve prostate cancer diagnostics in men aged 50-69 yr compared with current prostate cancer testing. *Eur Urol Focus*. 2018;4(5):707–710.

Elgamal AA, Holmes EH, Su SL, et al. Prostate-specific membrane antigen (PSMA): current benefits and future value. *Semin Surg Oncol*. 2000;18:10–16.

Elshafei A, Chevli KK, Moussa AS, et al. PCA3-based nomogram for predicting prostate cancer and high grade cancer on initial transrectal guided biopsy. *Prostate*. 2015;75:1951–1957.

Ercole CJ, Lange PH, Mathisen M, et al. Prostatic specific antigen and prostatic acid phosphatase in the monitoring and staging of patients with prostatic cancer. *J Urol*. 1987;138:1181–1184.

Erho N, Crisan A, Vergara IA, et al. Discovery and validation of a prostate cancer genomic classifier that predicts early metastasis following radical prostatectomy. *PLoS ONE*. 2013;8:e66855.

Etzioni RD, Howlader N, Shaw PA, et al. Long-term effects of finasteride on prostate specific antigen levels: results from the prostate cancer prevention trial. *J Urol*. 2005;174:877–881.

Eure G, Germany R, Given R, et al. Use of a 17-gene prognostic assay in contemporary urologic practice: results of an interim analysis in an observational cohort. *Urology*. 2017;107:67–75.

Ewing CM, Ray AM, Lange EM, et al. Germline mutations in HOXB13 and prostate-cancer risk. *N Engl J Med*. 2012;366:141–149.

Fair WR, Israeli RS, Heston WD. Prostate-specific membrane antigen. *Prostate*. 1997;32:140–148.

Freedland SJ, Gerber L, Reid J, et al. Prognostic utility of cell cycle progression score in men with prostate cancer after primary external beam radiation therapy. *Int J Radiat Oncol Biol Phys*. 2013;86:848–853.

Füzéry AK, Levin J, Chan MM, et al. Translation of proteomic biomarkers into FDA approved cancer diagnostics: issues and challenges. *Clin Proteomics*. 2013;10:13.

Giri VN, Beebe-Dimmer JL. Familial prostate cancer. *Semin Oncol*. 2016;43:560–565.

Goldfarb DA, Stein BS, Shamszadeh M, et al. Age-related changes in tissue levels of prostatic acid phosphatase and prostate specific antigen. *J Urol*. 1986;136:1266–1269.

Goldgar DE, Easton DF, Cannon-Albright LA, et al. Systematic population-based assessment of cancer risk in first-degree relatives of cancer probands. *J Natl Cancer Inst*.

1994;86:1600–1608.

Goodall J, Mateo J, Yuan W, et al. Circulating cell-free DNA to guide prostate cancer treatment with PARP inhibition. *Cancer Discov*. 2017;7:1006–1017.

Gopalan A, Leversha MA, Satagopan JM, et al. TMPRSS2-ERG gene fusion is not associated with outcome in patients treated by prostatectomy. *Cancer Res*. 2009;69:1400–1406.

Gore JL, Plessis du M, Santiago-Jiménez M, et al. Decipher test impacts decision making among patients considering adjuvant and salvage treatment after radical prostatectomy: interim results from the Multicenter Prospective PRO-IMPACT study. *Cancer*. 2017;123:2850–2859.

Gretzer MB, Epstein JI, Pound CR, et al. Substratification of stage T1C prostate cancer based on the probability of biochemical recurrence. *Urology*. 2002;60:1034–1039.

Groskopf J, Aubin SMJ, Deras IL, et al. APTIMA PCA3 molecular urine test: development of a method to aid in the diagnosis of prostate cancer. *Clin Chem*. 2006;52:1089–1095.

Grönberg H, Adolfsson J, Aly M, et al. Prostate cancer screening in men aged 50-69 years (STHLM3): a prospective population-based diagnostic study. *Lancet Oncol*. 2015;16:1667–1676.

Guazzoni G, Nava L, Lazzeri M, et al. Prostate-specific antigen (PSA) isoform p2PSA significantly improves the prediction of prostate cancer at initial extended prostate biopsies in patients with total PSA between 2.0 and 10 ng/ml: results of a prospective study in a clinical setting. *Eur Urol*. 2011;60:214–222.

Guess HA, Heyse JF, Gormley GJ. The effect of finasteride on prostate-specific antigen in men with benign prostatic hyperplasia. *Prostate*. 1993;22:31–37.

Haese A, Graefen M, Steuber T, et al. Human glandular kallikrein 2 levels in serum for discrimination of pathologically organ-confined from locally-advanced prostate cancer in total PSA-levels below 10 ng/ml. *Prostate*. 2001;49:101–109.

Haese A, la Taille de A, van Poppel H, et al. Clinical utility of the PCA3 urine assay in European men scheduled for repeat biopsy. *Eur Urol*. 2008;54:1081–1088.

Hale V, Weischer M, Park JY. CHEK2 (∗) 1100delC Mutation and Risk of Prostate Cancer. *Prostate Cancer*. 2014;2014:294575.

Hall MJ, Forman AD, Pilarski R, et al. Gene panel testing for inherited cancer risk. *J Natl Compr Canc Netw*. 2014;12:1339–1346.

Han S, Woo S, Kim YJ, et al. Impact of 68Ga-PSMA PET on the management of patients with prostate cancer: a systematic review and meta-analysis. *Eur Urol*. 2018;74:179–190.

Harden SV, Guo Z, Epstein JI, et al. Quantitative GSTP1 methylation clearly distinguishes benign prostatic tissue and limited prostate adenocarcinoma. *J Urol*. 2003;169:1138–1142.

Harden SV, Sanderson H, Goodman SN, et al. Quantitative GSTP1 methylation and the detection of prostate adenocarcinoma in sextant biopsies. *J Natl Cancer Inst*. 2003;95:1634–1637.

Hayek OR, Noble CB, la Taille de A, et al. The necessity of a second prostate biopsy cannot be predicted by PSA or PSA derivatives (density or free:total ratio) in men with prior negative prostatic biopsies. *Curr Opin Urol*. 1999;9:371–375.

Henttu P, Liao SS, Vihko P. Androgens up-regulate the human prostate-specific antigen messenger ribonucleic acid (mRNA), but down-regulate the prostatic acid phosphatase mRNA in the LNCaP cell line. *Endocrinology*. 1992;130:766–772.

Hernandez DJ, Han M, Humphreys EB, et al. Predicting the outcome of prostate biopsy: comparison of a novel logistic regression-based model, the prostate cancer risk calculator, and prostate-specific antigen level alone. *BJU Int*. 2009;103:609–614.

Herschman JD, Smith DS, Catalona WJ. Effect of ejaculation on serum total and free prostate-specific antigen concentrations. *URL*. 1997;50:239–243.

Hessels D, Klein Gunnewiek JMT, van Oort I, et al. DD3(PCA3)-based molecular urine analysis for the diagnosis of prostate cancer. *Eur Urol*. 2003;44:8–15 [discussion 15–6].

Hessels D, Smit FP, Verhaegh GW, et al. Detection of TMPRSS2-ERG fusion transcripts and prostate cancer antigen 3 in urinary sediments may improve diagnosis of prostate cancer. *Clin Cancer Res*. 2007;13:5103–5108.

Hirama H, Sugimoto M, Ito K, et al. The impact of baseline [-2]proPSA-related indices on the prediction of pathological reclassification at 1 year during active surveillance for low-risk prostate cancer: the Japanese multicenter study cohort. *J Cancer Res Clin Oncol*. 2014;140:257–263.

Hori S, Blanchet J-S, McLoughlin J. From prostate-specific antigen (PSA) to precursor PSA (proPSA) isoforms: a review of the emerging role of proPSAs in the detection and management of early prostate cancer. *BJU Int*. 2013;112:717–728.

Hovelson D, Salami SS, Kaplan JB, et al. Integrative molecular profiling challenges robustness of prognostic signature scores in multifocal prostate cancer. *J Clin Oncol*. 2018;36:96.

Huang H, Cai B. G84E mutation in HOXB13 is firmly associated with prostate cancer risk: a meta-analysis. *Tumour Biol*. 2014;35:1177–1182.

Israeli RS, Grob M, Fair WR. Prostate-specific membrane antigen and other prostatic tumor markers on the horizon. *Urol Clin North Am*. 1997;24:439–450.

Iwao-Koizumi K, Matoba R, Ueno N, et al. Prediction of docetaxel response in human breast cancer by gene expression profiling. *J Clin Oncol*. 2005;23:422–431.

Jansen FH, Roobol M, Jenster G, et al. Screening for prostate cancer in 2008 II: the importance of molecular subforms of prostate-specific antigen and tissue kallikreins. *Eur Urol*. 2009;55:563–574.

Jerónimo C, Usadel H, Henrique R, et al. Quantitation of GSTP1 methylation in non-neoplastic prostatic tissue and organ-confined prostate adenocarcinoma. *J Natl Cancer Inst*. 2001;93:1747–1752.

Jones PA, Baylin SB. The fundamental role of epigenetic events in cancer. *Nat Rev Genet*. 2002;3:415–428.

Kaplan SA, Lee RK, Chung DE, et al. Prostate biopsy in response to a change in nadir prostate specific antigen of 0.4 ng/ml after treatment with 5α-reductase inhibitors markedly enhances the detection rate of prostate cancer. *J Urol*. 2012;188:757–761.

Karnes RJ, Bergstralh EJ, Davicioni E, et al. Validation of a genomic classifier that predicts metastasis following radical prostatectomy in an at risk patient population. *J Urol*. 2013;190:2047–2053.

Karnes RJ, Choeurng V, Ross AE, et al. Validation of a genomic risk classifier to predict prostate cancer-specific mortality in men with adverse pathologic features. *Eur Urol*. 2018;73:168–175.

Katz A, Olsson C, Raffo A, et al. Molecular staging of prostate cancer with the use of an enhanced reverse transcriptase-PCR assay. *Urology*. 1994;43:765–775.

Keetch DW, Andriole GL, Ratliff TL, et al. Comparison of percent free prostate-specific antigen levels in men with benign prostatic hyperplasia treated with finasteride, terazosin, or watchful waiting. *Urology*. 1997;50:901–905.

Kirkali Z, Kirkali G, Esen A. Effect of ejaculation on prostate-specific antigen levels in normal men. *Eur Urol*. 1995;27:292–294.

Klein EA, Cooperberg MR, Magi-Galluzzi C, et al. A 17-gene assay to predict prostate cancer aggressiveness in the context of Gleason grade heterogeneity, tumor multifocality, and biopsy undersampling. *Eur Urol*. 2014;66:550–560.

Knezevic D, Goddard AD, Natraj N, et al. Analytical validation of the Oncotype DX prostate cancer assay - a clinical RT-PCR assay optimized for prostate needle biopsies. *BMC Genomics*. 2013;14:690.

Kote-Jarai Z, Leongamornlert D, Saunders E, et al. BRCA2 is a moderate penetrance gene contributing to young-onset prostate cancer: implications for genetic testing in prostate cancer patients. *Br J Cancer*. 2011;105:1230–1234.

Köllermann J, Schlomm T, Bang H, et al. Expression and prognostic relevance of annexin A3 in prostate cancer. *Eur Urol*. 2008;54:1314–1323.

Kumar A, Mikolajczyk SD, Goel AS, et al. Expression of pro form of prostate-specific antigen by mammalian cells and its conversion to mature, active form by human kallikrein 2. *Cancer Res*. 1997;57:3111–3114.

Kuriyama M, Wang MC, Papsidero LD, et al. Quantitation of prostate-specific antigen in serum by a sensitive enzyme immunoassay. *Cancer Res*. 1980;40:4658–4662.

Kwiatkowski MK, Recker F, Piironen T, et al. In prostatism patients the ratio of human glandular kallikrein to free PSA improves the discrimination between prostate cancer and benign hyperplasia within the diagnostic ‘gray zone’ of total PSA 4 to 10 ng/mL. *URL*. 1998;52:360–365.

Laxman B, Morris DS, Yu J, et al. A first-generation multiplex biomarker analysis of urine for the early detection of prostate cancer. *Cancer Res*. 2008;68:645–649.

Laxman B, Tomlins SA, Mehra R, et al. Noninvasive detection of TMPRSS2:ERG fusion transcripts in the urine of men with prostate cancer. *Neoplasia*. 2006;8:885–888.

Lazzeri M, Briganti A, Scattoni V, et al. Serum index test %[-2]proPSA and Prostate Health Index are more accurate than prostate specific antigen and %fPSA in predicting a positive repeat prostate biopsy. *J Urol*. 2012;188:1137–1143.

Lazzeri M, Haese A, la Taille de A, et al. Serum isoform [-2]proPSA derivatives significantly improve prediction of prostate cancer at initial biopsy in a total PSA range of 2-10 ng/ml: a multicentric European study. *Eur Urol*. 2013;63:986–994.

Le BV, Griffin CR, Loeb S, et al. [-2]Proenzyme prostate specific antigen is more accurate than total and free prostate specific antigen in differentiating prostate cancer from benign disease in a prospective prostate cancer screening study. *J Urol*. 2010;183:1355–1359.

Leinonen J, Lövgren T, Vornanen T, et al. Double-label time-resolved immunofluorometric assay of prostate-specific antigen and of its complex with alpha 1-antichymotrypsin. *Clin Chem*. 1993;39:2098–2103.

Levesque M, Hu H, D'Costa M, et al. Prostate-specific antigen expression by various tumors. *J Clin Lab Anal*. 1995;9:123–128.

Leyten GHJM, Hessels D, Jannink SA, et al. Prospective multicentre evaluation of PCA3 and TMPRSS2-ERG gene fusions as diagnostic and prognostic urinary biomarkers for prostate cancer. *Eur Urol*. 2014;65:534–542.

Li L-C, Okino ST, Dahiya R. DNA methylation in prostate cancer. *Biochim Biophys Acta*. 2004;1704:87–102.

Lichtenstein P, Holm NV, Verkasalo PK, et al. Environmental and heritable factors in the causation of cancer–analyses of cohorts of twins from Sweden, Denmark, and Finland. *N Engl*

J Med. 2000;343:78–85.

Lilja H, Christensson A, Dahlén U, et al. Prostate-specific antigen in serum occurs predominantly in complex with alpha 1-antichymotrypsin. *Clin Chem*. 1991;37:1618–1625.

Lilja H, Weiber H. Synthetic protease inhibitors and post-ejaculatory degradation of human semen proteins. *Scand J Clin Lab Invest*. 1984;44:433–438.

Lilja H. A kallikrein-like serine protease in prostatic fluid cleaves the predominant seminal vesicle protein. *J Clin Invest*. 1985;76:1899–1903.

Lilja H. Significance of different molecular forms of serum PSA. The free, noncomplexed form of PSA versus that complexed to alpha 1-antichymotrypsin. *Urol Clin North Am*. 1993;20:681–686.

Lilja H. Prostate-specific antigen: molecular forms and the human kallikrein gene family. *Br J Urol*. 1997;79(Suppl 1):44–48.

Lin DW, Newcomb LF, Brown EC, et al. Urinary TMPRSS2:ERG and PCA3 in an active surveillance cohort: results from a baseline analysis in the Canary Prostate Active Surveillance Study. *Clin Cancer Res*. 2013;19:2442–2450.

Liss MA, Chen H, Hemal S, et al. Impact of family history on prostate cancer mortality in white men undergoing prostate specific antigen based screening. *J Urol*. 2015;193:75–79.

Loeb S, Sanda MG, Broyles DL, et al. The prostate health index selectively identifies clinically significant prostate cancer. *J Urol*. 2015;193:1163–1169.

Loeb S, Shin SS, Broyles DL, et al. Prostate Health Index improves multivariable risk prediction of aggressive prostate cancer. *BJU Int*. 2017;120:61–68.

Lövgren J, Rajakoski K, Karp M, et al. Activation of the zymogen form of prostate-specific antigen by human glandular kallikrein 2. *Biochem Biophys Res Commun*.

1997;238:549–555.

Lövgren J, Tian S, Lundwall A, et al. Production and activation of recombinant hK2 with propeptide mutations resulting in high expression levels. *Eur J Biochem*. 1999;266:1050–1055.

Lundwall A, Lilja H. Molecular cloning of human prostate specific antigen cDNA. *FEBS Lett*. 1987;214:317–322.

Luo J, Zha S, Gage WR, et al. Alpha-methylacyl-CoA racemase: a new molecular marker for prostate cancer. *Cancer Res*. 2002;62:2220–2226.

Magklara A, Scorilas A, Stephan C, et al. Decreased concentrations of prostate-specific antigen and human glandular kallikrein 2 in malignant versus nonmalignant prostatic tissue. *Urology*. 2000;56:527–532.

Mahapatra S, Klee EW, Young CYF, et al. Global methylation profiling for risk prediction of prostate cancer. *Clin Cancer Res*. 2012;18:2882–2895.

Makarov DV, Isharwal S, Sokoll LJ, et al. Pro-prostate-specific antigen measurements in serum and tissue are associated with treatment necessity among men enrolled in expectant management for prostate cancer. *Clin Cancer Res*. 2009;15:7316–7321.

Marks LS, Andriole GL, Fitzpatrick JM, et al. The interpretation of serum prostate specific antigen in men receiving 5alpha-reductase inhibitors: a review and clinical recommendations. *J Urol*. 2006;176:868–874.

Masieri L, Minervini A, Vittori G, et al. The role of free to total PSA ratio in prediction of extracapsular tumor extension and biochemical recurrence after radical prostatectomy in patients with PSA between 4 and 10 ng/ml. *Int Urol Nephrol*. 2012;44:1031–1038.

McCormack RT, Rittenhouse HG, Finlay JA, et al. Molecular forms of prostate-specific antigen and the human kallikrein gene family: a new era. *URL*. 1995;45:729–744.

McGee RS, Herr JC. Human seminal vesicle-specific antigen is a substrate for prostate-specific antigen (or P-30). *Biol Reprod*. 1988;39:499–510.

Mejak SL, Bayliss J, Hanks SD. Long distance bicycle riding causes prostate-specific antigen to increase in men aged 50 years and over. *PLoS ONE*. 2013;8:e56030.

Meng FJ, Shan A, Jin L, et al. The expression of a variant prostate-specific antigen in human prostate. *Cancer Epidemiol Biomarkers Prev*. 2002;11:305–309.

Mikolajczyk SD, Grauer LS, Millar LS, et al. A precursor form of PSA (pPSA) is a component of the free PSA in prostate cancer serum. *URL*. 1997;50:710–714.

Mikolajczyk SD, Marker KM, Millar LS, et al. A truncated precursor form of prostate-specific antigen is a more specific serum marker of prostate cancer. *Cancer Res*. 2001;61:6958–6963.

Mikolajczyk SD, Marks LS, Partin AW, et al. Free prostate-specific antigen in serum is becoming more complex. *Urology*. 2002;59:797–802.

Mikolajczyk SD, Millar LS, Wang TJ, et al. A precursor form of prostate-specific antigen is more highly elevated in prostate cancer compared with benign transition zone prostate tissue. *Cancer Res*. 2000;60:756–759.

Mikropoulos C, Selkirk CGH, Saya S, et al. Prostate-specific antigen velocity in a prospective prostate cancer screening study of men with genetic predisposition. *Br J Cancer*. 2018;118:266–276.

Milowsky MI, Nanus DM, Kostakoglu L, et al. Vascular targeted therapy with anti-prostate-specific membrane antigen monoclonal antibody J591 in advanced solid tumors. *J Clin Oncol*. 2007;25:540–547.

Minner S, Wittmer C, Graefen M, et al. High level PSMA expression is associated with early PSA recurrence in surgically treated prostate cancer. *Prostate*. 2011;71:281–288.

Mitchell PS, Parkin RK, Kroh EM, et al. Circulating microRNAs as stable blood-based markers for cancer detection. *Proc Natl Acad Sci USA*. 2008;105:10513–10518.

Mitra A, Fisher C, Foster CS, et al. Prostate cancer in male BRCA1 and BRCA2 mutation carriers has a more aggressive phenotype. *Br J Cancer*. 2008;98:502–507.

Monne M, Croce CM, Yu H, et al. Molecular characterization of prostate-specific antigen messenger RNA expressed in breast tumors. *Cancer Res*. 1994;54:6344–6347.

Morote J, Encabo G, de Torres IM. Use of percent free prostate-specific antigen as a predictor of the pathological features of clinically localized prostate cancer. *Eur Urol*. 2000;38:225–229.

Morote Robles J, Ruibal Morell A, Palou Redorta J, et al. Clinical behavior of prostatic specific antigen and prostatic acid phosphatase: a comparative study. *Eur Urol*. 1988;14:360–366.

Nadler RB, Humphrey PA, Smith DS, et al. Effect of inflammation and benign prostatic hyperplasia on elevated serum prostate specific antigen levels. *J Urol*. 1995;154:407–413.

Nagrath S, Sequist LV, Maheswaran S, et al. Isolation of rare circulating tumour cells in cancer patients by microchip technology. *Nature*. 2007;450:1235–1239.

Nakayama M, Bennett CJ, Hicks JL, et al. Hypermethylation of the human glutathione S-transferase-pi gene (GSTP1) CpG island is present in a subset of proliferative inflammatory atrophy lesions but not in normal or hyperplastic epithelium of the prostate: a detailed study using laser-capture microdissection. *Am J Pathol*. 2003;163:923–933.

Nam RK, Diamandis EP, Toi A, et al. Serum human glandular kallikrein-2 protease levels predict the presence of prostate cancer among men with elevated prostate-specific antigen. *J Clin Oncol*. 2000;18:1036–1042.

Naya Y, Fritsche HA, Bhadkamkar VA, et al. Volume-based evaluation of serum assays for new prostate-specific antigen isoforms in the detection of prostate cancer. *Urology*. 2004;63:492–498.

Newcomb LF, Thompson IM, Boyer HD, et al. Outcomes of active surveillance for clinically localized prostate cancer in the prospective, multi-institutional Canary PASS Cohort. *J Urol*. 2016;195:313–320.

Nguyen PL, Haddad Z, Ross AE, et al. Ability of a genomic classifier to predict metastasis and prostate cancer-specific mortality after radiation or surgery based on needle biopsy specimens. *Eur Urol*. 2017;72:845–852.

Nordström T, Akre O, Aly M, et al. Prostate-specific antigen (PSA) density in the diagnostic algorithm of prostate cancer. *Prostate Cancer Prostatic Dis*. 2018;21:57–63.

Nurmikko P, Pettersson K, Piironen T, et al. Discrimination of prostate cancer from benign disease by plasma measurement of intact, free prostate-specific antigen lacking an internal cleavage site at Lys145-Lys146. *Clin Chem*. 2001;47:1415–1423.

Nurmikko P, Väisänen V, Piironen T, et al. Production and characterization of novel anti-prostate-specific antigen (PSA) monoclonal antibodies that do not detect internally cleaved Lys145-Lys146 inactive PSA. *Clin Chem*. 2000;46:1610–1618.

Oesterling JE, Chan DW, Epstein JI, et al. Prostate specific antigen in the preoperative and postoperative evaluation of localized prostatic cancer treated with radical prostatectomy. *J Urol*. 1988;139:766–772.

Oesterling JE, Jacobsen SJ, Chute CG, et al. Serum prostate-specific antigen in a community-based population of healthy men. Establishment of age-specific reference ranges. *J Am Med Assoc*. 1993;270:860–864.

Ohwaki K, Endo F, Muraishi O, et al. Relationship between prostate-specific antigen and hematocrit: does hemodilution lead to lower PSA concentrations in men with a higher body mass index? *Urology*. 2010;75:648–652.

Osborne JR, Green DA, Spratt DE, et al. A prospective pilot study of (89)Zr-J591/prostate specific membrane antigen positron emission tomography in men with localized prostate cancer undergoing radical prostatectomy. *J Urol*. 2013;191:1439–1445.

Otto A, Bär J, Birkenmeier G. Prostate-specific antigen forms complexes with human alpha 2-macroglobulin and binds to the alpha 2-macroglobulin receptor/LDL receptor-related protein. *J Urol*. 1998;159:297–303.

Pannek J, Marks LS, Pearson JD, et al. Influence of finasteride on free and total serum prostate specific antigen levels in men with benign prostatic hyperplasia. *J Urol*. 1998;159:449–453.

Pantel K, Alix-Panabières C. Circulating tumour cells in cancer patients: challenges and perspectives. *Trends Mol Med*. 2010;16:398–406.

Parekh DJ, Messer J, Fitzgerald J, et al. Perioperative outcomes and oncologic efficacy from a pilot prospective randomized clinical trial of open versus robotic assisted radical cystectomy. *J Urol*. 2013;189:474–479.

Partin AW, Brawer MK, Bartsch G, et al. Complexed prostate specific antigen improves specificity for prostate cancer detection: results of a prospective multicenter clinical trial. *J Urol*. 2003;170:1787–1791.

Partin AW, Brawer MK, Subong ENP, et al. Prospective evaluation of percent free-PSA and complexed-PSA for early detection of prostate cancer. *Prostate Cancer Prostatic Dis*. 1998;1:197–203.

Partin AW, Carter HB, Chan DW, et al. Prostate specific antigen in the staging of localized prostate cancer: influence of tumor differentiation, tumor volume and benign hyperplasia. *J Urol*. 1990;143:747–752.

Partin AW, Catalona WJ, Finlay JA, et al. Use of human glandular kallikrein 2 for the detection of prostate cancer: preliminary analysis. *Urology*. 1999;54:839–845.

Partin AW, Van Neste L, Klein EA, et al. Clinical validation of an epigenetic assay to predict negative histopathological results in repeat prostate biopsies. *J Urol*. 2014;192:1081–1087.

Peltola MT, Niemelä P, Väisänen V, et al. Intact and internally cleaved free prostate-specific antigen in patients with prostate cancer with different pathologic stages and grades. *Urology*. 2011;77:1009 [e1–8].

Pepe MS, Etzioni R, Feng Z, et al. Phases of biomarker development for early detection of cancer. *J Natl Cancer Inst*. 2001;93:1054–1061.

Pepe MS, Feng Z, Janes H, et al. Pivotal evaluation of the accuracy of a biomarker used for classification or prediction: standards for study design. *J Natl Cancer Inst*. 2008;100:1432–1438.

Perera M, Papa N, Christidis D, et al. Sensitivity, specificity, and predictors of positive (68)Ga-prostate-specific membrane antigen positron emission tomography in advanced prostate cancer: a systematic review and meta-analysis. *Eur Urol*. 2016;70:926–937.

Perner S, Hofer MD, Kim R, et al. Prostate-specific membrane antigen expression as a predictor of prostate cancer progression. *Hum Pathol*. 2007;38:696–701.

Peter J, Unverzagt C, Krogh TN, et al. Identification of precursor forms of free prostate-specific antigen in serum of prostate cancer patients by immunosorption and mass spectrometry. *Cancer Res*. 2001;61:957–962.

Polascik TJ, Oesterling JE, Partin AW. Prostate specific antigen: a decade of discovery–what we have learned and where we are going. *J Urol*. 1999;162:293–306.

Popa I, Fradet Y, Beaudry G, et al. Identification of PCA3 (DD3) in prostatic carcinoma by in situ hybridization. *Mod Pathol*. 2007;20:1121–1127.

Pound C, Partin A, Eisenberger M, et al. Natural history of progression after PSA elevation following radical prostatectomy. *J Am Med Assoc*. 1999;281:1591–1597.

Pound CR, Walsh PC, Epstein JI, et al. Radical prostatectomy as treatment for prostate-specific antigen-detected stage T1c prostate cancer. *World J Urol*. 1997;15:373–377.

Prensner JR, Rubin MA, Wei JT, et al. Beyond PSA: the next generation of prostate cancer biomarkers. *Sci Transl Med*. 2012;4:127rv3.

Rajaei M, Momeni A. Kheiri S, Ghaheri H. Effect of ejaculation on serum prostate specific antigen level in screening and non-screening population. *J Res Med Sci*. 2013;18:387–390.

Reid AHM, Reid AHM, Attard G, et al. Significant and sustained antitumor activity in post-docetaxel, castration-resistant prostate cancer with the CYP17 inhibitor abiraterone acetate. *J Clin Oncol*. 2010;28:1489–1495.

Rhodes T, Jacobson DJ, McGree ME, et al. Longitudinal changes of benign prostate-specific antigen and [-2]proprostate-specific antigen in seven years in a community-based sample of men. *Urology*. 2012;79:655–661.

Richiardi L, Fiano V, Grasso C, et al. Methylation of APC and GSTP1 in non-neoplastic tissue adjacent to prostate tumour and mortality from prostate cancer. *PLoS ONE*. 2013;8:e68162.

Richiardi L, Fiano V, Vizzini L, et al. Promoter methylation in

APC, RUNX3, and GSTP1 and mortality in prostate cancer patients. *J Clin Oncol*. 2009;27:3161–3168.

Ristau BT, O'Keefe DS, Bacich DJ. The prostate-specific membrane antigen: lessons and current clinical implications from 20 years of research. *Urol Oncol*. 2013.

Rittenhouse HG, Finlay JA, Mikolajczyk SD, et al. Human Kallikrein 2 (hK2) and prostate-specific antigen (PSA): two closely related, but distinct, kallikreins in the prostate. *Crit Rev Clin Lab Sci*. 1998;35:275–368.

Roobol MJ, Schröder FH, van Leenders GLJH, et al. Performance of prostate cancer antigen 3 (PCA3) and prostate-specific antigen in prescreened men: reproducibility and detection characteristics for prostate cancer patients with high PCA3 scores (≥ 100). *Eur Urol*. 2010;58:893–899.

Roobol MJ, Schröder FH, van Leeuwen P, et al. Performance of the prostate cancer antigen 3 (PCA3) gene and prostate-specific antigen in prescreened men: exploring the value of PCA3 for a first-line diagnostic test. *Eur Urol*. 2010;58:475–481.

Ross AE, Feng FY, Ghadessi M, et al. A genomic classifier predicting metastatic disease progression in men with biochemical recurrence after prostatectomy. *Prostate Cancer Prostatic Dis*. 2014;17:64–69.

Rubin MA, Bismar TA, Andrén O, et al. Decreased alpha-methylacyl CoA racemase expression in localized prostate cancer is associated with an increased rate of biochemical recurrence and cancer-specific death. *Cancer Epidemiol Biomarkers Prev*. 2005;14:1424–1432.

Rubin MA, Zhou M, Dhanasekaran SM, et al. alpha-Methylacyl coenzyme A racemase as a tissue biomarker for prostate cancer. *J Am Med Assoc*. 2002;287:1662–1670.

Salami SS, Schmidt F, Laxman B, et al. Combining urinary detection of TMPRSS2:ERG and PCA3 with serum PSA to predict diagnosis of prostate cancer. *Urol Oncol*. 2013;31:566–571.

Sanda MG, Feng Z, Howard DH, et al. Association between combined TMPRSS2:ERG and PCA3 RNA urinary testing and detection of aggressive prostate cancer. *JAMA Oncol*. 2017;3:1085–1093.

Scattoni V, Lazzeri M, Lughezzani G, et al. Head-to-head comparison of prostate health index and urinary PCA3 for predicting cancer at initial or repeat biopsy. *J Urol*. 2013;190:496–501.

Schedlich LJ, Bennetts BH, Morris BJ. Primary structure of a human glandular kallikrein gene. *DNA*. 1987;6:429–437.

Scher HI, Jia X, de Bono JS, et al. Circulating tumour cells as prognostic markers in progressive, castration-resistant prostate cancer: a reanalysis of IMMC38 trial data. *Lancet Oncol*. 2009;10:233–239.

Scher HI, Lu D, Schreiber NA, et al. Association of AR-V7 on circulating tumor cells as a treatment-specific biomarker with outcomes and survival in castration-resistant prostate cancer. *JAMA Oncol*. 2016;2:1441–1449.

Scher HI, Morris MJ, Larson S, et al. Validation and clinical utility of prostate cancer biomarkers. *Nat Rev Clin Oncol*. 2013;10:225–234.

Schostak M, Schwall GP, Poznanović S, et al. Annexin A3 in urine: a highly specific noninvasive marker for prostate cancer early detection. *J Urol*. 2009;181:343–353.

Schröder FH, Hugosson J, Roobol MJ, et al. Screening and prostate-cancer mortality in a randomized European study. *N Engl J Med*. 2009;360:1320–1328.

Seamonds B, Yang N, Anderson K, et al. Evaluation of prostate-specific antigen and prostatic acid phosphatase as prostate cancer markers. *URL*. 1986;28:472–479.

Sensabaugh GF. Isolation and characterization of a semen-specific protein from human seminal plasma: a potential new marker for semen identification. *J Forensic Sci*. 1978;23:106–115.

Shaffer DR, Leversha MA, Danila DC, et al. Circulating tumor cell analysis in patients with progressive castration-resistant prostate cancer. *Clin Cancer Res*. 2007;13:2023–2029.

Shariat SF, Abdel-Aziz KF, Roehrborn CG, et al. Pre-operative percent free PSA predicts clinical outcomes in patients treated with radical prostatectomy with total PSA levels below 10 ng/ml. *Eur Urol*. 2006;49:293–302.

Silver DA, Pellicer I, Fair WR, et al. Prostate-specific membrane antigen expression in normal and malignant human tissues. *Clin Cancer Res*. 1997;3:81–85.

Sokoll LJ, Ellis W, Lange P, et al. A multicenter evaluation of the PCA3 molecular urine test: pre-analytical effects, analytical performance, and diagnostic accuracy. *Clin Chim Acta*. 2008;389:1–6.

Sokoll LJ, Sanda MG, Feng Z, et al. A prospective, multicenter, National Cancer Institute Early Detection Research Network study of [-2]proPSA: improving prostate cancer detection and correlating with cancer aggressiveness. *Cancer Epidemiol Biomarkers Prev*. 2010;19:1193–1200.

Sparano JA, Gray RJ, Makower DF, et al. Adjuvant chemotherapy guided by a 21-gene expression assay in breast cancer. *N Engl J Med*. 2018;379:111–121.

Spratt DE, Dai DLY, Den RB, et al. Performance of a prostate cancer genomic classifier in predicting metastasis in men with prostate-specific antigen persistence postprostatectomy. *Eur Urol*. 2018;74:107–114.

Spratt DE, Yousefi K, Deheshi S, et al. Individual patient-level meta-analysis of the performance of the decipher genomic classifier in high-risk men after prostatectomy to predict development of metastatic disease. *J Clin Oncol*.

2017;35:1991–1998.

Srivastava S. *Early Detection Research Network*. [website] http://edrn.nci.nih.gov/about-edrn; 2014.

Srivastava S, Verma M, Henson DE. Biomarkers for early detection of colon cancer. *Clin Cancer Res*. 2001;7:1118–1126.

Stamey TA, Yang N, Hay AR, et al. Prostate-specific antigen as a serum marker for adenocarcinoma of the prostate. *N Engl J Med*. 1987;317:909–916.

Stenman UH, Hakama M, Knekt P, et al. Serum concentrations of prostate specific antigen and its complex with alpha 1-antichymotrypsin before diagnosis of prostate cancer. *Lancet*. 1994;344:1594–1598.

Stephan C, Cammann H, Deger S, et al. Benign prostatic hyperplasia-associated free prostate-specific antigen improves detection of prostate cancer in an artificial neural network. *Urology*. 2009;74:873–877.

Stephan C, Lein M, Jung K, et al. Re: editorial: can prostate specific antigen derivatives reduce the frequency of unnecessary prostate biopsies? *J Urol*. 1997;157:1371.

Stephenson RA, Stanford JL. Population-based prostate cancer trends in the United States: patterns of change in the era of prostate-specific antigen. *World J Urol*. 1997;15:331–335.

Steuber T, Nurmikko P, Haese A, et al. Discrimination of benign from malignant prostatic disease by selective measurements of single chain, intact free prostate specific antigen. *J Urol*. 2002;168:1917–1922.

Steuber T, Vickers A, Haese A, et al. Free PSA isoforms and intact and cleaved forms of urokinase plasminogen activator receptor in serum improve selection of patients for prostate cancer biopsy. *Int J Cancer*. 2007;120:1499–1504.

Steuber T, Vickers AJ, Serio AM, et al. Comparison of free and total forms of serum human kallikrein 2 and prostate-specific antigen for prediction of locally advanced and recurrent prostate cancer. *Clin Chem*. 2007;53:233–240.

Stewart GD, Van Neste L, Delvenne P, et al. Clinical utility of an epigenetic assay to detect occult prostate cancer in histopathologically negative biopsies: results of the MATLOC study. *J Urol*. 2013;189:1110–1116.

Stott SL, Hsu C-H, Tsukrov DI, et al. Isolation of circulating tumor cells using a microvortex-generating herringbone-chip. *Proc Natl Acad Sci USA*. 2010;107:18392–18397.

Tagawa ST, Milowsky MI, Morris M, et al. Phase II study of Lutetium-177-labeled anti-prostate-specific membrane antigen monoclonal antibody J591 for metastatic castration-resistant prostate cancer. *Clin Cancer Res*. 2013;19:5182–5191.

Takayama TK, Fujikawa K, Davie EW. Characterization of the precursor of prostate-specific antigen. Activation by trypsin and by human glandular kallikrein. *J Biol Chem*. 1997;272:21582–21588.

Takayama TK, McMullen BA, Nelson PS, et al. Characterization of hK4 (prostase), a prostate-specific serine protease: activation of the precursor of prostate specific antigen (pro-PSA) and single-chain urokinase-type plasminogen activator and degradation of prostatic acid phosphatase. *Biochemistry*. 2001;40:15341–15348.

Tchetgen MB, Song JT, Strawderman M, et al. Ejaculation increases the serum prostate-specific antigen concentration. *URL*. 1996;47:511–516.

Thompson D, Easton DF. Breast Cancer Linkage Consortium. Cancer incidence in BRCA1 mutation carriers. *J Natl Cancer Inst*. 2002;94:1358–1365.

Thompson IM, Chi C, Ankerst DP, et al. Effect of finasteride on the sensitivity of PSA for detecting prostate cancer. *J Natl Cancer Inst*. 2006;98:1128–1133.

Thompson IM, Goodman PJ, Tangen CM, et al. The influence of finasteride on the development of prostate cancer. *N Engl J Med*. 2003;349:215–224.

Tomlins SA, Aubin SMJ, Siddiqui J, et al. Urine TMPRSS2:ERG fusion transcript stratifies prostate cancer risk in men with elevated serum PSA. *Sci Transl Med*. 2011;3:94ra72.

Tomlins SA, Bjartell A, Chinnaiyan AM, et al. ETS gene fusions in prostate cancer: from discovery to daily clinical practice. *Eur Urol*. 2009;56:275–286.

Tomlins SA, Day JR, Lonigro RJ, et al. Urine TMPRSS2:ERG Plus PCA3 for individualized prostate cancer risk assessment. *Eur Urol*. 2016;70:45–53.

Tomlins SA, Rhodes DR, Perner S, et al. Recurrent fusion of TMPRSS2 and ETS transcription factor genes in prostate cancer. *Science*. 2005;310:644–648.

Tosoian JJ, Druskin SC, Andreas D, et al. Use of the Prostate Health Index for detection of prostate cancer: results from a large academic practice. *Prostate Cancer Prostatic Dis*. 2017;20:228–233.

Tosoian JJ, Loeb S, Feng Z, et al. Association of [−2]proPSA with biopsy reclassification during active surveillance for prostate cancer. *J Urol*. 2012;188:1131–1136.

Tremblay RR, Deperthes D, Tetu B, et al. Immunohistochemical study suggesting a complementary role of kallikreins hK2 and hK3 (prostate-specific antigen) in the functional analysis of human prostate tumors. *Am J Pathol*. 1997;150:455–459.

Trock BJ, Brotzman MJ, Mangold LA, et al. Evaluation of GSTP1 and APC methylation as indicators for repeat biopsy in a high-risk cohort of men with negative initial prostate biopsies. *BJU Int*. 2012;110:56–62.

Truong M, Yang B, Jarrard DF. Toward the detection of prostate cancer in urine: a critical analysis. *J Urol*. 2013;189:422–429.

Tryggvadóttir L, Vidarsdóttir L, Thorgeirsson T, et al. Prostate cancer progression and survival in BRCA2 mutation carriers. *J Natl Cancer Inst*. 2007;99:929–935.

van Gils MPMQ, Hessels D, Hulsbergen van de Kaa CA, et al. Detailed analysis of histopathological parameters in radical prostatectomy specimens and PCA3 urine test results. *Prostate*. 2008;68:1215–1222.

van Gils MPMQ, Hessels D, van Hooij O, et al. The time-resolved fluorescence-based PCA3 test on urinary sediments after digital rectal examination; a Dutch multicenter validation of the diagnostic performance. *Clin Cancer Res*. 2007;13:939–943.

Van Neste L, Hendriks RJ, Dijkstra S, et al. Detection of high-grade prostate cancer using a urinary molecular biomarker-based risk score. *Eur Urol*. 2016;70:740–748.

Van Neste L, Herman JG, Otto G, et al. The epigenetic promise for prostate cancer diagnosis. *Prostate*. 2012;72:1248–1261.

Veltri RW, Miller MC. Free/total PSA ratio improves differentiation of benign and malignant disease of the prostate: critical analysis of two different test populations. *URL*. 1999;53:736–745.

Vessella RL, Lange PH, Partin AW, et al. Probability of prostate cancer detection based on results of a multicenter study using the AxSYM free PSA and total PSA assays. *URL*. 2000;55:909–914.

Végvári A, Rezeli M, Welinder C, et al. Identification of prostate-specific antigen (PSA) isoforms in complex biological samples utilizing complementary platforms. *J Proteomics*. 2010;73:1137–1147.

Vickers AJ, Cronin AM, Aus G, et al. A panel of kallikrein markers can reduce unnecessary biopsy for prostate cancer: data from the European Randomized Study of Prostate Cancer Screening in Göteborg, Sweden. *BMC Med*.

2008;6:19.

Vickers A, Cronin A, Roobol M, et al. Reducing unnecessary biopsy during prostate cancer screening using a four-kallikrein panel: an independent replication. *J Clin Oncol*. 2010;28:2493–2498.

Vickers AJ, Vertosick EA, Sjoberg DD. Value of a statistical model based on four kallikrein markers in blood, commercially available as 4Kscore, in all reasonable prostate biopsy subgroups. *Eur Urol*. 2018;74:535–536.

Vickers A, Vertosick EA, Sjoberg DD, et al. Value of intact prostate specific antigen and human Kallikrein 2 in the 4 Kallikrein predictive model: an individual patient data meta-analysis. *J Urol*. 2018;199:1470–1474.

Vickers AJ, Thompson IM, Klein E, et al. A commentary on PSA velocity and doubling time for clinical decisions in prostate cancer. *Urology*. 2014;83:592–596.

Vickers AJ, Ulmert D, Serio AM, et al. The predictive value of prostate cancer biomarkers depends on age and time to diagnosis: towards a biologically-based screening strategy. *Int J Cancer*. 2007;121:2212–2217.

Vieira JG, Nishida SK, Pereira AB, et al. Serum levels of prostate-specific antigen in normal boys throughout puberty. *J Clin Endocrinol Metab*. 1994;78:1185–1187.

Wang MC, Papsidero LD, Kuriyama M, et al. Prostate antigen: a new potential marker for prostatic cancer. *Prostate*. 1981;2:89–96.

Wang TJ, Slawin KM, Rittenhouse HG, et al. Benign prostatic hyperplasia-associated prostate-specific antigen (BPSA) shows unique immunoreactivity with anti-PSA monoclonal antibodies. *Eur J Biochem*. 2000;267:4040–4045.

Waterhouse RL, Van Neste L, Moses KA, et al. Evaluation of an epigenetic assay for predicting repeat prostate biopsy outcome in African American men. *Urology*. 2018.

Wei JT, Feng Z, Partin AW, et al. Can urinary PCA3 supplement PSA in the early detection of prostate cancer? *J Clin Oncol*. 2014;32:4066–4072.

Wei L, Wang J, Lampert E, et al. Intratumoral and intertumoral genomic heterogeneity of multifocal localized prostate cancer impacts molecular classifications and genomic prognosticators. *Eur Urol*. 2017;71:183–192.

Woodrum DL, Brawer MK, Partin AW, et al. Interpretation of free prostate specific antigen clinical research studies for the detection of prostate cancer. *J Urol*. 1998;159:5–12.

Wozny W, Schroer K, Schwall GP, et al. Differential radioactive quantification of protein abundance ratios between benign and malignant prostate tissues: cancer association of annexin A3. *Proteomics*. 2007;7:313–322.

Yoshida K, Miki Y. Role of BRCA1 and BRCA2 as regulators of DNA repair, transcription, and cell cycle in response to DNA damage. *Cancer Sci*. 2004;95:866–871.

Young A, Palanisamy N, Siddiqui J, et al. Correlation of urine TMPRSS2:ERG and PCA3 to ERG+ and total prostate cancer burden. *Am J Clin Pathol*. 2012;138:685–696.

Young CY, Andrews PE, Montgomery BT, et al. Tissue-specific and hormonal regulation of human prostate-specific glandular kallikrein. *Biochemistry*. 1992;31:818–824.

Young CY, Andrews PE, Tindall DJ. Expression and androgenic regulation of human prostate-specific kallikreins. *J Androl*. 1995;16:97–99.

Yousef GM, Diamandis EP. The new human tissue kallikrein gene family: structure, function, and association to disease. *Endocr Rev*. 2001;22:184–204.

Yu H, Diamandis EP, Levesque M, et al. Ectopic production of prostate specific antigen by a breast tumor metastatic to the ovary. *J Clin Lab Anal*. 1994;8:251–253.

Yu H, Diamandis EP, Sutherland DJ. Immunoreactive prostate-specific antigen levels in female and male breast tumors and its association with steroid hormone receptors and patient age. *Clin Biochem*. 1994;27:75–79.

Yu H, Diamandis EP. Prostate-specific antigen in milk of lactating women. *Clin Chem*. 1995;41:54–58.

Yu JX, Chao L, Chao J. Prostasin is a novel human serine proteinase from seminal fluid. Purification, tissue distribution, and localization in prostate gland. *J Biol Chem*. 1994;269:18843–18848.

Yu M, Stott S, Toner M, et al. Circulating tumor cells: approaches to isolation and characterization. *J Cell Biol*. 2011;192:373–382.

Yuan JJ, Coplen DE, Petros JA, et al. Effects of rectal examination, prostatic massage, ultrasonography and needle biopsy on serum prostate specific antigen levels. *J Urol*. 1992;147:810–814.

Zaytoun OM, Kattan MW, Moussa AS, et al. Development of improved nomogram for prediction of outcome of initial prostate biopsy using readily available clinical information. *Urology*. 2011;78:392–398.

Zhang WM, Finne P, Leinonen J, et al. Determination of prostate-specific antigen complexed to alpha(2)-macroglobulin in serum increases the specificity of free to total PSA for prostate cancer. *Urology*. 2000;56:267–272.

Zhang WM, Leinonen J, Kalkkinen N, et al. Purification and characterization of different molecular forms of prostate-specific antigen in human seminal fluid. *Clin Chem*. 1995;41:1567–1573.

Zheng S, Sun J, Wiklund F, et al. Cumulative association of five genetic variants with prostate cancer. *N Engl J Med*. 2008;358:910–919.

Zhou M, Tokumaru Y, Sidransky D, et al. Quantitative GSTP1 methylation levels correlate with Gleason grade and tumor volume in prostate needle biopsies. *J Urol*. 2004;171:2195–2198.

Zon G, Barker MA, Kaur P, et al. Formamide as a denaturant for bisulfite conversion of genomic DNA: bisulfite sequencing of the GSTPi and RARbeta2 genes of 43 formalin-fixed paraffin-embedded prostate cancer specimens. *Anal Biochem*. 2009;392:117–125.

Prostate Biopsy

Techniques and Imaging

Edouard J. Trabulsi MD, FACS, Ethan J. Halpern MD, MSCE, Leonard G. Gomella MD, FACS

Transrectal ultrasonography (TRUS) of the prostate has become a standard tool in the practice of urology. Many image-guided prostate cancer interventions, including initial prostate biopsy, follow-up biopsy for active surveillance, low- and high-dose brachytherapy, cryotherapy, and high-intensity focused ultrasonography rely on TRUS. Fiducial and radiofrequency markers are being placed under TRUS guidance for real-time tumor tracking of the prostate during radiation therapy (Das et al., 2014; Linden et al., 2009). Polyethylene glycol hydrogel injection into anterior perirectal fat before prostate radiation therapy to decrease radiation dose is another new and evolving TRUS application (Strom et al., 2014) and has shown decreased rectal dose and improved rectal toxicity (Mariados et al., 2015). TRUS also has a role in benign conditions such as in the evaluation of treatment options for benign prostatic hyperplasia (BPH) and in some cases of male infertility. This chapter focuses primarily on the most common use of TRUS, namely prostate biopsy for the diagnosis of prostate cancer.

The detection and diagnosis of prostate cancer has benefited greatly from prostate-specific antigen (PSA) screening efforts along with the introduction and refinement of systematic TRUS-guided prostate biopsy techniques. However, these prostate cancer screening efforts are not without controversy (Gomella et al., 2011). When a decision is made to perform a diagnostic prostate biopsy, the 12-core TRUS prostate biopsy with local anesthesia is considered the preferred and current standard of care technique (Bjurlin et al., 2013).

Watanabe et al. (1968) was first to describe TRUS of the prostate. **The use of digitally directed prostate biopsy, common until the late 1980s, evolved into**

the expanded clinical use of TRUS-directed prostate biopsies. Improvements in ultrasound technology continued with the important introduction of the TRUS-guided systematic sextant (six core) biopsy protocol by Hodge et al. (1989). Concurrent with improved biopsy techniques including the increase in recommended biopsy cores to 12, the use of PSA screening increased the number of men undergoing early prostate cancer screening and prostate biopsy. Current estimates are that up to 1.3 million biopsies are performed annually in the United States alone (Aubry et al., 2013). Given the prevalence of clinically significant and insignificant prostate cancer and the frequency with which TRUS-guided prostate biopsies are performed, significant efforts have been focused on determining the appropriate indications for biopsy, the ideal technique by which to image and perform biopsy of the prostate, and how to best limit complications.

Ultrasonographic Anatomy of the Prostate

The prostate lies between the bladder neck and the urogenital diaphragm, just anterior to the rectum, an ideal position to be imaged via TRUS. The prostate gland is traditionally described based on a pathologic zonal architecture. These divisions consist of the anterior fibromuscular stroma, which is devoid of glandular tissue; transition zone (TZ); central zone (CZ); periurethral zone; and peripheral zone (PZ). Unfortunately, these regions are not visible sonographically as distinct entities (Halpern, 2002) (Fig. 150.1).

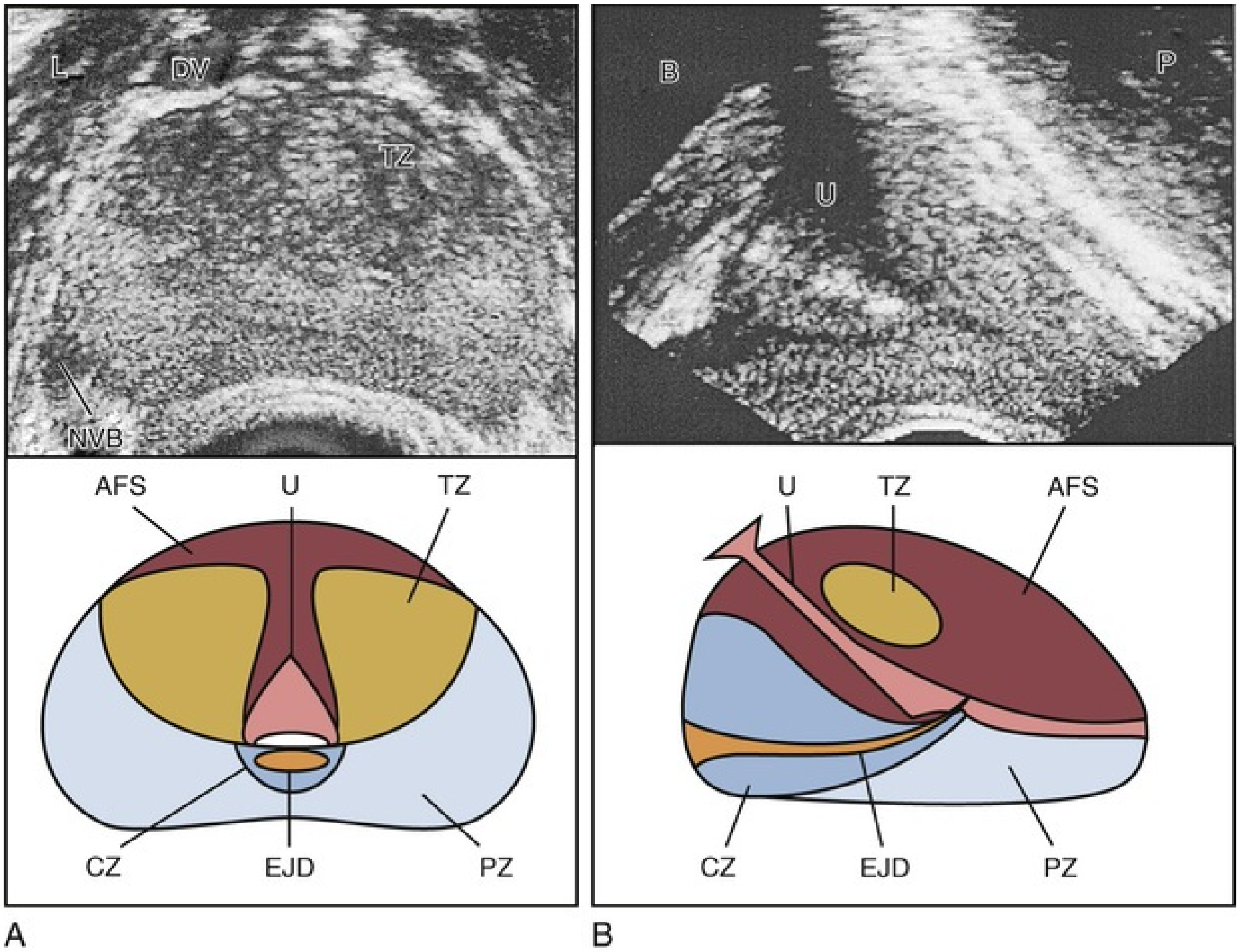

FIG. 150.1 Normal prostate ultrasound images *(top)* with diagrams *(bottom)* at approximately the level of the verumontanum demonstrating zonal anatomy. (A) Transverse view. (B) Sagittal view. *AFS,* anterior fibromuscular stroma; *B,* bladder; *CZ,* central zone; *DV,* dorsal vein complex; *EJD,* ejaculatory ducts; *L,* levator muscles; *NVB,* neurovascular

bundle; *PZ,* peripheral zone; *TZ,* transition zone; *U,* urethra.

However, the TZ often may be discernible from the PZ and CZ, particularly in glands with significant BPH. Located posteriorly, the normal CZ and PZ, from which a majority of adenocarcinomas arise, have a homogeneous echogenic appearance, whereas the anteriorly situated TZ is more heterogeneous. **Frequently, calcifications along the surgical capsule known as the *corpora amylacea* highlight the plane between the PZ and TZ (multiple diffuse calcifications are a normal, often incidental ultrasonographic finding in the prostate and represent a result of age rather than a pathologic entity.** Larger prostatic calculi associated with symptoms may be related to underlying infection or inflammation and require further evaluation (Geramoutsos et al., 2004).

The prostatic urethra traverses the length of the gland in the midline and thus must be imaged in the sagittal plane to be simultaneously viewed along the entirety of its course (Fig. 150.2A and B). The distended urethral lumen has a hypoechoic appearance, whereas periurethral calcifications may produce a thin echogenic outline. The smooth muscle of the internal sphincter extends from the bladder neck, encircling the urethra to the level of the verumontanum. These muscle fibers may be visualized sonographically as a hypoechoic ring around the upper prostatic urethra, giving it a funneled appearance proximally as it arises from the bladder neck. On reaching the verumontanum, the urethra angles anteriorly and runs through the remainder of the gland to exit at the apex of the prostate. This angle gives the prostatic urethra an anteriorly concave appearance when viewed along its entire course in the sagittal plane.

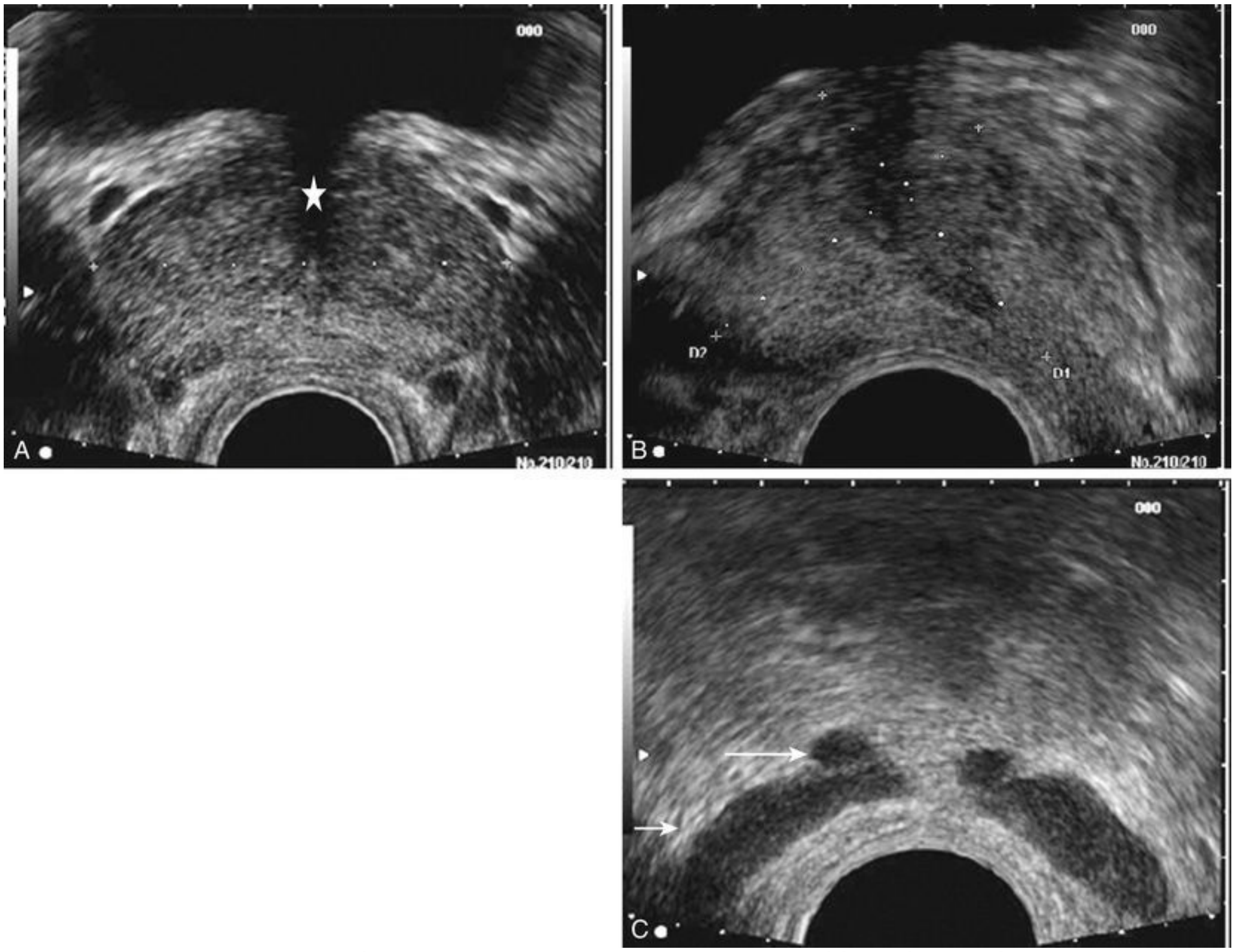

FIG. 150.2 Classic gray-scale transrectal ultrasound imaging of the prostate. (A) In the transverse plane, the hypoechoic urethra centrally located *(star)* and *dotted line* (between calipers) represent transverse measurement. (B) Midline sagittal view with the hypoechoic urethra running the length of the gland. D1 represents longitudinal measurement, and D2 represents anteroposterior measurement. (C) Seminal vesicles *(long arrow)* and vasa deferentia *(short arrow)* in the transverse plane.

The paired seminal vesicles (SVs) are positioned posteriorly at the base of the prostate (see Fig. 150.2C). **They have a smooth, saccular appearance and should be symmetrical. The normal SV measures 4.5 to 5.5 cm in length and 2 cm in width.** A cystic SV mass is presumptively benign, whereas a solid lesion has a very small probability of being malignant, especially if the patient has a primary neoplasm elsewhere. Schistosomiasis should be considered when making a differential diagnosis in patients who live in areas where infestation is endemic and have a solid SV mass (Al-Saeed et al., 2003). An absent SV is associated with a 79% ipsilateral renal agenesis. In the transverse plane, the vasa deferentia course just above their ipsilateral SV before diving caudally toward the prostate near the midline. Here they lie just medial to the tapering ipsilateral

SV before the two structures fuse to form an ejaculatory duct. The ejaculatory ducts (occasionally seen as a hypoechoic structure) enter the gland posteriorly and empty into the urethra at the verumontanum (see Fig. 150.2C). Their course parallels that of the prostatic urethra distal to the verumontanum.

Gray-Scale Transrectal Ultrasonography

Gray-scale TRUS has become the most common imaging modality for the prostate. Most commonly used for prostate cancer detection, TRUS also may be used in the evaluation of other conditions, such as infertility, or basic prostate volume measurements for interventions such as brachytherapy or in the management of BPH.

Commercially available endorectal probes are available in both side- and end-fire models and transmit frequencies of 6 to 10 MHz. Most modern US machines have optimized self-programming for TRUS and biopsy. Some newer biplane probes provide simultaneous sagittal and transverse imaging modes. Probes provide a scanning angle approaching 180 degrees to allow simultaneous visualization of the entire gland in both the transverse and sagittal planes. Increasing probe frequency is associated with increased spatial resolution. As the frequency of the probe is increased, the portion of the image that is in focus (focal range) is closer to the transducer (Kossoff, 2000). The commonly used 7-MHz transducer produces a high-resolution image with a focal range from 1 to 4 cm from the transducer (best for the PZ, where most cancers arise). Lower-frequency transducers (e.g., older 4-MHz transducers) have a focal range from 2 to 8 cm but at lower resolution. Lower-frequency transducers improve anterior delineation of large glands, increasing the accuracy of volume measurements, but provide poor internal architecture visualization. Many modern TRUS systems have an adjustable transmit frequency that may be varied during the examination, depending on the imaging depth of most interest.

Acoustic properties of soft tissue are similar to those of water, but clinically useful ultrasound energy does not propagate through air. For this reason, a water-density substance, termed a *coupling medium*, is required. The coupling medium, usually sonographic jelly or lubricant, is placed between the probe and the rectal surface. If the probe is covered with a protective condom, the coupling medium is placed between the probe and the condom, and between the condom and the rectal surface.

Various studies have compared the TRUS biopsy prostate cancer detection rates using the end-fire or side-fire probes. Prospective studies have confirmed that there is no significant difference in positive biopsy rates in the initial or repeat biopsy setting (Raber et al., 2012). However, in this study, the side-fire transrectal probe was associated with better patient tolerance.

Machine Settings

The image magnification should be adjusted so that most of the prostate is sufficiently magnified to allow detection of relevant abnormalities. In general, the magnification is low during prostate measurements so that the entire gland is visible on a single screen. During biopsies, magnification is increased to optimize visualization of needle passage. The ultrasonographer can manually alter the brightness (or gain) slightly with each new patient and occasionally during imaging of different areas within the same prostate. **The optimal brightness setting results in a medium-gray image of the normal PZ. This gray tone serves as the reference point for judging lesions as hypoechoic (darker than the normal PZ), isoechoic (similar to the normal PZ), hyperechoic (lighter than the normal PZ), or anechoic (completely black).**

Techniques

The complete TRUS evaluation of the prostate includes scanning in both the sagittal and transverse planes to obtain a volume calculation. The CZ and PZ are inspected for hypoechoic lesions and contour abnormalities, the periprostatic fat planes are evaluated, and the SVs and vasa deferentia are fully visualized.

Probe Manipulation

Patients are usually scanned in the left lateral decubitus position (see the Patient Positioning section later in this chapter) **to examine both the transverse and the sagittal planes.** There are two approaches to probe manipulation for transverse imaging (see Fig. 150.2A). With radial and some biplane probes, advancing the probe cephalad into the rectum images the prostate base, the SVs, and the bladder neck. Pulling the probe caudally toward the anal sphincter yields images of the prostatic apex and proximal urethra. Transverse imaging with end-fire, side-fire, and some biplane probes is accomplished by angling the handle of the probe right or left using the anal sphincter as a fulcrum (see Fig. 150.2B). Angling the probe toward the scrotum produces more cephalad images, and angling the probe toward the sacrum produces more caudal images.

There are also two approaches to probe manipulation for sagittal imaging. One method is rotation of the probe. Clockwise rotation yields images of the left side of the prostate, and counterclockwise rotation yields images of the right side; this method is generally employed for side-fire probes. Alternatively, sagittal imaging can be accomplished by angling the probe up or down using the anal sphincter as a fulcrum; this method is generally employed for end-fire probes. In the left lateral decubitus position, angling the handle of the probe down (toward the floor) yields images of the right side of the prostate, and angling the handle of the probe up (toward the ceiling) yields images of the left side. Urologists often prefer angling the probe because this method is similar to manipulation of a cystoscope and is less uncomfortable for the patient.

Joint guidelines concerning the reprocessing of equipment used for TRUS biopsy have been published in a joint American Urological Association (AUA)/Society for Urological Nurses and Associates (SUNA) white paper (American Urological Association, 2016).

Volume Calculations

A variety of formulas are used to calculate prostate volume and require measurement of up to three prostate dimensions. In the axial plane, the transverse and anteroposterior (AP) dimensions are measured at the point of widest transverse diameter (see Fig. 150.2A and B). The longitudinal dimension is measured in the sagittal plane just off the midline because the bladder neck may obscure the cephalad extent of the gland (see Fig. 150.2B). Most formulas assume that the gland conforms to an ideal geometric shape: either an **ellipse** ($\pi/6 \times$ transverse diameter $\times$ AP diameter $\times$ longitudinal diameter), **sphere** ($\pi/6 \times$ transverse diameter^3), or **prolate (egg-shaped) spheroid** ($\pi/6 \times$ transverse diameter$^2 \times$ AP diameter). Despite the inherent inaccuracies that arise from these geometric assumptions, all formulas reliably estimate gland volume and weight, with correlation coefficients greater than 0.90 with radical prostatectomy specimen weights, because 1 cm^3 equals approximately 1 g of prostate tissue (Terris and Stamey, 1991). **The mature prostate is between 20 and 25 g and remains relatively constant until approximately 50 years of age, when the gland enlarges in many men; the average prostate volume in a 60- to 70-year-old individual is approximately 48 g** (Griffiths, 1996).

Prostate volume determination can be an important aspect of assessment for benign prostatic hyperplasia (BPH) with lower urinary tract symptoms (LUTS) (see Chapters 144 to 146 for a detailed discussion of BPH). Accurate size calculation may affect the surgical technique when surgical intervention is considered for men with BPH failing medical therapy. As indicated in the AUA guideline “Surgical Management of Lower Urinary Tract Symptoms Attributed to Benign Prostatic Hyperplasia” released in 2018, the assessment of prostate size by TRUS or cross-sectional imaging should be considered before surgical intervention (Foster et al., 2018). This consensus guideline noted that minimally invasive surgical techniques for BPH are most effective for prostate volumes between 30 and 80 g, with larger prostate volumes best served with open, laparoscopic, or robotic enucleation procedures, further highlighting the importance of accurate volume determination.

Planimetry may be employed when a more precise determination of gland volume is required, such as for brachytherapy planning. With the patient in the lithotomy position, the probe is mounted to a stepping device and serial transverse images are obtained at set intervals (e.g., 3 to 5 mm) through the entire length of the gland. The surface area of each serial image is determined, and the sum of these measurements is then multiplied by total gland length to yield the prostate volume.

Prostate gland volume can be used to calculate derivatives such as the PSA density (PSAD = serum PSA/gland volume). PSAD is a method to differentiate benign versus malignant disease with an elevated PSA and benign digital rectal examination. Higher PSA density values (>0.15 ng/mL/cc) are more suggestive of prostate cancer; lower values suggest BPH. An elevated PSAD has a sensitivity and specificity of 75% and 44%, respectively, for predicting cancer on repeat biopsy (Djavan et al., 2000). Unfortunately, there is high interoperator and intraoperator variability in PSAD determinations, and similar predictive information now can be obtained using serum free-to-total PSA ratio (Djavan et al., 2003).

Cystic Lesions of the Prostate

Cystic prostatic structures are common on TRUS. Simple cysts have the same sonographic appearance as in any other part of the body: they are thin walled, are anechoic, and show acoustic enhancement beyond the cyst. Prostatic cysts may be congenital or acquired but are rarely clinically significant, regardless of cause.

Congenital prostatic cystic lesions may arise from either Müllerian (Müllerian duct cysts and prostatic utricles) or Wolffian (ejaculatory duct and SV cysts) structures. An enlarged prostatic utricle is a diverticular projection from the posterior urethra at the level of the verumontanum (Cochlin, 2002) and appears as a midline anechoic structure. These are associated with genital anomalies, including hypospadias (most common), ambiguous genitalia, undescended testes, and congenital urethral polyps (Gregg and Sty, 1989). Müllerian duct cysts also appear as midline anechoic lesions that result from failure of the Müllerian ducts to fuse with the urethra. They are generally ovoid to pear shaped, with the cyst neck oriented toward the verumontanum. When Müllerian duct cysts are present, men should be evaluated for unilateral renal agenesis (McDermott et al., 1993).

Lateral paraprostatic cystic structures include SV and vas deferens cysts (Wolffian in origin). Ejaculatory duct cysts are typically small, lie off of the midline, and may accompany ejaculatory duct obstruction/obliteration with azoospermia (Fig. 150.3). SV cysts can be caused by congenital or acquired obstruction of the ejaculatory duct and are associated with cystic renal disease; up to two-thirds of men with SV cysts also may have renal agenesis (King et al., 1991). Acquired cysts of the TZ result from hemorrhagic degeneration of BPH nodules (Hamper et al., 1990), whereas those of the outer gland have no proven cause.

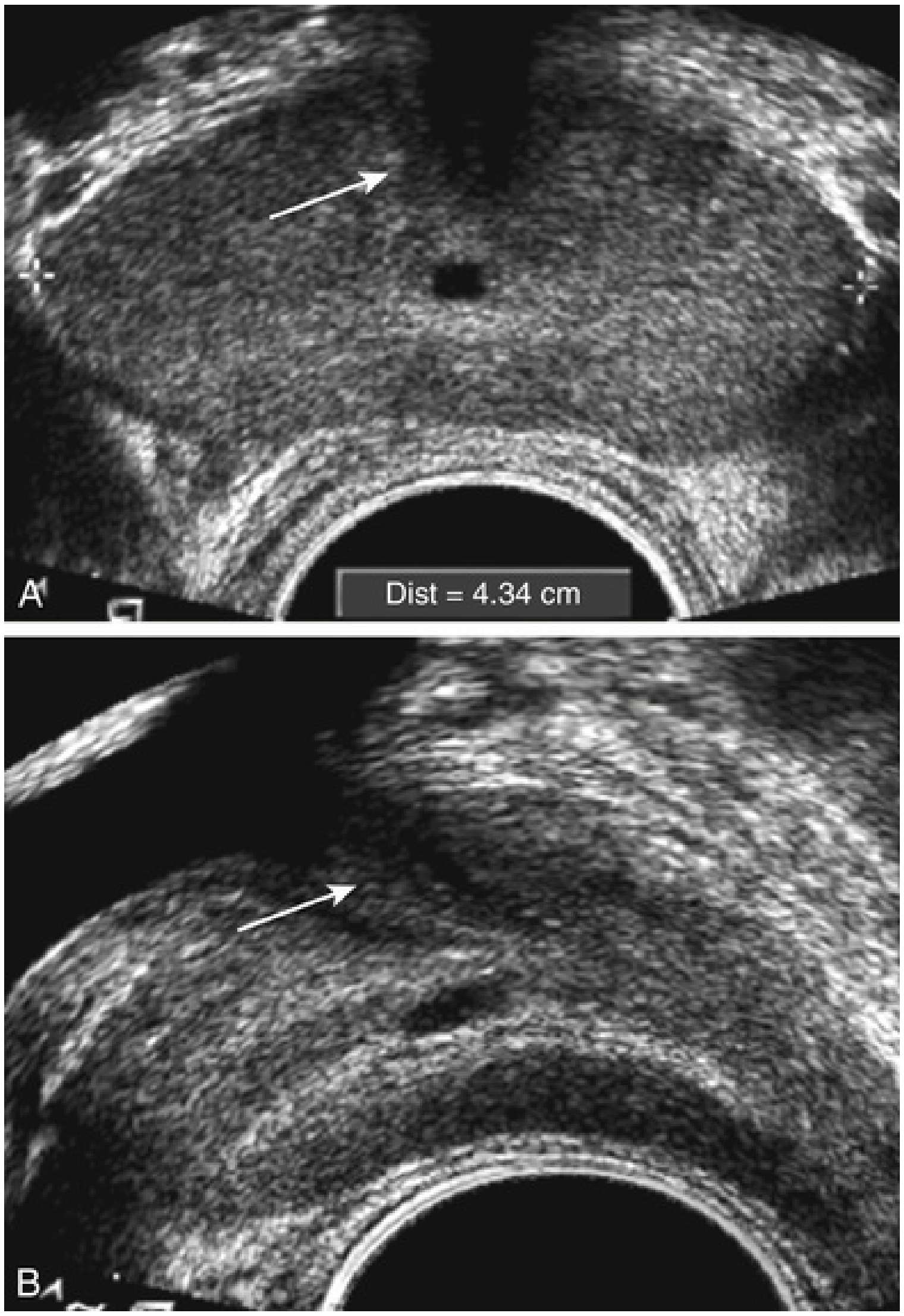

FIG. 150.3 A hypoechoic midline cystic structure *(arrow)* arising from the ejaculatory duct is shown in the transverse (A) and sagittal (B) planes and demonstrates through-transmission classic for simple cysts.

Prostate Cancer Imaging on Transrectal Ultrasonography

In early TRUS studies, hypoechoic lesions were considered pathognomonic for prostate cancer. All hypoechoic lesions within the PZ should be noted and included in the biopsy material (Fig. 150.4). However, the lack of a distinct hypoechoic focus does not preclude proceeding with biopsy, because 39% of all cancers are isoechoic, and up to 1% of tumors may be hyperechoic on conventional gray-scale TRUS (Shinohara et al., 1989). A study of almost 4000 men revealed that prostate cancer was detected in 25.5% with a hypoechoic lesion and in 25.4% without such a lesion, with a per-core distinction of 9.3% for hypoechoic and 10.4% for isoechoic areas for cancer (Onur et al., 2004). Conversely, another study noted that biopsy samples taken when a prostate lesion is identified by TRUS are almost twice as likely to show cancer than when no lesion is visible (Toi et al., 2007). They concluded that the search for and targeting of hypoechoic lesions on TRUS remains important for prostate cancer diagnosis. Other disease processes such as granulomatous prostatitis (Terris et al., 1997), prostatic infarct (Purohit et al., 2003), and lymphoma (Varghese and Grossfeld, 2000) may produce hypoechoic lesions. There is a need to perform a biopsy on hypoechoic lesions, but these lesions are not pathognomonic for cancer as once thought.

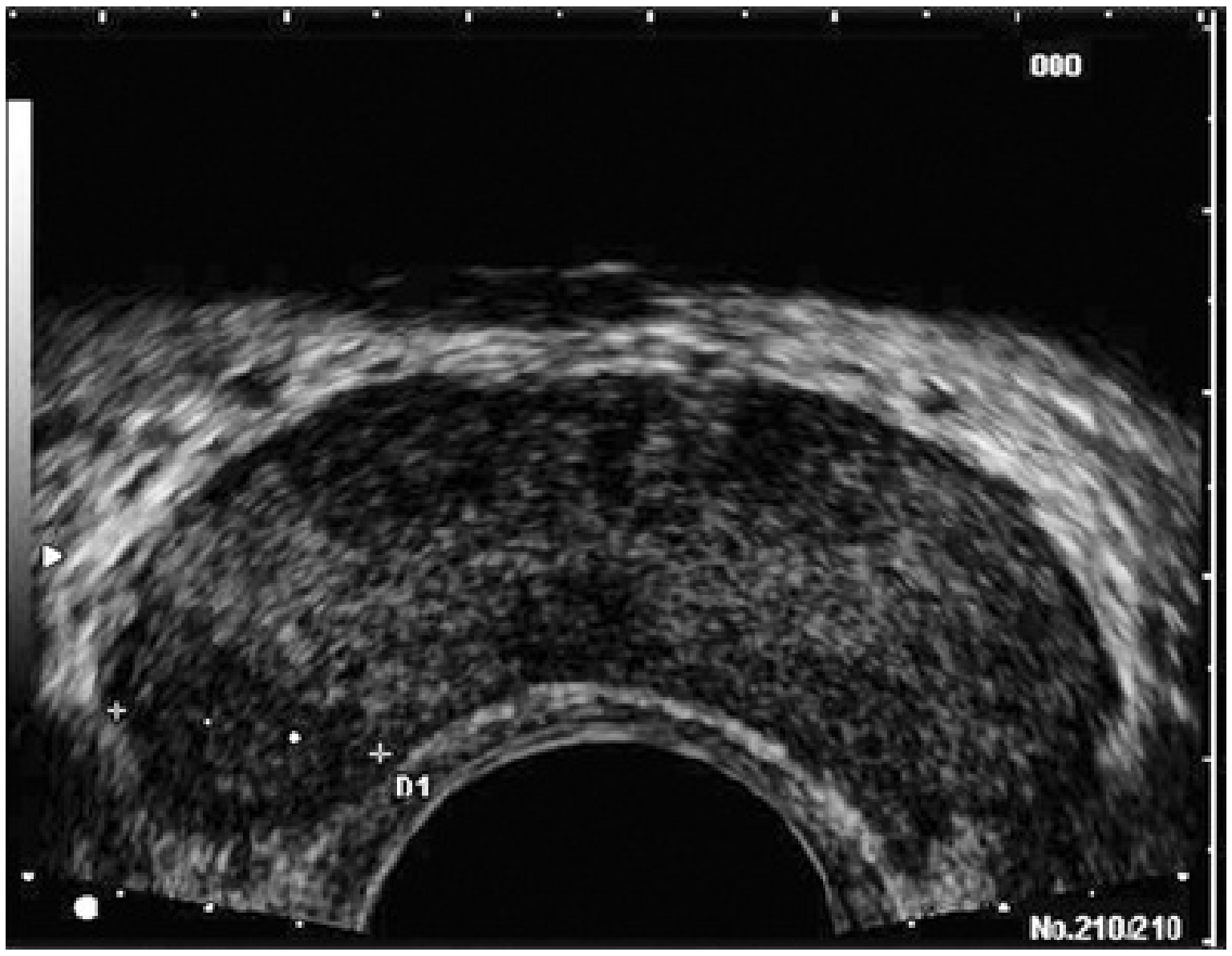

FIG. 150.4 Classic hypoechoic peripheral zone lesion *(dotted line between calipers)* in the right mid-gland that transrectal ultrasound–guided biopsy proved to be a Gleason 3 + 3 = 6 adenocarcinoma.

Any focal contour abnormalities along the outer edge of the gland and any asymmetries in echotexture from the PZ of one lobe to that of the other are noted. **Extracapsular extension of prostate cancer, although not well visualized if present as a microfocus, is suggested by a focal loss of the typically bright white periprostatic fat.**

Key Points: Gray-Scale Transrectal Ultrasonography

- TRUS technology has become a mainstay of many image-guided prostate interventions, including prostate biopsy, brachytherapy, cryotherapy, and high-intensity focused ultrasonography.
- The classic zonal anatomy of the prostate is not evident on TRUS, but the PZ typically may be distinguished from the TZ, allowing biopsies to be reliably aimed toward the more commonly cancer-bearing PZ.
- Benign cystic lesions of the prostate typically demonstrate thin-walled architecture with sonographic through-transmission and may become symptomatic if infected.
- Several formulas exist for determining prostate volume on TRUS. For highly accurate volume determinations such as for brachytherapy, planimetry using a template is required.
- Hypoechoic foci seen on gray-scale TRUS should be considered suggestive of adenocarcinoma of the prostate and included in the biopsy specimen. However, up to 39% of cancers are not visible on routine gray-scale ultrasound imaging.

Transrectal Ultrasonography Appearance After Treatment

External-beam radiation monotherapy usually results in decreased volume by 6 months after treatment. Irradiated prostates are diffusely hypoechoic, with poorly defined anatomy. Large hypoechoic tumors, particularly those not responding to therapy, show little change in echogenicity once irradiated, but smaller foci responding well to therapy tend to become isoechoic (Egawa et al., 1991). TRUS findings in general correlate poorly with pathologic findings and outcomes in irradiated prostates.

Initial postimplantation edema followed by long-term changes occurs with interstitial brachytherapy, as with external-beam radiation therapy (Whittington et al., 1999). With an ideal permanent implant, seeds should be distributed evenly throughout the gland, with periurethral sparing and no errant seeds outside of the prostate gland. These seeds are hyperechoic and demonstrate posterior shadowing. The prostate volume declines significantly after treatment, with a 37% size reduction at 1 year after treatment and over 50% reduction 8 years after implantation (Stone and Stock, 2007). This decline appears unaffected by the use of neoadjuvant hormonal therapy.

Androgen ablation with luteinizing hormone–releasing hormone analogues will cause an average 30% volume decrease with androgen deprivation in prostates with and without cancer (Whittington et al., 1999). The decrease ranges up to 60% in large glands and as little as 10% in small glands. Volume decreases by approximately 21% at 6 months using 5α-reductase inhibitors such as finasteride (Marks et al., 1997).

Post–radical prostatectomy TRUS is considered normal if there is smooth tapering of the bladder neck to the urethra (Kapoor et al., 1993). Many patients demonstrate a nodule of tissue anterior to the anastomosis, representing the ligated dorsal vein complex (Goldenberg et al., 1992). A nodular appearance of the bladder neck at the anastomosis may also be related to the surgical purse-string technique that is used to match the anatomically larger orifice of the bladder neck to the smaller diameter of the urethra. Any hyperechoic or hypoechoic lesions or interruptions of the retroanastomotic fat plane are considered suspicious (Kapoor et al., 1993). Hypoechoic lesions have been reported in 75% to 95% of patients with locally recurrent cancer, and color Doppler has been used to improve cancer detection in the prostatic fossa (Tamsel et al., 2006). Patients with detectable PSA who are candidates for salvage radiation therapy were once considered for routine biopsy of the anastomotic area. **Biopsy of the anastomotic region with PSA-indicated recurrence in the absence of a palpable nodule is not usually informative** (Scattoni et al., 2004). However, biopsy of an abnormality seen on TRUS, even with a normal digital rectal examination, can be diagnostic of locally recurrent disease (Naya et al., 2005).

Transrectal Ultrasonography and Other Malignancies

Prostatic involvement with transitional cell carcinoma (TCC) from the bladder is generally not detectable by TRUS, but 71% of prostatic stromal TCC lesions are hypoechoic. Prostatic TCC detected by TRUS must be confirmed by biopsy because granulomas resulting from instillation of bacillus Calmette-Guérin are common in patients with urothelial carcinoma and also are hypoechoic (Terris et al., 1997).

Extension of squamous cell carcinoma (SCC) to the prostate from the bladder or urethra is much more common than primary prostatic SCC. Prostatic SCC appears as an irregular, anterior mass demonstrating relative hyperechogenicity (Terris, 1999).

Adenoid cystic/basal cell carcinoma of the prostate is rare but potentially fatal. Histologically, cribriform or adenoid cystic patterns predominate. Numerous cystic glands give this tumor an unusual appearance on TRUS, characterized by multiple, evenly distributed, small anechoic cysts (Iczkowski et al., 2003).

Prostatic sarcoma TRUS appearance is typified by an irregular, hypoechoic mass with an anechoic area consistent with necrosis (Terris, 1998). The echogenicity of rhabdomyosarcoma is similar to that of normal prostate tissue. Hematologic and lymphoid malignancies involving the prostate are generally not visualized with TRUS (Terris and Freiha, 1998). Biopsy specimens may demonstrate a lymphocytic infiltrate, but this is often attributed to chronic inflammation if no suspicion of nonprostate malignancy exists. Bladder wall thickening can be seen on TRUS of the prostate and is often associated with bladder wall hypertrophy associated with BPH. Bladder thickening may also suggest malignancy of the bladder as does an incidentally discovered bladder mass.

Prostate Biopsy: Techniques and Outcomes

Indications for Prostate Biopsy

A detailed discussion of the controversy concerning screening asymptomatic men for prostate cancer is discussed elsewhere in this book. Before TRUS improvements and PSA testing became widespread, clinicians relied mainly on digital rectal examination to establish a suspicion of prostate cancer and performed digitally directed lesional biopsies. **PSA-based screening of asymptomatic men has resulted in the adaptation of TRUS biopsy as the standard of care when prostate biopsy is used to identify prostate cancer** (Bjurlin et al., 2013). In general, the TRUS without a biopsy has little utility in the evaluation of a patient for prostate cancer. Overall it estimated that an initial prostate biopsy carries a 30% rate of detecting prostate cancer. **Fine-needle aspiration biopsy is no longer considered state-of-the-art in the diagnosis of prostate cancer** (Heidenreich et al., 2014).

Early prostate cancer detection was markedly improved by PSA-based screening programs. These initiatives increased the rate of organ-confined and potentially curable disease (Catalona et al., 1993). The improvements led to the unintended consequence of the overdiagnosis and overtreatment of clinically insignificant cancers in many men. Historically, many clinicians would recommend prostate biopsy once a patient's serum PSA level rose above 4.0 ng/mL. **Subsequent data from the Prostate Cancer Prevention Trial demonstrated that there is no safe PSA threshold that can rule out prostate cancer in any age range** (Thompson et al., 2005). When examining men whose serum PSA level was 4.0 ng/mL or less, significant numbers were diagnosed with prostate cancer at all PSA levels, with an overall prostate cancer detection rate of 15% for all men with a PSA level less than 4.0 ng/mL and nearly 15% having a Gleason score of 7 or greater (Thompson et al., 2004).

Clinical trials that have attempted to provide an answer to the benefits of PSA screening have only added to the controversy (Gomella et al., 2011). Results from the European Randomized Screening for Prostate Cancer (ERSPC) demonstrated a net benefit, whereas the US-based Prostate, Lung, Colorectal, and Ovarian (PLCO) Cancer Screening Trial showed no benefit on prostate cancer–specific survival (Hayes and Barry, 2014). A recent analysis of the PLCO and ERSPC trials using mean lead time estimates concluded that both studies “provide compatible evidence that screening reduces PCa mortality” (Tsodikov et al., 2017). An accompanying editorial concludes “The controversy about PSA-based screening should no longer be whether it can do good, but whether we can change our behavior so that it does more good than harm” (Vickers, 2017). Recommendations by organizations vary greatly on screening asymptomatic men for prostate cancer, with some supporting screening based on informed decision making and others rejecting the performance of PSA-based screening in an asymptomatic man (Gomella et al., 2011; Hayes and Barry, 2014). Considerations concerning overall health, age of the patient, family history, therapeutic options, wishes of the patient, and other risk factors all need to be considered in recommending prostate biopsy. In addition, concerns are growing over the potential morbidity and mortality of prostate biopsy (Zlotta and Nam, 2012). A variety of online nomograms are available that may help with decision making (Nguyen and Kattan, 2013).

Organizations such as the AUA recommend shared decision making for men 55 to 69 years of age considering PSA-based screening, a target age group for whom benefits may outweigh harms (Carter et al., 2013). Outside this age range, the AUA recommends that PSA-based screening as a routine could not be recommended based on the available evidence. **Most organizations have abandoned absolute PSA level cutoff values for prostate biopsy and are relying increasingly on risk stratification approaches and changes in PSA level over time.** Men at elevated risk for having prostate cancer are those older than 50 years of age; those who have a family history of prostate cancer and are older than 45 years of age or African-American; or those with a PSA level greater than 1 ng/mL at 40 years of age and greater than 2 ng/mL at 60 years of age (Heidenreich et al., 2014).

Adjuncts to serum PSA testing have been advocated to improve the performance characteristics of PSA for prostate cancer detection, including free-to-total PSA ratio, PSA velocity, and PSAD, but are not uniformly reliable (Heidenreich et al., 2014). The National Comprehensive Cancer Network (NCCN) advocates the selective use of biomarkers, including PSA derivatives, tissue assays of stromal hypermethylation (Confirm MDx), as well as urinary assays for ERG (MiPS, ExoDx) and PCA3 in the decision to perform TRUS biopsy (NCCN, 2018). In the appropriate patient for prostate cancer screening, the NCCN recommends TRUS prostate biopsy in the following situations:

positive digital rectal examination regardless of PSA level; PSA level 4 to 10 ng/mL based on patient risk benefit; PSA level 2.5 ng/mL or less and PSA velocity 0.35 ng/mL or greater per year; PSA level 2.6 to 4.0 ng/mL; and PSA level 4.0 ng/mL or greater, especially if the free PSA level is 10% or less. As recommended by the NCCN, the presence of nodules on digital rectal examination usually should prompt TRUS biopsy regardless of PSA levels. In a recent study, 14% of cancers were diagnosed based on digital rectal examination alone (Okotie et al., 2007). However, the American Cancer Society guidelines now suggest that prostate cancer screening can be performed with or without a rectal examination (Smith et al., 2014). In 2018, the US Preventive Services Task Force (USPSTF) issued a new recommendation statement on screening patients for prostate cancer that for men 55 to 69 years of age, the decision to undergo PSA-based screening for prostate cancer should be an individual one with discussion of the risks and benefits (USPSTF, 2018). In addition to an initial prostate biopsy, there are several indications for repeat prostate biopsy, as noted in Box 150.1.

Box 150.1

Commonly Cited Indications for Transrectal Ultrasonography Alone and Transrectal Ultrasonography With Initial and Follow-Up Prostate Biopsy

Transrectal Ultrasonography Without Prostate Biopsy

- Treatment planning volume measurements: brachytherapy, cryotherapy, benign prostatic hyperplasia therapy (e.g., transurethral microwave thermotherapy, radiofrequency ablation)
- Volume measurement during hormonal downsizing for external-beam radiation therapy or brachytherapy
- Placement of fiducial or radiofrequency markers for external-beam radiation therapy
- Evaluation of azoospermia (e.g., ejaculatory duct cysts, seminal vesicle cysts)
- Therapeutic aspiration or unroofing of prostatic cysts; drainage of prostatic

abscess

Initial Prostate Biopsy

- Initial diagnosis of prostate cancer based on informed decision making in an asymptomatic patient (based on PSA and patient-specific risk factors; see text)
- Suspicious digital rectal examination findings/prostate nodule (5%–30% cancer risk)
- To diagnose prostate cancer with symptoms suggestive of prostate cancer
- To diagnose prostate cancer with findings suggestive of metastatic disease (bone lesions and/or adenopathy)
- In the setting of prostate cancer detected on routine transurethral resection of the prostate performed for presumed benign disease

Repeat Prostate Biopsy

- Rising and/or persistently elevated PSA
- Atypical small acinar proliferation (40% cancer risk)
- Extensive (multiple biopsy sites) with PIN (20%–30% cancer risk) (*Note:* isolated high-grade PIN is no longer considered an indication for repeat biopsy)
- Positive urinary PCA3 or other newer genomic tests such as ConfirmMDx[a] methylation assay
- Suspicious lesion on prostate magnetic resonance imaging
- Differentiate local recurrence versus systemic disease with PSA recurrence after local ablative therapy

Follow-Up Prostate Biopsy

- Active surveillance follow-up protocol

PIN, prostatic intraepithelial neoplasia; *PSA*, prostate-specific antigen.

---

[a] ConfirmMDx (MDxHealth, Irvine, CA).

Data from Heidenreich A, Bastian PJ, Bellmunt J, et al. EAU guidelines on prostate cancer. I. Screening, diagnosis, and local treatment with curative intent—update 2013. *Eur Urol* 65(1):124–137, 2014; Thomsen FB, Brasso K, Klotz LH, et al. Active surveillance for clinically localized prostate cancer: a systematic review. *J Surg Oncol* 109(8):830–835, 2014; Gomella L, Amirian M. PSA elevation following negative prostate biopsy. In: Gomella LG, ed. *The 5-minute urology consult*. 3rd ed. Philadelphia, PA: Wolters Kluwer; 2015.

The use of newer molecular techniques such as urinary determination of PCA3 to identify men at risk for a positive biopsy finding is evolving. Several studies have suggested that PCA3 provides supplemental information in determining the need for repeat prostate biopsy (Gittelman et al., 2013). In the largest study of this urinary marker to date, the mean PCA3 was 27.2 and 52.5 for patients without and with cancer, respectively, suggesting this is a useful tool in identifying patients at risk for prostate cancer before initial biopsy (Chevli et al., 2014). The use of genomic markers for prostate cancer detection is a growing and rapidly evolving field, with increased awareness of applicability to improve the known poor specificity of PSA alone. (Cucchiara et al., 2018). There is also a growing awareness of inherited risk for prostate cancer, with implications for prostate cancer detection and biopsy (Giri et al., 2018).

Contraindications to Prostate Biopsy

Significant coagulopathy, severe immunosuppression, and acute prostatitis are all contraindications to prostate biopsy. With painful anorectal conditions or anal stenosis, prostate biopsy under general or regional anesthesia should be considered.

Preparing Patients for Biopsy

Patients should be informed of the risks and benefits of the procedure, and informed consent should be obtained. Herbal supplements also should be discontinued because many contain undeclared agents. Low-dose aspirin does not need to be discontinued (Giannarini et al., 2007). Anticoagulant therapy (e.g., warfarin, clopidogrel) should be stopped 7 to 10 days before prostate biopsy. The novel oral anticoagulants apixaban, dabigatran, and rivaroxaban are stopped 2 to 5 days before biopsy (Culkin et al., 2014). Rivaroxaban may increase stroke risk if stopped; therefore bridging with some other anticoagulant such as heparin is recommended. For those patients with underlying coagulopathy or on warfarin, prostatic biopsy should not be performed until the international normalized ratio has been corrected below 1.5 if the patient has low risk for a thromboembolic event. **For patients at increased risk for thromboembolic events (e.g., mechanical valves) on warfarin, bridging anticoagulation with unfractionated heparin or low-molecular-weight heparin is suggested.**

A small amount of urine in the bladder is useful before the biopsy. This helps facilitate the examination by demonstrating the prostatic bladder junction.

Antibiotic Prophylaxis

An increasing frequency of complications has been recently noted with most postbiopsy hospitalizations resulting from infectious causes (Loeb et al., 2013). This has placed a renewed focus on antibiotic prophylaxis and other strategies to reduce postbiopsy infectious complications. Unlike other lower urinary tract procedures, antimicrobial prophylaxis is recommended for all patients undergoing prostate biopsy, irrespective of risk factors. The 2014 updated latest AUA best practice policy recommended antibiotics for prostate biopsy including fluoroquinolones; first-, second-, and third-generation cephalosporins; and aminoglycoside (level of evidence, Ib) (AUA, 2014). The 2014 update added oral trimethoprim-sulfamethoxazole as a prophylactic agent, and when using intramuscular or intravenous aminoglycoside or aztreonam as an alternative agent, metronidazole or clindamycin is no longer required. The intramuscular route is acceptable for all recommended agents, and the oral route is recommended only for quinolones (Table 150.1). For patients at risk for developing endocarditis or infection of prosthetic joints, pacemakers, and automated implanted cardiac defibrillators, prophylaxis should consist of intravenous ampicillin (vancomycin, if penicillin-allergic) and gentamicin preoperatively, followed by 2 to 3 days of an oral fluoroquinolone. **After an FDA warning and label change in 2016 regarding fluoroquinolone toxicity (musculoskeletal concerns [tendinitis and tendon rupture], peripheral neuropathy, central nervous system side effects, or myasthenia gravis), the AUA recommended shortening the use of fluoroquinolone prophylaxis to a maximum of 24 hours.**

TABLE 150.1

American Urological Association 2014 Best Practice Policy Recommended Antibiotics for Routine Prostate Biopsy[a]

DRUG	DOSAGE
FLUOROQUINOLONES[b]	
Levofloxacin	500 mg PO single dose
Ciprofloxacin	500 mg PO q12h
Ofloxacin	400 mg PO q12h
AMINOGLYCOSIDES[c]	
Gentamicin	5 mg/kg IV single dose
Tobramycin	5 mg/kg IV single dose
Amikacin	15 mg/kg IV single dose
FIRST-GENERATION CEPHALOSPORINS	
Cephalexin	500 mg PO q6h
Cephradine	500 mg PO q6h
Cefadroxil	500 mg PO q12h
Cefazolin	1 g IV q8h
SECOND-GENERATION CEPHALOSPORINS	
Cefaclor	500 mg PO q8h
Cefprozil	500 mg PO q12h
Cefuroxime	500 mg PO q12h
Cefoxitin	1–2 g IV q6h
THIRD-GENERATION CEPHALOSPORINS	
Ceftizoxime	1 g IV q8h
Ceftazidime	1 g IV q12h
Ceftriaxone	1–2 g IV single dose
Cefotaxime	1 g IV q8h
ALTERNATIVE AGENTS	
Aztreonam	1–2 g IV q8h
Trimethoprim-sulfamethoxazole	1 double-strength tablet PO q12h

[a] The recommended duration of antimicrobial prophylaxis is 24 hours or less (level of evidence: Ib).

[b] Fluoroquinolones are associated with an increased risk for tendinitis and tendon rupture.

[c] Aztreonam can be substituted for aminoglycosides in patients with renal insufficiency.

IV, intravenously; *PO,* by mouth.

Modified from American Urological Association. Best practice policy statement on urologic surgery antimicrobial prophylaxis. 2014 update. Available at: https://www.auanet.org/guidelines/antimicrobial-prophylaxis-best-practice-statement.

A 2011 Cochrane review on prophylaxis for TRUS prostate biopsy demonstrated a reduction in bacteriuria, bacteremia, fever, urinary tract infection (UTI), and hospitalization with antibiotics compared with placebo or no treatment (Zani et al., 2011). There was no definitive evidence demonstrating superiority of a longer course or multiple doses compared with a shorter course or single any-dose protocols.

As a result of the increasing resistance patterns to fluoroquinolones, there has been recent interest in using individual culture data to guide antibiotic prophylaxis by using a rectal swab culture before biopsy (Taylor et al., 2012). The presence of fluoroquinolone-resistant organisms on a rectal swab culture has not always translated into clinical infection. In one multi-institutional study, rectal swab cultures immediately before biopsy in 136 men who received ciprofloxacin and gentamicin for prophylaxis had fluoroquinolone-resistant *Escherichia coli* in 22% of cultures (Liss et al., 2011). Only 5 (4%) patients had postbiopsy fever, and only 1 of them had a positive rectal screen for resistant *E. coli.* Although this result might have been prevented through targeted prophylaxis, the low overall complication rate raises questions about the cost-effectiveness of such a strategy. Additional studies are needed to define culture-directed therapy and compare its cost-effectiveness to empirical therapy based on local susceptibility patterns (Loeb, 2013). A risk-adjusted strategy for decreasing infectious complications after biopsy, including prospective monitoring of antibiotic resistance patterns, combination oral and intramuscular antibiotic administration, and selective use of prebiopsy rectal swab screening of high-risk patients appeared effective in a recent prospective study (Woldu et al., 2018).

Cleansing Enema

We routinely have patients self-administer a cleansing enema at home before biopsy. **This practice decreases the amount of feces in the rectum, thereby producing a superior acoustic window for prostate imaging.** The enema's effect on reducing infections is debatable. However, many clinicians may elect not to use an enema because this may allow more spontaneous performance of a prostate biopsy.

Analgesia

TRUS-guided infiltration anesthesia near the nerve bundles with local

anesthetic can provide excellent pain control (Berger et al., 2003; Trucchi et al., 2005). A local prostatic block is achieved using 1% to 2% lidocaine, a long spinal needle (7-inch, 22-gauge), and TRUS guidance along the biopsy channel of the transducer. Multiple variations exist for the infiltration of local anesthetic for transrectal biopsy (Ismail and Gomella, 2013). We found that injecting 5 mL of lidocaine at the level of the SVs near the bladder base at the hyperechoic fat pad that demarcates the junction of the SVs and the prostate bilaterally produces an excellent block. Other approaches include infiltration of 10 mL starting at the junction of the SVs and infiltrating along the lateral aspect of the prostate from base to apex. **Direct infiltration into the prostate (intraprostatic injection) can augment the anesthetic benefit seen with periprostatic injection** (Cam et al., 2008). Saturation biopsy schemes may require up to 22 mL of 1% lidocaine. Caution is needed, however, to avoid direct intravascular injection because of the risk for systemic lidocaine absorption. Intrarectal (topical) instillation of a local anesthetic is inferior to periprostatic infiltration for pain control during biopsy (Heidenreich et al., 2014). However, topical lidocaine may be useful when the patient expresses tenderness to probe insertion. **Local anesthesia for transperineal biopsies also should include infiltration of the skin and subcutaneous tissues of the perineum initially.** Ultrasound guidance then may be employed to aid infiltration of deeper tissues along the anticipated tracts of the biopsy needle.

Patient Positioning

Patients are usually placed in the left lateral decubitus position with knees and hips flexed 90 degrees. An armboard attached parallel to the table and a pillow between the knees help maintain this position. The buttocks should be flush with the end of the table to allow manipulation of the probe and biopsy gun without obstruction. If necessary, the right lateral decubitus or lithotomy position can be used. **The lithotomy position is used by some clinicians and is preferred for transperineal biopsies, brachytherapy treatment planning, vascular examination of the prostate with color or power Doppler or contrast enhancement (for which gravity will alter or distort vascular patterns), or placement of fiducial gold markers for external-beam therapy** (Dehnad et al., 2003; Halpern et al., 2002).

Transrectal Prostate Biopsy Techniques

An initial digital rectal examination should be performed to evaluate for any prostate nodularity or anal pathologic processes. The prostate volume is determined, and imaging of the prostate in both the transverse and sagittal planes is begun. The examination usually starts at the base of the gland and extends to the apex. Most modern ultrasound units are automatically set for optimal prostate viewing, and the TRUS gray-scale examination of the prostate is conducted as described earlier, noting the location and characteristics of any lesions (i.e., hypoechoic, hyperechoic, calcifications, contour abnormalities, cystic structures).

A spring-driven 18-gauge needle core biopsy device or biopsy gun that can be passed through the needle guide attached to the ultrasound probe is most often used. Most ultrasound units provide best visualization of the biopsy needle path in the sagittal plane. Images are typically superimposed with a ruled puncture path that corresponds to the needle guide of the TRUS unit. The biopsy gun advances the needle 0.5 cm and samples the subsequent 1.5 cm of tissue with the tip extending 0.5 cm beyond the area sampled (Kaye, 1989). Therefore, when sampling the PZ, the needle tip may be placed 0.5 cm posterior to the prostate capsule before firing; advancing the needle to or through the capsule can result in sampling of more anterior tissue, missing the most common location of cancers. Avoiding adjustment of the probe position while the biopsy needle is in contact with the rectal surface and applying pressure with the probe to compress the rectal mucosa before biopsy can minimize rectal bleeding. Pressing the probe against the rectum also minimizes the discomfort of the biopsy needle traversing the rectal mucosa, similar to pulling the skin tight to minimize the discomfort of phlebotomy.

The biopsy sample is typically placed in 10% formalin or per local protocol. An AUA white paper recently outlined the recommended processing of prostate biopsy samples, and the review did not provide compelling evidence that individual site–specific labeling of cores benefits clinical decision making regarding the management of prostate cancer (Bjurlin et al., 2013). The paper recommends packaging no more than two cores in each jar to avoid reduction of the cancer detection rate through inadequate tissue sampling.

Sextant Biopsy

The original sextant biopsy scheme (one core from the base, mid, and apex bilaterally) significantly improved cancer detection over digitally directed biopsy of palpable nodules and ultrasound-guided biopsy of specific

hypoechoic lesions (Hodge et al., 1989). Taken in the parasagittal plane, these cores sampled a portion of the PZ but also included a significant amount of tissue from the TZ. Subsequent studies of radical prostatectomy specimens demonstrated that the vast majority of adenocarcinomas arise in the posterolateral PZ (McNeal et al., 1988), thus explaining some of the false-negative results of standard sextant biopsy (Eskew et al., 1997).

Extended-Core Biopsy Techniques

Modifications to the standard sextant biopsy scheme initially focused on the importance of laterally directed cores (Terris et al., 1992). Numerous studies have shown improved cancer detection rates by incorporating additional laterally directed cores into the standard systematic sextant technique. **At present, six cores are considered inadequate for routine prostate biopsy for cancer detection.** Fig. 150.5 depicts the originally proposed sextant technique and several common extended-core biopsy strategies.

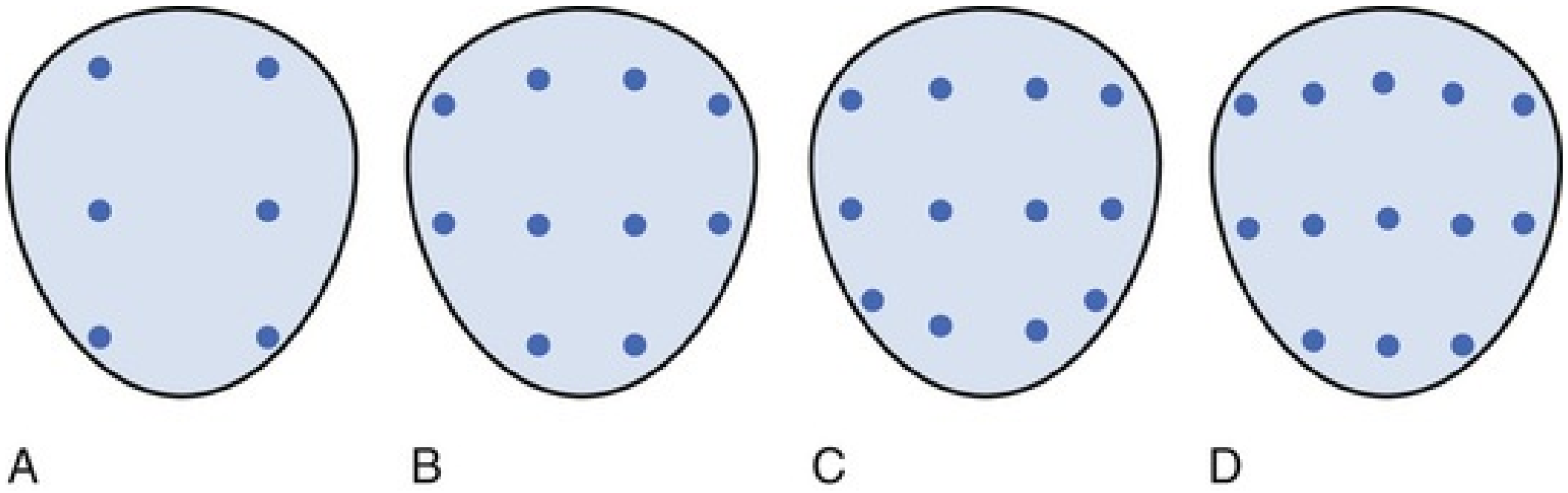

FIG. 150.5 Various reported systematic biopsy schemes. Base is at the top of the figure, apex is at bottom. (A) Sextant biopsy scheme originally proposed by Hodge et al. (1989). (B) The 10-core biopsy (Presti et al., 2000). (C) The 12-core, or double-sextant, biopsy. This is the currently recommended sequence endorsed by the American Urological Association (Bjurlin et al., 2013). (D) The 13-core, 5-region biopsy (Eskew et al., 1997).

Today the extended 12-core systematic biopsy that incorporates apical and far-lateral cores in the template distribution allows maximal cancer detection and avoidance of a repeat biopsy while minimizing the detection of insignificant prostate cancers. This approach has been endorsed in a recent AUA white paper (Bjurlin et al., 2013, 2014). Although increasing the cores from 6 to 12 results in a significant increase in cancer detection rate, increasing the number of cores to 18 or 21 (often termed *saturation biopsy*) as an initial biopsy strategy does not appear to result in a similar increase. However, a series of men from the Cleveland Clinic whose initial biopsy was by a transrectal saturation technique were less likely to have cancer identified during repeat biopsy. Further, if prostate cancer was diagnosed after negative initial saturation biopsy, it was much more likely to be clinically insignificant (Li et al., 2014). Their findings suggest that saturation biopsy may be less likely to miss clinically significant cancer during initial prostate biopsy. At present, saturation biopsy is more likely to be considered in the setting of a prior negative biopsy (see later discussion).

The TZ and SVs are not routinely sampled because these regions have been shown to have consistently low yields for cancer detection at initial biopsy (Epstein et al., 1997), but TZ and anteriorly directed biopsies may occasionally prove necessary to diagnose prostate cancer in those patients with persistently elevated PSA levels and prior negative biopsies (Mazal et al., 2001). **However, there may be a limited role for TZ sampling during the initial biopsy in men with gland size of more than 50 mL, with an additional yield of 15% cancer detection in these larger prostates** (Chang et al., 1998). Today, magnetic resonance imaging (MRI) is often used to detect and guide biopsies of these anterior tumors that may escape standard TRUS prostate biopsy (Volkin et al., 2014). SV biopsy is not routinely performed unless there is a palpable abnormality, with some authors recommending SV biopsy when the PSA value is greater than 30 or if brachytherapy is being considered (Gohji et al., 1995).

Repeat and Saturation Prostate Biopsy

The dilemma of a patient who has had one or more negative prostate biopsies yet continues to have an elevated PSA value or abnormal digital rectal examination of concern for prostate cancer is a common clinical scenario. Often these patients have undergone multiple biopsies despite the well-documented decline in cancer detection with each successive biopsy (Djavan et al., 2003). Keetch et al. (1994) reported an initial positive biopsy rate of 34% in 1136 men from their PSA-based prostate cancer screening program. Cancer detection rates then fell to 19%, 8%, and 7% on biopsy 2, 3, and 4, respectively. These findings were confirmed by results from an initial ERSPC series. **In this cohort of 1051 men with PSA values between 4.0 and 10.0 ng/mL, the initial cancer detection rate with sextant biopsy was 22%. Positive cores were then found in only 10%, 5%, and 4% of patients on subsequent biopsies 2, 3, and 4, respectively** (Djavan et al., 2001a). In a contemporary follow-up from the same ERSPC study, positive predictive values (PPVs) for men without previous biopsy remained equal throughout the three subsequent screenings (25.5%, 22.3%, and 24.8%, respectively) (Bokhorst et al., 2012). Conversely, PPVs for men with a previous negative biopsy result dropped significantly (12.0% and 15.2% at the second and third screening, respectively). In men with and without previous biopsy, the percentage of aggressive prostate cancers (clinical stage >T2b, Gleason score ≥7) decreased after the first round of screening from 44.4% to 23.8% in the second round and 18.6% in the third. Repeat biopsies accounted for 24.6% of all biopsies, but yielded only 8.6% of all aggressive cancers.

The diminishing returns coupled with improved cancer detection rates on initial biopsy with extended-core protocols have led some researchers to examine saturation biopsy techniques (i.e., >12-core biopsy) in this difficult subset of patients with negative previous biopsy results. In a study of 57 men with an average of two prior negative sextant biopsies, a cancer detection rate of 30% was obtained, with an average of 22.5 cores per patient (Borboroglu et al., 2000). Similar protocols from the Mayo Clinic (Stewart et al., 2001) and Toronto (Fleshner and Klotz, 2002) demonstrated improved cancer detection rates. **A drawback to these techniques is that additional anesthetic requirements often require these saturation biopsies to be performed in a hospital setting.** More recent reports question the benefit of a follow-up saturation biopsy scheme, considering the attendant increased cost and potential morbidity. In a reassessment of their previous work on saturation biopsy, investigators at the Mayo Clinic performed a large prospective study of standard systematic and saturation biopsy techniques and did not find a significant increase in prostate cancer detection (Ashley et al., 2008).

The use of a second prostate biopsy in all cases of a negative finding on initial biopsy appears justified if there are concerns about undetected cancer. Third and fourth repeat biopsies, however, should be obtained only in selected patients with high suspicion for cancer and/or poor prognostic factors on the first or second biopsy (Djavan et al., 2005). **When performing repeat biopsy, attention should be placed on the apex, which may not be adequately sampled by the TRUS biopsy approach.**

The role of additional modalities continues to evolve in the setting of repeat biopsy. Techniques such as contrast-enhanced TRUS (CE-TRUS) and MRI-targeted approaches discussed later in this chapter will have an impact on the approach to negative biopsy in the future (Halpern et al., 2005; Volkin et al., 2014). The use of newer molecular and genomic assays also will have an impact on the decision making in the future in the setting of a negative prostate biopsy

(Gittelman et al., 2013; Gomella and Amirian, 2015; Partin et al., 2014).

Transperineal Prostate Biopsy

Transperineal biopsy offers an approach to the prostate in those patients lacking a rectum (e.g., surgical extirpation, congenital anomaly). The potential for reduced infectious and other complication rates and improved identification of apical tumors are now considered benefits to the transperineal biopsy technique (Chang et al., 2013; Roberts et al., 2017). The main trade-off appears to be the need for more extensive anesthesia when using the perineum to approach the prostate, and the inferior visualization of the prostate, which reduces precision of the systematic targeting process.

The patient is positioned in the dorsal lithotomy position with the perineum shaved and prepped as for a sterile surgical procedure. An end-fire ultrasound transducer is used. Despite significant limitations in visualization via this technique compared with TRUS, the prostate can and should be imaged in both the coronal and sagittal planes with calculation of the gland volume. Via the transperineal window, focal PZ hypoechoic lesions are difficult to visualize, as are the SVs. The urethra will appear as a hypoechoic midline structure and may be readily identified by following the corpus spongiosum proximally from the base of the penis. Once the boundaries of the gland have been clearly delineated in the coronal plane, a minimum of six cores should be taken, three from either side of midline.

The diagnostic yield of transperineal ultrasound-guided prostate biopsy was compared with that of TRUS-guided biopsy in a routine biopsy setting (Vis et al., 2000). By using radical prostatectomy specimens with TRUS biopsy–detected prostate cancer, simulated transperineal biopsies were performed and transrectal biopsies were repeated. Significantly, 82.5% of the known tumors were detected with the longitudinal transperineal approach versus 72.5% of cancer detection with repeat transrectal biopsy. The authors postulate that the longitudinal orientation of their cores allows more efficient sampling of the PZ, thereby improving cancer detection. These results, however, assume appropriate systematic positioning of transperineal biopsy cores; unfortunately, freehand transperineal targeting of biopsy cores is often limited by technical factors.

Using a template for the transperineal approach in the repeat biopsy setting, Pinkstaff et al. (2005) obtained a mean of 21.2 cores (range, 12 to 41) in 210 men. The transperineal approach enhanced identification of TZ cancers not detected by previous transrectal prostate biopsy in high-risk patients. However, in a Japanese randomized trial comparing transrectal and transperineal techniques for initial prostate biopsy, the cancer detection rate was similar for both, with higher complications noted in the transperineal approach (Hara et al., 2008). Therefore the authors concluded that transrectal prostate biopsy should be the preferred technique for initial prostate biopsy. An increased rate of urinary retention is noted for the transperineal approach, especially in the saturation biopsy setting (Moran et al., 2006). More recently, numerous benefits have been cited: possible improved cancer detection rates, improved anterior and apical sampling, reduced false-negative results, and reduced risk for underestimating disease volume and grade. **The increasing incidence of antimicrobial resistance and patients with diabetes mellitus who are at high risk for sepsis also favors transperineal biopsy as a sterile alternative to standard TRUS-guided biopsy** (Chang et al., 2013; Roberts et al., 2017). The detection rate of anterior zone prostate cancer in patients undergoing initial and repeat transperineal prostate biopsy is increased by 10% in another series (Pepe et al., 2014).

The technique of three-dimensional transperineal mapping biopsy has been reported (Barqawi et al., 2011). This uses a transperineal brachytherapy template and can include over 50 mapping biopsy cores based on the size of the gland, far more than obtained with saturation biopsy. It may provide additional information and identify higher-risk disease in men thought to have low-risk disease on standard 10- to 12-core TRUS biopsy. Further investigations are needed to establish the utility of this approach.

Combining a transperineal biopsy strategy with MRI-targeted biopsies in the outpatient setting under local anesthesia offers several potential advantages, including lower sepsis and better detection of anterior and apical tumors (Pepe et al., 2017; Zhang et al., 2017). Commercial systems to incorporate transperineal biopsy with an MRI-targeted biopsy approach are being developed to gain the advantage of a transperineal approach in an outpatient setting (Kosarek et al., 2018). As clinical experience grows with these biopsy platforms, the incremental improvement in biopsy accuracy and decreased sepsis will require careful examination.

Transurethral Prostate Biopsy

Transurethral resection biopsy was once advocated for the diagnosis of TZ cancers or after negative TRUS sampling. In contemporary series, solitary TZ cancers, without concomitant PZ tumors, are estimated to occur in less than 5% of patients with prostate cancer (Pelzer et al., 2005). **With improved TRUS techniques including local anesthesia, the TZ can be adequately sampled, and the value of transurethral biopsy has been questioned for the vast majority of patients** (Bratt, 2006). In addition, MRI has shown utility in the identification of TZ and anterior prostate cancers and is particularly effective when used in a TRUS/MRI fusion biopsy system, further limiting the utility of the transurethral biopsy (Volkin et al., 2014).

Risks and Complications of Prostate Biopsy

Although generally considered a safe procedure, TRUS prostate biopsy can be associated with complications. The incidence of serious complications requiring hospitalization is relatively low (<1%). In a Canadian study of more than 41,000 men with negative biopsy results, the 30-day hospital admission rate after prostate biopsy increased from 1.0% in 1996 to 4.1% in 2010 (Nam et al., 2013). The majority of hospital admissions (72%) were related to bacterial infections. An overview of common complications include hematospermia, hematuria, rectal bleeding, prostatitis, fever greater than 101.3°F, epididymitis, urinary retention, and other complications requiring hospitalization (Heidenreich et al., 2014). Large screening series such as the PLCO and ERSPC show that prostate biopsy is not associated with excess mortality, and the overall rate of infectious complications is less than 1% (Pinsky et al., 2014). This low overall absolute risk for serious biopsy-related complications suggests that a fear of complications alone should not deter healthy men with a long life expectancy from pursuing early prostate cancer detection.

Postbiopsy Infections

Infection is the most common complication of prostate biopsy, with fluoroquinolone-resistant *E. coli* having a prominent role. Reported rates of infectious complications range from 0.1% to 7.0%, and sepsis rates range from 0.3% to 3.1% depending on antibiotic prophylaxis regimens (Liss et al., 2017). Most infectious complications after TRUS biopsy are limited to symptomatic UTI and low-grade febrile illness, which can be readily treated with oral or intravenous antibiotics; however, an increasing incidence of hospitalizations and fatal sepsis after prostate biopsy are being reported (Wagenlehner et al., 2014).

The contemporary risk for hospitalization for infectious complications ranges from 0.6% to 4.1%, with the reported incidence of UTI from 2% and 6% (Bjurlin et al., 2014; Nam et al., 2013). **Although hospitalizations for sepsis are increasing after prostate biopsy, data suggest that the mortality in this group was not excessive when compared with that of other similar systemic infections** (Carter et al., 2013; Loeb, 2013; Loeb et al., 2013). Sepsis is the clinical syndrome characterized by a systemic inflammatory reaction to an infectious process; the symptoms are nonspecific and may include fever, hypothermia, tachypnea, tachycardia, altered mental status, and hypotension (AUA/SUNA, 2012). Any patient who presents with a fever after a prostate biopsy should be assessed for the presence of sepsis. Septic shock refers to acute circulatory failure (hypotension) that persists despite adequate fluid resuscitation.

A main factor for severe infection seems to be the presence of fluoroquinolone-resistant fecal bacteria, likely related to the widespread use of these agents in health care settings, and in sources of the food supply (Heuer et al., 2009). The use of targeted prophylaxis after rectal flora swabbing and culture has been shown to have some utility compared with empirical antibiotic prophylaxis in some series. Various bowel preparations are under investigation, but none have been shown to significantly reduce infection rates. As discussed earlier, transperineal prostate biopsy is currently being evaluated to reduce infections, with limited data supporting this approach at present (Grummet et al., 2014).

Organisms reported to result in sepsis are predominantly *E. coli*, with high rates of resistance to fluoroquinolones, trimethoprim-sulfamethoxazole, and ampicillin. However, all isolates in this series were susceptible to second- and third-generation cephalosporins, amikacin, and carbapenems (e.g., imipenem, meropenem) (Loeb, 2013). **Risk factors for prostate biopsy–related infection include: nonwhite race, increased number of comorbidities, diabetes mellitus, prostate enlargement, foreign travel, and recent antibiotic use.** Another risk factor is the number of previous biopsies. The number of previous prostate biopsies was significantly associated with an increased risk for infectious complications in men on an active surveillance protocol (Ehdaie et al., 2014). **Familiarity with local antibiotic resistance patterns can aid in rapid treatment of symptomatic infection after prostate biopsy.**

Bleeding

Even with normal coagulation parameters, bleeding is the most common complication seen after prostate biopsy. Prostate biopsy is considered to pose an intermediate risk for bleeding (Naspro et al., 2013). As noted, any potential medications that can alter coagulation parameters, including herbal remedies, should be held for 5 to 7 days before biopsy and those on warfarin managed as noted. Two large European screening programs noted hematuria in 23% to 63% of men after sextant biopsy, with clot retention developing in 0.7% (Djavan et al., 2001b; Raaijmakers et al., 2002). Rectal bleeding is common and seen in 2.1% to 21.7% of patients (Djavan et al., 2001b; Enlund and Varenhorst, 1997). **Rectal bleeding is typically minor and readily controlled with direct pressure by the ultrasound probe or digitally; persistent brisk blood loss per rectum may require more aggressive intervention for control.** Additional measures include rectal tamponade with an inflated condom, anoscopy/colonoscopy with injection of epinephrine and polidocanol or use of sclerotherapeutic agents, angiography with embolization, transrectal exploration, and suturing (AUA/SUNA, 2012).

Hematospermia, commonly seen after biopsy, is of minimal clinical importance but can cause significant anxiety if not discussed at the time of biopsy; 9.8% to 50.4% of men experience some blood in their ejaculate (Djavan et al., 2001b; Raaijmakers et al., 2002). In one study, the mean duration of hemospermia was 4 (±1.4) weeks, with the number of ejaculations before resolution at six (±5.6). No factors predicted the duration of hemospermia (Abdelkhalek et al., 2013).

Other Complications

Excessive anxiety and discomfort from the endorectal probe may produce a moderate or severe vasovagal response in 1.4% to 5.3% of patients (Djavan et al., 2001b; Rodriguez and Terris, 1998) and may require termination of the procedure. Placing the patient in the Trendelenburg position and use of intravenous hydration usually resolve these symptoms, with further intervention as clinically indicated.

Acute urinary retention requiring temporary catheterization develops in 0.2% to 0.4% of patients after TRUS biopsy (Enlund and Varenhorst, 1997; Raaijmakers et al., 2002). Men with significantly enlarged glands and those with significant lower urinary tract symptoms, such as those with a high International Prostate Symptoms Score (IPSS), are more prone to develop retention (Rodriguez and Terris, 1998; Raaijmakers et al., 2002). Any prostate biopsy may increase the IPSS, but this appears to be transient.

The effects of prostate biopsy on erectile dysfunction have been incompletely characterized. Very early studies suggested that erectile dysfunction after TRUS biopsy was caused by damage to the neurovascular bundles (Zisman et al., 2001). Since that time the studies have been conflicting, with a more recent study suggesting erectile dysfunction is more pronounced in men who had a diagnosis of prostate cancer than in those who were cancer free (Helfand et al., 2013).

Advanced and Investigational Techniques for Prostate Biopsy

Color and Power Doppler Transrectal Ultrasonography

Color Doppler imaging is based on the frequency shift in the reflected sound waves from the frequency of insonation and thus depicts the velocity of blood flow in a directionally dependent manner (Fig. 150.6A). **Color assignment is based on the direction of blood flow related to the orientation of the transducer receiving the signal; by accepted convention in most institutions, flow toward the transducer is depicted in shades of red and flow away in shades of blue; the color is not specific for arterial or venous flow.** Power Doppler imaging (also known as *enhanced color Doppler, color amplitude imaging*, or *color angiography*) uses amplitude shift to detect flow in a velocity and directionally independent manner (Bude and Rubin, 1996) (see Fig. 150.6B). The advantages of power Doppler imaging are its ability to detect slower flow and less reliance on the Doppler angle, making it more suitable for detection of prostate cancer neovascularity. Although power Doppler imaging offers improved sensitivity to small amounts of flow, neither modality has yet proved itself superior to the other for cancer detection.

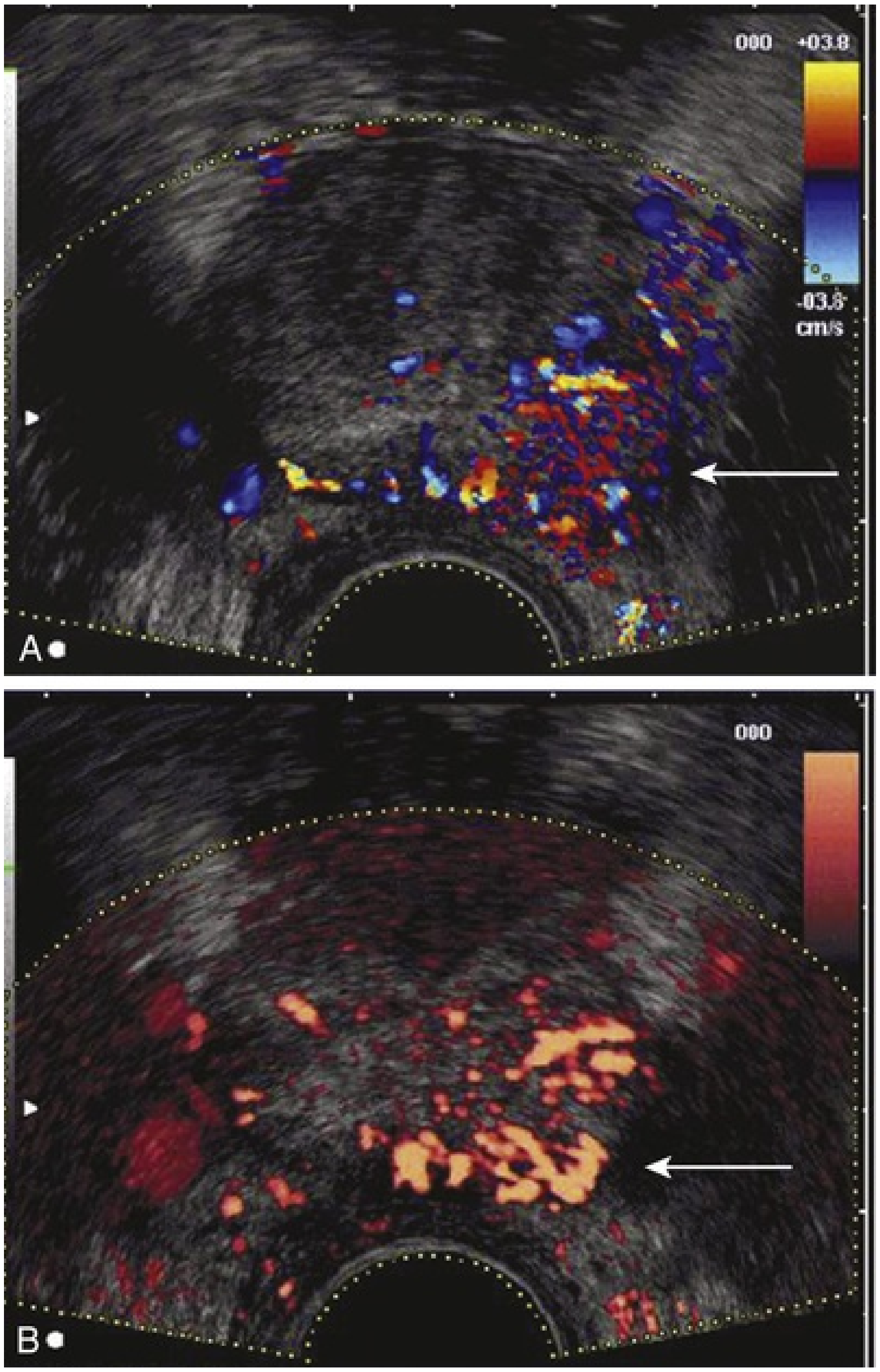

FIG. 150.6 Color Doppler (A) transrectal ultrasonography (TRUS) and power Doppler (B) TRUS identify a Gleason 4 + 4 = 8 adenocarcinoma *(arrows)* in the left mid-gland.

One series found color Doppler sensitivity and specificity of 14.6% and 93.9%, respectively, to identify cancer (Halpern and Strup, 2000). Whereas Doppler modes showed an improved diagnosis versus gray-scale TRUS, 45% of cancers still went unidentified by any sonographic modality. Others have shown increased cancer detection rates using Doppler-targeted biopsy strategies, but none is sufficiently accurate to replace systematic biopsy (Halpern et al., 2002). Enhancements in the technical aspects of color Doppler TRUS, including the use of contrast agents (see later discussion), may provide the necessary improvements to specifically identify cancer sites in the future.

Multiple studies have shown that angioneogenesis and the resultant increase in microvessel density that occurs within foci of prostatic adenocarcinoma correlates with the presence of metastases (Weidner et al., 1993), stage of disease (Bostwick et al., 1996), and disease-specific survival (Borre et al., 1998; Lissbrant et al., 1997). Interest in using color and power Doppler TRUS to aid in prostate cancer detection stems from studies of radical prostatectomy specimens demonstrating that foci of adenocarcinoma possess an increased density of microvessels compared with surrounding normal parenchyma (Bigler et al., 1993).

Patients with detectable color Doppler flow within their dominant tumor at the time of TRUS-guided biopsy are at a 10-fold increased risk for PSA recurrence after radical retropubic prostatectomy (Ismail et al., 1997). The presence of increased flow was also associated with higher Gleason grade, increased incidence of SV invasion, and a lower biochemical disease-free (bNED) survival rate versus subjects without increased flow on preoperative TRUS (Ismail et al., 1997). Other investigators also have shown the association of power Doppler flow signals as an indicator of microvessel density with higher Gleason score and have suggested a correlation with outcome (Wilson et al., 2004).

Current unenhanced Doppler modalities are not able to identify the microvessels of prostate cancer, which are typically 10 to 15 microns in diameter. The flow signals associated with malignant foci detected by unenhanced color and power Doppler imaging are caused by detection of larger feeding vessels (Ismail and Gomella, 2001). Intravenous microbubble ultrasound contrast agents, similar to those currently approved and used in echocardiography, have been infused systemically during gray-scale and TRUS Doppler imaging to amplify flow signals within the microvasculature of prostate tumors, allowing selective visualization of malignant foci in clinical trials (Halpern et al., 2000; Ismail and Gomella, 2001). **These intravenous “bubble” contrast agents are constructed with air or higher-molecular-weight gas agents encapsulated (albumin or polymer hard shell, lipid, or surfactant coated) for longevity and are generally 1 to 10 microns in diameter.**

Using CE-TRUS for prospective prostate cancer detection, Halpern et al. (2001) demonstrated an increase in sensitivity from 38% to 65% versus baseline unenhanced imaging, without significantly altering specificity. Subsequent studies by our group and others have improved sonographic detection of malignant foci using CE-TRUS and targeted biopsy of enhancing lesions (Kundavaram et al., 2012). In a multi-institutional trial involving several European centers, CE-TRUS has been recommended for routine care in prostate biopsy (Wink et al., 2008). Imaging using microbubble contrast agents combined with three-dimensional image reconstruction of enhanced power Doppler images also demonstrated increased diagnostic accuracy (Unal et al., 2000) (Fig. 150.7). **Flash-replenishment imaging, a software modification, gives better visualization of small neovessels, down to the capillary level, for the detection of prostate cancer** (Linden et al., 2007). Flash replenishment imaging uses a combination of high-power flash pulses to destroy contrast microbubbles, followed by low-power pulses to demonstrate contrast replenishment. A composite image is constructed depicting the vascular architecture through maximum intensity capture of temporal data in consecutive low-power images and can be used for real-time targeted transrectal biopsy of areas of increased or abnormal vascularity. Using this technique, we have demonstrated much finer vascular detail for targeting biopsy, and targeted biopsy cores were significantly more likely to be cancerous than random systematic biopsy cores (Linden et al., 2007). Future developments in these and other imaging modalities that can selectively visualize prostate cancers based on the presence of angioneogenesis may ultimately allow more accurate localization of the sites of cancer.

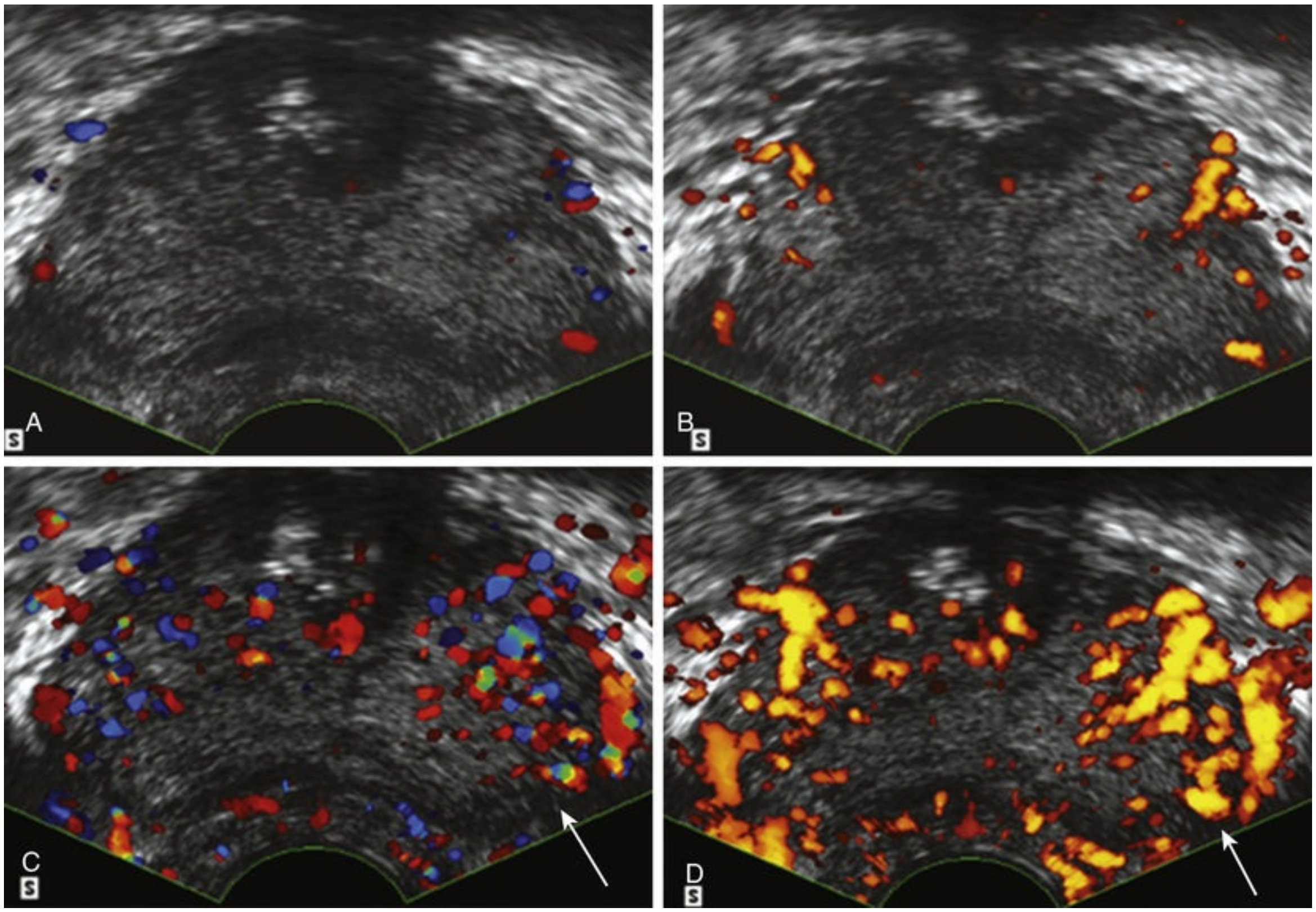

FIG. 150.7 Unenhanced color (A) transrectal ultrasonography (TRUS) and power Doppler (B) TRUS fail to detect evidence of an underlying malignancy. After infusion of a microbubble contrast agent, color (C) TRUS and power Doppler (D) TRUS demonstrate an area of increased flow in the left mid-gland that proved to be a Gleason 3 + 4 = 7 adenocarcinoma on targeted biopsy *(arrows).*

The technique of elastography may prove superior to color Doppler imaging in identification of malignant areas in the prostate (Nelson et al., 2007; Sumura et al., 2007). Early studies with elastography employed real-time sonographic imaging of the prostate at baseline, and under varying degrees of compression to add information about stiffness of the prostate tissue (Fig. 150.8). Through computerized calculations, differences in displacement between ultrasonic images from baseline and during compression may be visualized, and regions with decreased tissue elasticity (stiffness) may be suggestive of malignancy. More recent studies use the ultrasound beam itself to compress tissues, or rely on the velocity of shear waves to indicate the relative stiffness of underlying tissues; these newer techniques are independent of interuser variations related to the pressure applied during the examination. In a preliminary study of 404 cases with 151 cases positive for prostate cancer, the malignancy was found in 127 patients (84.1%) with real-time elastography directing the biopsy (Konig et al., 2005). Real-time elastography-targeted biopsy is an evolving method for increasing prostate cancer detection rates. Real-time elastography-targeted biopsies missed cancer in a high proportion of patients in one series of over 1000 men (Salomon and Schiffmann, 2014; Salomon et al., 2014). Another prospective study of shear wave elastography in 212 men undergoing prostatectomy who had prostate stiffness examined with shear wave elastography preoperatively and compared with final surgical pathology demonstrated differentiation of benign and malignant areas and increasing tissue stiffness with higher Gleason score (Wei et al., 2018). **With the conflicting data available at this time, elastography at present should be considered an additional technology to complement but not replace random biopsies** (Salomon et al., 2014).

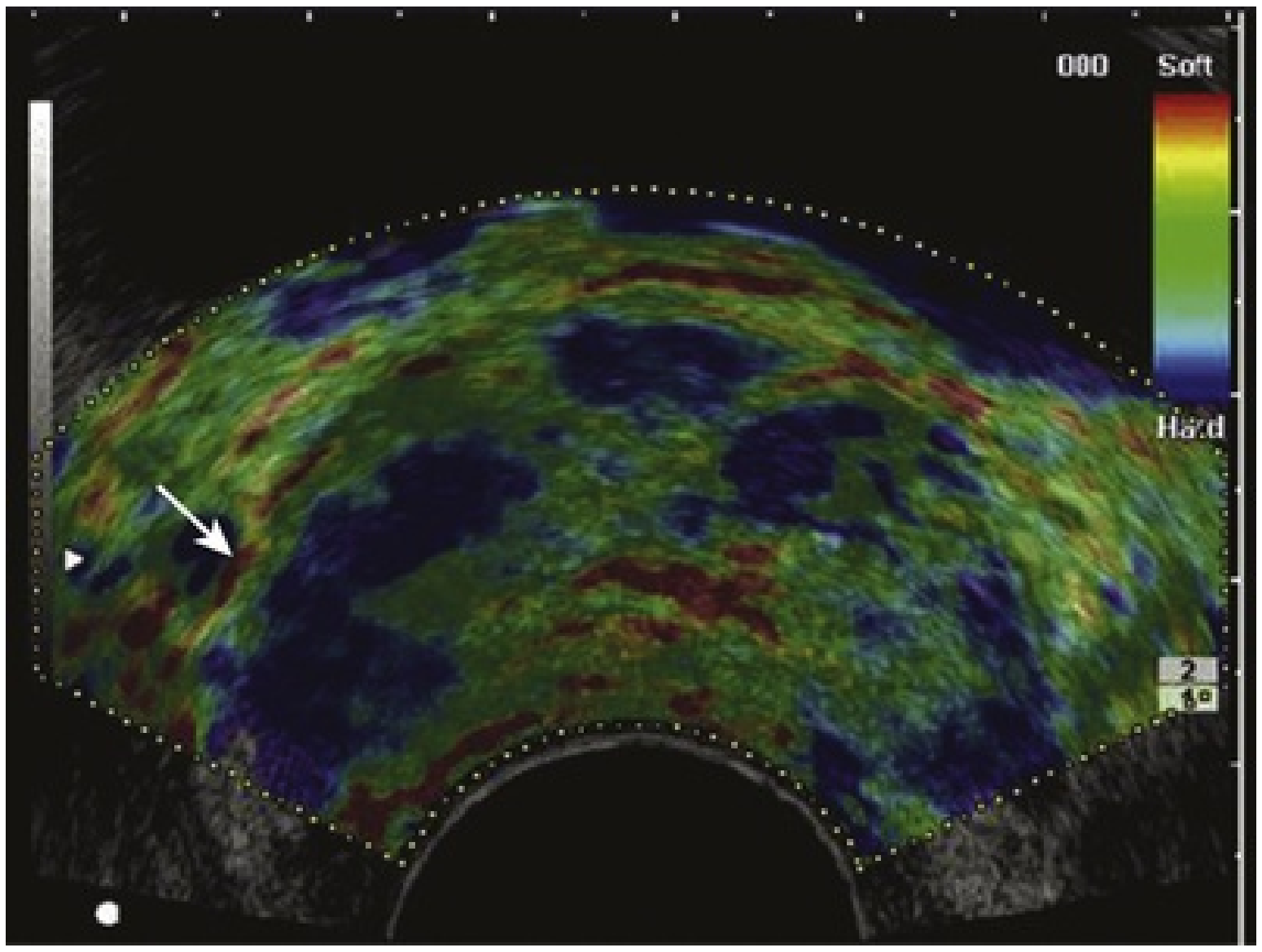

FIG. 150.8 Elastography demonstrates an area of decreased compliance in the right base consistent with an underlying malignancy *(blue near arrow).* Note color scale in upper right corner indicating relative tissue “firmness.” Targeted biopsy of this region revealed a Gleason 4 + 4 = 8 adenocarcinoma.

Other Newer and Investigational Imaging and Biopsy Techniques

Prostate HistoScanning (Advanced Medical Diagnostics, Waterloo, Belgium) is a proprietary tissue characterization technology reported to differentiate, characterize, and visualize prostate tissue, based on the analysis of backscattered ultrasound. It is an evolving technology, and a recent study of 105 patients suggested that the system could not reliably identify and characterize prostate cancer in a routine clinical setting (Javed et al., 2014). A more recent prospective study evaluating HistoScanning with mpMRI in men scheduled for radical prostatectomy also demonstrated inferior diagnostic accuracy as compared with mpMRI (Orczyk et al., 2016). This also calls into question the clinical impact of HistoScanning for prostate cancer biopsy.

Multiparametric Prostate Ultrasonography

Analogous to prostate MRI examined with multiple parameters, the concept of multiparameter prostate ultrasound evaluation is gaining enthusiasm as an alternative and/or complement to MRI. Parameters to evaluate prostate vascularity, including color and power Doppler and contrast enhancement, and assessment of tissue stiffness with elastographic parameters, can augment standard gray-scale ultrasonography for the accurate diagnosis of prostate cancer (Grey and Ahmed, 2016; Postema et al., 2015a, 2015b).

Multiparametric Magnetic Resonance Imaging of the Prostate

Improvements in the design and application of mpMRI have increased the ability to identify and localize prostate cancer. **Functional MRI parameters such as dynamic contrast enhancement and diffusion-weighted imaging alone or in combination have improved prostate cancer detection** (Turkbey and Choyke, 2012). The AUA created a Policy Statement on the use of mpMRI in the diagnosis, staging, and management of prostate cancer, and noted the rapid evolution of mpMRI in the management of prostate cancer (Fulgham et al., 2017). However, the diagnosis and histopathologic grading of prostate cancer still requires tissue for diagnosis. Although theoretically appealing, significant technical difficulties exist in performing real-time MRI-directed prostate biopsies. At the present time, there are three evolving techniques that combine MRI guidance for targeted prostate biopsies, namely direct “in-bore” MRI, cognitive fusion, and MRI/ultrasound fusion via software-based image coregistration (Logan et al., 2014).

The Prostate Image Reporting and Data System (PIRADS) categorization represents a consensus opinion to allow the systematic evaluation of lesions detected on mpMRI to estimate their potential risk for prostate cancer. Initially proposed by the European Society of Urogenital Radiology (ESUR) in 2012 (version 1), these guidelines helped standardize the interpretation and reporting of mpMRI prostate scans (Barentsz et al., 2012). A more recent update (version 2 or PIRADS v2) was compiled by the American College of Radiology (ACR), the ESUR, and the AdMeTech Foundation in 2015 and published in 2016 (Weinreb, et al., 2016). This update includes clinical and technical considerations for mpMRI and a standardized lexicon for reporting the results of these examinations. In PI-RADS v2, the scoring remains a Likert scale from 1 to 5, with higher numbers indicative of increased risk for a clinically significant malignancy (Box 150.2), defined as tumors with Gleason score greater than or equal to 7 and a volume greater than 0.5 cm^3 or extraprostatic extension (EPE). The peripheral zone and transitional/central zone are scored separately, with both reported in the examination synoptic. The scheme for assigning PI-RADS categories is dependent on multiple parameters of the MRI examination, including T2-weighted imaging (T2WI), dynamic contrast-enhanced (DCE) imaging, and diffusion-weighted imaging (DWI). Using this system, each suspicious lesion is scored from 1 to 5 for T2WI and DWI, and the DCE is classified as positive (presence of contrast enhancement) or negative (no contrast enhancement) to give a final PI-RADS score as shown in Tables 150.2 and 150.3. **Size and appearance are also an important aspect of distinguishing lesions seen either in the PZ or TZ, in addition to the MRI parameters (T2WI, DCE, DWI). Lesions that are greater than 1.5 cm on T2WI or with high suspicion of EPE are assigned as a PI-RADS 5 lesion** (Weinreb, et al., 2016). Recent prospective validation studies from Germany and the Netherlands confirmed the ability of the PI-RADS v2 system to detect prostate cancer on biopsy. Hofbauer et al. (2018) reported on 704 men undergoing MRI fusion biopsy, demonstrating a cancer detection rate for PI-RADS 3, 4, and 5 lesions of 39%, 72%, and 91%, respectively. When detection rates were calculated for only clinically significant tumors, the positive predictive rates for PI-RADS 3, 4, and 5 lesions were 23%, 49%, and 77%, respectively. At Nijmegen, similar results were reported in 1057 men, with an overall cancer detection rate of 35%, 60%, and 91% for PI-RADS 3, 4, and 5 lesions, respectively, and a clinically significant cancer detection rate of 17%, 34%, and 67%, respectively (Venderink et al., 2017).

Box 150.2

PI-RADS v2 Categories

- PI-RADS 1: Very low (clinically significant cancer is highly unlikely to be present)
- PI-RADS 2: Low (clinically significant cancer is unlikely to be present)
- PI-RADS 3: Intermediate (the presence of clinically significant cancer is equivocal)
- PI-RADS 4: High (clinically significant cancer is likely to be present)
- PI-RADS 5: Very high (clinically significant cancer is highly likely to be present)

TABLE 150.2

PI-RADS v2 Scheme for Peripheral Zone Lesion Assessment Categories

DWI	T2WI	DCE	PI-RADS ASSESSMENT CATEGORY
1	Any[a]	Any	1
2	Any	Any	2
3	Any	–	3
		+	4
4	Any	Any	4
5	Any	Any	5

[a] “Any” indicates any score from 1–5 can be assigned.

Data from Weinreb JC, Barentsz JO, Choyke PL, et al. PI-RADS prostate imaging—reporting and data system: 2015, version 2. *Eur Urol* 69(1):16–40, 2016.

TABLE 150.3

PI-RADS v2 Scheme for Transition Zone Lesion Assessment Categories

T2WI	DWI	DCE	PI-RADS ASSESSMENT CATEGORY
1	Any[a]	Any	1
2	Any	Any	2
3	≤ 4	Any	3
	5		4

4	Any	Any	4
5	Any	Any	5

[a] “Any” indicates any score from 1–5 can be assigned.

Data from Weinreb JC, Barentsz JO, Choyke PL, et al. PI-RADS prostate imaging—reporting and data system: 2015, version 2. *Eur Urol* 69(1):16–40, 2016.

Based on its superior detection rate for clinically significant cancer, multiparametric MRI might be able to guide and therefore limit the number of biopsies and cores for patients (Amsellem-Ouazana et al., 2005). “In-bore” MRI prostate biopsy is performed with the patient in the MRI unit. It requires highly specialized equipment and is limited by technical considerations such as limited space in the MRI, cost, and time considerations (Beyersdorff and Hamm, 2005). In one recent study of multiparametric MRI prostate biopsy in 223 men compared with TRUS biopsy, 142 (63.7%) had prostate cancer (Pokorny et al., 2014). TRUS prostate biopsy detected 126 cancers (56.5%), including 47 (37.3%) classed as low risk. MRI-directed biopsy detected 99 cases of cancer in 142 men (69.7%) with equivocal or suspicious MRI, of which 6 (6.1%) were low risk. The MRI pathway reduced the need for biopsy by 51%, decreased the diagnosis of low-risk prostate cancer by 89.4%, and increased the detection of intermediate-/high-risk prostate cancer by 17.7%. The estimated negative predictive values (NPVs) of TRUS biopsy and MRI biopsy for intermediate- and high-risk disease were 71.9% and 96.9%, respectively.

Cognitive fusion requires no additional equipment. This approach relies on an experienced operator reviewing a suspicious lesion on MRI and then directing the biopsy needle in the direction of those lesions during the standard TRUS biopsy procedure. A primary disadvantage of this technique is the inability to record and confirm biopsy needle placement and interuser variability (Logan et al., 2014). The utility of this technique will be limited when there are no obvious landmarks in the prostate by which to direct the biopsy.

One of the most promising biopsy techniques is TRUS/MRI fusion via a software platform. It combines the familiarity of real-time TRUS guidance with detailed information from a diagnostic multiparametric MRI and superimposes both images via software image reconstruction. The reconstruction involves image registration or image matching. A prebiopsy MRI must identify target lesions suspicious for cancer based on imaging characteristics. Based on the particular software platform, these targets are delineated before or after MRI data have been loaded onto the software platform. TRUS of the prostate is performed, and MRI and real-time TRUS images are superimposed, creating a three-dimensional prostate reconstruction and allowing rapid identification of the MRI targets for biopsy in a few minutes. Several MRI/US fusion systems are available in the United States and worldwide (Sarkar and Verma, 2018). The most commonly used systems in the United States are the UroNav platform (Phillips/Invivo, Gainesville, FL) and the Artemis platform with ProFuse (Eigen). The UroNav system has been under study at the National Cancer Institute since 2004 and has the largest collection of published data to date. Several other manufacturers are developing systems both in the United States and abroad (Raskolnikov et al., 2014; Sarkar and Verma, 2018).

The different fusion platforms use proprietary systems for image coregistration and fusion. The Artemis system employs a mechanical arm to direct the biopsy. The UroNav system employs a standard handheld probe with localization and tracking data recorded by an external magnetic field generator integrated with existing freehand ultrasound technology. Other differences include varying methods to acquire the transrectal ultrasound image, including freehand sweep through the prostate or mechanical stabilization (Sarkar and Verma, 2018). Real-time image fusion allows the physician to direct the biopsy using standard TRUS spring-loaded needle biopsy technique (Fig. 150.9).

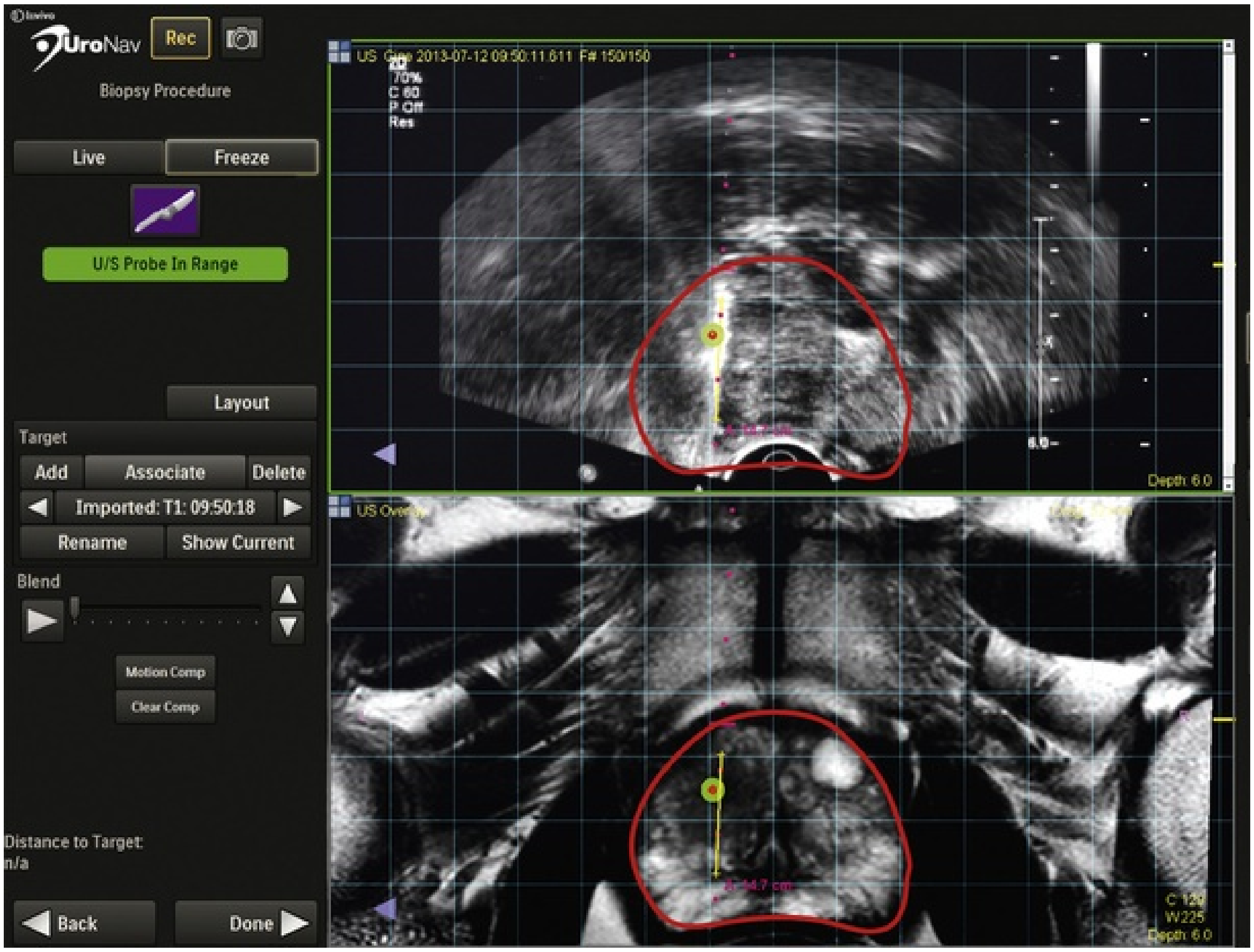
UroNav
Rec
Biopsy Procedure
Live
Freeze
U/S Probe In Range
Layout
Target
Add
Associate
Delete
Imported: T1: 09:50:18
Rename
Show Current
Blend
Motion Comp
Clear Comp
Distance to Target:
n/a
Back
Done
US Cine 2013-07-12 09:50:11.611 F# 150/150
Depth: 6.0
US Overlay
C 120
W225
Depth: 6.0

FIG. 150.9 Example of a screen shot when performing transrectal ultrasonography (TRUS) using the UroNav (Invivo) TRUS–magnetic resonance imaging (MRI) fusion biopsy system. *Upper panel* is the real-time ultrasound; *lower panel* shows the MRI. The *red line* outlines the prostate, and the *green circle with the red dot* represents the coregistered lesion of interest. The *yellow line* represents the needle tract. (Courtesy of Dr. Peter Pinto, Urologic Oncology Branch, National Cancer Institute, Bethesda, MD.)

Initial results were reported for two US TRUS/MRI fusion systems: the UroNav and Artemis. A study at the University of California–Los Angeles involving 171 men demonstrated that 94% (16 of 17 patients) with a PIRADS 5 (highly suspicious) MRI lesion had biopsy-positive prostate cancer. A 38% detection rate was found for intermediate- to high-risk prostate cancer identified only on targeted biopsy, with targeted cores three times more likely to detect intermediate- to high-risk disease versus systematic biopsy (Sonn et al., 2013).

An update series of 582 men studied on the UroNav system has demonstrated an increasing correlation between MRI suspicion and Gleason grade for prostate cancer with detection for Gleason 8 or greater prostate cancer showing a 98% sensitivity at the low-moderate cutoff and a 91% NPV at the moderate-high cutoff (Rais-Bahrami et al., 2013). Another TRUS/MRI fusion–guided biopsy study with the UroNav system demonstrated upgrading and detection of prostate cancer with higher Gleason score in 32% of patients compared with traditional 12-core biopsy alone (Siddiqui et al., 2013). Targeted biopsy with the TRUS/MRI fusion technique preferentially detected higher-grade prostate cancer and missed lower-grade tumors.

Implementation of MRI fusion prostate biopsy has expanded greatly over the past 5 years, and there is growing awareness of the importance of mpMRI and fusion biopsy in a variety of clinical settings. These include the initial evaluation of men with elevated PSA; follow-up of men with persistently elevated PSA and previous negative biopsy; active surveillance algorithms for men with low- and very-low-risk prostate cancer; and accurate clinical staging of men diagnosed with prostate cancer (Duvnjak et al., 2018). In a joint consensus statement, the AUA and the Society of Abdominal Radiology (SAR) in 2016 recommended mpMRI with targeted biopsies of PI-RADS lesions with a score greater than or equal to 3 in men with negative previous prostate biopsies and persistently elevated PSA (Rosenkrantz et al., 2016). This strategy was also incorporated in the NCCN Prostate Cancer Early Detection Guidelines in 2018 (NCCN, 2018).

For biopsy-naïve men with elevated PSA, the role of mpMRI and MRI-targeted biopsy is less clear. The PROMIS trial examined this issue, originating in the United Kingdom (Ahmed et al., 2017). In this prospective, paired cohort study of 576 men who completed the study, mpMRI was performed initially but was blinded to both patients and physicians. The patients underwent standard TRUS prostate biopsy (10 to 12 cores) and transperineal mapping prostate biopsies in a saturation fashion (biopsy every 5 mm) to serve as the gold standard reference range for prostate cancer detection in terms of lesion grade and location. The lesions detected on mpMRI were compared with the cancer detected on transperineal mapping to assess the accuracy of MRI in cancer detection. Additionally, the TRUS biopsy performance for cancer detection was also compared with the transperineal mapping reference. **MRI outperformed standard TRUS in prostate cancer detection for clinically significant disease,** with an improved sensitivity (93% vs 48%, respectively) and negative predictive value (89% vs 74%, respectively), while showing decreased specificity (41% vs 96%, respectively) and positive predictive value (51% vs 90%, respectively) (Ahmed et al., 2017).

The PRECISION trial recently reported similar results in the biopsy-naïve population of men with elevated PSA (Kasivisvanathan et al., 2018). In this multicenter trial in Europe and North America, men with elevated PSA referred for prostate biopsy were randomized to MRI-targeted biopsy versus standard 10- to 12-core TRUS biopsy, with the end point of detecting clinically significant cancer. **In this large, well-designed study, MRI-targeted biopsy had a higher detection rate of clinically significant disease and lower detection rate of clinically insignificant disease compared with standard TRUS biopsy** (Kasivisvanathan et al., 2018). These results confirm the previous single-institution study from the National Cancer Institute comparing standard TRUS prostate biopsy with MRI fusion biopsy utilizing the UroNav system, in which MRI fusion biopsies had significantly improved cancer detection for high-risk (clinically significant) tumors (Siddiqui et al., 2015).

Enthusiasm for MRI-targeted biopsies should tempered, however, with the realization that no technique has perfect performance in prostate cancer detection, even when restricted to clinically significant disease. The NCI group examined their large single-institution cohort of MRI biopsies and retrospectively examined the cohort that eventually underwent radical prostatectomy as the gold standard. **In this evaluation, from a center of excellence with a large cohesive multidisciplinary team for prostate MRI and MRI-targeted biopsy, the false-negative rate of mpMRI was 16% for detection of clinically significant cancer.** Of the lesions that were missed, the majority were favorable intermediate risk (Gleason 3 + 4 = 7) in 65%, but the remaining 35% of clinically significant lesions missed had primary Gleason pattern 4 disease (4 + 3 = 7 in 4%, 4 + 4 = 8 in 27%, and 4 + 5 = 9 in 4%) (Borofsky et al., 2018).

Technologies continue to evolve in improving the identification and diagnosis of prostate cancer. Beyond imaging technologies such as ultrasonography and MRI, the use of genomic and other molecular markers will play an increasing role in determining the need for a biopsy and in identifying patients who are in need of a repeat biopsy (Partin et al., 2014). Color Doppler, ultrasound contrast agents, elastography, multiparametric MRI, and TRUS/MRI fusion are undergoing refinements as imaging methods to guide and enhance the accuracy of prostate biopsies (Hong et al., 2014). An intriguing trial comparing mpMRI and multiparametric TRUS, entitled the CADMUS trial (Cancer Detection by Multiparametric Ultrasound of the prostate) has been initiated in the United Kingdom, which should provide prospective data comparing differing prostate biopsy strategies for the first time (Grey et al., 2018). Until these techniques are proved superior in the localization and diagnosis of prostate cancer, systematic

TRUS gray-scale 12-core needle biopsy will continue to be regarded as the gold standard for the diagnosis of prostate cancer.

Key Points: Prostate Biopsy

- TRUS and/or MRI alone cannot diagnose prostate cancer without a tissue biopsy.
- Local prostate anesthesia is commonplace and most useful when using extended-core biopsy schemes.
- Patients undergoing TRUS-guided prostate biopsy require oral antibiotic prophylaxis for up to 24 hours perioperatively.
- Sextant biopsy of the prostate for prostate cancer detection is inadequate, and systematic biopsy procedures should include a minimum of 12 cores based on AUA recommendations.
- Advanced ultrasound techniques (color and power Doppler, contrast-enhanced TRUS, elastography) can improve cancer detection but do not reliably identify all malignant foci and thus cannot obviate the need for systematic biopsy at the present time.
- TRUS/MRI fusion is a promising technique that takes advantage of the strengths of each modality when performing prostate biopsy.

Suggested Readings

Ahmed HU, El-Shater Bosaily A, Brown LC, et al. Diagnostic accuracy of multi-parametric MRI and TRUS biopsy in prostate cancer (PROMIS): a paired validating confirmatory study. *Lancet*. 2017;389(10071):815–822.

Bjurlin MA, Carter HB, Schellhammer P, et al. Optimization of initial prostate biopsy in clinical practice: sampling, labeling and specimen processing. *J Urol*. 2013;189(6):2039–2046.

Haffner J, Lemaitre L, Puech P, et al. Role of magnetic resonance imaging before initial biopsy: comparison of magnetic resonance imaging–targeted and systematic biopsy for significant prostate cancer detection. *BJU Int*. 2011;108(8 Pt 2):E171–E178.

Hodge KK, McNeal JE, Terris MK, et al. Random systematic versus directed ultrasound guided transrectal core biopsies of the prostate. *J Urol*. 1989;142(1):71–74 [discussion 74–75].

Ismail M, Gomella LG. Transrectal prostate biopsy. *Urol Clin North Am*. 2013;40(4):457–472.

Kundavaram CR, Halpern EJ, Trabulsi EJ. Value of contrast-enhanced ultrasonography in prostate cancer. *Curr Opin Urol*. 2012;22(4):303–309.

Li YH, Elshafei A, Li J, et al. Potential benefit of transrectal saturation prostate biopsy as an initial biopsy strategy: decreased likelihood of finding significant cancer on future biopsy. *Urology*. 2014;83(4):714–718.

Loeb S, Vellekoop A, Ahmed HU, et al. Systematic review of complications of prostate biopsy. *Eur Urol*. 2013;64(6):876–892.

Logan JK, Rais-Bahrami S, Turkbey B, et al. Current status of MRI and ultrasound fusion software platforms for guidance of prostate biopsies. *BJU Int*. 2014;114(5):641–652.

Patel AR, Jones JS. Optimal biopsy strategies for the diagnosis and staging of prostate cancer. *Curr Opin Urol*. 2009;19(3):232–237.

Shinohara K, Nguyen H, Masic S. Management of an increasing prostate-specific antigen level after negative prostate biopsy. *Urol Clin North Am*. 2014;41:327–338 [review].

Trucchi A, De Nunzio C, Mariani S, et al. Local anesthesia reduces pain associated with transrectal prostatic biopsy: a prospective randomized study. *Urol Int*. 2005;74(3):209–213.

Ukimura O, Coleman JA, de la Taille A, et al. Contemporary role of systematic prostate biopsies: indications, techniques, and implications for patient care. *Eur Urol*. 2013;63(2):214–230.

Weinreb JC, Barentsz JO, Choyke PL, et al. PI-RADS prostate imaging—reporting and data system: 2015, version 2. *Eur Urol*. 2016;69(1):16–40.

References

Abdelkhalek M, Abdelshafy M, Elhelaly H, et al. Hemospermia after transrectal ultrasound-guided prostatic biopsy: a prospective study. *Urol Ann*. 2013;5(1):30–33.

Ahmed HU, El-Shater Bosaily A, Brown LC, et al. Diagnostic accuracy of multi-parametric MRI and TRUS biopsy in prostate cancer (PROMIS): a paired validating confirmatory study. *Lancet*. 2017;389(10071):815–822.

Al-Saeed O, Sheikh M, Kehinde EO, et al. Seminal vesicle masses detected incidentally during transrectal sonographic examination of the prostate. *J Clin Ultrasound*. 2003;31(4):201–206.

American Urological Association. *Best practice policy statement on urologic surgery antimicrobial prophylaxis*. [update; Available at:] https://www.auanet.org/guidelines/antimicrobial-prophylaxis-best-practice-statement; 2014.

American Urological Association. *The Prevention and Treatment of the More Common Complications Related to Prostate Biopsy Update*. [Available at] https://www.auanet.org/guidelines/prostate-needle-biopsy-complications; 2016.

Amsellem-Ouazana D, Younes P, Conquy S, et al. Negative prostatic biopsies in patients with a high risk of prostate cancer: is the combination of endorectal MRI and magnetic resonance spectroscopy imaging (MRSI) a useful tool? A preliminary study. *Eur Urol*. 2005;47(5):582–586.

Ashley RA, Inman BA, Routh JC, et al. Reassessing the diagnostic yield of saturation biopsy of the prostate. *Eur Urol*. 2008;53(5):976–981.

Aubry W, Lieberthal R, Willis A, et al. Budget impact model:

epigenetic assay can help avoid unnecessary repeated prostate biopsies and reduce healthcare spending. *Am Health Drug Benefits*. 2013;6(1):15–24.

Barentsz JO, Richenberg J, Clements R, et al. ESUR prostate MR guidelines 2012. *Eur Radiol*. 2012;22(4):746–757.

Barqawi AB, Rove KO, Gholizadeh S, et al. The role of 3-dimensional mapping biopsy in decision making for treatment of apparent early stage prostate cancer. *J Urol*. 2011;186(1):80–85.

Berger AP, Frauscher F, Halpern EJ, et al. Periprostatic administration of local anesthesia during transrectal ultrasound-guided biopsy of the prostate: a randomized, double-blind, placebo-controlled study. *Urology*. 2003;61(3):585–588.

Beyersdorff D, Hamm B. MRI for troubleshooting detection of prostate cancer]. *Rofo*. 2005;177(6):788–795.

Bigler SA, Deering RE, Brawer MK. Comparison of microscopic vascularity in benign and malignant prostate tissue. *Hum Pathol*. 1993;24(2):220–226.

Bjurlin M, Wysock JS, Taneja S. Optimization of prostate biopsy review of technique and complications. *Urol Clin North Am*. 2014;41(2):299–313.

Bjurlin MA, Carter HB, Schellhammer P, et al. Optimization of initial prostate biopsy in clinical practice: sampling, labeling and specimen processing. *J Urol*. 2013;189(6):2039–2046.

Bokhorst LP, Zhu X, Bul M, et al. Positive predictive value of prostate biopsy indicated by prostate-specific-antigen-based prostate cancer screening: trends over time in a European randomized trial. *BJU Int*. 2012;110(11):1654–1660.

Borboroglu PG, Comer SW, Riffeburgh RH, et al. Extensive repeat transrectal ultrasound guided prostate biopsy in patients with previous benign sextant biopsies. *J Urol*. 2000;163(1):158–162.

Borofsky S, George AK, Gaur S, et al. What are we missing? false-negative cancers at multiparametric MR imaging of the prostate. *Radiology*. 2018;286(1):186–195.

Borre M, Offersen BV, Nerstrøm B, et al. Microvessel density predicts survival in prostate cancer patients subjected to watchful waiting. *Br J Cancer*. 1998;78(7):940–944.

Bostwick DG, Wheeler TM, Blute M, et al. Optimized microvessel density analysis improves prediction of cancer stage from prostate needle biopsies. *Urology*. 1996;48(1):47–57.

Bratt O. The difficult case in prostate cancer diagnosis: when is a diagnostic TURP indicated? *Eur Urol*. 2006;49(5):769–771.

Bude RO, Rubin JM. Power Doppler sonography. *Radiology*. 1996;200(1):21–23.

Cam K, Sener M, Kayikci A, et al. Combined periprostatic and intraprostatic local anesthesia for prostate biopsy: a double-blind, placebo controlled, randomized trial. *J Urol*. 2008;180(1):141–144 [discussion 144–145].

Carter HB, Albertsen PC, Barry MJ, et al. Early detection of prostate cancer: AUA guideline. *J Urol*. 2013;190(2):419–426.

Catalona WJ, Smith DS, Ratliff TL, et al. Detection of organ-confined prostate cancer is increased through prostate-specific antigen-based screening. *JAMA*. 1993;270(8):948–954.

Chang DT, Challacombe B, Lawrentschuk N. Transperineal biopsy of the prostate—is this the future? *Nat Rev Urol*. 2013;10(12):690–702.

Chang JJ, Shinohara K, Bhargava V, et al. Prospective evaluation of systematic sextant transition zone biopsies in large prostates for cancer detection. *Urology*. 1998;52(1):89–93.

Chevli KK, Duff M, Walter P, et al. Urinary PCA3 as a predictor of prostate cancer in a cohort of 3,073 men undergoing initial prostate biopsy. *J Urol*. 2014;191(6):1743–1748.

Cochlin DL. Cysts and congenital anomalies of the prostate and ejaculatory ducts. Halpern EJ, Cochlin DL, Goldberg BB. *Imaging of the prostate*. Martin Dunitz: London; 2002:115–128.

Cucchiara V, Cooperberg MR, Dall'Era M, et al. Genomic markers in prostate cancer decision making. *Eur Urol*. 2018;73(4):572–582.

Culkin D, Exaire EJ, Greed D, et al. *Anticoagulation and antiplatelet therapy in urologic practice: ICUD and AUA review paper*. [Available at:] https://www.auanet.org/guidelines/anticoagulation-and-antiplatelet-therapy; 2014.

Das S, Liu T, Jani AB, et al. Comparison of image-guided radiotherapy technologies for prostate cancer. *Am J Clin Oncol*. 2014;37(6):616–623.

Dehnad H, Nederveen AJ, van der Heide UA, et al. Clinical feasibility study for the use of implanted gold seeds in the prostate as reliable positioning markers during megavoltage irradiation. *Radiother Oncol*. 2003;67(3):295–302.

Djavan B, Zlotta A, Remzi M, et al. Optimal predictors of prostate cancer on repeat prostate biopsy: a prospective study of 1,051 men. *J Urol*. 2000;163(4):1144–1148 [discussion 1148–1149].

Djavan B, Ravery V, Zlotta A, et al. Prospective evaluation of prostate cancer detected on biopsies 1, 2, 3 and 4: when should we stop? *J Urol*. 2001;166(5):1679–1683.

Djavan B, Remzi M, Marberger M. When to biopsy and when to stop biopsying. *Urol Clin North Am*. 2003;30(2):253–262 [viii].

Djavan B, Waldert M, Zlotta A, et al. Safety and morbidity of first and repeat transrectal ultrasound guided prostate needle biopsies: results of a prospective European prostate cancer detection study. *J Urol*. 2001;166(3):856–860.

Djavan B, Milani S, Remzi M. Prostate biopsy: who, how and when—an update. *Can J Urol*. 2005;12(Suppl 1):44–48 [discussion 99–100].

Duvnjak P, Schulman AA, Holtz JN, et al. Multiparametric prostate MR imaging: impact on clinical staging and decision making. *Radiol Clin North Am*. 2018;56(2):239–250.

Egawa S, Wheeler TM, Scardino PT. The sonographic appearance of irradiated prostate cancer. *Br J Urol*. 1991;68(2):172–177.

Ehdaie B, Vertosick E, Spaliviero M, et al. The impact of repeat biopsies on infectious complications in men with prostate cancer on active surveillance. *J Urol*. 2014;191(3):660–664.

Enlund AL, Varenhorst E. Morbidity of ultrasound-guided transrectal core biopsy of the prostate without prophylactic antibiotic therapy: a prospective study in 415 cases. *Br J Urol*. 1997;79(5):777–780.

Epstein JI, Walsh PC, Sauvageot J, et al. Use of repeat sextant and transition zone biopsies for assessing extent of prostate cancer. *J Urol*. 1997;158(5):1886–1890.

Eskew LA, Bare RL, McCullough DL. Systematic 5 region prostate biopsy is superior to sextant method for diagnosing carcinoma of the prostate. *J Urol*. 1997;157(1):199–202 [discussion 202–203].

European Society of Urogenital Radiology. *Eur Radiol*. 2012;22(4):746–757.

Fleshner N, Klotz L. Role of saturation biopsy in the detection of prostate cancer among difficult diagnostic cases. *Urology*. 2002;60:93–97.

Foster HE, Barry MJ, Dahm P, et al. Surgical management of lower urinary tract symptoms attributed to benign prostatic hyperplasia: AUA Guideline. *J Urol*. 2018;200(3):612–619.

Fulgham PF, Rukstalis DB, Turkbey IB, et al. AUA policy statement on the use of multiparametric magnetic resonance imaging in the diagnosis, staging and management of prostate cancer. *J Urol*. 2017;198(4):832–838.

Geramoutsos I, Gyftopoulos K, Perimenis P, et al. Clinical correlation of prostatic lithiasis with chronic pelvic pain syndromes in young adults. *Eur Urol*. 2004;45(3):333–337 [discussion 337–338].

Giannarini G, Mogorovich A, Valent F, et al. Continuing or discontinuing low-dose aspirin before transrectal prostate biopsy: results of a prospective randomized trial. *Urology*. 2007;70(3):501–505.

Giri VN, Knudsen KE, Kelly WK, et al. Role of genetic testing for inherited prostate cancer risk: Philadelphia Prostate Cancer Consensus Conference 2017. *J Clin Oncol*. 2018;36(4):414–424.

Gittelman MC, Hertzman B, Bailen J, et al. PCA3 molecular urine test as a predictor of repeat prostate biopsy outcome in men with previous negative biopsies: a prospective multicenter clinical study. *J Urol*. 2013;190(1):64–69.

Gohji K, Morisue K, Kizaki T, et al. Correlation of transrectal ultrasound imaging and the results of systematic biopsy with pathological examination of radical prostatectomy specimens. *Br J Urol*. 1995;75(6):758–765.

Goldenberg SL, Carter M, Dashefsky S, et al. Sonographic characteristics of the urethrovesical anastomosis in the early post–radical prostatectomy patient. *J Urol*. 1992;147(5):1307–1309.

Gomella L, Amirian M. PSA elevation following negative prostate biopsy. Gomella LG. *The 5-minute urology consult*. ed 3. Wolters Kluwer: Philadelphia, PA; 2015.

Gomella L, Liu X, Trabulsi E, et al. Screening for prostate cancer: the current evidence and guidelines controversy. *Can J Urol*. 2011;18(5):5875–5883.

Gregg DC, Sty JR. Sonographic diagnosis of enlarged prostatic utricle. *J Ultrasound Med*. 1989;8(1):51–52.

Grey A, Ahmed HU. Multiparametric ultrasound in the diagnosis of prostate cancer. *Curr Opin Urol*. 2016;26(1):114–119.

Grey A, Scott R, Charman S, et al. The CADMUS trial—Multi-parametric ultrasound targeted biopsies compared to multi-parametric MRI targeted biopsies in the diagnosis of clinically significant prostate cancer. *Contemp Clin Trials*. 2018;66:86–92.

Griffiths K. Molecular control of prostate growth. Kirby R. *Textbook of benign prostatic hyperplasia*. Isis Medical Media: Oxford, UK; 1996.

Grummet JP, Weerakoon M, Huang S, et al. Sepsis and “superbugs”: should we favour the transperineal over the transrectal approach for prostate biopsy? *BJU Int*. 2014;114(3):384–388.

Halpern EJ. Anatomy of the prostate gland. Halpern EJ, Cochlin DL, Goldberg BB. *Imaging of the prostate*. Martin Dunitz: London; 2002:3–15.

Halpern EJ, Strup SE. Using gray-scale and color and power Doppler sonography to detect prostatic cancer. *Am J Roentgenol*. 2000;174(3):623–627.

Halpern EJ, Verkh L, Forsberg F, et al. Initial experience with contrast-enhanced sonography of the prostate. *Am J Roentgenol*. 2000;174(6):1575–1580.

Halpern EJ, Rosenberg M, Gomella LG. Prostate cancer: contrast-enhanced US for detection. *Radiology*. 2001;219(1):219–225.

Halpern EJ, Frauscher F, Forsberg F, et al. High-frequency Doppler US of the prostate: effect of patient position.

Radiology. 2002;222(3):634–639.

Halpern EJ, Ramey JR, Strup SE, et al. Detection of prostate carcinoma with contrast-enhanced sonography using intermittent harmonic imaging. *Cancer*. 2005;104(11):2373–2383.

Hamper UM, Epstein JI, Sheth S, et al. Cystic lesions of the prostate gland: a sonographic–pathologic correlation. *J Ultrasound Med*. 1990;9(7):395–402.

Hara R, Jo Y, Fujii T, et al. Optimal approach for prostate cancer detection as initial biopsy: prospective randomized study comparing transperineal versus transrectal systematic 12-core biopsy. *Urology*. 2008;71(2):191–195.

Hayes JH, Barry MJ. Screening for prostate cancer with the prostate-specific antigen test: a review of current evidence. *JAMA*. 2014;311(11):1143–1149.

Heidenreich A, Bastian PJ, Bellmunt J, et al. EAU guidelines on prostate cancer. I. Screening, diagnosis, and local treatment with curative intent—update 2013. *Eur Urol*. 2014;65(1):124–137.

Helfand BT, Glaser AP, Rimar K, et al. Prostate cancer diagnosis is associated with an increased risk of erectile dysfunction after prostate biopsy. *BJU Int*. 2013;111(1):38–43.

Heuer OE, Kruse H, Grave K, et al. Human health consequences of use of antimicrobial agents in aquaculture. *Clin Infect Dis*. 2009;49(8):1248–1253.

Hodge KK, McNeal JE, Terris M, et al. Random systematic versus directed ultrasound guided transrectal core biopsies of the prostate. *J Urol*. 1989;142(1):71–74 [discussion 74–75].

Hofbauer SL, Kittner B, Maxeiner A, et al. Validation of PI-RADS version 2 for the detection of prostate cancer. *J Urol*. 2018;288(2):485–491.

Hong CW, Amalou H, Xu S, et al. Prostate biopsy for the interventional radiologist. *J Vasc Interv Radiol*. 2014;25(5):675–684.

Iczkowski KA, Ferguson KL, Grier DD, et al. Adenoid cystic/basal cell carcinoma of the prostate: clinicopathologic findings in 19 cases. *Am J Surg Pathol*. 2003;27(12):1523–1529.

Ismail M, Gomella LG. Ultrasound for prostate imaging and biopsy. *Curr Opin Urol*. 2001;11(5):471–477.

Ismail M, Gomella LG. Transrectal prostate biopsy. *Urol Clin North Am*. 2013;40(4):457–472.

Ismail M, Petersen RO, Alexander AA, et al. Color Doppler imaging in predicting the biologic behavior of prostate cancer: correlation with disease-free survival. *Urology*. 1997;50(6):906–912.

Javed S, Chadwick E, Edwards AA, et al. Does prostate HistoScanning™ play a role in detecting prostate cancer in routine clinical practice? Results from three independent studies. *BJU Int*. 2014;114(4):541–548.

Kapoor DA, Wasserman DF, Zhang G, et al. Value of transrectal ultrasound in identifying local disease after radical prostatectomy. *Urology*. 1993;41(6):594–597.

Kasivisvanathan V, Rannikko AS, Borghi M, et al. MRI-targeted or standard biopsy for prostate-cancer diagnosis. *N Engl J Med*. 2018;378(19):1767–1777.

Kaye KW. Prostate biopsy using automatic gun. Technique for determination of precise biopsy site. *Urology*. 1989;34(2):111–112.

Keetch DW, Catalona WJ, Smith DS. Serial prostatic biopsies in men with persistently elevated serum prostate specific antigen values. *J Urol*. 1994;151(6):1571–1574.

King BF, Hattery RR, Lieber MM, et al. Congenital cystic disease of the seminal vesicle. *Radiology*. 1991;178(1):207–211.

Konig K, Scheipers U, Pesavento A, et al. Initial experiences with real-time elastography guided biopsies of the prostate. *J Urol*. 2005;174(1):115–117.

Kosarek CD, Mahmoud AM, Eyzaguirre EJ, et al. Initial series of magnetic resonance imaging (MRI)-fusion targeted prostate biopsy using the first transperineal targeted platform available in the USA. *BJU Int*. 2018;122(5):909–912.

Kossoff G. Basic physics and imaging characteristics of ultrasound. *World J Surg*. 2000;24(2):134–142.

Kundavaram CR, Halpern EJ, Trabulsi EJ. Value of contrast-enhanced ultrasonography in prostate cancer. *Curr Opin Urol*. 2012;22(4):303–309.

Li YH, Elshafei A, Li J, et al. Potential benefit of transrectal saturation prostate biopsy as an initial biopsy strategy: decreased likelihood of finding significant cancer on future biopsy. *Urology*. 2014;83(4):714–718.

Linden RA, Trabulsi EJ, Forsberg F, et al. Contrast enhanced ultrasound flash replenishment method for directed prostate biopsies. *J Urol*. 2007;178(6):2354–2358.

Linden RA, Weiner PR, Gomella LG, et al. Technique of outpatient placement of intraprostatic fiducial markers before external beam radiotherapy. *Urology*. 2009;73(4):881–886.

Liss MA, Chang A, Santos R, et al. Prevalence and significance of fluoroquinolone resistant *Escherichia coli* in patients undergoing transrectal ultrasound guided prostate needle biopsy. *J Urol*. 2011;185(4):1283–1288.

Liss MA, Ehdaie B, Loeb S, et al. An update of the American Urological Association white paper on the prevention and treatment of the more common complications related to prostate biopsy. *J Urol*. 2017;198(2):329–334.

Lissbrant IF, Stattin P, Damber JE, et al. Vascular density is a predictor of cancer-specific survival in prostatic carcinoma. *Prostate*. 1997;33(1):38–45.

Loeb S. *Antimicrobial prophylaxis for transrectal ultrasound biopsy*. [American Urology Association Update Series, Lesson 1, Vol. 32] 2013.

Loeb S, Vellekoop A, Ahmed HU, et al. Systematic review of complications of prostate biopsy. *Eur Urol*. 2013;64(6):876–892.

Logan JK, Rais-Bahrami S, Turkbey B, et al. Current status of MRI and ultrasound fusion software platforms for guidance of prostate biopsies. *BJU Int*. 2014;114(5):641–652.

Mariados N, Sylvester J, Shah D, et al. Hydrogel Spacer Prospective Multicenter Randomized Controlled Pivotal Trial: dosimetric and clinical effects of perirectal spacer application in men undergoing prostate image guided intensity modulated radiation therapy. *Int J Radiat Oncol Biol Phys*. 2015;92(5):971–977.

Marks LS, Partin AW, Gormley GJ, et al. Prostate tissue composition and response to finasteride in men with symptomatic benign prostatic hyperplasia. *J Urol*. 1997;157(6):2171–2178.

Mazal PR, Haitel A, Windischberger C, et al. Spatial distribution of prostate cancers undetected on initial needle biopsies. *Eur Urol*. 2001;39(6):662–668.

McDermott V, Orr JD, Wild SR. Duplicated Müllerian duct remnants associated with unilateral renal agenesis. *Abdom Imaging*. 1993;18(2):193–195.

McNeal JE, Redwine EA, Freiha FS, et al. Zonal distribution of prostatic adenocarcinoma: correlation with histologic pattern and direction of spread. *Am J Surg Pathol*. 1988;12(12):897–906.

Moran BJ, Braccioforte MH, Conterato DJ. Re-biopsy of the prostate using a stereotactic transperineal technique. *J Urol*. 2006;176(4 Pt 1):1376–1381.

Nam RK, Saskin R, Lee Y, et al. Increasing hospital admission rates for urological complications after transrectal ultrasound guided prostate biopsy. *J Urol*. 2013;189(1 Suppl):S12–S17 [discussion S17–S18].

Naspro R, Rossini R, Musumeci G, et al. Antiplatelet therapy in patients with coronary stent undergoing urologic surgery: is it still no man's land? *Eur Urol*. 2013;64(1):101–105.

National Comprehensive Cancer Network. *Guidelines. Version 2*. [Prostate cancer early detection; Available at:] https://www.nccn.org/professionals/physician_gls/pdf/prostat 2018.

Naya Y, Okihara K, Evans RB, et al. Efficacy of prostatic fossa biopsy in detecting local recurrence after radical prostatectomy. *Urology*. 2005;66(2):350–355.

Nelson ED, Slotoroff CB, Gomella LG, et al. Targeted biopsy of the prostate: the impact of color Doppler imaging and elastography on prostate cancer detection and Gleason score. *Urology*. 2007;70(6):1136–1140.

Nguyen CT, Kattan MW. Prediction models in prostate cancer diagnosis. Jones JS. *Prostate cancer diagnosis: PSA biopsy and beyond*. Humana Press: New York, NY; 2013.

Okotie OT, Roehl KA, Han M, et al. Characteristics of prostate cancer detected by digital rectal examination only. *Urology*. 2007;70(6):1117–1120.

Onur R, Littrup PJ, Pontes JE, et al. Contemporary impact of transrectal ultrasound lesions for prostate cancer detection. *J Urol*. 2004;172(2):512–514.

Orczyk C, Rosenkrantz AB, Deng FM, et al. A prospective comparative analysis of the accuracy of HistoScanning and multiparametric magnetic resonance imaging in the localization of prostate cancer among men undergoing radical prostatectomy. *Urol Oncol*. 2016;34(1):3.e1–3.e8.

Partin AW, Van Neste L, Klein EA, et al. Clinical validation of an epigenetic assay to predict negative histopathological results in repeat prostate biopsies. *J Urol*. 2014;192(4):1081–1087.

Pelzer AE, Bektic J, Berger AP, et al. Are transition zone biopsies still necessary to improve prostate cancer detection? Results from the Tyrol screening project. *Eur Urol*. 2005;48(6):916–921 [discussion 921].

Pepe P, Dibenedetto G, Pennisi M, et al. Detection rate of anterior prostate cancer in 226 patients submitted to initial and repeat transperineal biopsy. *Urol Int*. 2014;93(2):189–192.

Pepe P, Garufi A, Priolo G, et al. Transperineal versus transrectal MRI/TRUS fusion targeted biopsy: detection rate of clinically significant prostate cancer. *Clin Genitourin Cancer*. 2017;15(1):e33–e36.

Pinkstaff DM, Igel TC, Petrou SP, et al. Systematic transperineal ultrasound-guided template biopsy of the prostate: three-year experience. *Urology*. 2005;65(4):735–739.

Pinsky PF, Parnes HL, Andriole G. Mortality and complications after prostate biopsy in the PLCO Screening Trial. *BJU Int*. 2014;113(2):254–259.

Pokorny MR, de Rooij M, Duncan E, et al. Prospective study of diagnostic accuracy comparing prostate cancer detection by transrectal ultrasound–guided biopsy versus magnetic resonance (MR) imaging with subsequent MR-guided biopsy in men without previous prostate biopsies. *Eur Urol*. 2014;66(1):22–29.

Postema A, Idzenga T, Mischi M, et al. Ultrasound modalities and quantification: developments of multiparametric ultrasonography, a new modality to detect, localize and target prostatic tumors. *Curr Opin Urol*. 2015;25(3):191–197.

Postema A, Mischi M, de la Rosette J, et al. Multiparametric ultrasound in the detection of prostate cancer: a systematic review. *World J Urol*. 2015;33(11):1651–1659.

Presti JC Jr, Chang JJ, Bhargava V, et al. The optimal systematic prostate biopsy scheme should include 8 rather than 6 biopsies: results of a prospective clinical trial. *J Urol*. 2000;163(1):163–166 [discussion 166–167].

Purohit RS, Shinohara K, Meng MV, et al. Imaging clinically localized prostate cancer. *Urol Clin North Am*. 2003;30(2):279–293.

Raaijmakers R, Kirkels WJ, Roobol MJ, et al. Complication rates and risk factors of 5802 transrectal ultrasound-guided sextant biopsies of the prostate within a population-based screening program. *Urology*. 2002;60(5):826–830.

Raber M, Scattoni V, Gallina A, et al. Does the transrectal ultrasound probe influence prostate cancer detection in patients undergoing an extended prostate biopsy scheme? Results of a large retrospective study. *BJU Int*. 2012;109(5):672–677.

Rais-Bahrami S, Siddiqui MM, Turkbey B, et al. Utility of multiparametric magnetic resonance imaging suspicion levels for detecting prostate cancer. *J Urol*. 2013;190(5):1721–1727.

Raskolnikov D, Rais-Bahrami S, Turkbey B, et al. Current ability of multiparametric prostate magnetic resonance imaging and targeted biopsy to improve the detection of prostate cancer. *Urol Pract*. 2014;1(1):13–21.

Roberts MJ, Bennett HY, Harris PN, et al. Prostate biopsy-related infection: a systematic review of risk factors, prevention strategies, and management approaches. *Urology*. 2017;104:11–21.

Rodriguez LV, Terris MK. Risks and complications of transrectal ultrasound guided prostate needle biopsy: a prospective study and review of the literature. *J Urol*. 1998;160(6 Pt 1):2115–2120.

Rosenkrantz AB, Verma S, Choyke P, et al. Prostate magnetic resonance imaging and magnetic resonance imaging targeted biopsy in patients with a prior negative biopsy: a consensus statement by AUA and SAR. *J Urol*. 2016;196(6):1613–1618.

Salomon G, Drews N, Autier P, et al. Incremental detection rate of prostate cancer by real-time elastography targeted biopsies in combination with a conventional 10-core biopsy in 1024 consecutive patients. *BJU Int*. 2014;113(4):548–553.

Salomon G, Schiffmann J. Real-time elastography for the detection of prostate cancer. *Curr Urol Rep*. 2014;15(3):392.

Sarkar S, Verma S. MR imaging-targeted prostate biopsies. *Radiol Clin North Am*. 2018;56(2):289–300.

Scattoni V, Montorsi F, Picchio M, et al. Diagnosis of local recurrence after radical prostatectomy. *BJU Int*. 2004;93(5):680–688.

Shinohara K, Wheeler TM, Scardino PT. The appearance of prostate cancer on transrectal ultrasonography: correlation of imaging and pathological examinations. *J Urol*. 1989;142(1):76–82.

Siddiqui MM, Rais-Bahrami S, Truong H, et al. Magnetic resonance imaging/ultrasound-fusion biopsy significantly upgrades prostate cancer versus systematic 12-core transrectal ultrasound biopsy. *Eur Urol*. 2013;64(5):713–719.

Siddiqui MM, Rais-Bahrami S, Turkbey B, et al. Comparison of MR/ultrasound fusion-guided biopsy with ultrasound-guided biopsy for the diagnosis of prostate cancer. *JAMA*. 2015;313(4):390–397.

Smith RA, Manassaram-Baptiste D, Brooks D, et al. Cancer screening in the United States, 2014: a review of current American Cancer Society guidelines and current issues in cancer screening. *CA Cancer J Clin*. 2014;64(1):30–51.

Sonn GA, Natarajan S, Margolis DJ, et al. Targeted biopsy in the detection of prostate cancer using an office based magnetic resonance ultrasound fusion device. *J Urol*. 2013;189(1):86–91.

Stewart CS, Leibovich B, Weaver AL, et al. Prostate cancer diagnosis using a saturation needle biopsy technique after previous negative sextant biopsies. *J Urol*. 2001;166(1):86–91 [discussion 91–92].

Stone NN, Stock RG. The effect of brachytherapy, external beam irradiation and hormonal therapy on prostate volume. *J Urol*. 2007;177(3):925–928.

Strom TJ, Wilder RB, Fernandez DC, et al. A dosimetric study of polyethylene glycol hydrogel in 200 prostate cancer patients treated with high-dose rate brachytherapy ± intensity modulated radiation therapy. *Radiother Oncol*. 2014;111(1):126–131.

Sumura M, Shigeno K, Hyuga T, et al. Initial evaluation of prostate cancer with real-time elastography based on step-section pathologic analysis after radical prostatectomy: a preliminary study. *Int J Urol*. 2007;14(9):811–816.

Tamsel S, Killi R, Apaydin E, et al. The potential value of power Doppler ultrasound imaging compared with grey-scale ultrasound findings in the diagnosis of local recurrence after radical prostatectomy. *Clin Radiol*. 2006;61(4):325–330 [discussion 323–324].

Taylor AK, Zembower TR, Nadler RB, et al. Targeted antimicrobial prophylaxis using rectal swab cultures in men undergoing transrectal ultrasound guided prostate biopsy is associated with reduced incidence of postoperative infectious complications and cost of care. *J Urol*. 2012;187(4):1275–1279.

Terris MK. Transrectal ultrasound appearance of radiation-induced prostatic sarcoma. *Prostate*. 1998;37(3):182–186.

Terris MK. Transrectal ultrasound appearance of squamous cell carcinoma involving the prostate. *Urol Int*. 1999;63(2):133–

135.

Terris MK, Stamey TA. Determination of prostate volume by transrectal ultrasound. *J Urol*. 1991;145(5):984–987.

Terris MK, Freiha FS. Transrectal ultrasound appearance of hematolymphoid malignancies involving the prostate. *Urology*. 1998;51(2):339–341.

Terris MK, McNeal JE, Stamey TA. Detection of clinically significant prostate cancer by transrectal ultrasound-guided systematic biopsies. *J Urol*. 1992;148(3):829–832.

Terris MK, Macy M, Freiha FS. Transrectal ultrasound appearance of prostatic granulomas secondary to bacillus Calmette-Guérin instillation. *J Urol*. 1997;158(1):126–127.

Thompson IM, Ankerst DP, Chi C, et al. Operating characteristics of prostate-specific antigen in men with an initial PSA level of 3.0 ng/ml or lower. *JAMA*. 2005;294(1):66–70.

Thompson IM, Pauler D, Goodman PJ, et al. Prevalence of prostate cancer among men with a prostate-specific antigen level < or = 4.0 ng per milliliter. *N Engl J Med*. 2004;350(22):2239–2246.

Thomsen FB, Brasso K, Klotz LH, et al. Active surveillance for clinically localized prostate cancer: a systematic review. *J Surg Oncol*. 2014;109(8):830–835.

Toi A, Neill M, Gina A, et al. The continuing importance of transrectal ultrasound identification of prostatic lesions. *J Urol*. 2007;177(2):516–520.

Trucchi A, De Nunzio C, Mariani S, et al. Local anesthesia reduces pain associated with transrectal prostatic biopsy: a prospective randomized study. *Urol Int*. 2005;74(3):209–213.

Tsodikov A, Gulati R, Heijnsdijk EAM, et al. Reconciling the Effects of Screening on Prostate Cancer Mortality in the ERSPC and PLCO Trials. *Ann Intern Med*. 2017;167(7):449–455.

Turkbey B, Choyke PL. Multiparametric MRI and prostate cancer diagnosis and risk stratification. *Curr Opin Urol*. 2012;22(4):310–315.

Unal D, Sedelaar JP, Aarninck RG, et al. Three-dimensional contrast-enhanced power Doppler ultrasonography and conventional examination methods: the value of diagnostic predictors of prostate cancer. *BJU Int*. 2000;86(1):58–64.

US Preventive Services Task Force. Screening for prostate cancer: US Preventive Services Task Force Recommendation Statement. *JAMA*. 2018;319(18):1901–1913.

Varghese SL, Grossfeld GD. The prostatic gland: malignancies other than adenocarcinomas. *Radiol Clin North Am*. 2000;38(1):179–202.

Venderink W, van Luijtelaar A, Bomers JG, et al. Results of targeted biopsy in men with magnetic resonance imaging lesions classified equivocal, likely or highly likely to be clinically significant prostate cancer. *Eur Urol*. 2017; 10.1016/j.eururo.2017.02.021 [Epub ahead of print].

Vickers AJ. Prostate cancer screening: time to question how to optimize the ratio of benefits and harms. *Ann Intern Med*. 2017;167(7):509–510.

Vis AN, Boerma MO, Ciatto S, et al. Detection of prostate cancer: a comparative study of the diagnostic efficacy of sextant transrectal versus sextant transperineal biopsy. *Urology*. 2000;56(4):617–621.

Volkin D, Turkbey B, Hoang AN, et al. Multiparametric MRI and subsequent MR/ultrasound fusion-guided biopsy increase the detection of anteriorly located prostate cancers. *BJU Int*. 2014;114(6B):E43–E49.

Wagenlehner FM, Pilatz A, Waliszewski P, et al. Reducing infection rates after prostate biopsy. *Nat Rev Urol*. 2014;11(2):80–86.

Watanabe H, Kato H, Kato T, et al. Diagnostic application of ultrasonotomography to the prostate]. *Nippon Hinyokika Gakkai Zasshi*. 1968;59:273–279.

Wei C, Li C, Szewczyk-Bieda M, et al. Performance characteristics of transrectal shear wave elastography (SWE) imaging in the evaluation of clinically localized prostate cancer: a prospective study. *J Urol*. 2018;200(3):549–558.

Weidner N, Carroll PR, Flax J, et al. Tumor angiogenesis correlates with metastasis in invasive prostate carcinoma. *Am J Pathol*. 1993;143(2):401–409.

Weinreb JC, Barentsz JO, Choyke PL, et al. PI-RADS prostate imaging—reporting and data system: 2015, version 2. *Eur Urol*. 2016;69(1):16–40.

Whittington R, Broderick GA, Arger P, et al. The effect of androgen deprivation on the early changes in prostate volume following transperineal ultrasound guided interstitial therapy for localized carcinoma of the prostate. *Int J Radiat Oncol Biol Phys*. 1999;44(5):1107–1110.

Wilson NM, Masoud AM, Barsoum HB, et al. Correlation of power Doppler with microvessel density in assessing prostate needle biopsy. *Clin Radiol*. 2004;59(10):946–950.

Wink M, Frauscher F, Cosgrove D, et al. Contrast-enhanced ultrasound and prostate cancer: a multicentre European research coordination project. *Eur Urol*. 2008;54(5):982–992.

Woldu SL, Hutchinson RC, Singla N, et al. Prospective monitoring and adapting strategies for prevention of infection following transrectal prostate procedures. *Urol Pract*. 2018;5(2):124–131.

Zani EL, Clark OA, Rodrigues Netto N Jr. Antibiotic prophylaxis for transrectal prostate biopsy. *Cochrane Database Syst Rev*. 2011;(5) [CD006576].

Zhang Q, Wang W, Zhang B, et al. Comparison of free-hand transperineal mpMRI/TRUS fusion-guided biopsy with transperineal 12-core systematic biopsy for the diagnosis of prostate cancer: a single-center prospective study in China. *Int Urol Nephrol*. 2017;49(3):439–448.

Zisman A, Leibovici D, Kleinmann J, et al. The impact of prostate biopsy on patient well-being: a prospective study of pain, anxiety and erectile dysfunction. *J Urol*. 2001;165(2):445–454.

Zlotta AR, Nam RK. To biopsy or not to biopsy—thou shall think twice. *Eur Urol*. 2012;61(6):1115–1117 [discussion 1117–1118].

151

Pathology of Prostatic Neoplasia

Jonathan I. Epstein MD

This chapter covers the pathology of adenocarcinoma of the prostate from its precursor lesions to invasive carcinomas, from needle biopsies to radical prostatectomies. Other tumors involving the prostate are also discussed. In particular, practical points of pathology are emphasized, which are critical for urologists to know for the management of their patients.

Prostatic Intraepithelial Neoplasia

Prostatic intraepithelial neoplasia (PIN) consists of architecturally benign prostatic acini or ducts lined by cytologically atypical cells, and PIN is subclassified into low-grade PIN (LGPIN) and high-grade PIN (HGPIN) (McNeal, 1989; McNeal and Bostwick, 1986) (Fig. 151.1). **Diagnostic reports should not comment on LGPIN.** First, pathologists cannot reproducibly distinguish between LGPIN and benign prostate tissue (Epstein et al., 1995). Second, when LGPIN is diagnosed on needle biopsy, these patients are at no greater risk for having carcinoma on repeated biopsy than are men with a benign biopsy finding (Epstein and Herawi, 2006). Evidence that HGPIN is a precursor to some prostate carcinomas includes the following: There is an increase in the size and number of HGPIN foci in prostates with cancer compared with prostates without carcinoma; with increasing amounts of HGPIN, there is a greater number of multifocal carcinomas; and biomarkers and molecular changes show similarity between HGPIN and carcinoma (Bostwick et al., 1996; Häggman et al., 1997). About 20% of HGPIN lesions harbor a *TMPRSS2:ERG* fusion gene, which is a common molecular abnormality detectable in about 50% of prostate cancers (Cerveira et al., 2006; Perner et al., 2007). The finding of zones of HGPIN from which there appears to be budding off glands of carcinoma is further histologic evidence that HGPIN is a precursor to some prostate carcinomas (McNeal et al., 1991).

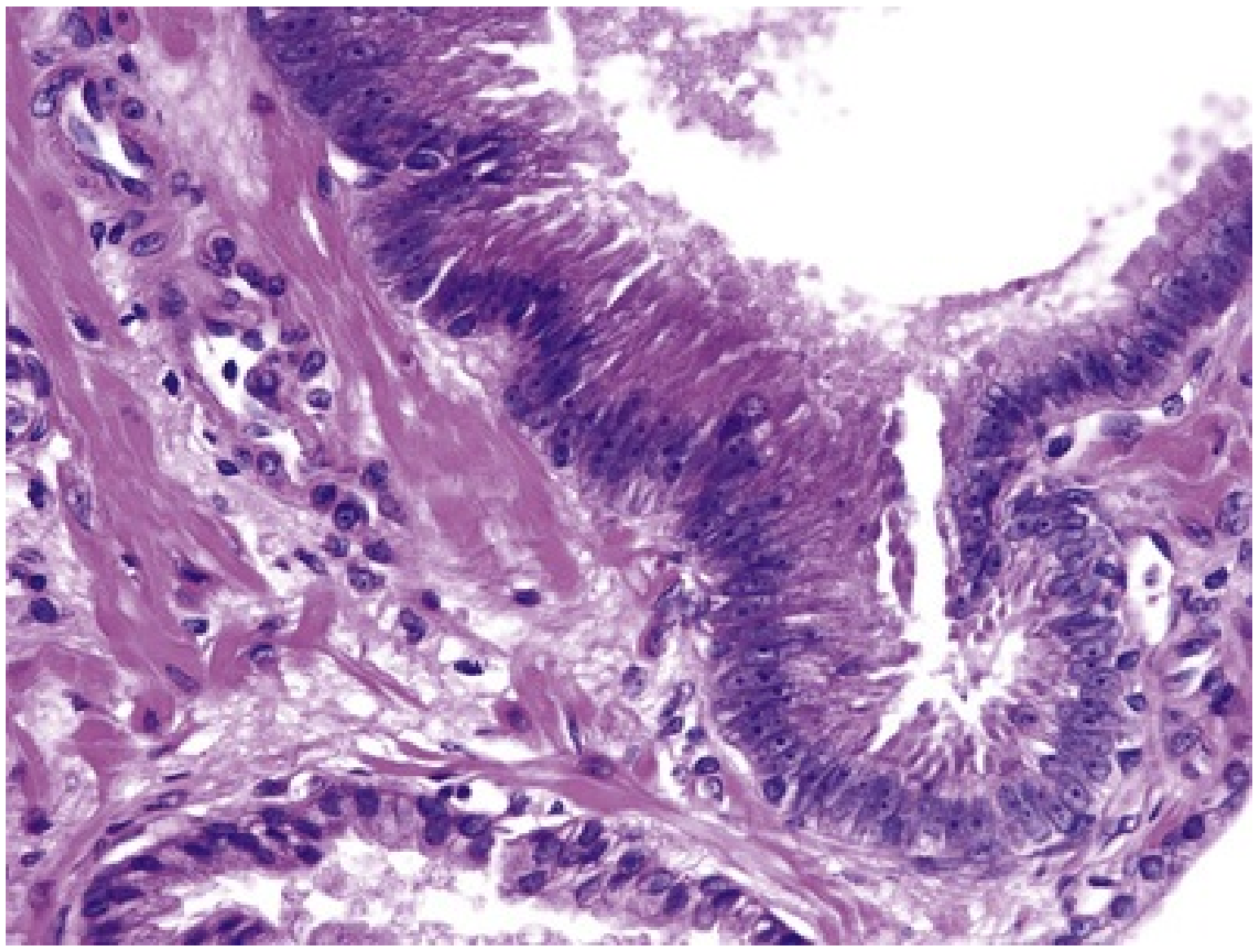

FIG. 151.1 High-grade prostatic intraepithelial neoplasia. Note cytologically atypical cells with prominent nucleoli in an architecturally benign gland *(top),* contrasted to a benign gland *(bottom).*

The incidence of HGPIN on biopsy averages in the 4% to 5% range (Epstein and Herawi, 2006). There is a tremendous variation in the percentages reported, ranging from 0% to 25%. The most likely explanation accounting for this variation is interobserver threshold. The distinction between LGPIN and HGPIN is based on the prominence of the nucleoli. This is a subjective exercise, and those pathologists with a lower threshold regarding the definition of prominent nucleoli will have a higher incidence of HGPIN. **The mean risk for cancer is 20% to 30% on subsequent biopsy within 1 year after diagnosis of HGPIN, which is not significantly higher than the risk for carcinoma following a repeat biopsy after a benign diagnosis** (Epstein and Herawi, 2006)**. In the majority of studies, serum prostate-specific antigen (PSA) levels, results of digital rectal examination, and transrectal ultrasonography findings do not enhance the prediction of who is more likely to exhibit carcinoma on repeat biopsy.** PIN by itself does not give rise to elevated serum PSA values (Epstein and Herawi, 2006; Ronnett et al., 1993). Approximately 80% of the cancers detected on repeat biopsy are Gleason score 6 (Grade Group 1) (Tosoian et al., 2018). **For patients diagnosed with unifocal HGPIN on extended initial core sampling, a repeat biopsy within the first year is unnecessary in the absence of other clinical indicators of cancer. HGPIN on greater than or equal to 2 cores is associated with approximately the same rick of subsequent cancer as an “atypical suspicious for carcinoma”**

diagnosis, where follow up is warranted with serum or urine tests, imaging, and in some cases repeat biopsy with relative increased sampling of the atypical site (Abdel-Khalek et al., 2004; Epstein and Herawi, 2006; Merrimen et al., 2009, 2010).

There are numerous benign and malignant mimickers of HGPIN. It may be difficult to distinguish between outpouchings or tangential sections of HGPIN with adjacent small atypical glands (PINATYP) as opposed to PIN with associated infiltrating carcinoma (Kronz et al., 2001). Most of these cases will require immunohistochemistry for basal cell markers, where cancer should be diagnosed only when there is a large cluster of entirely negative glands. The risk for carcinoma after a diagnosis of PINATYP is the same as an “atypical suspicious for carcinoma” diagnosis.

The significance of HGPIN on transurethral resection (TUR) is not clear, with conflicting data as to the risk for subsequent discovery of cancer (Gaudin et al., 1997; Pacelli and Bostwick, 1997). In an elderly patient with HGPIN on TUR, often no further workup is instituted. In a younger man, a more aggressive workup to rule out a clinically significant tumor may be warranted. **HGPIN is a precursor lesion to many peripheral intermediate- to high-grade adenocarcinomas of the prostate.** However, PIN need not be present for carcinoma to arise. Low-grade carcinomas, especially those present within the transition zone, are not closely related to HGPIN.

Intraductal carcinoma of the prostate (IDC-P) has either architectural or cytologic atypia that clearly exceeds that seen in HGPIN (Cohen et al., 2007; McNeal and Bostwick, 1986; McNeal and Yemoto, 1996a; McNeal et al., 1986; Robinson et al., 2012; Rubin et al., 1998; Wilcox et al., 1998). Rarely, IDC-P may be identified on biopsy material in the absence of infiltrating carcinoma (Guo and Epstein, 2006). IDC-P on prostate biopsies is frequently associated with high-grade cancer and poor prognostic parameters at radical prostatectomy (Guo and Epstein, 2006). These findings support the idea that in most cases IDC-P represents intraductal spread of carcinoma within preexisting ducts and acini and that IDC-P in the vast majority of cases should not be categorized as a preinvasive neoplastic condition (Haffner et al., 2016; Miyai et al., 2014). In the rare case in which IDC-P is treated by radical prostatectomy and no invasive cancer is found, the surgery is justified, as in these cases IDC-P is a high-grade preinvasive lesion that includes a high risk for developing invasive high-grade cancer. **We recommend that patients with IDC-P only on biopsy be treated with definitive therapy, although some clinicians perform repeat biopsy to**

document invasive carcinoma before initiating therapy. In cases that are borderline between IDC-P and HGPIN, repeat biopsy is warranted. Rarely, IDC-P will be seen on biopsy with only a Gleason score 3+3=6. It is important not to consider the patient to have only low-grade carcinoma and a candidate for active surveillance, because there is a high risk that there is unsampled higher-grade cancer present (Khani and Epstein, 2015).

Adenocarcinoma

Staging Classification

Stages T1a (≤5% cancer) and T1b (>5%) adenocarcinomas of the prostate are clinically unsuspected tumors that are discovered in either TUR of the prostate (TURP) or enucleation specimens removed for benign prostatic hyperplasia (Epstein et al., 2007). Stage T1c disease refers to nonpalpable prostate cancer found on needle biopsy, usually performed for an abnormal serum PSA level. If a patient undergoes radical prostatectomy, stages T1a to T1c are converted to pT2 or pT3 if the tumor is organ confined or shows extraprostatic extension (EPE), respectively. Pathologic stage T2 is defined as tumor localized to the prostate, which was until recently further subcategorized into T2a to T2c depending on the extent of cancer in an analogous manner to clinical staging of T2 disease. However, numerous studies have shown that subdividing pathologic stage T2 disease has no prognostic significance. The reason for this finding is that bilateral prostate cancer may represent (1) a dominant tumor nodule with contralateral small, low-grade, clinically insignificant tumor; (2) significant discrete right and left tumor nodules; or (3) a single, large, confluent tumor mass involving both sides. Consequently, the designation “pathologic stage T2c” (bilateral cancer) has no meaning, and the 2018 TNM (tumor, node, metastases) classification has as a mandatory field noting only pT2 with further subclassification into “T2a” or “T2b” or “T2c” as optional (Kheirandish and Chinegwundoh, 2011; van der Kwast et al., 2011). “Stage T2+” (stage T2x) refers to a tumor with no identifiable tumor in extraprostatic tissue but with a positive margin because of the surgeon's cutting into the prostate (intraprostatic incision). Because the edge of the prostate has been left in the patient, the pathologic stage cannot be assessed in the area of the intraprostatic incision. Pathologic stage T3 represents a tumor that has extended out of the prostate gland, which is further subclassified into T3a and T3b, depending on whether the extraprostatic tumor is without or with seminal vesicle invasion, respectively. Microscopic bladder neck invasion is pT3a.

Location

In clinical stage T2 carcinomas and in 85% of nonpalpable tumors

diagnosed on needle biopsy (stage T1c), the major tumor mass is located in the posterior portion of the prostate in the peripheral zone (Byar and Mostofi, 1972; Epstein et al., 1994a; McNeal, 1969). Approximately 15% of radical prostatectomy specimens show predominantly anterior tumors, some in the transition zone and others in the anterior horn of the peripheral zone (Al-Ahmadie et al., 2008). Anterior prostates tend to have a better prognosis and less seminal vesicle involvement than tumors located posteriorly (Kim et al., 2016). Adenocarcinoma of the prostate is multifocal in more than 85% of cases (Byar and Mostofi, 1972). In many of these bilateral or multifocal tumor cases, the other tumors are small, low grade, and clinically insignificant. In cases with bilateral cancer at radical prostatectomy, the contralateral tumor to the positive biopsy side at radical prostatectomy is typically small. However, 20% have some contralateral adverse pathology in terms of size, EPE, grade, or margins (Yoon et al., 2008).

Spread of Tumor

Because the prostate lacks a discrete histologic capsule, *extraprostatic extension,* rather than *capsular penetration,* is the preferable term to describe a tumor that has extended out of the prostate into the periprostatic soft tissue (Ayala et al., 1989). Some authors use the term *capsular invasion* when they believe that the “capsule” is infiltrated by a tumor but the tumor does not extend out of the prostate. Because there is no such entity as the prostatic capsule, “capsular invasion” makes no sense. Peripherally located adenocarcinomas of the prostate tend to extend out of the prostate through perineural space invasion (Villers et al., 1989). EPE preferentially occurs posteriorly and posterolaterally, paralleling the location of most adenocarcinomas.

Further local spread of the tumor may lead to seminal vesicle invasion, which is diagnosed when a tumor extends into the muscle wall of the seminal vesicle. The most common route of seminal vesicle invasion is by tumor penetration out of the prostate at the base of the gland, with growth and extension into the periseminal vesicle soft tissue and eventually into the seminal vesicles. Less commonly, there may be direct extension through the ejaculatory ducts into the seminal vesicles or direct extension from the base of the prostate into the wall of the seminal vesicles. Almost never are there discontinuous metastases to the seminal vesicle (Ohori et al., 1993). Local spread of prostate cancer may also rarely involve the rectum, where it may be difficult to distinguish from a rectal primary tumor (Fry et al., 1979; Lane et al., 2008).

The most frequent sites of metastatic prostate carcinoma are lymph nodes and bones. Prostate cancer may present with metastases to the left supradiaphragmatic, typically the supraclavicular, lymph nodes (Cho and Epstein, 1987). Lung metastases from prostate carcinoma are extremely common at autopsy, and almost all cases involve bone as well (Varkarakis et al., 1974). Metastatic lesions usually take the form of multiple small nodules or diffuse lymphatic spread rather than large metastatic deposits. Clinically, prostate carcinoma metastatic to the lung is usually asymptomatic. In addition to lymph nodes, bones, and lung, the next most common regions for the spread of prostate cancer at autopsy are bladder, liver, and adrenal gland (Hess et al., 2006).

Tumor Volume

In general, the size of a prostate cancer correlates with its stage. EPE is uncommon in tumors less than 0.5 cm^3, and tumors less than 4 cm^3 uncommonly show lymph node metastases or seminal vesicle invasion (McNeal et al., 1990). Tumor volume is also proportional to grade (see the following discussion). The location and grade of the tumor also modulate the effect of tumor volume (Christensen et al., 1990; Greene et al., 1991; McNeal et al., 1990). For example, **transition zone tumors extend out of the prostate at larger volumes than do peripheral zone tumors because of their lower grade and greater distance from the edge of the gland.** Reporting of tumor volume in various specimens is discussed later in this chapter.

Grade

The Gleason system is based on the glandular pattern of the tumor as identified at relatively low magnification (Gleason and Mellinger, 1974; Mellinger et al., 1967) (Fig. 151.2). Cytologic features play no role in the grade of the tumor. **Architectural patterns are identified and assigned a grade from 1 to 5, with 1 being the most differentiated and 5 being undifferentiated**. **Although in the original Gleason system, the most common and second most common grades were combined, in 2005 the Gleason system was updated and modified with one change being that on biopsy the *most common* and *highest-grade* patterns on a given core were added to result in the Gleason score** (Epstein et al., 2005). If a tumor has only one histologic pattern, then for uniformity, both patterns are assigned the same grade. In theory, however, the Gleason scores range from 2 (1 + 1 = 2), which represents tumors uniformly composed of Gleason pattern 1 tumor, to 10 (5 + 5 = 10), which represents totally undifferentiated tumors. Most cases with divergent patterns, especially on needle biopsy, do not differ by more than one pattern. It is reasonable to assign a full Gleason score even to small foci of cancer on needle biopsy because it has been demonstrated that the grade assigned to these minimal cancers is just as accurate compared with cases with more extensive cancer on biopsy (Steinberg et al., 1997).

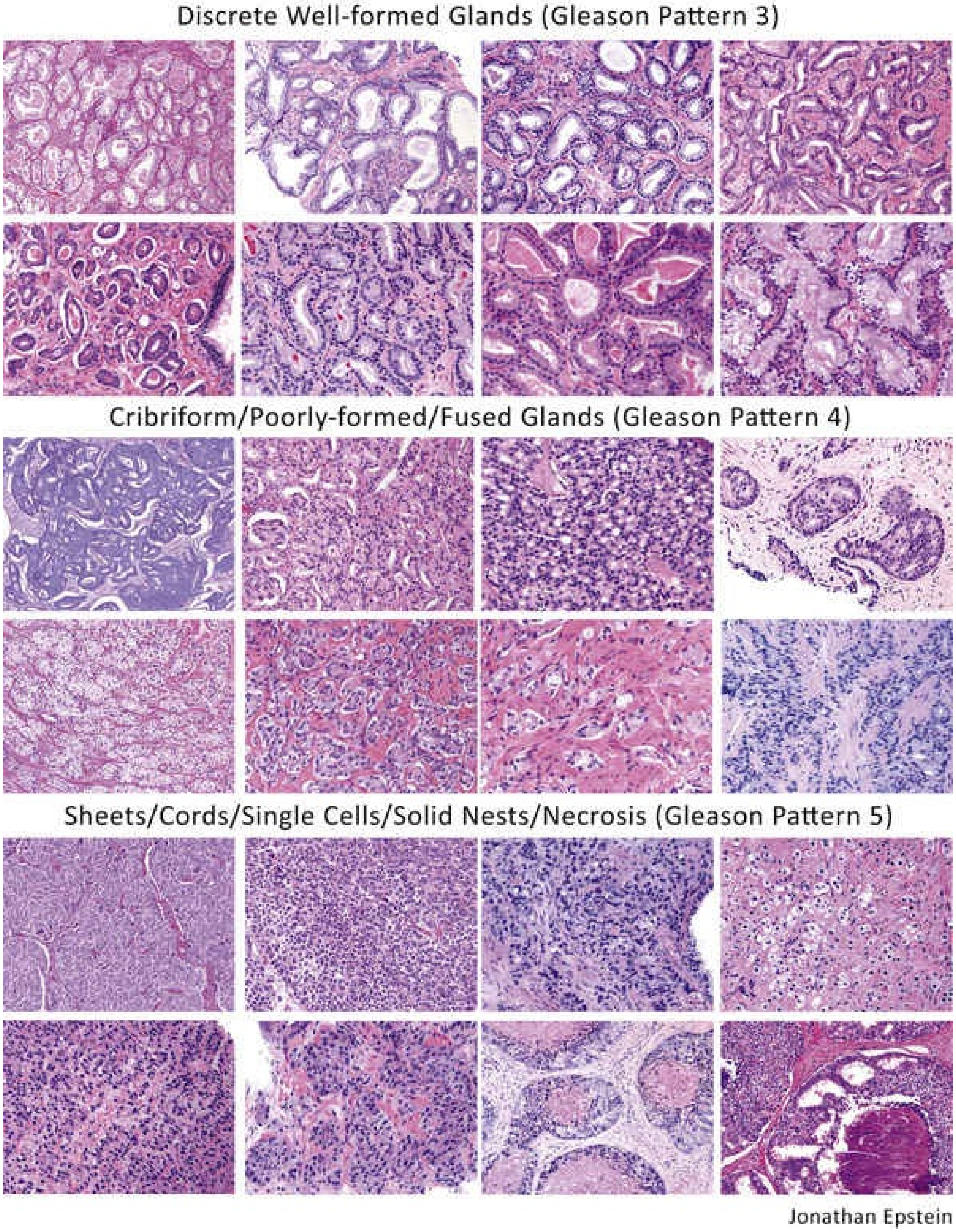
Discrete Well-formed Glands (Gleason Pattern 3)
Cribriform/Poorly-formed/Fused Glands (Gleason Pattern 4)
Sheets/Cords/Single Cells/Solid Nests/Necrosis (Gleason Pattern 5)

Jonathan Epstein

FIG. 151.2 The Gleason grading system and correlates with Grade Group morphologies. *From left to right: First row:* Closely packed uniformly sized and shaped large glands; large variably sized and shaped glands, some with infolding; uniform medium-sized glands; variably sized glands. *Second row:* Occasional tangentially sectioned glands among well-formed small glands; occasional tangentially sectioned glands among well-formed glands

with open lumina; back-to-back discrete glands; branching glands. *Third row:* Large irregular cribriform glands with well-formed lumina; irregular cribriform glands with slitlike lumina, glomeruloid structures, and fused glands; irregular cribriform glands with small round lumina; small round cribriform glands. *Fourth row:* Poorly formed glands with peripherally arranged nuclei; small poorly formed glands; small poorly formed glands; fused poorly-formed glands. *Fifth row:* Sheets of cancer; sheets of cancer with rosette formation; small nests and cords of tumor with scattered clear vacuoles; individual cells. *Sixth row:* Nests and cords of cells with only a vague attempt at lumina formation; solid nests of cancer; solid nests with comedonecrosis; cribriform glands with central necrosis.

It is not recommended that Gleason score 2 to 4 be assigned for adenocarcinoma of the prostate on needle biopsy because (1) most tumors graded as Gleason score 2 to 4 on needle biopsy are graded higher when reviewed by uropathology experts (Steinberg et al., 1997); (2) there is poor reproducibility in the diagnosis of Gleason score 2 to 4 on needle biopsy even among uropathology experts (Allsbrook et al., 2001); and (3) most important, assigning a Gleason score of 2 to 4 to an adenocarcinoma on needle biopsy is not necessarily associated with such favorable findings at radical prostatectomy (Epstein, 2000). Whereas 24% of pathologists rendered a diagnosis of Gleason score 2 to 4 on biopsy in 1991, this decreased to 2.4% in 2001 and is even much less common in today's practice (Ghani et al., 2005). **Gleason patterns 1 and 2 are for the most part not diagnosed on needle biopsy specimens, such that a problem with the current system is that Gleason score 6 is typically the lowest grade assigned on biopsy material. However, the Gleason scale ranges from 2 to 10, so patients are consequently unduly concerned when told they have Gleason score 6 cancer on biopsy; they logically but incorrectly assume that their tumor is in the midrange of aggressiveness.** Another consequence of the updated Gleason grading system is that there is an expanded definition of Gleason pattern 4 to include a broader range of histologic patterns and a greater proportion of cases. **There are several prognostic consequences of the reclassification of many former Gleason score 6 tumors to Gleason score 7 in the modified system. Gleason score 6 tumors are currently more homogeneous and have a uniformly more favorable prognosis.** For example, virtually no organ-confined Gleason score 6 tumor is associated with progression after radical prostatectomy, whereas this occasionally occurred using the original Gleason system (Hernandez et al., 2008). **In addition, Gleason score 6 carcinomas using the updated Gleason system do not have the ability to metastasize to lymph nodes** (Nunez

Bragayrac et al., 2017; Ross et al., 2012). Extraprostatic extension is also uncommon with Gleason score 3+3=6 at radical prostatectomy, reportedly seen in 0.28% of Gleason score 6 tumors in one study, with a higher frequency in our own experience with 3.9% for focal extraprostatic extension and 2.4% for nonfocal extraprostatic extension. Multiple cores of Gleason score 6 still correlate with favorable findings at radical prostatectomy (Ellis et al., 2013). **Using the modified Gleason system, in a study from Johns Hopkins Hospital of 6462 men, almost 95% and 97% of patients with Gleason score 6 cancer at biopsy and radical prostatectomy (no tertiary pattern 4 at radical prostatectomy), respectively, were predicted to be cured of disease at 5 years after radical prostatectomy** (Pierorazio et al., 2013b)**. Using the modified Gleason system, this study showed that Gleason score 3 + 4 = 7 tumor has a very favorable prognosis, with an estimated 5-year biochemical-free survival of 83% and 88% for biopsy and radical prostatectomy, respectively. Gleason scores 9 to 10 tumor had almost twice the risk for progression compared with Gleason score 8. Oversimplification of the Gleason grade classification, such as combining Gleason scores 8 to 10 or classifying patients into low-, intermediate-, and high-risk categories based on Gleason scores less than 7, 7, and greater than 7, loses critical prognostic information. A more contemporary grouping of Gleason scores based on differing prognoses is as follows: Gleason scores less than or equal to 6; 3 + 4 = 7; 4 + 3 = 7; 8; 9 to 10, which reflect Grade Groups 1 to 5, respectively (Box 151.1)** (Pierorazio et al., 2013b). The new Grade Groups system was validated in a multi-institutional study of almost 21,000 radical prostatectomy and 16,000 needle biopsy specimens assessing biochemical recurrence (BCR) (Epstein et al., 2016b). Subsequently, numerous studies have validated Grade Groups in relation to BCR after radiation, risk for distant metastases, and prostate cancer–specific mortality (Berney et al., 2016; Leapman et al., 2017). The new Grade Group system has been recommended by the 2016 World Health Organization (WHO), the College of American Pathology (CAP), and the 8th Edition AJCC Cancer Staging Manual. As of January 2018, Grade Groups need to be reported alongside Gleason grades for laboratories to be accredited by CAP, which is the major accrediting agency for pathology laboratories in the United States.

Box 151.1

Grade Groups Definitions

- Grade Group 1 (Gleason score 3 + 3 = 6): Only individual discrete well-formed glands
- Grade Group 2 (Gleason score 3 + 4 = 7): Predominantly well-formed glands with lesser component of poorly formed/fused/cribriform glands
- Grade Group 3 (Gleason score 4 + 3 = 7): Predominantly poorly formed/fused/cribriform glands with lesser component of well-formed glands
- Grade Group 4 (Gleason score 8)
  - Poorly formed/fused/cribriform glands or
  - Predominantly well-formed glands and any lesser component lacking glands
  - Predominantly lacking glands and second most common component of well-formed glands
- Grade Group 5 (Gleason scores 9 to 10): Lack gland formation (or with necrosis) with or without poorly formed/fused/cribriform glands

The Gleason grade on biopsy material has also been shown to correlate fairly well with that of the subsequent prostatectomy specimen (Fine and Epstein, 2008). In general, a Gleason score less than or equal to 6 on biopsy corresponds to a Gleason score less than or equal to 6 in the radical prostatectomy in about 65% of cases. An unavoidable cause of discrepant grading between the biopsy and subsequent prostatectomy specimen is that caused by sampling error by the needle biopsy. The following factors are associated with upgrading from the needle biopsy to the radical prostatectomy: increased cancer extent on biopsy; increased serum PSA levels; smaller prostates; and fewer cores sampling the prostate (Epstein et al., 2012).

Some men with low-grade cancers develop high-grade tumors after several years. It is not clear whether the residual low-grade cancer progressed or whether there was a subsequent development of a multifocal, more aggressive tumor. Although, in general, larger tumors are high grade and small tumors are low grade, exceptions occur (Epstein et al., 1994b). There is a tendency to hypothesize that tumors begin as low-grade tumors and, on reaching a certain size, dedifferentiate into higher-grade lesions, accounting for the relationship between size and grade. Alternatively, high-grade tumors may be high grade at their inception but are detected at an advanced size because of their rapid growth. Similarly, low-grade tumors may evolve so slowly that they tend to be detected at lower volumes. From a practical standpoint, during a 2- to 3-year period after biopsy, more than 80% of men's prostate cancer grades remain stable (Sheridan et al., 2008).

Assessment of Needle Biopsy Specimens

Processing

When biopsy specimens are taken from different sextant areas of the prostate, they should be submitted to pathology in separate containers (Box 151.2). As long as cores are submitted in separate containers, or the cores are in the same container yet specified by the urologist as to their location (i.e., by different colored inks), pathologists should assign individual Gleason scores to separate cores (Epstein et al., 2005, 2016a, 2017). If cores are combined in a container without designation, most pathologists provide an overall Gleason score as if all the cores were one long core.

Box 151.2

Reasons to Submit Needle Cores in Separate Jars for Each Sextant Site

- In “atypical” cases, the atypical site can be preferentially targeted on repeated biopsy, in addition to other sites.
- More specific location of cancer helps pathologists target additional tissue or block sampling in cases with no cancer on initial sampling of radical prostatectomy.
- Knowledge of sextant site helps pathologists to recognize certain diagnostic pitfalls (i.e., seminal vesicle tissue or central zone mimicking high-grade prostatic intraepithelial neoplasia at the base and Cowper gland mimicking cancer at the apex).
- With brachytherapy, this helps target areas where extra seeds can be distributed.
- Having a maximum of two cores per block or slide preparation with

complete visualization of cores helps prevent missing small foci of cancer that could be “buried” in the paraffin block.

- Maximum of two cores per block or slide helps prevent core fragmentation where one cannot determine the number of involved cores, their percentage involvement, and the highest grade of cancer in the case.

Differential Diagnosis

The underdiagnosis of limited adenocarcinoma of the prostate on needle biopsy is one of the most frequent problems in prostate pathology (Epstein, 2004). There are also numerous benign mimickers of adenocarcinoma of the prostate (Srigley, 2004). In some of these cases, the use of antibodies to high-molecular-weight cytokeratin and p63 may resolve the diagnosis (Wojno and Epstein, 1995). Benign glands contain basal cells and are labeled with these antibodies, whereas prostate cancer shows no staining. Immunohistochemistry with antibodies to α-methylacyl-CoA racemase, which preferentially labels prostatic carcinoma and HGPIN, can also be used as an adjunct in the diagnosis of limited cancer, yet pathologists must be careful because false-positive and false-negative staining with α-methylacyl-CoA racemase have been reported (Jiang et al., 2004, 2005). Nuclear immunoreactivity for ERG can be used as a surrogate for *TMPRSS2:ERG* gene fusion, a specific molecular event seen in approximately 50% of prostate carcinomas. The major limitation of this technique that limits its utility is that on limited foci of carcinoma on needle biopsy, the sensitivity may be somewhat lower, to around 30% to 40%, and positivity does not exclude HGPIN (Shah et al., 2013; Tomlins et al., 2012).

In certain cases, there are findings suggestive of, but not diagnostic of, carcinoma. **The incidence of atypical needle biopsy specimens is about 5%** (Epstein and Herawi, 2006)**. The likelihood of cancer after an atypical diagnosis is about 40%** (Burks et al., 2017; Chan and Epstein, 1999; Epstein and Herawi, 2006; Iczkowski et al., 1997; Tosoian et al., 2018)**. Clinical parameters, such as serum PSA levels, do not help in stratifying which men with atypical glands are at increased risk for being diagnosed with cancer. Approximately 80% of the subsequently detected cancers are Gleason score 6 (Grade Group 1), with the remaining cases of higher grade, including 5% with Gleason scores 8 to 10 (Grade Groups 4 to 5). Consequently, for cases with atypical glands on biopsy, follow–up is warranted with serum or urine tests, imaging, or repeat biopsy with relatively increased sampling of the atypical gland sites. Only about 40% of men have a repeat biopsy after a**

diagnosis of atypical glands suspicious for carcinoma (Burks et al., 2017)**. Cases diagnosed as atypical have the highest likelihood of being changed on expert review, and urologists should consider sending such cases for consultation to attempt to resolve the diagnosis as either definitively benign or malignant before subjecting the patient to repeat biopsy** (Chan and Epstein, 2005).

Prognosis

Adverse findings on needle biopsy, in terms of Gleason grade and tumor extent, generally predict adverse findings accurately in the radical prostatectomy specimen. However, as a result of sampling error, favorable findings on needle biopsy do not necessarily predict favorable findings in the radical prostatectomy specimen. The ways in which cancer may be measured on needle biopsy include number of positive cores, total millimeters of cancer among all cores, percentage of cancer per core, and total percentage of cancer in the entire specimen. An equal number of studies claim superiority of one technique over the other, with no one technique adopted uniformly (Epstein, 2011). It is proposed that pathologists report the number of positive cores along with one other measurement of tumor extent. By combining needle biopsy grade with clinical stage and serum PSA values, the extent of cancer within the prostate can be more accurately predicted (Makarov et al., 2007).

Although there are some conflicting data, the cumulative analysis shows a higher incidence of EPE in men with perineural invasion on prostate needle biopsy (Cozzi et al., 2013; Truong et al., 2017). Perineural invasion on biopsy is prognostic in men undergoing external-beam radiotherapy, but is less so with brachytherapy (Harnden et al., 2007). Perineural invasion should be noted on the biopsy pathology report. There are data showing that atrophy and associated inflammation are linked with prostate carcinogenesis (DeMarzo et al., 2003; Platz et al., 2017). However, atrophy of all morphologic types is very common on needle biopsy and is not associated with an increased risk for cancer or PIN on subsequent biopsy (Postma et al., 2005).

Probably the most powerful predictor of prognosis on biopsy is the Gleason score, which can be used to predict multiple outcomes including (1) pathologic stage; (2) side-specific EPE; (3) EPE into the neurovascular bundle; (4) progression after radical prostatectomy; (5) candidates for brachytherapy; (6) prognosis after radiotherapy; (7) candidates for active surveillance; (8) intervention criteria after active surveillance; (9) prognosis

after cryotherapy; (10) prognosis after high-intensity focused ultrasonography (HIFU); and (11) candidates for focal therapy (Epstein, 2013). Within Gleason score 7 on biopsy, increasing percentage of Gleason grade 4 correlates with adverse pathology at radical prostatectomy and biochemical recurrence (Cole et al., 2016). Men with needle biopsies showing Gleason score 3+4=7 with limited percent pattern 4 may also be candidates for active surveillance, factoring in patient's age, comorbidity, imaging results, extent of cancer on biopsy, and patient preferences. Consequently, it is recommended that pathologists report percent pattern 4 for Gleason score 3+4=7 at biopsy, and it is optional for Gleason score 4+3=7.

Assessment of Transurethral Resection Specimens

Processing

The recommended system is based on the percentage of the specimen involved by tumor, with 5% being the cutoff between stages T1a and T1b (Cantrell et al., 1981). All stage T1b tumors are detected by the processing of between 6 and 8 cassettes of a TUR specimen. By processing 8 to 10 cassettes, more than 90% of stage T1a lesions are identified (Murphy et al., 1986; Newman et al., 1982; Rohr, 1987; Vollmer, 1986). Depending on the institution, all TUR tissues may be examined in men younger than 65 years of age in whom aggressive therapy for stage T1a disease might be pursued.

Differential Diagnosis

One of the most common lesions to be confused with low-grade adenocarcinoma is adenosis (atypical adenomatous hyperplasia) (Gaudin and Epstein, 1994, 1995). Approximately 1.6% of benign TUR specimens and 0.8% of all needle biopsy specimens contain adenosis. It is characteristically found in the transition zone of the prostate, is frequently multifocal, and most often is an incidental finding in TURs performed for urinary obstruction. **Although adenosis mimics carcinoma, there is no evidence suggesting that patients with adenosis have an increased risk for harboring or developing adenocarcinoma of the prostate.**

Assessment of Radical Prostatectomy

Specimens

Assessment

Within institutions that do not totally embed radical prostatectomy specimens, there are sampling techniques that provide accurate pathologic staging (Hall et al., 1992; Sehdev et al., 2001). **Whole-mount sectioning of the prostate provides more aesthetically pleasing sections for teaching and publication, yet the information obtained by routine sections is identical.**

Prognosis

Gleason Score.

It is recommended that pathologists assign a separate grade to each major tumor nodule (Epstein et al., 2017). Most often, the largest tumor is associated with the highest stage and highest grade and is referred to as the "dominant nodule." If there are several nodules where the smaller nodule is either of higher stage or grade, one can descriptively refer to them as nodule #1, nodule #2, and so on, and record the grade for each nodule separately. **The Gleason score at radical prostatectomy correlates well with prognosis. The 5-year postoperative biochemical risk, free of disease, is 96.6%, 88.1%, 69.7%, 63.7%, and 34.5% for Gleason scores less than or equal to 6 (Grade Group 1); 3 + 4 = 7 (Grade Group 2); 4 + 3 = 7 (Grade Group 3); 8 (Grade Group 4); and 9 to 10 (Grade Group 5), respectively** (Pierorazio et al., 2013b). **A tertiary (third) grade pattern is recorded typically when there is a nodule with Gleason score 3 + 4 = 7 or 4 + 3 = 7 and a minor (<5%) component of Gleason pattern 5** (Epstein et al., 2017). The presence of a tertiary higher-grade component is associated with an increased risk for biochemical recurrence. In some studies, the presence of a tertiary pattern raises the risk for recurrence to a level intermediate between those of cancers without a tertiary component in the same Gleason score category and cancers in the next higher Gleason score category, and in some studies elevates the risk to the next highest Gleason score (Borhan and Epstein, 2017; Jang et al., 2017; Pan et al., 2000; Trock et al., 2009). In support of keeping 3 + 4 = 7 (Grade Group 2) with tertiary 5 and 4 + 3 = 7 (Grade Group 3) with tertiary 5 within their respective Grade Groups with a notation of tertiary 5, is that the less than 5% higher grade component does not increase the risk for lymph node metastases within a given Grade Group (Diolombi and Epstein, 2017). Within Gleason score 7 at radical prostatectomy, the percent of Gleason pattern 4 adds significantly to predicting postoperative prognosis, and it is recommended that pathologists report this added detailed information (Sauter et al., 2016).

Lymph Node Metastases.

The incidence of lymph node metastases has declined markedly in recent years because earlier tumors are detected by screening techniques. The incidence of nodal metastases is related to the clinical stage, preoperative PSA level, and biopsy grade, with some surgeons not removing pelvic lymph nodes in men with a low risk for metastases. Regional lymph node metastases at radical prostatectomy are uncommon with Gleason scores less than 8. The incidence for Gleason scores 3 + 3 = 6, 3 + 4 = 7, and 4 + 3 = 7 are 0%, 0.6%, and 4.3%, respectively (Diolombi and Epstein, 2017). Almost all patients with positive lymph nodes who undergo radical prostatectomy eventually show progression of their disease, indicative of distant occult metastases. The 15-year biochemical–recurrence-free, metastases-free, and cancer-specific survival for men undergoing radical prostatectomy with positive nodes is 7.1%, 41.5%, and 57.5%, respectively. Predictors of biochemical recurrence, metastases, and death from prostate cancer in multivariate analysis include prostatectomy Gleason score and the number and percent of positive lymph nodes, respectively (Pierorazio et al., 2013a).

Extraprostatic Extension and Seminal Vesicle Invasion.

The prostatic capsule is not well defined histologically, especially at the apex, the base, and anteriorly (Ayala et al., 1989). **Because the prostate lacks a discrete capsule, the term *extraprostatic extension*, rather than *capsular invasion* or *capsular penetration*, is recommended to denote non–organ-confined disease.** It can be difficult to recognize EPE because the boundaries where the prostate ends can be vague, and the tumor can also induce a dense desmoplastic response in the periprostatic adipose tissue (Epstein, 2001). The degree of EPE varies from only a few glands outside the prostate, which we term *focal extraprostatic extension*, to cases with more extensive extraprostatic spread, which we designate *nonfocal extraprostatic extension*. **The degree of EPE correlates with the risk for progression after radical prostatectomy** (Epstein, 2001; Maubon et al., 2016). Other more objective measurements of quantifying the extent of EPE have been proposed, but they correlate well with the subjective "focal" versus "nonfocal" dichotomy, and none have proven sufficiently superior to recommend as the preferred method (Magi-Galluzzi et al., 2011; van Veggel et al., 2011). **Seminal vesicle invasion is a much more dire prognostic finding, with a 65% 5-year progression rate after surgery** (Epstein, 2001; Pierorazio et al., 2011).

Margins.

Novara et al. (2012) reported the mean rate of positive margins in the robotic-assisted radical prostatectomy series, published between 2008 and 2011 (each including >100 cases), to be 15%, which ranged from 6.5% to 32%. **Only approximately 50% of men with positive margins progress after radical prostatectomy** (Epstein et al., 1993). A major source of this discrepancy is that even in cases in which margins histologically appear to be positive, additional tissue removed from the site does not always show a tumor (Epstein, 1990). A few studies have documented the performance of frozen section along the length of the prostate in the region of the neurovascular bundle with a positive intraoperative margin resulting in resection of the ipsilateral neurovascular bundle (Schlomm et al., 2012; von Bodman et al., 2013). In one study, it was noted that it took 5 cryostats with 2 pathologists and 4 technicians to perform one case in about 35 minutes, which is not practical for most laboratories. The technique includes a low false-negative and false-positive rate compared with the permanent sections of the same slides. However, in two studies in which a frozen-section margin was positive in the region of the neurovascular bundle and the bundle was removed, only 23% to 25% of the bundles showed residual cancer. Arguments posited in support of this procedure are (1) without the frozen sections most of these patients would have had the bundles resected because of preoperative high-risk characteristics; and (2) the overall sum of saved neurovascular bundles was markedly higher than the unnecessary secondary wide excisions (Schlomm et al., 2012; von Bodman et al., 2013). The preponderance of studies shows that the distance from tumor to ink does not affect the risk for recurrence, although one conflicting study exists (Bong et al., 2009; Emerson et al., 2005; Epstein, 1990; Epstein and Sauvageot, 1997; Lu et al., 2012). **Factors that can aid in the clinician's decision as to whether or not to administer adjuvant radiation therapy are the extent of positive margins and the grade of the tumor at the margins, and these factors have been shown to be prognostic** (Brimo et al., 2010; Cao et al., 2010; Chuang and Epstein, 2008; Huang et al., 2013; Kates et al., 2016; Shikanov et al., 2009; van Oort et al., 2010).

Positive margins also may arise as a result of the surgical transection of intraprostatic tumor (intraprostatic incision); although also referred to as *capsular incision,* this term is not recommended, as there is no prostatic capsule. The reported incidence of intraprostatic incision ranges from 1.3% to as high as 71% (Epstein, 2001). In my opinion, much of this variation relates to the difficulties described in the preceding text in recognizing EPE. If an extraprostatic tumor associated with a desmoplastic stromal response at a margin is misdiagnosed as organ confined, it will be misclassified as a positive margin because of intraprostatic incision. The other relatively frequent site of intraprostatic incision is in the regions of the neurovascular bundles, where the urologist attempts to preserve the bundle for potency, yet cuts into the prostate. Only if both tumor and benign glands are transected in the same area and are present at the inked margin do I diagnose a positive margin as a result of intraprostatic incision. **Intraprostatic incision is associated with an increased risk for postoperative progression equivalent to that associated with focal EPE and a positive margin** (Chuang and Epstein, 2008)**.**

In a multivariate analysis, Gleason grade, EPE, and margins of resection are strong independent predictors of biochemical progression.

Tumor Volume.

There are conflicting studies regarding whether or not tumor volume independently predicts post–radical prostatectomy progression after grade and pathologic stage are determined, with most of the larger series not showing prognostic significance (Epstein, 2001). Despite this fact, the International Society of Urological Pathology recommends that some objective measurement of tumor volume be reported in radical prostatectomy specimens (van der Kwast et al., 2011). The Society's rationale is that tumor volume is recorded for cancers in other organ systems. Because tumor volume is not an independent predictor and will in general not affect subsequent therapy, it is my recommendation that if one feels obliged to report a radical prostatectomy tumor, then the simplest and fastest method should be used, such as a rough estimate of the overall percentage of the prostate involved by the tumor or maximum dimension of tumor.

Perineural and Vascular Invasion.

The finding of perineural invasion in a radical prostatectomy specimen is very common, is not prognostic, and should not be included in the pathology

report. Vascular invasion is uncommonly identified in radical prostatectomy specimens, seen in 7% of tumors smaller than 4 cc (most tumors seen today at radical prostatectomy are smaller than 2 cc) (McNeal and Yemoto, 1996b). Vascular invasion correlates with other adverse findings (i.e., EPE, grade, margins, tumor volume), yet still offers independent prognostic information beyond those of routinely noted findings (Baydar et al., 2008; Epstein, 2001).

Adenocarcinoma With Treatment Effect

One of the problems with evaluating carcinomas that have been treated with hormone therapy is that the grade often appears artifactually higher (Smith and Murphy, 1994). **Pathologists should not assign a Gleason score to carcinomas with treatment effect.** However, if other areas of the tumor do not show a pronounced hormone effect, these areas can be Gleason graded. It has been demonstrated that finasteride does not alter the histology of either benign or malignant tissue (Baydar et al., 2008; Epstein, 2001).

Radiated adenocarcinoma of the prostate may either show no recognizable difference from nonradiated cancer or may show the effects of radiation damage. **When signing out postradiotherapy biopsies, they should be diagnosed as either: (1) benign prostate tissue with radiation effect; (2) cancer without treatment effect (a Gleason grade is assigned); or (3) cancer showing treatment effect (no Gleason grade assigned). The latter diagnosis is associated with an equivalent prognosis to a noncancerous diagnosis** (Crook et al., 2009). Radiation alters the histologic features of benign prostate tissue so that it may mimic prostate cancer (Bostwick et al., 1982). Radiation atypia in benign prostate glands may persist for a long time (up to 72 months) after the initial treatment, resulting in a significant pitfall in evaluating prostate biopsy specimens (Magi-Galluzzi et al., 2003). If clinicians are aware of such treatment, this information should be provided to the pathologist.

Cryotherapy or HIFU treatment results in infarction of benign and neoplastic prostate tissue. If residual cancer is seen following these therapies, there is no treatment affect present and a Gleason score can be assigned.

Subtypes of Prostate Adenocarcinoma

Mucinous adenocarcinomas of the prostate gland behave like usual prostate carcinomas, including a propensity to develop bone metastases with advanced disease (Epstein and Lieberman, 1985; Ro et al., 1990). **Mucinous adenocarcinoma of the prostate treated by radical prostatectomy is not more aggressive than nonmucinous prostate cancer** (Osunkoya et al., 2008; Samaratunga et al., 2017). Even in ordinary adenocarcinomas of the prostate without light microscopic evidence of neuroendocrine differentiation, almost one-half show neuroendocrine differentiation on evaluation with immunohistochemistry for multiple neuroendocrine markers (di Sant'Agnese, 1992). Most studies do not demonstrate a convincing relationship between the extent of neuroendocrine differentiation in ordinary prostate cancer and prognosis. Many small cell carcinomas of the prostate are identical to small cell carcinomas of the lung (Tetu et al., 1989). In approximately 50% of the cases, the tumors are mixed small cell carcinoma and adenocarcinoma of the prostate. There are cases in which it can be difficult to distinguish between small cell carcinoma and high acinar adenocarcinoma of the prostate, in part resulting from overlap cases with usual acinar carcinoma transdifferentiating to small cell carcinoma (Epstein et al., 2014). **The average survival of patients with small cell carcinoma of the prostate is less than 1 year.** There is no difference in prognosis between patients with pure small cell carcinoma and those with mixed glandular and small cell carcinomas. Small cell carcinomas are not assigned a Gleason grade.

Between 0.4% and 0.8% of prostatic adenocarcinomas arise from prostatic ducts (Christensen et al., 1991; Epstein and Woodruff, 1986). In about 5% of prostatic carcinomas, tumors showing both ductal and acinar differentiation are found. When prostatic duct adenocarcinomas arise in the large primary periurethral prostatic ducts, they may grow as an exophytic lesion into the urethra, most commonly in and around the verumontanum, and this gives rise to either obstructive symptoms or hematuria. Tumors arising in the more peripheral prostatic ducts may present similar to ordinary (acinar) adenocarcinomas of the prostate and may be diagnosed on needle biopsy (Brinker et al., 1999). Tumors are often underestimated clinically because rectal examination findings and serum PSA levels may be normal. **Most prostatic duct adenocarcinomas should be regarded as Gleason pattern 4 because of their shared cribriform**

morphologic features with acinar adenocarcinoma Gleason score 8 and a similar prognosis (Brinker et al., 1999). Exceptions are the PIN-like ductal adenocarcinoma, which is assigned a Gleason pattern 3 (Tavora and Epstein, 2008) and the ductal adenocarcinoma with comedonecrosis, which is assigned a Gleason pattern 5. There are conflicting studies regarding whether or not a ductal adenocarcinoma component that is assigned a Gleason pattern 4 (or pattern 5 if accompanied by comedonecrosis) is associated with a poorer prognosis than a comparably graded acinar carcinoma (Samaratunga et al., 2010; Seipel et al., 2013). **Pure primary squamous carcinoma of the prostate is rare and is associated with poor survival** (Parwani et al., 2004). These tumors develop osteolytic metastases and do not respond to hormonal therapy. More commonly, squamous differentiation occurs in the primary and metastatic deposits of adenocarcinomas that have been treated with estrogen therapy. Sarcomatoid carcinomas (carcinosarcomas) have also been reported within the prostate and have a dismal prognosis (Hansel and Epstein, 2006).

Mesenchymal Tumors

Sarcomas of the prostate account for 0.1% to 0.2% of all malignant prostatic tumors (Hansel et al., 2007). Rhabdomyosarcomas are the most frequent mesenchymal tumor within the prostate and are seen almost exclusively in childhood. Leiomyosarcomas are the most common sarcomas involving the prostate in adults (Cheville et al., 1995). A spindle cell lesion that can occur at any age and can closely simulate a leiomyosarcoma is an inflammatory myofibroblastic tumor, which may occur soon after TUR or without a history of TUR (Montgomery et al., 2006). There are also mesenchymal tumors of the prostate arising from the unique prostatic specialized stroma. These lesions range from prostatic stromal tumors of uncertain malignant potential (STUMP) to prostatic stromal sarcomas. On histologic examination, these lesions are variable; one subtype resembles a tumor seen in the breast and is termed *phyllodes tumor of the prostate* (Herawi and Epstein, 2006). Although most cases of prostatic STUMP do not behave in an aggressive fashion, occasional cases have been documented to recur rapidly after resection; cases with mixed STUMP and sarcomas exist, and a few STUMP have progressed to stromal sarcoma. **Although many STUMP may behave in an indolent fashion, their unpredictability in a minority of cases and the lack of correlation between different histologic patterns of STUMP and sarcomatous dedifferentiation**

warrant close follow-up and consideration of definitive resection in younger individuals. Stromal sarcomas have the potential for metastatic behavior.

Urothelial Carcinoma

Primary urothelial carcinoma of the prostate without bladder involvement accounts for 1% to 4% of all prostate carcinomas (Sawczuk et al., 1985). Primary urothelial carcinomas of the prostate show a propensity to infiltrate the bladder neck and the surrounding soft tissue such that more than 50% of patients present with stage T3 or T4 tumors (Greene et al., 1976). Twenty percent of patients present with distant metastases, with the bone (predominantly osteolytic), the lung, and the liver being the most common sites.

More commonly, urothelial carcinoma involves prostatic ducts and acini in patients with a history of carcinoma in situ (CIS) of the bladder who have been treated for a period of months to years with intravesical topical chemotherapy (Mahadevia et al., 1986; Njinou Ngninkeu et al., 2003; Schellhammer et al., 1977; Wood et al., 1989). Between 35% and 45% of cystoprostatectomies performed for urothelial carcinoma contain prostatic involvement. However, this number is dependent on the amount of histologic sampling of the prostate tissue and may be much higher in completely mapped specimens. If cystoprostatectomy is performed and only intraductal urothelial carcinoma is present, the prostatic involvement does not worsen the prognosis, which is determined by the stage of the bladder tumor (Esrig et al., 1996). Intraductal urothelial carcinoma of the prostate appears to involve the prostate by direct extension from the overlying urethra, which is usually involved by CIS. Intraductal and infiltrating urothelial carcinoma involving the prostate tends to be seen in higher-stage bladder tumors, in which the patients have a poor prognosis attributable to either advanced bladder or prostatic disease. A minority of these cases will have low-stage bladder tumor and a poorer prognosis, demonstrating the adverse effect of prostatic stromal infiltration (Esrig et al., 1996). **Urothelial carcinoma involving the prostate is substaged into pT1 when invasive carcinoma involves the suburethral tissue or pT2 when there is CIS involving prostatic acini with prostatic stromal invasion.** It is not clear how to report the staging of both the bladder urothelial carcinoma and prostatic involvement in cystoprostatectomy specimens. I report the findings in both the bladder and prostate, assigning separate stages for each organ. Alternatively, one can just report the bladder or prostatic stage, depending which is higher, and then describe the extent of disease in the other organ. **Extensive sampling of the periurethral area in cystoprostatectomy specimens performed for urothelial carcinoma is necessary to identify and to evaluate the prostate for urothelial carcinoma.**

Finally, one may find direct invasion from bladder urothelial carcinoma into the stroma of the prostate. The distinction between poorly differentiated urothelial carcinoma and poorly differentiated adenocarcinoma of the prostate can be difficult histologically and is compounded by the difficulty in distinguishing between a bladder and prostate primary clinically. Some cases of extensive high-grade prostatic adenocarcinoma involving the bladder neck are labeled as a “bladder tumor” by the urologist, which can contribute to a pathologic misdiagnosis of urothelial carcinoma. Approximately 95% of poorly differentiated prostatic adenocarcinomas show PSA staining, although it may be focal (Chuang et al., 2007). In some cases of poorly differentiated prostatic adenocarcinomas, there may be weak or negative PSA staining, where the tumor reacts to a greater degree with newer prostate-specific markers, including p501S (prostein) and NKX 3.1 (Chuang et al., 2007). Although CK7 and CK20 are more frequently seen in urothelial carcinoma as compared with adenocarcinoma of the prostate, they may also be positive in adenocarcinoma of the prostate. The most sensitive and specific marker that labels urothelial carcinoma and not prostate carcinoma is GATA3 (80%) (Chang et al., 2012; Higgins et al., 2007). Less sensitive markers include uroplakin and thrombomodulin (49% to 69% sensitivity) and p63 and high-molecular-weight cytokeratin (60% to 70% sensitivity) (Chuang et al., 2007).

Miscellaneous Malignant Tumors

Primary prostatic lymphoma without lymph node involvement appears to be much less common than secondary infiltration of the prostate (Bostwick and Mann, 1985). The most common form of leukemic involvement of the prostate is that of chronic lymphocytic leukemia, although monocytic, granulocytic, and lymphoblastic leukemias have also been found in the prostate (Dajani and Burke, 1976).

Key Points

- LGPIN should not be commented on in diagnostic reports, because the diagnosis is not reproducible among pathologists and it lacks clinical significance.
- For patients diagnosed with HGPIN on one core of an extended initial core sampling, repeat biopsy within the first year is unnecessary in the absence of other clinical indicators of cancer. The follow-up for biopsies with two or more cores involved by HGPIN is the same as for an atypical biopsy.
- Regardless of the serum PSA level, the risk for cancer after an atypical biopsy suspicious for carcinoma is approximately 40%. Given that 80% of the cancers detected on repeat biopsy are Gleason score 6, some urologists may choose to follow up with serum or urine tests, imaging, and only in some cases perform repeat biopsy with relative increased sampling of the atypical site. Other urologists, recognizing that 20% of cancers on repeat biopsy are Gleason score 7 or higher, may routinely recommend repeat biopsy after an atypical diagnosis.
- Cases diagnosed as atypical have the highest likelihood of being changed on expert review. Urologists should consider sending such cases for consultation to attempt to resolve the diagnosis as either definitively benign or malignant before subjecting the patient to repeat biopsy.
- Tumor volume measured in the radical prostatectomy specimen does not independently predict postsurgical progression after the grade, the pathologic stage, and the margins are considered.
- Gleason grade, whether it is assessed on needle biopsy, TUR, or radical prostatectomy specimens, remains one of the most influential prognostic factors.
- The new Grade Groups for prostate adenocarcinoma (based on Gleason's original grading system following multiple significant modifications) provide a simpler, more intuitive, and better prognostic grading system.

Suggested Readings

Eble JN, Sauter G, Epstein JI, et al. *Pathology and genetics: tumours of the urinary system and male genital organs*. IARC Press: Lyon (France; 2004.

Epstein JI, Cubilla AL, Humphrey PA. *AFIP atlas of tumor pathology, series 4: tumors of the prostate gland, seminal vesicles, penis, and scrotum*. ARP Press: Washington DC; 2011.

Epstein JI, Netto GJ. *Prostate biopsy interpretation*. Lippincott Williams & Wilkins: Philadelphia, PA; 2015.

Epstein JI. *The Gleason Grading System: a complete guide for pathologists and clinicians*. Lippincott Williams & Wilkins: Philadelphia; 2013.

Humphrey PA. *Prostate pathology*. ASCP Press: Chicago, IL; 2003.

References

Abdel-Khalek M, El-Baz M, Ibrahiem el-H. Predictors of prostate cancer on extended biopsy in patients with high-grade prostatic intraepithelial neoplasia: a multivariate analysis model. *BJU Int*. 2004;94(4):528–533.

Al-Ahmadie HA, Tickoo SK, Olgac S, et al. Anterior-predominant prostatic tumors: zone of origin and pathologic outcomes at radical prostatectomy. *Am J Surg Pathol*. 2008;32(2):229–235.

Allsbrook WC Jr, Mangold KA, Johnson MH, et al. Interobserver reproducibility of Gleason grading of prostatic carcinoma: urologic pathologists. *Hum Pathol*. 2001;32(1):74–80.

Ayala AG, Ro JY, Babaian R, et al. The prostatic capsule: does it exist? Its importance in the staging and treatment of prostatic carcinoma. *Am J Surg Pathol*. 1989;13(1):21–27.

Baydar DE, Baseskioglu B, Ozen H, et al. Prognostic significance of lymphovascular invasion in clinically localized prostate cancer after radical prostatectomy. *ScientificWorldJournal*. 2008;8:303–312.

Berney DM, Beltran L, Fisher G, et al. Validation of a contemporary prostate cancer grading system using prostate cancer death as outcome. *Br J Cancer*. 2016;114(10):1078–1083.

Bong GW, Ritenour CW, Osunkoya AO, et al. Evaluation of modern pathological criteria for positive margins in radical prostatectomy specimens and their use for predicting biochemical recurrence. *BJU Int*. 2009;103(3):327–331.

Borhan W, Epstein JI. Significance of Gleason Score 7 with tertiary pattern 5 at radical prostatectomy. *Urology*. 2017;100:175–179.

Bostwick DG, Mann RB. Malignant lymphomas involving the prostate. A study of 13 cases. *Cancer*. 1985;56(12):2932–2938.

Bostwick DG, Egbert BM, Fajardo LF. Radiation injury of the normal and neoplastic prostate. *Am J Surg Pathol*. 1982;6(6):541–551.

Bostwick DG, Pacelli A, Lopez-Beltran A. Molecular biology of prostatic intraepithelial neoplasia. *Prostate*. 1996;29(2):117–134.

Brimo F, Partin AW, Epstein JI. Tumor grade at margins of resection in radical prostatectomy specimens is an independent predictor of prognosis. *Urology*. 2010;76(5):1206–1209.

Brinker DA, Potter SR, Epstein JI. Ductal adenocarcinoma of the prostate diagnosed on needle biopsy: correlation with clinical and radical prostatectomy findings and progression. *Am J Surg Pathol*. 1999;23(12):1471–1479.

Burks FN, Hu JC, Telang D, et al. Repeat prostate biopsy practice patterns in a statewide quality improvement collaborative. *J Urol*. 2017;198(2):322–328.

Byar DP, Mostofi FK. Carcinoma of the prostate: prognostic evaluation of certain pathologic features in 208 radical prostatectomies. Examined by the step-section technique. *Cancer*. 1972;30(1):5–13.

Cantrell BB, DeKlerk DP, Eggleston JC, et al. Pathological factors that influence prognosis in stage A prostatic cancer: the influence of extent versus grade. *J Urol*. 1981;125(4):516–520.

Cao D, Kibel AS, Gao F, et al. The Gleason score of tumor at the margin in radical prostatectomy is predictive of biochemical recurrence. *Am J Surg Pathol*. 2010;34(7):994–1001.

Cerveira N, Ribeiro FR, Peixoto A, et al. TMPRSS2-ERG gene fusion causing ERG overexpression precedes chromosome copy number changes in prostate carcinomas and paired HGPIN lesions. *Neoplasia*. 2006;8(10):826–832.

Chan TY, Epstein JI. Follow-up of atypical prostate needle biopsies suspicious for cancer. *Urology*. 1999;53(2):351–355.

Chan TY, Epstein JI. Patient and urologist driven second opinion of prostate needle biopsies. *J Urol*. 2005;174(4 Pt 1):1390–1394 [discussion 1394; author reply 1394].

Chang A, Amin A, Gabrielson E, et al. Utility of GATA3 immunohistochemistry in differentiating urothelial carcinoma from prostate adenocarcinoma and squamous cell carcinomas of the uterine cervix, anus, and lung. *Am J Surg Pathol*. 2012;36(10):1472–1476.

Cheville JC, Dundore PA, Nascimento AG, et al. Leiomyosarcoma of the prostate. Report of 23 cases. *Cancer*. 1995;76(8):1422–1427.

Cho KR, Epstein JI. Metastatic prostatic carcinoma to supradiaphragmatic lymph nodes. A clinicopathologic and immunohistochemical study. *Am J Surg Pathol*. 1987;11(6):457–463.

Christensen WN, Partin AW, Walsh PC, et al. Pathologic findings in clinical stage A2 prostate cancer. Relation of tumor volume, grade, and location to pathologic stage. *Cancer*. 1990;65(4):1021–1027.

Christensen WN, Steinberg G, Walsh PC, et al. Prostatic duct adenocarcinoma. Findings at radical prostatectomy. *Cancer*. 1991;67(8):2118–2124.

Chuang AY, Epstein JI. Positive surgical margins in areas of capsular incision in otherwise organ-confined disease at radical prostatectomy: histologic features and pitfalls. *Am J Surg Pathol*. 2008;32(8):1201–1206.

Chuang AY, DeMarzo AM, Veltri RW, et al. Immunohistochemical differentiation of high-grade prostate carcinoma from urothelial carcinoma. *Am J Surg Pathol*. 2007;31(8):1246–1255.

Cohen RJ, Wheeler TM, Bonkhoff H, et al. A proposal on the identification, histologic reporting, and implications of intraductal prostatic carcinoma. *Arch Pathol Lab Med*. 2007;131(7):1103–1109.

Cole AI, Morgan TM, Spratt DE, et al. Prognostic value of percent Gleason grade 4 at prostate biopsy in predicting prostatectomy pathology and recurrence. *J Urol*. 2016;196(2):405–411.

Cozzi G, Rocco BM, Grasso A, et al. Perineural invasion as a predictor of extraprostatic extension of prostate cancer: a systematic review and meta-analysis. *Scand J Urol*. 2013;47(6):443–448.

Crook JM, Malone S, Perry G, et al. Twenty-four-month postradiation prostate biopsies are strongly predictive of 7-year disease-free survival: results from a Canadian randomized trial. *Cancer*. 2009;115(3):673–679.

Dajani YF, Burke M. Leukemic infiltration of the prostate: a case study and clinicopathological review. *Cancer*. 1976;38(6):2442–2446.

DeMarzo AM, Nelson WG, Isaacs WB, et al. Pathological and molecular aspects of prostate cancer. *Lancet*. 2003;361(9361):955–964.

di Sant'Agnese PA. Neuroendocrine differentiation in human prostatic carcinoma. *Hum Pathol*. 1992;23(3):287–296.

Diolombi ML, Epstein JI. Metastatic potential to regional lymph nodes with Gleason score ≤7, including tertiary pattern 5, at radical prostatectomy. *BJU Int*. 2017;119(6):872–878.

Ellis CL, Walsh PC, Partin AW, et al. Multiple cores of Gleason score 6 correlate with favourable findings at radical prostatectomy. *BJU Int*. 2013;111(8):E306–E309.

Emerson RE, Koch MO, Daggy JK, et al. Closest distance between tumor and resection margin in radical prostatectomy specimens: lack of prognostic significance. *Am J Surg Pathol*. 2005;29(2):225–229.

Epstein JI. Evaluation of radical prostatectomy capsular margins of resection. The significance of margins designated as negative, closely approaching, and positive. *Am J Surg Pathol*. 1990;14(7):626–632.

Epstein JI. Gleason score 2-4 adenocarcinoma of the prostate on needle biopsy: a diagnosis that should not be made. *Am J Surg Pathol*. 2000;24(4):477–478.

Epstein JI. Pathologic assessment of the surgical specimen. *Urol Clin North Am*. 2001;28(3):567–594.

Epstein JI. Diagnosis and reporting of limited adenocarcinoma of the prostate on needle biopsy. *Mod Pathol*. 2004;17:307–315.

Epstein JI. Prognostic significance of tumor volume in radical prostatectomy and needle biopsy specimens. *J Urol*. 2011;186(3):790–797.

Epstein JI. *The Gleason Grading system: a complete guide for pathologists and clinicians*. Lippincott Williams & Wilkins: Philadelphia, PA; 2013.

Epstein JI, Lieberman PH. Mucinous adenocarcinoma of the prostate gland. *Am J Surg Pathol*. 1985;9(4):299–308.

Epstein JI, Woodruff JM. Adenocarcinoma of the prostate with endometrioid features. A light microscopic and immunohistochemical study of ten cases. *Cancer*. 1986;57(1):111–119.

Epstein JI, Sauvageot J. Do close but negative margins in radical prostatectomy specimens increase the risk of postoperative progression? *J Urol*. 1997;157(1):241–243.

Epstein JI, Herawi M. Prostate needle biopsies containing prostatic intraepithelial neoplasia or atypical foci suspicious for carcinoma: implications for patient care. *J Urol*.

2006;175(3 Pt 1):820–834.

Epstein JI, Pizov G, Walsh PC. Correlation of pathologic findings with progression after radical retropubic prostatectomy. *Cancer*. 1993;71(11):3582–3593.

Epstein JI, Walsh PC, Brendler CB. Radical prostatectomy for impalpable prostate cancer: the Johns Hopkins experience with tumors found on transurethral resection (stages T1A and T1B) and on needle biopsy (stage T1C). *J Urol*. 1994;152(5 Pt 2):1721–1729.

Epstein JI, Carmichael MJ, Partin AW, et al. Small high grade adenocarcinoma of the prostate in radical prostatectomy specimens performed for nonpalpable disease: pathogenetic and clinical implications. *J Urol*. 1994;151(6):1587–1592.

Epstein JI, Grignon DJ, Humphrey PA, et al. Interobserver reproducibility in the diagnosis of prostatic intraepithelial neoplasia. *Am J Surg Pathol*. 1995;19(8):873–886.

Epstein JI, Allsbrook WC Jr, Amin MB, ISUP Grading Committee, et al. The 2005 International Society of Urological Pathology (ISUP) Consensus Conference on Gleason Grading of Prostatic Carcinoma. *Am J Surg Pathol*. 2005;29(9):1228–1242.

Epstein JI, Srigley J, Grignon D, et al. Recommendations for the reporting of prostate carcinoma. *Hum Pathol*. 2007;38(9):1305–1309.

Epstein JI, Feng Z, Trock BJ, et al. Upgrading and downgrading of prostate cancer from biopsy to radical prostatectomy: incidence and predictive factors using the modified Gleason grading system and factoring in tertiary grades. *Eur Urol*. 2012;61(5):1019–1024.

Epstein JI, Amin MB, Beltran H, et al. Proposed morphologic classification of prostate cancer with neuroendocrine differentiation. *Am J Surg Pathol*. 2014;38(6):756–767.

Epstein JI, Egevad L, Amin MB, et al. The 2014 International

Society of Urological Pathology (ISUP) Consensus Conference on Gleason Grading of Prostatic Carcinoma: definition of Grading Patterns and Proposal for a New Grading System. *Am J Surg Pathol*. 2016;40(2):244–252.

Epstein JI, Zelefsky MJ, Sjoberg DD, et al. A contemporary prostate cancer grading system: a validated alternative to the Gleason score. *Eur Urol*. 2016;69(3):428–435.

Epstein JI, Amin MB, Reuter VE, et al. Contemporary Gleason grading of prostatic carcinoma: an update with discussion on practical issues to implement the 2014 International Society of Urological Pathology (ISUP) Consensus Conference on Gleason Grading of Prostatic Carcinoma. *Am J Surg Pathol*. 2017;41(4):e1–e7.

Esrig D, Freeman JA, Elmajian DA, et al. Transitional cell carcinoma involving the prostate with a proposed staging classification for stromal invasion. *J Urol*. 1996;156(3):1071–1076.

Fine SW, Epstein JI. A contemporary study correlating prostate needle biopsy and radical prostatectomy Gleason score. *J Urol*. 2008;179(4):1335–1338 [discussion 1338–1339].

Fry DE, Amin M, Harbrecht PJ. Rectal obstruction secondary to carcinoma of the prostate. *Ann Surg*. 1979;189(4):488–492.

Gaudin PB, Epstein JI. Adenosis of the prostate. Histologic features in transurethral resection specimens. *Am J Surg Pathol*. 1994;18(9):863–870.

Gaudin PB, Epstein JI. Adenosis of the prostate. Histologic features in needle biopsy specimens. *Am J Surg Pathol*. 1995;19(7):737–747.

Gaudin PB, Sesterhenn IA, Wojno KJ, et al. Incidence and clinical significance of high-grade prostatic intraepithelial neoplasia in TURP specimens. *Urology*. 1997;49(4):558–563.

Ghani KR, Grigor K, Tulloch DN, et al. Trends in reporting Gleason score 1991 to 2001: changes in the pathologist's practice. *Eur Urol*. 2005;47(2):196–201.

Gleason DF, Mellinger GT. Prediction of prognosis for prostatic adenocarcinoma by combined histological grading and clinical staging. *J Urol*. 1974;111(1):58–64.

Greene LF, O'Dea MJ, Dockerty MB. Primary transitional cell carcinoma of the prostate. *J Urol*. 1976;116(6):761–763.

Greene DR, Wheeler TM, Egawa S, et al. A comparison of the morphological features of cancer arising in the transition zone and in the peripheral zone of the prostate. *J Urol*. 1991;146(4):1069–1076.

Guo CC, Epstein JI. Intraductal carcinoma of the prostate on needle biopsy: histologic features and clinical significance. *Mod Pathol*. 2006;19(12):1528–1535.

Haffner MC, Weier C, Xu MM, et al. Molecular evidence that invasive adenocarcinoma can mimic prostatic intraepithelial neoplasia (PIN) and intraductal carcinoma through retrograde glandular colonization. *J Pathol*. 2016;238(1):31–41.

Häggman MJ, Macoska JA, Wojno KJ, et al. The relationship between prostatic intraepithelial neoplasia and prostate cancer: critical issues. *J Urol*. 1997;158(1):12–22.

Hall GS, Kramer CE, Epstein JI. Evaluation of radical prostatectomy specimens. A comparative analysis of sampling methods. *Am J Surg Pathol*. 1992;16(4):315–324.

Hansel DE, Epstein JI. Sarcomatoid carcinoma of the prostate: a study of 42 cases. *Am J Surg Pathol*. 2006;30(10):1316–1321.

Hansel DE, Herawi M, Montgomery E, et al. Spindle cell lesions of the adult prostate. *Mod Pathol*. 2007;20(1):148–158.

Harnden P, Shelley MD, Clements H, et al. The prognostic significance of perineural invasion in prostatic cancer biopsies: a systematic review. *Cancer*. 2007;109(1):13–24.

Herawi M, Epstein JI. Specialized stromal tumors of the prostate: a clinicopathologic study of 50 cases. *Am J Surg Pathol*. 2006;30(6):694–704.

Hernandez DJ, Nielsen ME, Han M, et al. Natural history of pathologically organ-confined (pT2), Gleason score 6 or less, prostate cancer after radical prostatectomy. *Urology*. 2008;72(1):172–176.

Hess KR, Varadhachary GR, Taylor SH, et al. Metastatic patterns in adenocarcinoma. *Cancer*. 2006;106(7):1624–1633.

Higgins JP, Kaygusuz G, Wang L, et al. Placental S100 (S100P) and GATA3: markers for transitional epithelium and urothelial carcinoma discovered by complementary DNA microarray. *Am J Surg Pathol*. 2007;31(5):673–680.

Huang JG, Pedersen J, Hong MK, et al. Presence or absence of a positive pathological margin outperforms any other margin-associated variable in predicting clinically relevant biochemical recurrence in Gleason 7 prostate cancer. *BJU Int*. 2013;111(6):921–927.

Iczkowski KA, MacLennan GT, Bostwick DG. Atypical small acinar proliferation suspicious for malignancy in prostate needle biopsies: clinical significance in 33 cases. *Am J Surg Pathol*. 1997;21(12):1489–1495.

Jang WS, Yoon CY, Kim MS, et al. The prognostic role of tertiary Gleason pattern 5 in a contemporary grading system for prostate cancer. *Prostate Cancer Prostatic Dis*. 2017;20(1):93–98.

Jiang Z, Woda BA, Wu CL, et al. Discovery and clinical application of a novel prostate cancer marker:alpha-methylacyl CoA racemase (P504S). *Am J Clin Pathol*. 2004;122(2):275–289.

Jiang Z, Li C, Fischer A, et al. Using an AMACR (P504S)/34betaE12/p63 cocktail for the detection of small focal prostate carcinoma in needle biopsy specimens. *Am J*

Clin Pathol. 2005;123(2):231–236.

Kates M, Sopko NA, Han M, et al. Importance of reporting the Gleason score at the positive surgical margin site: analysis of 4,082 consecutive radical prostatectomy cases. *J Urol*. 2016;195(2):337–342.

Khani F, Epstein JI. Prostate biopsy specimens with Gleason 3+3=6 and intraductal carcinoma: radical prostatectomy findings and clinical outcomes. *Am J Surg Pathol*. 2015;39(10):1383–1389.

Kheirandish P, Chinegwundoh F. Ethnic differences in prostate cancer. *Br J Cancer*. 2011;105(4):481–485.

Kim M, Choi SK, Park M, et al. Characteristics of anteriorly located prostate cancer and the usefulness of multiparametric magnetic resonance imaging for diagnosis. *J Urol*. 2016;196(2):367–373.

Kronz JD, Shaikh AA, Epstein JI. High-grade prostatic intraepithelial neoplasia with adjacent small atypical glands on prostate biopsy. *Hum Pathol*. 2001;32(4):389–395.

Lane Z, Epstein JI, Ayub S, et al. Prostatic adenocarcinoma in colorectal biopsy: clinical and pathologic features. *Hum Pathol*. 2008;39(4):543–549.

Leapman MS, Cowan JE, Simko J, et al. Application of a prognostic Gleason grade grouping system to assess distant prostate cancer outcomes. *Eur Urol*. 2017;71(5):750–759.

Lu J, Wirth GJ, Wu S, et al. A close surgical margin after radical prostatectomy is an independent predictor of recurrence. *J Urol*. 2012;188(1):91–97.

Magi-Galluzzi C, Sanderson H, Epstein JI. Atypia in nonneoplastic prostate glands after radiotherapy for prostate cancer: duration of atypia and relation to type of radiotherapy. *Am J Surg Pathol*. 2003;27(2):206–212.

Magi-Galluzzi C, Evans AJ, Delahunt B, et al. International Society of Urological Pathology (ISUP) Consensus

Conference on Handling and Staging of Radical Prostatectomy Specimens. Working group 3: extraprostatic extension, lymphovascular invasion and locally advanced disease. *Mod Pathol*. 2011;24(1):26–38.

Mahadevia PS, Koss LG, Tar IJ. Prostatic involvement in bladder cancer. Prostate mapping in 20 cystoprostatectomy specimens. *Cancer*. 1986;58(9):2096–2102.

Makarov DV, Trock BJ, Humphreys EB, et al. Updated nomogram to predict pathologic stage of prostate cancer given prostate-specific antigen level, clinical stage, and biopsy Gleason score (Partin tables) based on cases from 2000 to 2005. *Urology*. 2007;69(6):1095–1101.

Maubon T, Branger N, Bastide C, et al. Impact of the extent of extraprostatic extension defined by Epstein's method in patients with negative surgical margins and negative lymph node invasion. *Prostate Cancer Prostatic Dis*. 2016;19(3):317–321.

McNeal JE. Origin and development of carcinoma in the prostate. *Cancer*. 1969;23(1):24–34.

McNeal JE. Significance of duct-acinar dysplasia in prostatic carcinogenesis. *Urology*. 1989;34(6 Suppl):9–15.

McNeal JE, Bostwick DG. Intraductal dysplasia: a premalignant lesion of the prostate. *Hum Pathol*. 1986;17(1):64–71.

McNeal JE, Yemoto CE. Spread of adenocarcinoma within prostatic ducts and acini. Morphologic and clinical correlations. *Am J Surg Pathol*. 1996;20(7):802–814.

McNeal JE, Yemoto CE. Significance of demonstrable vascular space invasion for the progression of prostatic adenocarcinoma. *Am J Surg Pathol*. 1996;20(11):1351–1360.

McNeal JE, Bostwick DG, Kindrachuk RA, et al. Patterns of progression in prostate cancer. *Lancet*. 1986;1(8472):60–63.

McNeal JE, Villers AA, Redwine EA, et al. Histologic differentiation, cancer volume, and pelvic lymph node metastasis in adenocarcinoma of the prostate. *Cancer*. 1990;66(6):1225–1233.

McNeal JE, Villers A, Redwine EA, et al. Microcarcinoma in the prostate: its association with duct-acinar dysplasia. *Hum Pathol*. 1991;22(7):644–652.

Mellinger GT, Gleason D, Bailar J 3rd. The histology and prognosis of prostatic cancer. *J Urol*. 1967;97(2):331–337.

Merrimen JL, Jones G, Walker D, et al. Multifocal high grade prostatic intraepithelial neoplasia is a significant risk factor for prostatic adenocarcinoma. *J Urol*. 2009;182(2):485–490 [discussion 490].

Merrimen JL, Jones G, Srigley JR. Is high grade prostatic intraepithelial neoplasia still a risk factor for adenocarcinoma in the era of extended biopsy sampling? *Pathology*. 2010;42(4):325–329.

Miyai K, Divatia MK, Shen SS, et al. Heterogeneous clinicopathological features of intraductal carcinoma of the prostate: a comparison between “precursor-like” and “regular type” lesions. *Int J Clin Exp Pathol*. 2014;7(5):2518–2526.

Montgomery EA, Shuster DD, Burkart AL, et al. Inflammatory myofibroblastic tumors of the urinary tract: a clinicopathologic study of 46 cases, including a malignant example inflammatory fibrosarcoma and a subset associated with high-grade urothelial carcinoma. *Am J Surg Pathol*. 2006;30(12):1502–1512.

Murphy WM, Dean PJ, Brasfield JA, et al. Incidental carcinoma of the prostate. How much sampling is adequate? *Am J Surg Pathol*. 1986;10(3):170–174.

Newman AJ Jr, Graham MA, Carlton CE Jr, et al. Incidental carcinoma of the prostate at the time of transurethral resection: importance of evaluating every chip. *J Urol*. 1982;128(5):948–950.

Njinou Ngninkeu B, Lorge F, Moulin P, et al. Transitional cell carcinoma involving the prostate: a clinicopathological retrospective study of 76 cases. *J Urol*. 2003;169(1):149–152.

Novara G, Ficarra V, Mocellin S, et al. Systematic review and meta-analysis of studies reporting oncologic outcome after robot-assisted radical prostatectomy. *Eur Urol*. 2012;62(3):382–404.

Nunez Bragayrac LA, Murekeyisoni C, Vacchio MJ, et al. Blinded review of archival radical prostatectomy specimens supports that contemporary Gleason score 6 prostate cancer lacks metastatic potential. *Prostate*. 2017;77(10):1076–1081.

Ohori M, Scardino PT, Lapin SL, et al. The mechanisms and prognostic significance of seminal vesicle involvement by prostate cancer. *Am J Surg Pathol*. 1993;17(12):1252–1261.

Osunkoya AO, Nielsen ME, Epstein JI. Prognosis of mucinous adenocarcinoma of the prostate treated by radical prostatectomy: a study of 47 cases. *Am J Surg Pathol*. 2008;32(3):468–472.

Pacelli A, Bostwick DG. Clinical significance of high-grade prostatic intraepithelial neoplasia in transurethral resection specimens. *Urology*. 1997;50(3):355–359.

Pan CC, Potter SR, Partin AW, et al. The prognostic significance of tertiary Gleason patterns of higher grade in radical prostatectomy specimens: a proposal to modify the Gleason grading system. *Am J Surg Pathol*. 2000;24(4):563–569.

Parwani AV, Kronz JD, Genega EM, et al. Prostate carcinoma with squamous differentiation: an analysis of 33 cases. *Am J Surg Pathol*. 2004;28(5):651–657.

Perner S, Mosquera JM, Demichelis F, et al. TMPRSS2-ERG fusion prostate cancer: an early molecular event associated with invasion. *Am J Surg Pathol*. 2007;31(6):882–888.

Pierorazio PM, Ross AE, Schaeffer EM, et al. A contemporary analysis of outcomes of adenocarcinoma of the prostate with seminal vesicle invasion (pT3b) after radical prostatectomy. *J Urol*. 2011;185(5):1691–1697.

Pierorazio PM, Gorin MA, Ross AE, et al. Pathological and oncologic outcomes for men with positive lymph nodes at radical prostatectomy: the Johns Hopkins Hospital 30-year experience. *Prostate*. 2013;73(15):1673–1680.

Pierorazio PM, Walsh PC, Partin AW, et al. Prognostic Gleason grade grouping: data based on the modified Gleason scoring system. *BJU Int*. 2013;111(5):753–760.

Platz EA, Kulac I, Barber JR, et al. A prospective study of chronic inflammation in benign prostate tissue and risk of prostate cancer: linked PCPT and SELECT Cohorts. *Cancer Epidemiol Biomarkers Prev*. 2017;26(10):1549–1557.

Postma R, Schroder FH, van der Kwast TH. Atrophy in prostate needle biopsy cores and its relationship to prostate cancer incidence in screened men. *Urology*. 2005;65(4):745–749.

Ro JY, Grignon DJ, Ayala AG, et al. Mucinous adenocarcinoma of the prostate: histochemical and immunohistochemical studies. *Hum Pathol*. 1990;21(6):593–600.

Robinson B, Magi-Galluzzi C, Zhou M. Intraductal carcinoma of the prostate. *Arch Pathol Lab Med*. 2012;136(4):418–425.

Rohr LR. Incidental adenocarcinoma in transurethral resections of the prostate. Partial versus complete microscopic examination. *Am J Surg Pathol*. 1987;11(1):53–58.

Ronnett BM, Carmichael MJ, Carter HB, et al. Does high grade prostatic intraepithelial neoplasia result in elevated serum prostate specific antigen levels? *J Urol*. 1993;150(2 Pt 1):386–389.

Ross HM, Kryvenko ON, Cowan JE, et al. Do adenocarcinomas of the prostate with Gleason score (GS) ≤6 have the potential to metastasize to lymph nodes? *Am J Surg Pathol*. 2012;36(9):1346–1352.

Rubin MA, de La Taille A, Bagiella E, et al. Cribriform carcinoma of the prostate and cribriform prostatic intraepithelial neoplasia: incidence and clinical implications. *Am J Surg Pathol*. 1998;22(7):840–848.

Samaratunga H, Duffy D, Yaxley J, et al. Any proportion of ductal adenocarcinoma in radical prostatectomy specimens predicts extraprostatic extension. *Hum Pathol*. 2010;41(2):281–285.

Samaratunga H, Delahunt B, Srigley JR, et al. Mucinous adenocarcinoma of prostate and prostatic adenocarcinoma with mucinous components: a clinicopathological analysis of 143 cases. *Histopathology*. 2017;71(4):641–647.

Sauter G, Steurer S, Clauditz TS, et al. Clinical utility of quantitative Gleason grading in prostate biopsies and prostatectomy specimens. *Eur Urol*. 2016;69(4):592–598.

Sawczuk I, Tannenbaum M, Olsson CA, et al. Primary transitional cell carcinoma of prostatic periurethral ducts. *Urology*. 1985;25(4):339–343.

Schellhammer PF, Bean MA, Whitmore WF Jr. Prostatic involvement by transitional cell carcinoma: pathogenesis, patterns and prognosis. *J Urol*. 1977;118(3):399–403.

Schlomm T, Tennstedt P, Huxhold C, et al. Neurovascular structure-adjacent frozen-section examination (NeuroSAFE) increases nerve-sparing frequency and reduces positive surgical margins in open and robot-assisted laparoscopic radical prostatectomy: experience after 11,069 consecutive patients. *Eur Urol*. 2012;62(2):333–340.

Sehdev AE, Pan CC, Epstein JI. Comparative analysis of sampling methods for grossing radical prostatectomy specimens performed for nonpalpable (stage T1c) prostatic adenocarcinoma. *Hum Pathol*. 2001;32(5):494–499.

Seipel AH, Wiklund F, Wiklund NP, et al. Histopathological features of ductal adenocarcinoma of the prostate in 1,051 radical prostatectomy specimens. *Virchows Arch*.

2013;462(4):429–436.

Shah RB, Tadros Y, Brummell B, et al. The diagnostic use of ERG in resolving an “atypical glands suspicious for cancer” diagnosis in prostate biopsies beyond that provided by basal cell and alpha-methylacyl-CoA-racemase markers. *Hum Pathol*. 2013;44(5):786–794.

Sheridan TB, Carter HB, Wang W, et al. Change in prostate cancer grade over time in men followed expectantly for stage T1c disease. *J Urol*. 2008;179(3):901–904 [discussion 904–905].

Shikanov S, Song J, Royce C, et al. Length of positive surgical margin after radical prostatectomy as a predictor of biochemical recurrence. *J Urol*. 2009;182(1):139–144.

Smith DM, Murphy WM. Histologic changes in prostate carcinomas treated with leuprolide (luteinizing hormone-releasing hormone effect). Distinction from poor tumor differentiation. *Cancer*. 1994;73(5):1472–1477.

Srigley JR. Benign mimickers of prostatic adenocarcinoma. *Mod Pathol*. 2004;17(3):328–348.

Steinberg DM, Sauvageot J, Piantadosi S, et al. Correlation of prostate needle biopsy and radical prostatectomy Gleason grade in academic and community settings. *Am J Surg Pathol*. 1997;21(5):566–576.

Tavora F, Epstein JI. High-grade prostatic intraepithelial neoplasia-like ductal adenocarcinoma of the prostate: a clinicopathologic study of 28 cases. *Am J Surg Pathol*. 2008;32(7):1060–1067.

Tetu B, Ro JY, Ayala AG, et al. Small cell carcinoma of prostate associated with myasthenic (Eaton-Lambert) syndrome. *Urology*. 1989;33(2):148–152.

Tomlins SA, Palanisamy N, Siddiqui J, et al. Antibody-based detection of ERG rearrangements in prostate core biopsies, including diagnostically challenging cases: ERG staining in prostate core biopsies. *Arch Pathol Lab Med*. 2012;136(8):935–946.

Tosoian JJ, Alam R, Ball MW, et al. Managing high-grade prostatic intraepithelial neoplasia (HGPIN) and atypical glands on prostate biopsy. *Nat Rev Urol*. 2018;15(1):55–66.

Trock BJ, Guo CC, Gonzalgo ML, et al. Tertiary Gleason patterns and biochemical recurrence after prostatectomy: proposal for a modified Gleason scoring system. *J Urol*. 2009;182(4):1364–1370.

Truong M, Rais-Bahrami S, Nix JW, et al. Perineural invasion by prostate cancer on MR/US fusion targeted biopsy is associated with extraprostatic extension and early biochemical recurrence after radical prostatectomy. *Hum Pathol*. 2017;66:206–211.

van der Kwast TH, Amin MB, Billis A, et al. International Society of Urological Pathology (ISUP) Consensus Conference on Handling and Staging of Radical Prostatectomy Specimens. Working group 2: t2 substaging and prostate cancer volume. *Mod Pathol*. 2011;24(1):16–25.

van Oort IM, Bruins HM, Kiemeney LA, et al. The length of positive surgical margins correlates with biochemical recurrence after radical prostatectomy. *Histopathology*. 2010;56(4):464–471.

van Veggel BA, van Oort IM, Witjes JA, et al. Quantification of extraprostatic extension in prostate cancer: different parameters correlated to biochemical recurrence after radical prostatectomy. *Histopathology*. 2011;59(4):692–702.

Varkarakis MJ, Winterberger AR, Gaeta J, et al. Lung metastases in prostatic carcinoma. Clinical significance. *Urology*. 1974;3(4):447–452.

Villers A, McNeal JE, Redwine EA, et al. The role of perineural space invasion in the local spread of prostatic adenocarcinoma. *J Urol*. 1989;142(3):763–768.

Vollmer RT. Prostate cancer and chip specimens: complete versus partial sampling. *Hum Pathol*. 1986;17(3):285–290.

von Bodman C, Brock M, Roghmann F, et al. Intraoperative frozen section of the prostate decreases positive margin rate while ensuring nerve sparing procedure during radical prostatectomy. *J Urol*. 2013;190(2):515–520.

Wilcox G, Soh S, Chakraborty S, et al. Patterns of high-grade prostatic intraepithelial neoplasia associated with clinically aggressive prostate cancer. *Hum Pathol*. 1998;29(10):1119–1123.

Wojno KJ, Epstein JI. The utility of basal cell-specific anti-cytokeratin antibody (34 beta E12) in the diagnosis of prostate cancer. A review of 228 cases. *Am J Surg Pathol*. 1995;19(3):251–260.

Wood DP Jr, Montie JE, Pontes JE, et al. Transitional cell carcinoma of the prostate in cystoprostatectomy specimens removed for bladder cancer. *J Urol*. 1989;141(2):346–349.

Yoon GS, Wang W, Osunkoya AO, et al. Residual tumor potentially left behind after local ablation therapy in prostate adenocarcinoma. *J Urol*. 2008;179(6):2203–2206 [discussion 2206].

Diagnosis and Staging of Prostate Cancer

Stacy Loeb MD, MSc, James A. Eastham MD

Prostate cancer rarely causes symptoms at an early stage. The presence of symptoms suggests locally advanced or metastatic disease. Manifestations of locally advanced prostate cancer include obstructive urinary symptoms; ureteral obstruction causing renal failure, hematospermia or decreased ejaculate volume; and, rarely, impotence. Manifestations of metastatic disease include bone pain, pathologic fractures, anemia, and lower extremity edema; less common are malignant retroperitoneal fibrosis, paraneoplastic syndromes, disseminated intravascular coagulation (DIC), and paralysis. Locally advanced and metastatic disease are uncommon presentations because of widespread screening with prostate-specific antigen (PSA) testing and digital rectal examination (DRE). A histologic diagnosis of prostate cancer is typically made by prostate needle biopsy with guidance from ultrasound and/or magnetic resonance imaging (MRI) before any symptoms develop.

After a diagnosis of prostate cancer, the goal of staging is the accurate determination of disease extent and risk for management decisions and prognostication. In addition to PSA level and DRE, the pathologic features on prostate biopsy (grade and volume of cancer) help inform management decisions. Imaging studies also may be used during the staging process to evaluate the locoregional extent of disease and/or to rule out metastases.

This chapter reviews diagnostic and staging modalities for prostate cancer.

Diagnosis

Screening

General Concepts of Screening

Screening refers to testing for disease in healthy, asymptomatic populations, whereas *diagnosis* is the identification of disease among individuals with signs or symptoms. The principal goal of screening is to improve overall health outcomes by identifying and treating disease at an earlier stage. Despite the common misperception that early diagnosis through screening is invariably beneficial, it also has the potential for harm (Welch, 2004). Strong evidence indicates that prostate cancer screening reduces the rates of advanced disease at the time of diagnosis (Aus et al., 2007; van der Cruijsen-Koeter et al., 2006), and more recent data show that it also reduces prostate cancer mortality (Hugosson et al., 2010; Schröder et al., 2012), but controversy exists regarding the balance of benefit and harm (Barry, 2009; U.S. Preventive Services Task Force [USPSTF], 2008). The precise balance of benefits and harms is highly dependent on the patient's characteristics and preferences (Heijnsdijk et al., 2012).

During the PSA era, the mortality rate from prostate cancer has declined by more than 40% (Surveillance, Epidemiology, and End Results [SEER] program), along with a 75% reduction in the proportion of advanced-stage disease at diagnosis. It was estimated by mathematical modeling that PSA screening could have accounted for 45% to 70% of this reduction in prostate cancer mortality in the United States (Etzioni et al., 2008). However, randomized trials comparing the disease-specific outcomes of men who are screened and those who are not represent the highest level of evidence for screening.

Randomized Trials

The Prostate, Lung, Colon, and Ovary (PLCO) trial of the National Cancer Institute (NCI) and the European Randomized Trial of Prostate Cancer Screening (ERSPC) were initiated in 1993 to compare prostate cancer–specific mortality (primary end point) between men who were randomized to screening and those who were not (Andriole et al., 2004; Auvinen et al., 1996; de Koning et al., 2002; Schröder, 2003). Reductions in high-grade cancer and locally advanced/metastatic disease with serial screening were reported in the ERSPC

(Aus et al., 2007; van der Cruijsen-Koeter et al., 2006), and a 21% reduction in prostate cancer–specific mortality among those screened compared with controls at a median follow-up of 13 years (Schröder et al., 2014). However, in the ERSPC it was estimated that to prevent one prostate cancer death would require inviting for screening 781 men and diagnosing an additional 27 men at 13 years (Schröder et al., 2014). By comparison, there was no difference in prostate cancer mortality between the screened and control arms of the PLCO at a median follow-up of 13 years (Andriole et al., 2012). Further, the disparate findings between the studies may result from high rates of screening in the control arm of the PLCO before and during the trial (contamination) (Shoag et al., 2016) and lower power to detect a mortality difference given that the PLCO had approximately threefold fewer events than the ERSPC (Barry, 2009).

These randomized trials emphasize the potential for overdiagnosis (detection of cancers that would have otherwise remained undetected) and overtreatment of prostate cancer with screening. Overtreatment is especially concerning among older men (older than 65 years of age), for whom treatment was associated with minimal benefit in a randomized trial of surgery versus watchful waiting (Bill-Axelson et al., 2011). Given that the average age at diagnosis today is approximately 66 years, the risk for overtreatment is high (National Cancer Institute, 2016).

Specialty Group Recommendations

Professional groups have published statements and guidelines on prostate cancer screening (Lim et al., 2008; Lin et al., 2008; National Comprehensive Cancer Network, 2014; U.S. Preventive Services Task Force, 2008). In 2008, the USPSTF concluded that the evidence was insufficient to assess the balance of benefit and harm of screening among men 75 years of age or younger, whereas screening was not recommended for men 75 years of age or older. In 2011, the USPSTF issued a grade D draft recommendation against prostate cancer screening, which was finalized in 2012. In 2017, the USPSTF issued a revised recommendation (finalized in 2018) with a grade of “C” for PSA-based prostate cancer screening for men 55 to 69 years of age. They recommend shared decision making for men 55 to 69 years of age and do not recommend screening for men 70 years of age and older. The USPSTF notes that the increased use of active surveillance (observation with selective delayed treatment) for low-risk prostate cancer has reduced the risks associated with screening.

The American College of Preventive Medicine determined there is insufficient evidence to recommend routine population screening with PSA and DRE (Lim et al., 2008) and suggests that men should be given information about benefits and harms to make an informed decision. The American Cancer Society recommends that men with at least a 10-year life expectancy should have an opportunity to make an informed decision with their health care provider about prostate cancer screening beginning at 50 years of age for average-risk men and before 50 years of age for groups at higher risk (American Cancer Society, 2016). Previously, the American Urological Association (AUA) recommended annual prostate cancer screening beginning at 50 years of age for average-risk men and earlier for men at higher risk (positive family history or black race). In 2013 the AUA issued updated guidelines that recommend shared decision making about screening for men 55 to 69 years of age (American Urological Association, 2013a; reviewed and confirmed 2015). Based on the ERSPC, they suggest that a 2-year screening interval would preserve the benefits and reduce harms from screening. The National Comprehensive Cancer Network recommends starting a risk to benefit discussion and offering baseline PSA screening at 45 years of age with the frequency of follow-up testing based on PSA test results (1- to 4-year intervals). Similarly, the Memorial Sloan Kettering Cancer Center guidelines recommend performing a baseline PSA test between 45 and 49 years of age and using PSA levels to guide screening intervals (Memorial Sloan Kettering Cancer Center, 2013). The European Association of Urology also recommends a risk-adapted approach based on the initial PSA level for well-informed men with good performance status and a 10- to 15-year life expectancy (Heidenreich et al., 2013). For example, if the PSA level is greater than 1 ng/mL at 40 years of age or >2 ng/mL at 60 years of age, screening should be done at 2-year intervals, whereas longer intervals up to 8 years can be used for men with lower levels. Overall, the appropriate age to start and discontinue screening (Catalona et al., 2006; Ross et al., 2005; Schaeffer et al., 2009) and the appropriate interval between screens will continue to be a matter of debate as additional randomized trials to address these questions are logistically unlikely (Carter et al., 1997a; Hugosson et al., 2003b; Ross et al., 2000).

Despite the controversy associated with prostate cancer screening, opportunistic prostate cancer screening is highly prevalent in the United States (Chan et al., 2006; Lu-Yao et al., 2003; Ross et al., 2004; Schwartz et al., 2004; Sirovich et al., 2003; Walter et al., 2006). **Men who present for periodic health examinations should be made aware of the benefits and risks of PSA screening so that they can make an informed decision whether to be**

screened.

Diagnostic Modalities

Digital Rectal Examination

Before the availability of PSA testing, physicians relied solely on DRE for early detection of prostate cancer (Catalona et al., 1994b; Cooner et al., 1990; Ellis et al., 1994; Okotie et al., 2007; Schröder et al., 1998; Vis et al., 2001). DRE has only fair reproducibility in the hands of experienced examiners (Smith and Catalona, 1995) and misses a substantial proportion of early cancers (Catalona et al., 1994b; Cooner et al., 1990; Ellis et al., 1994). It has been suggested that the value of DRE for screening at PSA levels below 3.0 ng/mL is limited (Schröder et al., 1998; Vis et al., 2001). **Because of the risk for prostate cancer among men with abnormalities on DRE and the simplicity of the examination, most urologists use PSA and DRE together for prostate cancer detection.**

Further, **PSA testing improves the positive predictive value (PPV) of DRE for cancer** (Schröder et al., 1998). The PPV of DRE ranged from 4% to 11% in men with PSA levels of 0 to 2.9 ng/mL and from 33% to 83% in men with PSA levels of 3 to 9.9 ng/mL or greater (Schröder et al., 1998).

Overall, when DRE and PSA tests are used in prostate cancer screening, detection rates are higher with PSA testing than with DRE and highest with the tests together (Catalona et al., 1991). Because DRE and PSA tests do not always detect the same cancers (Okotie et al., 2007), the tests are complementary. In addition, many contemporary nomograms incorporate DRE findings to provide more personalized projections of prostate cancer risk (Thompson et al., 2006).

Prostate-Specific Antigen

PSA is a member of the human kallikrein gene family, is secreted in high concentrations (milligrams per milliliter) into seminal fluid, and circulates in bound (complexed) and unbound (free) forms that can be measured using assays approved by the U.S. Food and Drug Administration (FDA).

Factors Influencing Prostate-Specific Antigen.

Serum PSA levels vary with age, race, and prostate volume. African-Americans without prostate cancer have higher PSA values than whites (Fowler et al., 1999;

Morgan et al., 1996). PSA increases 4% per milliliter of prostate volume; and 30% and 5% of the variance in PSA levels can be accounted for by prostate volume and age, respectively (Oesterling et al., 1993).

PSA expression is strongly influenced by androgens (Henttu et al., 1992; Young et al., 1991). Serum PSA becomes detectable at puberty with increasing levels of luteinizing hormone and testosterone (Vieira et al., 1994). In hypogonadal men with low testosterone levels, serum PSA level may be low because of decreased expression and may not reflect the presence of prostate disease such as cancer (Morgentaler et al., 1996).

Metabolic factors can influence serum PSA levels. Obese men have slightly lower PSA levels than nonobese men (Baillargeon et al., 2005), possibly because of hemodilution (Bañez et al., 2007). Statin use may reduce PSA levels (Hamilton et al., 2008).

Another factor that can influence PSA levels includes the assay that is used in the measurement, potentially resulting in pseudo-acceleration or pseudo-deceleration if different assays are used for serial measurements (Loeb et al., 2008a). Recent studies have suggested that genetic factors may influence PSA levels and have raised the possibility of genetically adjusted PSA values in the future (Gudmundsson et al., 2010; Helfand et al., 2013).

Overall, the presence of prostate disease (prostate cancer, benign prostatic hyperplasia [BPH], and prostatitis) is the most important factor affecting serum PSA levels (Dalton, 1989; Ercole et al., 1987; Nadler et al., 1995; Wang et al., 1981). Although PSA elevations may indicate the presence of prostate disease, not all men with prostate disease have elevated PSA levels, and PSA elevations are not specific for cancer.

It is postulated that serum PSA elevations occur from disruption of the normal prostatic architecture, allowing PSA to gain access to the circulation. This can occur in the setting of prostate disease (BPH, prostatitis, prostate cancer) and with prostate manipulation (e.g., prostate massage, prostate biopsy, transurethral resection) (Klein and Lowe, 1997). Although DRE can lead to slight increases in serum PSA level, the resultant change in PSA values falls within the error of the assay and rarely causes false-positive test results (Crawford et al., 1992).

Studies examining the effect of ejaculation on serum PSA have reported conflicting results (Heidenreich et al., 1997; Herschman et al., 1997; Kirkali et al., 1995; Simak et al., 1993; Stenner et al., 1998; Tchetgen et al., 1996; Yavascaoglu et al., 1998). A repeat PSA test after 48 hours of sexual abstinence may be helpful for interpreting serum PSA levels that are minimally elevated.

Prostate-directed treatments (for BPH or prostate cancer) can lower serum PSA levels by decreasing the volume of prostatic epithelium available for PSA production and by decreasing the amount of PSA produced per cell (Shingleton et al., 2000).

5α-Reductase inhibitors that are used for BPH treatment have been shown to lower PSA levels, including both type 2 isoenzyme inhibitors (finasteride) and dual type 1 and 2 isoenzyme inhibitors (dutasteride) (Guess et al., 1993; Roehrborn et al., 2002). Finasteride 1 mg (Propecia) used for male pattern hair loss (androgenic alopecia) results in the same decline in serum PSA levels as the 5-mg dosage used for the treatment of BPH (D'Amico and Roehrborn, 2007).

Men initiating treatment with 5α-reductase inhibitors should first have a baseline PSA measurement and should be followed with serial measurements. Although the PSA level is often multiplied by 2 to estimate the “true” PSA level of a patient who has been taking a 5α-reductase inhibitor for 12 months or more (Andriole et al., 1998), the PSA response to finasteride treatment can be highly variable (Marks et al., 2006). It has been suggested that the PSA should instead be multiplied by a factor of 2.3 after 2 years and 2.5 after 7 years of treatment (Etzioni et al., 2005; Thompson et al., 2007; Walsh, 2008). Because this “moving target” can complicate the use of PSA levels in daily clinical practice, some have recommended using the PSA nadir on finasteride as the new baseline and performing a biopsy for subsequent PSA increases (Morgentaler, 2007).

Surgical therapy for BPH can lead to reductions in the serum PSA level (Shingleton et al., 2000) and “reset” the PSA baseline to a variable extent by removing the main contributor to PSA production (transition zone).

Finally, prostate cancer treatments (medical or surgical) such as manipulation of the hormonal axis (e.g., luteinizing hormone–releasing hormone agonists, orchiectomy), radiation therapy, radical prostatectomy, and other ablative techniques (e.g., cryotherapy) lead to reductions in PSA levels.

The interpretation of PSA values should always take into account age, the presence of urinary tract infection or prostate disease, recent diagnostic procedures, and prostate-directed treatments.

Clinical Use for Diagnosis.

The initial assays for PSA that were approved by the FDA in 1994 for early detection of prostate cancer detected both free PSA (fPSA) and PSA complexed (cPSA) to α_1-antichymotrypsin (ACT). Thus measurement of fPSA and cPSA by these assays is generally referred to as the serum PSA level (Smith et al., 1996).

Specific assays that detect fPSA alone and PSA complexed to ACT alone have been evaluated and approved for prostate cancer detection (see later discussion).

It is now well established that the use of PSA increases the detection of prostate cancers that are more likely to be organ-confined when compared with detection without PSA (Chodak et al., 1989; Hoedemaeker et al., 2000; Mueller et al., 1988; Rietbergen et al., 1999; Thompson et al., 1987). Observational studies and randomized trials have shown that both the future risk for prostate cancer and the chance of finding cancer on a prostate biopsy increase incrementally with the serum PSA level (Andriole et al., 2005; Brawer et al., 1992; Catalona et al., 1991, 1994a; Fang et al., 2001; Gann et al., 1995; Labrie et al., 1992; Lilja et al., 2007; Loeb et al., 2006; Thompson et al., 2004; Whittemore et al., 2005).

Gann et al. (1995) were first to demonstrate the association between the baseline PSA level and subsequent prostate cancer detection, which has been verified by others (Antenor et al., 2004; Fang et al., 2001; Loeb et al., 2006; Whittemore et al., 2005). A study from the Malmo Preventive Project confirmed that baseline PSA measurements in the 40s predict the risk for prostate cancer metastasis and death more than 25 years later (Vickers et al., 2013).

In addition to predicting future risk, PSA is directly associated with the present risk for prostate cancer. The probability of detecting prostate cancer on biopsy increases directly with PSA across the full spectrum of PSA levels (Table 152.1) (Thompson et al., 2004).

TABLE 152.1

Prostate Cancer Detection as a Function of Serum Prostate-Specific Antigen Level and Digital Rectal Examination Findings in Contemporary Series

PSA LEVEL (ng/ml)	DRE FINDINGS[a]	CANCER DETECTION RATE (%)[b]	CANCER YIELD ON BIOPSY (%)[c]	RATE OF HIGH-GRADE CANCER ON BIOPSY (%)[d]
0–1	–		8.8	0.9
1–2	–		17.0	2.0
0–2	–		12	1.4
		0.7	8	
2–4	–		15–25	5.2
		2	21	
4–10	+	11	17–32	4.1

		11–27	45–51	11.7
>10	–	41	43–65	19.4
	+	31–76	70–90	50.5
<4	–		15	2.3
	+	1–3	13–17	
>4	–	14	23–38	5.8
	+	14–38	55–63	20.6

[a] −, DRE nonsuspicious for cancer; +, DRE suspicious for cancer.

[b] Cancer detection rate is the number of cancers found in those screened (total number of detected cancers divided by total number of men screened).

[c] Cancer yield is the total number of cancers detected divided by the total number of men undergoing a biopsy. For digital rectal examination (DRE) (−) this indicates the positive predictive value of prostate-specific antigen (PSA) at a specified level when the DRE is not suspicious for cancer; for DRE (+) it is the positive predictive value of a suspicious DRE when the PSA is at a specified level.

[d] Gleason score of 7 or more.

Data from Crawford ED, DeAntoni EP, Etzioni R, et al. Serum prostate-specific antigen and digital rectal examination for early detection of prostate cancer in a national community-based program. The Prostate Cancer Education Council. *Urology* 47(6):863–869, 1996; Catalona WJ, Partin AW, Slawin KM, et al. Use of the percentage of free prostate-specific antigen to enhance differentiation of prostate cancer from benign prostatic disease: a prospective multicenter clinical trial. *JAMA* 279(19):1542–1547, 1998; Schröder FH, van der Maas P, Beemsterboer P, et al. Evaluation of the digital rectal examination as a screening test for prostate cancer. Rotterdam section of the European Randomized Study of Screening for Prostate Cancer. *J Natl Cancer Inst* 90(23):1817–1823, 1998; Thompson IM, Pauler DK, Goodman PJ, et al. Prevalence of prostate cancer among men with a prostate-specific antigen level < or =4.0 ng per milliliter. *N Engl J Med* 350(22):2239–2246, 2004; Andriole GL, Levin DL, Crawford ED, et al. Prostate cancer screening in the Prostate, Lung, Colorectal and Ovarian (PLCO) Cancer Screening Trial: findings from the initial screening round of a randomized trial. *J Natl Cancer Inst* 97(6):433–438, 2005.

In summary, **both PSA and DRE are used to assess prostate cancer risk in conjunction with other clinical factors.**

Triggers for Biopsy.

The choice of a PSA threshold for recommending a prostate biopsy is controversial (Carter, 2004; Catalona et al., 1994a; Gann et al., 1995; Nadler et al., 2005; Thompson et al., 2005) and has previously been reviewed (Schröder et al., 2008). Gann et al. (1995) pointed out that “dichotomization of PSA results into normal and abnormal obscures important information contained in levels below the usual cutoff.” Data from the Prostate Cancer Prevention Trial clearly show that the risk for prostate cancer is continuous as PSA increases (Thompson et al., 2005). Some investigators have recommended against referring to PSA as "elevated" or "abnormal."

The use of higher PSA thresholds risks missing important cancers during the window for cure, whereas the use of lower thresholds increases the proportion of unnecessary biopsies and overdiagnosis. Although PSA was initially approved using 4 ng/mL as the upper limit of normal, many clinicians subsequently adopted lower thresholds (2.5 to 3 ng/mL) to trigger a biopsy. In the ERSPC, most centers used a threshold of 3 ng/mL to trigger a prostate biopsy. However, a higher cutoff, such as 10 ng/mL, was recently suggested to reduce the potential harms for men older than 70 years of age (American Urological Association, 2013b).

A PSA level that is considered suspicious for prostate cancer should be remeasured before performing a prostate biopsy because of fluctuations in PSA levels that could create false-positive elevations (Eastham et al., 2003). However, according to the Choosing Wisely Campaign, empiric antibiotics should not be given to patients exclusively for an elevated PSA without any other urinary symptoms (American Urological Association, 2013b).

Numerous organizations now recommend using PSA together with other methods of risk assessment, such as family history, race, and DRE findings (Murphy et al., 2014).

Prostate-Specific Antigen Derivatives and Molecular Forms

Numerous variations on PSA-based screening have been proposed to improve test performance, including the adjustment of the PSA level for total prostate volume (PSA density [PSAD]) (Babaian et al., 1990; Bazinet et al., 1994; Benson et al., 1992a, 1992b; Catalona et al., 2000b; Djavan et al., 2002; Egawa et al., 2002; Gjengstø et al., 2005; Littrup et al., 1991; Naya et al., 2002; Rommel et al., 1994; Veneziano et al., 1990) or transition zone volume (Djavan et al., 1999; Gjengstø et al., 2005; Singh et al., 2004; Taneja et al., 2001) and the evaluation of rate of change in PSA (PSA velocity [PSAV]) (Berger et al., 2005, 2007; Carter et al., 1992b; D'Amico et al., 2004, 2005; Eggener et al., 2008; Fang et al., 2002; Fowler et al., 2000; Loeb et al., 2007a, 2008b; Roobol et al., 2004; Schröder et al., 2006; Smith and Catalona 1994). The discovery that PSA circulates in both bound (complexed) and unbound (free) forms and development of assays to measure these forms separately have resulted in investigation of their use for prostate cancer detection (Gretzer and Partin, 2003; Lilja, 1997, 2003; McCormack et al., 1995; Polascik et al., 1999), and this topic has been reviewed previously (Jansen et al., 2009).

Volume-Based Prostate-Specific Antigen Parameters.

Distinguishing between men with PSA elevations driven by BPH or cancer is difficult because PSA is not specific for cancer and the prevalence of BPH is high. Volume-based PSA parameters (with prostate volume typically determined by ultrasonography or more recently with magnetic resonance imaging) have been evaluated to reduce confounding from BPH. These include PSA divided by prostate volume (PSAD), complexed PSAD (cPSA divided by prostate volume), and PSA transition zone density (PSA divided by transition zone volume) (Babaian et al., 1990; Bazinet et al., 1994; Benson et al., 1992a, 1992b; Catalona et al., 2000b; Djavan et al., 1999, 2002; Gjengstø et al., 2005; Littrup et al., 1991; Naya et al., 2002; Rommel et al., 1994; Veneziano et al., 1990).

Benson et al. (1992a, 1992b) suggested that adjusting PSA for prostate size—by dividing PSA by prostate volume (PSAD)—could help distinguish between PSA elevations caused by BPH and those caused by prostate cancer. A direct relationship between PSAD and the chance of cancer has been documented (Bazinet et al., 1994; Rommel et al., 1994; Seaman et al., 1993), and a PSAD of 0.15 or greater was proposed for recommending prostate biopsy in men with PSA levels between 4 and 10 ng/mL and normal DRE (Bazinet et al., 1994; Seaman et al., 1993). The usefulness of PSAD in prostate cancer detection has not been confirmed in all studies (Cooner, 1994; Taneja et al., 2001). An advantage of PSAD is that it has been directly associated with prostate cancer aggressiveness (Carter et al., 2002; Kundu et al., 2007) and therefore is currently used to help assess eligibility for active surveillance among men with prostate cancer (Bul et al., 2013; Tseng et al., 2010). PSA has been adjusted for the transition zone volume (Kalish et al., 1994), the prostatic region that is the major determinant of serum PSA in men without prostate cancer (Lepor et al., 1994).

In general, although PSAD and its associated measures are imperfect predictors of cancer, they represent an additional method of risk assessment with potential utility for counseling men with intermediate PSA levels (4 to 10 ng/mL) regarding the need for prostate biopsy (Benson and Olsson, 1994) or repeat biopsy if PSA is persistently elevated (Keetch et al., 1996). PSAD is also used for risk stratification and to determine eligibility for active surveillance among men with newly diagnosed prostate cancer (Loeb et al., 2015).

Prostate-Specific Antigen Velocity.

Short-term fluctuations in PSA can occur between measurements in the presence or absence of prostate cancer, primarily as a result of physiologic variation

(Carter et al., 1992a, 1995; Eastham et al., 2003; Prestigiacomo and Stamey, 1996; Riehmann et al., 1993). However, the rate of change in PSA (PSAV)—PSA corrected for the elapsed time between measurements (Carter et al., 1992b)—is associated with the risk for prostate cancer (Berger et al., 2005, 2007; Carter et al., 1992b; D'Amico et al., 2004, 2005; Eggener et al., 2008; Loeb et al., 2007a, 2007b, 2008b; Roobol et al., 2004; Sengupta et al., 2005; Schröder et al., 2006; Smith and Catalona, 1994; Vickers et al., 2009). Using frozen sera to measure PSA years before diagnosis, Carter et al. (1992b) showed that a PSAV greater than 0.75 ng/mL/year was a specific marker for the presence of prostate cancer in men with PSA levels between 4 and 10 ng/mL. Other studies demonstrated that men with prostate cancer have more rapid rises in PSA levels than men without prostate cancer (Carter et al., 1995; Loeb et al., 2008c; Raaijmakers et al., 2004b; Smith and Catalona, 1994; Thompson et al., 2004). It was later shown that PSAV might also be useful for prostate cancer detection among men with PSA levels below 4.0 ng/mL (Carter et al., 2006; Loeb et al., 2007b). Some investigators have suggested the use of lower PSAV thresholds of 0.4 ng/mL/year for men with lower total PSA (tPSA) levels (Loeb et al., 2007b; Moul et al., 2007).

Some studies have failed to demonstrate the value of PSAV for prostate cancer prediction beyond that of a single PSA measurement (Roobol et al., 2004; Vickers et al., 2009). Differences among studies could be a result of the method used to calculate PSAV (Yu et al., 2006; Connolly et al., 2007) and the point in the PSA history at which PSAV is calculated (Carter et al., 1992b; D'Amico et al., 2004).

PSAV may play a role in the prediction of life-threatening prostate cancer (Carter et al., 2006; D'Amico et al., 2004, 2005). A PSAV value greater than 0.35 ng/mL/year 10 to 15 years before diagnosis was associated with a fivefold increased risk for life-threatening prostate cancer more than 1 decade later (Carter et al., 2006); a PSAV value greater than 2 ng/mL/year during the year before a prostate cancer diagnosis was associated with prostate cancer–specific mortality after radical prostatectomy or radiation therapy (D'Amico et al., 2004, 2005; Sengupta et al., 2005). A systematic review of studies up to 2007 suggested that PSAV before treatment provides no additional information regarding prostate cancer outcome when compared with PSA alone (Vickers et al., 2009). However, several large recent studies have shown that PSA kinetics enhance predictive value for overall and high-risk disease beyond tPSA level alone (Loeb et al., 2012; Wallner et al., 2013).

Free Prostate-Specific Antigen.

Men with prostate cancer generally have a greater fraction of serum cPSA—and therefore a lower percentage of tPSA circulating in the free (unbound) form—than men without prostate cancer (Catalona et al., 1995, 1998, 2000a; Christensson et al., 1993; Gann et al., 2002; Hugosson et al., 2003a; Keetch et al., 1997; Leinonen et al., 1993; Lilja, 1993; Pannek et al., 1998; Raaijmakers et al., 2004a; Roehl et al., 2002; Stenman et al., 1994; Woodrum et al., 1998). This difference is thought to be caused by differential expression of PSA isoforms by transition zone (zone of origin of BPH) tissue compared with peripheral zone tissue (where most prostate cancers arise) (Chen et al., 1997; Mikolajczyk et al., 1997, 2000a, 2000b).

fPSA levels vary directly by age and prostate volume and vary indirectly with the tPSA level (Woodrum et al., 1998). In addition, because assays differ in their ability to determine both fPSA and tPSA, results may differ depending on the assay or combination of assays used (Woodrum et al., 1998). The percentage of fPSA (%fPSA) does not appear to be significantly altered by race (Catalona et al., 2000a) or 5α-reductase inhibitors (Keetch et al., 1997; Pannek et al., 1998).

%fPSA has been shown to significantly improve the ability to distinguish between individuals with and without prostate cancer, compared with tPSA alone (Christensson et al., 1993). The %fPSA cutoff that optimizes sensitivity and specificity for cancer detection depends on prostate size because overlap is greatest among men with enlarged prostates with or without concomitant prostate cancer (Catalona et al., 1995).

%fPSA appears to be most useful in distinguishing between those with and without prostate cancer at intermediate tPSA levels. In men with PSA levels of 4 to 10 ng/mL and palpably benign prostate glands, a %fPSA cutoff of 25% detected 95% of cancers while avoiding 20% of unnecessary biopsies (Catalona et al., 1998). The value of %fPSA to predict prostate cancer at levels below 4.0 ng/mL is unclear (Gann et al., 2002; Hugosson et al., 2003a; Raaijmakers et al., 2004a; Roehl et al., 2002).

%fPSA (at a cutoff of 25%) and PSAD (using a threshold of 0.078) have been shown to have comparable specificity (at a sensitivity of 95%), whereas %fPSA does not require volume measurement (Catalona et al., 2000b). Thus %fPSA or PSAD can be used to counsel men with PSA elevations in the range 4 to 10 ng/mL regarding their risk for cancer.

Complexed Prostate-Specific Antigen.

Because men with prostate cancer have a greater fraction of tPSA that is complexed to proteins than men without prostate cancer, measurement of cPSA has been studied as a marker for detection (Brawer, 2002; Brawer et al., 2000; Okegawa et al., 2000; Parsons et al., 2004). When tPSA levels were between 4 and 10 ng/mL, cPSA provided improved specificity compared with tPSA and similar specificity compared with the percentage of fPSA at a sensitivity of 95% (Brawer et al., 2000), findings that were subsequently confirmed (Okegawa et al., 2000). Similar results were reported in the PSA range of 2.6 to 4.0 ng/mL (Parsons et al., 2004). **Overall, at a high sensitivity, cPSA provides higher specificity than tPSA and comparable specificity to %fPSA in prostate cancer detection.** A potential advantage of cPSA is the requirement for one assay.

Prostate-Specific Antigens Isoforms.

PSA is secreted from the prostatic luminal epithelium in a precursor form (pPSA or proPSA) (see Chapter 149) (Canto et al., 2004; Catalona et al., 2003, 2004; Gretzer and Partin, 2003; Khan et al., 2003; Lilja, 2003; Lein et al., 2005; Makarov et al., 2008; Mikolajczyk et al., 2001, 2004; Peter et al., 2001). Active fPSA can be further cleaved to benign PSA (bPSA) or intact PSA (iPSA) that is inactive and not complexed. Assays have been developed to measure these different isoforms.

The relative concentration of these isoforms differs in the presence of prostatic disease. bPSA is found preferentially in nodular BPH tissue from the transition zone and can be considered a marker for BPH (Canto et al., 2004; Mikolajczyk et al., 2000b), whereas a larger relative proportion of proPSA has been associated with prostate cancer (Mikolajczyk et al., 1997, 2000a, 2001; Peter et al., 2001). Large studies have suggested that proPSA may improve the identification of prostate cancer among men with PSA levels of 2 to 4 ng/mL (Catalona et al., 2003, 2004), 4 to 10 ng/mL (Khan et al., 2003; Mikolajczyk et al., 2004), and 2 to 10 ng/mL (Catalona et al., 2003), whereas other studies have not shown incremental predictive value of specific subtypes beyond %fPSA (Lein et al., 2005).

Human Kallikrein 2.

Human kallikrein 2 *(hK2)* is a closely related serine protease in the PSA/kallikrein gene family that also has been evaluated for prostate cancer detection (Bangma et al., 2004; Becker et al., 2000, 2003; Haese et al., 2003;

Kwiatkowski et al., 1998; Partin et al., 1999; Steuber et al., 2005; Vickers et al., 2008). Expression of *hK2* is higher in more poorly differentiated cancer tissues than in normal and benign tissues (Tremblay et al., 1997). Although some studies have suggested that the ratio of *hK2* and fPSA might improve the ability of PSA to identify men with prostate cancer (Becker et al., 2000; Kwiatkowski et al., 1998; Partin et al., 1999; Vickers et al., 2008), other analyses have not (Bangma et al., 2004; Becker et al., 2003). *hK2* does appear to correlate directly with grade and cancer volume and could be useful in patient assessment after diagnosis (Haese et al., 2003; Steuber et al., 2005).

Multiplex Tests.

The discovery of these different PSA isoforms led to the development of combination tests. The Beckman Coulter Prostate Health Index (phi) is an FDA-approved test that combines tPSA, fPSA, and [−2] proPSA using a mathematical formula. In prospective multicenter trials, the use of phi demonstrated improved predictive accuracy for prostate cancer detection and high-grade disease compared with either tPSA or %fPSA (Catalona et al., 2011; Guazzoni et al., 2011). A similar test—the 4 kallikrein score (4K)—also has been developed, combining tPSA, fPSA, iPSA, and hK2 (Vickers et al., 2011). The 4K score also has been shown to predict the likelihood of clinically significant prostate cancer (Carlsson et al., 2013; Parekh et al., 2015).

Other Markers

Prostate cancer gene 3 *(PCA3)* is a noncoding prostate-specific messenger RNA (mRNA) overexpressed in prostate cancer tissue compared with benign tissue (see Chapter 149) (Bussemakers et al., 1999; Deras et al., 2008; Haese et al., 2008; Marks et al., 2007; Nakanishi et al., 2008; Sokoll et al., 2008; van Gils et al., 2008; Whitman et al., 2008). Urine assays have been developed to measure *PCA3* mRNA (Sokoll et al., 2008), which is associated with the likelihood of a positive initial or repeat prostate biopsy (Deras et al., 2008; Haese et al., 2008; Marks et al., 2007). There are conflicting results on the association between *PCA3* and prostate cancer aggressiveness (Nakanishi et al., 2008; van Gils et al., 2008; Whitman et al., 2008).

Another urinary marker is the *TMPRSS2:ERG* gene fusion (Salagierski and Schalken, 2012). The concept of gene fusions has a long history in other forms of malignancy (e.g., *BCR-ABL* in leukemia), and previous studies suggested that *TMPRSS2:ERG* gene fusions had increased specificity for prostate cancer. As with *PCA3*, however, there is conflicting data on the association of *TMPRSS2:ERG* with prostate cancer aggressiveness. Several new urinary markers have recently become commercially available, including the MiPS test combining PCA3 with TMPRSS2:ERG, SelectMDx which calculates a risk score based on a two-gene mRNA urine assay, and the ExoDx exosomal RNA (exoRNA)-based assay (McKiernan et al., 2016; Tomlins et al., 2016; Van Neste et al., 2016).

For patients with an initial negative prostate biopsy but with persistent suspicion for prostate cancer, molecular changes in the benign biopsy tissue may signify an increased or decreased risk for finding cancer in a subsequent biopsy. Confirm MDx (MDxHealth, Irvine, CA), a multiplex DNA methylation test performed on benign biopsy tissue, can select men with a low likelihood of having cancer on repeat prostate biopsy (negative predictive value >90%) (Partin et al., 2014). Such testing may reduce the need for unwarranted repeat biopsy sessions.

Overall, in the future, it is likely that panels of serum, urinary, and/or tissue biomarkers will be used in combination with standard measures of risk (age, family history, race) and imaging (MRI) to selectively identify men who should undergo further evaluation for the presence of prostate cancer (Etzioni et al., 2003).

Staging

General Concepts of Staging

The clinical staging of prostate cancer uses pretreatment parameters to predict the extent of disease, both for assessment of prognosis and to inform decisions regarding appropriate treatment. Available pretreatment modalities used to predict disease extent in men with prostate cancer include DRE (clinical T stage), PSA and its derivatives, prostate cancer features on needle biopsy, and radiologic imaging. Pelvic lymph node biopsy is rarely performed before definitive therapy.

Clinical Versus Pathologic Staging

Clinical staging is the assessment of disease extent using pretreatment parameters (DRE, PSA values, needle biopsy findings, and radiologic imaging), whereas pathologic stage is determined after prostate removal and involves histologic analysis of the prostate, seminal vesicles, and pelvic lymph nodes if lymphadenectomy is performed. Pathologic staging more accurately estimates disease burden and is more useful than clinical staging for outcome prediction (Pound et al., 1997). Biochemical recurrence-free survival and cancer-specific survival are both inversely related to the pathologic stage of disease (Roehl et al., 2004). The most important pathologic criteria that predict prognosis after radical prostatectomy are tumor grade, surgical margin status, extracapsular disease, seminal vesicle invasion, and pelvic lymph node involvement (Epstein, 1990, Epstein et al., 1993a, 1993b; Jewett, 1975; Partin et al., 1993a; Pound et al., 1997; Walsh and Jewett, 1980).

Classifications

The Whitmore and Jewett staging system is now of historical interest (Jewett, 1956; Whitmore, 1956). Today, clinical staging is based on the tumor, node, metastasis (TNM) classification system (Table 152.2). This system was first adopted in 1975 by the American Joint Committee on Cancer (AJCC) and since has undergone numerous modifications (American Joint Committee on Cancer, 2010; Schröder et al., 1992). In the most recent version, the TNM stage is combined with PSA level and grade group 1 to 5 (representing Gleason scores of

≤6, 3+4, 4+3, 8, and 9–10) to classify newly diagnosed cases into prognostic stage groupings (Buyyounouski et al., 2017).

TABLE 152.2

1997 and 1992 TNM Clinical Staging Systems for Prostate Cancer

1997	**1992**	**DESCRIPTION**
TX	TX	Primary tumor cannot be assessed
T0	T0	No evidence of primary tumor
T1	T1	Nonpalpable tumor—not evident by imaging
T1a	T1a	Tumor found in tissue removed at TUR; ≤5% is cancerous and histologic grade <7
T1b	T1b	Tumor found in tissue removed at TUR; >5% is cancerous or histologic grade >7
T1c	T1c	Tumor identified by prostate needle biopsy as a result of elevation in PSA
T2	T2	Palpable tumor confined to the prostate
T2a		Tumor involves one lobe or less
	T2a	Tumor involves less than one-half of one lobe by normal tissue on all sides
T2b		Tumor involves more than one lobe
	T2b	Tumor involves more than one-half of one lobe but not both lobes
None	T2c	Tumor involves more than one lobe
T3	T3	Palpable tumor beyond prostate
T3a	T3a	Unilateral extracapsular extension
T3b	T3b	Bilateral extracapsular extension
T3c	T3c	Tumor invades seminal vesicle(s)
T4	T4	Tumor is fixed or invades adjacent structures (not seminal vesicles)
T4a	T4a	Tumor invades bladder neck, external sphincter, and/or rectum
T4b	T4b	Tumor invades levator muscle and/or is fixed to pelvic wall
N(+)	N(+)	Involvement of regional lymph nodes
NX	NX	Regional lymph nodes cannot be assessed
N0	N0	No lymph node metastases
N1	N1	Metastases in single regional lymph node, ≤2 cm in dimension
N2	N2	Metastases in single (>2 but ≤5 cm) or multiple with none >5 cm
N3	N3	Metastases in regional lymph node >5 cm in dimension
M(+)	M(+)	Distant metastatic spread
MX	MX	Distant metastases cannot be assessed
M0	M0	No evidence of distant metastases
M1	M1	Distant metastases
M1a	M1a	Involvement of nonregional lymph nodes

M1b	M1b	Involvement of bones
M1c	M1c	Involvement of other distant sites

PSA, Prostate-specific antigen; *TNM,* tumor, node, metastasis; *TUR,* transurethral resection.

Prediction of Tumor Extent

Prostate-Specific Antigen

Despite controversy over its correlation with prostate cancer volume (Stamey et al., 2004), PSA levels are associated directly with pathologic stage and tumor extent (Stamey et al., 1987, 1989). PSA values cannot be used alone to accurately predict disease extent for an individual patient because of significant overlap in PSA levels between stages, the variable contribution from BPH to PSA, and the fact that—on average—poorly differentiated tumors produce less PSA per gram of tumor (Partin et al., 1990). Despite these confounding factors, pathologically organ-confined disease is found in 80% of men with a PSA less than 4.0 ng/mL, 66% of those with PSA levels between 4.0 and 10.0 ng/mL, and fewer than 50% of men with PSA levels greater than 10.0 ng/mL (Catalona et al., 1997; Rietbergen et al., 1999). Also, 20% of men with PSA levels greater than 20 ng/mL and 75% of those with PSA levels greater than 50 ng/mL are found to have pelvic lymph node involvement.

In addition to the tPSA level, fPSA, hK2, proPSA, PSAD, PSAV, and the newer PSA-based marker tests (see earlier discussion) have been evaluated as predictors of prostate cancer grade and extent (Cantiello et al., 2015; Carter et al., 1997b, 2006, 2007; D'Amico et al., 2004, 2005; Kundu et al., 2007; Loeb et al., 2008d; Southwick et al., 1999). Although prostatic acid phosphatase has been associated with pathologic stage and progression after radical prostatectomy (Moul et al., 1998; Han et al., 2001), the closer relationship between PSA levels and disease extent has virtually eliminated the clinical use of this parameter (Heller, 1987).

Digital Rectal Examination

DRE is used to determine whether a lesion is palpable and is associated with local disease extent (clinical T stage). Also, an abnormal DRE was associated with an increased risk for detecting high-grade (Gleason 8 to 10) prostate cancer in a screened population (Gosselaar et al., 2008).

However, because of its poor sensitivity and lack of reproducibility, DRE can both overestimate and underestimate the extent of disease (Byar and Mostofi, 1972; Turner and Belt, 1957; Walsh and Jewett, 1980). In one series of 565 men with presumed organ-confined disease based on DRE, the sensitivity and specificity were 52% and 81%, respectively, for prediction of organ-confined disease (Partin et al., 1993b). Nevertheless, DRE can be used in combination with other parameters to help predict tumor extent.

Prostate Needle Biopsy

Histologic grade is the most important information obtained from prostate needle biopsy, and the Gleason grading system is the most commonly used (Gleason, 1966). At low-power magnification, the sum of a grade (1 to 5) assigned to the predominant pattern (occupying the largest area of the specimen) and the second most common pattern yield a score ranging from 2 to 10.

Contemporary studies have shown that tertiary Gleason patterns may affect prognosis (Patel et al., 2007), leading a 2005 consensus conference to recommend modification of the Gleason grading system (see Chapter 151). Accordingly, a biopsy Gleason score of 3+4 or 4+3 with a tertiary pattern 5 would be considered Gleason 3+5 or 4+5, respectively (Epstein et al., 2005).

Over the years, the Gleason grading system has undergone several changes. Currently, Gleason total scores 2 to 5 are no longer assigned, and in practice the lowest total score is now assigned a 6, although the scale continues to range from 2 to 10. This results in confusion for patients and may present a barrier to active surveillance for patients with Gleason 6 disease (Loeb et al., 2016). To address these issues, a new 5-grade group system has been developed (Pierorazio et al., 2013):

Grade Group 1 (Gleason score ≤6)
Grade Group 2 (Gleason score 3+4=7)
Grade Group 3 (Gleason score 4+3=7)
Grade Group 4 (Gleason score 4+4=8)
Grade Group 5 (Gleason scores 9 and 10)

The new system simplifies the grading of prostate cancer, appropriately classifies the lowest risk as Grade Group 1 (rather than Gleason score 6), and accurately predicts prognosis (Pierorazio et al., 2013).

Although a higher Gleason score/grade group is associated with a poorer prognosis, it is not used alone for risk prediction (Epstein et al., 1993a, 1993b; Partin et al., 1993a; Stein et al., 1991; Zincke et al., 1994). Other biopsy findings provide information regarding the extent of disease, including the number of positive cores, percentage of positive cores, and presence of perineural invasion. These features are associated with radical prostatectomy findings and have been used to guide the selection of candidates for active surveillance programs (Bismar et al., 2003; Carter et al., 2002; de la Taille et al., 1999a; Egan and Bostwick, 1997; O'Malley et al., 2002).

Findings of seminal vesicle invasion or involvement of the periprostatic fat on prostate needle biopsy are associated with poorer prognosis (Stone et al., 1998). Although some authors have recommended biopsy of the seminal vesicles and/or prostatic capsule to improve staging (Ravery et al., 1994; Stone et al., 1995, 1998; Terris et al., 1993; Vallancien et al., 1994), others suggest biopsy of these structures only when there is a large palpable tumor located at the base of the prostate (Guillonneau et al., 1997; Terris et al., 1997).

Combined Use of Pretreatment Parameters

Nomograms and algorithms have been developed to integrate multiple clinical parameters for improved staging. Considering the primary T stage based on DRE findings, serum PSA level, and Gleason score/grade group, these algorithms and nomograms have been shown to more accurately predict both cancer extent and long-term outcomes after treatment compared with any single parameter (Humphrey et al., 1991; Kleer and Oesterling, 1993; Kattan et al., 1998; Han et al., 2003; Kleer et al., 1993; Makarov et al., 2007; Partin et al., 1993b, 1997, 2001; Stephenson et al., 2006; Tosoian et al., 2017).

Several classification schemes have been proposed that correlate with clinical outcomes. D'Amico et al. (1998, 2001) demonstrated that stratification into low-risk (clinical stage T1 to 2a, PSA ≤10 ng/mL, and Gleason score ≤6), intermediate-risk (stage T2b or PSA >10 but <20 ng/mL or Gleason score 7), and high-risk (stage T2c, or PSA >20 ng/mL or Gleason score 8 to 10) disease was significantly associated with freedom from disease at 10 years after radical prostatectomy; 83% for low-risk, 46% for intermediate-risk, and 29% for high-risk disease. Other validated classification schemes have been developed since, including the Cancer of the Prostate Risk Assessment (CAPRA) score (Cooperberg et al., 2005, 2006; May et al., 2007). Pretreatment risk stratification using multiple parameters is useful for patient counseling.

Imaging

Numerous imaging modalities have been evaluated for staging prostate cancer. In the United States, radionuclide bone scan (bone scintigraphy) is the most commonly employed modality for the detection of skeletal metastases (Terris et al., 1991). Bone survey films (skeletal radiography) have lower sensitivity for the identification of distant spread and are typically used only to confirm a positive bone scan in men at low risk for bone metastases. Because bone metastases at diagnosis are uncommon in asymptomatic men in the PSA era, the routine use of bone scans in this population may lead to false-positive results, and unnecessary anxiety and cost (Chybowski et al., 1991). Accordingly, recent guidelines recommend the use of bone scans for patients with clinical stage T1 and a PSA level greater than 20 ng/mL, clinical stage T2 and a PSA level greater than 10 ng/mL, a Gleason score of 8 to 10 (Grade group 4-5), clinical stage T3 or T4, or clinical symptoms (National Comprehensive Cancer Network, 2017). The Choosing Wisely Campaign emphasizes that routine bone scans are not necessary for men with low-risk prostate cancer (American Urological Association, 2013b).

Similarly, cross-sectional imaging to evaluate for lymphadenopathy is recommended for high-risk patients, such as those with clinical stage T3 or greater disease or greater than 10% nomogram probability of lymph node metastases (National Comprehensive Cancer Network, 2017). Given the rarity of lymph node involvement in contemporary screened populations, it appears that imaging is being overused (Abraham et al., 2007; Cooperberg et al., 2002; Kindrick et al., 1998).

Although magnetic resonance imaging (MRI) has been evaluated for staging prostate cancer for many years (Kurhanewicz et al., 2000; Yu et al., 1999), the technology has recently improved dramatically. In particular, the addition of functional sequences such as diffusion-weighted MRI and dynamic contrast-enhanced MRI in conjunction with the conventional T2-weighted MRI has improved the ability of MRI to characterize the locoregional extent of disease. It is currently used at some institutions for pretreatment planning before definitive local therapy or to assess candidacy for active surveillance (Somford et al., 2013; Vargas et al., 2012). In addition, MRI images may be fused with transrectal ultrasound to enable targeted prostate biopsy (Siddiqui et al., 2015; Sonn et al., 2014). A consensus statement from the AUA and the Society of Abdominal Radiology recommended that when high-quality MRI is available, it should be strongly considered for men with a prior negative biopsy under consideration for repeat biopsy (Rosenkrantz et al., 2016). Patients with a suspicious lesion on MRI warrant repeat biopsy with image-guided targeting.

Specialized techniques such as high-resolution MRI used in tandem with the intravenous administration of lymphotropic superparamagnetic nanoparticles may allow the detection of small and otherwise undetectable lymph node metastases in patients with prostate cancer (Harisinghani et al., 2003). These techniques, however, require further clinical evaluation before widespread use.

Advances in ultrasound imaging are also being studied for improving prostate cancer detection (Purohit et al., 2003). Color ultrasonography with power Doppler to evaluate the blood flow within prostate vessels and three-dimensional Doppler using contrast agents could improve the visualization of more subtle tissue alterations caused by cancer. Another new ultrasound-based technique is HistoScanning (BK Medical, Peabody, MA), a computer-aided process to help characterize potentially suspicious tissue (Simmons et al., 2012). Additional large-scale studies of these techniques are necessary before widespread use can be recommended.

Finally, monoclonal antibody radioimmunoscintigraphy (radiolabeled monoclonal antibody scan) has been used for identification of microscopic cancer deposits in regional and distant sites. The ProstaScint scan (Cytogen, Princeton, NJ) uses this technology but has had limited accuracy in the detection of lymph node metastases because the antibody targets an intracellular epitope that is exposed only in dying or dead cells (Chang et al., 1999; Troyer et al., 1997). Future generations of this technology circumventing this limitation are under development.

Molecular Staging

Molecular staging has focused on the detection of circulating prostate cancer cells either directly through centrifugation/immunostaining methods or indirectly by identifying the genetic material for prostate-specific biomarkers (e.g., PSA, prostate-specific membrane antigen) from circulating prostate cells (Moreno et al., 1992; Ts'o et al., 1997). Although these polymerase chain reaction (PCR)-based assays have been associated with pathologic stage, sensitivity for detecting circulating cancer cells is variable across studies (Cama et al., 1995; de la Taille et al., 1999b; Israeli et al., 1995). With FDA approval of the semiautomated CellSearch system (Veridex, Janssen Diagnostics, Raritan, NJ) for monitoring metastatic breast and prostate cancer, considerable investigation is underway to determine whether circulating tumor cells have a role in the staging of early disease (Davis et al., 2008; Helo et al., 2009).

Several new tissue-based tests have been introduced that may improve prostate cancer risk stratification. The Prolaris test (Myriad Genetics, Salt Lake City, UT) measures a panel of cell cycle progression genes involved in the process of cancer proliferation (Cooperberg et al., 2013). The Oncotype DX Prostate Cancer Test (Genomic Health, Redwood City, CA) is a quantitative RT-PCR assay for 17 genes involved from five different pathways involved in prostate carcinogenesis (Knezevic et al., 2013). Finally, the Decipher test measures the expression levels of 22 RNA biomarkers involved in multiple biologic pathways (Klein et al., 2016). Preliminary studies of these tests suggest a potential ability to further refine classification schemes beyond the standard risk groups (Klein et al., 2014); however, further prospective validation studies are necessary to demonstrate whether these tests are cost-effective.

Pelvic Lymphadenectomy

The presence of lymph node metastasis in men diagnosed with clinically localized prostate cancer portends a poorer prognosis. Identification of patients harboring nodal metastases could have important implications for treatment selection. Although the prevalence of pelvic lymph node metastases correlates directly with T stage, serum PSA level, and biopsy grade, pelvic lymphadenectomy remains the most accurate way to detect occult nodal involvement (Parker et al., 1999).

PSA screening has resulted in a decline in the rates of metastases from 20% to 40% in the 1970s and 1980s to less than 4% today (National Cancer Institute, 2013; Parker et al., 1999; Partin et al., 1997). Currently, lymphadenectomy often is omitted before curative treatment (e.g., radical prostatectomy, radiation therapy) (Bishoff et al., 1995; Kawakami et al., 2006). Laparoscopic pelvic lymphadenectomy before treatment is typically reserved for patients with a Gleason score greater than 8, extraprostatic extension on DRE, PSA value greater than 20 ng/mL, or suspicion of enlarged lymph nodes on radiologic evaluation, and it is rarely performed in the contemporary PSA era.

Given the individual variation in prostatic lymphatic drainage patterns (Mattei et al., 2008), some investigators favor an extended pelvic lymphadenectomy in lieu of a limited dissection (Bader et al., 2002; Burkhard et al., 2006).

Considering the greater complication rates with a more extended pelvic lymph node dissection, risks may outweigh benefits for most men diagnosed with low-risk cancer today (Klein et al., 2008). Information regarding the therapeutic value of these strategies is confounded by stage migration and is difficult to evaluate without prospective trials.

Key Points: Diagnosis and Staging of Prostate Cancer

- Although the value of PSA screening remains controversial, men who present for periodic health examinations should be made aware of the availability of the PSA test so they can make an informed decision about screening.
- The combination PSA level, DRE, and other clinical factors (e.g., age, race, family history) can be used in combination to predict the risk that prostate cancer is present. The presence of prostate disease (prostate cancer, BPH, and prostatitis) is the most important factor affecting serum levels of PSA.
- PSA testing increases detection rates of prostate cancer and leads to the detection of prostate cancers that are more likely to be organ-confined when compared with detection without the use of PSA.
- The future risk for prostate cancer detection and the chance of finding cancer on a prostate biopsy increase incrementally with serum PSA level.
- Biochemical recurrence-free survival and cancer-specific survival are both inversely related to the pathologic stage of disease.
- Pathologic criteria that predict prognosis after radical prostatectomy are tumor grade, surgical margin status, presence of extracapsular disease, seminal vesicle invasion, and pelvic lymph node involvement.
- The Gleason grading system is the most commonly used classification scheme for the histologic grading of prostate cancer.

Suggested Readings

Andriole GL, Crawford ED, Grub RL, et al. Prostate cancer screening in the randomized Prostate, Lung, Colorectal, and Ovarian Cancer Screening Trial: mortality results after 13 years of follow-up. *J Natl Cancer Inst*. 2012;104(2):125–132.

Catalona WJ, Smith DS, Ratliff TL, et al. Measurement of prostate-specific antigen in serum as a screening test for prostate cancer. *N Engl J Med*. 1991;324(17):1156–1161.

Hugosson J, Carlsson S, Aus G, et al. Mortality results from the Goteborg randomised population-based prostate-cancer screening trial. *Lancet Oncol*. 2010;11(8):725–732.

Partin AW, Yoo J, Carter HB, et al. The use of prostate specific antigen, clinical stage and Gleason score to predict pathological stage in men with localized prostate cancer. *J Urol*. 1993;150(1):110–114.

Schröder FH, Hugosson J, Roobol MJ, et al. Screening and prostate cancer mortality: results of the European Randomised Study of Screening for Prostate Cancer (ERSPC) at 13 years of follow-up. *Lancet*. 2014;384(9959):2027–2035.

References

Abraham N, Wan F, Montagnet C, et al. Decrease in racial disparities in the staging evaluation for prostate cancer after publication of staging guidelines. *J Urol*. 2007;178(1):82–87 [discussion 87].

American Cancer Society. *Recommendations for prostate cancer early detection*. [Available at] https://www.cancer.org/cancer/prostate-cancer/early-detection/acs-recommendations.html; 2016.

American Joint Committee on Cancer. *Staging*. [Available at] https://cancerstaging.org/Pages/default.aspx.

American Urological Association. *Early detection of prostate cancer: American Urological Association guideline*. [Available at] https://www.auanet.org/guidelines/prostate-cancer-early-detection-guideline; 2013.

American Urological Association. *Choosing wisely*. [Available at] http://www.choosingwisely.org/doctor-patient-lists/american-urological-association/; 2013.

Andriole GL, Guess HA, Epstein JI, et al. Treatment with finasteride preserves usefulness of prostate-specific antigen in the detection of prostate cancer: results of a randomized, double-blind, placebo-controlled clinical trial. PLESS Study Group, Proscar Long-term Efficacy and Safety Study. *Urology*. 1998;52(2):195–201 [discussion 201–202].

Andriole GL, Reding D, Hayes RB, et al. The prostate, lung, colon, and ovarian (PLCO) cancer screening trial: status and promise. *Urol Oncol*. 2004;22(4):358–361.

Andriole GL, Levin DL, Crawford ED, et al. Prostate cancer screening in the Prostate, Lung, Colorectal and Ovarian (PLCO) Cancer Screening Trial: findings from the initial screening round of a randomized trial. *J Natl Cancer Inst*.

2005;97(6):433–438.

Andriole GL, Crawford ED, Grubb RL 3rd, et al. Prostate cancer screening in the randomized Prostate, Lung, Colorectal, and Ovarian Cancer Screening Trial: mortality results after 13 years of follow-up. *J Natl Cancer Inst*. 2012;104(2):125–132.

Antenor JA, Han M, Roehl KA, et al. Relationship between initial prostate specific antigen level and subsequent prostate cancer detection in a longitudinal screening study. *J Urol*. 2004;172(1):90–93.

Aus G, Bergdahl S, Lodding P, et al. Prostate cancer screening decreases the absolute risk of being diagnosed with advanced prostate cancer: results from a prospective, population-based randomized controlled trial. *Eur Urol*. 2007;51(3):659–664.

Auvinen A, Rietbergen JB, Denis LJ, et al. Prospective evaluation plan for randomised trials of prostate cancer screening. The International Prostate Cancer Screening Trial Evaluation Group. *J Med Screen*. 1996;3(2):97–104.

Babaian RJ, Fritsche HA, Evans RB. Prostate-specific antigen and prostate gland volume: correlation and clinical application. *J Clin Lab Anal*. 1990;4(2):135–137.

Bader P, Burkhard FC, Markwalder R, et al. Is a limited lymph node dissection an adequate staging procedure for prostate cancer? *J Urol*. 2002;168(2):514–518 [discussion 518].

Baillargeon J, Pollock BH, Kristal AR, et al. The association of body mass index and prostate-specific antigen in a population-based study. *Cancer*. 2005;103(5):1092–1095.

Bañez LL, Hamilton RJ, Partin AW, et al. Obesity-related plasma hemodilution and PSA concentration among men with prostate cancer. *JAMA*. 2007;298(19):2275–2280.

Bangma CH, Wildhagen MF, Yurdakul G, et al. The value of (-7, -5)pro-prostate-specific antigen and human kallikrein-2 as serum markers for grading prostate cancer. *BJU Int*.

2004;93(6):720–724.

Barry MJ. Screening for prostate cancer: the controversy that refuses to die. *N Engl J Med*. 2009;360(13):1351–1354.

Bazinet M, Meshref AW, Trudel C, et al. Prospective evaluation of prostate-specific antigen density and systematic biopsies for early detection of prostatic carcinoma. *Urology*. 1994;43(1):44–51 [discussion 51–52].

Becker C, Piironen T, Pettersson K, et al. Clinical value of human glandular kallikrein 2 and free and total prostate-specific antigen in serum from a population of men with prostate-specific antigen levels 3.0 ng/mL or greater. *Urology*. 2000;55(5):694–699.

Becker C, Piironen T, Pettersson K, et al. Testing in serum for human glandular kallikrein 2, and free and total prostate specific antigen in biannual screening for prostate cancer. *J Urol*. 2003;170(4 Pt 1):1169–1174.

Benson MC, Olsson CA. Prostate specific antigen and prostate specific antigen density: roles in patient evaluation and management. *Cancer*. 1994;74(6):1667–1673.

Benson MC, Whang IS, Olsson CA, et al. The use of prostate specific antigen density to enhance the predictive value of intermediate levels of serum prostate specific antigen. *J Urol*. 1992;147(3 Pt 2):817–821.

Benson MC, Whang IS, Pantuck A, et al. Prostate specific antigen density: a means of distinguishing benign prostatic hypertrophy and prostate cancer. *J Urol*. 1992;147(3 Pt 2):815–816.

Berger AP, Deibl M, Steiner H, et al. Longitudinal PSA changes in men with and without prostate cancer: assessment of prostate cancer risk. *Prostate*. 2005;64(3):240–245.

Berger AP, Deibl M, Strasak A, et al. Large-scale study of clinical impact of PSA velocity: long-term PSA kinetics as method of differentiating men with from those without prostate cancer. *Urology*. 2007;69(1):134–138.

Bill-Axelson A, Holmberg L, Ruutu M, et al. Radical prostatectomy versus watchful waiting in early prostate cancer. *N Engl J Med*. 2011;364(18):1708–1717.

Bishoff JT, Reyes A, Thompson IM, et al. Pelvic lymphadenectomy can be omitted in selected patients with carcinoma of the prostate: development of a system of patient selection. *Urology*. 1995;45(2):270–274.

Bismar TA, Lewis JS Jr, Vollmer RT, et al. Multiple measures of carcinoma extent versus perineural invasion in prostate needle biopsy tissue in prediction of pathologic stage in a screening population. *Am J Surg Pathol*. 2003;27(4):432–440.

Brawer MK. Clinical usefulness of assays for complexed prostate-specific antigen. *Urol Clin North Am*. 2002;29(1):193–203 [xi].

Brawer MK, Chetner MP, Beatie J, et al. Screening for prostatic carcinoma with prostate specific antigen. *J Urol*. 1992;147(3 Pt 2):841–845.

Brawer MK, Cheli CD, Neaman IE, et al. Complexed prostate specific antigen provides significant enhancement of specificity compared with total prostate specific antigen for detecting prostate cancer. *J Urol*. 2000;163(5):1476–1480.

Bul M, Zhu X, Valdagni R, et al. Active surveillance for low-risk prostate cancer worldwide: the PRIAS study. *Eur Urol*. 2013;63(4):597–603.

Burkhard FC, Schumacher MC, Studer UE, et al. An extended pelvic lymph-node dissection should be performed in most patients if radical prostatectomy is truly indicated. *Nat Clin Pract Urol*. 2006;3(9):454–455.

Bussemakers MJ, van Bokhoven A, Verhaegh GW, et al. DD3: a new prostate-specific gene, highly overexpressed in prostate cancer. *Cancer Res*. 1999;59(23):5975–5979.

Buyyounouski MK, Choyke PL, McKenney JK, et al. Prostate cancer—major changes in the American Joint Committee on Cancer eighth edition cancer staging manual. *CA Cancer J Clin*. 2017;67:245–253.

Byar DP, Mostofi FK. Carcinoma of the prostate: prognostic evaluation of certain pathologic features in 208 radical prostatectomies—examined by the step-section technique. *Cancer*. 1972;30(1):5–13.

Cama C, Olsson CA, Raffo AJ, et al. Molecular staging of prostate cancer. II. A comparison of the application of an enhanced reverse transcriptase polymerase chain reaction assay for prostate specific antigen versus prostate specific membrane antigen. *J Urol*. 1995;153(5):1373–1378.

Cantiello F, Russo GI, Ferro M, et al. Prognostic accuracy of Prostate Health Index and urinary Prostate Cancer Antigen 3 in predicting pathologic features after radical prostatectomy. *Urol Oncol*. 2015;33(4):163.e15–163.e23.

Canto EI, Singh H, Shariat H, et al. Serum BPSA outperforms both total PSA and free PSA as a predictor of prostatic enlargement in men without prostate cancer. *Urology*. 2004;63(5):905–910 [discussion 910–911].

Carlsson S, Maschino A, Schröder F, et al. Predictive value of four kallikrein markers for pathologically insignificant compared with aggressive prostate cancer in radical prostatectomy specimens: results from the European Randomized Study of Screening for Prostate Cancer section Rotterdam. *Eur Urol*. 2013;64(5):693–699.

Carter HB. Prostate cancers in men with low PSA levels: must we find them? *N Engl J Med*. 2004;350(22):2292–2294.

Carter HB, Morrell CH, Pearson JD, et al. Estimation of prostatic growth using serial prostate-specific antigen measurements in men with and without prostate disease. *Cancer Res*. 1992;52(12):3323–3328.

Carter HB, Pearson JD, Metter EJ, et al. Longitudinal evaluation of prostate-specific antigen levels in men with and without prostate disease. *JAMA*. 1992;267(16):2215–2220.

Carter HB, Pearson JD, Waclawiw Z, et al. Prostate-specific antigen variability in men without prostate cancer: effect of sampling interval on prostate-specific antigen velocity. *Urology*. 1995;45(4):591–596.

Carter HB, Epstein JI, Chan DW, et al. Recommended prostate-specific antigen testing intervals for the detection of curable prostate cancer. *JAMA*. 1997;277(18):1456–1460.

Carter HB, Partin AW, Luderer AA, et al. Percentage of free prostate-specific antigen in sera predicts aggressiveness of prostate cancer a decade before diagnosis. *Urology*. 1997;49(3):379–384.

Carter HB, Walsh PC, Landis P, et al. Expectant management of nonpalpable prostate cancer with curative intent: preliminary results. *J Urol*. 2002;167(3):1231–1234.

Carter HB, Ferrucci L, Kettermann A, et al. Detection of life-threatening prostate cancer with prostate-specific antigen velocity during a window of curability. *J Natl Cancer Inst*. 2006;98(21):1521–1527.

Carter HB, Kettermann A, Warlick C, et al. Expectant management of prostate cancer with curative intent: an update of the Johns Hopkins experience. *J Urol*. 2007;178(6):2359–2364 [discussion 2364–2365].

Catalona WJ, Smith DS, Ratliff TL, et al. Measurement of prostate-specific antigen in serum as a screening test for prostate cancer. *N Engl J Med*. 1991;324(17):1156–1161.

Catalona WJ, Hudson MA, Scardino PT, et al. Selection of optimal prostate specific antigen cutoffs for early detection of prostate cancer: receiver operating characteristic curves. *J Urol*. 1994;152(6 Pt 1):2037–2042.

Catalona WJ, Richie JP, Ahmann FR, et al. Comparison of digital rectal examination and serum prostate specific antigen in the early detection of prostate cancer: results of a multicenter clinical trial of 6,630 men. *J Urol*. 1994;151(5):1283–1290.

Catalona WJ, Smith DS, Wolfert RL, et al. Evaluation of percentage of free serum prostate-specific antigen to improve specificity of prostate cancer screening. *JAMA*. 1995;274(15):1214–1220.

Catalona WJ, Smith DS, Ornstein DK. Prostate cancer detection in men with serum PSA concentrations of 2.6 to 4.0 ng/mL and benign prostate examination: enhancement of specificity with free PSA measurements. *JAMA*. 1997;277(18):1452–1455.

Catalona WJ, Partin AW, Slawin KM, et al. Use of the percentage of free prostate-specific antigen to enhance differentiation of prostate cancer from benign prostatic disease: a prospective multicenter clinical trial. *JAMA*. 1998;279(19):1542–1547.

Catalona WJ, Partin AW, Slawin KM, et al. Percentage of free PSA in black versus white men for detection and staging of prostate cancer: a prospective multicenter clinical trial. *Urology*. 2000;55(3):372–376.

Catalona WJ, Southwick PC, Slawin KM, et al. Comparison of percent free PSA, PSA density, and age-specific PSA cutoffs for prostate cancer detection and staging. *Urology*. 2000;56(2):255–260.

Catalona WJ, Bartsch G, Rittenhouse HG, et al. Serum pro prostate specific antigen improves cancer detection compared to free and complexed prostate specific antigen in men with prostate specific antigen 2 to 4 ng/ml. *J Urol*. 2003;170(6 Pt 1):2181–2185.

Catalona WJ, Bartsch G, Rittenhouse HG, et al. Serum pro-prostate specific antigen preferentially detects aggressive prostate cancers in men with 2 to 4 ng/ml prostate specific antigen. *J Urol*. 2004;171(6 Pt 1):2239–2244.

Catalona WJ, Loeb S, Han M. Viewpoint: expanding prostate cancer screening. *Ann Intern Med*. 2006;144(6):441–443.

Catalona WJ, Partin AW, Sanda MG, et al. A multicenter study of [-2]pro-prostate specific antigen combined with prostate specific antigen and free prostate specific antigen for prostate cancer detection in the 2.0 to 10.0 ng/ml prostate specific antigen range. *J Urol*. 2011;185(5):1650–1655.

Chan EC, Barry MJ, Vernon SW, et al. Brief report: physicians and their personal prostate cancer-screening practices with prostate-specific antigen: a national survey. *J Gen Intern Med*. 2006;21(3):257–259.

Chang SS, Reuter VE, Heston WD, et al. Five different anti-prostate-specific membrane antigen (PSMA) antibodies confirm PSMA expression in tumor-associated neovasculature. *Cancer Res*. 1999;59(13):3192–3198.

Chen Z, Chen H, Stamey TA. Prostate specific antigen in benign prostatic hyperplasia: purification and characterization. *J Urol*. 1997;157(6):2166–2170.

Chodak GW, Keller P, Schoenberg HW. Assessment of screening for prostate cancer using the digital rectal examination. *J Urol*. 1989;141(5):1136–1138.

Christensson A, Björk T, Nilsson O, et al. Serum prostate specific antigen complexed to alpha 1-antichymotrypsin as an indicator of prostate cancer. *J Urol*. 1993;150(1):100–105.

Chybowski FM, Keller JJ, Bergstralh EJ, et al. Predicting radionuclide bone scan findings in patients with newly diagnosed, untreated prostate cancer: prostate specific antigen is superior to all other clinical parameters. *J Urol*. 1991;145(2):313–318.

Connolly D, Black A, Murray LJ, et al. Methods of calculating prostate-specific antigen velocity. *Eur Urol*.

2007;52(4):1044–1050.

Cooner WH, Mosley BR, Rutherford CL Jr, et al. Prostate cancer detection in a clinical urological practice by ultrasonography, digital rectal examination and prostate specific antigen. *J Urol*. 1990;143(6):1146–1152 [discussion 1152–1154].

Cooner WH. Prostate cancer. *J Urol*. 1994;151:103–104.

Cooperberg MR, Lubeck DP, Grossfield GD, et al. Contemporary trends in imaging test utilization for prostate cancer staging: data from the cancer of the prostate strategic urologic research endeavor. *J Urol*. 2002;168(2):491–495.

Cooperberg MR, Pasta DJ, Elkin EP, et al. The University of California, San Francisco Cancer of the Prostate Risk Assessment score: a straightforward and reliable preoperative predictor of disease recurrence after radical prostatectomy. *J Urol*. 2005;173(6):1938–1942.

Cooperberg MR, Freedland SJ, Pasta DJ, et al. Multiinstitutional validation of the UCSF cancer of the prostate risk assessment for prediction of recurrence after radical prostatectomy. *Cancer*. 2006;107(10):2384–2391.

Cooperberg MR, Simko JP, Cowen JE, et al. Validation of a cell-cycle progression gene panel to improve risk stratification in a contemporary prostatectomy cohort. *J Clin Oncol*. 2013;31(11):1428–1434.

Crawford ED, Schutz MJ, Clejan S, et al. The effect of digital rectal examination on prostate-specific antigen levels. *JAMA*. 1992;267(16):2227–2228.

Dalton DL. Elevated serum prostate-specific antigen due to acute bacterial prostatitis. *Urology*. 1989;33(6):465.

D'Amico A, Roehrborn CG. Effect of 1 mg/day finasteride on concentrations of serum prostate-specific antigen in men with androgenic alopecia: a randomised controlled trial. *Lancet Oncol*. 2007;8(1):21–25.

D'Amico AV, Whittington R, Malkowicz SB, et al. Biochemical outcome after radical prostatectomy, external beam radiation therapy, or interstitial radiation therapy for clinically localized prostate cancer. *JAMA*. 1998;280(11):969–974.

D'Amico AV, Whittington R, Malkowicz SB, et al. Predicting prostate specific antigen outcome preoperatively in the prostate specific antigen era. *J Urol*. 2001;166(6):2185–2188.

D'Amico A, Chen MH, Roehl KA, et al. Preoperative PSA velocity and the risk of death from prostate cancer after radical prostatectomy. *N Engl J Med*. 2004;351(2):125–135.

D'Amico AV, Renshaw AA, Sussman B, et al. Pretreatment PSA velocity and risk of death from prostate cancer following external beam radiation therapy. *JAMA*. 2005;294(4):440–447.

Davis JW, Nakanishi H, Kumar VS, et al. Circulating tumor cells in peripheral blood samples from patients with increased serum prostate specific antigen: initial results in early prostate cancer. *J Urol*. 2008;179(6):2187–2191 [discussion 2191].

de Koning HJ, Auvinen A, Berenquer Sanchez A, et al. Large-scale randomized prostate cancer screening trials: program performances in the European Randomized Screening for Prostate Cancer trial and the Prostate, Lung, Colorectal and Ovary Cancer Trial. *Int J Cancer*. 2002;97(2):237–244.

de la Taille A, Katz A, Bagiella E, et al. Perineural invasion on prostate needle biopsy: an independent predictor of final pathologic stage. *Urology*. 1999;54(6):1039–1043.

de la Taille A, Olsson CA, Katz AE. Molecular staging of prostate cancer: dream or reality? *Oncology (Williston Park)*. 1999;13(2):187–194 [discussion 194–198, 204–205 pas].

Deras IL, Aubin SM, Blase A, et al. PCA3: a molecular urine assay for predicting prostate biopsy outcome. *J Urol*. 2008;179(4):1587–1592.

Djavan B, Zlotta A, Kratzik C, et al. PSA, PSA density, PSA density of transition zone, free/total PSA ratio, and PSA velocity for early detection of prostate cancer in men with serum PSA 2.5 to 4.0 ng/mL. *Urology*. 1999;54(3):517–522.

Djavan B, Remzi M, Zlotta AR, et al. Complexed prostate-specific antigen, complexed prostate-specific antigen density of total and transition zone, complexed/total prostate-specific antigen ratio, free-to-total prostate-specific antigen ratio, density of total and transition zone prostate-specific antigen: results of the prospective multicenter European trial. *Urology*. 2002;60(4 Suppl 1):4–9.

Eastham JA, Riedel E, Scardino PT, et al. Variation of serum prostate-specific antigen levels: an evaluation of year-to-year fluctuations. *JAMA*. 2003;289(20):2695–2700.

Egan AJ, Bostwick DG. Prediction of extraprostatic extension of prostate cancer based on needle biopsy findings: perineural invasion lacks significance on multivariate analysis. *Am J Surg Pathol*. 1997;21(12):1496–1500.

Egawa S, Suyama K, Matsumoto K, et al. Prospective evaluation of prostate cancer detection by prostate specific antigen related parameters: comparison in serum and plasma samples. *J Urol*. 2002;167(1):97–102.

Eggener SE, Yossepowitch O, Roehl KA, et al. Relationship of prostate-specific antigen velocity to histologic findings in a prostate cancer screening program. *Urology*. 2008;71(6):1016–1019.

Ellis WJ, Chetner MP, Preston SD, et al. Diagnosis of prostatic carcinoma: the yield of serum prostate specific antigen, digital rectal examination and transrectal ultrasonography. *J Urol*. 1994;152(5 Pt 1):1520–1525.

Epstein JI. Evaluation of radical prostatectomy capsular margins of resection: the significance of margins designated as negative, closely approaching, and positive. *Am J Surg Pathol*. 1990;14(7):626–632.

Epstein JI, Carmichael MJ, Pizov G, et al. Influence of capsular penetration on progression following radical prostatectomy: a study of 196 cases with long-term followup. *J Urol*. 1993;150(1):135–141.

Epstein JI, Pizov G, Walsh PC, et al. Correlation of pathologic findings with progression after radical retropubic prostatectomy. *Cancer*. 1993;71:3582–3593.

Epstein JI, Allsbrook WC Jr, Amin MB, et al. The 2005 International Society of Urological Pathology (ISUP) Consensus Conference on Gleason grading of prostatic carcinoma. *Am J Surg Pathol*. 2005;29(9):1228–1242.

Ercole CJ, Lange PH, Mathisen M, et al. Prostatic specific antigen and prostatic acid phosphatase in the monitoring and staging of patients with prostatic cancer. *J Urol*. 1987;138(5):1181–1184.

Etzioni R, Kooperberg C, Pepe M, et al. Combining biomarkers to detect disease with application to prostate cancer. *Biostatistics*. 2003;4(4):523–538.

Etzioni RD, Howlader N, Shaw PA, et al. Long-term effects of finasteride on prostate specific antigen levels: results from the prostate cancer prevention trial. *J Urol*. 2005;174(3):877–881.

Etzioni R, Tsodikov A, Mariotti A, et al. Quantifying the role of PSA screening in the US prostate cancer mortality decline. *Cancer Causes Control*. 2008;19(2):175–181.

Fang J, Metter EJ, Landis P, et al. Low levels of prostate-specific antigen predict long-term risk of prostate cancer: results from the Baltimore Longitudinal Study of Aging. *Urology*. 2001;58(3):411–416.

Fang J, Metter EJ, Landis P, et al. PSA velocity for assessing prostate cancer risk in men with PSA levels between 2.0 and 4.0 ng/ml. *Urology*. 2002;59(6):889–893 [discussion 893–894].

Fowler JE Jr, Bigler SA, Kilambi NK, et al. Relationships between prostate-specific antigen and prostate volume in black and white men with benign prostate biopsies. *Urology*. 1999;53(6):1175–1178.

Fowler JE Jr, Bigler SA, Miles D, et al. Predictors of first repeat biopsy cancer detection with suspected local stage prostate cancer. *J Urol*. 2000;163(3):813–818.

Gann PH, Hennekens CH, Stampfer MJ, et al. A prospective evaluation of plasma prostate-specific antigen for detection of prostatic cancer. *JAMA*. 1995;273(4):289–294.

Gann PH, Ma J, Catalona WJ, et al. Strategies combining total and percent free prostate specific antigen for detecting prostate cancer: a prospective evaluation. *J Urol*. 2002;167(6):2427–2434.

Gjengstø P, Paus E, Halvorsen OJ, et al. Predictors of prostate cancer evaluated by receiver operating characteristics partial area index: a prospective institutional study. *J Urol*. 2005;173(2):425–428.

Gleason DF. Classification of prostatic carcinomas. *Cancer Chemother Rep*. 1966;50(3):125–128.

Gosselaar C, Roobol MJ, Roemeling S, et al. The role of the digital rectal examination in subsequent screening visits in the European Randomized Study of Screening for Prostate Cancer (ERSPC), Rotterdam. *Eur Urol*. 2008;54(3):581–588.

Gretzer MB, Partin AW. PSA markers in prostate cancer detection. *Urol Clin North Am*. 2003;30(4):677–686.

Guazzoni G, Nava L, Lazzeri M, et al. Prostate-specific antigen (PSA) isoform p2PSA significantly improves the prediction of prostate cancer at initial extended prostate biopsies in patients with total PSA between 2.0 and 10 ng/ml: results of a prospective study in a clinical setting. *Eur Urol*. 2011;60(2):214–222.

Gudmundsson J, Besenbacher S, Sulem P, et al. Genetic correction of PSA values using sequence variants associated with PSA levels. *Sci Transl Med*. 2010;2(62):62ra92.

Guess HA, Heyse JF, Gormley GJ, et al. Effect of finasteride on serum PSA concentration in men with benign prostatic hyperplasia: results from the North American phase III clinical trial. *Urol Clin North Am*. 1993;20(4):627–636.

Guillonneau B, Debras B, Veillon B, et al. Indications for preoperative seminal vesicle biopsies in staging of clinically localized prostatic cancer. *Eur Urol*. 1997;32(2):160–165.

Haese A, Graefen M, Becker C, et al. The role of human glandular kallikrein 2 for prediction of pathologically organ confined prostate cancer. *Prostate*. 2003;54(3):181–186.

Haese A, de la Taille A, van Poppel H, et al. Clinical utility of the PCA3 urine assay in European men scheduled for repeat biopsy. *Eur Urol*. 2008;54(5):1081–1088.

Hamilton RJ, Goldberg KC, Platz EA, et al. The influence of statin medications on prostate-specific antigen levels. *J Natl Cancer Inst*. 2008;100(21):1511–1518.

Han M, Piantadosi S, Zahurak M, et al. Serum acid phosphatase level and biochemical recurrence following radical prostatectomy for men with clinically localized prostate cancer. *Urology*. 2001;57(4):707–711.

Han M, Partin AW, Zahurak M, et al. Biochemical (prostate specific antigen) recurrence probability following radical prostatectomy for clinically localized prostate cancer. *J Urol*. 2003;169(2):517–523.

Harisinghani MG, Barentsz J, Hahn PF, et al. Noninvasive detection of clinically occult lymph-node metastases in prostate cancer. *N Engl J Med*. 2003;348(25):2491–2499.

Heidenreich A, Vorreuther R, Neubauer S, et al. The influence of ejaculation on serum levels of prostate specific antigen. *J Urol*. 1997;157(1):209–211.

Heidenreich A, Abrahamsson PA, Artibani W, et al. Early detection of prostate cancer: European Association of Urology recommendation. *Eur Urol*. 2013;64(3):347–354.

Heijnsdijk EA, Wever EM, Auvinen A, et al. Quality-of-life effects of prostate-specific antigen screening. *N Engl J Med*. 2012;367(7):595–605.

Helfand BT, Loeb S, Cooper PR, et al. Personalized prostate specific antigen testing using genetic variants may reduce unnecessary prostate biopsies. *J Urol*. 2013;189(5):1697–1701.

Heller JE. Prostatic acid phosphatase: its current clinical status. *J Urol*. 1987;137(6):1091–1103.

Helo P, Cronin AM, Danila DC, et al. Circulating prostate tumor cells detected by reverse transcription-PCR in men with localized or castration-refractory prostate cancer: concordance with CellSearch assay and association with bone metastases and with survival. *Clin Chem*. 2009;55(4):765–773.

Henttu P, Liao SS, Vikho P. Androgens up-regulate the human prostate-specific antigen messenger ribonucleic acid (mRNA), but down-regulate the prostatic acid phosphatase mRNA in the LNCaP cell line. *Endocrinology*. 1992;130(2):766–772.

Herschman JD, Smith DS, Catalona WJ. Effect of ejaculation on serum total and free prostate-specific antigen concentrations. *Urology*. 1997;50(2):239–243.

Hoedemaeker RF, Rietbergen JB, Kranse R, et al. Histopathological prostate cancer characteristics at radical prostatectomy after population based screening. *J Urol*. 2000;164(2):411–415.

Hugosson J, Aus G, Bergdhal S, et al. Population-based screening for prostate cancer by measuring free and total serum prostate-specific antigen in Sweden. *BJU Int*. 2003;92(Suppl 2):39–43.

Hugosson J, Aus G, Lilja H, et al. Prostate specific antigen based biennial screening is sufficient to detect almost all prostate cancers while still curable. *J Urol*. 2003;169(5):1720–1723.

Hugosson J, Carlsson S, Aus G, et al. Mortality results from the Goteborg randomised population-based prostate-cancer screening trial. *Lancet Oncol*. 2010;11(8):725–732.

Humphrey PA, Walther PJ, Currin SM, et al. Histologic grade, DNA ploidy, and intraglandular tumor extent as indicators of tumor progression of clinical stage B prostatic carcinoma: a direct comparison. *Am J Surg Pathol*. 1991;15(12):1165–1170.

Israeli RS, Miller WH Jr, Su SL, et al. Sensitive detection of prostatic hematogenous tumor cell dissemination using prostate specific antigen and prostate specific membrane-derived primers in the polymerase chain reaction. *J Urol*. 1995;153(3 Pt 1):573–577.

Jansen FH, Roobol M, Jenster G, et al. Screening for prostate cancer in 2008. II. The importance of molecular subforms of prostate-specific antigen and tissue kallikreins. *Eur Urol*. 2009;55(3):563–574.

Jewett HJ. Significance of the palpable prostatic nodule. *JAMA*. 1956;160(10):838–839.

Jewett HJ. The present status of radical prostatectomy for stages A and B prostatic cancer. *Urol Clin North Am*. 1975;2(1):105–124.

Kalish J, Cooner WH, Graham SD Jr. Serum PSA adjusted for volume of transition zone (PSAT) is more accurate than PSA adjusted for total gland volume (PSAD) in detecting adenocarcinoma of the prostate. *Urology*. 1994;43(5):601–606.

Kattan MW, Eastham JA, Stapleton AM, et al. A preoperative nomogram for disease recurrence following radical prostatectomy for prostate cancer. *J Natl Cancer Inst*. 1998;90(10):766–771.

Kawakami J, Meng MV, Sadetsky N, et al. Changing patterns of pelvic lymphadenectomy for prostate cancer: results from CaPSURE. *J Urol*. 2006;176(4 Pt 1):1382–1386.

Keetch DW, McMurtry JM, Smith DS, et al. Prostate specific antigen density versus prostate specific antigen slope as predictors of prostate cancer in men with initially negative prostatic biopsies. *J Urol*. 1996;156(2 Pt 1):428–431.

Keetch DW, Andriole GL, Ratliff TL, et al. Comparison of percent free prostate-specific antigen levels in men with benign prostatic hyperplasia treated with finasteride, terazosin, or watchful waiting. *Urology*. 1997;50(6):901–905.

Khan MA, Partin AW, Rittenhouse HG, et al. Evaluation of proprostate specific antigen for early detection of prostate cancer in men with a total prostate specific antigen range of 4.0 to 10.0 ng/ml. *J Urol*. 2003;170(3):723–726.

Kindrick AV, Grossfeld GD, Stier DM, et al. Use of imaging tests for staging newly diagnosed prostate cancer: trends from the CaPSURE database. *J Urol*. 1998;160(6 Pt 1):2102–2106.

Kirkali Z, Kirkali G, Esen A. Effect of ejaculation on prostate-specific antigen levels in normal men. *Eur Urol*. 1995;27(4):292–294.

Kleer E, Oesterling JE. PSA and staging of localized prostate cancer. *Urol Clin North Am*. 1993;20(4):695–704.

Kleer E, Larson-Keller JJ, Zincke H, et al. Ability of preoperative serum prostate-specific antigen value to predict pathologic stage and DNA ploidy: influence of clinical stage and tumor grade. *Urology*. 1993;41(3):207–216.

Klein LT, Lowe FC. The effects of prostatic manipulation on prostate-specific antigen levels. *Urol Clin North Am*. 1997;24(2):293–297.

Klein EA, Kattan M, Stephenson A, et al. How many lymphadenectomies does it take to cure one patient? *Eur Urol*. 2008;53(1):13–15 [discussion 18–20].

Klein EA, Cooperberg MR, Magi-Galluzzi C, et al. A 17-gene assay to predict prostate cancer aggressiveness in the context of Gleason grade heterogeneity, tumor multifocality, and biopsy undersampling. *Eur Urol*. 2014;66(3):550–560.

Klein EA, Haddad Z, Yousefi K, et al. Decipher genomic classifier measured on prostate biopsy predicts metastasis risk. *Urology*. 2016;90:148–152.

Knezevic D, Goddard AD, Natraj N, et al. Analytical validation of the Oncotype DX prostate cancer assay: a clinical RT-PCR assay optimized for prostate needle biopsies. *BMC Genomics*. 2013;14:690.

Kundu SD, Roehl KA, Yu X, et al. Prostate specific antigen density correlates with features of prostate cancer aggressiveness. *J Urol*. 2007;177(2):505–509.

Kurhanewicz J, Vigneron DB, Males RG, et al. The prostate: MR imaging and spectroscopy: present and future. *Radiol Clin North Am*. 2000;38(1):115–138 [viii–ix].

Kwiatkowski MK, Recker F, Piironen T, et al. In prostatism patients the ratio of human glandular kallikrein to free PSA improves the discrimination between prostate cancer and benign hyperplasia within the diagnostic “gray zone” of total PSA 4 to 10 ng/mL. *Urology*. 1998;52(3):360–365.

Labrie F, Dupont A, Suburu R, et al. Serum prostate specific antigen as pre-screening test for prostate cancer. *J Urol*. 1992;147(3 Pt 2):846–851 [discussion 851–852].

Lein M, Semjonow A, Graefen M, et al. A multicenter clinical trial on the use of (-5, -7) pro prostate specific antigen. *J Urol*. 2005;174(6):2150–2153.

Leinonen J, Lövgren T, Vornanen T, et al. Double-label time-resolved immunofluorometric assay of prostate-specific antigen and of its complex with alpha 1-antichymotrypsin.

Clin Chem. 1993;39(10):2098–2103.

Lepor H, Wang B, Shapiro E, et al. Relationship between prostatic epithelial volume and serum prostate-specific antigen levels. *Urology*. 1994;44(2):199–205.

Lilja H. Significance of different molecular forms of serum PSA: the free, noncomplexed form of PSA versus that complexed to alpha 1-antichymotrypsin. *Urol Clin North Am*. 1993;20(4):681–686.

Lilja H. Prostate-specific antigen: molecular forms and the human kallikrein gene family. *Br J Urol*. 1997;79(Suppl 1):44–48.

Lilja H. Biology of prostate-specific antigen. *Urology*. 2003;62(5 Suppl 1):27–33.

Lilja H, Ulmert D, Björk T, et al. Long-term prediction of prostate cancer up to 25 years before diagnosis of prostate cancer using prostate kallikreins measured at age 44 to 50 years. *J Clin Oncol*. 2007;25(4):431–436.

Lim LS, Sherin K, ACPM Prevention Practice Committee. Screening for prostate cancer in U.S. men ACPM position statement on preventive practice. *Am J Prev Med*. 2008;34(2):164–170.

Lin K, Lipsitz R, Miller T, et al. Benefits and harms of prostate-specific antigen screening for prostate cancer: an evidence update for the U.S. Preventive Services Task Force. *Ann Intern Med*. 2008;149(3):192–199.

Littrup PJ, Kane RA, William CR, et al. Determination of prostate volume with transrectal US for cancer screening. I. Comparison with prostate-specific antigen assays. *Radiology*. 1991;178(2):537–542.

Loeb S, Roehl KA, Antenor JA, et al. Baseline prostate-specific antigen compared with median prostate-specific antigen for age group as predictor of prostate cancer risk in men younger than 60 years old. *Urology*. 2006;67(2):316–320.

Loeb S, Roehl KA, Catalona WJ, et al. Prostate specific antigen velocity threshold for predicting prostate cancer in young men. *J Urol*. 2007;177(3):899–902.

Loeb S, Roehl KA, Nadler RB, et al. Prostate specific antigen velocity in men with total prostate specific antigen less than 4 ng/ml. *J Urol*. 2007;178(6):2348–2352 [discussion 2352–2353].

Loeb S, Chan DW, Sokoll L, et al. Prostate specific antigen assay standardization bias could affect clinical decision making. *J Urol*. 2008;180(5):1959–1962 [discussion 1962–1963].

Loeb S, Kettermann A, Ferrucci L, et al. PSA doubling time versus PSA velocity to predict high-risk prostate cancer: data from the Baltimore Longitudinal Study of Aging. *Eur Urol*. 2008;54(5):1073–1080.

Loeb S, Roehl KA, Catalona WJ, et al. Is the utility of prostate-specific antigen velocity for prostate cancer detection affected by age? *BJU Int*. 2008;101(7):817–821.

Loeb S, Sutherland DE, D'Amico AV, et al. PSA velocity is associated with Gleason score in radical prostatectomy specimen: marker for prostate cancer aggressiveness. *Urology*. 2008;72(5):1116–1120 [discussion 1120].

Loeb S, Metter EJ, Kan D, et al. Prostate-specific antigen velocity (PSAV) risk count improves the specificity of screening for clinically significant prostate cancer. *BJU Int*. 2012;109(4):508–513 [discussion 513–514].

Loeb S, Bruinsma SM, Nicholson J, et al. Active surveillance for prostate cancer: a systematic review of clinicopathologic variables and biomarkers for risk stratification. *Eur Urol*. 2015;67(4):619–626.

Loeb S, Curnyn C, Sedlander E. Perspectives of prostate cancer patients on Gleason scores and the new grade groups: initial qualitative study. *Eur Urol*. 2016;70(6):1083–1085.

Lu-Yao G, Stukel TA, Yao SL, et al. Prostate-specific antigen screening in elderly men. *J Natl Cancer Inst*. 2003;95(23):1792–1797.

Makarov DV, Trock BJ, Humphreys EB, et al. Updated nomogram to predict pathologic stage of prostate cancer given prostate-specific antigen level, clinical stage, and biopsy Gleason score (Partin tables) based on cases from 2000 to 2005. *Urology*. 2007;69(6):1095–1101.

Makarov DV, Loeb S, Getzenberg RH, et al. Biomarkers for prostate cancer. *Annu Rev Med*. 2008;60:139–151 [2009].

Marks LS, Andriole GL, Fitzpatrick JM, et al. The interpretation of serum prostate specific antigen in men receiving 5alpha-reductase inhibitors: a review and clinical recommendations. *J Urol*. 2006;176(3):868–874.

Marks LS, Fradet Y, Deras IL, et al. PCA3 molecular urine assay for prostate cancer in men undergoing repeat biopsy. *Urology*. 2007;69(3):532–535.

Mattei A, Fuechsel FG, Bhatta Dahr N, et al. The template of the primary lymphatic landing sites of the prostate should be revisited: results of a multimodality mapping study. *Eur Urol*. 2008;53(1):118–125.

May M, Knoll N, Sigmund M, et al. Validity of the CAPRA score to predict biochemical recurrence-free survival after radical prostatectomy: results from a European multicenter survey of 1,296 patients. *J Urol*. 2007;178(5):1957–1962 [discussion 1962].

McCormack RT, Rittenhouse HG, Finlay JA, et al. Molecular forms of prostate-specific antigen and the human kallikrein gene family: a new era. *Urology*. 1995;45(5):729–744.

McKiernan J, Donovan MJ, O'Neill V, et al. A novel urine exosome gene expression assay to predict high-grade prostate cancer at initial biopsy. *JAMA Oncol*. 2016;2(7):882–889.

Memorial Sloan Kettering Cancer Center. *Prostate cancer:*

screening guidelines. [Available at] http://www.mskcc.org/cancer-care/screening-guidelines/screening-guidelines-prostate; 2013.

Mikolajczyk SD, Grauer LS, Millar LS, et al. A precursor form of PSA (pPSA) is a component of the free PSA in prostate cancer serum. *Urology*. 1997;50(5):710–714.

Mikolajczyk SD, Millar LS, Wang T, et al. A precursor form of prostate-specific antigen is more highly elevated in prostate cancer compared with benign transition zone prostate tissue. *Cancer Res*. 2000;60(3):756–769.

Mikolajczyk SD, Millar LS, Wang TJ, et al. “BPSA,” a specific molecular form of free prostate-specific antigen, is found predominantly in the transition zone of patients with nodular benign prostatic hyperplasia. *Urology*. 2000;55(1):41–45.

Mikolajczyk SD, Marker KM, Millar AS, et al. A truncated precursor form of prostate-specific antigen is a more specific serum marker of prostate cancer. *Cancer Res*. 2001;61(18):6958–6963.

Mikolajczyk SD, Catalona WJ, Evans CL, et al. Proenzyme forms of prostate-specific antigen in serum improve the detection of prostate cancer. *Clin Chem*. 2004;50(6):1017–1125.

Moreno JG, Croce CM, Fischer R, et al. Detection of hematogenous micrometastasis in patients with prostate cancer. *Cancer Res*. 1992;52(21):6110–6112.

Morgan TO, Jacobsen SJ, McCarthy WF, et al. Age-specific reference ranges for prostate-specific antigen in black men. *N Engl J Med*. 1996;335(5):304–310.

Morgentaler A, Bruning CO 3rd, De Wolf WC, et al. Occult prostate cancer in men with low serum testosterone levels. *JAMA*. 1996;276(23):1904–1906.

Morgentaler A. Re: the interpretation of serum prostate specific antigen in men receiving 5alpha-reductase inhibitors: a review and clinical recommendations. *J Urol*. 2007;177(5):1954.

Moul JW, Connelly RR, Perahia B, et al. The contemporary value of pretreatment prostatic acid phosphatase to predict pathological stage and recurrence in radical prostatectomy cases. *J Urol*. 1998;159(3):935–940.

Moul JW, Sun L, Hotaling JM, et al. Age adjusted prostate specific antigen and prostate specific antigen velocity cut points in prostate cancer screening. *J Urol*. 2007;177(2):499–503 [discussion 503–504].

Mueller EJ, Crain TW, Thompson IM, et al. An evaluation of serial digital rectal examinations in screening for prostate cancer. *J Urol*. 1988;140(6):1445–1447.

Murphy DG, Ahlering T, Catalona WJ, et al. The Melbourne Consensus Statement on the early detection of prostate cancer. *BJU Int*. 2014;113(2):186–188.

Nadler RB, Humphrey PA, Smith DS, et al. Effect of inflammation and benign prostatic hyperplasia on elevated serum prostate specific antigen levels. *J Urol*. 1995;154(2 Pt 1):407–413.

Nadler RB, Loeb S, Roehl KA, et al. Use of 2.6 ng/ml prostate specific antigen prompt for biopsy in men older than 60 years. *J Urol*. 2005;174(6):2154–2157 [discussion 2157].

Nakanishi H, Groskopf J, Fritsche HA, et al. PCA3 molecular urine assay correlates with prostate cancer tumor volume: implication in selecting candidates for active surveillance. *J Urol*. 2008;179(5):1804–1809 [discussion 1809–1810].

National Cancer Institute. Surveillance, Epidemiology and End Results (SEER). Program. *Cancer Stat Facts: Prostate cancer*. [Available at] https://seer.cancer.gov/statfacts/html/prost.html; 2016.

[National Cancer Institute. Surveillance, Epidemiology and End Results (SEER). Program; Available at] http://www.seer.cancer.gov; 2013.

National Comprehensive Cancer Network. *2017 NCCN guidelines for treatment of prostate cancer*. [Available at] https://www.nccn.org/professionals/physician_gls/pdf/prostat 2017.

National Comprehensive Cancer Network. *National Comprehensive Cancer Network clinical practice guidelines in oncology: prostate cancer early detection*. [Available at] http://www.nccn.org/professionals/physician_gls/PDF/prostat 2014.

Naya Y, Stamey TA, Cheli CD, et al. Can volume measurement of the prostate enhance the performance of complexed prostate-specific antigen? *Urology*. 2002;60(4 Suppl 1):36–41.

Oesterling JE, Jacobsen SJ, Chute CG, et al. Serum prostate-specific antigen in a community-based population of healthy men: establishment of age-specific reference ranges. *JAMA*. 1993;270(7):860–864.

Okegawa T, Noda H, Nutahara K, et al. Comparison of two investigative assays for the complexed prostate-specific antigen in total prostate-specific antigen between 4.1 and 10.0 ng/mL. *Urology*. 2000;55(5):700–704.

Okotie OT, Roehl KA, Han M, et al. Characteristics of prostate cancer detected by digital rectal examination only. *Urology*. 2007;70(6):1117–1120.

O'Malley KJ, Pound CR, Walsh PC, et al. Influence of biopsy perineural invasion on long-term biochemical disease-free survival after radical prostatectomy. *Urology*. 2002;59(1):85–90.

Pannek J, Marks LS, Pearson JD, et al. Influence of finasteride on free and total serum prostate specific antigen levels in men with benign prostatic hyperplasia. *J Urol*. 1998;159(2):449–453.

Parekh DJ, Punnen S, Sjoberg DD, et al. A multi-institutional prospective trial in the USA confirms that the 4Kscore accurately identifies men with high-grade prostate cancer. *Eur Urol*. 2015;68(3):464–470.

Parker CC, Husband J, Dearnaley DP, et al. Lymph node staging in clinically localized prostate cancer. *Prostate Cancer Prostatic Dis*. 1999;2(4):191–199.

Parsons JK, Brawer MK, Cheli CD, et al. Complexed prostate specific antigen (PSA) reduces unnecessary prostate biopsies in the 2.6-4.0 ng/mL range of total PSA. *BJU Int*. 2004;94(1):47–50.

Partin AW, Carter HB, Chan DW, et al. Prostate specific antigen in the staging of localized prostate cancer: influence of tumor differentiation, tumor volume and benign hyperplasia. *J Urol*. 1990;143(4):747–752.

Partin AW, Pound CR, Clemens JQ, et al. Serum PSA after anatomic radical prostatectomy: the Johns Hopkins experience after 10 years. *Urol Clin North Am*. 1993;20(4):713–725.

Partin AW, Yoo J, Carter HB, et al. The use of prostate specific antigen, clinical stage and Gleason score to predict pathological stage in men with localized prostate cancer. *J Urol*. 1993;150(1):110–114.

Partin AW, Kattan MW, Subong EN, et al. Combination of prostate-specific antigen, clinical stage, and Gleason score to predict pathological stage of localized prostate cancer: a multi-institutional update. *JAMA*. 1997;277(18):1445–1451.

Partin AW, Catalona WJ, Finlay JA, et al. Use of human glandular kallikrein 2 for the detection of prostate cancer: preliminary analysis. *Urology*. 1999;54(5):839–845.

Partin AW, Mangold LA, Lamm DM, et al. Contemporary update of prostate cancer staging nomograms (Partin Tables) for the new millennium. *Urology*. 2001;58(6):843–848.

Partin AW, Van Neste L, Klein EA, et al. Clinical validation of an epigenetic assay to predict negative histopathological results in repeat prostate biopsies. *J Urol*. 2014;192(4):1081–1087.

Patel AA, Chen MH, Renshaw AA, et al. PSA failure following definitive treatment of prostate cancer having biopsy Gleason score 7 with tertiary grade 5. *JAMA*. 2007;298(13):1533–1538.

Peter J, Unverzagt C, Krogh TN, et al. Identification of precursor forms of free prostate-specific antigen in serum of prostate cancer patients by immunosorption and mass spectrometry. *Cancer Res*. 2001;61(3):957–962.

Pierorazio PM, Walsh PC, Partin AW, et al. Prognostic Gleason grade grouping: data based on the modified Gleason scoring system. *BJU Int*. 2013;111(5):753–760.

Polascik TJ, Oesterling JE, Partin AW. Prostate specific antigen: a decade of discovery: what we have learned and where we are going. *J Urol*. 1999;162(2):293–306.

Pound CR, Partin AW, Epstein JI, et al. Prostate-specific antigen after anatomic radical retropubic prostatectomy: patterns of recurrence and cancer control. *Urol Clin North Am*. 1997;24(2):395–406.

Prestigiacomo AF, Stamey TA. Physiological variation of serum prostate specific antigen in the 4.0 to 10.0 ng./ml. range in male volunteers. *J Urol*. 1996;155(6):1977–1980.

Purohit RS, Shinohara K, Meng MV, et al. Imaging clinically localized prostate cancer. *Urol Clin North Am*. 2003;30(2):279–293.

Raaijmakers R, Blijenberg BG, Finlay JA, et al. Prostate cancer detection in the prostate specific antigen range of 2.0 to 3.9 ng/ml: value of percent free prostate specific antigen on tumor detection and tumor aggressiveness. *J Urol*. 2004;171(6 Pt 1):2245–2249.

Raaijmakers R, Wildhagen MF, Ito K, et al. Prostate-specific antigen change in the European Randomized Study of Screening for Prostate Cancer, section Rotterdam. *Urology*. 2004;63(2):316–320.

Ravery V, Boccon-Gibod LA, Dauge-Geffroy MC, et al. Systematic biopsies accurately predict extracapsular extension of prostate cancer and persistent/recurrent detectable PSA after radical prostatectomy. *Urology*. 1994;44(3):371–376.

Riehmann M, Rhodes PR, Cook TD, et al. Analysis of variation in prostate-specific antigen values. *Urology*. 1993;42(4):390–397.

Rietbergen JB, Hoedemaeker RF, Kruger AE, et al. The changing pattern of prostate cancer at the time of diagnosis: characteristics of screen detected prostate cancer in a population based screening study. *J Urol*. 1999;161(4):1192–1198.

Roehl KA, Antenor JA, Catalona WJ. Robustness of free prostate specific antigen measurements to reduce unnecessary biopsies in the 2.6 to 4.0 ng./ml. range. *J Urol*. 2002;168(3):922–925.

Roehl KA, Han M, Ramos CG, et al. Cancer progression and survival rates following anatomical radical retropubic prostatectomy in 3,478 consecutive patients: long-term results. *J Urol*. 2004;172(3):910–914.

Roehrborn CG, Boyle P, Nickel JC, et al. Efficacy and safety of a dual inhibitor of 5-alpha-reductase types 1 and 2 (dutasteride) in men with benign prostatic hyperplasia. *Urology*. 2002;60(3):434–441.

Rommel FM, Agusta VE, Breslin JA, et al. The use of prostate specific antigen and prostate specific antigen density in the diagnosis of prostate cancer in a community based urology practice. *J Urol*. 1994;151(1):88–93.

Roobol MJ, Kranse R, de Koenig HJ, et al. Prostate-specific antigen velocity at low prostate-specific antigen levels as screening tool for prostate cancer: results of second screening round of ERSPC (ROTTERDAM). *Urology*. 2004;63(2):309–313 [discussion 313–315].

Rosenkrantz AB, Verma S, Choyke P, et al. Prostate magnetic resonance imaging and magnetic resonance imaging targeted biopsy in patients with a prior negative biopsy: a consensus statement by AUA and SAR. *J Urol*. 2016;196(6):1613–1618.

Ross KS, Carter HB, Pearson JD, et al. Comparative efficiency of prostate-specific antigen screening strategies for prostate cancer detection. *JAMA*. 2000;284(11):1399–1405.

Ross KS, Guess HA, Carter HB. Estimation of treatment benefits when PSA screening for prostate cancer is discontinued at different ages. *Urology*. 2005;66(5):1038–1042.

Ross LE, Coates RJ, Breen N, et al. Prostate-specific antigen test use reported in the 2000 National Health Interview Survey. *Prev Med*. 2004;38(6):732–744.

Salagierski M, Schalken JA. Molecular diagnosis of prostate cancer: PCA3 and TMPRSS2:ERG gene fusion. *J Urol*. 2012;187(3):795–801.

Schaeffer EM, Carter HB, Kettermann A, et al. Prostate specific antigen testing among the elderly: when to stop? *J Urol*. 2009;181(4):1606–1614.

Schröder FH, Hermanek P, Denis L, et al. The TNM classification of prostate cancer. *Prostate Suppl*. 1992;4:129–138.

Schröder FH, van der Maas P, Beemsterboer P, et al. Evaluation of the digital rectal examination as a screening test for prostate cancer. Rotterdam section of the European Randomized Study of Screening for Prostate Cancer. *J Natl*

Cancer Inst. 1998;90(23):1817–1823.

Schröder FH. Screening for prostate cancer. *Urol Clin North Am*. 2003;30(2):239–251 [viii].

Schröder FH, Roobol MJ, van der Kwast TH, et al. Does PSA velocity predict prostate cancer in pre-screened populations? *Eur Urol*. 2006;49(3):460–465 [discussion 465].

Schröder FH, Carter HB, Ketterman A, et al. Early detection of prostate cancer in 2007. I. PSA and PSA kinetics. *Eur Urol*. 2008;53(3):468–477.

Schröder FH, Hugosson J, Roobol MJ, et al. Prostate-cancer mortality at 11 years of follow-up. *N Engl J Med*. 2012;366(11):981–990.

Schröder FH, Hugosson J, Roobol MJ, et al. Screening and prostate cancer mortality: results of the European Randomised Study of Screening for Prostate Cancer (ERSPC) at 13 years of follow-up. *Lancet*. 2014;384(9959):2027–2035.

Schwartz LM, Woloshin S, Fowler FJ Jr, et al. Enthusiasm for cancer screening in the United States. *JAMA*. 2004;291(1):71–78.

Seaman E, Whang M, Olsson CA, et al. PSA density (PSAD). Role in patient evaluation and management. *Urol Clin North Am*. 1993;20(4):653–663.

Sengupta S, Myers RP, Slezak JM, et al. Preoperative prostate specific antigen doubling time and velocity are strong and independent predictors of outcomes following radical prostatectomy. *J Urol*. 2005;174(6):2191–2196.

Shingleton WB, Terrell F, Kolski J, et al. Prostate specific antigen measurements after minimally invasive surgery of the prostate in men with benign prostatic hypertrophy. *Prostate Cancer Prostatic Dis*. 2000;3(3):200–202.

Shoag JE, Mittal S, Hu JC. Reevaluating PSA testing rates in the PLCO trial. *N Engl J Med*. 2016;374(18):1795–1796.

Siddiqui MM, Rais-Bahrami S, Turkbey B, et al. Comparison of MR/ultrasound fusion-guided biopsy with ultrasound-guided biopsy for the diagnosis of prostate cancer. *JAMA*. 2015;313(4):390–397.

Simak R, Madersbacher S, Zhang ZF, et al. The impact of ejaculation on serum prostate specific antigen. *J Urol*. 1993;150(3):895–897.

Simmons LA, Autier P, Zatura F, et al. Detection, localisation and characterisation of prostate cancer by prostate HistoScanning. *BJU Int*. 2012;110(1):28–35.

Singh H, Canto EI, Shariat SF, et al. Predictors of prostate cancer after initial negative systematic 12 core biopsy. *J Urol*. 2004;171(5):1850–1854.

Sirovich BE, Schwartz LM, Woloshin S. Screening men for prostate and colorectal cancer in the United States: does practice reflect the evidence? *JAMA*. 2003;289(11):1414–1420.

Smith DS, Catalona WJ. Rate of change in serum prostate specific antigen levels as a method for prostate cancer detection. *J Urol*. 1994;152(4):1163–1167.

Smith DS, Catalona WJ. Interexaminer variability of digital rectal examination in detecting prostate cancer. *Urology*. 1995;45(1):70–74.

Smith DS, Catalona WJ, Herschman JD. Longitudinal screening for prostate cancer with prostate-specific antigen. *JAMA*. 1996;276(16):1309–1315.

Sokoll LJ, Ellis W, Lange P, et al. A multicenter evaluation of the PCA3 molecular urine test: pre-analytical effects, analytical performance, and diagnostic accuracy. *Clin Chim Acta*. 2008;389(1–2):1–6.

Somford DM, Hamoen EH, Fütterer JJ, et al. The predictive value of endorectal 3 Tesla multiparametric magnetic resonance imaging for extraprostatic extension in patients with low, intermediate and high risk prostate cancer. *J Urol*. 2013;190(5):1728–1734.

Sonn GA, Chang E, Natarajan S, et al. Value of targeted prostate biopsy using magnetic resonance-ultrasound fusion in men with prior negative biopsy and elevated prostate-specific antigen. *Eur Urol*. 2014;65:809–815.

Southwick PC, Catalona WJ, Partin AW, et al. Prediction of post-radical prostatectomy pathological outcome for stage T1c prostate cancer with percent free prostate specific antigen: a prospective multicenter clinical trial. *J Urol*. 1999;162(4):1346–1351.

Stamey TA, Yang N, Hay AR, et al. Prostate-specific antigen as a serum marker for adenocarcinoma of the prostate. *N Engl J Med*. 1987;317(15):909–916.

Stamey TA, Kabalin JN, Ferrari M. Prostate specific antigen in the diagnosis and treatment of adenocarcinoma of the prostate. III. Radiation treated patients. *J Urol*. 1989;141(5):1084–1087.

Stamey TA, Caldwell M, McNeal JE, et al. The prostate specific antigen era in the United States is over for prostate cancer: what happened in the last 20 years? *J Urol*. 2004;172(4 Pt 1):1297–1301.

Stein A, deKernion JB, Dorey F. Prostatic specific antigen related to clinical status 1 to 14 years after radical retropubic prostatectomy. *Br J Urol*. 1991;67(6):626–631.

Stenman UH, Hakama M, Knekt P, et al. Serum concentrations of prostate specific antigen and its complex with alpha 1-antichymotrypsin before diagnosis of prostate cancer. *Lancet*. 1994;344(8937):1594–1598.

Stenner J, Holthaus K, Mackenzie SH, et al. The effect of ejaculation on prostate-specific antigen in a prostate cancer-screening population. *Urology*. 1998;51(3):455–459.

Stephenson AJ, Scardino PT, Eastham JA, et al. Preoperative nomogram predicting the 10-year probability of prostate cancer recurrence after radical prostatectomy. *J Natl Cancer Inst*. 2006;98(10):715–717.

Steuber T, Niemela P, Haese A, et al. Association of free-prostate specific antigen subfractions and human glandular kallikrein 2 with volume of benign and malignant prostatic tissue. *Prostate*. 2005;63(1):13–18.

Stone NN, Stock RG, Unger P, et al. Indications for seminal vesicle biopsy and laparoscopic pelvic lymph node dissection in men with localized carcinoma of the prostate. *J Urol*. 1995;154(4):1392–1396.

Stone NN, Stock RG, Parikh D, et al. Perineural invasion and seminal vesicle involvement predict pelvic lymph node metastasis in men with localized carcinoma of the prostate. *J Urol*. 1998;160(5):1722–1726.

Taneja SS, Tran K, Lepor H. Volume-specific cutoffs are necessary for reproducible application of prostate-specific antigen density of the transition zone in prostate cancer detection. *Urology*. 2001;58(2):222–227.

Tchetgen MB, Song JT, Strawderman M, et al. Ejaculation increases the serum prostate-specific antigen concentration. *Urology*. 1996;47(4):511–516.

Terris MK, Klonecke AS, McDougall IR, et al. Utilization of bone scans in conjunction with prostate-specific antigen levels in the surveillance for recurrence of adenocarcinoma after radical prostatectomy. *J Nucl Med*. 1991;32(9):1713–1717.

Terris MK, McNeal JE, Freiha FS, et al. Efficacy of transrectal ultrasound-guided seminal vesicle biopsies in the detection of seminal vesicle invasion by prostate cancer. *J Urol*. 1993;149(5):1035–1039.

Terris MK, Pham TQ, Issa MM, et al. Routine transition zone and seminal vesicle biopsies in all patients undergoing transrectal ultrasound guided prostate biopsies are not indicated. *J Urol*. 1997;157(1):204–206.

Thompson IM, Rounder JB, Teague JL, et al. Impact of routine screening for adenocarcinoma of the prostate on stage distribution. *J Urol*. 1987;137(3):424–426.

Thompson IM, Pauler DK, Goodman PJ, et al. Prevalence of prostate cancer among men with a prostate-specific antigen level < or =4.0 ng per milliliter. *N Engl J Med*. 2004;350(22):2239–2246.

Thompson IM, Ankerst DP, Chi C, et al. Operating characteristics of prostate-specific antigen in men with an initial PSA level of 3.0 ng/ml or lower. *JAMA*. 2005;294(1):66–70.

Thompson IM, Ankerst DP, Chi C, et al. Assessing prostate cancer risk: results from the Prostate Cancer Prevention Trial. *J Natl Cancer Inst*. 2006;98(8):529–534.

Thompson IM, Pauler Ankerst D, Chi C, et al. Prediction of prostate cancer for patients receiving finasteride: results from the Prostate Cancer Prevention Trial. *J Clin Oncol*. 2007;25(21):3076–3081.

Tomlins SA, Day JR, Lonigro RJ, et al. Urine TMPRSS2:ERG plus PCA3 for individualized prostate cancer risk assessment. *Eur Urol*. 2016;70(1):45–53.

Tosoian JJ, Chappidi M, Feng Z, et al. Prediction of pathological stage based on clinical stage, serum prostate-specific antigen, and biopsy Gleason score: Partin tables in the contemporary era. *BJU Int*. 2017;119(5):676–683.

Tremblay RR, Deperthes D, Têtu B, et al. Immunohistochemical study suggesting a complementary role of kallikreins hK2 and hK3 (prostate-specific antigen) in the functional analysis of human prostate tumors. *Am J Pathol*. 1997;150(2):455–459.

Troyer JK, Beckett ML, Wright GL Jr. Location of prostate-specific membrane antigen in the LNCaP prostate carcinoma cell line. *Prostate*. 1997;30(4):232–242.

Tseng KS, Landis P, Epstein JI, et al. Risk stratification of men choosing surveillance for low risk prostate cancer. *J Urol*. 2010;183(5):1779–1785.

Ts'o PO, Pannek J, Wang ZP, et al. Detection of intact prostate cancer cells in the blood of men with prostate cancer. *Urology*. 1997;49(6):881–885.

Turner RD, Belt E. The results of 1,694 consecutive simple perineal prostatectomies. *J Urol*. 1957;77(6):853–863.

U.S. Preventive Services Task Force. Screening for prostate cancer: U.S. Preventive Services Task Force recommendation statement. *Ann Intern Med*. 2008;149(3):185–191.

Vallancien G, Bochereau G, Wetzel O, et al. Influence of preoperative positive seminal vesicle biopsy on the staging of prostatic cancer. *J Urol*. 1994;152(4):1152–1156.

van der Cruijsen-Koeter IW, Roobol MJ, Wildhagen MF, et al. Tumor characteristics and prognostic factors in two subsequent screening rounds with four-year interval within prostate cancer screening trial, ERSPC Rotterdam. *Urology*. 2006;68(3):615–620.

van Gils MP, Hessels D, Hulsbergen-van de Kaa CA, et al. Detailed analysis of histopathological parameters in radical prostatectomy specimens and PCA3 urine test results. *Prostate*. 2008;68(11):1215–1222.

Van Neste L, Hendriks RJ, Dijkstra S, et al. Detection of high-grade prostate cancer using a urinary molecular biomarker-based risk score. *Eur Urol*. 2016;70(5):740–748.

Vargas HA, Akin O, Afaq A, et al. Magnetic resonance imaging for predicting prostate biopsy findings in patients considered for active surveillance of clinically low risk prostate cancer. *J Urol*. 2012;188(5):1732–1738.

Veneziano S, Pavlica P, Querzé R, et al. Correlation between prostate-specific antigen and prostate volume, evaluated by transrectal ultrasonography: usefulness in diagnosis of prostate cancer. *Eur Urol*. 1990;18(2):112–116.

Vickers AJ, Cronin AM, Aus G, et al. A panel of kallikrein markers can reduce unnecessary biopsy for prostate cancer: data from the European Randomized Study of Prostate Cancer Screening in Goteborg, Sweden. *BMC Med*. 2008;6:19.

Vickers AJ, Savage G, O'Brien MF, et al. Systematic review of pretreatment prostate-specific antigen velocity and doubling time as predictors for prostate cancer. *J Clin Oncol*. 2009;27(3):398–403.

Vickers AJ, Gupta A, Savage C, et al. A panel of kallikrein marker predicts prostate cancer in a large, population-based cohort followed for 15 years without screening. *Cancer Epidemiol Biomarkers Prev*. 2011;20(2):255–261.

Vickers AJ, Ulmert D, Sjoberg DD, et al. Strategy for detection of prostate cancer based on relation between prostate specific antigen at age 40-55 and long term risk of metastasis: case-control study. *BMJ*. 2013;346:f2023.

Vieira JG, Nishida SK, Pereira AB, et al. Serum levels of prostate-specific antigen in normal boys throughout puberty. *J Clin Endocrinol Metab*. 1994;78(5):1185–1187.

Vis AN, Hoedemaeker RF, Roobol M, et al. Tumor characteristics in screening for prostate cancer with and without rectal examination as an initial screening test at low PSA (0.0-3.9 ng/ml). *Prostate*. 2001;47(4):252–261.

Wallner LP, Frencher SK, Hsu JW, et al. Changes in serum prostate-specific antigen levels and the identification of prostate cancer in a large managed care population. *BJU Int*. 2013;111(8):1245–1252.

Walsh PC, Jewett HJ. Radical surgery for prostatic cancer. *Cancer*. 1980;45(7 Suppl):1906–1911.

Walsh PC. Urological survey. *J Urol*. 2008;179:543.

Walter LC, Bertenthal D, Lindquist K, et al. PSA screening among elderly men with limited life expectancies. *JAMA*. 2006;296(19):2336–2342.

Wang MC, Papsidero LD, Kuriyama M, et al. Prostate antigen: a new potential marker for prostatic cancer. *Prostate*. 1981;2(1):89–96.

Welch HG. *Should I be tested for cancer?: maybe not and here's why*. University of California Press: Oakland, CA; 2004.

Whitman EJ, Groskopf J, Ali A, et al. PCA3 score before radical prostatectomy predicts extracapsular extension and tumor volume. *J Urol*. 2008;180(5):1975–1978 [discussion 1978–1979].

Whitmore WF Jr. Hormone therapy in prostatic cancer. *Am J Med*. 1956;21(5):697–713.

Whittemore AS, Cirillo PM, Feldman D, et al. Prostate specific antigen levels in young adulthood predict prostate cancer risk: results from a cohort of Black and White Americans. *J Urol*. 2005;174(3):872–876 [discussion 876].

Woodrum DL, Brawer MK, Partin AW, et al. Interpretation of free prostate specific antigen clinical research studies for the detection of prostate cancer. *J Urol*. 1998;159(1):5–12.

Yavascaoglu I, Savci V, Oktay B, et al. The effects of ejaculation on serum prostate-specific antigen (PSA). *Int Urol Nephrol*. 1998;30(1):53–58.

Young CY, Montgomery BT, Andrews PE, et al. Hormonal regulation of prostate-specific antigen messenger RNA in human prostatic adenocarcinoma cell line LNCaP. *Cancer Res*. 1991;51(14):3748–3752.

Yu KK, Scheidler J, Hricak H, et al. Prostate cancer: prediction of extracapsular extension with endorectal MR imaging and three-dimensional proton MR spectroscopic imaging. *Radiology*. 1999;213(2):481–488.

Yu X, Han M, Loeb S, et al. Comparison of methods for calculating prostate specific antigen velocity. *J Urol*. 2006;176(6 Pt 1):2427–2431 [discussion 2431].

Zincke H, Oesterling JE, Blut ML, et al. Long-term (15 years) results after radical prostatectomy for clinically localized (stage T2c or lower) prostate cancer. *J Urol*. 1994;152(5 Pt 2):1850–1857.

153

Active Management Strategies for Localized Prostate Cancer

Samir S. Taneja MD, Marc A. Bjurlin DO, MSc

The active management of clinically localized prostate cancer has evolved immensely over the past two decades because of an expanding knowledge of the disease and the inherent risks it presents to the individual patient. With the advent of prostate-specific antigen (PSA) testing and community-based screening in the early 1990s, a uniform approach to the disease emerged with radical treatment for most men, regardless of disease risk. The apparent benefit of such an approach was supported by an observed serially declining rate of prostate cancer mortality among American men over the ensuing decades (Schroder et al., 2014; Tsodikov et al., 2018).

As experience with treatment increased, a number of observations drew into question the idea of aggressively treating all men with prostate cancer. Studies of observation among men with low-risk prostate cancer demonstrated low rates of metastatic progression and prostate cancer death. Randomized studies of treatment versus observation failed to demonstrate a reduction in prostate cancer mortality, largely because of a high rate of death from other causes during the early follow-up period (Wilt et al., 2012). Large randomized studies of PSA screening failed to demonstrate robust declines in prostate cancer mortality for all patients, despite prolonged follow-up (Andriole et al., 2009, 2012). Collectively, these observations drew harsh criticism for the practice of aggressive detection and treatment of prostate cancer.

Although it is clear that aggressive prostate cancer treatment does not benefit all men with prostate cancer, a number of men diagnosed with early stage disease remain at significant risk of prostate cancer mortality within their lifetime. As such, the contemporary approach to localized prostate cancer is highly individualized with careful assessment of longevity, disease aggressiveness and extent, and patient goals. **Current active management of prostate cancer requires an individualized assessment of the risk of prostate**

cancer mortality relative to other competing risks for death over time. For those men who are thought more likely to die of competing risks than prostate cancer, observation is a reasonable choice. For those men with good longevity, in whom it is not clear that treatment will be likely to improve longevity, active surveillance has emerged as a rational means of deferring therapy until more clear evidence emerges for need of therapy. Among those men deemed to be in need of therapy, a number of treatment options exist, including radical prostatectomy, externally delivered radiation therapy, interstitial radiation, and thermal ablative therapies for whole or partial gland ablation. **Selection of the appropriate therapeutic modality requires careful counseling regarding the risks and benefits, recognition of host factors influencing the risks and benefits of therapy, and patient preference.** The active management of localized prostate cancer requires careful evaluation of the host, cancer risk assessment, and patient counseling to include comparative data and detailed discussion of individual treatment options.

Host Evaluation

Longevity Assessment and Competing Risks for Mortality

The value of prostate cancer treatment has, in recent years, been considered in the context of life expectancy and risk of death from other causes. Such considerations are rooted in the observation of large trials assessing the efficacy of prostate cancer therapy in which high rates of death from competing causes dilute the survival benefits of treatment (Daskivich et al., 2015; Wilt et al., 2017). The National Comprehensive Cancer Network (NCCN) stresses that "Life expectancy estimation is critical to informed decision-making in prostate cancer early detection and treatment." Several randomized clinical trials have suggested that the risk of death from other causes exceeds the risk of death from prostate cancer (Bill-Axelson et al., 2014; Wilt et al., 2012). From data collected in the Prostate Cancer Outcomes Study, a US prospective cohort of men with localized prostate cancer, the risk of death from other causes can be modeled as a function of comorbidity and age (Daskivich et al., 2011b). The 10-year risk of death from prostate cancer ranged from 3% to 18% depending on the risk category, whereas men with any comorbidity had a 10-year mortality rate from other causes of 33% or higher (Daskivich et al., 2011b). Although conventional wisdom has resulted in the general dogma that men should have a perceived good likelihood of 10-year longevity to benefit from therapy, in practice broad application of this simple rule has resulted in lower rates of treatment among young men, and, perhaps, overtreatment in younger men. **In best practice, decisions regarding the benefit of treatment should be rooted in an individualized assessment that includes age, comorbidities, and risk of cancer mortality.**

The NCCN has recommended use of the Social Security Administration Tables or the World Health Organization's Life Tables in estimating longevity, but other tools have developed more specifically for assessment of men with prostate cancer (Daskivich et al., 2011a, 2015). In these models, the relationship of age and comorbidity becomes a critical component in applying longevity estimates at the time of diagnosis. Longevity assessment in the prostate cancer patient is an indirect measure of comorbidity and competing risks for mortality. Such risks influence not only the decision whether the patient should undergo therapy but also the type of treatment to be considered. In the case of significant cardiac, pulmonary, or hematologic comorbidity, reasonable longevity and estimated benefit for treatment may be preserved, but surgery, as an example, may be contraindicated because of anesthesia or bleeding risks. The most widely used scale of comorbidity is the Charlson Co-morbidity Index (CCI). The CCI was designed to weigh comorbidities in prediction of 1-year mortality among inpatients (Charlson et al., 1987) but ultimately has been identified as a significant prognostic indicator in the treatment of many types of cancer (Asano et al., 2017; Mayr et al., 2014; Simon et al., 2012). In 2011 Daskivich et al. (2011a) created a prostate cancer–specific CCI (PCCI) weighing comorbidities to predict 10-year risk of mortality among prostate cancer patients (Fig. 153.1). When adjustments were made for age when applying the PCCI to men with prostate cancer in the Veterans Affairs Medical Center (VAMC), segregated PCCI score at 0, 1-2, 3-4, 5-6, 7-9, and 10, the 10-year cumulative incidence of other cause mortality was 10%, 19%, 35%, 60%, 79%, and 99%, respectively (Daskivich et al., 2015).

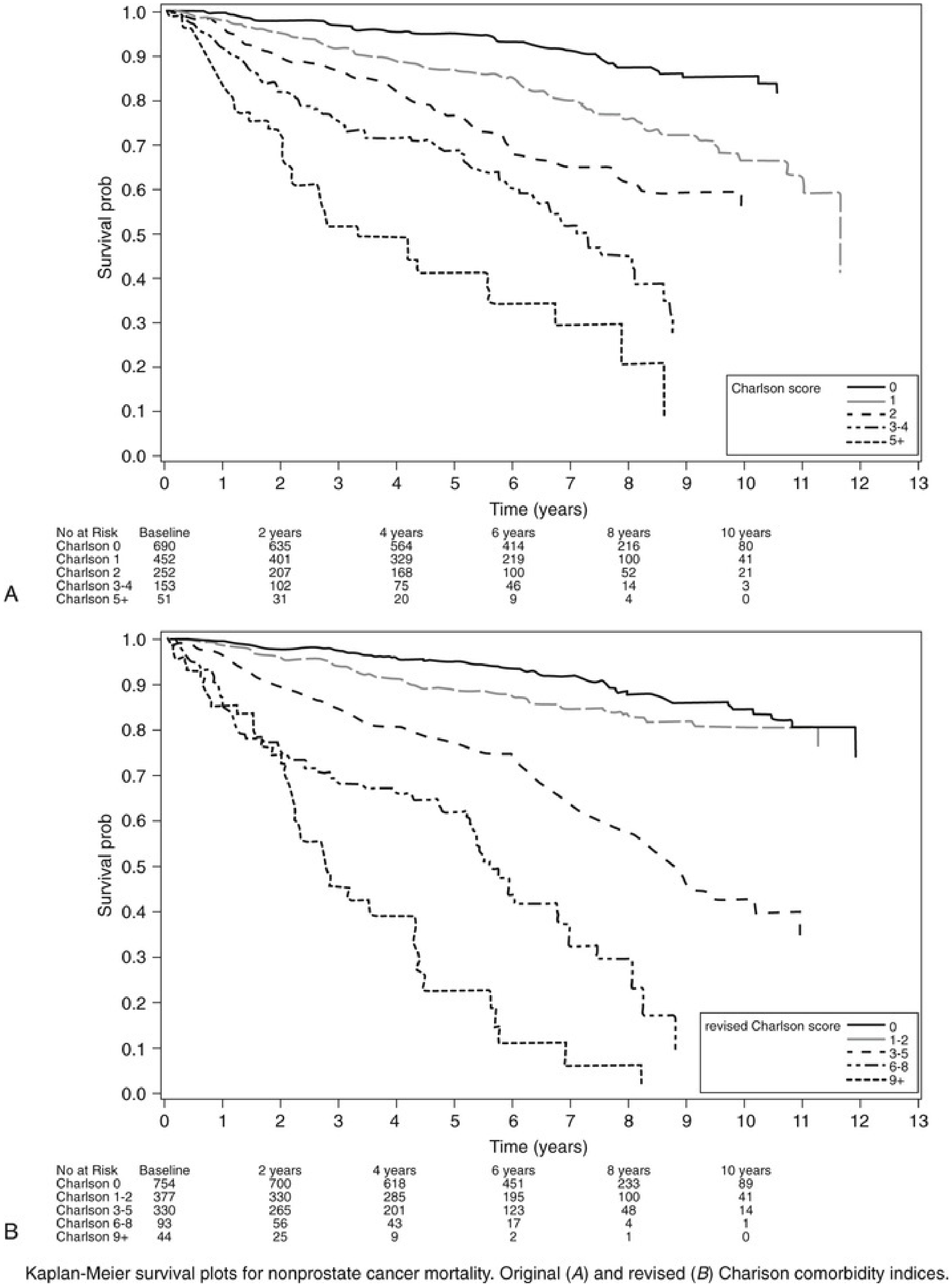

No at Risk	Baseline	2 years	4 years	6 years	8 years	10 years
Charlson 0	690	635	564	414	216	80
Charlson 1	452	401	329	219	100	41
Charlson 2	252	207	168	100	52	21
Charlson 3-4	153	102	75	46	14	3
Charlson 5+	51	31	20	9	4	0

No at Risk	Baseline	2 years	4 years	6 years	8 years	10 years
Charlson 0	754	700	618	451	233	89
Charlson 1-2	377	330	285	195	100	41
Charlson 3-5	330	265	201	123	48	14
Charlson 6-8	93	56	43	17	4	1
Charlson 9+	44	25	9	2	1	0

Kaplan-Meier survival plots for nonprostate cancer mortality. Original (*A*) and revised (*B*) Charlson comorbidity indices.

FIG. 153.1 Risks of other cause mortality associated with comorbidities in the original Charlson comorbidity index (A) and re-weighted comorbidity index identifying highest risk for other cause mortality (B) among men with prostate cancer. (From Daskivich TJ, Chamie K, Kwan L, et al.: Improved

prediction of long-term, other cause mortality in men with prostate cancer. *J Urol* 186(5):1868–1873, 2011.)

The perception of longevity in clinical practice is often based solely upon age rather than comorbidity. Daskivich et al. have previously demonstrated that among men with low-risk prostate cancer diagnosed in the VAMC, treatment rates were higher for men with CCI of at least 3 than those with age more than 75 years (54% vs. 16%), despite a much higher likelihood of other cause mortality within 10 years (70% vs. 24%) (Daskivich et al., 2011a). In addition, among men in the SEER-Medicare database, aggressive treatment for men with less than 10 years' life expectancy, based upon CCI, was dependent upon age, with 68% to 69% of men aged less than 75 receiving aggressive therapy compared with only 57% and 24% of those aged 75 to 79, or at least 80 (Daskivich et al., 2014). Similarly, Bratt et al. (2015) demonstrated that among men with high-risk prostate cancer in the National Prostate Cancer Register of Sweden, 50% of men younger than 70 years received radical treatment, as compared with only 10% of men aged 70 to 80, despite a 52% likelihood of 10-year longevity. **Improvements in appropriate candidate selection for treatment, and secondarily survival benefit, can be achieved through age-adjusted assessment of longevity on the basis of validated comorbidity indices and life tables.**

Longevity assessment must be contemplated within the context of cancer aggressiveness. Men with aggressive malignancies may benefit from diagnosis and treatment regardless of a shortened longevity, particularly if diagnosed at an advanced stage. In men with high-risk, poorly differentiated prostate cancer, within the SEER-Medicare dataset, when cancer-specific survival is compared, aggressive treatment resulted in mortality improvements of 11.3%, 7.9%, 8.6%, and 2.8% at 10 years' follow-up for men with Charlson scores of 0, 1, 2, and 3+, respectively; numbers needed to treat to prevent 1 cancer death at 10 years were 9, 13, 12, and 36 men (Daskivich et al., 2016). Lead time from diagnosis to symptoms and eventual cancer-related mortality are heavily influenced by Gleason score and tumor stage. This suggests that the relevance of expected longevity in treatment decision making must be framed within a temporal estimate of cancer progression and mortality risk. **Men with a high risk of metastatic progression or mortality within 10 years of diagnosis should be considered for aggressive therapy despite the presence of one or more competing risks for mortality within the same time period.**

Baseline Urinary, Sexual, and Bowel Function

Bladder Function

In consideration of the necessity for treatment and the appropriate type of treatment, the patient's baseline urinary, bowel, and sexual function are critical considerations because they influence the magnitude of benefit and risk to the patient with regard to quality of life. Patients with preexisting conditions may be at increased risk for either more intense morbidity or more protracted morbidity that may ultimately affect prostate cancer treatment choice. Careful assessment of baseline function using validated instruments to measure urinary and sexual function is necessary in formulating an individualized, balanced discussion of the risks and benefits of treatment in the shared decision-making process.

Baseline urinary function can be measured by a number of validated methods including, most commonly, the International Prostate Symptom Score (IPSS) and the UCLA Prostate Cancer Index (Barry et al., 1992; Litwin et al., 1998). In addition to an IPSS, a more detailed urinary history with analysis of the individual questions in the instrument is useful to delineate the nature of the symptoms. In men with obstructive symptoms resulting from benign prostatic hyperplasia (BPH), extirpative surgery may offer the added benefit of improvement in symptoms, although the patient may be at increased risk of retention if brachytherapy or external radiation is employed. In 2004 Lepor et al. demonstrated a 40% improvement in baseline urinary symptoms after radical prostatectomy among men with moderate to severe urinary symptoms (Lepor and Kaci, 2004), which was subsequently shown to persist through long-term follow-up without clinically significant age-related progression of lower urinary tract symptoms typically observed in the general population (Prabhu et al., 2014; Slova and Lepor, 2007; Xu et al., 2018). Others have subsequently made similar observations (Gordon et al., 2014, 2016), although Choi et al. (2011) and Kim et al. (2013) have observed that men with severe baseline urinary symptoms suffer more urinary bother in the early postoperative period. Among men with large prostates and moderate symptoms, these data should be considered given the long-term risk of progressive urinary symptoms and eventual retention. In these patients, prostatectomy may have long-term benefits in this regard.

The effect of radiotherapy on baseline urinary symptoms has been less well reported but is typically characterized as transient worsening, followed by normalization, followed by improvement in symptoms as the prostate regresses.

Men with severe irritative symptoms at time of diagnosis are at highest risk of worsening of symptoms after radiation because many may have underlying bladder overactivity and potential compliance abnormalities. Although the severity of urinary toxicity may vary with different forms of radiation therapy, in general the relative risk of short-term toxicity for men with severe baseline symptoms is comparable. Men with large prostates and obstructive symptoms are likely to be at increased risk of retention after brachytherapy, but this is not clearly shown after externally delivered forms of radiation therapy.

Prostate size is often an important consideration when selecting a therapy for early-stage disease. The American Brachytherapy Society guidelines suggest that prostate glands that are greater than 60 cm (Wilt et al., 2012) are technically more difficult to implant because of increased frequency of pubic arch interference and the large number of seeds required (Davis et al., 2012). Using cytoreductive androgen deprivation therapy (ADT) can reduce prostate volumes by approximately 25% to 40% and may be helpful to optimize gland size before brachytherapy. In patients with prostate volumes in excess of 80 g, neoadjuvant ADT may be required for cytoreduction before radiotherapy with the goal of reducing the volume of rectum or bladder exposed to the high doses of irradiation. For patients with early-stage disease with unusually large prostates, surgery may be the preferred intervention, which would avoid the need for several months of ADT and its associated side effects.

Among men with chronic retention requiring indwelling catheter or intermittent catheterization, surgery should be considered if the retention is deemed obstructive. If retention is due to bladder atony, surgery may still be performed, although bladder compliance, as assessed by urodynamic evaluation, will predict the likelihood of recovery of incontinence. With radiation therapy, removal of catheter, with conversion to intermittent catheterization, is advisable to allow cycling of the bladder wall and secondary prevention of bladder wall fibrosis resulting from radiation injury.

Transurethral resection of the prostate (TURP) before external radiation, rather than after, may be advisable for men in, or at risk of, retention. In these men, if post-treatment transurethral resection is performed, there may be a higher associated risk of incontinence (Polland et al., 2017), particularly after brachytherapy with up to 18% of men incontinent after TURP (Hu and Wallner, 1998; Kollmeier et al., 2005). Historically, TURP before brachytherapy was associated with a higher risk of post-implant incontinence (Blasko et al., 1991), although more contemporary experience challenged this notion (Stone et al., 2000; Wallner et al., 1997). More recently, a limited TUR approach, with resection of obstructing median lobe/bladder neck and minimal resection of the lateral lobes and apex, has been described to be safe before brachytherapy (Brousil et al., 2015).

For men who have had a previous aggressive TURP for outlet obstruction, the risk of urinary toxicity may be higher in those that undergo radiotherapy (Devisetty et al., 2010; Sandhu et al., 2000), but the rates of long-term severe urinary symptoms may lower. Delay of radiation for 6 to 8 weeks after TURP may reduce the risk of incontinence and bladder neck contracture (Mansfield and Stephenson, 1996). Patients with a history of a TURP, transurethral microwave, or laser procedures may have large defects that pose a dosimetric challenge for brachytherapy given the desire to place radiation dose predominantly within the gland periphery, avoiding the urethra and bladder neck. Similarly, if contemplating ablative cryosurgery, placement of needles is challenging in the setting of a large TURP defect, because of the risk of intraurethral needle placement. Small glands (<30 cm [Wilt et al., 2012]) with large TURP defects pose a particular challenge and may be better managed with alternative strategies.

Other forms of lower urinary tract dysfunction, because of neurogenic disease, should be carefully evaluated before prostate cancer therapy. In men with Parkinson disease, a careful urologic history should be undertaken to assess for any evidence of bladder dysfunction. Urodynamic evaluation before surgery or radiation may be useful in providing quantitative metrics by which to judge the likelihood of post-treatment incontinence and/or worsening of urinary symptoms. Men with severe compliance abnormalities may be better served by surgical therapy given the risk of progressive bladder fibrosis after radiation.

Sexual Function

Recovery of erectile function after therapeutic intervention is dependent upon several factors related to the quality and success of the treatment but also relates to several host attributes, including baseline sexual function, use of oral PDE5 inhibitors, frequency of sexual activity, and risk factors for sexual dysfunction, including diabetes, atherosclerotic disease, and hypercholesterolemia (Le et al., 2010). In a study of 966 men undergoing radical prostatectomy at a tertiary cancer center, age and preoperative erectile function were predictive of erectile function recovery after bilateral nerve preservation at 2 years postoperative (Krishnan et al., 2014). The same group has demonstrated that men with poor baseline erectile function are more likely to undergo non–nerve-sparing procedures, independent of the severity of their cancer (Stember et al., 2013), suggesting that baseline function influences the treatment plan. Increasing age has been associated with lower likelihood of potency recovery after surgery (Woo et al., 2014) and has similarly been shown to predict higher likelihood of sexual functional decline after radiation therapy (Litwin et al., 1999). Several groups have demonstrated a greater likelihood of postoperative sexual bother after prostatectomy, independent of sexual functional recovery, among men with more frequency of sexual activity preoperatively (Kimura et al., 2013; Steinsvik et al., 2012).

Bowel Function and Other Conditions Affecting Treatment Choice

In general, comparative data have suggested that men undergoing radiotherapy are at increased risk of bowel dysfunction after treatment than those undergoing surgery (Barocas et al., 2017; Resnick et al., 2013; Tyson et al., 2018). Although all men are generally at risk, a careful gastroenterologic history is essential for minimizing the risk among candidates considering radiation. Men with preexisting fecal frequency/urgency, irritable bowel, tenesmus, or extensive previous rectal surgery should be cautioned regarding an exacerbation of symptoms with treatment. For these men, a gastroenterologic evaluation before therapy is warranted. There has been a suggestion that patients with inflammatory bowel disease (e.g., Crohn disease, ulcerative colitis) have more severe acute and late toxicity with pelvic radiotherapy. Similarly, men with known neurogenic bladder dysfunction should be counseled regarding the risk of functional deterioration or incontinence after treatment. Similarly, men with preexisting bowel dysfunction resulting from neurogenic or inflammatory disease may be at risk of worsened bowel function upon administration of external radiation.

Previous radical pelvic irradiation is a specific contraindication to radiotherapy for prostate cancer and may influence the complexity of radical prostatectomy. A careful history regarding the dose and field of radiation will allow treatment planning and assessment of relative risk. Previous pelvic surgery, particularly those operations that potentially trap bowel within the pelvic field, may also be considered as risk factors for radiation enteritis. Similarly, the presence of substantial or susceptible bowel within the radiotherapy field, for example from a hernia, also is a relative contradiction for radiation treatment. Furthermore, some patients may not be optimal candidates for radiotherapy resulting from propensity for impaired tissue healing, such as those with poorly controlled diabetes. For similar reasons, chronic steroid therapy may be a relative contraindication to surgery given the risk of delayed healing.

Patient Preference and Biases

Patient preferences and values play an increasing role in medical decision making. In the specific setting of prostate cancer, largely because of the absence of compelling data supporting one treatment over another in individual cases, patient preference and views regarding treatment-related side effects play a major role in treatment choice. **Men often come to patient consultation with preconceived perceptions regarding prostate cancer treatment based upon the experiences and advice of family and friends, Internet research, and representations of treatment in the lay media.** In a recent survey of men diagnosed with prostate cancer before treatment, 59% of men indicated they only considered surgery as a treatment option (Zeliadt et al., 2010). Men choosing surgery are typically more concerned with cancer mortality, and those choosing nonsurgical options tend to be more concerned with quality of life. In addition, pretreatment urinary symptoms may influence treatment decision: men are more likely to elect surgery if confronted with obstructive urinary symptoms (Mazur and Merz, 1996).

Shared decision making involves a collaborative process in which patients and clinicians make decisions together. Given the controversy surrounding the relative benefit of prostate cancer screening and treatment, shared decision making, with regard to PSA testing and prostate cancer treatment, has been strongly advocated by a number of governing bodies. This shared decision-making model has been adopted into guidelines on localized prostate cancer management supported by the AUA, ASTRO, and the SUO (Sanda et al., 2018a). More recently, consensus has been achieved regarding strategies for implementation of shared decision making in clinical practice (Makarov et al., 2016).

In a recent multicenter, prospective, observational study of 454 men undergoing prostate cancer counseling and treatment, regardless of whether men expressed an initial desire to be actively or passively involved in decision making, after treatment, men who perceived their involvement in decision making as active were more well informed with regard to the disease and expressed less decisional regret in follow-up after treatment (van Stam et al., 2018).

Several interventions that include written material, in-person counseling, and web-based tools have been investigated. Although a meta-analysis of 14 randomized clinical trials investigating shared decision-making aids revealed only a negligible association with health outcomes (Violette et al., 2015), more recent trials demonstrate improved decision making and treatment selection, suggesting an emerging role for shared decision making. The available evidence suggests that interventions aimed at informing patients regarding the comparative effectiveness of prostate cancer management alternatives should include the influence of physician recommendations and family members' desires on patient decision making (Showalter et al., 2015). The urologist's recommendation for treatment, however, continues to have the most influence on decision making (Davison and Breckon, 2012).

Assessment of Prostate Cancer Risk

Tools for Risk Stratification

Risk assessment in prostate cancer is important from several perspectives. Accurately determining the risk of cancer mortality over time allows adequate decision making regarding necessity for therapy but also allows decisions regarding which treatment approaches may be reasonable options of consideration. Currently, the most acknowledged criteria used to risk-stratify prostate cancer are clinical stage, biopsy Gleason score, and pretreatment serum PSA level. No single criterion can precisely identify all men at high risk of disease progression and mortality with or without therapy. Although various risk classification systems have been developed, standardized criteria that define prostate cancer risk stratification are still lacking (D'Amico et al., 1998; Eberhardt et al., 2013; European Association of Urology, 2015; Heidenreich et al., 2011; Horwich et al., 2013; National Comprehensive Cancer Network, 2015; Roach et al., 2000; Thompson et al., 2007). This lack of consensus is a critical obstacle in patient counseling, evaluation of treatment outcomes, and design of clinical trials, as well as the establishment and appraisal of guidelines that include recommended staging protocols.

Definitions of Low, Intermediate, and High Risk

Among the large numbers of newly diagnosed prostate cancers that appear clinically indolent, those with unrecognized underlying aggressive biology continue to pose a challenge, regardless of chosen treatment strategy. A joint guideline from the AUA/ASTRO/SUO for clinically localized prostate cancer risk stratifies men with prostate cancer into very low, low, intermediate, and high risk (Sanda et al., 2018a). These guidelines do not substratify intermediate risk men into favorable and unfavorable, nor do they substratify high-risk men into high risk and very high risk as proposed by the NCCN (Table 153.1; Mohler et al., 2016). Men with low-risk and intermediate-risk prostate cancer, per National Comprehensive Cancer Network criteria, represent a broad range of disease aggressiveness, and understanding the optimal treatment strategies for these men continues to be a critical area of investigation.

TABLE 153.1

Risk Stratification and Staging Workup

NCCN RISK GROUP	CLINICAL/PATHOLOGIC FEATURES	IMAGING
Very low	• T1c AND • Gleason score ≤6/grade group 1 AND • PSA <10 ng/mL AND • Fewer than 3 prostate biopsy fragments/cores positive, ≤50% cancer in each fragment/core AND • PSA density <0.15 ng/mL/g	• Not indicated
• Low	• T1–T2a AND • Gleason score ≤6/grade group 1 AND • PSA <10 ng/mL	• Not indicated
• Favorable intermediate	• T2b–T2c OR • Gleason score 3+4=7/grade group 2 OR • PSA 10–20 ng/mL AND • Percentage of positive biopsy cores <50%	• Bone imaging: not recommended for staging • Pelvic ± abdominal imaging: recommended if nomogram predicts >10% probability of pelvic lymph node involvement
Unfavorable intermediate	• T2b–T2c OR • Gleason score 3+4=7/grade group 2 or Gleason score	• Bone imaging: recommended if T2 and PSA >10 ng/mL • Pelvic ± abdominal imaging:

	4+3=7/grade group 3 OR • PSA 10–20 ng/mL	recommended if nomogram predicts >10% probability of pelvic lymph
• High	• T3a OR • Gleason score 8/grade group 4 or Gleason score 4 + 5=9/grade group 5 OR • PSA >20 ng/mL	• Bone imaging: recommended • Pelvic ± abdominal imaging: recommended if nomogram predicts >10% probability of pelvic lymph
• Very high	• T3b–T4 OR • Primary Gleason pattern 5 OR • >4 cores with Gleason score 8–10/grade group 4 or 5	• Bone imaging: recommended • Pelvic ± abdominal imaging: recommended if nomogram predicts >10% probability of pelvic lymph

PSA, Prostate-specific antigen.

Risk group stratification may be useful in making decisions regarding the preferred management strategies as well as prognostic assessments. Worsening oncologic outcomes have been associated with increasing disease risk. For example, men with very-low–risk prostate cancer have been shown to be at significantly lower risk for adverse findings at surgery compared with those with low-risk disease (Tosoian et al., 2013). Favorable risk groups have been found to harbor adverse pathological features compared with those in the low-risk group that affect cancer progression and candidate selection for active surveillance (Aghazadeh et al., 2018; Gearman et al., 2018). Relative to high-risk prostate cancer, men with very high risk disease treated with radical prostatectomy have significantly worse pathological and oncologic outcomes and more frequently require additional therapies (Pompe et al., 2017). These observations, taken together, validate the risk stratification groups.

Gleason Scoring and Grade Groups

The Gleason scoring system was introduced in 1966 for the histologic assessment of prostate cancer aggressiveness and is based upon an assessment of the glandular patterns of cancer present in the specimen. The score is presented as a sum of the dominant pattern and the largest minority pattern present in the sample. Gleason initially described 5 patterns ranging from 1 to 5, with pattern 5 being the most poorly differentiated. In 2005 the International Society of Urologic Pathology (ISUP) recommended against the use of patterns 1 and 2, leaving a shortened scoring scale of 6 to 10 (Epstein, 2010; Epstein et al., 2005). In addition, the consensus recommended that a number of variant patterns previously graded as 3, and all cribriform patterns, should be considered pattern

4. In doing so, there has been an observation of Gleason scoring migration, with a greater number of cancers designated as Gleason score 3+4 or 4+3, as compared with historical cohorts. This migration has led to a reassessment of the accuracy of Gleason scoring in contemporary practice, with most such evaluations demonstrating improved prognostic accuracy (Billis et al., 2008; Epstein, 2010; Uemura et al., 2009). Although the grading system appears to be more prognostically accurate, it has created difficulty in comparing historical outcomes of treatment to contemporary cohorts, given the difference in what is meant by Gleason 3+3 and 3+4/4+3.

Given the difficulty of communicating prognosis to patients on a grading scale extending from 6 to 10, a, new prostate cancer grading scheme, consisting of grade groups, was proposed in 2013 (Pierorazio et al., 2013) and advocated by the ISUP in 2014 (Epstein et al., 2016) in an effort to better reflect and communicate true biologic aggressiveness and guide clinical management (Carter et al., 2012). The new prognostic grade groups use a scale of 1 to 5 with Gleason grade group (GGG) 1 consisting of Gleason 3+3, GGG 2 = 3+4, GGG 3 = 4+3, GGG 4 = 4+4, and GGG 5 = 4+5, 5+4, and 5+5. The Gleason grade group scheme has been investigated, and its correlation with prostate cancer–specific mortality has been validated (He et al., 2017; Loeb et al., 2016).

Epstein Criteria

Epstein et al. in 1994 developed PSA and needle biopsy-related criteria (PSA density < 0.15 ng/mL/g, absence of adverse pathological findings on biopsy (i.e., biopsy Gleason score ≤ 6), presence of prostate cancer in fewer than 3 cores (in 6-core biopsy samples), no more than 50% prostate cancer involvement in any of the cores for identifying insignificant prostate cancer (Epstein et al., 1994). According to these criteria the accuracy of predicting organ-confined (<pT3a stage) tumors with volume less than 0.5 mL and without high-grade components is 79%. Ten years later, Bastian et al. (2004) revised these criteria and reported a higher predictive accuracy, up to 83.9%. The Epstein Criteria remains one of the most commonly used tools for predicting insignificant prostate cancer and determining candidates for active surveillance (Tosoian et al., 2015).

The biopsy findings (Gleason score; the number of cores containing cancer; the distribution and volume of cancer in the biopsy cores; the presence of perineural space invasion, lymphovascular invasion, ductal, signet ring, or neuroendocrine differentiation) also correlate with cancer aggressiveness and the likelihood of the cancer's being organ confined.

Staging

Guidelines for initial diagnostic imaging in the newly diagnosed prostate cancer patient vary considerably (American Urological Association, 2007; Sanda et al., 2017). Although most definitions support radionuclide bone scan for the initial staging of high-risk prostate cancer, not all specifically address imaging for soft tissue metastases (Briganti et al., 2010; Crawford et al., 2014). Those that do commonly endorse pelvic CT or MRI. **Current NCCN guidelines recommend the use of technetium-99m bone scan and cross-sectional imaging (CT or MRI) among high-risk and unfavorable intermediate-risk men deemed to be at high risk for occult metastasis on the basis of clinical parameters or nomograms** (see Table 153.1). In cases of equivocal bone scans, PET/CT or MRI have been endorsed by several professional organizations.

In 2012 the American Society of Clinical Oncology (ASCO) and in 2013 the American Urological Association highlighted the need to reduce the overuse of imaging in staging low-risk prostate cancer, launching the “Choosing Wisely” campaign. Several studies show poor compliance with these guidelines, whereby men with low-risk prostate cancer continue to undergo guideline-discordant imaging, whereas men with high-risk disease paradoxically have lower rates of guideline-adherent imaging (Makarov et al., 2012). These findings suggest that imaging is often underused in men with high-risk prostate cancer who could potentially benefit from it. The guideline-discordant association between higher imaging rates and increasingly aggressive disease risk suggest that established guidelines have had limited impact on the high rates of inappropriate imaging use. **Although the publication of guidelines seems to lower national rates of inappropriate imaging, it also lowers the rate of appropriate prostate cancer imaging** (Abraham et al., 2007).

Bone scan has been the most widely used method for evaluating bone metastases of prostate cancer and remains the current standard imaging test for initial prostate cancer staging, recurrence, and metastatic disease. This technique is clinically easy to interpret, relatively cost effective, and widely available. Because of its relatively low specificity, however, patients with equivocal findings often require additional imaging modalities. The diagnostic yield of a bone scan is significantly influenced by the PSA level, clinical stage, and Gleason score (McArthur et al., 2012).

CT has a very limited role for local staging of high-risk prostate cancer because it generally does not visualize early metastases. The separation between the prostate and the levator ani muscle is poorly defined on CT, and intraprostatic anatomy is not well demonstrated. CT may be useful as a baseline examination in high-risk patients with grossly advanced local disease (gross extraprostatic disease, gross seminal vesicle invasion [SVI], or invasion of the surrounding structures) with resultant hydronephrosis or urinary retention. A fundamental shortcoming of CT in detecting lymph node metastases is its inability to detect architectural changes within normal-sized (<10 mm) lymph nodes. Although CT has limitations in detecting metastatic prostate cancer to the lymph nodes, **it remains the guideline-endorsed imaging choice for staging in men at risk for lymph node involvement** (Bekelman et al., 2018; Carroll et al., 2016; Sanda et al., 2018a).

Prostate magnetic resonance imaging (MRI) is increasingly used in the diagnostic and evaluation pathway for prostate cancer (Bjurlin et al., 2014; Siddiqui et al., 2015). Local staging includes assessment of extraprostatic extension (EPE), which affects surgical planning and aids in assessing risk for local symptoms arising from tumor volume and bladder neck invasion, along with seminal vesicle invasion (SVI). For identifying EPE and SVI, MRI is the only examination with sufficient accuracy to be used in clinical practice given its combination of high spatial and contrast resolution. Historically, assessment for EPE on MRI was based on T2-weighted imaging (T2WI), which provides the best spatial resolution of the MR sequences typically employed. The identification of EPE on T2WI alone is dependent on the amount of EPE present. Gross extension or disruption of the capsule is highly predictive of EPE, but more subtle findings such as irregularity or bulging of the "capsule" have a lower predictive value. In general, MRI is poor for the detection of focal EPE, but subtle findings, such as linear length of capsular contact at the region of suspicion, may improve the pretreatment prediction of the likelihood of EPE (Rosenkrantz et al., 2013, 2016). Accuracy for more subtle EPE is improved when T2WI is combined with diffusion-weighted imaging (DWI) (Chong et al., 2014) or dynamic contrast-enhanced (DCE) imaging (Futterer et al., 2005) primarily because these additional sequences improve dominant tumor localization, which in turn helps predict presence of EPE. However, uncertainty remains because these ancillary sequences have lower spatial resolution than T2WI.

Currently, multiparametric MRI sensitivity, specificity, positive predictive value (PPV), and negative predictive value (NPV) in determining EPE in high-risk PCa has been reported to be 65%, 73%, 89%, and 38%, respectively (Somford et al., 2013). Although the suboptimal sensitivity has limited application of MRI for local staging in some practices, a high PPV is important in high-risk patients because knowledge of the site of EPE may help reduce the risk of a positive surgical margin. SVI has also been evaluated largely using T2WI. SVI appears as a T2-hypointense mass within the seminal vesicles, typically in direct contiguity with tumor in the prostate base. Studies show improved accuracy for detecting SVI when combining T2WI with DWI. High sensitivity and specificity for SVI, 83% and 99% respectively, has been observed using MRI in recent reports (Cornud et al., 2012). Knowledge of EPE and SVI is critical for appropriate patient counseling as well as treatment selection and planning as it is associated with worsened oncologic outcomes and early biochemical recurrence.

Interest in PET imaging in prostate cancer is increasing because it provides more functional information than other imaging modalities and can detect metastases (Bjurlin et al., 2015, 2018). In PET imaging, radiolabeled biomolecules pertinent to cellular processes are used to detect metabolic activity or cell surface molecules that are usually associated with cancer. PET imaging is conventionally combined with CT or MRI sequences to improve anatomic localization of abnormal tracer uptake. Clinical experience with PET in prostate is increasing, although PET is not approved for primary staging of prostate cancer in the United States. Currently none of the existing PET agents are recommended in practice guidelines for localized prostate cancer diagnosis; however, among them, prostate-specific membrane antigen-based tracers seem to hold the most promise based on sensitivity and specificity (Han et al., 2018). Given its performance characteristics, PET may also be potentially useful for identifying patients suitable for active surveillance, for accurate preradical prostatectomy/preradiation therapy staging.

Nomograms for Prediction of Stage

Early in the PSA era, prognostic assessment before surgery was often based solely on the PSA level. Because of the realization that Gleason score and clinical stage often were disparate with the PSA level alone, Partin, et al. (1993) created predictive nomograms derived from these three variables that allowed prediction of stage at time of radical prostatectomy. Widely used, these nomograms, commonly referred to as the Partin tables, were validated on a multi-institutional cohort demonstrating relative accuracy of prediction 72.4% of the time (Partin et al., 1997). The tables have been tested in other populations and appear to be generalizable to other geographic and ethnic populations

(Bianco et al., 2003; Blute et al., 2000; Eschwege et al., 2003; Karakiewicz et al., 2005; Naito et al., 2008). The tables are derived from the cumulative experience of urologists performing radical prostatectomy at John Hopkins University and have been updated periodically to reflect the evolving clinical characteristics of the cohort (Makarov et al., 2007; Partin et al., 2001).

Since the inception of the Partin tables, a multitude of clinical nomograms have been described for predicting organ-confined disease within the pretreatment population (Briganti et al., 2006a, 2006b). Most of these nomograms use similar clinical variables to the Partin tables, or incorporate additional clinical variables such as age, digital rectal exam, PSA density, or percent cancer involvement on biopsy, and are validated on other clinical cohorts.

Risk Stratification Nomograms

In addition to prediction of radical prostatectomy pathologic outcome, a number of instruments have been developed to predict clinical outcomes after treatment, including relapse and survival after prostatectomy (Briganti et al., 2006b; Kattan et al., 1997, 1998). The initial description of such a nomogram by Kattan et al. (1998) incorporated PSA, clinical stage, and Gleason score and achieved an overall diagnostic accuracy of 0.79 as measured by area under the receiver operating characteristic curve (predicted probability vs. actual outcome). The UCSF Cancer of the Prostate Risk Assessment (CAPRA) score was developed for the prediction of predicting clinical outcomes using age, PSA level, clinical stage, biopsy Gleason score, and percentage of positive biopsy cores. In its initial description, the UCSF-CAPRA score was able to widely segregate risk from a 5-year recurrence-free survival of 85% among low-risk to 8% among high-risk patients (Fig. 153.2; Cooperberg et al., 2005). This stratification scheme has subsequently been shown to additionally predict prostate-cancer-specific mortality independently of the treatment given (Cooperberg et al., 2009).

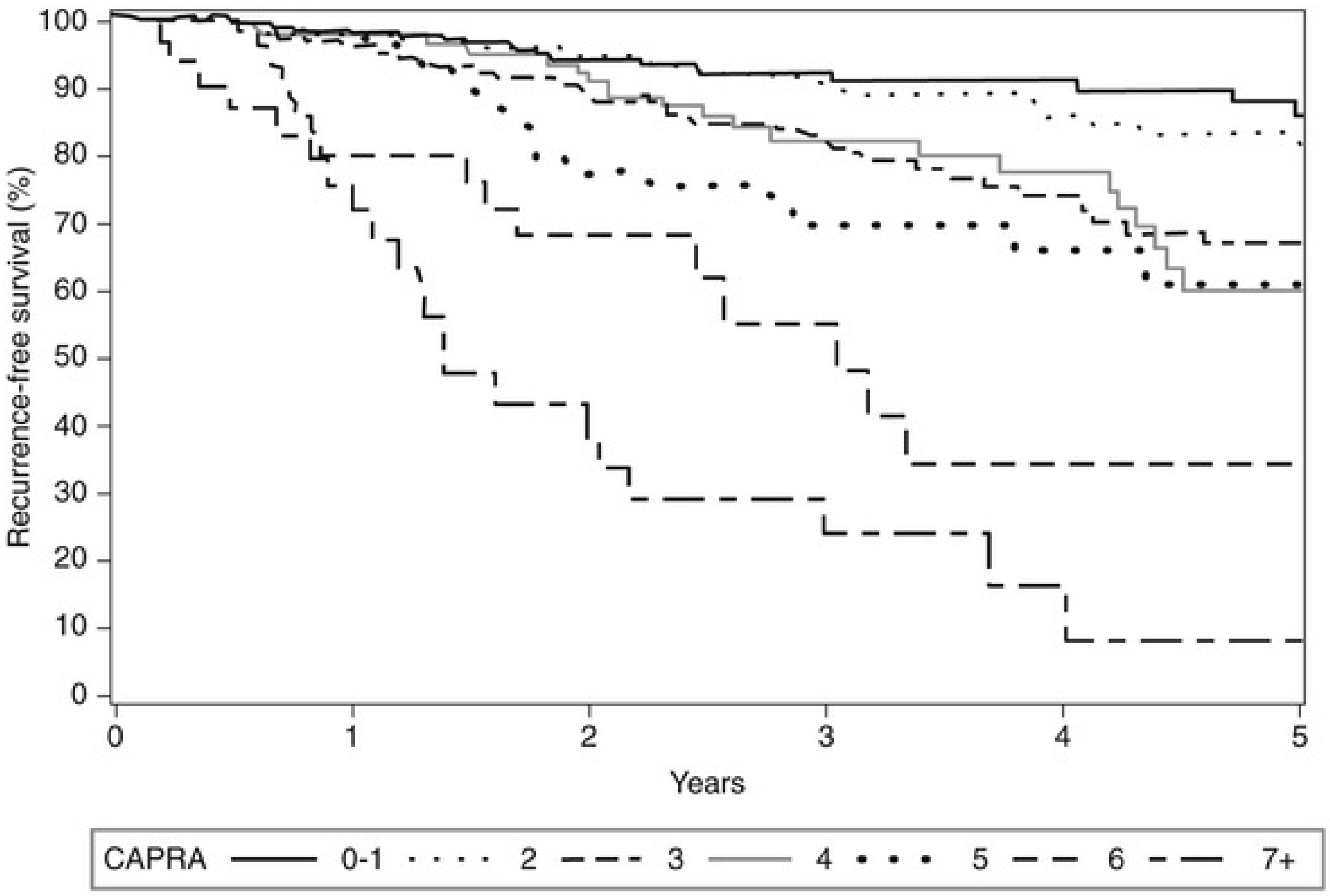

Survival curves for 5-year recurrence-free survival among patients with each UCSF-CAPRA score

FIG. 153.2 University of California, San Francisco (UCSF) Cancer of the Prostate Risk Assessment Score (CAPRA). (Reproduced from Cooperberg MR, Pasta DJ, Elkin EP, et al.: The University of California, San Francisco Cancer of the Prostate Risk Assessment score: a straightforward and reliable preoperative predictor of disease recurrence after radical prostatectomy. *J Urol* 173[6];1938–1942, 2005.)

Other parameters, such as the extent of cancer in needle biopsy, prediagnosis PSA velocity, PSA doubling time, or the presence of a tertiary Gleason pattern, have been explored as a means of enhancing risk stratification (Hattab et al., 2006; O'Brien et al., 2009; Ravery et al., 2000). The applicability of some of these parameters remains unclear because they are not routinely collected in clinical practice. Additional nomograms have been created to inform treatment decision making for men contemplating active surveillance (Kattan et al., 2008), radical prostatectomy (Stephenson et al., 2006), neurovascular bundle preservation, or omission of pelvic lymph node dissection during radical prostatectomy, brachytherapy, or external beam radiation therapy (Brockman et al., 2015; Kattan et al., 2003). Biochemical progression-free survival can be reassessed postoperatively using nomograms of age, diagnostic serum PSA, and pathological grade and stage. Potential success of adjuvant or salvage radiation therapy after unsuccessful radical prostatectomy can also be assessed using a nomogram.

Prostate Magnetic Resonance Imaging in Risk Assessment

Contemporary prostate MRI interpretation of the prostate is reported using the Prostate Imaging Reporting and Data System (PI-RADS version 2), which provides the minimum acceptable technical standards for MR image acquisition and suggests a structured method for prostate MRI reporting and conveyance of the level of suspicion for clinically significant prostate cancer (Weinreb et al., 2016). The PI-RADS score, or MRI suspicion score before the advent of PI-RADS, along with the apparent diffusion coefficient (ADC), measured on diffusion-weighted imaging, has been shown to correlate with clinical outcomes and thus can be used as a risk stratification tool (De Cobelli et al., 2015; Fuchsjager et al., 2010; Giles et al., 2011; Henderson et al., 2016; Ho et al., 2016; Lee et al., 2016; Park et al., 2011, 2014, 2016; Riaz et al., 2012; Rosenkrantz et al., 2015; Tamada et al., 2017; van As et al., 2009; Westphalen et al., 2011; Yamaguchi et al., 2016; Yoon et al., 2017). Recent data have explored the value of MRI in monitoring tumors in patients on an active surveillance protocol. In patients with low-risk, localized disease, tumor ADC on DWI may be a useful marker of prostate cancer progression and may help to identify patients who stand to benefit from radical treatment (Giles et al., 2011). As a preoperative imaging tool, tumor ADC and PI-RADS may also be useful to predict biochemical recurrence after radical prostatectomy and radiation therapy (Ho et al., 2016; Park et al., 2014; Westphalen et al., 2011). MRI data improve the prediction of biochemical failure within nomograms after external-beam radiation therapy (EBRT) (Westphalen et al., 2011). Pretreatment MRI findings have also been found to predict for biochemical recurrence in intermediate- and high-risk prostate cancer patients treated with combination brachytherapy and external-beam radiotherapy (Riaz et al., 2012).

MRI may add utility as a method for predicting treatment outcomes and progression on active surveillance. MRI, in conjunction with traditional clinical parameters and secondary biomarkers, may allow more accurate risk stratification and assessment of need for repeat prostate biopsy among men with discordant prostate biopsy and MRI findings. **As such, prostate MRI may aid in risk assessment of patients newly diagnosed with prostate cancer and allow improved decision making with regard to need for therapy, likelihood of treatment failure, and need for repeat biopsy for further risk assessment.**

Genomic Tests for Risk Stratification

Risk stratification based on traditional clinical parameters can stratify patients' risk of prostate cancer progression with relatively good reliability, but substantial heterogeneity persists within standard risk groups. With improved approaches to biomarker research, combined with lower cost and more efficient techniques, the potential of a personalized genomic approach for clinical decision making has recently been made possible.

An increased understanding of prostate cancer biology has led to the development of molecular tests specifically tailored to prostate cancer. Genomic testing has been shown to provide additional prognostic information, particularly when taken in conjunction with risk groups based on stage, Gleason score, and serum PSA. New molecular biomarkers are commonly divided into liquid and tissue (obtain from prostate biopsy) biomarkers. Compared with tissue-based assays, liquid biomarkers have minimal risks, as transrectal prostate biopsy carries with it the potential risk of infection and sepsis. Liquid biopsies commonly include Prostate Health Index (PHI) (Catalona et al., 2011; de la Calle et al., 2015), 4Kscore test (Parekh et al., 2015; Punnen et al., 2017), prostate cancer antigen 3 (PCA3) (Wu et al., 2012), Mi-Prostate Score (Salami et al., 2013), Select MDx (Van Neste et al., 2016), and ExoDx Prostate Intelliscore (Nilsson et al., 2009). Although significant strides have been made in the development of liquid biomarkers, tissue-based assays remain the gold standard for accurately representing the tumor environment in prostate cancer. Confirm MDx (Stewart et al., 2013), Polaris (Cuzick et al., 2011), Decipher (Erho et al., 2013), and OncotypeDx GPS (Klein et al., 2014) are now recommended by the Molecular Diagnostic Services Program, which aims to identify and establish coverage and insurance reimbursement for molecular diagnostic tests.

There is disagreement about whether and how genomic tests should be employed in selecting a treatment approach for men with prostate cancer. Consensus-based guidelines from the NCCN state that molecular testing should be considered for men who are potential candidates for active surveillance and have low-risk or favorable intermediate-risk disease with a life expectancy more than 10 years. However, 2018 guidelines from the American Urological Association (AUA)/American Society for Radiation Oncology (ASTRO)/Society of Urologic Oncology (SUO) for management of clinically localized prostate cancer, which were endorsed by the American Society of Clinical Oncology (ASCO), state that among most low-risk prostate cancers, tissue-based genomic biomarkers have not shown a clear role in the selection of candidates for active surveillance (Bekelman et al., 2018; Sanda et al., 2018a,b).

Although current data suggest that molecular tests can add additional, independent prognostic information that may aid in risk stratification of localized prostate cancer, head-to-head comparisons across multiple different patient populations with specifically designed, clinically relevant end points must be undertaken, taking into account relative effectiveness and cost. Furthermore, molecular prognostic studies are highly dependent on the tissue collected, particularly in the pretreatment setting or when extirpative treatment is not planned. With further clinical experience, these molecular prognostic tests may further risk stratify untreated and treated men with localized prostate cancer.

Selection of Treatment: Comparative Studies

Oncologic Outcomes

In offering patients recommendations regarding the relative efficacy of individual treatment options, there is a paucity of high-quality comparative data, with the majority of such studies carrying significant limitations to be considered in interpretation of results. The difficulty in comparing options, together with the high prevalence of the disease, led the Institute of Medicine to include localized prostate cancer among the top 25 priority conditions for future comparative effectiveness research (Institute of Medicine of the National Academies, 2009). A significant challenge in characterization of oncologic outcomes after treatment is the myriad of used end points and their varying definitions.

The use of biochemical-free survival as an oncologic end point is problematic for many reasons. First, there is tremendous variation in the definition of biochemical-free survival. Second, variation in posttreatment PSA kinetics may also affect observed differences in rates of biochemical-free survival after radical prostatectomy and radiation therapy because the cytotoxic effects of radiation therapy may take several months or years, and it does not eliminate all prostatic sources of PSA. Last, the differential use of ADT, which is especially common among high-risk radiation patients, may delay time to biochemical progression. Cancer-specific and overall mortality are generally considered to be the most valid end points for comparisons of efficacy but require a protracted follow-up given the known long lead-time from diagnosis to death. In some studies, poor candidate selection may lead to high rates of non-oncologic death, impairing the ability to assess the impact of treatments on cancer-specific survival. Taken together, direct comparisons between oncologic outcomes and various trials are challenging and underscore the importance of contextualizing the study question before making inferences about available data.

Comparative Population-Based Studies

Several population-based analyses have evaluated the comparative effectiveness of radiation therapy and radical prostatectomy in localized disease. In a large population-based trial of more than 34,000 Swedish men with localized prostate cancer, the risk of prostate cancer- specific mortality was higher among radiation therapy patients as compared with radical prostatectomy patients (HR 1/4 1.76 [95% CI 1.49–2.08]) (Fig. 153.3; Sooriakumaran et al., 2014). A similar study using data from CaPSURE found a higher prostate cancer-specific mortality rate after adjusting for age and disease risk (HR 1/4 2.21; 95% CI 1.50–3.24) (Cooperberg et al., 2010) as have several SEER-based investigations (Abdollah et al., 2011a,b; Liu et al., 2008). In a study of more than 1500 men with 15 years of follow-up from the Prostate Cancer Outcomes Study, radical prostatectomy was associated with a statistically significant overall (HR = 0.60; 95% CI 0.53–0.70) and disease-specific (HR = 0.35; 95% CI 0.26–0.49) survival advantage (Hoffman et al., 2013). However, well-known biases frequently confound the interpretation of observational comparative-effectiveness studies. Selection, detection, and confounding bias can produce systematically distorted results contradictory to randomized trial studies (Albertsen, 2016; Giordano et al., 2008).

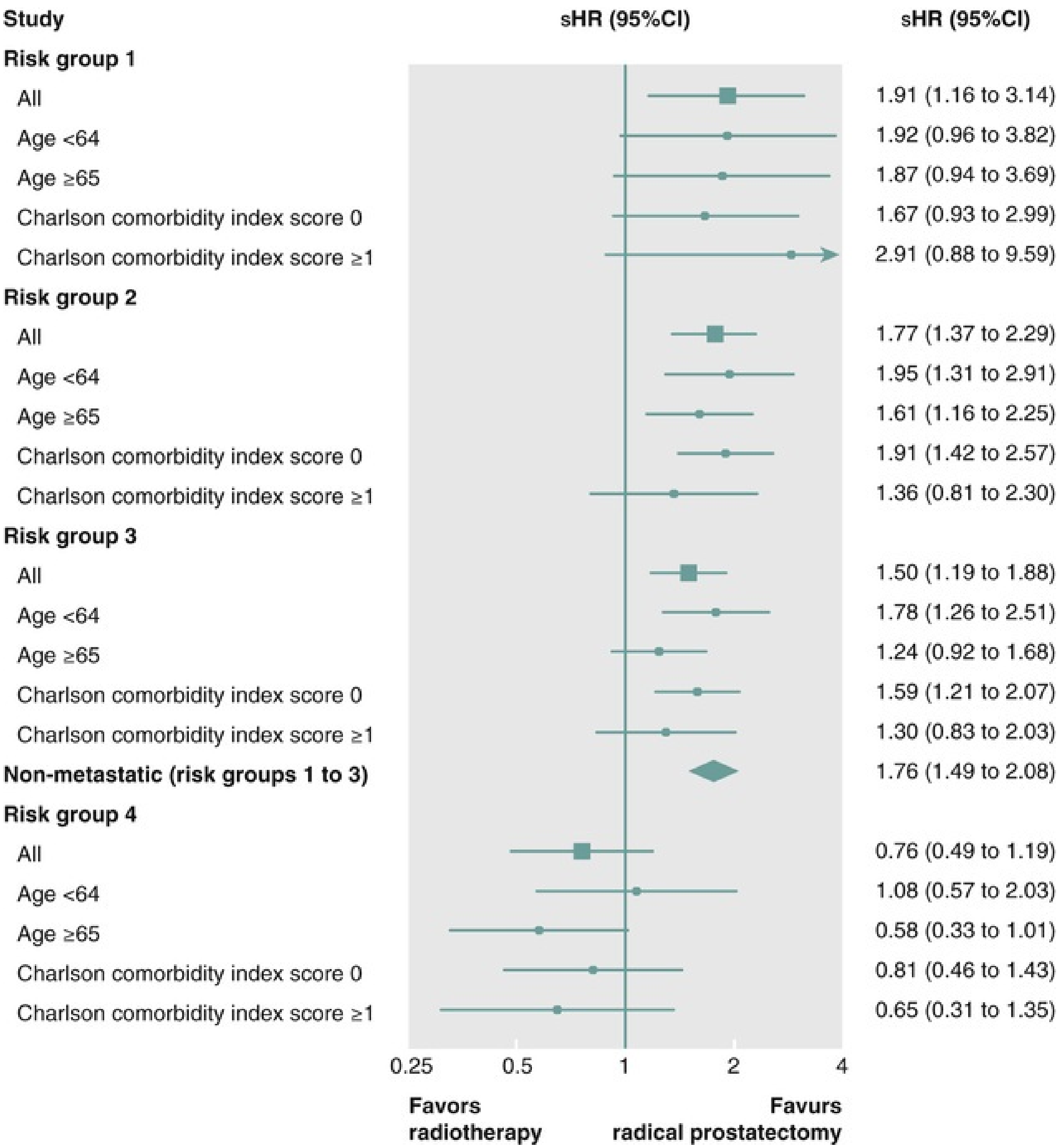

FIG. 153.3 Forest plot depicting propensity score adjusted subdistribution hazard ratios (sHR) for radiotherapy versus radical prostatectomy for cancer-specific mortality stratified by risk group, and substratified by age and Charlson comorbidity index score. (Data from Sooriakumaran P, Nyberg T, Akre O, et al.: Comparative effectiveness of radical prostatectomy and radiotherapy in prostate cancer: observational study of mortality outcomes. *BMJ* 348:g1502, 2014.)

Scandinavian Prostate Cancer Group Study Number 4.

The Scandinavian Prostate Cancer Group Study Number 4 (SPCG-4) is a randomized trial of radical prostatectomy versus watchful waiting in men with localized prostate cancer (Holmberg et al., 2002). The SPCG-4 was the first to publish a randomized intention-to-treat analysis comparing watchful waiting and radical prostatectomy using informative clinical end points such as overall and cancer-specific survival. Furthermore, the SPCG-4 offered the long-term follow-up necessary to characterize between-group differences in survival and employed rigorous study design methods such as blinded histopathologic review. However, because this trial enrolled men predominantly during the pre-PSA era, nearly 90% of the 695 participants harbored palpable disease. Although a number of important observations regarding the comparative effectiveness of radical prostatectomy in the treatment of localized prostate can be made from the SPCG-4 data this trial does not reflect current prostate cancer screening, detection, and treatment paradigms. During 23.2 years of follow-up, 200 of 347 men in the surgery group and 247 of the 348 men in the watchful-waiting group died (Bill-Axelson et al., 2014). Of the deaths, 63 in the surgery group and 99 in the watchful-waiting group were due to prostate cancer; the relative risk was 0.56 (95% CI 0.41–0.77; $P = 0.001$), and the absolute difference was 11.0 percentage points (95% CI 4.5–17.5). The number needed to treat to prevent 1 death was 8. The benefit of surgery with respect to death from prostate cancer was largest in men younger than 65 years of age (relative risk, 0.45) and in those with intermediate-risk prostate cancer (relative risk, 0.38). However, radical prostatectomy was associated with a reduced risk of metastases among older men (relative risk, 0.68; $P = 0.04$).

PIVOT.

PIVOT was a prospective randomized trial designed to address whether radical prostatectomy, as compared with observation, improved overall survival and prostate cancer-specific survival in men diagnosed with prostate cancer during the PSA era (Wilt et al., 2012). Initially designed to randomize 2000 men, the study recruited only 731 men, which was addressed by attempting to lengthen follow-up. At a median follow-up of 10 years, there was no difference in either overall or prostate-cancer specific mortality among the two treatment arms. Multivariate analysis showed that the effect of treatment on mortality did not vary according to age, race, performance status, or comorbid conditions. Subgroup analysis found no benefit of surgery for men with low-risk disease; however, radical prostatectomy reduced all-cause mortality in men with PSA values greater than 10 ng/mL and approached significance in those with intermediate and high-risk tumors. Notably, there was a statistically significant reduction in bone metastases in patients treated by radical prostatectomy (4.7%) versus expectant management (10.6%), which became more robust in patients with PSA exceeding 10 ng/mL and in those with intermediate- and high-risk disease.

PIVOT must be viewed in the light of its limitations. When enrollment goals were not met, the power calculation for the study was reformulated with lengthened follow-up, leaving a 91% power to detect a 25% relative reduction in all-cause mortality. The PIVOT study remained underpowered with the final enrollment of only 731 patients; it would have required 1200 patients to be adequately powered to detect a 25% relative reduction in overall mortality (Thompson and Tangen, 2012). Another shortcoming of the study is the large proportion of patients, nearly 20%, who were nonadherent to their assigned treatment group, thus even further diminishing the capacity to identify a treatment effect. In addition, only 10% of the men in their study were under the age of 60, therefore leaving the question of surgical management in a younger, healthier cohort unaddressed.

The follow-up of the original PIVOT analysis was published in 2017, after 19.5 years of follow-up, demonstrating an absolute risk reduction (ARR) of 5.5% (95% CI −1.5%–12.4%; $P = 0.06$) for all-cause mortality (61.3% vs. 66.8%) through prostatectomy (Wilt et al., 2017). An ARR of 4.0% (95% CI −0.2%–8.3%; $P = 0.06$) was found for prostate cancer-specific mortality (7.4% vs. 11.4%). On subgroup analysis, surgery reduced all-cause mortality among men with intermediate-risk disease (ARR = 14.5%; 95% CI 2.8%–25.6%). By contrast, no benefit was seen in the low- or high-risk groups. Although surgery reduced the need for treatment of progressive disease, there were increased incidences of therapy-related long-term complications such as urinary incontinence and erectile and sexual dysfunction.

One of the major concerns regarding the PIVOT study design was that the inclusion criterion for the study was life expectancy of more than 10 years. However, according to the analysis of all-cause mortality after 10 years of follow-up, nearly 40% of the study population had died, with only approximately 5% from prostate cancer. After 15 years, up to 60% had died, with approximately 10% from prostate cancer. These considerations suggest poor risk assessment at baseline inclusion and lessen the impact of the study. Since the design of the study, it is now well understood that patients with low-risk prostate cancer and comorbidities do not benefit within 10 years from radical interventions.

Prostate Cancer Outcomes Study.

To determine the relative rate of mortality in men undergoing radical prostatectomy or radiotherapy, an observational cohort from the population-based Prostate Cancer Outcomes Study was conducted, which included men aged 55 to 74 years diagnosed with localized prostate cancer between October 1994 and October 1995 who underwent either radical prostatectomy ($n = 1164$) or EBRT ($n = 491$) within 1 year of diagnosis. Patients were followed until death or study end. Overall and disease-specific mortality were assessed with multivariable analyses with propensity scores. After 15 years of follow-up, there were 568 deaths, including 104 from prostate cancer. Radical prostatectomy was associated with statistically significant advantages for overall (hazard ratio [HR] = 0.60; 95% CI 0.53–0.70; $P < 0.0001$) and disease-specific mortality (HR = 0.35; 95% CI 0.26–0.49; $P < 0.0001$). Although this study supports a long-standing idea that the benefit of surgery over radiation is greatest in younger men and those with lower disease risk features, it also supports an improved survival in older men and those with high-risk disease. In all subgroups differences in overall and cancer-specific mortality were recorded as early as 3 years after therapy. These results are inconsistent with early stage disease. Some of the findings are not intuitive and suggest the potential for selection bias in the prostatectomy cases despite the propensity scoring technique. For example, among men with low-risk disease the overall mortality was decreased in surgically treated patients compared with radiated patients, although cancer-specific mortality did not differ. This finding may be attributable to differences in the groups not recorded in the existing data set, such as disease volume, true stage and unrecorded predictors of non-oncologic mortality.

ProtecT.

The Prostate Testing for Cancer and Treatment (ProtecT) trial was a randomized trial of prostatectomy, external-beam radiation with androgen deprivation, or prostate-specific antigen–based active monitoring (Hamdy et al., 2016). Between 1999 and 2009, a total of 82,429 men 50 to 69 years of age received a PSA test; 2664 received a diagnosis of localized prostate cancer, and 1643 agreed to undergo randomization to active monitoring (545 men), surgery (553 men), or radiotherapy (plus 3–6 months of androgen deprivation therapy, 545 men). The primary outcome was prostate-cancer mortality at a median of 10 years of follow-up. Secondary outcomes included the rates of disease progression, metastases, and all-cause death. In total, 62% of eligible men accepted randomization, comprising a cohort with mostly low- to intermediate-risk tumors. Rates of immediate crossover were substantial. Only 88%, 71%, and 74% of the men assigned to monitoring, prostatectomy, and radiation, respectively, received their assigned management. A quarter of the men embarking on monitoring were treated within 3 years, and more than half within the first 10 years. The primary outcome of prostate cancer mortality was not different between the three arms at a median follow-up of 10 years. However, the incidence of metastases was higher in the active monitoring group. The majority of included patients had a low PSA and Gleason 6 tumors (grade group 1). Because the chance of low-risk patients dying from prostate cancer within 10 years is very low, longer follow-up may be needed to draw firm conclusions. The mortality in the study was approximately 1%, which is low in comparison with the predicted mortality of 15% at the time the study was designed, thereby reducing the power of the study to assess its intended purpose.

Functional Outcomes

Maximizing quality of life for patients with prostate cancer is a critical goal of active management and shared decision making. Because differences in oncologic outcomes for individual treatment approaches are controversial at best, patients must thoroughly consider acute and long-term effects on quality of life in choosing treatment modality. These quality-of-life concerns should be discussed in detail with patients during pretreatment counseling (Lardas et al., 2017).

Historically comparisons of functional outcomes of surgery and radiation have been based on large, single institution centers of excellence, thereby decreasing the generalizability of the findings and minimizing the accuracy of the comparison resulting from wide selection biases. Efforts to compare outcomes from large population data sets have similarly been limited by the inadequacy of the recorded data fields, inaccuracy of recording instruments, and wide skill sets and therapeutic approaches of the represented operators. Several large comparative trials have now been published, allowing new insight into the functional outcomes after prostate cancer treatment (see Table 2 in https://jamanetwork.com/journals/jama/fullarticle/2612617).

Prostate Cancer Outcomes Study.

Urinary, bowel, and sexual function at short and intermediate term as well as up to 15 years after prostatectomy or EBRT have been reported in men from the population-based Prostate Cancer Outcomes Study (PCOS), diagnosed with localized cancer in the mid-1990s (Resnick et al., 2013). Patients undergoing prostatectomy were more likely to have urinary incontinence than were those undergoing radiotherapy at 2 years (odds ratio, 6.22; 95% CI 1.92–20.29) and 5 years (odds ratio, 5.10; 95% CI 2.29–11.36) of follow-up. However, no significant between-group difference in the odds of urinary incontinence was noted at 15 years. Similarly, although patients undergoing prostatectomy were more likely to have erectile dysfunction at 2 years (odds ratio, 3.46; 95% CI 1.93–6.17) and 5 years (odds ratio, 1.96; 95% CI 1.05–3.63), no significant between-group difference was noted at 15 years. Patients undergoing prostatectomy were less likely to have bowel urgency at 2 years (odds ratio, 0.39; 95% CI 0.22–0.68) and 5 years (odds ratio, 0.47; 95% CI 0.26–0.84), again with no significant between-group difference in the odds of bowel urgency at 15 years. These data, taken together, appear to suggest patients in the PCOS had significant declines in sexual and urinary function over the duration of the study. The possible reasons for the first finding include declining sexual interest with age, acceptance of sexual dysfunction over time, or both. Likewise, the causes of urinary decline probably include advancing age and additional cancer treatments.

ProtecT.

Patient-reported outcomes from the ProtecT trial have shown that of the three treatments (active monitoring, radical prostatectomy, and radical radiotherapy with hormones), prostatectomy had the greatest negative effect on sexual function and urinary continence, and although there was some recovery, these outcomes remained worse in the prostatectomy group than in the other groups throughout the trial (Donovan et al., 2016). The negative effect of radiotherapy on sexual function was greatest at 6 months, but sexual function then recovered somewhat and was stable but below baseline thereafter. Radiotherapy had little effect on urinary continence. Sexual and urinary function declined gradually in the active-monitoring group. Bowel function was worse in the radiotherapy group at 6 months than in the other groups but then recovered somewhat, except for the increasing frequency of bloody stools. Bowel function was unchanged in the other groups. Urinary voiding and nocturia were worse in the radiotherapy group at 6 months but then recovered and were similar to the other groups after 12 months. Effects on quality of life mirrored the reported changes in function.

No significant differences were observed among the groups in measures of anxiety, depression, or general health-related or cancer-related quality of life.

Comparative Effectiveness Analysis of Surgery and Radiation.

Similar outcomes have been reported from the Comparative Effectiveness Analysis of Surgery and Radiation (CEASAR) study, a prospective, population-based, observational study that enrolled men with localized prostate cancer in 2011 and 2012 (Tyson et al., 2018). Low-risk EBRT patients reported 3-year sexual function scores 12 points higher than those of low-risk radial prostatectomy (RP) patients (RP, 39 points [95% CI 37–42] versus EBRT, 52 points [95% CI 47–56]; $P < 0.001$). The difference in 3-year scores for high-risk patients was not clinically significant (RP, 32 points [95% CI 28–35] vs. EBRT, 38 points [95% CI 33–42]; $P = 0.03$). However, with a commonly used binary definition of sexual function (erections firm enough for intercourse), no major differences were noted between RP and EBRT at 3 years of follow-up, across low-, intermediate-, and high-risk disease strata. These data have been updated to include functional outcomes of men on active surveillance. In this cohort of men with localized prostate cancer, 3 years after treatment, radical prostatectomy was associated with a greater decrease in sexual function and urinary incontinence than EBRT or active surveillance and was associated with fewer urinary irritative symptoms than active surveillance; however, no meaningful differences existed in either bowel or hormonal function beyond 12 months or in in other domains of health-related quality-of-life measures (Barocas et al., 2017).

Open versus Robotic Prostatecomy.

One randomized controlled phase III trial has been published comparing robotic-assisted laparoscopic and open radical prostatectomy, demonstrating the two techniques yield similar functional outcomes at 12 weeks (Yaxley et al., 2016). Robot-assisted radical prostatectomy has, however, been shown to improve functional and oncologic outcomes in a single surgeon's learning curve (Thompson et al., 2018). In an analysis of community-based outcomes, most patients experienced changes in urinary and sexual quality of life in the first 3 years after prostatectomy. The pattern of recovery over time was similar between open and robotic-assisted groups. The authors suggested patients should not expect different oncologic or quality-of-life outcomes based on surgical approach (Herlemann et al., 2018). Robot-assisted surgery also has been noted to facilitate easier identification of nerve preservation planes during radical prostatectomy as well as wider dissection for pT3 cases (Sooriakumaran et al., 2018), but such observations may reflect surgeon bias.

Patient Counseling: a Stepwise Decision Approach

In considering the management of newly diagnosed prostate cancer, men often become confused and anxious because of the multitude of options available to them and the conflicting information presented by individual treating physicians. Physicians may have trouble in offering objective advice regarding therapy because of the paucity of direct comparative data. **In approaching the newly diagnosed prostate cancer patient, using a methodical stepwise approach in considering the patient and presenting options to the patient can reduce confusion and anxiety** (Fig. 153.4). Through presentation of the relevant aspects of decision making, the patient is empowered to make an informed decision with regard to treatment necessity and treatment type. Patients are typically confronted with a decision about in which domain they are most willing to take on risk. In deciding between management strategies, the divergent risks are often those related to oncologic control/cancer mortality, and those related to treatment side effects and quality of life. As such, an approach of reviewing all options as a menu of choices is often without context and provides confusion because the goals of individual management strategies may be different.

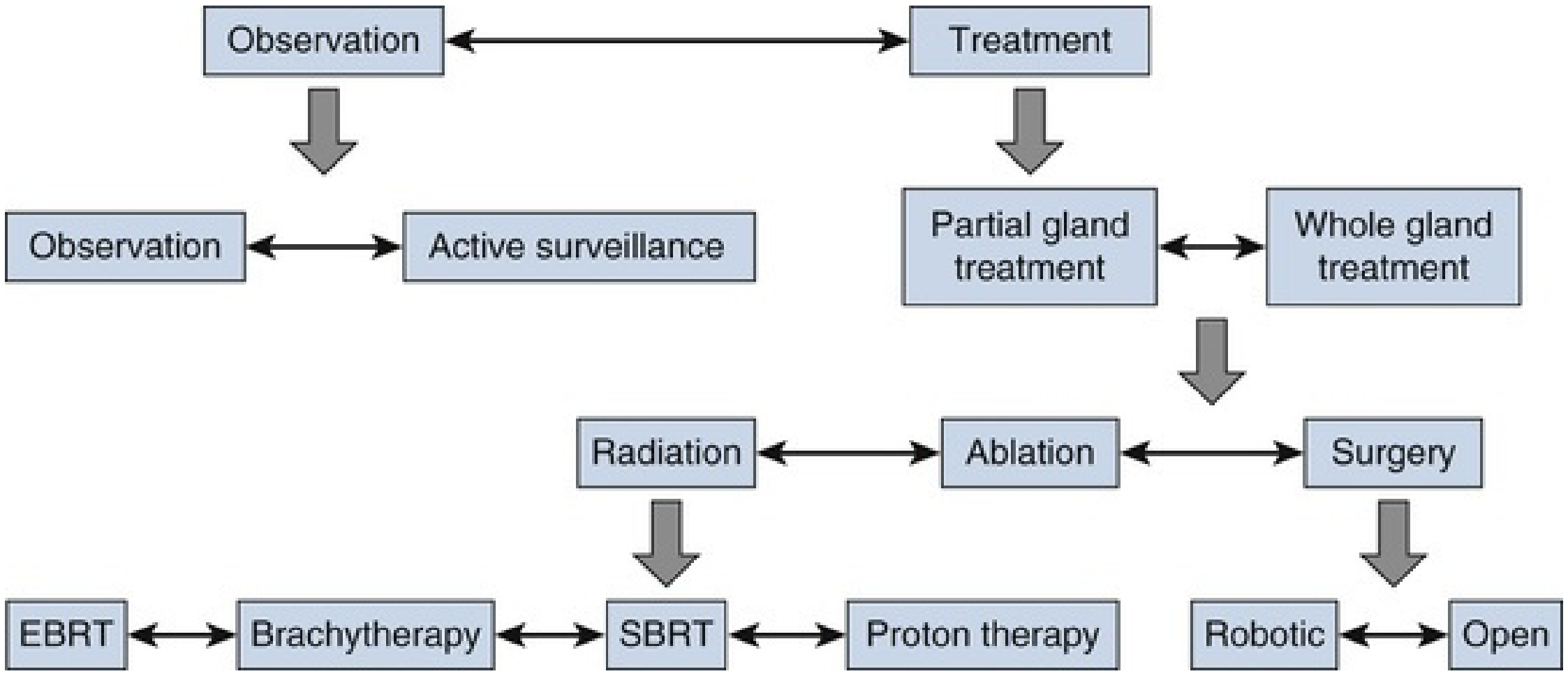
Observation
Treatment
Observation
Active surveillance
Partial gland treatment
Whole gland treatment
Radiation
Ablation
Surgery
EBRT
Brachytherapy
SBRT
Proton therapy
Robotic
Open

FIG. 153.4 Patient counseling in localized prostate cancer: a stepwise decision approach. *EBRT,* External-beam radiation therapy; *SBRT,* stereotactic body radiation therapy.

Decision One: Observation versus Active Treatment

The stepwise approach first asks whether observation or treatment is the best first step (see Fig. 153.4). In counseling patients in this regard, clinicians should make a distinction between observation and active surveillance, with the latter being a strategy of active monitoring through repetitive testing and the latter being a decision to passively monitor for symptomatic progression only. The goal of active surveillance is to observe the patient until a time that clear evidence of need for treatment arises. In this regard, for many younger men, it is a deferral of treatment. In the case of observation, or non-treatment, the patient and the physician agree to take on the potential risk of disease progression and mortality, with plan for treatment typically only at the time of symptoms or extensive metastatic progression. In practice, many patients are monitored by a combination of these strategies, without a clearly established goal; currently there is no consensus regarding the optimal method of monitoring among surveillance cohorts (Loeb et al., 2016).

Among men newly diagnosed, the option of observation is most frequently employed among those men who are deemed to be at low risk of prostate cancer death because of competing risks for mortality and prolonged lead time in disease progression. As such, potentially curative treatment is not considered in this group because it has a low likelihood of improving longevity. In these men, follow-up generally consists of periodic PSA testing to assess the rapidity of disease progression, clinical exam, and selective use of imaging to monitor disease progression. Although curative-intent therapy is typically not used, carefully timed intervention, to avoid disease-related morbidity, remains desirable. At time of symptomatic progression, androgen-deprivation remains the mainstay of therapy, with use of palliative radiotherapy and surgery reserved for disease refractory to systemic intervention.

Contrarily, men choosing to initiate a strategy of active surveillance or monitoring of the disease are typically men with a reasonable expectation of prolonged longevity and limited comorbidities, demonstrated to have low clinical risk for metastatic progression based upon disease characteristics. In these men, the goal of management is often deferral of treatment until a time when progression of disease risk becomes evident. **Although its safety is now well demonstrated in long-term follow-up, men choosing active surveillance**

must feel comfortable with some uncertainty with regard to cancer outcome in exchange for maximal preservation of quality of life. Men must understand a critical need for adherence to follow-up and have a willingness to proceed with treatment at the time of predetermined signs of disease progression. If the uncertainty of surveillance is anxiety provoking for the patient or his family, treatment should be considered. Importantly, men with intermediate- or high-risk disease should be strongly discouraged from surveillance, although increasing age and comorbidity, limiting the certainty of prolonged longevity, may allow consideration of surveillance in men with higher-risk disease features.

Current recommendations from the AUA, ASTRO, SUO, and NCCN endorse the use of active surveillance in men with low-risk disease, and its use has increased over time (Filson et al., 2014, 2016; Loeb et al., 2017, 2018). Specifically, **surveillance should be recommended as the best care option for men with very low risk and the preferable care option for most low-risk, localized prostate cancer.** Although this strategy is widely endorsed, one of the limitations in application includes a 25% to 45% chance of occult high-grade cancer among men diagnosed with low-grade disease by systematic biopsy, lack of consensus regarding appropriate monitoring techniques, declining adherence to surveillance protocols over time (Bokhorst et al., 2015; Loeb et al., 2015, 2016), and unclear trigger points for intervention during the course of surveillance. Despite these limitations, clinical outcomes have been favorable, and this may be explained by the fact that most occult upgrading is to grade group 2 (Gleason 3 +4), which may carry relatively low metastatic potential over the first decade of follow-up. On this basis, there has been a growing interest in considering men with low-volume Gleason grade group 2 prostate cancer for surveillance. However, there remains little consensus in this regard: the presence of any Gleason 4 pattern cancer has been demonstrated to confer an increased risk of eventual metastasis (Klotz et al., 2015). Thus the goals of surveillance include proper candidate selection through baseline risk assessment, monitoring for disease progression over time, and judicious implementation of treatment when appropriate.

Baseline risk stratification has suffered from the inaccuracies of standard biopsy techniques. In this regard risk assessment may be refined through application of MRI and MRI-targeted biopsy in selection of candidates for inclusion. MRI has recently been incorporated into many active surveillance algorithms (Bryant et al., 2018; Klotz et al., 2019; Thurtle et al., 2018). Although most guidelines advocate selective use of MRI, the National Institute for Health and Care Excellence (NICE) guidelines from the United Kingdom mandate an MRI in all active surveillance patients. In addition, genomic testing may offer insight into the risk of occult adverse pathology and may offer insight into the likelihood of progression (Sanda et al., 2018a). In a recent study of men undergoing genomic testing and MRI, high scores with either were associated with biopsy upgrade. Clinical parameters such as biopsy core cancer density and higher PSA density (>0.15) place men at increased risk of being reclassified on subsequent biopsy (Bul et al., 2012, 2013; Welty et al., 2015), although African-American race (Leapman et al., 2016) and age do not.

An inclusive approach (Toronto) (Klotz et al., 2015), including all low-risk and selected intermediate risk (Gleason 7 or PSA >10) patients, and a restrictive approach (Hopkins) (Tosoian et al., 2015) offering surveillance only to patients who fulfilled the Epstein criteria (Gleason 6 with no more than 2 positive cores, no core more than 50% involved, and PSA density <0.15) had been studied as active surveillance protocols (Table 153.2). The actuarial 15-year prostate cancer mortality rate is 5.7% in the inclusive group and a prostate cancer mortality rate of 0.6% in the restrictive (Klotz et al., 2015). Most of the metastatic cases were Gleason score 7 at initial diagnosis (Klotz et al., 2015). There is an emerging consensus that the appropriate strategy lies between these two extremes.

TABLE 153.2

Selection Criteria for Active Surveillance

	CLINICAL STAGE	PSA LEVEL	GLEASON SCORE ON BIOPSY	PSA DENSITY	NUMBER OF POSITIVE BIOPSY CORES
University of Toronto (Schroder et al., 2014)	T1c/T2a	≤10–15 ng/mL	≤ 3+3=6	Not included	Not included
Multicenter European study (PIRAS) (Tsodikov et al., 2018)	T1c/T2a	≤10 ng/mL	≤ 3+3=6	≤ 0.2 ng/mL/cm (Wilt et al., 2012)	2
Johns Hopkins (Wilt et al., 2012)	T1c	Not included	≤ 3+3=6	≤ 0.15 ng/mL/cm (Wilt et al., 2012)	2
Canary Collaboration	T1/T2	Any	≤ 7	Any	Any

(Andriole et al., 2009)					

Bokhorst LP, Alberts AR, Rannikko A, et al.: Compliance rates with the Prostate Cancer Research International Active Surveillance (PRIAS) Protocol and disease reclassification in noncompliers. *Eur Urol* 68:814, 2015; Klotz L, Vesprini D, Sethukavalan P, et al.: Long-term follow-up of a large active surveillance cohort of patients with prostate cancer. *J Clin Oncol* 33:272, 2015; Newcomb LF, Thompson IM Jr, Boyer HD, et al.: Outcomes of active surveillance for clinically localized prostate cancer in the prospective, multi-institutional canary PASS Cohort. *J Urol* 195:313, 2016; Tosoian JJ, Mamawala M, Epstein JI, et al.: Intermediate and longer-term outcomes from a prospective active-surveillance program for favorable-risk prostate cancer. *J Clin Oncol* 33:3379, 2015.

The appropriate method of surveillance remains controversial (Table 153.3). Traditionally, serial annual biopsy has allowed detection of occult high-grade disease and disease progression, although it is difficult to distinguish between the two. In general, a confirmatory biopsy, to be conducted within 6 to 12 months after diagnosis, is advocated by most protocols, but the frequency of subsequent biopsy is highly variable. A number of modeling evaluations have demonstrated that reduced sampling frequency may only slightly delay detection of disease progression while greatly reducing biopsy frequency (Inoue et al., 2018). One such protocol is that of the Prostate Cancer Research International Active Surveillance (PRIAS) program (van den Bergh et al., 2007), which is being increasingly used, particularly in Europe. Instead of annual pathological surveillance, patients undergo periodic PSA testing with less frequent biopsies. In these monitoring programs, PSA doubling time (PSADT) is used to determine the need for biopsy or intervention.

TABLE 153.3

National Active Surveillance Guidelines

ORGANIZATION	RECOMMENDATIONS FOR LOW-RISK PROSTATE CANCER	RECOMMENDATIONS FOR INTERMEDIATE-RISK PROSTATE CANCER	TESTS RECOMM FOR ACTI SURVEIL MONITOR
ASCO (Schroder et al., 2014)	AS is preferred management	Active treatment; active surveillance for select patients	PSA eve months DRE an Systema biopsy 6–12 m diagnos

			biopsy, every 3-
NCCN (Tsodikov et al., 2018)	Very low-risk prostate cancer: AS is preferred management Low-risk prostate cancer: all therapies are options	Active treatment; active surveillance for select patients	PSA eve months Biopsy annuall
AUA (Andriole et al., 2009; Wilt et al., 2012)	Very low-risk prostate cancer: AS is preferred management Low-risk prostate cancer: AS is preferred management. May offer definitive treatment to select patients with high probability of progression	Active treatment; active surveillance for select patients	Routine and DR Biopsy initial 2
NICE (Andriole et al., 2012)	AS is preferred management	Radical treatment for disease progression	PSA eve months, monitor kinetics DRE an Systema biopsy 6–12 m diagnos biopsy, every 3-

AS, Active surveillance; *ASCO,* American Society of Clinical Oncology; *AUA,* American Urological Association; *DRE,* digital rectal exam; *MRI,* magnetic resonance imaging; *NCCN,* National Comprehensive Cancer Network; *NICE,* National Institute for Health and Care Excellence; *PSA,* prostate-specific antigen.

Data from Bekelman JE, Rumble RB, Chen RC, et al.: Clinically localized prostate cancer: ASCO Clinical Practice Guideline Endorsement of an American Urological Association/American Society for Radiation Oncology/Society of Urologic Oncology Guideline. *J Clin Oncol* JCO1800606, 2018; NCCN Clinical Practice Guidelines in Oncology (NCCN Guidelines), Prostate cancer, version 1, 2017 (website): https://www.nccn.org/professionals/physician_gls/pdf/prostate.pdf; Sanda MG, Cadeddu JA, Kirkby E, et al.: Clinically localized prostate cancer: AUA/ASTRO/SUO Guideline.

Part I: Risk stratification, shared decision making, and care options. *J Urol* 199:683, 2018; Sanda MG, Cadeddu J A, Kirkby E, et al.: Clinically localized prostate cancer: AUA/ASTRO/SUO Guideline. Part II: Recommended approaches and details of specific care options. *J Urol* 199:990, 2018; National Institute for Health and Care Excellence: Cancer, 2014 (website): https://www.nice.org.uk/guidance/cg175/chapter/1-Recommendations.

Death in men on active surveillance occurs most commonly from cardiovascular disease and rarely occurs from prostate cancer. In a mature cohort from Toronto (Klotz et al., 2015), with a median follow-up of 9 years, the relative risk for non–prostate-cancer death was 10 times that for prostate cancer mortality. Overall, 15% of men died by 15 years of follow-up, with 1.5% dying from prostate cancer and 2.8% developing metastasis. The likelihood of treatment by 5, 10, and 15 years was 25%, 36%, and 45%, respectively. In the Johns Hopkins series, with more strictly applied criteria, the rate of treatment at 10 and 15 years was 50% and 57%, respectively, with only 26% and 31%, respectively, demonstrating grade progression (Klotz et al., 2015). The benefit of implementing therapy in men with PSA progression only is not clear. **As such, among men considering surveillance, outcomes support safety, but the high rate of treatment suggests a critical need for adherence to follow-up.**

Decision Two: Partial Gland versus Whole Gland Treatment

In men deemed to be in need of treatment, or choosing treatment, the next stepwise decision, in those programs offering focal therapy, is between conventional whole gland/radical therapy and partial gland treatment, typically through thermal ablation. Criteria for selection of men for focal ablation are controversial and vary widely according to institution but typically include demonstration of unifocal, or limited focality, cancer in which imaging and biopsy demonstrate spatial concordance. **In those men, careful counseling regarding risks and benefits is required, with a clear understanding regarding the investigational nature of the approach.** Men must understand the absence of long-term clinical follow-up, the potential need for re-treatment, and the risk of worsened treatment outcomes if conventional therapy is eventually employed as a salvage option. In an ideal setting, partial gland ablation or focal therapy should be considered within a clinical trial setting.

In general, there is little consensus regarding the appropriate selection criteria for focal ablation, as many groups select men on the basis of transperineal mapping template biopsies and others use imaging. Although there is general consensus that high-risk patients should not be treated with focal ablation, given the absence of long-term locoregional control estimates, there is not clear consensus on whether low-risk disease, typically suitable for surveillance, is appropriate for focal ablation (Donaldson et al., 2015; Tay et al., 2017). Some groups have advocated selection of indolent disease for treatment (Tay et al., 2017), whereas most have felt that such treatment would be best applied to men with intermediate risk, limited focality disease (Donaldson et al., 2015; van den Bos et al., 2014). In a recent joint workshop of the Food and Drug Administration, the Society of Urologic Oncology, and the American Urological Association, clinical trial design, optimal end points, and candidate selection were discussed, demonstrating the growing interest in the treatment paradigm (Jarow et al., 2016).

In a study of 1490 men who underwent radical prostatectomy between 2000 and 2007, Tareen et al. (2009) demonstrated that 27.3% of men found to have unilateral disease on systematic biopsy had unilateral disease on final pathology. Clinical parameters demonstrating low-risk disease were unable to improve the prediction of unilateral disease. Others have demonstrated that the use of transperineal mapping template biopsy may improve the demonstration of multifocality, but as of yet the optimal template is not agreed upon (Singh et al., 2014). More recently, MRI-targeted biopsies have been suggested to improve the selection of men suitable for focal ablation, accepting that additional foci of indolent prostate cancer may be untreated (Nassiri et al., 2018).

The premise of focal therapy is that the index lesion, or dominant tumor, remains the primary origin of metastasis and potential lethality (Ahmed, 2009; Liu et al., 2009). Although proper methods of defining the index lesion remain unclear, it is generally considered by most to be the largest tumor focus with the highest Gleason score, most likely seen on MRI. The rationale for focal therapy remains untested in long-term follow-up but has led many investigators and clinicians to expand inclusion criteria for focal therapy to include men with low-grade secondary and tertiary sites of disease to be knowingly left untreated at time of index lesion ablation (Ahmed et al., 2015; Bott et al., 2010). Because the goal of focal therapy is primarily in destroying the index lesion, men enlisting for a focal ablative approach should realize that there is a high likelihood or residual cancer foci, whether recognized or not recognized by the baseline biopsy. The long-term efficacy of such approaches, along with the eventual impact upon survival, is unknown.

Decision Three: Surgery vs. Radiation versus Whole-Gland Ablation

If men require or desire whole-gland therapy, the next stepwise decision is between surgery, radiation, and whole-gland ablation. Although whole-gland ablation exists as an option, in many regards, consideration of its use is similar to that of focal ablative treatments. There is a paucity of long-term follow-up data, re-treatment is often required, and, when needed, salvage surgery is complicated by periprostatic scarring and fibrosis. The primary attraction of whole-gland ablation is the potential to preserve sexual and urinary function. Although whole-gland cryoablation almost always results in erectile dysfunction, preservation of function with whole-gland high-intensity focused ultrasound (HIFU) is more common but may vary with the aggressiveness and oncologic efficacy of the procedure. In addition, the need for re-treatment is 29% to 38% (Crouzet et al., 2010, 2014; Dickinson et al., 2016) with an increased rate of erectile dysfunction and stricture after a second treatment. As such, men considering whole-gland ablation by HIFU should be counseled with regard to the paucity of long-term outcomes and the potential need for re-treatment.

In general, the majority of decision making in whole gland therapy is between surgery and radiation. In counseling men regarding this most difficult decision, full assessment of patient longevity, baseline function, and goals of treatment is warranted. Although the goal of surveillance and investigational focal therapy is preservation of function, men seeking radical therapy are often primarily concerned with durable cancer control. Assessment of the cancer risk using one of several risk models allows an informed discussion of treatment efficacy and potential need for secondary treatments or multimodal approaches.

Much of the counseling relates to relative efficacy, but more often patients are concerned with relative risks and toxicities. Although a number of forms of radiation exist, the general side effect profiles are comparable, and comparisons between surgery and radiation can be made in general. Although there is a general belief that comparative data have demonstrated relatively equivalent oncologic outcomes between surgery and radiation at 10 years of follow-up, physician recommendations regarding surgery and radiation are often rooted in perceptions of patient longevity, disease risk, and secondary benefits and risks of treatment related to urinary and sexual quality of life. **In general, the decision between surgery and radiation, for most men with localized prostate cancer, is dependent upon patient perception and preference, and a decision**

regarding which anticipated side effects seem most tolerable to the individual.

Although an extensive discussion of the outcomes of prostatectomy and radiation is beyond the scope of this chapter and is covered elsewhere in the text, several points are noteworthy within the context of patient counseling and decision making. When men elect to undergo whole-gland therapy, realistic expectations regarding early outcomes must be provided before the treatment. Among men undergoing radical prostatectomy, early urinary and sexual toxicity is the norm, and patients should be mentally prepared to suffer incontinence and impotence in the early postoperative period to avoid decisional regret and frustration (Schroeck et al., 2008, 2012). Establishing a realistic time line and probability for recovery, along with a therapeutic plan, allows patients to tolerate recovery better. It is desirable that surgeons provide such outcome data, and expected recovery rates, based upon their own experience; outcomes are shown to be highly surgeon dependent.

In deciding between surgery and radiation, baseline urinary and sexual function should be carefully considered as outlined earlier. Men with significant baseline obstructive and irritative symptoms may benefit from surgery despite the early deterioration in urinary quality of life. Although randomized studies suggest relative equivalence of outcomes at 10 years (Hamdy et al., 2016), there are limited data regarding 15 to 20 years of follow-up, and as such, younger patients should be counseled regarding outcomes within the context of their estimated longevity.

When choosing radiation therapy, men may avoid the noted short-term urinary and sexual functional side effects, but counseling should focus on the long-term risks because most studies show incremental decline in urinary and sexual function, greater than the matched general population, with each year of follow-up (Barocas et al., 2017; Resnick et al., 2013; Tyson et al., 2018). The risk of delayed secondary malignancies is perhaps more controversial, but several studies support an increased risk of rectal and bladder malignancy at 15 to 20 years after external beam radiation (Nieder et al., 2008; Rombouts et al., 2018; Zhu et al., 2018). If intermediate or high risk, the best evidence often supports use of concomitant androgen deprivation therapy, and, as such, the early toxicity after radiation may be primarily driven by this. Despite the long-term risks, many men opt for radiation because of the clearly better early urinary and sexual outcomes as compared with surgery. Young men should be cautioned regarding the long-term risks as they relate to recurrence and toxicity.

Decision Four: Type of Treatment Delivery

Once a decision regarding a type of whole-gland therapy is made, further stepwise decisions relate to the available options for delivery of that modality. A specialist highly experienced in the delivery of that particular modality generally is best suited to conduct such discussions. In the case of surgery decisions between robotic-assisted laparoscopic and robotic approaches are generally related to the individual surgeon's experience and comfort level. Radiation has a multitude of options for treatment delivery, including external beam radiotherapy using intensity-modulated, image-guided, and/or three-dimensional conformal techniques; interstitial radiation using permanent seed implants or high dose rate temporary insertion; stereotactic body radiotherapy; and proton therapy. Radiation can be delivered in combinations, with conventional or hypofractionated treatment schemes. There has been growing concern that counseling regarding individual treatment options is often biased by financial incentives and physician biases (Bekelman et al., 2013).

Conclusion

The active management of prostate cancer is a complex process rooted in careful evaluation of the cancer and the host. The relative risk of cancer progression, metastasis, and cancer-specific mortality over time must be framed within the context of competing risks for mortality and the patient's expected longevity. Cancer risk can be assessed by a growing number of tools including biopsy pathology, image-based staging, MRI, and genomic markers. Available data can be combined for prognostic predictions through one of a multitude of validated nomograms or risk assessment scores. Patient longevity can be predicted on the basis of age, comorbidities, and standardized scales of longevity assessment. Collectively, these data can be integrated to provide the patient with available, appropriate management options, and an individualized decision-making framework. Because the available treatments are many and the goals of differing management strategies are often divergent, a stepwise or decision-tree patient counseling approach can simplify patient counseling and offer more informed decisions, thereby reducing decisional regret.

References

Abdollah F, Sun M, Schmitges J, et al. Cancer-specific and other-cause mortality after radical prostatectomy versus observation in patients with prostate cancer: competing-risks analysis of a large North American population-based cohort. *Eur Urol*. 2011;60:920.

Abdollah F, Sun M, Thuret R, et al. A competing-risks analysis of survival after alternative treatment modalities for prostate cancer patients: 1988-2006. *Eur Urol*. 2011;59:88.

Abraham N, Wan F, Montagnet C, et al. Decrease in racial disparities in the staging evaluation for prostate cancer after publication of staging guidelines. *J Urol*. 2007;178:82.

Aghazadeh MA, Frankel J, Belanger M, et al. National comprehensive cancer network(r) favorable intermediate risk prostate cancer-is active surveillance appropriate? *J Urol*. 2018;199:1196.

Ahmed HU. The index lesion and the origin of prostate cancer. *N Engl J Med*. 2009;361:1704.

Ahmed HU, Dickinson L, Charman S, et al. Focal ablation targeted to the index lesion in multifocal localised prostate cancer: a prospective development study. *Eur Urol*. 2015;68:927.

Albertsen PC. Risk factors for prostate cancer: which are truly predictive of clinically significant disease? *J Clin Oncol*. 2016;34:4310.

American Urological Association. [Prostate cancer guideline for the management of clinically localized prostate cancer: 2007 update (website)] http://www.auanet.org/common/pdf/education/clinical-guidance/Prostate-Cancer.pdf; 2007.

Andriole GL, Crawford ED, Grubb RL 3rd, et al. Mortality results from a randomized prostate-cancer screening trial. *N Engl J Med*. 2009;360:1310.

Andriole GL, Crawford ED, Grubb RL 3rd, et al. Prostate cancer screening in the randomized Prostate, Lung, Colorectal, and Ovarian Cancer Screening Trial: mortality results after 13 years of follow-up. *J Natl Cancer Inst*. 2012;104:125.

Asano T, Yamada S, Fujii T, et al. The Charlson age comorbidity index predicts prognosis in patients with resected pancreatic cancer. *Int J Surg*. 2017;39:169.

Barocas DA, Alvarez J, Resnick MJ, et al. Association between radiation therapy, surgery, or observation for localized prostate cancer and patient-reported outcomes after 3 years. *J Am Med Assoc*. 2017;317:1126.

Barry MJ, Fowler FJ Jr, O'Leary MP, et al. The American Urological Association symptom index for benign prostatic hyperplasia. The Measurement Committee of the American Urological Association. *J Urol*. 1992;148:1549.

Bastian PJ, Mangold LA, Epstein JI, et al. Characteristics of insignificant clinical T1c prostate tumors. A contemporary analysis. *Cancer*. 2004;101:2001.

Bekelman JE, Suneja G, Guzzo T, et al. Effect of practice integration between urologists and radiation oncologists on prostate cancer treatment patterns. *J Urol*. 2013;190:97.

Bekelman JE, Rumble RB, Chen RC, et al. Clinically localized prostate cancer: ASCO clinical practice guideline endorsement of an American Urological Association/American Society for Radiation Oncology/Society of Urologic Oncology Guideline. *J Clin Oncol*. 2018.

Bianco FJ Jr, Kattan MW, Scardino PT, et al. Radical prostatectomy nomograms in black American men: accuracy and applicability. *J Urol*. 2003;170:73.

Bill-Axelson A, Holmberg L, Garmo H, et al. Radical prostatectomy or watchful waiting in early prostate cancer. *N Engl J Med*. 2014;370:932.

Billis A, Guimaraes MS, Freitas LL, et al. The impact of the 2005 international society of urological pathology consensus conference on standard Gleason grading of prostatic carcinoma in needle biopsies. *J Urol*. 2008;180:548.

Bjurlin MA, Meng X, Le Nobin J, et al. Optimization of prostate biopsy: the role of magnetic resonance imaging targeted biopsy in detection, localization and risk assessment. *J Urol*. 2014;192:648.

Bjurlin MA, Rosenkrantz AB, Beltran LS, et al. Imaging and evaluation of patients with high-risk prostate cancer. *Nat Rev Urol*. 2015;12:617.

Bjurlin MA, Turkbey B, Rosenkrantz AB, et al. Imaging the high-risk prostate cancer patient: current and future approaches to staging. *Urology*. 2018;116:3.

Blasko JC, Ragde H, Grimm PD. Transperineal ultrasound-guided implantation of the prostate: morbidity and complications. *Scand J Urol Nephrol Suppl*. 1991;137:113.

Blute ML, Bergstralh EJ, Partin AW, et al. Validation of Partin tables for predicting pathological stage of clinically localized prostate cancer. *J Urol*. 2000;164:1591.

Bokhorst LP, Alberts AR, Rannikko A, et al. Compliance rates with the Prostate Cancer Research International Active Surveillance (PRIAS) protocol and disease reclassification in noncompliers. *Eur Urol*. 2015;68:814.

Bott SR, Ahmed HU, Hindley RG, et al. The index lesion and focal therapy: an analysis of the pathological characteristics of prostate cancer. *BJU Int*. 2010;106:1607.

Bratt O, Folkvaljon Y, Hjalm Eriksson M, et al. Undertreatment of men in their seventies with high-risk nonmetastatic prostate cancer. *Eur Urol*. 2015;68:53.

Briganti A, Chun FK, Salonia A, et al. Validation of a nomogram predicting the probability of lymph node invasion among patients undergoing radical prostatectomy and an extended pelvic lymphadenectomy. *Eur Urol*. 2006;49:1019.

Briganti A, Chun FK, Salonia A, et al. Validation of a nomogram predicting the probability of lymph node invasion based on the extent of pelvic lymphadenectomy in patients with clinically localized prostate cancer. *BJU Int*. 2006;98:788.

Briganti A, Passoni N, Ferrari M, et al. When to perform bone scan in patients with newly diagnosed prostate cancer: external validation of the currently available guidelines and proposal of a novel risk stratification tool. *Eur Urol*. 2010;57:551.

Brockman JA, Alanee S, Vickers AJ, et al. Nomogram predicting prostate cancer-specific mortality for men with biochemical recurrence after radical prostatectomy. *Eur Urol*. 2015;67:1160.

Brousil P, Hussain M, Lynch M, et al. Modified transurethral resection of the prostate (TURP) for men with moderate lower urinary tract symptoms (LUTS) before brachytherapy is safe and feasible. *BJU Int*. 2015;115:580.

Bryant RJ, Yang B, Philippou Y, et al. Does the introduction of prostate multiparametric MRI into active surveillance of localised prostate cancer improve patient re-classification? *BJU Int*. 2018;122(5):794–800.

Bul M, van den Bergh RC, Rannikko A, et al. Predictors of unfavourable repeat biopsy results in men participating in a prospective active surveillance program. *Eur Urol*. 2012;61:370.

Bul M, Zhu X, Valdagni R, et al. Active surveillance for low-risk prostate cancer worldwide: the PRIAS study. *Eur Urol*. 2013;63:597.

Carroll PR, Parsons JK, Andriole G, et al. NCCN Guidelines Insights: prostate cancer early detection, Version 2.2016. *J Natl Compr Canc Netw*. 2016;14:509.

Carter HB, Partin AW, Walsh PC, et al. Gleason score 6 adenocarcinoma: should it be labeled as cancer? *J Clin Oncol*. 2012;30:4294.

Catalona WJ, Partin AW, Sanda MG, et al. A multicenter study of [-2]pro-prostate specific antigen combined with prostate specific antigen and free prostate specific antigen for prostate cancer detection in the 2.0 to 10.0 ng/ml prostate specific antigen range. *J Urol*. 2011;185:1650.

Charlson ME, Pompei P, Ales KL, et al. A new method of classifying prognostic comorbidity in longitudinal studies: development and validation. *J Chronic Dis*. 1987;40:373.

Choi EY, Jeong J, Kang DI, et al. Impact of robot-assisted radical prostatectomy on health-related quality of life in patients with lower urinary tract symptoms. *Int J Urol*. 2011;18:297.

Chong Y, Kim CK, Park SY, et al. Value of diffusion-weighted imaging at 3 T for prediction of extracapsular extension in patients with prostate cancer: a preliminary study. *AJR Am J Roentgenol*. 2014;202:772.

Cooperberg MR, Pasta DJ, Elkin EP, et al. The University of California, San Francisco Cancer of the Prostate Risk Assessment score: a straightforward and reliable preoperative predictor of disease recurrence after radical prostatectomy. *J Urol*. 2005;173:1938.

Cooperberg MR, Broering JM, Carroll PR. Risk assessment for prostate cancer metastasis and mortality at the time of diagnosis. *J Natl Cancer Inst*. 2009;101:878.

Cooperberg MR, Vickers AJ, Broering JM, et al. Comparative risk-adjusted mortality outcomes after primary surgery, radiotherapy, or androgen-deprivation therapy for localized prostate cancer. *Cancer*. 2010;116:5226.

Cornud F, Rouanne M, Beuvon F, et al. Endorectal 3D T2-weighted 1 mm-slice thickness MRI for prostate cancer staging at 1.5Tesla: should we reconsider the indirects signs of extracapsular extension according to the D'Amico tumor risk criteria? *Eur J Radiol*. 2012;81:e591.

Crawford ED, Stone NN, Yu EY, et al. Challenges and recommendations for early identification of metastatic disease in prostate cancer. *Urology*. 2014;83:664.

Crouzet S, Rebillard X, Chevallier D, et al. Multicentric oncologic outcomes of high-intensity focused ultrasound for localized prostate cancer in 803 patients. *Eur Urol*. 2010;58:559.

Crouzet S, Chapelon JY, Rouviere O, et al. Whole-gland ablation of localized prostate cancer with high-intensity focused ultrasound: oncologic outcomes and morbidity in 1002 patients. *Eur Urol*. 2014;65:907.

Cuzick J, Swanson GP, Fisher G, et al. Prognostic value of an RNA expression signature derived from cell cycle proliferation genes in patients with prostate cancer: a retrospective study. *Lancet Oncol*. 2011;12:245.

de la Calle C, Patil D, Wei JT, et al. Multicenter evaluation of the Prostate Health Index to detect aggressive prostate cancer in biopsy naive men. *J Urol*. 2015;194:65.

Daskivich TJ, Chamie K, Kwan L, et al. Improved prediction of long-term, other cause mortality in men with prostate cancer. *J Urol*. 2011;186:1868.

Daskivich TJ, Chamie K, Kwan L, et al. Overtreatment of men with low-risk prostate cancer and significant comorbidity. *Cancer*. 2011;117:2058.

Daskivich TJ, Lai J, Dick AW, et al. Variation in treatment associated with life expectancy in a population-based cohort of men with early-stage prostate cancer. *Cancer*.

2014;120:3642.

Daskivich TJ, Fan KH, Koyama T, et al. Prediction of long-term other-cause mortality in men with early-stage prostate cancer: results from the Prostate Cancer Outcomes Study. *Urology*. 2015;85:92.

Daskivich TJ, Kwan L, Dash A, et al. An age adjusted comorbidity index to predict long-term, other cause mortality in men with prostate cancer. *J Urol*. 2015;194:73.

Daskivich TJ, Lai J, Dick AW, et al. Questioning the 10-year life expectancy rule for high-grade prostate cancer: comparative effectiveness of aggressive vs nonaggressive treatment of high-grade disease in older men with differing comorbid disease burdens. *Urology*. 2016;93:68.

Davis BJ, Horwitz EM, Lee WR, et al. American Brachytherapy Society consensus guidelines for transrectal ultrasound-guided permanent prostate brachytherapy. *Brachytherapy*. 2012;11:6.

Davison BJ, Breckon E. Factors influencing treatment decision making and information preferences of prostate cancer patients on active surveillance. *Patient Educ Couns*. 2012;87:369.

D'Amico AV, Whittington R, Malkowicz SB, et al. Biochemical outcome after radical prostatectomy, external beam radiation therapy, or interstitial radiation therapy for clinically localized prostate cancer. *J Am Med Assoc*. 1998;280:969.

De Cobelli F, Ravelli S, Esposito A, et al. Apparent diffusion coefficient value and ratio as noninvasive potential biomarkers to predict prostate cancer grading: comparison with prostate biopsy and radical prostatectomy specimen. *AJR Am J Roentgenol*. 2015;204:550.

Devisetty K, Zorn KC, Katz MH, et al. External beam radiation therapy after transurethral resection of the prostate: a report on acute and late genitourinary toxicity. *Int J Radiat Oncol*

Biol Phys. 2010;77:1060.

Dickinson L, Arya M, Afzal N, et al. Medium-term outcomes after whole-gland high-intensity focused ultrasound for the treatment of nonmetastatic prostate cancer from a multicentre registry cohort. *Eur Urol*. 2016;70:668.

Donaldson IA, Alonzi R, Barratt D, et al. Focal therapy: patients, interventions, and outcomes–a report from a consensus meeting. *Eur Urol*. 2015;67:771.

Donovan JL, Hamdy FC, Lane JA, et al. Patient-reported outcomes after monitoring, surgery, or radiotherapy for prostate cancer. *N Engl J Med*. 2016;375:1425.

Eberhardt SC, Carter S, Casalino DD, et al. ACR Appropriateness Criteria prostate cancer–pretreatment detection, staging, and surveillance. *J Am Coll Radiol*. 2013;10:83.

Epstein JI. An update of the Gleason grading system. *J Urol*. 2010;183:433.

Epstein JI, Walsh PC, Carmichael M, et al. Pathologic and clinical findings to predict tumor extent of nonpalpable (stage T1c) prostate cancer. *J Am Med Assoc*. 1994;271:368.

Epstein JI, Allsbrook WC Jr, Amin MB, et al. The 2005 International Society of Urological Pathology (ISUP) Consensus Conference on Gleason Grading of Prostatic Carcinoma. *Am J Surg Pathol*. 2005;29:1228.

Epstein JI, Egevad L, Amin MB, et al. The 2014 International Society of Urological Pathology (ISUP) Consensus Conference on Gleason Grading of Prostatic Carcinoma: definition of grading patterns and proposal for a new grading system. *Am J Surg Pathol*. 2016;40:244.

Erho N, Crisan A, Vergara IA, et al. Discovery and validation of a prostate cancer genomic classifier that predicts early metastasis following radical prostatectomy. *PLoS ONE*. 2013;8:e66855.

Eschwege P, Ferlicot S, Droupy S, et al. A histopathologic investigation of PGE(2) pathways as predictors of proliferation and invasion in urothelial carcinomas of the bladder. *Eur Urol*. 2003;44:435.

[European Association of Urology: Guidelines on prostate cancer, 2015 (website)] http://uroweb.org/wp-content/uploads/EAU-Guidelines-Prostate-Cancer-2015-v2.pdf.

Filson CP, Schroeck FR, Ye Z, et al. Variation in use of active surveillance among men undergoing expectant treatment for early stage prostate cancer. *J Urol*. 2014;192:75.

Filson CP, Shelton JB, Tan HJ, et al. Expectant management of veterans with early-stage prostate cancer. *Cancer*. 2016;122:626.

Fuchsjager MH, Pucar D, Zelefsky MJ, et al. Predicting post-external beam radiation therapy PSA relapse of prostate cancer using pretreatment MRI. *Int J Radiat Oncol Biol Phys*. 2010;78:743.

Futterer JJ, Engelbrecht MR, Huisman HJ, et al. Staging prostate cancer with dynamic contrast-enhanced endorectal MR imaging prior to radical prostatectomy: experienced versus less experienced readers. *Radiology*. 2005;237:541.

Gearman DJ, Morlacco A, Cheville JC, et al. Comparison of pathological and oncologic outcomes of favorable risk Gleason Score 3 + 4 and low risk Gleason score 6 prostate cancer: considerations for active surveillance. *J Urol*. 2018;199:1188.

Giles SL, Morgan VA, Riches SF, et al. Apparent diffusion coefficient as a predictive biomarker of prostate cancer progression: value of fast and slow diffusion components. *AJR Am J Roentgenol*. 2011;196:586.

Giordano SH, Kuo YF, Duan Z, et al. Limits of observational data in determining outcomes from cancer therapy. *Cancer*.

2008;112:2456.

Gordon A, Skarecky DW, Ahlering T. Long-term outcomes in severe lower urinary tract symptoms in men undergoing robotic-assisted radical prostatectomy. *Urology*. 2014;84:826.

Gordon A, Skarecky D, Osann K, et al. Quantification of long-term stability and specific relief of lower urinary tract symptoms (LUTS) after robot-assisted radical prostatectomy. *Urology*. 2016;93:97.

Hamdy FC, Donovan JL, Lane JA, et al. 10-Year outcomes after monitoring, surgery, or radiotherapy for localized prostate cancer. *N Engl J Med*. 2016;375:1415.

Han S, Woo S, Kim YJ, et al. Impact of (68)Ga-PSMA PET on the management of patients with prostate cancer: a systematic review and meta-analysis. *Eur Urol*. 2018;74:179.

Hattab EM, Koch MO, Eble JN, et al. Tertiary Gleason pattern 5 is a powerful predictor of biochemical relapse in patients with Gleason score 7 prostatic adenocarcinoma. *J Urol*. 2006;175:1695.

He J, Albertsen PC, Moore D, et al. Validation of a contemporary Five-tiered Gleason grade grouping using population-based data. *Eur Urol*. 2017;71:760.

Heidenreich A, Bellmunt J, Bolla M, et al. EAU guidelines on prostate cancer. Part 1: screening, diagnosis, and treatment of clinically localised disease. *Eur Urol*. 2011;59:61.

Henderson DR, de Souza NM, Thomas K, et al. Nine-year follow-up for a study of diffusion-weighted magnetic resonance imaging in a prospective prostate cancer active surveillance cohort. *Eur Urol*. 2016;69:1028.

Herlemann A, Cowan JE, Carroll PR, et al. Community-based outcomes of open versus robot-assisted radical prostatectomy. *Eur Urol*. 2018;73:215.

Ho R, Siddiqui MM, George AK, et al. Preoperative multiparametric magnetic resonance imaging predicts biochemical recurrence in prostate cancer after radical prostatectomy. *PLoS ONE*. 2016;11:e0157313.

Hoffman RM, Koyama T, Fan KH, et al. Mortality after radical prostatectomy or external beam radiotherapy for localized prostate cancer. *J Natl Cancer Inst*. 2013;105:711.

Holmberg L, Bill-Axelson A, Helgesen F, et al. A randomized trial comparing radical prostatectomy with watchful waiting in early prostate cancer. *N Engl J Med*. 2002;347:781.

Horwich A, Parker C, de Reijke T, et al. Prostate cancer: ESMO Clinical Practice Guidelines for diagnosis, treatment and follow-up. *Ann Oncol*. 2013;24(Suppl 6):vi106.

Hu K, Wallner K. Urinary incontinence in patients who have a TURP/TUIP following prostate brachytherapy. *Int J Radiat Oncol Biol Phys*. 1998;40:783.

Inoue LYT, Lin DW, Newcomb LF, et al. Comparative analysis of biopsy upgrading in four prostate cancer active surveillance cohorts. *Ann Intern Med*. 2018;168:1.

Institute of Medicine of the National Academies. *100 initial priority topics for comparative effectiveness research*. [Available at:] http://www.nationalacademies.org/hmd/~/media/Files/Report
%20for%20web.ashx; 2009.

Jarow JP, Ahmed HU, Choyke PL, et al. Partial gland ablation for prostate cancer: report of a Food and Drug Administration, American Urological Association, and Society of Urologic Oncology Public Workshop. *Urology*. 2016;88:8.

Karakiewicz PI, Lattouf JB, Perrotte P, et al. Validation of 1997 Partin Tables' lymph node invasion predictions in men treated with radical prostatectomy in Montreal Quebec. *Can J Urol*. 2005;12:2588.

Kattan MW, Stapleton AM, Wheeler TM, et al. Evaluation of a nomogram used to predict the pathologic stage of clinically localized prostate carcinoma. *Cancer*. 1997;79:528.

Kattan MW, Eastham JA, Stapleton AM, et al. A preoperative nomogram for disease recurrence following radical prostatectomy for prostate cancer. *J Natl Cancer Inst*. 1998;90:766.

Kattan MW, Zelefsky MJ, Kupelian PA, et al. Pretreatment nomogram that predicts 5-year probability of metastasis following three-dimensional conformal radiation therapy for localized prostate cancer. *J Clin Oncol*. 2003;21:4568.

Kattan MW, Cuzick J, Fisher G, et al. Nomogram incorporating PSA level to predict cancer-specific survival for men with clinically localized prostate cancer managed without curative intent. *Cancer*. 2008;112:69.

Kim JH, Ha YS, Jeong SJ, et al. Impact of robot-assisted radical prostatectomy on lower urinary tract symptoms and predictive factors for symptom changes: a longitudinal study. *Urology*. 2013;81:787.

Kimura M, Banez LL, Polascik TJ, et al. Sexual bother and function after radical prostatectomy: predictors of sexual bother recovery in men despite persistent post-operative sexual dysfunction. *Andrology*. 2013;1:256.

Klein EA, Cooperberg MR, Magi-Galluzzi C, et al. A 17-gene assay to predict prostate cancer aggressiveness in the context of Gleason grade heterogeneity, tumor multifocality, and biopsy undersampling. *Eur Urol*. 2014;66:550.

Klotz L, Vesprini D, Sethukavalan P, et al. Long-term follow-up of a large active surveillance cohort of patients with prostate cancer. *J Clin Oncol*. 2015;33:272.

Klotz L, Loblaw A, Sugar L, et al. Active Surveillance Magnetic Resonance Imaging Study (ASIST): results of a randomized multicenter prospective trial. *Eur Urol*. 2019;75:300.

Kollmeier MA, Stock RG, Cesaretti J, et al. Urinary morbidity and incontinence following transurethral resection of the prostate after brachytherapy. *J Urol*. 2005;173:808.

Krishnan R, Katz D, Nelson CJ, et al. Erectile function recovery in patients after non-nerve sparing radical prostatectomy. *Andrology*. 2014;2:951.

Lardas M, Liew M, van den Bergh RC, et al. Quality of life outcomes after primary treatment for clinically localised prostate cancer: a systematic review. *Eur Urol*. 2017;72:869.

Le JD, Cooperberg MR, Sadetsky N, et al. Changes in specific domains of sexual function and sexual bother after radical prostatectomy. *BJU Int*. 2010;106:1022.

Leapman MS, Freedland SJ, Aronson WJ, et al. Pathological and biochemical outcomes among African-American and Caucasian men with low risk prostate cancer in the SEARCH Database: implications for active surveillance candidacy. *J Urol*. 2016;196:1408.

Lee H, Kim CK, Park BK, et al. Accuracy of preoperative multiparametric magnetic resonance imaging for prediction of unfavorable pathology in patients with localized prostate cancer undergoing radical prostatectomy. *World J Urol*. 2016;35(6):929–934.

Lepor H, Kaci L. The impact of open radical retropubic prostatectomy on continence and lower urinary tract symptoms: a prospective assessment using validated self-administered outcome instruments. *J Urol*. 2004;171:1216.

Litwin MS, Hays RD, Fink A, et al. The UCLA Prostate Cancer Index: development, reliability, and validity of a health-related quality of life measure. *Med Care*. 1998;36:1002.

Litwin MS, Flanders SC, Pasta DJ, et al. Sexual function and bother after radical prostatectomy or radiation for prostate cancer: multivariate quality-of-life analysis from CaPSURE. Cancer of the Prostate Strategic Urologic Research Endeavor. *Urology*. 1999;54:503.

Liu L, Coker AL, Du XL, et al. Long-term survival after radical prostatectomy compared to other treatments in older men with local/regional prostate cancer. *J Surg Oncol*. 2008;97:583.

Liu W, Laitinen S, Khan S, et al. Copy number analysis indicates monoclonal origin of lethal metastatic prostate cancer. *Nat Med*. 2009;15:559.

Loeb S, Folkvaljon Y, Makarov DV, et al. Five-year nationwide follow-up study of active surveillance for prostate cancer. *Eur Urol*. 2015;67:233.

Loeb S, Folkvaljon Y, Robinson D, et al. Evaluation of the 2015 Gleason Grade Groups in a Nationwide Population-based Cohort. *Eur Urol*. 2016;69:1135.

Loeb S, Walter D, Curnyn C, et al. How active is active surveillance? Intensity of followup during active surveillance for prostate cancer in the United States. *J Urol*. 2016;196:721.

Loeb S, Folkvaljon Y, Curnyn C, et al. Uptake of active surveillance for very-low-risk prostate cancer in Sweden. *JAMA Oncol*. 2017;3:1393.

Loeb S, Byrne N, Makarov DV, et al. Use of conservative management for low-risk prostate cancer in the Veterans Affairs Integrated Health Care System From 2005-2015. *JAMA*. 2018;319:2231.

Makarov DV, Trock BJ, Humphreys EB, et al. Updated nomogram to predict pathologic stage of prostate cancer given prostate-specific antigen level, clinical stage, and biopsy Gleason score (Partin tables) based on cases from 2000 to 2005. *Urology*. 2007;69:1095.

Makarov DV, Desai RA, Yu JB, et al. The population level prevalence and correlates of appropriate and inappropriate imaging to stage incident prostate cancer in the medicare population. *J Urol*. 2012;187:97.

Makarov DV, Chrouser K, Gore JL, et al. AUA White Paper on implementation of shared decision making into urological practice. *Urol Pract*. 2016;3:355.

Mansfield JT, Stephenson RA. Does transurethral resection of the prostate compromise the radical treatment of prostate cancer? *Semin Urol Oncol*. 1996;14:174.

Mayr R, May M, Burger M, et al. The Charlson comorbidity index predicts survival after disease recurrence in patients following radical cystectomy for urothelial carcinoma of the bladder. *Urol Int*. 2014;93:303.

Mazur DJ, Merz JF. How older patients' treatment preferences are influenced by disclosures about therapeutic uncertainty: surgery versus expectant management for localized prostate cancer. *J Am Geriatr Soc*. 1996;44:934.

McArthur C, McLaughlin G, Meddings RN. Changing the referral criteria for bone scan in newly diagnosed prostate cancer patients. *Br J Radiol*. 2012;85:390.

Mohler JL, Armstrong AJ, Bahnson RR, et al. Prostate cancer, version 1.2016. *J Natl Compr Canc Netw*. 2016;14:19.

Naito S, Kuroiwa K, Kinukawa N, et al. Validation of Partin tables and development of a preoperative nomogram for Japanese patients with clinically localized prostate cancer using 2005 International Society of Urological Pathology consensus on Gleason grading: data from the Clinicopathological Research Group for Localized Prostate Cancer. *J Urol*. 2008;180:904.

Nassiri N, Chang E, Lieu P, et al. Focal therapy eligibility determined by magnetic resonance imaging/ultrasound fusion biopsy. *J Urol*. 2018;199:453.

National Comprehensive Cancer Network. [NCCN clinical practice guidelines in oncology: prostate cancer, version 1, 2015 (website)] http://www.nccn.org/.

Nieder AM, Porter MP, Soloway MS. Radiation therapy for prostate cancer increases subsequent risk of bladder and rectal cancer: a population based cohort study. *J Urol*. 2008;180:2005.

Nilsson J, Skog J, Nordstrand A, et al. Prostate cancer-derived urine exosomes: a novel approach to biomarkers for prostate cancer. *Br J Cancer*. 2009;100:1603.

O'Brien MF, Cronin AM, Fearn PA, et al. Pretreatment prostate-specific antigen (PSA) velocity and doubling time are associated with outcome but neither improves prediction of outcome beyond pretreatment PSA alone in patients treated with radical prostatectomy. *J Clin Oncol*. 2009;27:3591.

Parekh DJ, Punnen S, Sjoberg DD, et al. A multi-institutional prospective trial in the USA confirms that the 4Kscore accurately identifies men with high-grade prostate cancer. *Eur Urol*. 2015;68:464.

Park JJ, Kim CK, Park SY, et al. Prostate cancer: role of pretreatment multiparametric 3-T MRI in predicting biochemical recurrence after radical prostatectomy. *AJR Am J Roentgenol*. 2014;202:W459.

Park SY, Kim CK, Park BK, et al. Prediction of biochemical recurrence following radical prostatectomy in men with prostate cancer by diffusion-weighted magnetic resonance imaging: initial results. *Eur Radiol*. 2011;21:1111.

Park SY, Oh YT, Jung DC, et al. Prediction of biochemical recurrence after radical prostatectomy with PI-RADS version 2 in prostate cancers: initial results. *Eur Radiol*. 2016;26:2502.

Partin AW, Yoo J, Carter HB, et al. The use of prostate specific antigen, clinical stage and Gleason score to predict pathological stage in men with localized prostate cancer. *J Urol*. 1993;150:110.

Partin AW, Kattan MW, Subong EN, et al. Combination of prostate-specific antigen, clinical stage, and Gleason score to predict pathological stage of localized prostate cancer. A multi-institutional update. *J Am Med Assoc*. 1997;277:1445.

Partin AW, Mangold LA, Lamm DM, et al. Contemporary update of prostate cancer staging nomograms (Partin Tables) for the new millennium. *Urology*. 2001;58:843.

Pierorazio PM, Walsh PC, Partin AW, et al. Prognostic Gleason grade grouping: data based on the modified Gleason scoring system. *BJU Int*. 2013;111:753.

Polland A, Vertosick EA, Sjoberg DD, et al. Preoperative symptoms predict continence after post-radiation transurethral resection of prostate. *Can J Urol*. 2017;24:8903.

Pompe RS, Karakiewicz PI, Tian Z, et al. Oncologic and functional outcomes after radical prostatectomy for high or very high risk prostate cancer: European Validation of the Current NCCN(R) Guideline. *J Urol*. 2017;198:354.

Prabhu V, Taksler GB, Sivarajan G, et al. Radical prostatectomy improves and prevents age dependent progression of lower urinary tract symptoms. *J Urol*. 2014;191:412.

Punnen S, Nahar B, Prakash NS, et al. The 4Kscore predicts the grade and stage of prostate cancer in the radical prostatectomy specimen: results from a multi-institutional prospective trial. *Eur Urol Focus*. 2017;3:94.

Ravery V, Chastang C, Toublanc M, et al. Percentage of cancer on biopsy cores accurately predicts extracapsular extension and biochemical relapse after radical prostatectomy for T1-T2 prostate cancer. *Eur Urol*. 2000;37:449.

Resnick MJ, Koyama T, Fan KH, et al. Long-term functional outcomes after treatment for localized prostate cancer. *N Engl J Med*. 2013;368:436.

Riaz N, Afaq A, Akin O, et al. Pretreatment endorectal coil magnetic resonance imaging findings predict biochemical tumor control in prostate cancer patients treated with combination brachytherapy and external-beam radiotherapy.

Int J Radiat Oncol Biol Phys. 2012;84:707.

Roach M, Lu J, Pilepich MV, et al. Four prognostic groups predict long-term survival from prostate cancer following radiotherapy alone on Radiation Therapy Oncology Group clinical trials. *Int J Radiat Oncol Biol Phys*. 2000;47:609.

Rombouts AJM, Hugen N, van Beek JJP, et al. Does pelvic radiation increase rectal cancer incidence? A systematic review and meta-analysis. *Cancer Treat Rev*. 2018;68:136.

Rosenkrantz AB, Chandarana H, Gilet A, et al. Prostate cancer: utility of diffusion-weighted imaging as a marker of side-specific risk of extracapsular extension. *J Magn Reson Imaging*. 2013;38:312.

Rosenkrantz AB, Ream JM, Nolan P, et al. Prostate cancer: utility of whole-lesion apparent diffusion coefficient metrics for prediction of biochemical recurrence after radical prostatectomy. *AJR Am J Roentgenol*. 2015;205:1208.

Rosenkrantz AB, Shanbhogue AK, Wang A, et al. Length of capsular contact for diagnosing extraprostatic extension on prostate MRI: assessment at an optimal threshold. *J Magn Reson Imaging*. 2016;43:990.

Salami SS, Schmidt F, Laxman B, et al. Combining urinary detection of TMPRSS2:ERG and PCA3 with serum PSA to predict diagnosis of prostate cancer. *Urol Oncol*. 2013;31:566.

Sanda MG, Cadeddu JA, Kirkby E, et al. Clinically localized prostate cancer: AUA/ASTRO/SUO Guideline. Part I: risk stratification, shared decision making, and care options. *J Urol*. 2018;199:683.

Sanda MG, Cadeddu JA, Kirkby E, et al. Clinically localized prostate cancer: AUA/ASTRO/SUO guideline. Part II: recommended approaches and details of specific care options. *J Urol*. 2018;199:990.

Sanda MG, Chen RC, Crispino T, et al. *Clinically Localized*

Prostate Cancer: AUA/ASTRO/SUO Guideline. [Available at:] https://www.auanet.org/guidelines/prostate-cancer-clinically-localized-guideline; 2017.

Sandhu AS, Zelefsky MJ, Lee HJ, et al. Long-term urinary toxicity after 3-dimensional conformal radiotherapy for prostate cancer in patients with prior history of transurethral resection. *Int J Radiat Oncol Biol Phys*. 2000;48:643.

Schroder FH, Hugosson J, Roobol MJ, et al. Screening and prostate cancer mortality: results of the European Randomised Study of Screening for Prostate Cancer (ERSPC) at 13 years of follow-up. *Lancet*. 2014;384:2027.

Schroeck FR, Krupski TL, Sun L, et al. Satisfaction and regret after open retropubic or robot-assisted laparoscopic radical prostatectomy. *Eur Urol*. 2008;54:785.

Schroeck FR, Krupski TL, Stewart SB, et al. Pretreatment expectations of patients undergoing robotic assisted laparoscopic or open retropubic radical prostatectomy. *J Urol*. 2012;187:894.

Showalter TN, Mishra MV, Bridges JF. Factors that influence patient preferences for prostate cancer management options: a systematic review. *Patient Prefer Adherence*. 2015;9:899.

Siddiqui MM, Rais-Bahrami S, Turkbey B, et al. Comparison of MR/ultrasound fusion-guided biopsy with ultrasound-guided biopsy for the diagnosis of prostate cancer. *J Am Med Assoc*. 2015;313:390.

Simon TG, Beland MD, Machan JT, et al. Charlson Comorbidity Index predicts patient outcome, in cases of inoperable non-small cell lung cancer treated with radiofrequency ablation. *Eur J Radiol*. 2012;81:4167.

Singh PB, Anele C, Dalton E, et al. Prostate cancer tumour features on template prostate-mapping biopsies: implications for focal therapy. *Eur Urol*. 2014;66:12.

Slova D, Lepor H. The short-term and long-term effects of radical prostatectomy on lower urinary tract symptoms. *J Urol*. 2007;178:2397.

Somford DM, Hamoen EH, Futterer JJ, et al. The predictive value of endorectal 3 Tesla multiparametric magnetic resonance imaging for extraprostatic extension in patients with low, intermediate and high risk prostate cancer. *J Urol*. 2013;190:1728.

Sooriakumaran P, Nyberg T, Akre O, et al. Comparative effectiveness of radical prostatectomy and radiotherapy in prostate cancer: observational study of mortality outcomes. *BMJ*. 2014;348:g1502.

Sooriakumaran P, Pini G, Nyberg T, et al. Erectile function and oncologic outcomes following open retropubic and robot-assisted radical prostatectomy: results from the LAParoscopic prostatectomy robot open trial. *Eur Urol*. 2018;73:618.

Steinsvik EA, Axcrona K, Dahl AA, et al. Can sexual bother after radical prostatectomy be predicted preoperatively? Findings from a prospective national study of the relation between sexual function, activity and bother. *BJU Int*. 2012;109:1366.

Stember DS, Nelson CJ, Mulhall JP. Preoperative erectile function is an independent predictor for decision to spare cavernous nerves during radical prostatectomy. *J Sex Med*. 2013;10:2101.

Stephenson AJ, Scardino PT, Eastham JA, et al. Preoperative nomogram predicting the 10-year probability of prostate cancer recurrence after radical prostatectomy. *J Natl Cancer Inst*. 2006;98:715.

Stewart GD, Van Neste L, Delvenne P, et al. Clinical utility of an epigenetic assay to detect occult prostate cancer in histopathologically negative biopsies: results of the MATLOC study. *J Urol*. 2013;189:1110.

Stone NN, Ratnow ER, Stock RG. Prior transurethral resection does not increase morbidity following real-time ultrasound-guided prostate seed implantation. *Tech Urol*. 2000;6:123.

Tamada T, Dani H, Taneja SS, et al. The role of whole-lesion apparent diffusion coefficient analysis for predicting outcomes of prostate cancer patients on active surveillance. *Abdom Radiol (NY)*. 2017;42:2340.

Tareen B, Godoy G, Sankin A, et al. Can contemporary transrectal prostate biopsy accurately select candidates for hemi-ablative focal therapy of prostate cancer? *BJU Int*. 2009;104:195.

Tay KJ, Scheltema MJ, Ahmed HU, et al. Patient selection for prostate focal therapy in the era of active surveillance: an International Delphi Consensus Project. *Prostate Cancer Prostatic Dis*. 2017;20:294.

Thompson I, Thrasher JB, Aus G, et al. Guideline for the management of clinically localized prostate cancer: 2007 update. *J Urol*. 2007;177:2106.

Thompson IM Jr, Tangen CM. Prostate cancer—uncertainty and a way forward. *N Engl J Med*. 2012;367:270.

Thompson JE, Egger S, Bohm M, et al. Superior biochemical recurrence and long-term quality-of-life outcomes are achievable with robotic radical prostatectomy after a long learning curve-updated analysis of a prospective single-surgeon cohort of 2206 consecutive cases. *Eur Urol*. 2018;73:664.

Thurtle D, Barrett T, Thankappan-Nair V, et al. Progression and treatment rates using an active surveillance protocol incorporating image-guided baseline biopsies and multiparametric magnetic resonance imaging monitoring for men with favourable-risk prostate cancer. *BJU Int*. 2018;122(1):59–65.

Tosoian JJ, JohnBull E, Trock BJ, et al. Pathological outcomes in men with low risk and very low risk prostate cancer:

implications on the practice of active surveillance. *J Urol*. 2013;190:1218.

Tosoian JJ, Mamawala M, Epstein JI, et al. Intermediate and longer-term outcomes from a prospective active-surveillance program for favorable-risk prostate cancer. *J Clin Oncol*. 2015;33:3379.

Tsodikov A, Gulati R, Etzioni R. Reconciling the effects of screening on prostate cancer mortality in the ERSPC and PLCO Trials. *Ann Intern Med*. 2018;168:608.

Tyson MD 2nd, Koyama T, Lee D, et al. Effect of prostate cancer severity on functional outcomes after localized treatment: comparative effectiveness analysis of surgery and radiation study results. *Eur Urol*. 2018;74:26.

Uemura H, Hoshino K, Sasaki T, et al. Usefulness of the 2005 International Society of Urologic Pathology Gleason grading system in prostate biopsy and radical prostatectomy specimens. *BJU Int*. 2009;103:1190.

van As NJ, de Souza NM, Riches SF, et al. A study of diffusion-weighted magnetic resonance imaging in men with untreated localised prostate cancer on active surveillance. *Eur Urol*. 2009;56:981.

van Stam MA, Pieterse AH, van der Poel HG, et al. Shared decision making in prostate cancer care—encouraging every patient to be actively involved in decision making or ensuring the patient preferred level of involvement? *J Urol*. 2018;200:582.

van den Bergh RC, Roemeling S, Roobol MJ, et al. Prospective validation of active surveillance in prostate cancer: the PRIAS study. *Eur Urol*. 2007;52:1560.

van den Bos W, Muller BG, Ahmed H, et al. Focal therapy in prostate cancer: international multidisciplinary consensus on trial design. *Eur Urol*. 2014;65:1078.

Van Neste L, Hendriks RJ, Dijkstra S, et al. Detection of high-grade prostate cancer using a urinary molecular biomarker-based risk score. *Eur Urol*. 2016;70:740.

Violette PD, Agoritsas T, Alexander P, et al. Decision aids for localized prostate cancer treatment choice: systematic review and meta-analysis. *CA Cancer J Clin*. 2015;65:239.

Wallner K, Lee H, Wasserman S, et al. Low risk of urinary incontinence following prostate brachytherapy in patients with a prior transurethral prostate resection. *Int J Radiat Oncol Biol Phys*. 1997;37:565.

Weinreb JC, Barentsz JO, Choyke PL, et al. PI-RADS prostate imaging - reporting and data system: 2015, version 2. *Eur Urol*. 2016;69:16.

Welty CJ, Cowan JE, Nguyen H, et al. Extended followup and risk factors for disease reclassification in a large active surveillance cohort for localized prostate cancer. *J Urol*. 2015;193:807.

Westphalen AC, Koff WJ, Coakley FV, et al. Prostate cancer: prediction of biochemical failure after external-beam radiation therapy–Kattan nomogram and endorectal MR imaging estimation of tumor volume. *Radiology*. 2011;261:477.

Wilt TJ, Brawer MK, Jones KM, et al. Radical prostatectomy versus observation for localized prostate cancer. *N Engl J Med*. 2012;367:203.

Wilt TJ, Jones KM, Barry MJ, et al. Follow-up of prostatectomy versus observation for early prostate cancer. *N Engl J Med*. 2017;377:132.

Woo SH, Kang DI, Ha YS, et al. Comprehensive analysis of sexual function outcome in prostate cancer patients after robot-assisted radical prostatectomy. *J Endourol*. 2014;28:172.

Wu AK, Reese AC, Cooperberg MR, et al. Utility of PCA3 in patients undergoing repeat biopsy for prostate cancer.

Prostate Cancer Prostatic Dis. 2012;15:100.

Xu AJ, Taksler GB, Llukani E, et al. Long-term natural history of lower urinary tract symptoms following radical retropubic prostatectomy: a prospective 15 year longitudinal study. *Urology*. 2018;120:167–172.

Yamaguchi H, Hori M, Suzuki O, et al. Clinical significance of the apparent diffusion coefficient ratio in prostate cancer treatment with intensity-modulated radiotherapy. *Anticancer Res*. 2016;36:6551.

Yaxley JW, Coughlin GD, Chambers SK, et al. Robot-assisted laparoscopic prostatectomy versus open radical retropubic prostatectomy: early outcomes from a randomised controlled phase 3 study. *Lancet*. 2016;388:1057.

Yoon MY, Park J, Cho JY, et al. Predicting biochemical recurrence in patients with high-risk prostate cancer using the apparent diffusion coefficient of magnetic resonance imaging. *Investig Clin Urol*. 2017;58:12.

Zeliadt SB, Moinpour CM, Blough DK, et al. Preliminary treatment considerations among men with newly diagnosed prostate cancer. *Am J Manag Care*. 2010;16:e121.

Zhu Z, Zhao S, Liu Y, et al. Risk of secondary rectal cancer and colon cancer after radiotherapy for prostate cancer: a meta-analysis. *Int J Colorectal Dis*. 2018;33:1149.

Active Surveillance of Prostate Cancer

Laurence Klotz MD, FRCSC

The past decade has witnessed a dramatic change in the approach to men with favorable-risk prostate cancer (Klotz, 2017). Ten years ago, more than 90% of men in the United States, Canada, and Europe diagnosed with this condition were treated radically, with either surgery or radiation. Today, in some regions more than 90% are treated expectantly, using an approach termed *active surveillance*. Most centers report at least 50% of low-risk patients being managed this way. This profound change had many drivers, including concerns about the risk for overtreatment expressed by many constituencies, particularly the U.S. Preventive Services Task Force (USPSTF); data on the favorable molecular genetics of Gleason pattern 3 cancer; long-term outcome data from prospective cohorts of patients managed with surveillance; enhanced ability to identify those patients at risk using modern imaging and molecular biomarkers; robust modeling studies confirming the benefit of active surveillance compared with definitive therapy; and, above all, patient acceptance and enthusiasm for a less aggressive approach. This chapter is a comprehensive review of the background, rationale, biologic basis, outcome, and technique of active surveillance.

The Overdiagnosis and Overtreatment Problem

In modern medical practice, the advent of sensitive diagnostic testing has resulted in the overdiagnosis of many disease states. Cancer overdiagnosis and overtreatment is a problem in many organs. It is estimated that the “overdiagnosis” rates for prostate, thyroid, and breast cancer if the entire reservoir of disease were being detected would be 87% to 94%, 99.7% to 99.9%, and 43% to 90%, respectively (Welch and Black, 2010). These estimates reflect the high prevalence of microfocal disease in the healthy population (30% to 70% for prostate, 36% to 100% for thyroid, and 7% to 39% for breast cancer).

Because of the high incidence of latent prostate cancer in aging men, the widespread availability of the prostate-specific antigen (PSA) test, and the long-term effects of definitive therapy, overdiagnosis and overtreatment pose significant risks in the management of prostate cancer.

Screening for prostate cancer with PSA is widely prevalent in North America and Europe. Compared with relying on clinical diagnosis in men presenting with symptoms or signs, it results in the identification of potentially lethal prostate cancer at a much more curable stage. The widespread use of PSA has been associated with significant decreases in prostate cancer mortality (Jemal et al., 2010). The cost, however, has been a high rate of diagnosis—and treatment—of prostate cancer, many cases of which are likely clinically insignificant.

The USPSTF recommendations on the use of PSA for screening, published in 2012, assign it to level D, mainly based on concerns about overdiagnosis and overtreatment (USPSTF, 2018). In 2018, after a great deal of debate, the recommendation regarding PSA screening was modified to a level C (neutral) recommendation, largely due to the uptake of active surveillance, resulting in a reduction in overtreatment (U.S. Preventive Services Task Force et al., 2018).

A solution to the problem of overtreatment is to identify patients at low risk for disease progression and manage them conservatively. This strategy is based on the concept that treatment is best individualized, and the timing and aggressiveness of treatment should reflect disease and patient characteristics.

Conservative management of localized prostate cancer is guided by two different practical strategies, either “active surveillance” or “watchful waiting.” Active surveillance is the approach taken in men whose age and general health make them candidates for radical local therapy if needed. These patients are regularly monitored over time, and if they are reclassified as being at higher risk for disease progression, then they are offered definitive therapy. In contrast, watchful waiting consists of minimal follow-up with palliative therapy of advanced disease in the unlikely event that it becomes clinically manifested; definitive local therapy is not a therapeutic option because of age and comorbidity. Many patients are initially managed with active surveillance and converted to watchful waiting once their average life expectancy is calculated to be less than 5 to 8 years (typically around 80 years of age, or earlier if they have significant comorbidity).

Active surveillance offers the benefit of avoiding the significant side effects of radical local therapy for those with indolent, stable, or regressive disease, with the option of definitive therapy for those patients who are reclassified over time as having higher risk for disease progression, usually based on finding higher-grade disease than on the initial biopsy.

This approach rests on the presumptions that the lead time from diagnosis to clinical progression for low-risk disease is usually long (Draisma et al., 2009) and that the cancer can be treated within the window of curability at the first signs of higher-risk disease. The distinction between surveillance and watchful waiting is important. Studies reporting on oncologic and quality-of-life (QoL) outcomes from older randomized trials (Bill-Axelson et al., 2011) or population-based registries (Albertsen et al., 2005b), where patients were managed with observation (i.e., watchful waiting), should not be considered representative of outcomes expected with contemporary active surveillance, where a significant proportion of men are eventually reclassified to higher risk and offered definitive therapy.

The Natural History of Prostate Cancer

Autopsy studies have demonstrated that the likelihood of harboring microfocal prostate cancer is approximately a man's age as a percentage: 30% of men in their thirties, 50% in their fifties, and 80% or more in men older than 80 years of age (Sakr et al., 1994). PSA testing followed by systematic biopsies of the prostate for those whose level is elevated results in diagnosing prostate cancer in 15% to 20% of men, depending on the threshold for biopsy. In contrast, the lifetime risk for death from prostate cancer in North America is 3%. Thus the ratio of harboring prostate cancer to death is about 20 : 1, and the ratio of diagnosis to death is about 6 : 1. Obviously, therefore, many men diagnosed with localized prostate cancer are not destined to die of the disease. Most of these men would have never had symptoms or been diagnosed without PSA testing. These are considered “clinically insignificant” cancers.

The indications for biopsy determine the likelihood of diagnosis of clinically insignificant cancer. Recognizing that 50% to 60% of men in the biopsy age group harbor microfocal prostate cancer, it is apparent that the lower the PSA threshold for biopsy, the more cores that are taken at each biopsy, and the more biopsy sessions a patient undergoes (despite an initial negative biopsy), the more likely clinically insignificant cancer will be discovered. The benefits and pitfalls of screening are thoroughly addressed elsewhere in this book.

Clinical parameters allow one to identify those men at low risk for disease progression. By far, the most powerful predictor of disease aggressivity is the Gleason grade grouping (until recently known as the Gleason score). For the purposes of this chapter, low-grade cancer refers to Gleason grade group 1, or a Gleason score of 6 (3+3). Intermediate-grade cancer is Gleason grade group 2 (Gleason 3+4) and group 4 (Gleason 4+3). High-risk cancer is Gleason grade group 4 (Gleason 8) and group 5 (Gleason 9 and 10).

The basic concept of active surveillance is to manage patients with low-grade prostate cancer conservatively, reserving treatment for those who are upgraded over time. Selected patients with intermediate-grade cancer are also candidates. The outcome of this approach and the principles of management are described later in this chapter.

Molecular Genetics of Gleason Pattern 3 Versus

Patterns 4 and 5

Molecular and genetic analyses have shown that the hallmarks of cancer differ profoundly between the two most common patterns of disease, Gleason 3 and Gleason 4. These hallmarks are a useful structure for determining the degree to which low-grade prostate cancer (Gleason pattern 3) “looks” like a true malignancy (Draisma et al., 2009).

The “hallmarks” of cancer include six biological capabilities acquired during the development of human tumors such as sustained proliferative signaling, activation of local invasion and metastasis, induction of angiogenesis, evasion of growth suppressors, resistance to cell death, and unlimited replicative potential (Hanahan and Weinberg, 2011). Analysis of alterations of these molecular pathways by gene amplification, mutation, or deletion has shown that most Gleason pattern 3 cells have relatively normal molecular features, and Gleason pattern 4 and 5 cells are altered (Ahmed et al., 2012).

This is particularly true of genes regulating key oncogenic pathways (Table 154.1). Genes involved in proliferation, including *AkT* and *HER2*, are expressed normally in Gleason pattern 3 and abnormally expressed in Gleason 4 (Ross et al., 2011; Skacel et al., 2001). Genes involved in cellular invasion and metastasis (True et al., 2006) and genes regulating cell cycle transition are not overexpressed in Gleason pattern 3, but are overexpressed in Gleason 4 (Padar et al., 2003; Susaki and Nakayama, 2007). Genes associated with resistance to apoptosis (Fleischman et al., 2012), angiogenesis, and the development of other pro-angiogenic factors (Erbersdobler et al., 2010; West et al., 2001), and genes involved in regulating cellular metabolism (Georgescu et al., 2016), including the reverse Warburg effect, tend to be abnormally expressed in Gleason pattern 4 but not in Gleason 3.

TABLE 154.1

Gleason 3 vs 4 and Hallmarks of Cancer

PATHWAY	**GLEASON 3**	**GLEASON 4**
EGF, EGFR (Ross et al., 2011)	No	Overexpressed
AKT, MAP2 kinase (Ross et al., 2011)	No	Aberrant
HER2neu (Skacel et al., 2001)	No	Amplified
Markers of tissue invasion and metastasis (Ross et al., 2011; True et al., 2006)	Normal	Overexpressed

Insensitivity to growth inhibitory signals (e.g., cyclin D2) (Susaki and Nakayama, 2007; Padar et al., 2003)	Expressed	Absent
Resisting Apoptosis, BCL2 (Fleischmann et al., 2012)	Negative	Strong expression
VEGF, Microvessel density, other pro-angiogenic factors (West et al., 2001; Erbersdobler et al., 2010)	Low expression	Increased
Metabolic pathways (reverse Warburg) (Georgescu et al., 2016)	Absent	Present
Absence of senescence, TMPRSS2-ERG (Bismar et al., 2012; Wang et al., 2006)	ERG normal	Increased
PTEN (Trock et al., 2016)	Present in 90%	Deleted in 70% to 90%
Clinical evidence of metastasis/prostate cancer mortality after surgical grading (Hubbard et al., 2016; Ross et al., 2012)	Absent	Present

Translocations of *TMPRSS2-ERG* (Bismar et al., 2012; Furusato et al., 2008; Wang et al., 2006) and *pTEN* deletions (Trock et al., 2016) are common in Gleason pattern 4, and are absent or only occasionally expressed in Gleason 3 (see Table 154.1). The implication is that most Gleason pattern 3 cells behave in a “benign” fashion, whereas higher-grade patterns harbor the ability to invade and metastasize.

It is remarkable how well the Gleason scoring system disaggregates prostate cancer between genetically normal and abnormal cells. According to those who knew him personally, Don Gleason himself thought that Gleason pattern 3 or less should not be called cancer.

The differences in gene expression are quantitative and qualitative. The mutational load of Gleason pattern 3 is dramatically less than for higher-grade cancer, but it is not zero. For example, about 10% of Gleason pattern 3 cancers have a *PTEN* deletion. This is found much more commonly in Gleason pattern 3 cells in men with coexistent Gleason pattern 4 (i.e., Gleason score 7 cancers) (Trock et al., 2016). This may indicate that a field defect is present or that Gleason 3 cells harboring the *PTEN* deletion rapidly dedifferentiate to a higher Gleason pattern. An alternative explanation is that the deleterious genetic alterations present in the higher-grade cancers are transferred by exosomes into the lower-grade cancers (Zomer and van Rheenen, 2016). As an isolated abnormality, *PTEN* deletion does not seem to confer a metastatic potential. Recent studies suggest that *MYC* amplification in conjunction with *PTEN* deletion induces genomic instability and metastatic prostate cancer, and both events may be required to confer a metastatic phenotype (Hubbard et al., 2016).

The favorable molecular profile of Gleason pattern 3 is associated, not surprisingly, with benign natural history. There is compelling data that Gleason pattern 6 cancer has no metastatic potential. One study of 14,000 men with pathologically confirmed Gleason pattern 6 cancer identified only 22 cases with lymph node metastases (Ross et al., 2012). All 22 men had higher-grade cancer on re-examination of the tissue. Thus, the rate of lymph node metastases in men who had the benefit of surgical pathologic confirmation that their prostate contained no higher-grade cancer was zero. Another study of 12,000 men treated with radical prostatectomy whose specimen had only Gleason 6 cancer found the prostate cancer mortality was 0.2% at 20 years (Eggener et al., 2011). The few cases who had metastases had evidence of higher-grade cancer on re-review of their original histology. It is therefore reasonable to conclude that the metastatic potential of Gleason pattern 3 cancer is, for all intents and purposes, zero.

Although coexistent higher-grade cancer is common, spontaneous-grade progression (from Gleason pattern 3 to pattern 4 or 5) is uncommon. This has been modeled by several groups; the estimate is that 1% to 2% of patients per year will undergo grade progression. In most cases, this occurs in high-volume Gleason 6 cancers (Inoue et al., 2014). The implications are that patients on active surveillance must be followed long term, and 10% to 20% will undergo true, biological grade progression after 10 years. Although evidence of grade progression should be sought as long as the patient is on surveillance, it would not necessarily warrant intervention. For example, progression to Gleason 3+4 after 10 to 15 years of surveillance in a man diagnosed at 65 years of age who is now 80 would not necessarily pose a threat to his life.

All series including men with low-risk prostate cancer managed conservatively report occasional cases of metastatic disease. In most cases, this is because the assessment of grade has relied on biopsy only. The adverse outcome in these cases reflected the presence of occult higher-grade cancer present in the prostate at the time of diagnosis that was missed on the diagnostic biopsy. This situation exists in about 30% of men diagnosed on the basis of a 10- to 12-core systematic biopsy. In 85% of these cases, the upgraded cancer is Gleason 3+4 (Porten et al., 2011); however, 10% of the undergraded 30% harbor Gleason 4+3, and 5% harbor Gleason 8 or higher cancer. These occult high-grade cancers are almost certainly responsible for the few patients who progress to metastatic disease despite being diagnosed with low-grade cancer.

Another explanation for the metastasis rate seen in earlier watchful waiting series was the change in Gleason grading system introduced in 2005. Many cancers previously graded as Gleason score 6 before 2005 are now graded as Gleason 7 (Epstein et al., 2017). This upgrading resulted in a typical stage migration phenomenon, resulting in an improvement in cancer-specific survival estimated at 26% (Albertsen et al., 2005a).

Key Points

- Microfocal Gleason pattern 3 occurs in most men with age, in all races and regions of the world.
- The mutational burden of Gleason pattern 3 cancer is very favorable and dramatically different from higher-grade cancer. Most oncogenic pathways characterized by specific genetic alterations are normal in Gleason pattern 3 and aberrant (e.g., deleted/amplified/mutated/overexpressed) in Gleason patterns 4 and 5.
- Gleason pattern 6 cancer (grade group 1) has no metastatic potential.
- Cancer deaths reported in men with low-risk cancer managed conservatively are thought to be caused by the coexistence of higher-grade cancer missed on the diagnostic biopsy.

Natural History

The natural history of untreated prostate cancer has been determined by both observational studies (Albertsen et al., 2005b) and several randomized studies comparing radical intervention to expectant management. These studies must be evaluated in the context of the diagnostic pathway in place at the time; in particular, studies of PSA-screened patients will reflect lead time bias of 5 to 10 years with respect to disease progression and survival compared with a nonscreened population. Most of these studies did not utilize an “active surveillance” approach in the nontreatment arm, whereby patients had close monitoring, serial biopsy, and so on. As mentioned earlier, the progression and mortality rates reflect the predictable presence of occult higher-grade cancer in 25% to 30% of the patients.

The study with the longest follow-up of conservative management followed 223 men in Sweden over 32 years (Popiolek et al., 2013). The majority were older than 70 years of age at diagnosis, and 99% of the cohort died. In this study, 64% remained untreated, and none of the untreated patients developed metastatic progression; 14% with Gleason 6 disease on biopsy developed metastatic disease. This study, and others, concluded that the rate of progression is stable for many years and does not increase significantly over time. The Swedish study did report an increase in prostate cancer mortality after 15 years. However, this increase appears to be an artifact related to the small numbers of men surviving beyond 15 years. In addition, these patients did not have the benefit of close monitoring and delayed intervention for risk reclassification.

There have been three large randomized trials that compared the outcome of expectant management (usually watchful waiting) to radical prostatectomy. The control arms of these studies provide insight into the natural history of untreated prostate cancer. The three studies are the Scandinavian Prostate Cancer Group Study Number 4 (SPCG-4) in Scandinavia (Bill-Axelson et al., 2014), the Prostate Cancer Intervention versus Observation Trial (PIVOT) in the United States (Wilt et al., 2017), and the Prostate Testing for Cancer and Treatment (ProtecT) study in the United Kingdom (Hamdy et al., 2016). Each of these is a critically important study.

The SPCG-4 randomized 695 men with a mean age of 65 years to radical prostatectomy versus observation (Bill-Axelson et al., 2014). Only 5% were diagnosed based on PSA testing; 75% had a palpable nodule; and the median PSA was 13. Thus this was largely an intermediate- to high-risk cohort. In this study, 21% of men in the observation arm died of prostate cancer. Among the low-risk observation cohort, defined as PSA less than 10 ng/mL, and Gleason score ≤6, the prostate cancer mortality was 11%. Revealingly, 7 men in the prostatectomy arm with low-risk disease on biopsy went on to die of prostate cancer; all of these were upgraded at radical prostatectomy. Although surgery resulted in a significant improvement in survival overall, the benefit was confined to men 65 years of age or younger. Men older than 65 years of age had no benefit from surgery compared with no treatment. Recognizing the important differences between this group and a contemporary active surveillance cohort (modern Gleason grading, PSA-based diagnosis, close monitoring with serial biopsy, and/or imaging), it is reassuring that the long-term prostate cancer mortality in the low-risk cohort was modest. Further, the data emphasizes the value of conservative management in older patients, including those with higher-risk disease. Importantly, stratification analysis showed that the benefit of surgery was confined to the GG3 and higher population; there was no benefit in

GG1 or GG2, emphasizing the potential benefit of surveillance in the favorable intermediate risk group (Bill-Axelson et al., 2018).

The PIVOT (Wilt et al., 2017), carried out in the VA hospitals in the United States, similarly randomized 731 men between surgery or observation. This was a somewhat more favorable cohort than the SPCG-4 group. The median PSA was 7.8, and most were diagnosed with PSA testing. There was little difference in prostate cancer mortality between the two arms. The modest difference that was seen was mostly in the intermediate-risk group. Prostate cancer mortality occurred in only 2.7% of the low-risk observation group (vs. 11% and 17% in the intermediate- and high-risk groups, respectively). The similarity in disease-specific mortality rate between the low-risk group in the SPCG-4 (11%) and the intermediate-risk group in the PIVOT (11%) likely reflects the stage-migration effects of PSA testing, the change in Gleason grading in 2005, and lead time effects.

The long-awaited ProtecT trial reported recently (Hamdy et al., 2016). This was a randomized trial comparing active monitoring, radical prostatectomy, and external-beam radiotherapy. The primary end point was prostate cancer mortality at 10 years. In this study, 1643 men identified in a screening trial agreed to undergo randomization among the three arms. There were 17 prostate cancer–specific deaths overall, and there was no difference among the three groups in disease-specific mortality or overall survival. The active monitoring group had more metastases (6.3 events per 1000 person-years versus 2.4 with surgery and 3 with radiation).

A key fact in this important trial is that patients with intermediate- and high-risk cancer were included in the active monitoring arm. At diagnosis, 23% of the patients had intermediate- or high-grade cancer on biopsy. Given the low rate of metastasis, a higher rate of progression in the 23% of patients in the intermediate- and high-risk groups is more than sufficient to explain the increase in metastasis rate in the expectant management group. That 77% of the cohort had low-risk disease is also a likely explanation for the failure to see a difference in mortality among any of the arms, as the study was therefore underpowered in terms of the number of clinically significant cancers to show a difference at 10 years.

Active monitoring in the ProtecT trial did not mean active surveillance as described earlier. Biopsies were not performed on an established schedule, and criteria for intervention were not clearly described. This may also have contributed to the higher metastasis rate in the expectant management arm.

Importantly, QoL on the active monitoring arm was the same or better in every domain measured (Donovan et al., 2016).

Outcome of Active Surveillance

Ten prospective phase II active surveillance studies have reported, comprising about 10,000 men in total (Bul et al., 2013; Dall'Era et al., 2008; Khatami et al., 2007; Klotz et al., 2015; Kovac et al., 2017; Patel et al., 2004; Roemeling et al., 2007; Selvadurai et al., 2013; Soloway et al., 2008; Tosoian et al., 2015). The largest and most mature studies are summarized in Table 154.2. Several of these studies include hundreds of patients followed for more than 15 years.

TABLE 154.2

Results of Mature Active Surveillance Cohorts

STUDY	*N*	MEDIAN FOLLOW-UP YEARS	FREEDOM FROM TREATMENT	bNED AFTER DEFERRED TREATMENT	PROSTATE CANCER MORTALITY %	OTH CAU MOR %
University of Toronto (Klotz et al., 2015)	993	8.5	70% at 5 years	5-years bNED: 47%	5% at 15 years (actuarial) 1.5% (actual)	10 ye
UCSF (Dall'Era et al., 2008)	321	3.6	67% at 5 years	One recurrence at 3 years	0	0
Multicenter PRIAS (Bul et al., 2013)	2494	1.6	77% at 2 years	No data	0	4 yea
University of Miami (Soloway et al., 2008)	230	2.6	85.7% at 5 years	No recurrences	0	No da
Johns Hopkins (Tosoian et al., 2015)	1298	5	59% at 5 years	90.6% recurrence free at 2 years	0.5% at 15 years	15 ye
Royal Marsden	471	5.7	70% at 5 years	85% PSA-failure free at 5	2% at 8 years	8 yea

(Selvadurai et al., 2013)				years		

bNED, no evidence of biochemical disease.

Consistent with the data from randomized trials described earlier, prostate cancer mortality is rare in men with low-risk disease managed with active surveillance. The most common cause of death in these patients is cardiovascular disease. In the most mature cohort (Klotz et al., 2015) with a median follow-up of 9 years, the relative risk for non–prostate-cancer death was 10 times that for prostate cancer mortality.

Active surveillance inclusion criteria have varied among groups. Two groups, Toronto (Klotz et al., 2015) and Hopkins (Tosoian et al., 2015), represent the two extremes of an inclusive and restrictive approach, respectively. Both groups have reported 15-year outcomes. A comparison between the outcomes in these groups allows one to define the relationship between patient selection and outcome.

The Toronto group took an inclusive approach, including all patients with Gleason 6 cancer, and selected intermediate-risk patients (Gleason 7 or PSA >10) (Selvadurai et al., 2013). The actuarial 15-year prostate cancer mortality rate was 5%. The hazard ratio (HR) for metastasis at 15 years was 3.75 times greater for intermediate-risk patients than for low-risk patients. PSA greater than 10 had very little correlation with the likelihood of eventual metastasis.

However, the patients with Gleason 7 at baseline were particularly at risk; these patients had a 20% or greater metastasis rate at 15 years (American Urological Association [AUA], 2017; Chen et al., 2016). This relatively high rate of metastasis occurred despite the fact that all of these patients were deemed to “progress” (based on substantial risk in PSA, or grade or volume progression) and were treated radically before they were found to have metastatic disease.

In contrast, the Hopkins group took a restrictive approach, offering surveillance only to patients who fulfilled the Epstein criteria (Gleason 6 with no more than two positive cores, no core >50% involved, and PSA density <0.15). The benefit was a prostate cancer mortality rate of 0.5% at 15 years. The cost was that only about 20% of newly diagnosed patients were eligible (vs. 50% in the Toronto cohort). Although the long-term mortality rate is clearly influenced by the inclusion criteria for surveillance, the intervention rate has been remarkably consistent. The rate of intervention is consistently around 25% at 5 years (Komisarenko et al., 2016).

In the beginning of the “active surveillance era,” the optimal strategy for follow up and intervention was unclear. The long-term surveillance studies have provided clarity. There is an emerging consensus that the appropriate strategy lies between the two extremes described earlier. Most Gleason 6 patients are appropriately managed with surveillance (i.e., not just those fulfilling Epstein criteria), and, in contrast, active surveillance should be offered selectively and cautiously to Gleason 7 patients.

All of the mature surveillance cohorts reflect the experience before the incorporation of magnetic resonance imaging (MRI) and molecular biomarkers. It is very likely that the incorporation of these augmented strategies will broaden the indications for surveillance while further reducing the already low rate of metastasis.

Key Points: Outcome of Conservative Management

- Three randomized trials comparing radical intervention to various versions of conservative management have shown little or no benefit to intervention in the low-risk group.
- Ten prospective active surveillance series have confirmed a very low rate of metastasis and prostate cancer mortality with an initial conservative approach. The disease-specific mortality varies between 0.5% and 5% at 15 years, depending on eligibility criteria.
- Approximately 25% of patients are reclassified to higher risk and managed with definitive therapy at 5 years. This figure is similar among all cohorts.
- These data reflect the pre-MRI era of surveillance. Incorporating MRI and biomarkers is likely to improve the already favorable outcome substantially by providing earlier identification of the aggressive cancers.

Patient Selection

Most men with grade group 1 (Gleason 3+3=6) prostate cancer should be managed with active surveillance. This view is now reflected in guidelines from many groups, including Cancer Care Ontario (Morash et al., 2015), the AUA (AUA, 2017); ASCO (Chen et al., 2016), and NICE (2017) (Table 154.3).

TABLE 154.3

Summary of Contemporary Active Surveillance Guidelines

	LOW-RISK PROSTATE CANCER	**INTERMEDIATE-RISK PROSTATE CANCER**	**TEST**
Cancer Care Ontario (Morash et al., 2015)	AS preferred management	Active treatment; AS for selected patients	PS 3– mo DR eve Sy bio wit 12 mo the 3–
ASCO (Chen et al., 2016)	Same (Klotz, 2017)	Same	Same
AUA 2017 (https://www.auanet.org/guidelines/prostate-cancer-clinically-localized-guideline)	Same	AS for selected patients	Same
NICE (2017)	Same	Radical treatment for "disease progression" (Welch and Black, 2010)	PSA ev month monito kinetic otherw same

5ARIs, 5α-reductase–specific antibodies; *AS,* active surveillance; *DRE,* digital rectal examination; *PSA,* prostate-specific antigen.

Currently, most guidelines make a distinction between very low risk (Epstein criteria, i.e., only one to two positive cores, no core with >50% involvement, and PSA density <0.15) and low risk (any grade group 1 with PSA <10). The distinction between low risk and very low risk does not reflect a difference in the metastatic potential of Gleason pattern 3 as a function of cancer volume. What it does reflect, rather, is the likelihood of coexistent occult higher-grade cancer, and (possibly) the risk for eventual grade progression. High-volume Gleason 6 cancer is associated with an increasing risk for coexistent higher-grade cancer. The higher volume manifests itself in a higher PSA density, increased number of systematic cores involved, and increased extent of core involvement. Several nomograms have been published that indicate the likelihood of coexistent higher-grade cancer based on these clinical and pathologic parameters (Jain et al., 2015; Mamawala et al., 2017). Thus a patient with high-volume Gleason 6 cancer is still a surveillance candidate, but requires closer scrutiny to exclude coexistent higher-grade disease, either with multiparametric magnetic resonance imaging (mpMRI) and targeted biopsy, repeat extended biopsy, and/or a tissue-based genetic assay.

Watchful Waiting

The conceptual basis for active surveillance is that patients are candidates for radical therapy based on age and comorbidity (usually meaning a life expectancy of 5 to 10 years or more), but do not require it because of the indolent nature of the disease.

Several studies have demonstrated that in the 5-year time frame, only patients with very aggressive, high-grade disease are at risk for cancer death (Albertsen et al., 2005b; Popiolek et al., 2013).

Therefore in elderly or comorbid patients, where the harm of radical therapy for localized disease is likely to outweigh the benefit, the approach of watchful waiting is more appropriate. This means monitoring patients only with infrequent PSA and clinical assessment, with no biopsies or imaging, and treatment only for symptomatic progression (or, rarely, for metastatic disease). The watchful waiting approach is often used for newly diagnosed elderly or comorbid patients with low- to intermediate-risk cancer. In addition, patients on long-term active surveillance are “switched” to watchful waiting when their life expectancy becomes less than 5 to 10 years. Determining when to make this switch is a judgment call that can be assisted by nomograms that predict life expectancy based on age and comorbidity.

A pitfall in following prostate cancer patients is the development of neuroendocrine dedifferentiation resulting in clinical progression without PSA progression. This is rare in the patient with an intact gonadal axis, but occasionally may be seen in the elderly male with unrecognized hypogonadism. Therefore PSA must be used as a guide and not relied on 100%, and testosterone should be assayed in those in whom hypogonadism is a possibility.

Hard rules for the timing of the switch to watchful waiting are unrealistic, reflecting the reality that some patients with a life expectancy of close to 10 years may still prefer definitive therapy if they are found to have significant disease. Patients may be motivated by concerns about “modus mortis” (manner of death), that is, the desire to avoid a prostate cancer death even if their risk is relatively modest. Further, our ability to predict survival based on age and comorbidity is inexact. Some patients live considerably longer than their median life expectancy. Patient preferences and tradeoffs play a role in this population.

Management of Men on Active Surveillance

Although safe for most men, there are two aspects of conservative management that warrant caution and scrutiny. The first and most common is misattribution of grade. As mentioned, about 30% of men found to have Gleason 6 (grade group 1) cancer on systematic biopsy are found to have higher-grade disease at radical prostatectomy (Epstein et al., 2012). Similarly, about the same proportion will be upgraded if subjected to annual biopsies over 10 years (Tosoian et al., 2013). Most are upgraded to GG2, and upgrading beyond GG3 is rare.

As mentioned, the presence of occult high-grade cancer (the “wolf in sheep's clothing”) can be predicted by a number of clinical factors. These include PSA density, PSA level, the free versus total ratio, the extent of disease on biopsy (number of cores and extent of core involvement), increasing age, and race. In addition, restricted diffusion on MRI is a powerful predictor of high-grade cancer.

The second phenomenon that puts patients at risk is true biologic grade progression, whereby Gleason pattern 3 progresses to pattern 4 or 5. This is much less common than the misattribution of grade based on systematic biopsies. Importantly, many of the cases in which patients have progressed to Gleason 3+4 will still have indolent disease. The proof of this is that, despite the known rate of undergrading, vagaries in pathology interpretation, and the rate of spontaneous grade progression, the mortality rate of “low-risk” men managed with surveillance is extremely low.

The experience with misattribution and undergrading described in the surveillance literature largely reflects the pre-MRI era. Increasingly, patients on surveillance have an MRI and targeted biopsy. The rate of undergrading is substantially less with targeted biopsy than with systematic biopsy (Ahmed et al., 2017; Radtke et al., 2016). It is reasonable to expect that, with the increasing use of MRI, this misattribution rate will decline substantially. This should have many positive benefits, including earlier identification of aggressive high-grade cancer; reassurance to patients with a negative MRI or targeted biopsy that their risk for harboring high-grade cancer is low; and a more accurate signal for intervention.

Other Risk Factors

Race

Racial differences in prostate cancer incidence and mortality are substantial, and these are relevant to the surveillance population. Black men appear to have an increased risk for harboring coexistent higher-grade cancer than Caucasians. Whether this represents patient selection or differential access to early detection is unclear (Iremashvili et al., 2012). One group reported an increased rate of definitive intervention and a higher rate of disease progression (Odom et al., 2014). The literature is inconsistent. A recent meta-analysis identified eleven studies on pathologic results of African-American men who would qualify for active surveillance (Gökce et al., 2017). In eight of these studies, African-American race was found to be associated with adverse pathologic outcomes such as positive surgical margins, upgrading, or upstaging. Three studies reported no significance in these parameters with respect to race.

Although they may have a higher risk for harboring higher-grade cancer, black men are unequivocally candidates for surveillance. With the increasing use of MRI to identify those harboring high-grade cancer, they should experience a level of safety comparable to Caucasians.

Family History

Although family history is relevant to an individual's risk for prostate cancer, in most cases it should not drive a decision toward radical treatment. There are several reasons for this. The advent of PSA screening resulted in a dramatic increase in prostate cancer diagnosis. Many of these cases were clinically insignificant. However, this may not have been recognized. The family members of an individual diagnosed with clinically insignificant prostate cancer only know that they now have a family history—and are thus more likely to be screened themselves, and in many cases also diagnosed with clinically insignificant disease. This phenomenon has resulted in “family history inflation.”

In most cases in which a family member was treated for localized prostate cancer, therefore, relatives diagnosed with low-grade disease are still surveillance candidates.

A history of metastatic disease at a young age (<60) in a first-degree relative is significant and may reflect a germline predisposition to prostate cancer. There is an increasing recognition that in such cases, screening for germline mutations, particularly in genes involved in DNA repair, should be performed in family members.

Germline mutations in DNA repair genes (*BRCA1* and *BRCA2*, and *ATM* in particular) confer an accelerated acquisition of mutations and an aggressive phenotype (Taylor et al., 2017). Recent studies that analyzed the genomes and methylomes of localized prostate cancer from *BRCA2* mutation carriers showed that these cancers had increased genomic instability and a mutational profile that resembled metastatic disease. In one study of surveillance in men with germ line DNA repair defects, the hazard ratio for any upgrading in men with BRCA2 mutations was 2.6, and for upgrading to ≥GG3 was 5.1. By 10 years, 80% of BRCA2 patients were upgraded. BRCA1 and ATM were also associated with increased risk, although not as great (Carter et al., 2019). This suggests that in men with *BRCA* mutations, definitive therapy should be considered, even if low-grade prostate cancer is present. The implication is that screening for DNA repair defects should be considered in many patients with prostate cancer, particularly when there is a family history of prostate, breast, or ovarian cancer. The role of genetic screening in this population is currently a matter of controversy.

Monitoring

Patients on surveillance should be managed with a combination of serial PSAs (usually every 6 months), digital rectal examination (annual), and MRI and/or prostate biopsy every 2 to 5 years after the initial confirmatory biopsy. The finding of Gleason score 7 or higher should, in most cases, prompt intervention. An increase in volume of Gleason 6 cancer alone should not prompt intervention; rather, it should prompt a search for higher-grade cancer using MRI or a molecular biomarker.

Magnetic Resonance Imaging

Multiparametric MRI incorporating diffusion-weighted imaging (DWI) is a sensitive and specific test for higher-grade prostate cancer. The diffusion of water through tissues correlates inversely with the Gleason score (Vargas et al., 2011). This reflects the fact that higher-grade prostate cancer has a smaller, more poorly designed lumen than lower-grade cancer, thus impairing diffusion of H_2O. Thus MRI including assessment of diffusion has the appeal of not identifying lower-grade cancer, while providing important information on the location, size, and severity of higher-grade cancer.

MpMRI clearly improves the accuracy of targeting significant cancer in men on surveillance compared with systematic biopsies. In a recent pooled review of 8 series comprising a total of 931 active surveillance candidates who underwent mpMRI before confirmatory biopsy, mpMRI was positive in 73% of patients (Schoots et al., 2015). A total of 32% of patients (297/931) were upgraded at confirmatory biopsy. Cancer upgrading occurred in 13% (121/931) on both systematic and targeted biopsies, in 11% (105/931) on systematic biopsy alone, and in 8% (71/931) on MRI-targeted biopsy alone.

The negative predictive value (NPV) of MRI for excluding clinically significant cancer ranges from 70% to 100% in various series. The NPV is in part a function of the underlying risk of upgrading. In men with a 30% chance of upgrading, the NPV is 88%; in men with a 60% chance (based on high PSA density and extensive disease on biopsy) the NPV is only 66% (Moldovan et al., 2017).

These data suggest that mpMRI is useful before confirmatory biopsy, but that systematic biopsies should be performed in addition to targeted biopsies. Performing mpMRI before confirmatory biopsy is now recommended by the NICE guidelines. In patients on active surveillance with a negative MRI, systematic biopsies can likely safely be deferred in very-low-risk patients. In those at higher risk for upgrading, systematic biopsies are still warranted.

Biomarkers

Prospective active surveillance cohorts now compose more than 10,000 patients, thousands of whom have been followed for longer than 10 years. Clinical parameters (PSA, PSA density, extent of disease on biopsy, race, T-stage) allow for risk stratification for coexistent higher-grade disease. Monitoring low-risk patients on surveillance is associated with a risk for clinical progression of 0.2% to 5% at 15 years. Therefore, the benefit to most patients of a biomarker to further stratify patients according to the risk for progression is modest.

However, selected patients, particularly those whose risk factors suggest they are at above average risk for higher-grade disease, may benefit from genomic testing. There are two potential benefits: (1) reassurance for patients with a favorable genomic risk score that conservative management is likely to be safe and (2) earlier identification of those at risk for disease progression on active surveillance who could benefit from treatment. Clinical studies have demonstrated a greater utilization of conservative management in those who have access to genomic testing.

Three genetic tissue assays have been approved to date by the U.S. Food and Drug Administration (FDA) for men with prostate cancer and are summarized as follows:

Genomic Classifier

This is a 22-marker genomic classifier (GC) based on RNA expression. GC had independent predictive value on multivariable analysis for predicting metastasis after prostatectomy, with an HR of 1.5 for each 10% increase in score (Klein et al., 2016), and these results were validated in two separate prostatectomy cohorts (Nguyen et al., 2017a, 2017b). A high score is associated with an increased risk for disease-specific mortality and progressive disease after salvage radiation. The Decipher biopsy test (Decipher Biosciences, San Diego, CA) can predict metastasis and disease-specific mortality from diagnostic biopsy specimens of primarily intermediate- and high-risk men treated with first-line radiotherapy or radical prostatectomy (Nguyen et al., 2017a). The Decipher test also is an accurate predictor for adverse pathology in the favorable intermediate risk population (Herlemann et al., 2019).

Genomic Prostate Score

This assay incorporates 12 cancer genes that represent four biological pathways of prostate cancer oncogenesis: the androgen receptor pathway, cellular organization, stromal response, and proliferation. A 20-point increase in the genomic prostate score (GPS) is associated with a statistically significant increased risk for high-grade and/or non–organ-confined disease (odds ratio

[OR] 1.9, 95% CI 1.3 to 2.9) (Brand et al., 2016; Cullen et al., 2015).

Cell Cycle Progression

This analyzes 31 cell-cycle–related genes and 15 housekeeping genes by quantitative reverse transcription polymerase chain reaction (RT-PCR). In one cohort of 349 men managed without primary treatment, the cumulative incidence of death was increased among those with cell cycle progression (CCP) scores greater than 2 (19% of the population) compared with those with lower CCP scores (Cuzick et al., 2012, 2015). Patient outcomes could not be differentiated in those with lower CCP scores. The HR of prostate cancer death was 1.7 per unit increase in CCP score to 10 or Cancer of the Prostate Risk Assessment (CAPRA) high-risk disease.

In patients with a strong family history of prostate, breast, and/or ovarian cancer, germ line testing for DNA repair defects (BRCA, ATM, etc.) is warranted. One study of men with DNA repair defects managed with active surveillance found that men with BRCA2 mutations had a 2.8 greater risk of progression to higher grade cancer. Since these mutations increase the rate of acquisition of a mutuational burden, the presence of a germ line DNA repair defect, particularly BRCA2, is a contraindication to surveillance (Carter et al., 2019).

Caveats of Tissue-Based Genomics

There are two major limitations of tissue-based genomic testing. The first is genetic heterogeneity. A recent study performed exomewide sequencing of individual prostate cancers microdissected from patients with multifocality. The genes utilized in the GC, GPS, and CCP assays described earlier were then compared (Wei et al., 2017). Marked heterogeneity of the scores of all three tests between cancers from the same prostate was observed. The confounding problem of genetic heterogeneity of individual cancers in the same gland is considerable.

A second important consideration in the Gleason 6 population is the "Bayesian" problem, related to the low *a priori* risk for metastasis. Thus if a patient with Gleason 6 cancer has a 3% chance of metastases at 15 years and a genetic biomarker has a specificity of 90% for significant cancer, the risk for overdiagnosis of significant cancer may be three times higher (10% vs. 3%) than the risk for metastases. Therefore genetic testing of the tissue should be restricted to higher-risk patients. This includes patients with high cancer volume on biopsy, those with high PSA density, or those with Gleason 7 who are surveillance candidates.

Key Points

- Misattribution of grade (25% to 30% of cases) is much more common than true biologic progression from Gleason 3 to 4 or 5 (1% to 2.3% per year).
- Factors that increase the risk for coexistent higher-grade cancer include PSA density (>0.15), race (African-American), and volume of cancer on biopsy (number of positive cores, extent of core involvement).
- Newly diagnosed men on active surveillance should have a confirmatory biopsy within 1 year, targeting the undersampled areas of the prostate.
- After this, they should have PSA every 6 months and periodic repeat biopsy (every 3 to 5 years).
- MRI and targeted biopsy may replace serial systematic biopsies in very-low-risk men. Because the NPV of MRI is a function of underlying risk, those at higher risk still warrant systematic biopsies.

Psychological Aspects

There is no evidence that adverse psychological effects are significant in men on active surveillance. Anxiety accompanies a diagnosis of prostate cancer, but seems to be influenced less by treatment. In the Scandinavian trial comparing radical prostatectomy to watchful waiting (without the option of definitive intervention), there was no difference in psychological functioning, anxiety, or depression between the two groups (Johansson et al., 2011).

However, the uncertainty of living with untreated cancer creates an undeniable psychological burden and may influence patient adherence to active surveillance. In the large cohorts of active surveillance, 10% to 15% of men elect to have treatment without a predefined indication (e.g., grade progression, rapid PSA increase). Men on surveillance have specific survivorship needs, related to reassurance and avoidance of psychological distress. Patient anxiety over time has been evaluated within the PRIAS study (van den Bergh et al., 2010). Somewhat counterintuitively, patient-reported anxiety and uncertainty about treatment decisions were lower in the surveillance group than in men who had definitive therapy. Anxiety did not increase over time. In fact, patients' confidence in their decision increases with time, as, with the passage of years, they experience no evidence of disease progression.

Several studies have identified those patients who do not fare well on surveillance. This includes those with chronic anxiety disorders and social isolation. Overall physical health correlates with reduced rates of anxiety and distress.

Lifestyle Management

For many men on active surveillance, their urologist is the only physician they see on a regular basis. This is therefore an opportunity to counsel patients regarding their overall health status and encourage them to adopt a healthy lifestyle. These lifestyle changes are discussed in the following sections.

Smoking Cessation

Advising men to quit smoking is the single most cost-effective health intervention in the entire edifice of medical practice. Although prostate cancer is not as closely linked to smoking as lung cancer or bladder cancer, the literature suggests that smoking may promote the development of more aggressive disease and increase disease-specific mortality (Kenfield et al., 2011a). Quitting seems to reduce this risk and also has other obvious health benefits. The patient with newly diagnosed cancer seeing a “specialist” is uniquely primed and receptive to this advice. Two minutes spent by the specialist in counseling smoking cessation may have an impact on a patient's smoking behavior. A patient who stops smoking because of this intervention will derive a great deal more benefit with respect to longevity and general health than any prostate cancer intervention is likely to provide!

Exercise

Regular exercise is a powerful health-promoting intervention. If it were a pill, everyone would take it! Regular exercise may inhibit the risk for prostate cancer prevention in many ways (Friedenreich et al., 2016; Galvão et al., 2016; Giovannucci et al., 2005; Kenfield et al., 2011b; Johnsen et al., 2009; Nilsen et al., 2006; Orsini et al., 2009). These include modulation of circulating growth factors and sex-steroid hormones; improved myokine and adipokine profiles; improved immune function; androgen receptor adaptation; reduction in systemic inflammation and oxidative stress; changes in tumor vascularization; modification of expression of a number of key regulatory genes; and alteration of telomeres (Nilsen et al., 2006). This is particularly true for strenuous exertion, that is, activity that requires an energy expenditure six or more times the resting metabolic rate. One group reported that more than 3 hours per week of vigorous activity in treated prostate cancer patients reduced the disease-specific mortality by 61% (Kenfield et al., 2011b). Brisk walking of 7 hours or more per week had a similar benefit. A Canadian long-term study with 17-year follow-up reported a 45% reduction in disease-specific mortality (Friedenreich et al., 2016). Given the many health benefits, counseling patients on surveillance regarding the importance of regular exercise is warranted.

Weight Control

Obesity contributes to prostate cancer progression in many ways, including alterations in leptin and adiponectin, which may play tumor-suppressor roles; increase in IGF-1 and decrease in IGF binding proteins 1 and 2, resulting in increased mitogenic signaling; lower sex hormone–binding protein and higher estrogen; increased systemic inflammation and oxidative stress; and increased insulin levels (Bandini et al., 2017). Many studies have reported an increase in high-grade cancer and prostate cancer mortality in obese men, independent of diet, physical activity, or clinical factors (Agalliu et al., 2015; Amling et al., 2004; Barrington et al., 2015; Bassett et al., 2005; Cao and Ma, 2011; Giovannucci et al., 2007; Haque et al., 2014; Kane et al., 2005; Ma et al., 2008; Moller et al., 2015; Pischon et al., 2008; Rodriguez et al., 2001; Strom et al., 2005; Yamoah et al., 2016). A recent meta-analysis estimated that a 5-kg/m^2 increase in body mass index (BMI) increased the risk for prostate cancer mortality by 20% (Barrington et al., 2015); a 0.1-unit increase in waist/hip ratio was associated with a similar increase (Cao and Ma, 2011). This relationship may be particularly strong in African-Americans (Pischon et al., 2008). Thus men should be counseled regarding the importance of maintaining a healthy weight.

Diet

Whether dramatic changes in diet and lifestyle will translate into a reduced risk for disease progression and mortality has not been proven. Most data come from epidemiologic studies or studies in treated patients, rather than specifically from studies of men on surveillance. However, a reasonable inference is that dietary modification can have a significant influence on the natural history of prostate cancer. To summarize a large body of diverse literature: men with prostate cancer on active surveillance should focus on consuming a varied diet rich in vegetables, especially cooked tomatoes and cruciferous vegetables, whole grains, skinless poultry, and fish, and limit meat consumption, especially processed meats (Peisch et al., 2017; Venkateswaran and Klotz, 2010). A prostate-healthy diet is essentially the same as a heart-healthy diet (Lin et al., 2019). One study examined comprehensive lifestyle modification including a vegan diet, exercise, and stress management. The study reported a decrease in PSA, improved treatment-free survival, and a favorable alteration in number of prostate cancer–related genes, and telomere length (Frattaroli et al., 2008; Ornish et al., 2008, 2013). This emphasized the positive effects of this approach in both the biologic and psychological spheres.

For patients or physicians who wish to be extremely proactive in this area, the approach of "holistic surveillance," utilizing a vegan diet and a wide range of micronutrients, has been described (Berg et al., 2016). This approach, although appealing to individuals committed to complementary medicine, is unproven. Further, high-dose micronutrients may be harmful and in the absence of evidence should be avoided (see next section).

Micronutrients

In general, there are no specific vitamins or supplements that have been demonstrated to be of value in men on active surveillance. Indeed, most large professional bodies do not recommend nutritional supplements for cancer prevention, either primary or secondary. The American Cancer Society 2012 summary on this topic states, "Evidence from both observational studies and clinical trials suggests that dietary supplements are unlikely to improve prognosis or overall survival after the diagnosis of cancer, and may actually increase mortality" (Rock et al., 2012).

An exception is vitamin D. Vitamin D deficiency is common in the elderly, particularly in Northern latitudes (Cashman et al., 2016; Chapuy et al., 1997). Low levels of vitamin D have been linked to prostate cancer. One study in a surveillance population reported a seasonal variation in PSA rise (slower in summer months), suggesting a beneficial role of higher levels of vitamin D (Vieth et al., 2006). Studies evaluating the role of vitamin D in overall cancer and cardiovascular disease prevention are ongoing.

Capsaicin, the active "hot" ingredient in red chili peppers, is a biologically active molecule that targets a number of prostate cancer–related pathways and may be useful in secondary prevention. In animal models, it significantly inhibits prostate cancer growth and induces apoptosis and cell cycle arrest (Venier et al., 2015). However, there is no evidence to date of its effectiveness in the active surveillance scenario.

Caution regarding the holus-bolus, enthusiastic adoption of unproven micronutrients is warranted. A recent selenium study of 4400 men with localized prostate cancer reported that those consuming greater than or equal to 140 µg/day of supplemental selenium after diagnosis had a 2.6 times greater disease-specific mortality (Kenfield et al., 2015). Patients taking vitamin E in the SELECT trial had an increased risk for prostate cancer compared with placebo (Klein et al., 2011). These micronutrients are generally contraindicated in men on active surveillance.

Pharmacologic Intervention

5α-reductase–specific antibodies (5ARIs) have a theoretical role in men on active surveillance by reducing the androgenic load. It is well known that men with 5α-reductase deficiency do not develop prostate cancer (Nelson et al., 2003). The Reduction by Dutasteride of Clinical Progression Events in Expectant Management of Prostate Cancer (REDEEM) study compared dutasteride to placebo in men on active surveillance (Fleshner et al., 2012). The primary end point was the rate of "progression," defined as volume progression of Gleason grade 1 beyond Epstein criteria, or grade progression. There was a 38% reduction in the rate of progression, but this was entirely a result of reduced numbers of patients with GG1 volume progression. This is not surprising, considering that the 5ARIs induce epithelial cytoreduction. There was no difference in upgrading between the two groups. Adverse effects on libido and erectile function were more common in the dutasteride group.

Given the effect of 5ARIs on libido, and lingering uncertainty about a slight increase in upgrading in the Reduction by Dutasteride of Prostate Cancer Events (REDUCE) trial and the Prostate Cancer Prevention Trial (PCPT), 5ARIs should not be used in men on active surveillance solely for prevention of "progression," or for PSA reduction. However, in men on active surveillance who have a benign prostatic hyperplasia/lower urinary tract symptom indication for a 5ARI, the prior diagnosis of low-grade prostate cancer should not influence the treatment decision.

Statins, which reduce cholesterol by inhibiting HMG-CoA (3-hydroxy-3-methyl-glutaryl-coenzyme A) reductase, may have a secondary chemoprevention role in men on active surveillance. Statins reduce lipid rafts, which may promote prostate cancer progression via the androgen receptor (AR), epidermal growth factor receptor (EGFR), and luteinizing hormone receptor (LHR) pathways, resulting in attenuated Akt signaling and apoptosis (Zhuang et al., 2005), as well as anti-inflammatory and anti-angiogenic effects (Demierre et al., 2005). Chronic inflammation is associated with an increased risk for prostate cancer, and the inhibitor effect on inflammation is a plausible mechanism for a statin prevention pathway (Allott et al., 2017). Statins may also inhibit androgen synthesis. They have been demonstrated to have a beneficial effect on prostate cancer progression in numerous, mostly epidemiologic, studies, and in men treated radically with surgery or radiation (Babcook et al., 2016). One study of

11,772 men with localized prostate cancer reported a postdiagnostic use of statins reduced disease-specific mortality by 24% (Yu et al., 2014), and another showed a 36% reduction in PSA recurrence (Allott et al., 2014). However, some studies failed to show a benefit (Chao et al., 2013; Ishak et al., 2014; Mondul et al., 2011). Given the benefits of lower cholesterol on cardiovascular health, particularly in men with underlying risk factors, the use of statins in many men with active surveillance seems reasonable.

Metformin reduces hepatic glucose production, increases insulin sensitivity, and increases glucose utilization. It has potential antineoplastic properties through multiple pathways including AMP-activated protein kinase–dependent and kinase-independent pathways, alteration of insulin and IGF signaling, and suppression of androgen signaling by reducing cyclin D1 activity (Hankinson et al., 2017; Miller et al., 2013; Zhang and Guo 2016).

A number of studies have demonstrated that diabetics on metformin have a decrease in prostate cancer–specific mortality (Margel et al., 2013; Spratt et al., 2013). However, several studies have not shown such a relationship (Allott et al., 2013; Mayer et al., 2017; Patel et al., 2010). Several studies are currently evaluating the role of metformin, specifically in men on active surveillance. Until further evidence is forthcoming, metformin is not indicated for secondary prevention in men on active surveillance.

Summary

Clinicians managing patients on active surveillance should use the opportunity of regular follow-up visits to counsel patients about the benefits of dietary and lifestyle modifications. These simple recommendations, which also benefit general and cardiovascular health, should include the following:

1. Exercise regularly, and include vigorous activity if possible.
2. Maintain a healthy weight.
3. Stop smoking.
4. Eat a vegetable- and grain-based diet; moderate red meat consumption, especially processed meats; if eating meat, rely on fish and skinless poultry.
5. Limit saturated fat intake.
6. Take vitamin D, 1000 to 2000 IU/day, especially during periods of reduced sunlight.
7. Consider a low-dose statin.

GAP 3

A major undertaking in this field has been the development of a global database of men on active surveillance. This extraordinary initiative, known as Global Action Plan Prostate Cancer Active Surveillance (GAP3), was funded by the Movember Foundation as part of their Global Action Plan initiative. The GAP3 initiative connected more than 250 researchers with an interest in active surveillance from virtually every region in the world. The initiative will address a number of key questions, including how to define low-risk prostate cancer; how best to establish a diagnosis; the role of comorbidity and life expectancy; the best monitoring tools and how to use them; how to define optimal triggers for active treatment and switch to watchful waiting; and criteria to evaluate the efficacy of active surveillance. The goal is to create an international consensus on these questions. This has been achieved to some degree (Bruinsma et al., 2017). With longer follow-up and increased incorporation of imaging and biomarkers, the data from this initiative will likely set an international standard for active surveillance.

Barriers to Active Surveillance

Important barriers can hinder a patient's decision to choose active surveillance. The evidence for this is the relatively low rate of uptake of active surveillance in many constituencies (Aizer et al., 2012; Cooperberg, 2015; Harlan et al., 2003). These include patient preconceptions about the meaning of “cancer”; misinformation provided to the patient by friends, family, or practitioners; provider preference/bias against active surveillance; and psychological factors. These can lead to difficulties in making the correct decision and poor health outcomes. How can these barriers to active surveillance be overcome? Patients need to be equipped with the correct information, and shared decision making must be supported by health care professionals. The key steps are to (1) inform patients about the multiple reasonable available options, and (2) thoroughly discuss these while balancing them with the patient's own preferences and values. Better-informed patients tend to prefer conservative management (Volk et al., 2014). A good decision aid can be invaluable in this process; a number of these specifically geared to the low-risk patient have been developed and are available online (Adsul et al., 2015; Ilic et al., 2015; Lin et al., 2009; Volk et al., 2007).

Shared decision making is the cornerstone of this approach. This implies four requisites (Charles et al., 2003). Each of these has communication skills as a central component:

1. Both physician and patient are involved in the decision-making process.
2. Both share information with each other.
3. Both take steps to participate in the decision-making process by expressing treatment preferences.
4. A decision is made, and both the physician and patient agree on this.

Physicians, in other words, should serve as the navigator, not the driver, of this process. Active surveillance is a journey, not just a destination. It has complexity influenced by many individual and contextual factors. Clinicians should be aware of these. Internal factors (i.e., patient values) and external factors (pressure brought to bear on the patient) both exert an influence leading to a final decision, and a shared decision-making approach led by a physician skilled in this technique is critical.

Active surveillance may have an impact on QoL in several respects:

1. Prostate biopsy: Of studies addressing the association between biopsies and erectile dysfunction and incontinence, three of four show none exists (Hilton et al., 2012; Parker et al., 2016; Pearce et al., 2015), and one showed an association (Fujita et al., 2009). This question warrants further evaluation.
2. Anxiety: Studies that address this generally report that men on active surveillance have a low rate of anxiety. Anxiety occurs with the diagnosis of prostate cancer, but is not increased by the selection of conservative management. A limitation of these studies is that they have been derived from men self-selecting for active surveillance.
3. GU QoL: Several long-term studies have reported good or better prostate-specific function and QoL than those who received active treatment (de Cerqueira et al., 2015; Jeldres et al., 2015; Pham et al., 2016; van den Bergh et al., 2012, 2014; Venderbos et al., 2017; Watson et al., 2016). Improved QoL was consistently seen using validated questionnaires covering voiding and sexual function (e.g., EORTC QLQ PR25, IIEF-15 score, FACT-P, EPIC). The QoL is comparable to that of men without prostate cancer. A limitation is a paucity of long-term data, and disentangling late treatment effects from aging effects on physical function is challenging.

Every active surveillance cohort reports a subset of men who discontinue active surveillance on their own, without meeting the criteria for intervention. This ranges from 7% to 15% in the quoted studies. In one systematic review of 17 studies, 20% discontinued active surveillance because of patient choice or anxiety (Simpkin et al., 2015). The proportion differs substantially among cohorts. QoL assessment on these patients is often discontinued, making assessment about the impact of treatment in the active surveillance cohort on QoL difficult.

Nomenclature

A continual challenge in the management of men on active surveillance is the impact of the word *cancer* on a patient's emotional response to his diagnosis, and his decisions regarding treatment. Patients understandably fear that they have an aggressive, lethal disease. In the context of the indolent, nonmetastatic characteristics of low-grade prostate cancer, it has been proposed that Gleason 6 be renamed. Two suggestions include indolent lesion of epithelial origin (IDLE) (Esserman et al., 2014) and prostatic neoplasm of low malignant potential (PNLMP). This change in nomenclature would have the benefit of reducing patient anxiety, facilitating conservative management, and enhancing retention of men on surveillance.

The problem with dropping the word *cancer* is that Gleason 6 cancer does fulfill the traditional pathological criteria for cancer. It can invade locally. The mutational landscape between Gleason 6 and higher-grade cancer is a continuous one; some Gleason 6 cancers harbor potentially significant mutations. Finally, metastatic phenotype is not a requirement for designating a lesion cancerous. Basal cell cancers of the skin and gliomas are two examples of nonmetastasizing cancers. Therefore it is unlikely that the term *cancer* will be discontinued.

Finally, the shift to the Gleason grade group system, whereby low-grade cancer has a score of 1 (rather than 6) has achieved many of the benefits discussed earlier.

Economics

The cost of prostate cancer management is high. This is a function of both the high prevalence and the cost of therapy. Active surveillance requires long-term follow-up, and this engenders costs. In general, however, these costs are less than those of active treatment. Clearly, overtreatment is costly, both in terms of the financial impact of unnecessary treatment and the personal cost to the individual's QoL.

One study calculated that for low-risk prostate cancer patients, the cost of definitive therapy compared with no active treatment within 1 year was over $18,000 per patient (Keegan et al., 2012). The costs of surveillance are a function of the frequency and type of diagnostic tests, and the rate of radical intervention. One Canadian study, which included the effects of other-cause mortality and cancer recurrence, calculated a cost savings of $100 million at 10 years compared with immediate treatment of all men (Dragomir et al., 2014).

Reducing the rate of biopsy significantly reduces cost. Biannual biopsies result in comparable costs to surgery by 10 years (Keegan et al., 2012). Cost savings are also dependent on a significant proportion of patients remaining on active surveillance long-term. In the two longest-term studies to date, the retention on surveillance at 15 years was 43% and 55% (Klotz et al., 2015; Tosoian et al., 2015). The increased utilization of MRI and biomarkers has the potential to add considerable expense. However, these technologies may prove to be cost-effective by improving patient selection, reducing the need for treatment, and reducing the need for repeat biopsies. For MRI in particular, there is a very wide range in cost, from less than $500 (UK National Health Service) to ten times that amount (some US private practices). Improvements in MRI efficiency and competition may bring these higher prices down over time. A scenario whereby MRI is performed every 3 to 5 years on surveillance patients, at a cost of under $1000, with an accuracy that allows biopsy to be avoided in most patients with a negative or stable MRI, is likely to be quite cost-effective compared with definitive therapy.

Research Questions

The controversies and unanswered questions in this field have moved from concept to application. Initial conservative management for low-risk disease is supported by preclinical genetic analysis, randomized trials (PIVOT, ProtecT), and prospective series of conservative management reviewed in this chapter. The major focus during the past decade was to reduce overtreatment. Now, the major concern is avoiding undertreatment in those whose risk is higher than anticipated. The questions are now related to who is a candidate for active surveillance, how they should be followed, when and at what interval diagnostic tests should be undertaken, and which tests are optimal. The areas of uncertainty cover a broad swath of current research in prostate cancer. Research is warranted at the molecular (genomic, proteomic, transcriptomic), epigenetic, epidemiologic, radiologic, and clinical trial levels.

The key questions are as follows: What are the molecular events that signal progression of low-grade disease? We are just at the beginning of learning which genetic and epigenetic aberrations alter the behavior of prostate cancer cells. Many tantalizing mechanisms have recently been identified; for example, the effect of circulating exosomes containing biologically active molecules, that is, mRNA, shed by more aggressive cancer cells and incorporated into low-grade cells resulting in more aggressive behavior. Another priority is determining whether patients with certain known germline mutations, for example, *BRCA1* or *BRCA2*, are candidates for surveillance. *BRCA* mutations confer marked genetic instability, and recent studies indicate that the mutational load of localized prostate cancer resembles that of castration-resistant prostate cancer, making these patients unreliable candidates for conservative management. We will learn much more about how these aberrant genetic pathways interact over the next decade. The behavior of prostate cancer in men with DNA repair germline defects and the role of screening for these defects and mutations is currently the subject of intense interest. Given what is known about the rapid accumulation of a large mutational burden in men with these germline abnormalities, active surveillance should be offered with caution to men with a known germline mutation of the DNA repair pathway (*BRCA1* and *BRCA2*, *ATM*).

How do we best identify the “wolf in sheep's clothing” (Schoots et al., 2017)? The limitation of active surveillance based on systematic biopsy is the misattribution of low-grade cancer in the 25% to 30% of patients who harbor a higher-grade cancer that was missed because of sampling. The increased use of MRI will address this substantially but not completely. We know much better today how to use baseline parameters to identify patients at risk (e.g., PSA density, extent of core involvement, race). The use of MRI and molecular biomarkers is further refining this, but uncertainty remains as to the reliability of mpMRI, the relationship between underlying risk and the need for systematic biopsies if the MRI is normal, and the role of molecular biomarkers. Other accurate imaging methods are emerging to identify significant cancer, including PSMA-PET, and high-resolution microultrasound.

Nomograms incorporating MRI and/or biomarker findings to predict the risk for coexistent higher-grade cancer are needed urgently. Sorting out how to use these tests optimally will require further research. For example, does the presence of restricted diffusion whose targeted biopsy shows Gleason grade 1 mean the patient has a biologically more aggressive cancer? Was a higher-grade cancer missed, or is it a false-positive MRI? The role of a genetic biomarker in this setting seems obvious, but there are little data on this situation. The field of radiomics, that is, the molecular events associated with restricted diffusion and other MRI abnormalities associated with cancer, is in its infancy. Similarly, the best strategy for a patient with microfocal Gleason 6 cancer whose Prolaris or Oncotype DX assay reveals a mildly elevated risk score is unclear. MRI with targeted biopsy also likely plays a role in this setting, but there are few data.

Which intermediate-risk patients are candidates for surveillance? Recent data, described in this chapter, indicate that the approach to surveillance, based on PSA and serial biopsy, is imperfect for Gleason 7 patients. Despite close monitoring and selective delayed intervention, 20% or more of these patients progress to metastasis by 15 years. Yet the glass is also more than half full; 80% remained free of metastases. Obviously, therefore, many intermediate-risk patients are candidates for surveillance. The key is to identify those with indolent disease accurately. Further studies using molecular biomarkers and MRI to select these patients are warranted.

The field of liquid biopsy, enabling a “global” assessment of the patient's mutational load, offers a lot of promise in this area.

Once patients have been selected for surveillance, a host of research questions present themselves. Which interventions (diet, exercise, micronutrients, and pharmacologic agents) are warranted to reduce the risk for biologic progression? This is a fruitful area for research. Many ongoing studies are evaluating the role of exercise, dietary modification, and naturally occurring micronutrients in men on surveillance. These patients are followed for many years; they are motivated, and a great deal of evidence suggests that prostate cancer progression is amenable to modification by dietary or other influences. Specific questions include the role of exercise, weight loss, reduction of animal protein or carbohydrate in the diet, and the use of natural dietary micronutrients, including pomegranate, capsaicin, and lycopene. A host of other compounds have been suggested as being useful in the surveillance setting, but are unproven. Often, micronutrients that look promising turn out to be harmful when studied in rigorous clinical trials. Common drugs with metabolic or cardiovascular benefits look promising, particularly statins and diabetic medications (i.e., metformin). Clinical intervention trials testing these agents are warranted.

What is the most efficient and cost-effective way to follow patients longitudinally? Is serial biopsy still required, and in whom? Can risk stratification allow patients to minimize the burden of follow-up? These questions have both QoL and economic ramifications. An unmet need in the field is to reduce excessive reliance on serial biopsy. Can MRI, if negative, replace systematic biopsy, and can targeted biopsy alone (i.e., 2 to 4 cores) replace the 12- to 14-core systematic approach? Can patients with a negative molecular biomarker avoid or reduce the frequency of biopsies? Is the negative predictive value of a negative MRI sufficiently high that a biopsy can be safely avoided, and how does the NPV vary according to patient risk? Aside from discontinuing surveillance because of short life expectancy, are there patients whose disease is so predictably indolent that no further follow-up is required despite a 15- to 20-year life expectancy? How do we identify these?

Several national health policy groups have recommended against PSA screening, largely because of the risk for overdetection and overtreatment. Can the widespread adoption of surveillance for low-risk disease rehabilitate prostate cancer screening and satisfy policy makers and methodologists that the benefits outweigh the risks at an acceptable cost? This will require modeling studies based on recent data.

Conclusion

Active surveillance has been widely adopted as a safe and effective strategy for men with low-risk prostate cancer. It is considered the primary treatment for most of these men by numerous national organizations, including the AUA and ASCO. It is an important antidote to the dilemma of overtreatment that accompanies screening and early detection. Although the concept is robust, many aspects of surveillance are still in the process of being defined, particularly the role of serial imaging and molecular biomarkers.

References

Adsul P, Wray R, Spradling K, et al. Systematic review of decision aids for newly diagnosed patients with prostate cancer making treatment decisions. *J Urol*. 2015;194(5):1247–1252.

Agalliu I, Williams S, Adler B, et al. The impact of obesity on prostate cancer recurrence observed after exclusion of diabetics. *Cancer Causes Control*. 2015;26(6):821–830.

Ahmed HU, Arya M, Freeman A, et al. Do low-grade and low-volume prostate cancers bear the hallmarks of malignancy? *Lancet Oncol*. 2012;13(11):e509–e517.

Ahmed HU, El-Shater Bosaily A, Brown LC, PROMIS study group, et al. Diagnostic accuracy of multi-parametric MRI and TRUS biopsy in prostate cancer (PROMIS): a paired validating confirmatory study. *Lancet*. 2017;389(10071):815–822.

Aizer AA, Paly JJ, Zietman AL, et al. Multidisciplinary care and pursuit of active surveillance in low-risk prostate cancer. *J Clin Oncol*. 2012;30(25):3071–3076.

Albertsen PC, Hanley JA, Barrows GH, et al. Prostate cancer and the Will Rogers phenomenon. *J Natl Cancer Inst*. 2005;97(17):1248–1253.

Albertsen PC, Hanley JA, Fine J. 20-year outcomes following conservative management of clinically localized prostate cancer. *JAMA*. 2005;293(17):2095–2101.

Allott EH, Abern MR, Gerber L, et al. Metformin does not affect risk of biochemical recurrence following radical prostatectomy: results from the SEARCH database. *Prostate Cancer Prostatic Dis*. 2013;16(4):391–397.

Allott EH, Howard LE, Cooperberg MR, et al. Postoperative statin use and risk of biochemical recurrence following radical prostatectomy: results from the Shared Equal Access Regional Cancer Hospital (SEARCH) database. *BJU Int*. 2014;114(5):661–666.

Allott EH, Howard LE, Vidal AC, et al. Statin use, serum lipids, and prostate inflammation in men with a negative prostate biopsy: results from the REDUCE trial. *Cancer Prev Res (Phila)*. 2017;10(6):319–326.

American Urological Association. *Clinically Localized Prostate Cancer: AUA/ASTRO/SUO Guideline*. [Available at] https://www.auanet.org/guidelines/prostate-cancer-clinically-localized-guideline; 2017.

Amling CL, Riffenburgh RH, Sun L, et al. Pathologic variables and recurrence rates as related to obesity and race in men with prostate cancer undergoing radical prostatectomy. *J Clin Oncol*. 2004;22(3):439–445.

Babcook MA, Joshi A, Montellano JA, et al. Statin use in prostate cancer: an update. *Nutr Metab Insights*. 2016;9:43–50.

Bandini M, Gandaglia G, Briganti A. Obesity and prostate cancer. *Curr Opin Urol*. 2017;27(5):415–421.

Barrington WE, Schenk JM, Etzioni R, et al. Difference in association of obesity with prostate cancer risk between US African American and non-Hispanic white men in the Selenium and Vitamin E Cancer Prevention Trial (SELECT). *JAMA Oncol*. 2015;1(3):342–349.

Bassett WW, Cooperberg MR, Sadetsky N, et al. Impact of obesity on prostate cancer recurrence after radical prostatectomy: data from CaPSURE. *Urology*. 2005;66(5):1060–1065.

Berg CJ, Habibian DJ, Katz AE, et al. Active holistic surveillance: the nutritional aspect of delayed intervention in prostate cancer. *J Nutr Metab*. 2016;2016:2917065.

Bill-Axelson A, Holmberg L, Ruutu M, et al. Radical prostatectomy versus watchful waiting in early prostate cancer. *N Engl J Med*. 2011;364:1708–1717.

Bill-Axelson A, Holmberg L, Garmo H, et al. Radical prostatectomy or watchful waiting in early prostate cancer. *N Engl J Med*. 2014;370(10):932–942.

Bill-Axelson A, Holmberg L, Garmo H, et al. Radical prostatectomy or watchful waiting in prostate cancer–29-year follow-up. *N Engl J Med*. 2018;379(24):2319–2329.

Bismar TA, Dolph M, Teng LH, et al. ERG protein expression reflects hormonal treatment response and is associated with Gleason score and prostate cancer specific mortality. *Eur J Cancer*. 2012;48(4):538–546.

Brand TC, Zhang N, Crager MR, et al. Patient-specific meta-analysis of 2 clinical validation studies to predict pathologic outcomes in prostate cancer using the 17-Gene Genomic Prostate Score. *Urology*. 2016;89:69–75.

Bruinsma SM, Roobol MJ, Carroll PR, Movember Foundation's Global Action Plan Prostate Cancer Active Surveillance (GAP3) consortium, et al. Expert consensus document: semantics in active surveillance for men with localized prostate cancer - results of a modified Delphi consensus procedure. *Nat Rev Urol*. 2017;14(5):312–322.

Bul M, Zhu X, Valdagni R, et al. Active surveillance for low-risk prostate cancer worldwide: the PRIAS study. *Eur Urol*. 2013;63(4):597–603.

Cao Y, Ma J. Body-mass index, prostate cancer-specific mortality and biochemical recurrence: a systematic review and meta-analysis. *Cancer Prev Res (Phila)*. 2011;4(4):486–501.

Carter HB, Helfand B, Mamawala M, et al. Germline mutations in ATM and BRCA1/2 are associated with grade reclassification in men on active surveillance for prostate cancer. *Eur Urol*. 2019;75(5):743–749.

Cashman KD, Dowling KG, Skrabakova Z, et al. Vitamin D deficiency in Europe: pandemic? *Am J Clin Nutr*. 2016;103(4):1033–1044.

Chao C, Jacobsen SJ, Xu L, et al. Use of statins and prostate cancer recurrence among patients treated with radical prostatectomy. *BJU Int*. 2013;111(6):954–962.

Chapuy MC, Preziosi P, Maamer M, et al. Prevalence of vitamin D insufficiency in an adult normal population. *Osteoporos Int*. 1997;7(5):439–443.

Charles CA, Whelan T, Gafni A, et al. Shared treatment decision making: what does it mean to physicians? *J Clin Oncol*. 2003;21(5):932–936.

Chen RC, Rumble RB, Loblaw DA, et al. Active surveillance for the management of localized prostate cancer (Cancer Care Ontario Guideline): American Society of Clinical Oncology Clinical Practice Guideline Endorsement. *J Clin Oncol*. 2016;34(18):2182–2190.

Cooperberg MR. Long term active surveillance: answers and questions. *J Clin Oncol*. 2015;33(3):238–240.

Cullen J, Rosner IL, Brand TC, et al. A biopsy-based 17-gene genomic prostate score predicts recurrence after radical prostatectomy and adverse surgical pathology in a racially diverse population of men with clinically low- and intermediate-risk prostate cancer. *Eur Urol*. 2015;68(1):123–131.

Cuzick J, Berney DM, Fisher G, et al. Prognostic value of a cell cycle progression signature for prostate cancer death in a conservatively managed needle biopsy cohort. *Br J Cancer*. 2012;106(6):1095–1099.

Cuzick J, Stone S, Fisher G, et al. Validation of an RNA cell cycle progression score for predicting death from prostate cancer in a conservatively managed needle biopsy cohort. *Br J Cancer*. 2015;113(3):382–389.

Dall'Era MA, Konety BR, Cowan JE, et al. Active surveillance for the management of prostate cancer in a contemporary cohort. *Cancer*. 2008;112(12):2664–2670.

de Cerqueira MA, Laranja WW, Sanches BC, et al. Burden of focal cryoablation versus brachytherapy versus active surveillance in the treatment of very low-risk prostate cancer: a preliminary head-to-head comprehensive assessment. *Eur J Cancer Care (Engl)*. 2015;24(6):929–937.

Demierre MF, Higgins PD, Gruber SB, et al. Statins and cancer prevention. *Nat Rev Cancer*. 2005;5(12):930–942 [Review].

Donovan JL, Hamdy FC, Lane JA, et al. ProtecT Study Group. patient-reported outcomes after monitoring, surgery, or radiotherapy for prostate cancer. *N Engl J Med*. 2016;375(15):1425–1437.

Dragomir A, Cury FL, Aprikian AG. Active surveillance for low-risk prostate cancer compared with immediate treatment: a Canadian cost comparison. *CMAJ*. 2014;2(2):E60–E68.

Draisma G, Etzioni R, Tsodikov A, et al. Lead time and overdiagnosis in prostate-specific antigen screening: importance of methods and context. *J Natl Cancer Inst*. 2009;101(6):374–383.

Eggener S, Scardino P, Walsh P, et al. 20 year prostate cancer specific mortality after radical prostatectomy. *J Urol*. 2011;185(3):869–875.

Epstein JI, Feng Z, Trock BJ, et al. Upgrading and downgrading of prostate cancer from biopsy to radical prostatectomy: incidence and predictive factors using the modified Gleason grading system and factoring in tertiary grades. *Eur Urol*. 2012;61(5):1019–1024.

Epstein JI, Amin MB, Reuter VE, et al. Contemporary Gleason grading of prostatic carcinoma: an update with discussion on practical issues to implement the 2014 International Society of Urological Pathology (ISUP) Consensus Conference on

Gleason Grading of Prostatic Carcinoma. *Am J Surg Pathol*. 2017;41(4):e1–e7.

Erbersdobler A, Isbarn H, Dix K, et al. Prognostic value of microvessel density in prostate cancer: a tissue microarray study. *World J Urol*. 2010;28(6):687–692.

Esserman LJ, Thompson IM, Reid B, et al. Addressing overdiagnosis and overtreatment in cancer: a prescription for change. *Lancet Oncol*. 2014;15(6):e234–e242.

Fleischmann A, Huland H, Mirlacher M, et al. Prognostic relevance of Bcl-2 overexpression in surgically treated prostate cancer is not caused by increased copy number or translocation of the gene. *Prostate*. 2012;72(9):991–997.

Fleshner NE, Lucia MS, Egerdie B, et al. Dutasteride in localised prostate cancer management: the REDEEM randomised, double-blind, placebo-controlled trial. *Lancet*. 2012;379(9821):1103–1111.

Frattaroli J, Weidner G, Dnistrian AM, et al. Clinical events in prostate cancer lifestyle trial: results from two years of follow-up. *Urology*. 2008;72(6):1319–1323.

Friedenreich CM, Wang Q, Neilson HK, et al. Physical activity and survival after prostate cancer. *Eur Urol*. 2016;70(4):576–585.

Fujita K, Landis P, McNeil BK, et al. Serial prostate biopsies are associated with an increased risk of erectile dysfunction in men with prostate cancer on active surveillance. *J Urol*. 2009;182(6):2664–2669.

Furusato B, Gao CL, Ravindranath L, et al. Mapping of TMPRSS2-ERG fusions in the context of multi-focal prostate cancer. *Mod Pathol*. 2008;21(2):67–75.

Galvão DA, Taaffe DR, Spry N, et al. Enhancing active surveillance of prostate cancer: the potential of exercise medicine. *Nat Rev Urol*. 2016;13(5):258–265.

Georgescu I, Gooding RJ, Doiron RC, et al. Molecular characterization of Gleason patterns 3 and 4 prostate cancer using reverse Warburg effect-associated genes. *Cancer Metab*. 2016;4:8.

Giovannucci EL, Liu Y, Leitzmann MF, et al. A prospective study of physical activity and incident and fatal prostate cancer. *Arch Intern Med*. 2005;165(9):1005–1010.

Giovannucci E, Liu Y, Platz EA, et al. Risk factors for prostate cancer incidence and progression in the Health Professionals Follow-up Study. *Int J Cancer*. 2007;121(7):1571–1578.

Gökce MI, Sundi D, Schaeffer E, et al. Is active surveillance a suitable option for African American men with prostate cancer? A systemic literature review. *Prostate Cancer Prostatic Dis*. 2017;20(2):127–136.

Hamdy FC, Donovan JL, Lane JA, ProtecT Study Group, et al. 10-Year outcomes after monitoring, surgery, or radiotherapy for localized prostate cancer. *N Engl J Med*. 2016;375(15):1415–1424.

Hanahan D, Weinberg RA. Hallmarks of cancer: the next generation. *Cell*. 2011;144(5):646–674.

Hankinson SJ, Fam M, Patel NN. A review for clinicians: prostate cancer and the antineoplastic properties of metformin. *Urol Oncol*. 2017;35(1):21–29.

Haque R, Van Den Eeden SK, Wallner LP, et al. Association of body mass index and prostate cancer mortality. *Obes Res Clin Pract*. 2014;8(4):e374–e381.

Harlan SR, Cooperberg MR, Elkin E, et al. Time trends and characteristics of men choosing watchful waiting for initial treatment of localized prostate cancer: results from CaPSURE. *J Urol*. 2003;170(5):1804–1807.

Herlemann A, Huang HC, Alam R, et al. Decipher identifies men with otherwise clinically favorable-intermediate risk disease who may not be good candidates for active surveillance. *Prostate Cancer Prostatic Dis*. 2019 [Epub ahead of print].

Hilton JF, Blaschko SD, Whitson JM, et al. The impact of serial prostate biopsies on sexual function in men on active surveillance for prostate cancer. *J Urol*. 2012;188(4):1252–1258.

Hubbard GK, Mutton LN, Khalili M, et al. Combined MYC activation and PTEN loss are sufficient to create genomic instability and lethal metastatic prostate cancer. *Cancer Res*. 2016;76(2):283–292.

Hussein AA, Welty CJ, Ameli N, et al. Untreated Gleason grade progression on serial biopsies during prostate cancer active surveillance: clinical course and pathological outcomes. *J Urol*. 2015;194(1):85–90.

Ilic D, Jammal W, Chiarelli P, et al. Assessing the effectiveness of decision aids for decision making in prostate cancer testing: a systematic review. *Psychooncology*. 2015;24(10):1303–1315.

Inoue LY, Trock BJ, Partin AW, et al. Modeling grade progression in an active surveillance study. *Stat Med*. 2014;33(6):930–939.

Iremashvili V, Soloway MS, Rosenberg DL, et al. Clinical and demographic characteristics associated with prostate cancer progression in patients on active surveillance. *J Urol*. 2012;187(5):1594–1599.

Ishak-Howard MB, Okoth LA, Cooney KA. Statin use and the risk of recurrence after radical prostatectomy in a cohort of men with inherited and/or early-onset forms of prostate cancer. *Urology*. 2014;83(6):1356–1361.

Jain S, Loblaw A, Vesprini D, et al. Gleason upgrading with time in a large prostate cancer active surveillance cohort. *J Urol*. 2015;194(1):79–84.

Jeldres C, Cullen J, Hurwitz LM, et al. Prospective quality-of-life outcomes for low-risk prostate cancer: active surveillance versus radical prostatectomy. *Cancer*. 2015;121(14):2465–2473.

Jemal A, Siegel R, Xu J, et al. Cancer statistics, 2010. *CA Cancer J Clin*. 2010;60(5):277–300.

Johansson E, Steineck G, Holmberg L, SPCG-4 Investigators, et al. Long-term quality-of-life outcomes after radical prostatectomy or watchful waiting: the Scandinavian Prostate Cancer Group-4 randomised trial. *Lancet Oncol*. 2011;12(9):891–899.

Johnsen NF, Tjønneland A, Thomsen BL, et al. Physical activity and risk of prostate cancer in the European Prospective Investigation into Cancer and Nutrition (EPIC) cohort. *Int J Cancer*. 2009;125(4):902–908.

Kane CJ, Bassett WW, Sadetsky N, et al. Obesity and prostate cancer clinical risk factors at presentation: data from CaPSURE. *J Urol*. 2005;173(3):732–736.

Keegan KA, Dall'Era MA, Durbin-Johnson B, et al. Active surveillance for prostate cancer compared with immediate treatment: an economic analysis. *Cancer*. 2012;118(14):3512–3518.

Kenfield SA, Stampfer MJ, Chan JM, et al. Smoking and prostate cancer survival and recurrence. *JAMA*. 2011;305(24):2548–2555.

Kenfield SA, Stampfer MJ, Giovannucci E, et al. Physical activity and survival after prostate cancer diagnosis in the health professionals follow-up study. *J Clin Oncol*. 2011;29(6):726–732.

Kenfield SA, Van Blarigan EL, DuPre N, et al. Selenium supplementation and prostate cancer mortality. *J Natl Cancer Inst*. 2015;107(1):360.

Khatami A, Aus G, Damber JE, et al. PSA doubling time predicts the outcome after active surveillance in screening-detected prostate cancer: results from the European randomized study of screening for prostate cancer, Sweden section. *Int J Cancer*. 2007;120(1):170–174.

Klein EA, Thompson IM Jr, Tangen CM, et al. Vitamin E and the risk of prostate cancer: the Selenium and Vitamin E Cancer Prevention Trial (SELECT). *JAMA*. 2011;306(14):1549–1556.

Klein EA, Haddad Z, Yousefi K, et al. Decipher genomic classifier measured on prostate biopsy predicts metastasis risk. *Urology*. 2016;90:148–152.

Klotz L. Active surveillance for low-risk prostate cancer. *Curr Opin Urol*. 2017;27(3):225–230.

Klotz L, Vesprini D, Sethukavalan P, et al. Long-term follow-up of a large active surveillance cohort of patients with prostate cancer. *J Clin Oncol*. 2015;33(3):272–277.

Komisarenko M, Timilshina N, Richard PO, et al. Stricter active surveillance criteria for prostate cancer do not result in significantly better outcomes: a comparison of contemporary protocols. *J Urol*. 2016;196(6):1645–1650.

Kovac E, Lieser G, Elshafei A, et al. Outcomes of active surveillance after initial surveillance prostate biopsy. *J Urol*. 2017;197(1):84–89.

Lin GA, Aaronson DS, Knight SJ, et al. Patient decision aids for prostate cancer treatment: a systematic review of the literature. *CA Cancer J Clin*. 2009;59(6):379–390.

Lin PH, Aronson W, Freedland SJ. An update of research evidence on nutrition and prostate cancer. *Urol Oncol*. 2019;37(6):387–401.

Ma J, Li H, Giovannucci E, et al. Prediagnostic body-mass index, plasma C-peptide concentration, and prostate cancer-specific mortality in men with prostate cancer: a long-term survival analysis. *Lancet Oncol*. 2008;9(11):1039–1047.

Mamawala MM, Rao K, Landis P, et al. Risk prediction tool for grade re-classification in men with favourable-risk prostate cancer on active surveillance. *BJU Int*. 2017;120(1):25–31.

Margel D, Urbach DR, Lipscombe LL, et al. Metformin use and all-cause and prostate cancer-specific mortality among men with diabetes. *J Clin Oncol*. 2013;31(25):3069–3075.

Mayer MJ, Klotz LH, Venkateswaran V. The effect of metformin use during docetaxel chemotherapy on prostate cancer specific and overall survival of diabetic patients with castration resistant prostate cancer. *J Urol*. 2017;197(4):1068–1075.

Miller RA, Chu Q, Xie J, et al. Biguanides suppress hepatic glucagon signalling by decreasing production of cyclic AMP. *Nature*. 2013;494(7436):256–260.

Moldovan PC, Van den Broeck T, Sylvester R, et al. NPV of MRI: meta-analysis from EAU Guidelines Panel. Can biopsy be avoided if MRI negative? *Eur Urol*. 2017;72(2):250–266.

Moller H, Roswall N, Van Hemelrijck M, et al. Prostate cancer incidence, clinical stage and survival in relation to obesity: a prospective cohort study in Denmark. *Int J Cancer*. 2015;136(8):1940–1947.

Mondul AM, Han M, Humphreys EB, et al. Association of statin use with pathological tumor characteristics and prostate cancer recurrence after surgery. *J Urol*. 2011;185(4):1268–1273.

Morash C, Tey R, Agbassi C, et al. Active surveillance for the management of localized prostate cancer: guideline recommendations. *Can Urol Assoc J*. 2015;9(5–6):171–178.

Nelson WG, De Marzo AM, Isaacs WB. Prostate cancer. *N Engl J Med*. 2003;349(4):366–381.

Nguyen PL, Haddad Z, Ross AE, et al. Ability of a genomic classifier to predict metastasis and prostate cancer-specific mortality after radiation or surgery based on needle biopsy specimens. *Eur Urol*. 2017;72(5):845–852.

Nguyen PL, Martin NE, Choeurng V, et al. Utilization of biopsy-based genomic classifier to predict distant metastasis after definitive radiation and short-course ADT for intermediate and high-risk prostate cancer. *Prostate Cancer Prostatic Dis*. 2017;20(2):186–192.

NICE. *National Collaborating Centre for Cancer. Prostate Cancer: Diagnosis and Treatment. Clinical Guideline*. [Available at] https://www.ncbi.nlm.nih.gov/pubmed/25340246; 2017.

Nilsen TI, Romundstad PR, Vatten LJ. Recreational physical activity and risk of prostate cancer: a prospective population-based study in Norway (the HUNT study). *Int J Cancer*. 2006;119(12):2943–2947.

Odom BD, Mir MC, Hughes S, et al. Active surveillance for low-risk prostate cancer in African American men: a multi-institutional experience. *Urology*. 2014;83(2):364–368.

Ornish D, Magbanua MJ, Weidner G, et al. Changes in prostate gene expression in men undergoing an intensive nutrition and lifestyle intervention. *Proc Natl Acad Sci USA.* 2008;105(24):8369–8374.

Ornish D, Lin J, Chan JM, et al. Effect of comprehensive lifestyle changes on telomerase activity and telomere length in men with biopsy-proven low-risk prostate cancer: 5-year follow-up of a descriptive pilot study. *Lancet Oncol*. 2013;14(11):1112–1120.

Orsini N, Bellocco R, Bottai M, et al. A prospective study of lifetime physical activity and prostate cancer incidence and mortality. *Br J Cancer*. 2009;101(11):1932–1938.

Padar A, Sathyanarayana UG, Suzuki M, et al. Inactivation of cyclin D2 gene in prostate cancers by aberrant promoter methylation. *Clin Cancer Res*. 2003;9(13):4730–4734.

Parker PA, Davis JW, Latini DM, et al. Relationship between illness uncertainty, anxiety, fear of progression and quality of life in men with favourable-risk prostate cancer undergoing active surveillance. *BJU Int*. 2016;117(3):469–477.

Patel MI, DeConcini DT, Lopez-Corona E, et al. An analysis of men with clinically localized prostate cancer who deferred definitive therapy. *J Urol*. 2004;171(4):1520–1524.

Patel T, Hruby G, Badani K, et al. Clinical outcomes after radical prostatectomy in diabetic patients treated with metformin. *Urology*. 2010;76(5):1240–1244.

Pearce SM, Wang CH, Victorson DE, et al. A longitudinal study of predictors of sexual dysfunction in men on active surveillance for prostate cancer. *Sex Med*. 2015;3(3):156–164.

Peisch SF, Van Blarigan EL, Chan JM, et al. Prostate cancer progression and mortality: a review of diet and lifestyle factors. *World J Urol*. 2017;35(6):867–874.

Pham KN, Cullen J, Hurwitz LM, et al. Prospective quality of life in men choosing active surveillance compared to those biopsied but not diagnosed with prostate cancer. *J Urol*. 2016;196(2):392–398.

Pischon T, Boeing H, Weikert S, et al. Body size and risk of prostate cancer in the European prospective investigation into cancer and nutrition. *Cancer Epidemiol Biomarkers Prev*. 2008;17(11):3252–3261.

Popiolek M, Rider JR, Andrén O, et al. Natural history of early, localized prostate cancer: a final report from three decades of follow-up. *Eur Urol*. 2013;63(3):428–435.

Porten SP, Whitson JM, Cowan JE, et al. Changes in prostate cancer grade on serial biopsy in men undergoing active surveillance. *J Clin Oncol*. 2011;29(20):2795–2800.

Radtke JP, Kuru TH, Bonekamp D, et al. Further reduction of disqualification rates by additional MRI-targeted biopsy with transperineal saturation biopsy compared with standard 12-core systematic biopsies for the selection of prostate cancer patients for active surveillance. *Prostate Cancer Prostatic*

Dis. 2016;19(3):283–291.

Rock CL, Doyle C, Demark-Wahnefried W, et al. Nutrition and physical activity guidelines for cancer survivors. *CA Cancer J Clin*. 2012;62(4):243–274.

Rodriguez C, Patel AV, Calle EE, et al. Body mass index, height, and prostate cancer mortality in two large cohorts of adult men in the United States. *Cancer Epidemiol Biomarkers Prev*. 2001;10(4):345–353.

Roemeling S, Roobol MJ, de Vries SH, et al. Active surveillance for prostate cancers detected in three subsequent rounds of a screening trial: characteristics, PSA doubling times, and outcome. *Eur Urol*. 2007;51(5):1244–1250.

Ross AE, Marchionni L, Vuica-Ross M, et al. Gene expression pathways of high grade localized prostate cancer. *Prostate*. 2011;71(14):1568–1577.

Ross HM, Kryvenko ON, Cowan JE, et al. Do adenocarcinomas of the prostate with Gleason Score (GS) ≤6 have the potential to metastasize to lymph nodes? *Am J Surg Pathol*. 2012;36(9):1346–1352.

Sakr WA, Grignon DJ, Crissman JD, et al. High grade prostatic intraepithelial neoplasia (HGPIN) and prostatic adenocarcinoma between the ages of 20-69: an autopsy study of 249 cases. *In Vivo*. 1994;8(3):439–443.

Schoots IG, Petrides N, Giganti F, et al. Magnetic resonance imaging in active surveillance of prostate cancer: a systematic review. *Eur Urol*. 2015;67(4):627–636.

Schoots IG, Moore CM, Rouvière O. Role of MRI in low-risk prostate cancer: finding the wolf in sheep's clothing or the sheep in wolf's clothing? *Curr Opin Urol*. 2017;27(3):238–245.

Selvadurai ED, Singhera M, Thomas K, et al. Medium-term outcomes of active surveillance for localised prostate cancer. *Eur Urol*. 2013;64(6):981–987.

Simpkin AJ, Tilling K, Martin RM, et al. Systematic review and meta-analysis of factors determining change to radical treatment in active surveillance for localized prostate cancer. *Eur Urol*. 2015;67(6):993–1005.

Skacel M, Ormsby AH, Pettay JD, et al. Aneusomy of chromosomes 7, 8, and 17 and amplification of HER-2/neu and epidermal growth factor receptor in Gleason score 7 prostate carcinoma: a differential fluorescent in situ hybridization study of Gleason pattern 3 and 4 using tissue microarray. *Hum Pathol*. 2001;32(12):1392–1397.

Soloway MS, Soloway CT, Williams S, et al. Active surveillance; a reasonable management alternative for patients with prostate cancer: the Miami experience. *BJU Int*. 2008;101(2):165–169.

Spratt DE, Zhang C, Zumsteg ZS, et al. Metformin and prostate cancer: reduced development of castration-resistant disease and prostate cancer mortality. *Eur Urol*. 2013;63(4):709–716.

Strom SS, Wang X, Pettaway CA, et al. Obesity, weight gain, and risk of biochemical failure among prostate cancer patients following prostatectomy. *Clin Cancer Res*. 2005;11(19 Pt 1):6889–6894.

Susaki E, Nakayama KI. Multiple mechanisms for p27(Kip1) translocation and degradation. *Cell Cycle*. 2007;6(24):3015–3020.

Taylor RA, Fraser M, Livingstone J, et al. Germline BRCA2 mutations drive prostate cancers with distinct evolutionary trajectories. *Nat Commun*. 2017;8:13671.

Tosoian JJ, JohnBull E, Trock BJ, et al. Pathological outcomes in men with low risk and very low risk prostate cancer: implications on the practice of active surveillance. *J Urol*. 2013;190(4):1218–1222.

Tosoian JJ, Mamawala M, Epstein JI, et al. Intermediate and longer-term outcomes from a prospective active-surveillance program for favorable-risk prostate cancer. *J Clin Oncol*. 2015;33(30):3379–3385.

Trock BJ, Fedor H, Gurel B, et al. PTEN loss and chromosome 8 alterations in Gleason grade 3 cores predicts the presence of un-sampled grade 4 tumor: implications for AS. *Mod Pathol*. 2016;29(7):764–771.

True L, Coleman I, Hawley S, et al. A molecular correlate to the Gleason grading system for prostate adenocarcinoma. *Proc Natl Acad Sci USA*. 2006;103(29):10991–10996.

U.S. Preventive Services Task Force. *Final recommendation statement. Prostate cancer screening*. [Available at] https://www.uspreventiveservicestaskforce.org/Page/Docume cancer-screening1; 2018.

US Preventive Services Task Force, Grossman DC, Curry SJ, et al. Screening for prostate cancer: US preventive services task force recommendation statement. *JAMA*. 2018;319(18):1901–1913.

van den Bergh RC, Essink-Bot ML, Roobol MJ, et al. Do anxiety and distress increase during active surveillance for low risk prostate cancer? *J Urol*. 2010;183(5):1786–1791.

van den Bergh RC, Korfage IJ, Roobol MJ, et al. Sexual function with localized prostate cancer: active surveillance vs radical therapy. *BJU Int*. 2012;110(7):1032–1039.

van den Bergh RC, de Blok W, van Muilekom E, et al. Impact on quality of life of radical prostatectomy after initial active surveillance: more to lose? *Scand J Urol*. 2014;48(4):367–373.

Vargas HA, Akin O, Franiel T, et al. Diffusion-weighted endorectal MR imaging at 3 T for prostate cancer: tumor detection and assessment of aggressiveness. *Radiology*. 2011;259(3):775–784.

Venderbos LDF, Aluwini S, Roobol MJ, et al. Long-term follow-up after active surveillance or curative treatment:

quality-of-life outcomes of men with low-risk prostate cancer. *Qual Life Res*. 2017;26(6):1635–1645.

Venier NA, Yamamoto T, Sugar LM, et al. Capsaicin reduces the metastatic burden in the transgenic adenocarcinoma of the mouse prostate model. *Prostate*. 2015;75(12):1300–1311.

Venkateswaran V, Klotz LH. Diet and prostate cancer: mechanisms of action and implications for chemoprevention. *Nat Rev Urol*. 2010;7(8):442–453.

Vieth R, Choo R, Deboer L, et al. Rise in prostate-specific antigen in men with untreated low-grade prostate cancer is slower during spring-summer. *Am J Ther*. 2006;13(5):394–399.

Volk RJ, Hawley ST, Kneuper S, et al. Trials of decision aids for prostate cancer screening: a systematic review. *Am J Prev Med*. 2007;33(5):428–434.

Volk RJ, McFall SL, Cantor SB, et al. “It's not like you just had a heart attack”: decision-making about active surveillance by men with localized prostate cancer. *Psychooncology*. 2014;23(4):467–472.

Wang J, Cai Y, Ren C, et al. Expression of variant TMPRSS2/ERG fusion messenger RNAs is associated with aggressive prostate cancer. *Cancer Res*. 2006;66:8347–8351.

Watson E, Shinkins B, Frith E, et al. Symptoms, unmet needs, psychological well-being and health status in survivors of prostate cancer: implications for redesigning follow-up. *BJU Int*. 2016;117(6B):E10–E19.

Wei L, Wang J, Lampert E, et al. Intratumoral and intertumoral genomic heterogeneity of multifocal localized prostate cancer impacts molecular classifications and genomic prognosticators. *Eur Urol*. 2017;71(2):183–192.

Welch HG, Black WC. Overdiagnosis in cancer. *J Natl Cancer Inst*. 2010;102(9):605–613.

West AF, O'Donnell M, Charlton RG, et al. Correlation of vascular endothelial growth factor expression with fibroblast growth factor-8 expression and clinico-pathologic parameters in human prostate cancer. *Br J Cancer*. 2001;85(4):576–583.

Wilt TJ, Jones KM, Barry MJ, et al. Follow-up of prostatectomy versus observation for early prostate cancer. *N Engl J Med*. 2017;377(2):132–142.

Yamoah K, Zeigler-Johnson CM, Jeffers A, et al. The impact of body mass index on treatment outcomes for patients with low-intermediate risk prostate cancer. *BMC Cancer*. 2016;16:557.

Yu O, Eberg M, Benayoun S, et al. Use of statins and the risk of death in patients with prostate cancer. *J Clin Oncol*. 2014;32(1):5–11.

Zhang HH, Guo XL. Combinational strategies of metformin and chemotherapy in cancers. *Cancer Chemother Pharmacol*. 2016;78(1):13–26.

Zhuang L, Kim J, Adam RM, et al. Cholesterol targeting alters lipid raft composition and cell survival in prostate cancer cells and xenografts. *J Clin Invest*. 2005;115(4):959–968.

Zomer A, van Rheenen J. Implications of extracellular vesicle (EV) transfer on cellular heterogeneity in cancer: what are the potential clinical ramifications. *Cancer Res*. 2016;76(8):2071–2075.

155

Open Radical Prostatectomy

Edward M. Schaeffer MD, PhD, Alan W. Partin MD, PhD, Herbert Lepor MD

There is no better way to cure cancer that is confined to the prostate than total surgical removal. Radical prostatectomy is the only form of treatment for localized prostate cancer that has been shown in a randomized controlled trial to reduce progression to metastases and death from the disease (Bill-Axelson et al., 2008; Holmberg et al., 2002). Furthermore, on the basis of improved understanding of the periprostatic anatomy, today less bleeding and improved rates of postoperative continence and potency are seen (Nielsen et al., 2008; Walsh, 1998, 2000).

Technically, radical retropubic prostatectomy (RRP) is one of the most difficult operations in the field of urology. The three goals of surgery, in order of importance, are cancer control, preservation of urinary control, and preservation of sexual function. Great skill and experience in the selection of surgical candidates and operative technique are necessary to achieve all three. This chapter summarizes our experience, with the hope that it will shorten the reader's learning curve. Video 155.1▶ demonstrates a detailed description of the surgical technique (Walsh and Garcia, 2004).

Radical Retropubic Prostatectomy: Surgical Anatomy

Venous and Arterial Anatomy

The veins of the prostate drain into the Santorini plexus. It is necessary to have a complete understanding of these veins to avoid excessive bleeding and to ensure a bloodless field in exposing the membranous urethra and the apex of the prostate. **The deep dorsal vein leaves the penis under the Buck fascia between the corpora cavernosa and penetrates the urogenital diaphragm, dividing into three major branches: the superficial branch and the right and left lateral venous plexuses** (Reiner and Walsh, 1979) (Fig. 155.1). The superficial branch, which travels between the puboprostatic ligaments, is the centrally located vein overlying the bladder neck and prostate. This vein is easily visualized early in retropubic operations and has communicating branches over the bladder itself and into the endopelvic fascia. The superficial branch lies outside the anterior prostatic fascia.

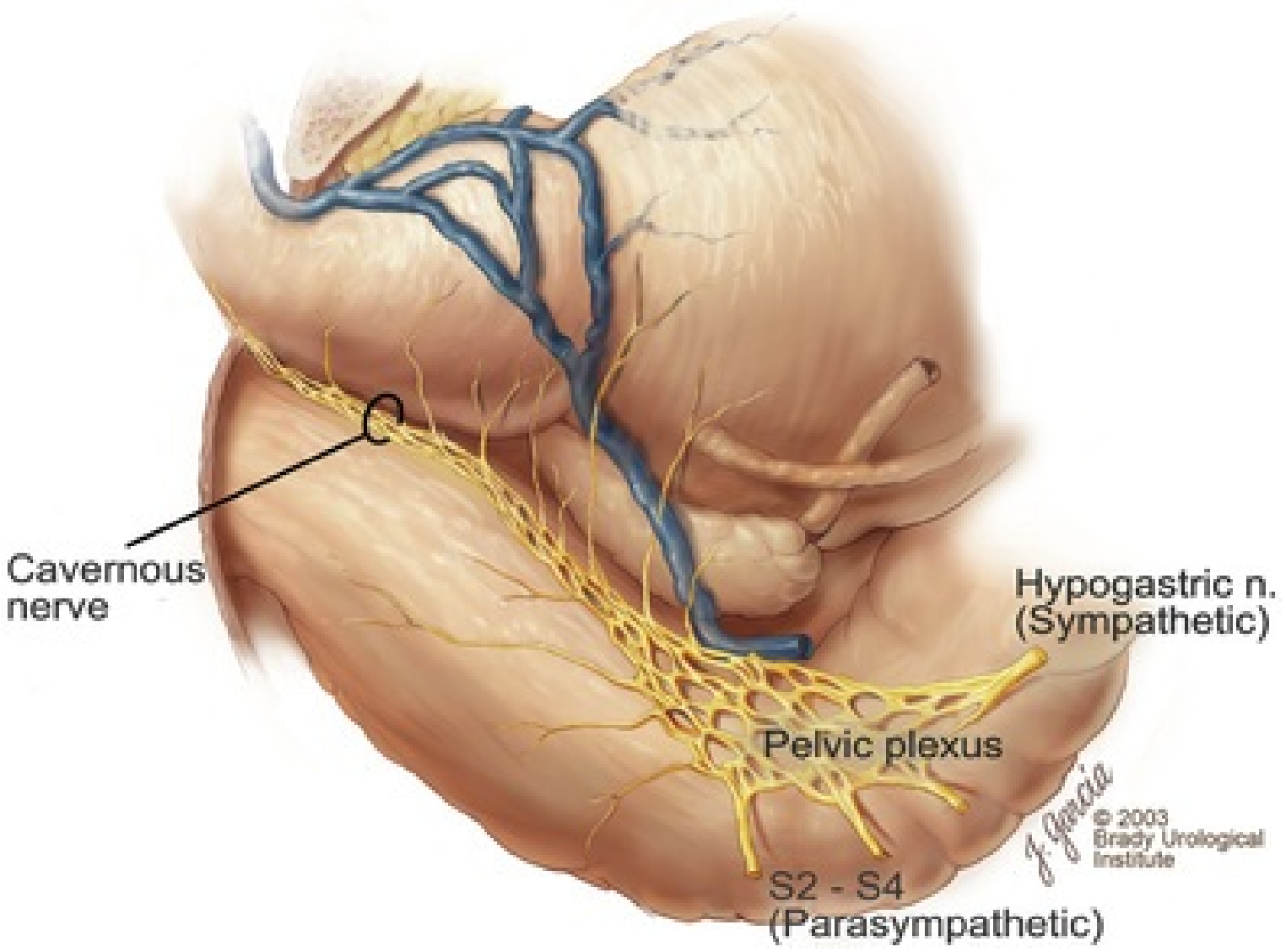
Cavernous nerve
Hypogastric n. (Sympathetic)
Pelvic plexus
S2 - S4 (Parasympathetic)
J. García
© 2003 Brady Urological Institute

FIG. 155.1 Location of the superficial and deep branches of the dorsal vein as they travel over the anterior and anterolateral surfaces of the prostate. Note the common trunk located immediately over the urethra. This is the site where the dorsal vein is transected. The pelvic plexus: The autonomic innervation of the pelvic organs arises from the pelvic plexus, which is formed by parasympathetic fibers that arise from the sacral center

(S2–S4) and sympathetic fibers via the hypogastric nerve from the thoracolumbar center. The pelvic plexus provides visceral branches that innervate the bladder, ureter, seminal vesicles, prostate, rectum, membranous urethra, and corpora cavernosa. The branches that innervate the corpora cavernosa enter in a spraylike distribution 20 to 30 mm distal to the junction of the prostate and bladder, where they continue distally posterolateral to the prostate. *n.,* nerve. (© Brady Urological Institute.)

The common trunk and lateral venous plexuses are covered and concealed by the prostatic and endopelvic fascia. The lateral venous plexuses traverse posterolaterally and communicate freely with the pudendal, obturator, and vesical plexuses. Near the puboprostatic ligaments, small branches from the lateral plexus often penetrate the pelvic sidewall musculature and communicate with the internal pudendal vein. The lateral plexus interconnects with other venous systems to form the inferior vesical vein, which empties into the internal iliac vein. With the complex of veins and plexuses anastomosing freely, any laceration of these friable structures can lead to considerable blood loss.

The prostate receives arterial blood supply from the inferior vesical artery. According to Flocks (1937)**, after the inferior vesical artery provides small branches to the seminal vesicle and the base of the bladder and prostate, the artery terminates in two large groups of prostatic vessels: the urethral and capsular groups** (Fig. 155.2). The urethral vessels enter the prostate at the posterolateral vesicoprostatic junction and supply the vesical neck and periurethral portion of the gland. The capsular branches run along the pelvic sidewall in the lateral pelvic fascia posterolateral to the prostate, providing branches that course ventrally and dorsally to supply the outer portion of the prostate. The capsular vessels terminate as a small cluster of vessels that supply the pelvic floor. On histologic examination, the capsular arteries and veins are surrounded by an extensive network of nerves (Lepor et al., 1985; Lue et al., 1984; Walsh and Donker, 1982; Walsh et al., 1983). **These capsular vessels provide the macroscopic landmark to aid in the identification of the microscopic branches of the pelvic plexus that innervate the corpora cavernosa.**

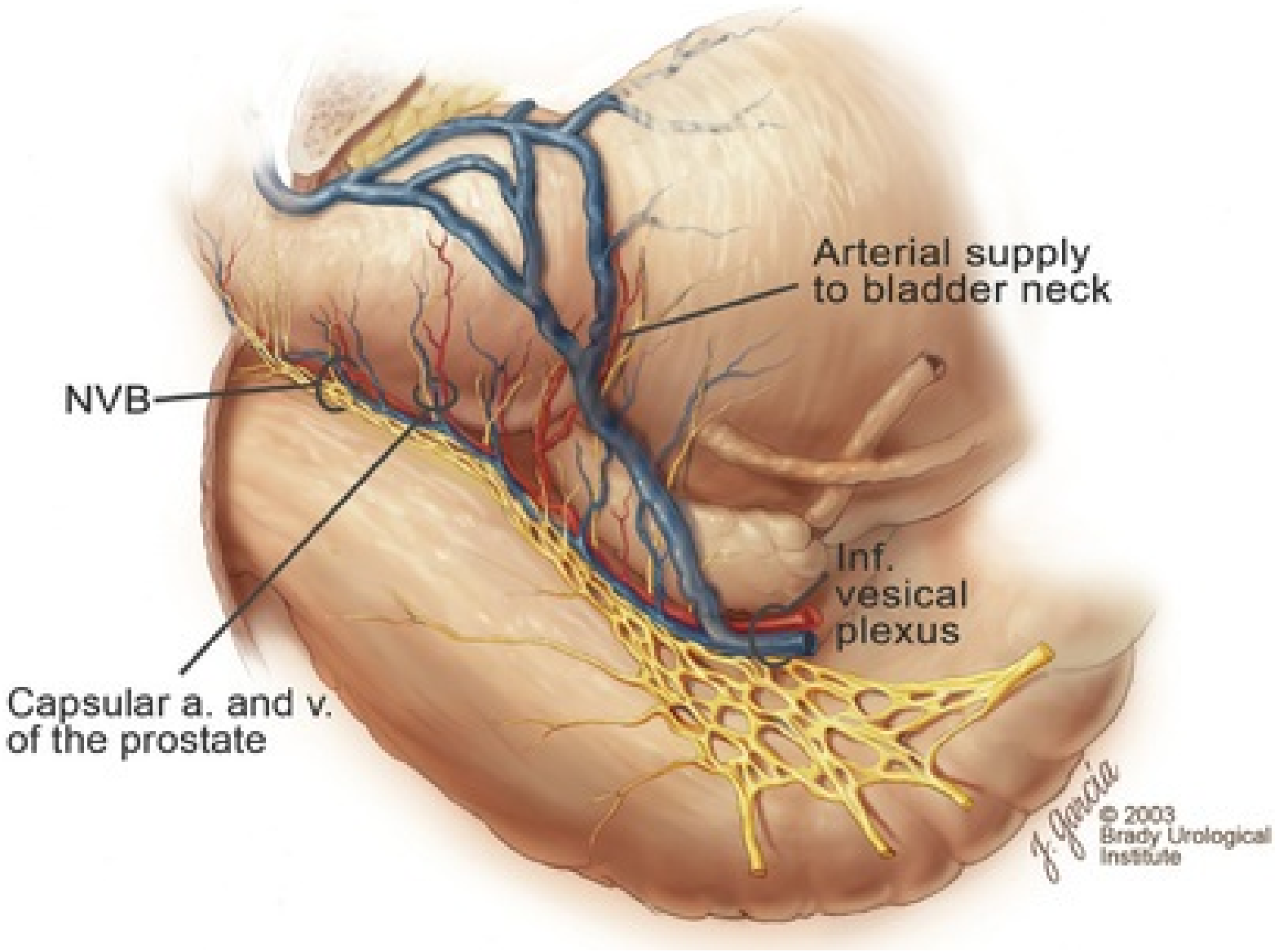

FIG. 155.2 Arterial supply to the prostate. The inferior vesical artery terminates in two large groups of vessels. One group, the urethral vessels, enters the prostate at the posterolateral vesicoprostatic junction to supply the bladder neck and periurethral portions of the gland. The second group, the capsular branches, runs along the pelvic sidewall in the lateral pelvic fascia posterolateral to the prostate, providing branches that course ventrally and dorsally to supply the outer portion of the prostate. These capsular arteries and veins are intimately associated with the branches of the pelvic plexus forming the neurovascular bundle (NVB), which is used as the macroscopic landmark to aid in the identification of the microscopic branches of these nerves. Note at the apex that small branches of the nerves travel anteriorly away from the vessels. *a.,* artery; *inf.,* inferior; *v.,* vein. (© Brady Urological Institute.)

The major arterial supply to the corpora cavernosa is derived from the internal pudendal artery. However, **pudendal arteries can arise from the obturator, inferior vesical, and superior vesical arteries. Because these aberrant branches travel along the lower part of the bladder and anterolateral surface of the prostate, they are divided during radical prostatectomy.** This may compromise arterial supply to the penis, especially in older patients with borderline penile blood flow (Breza et al., 1989; Polascik and Walsh, 1995; Rogers et al., 2004).

Pelvic Plexus

The autonomic innervation of the pelvic organs and external genitalia arises from the pelvic plexus, which is formed by parasympathetic, visceral,

efferent, preganglionic fibers that arise from the sacral center (S2 to S4), and sympathetic fibers via the hypogastric nerve from the thoracolumbar center (Lepor et al., 1985; Lue et al., 1984; Schlegel and Walsh, 1987; Walsh and Donker, 1982; Walsh, 2007) (see Fig. 155.1). The pelvic plexus in men is located retroperitoneally beside the rectum 5 to 11 cm from the anal verge and forms a fenestrated rectangular plate that is in the sagittal plane with its midpoint at the level of the tip of the seminal vesicle.

The branches of the inferior vesical artery and vein that supply the bladder and prostate perforate the pelvic plexus. For this reason, ligation of the so-called *lateral pedicle* in its midportion not only interrupts the vessels but also transects the nerve supply to the prostate, urethra, and corpora cavernosa. The pelvic plexus provides visceral branches that innervate the bladder, ureter, seminal vesicles, prostate, rectum, membranous urethra, and corpora cavernosa. In addition, branches that contain somatic motor axons travel through the pelvic plexus to supply the levator ani, coccygeus, and striated urethral musculature. **The nerves innervating the prostate travel outside the capsule of the prostate and Denonvilliers fascia until they perforate the capsule where they enter the prostate.**

The branches to the membranous urethra and corpora cavernosa also travel outside the prostatic capsule in the lateral pelvic fascia dorsolaterally between the prostate and rectum (see Fig. 155.1). Although these nerves are microscopic, their anatomic location can be estimated intraoperatively by use of the capsular vessels as a landmark. This structure, which is referred to here as the neurovascular bundle (NVB), has been termed the *NVB of Walsh* (*Stedman's Medical Dictionary,* 2000) (see Fig. 155.2). As emphasized by Takenaka et al. (2004) and Costello et al. (2004), the cavernous branches join the capsular arteries and veins in a spraylike distribution to form the NVB 20 to 30 mm distal to the junction of the bladder and prostate (see Fig. 155.2). The NVBs are located in the lateral pelvic fascia *between* the prostatic fascia and the levator fascia. At the apex of the prostate, the branches of the nerves to the cavernous bodies and striated sphincter also have a spraylike distribution both anteriorly and posteriorly with wide variation (Costello et al., 2004; Takenaka et al., 2005). After piercing the urogenital diaphragm, the nerve branches pass behind the dorsal penile artery and dorsal penile nerve before entering the corpora cavernosa (Walsh and Donker, 1982).

Striated Urethral Sphincter

The external sphincter, at the level of the membranous urethra, is often depicted as a “sandwich” of muscles in the horizontal plane. However, Oelrich (1980) demonstrated clearly that the striated urethral sphincter with its surrounding fascia is a vertically oriented tubular sheath that surrounds the membranous urethra. In utero, this sphincter extends without interruption from the bladder to the perineal membrane. As the prostate develops from the urethra, it invades and thins the sphincter muscle, causing a reduction or atrophy of some of the muscle (Fig. 155.3).

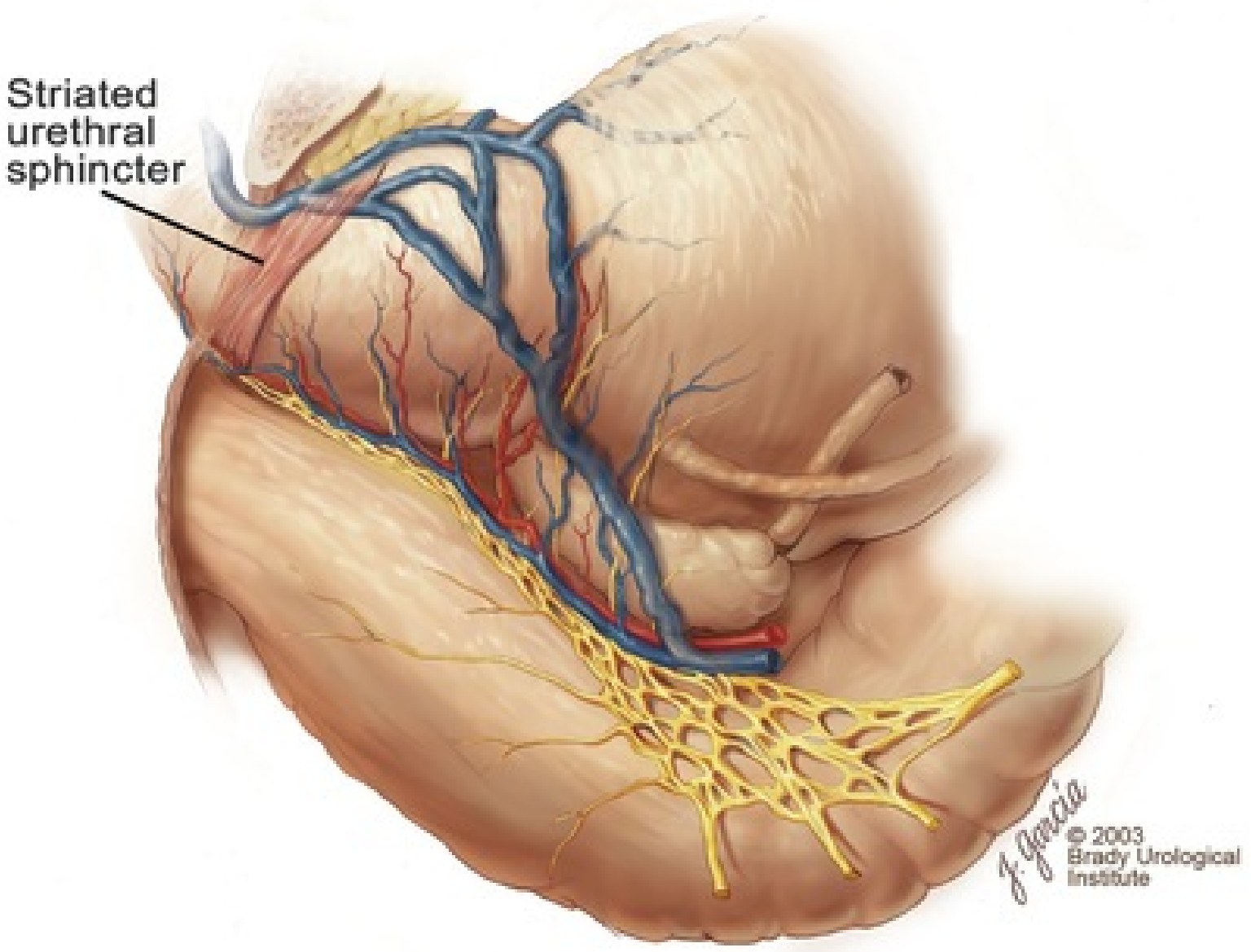
Striated urethral sphincter
© 2003 Brady Urological Institute

FIG. 155.3 The striated urethral sphincter with its surrounding fascia is a vertically oriented tubular sheath that surrounds the membranous urethra. The dorsal vein complex travels through the sphincteric complex. (© Brady Urological Institute.)

In the adult, the fibers at the apex of the prostate are horseshoe shaped and form a tubular, striated sphincter surrounding the membranous urethra. Near the apex of the prostate, the edges fuse in the midline posteriorly (Fig. 155.4A). Thus, as Myers et al. (1987) have shown, the prostate does not rest on a flat, transverse urogenital diaphragm like an apple on a shelf, with no striated muscle proximal to the apex. Rather, the external striated sphincter is more tubular and has broad attachments over the fascia of the prostate near the apex. This has important implications in the apical dissection and reconstruction of the urethra for preservation of urinary control postoperatively (Walsh et al., 1990).

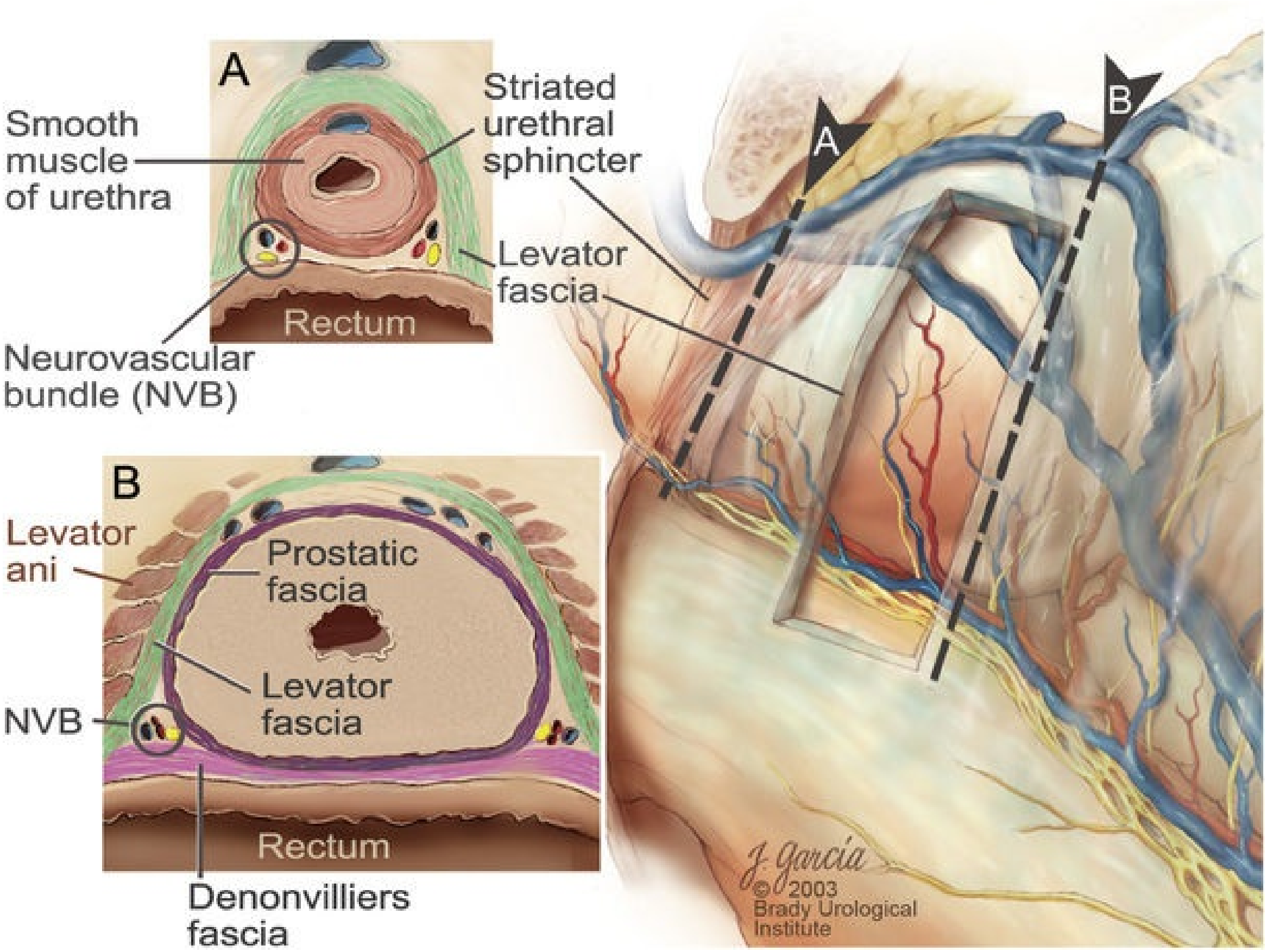
A
Smooth muscle of urethra
Striated urethral sphincter
Levator fascia
Rectum
Neurovascular bundle (NVB)
B
Levator ani
Prostatic fascia
Levator fascia
NVB
Rectum
Denonvilliers fascia
A
B
J. Garcia
© 2003
Brady Urological Institute

FIG. 155.4 (A) A cross section through the apex of the prostate demonstrating the relationship among the fascia surrounding the striated sphincter and smooth muscle of the urethra. Note that at this level, the striated sphincter circumferentially surrounds the urethra. Note that the neurovascular bundles *(NVBs)* are posterolateral to the circumferential striated sphincter. (B) A cross-section through the midportion of the prostate demonstrating the relationship among the levator fascia, Denonvilliers fascia, and prostatic fascia. Note that the NVBs are located between the layers of the levator fascia and prostatic fascia. In performing a proper nerve-sparing operation, the prostatic fascia must remain on the prostate. (© Brady Urological Institute.)

The striated sphincter contains fatigue-resistant, slow-twitch fibers that are responsible for passive urinary control. Active continence is achieved by voluntary contraction of the levator ani musculature, which surrounds the apex of the prostate and membranous urethra. Some fibers of the levator ani (levator urethrae, pubourethralis) surround the proximal urethra and the apex of the prostate and insert into the perineal body in the midline posteriorly (Myers, 1991, 1994). **The pudendal nerve provides the major nerve supply to the striated sphincter and levator ani.** When patients are instructed to perform sphincter exercises postoperatively, they are actually contracting the levator ani musculature. However, because the striated urethral sphincter has similar innervation, patients are exercising this important muscle as well. Somatic motor nerves traveling through the pelvic plexus provide additional innervation to the pelvic floor musculature (Costello et al., 2004, Takenaka et al., 2005; Zvara et al., 1994).

Pelvic Fascia

The prostate is covered with three distinct and separate fascial layers: Denonvilliers fascia, the prostatic fascia (also called the *capsule of the prostate*), and the levator fascia. Denonvilliers fascia is a filmy, delicate layer of connective tissue located between the anterior walls of the rectum and prostate (see Fig. 155.4B). This fascial layer extends cranially to cover the posterior surface of the seminal vesicles and lies snugly against the posterior prostatic capsule. This fascia is most prominent and dense near the base of the prostate and the seminal vesicles and thins dramatically as it extends caudally to its termination at the striated urethral sphincter. On microscopic examination, it is impossible to discern posterior and anterior layers of this fascia (Jewett et al., 1972). For this reason, one must excise this fascia completely to obtain an adequate surgical margin.

In addition to Denonvilliers fascia, the prostate is also invested with the prostatic fascia and levator fascia. Anteriorly and anterolaterally, the prostatic fascia is in direct continuity with the parenchyma of the prostate. The major tributaries of the dorsal vein of the penis and Santorini plexus travel within the anterior prostatic fascia. Laterally, the prostatic fascia fuses with the levator fascia, which covers the pelvic musculature, to form the lateral pelvic fascia (Fig. 155.5) (Myers, 1991, 1994). Posterolaterally, the levator fascia separates from the prostate to travel immediately adjacent to the pelvic musculature surrounding the rectum. **The prostate receives its blood supply and autonomic innervation between the layers of the levator fascia and prostatic fascia** (see Figs. 155.4B and 155.5).

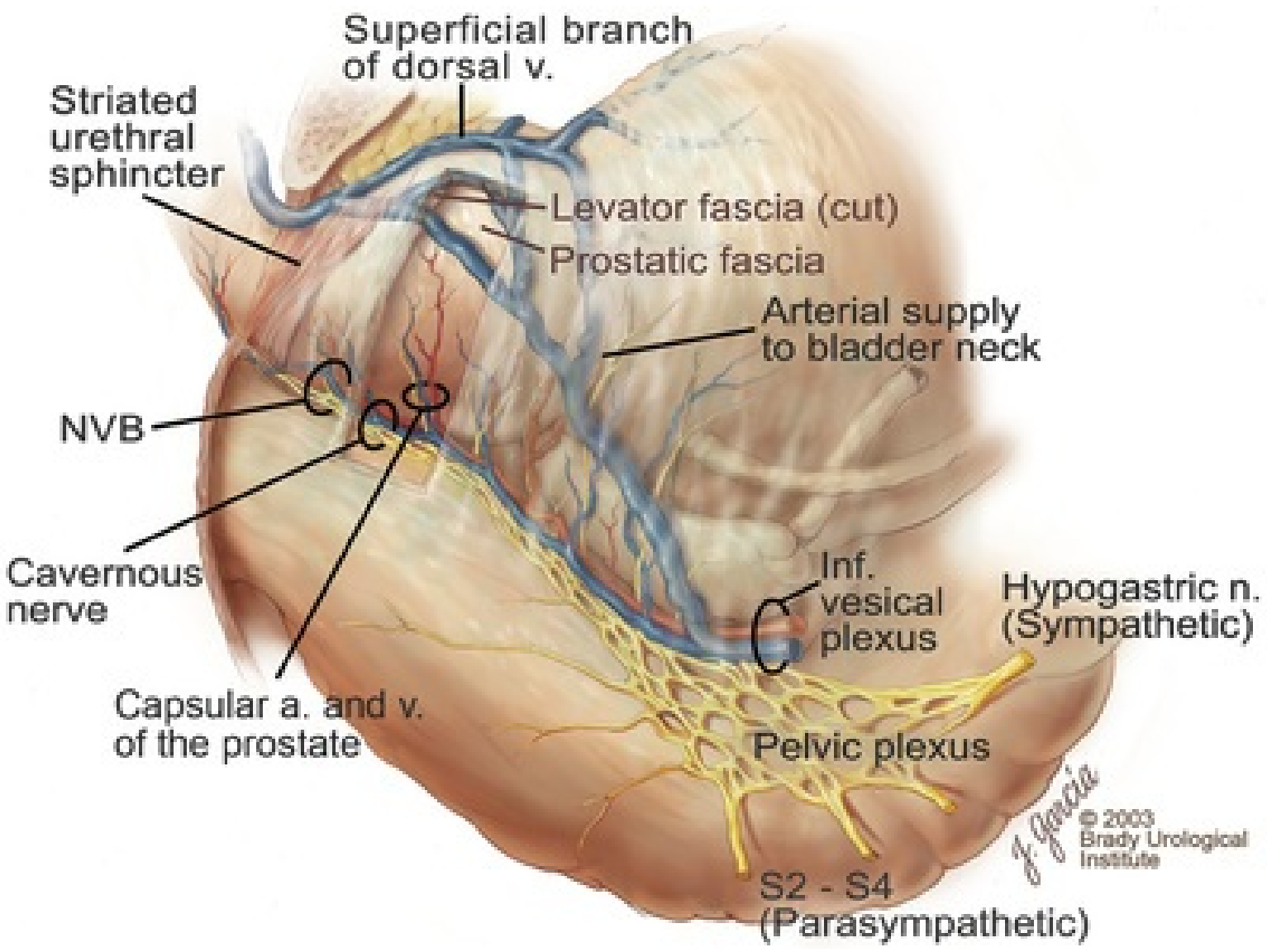
Superficial branch of dorsal v.
Striated urethral sphincter
Levator fascia (cut)
Prostatic fascia
Arterial supply to bladder neck
NVB
Cavernous nerve
Capsular a. and v. of the prostate
Inf. vesical plexus
Hypogastric n. (Sympathetic)
Pelvic plexus
S2 - S4 (Parasympathetic)
J. Garcia
© 2003 Brady Urological Institute

FIG. 155.5 A lateral view illustrating that the prostate receives its blood supply and autonomic innervation between the layers of the levator fascia and prostatic fascia. *a.,* artery; *inf.,* inferior; *NVB,* neurovascular bundle; *v.,* vein. (© Brady Urological Institute.)

In an effort to avoid injury to the dorsal vein of the penis and Santorini plexus during radical perineal prostatectomy, the lateral and anterior pelvic fasciae are reflected off the prostate. This accounts for the reduced blood loss associated with radical perineal prostatectomy. In performing RRP, the prostate is approached from outside these fascial investments. For this reason, the dorsal vein complex must be ligated and the lateral pelvic fascia must be divided (Walsh et al., 1983).

Surgical Technique

Preoperative Preparation

The preoperative assessment must include a focused review of systems; a complete medical, surgical, and anesthesia history; an inquiry of all prescription and nonprescription medications; a physical examination; and routine preoperative laboratory testing. Life-threatening complications associated with RRP are rare and include myocardial infarction, cerebrovascular accident (stroke), cardiac arrhythmias, pulmonary embolus, hemorrhage, and anesthesia reactions. The preoperative assessment must identify candidates who are at increased risk for these mortality events to intervene to attenuate these risks. The preoperative assessment should also identify factors that may add to the technical challenge of the surgical procedure, including prior abdominal or pelvic surgery and irradiation, prior transurethral surgery, extensive prostate biopsies, history of significant inflammatory bowel disease, prior use of mesh during inguinal or incisional hernia repair, and the size of the prostate. Although none of these factors are contraindications for RRP, a greater level of skill and experience may be required to minimize complications.

The observation that up to 15% to 20% of men develop an inguinal hernia after RRP implied that this surgical procedure directly predisposes to the development of hernia (Lodding et al., 2001; Nielsen and Walsh, 2005; Regan et al., 1996). Approximately 15% of men undergoing radical prostatectomy will have a coexisting inguinal hernia detected if an appropriate inguinal examination is performed (Lepor and Robbins, 2007). In most of these cases, the inguinal hernia is asymptomatic. These observations suggest that an RRP may transform an asymptomatic inguinal hernia into a symptomatic hernia. Therefore examination of the inguinal canal with the Valsalva maneuver should be performed, enabling pre-peritoneal hernia repairs at the time of the radical prostatectomy.

Surgery is deferred for 6 to 8 weeks after needle biopsy of the prostate and 12 weeks after transurethral resection of the prostate. This delay enables inflammatory adhesions or hematomas to resolve so that the anatomic relationships between the prostate and the surrounding structures return to a nearly normal state before surgery. This is especially important if one hopes to preserve the NVBs intraoperatively and avoid rectal injury.

Donation of autologous blood is not performed at our institutions because transfusion rates are less than 1%. Erythrocyte-stimulating proteins, which are not approved by the U.S. Food and Drug Administration (FDA), have been shown to raise the hematocrit on average 2.8 percentage points, diminishing postprostatectomy anemia (Rosenblum et al., 2000). High hematocrit at hospital discharge can improve the pace of recovery (Sultan et al., 2006).

The recommended prophylactic regimens for open or laparoscopic surgery involving entry into the urinary tract are a first- or second-generation cephalosporin or an aminoglycoside in combination with metronidazole or clindamycin (Wolf et al., 2008).

The preoperative management of anticoagulants and antiplatelet agents used for the treatment of specific medical conditions, such as prosthetic valves, atrial fibrillation, and coronary artery stent implants, should be performed in conjunction with the internist or cardiologist. With nearly 1 million coronary interventions occurring every year and the majority including an implant of a drug-eluting stent, managing prescribed antiplatelet therapy can create a dilemma in balancing the risks for stent stenosis and perioperative bleeding. In the majority of cases, stent thrombosis is a catastrophic event resulting in life-threatening complications (Cutlip et al., 2001). The optimal preoperative regimen is often best developed through communication between the surgical/anesthesia team and treating physician (Grines et al., 2007).

Patients are prescribed a clear liquid diet on the day before surgery, are requested to drink one-half bottle of magnesium citrate in the evening, and have an enema on the morning of surgery. Patients are admitted to the hospital on that day.

Special Instruments

RRP requires few special instruments. A fiberoptic headlight is essential because much of the procedure is performed beneath the pubis in an area where visualization can be difficult. A standard Balfour retractor with both narrow and wide malleable blades is useful during lymph node dissection and is necessary during radical prostatectomy to provide cranial and posterior retraction on the peritoneum and bladder. Coagulating forceps; small, fine, and regular right-angled clamps; Metzenbaum and Jamison scissors; and 2.5- to 4.5-power loupes are the only other specialized instruments that should be available.

Anesthesia, Incision, and Lymphadenectomy

General endotracheal anesthesia is the preferred anesthesia. The anesthesiologist is encouraged to maintain relative hypotension with systolic blood pressure of no more than 100 mm Hg and to limit the replacement of crystalloid to 1500 mL until the prostate is removed (Davies et al., 2004). The patient is placed in the supine position. The table can be flexed in obese men to increase the distance between the umbilicus and pubis.

The skin is prepared and draped in the usual way. A No. 16 Silastic Foley catheter is passed into the bladder, inflated with 20 mL of saline, and connected to sterile, closed, continuous drainage. The use of a 16-Fr catheter facilitates placement of sutures in the mucosa of the urethra. A right-handed surgeon always stands on the left side of the patient.

An extraperitoneal, lower abdominal incision is made extending from the pubis toward the umbilicus. The anterior fascia is incised down to the pubis, the rectus muscles are separated in the midline, and the transversalis fascia is opened sharply to expose the space of Retzius. Laterally, the peritoneum is mobilized off the external iliac vessels to the bifurcation of the common iliac artery. **Care is taken to preserve the soft tissue covering the external iliac artery that contains the lymphatics draining the lower extremity. Interruption of these lymphatics may lead to lower extremity edema and lymphocele formation.** This maneuver is accomplished without dividing the vas deferens. Next, a self-retaining Balfour retractor is placed. Exposure for the lymph node dissection is facilitated by placement of a narrow, malleable blade attached to the Balfour retractor beneath the mobilized vas deferens to displace the peritoneum superiorly and a deep Deaver retractor to retract the bladder medially.

Pelvic lymph node dissection is performed before the radical prostatectomy. The dissection begins on the ipsilateral side of the major tumor in the prostate by dividing the adventitia over the external iliac vein (Fig. 155.6). The lymphatics overlying the external iliac artery are preserved. The dissection proceeds beneath the external iliac vein out to the pelvic sidewall and then inferiorly to the femoral canal, where the lymphatic channels are ligated at a convenient point. There is no need to remove the Cloquet node. The dissection then proceeds cranially along the pelvic sidewall to the bifurcation of the common iliac artery, where the lymph nodes in the angle between the external iliac and hypogastric arteries are removed. Next, the obturator lymph nodes are removed with care to avoid injury to the obturator nerve. The obturator artery and vein are skeletonized but usually are left undisturbed and not ligated unless excessive bleeding occurs. The dissection then continues down to the pelvic floor, exposing the hypogastric veins. This is an extended dissection and removes more lymph nodes than a limited one, improving staging and providing potential therapeutic benefit in some patients (Allaf et al., 2004; Palapattu et al., 2004). A similar procedure is performed on the opposite side (Cadeddu et al., 1997; Sgrignoli et al., 1994).

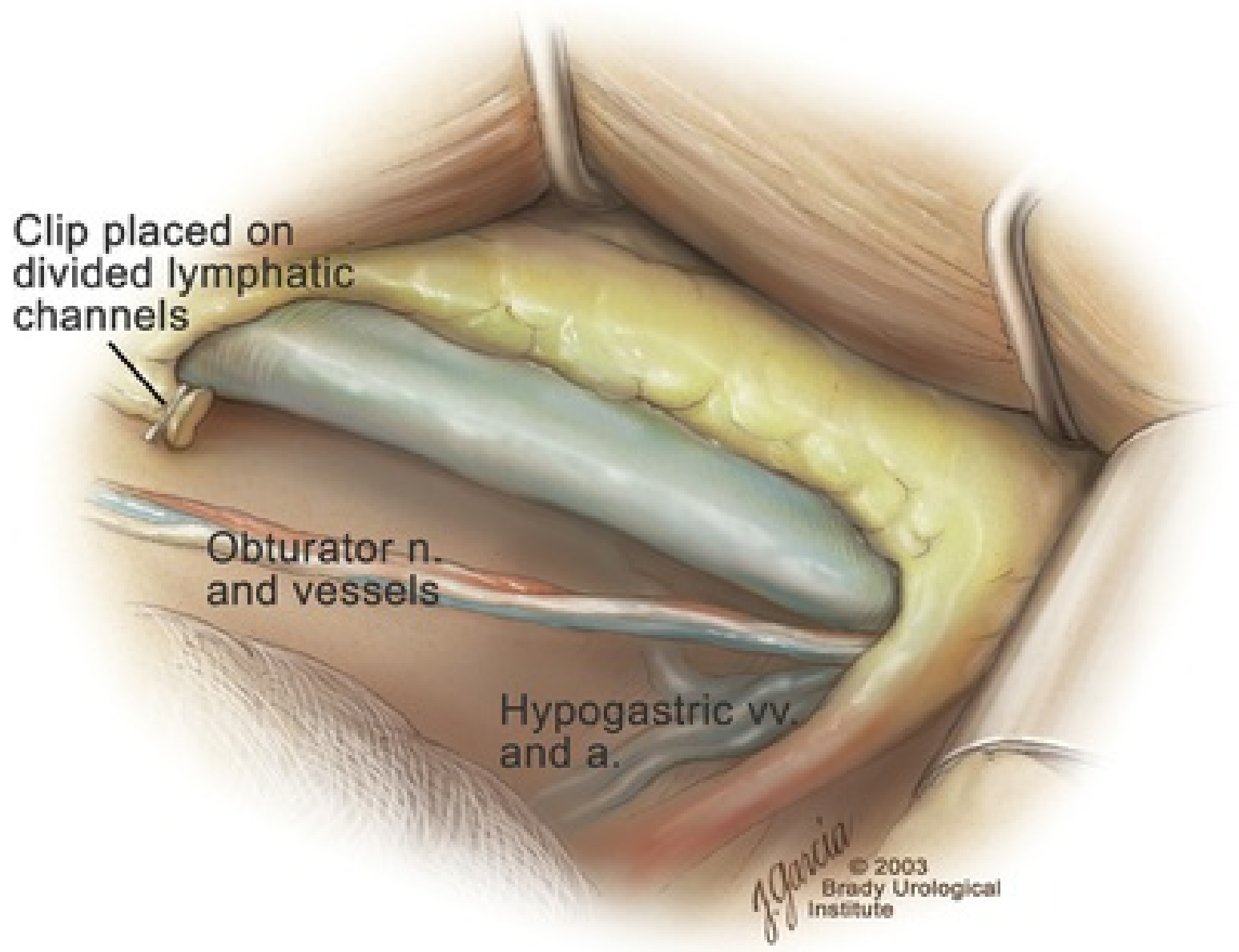

FIG. 155.6 View of the right pelvis after completion of the staging pelvic lymph node dissection. Note that the fibroadipose tissue overlying the external iliac artery has not been disturbed and that the obturator nerve, obturator vessels, and hypogastric veins *(vv.)* over the pelvic floor have been skeletonized. *a.,* artery; *n.,* nerve. (© Brady Urological Institute.)

Exposure

To expose the anterior surface of the prostate, it is necessary to displace the peritoneum superiorly. A malleable blade is used to retract the peritoneum superiorly and to gently displace the bladder posteriorly.

Incision in the Endopelvic Fascia

The fibroadipose tissue covering the prostate is carefully dissected away to expose the pelvic fascia, puboprostatic ligaments, and superficial branch of the dorsal vein.

The endopelvic fascia is entered where it reflects over the pelvic sidewall, well away from its attachments to the bladder and prostate (Fig. 155.7). The point of incision is where the fascia is transparent, revealing the underlying levator ani musculature. Incision more medially can lead to entry into the lateral venous plexus of Santorini running alongside the prostate, resulting in persistent venous bleeding. Beneath this venous complex lie the prostatic arteries and the branches of the pelvic plexus that course toward the prostate, urethra, and corpora cavernosa.

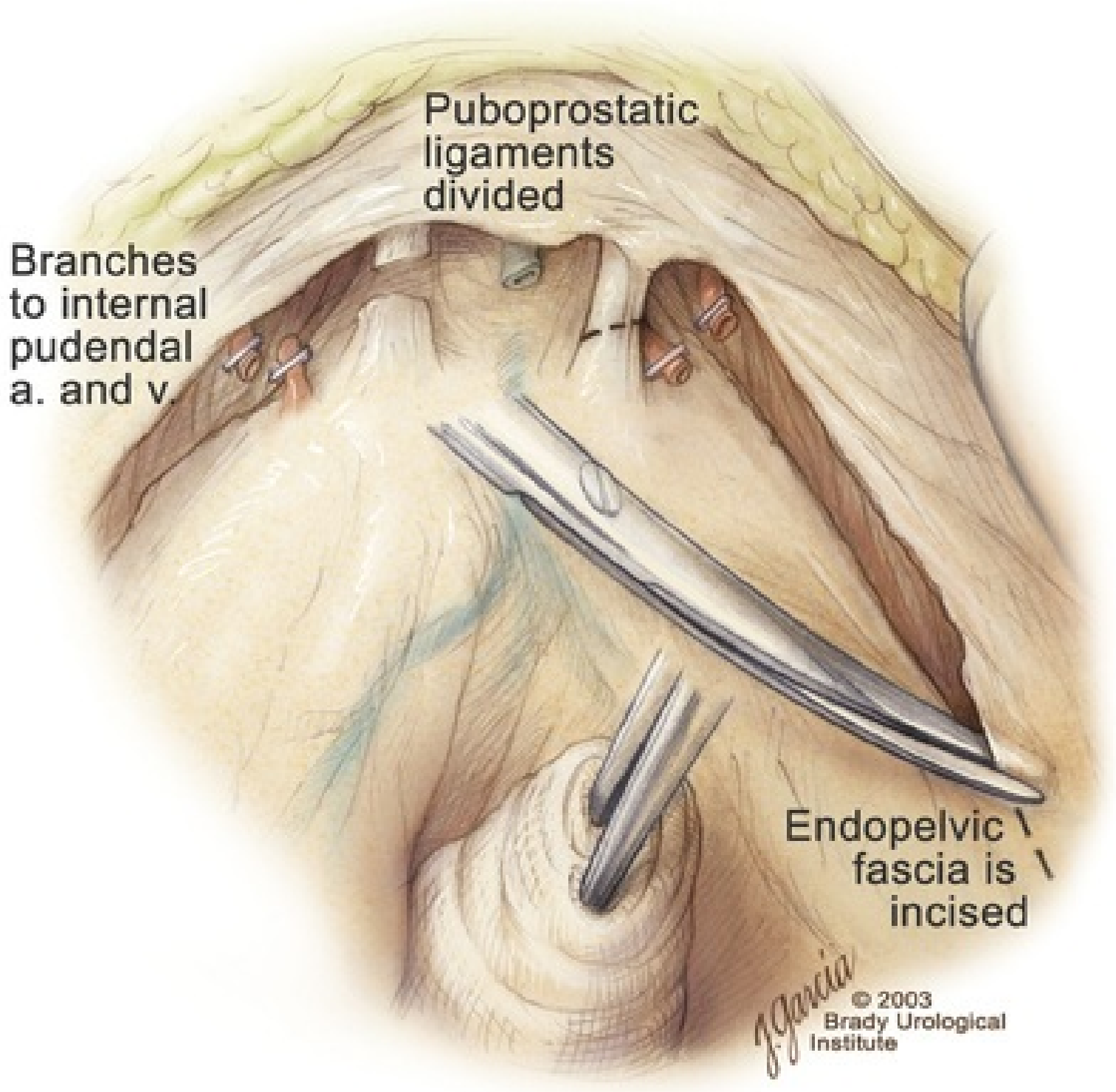
Puboprostatic ligaments divided
Branches to internal pudendal a. and v.
Endopelvic fascia is incised
J Garcia
© 2003 Brady Urological Institute

FIG. 155.7 Incision in the endopelvic fascia and division of the puboprostatic ligaments. The incision in the endopelvic fascia is made at the juncture with the pelvic sidewall, well away from the prostate and bladder. Anteriorly, near the puboprostatic ligaments, small arterial and venous branches from the internal pudendal vessels have been clipped and divided. The puboprostatic ligaments are divided superficially far enough down to expose the juncture between the apex of the prostate and the anterior surface of the dorsal vein complex. However, the pubourethral component of the complex is intact to preserve anterior fixation of the striated sphincter to the pubis. *a.,* artery; *v.,* vein. (© Brady Urological Institute.)

The incision in the endopelvic fascia is then carefully extended in an anteromedial direction toward the puboprostatic ligaments. This allows the surgeon to palpate the lateral surface of the prostate. **At this point, small arterial and venous branches from the pudendal vessels are typically encountered that perforate the pelvic musculature to supply the prostate. These vessels should be ligated with clips to avoid coagulation injury to the pudendal artery and nerve, which are located just deep to this muscle as they travel along the pubic ramus.**

Division of the Puboprostatic Ligaments

The fibrofatty tissue covering the superficial branch of the dorsal vein and puboprostatic ligaments is gently teased away to prepare for division of the ligaments without injury to the superficial branch of the dorsal vein. After the superficial branch has been dissected away from the medial edge of the ligaments, it is coagulated and divided. After all fibrofatty tissue has been removed, a sponge stick is used to gently displace the prostate posteriorly, and scissors are used to divide each ligament (see Fig. 155.7).

The dissection should continue down far enough to expose the juncture between the apex of the prostate and the anterior surface of the dorsal vein complex at the point where it will be divided. The pubourethral component of the complex should be spared to preserve the anterior fixation of the striated urethral sphincter to the pubis (Burnett and Mostwin, 1998).

Preservation of Accessory Pudendal Arteries

Arterial insufficiency is a factor contributing to erectile dysfunction in patients after nerve-sparing RRP. One source for this insufficiency may arise from accessory pudendal arteries that travel over the anterolateral surface of the prostate. These arteries have been found in 70% of cadaveric dissections and 7% of patients by selective internal pudendal angiography. Large visible accessory pudendal arteries are present in 4% of men (Rogers et al., 2004).

Because release of accessory arteries may be associated with significant blood loss necessitating prompt ligation and division of the dorsal vein complex, it is useful to have the contralateral dissection completed before accessory vessels are released. For this reason, when these vessels appear to be prominent and are present unilaterally, the endopelvic fascia and puboprostatic ligament on the contralateral side should be divided first. The surgical technique for preservation of the arteries begins with division of the endopelvic fascia lateral to the vessels and division of the puboprostatic ligament (the vessels are beneath the puboprostatic ligament) (Rogers et al., 2004). Next, a vessel loop is used to elevate the artery; then with sharp dissection and a right-angled clamp, the accessory artery is released from its investing fascia (Fig. 155.8). As the dissection proceeds, venous tributaries are divided. At times, there may be substantial blood loss from the venous complex over the prostate; hemostasis, however, is usually easily obtained with a 4-0 running absorbable suture. The dissection must extend caudally beyond the site at which the dorsal vein complex will be divided.

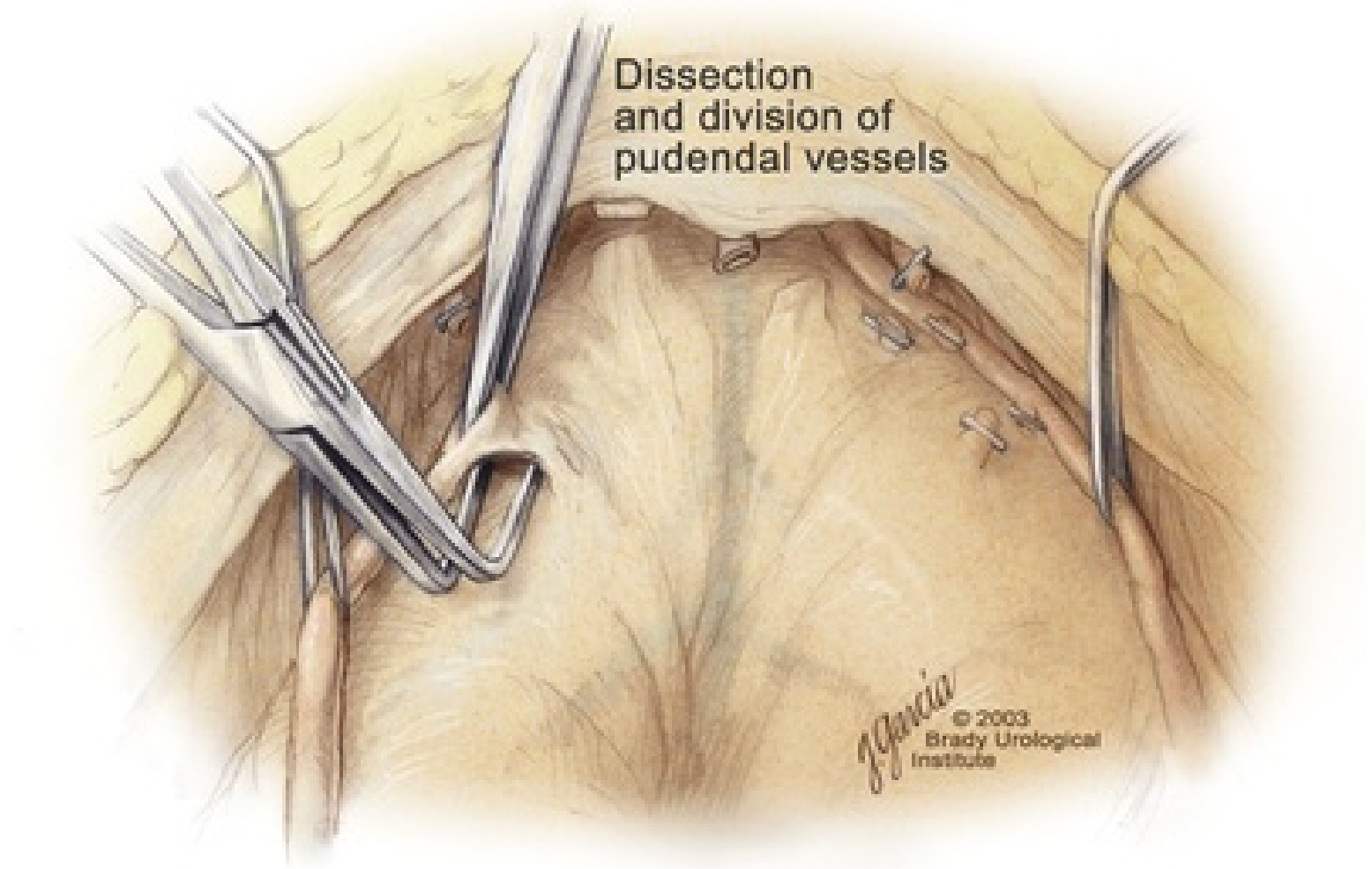

FIG. 155.8 Preservation of bilateral large accessory pudendal arteries. The anterior prostatic fascia is elevated with a right-angled clamp to facilitate release of the accessory pudendal vessels. (© Brady Urological Institute.)

Ligation and Division of the Dorsal Vein Complex

The goal is to divide the complex with minimal blood loss while avoiding damage to the striated sphincter and inadvertent entry into the anterior apex of the prostate. This can be accomplished with several approaches. Today we typically utilize an Endo GIA stapler (Medtronic, Minneapolis, MN) with a vascular load. After the apex is dissected, a Babcock clamp is used to bunch the two edges of the endopelvic fascia. Then the Endo GIA stapler is advanced over the dorsal vein approximately 4 cm and the GIA is then engaged, which will nicely delineate the apical anatomy. Next, the Foley catheter is manipulated; it should be moved in and out to ensure that the GIA stapler is not compressing the urethra. If the catheter moves freely, then the staples can be deployed. Over the past 4 years, Partin/Schaeffer have stapled approximately 800 dorsal vein complexes and have not “caught” the urethra in the GIA staple line. After deployment, the device is removed with nice delineation of apical anatomy with minimal to no blood loss. If a small amount of dorsal vein remains, a 3-0 Monocryl suture can be placed to control the residual vein. Once this is accomplished, the surgeon can progress to the urethral dissection.

This approach has several advantages. First, we estimate that there is substantially less blood loss (between 200 and 400 mL less) compared with more traditional ligation approaches. Second, a reduced amount of traction is needed to complete dorsal vein complex control. We believe this minimizes stretch injury to the NVBs and striated sphincter. Lastly, the design of the GIA stapler leaves three rows of staples on each side of the divided tissue. This provides excellent hemostasis of both the proximal and distal dorsal vein complex, and on the apical (prostate) side, the tissue contained in these staples provides ample coverage of the apex of the prostate, which can help with margins around anterior apical tumors.

A second, more traditional approach utilizes suture ligation. With use of a sponge stick to push the prostate posteriorly, a 3-0 Monocryl suture is passed through the dorsal vein complex just distal to the apex of the prostate (Fig. 155.9). In placing this stitch, the surgeon should face the head of the table, holding the needle driver against the pubis perpendicular to the patient. Next, the needle is reversed in the needle holder, and the same suture is placed through the perichondrium of the pubic symphysis (Fig. 155.10). Once this horizontal mattress suture is tied, three important goals are accomplished: (1) control of much of the venous bleeding without a “bunching” effect—this flat surface is much easier to divide; (2) recapitulation of the puboprostatic ligaments to provide additional anterior support of the striated sphincter; and (3) fixation of the dorsal vein complex anteriorly. This enables the surgeon to visualize the plane on the anterior apex of the prostate during division of the dorsal vein complex. The suture is not cut; it will be used once the dorsal vein is divided to oversew bleeders. Next, a Babcock clamp is used to bunch the two edges of the endopelvic fascia. A figure-of-eight 2-0 Caprosyn suture is then placed through this bunched tissue on the anterior surface of the prostate near the bladder neck. This reduces bleeding from the proximal dorsal veins, which can be excessive in some patients who have incompetent venous valves (Fig. 155.11).

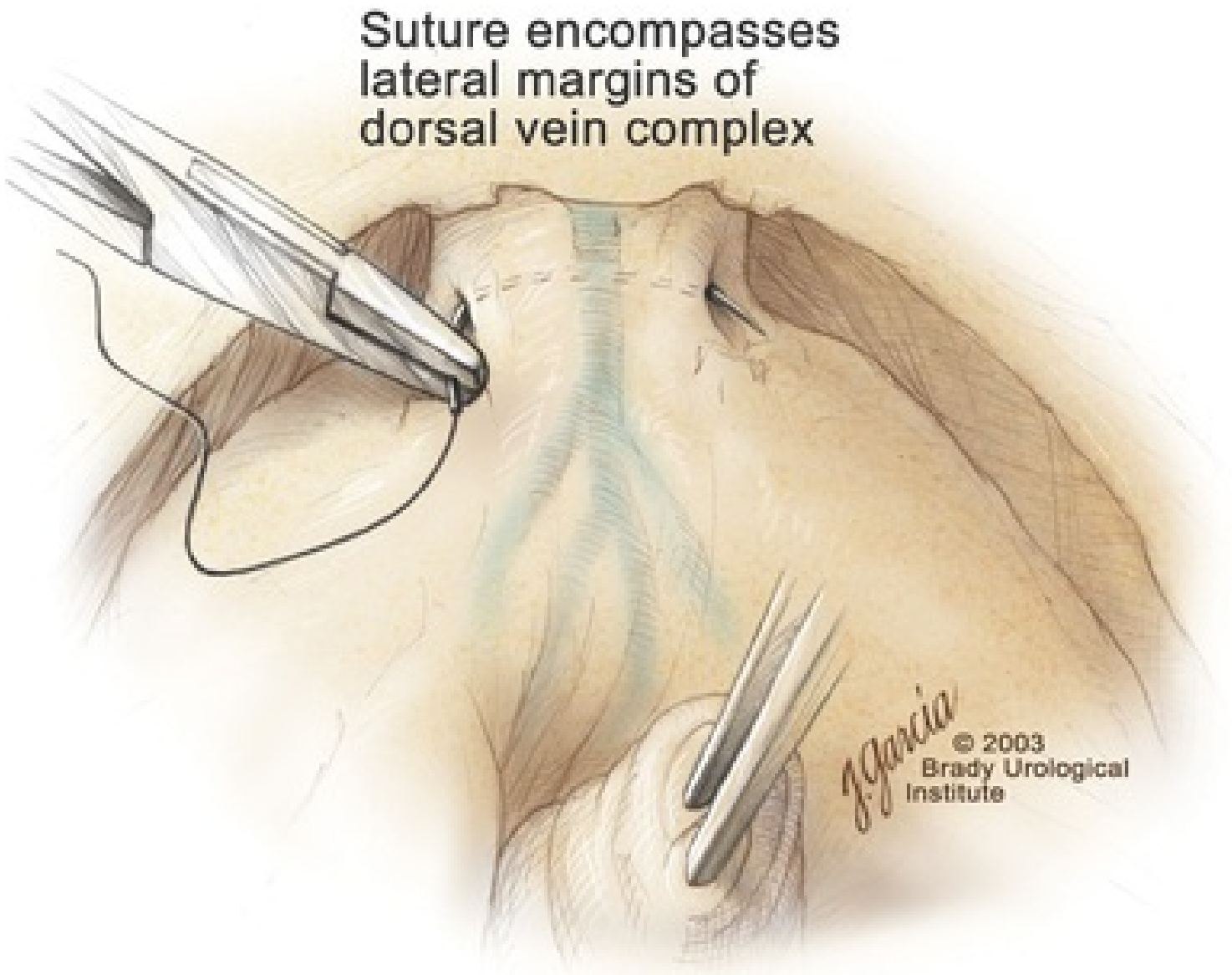
Suture encompasses lateral margins of dorsal vein complex
J. Garcia
© 2003 Brady Urological Institute

FIG. 155.9 Steps in ligation and division of the dorsal vein complex. A 3-0 Monocryl suture is passed superficially through the dorsal vein complex just distal to the apex of the prostate. (© Brady Urological Institute.)

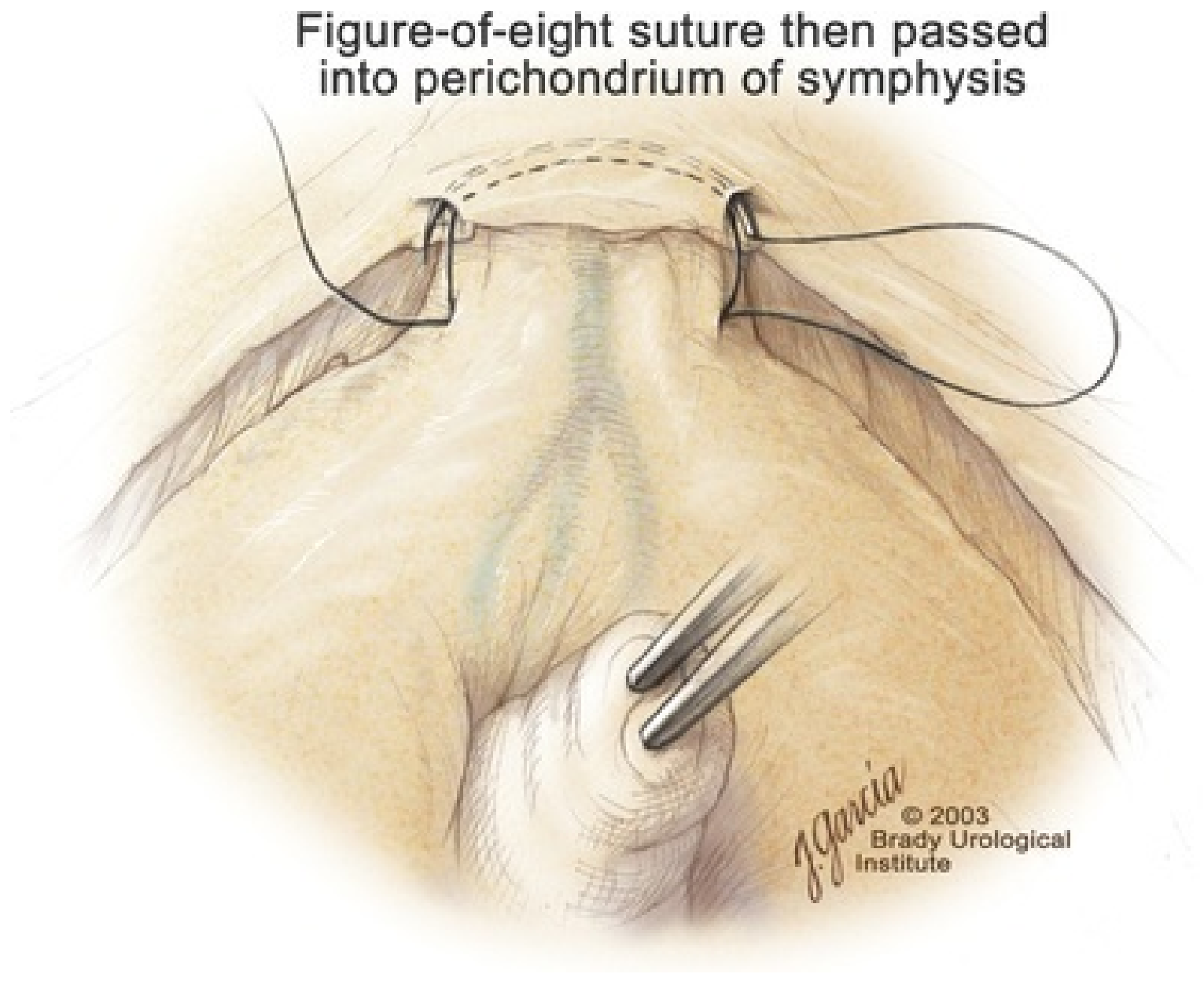
Figure-of-eight suture then passed into perichondrium of symphysis
J. Garcia
© 2003 Brady Urological Institute

FIG. 155.10 Next, the needle is reversed in the needle holder, and the same suture is passed through the perichondrium of the pubic symphysis. This maneuver is repeated to form a figure-of-eight horizontal mattress suture, which is then tied. (© Brady Urological Institute.)

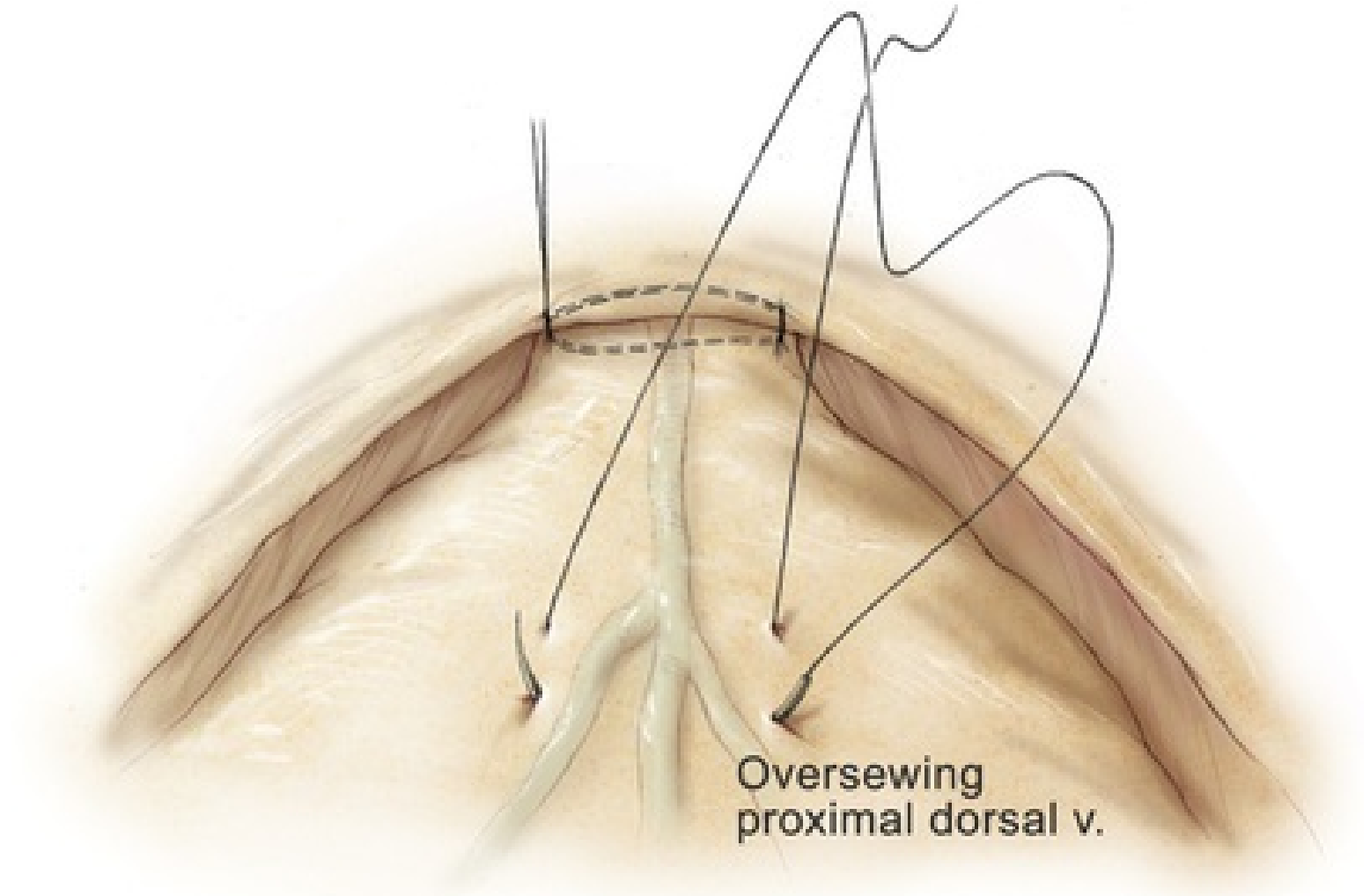

FIG. 155.11 A figure-of-eight 2-0 absorbable suture is placed on the anterior surface of the prostate to reduce bleeding from the proximal dorsal venous complex. *v.,* vein. (© Brady Urological Institute.)

Division of the Dorsal Vein Complex

Once the dorsal vein complex is ligated, one gently applies downward pressure on the anterior surface of the prostate with a sponge stick and a Metzenbaum scissors, or a No. 15 blade, is used to divide the complex. This is usually started on the left edge of the complex, where the junction with the apex of the prostate usually can be seen well (Fig. 155.12). Because the distal complex is fixed anteriorly, with downward pressure on the sponge stick, the exact plane between the juncture of the anterior surface of the prostate and the striated musculature can be visualized. Here loupes enable the surgeon to distinguish tissue textures and avoid positive margins. This is the most common site for positive surgical margins because it can be difficult to identify the anterior apical surface of the prostate. It also helps to rest the scissors on the anterior apex to find the correct plane.

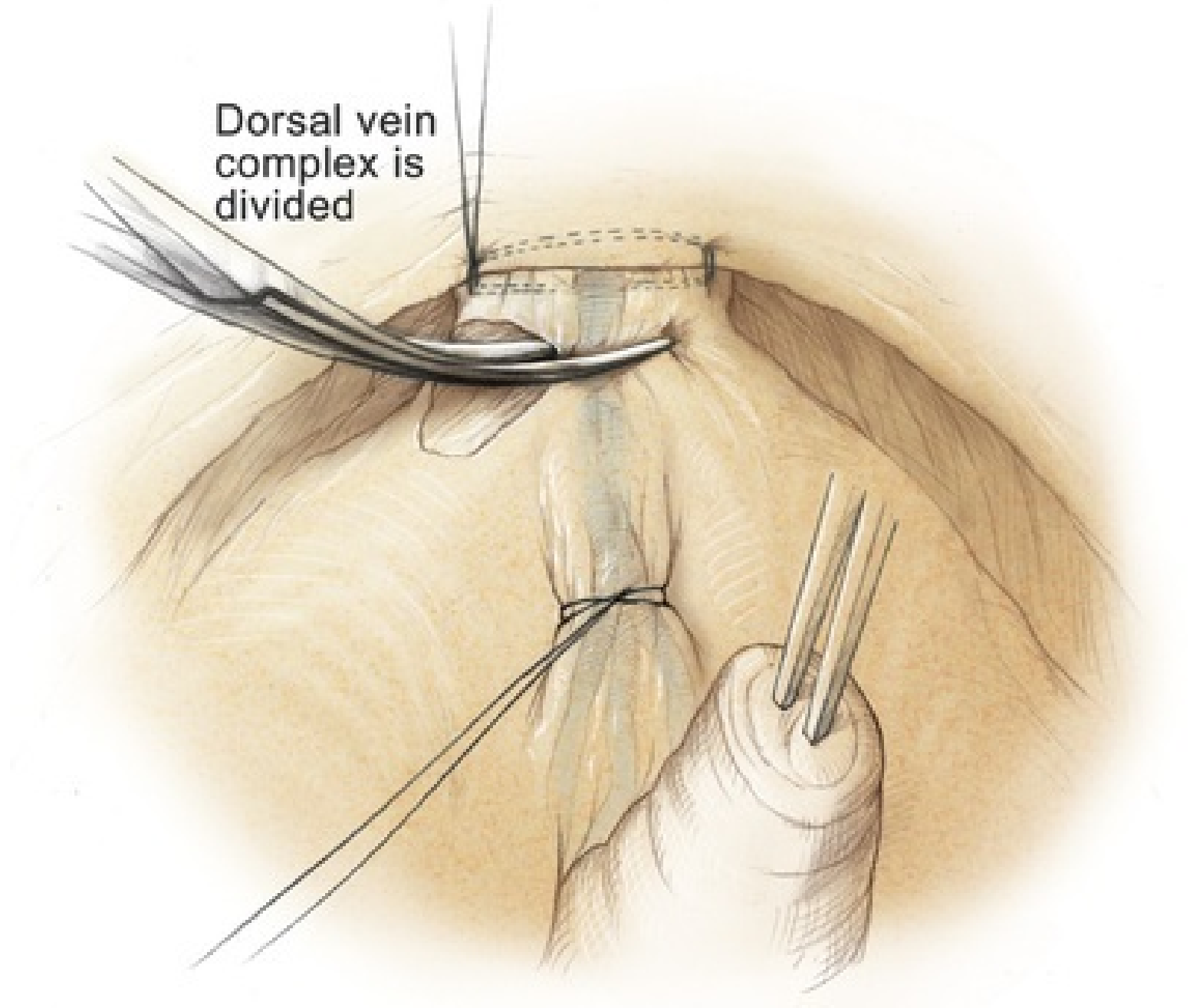

FIG. 155.12 With a sponge stick depressing the prostate posteriorly, the dorsal vein complex is divided beginning at the left edge. (© Brady Urological Institute.)

There is one important caveat in performing this maneuver. As the dissection proceeds posteriorly, **if the striated sphincter is divided too close to the apex of the prostate, there is risk that the NVB may be damaged**. **As the NVB approaches the apex of the prostate, it is often fixed medially beneath the striated sphincter by an apical vessel** (Walsh et al., 2000b). For this reason, the lateral edges of the sphincter along the urethra should be divided obliquely midway between the apex of the prostate and the pelvic floor. Absolute control of venous bleeding from the dorsal vein complex is mandatory so that the remainder of the procedure can be performed in a bloodless field. To achieve hemostasis, the 3-0 Monocryl suture on a ⅝ circle needle that was placed previously is used to oversew the superficial edges of the striated urethral sphincter–dorsal vein complex (Fig. 155.13). **In placing this running suture, the surgeon should face the head of the table, holding the needle driver against the pubis perpendicular to the patient.** If the needle driver is held loosely, the superficial edges of the complex can be easily approximated, forming a hood over the anterior urethra. Circumflex veins often are present at the posterior edge of the complex at the 5- and 7-o'clock positions; hemoclips often are used to control these bleeders. At the completion of this maneuver, hemostasis should be excellent.

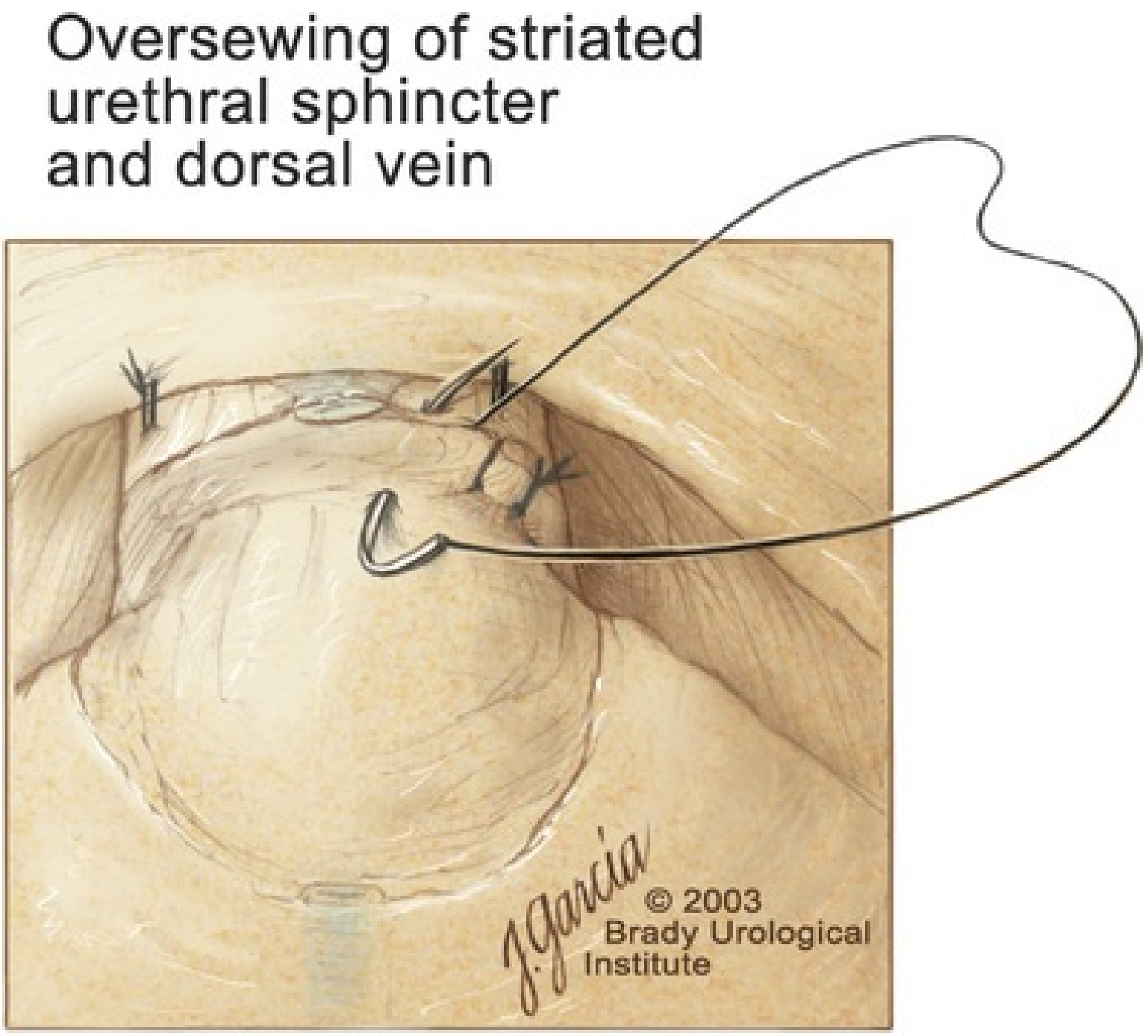
Oversewing of striated
urethral sphincter
and dorsal vein
J. Garcia
© 2003
Brady Urological
Institute

FIG. 155.13 With the same 3-0 Monocryl suture that was used earlier to ligate the dorsal vein complex, the superficial edge of the distal striated urethral sphincter–dorsal vein complex is gently oversewn to perfect hemostasis. (© Brady Urological Institute.)

Finally, to control back-bleeding from the anterior surface of the prostate, **the edges of the proximal dorsal vein complex on the anterior surface of the prostate are sewn together with the preplaced 2-0 suture** (Fig. 155.14). By pulling these edges together, tension on the prostatic fascia is evenly distributed, which can facilitate high release of the nerve bundles if the surgeon chooses to perform this maneuver (see detailed description later in this chapter).

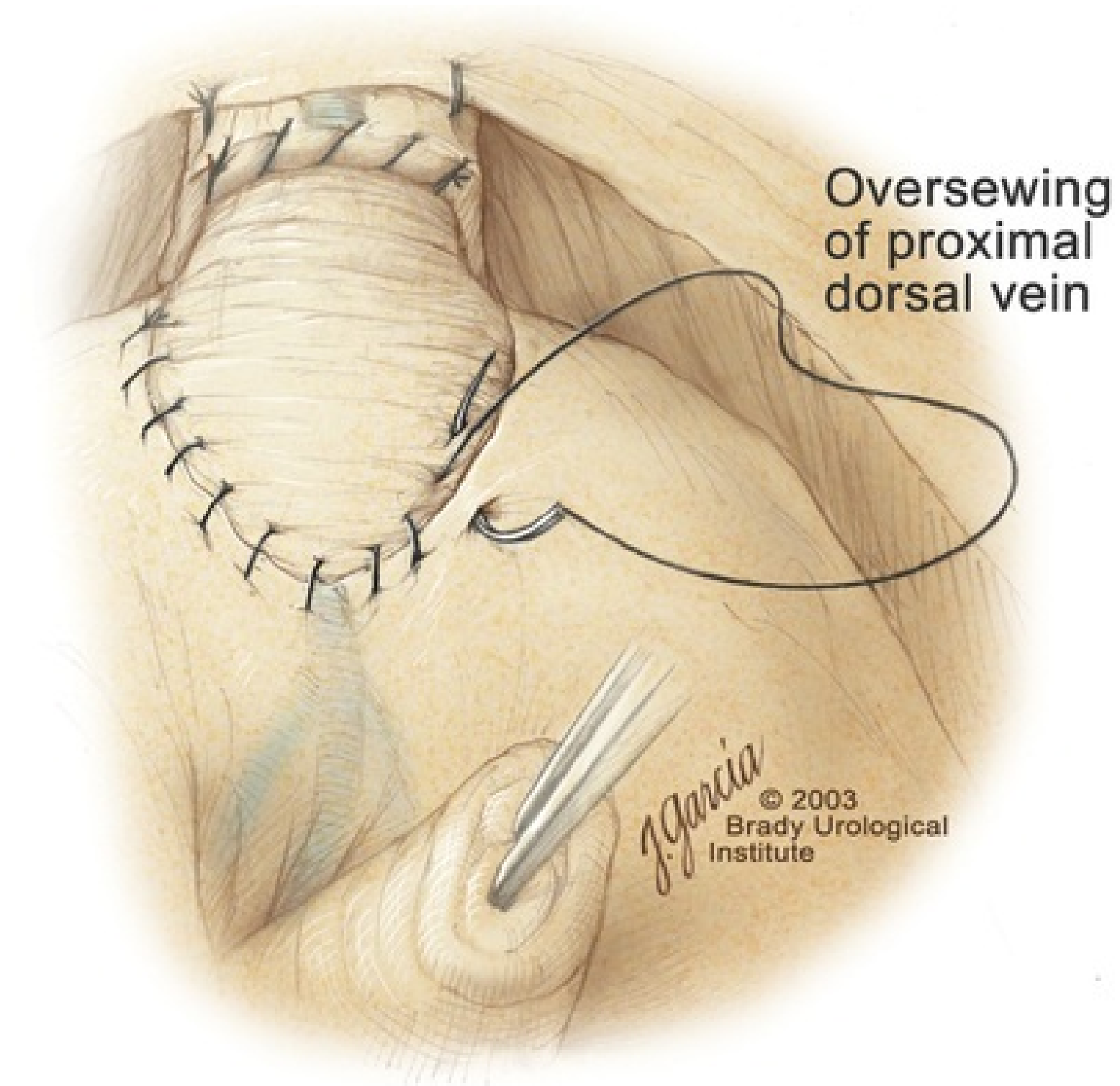

FIG. 155.14 The dorsal vein complex over the anterior surface of the prostate is oversewn in the shape of a *V* with a running 2-0 absorbable suture. (© Brady Urological Institute.)

Division of the Urethra and Placement of Urethral Sutures

The urethra should be divided first in performing a standard nerve release. If more aggressive nerve preservation is performed, the urethral incision should occur after nerve release (see later description). By gently displacing the prostate posteriorly with a sponge stick, the prostatourethral junction should be well visualized. The lateral bands of the striated musculature should be released as described earlier at their midpoint to free up as much of the urethra as possible. A right-angled clamp is then passed around the smooth musculature of the urethra near the apex of the prostate to ensure that the urethra is transected as close to the apex as possible (Fig. 155.15). This maneuver defines several key anatomic landmarks at the apex. First, it defines the posterior urethra from the posterior component of the striated sphincter. Second, if excellent hemostasis has been obtained, the association between the posterior striated sphincter and the nerve bundle should be able to be appreciated. With scissors, the anterior two-thirds of the urethra is divided with care to avoid damage to the Foley catheter. This provides excellent exposure for placement of six sutures in the distal urethral segment at the 1-, 3-, 5-, 7-, 9- and 11-o'clock positions. With 3-0 Monocryl on a ⅝ circle tapered needle, **the needle should incorporate just the urethral mucosa and submucosa but not the smooth muscle** (Fig. 155.16). As stated previously, the surgeon should face the head of the table to place these sutures and should hold the needle driver against the pubis, perpendicular to the patient. The first suture is placed in the mucosa and submucosa of the urethra at the 1- and 11-o'clock positions. By use of a 16-Fr catheter, the mucosa is easily identified. The smooth muscle should not be incorporated in this stitch because stitches in the smooth muscle delay the recovery of urinary control. If the urethral tissue appears flimsy, this suture should then be placed through the dorsal vein complex to improve tensile strength. Once the mucosa and submucosa have been elevated by these stitches, the remaining sutures are more easily placed. We place all sutures from the outside of the lumen to the inside; however, if sutures are more easily placed beginning on the luminal surface and then proceeding outside, a French eye needle can be used to place these sutures through the lumen of the bladder at the end of the case. The sutures are covered with towels to avoid inadvertent traction or displacement.

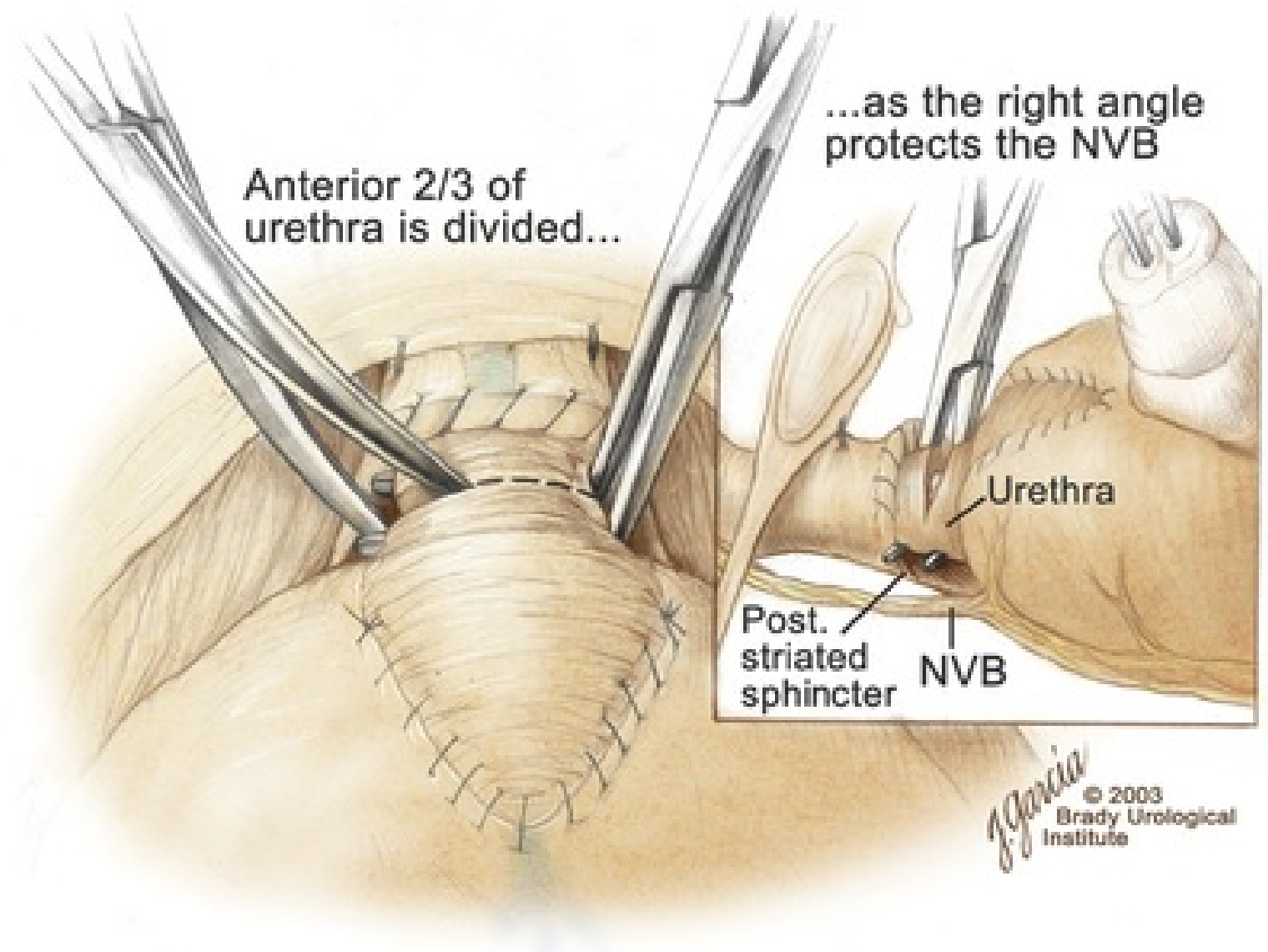
Anterior 2/3 of urethra is divided...
...as the right angle protects the NVB
Urethra
Post. striated sphincter
NVB
J Garcia
© 2003 Brady Urological Institute

FIG. 155.15 A right-angled clamp is placed around the smooth muscle of the urethra close to the apex of the prostate. Note that the neurovascular bundles *(NVBs)* are protected from injury by the posterior component of the striated sphincter, which is still intact *(inset).* Also see Fig. 155.5. *Post.,* posterior. (© Brady Urological Institute.)

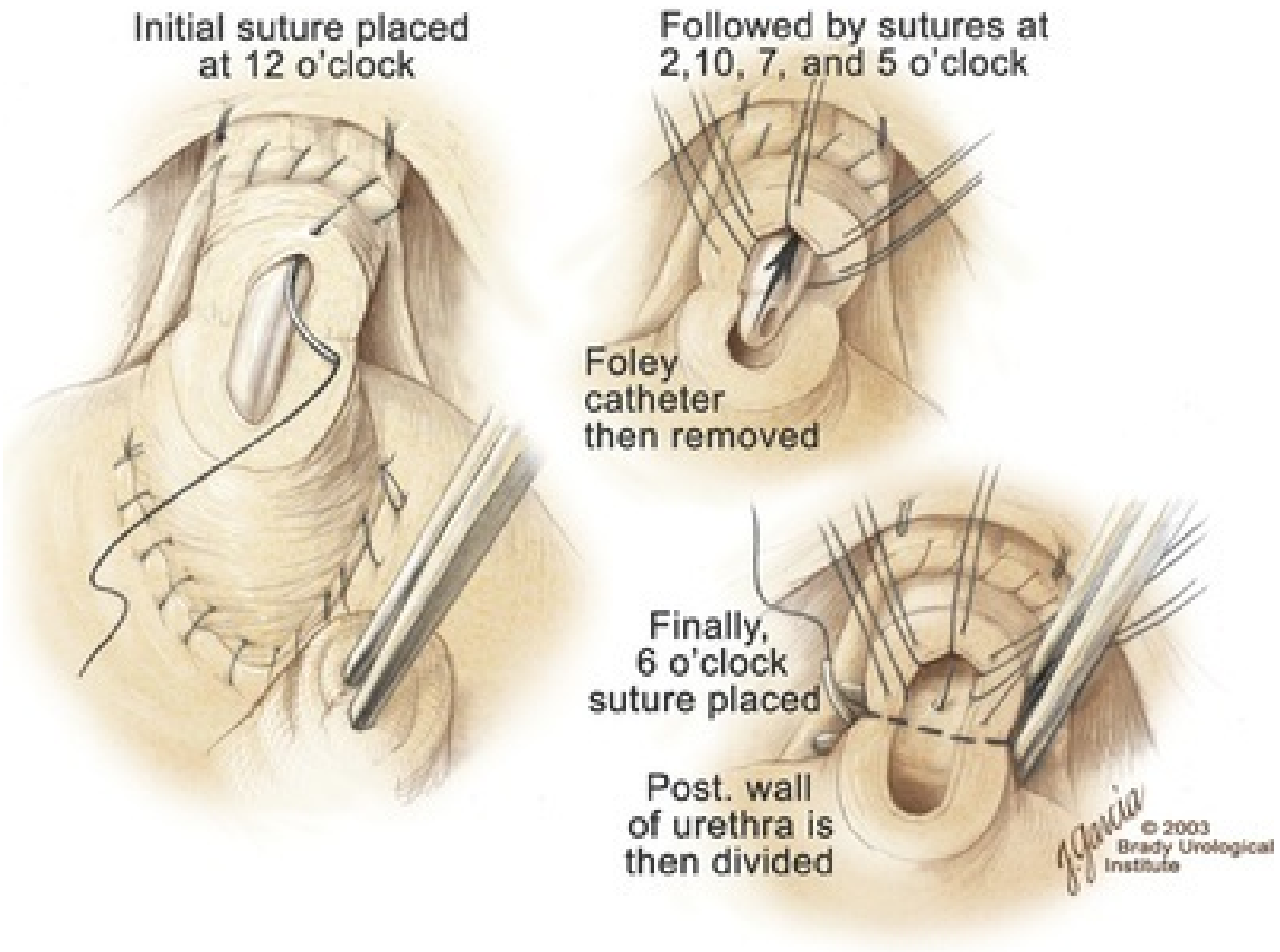
Initial suture placed at 12 o'clock
Followed by sutures at 2,10, 7, and 5 o'clock
Foley catheter then removed
Finally, 6 o'clock suture placed
Post. wall of urethra is then divided
© 2003 Brady Urological Institute

FIG. 155.16 The 3-0 Monocryl sutures are placed in the distal urethral mucosa and submucosa at the 12-, 2-, 10-, 7-, and 5-o'clock positions. The Foley catheter is then removed, the 6-o'clock suture is placed, and the posterior wall of the urethra is divided. *Post.,* posterior. (© Brady Urological Institute.)

The posterior band of the urethra is now divided to expose the posterior portion of the striated urethral sphincter complex (see Fig. 155.16). The posterior wall of the striated sphincter complex is composed of skeletal muscle and fibrous tissue. **Identification and precise division of this complex are important in (1) obtaining adequate margins of resection for apical lesions, (2) identifying the correct plane on the anterior wall of the rectum to ensure that all layers of Denonvilliers fascia are excised, (3) avoiding blunt trauma to the NVBs that are located immediately posteriorly, and (4) preserving urinary continence.**

To divide the posterior portion of the sphincter safely, a right-angled clamp is passed immediately beneath the left edge of this complex (Fig. 155.17). The clamp should pass midway between the apex of the prostate and the urethra. If it is passed too close to the apex of the prostate, it may damage the NVB. However, midway, the NVB is located more posteriorly and is beneath the right-angled clamp (Walsh et al., 2000b) (see Fig. 155.15).

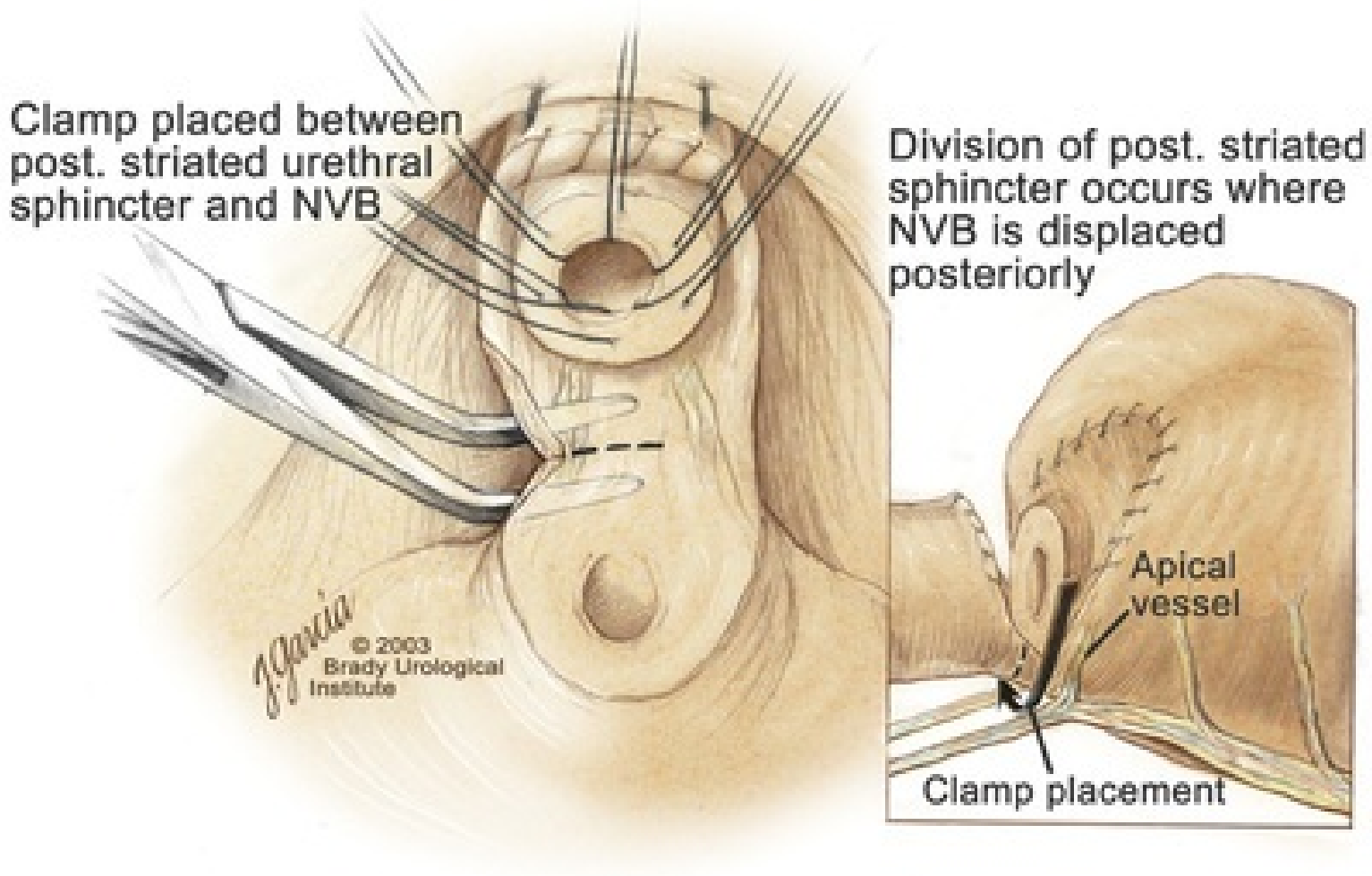
Clamp placed between post. striated urethral sphincter and NVB
Division of post. striated sphincter occurs where NVB is displaced posteriorly
Apical vessel
Clamp placement
J. Garcia
© 2003 Brady Urological Institute

FIG. 155.17 Division of the posterior component of the striated sphincter. A right-angled clamp is passed beneath the left edge of the striated sphincter midway between the apex of the prostate and urethra, at a site where the neurovascular bundles *(NVBs)* have fallen posteriorly. After the left edge of the complex is divided, a right-angled clamp is then passed along the right edge and the maneuver is repeated. *post.,* posterior. (© Brady Urological Institute.)

The left border of the complex is then divided with scissors. Next, the right-angled clamp is placed beneath the right edge of the complex, and the complex is divided. It is necessary to divide the complex from each side, because if division of the entire complex from one side is attempted, the contralateral NVB may be damaged. Finally, the central component of the complex is divided.

Identification and Preservation of the Nerve Bundle

Today, in most men who are candidates for surgery, it is safe to preserve both NVBs and rarely necessary to excise both of them (Walsh, 2001). With improved surgical techniques and the availability of phosphodiesterase type 5 (PDE5) inhibitors, most healthy potent men younger than 65 years of age should be potent after surgery. The NVB is outside the prostate between layers of lateral pelvic fascia (the levator fascia and prostatic fascia). If nerve sparing is performed correctly, the prostatic fascia must remain on the prostate. This is called an *interfascial* dissection. Furthermore, when cancer extends through the capsule, it rarely penetrates more than 1 to 2 mm, and this much tissue is often present even when the NVB is preserved (Hernandez et al., 2005). As Costello et al. (2004) have shown, the cavernous branches are positioned posterior to the capsular vessels, and the nerves immediately adjacent to the prostatic capsule are nerves going into the prostate, not the cavernous nerves.

To avoid bleeding from the capsular arteries and veins, some surgeons dissect beneath the prostatic fascia. This is called an *intrafascial* dissection. Because this plane is directly on the prostatic parenchyma, the risk for positive surgical margins is high. For this reason, this approach should never be used. Many well-meaning surgeons believe that if they excise the NVB, they can avoid a positive surgical margin. Unfortunately, this is not the case because the NVB is not the most common site for positive margins. Rather, the most common site is the apex, followed by posterior and then posterolateral sites. In 22%, the positive margins are multiple. In multiple studies, it has been demonstrated that the rate of positive margins in nerve-sparing and non–nerve-sparing procedures is the same (Ward et al., 2004). In Walsh's hands, the NVBs are preserved bilaterally in 87% of patients; one NVB is excised in 13%. This has resulted in an overall rate of positive surgical margins of approximately 5% (Epstein, 2001). The NVBs are rarely, if ever, excised bilaterally. We have always thought that if there is capsular penetration bilaterally to the point at which it is necessary to excise both NVBs, the patient most likely has distant dissemination and is not curable. Between 1986 and 1999, only seven potent men had both NVBs excised. Four were not cured because they had positive lymph nodes, positive seminal vesicles, or positive surgical margins elsewhere. In the three other patients, it was not necessary to excise both NVBs because there was no capsular penetration on one side.

How is the decision made as to when and where to excise the NVB? Preoperatively, no definite decision is made. Consideration is given to the status of sexual function, but in impotent patients, we do not always excise the NVBs because there is evidence that the bundles provide both somatic and autonomic innervation to the continence mechanism and that patients who undergo excision of both NVBs have more incontinence than do patients in whom the NVBs are preserved (Nelson et al., 2003). Consideration is also given to other important factors such as the presence of a *palpable apical lesion* and a high probability of capsular penetration based on the Partin tables (Partin et al., 1997, 2001). **However, no final decision is made until the time of surgery. When the endopelvic fascia is opened, if induration is palpable in the lateral pelvic fascia, the NVB on that side is widely excised. If there is no induration but the NVB appears to be fixed to the prostate at the time it is being released, it is also excised. However, the final decision about preservation or wide excision of the NVB does not need to be made until the prostate is removed. If there appears to be inadequate tissue over the**

posterolateral surface after the prostate has been removed, the NVB can then be widely excised.

Identification of the Neurovascular Bundle

This is where the tactile sensation provided by open surgery is so important. If induration is palpable in the lateral pelvic fascia, the bundle should be excised. Also, in gently releasing the bundle with a right-angled clamp, if the bundle is fixed to the prostate, it should not be preserved. When the NVB is released, there should be no upward traction on the prostate. Rather, the prostate should be rolled from side to side. Also, the prostate is softer with the catheter out, and it appears easier to identify the correct plane for release of the NVB.

Standard Preservation of the Neurovascular Bundles

Standard nerve release begins after incision of the urethra, placement of urethral sutures, and release of the posterior striated sphincter. Recall that the lateral pelvic fascia is composed of two layers: the levator fascia and the prostatic fascia. The NVB travels between these two layers (see Figs. 155.4B and 155.5). With a right-angled clamp, the superficial layers of levator pelvic fascia are released. The use of loupes is helpful during this maneuver to ensure that the prostatic fascia has not been violated. The magnification also facilitates a more gentle dissection with less traction on the NVB. **A Babcock clamp or sponge stick is used during release of the NVB to manipulate the prostate. The clamp facilitates gentle elevation of the prostate during the release and can result in less traction on the NVB because the prostate is released from the bundle rather than the bundle being released from the prostate.** This dissection should begin at the bladder neck, where the fascia forms a thick band (Fig. 155.18). When this band is divided, the prostate immediately becomes more mobile. The superficial fascia should be released from the bladder neck to the apex. This maneuver releases the bundle laterally, thus making it easier to perform the next step, in which the bundle is released posteriorly at the apex.

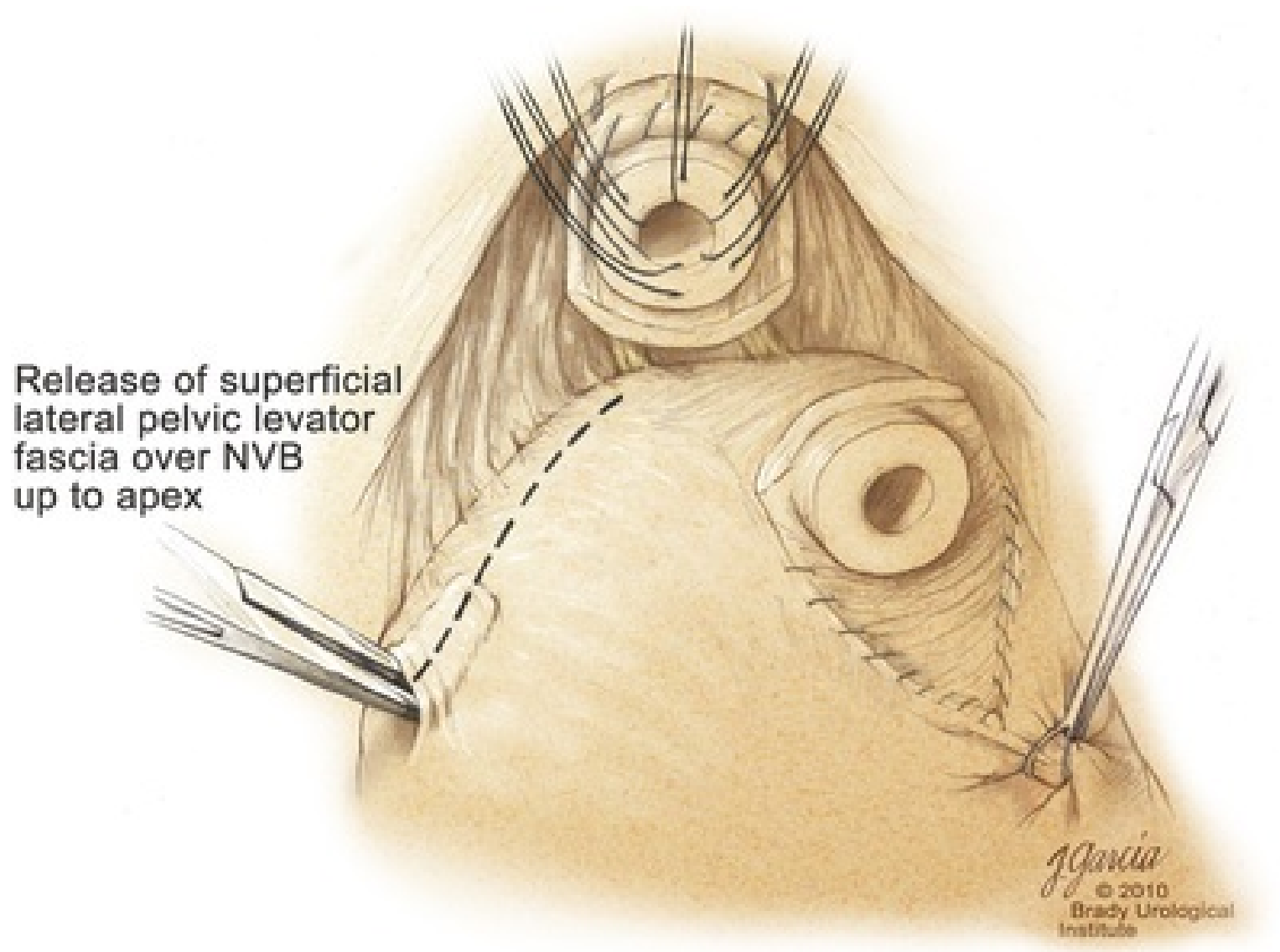
Release of superficial lateral pelvic levator fascia over NVB up to apex
J.Garcia
© 2010
Brady Urological Institute

FIG. 155.18 The lateral surface of the prostate is exposed by displacing the prostate on its side with use of a Babcock clamp. A right-angled clamp is then inserted under the superficial layer of the levator fascia, beginning at the bladder neck and continuing all the way out to the apex. *NVB,* neurovascular bundle. (© Brady Urological Institute.)

Once the superficial fascia has been released, the location of the NVB can be identified by the presence of a subtle “groove” on the posterolateral edge of the prostate (Fig. 155.19). **By tracing this groove to the apex of the prostate, one can determine where the NVB begins to travel caudally and laterally away from the prostatic apex toward the urethra. Once the medial border of the NVB has been identified at the apex, the dissection in the midline can be safely carried posteriorly toward the rectum.**

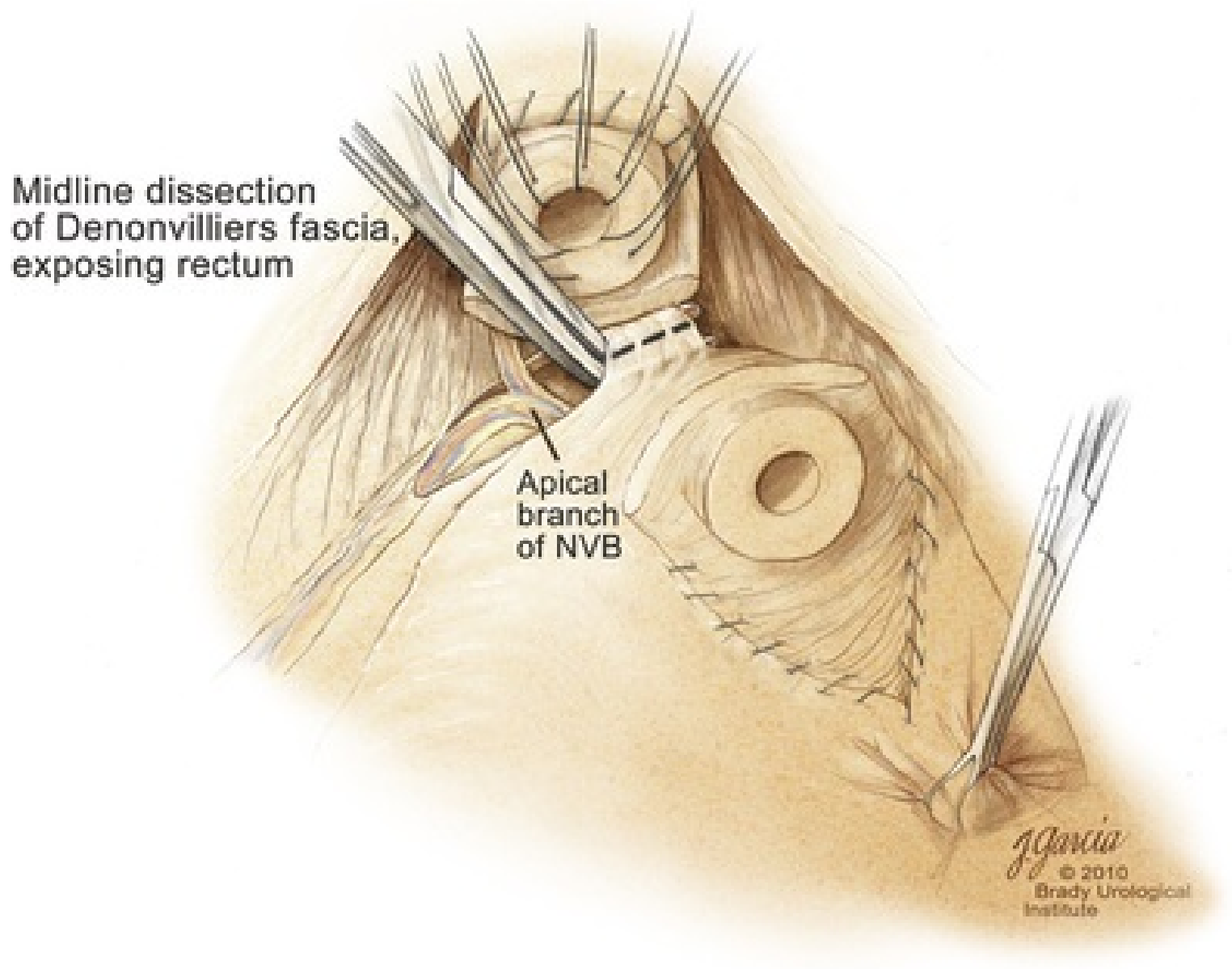
Midline dissection of Denonvilliers fascia, exposing rectum
Apical branch of NVB
J.Garcia
© 2010 Brady Urological Institute

FIG. 155.19 Once the levator fascia has been released, the neurovascular bundle *(NVB)* can be located by the presence of a subtle "groove" on the posterolateral edge of the prostate. This groove should be traced out to the apex of the prostate, and once the medial border has been identified, the dissection in the midline can be pursued, dividing residual layers of Denonvilliers fascia down to the rectum. (© Brady Urological Institute.)

The plane between the rectum and prostate having been developed in the midline, it is then possible to release the NVB from the prostate, beginning at the apex and moving toward the base, elevating and displacing the prostate over on its side. **Beginning on the rectal surface, the bundle is released from the prostate by spreading a right-angled clamp gently.** At the apex, there are often prominent apical vessels (Fig. 155.20). Because the prostate has been elevated on its side across the midline, this distorts the direction of the NVB by kinking it (see Fig. 155.20). If this artifact is not recognized, the NVB can be inadvertently transected. These vessels should be clipped and divided. Once the dissection has been initiated at the apex, it should proceed to the midpoint of the prostate. Because the superficial layers of the levator fascia have already been released, this dissection often proceeds easily. Furthermore, in using this plane, the Denonvilliers fascia and prostatic fascia remain on the prostate; only the residual fragments of the levator fascia are released from the prostate laterally. At this point in the procedure, the bundle should be released to the seminal vesicle (Fig. 155.21).

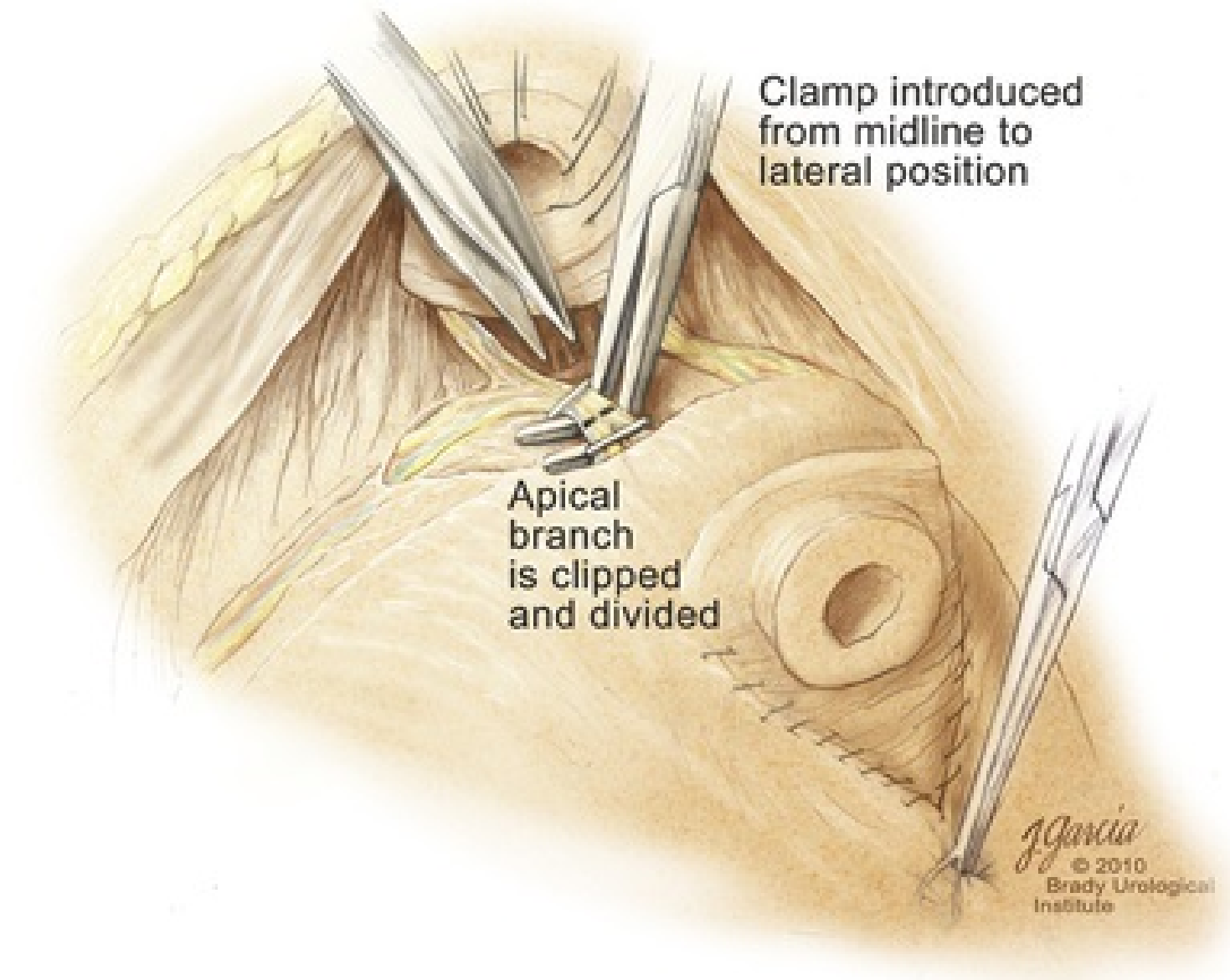
Clamp introduced
from midline to
lateral position
Apical
branch
is clipped
and divided
J Garcia
© 2010
Brady Urological
Institute

FIG. 155.20 At the apex, there are often prominent apical vessels. Because the prostate has been elevated on its side across the midline, note that the neurovascular bundle *(NVB)* appears to be kinked. If this artifact is not recognized, the NVB can be inadvertently transected. Once these vessels are clipped and divided, the NVB returns to its natural straight course. (© Brady Urological Institute.)

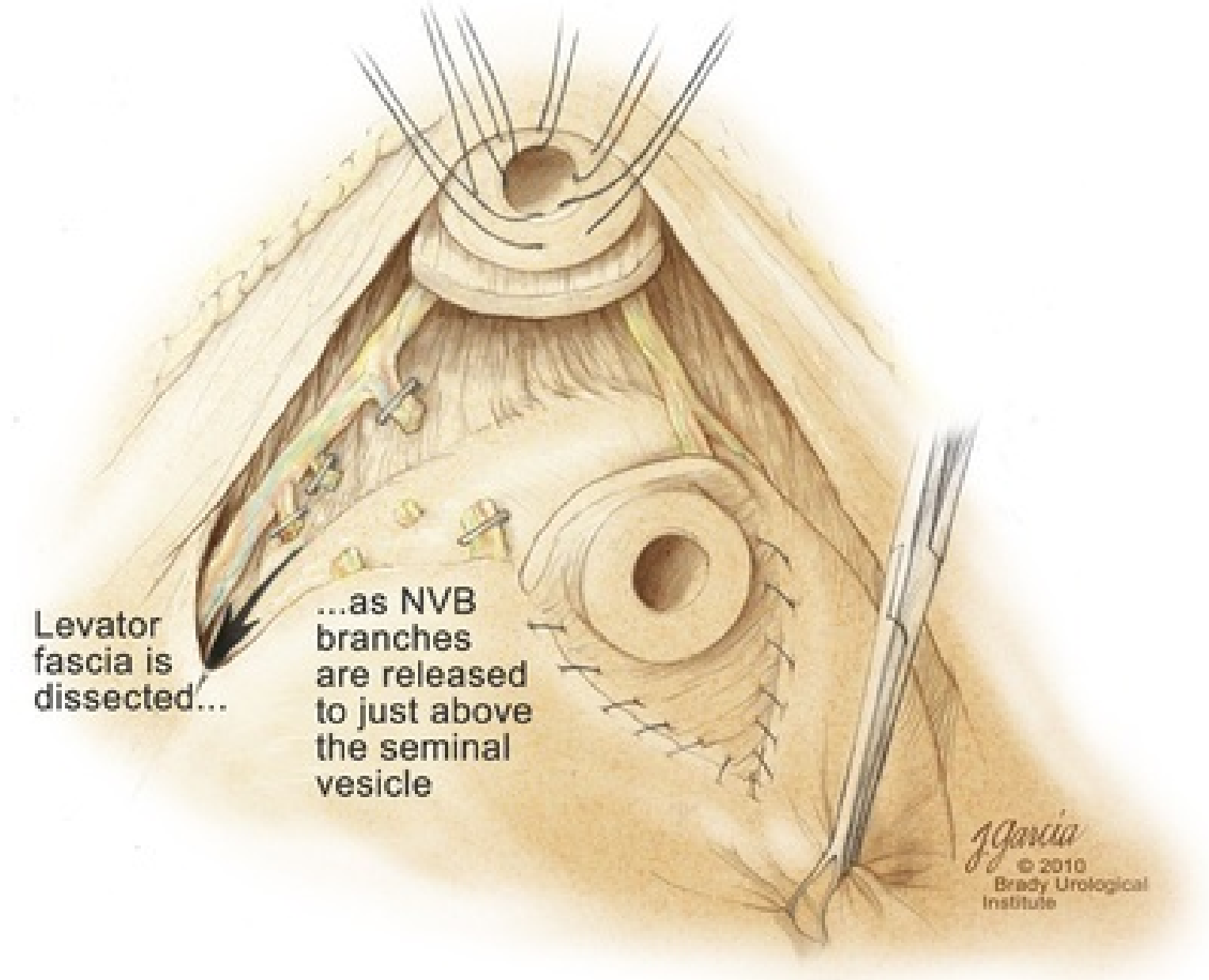
Levator
fascia is
dissected...
...as NVB
branches
are released
to just above
the seminal
vesicle
J Garcia
© 2010
Brady Urological
Institute

FIG. 155.21 The neurovascular bundle (NVB) has been released to just above the seminal vesicle. (© Brady Urological Institute.)

The vascular branches to the NVBs are best controlled by small hemoclips placed parallel to the bundle. Thermal energy of any form (unipolar, bipolar, or Harmonic scissors) should never be used on the NVB or its branches (Ong et al., 2004). Usually it is not necessary to clip the prostatic side of these tiny vessels; fine scissors should be used to divide them. The number of arterial and venous branches is extremely variable. By starting at the apex, however, one can easily identify them prospectively. If the fixation of the bundle to the prostate cannot be explained by vascular branches, the NVB should be excised. The surgeon should be aware that the bundle may travel more anteriorly in some patients. In these patients, one can confuse the groove with the potential space between the prostate and rectum. This is another good reason to release the bundle at the apex first. In addition, some patients have many veins on the lateral surface of the prostate that anastomose between the Santorini plexus anteriorly and the NVB posteriorly. The apical approach to the bundle facilitates management of this condition as well.

Furthermore, to make certain the Denonvilliers fascia is maintained on the prostate, the NVBs should be released by dissecting from the rectal surface anteriorly. Using the principles described earlier, positive surgical margins in patients with organ-confined disease that are caused by inadvertently cutting into the prostate are rare. Also, because the NVB is more mobile, it is easier to interrogate the surgical field with tactile sensation and magnification to find the correct plane. For this reason, even in patients with extraprostatic extension in the region of the NVB, it is possible to partially excise the bundle, preserve potency, and obtain negative margins of excision (Hernandez et al., 2005).

To avoid traction on the NVB, this dissection should continue cephalad to the level of the seminal vesicles (Masterson et al., 2008). At this point, the surgeon should look for a prominent arterial branch traveling from the NVB over the seminal vesicles to supply the base of the prostate (Fig. 155.22). This posterior vessel should be ligated on each side and divided. In doing so, the NVBs are no longer tethered to the prostate and fall posteriorly.

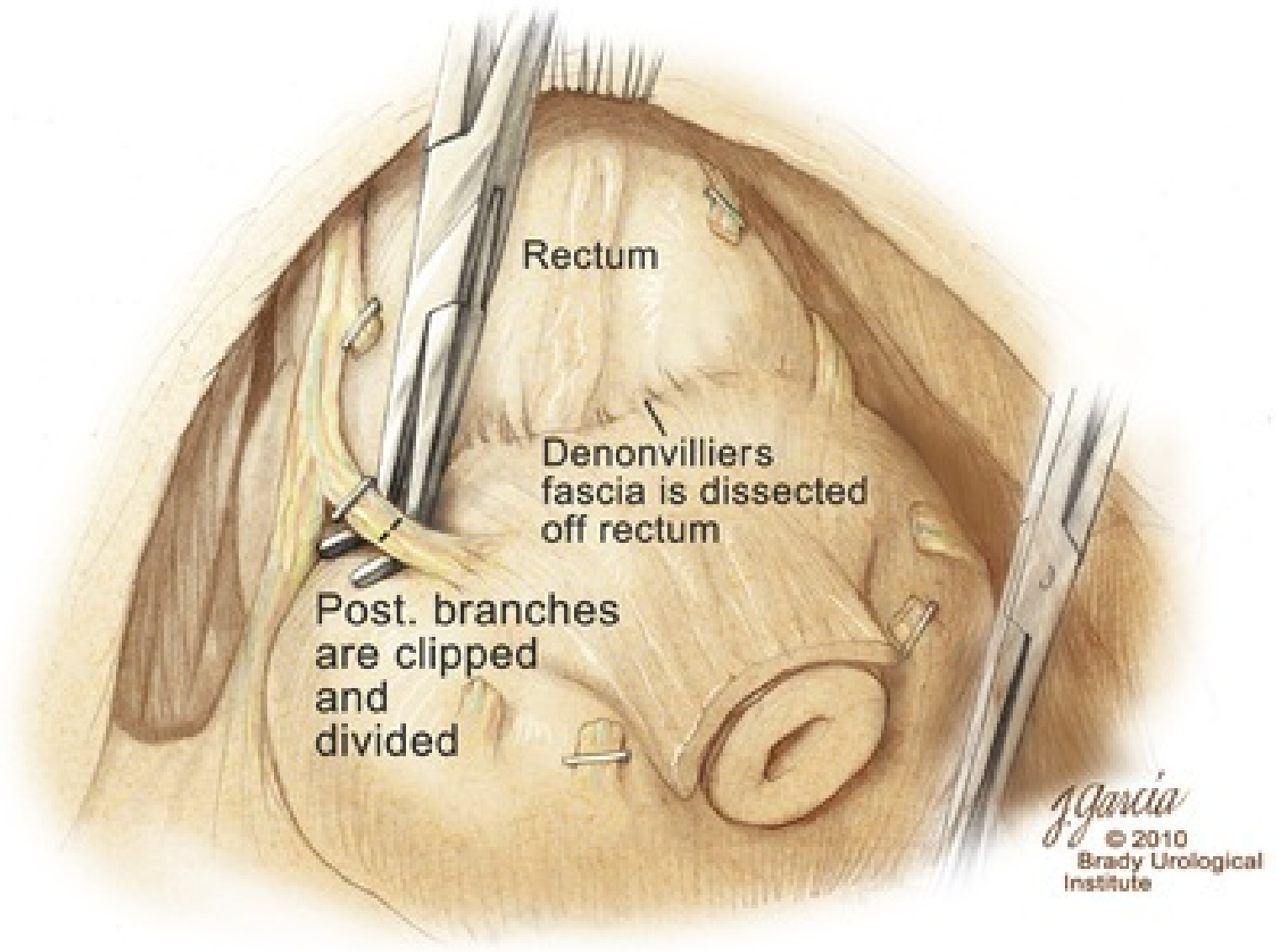
Rectum
Denonvilliers fascia is dissected off rectum
Post. branches are clipped and divided
J. Garcia
© 2010 Brady Urological Institute

FIG. 155.22 Posterior dissection. The attachment of Denonvilliers fascia to the rectum is released, maintaining all layers of Denonvilliers fascia over the posterior surface of the prostate and seminal vesicles. Prominent branches from the neurovascular bundle *(NVB)* to the posterior surface of the prostate are identified at the posterolateral angle of the rectum. By dividing these posterior branches, the NVB is free to fall away from the prostate posteriorly. *Post.,* posterior. (© Brady Urological Institute.)

High Anterior Release of the Neurovascular Bundles at the Apex

The purpose of this approach is to speed up the recovery of sexual function and continence by reducing traction on the branches of the nerves to the cavernous bodies and striated sphincter or to avoid inadvertent transection of the small branches that travel anteriorly (Costello et al., 2004; Horninger et al., 2005; Menon et al., 2005; Montorsi et al., 2005; Takenaka et al., 2004, 2005)**. However, because there is less soft tissue at the apex, the risk for positive surgical margins could be increased by this approach. We select candidates for this approach using parameters that identify patients with a low risk for extraprostatic extension in the region of the NVB** (Tsuzuki et al., 2005). Tsuzuki et al. (2005) defined preoperative parameters to identify patients with a higher likelihood of extraprostatic extension in the region of the NVB. If patients have two or more of the following criteria, the risk for extraprostatic extension in the region of the NVB on that side is greater than 10%: prostate-specific antigen (PSA) level above 10 ng/mL, Gleason score higher than 6, average percentage of biopsy core on the side involved greater than 20%, percentage of cores with tumor on that side greater than 33%, or an abnormal finding on digital rectal examination.

The procedure begins after ligation of the dorsal venous complex and before incision of the urethra. Once total hemostasis is obtained, the levator fascia over the anterior apex of the prostate is incised and the incision is extended distally along the lateral edge of the apex of the prostate, preserving the underlying prostatic fascia (Fig. 155.23). The prostatic fascia is the glistening white fascia immediately below the veins that travel along the lateral surface of the prostate. **To identify the correct plane and avoid inadvertent incision into the prostate, it is essential to have excellent visualization and magnification.** In many patients, these venous tributaries must be divided and controlled. Cautery should not be used. Instead, hemostasis should be achieved by use of small hemoclips. As the dissection proceeds distally, the levator fascia should be released from the lateral shoulders of the prostate, with care taken not to enter the underlying prostatic fascia. **Because the recovery of sexual function at 12 months after unilateral high release was the same as with bilateral high release, we now routinely perform it on only one side, the side with the most favorable pathologic status.** Once the dissection has extended distally beyond the apex of the prostate, the NVB is exposed and released. Because the levator fascia has previously been released, prominent NVB usually can be visualized lateral to the urethra. At this point, as described by Masterson et al. (2008), the NVB is released from the lateral surface of the prostate to just above the seminal vesicles (Fig. 155.24). This approach avoids traction on the NVBs and makes the subsequent steps in preservation of the NVBs much easier (Fig. 155.25).

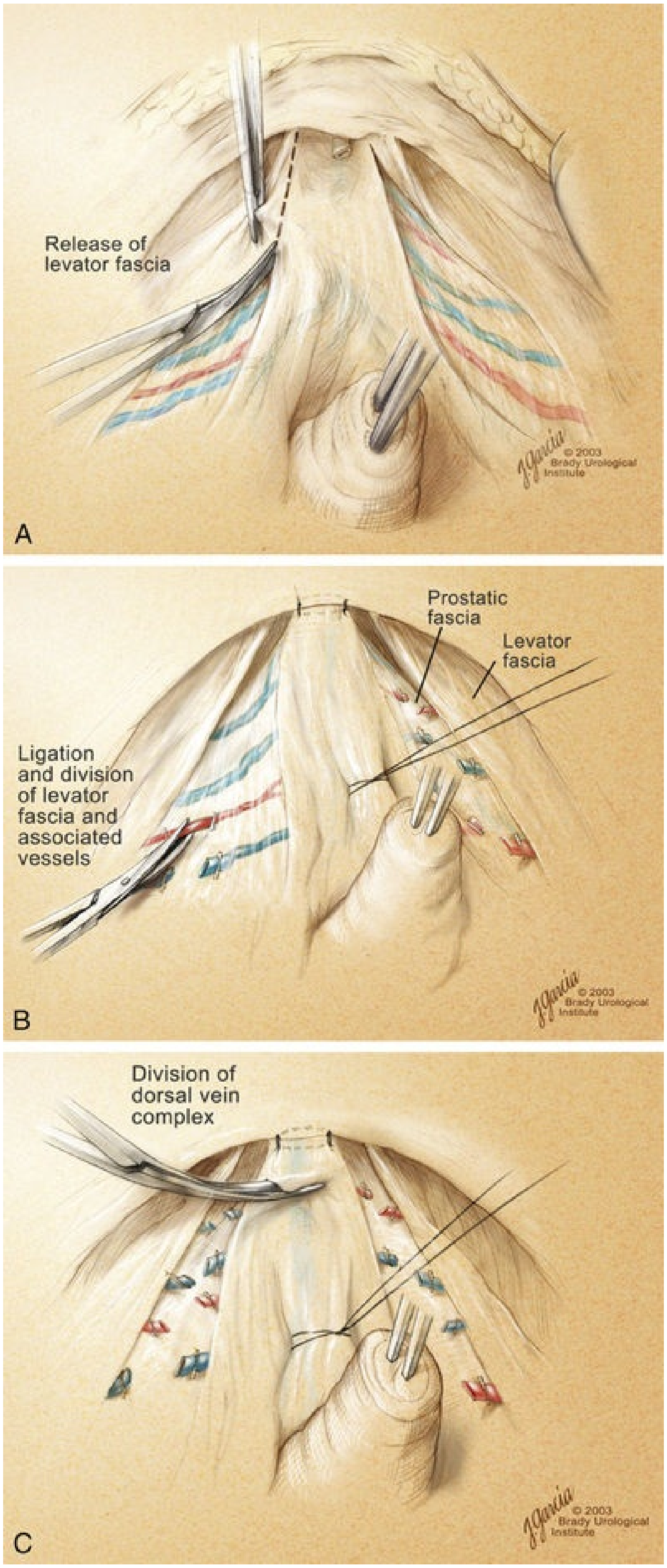
Release of levator fascia
J Garcia
© 2003 Brady Urological Institute
A
Prostatic fascia
Levator fascia
Ligation and division of levator fascia and associated vessels
J Garcia
© 2003 Brady Urological Institute
B
Division of dorsal vein complex
J Garcia
© 2003 Brady Urological Institute
C

FIG. 155.23 High anterior release of the levator fascia. (A) The levator fascia over the anterior apex of the prostate is incised along the lateral edge of the dorsal vein complex, preserving the underlying prostatic fascia. (B) The dissection extends distally beyond where the dorsal vein was ligated. Venous tributaries are controlled with clips. (C) The dorsal vein complex is divided to the urethra between the two preplaced dorsal vein sutures. (© Brady Urological Institute.)

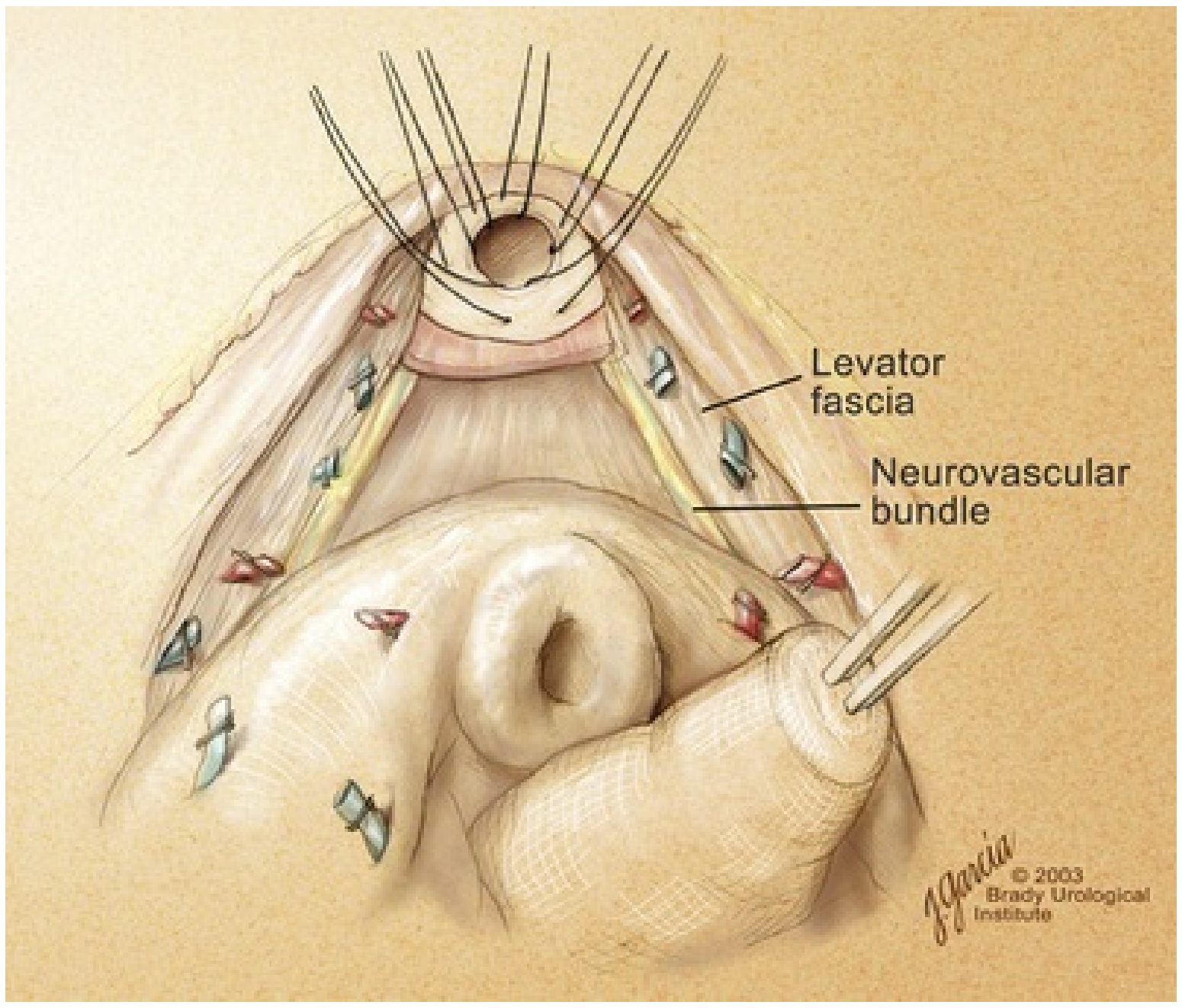
Levator fascia
Neurovascular bundle
J Garcia
© 2003 Brady Urological Institute

FIG. 155.24 A view of the completed dissection. (© Brady Urological Institute.)

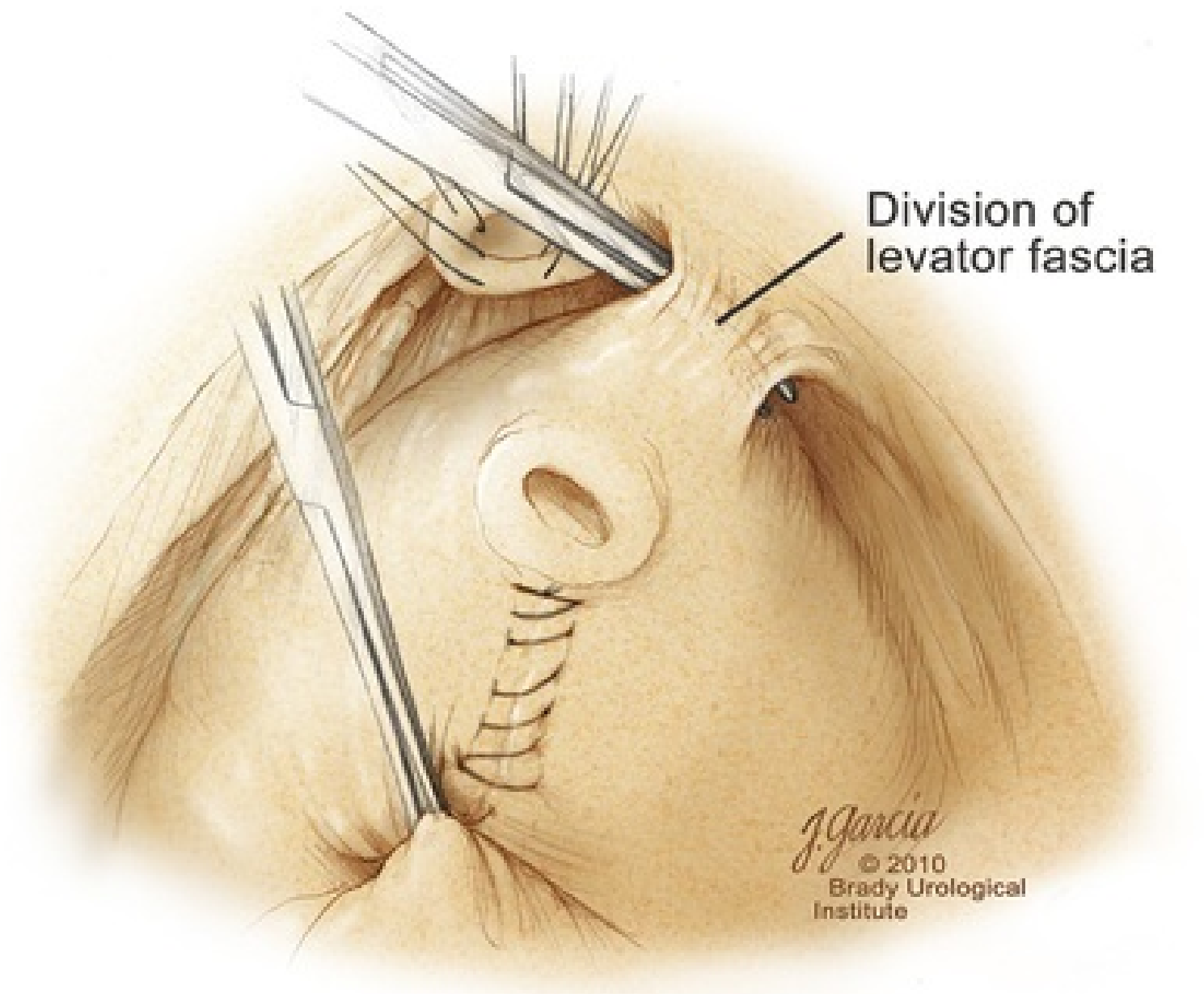

FIG. 155.25 If high release of the levator fascia was performed only unilaterally, after the posterior component of the striated sphincter has been divided, a right-angled clamp is inserted under the levator fascia on the side contralateral to the high release at the apex. This facilitates identification of the same dissection plane beneath the levator fascia as on the contralateral side without the need for approaching the plane by first dividing the levator fascia from the outside. (© Brady Urological Institute.)

Next, the urethra is transected and urethral sutures placed. The posterior component of the striated sphincter is transected. If high release of the levator fascia was performed only unilaterally, a right-angled clamp is inserted under the levator fascia at the apex on the side contralateral to the high release. This facilitates identification of the same dissection plane beneath the levator fascia as on the contralateral side without the need for approaching the plane by first dividing the levator fascia from the outside (see Fig. 155.25).

Wide Excision of the Neurovascular Bundles

Before excision of the NVB unilaterally, the contralateral NVB should be freed from the prostate, starting at the apex. This avoids traction injury, which can occur during wide excision of the contralateral bundle. The NVB to be excised is identified at the apex, and a right-angled clamp is passed from medial to lateral, immediately on the anterior surface of the rectum (Fig. 155.26). The bundle is divided without ligation in an effort to excise as much soft tissue as possible. Later, if bleeding is troublesome, the distal end can be clipped. The dissection is continued by dividing the fascia on the lateral surface of the rectum from the apex to the base so that the NVB and abundant fascial tissue are included in the specimen. This procedure is performed under direct vision, with the dissection terminating at the tip of the seminal vesicle, where the NVB is ligated and divided. In this way, the NVB and the lateral pelvic fascia are excised under direct vision in a more complete way than was previously possible (Fig. 155.27).

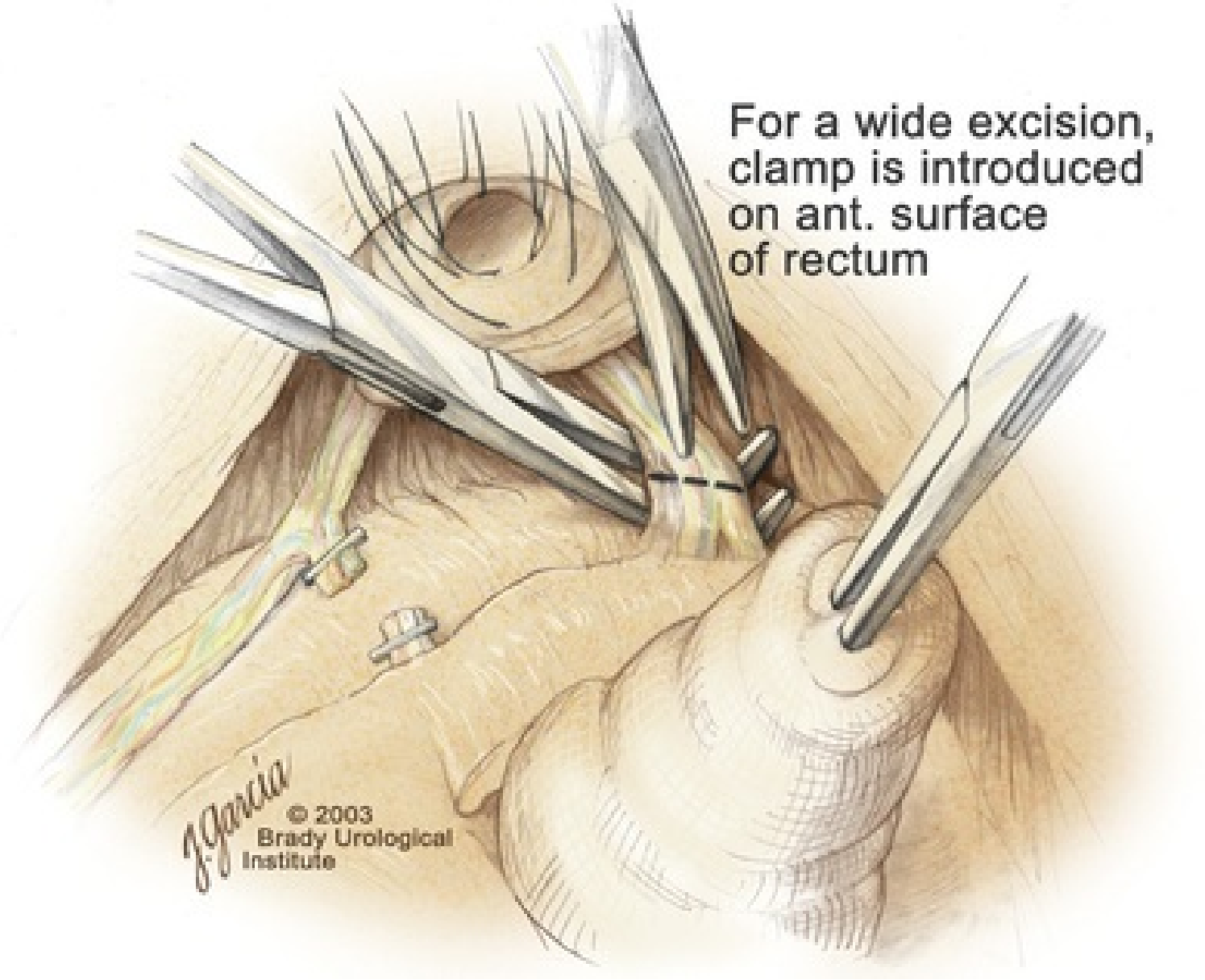
For a wide excision,
clamp is introduced
on ant. surface
of rectum
J.Garcia
© 2003
Brady Urological
Institute

FIG. 155.26 Wide excision of the neurovascular bundle *(NVB).* Once the contralateral NVB has been released and residual attachments of the rectum to the prostate at the apex are freed, a right-angled clamp is then passed directly on the anterior surface of the rectum from the midline laterally. If the right-angled clamp is passed lateral to medial, a rectal injury is more likely to occur. *ant.,* anterior. (© Brady Urological Institute.)

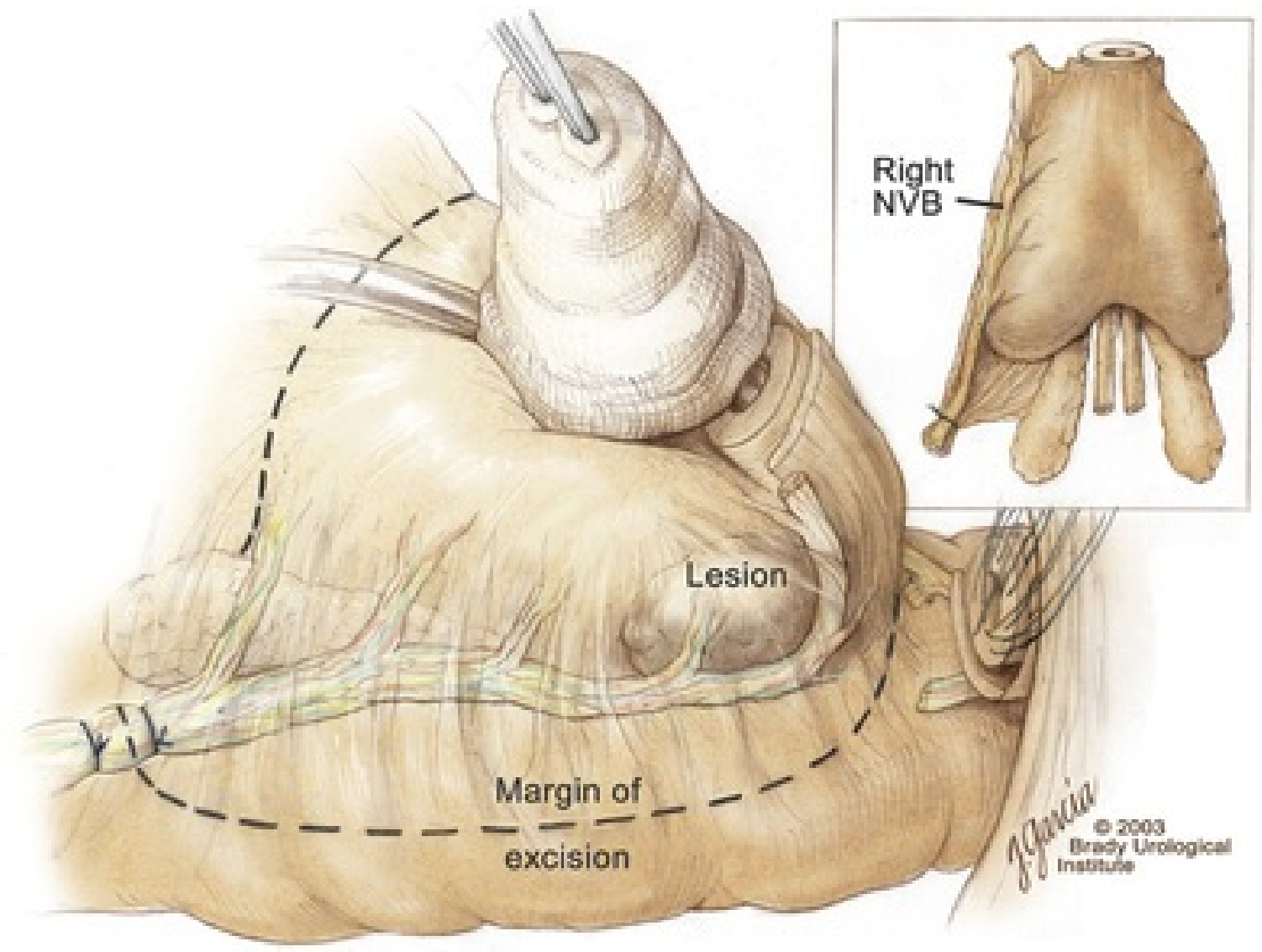

FIG. 155.27 Extent of the division of the neurovascular bundle *(NVB)* from the apex laterally to the tip of the seminal vesicle, where the NVB is ligated. This provides excellent soft tissue covering the primary lesion. (© Brady Urological Institute.)

Posterior Dissection and Division of the Lateral Pedicles

Once the NVBs have been either preserved at the apex or widely excised and the prostate has been mobilized to the level of the seminal vesicles, the catheter is replaced and, with light upward traction on the catheter, the attachment between the rectum and Denonvilliers fascia is divided in the midline posteriorly (Fig. 155.28). Because the NVBs have been freed up, traction can be applied to the catheter to gain exposure to the base of the prostate and seminal vesicles. However, to improve exposure, the sponge stick should never be placed on the prostate itself as it may displace tissue, producing a false-positive margin. Instead, the sponge stick should be placed on the catheter. In developing this plane, all layers of Denonvilliers fascia should be left covering the seminal vesicles.

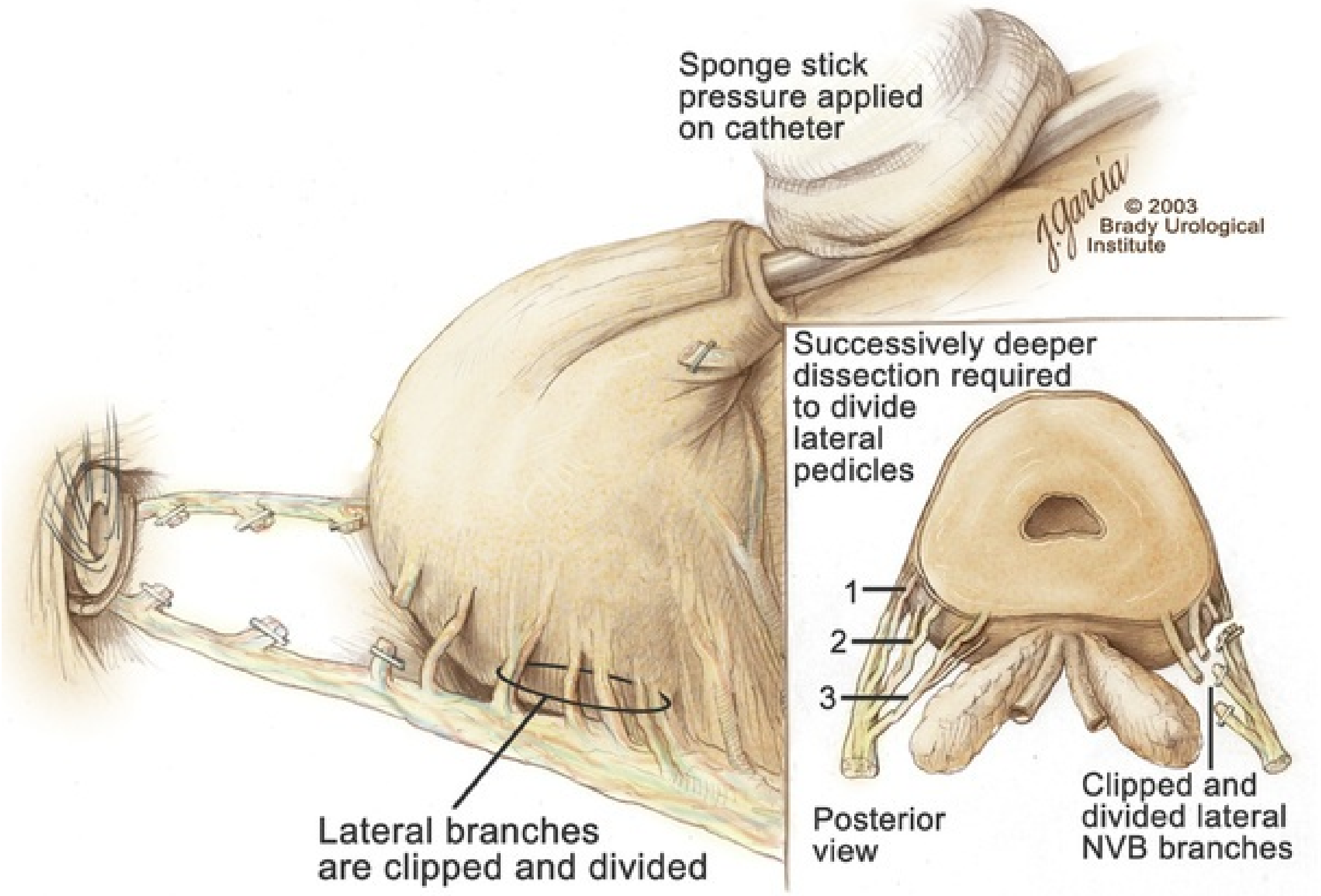
Sponge stick
pressure applied
on catheter
J. Garcia
© 2003
Brady Urological
Institute
Successively deeper
dissection required
to divide
lateral
pedicles
1
2
3
Posterior
view
Clipped and
divided lateral
NVB branches
Lateral branches
are clipped and divided

FIG. 155.28 Lateral view demonstrating the location of the neurovascular bundle *(NVB)* after ligation of the posterior branch to the prostate. The site for division of the lateral pedicle is indicated. The lateral pedicle is thick and should be divided in layers: *1,* superficially; *2,* in the middle; and then *3,* deep next to the seminal vesicle. Trying to divide this thick pedicle all at once risks cutting into the overlying prostate. (© Brady Urological Institute.)

At this point, the lateral pedicle can be divided safely on the lateral surface of the seminal vesicles without injury to the NVB (see Fig. 155.28)**. The lateral pedicles are thick, and therefore need to be divided in a sequential way: superficial, middle, deep (next to the seminal vesicles). If one tries to divide them all at once, there is a risk for cutting into the overlying prostate.**

Obvious arterial bleeders are simply controlled with hemoclips. With this approach, one can leave more soft tissue on the prostate and protect the NVBs from injury. The dissection proceeds superiorly onto the anterolateral surface of the junction between the bladder and the prostate. Finally, Denonvilliers fascia is divided over the tips of seminal vesicles to facilitate removal. At this point, many surgeons elect to divide the vasa deferentia and free up the seminal vesicles.

Division of the Bladder Neck and Excision of the Seminal Vesicles

The prostate has now been mobilized almost completely. The bladder neck is incised anteriorly at the prostatovesicular junction (Fig. 155.29). The incision is carried down to the mucosa, the mucosa is incised, the Foley balloon is deflated, and the two ends of the catheter are clamped together to provide traction. As the incision in the bladder neck is widened, branches running from the inferior vesical pedicle to the prostate are noted at 5-o'clock and 7-o'clock positions (Fig. 155.30). **After these pedicles are divided, it should be possible to visualize the plane between the anterior surface of the seminal vesicles and the posterior wall of the bladder. By scissor dissection hugging the anterior surface of the seminal vesicles, the posterior bladder neck can be divided safely while observing the location of the ureteric orifices** (Fig. 155.31).

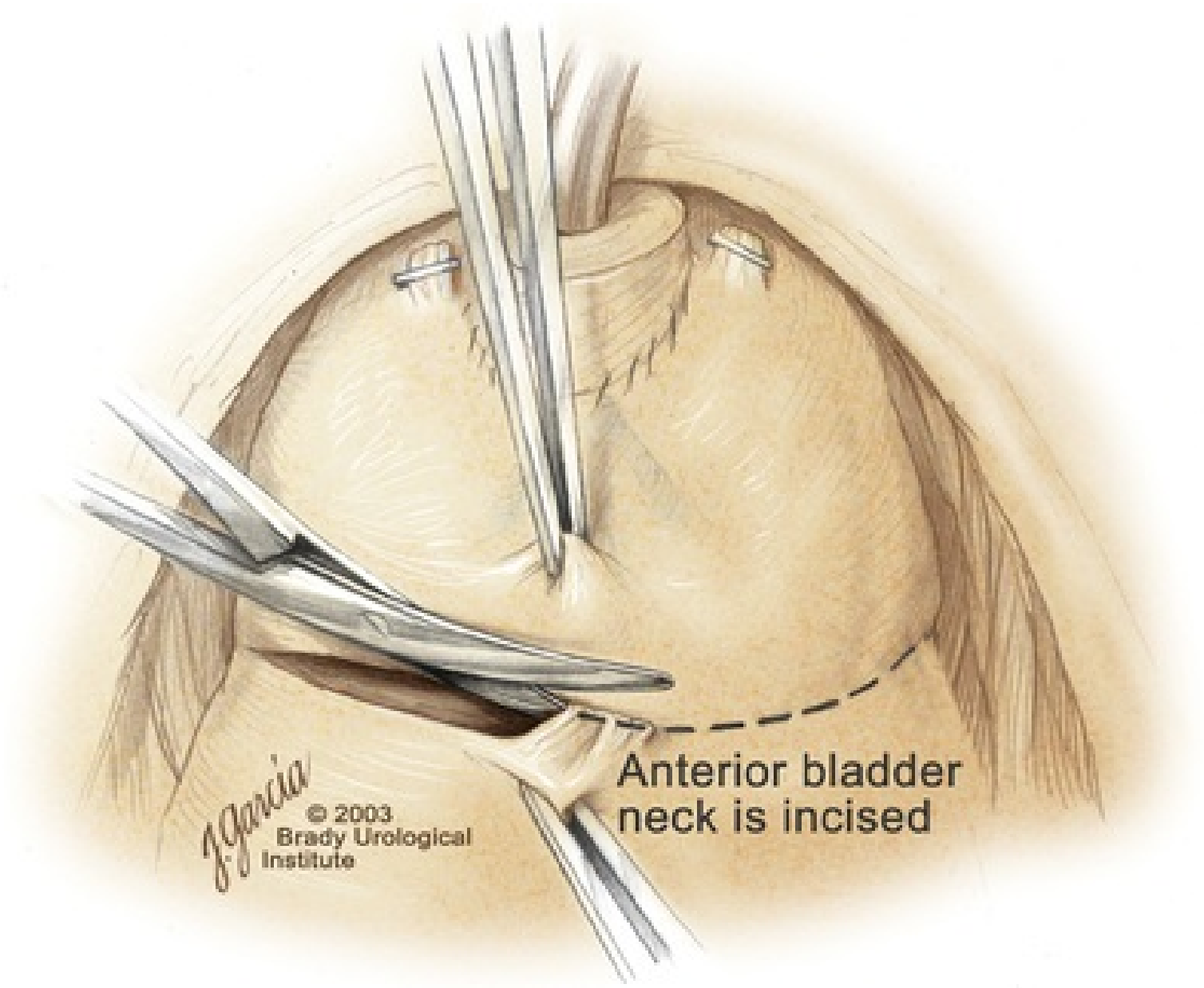
Anterior bladder neck is incised
J. Garcia
© 2003 Brady Urological Institute

FIG. 155.29 Division of the anterior bladder neck. (© Brady Urological Institute.)

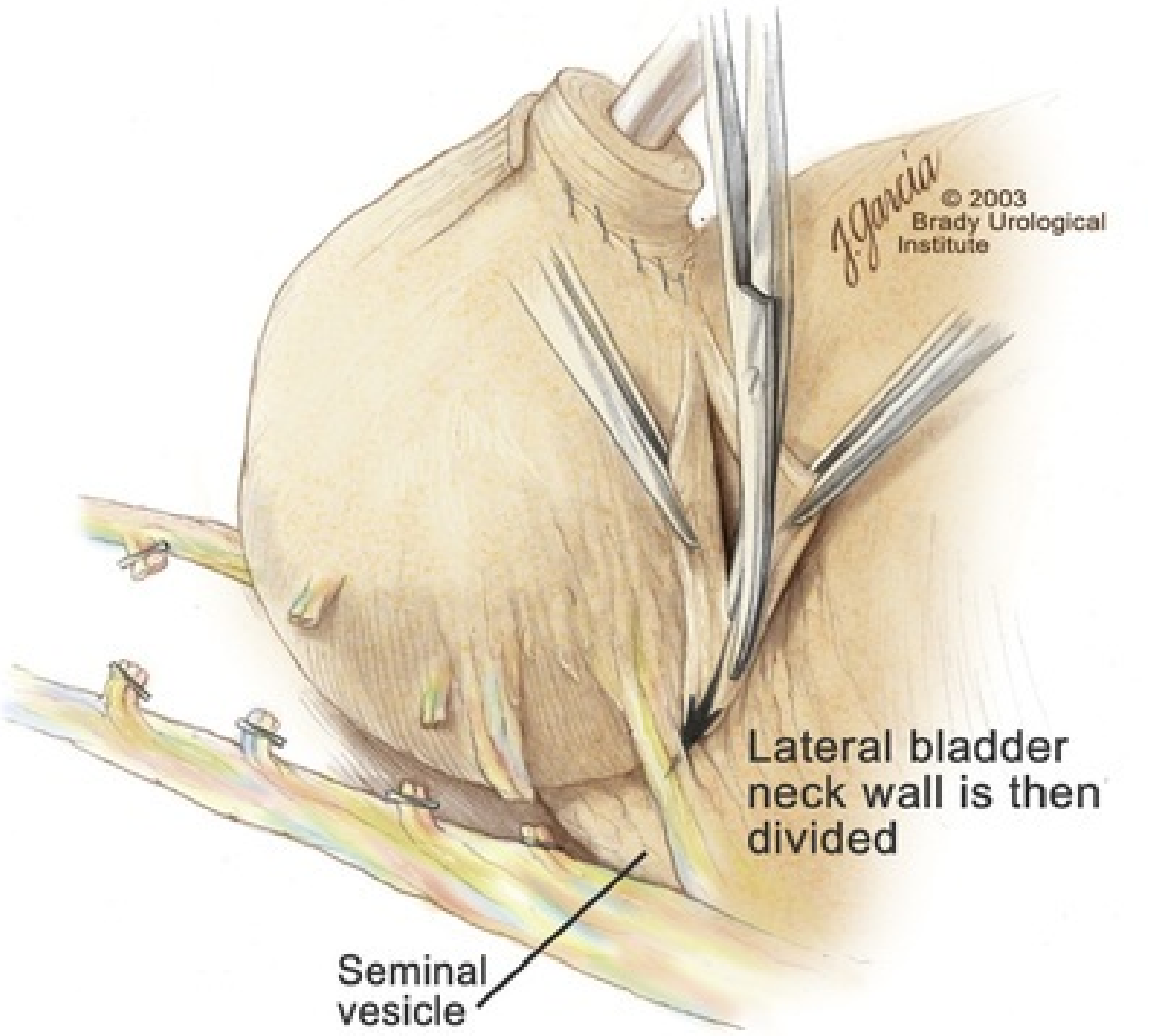
J.Garcia © 2003 Brady Urological Institute
Lateral bladder neck wall is then divided
Seminal vesicle

FIG. 155.30 Ligation of the branches from the inferior vesical pedicle at 5-o'clock and 7-o'clock. This exposes the angle between the bladder and seminal vesicles. (© Brady Urological Institute.)

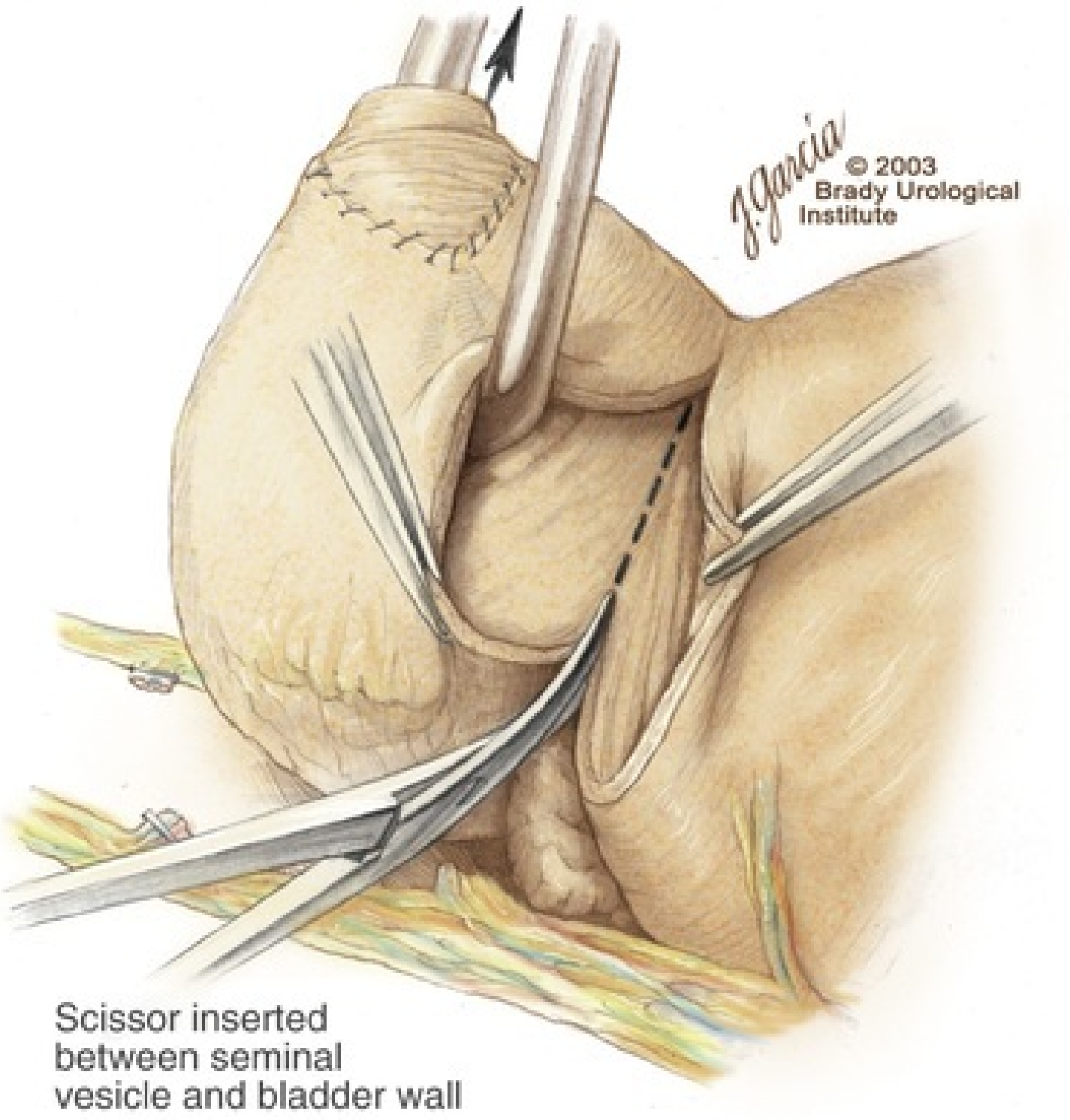
J.Garcia © 2003 Brady Urological Institute
Scissor inserted between seminal vesicle and bladder wall

FIG. 155.31 The plane between the anterior wall of the seminal vesicles

and the posterior wall of the bladder neck for division of the posterior bladder wall. (© Brady Urological Institute.)

After the posterior bladder wall is divided, the bladder neck is retracted with an Allis clamp, and the vasa deferentia are ligated with hemoclips and divided. The seminal vesicles are dissected free from surrounding structures (Fig. 155.32). Recall that the pelvic plexus is located on the lateral surface of the seminal vesicles. **To avoid injury to the pelvic plexus, the surgeon should perform this dissection with great care, especially laterally, and direct vision should identify the small arterial branches that travel to the seminal vesicles and stay close to the seminal vesicles when these small vessels are ligated with small clips.** As the tips of the seminal vesicles are freed, small arterial branches at the tip of each seminal vesicle should be identified, ligated, and divided. Any residual attachments of Denonvilliers fascia are then divided, and the specimen is removed. The specimen is inspected carefully to identify any areas where the margin of resection is uncertain. If there is any concern about the margin on the posterolateral surface of the prostate, the NVB on that side should be excised.

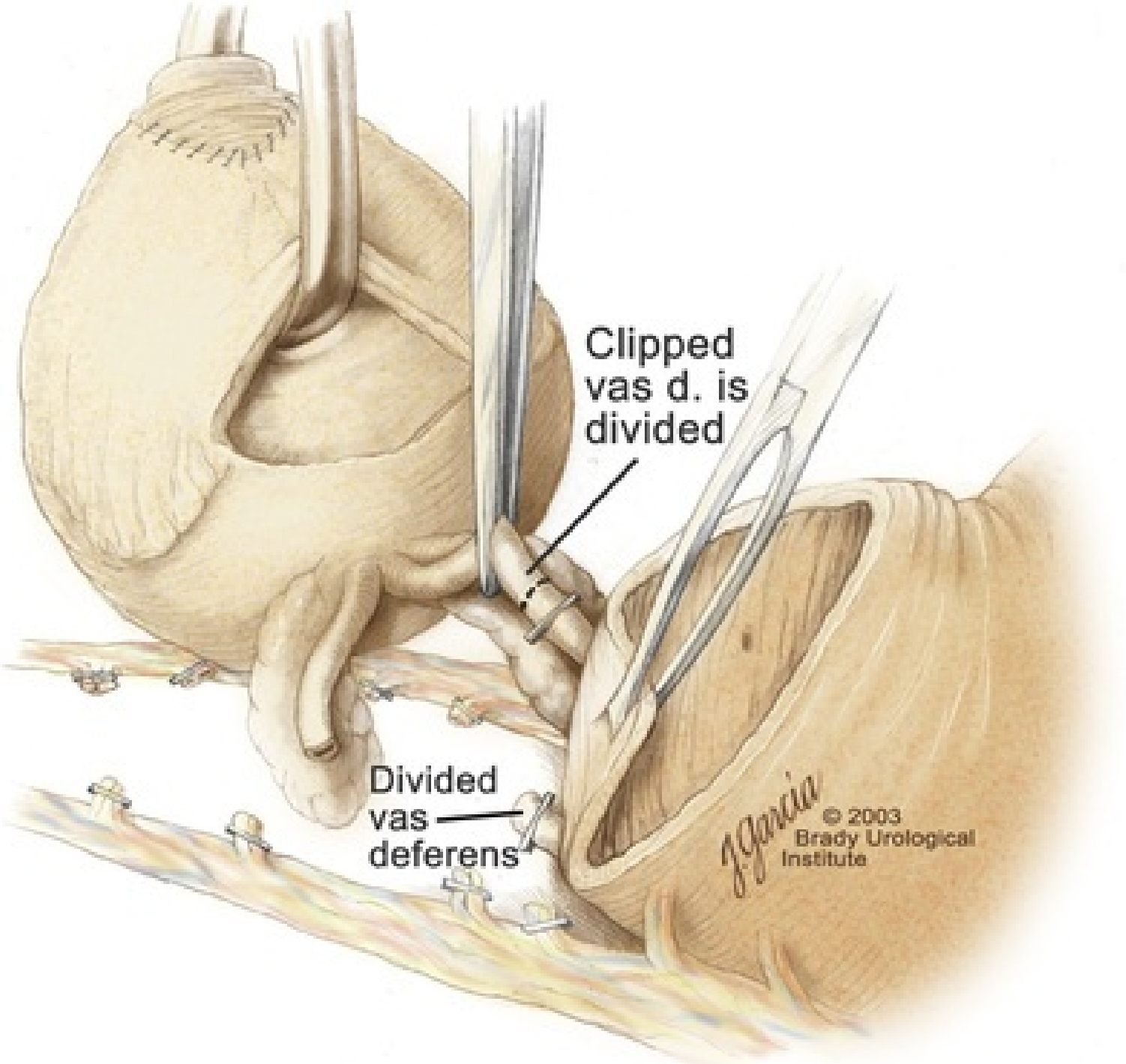

FIG. 155.32 Dissection of the vas deferens and seminal vesicles. The left vas deferens has been divided and ligated. The seminal vesicles are carefully dissected free from the pelvic plexus with direct visualization and

ligation of small arterial branches. *d.,* deferens. (© Brady Urological Institute.)

The operative site is inspected carefully for bleeding. **To avoid injury to the fine nerve fibers, small bleeding vessels near the NVB should not be cauterized.** Bleeding from these small vessels should be controlled with small hemoclips as the patient may develop a hematoma between the rectum and bladder. Inflammation surrounding the NVBs secondary to this hematoma may delay the return of sexual function (Walsh et al., 2000b). To avoid this adverse event, a small opening can be made in the peritoneum in the rectovesical cul-de-sac to facilitate decompression of a hematoma if it develops.

Bladder Neck Reconstruction and Anastomosis

The bladder neck is reconstructed with a running suture or interrupted 2-0 absorbable sutures to approximate full-thickness muscularis and mucosa, forming a tennis racquet closure (Fig. 155.33). At this point, it is useful to have previously injected indigo carmine to facilitate visualization of the ureteric orifices; ureteral catheters are not usually necessary. **By incorporating the mucosa in the closure, troublesome hematuria can be avoided.** The closure is initiated in the midline posteriorly and proceeds anteriorly until the bladder neck is narrowed to approximate the diameter of the urethra. Interrupted or running 4-0 absorbable sutures are used to advance the mucosa over the raw musculature of the bladder neck. In this way, a rosette of mucosa covers the bladder neck, facilitating a mucosa-to-mucosa urethrovesical anastomosis. The suture at the 6-o'clock position is left long to facilitate placement of the urethral sutures for the final anastomosis (see later description).

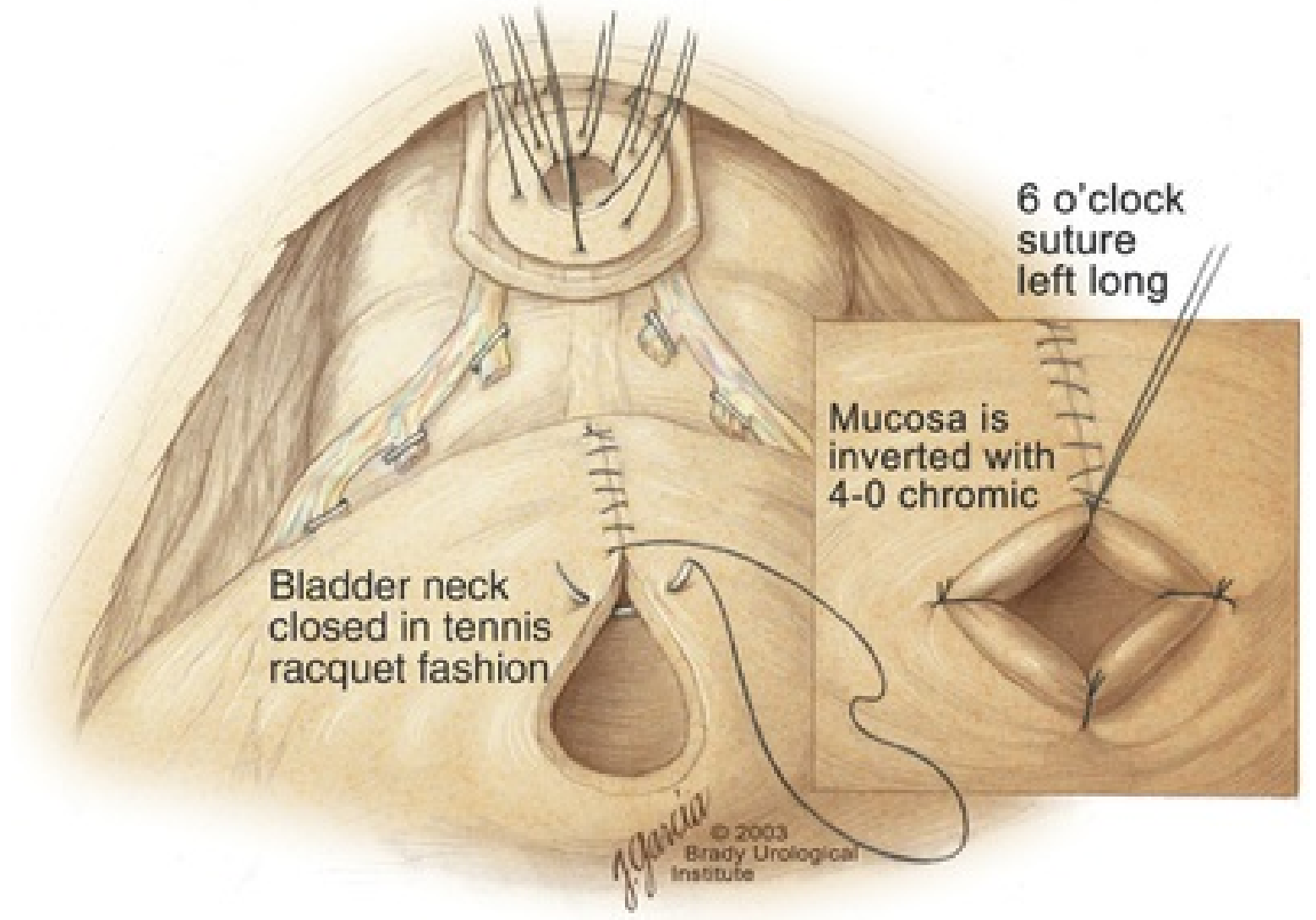

FIG. 155.33 Tennis racquet closure of the bladder neck with a running 2-0 absorbable suture incorporating all layers of the bladder wall. The bladder mucosa is then advanced over the raw bladder edges with interrupted 4-0 absorbable suture material to ensure a mucosa-to-mucosa anastomosis. The posterior midline suture (at the 6-o'clock position) is left long. (© Brady Urological Institute.)

At this point, the bladder neck can be anastomosed to the urethra, or buttressing sutures can be used to intussuscept the bladder neck (Walsh and Marschke, 2002)**. These sutures prevent the bladder neck from pulling open as the bladder fills.** The standard surgical technique described in this chapter emphasizes ample margins to ensure excellent cancer control, especially at the apex. Some surgeons preserve the puboprostatic ligaments and dissect beneath them closer to the apical prostate. Although this may preserve more of the striated sphincter, there is concern that it may lead to inadequate apical margins. The technique described herein may excise more striated musculature, and, consequently, it takes longer for some men to be pad-free. Parsons et al. (2004) found that with intussusception of the bladder neck, 80% of men are pad-free at 3 months and 98% at 1 year. A 2-0 Maxon suture is placed into the edges of the posterior bladder wall, where the bladder was previously attached to the prostate, approximately 2 cm from the reconstructed bladder neck (Fig. 155.34). If any hemoclips are in this area, they should be removed because they may be folded into the bladder neck, causing a bladder neck contracture. The suture is tied in the midline. The next suture is placed more anteriorly. Before this suture is placed, it is wise to release tension on the anterior bladder wall by loosening the malleable blade. This will aid in identifying the loose perivesical tissue that should be incorporated into this stitch. A second figure-of-eight 2-0 Maxon suture is placed approximately 2 cm lateral to the bladder neck on each side (Fig. 155.35). At this point, the bladder neck should protrude beneath the anterior hood of tissue that was created by the anterior stitch, resembling a turtle that is poking its head outside its shell. When the bladder neck is filled with saline, it should be competent with little leakage. After this test is completed, the bladder should be emptied completely by placing forceps through the bladder neck. The 6-o'clock suture should again be placed on traction to facilitate placement of the urethral sutures.

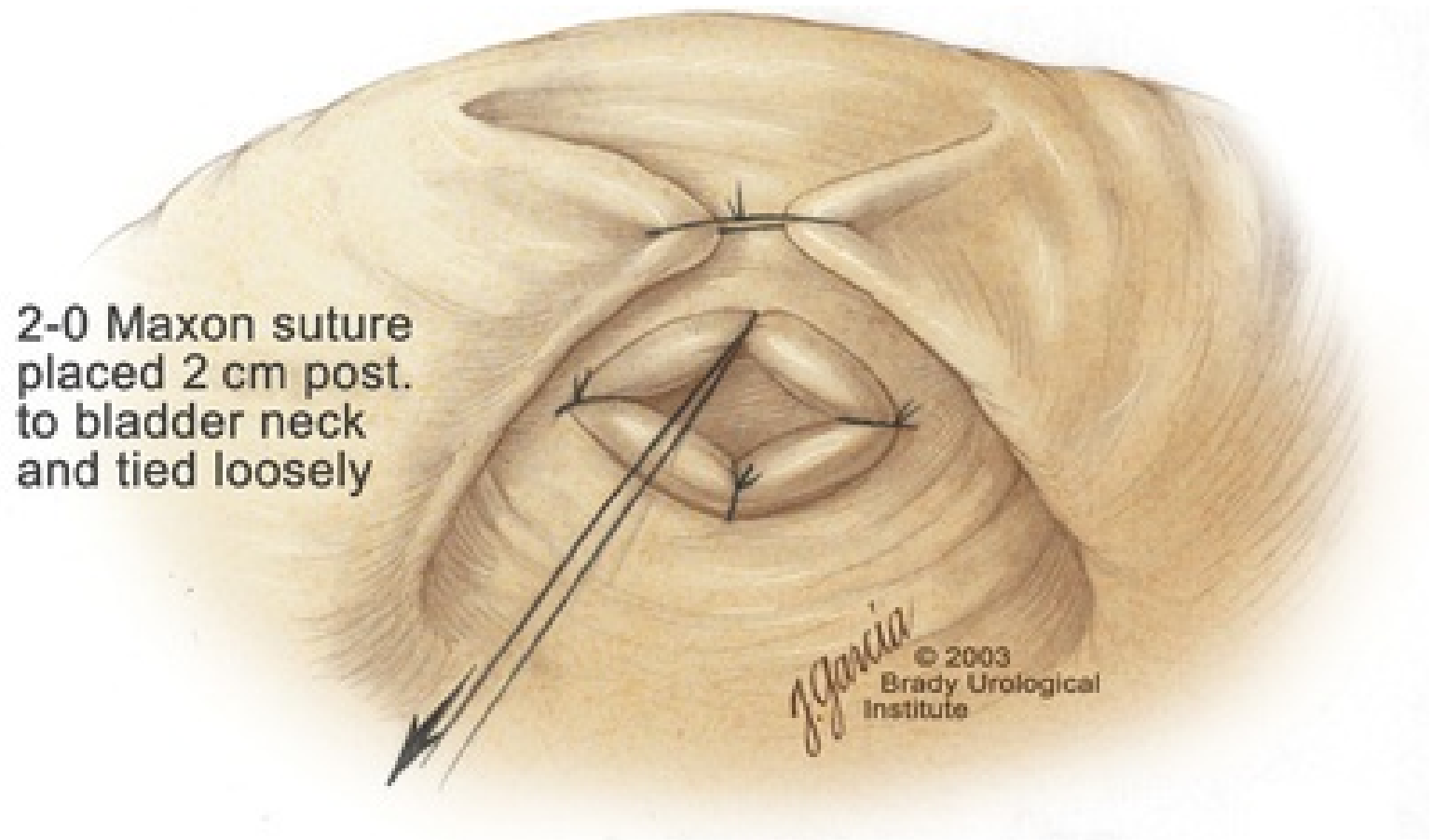
2-0 Maxon suture
placed 2 cm post.
to bladder neck
and tied loosely
J. Garcia
© 2003
Brady Urological
Institute

FIG. 155.34 Intussusception of the bladder neck. A 2-0 Maxon suture is placed in the edges of the posterior bladder wall, where the bladder was previously attached to the prostate, approximately 2 cm from the reconstructed bladder neck and tied in the midline. *post.,* posterior. (© Brady Urological Institute.)

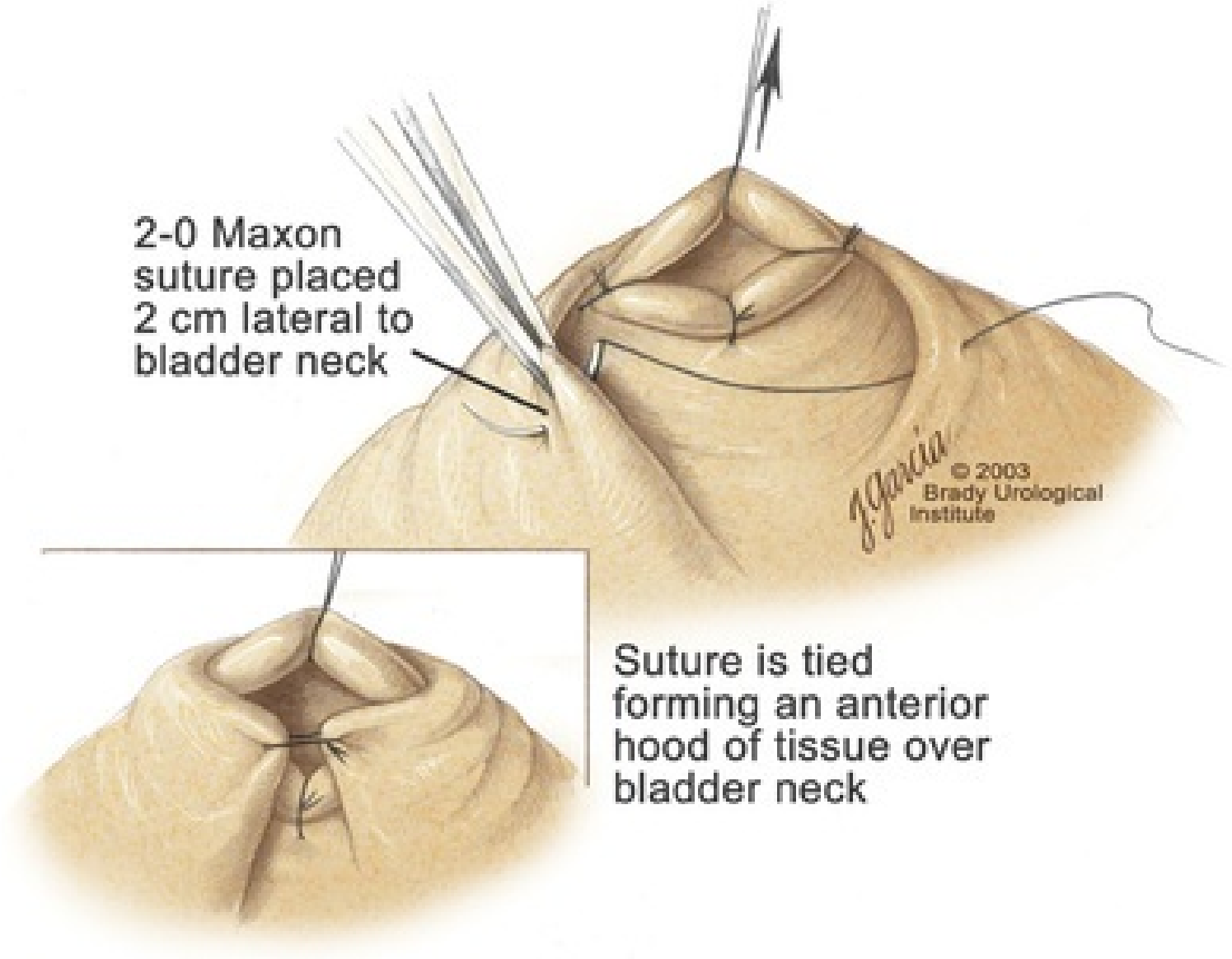
2-0 Maxon suture placed 2 cm lateral to bladder neck
JGarcia
© 2003 Brady Urological Institute
Suture is tied forming an anterior hood of tissue over bladder neck

FIG. 155.35 Intussusception of the bladder neck. A second figure-of-eight 2-0 Maxon suture is placed anteriorly about 2 cm lateral to the bladder neck on either side and tied. (© Brady Urological Institute.)

The operative site is inspected carefully for bleeding. A new silicone Foley catheter (16-Fr, 5-mL balloon) is placed through the urethra into the pelvis. The six 3-0 Monocryl sutures that were previously placed in the distal urethra are now placed through the bladder neck in their corresponding positions from inside to outside (Fig. 155.36). Use of traction on the 4-0 suture that was placed at the 6-o'clock position to exteriorize the mucosa facilitates placement of the sutures. As mentioned earlier, a French eye needle is used for placement of the 12-, 2-, and 5-o'clock sutures. The catheter is irrigated free of clots, the balloon is tested, and the catheter is placed through the bladder neck and inflated with 15 mL of saline. The catheter is no longer placed on traction while the sutures are tied. Instead, a Babcock clamp, which is placed on the anterior bladder wall close to the reconstructed bladder neck, is used to hold the bladder in place while the sutures are tied (Fig. 155.37). This ensures excellent coaptation of the mucosa to mucosa and has markedly reduced the probability of bladder neck contractures.

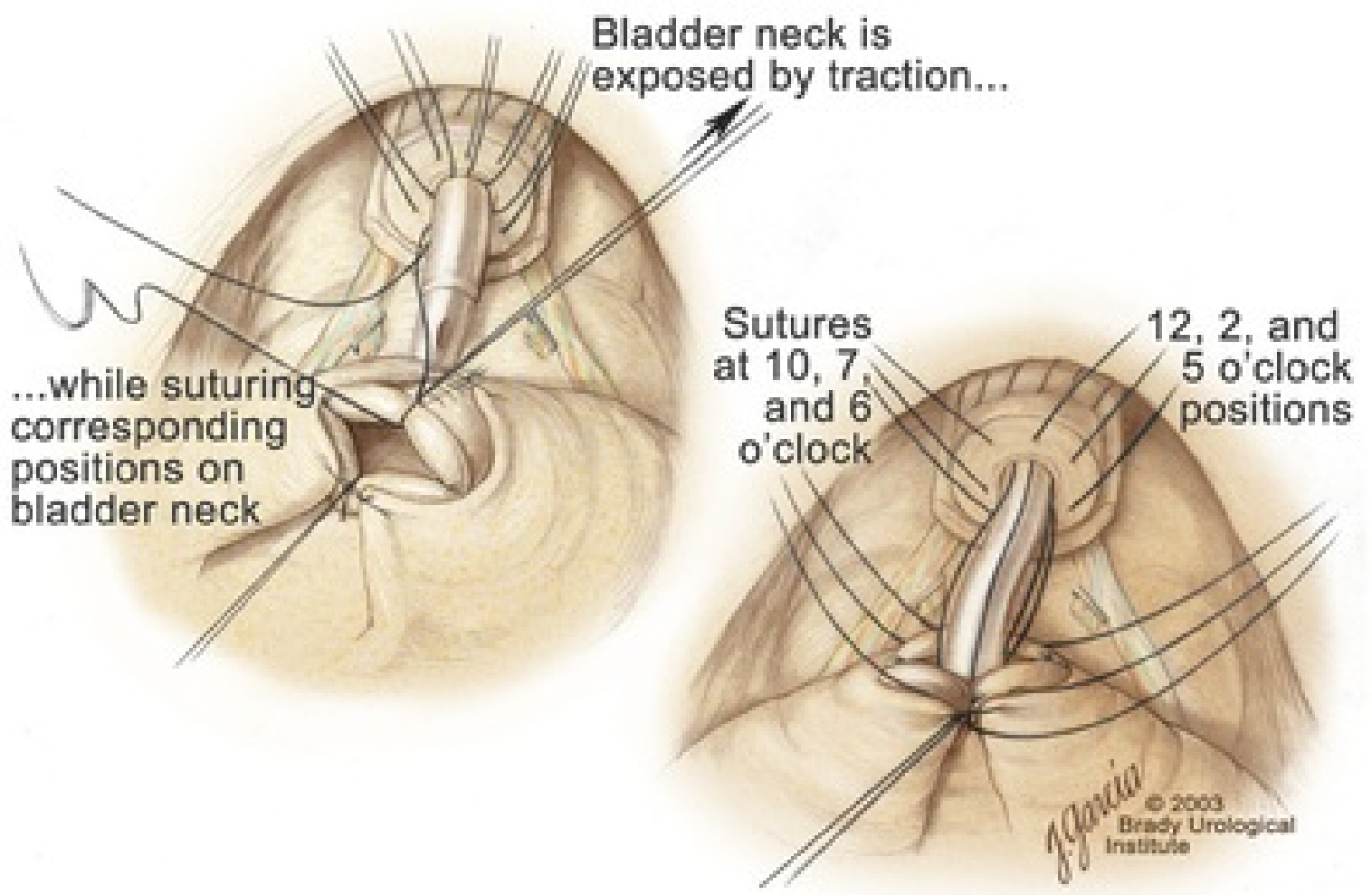
Bladder neck is exposed by traction...
...while suturing corresponding positions on bladder neck
Sutures at 10, 7, and 6 o'clock
12, 2, and 5 o'clock positions
J.Garcia
© 2003 Brady Urological Institute

FIG. 155.36 The bladder neck is exposed by placing traction on the 4-0 absorbable suture at the 6-o'clock position. The final anastomosis is performed by placing 3-0 Monocryl sutures at the 12-, 2-, 5-, 7-, and 10-o'clock positions. (© Brady Urological Institute.)

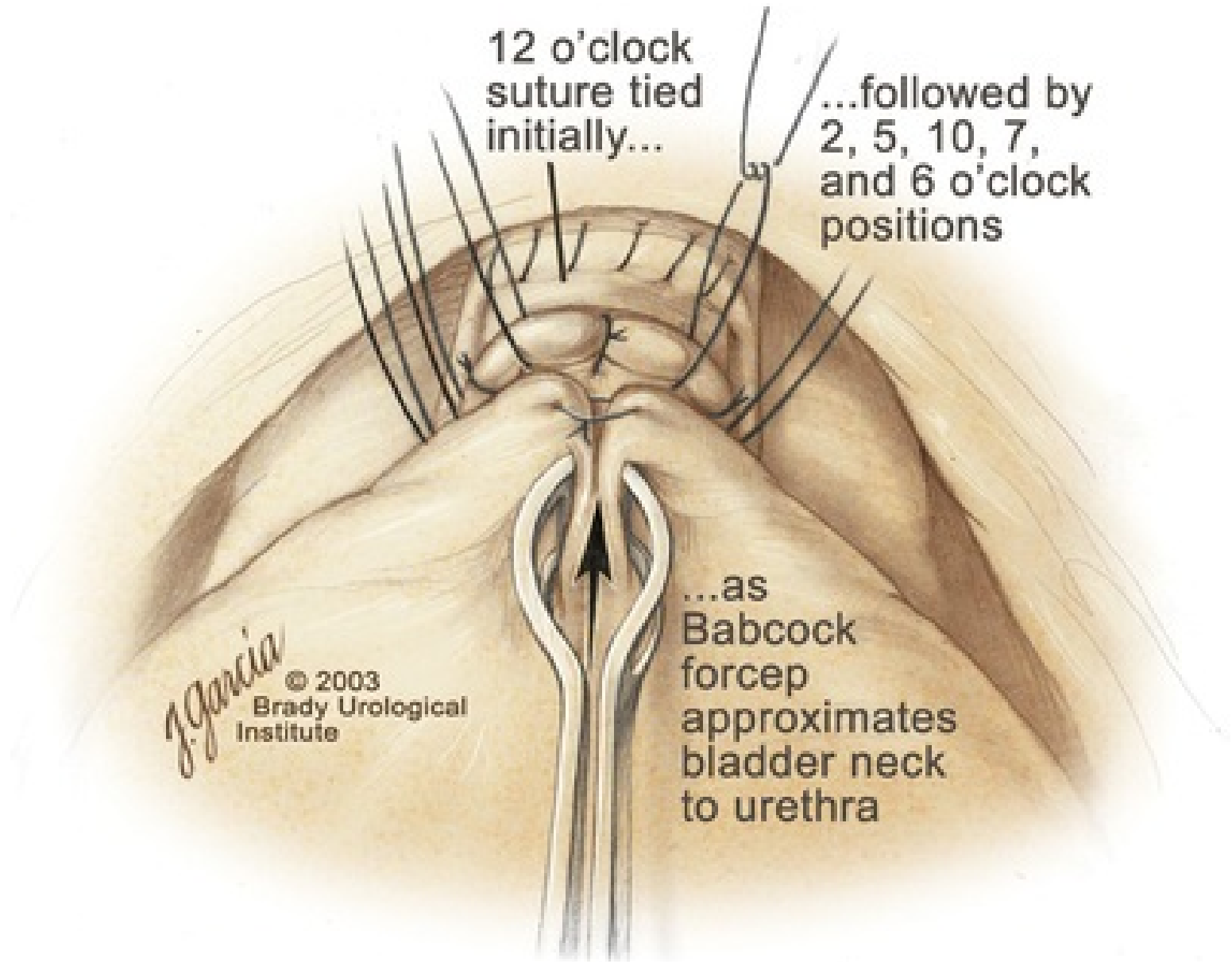
12 o'clock suture tied initially...
...followed by 2, 5, 10, 7, and 6 o'clock positions
...as Babcock forcep approximates bladder neck to urethra
J.Garcia
© 2003 Brady Urological Institute

FIG. 155.37 A Babcock clamp is used to displace the reconstructed bladder neck into the pelvis and is held in place until all sutures are tied. This maneuver ensures that there is excellent coaptation of the reconstructed bladder neck to the urethra while the sutures are being tied. (© Brady Urological Institute.)

The anterior suture is tied initially. There should be no tension. Should tension arise, the bladder should be released from the peritoneum. The 2-, 5-

, 10-, 7-, and 6-o'clock sutures are tied sequentially. After all sutures are tied, the catheter is manipulated to make certain it is not caught in one of the sutures. The catheter is irrigated with saline to eliminate clots. After the operative site is irrigated vigorously with saline, a small suction drain is placed through the fascia (away from the midline) and directed into the operative site in the midline, between (not through) the rectus muscles. The incision is closed with a running No. 2 nylon suture and skin clips. The catheter is carefully taped to the thigh.

Postoperative Management

The postoperative recovery of men who undergo open RRP is often uneventful. The complication rates after open radical RRP have greatly improved over the past decade and were recently reviewed (Dasgupta and Kirby, 2009). A summary of the findings showed a marked decrease in length of stay (now averaging 1.7 days), lower urine leak rates (0.17%), lower need for transfusion (0.13%), lower postoperative ileus rate (0.6%), and a lower re-exploration rate for hemorrhage (0.08%).

Traditionally, men ambulate the evening of the procedure and are discharged on postoperative day 1 or 2. Pain control can be achieved by either intravenous patient-controlled analgesia with Dilaudid, fentanyl, or morphine on the night of surgery or with ketorolac. We use ketorolac in an effort to decrease the need for narcotics after surgery. Men with normal renal function (preoperative creatinine <1.2 mg/dL), no excess blood loss during the procedure (estimated blood loss <1500 mL), and no history of uncontrolled diabetes or postoperative hematuria receive a dose of intravenous ketorolac tromethamine, a nonsteroidal anti-inflammatory drug (NSAID), either before transfer to the recovery room or the morning after surgery. Recently, intravenous acetaminophen also has been administered to men for postoperative pain control with similar results but at present is quite costly. **This combination of analgesic agents reduces postoperative ileus.** Patients are offered a clear liquid diet on the evening of surgery and a regular low-fat diet the next day. A single closed-suction drain is left in place until discharge or it produces less than 50 mL/day off of suction.

The urinary catheter is left in place for 7 to 10 days postoperatively and represents a source of significant bother (Lepor et al., 2001), limiting the return to activities and work (Sultan et al., 2006). Therefore the urinary catheter should be removed as soon as possible without compromising outcomes (e.g., urinary retention and bladder neck contracture). Most would agree that removing the urinary catheter in the presence of significant urine extravasation would be unwise. Although 80% of vesicourethral anastomoses exhibit no evidence of cystographic extravasation by the fourth postoperative day, removal of the urinary catheter at this time is not recommended because of the high rate of acute urinary retention (Patel and Lepor, 2003). Approximately 10% of men will exhibit moderate extravasation on postoperative cystography performed 1 week after surgery. Routinely performing cystography at 1 week allows “early” removal of the urinary catheter while also identifying the small subset of men who might benefit from longer bladder drainage. However, this requires patients to return to the hospital/clinic, exposes them to radiation, and incurs additional expense to the process. Alternatively, our experience has shown that the urinary catheter may be removed safely by patients in their own home after 10 days. Bladder spasms will generally spontaneously subside, and reassurance is often sufficient. In cases of severe bladder spasms, an oral anticholinergic agent (oral oxybutynin [Ditropan] 5 mg) or diazepam (oral Valium, 5 to 10 mg) may be administered.

Complications

RRP is well tolerated, with minimal morbidity and low mortality (0.2%). Complications can be divided into those occurring intraoperatively and those occurring postoperatively.

Intraoperative Complications

The most common intraoperative problem is hemorrhage, usually arising from venous structures. Venous injury often can be controlled temporarily with packing, exposure, and suture or surgical clip ligation. If this is not successful, fine (No. 5-0) cardiovascular sutures may be required. Hemorrhage also can occur during incision in the endopelvic fascia, during division of the puboprostatic ligaments, or during exposure of the apex of the prostate with transection of the dorsal vein complex. If one understands fully the anatomy of the dorsal vein complex, this bleeding is usually satisfactorily controlled once the dorsal vein has been divided and carefully suture ligated. **If there is troublesome bleeding from the dorsal vein complex at any point, the surgeon should completely divide the dorsal vein complex over the urethra and oversew the end. This is the single best means to control bleeding from the dorsal vein complex.** While obtaining exposure for the prostatectomy, gentle traction must be put on the prostate. If the dorsal vein is not completely divided and ligated, this traction opens the partially transected veins and usually worsens the bleeding. With careful technique and a thorough knowledge of anatomy, the average blood loss during radical prostatectomy is 300 to 1000 mL routinely and rarely (<1%) requires intraoperative homologous blood transfusion. Because of these low transfusion rates, we no longer require the patients to donate/bank autologous blood before surgery. However, every case is required to undergo a type and screen sample before initiation of surgery.

Less common intraoperative complications include obturator nerve injury during pelvic lymph node dissection, rectal injury, and ureteral injury. If the obturator nerve is inadvertently severed, an attempt should be made at reanastomosis with fine nonabsorbable sutures. Rectal injury is an infrequent (<0.3%) but serious complication. Rectal injury occurs most often during apical dissection in attempting to develop the plane between the rectum and Denonvilliers fascia. When a rectal injury occurs, the prostatectomy should be completed, the bladder neck should be reconstructed, and hemostasis should be excellent. It is critical to attempt to interpose omentum between the rectal closure and the vesicourethral anastomosis to reduce the possibility of a rectourethral fistula. This maneuver can be accomplished simply by making a small opening in the peritoneum; finding the omentum and fashioning a slender, well-vascularized pedicle that will be long enough to reach the pelvic floor; dividing the peritoneum in the rectovesical cul-de-sac; and feeding the end of the omental pedicle through this opening. The anal sphincter is digitally dilated widely by an assistant, and the rectal injury is clearly delineated. With excellent visualization, the edges of the rectal wound are freshened and closed in two layers. The omental pedicle is immobilized over the repair with absorbable sutures, and the vesicourethral anastomosis is performed. The wound should be copiously irrigated with antibiotic solution, and the patient should be maintained for several days on broad-spectrum antibiotics for both aerobic and anaerobic bacteria. When this technique was used, all recovered without development of a wound infection, pelvic abscess, or rectourethral fistula (Borland and Walsh, 1992). However, if the patient has received prior radiotherapy (salvage prostatectomy), it is prudent to perform a diverting colostomy. Ureteral injury is also very rare and usually occurs secondary to inadvertent dissection within the layers of the trigone while attempting to identify the proper cleavage plane between the bladder and seminal vesicles. If this injury occurs, ureteral reimplantation should be undertaken.

Postoperative Complications

Life-threatening delayed hemorrhage is a rare complication of RRP. Significant bleeding after radical prostatectomy is defined as postoperative hemorrhage requiring the acute transfusion of blood to support blood pressure (Hedican and Walsh, 1994). Rarely a patient will require exploration for delayed bleeding, and most cases are managed expectantly. The mean blood product requirements for patients who were explored were comparable with those for patients managed conservatively, although total hospitalization was shorter in patients who underwent a secondary operation. In patients managed nonoperatively, the pelvic hematoma may drain through the urethrovesical anastomosis, resulting in symptomatic bladder neck contractures and long-term problems with urinary control. In this study, only 25% of men explored for delayed bleeding experienced prolonged mild incontinence (Hedican and Walsh, 1994). **These**

results suggest that patients requiring acute transfusions for severe hypotension after radical prostatectomy should be explored early to evacuate the pelvic hematoma in an effort to decrease the likelihood of bladder neck contracture and incontinence.

Thromboembolic Events

Deep venous thrombosis (DVT) with pulmonary embolism is a major cause of mortality after radical prostatectomy. A recent review of over 45,000 surgical prostate procedures completed in Sweden demonstrated that the highest rates were seen when pelvic lymph node dissection was performed as part of the procedure and that the highest likelihood occurred between 14 and 28 days after the procedure. This highlights the need for continued attention to risk as long as 4 weeks after the procedure. Measures to prevent this complication include careful positioning on the operating room table to avoid compression of the veins in the lower extremity, use of intermittent compression devices, and early ambulation. Mini-dose heparin or low-dose, low-molecular-weight heparin is used at some centers (but not at ours).

Most importantly, all patients should be repeatedly informed of the signs and symptoms of DVT and pulmonary embolism before discharge and should be instructed verbally and in writing to call immediately if they have any of the following symptoms: swelling or pain in the leg, especially in the calf; sudden chest pain that is worse on taking a deep breath; hemoptysis; shortness of breath; or the sudden onset of weakness or fainting. We have found that an informed patient is the best way to reduce the morbidity and mortality from thromboembolic events. When patients develop DVT or pulmonary embolism events, twice-daily subcutaneous administration of low-molecular-weight heparin without monitoring of clotting factors appears to be at least as effective and safe as an adjusted-dose, intravenous administration of unfractionated heparin (Büller et al., 2003).

Bladder Neck Contracture

Bladder neck contractures historically occur in 0.5% to 10% of patients after radical prostatectomy, and the rate has diminished dramatically over the past decade. They arise from inadequate coaptation of the mucosal surfaces. This may be a result of inadequate approximation at the time of surgery, urinary extravasation, or distraction of the bladder neck from a

hematoma. The diagnosis should be considered in any patient who complains of a poor urinary stream or in patients who have prolonged unexplained incontinence. If treatment with simple cystoscopic dilation fails, direct cold-knife incision of the bladder neck at 3-, 6-, and 9-o'clock followed by intermittent self-catheterization for a limited time usually corrects the problem. In patients with recalcitrant bladder neck contractures, the injection of triamcinolone acetonide (200 mg in 5 mL) at the bladder neck after cold-knife incision may be useful.

Urinary Incontinence

After radical prostatectomy, incontinence is usually secondary to intrinsic sphincter deficiency. Kim et al. (2013) demonstrated in a Surveillance, Epidemiology, and End Results (SEER) Program population that only 6% of over 16,000 men older than 65 years of age had undergone an “incontinence procedure” within the first 2 years after prostatectomy. In some men, the striated sphincter may be poorly developed; in older men, it is thinner and contains more collagen (Burnett and Mostwin, 1998; Strasser et al., 1999). However, the predominant cause of this deficiency is injury during ligation and division of the dorsal vein complex. The smooth musculature of the urethra, which also contributes to continence, can be damaged by placement of large, deep sutures for the anastomosis or denervated by injury to the NVBs. Furthermore, the bladder neck must be supple, with a diameter that is not excessively large, because urinary continence can be hampered by the development of a bladder neck contracture or a wide bladder neck (Groutz et al., 2000; Horie et al., 1999). To avoid these complications, as outlined earlier, it is important to preserve the striated sphincter during the apical dissection, to avoid tension on the final anastomosis, to reconstruct the bladder neck so that the opening is small and supple, and to accomplish a precise mucosa-to-mucosa anastomosis. Many men have detrusor hypertrophy and decreased bladder compliance from preexisting bladder outlet obstruction. It takes these patients longer to achieve full urinary control. For this reason, it is important to avoid excessive traction on the bladder intraoperatively, which may aggravate this condition.

During their recovery, patients need constant encouragement and advice at regular intervals. Until urinary control has returned completely, patients are advised to reduce their fluid intake, avoid caffeinated beverages and alcohol, and stop α-adrenergic antagonists if they take them for the treatment of hypertension. Treatment with imipramine or α agonists in men who are not hypertensive can be helpful.

Erectile Dysfunction

Three factors are important in the recovery of erectile function after radical prostatectomy: age of the patient (younger than 65 years), status of potency preoperatively, and ability to intraoperatively preserve both NVBs. Walsh et al. (2000a) evaluated impotence by a validated questionnaire sent to an independent third party for review. In his hands, 86% of the patients were able to have unassisted intercourse with or without sildenafil citrate at 18 months. Although one-third of patients were taking sildenafil citrate, only 4% of men reported that they could not have intercourse without it. The important message for the patient is that the recovery of sexual function occurs gradually: 38% of Walsh's patients were potent at 3 months, 54% at 6 months, 73% at 12 months, and 86% at 18 months. The patient's age at the time of surgery also affects recovery of sexual function (Parsons et al., 2004).

High anterior release of the NVB as demonstrated in Video 155.2 is associated with significantly earlier recovery and return to baseline sexual function. In potent men undergoing high anterior release, 93% were potent 12 months after surgery, and 70% reported a return to their baseline erectile function. In men who preoperatively reported a frequency of intercourse more than once per week, 78% reported a return to their baseline sexual function at 12 months (Nielsen et al., 2008). Interestingly, this recovery and return to baseline function was noted in men who underwent either a unilateral or bilateral high release. This suggests that the improved sexual recovery associated with this technique is not likely caused by preservation of anterior branches of the cavernous nerves but rather by improved accuracy in the preservation of the nerves with less traction. **Other experienced surgeons also have noted improved recovery of sexual function using similar early nerve release techniques, providing further merit to this technical modification** (Masterson et al., 2008).

In patients who are medically cleared, PDE5 inhibitors augment sexual recovery after radical prostatectomy. Montorsi et al. (2008) reported on a multi-institutional randomized, double-blind study examining recovery of erectile function using either vardenafil “on demand,” nightly, or placebo for 9 months. At the end of the blinded treatment period, vardenafil on demand was of greater benefit than nightly treatment. In a similarly devised trial, Pavlovich et al. (2009)

noted no difference in recovery of sexual function in patients using either on-demand or nightly sildenafil, with a trend toward improved recovery in the on-demand arm. **Thus, on-demand dosing of PDE5 inhibitors appears to be the most effective method to aid in recovery of sexual function.**

Summary of Radical Retropubic Prostatectomy

A number of advances have been made in the diagnosis and treatment of localized prostate cancer. Today, more men are diagnosed with curable disease at a younger age. Men are also living longer; a man 65 to 70 years of age has a 50% chance of living for another 15 years. Open radical prostatectomy is an ideal form of treatment for patients who can be cured and who will live long enough to benefit from it. These are also the patients who will have the best quality of life postoperatively (Walsh, 2000).

Over the past decade, there has been increasing adoption of robotic-assisted laparoscopic radical prostatectomy. Some experts claim that the open approach is of only historical interest because of superior outcomes after the robotic approach. The primary advantage of the robotic approach is less blood loss. Even proponents of the robotic approach concede after 10 years there is no meaningful advantage of the robotic approach (Lavery et al., 2012). Despite public demand, the authors of this chapter continue to perform the open approach.

Key Points: Anatomic Radical Retropubic Prostatectomy

- There is no better way to cure cancer that is confined to the prostate than total surgical removal.
- The three goals of the surgeon, in order of importance, are cancer control, preservation of urinary control, and preservation of sexual function.
- Surgery is deferred for 6 to 8 weeks after needle biopsy of the prostate and 12 weeks after transurethral resection of the prostate.
- A fiberoptic headlight and 2.5- to 4.5-power loupes are most useful because much of the procedure is performed beneath the pubis in an area where visualization can be difficult. Magnification can enable the surgeon to exert less traction on the NVBs and more easily identify the correct plane of dissection.

- Regional anesthesia is associated with less blood loss and a lower frequency of pulmonary emboli.
- If the patient has a well-differentiated to moderately well-differentiated tumor (Gleason grade <8) and the lymph nodes are normal to palpation, frozen-section analysis is not performed.
- With the recent recognition that branches of the nerves innervating the striated sphincter and cavernous bodies may travel more anteriorly at the apex, an alternative technique involving high anterior release of the NVBs at the apex before division of the dorsal vein is described. This technique is associated with earlier recovery of sexual function.
- In most men who are candidates for surgery, it is safe to preserve both NVBs and rarely necessary to excise both of them, thus making cavernous nerve replacement or transplantation unnecessary in most cases.
- The tactile sensation provided by open surgery is very important. If induration is palpable in the lateral pelvic fascia, the bundle should be excised. In gently releasing the bundle with a right-angled clamp, if the bundle is fixed to the prostate, it should not be preserved. With the laparoscopic technique, tactile sensation is muted; with the robotic-assisted technique, it is absent.
- Patients requiring acute transfusions for hypotension after radical prostatectomy should be explored to evacuate the pelvic hematoma in an effort to decrease the likelihood of bladder neck contracture and incontinence.
- Thrombophlebitis with pulmonary embolism is the major cause of mortality after radical prostatectomy. Measures to prevent this complication include careful positioning on the operating room table to avoid compression of the veins in the lower extremity, the use of intermittent compression devices, and early ambulation.
- Complete excision of the seminal vesicle during radical prostatectomy is essential for cancer control.
- Open radical prostatectomy is an ideal form of treatment for patients who can be cured and who will live long enough to benefit from it.

Videos 155.3 to 155.11 demonstrate techniques related to this chapter.

Suggested Readings

Allaf ME, Palapattu GS, Trock BJ, et al. Anatomical extent of lymph node dissection: impact on men with clinically localized prostate cancer. *J Urol*. 2004;172(5 Pt 1):1840–1844.

Costello AJ, Brooks M, Cole OJ. Anatomical studies of the neurovascular bundle and cavernosal nerves. *BJU Int*. 2004;94(7):1071–1076.

Lepor H, Gregerman M, Crosby R, et al. Precise localization of the autonomic nerves from the pelvic plexus to the corpora cavernosa: a detailed anatomical study of the adult male pelvis. *J Urol*. 1985;133(2):207–212.

Myers RP. Radical prostatectomy: pertinent surgical anatomy. *Atlas Urol Clin North Am*. 1994;2:1–18.

Nielsen ME, Schaeffer EM, Marschke P, et al. High anterior release of the levator fascia improves sexual function following open radical retropubic prostatectomy. *J Urol*. 2008;180(6):2557–2564.

Rogers CG, Trock BP, Walsh PC. Preservation of accessory pudendal arteries during radical retropubic prostatectomy: surgical technique and results. *Urology*. 2004;64(1):148–151.

Takenaka A, Murakami G, Soga H, et al. Anatomical analysis of the neurovascular bundle supplying penile cavernous tissue to ensure a reliable nerve graft after radical prostatectomy. *J Urol*. 2004;172(3):1032–1035.

Walsh PC. Anatomic radical prostatectomy: evolution of the surgical technique. *J Urol*. 1998;160(6 Pt 2):2418–2424.

Walsh PC, Donker PJ. Impotence following radical prostatectomy: insight into etiology and prevention. *J Urol*. 1982;128(3):492–497.

Walsh PC, Garcia JR. *Radical retropubic prostatectomy: a* *detailed description of the surgical technique—a video presentation*. [Available at] https://urology.jhu.edu/videos/surgical.php; 2004.

Walsh PC, Lepor H, Eggleston JC. Radical prostatectomy with preservation of sexual function: anatomical and pathological considerations. *Prostate*. 1983;4(5):473–485.

Walsh PC, Marschke P, Ricker D, et al. Use of intraoperative video documentation to improve sexual function after radical retropubic prostatectomy. *Urology*. 2000;55(1):62–67.

References

Radical Retropubic Prostatectomy

Allaf ME, Palapattu GS, Trock BJ, et al. Anatomical extent of lymph node dissection: impact on men with clinically localized prostate cancer. *J Urol*. 2004;172(5 Pt 1):1840–1844.

Bill-Axelson A, Holmberg L, Filén F, et al. Radical prostatectomy versus watchful waiting in localized prostate cancer: the Scandinavian prostate cancer group-4 randomized trial. *J Natl Cancer Inst*. 2008;100(16):1144–1154.

Borland RN, Walsh PC. The management of rectal injury during radical retropubic prostatectomy. *J Urol*. 1992;147(3 Pt 2):905–907.

Breza J, Abuseif SR, Orvis BR, et al. Detailed anatomy of penile neurovascular structures: surgical significance. *J Urol*. 1989;141(2):437–443.

Büller HR, Davidson BL, Decousus H, et al. Subcutaneous fondaparinux versus intravenous unfractionated heparin in the initial treatment of pulmonary embolism. *N Engl J Med*. 2003;349(18):1695–1702.

Burnett AL, Mostwin JL. In situ anatomical study of the male urethral sphincteric complex: relevance to continence preservation following major pelvic surgery. *J Urol*. 1998;160(4):1301–1306.

Cadeddu JA, Partin AW, Epstein JI, et al. Stage D1 (T1-3, N1-3, M0) prostate cancer: a case-controlled comparison of conservative treatment versus radical prostatectomy. *Urology*. 1997;50(2):251–255.

Costello AJ, Brooks M, Cole OJ. Anatomical studies of the neurovascular bundle and cavernosal nerves. *BJU Int*.

2004;94(7):1071–1076.

Cutlip DE, Baim DS, Ho KK, et al. Stent thrombosis in the modern era: a pooled analysis of multicenter coronary stent clinical trials. *Circulation*. 2001;103(15):1967–1971.

Dasgupta P, Kirby RS. Outcomes of robotic assisted radical prostatectomy. *Int J Urol*. 2009;16(3):244–248.

Davies BJ, Chung SY, Nelson JB. Delayed intraoperative hydration limits blood loss during radical retropubic prostatectomy. *Urology*. 2004;64(4):712–716.

Epstein JI. Pathologic assessment of the surgical specimen. *Urol Clin North Am*. 2001;28(3):567–594.

Flocks RH. Arterial distribution within prostate gland: its role in transurethral prostatic resection. *J Urol*. 1937;37:524–548.

Grines CL, Bonow RO, Casey DE Jr, et al. Prevention of premature discontinuation of dual antiplatelet therapy in patients with coronary artery stents: a science advisory from the American Heart Association, American College of Cardiology, Society of Surgeons and American Dental Association with representatives from the American College of Physicians. *J Am Coll Cardiol*. 2007;49(6):734–739.

Groutz A, Blaivas JG, Chaikin DC, et al. The pathophysiology of post-radical prostatectomy incontinence: a clinical and video urodynamic study. *J Urol*. 2000;163(6):1767–1770.

Hedican SP, Walsh PC. Postoperative bleeding following radical retropubic prostatectomy. *J Urol*. 1994;152(4):1181–1183.

Hernandez DJ, Epstein JI, Trock BJ, et al. Radical retropubic prostatectomy: how often do experienced surgeons have positive surgical margins when there is extraprostatic extension in the region of the neurovascular bundle? *J Urol*. 2005;173(2):446–449.

Holmberg L, Bill-Axelson A, Helgesen F, et al. A randomized trial comparing radical prostatectomy with watchful waiting in early prostate cancer. *N Engl J Med*. 2002;347(11):781–

789.

Horie S, Tobisu KI, Fujimoto H, et al. Urinary incontinence after non–nerve-sparing radical prostatectomy with neoadjuvant androgen deprivation. *Urology*. 1999;53(3):561–567.

Horninger W, Strasser H, Bartsch G. Radical retropubic prostatectomy: apical preparation and curtain dissection of the neurovascular bundle. *BJU Int*. 2005;95(6):911–923.

Jewett HJ, Eggleston JC, Yawn DH. Radical prostatectomy in the management of carcinoma of the prostate: probable causes of some therapeutic failures. *J Urol*. 1972;107(6):1034–1040.

Kim PH, Pinheiro LC, Atoria CL, et al. Trends in the use of incontinence procedures after radical prostatectomy: a population based analysis. *J Urol*. 2013;189(2):602–608.

Lavery HJ, Levinson AW, Samadi DB. Robotic-assisted vs. open radical prostatectomy: when can we stop the debate? *Urol Oncol*. 2012;30(5):549–552.

Lepor H, Gregerman M, Crosby R, et al. Precise localization of the autonomic nerves from the pelvic plexus to the corpora cavernosa: a detailed anatomical study of the adult male pelvis. *J Urol*. 1985;133(2):207–212.

Lepor H, Niede AM, Fraiman MC. Early removal of urinary catheter after radical retropubic prostatectomy is both feasible and desirable. *Urology*. 2001;58(3):425–429.

Lepor H, Robbins D. Inguinal hernias in men undergoing open radical retropubic prostatectomy. *Urology*. 2007;70(5):961–964.

Lodding P, Bergdahl C, Nyberg M, et al. Inguinal hernia after radical retropubic prostatectomy for prostate cancer: a study of incidence and risk factors in comparison to no operation and lymphadenectomy. *J Urol*. 2001;166(3):964–967.

Lue TF, Zeineh SJ, Schmidt RA, et al. Neuroanatomy of penile erection: its relevance to iatrogenic impotence. *J Urol*. 1984;131(2):273–280.

Masterson TA, Serio AM, Mulhall JP, et al. Modified technique for neurovascular bundle preservation during radical prostatectomy: association between technique and recovery of erectile function. *BJU Int*. 2008;101(10):1217–1222.

Menon M, Kaul S, Bhandari A, et al. Prospective non-randomized comparison of standard nerve sparing and the “veil of Aphrodite”: analysis of postoperative potency using the international index of erectile function—5 questions. *J Urol*. 2005;173(4):270.

Montorsi F, Salonia A, Suardi N, et al. Improving the preservation of the urethral sphincter and neurovascular bundles during open radical retropubic prostatectomy. *Eur Urol*. 2005;48(6):938–945.

Montorsi F, Brock G, Lee J, et al. Effect of nightly versus on-demand vardenafil on recovery of erectile function in men following bilateral nerve-sparing radical prostatectomy. *Eur Urol*. 2008;54(4):924–931.

Myers RP, Goellner JR, Cahill DR. Prostate shape, external striated urethral sphincter, and radical prostatectomy: the apical dissection. *J Urol*. 1987;138(3):543–550.

Myers RP. Male urethral sphincteric anatomy and radical prostatectomy. *Urol Clin North Am*. 1991;18(2):211–227.

Myers RP. Radical prostatectomy: pertinent surgical anatomy. *Atlas Urol Clin North Am*. 1994;2:1–18.

Nelson CP, Montie JE, McGuire EJ, et al. Intraoperative nerve stimulation with measurement of urethral sphincter pressure changes during radical retropubic prostatectomy: a feasibility study. *J Urol*. 2003;169(6):2225–2228.

Nielsen ME, Walsh PC. Systematic detection and repair of subclinical inguinal hernias at radical retropubic prostatectomy. *Urology*. 2005;66(5):1034–1037.

Nielsen ME, Schaeffer EM, Marschke P, et al. High anterior release of the levator fascia improves sexual function following open radical retropubic prostatectomy. *J Urol*. 2008;180(6):2557–2564.

Oelrich TM. The urethral sphincter muscle in the male. *Am J Anat*. 1980;158(2):229–296.

Ong AM, Su LM, Varkarakis I, et al. Nerve sparing radical prostatectomy: effects of hemostatic energy sources on the recovery of cavernous nerve function in a canine model. *J Urol*. 2004;172(4 Pt 1):1318–1322.

Palapattu GS, Allaf ME, Trock BJ, et al. Prostate specific antigen progression in men with lymph node metastases following radical prostatectomy: results of long-term followup. *J Urol*. 2004;172(5 Pt 1):1860–1864.

Parsons JK, Marschke P, Maples P, et al. Effect of methylprednisolone on return of sexual function after nerve-sparing radical retropubic prostatectomy. *Urology*. 2004;64(5):987–990.

Partin AW, Kattan MW, Subong EN, et al. Combination of prostate-specific antigen, clinical stage, and Gleason score to predict pathological stage of localized prostate cancer. *JAMA*. 1997;277(18):1445–1451.

Partin AW, Mangold LA, Lamm DM, et al. Contemporary update of prostate cancer staging nomograms (Partin Tables) for the new millennium. *Urology*. 2001;58(6):843–848.

Patel R, Lepor H. Removal of the urinary catheter on postoperative days 3 or 4 following radical retropubic prostatectomy. *Urology*. 2003;61(1):156–160.

Pavlovich CP, Mettee LZ, Su L, et al. Nightly sildenafil is unnecessary after minimally-invasive nerve-sparing radical prostatectomy: on-demand sildenafil provides equivalent restoration of erectile function. *J Urol*. 2009;181(4):485–486.

Polascik TJ, Walsh PC. Radical retropubic prostatectomy: the influence of accessory pudendal arteries on the recovery of sexual function. *J Urol*. 1995;154(1):150–152.

Regan TC, Mordkin RM, Constantinople NL, et al. Incidence of inguinal hernias following radical retropubic prostatectomy. *Urology*. 1996;47(4):536–537.

Reiner WG, Walsh PC. An anatomical approach to the surgical management of the dorsal vein and Santorini's plexus during radical retropubic surgery. *J Urol*. 1979;121(2):198–200.

Rogers CG, Trock BP, Walsh PC. Preservation of accessory pudendal arteries during radical retropubic prostatectomy: surgical technique and results. *Urology*. 2004;64(1):148–151.

Rosenblum N, Levine MA, Handler T, et al. The role of preoperative epoetin alpha in men undergoing radical retropubic prostatectomy. *J Urol*. 2000;163(3):829–833.

Schlegel PN, Walsh PC. Neuroanatomical approach to radical cystoprostatectomy with preservation of sexual function. *J Urol*. 1987;138(6):1402–1406.

Sgrignoli AR, Walsh PC, Steinberg GD, et al. Prognostic factors in men with stage D1 prostate cancer: identification of patients less likely to have prolonged survival after radical prostatectomy. *J Urol*. 1994;152(4):1077–1081.

Stedman's medical dictionary. ed 27. Lippincott Williams & Wilkins: Philadelphia, PA; 2000:257.

Strasser H, Tiefenthaler M, Steinlechner M, et al. Urinary incontinence in the elderly and age-dependent apoptosis of rhabdosphincter cells. *Lancet*. 1999;354(9182):918–919.

Sultan R, Slova D, Thiel B, et al. Time to return to work and physical activities following open radical retropubic prostatectomy. *J Urol*. 2006;176(4 Pt 1):1420–1423.

Takenaka A, Murakami G, Soga H, et al. Anatomical analysis of the neurovascular bundle supplying penile cavernous tissue to ensure a reliable nerve graft after radical prostatectomy. *J Urol*. 2004;172(3):1032–1035.

Takenaka A, Murakami G, Matsubara A, et al. Variation in course of cavernous nerve with special reference to details of topographic relationships near prostatic apex: histologic study using male cadavers. *Urology*. 2005;65(1):136–142.

Tsuzuki T, Hernandez DJ, Aydin H, et al. Prediction of extraprostatic extension in the neurovascular bundle based on prostate needle biopsy pathology, serum prostate specific antigen and digital rectal examination. *J Urol*. 2005;173(2):450–453.

Walsh PC. Anatomic radical prostatectomy: evolution of the surgical technique. *J Urol*. 1998;160(6 Pt 2):2418–2424.

Walsh PC. Radical prostatectomy for localized prostate cancer provides durable cancer control with excellent quality of life: a structured debate. *J Urol*. 2000;163(6):1802–1807.

Walsh PC. Nerve grafts are rarely necessary and are unlikely to improve sexual function in men undergoing anatomic radical prostatectomy. *Urology*. 2001;57(6):1560–1564.

Walsh PC. The discovery of the cavernous nerves and development of nerve sparing radical retropubic prostatectomy. *J Urol*. 2007;177(5):1632–1635.

Walsh PC, Donker PJ. Impotence following radical prostatectomy: insight into etiology and prevention. *J Urol*. 1982;128(3):492–497.

Walsh PC, Marschke PL. Intussusception of the reconstructed bladder neck leads to earlier continence following radical prostatectomy. *Urology*. 2002;59(6):934–938.

Walsh PC, Garcia JR. *Radical retropubic prostatectomy: a detailed description of the surgical technique—a video presentation*. [Available at] https://urology.jhu.edu/videos/surgical.php; 2004.

Walsh PC, Lepor H, Eggleston JC. Radical prostatectomy with preservation of sexual function: anatomical and pathological considerations. *Prostate*. 1983;4(5):473–485.

Walsh PC, Quinlan DM, Morton RA, et al. Radical retropubic prostatectomy: improved anastomosis and urinary continence. *Urol Clin North Am*. 1990;17(3):679–684.

Walsh PC, Marschke P, Ricker D, et al. Patient-reported urinary continence and sexual function after anatomic radical prostatectomy. *Urology*. 2000;55(1):58–61.

Walsh PC, Marschke P, Ricker D, et al. Use of intraoperative video documentation to improve sexual function after radical retropubic prostatectomy. *Urology*. 2000;55(1):62–67.

Ward JF, Zincke H, Bergstralh EJ, et al. The impact of surgical approach (nerve bundle preservation versus wide local excision) on surgical margins and biochemical recurrence following radical prostatectomy. *J Urol*. 2004;172(4 Pt 1):1328–1332.

Wolf JS Jr, Bennett CJ, Dmochowski RR, et al. Best practice policy statement on urologic surgery antimicrobial prophylaxis. *J Urol*. 2008;179(4):1379–1390.

Zvara P, Carrier S, Kour NW, et al. The detailed neuroanatomy of the human striated urethral sphincter. *Br J Urol*. 1994;74(2):182–187.

Radical Perineal Prostatectomy

Reiner WG, Walsh PC. An anatomic approach to the surgical management of the dorsal vein and Santorini's plexus during radical retropubic surgery. *J Urol*. 1979;121(2):198–200.

Sullivan LD, Weir MJ, Kinahan JF, et al. A comparison of the relative merits of radical perineal and radical retropubic prostatectomy. *BJU Int*. 2000;85(1):95–100.

Walsh PC, Donker PJ. Impotence following radical prostatectomy: insight into etiology and prevention. *J Urol*. 1982;128(3):492–497.

Walsh PC, Lepor H, Eggleston JC. Radical prostatectomy with preservation of sexual function: anatomical and pathological considerations. *Prostate*. 1983;4(5):473–485.

Laparoscopic and Robotic-Assisted Laparoscopic Radical Prostatectomy and Pelvic Lymphadenectomy

---

Li-Ming Su MD, Brandon J. Otto MD, Anthony J. Costello FRACS, MD

Evolution of Minimally Invasive Laparoscopic Prostatectomy

In the late 1970s and early 1980s, several detailed anatomic studies performed in fetal and adult cadavers provided important insights into the periprostatic anatomy, especially that of the dorsal venous complex (DVC) (Reiner and Walsh, 1979), the neurovascular bundle (NVB) (Walsh and Donker, 1982), and the striated urethral sphincter (Oelrich, 1980). These observations provided a more anatomic approach to radical prostatectomy for prostate cancer, resulting in a significant reduction in operative morbidity. Subsequently, the anatomic, nerve-sparing open radical prostatectomy maintained a central role in the management of localized prostate cancer for more than two decades.

It was not until 1997 that an attempt at a less invasive approach to radical prostatectomy was explored. Schuessler et al. (1997) performed the first successful laparoscopic radical prostatectomy (LRP) in 1997. In their series of nine patients, operative duration was lengthy (8 to 11 hours), and the length of hospital stay was on average 7.3 days. Although the authors concluded that cure rates with LRP appeared comparable with those in open surgery, they could not define any significant advantages. As a result, LRP was not widely adopted in the field of urology.

Advances in task-specific surgical instrumentation, optics, digital video equipment, and computer and robotic technology opened a new frontier for minimally invasive laparoscopic prostatectomy. These advances led urologists to revisit LRP, spearheaded by two centers in France that reported on their techniques and early results (Abbou et al., 2000; Guillonneau and Vallancien, 2000). Their stepwise surgical approach to LRP proved to be both reproducible and teachable, although the learning curve remained challenging. Operative times were in a more acceptable 4- to 5-hour range, with reported overall positive margin rates of 15% to 28%. This work rekindled worldwide interest in LRP, and in the ensuing years, surgeons at a number of centers throughout the world acquired the skills and experience to perform this technique. However, advanced laparoscopic skills were necessary to perform a proficient LRP, especially for suturing of the vesicourethral anastomosis.

Computer-assisted surgical devices using mechanical robotic arms were adopted for use with radical prostatectomy in part because of their ability to aid the surgeon in performing the challenging task of laparoscopic suturing. One such device, the da Vinci Surgical System (Intuitive Surgical, Sunnyvale, CA) quickly became the dominant robotic surgical device in the field of urology. By incorporating sophisticated wristed technology at the terminal ends of the robotic instruments, this robotic system offered surgeons the ability to operate, dissect, and suture with the facility of a human wrist. In addition, the 10× magnified, three-dimensional image provided by the specialized stereo-endoscope lens and camera offered an unprecedented view of the operative field and periprostatic anatomy, far superior to the two-dimensional view of conventional laparoscopy. The first-generation robotic platform, originally launched in the United States in 2000, allowed surgeons to control three robotic arms simultaneously: two arms for robotic instrumentation and a third arm for control of the stereo-endoscope and camera. The second-generation da Vinci S system, made available in 2006, incorporated high-definition image capability with an additional fourth robotic arm for grasping and retraction. The third-generation da Vinci Si HD was released in 2009 and offered two separate surgeon consoles, allowing two surgeons to operate simultaneously and providing an opportunity for improved operative efficiency and training. Finally, the latest-generation robot, the da Vinci Xi HD, launched in 2014, allows for multi-quadrant surgery and simpler, single-quadrant surgery.

Since its introduction in the United States in 2000, robotic-assisted laparoscopic radical prostatectomy (RALRP) has rapidly grown in popularity with surgeons and patients alike. However, there are continued questions regarding the relative merits of RALRP versus open surgery with regard to oncologic and functional outcomes, weighed against the significant equipment expense and learning curve for the surgeon and surgical team. **Nevertheless, with rapid dissemination of robotic platforms into large tertiary referral centers and community hospitals, RALRP has become the dominant surgical approach for radical prostatectomy in the United States**.

This chapter highlights some of the surgical advances for both LRP and RALRP. Further, technical details for the surgical dissection and currently available data on oncologic and functional outcomes are presented with reference to comparative effectiveness with radical retropubic prostatectomy (RRP). Finally, the authors review the role of robotic salvage prostatectomy, laparoscopic pelvic lymph node dissection (PLND), and complications of minimally invasive prostatectomy.

Patient Selection

Indications and Contraindications

The indications for LRP and RALRP are identical to those for open surgery (i.e., patients whose cancer is suspected to be clinically localized). Patients should have a pathologically confirmed cancer clinically confined within the prostate (stage T1 or T2) or a cancer that extends beyond the margins of the prostate (T3) but still seems amenable to surgical extirpation with a wide resection. Based on the 2018 Clinically Localized Prostate Cancer: AUA/ASTRO/SUO guideline, radiographic staging with CT and bone scan is recommended only for patients with suspected locally advanced disease, Gleason score of 8 or greater, or prostate-specific antigen (PSA) level greater than 20 ng/mL (Sanda et al., 2018). Absolute contraindications to minimally invasive laparoscopic prostatectomy include uncorrectable bleeding diathesis and the inability to undergo general anesthesia because of severe cardiopulmonary compromise. Patients who have received neoadjuvant hormonal therapy or who have a history of prior complex lower abdominal and pelvic surgery such as partial colectomy or inguinal mesh herniorrhaphy pose a greater technical challenge because of distortion of normal anatomic landmarks and adhesions but are not an absolute contraindication to LRP and RALRP. In patients with a history of prior laparoscopic extraperitoneal mesh herniorrhaphy, a transperitoneal approach may be preferred over the extraperitoneal approach because dense adhesions in the retropubic space often make attempts at initial access to the space of Retzius challenging.

Morbidly obese patients pose additional challenges, even to experienced surgeons. These patients are more prone to positioning injuries such as compression nerve injuries, therefore extra care must be taken, and additional padding of pressure points is often required. Additionally, they are at an increased risk for potential respiratory compromise when placed in the steep Trendelenburg position, making communication with the anesthesia team key once they are positioned and pneumoperitoneum is established. Deep venous thrombosis risk may be increased in these patients, and consideration should be given to the use of pharmacologic prophylaxis in addition to the routine use of sequential compression devices and early ambulation. From a technical standpoint, the relatively limited working space and limitations of trocar size and instrumentation length can pose additional problems. Modifications that may help improve surgeon visualization and maneuverability in a morbidly obese patient include using extra-long trocars; placing trocars 1 to 2 cm more cephalad to improve the angle of approach to reduce instrument collision with the pubic symphysis; dividing the urachus at a more cephalad location to eliminate fat from the abdominal wall obscuring the field; and decreasing the pneumoperitoneum to 10 mm Hg with deeper insertion of trocars to allow instruments to reach the apex or the vesicourethral anastomosis (Ganapathi et al., 2017). In experienced hands, it is possible to obtain adequate operative, functional, and oncologic outcomes in morbidly obese patients (Abdul-Muhsin et al., 2014).

Patients with large prostate volumes (e.g., >80 g) often offer technical challenges to the surgeon. Larger prostates tend to fill most of the pelvic cavity making maneuverability of the prostate more difficult. Additionally, a concomitant median lobe can make division of the posterior bladder neck with respect to the nearby ureteral orifices more challenging and may require a more extensive bladder neck reconstruction. These patients may also have a wider DVC and wider and more vascular pedicles, and the neurovascular bundle may be displaced posteriorly making visualization more difficult (Ganapathi et al., 2017). Tips for dealing with these challenging situations are presented later in this chapter at the corresponding steps of the operation. Review of the preoperative transrectal ultrasound scan or imaging before surgery can alert one to the presence of a large prostate or a prostate with a median lobe, allowing the surgeon to better prepare for the operation. These patients can have longer operative times, more blood loss, and longer hospital stay than those with smaller glands; however, long-term urinary outcomes appear comparable (Levinson et al., 2008, 2009; Link et al., 2008).

Patients who have undergone a prior transurethral resection of the prostate (TURP) can also have more complex bladder neck anatomy. Identification of the ureteral orifices is imperative before beginning the posterior bladder neck dissection. The normal planes between the prostate and bladder may be altered making dissection more difficult. These cases are often difficult, and both oncologic and functional outcomes may be compromised (Gupta et al., 2011). Salvage surgery after failure of primary treatment (e.g., radiation, brachytherapy, cryotherapy, high-intensity focused ultrasonography) has been successfully reported in properly selected patients but should be approached with caution because of the attendant risks and complications related to periprostatic adhesions (Boris et al., 2009; Chauhan et al., 2011; Kaffenberger et al., 2013; Kaouk et al., 2008; Yuh et al., 2014). As a result of the effects of prior local radiotherapy or ablation, the tissue planes surrounding the prostate, and especially between the posterior prostate and anterior rectum, are often fibrotic and obliterated, increasing the risk for inadvertent entry into the rectum during salvage surgery. As a result, patients undergoing salvage prostatectomy need to undergo a full bowel preparation and be counseled on the potential risk for rectal injury and colonic diversion in addition to the higher incidence of impotence and incontinence compared with surgery in the primary setting. Further discussion regarding the nuances of salvage robotic prostatectomy can be found in the Surgical Technique section later in this chapter. **It is strongly advised that these more complex patient scenarios be avoided in a surgeon's early experience with LRP and RALRP; however, these patient features are not by themselves absolute contraindications for a minimally invasive approach to prostatectomy** (Brown et al., 2005b; Erdogru et al., 2005; Kaffenberger et al., 2013; Singh et al., 2005; Stolzenburg et al., 2005).

Use of Preoperative Multiparametric Magnetic Resonance Imaging

Multiparametric magnetic resonance imaging (mpMRI) of the prostate is increasingly being performed to assist with the diagnosis, staging, and management of prostate cancer. mpMRI has been shown to have high specificity (0.88) and low sensitivity (0.61) for staging of localized prostate cancer (de Rooij et al., 2016). However, mpMRI is often reader dependent, and having a dedicated reader can improve its ability to predict adverse pathology (Tay et al., 2016). **The addition of mpMRI to commonly used clinical risk classification tools seems to improve their ability to predict extracapsular extension** (Feng et al., 2015; Morlacco et al., 2017)**. This information may help improve both patient counseling and surgical planning.** Studies are beginning to suggest that the addition of preoperative mpMRI can help with nerve-sparing planning, allowing for a more tailored approach and reducing positive surgical margins with the use of improved planning or intraoperative frozen sections in areas of concern at the time of prostatectomy, even in high-risk patients (Radtke et al., 2015; Rud et al., 2015; Schiavina et al., 2018). It remains to be seen if preoperative mpMRI is necessary in all patients undergoing RALRP, but when available, it should be reviewed for surgical planning.

Instrumentation

Instrumentation required for LRP and RALRP depends on the chosen approach and model of da Vinci system being used (i.e., three- vs. four-arm robot) in the case of RALRP. Box 156.1 lists suggested instrumentation for LRP and RALRP. For LRP, the AESOP 3000 robotic arm (Intuitive Surgical) may be used to stabilize and control the laparoscopic lens and camera by handheld remote control, voice activation, or foot-pedal control. Alternatively, a surgical assistant can be used for this purpose. During RALRP, the use of the da Vinci S, Si, or Xi system allows the surgeon to control a total of four robotic arms, with one being the stereo-endoscope. The operation begins by using a 0-degree stereo-endoscope and controlling a grasping forceps in the left robotic arm (such as the Maryland curved bipolar forceps or plasma kinetic dissector) and the curved monopolar scissors in the right robotic arm. The fourth robotic arm controls the ProGrasp forceps (Intuitive Surgical), a large atraumatic blunt grasper for retraction and exposure of tissues. The surgeon then toggles between control of any two of the three working robotic arms at any given time to allow for greater autonomy and to achieve optimal exposure and dissection.

Box 156.1

Suggested Instrumentation for Laparoscopic and Robotic-Assisted Laparoscopic Radical Prostatectomy

Laparoscopic Radical Prostatectomy

- AESOP 3000 Robotic arm (Intuitive Surgical, Sunnyvale, CA) (optional)
- Monopolar electrocautery scissors
- Monopolar electrocautery hook device
- Bipolar forceps
- Ultrasonic shears
- Maryland dissector
- Laparoscopic needle drivers (two)
- Suction-irrigation device

- 10-mm, 0-degree and 30-degree laparoscope lens
- Veress needle
- 5-mm trocars (three)
- 12-mm trocars (two)
- 20-Fr van Buren urethral sound
- 18-Fr urethral catheter
- Small and medium-large Hem-o-lok clips (Teleflex Medical, Research Triangle Park, NC)
- 0 polyglactin suture (GS21) for dorsal venous complex
- 2-0 polydioxanone suture for posterior reconstruction
- 3-0 poliglecaprone (Monocryl) double-armed suture for anastomosis

Robotic-Assisted Laparoscopic Prostatectomy

- da Vinci S or Si HD Surgical System
- Endowrist Maryland bipolar forceps or PK dissector
- Endowrist curved monopolar scissors
- Endowrist ProGrasp forceps
- Endowrist large needle drivers (two)
- InSite Vision System with 0-degree and 30-degree lens
- 12-mm trocars (two)
- 8-mm metal robotic trocars (three if using a fourth robotic arm)
- 18-Fr urethral catheter
- Small and medium-large Hem-o-lok clips (Teleflex Medical)
- 0 polydioxanone suture for dorsal venous complex
- 2-0 polydioxanone suture for posterior reconstruction
- 3-0 Monocryl double-armed suture for anastomosis

Preoperative Preparation

Patient Preparation

The authors typically do not use a formal bowel preparation; however, a preoperative mechanical bowel preparation with magnesium citrate and a Fleet enema (C.B. Fleet Company, Inc., Lynchburg, VA) can be considered to help reduce colonic distention. A broad-spectrum antibiotic such as cefazolin is administered intravenously 30 minutes before skin incision. Continuing low-dose aspirin appears to be safe in patients undergoing RALRP; however, other blood thinners should be held for the appropriate durations (Leyh-Bannurah et al., 2014).

Informed Consent

In addition to bleeding, transfusion, and infection, patients undergoing LRP and RALRP must be aware of the potential for conversion to open surgery. As with open surgery, patients must be counseled on the risk for impotence, incontinence, incisional hernia, and adjacent organ injury (e.g., ureter, rectum, bladder, small bowel). The risks with general anesthesia must be presented to the patient because LRP and RALRP cannot be performed under regional anesthesia. In addition, it is appropriate for the surgeon to discuss his or her overall operative experience with radical prostatectomy, specifically in addition to the laparoscopic or robotic approach, and provide a realistic forecast of cancer control, as well as return to normal urinary and sexual function on the basis of each patient's unique characteristics. Use of validated questionnaires such as the Sexual Health Inventory for Men and the International Prostate Symptom Score allows for an objective assessment of baseline function and can help with forecasting postoperative recovery of sexual and urinary function.

Operating Room Personnel

LRP and RALRP require that the surgical team, including the scrub technician, circulating nurse, and surgical assistant(s), be fully trained and skilled in the instrumentation, operative setup, and technical steps of these minimally invasive procedures. Only one skilled assistant is generally required for these procedures, but a second assistant may be used if available to provide retraction of tissues. **For RALRP, it is important for the tableside assistant to have adequate training in not only basic laparoscopy but also specifically the mechanics, setup, and troubleshooting of the robotic system.** The scrub technician is also an integral part of the operative team and must be versed in the wide array of laparoscopic and robotic instruments that may be used to accomplish this procedure. Finally, using an anesthesiologist who is versed in the nuances and physiologic effects of prolonged pneumoperitoneum is vital in the success of this operation. Typical operating room equipment and setup for RALRP and LRP are shown in Fig. 156.1.

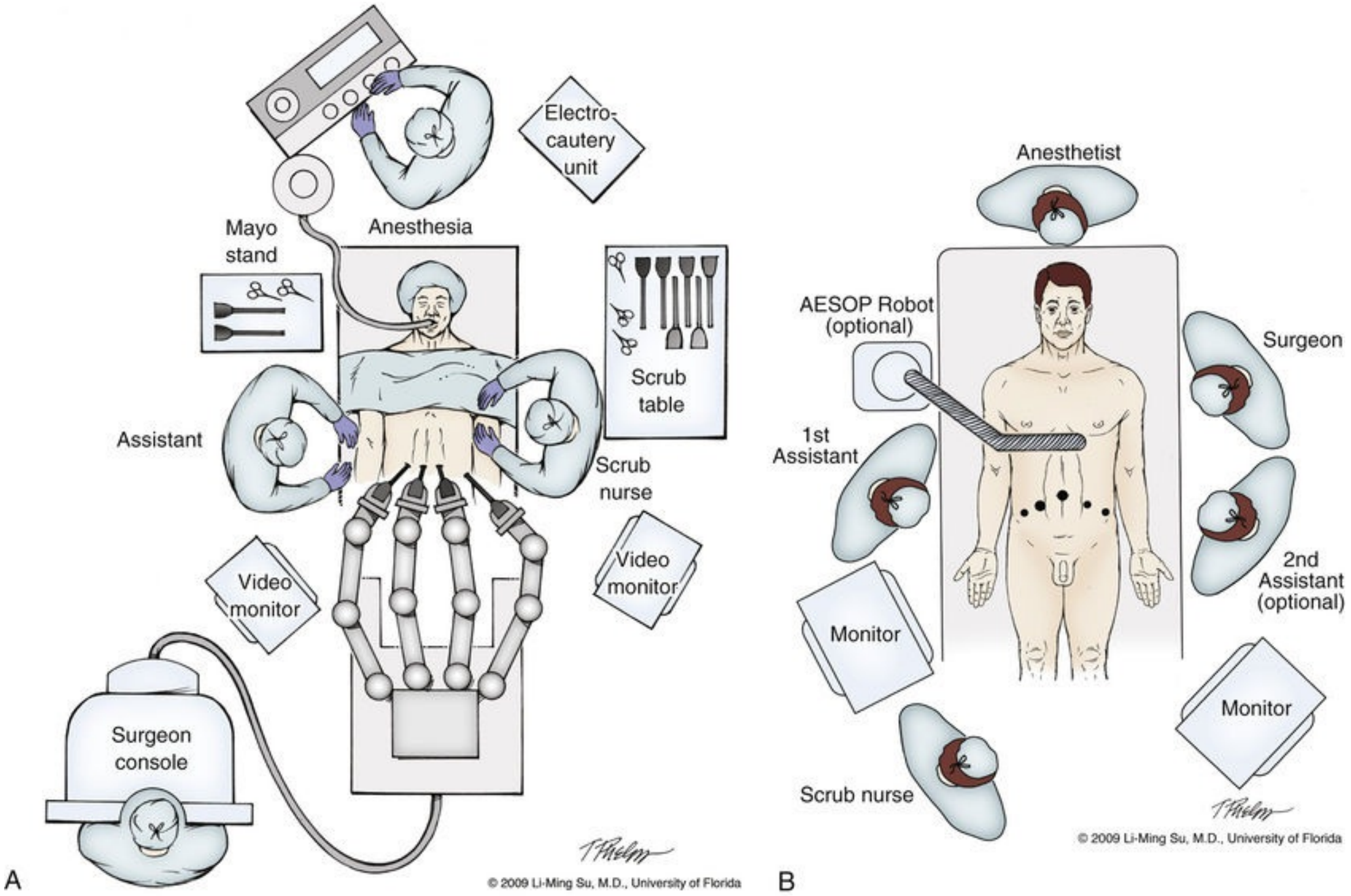
Electro-
cautery
unit
Mayo
stand
Anesthesia
Scrub
table
Assistant
Scrub
nurse
Video
monitor
Video
monitor
Surgeon
console
A
© 2009 Li-Ming Su, M.D., University of Florida
B
Anesthetist
AESOP Robot
(optional)
Surgeon
1st
Assistant
2nd
Assistant
(optional)
Monitor
Monitor
Scrub nurse
© 2009 Li-Ming Su, M.D., University of Florida

FIG. 156.1 Operating room equipment and setup for robotic-assisted prostatectomy (A) and pure laparoscopic radical prostatectomy (B). (Copyright Li-Ming Su, MD, University of Florida, 2009.)

Patient Positioning

After induction of general endotracheal anesthesia, the patient is placed in the steep Trendelenburg position with the arms and hands carefully tucked and padded at the sides with “egg crate” padding to avoid injury to the median and ulnar nerves (Fig. 156.2A–C). Sequential compression stocking devices are placed on both legs and activated. The patient's legs are spread apart and supported by spreader bars to allow for access to the rectum and perineum. Alternatively, the patient's legs may be placed in stirrups in the low lithotomy position. The patient is then secured firmly to the table using heavy cloth tape and egg crate padding across the chest to help prevent the patient from sliding when in the steep Trendelenburg position (see Fig. 156.2D). This binding across the patient's chest may limit chest excursion and thereby decrease pulmonary compliance, making it important to check with anesthesia before moving on from this step in patient positioning. **Fixed shoulder rests should be avoided because this can result in compression injury to the shoulders and brachial plexus when in the steep Trendelenburg position.** Slight flexion of the table at the level of the hips may be required to properly dock the robotic arms; however, exaggerated flexion should be avoided so as to minimize the risk for femoral neurapraxia (see the Complications of Robotic Prostatectomy section later in this chapter). An orogastric tube and urethral catheter are placed to decompress the stomach and bladder, respectively. **Careful history-taking and padding of vulnerable body parts such as the hips, shoulders, knees, and calves are important to prevent pressure injury and neuromuscular complications** (see the Complications of Robotic Prostatectomy section).

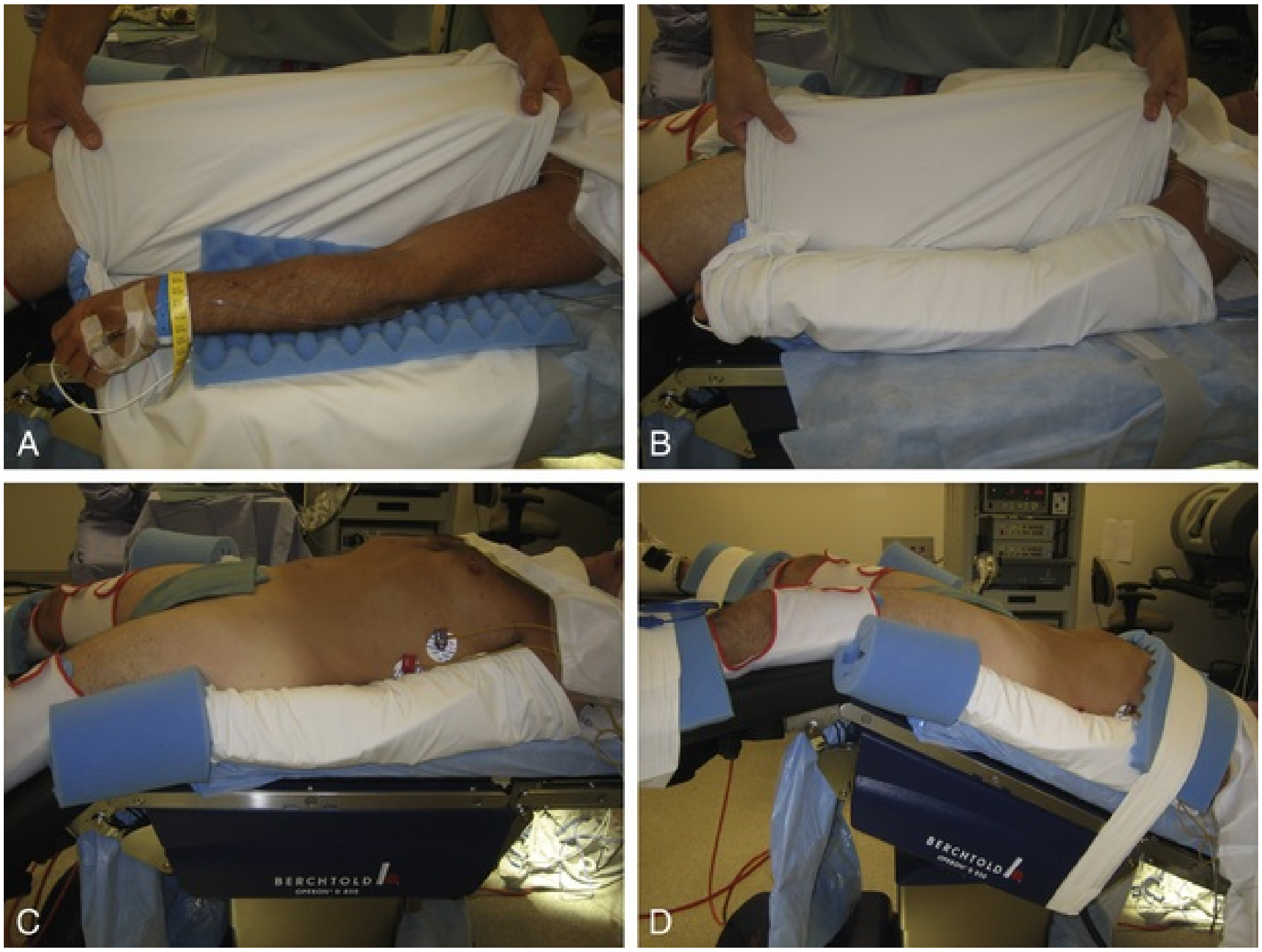

FIG. 156.2 Patient positioning for robotic-assisted radical prostatectomy. During positioning on the operating room table, the draw sheet and egg crate padding are used to help secure the patient's hands and arms to the side in the neutral position, taking great care to protect from injury to the median and ulnar nerves (A–C). To prevent the patient from sliding when in the steep Trendelenburg position, heavy cloth tape and egg crate padding are placed across the patient's chest (D).

Anesthesia Considerations

Both LRP and RALRP require general anesthesia. Because the patient's arms are tucked at the side and difficult to access, establishing accurate pulse oximetry, blood pressure cuff placement, and intravenous access is critical before final patient positioning. **The anesthesiologist must be aware of the potential consequences of carbon dioxide insufflation and pneumoperitoneum, including an initial vagal response, oliguria, and hypercarbia. Prompt adjustment in minute and tidal volumes may be required by the anesthesiologist in the event of rising end-tidal CO_2 levels and hypercarbia, which may lead to systemic acidosis if left uncorrected** (Meininger et al., 2004). **This is especially true in the early experience of a robotic surgeon and his or her team because operative times generally can be long.** Likewise, adjustments in CO_2 insufflation pressures may be required by the surgeon to reduce the risk for continued hypercarbia.

Intravenous fluid management can be difficult during RALRP, especially given that urine output is not reliably recorded secondary to the oliguria from the pneumoperitoneum and the bladder being opened for the majority of the procedure. The goal is to avoid too much urine being produced, thereby obscuring the operative field while maintaining appropriate intravascular volume and cardiac output (Giordano et al., 2017). A typical fluid resuscitation is 1.5 to 2 L of crystalloid solution, with the majority being given after the anastomosis is complete. Additional fluids should be consistent with blood loss and insensible fluid losses.

The steep Trendelenburg position can lead to facial, orbital, pulmonary, and laryngeal edema. Increased intraocular pressure can occur in patients in the exaggerated Trendelenburg position, but in patients undergoing RALRP this does not appear to have any apparent clinical long-term consequence, at least in healthy patients. However, there may be an increased risk for corneal edema and abrasion, making it even more important for the anesthesiologist to maintain good eye lubrication and protection. If significant facial or orbital edema is noted, laryngeal edema should be considered, and the anesthesia team should think about delaying extubation until the edema is reduced to avoid a potentially tenuous airway and the need for reintubation (Giordano et al., 2017). Taken together, given the potential for prolonged surgical times with a patient in the steep Trendelenburg position, especially in a surgeon's early experience, it is important to recognize these unique complications and maintain excellent communication between the surgeon and anesthesia team throughout the operation.

Key Points: Patient Selection, Instrumentation, and Preoperative Preparation for Laparoscopic and Robotic-Assisted Laparoscopic Radical Prostatectomy

- Regarding patient selection, it is strongly advised that patients with more complex anatomic challenges (e.g., large prostate size, large median lobe, morbid obesity, prior pelvic surgery, after radiation, after TURP) be avoided in a surgeon's early experience with LRP and RALRP; however, these patient features are not by themselves absolute contraindications for a minimally invasive approach to prostatectomy.

- Having a skilled bedside assistant who is well versed in basic laparoscopy, but also specifically in the mechanics, setup, and troubleshooting of the robotic system, can greatly facilitate RALRP procedures.
- Both the surgeon and anesthesiologist must be aware of the unique physiologic effects of prolonged pneumoperitoneum with patients in the steep Trendelenburg position, including hypercarbia and acidosis, corneal edema, increased intraocular pressure, and neurapraxia, and take the proper steps to prevent such complications.

Surgical Technique

Robotic-Assisted Versus Pure Laparoscopic Approach

Most of the principles and considerations for the surgical dissection are similar regardless of whether a pure laparoscopic or robotic-assisted approach is used. In general, the following discussion of technique and the pros and cons of various maneuvers and approaches apply to either surgical approach; however, the primary focus of this chapter will be on RALRP.

For RALRP, the da Vinci Surgical System is a master/slave system with three components: surgical robot (also called the patient side cart), surgeon console, and video cart. For the purpose of this chapter and for simplicity, the technique using the four-armed da Vinci Si HD system is described. The robot is docked at the foot of the operating table between the patient's legs. The da Vinci Xi system allows for side docking. The tableside assistant is responsible for docking/undocking the robot, suction-irrigation, retraction of tissues, passing sutures into the operative field, and robotic instrument changes. The surgeon is seated at the surgeon console, which provides a three-dimensional, 10× magnified, high-definition operative view and allows the surgeon to have complete control of all camera movements and three additional robotic arms. The surgeon's thumb and index or third fingers are inserted into master controls that allow natural hand and wrist movements to be precisely replicated by wristed instruments at the terminal ends of the robotic arms in real time.

Surgeons highly skilled in laparoscopy may find the robotic technology unnecessary and discover that they are equally as facile with pure laparoscopic suturing and dissection as with the robot (Guillonneau, 2005). **For most surgeons, however, the robotic technology significantly facilitates suturing of the vesicourethral anastomosis and aids in other aspects of the surgical dissection such as achieving the critical angles of dissection required to optimize cavernous nerve preservation.**

Transperitoneal Approach

The most common approach to LRP and RALRP is the transperitoneal anterior approach in which, after transperitoneal access and insufflation, the space of

Retzius is immediately entered and the prostate gland, seminal vesicle, and vasa are dissected from an anterior approach. This is in contrast with the transperitoneal retrovesical (or posterior) approach in which the seminal vesicles and vasa are initially approached and completely dissected behind the bladder near the cul-de-sac *before* the space of Retzius is entered. The transperitoneal access and approach is favored by most surgeons over the extraperitoneal approach because of the greater working space and familiar landmarks of the pelvis. For the purposes of this chapter, the transperitoneal anterior approach will be primarily described, with brief mention of the extraperitoneal approach.

Abdominal Access, Insufflation, and Trocar Placement

For a transperitoneal approach, pneumoperitoneum is established using either a Veress needle inserted at the base of the umbilicus or an open Hasson technique. Many patients have had prior abdominal or inguinal surgeries and the amount of adhesions can be difficult to predict. One must consider both the location of the incision and the procedure performed when deciding where to establish pneumoperitoneum. The left upper quadrant is often a safe location in patients with prior midline scars. After initial insufflation, we prefer to use a visual obturator to enter the peritoneal cavity. An offset working laparoscope can be used through a single trocar to release adhesions to create enough space for additional trocar placement in patients who have had prior surgery and present with significant adhesions. Once additional trocars are placed, the robot can be used to release any additional adhesions in the lower abdomen and pelvis. After initial trocar placement, CO_2 insufflation pressure in general is maintained between 12 and 15 mm Hg. Secondary trocars are then placed under laparoscopic view. For RALRP, an example of a trocar configuration is shown in Fig. 156.3A. A 12-mm trocar is initially placed slightly inferior to or above the umbilicus for insertion of the stereo-endoscope at a distance of 15 to 17 cm from the pubic symphysis. Three 8-mm metal robotic trocars are used by the working robotic arms of the surgeon while the assistant provides retraction, suction, and irrigation and passes clips and sutures via the 12- and 5-mm trocars placed along the patient's right side. The surgeon controls camera movement by depressing a foot pedal and using brief, simultaneous arm movements to control camera positioning and rotation. Endoscopes with either angled (30-degree) or straight-ahead (0-degree) viewing are available and interchangeable at various portions of the procedure. In general, most surgeons use the 0-degree endoscope lens throughout the operation; however, some surgeons prefer to switch to the 30-

degree down lens when approaching the bladder neck, NVBs, and apical dissection, especially in complex cases such as morbidly obese patients, large prostates, prior TURPs, and patients with a narrow pelvis (Ganapathi et al., 2017). Fig. 156.3B depicts the trocar configuration for LRP. The surgeon stands at the patient's left side and operates through the two pararectus trocars, while one or two assistants use the lateral-most trocars. The endoscope may be held and controlled by the surgical assistant or alternatively stabilized by an automated endoscopic system for optimal positioning of the AESOP robotic arm.

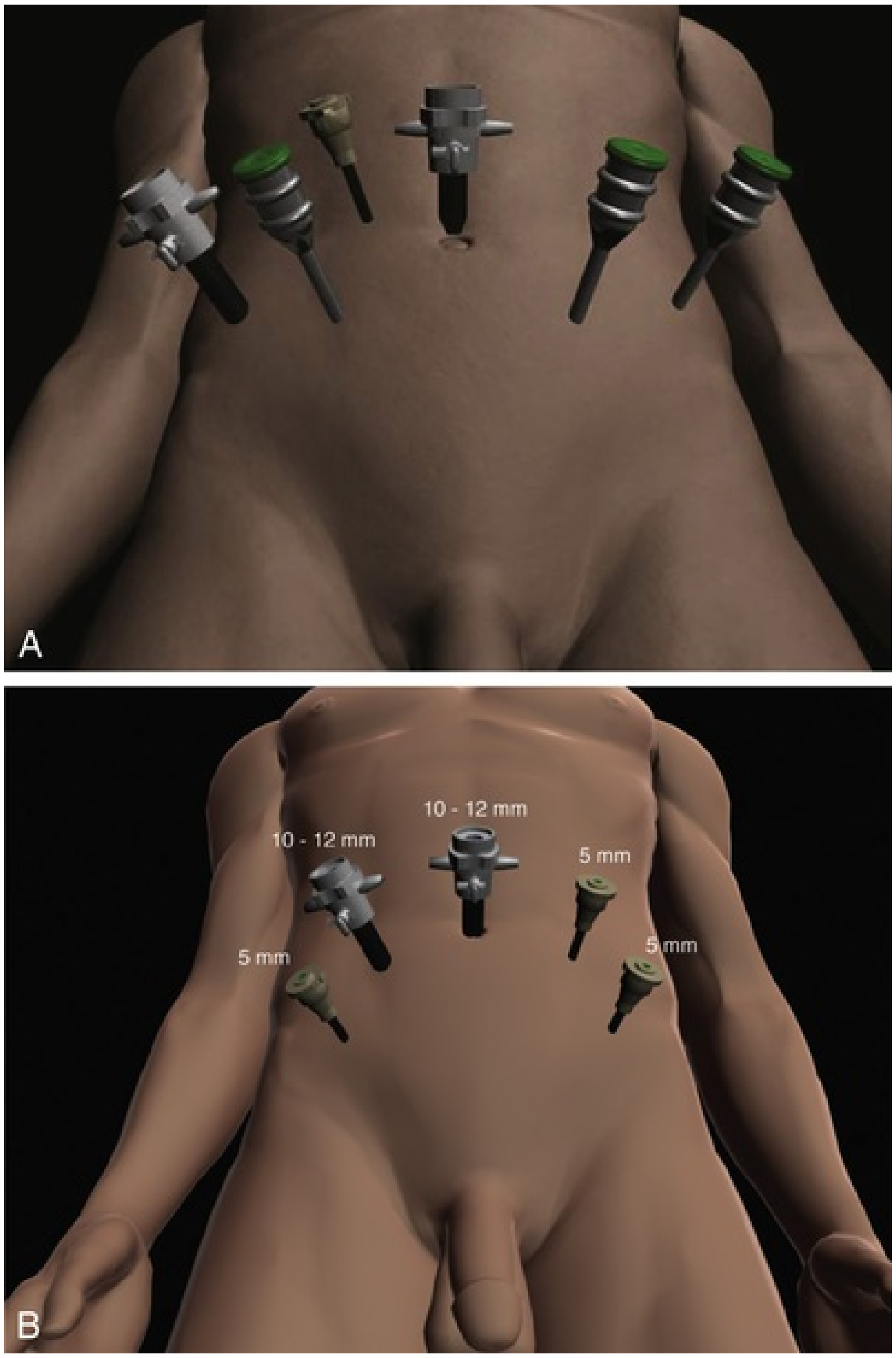

FIG. 156.3 Trocar configuration for robotic-assisted laparoscopic prostatectomy (A) and laparoscopic radical prostatectomy (B).

Extraperitoneal Approach

For an extraperitoneal approach, a 1.5-cm incision is made at the level just beneath the umbilicus, and dissection is carried out down through the anterior rectus sheath. Using blunt finger dissection, a space is created immediately anterior to the posterior rectus sheath and underlying peritoneum. A trocar-mounted balloon dilator device (PDB Balloon, Covidien Autosuture, Mansfield, MA) is inserted into the preperitoneal space anterior to the posterior rectus sheath and advanced down to the pubis along the midline. Using a 0-degree, 10-mm endoscope inserted through the balloon trocar, approximately 500 mL of air is inflated to develop the space of Retzius under direct laparoscopic view (Fig. 156.4). Secondary trocars are then inserted as described earlier in the discussion of the laparoscopic view. The operation then proceeds in the exact manner as in the transperitoneal anterior approach.

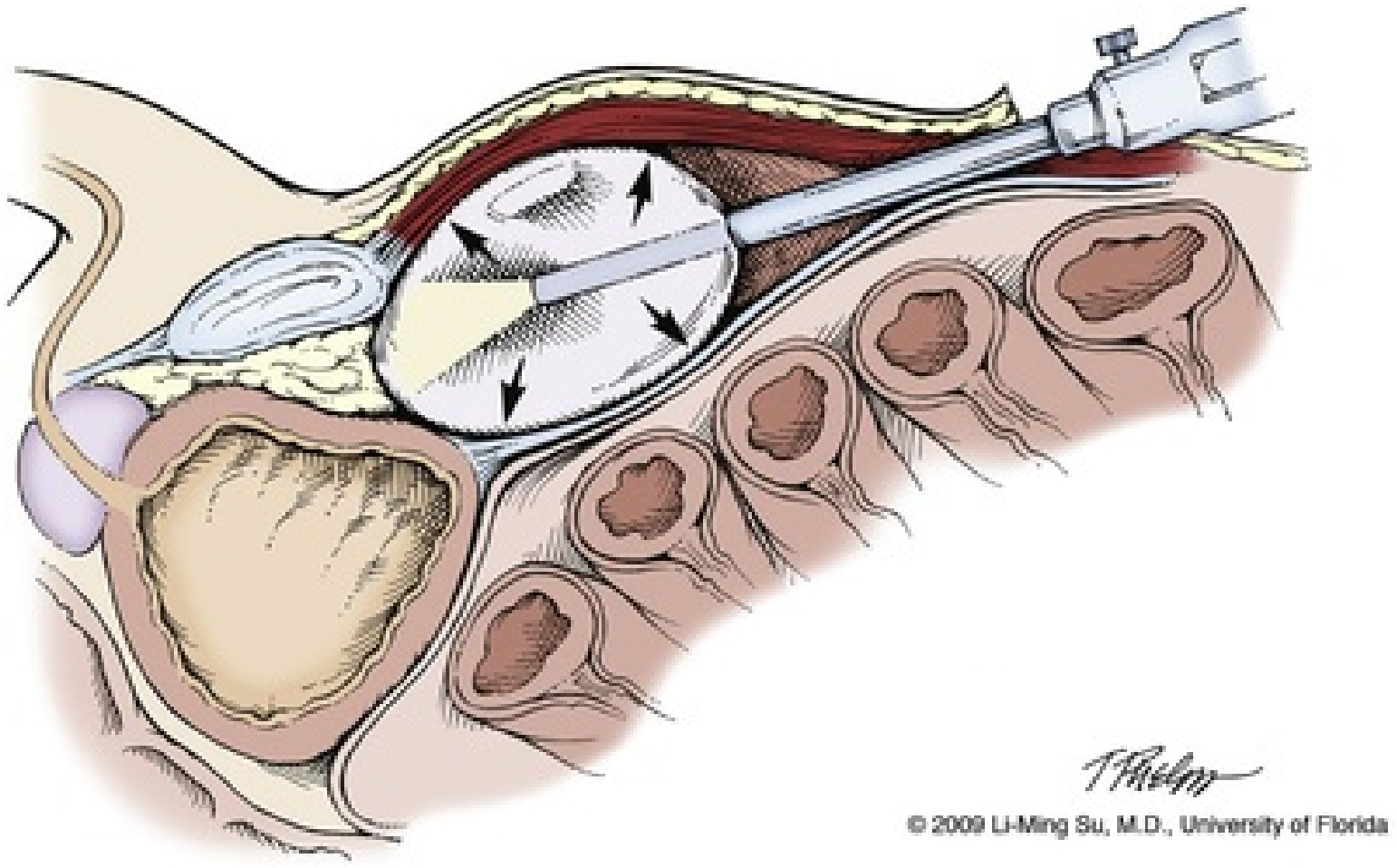

FIG. 156.4 Creation of working space for extraperitoneal pure laparoscopic or robotic-assisted radical prostatectomy using a trocar-mounted balloon dilator device. (Copyright Li-Ming Su, MD, University of Florida, 2009.)

Pros and Cons of Extraperitoneal Versus Transperitoneal Approach

In a retrospective comparison between extraperitoneal and transperitoneal LRP, Hoznek et al. (2003) found that the mean operative time was shorter with the extraperitoneal approach (169.6 vs. 224.2 minutes, $P < .001$), with the greatest time saved during access to the space of Retzius. They suggested that time to full diet was less with the extraperitoneal approach versus the transperitoneal LRP approach (1.6 vs. 2.6 days, $P = .002$) because the peritoneum had not been violated and postoperative ileus was minimized. Eden et al. found a statistically significant advantage in operative time, hospital stay, and return of early continence favoring patients undergoing extraperitoneal versus transperitoneal LRP, postulating that earlier return to urinary control may be secondary to less bladder dissection and, perhaps, less bladder dysfunction compared with transperitoneal LRP (Eden et al., 2004). **Most studies, however, found little or no difference in operative time and perioperative outcomes between transperitoneal and extraperitoneal approaches** (Atug et al., 2006; Brown et al., 2005a; Cathelineau et al., 2004; Erdogru et al., 2004).

With an extraperitoneal approach, the simultaneous laparoscopic management of concurrent inguinal hernias using prosthetic mesh is feasible (Stolzenburg et al., 2003). Simultaneous inguinal herniorrhaphy has also been reported during transperitoneal LRP; however, proper coverage of the mesh prosthesis is necessary using peritoneal flaps, omentum, or a second absorbable mesh to reduce the risk for direct contact between the mesh and bowel with subsequent fistula (Allaf et al., 2003). The extraperitoneal technique may be preferable in patients with previous extensive abdominal surgery or morbid obesity. **With the extraperitoneal approach, the peritoneum acts as a natural barrier, minimizing the potential for bowel injury and preventing the bowels from falling into the operative field and obscuring the surgeon's view. Additionally, the patient may not need to be in the steep Trendelenburg position, which could be beneficial in obese patients or patients with pulmonary compromise. One limitation with the extraperitoneal approach is the reduced working space compared with the relatively larger working space of the peritoneal cavity gained with transperitoneal access.** This is especially relevant when a well-meaning assistant attempts to clear the operative field of blood or smoke. Suctioning can evacuate CO_2 and rapidly collapse the already limited extraperitoneal working space, thus significantly compromising visualization; however, this may be less of a problem with high-flow insufflators. A second limitation to the extraperitoneal approach is in patients with a history of laparoscopic extraperitoneal mesh herniorrhaphy because the retropubic space is often obliterated, making attempts at extraperitoneal access challenging. Finally, higher CO_2 absorption has been reported with extraperitoneal versus transperitoneal insufflation, requiring a higher minute volume to compensate for hypercarbia and associated acidosis (Meininger et al., 2004). **Overall, whether to use an extraperitoneal or transperitoneal approach for LRP or RALRP is largely a matter of surgeon preference and experience, and there is no consistently demonstrated advantage for either approach. Surgeons should consider becoming proficient in both techniques to best individualize patient care.**

Developing the Space of Retzius

After abdominal access and trocar placement for the transperitoneal anterior approach, the pelvic contents are inspected (Fig. 156.5) and adhesions are lysed if present. Frequently, adhesions are noted between the sigmoid colon and the left lateral pelvic side wall. These adhesions should be sharply released to allow the sigmoid colon to be retracted out of the pelvic cavity, providing optimal visualization of the bladder and prostate during subsequent steps of the operation. The initial step is entry and development of the space of Retzius. The bladder is dissected from the anterior abdominal wall by dividing the urachus high above the bladder and incising the peritoneum bilaterally immediately lateral to the medial umbilical ligaments using monopolar scissors. Care should be taken to thoroughly cauterize the obliterated umbilical vessels to avoid unwanted bleeding. The presence of prevesical fatty alveolar tissue confirms the proper plane of dissection within the space of Retzius. Applying posterior and cephalad traction on the urachus, the retropubic space is rapidly developed with a combination of blunt and sharp dissection along the relatively avascular plane (Fig. 156.6). Dissection should be maintained within the pelvic brim to avoid inadvertent injury to the epigastric vessels anteriorly and the iliac vessels laterally. **Lateral dissection of the bladder is carried out down toward the crossing of the medial umbilical ligaments and vas deferens to ensure optimal mobility of the bladder, which minimizes tension when accomplishing the vesicourethral anastomosis later in the operation.** All adipose tissue overlying the prostate is removed using sharp dissection and electrocautery as needed, and the superficial branches of the DVC are coagulated using bipolar electrocautery.

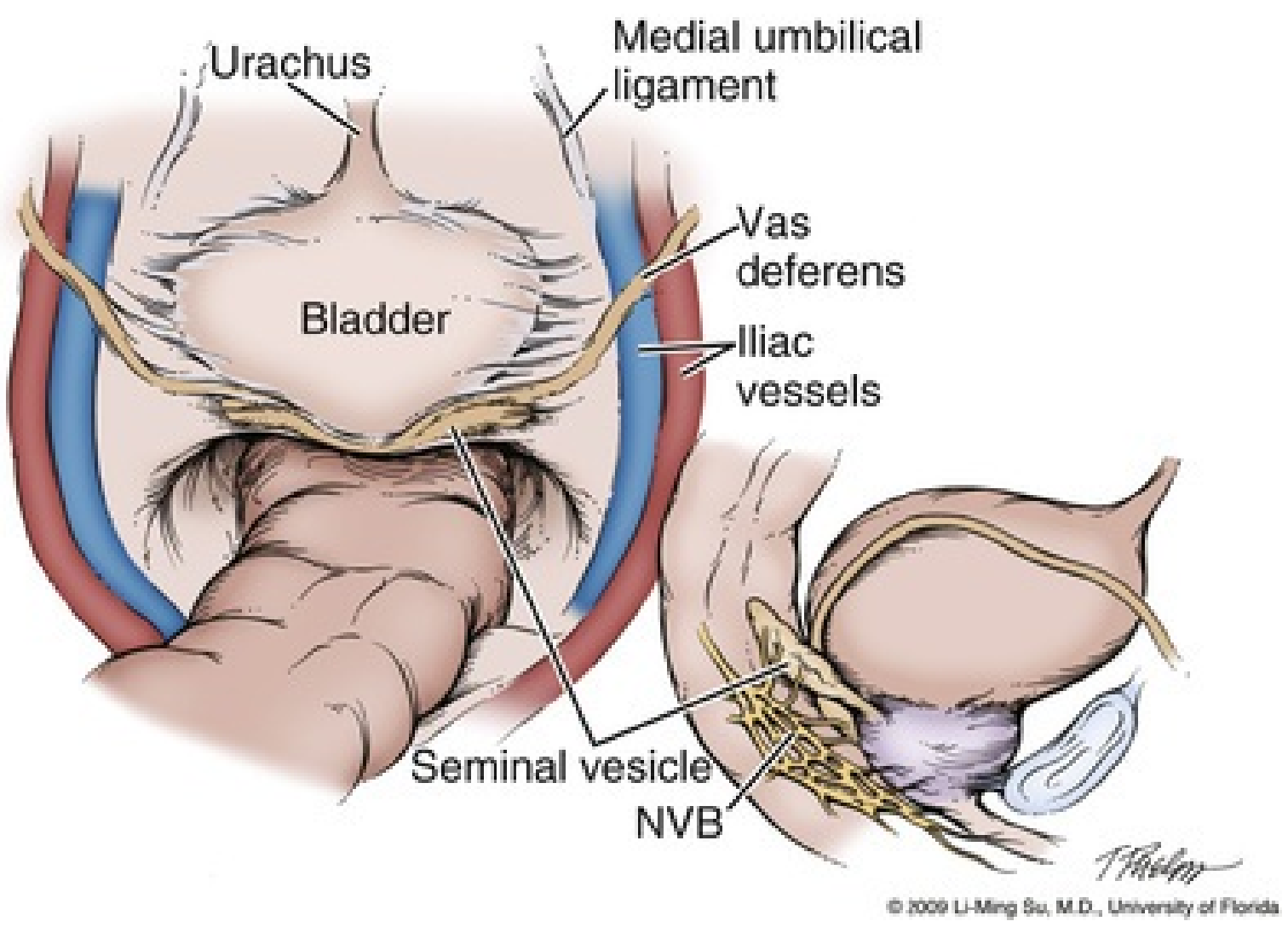
Urachus
Medial umbilical ligament
Vas deferens
Bladder
Iliac vessels
Seminal vesicle
NVB
© 2009 Li-Ming Su, M.D., University of Florida

FIG. 156.5 Initial transperitoneal view detailing the relevant landmarks within the male pelvis. *NVB,* neurovascular bundle. (Copyright Li-Ming Su, MD, University of Florida, 2009.)

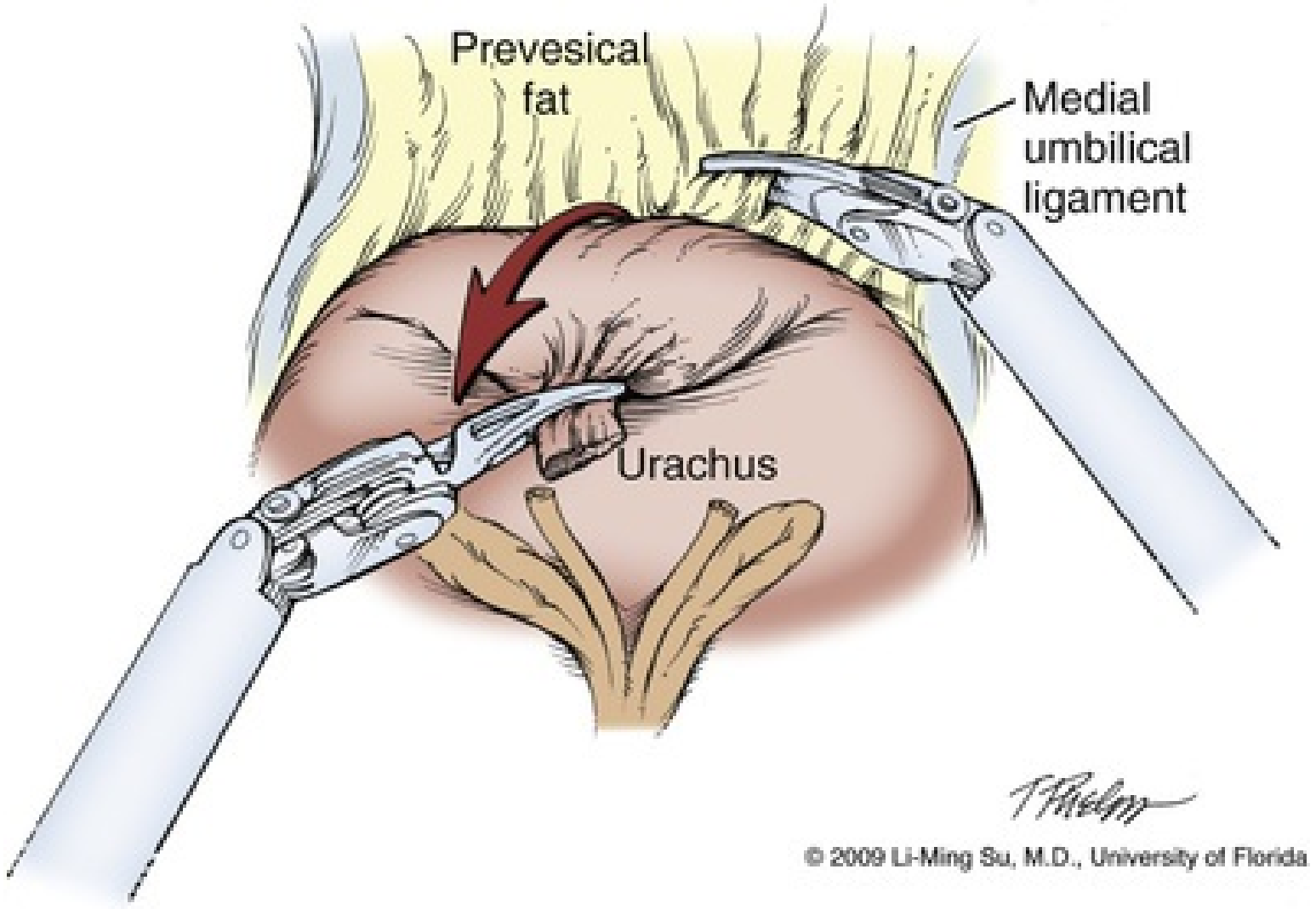
Prevesical fat
Medial umbilical ligament
Urachus
© 2009 Li-Ming Su, M.D., University of Florida

FIG. 156.6 Division of urachus and entry into the space of Retzius. Cephalad traction on the urachus with the left hand helps identify the fatty alveolar tissue immediately anterior to the bladder, which marks the proper plane of dissection. (Copyright Li-Ming Su, MD, University of Florida, 2009.)

At this point, visible landmarks include the anterior aspect of the bladder and prostate, puboprostatic ligaments, endopelvic fascia, and pubis (Fig. 156.7). The endopelvic fascia and puboprostatic ligaments are sharply divided, exposing levator muscle fibers attached to the lateral and apical portions of the prostate.

These fibers are meticulously preserved and bluntly dissected from the surface of the prostate exposing the deep DVC and urethra at their confluence with the prostatic apex. Electrocautery is avoided if possible to minimize thermal damage to the pelvic musculature, external sphincter, and nearby NVBs.

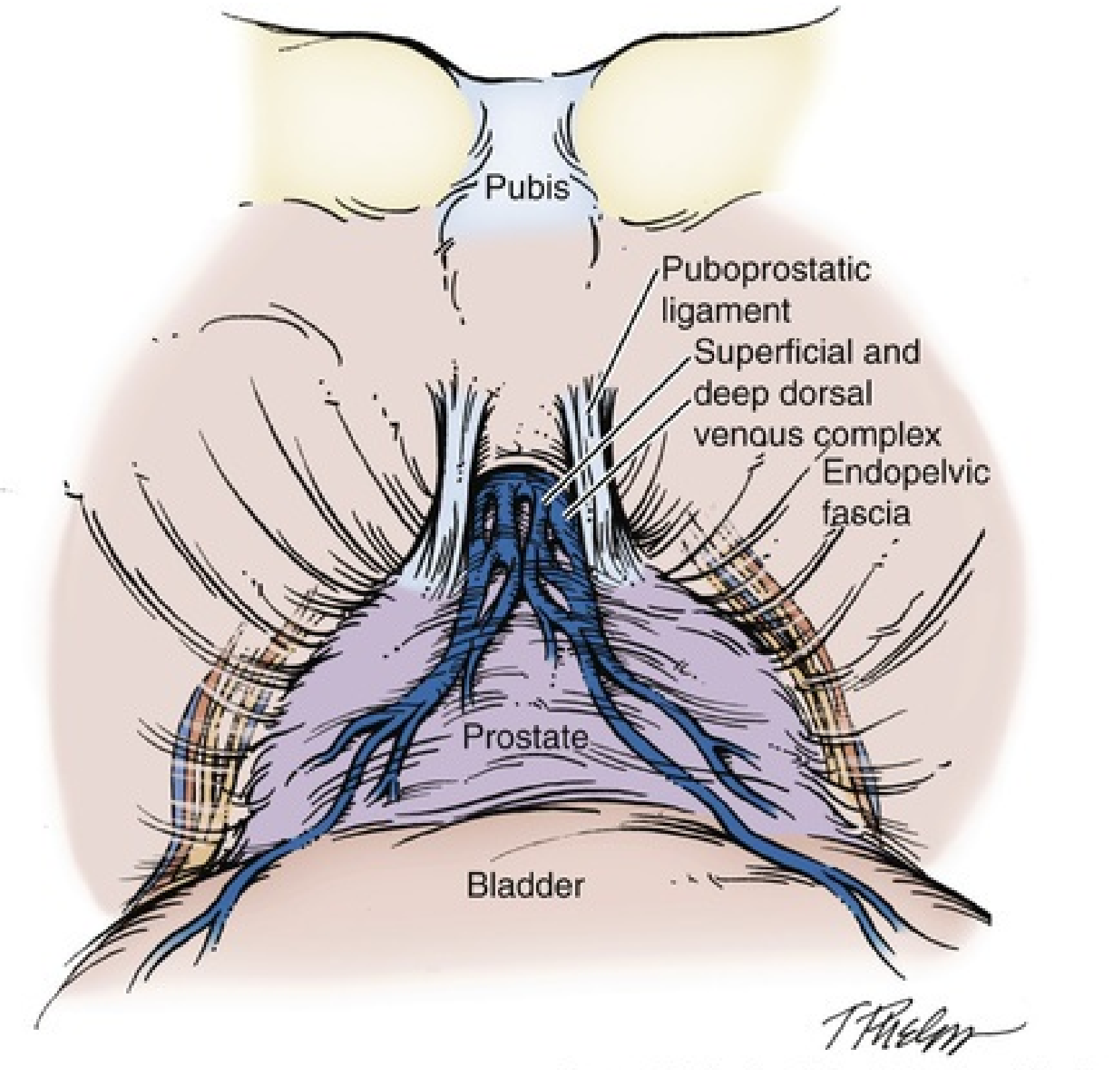

© 2009 Li-Ming Su, M.D., University of Florida

FIG. 156.7 Retropubic view of the bladder and prostate after entry into the space of Retzius. The fatty tissue overlying the anterior aspect of the prostate has been removed, exposing the puboprostatic ligaments, superficial and deep dorsal venous complex, and endopelvic fascia. (Copyright Li-Ming Su, MD, University of Florida, 2009.)

Accessory pudendal arteries traveling longitudinally along the anteromedial aspect of the prostate are easily recognized during LRP and RALRP. Attempt at preservation of these arteries is important for erectile function because in some men these arteries may be the dominant source of arterial blood supply to the corpora cavernosa (Nehra et al., 2008). These accessory arteries can usually be preserved, although separation of the artery from the prostatic apex and deep DVC can sometimes be challenging.

Ligation of the Deep Dorsal Venous Complex

As with open surgery, different methods have been described for control of the deep DVC. **A common observation, though, is that the profuse bleeding, which is sometimes encountered during open surgery, is less apparent because of the tamponade effect on venous bleeding offered by the pneumoperitoneum, even when the DVC is inadvertently entered.** During RALRP, the ProGrasp forceps can be used for fixed cephalad retraction of the prostate and bladder to achieve optimal exposure of the DVC and prostatic apex before DVC ligation. Similar retraction can be applied by the surgical assistant during LRP. The deep DVC is suture ligated using a 0-polydioxanone suture or polyglactin suture as close to the pubis and as far from the prostatic apex as possible (Fig. 156.8). **Securing the deep DVC as far distal from the prostatic apex as possible can help minimize iatrogenic entry into the prostatic apex during later division of the DVC.** For this reason, it is the authors’ opinion that the puboprostatic ligaments should be completely divided before ligation of the DVC to allow for adequate exposure and access to the most distal portion of the DVC as it traverses beneath the pubic symphysis. The needle is passed beneath the DVC and anterior to the urethra. A second more distal DVC stitch can be placed and used to suspend the DVC to the inferior pubic symphysis.

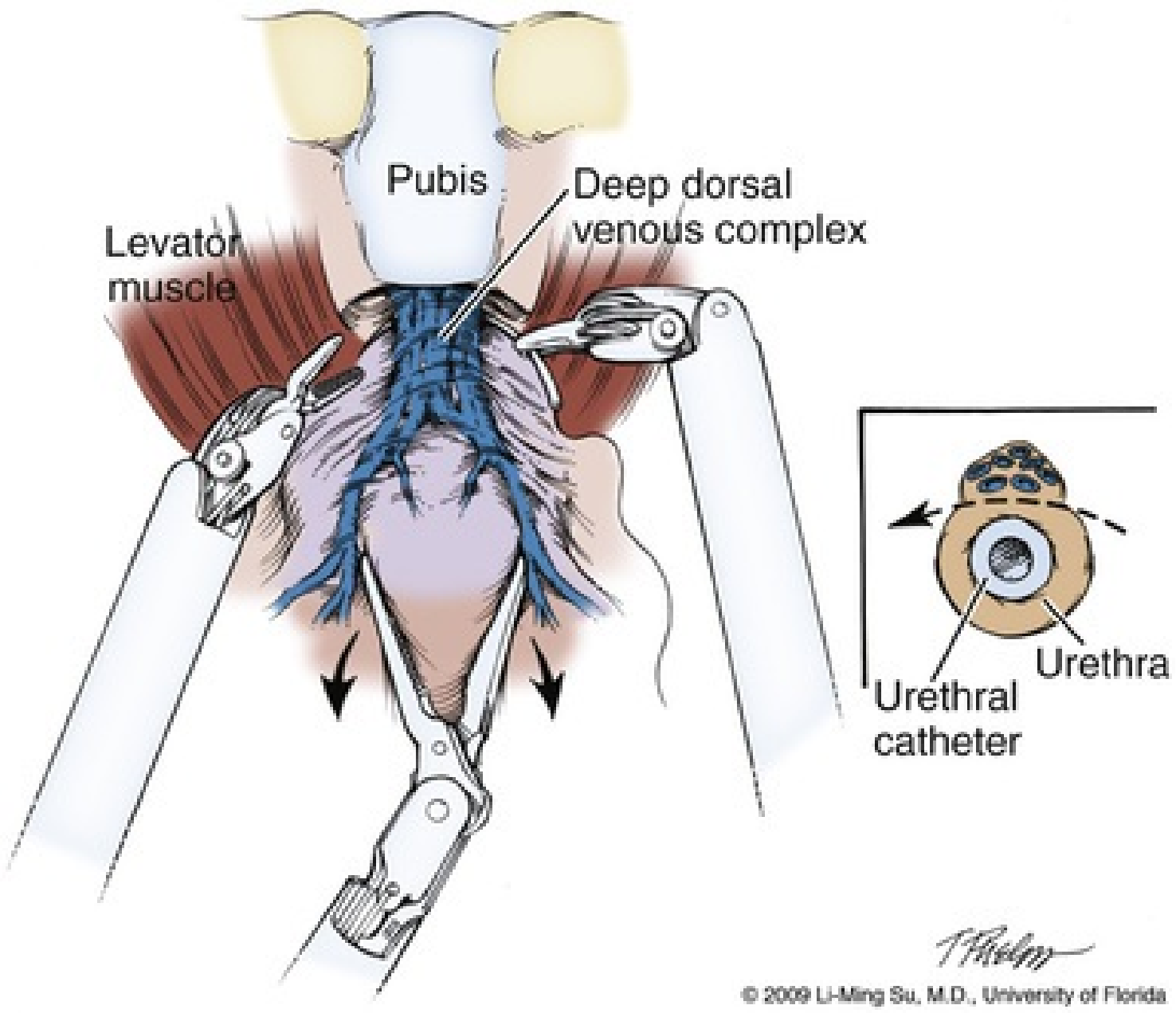
Pubis
Deep dorsal venous complex
Levator muscle
Urethra
Urethral catheter
© 2009 Li-Ming Su, M.D., University of Florida

FIG. 156.8 Ligation of the deep dorsal venous complex. A suture is passed from right to left, ligating the dorsal vein as distal as possible from

the apex. *Inset* demonstrates the proper passage of the needle immediately anterior to the urethra. (Copyright Li-Ming Su, MD, University of Florida, 2009.)

An alternative method to DVC ligation is the use of a laparoscopic linear stapling device, which ligates and divides the DVC in one step (Ahlering et al., 2004; Nguyen et al., 2008). Lastly, management of the DVC can also be left until the final steps of prostatic apical dissection and division of the urethra. At this point, the DVC can be sharply divided and then oversewn in a vertical mattress fashion. It may be helpful to briefly increase the pneumoperitoneum to 20 mm Hg during this step to tamponade venous bleeding and improve visualization. A back-bleeding suture may be placed along the anterior base of the prostate to help identify the contour of the prostate and aid in subsequent bladder neck identification and transection.

Bladder Neck Identification and Transection

Proper identification of the bladder neck during RALRP and LRP can be initially challenging because of the lack of tactile feedback in delineating the precise margin between the prostate and bladder. **Several maneuvers are helpful in identifying the proper plane of dissection and in minimizing inadvertent entry into the base of the prostate. First, visual identification of the point of transition of the prevesical fat to the anterior prostate now devoid of fat can serve as a guide. Second, intermittent and repetitive caudal retraction of an inflated urethral catheter balloon can help identify and confirm the approximate transition between bladder neck and prostate. Note that any deviation of the balloon away from the midline signifies the likely presence of a median lobe of the prostate. Note that this maneuver may be less reliable in patients with a TURP, where the balloon may fall into the TURP defect, misleading the surgeon in transecting the bladder neck in a too-distal location. In such cases, a more proximal division of the bladder neck is advised. Third, using a forceps to grasp and retract the dome of the bladder in a cephalad direction results in tenting of the bladder neck at its attachment to the prostate. Finally, further confirmation of this margin between the bladder and prostate is made by a bimanual “palpation” or pinch of the bladder neck using the tips of two robotic or laparoscopic instruments.**

The anterior bladder is divided horizontally using monopolar scissors along the midline until the urethral catheter is identified. **The anterior bladder neck incision should not be carried too far laterally because branches of the bladder pedicle are often encountered, resulting in unwanted bleeding.** The balloon is decompressed, and the tip of the urethral catheter is brought through the bladder neck opening and lifted anteriorly with the assistant applying countertraction externally at the penile meatus to “suspend” the prostate.

The posterior bladder neck is inspected for the presence of a median lobe and to locate the ureteric orifices. If a vertical drop-off of the posterior bladder neck mucosa is noted, this often suggests the absence of a median lobe. Alternatively, if a mass effect from a large median lobe is identified, it may be delivered out of the bladder by anterior retraction with a ProGrasp forceps. However, further exposure by a transverse or even sagittal cystotomy may be required to visualize beneath a large, protruding median lobe and identify the posterior bladder neck. **The posterior bladder neck is horizontally divided with monopolar scissors, staying again along the midline to avoid bleeding from the lateral pedicles** (Fig. 156.9). **Dissection is carried out in a 45-degree downward angle to avoid entry into the base of the prostate or inadvertent entry into the posterior wall of the bladder.** In case of a prior TURP, the bladder neck margin is less evident and often distorted as a result of prior resection and scarring. Careful inspection is made of the posterior bladder neck, paying specific attention to the location of the ureteric orifices because they are often found very close to the posterior bladder neck margin. Attempt at bladder neck sparing should be avoided in post-TURP and median lobe cases. Switching to a 30-degree down lens may improve visualization in these cases. When in doubt, the posterior bladder neck should be divided slightly more proximally in these particular cases so as to avoid inadvertent entry into the prostate gland with a resultant positive bladder neck margin.

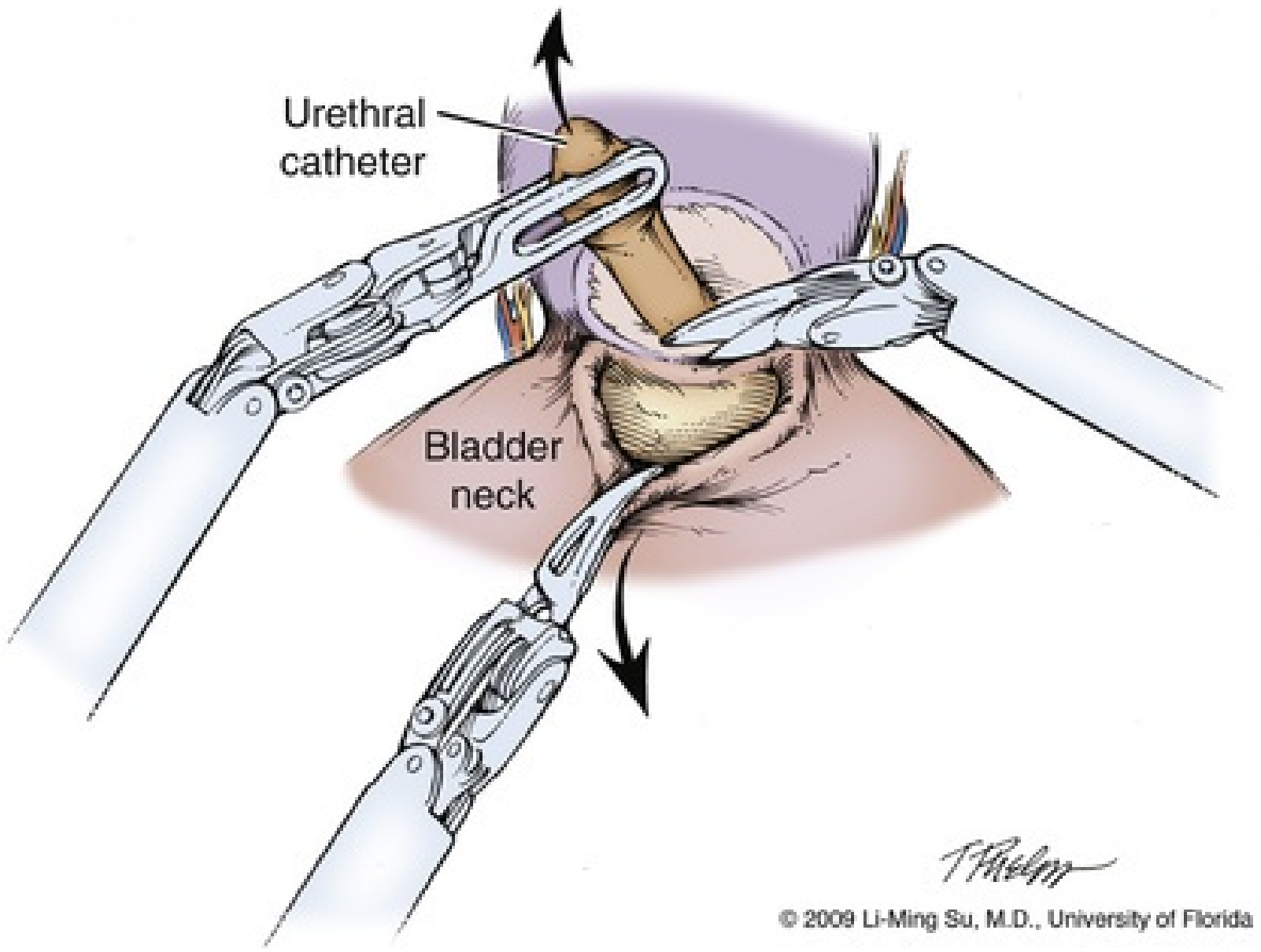

FIG. 156.9 Division of the posterior bladder neck. An assistant or ProGrasp forceps is used to grasp and elevate the urethral catheter anteriorly, providing exposure to the posterior bladder neck. Dissection is carried out along the midline, avoiding bleeding from the lateral pedicles. (Copyright Li-Ming Su, MD, University of Florida, 2009.)

Dissection of the Seminal Vesicles and Vasa Deferentia

After bladder neck transection, the seminal vesicles and vasa deferentia are individually identified, dissected, and divided, minimizing electrocautery if possible to prevent damage to the nearby NVBs (Fig. 156.10). One unique distinction between the transperitoneal anterior and retrovesical approaches is in dissection of the seminal vesicles and vasa deferentia. During the transperitoneal retrovesical approach, the initial step of the operation is dissection of the vasa deferentia and seminal vesicles deep within the cul-de-sac. After abdominal access, the vasa are dissected from lateral to medial toward their confluence at the ejaculatory ducts. The seminal vesicles are found immediately lateral and slightly posterior to the distal portion of the vasa and are dissected free from the nearby NVB using hemoclips while avoiding the use of thermal energy (Fig. 156.11). With the dissection of the seminal vesicles and vasa now completed under excellent vision, these structures are simply grasped and brought through the opening once the bladder neck is divided from the prostate base later in the operation. **This retrovesical approach to the seminal vesicles and vasa**

deferentia is particularly useful in cases of a median lobe in which identification and dissection of these structures by the anterior approach may be more challenging because of the physical presence of the protruding median lobe, which may obscure the identification of the vasa and seminal vesicles, in addition to the presence of urine and blood in the operative field.

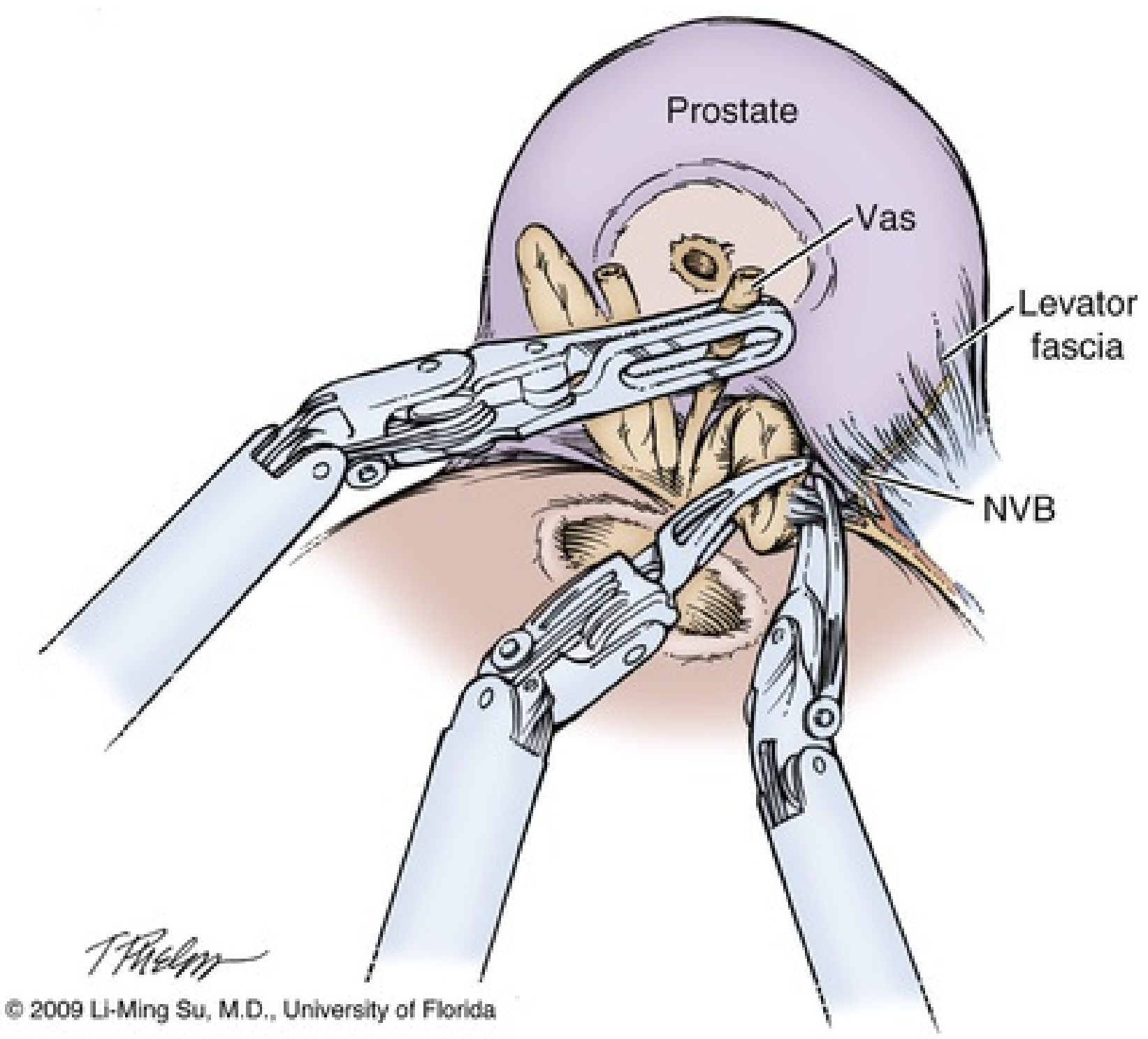

FIG. 156.10 Dissection of seminal vesicles and vasa deferentia via the transperitoneal anterior approach. The seminal vesicles and vasa are identified and dissected within the opening created between the posterior bladder neck and prostate following division of the bladder neck. Hemoclips are used in lieu of electrocautery to avoid thermal injury to the nearby neurovascular bundles (NVBs). (Copyright Li-Ming Su, MD, University of Florida, 2009.)

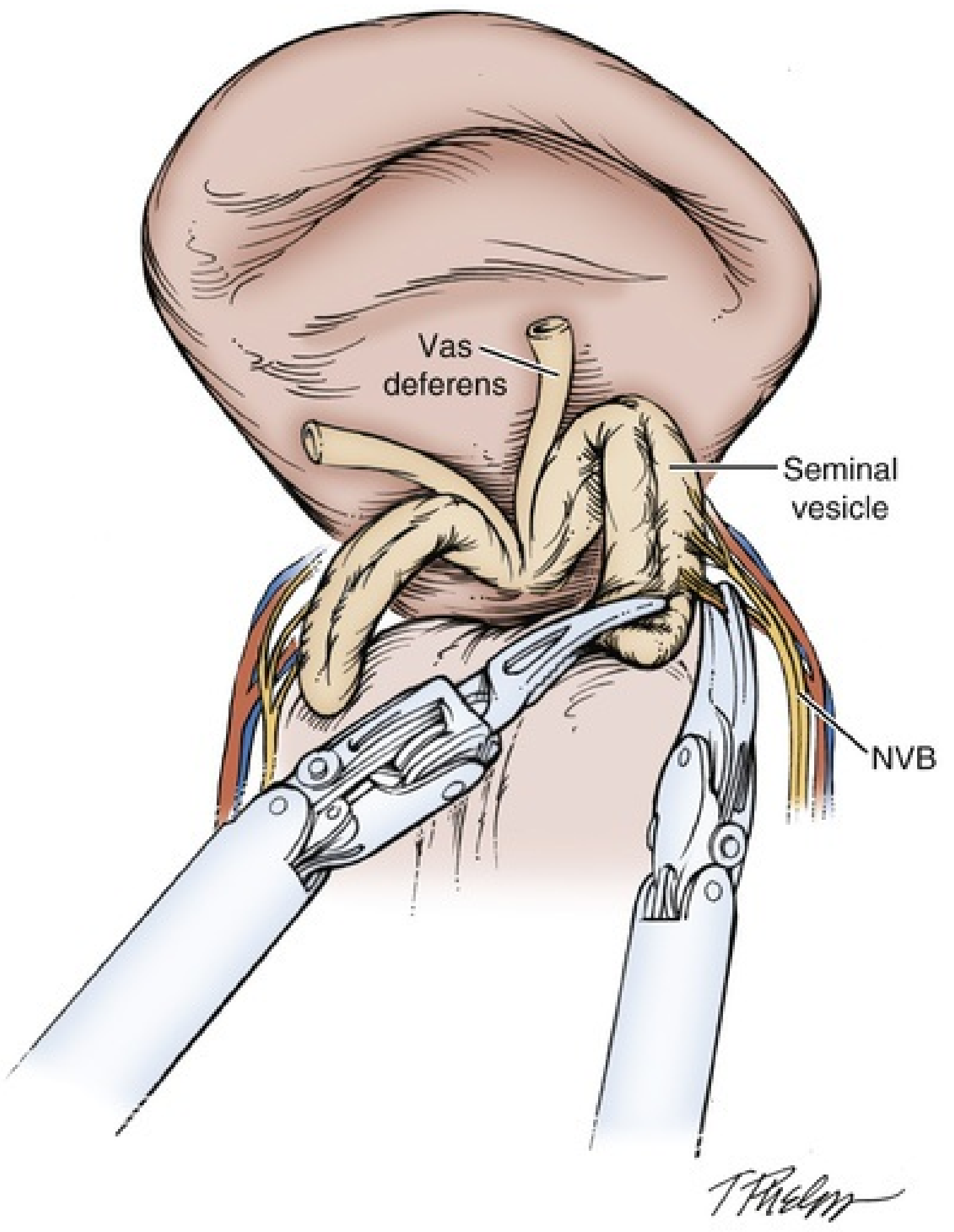

© 2009 Li-Ming Su, M.D., University of Florida

FIG. 156.11 Dissection of seminal vesicles and vasa deferentia via the transperitoneal retrovesical approach. The vasa and seminal vesicles are identified as the initial step in this approach deep within the retrovesical space. The neurovascular bundles (NVBs) are dissected off of the seminal vesicles in an antegrade direction from the tip toward the base using hemoclips. (Copyright Li-Ming Su, MD, University of Florida, 2009.)

Development of the Plane Between the Prostate and Rectum

Separation of the posterior prostate from the anterior rectal wall is a key surgical maneuver to avoid rectal injury but also permit adequate identification of the medial aspect of the prostatic pedicles and establish the medial border of the NVBs. Development of this plane in an antegrade fashion is a maneuver that is less familiar to surgeons who are experienced with open surgery but one that is rapidly adaptable to laparoscopic and robotic approaches. Anterior retraction of the vasa deferentia and seminal vesicles by a surgical assistant or the robotic ProGrasp forceps helps with identification of the proper plane for the initial dissection (Fig. 156.12). The authors typically make a 2- to 3-cm horizontal incision through the posterior layer of Denonvilliers fascia approximately 0.5 cm below the base of the seminal vesicles.

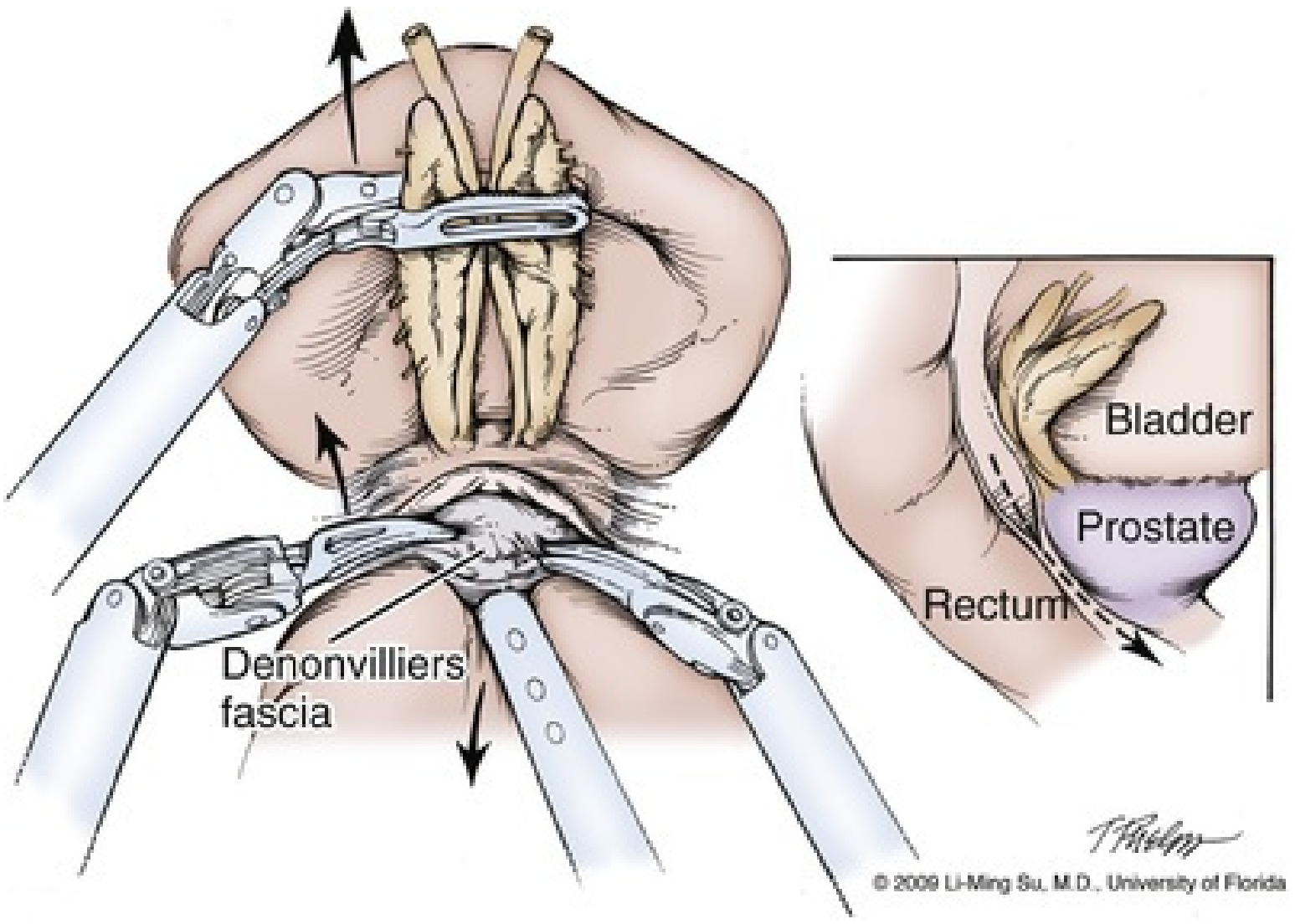

FIG. 156.12 Development of the plane between the prostate and rectum. As the assistant or ProGrasp forceps is used to apply anterior traction on the seminal vesicles and vasa deferentia and downward traction on the rectum, a transverse incision is made in Denonvilliers fascia below the seminal vesicles, and blunt dissection is used to develop a plane between the posterior prostate and the rectum. *Inset* demonstrates the direction of dissection toward the prostatic apex without electrocautery. (Copyright Li-Ming Su, MD, University of Florida, 2009.)

Denonvilliers fascia is an inferior extension of the peritoneal cul-de-sac that lies between the prostate and rectum. In patients with low-risk and low-volume disease for whom extensive NVB dissection is planned, Denonvilliers fascia can be separated from the posterior prostate by careful blunt and sharp dissection, dissecting between this layer and the prostatic fascia. This plane of dissection is relatively avascular and should be carried all the way to the prostatic apex and laterally to the medial aspect of the prostatic pedicle. Switching to a 30-degree up lens may facilitate further apical dissection. **Alternatively, when a wider margin of tissue is desired along the posterior aspect of the prostate, such as in cases of palpable disease, Denonvilliers fascia should be sharply incised.**

This allows immediate entry into the anterior perirectal fat plane of dissection. Good visualization can be achieved as the dissection proceeds distally toward the apex staying between Denonvilliers fascia anteriorly and the anterior propria fascia of the rectum posteriorly.

Substantial bleeding typically suggests that the dissection may be too close to the prostate. If difficulty is encountered in establishing the proper plane of dissection, a new attempt can be directed to one side or the other of the initial entry point. Once the proper plane is entered, the dissection characteristically progresses rather smoothly by blunt dissection. The rectal wall should be mobilized far enough laterally and distally so as to minimize any further risk for rectal entry on subsequent steps of the operation.

Prostatic Pedicle Control

Various methods have been described for control of the prostatic pedicle. Some techniques use pure electrocautery, either monopolar or bipolar. **Because of the propagation of thermal energy through tissue, which may result in damage to the nearby NVB, limitation of the use of electrocautery is advised and, if possible, should be avoided during division of the prostatic pedicle.** Locking polymer Hem-o-lok clips (Teleflex Medical, Research Triangle Park, NC) are commonly employed for ligation of the prostatic pedicles with sharp athermal transection. However, engagement of the clipping mechanism with these hemoclips does require good proximal and distal delineation and thinning of the pedicle tissue for the clipping mechanism to engage. It is important to remove any clips that fall off and to avoid placing these clips in close proximity to the vesicourethral anastomosis as migration of the clips into the bladder can lead to postoperative voiding symptoms, hematuria, recurrent urinary tract infections, and bladder stones (Fig. 156.13). This is best facilitated by adequate mobilization of the rectum and lateral prostate for identification of the prostatic pedicle. Application of a temporary bulldog clamp to the pedicle with subsequent suturing of the pedicle after the prostate specimen has been removed also has been described (Ahlering et al., 2005; Gill et al., 2005). Regardless of the method used, though, successful division of the prostatic pedicle in the correct anatomic location is an important step in avoiding positive margins and damage to the nearby NVB.

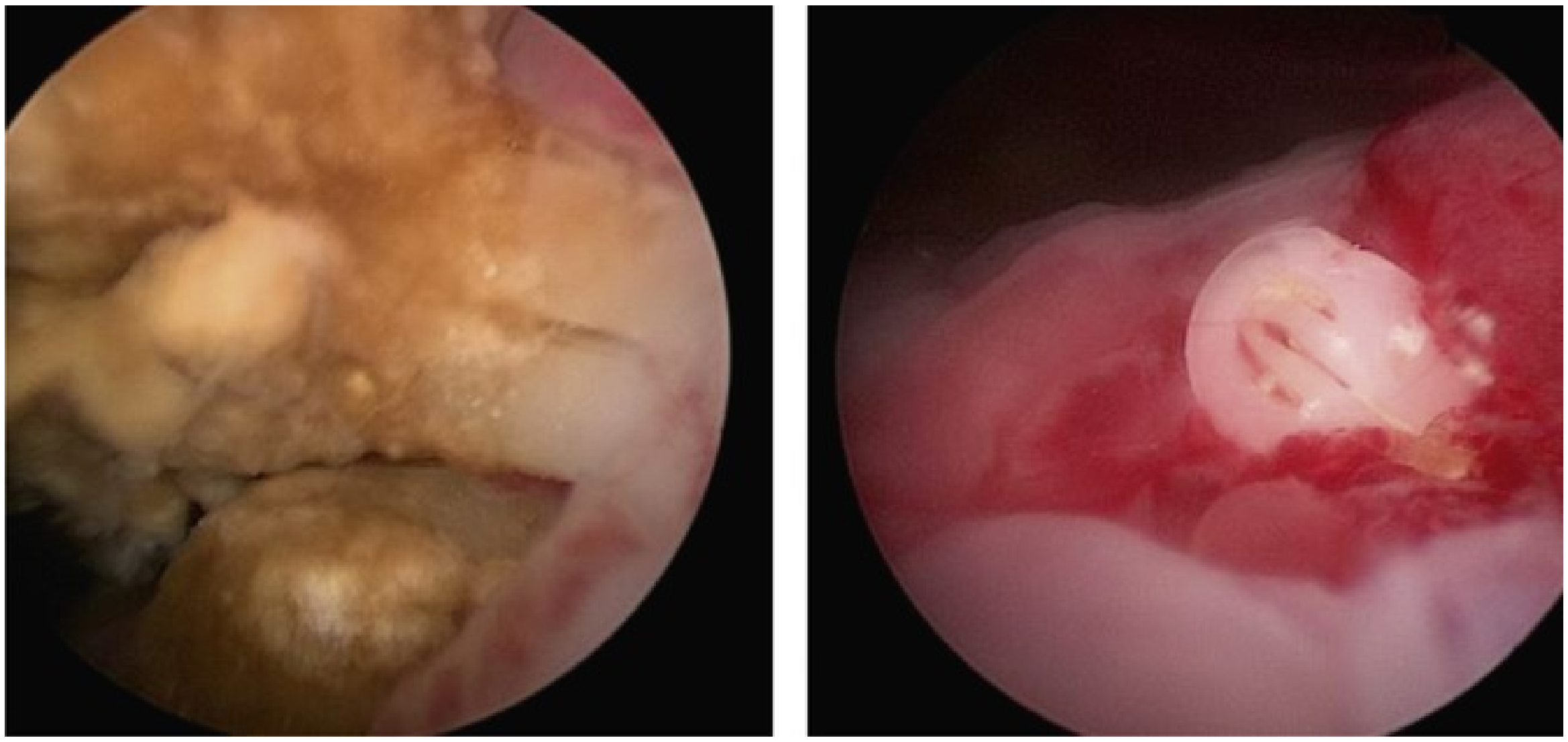

FIG. 156.13 Eroded Hem-o-lok clips discovered at time of cystoscopy in a patient with gross hematuria secondary to a bladder stone that formed on the eroded clip following robotic-assisted laparoscopic prostatectomy. (Courtesy of Li-Ming Su, MD.)

Preservation of the Neurovascular Bundle

Preservation of the periprostatic parasympathetic nerve fibers important for erectile function is one of the key and most technically demanding maneuvers during radical prostatectomy, regardless of surgical approach. **Increasingly, it is recognized that the periprostatic nerves of significance have a more diffuse and highly variable course than previously thought**, **but there is a confluence of nerves along the posterolateral aspect of the prostate commonly believed to be the predominant nerves responsible for penile erections** (Costello et al., 2004; Lunacek et al., 2005; Takenaka et al., 2004). Nerve tissue extends posteriorly around the prostate, forming a virtual hammock of nerves. In addition, nerve fibers can be identified in the periprostatic tissue along the more anteromedial portion of the prostate gland, although there is still debate about their relative function and contribution to penile erections. A well-performed, nerve-sparing radical prostatectomy takes all of these considerations into account and preserves as much periprostatic nerve tissue as possible, both from a qualitative and quantitative standpoint.

The superb visualization of the periprostatic tissues with minimally invasive surgery has led to a greater appreciation of the periprostatic fascial layers. Although there is some confusion in the literature regarding the terminology used for the various fascial layers, an *extrafascial* dissection typically implies dissection laterally between the lateral prostatic fascia and the levator fascia and posteriorly between Denonvilliers fascia and the anterior propria rectal fascia. **An *interfascial* dissection is carried out laterally between the prostatic fascia and the levator fascia and posteriorly between Denonvilliers fascia and the posterior surface of the prostate** (Fig. 156.14). **This is the preferred approach in patients with presumed organ-confined disease because it permits safe preservation of the cavernous nerves without violating the anatomic limits of the prostate gland and capsule.** Historically the periprostatic vasculature within the interfascial space has been used as a macroscopic landmark and visual surrogate for identifying and preserving the cavernous nerves. Patel et al. suggested that a dominant periprostatic artery specifically can be identified in 73% of cases during RALRP and can serve as a consistent landmark for cavernous nerve preservation (Patel et al., 2012). Finally, an *intrafascial* dissection is carried out between the prostatic capsule and the prostatic fascia and leaves virtually no periprostatic tissue overlying the prostate. Although technically feasible, this approach risks a higher incidence of positive margins because of the relatively closer dissection to the prostate gland.

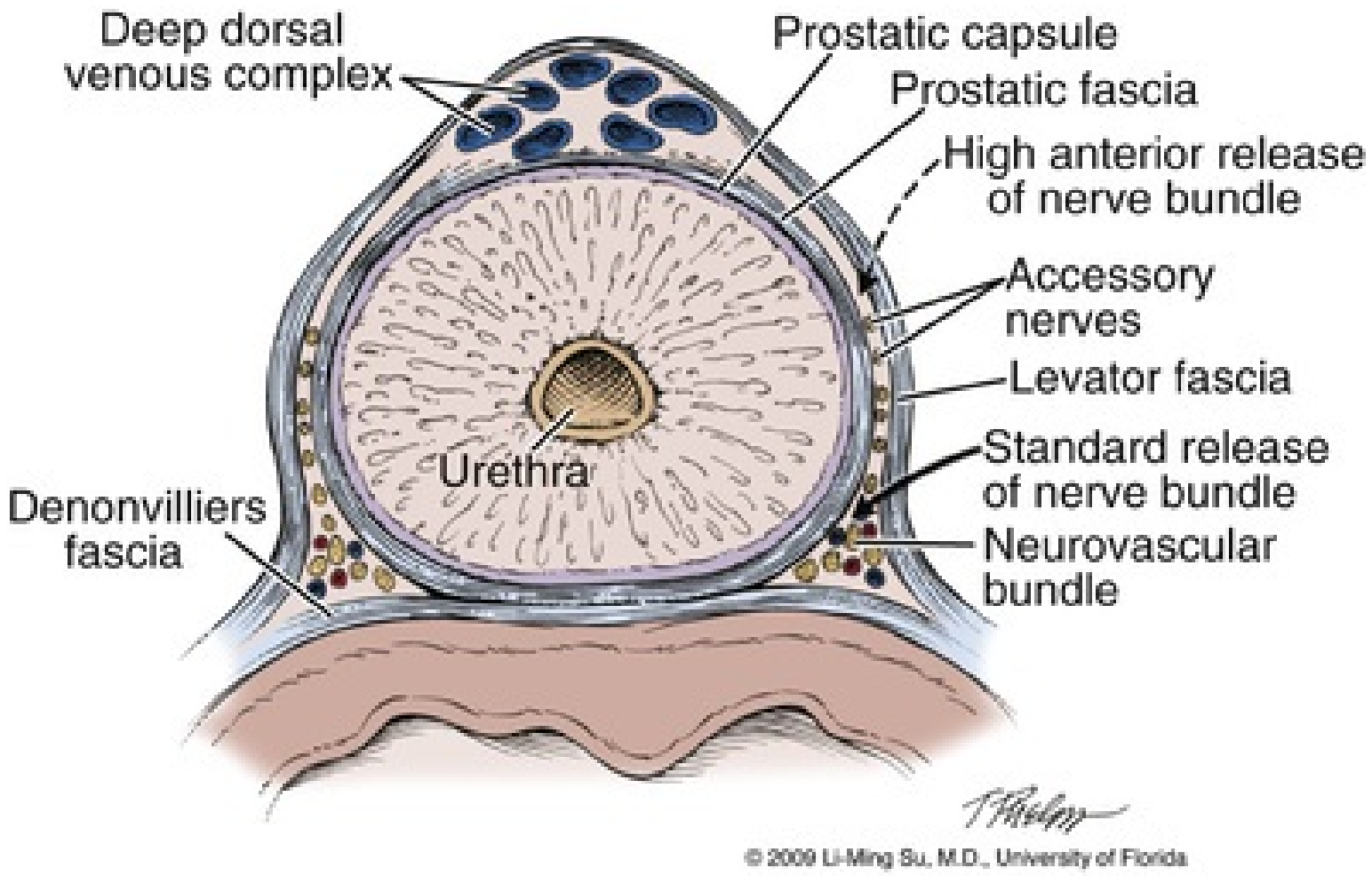
Deep dorsal venous complex
Prostatic capsule
Prostatic fascia
High anterior release of nerve bundle
Accessory nerves
Levator fascia
Urethra
Standard release of nerve bundle
Denonvilliers fascia
Neurovascular bundle
© 2009 Li-Ming Su, M.D., University of Florida

FIG. 156.14 Cross-section of the prostate demonstrating the periprostatic fascial planes with respect to the location of the neurovascular bundles (NVBs). The dashed line indicates the direction of interfascial dissection (i.e., between the levator and prostatic fascia) to accomplish a high anterior release of the NVB from the prostate and establish the lateral NVB groove. The solid line indicates the incision made for a standard release of the NVB. (Copyright Li-Ming Su, MD, University of Florida, 2009.)

Damage to the NVB can occur because of direct incision, entrapment in a suture or clip, thermal injury, or traction. Some surgeons advocate release of the NVB from the prostate before mobilization of the specimen to help avoid traction injury. **With the antegrade approach to NVB dissection typically used for LRP and RALRP, identification and at least partial release of the NVB along the lateral aspect of the prostate before controlling the prostatic pedicle can help drop the neurovascular tissue away from the gland and permit a more precise placement of hemoclips on the pedicle while preventing inadvertent entrapment of the nerve bundles.** To accomplish this, the levator fascia is first incised sharply along the anteromedial aspect of the midportion of the prostate entering into the interfascial plane of dissection (Fig. 156.15). Blunt dissection is carried out along the shiny, white-appearing prostatic fascial plane, gently sweeping the NVB off of the prostate in a posterolateral direction, thus partially releasing the NVB and developing a visible NVB groove. This groove serves as a visible landmark for precise hemoclip placement and division of the prostatic pedicle while avoiding entrapment of the NVB (Fig. 156.16). The ergonomics and scaled motion of the wristed robotic instruments are helpful in achieving this delicate dissection. During LRP, specially designed fine-tipped (0.8-mm) dissectors have been described to aid in NVB dissection and preservation (Su et al., 2004). Some discussion and debate has centered on how far anteriorly on the prostate the interfascial dissection of the nerve bundles should be performed. It is uncertain whether high release (vs. standard release) of the NVBs preserves important nerves or simply allows for a physical handle to permit more precise, meticulous dissection and preservation of the true cavernous nerves located at the 5-o'clock and 7-o'clock positions without direct manipulation of these main nerve fibers (see Fig. 156.14). **However, there is a general consensus that thermal energy should be minimized and, ideally, completely avoided during dissection of the NVB as these microscopic parasympathetic nerve fibers are highly susceptible to thermal injury, as demonstrated in both animal and human studies** (Ahlering et al., 2005; Ong et al., 2004). After completion of the NVB dissection, bleeding along the NVBs is generally minimal and may require no specific hemostatic measures. However, small arteries or a larger venous sinus may require suturing to achieve hemostasis with site-specific small tissue bites used to avoid entrapment of adjacent nerves.

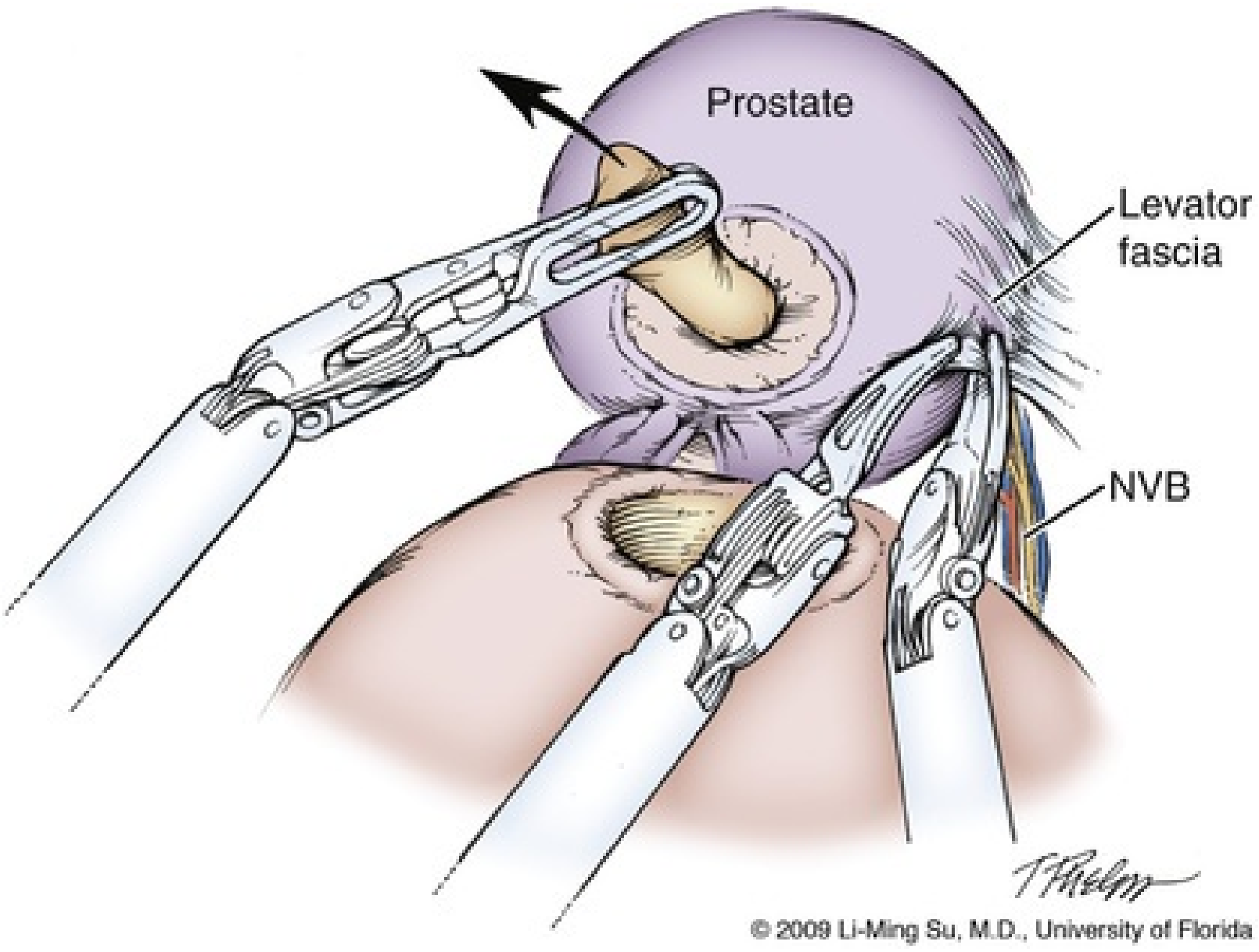
Prostate
Levator fascia
NVB
© 2009 Li-Ming Su, M.D., University of Florida

FIG. 156.15 Entering into the interfascial plane of dissection for neurovascular bundle *(NVB)* preservation. The levator fascia is first incised along the anteromedial aspect of the midprostate, allowing entry into the interfascial plane of dissection. (Copyright Li-Ming Su, MD, University of Florida, 2009.)

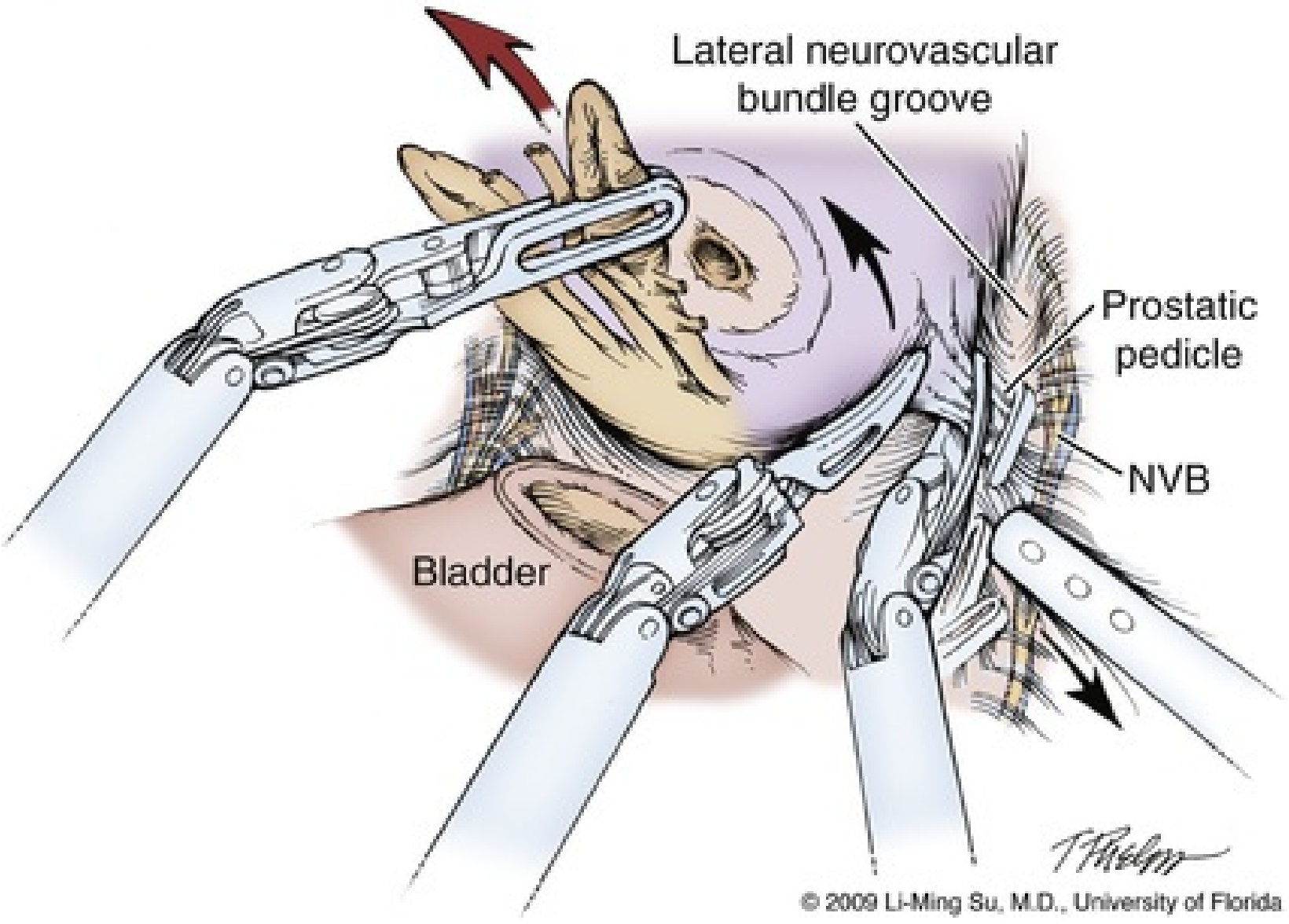
Lateral neurovascular bundle groove
Prostatic pedicle
NVB
Bladder
© 2009 Li-Ming Su, M.D., University of Florida

FIG. 156.16 Developing the interfascial plane of dissection. Using blunt dissection, the nerve bundle is partially released from the prostate in a posterolateral direction, forming a visible lateral neurovascular bundle *(NVB)* groove. This step serves to delineate the prostatic pedicle and course of the nerve bundle and allow for precise placement of hemoclips, while avoiding nerve entrapment. (Copyright Li-Ming Su, MD, University of

Florida, 2009.)

Patients with extremely large prostate glands (especially those >100 g) offer a unique challenge during preservation of the NVB. Maneuvering a large prostate gland in the tight confines of the pelvic cavity can be challenging, especially during exposure of the prostatic pedicles and NVB. Effective exposure of tissues by the surgical assistant, as well as the fourth robotic arm, and potentially switching to a 30-degree down lens may be useful in such cases.

Apical Dissection

The prostatic apex is a common location for tumor involvement and the most common site of positive margins with radical prostatectomy. Further, the steps required for apical dissection are crucial to preservation of erectile function and avoidance of urinary incontinence. The visualization of the operative field and the ability to limit bleeding from the deep DVC facilitate apical prostatic dissection during LRP and RALRP.

Up to this point in the operation, antegrade dissection of the prostate has permitted complete mobilization of the lateral, base, and posterior prostate, leaving division of the deep DVC and urethra from the prostatic apex for last. **It is critical to avoid entry into the anterior prostate during division of the deep DVC because this may result in an iatrogenic positive margin.** If the previously placed DVC suture appears to be too proximal in its location, risking iatrogenic entry into the prostatic apex during transection, the surgeon should feel comfortable removing this stitch to achieve a wide enough margin of transection at the apex and simply resuturing the DVC once it is divided. Bleeding from the deep DVC can be kept to a minimum by transiently increasing the CO_2 insufflation pressure to 20 mm Hg to improve the tamponade effect on venous bleeding.

Once the DVC is divided, there should be good visualization of the prostatic apex and its junction with the urethra (Fig. 156.17). **The anatomy of the prostatic apex is highly variable and should be carefully inspected before division of the urethra. As much urethral length as possible should be maintained, but a protruding anterior or posterior lip of prostate must be recognized, so as to avoid inadvertently leaving prostatic tissue behind.** Leaving a small rim of urethra along the prostatic apex may be advisable to reduce the incidence of apical positive margins because this does not appear to have an adverse effect on the return of urinary continence (Borin et al., 2007). Sharp dissection with limited use of electrocautery is preferred during the prostatic apical dissection and division of the urethra, to prevent thermal injury to the nearby external striated sphincter and NVBs.

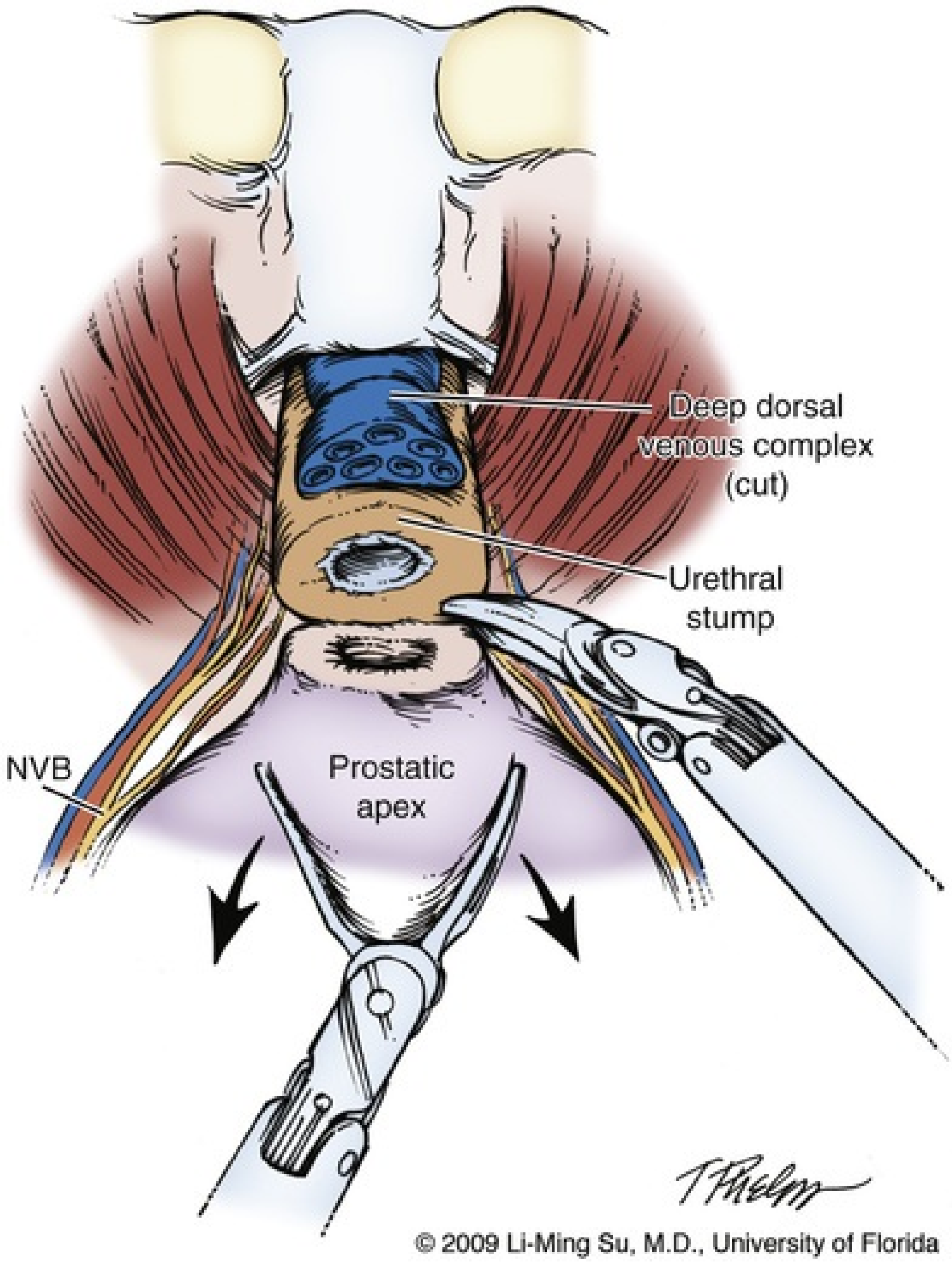

© 2009 Li-Ming Su, M.D., University of Florida

FIG. 156.17 Division of urethra. After division of the deep dorsal venous complex, the anterior and posterior urethra is divided sharply without electrocautery. A small rim of urethra may be safely left on the prostatic apex to avoid an iatrogenic positive apical margin. Great care must be taken to avoid damage to the nearby nerve bundles. *NVB,* neurovascular bundle. (Copyright Li-Ming Su, MD, University of Florida, 2009.)

Intraoperative Inspection of Prostate

On completely freeing the prostate gland and before entrapment of the

specimen, the entire surface of the gland can be inspected to assess the adequacy of resection and integrity of the tissues covering the prostate specimen. If concern exists regarding a close surgical margin, additional tissue may be excised specific to the location of concern; however, with experience this should rarely be necessary.

Pelvic Lymphadenectomy

It is generally at this time that pelvic lymphadenectomy takes place, because prior mobilization of the bladder allows for excellent exposure of the obturator lymph node region and iliac vessels. The extent of pelvic lymphadenectomy remains controversial but can be tailored on the basis of cancer risk categorization, including PSA, clinical stage, and Gleason score. Technical description of a standard versus extended laparoscopic pelvic lymphadenectomy follows later in this chapter. It is advised that hemoclips be used during pelvic lymphadenectomy to minimize the risk for developing a postoperative lymphocele.

Entrapment of Specimens

The prostate and pelvic lymph nodes are entrapped within a 10-mm laparoscopic entrapment sack introduced into the abdomen by the surgical assistant through the 12-mm assistant trocar and stored in the abdomen until completion of the operation.

Bladder Neck Reconstruction

The bladder opening is often slightly larger than the urethral lumen, but a parachuting effect can be achieved during the vesicourethral anastomosis that allows direct approximation of the bladder neck to the urethra. **In the event of a large prostate gland, median lobe, or prior TURP, the bladder neck often may be disproportionately larger than the urethra and thus may require extensive reconstruction before performing the anastomosis. In such cases, a tennis racquet handle closure can be performed using absorbable suture either posteriorly or anteriorly to reduce the size discrepancy between the bladder neck and urethra. Often, in these circumstances, the ureteric orifices are located at or near the posterior margin of the bladder neck,**

where they are at risk for injury or obstruction during suturing of the anastomosis. It is imperative to identify their precise location in these unique circumstances before proceeding with bladder neck reconstruction. If they cannot be adequately visualized, intravenous methylene blue or indigo carmine can be given. In such cases, the ureteric orifices can be imbricated by placing a few interrupted sutures at the 5-o'clock and 7-o'clock positions along the posterior bladder neck using 3-0 polyglactin or polydioxanone suture. This maneuver can help avoid inadvertent sutures passing through or near the ureteric orifices during the anastomosis and at the same time reduce the size of the bladder neck opening. Alternatively, ureteral stents may be placed to protect the integrity of the ureteric orifices during completion of the anastomosis and then removed immediately or postoperatively in a delayed fashion once the anastomosis has healed.

Posterior Support of the Vesicourethral Anastomosis

As a result of prostatectomy, the posterior supportive layers of the bladder and prostate are divided, including Denonvilliers fascia and its confluence with the posterior rhabdosphincter. Reports of attempts at reconstruction of these posterior supportive structures have suggested improvement in earlier postoperative return of urinary continence (Rocco et al., 2007). Although the exact mechanism remains unclear, suggested mechanisms include reestablishment of the posterior anatomic support to the bladder and urethra, improving urethral coaptation during voiding, reduced tension at the vesicourethral anastomosis, and increase in the functional length of the striated urethral sphincteric complex. Others have found no significant benefits to reconstructing the support of the vesicourethral anastomosis (Menon et al., 2008). **Despite this ongoing debate, many believe that, at the very least, this step reduces the distance between the bladder neck and urethra, thus facilitating completion of a tension-free vesicourethral anastomosis.** Reconstituting the posterior support to the anastomosis is accomplished by reapproximating the remnant Denonvilliers fascia and posterior bladder neck to the posterior rhabdosphincter beneath the urethra using a running continuous 2-0 poliglecaprone (Monocryl) suture before completion of the vesicourethral anastomosis (Fig. 156.18). Resuspension of the anastomosis and distal bladder neck to the arcus tendineus is used by some to restore anterior urethral support and preserve the vesicourethral angle (Tewari et al., 2007).

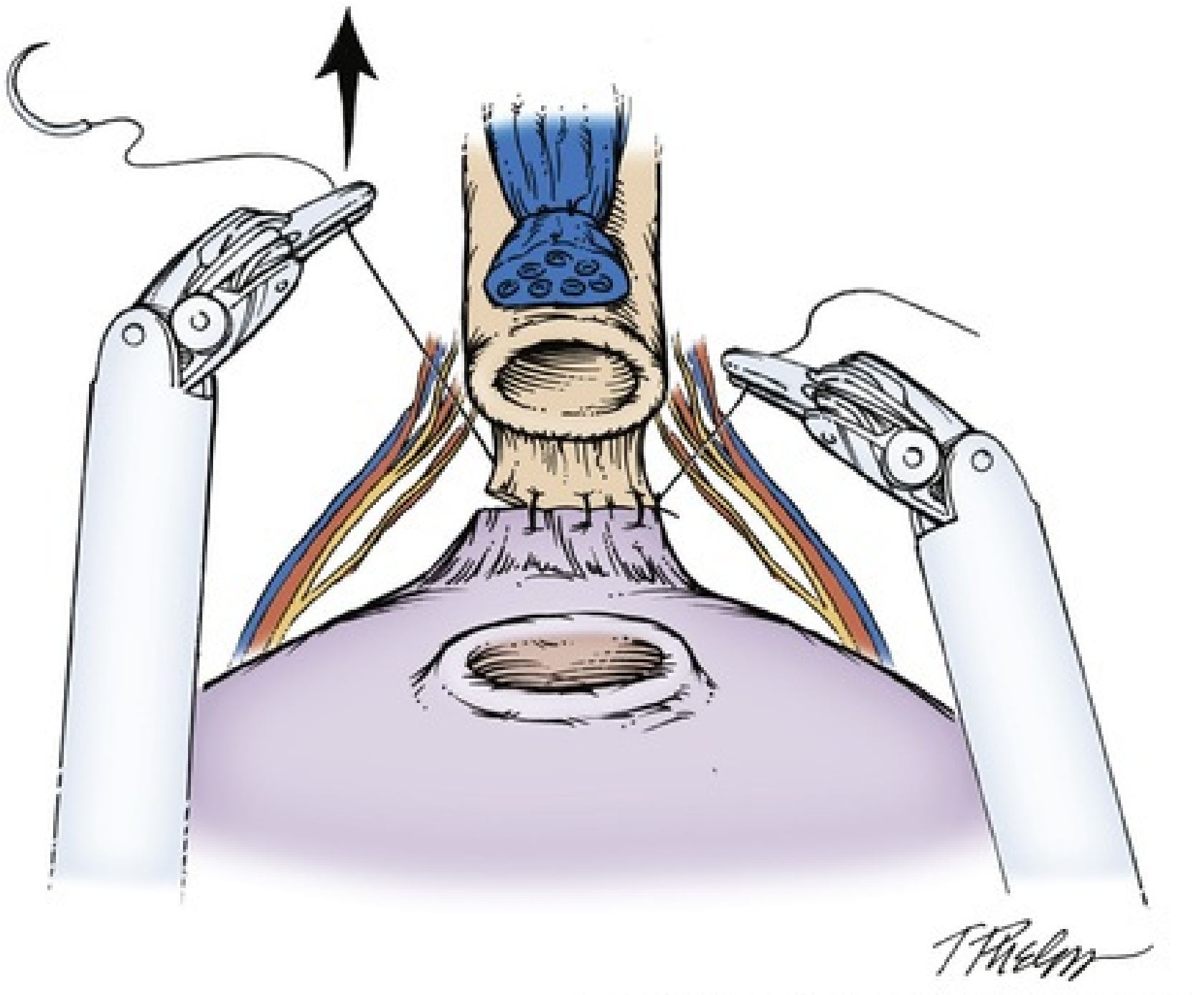

FIG. 156.18 Modified Rocco stitch. Posterior support is provided to the vesicourethral anastomosis by reapproximating the remnant Denonvilliers fascia and posterior detrusor along the posterior bladder neck to the posterior rhabdosphincter using a running continuous 2-0 Monocryl suture. (Copyright Li-Ming Su, MD, University of Florida, 2009.)

Vesicourethral Anastomosis

With LRP, the vesicourethral anastomosis is one of the most technically challenging aspects of the procedure because of the need for laparoscopic suturing. The da Vinci surgical robot greatly facilitates suturing of the anastomosis because of the ergonomics of the wristed robotic instrumentation. Although interrupted sutures may be used for the anastomosis, van Velthoven et al. (2003) described a running suture technique that distributes tension broadly across multiple points along the bladder neck and urethra. Typically, two separate sutures are tied together at their ends, each 6 to 8 inches in length. More commonly, double-armed barbed sutures are used to accomplish this step. The anastomosis between the bladder and urethra begins posteriorly, leaving two needles to run progressively in an anterior direction on either side. **Dedicated**

mucosal eversion sutures at the bladder neck, commonly used during RRP, are unnecessary with the excellent running mucosa-to-mucosa anastomosis achieved with LRP and RALRP. Multiple sutures are first placed through the urethra and bladder before progressive cinching of the anastomosis by lifting each arm of the suture in an anterior direction (Fig. 156.19). Either an assistant or the robotic ProGrasp forceps can be used to grasp one arm of the suture to maintain tension and approximation of the posterior anastomosis while the surgeon reapproximates the contralateral side of the anastomosis using the second suture. The final urethral catheter is passed under direct vision immediately before completion of the anastomosis, and the bladder is irrigated to ensure that there are no leaks. Further interrupted sutures may be required if a leak is identified.

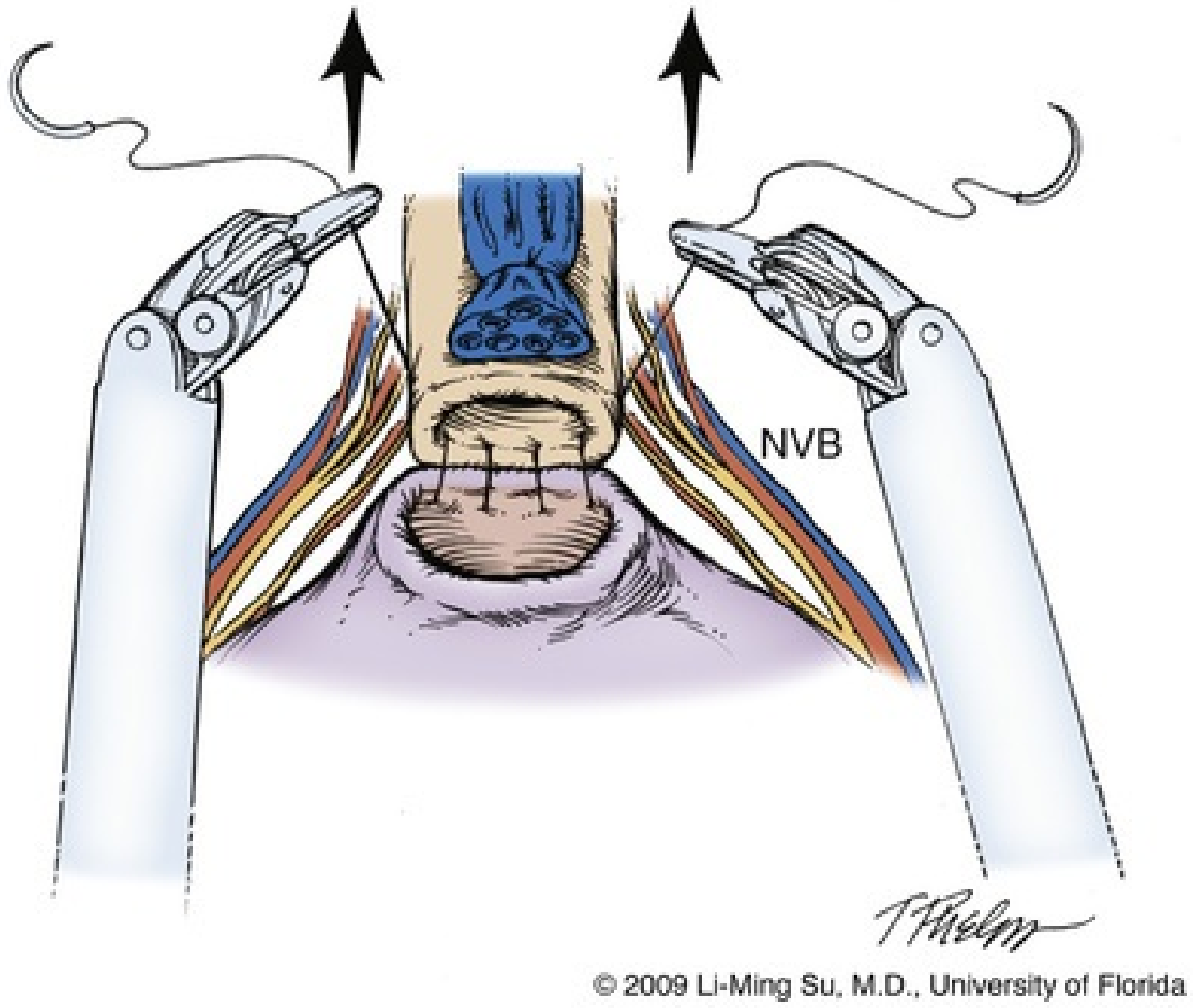

FIG. 156.19 Running vesicourethral anastomosis. The posterior anastomosis is reapproximated after preplacing two or three suture throws on either side starting at the 6 o'clock position and cinching the sutures by lifting anteriorly. Great care must be taken to avoid incorporating the neurovascular bundles *(NVBs)* when placing sutures within the urethra. (Copyright Li-Ming Su, MD, University of Florida, 2009.)

Delivery of the Specimens and Exiting the Abdomen

Before undocking the robot and removal of the specimens, the pelvis and operative field should be carefully inspected for bleeding under low insufflation pressure (<10 mm Hg). The nearby bowel should be examined closely to make certain there is no injury resulting from instrument exchanges. Closure of the fascial defect for the 5- and 8-mm trocar sites is generally not necessary. Because of the potential risk for a trocar site hernia, it is advisable to close the 12-mm trocar sites with a Carter-Thomason fascial closure device (Cooper Surgical, Trumbull, CT). The string for the laparoscopic entrapment sack is transferred to the camera port site at the umbilicus, and the abdomen is completely desufflated. The specimens within the entrapment sack are extracted intact through extension of the umbilical trocar site. The fascial defect is then closed by open suture placement, and the skin defects are closed with a subcuticular absorbable suture.

Key Points: Technique of Laparoscopic and Robotic-Assisted Laparoscopic Radical Prostatectomy

- Use of a transperitoneal or extraperitoneal approach is based primarily on surgeon preference because there does not appear to be a significant advantage of one approach over the other.
- Robotic technology facilitates suturing and dissection for surgeons who may not have advanced laparoscopic skills.
- Identification of the precise margin between the bladder neck and prostate can be accomplished by using a set of physical maneuvers and visual cues.
- After division of the anterior bladder neck, the presence or absence of a median lobe should be defined before division of the posterior bladder neck.
- Complete mobilization of the plane between the posterior prostate and rectum is an important step in avoiding rectal injury and defining the medial aspect of the prostatic pedicles and NVBs.
- Use of thermal energy should be minimized during control of the prostatic pedicles and dissection near the NVBs as thermal energy has been shown to be deleterious to cavernous nerve function in both animal and human studies.
- An interfascial dissection of the NVB is preferred in patients with presumed

organ-confined cancer who desire NVB preservation for potency.

- An anterior or posterior protruding lip of prostate should be anticipated when dividing the prostatic apex from the urethra so as to avoid an iatrogenic positive apical margin.
- Bladder neck reconstruction may be required if there is a size discrepancy between the bladder neck and urethra, especially in patients with prior TURP, a median lobe, or a large prostate gland.
- The vesicourethral anastomosis is most efficiently accomplished with a running continuous suture.

Postoperative Management

Pain Management Post-Prostatectomy

Parenteral narcotic medications may be required for the first 24 hours after surgery but should be used sparingly. Instead, ketorolac may be used in appropriate patients for postoperative pain control. It is relatively unusual for the post-prostatectomy patient to need significant narcotic medications on discharge. A combination of more simple analgesia with acetaminophen or anti-inflammatory medications is generally sufficient in the majority of men following surgery.

Diet

Occasionally after radical prostatectomy, a mild ileus develops that often resolves within 24 to 48 hours. Postoperative narcotic use for pain management can exacerbate this problem and as such should be minimized as discussed earlier. The majority of patients can resume oral fluids and diet within 8 to 12 hours of surgery. Constipation can be a postoperative issue, and the patient should be discharged with advice about minimizing narcotic use and the role of stool softeners.

Deep Venous Thrombosis Prophylaxis

Pneumatic compression stockings are routinely applied at the commencement of surgery and used postoperatively. Subcutaneous heparin, usually administered at the commencement of surgery, also can be instituted until the patient is ambulating. Fortunately, the observed rate of thromboembolic events with minimally invasive prostatectomy is very low.

Pelvic Drain

With the secure and watertight running anastomosis typically achieved, a pelvic drain may not always be necessary. If a drain is placed, it may be introduced through one of the 8-mm robotic trocar sites and does not require a separate stab wound. The drain may evacuate an unanticipated urine leak or lymphatic fluid collection. Often, though, drainage is minimal and the drain typically can be removed on the first or second postoperative day.

Urethral Catheter

The duration of time required for the urethral catheter depends to a great extent on the preferred approach of the surgeon and the extent of bladder neck reconstruction. The 2-week period commonly used with open surgery is generally unnecessary if a watertight vesicourethral anastomosis is achieved. With 1 week or more of an indwelling urethral catheter, the vast majority of patients are able to void adequately with minimal risk for postoperative urinary retention and need for catheter replacement. In these routine cases, a cystogram is generally not required. **The exception, however, is when extensive reconstruction of the bladder neck is necessary (e.g., very large volume prostate gland, large median lobe, post-TURP case) or if there is some doubt about the integrity of the vesicourethral anastomosis. In these circumstances, it may be prudent to leave the catheter for at least 10 days and obtain a cystogram in radiology to confirm the security of a watertight anastomosis.** In cases of extravasation, longer duration of the urethral catheter is required to allow for spontaneous healing. Although this may prolong the time to achieve complete urinary continence, long-term urinary outcomes do not appear to be affected (Patil et al., 2009). To avoid the use of a urethral catheter, some surgeons have investigated the use of suprapubic catheter drainage of the bladder with a specially designed anastomotic splint with good initial results (Tewari et al., 2008).

Return to Normal Activity

Following catheter removal at 1 week, patients spend the next week recovering without particular restriction of activity. Most patients are able to return to all normal physical activity by 4 to 6 weeks. Strenuous exercise can be recommenced at 6 weeks. This is a clear advantage for patients undergoing robotic surgery compared with the open radical prostatectomy technique.

Role of Continence Physiotherapy

It is helpful for the patient to have a session with the specialist physical therapist before the surgery. The patient can be instructed in pelvic floor strengthening with particular emphasis on the external striated sphincter (Centemero et al., 2010). The therapist can use transperineal ultrasonography to help the patient visualize the appropriate musculature to be exercised (Stafford et al., 2014). **There is evidence to suggest that pelvic floor education by physical therapy can shorten the time to recovery of urinary continence** (Overgard et al., 2008; Patel et al., 2013)**. It is therefore important to have the services of a qualified pelvic floor physiotherapist.** The patient is instructed not to commence pelvic floor exercises to strengthen the striated external sphincter muscle for at least 3 days after catheter removal, as early participation in pelvic floor strengthening can cause perineal pain. This can be quite disabling early on. Some men do complain of perineal pain clearly originating from the operative bed for several weeks following catheter removal.

Role of Penile Rehabilitation

Post-prostatectomy erectile dysfunction (ED) is thought to arise from the interaction of three factors: neural injury, vascular injury, and corporal smooth muscle damage (Jenkins and Mulhall, 2016). Recovery is thought to depend on nerve-sparing status, patient age, baseline erectile function, and surgeon experience/volume. Penile rehabilitation programs have been developed in an effort to improve both the time to and degree of erectile function recovery following RALRP.

Most protocols use phosphodiesterase type 5 inhibitors (PDE5Is) as they appear to help preserve erectile tissue through their protective effects on both endothelial and smooth muscle cells. The Memorial Sloan-Kettering Cancer Center (MSKCC) penile rehabilitation program has patients take a low-dose PDE5I nightly starting 2 weeks before surgery and continuing until 2 weeks after RALRP. From weeks 3 to 6, the patient continues the low-dose PDE5I 6 nights a week and takes a maximum dose of a PDE5I once a week. At this point, patients are classified as PDE5I responders or PDE5I failures. Responders continue on PDE5I, whereas failures are started on intracavernosal injection (ICI) therapy or alternative strategies (Jenkins and Mulhall, 2016).

ICI therapy has also been shown to help with recovery of erectile function post-prostatectomy and is often used in patients who do not respond to PDE5Is. In the MSKCC penile rehabilitation program, PDE5I failures start ICI 6 weeks post-prostatectomy. Their protocol has patients perform ICI twice a week and take a low-dose PDE5I nightly on non-ICI nights. Additionally, they challenge themselves with a maximum-dose PDE5I once a month, starting 12 months post-prostatectomy. If they develop a natural response or become PDE5I responders, ICI can be stopped (Jenkins and Mulhall, 2016).

An alternative method that is commonly used in penile rehabilitation protocols is the vacuum erection device (VED). The VED has been used to treat ED for a long time; however, it does not appear to help with the overall penile rehabilitation process, but may help preserve penile length post-prostatectomy (Köhler et al., 2007).

Robotic Prostatectomy Outcomes

Since its introduction into urology in 2002, there has been controversy as to whether RALRP could achieve equivalent outcome in terms of cancer margins, continence, and potency when compared with the standard retropubic open prostatectomy. Many early reports suggested remarkable outcomes of RALRP with regard to potency and continence. These were mostly single-institution reported outcomes. A randomized trial conducted by Yaxley et al. (2016) suggested that outcomes for potency and continence of both robotic and open prostatectomy were equivalent at 3 months. Clearly, the cost of robotic instrumentation and the high capital cost of robotic machines have been barriers to more widespread implementation of robotic surgery (Barbash and Glied, 2010; Barbash et al., 2014).

Studies from Scandinavia comparing individual surgeon outcomes by robotic or open method strongly suggested that outcomes are very dependent on the individual surgeon's ability and experience, and outcomes improve when surgery is performed by high-volume surgeons at high-volume centers (Carlsson et al., 2016; Groeben et al., 2017; Haglind et al., 2015). The study by Yaxley et al. (2016) compared two surgeons, one performing open prostatectomy and the other performing RALRP, in a randomized trial. There was no difference in oncology and continence outcomes, but there was a difference in favor of robotics when blood loss and length of stay were assessed. The advantages of RALRP relate to the minimally invasive nature of this procedure and the ability to obtain at least equivalent outcomes in terms of cancer margins, continence, and potency. Patients undergoing RALRP can return to normal activity more quickly than after open surgery. Furthermore, because of the safety of the minimally invasive approach, more patients can be offered prostatectomy, whereas formerly they were recommended to receive external-beam radiation therapy. Patients in this context are those with previous mesh hernia repair, older patients with medical comorbidities, or those who have had previous abdominal or pelvic surgery.

Complications of Robotic Prostatectomy

Patient Positioning: Neural Injury

Obtaining a thorough history of any preexisting musculoskeletal issues in the preoperative setting is important to help minimize and address these problems in a patient-specific manner. It is important to position the patient on the operating table to prevent excessive neural pressure, particularly cervical, axillary, brachial, and radial. Specific padding needs to be applied to the arms and hands, and care must be taken with the brachial plexus if the arms are extended. Typically, Yellowfins stirrups (Allen Medical, Acton, MA) are used in many operating rooms to protect the legs. The Trendelenburg position used should have between 22 and 25 degrees of tilt. Prolonged operating time in Trendelenburg tilt can cause postoperative edema of the eyes and even sometimes cerebral irritation (Awad et al., 2009). Excessive hip flexion of the operating table should be avoided as this may lead to femoral nerve injury.

Blood Loss/Transfusion

Since the inception of RALRP, many authors have reported a dramatic reduction in blood loss at the surgery compared with the open method (Ficarra et al., 2012a). Most report blood transfusion rates of 1% to 2% after radical prostatectomy (Farnham et al., 2006; Ficarra et al., 2012a). The CO_2 pneumoperitoneum compresses venous bleeding, and the excellent visualization readily allows identification of bleeding vessels requiring hemostasis. In the randomized report from Yaxley et al. (2016), there was a significant difference in blood loss between the open radical prostatectomy and the RALRP surgery. Mean blood loss in the open prostatectomy was 1400 mL, and average blood loss in the robotic cohort was 300 mL.

Bowel Injury

Injuries to rectum, sigmoid, and small bowel are rare but serious complications following RALRP (Kheterpal et al., 2011). If an injury to bowel is recognized at the time it occurs, then that injury can be repaired immediately (Wedmid et al., 2011). Multilayered primary closure of a recognized rectal injury with interposition of omentum between the rectum and anastomosis will usually avoid long-term problems. A rectal injury that is not recognized, however, often presents as a recto-vesical fistula. This will almost always require colostomy diversion. An unrecognized small bowel injury possibly caused by an off-site injury during surgery can be serious. The assistant must be careful to avoid small bowel injury along the path of the multiple instruments that are interchanged and directed into the pelvis during the procedure. The small bowel can also be injured at the commencement of surgery when taking down adhesions. An unrecognized small bowel injury during RALRP can lead to a delay in diagnosis of leakage of small bowel contents. The patient may not present with signs of an acute abdomen and peritonitis. After diagnosis, immediate repair and drainage is generally necessary.

Ureteral Injury

Ureteral injuries are rare during RALRP, with few reports in the literature. Injuries to the ureter can in theory occur during three steps of a RALRP. First, the ureter may be encountered during dissection of the vas deferens during a posterior approach to RALRP. Maintaining close dissection to the adventitia of the vas will help prevent inadvertent compromise to the nearby ureter traveling just posterior to the vas. Second, the ureter may be injured at the level of the trigone (Hu et al., 2006). In cases in which there has been previous TURP, the bladder neck has been obliterated and ureters can be perilously close to the anastomotic site. This is also the case when there is a large median lobe, where a large bladder resection leaves the ureteral orifices in close proximity to the posterior bladder neck edge. In such cases, imbrication of the ureteral orifices before performing the anastomosis may reduce compromise to the ureters as mentioned earlier. Alternatively, a double-pigtail stent can be placed intraoperatively without great difficulty and removed at a later date. Lastly, the ureter may in theory be encountered during dissection of the pelvic lymph nodes. During dissection of the proximal extent of the lymph node packet at the iliac bifurcation, use of thermal energy should be minimized as this may compromise the ureter as it passes over the iliac vessels.

Robotic Machine Failure

Robotic machine failure is a rare event during RALRP. In a study of robotic equipment malfunction encompassing 8240 cases with a mean per-surgeon volume of 700 cases, critical robotic failures occurred in 0.4% cases, leading to a cancellation of 24 cases before the procedure, or conversion to laparoscopic or open procedures in the remainder (Lavery et al., 2008). The most common components of the robot malfunction were the robotic arms and optical system**.** **In conclusion, critical robotic equipment malfunction is extremely rare in institutions performing high-volume RALRP, with a nonrecoverable malfunction rate of only 0.4%.**

Postoperative Complications

Intraperitoneal Urine Leak

If there is a leak from the anastomosis in the immediate post-prostatectomy period, the patient can develop a significant paralytic ileus. If a drain has not been left in place at the conclusion of surgery, a percutaneous drain may be placed by an interventional radiologist to drain any collection. In such cases, a prolonged urethral catheterization can be anticipated in addition to the need for a postoperative cystogram to confirm resolution of the anastomotic leak.

Bladder Neck Stricture

This complication was common following open radical prostatectomy, and there are reports of up to 16% of patients suffering a stricture at the bladder neck following open radical prostatectomy (Breyer and McAninch, 2011). **Since the introduction of RALRP, the incidence of reported bladder neck strictures is low and is less than 2%** (Msezane et al., 2008). The complication is managed by bladder neck incision followed by a period of catheter drainage. Usually this is all that is necessary to restore a satisfactory bladder neck caliber.

Pelvic Node Dissection Complications

The role of pelvic node dissection at the time of radical prostatectomy, limited or extended, remains controversial (Yaxley et al., 2018). It is clear that patients with low-volume primary cancer of low Gleason sum do not require lymph node dissection during prostatectomy. Controversy exists as to whether an extended node dissection in patients with intermediate- or high-risk disease has both a staging and therapeutic benefit. The advent of improved PSMA PET scanning for staging means that many nodes previously not imaged are now seen before surgery. In some patients with advanced local disease, node metastasis is discovered in extrapelvic sites. To date, there has been no study to demonstrate a therapeutic benefit associated with extended pelvic node dissection in high-risk prostate cancer. Pelvic node dissection, however, does carry a risk for morbidity including the development of a postoperative lymphocele, deep venous thrombosis, lower extremity edema, obturator nerve injury, and ureteral injury.

Further details of complications following PLND are discussed later in this chapter.

Quality-of-Life Outcomes After Radical Robotic Prostatectomy

Those surgeons trained in the era of open radical prostatectomy appreciate the dramatic change in outcome for patients undergoing contemporary RALRP. Until Walsh (1980) described a safe technique for open radical prostatectomy in the 1980s, the operation was attended with serious morbidity. Significant blood loss requiring transfusion, a 3-week hospital stay, a 3-week indwelling catheter, almost-certain impotence, and a high likelihood of urinary incontinence was not unusual. The combination of PSA testing with safe open radical prostatectomy meant that many men could now be offered the opportunity for early potentially curative surgery. Robotic radical prostatectomy was first performed in 2000 and became a routine operation within 7 years. Despite the potential and obvious advantages of 12× magnified vision in three dimensions and digitized reproduced hand movements with motion scaling and tremor filter, it was difficult to prove superiority of the robotic technique over the open method. Because of the high capital cost of the robotic machine and disposable instruments, many centers were unable to afford this technology. A technology arms race occurred between centers with and without a robotic surgery platform. Marketing of the superiority of robotic surgery occurred without clear evidence of benefit of the technology. The real benefit of minimally invasive surgery (reduced blood loss, early return to activity and employment, and more favorable outcomes for potency) have since emerged (Costello, 2005). The advent of new, less-expensive versions of robotic surgical technology means that there will be a much greater uptake of robotic surgery, not only for robotic radical prostatectomy, but also other robotic procedures. It has been difficult to perform appropriate randomized controlled studies to prove the superiority of one method over the other. The key outcome measures, or trifecta of outcomes, relate to positive surgical margin rates (oncologic efficacy), postoperative urinary continence, and return of erectile function. Where there have been appropriate comparative studies, RALRP appears superior in returning a higher number of men to previous erectile function (Haglind et al., 2015).

Unfortunately, the adoption of RALRP occurred in the absence of high-level evidence of superiority of robotic technique over open prostatectomy. There were many claims from single surgeons' series of superiority of robotic potency technique and improved potency outcomes (Menon et al., 2005). Claims of near 90% potency from some institutions following robotic radical prostatectomy could not be substantiated in other centers. The Laparoscopic Prostatectomy Robot Open (LAPPRO) study from Scandinavia compared urinary incontinence and ED after open and robotic radical prostatectomy (Haglind et al., 2015). This study was a prospective controlled, nonrandomized cohort of patients undergoing prostatectomy at 14 centers, by either the open or the robotic method. There were 2625 eligible men in the study. In this study, there was a mixture of high- and low-volume hospitals and surgeons to reflect everyday reality. There was no statistically different outcome in reported urinary continence after prostatectomy by either type of surgical technique. There was a statistically significant improvement regarding erectile function after robotic-assisted surgery. The LAPPRO study reports that there appears to be no statistically different outcome in oncologic efficacy of either method (Haglind et al., 2015). Many of the other outcome papers published of RALRP represent single series selected after a long learning curve by a very experienced surgeon. They report excellent outcomes, and this may reflect the fact that the surgeon is now very technically capable (Patel et al., 2011).

What are **true benefits** of robotic radical prostatectomy over open prostatectomy beyond the simple trifecta of margin status, continence, and potency? The clear advantages of the RALRP method relate to the significantly reduced blood loss associated with the procedure as compared with open surgery, next-day hospital discharge, and earlier return to normal activity. In addition, many patients who had previously been considered not suitable for open radical prostatectomy because of issues such as prior mesh hernia surgery, medical comorbidities, morbid obesity, or previous abdominal surgery, are now able to be offered radical prostatectomy.

Functional Outcomes

Urinary Continence After Robotic Radical Prostatectomy

To achieve an optimal outcome for urinary continence following robotic radical prostatectomy, it is important for the surgeon to understand the anatomy of the striated sphincter and the physiologic mechanisms of urinary continence (Koraitim, 2008). Urinary continence has both passive and active components. The passive component is provided by the smooth muscle of the bladder neck, prostatic urethra, and urethra. Thus, when the patient is sitting or lying, passive continence is achieved by the smooth muscle component (Fig. 156.20). When the patient becomes active, the external striated sphincter is activated to angulate the urethra. This is achieved by contraction of the horseshoe-shaped external sphincter skeletal muscle, which surrounds the urethra at the apex (Fig. 156.21). Skeletal muscle of the striated sphincter is composed of fast-twitch fibers. The pudendal nerve supplies this striated external sphincter that surrounds the urethra. The pudendal nerve runs in Alcock's canal. Branches of the pudendal nerve to supply the external sphincter swing from beneath the levator ani muscles into the skeletal muscle of the sphincter at the prostatic apex (Fig. 156.22). There is potential for damage to the pudendal branches when there is excessive dissection, thermal energy, or suturing in this area. The superb visualization provided by the robotic technology facilitates apical dissection and thus preservation of external striated sphincter function.

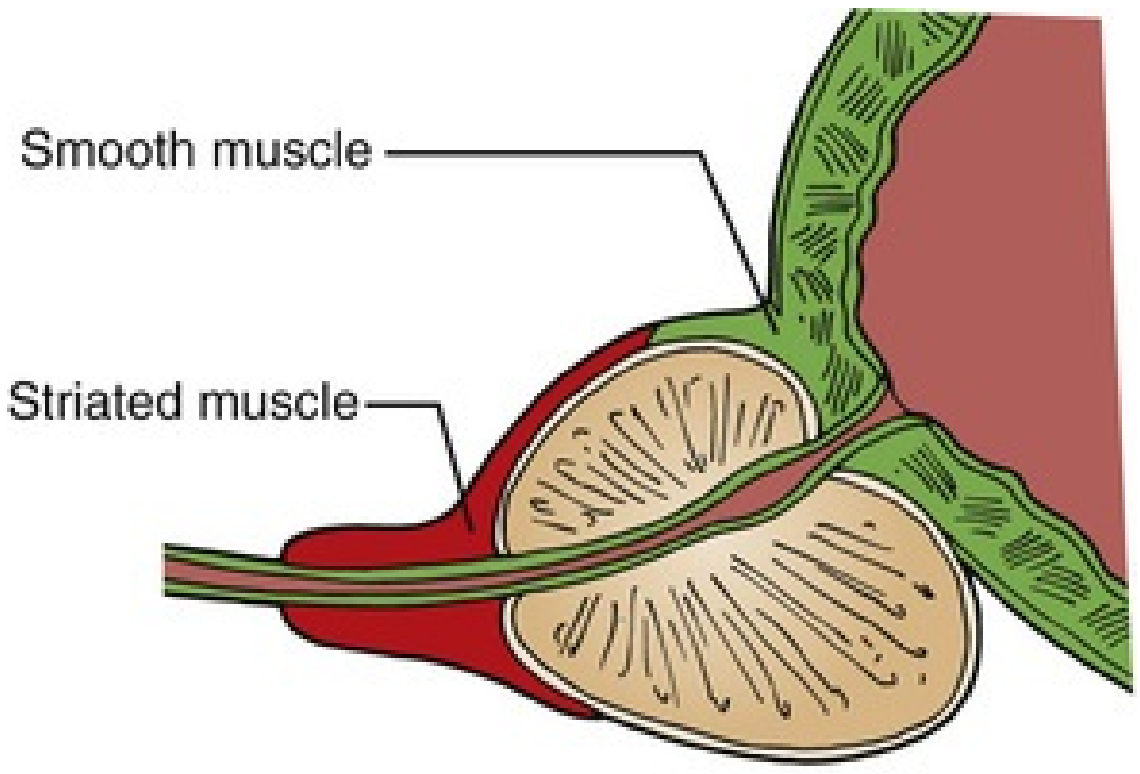

FIG. 156.20 Muscle components of the male urinary sphincter. The passive component of urinary continence is provided by the smooth muscle

(green) of the bladder neck, prostatic urethra, and urethra. The active component of urinary continence is provided by the striated muscle *(red)* of the external urinary sphincter.

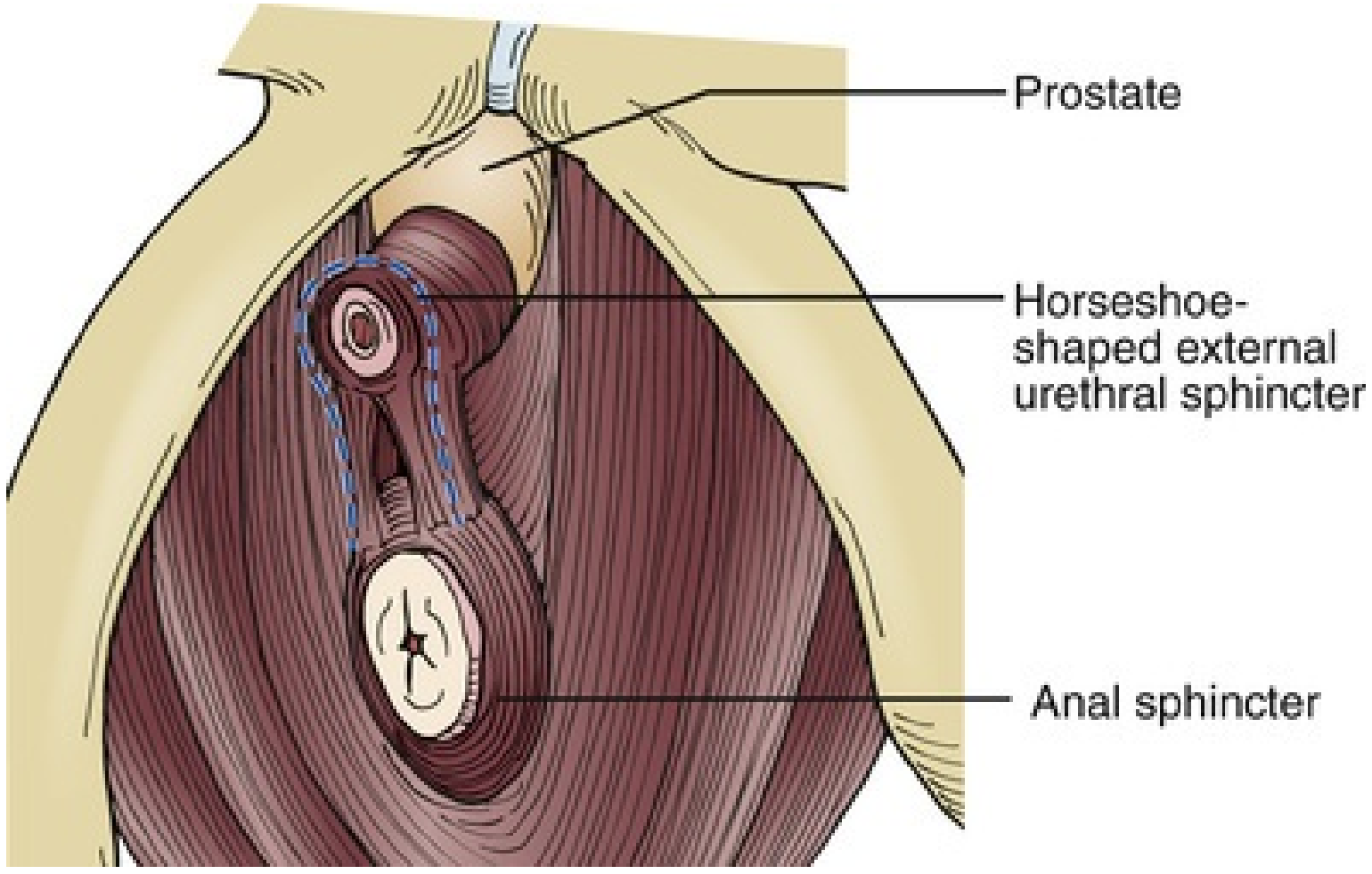
Prostate
Horseshoe-shaped external urethral sphincter
Anal sphincter

FIG. 156.21 Schematic of the horseshoe-shaped external urethral sphincter.

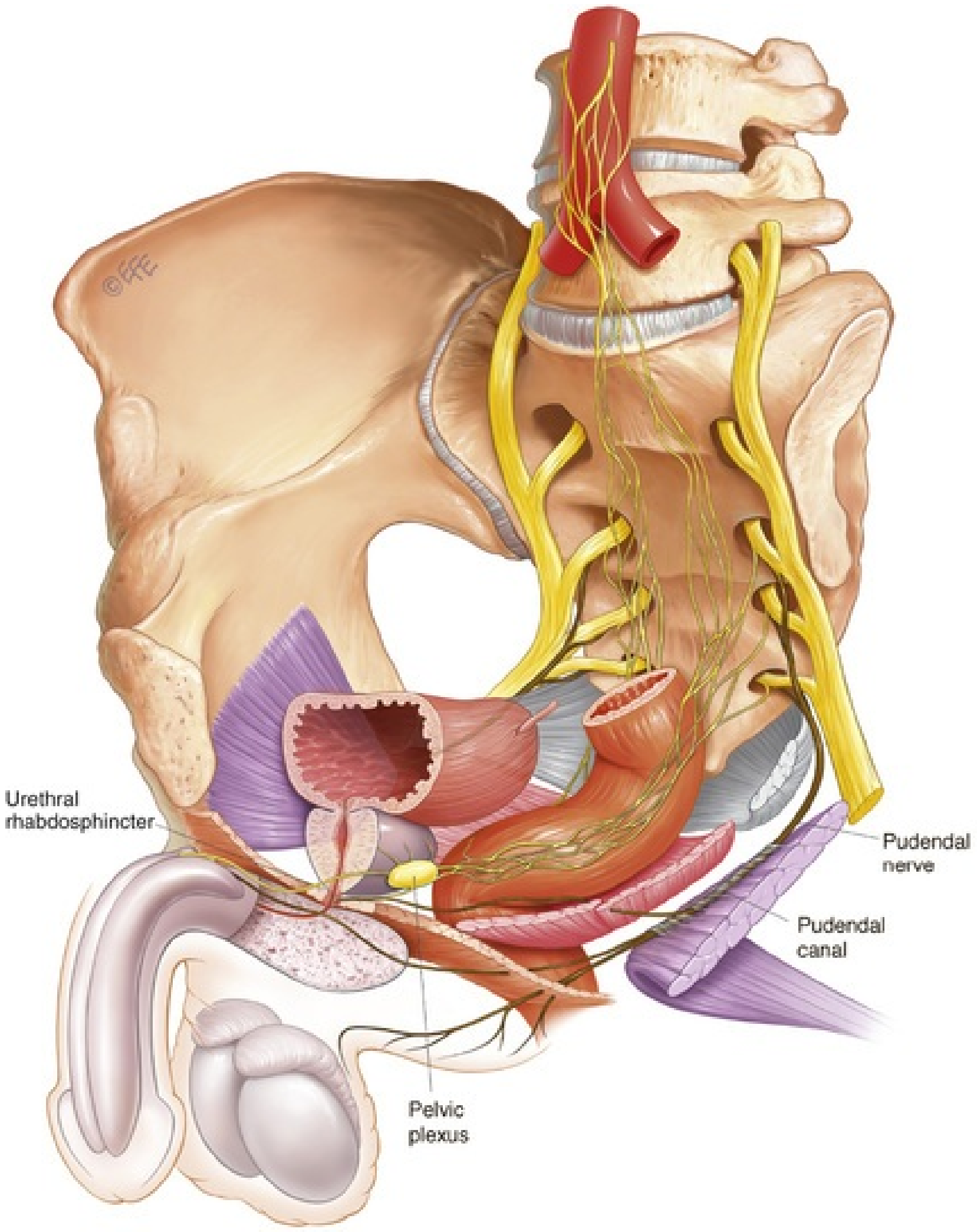

FIG. 156.22 Pudendal nerve innervation of the external urinary sphincter. Note the pudendal nerve branches to the sphincter. The nerve exits through the levator ani and swings close to the prostate near the apex. It is here that the pudendal nerve can be injured during radical prostatectomy.

A problem when discussing continence outcomes with men before RALRP is the variety of definitions of urinary continence and measures used to report continence outcomes following RALRP (Gandaglia et al., 2018). The comparative studies between open and robotic radical prostatectomy have found that 12-month continence outcomes are roughly equivalent. It also must be understood that some men prior to radical prostatectomy have continence issues caused by lower urinary tract obstructive symptoms. From the multiple studies presented, in particular those from community-based practices, the likelihood of developing urinary incontinence requiring use of one or more pads following surgery is 21%. In the LAPPRO study, of the 21% of men requiring pad use following prostatectomy, 13% required one pad every 24 hours and 8% required more than one pad per 24 hours. These results reflect real-world practice and allow the urologist to reliably counsel a man before radical prostatectomy regarding his likelihood of developing urinary incontinence. The more recent advent of suburethral sling surgery has meant that men who are not severely incontinent following robotic radical prostatectomy can be offered restorative surgery to overcome this urinary incontinence (Bauer et al., 2009). In the few men, usually 2% or less, who have severe urinary incontinence (meaning urinary loss of over 500 mL/day), artificial urethral sphincter surgery is beneficial (Van der Aa et al., 2013).

Erectile Dysfunction After Robotic Radical Prostatectomy

Before the anatomic insights into the anatomy of the NVB by Walsh and Donker (1982), impotence following radical prostatectomy was the norm. Further anatomic studies by Costello et al. (2004) demonstrated more clearly the anatomy of the pelvic plexus, NVB, and cavernous nerves (Fig. 156.23). The NVB is made up of a sympathetic neural component via the hypogastric nerve (T12–L1), which joins the parasympathetic component S2–S4 just below the base of the prostate. There is a ganglion below the base of the prostate situated posterolateral to the capsule of the prostate from which the cavernous nerves travel in a separate fascial sheath in most instances. There are nerves to the prostate, seminal vesicle, rectum, and levator ani muscles in separate fascial compartments adjacent to the cavernous nerves. There is a functional organization of the nerves in the bundle running posterolateral to the prostate and anterolateral to the rectum. These nerves run in a separate fascial compartment outside the capsule of the prostate (see Fig. 156.14). Identification of the NVB at the time of RALRP and meticulous dissection of this group of nerves is critical in preservation of potency. At the prostatic apex, cavernous nerves swing medially and anterior to about the mid-urethra and the 3 o'clock and 9 o'clock positions. **It is here during apical dissection when it is most likely that the neurovascular component of erectile function can be damaged** (Fig. 156.24). There is a separation of 3 to 5 mm between the NVB and the capsule of the prostate. This means that **most men being operated on for *localized* prostate cancer can be offered nerve-sparing surgery.** In some cases, where there have been extensive preoperative biopsies or multiple biopsies particularly by the transperineal route, scarring at the apex occurs, making the apical dissection more difficult and more likely that there will be damage to the cavernous nerves at this point. In men with locally extensive disease outside the capsule of the prostate that is palpable on digital rectal examination preoperatively, it may be necessary to perform a wider dissection and sacrifice one or both NVBs.

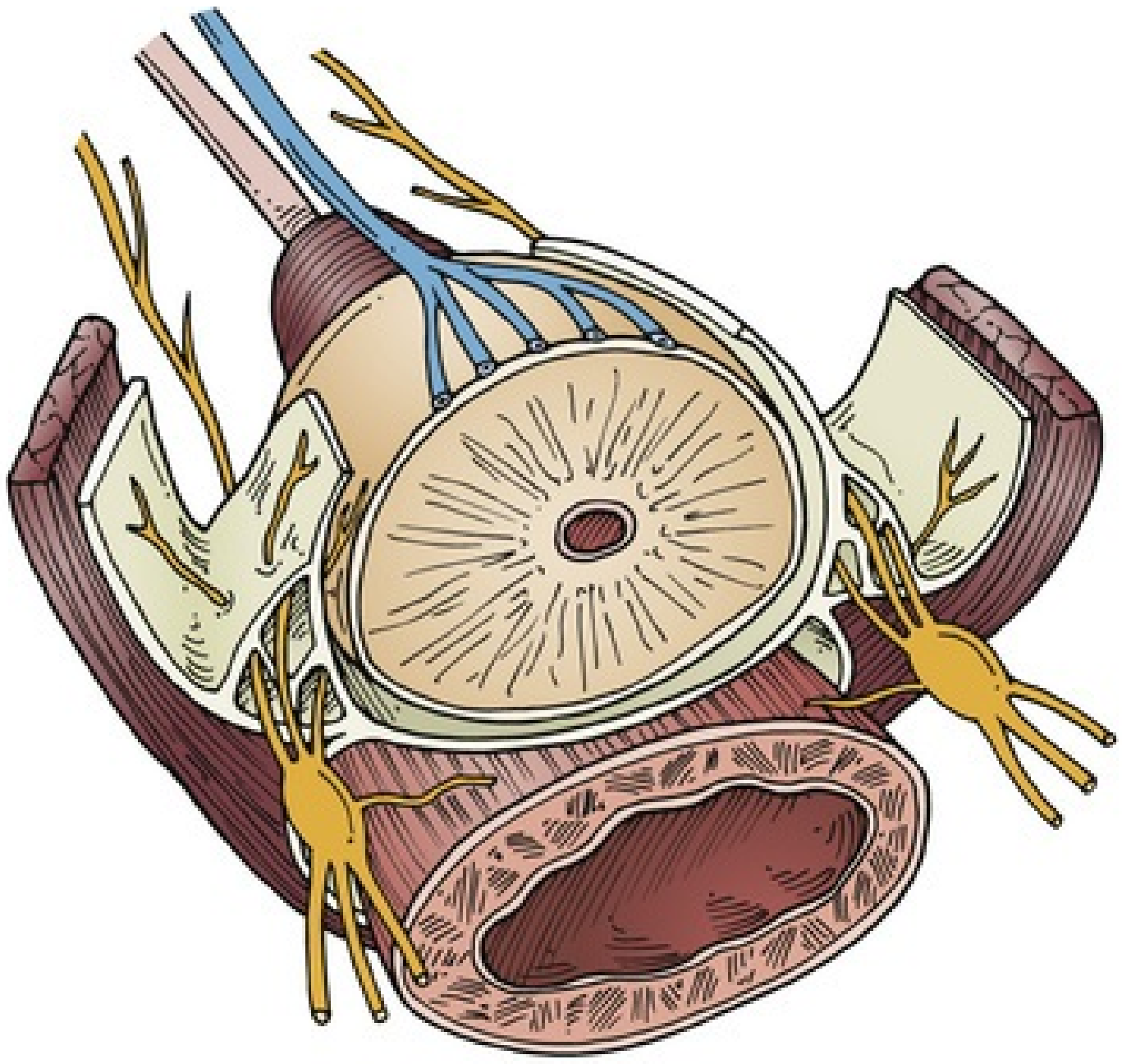

FIG. 156.23 Neurovascular bundle anatomy. There is a functional organization of the nerves in the bundle running posterolateral to the prostate and anterolateral to the rectum. These nerves run in a separate fascial compartment outside the capsule of the prostate.

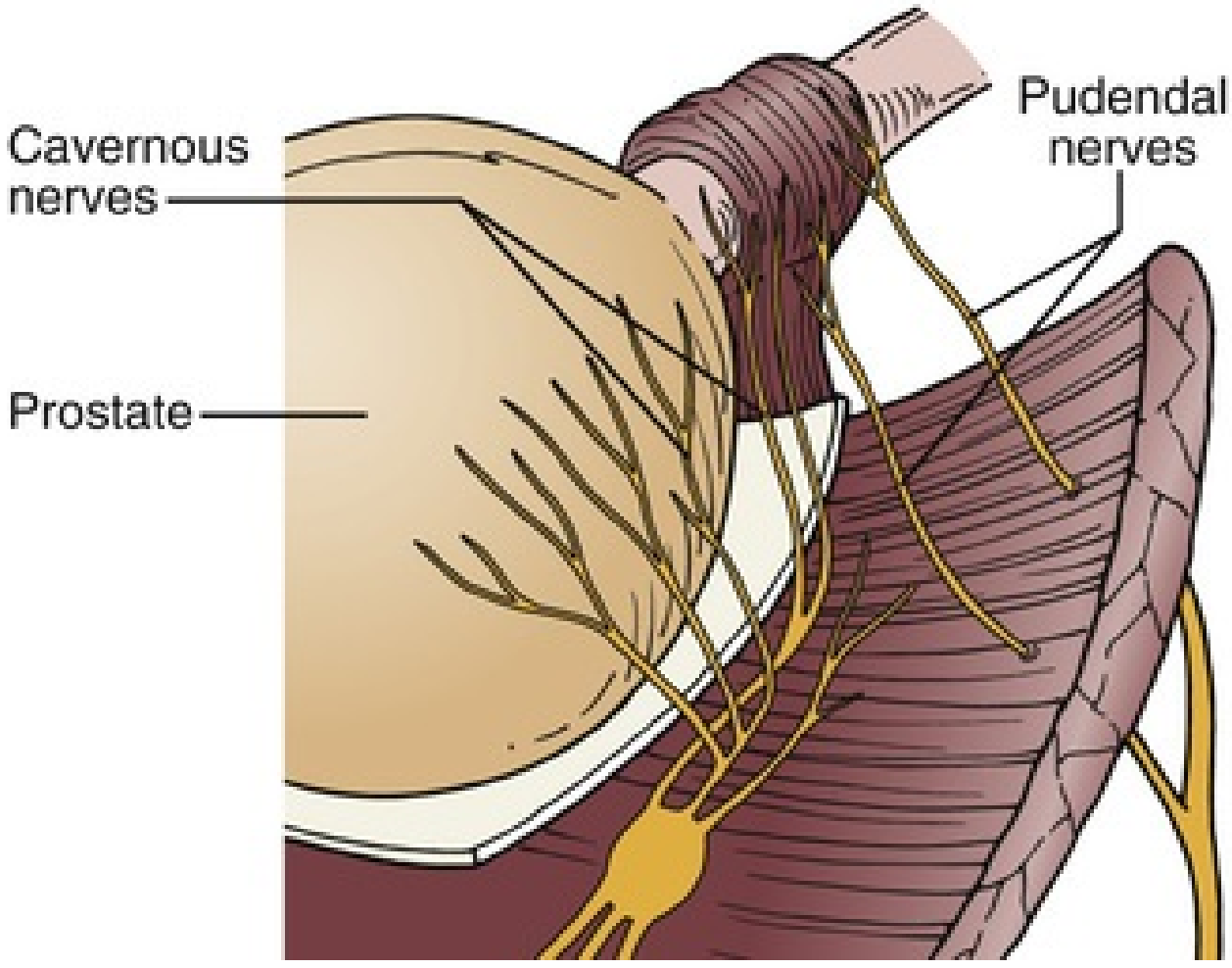

FIG. 156.24 Relationship of neurovascular bundle to the apex at the time of radical prostatectomy.

The development of ED after radical prostatectomy remains one of the most challenging side effects of the operation. Reporting of this complication following radical prostatectomy is bedeviled by a multiplicity of outcome measures used to assess erectile function. In fact, many men 60 years of age and older have preexisting ED before their radical prostatectomy surgery. Younger men, those in their 40s and early 50s, generally have better erectile function before surgery and are more likely to recover function than older men (Ficarra et al., 2012a). Many reports of outcomes following radical prostatectomy failed to acknowledge the use of PDE5Is or intracavernosal injections to aid in restoration of function. It is also well recognized that erectile function can return up to 5 years after surgery, and a 12-month ED definition point is possibly too early to assess eventual outcome. From the Scandinavian and other studies, it is clear that NVB is very surgeon-dependent, and some surgeons are able to achieve more favorable outcomes than others in terms of potency preservation (Carlsson et al., 2016). Reliable outcome data from Scandinavia suggest that a reasonable expectation of return to erectile function in a previously potent man will be between 30% and 50% (Carlsson et al., 2016). **When RALRP is performed in high-volume centers, more favorable potency outcomes are reported** (Patel et al., 2011).

Oncologic Outcomes of Robotic Radical Prostatectomy

Oncologic outcomes after radical prostatectomy are evaluated by assessment of margin positivity and late biochemical recurrence with elevation of PSA following prostatectomy above 0.1 ng/mL. An extensive systematic review and meta-analysis of studies of reported oncologic outcome after RALRP by Novara et al. (2012) showed no difference in positive surgical margin rates between open radical prostatectomy and RALRP. A further study has supported this finding (Coelho et al., 2010). These authors reported a 7-year biochemical recurrence-free survival rate after RALRP around 80% (Novara et al., 2012). Meaningful cancer-specific survival rates need to be assessed at 15- to 20-year intervals from prostatectomy.

Surgical margin status after radical prostatectomy has often been used as a surrogate measure of surgeon performance. **It is clear that in centers where a high volume of robotic radical prostatectomy cases are undertaken, positive margin rates are less than in lower-volume community centers.** However, even in centers of excellence, there is heterogeneity of outcomes for positive surgical margins, with individual surgeons demonstrating different positive surgical margin rates (Haglind et al., 2015). Higher Gleason score and tumor stage are key factors in margin positivity. Tumor characteristics such as Gleason grade 7 or above, perineural invasion, and high tumor stage are all associated with higher levels of margin positivity. Interestingly, factors such as obesity with high BMI, large prostate volume, and prior abdominal surgery do not increase positive surgical margins (Coelho et al., 2010; Khaira et al., 2006). Zorn et al. (2009) compared oncologic outcomes of 60 robotic prostatectomies performed by two fellowship-trained urologists to the outcomes of 90 robotic prostatectomies performed by three open surgeons adopting RALRP. This comparison showed that 3-month PSA recurrence was higher for patients operated on by the non–fellowship-trained surgeons (10%) as compared with the fellowship-trained surgeons (2%). Zorn et al. also demonstrated that the risk for biochemical recurrence remained stable over 700 cases after the learning curve of the operation was overcome. Novara et al. (2012) reported in a meta-analysis, after reviewing 79 papers, a mean positive surgical margin rate of 15% in all-comers, and 9% positive margin rate in pathologically localized cancers, with specific tumor characteristics being the most relevant predictors of positive surgical margins.

In conclusion, positive surgical margin rates are similar following open radical prostatectomy and RALRP. Positive margin rates and biochemical recurrences are lower in centers with high-volume surgeons and where

RALRP is performed. Fellowship-trained surgeons perform better than those who are not fellowship-trained. There is heterogeneity of outcome between surgeons, even in centers of excellence.

Key Points: Complications and Outcomes of Robotic-Assisted Laparoscopic Radical Prostatectomy

- **Patient positioning:** Care must be taken when positioning in the Trendelenburg position that any potential area of neural compression is padded.
- **Blood loss:** Blood loss of robotic prostatectomy is usually minimal, and transfusion requirements should be less than 2%.
- **Bowel injury:** Injury to the rectum is well reported but rare, and should be repaired when recognized. The rectal injury rate is higher in salvage surgery.
- **Urine leak:** This occasionally occurs through a nonwatertight anastomosis and requires a longer urinary catheter period.
- **Bladder neck stricture:** The occurrence of bladder neck stricture is much reduced since the introduction of robotic anastomotic technique. The rate should be less than 5%.
- **Machine failure:** Machine failure is rare and affects less than 0.5% of cases.
- **Oncologic outcomes:** There is equivalence in oncologic outcomes between robotic and open radical prostatectomy. The robotic oncologic outcomes (margin negative) are better when surgery is performed in a high-volume center.
- **Potency outcomes:** There is a statistically more favorable outcome for potency recovery following robotic prostatectomy versus the open method.
- **Continence outcomes:** Even in the best hands, at least 20% of men following robotic prostatectomy will not be pad free, and 5% will have severe incontinence irrespective of technical excellence.
- **Minimally invasive surgery outcomes:** After robotic prostatectomy, patients can be discharged in 24 hours and return to normal activity within 3 weeks. This is a significant advantage of the minimally invasive surgical

approach.

Salvage Robotic-Assisted Radical Prostatectomy

After introduction of RALRP, there has been increased usage of the technique after failure of localized therapies. These therapies include external-beam radiation therapy, seed brachytherapy, high-intensity focused ultrasonography (HIFU), and cryotherapy (Stephenson and Eastham, 2005). Before the introduction of RALRP, most surgeons were not comfortable offering salvage radical prostatectomy by the open method after failure of external-beam radiation therapy or brachytherapy. The reason for a reluctance to surgically intervene after failure of these therapies was the reported high incidence of complications, particularly urinary incontinence, ED, bladder neck stenosis, and rectal injury. The incidence of rectal injury during salvage prostatectomy has been reported to be more than 15% at some centers (Philippou et al., 2016). Although it has been reported that salvage robotic-assisted radical prostatectomy incurred a higher rate of complications, recent reports suggest that outcomes show this is still a feasible procedure (Philippou et al., 2016). The improved visualization afforded by the robotic technology allows the surgeon precise dissection technique in the presence of significant fibrosis caused by these therapies. The stage-specific 5-year cancer control rates of salvage radical prostatectomy are equivalent to those of the author's standard open radical prostatectomy. When offering the patient salvage RALRP following failed external-beam radiation therapy, brachytherapy, HIFU, or cryotherapy, establishing biopsy-proven persistence or recurrence of cancer is imperative as is a full metastatic workup to exclude occult metastatic disease. A fluciclovine F18 PET scan is especially beneficial to assess the possibility of disease outside of the prostate gland region. The PSA should ideally be lower than 10 ng/mL. These cases are perhaps best performed at high-volume centers by experienced robotic surgeons as they can be very challenging.

Salvage Prostatectomy Technique

Development of the extraperitoneal space along the pelvic sidewall, as well as the space of Retzius, can be more difficult in patients previously treated with external-beam radiation. Caution must be used in dissecting the bladder from the iliac vessels because of the desmoplastic reaction that is often encountered. These tissue planes typically are preserved in patients who received brachytherapy, cryotherapy, or HIFU.

Incision of the endopelvic fascia is performed to help identify the contour of the prostate. Suture control of the DVC may sometimes be unnecessary as an initial step because clear identification of the prostatic apex can be difficult at this point, and only minimal back bleeding occurs because of radiation effects. The bladder neck is identified primarily by exposing the lateral margins of the prostate and performing a pinch maneuver with robotic instruments to demonstrate the prostate bladder neck junction. The bladder neck may be pale and thickened. Complete dissection of the seminal vesicles should be performed, because the incidence of invasion is higher in these patients with recurrent prostate cancer.

Even though there is typically fibrosis surrounding the entire prostate in a salvage setting, the posterior dissection can be particularly difficult because of the periprostatic inflammation and scarring as a result of prior local therapy. The plane posterior to Denonvilliers fascia is where rectal injury can occur. As such, patients who are candidates for salvage prostatectomy are advised to undergo a full mechanical bowel preparation before surgery in the event that a rectal injury occurs. The perirectal fat plane is dissected along the anterior rectal wall with patience and great care so as to minimize the risk for rectal injury. Robotic technology provides a distinct advantage over the open approach in salvage prostatectomy with much better visualization in the performance of an antegrade release of the rectum from the posterior prostate. The plane is developed with sharp and blunt dissection. If brachytherapy has been used, the brachytherapy seeds are encountered here, although they can be found during the dissection at any stage of the surgery. The rectum should be carefully inspected after removal of the prostate. An air bubble test can be performed to localize a small rectal injury that is suspected but not visually apparent. A rectal injury can be repaired primarily, but it is essential to perform a two-layered closure that is secure. The omentum may be mobilized to interpose between the bladder and rectum. If there is any doubt about the quality of rectal repair, intraoperative consultation with a colorectal surgeon with consideration of a colostomy should be performed.

The anastomosis is performed in the same running fashion as for those patients who have had no prior therapy. However, these patients are at higher risk for urinary extravasation at the anastomosis, and later for bladder neck strictures, because of the radiation effect or fibrosis effect from these other therapies. The urinary catheter should be left in place for 3 weeks in these patients because of delayed healing of previously treated tissue. A cystogram should be strongly considered before catheter removal to ensure watertight closure.

There is a higher rate of urinary incontinence following salvage prostatectomy as compared with RALRP performed in the primary setting, with between 50% to 70% of patients regaining reasonable continence (Stephenson and Eastham, 2005). Nerve sparing is technically difficult because of extensive periprostatic scarring, and the patient is most often impotent after this procedure. It should be noted that most patients suitable for salvage prostatectomy are more likely to have existing ED resulting from the prior treatment. In any case, realistic expectations of significant postoperative ED should be made in the preoperative counseling session.

Minimally Invasive Pelvic Lymph Node Dissection

Indications

Currently, PLND is rarely indicated as an independent staging procedure. In some patients with a significant risk for nodal metastasis, such as those with a high Gleason grade tumor, a large tumor volume, or a markedly elevated PSA level, PLND may be useful for staging and selection of therapy before external-beam radiation. Also, staging PLND may have a role in some patients in whom radical perineal prostatectomy is planned. With RRP, LRP, or RALRP, it is the usual practice that PLND be performed simultaneously with the radical prostatectomy.

Expert opinion about the role of PLND in patients undergoing surgery for carcinoma of the prostate continues to evolve. **Current debate centers around the anatomic boundaries for the procedure, the merits of an extended lymph node dissection, and whether there is any meaningful therapeutic benefit to surgical removal of involved nodes.** Several different anatomic templates have been studied. A limited PLND generally includes only the obturator nodes; a standard PLND (sPLND) includes the obturator and external iliac nodes; an extended PLND (ePLND) includes the obturator, external, and internal iliac nodes; and a superextended PLND includes the ePLND template plus common iliac and presacral nodes (Fossati et al., 2017). A template mapping study found that using a sPLND template would capture 38% of the lymph nodes that drain the prostate, an ePLND template can capture 63% of these lymph nodes, and including the common iliac nodes can increase this to 75% (Mattei et al., 2008). **As such, most contemporary thought and evidence supports an extended node dissection in cases in which node dissection is indicated. The rationale for this approach is a significantly higher yield of nodal tissue and identification of nodal metastasis with extended versus a standard dissection.** With respect to the therapeutic benefit of PLND, a systematic review found conflicting results with respect to biochemical and clinical recurrence, with no significant improvements in cancer-specific or overall survival, while also observing increased operative time, blood loss, length of stay, and postoperative complications as the extent of the PLND increased (Fossati et al., 2017). Despite these findings and given the overall low quality of data on this subject, the authors concluded that PLND remains justified as it is our best method of assessing for nodal metastasis at this time.

Most studies show histologic evidence of nodal metastasis in less than 5% of patients with low-risk features in the primary tumor. Consequently, PLND may not be required in patients with low-risk prostate cancer. **The 2017 Clinically Localized Prostate Cancer: AUA/ASTRO/SUO guideline states that pelvic lymphadenectomy can be considered for any localized prostate cancer patient undergoing radical prostatectomy and is recommended for those with unfavorable intermediate- or high-risk disease** (Sanda et al., 2018)**. The European Urology Association recommends an extended lymph node dissection in all patients with a risk for nodal metastasis greater than 5% based on preoperative risk nomograms that utilize an extended PLND template (Briganti nomogram, MSKCC, or Roach formula)** (Mottet et al., 2017)**.**

Surgical Technique

In laparoscopic staging PLND, trocar configuration is similar to that for LRP and RALRP, but only one assistant trocar is generally necessary. Abdominal access is established, and an incision is made just lateral to the medial umbilical ligament back toward its confluence with the hypogastric artery and down to the pubis (Fig. 156.25). Great care must be taken to avoid injury to the nearby ureter. If PLND is performed during LRP or RALRP, the dissection is simplified because previous mobilization of the bladder provides excellent exposure of the obturator space.

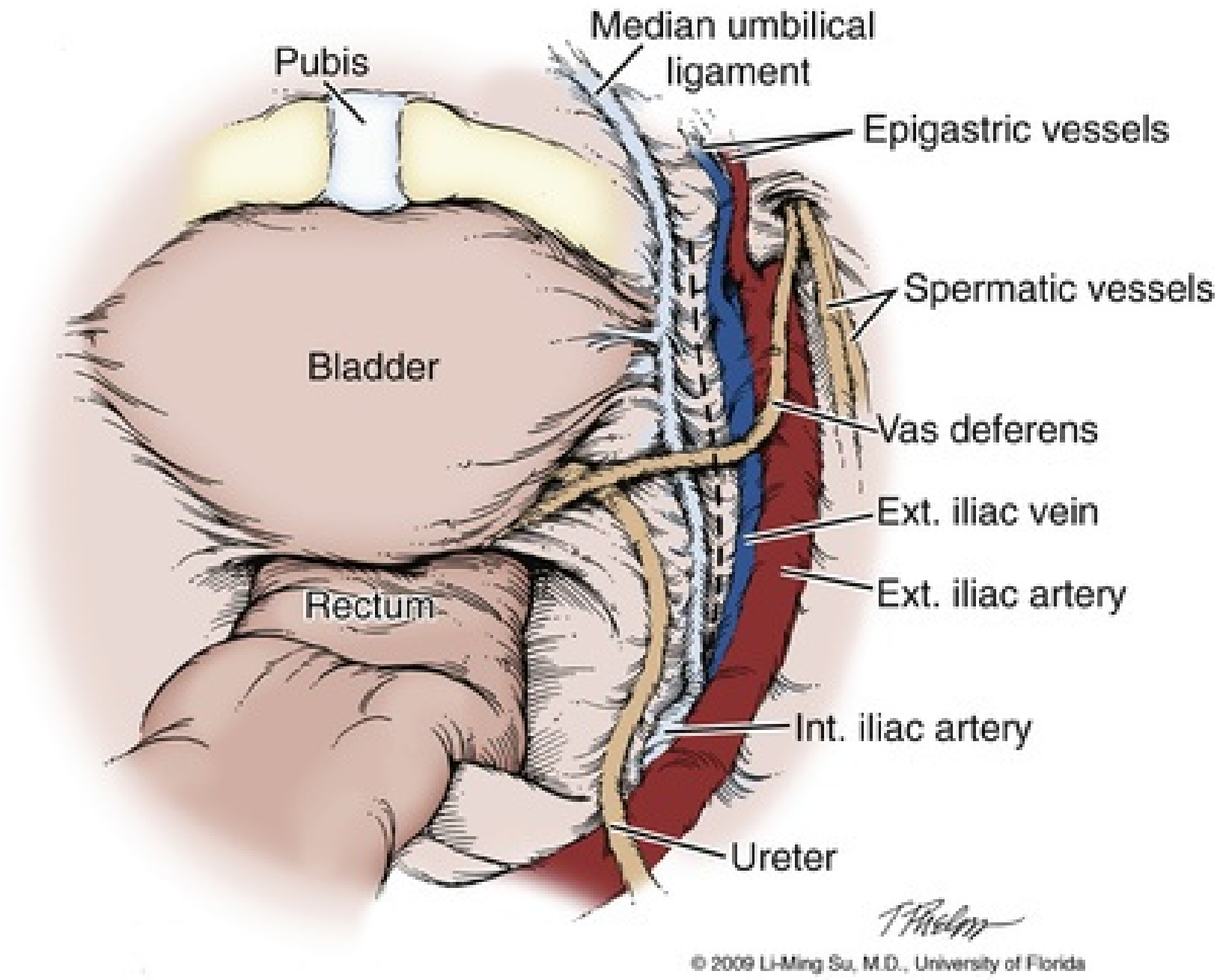
Pubis
Median umbilical ligament
Epigastric vessels
Spermatic vessels
Bladder
Vas deferens
Ext. iliac vein
Ext. iliac artery
Rectum
Int. iliac artery
Ureter
© 2009 Li-Ming Su, M.D., University of Florida

FIG. 156.25 Laparoscopic pelvic lymph node dissection. Initial transperitoneal view of the obturator fossa and relevant anatomy. The *dashed line* indicates the longitudinal incision that is made in the peritoneum lateral and parallel to the median umbilical ligament back toward the bifurcation of the iliac vessels in effort to provide exposure to the obturator fossa and lymph nodes. *Ext.,* exterior; *Int.,* interior. (Copyright Li-Ming Su, MD, University of Florida, 2009.)

As with an open approach, a key initial step to standard laparoscopic PLND is separation of the nodal packet from the external iliac vein. The lymph node packet is grasped and retracted medially. A relatively avascular plane between the lymph node packet and lateral pelvic sidewall is identified and can be dissected bluntly. Dissection is carried out proximally to the iliac bifurcation and distally to the pubis, thus defining the lateral extent of the lymph node packet. By retracting the lymph node packet medially, the precise course of the obturator nerve and vessels can be identified and protected (Fig. 156.26). After securing the distal extent of the lymph nodes with hemoclips, the packet is divided, retracted cranially, and bluntly separated from the obturator vessels and nerve by blunt dissection. Hemoclips are again placed on the proximal extent of the lymph node packet (Fig. 156.27). Further dissection of the neighboring lymph nodes is performed based on the desired template (i.e., sPLND vs ePLND). The lymph nodes usually can be removed as a single packet and extracted either through the 12-mm trocar or by placing them in the entrapment sack along with the prostate specimen.

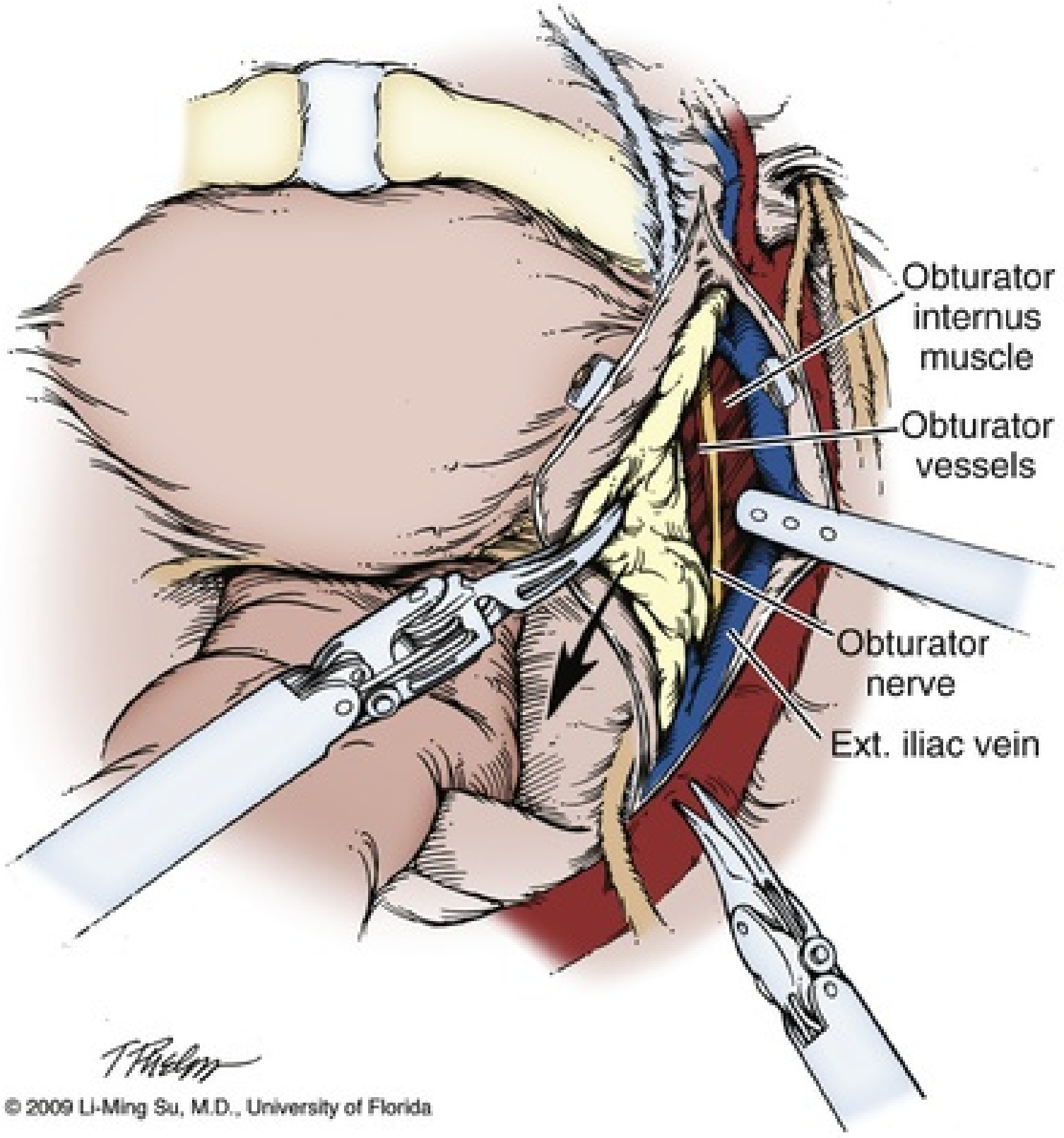
Obturator internus muscle
Obturator vessels
Obturator nerve
Ext. iliac vein

© 2009 Li-Ming Su, M.D., University of Florida

FIG. 156.26 Initial dissection of a standard pelvic lymph node template. The vas deferens has been clipped and divided. With medial traction on the lymph node packet, the lateral extent of the dissection is defined using mainly blunt dissection. *Ext.,* exterior. (Copyright Li-Ming Su, MD, University of Florida, 2009.)

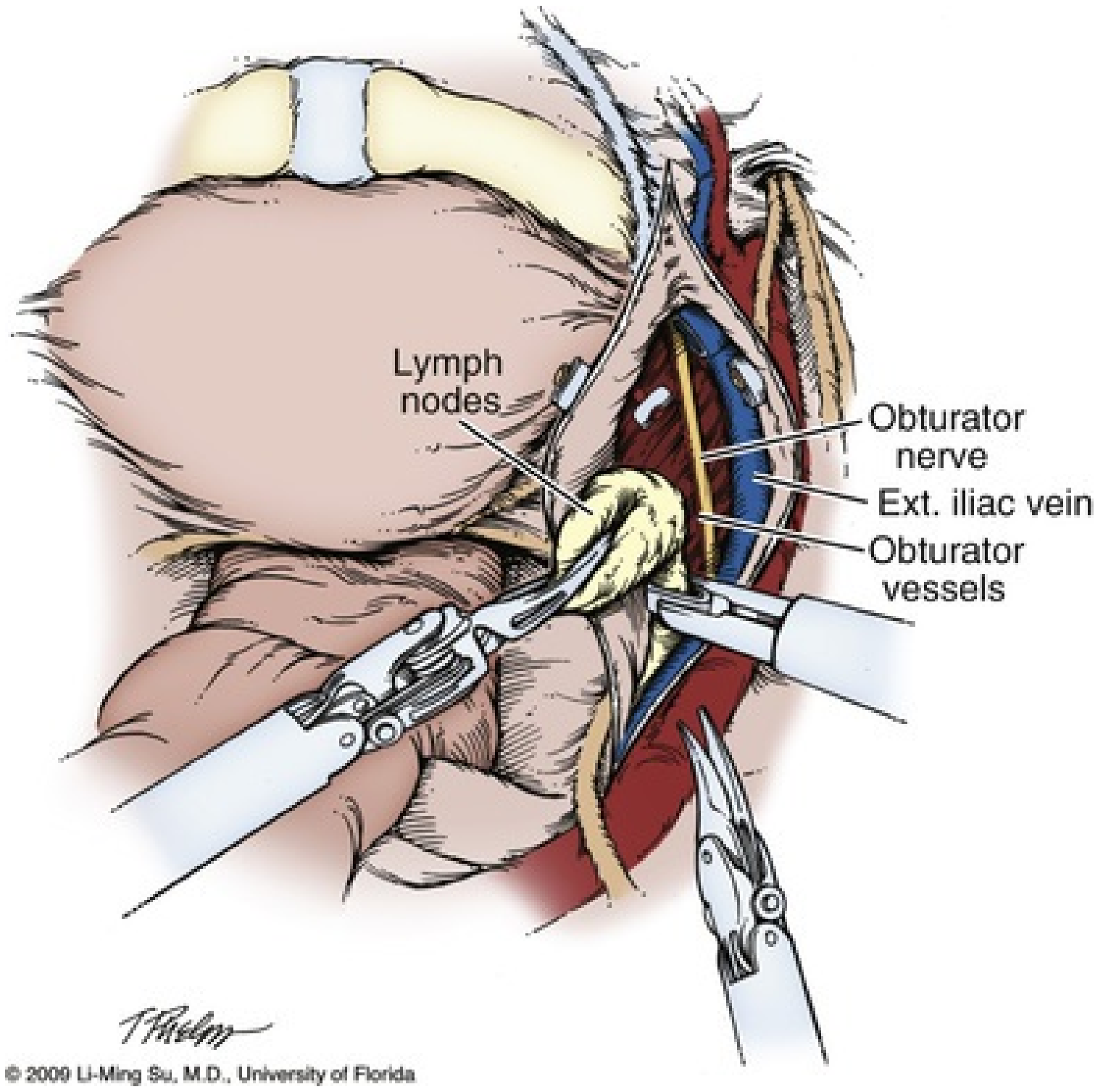

© 2009 Li-Ming Su, M.D., University of Florida

FIG. 156.27 Final dissection of a standard pelvic lymph node template. The proximal and distal extent of the lymph node packet are clipped and divided, taking great care to avoid injury to the obturator nerve and vessels, as well as the accessory obturator vein. (Copyright Li-Ming Su, MD, University of Florida, 2009.)

Some controversy remains about the precise anatomic boundaries of an extended node dissection for patients with prostate cancer; however, an ePLND is now generally recommended (Mottet et al., 2017). **Commonly, though, the boundaries are 2 cm cephalad to the bifurcation of the common iliac artery at the point where the ureter crosses over the vessels and distally to the node of Cloquet. The lateral margin should be the genitofemoral nerve, and the medial border is the bladder wall. Complete removal of all nodal tissue surrounding the obturator nerve is essential, and the bladder pedicle should be skeletonized. Presacral nodes often are included with a superextended dissection.** Extended lymph node dissection can be performed laparoscopically and robotically. The da Vinci Si system allows more proximal angulation of the instruments, and this can significantly facilitate dissection around the bifurcation of the common iliac artery. A thorough dissection adds time to the surgical procedure, but this is true regardless of whether laparoscopic, robotic, or open surgery is performed.

No valid comparative studies exist to support the superiority of open versus laparoscopic PLND. Using lymph node count as a surrogate for adequacy of the dissection is problematic because the method and thoroughness of pathologic evaluation is perhaps even more influential than the anatomic extent of the surgical dissection. With careful attention to meticulous dissection, though, all of the fibrous, fatty, and lymphatic tissue within the commonly accepted anatomic boundaries for an extended lymph node dissection can be removed laparoscopically or robotically. Use of clips on identifiable lymphatic channels can minimize the occurrence of a postoperative lymphocele.

Complications

In 2013, Van der Poel et al. reported a 14.1% overall complication rate in 440 patients undergoing PLND. Because, by definition, PLND requires skeletonization of portions of the common iliac, external iliac, and hypogastric arteries and veins, the possibility of major vascular injury exists. A small venotomy or arteriotomy can be closed laparoscopically or robotically with a fine polypropylene (Prolene) suture. A major injury may require rapid conversion to an open approach. However, the incidence of major vascular injury resulting in enough bleeding to require transfusion is well under 1% with PLND.

Transection of the obturator nerve may occur, leading to loss of sensation in the medial thigh and difficulty with adduction of the leg. Direct repair with suturing of the ends of the obturator nerve using a fine polypropylene suture can restore partial function. Ureteral injury is uncommon, but caution must be observed during the proximal portion of the dissection as the ureter crosses the anterior portion of the common iliac artery.

The major complication of pelvic node dissection relates to the development of postoperative lymphocele. **Theoretically, the communication with the entire peritoneum would allow distribution and absorption of any lymphatic fluid throughout the peritoneal lining of the abdomen and decrease the risk for lymphocele. Despite this, however, a loculation of lymphatic fluid can occur. As such, a transperitoneal RALRP approach is not protective against the formation of a postoperative lymphocele. Lymphocele is the most common complication of PLND and has been reported to occur in up to 60% of patients.** However, the clinically significant lymphocele rate is reported between 2% and 5% (Ploussard et al., 2014). Asymptomatic lymphoceles do not necessarily require drainage or treatment. A larger collection can compress the bladder and cause new-onset or worsening irritative voiding symptoms. Compression of the external iliac vein can predispose a patient to DVT in the lower extremity. Secondary infection of lymphoceles also may occur. In the presence of symptoms or complications from a lymphocele, temporary placement of a percutaneous drain with or without injection of a sclerosing agent is typically successful. However, lymphatic fluid can reaccumulate, requiring repeat drainage with injection of a sclerosing agent or surgical opening of a window with marsupialization of the lymphocele wall by laparoscopic means. Late development of bilateral leg edema is rarely seen after some cases (Musch et al., 2008).

Key Points: Minimally Invasive Pelvic Lymph Node Dissection and Complications

- PLND is generally recommended in patients with intermediate- or high-risk prostate cancer or those with a greater than 5% risk for nodal metastasis using a clinical nomogram.
- Although an extended PLND may yield a higher lymph node count, debate continues as to the extent of PLND and the clinical benefit of removing cancerous nodes given the increased time and complication rates.
- Use of clips on identifiable lymphatic channels can minimize the occurrence of postoperative lymphoceles.
- A transperitoneal approach is not protective against the formation of a lymphocele because loculation of lymphatic fluid can still occur within the peritoneal cavity.
- Symptomatic lymphoceles, which cause local problems such as venous or bladder compression, may require percutaneous or laparoscopic drainage.

Genomic Research on Fresh Prostatic Cancer Tissues and Tissue Banking

In centers where research on prostate cancer is performed in association with high-volume radical prostatectomy programs, prostate cancer tissue is available for genomic research. Although DNA can be extracted from formalin-fixed tissue, ideally fresh prostate cancer tissue is best for genomic research. Kerger et al. (2012) described a technique to identify by frozen section the index cancer, which is then preserved in liquid nitrogen. Aggregation of this tissue in biobanks is then possible, which can be matched to patient informatics. Subsequently, patients who have had their primary prostate cancer removed and banked and who have developed bone metastases can consent to biopsy of the bony metastasis. Thus a linear history of the mutational ability of an individual cancer can be mapped.

Future of Robotic Surgery

Rassweiler et al. (2017) recently described the numerous new robotic systems that will be available after the relevant patents for the first-generation da Vinci platform expire in 2019. **Several new console-base robots for laparoscopic multi- and single-port surgery will come to market in the coming years. One example of a single port platform that is now available is the da Vinci SP system. There will be significant differences in the features of the new robotic machines. There will be a variety of instrumentation, consoles, and video technology**. Clearly the da Vinci systems have set a high bar of engineering excellence that other competitors will find difficult to match. However, cost reduction will likely permit more widespread uptake of new robotic platforms. We have entered the second generation of robotic surgical technology.

The advent in 2018 of less-expensive robotic technology will mean broadening of the patient base being offered this surgery. The major concern in application of robotics has been the economic cost burden. The availability of modular robotic systems with equivalent instrumentation costs to laparoscopic surgery will allow for wide dissemination of robotic through pelvic and abdominal surgery. Medtronic Surgery, Cambridge Robotic Systems, and a number of other vendors are entering the market in robotic surgical technology. In urologic surgery beyond radical prostatectomy, other applications of robotics will include pyeloplasty, partial nephrectomy, and radical cystoprostatectomy. **This broadening of robotic surgery beyond radical prostatectomy will mandate the embedding of a robotic surgery curriculum in all urology residency and fellowship training programs.** Appropriate simulation and virtual reality systems will need to be employed in the teaching curriculum (Ficarra et al., 2012b).

Summary

RALRP has now become the operation of choice for both localized and even locally advanced prostate cancer. Open radical prostatectomy is now uncommonly performed in the United States. There has been wide dissemination of RALRP in Europe and throughout Asia. The robotic technology vision system and superb laparoscopic instrumentation provide clear advantages to patients undergoing this procedure. These advantages relate to minimally invasive surgery in a 12× magnified operative field in three dimensions. This allows the procedure to be performed as an overnight stay case, with much earlier return to normal activity as compared with open surgery. There is now evidence to demonstrate equivalence in oncologic and urinary continence outcomes and improved outcomes with regard to erectile function. Implementation of robotic technology in surgery has allowed more patients to be offered surgery as a choice of treatment for localized prostate cancer, and in the salvage prostate cancer surgery setting.

Cost still remains an issue with this technology. The entry of new vendors with alternative robotic platforms with a lower cost base promises wider implementation of robotics beyond radical prostatectomy. Dissemination of robotic technology in surgery will mandate a significant change in approach to surgery training and in particular urology residency training. There is now the ability to teach robotic surgery with virtual reality and simulation away from the operating room. Urology residents can be monitored during performance of repetitive tasks evaluable by mentors. This training can then take place before the performance of live surgery on patients in the operating room (Ficarra et al., 2012b). This may make robotic surgery training more analogous to aviation education with improved communication and operating room safety.

▶Videos 156.1 to 156.16 show procedures related to this chapter.

References

Abbou CC, Salomon L, Hoznek A, et al. Laparoscopic radical prostatectomy: preliminary results. *Urology*. 2000;55(5):630–634.

Abdul-Muhsin H, Giedelman C, Samavedi S, et al. Perioperative and early oncological outcomes after robot-assisted radical prostatectomy (RARP) in morbidly obese patients: a propensity score-matched study. *BJU Int*. 2014;113(1):84–91.

Ahlering TE, Woo D, Eichel L, et al. Robot-assisted versus open radical prostatectomy: a comparison of one surgeon's outcomes. *Urology*. 2004;63(5):819–822.

Ahlering TE, Eichel L, Chou D, et al. Feasibility study for robotic radical prostatectomy cautery-free neurovascular bundle preservation. *Urology*. 2005;65(5):994–997.

Allaf ME, Hsu TH, Sullivan W, et al. Simultaneous laparoscopic prosthetic mesh inguinal herniorrhaphy during transperitoneal laparoscopic radical prostatectomy. *Urology*. 2003;62(6):1121.

Atug F, Castle EP, Woods M, et al. Transperitoneal versus extraperitoneal robotic-assisted radical prostatectomy: is one better than the other? *Urology*. 2006;68(5):1077–1081.

Awad H, Santilli S, Ohr M, et al. The effects of steep Trendelenburg positioning on intraocular pressure during robotic radical prostatectomy. *Anesth Analg*. 2009;109(2):473–478.

Barbash GI, Friedman B, Glied SA, et al. Factors associated with adoption of robotic surgical technology in US hospitals and relationship to radical prostatectomy procedure volume. *Ann Surg*. 2014;259(1):1–6.

Barbash GI, Glied SA. New technology and health care costs—

the case of robot-assisted surgery. *N Engl J Med*. 2010;363(8):701–704.

Bauer RM, Mayer ME, Gratzke C, et al. Prospective evaluation of the functional sling suspension for male postprostatectomy stress urinary incontinence: results after 1 year. *Eur Urol*. 2009;56(6):928–933.

Borin JF, Skarecky DW, Narula N, et al. Impact of urethral stump length on continence and positive surgical margins in robot-assisted laparoscopic prostatectomy. *Urology*. 2007;70(1):173–177.

Boris RS, Bhandari A, Krane LS, et al. Salvage robotic-assisted radical prostatectomy: initial results and early report of outcomes. *BJU Int*. 2009;103(7):952–956.

Breyer BN, McAninch JW. Management of recalcitrant bladder neck contracture after radical prostatectomy for prostate cancer. Endoscopic and open surgery. *J Urol*. 2011;185(2):390–391.

Brown JA, Rodin D, Lee B, et al. Transperitoneal versus extraperitoneal approach to laparoscopic radical prostatectomy: an assessment of 156 cases. *Urology*. 2005;65(2):320–324.

Brown JA, Rodin DM, Lee B, et al. Laparoscopic radical prostatectomy and body mass index: an assessment of 151 sequential cases. *J Urol*. 2005;173(2):442–445.

Carlsson S, Jaderling F, Wallerstedt A, et al. Oncological and functional outcomes 1 year after radical prostatectomy for very-low-risk prostate cancer: results from the prospective LAPPRO trial. *BJU Int*. 2016;118(2):205–212.

Cathelineau X, Cahill D, Widmer H, et al. Transperitoneal or extraperitoneal approach for laparoscopic radical prostatectomy: a false debate over a real challenge. *J Urol*. 2004;171(2 Pt 1):714–716.

Centemero A, Rigatti L, Giraudo D, et al. Preoperative pelvic floor muscle exercise for early continence after radical prostatectomy: a randomised controlled study. *Eur Urol*. 2010;57(6):1039–1043.

Chauhan S, Patel MB, Coelho R, et al. Preliminary analysis of the feasibility and safety of salvage robot-assisted radical prostatectomy after radiation failure: multi-institutional perioperative and short-term functional outcomes. *J Endourol*. 2011;25(6):1013–1019.

Coelho RF, Rocco B, Patel MB, et al. Retropubic, laparoscopic, and robot-assisted radical prostatectomy: a critical review of outcomes reported by high-volume centers. *J Endourol*. 2010;24(12):2003–2015.

Costello AJ. Beyond marketing: the real value of robotic radical prostatectomy. *BJU Int*. 2005;96(1):1–2.

Costello AJ, Brooks M, Cole OJ. Anatomical studies of the neurovascular bundle and cavernosal nerves. *BJU Int*. 2004;94(7):1071–1076.

de Rooij M, Hamoen EH, Witjes JA, et al. Accuracy of magnetic resonance imaging for local staging of prostate cancer: a diagnostic meta-analysis. *Eur Urol*. 2016;70(2):233–245.

Eden CG, King D, Kooiman GG, et al. Transperitoneal or extraperitoneal laparoscopic radical prostatectomy: does the approach matter? *J Urol*. 2004;172(6 Pt 1):2218–2223.

Erdogru T, Teber D, Frede T, et al. Comparison of transperitoneal and extraperitoneal laparoscopic radical prostatectomy using match-pair analysis. *Eur Urol*. 2004;46(3):312–319 [discussion 320].

Erdogru T, Teber D, Frede T, et al. The effect of previous transperitoneal laparoscopic inguinal herniorrhaphy on transperitoneal laparoscopic radical prostatectomy. *J Urol*. 2005;173(3):769–772.

Farnham SB, Webster TM, Herrell SD, et al. Intraoperative blood loss and transfusion requirements for robotic-assisted radical prostatectomy versus radical retropubic prostatectomy. *Urology*. 2006;67(2):360–363.

Feng TS, Sharif-Afshar AR, Wu J, et al. Multiparametric MRI improves accuracy of clinical nomograms for predicting extracapsular extension of prostate cancer. *Urology*. 2015;86(2):332–337.

Ficarra V, Novara G, Ahlering TE, et al. Systematic review and meta-analysis of studies reporting potency rates after robot-assisted radical prostatectomy. *Eur Urol*. 2012;62(3):418–430.

Ficarra V, Novara G, Rosen RC, et al. Systematic review and meta-analysis of studies reporting urinary continence recovery after robot-assisted radical prostatectomy. *Eur Urol*. 2012;62(3):405–417.

Fossati N, Willemse PM, Van den Broeck T, et al. The benefits and harms of different extents of lymph node dissection during radical prostatectomy for prostate cancer: a systematic review. *Eur Urol*. 2017;72(1):84–109.

Ganapathi HP, Ogaya-Pinies G, Mouraviev V, et al. Robotic radical prostatectomy: complex case management. Su L-M. *Atlas of robotic urologic surgery*. ed 2. Springer: Switzerland; 2017:297–308.

Gandaglia G, Zaffuto E, Fossati N, et al. Identifying candidates for super-extended staging pelvic lymph node dissection among patients with high-risk prostate cancer. *BJU Int*. 2018;121(3):421–427.

Gill IS, Ukimura O, Rubinstein M, et al. Lateral pedicle control during laparoscopic radical prostatectomy: refined technique. *Urology*. 2005;65(1):23–27.

Giordano C, Gravenstein N, Le HTT. Anesthetic considerations with robotic surgery. Su L-M. *Atlas of robotic urologic surgery*. ed 2. Springer: Switzerland; 2017:41–60.

Groeben C, Koch R, Baunacke M, et al. High volume is the key for improving in-hospital outcomes after radical prostatectomy: a total population analysis in Germany from 2006 to 2013. *World J Urol*. 2017;35(7):1045–1053.

Guillonneau B, Vallancien G. Laparoscopic radical prostatectomy: the Montsouris technique. *J Urol*. 2000;163(6):1643–1649.

Guillonneau BD. Laparoscopic versus robotic radical prostatectomy. *Nat Clin Pract Urol*. 2005;2(2):60–61.

Gupta NP, Singh P, Nayyar R. Outcomes of robot-assisted radical prostatectomy in men with previous transurethral resection of prostate. *BJU Int*. 2011;108(9):1501–1505.

Haglind E, Carlsson S, Stranne J, et al. Urinary incontinence and erectile dysfunction after robotic versus open radical prostatectomy: a prospective, controlled, nonrandomised trial. *Eur Urol*. 2015;68(2):216–225.

Hoznek A, Antiphon P, Borkowski T, et al. Assessment of surgical technique and perioperative morbidity associated with extraperitoneal versus transperitoneal laparoscopic radical prostatectomy. *Urology*. 2003;61(3):617–622.

Hu JC, Nelson RA, Wilson TG, et al. Perioperative complications of laparoscopic and robotic assisted laparoscopic radical prostatectomy. *J Urol*. 2006;175(2):541–546 [discussion 546].

Jenkins LC, Mulhall JP. Impact of prostate cancer treatments on sexual health. Mydlo JH, Godec CJ. *Prostate cancer science and clinical practice*. ed 2. Academic Press: Cambridge, MA; 2016.

Kaffenberger SD, Keegan KA, Bansal NK, et al. Salvage robotic assisted laparoscopic radical prostatectomy: a single institution, 5-year experience. *J Urol*. 2013;189(2):507–513.

Kaouk JH, Hafron J, Goel R, et al. Robotic salvage retropubic prostatectomy after radiation/brachytherapy: initial results.

BJU Int. 2008;102(1):93–96.
Kerger M, Hong MK, Pedersen J, et al. Microscopic assessment of fresh prostate tumour specimens yields significantly increased rates of correctly annotated samples for downstream analysis. *Pathology*. 2012;44(3):204–208.
Khaira HS, Bruyere F, O'Malley PJ, et al. Does obesity influence the operative course or complications of robot-assisted laparoscopic prostatectomy. *BJU Int*. 2006;98(6):1275–1278 [discussion 1278].
Kheterpal E, Bhandari A, Siddiqui S, et al. Management of rectal injury during robotic radical prostatectomy. *Urology*. 2011;77(4):976–979.
Koraitim MM. The male urethral sphincter complex revisited: an anatomical concept and its physiological correlate. *J Urol*. 2008;179(5):1683–1689.
Köhler TS, Pedro R, Hendlin K, et al. A pilot study on the early use of the vacuum erection device after radical retropubic prostatectomy. *BJU Int*. 2007;100(4):858–862.
Lavery HJ, Thaly R, Albala D, et al. Robotic equipment malfunction during robotic prostatectomy: a multi-institutional study. *J Endourol*. 2008;22(9):2165–2168.
Levinson AW, Bagga HS, Pavlovich CP, et al. The impact of prostate size on urinary quality of life indexes following laparoscopic radical prostatectomy. *J Urol*. 2008;179(5):1818–1822.
Levinson AW, Ward NT, Sulman A, et al. The impact of prostate size on perioperative outcomes in a large laparoscopic radical prostatectomy series. *J Endourol*. 2009;23(1):147–152.
Leyh-Bannurah SR, Hansen J, Isbarn H, et al. Open and robot-assisted radical retropubic prostatectomy in men receiving ongoing low-dose aspirin medication: revisiting an old paradigm? *BJU Int*. 2014;114(3):396–403.

Link BA, Nelson R, Josephson DY, et al. The impact of prostate gland weight in robot assisted laparoscopic radical prostatectomy. *J Urol*. 2008;180(3):928–932.

Lunacek A, Schwentner C, Fritsch H, et al. Anatomical radical retropubic prostatectomy: “curtain dissection” of the neurovascular bundle. *BJU Int*. 2005;95(9):1226–1231.

Mattei A, Fuechsel FG, Bhatta Dhar N, et al. The template of the primary lymphatic landing sites of the prostate should be revisited: results of a multimodality mapping study. *Eur Urol*. 2008;53(1):118–125.

Meininger D, Byhahn C, Wolfram M, et al. Prolonged intraperitoneal versus extraperitoneal insufflation of carbon dioxide in patients undergoing totally endoscopic robot-assisted radical prostatectomy. *Surg Endosc*. 2004;18(5):829–833.

Menon M, Kaul S, Bhandari A, et al. Potency following robotic radical prostatectomy: a questionnaire based analysis of outcomes after conventional nerve sparing and prostatic fascia sparing techniques. *J Urol*. 2005;174(6):2291–2296 [discussion 2296].

Menon M, Muhletaler F, Campos M, et al. Assessment of early continence after reconstruction of the periprostatic tissues in patients undergoing computer assisted (robotic) prostatectomy: results of a 2 group parallel randomized controlled trial. *J Urol*. 2008;180(3):1018–1023.

Morlacco A, Sharma V, Viers BR, et al. The incremental role of magnetic resonance imaging for prostate cancer staging before radical prostatectomy. *Eur Urol*. 2017;71(5):701–704.

Mottet N, Bellmunt J, Bolla M, et al. EAU-ESTRO-SIOG guidelines on prostate cancer. Part 1: Screening, diagnosis, and local treatment with curative intent. *Eur Urol*. 2017;71(4):618–629.

Msezane LP, Reynolds WS, Gofrit ON, et al. Bladder neck contracture after robot-assisted laparoscopic radical prostatectomy: evaluation of incidence and risk factors and impact on urinary function. *J Endourol*. 2008;22(1):97–104.

Musch M, Klevecka V, Roggenbuck U, et al. Complications of pelvic lymphadenectomy in 1,380 patients undergoing radical retropubic prostatectomy between 1993 and 2006. *J Urol*. 2008;179(3):923–928 [discussion 928–929].

Nehra A, Kumar R, Ramakumar S, et al. Pharmacoangiographic evidence of the presence and anatomical dominance of accessory pudendal artery(s). *J Urol*. 2008;179(6):2317–2320.

Nguyen MM, Turna B, Santos BR, et al. The use of an endoscopic stapler vs suture ligature for dorsal vein control in laparoscopic prostatectomy: operative outcomes. *BJU Int*. 2008;101(4):463–466.

Novara G, Ficarra V, Mocellin S, et al. Systematic review and meta-analysis of studies reporting oncologic outcome after robot-assisted radical prostatectomy. *Eur Urol*. 2012;62(3):382–404.

Oelrich TM. The urethral sphincter muscle in the male. *Am J Anat*. 1980;158(2):229–246.

Ong AM, Su LM, Varkarakis I, et al. Nerve sparing radical prostatectomy: effects of hemostatic energy sources on the recovery of cavernous nerve function in a canine model. *J Urol*. 2004;172(4 Pt 1):1318–1322.

Overgard M, Angelsen A, Lydersen S, et al. Does physiotherapist-guided pelvic floor muscle training reduce urinary incontinence after radical prostatectomy? A randomised controlled trial. *Eur Urol*. 2008;54(2):438–448.

Patel MI, Yao J, Hirschhorn AD, et al. Preoperative pelvic floor physiotherapy improves continence after radical retropubic prostatectomy. *Int J Urol*. 2013;20(10):986–992.

Patel VR, Sivaraman A, Coelho RF, et al. Pentafecta: a new concept for reporting outcomes of robot-assisted laparoscopic radical prostatectomy. *Eur Urol*. 2011;59(5):702–707.

Patel VR, Schatloff O, Chauhan S, et al. The role of the prostatic vasculature as a landmark for nerve sparing during robot-assisted radical prostatectomy. *Eur Urol*. 2012;61(3):571–576.

Patil N, Krane L, Javed K, et al. Evaluating and grading cystographic leakage: correlation with clinical outcomes in patients undergoing robotic prostatectomy. *BJU Int*. 2009;103(8):1108–1110.

Philippou Y, Parker RA, Volanis D, et al. Comparative oncologic and toxicity outcomes of salvage radical prostatectomy versus nonsurgical therapies for radiorecurrent prostate cancer: a meta-regression analysis. *Eur Urol Focus*. 2016;2(2):158–171.

Ploussard G, Briganti A, de la Taille A, et al. Pelvic lymph node dissection during robot-assisted radical prostatectomy: efficacy, limitations, and complications—a systematic review of the literature. *Eur Urol*. 2014;65(1):7–16.

Radtke JP, Hadaschik BA, Wolf MB, et al. The impact of magnetic resonance imaging on prediction of extraprostatic extension and prostatectomy outcome in patients with low-, intermediate- and high-risk prostate cancer: try to find a standard. *J Endourol*. 2015;29(12):1396–1405.

Rassweiler JJ, Autorino R, Klein J, et al. Future of robotic surgery in urology. *BJU Int*. 2017;120(6):822–841.

Reiner WG, Walsh PC. An anatomical approach to the surgical management of the dorsal vein and Santorini's plexus during radical retropubic surgery. *J Urol*. 1979;121(2):198–200.

Rocco F, Carmignani L, Acquati P, et al. Early continence recovery after open radical prostatectomy with restoration of the posterior aspect of the rhabdosphincter. *Eur Urol*. 2007;52(2):376–383.

Rud E, Baco E, Klotz D, et al. Does preoperative magnetic resonance imaging reduce the rate of positive surgical margins at radical prostatectomy in a randomised clinical trial? *Eur Urol*. 2015;68(3):487–496.

Sanda MG, Cadeddu JA, Kirkby E, et al. Clinically localized prostate cancer: AUA/ASTRO/SUO guideline. Part I: Risk stratification, shared decision making, and care options. *J Urol*. 2018;199(3):683–690.

Schiavina R, Bianchi L, Borghesi M, et al. MRI displays the prostatic cancer anatomy and improves the bundles management before robot assisted radical prostatectomy. *J Endourol*. 2018;32(4):315–321.

Schuessler WW, Schulam PG, Clayman RV, et al. Laparoscopic radical prostatectomy: initial short-term experience. *Urology*. 1997;50(6):854–857.

Singh A, Fagin R, Shah G, et al. Impact of prostate size and body mass index on perioperative morbidity after laparoscopic radical prostatectomy. *J Urol*. 2005;173(2):552–554.

Stafford RE, Mazzone S, Ashton-Miller JA, et al. Dynamics of male pelvic floor muscle contraction observed with transperineal ultrasound imaging differ between voluntary and evoked coughs. *J Appl Physiol*. 2014;116(8):953–960.

Stephenson AJ, Eastham JA. Role of salvage radical prostatectomy for recurrent prostate cancer after radiation therapy. *J Clin Oncol*. 2005;23(32):8198–8203.

Stolzenburg JU, Rabenalt R, Dietel A, et al. Hernia repair during endoscopic (laparoscopic) radical prostatectomy. *J Laparoendosc Adv Surg Tech A*. 2003;13(1):27–31.

Stolzenburg JU, Ho KM, Do M, et al. Impact of previous surgery on endoscopic extraperitoneal radical prostatectomy. *Urology*. 2005;65(2):325–331.

Su LM, Link RE, Bhayani SB, et al. Nerve-sparing laparoscopic radical prostatectomy: replicating the open surgical technique. *Urology*. 2004;64(1):123–127.

Takenaka A, Murakami G, Soga H, et al. Anatomical analysis of the neurovascular bundle supplying penile cavernous tissue to ensure a reliable nerve graft after radical prostatectomy. *J Urol*. 2004;172(3):1032–1035.

Tay KJ, Gupta RT, Brown AF, et al. Defining the incremental utility of prostate multiparametric magnetic resonance imaging at standard and specialized read in predicting extracapsular extension of prostate cancer. *Eur Urol*. 2016;70(2):211–213.

Tewari AK, Bigelow K, Rao S, et al. Anatomic restoration technique of continence mechanism and preservation of puboprostatic collar: a novel modification to achieve early urinary continence in men undergoing robotic prostatectomy. *Urology*. 2007;69(4):726–731.

Tewari A, Rao S, Mandhani A. Catheter-less robotic radical prostatectomy using a custom-made synchronous anastomotic splint and vesical urinary diversion device: report of the initial series and perioperative outcomes. *BJU Int*. 2008;102(8):1000–1004.

Van der Aa F, Drake MJ, Kasyan GR, et al. Young Academic Urologists Functional Urology Group. The artificial urinary sphincter after a quarter of a century: a critical systematic review of its use in male non-neurogenic incontinence. *Eur Urol*. 2013;63(4):681–689.

van der Poel HG, Tillier C, de Blok W, et al. Salvage radiotherapy after robot-assisted laparoscopic radical prostatectomy. *Urology*. 2013;82(4):834–838.

Van Velthoven RF, Ahlering TE, Peltier A, et al. Technique for laparoscopic running urethrovesical anastomosis: the single knot method. *Urology*. 2003;61(4):699–702.

Walsh PC. Radical prostatectomy for the treatment of localized prostatic carcinoma. *Urol Clin North Am*. 1980;7(3):583–591.

Walsh PC, Donker PJ. Impotence following radical prostatectomy: insight into etiology and prevention. *J Urol*. 1982;128(3):492–497.

Wedmid A, Mendoza P, Sharma S, et al. Rectal injury during robot-assisted radical prostatectomy: incidence and management. *J Urol*. 2011;186(5):1928–1933.

Yaxley JW, Coughlin GD, Chambers SK, et al. Robot-assisted laparoscopic prostatectomy versus open radical retropubic prostatectomy: early outcomes from a randomised controlled phase 3 study. *Lancet*. 2016;388(10049):1057–1066.

Yaxley JW, Dagher J, Delahunt B, et al. Reconsidering the role of pelvic lymph node dissection with radical prostatectomy for prostate cancer in an era of improving radiological staging techniques. *World J Urol*. 2018;36(1):15–20.

Yuh B, Ruel N, Muldrew S, et al. Complications and outcomes of salvage robot-assisted radical prostatectomy: a single-institution experience. *BJU Int*. 2014;113(5):769–776.

Zorn KC, Wille MA, Thong AE, et al. Continued improvement of perioperative, pathological and continence outcomes during 700 robot-assisted radical prostatectomies. *Can J Urol*. 2009;16(4):4742–4749 [discussion 4749].

157

Radiation Therapy for Prostate Cancer

Ryan Phillips MD, PhD, Sarah Hazell MD, Daniel Y. Song MD

Historical Perspective and Technological Advances

Wilhelm Conrad Roentgen is generally credited with the first description of what he called “x-rays” when in 1896 he presented a lecture entitled “Concerning a New Kind of Ray.” His work led to the rapid emergence of the study of diagnostic radiology and earned him the first Nobel Prize in Physics in 1901. Shortly thereafter, radiation was also being utilized to treat a variety of skin diseases, including cancer (n.a., 1983). However, it took several more decades and the discovery of deoxyribonucleic acid (DNA) before it was understood that the primary mechanism for the effect of radiographs on tissues was via ionization and production of DNA damage, either directly or via free radical production.

The first documented radiotherapeutic approach to treatment of prostate cancer was by Pasteau and Degrais in 1911, who described using an intraurethral radium source, with modifications of this approach later utilized by Young and Fronz in 1917.

There are reports of external beam radiotherapy (EBRT) using kilovoltage radiation for the treatment of prostate cancer between 1930 and 1955 (Attwater, 1930; Hultberg, 1946). However, a problem inherent to kilovoltage radiation is a high deposition of dose at the skin, limiting the ability to deliver tumoricidal doses of radiation to the prostate because of unacceptable skin and normal tissue toxicity. Further technical advances would be required before RT could achieve greater efficacy and safety. Several relevant considerations exist when delivering therapeutic radiation, particularly in a relatively deep-seated internal organ such as the prostate:

1. Need for tissue penetration of beams with minimal energy deposition to superficial structures to reduce skin and tissue toxicity
2. Proximity of and need for sparing of adjacent normal tissues such as the rectum, bladder, and femoral heads
3. Minimizing the potential for targeting errors resulting from organ motion and tissue deformation

The need to overcome these issues led to the improvements that occurred over subsequent years and resulted in the modern techniques available today.

High-Energy Linear Accelerators

Following the development and availability of high-energy megavoltage radiation therapy (RT) units in the 1960s, definitive treatment to the prostate could be delivered without severe damage to normal structures because of superior tissue penetration and reduced skin doses (Bagshaw and Kaplan, 1962). Linear accelerators function by accelerating charged particles (usually electrons) to high speeds using a series of oscillating electric potentials along a linear beamline. The electrons strike a target (typically tungsten) that then produces **photons** (x-rays). The photon beam can then be shaped using variable collimators or tungsten “leaves” within the machine before exiting to the patient (older units used custom-cut lead blocks). The physical property that permits the photon radiation generated from a linear accelerator to penetrate deeply and spare normal tissue is high-beam energy. As the energy of the beam increases, the beam penetrates deeper before exerting its cytotoxic effect. Whereas older orthovoltage (100 to 500 kilovolts) and cobalt-60 units (1.17 to 1.33 megavolts) deposited their maximum dose at approximately 1.25 cm below the skin surface, modern high-energy linear accelerators (6 to 15 megavolts) deliver the maximum dose of radiation at 15 cm or more below the skin surface.

Further significant advancements in the radiotherapeutic management of prostate cancer occurred in the early 1980s and 1990s. The first was the development of more conformal techniques capable of delivering higher doses of radiation deep within the pelvis while simultaneously respecting the radiation tolerance of the anterior rectal wall, prostatic urethra, femoral heads, and bladder neck. This period was notable for the development and widespread adoption of CT-based, three-dimensional conformal radiotherapy (3D-CRT), followed by intensity-modulated radiation therapy (IMRT).

CT-Based Treatment Planning and Three-Dimensional Conformal Radiotherapy

Early radiation oncologists had to treat cancers without precise knowledge of their location within the body. Knowledge of normal anatomy, routes of spread of a particular cancer, and limited information from diagnostic radiology were used for treatment planning (Asbell et al., 1980). Radiation oncologists became adept at designing radiation fields on the basis of skeletal anatomy. For the treatment of prostate cancer, the radiation portals were centered near the pubic symphysis and femoral heads. The location of the prostate was often inferred indirectly by introducing a contrast-filled Foley catheter and rectal tube into the patient and obtaining orthogonal x-ray images. These techniques were employed as recently as the mid-1980s. In this era before computed tomography (CT), radiation treatment technique was sometimes referred to as **conventional radiation.** Clinicians knew as early as 1980 that they were potentially making significant errors in field placement without CT data, but limitations in computer hardware and software allowed no solution to the problem (Fraass, 1995; Rosenman et al., 1991). They also knew that radiation doses received by surrounding organs caused morbidity, but lacked accurate methods for calculating doses received by these organs, and typically would rely on calculations of dose to one or two particular points projected to be within the organ of interest.

The ability to visualize the prostate during radiation treatment planning arrived in the 1990s with the advent of CT scanners and use of CT for radiation planning. This was a dramatic breakthrough in radiation treatment for prostate cancer, because it allowed the ability to design radiation beams to directly target the prostate and for the first time accurately calculate doses received by nearby organs such as the rectum and bladder (Mohan et al., 1992; Niemierko et al., 1992). Radiation penetration and dose deposited within tissues is generally a function of electron density, which varies most significantly among bone, air, and soft tissues. The combination of widespread CT availability and computers with improved graphics and computational power significantly changed the field of radiation oncology by allowing better tissue delineation and advanced dose computation that accurately accounted for tissue inhomogeneities.

With modern CT-based treatment planning, the treatment process is initiated by having the patient scanned with CT in the treatment position to be utilized for daily treatment, a procedure called ***simulation***. The imaging data are then transferred to a treatment-planning system which allows the radiation oncologist to delineate the target volume (i.e., the prostate) and relevant normal tissues (otherwise known as ***regions of interest***, *or* ***ROIs***). The radiation oncologist determines and prescribes the dose of radiation to be delivered to the target (and acceptable degree of variation within the target volume) and the constraints on the amount of radiation the relevant normal tissues can receive without undue risk for toxicity. Under the radiation oncologist's supervision, medical dosimetrists and physicists use the treatment-planning system to define, calculate, and optimize the treatment beams or arcs to achieve the desired dose to the target volume while maximally sparing other tissues. Doses received by the delineated tissues/tumor can be represented graphically using a **dose-volume histogram (DVH),** which plots the dose received by varying volumes of the target and the normal tissues/organs. An example is **IMRT.** An IMRT dose-volume histogram is shown in Fig. 157.1. Using CT, the prostate and surrounding structures could be identified with increased precision, and the beam's-eye view, a technique allowing visualization of the regional anatomy from the perspective of the beam apertures, enabled the design of plans that could more accurately treat the prostate target while minimizing dose to the surrounding normal tissues using custom beam shaping. The result is described as 3D-CRT because the radiation beams conform to the shape of the treatment target (Fraass, 1995).

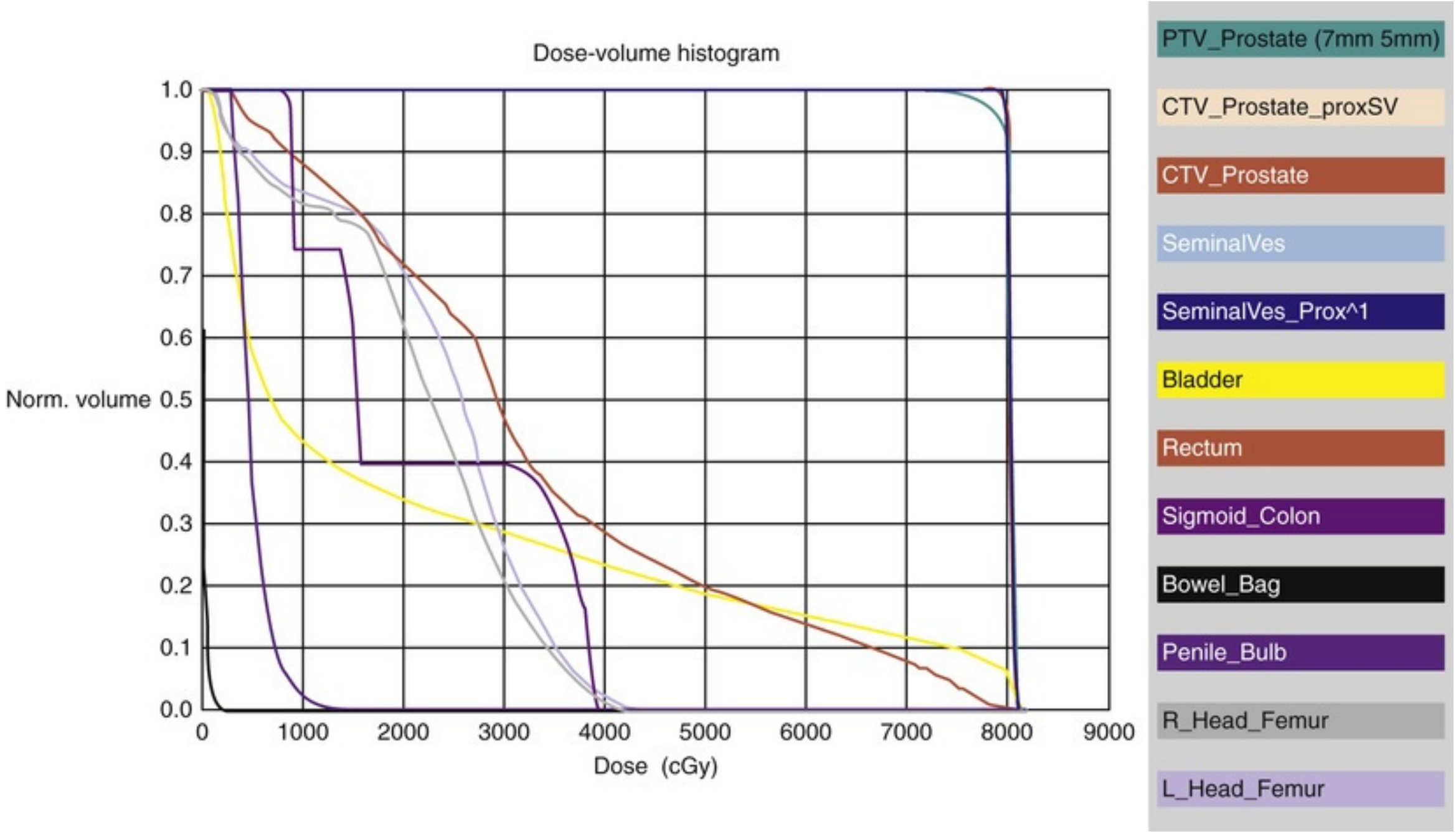

FIG. 157.1 Dose-volume histogram (DVH) of conventionally fractionated, intensity-modulated radiation treatment plan. Both volume (*y*-axis) and dose (x-axis) are typically evaluated and shown as percentages of total. Prescription dose is 78 Gy. Note that this plan has nearly 100% of target volume (PTV) receiving prescribed dose, yet there is steep fall-off in target volume coverage beyond 78 to 80 Gy. This is typical for conventionally fractionated plans to avoid excessive dose within the prostate and immediate adjacent tissues. In contrast, stereotactic body radiation plans (see the Stereotactic Body Radiotherapy section in text) often have

portions of target volume intentionally receiving a higher-than-prescribed dose, with the rationale of increasing the dose to the intraprostatic tumor.

One of the goals of conformal prostate radiation is to lower the dose to the surrounding normal tissues, such as the rectum and bladder, while simultaneously increasing the dose delivered to the prostate itself (Burman et al., 1991; Niemierko et al., 1992). The use of CT data allows more accurate placement of the radiation fields; this was first demonstrated by Pilepich et al. (1982), who found a 53% error rate in field placement and portal size in patients simulated without CT data. In theory, better pretreatment visualization and localization of the prostate eliminate the need to enlarge the radiation portal to account for anatomic and geometric uncertainties. It logically follows that smaller radiation portals allow less irradiation of nontarget structures such as the bladder or rectum, thereby reducing treatment-related morbidity.

Intensity-Modulated Radiation Therapy

The ability to accurately calculate radiation doses to the prostate and surrounding organs facilitated further technologic developments that allowed delivery of higher radiation doses to the prostate while simultaneously lowering doses to surrounding organs. Another major advance in the delivery of radiation is IMRT. IMRT employs a similar process to 3D-CRT, but rather than the static, fixed-shape beams utilized in 3D-CRT, IMRT employs more complex, dynamic beam shapes wherein the intensity of radiation is varied across the beam (as opposed to uniform intensity across the beam). This allows for finer control of spatial variations in dose and can produce steeper dose gradients with improved sparing of normal tissues, particularly when tumors or tissues have complex, convex, or concave shapes. IMRT employs a complex treatment-planning approach referred to as *inverse treatment planning,* wherein users manipulate computer algorithms to calculate doses to achieve specified goals regarding areas where radiation dose is to be minimized (i.e., organs) and areas that are to receive high-dose treatment (i.e., prostate). This computer-optimized inverse planning requires use of advanced software, specialized personnel, and hardware adaptations to linear accelerators (Burman et al., 1997). With this technology, plans can be generated in which the majority of the adjacent bladder and rectum receive less than one-half of the dose given to the prostate. An example of an intensity-modulated plan is shown in Fig. 157.2, demonstrating a distribution of radiation that follows the contours of the prostate while sparing much of the rectum and bladder.

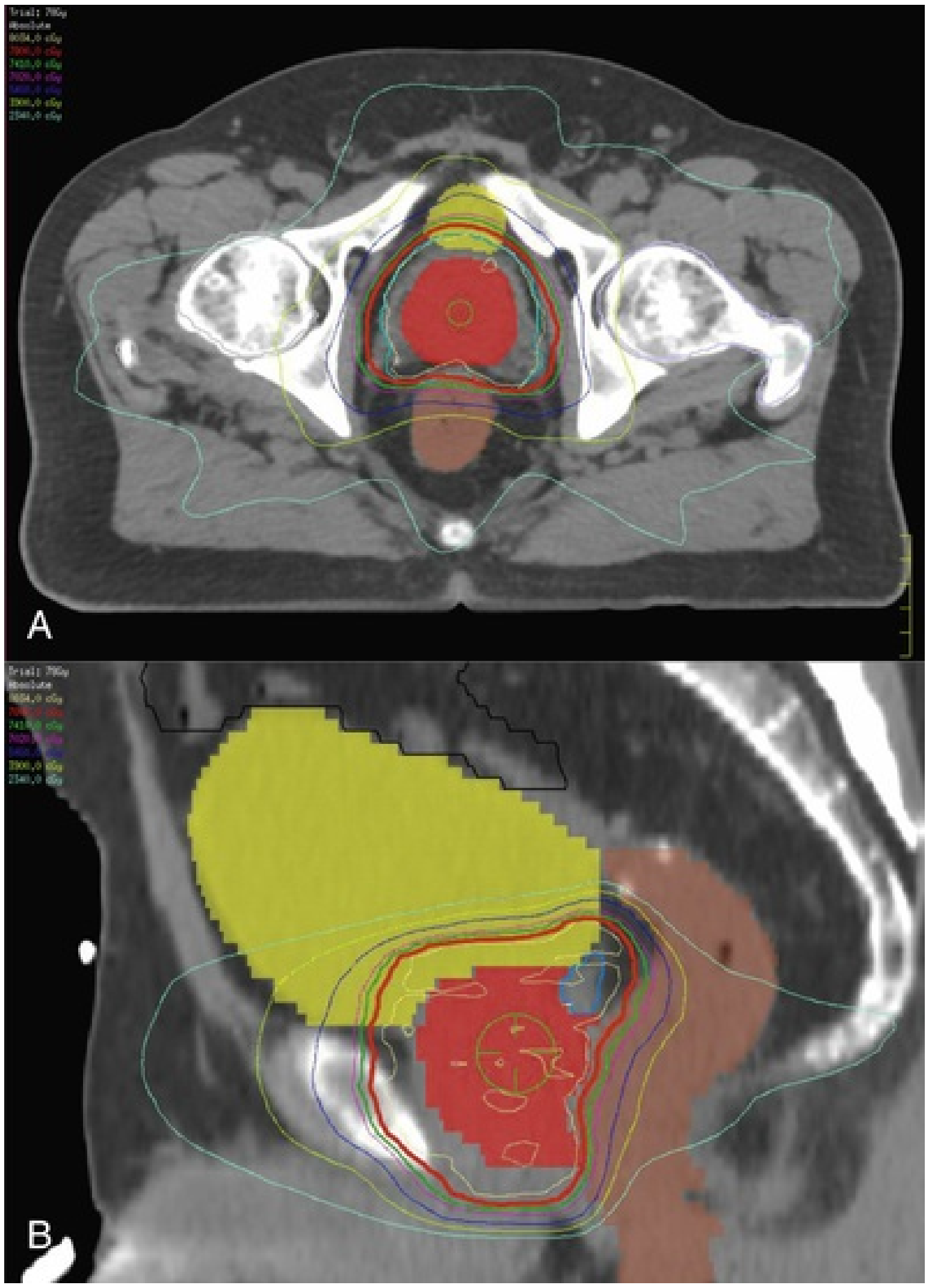

FIG. 157.2 Axial (A) and sagittal (B) views of an intensity-modulated radiation treatment plan (IMRT) showing prostate *(solid red),* bladder (base, *solid yellow*), and rectum *(solid brown).* Dose lines (isodoses) are shown in *thin colored lines* (key in *upper left* of image). Prescription dose isodose line (78 Gy, *thick red*) includes a margin around the prostate, with less margin posteriorly to minimize rectal dose. Note skin sparing, and concavity of posterior dose lines achieved by IMRT.

In multiple treatment-planning studies, IMRT has consistently demonstrated lowering of radiation doses to the rectum, bladder, femoral heads, and small bowel compared with 3D-CRT (Table 157.1). In 2000, almost every patient with prostate cancer in the United States treated with RT received conformal radiation; by 2009, almost 100% of prostate radiation was given using IMRT

(Sheets et al., 2012). The minor potential disadvantages to IMRT include increased treatment time and increased total monitor units ("beam on") required; however the advantages are considered to far outweigh these disadvantages. One solution to the increased treatment time is use of volumetric modulated arc therapy (VMAT), an innovative form of IMRT optimization in which radiation doses are efficiently delivered in a single 360-degree gantry rotation arc (Palma et al., 2008). In a comparison of intrafractional motion during VMAT treatment versus IMRT treatment, the average VMAT fraction was significantly shorter at 2 minutes and 43 seconds compared with the IMRT fraction at 6 minutes and 13 seconds (Ballhausen et al., 2018).

TABLE 157.1

Treatment Planning Studies Comparing Three-Dimensional Conformal Radiation Therapy vs. Intensity-Modulated Radiation Therapy

	TARGET	DOSIMETRIC MEASURE	RECTUM IMRT/3D-CRT	BLADDER IMRT/3D-CRT	FEMORAL HEAD IMRT/3D-CRT
Hardcastle et al., 2010	Prostate + SV	V25 (%)	68.5/89.1[a]		
		V50 (%)	43.8/57.3[a]		
		V75 (%)	9.9/23.2[a]		
Luxton et al., 2004	Prostate + SV (± LN)	Mean dose (− LN) (Gy)	36.8/38.5	33.3/35.7	12.4/28.2
		Mean dose (+ LN) (Gy)	45.5/54.1	46.2/57.3	14.9/31.2
Palma et al., 2008	Prostate	Mean EUD (Gy)	50.6/53.5[a]	32.4/43.2[a]	
		V20 (%)	34.3/75.2	41.5/67.6	
		V40 (%)	17.1/66.8	26.7/55.2	3.4/9.8
		V70 (%)	4.1/7.1		
Mock et al., 2005	Prostate + SV	Max dose (Gy)	48.9/53.9	35.1/42.9	29.1/36.3
		Mean dose (Gy)	41.7/45.7	18.9/21.5	20.9/28.9
Kao et al., 2004	Prostate + SV	Max dose (Gy)	80.1/75.5[a]	79.6/76.1[a]	
		Mean dose (Gy)	39.1/49.2[a]	47.8/48.7	
		V70 (%)	18.4/21.9[a]	25.2/26.1	

[a] Statistically significant difference.

3D-CRT, three-dimensional conformal radiotherapy; *EUD,* equivalent uniform dose; *IMRT,* intensity-modulated radiation therapy; *LN,* lymph nodes; *SV,* seminal vesicles.

V*x* represents the percentage of an organ receiving *x* Gy of radiation dose.

Image-Guided Radiation Therapy and Treatment Margins

In addition to improvements in shaping the treatment to the target, methods for aligning the beams to the prostate with greater spatial accuracy have also been developed. A more recent and clinically important development has been the addition of **image guidance** to prostate cancer RT. Image guidance was developed based on a realization that (1) the daily location of the prostate within the pelvis throughout the course of RT is not identical (interfraction motion) (Beard et al., 1996; Ten Haken et al., 1991) and (2) the prostate is mobile, even during a single session of RT (intrafraction motion) (Huang et al., 2002).

Treatment margins or target volume expansions are utilized in the treatment-planning process to consider the potential for several uncertainties and variables in targeting, including daily patient alignment, patient or prostate motion, microscopic extension of disease, and uncertainty in defining target/tissue boundaries on simulation imaging and contouring. The International Commission on Radiation Units and Measurements has defined three major concepts for target volumes in *Radiation Oncology:* **gross tumor volume (GTV), clinical target volume (CTV), and planning target volume (PTV).** During the treatment-planning process, these structures are defined on images by the radiation oncologist and utilized for planning treatment. The definitions of these volumes can be summarized as follows:

- GTV: the grossly palpable or visible location of malignant growth
- CTV: tissue volume that contains the GTV plus any subclinical microscopic disease
- PTV: takes into consideration the net effect of all possible geometric variations and inaccuracies to ensure that the prescribed dose is actually absorbed in the CTV. Used to compensate for effects of organ and patient movement, and inaccuracies in beam and patient setup.

In the case of prostate cancer, the entire prostate (plus any visible extraprostatic extension of disease) is contoured as the GTV. The CTV typically includes GTV plus a portion of adjacent seminal vesicle, depending on the clinical stage, Gleason score, and other prognostic factors associated with seminal vesicle invasion (Kestin et al., 2002b), and may also include pelvic nodes (typically including external iliac, internal iliac, obturator, and presacral) for patients deemed at risk for nodal involvement (Harris et al., 2015). The prophylactic inclusion of clinically uninvolved lymph nodes in the target volume is controversial, however, and is discussed in the Role of Prophylactic Pelvic Node Treatment section later in this chapter.

The use of treatment margins allows for greater confidence that the target volume will reliably include the tumor, but comes with a tradeoff for increased toxicity because greater volumes of normal tissue are added to the treated volume. In the past, uncertainty in patient and prostate positioning reproducibility forced radiation oncologists to utilize larger margins and accept the risk for increased morbidity. With image guidance, the treatment margins are reduced significantly because the location of the prostate can be verified daily before delivering radiation.

Online **image-guided radiation therapy (IGRT)** refers to daily treatment imaging to localize the prostate and make positional adjustments to the patient immediately before each treatment (Boda-Heggemann et al., 2011). The use of implanted fiducial markers, cone-beam CT, and three-dimensional ultrasonography are all prostate-targeting techniques that can improve treatment accuracy. Because determining the exact alignment of the prostate on CT images can be subject to interuser variability, intraprostatic fiducial markers (typically 2 to 4 gold or gold-containing seeds or coils ~5 × 1 mm in size placed under ultrasound guidance) are frequently utilized to improve the accuracy and reproducibility of prostate localization. These allow for ready visualization and alignment of the patient on the linear accelerator by serving as a simple surrogate for prostate position. With the use of soft-tissue images for daily alignment, treatment margins of 3 to 7 mm are generally employed and account for potential misalignments resulting from interuser variability of image interpretation (Kupelian et al., 2008).

There are several “in-room” CT solutions used for IGRT that allow for direct imaging of the pelvis and prostate within the same treatment room as the linear accelerator, including helical kilovoltage on-rail CT (the patient can be moved from the scanner to the linear accelerator while remaining on the treatment table), kilovoltage cone-beam CT (the linear accelerator also has an integrated kilovoltage source along with cone-beam imaging flat panels), or helical megavoltage CT scanners (the imaging energy source is the megavoltage beam itself). These daily in-room CT techologies allow use of bony anatomy, implanted fiducials, and soft-tissue images to align the prostate (Fig. 157.3A–C). In addition, soft-tissue images can also identify daily variations in filling of other structures such as the rectum and bladder. The use of IGRT has been shown to be associated with both improvements in biochemical tumor control and lower rates of late urinary toxicity (Zelefsky et al., 2012). IGRT can also reduce the amount of rectum receiving the high-dose radiation volume, leading to lower rates of radiation-induced proctitis (Jani et al., 2003). The disadvantage to the cone-beam CT technique is the additional dose received by the patient (van Zijtveld et al., 2010) at around 2 to 3 centiGray (cGy) per cone-beam CT acquisition (Alaei and Spezi, 2015). Although transabdominal ultrasound systems are another method for visualizing the prostate and bladder, significant interuser variability exists (Langen et al., 2003; Pinkawa et al., 2008). This technique has fallen out of favor because of concerns regarding displacement of the prostate during imaging that does not persist at the time of treatment and results in systematic positioning error (Lin et al., 2008).

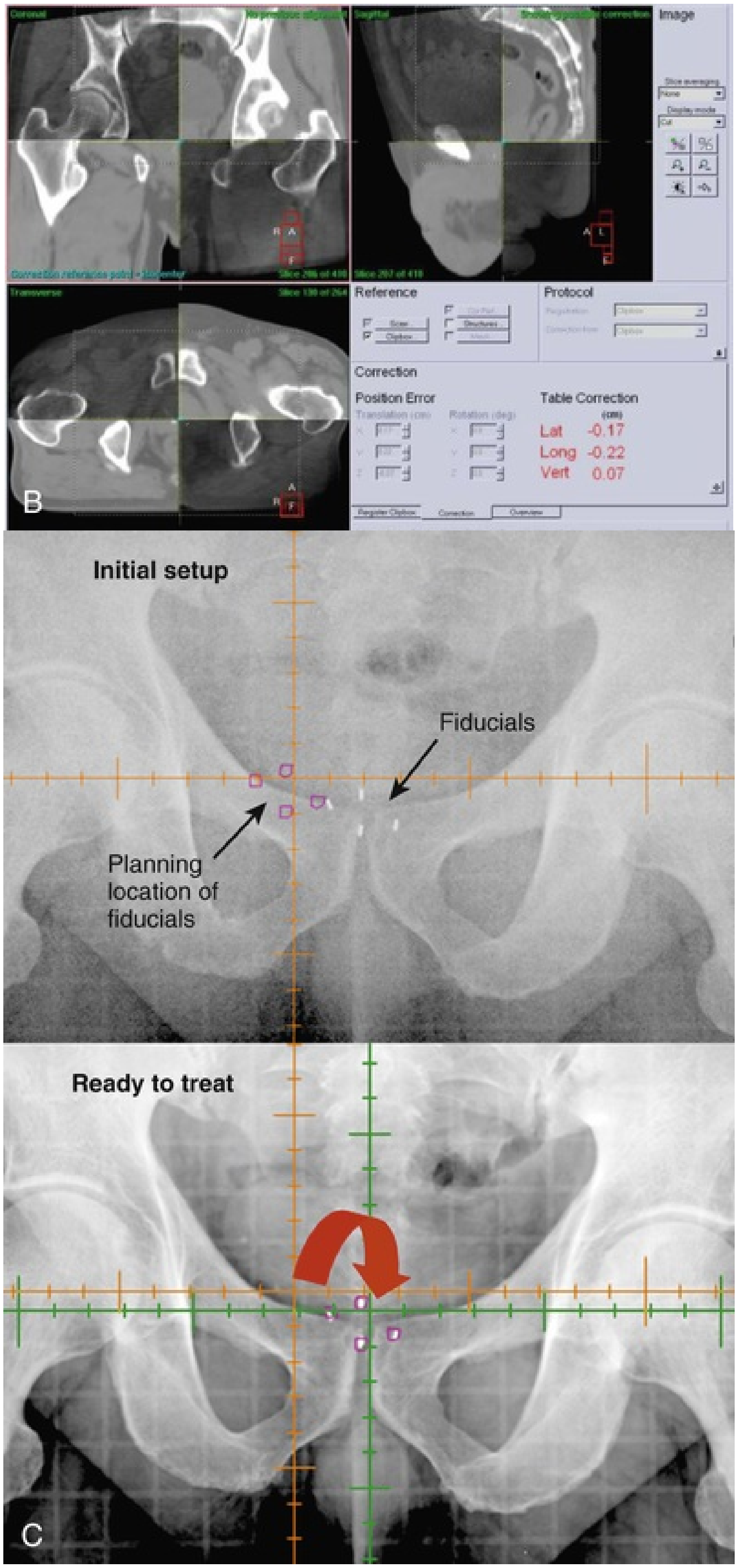
Image
Reference
Protocol
Correction
B
Initial setup
Fiducials
Planning location of fiducials
Ready to treat
C

Position Error

Table Correction (cm)

Lat -0.17

Long -0.22

Vert 0.07

FIG. 157.3 Modern linear accelerator with imaging capability. (A) The radiation treatment beam is shaped by a collimator contained within the

treatment head *(top).* The panel *(right)* contains a kilovoltage unit for generating cone-beam computed tomography (CT) images. Two moveable imaging panels are present. The imager panel *(left)* is for capturing kilovoltage two-dimensional or cone-beam images (obtained by rotating the entire unit around the patient), whereas the unit on the bottom (opposite from the treatment head) allows for megavoltage imaging confirmation of beam shape in addition to three-dimensional CT reconstruction. The patient lies on the carbon-fiber treatment couch *(black),* which can be moved in three dimensions *(x, y, z),* and rotated in all directions (pitch, yaw, roll). (B) Example of cone-beam alignment images. Planning (simulation) images *(light gray panels)* are overlain with a cone-beam image acquired before each treatment *(dark gray panels).* Internal anatomy is aligned between the two image sets, and the treatment couch is moved accordingly (i.e., table correction). (C) Example of a fiducial marker-based alignment. Fiducial (typically gold) markers within the prostate allow for either orthogonal two-dimensional *(shown)* or three-dimensional on-board CT imaging alignment of prostate before each daily treatment session. (A, Used with permission from Elekta Inc.)

Neither approach, however, addresses the issue of **intrafraction motion.** One solution to the intrafraction motion problem is prostate immobilization, which can be achieved using an intrarectal balloon introduced into the rectum and inflated before daily RT. Inflation of the balloon pins the prostate against the pubic bone and prevents rectal motion. Because the immobilized prostate does not move during treatment, relatively tighter posterior margins can be used (Fig. 157.4). Also, although the anterior rectal wall may be pushed closer to the prostate, the lateral and posterior walls are pushed further away, thereby reducing the overall dose to the rectum (Sanghani et al., 2004). Another option for intrafraction tracking is with implanted radiofrequency transponders that generate electromagnetic signals that allow three-dimensional localization during treatment (Kupelian et al., 2007). Traditionally these transponders required percutaneous implantation with a 14G needle. However, newer versions use a smaller 17G beacon. A potential disadvantage of this system is the significant artifact caused by the transponders on any magnetic resonance imaging (MRI) scans the patient may require in the future. Interfraction and intrafraction motion of the prostate can also be reduced with daily pretreatment bladder filling (having patients drink 16 to 30 ounces of water before treatment (Mullaney et al., 2014)) and with rectal emptying to minimize peristaltic and gas-related motion (Stasi et al., 2006).

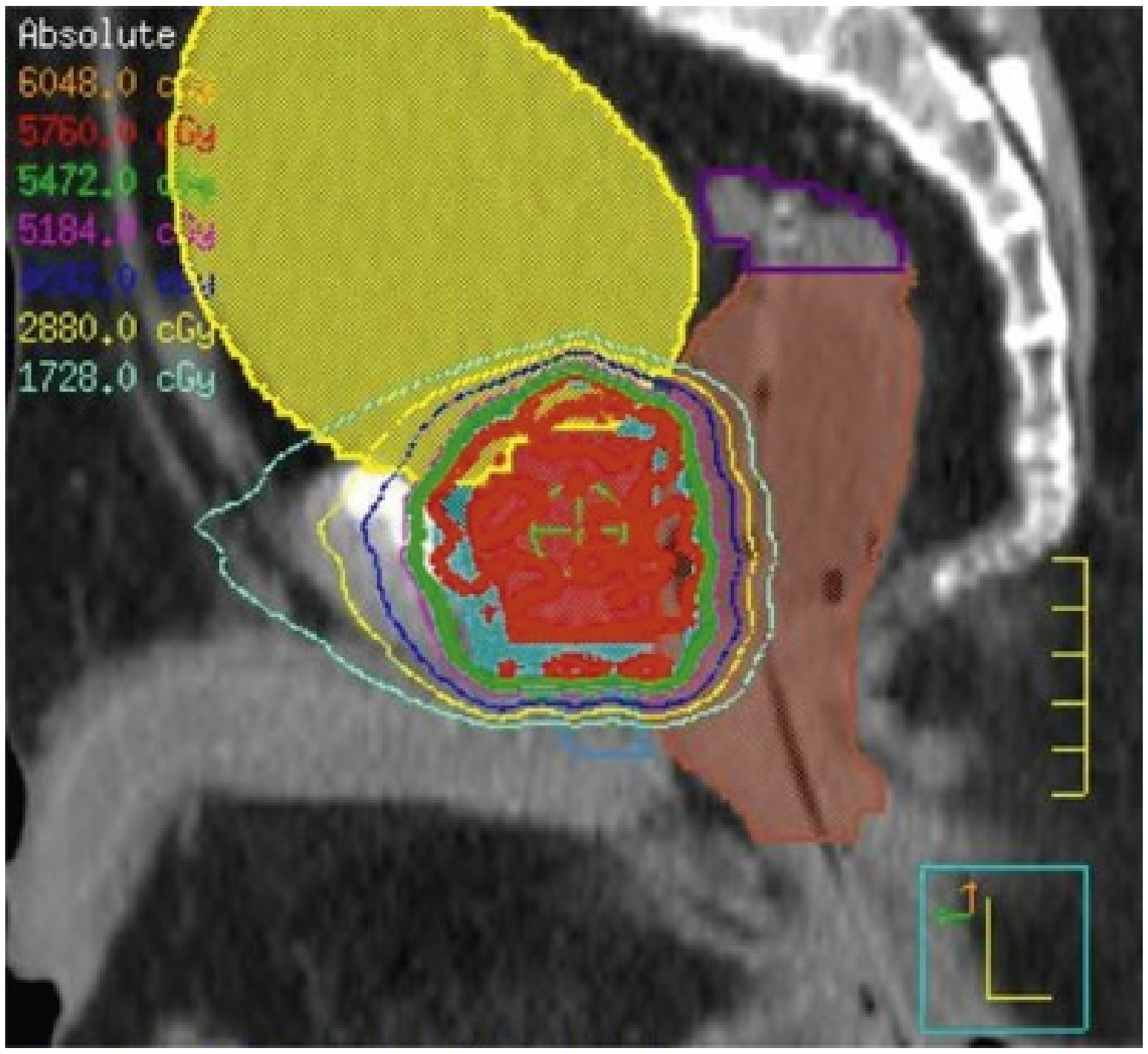

FIG. 157.4 Sagittal view of a treatment plan utilizing a rectal balloon.

The ability to account and correct for uncertainties in the location of the prostate on a daily basis allows for accurate delivery of radiation to the prostate while further lowering incidental doses received by surrounding organs. This becomes increasingly important when using hypofractionated or stereotactic body radiation therapy (SBRT) (discussed later), which is dependent on the ability to precisely direct treatment to the intended target. Image guidance is now a recommended standard of care for prostate cancer RT (National Comprehensive Cancer Network [NCCN], 2016).

Multiparametric Magnetic Resonance Imaging in Radiation Treatment Planning

Multiparametric MRI combines morphologic and functional MRI sequences including T2-weighted, diffusion-weighted, dynamic contrast-enhanced (DCE) and magnetic resonance spectroscopic imaging, and its use in conjunction with an endorectal coil and a higher-strength (3-tesla [T]) magnet may have significant prognostic utility. Researchers from the National Cancer Institute (NCI) found a strong correlation between apparent diffusion coefficients (ADC) derived from diffusion-weighted imaging and both Gleason score (P = .003) and clinical risk group (P < .0001) (Turkbey et al., 2011). In addition, in a study of

100 favorable-risk men who received radical prostatectomy (RP), 3T multiparametric endorectal MRI was 75% and 95% accurate at predicting pathologic extracapsular extension and seminal vesicle invasion, respectively (Hegde et al., 2013). Therefore MRI may be a useful tool in further stratifying risk in patients who are borderline between two treatment options, such as intermediate-risk patients considering monotherapy with radiation alone versus combined modality therapy with radiation and short-course androgen deprivation therapy (ADT). Multi-parametric MRI can also be incorporated with MRI-TRUS fusion for targeted biopsies, which increases the diagnosis of high-grade prostate cancer with fewer biopsy cores needed (Rastinehad et al., 2014; Wysock et al., 2014). (see Chapter 152 for further discussion regarding diagnostic MRI techniques and prostate cancer staging).

At some centers, MRI is integrated into the radiation treatment-planning process. Because CT is still required to accurately calculate dose (based on tissue density), MRI images are coregistered and fused with CT to allow simultaneous visualization of both. Studies have demonstrated that prostate volumes delineated on MRI are 10% smaller than those delineated on CT, with improved identification of the prostate particularly at the apex and the base (Ménard et al., 2018). MRI also can be especially useful when CT image quality is compromised, such as artifact from prosthetic hip implants, or when PTV margins are small. MRI can also improve dosimetric accuracy in post-planning low-dose-rate (LDR) brachytherapy to help delineate the prostate.

MRI T2 sequences in addition to an MRI angiogram have been used to delineate and avoid erectile vasculature in a vessel-sparing RT approach (Lee et al., 2016b). In a prospective single-arm study by Spratt et al. (2017b), of 135 men treated with vessel-sparing RT utilizing planning MRI and MRI-angiogram, 88% of men were sexually active at 5-year follow-up, which is significantly higher than previous studies utilizing radiation or nerve-sparing prostatectomy. However, further research is needed to determine whether this approach truly reduces the risk for post-treatment erectile dysfunction (ED), particularly given the uncertainty regarding which normal tissue is sensitive to and responsible for radiation-induced ED.

Transrectal Ultrasound-Guided Brachytherapy

Brachytherapy (from the Greek word *brakhus*, meaning “short”) is the placement of radioactive sources into or near tumors for therapeutic purposes.

As noted earlier, Pasteau (1913) first described the temporary placement of radium-containing needles into the prostate through the urethra. During the 1920s, Hugh Hampton Young (1922) at Johns Hopkins University performed prostate brachytherapy using intracavitary radium sources in the bladder, rectum, and urethra with the overlapping dose “cross-firing” into the prostate. This technique was refined at Memorial Hospital in New York by Benjamin Stockwell Barrington, who pioneered implanting needles containing radioactive radon gas into the prostate by a transperineal approach. Whitmore et al. (1972) at Memorial Sloan Kettering Cancer Center in New York performed ^{125}I implantation in patients in conjunction with lymph node dissection. The prostate would be exposed for implantation via a retropubic surgical incision, with the prostate measured using calipers to determine the number of seeds required. Needles were inserted in an anterior-to-posterior direction, with seed placement also palpably guided by having a gloved finger in the rectum to avoid needle penetration through the anterior rectal wall. However, this “freehand” technique resulted in suboptimal distribution of seeds because of multiple factors, including lack of visualization, difficulty achieving regular and parallel needle spacing, bleeding from puncture of the periprostatic venous plexus, and inadvertent passage of needles through the rectum or bladder, with associated infection risk (Kumar and Bartone, 1981; Zelefsky and Whitmore, 1997).

Holm et al. developed the basis for the modern method of brachytherapy using transrectal ultrasound (TRUS), which allowed the insertion of radioactive sources under live image guidance (Iversen et al., 1989). For this procedure, the patient is placed in a high lithotomy position to maximize the transperineal exposure of the prostate. The transrectal ultrasound probe is inserted and held within a mount (also referred to as a *stepper*) that itself is held within a pedestal that is either mounted to the procedure table or the floor. The stepper allows for precise rotation of the probe along its axis, and/or cranial-caudal movement of the probe in measured increments. This setup provides relatively fixed positioning of the prostate throughout the procedure, and subsequently more accurate and reproducible imaging. A template with a predrilled pattern of parallel holes is held against the perineum by the stepper. The template pattern is also superimposed over the ultrasound image by computer software in the ultrasound base unit, allowing for correlation of the template grid pattern to specific positions within the prostate. Needles of 17- or 18-G are inserted through the template into the prostate. The position of the needle tip can be confirmed by transverse or parasagittal imaging. Sealed metallic seeds containing the radioactive isotope are deployed as the needle is withdrawn (Fig. 157.5).

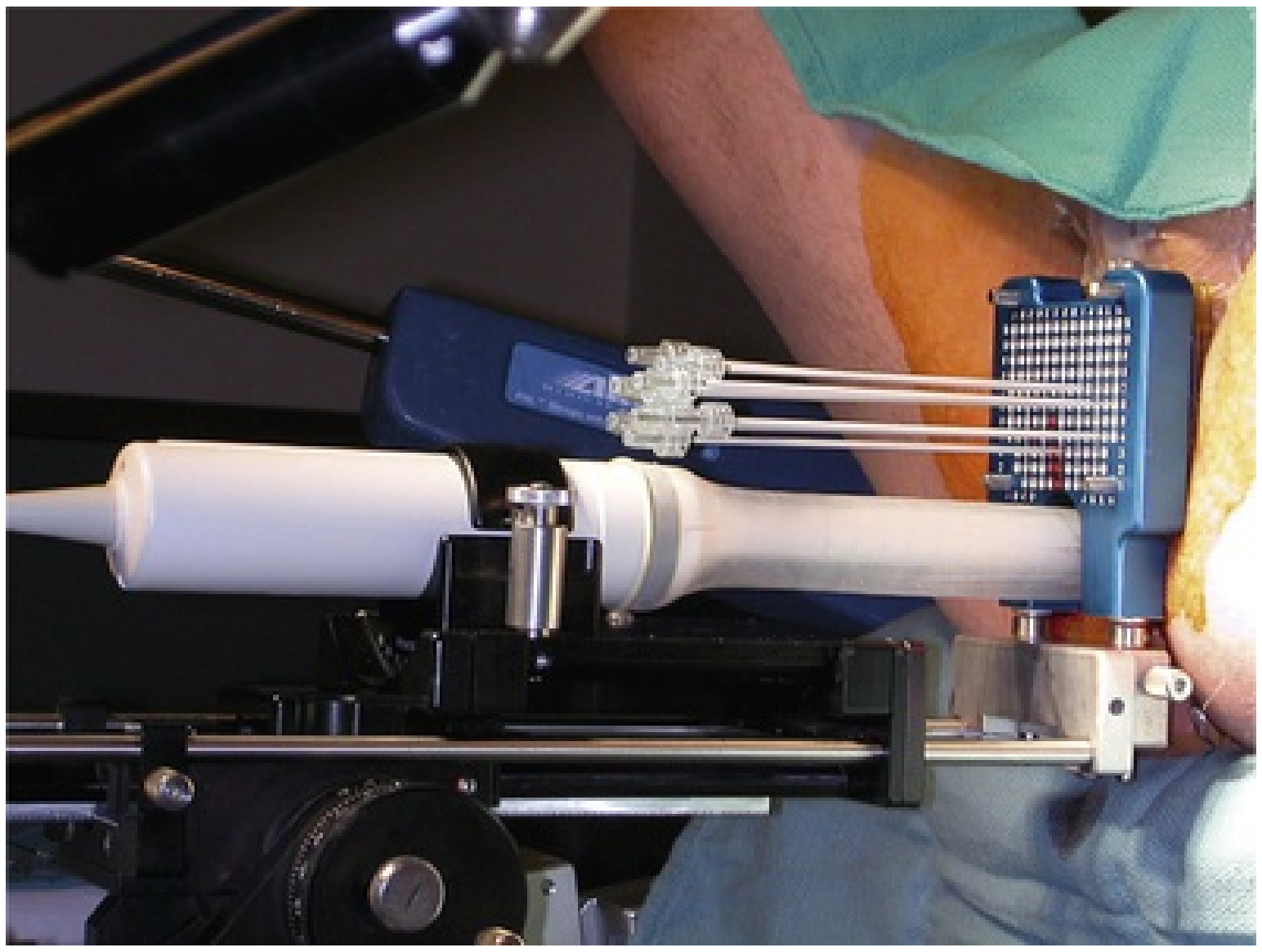

FIG. 157.5 Lateral view of a transrectal ultrasound probe (TRUS) held within a stepper cradle *(black).* The patient is in the high lithotomy position. The template grid is positioned against the perineum, and either needles (low-dose-rate) or catheters (high-dose-rate) are placed through the grid into the prostate. (From Morton GC. The emerging role of high-dose-rate brachytherapy for prostate cancer. *Clin Oncol* 17[4]:219–227, 2005.)

With this approach, the needles used to insert the radioactive seeds can be visualized, with significant improvement in the accuracy of seed placement. This was a significant step forward over the prior imprecise freehand technique, in which access to the apex was limited and achievement of source distribution and dose coverage technically challenging.

The use of the TRUS guidance technique intraoperatively provided the potential for delivering more uniform coverage and adequate doses of radiation within the prostate gland while limiting dose to the prostatic urethra and the anterior rectal wall.

Other noteworthy methods that have been employed for seed implantation include a trans-sacral, CT-guided approach (Koutrouvelis, 1998) and a method using intraoperative MRI guidance (D'Amico et al., 1998; Susil et al., 2004), but neither method appears to be in utilization today.

Key Points: Historical Perspectives and Technological Advances

- Linear accelerators produce photons (x-rays); increasing photon energy results in more skin sparing and deeper penetration of dose into tissues.
- Dose-volume histograms (DVHs) are used to graphically summarize the amount of radiation received by the different regions of interest (tumor and normal tissues/organs).
- Treatment margins are utilized to account for potential subclinical extension of disease, setup variability, and potential interfraction and intrafraction motion. Advances in radiation treatment planning and imaging have resulted in the ability to use subcentimeter treatment margins while maintaining targeting accuracy, thereby reducing toxicity.
- Intensity-modulated radiation therapy (IMRT) is most commonly utilized for definitive prostate cancer treatment. IMRT allows for dose distributions that have higher conformality to the target via improved shaping of dose within and around tissues, thereby maximizing the dose of radiation that can be safely delivered.
- Prostate brachytherapy is performed under transrectal ultrasound guidance; seeds are placed in a peripherally loaded pattern to minimize the dose to the urethra.

External Beam Radiation Treatment (Also See Outcomes for External Beam Radiation)

Fractionation in Radiation Therapy

Fractionated treatment has been used since the early days of RT, when it was found that tumor control could be achieved with less normal tissue injury when the radiation dose was split into many small fractions (Coutard, 1932). For decades, EBRT has been routinely delivered in a fractionated manner using daily doses of 1.8 to 2.0 Gray (Gy; the SI unit for radiation, defined as the absorption of 1 Joule per kilogram of matter). This fraction size was based on early clinical experience and animal data, and supported by experimentally derived mathematical models of normal tissue and tumor response to fraction size. The most widely used of these models is the **linear-quadratic formula**, which predicts responses to different fraction sizes based on the **alpha/beta ratio** of any given tissue (Fowler, 1989).

One of the main motivations for delivering a treatment at low-dose rate or with many fractions is that late-responding normal tissues are generally more sensitive than early-responding tissues (i.e., tumor) to increases in fraction size. In particular, what is generally considered “late” radiation toxicity (occurring ≥90 days after completion of treatment) was found to be reduced with the use of fractionation. Therefore increasing the number of fractions generally spares late-responding tissues more than the tumor. This can be quantified in terms of the alpha/beta ratio:

- Small alpha/beta ratio (2 to 4 Gy), typical of late sequelae, means high sensitivity to fractionation changes.
- Large alpha/beta ratio (>8 Gy), typical of tumor control, means low sensitivity to fractionation changes.

Radiobiologic Basis for Hypofractionation

It is generally assumed that the mechanistic basis for the different fractionation responses of tumors and late-responding normal tissues relates to the larger proportion of cycling cells in tumors. But prostate tumors contain unusually small fractions of cycling cells (Haustermans et al., 1997). Brenner and Hall (1999) and Duchesne and Peters (1999) have reasoned that prostate tumors might not respond to changes in fractionation in the same way as other cancers; both papers hypothesize that prostate tumors might respond to changes in fractionation or dose rate more like a late-responding normal tissue. In mathematical terms, the suggestion is that the alpha/beta ratio for prostate cancer might be low, comparable to that for late-responding tissues or even lower. Previous estimates of alpha/beta ratios of normal tissue and tumor tissue have generally been 3 and 10, respectively, but recent evidence has estimated the alpha/beta ratio of prostate cancer to be as low as 1.5. If these hypotheses are true, then the optimal therapeutic ratio for prostate cancer would be achieved using daily doses higher than 2 Gy (Valdagni et al., 2005). By exploiting the low alpha/beta of prostate cancer and using higher than standard doses per fraction, one could potentially lower total dose, thus lessening the risk for normal organ injury, while maintaining similar or even improving prostate cancer control (Withers, 1985).

The support for this hypothesis is based on clinical studies in which the treatment dose was varied. The first report suggesting this relatively unique sensitivity to high dose per fraction was by Brenner and Hall (1999), who used the 3-year freedom from biochemical failure rates of 134 patients receiving permanent brachytherapy and 233 patients receiving EBRT to calculate an alpha/beta ratio of 1.5 Gy. This radiobiologic value is used to calculate the radiosensitivity of a tissue. For comparison, the alpha/beta ratio of head and neck cancers is thought to be between 13 and 16 Gy, whereas late-responding skin fibrosis has an alpha/beta ratio of 1.7 Gy (Zeman, 2006). Although intriguing, this study brought criticism for its comparison of data from several radiation modalities, which vary not only in dose per fraction but also in spatial distribution qualities of the radiation delivered. However, more recent studies evaluating large cohorts treated with EBRT continue to support the premise of prostate cancer sensitivity to high dose per fraction. Dasu and Toma-Dasu (2012) evaluated the 5-year biochemical control from 11,330 patients treated with EBRT, accounting for overall treatment time, and found that, depending on risk category, the alpha/beta ratio varied from 1.0 to 1.7 Gy. A second study found an alpha/beta ratio of 1.4 Gy using 5969 patients receiving EBRT (Miralbell et al., 2012). Table 157.2 illustrates how hypofractionation may provide a greater effective dose to the prostate without greater effect on normal tissues, assuming the alpha/beta ratio for prostate is lower than for normal tissues.

TABLE 157.2

Example of Alpha/Beta Ratio and Effect of Hypofractionation for Prostate, Bladder, and Rectum

TISSUE OF INTEREST	ALPHA/BETA RATIO (Gy)	BIOLOGICALLY EQUIVALENT DOSE (IN 2-Gy FRACTIONS) of 37.5 Gy IN 5 FRACTIONS
Prostate cancer	1.5	96 Gy
Rectum/bladder	3	79 Gy

The biologically equivalent dose in 2-Gy fractions is shown using the alpha/beta ratio for prostate and for late effects on rectum and bladder. Intensity-modulated radiation therapy has shown an acceptable safety profile up to ~78 to 81 Gy in 2-Gy fractions (Alicikus et al., 2011). If alpha/beta of prostate is 1.5 Gy, then a 5-fraction regimen totaling 37.5 Gy has relatively greater effect on prostate cancer similar to 96 Gy in standard fractionation, while maintaining similar effect on the rectum and bladder.

Stereotactic Body Radiation Therapy

Varying regimens of hypofractionation have been employed in clinical trials, and terminology has been coined to describe the degree of hypofractionation. Moderate **hypofractionation** is generally considered to be that which uses doses of 2.4 to 4 Gy per day, whereas ultra (or extreme) hypofractionation uses doses of 6 to 10 Gy per fraction (Cabrera and Lee, 2013). When ultrahypofractionation is given, treatment is often delivered fewer than 5 days per week (i.e., every other day) to allow normal tissue recovery between treatments. An entire treatment course of ultrahypofractionation is typically completed within 2 weeks.

Although the potentially low alpha/beta ratio of prostate cancer supports treatment with a few large fractions, care still must be taken to protect the nearby bladder and rectum, which also are relatively sensitive to high dose per fraction. The advent of ultrahypofractionation was concurrent with technology that allowed for higher accuracy and conformality. SBRT is defined as RT that delivers a relatively high dose per fraction, using tighter treatment margins than are typically employed for conventionally fractionated treatment (often 3 to 5 mm, vs. 10 to 5 mm for conventional fractionation). More stringent methods for intrafraction monitoring of prostate position are employed, either via onboard

CT captured at times during beam delivery, or intermittent tracking of implanted fiducial markers using kV imagers. Dose within the plan may also be more heterogeneous, with the goal of delivering higher doses to portions of the prostate (Benedict et al., 2010). SBRT can be performed in a traditional **linear accelerator,** but is also commonly performed using a compact X-band linear accelerator mounted on a robotic arm (CyberKnife, Accuray, Sunnyvale, CA). The robotic arm allows 6 degrees of freedom in conjunction with two cross-firing kilovoltage imagers to allow for intrafractional tracking of target motion, which requires implanted fiducial markers within the prostate (Kilby et al., 2010). One potential disadvantage of the robotic system is the longer treatment delivery time, typically 30 to 40 minutes (compared with 15 to 20 minutes on a conventional linear accelerator).

A recent analysis of the U.S. National Cancer Database from 2004 to 2012 showed that the relative utilization of SBRT increased from 0.1% in 2004 to 4.0% in 2012. Initially SBRT was more commonly used in academic programs, though as time progressed there was a shift to favor an increased absolute number of men treated in the community setting. Delivery of five separate treatments was the most commonly utilized fractionation pattern, with 91% receiving this number of treatments. The most common dosing pattern was 725 cGy × 5 fractions (49.6%) followed by 700 cGy × 5 fractions (21.3%) (Weiner et al., 2017).

Heavy Particle Beams/Proton Therapy

A common application of particle therapy is with the **electron** beam, which can be generated by all modern linear accelerators. As compared with photons, electrons have much shallower depth penetration, and are therefore used for skin or other superficially located tumors. Other particles such as protons, neutrons, helium ions, heavy ions (neon, argon, carbon), and negative ions are available as well. These **heavy particle beams** are much more difficult to produce and to control, but have certain physical advantages over photon and electron beams that have led to great interest in exploiting these advantages. Because they have greater **linear energy transfer** (amount of energy deposited by radiation per unit length of travel) when compared with photons, they are more densely destructive to cellular DNA, and the damage they create is less easily repaired by tumor cells. This results in their having a slightly higher **relative biological effectiveness,** or clinical effect per given dose in tissue compared with photons.

In addition, they travel differently in tissue and exhibit a **Bragg peak**, which refers to a sharp increase and subsequent cutoff in dose at the end of the particle's range. Thus, in theory it could be easier to spare the normal tissues surrounding the cancerous target. However, the sharp increase followed by decrease of dose in the Bragg peak is impractical for treating most tumors because the thickness of the target is usually greater than the Bragg peak. Therefore, in practice the proton beams are modified such that the dose is more spread out over a distance, referred to as a **spread-out Bragg peak** (Fig. 157.6) (Bortfeld and Schlegel, 1996).

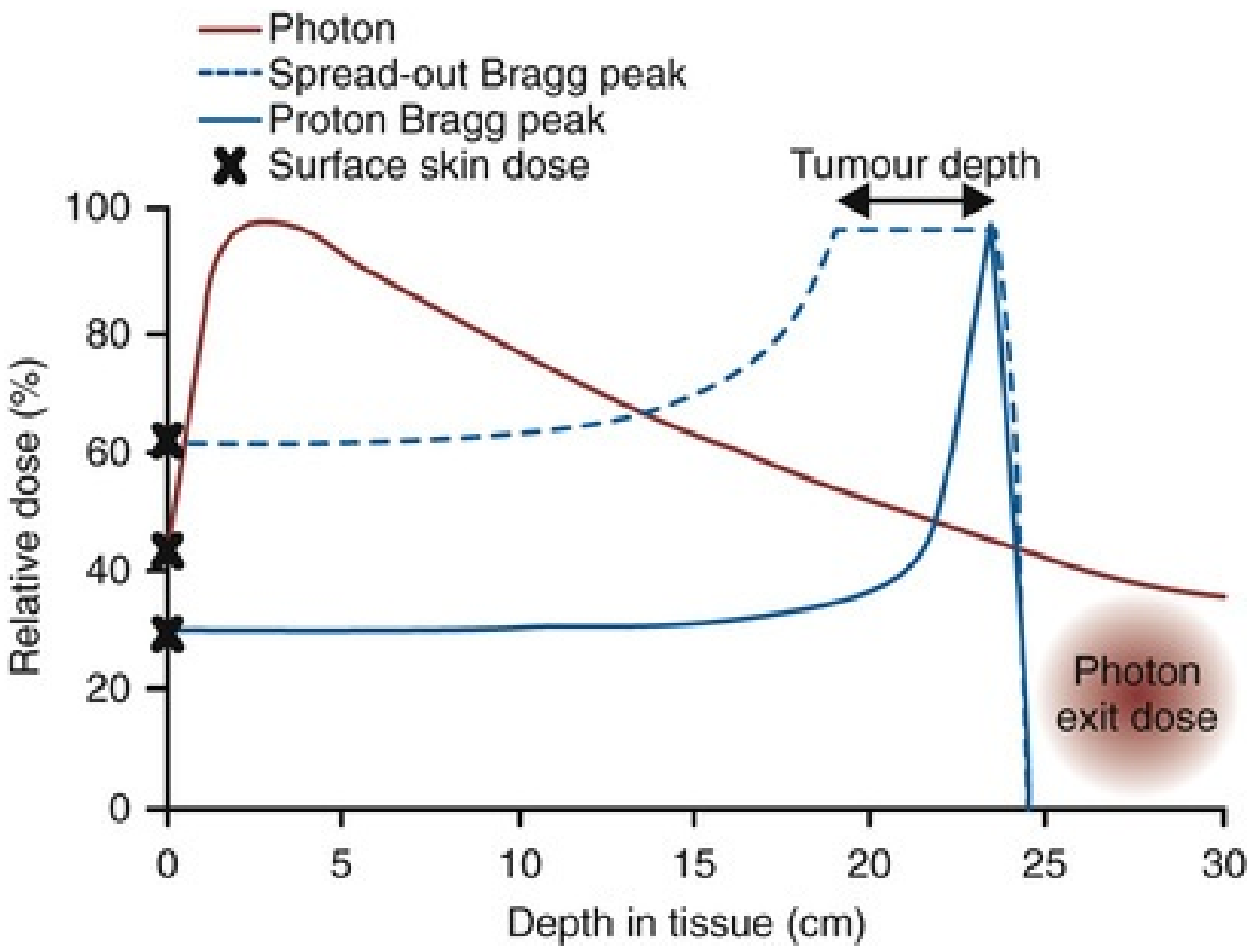

FIG. 157.6 Dose-depth characteristics of protons and photons. Protons have improved skin- and tissue-sparing properties, as a result of the Bragg peak. However, because of the narrow effective range of the Bragg peak differing from the thickness of most tumors, clinical treatments modulate the protons to create a spread-out Bragg peak (SOBP). (From Leeman JE, Romesser PB, Zhou Y, et al. Proton therapy for head and neck cancer: expanding the therapeutic window. *Lancet Oncol* 18[5]:e254–e265, 2017.)

Proton and heavy ion dose calculations are also susceptible to uncertainties that could lead to underdosing of the target or overdosing of normal structures. Variations in patient positioning, tissue/organ motion, and tissue heterogeneity have potentially larger effects on proton dose calculation and distributions as compared with photons because of greater complexities of calculating beam range, i.e., **range uncertainty** (McGowan et al., 2013). Also, challenges in accounting for variations in relative biologic effectiveness, particularly within the edges of the spread-out-Bragg peak, can create uncertainties in predicting the clinical effects of a treatment plan (Britten et al., 2013).

The most commonly used particles are **neutrons** and protons. The Radiation Therapy Oncology Group (RTOG) sponsored a phase III trial in 1977 in which 91 patients with prostate cancer were randomly assigned to receive treatment with neutrons or conventional radiation (photons) (Lawton et al., 1991). At 10 years, survival was better in the neutron arm (46%) than in the photon arm (26%). However, patient characteristics were not equally balanced between the two arms. Poor prognosticators such as stage D1 disease were more common in the photon arm, and the observed survival difference between the two groups may have been because of this aspect more than any therapeutic benefit of neutrons per se. However, the data were compelling enough to lead the NCI to fund the construction of several state-of-the-art neutron beam facilities, and trials were undertaken to study the efficacy and morbidity of neutron treatment. In the mid-1980s, a second prospective randomized trial was undertaken by the RTOG. A group of 178 patients with prostate cancer were randomly assigned to receive either neutron beam or conventional photon treatment. The local control rate was higher for the patients who received neutron therapy than for those who received photons (89% vs. 68%), as was the 5-year rate of freedom from PSA failure (83% vs. 55%). However, survival rates were no different in the two arms. Morbidity was higher in patients who received neutron beam treatment and was described as severe in 11%, compared with 3% for those who underwent photon irradiation.

In general, acceptance of neutron beam therapy by radiation oncologists has been limited because of the perception that complication rates are high without much gain in tumor control, and because of the limited availability and expense associated with neutron production. Over time, a form of conformal neutron beam therapy was developed and became possible in several centers (Forman et al., 1995). At Wayne State University, 300 patients were entered into a phase III trial and randomly assigned to conformal neutron therapy followed by standard CRT or CRT followed by a neutron therapy boost. A statistically significant difference in 5-year disease-free survival was seen for patients treated with neutrons first (93% compared with 73%, $P = .008$) (Forman et al., 2002). Treatment-related morbidity was the same for both groups in this study. A larger retrospective review from the same group of neutron therapy and photon CRT revealed a statistically significant improvement in 5-year relapse-free survival for the group that received neutrons as any component of their therapy. The effect was most pronounced for high-risk patients who had a 35% 5-year relapse-free survival rate versus 7% in the photon-only group ($P = .0004$). Although these data are provocative, one criticism is that the relapse-free survival in the photon-only group from Wayne State University was much lower than that of other series reporting on the same population of patients.

Despite the data from Wayne State University, most radiation oncologists believe that neutron beam therapy causes greater normal tissue damage than photon beam therapy. Investigators from the Catholic University of Louvain, Belgium, used a mailed questionnaire to assess quality-of-life changes in 262 patients who received mixed neutron-photon irradiation. Of the 230 patients who replied, 22% had four or more bowel movements per day. Retaining stool was a problem in 26% of the patients, and only 38% reported full bowel continence. The patients in this trial received neutron beam therapy using equipment that was not conformal. These data were sufficiently concerning to close their program and they demonstrate the importance of up-to-date equipment and technology for the delivery of neutron beam therapy. Today, few patients with prostate cancer in the United States are treated with neutron RT.

Proton beams are also used to treat cancer. Although proton radiation is not a new treatment for prostate cancer, there has been significant recent interest in its use for prostate cancer (MacReady, 2012; Zietman, 2007). Protons are charged particles generated by a linear accelerator, cyclotron, or synchrotron. In the 1980s, a prospective randomized trial was undertaken in men with locally advanced prostate cancer (Shipley et al., 1995). Patients treated with proton beams had a 95% incidence of clinical local control at 5 years, compared with a 64% incidence for those treated with photons. Although no grade 3 to 5 toxicities were reported in either arm of this trial, grade 1 and 2 rectal bleeding rates were higher in the proton group (32% vs. 12%, $P = .002$), as were urethral strictures (19% vs. 8%, $P = .07$). When the group with rectal bleeding was carefully analyzed, a relationship between the volume of rectum treated and the dose of protons given was established and guidelines were developed for future trials (Hartford and Zietman, 1999).

Another early study utilizing protons was a dose escalation study in which men with low- and intermediate-risk prostate cancer all received conformal photon radiation to 50.4 Gy followed by a proton boost to either 70.2 Gy or 79.2 Gy (Zietman et al., 2010). Ten-year biochemical failure rates were 32.4% in the conventional dose group compared with 16.7% in the high-dose group. There was no difference in overall survival or grade ≥3 urinary or bowel toxicity between the treatment arms. Given that both arms were treated with protons, however, this study did not allow for a true comparison of proton versus photon effectiveness.

Studies comparing proton therapy to modern IMRT for prostate cancer are mostly limited to treatment-planning studies, which have shown that proton radiation can reduce the volumes of nearby organs that receive low to medium—but not high—doses of radiation (Table 157.3). For example, in a study by Trofimov et al. (2007), proton plans to 79.2 cobalt Gray-equivalent (CGE) were created for 10 patients using parallel opposed lateral fields, a commonly used technique for prostate cancer. They noted that proton therapy allowed a smaller proportion of the rectum to receive low doses of radiation (<30 CGE) compared with IMRT. However, proton plans did not reduce the volume of rectum receiving high doses of radiation. Another study by Vargas et al. (2008), using two proton beams but with angles optimized to minimize rectal and bladder dose, similarly demonstrated a reduction in rectal volume receiving low-to-moderate radiation doses, but minimal benefit in the volume of rectum receiving high-dose radiation. Studies that found improvements in rectal sparing with proton therapy tended to find improvements in bladder sparing as well. Again, the most significant benefit was in reducing the volume of bladder receiving low-to-medium doses, but not high doses (Chera et al., 2009; Mock et al., 2005; Trofimov et al., 2007; Vargas et al., 2008). The study by Trofimov et al. (2007) reported better bladder sparing by proton therapy at doses lower than 30 CGE compared with IMRT, but protons actually resulted in a higher volume of the bladder receiving a high dose of 70 CGE (17% for proton vs. 11% for IMRT). Similarly, Vargas et al. (2008) found bladder sparing at doses from 10 to 35 Gy, but not at doses above 60 Gy.

TABLE 157.3

Treatment Planning Studies Comparing Intensity-Modulated Radiation Therapy vs. Conformal Proton Therapy

REFERENCE	TREATMENT TARGET	DOSIMETRIC MEASURE	RECTUM IMRT/PROTON	BLADDER IMRT/PROTON
Chera et al., 2009	Prostate + SV + LN	Max dose (Gy)		
		Mean dose (Gy)	40.9/16.6	42.1/21.2
		V10 (%)	92.7/35.1[a]	100/46.2[a]
		V50 (%)	27.3/15.1	25.6/18.2

		V70 (%)	11.5/7.9	9.7/9.8
Vargas et al., 2008	Prostate ± SV	Mean dose (Gy)	34.8/14.2[a]	28.4/18.4[a]
		V10 (%)	72.1/29.8[a]	60.0/36.4[a]
		V30 (%)	55.4/20.7[a]	42.8/27.7[a]
		V50 (%)	31.3/14.6[a]	
		V70 (%)	14.0/7.9[a]	
		V78 (%)	5.0/2.9[a]	
Trofimov et al., 2007	Prostate + SV	Mean dose (Gy)	39.4/29.2[a]	29.9/24.1[a]
		V30 (%)	65.3/43.8[a]	44.5/32.8[a]
		V50 (%)	34.4/28.2[a]	23.7/25.4
		V70 (%)	14.5/14.0	11.4/17.3[a]
		V75 (%)	9.7/10.3	

[a] Statistically significant difference.

IMRT, intensity-modulated radiation (photon) therapy; *LN,* lymph nodes; *SV,* seminal vesicles.

Unlike IMRT, which employs several beams or arcs, proton treatment for prostate cancer often involves only two beams, which are typically two opposed (opposing) lateral beams. This is done to keep the beams parallel to the prostate-rectum interface and thus minimize the risk for range uncertainty leading to underestimation of dose to the rectum. The opposed lateral beam arrangement used in proton therapy raises concern over the dose received by **femoral heads**, with associated risk for **avascular necrosis.** Several studies identified similar or worse femoral head dose distributions using protons compared with IMRT, especially when pelvic nodes are included in the treatment target as reported by Chera et al. (mean femoral dose 31 CGE for proton vs. 22 Gy for IMRT) (Chera et al., 2009; Mock et al., 2005; Trofimov et al., 2007). In a case-matched study of toxicity after either proton therapy or IMRT, Fang et al. (2015) found no significant difference in risk for grade ≥2 acute or late gastrointestinal (GI) or genitourinary (GU) toxicity. Whether the reduction in low-to-moderate doses of radiation to the rectum from proton therapy results in lower GI toxicity rates compared with IMRT is unknown; conversely, it is unknown if proton therapy causes higher rates of GU toxicity or pelvic fracture and avascular necrosis rates as a result of somewhat higher doses to the bladder and femoral heads. A matched-pair analysis of Harvard cyclotron patients versus SEER registry data also found no benefit from protons in reducing the incidence of secondary malignancies compared with photon therapy (Chung et al., 2013).

To date, no clinical trial has directly compared patient outcomes of proton therapy versus modern IMRT for prostate cancer. Available studies include single-arm (proton therapy) series mostly from a single institution or a few institutions (Bryant et al., 2016; Coen et al., 2011; Mendenhall et al., 2012; Slater et al., 2004). Among 1327 men treated with dose-escalated proton therapy, Bryant et al. (2016) reported that 5-year freedom from biochemical progression was 99%, 94%, and 74% in low-risk, intermediate-risk, and high-risk patients, respectively. Ho et al. (2018) also showed promising long-term patient-reported outcomes after proton therapy. Among 254 men treated with proton therapy with a median follow-up of 7.1 years, biochemical recurrence–free survival was 97.8%, with sexual potency reported of 72% at 1 year and 67% at 5 years compared with a baseline of 90%. The urinary irritative and bowel scores declined initially from baseline at year 1, but improved over the following 3 to 4 years to near baseline. These data suggest that proton therapy is safe and effective for prostate cancer treatment and likely results in cancer control and morbidity outcomes similar to those with IMRT. However, because proton-beam treatment units are extremely expensive to construct and operate, proton therapy represents an expensive treatment option for prostate cancer that currently has not demonstrated a clinical benefit over standard IMRT (Schroeck et al., 2017; Sheets et al., 2012). In light of this knowledge, insurer reimbursement for proton treatment has declined over the past few years, and has put financial pressure on some proton centers (Piana, 2015). An ongoing multi-institutional randomized clinical trial (PARTIQoL) is comparing proton therapy to IMRT in men with low- or intermediate-risk prostate cancer. The primary outcome measured is mean Expanded Prostate Cancer Index Composite (EPIC) bowel scores at 24 months after radiation. Results of this study may provide randomized evidence to help guide treatment decisions regarding proton therapy in the treatment of prostate cancer.

Key Points: External Beam Radiation Treatment

- Hypofractionated regimens may increase the therapeutic ratio of treatment if prostate cancer has a low alpha/beta ratio.
- Ultrahypofractionated RT employs fractions of 6 to 10 Gy, typically in 5 fractions or less.
- Protons have higher relative biologic effectiveness compared with photons, and doses must be considered accordingly.

- The Bragg peak allows for protons to achieve very low entrance and exit doses to nontarget tissues. A spread-out Bragg peak is often used clinically to allow adequate dosing of the entire tumor depth.
- No randomized clinical trial has directly compared patient outcomes of proton therapy versus IMRT for prostate cancer.

Brachytherapy[a]

Low-Dose-Rate Brachytherapy Technique and Trends

The advantage of brachytherapy is a result of the placement of sources directly into the target tissue, and the low energy of the radioactive sources used—only 21 and 28 kiloelectron-volts for ^{103}Palladium and ^{125}Iodine, respectively. This results in rapid dose falloff (a few millimeters) beyond the target volume, and hence a high ratio of target to nontarget dose. This rapid falloff, however, also mandates a high degree of precision in the placement of these sources to ensure that any tumor-bearing regions within the prostate gland are not underdosed.

Beginning in the early 1990s, the number of prostate cancer patients undergoing brachytherapy for low-risk cancers increased dramatically, with the CaPSURE database reporting an increase in the use of brachytherapy from 4% in 1990 to 15% by 2007 (Cooperberg, Broering, Carroll 2010). More recent data indicate that the use of brachytherapy has declined since the early 2000s, with some estimates of as much as a 60% decrease in utilization. Although the reasons for this decline remain open for debate, competition from ultrahypofractionated RT, robotic prostatectomy, and increased patterns of self-referral from urology practices with ownership of linear accelerators are the most frequently suspected causes (Burt et al., 2018; Mitchell, 2013). However, recent comparative efficacy data also suggest that the addition of brachytherapy improves control and survival rates for patients with intermediate- and high-risk localized cancers; it remains to be seen if these new data will reverse the decline in brachytherapy utilization (Morris et al., 2017; Orio et al., 2016).

Computer programs using algorithms with optimization of dosimetric coverage of the entire prostate while minimizing dose to the intraprostatic urethra and rectum are employed for planning and executing brachytherapy (Fig. 157.7). The seeds are implanted in a pattern that employs more seeds toward the outer areas of the gland and fewer seeds toward the center, a pattern termed **peripheral (or modified-peripheral) loading.** This allows for the preferential sparing of the urethra to reduce urinary morbidity (Wallner et al., 1995). Several methods for designing seed placement have been described for permanent radioactive seed implantation. The **preplanned** method popularized by Blasko et al. (1993) in Seattle uses preimplant transrectal ultrasound images obtained preoperatively, with the patient in the same lithotomy position as for the actual implant, to calculate seed placement for an optimal dosimetric plan. Stone and Stock (1999) described a method for determining the number of seeds to be implanted on the basis of the size of the gland and a nomogram reported by Anderson (1976). The seeds are implanted using empirical rules defined by Patterson and Parker in the 1930s (Fletcher, 1980). Kaplan et al. (2000) described a method in which the dosimetric plan is calculated on TRUS images obtained intraoperatively, called **intraoperative planning**. Zelefsky et al. (2000) reported a comparison of implant results using all three of these methods, and found that intraoperative **dosimetry** (distribution of radiation) was associated with superior prostate dose coverage and reductions in average and maximal doses to the urethra. Cystoscopy is often but not always performed with the purpose of removing any blood clots from the bladder, or in rare instances to retrieve any seeds placed inadvertently into the bladder.

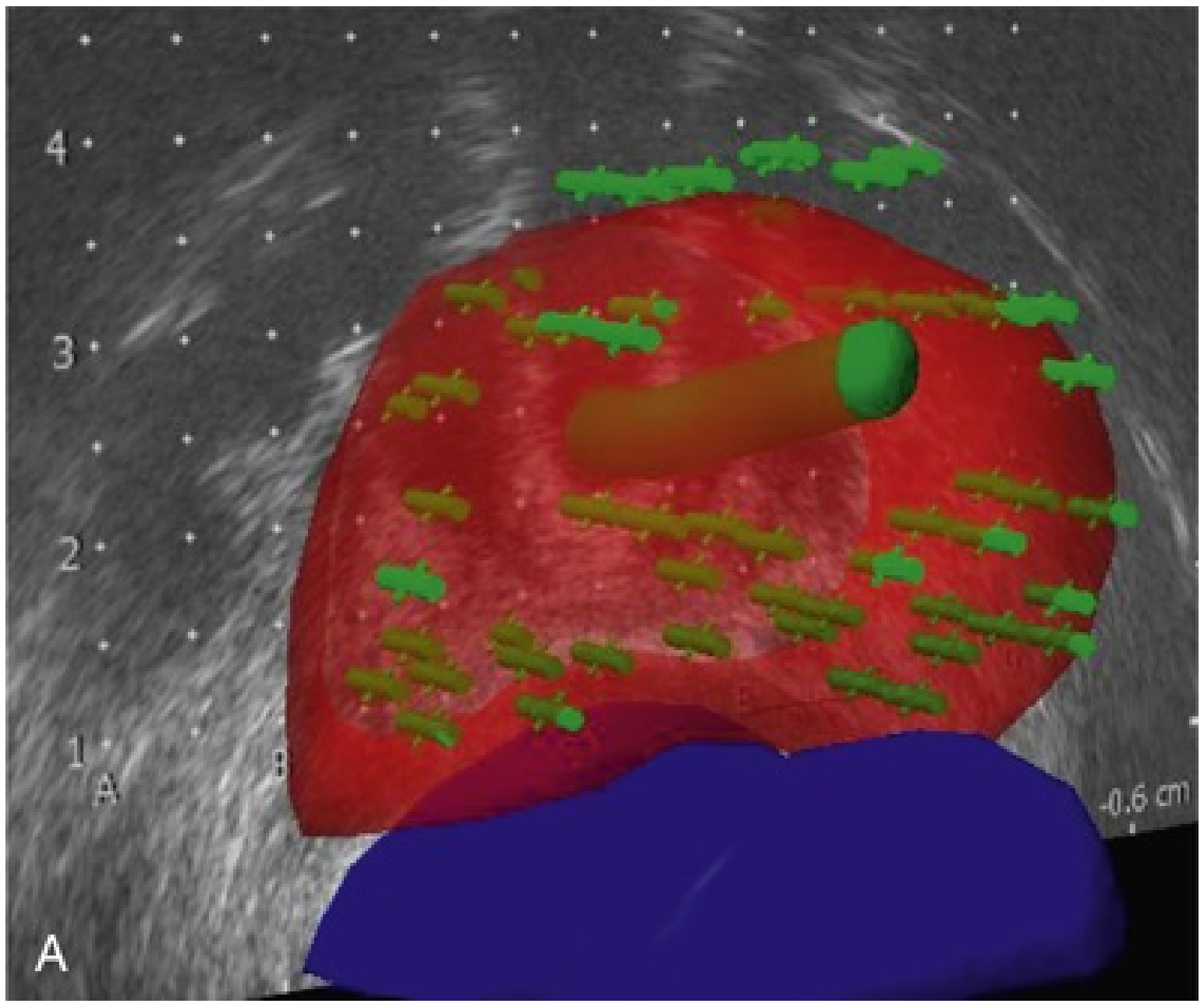

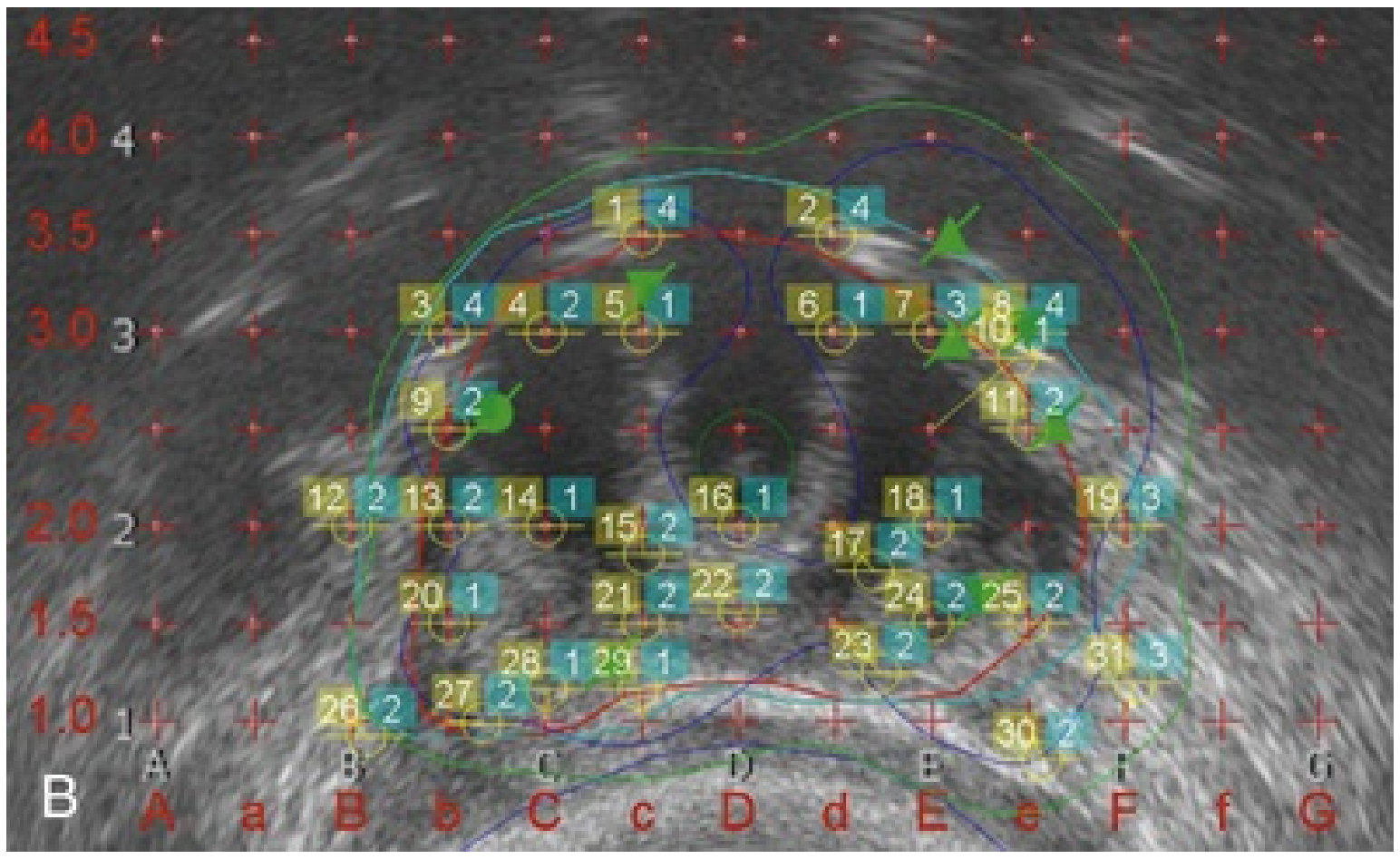

FIG. 157.7 (A) Off-axis view of a brachytherapy treatment plan showing needle paths and seed locations. The prostate *(red),* rectum *(blue),* and urethra *(green)* are shown. Note peripheral loading of seeds to minimize the dose to the central urethra. (B) Axial view of brachytherapy treatment plan superimposed on TRUS image. Seeds that have been placed are denoted by *green triangles with lines.* The grid coordinates superimposed on the TRUS correlate with the holes in the template grid and allow the treatment team to communicate regarding specific seeds/needles.

There are three generally utilized choices of isotope for permanent seed implantation. ^{125}Iodine emits low-energy x-rays at 27 keV, with a half-life of 59.6 days. ^{103}Palladium was introduced in 1986 because it has an energy spectrum similar to that of ^{125}I, with 21-keV x-rays, but with a significantly shorter half-life of 17 days. However, some prefer the slightly higher energy of ^{125}I because it offers “more forgiving” dosimetric properties in terms of ease of achieving good prostatic coverage. The most recently introduced isotope, in use since 2004, is ^{131}Cesium, which emits x-rays at 30 keV (thereby offering dose characteristics similar to ^{125}I), but with a half-life of 9.7 days. Treatments are delivered over a shorter period with ^{131}Cs compared with ^{103}Pd and ^{125}I, with 90% of the dose delivered in 33, 58, and 204 days respectively. The recommended monotherapy (i.e., brachytherapy alone, without EBRT) dose prescription for ^{125}I is 140 to 160 Gy, for ^{103}Pd is 110 to 125 Gy, and for ^{131}Cs is 100–115 Gy. A randomized trial comparing ^{125}I versus ^{103}Pd in patients with early stage, low-grade cancers (stage ≤cT2a, Gleason ≤6, PSA ≤10 ng/mL) found no differences in biochemical control between the two. Urinary symptoms were statistically worse at 1 month for the patients receiving ^{103}Pd (mean AUA symptom score 18.6 vs. 14.8) but then resolved more rapidly, with 6-month mean scores of 9.9 for ^{103}Pd versus 12.0 for ^{125}I, consistent with their differences in half-life (Herstein et al., 2005).

Although outcomes in patients with low-risk prostate cancer using brachytherapy have been demonstrated in numerous series to be generally excellent (see Evaluating the Response to Radiation Therapy), patients with unfavorable intermediate- or high-risk prostate cancer are often managed with a combination of brachytherapy with EBRT. The goal of adding EBRT is to increase the dose to the periprostatic tissues and seminal vesicles, and allow for treatment of lymph nodes if indicated. Also, EBRT may help make up for any regions potentially not receiving an adequate brachytherapy dose because of variations in seed distribution. The total combined dose from brachytherapy plus EBRT is greater than what can be given safely using either modality alone. Typically, when EBRT is to be combined with brachytherapy, a dose of 45 Gy is delivered (compared with 75 to 80 Gy when EBRT is used alone). The dose of the implant boost in such combination therapy is generally 60% to 70% of the dose prescribed for patients treated with implant alone: 108 to 110 Gy for ^{125}I, 90 to 100 Gy for ^{103}Pd, and 80 to 85 Gy for ^{131}Cs (Davis et al., 2012).

Assessment of Permanent Implant Quality

The goal of prostate brachytherapy is to deliver a tumoricidal dose to the prostate while minimizing dose to nearby sensitive normal structures such as the rectum and urethra. Postimplant assessment of dosimetry both within the prostate and in these dose-limiting regions is important to assess implant quality. Postimplantation CT with or without MRI is performed to determine seed locations and calculate the dose received by the prostate and other structures of importance (Fig. 157.8) (Mizowaki et al., 2002; Willins and Wallner, 1997). Commonly utilized and validated parameters of implant quality include but are not limited to the following:

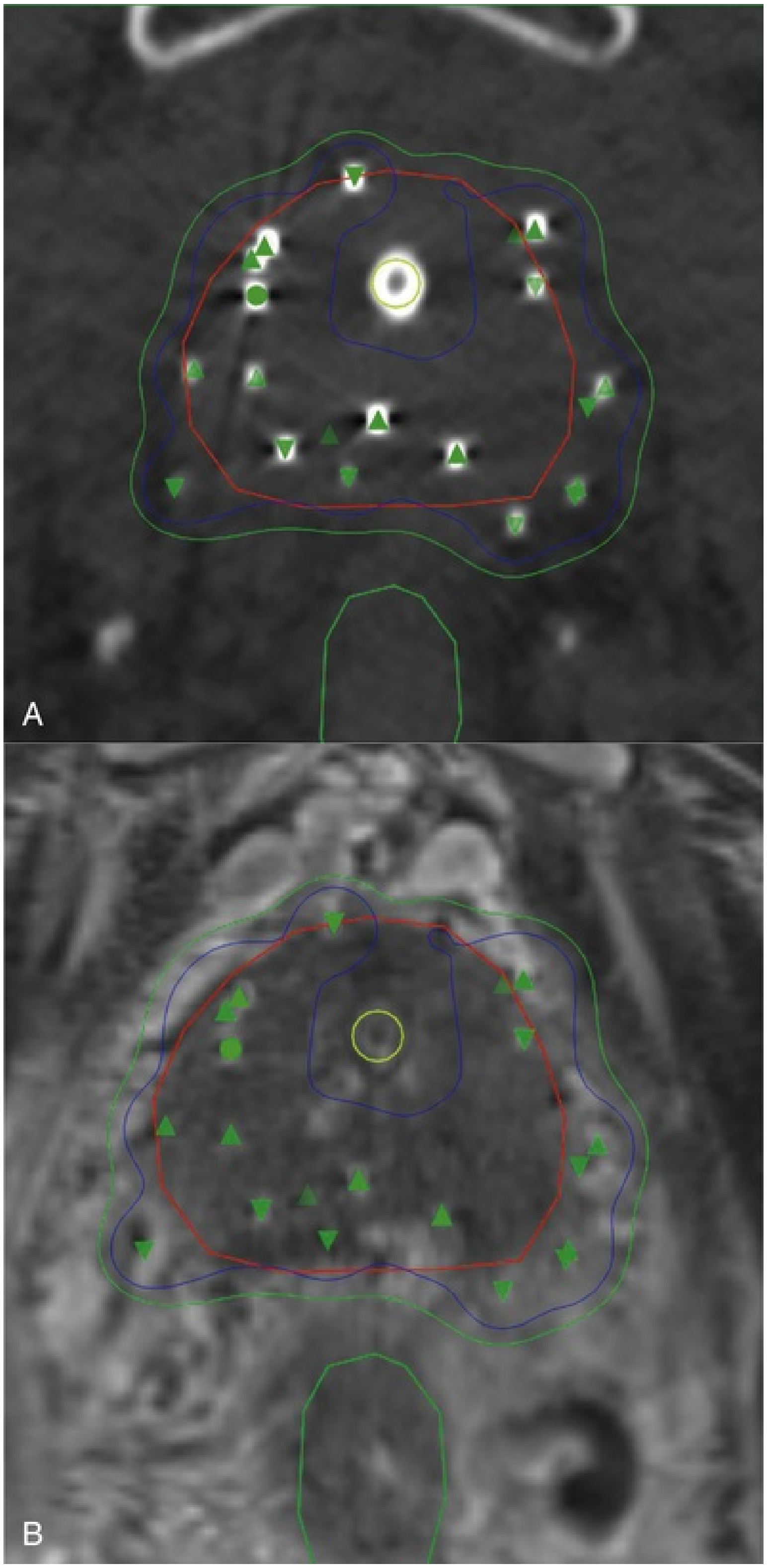

FIG. 157.8 Brachytherapy postimplant computed tomography (CT) (A) and T2 magnetic resonance imaging (MRI) (B) axial images. Seeds are well-visualized on CT, but prostate delineation is obscured by seed artifact. MRI imaging allows for improved prostate delineation. Image sets are

spatially registered/fused for accurate correlation between dose and normal anatomy. The prostate *(red),* urethra *(yellow),* and rectum *(light green)* are shown. 100% and 150% prescription isodose lines are shown in *green* and *blue*, respectively.

- Prostate **D90:** minimum dose received by the “hottest” 90% of the prostate, or alternatively described as the highest isodose line encompassing 90% of the prostate)
- Prostate **V100:** volume of the prostate receiving the prescribed dose (i.e., 100%), expressed as a percentage

The American Brachytherapy Society (ABS) recommends using the prostate D90 and V100 and V150 (the percent volume of the prostate receiving 100% and 150% of the prescribed dose, respectively) as parameters to assess implant quality (Davis et al., 2012). Ideal implant parameters are shown in Table 157.4.

TABLE 157.4

Ideal Permanent Prostate Brachytherapy Postimplantation Guidelines

ORGAN	PARAMETER	CONSTRAINT
Prostate	Dose received by 90% of the prostate volume (D90)	>100% of prescription dose
	Volume of prostate receiving 100% of prescription dose (V100)	>95% of the prostate
	Volume of prostate receiving 150% of prescription dose (V150)	<50% of the prostate
Rectum	Volume of rectum receiving 100% of prescription dose (R100 or RV100)	<1–1.3 cm^3

Data from Nath R, Bice WS, Butler WM et al: AAPM recommendations on dose prescription and reporting methods for permanent interstitial brachytherapy for prostate cancer: Report of Task Group 137. *Med Phys* 36(11):5310–5322.

Since the advent of transperineal brachytherapy, advances in technique and physician experience have resulted in improved dosimetric outcomes. However, factors such as needle deviation during insertion, tissue deformation, intraoperative prostatic edema, and relaxation of tissues and possible source shift after needle removal can result in variations from the idealized dosimetric plan

(Roberson et al., 1997; Stone et al., 2002; Yamada et al., 2003). Edema results in an average 30% increase in prostate size when evaluated at day 1 postimplantation, but can vary anywhere from 15% to 148% (Leclerc et al., 2006). Although edema typically subsides after 2 to 4 weeks, a significant portion of the dose may be already delivered by then, depending on the half-life of the isotope used. Brachytherapy practitioners vary in their preferred timing of postoperative imaging, with most utilizing somewhere between day 0 (date of implant) to day 30. Earlier assessment allows for immediate feedback and "worst-case" determination of prostatic dose coverage, whereas later times allow for resolution of edema with associated improvement in prostate dosimetric values.

PSA control rates after brachytherapy have been well-demonstrated to be related to postimplant dosimetry. Potters et al. evaluated 883 patients with T1 to T2 prostate cancer who underwent brachytherapy, and found that biochemical failure was associated with Gleason score, PSA, and lower prostate D90 (Potters et al., 2003). A multi-institutional analysis of over 2600 patients treated at 11 institutions also found that prostate D90 on postimplant dosimetry was significantly associated with biochemical outcome for both ^{125}I and ^{103}Pd (Zelefsky et al., 2007).

Because of the challenge of reproducibility of implant quality, there has been interest in developing better methods for monitoring source position and edema during the implant procedure. A commercially available and widely utilized method involves updating source positions intraoperatively by marking the position of each source at the time of deposition based on the visible needle tip or source itself on sagittal TRUS view, a technique often termed **real-time or ultrasound dosimetry.** Because this does not update source position after the time of placement, it may not account for tissue or source position changes and/or early edema occurring during the implant. Nag et al. (2008) compared real-time dosimetry to postimplant CT scans and found that despite some correlations between the two, there were large variations in commonly utilized dosimetric reporting parameters, and a tendency for ultrasound dosimetry to underestimate high-dose regions and dose to normal organs.

In contrast with the method described earlier, another approach is to visualize intraprostatic sources using fluoroscopy or in-room CT, which allows for reliable and repeatable imaging over the course of the implant. Termed **dynamic dosimetry,** this approach allows intraoperative continuous monitoring of source positions and plan modification. Westendorp et al. described their experience using a C-arm cone-beam CT unit, in which intraoperative TRUS and CT images were coregistered based on implanted fiducial gold markers, and doses to prostate and urethra evaluated. They reported that in 17% of the procedures, they identified prostatic regions that required dose modification and remedial seeds placed (Westendorp et al., 2017).

Another method for dynamic dosimetry reported by Song et al. (2011) utilizes a nonisocentric fluoroscopy unit, with the advantage of being more readily available than intraoperative cone-beam CT units. When updated dosimetry is desired during the brachytherapy procedure, three fluoroscopic images are acquired and processed to calculate a three-dimensional seed distribution, which is then coregistered to the TRUS images based on seed matching (Kuo et al., 2012; Song et al., 2011). Results from a phase II trial suggest high reliability in achieving excellent prostate dosimetric values utilizing this technique, with 44/45 patients having prostate V100 greater than or equal to 95% (Lee et al., 2018).

High-Dose-Rate Brachytherapy

Permanent seed implantation delivers a dose over a number of weeks to months depending on the isotope chosen, hence the term low-dose-rate (not to be confused with *low dose*). An alternative method of brachytherapy is **high-dose-rate (HDR) brachytherapy,** which delivers short but high doses of radiation using temporary catheters. For HDR brachytherapy, hollow catheters are placed through the perineum into the prostate using the same procedure as for LDR brachytherapy. Imaging and treatment planning are performed based on either CT, MRI, or directly on TRUS used for catheter insertion. Treatment utilizes an iridium-192 (^{192}Ir) source that emits 400-keV gamma radiation, and a single source can be migrated along the length of each catheter at various positions for variable lengths of time on the order of seconds to minutes. The source is manipulated robotically to minimize radiation exposure to medical staff. The radiation dose is delivered in this way over several applications. No postimplantation dosimetry is performed, because no sources are left inside the patient.

Initially, HDR was mostly employed as a boost in combination with EBRT for patients with intermediate- or high-risk features. Most recently, it has become more common to also use it as monotherapy in patients with low-risk disease.

There are some potential advantages and disadvantages of HDR versus LDR brachytherapy, summarized as follows:

Potential advantages for HDR versus LDR brachytherapy include:

- The use of catheters allows for more ready inclusion of extracapsular disease and seminal vesicles, if desired.
- There is greater opportunity for dose optimization by modifying dwell times and positions of the source within the catheters.
- The use of high doses per fraction has a potential biologic dose advantage for prostate cancer if a low alpha/beta ratio exists.
- No need for personnel to handle the radioactive source during treatment.
- The use of a single source for all patients using a multipurpose facility makes HDR brachytherapy potentially more cost-effective.

Potential disadvantages for HDR versus LDR brachytherapy include:

- There are potential treatment inaccuracies caused by catheter and organ/patient movement between imaging and time of source insertion (during treatment planning) or between fractions, interobserver contouring variabilities, and effects of edema (De Brabandere et al., 2012; Foster et al., 2011; Kawakami et al., 2014; Mullokandov and Gejerman, 2004; Whitaker et al., 2011; Yoshida et al., 2010)
- Established fractionation regimens with long-term results employ multiple fractions (with 6-hour interfraction intervals) and/or more than one catheter implant session, resulting in less patient convenience and more logistical and quality assurance workload per patient.
- The relatively high activity and energy of the ^{192}Ir source requires availability of a shielded room for treatment delivery.
- There are less favorable pathologic response results from available post-treatment biopsy studies (Kestin et al., 2002a; Stone et al., 2010).

- No comparable randomized phase III data exist to support the efficacy of HDR in high-risk prostate cancer.

High Dose Rate as a Boost With External Beam Radiation Therapy

There are a wide range of EBRT target volume treatment schedules reported in the literature, and published schedules include the following (Hoskin et al., 2013):

- 45 Gy in 25 fractions over 5 weeks
- 46 Gy in 23 fractions over 4.5 weeks
- 35.7 Gy in 13 fractions over 2.5 weeks
- 37.5.Gy in 15 fractions over 3 weeks

HDR brachytherapy doses that have been prescribed with these schedules include the following:

- 15 Gy in 3 fractions
- 11 to 22 Gy in 2 fractions
- 12 to 15 Gy in 1 fraction

High-Dose-Rate Monotherapy

HDR monotherapy regimens utilizing multiple fractions and/or multiple implant sessions (~4 to 6 fractions) have the longest follow-up and have been associated with low acute toxicity and high biochemical control rates in the series published to date. Published schedules that have been used include the following:

- 34 Gy in 4 fractions
- 36 to 38 Gy in 4 fractions
- 31.5 Gy in 3 fractions
- 26 Gy in 2 fractions

Whether single-fraction HDR brachytherapy is also feasible has been evaluated in recent studies. Krauss et al. (2018) reported results of a trial utilizing a single 19-Gy fraction of HDR brachytherapy, but the 5-year biochemical control rate was a disappointing 73.9%, with no significant difference between low- and intermediate-risk patients. Biopsy-proven local failure at 5 years was 19%, occurring at median of 3.9 years post-treatment. Another trial by Morton et al. (2017) randomized patients to either 19 Gy in a single fraction versus a 2-fraction regimen using 13.5 Gy per fraction. At median follow-up of 27 months, 7/87 patients in the single-fraction arm had relapsed biochemically, most of whom were found to have local recurrence. In the 2-fraction arm, one patient developed biochemical failure and was found to have distant metastases. These results suggest that either single-fraction doses greater than 19 Gy are required, or continued use of fractionation in HDR is necessary.

No randomized trials directly comparing HDR versus LDR brachytherapy have been performed. Using the SEER Medicare database, Tward et al. (2016) compared the incidence of grade 3 adverse events after LDR and HDR brachytherapy, and after LDR plus EBRT and HDR plus EBRT. At 8 years, the propensity-weighted cumulative adverse event incidence was highest after HDR plus EBRT (26.6%) and lowest after LDR alone (15.7%). The absolute excess risk over nontreated controls at 8 years was 1.9%, 3.8%, 8.4%, and 12.9% for LDR, HDR, LDR plus EBRT, and HDR plus EBRT, respectively. No statistically significant differences were observed between LDR and HDR.

Patient Selection for Brachytherapy

The major acute toxicity of brachytherapy is obstructive and irritative uropathy, with a low but non-negligible risk of need for temporary catheterization. This is a major consideration in determining the eligible patient population for brachytherapy.

The American Brachytherapy Society and Groupe Européen de Curiethérapie (GEC) and the European Society for Radiotherapy & Oncology (ESTRO) have published consensus guidelines regarding LDR and HDR brachytherapy, respectively (Davis et al., 2012; Hoskin et al., 2013). Patient inability to undergo general anesthesia is considered a contraindication to brachytherapy. Although published reports have described use of local anesthesia for the procedure, the majority of experience is with patients having general anesthesia, which minimizes the risk for patient movement disrupting the spatial accuracy of the procedure (Wallner, 2002).

Other relative contraindications include the following:

- Large TURP defects, or TURP within prior 3 to 6 months (some association with increased risk for urinary incontinence and/or technical challenges (Talcott et al., 2001)
- Factors associated with poor urinary outcomes or obstruction (Martens et al., 2006)
  - Maximum urinary flow rate (Qmax) less than 10 mL/s
  - International Prostate Symptom Score greater than 20
  - Large median lobe hypertrophy (Nguyen et al., 2002)
- Prior pelvic RT
- Connective tissue disease or inflammatory bowel disease
- Pubic arch interference (inability to access anterior/lateral prostate with needles)
- Lithotomy position not possible
- Rectal fistula or lack of TRUS access (e.g., patient who has abdominoperineal resection)

Patients with large glands or median lobe hypertrophy may be treated with androgen suppression to reduce gland size before brachytherapy, using either luteinizing hormone–releasing hormone (LHRH) analogues or androgen receptor blockade. Approximately 30% gland shrinkage may be achieved with these drugs (Kucway et al., 2002; Merrick et al., 2006). However, the morbidity associated with LHRH analogues is well-described (Bosco et al., 2015; Tsai et al., 2015) and has specifically been correlated with increased cardiovascular mortality in patients who were treated for gland downsizing before brachytherapy (Nanda et al., 2013). Recently, Bae et al. (2018) described their results utilizing 5α-reductase inhibitors for this purpose, thereby avoiding the negative effects of LHRH analogues or androgen blockers. Although less robust gland size reduction was achieved (approximately 20%), this may be considered as a less morbid alternative to the other regimens.

Of note, unlike with EBRT, the value of androgen suppression combined with brachytherapy is unproven by randomized trial data and remains a subject of some controversy. Although its use in patients with high-risk disease receiving brachytherapy or brachytherapy plus EBRT is generally accepted, the role of ADT is unclear, particularly among patients receiving brachytherapy for unfavorable intermediate-risk disease or even high-risk disease with limited risk factors (Keyes et al., 2017).

Brachytherapy Combined With External Irradiation

Although outcomes in patients with low-risk prostate cancer using brachytherapy alone are excellent and brachytherapy alone is well-proven and established, the potential benefit of combining EBRT with brachytherapy for patients with intermediate-risk disease has been debated. EBRT is employed in these patients to treat the prostate and periprostatic tissues. This strategy allows targeting of high-risk areas outside the prostatic capsule and increases the dose to the prostate itself. Typically, a dose of 4500 cGy of conventionally fractionated EBRT is delivered (compared with 7560 to 7920 cGy when EBRT is used alone). The dose of the implant boost in such combination therapy is generally 60% to 70% of the dose prescribed for patients treated with implant alone.

Merrick et al. (2017) pooled results from two randomized trials evaluating the role of supplemental EBRT in patients with higher-risk features. Patients were stratified into unfavorable intermediate (primary Gleason pattern 4, ≥50% positive biopsies, or ≥2 irradiation features), favorable intermediate, and high-risk cohorts. The median follow-up was 7.5 years. The 10-year biochemical failure for favorable intermediate, unfavorable intermediate, and high risk was 1.7%, 6.6%, and 15.5%, respectively ($P < 0.001$). Although unfavorable intermediate-risk patients had a greater incidence of PSA relapse and disease-specific mortality when compared with favorable intermediate-risk patients, neither the addition nor dose of supplemental EBRT influenced outcome.

RTOG 02-32 was another randomized trial that evaluated patients with intermediate risk to determine if there was a benefit derived from adding 45 Gy of EBRT to brachytherapy. At an interim analysis, of the required 443 patients with 5 years of follow-up, the 5-year progression-free survival was 85% for the EBRT + brachytherapy arm and 86% for the brachytherapy alone arm (hazard ratio [HR] 1.02), indicating no improvement. However, it should be noted that the study population was predominantly patients with favorable intermediate-risk disease, and therefore the study is not conclusive regarding the value of combined therapy in patients with more unfavorable disease (Prestidge et al., 2016). Also, both trials allowed physician discretion regarding the use of androgen suppression, and therefore this remains a potential confounding factor.

Whereas brachytherapy alone is accepted in general for low- and favorable intermediate–risk cancers, biochemical control is considered to be improved for high-risk patients, and possibly for unfavorable intermediate–risk patients, by combining brachytherapy with EBRT (Spratt and Zelefsky, 2013; Spratt et al., 2017a). Biochemical disease–free survival for high-risk men using this strategy can range from 80% to 90%, particularly when combined with ADT (Koontz et al., 2009; Merrick et al., 2011; Shilkrut et al., 2013a, 2013b; Taira et al., 2010). HDR brachytherapy series with at least 5 years of follow-up also show very good biochemical control for both intermediate-risk (83% to 100%) and high-risk (74% to 91%) patients (Morton and Hoskin, 2013). In the ASCENDE-RT trial, men with high-risk disease were treated with 12 months of ADT and pelvic irradiation to 46 Gy followed by either an EBRT boost to 78 Gy or an LDR brachytherapy boost. At a median follow up of 6.5 years, men who received an EBRT boost were twice as likely to experience biochemical failure compared with men who were treated with the brachytherapy boost (HR 2.04; $P = .004$). However, there was no significant difference in overall survival between the two treatment arms (Morris et al., 2017).

Recent pooled retrospective analyses suggest that patients with very-high-risk prostate cancers have improvements not only in biochemical control, but also in disease-specific survival with this approach. Kishan et al. (2018) analyzed 1809 men treated for Gleason 9 to 10 cancer at 12 centers between 2000 and 2013. Of 1809 men, 639 underwent RP, 734 underwent EBRT, and 436 underwent EBRT + brachytherapy. The adjusted 5-year disease-specific mortality rates were RP, 12%; EBRT, 13%; and EBRT + brachytherapy, 3% (95% confidence interval [CI], 1% to 5%). EBRT + brachytherapy was associated with significantly lower disease-specific mortality than either RP or EBRT (cause-specific HRs of 0.38 and 0.41). EBRT + brachytherapy was also associated with a significantly lower rate of distant metastasis (propensity-score–adjusted cause-specific HRs of 0.27 for RP and 0.30 for EBRT) (Kishan et al., 2018).

Key Points: Brachytherapy

- Prostate brachytherapy can be performed using either LDR (permanent implant) or HDR (temporary catheter) approaches.
- Postimplant dosimetry after LDR brachytherapy is important to assess implant quality.

- Dosimetric measures such as prostate V100 and D90 are used to describe adequate dose coverage of the prostate.
- Patients who have preexisting obstructive uropathy (IPSS >20 or Qmax <10 cc/s) are relatively contraindicated for brachytherapy.
- Combined brachytherapy and EBRT is not indicated for patients with low-risk disease, but is supported by data for a role in the management of high-risk disease.

Androgen Suppression Combined With Radiation

Background and Potential Mechanisms

In 1941, Huggins and Hodges (1941) reported the androgen-dependent nature of prostate cancer. This seminal work provided, in part, the rationale for the use of hormonal therapy as an adjunct to RT in the definitive management of local and locally advanced prostate cancer. As early as 1967, hormonal therapy was being added to RT in an attempt to modify the outcomes of patients with stage C (T3) prostate cancer (del Regato, 1967). Such T3 tumors were often quite large, and cytoreductive ADT provided more favorable geometry for external irradiation, and reduction in tumor burden (Green et al., 1984). However, the use of hormonal therapy in combination with radiation remained controversial throughout the 1970s and 1980s as radiation techniques were improving, and results from early series evaluating the benefit of ADT with radiation were often negative (Neglia et al., 1977). In one of the earliest favorable reports, Pilepich et al. reported that patients with histologically unfavorable lesions treated on the RTOG 75-06 trial and who had received androgen suppression and EBRT had similar disease-free survival and overall survival as patients with more favorable tumors who did not receive androgen suppression (Pilepich et al., 1995).

Combined-modality approaches are well-established in the treatment of many types of cancer. Androgen-responsive prostate cells undergo programmed cell death (apoptosis) when deprived of androgens (Denmeade et al., 1996; Furuya et al., 1995). Similar to radiation, this death does not appear to be p53-dependent (Furuya et al., 1995). Recently, Tarish et al. (2015) used pre- and post-treatment biopsies in 48 patients to monitor molecular responses to AST and RT. They found that castration impaired nonhomologous end joining repair of DNA double-strand breaks, with reduced amounts of the repair protein Ku70 and higher amounts of residual unrepaired double-strand breaks from radiation. Similarly, Al-Ubaidi et al. (2013) showed that castration reduced Ku70 protein levels in prostate cancer biopsy samples. These results offer an explanation for the enhanced radiosensitivity of prostate cancer after castration.

Spratt et al. (2015) also showed that androgen receptor expression and activity are durably upregulated after RT in multiple human prostate cancer models in vitro and in vivo. The degree of androgen receptor upregulation correlated with survival in vitro and time to tumor progression in animal models. Androgen receptor pathway upregulation, measured by a rise in serum levels of androgen receptor–regulated hK2 protein, was found in nearly 20% of patients after RT, and these men were threefold more likely to experience subsequent biochemical failure. Their data suggest that the value of adjuvant ADT after RT is through mitigation of RT-induced upregulation of androgen receptor signaling.

Androgen Suppression Therapy and Localized Disease

Several prospective randomized studies have investigated the role of ADT with radiation for men with intermediate- to higher-risk localized prostate cancer relative to radiation alone (D'Amico et al., 2008; Denham et al., 2011; Jones et al., 2011; Pisansky et al., 2013; Zapatero et al., 2015). As outlined in Table 157.5, trials have investigated radiation alone versus radiation in combination with androgen suppression and the duration of hormonal therapy with the radiation.

TABLE 157.5

Selected Randomized Controlled Trials Investigating the Use of Androgen Suppression Therapy With Radiation

STUDY	TNM STAGE (%)	GLEASON SCORE (%)	*N*	MEDIAN FOLLOW-UP (YEARS)	TREATMENT ARMS	OVERALL SURVIVAL: %	P C S M %
LOCALIZED DISEASE							
TROG 96.01 (Denham et al., 2011)	T2b (26), T2c (34), T3,4 (40), N0M0	≤6 (44), 7 (38), ≥8 (17)	818	10.6	RT: 66 Gy	10 yr: 57.5	1
					RT + 3 mo ADT	10 yr: 63.3[a]	1
					RT + 6 mo ADT	10 yr: 70.8	1
Dana-Farber 95-096	T1b (2), T1c (46),	≤6 (28), 7 (58), ≥8 (15)	206	7.6	RT: 70 Gy	8 yr: 61	8
					RT + 6 months	8 yr: 74	8

(D'Amico et al., 2008)	T2a (23%), T2b (30), N0M0				ADT		
RTOG 94-08 (Jones et al., 2011)	T1 (49), T2 (51), N0M0	≤6 (62), 7 (28), ≥8 (9)	1979	9.1	RT: 66.6 Gy	10 yr: 57	1
					RT + 4 mo ADT	10 yr: 62	1
LOCALLY ADVANCED DISEASE: RT vs. RT + ADT							
RTOG 86-10 (Roach et al., 2008)	T2 (30), T3,4 (70), N0 (92), N1 (8), M0	≤6 (30), ≥7 (70)	471	12.6	RT: 65–70 Gy	10 yr: 34	1
					RT + 4 mo ADT	10 yr: 43[a]	1
EORTC 22863 (Bolla et al., 2010)	T1 (1), T2 (10), T3 (80), T4 (9), N0 (89), M0	≤6 (62), 7 (28), ≥ 8 (9)	415	9.1	RT: 70 Gy	10 yr: 39.8	1
					RT + 36 mo ADT	10 yr: 58.1	1
LOCALLY ADVANCED DISEASE: ADT vs. ADT + RT							
SPCG-7 (Widmark et al., 2009)	T1 (2), T2 (19), T3 (78), N0M0	NA	875	7.6	ADT	10 yr: 61	1
					ADT + RT: 70 Gy	10 yr: 70	1
PR.3/PRO7 (Warde et al., 2011)	T2 (13), T3 (83), T4 (4), NXM0	≤7 (81), 8–10 (18)	1205	6	ADT	7 yr: 66	7
					ADT + RT: 65–69 Gy	7 yr: 74	7
DURATION OF ADT							
RTOG 92-02 (Horwitz et al., 2008)	T2 (45), T3 (51), T4 (4), N0 (97), M0	≤6 (38), 7 (31), ≥ 8 (24%)	1554	11.3	RT + 4 mo ADT	10 yr: 51.6	1
					RT + 28 mo ADT	10 yr: 53.9[a]	1

EORTC 22961 (Bolla et al., 2009)	T2c (19), T3 (73), T4 (4), N1 (3), M0	≤6 (47), 7 (30), ≥ 8 (18)	970	6.4	RT + 6 mo ADT	5 yr: 81	5
					RT + 36 mo ADT	5 yr: 85	5
PCS IV (Nabid et al., 2018)	T1c (24), T2a (20), T2b (31%), T3 (24%)	NA	630	6.5	RT + 18 mo ADT	5 yr: 86	5
					RT + 36 mo ADT	5 yr: 91[a]	5
RTOG 99-10 (Pisansky et al., 2013)	T1b–T4, N0M0	≤7 (90)	1490	8.7	RT: 70.2 Gy + 4 mo ADT	10 yr: 66	1
					RT + 9 mo ADT	10 yr: 67[a]	1

[a] Not statistically significant.

ADT, androgen deprivation therapy; *DFCI,* Dana-Farber Cancer Institute; *EORTC,* European Organization for Research and Treatment of Cancer; *mo,* months; *NA,* not available; *PCS IV,* Duration of Androgen Blockade Combined with Pelvic Irradiation in Prostate Cancers; *RT,* radiation therapy; *RTOG,* Radiation Therapy Oncology Group; *SPCG,* Scandinavian Prostate Cancer Group; *TROG,* Trans-Tasman Radiation Oncology Group; *yr,* year.

The Trans-Tasman Radiation Oncology Group (TROG) performed a three-arm randomized trial comparing RT alone to RT plus 3 or 6 months of androgen suppression for 818 men with T2b to T4 disease (Denham et al., 2011). With 10.6 years of follow-up, the 6-month arm showed significant improvements in disease-free, metastasis-free, disease-specific, and overall survival relative to RT alone. D'Amico et al. studied 206 men, all with clinical T1 to T2 disease and followed them for a median of 7.6 years (Boorjian et al., 2008; D'Amico et al., 2008). Their median PSA was 11 ng/mL, and 73% had a Gleason score of 7 or greater. Benefits in both overall and disease-specific survival were noted. Of note, it appeared that the survival benefit may have been limited to only those men with no or minimal comorbid illness.

RTOG 94-08 randomized 1979 men with T1b to T2b and PSA less than 20 ng/mL disease to RT alone versus RT with 4 months of combined androgen blockade (Jones et al., 2011). With a median follow-up of 9.1 years, the 10-year overall survival was 62% in the arm with androgen suppression compared with

57% in the RT alone arm. In unplanned subgroup analyses, it appeared that the 54% of men with intermediate-risk disease derived the greatest benefit, with the low-risk group (35%) showing no significant benefit to hormonal therapy.

DART01/05 randomized 178 men with T1c to T3 intermediate- or high-risk prostate adenocarcinoma receiving radiation to either 4 months of short-term ADT or 24 months of long-term ADT (Zapatero et al., 2015). The 5-year overall survival with long-term ADT was 95% compared with 86% in the short-term group. In the subgroup analysis by risk group, the benefit in overall survival was more evident for patients with high-risk disease, but not for those with intermediate-risk disease.

Androgen Suppression Therapy and Locally Advanced Disease

Several trials have also evaluated the role of ADT with RT for patients with locally advanced or high-risk cancers, and identified beneficial effects on biochemical control and overall survival.

In RTOG 86-10, 456 patients with large (25 cm^3), stage T2b to T4, Nx tumors who were randomly assigned to 4 months of total androgen suppression with RT given after the first 2 months had improved local control, disease-free survival, and freedom from metastases compared with patients receiving 65 to 70 Gy of RT alone (Roach et al., 2008). At a median follow-up of over 12 years, the 10-year overall survival rates were no different between the two arms, but there was a significant improvement in disease-specific mortality of 36% versus 23% ($P = .01$).

In EORTC 22863, a phase III trial of androgen suppression, Bolla et al. (2010) reported an overall survival advantage for patients receiving 3 years of goserelin starting at the initiation of RT over RT to 70 Gy alone. More than 90% of the 415 patients had either T3 or T4 disease, and the remainder were eligible as a result of high-grade tumors. With 9.1 years of follow-up, there were significant improvements in both overall survival and disease-specific survival with the addition of androgen suppression.

A meta-analysis of prospective trials of ADT in nonmetastatic prostate cancer showed a 30% reduction in relative risk for disease-specific mortality and a 14% reduction in the relative risk for all-cause mortality with the use of ADT (Nguyen et al., 2011).

Benefit of Radiation in Addition to Androgen Suppression for Locally Advanced Disease

Two multicenter randomized trials have investigated the opposite question, of whether the addition of RT improves outcomes for men with locally advanced, nonmetastatic disease when treated with primary androgen suppression (Warde et al., 2011; Widmark et al., 2009). In the first trial, 875 men with a PSA of 70 ng/mL, N0, M0, and mostly T3 disease were randomized to 3 months of combined androgen blockade followed by lifelong flutamide with or without 70 Gy of RT. After a median of 7.6 years of follow-up, trial investigators reported a relative risk for disease-specific death of 0.44 (95% CI, 0.30 to 0.66, $P < .001$), favoring the addition of RT (Widmark et al., 2009).

In the study conducted by the NCI of Canada, 1205 men with mostly T3 and T4 disease were randomized to lifelong androgen suppression with or without 65 to 69 Gy of RT. With a median of 6 years of follow-up, an HR of 0.54 (95% CI, 0.27 to 0.78) for disease-specific survival favored the RT + ADT arm. The overall survival at 7 years was 74% (95% CI, 90 to 78) for the combined arm versus 66% (95% CI, 60 to 70) for the arm with androgen suppression alone (Warde et al., 2011).

In the STAMPEDE trial of men with newly diagnosed, locally advanced, or metastatic disease or those with relapsing disease and poor prognostic features, use of 24 months of ADT plus abiraterone and prednisolone as compared with ADT alone was associated with a 71% relative improvement in the time to treatment failure and a 37% difference in overall survival. The addition of radiation beginning 6 to 9 months after randomization was mandatory for patients with node-negative disease and was encouraged for patients with node-positive, nonmetastatic disease (James et al., 2017).

Optimal Duration of Androgen Suppression

Evaluation of the optimal type, timing, and duration of androgen suppression in combination with RT has been the subject of several trials.

In RTOG 99-10, which randomized 1490 men, 84% of whom had intermediate-risk disease, to 4 versus 8 months of neoadjuvant and concurrent androgen suppression with radiation, no advantage was identified in biochemical control or overall survival to longer course treatment (Pisansky et al., 2013). NCCN guidelines recommend a duration of 4 to 6 months of ADT for patients with unfavorable intermediate-risk cancers, and none for patients with favorable intermediate-risk disease (Mohler et al., 2016).

Other studies have investigated duration of androgen suppression among men with higher risk disease. In RTOG 92-02, 1521 patients with stage T2c to T4, N0 to N1, M0 disease were randomly assigned to 4 months of total androgen suppression with radiation administered after 2 months, or the same regimen followed by an additional 2 years of goserelin (Horwitz et al., 2008). A hypothesis-generating subgroup analysis revealed significant improvement in overall survival, 80% versus 69%, and disease-specific survival, 90% versus 78%, in patients with Gleason grade 8 to 10 tumors.

The EORTC randomized 970 men who had received 6 months of combined androgen blockade and RT to no further androgen suppression versus 30 months of an LHRH analogue (Bolla et al., 2009). Powered as a noninferiority study, at 6.4 years of follow-up, the 5-year cause-specific mortality was 4.7% (95% CI, 2.7 to 6.7) versus 3.2% (95% CI, 1.6 to 4.8), favoring long-term hormonal therapy. The DART01/05 GICOR trial showed similar results when comparing 24 months of ADT to 4 months of ADT with EBRT. The 5-year biochemical disease–free survival, metastasis-free survival, and overall survival benefit to long-term ADT was more evident in the patients with high-risk disease (Zapatero et al., 2015).

In a study investigating RT with 18 months relative to RT with 36 months of goserelin for men with T3 to T4, PSA greater than 20 ng/mL, or Gleason 8 to 10 disease, Nabid et al. (2018) reported that with 9.4 years of follow-up, there was no difference in survival between the groups and 18 months was associated with significantly better quality of life.

Currently, NCCN guidelines recommend a total duration of 24 to 36 months for patients with high-risk or very-high-risk prostate cancer when treated with EBRT, or 12 to 36 months when treated with combined brachytherapy + EBRT (Mohler et al., 2016).

Key Points: Radiation Therapy and Androgen Suppression Therapy

- Randomized controlled trials have shown a survival benefit to the combination of radiation and hormonal therapy relative to either radiation or hormonal therapy alone for men with intermediate- to high-risk disease.

- For men with locally advanced, high-risk disease, 28 to 36 months of hormonal therapy appears superior to 4 to 6 months for reducing death from prostate cancer.

Role of Prophylactic Pelvic Nodal Treatment

Given that the pelvic lymph nodes are a natural route of spread for prostate cancer, there has been understandable interest in the potential for prophylactic nodal radiation to reduce the recurrence rates of intermediate- and high-risk cancers.

The question of timing of hormonal therapy and impact of radiation field size was addressed by RTOG 94-13, a four-arm study comparing whole-pelvis versus small-field radiation with 4 months of either neoadjuvant or adjuvant total androgen suppression. Eligible patients had adverse risk factors, with estimated risk for positive-node disease of more than 15%. A difference was initially seen in progression-free survival at 4 years, 54% versus 47% for the whole-pelvis versus prostate-only radiation, respectively ($P = .022$), but no difference was seen in overall survival (Roach et al., 2003). An update of this study showed a loss of this benefit in biochemical control, highlighting the need for additional studies investigating the inclusion of nodal volumes in men with a high risk for lymph node involvement (Lawton et al., 2007).

GETUG-01 asked a similar question regarding the benefit and toxicity of pelvic normal irradiation in nonmetasatic T1b to T3 N0 prostate cancer patients. Patients were randomized to either pelvic and prostate radiation or prostate-only radiation. The addition of 6 months of neoadjuvant ADT was allowed for patients in the high-risk group. The 5-year progression-free survival and overall survival was similar between the two groups (Pommier et al., 2007). There were no significant differences between acute and late GI toxicities or quality-of-life scores.

Although randomized clinical trials have not shown a benefit to pelvic radiation, there have been retrospective studies that have suggested a benefit (Aizer et al., 2009; Pan et al., 2002). A retrospective study by Aizer et al. (2009) compared 277 consecutive patients with at least a 15% likelihood of lymph node involvement who had undergone either whole-pelvis radiation or prostate-only radiation. After adjusting for confounding variables, the use of whole-pelvis RT predicted biochemical disease–free survival. Patients who received whole-pelvis RT had an increased risk for acute GI toxicity, but no difference in acute GU toxicity or late toxicity. In a study of 234 patients treated with VMAT to either prostate-only or whole-pelvis radiation, at 24-month follow-up bowel-related and urinary health–related quality of life were similar between the two groups (Ishii et al., 2018).

It has been suggested the reason past randomized trials have not shown a benefit of pelvic radiation may be partly a result of undercoverage of superior pelvic lymph node basins given that superior fields ended at S1/2 and L5/S1 (Morikawa and Roach, 2011). In a study examining patterns of pelvic recurrence in men with localized prostate cancer treated with prostate-only RT, the common iliac lymph node station was involved in 55% of patients who experienced a first recurrence in the pelvic lymph nodes (Spratt et al., 2017c). Using a conventional pelvic field at L5/S1 would have only fully covered 42% of the first recurrences among these patients, but extending the field to cover the common iliac station would increase coverage to 93%. The current open randomized trial assessing the benefit of whole-pelvis RT (RTOG 09-24) recommends that the superior border of the pelvic field be at the level of the L4/L5 vertebral disk (National Institutes of Health, n.d.).

Key Point: Role of Prophylactic Nodal Radiation

- Prophylactic pelvic nodal RT has not been shown to improve disease recurrence rates in randomized trials.

Treatment Morbidity and Quality-of-Life Outcomes

For many years, a radiation dose of 70 Gy was considered the maximum that could be safely delivered. With the advent of conformal RT and the ability to visualize and improve targeting of the prostate and to visualize and improve avoidance of surrounding organs, higher-dose RT was made possible, with acceptable rates of treatment-related morbidity. However, further studies that demonstrated an association between radiation doses to organs and treatment-related morbidity presented opportunities for further improvement. For example, in the MD Anderson Cancer Center trial, the 5-year freedom from a complication above grade 2 was 26% in the 78-Gy arm and 12% for the 70-Gy arm, nicely demonstrating the relationship that can exist between dose and complications. When further analysis was performed to identify factors other than total dose that might be used to predict for rectal toxicity, it was shown that the risk for complications increased from 25% to 46% when the rectal volume exposed to 70 Gy increased from less than 25% to greater than 25% (Pollack et al., 2002b). Therefore, technologies such as IMRT that can reduce radiation doses to these organs have the potential of reducing side effects associated with RT, which in general include GI and GU toxicity.

Tables 157.6 and 157.7 summarize acute and late toxicity rates in published series comparing conformal radiation and IMRT for prostate cancer. Consistently in these series, IMRT was associated with lower rates of acute and late GI toxicity, but not GU toxicity, compared with 3D-CRT, despite being used to give higher doses to the prostate. Therefore, advances in radiation technology have simultaneously allowed a higher radiation dose to be given while resulting in lower toxicity.

TABLE 157.6

Acute Toxicity in Patients Treated With Three-Dimensional Conformal Radiation Therapy vs. Intensity-Modulated Radiation Therapy

REFERENCE	*N*	RADIATION TECHNIQUE	RADIATION DOSE (GY)	TOXICITY DEFINITION	GI TOXICITY	*P*-VA

					(%)	
(Zelefsky et al., 2008a)	1571	IMRT	81	CTCAE ≥2	3	0.0
		3D-CRT	66–81		1	
(Al-Mamgani, et al., 2009)	78	IMRT	78	RTOG ≥2	20	0.0
		3D-CRT	78		6	
(Sharma et al., 2011)	293	IMRT	Median 76	LENTTF ≥2	3D-CRT higher (OR 4)	0.0
		3D-CRT	Median 76			
(Dolezel et al., 2015)	553	IMRT	78	RTOG ≥2	14.3	
		3D-CRT	74		34.1	
(Alongi et al., 2009)	172	IMRT	72–77.4	RTOG ≥2	6.6[a]	0.0
		3D-CRT	70.2–75.6		22.2[a]	
(Wortel et al., 2015)	475	IMRT	78	RTOG ≥2	29	0.0
		3D-CRT	78		49	

[a] Rates of upper-GI toxicity.

3D-CRT, three-dimensional conformal radiotherapy; *CTCAE,* NCI Common Terminology Criteria for Adverse Events; *GI,* gastrointestinal; *GU,* genitourinary; *IMRT,* intensity-modulated radiation therapy; *LENTTF,* Fox Chase Modified Late Effects Normal Tissue Task Force radiation morbidity scale; *OR,* odds ratio; *RTOG,* Radiation Therapy Oncology Group scoring system.

TABLE 157.7

Long-Term Toxicity in Patients Treated With Three-Dimensional Conformal Radiation Therapy vs. Intensity-Modulated Radiation Therapy

REFERENCE	*N*	RADIATION TECHNIQUE	RADIATION DOSE (GY)	FOLLOW-UP (YR)	TOXICITY DEFINITION	GI TO (%)
(Zelefsky et al., 2008a)	1571	IMRT	81	6.5	10-yr CTCAE ≥2	5
		3D-CRT	66–81	10		13
(Al-Mamgani et al., 2009)	78	IMRT	78	4.7	5-yr RTOG/EORTC ≥2	21
		3D-CRT	78	6.3		37
(Sharma et al., 2011)	293	IMRT	Median 76	3.3	5-yr LENTTF ≥2	8
		3D-CRT	Median 76	7.2		20
(Michalski et al., 2013)	763	IMRT	79.2	3.5	RTOG/EORTC ≥2	15.
		3D-CRT	79.2	4.6		22
(Dolezel et al., 2015)	553	IMRT	78	5.0	5-yr LENTTF ≥2	42.

		3D-CRT	74	8.6		20.
(Wortel et al., 2016)	431	IMRT	78	4.75	5-yr RTOG/EORTC ≥2	24.
		3D-CRT	78	5.2		37.

3D-CRT, three-dimensional conformal radiotherapy; *CTCAE,* NCI Common Terminology Criteria for Adverse Events; *GI,* gastrointestinal; *GU,* genitourinary; *IMRT,* intensity-modulated radiation therapy; *LENTTF,* Fox Chase Modified Late Effects Normal Tissue Task Force radiation morbidity scale; *RTOG/EORTC,* Radiation Therapy Oncology Group/European Organization for Research and Treatment of Cancer scoring system; *yr,* years.

Several studies have suggested increases in GI and GU toxicity when utilizing combined brachytherapy + EBRT as compared with either modality alone, although this finding is not universal for all analyses (Merrick et al., 2017; Spratt et al., 2017a). Given the benefits of this combined approach may be partially offset by enhanced risk for morbidity, patients being considered for a combination approach should be appropriately counseled (Lee et al., 2007; Tward et al., 2016).

Rectal Toxicity and Management

Acute minor rectal symptoms secondary to RT are usually self-limited. **Late rectal toxicity,** specifically rectal bleeding secondary to radiation proctitis, often occurs between 6 and 18 months after completion of treatment. Proctitis can be a minor, self-limited side effect of radiation treated with steroid suppositories (Someya et al., 2014) or sucralfate enemas (Kochhar et al., 1999). However, for a small percentage of patients, there can be a major toxicity requiring procedural intervention such as argon plasma coagulation (APC), hyperbaric oxygen (Bennett et al., 2012), or in the worst cases diverting colostomy. A retrospective review of 35 patients treated with APC for radiation proctitis found eventual bleeding control in 85.7% of patients, but with 22.9% of patients having post-APC ulceration and a 5.7% risk for colovesicular fistula formation.

A large series of IMRT patients from Memorial Sloan Kettering Cancer Center found 10-year actuarial rates of grade 2 or greater GI toxicity with IMRT to 81 Gy of 5%, with less than 1% of patients developing grade 3 toxicity (Zelefsky et al., 2008a). In a more recent update of this series, patient outcomes of those who received IMRT with image guidance (implanted fiducial markers) were compared with those who received IMRT without image guidance. Rates of grade 2 or greater GI toxicity were low in both groups (1.0% vs. 1.6%, respectively; *P* = .81) (Zelefsky et al., 2012).

Patient-reported outcomes complement toxicity assessment by physicians to provide a fuller picture of a patient's experience after treatment. In one study, 292 patients with a median age of 69 years who received either CRT or IMRT were followed prospectively using the validated EPIC instrument (Sanda et al., 2008). Patients reported acute bowel symptoms that recovered over time including rectal urgency (18% at 2 months compared with 3% at baseline) and frequency (16% at 2 months compared with 2% at baseline), which partially recovered with longer time points of assessment. Analysis of patient-reported outcomes in the ProtectT trial found that treatment of localized prostate cancer with CRT, as compared with active monitoring or RP, was associated with higher bowel bother scores and decreased quality of life because of bowel habits (Donovan et al., 2016). This was most pronounced at 6 months after treatment, with gradual improvement thereafter, but with residual increase in likelihood of bloody stools 2 to 6 years after radiation. No significant differences were seen in the frequency of loose stools or incontinence of stool.

The incidence of all significant rectal complications after brachytherapy has been reported to be 1% to 2% (Barkati et al., 2012; Zamboglou et al., 2013), with a rate of rectal bleeding of approximately 1% (Mohammed et al., 2012; Zelefsky et al., 1999). Studies evaluating comparative morbidity between treatments have confirmed that rates of GI complications are lower than those observed for EBRT (Chen et al., 2017). However, recto-urethral fistula is a rare but feared complication after brachytherapy. A postimplantation colostomy rate of 0.3% was observed in a study of Medicare claims (Benoit et al., 2000a, 2000b). The rate of rectal complications from brachytherapy is correlated with the dose and the volume of rectum receiving a high dose. Merrick et al. (2003) reported that rectal complications were rarely observed when the rectal wall received 85% of the prescribed dose. For brachytherapy alone, a rectal V100 of less than 1.0 cc (if day 1 dosimetry) or less than 1.3 cc (if day 30 dosimetry) is generally recommended (Davis et al., 2012).

Shiraishi et al. evaluated patients receiving combined brachytherapy and EBRT, and correlated risk for bleeding with rectal V100 of greater than 0.5 cc, and EBRT rectal V30 of greater than 35%. Patients who met both dose criteria had a grade 2 rectal bleeding incidence of 4.2% (Shiraishi et al., 2011).

Rectal-Sparing Strategies

As discussed earlier, improvements in the precision of delivery of RT to the prostate while avoiding organs at risk have resulted in decreases in rectal toxicity. Additional approaches to decreasing rectal dose and toxicity include precise delineation of the anorectal volume using MRI, endorectal balloon placement, and implantation of a saline-filled balloon between the prostate and rectum (Gez et al., 2013; Wortel et al., 2017). The most widely reported contemporary approach for decreasing rectal toxicity by lowering rectal radiation dose involves creating physical separation between the prostate and the anterior rectal wall through implantation of a biodegradable hydrogel spacer (Fig. 157.9). In cadaveric experiments, Susil et al. demonstrated that hydrogel spacer could be accurately placed into Denonvilliers’ fascia via a transperineal needle approach, with histologic confirmation of anatomic separation between the prostate and rectum (Susil et al., 2010). This strategy has been shown to be safe and well-tolerated for patients receiving LDR or HDR brachytherapy (Beydoun et al., 2013; Nguyen et al., 2013), EBRT (Mariados et al., 2015; Song et al., 2013), or combination therapy (Yeh et al., 2016) and can be implemented either before treatment initiation or in response to suboptimal dosimetry after a permanent brachytherapy implant. In a multi-institutional study of 222 men with clinical T1 to T2 prostate cancer randomized to spacer injection versus no injection and subsequently treated with IG-IMRT to 79.2 Gy, late rectal toxicity was significantly lower in the spacer group (2.0% vs. 7.0%, $P = 0.04$) (Mariados et al., 2015).

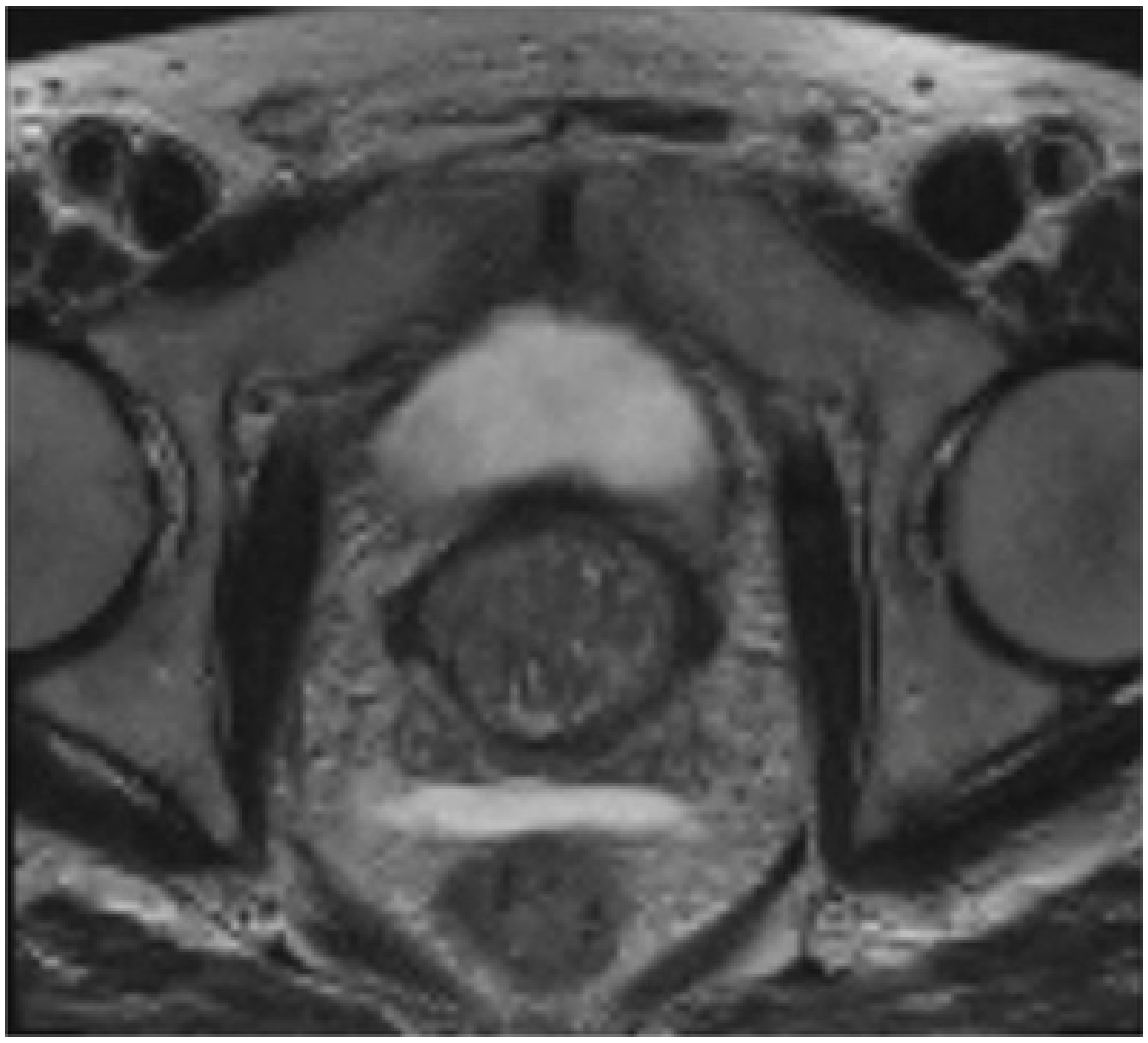

FIG. 157.9 Axial view of MRI T2 image showing hydrogel positioned between the prostate/seminal vesicles and the rectum.

Urinary Toxicity and Management

In the Memorial Sloan Kettering series, the 10-year rate of grade 2 or greater urinary toxicity was 20% with IMRT; grade 3 GU toxicity was rare (Spratt et al., 2013; Zelefsky et al., 2008a, 2012). Patients who received IMRT with image guidance had lower rates of late GU toxicity (3-year rates of grade ≥ 2 toxicity: 10.4% with image guidance vs. 20.0% without, $P = .02$). Sanda et al. (2008) observed that at 2 months after RT, 12% of patients reported dysuria (compared with 1% at baseline), 23% reported weak stream (13% baseline), and 34% reported urinary frequency (16% baseline); symptoms improved by 6 months and were back to baseline levels by 12 months. Urinary incontinence was uncommon after RT. Secondary analysis of urinary toxicity in men receiving prostate CRT on RTOG 94-08 (Mak et al., 2016) identified acute grade ≥2 and ≥3 toxicity in 30.8% and 3.8% of patients, respectively. Late grade ≥2 and ≥3 urinary toxicity at 5 years was 18.3% and 3.3%, respectively. These results were contrasted against the RTOG 96-01 in which men who received post-prostatectomy RT experienced lower rates of acute grade ≥2 at 14%, but similar acute grade ≥3 and late grade ≥2 and ≥3 urinary toxicity.

After brachytherapy, the International Prostate Symptom Score (IPSS) tends to increase significantly immediately after implantation and then decrease at a rate that depends on the half-life of the isotope used (Kollmeier et al., 2012; Sanda et al., 2008). In series of permanent implants, the rate of chronic grade 2 or greater urinary toxicity is approximately 20% (Buckstein, et al., 2013; Mohammed et al., 2012). The use of α-blockers before implantation may decrease the severity and duration of urinary symptoms (Merrick et al., 2002c). Wallner et al. (1995) reported the risk for urinary toxicity to be a function of the length of the urethra receiving a high dose. Grade 2 to 3 morbidity was observed when 20 mm + 11 mm of the urethra received more than 400 Gy with ^{125}I implants. Larger prostatic volumes—specifically, glands greater than 60.0 cm^3—also were associated with higher rates of urinary toxicity. Terk et al. (1998) reported on 251 patients using the IPSS to assess urinary function before and after ^{125}I or ^{103}Pd implantation. Patients with a pretreatment IPSS above 20 demonstrated a 29% risk for developing urinary retention, and a pretreatment score less than 10 was associated with only a 2% risk. For HDR, brachytherapy appears to show a similar pattern, with 15% to 18% showing grade 2 or greater acute urinary symptoms and low rates of chronic grade 3+ urinary morbidity (5% to 10%) (Barkati et al., 2012; Zamboglou et al., 2013).

In the ASCENDE-RT trial (Rodda et al., 2017), men treated with pelvic RT to 46 Gy followed by an LDR brachytherapy boost experienced significantly higher 5-year cumulative rates of grade 3 urinary toxicity as compared with patients treated with EBRT to 78 Gy (18.4% vs. 5.2%, $P < 0.001$).

Brachytherapy after TURP has been associated with increased risk for **urinary incontinence** in some studies, whereas incontinence has been shown to be uncommon in men without any preexisting urethral trauma (~3%). Mock et al. (2013) reported a 19% incidence in patients with one previous TURP and up to 53% in those with a history of multiple procedures (although numbers were small).

Erectile Dysfunction and Management

As discussed earlier, with advances in radiation technology that can reduce incidental radiation doses to the bladder and rectum, radiation-associated GU and GI toxicity and impact on patient-reported outcomes have declined over time. However, the anatomic structure causing radiation-associated ED is not known. Published reports suggest that ED after radiation is caused predominantly by vascular damage, and some data suggest that dose to the penile bulb may be correlated with ED (DiBiase et al., 2000; Fisch et al., 2001; Merrick et al., 2001; Roach et al., 2000).

Patients in the Sanda study reported sexual dysfunction after RT (Sanda et al., 2008). By 24 months after treatment, 60% of patients reported poor erections (compared with 37% at baseline); however, decline in sexual function was mostly from patients who received radiation in combination with ADT, whereas sexual function decline was more modest in patients who received RT alone. Dess et al. (2018b) found similar results among 373 consecutive patients with localized prostate cancer who underwent SBRT, with 24- and 60-month potency preservation rates of 57% and 45%, respectively, among men with functional erections before therapy. Multivariate analysis of this population identified baseline health-related quality of life (HRQoL) and age as important factors at 24 months, and HRQoL and body mass index were significant predictors of erectile function at 60 months.

Potency preservation rates for patients undergoing brachytherapy alone appear superior to those reported for patients receiving prostatectomy, EBRT, or neoadjuvant hormonal therapy/EBRT/brachytherapy boost. Snyder et al. reported that 5 years after treatment, potency was maintained in 76% of patients undergoing brachytherapy compared with 71% receiving EBRT plus brachytherapy, and 58% in those undergoing EBRT, brachytherapy, and ADT (Snyder et al., 2012).

Potters et al. (2001) reported a 5-year potency maintenance rate of 76% with brachytherapy monotherapy and 56% with combined EBRT and brachytherapy boost. The addition of hormones to EBRT and brachytherapy boosted lower potency rates to 52%. Age was a significant prognostic factor in a univariate analysis (Merrick et al., 2002a), and the addition of EBRT and a history of diabetes mellitus were significant factors in a multivariate analysis (Robinson et al., 2002). In this meta-analysis, the probability of maintaining potency at 1 year after treatment was 76% (69% to 82%) with brachytherapy monotherapy and 60% (48% to 73%) with external beam and brachytherapy boost.

Sildenafil citrate and other phosphodiesterase type 5 inhibitors (PDE5Is) have been reported to be effective in 74% to 81% of patients who avail themselves of oral therapy for ED (Merrick et al., 2003; Raina et al., 2003). A study of 471 men who were treated with SBRT for localized prostate cancer found that sexual aids, primarily PDE5Is, showed efficacy at 5 years postradiation in 89% of men who found these aids helpful before radiation and 70% of previously aid-naïve patients (Dess et al., 2018a). This study also found that at 2 years, patients treated with radiation were significantly less likely than patients treated with prostatectomy to have tried non-PDE5I sexual aids including the Medicated Urethral System for Erection (3% vs. 15%), penile injections (3% vs. 14%), and vacuum device (5% vs. 19%). However, it is not clear if this reflected a difference in intervention utilization among radiation oncologists as compared with urologists or a difference in the prevalence of sexual dysfunction.

Key Points: Treatment Morbidity and Quality-of-Life Outcomes

- Most rectal bleeding that occurs after RT is mild and self-limited, or manageable with suppositories or enemas.
- Recently developed rectal sparing strategies such as injectable hydrogel can reduce the risk for radiation proctitis.
- Urinary incontinence is uncommon after either EBRT or brachytherapy.
- PDE5Is are frequently effective in patients who experience post-RT ED.

Evaluating the Response to Radiation Therapy

Prostate-Specific Antigen Follow-up: Definition of Failure

Serum PSA is widely accepted as a surrogate end point for monitoring the success of definitive treatment for localized prostate cancer. The PSA-based definition of biochemical failure after RT has evolved over time. Unlike RP, residual benign glands may be responsible for a low level of PSA production after RT, but an "acceptable" PSA level after successful RT is markedly lower than the range of normal for an age-matched population because of atrophy of nonmalignant acini (Grignon, 1995).

Ablation of normal prostatic epithelium is dose dependent. Median PSA nadirs range from 0.6 ng/mL after 70 Gy, to 0.3 ng/mL for radiation doses of 79 Gy, to 0.1 ng/mL or less for those receiving EBRT and a brachytherapy boost (Roach et al., 2006). **Nadir PSA** value is a significant predictor of outcome, but no absolute nadir threshold can or should be used to define cure (DeWitt et al., 2003). Although a standard definition of failure is essential for the purposes of clinical trials and reporting of data, it must be emphasized that establishing that a patient meets the criteria for biochemical failure is not justification for intervention.

Historically, the 1996 ASTRO Consensus Conference proposed the initial standardized definition of biochemical failure after RT (Roach et al., 2006). Recognizing that PSA stability after the nadir is important, the panel proposed to define failure as three consecutive increases in PSA, with "backdating" of such failure to a date midway between the nadir and the first increase. Although the ASTRO definition provided uniformity in reporting of results, it became clear with additional data that it was not an ideal solution to the problem of defining biochemical failure after RT. Waiting for three rises delayed the establishment of failure by 18 months or more (Cherullo et al., 2002); also, backdating biased the Kaplan-Meier estimate, an effect that was worse with shorter follow-up. In addition, the original ASTRO consensus definition of biochemical failure was not predictive of clinical progression or survival and was not developed using data from patients treated with combined radiation and ADT or those treated with brachytherapy.

To address these issues, a second consensus conference was held in Phoenix, Arizona, in 2005, and recommended that the standard definition of **biochemical failure after RT,** with or without short-term ADT, be established as a rise of 2 ng/mL or more above the nadir. This definition is known as the **“Phoenix”** or **“nadir + 2”** definition. This was informed by prior studies that compared various definitions and found that the nadir + 2 ng/mL definition best correlated with clinical local and distant relapse (Pickles et al., 2003; Thames et al., 2003). Instead of being backdated, failure is defined as occurring when the nadir + 2 ng/mL threshold is reached. Also, if salvage treatment is instituted before meeting the nadir + 2 ng/mL criteria, failure is considered to have occurred at the time of initiation of salvage treatment. PSA rises that can be clearly attributed to other causes, such as laboratory error, prostatitis that responds to antibiotics, or a benign PSA “bounce” that resolves without any intervention, should not be declared as biochemical failures (Horwitz et al., 2006). Kupelian et al. showed that adherence to the Phoenix definition resulted in apparent biochemical recurrence–free survival rates that were higher at 5 years but lower at 10 years compared with the original ASTRO definition (Kupelian et al, 2006).

Significance of Time to Nadir

Serum PSA declines slowly after completion of RT when ADT is not used. The manner in which PSA nadir and time to nadir reflect the type of failure requires explanation. Three sources of PSA potentially contribute to the nadir: residual benign prostatic epithelium, residual local prostate cancer cells, and subclinical disseminated micrometastases. The longer the time to nadir and the lower the absolute nadir, the more likely it is that only benign prostatic epithelium remains, hence the NED status. A higher radiation dose achieves a more complete ablation of normal epithelium and thus a lower nadir. For patients in whom RT fails to eradicate all the local tumor, the PSA declines progressively until the rate of growth of the surviving prostate cancer cells is greater than the death rate of those fatally damaged by the radiation, at which point the PSA begins to rise, generally relatively slowly. In the third scenario, subclinical micrometastases continue to grow unchecked despite successful treatment of the primary tumor. This growth rate outstrips the rate of decline in the local tumor population relatively early after treatment, leading to a higher and earlier nadir and a more rapid doubling time.

Both the level and timing of the nadir have correlated with distant metastases and disease-specific survival (Hanlon et al., 2002; Pollack et al., 2002a). Lee et al. (1996) reported that 75% of men whose PSA reached nadir in less than 12 months had distant metastases by 5 years, compared with 25% of those whose PSA took more than 12 months to reach a nadir ($P < .001$). Denham et al. (2008) analyzed the results of the TROG 96.01 trial, which randomized men with locally advanced prostate cancer to 0, 3, or 6 months of ADT in combination with EBRT. Biochemical failure before 24 months was associated with lower disease-specific survival. Buyyounouski et al. (2008) identified 18 months as the cut point for time to nadir that was an optimal surrogate for disease-specific survival in a population of men who were treated with 3D-CRT. An interval to biochemical failure of less than 18 months was independently predictive of distant metastases ($P = .008$) and was the only predictor of disease-specific mortality ($P = .0003$). The actuarial 5-year distant metastatic rate for biochemical failure occurring before or after 18 months was 52% versus 20% ($P < .0001$), and the actuarial disease-specific mortality was 36% versus 6% ($P = .0001$).

The previous two reports were based either on “conventional” radiation doses (66 Gy) or a range of doses. Kapadia et al. (2012) studied the interval to biochemical failure in a population of patients treated with dose-escalated RT in the range of 76 to 78 Gy, with or without ADT. Biochemical failure occurring before 18 months (short interval) predicted decreased disease-specific survival ($P <.0001$) and overall survival ($P < .0001$). Overall survival at 8 years was 87% for those with a long interval to biochemical failure, whereas it was 38% with a short interval to biochemical failure (HR 3.7). On multivariate analysis, biochemical failure before 18 months increased the risk for prostate cancer death and all-cause mortality, whereas biochemical failure after 18 months did not.

Significance of Nadir Value and Doubling Time

The level of PSA nadir achieved reflects the dose of radiation and the type of failure. With conventional-dose RT (~66 to 72 Gy), the median PSA nadir for patients with no evidence of disease (NED) in most series is 0.4 to 0.5 ng/mL (Critz et al., 1999; Crook et al., 2000; Zietman et al., 1996), whereas it is greater than 1.0 ng/mL for those with local failure and greater than 2 ng/mL for those with distant failure. Hanlon et al. (2004) reported that freedom from distant metastases was 96% for a nadir less than 1 ng/mL, 89% for nadirs 1.1 to 2 ng/mL, and 61% for nadirs greater than 2 ng/mL. Alcantara et al. (2007) evaluated patients who were treated with RT alone (median 76 Gy) and found that nadir PSA at 1 year independently predicted biochemical failure, distant metastasis, disease-specific mortality, and overall mortality. The 10-year distant metastasis rates for patients with a PSA nadir at 1 year of less than or equal to 2 ng/mL versus greater than 2 ng/mL were 4% and 19%, respectively ($P < 0.0001$). Zelefsky et al. (2009) analyzed patients who were treated with doses ranging from 64.8 to 81 Gy. A nadir less than 1.5 ng/mL at 2 years after treatment was predictive for long-term freedom from distant metastases and disease-specific mortality. The 10-year rates of distant metastases were 17.5% for men with nadirs greater than 1.5 ng/mL at 2 years compared with 7.9% for nadirs less than 1.5 ng/mL. In a stratified competing risks analysis, nadir PSA greater than 1.5 ng/mL at 2 years was an independent risk factor for distant metastases after adjusting for T stage, Gleason score, pre-RT PSA, and radiation dose ($P < .001$).

Royce et al. (2017) evaluated the performance of several candidate surrogates for all-cause mortality in men with unfavorable-risk prostate cancer and no or minimal medical comorbidities treated with radiation (70.2 Gy using 3D-conformal technique) with or without 6 months of ADT. They found that PSA nadir greater than 0.5 ng/mL predicted age-adjusted all-cause mortality (adjusted HR 1.72; 95% CI, 1.17 to 2.52; $P = 0.01$).

For patients treated with permanent seed brachytherapy, Grimm et al. (2001) found that the lower the PSA nadir, the higher the probability of long-term success. A PSA nadir less than 0.5 ng/mL is associated with significantly better long-term freedom from biochemical failure (95.2% vs. 71.5%) (Ko et al., 2012). PSA level at 5 years after brachytherapy is highly predictive of outcome, with 97.4% 10-year biochemical control in men with PSA less than 0.2 ng/mL at 5 years after brachytherapy. Hayden et al. (2010) found only one late biochemical relapse among 762 patients with a PSA less than 0.2 ng/mL at 4 to 5 years after implant.

PSA nadir and time to nadir differ after brachytherapy compared with EBRT. Crook et al. (2011) reported that if a mean ^{125}I dose to 90% of the prostate (D90) of 160 Gy is achieved, only 10% of such patients have a PSA level greater than 0.2 ng/mL at 5 years, with two-thirds of these patients still showing a decreasing trend. These results are very similar to observations by Stock et al. (2009) in which only 10.9% of brachytherapy-treated patients had a PSA level greater than 0.2 ng/mL at 5 years. The 10-year freedom from biochemical failure was 98%

for a 5-year PSA level less than 0.2 and 81% for a PSA level greater than 0.2 ng/mL. Grimm et al. (2001) reported that the proportion of patients with a PSA level less than 0.2 ng/mL continues to increase for up to 7 to 8 years. Freiberger et al. (2017) compared patients receiving brachytherapy +/– EBRT versus EBRT alone, and found that patients reached a mean nadir of 0.05 ng/mL when treated with LDR-BT and a mean nadir of 0.1 ng/mL after HDR-BT + EBRT. Both were significantly lower in comparison to patients treated with EBRT alone, who achieved mean nadir of 0.52 ng/mL ($P < 0.01$). Mean time to nadir was 32 months after LDR-BT, 31 months after HDR-BT + EBRT, and 19 months after EBRT.

The **postnadir doubling time** of the PSA level also correlates with the type of failure, with distant failures having shorter PSA doubling times of 3 to 6 months, whereas doubling times for those with local failures are 1 year or more. D'Amico et al. (2003) reported that a PSA doubling time of less than 3 months is associated with prostate cancer mortality. Valicenti et al. (2006) focused on PSA doubling time in an analysis of RTOG trial 92-02, which randomized men with locally advanced prostate cancer to 65 to 70 Gy of EBRT and short-term ADT plus or minus 24 months of adjuvant ADT. At 5 years, the actuarial disease-specific survival was 84.7% in the cohort of patients with a PSA doubling time of less than 12 months, compared with 94.3% for longer doubling times (HR 5.63, 95% CI, 3.78 to 8.3). PSA doubling time was significantly associated with disease-specific survival. Denham et al. (2008), in the analysis of the previously mentioned TROG 96.01 trial, used a cut point of PSA doubling time of less than 12 months. For these patients, the HR for prostate cancer death was 23.49 (CI, 12.94 to 42.63, $P < .001$).

Early surrogates such as PSA doubling time may help guide management of individual patients, suggesting earlier intervention in those with a PSA doubling time of less than 12 months while increasing the comfort level with continued observation in those with longer doubling times. Doubling time, however, may not be an ideal surrogate end point. The calculation of doubling time depends on the number of values available, being more reliable with a wide range of values (Denham et al., 2008).

Brachytherapy and the Benign Bounce Phenomenon

Benign PSA bounces or spikes are a well-recognized phenomenon after prostate brachytherapy. A spike or bounce is most frequently defined as a rise greater than 0.2 ng/mL followed by a durable decline (Critz et al., 2000) and is seen after both LDR and HDR brachytherapy. Overall, approximately 35% of men will experience a **PSA bounce** of 0.2 ng/mL or greater after LDR brachytherapy (Caloglu et al., 2011; Ciezki et al., 2006; Critz et al., 2000; Hinnen et al., 2012; Merrick et al., 2002b; Mitchell et al., 2008; Toledano et al., 2006), but in younger men the frequency may reach 65% (Gómez-Iturriaga Piña et al., 2010). The mean increase is 1 ng/mL but can be up to 10 ng/mL. Bounces may last as long as 12 to 18 months, and double peaks can be seen. Freiberger et al. (2017) studied 295 patients with localized prostate cancer, of whom 160 received brachytherapy either alone or in combination with EBRT, and found that PSA bounce was associated with significant improvements in 10-year biochemical control (83% vs. 34%, $P < 0.01$) and overall survival (82% vs. 59%, $P < 0.01$) as compared with patients who did not experience this phenomenon. Biopsies performed to investigate the rising PSA may show residual cancer with treatment effect (i.e., indeterminate) (Reed et al., 2003). Currently, there is no reliable way to discern whether a rising PSA in the first 3 years after brachytherapy represents treatment failure. Kirilova et al. (2011) investigated patients undergoing a PSA bounce with magnetic resonance spectroscopy and reported a diffuse increase in the ratio of choline to citrate across the gland, rather than the focal phenomenon that might be expected if the PSA increase were associated with tumor activity. It is recommended that a rising PSA within 30 months of brachytherapy be simply monitored. If the rise approaches 10 ng/mL, systemic staging is warranted, and, if the bounce persists beyond 30 months, a prostate biopsy is warranted. Only patience and careful follow-up demonstrate the subsequent spontaneous PSA decline to low levels.

Biochemical Failure and Impact of Neoadjuvant Hormones

When neoadjuvant ADT is used before RT, patients often start RT with an already undetectable PSA. If the PSA remains undetectable, it is impossible to determine a true nadir or time to nadir. A substantial proportion of patients treated with EBRT and ADT experience a PSA increase when the testosterone recovers. Zietman et al. (2005a) reported that the median time to PSA bounce (defined as an increase of 0.2 ng/mL) after EBRT (68.4 to 72 Gy) and ADT was 2.2 years. The median magnitude was 0.9 ng/mL, and 18.6% met the ASTRO nadir + 2 definition of failure. Subsequently, as the effect of the RT continues, the PSA declines once again. Based on a data set of 1865 men treated with EBRT, Pickles et al. (2006) reported a bounce duration of 12.5 months and a median height of 0.8 ng/mL, but only 2.1% met the nadir + 2 definition of failure. Interestingly, only 20% of bounces occurred during the testosterone recovery period, with the rest occurring once the testosterone had normalized. This may represent a delayed response to testosterone stimulation or may implicate other causes such as inflammation or instrumentation. Closer follow-up and more frequent PSA testing is more likely to detect PSA fluctuations or bounces. The Phoenix (i.e., nadir + 2) definition of failure is associated with fewer false calls of failure than the original ASTRO consensus definition of 3 rises after the nadir.

Post–Radiation Therapy Imaging

PSA measurement remains the standard for monitoring treatment response after RT. Although clinical trials to better understand the changes seen on MRI after RT and to evaluate the predictive value of postradiation MRI with regard to local recurrence are ongoing (e.g., the NCI-based NCT01834001 and MSKCC-based NCT02312401), it is not yet clear how this information should guide management after treatment.

The American Urological Association (AUA) has recognized the value of multiparametric magnetic resonance imaging (mpMRI) in the detection of recurrent prostate cancer in the setting of biochemical recurrence (Fulgham et al., 2017). mpMRI is recommended for men with a rising PSA after definitive prostate cancer treatment after a negative standard biopsy as it has been shown to improve biopsy positivity when a lesion is identified as compared with TRUS-guided prostatic fossa biopsy alone. With regard to routine follow-up after treatment, however, PSA remains the AUA-recommended test, and there is no clear role for follow-up imaging in the absence of PSA elevation.

The ACR Appropriateness Criteria identifies MRI of pelvis with and without intravenous contrast as “Usually Appropriate” for post-treatment follow-up of prostate cancer after RP if clinical concern for residual or recurrent disease is present (Casalino et al., 2011). In postradiation biochemical recurrence, however, radionuclide bone scan is recommended as the initial imaging with no further evaluation necessary for a positive scan. CT and MRI are reserved for patients with a negative or inconclusive radionuclide bone scan to evaluate for nodal enlargement or distant metastases. Again, there is no indication per these guidelines for routine follow-up imaging after definitive management.

Post–Radiation Therapy Biopsy, Timing, and Interpretation

Although serum PSA nadir has been widely adopted as a surrogate end point to determine treatment efficacy, it cannot distinguish between local and systemic failure. Post-RT prostate biopsies are a logical means of evaluating the local effect of RT. The major issues involve timing of the biopsies with respect to completion of RT, interpretation of indeterminate biopsies that show marked radiation effect, and the uncertainty imposed by sampling error.

In early reports, little was understood about the rate of histologic clearance of irradiated tumor, and failures were declared as early as 6 months after completion of RT (Scardino and Wheeler, 1985). It is now recognized that the time for histologic resolution of tumor parallels the time to serum PSA nadir and for the same reasons. Radiation causes postmitotic cell death, and fatally damaged cells may survive a limited number of cell divisions (Mostofi et al., 1992, 1993). Biopsies performed before histologic resolution is complete show a moderate-to-marked radiation effect (Crook et al., 1997). The ultimate viability of these cells cannot be predicted. Crook et al. (1995) determined that the optimal time to biopsy is 30 to 36 months after RT to allow histologic resolution of postmitotic cell death.

Gleason scoring of irradiated prostate cancer should be performed only if the histologic evidence of radiation effect is absent or minimal. Gleason's original work was based on surgically obtained material that had not been exposed to prior RT or hormonal therapy. It is based on gland architecture, which is known to be markedly altered by RT. Inappropriate application of the Gleason scoring system to disintegrating malignant glands showing a marked RT effect (Grignon and Sakr, 1995; Siders and Lee, 1992) results in a **false-positive biopsy** often misinterpreted as high grade and may lead to unnecessary salvage therapy (Reed et al., 2003). Along this same vein, most prostate adenocarcinomas treated with ADT resemble Gleason 4 or 5 tumors, further complicating the interpretation of post-treatment biopsies (Bostwick and Meiers, 2007).

Radiation atypia in benign glands can be severe enough to mimic malignancy (Bostwick et al., 1982; Cheng et al., 1999; Grignon, 1995). Anticytokeratin monoclonal antibody for high-molecular-weight keratin labels the basal cell layer of benign glands and therefore helps distinguish radiation atypia in benign glands from residual tumor where the basal cell layer would be absent (Brawer et al., 1989).

Scoring systems for the degree of radiation effect have been proposed (Böcking and Auffermann, 1987; Dhom and Degro, 1982) on the basis of cytoplasmic and nuclear changes (Box 157.1) and can be helpful in interpreting the biopsy (Crook et al., 1997). Their importance is to emphasize the need to differentiate between biopsies showing no or minimal radiation effect and those showing marked treatment effect (Zelefsky et al., 2004). Failure to recognize these differences dilutes the prognostic significance of biopsy status and may lead to inappropriate salvage therapy. Immunohistochemical stains for markers of cellular proliferation associated with subsequent failure such as proliferative cell nuclear antigen (Crook et al., 1994; Ljung et al., 1996) and Ki-67 have been used in interpretation of the significance of residual tumor (Crook et al., 2000).

Box 157.1

Grading Scheme for Cytoplasmic and Nuclear Radiation Effect[a]

Cytoplasmic Changes

0: No identifiable RT effect
1: Swelling and microvesicular change
2: Extensive vacuolation, macrovesicular change, and voluminous cytoplasm
3: Indistinct or ruptured cytoplasm
or
Lipofuscin pigment accumulation
or
Glands dilated or just single cells with no glandular formation

Nuclear Changes

0: No identifiable RT effect
Some swelling or smudging of nuclei but nucleoli still visible
or

Smudged and distorted chromatin
or
Nucleoli rare or absent
or
Large bizarre nuclei
or
Pyknotic small condensed nuclei

RT, radiation therapy.

---

[a] The scores for cytoplasmic and nuclear changes are added together. A score of 5 to 6 represents marked treatment effect, 3 to 4 is moderate, and 0 to 2 is minimal.

Zelefsky et al. (2008b) studied men treated with 3D-CRT with a median follow-up of 10 years. The 2-year biopsy status was strongly predictive of 10-year biochemical NED rate, freedom from distant metastases ($P = .004$), and disease-specific survival ($P = .007$). Importantly, patients with biopsies with marked treatment effect behaved as negative. This was confirmed by Crook et al. (2009) in a report on men who participated in a randomized trial of 3 versus 8 months of ADT before conventional EBRT. Biopsies were performed between 24 and 30 months after completion of RT. In multivariate analysis, biopsy status ($P < .0001$) and Gleason score ($P < .0001$) were the two strongest determinants of biochemical disease–free survival.

Imaging and Sampling Error

TRUS alone is of limited diagnostic use after RT because the increase in fibrosis alters the echogenic characteristics of the irradiated prostate (Crook et al., 1993; Svetec et al., 1998). MRI offers vastly improved soft tissue definition over either CT or ultrasonography, and mpMRI has greater accuracy in the detection of recurrent prostate cancer after RT than T2-weighted imaging alone. Westphalen et al. (2010) reported that the addition of magnetic resonance spectroscopy to T2-weighted imaging in men with suspected recurrence after EBRT increased the area under the receiver operating curve (AUC) to 0.79 from 0.67, detecting recurrence in 37 of 64 men. Donati et al. (2013) compared T2-weighted imaging to T2 with the addition of diffusion weighting (DW) and DCE and found that

T2-weighted imaging with DW improved the AUC for two independent readers but that DCE offered no additional benefit in a study of 53 men with suspected recurrence. Arrayeh et al. (2012) reported that pre-RT and post-RT endorectal 1.5-T MRI scans in 9 men with local recurrence were able to image the recurrence at the same site as the original dominant nodule, confirmed on whole-mount step-sectioned salvage prostatectomy. Although computational fusion of images from prior MRI acquisitions to inform TRUS-guided biopsy is now well established, several groups (Ménard et al., 2015; Penzkofer et al., 2015) have demonstrated the safety and efficacy of in-bore MRI-guided prostate biopsy.

Key Points: Evaluating the Response to Radiation Therapy

- Local therapy should be evaluated in terms of local tumor eradication. Local failures can be reduced by treatment refinements such as dose escalation and improvements in treatment planning and delivery.
- PSA nadir value and time to PSA nadir are associated with long-term outcome. Lower nadir values and longer time to nadir are favorable predictors of disease control.
- Benign PSA bounces most commonly occur after brachytherapy, and also occur after ADT + RT.
- Post-RT prostate biopsies are fraught with problems of timing, interpretation, and sampling error. mpMRI is a promising advance in the investigation of patients with suspected recurrence and can be used to guide confirmatory biopsies. Clearly viable residual tumor should be in evidence before considering radical local salvage for radiation failure.

Treatment Efficacy

Outcomes for External Beam Radiotherapy

The concept that higher radiation dose is associated with improved tumor control is a logical one, and is established from the earliest radiation experiments. The general applicability of the principle of **dose escalation** for prostate cancer was confirmed from the Patterns of Care studies performed in the 1980s. In these studies, patient treatment records were reviewed from 163 randomly selected radiation oncology departments located across the United States (Hanks et al., 1988; Leibel et al., 1984). Tumor control was better in patients who received higher doses of radiation to larger fields, albeit at the expense of increased complications. These studies sparked an intense interest in efforts to improve outcomes in men with prostate cancer by providing the best treatment-planning and delivery systems possible, and also by increasing the total dose given to the prostate (Leibel et al., 1994).

The improved effectiveness of higher-dose radiation for prostate cancer has been confirmed in six randomized trials (Table 157.8). In the MD Anderson Cancer Center trial, patients with low-, intermediate-, and high-risk prostate cancers were randomized to receive 70 or 78 Gy without ADT (Kuban et al., 2008). Higher radiation dose improved the 10-year freedom from failure rate from 50% (70 Gy) to 73% (78 Gy). The Proton Radiation Oncology Group (PROG) 95-09 trial randomized patients with low- and intermediate-risk prostate cancer to 70.2 or 79.2 Gy using a combination of conformal photon and proton radiation, without ADT (Zietman et al., 2005b, 2010). This trial also found a reduction in 10-year biochemical failure rates associated with higher radiation dose: 32.0% failure (low dose) versus 17.4% (high dose, $P < .001$). Subgroup analysis showed a benefit from higher dose applicable in both low- and intermediate-risk patients. A Dutch trial that randomized patients to 68 or 78 Gy included mostly high-risk prostate cancers (56%) (Al-Mamgani et al., 2008; Peeters et al., 2006). Approximately 21% to 22% of patients in each arm received 3 to 6 months of ADT per institutional practice. Higher-dose radiation demonstrated improved disease control: 7-year freedom from failure rates were 45% for 68 Gy versus 56% for 78 Gy ($P = .03$). Subgroup analysis found a benefit from higher-dose radiation for intermediate- and high-risk prostate cancers. A fourth trial by the MRC (RT01), which randomized patients to 64 or

74 Gy, differed from the others in that all patients received an LHRH agonist that started 3 to 6 months before and throughout RT (Dearnaley et al., 2007). This study included a mixture of low-risk (24%), intermediate-risk (32%), and high-risk (43%) patients. Again, high-dose radiation improved biochemical progression-free survival (60% vs. 71% at 5 years, $P < .001$). In subgroup analysis, the benefit of **dose escalation** was seen in all prostate cancer risk groups.

TABLE 157.8

Randomized Trials of Conventionally Fractionated Standard Dose vs. Dose-Escalated Radiation Therapy for Prostate Cancer

STUDY	MEDIAN FOLLOW-UP (YR)	PATIENT INCLUSION AND RISK (%)	RADIATION TECHNIQUE	TREATMENT ARMS	CA CO (%)
MD Anderson (Kuban et al., 2008) (*N* = 301)	8.7	Low: 20 Intermediate: 46 High: 34	Conventional plus 3D conformal	70 Gy 78 Gy	
PROG 95-09 (Zietman et al., 2010) (*N* = 391)	8.9	Low: 58 Intermediate: 37 High: 4	3D conformal or 3D plus proton	70.2 Gy-equivalent 79.2 Gy-equivalent	10-y bioc failu surv 67.7
Dutch (Al-Mamgani et al., 2008) (*N* = 664)	5.8	Low: 18 Intermediate: 27 High: 55	3D conformal	68 Gy 78 Gy[a]	
MRC RT01 (Dearnaley et al., 2007) (*N* = 843)	5.25	Low: 24 Intermediate: 32 High: 44	3D conformal	64 Gy 74 Gy[b]	
GETUG 06 (Beckendorf	5.1	Low/Intermediate: 71	3D conformal	70 Gy 80 Gy	5-yr bioc

et al., 2011) (*N* = 306)		High: 29			fail surv 61 (
RTOG 0126 (Michalski et al., 2018) (*N* = 1499)	8.4	Low and Intermediate	3D conformal (66%) or IMRT (33%)	70 Gy 79.2 Gy	8-y bioc fail surv 65 (

[a] 21% to 22% of patients in each arm received androgen deprivation therapy per institutional preference.

[b] All patients received androgen deprivation for 3 to 6 months before radiation and through radiation treatment.

3D, three-dimensional; *MRC,* Medical Research Council; *PROG,* Proton Radiation Oncology Group.

Taken together, these trials consistently demonstrated improved cancer control outcomes from higher-dose radiation that applied to prostate cancer patients in a variety of clinical settings including all risk groups and also with or without ADT. These trials provide level 1 evidence for the use of dose-escalated RT in prostate cancer, which is recommended as a standard of care by current guidelines (NCCN, 2016).

Although all six trials showed statistical improvements in biochemical control with dose-escalated RT, none were able to demonstrate an improvement in overall survival. In the MD Anderson trial, the observed reduction in biochemical failure was correlated with a reduced rate of distant metastasis, but this difference did not achieve statistical significance ($P = 0.059$). The largest trial, RTOG 01-26, was recently updated with an 8-year follow-up, but continues to show no improvement in overall survival (Michalski et al., 2018). The 8-year rates of overall survival were 76% with 79.2 Gy and 75% with 70.2 Gy (HR 1.00). The 8-year cumulative rates of distant metastases were slightly improved but again with borderline significance, at 4% for the 79.2-Gy arm and 6% for the 70.2-Gy arm (HR, 0.65; 95% CI, 0.42 to 1.01; $P = .05$). The high-dose arm had a lower rate of salvage therapy use. The reasons for this absence of survival benefit are likely due to the numerous and continually evolving salvage therapies available for men who have failed primary management.

Because modern RT (IMRT with image guidance as the standard) for prostate cancer looks nothing like RT from the 1990s (pre-CT era) or even early 2000s (pre-IMRT), review of the literature on the efficacy of RT must take into consideration type of radiation used and dose delivered.

Given that RT is a local treatment modality, the primary principle is to achieve local control, with the expectation that such control will prevent secondary dissemination beyond the prostate.

Role of Radiation Therapy in High-Risk or Locally Advanced Disease

Two major trials compared RT to conservative management in patients with high-risk disease, and demonstrated the ability of radiation treatment to improve survival in patients with prostate cancer. In both trials, patients were randomized to ADT with or without EBRT. In a multi-institutional trial sponsored by the National Cancer Institute of Canada (NCIC) and Medical Research Council UK (MRC) (NCIC CTG PR.3/MRC UK PR07), 1205 patients with high-risk or locally advanced prostate cancer were randomized from 1995 to 2005 to lifelong ADT (either bilateral orchiectomy or LHRH agonist) with or without RT to 65 to 69 Gy (Warde et al., 2011). The addition of RT significantly improved overall survival: 7-year survival was 66% for ADT versus 74% for ADT/RT ($P = .033$). In a Scandinavian trial (SPCG-7/SFUO-3), 875 patients with high-risk or locally advanced prostate cancer were randomized from 1996 to 2002 to lifelong ADT (3 months of combined androgen blockade followed by lifelong flutamide) with or without RT to a median of 70 Gy (Widmark et al., 2009). Again, RT decreased overall mortality: 10-year mortality was 39.4% for ADT versus 29.6% for ADT/RT ($P < .05$). These two trials show that RT improves overall survival in high-risk prostate cancer by an absolute magnitude of 8% (at 7 years) to 10% (at 10 years) compared with ADT alone. Of note, radiation doses used in the modern era for prostate cancer are much higher than those used in these trials and should be even more effective.

Key Points: Tumor Control After External Beam Radiotherapy

- EBRT improves overall survival compared with conservative management with ADT alone.
- At least six randomized trials have consistently shown that higher-dose radiation improves disease control. These studies have led to the current

standard of care, which is to use dose-escalated RT.

Outcomes for External Beam Hypofractionation

Although the evidence for prostate SBRT is still evolving, multiple phase III trials of moderate hypofractionation (Table 157.9) have been published.

TABLE 157.9

Randomized Trials of Moderate Hypofractionation

REFERENCE	N	MEDIAN FOLLOW-UP (Yr)	DOSE TOTAL (Gy) (FRACTION [Gy])	OUTCOME STANDARD VS. HYPOFRACTIONATION (%)	LATE TOXIC (%)
Lukka et al., 2005	936	5.7	66 (2) 52.5 (2.625)	5-yr FFBF,[a] 53 vs. 60 (NS)	Grade GI/GU, vs. 2 (
Yeoh et al., 2011	217	7.5	64 (2) 55 (2.75)	7.5-yr BRFS, 34 vs. 53 (*P* < .05)	NS
Arcangeli et al., 2010	168	5.8	80 (2) 62 (3.1)	5-yr FFBF, 79 vs. 85 (*P* = .065)	Gra 2+ 11 14 Gra 2+ 14 17
Pollack et al., 2011	303	5.5	76 (2) 70.2 (2.7)	5-yr BF, 15 vs. 19 (*P* = .34)	Gra 2+ 8 v (*P* .03 Gra 2+ 4 v (N
Kuban et al., 2010	204	4.7	75.6 (1.8) 72 (2.4)	5-yr FFBF, 94 vs. 97 (NS)	Gra 2+ 19 Gra GI,

					vs. (*P* .06 gra GI)
(Dearnaley et al., 2012)	3216	5.2	74 (2) 60 (3) 57 (3)	5-yr FFBF, 88.3 vs. 90.6 vs. 85.9 (60 noninferior to 74)	NS
Lee et al., 2016a	1115	5.8	73.8 (1.8) 70 (2.5)	5-yr DFS, HR 0.85, 95% CI 0.64–1.14	Grade GI and HR 1.3 1.59
(Incrocci et al., 2016)	804	5.0	78 (2) 64.6 (3.4)	5-yr RFS, HR 0.86, 95% CI 0.63–1.16	
(Catton et al., 2017)	1206	6.0	78 (2) 60 (3)	5-yr BRFS, 85 vs. 85 (NS)	NS

[a] Failure defined as three consecutive rises.

Prostate-specific antigen failure defined using nadir + 2 ng/mL except where marked.

BF, biochemical failure; *BRFS,* biochemical relapse–free survival; *CI,* confidence interval; *DFS,* disease-free survival; *FFBF,* free from biochemical failure; *GI,* gastrointestinal; *GU,* genitourinary; *HR,* hazard ratio; *NS,* not statistically significant; *RFS,* relapse-free survival; *yr,* years.

A multi-institutional noninferiority trial from the NCIC randomized 936 predominantly low-risk men to 66 Gy in 2-Gy fractions over 6.5 weeks versus 52.5 Gy in 2.625 Gy over 4 weeks (Lukka et al., 2005). The median follow-up was 5.7 years. The 5-year risk for biochemical or clinical failure was 53% in the standard fractionation arm and 60% in the hypofractionation arm (difference −7%, 90% CI, −12.6% to −1.4%). Although acute toxicity was slightly higher with hypofractionation (11.4 % vs. 7%, difference −4.4%; 90% CI, −8.1% to −0.6%), late toxicity was low for both arms (3.2%). The major weakness of this trial was the low dose used for both arms that resulted in high failure rates. It was designed before development of the alpha/beta ratio hypothesis, and the hypofractionated dose was biologically less effective than the standard arm using an alpha/beta ratio of 1.5.

Yeoh et al. (2011) reported a randomized trial of 217 cT1–T2 patients comparing 64 Gy in 2-Gy fractions over 6.5 weeks to 55 Gy in 2.75-Gy fractions in 4 weeks. Median follow-up was 90 months and showed improved 7.5-year biochemical relapse-free survival in the hypofractionated arm (34% vs. 53%, comparatively, $P < .05$). Although this study offers support for the rationale of hypofractionation, the numbers are small and the total doses are again low.

Pollack et al. (2011) reported the results of the Fox Chase randomized study of 303 men with intermediate- or high-risk cancer. Standard fractionation was 76 Gy in 2-Gy fractions versus 70.2 Gy in 2.7-Gy fractions. There were no significant differences in 5-year biochemical failure (15% vs. 19%, *P* = .342) and worse late grade 2+ GU toxicity in the hypofractionated arm (18% vs. 8%, *P* = .028).

A randomized trial of moderate hypofractionation from MD Anderson Cancer Center randomized 204 predominantly low- and intermediate-risk men to 75.6 Gy in 1.8-Gy fractions or 72 Gy in 2.4-Gy fractions (Kuban et al., 2010). With a median follow-up of 4.7 years, 5-year freedom from biochemical failure was not significantly different (*P* = .23) between standard fractionation (92%) and hypofractionation (92%). Toxicity was likewise similar, although there was a trend toward worse late GI toxicity with hypofractionation (*P* = .058).

In the Conventional versus Hypofractionated High-dose Intensity Modulated Radiotherapy for Prostate Cancer (CHHiP) study, Dearnaley et al. (2012) randomized 3216 men with localized prostate cancer (T1b to T3a N0M0) to conventionally fractionated (74 Gy in 37 fractions) or hypofractionated (60 Gy in 20 fractions or 57 Gy in 19 fractions) RT. With a median follow-up of 62.4 months, 5-year biochemical or clinical failure–free survival was 88.3%, 90.6%, and 85.9%, respectively. With a critical HR for noninferiority set at 1.208, the 60-Gy group was noninferior to conventional fractionation (HR 0.84, 90% CI, 0.68 to 1.03), and the 57-Gy group did not meet the threshold (HR 1.2, 90% CI, 0.99 to 1.46). There were no significant differences in toxicity between groups.

Lee et al. (2016a) reported the results of RTOG 04-15, which randomized 1115 men with low-risk prostate cancer to conventionally fractionated (73.8 Gy in 41 fractions) or hypofractionated (70 Gy in 28 fractions) RT. With a median follow-up of 5.8 years and using a noninferiority threshold HR of 1.52, hypofractionation was noninferior to conventional fractionation with regard to disease-free survival (HR 0.85, 95% CI, 0.64 to 1.14). Hypofractionation was associated with increased late grade 2 and 3 GI and GU side effects (HR 1.31 to 1.59).

In the Hypofractionated versus Conventionally Fractionated Radiotherapy for Patients with Localised Prostate Cancer (HYPRO) trial, 804 men with intermediate- to high-risk prostate cancer were randomized to receive 78 Gy in 39 fractions or 64.6 Gy in 19 fractions (3 days per week) (Incrocci et al., 2016). At 60 months median follow-up, hypofractionated RT was not superior to conventional fractionation for relapse-free survival (adjusted HR 0.86, 95% CI, 0.63 to 1.16, $P = 0.36$).

Finally, the Prostate Fractionated Irradiation Trial (PROFIT) through the Ontario Clinical Oncology Group randomized 1206 men with intermediate-risk prostate cancer to conventionally fractionated (78 Gy in 39 fractions) or hypofractionated (60 Gy in 20 fractions) RT (Catton et al., 2017). With a noninferiority HR less than 1.32, they found hypofractionation to be noninferior (HR 0.96, 90% CI, 0.77 to 1.2) with regard to biochemical-clinical failure. Additionally, they found no significant differences in grade ≥3 late GI or GU toxicity.

In summary, multiple large randomized trials comparing conventionally fractionated and hypofractionated RT suggest that hypofractionation provides similar outcomes while shortening treatment courses. Patients should be advised, however, that there may be an increased risk for acute GU and GI toxicity associated with higher dose-per-fraction regimens.

Studies of ultrahypofractionation are largely limited to phase I/II studies (Table 157.10). King et al. (2013) performed a pooled analysis of prospective phase II trials at 8 institutions and including 1100 patients with low- (58%), intermediate- (30%), and high-risk (11%) prostate cancer who received prostate SBRT. With a median follow-up of 36 months, 5-year biochemical relapse–free survival was 95%, 84%, and 81% for low-, intermediate-, and high-risk disease, and neither total dose nor use of ADT had a significant influence on outcome in any risk group. Some studies have shown a marked increase in late morbidity compared with studies of moderate hypofractionation, with grade 2 urinary toxicity in some studies greater than 30%. Although it is a rare occurrence, one study did note a grade 4 rectal ulcer in a patient receiving 50 Gy in 5 fractions (Boike et al., 2011), and another reported a rectal fistula (Loblaw et al., 2013).

TABLE 157.10

Selected Series of Ultra-Hypofractionation

REFERENCE	N	MEDIAN FOLLOW-UP (MONTHS)	TOTAL DOSE/NUMBER OF FRACTIONS	OUTCO (%)
(Friedland et al., 2009)	Low/intermediate/high: 112 (21 received ADT)	24	35–36 Gy/5	Crude, 9

(King et al., 2012)	Low: 67	32	36.25 Gy/5	4-yr BRF
(Bolzicco et al., 2013)	Low: 41 Intermediate: 42 High: 17	36	35 Gy/5	3-yr BRF
(Chen et al., 2013)	Low: 37 Intermediate: 55 High: 8 (11 received ADT)	28	35 Gy/5 36.25 Gy/5	2-yr BRF
(Loblaw et al., 2013)	Low: 84	55	35 Gy/5	5-yr BC,
(Oliai et al., 2013)	Low: 36 Intermediate: 22 High: 12 (23 received ADT)	31	35 Gy/5 36.25 Gy/5 37.5 Gy/5	3-yr Low: Inter 95 High
(Katz and Kang, 2014)	Low: 324 Intermediate: 153	72	35 Gy/5 36.25/5	7-yr Low: Inter 89.6
(Hannan et al., 2016)	Low: 33 Intermediate: 58	54	45 Gy/5 47.5 Gy/5 50 Gy/5	5-yr 98.6 5-yr 89.7
(Meier et al.,	Low: 172	61	40 Gy/5	5-yr

2018)	Intermediate: 137			97.1 5-yr 95.6

[a] Used rectal amifostine.

ADT, androgen deprivation therapy; *BC,* biochemical control; *BFRS,* biochemical relapse–free survival; *DFS,* disease-free survival; *ED,* erectile dysfunction; *FFBF,* free from biochemical failure; *GI,* gastrointestinal; *GU,* genitourinary; *OS,* overall survival; *yr,* years.

Data from Katz and Kang, 2014.

There is one phase III trial of ultrahypofractionation, the Swedish ISRCTN 4590531 or “HYPO-RT-PC” trial, which has randomized intermediate-risk men to 78 Gy in 2-Gy fractions with 42.7 Gy in 6.1-Gy fractions. Preliminary toxicity data (Widmark et al., 2016) suggest that ultrahypofractionation may carry an increased risk for acute GI toxicity (9.4% vs. 5.3%, $P = 0.23$) at end of treatment but no differences in toxicity at 2 years. Primary outcomes data are forthcoming.

The use of moderate hypofractionation for postoperative RT has been studied in multiple retrospective and phase I/II studies. Siepe et al. (2018) recently completed a comprehensive review of this literature and found 17 published reports of 1208 men treated with hypofractionated RT after prostatectomy. The majority of these studies described fewer than 50 patients, median follow-up was 30 months, and treatment regimens varied across studies. Overall no acute ≥grade 3 GI toxicity was reported, and late ≥grade 2 toxicity ranged from 0% to 9%; acute ≥grade 3 GU toxicity was similarly rare, ranging from 0% to 3%. Reports of late ≥grade 2 GU toxicity varied from 0% to 66% (median 12%) without a single clear etiology for the level of variability. Disease outcomes in this setting are difficult to contextualize given the heterogeneous landscape of the available studies, and prospective randomized trials are needed.

Key Points: Hypofractionation and Stereotactic Body Radiation Therapy

- Hypofractionation reduces the overall treatment course by delivering higher doses per fraction. Safe treatment delivery requires accurate patient setup and conformal treatment planning.
- Doses in the range of 2.4 to 3.4 Gy have been delivered in phase III trials with low morbidity. Patient risk selection and biologically effective doses have resulted in excellent biochemical control reported up to 5 years, but it

is not clear if moderate hypofractionation is more efficacious.

- Early studies of ultrahypofractionation (7 to 10 Gy) show good biochemical control rates, but the duration of follow-up is limited. Toxicity rates vary. Larger phase III trials are needed.

Outcomes for Brachytherapy

Post-treatment biopsies can be used to assess the efficacy of local therapies to control cancer, but there are several limitations to using this technique in prostate cancer, which were discussed earlier in this chapter. Early studies of prostate brachytherapy included postimplantation biopsy; these studies showed a very low rate of 4% to 5% positive biopsy results 2 years after good dosimetry implants (Prestidge et al., 1997; Stone et al., 2004). More recently, biochemical surrogates for cancer control have been used in addition to survival parameters.

Serum PSA is the most useful marker to assess relapse. A rising PSA level after irradiation predicts local or distant relapse, or both, often many years before clinical evidence of recurrence (Kaplan et al., 1993). However, the variability of PSA, especially at low levels, often makes interpretation problematic. In addition, the suppression of PSA with even short courses of ADT can complicate the interpretation of results. A PSA bounce has been reported in approximately 30% of patients after brachytherapy (Critz et al., 2000; Hinnen et al., 2012). Some investigators have reported improved rates of cancer control in patients who experience a PSA bounce (Hinnen et al., 2012; Patel et al., 2004).

Comparative Efficacy of External Beam Radiation Therapy Versus Brachytherapy

Goy et al. (2016) retrospectively compared 93 patients treated with ^{125}I brachytherapy to 145 Gy and 597 patients treated with EBRT (median dose 75.3 Gy) during the same period. All patients had intermediate-risk prostate cancer. With a median follow-up of 7.8 years, 10-year freedom from biochemical failure was 81.7% for brachytherapy versus 54.5% for EBRT ($P = 0.002$), though there were no significant differences in distant metastasis-free, disease-specific, or overall survival. Neoadjuvant ADT was utilized in 10.8% of brachytherapy patients versus 59.5% of EBRT patients. Although patients receiving brachytherapy were younger and generally had less aggressive disease, brachytherapy remained an independent predictor of freedom from biochemical failure after propensity score–matched multivariate analysis.

In a retrospective comparison of 950 patients treated with brachytherapy and 785 patients treated with EBRT (484 treated to < 72 Gy and 301 ≥ 72 Gy), Kupelian et al. (2004) found that all patients had localized disease (cT1 to T2) and comprised all risk categories by PSA and Gleason score criteria. After multivariate analysis, EBRT to < 72 Gy was associated with inferior 5- and 7-year biochemical recurrence–free survival, but otherwise treatment modality was not associated with outcome. This study also found no difference in outcome for RP or combined EBRT and brachytherapy.

Table 157.11 summarizes the clinical outcomes of permanent implant monotherapy in several large series, which also provide comparisons against same-institution results with EBRT. Although these are retrospective single-institution studies, they represent results from a uniform population of patients. As seen, these results compare favorably with those of similarly selected patients treated with EBRT. However, to date no randomized trials have directly compared brachytherapy alone versus EBRT alone. Early results with HDR monotherapy for patients with low-risk prostate cancer have demonstrated acceptable toxicity and early rates of biochemical freedom from relapse similar to those for permanent seed implants. Table 157.12 summarizes the results of trials of HDR monotherapy.

TABLE 157.11

Selected Series Comparing Freedom from Biochemical Relapse: Implant versus External Beam Radiation Therapy

REFERENCE	NUMBER OF PATIENTS	MEDIAN FOLLOW-UP (MONTHS)	TECHNIQUE	OUTCOME
(Delouya et al., 2017)	475	56	76–80 Gy EBRT (interquartile range, 3D-CRT or IMRT) vs. LDR BT (D90 145–176 interquartile range)	EBRT (intermediate risk): PSA-RFS, 85.8% BT (intermediate risk): PSA-RFS, 95.6%, *P* =

				0.042 in CAPRA 0–2 points; $P = 0.5$ in CAPRA 3–5
(Smith et al., 2015)	7974 across 3 cohorts	32–88	≥144 Gy I-125 LDR BT vs. 70–74 Gy 3D-CRT or IMRT 10–20 Gy HDR BT + 40–50 Gy 3D-CRT or IMRT vs 70–74 Gy 3D-CRT or IMRT	EBRT vs. LDR BT (low risk): bFFS, HR 2.9, $P = 0.004$ (low risk) EBRT vs. LDR BT (intermediate risk): bFFS, HR 4.58, $P = 0.001$ EBRT vs. EBRT + HDR BT (intermediate risk): bFFS, HR 2.08, $P = 0.007$
(Tanaka et al., 2017)	610	75	145–160 Gy I-125 LDR BT (low and favorable intermediate risk) or 110 Gy I-125 LDR BT + 45 Gy IMRT (unfavorable intermediate or high risk) vs 74–76 Gy IMRT	BT: 5-yr BCR-free rate (Phoenix), 95.0% 5-yr BCR-free rate (PSA ≥0.2), 80.1% IMRT: 5-yr BCR-free rate (Phoenix), 89.5% 5-yr BCR-free rate (PSA ≥0.2), 59.1%
(Tsubokura et al., 2018)	758	68	145 Gy I-125 LDR BT (≤T3 and Gleason ≤3+4) or 110 Gy I-125	BT: 5-yr bFFS, 96.7% EBRT: 5-yr bFFS, 88.7%

			LDR BT + 40 Gy IG-IMRT (≥T3 or Gleason ≥4+3) vs. 72–74.8 Gy IG-IMRT	*Significant difference in high-risk patients only

3D-CRT, three-dimensional conformal radiotherapy; *bFFS,* biochemical failure–free survival; *BT,* brachytherapy; *DMFS,* distant metastasis–free survival; *EBRT,* external beam radiation therapy; *HDR,* high-dose rate; *HR,* hazard ratio; *IG,* image-guided; *IMRT,* intensity-modulated radiation therapy; *LDR,* low-dose-rate, *PSA,* prostate-specific antigen; *PSA-RFS,* PSA-relapse–free survival; *yr,* year.

TABLE 157.12

High-Dose-Rate Brachytherapy as Monotherapy

REFERENCE	NUMBER OF PATIENTS	MEDIAN FOLLOW-UP (MONTHS)	BIOCHEMICAL DISEASE–FREE SURVIVAL (%)	HIGH DOSE RATE/ NUMBER OF FRACTIONS
Demanes et al., 2011	298	62	97	42 Gy/6
				38 Gy/4
Shah et al., 2012	252	58	91	38 Gy/4
Barkati et al., 2012	79	40	89	30 Gy/3
				31.5 Gy/3
				33 Gy/3
				34.5 Gy/3
Zamboglou et al., 2013)	718	53	94	34.5 Gy 3
				38 Gy/4
Ghadjar et al., 2014	36	83	97	38 Gy/4
Potharaju et al., 2015	44	68	91	31.5 Gy/3
Yamazaki et al., 2018	353	76	93	45.5 Gy/7
				49 Gy/7
				54 Gy/9

Brachytherapy Combined With External

Irradiation

Biochemical disease–free survival for high-risk men using this strategy can range from 80% to 90%, particularly when combined with ADT (Koontz et al., 2009; Merrick et al., 2011; Shilkrut et al., 2013a, 2013b; Taira et al., 2010). HDR brachytherapy series with at least 5 years of follow-up also show very good biochemical control for both intermediate-risk (83% to 100%) and high-risk (74% to 91%) patients (Morton and Hoskin, 2013).

The role of external beam with permanent seed brachytherapy versus brachytherapy alone for selected intermediate-risk men was investigated in the randomized clinical trial RTOG 0232 (Prestidge et al., 2016). This study randomized men with intermediate-risk prostate cancer (clinical T1c to T2b by the *American Joint Committee on Cancer (AJCC) Cancer Staging Manual*, 6th edition, Gleason 2 to 6 and PSA ≥10 but <20 or Gleason 7 and PSA <10) to prostate brachytherapy alone (^{103}Pd to 125 Gy or ^{125}I to 145 Gy) or partial pelvis EBRT (45 Gy) followed 2 to 4 weeks later by brachytherapy (^{103}Pd to 100 Gy or ^{125}I to 110 Gy). In the initial report at 5 years, no difference in freedom from progression was measured, but brachytherapy alone resulted in lower rates of late toxicity Grade ≥2 (37% vs. 53%, $P = 0.0001$ and late grade ≥3 (12% vs. 7%, $P = 0.039$). Of note, this study did not stratify into favorable and unfavorable intermediate risk, and also allowed for use of ADT at each investigator's discretion, so there are some potential confounding factors in the trial.

The ASCENDE-RT trial compared EBRT alone to EBRT with a brachytherapy boost in intermediate- and high-risk prostate cancer (Morris et al., 2017). In this trial, 398 men were enrolled, stratified by NCCN risk group, and randomized to treatment groups. All men received 12 months of ADT beginning 8 months before RT, followed by EBRT to 46 Gy to the prostate, seminal vesicles, and regional nodes. The EBRT-alone group then received an additional 32 Gy prostate boost, and the EBRT plus brachytherapy group received a ^{125}I implant to 115 Gy delivered 2 to 3 weeks after EBRT. With a median follow-up of 6.5 years, EBRT alone was associated with significantly higher biochemical failure (HR 2.04, $P = 0.004$) relative to EBRT with a brachytherapy boost.

Suggested Readings

D'Amico AV, Whittington R, Malkowicz S, et al. Biochemical outcome after radical prostatectomy, external beam radiation therapy, or interstitial radiation therapy for clinically localized prostate cancer. *JAMA*. 1998;280(11):969–974.

Mitchell JM. Urologists’ use of intensity-modulated radiation therapy for prostate cancer. *N Engl J Med*. 2013;369:1629–1637.

Parker C, Nilsson S, Heinrich D, et al. ALSYMPCA Investigators. Alpha emitter radium-223 and survival in metastatic prostate cancer. *N Engl J Med*. 2013;369(3):213–223.

Tepper JE. Curing prostate cancer is on the horizon: a guide on how to get there. *Semin Radiat Oncol*. 2013;23(special issue):3 [ed].

Zumsteg ZS, Spratt DE, Pei I, et al. A new risk classification system for therapeutic decision making with intermediate-risk prostate cancer patients undergoing dose-escalated external-beam radiation therapy. *Eur Urol*. 2013;64(6):895–902.

References

Aizer A, Yu J, McKeon A, et al. Whole pelvic radiotherapy versus prostate only radiotherapy in the management of locally advanced or aggressive prostate adenocarcinoma. *Int J Radiat Oncol Biol Phys*. 2009;75(5):1344–1349.

Alaei P, Spezi E. Imaging dose from cone beam computed tomography in radiation therapy. *Phys Med*. 2015;31(7):647–658.

Alcantara P, Hanlon A, Buyyounouski MK, et al. Prostate-specific antigen nadir within 12 months of prostate cancer radiotherapy predicts metastasis and death. *Cancer*. 2007;109(1):41–47.

Alicikus Z, Yamada Y, Zhang Z, et al. Ten-year outcomes of high-dose, intensity-modulated radiotherapy for localized prostate cancer. *Cancer*. 2011;117(7):1429–1437.

Al-Mamgani A, van Putten WLJ, Heemsbergen WD, et al. Update of Dutch multicenter dose-escalation trial of radiotherapy for localized prostate cancer. *Int J Radiat Oncol Biol Phys*. 2008;72(4):980–988.

Al-Mamgani A, Heemsbergen WD, Peeters ST, et al. Role of intensity-modulated radiotherapy in reducing toxicity in dose escalation for localized prostate cancer. *Int J Radiat Oncol Biol Phys*. 2009;73(3):685–691.

Alongi F, Fiorino C, Cozzarini C, et al. IMRT significantly reduces acute toxicity of whole-pelvis irradiation in patients treated with post-operative adjuvant or salvage radiotherapy after radical prostatectomy. *Radiother Oncol*. 2009;93(2):207–212.

Al-Ubaidi FL, Schultz N, Loseva O, et al. Castration therapy results in decreased Ku70 levels in prostate cancer. *Clin Cancer Res*. 2013;19(6):1547–1556.

Anderson LL. Spacing nomograph for interstitial implants of 125I seeds. *Med Phys*. 1976;3(1):48–51.

Arcangeli G, Saracino B, Gomellini S, et al. A prospective phase III randomized trial of hypofractionation versus conventional fractionation in patients with high-risk prostate cancer. *Int J Radiat Oncol Biol Phys*. 2010;78(1):11–18.

Arrayeh E, Westphalen AC, Kurhanewicz J, et al. Does local recurrence of prostate cancer after radiation therapy occur at the site of primary tumor? Results of a longitudinal MRI and MRSI study. *Int J Radiat Oncol Biol Phys*. 2012;82(5):e787–e793.

Asbell SO, Schlager BA, Baker AS. Revision of treatment planning for carcinoma of the prostate. *Int J Radiat Oncol Biol Phys*. 1980;6(7):861–865.

Attwater HL. Malignant disease of the prostate and bladder. *Postgrad Med J*. 1930;6(61):6–10.

Bae HJ, Mian O, Vaidya D, et al. Use of 5-alpha-reductase inhibitors as alternatives to luteinizing-hormone releasing hormone (LHRH) analogs or anti-androgens for prostate downsizing before brachytherapy. *Pract Radiat Oncol*. 2018;8(3):e159–e165.

Bagshaw MA, Kaplan HS. *Radical external radiotherapy of localized prostatic carcinoma*. [In Presented at the Tenth International Congress of Radiology, Montreal, Canada, September] 1962.

Ballhausen H, Li M, Ganswindt U, et al. Shorter treatment times reduce the impact of intra-fractional motion : a real-time 4DUS study comparing VMAT vs. step-and-shoot IMRT for prostate cancer. *Strahlenther Onkol*. 2018;194(7):664–674.

Barkati M, Williams SG, Foroudi F, et al. High-dose-rate brachytherapy as a monotherapy for favorable-risk prostate cancer: a Phase II trial. *Int J Radiat Oncol Biol Phys*. 2012;82(5):1889–1896.

Beard CJ, Kijewski P, Bussière M, et al. Analysis of prostate and seminal vesicle motion: implications for treatment planning. *Int J Radiat Oncol Biol Phys*. 1996;34(2):451–458.

Beckendorf V, Guerif S, Le Prisé E, et al. 70 Gy versus 80 Gy in localized prostate cancer: 5-year results of GETUG 06 randomized trial. *Int J Radiat Oncol Biol Phys*. 2011;80(4):1056–1063.

Benedict SH, Yenice KM, Followill D, et al. Stereotactic body radiation therapy: the report of AAPM Task Group 101. *Med Phys*. 2010;37(8):4078–4101.

Bennett MH, Feldmeier J, Hampson N, et al. Hyperbaric oxygen therapy for late radiation tissue injury. *Cochrane Database Syst Rev*. 2012;(5) [CD005005].

Benoit RM, Naslund MJ, Cohen JK. A comparison of complications between ultrasound-guided prostate brachytherapy and open prostate brachytherapy. *Int J Radiat Oncol Biol Phys*. 2000;47(4):909–913.

Benoit RM, Naslund MJ, Cohen JK. Complications after prostate brachytherapy in the Medicare population. *Urology*. 2000;55(1):91–96.

Beydoun N, Bucci JA, Chin YS, et al. First report of transperineal polyethylene glycol hydrogel spacer use to curtail rectal radiation dose after permanent iodine-125 prostate brachytherapy. *Brachytherapy*. 2013;12(4):368–374.

Blasko JC, Grimm PD, Ragde H. Brachytherapy and organ preservation in the management of carcinoma of the prostate. *Semin Radiat Oncol*. 1993;3(4):240–249.

Böcking A, Auffermann W. Cytological grading of therapy-induced tumor regression in prostatic carcinoma: proposal of a new system. *Diagn Cytopathol*. 1987;3(2):108–111.

Boda-Heggemann J, Lohr F, Wenz F, et al. kV cone-beam CT-based IGRT: a clinical review. *Strahlenther Onkol*. 2011;187(5):284–291.

Bolla M, de Reijke TM, Van Tienhoven G, EORTC Radiation Oncology Group and Genito-Urinary Tract Cancer Group, et al. Duration of androgen suppression in the treatment of prostate cancer. *N Engl J Med*. 2009;360(24):2516–2527.

Bolla M, Van Tienhoven G, Warde P, et al. External irradiation with or without long-term androgen suppression for prostate cancer with high metastatic risk: 10-year results of an EORTC randomised study. *Lancet Oncol*. 2010;11(11):1066–1073.

Bolzicco G, Favretto MS, Satariano N, et al. A single-center study of 100 consecutive patients with localized prostate cancer treated with stereotactic body radiotherapy. *BMC Urol*. 2013;13:49.

Boorjian SA, Karnes RJ, Rangel LJ, et al. Mayo Clinic validation of the D'Amico risk group classification for predicting survival following radical prostatectomy. *J Urol*. 2008;179(4):1354–1360 [discussion 1360–1361].

Bortfeld T, Schlegel W. An analytical approximation of depth-dose distributions for therapeutic proton beams. *Phys Med Biol*. 1996;41(8):1331–1339.

Bosco C, Bosnyak Z, Malmberg A, et al. Quantifying observational evidence for risk of fatal and nonfatal cardiovascular disease following androgen deprivation therapy for prostate cancer: a meta-analysis. *Eur Urol*. 2015;68(3):386–396.

Bostwick DG, Egbert BM, Fajardo LF. Radiation injury of the normal and neoplastic prostate. *Am J Surg Pathol*. 1982;6(6):541–551.

Bostwick DG, Meiers I. Diagnosis of prostatic carcinoma after therapy: review 2007. *Arch Pathol Lab Med*. 2007;131(3):360–371.

Brawer MK, Nagle RB, Pitts W, et al. Keratin immunoreactivity as an aid to the diagnosis of persistent adenocarcinoma in irradiated human prostates. *Cancer*. 1989;63(3):454–460.

Brenner DJ, Hall EJ. Fractionation and protraction for radiotherapy of prostate carcinoma. *Int J Radiat Oncol Biol Phys*. 1999;43(5):1095–1101.

Britten RA, Nazaryan V, Davis LK, et al. Variations in the RBE for cell killing along the depth-dose profile of a modulated proton therapy beam. *Radiat Res*. 2013;179(1):21–28.

Bryant C, Smith T, Henderson R, et al. Five-year biochemical results, toxicity, and patient-reported quality of life after delivery of dose-escalated image guided proton therapy for prostate cancer. *Int J Radiat Oncol Biol Phys*. 2016;95(1):422–434.

Buckstein M, Carpenter TJ, Stone NN, et al. Long-term outcomes and toxicity in patients treated with brachytherapy for prostate adenocarcinoma younger than 60 years of age at treatment with minimum 10 years of follow-up. *Urology*. 2013;81(2):364–368.

Burman C, Kutcher GJ, Emami B, et al. Fitting of normal tissue tolerance data to an analytic function. *Int J Radiat Oncol Biol Phys*. 1991;21(1):123–135.

Burman C, Chui CS, Kutcher G, et al. Planning, delivery, and quality assurance of intensity-modulated radiotherapy using dynamic multileaf collimator: a strategy for large-scale implementation for the treatment of carcinoma of the prostate. *Int J Radiat Oncol Biol Phys*. 1997;39(4):863–873.

Burt LM, Shrieve DC, Tward JD. Factors influencing prostate cancer patterns of care: an analysis of treatment variation using the SEER database. *Adv Radiat Oncol*. 2018;3(2):170–180.

Buyyounouski MK, Hanlon AL, Horwitz EM, et al. Interval to biochemical failure highly prognostic for distant metastasis and prostate cancer-specific mortality after radiotherapy. *Int J Radiat Oncol Biol Phys*. 2008;70(1):59–66.

Cabrera AR, Lee WR. Hypofractionation for clinically localized prostate cancer. *Semin Radiat Oncol*. 2013;23(3):191–197.

Caloglu M, Ciezki JP, Reddy CA, et al. PSA bounce and biochemical failure after brachytherapy for prostate cancer: a study of 820 patients with a minimum of 3 years of follow-up. *Int J Radiat Oncol Biol Phys*. 2011;80(3):735–741.

Casalino DD, Remer EM, Arellano RS, et al. ACR Appropriateness Criteria® posttreatment follow-up of prostate cancer. *J Am Coll Radiol*. 2011;8(12):863–871.

Catton CN, Lukka H, Gu CS, et al. Randomized trial of a hypofractionated radiation regimen for the treatment of localized prostate cancer. *J Clin Oncol*. 2017;35(17):1884–1890.

Chen LN, Suy S, Uhm S, et al. Stereotactic body radiation therapy (SBRT) for clinically localized prostate cancer: the Georgetown University experience. *Radiat Oncol*. 2013;8(1):58.

Chen RC, Basak R, Meyer A-M, et al. Association between choice of radical prostatectomy, external beam radiotherapy, brachytherapy, or active surveillance and patient-reported quality of life among men with localized prostate cancer. *JAMA*. 2017;317(11):1141–1150.

Cheng L, Cheville JC, Bostwick DG. Diagnosis of prostate cancer in needle biopsies after radiation therapy. *Am J Surg Pathol*. 1999;23(10):1173–1183.

Chera BS, Vargas C, Morris CG, et al. Dosimetric study of pelvic proton radiotherapy for high-risk prostate cancer. *Int J Radiat Oncol Biol Phys*. 2009;75(4):994–1002.

Cherullo EE, Ponsky LE, Goyal KK, et al. Variable definitions influence the reporting of biochemical failure rates. *Prostate Cancer Prostatic Dis*. 2002;5(1):54–58.

Chung CS, Yock TI, Nelson K, et al. Incidence of second malignancies among patients treated with proton versus photon radiation. *Int J Radiat Oncol Biol Phys*. 2013;87(1):46–52.

Ciezki JP, Reddy CA, Garcia J, et al. PSA kinetics after prostate brachytherapy: PSA bounce phenomenon and its implications for PSA doubling time. *Int J Radiat Oncol Biol Phys*. 2006;64(2):512–517.

Coen JJ, Bae K, Zietman AL, et al. Acute and late toxicity after dose escalation to 82 GyE using conformal proton radiation for localized prostate cancer: initial report of American College of Radiology Phase II Study 03-12. *Int J Radiat Oncol Biol Phys*. 2011;81(4):1005–1009.

Cooperberg M, Broering J, Carroll P. Time trends and local variation in primary treatment of localized prostate cancer. *J Clin Oncol*. 2010;28(7):1117–1123.

Coutard H. Roentgentherapy of epitheliomas of the tonsillar region, hypopharynx, and larynx from 1920 to 1926. *Am J Roentgenol*. 1932;28:313–331.

Critz FA, Levinso AK, Williams WH, et al. Prostate specific antigen nadir achieved by men apparently cured of prostate cancer by radiotherapy. *J Urol*. 1999;161(4):1199–1203 [discussion 1203–1205].

Critz FA, Williams WH, Benton JB, et al. Prostate specific antigen bounce after radioactive seed implantation followed by external beam radiation for prostate cancer. *J Urol*. 2000;163(4):1085–1089.

Crook J, Robertson S, Collin G, et al. Clinical relevance of trans-rectal ultrasound, biopsy, and serum prostate-specific antigen following external beam radiotherapy for carcinoma of the prostate. *Int J Radiat Oncol Biol Phys*. 1993;27(1):31–37.

Crook J, Robertson S, Esche B. Proliferative cell nuclear antigen in postradiotherapy prostate biopsies. *Int J Radiat Oncol Biol Phys*. 1994;30(2):303–308.

Crook JM, Perry GA, Robertson S, et al. Routine prostate biopsies following radiotherapy for prostate cancer: results for 226 patients. *Urology*. 1995;45(4):624–632.

Crook JM, Bahadur YA, Robertson SJ, et al. Evaluation of radiation effect, tumor differentiation, and prostate specific antigen staining in sequential prostate biopsies after external beam radiotherapy for patients with prostate carcinoma. *Cancer*. 1997;79(1):81–89.

Crook J, Malone S, Perry G, et al. Postradiotherapy prostate biopsies: what do they really mean? Results for 498 patients. *Int J Radiat Oncol Biol Phys*. 2000;48(2):355–367.

Crook JM, Malone S, Perry G, et al. Twenty-four-month postradiation prostate biopsies are strongly predictive of 7-year disease-free survival: results from a Canadian randomized trial. *Cancer*. 2009;115(3):673–679.

Crook J, Borg J, Evans A, et al. 10-year experience with I-125 prostate brachytherapy at the Princess Margaret Hospital: results for 1,100 patients. *Int J Radiat Oncol Biol Phys*. 2011;80(5):1323–1329.

D'Amico AV, Cormack R, Tempany CM, et al. Real-time magnetic resonance image-guided interstitial brachytherapy in the treatment of select patients with clinically localized prostate cancer. *Int J Radiat Oncol Biol Phys*. 1998;42(3):507–515.

D'Amico AV, Moul JW, Carroll PR, et al. Surrogate end point for prostate cancer-specific mortality after radical prostatectomy or radiation therapy. *J Natl Cancer Inst*. 2003;95(18):1376–1383.

D'Amico AV, Chen MH, Renshaw AA, et al. Androgen suppression and radiation vs radiation alone for prostate cancer. *JAMA*. 2008;299(3):289–295.

Dasu A, Toma-Dasu I. Prostate alpha/beta revisited—an analysis of clinical results from 14 168 patients. *Acta Oncol*.

2012;51(8):963–974.

Davis BJ, Horwitz EM, Lee WR, American Brachytherapy Society, et al. American Brachytherapy Society consensus guidelines for transrectal ultrasound-guided permanent prostate brachytherapy. *Brachytherapy*. 2012;11(1):6–19.

De Brabandere M, Hoskin P, Haustermans K, et al. Prostate post-implant dosimetry: interobserver variability in seed localisation, contouring and fusion. *Radiother Oncol*. 2012;104(2):192–198.

Dearnaley DP, Sydes MR, Graham JD, et al. RT01 collaborators. Escalated-dose versus standard-dose conformal radiotherapy in prostate cancer: first results from the MRC RT01 randomised controlled trial. *Lancet Oncol*. 2007;8(6):475–487.

Dearnaley D, Syndikus I, Sumo G, et al. Conventional versus hypofractionated high-dose intensity-modulated radiotherapy for prostate cancer: preliminary safety results from the CHHiP randomised controlled trial. *Lancet Oncol*. 2012;13(1):43–54.

del Regato JA. Radiotherapy in the conservative treatment of operable and locally inoperable carcinoma of the prostate. *Radiology*. 1967;88(4):761–766.

Delouya G, Lambert C, Bahary JP, et al. Comparison of external beam radiotherapy versus permanent seed brachytherapy as monotherapy for intermediate-risk prostate cancer - a single center Canadian experience. *Can J Urol*. 2017;24(3):8822–8826.

Demanes DJ, Martinez AA, Ghilezan M, et al. High-dose-rate monotherapy: safe and effective brachytherapy for patients with localized prostate cancer. *Int J Radiat Oncol Biol Phys*. 2011;81(5):1286–1292.

Denham JW, Steigler A, Wilcox C, Trans-Tasman Radiation Oncology Group 96.01 Trialists, et al. Time to biochemical failure and prostate-specific antigen doubling time as surrogates for prostate cancer-specific mortality: evidence from the TROG 96.01 randomised controlled trial. *Lancet Oncol*. 2008;9(11):1058–1068.

Denham JW, Steigler A, Lamb DS, et al. Short-term neoadjuvant androgen deprivation and radiotherapy for locally advanced prostate cancer: 10-year data from the TROG 96.01 randomised trial. *Lancet Oncol*. 2011;12(5):451–459.

Denmeade SR, Lin XS, Isaacs JT. Role of programmed (apoptotic) cell death during the progression and therapy for prostate cancer. *Prostate*. 1996;28(4):251–265.

Dess RT, Devasia TP, Aghdam N, et al. Patient-reported sexual aid utilization and efficacy after radiation therapy for localized prostate cancer. *Int J Radiat Oncol Biol Phys*. 2018;101(2):376–386.

Dess RT, Hartman HE, Aghdam N, et al. Erectile function after stereotactic body radiotherapy for localized prostate cancer. *BJU Int*. 2018;121(1):61–68.

DeWitt KD, Sandler HM, Weinberg V, et al. What does postradiotherapy PSA nadir tell us about freedom from PSA failure and progression-free survival in patients with low and intermediate-risk localized prostate cancer? *Urology*. 2003;62(3):492–496.

Dhom G, Degro S. Therapy of prostatic cancer and histopathologic follow-up. *Prostate*. 1982;3(6):531–542.

DiBiase SJ, Wallner K, Tralins K, et al. Brachytherapy radiation doses to the neurovascular bundles. *Int J Radiat Oncol Biol Phys*. 2000;46(5):1301–1307.

Dolezel M, Odrazka K, Zouhar M, et al. Comparing morbidity and cancer control after 3D-conformal (70/74 Gy) and intensity modulated radiotherapy (78/82 Gy) for prostate cancer. *Strahlentherapie Und Onkologie*. 2015;191(4):338–

346.

Donati OF, Jung SI, Vargas HA, et al. Multiparametric prostate MR imaging with T2-weighted, diffusion-weighted, and dynamic contrast-enhanced sequences: are all pulse sequences necessary to detect locally recurrent prostate cancer after radiation therapy? *Radiology*. 2013;268(2):440–450.

Donovan JL, Hamdy FC, Lane JA, et al. Patient-reported outcomes after monitoring, surgery, or radiotherapy for prostate cancer. *N Engl J Med*. 2016;375(15):1425–1437.

Duchesne GM, Peters LJ. What is the alpha/beta ratio for prostate cancer? Rationale for hypofractionated high-dose-rate brachytherapy. *Int J Radiat Oncol Biol Phys*. 1999;44(4):747–748.

Fang P, Mick R, Deville C, et al. A case-matched study of toxicity outcomes after proton therapy and intensity-modulated radiation therapy for prostate cancer. *Cancer*. 2015;121(7):1118–1127.

Fisch BM, Pickett B, Weinberg V, et al. Dose of radiation received by the bulb of the penis correlates with risk of impotence after three-dimensional conformal radiotherapy for prostate cancer. *Urology*. 2001;57(5):955–959.

Fletcher S. *Textbook of radiotherapy*. Lea & Febiger: Philadelphia, PA; 1980.

Forman JD, Warmelink C, Devi S, et al. Alternating conformal neutron and photon irradiation for locally advanced adenocarcinoma of the prostate. *Am J Clin Oncol*. 1995;18(3):231–238.

Forman JD, Yudelev M, Bolton S, et al. Fast neutron irradiation for prostate cancer. *Cancer Metastasis Rev*. 2002;21(2):131–135.

Foster W, Cunha JA, Hsu IC, et al. Dosimetric impact of interfraction catheter movement in high-dose rate prostate brachytherapy. *Int J Radiat Oncol Biol Phys*. 2011;80(1):85–90.

Fowler JF. The linear-quadratic formula and progress in fractionated radiotherapy. *Br J Radiol*. 1989;62(740):679–694.

Fraass BA. The development of conformal radiation therapy. *Med Phys*. 1995;22(11 Pt 2):1911–1921.

Freiberger C, Berneking V, Vögeli TA, et al. Long-term prognostic significance of rising PSA levels following radiotherapy for localized prostate cancer - focus on overall survival. *Radiat Oncol*. 2017;12(1):98.

Friedland JL, Freeman DE, Masterson-McGary ME, et al. Stereotactic body radiotherapy: an emerging treatment approach for localized prostate cance. *Technol Cancer Res Treat*. 2009;8(5):387–392.

Fulgham PF, Rukstalis DB, Turkbey IB, et al. AUA policy statement on the use of multiparametric magnetic resonance imaging in the diagnosis, staging and management of prostate cancer. *J Urol*. 2017;198(4):832–838.

Furuya Y, Lin XS, Walsh JC, et al. Androgen ablation-induced programmed death of prostatic glandular cells does not involve recruitment into a defective cell cycle or p53 induction. *Endocrinology*. 1995;136(5):1898–1906.

Gez E, Cytron S, Ben Yosef R, et al. Application of an interstitial and biodegradable balloon system for prostate-rectum separation during prostate cancer radiotherapy: a prospective multi-center study. *Radiat Oncol*. 2013;8:96.

Ghadjar P, Oesch SL, Rentsch CA, et al. Late toxicity and five year outcomes after high-dose-rate brachytherapy as a monotherapy for localized prostate cancer. *Radiat Oncol*. 2014;9(1):122.

Gómez-Iturriaga Piña A, Crook J, Borg J, et al. Median 5 year follow-up of ^{125}Iodine brachytherapy as monotherapy in men aged ≤ 55 years with favorable prostate cancer. *Urology*. 2010;75(6):1412–1416.

Goy BW, Soper MS, Chang T, et al. Treatment results of brachytherapy vs. external beam radiation therapy for intermediate-risk prostate cancer with 10-year followup. *Brachytherapy*. 2016;15(6):687–694.

Green N, Bodner H, Broth E, et al. Improved control of bulky prostate carcinoma with sequential estrogen and radiation therapy. *Int J Radiat Oncol Biol Phys*. 1984;10(7):971–976.

Grignon D. Histologic effects of radiation therapy and total androgen blockade on prostate cancer. *Cancer*. 1995;75(S7):1837–1841.

Grignon DJ, Sakr WA. Histological effects of radiation therapy and total androgen blockade on prostate cancer. *Cancer*. 1995;75(Suppl 7):1837–1841.

Grimm PD, Blasko JC, Sylvester JE, et al. 10-year biochemical (prostate-specific antigen) control of prostate cancer with ^{125}I brachytherapy. *Int J Radiat Oncol Biol Phys*. 2001;51(1):31–40.

Hanks GE, Martz KL, Diamond JJ. The effect of dose on local control of prostate cancer. *Int J Radiat Oncol Biol Phys*. 1988;15(6):1299–1305.

Hanlon AL, Diratzouian H, Hanks GE. Posttreatment prostate-specific antigen nadir highly predictive of distant failure and death from prostate cancer. *Int J Radiat Oncol Biol Phys*. 2002;53(2):297–303.

Hanlon AL, Horowitz EM, Feigenberg SJ, et al. Identification of groups at risk for distant metastasis and death in men with rising PSA after radiotherapy for prostate cancer. *Int J Radiat Oncol Biol Phys*. 2004;60(1 Suppl):S233–S234.

Hannan R, Tumati V, Xie XJ, et al. Stereotactic body radiation therapy for low and intermediate risk prostate cancer-Results from a multi-institutional clinical trial. *Eur J Cancer*.

2016;59:142–151.

Hardcastle N, Davies A, Foo K, et al. Rectal dose reduction with IMRT for prostate radiotherapy. *J Med Imaging Radiat Oncol*. 2010;54(3):235–248.

Harris VA, Staffurth J, Naismith O, et al. PIVOTAL Trialists. Consensus guidelines and contouring atlas for pelvic node delineation in prostate and pelvic node intensity modulated radiation therapy. *Int J Radiat Oncol Biol Phys*. 2015;92(4):874–883.

Hartford A, Zietman A, Shipley W. Proton radiotherapy. D'Amico AV, Hanks GE. *Radiotherapeutic management of prostate cancer*. Oxford University Press: New York, NY; 1999:61–72.

Haustermans KM, Hofland I, Van Poppel H, et al. Cell kinetic measurements in prostate cancer. *Int J Radiat Oncol Biol Phys*. 1997;37(5):1067–1070.

Hayden A, Morris WJ, LaPointe V, et al. Predicting biochemical failure free survival after permanent prostate brachytherapy: prognostic utility of the 4–5 year PSA value. *Radiother Oncol*. 2010;96:S2.

Hegde JV, Chen MH, Mulkern RV, et al. Preoperative 3-Tesla multiparametric endorectal magnetic resonance imaging findings and the odds of upgrading and upstaging at radical prostatectomy in men with clinically localized prostate cancer. *Int J Radiat Oncol Biol Phys*. 2013;85(2):e101–e107.

Herstein A, Wallner K, Merrick G, et al. I-125 versus Pd-103 for low-risk prostate cancer: long-term morbidity outcomes from a prospective randomized multicenter controlled trial. *Cancer J*. 2005;11(5):385–389.

Hinnen KA, Monninkhof EM, Battermann JJ, et al. Prostate specific antigen bounce is related to overall survival in prostate brachytherapy. *Int J Radiat Oncol Biol Phys*. 2012;82(2):883–888.

Ho CK, Bryant CM, Mendenhall NP, et al. Long-term outcomes following proton therapy for prostate cancer in young men with a focus on sexual health. *Acta Oncol*. 2018;57(5):582–588.

Horwitz EM, Levy LB, Thame HD, et al. Biochemical and clinical significance of the posttreatment prostate-specific antigen bounce for prostate cancer patients treated with external beam radiation therapy alone. *Cancer*. 2006;107(7):1496–1502.

Horwitz EM, Bae K, Hanks GE, et al. Ten-year follow-up of radiation therapy oncology group protocol 92-02: a phase III trial of the duration of elective androgen deprivation in locally advanced prostate cancer. *J Clin Oncol*. 2008;26(15):2497–2504.

Hoskin PJ, Colombo A, Henry A, et al. GEC/ESTRO recommendations on high dose rate afterloading brachytherapy for localised prostate cancer: an update. *Radiother Oncol*. 2013;107(3):325–332.

Huang E, Dong L, Chandra A, et al. Intrafraction prostate motion during IMRT for prostate cancer. *Int J Radiat Oncol Biol Phys*. 2002;53(2):261–268.

Huggins C, Hodges CV. Studies on prostatic cancer. I. The effect of castration, of estrogen and androgen injection on serum phosphatases in metastatic carcinoma of the prostate. *Cancer Research I*. 1941;293–297.

Hultberg S. Results of treatment with radiotherapy in carcinoma of the prostate. *Acta Radiol*. 1946;27(3–4):339–350.

Incrocci L, Wortel RC, Alemayehu WG, et al. Hypofractionated versus conventionally fractionated radiotherapy for patients with localised prostate cancer (HYPRO): final efficacy results from a randomised, multicentre, open-label, phase 3 trial. *Lancet Oncol*. 2016;17(8):1061–1069.

Ishii K, Yamanaga T, Ogino R, et al. Bowel and urinary quality of life after whole-pelvic versus prostate-only volumetric-modulated arc therapy for localized prostate cancer. *Pract Radiat Oncol*. 2018;8(2):e49–e55.

Iversen P, Bak M, Juul N, et al. Ultrasonically guided ^{125}iodine seed implantation with external radiation in management of localized prostatic carcinoma. *Urology*. 1989;34(4):181–186.

James N, de Bono J, Spears M, et al. Abiraterone for prostate cancer not previously treated with hormone therapy. *N Engl J Med*. 2017;377(4):338–351.

Jani AB, Roeske JC, Rash C. Intensity-modulated radiation therapy for prostate cancer. *Clin Prostate Cancer*. 2003;2(2):98–105.

Jones CU, Hunt D, McGowan DG, et al. Radiotherapy and short-term androgen deprivation for localized prostate cancer. *N Engl J Med*. 2011;365(2):107–118.

Kao J, Turian J, Meyers A, et al. Sparing of the penile bulb and proximal penile structures with intensity-modulated radiation therapy for prostate cancer. *Br J Radiol*. 2004;77(914):129–136.

Kapadia NS, Olson K, Sandler HM, et al. Interval to biochemical failure as a biomarker for cause-specific and overall survival after dose-escalated external beam radiation therapy for prostate cancer. *Cancer*. 2012;118(8):2059–2068.

Kaplan ID, Cox RS, Bagshaw MA. Prostate specific antigen after external beam radiotherapy for prostatic cancer: followup. *J Urol*. 1993;149(3):519–522.

Kaplan ID, Holupka EJ, Meskell P, et al. Intraoperative treatment planning for radioactive seed implant therapy for prostate cancer. *Urology*. 2000;56(3):492–495.

Katz AJ, Kang J. Stereotactic body radiotherapy as treatment for organ confined low- and intermediate-risk prostate carcinoma, a 7-year study. *Front Oncol*. 2014;4:240.

Kawakami S, Ishiyama H, Terazaki T, et al. Catheter displacement prior to the delivery of high-dose-rate brachytherapy in the treatment of prostate cancer patients. *J Contemp Brachyther*. 2014;6(2):161–166.

Kestin LL, Goldstein NS, Vicini FA, et al. Pathologic evidence of dose-response and dose-volume relationships for prostate cancer treated with combined external beam radiotherapy and high-dose-rate brachytherapy. *Int J Radiat Oncol Biol Phys*. 2002;54(1):107–118.

Kestin L, Goldstein N, Vicini F, et al. Treatment of prostate cancer with radiotherapy: should the entire seminal vesicles be included in the clinical target volume? *Int J Radiat Oncol Biol Phys*. 2002;54(3):686–697.

Keyes M, Merrick G, Frank SJ, et al. American Brachytherapy Society Task Group report: use of androgen deprivation therapy with prostate brachytherapy—A systematic literature review. *Brachytherapy*. 2017;16(2):245–265.

Kilby W, Dooley JR, Kuduvalli G, et al. The CyberKnife robotic radiosurgery system in 2010. *Technol Cancer Res Treat*. 2010;9(5):433–452.

King CR, Brooks JD, Gill H, et al. Long-term outcomes from a prospective trial of stereotactic body radiotherapy for low-risk prostate cancer. *Int J Radiat Oncol Biol Phys*. 2012;82(2):877–882.

King CR, Freeman D, Kaplan I, et al. Stereotactic body radiotherapy for localized prostate cancer: pooled analysis from a multi-institutional consortium of prospective phase II trials. *Radiother Oncol*. 2013;109(2):217–221.

Kirilova A, Damyanovich A, Crook J, et al. 3D MR-spectroscopic imaging assessment of metabolic activity in the prostate during the PSA “bounce” following 125iodine brachytherapy. *Int J Radiat Oncol Biol Phys*. 2011;79(2):371–378.

Kishan AU, Cook RR, Ciezki JP, et al. Radical prostatectomy, external beam radiotherapy, or external beam radiotherapy with brachytherapy boost and disease progression and mortality in patients with Gleason score 9-10 prostate cancer. *JAMA*. 2018;319(9):896–905.

Ko EC, Stone NN, Stock RG. PSA nadir of < 0.5 ng/mL following brachytherapy for early-stage prostate adenocarcinoma is associated with freedom from prostate-specific antigen failure. *Int J Radiat Oncol Biol Phys*. 2012;83(2):600–607.

Kochhar R, Sriram PV, Sharma SC, et al. Natural history of late radiation proctosigmoiditis treated with topical sucralfate suspension. *Dig Dis Sci*. 1999;44(5):973–978.

Kollmeier MA, Pei X, Algur E, et al. A comparison of the impact of isotope ((125)I vs. (103)Pd) on toxicity and biochemical outcome after interstitial brachytherapy and external beam radiation therapy for clinically localized prostate cancer. *Brachytherapy*. 2012;11(4):271–276.

Koontz BF, Chino J, Lee WR, et al. Morbidity and prostate-specific antigen control of external beam radiation therapy plus low-dose-rate brachytherapy boost for low, intermediate, and high-risk prostate cancer. *Brachytherapy*. 2009;8(2):191–196.

Koutrouvelis PG. Three-dimensional stereotactic posterior ischiorectal space computerized tomography guided brachytherapy of prostate cancer: a preliminary report. *J Urol*. 1998;159(1):142–145.

Krauss D, Ye H, Martinez A, et al. 5-year outcomes of a single institution prospective trial of 19 Gy single fraction high dose rate brachytherapy for low and intermediate risk prostate cancer. *Brachytherapy*. 2018;17(4):S41.

Kuban DA, Tucker SL, Dong L, et al. Long-term results of the MD anderson randomized Dose-Escalation trial for prostate cancer. *Int J Radiat Oncol Biol Phys*. 2008;70(1):67–74.

Kuban DA, Nogueras-Gonzalez GM, Hamblin L, et al. Preliminary report of a randomized dose escalation trial for prostate cancer using hypofractionation. *Int J Radiat Oncol Biol Phys*. 2010;78(3):S58–S59.

Kucway R, Vicini F, Huang R, et al. Prostate volume reduction with androgen deprivation therapy before interstitial brachytherapy. *J Urol*. 2002;167(6):2443–2447.

Kumar PP, Bartone FF. I-125 implant of the prostate: a new technique. *J Natl Med Assoc*. 1981;73(2):121–123.

Kuo N, Kang HJ, Song DY, et al. Real-time photoacoustic imaging of prostate brachytherapy seeds using a clinical ultrasound system. *J Biomed Opt*. 2012;17(6):066005.

Kupelian PA, Potters L, Khuntia D, et al. Radical prostatectomy, external beam radiotherapy. *Int J Radiat Oncol Biol Phys*. 2004;58(1):25–33.

Kupelian PA, Mahadevan A, Reddy CA, et al. Use of different definitions of biochemical failure after external beam radiotherapy changes conclusions about relative treatment efficacy for localized prostate cancer. *Urology*. 2006;68(3):593–598.

Kupelian P, Willoughby T, Mahadevan A, et al. Multi-institutional clinical experience with the Calypso System in localization and continuous, real-time monitoring of the prostate gland during external radiotherapy. *Int J Radiat Oncol Biol Phys*. 2007;67(4):1088–1098.

Kupelian P, Langen K, Willoughby T, et al. Image-guided radiotherapy for localized prostate cancer: treating a moving target. *Semin Radiat Oncol*. 2008;18(1):58–66.

Langen KM, Pouliot J, Anezinos C, et al. Evaluation of ultrasound-based prostate localization for image-guided radiotherapy. *Int J Radiat Oncol Biol Phys*. 2003;57(3):635–644.

Lawton CA, Won M, Pilepich MV, et al. Long-term treatment sequelae following external beam irradiation for adenocarcinoma of the prostate: analysis of RTOG studies 7506 and 7706. *Int J Radiat Oncol Biol Phys*. 1991;21(4):935–939.

Lawton CA, DeSilvio M, Roach M, et al. An update of the phase III trial comparing whole pelvic to prostate only radiotherapy and neoadjuvant to adjuvant total androgen suppression: updated analysis of RTOG 94-13, with emphasis on unexpected hormone/radiation interactions. *Int J Radiat Oncol Biol Phys*. 2007;69(3):646–655.

Leclerc G, Lavallée M-C, Roy R, et al. Prostatic edema in 125I permanent prostate implants: dynamical dosimetry taking volume changes into account. *Med Phys*. 2006;33(3):574–583.

Lee WR, Hanlon AL, Hanks GE. Prostate specific antigen nadir following external beam radiation therapy for clinically localized prostate cancer: the relationship between nadir level and disease-free survival. *J Urol*. 1996;156(2 Pt 1):450–453.

Lee WR, Bae K, Lawton C, et al. Late toxicity and biochemical recurrence after external-beam radiotherapy combined with permanent-source prostate brachytherapy. *Cancer*. 2007;109(8):1506–1512.

Lee WR, Dignam JJ, Amin MB, et al. Randomized phase III noninferiority study comparing two radiotherapy fractionation schedules in patients with low-risk prostate cancer. *J Clin Oncol*. 2016;34(20):2325–2332.

Lee J, Spratt D, Liss A, et al. Vessel-sparing radiation and functional anatomy-based preservation for erectile function after prostate radiotherapy. *Lancet Oncol*. 2016;17(5):e198–e208.

Lee J, Hobbs RF, Zahurak M, et al. Phase II study of intraoperative dosimetry for prostate brachytherapy using registered ultrasound and fluoroscopy. *Brachytherapy*.

2018;17(6):858–865.

Leeman JE, Romesser PB, Zhou Y, et al. Proton therapy for head and neck cancer: expanding the therapeutic window. *Lancet Oncol*. 2017;18(5):e254–e265.

Leibel SA, Hanks GE, Kramer S. Patterns of care outcome studies: results of the national practice in adenocarcinoma of the prostate. *Int J Radiat Oncol Biol Phys*. 1984;10(3):401–409.

Leibel SA, Heimann R, Kutcher GJ, et al. Three-dimensional conformal radiation therapy in locally advanced carcinoma of the prostate: preliminary results of a phase I dose-escalation study. *Int J Radiat Oncol Biol Phys*. 1994;28(1):55–65.

Lin SH, Sugar E, Teslow T, et al. Comparison of daily couch shifts using MVCT (TomoTherapy) and B-mode ultrasound (BAT system) during prostate radiotherapy. *Technol Cancer Res Treat*. 2008;7(4):279–285.

Ljung G, Egevad L, Norberg M, et al. Assessment of proliferation indicators in residual prostatic adenocarcinoma cells after radical external beam radiotherapy. *Prostate*. 1996;29(5):303–310.

Loblaw A, Cheung P, D'Alimonte L, et al. Prostate stereotactic ablative body radiotherapy using a standard linear accelerator: toxicity, biochemical, and pathological outcomes. *Radiother Oncol*. 2013;107(2):153–158.

Lukka H, Hayter C, Julian JA, et al. Randomized trial comparing two fractionation schedules for patients with localized prostate cancer. *J Clin Oncol*. 2005;23(25):6132–6138.

Luxton G, Hancock SL, Boyer AL. Dosimetry and radiobiologic model comparison of IMRT and 3D conformal radiotherapy in treatment of carcinoma of the prostate. *Int J Radiat Oncol Biol Phys*. 2004;59(1):267–284.

MacReady N. The promise of protons in cancer therapy. *J Natl*

Cancer Inst. 2012;104(9):648–649.

Mak RH, Hunt D, Efstathiou JA, et al. Acute and late urinary toxicity following radiation in men with an intact prostate gland or after a radical prostatectomy: a secondary analysis of RTOG 94-08 and 96-01. *Urol Oncol*. 2016;34(10):430.e1–430.e7.

Mariados N, Sylvester J, Shah D, et al. Hydrogel spacer prospective multicenter randomized controlled pivotal trial: dosimetric and clinical effects of perirectal spacer application in men undergoing prostate image guided intensity modulated radiation therapy. *Int J Radiat Oncol Biol Phys*. 2015;92(5):971–977.

Martens C, Pond G, Webster D, et al. Relationship of the International Prostate Symptom score with urinary flow studies, and catheterization rates following 125I prostate brachytherapy. *Brachytherapy*. 2006;5(1):9–13.

McGowan SE, Burnet NG, Lomax AJ. Treatment planning optimisation in proton therapy. *Br J Radiol*. 2013;86(1021) [20120288].

Meier RM, Bloch DA, Cotrutz C, et al. Multicenter trial of stereotactic body radiation therapy for low- and intermediate-risk prostate cancer: survival and toxicity endpoints. *Int J Radiat Oncol Biol Phys*. 2018;102(2):296–303.

Ménard C, Iupati D, Publicover J, et al. MR-guided prostate biopsy for planning of focal salvage after radiation therapy. *Radiology*. 2015;274(1):181–191.

Ménard C, Paulson E, Nyholm T, et al. Role of prostate MR imaging in radiation oncology. *Radiol Clin North Am*. 2018;56(2):319–325.

Mendenhall NP, Li Z, Hoppe BS, et al. Early outcomes from three prospective trials of image-guided proton therapy for prostate cancer. *Int J Radiat Oncol Biol Phys*. 2012;82(1):213–221.

Merrick GS, Wallner K, Butler WM, et al. A comparison of radiation dose to the bulb of the penis in men with and without prostate brachytherapy-induced erectile dysfunction. *Int J Radiat Oncol Biol Phys*. 2001;50(3):597–604.

Merrick GS, Butler WM, Galbreath RW, et al. Erectile function after permanent prostate brachytherapy. *Int J Radiat Oncol Biol Phys*. 2002;52(4):893–902.

Merrick GS, Butler WM, Wallner KE, et al. Prostate-specific antigen spikes after permanent prostate brachytherapy. *Int J Radiat Oncol Biol Phys*. 2002;54(2):450–456.

Merrick GS, Butler WM, Wallner KE, et al. Prophylactic versus therapeutic alpha-blockers after permanent prostate brachytherapy. *Urology*. 2002;60(4):650–655.

Merrick GS, Butler WM, Wallner KE, et al. Long-term urinary quality of life after permanent prostate brachytherapy. *Int J Radiat Oncol Biol Phys*. 2003;56(2):454–461.

Merrick GS, Butler WM, Wallner KE, et al. Efficacy of neoadjuvant bicalutamide and dutasteride as a cytoreductive regimen before prostate brachytherapy. *Urology*. 2006;68(1):116–120.

Merrick GS, Butler WM, Galbreath RW, et al. Prostate cancer death is unlikely in high-risk patients following quality permanent interstitial brachytherapy. *BJU Int*. 2011;107(2):226–232.

Merrick GS, Tennant A, Wallner KE, et al. Does supplemental external beam radiation therapy impact urinary, bowel, and erectile function following permanent prostate brachytherapy?: results of two prospective randomized trials. *J Contemp Brachyther*. 2017;9(5):403–409.

Michalski JM, Moughan J, Purdy J, et al. Effect of standard vs dose-escalated radiation therapy for patients with intermediate-risk prostate cancer. *JAMA Oncol*. 2018;4(6):e180039.

Michalski JM, Yan Y, Watkins-Bruner D, et al. Preliminary toxicity analysis of 3-dimensional conformal radiation therapy versus intensity modulated radiation therapy on the high-dose arm of the Radiation Therapy Oncology Group 0126 prostate cancer trial. *Int J Radiat Oncol Biol Phys*. 2013;87(5):932–938.

Miralbell R, Roberts SA, Zubizarreta E, et al. Dose-fractionation sensitivity of prostate cancer deduced from radiotherapy outcomes of 5,969 patients in seven international institutional datasets: α/β = 1.4 (0.9–2.2) gy. *Int J Radiat Oncol Biol Phys*. 2012;82(1):e17–e24.

Mitchell DM, Swindell R, Elliott T, et al. Analysis of prostate-specific antigen bounce after I(125) permanent seed implant for localised prostate cancer. *Radiother Oncol*. 2008;88(1):102–107.

Mitchell JM. Urologists' use of intensity-modulated radiation therapy for prostate cancer. *N Engl J Med*. 2013;369(17):1629–1637.

Mizowaki T, Cohen GN, Fung AY, et al. Towards integrating functional imaging in the treatment of prostate cancer with radiation: the registration of the MR spectroscopy imaging to ultrasound/CT images and its implementation in treatment planning. *Int J Radiat Oncol Biol Phys*. 2002;54(5):1558–1564.

Mock U, Bogner J, Georg D, et al. Comparative treatment planning on localized prostate carcinoma. *Strahlenther Onkol*. 2005;181(7):448–455.

Mock S, Leapman M, Stock RG, et al. Risk of urinary incontinence following post-brachytherapy transurethral resection of the prostate and correlation with clinical and treatment parameters. *J Urol*. 2013;190(5):1805–1810.

Mohammed N, Kestin L, Ghilezan M, et al. Comparison of acute and late toxicities for three modern high-dose radiation treatment techniques for localized prostate cancer. *Int J Radiat Oncol Biol Phys*. 2012;82(1):204–212.

Mohan R, Mageras GS, Baldwin B, et al. Clinically relevant optimization of 3-D conformal treatments. *Med Phys*. 1992;19(4):933–944.

Mohler JL, Lee RJ, Armstrong AJ, et al. NCCN clinical practice guidelines in oncology. *J Natl Compr Canc Netw*. 2016.

Morikawa L, Roach M 3rd. Pelvic nodal radiotherapy in patients with unfavorable intermediate and high-risk prostate cancer: evidence, rationale, and future directions. *Int J Radiat Oncol Biol Phys*. 2011;80(1):6–16.

Morris WJ, Tyldesley S, Rodda S, et al. Androgen Suppression Combined with Elective Nodal and Dose Escalated Radiation Therapy (the ASCENDE-RT Trial): an analysis of survival endpoints for a randomized trial comparing a low-dose-rate brachytherapy boost to a dose-escalated external beam boost for high- and intermediate-risk prostate cancer. *Int J Radiat Oncol Biol Phys*. 2017;98(2):275–285.

Morton GC. The emerging role of high-dose-rate brachytherapy for prostate cancer. *Clin Oncol*. 2005;17(4):219–227.

Morton GC, Hoskin PJ. Brachytherapy: current status and future strategies—Can high dose rate replace low dose rate and external beam radiotherapy? *Clin Oncol*. 2013;25(8):474–482.

Morton G, Chung H, McGuffin M, et al. Prostate HDR monotherapy: initial efficacy results from a randomized trial of one versus two fractions. *Brachytherapy*. 2017;16(3):S19–S20.

Mostofi FK, Davis CJ, Sesterhenn IA. Pathology of carcinoma of the prostate. *Cancer*. 1992;70(1 Suppl):235–253.

Mostofi FK, Sesterhenn IA, Davis CJ. A pathologist's view of prostatic carcinoma. *Cancer*. 1993;71(3 Suppl):906–932.

Mullaney LM, O'Shea E, Dunne MT. A randomized trial comparing bladder volume consistency during fractionated prostate radiation therapy. *Pract Radiat Oncol*. 2014;4(5):e203–e212.

Mullokandov E, Gejerman G. Analysis of serial CT scans to assess template and catheter movement in prostate HDR brachytherapy. *Int J Radiat Oncol Biol Phys*. 2004;58(4):1063–1071.

n.a. Roentgen-rays in the treatment of skin diseases and for the removal of hair. July 1900 (J Cutan Genitourin Dis). *Arch Dermatol*. 1983;119(2):162–177.

Nabid A, Carrier N, Martin AG, et al. Duration of androgen deprivation therapy in high-risk prostate cancer: a randomized phase III trial. *Eur Urol*. 2018;74(4):432–441.

Nag S, Shi P, Liu B, et al. Comparison of real-time intraoperative ultrasound-based dosimetry with postoperative computed tomography-based dosimetry for prostate brachytherapy. *Int J Radiat Oncol Biol Phys*. 2008;70(1):311–317.

Nanda A, Chen MH, Moran BJ, et al. Cardiovascular comorbidity and mortality in men with prostate cancer treated with brachytherapy-based radiation with or without hormonal therapy. *Int J Radiat Oncol Biol Phys*. 2013;85(5):e209–e215.

National Comprehensive Cancer Network Inc. *NCCN clinical practice guidelines in oncology (NCCN guidelines) acute lymphoblastic leukemia*. [Available from:] https://www.nccn.org/professionals/physician_gls/pdf/prostat 2016.

National Institutes of Health. *U.S. National Library of Medicine. Androgen-deprivation therapy and radiation therapy in treating patients with prostate cancer*. [n.d.; Available from:] https://clinicaltrials.gov/ct2/show/NCT01368588.

Neglia WJ, Hussey DH, Johnson DE. Megavoltage radiation therapy for carcinoma of the prostate. *Int J Radiat Oncol Biol Phys*. 1977;2(9–10):873–883.

Nguyen J, Wallner K, Han B, et al. Urinary morbidity in brachytherapy patients with median lobe hyperplasia. *Brachytherapy*. 2002;1(1):42–47.

Nguyen PL, Je Y, Schutz FA, et al. Association of androgen deprivation therapy with cardiovascular death in pateints with prostate cancer: a meta-analysis of randomized trials. *JAMA*. 2011;306(21):2359–2366.

Nguyen PL, Devlin PM, Beard CJ, et al. High-dose-rate brachytherapy for prostate cancer in a previously radiated patient with polyethylene glycol hydrogel spacing to reduce rectal dose: case report and review of the literature. *Brachytherapy*. 2013;12(1):77–83.

Niemierko A, Urie M, Goitein M. Optimization of 3D radiation therapy with both physical and biological end points and constraints. *Int J Radiat Oncol Biol Phys*. 1992;23(1):99–108.

Oliai C, Lanciano R, Sprandio B, et al. Stereotactic body radiation therapy for the primary treatment of localized prostate cancer. *J Radiat Oncol*. 2013;2(1):63–70.

Orio PF 3rd, Nguyen PL, Buzurovic I, et al. The decreased use of brachytherapy boost for intermediate and high-risk prostate cancer despite evidence supporting its effectiveness. *Brachytherapy*. 2016;15(6):701–706.

Palma D, Vollans E, James K, et al. Volumetric modulated arc therapy for delivery of prostate radiotherapy: comparison with intensity-modulated radiotherapy and three-dimensional conformal radiotherapy. *Int J Radiat Oncol Biol Phys*. 2008;72(4):996–1001.

Pan C, Kim K, Taylor J, et al. Influence of 3D-CRT pelvic irradiation on outcome in prostate cancer treated with external beam radiotherapy. *Int J Radiat Oncol Biol Phys*. 2002;53(5):1139–1145.

Pasteau O. Traitement du cancer de la prostate par le radium. *Rev Maladies Nutr*. 1911;363–398.

Pasteau D. The radium treatment of cancer of the prostate. *Arch Roentgenol Ray*. 1913;28:396.

Patel C, Elshaikh MA, Angermeier K, et al. PSA bounce predicts early success in patients with permanent iodine-125 prostate implant. *Urology*. 2004;63(1):110–113.

Peeters ST, Heemsbergen WD, Koper PC, et al. Dose-response in radiotherapy for localized prostate cancer: results of the Dutch multicenter randomized phase III trial comparing 68 Gy of radiotherapy with 78 Gy. *J Clin Oncol*. 2006;24(13):1990–1996.

Penzkofer T, Tuncali K, Fedorov A, et al. Transperineal in-bore 3-T MR imaging–guided prostate biopsy: a prospective clinical observational study. *Radiology*. 2015;274(1):170–180.

Piana R. *Is Proton-Beam Therapy Facing a Difficult Future?*. [The ASCO Post; n.d.; Available from] http://www.ascopost.com/issues/august-10-2015/is-proton-beam-therapy-facing-a-difficult-future/; 2015.

Pickles T, Kim-Sing C, Morris WJ, et al. Evaluation of the Houston biochemical relapse definition in men treated with prolonged neoadjuvant and adjuvant androgen ablation and assessment of follow-up lead-time bias. *Int J Radiat Oncol Biol Phys*. 2003;57(1):11–18.

Pickles T. Prostate-specific antigen (PSA) bounce and other fluctuations: which biochemical relapse definition is least prone to PSA false calls? An analysis of 2030 men treated for prostate cancer with external beam or brachytherapy with or without adjuvant androgen deprivation therapy. [the; British Columbia Cancer Agency Prostate Cohort Outcomes Initiative] *Int J Radiat Oncol Biol Phys*. 2006;64(5):1355–1359.

Pilepich MV, Prasad SC, Perez CA. Computed tomography in definitive radiotherapy of prostatic carcinoma, part 2: definition of target volume. *Int J Radiat Oncol Biol Phys*. 1982;8(2):235–239.

Pilepich MV, Krall JM, al-Sarraf M, et al. Androgen deprivation with radiation therapy compared with radiation therapy alone for locally advanced prostatic carcinoma: a randomized comparative trial of the Radiation Therapy Oncology Group. *Urology*. 1995;45(4):616–623.

Pinkawa M, Pursch-Lee M, Asadpour B, et al. Image-guided radiotherapy for prostate cancer. Implementation of ultrasound-based prostate localization for the analysis of inter- and intrafraction organ motion. *Strahlenther Onkol*. 2008;184(12):679–685.

Pisansky TM, Hunt D, Gomella LG, et al. Radiation Therapy Oncology Group 9910. Phase 3 trial to evaluate the duration of neoadjuvant (NEO) total androgen suppression (TAS) and radiation therapy (RT) in intermediate-risk prostate cancer (PCa). *Int J Radiat Oncol Biol Phys*. 2013;87(2 Suppl):S1.

Pollack A, Walker G, Buyyounouski M, et al. Five year results of a randomized external beam radiotherapy hypofractionation trial for prostate cancer. *Int J Radiat Oncol Biol Phys*. 2011;81(2 Suppl):S1.

Pollack A, Zagars GK, Antolak JA, et al. Prostate biopsy status and PSA nadir level as early surrogates for treatment failure: analysis of a prostate cancer randomized radiation dose escalation trial. *Int J Radiat Oncol Biol Phys*. 2002;54(3):677–685.

Pollack A, Zagars GK, Starkschall G, et al. Prostate cancer radiation dose response: results of the M D Anderson phase III randomized trial. *Int J Radiat Oncol Biol Phys*. 2002;53(5):1097–1105.

Pommier P, Chabaud S, Lagrange J, et al. Is there a role for pelvic irradiation in localized prostate adenocarcinoma? Preliminary results of GETUG-01. *J Clin Oncol*. 2007;25(34):5366–5373.

Potharaju M, Subramanaiam R, Venkataraman M, et al. A Report on the clinical outcome after high-dose rate (HDR) brachytherapy as monotherapy in early prostate cancer. *Cureus*. 2015;7(8):e303.

Potters L, Torre T, Fearn PA, et al. Potency after permanent prostate brachytherapy for localized prostate cancer. *Int J Radiat Oncol Biol Phys*. 2001;50(5):1235–1242.

Potters L, Huang D, Calugaru E, et al. Importance of implant dosimetry for patients undergoing prostate brachytherapy. *Urology*. 2003;62(6):1073–1077.

Prestidge BR, Hoak DC, Grimm PD, et al. Posttreatment biopsy results following interstitial brachytherapy in early-stage prostate cancer. *Int J Radiat Oncol Biol Phys*. 1997;37(1):31–39.

Prestidge BR, Winter K, Sanda MG, et al. Initial Report of NRG Oncology/RTOG 0232: a phase 3 study comparing combined external beam radiation and transperineal interstitial permanent brachytherapy with brachytherapy alone for selected patients with intermediate-risk prostatic carcinoma. *Int J Radiat Oncol Biol Phys*. 2016;96(2):S4.

Raina R, Agarwal A, Goyal KK, et al. Long-term potency after iodine-125 radiotherapy for prostate cancer and role of sildenafil citrate. *Urology*. 2003;62(6):1103–1108.

Rastinehad A, Turkbey B, Salami S, et al. Improving detection of clinically significant prostate cancer: magnetic resonance imaging/transrectal ultrasound fusion guided prostate biopsy. *J Urol*. 2014;191(6):1749–1754.

Ray GR, Bagshaw MA. The role of radiation therapy in the definitive treatment of adenocarcinoma of the prostate. *Ann Rev Med*. 1975;26(1):567–588.

Reed D, Wallner K, Merrick G, et al. Clinical correlates to PSA spikes and positive repeat biopsies after prostate brachytherapy. *Urology*. 2003;62(4):683–688.

Roach M 3rd, Winter K, Michalski J, et al. Mean dose of radiation to the bulb of the penis correlates with risk of erectile dysfunction at 24 months: preliminary analysis of Radiation Therapy Oncology Group (RTOG) phase I/II dose escalation trial 94-06. *Int J Radiat Oncol Biol Phys*. 2000;48(Suppl):316.

Roach M, DeSilvio M, Lawton C, Radiation Therapy Oncology Group 9413, et al. Phase III trial comparing whole-pelvic versus prostate-only radiotherapy and neoadjuvant versus adjuvant combined androgen suppression: radiation therapy oncology group 9413. *J Clin Oncol*. 2003;21(10):1904–1911.

Roach M, Hanks G, Thames H, et al. Defining biochemical failure following radiotherapy with or without hormonal therapy in men with clinically localized prostate cancer: recommendations of the RTOG-ASTRO Phoenix Consensus Conference. *Int J Radiat Oncol Biol Phys*. 2006;65(4):965–974.

Roach M, Bae K, Speight J, et al. Short-term neoadjuvant androgen deprivation therapy and external-beam radiotherapy for locally advanced prostate cancer: long-term results of RTOG 8610. *J Clin Oncol*. 2008;26(4):585–591.

Roberson PL, Narayana V, McShan DL, et al. Source placement error for permanent implant of the prostate. *Med Phys*. 1997;24(2):251–257.

Robinson JW, Moritz S, Fung T. Meta-analysis of rates of erectile function after treatment of localized prostate carcinoma. *Int J Radiat Oncol Biol Phys*. 2002;54(4):1063–1068.

Rodda S, Tyldesley S, Morris WJ, et al. ASCENDE-RT: an analysis of treatment-related morbidity for a randomized trial comparing a low-dose-rate brachytherapy boost with a dose-escalated external beam boost for high- and intermediate-risk prostate cancer. *Int J Radiat Oncol Biol Phys*. 2017;98(2):286–295.

Rosenman J, Chaney EL, Sailer S, et al. Recent advances in radiotherapy treatment planning. *Cancer Invest*. 1991;9(4):465–481.

Royce TJ, Chen MH, Wu J, et al. Surrogate end points for all-cause mortality in men with localized unfavorable-risk prostate cancer treated with radiation therapy vs radiation therapy plus androgen deprivation therapy. *JAMA Oncol*. 2017;3(5):652–658.

Sanda MG, Dunn RL, Michalski J, et al. Quality of life and satisfaction with outcome among prostate-cancer survivors. *N Engl J Med*. 2008;358(12):1250–1261.

Sanghani MV, Ching J, Schultz D, et al. Impact on rectal dose from the use of a prostate immobilization and rectal localization device for patients receiving dose escalated 3D conformal radiation therapy. *Urol Oncol*. 2004;22(3):165–168.

Scardino PT, Wheeler TM. Prostatic biopsy after irradiation therapy for prostatic cancer. *Urology*. 1985;25(2 Suppl):39–46.

Schroeck F, Jacobs B, Bhayani S, et al. Cost of new technologies in prostate cancer treatment: systematic review of costs and cost effectiveness of robotic-assisted laparoscopic prostatectomy, intensity-modulated radiotherapy, and proton beam therapy. *Eur Urol*. 2017;72(5):712–735.

Shah C, Lanni TB, Ghilezan MI, et al. Brachytherapy provides comparable outcomes and improved cost-effectiveness in the treatment of low/intermediate prostate cancer. *Brachytherapy*. 2012;11(6):441–445.

Sharma NK, Li T, Chen DY, et al. Intensity-modulated radiotherapy reduces gastrointestinal toxicity in patients treated with androgen deprivation therapy for prostate cancer. *Int J Radiat Oncol Biol Phys*. 2011;80(2):437–444.

Sheets N, Goldin G, Meyer A, et al. Intensity-modulated radiation therapy, proton therapy, or conformal radiation therapy and morbidity and disease control in localized prostate cancer. *JAMA*. 2012;307(15):1611–1620.

Shilkrut M, McLaughlin PW, Merrick GS, et al. Interval to biochemical failure predicts clinical outcomes in patients with high-risk prostate cancer treated by combined-modality radiation therapy. *Int J Radiat Oncol Biol Phys*. 2013;86(4):721–728.

Shilkrut M, Merrick GS, McLaughlin PW, et al. The addition of low-dose-rate brachytherapy and androgen-deprivation therapy decreases biochemical failure and prostate cancer death compared with dose-escalated external-beam radiation therapy for high-risk prostate cancer. *Cancer*. 2013;119(3):681–690.

Shipley WU, Verhey LJ, Munzenrider JE, et al. Advanced prostate cancer: the results of a randomized comparative trial of high dose irradiation boosting with conformal protons compared with conventional dose irradiation using photons alone. *Int J Radiat Oncol Biol Phys*. 1995;32(1):3–12.

Shiraishi Y, Yorozu A, Ohashi T, et al. Dose constraint for minimizing grade 2 rectal bleeding following brachytherapy combined with external beam radiotherapy for localized prostate cancer: rectal dose-volume histogram analysis of 457 patients. *Int J Radiat Oncol Biol Phys*. 2011;81(3):e127–e133.

Siders DB, Lee F. Histologic changes of irradiated prostatic carcinoma diagnosed by transrectal ultrasound. *Hum Pathol*. 1992;23(4):344–351.

Siepe G, Buwenge M, Nguyen NP, et al. Postoperative hypofractionated radiation therapy in prostate carcinoma: a systematic review. *Anticancer Res*. 2018;38(3):1221–1230.

Slater JD, Rossi CJ, Yonemoto LT, et al. Proton therapy for prostate cancer: the initial Loma Linda University experience. *Int J Radiat Oncol Biol Phys*. 2004;59(2):348–352.

Smith GD, Pickles T, Crook J, et al. Brachytherapy improves biochemical failure–free survival in low- and intermediate-risk prostate cancer compared with conventionally fractionated external beam radiation therapy: a propensity score matched analysis. *Int J Radiat Oncol Biol Phys*. 2015;91(3):505–516.

Snyder KM, Stock RG, Buckstein M, et al. Long-term potency preservation following brachytherapy for prostate cancer. *BJU Int*. 2012;110(2):221–225.

Someya M, Hori M, Tateoka K, et al. Results and DVH analysis of late rectal bleeding in patients treated with 3D-CRT or IMRT for localized prostate cancer. *J Radiat Res*. 2014;56(1):122–127.

Song DY, Jain AK, Zhang Z, et al. Dynamic intraoperative dosimetry for prostate brachytherapy using a nonisocentric C-arm. *Brachytherapy*. 2011;10(2):98–106.

Song DY, Herfarth KK, Uhl M, et al. A multi-institutional clinical trial of rectal dose reduction via injected polyethylene-glycol hydrogel during intensity modulated radiation therapy for prostate cancer: analysis of dosimetric outcomes. *Int J Radiat Oncol Biol Phys*. 2013;87(1):81–87.

Spratt DE, Zelefsky MJ. Point: there is a need for supplemental XRT with brachytherapy in the treatment of intermediate-risk prostate cancer patients. *Brachytherapy*. 2013;12(5):389–392.

Spratt DE, Pei X, Yamada J, et al. Long-term survival and toxicity in patients treated with high-dose intensity modulated radiation therapy for localized prostate cancer. *Int J Radiat*

Oncol Biol Phys. 2013;85(3):686–692.

Spratt DE, Evans MJ, Davis BJ, et al. Androgen receptor upregulation mediates radioresistance after ionizing radiation. *Cancer Res*. 2015;75(22):4688–4696.

Spratt DE, Soni PD, McLaughlin PW, et al. American Brachytherapy Society Task Group report: combination of brachytherapy and external beam radiation for high-risk prostate cancer. *Brachytherapy*. 2017;16(1):1–12.

Spratt D, Lee J, Dess R, et al. Vessel-sparing radiotherapy for localized prostate cancer to preserve erectile function: a single-arm phase 2 trial. *Eur Urol*. 2017;72(4):617–624.

Spratt D, Vargas H, Zumsteg Z, et al. Patterns of lymph node failure after dose-escalated radiotherapy: implications for extended pelvic lymph node coverage. *Eur Urol*. 2017;71(1):37–43.

Stasi M, Munoz F, Fiorino C, et al. Emptying the rectum before treatment delivery limits the variations of rectal dose–volume parameters during 3DCRT of prostate cancer. *Radiother Oncol*. 2006;80(3):363–370.

Stock RG, Klein TJ, Cesaretti JA, et al. Prognostic significance of 5-year PSA value for predicting prostate cancer recurrence after brachytherapy alone and combined with hormonal therapy and/or external beam radiotherapy. *Int J Radiat Oncol Biol Phys*. 2009;74(3):753–758.

Stone NN, Stock RG. Prostate brachytherapy: treatment strategies. *J Urol*. 1999;162(2):421–426.

Stone NN, Roy J, Hong S, et al. Prostate gland motion and deformation caused by needle placement during brachytherapy. *Brachytherapy*. 2002;1(3):154–160.

Stone NN, Stock RG, Unger P. Eradication of prostate cancer by brachytherapy: post-treatment prostate biopsy results in a large cohort of men treated with mono- or multimodality therapy. *Int J Radiat Oncol Biol Phys*. 2004;60(1

Suppl):S436.

Stone NN, Stock RG, Cesaretti JA, et al. Local control following permanent prostate brachytherapy: effect of high biologically effective dose on biopsy results and oncologic outcomes. *Int J Radiat Oncol Biol Phys*. 2010;76(2):355–360.

Susil RC, Camphausen K, Choyke P, et al. System for prostate brachytherapy and biopsy in a standard 1.5 T MRI scanner. *Magn Reson Med*. 2004;52(3):683–687.

Susil RC, McNutt TR, DeWeese TL, et al. Effects of prostate-rectum separation on rectal dose from external beam radiotherapy. *Int J Radiat Oncol Biol Phys*. 2010;76(4):1251–1258.

Svetec D, McCabe K, Peretsman S, et al. Prostate rebiopsy is a poor surrogate of treatment efficacy in localized prostate cancer. *J Urol*. 1998;159(5):1606–1608.

Taira AV, Merrick GS, Galbreath RW, et al. Natural history of clinically staged low- and intermediate-risk prostate cancer treated with monotherapeutic permanent interstitial brachytherapy. *Int J Radiat Oncol Biol Phys*. 2010;76(2):349–354.

Talcott JA, Clark JA, Stark PC, et al. Long-term treatment related complications of brachytherapy for early prostate cancer: a survey of patients previously treated. *J Urol*. 2001;166(2):494–499.

Tanaka N, Asakawa I, Nakai Y, et al. Comparison of PSA value at last follow-up of patients who underwent low-dose rate brachytherapy and intensity-modulated radiation therapy for prostate cancer. *BMC Cancer*. 2017;17(1):573.

Tarish FL, Schultz N, Tanoglidi A, et al. Castration radiosensitizes prostate cancer tissue by impairing DNA double-strand break repair. *Sci Transl Med*. 2015;7(312):312re11.

Ten Haken RK, Forman JD, Heimburger DK, et al. Treatment planning issues related to prostate movement in response to differential filling of the rectum and bladder. *Int J Radiat Oncol Biol Phys*. 1991;20(6):1317–1324.

Terk MD, Stock RG, Stone NN. Identification of patients at increased risk for prolonged urinary retention following radioactive seed implantation of the prostate. *J Urol*. 1998;160(4):1379–1382.

Thames H, Kuban D, Levy L, et al. Comparison of alternative biochemical failure definitions based on clinical outcome in 4839 prostate cancer patients treated by external beam radiotherapy between 1986 and 1995. *Int J Radiat Oncol Biol Phys*. 2003;57(4):929–943.

Toledano A, Chauveinc L, Flam T, et al. PSA bounce after permanent implant prostate brachytherapy may mimic a biochemical failure: a study of 295 patients with a minimum 3-year followup. *Brachytherapy*. 2006;5(2):122–126.

Trofimov A, Nguyen PL, Coen JJ, et al. Radiotherapy treatment of early-stage prostate cancer with IMRT and protons: a treatment planning comparison. *Int J Radiat Oncol Biol Phys*. 2007;69(2):444–453.

Tsai HT, Keating NL, Van Den Eeden SK, et al. Risk of diabetes among patients receiving primary androgen deprivation therapy for clinically localized prostate cancer. *J Urol*. 2015;193(6):1956–1962.

Tsubokura T, Yamazaki H, Masui K, et al. Comparison of image-guided intensity-modulated radiotherapy and low-dose rate brachytherapy with or without external beam radiotherapy in patients with localized prostate cancer. *Sci Rep*. 2018;8(1):10538.

Turkbey B, Shah VP, Pang Y, et al. Is apparent diffusion coefficient associated with clinical risk scores for prostate cancers that are visible on 3-T MR images? *Radiology*. 2011;258(2):488–495.

Tward JD, Jarosek S, Chu H, et al. Time course and accumulated risk of severe urinary adverse events after high- versus low-dose-rate prostate brachytherapy with or without external beam radiation therapy. *Int J Radiat Oncol Biol Phys*. 2016;95(5):1443–1453.

Valdagni R, Italia C, Montanaro P, et al. Is the alpha-beta ratio of prostate cancer really low? A prospective, non-randomized trial comparing standard and hyperfractionated conformal radiation therapy. *Radiother Oncol*. 2005;75(1):74–82.

Valicenti RK, DeSilvio M, Hanks GE, et al. Posttreatment prostatic-specific antigen doubling time as a surrogate endpoint for prostate cancer-specific survival: an analysis of Radiation Therapy Oncology Group Protocol 92-02. *Int J Radiat Oncol Biol Phys*. 2006;66(4):1064–1071.

van Zijtveld M, Dirkx M, Breuers M, et al. Evaluation of the "dose of the day" for IMRT prostate cancer patients derived from portal dose measurements and cone-beam CT. *Radiother Oncol*. 2010;96(2):172–177.

Vargas C, Fryer A, Mahajan C, et al. Dose-volume comparison of proton therapy and intensity-modulated radiotherapy for prostate cancer. *Int J Radiat Oncol Biol Phys*. 2008;70(3):744–751.

Wallner K. Prostate brachytherapy under local anesthesia; lessons from the first 600 patients. *Brachytherapy*. 2002;1(3):145–148.

Wallner K, Roy J, Harrison L. Dosimetry guidelines to minimize urethral and rectal morbidity following transperineal I-125 prostate brachytherapy. *Int J Radiat Oncol Biol Phys*. 1995;32(2):465–471.

Warde P, Mason M, Ding K, et al. NCIC CTG PR3/MRC UK PR07 investigators. Combined androgen deprivation therapy and radiation therapy for locally advanced prostate cancer: a randomised, phase 3 trial. *Lancet*. 2011;378(9809):2104–

2111.

Weiner JP, Schwartz D, Shao M, et al. Stereotactic radiotherapy of the prostate: fractionation and utilization in the United States. *Radiat Oncol J*. 2017;35(2):137–143.

Westendorp H, Hoekstra CJ, Immerzeel JJ, et al. Cone-beam CT-based adaptive planning improves permanent prostate brachytherapy dosimetry: an analysis of 1266 patients. *Med Phys*. 2017;44(4):1257–1267.

Westphalen AC, Coakley FV, Roach M, et al. Locally recurrent prostate cancer after external beam radiation therapy: diagnostic performance of 1.5-t endorectal MR imaging and MR spectroscopic imaging for detection. *Radiology*. 2010;256(2):485–492.

Whitaker M, Hruby G, Lovett A, et al. Prostate HDR brachytherapy catheter displacement between planning and treatment delivery. *Radiother Oncol*. 2011;101(3):490–494.

Whitmore WF, Hilaris B, Grabstald H. Retropubic implantation to iodine 125 in the treatment of prostatic cancer. *J Urol*. 1972;108(6):918–920.

Widmark A, Klepp O, Solberg A, Swedish Association for Urological Oncology 3, et al. Endocrine treatment, with or without radiotherapy, in locally advanced prostate cancer (SPCG-7/SFUO-3): an open randomised phase III trial. *Lancet*. 2009;373(9660):301–308.

Widmark A, Gunnlaugsson A, Beckman L, et al. Extreme hypofractionation versus conventionally fractionated radiotherapy for intermediate risk prostate cancer: early toxicity results from the scandinavian randomized phase III trial “HYPO-RT-PC.”. *Int J Radiat Oncol Biol Phys*. 2016;96(5):938–939.

Willins J, Wallner K. CT-based dosimetry for transperineal I-125 prostate brachytherapy. *Int J Radiat Oncol Biol Phys*. 1997;39(2):347–353.

Withers HR. Biologic basis for altered fractionation schemes. *Cancer*. 1985;55(9 Suppl):2086–2095.

Wortel RC, Incrocci L, Pos FJ, et al. Acute toxicity after image-guided intensity modulated radiation therapy compared to 3D conformal radiation therapy in prostate cancer patients. *Int J Radiat Oncol Biol Phys*. 2015;91(4):737–744.

Wortel RC, Incrocci L, Pos FJ, et al. Late side effects after image guided intensity modulated radiation therapy compared to 3D-conformal radiation therapy for prostate cancer: results from 2 prospective cohorts. *Int J Radiat Oncol Biol Phys*. 2016;95(2):680–689.

Wortel RC, Heemsbergen WD, Smeenk RJ, et al. Local protocol variations for image guided radiation therapy in the multicenter Dutch Hypofractionation (HYPRO) Trial: impact of rectal balloon and MRI delineation on anorectal dose and gastrointestinal toxicity levels. *Int J Radiat Oncol Biol Phys*. 2017;99(5):1243–1252.

Wysock J, Rosenkrantz A, Huang W, et al. A prospective, blinded comparison of magnetic resonance (MR) imaging-ultrasound fusion and visual estimation in the performance of MR-targeted prostate biopsy: the PROFUS trial. *Eur Urol*. 2014;66(2):343–351.

Yamada Y, Potters L, Zaider M, et al. Impact of intraoperative edema during transperineal permanent prostate brachytherapy on computer-optimized and preimplant planning techniques. *Am J Clin Oncol*. 2003;26(5):e130–e135.

Yamazaki H, Masui K, Suzuki G, et al. High-dose-rate brachytherapy monotherapy versus image-guided intensity-modulated radiotherapy with helical tomotherapy for patients with localized prostate cancer. *Cancers (Basel)*. 2018;10(9).

Yeh J, Lehrich B, Tran C, et al. Polyethylene glycol hydrogel rectal spacer implantation in patients with prostate cancer undergoing combination high-dose-rate brachytherapy and external beam radiotherapy. *Brachytherapy*. 2016;15(3):283–287.

Yeoh EE, Botten RJ, Butters J, et al. Hypofractionated versus conventionally fractionated radiotherapy for prostate carcinoma: final results of phase III randomized trial. *Int J Radiat Oncol Biol Phys*. 2011;81(5):1271–1278.

Yoshida K, Yamazaki H, Nose T, et al. Needle applicator displacement during high-dose-rate interstitial brachytherapy for prostate cancer. *Brachytherapy*. 2010;9(1):36–41.

Young HH. Technique of radium treatment of cancer of the prostate and seminal vesicles. *Surg Gynecol Obstet*. 1922;34:93–98.

Zamboglou N, Tselis N, Baltas D, et al. High-dose-rate interstitial brachytherapy as monotherapy for clinically localized prostate cancer: treatment evolution and mature results. *Int J Radiat Oncol Biol Phys*. 2013;85(3):672–678.

Zapatero A, Guerrero A, Maldonado X, et al. High-dose radiotherapy with short-term or long-term androgen deprivation in localised prostate cancer (DART01/05 GICOR): a randomised, controlled, phase 3 trial. *Lancet Oncol*. 2015;16(3):320–327.

Zelefsky MJ, Whitmore WF. Long-term results of retropubic permanent 125iodine implantation of the prostate for clinically localized prostatic cancer. *J Urol*. 1997;158(1):23–29 [discussion 29–30].

Zelefsky MJ, Cowen D, Fuks Z, et al. Long term tolerance of high dose three-dimensional conformal radiotherapy in patients with localized prostate carcinoma. *Cancer*. 1999;85(11):2460–2468.

Zelefsky MJ, Yamada Y, Cohen G, et al. Postimplantation dosimetric analysis of permanent transperineal prostate implantation: improved dose distributions with an intraoperative computer-optimized conformal planning technique. *Int J Radiat Oncol Biol Phys*. 2000;48(2):601–608.

Zelefsky M, Chan HM, Fuks Z, et al. Correlation of long-term biochemical outcome with post-treatment biopsy results for patients treated with 3-dimensional conformal radiotherapy for prostate cancer. *Int J Radiat Oncol Biol Phys*. 2004;60(Suppl 1):S170.

Zelefsky MJ, Kuban DA, Levy LB, et al. Multi-institutional analysis of long-term outcome for stages T1–T2 prostate cancer treated with permanent seed implantation. *Int J Radiat Oncol Biol Phys*. 2007;67(2):327–333.

Zelefsky MJ, Levin EJ, Hunt M, et al. Incidence of late rectal and urinary toxicities after three-dimensional conformal radiotherapy and intensity-modulated radiotherapy for localized prostate cancer. *Int J Radiat Oncol Biol Phys*. 2008;70(4):1124–1129.

Zelefsky MJ, Reuter VE, Fuks Z, et al. Influence of local tumor control on distant metastases and cancer related mortality after external beam radiotherapy for prostate cancer. *J Urol*. 2008;179(4):1368–1373.

Zelefsky MJ, Shi W, Yamada Y, et al. Postradiotherapy 2-year prostate-specific antigen nadir as a predictor of long-term prostate cancer mortality. *Int J Radiat Oncol Biol Phys*. 2009;75(5):1350–1356.

Zelefsky MJ, Kollmeier M, Cox B, et al. Improved clinical outcomes with high-dose image guided radiotherapy compared with non-IGRT for the treatment of clinically localized prostate cancer. *Int J Radiat Oncol Biol Phys*. 2012;84(1):125–129.

Zeman EM. The biological basis of radiation oncology. Gunderson LL, Tepper JE. *Clinical radiation oncology*. ed 4. Elsevier: Philadelphia, PA; 2016:2–40.

Zietman AL. The titanic and the iceberg: prostate proton therapy and health care economics. *J Clin Oncol*. 2007;25(24):3565–3566.

Zietman AL, Tibbs MK, Dallow KC, et al. Use of PSA nadir to predict subsequent biochemical outcome following external beam radiation therapy for T1-2 adenocarcinoma of the prostate. *Radiother Oncol*. 1996;40(2):159–162.

Zietman AL, Christodouleas JP, Shipley WU. PSA bounces after neoadjuvant androgen deprivation and external beam radiation: impact on definitions of failure. *Int J Radiat Oncol Biol Phys*. 2005;62(3):714–718.

Zietman AL, DeSilvio ML, Slater JD, et al. Comparison of conventional-dose vs high-dose conformal radiation therapy in clinically localized adenocarcinoma of the prostate: a randomized controlled trial. *JAMA*. 2005;294(10):1233–1239.

Zietman AL, Bae K, Slater JD, et al. Randomized trial comparing conventional-dose with high-dose conformal radiation therapy in early-stage adenocarcinoma of the prostate: long-term results from Proton Radiation Oncology Group/American College of Radiology 95-09. *J Clin Oncol*. 2010;28(7):1106–1111.

---

[a] See also Outcomes for Brachytherapy

Focal Therapy for Prostate Cancer

Kae Jack Tay MBBS, MRCS(Ed), MMed(Surgery), MCI, FAMS (Urology),
Thomas J. Polascik MD

Introduction

The global incidence of prostate cancer is estimated at 30.6 per 100,000 per year and is the second most incident cancer among men (Ferlay et al., 2013). In the United States, it is the most common solid organ malignancy among men and the third leading cause of death (American Cancer Society, 2016). In a similar pattern, the incidence of prostate cancer has been observed to increase over a 10-year period, particularly in countries with a high human development index and per capita gross domestic product (Wong et al., 2016). Much of the controversy that has arisen regarding prostate cancer overdiagnosis and overtreatment is a result of the concern that many more men have been exposed to the side effects of traditional radical treatments than necessary. Although these treatments have been highly effective in the oncologic sense, there is often collateral damage to the surrounding cavernosal nerves, urinary sphincter, and other adjacent organs (Resnick et al., 2013). Tools for early detection of prostate cancer such as multiparametric magnetic resonance imaging (mpMRI) and MRI-fusion targeted biopsies, as well as the recognition that Gleason grade 4 and 5 cancers are the biologically lethal subgroup of cancers, have now led to an interest in the use of gland-sparing targeted therapies to achieve oncologic control with less morbidity (Mendez et al., 2015).

Concepts and Historical Perspective

The idea of prostate focal therapy followed on the heels of the successful paradigm shift in breast cancer treatment among breast surgeons. The traditional Halsted mastectomy had given way to breast preservation utilizing local excision and reconstructive techniques. Early attempts in prostate gland–sparing treatments involved subtotal ablations, whereby the sparing of one, or possibly both, neurovascular bundles was attempted (Onik et al., 2002). The term *male lumpectomy* was then coined to describe hemiablation of the prostate as the first form of focal therapy (Mouraviev and Polascik, 2012; Onik et al., 2007b). Many early ablations were performed without the benefit of advanced imaging, and lesion localization techniques varied from standard transrectal biopsies to 5-mm transperineal template grids. Steady advances in technology now allow surgeons to better visualize the prostate and localize the cancer, making possible true image-guided focal destruction of the offending cancer with a margin of normal tissue.

Treatment of prostate cancer is contingent on a balance between cancer aggressiveness and life expectancy. The goal of focal therapy is to treat only those foci of cancer within the prostate gland that will affect the patient's survival or quality of life while preserving surrounding tissue and structures and in turn, the patient's sexual and urinary function.

Biologic Basis for Prostate Focal Therapy

Using Cancer Grade as an Indication of Aggressiveness

Natural history studies suggest that tumor grade, serum prostate-specific antigen (PSA) levels, and clinical stage are the best predictors of prostate cancer–related mortality. Among these phenotypic expressions of aggressivity, cancer grade remains the earliest indication of lethal potential in low-volume, localized prostate cancer. A modification of the Gleason grading system described by Donald Gleason in 1973 remains the most effective and practical prognosticator of cancer aggressiveness today.

Hanahan and Weinberg famously defined the hallmarks of cancer in a 2000 review paper, further expanded in 2011, listing the acquisition of cell self-sustenance, immortality, and invading capabilities as the distinguishing features of cancer (Fig. 158.1). Gleason grade 4 and 5 cancers, compared with grade 3 cancers, do possess many characteristic molecular hallmarks of malignancy.

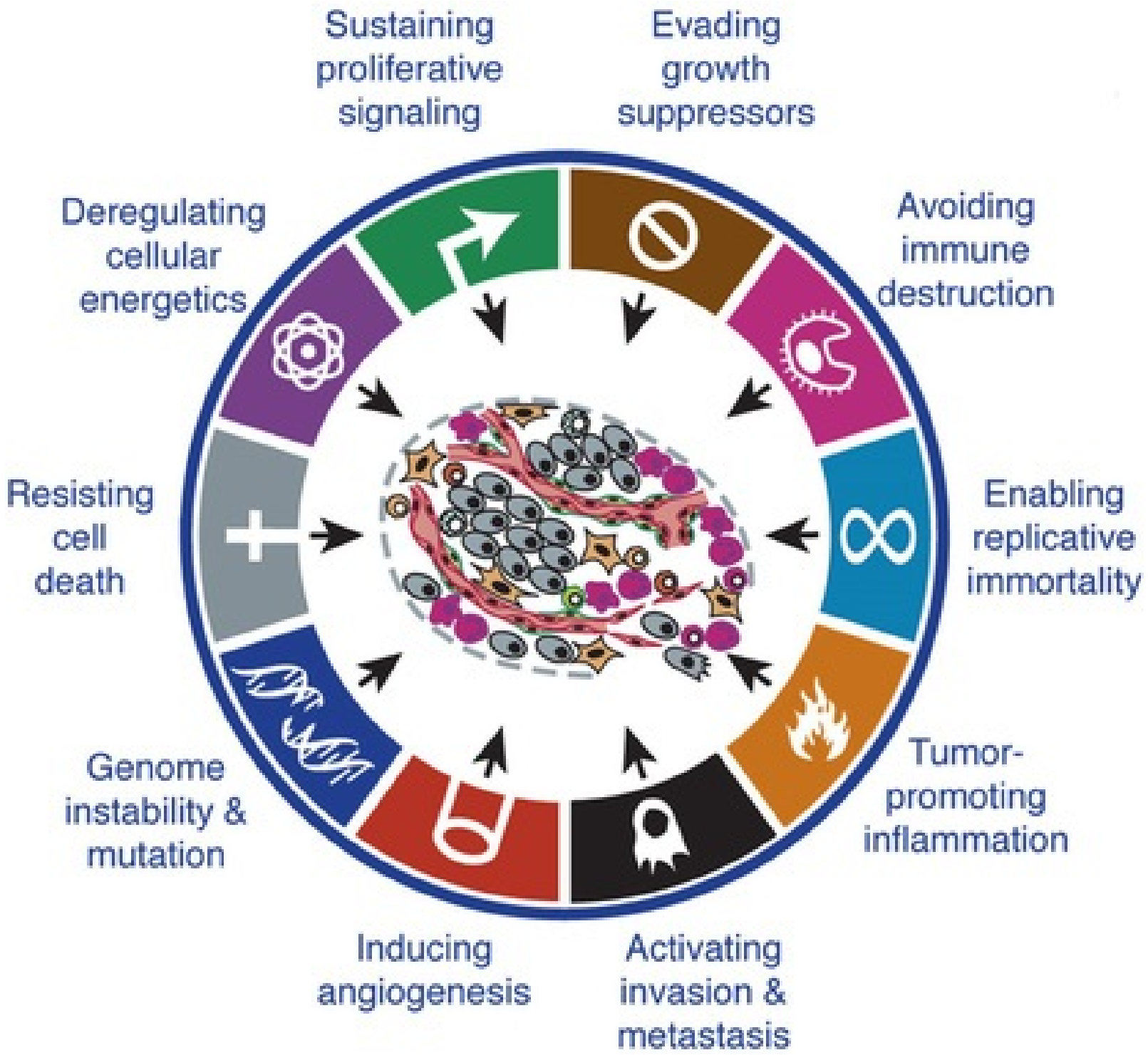
Sustaining proliferative signaling
Evading growth suppressors
Avoiding immune destruction
Enabling replicative immortality
Tumor-promoting inflammation
Activating invasion & metastasis
Inducing angiogenesis
Genome instability & mutation
Resisting cell death
Deregulating cellular energetics

FIG. 158.1 Emerging and established hallmark capabilities and enabling characteristics of cancer. (Modified from Hanahan D, Weinberg RA. Hallmarks of cancer: the next generation. *Cell* 144(5):646–674, 2011.)

Unopposed growth is a key feature in high-grade prostate cancers. Ross et al. (2011) described 670 genes expressed differentially between Gleason 3+3 and Gleason 4+4 cancers isolated by laser capture microdissection. These included genes involved in the developmental processes, signal transduction, and chemokine and embryonal stem cell pathways, particularly involving the androgen receptor, EGFR, TNF-alpha, and Notch signaling cascades. This explained earlier findings that *EGFR* gene copy numbers were not increased when examined using fluorescent in situ hybridization of Gleason pattern 3 and 4 areas obtained from Gleason 3+4 radical prostatectomy specimens (Skacel et al., 2001). However, the same investigators did find that aneusomy of chromosomes 7, 8, and 17 and amplification of HER-2/neu occurred almost exclusively in pattern 4 areas, further supporting the view that Gleason grade 4 carries a higher malignant potential compared with grade 3.

Loss of tumor suppression is an important cause of unopposed growth. The majority of gene deletions in prostate cancer typically involve large chromosomal segments. Kluth et al. (2017) demonstrated that the size of heterozygous deletions of 6q and 16q, the most commonly deleted segments in prostate cancer and those that contain large numbers of tumor suppressors, were highly correlated with Gleason score.

Loss of cell cycle regulation is also a prominent feature of cancers with a higher Gleason grade. Cyclin D2, a critical cell cycle regulatory gene (Susaki and Nakayama, 2007), has also been found to be inactivated via promoter methylation at greater levels where Gleason score was higher (Padar et al., 2003). Loss of cyclin-dependent kinase inhibitor p27(kip1) protein is also correlated with Gleason grade (Guo et al., 1997).

Higher Gleason grade cancers are more likely to exhibit antiapoptotic features compared with their low-grade counterparts. True et al. discovered an 86-gene panel differentiating Gleason pattern 3 from Gleason pattern 4 or 5 prostate cancer cells obtained from laser capture microdissection of radical prostatectomy specimens (True et al., 2006). Among this panel, they reported a specific finding of more intense staining in grade 4 and 5 cancers for the defender against apoptosis 1 *(DAD1)* gene, a downstream target of the NF-κB survival pathway that exhibits antiapoptotic functions (Patel et al., 2000) and has been associated with perineural invasion–associated prostate cancer in vitro (Ayala et al., 2004). Fleischmann et al. (2012), showed that *Bcl-2,* an antiapoptotic gene known to have increased gene copy numbers in androgen-independent prostate cancer, was already overexpressed in the hormone-naïve setting, and especially so in cancers with high Gleason score, advanced stage, and high proliferation index.

Aggressive cancers have also been found to have increased angiogenesis, with vessels that are primitive in morphology and function. Mucci et al. (2009), using immunostaining of CD34 to identify and measure vessel density in 572 prostatectomy tumor tissue blocks, reported that men with tumors exhibiting the smallest vessel diameter and the most irregularly shaped vessels were 5 and 17 times more likely to die from lethal cancer, respectively. Angiogenic growth factors such as VEGF/PK-1 are also progressively expressed in prostate cancer as Gleason score increases (Pasquali et al., 2006). Angiogenesis, through increased sustenance and providing a path for metastasis, contributes to the lethal potential of high Gleason grade cancers.

Metastasis is a hallmark of malignancy, and epithelial-mesenchymal transition (EMT) is thought to be an important step in the development of pathologic migratory properties. Jędroszka et al. (2017) found that the expression profiles of 43 genetic EMT markers were strongly associated with Gleason score. SRFP-4, a regulator of the Wnt signaling pathway that is implicated in carcinogenesis and EMT (Sandsmark et al., 2017b), was found to be significantly more expressed in high Gleason grade groups (Mendez et al., 2015; Resnick et al., 2013; Wong et al., 2016), lethal cancer, and metastatic prostate cancer (Sandsmark et al., 2017a).

In summary, Gleason pattern 4 and 5 demonstrate many of the hallmarks of malignancy compared with Gleason pattern 3, and these represent priority targets for elimination. In early-stage, low-volume prostate cancer, focal treatment of these areas may be able to eradicate potentially lethal cancer, with the remainder of the benign/pattern 3–bearing gland being subjected to surveillance.

Multifocality of Prostate Cancer Versus the Index Lesion Hypothesis

On pathologic examination of radical prostatectomy specimens, it appears that the majority of prostate cancer (50% to 91%) is multifocal except for one Korean study reporting a unifocal cancer rate of 67% (Song et al., 2003) (Table 158.1). However, it is thought that the index lesion, the largest tumor focus within the prostate, determines the subsequent course of the cancer (Ahmed, 2009). This hypothesis is supported by the following data:

TABLE 158.1

Whole-Mount Histology Studies Demonstrating the Multifocality of Prostate Cancer

AUTHOR	POPULATION/INSTITUTION	YEAR OF PUBLICATION	PERIOD UNDER REVIEW	*N*	PSA
Villers et al., 1992	Stanford University	1992	1983–1989	234	–
Miller et al., 1994	University of Colorado	1994	–	151	–
Ruijter et al., 1996	University Hospital Nijmegen, The Netherlands	1996	1992–1994	61	–
Djavan et al., 1999	University of Vienna, Austria	1999	–	206	–
Chen et al., 2000	MD Anderson Cancer Center	2000	1990–1996	180	Mea 9.9 med

					7.5
Rukstalis et al., 2002	MCP Hahnemann University School of Medicine	2002	1998–2000	112	Med 7 (0. 200)
Wise et al., 2002	Stanford University	2002	1992–1996	486	Mea 3.37 (2.2)
Noguchi et al., 2003	Stanford University (non-palpable cancer subgroup)	2003	1988–1997	222	Mea 8.8 (50.4
Song et al., 2003	Samsung Medical Center, Korea	2003	1995–2002	132	Mea 16.4 (24.
Ng et al., 2004	Indiana University School of Medicine	2005	1999–2003	364	Med 6.2 (mea 8.4, 0.3– 150)
Horninger et al., 2004	University of Innsbruck, Austria (Tyrol PSA screening project)	2004	–	82	Mea 3.1
Iczkowski et al., 2008	University of Colorado	2008	2000–2003	393	Med 5.5 (2.5- 48.7
Rice et al., 2009	Walter Reed Army Medical Center	2009	1993–2008	1056	Mea 7.6
Karavitakis et al., 2011	Imperial College, UK	2011	2001–2003	100	Mea 9.5 (1.1- 28)
Catto et al., 2011	ProtecT study participants, UK	2011	–	525	Mea 6.1 (3.6)
Karavitakis et al., 2012	Imperial College, UK	2012	2007–2009	95	Mea 11.9
Huang et al., 2014	New York University Langone Medical Center	2014	2011–2012	201	Mea 8.3 (0.5- 19)

Le et al., 2015	University of California, Los Angeles	2015	2010–2013	122	Mea 6.0 (4.8-8.3)
Hollmann et al., 2015	The Netherlands Cancer Institute, The Netherlands	2015	2010–2012	61	Med 11 (4.1-37)

PSA, prostate-specific antigen; *pT2,* pathologic tumor stage.

1. **Most of the time, the grade/stage is determined by the index lesion.** In a series of 961 radical prostatectomy specimens, Ohori et al. (2006) reported that 377 lesions exhibited extracapsular extension, of which 84% were from the main or index lesion, and 16% were from nonindex lesions. Analyzing the subpopulation of 470 men with a serum PSA less than 10 ng/mL, they found that 92% of the time, extracapsular extension occurred in the index lesion only, 3% in the non-index lesions, and 5% in both.
2. **Most of the tumor volume is contributed by index lesion.** Ohori et al. (2006) reported on 961 radical prostatectomy specimens and found that the index lesion accounted for 80% of the tumor burden. In a series of 61 radical prostatectomies, Hollmann et al. (2015) reported that the index lesion accounted for 88% of total tumor volume within the prostate. Both total and index tumor volumes have been found to be important predictors of biochemical recurrence after radical prostatectomy (Shin et al., 2016), and the data suggest that the majority of intraglandular tumor volume can be dealt with by treating the index lesion.
3. **The majority of satellite tumors are small and low grade.** The definition of an insignificant cancer using <0.5 mL as a cutoff was created by Stamey et al. in 1993—a conclusion based on findings that (a) SEER data suggested a lifetime probability of significant prostate cancer to be 8% and (b) the largest 8% of cancers in the Stanford University bladder cancer cystoprostatectomy series were of the volume 0.5 to 6.1 mL. Among six radical prostatectomy series (Catto et al., 2011; Hollmann et al., 2015; Karavitakis et al., 2011, 2012; Noguchi et al., 2003; Wise et al., 2002) in which the sizes of the satellite lesions were measured, the incidence of unifocal cancer ranged from 12.4% to

25%, but when accounting for cases in which satellite lesions were <0.5 mL in aggregate, this figure rose to between 52% and 93.4%. Villers et al. (1992) found that 80% of secondary cancers were less than 0.5 mL in volume. Application of Stamey's rationale to modern series such as the Charing Cross cystoprostatectomy series or the Rotterdam arm of the European Randomized Screening for Prostate Cancer trial yields thresholds of less than 1.03 mL (Winkler et al., 2007) or <1.31 mL (Wolters et al., 2011), respectively, for clinically significant cancer. This suggests that if these small lesions of doubtful clinical significance were to be left untreated and on observation, a much larger proportion of patients would be eligible for focal therapy than the earlier pathologic data suggest.

4. **Genetic studies suggest a monoclonal origin of metastatic or lethal prostate cancer.** Besides grade heterogeneity among the multiple lesions in multifocal prostate cancer, these lesions tend to be diverse in gene mutations (Cooper et al., 2015), copy number (Ibeawuchi et al., 2013), methylation (Serenaite et al., 2015), and genetic expression (Wei et al., 2017), suggesting the presence of multiple cancer lineages within the prostate that may have differing aggressivity (Fig. 158.2). Further, Liu et al. (2009) analyzed prostate cancer metastases in autopsies of men who had died from prostate cancer and found that most, if not all, metastatic prostate cancers have a monoclonal origin and maintain a unique signature copy number pattern of the parent cancer cell while also accumulating separate subclinical, sustained changes.

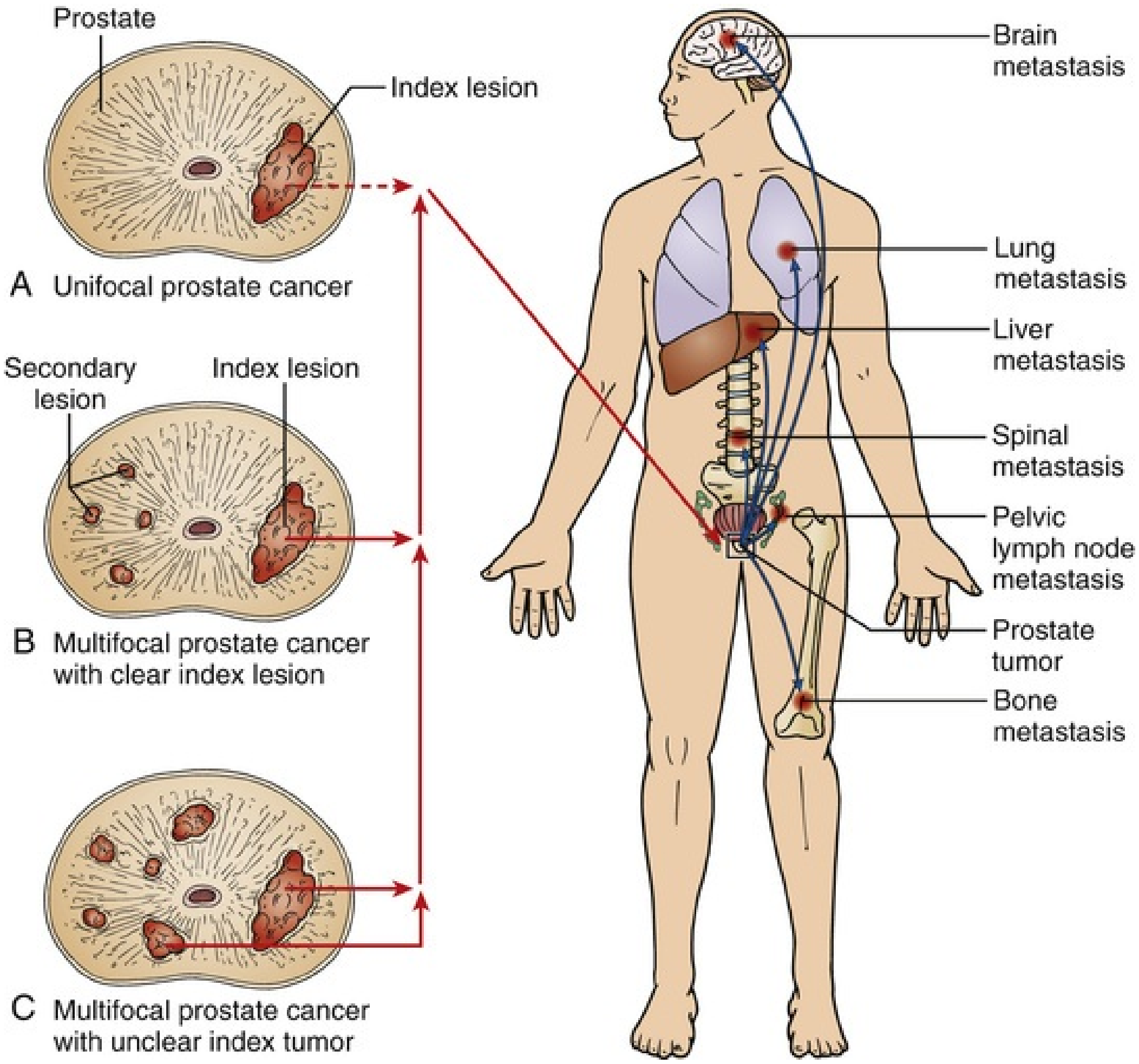
Prostate
Index lesion
A Unifocal prostate cancer
Secondary lesion
Index lesion
B Multifocal prostate cancer with clear index lesion
C Multifocal prostate cancer with unclear index tumor
Brain metastasis
Lung metastasis
Liver metastasis
Spinal metastasis
Pelvic lymph node metastasis
Prostate tumor
Bone metastasis

FIG. 158.2 (A) Unifocal prostate cancer. (B) Multifocal prostate cancer with clear index lesion and one or more separate secondary tumor foci with smaller volumes (most common). (C) Multifocal cancer with unclear index tumor. (From Perera, Krishnananthan N, Lindner U, Lawrentschuk N. An update on focal therapy for prostate cancer. *Nat Rev Urol* 13(11):641–653, 2016.)

In summary, if the index lesion can be accurately identified and ablated, the majority of tumor within the prostate, and its most aggressive components, can be treated. By removing the lethal component of the prostate cancer, theoretically, metastasis and death could be prevented.

On the other hand, it is important to note that pathologic features of aggression such as largest tumor size, highest Gleason score, or highest stage, do not always occur in the same nodules, and in fact, may occur in satellite rather than index lesions 12% to 38% of the time. Ruijter et al. (1996) found that 18% of index lesions had a Gleason score lower than that of adjacent nonindex lesions, and extraprostatic extension (EPE) was found in two nonindex lesions.

Arora et al. (2004) found that the Gleason score of the index lesion was correlated with the overall Gleason score in only 68% of specimens. Huang et al. (2014) found that in most of the multifocal cases (156/176 or 88.7%), the highest Gleason score, tumor volume, and presence of EPE was found in the index lesion. To further confound matters, in one case report of a man dying from metastatic prostate cancer, the lethal clone was traced back to a small, low-grade (Gleason pattern 3) focus, rather than other high-grade lesions (Haffner et al., 2013).

These biologic variations will contribute to treatment failures in focal therapy applied to the index lesion and are a reminder that close post-treatment surveillance is necessary so that salvage interventions can be undertaken in a timely manner. These same biologic exceptions can also be associated with treatment failure with conventional whole-gland approaches and also active surveillance. Nonetheless, the advances in biologic understanding have driven contemporary clinical concepts in focal therapy, which will undoubtedly continue to evolve as we further our knowledge in this area.

Clinical Applications of Focal Therapy

Treating the Index Lesion

The concept that the natural history of prostate cancer is typically driven by a primary lesion, rather than secondary lesions (Stamey et al., 2001), is being increasingly accepted. If the dangerous foci in the prostate could be eradicated, oncologic control of the cancer could be achieved while maintaining quality of life. The secondary lesions in the remainder of the prostate gland could then be placed on active surveillance.

The Complementary Roles of Focal Therapy and Active Surveillance

Two of the largest active surveillance cohorts have reached 10 to 15 years of follow-up, showing an extremely low metastasis rate among men with D'Amico low-risk prostate cancer (Klotz et al., 2015; Tosoian et al., 2015). In one of the cohorts with more inclusive criteria (up to low-volume Gleason 3+4 cancer), it was found that the majority of those in whom cancer progressed had Gleason 3+4 disease (Yamamoto et al., 2016). In the Prostate Intervention Versus Observation Trial (PIVOT), a survival benefit was seen in the intermediate-risk subgroup with prostatectomy rather than observation (Wilt et al., 2012). Indeed, Gleason grade 4 cancers appear to have many more hallmarks of cancer compared with Gleason grade 3, and likely represent the relevant therapeutic target (Klotz, 2013).

These findings support a complementary strategy of treating intermediate or high-grade cancer foci with focal therapy, while monitoring the remainder of the gland having low-grade cancer with active surveillance (Klotz and Polascik, 2014). During surveillance, if any higher-grade cancers are detected, they could potentially be treated focally again. This would provide long-term oncologic control and effectively transform prostate cancer into a chronic disease, commensurate with its long natural history.

To these ends, a successful focal strategy depends on a multidisciplinary team of uro-oncologists, radiologists, pathologists, and others to do the following:

1. Accurately determine the disease extent/location through advanced

imaging and biopsy
2. Ascertain that the patient will benefit from treatment and be compliant to follow-up
3. Completely ablate the index lesion(s)
4. Monitor the patient post-treatment utilizing advanced imaging and biopsy with a view to future targeted treatment of either persistent or de novo disease, or conversion to whole-gland treatment as necessary

Patient Selection

Patient selection is the fundamental tenet of achieving a successful focal therapy strategy. The aggressive lesion within the prostate must be identified and its extent carefully delineated to completely ablate it. Because of the small risk for infield recurrence resulting from incomplete ablation or outfield ablation caused by small satellite lesions being missed or de novo occurrence of prostate cancer in the untreated gland, the patient must be compliant, willing, and psychologically suited for close surveillance after treatment.

The lesion is first identified with a combination of histologic and/or radiologic methods. Advanced radiologic techniques such as mpMRI allow the entire prostate gland to be visualized and, in some cases, predict a more aggressive histology. However, because of limitations in current technology, there remains consensus to histologically confirm the aggressiveness of the lesion through biopsy. Furthermore, current imaging studies remain imperfect in predicting the absence of aggressive cancer, and many experts would advocate a systematic biopsy to more comprehensively evaluate the gland.

Biopsy-Based Lesion Identification

Much of the work in biopsy-based lesion localization was directed toward intraglandular cancer lateralization for the purposes of focal hemiablation. At this time, focal hemiablation was reserved primarily for low-grade cancer patients, many of whom might be placed on active surveillance today. However, the data provide a valuable insight on the ability of biopsy to accurately map cancer. Among men who had undergone radical prostatectomy, Polascik et al. (2009) showed that transrectal ultrasound-guided (TRUS) biopsy unilaterality was the strongest predictor of pathologic unilaterality, with a sensitivity of 88.4%, a specificity of 34%, and positive and negative predictive values of 28% and 91%, respectively. It seems logical that increasing the biopsy intensity would improve the performance of the biopsy in cancer detection/lateralization. Tsivian et al. (2010) showed that extended versus sextant TRUS biopsies had better specificity (53.9% vs. 37.1%) and negative predictive value (95.8% vs. 91.8%). On the other hand, Abdollah et al. (2011) showed that at 24-core TRUS biopsy, specificity in predicting unilateral disease remained at 49.4%, and positive and negative predictive values remained at 22.6% and 98.9%, respectively, suggesting that there was a limitation strategy of increasing the number of biopsy cores transrectally. This may be caused by the inherently random nature of the TRUS systematic biopsy and poor access to the anterior zone of the prostate gland through a transrectal approach.

In the 1990s, many operators turned to transperineal mapping biopsy (TMB) to overcome these limitations. The transperineal approach allows equal access to the anterior and posterior prostate gland. The use of a 5-mm grid or a systematic biopsy template ensures a consistent biopsy intensity as well as distribution of biopsy cores. Barzell and Melamed (2007) showed that staging (TRUS) biopsies had a false-negative rate as high as 47% and a sensitivity and negative predictive value as low as 54% and 49%, respectively, compared with TMB in determining suitability for hemiablative cryotherapy (Barzell and Melamed, 2007). Onik and Barzell (2008) reported that among 110 men with unilateral cancer defined on TRUS biopsy, more than one-half were disqualified after undergoing TMB.

Several groups have attempted to create predictive models combining biopsy and other clinical parameters to accurately predict cancer laterality. Fu et al. (2012), in a cohort of 1495 men, found that only PSA less than or equal to 4 ng/mL and unilateral cancer on biopsy were significant factors in predicting unilateral disease at radical prostatectomy. Gallina et al. (2012) were unable to develop a model in a cohort of 321 men, finding only that the number of positive cores was significant with an AUC of 0.52. Truesdale et al. (2010) found that an increased burden on TRUS biopsy (≤2 vs. >2 positive cores) led to a greater likelihood to experience pathologic persistence of cancer or biochemical recurrence after focal treatment. Most of the data presented in this section were obtained with the objective of predicting the location of all, including low-risk, cancer. There is current interest in preferential detection of Gleason pattern 4 and 5 cancers—thought to be the culprits in prostate cancer progression, metastasis, and mortality—rather than Gleason pattern 3 cancers that are suitable for active surveillance and the excessive detection of which may lead to overtreatment.

Advanced Imaging Techniques in Prostate Cancer

Multiparametric Magnetic Resonance Imaging

Improvements in MRI technology such as high field-strength magnets, development of MRI contrast agents, and improved MRI protocols have improved the resolution of anatomic imaging and led to the addition of functional imaging, leading to multiparametric or mpMRI, which has a high diagnostic accuracy. These developments have positioned mpMRI as a key enabler for prostate focal therapy and have been responsible for renewed interest in this area because of its ability to do the following:

1. **Preferentially detect high-grade lesions.** Dynamic contrast-enhanced (DCE) imaging using gadolinium-based MRI contrast is highly sensitive to vascularized lesions and preferentially detects larger and higher-grade cancer foci (Arumainayagam et al., 2013; Rosenkrantz et al., 2012). Diffusion-weighted imaging (DWI) quantifies the mobility of water molecules to highlight regions with high cellular density that are often correlated with the loss of glandular architecture in high-grade cancer (Gupta et al., 2013).
2. **Improve the detection of anterior zone prostate cancers.** Anterior-zone cancers, accounting for 15% to 33% of prostate cancers in cystoprostatectomy series (Nevoux et al., 2012) and radical prostatectomy series (Al-Ahmadie et al., 2008; Bott et al., 2002), are generally diagnosed at a late stage because the location is relatively inaccessible to TRUS biopsy. Anterior-zone cancers are readily detected (Komai et al., 2013) and characterized on mpMRI (Ouzzane et al., 2011). If done so at an early stage, these are ideal lesions for focal therapy as they are amenable to complete ablation while sparing both neurovascular bundles (Tay et al., 2016a).
3. **Improve the detection of EPE.** Contemporary mpMRI series report an accuracy of 62% to 74%, a sensitivity of 35% to 63%, a specificity of 73% to 91%, a positive predictive value of 36% to 85%, and a negative

predictive value of 57% to 92% in the detection of EPE (Cerantola et al., 2013; Feng et al., 2015; Kayat Bittencourt et al., 2015; Raskolnikov et al., 2015; Somford et al., 2013). mpMRI staging has also been shown to outperform the Partin tables in predicting pathologic EPE (AUC 0.88 vs. 0.70) (Gupta et al., 2016).

4. **Accurately identify the index lesion.** Le et al. (2015) evaluated 122 men with preprostatectomy mpMRI and reported that although the overall mpMRI sensitivity for tumor detection was 47%, this increased to 72% for larger (>1 cm), 72% for higher-grade (Gleason ≥7), and 80% for index tumors. Baco et al. (2015), in an analysis of 135 men, demonstrated that the concordance between the index tumor location on mpMRI and radical prostatectomy specimens was 95%. Delongchamps et al. (2015) evaluated 125 men undergoing presurgical MRI fusion biopsy and reported that mpMRI failed to detect 95 cancer foci, of which the 14 that were clinically significant harbored only 1 index lesion, with the remainder harboring <20% pattern 4.

Despite the vast improvements brought with the advent of mpMRI, it is important to note that the technique remains imperfect. The PROMIS study, comparing mpMRI to a 5-mm grid TMB, reported a sensitivity for clinically significant cancer of 93%, a specificity of 41%, a positive predictive value of 51%, and a negative predictive value of 89% (Ahmed et al., 2017). The strength of this study was that it encompassed 11 centers with varying types of equipment and levels of radiologist expertise. Indeed, mpMRI performance is subject to technical variations such as magnetic coil strength (3 Tesla is more accurate than 1.5 Tesla) (Chang et al., 2008), the use of an endorectal coil (recommended to augment field strength when using 1.5 Tesla) (Hricak et al., 2007), and the scanning protocol. Accurate index lesion identification (Gaziev et al., 2016) and interpretation of EPE (Tay et al., 2016b) are heavily dependent on reader experience. The PROMIS data suggest that mpMRI lesions require histologic confirmation, systematic biopsies of mpMRI-negative areas may not yet be omitted, and a treatment approach heavily reliant on mpMRI may result in a small but not insignificant number of outfield recurrences.

Complete treatment of the index lesion would require an accurate estimation of its three-dimensional volume with the addition of a safety margin. Historadiologic correlation studies consistently show that mpMRI underestimates histologic tumor volume by 5% to 30%, after accounting for shrinkage and other artifacts (Baco et al., 2015; Cornud et al., 2014; Le Nobin et al., 2015; Priester et al., 2017; Radtke et al., 2016; Rud et al., 2014; Turkbey et al., 2012). Furthermore, Priester et al. (2017) reported that the mean axial diameter of an index lesion is underestimated by 11 mm. However, it is not known if the degree of underestimation would be reduced if only pattern 4 and 5 areas were taken into consideration. Nonetheless, this poses significant challenges for lesion-based ablation, and complete ablation may ultimately require hemiablation or zonal ablation.

MRI-Targeted/Fusion Biopsy

Because of the high sensitivity but low specificity of mpMRI, histologic confirmation of suspicious lesions remains critical. The American College of Radiology and European Society of Urogenital Radiology have jointly developed a grading system known as PI-RADS (Prostate Imaging–Reporting and Data System) (Barentsz et al., 2012), which is now in its second iteration (ACR, 2015). This 5-point Likert scale primarily aids radiologists in identifying clinically significant cancer, and data suggest that as the PI-RADS score increases, the higher the Gleason score of the lesion tends to be (Jordan et al., 2018). Nonetheless, at this point, histologic confirmation of the Gleason score as a marker of lesion aggressiveness remains important in clinical decision making. A 2016 consensus on patient selection for prostate focal therapy defined Gleason 3+4 lesions as the “sweet spot” for focal therapy (Tay et al., 2017d). With higher-grade lesions, there is a concern about increasingly aggressive cancer portending a higher likelihood of EPE outside the image-guided target zone that may need to be met with more radical types of treatment.

In-bore MRI-guided biopsy is performed using live MRI guidance within the MRI machine itself. Such procedures carry high accuracy but are time-consuming, costly, require specialized MRI-compatible equipment, and tend to be available only in academic centers.

MRI-TRUS fusion biopsy is a technique in which the biopsy is performed in a standard ultrasound-guided fashion but with the MRI targets overlaid onto the ultrasound image. There are now several commercial systems offering various approaches (transrectal or transperineal) to MRI fusion biopsy (Kongnyuy et al., 2016). These typically create an MRI three-dimensional prostate (MRI segmentation) and an ultrasound three-dimensional prostate (ultrasound segmentation), which are then overlapped (registration) to translate the mpMRI lesions onto the ultrasound model using either rigid or elastic deformation to match the two. The probe/needle guide is then navigated toward the lesion by the operator using mechanical, visual, or combined assistance, and the biopsy is performed. However, software fusion has a learning curve as well because the overlay of the magnetic resonance image onto the ultrasound image is often imperfect, and the user has to compensate accordingly to achieve an accurate biopsy (Tay et al., 2016c).

Another approach is to perform visual estimation targeting (VET), or cognitive/mental fusion, in which the operator estimates the position of the suspicious lesion based on its appearance on the mpMRI. In expert hands, this has been shown to be as good as software fusion (Wysock et al., 2014). Ultimately, patients can only be identified accurately for focal therapy by an experienced multidisciplinary team of radiologists and urologists. Such a team who will mount the learning curve together is a critical component of a focal therapy program.

Promising Imaging Modalities

Positron Emission Tomography (PET)

Positron emission tomography (PET) with choline-based tracers or fluorodeoxyglucose has been investigated for use in prostate cancer staging (Umbehr et al., 2013). Prostate-specific membrane antigen (PSMA) is a type 2 transmembrane protein that is expressed 100- to 1000-fold in prostate cancer cells compared with normal cells. This led to much early interest in the application of radioisotope-labeled molecules linked to PSMA in imaging for prostate cancer. Ultimately, preoperative ^{111}In-capromab pentatide correlated to radical prostatectomy failed to reliably localize prostate cancer for quadrant focal ablation (Mouraviev et al., 2009).

More recently, the development of small molecules targeting the external epitope of PSMA has led to ligands radiolabeled with ^{18}F or ^{68}Ga that are associated with high levels of accumulation within tumor tissue and rapid clearance from nontarget tissue, leading to high contrast for improved prostate cancer detection compared with early PSMA-linked radiotracers (Eder et al., 2012). One potential advantage of PSMA PET over mpMRI is that interpretation is not influenced by biopsy-related artifacts such as hemorrhage or inflammation (Eiber et al., 2015). Rowe et al. (2015) reported in 13 patients that although mpMRI had a greater sensitivity for prostate cancer, ^{18}F-DCFBC PET had a higher specificity overall and for detection of high-grade lesions (Gleason 8 and 9) confirmed on radical prostatectomy. Additionally, although mpMRI interpretation is transiently impaired by early biopsy-related artifacts such as hemorrhage or inflammation, PSMA PET does not appear to have such a limitation. Bonnal et al. demonstrated that it was feasible to fuse both choline-PET and mpMRI targets to three-dimensional TRUS to take advantage of the excellent anatomic resolution of mpMRI as well as functional PET information to define a target for biopsy (Bonnal et al., 2017).

Multiparametric Ultrasonography

Because of the resource intensity of mpMRI along with the limitations of fusion (Tay et al., 2016c), there is now significant interest in extending the capabilities of ultrasonography. Ultrasonography is already a widely available real-time technique that can be performed at the point of care, and multiparametric ultrasonography could remove the potential pitfalls associated with the MRI-ultrasound fusion process and target registration. Contrast-enhanced (CE) TRUS produces a detailed image of microvascular distribution within the prostate using highly echogenic microbubble contrast agents that are minute enough to flow within capillaries. TRUS elastography evaluates the distribution of tissue stiffness within the prostate by measuring the properties of a reflected mechanical wave. Further refinements in this area include shear wave elastography (SWE) in which the mechanical wave is no longer operator dependent, but a reproducible signal that is produced by the ultrasound probe itself. Using SWE, Boehm et al. (2015) reported a sensitivity of 80.9% and specificity of 69.1% for cancer detection using a cutoff of 50 kPa compared with whole-mount examination of radical prostatectomy specimens. Palmeri et al. (2016) explored the use of acoustic radiation force impulse (ARFI) imaging, a technique in which the generated waves occur in a synchronized fashion to eliminate interference from subsequent unwanted internally reflected waves, and found a good correlation with mpMRI in a preliminary study of 29 patients.

A multiparametric approach to ultrasonography would encompass the strengths of the individual modalities, and this combination providing functional information may improve on the sensitivities of individual modalities by 13% to 59% (Postema et al., 2015). There is a need for further prospective work in this area. Computerized TRUS (C-TRUS), first explored for quantifying gray-scale TRUS images in the 1990s, is a technique in which the ultrasound image is transformed into digital signals for statistical analysis. With the aforementioned advances in ultrasound imaging, a wealth of data are now available for correlation to pathology that could pave the way for multiparametric ultrasonography driven by artificial intelligence in the near future.

Contemporary Patient Selection Criteria

There has been a constant evolution in the criteria for patient selection because of the rapid advances in knowledge and biologic understanding of prostate cancer in the past two decades since focal therapy was first explored. Indeed, many early focal therapy cohorts included men with low-risk prostate cancer who would today be considered candidates for active surveillance. Furthermore, there have been few comparative trials between various modalities in prostate cancer because of the highly patient-centric nature of treatment selection. As a result, there is a paucity of data for which to guide development of patient selection criteria for prostate focal therapy, and the majority of focal therapy practice has been shaped by a consensus-based approach (Table 158.2).

TABLE 158.2

Summary of Contemporary Consensus on Patient Selection

YEAR OF CONSENSUS		**2010**	**2012**	**2013**	**2016**
Author/publication year		de la Rosette et al., 2010	Ahmed et al., 2012	Donaldson et al., 2015	Tay et 2017d
Goal of focal therapy		Eradication of all cancer	Eradication of all cancer	Eradication of clinically significant cancer	Eradic clinica signifi cancer
Cancer determination	Overall	TMB	TMB and mpMRI	TMB or systematic + mpMRI	mpMI systen biopsy
	mpMRI	Can be recommended at state-of-the-art centers	Recommended	No clear recommendation	Recon as far possib
	Biopsy of suspicious lesion	–	To be studied	Recommended	Recon MRI-T Fusion
	Biopsy of non-suspicious area	–	TMB	Recommended	Recon at leas TRUS
Disease factors	Risk group	Low to moderate risk	–	Intermediate	Interm
	Maximum grade	–	–	–	4 + 3
	Maximum size	T2a clinically or T2b radiologically	–	No agreement	Up to or 3 m crossi midlin 20% o prosta volum

					if cros midlin
	Residual disease permissible	None	None	3 + 3 up to core length 5 mm	3 + 3 core le mm
Patient factors	Age/life expectancy	At least 10-year life expectancy	NA	Not a primary determinant; best suited to life expectancy >10 years and not <5 years	Accor major guidel upper limit focal contra
	Sexual function	Effect unknown, counseling recommended	NA	NA	Impor not the indica choosi therap

mpMRI, multiparametric magnetic resonance imaging; *TMB,* transperineal mapping biopsy.

In a 2009 consensus meeting, the stated aim of focal therapy was to eradicate all known prostate cancer while preserving uninvolved tissue to spare genitourinary function (de la Rosette et al., 2010). Later, a 2010 consensus stated that the aim of focal therapy was to treat cancer and leave intact the benign prostate and surrounding normal structures (Ahmed et al., 2012). By 2013, the consensus was that the aim was to treat the dominant or index lesion (Donaldson et al., 2015). Here, residual untreated disease was first quantified, with the panel agreeing that it was acceptable not to treat lesions of Gleason grade 3+3 up to a length of 5 mm, though the issue of the type or intensity of biopsy necessary was not addressed. In yet another consensus panel in 2016, a Gleason 3+4 lesion, when capable of being completely ablated, was determined to be the “sweet spot” for focal therapy (Tay et al., 2017d). This panel also suggested Gleason 4+3 as a maximum grade for focal therapy, with most members reluctant to extend the role of focal therapy to high-grade cancers.

Recommendations for the best approach to patient assessment have evolved as well. In the 2010 consensus, mpMRI was recommended only in state-of-the-art centers, but in the 2016 consensus, it was recommended as far as possible. In 2010 and 2012, TMB was considered state-of-the-art, and in the 2016 consensus, MRI-TRUS fusion biopsy was the recommended modality for evaluating a suspicious lesion. Notably, the most recent consensus still recommends a systematic biopsy to evaluate the mpMRI “normal” prostate, recognizing that though mpMRI represents an advancement in prostate imaging, it still has a small but significant false-negative rate.

Sexual function was addressed in the 2016 consensus on patient selection and another 2013 consensus on focal therapy trial design in which the expert panels found that erectile dysfunction was not a contraindication to prostate focal therapy. In the 2016 consensus, although the expert panel agreed that the potential for preservation of erectile function is an important reason to choose focal therapy over other modalities, the majority of the experts would not deny focal therapy to a man who was already impotent. This may be a result of increasing awareness of the impact of urinary, rectal, or other toxicities that may be associated with the indiscriminate use of whole-gland therapy.

Ultimately, treatment selection for prostate cancer remains a complex interplay of disease characteristics and patient factors. Advances and improvements in the tools available to select patients have improved confidence in the ability to recommend focal therapy to a suitable subset of patients. Further research is needed to determine the most effective strategy to identify patients for focal therapy, keeping in mind the cost and morbidity of treating recurrent cancer that might arise as a result of poor selection.

Ablation Patterns and Current Technologies

Types of Ablation

Many different ablation patterns have been termed *focal therapy*, leading to significant heterogeneity within the focal therapy literature. Some of these techniques, such as “hockey stick” type ablations, would be more appropriately classified under the umbrella term of *partial prostate ablation* (Fig. 158.3). In an international consensus meeting on definitions in focal therapy, Postema et al. (2016) reported that focal therapy should include treatment of a lesion, quadrant ablation, and hemiablation. Some authors would further argue that treatment of a lesion can be further classified into image-targeted lesion ablation versus non–image-targeted ablation, whereby the lesion is treated based on biopsy information.

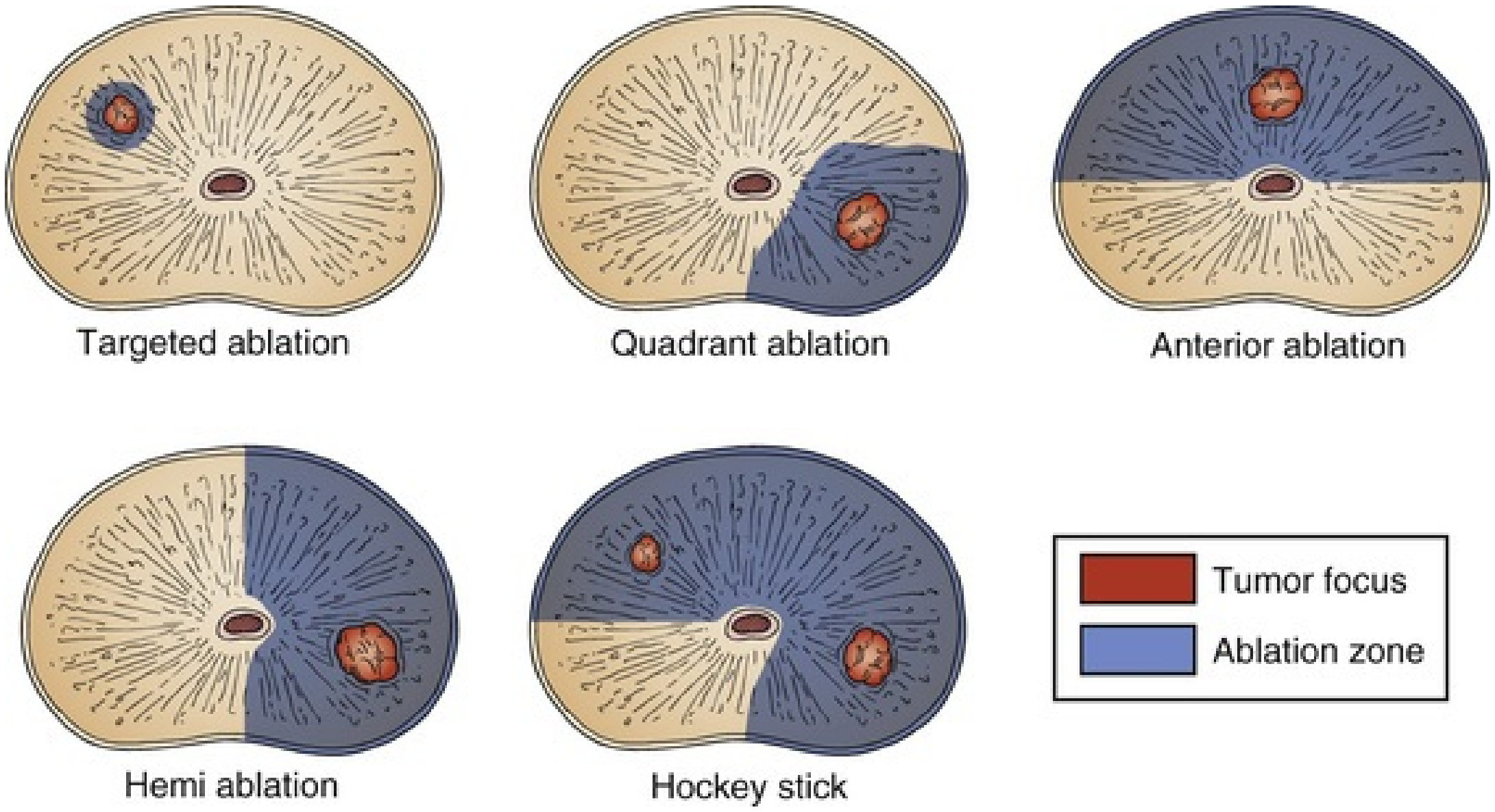
Targeted ablation
Quadrant ablation
Anterior ablation
Hemi ablation
Hockey stick
Tumor focus
Ablation zone

FIG. 158.3 Patterns of ablation.

Ablation Approach

The prostate can be accessed for ablation via a transrectal, transperineal, or less commonly, a transurethral approach. The approach chosen will depend largely on the following:

1. Location of the tumor
2. Desired ablative technology that is available
3. Any other anatomic consideration unique to the patient

Transrectal approaches allow for ease of access to the posterior zone, and transperineal approaches offer better access to the anterior zone of the prostate. Cryoprobes and electrodes for irreversible electroporation (IRE) are typically constructed of metal and are at least 17-gauge in size, making them less suited for a transrectal approach. High-intensity focused ultrasonography (HIFU) is produced within an ultrasound transducer that, because of necessary housing of sufficient transducer rings to produce the desired intensity/focal distance (Constanciel et al., 2013), is usually introduced transrectally. Laser energy, on the other hand, is delivered through highly flexible fibers that can be delivered through either transrectal or transperineal routes. Ultimately, as urologists become conversant with multiple techniques, an “à la carte” approach may be adopted, where the modality/delivery combination is adapted to the patient/lesion (Sivaraman and Barret, 2016).

Cryotherapy

Cryotherapy is a thermal ablative modality achieving cell kill through extraction of heat producing lethal cold temperatures. Cryosurgery kills target tissues via physical and physiologic changes including mechanical forces resulting in membrane disruption created by intracellular and extracellular ice formation, recrystallization, vascular stasis/ischemia, apoptosis, and immune effects (Baust et al., 2014). Although it has been in use for the past two decades, recent developments have made it increasingly suited for focal therapy. First, the new third-generation cryoprobes utilizing the Joule-Thomson effect to generate lethal ice are as fine as 17-gauge, allowing them to be maneuvered to the appropriate position within the prostate. Second, variable ice length adjustment allows the ice ball to be contoured exactly to the lesion that is to be ablated. Third, the ice edge can be clearly seen using TRUS (Onik et al., 1988), CT, or MRI, and thus the extent of ablation and the ablation margin can be monitored and adjusted in real time by the treating urologist. Fourth, the use of a urethral warmer has greatly reduced the risk for urethral complications arising from cold injury to the urethral mucosa (Cespedes et al., 1997; Donnelly et al., 2001; Vellet et al., 1997). Typically, thermocouples are placed within the intended ablation zone or its margin, along vital structures such as the external sphincter, neurovascular bundles, or Denonvilliers fascia to monitor temperatures in real time (Wong et al., 1997). Excerpts of a video depicting the steps of focal cryotherapy in the form of anterior prostate cryoablation are shown in Fig. 158.4.

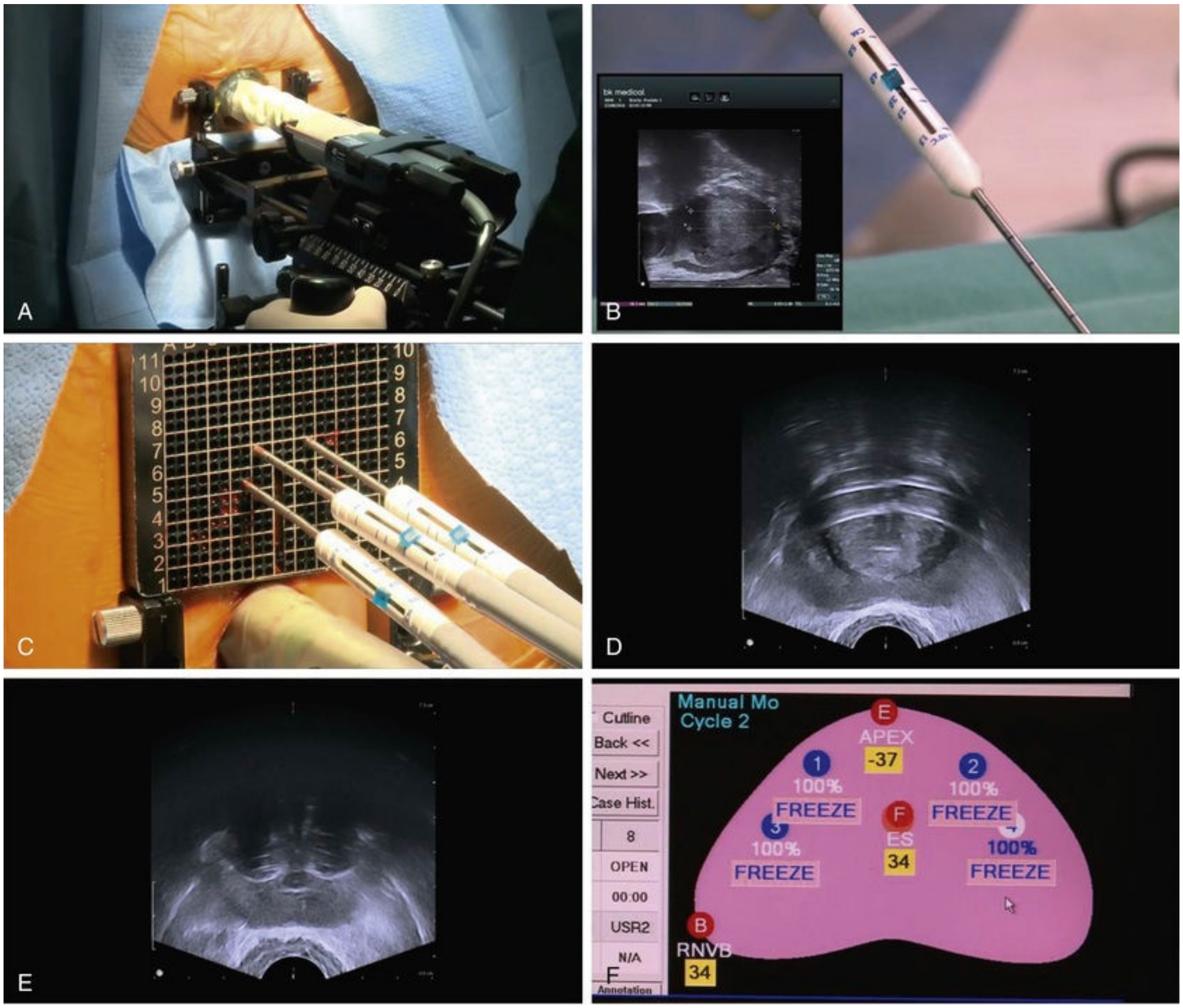
A
B
bk medical
C
11
10
9
8
7
6
5
4
3
2
10
9
8
7
6
5
D
E
Cutline
Back <<
Next >>
Case Hist.
8
OPEN
00:00
USR2
N/A
F
Annotation
Manual Mo
Cycle 2
E
APEX
-37
1
100%
FREEZE
2
100%
FREEZE
F
ES
34
3
100%
FREEZE
4
100%
FREEZE
B
RNVB
34

FIG. 158.4 Focal cryoablation procedure. (A) Biplanar ultrasound probe is placed in the rectum. (B) Variable length cryoprobes are set to prostate measurements. (C,D) An anterior ablation pattern is being used here with four probes in the anterior prostate. (E) The ice in the anterior prostate. The leading ice edge has a hyperechoic rim and can be monitored easily. (F) Console readout showing lethal temperature in the anterior apex and safe temperatures in the external sphincter *(ES)* and the right neurovascular bundle *(RNVB).* The full video may be viewed at http://www.liebertpub.com/videourology. (From Tay KJ, Polascik TJ.

Anterior prostate cancer cryoablation: a technique in prostate focal therapy, *Videourology* 31:2, 2017.)

Tay and Polascik (2016) reviewed nine contemporary cohort studies of prostate focal cryotherapy (Table 158.3). The majority of studies used a hemiablation template, as that was the original model of focal therapy for prostate cancer (Onik et al., 2007b). Over a median follow-up between 13 and 63 months, the biochemical progression–free survival (BPFS) rate was 71% to 98%. Among five cohorts (total of 272 men) that mandated a rebiopsy between 6 and 12 months, the compliance rate was 79%, and the positive biopsy rate was 21.8%, one-fourth of which were clinically significant cancer. As demonstrated in the table, biopsy criteria for patient selection before therapy and post-treatment biopsy varied across studies. Also, D'Amico risk groups were mixed, but the vast majority of patients treated with focal cryotherapy were of low- and intermediate-risk groups. The reported post-treatment pad-free continence and potency rates were 96% to 100% and 58% to 100%, respectively. Approximately one-half of patients reporting potency after hemiablation utilized phosphodiesterase type 5 inhibitors (PDE5Is) (Ellis et al., 2007). The reported rate of rectourethral fistula, the most feared complication after cryotherapy, was 0% to 0.1%.

TABLE 158.3

Summary of Published Focal Cryotherapy Series

AUTHOR	*N*	PREDIAGNOSTIC WORKUP	DECLARED INCLUSION CRITERIA	FINAL DEMOGRAPHIC	ABLAT PLAN
Onik et al., 2008	48	TRUS Biopsy (restaging TMB after 2001)	Unilateral cancer	Low risk 23 (48%) Intermediate risk 18 (38%) High risk 7 (14%)	Hemi-ablation
Truesdale et al., 2010	77	TRUS Biopsy	Unilateral cancer	Low risk 44 (57%) Intermediate risk 31 (40.3%)	Hemi-ablation

				High risk 2 (2.6%)	
Bahn et al., 2012	73	TRUS biopsy	Unilateral, Gleason 7 or less	Low risk 24 (33%) Intermediate risk 49 (67%)	Hemi-ablation
Ward and Jones, 2012	1160[a]	NR	NR	Low risk 541 (47%) Intermediate risk 473 (41%) High risk 143 (12%)	NR
Hale et al., 2013	26	Staging TMB	Low-intermediate risk	Low risk 23 (88.5%) Intermediate risk 3 (11.5%)	Hemi-ablation
Barqawi et al., 2014	62	TMB	40–85 years cT1–T2b Gleason 3+4 or less Less than 50% positive core After TMB, <20% total prostate, index lesion <5 cc, 4 or less zones involved	All low risk	Targeted sectoral ablation
Durand et al., 2014	48	12-core staging TRUS biopsy + mpMRI	PSA <10 Positive cores <33% % core <50 Unilateral Gleason 6 or less	All low risk	Hemi-ablation

Lian et al., 2016	41	Minimum 12-core biopsy	Unilateral cancer PSA <20 1–2 cores <50% involvement Gleason 6–7 cT2b or less	Low risk 23 (56%) Intermediate risk 18 (44%)	Hemi-ablation

[a] This was a Cryo On-Line Data (COLD) registry series.

BCR, biochemical recurrence; *BPFS,* biochemical progression–free survival; *DRE,* digital rectal examination; *IIEF,* international index for erectile function; *mpMRI,* multiparametric magnetic resonance imaging; *NR,* not reported, *NA,* not applicable; *PSA,* prostate-specific antigen; *TRUS,* transrectal ultrasonography; *TMB,* transperineal mapping biopsy.

There are no studies comparing focal cryotherapy to established treatments such as radical prostatectomy or radiation. One study compared partial- to whole-gland cryotherapy using a matched pair analysis in patients with low-risk prostate cancer in the Cryo-Online Data (COLD) registry (Mendez et al., 2015). No difference was observed in 60-month BPFS, and the rates of erectile recovery were noted to be significantly better with partial ablation (68.8% vs. 46.8%). A second study used propensity score matching to compare partial- to whole-gland cryotherapy in patients from the same registry with intermediate-risk prostate cancer (Tay et al., 2017a). This study reflects a more contemporary approach to selecting focal cryoablation for patients with intermediate-risk disease. There was no difference observed in early BPFS, and those receiving partial ablation were 2.1 times as likely to recover erectile function by 12 months compared with those undergoing whole-gland cryoablation (46.8% vs. 29.5%, $P = .001$).

High-Intensity Focused Ultrasonography

A transducer focuses multiple ultrasound beams onto a preset point, generating a temperature of at least 55°C (Hildebrandt et al., 2002; Napoli et al., 2013) to produce coagulative necrosis within the desired target. The transducer is typically built into the TRUS probe, which is also used for treatment planning and monitoring. Transrectal HIFU is well suited for treatment of posterior-zone lesions. However, the anterior gland may be more difficult to treat because of energy dissipation over the intervening prostate tissue and displacement of anterior zone targets with gradual edema of the prostate tissue as treatment progresses (Clyne, 2013; Shoji et al., 2013; Sivaraman and Barret, 2016). Typically, there are restrictions based on which prostates are ideal for treatment matched to a particular HIFU technology, with such limitations as prostate size, height, and calcifications in the treatment zone. Also, to better allow targeting and reduction of prostate height, some would recommend that transurethral resection of the prostate (TURP) be performed before HIFU treatment. Finally, although whole-gland HIFU takes some time to accomplish, it is well-suited to focal therapy as the treatment time is shorter.

The majority of focal HIFU series are hemiablative and rely on cognitive or software MRI fusion. El Fegoun et al. (2011) first reported a series of 12 men who underwent biopsy-directed HIFU hemiablation with a median follow-up of 127 months. They reported that the recurrence-free rate was 90% at 5 years and 38% at 10 years, with an overall 41.7% positive biopsy rate, though notably, 10 of 12 men had low-risk cancer, and most treatments were carried out in the pre-MRI era. Six more recent cohorts reported using mpMRI as a patient selection tool (Ahmed et al., 2015; Feijoo et al., 2016; Ganzer et al., 2018; Rischmann et al., 2017; van Velthoven et al., 2016). Of these, the French hemiablation trial is the largest series, with 111 men. Three of these with mandatory post-treatment rebiopsy at 6 to 12 months reported an infield positive biopsy rate of 15.5% to 34.6% for all cancer and 8.2% to 11.5% for clinically significant cancer, and an outfield positive biopsy rate of 7.7% to 36.7% for all cancer and up to 2% for clinically significant cancer (Ahmed et al., 2015; Feijoo et al., 2016; Ganzer et al., 2018). Overall post-treatment recovery of erectile function seems to vary between 60% and 78% (Table 158.4).

TABLE 158.4

Summary of Published Focal High-Intensity Focused Ultrasound Series

AUTHOR	*N*	PREDIAGNOSTIC WORKUP	DECLARED INCLUSION CRITERIA	FINAL DEMOGRAPHIC	ABLATIO PLAN
El Fegoun et al., 2011	12	NR	PSA ≤10 ng/mL, ≤3 positive biopsies with	Low risk – 10 (83%) Int. risk – 2 (17%)	Hemi-ablation

			only one lobe involved, clinical stage ≤T2a, Gleason score ≤7 (3+4)		
Ahmed et al., 2015	56	mpMRI + TRUS biopsy or TMB	PI-RADS 4/5 with concordant biopsy findings Gleason ≤4+3 PSA ≤20 Stage ≤T3a	Low risk – 7 (12.5%) Int. risk – 47 (83.9%) High risk – 2 (3.6%)	Focal ablation
van Velthoven et al., 2016	50	mpMRI + targeted biopsy	Concordant biopsy with mpMRI Stage ≤T2 PSA <15 Prostate volume <40 mL Life expectancy ≥5 years	Low risk – 24 (48%) Int. risk – 26 (52%)	Hemi-ablation
Feijoo et al., 2016	71	TRUS biopsy (20-core) + mpMRI	Unilateral disease Stage T1c–T2a, positive biopsies	Gleason 3+3 – 58 (86.6%) Gleason 3+4 – 9 (13.4%)	Hemi-ablation

			<33% Gleason score ≤3+4 PSA <15 Life expectancy >10 years		
Rischmann et al., 2017	111	mpMRI + targeted biopsy	Unilateral cancer, Gleason score ≤3+4	Gleason 3+3 – 82 (74%) Gleason 3+4 – 29 (26%)	Hemi-ablation
Tay et al., 2017c	12	mpMRI + rTMB	Up to two lesions <10 mm Stage <T2b Gleason 3+3 only	Gleason 3+3 – 12 (100%)	Sectoral ablation
Ganzer et al., 2018	51	TRUS biopsy (12-core) + mpMRI	Unilateral disease Stage T1c–T2a, positive biopsies <30% Gleason score ≤3+4, maximum core length	Gleason 3+3 – 43 (84%) Gleason 3+4 – 8 (16%)	Hemi-ablation

			5 mm PSA <10		

[a] The majority of men were not interested in sexual function in this study.

BCR, biochemical recurrence; *BPFS,* biochemical progression–free survival; *DRE,* digital rectal examination; *IIEF,* international index for erectile function; *mpMRI,* multiparametric magnetic resonance imaging; *NR,* not reported; *NA,* not applicable; *PSA,* prostate-specific antigen; *TRUS,* transrectal ultrasonography; *TMB,* transperineal mapping biopsy.

In-bore MRI-guided focused ultrasonography (MRgFUS) allows for monitoring of treatment temperatures within the target area using MR thermometry, as well as ensuring safe temperatures in the urethra and sphincter (Fig. 158.5). Tay et al. (2017c) reported a phase II clinical trial of MRgFUS, finding a slight insignificant deterioration of Expanded Prostate Cancer Index Composite (EPIC) urinary symptoms score at 1 month that returned to baseline at 3 months with no changes in other EPIC subdomain scores over a 2-year period.

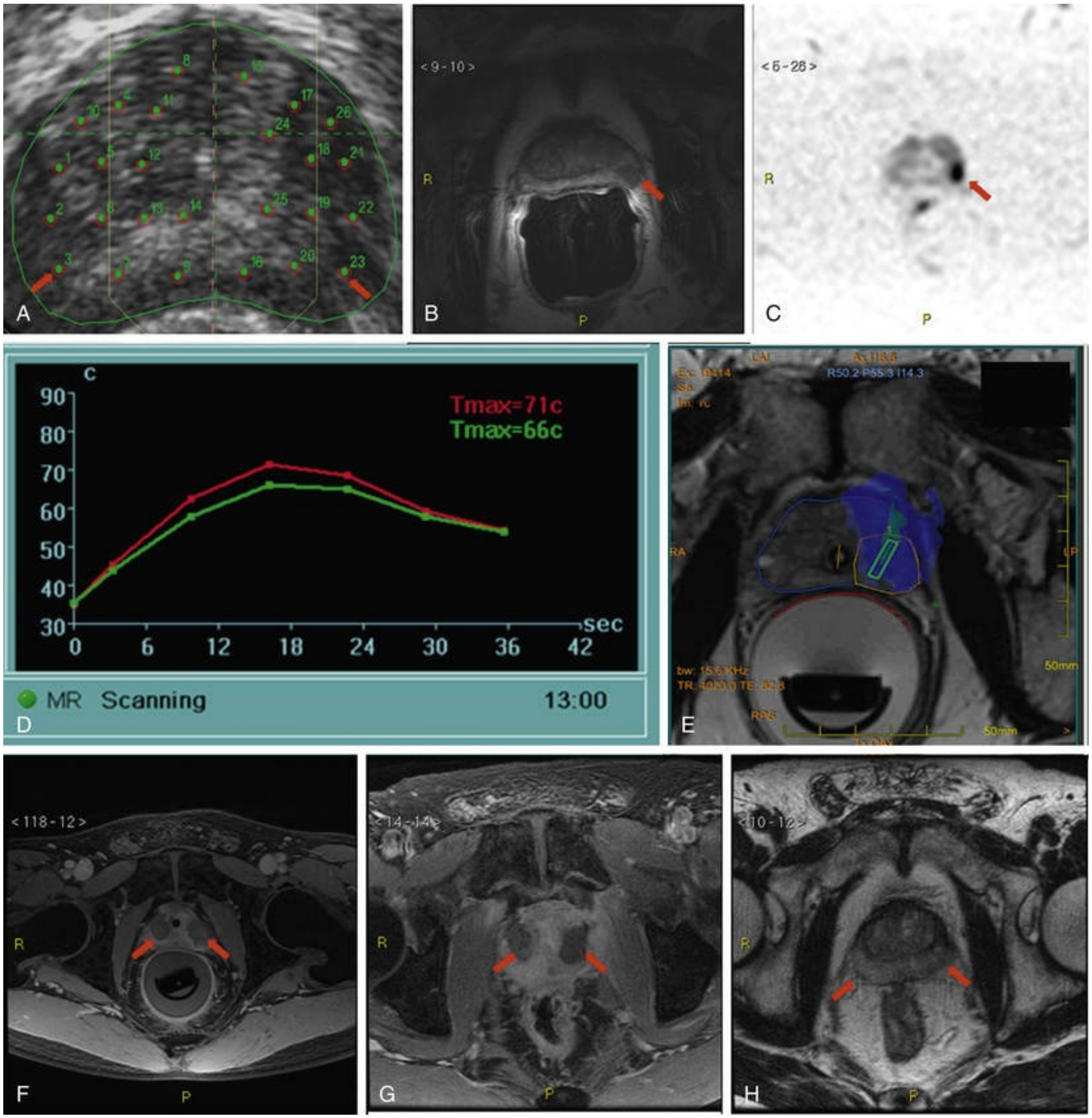

FIG. 158.5 54-year-old male patient with PSA 7.7 and biopsy-proven Gleason 3+3 prostate carcinoma. (A) Saturation biopsy map showing positions of 26 cores taken. Core 3 and 23 were positive for Gleason 3+3 prostate carcinoma *(arrows),* measuring 3 mm and 4 mm in the mid-cores, respectively. (B,C) Pretreatment axial T2-weighted fast spin-echo MR image (TR/TE, 3300/90) and corresponding axial DWI (TR/TE, 105/6000, *b* = 2000 mm/s^2) showing well-demarcated lesion in left posterior peripheral zone at mid-gland level corresponding to core 23 *(arrow).* It also shows suspicious type 3 curve on DCE MRI *(not shown).* The other lesion in the right posterior peripheral zone was not visualized. (D,E) Intraoperative MRgFUS image showing focused ultrasound beam path overlaid on treatment plan for left posterior peripheral zone lesion (E) with real-time thermal map (D). (F) Immediate post-treatment T1-weighted postcontrast MR image (TR/TE, 400/6) showing nonperfused devascularized ablated volumes in bilateral peripheral zones *(arrows).* (G) One-month post-

treatment T1-weighted postcontrast MR image (TR/TE, 400/6) showing persistence of nonperfused devascularized ablated volumes in bilateral peripheral zones *(arrows).* (H) Axial T2-weighted fast spin-echo MR image (TR/TE, 3300/90) on 2-year follow-up showing loss of volume with fibrosis in treated area *(arrow).* (From Tay KJ, Cheng CWS, Lau WKO, et al. Focal therapy for prostate cancer with in-bore MR-guided focused ultrasound: two-year follow-up of a phase I trial—complications and functional outcomes. *Radiology* 285(2):620–628, 2017.)

Another new development that has arisen as a result of miniaturization of HIFU probes is MRI-guided transurethral ultrasound ablation (TULSA) (Fig. 158.6) (Burtnyk et al., 2015). In-bore MRI guidance offers the advantages of thermometry and anatomic resolution, and via a transurethral approach, TULSA could potentially be much more efficiently applied to the anterior prostate. Chin et al. (2016) reported a multicenter phase I clinical trial of whole-gland TULSA showing the technology to be safe and technically precise, achieving spatial control of thermal ablation to be within 1.3 mm on MRI thermometry, no post-treatment changes in functional scores, and a 3.3% grade 3 complication rate with no grade 4/5 complications. Although further clinical experience is required with this modality, TULSA appears to be promising for application to focal therapy.

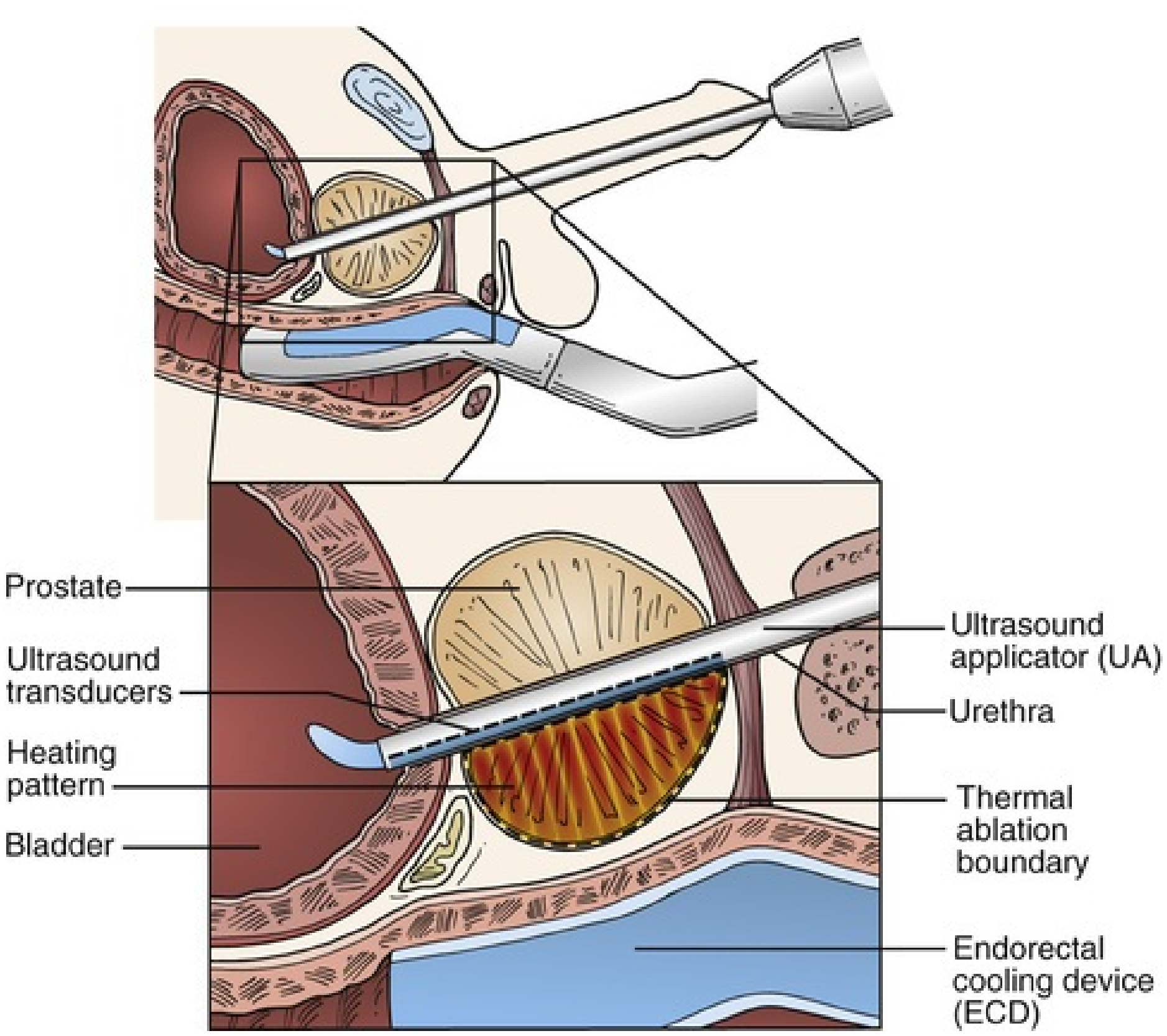
Prostate
Ultrasound transducers
Heating pattern
Bladder
Ultrasound applicator (UA)
Urethra
Thermal ablation boundary
Endorectal cooling device (ECD)

FIG. 158.6 Treatment with magnetic resonance imaging–guided transurethral ultrasound ablation. *ECD,* endorectal cooling device; *UA,* ultrasound applicator. (Chin JL, Billia M, Relle J, et al. Magnetic resonance imaging-guided transurethral ultrasound ablation of prostate tissue in patients with localized prostate cancer: a prospective phase 1 clinical trial. *Eur Urol* 70(3):447–455, 2016.)

Laser

Focal laser ablation (FLA) refers to the creation of coagulative necrosis using an interstitially placed laser fiber. The ablation zone is guided by the laser fiber, and tissue destruction occurs only within a fixed distance from the fiber tip, offering the possibility of true focal ablation where accurate and predictable tissue destruction zones can theoretically be safe within close proximity to vital structures (Oto et al., 2013). The disadvantages are that longer procedure times or extra laser fibers may be necessary for ablation of larger lesions, and additional care may be needed to treat the lesion with an adequate margin. Histopathologic analysis of the ablation zone shows neovascularization and increased tumor mitotic activity at the edge, reinforcing the need for a safety margin during treatment (Fig. 158.7) (Bomers et al., 2017). The laser fiber can be placed transperineally or transrectally via a delivery trocar.

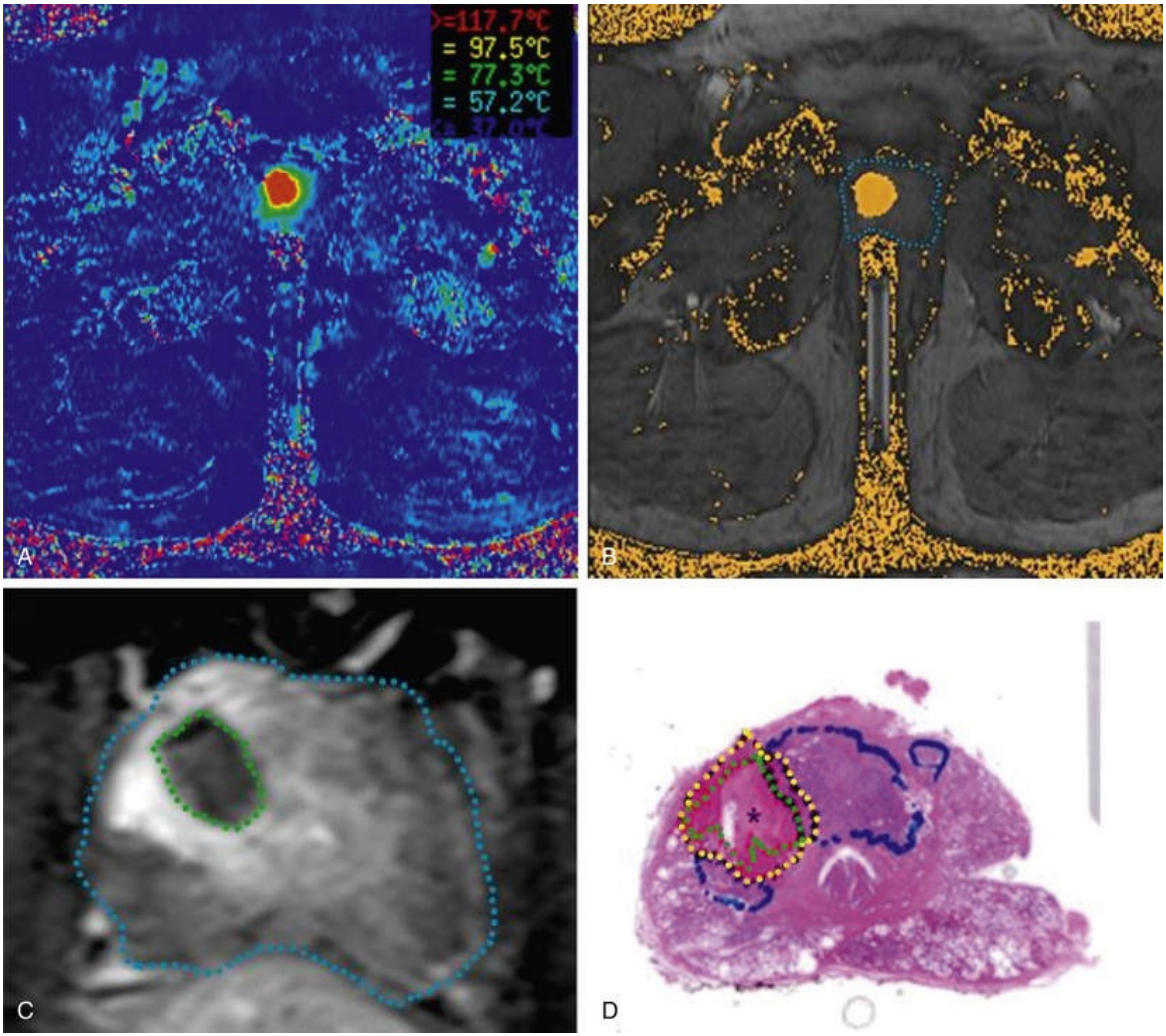

FIG. 158.7 Images of a 67-year-old male patient with a Gleason score of 3 + 4 = 7 in his right transition zone. (A) Real-time MRI-temperature map acquired during focal laser ablation. (B) Anatomical MRI of the prostate *(delineated in blue)* with the Arrhenius-based damage-estimation zone as *orange overlay.* (C) Postablation axial T1-weighted contrast-enhanced image. The prostate is delineated in *blue,* and the nonenhancing necrotic tissue is in green. (D) Whole-mount H&E stain of the prostate. The necrotic tissue is delineated in *green,* the perinecrotic tissue in *yellow,* and vital tumor in *blue.* (From Bomers JGR, Cornel EB, Futterer JJ, et al. MRI-guided focal laser ablation for prostate cancer followed by radical prostatectomy: correlation of treatment effects with imaging. *World J Urol* 35(5):703–711, 2017. Open Access via Creative Commons Attribution 4.0 International License: http://creativecommons.org/licenses/by/4.0/)

Reported outcomes regarding the utilization of FLA to date are very small series with short follow-up (Table 158.5). Eggener et al. (2016) treated 27 men in a phase II trial of in-bore MRI-guided FLA, reporting an 11% infield and 30% outfield positive biopsy rate at 12 months with no change in IIEF from baseline. The authors described the use of a 14-gauge titanium introducer with a polytetrafluoroethylene catheter placed in the target lesion followed by a 17-gauge laser applicator placed through each catheter (Fig. 158.8). Treatment duration was 60 to 120 seconds at 6 to 15 W based on the intended size of the ablative zone and repeated as needed. The target ablation temperature was a minimum of 60°C with ablation extending more than 5 mm beyond the lesion. Notably, 85% of this cohort comprised low-risk patients.

TABLE 158.5

Summary of Published Focal Laser Ablation Series

AUTHOR	*N*	PREDIAGNOSTIC WORKUP	DECLARED INCLUSION CRITERIA	FINAL DEMOGRAPHIC	ABLATION PLAN
Lindner et al., 2009	12	12-core TRUS biopsy and mpMRI	≤T2a, PSA <10 ng/mL Gleason sum ≤6 ≤30% of all cores positive ≤50% of one core involved by cancer Sectoral correlation with mpMRI	Gleason 3+3 – 12 (100%)	MRI-US fusion focal ablation monitored with CEUS
Eggener et al., 2016	27	mpMRI	cT1c–T2a PSA <15 ng/mL PSAD <0.15 Gleason	Gleason 3+3 – 23 (85%) Gleason 3+4 – 3 (11%) Gleason 4+3 – 1 (4%)	Focal ablation with 5-mm margin

			score ≤7 in ≤25% of cores mpMRI maximum 2 lesions, maximum diameter 15 mm, maximum volume 2 mL		
Natarajan et al., 2017	10	mpMRI + MRI-US fusion biopsy	Clinical stage ≤T2b Maximum Gleason 3+4 Maximum diameter 2 cm	Gleason 6 – 2 Gleason 7 – 8	Focal ablation

BCR, biochemical recurrence; *BPFS,* biochemical progression–free survival; *CEUS,* contrast-enhanced ultrasonography; *DRE,* digital rectal examination; *IIEF,* international index for erectile function; *mpMRI,* multiparametric magnetic resonance imaging; *NR,* not reported; *NA,* not applicable; *PSA,* prostate-specific antigen; *ROI,* region of interest; *TRUS,* transrectal ultrasonography; *TMB*, transperineal mapping biopsy; *US,* ultrasound.

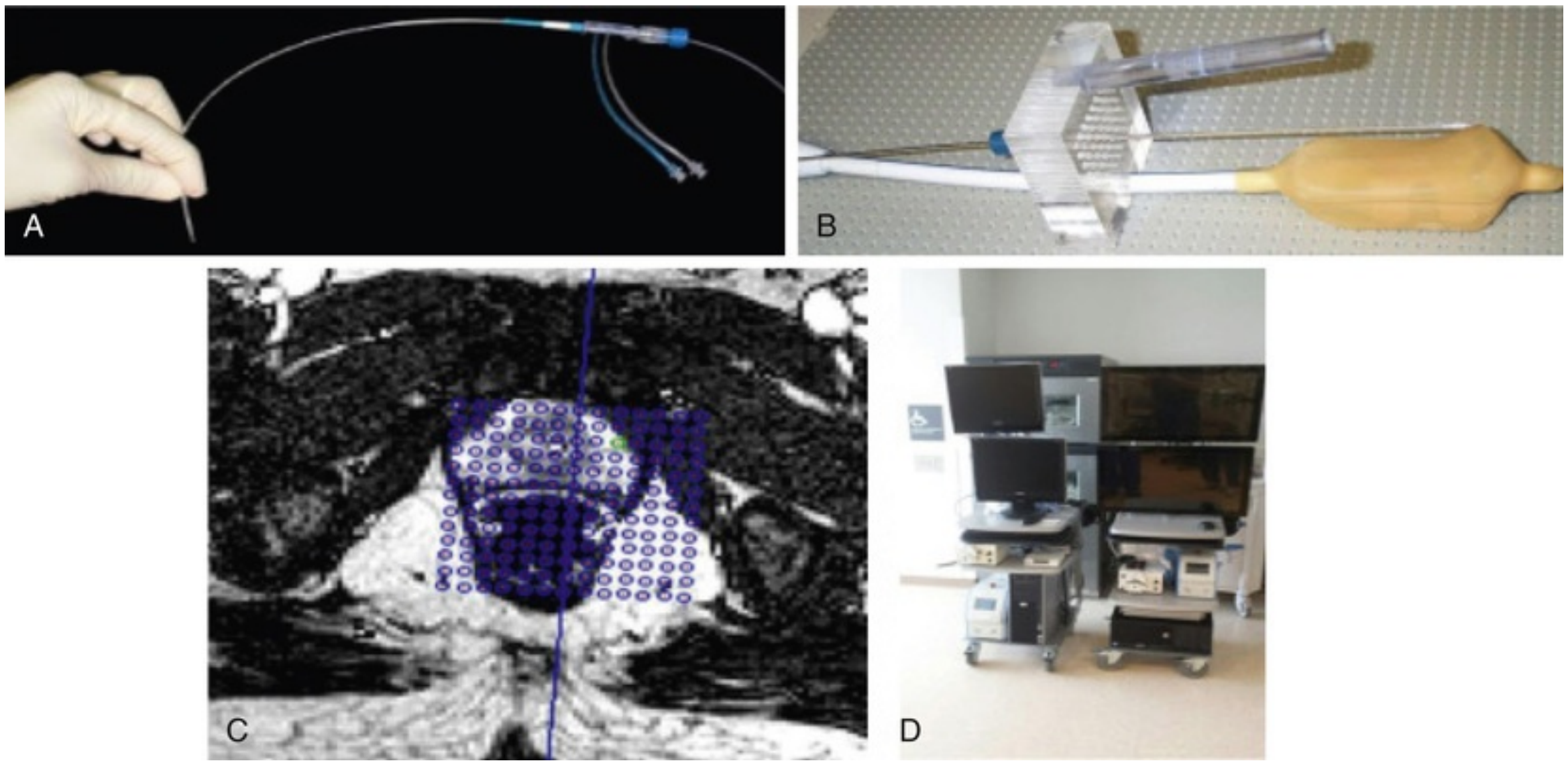

FIG. 158.8 Laser fiber in cooling catheter (A), perineal template with endorectal coil and titanium catheter (B), overlay of template grid on MRI (C), and laser workstation (D). (From Eggener SE, Yousuf A, Watson S, et al. Phase II evaluation of magnetic resonance imaging guided focal laser ablation of prostate cancer. *J Urol* 196(6):1670–1675, 2016.)

Natarajan et al. (2017) reported on 10 men with mainly Gleason 7 cancer (80%) undergoing FLA under local anesthesia using a modified MRI-TRUS fusion biopsy device where a higher recurrence rate (40% infield and outfield for clinically significant cancer) was observed. They concluded that, although it is safe and efficient to perform FLA in a clinic setting, close attention should be paid to achieving an adequate treatment margin.

Irreversible Electroporation

IRE is a nonthermal ablative technique that uses short pulses of direct-current electricity to produce irreversible pores in the cell membrane, leading to cell death (Onik et al., 2007a). IRE preferentially damages cells while preserving connective tissue architecture that could theoretically serve as a scaffolding for new cells to grow. The ablation occurs between two or more probes, typically placed 10 to 20 mm apart (Fig. 158.9). Energy is usually delivered in two components, with the first 20 pulses delivered to characterize the electrical current dynamics between the probe pair. Once adjustments are finalized, the patient is placed in deep anesthesia to avoid muscle depolarization, and the final component of 70 pulses per probe pair is delivered to produce the final tissue ablation. The effective field strength to be achieved is higher than 1600 volts/cm between any given probe pair.

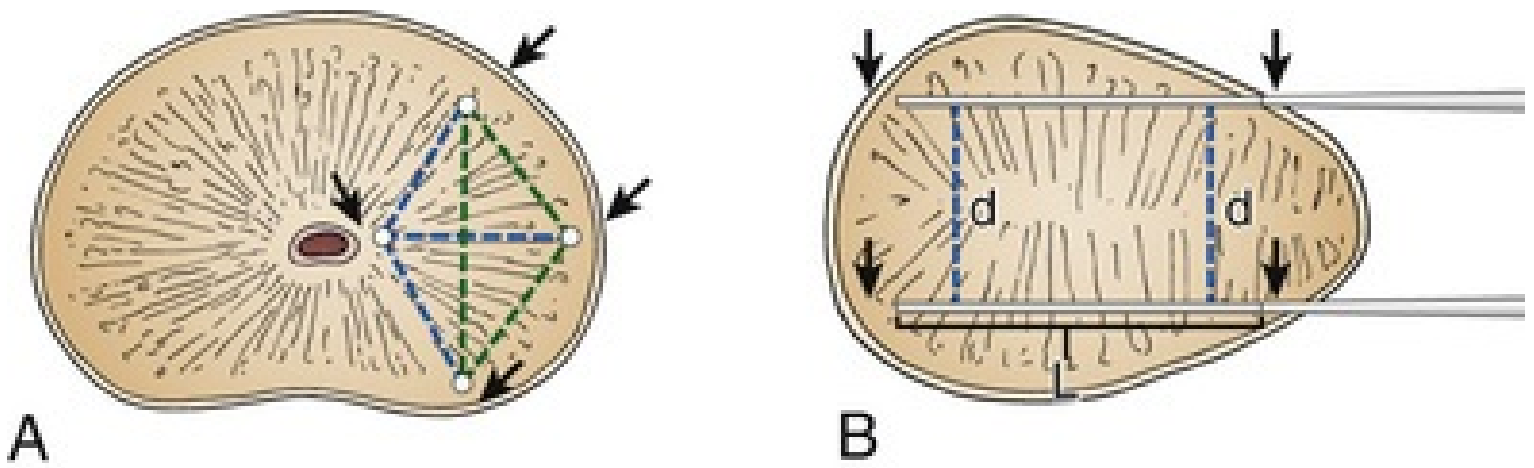

FIG. 158.9 Electrode metrics. (A) Axial representation of probe placement geometry using probe insertion initiated in periurethral position with additional probes configured radially *(blue dashed lines)* from this point. The closest distance from each probe to the capsule or urethra *(arrows)* was no more than 5 mm. The distance between probe pairs *(blue dashed lines)* used for ablation was between 10 and 20 mm. (B) Distances between probes *(d)* and length of needle exposure within tissues *(L)* are obtained to provide data for initial energy settings. Measurements were obtained to confirm parallel orientation *(d)* and 5 mm or greater distance tip to capsule *(arrows).* (From Murray KS, Ehdaie B, Musser J, et al. Pilot study to assess safety and clinical outcomes of irreversible electroporation for partial gland ablation in men with prostate cancer. *J Urol* 196(3):883–890, 2016.)

There are three early-phase studies with an aggregate of 104 men who have undergone focal IRE for prostate cancer (Murray et al., 2016; Valerio et al., 2017; van den Bos et al., 2018) (Table 158.6). One study reported the use of IRE with hemiablation or anterior zonal ablation (Murray et al., 2016), and the other two treated men with focal ablation using a template grid (Valerio et al., 2017; van den Bos et al., 2018). Overall, the procedure appears to be safe with no grade 4 to 5 complications reported. Urinary function appeared to be maintained well with almost all men remaining continent, though some reduction in erectile function scores were noted, withslightly fewer men having erections sufficient for sexual intercourse. Further evaluation with larger cohorts is necessary to determine whether the theoretical benefit of connective tissue preservation bears fruition. Indeed, in a 16-patient ablate and resect study, the majority of the men did have fibrinoid necrosis in the unilateral neurovascular bundle and denudation of the prostatic urethra (van den Bos et al., 2016b). In this study, the interval between ablation and resection was only 1 month, and whether the remaining connective tissue does allow later regrowth and functional recovery is unknown (Fig. 158.10).

TABLE 158.6

Summary of Published Focal Irreversible Electroporation Series

AUTHOR	*N*	PREDIAGNOSTIC WORKUP	DECLARED INCLUSION CRITERIA	FINAL DEMOGRAPHIC	ABLATIO PLAN
Murray et al., 2016	25	mpMRI + targeted + systematic 12-core biopsy	Maximum Gleason 3+4	3+3 – 18 (72%) 3+4 – 6 (24%) 4+3 – 1 (4%)	Hemi- or anterior ablations
Valerio et al., 2017	16	mpMRI + TPM	mpMRI lesions concordant to TPM. Untreated secondary cancers insignificant by UCL2 definition allowed	3+3 – 8 (42.1%) 3+4 – 11 (57.9%)	Focal ablation based on template grid
Van den Bos et al., 2018	63	mpMRI + targeted biopsy + systematic (12-core TRUS or TMB) biopsy	Max Gleason score 7 Single lesion	3+3 – 9 3+4 – 38 4+3 – 16	Focal ablation based on template grid

BCR, biochemical recurrence; *BPFS,* biochemical progression–free survival; *DRE,* digital rectal examination; *ESI,* erections sufficient for intercourse; *IIEF,* international index for erectile function; *mpMRI,* multiparametric magnetic resonance imaging; NR, not reported; *NA,* not applicable; *PSA,* prostate-specific antigen; *TRUS,* transrectal ultrasonography; *TMB,* transperineal mapping biopsy; *TPM,* template prostate mapping.

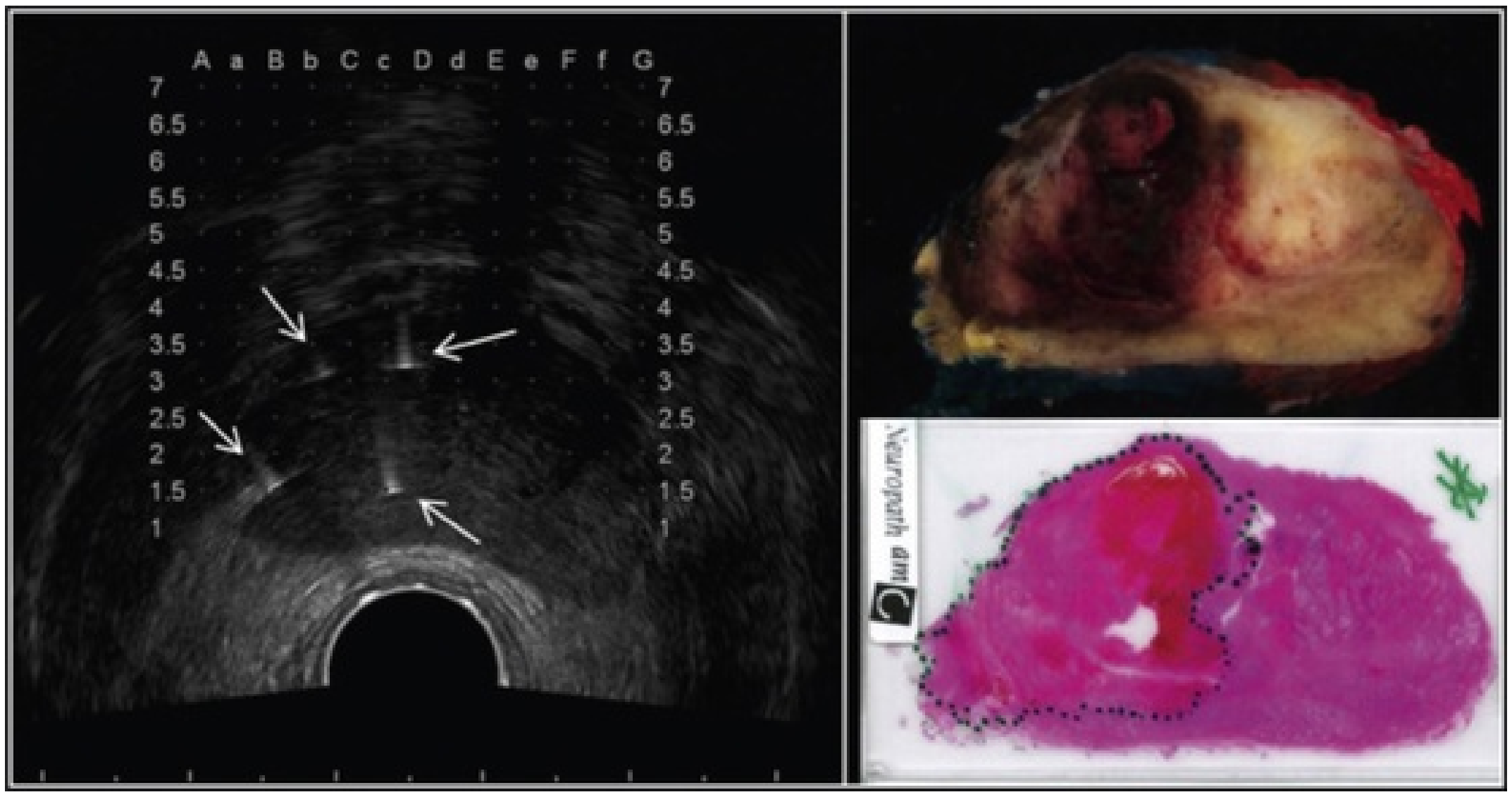

FIG. 158.10 Perioperative TRUS image with inserted irreversible electroporation electrode *(arrows),* with corresponding whole-mounted prostate section and H&E slide. (From van den Bos W, Jurhill RR, de Bruin DM, et al. Histopathological outcomes after irreversible electroporation for prostate cancer: results of an ablate and resect study. *J Urol* 196(2):552–559, 2016b.)

A significant infield positive biopsy rate, including that of clinically significant cancer, was noted in the two studies using focal ablation, but this was much less so in the study in which zonal ablation was deployed. This suggests that the treatment effect when IRE is performed in a focal manner warrants closer examination, and attention to the ablation margin is necessary when focal ablation is planned.

Although a head-to-head trial does not exist, Scheltema et al. (2018) analyzed 50 matched pairs of men who underwent focal IRE or robotic-assisted radical prostatectomy and found that IRE was significantly superior to robotic-assisted radical prostatectomy in preserving pad-free continence and erections sufficient for intercourse, though the focal IRE patients continued to experience cancer recurrence, with 13 men having residual significant prostate cancer and requiring salvage therapy.

Vascular-Targeted Photodynamic Therapy

In vascular-targeted photodynamic (VTP) therapy, low-power near-infrared laser light of specific wavelength destroys targeted tissues that have been photosensitized with an intravascular agent, preferentially taken up by tumor cells (Azzouzi et al., 2013). This occurs via the production of reactive oxygen species in the target zone, causing irreversible damage to cell membranes and small arterioles and leading to tumor necrosis (Vakrat-Haglili et al., 2005).

TOOKAD Soluble (WST11, padeliporfin; palladium bacteriopheophorbide monolysotaurine) is a photosensitizer of the bacteriochlorophyll derivatives family. Compared with predecessor agents, it is highly soluble, remains confined to the vasculature even at high doses, and is rapidly cleared by the renal and hepatic systems. Three phase II trials (Table 158.7) using the TOOKAD Soluble photosensitizer for focal VTP of men with Gleason 3+3 prostate cancer have shown the technology to be safe (Azzouzi et al., 2015). The authors describe a single intravenous administration of TOOKAD Soluble at 4 mg/kg followed by local illumination of the targeted zone using a 753-nm laser light at 150 mW/cm and 200 J/cm via a transperineally positioned laser fiber within the prostate. The total anesthesia time was 2 hours, and on completion the patients were required to wear protective eyewear and stay in low-level light for the following hour post-treatment. A combined analysis of the three trials showed an infield positive biopsy rate of 31.6% overall and 19.4% in those who underwent hemiablation.

TABLE 158.7

Summary of Published Focal Vascular-Targeted Photodynamic Series

AUTHOR	*N*	PREDIAGNOSTIC	DECLARED INCLUSION	FINAL	ABLATION

		WORKUP	CRITERIA	DEMOGRAPHIC	PLAN
Azzouzi et al., 2015	117[a]	mpMRI+ TMB	PSA <10 ng/mL Gleason pattern 4 allowed at low volume (<3 cores, ≤3 mm max cancer core length)	Gleason 3+3 – 116 (99.1%)	Hemi-ablation (Abdollah et al., 2011) and subtotal ablation (Djavan et al., 1999)

[a] This was a combined analysis of three phase II trials.

BCR, biochemical recurrence; *BPFS,* biochemical progression–free survival; *DRE,* digital rectal examination; *IIEF,* international index for erectile function; *mpMRI,* multiparametric magnetic resonance imaging; NR, not reported; *NA,* not applicable; *PSA,* prostate-specific antigen; *TRUS,* transrectal ultrasonography; *TMB,* transperineal mapping biopsy.

Azzouzi et al. (2017) randomized 415 men with low-risk prostate cancer to focal VTP or active surveillance and demonstrated that focal therapy significantly improved negative biopsy at 2 years and decreased disease progression and the requirement for definitive disease intervention. Of the 216 men assigned to VTP, 196 received the treatment and 195 completed 24 months of follow-up. In the active surveillance arm, 174 men completed 24 months of follow-up. Overall, cancer progression rate (volume, grade, or PSA progression) in the active surveillance arm was 58% compared with 28% in the VTP arm. This is the first randomized trial with level 1 evidence comparing focal therapy to an accepted management strategy demonstrating a meaningful clinical benefit. The study limitations include a Gleason 6 cohort, short follow-up, use of surrogate end points that do not necessarily reflect overall/disease-specific survival, and the fact that the outcome measure may represent reclassification rather than true progression.

Brachytherapy

Treatment simulation studies show that an adequate dose delivery to perform focal therapy can be achieved with brachytherapy (Butler and Merrick, 2016;

Haworth et al., 2016). The benefit of brachytherapy is the sharp falloff in radiation dose within a few millimeters of the radiation source. The radiation dose can be further conformed to the desired treatment area by modulating the rate of radioisotope flow through the interstitial catheters when high-dose-rate (HDR) brachytherapy is performed. With seed or low-dose-rate (LDR) brachytherapy, reported urinary toxicity rates are low, and seem dependent on pretreatment symptoms and urethral dose (Gutman et al., 2006). On the other hand, high-dose-rate (HDR) brachytherapy can be associated with a urethral stricture rate as high as 8.2% within the first 2 years of treatment (Hindson et al., 2013). These typically occur at the level of the prostatic apex or bulbous urethra. Studies involving the use of radiation for focal ablation of prostate cancer are ongoing.

Other Modalities

Technical advances in external beam radiation have made it possible to deliver a highly focused dose within the prostate, sparing vital structures (Vainshtein et al., 2012). Dosimetric feasibility has been demonstrated in the use of stereotactic body radiotherapy for focal therapy though there has not been any clinical trial (Kishan et al., 2015).

Another promising modality is the photothermal excitation of nanoshells. These preferentially accumulate in fenestrated perivascular spaces of tumors, causing the preferential death of cancer cells (Stern et al., 2016). An open-label multicenter trial treating men with low- to intermediate-risk prostate cancer is now under way (NCT02680535).

PRX302 is a genetically modified pore-forming protein (aerolysin) that is activated by enzymatically active PSA within the prostate, subsequently causing cell death. A pilot study of 18 patients showed that a single MR-fusion transperineal administration of PRX302 was well tolerated, with two patients having complete and seven partial histologic responses (Shanmugabavan et al., 2017).

NanoPac, sterilized nanoparticles of paclitaxel, is another modality being studied in the phase IIa setting as an intratumoral injectable agent (NCT03077659). More devices and pharmaceuticals are expected to be trialed in the field of FT.

Adjuvants to Focal Therapy

Many of the proponents of FT believe that a successful treatment will ultimately hinge not on a device alone but rather on a combinatorial approach (Baust et al., 2015, 2018). Stereotactic Body Radiation Therapy (SBRT) strategies routinely utilize a boost directed to the tumor focus within the prostate, with only 5-10 external beam fractions required. A pilot study of 50 patients undergoing SBRT with a boost to the MR-visible tumor showed no biochemical recurrence at 2-year follow-up and an acute GU/GI toxicity rate of 8%/2% and late toxicity rate of 6%/0% (grade 3) (Aluwini et al., 2013). The added efficacy of combining a nonradiation focal ablative therapy with low dose/fraction external beam irradiation is yet to be determined. In another investigative approach, DOTA-AR, a bombesin-antagonist peptide targeting Gastrin-related Peptide receptor (GRPr), when conjugated to a radioisotope has been found to cause tumor growth delay when used in combination with WST11 (TOOKAD® Soluble) in GRPr-positive prostate cancer xenographs (Kim et al., 2017).

In focal cryotherapy, there has been early research exploring means to enhance cell kill. The use of androgen deprivation in combination with cryoablation has not been deemed useful to increase cell kill (Grossgold et al., 2014). Alteration of the extracellular environment by infusing a solution with a higher than physiologic eutectic temperature can enhance cryoablation by promoting extra- and intra-cellular eutectic ice formation to provide a cell-kill mechanism in addition to intracellular lethal ice (Han and Bischof, 2004). Several studies have shown the benefits of chemotherapeutic agents (e.g., 5-fluoruracil, cisplatin, doxorubicin, mitomycin and bleomycin, vinorelbine, navelbine and tumor necrosis factor [TNF]-related apoptosis-inducing ligand) as apoptosis inducers to enhance cell destruction at milder temperatures in vitro (Baust et al., 2015). TNF-alpha, a proinflammatory cytokine, is also being explored as an enhancer to cryoablation (Jiang et al., 2008). Vitamin D3 has been found to improve the apoptotic effects of cryoablation at sublethal isotherms in murine models (Santucci et al., 2011).

At present, there is no widely applicable and ubiquitous substance that can be utilized to augment device-mediated cell kill but further research in this area will likely yield further refinements to techniques in prostate focal therapy.

Post–Focal Therapy Follow-Up

With focal therapy, traditional markers of therapeutic success may be less relevant. After curative radical prostatectomy, PSA is expected to be undetectable, and after radiation therapy, a significant rise is needed to define biochemical recurrence. After focal therapy, however, the expected fall in PSA has been variable, with some studies reporting a 50% to 80% reduction. The PSA level would depend on the amount of residual prostate epithelium that may continue to grow and is thus less informative as an absolute marker.

Similarly, clinical examination of the prostate may be affected by post-treatment scarring and contraction of the original tumor site, making follow-up biopsy less reliable. These post-treatment findings are seen on mpMRI, TRUS, and contrast-enhanced ultrasonography (CEUS), with increasing ablation zone volume in the early post-treatment period followed by a gradual overall reduction in prostate volume caused by ablation zone fibrosis and deformation (Scheltema et al., 2017).

Compared with traditional treatments, there are additional dimensions to cancer recurrence after focal therapy that affect downstream management of these patients. In a 2015 Joint International Consultation on Urological Diseases (ICUD)/Society Internationale de Urologie (SIU) project on image-guided focal therapy, success was defined as the following (Polascik & Amin, 2015):

1. Within the treated or infield area as the:
    a. eradication of the tumor focus in the short term.
    b. absence of clinically significant cancer in the intermediate to long-term.
2. Within the untreated or outfield area for the development of clinically significant cancer. In the short term, this outfield cancer focus likely represents selection failure, and in the intermediate- to long-term, this may represent de novo cancer.

This consultation recommended an mpMRI with mandatory targeted biopsy of 4 to 6 cores in the treated area at 3 to 6 months, then mpMRI at 1 to 2 years and 5 years with targeted biopsy as needed, especially if a new lesion should become manifest. A systematic biopsy was also recommended at 1 to 2 years and 5 years to provide further histologic evaluation of the untreated zone for potential outfield recurrence.

It should be noted that there is limited experience with mpMRI in the post–focal treatment arena, and it is unknown how post-treatment changes interact with mpMRI performance. In one whole-gland HIFU series, the sensitivity and specificity of DCE-MRI were reported to be 73% to 87% and 73% to 82%, respectively (Punwani et al., 2012). As radiologic experience in the post–focal therapy prostate accrues, there will be much to for practitioners to learn, especially in those patients experiencing treatment failure.

Because of the intensity of follow-up, investigators have also sought alternative imaging modalities to mitigate the cost of mpMRI and the morbidity of repeated biopsies. One group analyzed 16 men in a pilot study of focal IRE before radical prostatectomy and found that CEUS was as good as mpMRI in determining early ablation success, whereas TRUS was not able to visualize the ablation zone post-treatment (van den Bos et al., 2016a). This is an important area for further research.

Conclusions and Areas for Future Research

“Is cure possible when necessary and necessary when possible?”

—Willet Whitmore

Better health care leading to longer life expectancy, an increasing awareness of prostate cancer, and widespread use of PSA screening have led to more prostate cancers being diagnosed. Meanwhile, advances in imaging and biopsy have resulted in these cancers being diagnosed at an earlier stage when, in a subset of patients, focal therapy may render the cancer cured, or at least controlled for a significant duration. Because the biology of prostate cancer for the most part is one of a slowly growing disease, the management of prostate cancer has the potential to convert this from an acute to a chronic disease. Focal therapy, with its combination of eradicating clinically significant cancer while monitoring uninvolved parenchyma on an active surveillance protocol, has the ability to avoid overtreatment and preserve genitourinary function for many years. Many men today equally value quality of life as much as cancer control, and image-guided ablation is well positioned to achieve both functional metrics and cancer control. However, the journey remains filled with challenges, and focal therapy remains a work in progress with significant room for further research (Tay et al., 2017b).

First, it remains unknown whether satellite, insignificant cancers can remain safely untreated. Present efforts have focused on identifying the index lesion, or the lesion with the highest stage/grade, within the prostate for ablation. However, cancers that are small or insignificant at the time of treatment may progress to a more aggressive phenotype. Indeed, the only randomized trial of prostate focal therapy compared with active surveillance found a progression-free survival benefit in men with low-risk prostate cancer, suggesting that there is some value to treating lower-grade lesions (Azzouzi et al., 2017). Further research is needed to develop clinical, imaging, and genetic biomarkers that can help to profile all the truly aggressive lesions within the prostate. Techniques focusing on functional and metabolic imaging, in addition to anatomic imaging, may be an area where such profiling can converge such that genetic and metabolic markers can be detected by imaging for highly accurate and appropriate image-guided ablation. In the meantime, continued close surveillance of any small, insignificant lesions remains necessary.

Second, the long-term cost-effectiveness of focal therapy remains unknown. Up to one-half of men on active surveillance for prostate cancer eventually undergo radical intervention (Hamdy et al., 2016; Klotz et al., 2015). By restricting treatment to the clinically significant lesion and placing the remainder of the gland on surveillance, we expect to observe that a substantial of proportion of men *will* progress and require either additional focal ablation or radical intervention. This might be viewed as the cost for using focal therapy as an extender of active surveillance to preserve quality of life, but patients will have to be prepared to undergo repeated treatments. In the long term, the cost and morbidity of surveillance and repeated focal therapy are not known. Additionally, the morbidity of radical intervention after repeated focal therapy is unknown. The incremental cost-effectiveness of the entire focal therapy strategy remains to be defined.

Third, focal therapy may have to be further optimized using adjuvants to obtain lasting oncologic control. Excellent outcomes with wide excision as compared with mastectomy for breast cancer have often been cited as the model for successful prostate focal therapy. However, although wide excision in breast cancer is routinely paired with adjuvant radiotherapy, there have been no trials exploring adjuvants such as whole-gland irradiation in conjunction with focal ablation in prostate cancer. There are several promising adjuvants in early development, and the downstream challenge is to demonstrate clinical safety and efficacy of such adjuncts in human trials.

Key Points

- The biologic basis of focal therapy is predicated on the index lesion being the dominant tumor focus in the prostate that drives cancer progression and metastasis. Although the majority of prostate cancers are multifocal, most of the time, secondary cancers (cancers other than the index lesion) tend to be small, low grade and of low clinical significance. Hence, if the index lesion could be completely ablated, men could potentially be cured of cancer or have their low-grade cancer monitored with active surveillance.

- A successful focal therapy strategy depends on a multidisciplinary team to accurately determine the disease extent/location through advanced imaging and biopsy, ascertain that the patient will be compliant to follow-up, completely ablate the index lesion(s), and monitor the patient post-treatment with a view to future targeted treatment of either persistent or de novo disease, or conversion to whole-gland treatment as necessary.
- mpMRI has become a key enabler for prostate focal therapy because of its ability to preferentially detect high-grade lesions, improve the detection of anterior-zone cancers, improve the detection of EPE, and accurately identify the index lesions for targeted biopsy. However, systematic biopsy remains necessary to evaluate the prostate gland before focal therapy because of the 10% to 15% miss rate with mpMRI. Other imaging modalities such as multiparametric ultrasonography, or PSMA-PET CT/MRI have potential use in this area but remain to be further evaluated.
- Focal therapy can be applied in various patterns (hemiablation, quadrant ablation, lesion ablation) using different technologies (e.g., cryotherapy, HIFU, IRE, laser). The chosen approach depends on the location of the tumor, the desired ablative technology that is available, and other anatomic considerations that may be peculiar to the patient.
- After prostate focal therapy, PSA, which is a traditional marker of therapeutic success, is less relevant because its levels are affected by the amount of residual prostate epithelium that may continue to grow. MRI and prostate biopsies are recommended to assess the treated (infield) area and the untreated (outfield) area.
- Future research endeavors should focus on better patient selection using clinical, imaging, and/or genetic biomarkers, cost-effectiveness studies, and the investigation of adjuvant agents to improve the efficacy of focal therapy in prostate cancer.

References

Abdollah F, Scattoni V, Raber M, et al. The role of transrectal saturation biopsy in tumour localization: pathological correlation after retropubic radical prostatectomy and implication for focal ablative therapy. *BJU Int*. 2011;108(3):366–371.

ACR. *PI-RADS: Prostate Imaging - Reporting and Data System version 2 2015*. [April 1, 2016]; Available at] http://www.acr.org/~/media/ACR/Documents/PDF/QualitySa

Ahmed HU. The index lesion and the origin of prostate cancer. *N Engl J Med*. 2009;361(17):1704–1706.

Ahmed HU, Akin O, Coleman JA, et al. Transatlantic Consensus Group on active surveillance and focal therapy for prostate cancer. *BJU Int*. 2012;109(11):1636–1647.

Ahmed HU, Dickinson L, Charman S, et al. Focal ablation targeted to the index lesion in multifocal localised prostate cancer: a prospective development study. *Eur Urol*. 2015;68(6):927–936.

Ahmed HU, El-Shater Bosaily A, Brown LC, et al. Diagnostic accuracy of multi-parametric MRI and TRUS biopsy in prostate cancer (PROMIS): a paired validating confirmatory study. *Lancet*. 2017;389(10071):815–822.

Al-Ahmadie HA, Tickoo SK, Olgac S, et al. Anterior-predominant prostatic tumors: zone of origin and pathologic outcomes at radical prostatectomy. *Am J Surg Pathol*. 2008;32(2):229–235.

Aluwini S, van Rooij P, Hoogeman M, et al. Stereotactic body radiotherapy with a focal boost to the MRI-visible tumor as monotherapy for low- and intermediate-risk prostate cancer: early results. *Radiat Oncol*. 2013;8:84.

American Cancer Society. *Cancer Facts and Figures 2016*.

[Available at] http://www.cancer.org/acs/groups/content/@research/docume 047074.pdf.

Arora R, Koch MO, Eble JN, et al. Heterogeneity of Gleason grade in multifocal adenocarcinoma of the prostate. *Cancer*. 2004;100(11):):2362–2366.

Arumainayagam N, Ahmed HU, Moore CM, et al. Multiparametric MR imaging for detection of clinically significant prostate cancer: a validation cohort study with transperineal template prostate mapping as the reference standard. *Radiology*. 2013;268(3):761–769.

Ayala GE, Dai H, Ittmann M, et al. Growth and survival mechanisms associated with perineural invasion in prostate cancer. *Cancer Res*. 2004;64(17):6082–6090.

Azzouzi AR, Barret E, Moore CM, et al. TOOKAD® Soluble vascular-targeted photodynamic (VTP) therapy: determination of optimal treatment conditions and assessment of effects in patients with localised prostate cancer. *BJU Int*. 2013;112(6):766–774.

Azzouzi AR, Barret E, Bennet J, et al. TOOKAD® Soluble focal therapy: pooled analysis of three phase II studies assessing the minimally invasive ablation of localized prostate cancer. *World J Urol*. 2015;33(7):945–953.

Azzouzi AR, Vincendeau S, Barret E, et al. Padeliporfin vascular-targeted photodynamic therapy versus active surveillance in men with low-risk prostate cancer (CLIN1001 PCM301): an open-label, phase 3, randomised controlled trial. *Lancet Oncol*. 2017;18(2):181–191.

Baco E, Ukimura O, Rud E, et al. Magnetic resonance imaging–transectal ultrasound image-fusion biopsies accurately characterize the index tumor: correlation with step-sectioned radical prostatectomy specimens in 135 patients. *Eur Urol*. 2015;67(4):787–794.

Bahn D, de Castro Abreu AL, Gill IS, et al. Focal cryotherapy for clinically unilateral, low-intermediate risk prostate cancer in 73 men with a median follow-up of 3.7 years. *Eur Urol*. 2012;62(1):55–63.

Barentsz JO, Richenberg J, Clements R, et al. ESUR prostate MR guidelines 2012. *Eur Radiol*. 2012;22(4):746–757.

Barqawi AB, Stoimenova D, Krughoff K, et al. Targeted focal therapy for the management of organ confined prostate cancer. *J Urol*. 2014;192(3):749–753.

Barzell WE, Melamed MR. Appropriate patient selection in the focal treatment of prostate cancer: the role of transperineal 3-dimensional pathologic mapping of the prostate—a 4-year experience. *Urology*. 2007;70(6 Suppl):27–35.

Baust JG, Gage AA, Bjerklund Johansen TE, et al. Mechanisms of cryoablation: clinical consequences on malignant tumors. *Cryobiology*. 2014;68(1):1–11.

Baust JG, Bischof JC, Jiang-Hughes S, et al. Re-purposing cryoablation: a combinatorial “therapy” for the destruction of tissue. *Prostate Cancer Prostatic Dis*. 2015;18:87–95.

Baust JM, Rabin Y, Polascik TJ, et al. Defeating cancers’ adaptive defensive strategies using thermal therapies: examining cancer's therapeutic resistance, ablative, and computational modeling strategies as a means for improving therapeutic outcome. *Technol Cancer Res Treat*. 2018;17.

Boehm K, Salomon G, Beyer B, et al. Shear wave elastography for localization of prostate cancer lesions and assessment of elasticity thresholds: implications for targeted biopsies and active surveillance protocols. *J Urol*. 2015;193(3):794–800.

Bomers JGR, Cornel EB, Futterer JJ, et al. MRI-guided focal laser ablation for prostate cancer followed by radical prostatectomy: correlation of treatment effects with imaging. *World J Urol*. 2017;35(5):703–711.

Bonnal JL, Marien A, Rock A, et al. V49–Trimodal (18) F-choline-PET/mpMRI/TRUS targeted prostate biopsies: first clinical experience. *Eur Urol Suppl*. 2017;16(3):e2102–e2103.

Bott SR, Young MP, Kellett MJ, et al. Contributors to the UCL Hospitals' Trust Radical Prostatectomy database. Anterior prostate cancer: is it more difficult to diagnose? *BJU Int*. 2002;89(9):886–889.

Burtnyk M, Hill T, Cadieux-Pitre H, et al. Magnetic resonance image guided transurethral ultrasound prostate ablation: a preclinical safety and feasibility study with 28-day followup. *J Urol*. 2015;193(5):1669–1675.

Butler WM, Merrick GS. Focal prostate brachytherapy with (103)Pd seeds. *Phys Med*. 2016;32(3):459–464.

Catto JW, Robinson MC, Albertsen PC, et al. Suitability of PSA-detected localised prostate cancers for focal therapy: experience from the ProtecT study. *Br J Cancer*. 2011;105(7):931–937.

Cerantola Y, Valerio M, Kawkabani Marchini A, et al. Can 3T multiparametric magnetic resonance imaging accurately detect prostate cancer extracapsular extension? *Can Urol Assoc J*. 2013;7(11–12):E699–E703.

Cespedes RD, Pisters LL, Von Eschenbach AC, et al. Long-term followup of incontinence and obstruction after salvage cryosurgical ablation of the prostate: results in 143 patients. *J Urol*. 1997;157(1):237–240.

Chang KJ, Kamel IR, Macura KJ, et al. 3.0-T MR imaging of the abdomen: comparison with 1.5 T. *Radiographics*. 2008;28(7):1983–1998.

Chen ME, Johnston DA, Tang K, et al. Detailed mapping of prostate carcinoma foci: biopsy strategy implications. *Cancer*. 2000;89(8):1800–1809.

Chin JL, Billia M, Relle J, et al. Magnetic resonance imaging-guided transurethral ultrasound ablation of prostate tissue in patients with localized prostate cancer: a prospective phase 1 clinical trial. *Eur Urol*. 2016;70(3):447–455.

Clyne M. Prostate cancer: prostatic swelling and shift upon HIFU. *Nat Rev Urol*. 2013;10(6):306.

Constanciel E, N'Djin WA, Bessiere F, et al. Design and evaluation of a transesophageal HIFU probe for ultrasound-guided cardiac ablation: simulation of a HIFU mini-maze procedure and preliminary ex vivo trials. *IEEE Trans Ultrason Ferroelectr Freq Control*. 2013;60(9):1868–1883.

Cooper CS, Eeles R, Wedge DC, et al. Analysis of the genetic phylogeny of multifocal prostate cancer identifies multiple independent clonal expansions in neoplastic and morphologically normal prostate tissue. *Nat Genet*. 2015;47(4):367–372.

Cornud F, Khoury G, Bouazza N, et al. Tumor target volume for focal therapy of prostate cancer—Does multiparametric magnetic resonance imaging allow for a reliable estimation? *J Urol*. 2014;191(5):1272–1279.

de la Rosette J, Ahmed H, Barentsz J, et al. Focal therapy in prostate cancer—report from a consensus panel. *J Endourol*. 2010;24(5):775–780.

Delongchamps NB, Lefevre A, Bouazza N, et al. Detection of significant prostate cancer with magnetic resonance targeted biopsies—should transrectal ultrasound-magnetic resonance imaging fusion guided biopsies alone be a standard of care? *J Urol*. 2015;193(4):1198–1204.

Djavan B, Susani M, Bursa B, et al. Predictability and significance of multifocal prostate cancer in the radical prostatectomy specimen. *Tech Urol*. 1999;5(3):139–142.

Donaldson IA, Alonzi R, Barratt D, et al. Focal therapy: patients, interventions, and outcomes—a report from a consensus meeting. *Eur Urol*. 2015;67(4):771–777.

Donnelly BJ, Saliken JC, Ali-Ridha N, et al. Histological findings in the prostate two years following cryosurgical ablation. *Can J Urol*. 2001;8(2):1237–1239.

Durand M, Barret E, Galiano M, et al. Focal cryoablation: a treatment option for unilateral low-risk prostate cancer. *BJU Int*. 2014;113(1):56–64.

Eder M, Schafer M, Bauder-Wust U, et al. 68Ga-complex lipophilicity and the targeting property of a urea-based PSMA inhibitor for PET imaging. *Bioconjug Chem*. 2012;23(4):688–697.

Eggener SE, Yousuf A, Watson S, et al. Phase II evaluation of magnetic resonance imaging guided focal laser ablation of prostate cancer. *J Urol*. 2016;196(6):1670–1675.

Eiber M, Nekolla SG, Maurer T, et al. ^{68}Ga-PSMA PET/MR with multimodality image analysis for primary prostate cancer. *Abdom Imaging*. 2015;40(6):1769–1771.

El Fegoun AB, Barret E, Prapotnich D, et al. Focal therapy with high-intensity focused ultrasound for prostate cancer in the elderly. A feasibility study with 10 years follow-up. *Int Braz J Urol*. 2011;37(2):213–219 [discussion 220–222].

Ellis DS, Manny TB Jr, Rewcastle JC. Focal cryosurgery followed by penile rehabilitation as primary treatment for localized prostate cancer: initial results. *Urology*. 2007;70(6 Suppl):9–15.

Feijoo ER, Sivaraman A, Barret E, et al. Focal high-intensity focused ultrasound targeted hemiablation for unilateral prostate cancer: a prospective evaluation of oncologic and functional outcomes. *Eur Urol*. 2016;69(2):214–220.

Feng TS, Sharif-Afshar AR, Smith SC, et al. Multiparametric magnetic resonance imaging localizes established extracapsular extension of prostate cancer. *Urol Oncol*. 2015;33(3):109.e15–109.e22.

Ferlay J, Soerjomataram I, Ervik M, et al. *GLOBOCAN 2012 v1.0, Cancer incidence and mortality worldwide: IARC*

CancerBase No. 11 [Internet]. [Lyon, France: International Agency for Research on Cancer; Available at] http://globocan.iarc.fr; 2013.

Fleischmann A, Huland H, Mirlacher M, et al. Prognostic relevance of Bcl-2 overexpression in surgically treated prostate cancer is not caused by increased copy number or translocation of the gene. *Prostate*. 2012;72(9):991–997.

Fu Q, Moul JW, Bañez LL, et al. Preoperative predictors of pathologic stage T2a in low-risk prostate cancer: implications for focal therapy. *Urol Int*. 2012;89(3):296–300.

Gallina A, Maccagnano C, Suardi N, et al. Unilateral positive biopsies in low risk prostate cancer patients diagnosed with extended transrectal ultrasound-guided biopsy schemes do not predict unilateral prostate cancer at radical prostatectomy. *BJU Int*. 2012;110(2 Pt 2):E64–E68.

Ganzer R, Hadaschik B, Pahernik S, et al. Prospective multicenter phase ii study on focal therapy (hemiablation) of the prostate with high intensity focused ultrasound. *J Urol*. 2018;199(4):983–989.

Gaziev G, Wadhwa K, Barrett T, et al. Defining the learning curve for multiparametric magnetic resonance imaging (MRI) of the prostate using MRI-transrectal ultrasonography (TRUS) fusion-guided transperineal prostate biopsies as a validation tool. *BJU Int*. 2016;117(1):80–86.

Grossgold E, Given R, Ruckle H, et al. Does neoadjuvant androgen deprivation therapy before primary whole gland cryoablation of the prostate affect the outcome? *Urology*. 2014;83(2):379–383.

Guo Y, Sklar GN, Borkowski A, et al. Loss of the cyclin-dependent kinase inhibitor p27(Kip1) protein in human prostate cancer correlates with tumor grade. *Clin Cancer Res*. 1997;3(12 Pt 1):2269–2274.

Gupta RT, Kauffman CR, Polascik TJ, et al. The state of prostate MRI in 2013. *Oncology (Williston Park)*. 2013;27(4):262–270.

Gupta RT, Brown AF, Silverman RK, et al. Can radiologic staging with multiparametric MRI enhance the accuracy of the Partin tables in predicting organ-confined prostate cancer? *AJR Am J Roentgenol*. 2016;207(1):87–95.

Gutman S, Merrick GS, Butler WM, et al. Severity categories of the International Prostate Symptom Score before, and urinary morbidity after, permanent prostate brachytherapy. *BJU Int*. 2006;97(1):62–68.

Haffner MC, Mosbruger T, Esopi DM, et al. Tracking the clonal origin of lethal prostate cancer. *J Clin Invest*. 2013;123(11):4918–4922.

Hale Z, Miyake M, Palacios DA, et al. Focal cryosurgical ablation of the prostate: a single institute's perspective. *BMC Urol*. 2013;13:2.

Hamdy FC, Donovan JL, Lane JA, et al. 10-Year outcomes after monitoring, surgery, or radiotherapy for localized prostate cancer. *N Engl J Med*. 2016;375(15):1415–1424.

Han B, Bischof JC. Direct cell injury associated with eutectic crystallization during freezing. *Cryobiology*. 2004;48(1):8–21.

Hanahan D, Weinberg RA. The hallmarks of cancer. *Cell*. 2000;100(1):57–70.

Hanahan D, Weinberg RA. Hallmarks of cancer: the next generation. *Cell*. 2011;144(5):646–674.

Haworth A, Mears C, Betts JM, et al. A radiobiology-based inverse treatment planning method for optimisation of permanent l-125 prostate implants in focal brachytherapy. *Phys Med Biol*. 2016;61(1):430–444.

Hildebrandt B, Wust P, Ahlers O, et al. The cellular and molecular basis of hyperthermia. *Crit Rev Oncol Hematol*. 2002;43(1):33–56.

Hindson BR, Millar JL, Matheson B. Urethral strictures following high-dose-rate brachytherapy for prostate cancer: analysis of risk factors. *Brachytherapy*. 2013;12(1):50–55.

Hollmann BG, van Triest B, Ghobadi G, et al. Gross tumor volume and clinical target volume in prostate cancer: how do satellites relate to the index lesion. *Radiother Oncol*. 2015;115(1):96–100.

Horninger W, Berger AP, Rogatsch H, et al. Characteristics of prostate cancers detected at low PSA levels. *Prostate*. 2004;58(3):232–237.

Hricak H, Choyke PL, Eberhardt SC, et al. Imaging prostate cancer: a multidisciplinary perspective. *Radiology*. 2007;243(1):28–53.

Huang CC, Deng FM, Kong MX, et al. Re-evaluating the concept of “dominant/index tumor nodule” in multifocal prostate cancer. *Virchows Arch*. 2014;464(5):589–594.

Ibeawuchi C, Schmidt H, Voss R, et al. Genome-wide investigation of multifocal and unifocal prostate cancer-are they genetically different? *Int J Mol Sci*. 2013;14(6):11816–11829.

Iczkowski KA, Hossain D, Torkko KC, et al. Preoperative prediction of unifocal, unilateral, margin-negative, and small volume prostate cancer. *Urology*. 2008;71(6):1166–1171.

Jędroszka D, Orzechowska M, Hamouz R, et al. Markers of epithelial-to-mesenchymal transition reflect tumor biology according to patient age and Gleason score in prostate cancer. *PLoS ONE*. 2017;12(12):e0188842.

Jiang J, Goel R, Iftekhar MA, et al. Tumor necrosis factor-alpha-induced accentuation in cryoinjury: mechanisms in vitro and in vivo. *Mol Cancer Ther*. 2008;7(8):2547–2555.

Jordan EJ, Fiske C, Zagoria R, et al. PI-RADS v2 and ADC values: is there room for improvement? *Abdom Radiol (NY)*. 2018;43(11):3109–3116.

Karavitakis M, Winkler M, Abel P, et al. Histological characteristics of the index lesion in whole-mount radical prostatectomy specimens: implications for focal therapy. *Prostate Cancer Prostatic Dis*. 2011;14(1):46–52.

Karavitakis M, Ahmed HU, Abel PD, et al. Anatomically versus biologically unifocal prostate cancer: a pathological evaluation in the context of focal therapy. *Ther Adv Urol*. 2012;4(4):155–160.

Kayat Bittencourt L, Litjens G, Hulsbergen-van de Kaa CA, et al. Prostate cancer: the European Society of Urogenital Radiology Prostate Imaging Reporting and Data System criteria for predicting extraprostatic extension by using 3-T multiparametric MR imaging. *Radiology*. 2015;276(2):479–489.

Kim K, Zhang H, LaRosa S, et al. Bombesin antagonist based radiotherapy of prostate cancer combined with WST-11 vascular targeted photodynamic therapy. *Clin Cancer Res*. 2017;23(13):3343–3351.

Kishan AU, Park SJ, King CR, et al. Dosimetric benefits of hemigland stereotactic body radiotherapy for prostate cancer: implications for focal therapy. *Br J Radiol*. 2015;88(1056):20150658.

Klotz L. Active surveillance: patient selection. *Curr Opin Urol*. 2013;23(3):239–244.

Klotz L, Polascik TJ. Low-risk and very-low-risk prostate cancer: is there a role for focal therapy in the era of active surveillance? Yes, the two approaches complement each other. *Oncology (Williston Park)*. 2014;28(11):951-c3.

Klotz L, Vesprini D, Sethukavalan P, et al. Long-term follow-up of a large active surveillance cohort of patients with prostate cancer. *J Clin Oncol*. 2015;33(3):272–277.

Kluth M, Jung S, Habib O, et al. Deletion lengthening at chromosomes 6q and 16q targets multiple tumor suppressor genes and is associated with an increasingly poor prognosis in prostate cancer. *Oncotarget*. 2017;8(65):108923–108935.

Komai Y, Numao N, Yoshida S, et al. High diagnostic ability of multiparametric magnetic resonance imaging to detect anterior prostate cancer missed by transrectal 12-core biopsy. *J Urol*. 2013;190(3):867–873.

Kongnyuy M, George AK, Rastinehad AR, et al. Magnetic resonance imaging-ultrasound fusion-guided prostate biopsy: review of technology, techniques, and outcomes. *Curr Urol Rep*. 2016;17(4):32.

Le JD, Tan N, Shkolyar E, et al. Multifocality and prostate cancer detection by multiparametric magnetic resonance imaging: correlation with whole-mount histopathology. *Eur Urol*. 2015;67(3):569–576.

Le Nobin J, Rosenkrantz AB, Villers A, et al. Image guided focal therapy for magnetic resonance imaging visible prostate cancer: defining a 3-dimensional treatment margin based on magnetic resonance imaging histology co-registration analysis. *J Urol*. 2015;194(2):364–370.

Lian H, Zhuang J, Yang R, et al. Focal cryoablation for unilateral low-intermediate-risk prostate cancer: 63-month mean follow-up results of 41 patients. *Int Urol Nephrol*. 2016;48(1):85–90.

Lindner U, Weersink RA, Haider MA, et al. Image guided photothermal focal therapy for localized prostate cancer: phase I trial. *J Urol*. 2009;182(4):1371–1377.

Liu W, Laitinen S, Khan S, et al. Copy number analysis indicates monoclonal origin of lethal metastatic prostate cancer. *Nat Med*. 2009;15:559.

Mendez MH, Passoni NM, Pow-Sang J, et al. Comparison of outcomes between preoperatively potent men treated with focal versus whole gland cryotherapy in a matched population. *J Endourol*. 2015;29(10):1193–1198.

Miller GJ, Cygan JM. Morphology of prostate cancer: the effects of multifocality on histological grade, tumor volume and capsule penetration. *J Urol*. 1994;152(5 Pt 2):1709–1713.

Mouraviev V, Polascik TJ. Focal therapy: prostate hemiablation as the first historical treatment model for focal therapy of early stage prostate cancer. Klein EA, Jones JS. *Management of prostate cancer. Current clinical urology*. ed 3. Springer, Humana Press: New York, NY; 2012:225–241.

Mouraviev V, Madden JF, Broadwater G, et al. Use of 111in-capromab pendetide immunoscintigraphy to image localized prostate cancer foci within the prostate gland. *J Urol*. 2009;182(3):938–947.

Mucci LA, Powolny A, Giovannucci E, et al. Prospective study of prostate tumor angiogenesis and cancer-specific mortality in the health professionals follow-up study. *J Clin Oncol*. 2009;27(33):5627–5633.

Murray KS, Ehdaie B, Musser J, et al. Pilot study to assess safety and clinical outcomes of irreversible electroporation for partial gland ablation in men with prostate cancer. *J Urol*. 2016;196(3):883–890.

Napoli A, Anzidei M, De Nunzio C, et al. Real-time magnetic resonance–guided high-intensity focused ultrasound focal therapy for localised prostate cancer: preliminary experience. *Eur Urol*. 2013;63(2):395–398.

Natarajan S, Jones TA, Priester AM, et al. Focal laser ablation of prostate cancer: feasibility of magnetic resonance imaging-ultrasound fusion for guidance. *J Urol*. 2017;198(4):839–847.

Nevoux P, Ouzzane A, Ahmed HU, et al. Quantitative tissue analyses of prostate cancer foci in an unselected cystoprostatectomy series. *BJU Int*. 2012;110(4):517–523.

Ng JC, Koch MO, Daggy JK, et al. Perineural invasion in radical prostatectomy specimens: lack of prognostic significance. *J Urol*. 2004;172(6 Pt 1):2249–2251.

Noguchi M, Stamey TA, McNeal JE, et al. Prognostic factors for multifocal prostate cancer in radical prostatectomy specimens: lack of significance of secondary cancers. *J Urol*. 2003;170(2 Pt 1):459–463.

Ohori M, Eastham JA, Koh H, et al. Is focal therapy reasonable in patients with early stage prostate cancer (CAP)? An analysis of radical prostatectomy (RP) specimens. *J Urol*. 2006;175(Suppl):507 [AUA Annual Meeting, Atlanta 2006. Abstract #1574].

Onik G, Barzell W. Transperineal 3D mapping biopsy of the prostate: an essential tool in selecting patients for focal prostate cancer therapy. *Urol Oncol*. 2008;26(5):506–510.

Onik G, Cobb C, Cohen J, et al. US characteristics of frozen prostate. *Radiology*. 1988;168(3):629–631.

Onik G, Narayan P, Vaughan D, et al. Focal “nerve-sparing” cryosurgery for treatment of primary prostate cancer: a new approach to preserving potency. *Urology*. 2002;60(1):109–114.

Onik G, Mikus P, Rubinsky B. Irreversible electroporation: implications for prostate ablation. *Technol Cancer Res Treat*. 2007;6(4):295–300.

Onik G, Vaughan D, Lotenfoe R, et al. “Male lumpectomy”: focal therapy for prostate cancer using cryoablation. *Urology*. 2007;70(6 Suppl):16–21.

Onik G, Vaughan D, Lotenfoe R, et al. The “male lumpectomy”: focal therapy for prostate cancer using cryoablation results in 48 patients with at least 2-year follow-up. *Urol Oncol*. 2008;26(5):500–505.

Oto A, Sethi I, Karczmar G, et al. MR imaging-guided focal laser ablation for prostate cancer: phase I trial. *Radiology*. 2013;267(3):932–940.

Ouzzane A, Puech P, Lemaitre L, et al. Combined multiparametric MRI and targeted biopsies improve anterior prostate cancer detection, staging, and grading. *Urology*. 2011;78(6):1356–1362.

Padar A, Sathyanarayana UG, Suzuki M, et al. Inactivation of cyclin D2 gene in prostate cancers by aberrant promoter methylation. *Clin Cancer Res*. 2003;9(13):4730–4734.

Palmeri ML, Glass TJ, Miller ZA, et al. Identifying clinically significant prostate cancers using 3-D in vivo acoustic radiation force impulse imaging with whole-mount histology validation. *Ultrasound Med Biol*. 2016;42(6):1251–1262.

Pasquali D, Rossi V, Staibano S, et al. The endocrine-gland-derived vascular endothelial growth factor (EG-VEGF)/prokineticin 1 and 2 and receptor expression in human prostate: up-regulation of EG-VEGF/prokineticin 1 with malignancy. *Endocrinology*. 2006;147(9):4245–4251.

Patel NM, Nozaki S, Shortle NH, et al. Paclitaxel sensitivity of breast cancer cells with constitutively active NF-kappaB is enhanced by IkappaBalpha super-repressor and parthenolide. *Oncogene*. 2000;19(36):4159–4169.

Polascik TJ, Amin MB. Surveillance after focal therapy. Sanchez-Salas R, Desai M. *Image-guided therapy in urology. SIU-ICUD Joint Consultations*. Societé Internationale d'Urologie;: Melbourne, Australia; 2015.

Polascik TJ, Mayes JM, Schroeck FR, et al. Patient selection for hemiablative focal therapy of prostate cancer: variables predictive of tumor unilaterality based upon radical prostatectomy. *Cancer*. 2009;115(10):2104–2110.

Postema A, Mischi M, de la Rosette J, et al. Multiparametric ultrasound in the detection of prostate cancer: a systematic review. *World J Urol*. 2015;33(11):1651–1659.

Postema AW, De Reijke TM, Ukimura O, et al. Standardization of definitions in focal therapy of prostate cancer: report from a Delphi consensus project. *World J Urol*. 2016;34(10):1373–1382.

Priester A, Natarajan S, Khoshnoodi P, et al. Magnetic resonance imaging underestimation of prostate cancer geometry: use of patient specific molds to correlate images with whole mount pathology. *J Urol*. 2017;197(2):320–326.

Punwani S, Emberton M, Walkden M, et al. Prostatic cancer surveillance following whole-gland high-intensity focused ultrasound: comparison of MRI and prostate-specific antigen for detection of residual or recurrent disease. *Br J Radiol*. 2012;85(1014):720–728.

Radtke JP, Schwab C, Wolf MB, et al. Multiparametric magnetic resonance imaging (MRI) and MRI-transrectal ultrasound fusion biopsy for index tumor detection: correlation with radical prostatectomy specimen. *Eur Urol*. 2016;70(5):846–853.

Raskolnikov D, George AK, Rais-Bahrami S, et al. The role of magnetic resonance image guided prostate biopsy in stratifying men for risk of extracapsular extension at radical prostatectomy. *J Urol*. 2015;194(1):105–111.

Resnick MJ, Koyama T, Fan KH, et al. Long-term functional outcomes after treatment for localized prostate cancer. *N Engl J Med*. 2013;368(5):436–445.

Rice KR, Furusato B, Chen Y, et al. Clinicopathological behavior of single focus prostate adenocarcinoma. *J Urol*. 2009;182(6):2689–2694.

Rischmann P, Gelet A, Riche B, et al. Focal high intensity focused ultrasound of unilateral localized prostate cancer: a prospective multicentric hemiablation study of 111 patients. *Eur Urol*. 2017;71(2):267–273.

Rosenkrantz AB, Mendrinos S, Babb JS, et al. Prostate cancer foci detected on multiparametric magnetic resonance imaging are histologically distinct from those not detected. *J Urol*. 2012;187(6):2032–2038.

Ross AE, Marchionni L, Vuica-Ross M, et al. Gene expression pathways of high grade localized prostate cancer. *Prostate*. 2011;71(14):1568–1577.

Rowe SP, Gage KL, Faraj SF, et al. (1)(8)F-DCFBC PET/CT for PSMA-based detection and characterization of primary prostate cancer. *J Nucl Med*. 2015;56(7):1003–1010.

Rud E, Klotz D, Rennesund K, et al. Detection of the index tumour and tumour volume in prostate cancer using T2-weighted and diffusion-weighted magnetic resonance imaging (MRI) alone. *BJU Int*. 2014;114(6b):E32–E42.

Ruijter ET, van de Kaa CA, Schalken JA, et al. Histological grade heterogeneity in multifocal prostate cancer. Biological and clinical implications. *J Pathol*. 1996;180(3):295–299.

Rukstalis DB, Goldknopf JL, Crowley EM, et al. Prostate cryoablation: a scientific rationale for future modifications. *Urology*. 2002;60(2 Suppl 1):19–25.

Sandsmark E, Andersen MK, Bofin AM, et al. SFRP4 gene expression is increased in aggressive prostate cancer. *Sci Rep*. 2017;7(1):14276.

Sandsmark E, Hansen AF, Selnaes KM, et al. A novel non-canonical Wnt signature for prostate cancer aggressiveness. *Oncotarget*. 2017;8(6):9572–9586.

Santucci KL, Snyder KK, Baust JM, et al. Use of 1,25alpha dihydroxyvitamin D3 as a cryosensitizing agent in a murine prostate cancer model. *Prostate Cancer Prostatic Dis*. 2011;14(2):97–104.

Scheltema MJ, Postema AW, de Bruin DM, et al. Irreversible electroporation for the treatment of localized prostate cancer: a summary of imaging findings and treatment feedback. *Diagn Interv Radiol*. 2017;23(5):365–370.

Scheltema MJ, Chang JI, Böhm M, et al. Pair-matched patient-reported quality of life and early oncological control following focal irreversible electroporation versus robot-assisted radical prostatectomy. *World J Urol*.

2018;36(9):1383–1389.

Serenaite I, Daniunaite K, Jankevicius F, et al. Heterogeneity of DNA methylation in multifocal prostate cancer. *Virchows Arch*. 2015;466(1):53–59.

Shanmugabavan Y, Bass E, Hulme A, et al. Intra-prostatic injection of PRX302 to focally ablate clinically significant prostate cancer: an open label, phase 2a study. *Eur Urol Suppl*. 2017;16(3):e1308–e1309.

Shin SJ, Park CK, Park SY, et al. Total intraglandular and index tumor volumes predict biochemical recurrence in prostate cancer. *Virchows Arch*. 2016;469(3):305–312.

Shoji S, Uchida T, Nakamoto M, et al. Prostate swelling and shift during high intensity focused ultrasound: implication for targeted focal therapy. *J Urol*. 2013;190(4):1224–1232.

Sivaraman A, Barret E. Focal therapy for prostate cancer: an “A la Carte” approach. *Eur Urol*. 2016;69(6):973–975.

Skacel M, Ormsby AH, Pettay JD, et al. Aneusomy of chromosomes 7, 8, and 17 and amplification of HER-2/neu and epidermal growth factor receptor in Gleason score 7 prostate carcinoma: a differential fluorescent in situ hybridization study of Gleason pattern 3 and 4 using tissue microarray. *Hum Pathol*. 2001;32(12):1392–1397.

Somford DM, Hamoen EH, Futterer JJ, et al. The predictive value of endorectal 3 Tesla multiparametric magnetic resonance imaging for extraprostatic extension in patients with low, intermediate and high risk prostate cancer. *J Urol*. 2013;190(5):1728–1734.

Song SY, Kim SR, Ahn G, et al. Pathologic characteristics of prostatic adenocarcinomas: a mapping analysis of Korean patients. *Prostate Cancer Prostatic Dis*. 2003;6(2):143–147.

Stamey TA, Freiha FS, McNeal JE, et al. Localized prostate cancer. Relationship of tumor volume to clinical significance for treatment of prostate cancer. *Cancer*. 1993;71(3

Suppl):933–938.

Stamey TA, McNeal JM, Wise AM, et al. Secondary cancers in the prostate do not determine PSA biochemical failure in untreated men undergoing radical retropubic prostatectomy. *Eur Urol*. 2001;39(Suppl 4):22–23.

Stern JM, Kibanov Solomonov VV, Sazykina E, et al. Initial evaluation of the safety of nanoshell-directed photothermal therapy in the treatment of prostate disease. *Int J Toxicol*. 2016;35(1):38–46.

Susaki E, Nakayama KI. Multiple mechanisms for p27(Kip1) translocation and degradation. *Cell Cycle*. 2007;6(24):3015–3020.

Tay KJ, Polascik TJ. Focal cryotherapy for localized prostate cancer. *Arch Esp Urol*. 2016;69(6):317–326.

Tay KJ, Villers A, Polascik TJ. Targeted anterior gland focal therapy-a novel treatment option for a better defined disease. *Curr Urol Rep*. 2016;17(10):69.

Tay KJ, Gupta RT, Brown AF, et al. Defining the incremental utility of prostate multiparametric magnetic resonance imaging at standard and specialized read in predicting extracapsular extension of prostate cancer. *Eur Urol*. 2016;70(2):211–213.

Tay KJ, Gupta RT, Rastinehad AR, et al. Navigating MRI-TRUS fusion biopsy: optimizing the process and avoiding technical pitfalls. *Expert Rev Anticancer Ther*. 2016;16(3):303–311.

Tay KJ, Polascik TJ, Elshafei A, et al. Propensity score-matched comparison of partial to whole-gland cryotherapy for intermediate-risk prostate cancer: an analysis of the Cryo On-Line Data Registry Data. *J Endourol*. 2017;31(6):564–571.

Tay KJ, Schulman AA, Sze C, et al. New advances in focal therapy for early stage prostate cancer. *Expert Rev Anticancer Ther*. 2017;17(8):737–743.

Tay KJ, Cheng CWS, Lau WKO, et al. Focal therapy for prostate cancer with in-bore MR-guided focused ultrasound: two-year follow-up of a phase I trial—complications and functional outcomes. *Radiology*. 2017;285(2):620–628.

Tay KJ, Scheltema MJ, Ahmed HU, et al. Patient selection for prostate focal therapy in the era of active surveillance: an International Delphi Consensus Project. *Prostate Cancer Prostatic Dis*. 2017;20(3):294–299.

Tosoian JJ, Mamawala M, Epstein JI, et al. Intermediate and longer-term outcomes from a prospective active-surveillance program for favorable-risk prostate cancer. *J Clin Oncol*. 2015;33(30):3379–3385.

True L, Coleman I, Hawley S, et al. A molecular correlate to the Gleason grading system for prostate adenocarcinoma. *Proc Natl Acad Sci USA*. 2006;103(29):10991–10996.

Truesdale MD, Cheetham PJ, Hruby GW, et al. An evaluation of patient selection criteria on predicting progression-free survival after primary focal unilateral nerve-sparing cryoablation for prostate cancer: recommendations for follow up. *Cancer J*. 2010;16(5):544–549.

Tsivian M, Kimura M, Sun L, et al. Predicting unilateral prostate cancer on routine diagnostic biopsy: sextant vs extended. *BJU Int*. 2010;105(8):1089–1092.

Turkbey B, Mani H, Aras O, et al. Correlation of magnetic resonance imaging tumor volume with histopathology. *J Urol*. 2012;188(4):1157–1163.

Umbehr MH, Muntener M, Hany T, et al. The role of 11C-choline and 18F-fluorocholine positron emission tomography (PET) and PET/CT in prostate cancer: a systematic review and meta-analysis. *Eur Urol*. 2013;64(1):106–117.

van den Bos W, de Bruin DM, van Randen A, et al. MRI and contrast-enhanced ultrasound imaging for evaluation of focal irreversible electroporation treatment: results from a phase I-

II study in patients undergoing IRE followed by radical prostatectomy. *Eur Radiol*. 2016;26(7):2252–2260.

van den Bos W, Jurhill RR, de Bruin DM, et al. Histopathological outcomes after irreversible electroporation for prostate cancer: results of an ablate and resect study. *J Urol*. 2016;196(2):552–559.

van den Bos W, Scheltema MJ, Siriwardana AR, et al. Focal irreversible electroporation as primary treatment for localized prostate cancer. *BJU Int*. 2018;121(5):716–724.

van Velthoven R, Aoun F, Marcelis Q, et al. A prospective clinical trial of HIFU hemiablation for clinically localized prostate cancer. *Prostate Cancer Prostatic Dis*. 2016;19(1):79–83.

Vainshtein J, Abu-Isa E, Olson KB, et al. Randomized phase II trial of urethral sparing intensity modulated radiation therapy in low-risk prostate cancer: implications for focal therapy. *Radiat Oncol*. 2012;7:82.

Vakrat-Haglili Y, Weiner L, Brumfeld V, et al. The microenvironment effect on the generation of reactive oxygen species by Pd-bacteriopheophorbide. *J Am Chem Soc*. 2005;127(17):6487–6497.

Valerio M, Dickinson L, Ali A, et al. Nanoknife electroporation ablation trial: a prospective development study investigating focal irreversible electroporation for localized prostate cancer. *J Urol*. 2017;197(3 Pt 1):647–654.

Vellet AD, Saliken J, Donnelly B, et al. Prostatic cryosurgery: use of MR imaging in evaluation of success and technical modifications. *Radiology*. 1997;203(3):653–659.

Villers A, McNeal JE, Freiha FS, et al. Multiple cancers in the prostate. Morphologic features of clinically recognized versus incidental tumors. *Cancer*. 1992;70(9):2313–2318.

Ward JF, Jones JS. Focal cryotherapy for localized prostate cancer: a report from the National Cryo On-Line Database

(COLD) registry. *BJU Int*. 2012;109(11):1648–1654.

Wei L, Wang J, Lampert E, et al. Intratumoral and intertumoral genomic heterogeneity of multifocal localized prostate cancer impacts molecular classifications and genomic prognosticators. *Eur Urol*. 2017;71(2):183–192.

Wilt TJ, Brawer MK, Jones KM, et al. Radical prostatectomy versus observation for localized prostate cancer. *N Engl J Med*. 2012;367(3):203–213.

Winkler MH, Livni N, Mannion EM, et al. Characteristics of incidental prostatic adenocarcinoma in contemporary radical cystoprostatectomy specimens. *BJU Int*. 2007;99(3):554–558.

Wise AM, Stamey TA, McNeal JE, et al. Morphologic and clinical significance of multifocal prostate cancers in radical prostatectomy specimens. *Urology*. 2002;60(2):264–269.

Wolters T, Roobol MJ, van Leeuwen PJ, et al. A critical analysis of the tumor volume threshold for clinically insignificant prostate cancer using a data set of a randomized screening trial. *J Urol*. 2011;185(1):121–125.

Wong MC, Goggins WB, Wang HH, et al. Global incidence and mortality for prostate cancer: analysis of temporal patterns and trends in 36 countries. *Eur Urol*. 2016;70(5):862–874.

Wong WS, Chinn DO, Chinn M, et al. Cryosurgery as a treatment for prostate carcinoma. Results and complications. *Cancer*. 1997;79(5):963–974.

Wysock JS, Rosenkrantz AB, Huang WC, et al. A prospective, blinded comparison of magnetic resonance (MR) imaging-ultrasound fusion and visual estimation in the performance of MR-targeted prostate biopsy: the PROFUS trial. *Eur Urol*. 2014;66(2):343–351.

Yamamoto T, Musunuru B, Vesprini D, et al. Metastatic prostate cancer in men initially treated with active surveillance. *J Urol*. 2016;195(5):1409–1414.

159

Treatment of Locally Advanced Prostate Cancer

Maxwell V. Meng MD, Peter R. Carroll MD, MPH

The widespread application of prostate cancer early-detection efforts in the United States has resulted in both an increased number of prostate cancers diagnosed and the earlier identification of these tumors. Despite the stage migration associated with prostate-specific antigen (PSA) testing and the growing number of low-stage and organ-confined tumors, at least 10% of men with newly diagnosed prostate cancer have locally advanced disease (T3NX/+M0). Although this proportion has declined somewhat, it remains significant and has been relatively constant during the past decade. Those men with locally advanced or metastatic prostate cancer at the time of presentation contribute disproportionately to prostate cancer mortality, and improved treatments for such men could have a significant positive impact on overall morbidity and mortality caused by this disease.

Currently, no consensus exists regarding the optimal management of locally advanced prostate cancer. Unlike with clinically localized and low-grade prostate cancer, for which comparable and excellent outcomes may be achieved with a variety of interventions, treatment of disease with local or regional spread by any single modality is associated with significant risk for recurrent disease. Ongoing interest in, and the development and evaluation of, combination therapy, as well as improvements in risk assessment, should improve cancer outcomes while minimizing treatment-related morbidity and adverse impact on quality of life in these patients. Three analyses suggest that men with higher-risk disease characteristics may have reductions in disease-specific mortality and metastatic progression after radical prostatectomy compared with other treatment modalities (Cooperberg et al., 2010; Sooriakumaran et al., 2016; Zelefsky et al., 2010).

Definition

Traditionally, the identification of patients with locally advanced disease was based on clinical examination (e.g., digital rectal examination) and clear evidence of spread outside of the prostate capsule (clinical stage T3a), involvement of the seminal vesicles (cT3b), or involvement of adjacent organs (cT4) (Greene et al., 2002). However, the contemporary use of PSA testing has led to the majority of men diagnosed with prostate cancer initially having nonpalpable cancers (cT1c). **Features other than clinical T stage most often contribute to the identification of men with advanced disease and a concomitant increased risk for failure after primary therapy.** Thus improved methods of risk assessment have facilitated categorization of men as “high risk” and involve consideration of variables such as serum PSA level and Gleason score in addition to clinical stage. The subsequent discussion focuses on this broader definition of locally advanced disease, with inclusion of those patients with regional or lymph node involvement without distant metastasis (T3–4N ±M0).

Contemporary Risk Assessment

Multiple methods are currently available to accurately risk stratify men with prostate cancer (D'Amico et al., 1999; Partin et al., 1997; Shariat et al., 2008; Tewari et al., 2001). The Partin tables were initially constructed in the 1990s and updated in 2001, 2013, and 2017, assisting in the preoperative prediction of final pathologic stage in men with clinically localized prostate cancer undergoing radical prostatectomy (Eifler et al., 2013; Partin et al., 2001). Although clinical stage, serum PSA level, and Gleason score individually predict pathologic stage and prognosis, the combination of these three variables increases the accuracy of this assessment. These data continue to illustrate that a significant number of men thought to harbor organ-confined tumors have more advanced disease. The ability to assess pathologic stage permits better pretreatment counseling of patients and more appropriate selection of therapy, and consideration of those with more advanced disease for novel clinical trials. **The most important pathologic criteria predicting prognosis after radical prostatectomy are Gleason score, surgical margin status, and presence of non–organ-confined disease (e.g., extracapsular extension, seminal vesicle invasion, lymph node**

involvement).

In addition, to help predict pathologic stage, biopsy information has been incorporated into models estimating cancer outcomes, primarily PSA- or biochemical disease-free survival (BDFS), after treatment. Whereas BDFS is a frequent end point of current prostate cancer studies, it merely represents an intermediate surrogate outcome variable; further trials and studies are necessary to confirm the utility of biochemical recurrence as a marker for reduced prostate cancer–specific survival after treatment. The most widely used tools to predict disease recurrence after local therapy are the nomograms developed by Kattan et al. (1998, 2000). In all pretreatment nomograms, clinical stage, biopsy Gleason grade, and pretreatment serum PSA level are incorporated to predict the continuous risk for disease progression after definitive local therapy; models for radiation therapy (RT) also include data on use of androgen deprivation (AD), total radiation dose, and combination treatment (i.e., external-beam and permanent brachytherapy). The radical prostatectomy nomogram was based on nearly 1000 patients with clinically localized disease (T1c–T3aNXM0); thus this model is not applicable for those men with evidence of seminal vesicle involvement or regional spread.

Key Points: Risk Assessment

- Risk assessment is best performed by a combination of serum PSA level, T stage, cancer grade, and extent of cancer on biopsy.
- Imaging plays a limited role in identifying most patients with high-risk features for whom local therapy may fail.

To simplify risk stratification, men with prostate cancer can be grouped into fewer categories but with maintenance of the ability to predict disease behavior and response to intervention. D'Amico et al. (1998) defined patients at low, intermediate, and high risk for biochemical failure, still based on pretreatment disease characteristics (clinical stage, PSA value, Gleason score). Recurrence after treatment may be caused by unrecognized micrometastatic disease or persistence of locoregional disease. Other variations of simplified risk stratification have been developed and validated, with inclusion of features such as ethnicity and pathologic findings (Cooperberg et al., 2005; Moul et al., 2001). The Cancer of the Prostate Risk Assessment (CAPRA) score, ranging from 0 to

10, provides another method to assess risk, with each 2-point increase in score doubling the risk for recurrence after prostatectomy. It is easily calculated from PSA, T stage, patient age, cancer grade and volume; has been validated in several populations; and also predicts disease-specific and overall mortality (Cooperberg et al., 2009). **Although men with "low-risk" disease generally do well and are unlikely to have biochemical recurrence, men in the intermediate- and high-risk groups may have widely discrepant outcomes. Therefore men in these groups benefit from more modern and accurate risk prediction models and nomograms** (Mitchell et al., 2005).

Imaging Modalities

Although observations on traditional gray-scale ultrasonography can identify extraprostatic disease, the general ability to improve cancer staging is limited (Figs. 159.1 and 159.2). Directed biopsy of the seminal vesicles or prostate capsule can be obtained to confirm cT3 disease. Smith et al. (1997) found that transrectal ultrasonography did not improve the ability to stage prostate cancer; the area under the curve was .69 and .74 for transrectal ultrasonography in predicting extracapsular extension and seminal vesicle invasion, respectively, compared with .72 and .69 for digital rectal examination, respectively. Salo et al. (1987) reported high sensitivity (86%), specificity (94%), positive predictive value (92%), and negative predictive value (89%) of ultrasonography in predicting extracapsular extension in patients undergoing radical prostatectomy. However, more contemporary studies suggest otherwise, with lower sensitivities (23% to 66%), specificities (46% to 86%), positive predictive values (50% to 62%), and negative predictive values (49% to 69%). The inaccuracy of ultrasound staging for prostate cancer is likely a result of significant interobserver variability, often subtle signs of extraprostatic spread, and lower-volume tumors currently diagnosed. In general, transrectal ultrasonography understages rather than overstages prostate cancer. Newer ultrasound techniques such as color and power Doppler studies are under investigation to determine if observations of abnormal blood flow can increase the ability to detect and stage prostate tumors.

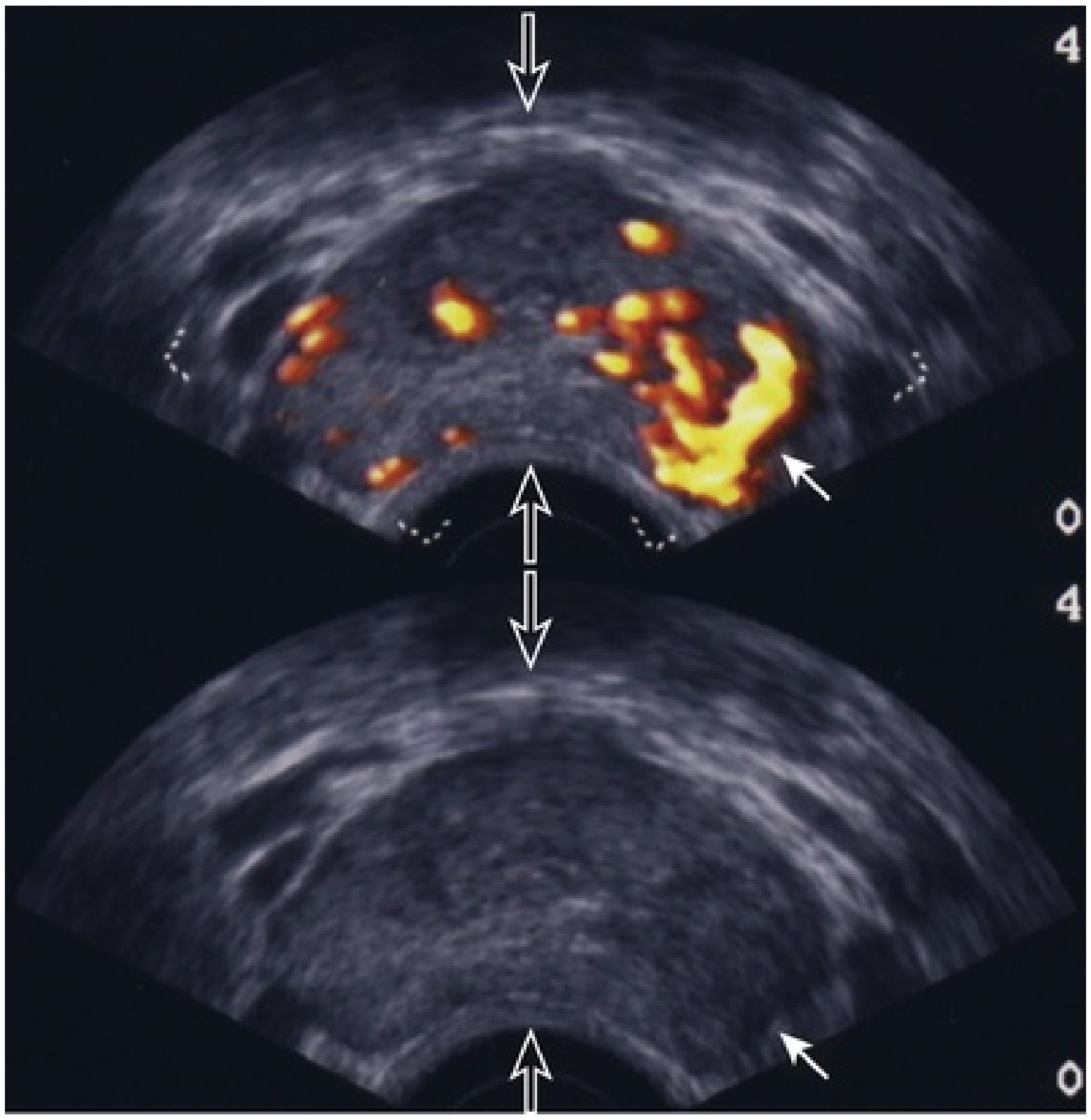

FIG. 159.1 Transrectal ultrasound examination demonstrates increased flow on color Doppler study at the left posterior *(upper panel, arrow)* with corresponding hypoechoic area on gray-scale images *(lower panel, arrow)*. Note the left lateral distortion and squaring of the capsule, suggesting extracapsular extension. (Courtesy of Dr. Katsuto Shinohara.)

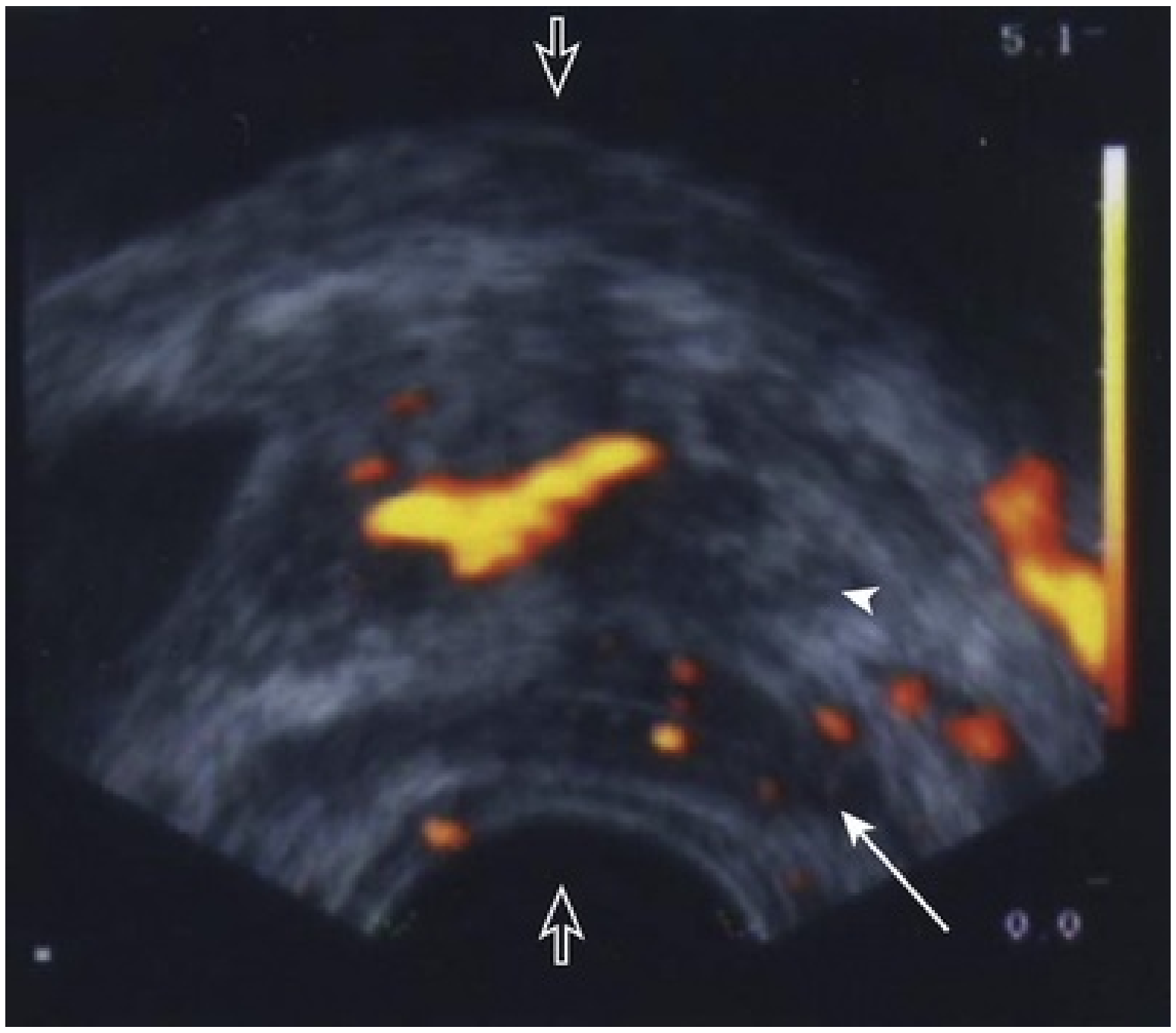

FIG. 159.2 Transrectal ultrasound examination demonstrates hypoechoic tumor in the left base *(arrowhead)* with likely extension into the ipsilateral seminal vesicle *(arrow)*. (Courtesy of Dr. Katsuto Shinohara.)

Endorectal magnetic resonance imaging (MRI) uses a magnetic coil placed in the rectum to achieve better visualization of the zonal anatomy of the prostate and may delineate subtle distinctions between T2a/b disease and T3 disease (Fig. 159.3). However, use of multiparametric MRI alone or in combination with magnetic resonance spectroscopy for tumor staging remains controversial, as is the necessity of the endorectal coil (Fulgham et al., 2017). Variable sensitivities (13% to 91%) and specificities (49% to 97%) have been reported for predicting extracapsular extension, in part attributed to variability in interpreting MRI and lack of uniform diagnostic criteria, and the revised structured reporting scheme of PI-RADS v2 should be adopted. Sauer et al. (2018) evaluated the accuracy of neurovascular bundle infiltration using multiparametric MRI at 3T and PI-RADS v2 in 198 men undergoing prostatectomy. Sensitivity and specificity of T staging were 64% and 89%, respectively, and the positive and negative predictive value of bundle infiltration were 80% and 92%, respectively. However, PI-RADS v2 score in the area adjacent to the neurovascular bundle had poor specificity (39%) and may not aid in determining eligibility for nerve preservation. In a cohort of 336 men with more than three cores involved with cancer, abnormal findings on digital rectal examination, and PSA level higher than 10 ng/mL undergoing radical prostatectomy, the specificity of MRI in predicting pT3 disease was 95%

(Cornud et al., 2002). Thus the use of MRI may be best limited to those patients with higher-risk features.

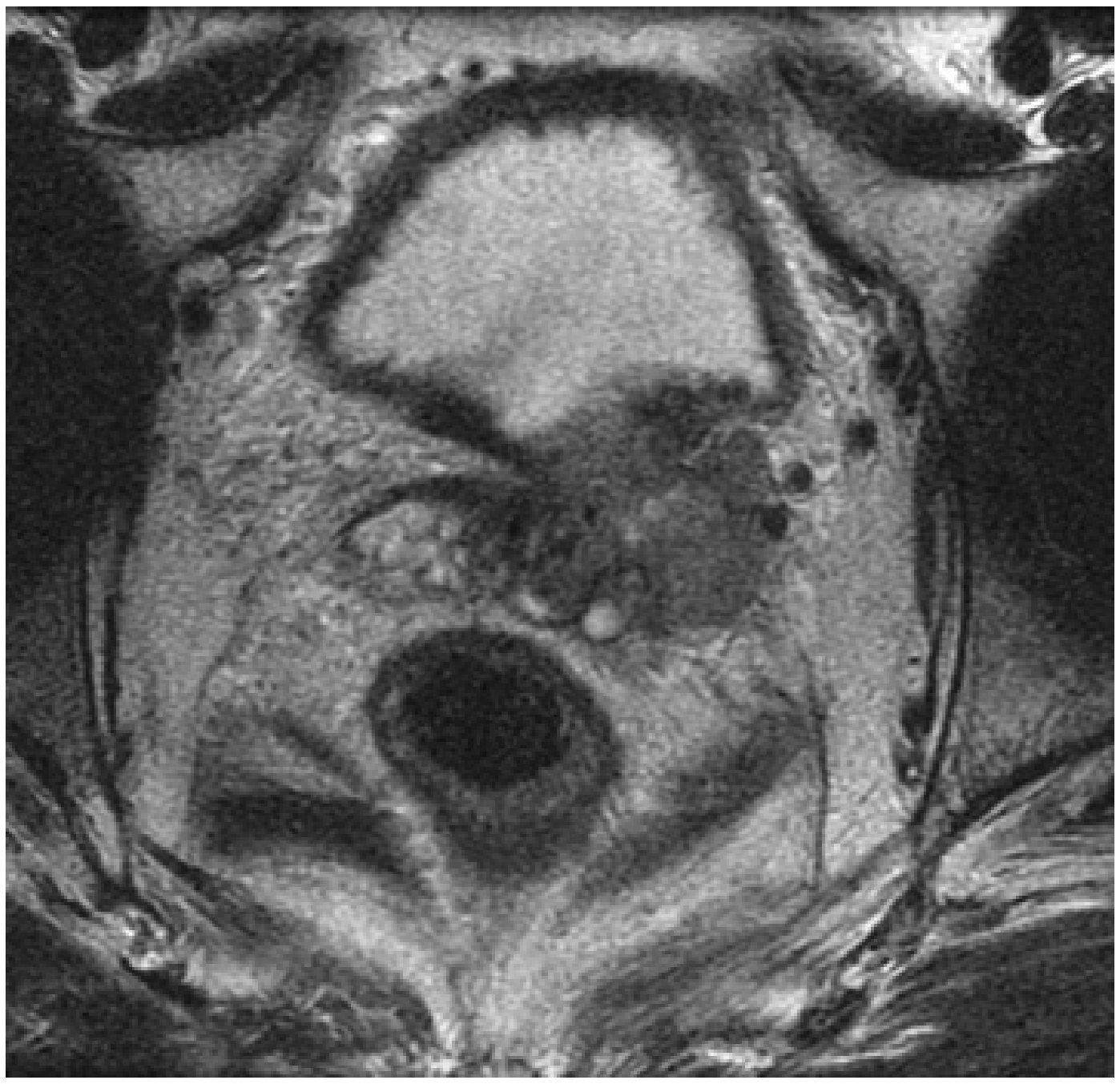

FIG. 159.3 Axial T2-weighted magnetic resonance image shows tumor involving the seminal vesicle and bladder base and extending into the adjacent fat.

Newer molecular imaging agents may gain a role in helping differentiate localized or locally advanced disease from regional and metastatic cancer. Although several radiotracers are approved by the Food and Drug Administration for PET imaging, most have focused on biochemical recurrence after definitive therapy (e.g., ^{18}F-fluciclovine) or improved detection of bony disease (e.g., ^{18}F-NaF). Prostate-specific membrane antigen (PSMA) targeting may have utility in identifying oligometastatic disease in high-risk disease by improving detection of limited lymph node involvement (Fig. 159.4). ^{68}Ga-PSMA-11 detected lymph nodes with 66% sensitivity and 99% specificity in men with intermediate- or high-risk disease undergoing prostatectomy (Maurer et al., 2016; van Leeuwen et al., 2017).

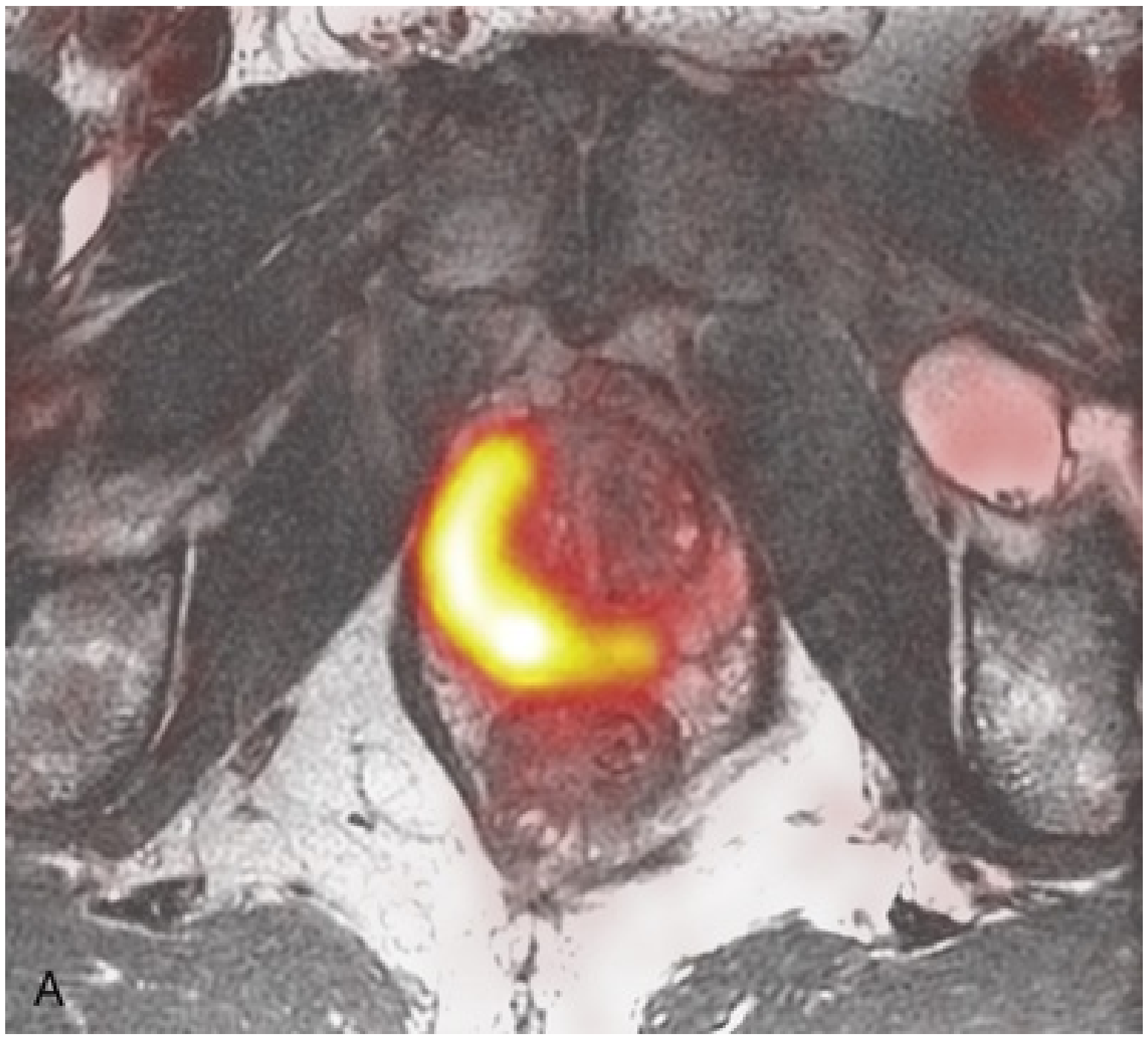
A

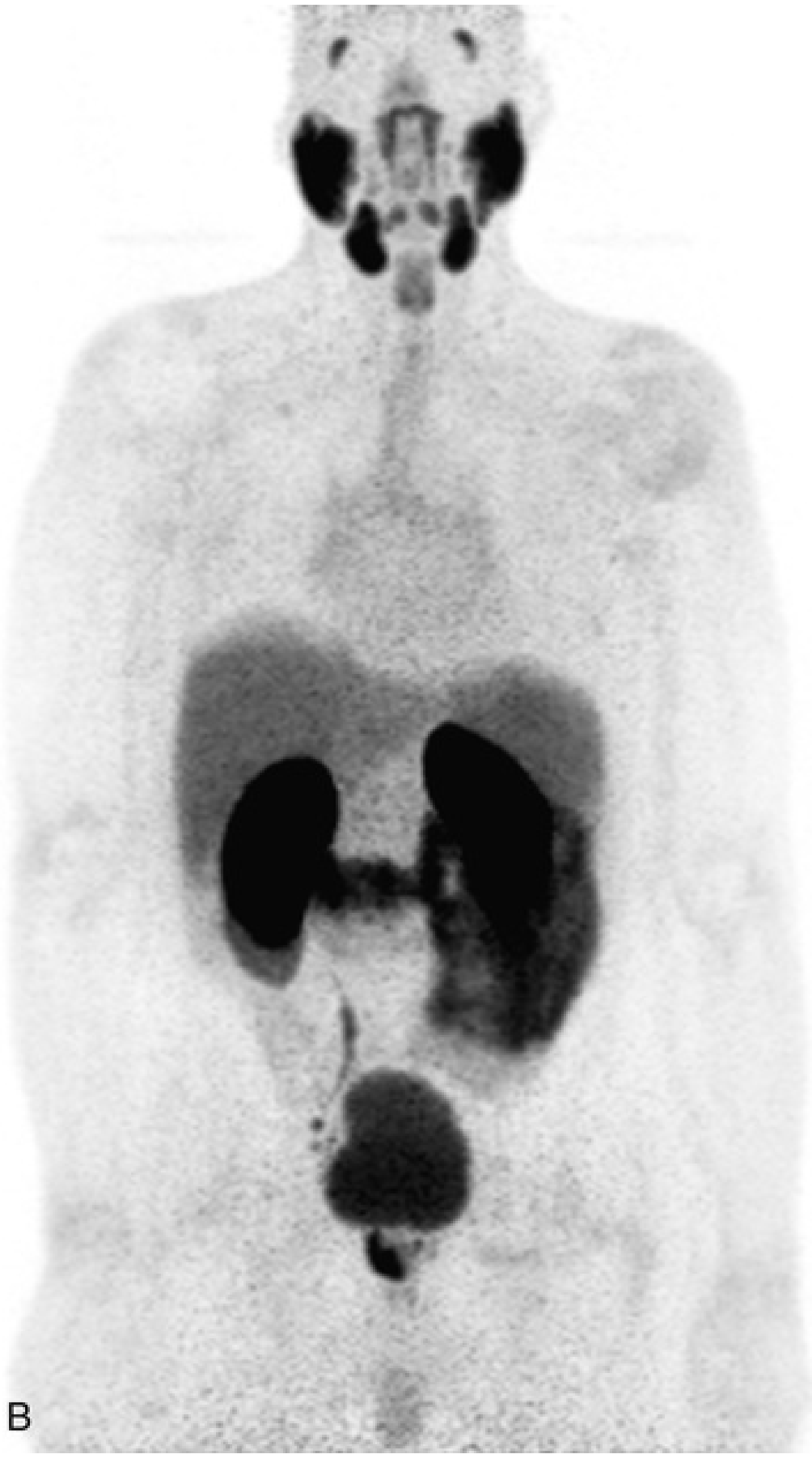
B

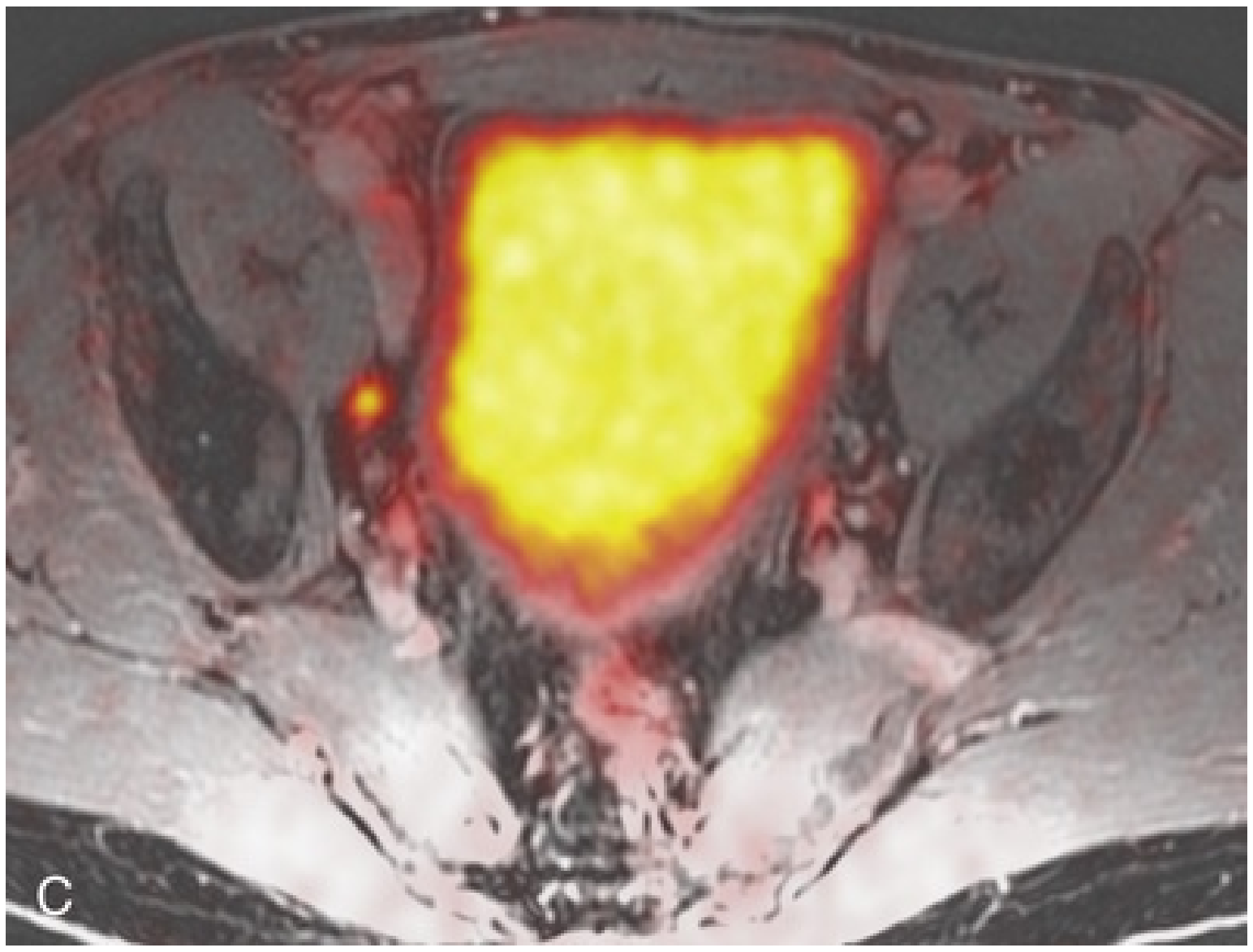

FIG. 159.4 ^{68}Ga-PSMA-11 PET/MRI demonstrating right-sided uptake within the peripheral prostate (A) and in right pelvic side wall and external iliac lymph nodes (B,C). (Courtesy of Dr. Thomas Hope.)

Novel Markers

It is clear that traditional clinical and pathologic parameters are limited in their ability to accurately predict local extent of tumor before treatment. Given the importance of assessing true pathologic stage, novel markers of advanced disease are necessary. Chu et al. (2003) used comparative genomic hybridization in primary prostate specimens and identified chromosomal regions potentially useful in discriminating between organ-confined and locally advanced tumors (Table 159.1). Prediction of stage by a model incorporating six aberrations in a stepwise fashion was accurate in 91.1% of cases. Further metabolic, genetic, and proteomic signatures will likely better define and discriminate between organ-confined and non–organ-confined prostate cancer (Ashida et al., 2004; Mehra et al., 2007; Paris et al., 2004; Sreekumar et al., 2009). Chromosomal rearrangements involving the androgen-regulated gene *TMPRSS2* and the *ETS* family genes are associated with higher pathologic stage, whereas the glycine metabolite sarcosine was more often elevated in metabolomic profiles of men with metastatic prostate cancer.

TABLE 159.1

Chromosome Abnormalities Associated With Pathologic Stage

CHROMOSOME ABERRATION (INDEPENDENT OR IN COMBINATION)	***P*-VALUE**
−8p	.001
−8p/−10q23 → qter	.002
−10q25 → qter	.029
−6p21	.031
−6q24 → qter	.031
−18cen-q12	.035
−5q31/−10q24 → qter	.04
−5q31 → qter/−8p	.04
−6p21/−10q24 → qter	.04
−6p12 → pter/−6q24 → qter	.04
−6q25 → qter/−11q23 → qter	.04
+7p11/−10q24 → qter	.04
−8p/−15q22	.04
−8p/−11q24 → qter	.42

Preliminary genomic and transcriptome profiling of high-risk, clinically localized cases from men enrolled in CALGB 90203, which compared the outcomes of surgery alone versus neoadjuvant docetaxel and AD, confirms frequent alterations in *TMPRSS2-ERG* fusion, *TP53*, *PTEN*, *FOXA1*, and *SPOP*, but without *AR* amplification or mutations (Beltran et al., 2017). Linch et al. (2017) reported similar findings and also observed extensive genomic and inflammatory infiltrate heterogeneity and a correlation between Wnt signaling and immune suppression.

Several genomic biomarkers (Decipher, Oncotype DX, Prolaris) are now commercially available and variably applied in clinical practice to improve risk stratification compared with the use of clinical criteria alone. Spratt et al. (2018) developed and validated a novel clinical-genomic risk grouping system, which combined standard clinicopathologic variables with genomic results from the 22-gene Decipher test. Both 3- and 6-tier clinical-genomic risk groups outperformed traditional systems such as NCCN risk grouping and CAPRA score for prediction of metastasis and disease-specific survival. Moreover, 66.6% of patients classified by the NCCN 6-tier system would be reclassified using their novel 6-tier clinical-genomic risk groups. Similar application of genomics in men with adverse pathologic features at radical prostatectomy helps identify those at higher risk for disease-specific mortality and may guide decision making regarding adjuvant treatments (Karnes et al., 2018).

Trends in Incidence and Treatment

Within the Cancer of the Prostate Strategic Urological Research Endeavor (CaPSURE), Cooperberg et al. (2003) observed **a significant decrease in the fraction of men presenting with high-risk disease characteristics, as defined by D'Amico criteria, from 40.9% in 1989 to 1990 to 14.8% in 2001 to 2002.** However, alterations in cancer screening and use of PSA screening are likely to account for this reduction, with significantly fewer men presenting with elevations in PSA level higher than 20 ng/mL (32.8% to 7.2%); indeed, currently, higher Gleason grade defines a larger number of high-risk patients (61.5%). Overall, **the presence of clinically advanced disease (i.e., T3-4) decreased from 11.8% to 3.5%, with a decline from 32.3% to 21.9% in the high-risk group during the observation period.** Similar findings were reported from Johns Hopkins, with 69% of men classified as high risk solely by Gleason score in the contemporary cohort (2001 to 2010) compared with 29% in the earlier cohort (1992 to 2000) (Pierorazio et al., 2012). Outcomes over time, however, were comparable with respect to PSA outcomes and metastasis-free and disease-specific survival.

In men undergoing radical prostatectomy, the number with clinical evidence of locally advanced disease as defined by clinical stage (T3) has declined from 25.3% in 1987 to 2.8% in 2001 (Ward and Zincke, 2003). Although the use of PSA screening can account for part of this change, the more selective application of surgery and improved techniques of RT may also explain the decline in patients with cT3 disease undergoing prostatectomy. Within reports of men undergoing radical prostatectomy, the fraction of men with pT3 disease has decreased; these are highly selected patients with largely clinically localized disease at the time of treatment (Table 159.2). Roehl et al. (2004) reported that pathologically advanced disease decreased from 39% (1983 to 1991) to 31% (1992 to 2003). In men undergoing radical prostatectomy alone at the Cleveland Clinic, the overall rate of extracapsular extension decreased from 65.8% (1987 to 1989) to 25.2% (2000 to 2001), and this trend was true for all clinical tumor stages (T1c–T2b/c) and for pretreatment variables (PSA value, Gleason score).

TABLE 159.2

Pathologic Findings in Men Undergoing Radical Prostatectomy

AUTHOR (yr)	NO. PATIENTS	ERA	ECE	SEMINAL VESICLE/LYMPH NODE
Stamey et al., 1998	896	1988	60%	18%/NR
		1996	25%	5%/NR
Quinn et al., 2001	732	1986–1999	42.8%	13.1%/2.3%
Hull et al., 2002	1000	1993–1998	25%	8.1%/6.9%
Han et al., 2003	2091	1982–1999	41%	4%/5%
Derweesh et al., 2004	1505	1987–1998	66%	NR
		2000–2001	25%	NR
Roehl et al., 2004	3478	1983–1991	25%	14% (combined)
		1992–2003	27%	4% (combined)
Bott et al., 2005	1001	1988–2001	47%	10%/2%
Badani et al., 2007	2766	2000–2006	16.9%	5.1%/9%
Patel et al., 2008	1500	NR	13.8%	5.7%/NR
UCSF	2349	1986–2009	16%	11%/3%

ECE, extracapsular extension; *NR,* not reported; *UCSF,* University of California, San Francisco.

Key Points: Trends in Incidence and Treatment

- Fewer men are presenting with locally advanced prostate cancer.
- There has been an increase in organ-confined cancers identified after radical prostatectomy.
- There was an increasing use of treatment modalities other than surgery for high-risk prostate cancers, yet this has evolved in recent years.

The National Comprehensive Cancer Network (NCCN) provided updated decision trees for men with prostate cancer to aid in treatment selection (NCCN, 2014, 2017). High risk for recurrence includes men with clinically advanced disease, both cT3a and cT3b–T4. Bone scans are indicated in these men and in those with T1 and PSA level greater than 20 ng/mL, or T2 and PSA level greater than 10 ng/mL, or Gleason score 8 or higher; pelvic computed tomography or MRI is also indicated for cT3–T4 disease or if the calculated probability of lymph node involvement is greater than 10%. In general, radical prostatectomy with extended pelvic lymphadenectomy is reserved for those high-risk men with low-volume tumors that can be completely excised. The alternative treatment strategy for these men with locally advanced disease and higher risk for biochemical failure is AD therapy combined with RT. The shift in treatment is also reflected within the CaPSURE database (Meng et al., 2005). A total of 6074 men with prostate cancer (clinical stage lower than T3aN0M0) were stratified according to risk group, of whom 26% were high risk. Fewer men in this group underwent radical prostatectomy compared with the low-risk cohort, with older age, advanced disease, and increased number of comorbidities significant predictors of treatment (external-beam RT or AD therapy) in multivariate modeling. In addition, more than half of high-risk men receiving RT also received AD, significantly more than in the low- and intermediate-risk groups ($P < .0001$). Data from the Surveillance, Epidemiology, and End Results (SEER) cancer registry between 1998 and 2005 show that nearly one-half of men with cT3–4M0 prostate cancer received a combination of AD and RT, while the rate of prostatectomy increased but was only 10% in 2005 (Lowrance et al., 2012). These trends, however, continue to evolve, and a recent report from CaPSURE has shown a significant increase in surgery for men with CAPRA score 6 to 10 (Fig. 159.5) (Cooperberg and Carroll, 2015).

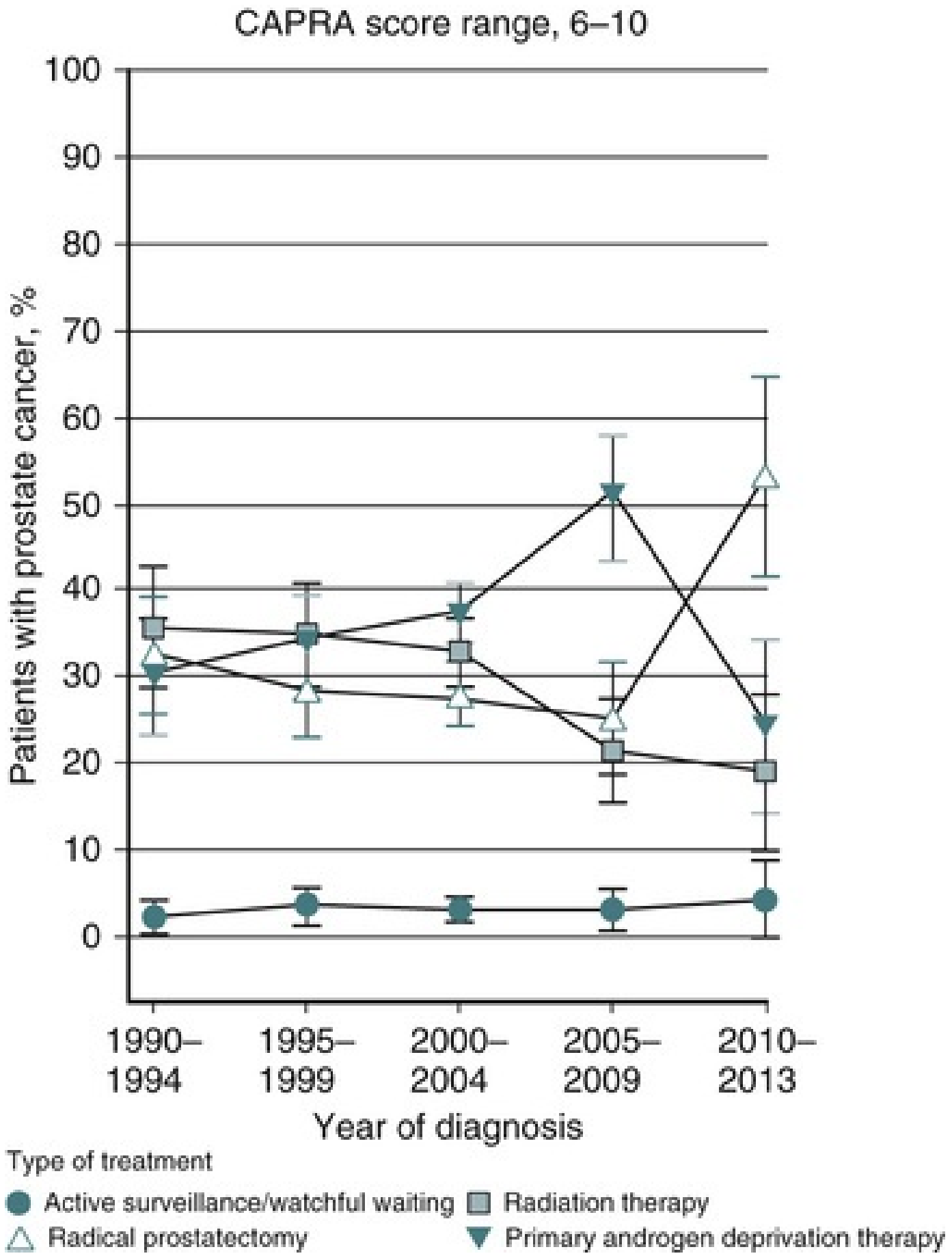

FIG. 159.5 Treatment trends in the Cancer of the Prostate Strategic Urologic Research Endeavor (CaPSURE) Registry for men with CAPRA score range 6–10. Error bars indicate 95% confidence intervals. (Modified from Cooperberg MR, Carroll PR. Trends in management for patients with localized prostate cancer, 1990–2013. *JAMA* 314[1]:80–82, 2015.)

Natural History

Active surveillance, with deferred treatment when necessary, is a viable treatment alternative in men with prostate cancer. Multiple studies have suggested that disease-specific mortality is low and primarily associated with higher-grade and higher-stage disease. Even in those low-risk cancers, however, an increased and unexpected progression of disease and associated prostate cancer mortality may be seen during an extended period (Johansson et al., 2004). In men with higher-risk disease characteristics, it has been recognized that disease progression occurs more rapidly and that some form of intervention is typically warranted in healthy patients. Nevertheless, the indications for active surveillance are expanding, and appropriate selection may be facilitated by novel genomic tests (Cooperberg et al., 2011; Cary and Cooperberg, 2013).

Few reports address the specific question of outcome in men with locally advanced cancers merely observed for a prolonged period. Older studies such as that from Nesbit and Plumb (1946) have little relevance to current disease management. Other studies have included only a small number of patients with higher clinical stage. A range of clinical progression (22% to 75%), local progression (22% to 84%), and development of distant metastases (27% to 56%) has been reported during 5 and 10 years of follow-up. **Overall survival ranging from 10% to 92% at 5 years and from 14% to 78% at 10 years is reported for patients who harbor cancers of high grade or stage.** The Veterans Administration Cooperative Urological Research Group (VACURG) study reported a 58% overall 5-year survival in 248 men with clinical stage III disease treated with placebo (Byar, 1973). Comparable survival outcomes were reported within the Medical Research Council (MRC) study (Adib et al., 1997) randomizing previously untreated patients with locally advanced, nonmetastatic disease (*n* = 501) to early or delayed AD therapy (castration or luteinizing hormone–releasing hormone [LHRH] agonist). The median time to clinical progression and death from prostate cancer in the 244 patients receiving delayed treatment was 10 months and 48 months, respectively.

In the analysis from Chodak et al. (1994), grade 3 tumors were significantly associated with disease-specific mortality (risk ratio 10.04) in men treated conservatively, compared with low-grade (grade 1) cancers. The 10-year disease-specific survival was 87% in men with grade 1 or grade 2 tumor and 34% with grade 3 tumor, with metastasis-free survival of 81% for grade 1, 58% for grade

2, and 25% for grade 3 diseases. Johansson et al. (1997) prospectively observed 642 men with prostate cancer diagnosed between 1977 and 1984 with any stage of disease. Of those men with clinically localized disease, 11% died of prostate cancer, with corrected 15-year survival comparable for those who received initial and deferred treatment. Conversely, the corrected 15-year survival was 57% in patients with locally advanced cancer. Approximately one-half of men had well-differentiated tumors, and only 6% of these men died of prostate cancer. Death from prostate cancer increased with moderately differentiated (17%) and poorly differentiated (56%) disease. These data are summarized in Table 159.3.

TABLE 159.3

Conservative Management of Patients With Prostate Cancer

CLINICAL STAGE	NUMBER OF PATIENTS	PROGRESSION-FREE SURVIVAL		DISEASE-SPECIFIC SURVIVAL	
		%	95% CI (%)	%	95% CI (%)
T1–T2	300	48	37–59	81	74–88
T3–T4	183	47	33–61	57	45–68
M+	159	6	0.8–11	6	−0.1–12

CI, confidence interval.

From Johansson JE, Holmberg L, Johansson S, et al. Fifteen-year survival in prostate cancer. A prospective, population-based study in Sweden. *JAMA* 277(6):467–471, 1997.

Albertsen et al. (1998) reported the long-term outcomes of watchful waiting in 767 men identified from the Connecticut Tumor Registry with clinically localized prostate cancer (1971 to 1984). The 15-year disease-specific mortality in men with Gleason sum 6 was 18% to 30%, compared with the 25% to 59% risk for death from other causes. The chances of death from prostate cancer increased with Gleason score 7 (42% to 70%) and 8 to 10 (60% to 87%). It is likely that a significant proportion of this cohort had non–organ-confined disease because none of the men underwent PSA testing, therefore they probably had more advanced stages of disease compared with contemporary cohorts. In contrast with the report from Johansson et al. (2004), the annual mortality rate from low-grade prostate cancer appears to remain stable beyond 15 years after diagnosis (Albertsen et al., 2005) (Fig. 159.6). **Men with high-risk prostate cancer, including those with locally advanced disease, are at significant risk for disease progression and disease-specific death if left untreated.**

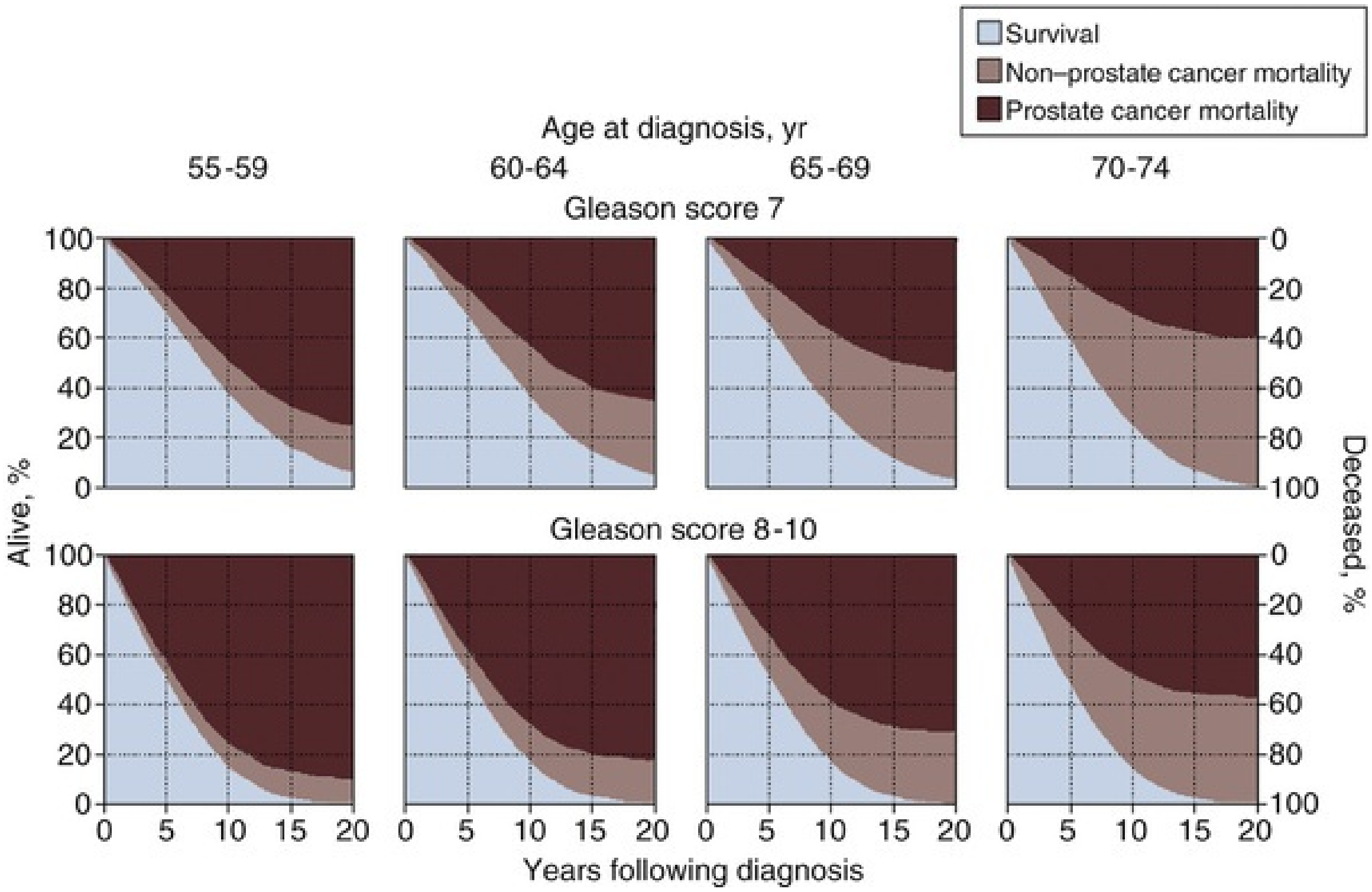

FIG. 159.6 Prostate cancer mortality as a factor of Gleason grade and age at diagnosis in men managed conservatively. *Brown-shaded areas* represent proportion of patients dying of prostate cancer. *Light brown–shaded areas* represent death from competing causes. *Light-blue areas* represent proportion of patients alive. (Modified from Albertsen PC, Hanley JA, Fine J. 20-year outcomes following conservative management of clinically localized prostate cancer. *JAMA* 293[17]:2095–2101, 2005.)

Indeed, there is undertreatment in some men with high-risk disease. Within the National Prostate Cancer Register of Sweden, the proportion of men younger than 70 years of age with high-risk, nonmetastatic prostate cancer receiving definitive therapy varied with life expectancy as estimated by age and Charlson comorbidity index (Bratt et al., 2015). In contrast, use of surgery and RT in otherwise healthy men in their seventies was significantly lower despite comparable life expectancy. In men older than 70 years of age with life expectancy greater than 10 years, RT and surgery were applied in only 40% and 10% of cases, respectively. Comparable findings were reported within the UK from the National Prostate Cancer Audit (Sujenthiran et al., 2017).

Radical Prostatectomy

The use of radical prostatectomy for management of locally advanced prostate cancer had decreased 10 years ago. In part, the shift in paradigm was caused by the recognition that prostatectomy alone is often insufficient. In addition, improved risk assessment has permitted better identification of these patients before treatment. Advances in delivery of RT and recognition that combined modality treatment (e.g., RT and AD) improved outcomes compared with monotherapy have further contributed to the migration away from surgery for high-risk and locally advanced tumors. Nevertheless, radical prostatectomy can cure some men with high-risk disease features, and the addition of adjuvant and combined therapy may further improve outcomes of surgery alone; this is reflected by increased rates of prostatectomy for more aggressive disease.

Surgery for Clinical Stage T3 Prostate Cancer

Several series report outcomes of radical prostatectomy for clinical stage T3 tumors (Table 159.4). In examining all reports, **overall survival ranges from 64% to 96% at 5 years, 12.5% to 72% at 10 years, and 20% to 51% at 15 years after treatment.** Earlier data reflected less accurate risk assessment and a potentially greater number of patients with unsuspected lymph node metastases and associated earlier progression and death. Less variability exists in more contemporary cohorts, in which the **disease-specific survival rates are 85% to 92% and 79% to 82% at 5 and 10 years, respectively, regardless of adjuvant therapy.**

TABLE 159.4

Radical Prostatectomy for Higher Clinical Stage in Contemporary Series

---

AUTHOR (yr)	NUMBER OF PATIENTS	ADJUVANT TREATMENT	OVERALL SURVIVAL		DISEASE-SPECIFIC SURVIVAL	
			5 Yr	10 Yr (15 Yr)	5 Yr	10 Yr (15 Yr)
Morgan et al.,	232	54%	85%	72%	89%	82%

1991						
van den Ouden et al., 1994	59	—	83%	—	90%	—
Lerner et al., 1995	812	60%	86%	70%	90%	80%
Gerber et al., 1997	242	NR	—	—	88%	70%
van den Ouden et al., 1998	83	0%	75%	60%	85%	72%
Pound et al., 1999[a]	55	0%	—	—	60%[b]	49%[b]
Ward et al., 2005	842	62%	90%	76% (53%)	95%	90% (79%)
Carver et al., 2006	176	36%[c]	88%	75% (69%)	94%	85% (76%)
Loeb et al., 2007	288	15%	91%[d]	74%	92%[d]	88%
Freedland et al., 2007	56	0%	—	—	98%	91% (84%)
Xylinas et al., 2009	100	25%	85%	—	90%	—

[a] Updated data from Han M, Partin AW, Pound CR, et al. Long-term biochemical disease-free and cancer-specific survival following anatomic radical retropubic prostatectomy. The 15-year Johns Hopkins experience. *Urol Clin North Am* 28(3):555–565, 2001.

[b] Biochemical disease-free survival (PSA <0.2 ng/mL); 15-year actuarial metastasis-free survival of 82% in entire cohort.

[c] Neoadjuvant therapy.

[d] Seven-year figures.

NR, not reported; *yr,* year.

Pound et al. (1999) found that a reasonable outcome was possible after prostatectomy for clinical stage T3a disease, with a 52% 8-year recurrence-free survival. Similarly, Ward and Zincke (2003) reported 5- and 10-year disease-free survival of 60% and 44%, respectively, without application of adjuvant AD. Freedom from local or systemic disease at 5 and 15 years after surgery was 73% and 67%, respectively (Ward et al., 2005). In the 812 patients from the series by Lerner et al. (1995), 10-year disease-specific survival was 80%, with only 31% of men with clinical stage T3 disease dying of prostate cancer 15 years after radical prostatectomy. It is unclear, however, whether surgical intervention improves survival compared with alternative treatment strategies. Another interesting observation from the Mayo Clinic was that clinical *overstaging* was identified in 27% of patients, consistent with other reported rates of 7% to 26%, suggesting that uniformly excluding patients from prostatectomy on the basis of clinical staging may not be appropriate (Ward et al., 2005). The long-term update from this series demonstrated local recurrence-free, systemic progression-free, and disease-specific survival of 76%, 72%, and 81%, respectively, at 20 years (Mitchell et al., 2012). Gerber et al. (1997) reviewed results in 298 men with clinical stage T3 disease undergoing radical prostatectomy and pelvic lymphadenectomy. Although the overall 10-year disease-specific survival was 57%, an apparent benefit of radical prostatectomy in some men with locally advanced disease was suggested by the increased survival (70%) in those who actually underwent prostatectomy and lymph node dissection. In a high-risk cohort undergoing surgery between 1987 and 2009, 37% had specimen-confined disease (pT2–pT3a), and a nomogram was developed incorporating PSA level, age, clinical stage, and biopsy Gleason sum to predict this with 72% accuracy (Briganti et al., 2012). **Many men with clinical stage T3 disease have regional spread and may not benefit from prostatectomy; however, select patients (e.g., lower-volume disease) may benefit because local control may be achieved in most, and complete cancer excision is possible in some men.**

Biochemical progression after radical prostatectomy is difficult to assess, given the frequent use of adjuvant therapy (e.g., RT or AD). Without the use of secondary treatment, 5-year biochemical relapse is higher than 60% (van den Ouden et al., 1998). In other series with variable use of adjuvant therapy, 5- and 10-year biochemical progression was observed in 42% to 49% and 59% to 62%, respectively. The impact of adjuvant therapy may be minimal with respect to clinical progression (i.e., biopsy-proven local recurrence or objective distant metastasis) after radical prostatectomy. Rates of clinical progression at 5, 10, and 15 years are 12% to 45%, 39% to 49%, and 50% to 71%, respectively.

Outcomes of Prostatectomy for Pathologically Advanced Disease

A significant minority of patients undergoing radical prostatectomy for clinically organ-confined disease will ultimately be found to have *pathologic* evidence of spread outside the prostate. Although these patients may be expected to have progression and survival rates comparable with those of patients with clinically advanced disease, as defined by grade and serum PSA level, those men who present with clinical stage T3 disease are likely to have greater tumor volume, higher grade, and increased likelihood of regional spread. Currently, the majority of men undergoing prostatectomy for pathologically advanced disease are categorized as high risk on the basis of serum PSA value or biopsy Gleason score. Nevertheless, there is overlap in the groups of men undergoing radical prostatectomy for *clinical* stage T3 and *pathologic* stage T3.

As discussed, pathologic stage after radical prostatectomy provides important prognostic information and is a powerful predictor of outcome, considering all clinical and pathologic factors (Fig. 159.7). **The presence of focal or established extracapsular extension increases the rate of clinical progression from 7% for organ-confined disease to 18% and 35%, respectively, at 5 years.** Patients with evidence of seminal vesicle invasion or lymph node metastasis are highly likely to develop clinical progression (86% and 95%, respectively) after radical prostatectomy. In men undergoing radical prostatectomy for clinically organ-confined disease, Hull et al. (2002) reported 5-year PSA-free survival of 95%, 76%, 37%, and 18% for men with pathologic organ-confined disease, extracapsular extension, seminal vesicle invasion, and positive lymph nodes, respectively. In a multivariate analysis, pathologic parameters increasing the relative risk (RR) for progression included extracapsular extension (RR 2.17 to 2.72), seminal vesicle involvement (RR 2.61), and lymph node involvement (RR 3.31). The presence of a positive surgical margin was associated with the greatest RR (4.37, 95% confidence interval [CI] 2.90 to 6.58). This reinforces the concept that complete surgical removal of all prostatic tissue, regardless of clinical or pathologic stage, should be accomplished when prostatectomy is undertaken. Even with seminal vesicle invasion, however, men without concomitant lymph node involvement can achieve 15-year disease-specific survival and BDFS rates of 81% and 32%, respectively (Secin et al., 2006).

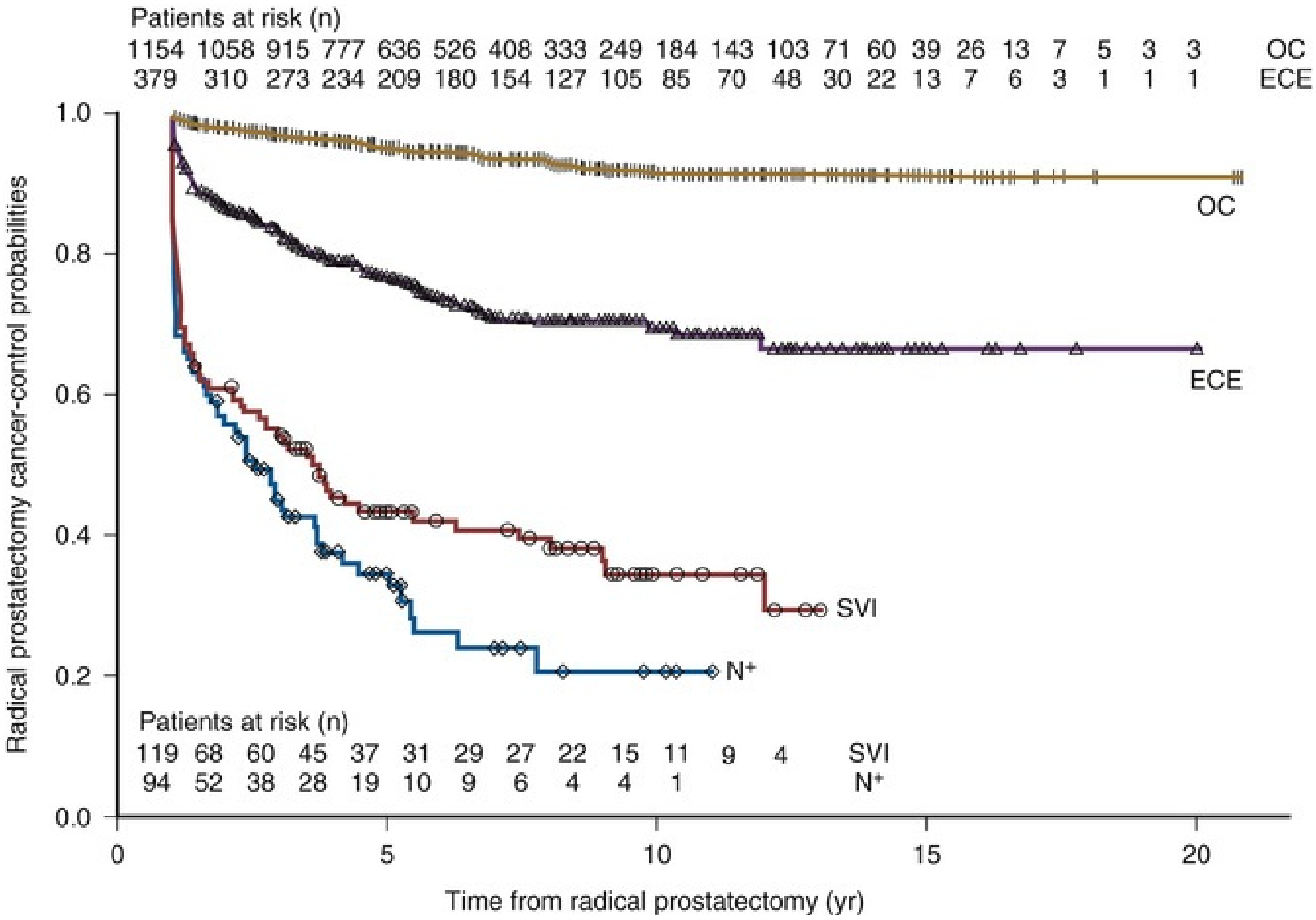

FIG. 159.7 Probabilities of cancer control after radical prostatectomy based on pathologic stage. *ECE,* extracapsular extension; *N*$^+$, node positive; *OC,* organ confined; *SVI,* seminal vesicle invasion. (Modified from Bianco FJ Jr, Scardino PT, Eastham JA. Radical prostatectomy: long-term cancer control and recovery of sexual and urinary function [“trifecta”]. *Urology* 66[5 Suppl]:83–94, 2005.)

Biochemical progression after prostatectomy for pathologically advanced tumors depends on the definition applied. Five-year rates of biochemical recurrence have been as high as 65% to 72% when a PSA threshold of 0.2 ng/mL is used; less stringent thresholds such as 0.4 ng/mL may yield recurrence rates of 26% at 5 years and at least 50% at 10 years. In a cohort of 747 men with pT3bN0 tumors identified after prostatectomy, the 10-year biochemical recurrence–free, metastasis-free, and disease-specific survival rates were approximately 25%, 70%, and 80%, respectively (Pierorazio et al., 2011). Seminal vesicle involvement not only increases the risk for biochemical recurrence but also significantly increases the risk for local recurrence after radical prostatectomy. With prolonged follow-up, Hawkins et al. (1995) reported local recurrence in nearly one-half of patients. This risk appears to be lower in contemporary series of patients because of improved selection of patients for surgery, improved surgical technique, and earlier use of secondary treatment, either as adjuvant therapy or at the time of biochemical relapse. The minimally invasive approach has been increasingly applied in higher-risk cases, and overall the outcomes appear reasonable and comparable to the open approach. Both oncologic and functional outcomes have not been reported to be significantly different, although variability in performing and the extent of pelvic lymphadenectomy require further study (Pierorazio et al., 2013; Punnen et al., 2013).

Predictive models have permitted preoperative estimation of PSA-free survival after prostatectomy. Patients with higher biopsy Gleason score and more elevated serum PSA level are at increased risk for failure after surgery. **Overall, the actuarial PSA-free survival after surgery in high-risk men is approximately 50% at 5 to 7 years.** The validity of the Kattan preoperative nomogram was examined in a community-based cohort of patients undergoing radical prostatectomy (Greene et al., 2004). Interestingly, although the overall concordance index (.68) supported the applicability of the tool to a broad spectrum of patients, the nomogram underestimated recurrence in lower-risk men and overestimated recurrence in men at higher calculated risk. Indeed, up to one-half of men with Gleason sum 8 to 10 or higher PSA level (>20 ng/mL) may achieve prolonged disease-free survival with prostatectomy alone. Further refinements of risk assessment and novel markers will help determine which high-risk men and locally advanced tumors truly benefit from aggressive surgical intervention, either alone or in combination with other therapy.

Outcomes of Prostatectomy for Node-Positive Disease

Despite poorer outcomes with node-positive disease, there is renewed interest in aggressive local therapy, including prostatectomy, given contemporary multimodal approaches, longer life expectancy, and potential oncologic and symptomatic benefits of surgical removal of the primary tumor. Selection of appropriate patients remains to be determined and may be aided by novel preoperative imaging modalities such as ^{68}Ga-PSMA-11 PET, identifying men with limited metastatic disease or where complete excision of gross disease (e.g., pelvic nodes) may be possible. An important question is whether surgery in this setting is feasible with acceptable morbidity. Several studies have demonstrated acceptable rates of complications and urinary incontinence after cytoreductive prostatectomy for M1 disease (Heidenreich et al., 2015; Sooriakumaran et al., 2016). In addition, performing surgery after neoadjuvant systemic therapy, a likely scenario, does not appear to increase the risk for perioperative complications, and CALGB 90203 should address this question (Williams et al., 2016).

After long-term follow-up of 88 men with node-positive disease after surgery, overall survival was 51% at 10 years (Seiler et al., 2014). In those with a single positive node, nearly one-half did not exhibit clinical progression and 57% did not require AD, with over 80% disease-specific survival. Touijer et al. (2014) reported similar findings in a group of men with node-positive disease who did not receive adjuvant AD or RT. Ten-year overall and disease-specific survival were 60% and 72%, respectively, and rates of freedom from metastases and biochemical recurrence were 65% and 28%, respectively. Gleason grade (>8) and greater number of lymph nodes (>3) predicted poorer outcome. Gandaglia et al. (2017) reported on a selected cohort of 11 men with oligometastatic disease (≤5 bone metastases) treated with prostatectomy and extended lymph node dissection, where 91% had node-positive disease and adjuvant AD was administered in nearly all patients. At median follow-up of 63 months, progression-free and disease-specific survival rates were 45% and 82%, respectively. The findings from Nini et al. (2015) also suggest a subset of node-positive patients where surgery may be appropriate. Among those with biochemical recurrence after surgery, nearly one-third had local and/or nodal disease as the first site of clinical recurrence, and this was associated with significantly improved disease-specific survival (79% at 5 years). Many ongoing clinical trials are specifically examining the role of local therapy in the setting of oligometastatic disease and should inform us regarding surgery for node-positive prostate cancer.

Neoadjuvant Androgen Deprivation

To improve outcomes of radical prostatectomy in men with locally advanced or high-risk tumors, several investigators have assessed the use of neoadjuvant androgen deprivation (NAD) before radical prostatectomy. In 1944, Vallet reported performing radical perineal prostatectomy after orchiectomy in a 59-year-old man with prostate cancer. Others reported the use and efficacy of diethylstilbestrol (DES) before surgery. In 1964, Scott evaluated the results of NAD in 31 men who were observed for 10 years. The majority of patients (52%) were alive and free from clinical recurrence. The prospective randomized trials of NAD in patients with stage cT1–T3 prostate cancer before radical prostatectomy are summarized in Table 159.5.

TABLE 159.5

Prospective Randomized Trials of Neoadjuvant Androgen Deprivation in Patients with Prostate Cancer (Stage cT1–T3) Before Radical Prostatectomy

AUTHOR (yr)	LHRH AGONIST	ANTIANDROGEN	DURATION (mo)
Labrie et al., 1997	Leuprolide	Flutamide	3
Witjes et al., 1997[a]	Goserelin	Flutamide	3
Soloway et al., 1995[b]	Leuprolide	Flutamide	3
Hugosson et al., 1996[c]	Triptorelin	Cyproterone	3
Dalkin et al., 1996	Goserelin		3
Goldenberg et al., 1996[d]		Cyproterone	3
Van Poppel et al., 1995	Estramustine[e]		1.5

[a] Follow-up report: Schulman et al., 2000.

[b] Follow-up report: Soloway et al., 2002.

[c] Follow-up report: Aus et al., 1998.

[d] Follow-up report: Klotz et al., 1999.

[e] Antimicrotubule agent derived from estradiol that also lowers serum testosterone levels.

LHRH, luteinizing hormone–releasing hormone; *mo,* months; *yr,* year.

Key Points: Radical Prostatectomy

- Radical prostatectomy alone can result in disease-free survival in at least one-half of men at 8 to 10 years despite clinically advanced disease.
- The risk for cancer recurrence after surgery can be quantitated on the basis of pathologic stage, cancer grade, and surgical margin status.
- NAD therapy before radical prostatectomy does not appear to improve disease-specific or overall survival.

Various measures of outcome have been evaluated in these studies, including changes in digital rectal examination (clinical stage), appearance of tumor on imaging, detection of micrometastatic or circulating cancer cells, and pathologic features such as T stage, surgical margin and lymph node status, and histopathologic changes. Ultimately, the utility of NAD must be assessed by its impact on disease-specific survival or its current surrogate, BDFS. It is clear that NAD affects tumor behavior and biology, evaluable by changes in metabolic patterns of atrophy on magnetic resonance spectroscopy, lowering of serum PSA level, and histologic atrophy (fibrosis, vacuolization, glandular collapse). Studies have demonstrated that significant reductions in prostate volume (30% to 50%), tumor volume, and PSA level (90%) are consistently noted, with maximal effects occurring during the first 2 months of treatment. However, conflicting results have been reported with respect to pathologic downstaging after NAD in patients with clinical stage T3 cancer. **Overall, only 20% of such patients have organ-confined disease at the time of radical prostatectomy despite clinical downstaging in 32% to 90%.** Schulman et al. (2000) described 402 patients with cT2–T3N0M0 tumors randomized to either radical prostatectomy alone or 3 months of total androgen blockade followed by surgery. Pathologic downstaging was seen more frequently in the neoadjuvant group (15%) than in the prostatectomy-alone group (7%; $P < .01$); however, in men with cT3 disease, there was no difference in pathologic downstaging ($P = .18$) or the incidence of lymph node metastases ($P = .36$) in the neoadjuvant and surgery-alone cohorts. Thus whereas clinical downstaging may occur frequently, **pathologic downstaging is significantly less common after NAD, ranging between 8% and 31%.** Most studies do not show decreased seminal vesicle invasion (Table 159.6). Similarly, rates of lymph node metastases are not altered, with the incidence varying between 3.3% and 16% in both the prostatectomy-alone and NAD groups.

TABLE 159.6

Pathologic Findings From Studies of Neoadjuvant Androgen Deprivation in Patients With cT1–T3 Prostate Cancer Before Radical Prostatectomy

AUTHOR (yr)	NUMBER OF PATIENTS	SEMINAL VESICLE		LYMPH NODE	
		CONTROL	NAD	CONTROL	NAD
Vailancourt et al., 1996	96	6%	0%	NR	NR
Soloway et al.,	282	22%	15%	5.8%	6.3%

1995					
Dalkin et al., 1996	56	14%	18%	NR	NR
Aus et al., 1998	122	14.5%	21.8%	16%	5.5%
Meyer et al., 1999	680	16%	17%	16%	14%
Klotz et al., 1999	213	14%	28%[a]	6.9%	3.3%
Schulman et al., 2000	402	23%	20%	23%	15%

[a] $P = .035$.

NAD, neoadjuvant androgen deprivation; *NR,* not reported.

Klotz et al. (2003) provided long-term follow-up (median, 6 years) of a prospective randomized trial comparing 3 months of NAD before prostatectomy and surgery alone. There was no overall benefit of NAD as measured by biochemical recurrence (34% to 38%), although in the subgroup of men with PSA level above 20 ng/mL, those receiving NAD had greater PSA-free survival (53%) compared with those undergoing prostatectomy alone (35%, $P = .015$). Southwest Oncology Group (SWOG) 9109 was a phase II feasibility study of 16 weeks of goserelin and flutamide before radical prostatectomy in men with T3–T4N0M0 prostate cancer (Powell et al., 2002). Of the 55 patients who underwent prostatectomy, 31% had seminal vesicle invasion and 19% had lymph node metastasis. Organ-confined disease was identified in 67% of cases. At median follow-up of 6.1 years, 5-year progression-free and overall survival estimates were 70% and 90%, respectively. The study demonstrated the feasibility of 4 months of AD before surgery, with acceptable morbidity and outcomes comparable with RT for this population of patients. Extended follow-up at a median of 10.6 years revealed that only 55% had disease progression, with progression-free survival of 40% and overall survival of 68% (Berglund et al., 2012).

Studies have also examined the incidence of positive surgical margins in those with cT3 disease. Witjes et al. (1997) reported similar rates of positive margins in men receiving NAD and those undergoing radical prostatectomy alone (43% and 59%, respectively; $P = .14$). Van Poppel et al. (1995) did not find a statistically significant difference between these groups with respect to positive margins—41.3% in the neoadjuvant cohort and 44% in the surgery-alone group. SWOG 9109 reported positive surgical margins in 30% of patients. In contrast, the randomized and nonrandomized studies of NAD in men with lower clinical stage (cT1–T2) clearly demonstrate a reduction in the rate of positive surgical margins. This advantage has not translated into improved long-term PSA-free survival. **For locally advanced tumors (specifically cT3), current data, both retrospective and prospective, do not support a significant benefit of NAD before surgery (Table 159.7).**

TABLE 159.7

Neoadjuvant Androgen Deprivation Therapy for 3 Months Before Radical Prostatectomy in Patients With Localized Prostate Cancer: Impact on PSA Recurrence After Surgery

AUTHOR (yr)	NUMBER OF PATIENTS	CONTROL	NAD	FOLLOW-UP (mo)
Fair et al., 1997	194	16%	11%	29
Aus et al., 1998	122	41%	35%	38
Meyer et al., 1999	680	30%	35%	38
Klotz et al., 1999	213	30%	40%	36
Schulman et al., 2000	398	32.5%	26.4%	48
Soloway et al., 2002	255	32%	35%	60

mo, months; *NAD,* neoadjuvant androgen deprivation; *PSA,* prostate-specific antigen; *yr,* year.

The apparent lack of benefit of NAD before radical prostatectomy in men with both lower-stage and locally advanced prostate cancer may be caused by a number of factors. It has been suggested that 3 months of AD may be insufficient to cause an improvement in disease-free survival compared with prostatectomy alone. Meyer et al. (1999) followed 680 men treated with radical prostatectomy, of whom 292 received NAD. Although there was no difference in risk for biochemical recurrence between the two groups, patients receiving both an LHRH agonist and antiandrogen for more than 3 months had a significantly lower risk for PSA failure than did those treated with surgery alone (hazard ratio [HR] 0.52, 95% CI, 0.29 to 0.93). Subsequently, the Canadian Urologic Oncology Group randomized patients with clinically localized disease to either 3 or 8 months of NAD before radical prostatectomy (Gleave et al., 2001). In the 500 patients with pathologic staging, positive surgical margins were identified in 23% of the 3-month group and 12% of the 8-month group (*P* = .011); organ-confined disease was found in 68% and 80% of the 3-month and 8-month groups, respectively (*P* = .0019). In addition, the rate of non–specimen-confined disease or lymph node extension was greater in the 3-month group (25.6%)

compared with the 8-month group (12.6%). However, despite evidence of continued biochemical and pathologic regression of the tumor between 3 and 8 months, no significant difference in PSA recurrence rates was observed at 4 years. Ongoing studies are evaluating the potential utility of other AD agents before surgery, including degarelix, abiraterone, and enzalutamide.

Neoadjuvant Chemotherapy and Chemotherapy–Hormonal Therapy

The role of chemotherapy in the treatment of prostate cancer has primarily been limited to men with the most advanced disease. Taxanes, alone or in combination with other agents, have proved effective in those with hormone-refractory prostate cancer, with significant PSA declines (>50%) in more than one-half of patients and measurable disease response in 28% to 75% (Oh, 2004). Mitoxantrone plus low-dose steroids has shown benefit in pain relief compared with steroids alone and is approved for use in hormone-refractory disease (Kantoff et al., 1999; Tannock et al., 1996). On the basis of these observations, interest has increased in earlier use of chemotherapy in high-risk patients or those with locally advanced disease. These studies are summarized in Table 159.8.

TABLE 159.8

Trials of Chemotherapy, Hormonal Therapy, and Combined Chemotherapy–Hormonal Therapy Before Radical Prostatectomy

	PETTAWAY ET AL., 2000)	CLARK ET AL., 2001)	KONETY ET AL., 2004)	MAGI-GALLUZZI ET AL., 2007)	CHI ET AL., 2008)	NAD[a]
Number of patients	33	16	36	28	64	—
Clinical stage T3	55%	13%	75%	18%	39%	100%
Regimen	KAVE	E/VP-16	TEC	D	D	—
Androgen deprivation	3 mo	—	4–6 mo	—	6 mo	—
Organ confined	33%	31%	36%	18%	53%	21%

Positive margins	17%	44%	22%	25%	27%	37%
Positive lymph nodes	37%	13%	5.50%	14%	6%	21%
Seminal vesicle invasion	85%	—[b]	56%	39%	22%	39%
Undetectable preoperative PSA	50%	50%	45%	—	—[c]	—
pT0	0%	0%	0%	0%	3%	0%–4%

[a] Combined results of 23 trials of neoadjuvant hormonal therapy in cT3 disease.

[b] Grouped together with positive lymph nodes.

[c] Median PSA 0.15 ng/mL (range 0.02 to 3.8).

D, docetaxel; *E/VP-16,* estramustine + etoposide; *KAVE,* ketoconazole + doxorubicin/vinblastine + estramustine; *NAD,* neoadjuvant androgen deprivation; *PSA,* prostate-specific antigen; *TEC,* paclitaxel + estramustine + carboplatin.

Pettaway et al. (2000) treated 33 higher-risk patients with a 3-month combination regimen consisting of two 6-week cycles of ketoconazole and doxorubicin alternating with vinblastine and estramustine. In addition, concurrent AD was accomplished with an LHRH agonist and an antiandrogen. Lower pathologic stage was found in 18% of patients with cT3 disease, and the overall positive surgical margin rate of only 17% suggests that the regimen may have improved the ability to resect the cancer above that achieved with NAD alone. A second report of chemotherapy and hormone therapy before surgery combined 4 to 6 months of NAD with paclitaxel, estramustine, and carboplatin in patients with androgen-dependent, high-risk prostate cancer (Konety et al., 2004). No patients were downstaged to pT0 after neoadjuvant therapy, and organ-confined disease was reported in 36%, with a 22% positive surgical margin rate. Overall, 45% remained without biochemical relapse, defined as PSA level above 0.05 ng/mL on three occasions, at median follow-up of 29 months, and no patient has had documented local recurrence. At 43 months of follow-up, Chi et al. (2008) reported a 3% complete pathologic response rate and a distant relapse rate of 30% in patients treated with NAD and docetaxel.

Other centers have used chemotherapy without concurrent NAD. At the Cleveland Clinic, 16 patients with locally advanced disease (clinical M0) underwent three cycles of oral estramustine and etoposide and subsequent surgery (Clark et al., 2001). Although grade 3 or grade 4 toxicity was seen in 34% of patients, surgery was not delayed in any individual, and surgical outcomes were comparable with those in series of prostatectomy without neoadjuvant therapy. With a median follow-up of 14 months, 88% were free from disease, and the early PSA failures occurred in the two patients with lymph node metastases.

Single-agent docetaxel is well tolerated before radical prostatectomy, with minimal toxicity (Dreicer et al., 2004; Oh et al., 2001). No cases of complete pathologic response were observed, but no lymph node metastases were identified in one series, whereas the other reported 11% with organ-confined disease. Two-thirds and 24% of patients, respectively, experienced a more than 50% reduction in PSA level in response to docetaxel alone. Similar observations have been made using a novel nanoparticle-based formulation of paclitaxel, with no complete pathologic responses (Shepard et al., 2009). Combination therapy with mitoxantrone or estramustine has been reported in small numbers. Garzotto et al. (2010) treated 57 men with docetaxel and dose-escalated mitoxantrone during the 16 weeks before surgery. One-half of patients were free from relapse at 5 years, and the rate of positive surgical margins was 33%. Agents described in recent reports include granulocyte-macrophage colony-stimulating factor and thalidomide (Garcia et al., 2008), and the epidermal growth factor receptor inhibitor gefitinib (Vuky et al., 2009). It remains to be determined whether new, targeted agents (e.g., custirsen) and immunotherapy (e.g., sipuleucel-T, ipilimumab, PD-1/PD-L1 inhibitors) will play a role in the neoadjuvant setting.

Adjuvant Radiation Therapy

Withholding regional or systemic therapy until after the prostate has been removed may (1) prevent delay in time to surgery, (2) reduce operative morbidity, and most importantly (3) identify those men with adverse pathologic features or evidence of residual disease who truly need additional therapy, thereby avoiding overtreatment in those found to have more favorable disease. The selection of appropriate adjuvant therapy remains difficult because knowledge of the ultimate site of failure (discriminating local-regional from distant recurrence) determines the actual type, timing, and efficacy of such intervention.

Until recently, adjuvant RT was not clearly demonstrated to be beneficial after radical prostatectomy; older studies demonstrated no impact on development of distant metastasis or disease-specific survival, and more recent data show improved biochemical control. Table 159.9 summarizes selected comparative series of adjuvant RT for pathologically advanced disease. In the matched-pair analysis of Valicenti et al. (1999), early adjuvant RT was administered within 3 to 6 months of surgery with undetectable PSA; control subjects were observed until PSA recurrence. The reduction in risk for PSA relapse was 88% after adjuvant RT, with 5-year PSA-free survival of 89%. Anscher et al. (1995) provided long-term follow-up (median, 10 years) in 46 patients receiving adjuvant RT after radical prostatectomy for pT3–T4 tumors. At 10 and 15 years, overall survival and disease-free survival in the RT group were 62% and 62% and 55% and 48%, respectively; these were not statistically different from the rates in the group not receiving adjuvant RT. In addition, development of distant metastases was comparable in the two cohorts. Nevertheless, local control was better after adjuvant RT (82% at 15 years) compared with surgery alone (53%).

TABLE 159.9

Early Adjuvant Radiation Therapy for Locally Advanced Prostate Cancer (pT3N0M0)

AUTHOR (yr)	NUMBER OF PATIENTS	RADIATION DOSE (Gy)	PROGRESSION-FREE SURVIVAL	*P*-VALUE	FOLLOW-UP (mo)
Morgan et al., 1991	33	—	64%	.02	11
	17	60–66	94%		
Stein et al., 1992	91	—	43%	.04	48
	24	55–60	75%		
Anscher et al., 1995	113	—	37%	.16	120
	46	55–65	55%		
Schild, 1998	228	—	40%	.0003	32
	60	57–68	90%		
Valicenti et al., 1998a	20	—	48%	.01	36
	15	64.8	85%		
Valicenti et al., 1999	36	—	55%	—	41
	36	59–70	88%		
Petrovich et al., 1999	40	—	69%	NS	60
	201	48	68%		
Eggener et al., 2005	144	—	53%/37%[a]	.4/.9[a]	48
	58	NR	62%/38%[a]		
Thompson	211	—	61%[b]	.016	151

et al., 2009	214	60–64	71%[b]		

[a] Negative surgical margin/positive surgical margin.

[b] Metastasis-free survival at 10 years.

Gy, gray; *mo,* months; *yr,* year.

The use of adjuvant RT is associated with a range of BDFS from 50% to 88% at 5 years. This appears to be an improvement (30% to 50%) compared with the results of surgery alone in high-risk patients. Nevertheless, the benefit of adjuvant RT needed to be proven in appropriately designed clinical trials, of which the European Organisation for Research and Treatment of Cancer (EORTC) 22911 (Bolla et al., 2005) and SWOG 8794 (Thompson et al., 2006) have been reported. Both studies randomized patients with pathologically advanced disease, defined as extraprostatic extension (pT3) and/or positive surgical margins without lymph node metastasis, to either immediate RT or observation after surgery. In EORTC 22911, immediate RT was associated with improved BDFS (74% vs. 53% without RT, $P < .001$) at 5 years. Similarly, SWOG 8794, with median 10.6 years of follow-up, supported immediate RT with a nearly 50% reduction in biochemical recurrence (35% vs. 64% without RT, $P < .001$) in those with PSA less than 0.4 ng/mL after prostatectomy. In addition, adjuvant RT significantly reduced the risk for clinical local recurrence in both trials. SWOG 8794 demonstrated a surprisingly low risk for metastatic disease (16%) in patients with adverse pathologic features that was further reduced with adjuvant RT (7%) (Swanson et al., 2007), and improved freedom from subsequent AD. Moreover, both metastasis-free and overall survival were improved with adjuvant RT (HR 0.71 and 0.72, respectively) (Thompson et al., 2009). A third randomized, controlled trial studying adjuvant RT for pT3N0 tumors after prostatectomy achieving an undetectable PSA confirmed the benefit with respect to BDFS (HR 0.53) (Wiegel et al., 2009).

The decision to administer adjuvant RT is often based on various adverse pathologic features, not all of which carry the same prognosis; indeed, SWOG 8794 combined extracapsular extension, seminal vesicle invasion, and positive surgical margin within a single classification. Thus it is difficult to assess the outcomes of adjuvant RT when the populations are composed, variably, of those with positive surgical margins, extracapsular extension, seminal vesicle invasion, or a combination of these features. Those men with positive surgical margins are at an increased risk for biochemical recurrence. A decision analytical model examining this question demonstrated that the benefit may be limited to those with high likelihood of recurrent local, rather than distant, disease; thus initial RT was recommended for patients with low- to intermediate-grade disease without evidence of seminal vesicle invasion (Grossfeld et al., 2000). This report suggested that adjuvant RT should be considered in those patients with extensive or multiple positive surgical margins. Secondary analyses of EORTC 22911 also support the role of immediate RT in the specific subset with positive surgical margins (Van der Kwast et al., 2007). The treatment benefit of adjuvant RT was primarily seen in patients with positive surgical margins (HR 0.38, $P < .0001$), whereas no benefit was observed in those with negative margins independent of other risk factors. However, the report from Stephenson et al. (2004) suggests that the application of adjuvant RT in a broader group of men may be beneficial; 501 men received salvage RT for biochemical recurrence after radical prostatectomy, and 50% experienced disease progression after treatment at a median follow-up of 45 months. Although higher Gleason score and seminal vesicle invasion were poor prognostic variables in predicting response to salvage RT, selected patients with high-grade disease or other adverse features (e.g., rapid PSA doubling time) could still achieve a durable response. Indeed, more than one-half of patients with Gleason sum 8 to 10 and positive surgical margins had a PSA nadir of 0.1 ng/mL or less without subsequent rise above this level. **Thus early use of secondary therapy, be it RT or AD, may be beneficial in locally advanced tumors, and at the time of biochemical recurrence in select patients.** However, the optimal timing and how these interventions may differentially affect local control, development of distant disease, and survival remain to be determined. Trock et al. (2008) reported an improvement in overall survival in patients with pT3 disease receiving salvage RT, with 5-year overall survival of 98%.

In general, men with seminal vesicle invasion are at significant risk for distant metastasis and may not benefit from local or regional RT; nevertheless, some men with pT3b disease may have local recurrence alone. Valicenti et al. (1998b) identified a group of 53 men with pT3bN0 disease undergoing radical prostatectomy, with 35 achieving undetectable PSA after surgery. The BDFS (3 years) in the 15 patients receiving adjuvant RT was 86% compared with 48% in the 20 men who were observed ($P = .01$). In EORTC 22911, there was no statistically significant predictive impact of seminal vesicle invasion on the benefit from RT as measured by BDFS, regardless of whether PSA was less than or greater than 0.2 ng/mL after surgery (Van der Kwast et al., 2007). However, even with pT3b disease, there was a benefit of adjuvant RT in patients with positive surgical margins. Men in SWOG 8794 with seminal vesicle invasion receiving RT had improved 10-year BDFS (36% vs. 12% for observation) but no significant improvement in metastasis-free and overall survival. Conversely, subgroup analysis of the ARO trial suggested that extracapsular extension without infiltration of the seminal vesicles was a predictor of more favorable outcome with RT (Wiegel et al., 2014). **On the basis of limited data, it appears that men with seminal vesicle invasion who achieve a low PSA level (<0.3 ng/mL) after prostatectomy or have positive surgical margins may be a more favorable group in whom adjuvant RT may be considered. Conversely, those men with more advanced disease never reaching an undetectable PSA level generally constitute a poor prognostic group likely harboring unrecognized lymph node or distant disease.** Novel genomic or biomarkers may help identify those most likely to benefit. Zhao et al. (2016) developed a score based on a 24-gene expression signature and found that those with a higher score who received postoperative RT were less likely to develop metastasis at 10 years, suggesting that this molecular signature may predict response to RT.

Traditionally, adjuvant RT has been delivered in lower doses compared with the dose for salvage therapy, with the range from 45 Gy to more than 60 Gy. Most contemporary series of adjuvant RT report doses greater than 60 Gy. Valicenti et al. (1998a) evaluated the dose response in a small number of patients ($N = 52$) receiving adjuvant RT for pT3N0 disease. The difference in 3-year BDFS between those treated with less than 61.2 Gy (64%) and more than 61.2 Gy (90%) was statistically significant ($P = .015$), suggesting that higher doses may be necessary. In 27 men with detectable PSA 6 months after prostatectomy, Schild et al. (1994) noted that RT doses of 64 Gy or more had improved 30-month freedom from failure (62%) compared with lower RT doses (17%; $P = .03$), supporting the hypothesis of a postoperative RT dose response similar to what has been observed for primary RT in prostate cancer (Schild et al., 1994).

The results from Radiation Therapy Oncology Group (RTOG) 0621 suggest a benefit of combined local and systemic therapy in the adjuvant setting (Hurwitz et al., 2017). High-risk men (96% pT3–T4, 82% Gleason ≥8) received 6 months of AD along with RT and 6 cycles of docetaxel. The 3-year freedom from progression was 73%, exceeding the expected rate of 50% and supporting phase III trials of similar design.

Key Points: Adjuvant Radiation Therapy

- Adjuvant RT improves local control and reduces biochemical relapse in selected patients after radical prostatectomy and likely improves metastasis-free and overall survival.
- The benefit of adjuvant RT may be greatest in cases with positive surgical margins.
- Improved outcomes of adjuvant RT are associated with dose escalation (64 Gy).

Adjuvant Androgen Deprivation

Indirect evidence from the MRC and VACURG trials suggesting a benefit of early AD compared with delayed AD in men with various stages of prostate cancer served as the impetus for studying adjuvant AD after radical prostatectomy. In addition, evidence of a benefit of continued AD after therapeutic RT supports a potential role for combined systemic treatment after local therapy in the form of prostatectomy. However, limited clinical data are currently published on this issue in men with locally advanced tumors.

Beyer et al. (1993) retrospectively reviewed the outcomes of 86 patients undergoing radical prostatectomy and any form of adjuvant therapy (89% endocrine treatment). In the subset of patients with stage pT3N0 tumors, adjuvant treatment did not demonstrate an advantage with respect to time to progression or survival. Cheng et al. (1993) reviewed the Mayo Clinic experience with 1035 patients undergoing radical prostatectomy for pathologic stage C prostate cancer; a significant number ($N = 103$) received adjuvant AD with orchiectomy. Adjuvant therapy of any type (AD or RT) decreased the rate of progression but did not improve disease-specific or overall survival, with no difference between the two modalities. Prayer-Galetti et al. (2000) presented data on 201 men with pT3 disease receiving adjuvant goserelin, demonstrating a 25.4% improvement in disease-free survival at median follow-up of 5 years ($P < .05$).

Recent publications provide some evidence supporting a benefit of early AD after radical prostatectomy in high-risk men with locoregional disease spread. Zincke et al. (2001) retrospectively reviewed data on men with stage pT3b cancer and found that early, adjuvant AD positively affected time to progression and disease-specific survival. These findings were true not only with seminal vesicle invasion but also with limited lymph node disease, with a 10-year cause-specific survival of 94% after prostatectomy and adjuvant AD with a single positive lymph node. Similar findings arose from the Eastern Cooperative Oncology Group study 7887 randomizing men with nodal metastases after radical prostatectomy (cT1–T2 disease) to immediate (adjuvant) or delayed AD (Messing et al., 1999). At a median follow-up of 11.9 years, men receiving adjuvant AD had improved overall (HR 1.84), disease-specific (HR 4.09), and progression-free (HR 3.42) survival. A matched-pair analysis of men with pT2–4N1 disease treated with prostatectomy suggested that adjuvant AD plus RT yielded significantly higher disease-specific and overall survival rates at 10 years (86% and 74%, respectively) compared with adjuvant AD alone (70% and 55%, respectively) (Briganti et al., 2011). Touijer et al. (2018) compared the outcomes of node-positive men managed with observation, lifelong adjuvant AD, or adjuvant AD plus RT after prostatectomy. Better overall survival was observed for adjuvant AD with RT (HR 0.41–0.46), and higher-risk patients benefited more than lower-risk patients. Improved disease-specific survival was also associated with adjuvant AD plus RT, and AD alone increased the risk for other-cause mortality relative to observation (HR 3.05).

Radiation Therapy

The contemporary trend is to treat high-risk or locally advanced prostate tumors with methods other than surgery. Although a plethora of studies describe the results of RT for clinical stage C and T3 disease, many were performed before the widespread use of serum PSA determination for early detection and modern radiotherapy techniques for treatment, such as three-dimensional conformal RT, intensity-modulated RT, and whole-pelvis irradiation in addition to the prostate (Kupelian et al., 2003). In addition, contemporary data suggest that the optimal radiation dose is higher than that used in previous reports. In higher-risk patients, improved biochemical control has been observed with 81 Gy or more for external-beam RT (Zelefsky et al., 2011). An earlier dose-escalation trial demonstrated improved outcomes with 78 Gy compared with 70 Gy, with the greatest benefits in the high-risk group with PSA greater than 10 ng/mL (Kuban et al., 2008). In the treatment of men with locally advanced or high-risk prostate tumors, monotherapy with RT or permanent interstitial brachytherapy is likely to be inadequate. Yet it must be emphasized that the outcome measures with demonstrated benefit of AD plus RT compared with RT alone often do not include overall survival. The focus has shifted to improving outcomes by combining RT with AD, often in conjunction with whole-pelvis irradiation (Table 159.10).

TABLE 159.10

Trials of Androgen Deprivation With External-Beam Radiation Therapy

STUDY (AUTHOR, YEAR)	NUMBER OF PATIENTS	ELIGIBILITY	RT DOSE (Gy)	STUDY ARM	DISEASE-FREE SURVIVAL	OVERA SURVIV
NEOADJUVANT						
RTOG 86-10 (Pilepich et al., 2001)[a]	471	cT2–4, ≥25 cm^2	44–46 WP	RT	3%[b]	34%[c]
			65–70 p	RT + nAD + cAD	11%[b]	43%[c]
Canadian trial (Laverdière	120	cT2b–4	64 p	RT	22%	NR
				RT + nAD	72%	NR

et al., 1997)				RT + n/c/aAD (6 mo)	90%	NR
Canadian trial (Crook et al., 2009)	378		66–67 p	RT + nAD (3 mo)	58%	81%
				RT + nAD (8 mo)	65%	79%
ADJUVANT						
RTOG 85-31 (Pilepich et al., 2003)	977	cT3, pT3 or N1	44–46 WP	RT	8%	38%
			65–70 p	RT + aAD (∞)	32%	53%
EORTC 22863 (Bolla et al., 2002)	412	T1–2 + grade 3, T3–4	50 WP	RT	40%	62%[d]
			70 p	RT + aAD (3 yr)	74%	78%[d]
Swedish trial (Granfors et al., 1998)	91	T1–4, pN0–3, M0	50 WP	RT	39%	38%[b]
			65 p	RT + orchiectomy	69%	61%[b]
RTOG 92-02 (Hanks et al., 2003)	1514	T2c–4 + PSA <150 ng/mL	44–50 WP	RT + n/cAD	28%	79%
			65–70 p	RT + n/c/aAD (2 yr)	46%	80%
RTOG 94-13 (Roach et al., 2003)[e]	1292	PSA <100 ng/mL +	50.4 WP	n/cAD + WP	38%	67%
		>15% risk for nodes	70.2 p	n/cAD + pRT	34%	69%
				WP + aAD (4 mo)	31%	59%[e]
				pRT + aAD (4 mo)	38%	68%

[a] Updated data from Roach M 3rd, Bae K, Speight J, et al. Short-term neoadjuvant androgen deprivation therapy and external-beam radiotherapy for locally advanced prostate cancer: long-term results of RTOG 8610. *J Clin Oncol* 26(4):585–591, 2008.

[b] *P* = .02.

[c] *P* = .12, different only for Gleason 2–6.

[d] *P* = .0002.

[e] Updated data from Lawton CA, DeSilvio M, Roach M 3rd, et al. An update of the phase III trial

comparing whole pelvic to prostate only radiotherapy and neoadjuvant to adjuvant total androgen suppression: updated analysis of RTOG 94-13, with emphasis on unexpected hormone/radiation interactions. *Int J Radiat Oncol Biol Phys* 69(3):646–655, 2007; lower survival with WP + aAD (*P* = .027).

aAD, adjuvant androgen deprivation; *cAD,* concurrent androgen deprivation; *mo,* month; *nAD,* neoadjuvant androgen deprivation; *p,* prostate; *PSA,* prostate-specific antigen; *RT,* radiation therapy; *WP,* whole pelvis; *yr,* year.

Overall survival after RT alone for stage C cancer is approximately 60% to 70% at 5 years and below 50% at 10 years. In high-risk patients, defined by individual parameters alone or in combination, the 5-year progression-free survival rates after RT are typically less than 50%.

Neoadjuvant Androgen Deprivation and Radiation Therapy

The theoretical benefits of AD before RT in men with locally advanced cancers are the ability to reduce target volume and the potential cytotoxic synergy of radiation and hormone manipulation. Several RTOG trials (75-06, 83-07, 85-19) examined the combination of AD and RT in locally advanced disease, suggesting that the regimen was tolerable and improved local tumor control. On the basis of this information, RTOG 86-10 was designed to compare short-term AD combined with RT with RT alone (Pilepich et al., 2001; Roach et al., 2008). The phase III trial randomized 471 men with cT2–T4 tumors (surface area >25 cm^2 on rectal examination) to either goserelin plus flutamide for 2 months before and during external-beam RT or RT alone. The 4 months of AD were associated with reduction in distant metastases and improvements in local control, disease-free survival, and disease-specific mortality. At 10 years, the disease-free survival in the AD plus RT and RT-alone groups was 11% and 3%, respectively ($P < .0001$), whereas disease-specific mortality was 23% and 36%, respectively ($P = .01$). No difference in overall survival between the two groups (43% AD plus RT vs. 34% RT) was found, although men with lower Gleason sum (2 to 6) appeared to have a survival benefit from combined AD and RT. In men with Gleason sum 7 to 10, no significant improvement was observed from AD with respect to locoregional control or survival. Subsequent analysis of RTOG 86-10 (Chakravarti et al., 2003) revealed that loss of p16 expression on immunohistochemistry was associated with reduced overall survival ($P = .039$), disease-specific survival ($P = .006$), and higher risk for local progression ($P = .0007$) and distant metastasis ($P = .026$); overall survival was not significantly associated ($P = .07$) in multivariate analysis. Other correlative studies of tissue from RTOG 86-10 found that the proliferative marker Ki-67 was significantly associated with distant metastasis and disease-specific survival but not with overall survival (Li et al., 2004).

Laverdière et al. (1997) made similar observations in a prospective randomized study of 120 men with cT2b–T4 disease. Treatments included (1) external-beam RT alone, (2) 3 months of NAD before RT, and (3) 3 months of NAD before RT and 6 months of adjuvant AD. Evidence of residual cancer on prostate biopsy was present in 62%, 30%, and 4% of the treatment arms, respectively, at 12 months and 65%, 28%, and 5%, respectively, at 24 months. BDFS at 12 and 24 months paralleled the biopsy data, with the difference between the neoadjuvant and adjuvant AD groups disappearing at 24 months. These observations not only support neoadjuvant and concurrent AD with RT but also suggest a benefit of prolonged AD. In a group of men randomized to either 3 or 8 months of NAD before RT, of whom 31% were categorized as high risk, longer NAD did not improve freedom from or pattern of failure; the only benefit of 8 months of NAD was improved 5-year disease-free survival (71% vs. 42%) (Crook et al., 2009). Long-term outcomes (median 10.6 years) from the Trans-Tasman Radiation Oncology Group (TROG) 96.01 trial demonstrated that 6 months of NAD before RT at 66 Gy was associated with reduced PSA and local progression and event-free survival (HR 0.51) in men with cT2b–4N0M0 prostate cancer (Denham et al., 2011). Although 3 months of NAD had no effect on distant progression or disease-specific and all-cause mortality, 6 months of treatment decreased rates of all three compared with RT alone (HR 0.49, 049, and 0.63, respectively). However, there does not appear to be a general benefit of more prolonged AD before RT. RTOG 9910 randomized 1489 men with intermediate-risk disease to either 8 or 28 weeks of NAD along with 8 weeks of AD concurrent with RT (Pisansky et al., 2015). No differences between the two groups were observed with respect to disease-specific and overall survival, locoregional and distant progression, and biochemical recurrence; whether these findings apply to high-risk disease remains to be determined.

Key Points: Neoadjuvant Androgen Deprivation and Radiation Therapy

- Neoadjuvant and concurrent AD appears to be appropriate in high-risk

patients undergoing RT.
- Adjuvant AD after RT may benefit those with very high-risk disease.

Adjuvant Androgen Deprivation and Radiation Therapy

Several prospective studies have assessed the role of adjuvant AD after RT and the appropriate duration of such therapy. RTOG 85-31 randomized 977 patients with T3NXM0 or T1–T2N+M0 prostate cancer to RT and either goserelin started during the last week of RT and continued indefinitely, or goserelin started at the time of relapse (i.e., early or late AD). The groups were matched with respect to disease risk characteristics, and fewer than 30% had lymph node involvement. Improved local control and BDFS and metastasis-free survival were noted in the adjuvant AD group at 8 years of follow-up, and this advantage was most prominent with Gleason sum 8 to 10. Overall survival was not statistically different at 5 years (75% vs. 72%) and 8 years (49% vs. 42%). In those patients with high-grade tumors, adjuvant AD improved disease-specific survival (90% vs. 78%) and overall survival (80% vs. 69%) at 5 years.

In the EORTC 22863 study, men undergoing external-beam RT for clinically localized disease (cT1–T2 and grade 3, cT3–T4 and any grade) were randomized to RT alone or the addition of goserelin starting at the beginning of treatment and continuing for 3 years (Bolla et al., 1997). This is the only study to demonstrate an overall survival benefit, with 5-year survival of 79% in the adjuvant AD group and 62% in the RT-alone group ($P = .001$). Disease-free survival was 85% and 48%, respectively, and local control was also improved with AD (97% vs. 79%). Of note, the cohort presented with very high-risk disease, with a median PSA level of 30 ng/mL, and this may account for the relatively low overall survival in the RT-alone cohort.

It does not appear that the method of AD affects the outcome of combined treatment with RT. Granfors et al. (1998) randomized men with cT1–T4pN0–3M0 cancer to either external-beam RT alone or combined orchiectomy and RT; men treated with RT alone received AD at clinical disease progression. At median follow-up of 9.3 years, clinical progression in the RT-alone and RT-plus-AD patients was 61% and 31%, respectively ($P = .005$). Disease-specific mortality was not different; overall mortality was 61% and 38%, respectively ($P = .02$). However, in men with negative lymph nodes, there was no significant difference in survival rates, and the poor survival was primarily caused by metastatic disease at the time of initial treatment.

A meta-analysis of 2742 men treated for clinically localized prostate cancer within RTOG trials from 1975 to 1992 supports the use of adjuvant AD in subsets of patients (Roach et al., 2000). Patients were stratified into four prognostic risk groups, and those in risk group 2 (cT3NX, Gleason 2 to 6; or cT1–T2NX, Gleason 7; or node-positive, Gleason 2 to 6) appeared to have improved disease-specific survival with the addition of short-term (4 months) AD. In further refining the population of patients, limiting the analysis to men with bulky or cT3 disease alone demonstrated a significant survival advantage.

If adjuvant AD is of benefit, the duration of such therapy remains uncertain. RTOG 92-02 supports the use of long-term AD after initial AD with external-beam RT (Hanks et al., 2003). Men with locally advanced tumors (cT2c–T4N0–1M0) received either 4 months of AD (2 months neoadjuvant and 2 months concurrent) with RT or that and 24 additional months of AD. Long-term AD was beneficial in all end points evaluated *except* overall survival, with 5-year rates for both approximately 80%. Subset analysis of men with Gleason sum 8 to 10 noted improved overall survival with 24 months of AD (81%) compared with short-term AD (71%; $P = .044$) and improved disease-specific survival; these findings were confirmed during 10-year follow-up (Horwitz et al., 2008). D'Amico et al. (2004) described 206 men with clinically localized but higher-risk (PSA ≥10 ng/mL, Gleason sum ≥7, cT3) prostate cancer randomized to RT alone (70 Gy) or RT with 6 months of AD. Overall and disease-specific survival rates were improved with AD compared with RT alone. Actuarial 5-year survival and freedom from salvage AD were 88% and 82%, respectively, after early AD and 78% and 57% with RT alone. In conjunction with high-dose RT, 2 years of adjuvant AD was superior to short-term, concurrent AD with respect to biochemical recurrence, overall survival, and metastasis-free survival (Zapatero et al., 2015); the benefit was more pronounced in the high-risk group compared with those with intermediate-risk disease. **Thus a limited period of AD (2 to 4 months) appears to be appropriate for men with intermediate-risk cancers; more prolonged AD may be beneficial for those with high-risk disease characteristics, including high-stage cancers, or men with high pretreatment serum PSA values.**

Other aspects of RT for men with more advanced tumors require clarification, including the dose and extent (i.e., prostate only vs. prostate and pelvis) applied. RTOG 94-13 randomized men with an estimated risk for lymph node metastasis of 15% into one of four arms: (1) whole-pelvis RT plus neoadjuvant and concurrent AD, (2) prostate-only RT plus neoadjuvant and concurrent AD, (3) whole-pelvis RT plus adjuvant AD, and (4) prostate-only RT plus adjuvant AD (Lawton et al., 2007; Roach et al., 2003). Initial analysis suggested improved progression-free survival for whole-pelvis compared with prostate-only RT and no difference for the two types of AD. In comparing the four groups after longer follow-up, however, progression-free survival rates were similar, with significant difference only in overall survival among the groups (*P* = .027). Surprisingly, overall survival was poorer in patients receiving whole-pelvis RT plus adjuvant AD compared with all other cohorts.

The differences in RT dose among the various prior and contemporary studies make comparisons of efficacy difficult because emerging data support doses greater than 72 Gy as being more effective (Cheung et al., 2005; Jacob et al., 2005). In addition, the role of combined external-beam RT and brachytherapy (both permanent and high-dose rate) needs to be better elucidated. Brachytherapy has generally been used to treat patients with lower-risk features. Its use in those with high-risk disease characteristics, often in combination with AD and external-beam RT, has been less well studied. Potters et al. (2005) noted a 63% BDFS in those treated with permanent prostate brachytherapy. A similar outcome was noted with the use of high-dose-rate intensity-modulated brachytherapy with external-beam RT (Demanes et al., 2005). Sylvester et al. (2003) treated men with interstitial permanent brachytherapy combined with moderate-dose (45 Gy) neoadjuvant external-beam RT. In those with high-risk disease (by D'Amico criteria), the 10-year BDFS was 48%; of note, AD was not used. Stock et al. (2004) evaluated a multimodal protocol using neoadjuvant and concomitant AD (9 months total), brachytherapy, and three-dimensional conformal RT in a high-risk cohort. The 5-year BDFS was 86%, with Gleason sum the only variable associated with PSA failure. Excellent local control was also demonstrated, with no patient harboring cancer on the last post-treatment biopsy. The ASCENDE-RT trial randomized 398 men with NCCN high- and intermediate-risk disease to treatment with 12 months of AD, pelvic irradiation to 46 Gy, and either dose-escalated external-beam RT (78 Gy) or low-dose-rate prostate brachytherapy (Morris et al., 2017). Although no difference in overall survival was observed between the two prostate radiation treatment arms, biochemical recurrence was significantly higher in the external-beam RT group (HR 2.04). The 20% estimated difference at 9 years (85% vs. 65%), especially in the high-risk subset, may further increase with longer follow-up given the sharp divergence at 4 years.

Radiation Therapy and Chemotherapy

The role of chemotherapy in conjunction with RT is less well studied than that for surgery and chemotherapy. Khil et al. (1997) administered estramustine and vinblastine concurrently with RT (total 65 to 70 Gy) in men with locally advanced disease. Although clinical control was reasonable at 5 years at 81%, only 48% of patients had a PSA level below 4 ng/mL at this time. Zelefsky et al. (2000) enrolled 27 patients with high-risk disease (Gleason sum ≥8 and PSA >10 ng/mL; Gleason sum 7 and PSA >20 ng/mL; cT3N0M0 and PSA >20 ng/mL; cT4N0M0; cTXN1M0) in a phase II clinical trial of the same agents, with RT at 75.6 Gy. Only a modest increase in grade 2 toxicity was noted, and no late grade 3 or grade 4 toxicities were observed. The 2-year BDFS was 60%. An update reported median time to PSA relapse of 12 months, with 48% of patients receiving no additional therapy, and median time to metastasis had not been reached (Ryan et al., 2004).

An estramustine-based regimen has also been examined with etoposide before and during definitive RT (Ben-Josef et al., 2001). Actuarial disease-free survival and overall survival were 73% and 88%, respectively, at 3 years. Local control as determined by biopsy was 71% at 18 months. A phase I study examined concurrent docetaxel and RT (70.2 Gy) in 22 men (Kumar et al., 2004). The maximal tolerated dose was determined to be 20 mg/m^2, with diarrhea and dysuria the primary toxic effects. All patients were alive at last follow-up, and 77% had continued biochemical response. These promising results support further study of the combined use of RT and chemotherapeutic agents.

RTOG 9902 does not suggest that the addition of adjuvant paclitaxel, estramustine, and etoposide to long-term AD and RT benefits men with high-risk disease (Rosenthal et al., 2015). At median follow-up of 9.2 years, there was no significant difference for all endpoints including overall and disease-specific survival, and biochemical and clinical progression. It should be noted that the trial was closed early as a result of thromboembolic events associated with the chemotherapy arm.

GETUG 12 randomized patients with cT3/T4, Gleason ≥8, PSA ≥ 20 ng/mL, or node-positive disease identified by lymphadenectomy without metastases to prolonged AD alone or combined with docetaxel and estramustine (Fizazi et al., 2015). Nodal disease was present in 29% of the cohort, and local therapy was predominantly RT (87%). The chemotherapy group had better relapse-free survival (62% vs. 50%, HR 0.71) with no increase in toxicity or secondary cancers.

The landmark STAMPEDE trial provides additional evidence that outcomes of RT may be improved with combination systemic therapy. Approximately 50% of enrolled men had high-risk or N+M0 prostate cancer, with most receiving RT for local therapy. The addition of either docetaxel or abiraterone at the time of AD initiation resulted in significant improvements in both overall and failure-free survival (James et al., 2016, 2017). It remains to be determined whether aggressive treatment of the prostate is essential and whether the benefit is primarily limited to those with metastatic spread, rather than locally advanced or regional disease.

Focal Ablative Therapy

Advances in technology have provided methods to ablate prostate tissue while being minimally invasive. There is renewed interest in primary cryoablation, particularly as focal treatment for localized disease and salvage therapy, and high-intensity focused ultrasonography (HIFU) appears promising. The ability to treat local disease within the prostate by these modalities may play a role, even in men with locally advanced disease, most likely in combination with AD or other systemic therapy.

Cryoablation

Several series have been reported regarding primary cryoablation of the prostate and include many men with high-risk disease (Ahmed et al., 2009). Long et al. (2001) reported on 975 men undergoing cryoablation. In this study, 41% were high risk and 24% were stage cT3. At a median follow-up of 24 months, the 5-year actuarial BDFS, defined as PSA less than 1 ng/mL, was 41%. A similar PSA outcome (35%) using the same definition was observed in another group of men with PSA 10 ng/mL or greater and/or Gleason sum 8 or higher undergoing primary cryoablation (Prepelica et al., 2005). However, use of more stringent PSA cutoff values may result in significantly poorer outcomes, with 2-year rates of biochemical failure higher than 80% if thresholds of 0.5 or 0.2 ng/mL are applied (El Hayek et al., 2008). Chin et al. (2008) randomized men with clinical stage T2c–T3 disease to 6 months of AD and either cryoablation or RT at 66 Gy. At a mean follow-up of 37 months, there were no differences in disease-specific (95% to 97%) and overall (87%) survival, but cryoablation was associated with shorter PSA-free survival (28 months vs. 41 months) and higher biochemical failure (87% vs. 53%).

High-Intensity Focused Ultrasonography

The role of HIFU continues to be elucidated, particularly in men with locally advanced prostate cancer. The limited existing data are confounded by frequent omission of risk stratification and common use of AD to reduce prostate size. At 1-year follow-up, 30 men with locally advanced or high-risk disease receiving AD plus HIFU had reasonable local control, with PSA less than 0.3 ng/mL and negative sextant biopsies in 90%; no patient had clinical disease progression (Ficarra et al., 2006). A larger series by Sumitomo et al. (2008) compared men receiving HIFU with and without NAD and without subsequent adjuvant therapy. In the 29% with high-risk cancers (by D'Amico criteria), NAD reduced both positive biopsy rate and biochemical failure. Three-year disease-free survival was independently affected by stage cT2c or higher (HR 2.34) and lack of NAD (HR 2.19) in multivariate analysis. Parallel to studies of RT, outcomes of local treatment using HIFU may be improved when combined with NAD, primarily in men with intermediate- and high-risk disease characteristics.

Androgen Deprivation and Its Timing

The VACURG and MRC trials suggest a benefit to early application of AD in men with locally advanced prostate cancer. The first VACURG study randomized 1050 patients with stage III disease and 853 patients with stage IV disease to placebo, 5 mg of DES, orchiectomy plus placebo, or orchiectomy plus 5 mg of DES. All three AD arms had significantly less progression than the placebo group, but this did not translate into an overall survival benefit. The inability to demonstrate a survival benefit cannot be completely attributed to the increased cardiovascular deaths within the DES groups because survival in the orchiectomy plus placebo group was not significantly different from that in the placebo-alone group. The second VACURG study randomized 1506 men with stage III and stage IV disease to placebo or one of three doses of DES (0.2 mg, 1 mg, 5 mg). DES at 1 mg and 5 mg delayed progression of stage III disease, and patients receiving 1 mg had improved overall survival. However, the 5-mg dose of DES again resulted in increased cardiovascular death. Subsequent analysis suggested that immediate estrogen therapy was most beneficial in patients younger than 75 years with high-grade tumors (Gleason sum 7 to 10). The third VACURG study supported that only a subset of men with prostate cancer benefit from early AD. In men with stage II disease, 5-year survival was 48% with placebo and 75% with 1 mg of DES. **Taken together, the VACURG data provide evidence of benefit for early AD with respect to disease progression and potential survival only in subsets of men with more aggressive disease** (Byar, 1973; Byar and Corle, 1988)**. The studies also clearly show that alternatives to estrogen should be used, given the cardiovascular toxicity associated with higher doses of DES.** The current ability to better monitor disease progression, with use of PSA kinetics and imaging modalities, may improve the outcomes of delayed AD by better determining when institution of AD is necessary.

The MRC also evaluated the issue of early versus delayed AD (orchiectomy or LHRH agonist) in 938 patients with prostate cancer, of whom 501 had locally advanced disease. The majority of deaths (67%) were attributed to prostate cancer. Disease-specific mortality was 55% in the early AD group and 43% in the deferred group ($P = .001$). Overall survival was also improved in the immediate AD arm ($P = .02$). The reduction in prostate cancer deaths was primarily a result of patients with M0 disease. This study also provides important data for comparison to other forms of treatment. Median time to death from prostate cancer (cT3M0) was 90 months, comparing favorably to EORTC 22863, in which median time was not reached after 65.7 months. Similarly, median overall survival in the MRC study was 64 months but not reached in EORTC 22864 (56.7 months of follow-up). Thus the apparent beneficial effects of combined AD and RT may be in part caused by AD alone with uncertain incremental advantage of RT. The results from the Scandinavian Prostate Cancer Group Study 7/Swedish Association for Urological Oncology 3 (SPCG-7/SFUO-3) trial suggest an important role of RT, in addition to AD, in men with locally advanced disease (78% cT3) (Widmark et al., 2009). Men were randomized to either total AD followed by continuous flutamide or endocrine therapy combined with RT. At median follow-up of 7.6 years, both prostate cancer–specific and overall mortality were decreased in the group receiving AD plus RT (RR 0.44 and 0.68, respectively), and PSA recurrence was higher in men receiving AD alone (75%) compared with the RT group (26%). Despite limitations including the unconventional endocrine regimen and open study design, use of RT and potentially other local treatment modalities appears warranted in men with locally advanced prostate cancer. The MRC UK PR07 trial similarly compared AD only with AD and RT; in this study, patients had more advanced disease, AD was accomplished by either continuous LHRH agonist or orchiectomy, and pelvic nodes were treated with RT. The addition of RT to AD improved disease-specific (HR 0.54) and overall (HR 0.77) survival at 7 years (Warde et al., 2011). These findings were confirmed with further follow-up, and death from prostate cancer was significantly reduced by the addition of RT to AD (HR 0.46) (Mason et al., 2015).

Studer et al. (2004) evaluated the timing of AD in a study randomizing 197 asymptomatic men with prostate cancer to either immediate or deferred subcapsular orchiectomy; of note, patients were either unsuitable for or unwilling to undergo surgery or RT. A significant fraction of the cohort had higher-risk features, with clinical stage T3 or higher in 67% and median serum PSA level above 46 ng/mL. Of the 92 men in the deferred treatment arm, 42% never required AD; the majority died of causes unrelated to prostate cancer. The median time to deferred AD was 3.2 years, the most common indication being skeletal metastases (45%) and ureteral obstruction (25%). Although overall survival was not different between the immediate and deferred groups (P = .96), a trend toward improved disease-specific survival was noted in those men receiving immediate AD, with an HR for death from prostate cancer of 0.63 (P =

.09).

To minimize adverse impact on quality of life, antiandrogen therapy alone has been proposed as an alternative to orchiectomy or LHRH agonists. Iversen et al. (2004) reported on the effects of 150 mg of bicalutamide in men with localized or locally advanced prostate cancer, the majority of whom were untreated initially (81%). At median 5.3 years of follow-up, survival in those with locally advanced disease was improved with bicalutamide compared with placebo (HR 0.68). Overall, risk for disease progression was reduced by 43%, with the greatest benefit in locally advanced tumors (HR 0.4). The combined analysis of the three Early Prostate Cancer bicalutamide trials (N = 8113) confirmed improved progression-free survival in the bicalutamide group (Wirth et al., 2004a). Overall survival was not different between the treatment and placebo arms in each trial, but men with locally advanced disease receiving bicalutamide alone (i.e., no surgery or RT) appeared to have improved survival. Although apparently promising in men with high-risk tumors, bicalutamide at 150 mg must be approached cautiously, both in men deferring local therapy and after definitive treatment. In analysis of the Early Prostate Cancer data (median follow-up of 5.4 years), men with localized prostate cancer receiving bicalutamide as primary therapy had an increased risk for death (HR 1.23, 95% CI, 1.00 to 1.50) compared with surveillance alone. Immediate high-dose bicalutamide is not currently appropriate in men with low risk for disease progression, and potentially adverse effects should be sought in higher-risk patients with extended follow-up.

Wirth et al. (2004b) tested adjuvant flutamide (750 mg) after radical prostatectomy in men with pT3–T4N0 disease. Recurrence-free survival, defined as a single PSA value above 5 ng/mL or two PSA values above 2 ng/mL, was improved with flutamide (HR 0.51) at median follow-up of 6.1 years; however, overall survival was comparable (HR 1.04). Significant toxicity was associated with flutamide and accounted for nearly one-half of withdrawals from the treatment arm.

Key Points: Androgen Deprivation

- Early AD may improve survival.
- Alternative methods of androgen manipulation (antiandrogen, intermittent) remain investigational.

Intermittent Androgen Deprivation

Another approach to minimizing AD-related morbidity is the intermittent application of androgen suppression. Forty-nine patients (28 with cT3–T4N0M0 disease) were treated with total AD until the PSA level was less than 4.0 ng/mL between 24 and 32 weeks, after which treatment was withheld after 36 weeks (Sato et al., 2004). PSA level was then monitored and treatment was recommended when the PSA level reached either pretreatment level (when it was <15 ng/mL) or 15 ng/mL (when the initial PSA level was higher than that). During median follow-up of 126.1 weeks, mean time off treatment during cycles 1, 2, and 3 was 46.1, 36.9, and 23.3 weeks, respectively. No symptomatic or clinical disease was reported in the nonmetastatic subgroup, and PSA failure was observed in 3 (11%) of these patients, with all patients alive at last evaluation. The optimal timing of intermittent AD for reduction of patient morbidity and disease-specific end points remains to be determined, particularly in light of data from the trial of intermittent versus continuous AD in men with metastatic, hormone-sensitive prostate cancer (Hussain et al., 2013).

Quality of Life

The early institution of AD in men with prostate cancer, whether the cancer is localized or locally advanced, must be balanced against the known side effects and long-term morbidity. Only recently has the impact of AD on bone events, cognitive function, and quality of life been appreciated and reported. In comparing bicalutamide (150 mg) and castration with locally advanced but nonmetastatic disease, both sexual interest and physical capacity were better with bicalutamide monotherapy (Iversen et al., 2000). Although hot flashes were more common with castration, a trend toward reduced quality of life was associated with bicalutamide, including higher incidence of gynecomastia, breast pain, and asthenia. In the study of intermittent AD from Sato et al. (2004), many quality-of-life domains were improved during off-treatment cycles, including potency and social and family well-being.

The multimodal approach with AD and RT may increase the relative toxicity compared with each intervention alone. Schultheiss et al. (1997) reported that NAD was correlated with later gastrointestinal and genitourinary (grade 2 or higher) morbidity. Another study found that adjuvant AD after RT predicted for late grade 2 to grade 4 rectal toxicity (Sanguineti et al., 2002). Within RTOG 86-

10, potency after RT with or without AD was similar at 81% and 74%, respectively. Chen et al. (2001) also found that the addition of AD did not further contribute to decline in sexual function after RT. Zelefsky et al. (1999) evaluated predictors of late toxicity in men treated with three-dimensional conformal radiotherapy. Although the 5-year actuarial likelihood of gastrointestinal and urinary toxicities was low (<10% overall), use of NAD was an independent predictor ($P = .01$) of post-treatment erectile dysfunction. The incidence of rectal morbidity and sexual dysfunction may be related to duration of AD longer than 6 or 9 months.

The benefits of adjuvant AD plus RT for locally advanced prostate cancer, both short and long term, appeared to outweigh the associated side effects in a number-needed-to-treat analysis (Jani et al., 2003). A model that compared treatment options while incorporating benefit and complications was constructed, and data from randomized trials of RT with or without AD for cT2c–T4N0–1 disease were input into the calculation. Even considering the increased incidence of side effects of long-term AD, this approach appeared to be better than short-term AD for virtually all end points evaluated.

Given concerns regarding AD and impact on body mass index, lipid profile, diabetes, and cardiovascular disease, Efstathiou et al. (2009) assessed the relationship between AD and cardiovascular events within RTOG 85-31. Adjuvant AD (median duration 4.2 years) was not associated with increased cardiovascular mortality. Additional evidence from RTOG 86-10 suggests that short-term NAD also does not increase the risk for fatal cardiac events.

Management of Delayed Sequelae

The direct comparison of prostatectomy and RT in the treatment of locally advanced prostate cancer is challenging and primarily based on historical studies. Even with the addition of neoadjuvant and adjuvant systemic therapy, leaving the prostate gland in situ poses potential problems. First, effective local control of some high-risk cancers may influence survival. Second, local recurrence may lead to the need for additional treatment of the prostate. At 10 years, local recurrence rates after RT for cT3 or stage C disease range from 24% to 74%. Holzman et al. (1991) reported that 36% of patients required transurethral resection of the prostate because of urinary obstruction after RT alone, without AD. Other morbidities included hydronephrosis (20%) and incontinence (13%). An older report also demonstrated significant local complications of stage C prostate cancer with nonextirpative interventions—infection (80%), bladder outlet obstruction (75%), gross hematuria (45%), and ureteral obstruction (40%) (Tomlinson et al., 1977). Systemic therapy in the form of AD may not prevent local progression or reduce the need for palliative intervention. Despite orchiectomy for bladder outlet obstruction, 31% of men with locally advanced disease required transurethral prostate resection because of persistent voiding dysfunction after 60 days. Similarly, in 277 patients with cT2–T4 disease randomized to orchiectomy, RT, or both, rates of local disease control were comparable (Fellows et al., 1992). Studer et al. (2004) demonstrated that AD alone, whether it is instituted early or late, does not prevent local morbidity. More than one-half of the men in their study required transurethral resection of the prostate. In addition, delayed institution of AD was necessary because of ureteral obstruction (25%), anticipation of local complications (10%), and rectal infiltration (4%).

Quality of life is an increasingly important end point for prostate cancer. However, the impact of untreated local tumor progression or the various treatment modalities for locally advanced disease on quality-of-life outcomes is poorly characterized. Rosenfeld et al. (2004) examined the relationship between cancer stage and quality of life in 341 ambulatory men with prostate cancer. Instruments used included the Functional Assessment of Cancer Therapy (FACT), the urinary function subscale of the UCLA Prostate Cancer Index, and the Hospital Anxiety and Depression Scale (HADS). The stage of prostate cancer was significantly associated with most FACT subscales—increasing stage was negatively correlated with nearly every FACT subscale score; the observation persisted in multivariate models, accounting for covariables such as comorbidity and time since diagnosis. Interestingly, stage was more strongly associated with physical domains of health-related quality of life, and there was no association with psychological symptoms as measured by HADS.

Berg et al. (2007) treated high-risk patients with RT monotherapy and characterized quality of life using validated instruments. Although mean scores for bowel function were similar to those for a normative control population, bowel bother and diarrhea were greater after RT. Patients who had clinical progression or required AD reported poorer sexual, urinary, and social function and more sleeping problems and exhibited great declines in all domains over time. Data from CaPSURE also suggest that men with high-risk cancer are likely to suffer negative effects beyond cancer outcomes (Wu et al., 2008). Use of AD with both surgery and RT was associated with a loss of sexual function that improved within 9 months, whereas the combination of external-beam RT and brachytherapy resulted in continuous worsening of urinary function and bother.

Additional evidence from SWOG 8794 supports an adverse impact of multimodal therapy on quality of life (Moinpour et al., 2008). Men receiving adjuvant RT reported poorer bowel and urinary function, but not erectile function, compared with surgery alone. Although symptom distress was significantly worse for the adjuvant RT group, likely correlating with bowel and urinary problems, there were no differences in other general measures of health-related quality of life, whereas global health-related quality of life was initially poorer but continuously improved over time after adjuvant RT.

Clinical Trials

Given that outcomes of therapy are not optimal for those men with high-risk disease features, patients who present with such cancers should be considered for enrollment in novel clinical trials (http://clinicaltrials.gov/). SPCG 15 (NCT 02102477) plans to randomize 1200 men with newly diagnosed high-risk prostate cancer (cT3N0M0 and Gleason 4 and PSA <100 ng/mL) to either prostatectomy or RT + AD, with disease-specific survival as the primary endpoint. Table 159.11 summarizes phase III clinical trials for high-risk or locally advanced prostate cancer; some of these trials have completed accrual, and others are ongoing. The resulting data should answer some of the current questions regarding the optimal type and timing of traditional combination treatment, and the role of chemotherapy, in men with locally advanced and high-risk prostate cancer.

TABLE 159.11

Current and Pending Phase III Clinical Trials in Locally Advanced/High-Risk Prostate Cancer

STUDY	ELIGIBILITY CRITERIA	TREATMENTS
RADICAL PROSTATECTOMY		
AUO AP 55/09 (SEAL)	Gleason 7–10 or PSA >10 ng/mL surgery + limited vs. extended pelvic lymphadenectomy	
NEOADJUVANT		
CALGB 90203[a]	Clinically localized, ≤60% 5-yr disease free, Gleason 8–10	Surgery alone vs. estramustine/docetaxel
ADJUVANT		
SWOG 9921[a]	Gleason 8–10, pT3b–4, PSA >20 ng/mL, N1, Gleason 7 and + margin	AD (2 yr) vs. AD + mitoxantrone/prednisone
VA Study 553[b]	pT3b–4, pT3a and Gleason ≥7, pT2 and Gleason 8–10 and + margin, PSA >20 ng/mL	Surveillance vs. docetaxel/prednisone
SPCG 12[b]	pT3a and Gleason ≥4+3, pT2 and + margin and Gleason ≥4+3, pT3b and Gleason ≥7	Surveillance vs. docetaxel
NCT 00667069	>pT2 or R1 N0/x and PSA ≤0.1 ng/mL	Immediate vs. delayed RT + triptorelin

(GETUG-17)		
MRC PR 10[a] (RADICALS)	After radical prostatectomy with PSA ≤0.2 ng/mL: pT3–4, Gleason 7–10, preoperative PSA ≥10 ng/mL, + margin	Immediate vs. delayed RT RT vs. RT + 6 mo AD vs. RT + 24 mo AD
NCT 00860652 (RAVES)	After radical prostatectomy with PSA ≤0.1 ng/mL and + margin or pT3a or pT3b	Immediate vs. delayed RT
NCT 01442246 (AFU-GETUG 20)	After radical prostatectomy with PSA <0.1 ng/mL and pT3b or Gleason >7 or Gleason 7 with tertiary 5	Surveillance vs. 24 mo AD
EXTERNAL-BEAM RADIATION THERAPY		
RTOG 0924	Gleason 7–10 and cT1c–2b and PSA <50 ng/mL, Gleason 6 and cT2c–4 or >50% biopsies and PSA <50 ng/mL, Gleason 6 and cT1c–2b and PSA >20 ng/mL	NAD + prostate/seminal vesicle RT + RT boost vs. NAD + whole-pelvic RT + RT boost
NCT 00967863[a] (GETUG-AFU 18)	cT3–T4 or PSA ≥20 ng/mL or Gleason ≥8–10 and N0	AD (3 yr) + 70 Gy vs. 80 Gy RT
NCT 01952223 (PEACE 2)	2 or more of: cT3–T4, Gleason ≥8, PSA ≥20 ng/mL	Assessing addition of pelvic RT, cabazitaxel to standard prostate RT + 3 yrs AD
NEOADJUVANT		
CAN-NCIC-PR12	≥T3a, Gleason ≥8, PSA >20 ng/mL	NAD + docetaxel vs. NAD
ADJUVANT		
NCT 116142	cT1–T2a and PSA <10 ng/mL or Gleason ≥4+3 or PSA velocity >2 ng/mL/yr, cT2c–4 and tertiary Gleason 5 or T3b or Gleason ≥3+4 with ≥50% cores positive	AD vs. AD + docetaxel
RTOG 0521	Gleason ≥9 and PSA ≤150 ng/mL, Gleason 8 and PSA <20 ng/mL and ≥cT2, Gleason 7 or 8 and PSA 20–150 ng/mL	AD vs. AD + docetaxel/prednisone
RTOG 1115	Gleason ≥9 and PSA ≤150 ng/mL and any T stage, Gleason 8 and PSA <20 ng/mL and ≥T2, Gleason 8 and PSA 20–150 ng/mL and any T stage, Gleason 7 and PSA 20–150 ng/mL and any T stage	AD (24 mo) + dose-escalated RT vs. AD (24 mo) + TAK-700 + dose-escalated RT

SPCG 13[a]	cT2 and Gleason 4+3 and PSA 10–70 ng/mL, cT2 and Gleason 8–10 and PSA <70 ng/mL, cT3	AD vs. AD + docetaxel
ANDROGEN DEPRIVATION		
NCT 223171 (PCS IV)	cT3–T4 or Gleason 8–10 or PSA >20 ng/mL	RT + 36 vs. 18 months AD

[a] Fully accrued.

[b] Abstract presented.

AD, androgen deprivation; *Gy,* gray; *mo,* month; *NAD,* neoadjuvant androgen deprivation; *PSA,* prostate-specific antigen; *RT,* radiation therapy; *yr,* year.

Suggested Readings

Albertsen PC, Hanley JA, Fine J. 20-year outcomes following conservative management of clinically localized prostate cancer. *JAMA*. 2005;293(17):2095–2101.

Berglund RK, Tangen CM, Powell IJ, et al. Ten-year follow-up of neoadjuvant therapy with goserelin acetate and flutamide before radical prostatectomy for clinical T3 and T4 prostate cancer: update on Southwest Oncology Group Study 9109. *Urology*. 2012;79(3):633–637.

Bolla M, Collette L, Blank L, et al. Long-term results with immediate androgen suppression and external irradiation in patients with locally advanced prostate cancer (an EORTC study): a phase III randomised trial. *Lancet*. 2002;360(9327):103–106.

Bolla M, van Poppel H, Collette L, et al. Postoperative radiotherapy after radical prostatectomy: a randomised controlled trial (EORTC trial 22911). *Lancet*. 2005;366(9485):572–578.

Briganti A, Joniau S, Gontero P, et al. Identifying the best candidate for radical prostatectomy among patients with high-risk prostate cancer. *Eur Urol*. 2012;61(3):584–592.

Cooperberg MR, Vickers AJ, Broering JM, et al. Comparative risk-adjusted mortality outcomes after primary surgery, radiotherapy, or androgen-deprivation therapy for localized prostate cancer. *Cancer*. 2010;116:5226–5234.

Johansson JE, Andren O, Andersson SO, et al. Natural history of early, localized prostate cancer. *JAMA*. 2004;291(22):2713–2719.

Mitchell CR, Boorjian SA, Umbreit EC, et al. 20-year survival after radical prostatectomy as initial treatment for cT3 prostate cancer. *BJU Int*. 2012;110(11):1709–1713.

Thompson I, Tangen CM, Paradelo J, et al. Adjuvant radiotherapy for pathological T3N0M0 prostate cancer significantly reduces risk of metastases and improves survival: long-term followup of a randomized clinical trial. *J Urol*. 2009;181(3):956–962.

Thompson IM Jr, Tangen CM, Paradelo J, et al. Adjuvant radiotherapy for pathologically advanced prostate cancer: a randomized clinical trial. *JAMA*. 2006;296(19):2329–2335.

Warde P, Mason M, Ding K, et al. Combined androgen deprivation therapy and radiation therapy for locally advanced prostate cancer: a randomised, phase 3 trial. *Lancet*. 2011;378(9809):2104–2111.

Widmark A, Klepp O, Solberg A, et al. Endocrine treatment, with or without radiotherapy, in locally advanced prostate cancer (SPCG-7/SFUO-3): an open randomised phase III trial. *Lancet*. 2009;373(9660):301–308.

References

Adib RS, Anderson JB, Ashken MH, et al. Immediate versus deferred treatment for advanced prostatic cancer: initial results of the Medical Research Council trial. *Br J Urol*. 1997;79(2):235–246.

Ahmed HU, Moore C, Emberton M. Minimally-invasive technologies in uro-oncology: the role of cryotherapy, HIFU and photodynamic therapy in whole gland and focal therapy of localized prostate cancer. *Surg Oncol*. 2009;18(3):219–232.

Albertsen PC, Hanley JA, Gleason DF, et al. Competing risk analysis of men aged 55 to 74 years at diagnosis managed conservatively for clinically localized prostate cancer. *JAMA*. 1998;280(11):975–980.

Albertsen PC, Hanley JA, Fine J. 20-year outcomes following conservative management of clinically localized prostate cancer. *JAMA*. 2005;293(17):2095–2101.

Anscher MS, Robertson CN, Prosnitz R. Adjuvant radiotherapy for pathologic stage T3/4 adenocarcinoma of the prostate: ten-year update. *Int J Radiat Oncol Biol Phys*. 1995;33(1):37–43.

Ashida S, Nakagawa H, Katagiri T, et al. Molecular features of the transition from prostatic intraepithelial neoplasia (PIN) to prostate cancer: genome-wide gene-expression profiles of prostate cancers and PINs. *Cancer Res*. 2004;64(17):5963–5972.

Aus G, Abrahamsson PA, Ahlgren G, et al. Hormonal treatment before radical prostatectomy: a 3-year followup. *J Urol*. 1998;159(6):2013–2106.

Badani KK, Kaul S, Menon M. Evolution of robotic radical prostatectomy: assessment after 2766 procedures. *Cancer*.

2007;110(9):1951–1958.

Beltran H, Wyatt AW, Chedgy EC, et al. Impact of therapy on genomics and transcriptomics in high-risk prostate cancer treated with neoadjuvant docetaxel and androgen deprivation therapy. *Clin Cancer Res*. 2017;23(22):6802–6811.

Ben-Josef E, Porter AT, Han S, et al. Neoadjuvant estramustine and etoposide followed by concurrent estramustine and definitive radiotherapy for locally advanced prostate cancer: feasibility and preliminary results. *Int J Radiat Oncol Biol Phys*. 2001;49(3):699–703.

Berg A, Lilleby W, Bruland OS, et al. 10-year survival and quality of life in patients with high-risk pN0 prostate cancer following definitive radiotherapy. *Int J Radiat Oncol Biol Phys*. 2007;69(4):1074–1083.

Berglund RK, Tangen CM, Powell IJ, et al. Ten-year follow-up of neoadjuvant therapy with goserelin acetate and flutamide before radical prostatectomy for clinical T3 and T4 prostate cancer: update on Southwest Oncology Group Study 9109. *Urology*. 2012;79(3):633–637.

Beyer A, Leitenberger A, Altwein JE. Adjuvant hormone therapy following radical prostatectomy. *Eur Urol*. 1993;4:51–56.

Bolla M, Gonzalez D, Warde P, et al. Improved survival in patients with locally advanced prostate cancer treated with radiotherapy and goserelin. *N Engl J Med*. 1997;337(23):295–300.

Bolla M, Collette L, Blank L, et al. Long-term results with immediate androgen suppression and external irradiation in patients with locally advanced prostate cancer (an EORTC study): a phase III randomised trial. *Lancet*. 2002;360(9327):103–106.

Bolla M, van Poppel H, Collette L, et al. Postoperative radiotherapy after radical prostatectomy: a randomised controlled trial (EORTC trial 22911). *Lancet*. 2005;366(9485):572–578.

Bott SR, Freeman AA, Stenning S, et al. Radical prostatectomy: pathology findings in 1001 cases compared with other major series and over time. *BJU Int*. 2005;95(1):34–39.

Bratt O, Folkvaljon Y, Eriksson MH, et al. Undertreatment of men in their seventies with high-risk nonmetastatic prostate cancer. *Eur Urol*. 2015;68(1):53–58.

Briganti A, Karnes RJ, Da Pozzo LF, et al. Combination of adjuvant hormonal and radiation therapy significantly prolongs survival of patients with pT2-4 pN+ prostate cancer: results of a matched analysis. *Eur Urol*. 2011;59(5):832–840.

Briganti A, Joniau S, Gontero P, et al. Identifying the best candidate for radical prostatectomy among patients with high-risk prostate cancer. *Eur Urol*. 2012;61(3):584–592.

Byar DP. The Veterans’ Administration Cooperative Urologic Research Group's studies of cancer of the prostate. *Cancer*. 1973;32(5):1126–1130.

Byar DP, Corle DK. Hormone therapy for prostate cancer: results of the Veterans’ Administration Cooperative Urologic Research Group studies. *NCI Monogr*. 1988;7:165–170.

Carver BS, Bianco FJ Jr, Scardino PT, et al. Long-term outcome following radical prostatectomy in men with clinical stage T3 prostate cancer. *J Urol*. 2006;176(2):564–568.

Cary KC, Cooperberg MR. Biomarkers in prostate cancer surveillance and screening: past, present, and future. *Ther Adv Urol*. 2013;5(6):318–329.

Chakravarti A, Heydon K, Wu CL, et al. Loss of p16 expression is of prognostic significance in locally advanced prostate cancer: an analysis from the Radiation Therapy Oncology Group protocol 86-10. *J Clin Oncol*. 2003;21(17):3328–3334.

Chen CT, Valicenti RK, Lu J, et al. Does hormonal therapy influence sexual function in men receiving 3D conformal radiation therapy for prostate cancer? *Int J Radiat Oncol Biol Phys*. 2001;50(3):591–595.

Cheng WS, Frydenberg M, Bergstralh EJ, et al. Radical prostatectomy for pathologic stage C prostate cancer: influence of pathologic variables and adjuvant treatment on disease outcome. *Urology*. 1993;42(3):283–291.

Cheung R, Tucker SL, Lee AK, et al. Dose-response characteristics of low- and intermediate-risk prostate cancer treated with external beam radiotherapy. *Int J Radiat Oncol Biol Phys*. 2005;61(4):993–1002.

Chi KN, Chin JL, Winquist E, et al. Multicenter phase II study of combined neoadjuvant docetaxel and hormone therapy before radical prostatectomy for patients with high risk localized prostate cancer. *J Urol*. 2008;180(2):565–570.

Chin JL, Ng C-K, Touma NJ, et al. Randomized trial comparing cryoablation and external beam radiotherapy for T2C-T3B prostate cancer. *Prostate Cancer Prostatic Dis*. 2008;11(1):40–45.

Chodak GW, Thisted RA, Gerber GS, et al. Results of conservative management of clinically localized prostate cancer. *N Engl J Med*. 1994;330(4):242–248.

Chu LW, Troncoso P, Johnston DA, et al. Genetic markers useful for distinguishing between organ-confined and locally advanced prostate cancer. *Genes Chromosomes Cancer*. 2003;36(3):303–312.

Clark PE, Peereboom DM, Dreicer R, et al. Phase II trial of neoadjuvant estramustine and etoposide plus radical prostatectomy for locally advanced prostate cancer. *Urology*. 2001;57(2):281–285.

Cooperberg MR, Carroll PR. Trends in management for patients with localized prostate cancer, 1990–2013. *JAMA*. 2015;314(1):80–82.

Cooperberg MR, Lubeck DP, Mehta SS, et al. Time trends in clinical risk stratification for prostate cancer: implications for outcomes (data from CaPSURE). *J Urol*. 2003;170(6 Pt 2):S21–S27.

Cooperberg MR, Pasta DJ, Elkin EE, et al. The University of California, San Francisco Cancer of the Prostate Risk Assessment score: a straightforward and reliable preoperative predictor of disease recurrence after radical prostatectomy. *J Urol*. 2005;173(6):1938–1942.

Cooperberg MR, Broering JM, Carroll PR. Risk assessment for prostate cancer metastasis and mortality at the time of diagnosis. *J Natl Cancer Inst*. 2009;101(12):878–887.

Cooperberg MR, Vickers AJ, Broering JM, et al. Comparative risk-adjusted mortality outcomes after primary surgery, radiotherapy, or androgen-deprivation therapy for localized prostate cancer. *Cancer*. 2010;116(22):5226–5234.

Cooperberg MR, Cowan JE, Hilton JF, et al. Outcomes of active surveillance for men with intermediate-risk prostate cancer. *J Clin Oncol*. 2011;29(2):228–234.

Cornud F, Flam T, Chauveinc L, et al. Extraprostatic spread of clinically localized prostate cancer: factors predictive of pT3 tumor and of positive endorectal MR imaging examination results. *Radiology*. 2002;224(1):203–210.

Crook J, Ludgate C, Malone S, et al. Final report of multicenter Canadian Phase III randomized trial of 3 versus 8 months of neoadjuvant androgen deprivation therapy before conventional-dose radiotherapy for clinically localized prostate cancer. *Int J Radiat Oncol Biol Phys*. 2009;73(2):327–333.

Dalkin BL, Ahmann FR, Nagle R, et al. Randomized study of neoadjuvant testicular androgen ablation therapy before radical prostatectomy in men with clinically localized prostate cancer. *J Urol*. 1996;155(4):1357–1360.

D'Amico AV, Whittington R, Malkowicz SB, et al. Biochemical outcome after radical prostatectomy, external beam radiation therapy, or interstitial radiation therapy for clinically localized prostate cancer. *JAMA*. 1998;280(11):969–974.

D'Amico AV, Whittington R, Malkowicz SB, et al. Pretreatment nomogram for prostate-specific antigen recurrence after radical prostatectomy or external-beam radiation therapy for clinically localized prostate cancer. *J Clin Oncol*. 1999;17(1):168–172.

D'Amico AV, Manola J, Loffredo M, et al. 6-month androgen suppression plus radiation therapy vs radiation therapy alone for patients with clinically localized prostate cancer: a randomized controlled trial. *JAMA*. 2004;292(7):821–827.

Demanes DJ, Rodriguez RR, Schour L, et al. High-dose-rate intensity-modulated brachytherapy with external beam radiotherapy for prostate cancer: California endocurietherapy's 10-year results. *Int J Radiat Oncol Biol Phys*. 2005;61(6):1306–1316.

Denham JW, Steigler A, Lamb DS, et al. Short-term neoadjuvant androgen deprivation and radiotherapy for locally advanced prostate cancer: 10-year data from the TROG 9601 randomised trial. *Lancet Oncol*. 2011;12(5):451–459.

Derweesh IH, Kupelian PA, Zippe C, et al. Continuing trends in pathological stage migration in radical prostatectomy specimens. *Urol Oncol*. 2004;22(4):300–306.

Dreicer R, Magi-Galluzzi C, Zhou M, et al. Phase II trial of neoadjuvant docetaxel before radical prostatectomy for locally advanced prostate cancer. *Urology*. 2004;63(6):1138–1142.

Efstathiou JA, Bae K, Shipley WU, et al. Cardiovascular mortality after androgen deprivation therapy for locally advanced prostate cancer: RTOG 85-31. *J Clin Oncol*. 2009;27(1):92–99.

Eggener SE, Roehl KA, Smith ND, et al. Contemporary survival results and the role of radiation therapy in patients with node negative seminal vesicle invasion following radical prostatectomy. *J Urol*. 2005;173(4):1150–1155.

Eifler JB, Feng Z, Lin BM, et al. An updated prostate cancer staging nomogram (Partin tables) based on cases from 2006 to 2011. *BJU Int*. 2013;111(1):22–29.

El Hayek OR, Alfer W Jr, Reggio E, et al. Prostate cryoablation: prospective analysis comparing high- and low-risk prostate cancer outcomes. *Urol Int*. 2008;81(2):186–190.

Fair WR, Cookson MS, Stroumbakis N, et al. The indications, rationale, and results of neoadjuvant androgen deprivation in the treatment of prostatic cancer: Memorial Sloan-Kettering Cancer Center results. *Urology*. 1997;49(3A Suppl):46–55.

Fellows GJ, Clark PB, Beynon LL, Urological Cancer Working Party—Subgroup on Prostatic Cancer, et al. Treatment of advanced localised prostatic cancer by orchiectomy, radiotherapy, or combined treatment. A medical Research Council Study. *Br J Urol*. 1992;70(3):304–309.

Ficarra V, Antoniolli SZ, Novara G, et al. Short-term outcome after high-intensity focused ultrasound in the treatment of patients with high-risk prostate cancer. *BJU Int*. 2006;98(6):1193–1198.

Fizazi K, Faivre L, Lesaunier F, et al. Androgen deprivation therapy plus docetaxel and estramustine versus androgen deprivation therapy alone for high-risk localised prostate cancer (GETUG 12): a phase 3 randomised controlled trial. *Lancet Oncol*. 2015;16(7):787–794.

Freedland SJ, Partin AW, Humphreys EB, et al. Radical prostatectomy for clinical stage T3a disease. *Cancer*. 2007;109(7):1273–1278.

Fulgham PF, Rukstalis DB, Turkbey IB, et al. AUA policy statement on the use of multiparametric magnetic resonance imaging in the diagnosis, staging and management of prostate cancer. *J Urol*. 2017;198(4):832–838.

Gandaglia G, Fossati N, Stabile A, et al. Radical prostatectomy in men with oligometastatic prostate cancer: results of a single-institution series with long-term follow-up. *Eur Urol*. 2017;72(2):289–292.

Garcia JA, Klein EA, Magi-Galluzzi C, et al. Clinical and biological effects of neoadjuvant sargramostim and thalidomide in patients with locally advanced prostate cancer. *Clin Cancer Res*. 2008;14(10):3052–3059.

Garzotto M, Higano CS, O'Brien C, et al. Phase 1/2 study of preoperative docetaxel and mitoxantrone for high-risk prostate cancer. *Cancer*. 2010;116(7):1699–1708.

Gerber GS, Thisted RA, Chodak GW, et al. Results of radical prostatectomy in men with locally advanced prostate cancer: multi-institutional pooled analysis. *Eur Urol*. 1997;32(4):385–390.

Gleave ME, Goldenberg SL, Chin JL, Canadian Uro-Oncology Group, et al. Randomized comparative study of 3 versus 8-month neoadjuvant hormonal therapy before radical prostatectomy: biochemical and pathological effects. *J Urol*. 2001;166(2):500–506.

Goldenberg SL, Klotz LH, Srigley J, Canadian Urologic Oncology Group, et al. Randomized, prospective, controlled study comparing radical prostatectomy alone and neoadjuvant androgen withdrawal in the treatment of localized prostate cancer. *J Urol*. 1996;156(3):873–877.

Granfors T, Modig H, Damber JE, et al. Combined orchiectomy and external radiotherapy versus radiotherapy alone for nonmetastatic prostate cancer with or without pelvic lymph node involvement: a prospective randomized study. *J Urol*. 1998;159(6):2030–2034.

Greene FL, Page DL, Fleming ID. *AJCC cancer staging* *manual*. ed 6. Springer Verlag: New York, NY; 2002:309–316.

Greene KL, Meng MV, Elkin EP, et al. Validation of the Kattan preoperative nomogram for prostate cancer recurrence using a community based cohort: results from Cancer of the Prostate Strategic Urological Research Endeavor (CaPSURE). *J Urol*. 2004;171(6 Pt 1):2255–2259.

Grossfeld GD, Tigrani VS, Nudell D, et al. Management of a positive surgical margin after radical prostatectomy: decision analysis. *J Urol*. 2000;164(1):93–99.

Han M, Partin AW, Zahurak M, et al. Biochemical (prostate specific antigen) recurrence probability following radical prostatectomy for clinically localized prostate cancer. *J Urol*. 2003;169(2):517–523.

Hanks GE, Pajak TF, Porter A, et al. Phase III trial of long-term adjuvant androgen deprivation after neoadjuvant hormonal cytoreduction and radiotherapy in locally advanced carcinoma of the prostate: the Radiation Therapy Oncology Group Protocol 92-02. *J Clin Oncol*. 2003;21(21):3972–3978.

Hawkins CA, Bergstralh EJ, Lieber MM, et al. Influence of DNA ploidy and adjuvant treatment on progression and survival in patients with pathologic stage T3 (pT3) prostate cancer after radical retropubic prostatectomy. *Urology*. 1995;46(3):356–364.

Heidenreich A, Pfister D, Porres D. Cytoreductive radical prostatectomy in patients with prostate cancer and low volume skeletal metastases: results of a feasibility and case-control study. *J Urol*. 2015;193(3):832–838.

Holzman M, Carlton CE Jr, Scardino PT. The frequency and morbidity of local tumor recurrence after definitive radiotherapy for stage C prostate cancer. *J Urol*. 1991;146(6):1578–1582.

Horwitz EM, Bae K, Hanks GE, et al. Ten-year follow-up of Radiation Therapy Oncology Group protocol 92-02: a phase III trial of the duration of elective androgen deprivation in locally advanced prostate cancer. *J Clin Oncol*. 2008;26(15):2497–2504.

Hugosson J, Abrahamsson PA, Ahlgren G, et al. The risk of malignancy in the surgical margin at radical prostatectomy reduced almost three-fold in patients given neo-adjuvant hormone treatment. *Eur Urol*. 1996;29(4):413–419.

Hull GW, Rabbani F, Abbas F, et al. Cancer control with radical prostatectomy alone in 1,000 consecutive patients. *J Urol*. 2002;167(2 Pt 1):528–534.

Hurwitz MD, Harris J, Sartor O, et al. Adjuvant radiation therapy, androgen deprivation, and docetaxel for high-risk prostate cancer postprostatectomy: results of NRG Oncology/RTOG study 0621. *Cancer*. 2017;123(13):2489–2496.

Hussain M, Tangen CM, Berry DL, et al. Intermittent versus continuous androgen deprivation in prostate cancer. *N Engl J Med*. 2013;368(14):1314–1325.

Iversen P, Johansson JE, Lodding P, et al. Bicalutamide (150 mg) versus placebo as immediate therapy alone or as adjuvant to therapy with curative intent for early nonmetastatic prostate cancer: 5.3-year median followup from the Scandinavian Prostate Cancer Group Study Number 6. *J Urol*. 2004;172(5 Pt 1):1871–1876.

Iversen P, Tyrrell CJ, Kaisary AV, et al. Bicalutamide monotherapy compared with castration in patients with nonmetastatic locally advanced prostate cancer: 6.3 years of followup. *J Urol*. 2000;164(5):1579–1582.

Jacob R, Hanlon AL, Horwitz EM, et al. Role of prostate dose escalation in patients with greater than 15% risk of pelvic lymph node involvement. *Int J Radiat Oncol Biol Phys*.

2005;61(3):695–701.

James ND, Sydes MR, Clarke NW, et al. Addition of docetaxel, zoledronic acid, or both to first-line long-term hormone therapy in prostate cancer (STAMPEDE): survival results from an adaptive, multiarm, multistage, platform randomised controlled trial. *Lancet*. 2016;387(10024):1163–1177.

James ND, de Bono JS, Spears MR, et al. Abiraterone for prostate cancer not previously treated with hormone therapy. *N Engl J Med*. 2017;377:338–351.

Jani AB, Kao J, Hellman S. Hormone therapy adjuvant to external beam radiotherapy for locally advanced prostate carcinoma: a complication-adjusted number-needed-to-treat analysis. *Cancer*. 2003;98(11):2351–2361.

Johansson JE, Holmberg L, Johansson S, et al. Fifteen-year survival in prostate cancer. A prospective, population-based study in Sweden. *JAMA*. 1997;277(6):467–471.

Johansson JE, Andren O, Andersson SO, et al. Natural history of early, localized prostate cancer. *JAMA*. 2004;291(22):2713–2719.

Kantoff PW, Halabi S, Conaway M, et al. Hydrocortisone with or without mitoxantrone in men with hormone-refractory prostate cancer: results of the Cancer and Leukemia Group B 9182 study. *J Clin Oncol*. 1999;17(8):2506–2513.

Karnes RJ, Choeurng V, Ross AE, et al. Validation of a genomic risk classifier to predict prostate cancer-specific mortality in men with adverse pathologic features. *Eur Urol*. 2018;73(2):168–175.

Kattan MW, Eastham JA, Stapleton AM, et al. A preoperative nomogram for disease recurrence following radical prostatectomy for prostate cancer. *J Natl Cancer Inst*. 1998;90(10):766–771.

Kattan MW, Zelefsky MJ, Kupelian PA, et al. Pretreatment nomogram for predicting the outcome of three-dimensional conformal radiotherapy in prostate cancer. *J Clin Oncol*. 2000;18(19):3352–3359.

Khil MS, Kim JH, Bricker LJ, et al. Tumor control of locally advanced prostate cancer following combined estramustine, vinblastine, and radiation therapy. *Cancer J Sci Am*. 1997;3(5):289–296.

Klotz LH, Goldenberg SL, Jewett M, et al. CUOG randomized trial of neoadjuvant androgen ablation before radical prostatectomy: 36-month post-treatment PSA results. *Urology*. 1999;53(4):757–763.

Klotz LH, Goldenberg SL, Jewett MA, et al. Long-term followup of a randomized trial of 0 versus 3 months of neoadjuvant androgen ablation before radical prostatectomy. *J Urol*. 2003;170(3):791–794.

Konety BR, Eastham JA, Reuter VE, et al. Feasibility of radical prostatectomy after neoadjuvant chemohormonal therapy for patients with high risk or locally advanced prostate cancer: results of a phase I/II study. *J Urol*. 2004;171(2 Pt 1):709–713.

Kuban DA, Tucker SL, Dong L, et al. Long-term results of the M.D. Anderson randomized dose-escalation trial for prostate cancer. *Int J Radiat Oncol Biol Phys*. 2008;70(1):67–74.

Kumar P, Perrotti M, Weiss R, et al. Phase I trial of weekly docetaxel with concurrent three-dimensional conformal radiation therapy in the treatment of unfavorable localized adenocarcinoma of the prostate. *J Clin Oncol*. 2004;22(10):1909–1915.

Kupelian PA, Buchsbaum JC, Elshaikh MA, et al. Improvement in relapse-free survival throughout the PSA era in patients with localized prostate cancer treated with definitive radiotherapy: year of treatment an independent predictor of outcome. *Int J Radiat Oncol Biol Phys*. 2003;57(3):629–634.

Labrie F, Cusan L, Gomez JL, et al. Neoadjuvant hormonal therapy: the Canadian experience. *Urology*. 1997;49(3A Suppl):56–64.

Laverdière J, Gomez JL, Cusan L, et al. Beneficial effect of combination hormonal therapy administered prior and following external beam radiation therapy in localized prostate cancer. *Int J Radiat Oncol Biol Phys*. 1997;37(2):247–252.

Lawton CA, DeSilvio M, Roach M 3rd, et al. An update of the phase III trial comparing whole pelvic to prostate only radiotherapy and neoadjuvant to adjuvant total androgen suppression: updated analysis of RTOG 94-13, with emphasis on unexpected hormone/radiation interactions. *Int J Radiat Oncol Biol Phys*. 2007;69(3):646–655.

Lerner SE, Blute ML, Zincke H. Extended experience with radical prostatectomy for clinical stage T3 prostate cancer: outcome and contemporary morbidity. *J Urol*. 1995;154(4):1447–1452.

Li R, Heydon K, Hammond ME, et al. Ki-67 staining index predicts distant metastasis and survival in locally advanced prostate cancer treated with radiotherapy: an analysis of patients in Radiation Therapy Oncology Group protocol 86-10. *Clin Cancer Res*. 2004;10(12 Pt 1):4118–4124.

Linch M, Goh G, Hiley C, et al. Intratumoral evolutionary landscape of high-risk prostate cancer: the PROGENY study of genomic and immune parameters. *Ann Oncol*. 2017;28(10):2472–2480.

Loeb S, Smith ND, Roehl KA, et al. Intermediate-term potency, continence, and survival outcomes of radical prostatectomy for clinically high-risk or locally advanced prostate cancer. *Urology*. 2007;69(6):1170–1175.

Long JP, Bahn D, Lee F, et al. Five-year retrospective, multi-institutional pooled analysis of cancer-related outcomes after cryosurgical ablation of the prostate. *Urology*.

2001;57(3):518–523.

Lowrance WT, Elkin EB, Yee DS, et al. Locally advanced prostate cancer: a population-based study of treatment patterns. *BJU Int*. 2012;109(9):1309–1314.

Magi-Galluzzi C, Zhou M, Reuther AM, et al. Neoadjuvant docetaxel treatment for locally advanced prostate cancer: a clinicopathologic study. *Cancer*. 2007;110(6):1248–1254.

Mason MD, Parulekar WR, Sydes MR, et al. Final report of the intergroup randomized study of combined androgen-deprivation therapy plus radiotherapy versus androgen-deprivation therapy alone in locally advanced prostate cancer. *J Clin Oncol*. 2015;33(19):2143–2150.

Maurer T, Gschwend JE, Rauscher I, et al. Diagnostic efficacy of (68)Gallium-PSMA positron emission tomography compared to conventional imaging for lymph node staging of 130 consecutive patients with intermediate to high risk prostate cancer. *J Urol*. 2016;195(5):1436–1443.

Mehra R, Tomlins SA, Shen R, et al. Comprehensive assessment of TMPRSS2 and ETS family gene aberrations in clinically localized prostate cancer. *Mod Pathol*. 2007;20(5):538–544.

Meng MV, Elkin EP, Latini DM, et al. Treatment of patients with high-risk localized prostate cancer: results from cancer of the prostate strategic urological research endeavor (CaPSURE). *J Urol*. 2005;173(5):1557–1561.

Messing EM, Manola J, Sarosdy M, et al. Immediate hormonal therapy compared with observation after radical prostatectomy and pelvic lymphadenectomy in men with node-positive prostate cancer. *N Engl J Med*. 1999;341(24):1781–1788.

Meyer F, Moore L, Bairati I, et al. Neoadjuvant hormonal therapy before radical prostatectomy and risk of prostate specific antigen failure. *J Urol*. 1999;162(6):2024–2028.

Mitchell JA, Cooperberg MR, Elkin EP, et al. Ability of 2 pretreatment risk assessment methods to predict prostate cancer recurrence after radical prostatectomy: data from CaPSURE. *J Urol*. 2005;173(4):1126–1131.

Mitchell CR, Boorjian SA, Umbreit EC, et al. 20-year survival after radical prostatectomy as initial treatment for cT3 prostate cancer. *BJU Int*. 2012;110(11):1709–1713.

Moinpour CM, Hayden KA, Unger JM, et al. Health-related quality of life results in pathologic stage C prostate cancer from a Southwest Oncology Group trial comparing radical prostatectomy alone with radical prostatectomy plus radiation therapy. *J Clin Oncol*. 2008;26(1):112–120.

Morgan WR, Zincke H, Rainwater LM, et al. Prostate specific antigen values after radical retropubic prostatectomy for adenocarcinoma of the prostate: impact of adjuvant treatment (hormonal and radiation). *J Urol*. 1991;145(2):319–323.

Morris WJ, Tyldesley S, Rodda S, et al. Androgen suppression combined with elective nodal and dose escalated radiation therapy (the ASCENDE-RT Trial): an analysis of survival endpoints for a randomized trial comparing a low-dose-rate brachytherapy boost to a dose-escalated external beam boost for high- and intermediate-risk prostate cancer. *Int J Radiat Oncol Biol Phys*. 2017;98(2):275–285.

Moul JW, Connelly RR, Lubeck DP, et al. Predicting risk of prostate specific antigen recurrence after radical prostatectomy with the Center for Prostate Disease Research and Cancer of the Prostate Strategic Urologic Research Endeavor databases. *J Urol*. 2001;166(4):1322–1327.

National Comprehensive Cancer Network. *Clinical practice guidelines in oncology: prostate cancer, version 1.2014*. [Available at] http://www.nccn.org/professionals/physician_gls/PDF/prostat 2014.

National Comprehensive Cancer Network. *Clinical practice guidelines in oncology: prostate cancer, version 2.2017*. [Available at] https://www.nccn.org/professionals/physician_gls/PDF/prosta 2017.

Nesbit RM, Plumb RT. Prostatic carcinoma—a follow-up of 765 patients treated prior to endocrine era and comparison of survival rate between these and patients treated with endocrine therapy. *Surgery*. 1946;20:263.

Nini A, Gandaglia G, Fossati N, et al. Patterns of clinical recurrence of node-positive prostate cancer and impact on long-term survival. *Eur Urol*. 2015;68(5):777–784.

Oh WK. An overview of chemotherapy trials in localized and recurrent nonmetastatic prostate cancer. *J Urol*. 2004;172(5 Pt 2):S34–S37.

Oh WK, George DJ, Kaufman DS, et al. Neoadjuvant docetaxel followed by radical prostatectomy in patients with high-risk localized prostate cancer: a preliminary report. *Semin Oncol*. 2001;28(4 Suppl 15):40–44.

Paris PL, Andaya A, Fridlyand J, et al. Whole genome scanning identifies genotypes associated with recurrence and metastasis in prostate tumors. *Hum Mol Genet*. 2004;13(13):1303–1313.

Partin AW, Kattan MW, Subong EN, et al. Combination of prostate-specific antigen, clinical stage, and Gleason score to predict pathological stage of localized prostate cancer. A multi-institutional update. *JAMA*. 1997;277(18):1445–1451.

Partin AW, Mangold LA, Lamm DM, et al. Contemporary update of prostate cancer staging nomograms (Partin tables) for the new millennium. *Urology*. 2001;58(6):843–848.

Patel VR, Palmer KJ, Coughlin G, et al. Robot-assisted laparoscopic radical prostatectomy: perioperative outcome of 1500 cases. *J Endourol*. 2008;22(10):2299–2305.

Petrovich Z, Lieskovsky G, Langholz B, et al. Comparison of outcomes of radical prostatectomy with and without adjuvant pelvic irradiation in patients with pathologic stage C (T3N0) adenocarcinoma of the prostate. *Am J Clin Oncol*. 1999;22:323–331.

Pettaway CA, Pisters LL, Troncoso P, et al. Neoadjuvant chemotherapy and hormonal therapy followed by radical prostatectomy: feasibility and preliminary results. *J Clin Oncol*. 2000;18(5):1050–1057.

Pierorazio PM, Ross AE, Schaeffer EM, et al. A contemporary analysis of outcomes of adenocarcinoma of the prostate with seminal vesicle invasion (pT3b) after radical prostatectomy. *J Urol*. 2011;185(5):1691–1697.

Pierorazio PM, Ross AE, Han M, et al. Evolution of the clinical presentation of men undergoing radical prostatectomy for high-risk prostate cancer. *BJU Int*. 2012;109(7):988–993.

Pierorazio PM, Mullins JK, Eifler JB, et al. Contemporaneous comparison of open vs minimally-invasive radical prostatectomy for high-risk prostate cancer. *BJU Int*. 2013;112(6):751–757.

Pilepich MV, Winter K, John MJ, et al. Phase III radiation therapy oncology group (RTOG) trial 86-10 of androgen deprivation adjuvant to definitive radiotherapy in locally advanced carcinoma of the prostate. *Int J Radiat Oncol Biol Phys*. 2001;50(5):1243–1252.

Pilepich MV, Winter K, Lawton C, et al. Phase III trial of androgen suppression adjuvant to definitive radiotherapy: long term results of RTOG study 85-31. *Proc Am Soc Clin Oncol*. 2003;22:381.

Pisansky TM, Hunt D, Gomella LG, et al. Duration of androgen suppression before radiotherapy for localized prostate cancer: radiation therapy oncology group randomized clinical trial 9910. *J Clin Oncol*. 2015;33(4):332–339.

Potters L, Morgenstern C, Calugaru E, et al. 12-year outcomes following permanent prostate brachytherapy in patients with clinically localized prostate cancer. *J Urol*. 2005;173(5):1562–1566.

Pound CR, Partin AW, Eisenberger MA, et al. Natural history of progression after PSA elevation following radical prostatectomy. *JAMA*. 1999;281(17):1591–1597.

Powell IJ, Tangen CM, Miller GJ, et al. Neoadjuvant therapy before radical prostatectomy for clinical T3/T4 carcinoma of the prostate: 5-year followup, Phase II Southwest Oncology Group Study 9109. *J Urol*. 2002;168(5):2016–2019.

Prayer-Galetti T, Zattoni F, Capizzi A, et al. Disease-free survival in patients with pathological C stage prostate cancer at radical prostatectomy submitted to adjuvant hormone treatment. *Eur Urol*. 2000;38:48.

Prepelica KL, Okeke Z, Murphy A, et al. Cryosurgical ablation of the prostate: high risk patient outcomes. *Cancer*. 2005;103(8):1625–1630.

Punnen S, Meng MV, Cooperberg MR, et al. How does robot-assisted radical prostatectomy (RARP) compare with open surgery in men with high-risk prostate cancer? *BJU Int*. 2013;112(4):E314–E320.

Quinn DI, Henshall SM, Haynes AM, et al. Prognostic significance of pathologic features in localized prostate cancer treated with radical prostatectomy: implications for staging systems and predictive models. *J Clin Oncol*. 2001;19(16):3692–3705.

Roach M 3rd, Lu J, Pilepich MV, et al. Predicting long-term survival, and the need for hormonal therapy: a meta-analysis of RTOG prostate cancer trials. *Int J Radiat Oncol Biol Phys*. 2000;47(3):617–627.

Roach M 3rd, DeSilvio M, Lawton C, et al. Phase III trial comparing whole-pelvic versus prostate-only radiotherapy and neoadjuvant versus adjuvant combined androgen suppression: Radiation Therapy Oncology Group 9413. *J Clin Oncol*. 2003;21(10):1904–1911.

Roach M 3rd, Bae K, Speight J, et al. Short-term neoadjuvant androgen deprivation therapy and external-beam radiotherapy for locally advanced prostate cancer: long-term results of RTOG 8610. *J Clin Oncol*. 2008;26(4):585–591.

Roehl KA, Han M, Ramos CG, et al. Cancer progression and survival rates following anatomical radical retropubic prostatectomy in 3,478 consecutive patients: long-term results. *J Urol*. 2004;172(3):910–914.

Rosenfeld B, Roth AJ, Gandhi S, et al. Differences in health-related quality of life of prostate cancer patients based on stage of cancer. *Psychooncology*. 2004;13(11):800–807.

Rosenthal SA, Hunt D, Sartor AO, et al. A phase 3 trial of 2 years of androgen suppression and radiation therapy with or without adjuvant chemotherapy for high-risk prostate cancer: final results of radiation therapy oncology group phase 3 randomized trial NRG oncology RTOG 9902. *Int J Radiat Oncol Biol Phys*. 2015;93(2):294–302.

Ryan CJ, Zelefsky MJ, Heller G, et al. Five-year outcomes after neoadjuvant chemotherapy and conformal radiotherapy in patients with high-risk localized prostate cancer. *Urology*. 2004;64(1):90–94.

Salo JO, Kivisaari L, Rannikko S, et al. Computerized tomography and transrectal ultrasound in the assessment of local extension of prostate cancer before radical retropubic prostatectomy. *J Urol*. 1987;137(3):435–438.

Sanguineti G, Agostinelli S, Foppiano F, et al. Adjuvant androgen deprivation impacts late rectal toxicity after conformal radiotherapy of prostate carcinoma. *Br J Cancer*. 2002;86(12):1843–1847.

Sato N, Akakura K, Isaka S, Chiba Prostate Study Group, et al.

Intermittent androgen suppression for locally advanced and metastatic prostate cancer: preliminary report of a prospective multicenter study. *Urology*. 2004;64(2):341–345.

Sauer M, Weinrich JM, Fraune C, et al. Accuracy of multiparametric MR imaging with PI-RADS V2 assessment in detecting infiltration of the neurovascular bundles prior to prostatectomy. *Eur J Radiol*. 2018;98:187–192.

Schild SE. Radiation therapy after prostatectomy: now or later? *Semin Radiat Oncol*. 1998;8(2):132–139.

Schild SE, Wong WW, Grado GL, et al. Radiotherapy for isolated increases in serum prostate-specific antigen levels after radical prostatectomy. *Mayo Clin Proc*. 1994;69(7):613–619.

Schulman CC, Debruyne FMJ, Forster G, et al. 4-year follow-up results of a European prospective randomized study on neoadjuvant hormonal therapy prior to radical prostatectomy in T2-3N0M0 prostate cancer. *Eur Urol*. 2000;38(6):706–713.

Schultheiss TE, Lee WR, Hunt MA, et al. Late GI and GU complications in the treatment of prostate cancer. *Int J Radiat Oncol Biol Phys*. 1997;37(1):3–11.

Scott WW. An evaluation of endocrine therapy plus radical prostatectomy in the treatment of advanced carcinoma of the prostate. *J Urol*. 1964;91:97–102.

Secin FP, Bianco FJ Jr, Vickers AJ, et al. Cancer-specific survival and predictors of prostate-specific antigen recurrence and survival in patients with seminal vesicle invasion after radical prostatectomy. *Cancer*. 2006;106(11):2369–2375.

Seiler R, Studer UE, Tschan K, et al. Removal of limited nodal disease in patients undergoing radical prostatectomy: long-term results confirm a chance for cure. *J Urol*. 2014;191(5):1280–1285.

Shariat SF, Karakiewicz PI, Roehrborn CG, et al. An updated catalog of prostate cancer predictive tools. *Cancer*. 2008;113(11):3075–3099.

Shepard DR, Dreicer R, Garcia J, et al. Phase II trial of neoadjuvant nab-paclitaxel in high risk patients with prostate cancer undergoing radical prostatectomy. *J Urol*. 2009;181(4):1672–1677.

Smith JA Jr, Scardino PT, Resnick MI, et al. Transrectal ultrasound versus digital rectal examination for the staging of carcinoma of the prostate: results of a prospective, multi-institutional trial. *J Urol*. 1997;157(3):902–906.

Soloway MS, Sharifi R, Wajsman Z, The Lupron Depot Neoadjuvant Prostate Cancer Study Group, et al. Randomized prospective study comparing radical prostatectomy alone versus radical prostatectomy preceded by androgen blockade in clinical stage B2 (T2bNxM0) prostate cancer. *J Urol*. 1995;154(2 Pt 1):424–428.

Soloway MS, Pareek K, Sharifi R, Lupron Depot Neoadjuvant Prostate Cancer Study Group, et al. Neoadjuvant androgen ablation before radical prostatectomy in cT2bNxM0 prostate cancer: 5-year results. *J Urol*. 2002;167(1):112–116.

Sooriakumaran P, Karnes J, Stief C, et al. A multi-institutional analysis of perioperative outcomes in 106 men who underwent radical prostatectomy for distant metastatic prostate cancer at presentation. *Eur Urol*. 2016;69(5):788–794.

Spratt DE, Zhang J, Santiago-Jiménez M, et al. Development and validation of a novel integrated clinical-genomic risk group classification for localized prostate cancer. *J Clin Oncol*. 2018;36(6):581–590.

Sreekumar A, Poisson LM, Rajendiran TM, et al. Metabolomic profiles delineate potential role for sarcosine in prostate cancer progression. *Nature*. 2009;457(7231):910–914.

Stamey TA, Donaldson AN, Yemoto CE, et al. Histological and clinical findings in 896 consecutive prostates treated only with radical retropubic prostatectomy: epidemiologic significance of annual changes. *J Urol*. 1998;160(6 Pt 2):2412–2417.

Stein A, deKernion JB, Dorey F, et al. Adjuvant radiotherapy in patients post radical prostatectomy with tumor extending through capsule or positive seminal vesicles. *Urology*. 1992;39:59–62.

Stephenson AJ, Shariat SF, Zelefsky MJ, et al. Salvage radiotherapy for recurrent prostate cancer after radical prostatectomy. *JAMA*. 2004;291(11):1325–1332.

Stock RG, Cahlon O, Cesaretti JA, et al. Combined modality treatment in the management of high-risk prostate cancer. *Int J Radiat Oncol Biol Phys*. 2004;59(5):1352–1359.

Studer UE, Hauri D, Handelmann S, et al. Immediate versus deferred hormonal treatment for patients with prostate cancer who are not suitable for curative local treatment: results of the randomized trial SAKK 08/88. *J Clin Oncol*. 2004;22(20):4109–4118.

Sujenthiran A, Nossiter J, Charman S, et al. Current national trends in the management of locally advanced prostate cancer with radical therapies: results from the English national prostate cancer audit. *Eur Urol*. 2017;16:e1330.

Sumitomo M, Hayashi M, Watanabe T, et al. Efficacy of short-term androgen deprivation with high-intensity focused ultrasound in the treatment of prostate cancer in Japan. *Urology*. 2008;72(6):1335–1340.

Swanson GP, Hussey MA, Tangen CM, et al. Predominant treatment failure in postprostatectomy patients is local: analysis of patterns of treatment failure in SWOG 8794. *J Clin Oncol*. 2007;25(16):2225–2229.

Sylvester JE, Blasko JC, Grimm PD, et al. Ten-year biochemical relapse-free survival after external beam radiation and brachytherapy for localized prostate cancer: the Seattle experience. *Int J Radiat Oncol Biol Phys*. 2003;57(4):944–952.

Tannock IF, Osoba D, Stockley MR, et al. Chemotherapy with mitoxantrone plus prednisone or prednisone alone for symptomatic hormone-resistant prostate cancer: a Canadian randomized trial with palliative end point. *J Clin Oncol*. 1996;14(6):1756–1764.

Tewari A, Issa M, El-Galley R, et al. Genetic adaptive neural network to predict biochemical failure after radical prostatectomy: a multi-institutional study. *Mol Urol*. 2001;5(4):163–169.

Thompson IM Jr, Tangen CM, Paradelo J, et al. Adjuvant radiotherapy for locally advanced prostate cancer: results of a randomized, prospective clinical trial. *JAMA*. 2006;296(19):2329–2335.

Thompson I, Tangen CM, Paradelo J, et al. Adjuvant radiotherapy for pathological T3N0M0 prostate cancer significantly reduces risk of metastases and improves survival: long-term followup of a randomized clinical trial. *J Urol*. 2009;181(3):956–962.

Tomlinson RL, Currie DP, Boyce WH. Radical prostatectomy: palliation for stage C carcinoma of the prostate. *J Urol*. 1977;117(1):85–87.

Touijer KA, Mazzola CR, Sjoberg DD, et al. Long-term outcome of patients with lymph node metastasis treated with radical prostatectomy without adjuvant androgen deprivation therapy. *Eur Urol*. 2014;65(1):20–25.

Touijer KA, Karnes RJ, Passoni N, et al. Survival outcomes of men with lymph node-positive prostate cancer after radical prostatectomy: a comparative analysis of different postoperative management strategies. *Eur Urol*. 2018;73(6):890–896.

Trock BJ, Han M, Freedland SJ, et al. Prostate cancer–specific survival following salvage radiotherapy vs observation in men with biochemical recurrence after radical prostatectomy. *JAMA*. 2008;299(23):2760–2769.

Vailancourt L, Ttu B, Fradet Y, et al. Effect of neoadjuvant endocrine therapy (combined androgen blockade) on normal prostate and prostatic carcinoma. A randomized study. *Am J Surg Pathol*. 1996;20(1):86–93.

Valicenti RK, Gomella LG, Ismail M, et al. Durable efficacy of early postoperative radiation therapy for high-risk pT3N0 prostate cancer: the importance of radiation dose. *Urology*. 1998;52(6):1034–1040.

Valicenti RK, Gomella LG, Ismail M, et al. Pathologic seminal vesicle invasion after radical prostatectomy for patients with prostate carcinoma: effect of early adjuvant radiation therapy on biochemical control. *Cancer*. 1998;82(10):1909–1914.

Valicenti RK, Gomella LG, Ismail M, et al. The efficacy of early adjuvant radiation therapy for pT3N0 prostate cancer: a matched-pair analysis. *Int J Radiat Oncol Biol Phys*. 1999;45(1):53–58.

Vallet BB. Radical perineal prostatectomy subsequent to bilateral orchiectomy. *Del Med J*. 1944;16:19–20.

van den Ouden D, Davidson PJ, Hop W, et al. Radical prostatectomy as a monotherapy for locally advanced (T3) prostate cancer. *J Urol*. 1994;151(3):646–651.

van den Ouden D, Hop WC, Schroder FH. Progression in and survival of patients with locally advanced prostate cancer (T3) treated with radical prostatectomy as monotherapy. *J Urol*. 1998;160(4):1392–1397.

Van der Kwast TH, Bolla M, Van Poppel H, et al. Identification of patients with prostate cancer who benefit from immediate postoperative radiotherapy: EORTC 22911. *J Clin Oncol*. 2007;25(27):4178–4186.

van Leeuwen PJ, Emmett L, Ho B, et al. Prospective evaluation of 68Gallium-prostate-specific membrane antigen positron emission tomography/computed tomography for preoperative lymph node staging in prostate cancer. *BJU Int*. 2017;119(2):209–215.

Van Poppel H, De Ridder D, Elgamal AA, et al. Neoadjuvant hormonal therapy before radical prostatectomy decreases the number of positive margins in stage T2 prostate cancer: interim results of a prospective randomized trial. *J Urol*. 1995;154(2 Pt 1):429–434.

Vuky J, Porter C, Isacson C, et al. Phase II trial of neoadjuvant docetaxel and gefitinib followed by radical prostatectomy in patients with high-risk, locally advanced prostate cancer. *Cancer*. 2009;115(4):784–791.

Ward JF, Zincke H. Radical prostatectomy for the patient with locally advanced prostate cancer. *Curr Urol Rep*. 2003;4(3):196–204.

Ward JF, Slezak JM, Blute ML, et al. Radical prostatectomy for clinically advanced (cT3) prostate cancer since the advent of prostate-specific antigen testing: 15-year outcome. *BJU Int*. 2005;95(6):751–756.

Warde P, Mason M, Ding K, et al. Combined androgen deprivation therapy and radiation therapy for locally advanced prostate cancer: a randomised, phase 3 trial. *Lancet*. 2011;378(9809):2104–2111.

Widmark A, Klepp O, Solberg A, et al. Endocrine treatment, with or without radiotherapy, in locally advanced prostate cancer (SPCG-7/SFUO-3): an open randomised phase III trial. *Lancet*. 2009;373(9660):301–308.

Wiegel T, Bottke D, Steiner U, et al. Phase III postoperative adjuvant radiotherapy after radical prostatectomy compared with radical prostatectomy alone in pT3 prostate cancer with postoperative undetectable prostate-specific antigen: ARO

96-02/AUO AP 09/95. *J Clin Oncol*. 2009;27(18):2924–2930.

Wiegel T, Bartkowiak D, Bottke D, et al. Adjuvant radiotherapy versus wait-and-see after radical prostatectomy: 10-year follow-up of the ARO 96-02/AUO AP 09/95 trial. *Eur Urol*. 2014;66(2):243–250.

Williams SB, Davis JW, Wang X, et al. Neoadjuvant systemic therapy before radical prostatectomy in high-risk prostate cancer does not increase surgical morbidity: contemporary results using the Clavien system. *Clin Genitourin Cancer*. 2016;14(2):130–138.

Wirth MP, See WA, McLed DG, et al. Bicalutamide 150 mg in addition to standard care in patients with localized or locally advanced prostate cancer: results from the second analysis of the Early Prostate Cancer program at median followup of 5.4 years. *J Urol*. 2004;172(5 Pt 1):1865–1870.

Wirth MP, Weissbach L, Marx FJ, et al. Prospective randomized trial comparing flutamide as adjuvant treatment versus observation after radical prostatectomy for locally advanced, lymph-node negative prostate cancer. *Eur Urol*. 2004;45(3):267–270.

Witjes WP, Schulman CC, Debruyne FM, The European Study Group on Neoadjuvant Treatment of Prostate Cancer. Preliminary results of a prospective randomized study comparing radical prostatectomy versus radical prostatectomy associated with neoadjuvant hormonal combination therapy in T2-3 N0M0 prostatic carcinoma. *Urology*. 1997;49(3A Suppl):65–69.

Wu AK, Cooperberg MR, Sadetsky N, et al. Health related quality of life in patients treated with multimodal therapy for prostate cancer. *J Urol*. 2008;180(6):2415–2422.

Xylinas E, Drouin SJ, Comperat E, et al. Oncological control after radical prostatectomy in men with clinical T3 prostate cancer: a single-centre experience. *BJU Int*. 2009;103(9):1173–1178.

Zapatero A, Guerrero A, Maldonado X, et al. High-dose radiotherapy with short-term or long-term androgen deprivation in localised prostate cancer (DART01/05 GICOR): a randomised, controlled, phase 3 trial. *Lancet Oncol*. 2015;16(3):320–327.

Zelefsky MJ, Cowen D, Fuks Z, et al. Long term tolerance of high dose three-dimensional conformal radiotherapy in patients with localized prostate cancer. *Cancer*. 1999;85(11):2460–2468.

Zelefsky MJ, Kelly WK, Scher HI, et al. Results of a phase II study using estramustine phosphate and vinblastine in combination with high-dose three-dimensional conformal radiotherapy for patients with locally advanced prostate cancer. *J Clin Oncol*. 2000;18(9):1936–1941.

Zelefsky MJ, Eastham JA, Cronin AM, et al. Metastasis after radical prostatectomy or external beam radiotherapy for patients with clinically localized prostate cancer: a comparison of clinical cohorts adjusted for case mix. *J Clin Oncol*. 2010;28(9):1508–1513.

Zelefsky MJ, Pei X, Choud JF, et al. Dose escalation for prostate cancer radiotherapy: predictors of long-term biochemical tumor control and distant metastases-free survival outcomes. *Eur Urol*. 2011;60(6):1133–1139.

Zhao SG, Chang SL, Spratt DE, et al. Development and validation of a 24-gene predictor of response to postoperative radiotherapy in prostate cancer: a matched, retrospective analysis. *Lancet Oncol*. 2016;17(11):1612–1620.

Zincke H, Lau W, Bergstralh E, et al. Role of early adjuvant hormonal therapy after radical prostatectomy for prostate cancer. *J Urol*. 2001;166(6):2208–2215.

Management Strategies for Biochemical Recurrence of Prostate Cancer

---

Eugene K. Lee MD, J. Brantley Thrasher MD, FACS

Radical Prostatectomy

Definition of Biochemical Recurrence After Radical Prostatectomy

Radical prostatectomy is one of the most common treatment modalities for localized prostate cancer, and despite advances in surgical technique and careful patient selection, approximately 25% to 41% of men will develop prostate-specific antigen (PSA) recurrence 10 years after surgery (Amling et al., 2000; Hull et al., 2002; Roehl et al., 2004). Additionally, since the U.S. Preventive Services Task Force grade D recommendation for PSA screening in 2012 (grade C on 2017 updated draft), there has been a decrease in overall screening and a "reverse" stage migration for more aggressive disease (Fleshner et al., 2017). When evaluating men with high-risk prostate cancer, the risk for PSA recurrence can be as high as 60% at 5 years (Beauval et al., 2016).

It is clear that not all men with a detectable PSA after surgery are destined to clinical progression defined as development of metastatic disease, need for second-line treatment, or death from prostate cancer. In fact, some men will have a detectable PSA postprostatectomy that plateaus and does not subsequently rise. In fact, Spahn et al. (2017) recently reported in their cohort of 622 patients with intermediate- and high-risk disease that only 52% went on to have clinical failure (14% local recurrence only, 9% lymph node metastasis, 24% distant metastasis) at a median time of 9.9 years, 4.9 years, and 5.6 years, respectively.

Several hypotheses exist as to why detectable PSAs do not always translate to clinically relevant disease. First, benign disease remains in the prostatic bed (often the rationale for detectable PSA after radiation therapy). Second, PSA is produced at low levels by cells of nonprostatic origin (Diamandis and Yu, 1995). Third, PSA elevation is a result of residual low-grade prostate cancer destined to follow an indolent course (Amling et al., 2001).

In the prostate cancer literature, specifically after radical prostatectomy, there are greater than 50 separate definitions of biochemical recurrence (Cookson et al., 2007; Moul et al., 1996; Zincke et al., 1994). A standard definition of PSA recurrence is necessary to accurately predict for progression to clinically meaningful end points. This must be tempered by the need for this same definition to identify patients at low enough PSA levels (disease burden) to intervene with second-line therapies at a point in the disease course that will prevent further risk for advanced prostate cancer.

Stephenson et al. (2006a) reviewed the Memorial Sloan Kettering experience of 3125 patients who underwent radical prostatectomy. Using a goodness-of-fit (R^2) statistic, they examined 10 candidate definitions and determined that a PSA of at least 0.4 ng/mL followed by subsequent increase was the best fit for metastatic progression, high predictability for secondary therapy, further PSA progression, and rapid doubling time. Furthermore, Amling et al. (2001) also determined significance in using a definition of PSA 0.4 ng/mL or greater. Lost in a "standard" definition of PSA recurrence is clinical progression risk and how it relates to different definitions of failure. For example, a PSA of 0.1 ng/mL may mean a different clinical outcome in a patient who had a radical prostatectomy 8 years prior with pathologic Gleason 6 disease versus a patient who had surgery 6 months prior for high-volume Gleason 9 prostate cancer with T3b disease. Mir et al. (2014) addressed this issue by examining 14 definitions of biochemical recurrence and how they relate to the probability of subsequent rise in PSA, usage of secondary treatment, or clinical progression. In the entire cohort, a single detectable PSA, even at low levels (≤0.1 ng/mL), was associated with a subsequent rise in 30% to 55% of patients. In patients with high-risk features, a detectable PSA was associated with a PSA progression probability of 73% to 88% compared with only 18% to 25% in patients with low-risk features. The optimal definition for patients with a 5-year progression-free probability of less than 50% (high-risk patients) was a single PSA greater than or equal to 0.05 ng/mL, and the ideal cut point in those with a progression-free probability greater than 90% (low-risk patients) was a PSA greater than or equal to 0.4 ng/mL. These data can assist clinicians in counseling patients on the need for appropriate salvage therapies while sparing those at low risk for ever developing metastasis (Morgan et al., 2014).

Because of the wide variation in definition of biochemical recurrence, the American Urological Association (AUA) Guidelines Panel for Localized Prostate Cancer released their recommendations for reporting PSA recurrence in 2007. Their goals in a unifying definition was to determine an early marker of treatment failure in advance of clinical progression, use a low enough value to allow for patients to be candidates for early salvage therapy, and for a standard definition to be used as comparisons among different patient series. **The AUA Guidelines Panel ultimately defined PSA recurrence as a value of greater than or equal to 0.2 ng/mL with a second confirmatory laboratory value** (Cookson et al., 2007). This has also been adopted by the European Guidelines on Prostate Cancer (Cornford et al., 2017).

The Prediction of Biochemical Recurrence Postprostatectomy

It is clear that all clinically relevant recurrences are predicted by a rise in PSA, and identifying patients who will have biochemical recurrence is important in terms of counseling, identifying patients needing secondary therapy, and potentially treating with neoadjuvant treatments on clinical trials. Using data from large operative series in men with prostate cancer, it has become clear that clinical factors can be used to predict for biochemical failure. Roehl et al. (2004) determined that the most important factors for predicting biochemical recurrence were pretreatment PSA, clinical stage, Gleason sum, pathologic stage, and era in which the radical prostatectomy was performed. Others have confirmed the importance of Gleason score, clinical stage, PSA before surgery, and pathologic stage as the most significant covariates for predicting biochemical recurrence (Han et al., 2003).

Achieving negative surgical margins is critical, as this is an important predictor of biochemical failure (Stephenson et al., 2005). Compared with a negative margin, men with positive margins in pT2 prostate cancer had a 12% increased risk for biochemical recurrence, and in pT3a and pT3b, the increased risk was 12% and 18%, respectively (Budaus et al., 2010). In fact, in this cohort of patients, those with pT3a and negative margins had a lower risk for biochemical recurrence than patients with pT2 cancer and positive margins (Budaus et al., 2010). The length of positive margin has also been predictive of biochemical recurrence, as those with margins greater than 1 mm have a statistically significant increased risk for biochemical failure (Shikanov et al., 2009). Others have found that multiple positive margins and location of margin may be significant (Sofer et al., 2002; Stephenson et al., 2005). Recently, it has been shown that a Gleason score greater than or equal to 4 at the location of positive margin was predictive of biochemical failure (Chapin et al., 2018). Taken together, these data emphasize the importance of meticulous surgical dissection.

In the age of evidence-based medicine and data-driven decisions, it is critical to utilize as much objective information as possible. Using the parameters of clinical stage, serum PSA, Gleason score, and systematic biopsy results, Stephenson et al. (2006b) created a prognostic tool with a concordance index of

0.76 to 0.79 for predicting disease progression defined as serum PSA value of 0.4 ng/mL or greater and confirmed with a higher value, secondary therapy, clinical recurrence, or positive lymph nodes on frozen section during radical prostatectomy. Postoperatively, a similar tool using PSA, Gleason score, presence of extracapsular extension, seminal vesicle invasion, lymph node involvement, margin status, and adjuvant radiation can predict 10-year biochemical recurrence survival with a concordance index of 0.79 to 0.81 (Stephenson et al., 2006b). One important modification of this tool is that it calculates the 10-year progression-free probability based on the current disease-free interval already achieved. Nomograms have become popularized and are easily accessible and frequently used in patient counseling. The most commonly used prostate cancer nomograms accessible on-line are demonstrated in Table 160.1.

TABLE 160.1

Online Risk Stratification Nomograms for Prostate Cancer

CLINICAL STATE	TITLE	WEBSITE	VARI
Risk for prostate cancer	Prostate Cancer Prevention Trial Prostate Cancer Risk Calculator	https://prostatecancerinfolink.net/risk-prevention/pcpt-prostate-cancer-risk-calculator/	Race, a PSA le family digital exami prior p biopsy
Pretreatment	Memorial Sloan Kettering Pretreatment Nomogram	https://www.mskcc.org/nomograms/prostate/pre_op	Pretrea PSA le age, bi Gleaso clinica numbe positiv biopsi
	Partin tables	https://www.hopkinsmedicine.org/brady-urology-institute/specialties/conditions-and-treatments/prostate-cancer/fighting-prostate-cancer/partin-table.html	PSA le biopsy Gleaso clinica
	UCSF CAPRA	https://urology.ucsf.edu/research/cancer/prostate-cancer-risk-assessment-and-the-ucsf-capra-score	Age, P level,

	score		Gleaso clinica percen biopsy positiv
Post-treatment	Memorial Sloan Kettering Post-treatment Nomogram	https://www.mskcc.org/nomograms/prostate/post_op	Pretrea PSA le age, patholo Gleaso era of prostat months cancer, status, extraca extensi semina vesicle involve lymph involve hormo therapy radiatio therapy

PSA, Prostate-specific antigen (test); *UCSF CAPRA,* University of California, San Francisco Cancer of the Prostate Risk Assessment.

Recently, magnetic resonance imaging (MRI) has become increasingly utilized in the diagnosis and treatment planning of patients with prostate cancer. Tan et al. (2018) reported that MRI tumor volume, Gleason score, stage, and margin status were all significant predictors of biochemical recurrence. Additionally, prostate health index (PHI) derived from total PSA, free PSA, and [–2] proPSA has been demonstrated to predict for biochemical recurrence in men undergoing radical prostatectomy (Maxeiner et al., 2017). Other groups have identified nonpathologic factors including ethnicity and obesity as predictors of biochemical recurrence after radical prostatectomy, and others continue to look at genetic and molecular markers of disease such as miRNA and genetic risk scores (Grossfeld et al., 2003; Maj-Hes et al., 2017; Oh et al., 2017; Pashaei et al., 2017). Clearly, the utilization of noninvasive and nonpathologic markers of biochemical failure is important as we move forward with improving patient counseling and decision making for treatment.

Natural History of Biochemical Recurrence Postprostatectomy

Recurrence of PSA normally precedes clinically meaningful events in an extremely protracted and variable manner. In the seminal article describing the natural history of biochemical recurrence after radical prostatectomy, Pound et al. determined that the median actuarial time from biochemical recurrence to metastasis was 8 years (Pound et al., 1999). Furthermore, the median actuarial time to death was 5 years, although this was dependent on the time from biochemical recurrence to metastasis, as patients who developed metastatic disease early had decreased median survival (Pound et al., 1999). In their initial analysis, they determined that the risk for metastasis was dependent on time to biochemical recurrence, Gleason score, and PSA doubling time. In a recent update, metastasis-free survival was 10 years, potentially reflecting improvements in patient selection and management (Antonarakis et al., 2012).

The majority of men who experience biochemical recurrence after radical prostatectomy will not succumb to disease. In fact, even in patients with documented intermediate and high-risk prostate cancer, approximately 50% of patients will not have clinical failure after a median follow-up of 9.4 years. Of the patients with clinical failure, the 5-year disease-specific survival is 90% with local recurrence only, 70% with lymph node disease, and 47% with metastases (Spahn et al., 2017). Risk factors for aggressive progression to clinically relevant disease and death are extremely important for patient counseling, clinical trials, and for early implementation of salvage therapies. Using an established nomogram for prostate cancer recurrence (Kattan et al., 1998), Stephenson et al. (2009) demonstrated that 15-year disease-specific mortality was 5% in the most favorable quartile of PSA recurrence, and patients in the least favorable 5-year PSA progression-free probability quartile had a 15-year disease-specific mortality of 38%. Further, it is important to note that evaluation of PSA after prostatectomy should occur indefinitely as up to 27% of men will recur after 5 years, and these patients are still at risk for clinical progression (Ward et al., 2003).

Ultrasensitive Prostate-Specific Antigen

Traditionally, the lower limits of PSA detection have been in the range of less than 0.1 and 0.2 ng/mL. In the early 1990s, ultrasensitive PSA (uPSA) testing was first introduced and has brought about increased sensitivity but also controversy. It is thought that early second-line treatment in patients destined for clinical failure portends improved survival. However, this is tempered by the risk for overtreating those patients who may never experience clinical failure despite continuous detectable values of extremely low PSA. Hong et al. (2010) demonstrated the utility of the uPSA in predicting biochemical recurrence defined as two consecutive rises in PSA of 0.2 ng/mL or greater. On multivariable analysis, they found that an undetectable uPSA along with preoperative PSA level, pathologic stage, and pathologic Gleason score were all significant predictors of biochemical failure (Hong et al., 2010). Patients with a nadir PSA less than 0.001 had a 3-year biochemical recurrence-free survival of 95.5% compared with 41.5% for those with a nadir PSA greater than or equal to 0.05 (Hong et al., 2010). These findings were confirmed by Shen et al. (2005), who determined PSA relapse (two consecutive PSA ≥0.1 ng/mL) in those with a PSA nadir less than 0.01 was 4% compared with 89% for those with nadir of 0.04 or greater.

Ultrasensitive PSA has demonstrated clinical utility in several scenarios. For instance, patients with undetectable uPSA at 2 years have been found to be unlikely to develop PSA doubling time less than 9 months (defined as a high-risk recurrence) after biochemical failure (Chang et al., 2010). In fact, for every month without a detectable uPSA, the odds of high-risk recurrence were decreased by 4% (Chang et al., 2010). Furthermore, uPSA value at 3 years after radical prostatectomy is also predictive of eventual biochemical failure as patients with a PSA between 0.04 and 0.1 have a 10.8 times greater likelihood of developing eventual biochemical recurrence compared with those with a PSA less than or equal to 0.04 (Malik et al., 2011). This is clinically relevant as patients who are free of disease at the 3-year mark can be counseled about their low-probability of ever developing clinically relevant recurrence, which may ease some anxiety. Even after controlling for risk factors, ultrasensitive PSA nadir seems to be effective in predicting biochemical recurrence. Patients with pathologic T3 prostate cancer with undetectable ultrasensitive PSA have a 5-year biochemical recurrence–free survival of 78% compared with 40% for those who have a detectable ultrasensitive PSA (Eisenberg et al., 2010). Interestingly, in patients with low-risk disease, the difference between patients with undetectable versus detectable ultrasensitive PSA was only 91% versus 89%, respectively, arguing that perhaps the significance of testing may lie in patients with intermediate- and high-risk cancer (Eisenberg et al., 2010).

Recently, the group from Johns Hopkins evaluated banked serum samples using an ultrasensitive PSA assay in men who underwent radical prostatectomy and had undetectable traditional PSA with a cutoff of 0.1 ng/mL. They identified a significant cutoff using a threshold uPSA of 0.01, whereas those with levels below 0.01 had a median biochemical recurrence–free survival of 15.2 years versus 10 years for those with a uPSA of 0.01 or greater (Skove et al., 2017). Similarly, Freedland et al. recently published their results from the SEARCH database identifying that nadir uPSA 1 to 6 months after radical prostatectomy was predictive of eventual biochemical failure. Interestingly, 53% of patients with detectable uPSA at 1 to 3 months had lower values on repeated testing at 3 to 6 months (Skove et al., 2017).

Imaging in Patients With Biochemical Recurrence After Radical Prostatectomy

Patients who experience biochemical recurrence after definitive radical prostatectomy are at risk for both local recurrence and/or distant failure. Identifying patients with local failure only is critical to initiate salvage therapies while sparing those with distant metastatic disease the burden of local salvage therapy. Traditionally, imaging techniques have been limited in the diagnosis of recurrence when PSA levels have been low. For instance, the routine usage of bone scans in patients with PSA levels less than 10 ng/mL is of limited value as only 4% will demonstrate a positive scan (Dotan et al., 2005). Similarly, traditional computed tomography (CT) is also unlikely to be positive in patients with PSA levels less than 10 ng/mL (Okotie et al., 2004). Conversely, transrectal ultrasonography (TRUS) has demonstrated reasonable sensitivity at low PSA levels, especially with masses at the vesicourethral anastomosis. Scattoni et al. (2003) demonstrated that TRUS followed by biopsy was positive in 45% of patients with a PSA less than or equal to 0.5 ng/mL and had 100% sensitivity in patients with a PSA greater than or equal to 2.0 ng/mL. Clearly, the ability to identify the sites of recurrences at low levels of PSA are necessary for planning of secondary treatments.

Indium In 111 capromab pendetide scanning (ProstaScint; Cytogen, Princeton, NJ) incorporates an immunoglobulin G monoclonal antibody that binds to prostate-specific membrane antigen (PSMA). Its usage in patients with biochemical recurrence has been limited as sensitivities and specificities are approximately 60% to 70% (Apolo et al., 2008). Further limiting the clinical adoption of ProstaScint is that the monoclonal antibody has been found to bind to intracellular domains only exposed at apoptosis or necrosis (Troyer et al., 1997). Newer modalities including ^{68}Ga-PSMA positron emission tomography/computed tomography (PET/CT) have shown promise, as the level of detection seems to be lower than in other modalities. Detection rates as high as 65% (for PSA value 0.2 to <0.5 ng/mL), 85.7% (for 0.5 to <1), 85.7% (for 1 to <2), and 100% (for ≥2) have been demonstrated in patients with biochemical recurrence after radical prostatectomy (Grubmüller et al., 2018). Further, in a study of 129 patients with primary prostate cancer, PSA relapse, and persistent disease after prostatectomy, the detection rate was 33.3% at a PSA less than or equal to 0.2 ng/mL, 41.2% at a PSA of 0.21 to 0.5 ng/mL, and 69.2% at a PSA of 0.51 to 1.0 ng/mL. The authors conclude that its ability to identify both presence and location of recurrence can assist in decision making, both with primary and salvage radiation (Schmidt-Hegemann et al., 2017).

Although the usage of ^{18}F-fluoro-2-deoxy-D-glucose (FDG) has been limited by low sensitivity secondary to modest glucose consumption in prostate cancer cells, similar uptake in benign tissue or postoperative scar, and high urinary excretion limiting anatomic delineation, radiotracers such as acetate, choline, and fluorocholine have demonstrated promise (Martino et al., 2011). In fact, the U.S. Food and Drug Administration (FDA) recently approved choline PET for the detection of prostate cancer recurrence, which has demonstrated improvement over FDG PET scans (Picchio et al., 2003). Two radiotracers for choline have been studied with similar results; however, ^{11}C-choline has the advantage of low urinary excretion and quality pelvic imaging. Conversely, ^{18}F-choline demonstrates higher urinary excretion but has a longer half-life, which makes it suitable for centers without a cyclotron (Picchio et al., 2011). The validity of choline PET has been seen at PSA levels less than 2.5 ng/mL as up to 90% of patients will demonstrate positive scans with a specificity of 50% (Rinnab et al., 2007). Similarly, approximately 50% of patients with PSA less than 5.0 ng/mL were found to have a positive focus using ^{18}F-fluorocholine PET/CT. One study has shown the sensitivity and specificity of choline PET to be as high as 98% and 99%, respectively, for bone metastasis (Kitajima et al., 2017). Unfortunately, PET scan with choline may be limited in patients with very low levels of PSA recurrence as only one-half will be positive in patients with PSA less than 1.0 ng/mL (Vees et al., 2007). Another study demonstrated positive scans in only 5% of patients with PSA less than 1.0 ng/mL and 15% of patients with PSA 1.0 to 2.0 ng/mL (Giovacchini et al., 2010). More recently, in 50 patients with biochemical recurrence after prostatectomy or radiation therapy, at PSA levels below 1 ng/mL, 21 (42%) were found to have abnormal ^{11}C-choline PET/CT scans. Tumor recurrence was confirmed in 7/21. In the 29 patients without evidence of positive ^{11}C-choline PET/CT, 2 patients were documented to have a recurrence at 30 months (Gómez-de la Fuente et al., 2018). Contributing to the lack of specificity for choline PET scan may be the findings of uptake in other physiologic conditions including inflammation, as evidenced in a large Italian study of 1000 prostate cancer patients who underwent PET/CT with ^{18}F-choline (Calabria et al., 2017). Current usage of choline PET scan in prostate cancer recurrence is limited.

^{11}C-acetate PET scans are another modality that is gaining favor in the evaluation of recurrent PSA after radical prostatectomy, with a sensitivity as high as 75% in 20 men with a median PSA level of 2.0 ng/mL (Sandblom et al., 2006). Almeida et al. (2012) found an 85% overall detection rate of recurrent or metastatic disease using ^{11}C-acetate PET/CT. Patients with PSA values of 0.4 to 1.0 ng/mL had a detection rate of 73%, and patients with PSA greater than 2.0 ng/mL had a detection rate of 93%. In an update of their series, the authors found positive ^{11}C-acetate PET/CT scans in 637/721 (88%) of patients with biochemical recurrence after radical prostatectomy or radiotherapy. They determined the ideal cut point PSA of 1.09 ng/mL where sensitivity of the scan reached 80% (Fig. 160.1). Additionally, using a PSA doubling time less than 3.8 months, the sensitivity was 85% for a positive scan (Almeida et al., 2017). However, Esch et al. (2017) report the limited utility at low levels of PSA value to be a barrier for usage and question its value in guiding local treatment. More recently, ^{18}F-NaF PET/CT has shown improved sensitivity over traditional bone scans for identifying bone metastasis, and further studies will define its role in usage in the setting of biochemical recurrence (Beheshti et al., 2016).

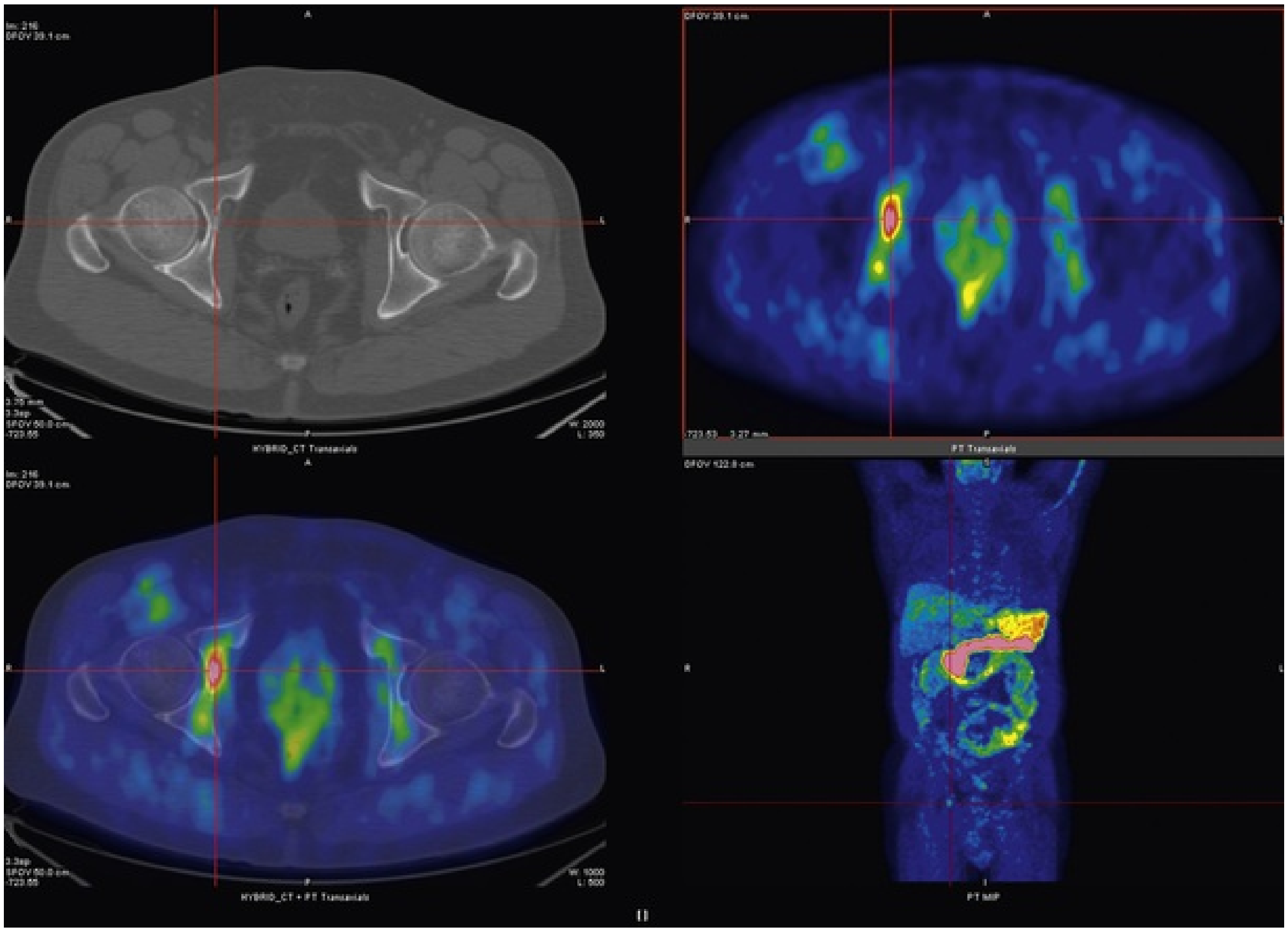

FIG. 160.1 ^{11}C-acetate positron emission tomography scan in biochemical recurrence.

In the evaluation of newer modalities of imaging, tissue correlation with positive scans should be considered the gold standard. When examining ^{68}Ga-PSMA PET/CT, there are very few studies that use histology as the standard reference. In one such study of 42 patients, the authors took a lesional approach to evaluation and demonstrated a sensitivity of 76.6%, specificity of 100%, positive predictive value of 100%, and negative predictive value of 91.4% (Afshar-Oromieh et al., 2015). Similarly, when using tissue or strict clinical definition of recurrence, the detection rate on a recently performed meta-analysis was 62% for choline PET/CT (Fanti et al., 2016). Although historical studies of ^{11}C-acetate PET scans demonstrate positive correlation as low as 40%, more recent reports demonstrate positive predictive values as high as 91% using tissue confirmation (Almeida et al., 2017; Esch et al., 2017; Sandblom et al., 2006). Clearly, further studies utilizing tissue as the reference standard are necessary to help define the usage of PET/CT in patients with recurrent prostate cancer. **PET/CT has demonstrated promise in the detection of prostate cancer recurrence; however, its cost and variable clinical utility at extremely low**

PSA levels currently limit its widespread usage.

MRI can be used in the detection of local recurrence after biochemical failure. Sella et al. (2004) analyzed endorectal MRI in 48 patients with biochemical failure after radical prostatectomy and found a sensitivity and specificity of 95% and 100%, respectively. Lesions were isointense to muscle on T1-weighted images and slightly hyperintense to muscle on T2-weighted images. The mean PSA before imaging was 2.18 ng/mL but included 25 patients (64%) with PSA less than 1.5 ng/mL. The addition of dynamic contrast enhancement (DCE) has demonstrated an increase in accuracy over standard MRI with a sensitivity of 88%, specificity of 100%, positive predictive value of 100%, and negative predictive value of 88%. This was despite lower PSA values (mean 1.9 ng/mL) (Casciani et al., 2008). Furthermore, the combination of DCE and magnetic resonance spectroscopic imaging (MRSI) has demonstrated sensitivities as high as 86% in patients with PSAs in the 0.4 to 1.4 ng/mL range (Sciarra et al., 2008). **Compared with PET/CT, multiparametric magnetic resonance imaging (mpMRI) performs better in identification of local recurrence, especially at low levels of biochemical failure** (Panebianco et al., 2012).

Salvage Radiation Therapy

The state of a persistent or rising PSA after radical prostatectomy is challenging for patients and clinicians alike. Despite surgical management in patients with clinically localized prostate cancer, up to 40% of men will continue to harbor or develop a detectable PSA (Amling et al., 2000; Han et al., 2001; Hull et al., 2002; Roehl et al., 2004; Ward and Moul, 2005). Current limitations in imaging modalities to identify local versus metastatic disease, especially at low levels of PSA, create a treatment dilemma for clinicians. Despite being a noncurative treatment for a rising PSA after radical prostatectomy, approximately 60% of patients will undergo androgen deprivation therapy (ADT) as second-line treatment (Agarwal et al., 2008). **Salvage radiation therapy remains the clearest choice and best chance for long-term freedom from progression in men with PSA recurrence after radical prostatectomy.**

In 2004, a large multi-institutional group published the results of salvage radiation therapy in 501 patients who had a detectable or rising PSA after radical prostatectomy (Stephenson et al., 2004). Four-year freedom from progression was 45% despite including a significant portion of patients with high-risk features thought to predict for metastatic disease (high-grade disease and rapid

PSA doubling time) (Stephenson et al., 2004). On multivariable analysis, Gleason grade, pretreatment PSA, margin status, PSA doubling time, and seminal vesicle invasion were independent predictors of durable response (Stephenson et al., 2004). Other groups have demonstrated similar 5-year biochemical recurrence–free survival in 35% to 46% of patients treated with salvage radiation (Bastide et al., 2010 Buskirk et al., 2006; Geinitz et al., 2012;). Boorjian et al. (2009) demonstrated in their series of 856 men who received salvage radiation therapy that 534 (63.6%) achieved an undetectable PSA after therapy. On multivariable analysis, patients who received salvage radiation were at a 90% decreased risk for local recurrence, a 20% decreased risk for late administration of ADT, and a 75% decreased risk for systemic progression (Boorjian et al., 2009).

Although several groups have demonstrated the value of salvage radiation therapy in improving biochemical endpoints, Trock et al. (2008) reported that salvage radiotherapy, compared with observation, also improved disease-specific survival. They found a three-fold increase in disease-specific survival with salvage radiation compared with observation. This was identified in patients who received therapy within 2 years of biochemical recurrence and with a PSA doubling time of less than 6 months (Trock et al., 2008). It is clear that many patients will have a long-term, durable disease-free interval after salvage radiation. Further, Ying et al. (2017) also demonstrated that despite PSA failure after salvage radiation, the men in their cohort had a median overall survival of 13.6 years.

Failure after salvage radiation therapy can be a result of persistent local disease, recurrence of local disease, persistence of metastasis, or development of metastatic disease. It is important to identify factors that may predict for failure after salvage therapy for patient counseling and for surveillance. Using a large multi-institutional cohort of 1540 men, Stephenson et al. created a nomogram that predicts outcomes after salvage radiation therapy (Stephenson et al., 2007). PSA before salvage radiation, pathologic Gleason score, PSA doubling time, margin status, lymph node status, and ADT were included for the nomogram and had a concordance index of 0.69 (Stephenson et al., 2007). Furthermore, time to biochemical failure has been found to predict for development of distant metastatic disease, disease-specific mortality, and overall mortality (Johnson et al., 2013). Conversely, location and number of positive surgical margins are not predictive of biochemical recurrence after salvage radiation therapy (Bastide et al., 2010).

Previous studies have identified a PSA of 0.5 ng/mL or less as an appropriate cutoff for the initiation of salvage radiation (Heidenreich et al., 2014). Clearly, lower levels of PSA result in improved outcomes, as King confirms that for every increment of 0.1 ng/mL, there is a 2.6% loss of recurrence-free survival (King, 2012). This again is clearly shown in patient cohorts with long-term follow-up, where presalvage radiation therapy PSA values predict for eventual failure along with other parameters such as Gleason score, T-stage, and positive surgical margin (Rodin et al., 2017). The treatment dilemma for the clinician is finding a suitable cutoff for early therapy leading to good outcomes but sparing those who will not have clinical failure. This is especially true as radiation is not without some risk for side effects including cystitis and strictures, bowel complications such as proctitis, urgency and tenderness, along with erectile dysfunction and sexual bother. However, robust quality-of-life studies are lacking, and the risks for complications must be tempered compared with the potential for curative treatment (Raziee and Berlin, 2016). Recently, the incorporation of imaging data including mpMRI has garnered attention. The group from the Mayo Clinic has shown that the addition of mpMRI findings in a nomogram assisted in predicting failure of salvage radiation. They found that patients without prostate lesions on preoperative mpMRI were at a higher likelihood to have failure after salvage radiation for PSA failure as these patients may have occult metastatic disease (Sharma et al., 2018). Additionally, ^{68}Ga-PSMA-11 PET/CT scans have also shown significant promise in salvage radiation planning. In a study of 270 men with PSA recurrences less than 0.1 ng/mL, ^{68}Ga-PSMA-11 PET/CT identified 52/270 (19%) lesions outside of the planned radiation zone of which the most common sites were bone and perirectal (Calais et al., 2018).

Dose Response With Salvage Radiation Therapy

The primary treatment of prostate cancer with radiation therapy has taught us that higher dosages of treatment lead to improved prostate cancer outcomes with limited side effects (Zietman et al., 2005). Using the same logic, many groups have developed protocols of salvage therapy enhancing both the dosages administered and the planned targeting using intensity-modulated radiotherapy (IMRT) versus conformal therapy, which was administered in older cohorts (Buskirk et al., 2006; Geinitz et al., 2012). In 1999, the American Society for Therapeutic Radiology and Oncology (ASTRO) Consensus Panel released recommendations on salvage radiation stating that dosages of at least 64 Gy should be administered to the prostatic bed (Cox et al., 1999). Clearly, these guidelines are outdated, and more recent data demonstrate improved cancer control with higher dosages of therapy associated with minimal changes in side-effect profile.

De Meerleer et al. (2008) published their results with a planned target volume of 75 Gy in 37 fractions and demonstrated a biochemical freedom from disease of 67% at 5 years. There were no acute grade 3 gastrointestinal toxicities and only 3% genitourinary toxicities. Accordingly, there were minimal late gastrointestinal or genitourinary toxicities on further follow-up (De Meerleer et al., 2008). Gleason score at radical prostatectomy, perineural invasion, and capsular perforation of disease were all significant predictors of biochemical recurrence (De Meerleer et al., 2008). When stratifying patients into groups based on dosages of radiation; low (<64.8 Gy), moderate (64.8 to 66.6 Gy), and high (>66.6 Gy), the estimated cumulative rate of biochemical failure at 5 years was 57%, 46%, and 39%, respectively (Bernard et al., 2010). These results have been confirmed in a multi-institutional study of 10 institutions and 1108 patients in which a dosage of greater than 66.0 Gy correlated with reduced biochemical failure rates (Pisansky et al., 2016). Most recently, Ost et al. demonstrated that using a median dosage of 76 Gy, they achieved 5-year biochemical recurrence–free survival of 56% and clinical recurrence free survival of 86% (Ost et al., 2011). This was achieved while keeping toxicity rates low with total genitourinary grade 2 and 3 toxicities of 22% and gastrointestinal grade 2 and 3 toxicities of 8% (Ost et al., 2011). In a meta-analysis of 71 studies, increased salvage radiation doses conferred improved outcomes, where each increase in Gray resulted in a 2% improvement in recurrence free survival (King, 2016). **Modern series of radiation therapy using higher dosages clearly demonstrate improved cancer control results. Despite the biases involved with stage migration in more contemporary series, the improved toxicity profile with modern radiation delivery systems should make higher dosages of therapy the standard in salvage radiation therapy.**

Concurrent Androgen Deprivation Therapy With Salvage Radiation

Theoretically, the usage of systemic therapy with androgen deprivation may sterilize micrometastatic disease, shrink tumor burden making it more amenable to local salvage therapy, and potentially work in synergy with radiation therapy to treat remaining cancer cells. RTOG 96-01 is a trial comparing salvage radiation therapy (64.8 Gy) with and without 2 years of bicalutamide therapy for patients with a detectable PSA (0.2 to 4.0 ng/mL) at least 8 weeks after radical prostatectomy (pT3N0M0 or pT2 with positive margins). After 12 years of follow-up, results were recently published demonstrating an overall survival benefit of 76.3% versus 71.3% favoring the bicalutamide plus radiation arm. Further, death from prostate cancer at 12 years was 5.8% versus 13.4%, and incidence of metastasis was 14.5% versus 23% in favor of the bicalutamide plus radiation arm (Shipley et al., 2017). Additionally, the GETUG-16 trial of 743 men demonstrated an improvement in biochemical progression at 5 years with the addition of 6 months of goserelin to salvage radiation therapy with minimal adverse effects (Carrie et al., 2016). The RADICALS (Radiotherapy and Androgen Deprivation In Combination After Local Surgery) trial is a randomized phase III controlled trial evaluated the timing of radiotherapy (adjuvant vs. early salvage) and the duration of concurrent ADT. Patients will receive either none, 6 months, or 2 years of androgen deprivation with a gonadotropin-releasing hormone analogue or bicalutamide. The outcomes evaluated are disease-specific and overall survival (Parker et al., 2007). The results of the RADICALS trial may further support the addition of ADT to salvage radiation and perhaps give guidance regarding the ideal length of therapy.

Whole Pelvis Versus Prostatic Bed Radiation Therapy

Very few series evaluate the role of whole pelvis versus prostatic bed only salvage radiation therapy after biochemical recurrence. Spiotto et al. (2007) evaluated their experience in 160 men who underwent both adjuvant and salvage radiation therapy of which 114 were considered high-risk for lymph node involvement (Gleason score ≥8, preoperative PSA >20 ng/mL, seminal vesicle involvement, capsular extension, and lymph node positivity). Seventy-two patients received whole pelvis radiation versus 42 who underwent prostatic bed only radiation. The benefit of whole pelvis radiation was limited to those with high-risk features with 5-year biochemical recurrence–free survival of 47% versus 21% for prostatic bed alone (Spiotto et al., 2007). On multivariable analysis, whole pelvis radiation and preoperative PSA less than 1 ng/mL were predictors of biochemical recurrence–free survival (Spiotto et al., 2007). Furthermore, in patients with high-risk features, concurrent androgen deprivation with whole pelvis radiation conferred improved recurrence free survival (Spiotto et al., 2007).

Moghanaki et al. (2013) published their series of 247 patients undergoing salvage radiation therapy. This study compared two separate institutions with differing approaches to salvage radiation, with one group performing prostatic bed radiation (135 patients) and the other group performing pelvic nodal radiation in addition to prostatic bed radiation (112 patients) (Moghanaki et al., 2013). Pretreatment PSA and pathologic Gleason score were independent predictors of biochemical recurrence, but whole pelvic radiation was not an independent predictor associated with PSA recurrence free survival (Moghanaki et al., 2013). Even after separating patients into low- and high-risk features, there was no benefit to whole pelvis irradiation. However, when examining a subset of patients with preradiation PSA levels greater than or equal to 0.4 ng/mL, there was a 53% risk reduction in biochemical progression with whole pelvis radiation (Moghanaki et al., 2013). Conversely, in a retrospective multi-institutional study of 1861 patients with detectable PSA after radical prostatectomy for Gleason 7 or greater prostate cancer at 10 academic centers, whole-pelvis radiation was associated with improved 5-year freedom from biochemical failure of 62% versus 49% (Ramey et al., 2018). Clearly, results from retrospective analyses are limited by selection bias, and randomized trials are necessary.

RTOG 0534 is a randomized controlled trial currently accruing patients with high-risk prostate cancer features on radical prostatectomy and with postsurgery PSA greater than or equal to 0.1 ng/mL to less than 2.0 ng/mL. Patients will be stratified by seminal vesicle involvement, Gleason score, pretreatment PSA level, and stage. Patients will be randomized to prostatic bed radiation alone, prostatic bed radiation plus 6 months of androgen deprivation, and prostatic bed radiation therapy plus pelvic lymph node radiation therapy along with 6 months of ADT. Patients will either undergo three-dimensional CRT or IMRT at 64.8 to 70.2 Gy for the prostatic bed and 45 Gy for the pelvic lymph nodes. The primary objective is to evaluate freedom from biochemical progression, clinical failure, and overall survival. The results of this trial will help clarify this treatment dilemma (Figs. 160.2 and 160.3).

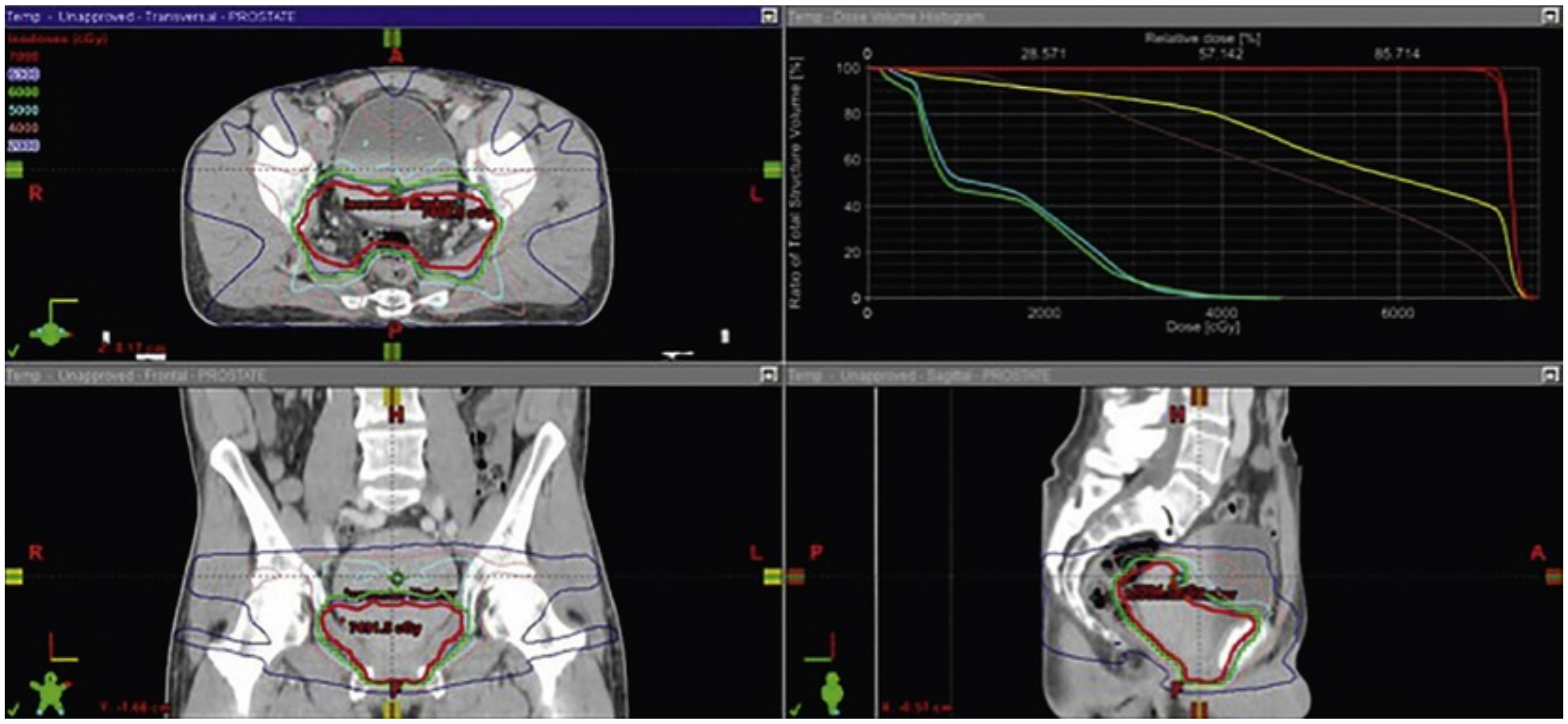
Temp - Unapproved - Transversal - PROSTATE
Temp - Dose Volume Histogram
Relative dose [%]
0
28.571
57.142
85.714
100
80
60
40
20
0
Ratio of Total Structure Volume [%]
2000
4000
6000
Dose [cGy]
Temp - Unapproved - Frontal - PROSTATE
Temp - Unapproved - Sagittal - PROSTATE
A
P
R
L
H
7000
6000
5000
4000

FIG. 160.2 Prostate bed–only salvage radiotherapy after radical prostatectomy.

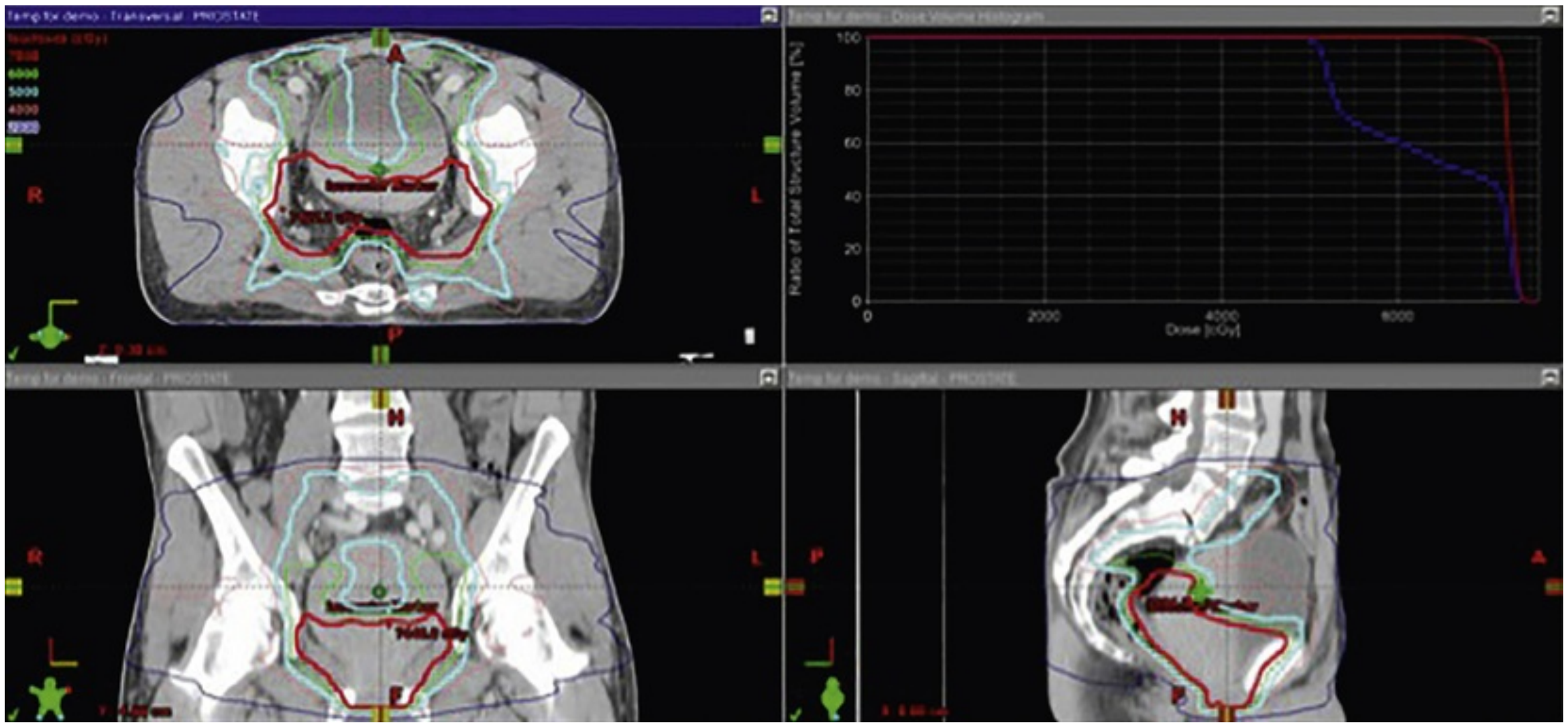
Temp for demo - Transversal - PROSTATE
Temp for demo - Dose Volume Histogram
Temp for demo - Frontal - PROSTATE
Temp for demo - Sagittal - PROSTATE
100
80
60
40
20
0
Ratio of Total Structure Volume [%]
2000
4000
6000
Dose [cGy]
A
P
R
L
H
7000
6000
5000
4000

FIG. 160.3 Whole-pelvis radiotherapy after radical prostatectomy.

Salvage Versus Adjuvant Radiation Therapy for Prostate Cancer

Randomized phase III clinical trials are desperately needed to determine the role of adjuvant radiation versus early salvage radiation therapy. The RADICALS trial is a multi-institutional phase III clinical trial examining adjuvant radiation within 22 weeks of surgery versus early salvage therapy at PSA relapse, which is defined as either two consecutive rises in PSA level and a PSA greater than 0.1 ng/mL or three consecutive rises in PSA level (Parker et al., 2007). If biochemical recurrence is detected, patients will undergo either 66 Gy in 33 daily fractions over 6.5 weeks or 52.5 Gy on a 4-week treatment schedule. The RAVES (Radiotherapy—Adjuvant Versus Early Salvage) trial is a phase III trial randomizing patients with pathologic T3 disease and/or positive margins. The primary endpoint is biochemical cancer control, with secondary outcomes including quality of life, toxicity, anxiety/depression, biochemical failure free survival, overall survival, disease-specific survival, time to distant failure, time to local failure, time to initiation of androgen ablation, quality-adjusted life years, and cost-utility (Pearse et al., 2014). Finally, the GETUG-17 trial will evaluate a similar patient population but will randomize patients to immediate adjuvant radiation therapy versus observation patients and treat with salvage radiation when PSA levels read a level of 0.2 ng/mL. Both groups will undergo a short course of ADT. As these trials complete accrual and mature, we will gain a better understanding about the timing of radiation therapy along with the utility of concomitant ADT.

Androgen Deprivation Therapy for Biochemical Failure After Radical Prostatectomy

ADT in the postprostatectomy setting has been underevaluated, and the scope of its utility is lacking. Unfortunately, randomized controlled trials are limited, and the exact role in the comprehensive care of aggressive prostate cancer is not completely understood. Large retrospective series have demonstrated mixed results. Early ADT in men who have experienced biochemical recurrence has been found to decrease the rate of clinical metastasis in patients with high-risk features defined as Gleason sum greater than 7 or PSA doubling time less than 12 months (Moul et al., 2004). Delineation between early and late administration of androgen deprivation was significant at PSA cut points of 5 and 10 ng/mL (Moul et al., 2004). Similarly, the adjuvant ADT before signs of biochemical progression in select patients demonstrates improved 10-year progression-free and disease-specific survival (Siddiqui et al., 2011). This was true, even compared with a cohort of patients who received systemic therapy at PSA values of 0.4 ng/mL and above. Regardless of improvements in biochemical and disease-specific outcomes, there is no evidence of improved overall survival

(Siddiqui et al., 2011). Furthermore, the benefits in administration of ADT must be tempered by the potential for increased risk for cardiac disease and diabetes (Keating et al., 2006).

Not all patients who experience biochemical recurrence require ADT, and the identification of subgroups at highest risk for systemic failure will optimize selection and prevent morbidity. Patients with pathologic T3b tumors benefit from the adjuvant administration of ADT and experience improved 10-year biochemical progression free survival of 60% versus 16% (Siddiqui et al., 2008). These patients also demonstrated improved local recurrence-free, systemic progression-free and disease-specific survival. But again, there was no statistically significant improvement in overall survival (Siddiqui et al., 2008). Patients with high-risk features, such as Gleason score of 8 or higher; PSA 15 ng/mL or higher; pathologic stage T3b, T4, or N1; or Gleason score 7 with concomitant PSA greater than 10 ng/mL or a positive margin, were found to have a biochemical failure–free survival of 92.5% at 5 years, with an overall survival of 95.9% in patients treated with adjuvant ADT as part of a randomized clinical trial (Dorff et al., 2011). Patients who have positive lymph nodes at radical prostatectomy are at highest risk for micrometastatic disease and eventual systemic failure. In a randomized clinical trial of immediate versus deferred ADT, patients who received immediate therapy demonstrated improved overall survival, disease-specific survival, and progression-free survival at a follow-up of 11.9 years (Messing et al., 2006).

In patients with persistent or rising PSA after definitive therapy for prostate cancer (radiation or prostatectomy), a retrospective analysis of 2096 men using the CaPSURE database found similar survival whether ADT was initiated within 3 months of PSA recurrence versus within 3 months of clinical progression (Garcia-Albeniz et al., 2015). Similarly, in a report of 5804 men within three large managed care health care organizations, salvage ADT was not associated with decreasing all-cause or disease-specific mortality. However, there was a benefit in all-cause and disease-specific mortality in patients with PSA doubling times less than 9 months (Fu et al., 2017). **Clearly, patients at the highest risk for local and systemic recurrence are those who likely benefit the most from adjuvant hormone therapy.**

Radiation Therapy

PSA Recurrence After Definitive Radiotherapy

Similar to PSA recurrence after radical prostatectomy, biochemical recurrence after definitive radiotherapy precedes clinical failure. This gives warning of potential disease progression to initiate secondary/salvage therapies.

In 2005, a multidisciplinary panel of experts met in Phoenix, Arizona, to discuss a new definition of biochemical failure after definitive radiation therapy for prostate cancer (Roach et al., 2006). This group defined PSA recurrence as a rise of 2 ng/mL or more above the nadir PSA and the date of failure was at call (Roach et al., 2006). Importantly, the stated biochemical outcomes should be 2 years short of the median follow-up for the group to avoid any overestimations of biochemical recurrence–free survival. Furthermore, the definition was created for usage in patients who also received concurrent ADT (Roach et al., 2006).

It is now clear that the “Phoenix” definition of biochemical recurrence is more robust in predicting clinical outcomes. In a contemporary series of definitive radiotherapy for prostate cancer, 1831 men with clinical stage T1 to T4 prostate cancer without nodal or metastatic disease was compared using the ASTRO and Phoenix definitions of biochemical recurrence to predict for metastatic disease, disease-specific mortality, and overall mortality (Abramowitz et al., 2008). Accounting for covariates such as T-stage, initial hormonal treatment, Gleason score, radiation dosage, PSA, and age, the **Phoenix definition was found to be a significant predictor of metastatic disease, disease-specific mortality, and overall mortality on univariable and multivariable analysis.** The ASTRO definition was significant for metastatic disease and disease-specific mortality to a lesser degree and not significant at all for overall survival (Abramowitz et al., 2008). In fact, on multivariable analysis, PSA nadir +2 ng/mL was the most significant predictor of all three outcomes compared with all other covariates, confirming the validity of this definition of PSA recurrence (Abramowitz et al., 2008).

Postradiation PSA Bounce

Postradiation PSA “bounce” is a varied definition of an elevated PSA of 0.1

ng/mL to 0.5 ng/mL over the prebounce PSA with a subsequent decrease in PSA (Cavanagh et al., 2000; Critz et al., 2000; Hanlon et al., 2001; Rosser et al., 2002). It is thought that this phenomenon occurs secondary to post-treatment prostatitis (Critz et al., 2000) or even from the delivery of a sublethal dosage of radiation with associated delayed cellular death. Rosser et al. (2002) defined PSA bounce among their cohort as a rise of PSA of at least 0.5 ng/mL followed by a decrease to baseline value and found in their group of men that the bounce occurred at a mean time of 9 months from therapy and was associated with an improvement in biochemical recurrence–free survival compared with those who did not have a bounce. These results have recently been confirmed in men undergoing dose escalation. In 776 patients with a median radiation dose of 81 Gy, PSA bounce (≥2 ng/mL above nadir with return to nadir or below) correlated with decreased risk for eventual PSA recurrence, distant metastasis, and all-cause mortality at a median follow-up of 9.2 years (Romesser et al., 2018). Series of brachytherapy in addition to external-beam radiation demonstrate similar rates of PSA bounce of approximately 35% (Cavanagh et al., 2000; Critz et al., 2000). Additionally, the probability of PSA bounce may depend on fraction size in high-dose-rate brachytherapy (Hauck et al., 2017). **It is quite clear that patients who undergo a transient rise in their PSA should be closely monitored as not all men are destined for biochemical failure, let alone clinical failure.**

Natural History of PSA Recurrence After Definitive Radiation

PSA-only recurrence after definitive radiation therapy for prostate cancer leads to clinically relevant outcomes such as local and distant failure along with disease-specific death. Lee et al. (1997) demonstrated in their cohort of 151 men that men with higher pretreatment PSA levels, higher Gleason scores, and higher stage were more likely to develop an increasing PSA profile (PSA ≥1.5 ng/mL on two occasions). Furthermore, 5 years after PSA elevation, the estimated rate of local recurrence was 26% and distant metastasis was 47% (Lee et al., 1997). Overall and disease-specific survival at 5 years was 65% and 76%, respectively (Lee et al., 1997). Although rapid PSA doubling time and short interval from treatment to PSA elevation were predictors of subsequent metastatic disease, Gleason grade was the only predictor for overall and disease-specific survival (Lee et al., 1997).

In a larger series of 2694 men treated with radiation therapy (75.6 to 86.4 Gy), 609 men experienced biochemical recurrence defined as PSA nadir greater than 2 ng/mL. Of these men, the median time to metastasis and disease-specific death was 5.4 years and 10.5 years, respectively. Predictors of clinical significant outcomes were shorter post-treatment PSA doubling time, pretreatment clinical stage, Gleason score, and short interval from radiation to biochemical recurrence (Zumsteg et al., 2015). Men with PSA elevation after definitive radiotherapy are candidates for salvage therapy. Defining those at greatest risk for local versus distant failure is key to deciding on second-line therapy. Further, patient comorbidity and age must be considered before initiation of treatment.

Biopsy After Radiotherapy

The goals of biopsy after definitive radiation is to identify the presence or absence of locally residual or recurrent disease and to identify grade of remaining disease. Crook et al. (2000) recommended biopsies to be performed at least 2 to 3 years after the completion of radiation therapy to decrease the rates of false-positive and false-negative biopsies. Biopsy based on guided ultrasonography or MRI should target abnormal lesions, the seminal vesicles, and a systematic sampling of the entire prostate gland. The information from prostate biopsy will guide further treatment strategies and should be reserved for patients in which salvage local therapy is considered. One should keep in mind that tumor architecture is altered after radiation therapy and may represent dedifferentiation of cancer cells. Further, Gleason grading after radiation therapy may or may not be accurate, and its utility is controversial (Cheng et al., 1998, 1999; Letran et al., 1998).

Imaging After Biochemical Recurrence Following Radiotherapy

Imaging of the prostate after definitive radiotherapy remains challenging with traditional modalities because of fibrosis and shrinkage of the prostate (Martino et al., 2011). Transrectal ultrasonography has limited ability to identify suspicious lesions of the prostate and has a sensitivity and specificity profile no better than rectal examination (Crook et al., 1993). Furthermore, although CT is useful for the detection of bone and lymph node metastasis in patients with significantly elevated PSA levels (>20 ng/mL), the ability to identify recurrent cancer after radiotherapy is limited. Recently, MRI has emerged as the most promising technique for identifying recurrent tumors of the prostate in biochemical recurrence.

T2-weighted MRI of the prostate is capable of excellent soft tissue differentiation; however, its usage in postirradiated tissue is limited by diffusely decreased signal intensity in the prostate (Coakley et al., 2001). Sensitivity of T2-weighted MRI is as low as 27% with limited positive predictive value of 32% (Kim et al., 2010). Therefore, dynamic imaging studies have been pursued to better identify potential recurrent lesions amenable for salvage therapy. DCE gives the ability to identify vascularization of the prostate and tumor along with angiogenesis and capillary permeability characteristics (Franiel et al., 2011). When comparing DCE-MRI with T2-weighted MRI, DCE-MRI had better sensitivity (72% vs. 38%), positive predictive value (46% vs. 24%), and negative predictive value (95% vs. 88%). Specificity was similarly high for both groups (Haider et al., 2008). Yakar et al. (2010) determined that the combination of DCE imaging along with MRI-guided biopsy of suspicious lesions led to a positive predictive value of 75% and 68% for per patient and per tumor suspicious region, respectively.

MRSI distinguishes residual prostate cancer by identifying a relative increase of choline plus creatinine-to-citrate ratio or by identifying an increase in the choline peak with no citrate identified. Using these criteria, MRSI has demonstrated sensitivity of 77% compared with sextant biopsy and rectal examination, which revealed sensitivities of 48% and 16%, respectively, in the same patient cohort (Pucar et al., 2005). However, it is important to note that benign glands can exhibit high choline levels after radiation and may cause false-positive findings (Pucar et al., 2005). Furthermore, the addition of MRSI to T2-weighted imaging significantly improved the detection of locally recurrent prostate cancer after radiation therapy (Westphalen et al., 2010).

Diffusion-weighted imaging magnetic resonance imaging (DWI-MRI) has also demonstrated feasibility in the clinical setting. Kim et al. (2010) found the utility alone and in combination of DCE imaging revealing an accuracy of biopsy as high as 83%. This was in comparison to T2-weighted MRI, which demonstrated an accuracy rate of 67% (Kim et al., 2010). Further illustrating the benefit of DWI-MRI, Hara et al. (2012) found a sensitivity and specificity of 100% and 100%, respectively, on a per-patient basis when comparing MRI findings to a 22-core three-dimensional prostate mapping biopsy as the standard reference. On a region-by-region basis, the sensitivity and specificity was 69%

and 91%, respectively. Abd-Alazeez et al. (2015) recently demonstrate that their receiver-operator characteristic area under the curve was as high as 0.84 when using mpMRI in radiorecurrent prostate cancer when using transperineal systematic template prostate mapping as the standard. Additionally, the Mayo Clinic report their experience in patients undergoing mpMRI using a 3 Tesla magnet and endorectal coil before salvage radical prostatectomy and found reasonable accuracy for detecting extraprostatic extension, seminal vesicle invasion, and lymph node metastasis (Zattoni et al., 2017). These data demonstrate the utility of MRI in patients with biochemical recurrence after radiation therapy. The optimal timing of MRI and level of PSA at imaging are yet to be determined and will need further investigation.

^{68}Ga-PSMA PET scanning has demonstrated utility in patients who fail after radiation therapy. In a large series of 419 men, 70 were found to have biochemical failure defined by the Phoenix definition of which 48 men underwent ^{68}Ga-PSMA PET scans. With a median PSA of 5 ng/mL, all patients were found to have “unequivocally positive” positive scans. There were 25 distant failures, 15 local and distant failures, and 8 local only failures (Hruby et al., 2017). Parker et al. (2017) evaluated ^{11}C-choline PET/CT in 184 patients who met the Phoenix definition of PSA recurrence after radiotherapy. They identified 161/184 patients with positive ^{11}C-choline PET/CT scans, with 54.3% within the pelvic soft tissue and 33% with extrapelvic disease. On multivariable analysis, they determined that the difference between PSA nadir and PSA at PET scan, time from radiation therapy, and National Comprehensive Cancer Network (NCCN) risk groups were predictive of distant disease. Additionally, the authors created a nomogram with a predictive index of 0.79. Clearly, sensitive scans that can detect local versus distant failures are critical in deciding on the utility of local salvage therapies.

Salvage Radical Prostatectomy

Salvage radical prostatectomy is considered the most definitive way to eradicate localized radiorecurrent prostate cancer. Despite the infrequent usage of salvage surgery in the setting of radiorecurrence, multiple studies have demonstrated the 10-year disease-specific survival to be as high as 70% to 83% (Bianco et al., 2005; Chade et al., 2011; Lerner et al., 1995; Ward and Moul, 2005). However, survival outcomes directly correlate with pathologic stage whereby organ-confined disease and isolated extracapsular extension confer a 5-year progression-free probability of 77% and 71%, respectively. Conversely, those with seminal vesicle invasion and lymph node involvement have poorer 5-year outcomes of 28% and 22%, respectively (Bianco et al., 2005; Stephenson and Eastham, 2005). Given the high propensity for prostate cancer to recur despite radiation therapy, it is of utmost importance to treat with definitive salvage therapy before local invasion and metastasis.

Despite successful cancer outcomes in traditional and contemporary series of salvage radical prostatectomy, the hesitance to perform such operations is a result of the inherent risks of significant morbidity. Historically, up to 50% of patients who undergo salvage surgery will suffer a major complication (Moul and Paulson, 1991). As a result of significant fibrosis from radiation, rectal injury rates of 6% to 15% and bladder neck contracture rates of 20% to 28% have been reported. Further, rates of urinary incontinence ranged from 40% to 60% (Lerner et al., 1995; Rogers et al., 1995). It is worth mentioning that in these surgical series, some patients had received preradiation pelvic lymph node dissection; retropubic brachytherapy; and nonconformal radiation delivery, which added to the morbidity. As a result of the high complication rates, clinicians have been hesitant to perform salvage radical prostatectomy. This is reflected in the CaPSURE database demonstrating that only 2% of patients underwent surgery as secondary treatment after radiation failure, and 92% underwent noncurative ADT (Grossfeld et al., 2002). **Patients selected for salvage radical prostatectomy should have biopsy-proven radiorecurrent prostate cancer, at least 10 years of life expectancy, lack of identifiable metastasis on imaging, and a PSA of less than 10 ng/mL (Table 160.2).**

TABLE 160.2

Outcomes of Salvage Radical Prostatectomy for Radiorecurrent Prostate Cancer

STUDY	*N*	YEARS	MEDIAN FOLLOW-UP (YEARS)	% DISEASE-FREE INTERVAL (YEARS)	% CANCER-SPECIFIC SURVIVAL (YEARS)
Chade et al., 2011	404	1985–2009	4.4	37.5 (10)	83 (10)
Paparel et al., 2009	146	1984–2006	3.8	54 (5)	–
Ward et	138	1967–	6.4	–	90 and 77 (5, 10)

al., 2005		2000			
Bianco et al, 2005	100	1984–2003	5	55 and 30 (5, 10)	73 and 60 (10, 15)

Within the past 10 years, there has been a preponderance in robotic-assisted laparoscopic prostatectomy, and naturally this approach has begun to gain favor among urologists who are willing to tackle salvage prostatectomy. Perceived advantages to the robotic approach include decreased blood loss, better visualization, and shorter hospitalization. In a meta-analysis of 197 patients undergoing robotic salvage prostatectomy, Zargar et al. (2017) demonstrated that approximately two-thirds of all patients were free from recurrence. Additionally, 60% were continent, 26% were potent, and 16% suffered complications requiring intervention. As both data and surgeon experience mature, both oncologic and morbidity outcomes will likely demonstrate improvement. Similar to open surgery, patient selection and close adherence to surgical principles are of utmost importance.

Salvage Cryotherapy

In the United States, approximately one-third of newly diagnosed men with prostate cancer are treated with external-beam radiation and/or brachytherapy as the primary modality of therapy (Mettlin et al., 1998, 1999). Depending on the series and definition, approximately 30% to 40% of patients treated with primary radiation will have failure (Crook et al., 2000; D'Amico et al., 2008; Shipley et al., 1999; Touma et al., 2005). In the carefully selected patient, cryotherapy may be an effective and safe option for treatment of radiorecurrent disease.

Patients best suited for cryotherapy are those with localized treatment failure after radiation therapy with biopsy-proven disease as approximately one-third of patients with biochemical failure will have a positive biopsy (Crook et al., 1995). Regardless of definition, biochemical failure determination and histologic failure is ideally identified at least 2 years after primary treatment to account for PSA bounce and ongoing histologic changes postradiation (Chin et al., 2007; Crook et al., 2000). In addition to standard, multicore prostate biopsy, it may be prudent to include the seminal vesicles as up to 29% may have involvement and predict for poor outcomes (Gheiler et al., 1998). Candidates for salvage cryotherapy should have a reasonable life expectancy and must undergo a full metastatic workup with cross-sectional imaging (CT abdomen/pelvis or MRI) along with a radionuclide bone scan (Babaian et al., 2008). Pelvic lymph node biopsy may also be considered in high-risk patients (Babaian et al., 2008). Patients with a presalvage PSA of less than 10 ng/mL, ideally less than 4 ng/mL (Ng et al., 2007), and a PSA doubling time greater than or equal to 16 months have been shown to be predictive for successful treatment (Spiess et al., 2006).

To date, there is no universal definition of “success” using salvage cryotherapy. Using a definition of 2 ng/mL above the postcryotherapy nadir, Pisters et al. (1999) demonstrated a 74% 2-year disease-free survival for patients with a postradiation PSA less than 10 ng/mL and 58% for patients with a preradiation Gleason score of 8 or less. In a contemporary analysis of the COLD (cryo on-line data) Registry including 156 patients, 3-year biochemical disease-free survival using the Phoenix definition of nadir plus 2 ng/mL was determined to be 66.7% (Spiess et al., 2013). Williams et al. (2011) report their outcomes in 176 patients with a mean follow-up of 7.46 years. Primary outcome of overall survival was 95%, 91%, and 87% at 5, 8, and 10 years, respectively.

Clearly, the success of any salvage therapy is tempered by the significant risks for side effects. Third-generation cryotherapy involves the adoption of a liquid Argon gas system, smaller-diameter probes, a pinpoint thermocoupler, and continued usage of transrectal ultrasound guidance and urethral warmers. Historically, salvage cryotherapy was wrought with a high complication rate. In terms of urinary morbidity, one of the largest quality-of-life series of 112 men demonstrated that 72% of men had urinary incontinence, with 66% of men describing their symptoms as moderate to severe in nature. Only 33% felt satisfied by the therapy they had received (Perrotte et al., 1999). However, more recent data demonstrate improved urinary incontinence rates from 4.3% to 6.5% (Bahn et al., 2003; Donnelly et al., 2005; Pisters et al., 2008). This drastic improvement in results is likely caused by the universal usage of urethral warming, which helps protect the urinary sphincter mechanism. Erectile dysfunction has been difficult to gauge in salvage cryotherapy series secondary to inconsistent reporting and lack of validation. In the series from Perrotte et al. (1999), 15% of patients who were potent pretreatment maintained erectile function sufficient for sexual intercourse. Ismail et al. (2007) reported a rate of erectile dysfunction of 86%. Clearly, erectile dysfunction is a significant risk from the primary treatment, and further cryotherapy is likely to worsen symptoms. Current exploration into nerve-sparing and subtotal cryotherapy is underway. The most dreaded complication risk for salvage cryotherapy is urethrorectal fistula, which has decreased significantly in recent series. Some reports demonstrate lower rates of 1% to 3.4% (Bahn et al., 2003; Ismail et al., 2007; Ng et al., 2007; Pisters et al., 2008). Other reported complications include urinary obstruction, urethral sloughing, urethral stricture, rectal pain, scrotal edema, and hematuria (Chin et al., 2007; Finley and Belldegrun 2011). Recently, Li et al. (2015) reported outcomes from the COLD registry using focal cryotherapy. In 91 patients, biochemical recurrence–free survival was 95.3%, 72.4%, and 46.5% at 1, 3, and 5 years, respectively. There was a 3.3% rate of rectourethral fistula, 6.6% rate of urinary retention, 5.5% rate of incontinence, and 10 of 20 patients who were potent before salvage cryotherapy were potent afterward. It is clear that in the carefully selected patient, salvage cryotherapy is a reasonable approach with adequate disease-specific outcomes and limited morbidity (Table 160.3).

TABLE 160.3

Outcomes of Salvage Cryotherapy for Prostate Cancer

STUDY	*N*	TECHNIQUE	PSA CUTOFF (ng/mL)	RECURRENCE-FREE RATE (%)	MEAN/MEDIAN FOLLOW-UP (MONTHS)	FIST
Donnelly et al., 2005	46	Argon	0.3	51	20	2.2
Ng et al., 2007	187	Argon	Phoenix	56	39	2
Ismail et al., 2007	100	Argon	ASTRO	59	34	1
Pisters et al., 2008	279	Argon/nitrogen	ASTRO	59	22	1

ASTRO, American Society for Therapeutic Radiology and Oncology; *LUTS,* lower urinary tract symptoms; *PSA,* prostate-specific antigen (test).

Salvage Brachytherapy

The evidence for salvage brachytherapy after radiation failure is lacking compared with salvage prostatectomy and salvage cryotherapy. However, several groups have published contemporary series including modern techniques that not only demonstrate improved cancer control outcomes but also have comparable morbidity outcomes to cryotherapy and surgery. Randomized controlled trials of salvage therapies are desperately needed.

Recently, high-dose rate brachytherapy (HDRB) has gained attention as it has the ability to implant the seminal vesicles and treat extracapsular extension while limiting the dosage to surrounding organs through a conformal delivery (Chen et al., 2013; Hsu et al., 2005; Syed et al., 2001). In the largest series of HDRB, 52 patients underwent therapy, with a median follow-up of 59.6 months. All patients had biopsy-confirmed recurrent disease, negative workup for systemic disease, and no previous prostatectomy. Patients received 36 Gy in 6 fractions in two separate implants 1 week apart (Chen et al., 2013). The 5-year overall survival was 92%, and biochemical recurrence–free survival was 51%. As expected, patients with lower post-therapy nadir were more likely to have biochemical recurrence–free survival (Chen et al., 2013). Only one patient had distant failure and had a nadir PSA of 7.2 ng/mL. The toxicity profile was excellent in this cohort, with only one patient having a grade 3 acute and late genitourinary toxicity and no patients having any grade 3 or 4 acute or late gastrointestinal toxicity (Chen et al., 2013). Although no factors were statistically significant as predictors for biochemical outcome, the factors that were borderline in significance were disease-free interval after initial definitive radiation, percent of positive cores at diagnosis, time from recurrence to salvage HDRB, and presalvage therapy PSA (Chen et al., 2013). More recently in a cohort of 22 patients with at least 60 months of follow-up, 5-year biochemical free survival was 45% with minimal urinary or gastrointestinal-related side effects (no grade 3 or above) (Jiang et al., 2017). Salvage HDRB is a promising modality for patients with radiorecurrent prostate cancer. Similarly to low-dose-rate brachytherapy, patients likely to be most suitable are those with prolonged disease-free interval from primary treatment to recurrence, longer PSA doubling times, Gleason score less than or equal to 6, PSA less than 10 ng/mL, and no evidence of extracapsular extension or seminal vesicle invasion (Beyer, 2003). Recently, an analysis of low-dose versus high-dose brachytherapy was performed in 98 patients. After a median follow-up of 31 months, there were no difference in PSA recurrence-free survival and no difference in toxicity. Additionally, only PSA doubling time before salvage therapy was predictive of eventual PSA failure (Kollmeier et al., 2017).

Salvage High-Intensity Focused Ultrasonography

Salvage high-intensity focused ultrasonography (HIFU) has been evaluated in the treatment of radiorecurrent prostate cancer with acceptable cancer control outcomes. In an open-label clinical trial between 2009 and 2012, 100 men were enrolled at 16 sites to receive salvage HIFU at least 2 years after external-beam radiation. Primary end points were a PSA nadir of 0.5 ng/mL or less along with a negative prostate biopsy at 12 months. Of the 78 patients who completed the 12-month biopsy, 63 (81%) were negative for cancer. Additionally 50/78 patients achieved a PSA nadir below 0.5 ng/mL in conjunction with the negative biopsy. There were 80 patients with grade 2 toxicity and 20 patients with grade 3 toxicity. These included 5 men with rectal fistulas, 3 patients with osteitis pubis, and 3 who had recalcitrant hematuria requiring intervention (Jones et al., 2018). Although short- to intermediate-term follow-up has been demonstrated with HIFU, further studies are necessary to establish its place as a viable alternative in the radiorecurrent setting.

Androgen Deprivation Therapy After Biochemical Recurrence Following Radiation Therapy to the Prostate

PSA elevation after definitive radiotherapy may be a result of local versus distant metastatic disease. Patients with biopsy-proven local disease, no evidence of distant metastatic disease, and substantial life expectancy should be counseled about salvage local therapy such as prostatectomy, radiation approaches, and cryotherapy. Some patients may refuse local therapy, may have too many comorbidities to undergo potentially morbid procedures, or have decreased life expectancy. Even in younger patients who are candidates for local therapy, survey results demonstrate that up to 54% of clinicians would recommend observation or ADT. This is more pronounced in a scenario of older men, where 78% would recommend observation or ADT (Sylvester et al., 2001). The reality is that 93.5% of men undergo ADT as second-line therapy after radiation failure, and therefore this approach should be clearly defined (Agarwal et al., 2008).

Not all patients with biochemical recurrence after radiation approaches are destined for clinical failure. Defining the patient population who is at highest risk is important to treat the patients with early ADT who are likely to benefit while sparing the significant side effects to those who are at low risk to fail. PSA doubling time has consistently demonstrated the ability to predict the patients who are at highest risk for failure after radiotherapy and has been linked to freedom from biochemical recurrence, local relapse, distant metastasis, and increased overall survival (Hanks et al., 1996; Lee et al., 2005; Pollack et al., 1994; Zelefsky et al., 2005). Although multiple cut points under 12 months have been described to be significant for increased risk for clinical failure, it is likely that this end point is linear (D'Amico and Hanks, 1993), and clinical judgment must be used taking into consideration the patient's comorbidities and likelihood of disease-related death for the initiation of ADT. Furthermore, side effects of ADT therapy including sexual side effects, hot flashes, decreased bone mineral density, decreased muscle mass, cognitive dysfunction, metabolic syndrome, potential cardiovascular morbidity, fatigue, anemia, and depression must be taken into consideration (Cherrier et al., 2003; D'Amico et al., 2007; Green et al., 2002; Higano et al., 2004; Harle et al., 2006; Keating et al., 2006; Spry et al., 2009).

Considering the potential morbidity of ADT and the substantial cost, it is reasonable to start treatment in those patients at highest risk for distant failure. This is confirmed as patients with PSA doubling times less than 12 months have been demonstrated to benefit from ADT with freedom from distant metastatic disease of 57% versus 78%. Further, patients who received ADT had median time from distant failure of 6 months compared with 25 months (Pinover et al., 2003). This benefit of therapy with ADT was not seen in the patient cohort with PSA doubling time greater than 12 months, confirming the notion that patients at decreased risk for systemic disease are unlikely to benefit from the early initiation of systemic therapy. Faria et al. (2006) reviewed their series of 113 men with long PSA doubling time of 26.4 months who experienced biochemical failure but did not undergo ADT. At a median follow-up of 43 months, no patients had died of prostate cancer, but 12 patients had died from other causes. These data illustrate the importance of risk stratification in patients after biochemical recurrence after radiation therapy. Recently, the results of a randomized trial of immediate versus delayed ADT in men with biochemical failure after attempt at definitive therapy (surgery and/or radiation) or in patients not suitable for definitive therapy demonstrated an improvement in overall survival in the immediate therapy arm. However, this benefit does come with detrimental effects on quality of life (Duchesne et al., 2016, 2017). Lastly, the ideal management of PSA recurrence in patients at high risk for failure may be the initiation of intermittent ADT. In a recent clinical trial, intermittent ADT was found to be noninferior compared with continuous therapy in patients with PSA levels greater than 3 ng/mL without evidence of metastatic disease. This came with the benefit of potential improvement in physical function, fatigue, urinary problems, hot flashes, libido, and erectile function (Crook et al., 2012). Clearly, further studies are necessary to identify the ideal timing of ADT initiation, the benefits of intermittent ADT, and the ideal patient group who will benefit the most from therapy.

Summary

Patients who experience biochemical recurrence after primary therapy of prostate care are at higher risk for clinical progression and anxiety from disease progression. However, not all men with PSA progression will experience clinically significant outcomes such as metastasis, need for secondary treatment, and death from prostate cancer. Therefore, risk stratification is of the utmost importance. Furthermore, advances in diagnostic imaging and therapeutics will improve the identification of those with local recurrence and enhance cancer eradication with limited morbidity.

Key Points

- The AUA and the EAU have defined biochemical recurrence after radical prostatectomy as a value of greater than or equal to 0.2 ng/mL with a second confirmatory value.
- Salvage radiation therapy should be discussed with patients with nonmetastatic prostate cancer and a rising PSA after radical prostatectomy.
- ADT should be considered in patients receiving salvage radiation therapy, especially in those with high-risk features.
- mpMRI can be a useful tool for detection of local recurrence after radical prostatectomy.
- Patients who undergo a transient rise in their PSA should be closely monitored, because not all men are destined for biochemical failure, let alone clinical failure.
- The ideal candidate for salvage radical prostatectomy has at least 10 years of life expectancy, lack of metastasis on imaging, and a PSA less than 10 ng/mL.

References

Abd-Alazeez M, Ramachandran N, Dikaios N, et al. Multiparametric MRI for detection of radiorecurrent prostate cancer: added value of apparent diffusion coefficient maps and dynamic contrast-enhanced images. *Prostate Cancer Prostatic Dis*. 2015;18(2):128–136.

Abramowitz MC, Li T, Buyyounouski MK, et al. The Phoenix definition of biochemical failure predicts for overall survival in patients with prostate cancer. *Cancer*. 2008;112(1):55–60.

Afshar-Oromieh A, Avtzi E, Giesel FL, et al. The diagnostic value of PET/CT imaging with the ^{68}Ga-labelled PSMA ligand HBED-CC in the diagnosis of recurrent prostate cancer. *Eur J Nucl Med Mol Imaging*. 2015;42(2):197–209.

Agarwal PK, Sadetsky N, Konety BR, et al. Treatment failure after primary and salvage therapy for prostate cancer: likelihood, patterns of care, and outcomes. *Cancer*. 2008;112(2):307–314.

Almeida F, Blackwell E, Patiño CD, et al. *C11-Acetate PET/CT compared to F-18 FDG PET for men with early recurrent prostate adenocarcinoma*. [Conference: Radiological Society of North America 2012 Scientific Assembly and Annual Meeting] 2012.

Almeida FD, Yen CK, Scholz MC, et al. Performance characteristics and relationship of PSA value/kinetics on carbon-11 acetate PET/CT imaging in biochemical relapse of prostate cancer. *Am J Nucl Med Mol Imaging*. 2017;7(1):1–11.

Amling CL, Blute ML, Bergstralh EJ, et al. Long-term hazard of progression after radical prostatectomy for clinically localized prostate cancer: continued risk of biochemical failure after 5 years. *J Urol*. 2000;164(1):101–105.

Amling CL, Bergstralh EJ, Blute ML, et al. Defining prostate specific antigen progression after radical prostatectomy: what is the most appropriate cut point? *J Urol*. 2001;165(4):1146–1151.

Antonarakis ES, Feng Z, Trock BJ, et al. The natural history of metastatic progression in men with prostate-specific antigen recurrence after radical prostatectomy: long-term follow-up. *BJU Int*. 2012;109(1):32–39.

Apolo AB, Pandit-Taskar N, Morris MJ. Novel tracers and their development for the imaging of metastatic prostate cancer. *J Nucl Med*. 2008;49(12):2031–2041.

Babaian RJ, Donnelly B, Bahn D, et al. Best practice statement on cryosurgery for the treatment of localized prostate cancer. *J Urol*. 2008;180(5):1993–2004.

Bahn DK, Lee F, Silverman P, et al. Salvage cryosurgery for recurrent prostate cancer after radiation therapy: a seven-year follow-up. *Clin Prostate Cancer*. 2003;2(2):111–114.

Bastide C, Savage C, Cronin A, et al. Location and number of positive surgical margins as prognostic factors of biochemical recurrence after salvage radiation therapy after radical prostatectomy. *BJU Int*. 2010;106(10):1454–1457.

Beauval JB, Roumiguie M, Filleron T, et al. Biochemical recurrence-free survival and pathological outcomes after radical prostatectomy for high-risk prostate cancer. *BMC Urol*. 2016;16(1):26.

Beheshti M, Rezaee A, Geinitz H, et al. Evaluation of prostate cancer bone metastases with 18F-NaF and 18F-Fluorocholine PET/CT. *J Nucl Med*. 2016;57(Suppl 3):55S–60S.

Bernard JR Jr, Buskirk SJ, Heckman MG, et al. Salvage radiotherapy for rising prostate-specific antigen levels after radical prostatectomy for prostate cancer: dose-response analysis. *Int J Radiat Oncol Biol Phys*. 2010;76(3):735–740.

Beyer DC. Brachytherapy for recurrent prostate cancer after radiation therapy. *Semin Radiat Oncol*. 2003;13(2):158–165.

Bianco FJ Jr, Scardino PT, Stephenson AJ, et al. Long-term oncologic results of salvage radical prostatectomy for locally recurrent prostate cancer after radiotherapy. *Int J Radiat Oncol Biol Phys*. 2005;62(2):448–453.

Boorjian SA, Karnes RJ, Crispen PL, et al. Radiation therapy after radical prostatectomy: impact on metastasis and survival. *J Urol*. 2009;182(6):2708–2714.

Budaus L, Isbarn H, Eichelberg C, et al. Biochemical recurrence after radical prostatectomy: multiplicative interaction between surgical margin status and pathological stage. *J Urol*. 2010;184(4):1341–1346.

Buskirk SJ, Pisansky TM, Schild SE, et al. Salvage radiotherapy for isolated prostate specific antigen increase after radical prostatectomy: evaluation of prognostic factors and creation of a prognostic scoring system. *J Urol*. 2006;176(3):985–990.

Calabria F, Chiaravalloti A, Ciccio C, et al. PET/CT with (18)F-choline: physiological whole bio-distribution in male and female subjects and diagnostic pitfalls on 1000 prostate cancer patients: (18)F-choline PET/CT bio-distribution and pitfalls. A southern Italian experience. *Nucl Med Biol*. 2017;51:40–54.

Calais J, Czernin J, Cao M, et al. ^{68}Ga-PSMA-11 PET/CT mapping of prostate cancer biochemical recurrence after radical prostatectomy in 270 patients with a PSA level of less than 1.0 ng/mL: impact on salvage radiotherapy planning. *J Nucl Med*. 2018;59(2):230–237.

Carrie C, Hasbini A, de Laroche G, et al. Salvage radiotherapy with or without short-term hormone therapy for rising prostate-specific antigen concentration after radical prostatectomy (GETUG-AFU 16): a randomised, multicentre, open-label phase 3 trial. *Lancet Oncol*. 2016;17(6):747–756.

Casciani E, Polettini E, Carmenini E, et al. Endorectal and dynamic contrast-enhanced MRI for detection of local recurrence after radical prostatectomy. *AJR Am J Roentgenol*. 2008;190(5):1187–1192.

Cavanagh W, Blasko JC, Grimm PD, et al. Transient elevation of serum prostate-specific antigen following (125)I/(103)Pd brachytherapy for localized prostate cancer. *Semin Urol Oncol*. 2000;18(2):160–165.

Chade DC, Shariat SF, Cronin AM, et al. Salvage radical prostatectomy for radiation-recurrent prostate cancer: a multi-institutional collaboration. *Eur Urol*. 2011;60(2):205–210.

Chang SL, Freedland SJ, Terris MK, et al. Freedom from a detectable ultrasensitive prostate-specific antigen at two years after radical prostatectomy predicts a favorable clinical outcome: analysis of the SEARCH database. *Urology*. 2010;75(2):439–444.

Chapin BF, Nguyen JN, Achim MF, et al. Positive margin length and highest Gleason grade of tumor at the margin predict for biochemical recurrence after radical prostatectomy in patients with organ-confined prostate cancer. *Prostate Cancer Prostatic Dis*. 2018;21(2):221–227.

Chen CP, Weinberg V, Shinohara K, et al. Salvage HDR brachytherapy for recurrent prostate cancer after previous definitive radiation therapy: 5-year outcomes. *Int J Radiat Oncol Biol Phys*. 2013;86(2):324–329.

Cheng L, Sebo TJ, Slezak J, et al. Predictors of survival for prostate carcinoma patients treated with salvage radical prostatectomy after radiation therapy. *Cancer*. 1998;83(10):2164–2171.

Cheng L, Cheville JC, Bostwick DG. Diagnosis of prostate cancer in needle biopsies after radiation therapy. *Am J Surg Pathol*. 1999;23(10):1173–1183.

Cherrier MM, Rose AL, Higano C. The effects of combined androgen blockade on cognitive function during the first cycle of intermittent androgen suppression in patients with prostate cancer. *J Urol*. 2003;170(5):1808–1811.

Chin JL, Lim D, Abdelhady M. Review of primary and salvage cryoablation for prostate cancer. *Cancer Control*. 2007;14(3):231–237.

Coakley FV, Hricak H, Wefer AE, et al. Brachytherapy for prostate cancer: endorectal MR imaging of local treatment-related changes. *Radiology*. 2001;219(3):817–821.

Cookson MS, Aus G, Burnett AL, et al. Variation in the definition of biochemical recurrence in patients treated for localized prostate cancer: the American Urological Association Prostate Guidelines for Localized Prostate Cancer Update Panel report and recommendations for a standard in the reporting of surgical outcomes. *J Urol*. 2007;177(2):540–545.

Cornford P, Bellmunt J, Bolla M, et al. EAU-ESTRO-SIOG guidelines on prostate cancer. Part II: treatment of relapsing, metastatic, and castration-resistant prostate cancer. *Eur Urol*. 2017;71(4):630–642.

Cox JD, Gallagher MJ, Hammond EH, et al. Consensus statements on radiation therapy of prostate cancer: guidelines for prostate re-biopsy after radiation and for radiation therapy with rising prostate-specific antigen levels after radical prostatectomy. American Society for Therapeutic Radiology and Oncology Consensus Panel. *J Clin Oncol*. 1999;17(4):1155.

Critz FA, Williams WH, Benton JB, et al. Prostate specific antigen bounce after radioactive seed implantation followed by external beam radiation for prostate cancer. *J Urol*. 2000;163(4):1085–1089.

Crook J, Robertson S, Collin G, et al. Clinical relevance of trans-rectal ultrasound, biopsy, and serum prostate-specific antigen following external beam radiotherapy for carcinoma of the prostate. *Int J Radiat Oncol Biol Phys*. 1993;27(1):31–37.

Crook JM, Perry GA, Robertson S, et al. Routine prostate biopsies following radiotherapy for prostate cancer: results for 226 patients. *Urology*. 1995;45(4):624–631 [discussion 631–622].

Crook J, Malone S, Perry G, et al. Postradiotherapy prostate biopsies: what do they really mean? Results for 498 patients. *Int J Radiat Oncol Biol Phys*. 2000;48(2):355–367.

Crook JM, O'Callaghan CJ, Duncan G, et al. Intermittent androgen suppression for rising PSA level after radiotherapy. *N Engl J Med*. 2012;367(10):895–903.

D'Amico AV, Hanks GE. Linear regressive analysis using prostate-specific antigen doubling time for predicting tumor biology and clinical outcome in prostate cancer. *Cancer*. 1993;72(9):2638–2643.

D'Amico AV, Denham JW, Crook J, et al. Influence of androgen suppression therapy for prostate cancer on the frequency and timing of fatal myocardial infarctions. *J Clin Oncol*. 2007;25(17):2420–2425.

D'Amico AV, Chen MH, Renshaw AA, et al. Risk of prostate cancer recurrence in men treated with radiation alone or in conjunction with combined or less than combined androgen suppression therapy. *J Clin Oncol*. 2008;26(18):2979–2983.

De Meerleer G, Fonteyne V, Meersschout S, et al. Salvage intensity-modulated radiotherapy for rising PSA after radical prostatectomy. *Radiother Oncol*. 2008;89(2):205–213.

Diamandis EP, Yu H. New biological functions of prostate-specific antigen? *J Clin Endocrinol Metab*. 1995;80(5):1515–1517.

Donnelly BJ, Saliken JC, Ernst DS, et al. Role of transrectal ultrasound guided salvage cryosurgery for recurrent prostate carcinoma after radiotherapy. *Prostate Cancer Prostatic Dis*.

2005;8(3):235–242.

Dorff TB, Flaig TW, Tangen CM, et al. Adjuvant androgen deprivation for high-risk prostate cancer after radical prostatectomy: SWOG S9921 study. *J Clin Oncol*. 2011;29(15):2040–2045.

Dotan ZA, Bianco FJ Jr, Rabbani F, et al. Pattern of prostate-specific antigen (PSA) failure dictates the probability of a positive bone scan in patients with an increasing PSA after radical prostatectomy. *J Clin Oncol*. 2005;23(9):1962–1968.

Duchesne GM, Woo HH, Bassett JK, et al. Timing of androgen-deprivation therapy in patients with prostate cancer with a rising PSA (TROG 03.06 and VCOG PR 01-03 [TOAD]): a randomised, multicentre, non-blinded, phase 3 trial. *Lancet Oncol*. 2016;17(6):727–737.

Duchesne GM, Woo HH, King M, et al. Health-related quality of life for immediate versus delayed androgen-deprivation therapy in patients with asymptomatic, non-curable prostate cancer (TROG 03.06 and VCOG PR 01-03 [TOAD]): a randomised, multicentre, non-blinded, phase 3 trial. *Lancet Oncol*. 2017;18(9):1192–1201.

Eisenberg ML, Davies BJ, Cooperberg MR, et al. Prognostic implications of an undetectable ultrasensitive prostate-specific antigen level after radical prostatectomy. *Eur Urol*. 2010;57(4):622–629.

Esch LH, Fahlbusch M, Albers P, et al. 11C-acetate positron-emission tomography/computed tomography imaging for detection of recurrent disease after radical prostatectomy or radiotherapy in patients with prostate cancer. *BJU Int*. 2017;120(3):337–342.

Fanti S, Minozzi S, Castellucci P, et al. PET/CT with (11)C-choline for evaluation of prostate cancer patients with biochemical recurrence: meta-analysis and critical review of available data. *Eur J Nucl Med Mol Imaging*. 2016;43(1):55–

69.

Faria SL, Mahmud S, Souhami L, et al. No immediate treatment after biochemical failure in patients with prostate cancer treated by external beam radiotherapy. *Urology*. 2006;67(1):142–146.

Finley DS, Belldegrun AS. Salvage cryotherapy for radiation-recurrent prostate cancer: outcomes and complications. *Curr Urol Rep*. 2011;12(3):209–215.

Fleshner K, Carlsson SV, Roobol MJ. The effect of the USPSTF PSA screening recommendation on prostate cancer incidence patterns in the USA. *Nat Rev Urol*. 2017;14(1):26–37.

Franiel T, Hamm B, Hricak H. Dynamic contrast-enhanced magnetic resonance imaging and pharmacokinetic models in prostate cancer. *Eur Radiol*. 2011;21(3):616–626.

Fu AZ, Tsai HT, Haque R, et al. Mortality and androgen deprivation therapy as salvage treatment for biochemical recurrence after primary therapy for clinically localized prostate cancer. *J Urol*. 2017;197(6):1448–1454.

Garcia-Albeniz X, Chan JM, Paciorek A, et al. Immediate versus deferred initiation of androgen deprivation therapy in prostate cancer patients with PSA-only relapse. An observational follow-up study. *Eur J Cancer*. 2015;51(7):817–824.

Geinitz H, Riegel MG, Thamm R, et al. Outcome after conformal salvage radiotherapy in patients with rising prostate-specific antigen levels after radical prostatectomy. *Int J Radiat Oncol Biol Phys*. 2012;82(5):1930–1937.

Gheiler EL, Tefilli MV, Tiguert R, et al. Predictors for maximal outcome in patients undergoing salvage surgery for radio-recurrent prostate cancer. *Urology*. 1998;51(5):789–795.

Giovacchini G, Picchio M, Briganti A, et al. [11C]choline positron emission tomography/computerized tomography to restage prostate cancer cases with biochemical failure after radical prostatectomy and no disease evidence on conventional imaging. *J Urol*. 2010;184(3):938–943.

Gómez-de la Fuente FJ, Martinez-Rodríguez I, de Arcocha-Torres M, et al. Contribution of (11)C-Choline PET/CT in prostate carcinoma biochemical relapse with serum PSA level below 1 ng/ml. *Rev Esp Med Nucl Imagen Mol*. 2018;37(3):156–162.

Green HJ, Pakenham KI, Headley BC, et al. Altered cognitive function in men treated for prostate cancer with luteinizing hormone-releasing hormone analogues and cyproterone acetate: a randomized controlled trial. *BJU Int*. 2002;90(4):427–432.

Grossfeld GD, Li YP, Lubeck DP, et al. Predictors of secondary cancer treatment in patients receiving local therapy for prostate cancer: data from cancer of the prostate strategic urologic research endeavor. *J Urol*. 2002;168(2):530–535.

Grossfeld GD, Latini DM, Lubeck DP, et al. Predicting recurrence after radical prostatectomy for patients with high risk prostate cancer. *J Urol*. 2003;169(1):157–163.

Grubmüller B, Baltzer P, D'Andrea D, et al. ^{68}Ga-PSMA 11 ligand PET imaging in patients with biochemical recurrence after radical prostatectomy - diagnostic performance and impact on therapeutic decision-making. *Eur J Nucl Med Mol Imaging*. 2018;45(2):235–242.

Haider MA, Chung P, Sweet J, et al. Dynamic contrast-enhanced magnetic resonance imaging for localization of recurrent prostate cancer after external beam radiotherapy. *Int J Radiat Oncol Biol Phys*. 2008;70(2):425–430.

Han M, Partin AW, Pound CR, et al. Long-term biochemical disease-free and cancer-specific survival following anatomic radical retropubic prostatectomy. The 15-year Johns Hopkins experience. *Urol Clin North Am*. 2001;28(3):555–565.

Han M, Partin AW, Zahurak M, et al. Biochemical (prostate specific antigen) recurrence probability following radical prostatectomy for clinically localized prostate cancer. *J Urol*. 2003;169(2):517–523.

Hanks GE, Hanlon AL, Lee WR, et al. Pretreatment prostate-specific antigen doubling times: clinical utility of this predictor of prostate cancer behavior. *Int J Radiat Oncol Biol Phys*. 1996;34(3):549–553.

Hanlon AL, Pinover WH, Horwitz EM, et al. Patterns and fate of PSA bouncing following 3D-CRT. *Int J Radiat Oncol Biol Phys*. 2001;50(4):845–849.

Hara T, Inoue Y, Satoh T, et al. Diffusion-weighted imaging of local recurrent prostate cancer after radiation therapy: comparison with 22-core three-dimensional prostate mapping biopsy. *Magn Reson Imaging*. 2012;30(8):1091–1098.

Harle LK, Maggio M, Shahani S, et al. Endocrine complications of androgen-deprivation therapy in men with prostate cancer. *Clin Adv Hematol Oncol*. 2006;4(9):687–696.

Hauck CR, Ye H, Chen PY, et al. Increasing fractional doses increases the probability of benign PSA bounce in patients undergoing definitive HDR brachytherapy for prostate cancer. *Int J Radiat Oncol Biol Phys*. 2017;98(1):108–114.

Heidenreich A, Bastian PJ, Bellmunt J, et al. EAU guidelines on prostate cancer. Part II: treatment of advanced, relapsing, and castration-resistant prostate cancer. *Eur Urol*. 2014;65(2):467–479.

Higano C, Shields A, Wood N, et al. Bone mineral density in patients with prostate cancer without bone metastases treated with intermittent androgen suppression. *Urology*. 2004;64(6):1182–1186.

Hong SK, Park HZ, Lee WK, et al. Prognostic significance of undetectable ultrasensitive prostate-specific antigen nadir after radical prostatectomy. *Urology*. 2010;76(3):723–727.

Hruby G, Eade T, Kneebone A, et al. Delineating biochemical failure with ^{68}Ga-PSMA-PET following definitive external beam radiation treatment for prostate cancer. *Radiother Oncol*. 2017;122(1):99–102.

Hsu IC, Cabrera AR, Weinberg V, et al. Combined modality treatment with high-dose-rate brachytherapy boost for locally advanced prostate cancer. *Brachytherapy*. 2005;4(3):202–206.

Hull GW, Rabbani F, Abbas F, et al. Cancer control with radical prostatectomy alone in 1,000 consecutive patients. *J Urol*. 2002;167(2 Pt 1):528–534.

Ismail M, Ahmed S, Kastner C, et al. Salvage cryotherapy for recurrent prostate cancer after radiation failure: a prospective case series of the first 100 patients. *BJU Int*. 2007;100(4):760–764.

Jiang P, van der Horst C, Kimmig B, et al. Interstitial high-dose-rate brachytherapy as salvage treatment for locally recurrent prostate cancer after definitive radiation therapy: toxicity and 5-year outcome. *Brachytherapy*. 2017;16(1):186–192.

Johnson S, Jackson W, Li D, et al. The interval to biochemical failure is prognostic for metastasis, prostate cancer-specific mortality, and overall mortality after salvage radiation therapy for prostate cancer. *Int J Radiat Oncol Biol Phys*. 2013;86(3):554–561.

Jones TA, Chin J, McLeod D, et al. High intensity focused ultrasound for radiorecurrent prostate cancer: a North American clinical trial. *J Urol*. 2018;199(1):133–139.

Kattan MW, Eastham JA, Stapleton AM, et al. A preoperative nomogram for disease recurrence following radical prostatectomy for prostate cancer. *J Natl Cancer Inst*. 1998;90(10):766–771.

Keating NL, O'Malley AJ, Smith MR. Diabetes and cardiovascular disease during androgen deprivation therapy for prostate cancer. *J Clin Oncol*. 2006;24(27):4448–4456.

Kim CK, Park BK, Park W, et al. Prostate MR imaging at 3T using a phased-arrayed coil in predicting locally recurrent prostate cancer after radiation therapy: preliminary experience. *Abdom Imaging*. 2010;35(2):246–252.

King CR. The timing of salvage radiotherapy after radical prostatectomy: a systematic review. *Int J Radiat Oncol Biol Phys*. 2012;84(1):104–111.

King CR. The dose-response of salvage radiotherapy following radical prostatectomy: a systematic review and meta-analysis. *Radiother Oncol*. 2016;121(2):199–203.

Kitajima K, Fukushima K, Yamamoto S, et al. Diagnostic performance of ^{11}C-choline PET/CT and bone scintigraphy in the detection of bone metastases in patients with prostate cancer. *Nagoya J Med Sci*. 2017;79(3):387–399.

Kollmeier MA, McBride S, Taggar A, et al. Salvage brachytherapy for recurrent prostate cancer after definitive radiation therapy: a comparison of low-dose-rate and high-dose-rate brachytherapy and the importance of prostate-specific antigen doubling time. *Brachytherapy*. 2017;16(6):1091–1098.

Lee WR, Hanks GE, Hanlon A. Increasing prostate-specific antigen profile following definitive radiation therapy for localized prostate cancer: clinical observations. *J Clin Oncol*. 1997;15(1):230–238.

Lee AK, Levy LB, Cheung R, et al. Prostate-specific antigen doubling time predicts clinical outcome and survival in prostate cancer patients treated with combined radiation and hormone therapy. *Int J Radiat Oncol Biol Phys*. 2005;63(2):456–462.

Lerner SE, Blute ML, Zincke H. Critical evaluation of salvage surgery for radio-recurrent/resistant prostate cancer. *J Urol*. 1995;154(3):1103–1109.

Letran JL, Brawer MK. Management of radiation failure for localized prostate cancer. *Prostate Cancer Prostatic Dis*. 1998;1(3):119–127.

Li YH, Elshafei A, Agarwal G, et al. Salvage focal prostate cryoablation for locally recurrent prostate cancer after radiotherapy: initial results from the cryo on-line data registry. *Prostate*. 2015;75(1):1–7.

Maj-Hes AB, Mathieu R, Özsoy M, et al. Obesity is associated with biochemical recurrence after radical prostatectomy: a multi-institutional extended validation study. *Urol Oncol*. 2017;35(7):460.e1–460.e8.

Malik RD, Goldberg JD, Hochman T, et al. Three-year postoperative ultrasensitive prostate-specific antigen following open radical retropubic prostatectomy is a predictor for delayed biochemical recurrence. *Eur Urol*. 2011;60(3):548–553.

Martino P, Scattoni V, Galosi AB, et al. Role of imaging and biopsy to assess local recurrence after definitive treatment for prostate carcinoma (surgery, radiotherapy, cryotherapy, HIFU). *World J Urol*. 2011;29(5):595–605.

Maxeiner A, Kilic E, Matalon J, et al. The prostate health index PHI predicts oncological outcome and biochemical recurrence after radical prostatectomy—analysis in 437 patients. *Oncotarget*. 2017;8(45):79279–79288.

Messing EM, Manola J, Yao J, et al. Immediate versus deferred androgen deprivation treatment in patients with node-positive prostate cancer after radical prostatectomy and pelvic lymphadenectomy. *Lancet Oncol*. 2006;7(6):472–479.

Mettlin CJ, Murphy GP, Rosenthal DS, et al. The National Cancer Data Base report on prostate carcinoma after the peak in incidence rates in the U.S. The American College of Surgeons Commission on Cancer and the American Cancer Society. *Cancer*. 1998;83(8):1679–1684.

Mettlin CJ, Murphy GP, McDonald CJ, et al. The National

Cancer Data base Report on increased use of brachytherapy for the treatment of patients with prostate carcinoma in the U.S. *Cancer*. 1999;86(9):1877–1882.

Mir MC, Li J, Klink JC, et al. Optimal definition of biochemical recurrence after radical prostatectomy depends on pathologic risk factors: identifying candidates for early salvage therapy. *Eur Urol*. 2014;66(2):204–210.

Moghanaki D, Koontz BF, Karlin JD, et al. Elective irradiation of pelvic lymph nodes during postprostatectomy salvage radiotherapy. *Cancer*. 2013;119(1):52–60.

Morgan TM, Meng MV, Cooperberg MR, et al. A risk-adjusted definition of biochemical recurrence after radical prostatectomy. *Prostate Cancer Prostatic Dis*. 2014;17(2):174–179.

Moul JW, Paulson DF. The role of radical surgery in the management of radiation recurrent and large volume prostate cancer. *Cancer*. 1991;68(6):1265–1271.

Moul JW, Douglas TH, McCarthy WF, et al. Black race is an adverse prognostic factor for prostate cancer recurrence following radical prostatectomy in an equal access health care setting. *J Urol*. 1996;155(5):1667–1673.

Moul JW, Wu H, Sun L, et al. Early versus delayed hormonal therapy for prostate specific antigen only recurrence of prostate cancer after radical prostatectomy. *J Urol*. 2004;171(3):1141–1147.

Ng CK, Moussa M, Downey DB, et al. Salvage cryoablation of the prostate: followup and analysis of predictive factors for outcome. *J Urol*. 2007;178(4 Pt 1):1253–1257 [discussion 1257].

Oh JJ, Park S, Lee SE, et al. Genetic risk score to predict biochemical recurrence after radical prostatectomy in prostate cancer: prospective cohort study. *Oncotarget*. 2017;8(44):75979–75988.

Okotie OT, Aronson WJ, Wieder JA, et al. Predictors of metastatic disease in men with biochemical failure following radical prostatectomy. *J Urol*. 2004;171(6 Pt 1):2260–2264.

Ost P, Lumen N, Goessaert AS, et al. High-dose salvage intensity-modulated radiotherapy with or without androgen deprivation after radical prostatectomy for rising or persisting prostate-specific antigen: 5-year results. *Eur Urol*. 2011;60(4):842–849.

Panebianco V, Sciarra A, Lisi D, et al. Prostate cancer: 1HMRS-DCEMR at 3T versus [(18)F]choline PET/CT in the detection of local prostate cancer recurrence in men with biochemical progression after radical retropubic prostatectomy (RRP). *Eur J Radiol*. 2012;81(4):700–708.

Paparel P, Cronin AM, Savage C, et al. Oncologic outcome and patterns of recurrence after salvage radical prostatectomy. *Eur Urol*. 2009;55(2):404–410.

Parker C, Clarke N, Logue J, et al. RADICALS (radiotherapy and androgen deprivation in combination after local surgery). *Clin Oncol (R Coll Radiol)*. 2007;19(3):167–171.

Parker WP, Davis BJ, Park SS, et al. Identification of site-specific recurrence following primary radiation therapy for prostate cancer using C-11 choline positron emission tomography/computed tomography: a nomogram for predicting extrapelvic disease. *Eur Urol*. 2017;71(3):340–348.

Pashaei E, Pashaei E, Ahmady M, et al. Meta-analysis of miRNA expression profiles for prostate cancer recurrence following radical prostatectomy. *PLoS ONE*. 2017;12(6):e0179543.

Pearse M, Fraser-Browne C, Davis ID, et al. A Phase III trial to investigate the timing of radiotherapy for prostate cancer with high-risk features: background and rationale of the Radiotherapy—Adjuvant Versus Early Salvage (RAVES) trial. *BJU Int*. 2014;113(Suppl 2):7–12.

Perrotte P, Litwin MS, McGuire EJ, et al. Quality of life after salvage cryotherapy: the impact of treatment parameters. *J Urol*. 1999;162(2):398–402.

Picchio M, Messa C, Landoni C, et al. Value of [11C]choline-positron emission tomography for re-staging prostate cancer: a comparison with [18F]fluorodeoxyglucose-positron emission tomography. *J Urol*. 2003;169(4):1337–1340.

Picchio M, Briganti A, Fanti S, et al. The role of choline positron emission tomography/computed tomography in the management of patients with prostate-specific antigen progression after radical treatment of prostate cancer. *Eur Urol*. 2011;59(1):51–60.

Pinover WH, Horwitz EM, Hanlon AL, et al. Validation of a treatment policy for patients with prostate specific antigen failure after three-dimensional conformal prostate radiation therapy. *Cancer*. 2003;97(4):1127–1133.

Pisansky TM, Agrawal S, Hamstra DA, et al. Salvage radiation therapy dose response for biochemical failure of prostate cancer after prostatectomy—a multi-institutional observational study. *Int J Radiat Oncol Biol Phys*. 2016;96(5):1046–1053.

Pisters LL, Perrotte P, Scott SM, et al. Patient selection for salvage cryotherapy for locally recurrent prostate cancer after radiation therapy. *J Clin Oncol*. 1999;17(8):2514–2520.

Pisters LL, Rewcastle JC, Donnelly BJ, et al. Salvage prostate cryoablation: initial results from the cryo on-line data registry. *J Urol*. 2008;180(2):559–563 [discussion 563–564].

Pollack A, Zagars GK, Kavadi VS. Prostate specific antigen doubling time and disease relapse after radiotherapy for prostate cancer. *Cancer*. 1994;74(2):670–678.

Pound CR, Partin AW, Eisenberger MA, et al. Natural history of progression after PSA elevation following radical prostatectomy. *JAMA*. 1999;281(17):1591–1597.

Pucar D, Shukla-Dave A, Hricak H, et al. Prostate cancer: correlation of MR imaging and MR spectroscopy with pathologic findings after radiation therapy-initial experience. *Radiology*. 2005;236(2):545–553.

Ramey SJ, Agrawal S, Abramowitz MC, et al. Multi-institutional evaluation of elective nodal irradiation and/or androgen deprivation therapy with postprostatectomy salvage radiotherapy for prostate cancer. *Eur Urol*. 2018;74(1):99–106.

Raziee H, Berlin A. Gaps between evidence and practice in postoperative radiotherapy for prostate cancer: focus on toxicities and the effects on health-related quality of life. *Front Oncol*. 2016;6:70.

Rinnab L, Mottaghy FM, Blumstein NM, et al. Evaluation of [11C]-choline positron-emission/computed tomography in patients with increasing prostate-specific antigen levels after primary treatment for prostate cancer. *BJU Int*. 2007;100(4):786–793.

Roach M 3rd, Hanks G, Thames H Jr, et al. Defining biochemical failure following radiotherapy with or without hormonal therapy in men with clinically localized prostate cancer: recommendations of the RTOG-ASTRO Phoenix Consensus Conference. *Int J Radiat Oncol Biol Phys*. 2006;65(4):965–974.

Rodin D, Drumm M, Clayman R, et al. Risk factors for disease progression after postprostatectomy salvage radiation: long-term results of a single-institution experience. *Clin Genitourin Cancer*. 2017 [pii: S1558-7673(17)30236-7].

Roehl KA, Han M, Ramos CG, et al. Cancer progression and survival rates following anatomical radical retropubic prostatectomy in 3,478 consecutive patients: long-term results. *J Urol*. 2004;172(3):910–914.

Rogers E, Ohori M, Kassabian VS, et al. Salvage radical prostatectomy: outcome measured by serum prostate specific antigen levels. *J Urol*. 1995;153(1):104–110.

Romesser PB, Pei X, Shi W, et al. Prostate-specific antigen (PSA) bounce after dose-escalated external beam radiation therapy is an independent predictor of PSA recurrence, metastasis, and survival in prostate adenocarcinoma patients. *Int J Radiat Oncol Biol Phys*. 2018;100(1):59–67.

Rosser CJ, Kuban DA, Levy LB, et al. Prostate specific antigen bounce phenomenon after external beam radiation for clinically localized prostate cancer. *J Urol*. 2002;168(5):2001–2005.

Sandblom G, Sorensen J, Lundin N, et al. Positron emission tomography with C11-acetate for tumor detection and localization in patients with prostate-specific antigen relapse after radical prostatectomy. *Urology*. 2006;67(5):996–1000.

Scattoni V, Roscigno M, Raber M, et al. Multiple vesico-urethral biopsies following radical prostatectomy: the predictive roles of TRUS, DRE, PSA and the pathological stage. *Eur Urol*. 2003;44(4):407–414.

Schmidt-Hegemann NS, Fendler WP, Buchner A, et al. Detection level and pattern of positive lesions using PSMA PET/CT for staging prior to radiation therapy. *Radiat Oncol*. 2017;12(1):176.

Sciarra A, Panebianco V, Salciccia S, et al. Role of dynamic contrast-enhanced magnetic resonance (MR) imaging and proton MR spectroscopic imaging in the detection of local recurrence after radical prostatectomy for prostate cancer. *Eur Urol*. 2008;54(3):589–600.

Sella T, Schwartz LH, Swindle PW, et al. Suspected local recurrence after radical prostatectomy: endorectal coil MR imaging. *Radiology*. 2004;231(2):379–385.

Sharma V, Nehra A, Colicchia M, et al. Multiparametric magnetic resonance imaging is an independent predictor of salvage radiotherapy outcomes after radical prostatectomy. *Eur Urol*. 2018;73(6):879–887.

Shen S, Lepor H, Yaffee R, et al. Ultrasensitive serum prostate specific antigen nadir accurately predicts the risk of early relapse after radical prostatectomy. *J Urol*. 2005;173(3):777–780.

Shikanov S, Song J, Royce C, et al. Length of positive surgical margin after radical prostatectomy as a predictor of biochemical recurrence. *J Urol*. 2009;182(1):139–144.

Shipley WU, Thames HD, Sandler HM, et al. Radiation therapy for clinically localized prostate cancer: a multi-institutional pooled analysis. *JAMA*. 1999;281(17):1598–1604.

Shipley WU, Seiferheld W, Lukka HR, et al. Radiation with or without antiandrogen therapy in recurrent prostate cancer. *N Engl J Med*. 2017;376(5):417–428.

Siddiqui SA, Boorjian SA, Blute ML, et al. Impact of adjuvant androgen deprivation therapy after radical prostatectomy on the survival of patients with pathological T3b prostate cancer. *BJU Int*. 2011;107(3):383–388.

Siddiqui SA, Boorjian SA, Inman B, et al. Timing of androgen deprivation therapy and its impact on survival after radical prostatectomy: a matched cohort study. *J Urol*. 2008;179(5):1830–1837 [discussion 1837].

Skove SL, Howard LE, Aronson WJ, et al. Timing of prostate-specific antigen nadir after radical prostatectomy and risk of biochemical recurrence. *Urology*. 2017;108:129–134.

Sofer M, Hamilton-Nelson KL, Civantos F, et al. Positive surgical margins after radical retropubic prostatectomy: the influence of site and number on progression. *J Urol*. 2002;167(6):2453–2456.

Spahn M, Kruithof-de Julio M, Boxler S, et al. PSA-recurrence after radical prostatectomy for intermediate/high risk prostate cancer: a helpful parameter or just a patient stress amplifier. *J Clin Oncol*. 2017;35(15 Suppl):e16535.

Spiess PE, Lee AK, Leibovici D, et al. Presalvage prostate-specific antigen (PSA) and PSA doubling time as predictors of biochemical failure of salvage cryotherapy in patients with locally recurrent prostate cancer after radiotherapy. *Cancer*. 2006;107(2):275–280.

Spiess PE, Levy DA, Mouraviev V, et al. Predictors of biochemical failure in patients undergoing prostate whole-gland salvage cryotherapy: a novel risk stratification model. *BJU Int*. 2013;112(4):E256–E261.

Spiotto MT, Hancock SL, King CR. Radiotherapy after prostatectomy: improved biochemical relapse-free survival with whole pelvic compared with prostate bed only for high-risk patients. *Int J Radiat Oncol Biol Phys*. 2007;69(1):54–61.

Spry NA, Galvao DA, Davies R, et al. Long-term effects of intermittent androgen suppression on testosterone recovery and bone mineral density: results of a 33-month observational study. *BJU Int*. 2009;104(6):806–812.

Stephenson AJ, Eastham JA. Role of salvage radical prostatectomy for recurrent prostate cancer after radiation therapy. *J Clin Oncol*. 2005;23(32):8198–8203.

Stephenson AJ, Shariat SF, Zelefsky MJ, et al. Salvage radiotherapy for recurrent prostate cancer after radical prostatectomy. *JAMA*. 2004;291(11):1325–1332.

Stephenson AJ, Scardino PT, Eastham JA, et al. Postoperative nomogram predicting the 10-year probability of prostate cancer recurrence after radical prostatectomy. *J Clin Oncol*. 2005;23(28):7005–7012.

Stephenson AJ, Kattan MW, Eastham JA, et al. Defining biochemical recurrence of prostate cancer after radical prostatectomy: a proposal for a standardized definition. *J Clin*

Oncol. 2006;24(24):3973–3978.

Stephenson AJ, Scardino PT, Eastham JA, et al. Preoperative nomogram predicting the 10-year probability of prostate cancer recurrence after radical prostatectomy. *J Natl Cancer Inst*. 2006;98(10):715–717.

Stephenson AJ, Scardino PT, Kattan MW, et al. Predicting the outcome of salvage radiation therapy for recurrent prostate cancer after radical prostatectomy. *J Clin Oncol*. 2007;25(15):2035–2041.

Stephenson AJ, Kattan MW, Eastham JA, et al. Prostate cancer-specific mortality after radical prostatectomy for patients treated in the prostate-specific antigen era. *J Clin Oncol*. 2009;27(26):4300–4305.

Syed AM, Puthawala A, Sharma A, et al. High-dose-rate brachytherapy in the treatment of carcinoma of the prostate. *Cancer Control*. 2001;8(6):511–521.

Sylvester J, Grimm P, Blasco J, et al. The role of androgen ablation in patients with biochemical or local failure after definitive radiation therapy: a survey of practice patterns of urologists and radiation oncologists in the United States. *Urology*. 2001;58(2 Suppl 1):65–70.

Tan N, Shen L, Khoshnoodi P, et al. Pathological and 3 Tesla volumetric MR predictors of biochemical recurrence after robotic assisted radical prostatectomy: correlation with whole mount histopathology. *J Urol*. 2018;199(5):1218–1223.

Touma NJ, Izawa JI, Chin JL. Current status of local salvage therapies following radiation failure for prostate cancer. *J Urol*. 2005;173(2):373–379.

Trock BJ, Han M, Freedland SJ, et al. Prostate cancer-specific survival following salvage radiotherapy vs observation in men with biochemical recurrence after radical prostatectomy. *JAMA*. 2008;299(23):2760–2769.

Troyer JK, Beckett ML, Wright GL Jr. Location of prostate-specific membrane antigen in the LNCaP prostate carcinoma cell line. *Prostate*. 1997;30(4):232–242.

Vees H, Buchegger F, Albrecht S, et al. ^{18}F-choline and/or 11C-acetate positron emission tomography: detection of residual or progressive subclinical disease at very low prostate-specific antigen values (<1 ng/mL) after radical prostatectomy. *BJU Int*. 2007;99(6):1415–1420.

Ward JF, Moul JW. Rising prostate-specific antigen after primary prostate cancer therapy. *Nat Clin Pract Urol*. 2005;2(4):174–182.

Ward JF, Blute ML, Slezak J, et al. The long-term clinical impact of biochemical recurrence of prostate cancer 5 or more years after radical prostatectomy. *J Urol*. 2003;170(5):1872–1876.

Ward JF, Sebo TJ, Blute ML, et al. Salvage surgery for radiorecurrent prostate cancer: contemporary outcomes. *J Urol*. 2005;173(4):1156–1160.

Westphalen AC, Coakley FV, Roach M 3rd, et al. Locally recurrent prostate cancer after external beam radiation therapy: diagnostic performance of 1.5-T endorectal MR imaging and MR spectroscopic imaging for detection. *Radiology*. 2010;256(2):485–492.

Williams AK, Martinez CH, Lu C, et al. Disease-free survival following salvage cryotherapy for biopsy-proven radio-recurrent prostate cancer. *Eur Urol*. 2011;60:405–410.

Yakar D, Hambrock T, Huisman H, et al. Feasibility of 3T dynamic contrast-enhanced magnetic resonance-guided biopsy in localizing local recurrence of prostate cancer after external beam radiation therapy. *Invest Radiol*. 2010;45(3):121–125.

Ying J, Wang CJ, Yan J, et al. Long-term outcome of prostate cancer patients who exhibit biochemical failure despite salvage radiation therapy after radical prostatectomy. *Am J*

Clin Oncol. 2017;40(6):612–620.

Zargar H, Lamb AD, Rocco B, et al. Salvage robotic prostatectomy for radio recurrent prostate cancer: technical challenges and outcome analysis. *Minerva Urol Nefrol*. 2017;69(1):26–37.

Zattoni F, Kawashima A, Morlacco A, et al. Detection of recurrent prostate cancer after primary radiation therapy: an evaluation of the role of multiparametric 3T magnetic resonance imaging with endorectal coil. *Pract Radiat Oncol*. 2017;7(1):42–49.

Zelefsky MJ, Ben-Porat L, Scher HI, et al. Outcome predictors for the increasing PSA state after definitive external-beam radiotherapy for prostate cancer. *J Clin Oncol*. 2005;23(4):826–831.

Zietman AL, DeSilvio ML, Slater JD, et al. Comparison of conventional-dose vs high-dose conformal radiation therapy in clinically localized adenocarcinoma of the prostate: a randomized controlled trial. *JAMA*. 2005;294(10):1233–1239.

Zincke H, Oesterling JE, Blute ML, et al. Long-term (15 years) results after radical prostatectomy for clinically localized (stage T2c or lower) prostate cancer. *J Urol*. 1994;152(5 Pt 2):1850–1857.

Zumsteg ZS, Spratt DE, Romesser PB, et al. The natural history and predictors of outcome following biochemical relapse in the dose escalation era for prostate cancer patients undergoing definitive external beam radiotherapy. *Eur Urol*. 2015;67(6):1009–1016.

161

Hormonal Therapy for Prostate Cancer

Scott Eggener MD

Historical Overview

The seeds of androgen ablation therapy date back as far as 1786, when Hunter described seasonal variation in prostate size among animals (Palmer, 1893). As early as 1893, White proposed castration to treat urinary obstruction disorders based upon his research on aging dogs (White, 1893). The impact of castration on metastatic prostate cancer was championed by Charles Huggins in 1941, when he and Clarence Hodges reported **"significant improvement often occurs in the clinical condition of patients with far advanced cancer of the prostate after they have been subjected to castration. Conversely, the symptoms are aggravated when androgens are injected"** (Huggins, 1941). This paradigm shift in cancer therapy initiated the era of hormone therapy for prostate cancer for which Huggins received the Nobel Prize in 1966. The Nobel committee noted Huggins' discoveries have "already given many years of an active and useful life to patients with advanced cancer over the entire civilized world—patients who would have been lost to other forms of therapy."

Critical to understanding the control of prostatic volume by hormones was the discovery of testosterone. It had long been known that extracts of male testicles exhibited invigorating effects when injected into humans. In 1926 Fred Koch and colleagues at the University of Chicago isolated 20 mg of testosterone from 40 lb of bull testes obtained from the local stockyards (Gallagher, 1929). To illustrate its effect, they injected a neutered rooster (capon) with the substance, and within a few weeks the animal exhibited the appearance and behavior of a hormonally intact rooster. In 1935 Laqueur determined the molecular structure and Ruzicka and Butendant reported the ability to synthesize testosterone from cholesterol (Butenandt, 1935; David et al., 1935; Ruzicka, 1935).

Huggins' seminal work on prostate cancer was greatly aided by the work of Kutscher and Wohlbergs, and Gutman and Gutman (1938), who reported the discovery of serum prostatic acid phosphatase (PAP) in humans and dogs, which served as an early biomarker to track prostatic volume, much like prostate-specific antigen (PSA) is used currently. Large amounts of acid phosphatase were found in the prostate glands of men, monkeys, and dogs, in primary and metastatic prostate cancer (Gutman et al., 1936), and levels appeared to be associated with testosterone levels. Serum levels of acid phosphatase were increased in men with disseminated prostate cancer (Gutman and Gutman, 1938). **A key step was the localization of the phosphatase to prostatic**

epithelial cells, including primary and metastatic prostatic cancer cells. Subsequently, Huggins demonstrated administration of estrogen in dogs mimicked the effects of castration and resulted in prostatic atrophy, reporting that castration or estrogen administration resulted in rapid atrophy of enlarged prostates of older dogs (Huggins and Clark, 1940).

Extending his findings to humans, Huggins also reported in 1940 that castration had beneficial effects for benign prostatic hyperplasia. In 1941 Huggins published three seminal papers under the heading "Studies on Prostate Cancer I-III" (Huggins and Hodges, 1941; Huggins et al., 1941a,b). **In an important prelude to current cell-of-origin studies, Huggins examined acid phosphatase levels in prostate tissues and demonstrated increased phosphatase expression in prostate tumors, normal adult, and hypertrophic prostate, but little to undetectable enzyme in newborn infant prostate tissues** (Huggins, 1941)**. Consequently, Huggins made an important observation: "Prostatic carcinomas examined consisted of a malignant type of adult epithelium rather than of neoplastic cells of a more primitive type"** (1941). In "Studies on Prostate Cancer II" they conducted orchiectomies on 21 patients, 15 of which had detectable metastatic disease. Huggins et al. (1941b) reported "noticeable improvement" in all but three patients and demonstrated a "prompt and sharp reduction" in serum acid phosphatase levels that was maintained for many months after orchiectomy. **Huggins also noted consistent weight gain, upward red blood cell count, significant improvement of pain symptoms, edema of lower extremities, loss of sexual capacity, and hot flashes** (Huggins, 1941)**. Most importantly, this included prolonged patient survival and improved quality of life.** Case 1, marked by Huggins as "A.J.", was 50 kg with urine retention and metastatic prostate cancer, including extensive osteolytic metastases to both sides of the pelvis, with a pathological fracture of the right pubis. He was castrated on Oct 16, 1939, and on March 20, 1941, was 64 kg with no apparent cancer-related symptoms (Huggins, 1941).

No less significant than the use of surgical orchiectomy for advanced metastatic disease was the use of oral estrogens to accomplish the same effect. In the 1960s this approach was vetted by the Veterans Administration Cooperative Urologic Research Group (VACURG), when they compared the estrogen diethylstilbestrol (DES) with orchiectomy for advanced prostate cancer and found them equally effective. However, it was also found that lowering testosterone using oral estrogens caused significant cardiovascular and thromboembolic toxicities (Byar, 1973; Byar and Corle, 1988).

Unfortunately, for the men benefitting from Huggins' significant discoveries, the eventual development of castration-resistant disease progression meant hormone therapy was rarely curative and eventually led to a more aggressive and lethal form of the disease. Huggins suspected a key role for adrenal androgen synthesis in producing enough androgens to support prostate cancer growth and attempted bilateral adrenalectomies to men with castration-resistant prostate cancer (CRPC) (Huggins and Scott, 1945). Such an approach led to modest, short-term responses but carried severe shortcomings revolving around the surgical approach and side effects of removing both adrenal glands.

Given the substantial need for new avenues of decreasing testosterone production for prostate cancer treatment, other labs directed their attention upstream of testosterone-secreting cells to endocrine signaling by the hypothalamic-pituitary-gonadal axis. First, the mechanistic underpinnings of estrogens decreasing testosterone production was demonstrated by Swerdloff and Walsh, whereby estradiol potently inhibited luteinizing hormone (LH) secretion (Walsh et al., 1973). Second, the isolation of luteinizing hormone–releasing hormone (LHRH) by Schally et al. (1971) led to the development of synthetic LHRH analogues (agonists and antagonists). Such LHRH agonists lead to an initial surge of testosterone release (i.e., flare) but ultimate loss of pituitary stimulation results in decreased LH levels and decreased production of testosterone by Leydig cells. LHRH agonists were then re-engineered as long-acting depot preparations, lasting several months, and established LHRH agonists as the dominant treatment in hormone therapy for prostate cancer.

The discovery of the protein target for hormone therapy, the androgen receptor (AR), ushered in a new era of chemical anti-androgenic compounds directly blocking the key oncogenic driver of prostate cancer. **Such therapies attempt to interrupt ligand-receptor binding to reduce AR activity and signaling in prostate cancer cells.** However, many antiandrogenic compounds block feedback to the hypothalamic-pituitary axis, leading to increased LH and testosterone production when used as single agents without concurrent chemical or surgical castration.

Molecular Biology of the Androgen Axis

The AR is a member of the nuclear receptor superfamily, which includes receptors for the sex steroids (androgen, estrogen, progestin), adrenal steroids (mineralocorticoids, glucocorticoids), thyroid hormones, vitamin D, and retinoids. **These receptors act as ligand-inducible transcription factors, containing three key functional domains: ligand-binding (LBD), DNA-binding, and transactivation.** Membrane-permeable steroid ligands diffuse into the cell, where they engage the LBD and activate the DNA-binding domains; the transactivation domain binds and recruits other gene transcriptional partners to thus regulate gene expression, either by repression or activation (Fig. 161.1). **The AR gene is located on the X chromosome, meaning only one copy is inherited in XY males.** Sequencing, ligand-binding, and transcriptional activation of mutant AR forms from cancer and androgen insensitivity syndromes have enabled detailed functional mapping of the AR to identify key amino acids necessary for proper function (Gottlieb et al., 2012). Proper regulation of the AR is essential for prostate development, adult glandular homeostasis, and cancer progression. Furthermore, all forms of androgen deprivation therapy (ADT) orbit around blocking AR activity, either by reducing levels of AR ligand or inhibiting AR activity directly (Table 161.1).

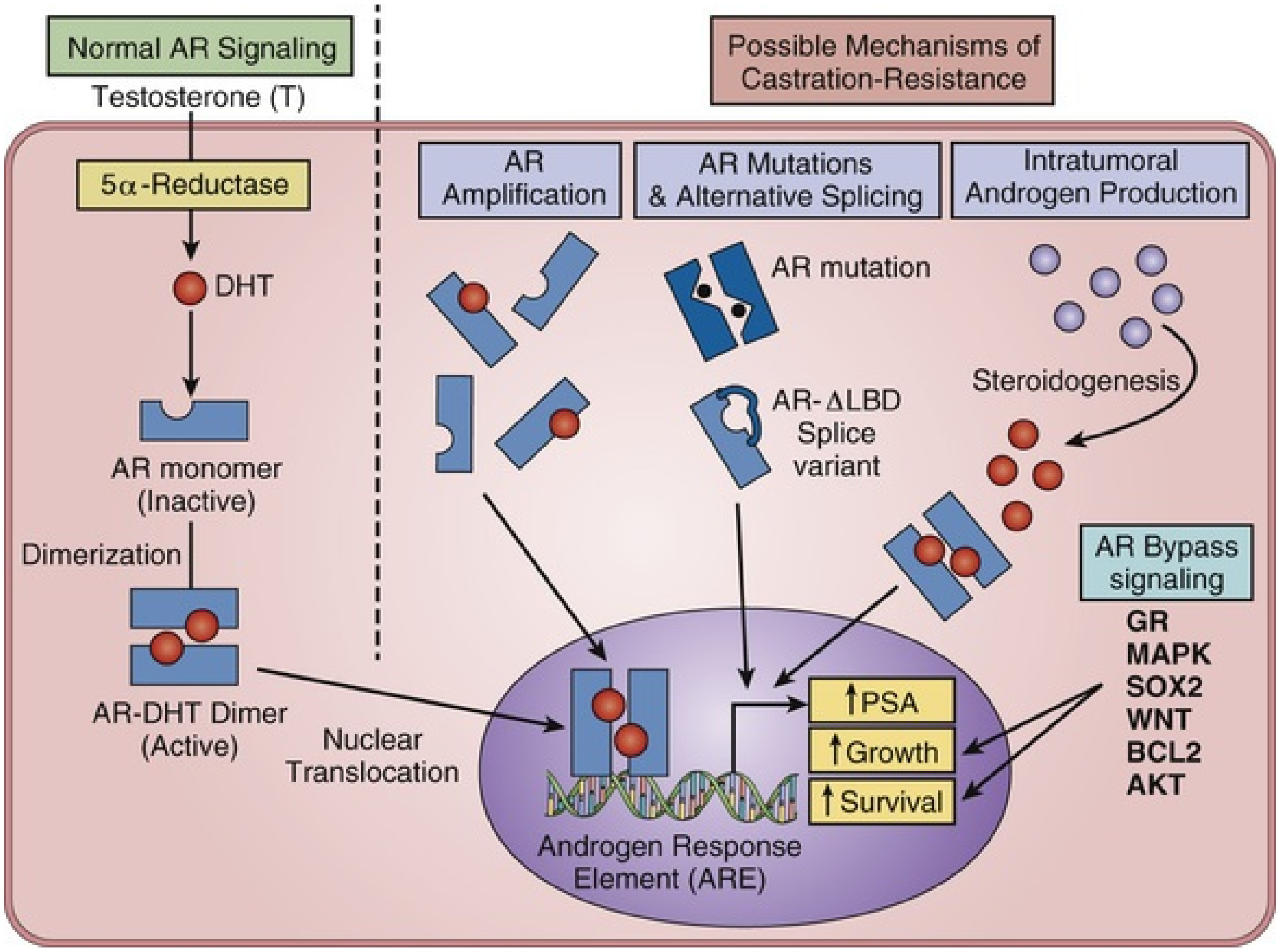
Normal AR Signaling
Testosterone (T)
5α-Reductase
DHT
AR monomer (Inactive)
Dimerization
AR-DHT Dimer (Active)
Nuclear Translocation
Possible Mechanisms of Castration-Resistance
AR Amplification
AR Mutations & Alternative Splicing
Intratumoral Androgen Production
AR mutation
AR-ΔLBD Splice variant
Steroidogenesis
AR Bypass signaling
GR
MAPK
SOX2
WNT
BCL2
AKT
↑PSA
↑Growth
↑Survival
Androgen Response Element (ARE)

FIG. 161.1 Molecular biology of the androgen receptor (AR) and putative mechanism of resistance to AR blockade.

TABLE 161.1

Hormonal Interventions and Endocrine Axis in Prostate Cancer

CLASS OF DRUGS	DRUG NAMES	SITE OF ACTION	MECHANISM OF ACTION	COMMENTS
GnRH agonists	Leuprolide Goserelin Triptorelin	Pituitary gland	Stimulates release of LH; feedback loop ultimately decreases LH production	Mainstay of therapy for metastatic disease; leads to increase in FSH; considerable side effects
GnRH antagonists	Degarelix Abarelix Cetrorelix	Pituitary gland	Binds to receptors and blocks release of GnRH	Prevents testosterone surge; leads to decrease in FSH; considerable side effects
Adrenal-	Ketoconazole	Adrenal	Decreases	Selective CYP17

targeting drugs	Abiraterone Oreteronel (TAK-700) Galeterone	gland	androgen production from steroid precursors by blocking cytochrome P450 enzymes	inhibitors administered with low-dose prednisone; side effects can include hypertension, edema, and hypokalemia
First-generation AR antagonists	Flutamide Nilutamide Bicalutamide	Prostate Prostate cancer	Nonsteroidal antiandrogen inhibits binding of testosterone and DHT to the AR	Monotherapy not indicated; associated with gynecomastia
Second-generation AR antagonists	Enzalutamide Apalutamide	Prostate Prostate cancer	Blocks AR, minimizes nuclear translocation of AR, and diminishes AR-mediated transcription	Associated with falls, fatigue, and decreased appetite
5α-Reductase inhibitors	Finasteride (type II isoenzyme inhibition) Dutasteride (type I and II isoenzyme inhibition)	Prostate Prostate cancer	Inhibits the conversion of testosterone to DHT	Commonly administered for BPH; not indicated for prostate cancer management

AR, Androgen receptor; *BPH,* benign prostatic hyperplasia; *DHT,* dihydrotestosterone; *FSH,* follicle-stimulating hormone; *GnRH,* Gonadotropin-releasing hormone; *LH,* luteinizing hormone.

The initial paradigm of castration-resistance (previously termed “androgen-independent” or “hormone-refractory”) prostate cancer was, after blocking AR activity by removing ligand, prostate cancer cells would adapt by using non–AR-mediated resistance mechanisms to maintain cancer cell survival and drive proliferation. **Analyses of rapid/warm autopsies, however, of men succumbing to advanced CRPC demonstrated AR pathway activation is still necessary and sufficient for CRPC** (Rubin et al., 2000). Such studies thus refocused attention back to the AR as a key driver of CRPC. Moreover, such revelations led to a refinement of terminology from “androgen-dependent vs.

androgen-independent” to “castration-resistant” to reflect the continued dependency of CRPC on AR signaling (see Fig. 161.1) (Scher et al., 2004).

All current forms of hormonal therapy in prostate cancer function by reducing the ability of androgen to activate the AR, whether through lowering levels of androgen, decreasing conversion of testosterone to the more potent AR-ligand dihydrotestosterone, (DHT) or by blocking androgen-AR binding (see Table 161.1). A variety of molecular mechanisms are implicated in this process of castration-resistance (see Fig. 161.1). First, the AR gene is overexpressed in approximately 20% to 30% of CRPC metastases (Edwards et al., 2003; Koivisto et al., 1997), although more sensitive techniques such as gene expression profiling suggest amplification is more common when hormone-resistant human prostate cancer cell lines are compared with the hormone-sensitive tumors from which they were derived (Chen et al., 2004). Such alterations are thought to enhance the response of the cancer cell to low levels of endogenous androgens (Hyytinen et al., 2002; Mohler et al., 2004). Second, activating mutations in the AR gene have also been reported (Suzuki et al., 1996; Taplin et al., 1995). Mutations in the steroid-binding domain may alter ligand specificity, allowing other non-androgenic steroids as well as antiandrogens to bind and activate the mutant AR, even when the level of systemic androgen is fully suppressed. AR mutations have been most intensely studied in the context of the antiandrogen withdrawal response, in which acquired mutations in the AR are thought to result in a paradoxical stimulatory effect of antiandrogens on prostate tumor cells. Mutations in the ligand-binding domain of the AR have been detected in a small fraction of bone marrow specimens of men with castrate-resistant prostate cancer (Suzuki et al., 1996; Taplin et al., 1995, 2003a). In functional studies, these mutant receptors were stimulated rather than inhibited by some but not all antiandrogens. Third, other specific AR mutations and splice variants deleting the LBD provide an additional pathway for androgen escape in prostate cancer cells by producing AR variants that are no longer dependent on androgen ligand for activation (Antonarakis et al., 2014; Dehm et al., 2008). The predominant **androgen-receptor splice variant 7 (AR-V7)** has been strongly associated with castration resistance and overall poor patient survival (Antonarakis et al., 2014). Finally, non–AR-mediated pathways for maintaining cell survival or co-opting other steroid hormone receptors (such as the glucocorticoid receptor) have been shown to drive AR pathway–inhibited CRPC (Arora et al., 2013; Isikbay et al., 2014).

Key Points

- Steroid receptors, such as the AR, act as ligand-inducible transcription factors, containing three key functional domains: ligand binding, DNA binding, and transactivation.
- All current forms of hormonal therapy in prostate cancer reduce AR activity.
- Men succumbing to advanced CRPC continue to have AR pathway activation.
- Methods of AR pathway adaptation to hormonal therapy include mutation, amplification, de novo steroidogenesis, and AR splice variants.

Sources of Androgen

The hydrophobic properties of testosterone render it able to diffuse in and out of cells without any cellular transport machinery**. Cells that are primed to respond to testosterone (i.e., prostate, muscle) also express AR and the enzyme 5α-reductase.** Within the cellular cytosol, testosterone undergoes conversion to dihydrotestosterone (DHT) via the enzyme 5α-reductase. DHT binds and activates AR at approximately 13-fold that of testosterone and is the preferred ligand for AR (Wright et al., 1999). Engagement of AR by DHT results in translocation of AR into the nucleus, where it binds androgen response elements (AREs) in gene promoters to regulate gene expression (Chang et al., 2005; Heinlein and Chang, 2004).

Androgens produced by the adrenal gland are androstenedione and dehydroepiandrosterone (DHEA). Their production is stimulated by adrenocorticotropic hormone (ACTH), released by the pituitary gland in response to corticotropin-releasing factor. **Adrenal androgens are relatively weak compared with testosterone** and DHT and are insufficient to maintain prostate epithelium in castrated men (Walsh and Siiteri, 1975).

A final source of androgens is the induction of steroidogenesis by prostate cancer cells to produce their own AR ligands in an autocrine manner. In some instances, **tissue from prostate metastases has elevated androgens, and prostate cancer cells have increased the expression of steroidogenic enzymes necessary to synthesize androgens** (Montgomery et al., 2008). The discovery of alternative sources for androgen production, along with the improved understanding of adaptive changes within the AR that promote resistance to AR antagonists, have led to a new class of inhibitors to block steroid production as (discussed in the Inhibition of Androgen Synthesis section). The sources and relative potency of systemic androgens are summarized in Table 161.2.

TABLE 161.2

Major Circulating Androgens

SOURCE	ANDROGEN	AMOUNT PRODUCED/DAY (mg)	RELATIVE POTENCY	RELATIVE POTENCY/AM PRODUCED
Testes	Testosterone	6.6	100	15.2
Testes and peripheral tissues	Dihydrotestosterone	0.3	160–190	533–633
Adrenal glands	Androstenedione	1.4	39	27.9
Adrenal glands	Dehydroepiandrosterone	29	15	0.5

Key Points

- Cells responsive to testosterone express AR and the enzyme 5α-reductase, which converts testosterone (T) to DHT.
- Engagement of AR by DHT results in translocation of AR into the nucleus, where it binds AREs in gene promoters to regulate gene expression.
- Adrenal androgens are relatively weak compared with testosterone.

Mechanisms of Androgen Blockade

Four general approaches for androgen signaling blockade are currently available: (1) surgical removal of the testicles (orchiectomy), (2) AR antagonism, (3) inhibition of LHRH and/or LH, and (4) inhibition of androgen synthesis (see Table 161.1). Classically, ADT refers to chemical or surgical castration.

Orchiectomy

Because 95% of circulating testosterone originates from the testicles, bilateral orchiectomy quickly and dramatically reduces circulating testosterone levels to less than 50 ng/dL (1.7 nmol/L), which is considered within the castrate range. Within 6 hours of surgical castration, testosterone levels are within the castrate level (Maatman et al., 1985), and within 12 hours nearly all men have testosterone levels below 20 ng/dL (0.7 nmol/L) (Lin et al., 1994). Median testosterone levels after orchiectomy is 15 ng/dL (0.5 nmol/L) with all men achieving less than 30 ng/dL (1.0 nmol/L) (Oefelein et al., 2000). VACURG conducted a series of large clinical trials demonstrating the clinical effectiveness of surgical castration in reducing pain and improving performance status in men with advanced or metastatic disease (Byar, 1973; Byar and Corle, 1988). Subcapsular orchiectomy, with preservation of nonfunctional tissue, has been advocated as a technique of ADT that avoids the cosmetic and psychological consequences of a completely empty scrotum (Desmond et al., 1988). Because this approach relies on the complete removal of all intratesticular tissue and Leydig cells, it is more operator dependent than a simple orchiectomy. When a subcapsular orchiectomy is executed properly, the hormonal and cancer responses are indistinguishable from a simple, complete orchiectomy (Zhang et al., 1996). Although orchiectomy rather than chemical castration would lead to a dramatic decrease in US and worldwide health care costs, only 2% of men age 65 and older who started androgen deprivation between 2003 and 2005 had a simple orchiectomy (Shahinian et al., 2010). In a comparative population-based cohort, orchiectomy (compared with LHRH agonists) appeared to have significantly lower risks of cardiac events, peripheral arterial disease, and skeletal fractures (Sun et al., 2016). For those with prolonged therapy (≥35 months), lower rates of thromboembolism and diabetes were also observed.

Antiandrogens

Antiandrogens as a class of medications are molecularly AR antagonists. All antiandrogens in use currently rely on binding the AR's ligand-binding domain, resulting in competitive and allosteric inhibition of agonist ligand binding. There are steroidal antiandrogens such as cyproterone acetate that are no longer in clinical use, as well as early generation nonsteroidal antiandrogens (flutamide, bicalutamide, nilutamide), as well as the more potent third-generation antiandrogens enzalutamide, apalutamide, and darolutamide (the first two are FDA approved and in clinical use) (Crawford et al., 2018; Fizazi et al., 2017; Fig. 161.2).

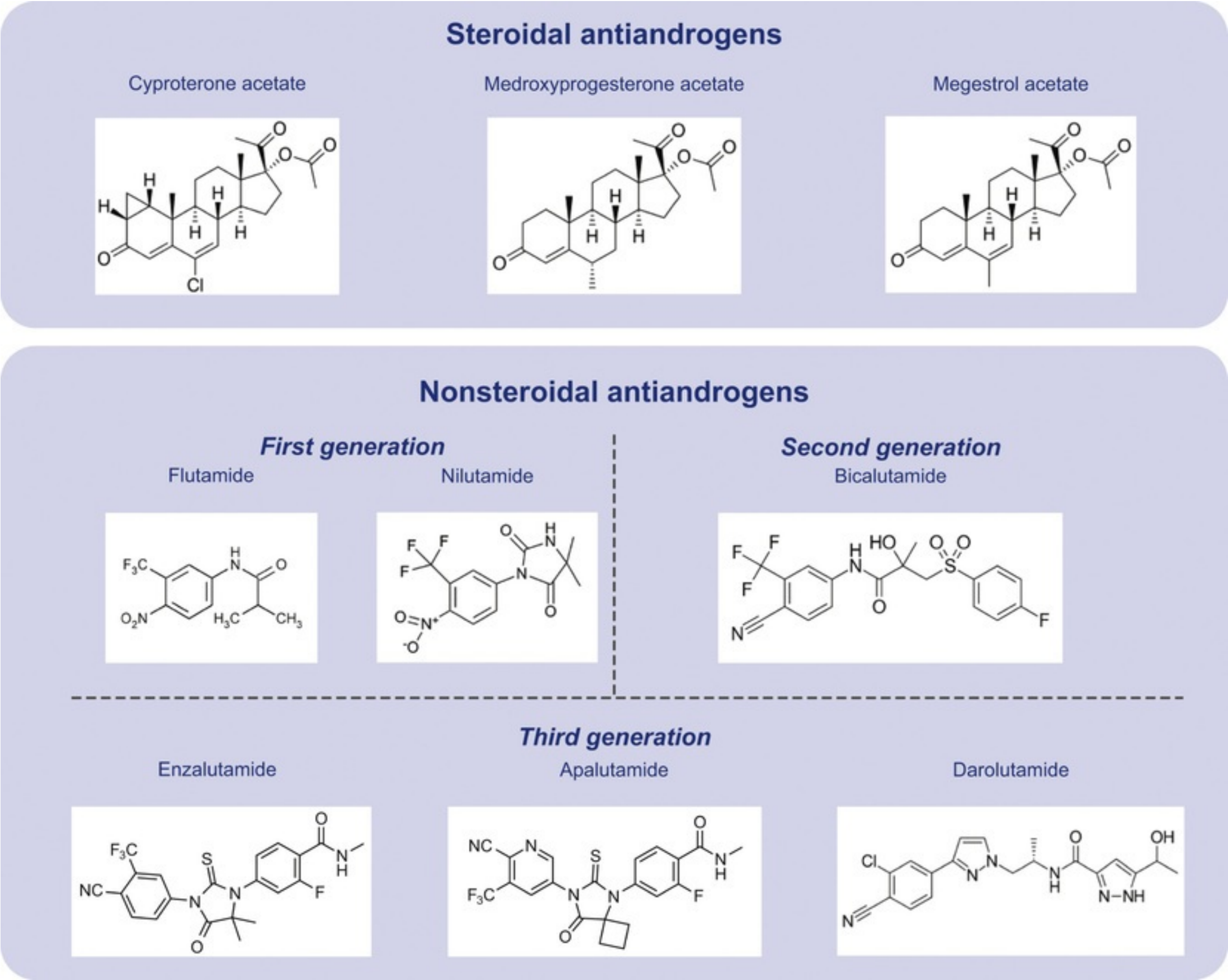
Steroidal antiandrogens
Cyproterone acetate
Medroxyprogesterone acetate
Megestrol acetate
Nonsteroidal antiandrogens
First generation
Flutamide
Nilutamide
Second generation
Bicalutamide
Third generation
Enzalutamide
Apalutamide
Darolutamide

FIG. 161.2 Chemical structures of steroidal and nonsteroidal antiandrogens. (Figure 3 from Crawford ED, Schellhammer PF, McLeod DG, et al.: Androgen receptor targeted treatments of prostate cancer: 35 years of progress with antiandrogen. *Urology* 200[5]:955–956, 2018 [online journal]: https://www.ncbi.nlm.nih.gov/pubmed/29730201.)

Steroidal First Generation

Cyproterone acetate, the classic steroidal antiandrogen with direct AR-blocking effects, also rapidly lowers testosterone levels by 70% to 80% through its progestational central inhibition of the androgen axis (Barradell and Faulds, 1994; Goldenberg and Bruchovsky, 1991; Jacobi et al., 1980). An oral agent, the recommended dose is 100 mg two to three times per day. Side effects are consistent with the hypogonadal state and include loss of libido, erectile dysfunction, and lethargy. Compared with an LHRH analog (goserelin acetate), cyproterone for men with metastatic prostate cancer was associated with shorter median time to clinical progression (Thorpe et al., 1996). An unblinded trial of 366 men randomized to intermittent versus continuous cyproterone acetate (100 mg PO three times daily) for men with prostate cancer metastatic to bone suggested quality-of-life advantages without meaningful differences in clinical progression or survival, although the sample size and power obviate definitive proof of oncologic equivalence (Verhagen et al., 2014). Severe cardiovascular complications (up to 10% of patients), gynecomastia (20%), and rare cases of fulminant hepatotoxicity can occur (Parys et al., 1991). For these reasons, it is rarely used, although it has been used at doses of 50 to 100 mg/day for the treatment of hot flashes (Goldenberg and Bruchovsky, 1991).

Nonsteroidal First- and Second-Generation

Considered early generation AR antagonists, traditional nonsteroidal antiandrogens (flutamide, nilutamide, bicalutamide) block AR activity but, when used as single agents, cause LH and testosterone levels to increase. Testosterone levels reach about 1.5 times the normal levels of hormonally intact men, allowing putative antiandrogen activity without inducing hypogonadism: potency therefore can be preserved (Brufsky et al., 1997). However, in clinical trials specifically examining erectile function and sexual activity in men on flutamide monotherapy, long-term preservation occurred in only 20% (Schroder et al., 2000). The peripheral aromatization of increased testosterone to estradiol commonly leads to gynecomastia and mastodynia with these agents (Knuth et al., 1984). Gastrointestinal toxicity, most notably diarrhea, is more common with flutamide than other nonsteroidal antiandrogens (Han and Nelson, 2000). Liver toxicity, ranging from reversible hepatitis to fulminant hepatic failure, is associated with all nonsteroidal antiandrogens and requires periodic monitoring of liver function tests (Thole et al., 2004). Interstitial pneumonitis with the possibility of progressing to pulmonary fibrosis has been associated with all available nonsteroidal antiandrogens (Bennett et al., 2002), the highest rate occurring with nilutamide (1% to 2% of patients) (Pfitzenmeyer et al., 1992).

Flutamide.

Flutamide was the first “pure” antiandrogen (Neri et al., 1967). Unlike the steroidal antiandrogens, there are no associated side effects of fluid retention or thromboembolism (Delaere and Van Thillo, 1991). In a randomized, double-blind study comparing flutamide with DES (3 mg/day) in metastatic prostate cancer, overall survival was significantly shorter with flutamide (28.5 months) compared with DES (43.2 months) (Chang et al., 1996). Because of the short half-life (6 hours) of the active metabolite, 2-hydroxyflutamide, this oral agent must be given three times a day at 250 mg per dose. For these reasons, it is rarely used in contemporary practice.

Bicalutamide.

A nonsteroidal antiandrogen with a long serum half-life (6 days), bicalutamide has a once-daily dosing schedule at 50 to 150 mg. It is the most potent of the “first-generation” nonsteroidal antiandrogens (Kolvenbag and Nash, 1999) and the best tolerated (Fradet, 2004; Kolvenbag and Blackledge, 1996; Schellhammer and Davis, 2004). The pharmacokinetics of bicalutamide are not affected by age, renal insufficiency, or moderate hepatic impairment (Mahler et al., 1998). As with other antiandrogens, bicalutamide is associated with maintenance of serum testosterone levels: in the majority of patients, these remain within the normal range (Denis and Mahler, 1996; Tay et al., 2004).

In a series of randomized trials, bicalutamide monotherapy at a 50 mg/day dose was inferior to medical or surgical castration for survival of men with metastatic disease (Bales Chodak, 1996; Kaisary et al., 1995; Kolvenbag and Nash, 1999). At a higher dose of 150 mg/day, bicalutamide monotherapy appeared to have equivalent efficacy to medical or surgical castration (Anderson, 2003; Iversen et al., 2000, 2004; McLeod et al., 2006; Tyrrell et al., 1998; Wirth et al., 2004) in men with locally advanced or metastatic disease. In these large phase III studies, bicalutamide monotherapy (150 mg/day) had significantly better quality of life in the domains of sexual interest and physical capacity (Iversen, 2003). There was, however, a high rate of gynecomastia (66%) and breast pain (73%) (Iversen, 2003). More concerning, in men with low-risk, localized prostate cancer, bicalutamide was associated with significantly worse overall survival compared with watchful waiting (Iversen et al., 2010). For these reasons, it was never widely adopted as monotherapy for men with clinically localized or metastatic prostate cancer.

Nilutamide.

The plasma half-life of nilutamide is 56 hours, and elimination is via hepatic clearance employing the cytochrome P450 system. Because steady-state plasma levels are achieved in 14 days with daily dosing (Creaven et al., 1991), dosing recommendations are a single 300-mg daily dose for the first month of treatment followed by a single 150-mg daily dose (Mahler et al., 1998). **About one-quarter of men on nilutamide therapy note a delayed adaptation to darkness after exposure to bright illumination** (Creaven et al., 1991). The early effects are usually reversible with cessation of nilutamide (Desai et al., 2001). Nilutamide is primarily of historical note and rarely used.

The first-generation antiandrogens are primarily used clinically for combined androgen blockade (CAB) with LHRH agonists. They have a definitive role in blocking the testosterone surge associated with initiation of LHRH agonists (see LHRH Agonist). Beyond the first approximately 30 days, during which the testosterone surge can be observed, long-term combined androgen blockade with an antiandrogen and chemical/surgical castration is discussed later under Combination Hormonal Therapy.

Nonsteroidal Second Generation

Enzalutamide.

This “second-generation” antagonist inhibits function by blocking the AR, inhibiting nuclear translocation and preventing DNA binding, and is a much more pharmacologically potent AR antagonist in comparison with first-generations antiandrogens such as bicalutamide (Tran et al., 2009). A phase III trial of enzalutamide (160 mg) in men with metastatic castration-resistant prostate cancer (mCRPC) who had failed docetaxel chemotherapy (AFFIRM) showed significant improvements in radiographic progression-free and overall survival, leading to FDA approval in 2012 (Scher et al., 2012). Similarly, another phase III trial in men with mCRPC who had not received chemotherapy (PREVAIL) also showed significant improvements in radiographic progression-free and overall survival (Beer and Tombal, 2014). Two randomized phase II study (TERRAIN, STRIVE) comparing enzalutamide with bicalutamide in a similar clinical state showed a significant improvement in median progression-free survival (15.7 vs. 5.8; 19.4 vs. 5.7 months) (Penson et al., 2016; Shore et al., 2016). Most recently, the phase III PROSPER trial of enzalutamide versus placebo in the nonmetastatic CRPC state showed a significant improvement in time to metastatic progression or death by nearly 2 years (36.6 vs. 14.7 months; hazard ratio (HR) = 0.29, $P < 0.001$) (Clegg et al., 2012; Hussain et al., 2018). Enzalutamide is now FDA approved across the entire spectrum of CRPC (nonmetastatic and metastatic, regardless of previous exposure to chemotherapy). The most common side effects of enzalutamide are fatigue, breast enlargement/tenderness, diarrhea, and hot flashes. Seizures were more common in men taking enzalutamide compared with placebo but occurred in less than 1%.

Apalutamide.

Apalutamide (ARN-509) is another "second-generation" AR antagonist without significant agonist activity that, like enzalutamide, potently inhibits AR nuclear localization, DNA binding, and androgen-mediated gene transcription within prostate cancer cells (Clegg et al., 2012). Safety and efficacy profiles in early stage clinical trials (Rathkopf et al., 2013; Smith et al., 2016) led to a large randomized Phase III trial (SPARTAN) of daily oral apalutamide (240 mg), which demonstrated a significant improvement in metastasis-free survival (40.5 vs. 16.2 months; HR = 0.28, $P < 0.001$) compared with placebo in men with nonmetastatic castrate-resistant prostate cancer with a PSA doubling time of 10 months or less (Smith et al., 2018). Consequently, it received FDA approval in 2018, for men with nonmetastatic castrate-resistant prostate cancer, irrespective of PSA doubling time. Approximately 25% of men experienced a rash, 12% experienced falls and fractures, and 8% had hypothyroidism.

Antiandrogen Withdrawal Syndrome

Patients treated with a combination of an antiandrogen and LHRH agonist can experience a decline in PSA and even objective responses after withdrawal of the antiandrogen from the combination. Based on this response, it appears the antiandrogen can paradoxically exert agonistic activity on prostate cancer cells. This phenomenon, first described with flutamide (Kelly and Scher, 1993), has now been demonstrated with all antiandrogens, including cyproterone acetate, as well as with DES and progestational agents (Kelly et al., 1997). Biologically, this phenomenon is believed to be secondary to adaptive mutations in the AR, which render the “antiandrogens” as AR agonists (Taplin et al., 1995, 2003b). Declines in PSA are seen within 4 weeks with flutamide withdrawal and within 6 weeks with bicalutamide and nilutamide withdrawal (Nieh, 1995). Between 15% and 30% of patients may have PSA declines of greater than 50% after antiandrogen withdrawal, and the declines have a median duration of 3½ to 5 months (Scher and Kelly, 1993; Small and Srinivas, 1995). The incidence of antiandrogen withdrawal syndrome (AAWS) with “second-generation” AR antagonists such as enzalutamide is considerably lower (0 to 10%), is also typically short-lived without objective radiographic responses, and presumptively is due to less AR agonist activity compared with “first-generation” AR antagonists (Rodriguez-Vida et al., 2015; von Klot et al., 2014). Overall survival has not been shown to be increased in those patients demonstrating AAWS (Small and Srinivas, 1995).

Inhibition of Luteinizing Hormone–Releasing Hormone

Luteinizing Hormone–Releasing Hormone Agonists

LHRH agonists (leuprolide, goserelin, triptorelin, histrelin) exploit the desensitization of LHRH receptors in the anterior pituitary after chronic exposure to LHRH, thereby decreasing production of LH, which subsequently leads to decreased production of testosterone. **The clinical utility of current LHRH agonists is based on synthesis of LHRH analogues by amino acid substitutions, particularly position 6 in the peptide, increasing their potency and half-lives.** Depot preparations and osmotic pump devices allow dosing intervals to extend from 28 days to 1 year, respectively, with a variety of intervening dosing options. **In a review of 24 trials involving more than 6600 patients, survival after therapy with an LHRH agonist was equivalent to orchiectomy** (Seidenfeld et al., 2000).

Initial exposure to LHRH agonists can result in a flare of LH and testosterone levels, resulting in a severe, life-threatening exacerbation of symptoms, almost exclusively occurring in men with metastases in the spine or weight-bearing regions (Waxman et al., 1985). The flare, associated with up to a 10-fold increase in LH, may last for 10 to 20 days (Weckermann and Harzmann, 2004). Fortunately, premedicating and co-administration of an antiandrogen functionally blocks the testosterone surge (Kuhn et al., 1989; Labrie et al., 1987;

Schulze and Senge, 1990). Although it had been argued the administration of the antiandrogen should precede the administration of the LHRH agonist by a week, others have found no differences in PSA levels with the simultaneous administration of both agents (Tsushima et al., 2001). Given the predictable length of the flare phenomenon, antiandrogen pre-administration or co-administration is required for only 21 to 28 days.

Luteinizing Hormone–Releasing Hormone Antagonists

LHRH antagonists (e.g., abarelix, cetrorelix, degarelix, ganirelix) bind immediately and competitively to LHRH receptors in the pituitary, reducing LH concentrations by 84% within 24 hours of administration (Weckermann and Harzmann, 2004). The direct antagonistic activity eliminates the LH and testosterone flare, which is a major therapeutic advantage of these agents: no need for antiandrogen pre-administration or co-administration. Eugonadal patients with impending spinal cord compression or severe bone pain for whom surgical castration is not appropriate may preferentially benefit from this class of agents.

In clinical trials of LHRH antagonist abarelix, testosterone levels dropped quickly, with 35%, 61%, and 98% of men chemically castrated at 2, 4, and 28 days, respectively (Tomera et al., 2001). Compared with an LHRH agonist and antiandrogen, abarelix was equally effective in achieving castrate levels of testosterone (Trachtenberg et al., 2002). Ninety-percent of men with symptomatic prostate cancer treated in an open-label fashion had improvements in pain and/or disease-related symptoms (Koch et al., 2003).

Many of the first- and second-generation antagonists induced significant histamine-mediated side effects, complications not observed as frequently in third- and fourth-generation agents (Weckermann and Harzmann, 2004). Nevertheless, **severe allergic reactions can occur with abarelix, even after previously uneventful treatment** (Koch et al., 2003). Abarelix is approved in the United States for the treatment of advanced prostate cancer in patients who cannot take other hormonal therapies and have refused surgical castration. Given the rare but serious allergic reactions, patients must be monitored for at least 30 minutes after administration.

Follicle-stimulating hormone (FSH) levels are only partially suppressed by LHRH agonists and are significantly elevated after surgical castration given the loss of inhibitory feedback. LHRH antagonists reduce LH and FSH levels (Lamharzi et al., 1998). In men with disease progression after surgical castration, treatment with abarelix reduced FSH levels by nearly 90% but did not meet criteria for PSA response (Beer et al., 2004). The clinical impact of lowering FSH levels is largely unknown.

Unlike abarelix, the LHRH antagonist degarelix has no known systemic allergic reactions (Gittelman et al., 2008; Klotz et al., 2008). In a phase III study, two separate dosing regimens of degarelix were compared with leuprolide (Klotz et al., 2008). At 3 days after administration, degarelix achieved testosterone levels of less than 50 ng/mL in more than 95% of patients, whereas leuprolide achieved this in 0 patients. Between months 1 and 12, testosterone was less than 50 ng/dL in 96% to 98% of men at all measurements, without significant difference between formulations or drug. Degarelix was more commonly associated with injection-site reactions and chills but had lower rates of urinary tract infection and arthralgia. Based on these non-inferior results, it was approved for use in the United States. **Pooled survival data from 5 prospective trials *suggest* biochemical, progression-free, and overall survival may be more favorable with degarelix compared with leuprolide or goserelin** (Klotz et al., 2014)**, although direct randomized comparison is lacking.**

Inhibition of Androgen Synthesis

Aminoglutethimide

Aminoglutethimide inhibits conversion of cholesterol to pregnenolone, an early step in steroidogenesis (Blankenstein and Bakker, 1985; Cash et al., 1967). **Given its inhibition of a very proximal step in adrenal function, aminoglutethimide blocks production of aldosterone and cortisol. As the medical version of a total adrenalectomy, the use of this agent requires replacement of cortisone and fludrocortisone.** Side effects include anorexia, nausea, skin rash, lethargy, vertigo, hypothyroidism, and nystagmus. Clinical responses have been observed in a subset of patients with castration-resistant prostate cancer treated with aminoglutethimide plus cortisone (Ponder et al., 1984; Sanford et al., 1976). In the PSA era, it is uncommonly used; however, treatment with aminoglutethimide (1000 mg/day) and hydrocortisone acetate (40 mg/day) resulted in a greater than 50% decline in PSA in 37% of patients, with median response times lasting 9 months (Kruit et al., 2004).

Ketoconazole

An orally active, broad-spectrum azole antifungal agent, ketoconazole is a nonselective P450-dependent pathway inhibitor. However, the principal mode of action intended for use in prostate cancer is blocking 17,20-desmolase, limiting the conversion of C_{21} to C_{19} steroids (e.g., DHEA-S and androstenedione). Based on the observation that some patients taking the drug developed gynecomastia, investigations of its effects on steroid synthesis demonstrated loss of adrenal steroid synthesis (Pont, 1987) and testosterone synthesis by Leydig cells (Ponder et al., 1984). The effects were rapid, with testosterone levels dropping to castrate level within 4 hours of administration in some cases (Trachtenberg et al., 1983). The effects were also immediately reversible, indicating dosing must be continuous (400 mg every 8 hours) to maintain low testosterone levels.

Early experience with ketoconazole in the treatment of prostate cancer showed it was tolerable, durable, and effective (Trachtenberg and Pont, 1984) and palliative for those who had failed first-line androgen ablation therapy (Pont, 1987). **Although ketoconazole is effective in rapidly bringing testosterone levels into the castrate range, with continuous treatment in the otherwise hormonally intact individual (no other surgical or chemical ADT), testosterone levels begin to rise and can reach low-normal ranges within 5 months of therapy** (Vanuytsel et al., 1987). Ketoconazole is uncommonly used subsequent to the development of more potent and selective androgen synthesis inhibitors, but it can be administered as a secondary hormonal manipulation in abiraterone-naive patients; although no improvement in survival, a randomized trial did show a higher rate of biochemical and objective responses when combined with antiandrogen withdrawal compared with antiandrogen withdrawal alone (Small et al., 2004). In addition to gynecomastia, ketoconazole is associated with lethargy, weakness, hepatic dysfunction, visual disturbance, and nausea (Scholz et al., 2005; Wilkinson and Chodak, 2004). Because of non-androgenic adrenal suppression, ketoconazole must be given with hydrocortisone (5–20 mg twice per day).

Abiraterone

Unlike ketoconazole, which inhibits several cytochrome P pathways, abiraterone is a potent and selective inhibitor of cytochrome P17 (CYP17), a key enzyme in androgen synthesis (Chang et al., 1996). Specifically, abiraterone inhibits 17α-hydroxylase and $C_{17,20}$-lyase, resulting in suppression of cortisol and androgen production (Fig. 161.3) but has the potential for a compensatory rise in ACTH leading to increased synthesis of aldosterone and its precursors.

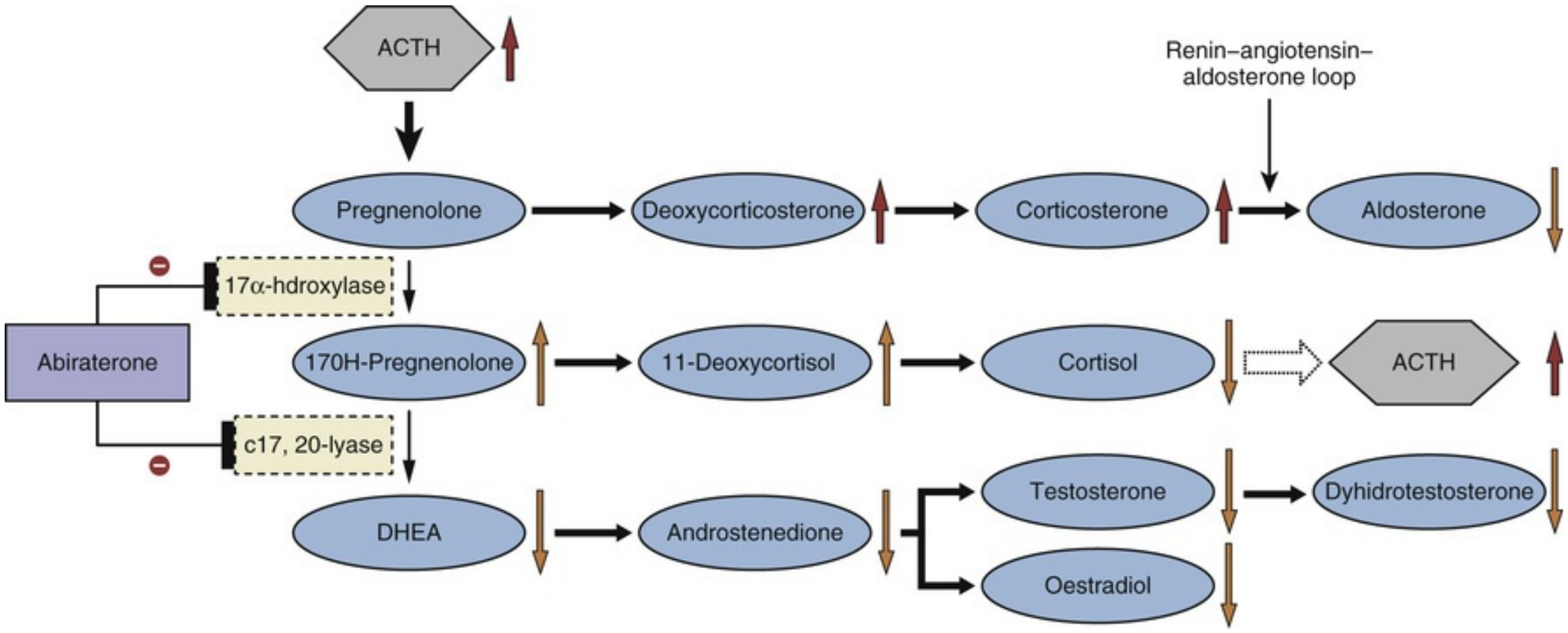
ACTH
Renin–angiotensin–aldosterone loop
Pregnenolone
Deoxycorticosterone
Corticosterone
Aldosterone
17α-hdroxylase
Abiraterone
17OH-Pregnenolone
11-Deoxycortisol
Cortisol
ACTH
c17, 20-lyase
DHEA
Androstenedione
Testosterone
Dyhidrotestosterone
Oestradiol

FIG. 161.3 Mechanism of action of abiraterone and potential side effects. *ACTH,* Adrenocorticotropic hormone.

Abiraterone was developed based on work showing castration-resistant prostate cancer remains androgen-responsive and remains driven by low levels of androgens. Toxicities stem from the effects of blocking the conversion of pregnenolone to 17-hydroxypregnenolone, resulting in an increase in the mineralocorticoids deoxycorticosterone and corticosterone (see Fig. 161.2). Untreated, this can result in hypokalemia, hypertension, and fluid overload (Attard et al., 2008). Co-administration of prednisone (5 mg one to two times daily) suppresses the ACTH increase and lowers the likelihood of mineralocorticoid excess. The seminal phase III trial of abiraterone was in men with metastatic castration-resistant prostate cancer after treatment with docetaxel (COU-AA-301 trial); abiraterone (1000 mg) plus prednisone significantly improved median progression-free (5.6 vs. 3.6 months) and overall survival (14.8 vs. 10.9 months) compared with placebo plus prednisone. Declines in PSA of 50% or more and radiographic responses occurred in 29% and 14% of men on abiraterone, respectively (de Bono et al., 2011). Similarly, in men with metastatic castration-resistant prostate cancer before chemotherapy (COU-AA-302 trial), abiraterone plus prednisone significantly improved median radiographic progression-free survival (16.5 vs. 8.3 months) and overall survival (not reached vs. 27.2 months) compared with placebo plus prednisone (Ryan et al., 2013). Most recently, **in men with newly diagnosed high-risk castrate-sensitive**

metastatic prostate cancer, a large Phase III trial (LATITUDE) was closed early when interim analysis showed abiraterone plus prednisone (plus maintenance of traditional ADT) was superior to traditional ADT by extending median radiographic progression-free (33.0 vs. 14.8 months) and overall survival (not reached vs 34.7 months, HR = 0.62) (Table 161.3; Fizazi et al., 2017**).**

TABLE 161.3

Landmark Phase III Clinical Trials in the Castration-Sensitive Biochemical Recurrent or Metastatic Setting

TRIAL	PATIENT POPULATION	INTERVENTION/CONTROL	PATIENTS (N)	PRIM POINT
NCIC PR.7	Rising PSA post-radiation, nonmetastatic	Intermittent ADT vs. continuous ADT	1386	OS nor establis median 9.1 yea 1.02 (9 0.86–1.
SWOG-9346	Metastatic	Intermittent ADT vs. continuous ADT	1535	OS nor not esta median 5.8, HF (95% C 1.23)
GETUG-AFU15	Metastatic	ADT + docetaxel 75 mg/m (White, 1893) up to 9 cycles vs. ADT	385	OS not median vs. 48.(= 0.88 0.68–1. 0.3)

CHAARTED ECOG 3805	Metastatic (predominantly high volume)	ADT + docetaxel 75 mg/m (White, 1893) 6 cycles vs. ADT	790	OS sup median vs. 44 0.61 (9 0.47–0. 0.001)
STAMPEDE	61% metastatic 15% nodal+ 24% N0M0	ADT + docetaxel 75 mg/m (White, 1893) 6 cycles + prednisolone 10 mg/day vs. ADT	1184- ADT 592- ADT + docetaxel	OS Me 81 mo 0.7 CI 0.9 0.0
STAMPEDE	52% metastatic 20% nodal+ 28% N0M0	ADT + abiraterone acetate 1000 mg/day + prednisolone 5 mg/day vs. ADT alone	1917	OS sup = 0.63 0.52–0. 0.001)
LATITUDE	Metastatic, high-risk (2 out of 3: Gleason sum ≥8, ≥3 bone lesions, visceral metastases	ADT + abiraterone acetate 1000 mg/day + prednisone 5 mg/day vs. ADT + dual placebo	1199	OS me not vs. HR (95 0.5 < 0 Ra PF sup

					me vs. HR (*P*

ADT, Androgen deprivation therapy; *CI,* confidence interval; *HR,* hazard ratio; *OS,* overall survival; *PFS,* progression-free survival; *PSA,* prostate-specific antigen; *QOL,* quality of life.

Key Points

- Androgen deprivation can be achieved by orchiectomy, inhibition of LH production, AR antagonism, or blocking androgen synthesis.
- Orchiectomy leads to an approximate 95% decrease in serum testosterone within 6 hours.
- Because of a multifaceted mechanism of action, newer generation AR antagonists have greater efficacy than early generation AR antagonists.
- Withdrawal of antiandrogens can lead to PSA decreases in some men but have not been associated with a survival advantage.
- LHRH antagonists eliminate testosterone flare seen with LHRH agonists.

Clinical Follow-Up on Hormonal Therapy

Depending on the indication for androgen blockade (M0 vs. M1, castrate-sensitive vs. castrate-resistant) and overall condition of the patient, monitoring frequency varies. For metastatic disease, clinical monitoring is typically performed every 3 months. Standard chemistries, blood counts as well as PSA should be performed at this interval, and testosterone can be added, especially before and initially after treatment changes. Standard imaging also varies based on symptoms, change in clinical state (i.e., from castrate-sensitive to castrate-resistant), and/or every 3 to 12 months.

Castrate level of testosterone (<50 ng/mL) should be maintained throughout ADT, a definition largely based on early serum testosterone assays relying on thin-layer chromatography and limited ability to measure very low levels (Oefelein et al., 2000). Since the introduction of radioimmunoassay (RIA), chemiluminescent, and mass spectrometry, accurate detection of significantly lower levels is possible. Trial data evaluating the addition of abiraterone along with data from 11 other studies (5 prospective and 6 retrospective) suggest a lower level of testosterone (even within the castrate range) may afford additional clinical benefit (Klotz et al., 2017). However, this has not been definitively shown in a prospective pre-specified manner, specifically whether early additive measures to further decrease testosterone levels are beneficial. If testosterone level has not achieved an appropriate nadir, consideration should be given to a different method of androgen deprivation (switching to a different LHRH agonist/antagonist; adding estrogen, an antiandrogen or biosynthesis inhibitor; or considering orchiectomy). In a small study of 8 patients with CRPC and a testosterone level between 20 and 50 ng/dL, switching from an LHRH agonist to antagonist led to 5 (63%) experiencing a PSA decline to less than 20 ng/dL (Soga et al., 2016). A continuously rising PSA with a sufficiently suppressed testosterone represents the emergence of castration resistance.

If there are concerns for clinical progression based on biochemical, symptomatic, or exam findings, traditional imaging typically includes chest (x-ray or CT), skeleton (bone scan), and abdomen/pelvis (CT or MRI). Consideration can also be given to newer molecular imaging modalities such as C choline, F fluciclovine, F sodium fluoride, prostate-specific membrane antigen (PSMA)–labeled imaging, Ga PET/CT or PET/MRI.

Response to Androgen Blockade

Prognostic Model

Based on 385 men from the GETUG-15 Phase III trial with castration-sensitive advanced prostate cancer (72% with metastases), clinical factors such as bone metastases and pain intensity and laboratory values such as alkaline phosphatase (ALP), hemoglobin, and LDH levels were directly related to prognosis (Gravis et al., 2015). Good-, intermediate-, and poor-risk categories (49%, 29%, and 22% of the population) were constructed with respective median overall survivals of 69, 47, and 37 months. **The strongest predictor for overall survival was ALP, a surrogate for volume of skeletal metastases.** This proposed model awaits validation in other cohorts and only considers laboratory values as “normal” versus “abnormal” rather than integration as continuous variables.

Prostate-Specific Antigen Metrics

After initiation of ADT, the majority of prostate cancer patients exhibit a clinical response: the magnitude and rapidity remain the best predictors of its durability. Assuming ADT effectively targets the androgen-sensitive population of prostate cancer cells, an incomplete or sluggish response is evidence of a significant castrate-resistant cell population.

Rapid PSA rise before starting ADT (PSA doubling time) has been independently associated with prostate cancer–specific mortality (D'Amico et al., 2005). For those destined to achieve an undetectable PSA (<0.2 ng/dL), shorter time from ADT initiation to undetectable PSA has been directly and independently correlated with improved cancer-specific mortality (D'Amico et al., 2007).

Among men with advanced or metastatic prostate cancer, the likelihood for progressing to castration-resistant disease within 24 months of starting ADT was nearly 15 times higher for patients who did not achieve an undetectable PSA (Benaim et al., 2002) and directly correlated to each interval increase in Gleason score (Benaim et al., 2002). In a cohort of Asian men, nadir PSA was the most accurate predictor of disease progression and independently associated with survival; achieving a PSA level of 1.1 ng/mL or less at 6 months after initiating ADT was directly correlated with progression at 2 years (Kwak et al., 2002). **In a significantly larger cohort of men with newly diagnosed metastatic prostate cancer started on ADT (*n* = 1345), 84% achieved a PSA less than 4**

ng/mL, 71% maintained a PSA less than 4 ng/mL at 7 months, and 45% maintained a PSA less than 0.2 ng/mL at 7 months. PSA after 7 months of ADT was a strong, independent predictor of survival (Hussain et al., 2009). Median survival was 75 months for men achieving a PSA nadir less than 0.2 ng/mL, 44 months for PSA between 0.2 and 4.0 ng/mL, and 13 months for more than 4 ng/mL. In a contemporary study randomizing men with metastatic castration-sensitive prostate cancer (mCSPC) to ADT with or without docetaxel, PSA less than 0.2 ng/mL at 7 months and low-volume metastases (no visceral metastases, 3 bone lesions or fewer, or at least 4 bone lesions limited to vertebral bodies and pelvis) were associated with prolonged survival, regardless of docetaxel administration, although docetaxel did increase the likelihood of achieving an undetectable nadir PSA (Harshman et al., 2018).

Other Clinical Predictors

Among men with a biochemical recurrence after local therapy and a PSA doubling time less than 6 months, higher Gleason score has been associated with time to cancer-specific mortality (Rodrigues et al., 2006). Among men with newly diagnosed metastatic prostate cancer starting ADT, performance status, bone pain, higher Gleason score, and PSA before initiating therapy were associated with survival (Hussain et al., 2006).

Bone Scan Index

Bone scan index (BSI), an automated method of estimating the percentage of skeleton with metastatic disease, has been directly and independently associated with time from castration-sensitive prostate cancer to castration resistance (Poulsen et al., 2016; Zacho et al., 2017). A BSI of more than 1% is considered an adverse prognostic feature. In a pre-specified analysis of 721 men with metastatic CRPC who had not received chemotherapy, BSI was independently associated with time to opiate use, symptomatic progression, and overall survival (Armstrong et al., 2018). The median overall survivals by BSI quartile (0.05%, 0.58%, 2.06%, 6.72%) were 34.7, 27.3, 21.7, and 13.3 months, respectively. However, BSI is not routinely performed in clinical practice.

Genomic Predictors

In addition to clinical predictors of response to hormonal therapies in prostate cancer, the growing field of genomic biomarkers is gaining relevance in prostate cancer. HSD3B1 is a steroidogenic enzyme that encodes for 3β-hydroxysteroid dehydrogenase-1 (3βHSD1), primarily responsible for converting adrenal androgens into DHT. A specific acquired mutation in HSD3B1 (nucleotide polymorphism 1245A>C), but also present via germline single nucleotide polymorphism in 15% to 35% of men, causes 3βHSD1 resistance to degradation, increased conversion of androgen from extragonadal sources, and excessive intratumoral DHT. In a multicohort study of men receiving ADT for biochemical recurrence after radical prostatectomy, progression-free survival, metastasis-free, and overall survival decreased as the number of variant HSD3B1 alleles increased (Hearn et al., 2016). Median PFS after starting ADT among homozygous wild-type, heterozygous, and homozygous variant men were 6.6, 4.1, and 2.5 years, respectively, and median MFS was 9.1, 6.8, and 3.6 years, respectively. Inheritance of two variant HSD3B1 alleles was independently associated with progression-free, metastasis-free, and overall survival. This provocative finding has been independently replicated and validated for progression-free survival in another cohort (Whitley et al., 1987).

Similar observations were seen in a cohort of men treated with ADT for biochemical failure after radiation therapy (Hearn et al., 2018) with median time to metastases for wild-type, heterozygous, or homozygous variant alleles being 7.4, 5.8, and 4.4 years, respectively. On multivariable analysis, presence of 2 variant HSD3B1 alleles (homozygous variant) was associated with a twofold increased rate of metastases (HR = 2.01, 95% CI 1.02 – 3.97, $P = 0.045$). **Collectively, the data suggest germline HSD3B1 variants are a predictive biomarker for response and ultimate resistance to ADT.** A clinical grade test for HSD3B1 is not yet available.

Key Points

- After androgen blockade, the rapidity and magnitude of PSA decrease are associated with duration and efficacy of response.
- HSD3B1 converts adrenal androgens into DHT, and variant alleles are associated with less favorable responses to ADT.
- In castration-sensitive prostate cancer, treatment response is associated with bone metastases, symptoms, and serum ALP, hemoglobin, and LDH levels.

General Complications of Androgen Ablation

Osteoporosis

Androgen ablation predisposes to loss of bone mineral density (BMD) with subsequent osteopenia and osteoporosis. Fragile bones increase the risk of skeletal fracture. Before the initiation of ADT, more than half of older men meet BMD criteria for osteopenia or osteoporosis—defined as more than 2.5 standard deviations below an age-specific reference mean (Conde et al., 2004; Wei et al., 1999). In men with nonmetastatic prostate cancer on ADT, population-based assessments have suggested a 20% to 45% increased risk of fracture compared with a control group (Smith et al., 2005, 2006).

The longer a man remains on ADT, the greater the risk of fracture (Daniell et al., 2000; Krupski et al., 2004). After 5 years on ADT, 19% of men experienced fractures compared with 13% of controls (Shahinian et al., 2005); over 15 years the cumulative incidence of fractures was 40% compared with 19% in non-castrate controls (Melton et al., 2003).

Treatment of osteoporosis begins with recognition. BMD of the hip as measured by dual-energy x-ray absorptiometry (DEXA) should be considered for all men who are anticipated to be on long-term ADT (Bae and Stein, 2004; Diamond et al., 2004). Fracture risk can be assessed using FRAX, an assessment tool provided by the World Health Organization (WHO) (Kanis et al., 2007). BMD testing among men receiving ADT is low in multiple practice settings, such as the Veterans Administration (15%) and among men in SEER-Medicare (10%) (Kirk et al., 2018; Morgans et al., 2013).

To mitigate risk of fracture, all men starting ADT (regardless of fracture risk) should ensure adequate intake of calcium and vitamin D_3, engage in regular weight-bearing exercise, and be encouraged to quit smoking tobacco. The NCCN Guidelines Panel derives its recommendation from the National Osteoporosis Foundation: calcium 1000 to 1200 mg/daily and vitamin D3 400 to 1000 IU/daily for all men with additional measures for men with low bone mass (T-score between −1.0 and −2.5 at the femoral neck, total hip, or lumbar spine by DEXA) and 10-year probability of hip fracture exceeding 3% or major fracture exceeding 20%. Secondary preventive measures include denosumab (60 mg SQ every 6 months), zoledronic acid (4–5 mg IV annually), or alendronate (70 mg PO weekly). For men on these medications, a follow-up DEXA scan is recommended 1 year after treatment to assess response. In all other clinical scenarios, there are no specific guidelines on value and frequency of bone health monitoring via calcium or vitamin D levels or DEXA scan.

Hot Flashes

Described as a subjective feeling of warmth in the upper torso and head followed by objective perspiration, hot flashes (alternatively referred to as hot flushes or vasomotor symptoms) are among the most common side effects of patients undergoing androgen ablation, affecting between 50% and 80% (Moyad, 2002; Nishiyama et al., 2004; Spetz et al., 2003). Occurring spontaneously and precipitated by changes in body position, ingestion of hot liquids, or changes in environmental temperature, the exact cause of hot flashes remains undefined. The proposed mechanisms have included increases in hypothalamic adrenergic concentrations and alterations in β-endorphins and calcitonin gene–related peptides acting on the thermoregulatory center in the hypothalamus (Yuzurihara et al., 2003). Hot flashes generally decrease in frequency and intensity over time but can persist in some men (Holzbeierlein et al., 2004).

Treatment of hot flashes should be reserved for those men who find them particularly bothersome. In a double-blind, placebo-controlled crossover study, the progestational agent megestrol acetate (20 mg twice per day) significantly reduced the frequency of hot flashes (Loprinzi et al., 1994). The dose can be reduced to 5 mg twice daily, which may help reduce the appetite-stimulating effect of this agent. The efficacy of cyproterone acetate in counteracting hot flashes is based on its progestational effects (Cervenakov et al., 2000). Dosing should start at 50 mg/day and can be titrated to 300 mg/day. Estrogenic compounds such as low-dose DES and transdermal estradiol appear to be the most effective treatment, with up to 90% partial or complete resolution of symptoms (Gerber et al., 2000; Miller et al., 1992; Smith, 1994). However, high rates of gynecomastia and thromboembolic effects have limited their use. **In a phase III randomized, double-blind, placebo-controlled trial, the highest studied dose of gabapentin (900 mg) decreased hot flashes to a moderate degree** (Loprinzi et al., 2009).

Antidepressant agents, particularly the selective serotonin reuptake inhibitor venlafaxine (12.5 mg twice daily), have reduced hot flashes in more than 50% of men (Loprinzi et al., 2004; Quella et al., 1999). **A randomized trial of 311 men on ADT with hot flashes evaluated venlafaxine (75 mg/daily), medroxyprogesterone acetate (20 mg/daily), and cyproterone acetate (100 mg/daily), suggesting benefit for all but superiority to medroxyprogesterone and cyproterone** (Irani et al., 2010).

Clonidine, a centrally acting α agonist that decreases vascular reactivity, has previously been used; however, in a small placebo-controlled study of 70 men, transdermal clonidine did not significantly decrease hot flashes (Loprinzi et al., 1994). Acupuncture has been evaluated in single-arm designs with encouraging results and is worthy of further study but has not been subjected to placebo-controlled trials (Ashamalla et al., 2011; Harding et al., 2009). Soy protein has been proposed as a remedy but failed to decrease hot flash symptom severity score in a randomized trial (Vitolins et al., 2013). A small randomized trial evaluated cognitive behavioral therapy compared with standard treatment and showed a decrease in hot flash frequency and intensity at 6 weeks, which was not maintained at 32 weeks (Stefanopoulou et al., 2015). In sum, medications such as progestins have a role in treating hot flashes; however, side effects must be balanced, and thus their use is typically reserved for hot flashes that significantly interrupt quality of life.

Sexual Dysfunction (Erectile Dysfunction and Loss of Libido)

The effects of ADT on sexual function are profound, as first described by Huggins (1941): “Sexual desire and penile erections were absent in all cases following castration.” **Loss of sexual functioning is not inevitable.** Specifically, between 10% and 17% of men undergoing ADT can maintain an erection adequate for intercourse (Potosky et al., 2001; Tomic, 1983). **Libido is more severely compromised, with only 5% of men maintaining a high level of sexual interest after ADT** (Potosky et al., 2001). Loss of penile volume, decreasing penile length, and loss of nocturnal penile tumescence are common (Higano, 2003; Marumo et al., 1999).

Treatment for loss of libido is extremely difficult—if not impossible—for those on ADT. Oral phosphodiesterase-5 inhibitors (e.g., sildenafil, vardenafil, tadalafil) typically are not effective, but treatments such as intraurethral suppositories, vacuum erection devices, intracavernosal injections, or placement of an inflatable penile prosthesis can be effective in selected patients. A study evaluated the role of an exercise program in 57 men on ADT. After 12 weeks, the exercise group reported a higher percentage of men reporting a major interest in sex (17% vs. 0, *P* = 0.024) (Cormie et al., 2013).

Cognitive Function

Neuropsychological testing in men ages 50 to 91 and followed for an average of 10 years showed hypogonadism led to worse memory, worse visuospatial performance, and a faster rate of decline in visual memory with no impact observed for measures of verbal knowledge, mental status, or depressive symptoms (Moffat et al., 2002). In a study of 82 men with prostate cancer randomized to LHRH agonist, cyproterone, or observation, 50% of men with androgen deprivation experienced significant cognitive decline at 6 months, specifically in tasks requiring complex information processing, compared with no men under observation (Green et al., 2002, 2004). However, a larger case-control study of 241 men (prostate cancer with ADT, prostate cancer without ADT, and healthy controls) undergoing 14 neuropsychological tests did not show a meaningful decline in cognitive function associated with ADT at 6, 12, or 36 months (Alibhai et al., 2010a, 2017).

In a small study of men on ADT and functional MRI, there was reduced activation in the right parieto-occipital region when involving manipulation and spatial information (Cherrier et al., 2010). There have been reports of an association between ADT and dementia (Alzheimer and non-Alzheimer), although most studies are methodologically suboptimal, and there are studies supporting and refuting the association (Baik et al., 2017; McHugh et al., 2018; Nead et al., 2017).

Changes in Body Habitus

As noted by Huggins (1941) and colleagues, ADT is associated with an increase in appetite, and low testosterone is associated with increased insulin levels and abdominal girth (Seidell et al., 1990). A loss of muscle mass and increase in percent fat are common in men undergoing ADT, and these changes are most pronounced after initiation of ADT (van Londen et al., 2008). After 1 year of ADT, the mean overall weight increases by 1.8% to 3.8%, which translates into about 5 lb for a 200-lb man (Berruti et al., 2002; Smith, 2004; Smith et al., 2002). Another study found significantly more weight increase: a median of 6 kg (13.2 lb) (Higano et al., 1996). Lean body mass usually decreases (sarcopenia), with average loss of 1.0%, 2.1%, and 2.4% at 1, 2, and 3 years, respectively, after initiating ADT (Smith et al., 2012). Weight gain is largely due to an increase in fat mass (Levy et al., 2008). The average increase in fat mass ranges from 9.4% to 23.8% (Berruti et al., 2002; Smith, 2004; Smith et al., 2002). In a study evaluating 259 men, nearly evenly split among those with prostate cancer on ADT versus men with prostate cancer not on ADT versus healthy controls, there was also a significant decrease in endurance (as measured by a 6-minute walk test) and grip strength evident within 3 months of starting ADT (Alibhai et al., 2010b, 2017).

Diabetes and Metabolic Syndrome

Given the aforementioned changes in body habitus, it is not surprising that metabolic syndrome, a clustering of specific cardiovascular disease risk factors related to insulin resistance, is present in more than 50% of men undergoing long-term ADT (Braga-Basaria et al., 2006). Unlike classic metabolic syndrome characterized by visceral fat accumulation, ADT preferentially increases subcutaneous fat and leads to an increase of high-density lipoprotein (HDL) cholesterol concentrations (Smith et al., 2008). In a small, but carefully controlled prospective study, ADT significantly decreased insulin sensitivity in men with prostate cancer (Smith et al., 2006). These findings were supported by a very large observational study (73,196 men with prostate cancer) in which there was a significant risk of developing diabetes with a GnRH agonist (adjusted HR; 1.44, $P < 0.001$) or orchiectomy (adjusted HR; 1.34, $P < 0.001$) (Keating et al., 2006), findings subsequently replicated among 37,000 men within the Veterans Healthcare Administration (Keating et al., 2010). In addition, for men with diabetes starting ADT, there appears to be a higher likelihood of needing additional diabetes medications and worsening of HgA1c levels (Keating et al., 2014).

Cardiovascular Morbidity and Mortality

Given the generally adverse effects of ADT on body habitus, glucose metabolism, and lipid profiles, it is not surprising ADT is associated with increased cardiovascular morbidity and mortality. The effects appear to be most pronounced in men with lower-risk prostate cancer treated with ADT. In a large (22,816 subjects) population-based registry, newly diagnosed prostate cancer patients who received ADT for at least 1 year had a 20% higher risk of cardiovascular morbidity compared with similar men who did not receive ADT (Saigal et al., 2007). In men over age 65 undergoing radical prostatectomy who also received ADT, the cumulative incidence of cardiovascular death was 5.5% over 5 years compared with 2.0% in those not receiving ADT (Tsai et al., 2007). In contrast, in men with locally advanced prostate cancer treated with radiation therapy and ADT, there was not an increase in cardiovascular mortality compared with men receiving radiation therapy alone (Efstathiou et al., 2008). In a very large population-based cohort of men receiving androgen deprivation, a GnRH agonist was associated with an increased risk of coronary artery disease (adjusted HR 1.16, $P < 0.001$), myocardial infarction (adjusted HR 1.11, $P = 0.03$), and sudden cardiac death (adjusted HR 1.16, $P = 0.04$) (Keating et al., 2006). Among 182,000 men age 66 or older with nonmetastatic prostate cancer on ADT, risk of peripheral artery disease and venous thromboembolism were increased (Hu et al., 2012).

Gynecomastia

Depending on the agents used in ADT, alterations in breast tissue are common. Gynecomastia (an increase in breast tissue) and mastodynia (breast tenderness) may occur together or independently. In a randomized trial of leuprolide versus DES, rates of gynecomastia/breast tenderness were reported in 3% versus 49% of men, respectively (Leuprolide Study G, 1984). Other series have suggested rates of 13% to 16% with leuprolide (Crawford et al., 1989; Rizzo et al., 1990). Rates of gynecomastia with or without mastodynia in men undergoing bilateral orchiectomy or using GnRH agonists are approximately 5% or less (Dobs and Darkes, 2005). Likewise, the peripheral conversion of testosterone to estradiol associated with the antiandrogens induces gynecomastia and/or mastodynia in approximately half of all men taking bicalutamide at 150 mg (See et al., 2002; Wirth et al., 2001) or enzalutamide.

Prophylactic radiation therapy (10–15 Gy, single fraction) has been used to prevent or reduce painful gynecomastia (Tyrrell et al., 2004; Widmark et al., 2003) as a result of DES or antiandrogen therapy. Radiation has no benefit once gynecomastia has begun. Liposuction and subcutaneous endoscopic-assisted mastectomy have been used to treat established gynecomastia (Higano, 2003). The selective estrogen receptor modulator tamoxifen (20 mg/day) has been successfully used to reduce rates of gynecomastia/mastodynia in men being treated with antiandrogen monotherapy (Autorino et al., 2006), but its use is non-standard.

Anemia

The anemia associated with ADT is normochromic, normocytic, and very common: 90% of men receiving combined androgen blockade experience declines in hemoglobin concentration of at least 10% (Strum et al., 1997). In a population-based UK cohort of 10,000 men with nonmetastatic prostate cancer, ADT was associated with an approximately threefold increased rate of anemia, present within 6 months of initiating treatment and chronic in duration (Hicks et al., 2017). In men undergoing orchiectomy, 78% had a median hemoglobin decrease of 1 g/dL or more (Fonseca et al., 1998). Although anemia can be further complicated by tumor growth in the marrow space, compromising hematopoiesis, even men with nonmetastatic prostate cancer experience anemia with ADT (Choo et al., 2005). Unfortunately, anemia (defined as hemoglobin <12 g/dL) is associated with a shorter survival in those patients who were anemic before initiation of ADT (Beer et al., 2004). Compensatory mechanisms limit the symptomatic effects of anemia to a small subset (13%) of men (Strum et al., 1997). The anemia is reversible after stopping ADT, but this may take up to a year (Strum et al., 1997).

Key Points

- Androgen deprivation–based therapies for prostate cancer are associated with cumulative bone mineral density loss, and patients should have regular bone mineral density examinations, take calcium/vitamin D supplements, and be considered for bone-strengthening agents.
- ADT commonly causes increased adiposity, and prolonged exposure is associated with an increased risk of developing metabolic syndrome, diabetes mellitus, and cardiovascular disease.
- There are data to suggest that long-term androgen deprivation may lead to changes in cognition and memory function; however, the data are somewhat conflicting.

Combination Therapy

The advent of nonsurgical, reversible hormone therapy coupled with its profound effects on prostate cancer have led to broad investigations of the combination of ADT with nearly every other treatment applied to prostate cancer. In some cases, most notably external beam radiotherapy and chemotherapy, the combination clearly improves the outcomes; in others, most notably radical prostatectomy, there is no apparent benefit.

With Radical Prostatectomy

Early clinical studies combining hormonal therapy before surgery (neoadjuvant) were promising. In nonrandomized clinical trials of ADT (chemical castration) before radical prostatectomy, the effects on the final surgical specimen were dramatic. Positive surgical margin rates fell from nearly 50% in hormonal intact patients to 15% in ADT patients (Lee et al., 1997). There was a nonsignificant trend toward improved biochemical outcome with neoadjuvant ADT. Based on these findings and a perception that neoadjuvant ADT reduced blood loss and rendered the procedure easier to perform, three randomized prospective studies compared 3 months of ADT followed by radical retropubic prostatectomy (RRP) to RRP alone (Klotz et al., 2003; Soloway et al., 2002; Witjes et al., 1997). With adequate follow-up, there was no significant difference in PSA progression between the groups. The lack of improved biochemical recurrence in these three randomized prospective trials using 3 months of neoadjuvant ADT before RRP argues this combination is not standard in the treatment of prostate cancer. Further studies of different duration of hormonal and with more potent hormonal agents are ongoing.

With Radiation Therapy

Unlike the lack of long-term improved cancer-specific progression with the combination of ADT and radical prostatectomy, several phase III clinical trials have shown a benefit with the combination of ADT and external beam radiation in overall survival, cancer-specific survival, and freedom from disease progression. The benefit appears to be in men with locally advanced disease and/or those with high-grade, high-risk disease.

In brief, there are several landmark trials that established a role for ADT in conjunction with radiation for prostate cancer. A phase III study comparing radiation alone to the combination of radiation and orchiectomy in men undergoing pelvic lymph node dissection was closed because of a high frequency of progression in the radiation-only arm (Granfors et al., 1998). At a median 9.3 years of follow-up, a significant difference in clinical progression (61% vs. 31%), overall mortality (61% vs. 38%), and prostate cancer–specific mortality (44% vs. 27%) favored radiation and orchiectomy versus radiation alone (Granfors et al., 1998). These observations were supported by another study randomizing men with locally advanced prostate cancer to radiation alone versus radiation combined with goserelin for 3 years (Bolla et al., 1997). With long-term follow-up, there was a dramatic improvement in progression-free survival (HR = 0.42, $P < 0.0001$) and overall survival (HR = 0.6, $P = 0.0004$) (Bolla et al., 2010). **Clearly, in locally advanced, high-risk disease, the combination of radiation therapy with ADT is better than radiation alone.** Furthermore, the duration of ADT matters. In the RTOG 92-02 study, 4 months of concurrent ADT+RT followed by 24 months of ADT versus the concurrent 4 months alone demonstrated a significant improvement in disease-specific survival and showed an improvement in overall survival for the highest risk (Gleason score 8 and above) individuals (Horwitz et al., 2008).

Combination Hormonal Therapy

Among all the efforts to improve the efficacy of ADT, none has been as widely studied as combinations of the various forms of hormone therapy, particularly if mechanistically nonredundant. For example, ablation of the source of androgen (castration) coupled with inhibition of LHRH with DES was one of the first combinations studied clinically to suggest improved survival (Nesbit and Baum, 1951); upon closer scrutiny of the first VACURG study, the survival advantage of this combination was lost (Blackard et al., 1973). Likewise, an early experience with an LHRH analogue and a first-generation antiandrogen in 30 patients suggested improved outcomes compared with standard treatment (Labrie et al., 1983). A meta-analysis of 27 prospective, randomized, international clinical trials of the combination of first-generation antiandrogens with either castration or an LHRH agonist (referred to as “combined androgen blockade, or CAB”) has been performed to coalesce disparate findings between trials. In the meta-analysis, 5-year survival with CAB was 25.4% compared with

23.6% with standard ADT, a nonsignificant gain in favor of CAB of 1.8%. Studies including the steroidal antiandrogen cyproterone acetate had a slightly worse outcome on the CAB arms (5-year survival 15.4% vs. 18.1% for ADT alone), suggesting increased non–prostate cancer deaths or inferior cancer-specific activity in those receiving cyproterone acetate. When studies examining the outcomes of the nonsteroidal antiandrogens flutamide or nilutamide were considered independent of those with cyproterone acetate, the 5-year survival improved from 24.7% (standard ADT) to 27.6% for CAB. This 2.9% improvement was significant, but the meta-analysis had a 0 to 5% range of uncertainty about the true size of the benefit; therefore the magnitude of this benefit is of unclear clinical relevance**.**

The idea of trying to eliminate all sources of endogenous androgen (testicular and adrenal) in treating prostate cancer is not new: bilateral surgical adrenalectomy was performed with failure far outweighing success (Huggins and Scott, 1945). Although the blockade of androgen signaling with classic combined androgen blockade has largely resulted in a nonsignificant improvement in outcomes, the advent of more potent hormone signaling inhibitors is changing the paradigm of hormonal treatment for metastatic prostate cancer. Specifically, the adrenal androgen synthesis abiraterone acetate (see Fig. 161.2) has been combined with chemical/surgical castration for metastatic castration-sensitive prostate cancer (mCSPC). In a landmark phase III study of abiraterone+ADT for patients with mCSPC with high-risk disease (defined as having at least two high-risk features: Gleason score 8 or higher, at least three bone metastases, visceral disease) showed a significant improvement in overall survival (HR = 0.62, $P < 0.0001$) with the addition of abiraterone. All secondary end points, including time to pain progression, initiation of chemotherapy, symptomatic skeletal events, and PSA progression also favored the abiraterone arm (Fizazi et al., 2017). Confirming these results, the abiraterone+ADT arm of the STAMPEDE trial, which had looser inclusion criteria allowing advanced CSPC (52% metastatic, 28% node-negative localized, 20% node-positive localized), showed a near identical improvement in overall survival (HR = 0.63, $P < 0.001$) (James et al., 2017). **These two trials have solidified the inclusion of abiraterone to ADT as a standard of care for mCSPC (see Table 161.3).**

With Chemotherapy

Docetaxel chemotherapy has established, but modest, efficacy for the treatment of metastatic castration-resistant prostate cancer (mCRPC) (Tannock et al., 2004). Based on the improvement in overall survival seen with docetaxel in mCRPC, several phase III trials combined docetaxel with first-line castration-based hormonal therapy for the treatment of mCSPC (see Table 161.3). The GETUG-AFU15 trial compared up to 9 cycles of standard dosed docetaxel (75 mg/m^2 every 21 days) with ADT versus ADT alone and showed no improvement in overall survival, although progression-free survival was improved (Gravis et al., 2013, 2016). However, two subsequent large prospective phase III studies have shown an improvement in overall survival. The E2805 CHAARTED study randomized 790 patients to receive 6 cycles of standard docetaxel+ADT versus ADT alone and showed a significant improvement in overall survival (HR = 0.61, $P < 0.001$). This improvement was driven by the patients with high-volume disease (four or more bone metastases and/or visceral disease) in whom there was an 18-month (49.2 vs. 32.2 months) improvement in median overall survival (Sweeney et al., 2015). The docetaxel arm of the STAMPEDE trial also showed an improvement in overall survival with the addition of docetaxel to long-term ADT (HR = 0.78, $P < 0.06$) (James et al., 2015). A meta-analysis of the randomized phase III studies was performed and concluded a legitimate survival advantage for the addition of docetaxel to first-line ADT for mCSPC (The Medical Research Council Prostate Cancer Working Party Investigators Group, 1997).

Key Points

- There is no proven role for presurgical hormonal therapy in combination with surgery; however, for patients with node-positive disease at prostatectomy, androgen deprivation can be considered.
- Androgen deprivation therapy concurrent with and after radiation is the standard of care for high-risk localized disease getting treated with radiation.
- Potent combination hormonal therapy with abiraterone acetate and standard medical or surgical castration is a standard of care for castration-sensitive metastatic prostate cancer.
- For patients with high-volume metastatic castration-sensitive prostate cancer, docetaxel chemotherapy with androgen deprivation therapy is also a

standard of care.

Timing of Therapy

The timing of the initiation of ADT is a somewhat controversial area of prostate cancer management. The spectrum of opinions ranges from primary ADT at time of diagnosis to the initiation of ADT at the first sign of primary prostate cancer failure (early) to initiation of ADT only with objective evidence of distant metastatic disease (late) (Loblaw et al., 2004; Miyamoto et al., 2004; Reese, 2000; Sharifi et al., 2005; Walsh et al., 2001). There is no question that early ADT delays biochemical and clinical disease progression, but the effects of early ADT on survival remain unclear (Ryan and Small, 2005). For the sake of this discussion, ADT will be considered continuous, from initiation until death; intermittent ADT is discussed in a subsequent section. Likewise, this discussion focuses on overall and prostate cancer–specific survival resulting from ADT. The morbidity from ADT also must be integrated into clinical decision-making.

Continuous Androgen Deprivation Therapy: Immediate Versus Delayed

Debates about the timing of ADT are not new. In 1973 the results of a large (more than 1900 men) study performed in the Veterans Administration of early versus late hormonal therapy for prostate cancer, across a spectrum of disease states, were reported (Byar, 1973). In men with metastatic disease, death from prostate cancer occurred in 48% of those treated early versus 47% of those treated late. In men with locally advanced disease, death from prostate cancer occurred in 14% of those treated early versus 17% of those treated late. Since that time, several randomized studies have applied ADT at different times in the natural history of prostate cancer; the results of those studies must be considered within the context of when ADT is used and the circumstances of the study.

Results in Clinically Localized Disease

In the bicalutamide Early Prostate Cancer program, men were randomized to bicalutamide 150 mg or placebo in addition to standard care (See et al., 2003). End points of these trials included overall survival, progression-free survival, and tolerability. In the subset of men with clinically localized disease, the overall survival was significantly *worse* in those undergoing ADT with bicalutamide

150 mg compared with placebo (Iversen et al., 2004). No specific cause for this decline in overall survival with ADT was identified, but it appeared to be the result of increased deaths from non–prostate cancer causes for those on bicalutamide.

A large study of 19,271 men 66 years or older with localized prostate cancer who did not receive definitive local therapy found that primary ADT was associated with lower 10-year prostate cancer–specific survival compared with those on conservative management (Lu-Yao et al., 2008). Although this finding could be the result of more aggressive prostate cancers requiring immediate primary ADT, there was no increase in 10-year overall survival with primary ADT. The authors concluded “primary ADT is not associated with improved survival in the majority of elderly men with localized prostate cancer when compared with conservative management” (Lu-Yao et al., 2008). Finally, in a retrospective, matched cohort study of patients who received adjuvant ADT (within 90 days of node-negative, radical prostatectomy) compared with those who did not, there was a 3% improved prostate cancer–specific survival (98% vs. 95%, respectively, $P = 0.009$) but no improvement in overall survival (83% in both groups) (Siddiqui et al., 2008).

Primary ADT—defined as the administration of ADT to men without metastases as sole therapy at the time of diagnosis—has previously been widespread, particularly in men more than 65 years old: in one study, up to 40% of these men received primary ADT (Shahinian et al., 2006). A retrospective cohort study from three integrated health care plans found that primary ADT did not alter the risk of all-cause mortality nor risk of prostate cancer–specific mortality (Potosky et al., 2014). Primary ADT was associated with decreased risk of all-cause mortality only in men with high risk of prostate cancer progression. There has been a prospective, randomized study conducted by the European Organisation for the Research and Treatment of Cancer trial of immediate versus delayed ADT in pN1-3M0 patients without local treatment of the primary tumor; 302 men were randomized to delayed ADT ($n = 115$) or immediate ADT ($n = 119$), with a primary end point aimed at proving noninferiority of delayed ADT. At final analysis, with a median follow-up of 13 years, the median overall survival in the immediate ADT group was 7.6 years (95% CI 6.3–8.3 years) versus 6.1 years (95% CI 5.7–7.3 years) in the delayed ADT group. The 10-year cumulative incidence of death from prostate cancer was 55.6% in the delayed ADT group versus 52.1% in the immediate ADT group, and noninferiority was not established (Schroder et al., 2009). The study was not designed or powered to show superiority of immediate ADT. **In sum, primary ADT does not provide a survival benefit for most men with clinically localized prostate cancer but may for those with high-risk disease**.

Results in Lymph Node Metastatic Prostate Cancer as Adjuvant Therapy

A randomized prospective study of immediate ADT compared with delayed ADT was performed by the Eastern Cooperative Oncology Group (ECOG) in men with histologic evidence of metastatic prostate cancer in regional lymph nodes after radical prostatectomy. At the time of the initial report, at 7.1 years of median follow-up, overall survival significantly ($P < 0.02$) favored the immediate ADT group compared with the delayed ADT group: in the immediate ADT group, only 3 of the 7 deaths were due to prostate cancer compared with 16 of the 18 cancer-specific deaths in the delayed ADT group (Messing et al., 1999). In the final analysis, with a median 11.9 years of follow-up, there was a significant improvement in overall survival (HR = 1.84, $P = 0.04$) and progression-free survival (HR = 4.09, $P = 0.004$) associated with immediate ADT (Messing et al., 2006). Based on this randomized, prospective trial, there appears to be a benefit to immediate ADT in those men with histologic evidence of lymph node metastases at the time of radical prostatectomy. However, in addition to being a relatively small study, there were limitations that limit its applicability in modern practice. The delayed arm initiated hormonal therapy at clinical progression. Twenty percent of patients on the trial had a detectable postoperative PSA and thus had biochemical evidence of disease persistence. This further dilutes the study's interpretability in the adjuvant, no evidence of disease population. Finally, this was largely a study of bulky nodal disease, with a median number of positive nodes of 2, with some patients having up to 20 affected nodes. It is not clear these data apply to the patient with low-volume positive nodes with an undetectable PSA, because 20% to 40% can be cured with surgery alone (Moschini et al., 2016; Touijer et al., 2014).

Results in Locally Advanced or Asymptomatic Metastatic Disease or Disease Not Suitable to Local Treatment

A trial of immediate versus delayed ADT in men with locally advanced or asymptomatic prostate cancer was conducted by the Medical Research Council (MRC) Prostate Cancer Working Party Investigators Group (The Medical

Research Council Prostate Cancer Working Party Investigators Group, 1997). A total of 934 men were included (500 M0, 261 M1, and 173 Mx), with 469 randomized to immediate ADT and 465 randomized to delayed ADT. The study initially reported an improvement in the progression from M0 to M1 disease, improvement in local complication and pain, as well as an improvement in overall and prostate cancer–specific survival to immediate ADT. With longer follow-up, although the cancer-specific mortality remained statistically improved with early ADT, the overall survival advantage was no longer significant ($P = 0.09$) (Kirk, 2004). In addition, men in the delayed ADT arm had significantly more symptoms related to disease progression. Based on these data, the benefits of immediate ADT would seem to support its use.

Immediate versus delayed ADT was studied in another group ($n = 985$) of men not suitable for local treatment (refused local treatment; had decreased life expectancy, advanced local tumor stage, and/or severe comorbidities) (Studer et al., 2006). Unlike the MRC study, immediate ADT resulted in a significant, albeit small, improvement in overall survival but no difference in prostate cancer–specific mortality or overall symptom-free survival. Interestingly and importantly, in the delayed ADT arm, 30% died without ever needing treatment.

Results in Biochemically Recurrent Prostate Cancer

With serum PSA, there is a biochemically recurrent disease state defined as a rising PSA without clinical or radiographic evidence of metastatic disease after curative-intent local therapy. The timing of initiation of ADT in this setting is not clear, with many clinicians using a combination of factors including clinical comorbidities, absolute PSA level, PSA doubling times, and patient-driven anxiety to guide initiation of ADT (Dale et al., 2009). There has been one reported randomized prospective trial of 293 patients (261 had rising PSA after definitive local therapy and 32 had locally advanced disease) to immediate or delayed androgen deprivation (Duchesne et al., 2016). Patients with the most aggressive disease, as indicated by PSA doubling time less than 3 months were excluded. Patients randomized to the delayed arm, were recommended to wait to start ADT for at least 2 years, unless metastatic disease, symptoms from disease, or PSA doubling time decrease to less than 6 months occurred. **Interestingly, there was an overall survival advantage to immediate ADT (HR = 0.55, $P = 0.047$) found in this study, suggesting early ADT may be of value for some patients with recurrent disease.**

Immediate Versus Delayed Androgen Deprivation Therapy: Integrating the Data

1. **There is no survival benefit to immediate ADT in low-risk, localized prostate cancer.** For overall survival, men treated in this fashion appear to do significantly worse than those spared ADT in this setting.
2. **In locally advanced or asymptomatic metastatic prostate cancer, immediate ADT results in significantly better prostate cancer–specific survival and risk of local complications and pain progression, but not better overall survival.**
3. **In node-positive disease without primary treatment, there may be an advantage to immediate ADT. In bulky node-positive disease with radical prostatectomy, there is a significant survival advantage favoring immediate ADT.**
4. **In node-positive disease after surgery and in biochemically-recurrent disease, immediate ADT is associated with an improvement overall survival.**

Intermittent Versus Continuous Androgen Deprivation Therapy

Given the clear side effects associated with hormonal therapy, along with the often protracted disease course, depending on clinical stage, there has been an effort to decrease the duration of hormonal therapy, when appropriate. In addition to consideration of delayed ADT, a strategy of intermittent androgen deprivation would also decrease exposure to ADT.

Intermittent ADT was studied in a group of men with a rising PSA after primary or salvage radiotherapy (Crook et al., 2012). Specifically, men were randomized to receive intermittent or continuous androgen deprivation with a primary end point of overall survival. Intermittent treatment was provided in 8-month cycles, with nontreatment periods based on PSA levels. At a median follow-up of 6.9 years, there were 268 deaths in the intermittent therapy group and 256 deaths in the continuous therapy group: median overall survival was 8.8 years in the intermittent group versus 9.1 years in the continuous group (see Table 161.3). **Based on a noninferiority trial design, intermittent therapy was not inferior to continuous therapy for overall survival**. Disease-specific death (prostate cancer and related treatments) was more common in the intermittent therapy arm compared with the continuous-therapy arm (120 vs. 94, respectively). Conversely, deaths unrelated to prostate cancer were more common in the continuous-therapy arm compared with the intermittent-therapy arm (162 vs. 148, respectively).

Attrition from intermittent androgen deprivation progressively increased over time as patients either developed castration-resistant prostate cancer or died of another cause. Attrition only occurred in 5% of men in the first interval, whereas 68% had stopped intermittent therapy by the third interval. On the other hand, duration of intermittent ADT progressively shortened over time: the median nontreatment interval between cycles was 20.1 months for the first treatment cycle, 13.2 months for the second cycle, 9.1 months for the third, and 4 to 5 months thereafter. A secondary end point, improved quality of life in the intermittent therapy arm, was associated with significantly better scores for hot flashes, desire for sexual activity, and urinary symptoms. For the functional domains of physical, role, and global health the intermittent therapy arm was slightly better, but the differences were not significant.

Noninferiority trials require fewer subjects than for an equivalence trial, making them easier to accrue and complete. It is important to recognize that noninferiority is not the same as equivalence; trial design is based on a definition of noninferiority if a prespecified upper margin of a hazard ratio is not exceeded. In this trial, the upper limit was 1.25, meaning up to 25% more men on the intermittent arm could die of any cause and intermittent treatment would still be considered noninferior. In this trial, the upper limit of the 95% CI was 1.22, which is below 1.25 and therefore met the prespecified definition; however, intermittent ADT at the upper bound could be as high as 22% worse.

Intermittent ADT was also studied in a group of men with newly diagnosed metastatic prostate cancer (Hussain et al., 2013). After a 7-month induction of ADT in all patients, men whose PSA level had declined to 4 ng/mL or lower (indicating androgen sensitivity) were randomized to receive intermittent or continuous androgen deprivation with coprimary end points of overall survival and quality of life at 3 months after randomization. At a median follow-up of 9.8 years, median overall survival was 5.8 years in the continuous arm and 5.1 years in the intermittent arm (HR for death with intermittent therapy, 1.10; 90% CI 0.99–q1.23) (see Table 161.3). In this study, the CI for survival exceeded the upper boundary for noninferiority (1.20), meaning it is not possible to conclude that intermittent therapy was noninferior to continuous therapy. Furthermore, because the lower limit of the CI (0.99) did not exclude 1.00, it is not possible to conclude that intermittent therapy was significantly inferior to continuous therapy. **A reasonable clinical interpretation of this study is that intermittent therapy in men with metastatic prostate cancer may be worse**. Quality-of-life scores were significantly better in the intermittent arm (less likely to report impotence, better mental health) at 3 months. At 9 and 15 months, the quality-of-life scores favored intermittent therapy, but the differences were not significant.

The treatment schedules for intermittent androgen deprivation vary slightly between the rising PSA after radiation therapy trial (Crook et al., 2012) and the metastatic disease trial (Hussain et al., 2013): both used an induction period of ADT (8 months and 7 months, respectively). If the PSA was less than 4 ng/mL, both trials stopped ADT (in the intermittent arms). Androgen deprivation was restarted if the PSA reached 10 or 20 ng/mL, respectively, or for clinical symptoms. In the metastatic disease trial, ADT could also be restarted when the PSA reached baseline. The development of castration-resistant prostate cancer required the patient be on ADT and demonstrate clinical progression or PSA increases monthly for 3 months. In both trials, castration-resistant prostate cancer was managed with continuous ADT. The treatment schedules provide some guidance in managing patients on intermittent ADT, but there is no consensus on the ideal schedule (Hussain et al., 2016). When interpreting these non-inferiority intermittent ADT trials, clinicians should remember the “devil is in the details,” and a careful discussion with the individual patient is necessary to weigh advantages and potential advantages (Hussain et al., 2016).

Emerging Androgen Receptor–Associated Biomarkers

At the hub of androgen pathway inhibition therapy for prostate cancer lies the AR nuclear hormone receptor (Scher and Sawyers, 2005). Hormonal therapies for prostate cancer are ultimately dependent on blocking the activity of the AR. It is thus not surprising molecular aberrations in the AR, including truncating splice variants, missense mutations, and genomic amplifications, are emerging as powerful predictive biomarkers for therapeutic efficacy.

Androgen Receptor Splice Variants

One of the most common molecular alterations within the AR emerges under the selective pressure of androgen deprivation and androgen pathway blockade are a series of AR splicing aberrations that result in truncated mRNA and AR proteins that lack the ligand-binding domain (Guo et al., 2009; Li et al., 2013). These truncated splice variants that lack the ligand-binding domain are believed to be active as transcription factors in a similar fashion to full-length AR but are constitutively active and independent of the presence of androgen ligand (Li et al., 2013). Furthermore, all of the current hormonal therapies for prostate cancer rely on an intact ligand-binding domain; medical/surgical castration and abiraterone are effective through depletion of androgen ligands, and AR antagonists (bicalutamide, enzalutamide, apalutamide) act at the ligand-binding domain of the AR and disrupt ligand binding or interaction of transcriptional coactivators. It is therefore not surprising prostate cancers expressing these AR splicing variants would be insensitive to androgen pathway–targeted therapies.

The most clinically validated AR alteration emerging as a negative predictive biomarker for potent hormonal therapies such as abiraterone and enzalutamide is the splice variant named AR-V7. AR-V7 is a common splice variant lacking a full ligand-binding domain and, in its place, has a small unique cryptic exon that can be detected with modern molecular biology techniques. In a landmark study of patients with castration-resistant prostate cancer (CRPC) who were to receive either abiraterone or enzalutamide, the presence of AR-V7 transcript within the blood (extracted from circulating tumor cells) was strongly associated with a lack of benefit from these therapies (Antonarakis et al., 2014)**. None of the AR-V7–positive patients achieved a PSA response with either abiraterone or enzalutamide, compared with a response rate of more than 50% for AR-V7–negative patients.** Furthermore, the hazard ratio associated with AR-V7–positive status for clinical or radiographic progression was 8.5 for enzalutamide and 16.5 for abiraterone treatment (both $P < 0.001$). The AR-V7 cryptic exon within the AR protein can also be detected by specific antibodies in addition to mRNA detection techniques. With use of an immunofluorescence assay detecting AR-V7 protein within circulating tumor cells in patient blood, AR-V7 positivity with this assay was also strongly associated with lack of benefit to potent AR signaling inhibitors (e.g., abiraterone/enzalutamide) (Scher et al., 2016). **Patients with AR-V7–positive CTC had a much shorter median radiographic progression free survival (2.3 vs. 14.5 months, $P < 0.001$), and importantly, on multivariate analysis, AR-V7 status was the strongest predictor of overall survival (HR = 4.15, $P < 0.001$). Interestingly, AR-V7–**

positive patients had a more favorable survival if treated with taxane chemotherapy compared with AR-targeted therapy (HR = 0.24, *P* = 0.035). Notably, the presence of AR-V7 in the CRPC setting increases with line of therapy from less than 5% incidence in the first line to more than 30% in the third or more line. This assay, which is now clinically available, can aid in therapeutic decision making in the refractory CRPC setting.

Androgen Receptor Gene Amplification and Mutation

In addition to ligand-binding domain deficient splice variants, there are other emerging AR-centric biomarkers to be considered in the context of potent hormonal therapies. A well-annotated adaptation mechanism for CRPC under the selection pressure of ligand deprivation is amplification or overexpression of the *AR* gene (Koivisto et al., 1997; Visakorpi et al., 1995). Modern molecular biology techniques can extract and analyze cell-free DNA (cfDNA) from the blood of patients with prostate cancer and allow for the interrogation of cancer-specific AR genomic events such as amplification (Kohli et al., 2018; Lallous et al., 2016; Wyatt et al., 2016). Similar to AR splice variants, ***AR* gene amplification has been strongly associated with poor outcomes for patient with metastatic CRPC including a significant decrease in the likelihood of PSA response (~10% versus ~50%), progression-free survival (HR ~3), and even overall survival (HR ~3-5)** (Conteduca et al., 2017; Kohli et al., 2018; Wyatt et al., 2016)**.** It is not yet known whether this association is independent of other prognostic indices, including AR-V7 status. It has been well recognized that ligand-binding domain (LBD) mutations can emerge in the context of AR blockade and can confer resistance to AR antagonists (e.g., bicalutamide, flutamide). Analyses of metastatic bone biopsies suggest the mutation rate in CRPC may be as high as 10% (Taplin et al., 2003a). Using cfDNA analysis from patients being treated with and progressing on second-generation potent abiraterone has revealed that AR LBD mutations that become sensitive to glucocorticoids can develop in more than 20% of patients (Carreira et al., 2014). Similar mutations have been detected upon resistance to other potent AR antagonists such as enzalutamide and apalutamide, and these AR mutations are associated with worse outcomes (Conteduca et al., 2017; Joseph et al., 2013; Lallous et al., 2016; Rathkopf et al., 2017). AR antagonists, such as darolutamide, have been developed that may overcome these AR LBD mutations (Moilanen et al., 2015). As the AR aberrations in the LBD (amplification, splice variants, mutations) are adaptive causes of resistance to potent AR-targeted therapies, current efforts are underway to develop novel therapeutics that either degrade or target other domains (N-terminal) of the AR (Liu et al., 2014; Moilanen et al., 2015).

References

Alibhai SM, Breunis H, Timilshina N, et al. Impact of androgen-deprivation therapy on cognitive function in men with nonmetastatic prostate cancer. *J Clin Oncol*. 2010;28(34):5030–5037.

Alibhai SM, Breunis H, Timilshina N, et al. Impact of androgen-deprivation therapy on physical function and quality of life in men with nonmetastatic prostate cancer. *J Clin Oncol*. 2010;28(34):5038–5045.

Alibhai SM, Timilshina N, Duff-Canning S, et al. Effects of long-term androgen deprivation therapy on cognitive function over 36 months in men with prostate cancer. *Cancer*. 2017;123(2):237–244.

Anderson J. The role of antiandrogen monotherapy in the treatment of prostate cancer. *BJU Int*. 2003;91(5):455–461.

Antonarakis ES, Lu C, Wang H, et al. AR-V7 and resistance to enzalutamide and abiraterone in prostate cancer. *N Engl J Med*. 2014;371(11):1028–1038.

Armstrong AJ, Anand A, Edenbrandt L, et al. Phase 3 assessment of the Automated Bone Scan Index as a prognostic imaging biomarker of overall survival in men with metastatic castration-resistant prostate cancer: a secondary analysis of a randomized clinical trial. *JAMA Oncol*. 2018;4(7):944–951.

Arora VK, Schenkein E, Murali R, et al. Glucocorticoid receptor confers resistance to antiandrogens by bypassing androgen receptor blockade. *Cell*. 2013;155(6):1309–1322.

Ashamalla H, Jiang ML, Guirguis A, et al. Acupuncture for the alleviation of hot flashes in men treated with androgen ablation therapy. *Int J Radiat Oncol Biol Phys*. 2011;79(5):1358–1363.

Attard G, Reid AH, Yap TA, et al. Phase I clinical trial of a selective inhibitor of CYP17, abiraterone acetate, confirms that castration-resistant prostate cancer commonly remains hormone driven. *J Clin Oncol*. 2008;26(28):4563–4571.

Autorino R, Perdona S, D'Armiento M, et al. Gynecomastia in patients with prostate cancer: update on treatment options. *Prostate Cancer Prostatic Dis*. 2006;9(2):109–114.

Bae DC, Stein BS. The diagnosis and treatment of osteoporosis in men on androgen deprivation therapy for advanced carcinoma of the prostate. *J Urol*. 2004;172(6 Pt 1):2137–2144.

Baik SH, Kury FSP, McDonald CJ. Risk of Alzheimer's disease among senior medicare beneficiaries treated with androgen deprivation therapy for prostate cancer. *J Clin Oncol*. 2017;35(30):3401–3409.

Bales GT, Chodak GW. A controlled trial of bicalutamide versus castration in patients with advanced prostate cancer. *Urology*. 1996;47(1A Suppl):38–43 [discussion 48–53].

Barradell LB, Faulds D. Cyproterone. A review of its pharmacology and therapeutic efficacy in prostate cancer. *Drugs Aging*. 1994;5(1):59–80.

Beer TM, Tombal B. Enzalutamide in metastatic prostate cancer before chemotherapy. *N Engl J Med*. 2014;371(18):1755–1756.

Beer TM, Tangen CM, Bland LB, et al. Prognostic value of anemia in newly diagnosed metastatic prostate cancer: a multivariate analysis of southwest oncology group study 8894. *J Urol*. 2004;172(6 Pt 1):2213–2217.

Benaim EA, Pace CM, Roehrborn CG. Gleason score predicts androgen independent progression after androgen deprivation therapy. *Eur Urol*. 2002;42(1):12–17.

Benaim EA, Pace CM, Lam PM, et al. Nadir prostate-specific antigen as a predictor of progression to androgen-independent prostate cancer. *Urology*. 2002;59(1):73–78.

Bennett CL, Raisch DW, Sartor O. Pneumonitis associated with nonsteroidal antiandrogens: presumptive evidence of a class effect. *Ann Intern Med*. 2002;137(7):625.

Berruti A, Dogliotti L, Terrone C, et al. Changes in bone mineral density, lean body mass and fat content as measured by dual energy x-ray absorptiometry in patients with prostate cancer without apparent bone metastases given androgen deprivation therapy. *J Urol*. 2002;167(6):2361–2367 [discussion 2367].

Blackard CE, Byar DP, Jordan WP Jr. Orchiectomy for advanced prostatic carcinoma. A reevaluation. *Urology*. 1973;1(6):553–560.

Blankenstein MA, Bakker GH. Rationale for suppression of adrenal steroidogenesis in advanced prostatic cancer. *Prog Clin Biol Res*. 1985;185A:161–185.

Bolla M, Gonzalez D, Warde P, et al. Improved survival in patients with locally advanced prostate cancer treated with radiotherapy and goserelin. *N Engl J Med*. 1997;337(5):295–300.

Bolla M, Van Tienhoven G, Warde P, et al. External irradiation with or without long-term androgen suppression for prostate cancer with high metastatic risk: 10-year results of an EORTC randomised study. *Lancet Oncol*. 2010;11(11):1066–1073.

Braga-Basaria M, Dobs AS, Muller DC, et al. Metabolic syndrome in men with prostate cancer undergoing long-term androgen-deprivation therapy. *J Clin Oncol*. 2006;24(24):3979–3983.

Brufsky A, Fontaine-Rothe P, Berlane K, et al. Finasteride and flutamide as potency-sparing androgen-ablative therapy for advanced adenocarcinoma of the prostate. *Urology*. 1997;49(6):913–920.

Butenandt AHG. The transformation of dehydroandrosterone into androstendiol and testosterone; a method for producing testosterone from cholesterin. *Hoppe-Seyler's Z Physiol Chem*. 1935;237(89–98).

Byar DP. Proceedings: the Veterans Administration Cooperative Urological Research Group's studies of cancer of the prostate. *Cancer*. 1973;32(5):1126–1130.

Byar DP, Corle DK. Hormone therapy for prostate cancer: results of the Veterans Administration Cooperative Urological Research Group studies. *NCI Monogr*. 1988;7:165–170.

Carreira S, Romanel A, Goodall J, et al. Tumor clone dynamics in lethal prostate cancer. *Sci Transl Med*. 2014;6(254):254ra125.

Cash R, Brough AJ, Cohen MN, et al. Aminoglutethimide (Elipten-Ciba) as an inhibitor of adrenal steroidogenesis: mechanism of action and therapeutic trial. *J Clin Endocrinol Metab*. 1967;27(9):1239–1248.

Cervenakov I, Kopecny M, Jancar M, et al. ‘Hot flush’, an unpleasant symptom accompanying antiandrogen therapy of prostatic cancer and its treatment by cyproterone acetate. *Int Urol Nephrol*. 2000;32(1):77–79.

Chang A, Yeap B, Davis T, et al. Double-blind, randomized study of primary hormonal treatment of stage D2 prostate carcinoma: flutamide versus diethylstilbestrol. *J Clin Oncol*. 1996;14(8):2250–2257.

Chang SS, Benson MC, Campbell SC, et al. Society of Urologic Oncology position statement: redefining the management of hormone-refractory prostate carcinoma. *Cancer*. 2005;103(1):11–21.

Chen CD, Welsbie DS, Tran C, et al. Molecular determinants of resistance to antiandrogen therapy. *Nat Med*. 2004;10(1):33–39.

Cherrier MM, Borghesani PR, Shelton AL, et al. Changes in neuronal activation patterns in response to androgen deprivation therapy: a pilot study. *BMC Cancer*. 2010;10:1.

Choo R, Chander S, Danjoux C, et al. How are hemoglobin levels affected by androgen deprivation in non-metastatic prostate cancer patients? *Can J Urol*. 2005;12(1):2547–2552.

Clegg NJ, Wongvipat J, Joseph JD, et al. ARN-509: a novel antiandrogen for prostate cancer treatment. *Cancer Res*. 2012;72(6):1494–1503.

Conde FA, Sarna L, Oka RK, et al. Age, body mass index, and serum prostate-specific antigen correlate with bone loss in men with prostate cancer not receiving androgen deprivation therapy. *Urology*. 2004;64(2):335–340.

Conteduca V, Wetterskog D, Sharabiani MTA, et al. Androgen receptor gene status in plasma DNA associates with worse outcome on enzalutamide or abiraterone for castration-resistant prostate cancer: a multi-institution correlative biomarker study. *Ann Oncol*. 2017;28(7):1508–1516.

Cormie P, Newton RU, Taaffe DR, et al. Exercise maintains sexual activity in men undergoing androgen suppression for prostate cancer: a randomized controlled trial. *Prostate Cancer Prostatic Dis*. 2013;16(2):170–175.

Crawford ED, Eisenberger MA, McLeod DG, et al. A controlled trial of leuprolide with and without flutamide in prostatic carcinoma. *N Engl J Med*. 1989;321(7):419–424.

Crawford ED, Schellhammer PF, McLeod DG, et al. Androgen receptor targeted treatments of prostate cancer: 35 years of progress with antiandrogens. *J Urol*. 2018;200(5):956–966.

Creaven PJ, Pendyala L, Tremblay D. Pharmacokinetics and metabolism of nilutamide. *Urology*. 1991;37(2 Suppl):13–19.

Crook JM, O'Callaghan CJ, Duncan G, et al. Intermittent androgen suppression for rising PSA level after radiotherapy. *N Engl J Med*. 2012;367(10):895–903.

Dale W, Hemmerich J, Bylow K, et al. Patient anxiety about prostate cancer independently predicts early initiation of androgen deprivation therapy for biochemical cancer recurrence in older men: a prospective cohort study. *J Clin Oncol*. 2009;27(10):1557–1563.

Daniell HW, Dunn SR, Ferguson DW, et al. Progressive osteoporosis during androgen deprivation therapy for prostate cancer. *J Urol*. 2000;163(1):181–186.

David KDE, Freud J, Laquer E. Crystalline male hormone from the testes (Testosterone) is more effective than androsterone derived from urine or cholesterin. *Hoppe-Seyler's Z Physiol Chem*. 1935;233:281–282.

D'Amico AV, Moul J, Carroll PR, et al. Surrogate end point for prostate cancer specific mortality in patients with nonmetastatic hormone refractory prostate cancer. *J Urol*. 2005;173(5):1572–1576.

D'Amico AV, McLeod DG, Carroll PR, et al. Time to an undetectable prostate-specific antigen (PSA) after androgen suppression therapy for postoperative or postradiation PSA recurrence and prostate cancer-specific mortality. *Cancer*. 2007;109(7):1290–1295.

de Bono JS, Logothetis CJ, Molina A, et al. Abiraterone and increased survival in metastatic prostate cancer. *N Engl J Med*. 2011;364(21):1995–2005.

Dehm SM, Schmidt LJ, Heemers HV, et al. Splicing of a novel androgen receptor exon generates a constitutively active androgen receptor that mediates prostate cancer therapy resistance. *Cancer Res*. 2008;68(13):5469–5477.

Delaere KP. Van Thillo EL. Flutamide monotherapy as primary treatment in advanced prostatic carcinoma. *Semin Oncol*. 1991;18(5 Suppl 6):13–18.

Denis L, Mahler C. Pharmacodynamics and pharmacokinetics of bicalutamide: defining an active dosing regimen. *Urology*. 1996;47(1A Suppl):26–28 [discussion 29–32].

Desai A, Stadler WM, Vogelzang NJ. Nilutamide: possible utility as a second-line hormonal agent. *Urology*. 2001;58(6):1016–1020.

Desmond AD, Arnold AJ, Hastie KJ. Subcapsular orchiectomy under local anaesthesia. Technique, results and implications. *Br J Urol*. 1988;61(2):143–145.

Diamond TH, Higano CS, Smith MR, et al. Osteoporosis in men with prostate carcinoma receiving androgen-deprivation therapy: recommendations for diagnosis and therapies. *Cancer*. 2004;100(5):892–899.

Dobs A, Darkes MJ. Incidence and management of gynecomastia in men treated for prostate cancer. *J Urol*. 2005;174(5):1737–1742.

Duchesne GM, Woo HH, Bassett JK, et al. Timing of androgen-deprivation therapy in patients with prostate cancer with a rising PSA (TROG 03.06 and VCOG PR 01-03 [TOAD]): a randomised, multicentre, non-blinded, phase 3 trial. *Lancet Oncol*. 2016;17(6):727–737.

Edwards J, Krishna NS, Grigor KM, et al. Androgen receptor gene amplification and protein expression in hormone refractory prostate cancer. *Br J Cancer*. 2003;89(3):552–556.

Efstathiou JA, Bae K, Shipley WU, et al. Cardiovascular mortality and duration of androgen deprivation for locally advanced prostate cancer: analysis of RTOG 92-02. *Eur Urol*. 2008;54(4):816–823.

Fizazi K, Massard C, Bono P, et al. Safety and antitumour activity of ODM-201 (BAY-1841788) in Castration-resistant, CYP17 Inhibitor-naive prostate cancer: results from extended follow-up of the ARADES trial. *Eur Urol Focus*. 2017;3(6):606–614.

Fizazi K, Tran N, Fein L, et al. Abiraterone plus prednisone in metastatic, castration-sensitive prostate cancer. *N Engl J Med*. 2017;377(4):352–360.

Fonseca R, Rajkumar SV, White WL, et al. Anemia after orchiectomy. *Am J Hematol*. 1998;59(3):230–233.

Fradet Y. Bicalutamide (Casodex) in the treatment of prostate cancer. *Expert Rev Anticancer Ther*. 2004;4(1):37–48.

Gallagher JR. The colour vision of fish. *Yale J Biol Med*. 1929;1(5):283–293.

Gerber GS, Zagaja GP, Ray PS, et al. Transdermal estrogen in the treatment of hot flushes in men with prostate cancer. *Urology*. 2000;55(1):97–101.

Gittelman M, Pommerville PJ, Persson BE, Degarelix Study G, et al. A 1-year, open label, randomized phase II dose finding study of degarelix for the treatment of prostate cancer in North America. *J Urol*. 2008;180(5):1986–1992.

Goldenberg SL, Bruchovsky N. Use of cyproterone acetate in prostate cancer. *Urol Clin North Am*. 1991;18(1):111–122.

Gottlieb B, Beitel LK, Nadarajah A, et al. The androgen receptor gene mutations database: 2012 update. *Hum Mutat*. 2012;33(5):887–894.

Granfors T, Modig H, Damber JE, et al. Combined orchiectomy and external radiotherapy versus radiotherapy alone for nonmetastatic prostate cancer with or without pelvic lymph node involvement: a prospective randomized study. *J Urol*. 1998;159(6):2030–2034.

Gravis G, Fizazi K, Joly F, et al. Androgen-deprivation therapy alone or with docetaxel in non-castrate metastatic prostate cancer (GETUG-AFU 15): a randomised, open-label, phase 3 trial. *Lancet Oncol*. 2013;14(2):149–158.

Gravis G, Boher JM, Fizazi K, et al. Prognostic factors for survival in noncastrate metastatic prostate cancer: validation of the glass model and development of a novel simplified prognostic model. *Eur Urol*. 2015;68(2):196–204.

Gravis G, Boher JM, Joly F, et al. Androgen Deprivation Therapy (ADT) plus docetaxel versus ADT alone in metastatic non castrate prostate cancer: impact of metastatic burden and long-term survival analysis of the randomized phase 3 GETUG-AFU15 trial. *Eur Urol*. 2016;70(2):256–262.

Green HJ, Pakenham KI, Headley BC, et al. Altered cognitive function in men treated for prostate cancer with luteinizing hormone-releasing hormone analogues and cyproterone acetate: a randomized controlled trial. *BJU Int*. 2002;90(4):427–432.

Green HJ, Pakenham KI, Headley BC, et al. Quality of life compared during pharmacological treatments and clinical monitoring for non-localized prostate cancer: a randomized controlled trial. *BJU Int*. 2004;93(7):975–979.

Guo Z, Yang X, Sun F, et al. A novel androgen receptor splice variant is up-regulated during prostate cancer progression and promotes androgen depletion-resistant growth. *Cancer Res*. 2009;69(6):2305–2313.

Gutman AB, Gutman EB. An “acid “ phosphatase occurring in the serum of patients with metastasizing carcinoma of the prostate gland. *J Clin Invest*. 1938;17(4):473–478.

Gutman AB, Gutman EB, Jillson R, et al. Acid-base equivalence of the blood in diseases associated with hyperglobulinemia; with special reference to lymphogranuloma inguinale and multiple myeloma. *J Clin Invest*. 1936;15(5):475–484.

Han M, Nelson JB. Non-steroidal anti-androgens in prostate cancer–current treatment practice. *Expert Opin Pharmacother*. 2000;1(3):443–449.

Harding C, Harris A, Chadwick D. Auricular acupuncture: a novel treatment for vasomotor symptoms associated with luteinizing-hormone releasing hormone agonist treatment for prostate cancer. *BJU Int*. 2009;103(2):186–190.

Harshman LC, Chen YH, Liu G, et al. Seven-month prostate-specific antigen is prognostic in metastatic hormone-sensitive prostate cancer treated with androgen deprivation with or without docetaxel. *J Clin Oncol*. 2018;36(4):376–382.

Hearn JWD, AbuAli G, Reichard CA, et al. HSD3B1 and resistance to androgen-deprivation therapy in prostate cancer: a retrospective, multicohort study. *Lancet Oncol*. 2016;17(10):1435–1444.

Hearn JWD, Xie W, Nakabayashi M, et al. Association of HSD3B1 genotype with response to androgen-deprivation therapy for biochemical recurrence after radiotherapy for localized prostate cancer. *JAMA Oncol*. 2018;4(4):558–562.

Heinlein CA, Chang C. Androgen receptor in prostate cancer. *Endocr Rev*. 2004;25(2):276–308.

Hicks BM, Klil-Drori AJ, Yin H, et al. Androgen deprivation therapy and the risk of anemia in men with prostate cancer. *Epidemiology*. 2017;28(5):712–718.

Higano CS. Side effects of androgen deprivation therapy: monitoring and minimizing toxicity. *Urology*. 2003;61(2 Suppl 1):32–38.

Higano CS, Ellis W, Russell K, et al. Intermittent androgen suppression with leuprolide and flutamide for prostate cancer: a pilot study. *Urology*. 1996;48(5):800–804.

Holzbeierlein JM, McLaughlin MD, Thrasher JB. Complications of androgen deprivation therapy for prostate cancer. *Curr Opin Urol*. 2004;14(3):177–183.

Horwitz EM, Bae K, Hanks GE, et al. Ten-year follow-up of radiation therapy oncology group protocol 92-02: a phase III trial of the duration of elective androgen deprivation in locally advanced prostate cancer. *J Clin Oncol*. 2008;26(15):2497–2504.

Hu JC, Williams SB, O'Malley AJ, et al. Androgen-deprivation therapy for nonmetastatic prostate cancer is associated with an increased risk of peripheral arterial disease and venous thromboembolism. *Eur Urol*. 2012;61(6):1119–1128.

Huggins C, Clark PJ. Quantitative studies of prostatic secretion: II. The effect of castration and of estrogen injection on the normal and on the hyperplastic prostate glands of dogs. *J Exp Med*. 1940;72(6):747–762.

Huggins C, Hodges CV. Studies on prostatic cancer I: the effect of castration, of estrogen and of androgen injection on serum phosphatases in metastatic carcinoma of the prostate. *Cancer Res*. 1941;1:293–297.

Huggins C, Scott WW. Bilateral adrenalectomy in prostatic cancer: clinical features and urinary excretion of 17-ketosteroids and estrogen. *Ann Surg*. 1945;122(6):1031–1041.

Huggins C, Scott WW, Hodges CV. Studies on prostatic cancer III: the effects of fever, of deoxycorticosterone and of estrogen on clinical patients with metastatic carcinoma of the prostate. *J Urol*. 1941;46(5):997–1006.

Huggins C, Stevens RE, Hodges CV. Studies on prostating cancer II: the effects of castration on advanced cardinoma of the prostate gland. *Arch Surg*. 1941;43(2):209–223.

Huggins ML. A new society for X-ray and electron diffraction research workers. *Science*. 1941;93(2421):489–490.

Hussain M, Tangen CM, Higano C, et al. Absolute prostate-specific antigen value after androgen deprivation is a strong independent predictor of survival in new metastatic prostate cancer: data from Southwest Oncology Group Trial 9346 (INT-0162). *J Clin Oncol*. 2006;24(24):3984–3990.

Hussain M, Goldman B, Tangen C, et al. Prostate-specific antigen progression predicts overall survival in patients with metastatic prostate cancer: data from Southwest Oncology Group Trials 9346 (Intergroup Study 0162) and 9916. *J Clin Oncol*. 2009;27(15):2450–2456.

Hussain M, Tangen CM, Berry DL, et al. Intermittent versus continuous androgen deprivation in prostate cancer. *N Engl J Med*. 2013;368(14):1314–1325.

Hussain M, Tangen C, Higano C, et al. Evaluating intermittent androgen-deprivation therapy Phase III clinical trials: the devil is in the details. *J Clin Oncol*. 2016;34(3):280–285.

Hussain M, Fizazi K, Saad F, et al. Enzalutamide in men with nonmetastatic, castration-resistant prostate cancer. *N Engl J Med*. 2018;378(26):2465–2474.

Hyytinen ER, Haapala K, Thompson J, et al. Pattern of somatic androgen receptor gene mutations in patients with hormone-refractory prostate cancer. *Lab Invest*. 2002;82(11):1591–1598.

Irani J, Salomon L, Oba R, et al. Efficacy of venlafaxine, medroxyprogesterone acetate, and cyproterone acetate for the treatment of vasomotor hot flushes in men taking gonadotropin-releasing hormone analogues for prostate cancer: a double-blind, randomised trial. *Lancet Oncol*. 2010;11(2):147–154.

Isikbay M, Otto K, Kregel S, et al. Glucocorticoid receptor activity contributes to resistance to androgen-targeted therapy in prostate cancer. *Horm Cancer*. 2014;5(2):72–89.

Iversen P. Bicalutamide monotherapy for early stage prostate cancer: an update. *J Urol*. 2003;170(6 Pt 2):S48–S52 [discussion S52–44].

Iversen P, Tyrrell CJ, Kaisary AV, et al. Bicalutamide monotherapy compared with castration in patients with nonmetastatic locally advanced prostate cancer: 6.3 years of followup. *J Urol*. 2000;164(5):1579–1582.

Iversen P, Wirth MP, See WA, et al. Is the efficacy of hormonal therapy affected by lymph node status? data from the bicalutamide (Casodex) Early Prostate Cancer program. *Urology*. 2004;63(5):928–933.

Iversen P, McLeod DG, See WA, et al. Antiandrogen monotherapy in patients with localized or locally advanced prostate cancer: final results from the bicalutamide Early Prostate Cancer programme at a median follow-up of 9.7 years. *BJU Int*. 2010;105(8):1074–1081.

Jacobi GH, Altwein JE, Kurth KH, et al. Treatment of advanced prostatic cancer with parenteral cyproterone acetate: a phase III randomised trial. *Br J Urol*. 1980;52(3):208–215.

James ND, Sydes MR, Clarke NW, et al. Addition of docetaxel, zoledronic acid, or both to first-line long-term hormone therapy in prostate cancer (STAMPEDE): survival results from an adaptive, multiarm, multistage, platform randomised controlled trial. *Lancet*. 2015.

James ND, de Bono JS, Spears MR, et al. Abiraterone for prostate cancer not previously treated with hormone therapy. *N Engl J Med*. 2017;377(4):338–351.

Joseph JD, Lu N, Qian J, et al. A clinically relevant androgen receptor mutation confers resistance to second-generation antiandrogens enzalutamide and ARN-509. *Cancer Discov*. 2013;3(9):1020–1029.

Kaisary AV, Tyrrell CJ, Beacock C, et al. A randomised comparison of monotherapy with Casodex 50 mg daily and castration in the treatment of metastatic prostate carcinoma. Casodex Study Group. *Eur Urol*. 1995;28(3):215–222.

Kanis JA, Oden A, Johnell O, et al. The use of clinical risk factors enhances the performance of BMD in the prediction of hip and osteoporotic fractures in men and women. *Osteoporos Int*. 2007;18(8):1033–1046.

Keating NL, O'Malley AJ, Smith MR. Diabetes and cardiovascular disease during androgen deprivation therapy for prostate cancer. *J Clin Oncol*. 2006;24(27):4448–4456.

Keating NL, O'Malley AJ, Freedland SJ, et al. Diabetes and cardiovascular disease during androgen deprivation therapy: observational study of veterans with prostate cancer. *J Natl*

Cancer Inst. 2010;102(1):39–46.

Keating NL, Liu PH, O'Malley AJ, et al. Androgen-deprivation therapy and diabetes control among diabetic men with prostate cancer. *Eur Urol*. 2014;65(4):816–824.

Kelly WK, Scher HI. Prostate specific antigen decline after antiandrogen withdrawal: the flutamide withdrawal syndrome. *J Urol*. 1993;149(3):607–609.

Kelly WK, Slovin S, Scher HI. Steroid hormone withdrawal syndromes. Pathophysiology and clinical significance. *Urol Clin North Am*. 1997;24(2):421–431.

Kirk D. Timing and choice of androgen ablation. *Prostate Cancer Prostatic Dis*. 2004;7(3):217–222.

Kirk PS, Borza T, Shahinian VB, et al. The implications of baseline bone-health assessment at initiation of androgen-deprivation therapy for prostate cancer. *BJU Int*. 2018;121(4):558–564.

Klotz L, Boccon-Gibod L, Shore ND, et al. The efficacy and safety of degarelix: a 12-month, comparative, randomized, open-label, parallel-group phase III study in patients with prostate cancer. *BJU Int*. 2008;102(11):1531–1538.

Klotz L, Miller K, Crawford ED, et al. Disease control outcomes from analysis of pooled individual patient data from five comparative randomised clinical trials of degarelix versus luteinising hormone-releasing hormone agonists. *Eur Urol*. 2014;66(6):1101–1108.

Klotz L, Breau RH, Collins LL, et al. Maximal testosterone suppression in the management of recurrent and metastatic prostate cancer. *Can Urol Assoc J*. 2017;11(1–2):16–23.

Klotz LH, Goldenberg SL, Jewett MA, et al. Long-term followup of a randomized trial of 0 versus 3 months of neoadjuvant androgen ablation before radical prostatectomy. *J Urol*. 2003;170(3):791–794.

Knuth UA, Hano R, Nieschlag E. Effect of flutamide or cyproterone acetate on pituitary and testicular hormones in normal men. *J Clin Endocrinol Metab*. 1984;59(5):963–969.

Koch M, Steidle C, Brosman S, et al. An open-label study of abarelix in men with symptomatic prostate cancer at risk of treatment with LHRH agonists. *Urology*. 2003;62(5):877–882.

Kohli M, Li J, Du M, et al. Prognostic association of plasma cell-free DNA-based androgen receptor amplification and circulating tumor cells in pre-chemotherapy metastatic castration-resistant prostate cancer patients. *Prostate Cancer Prostatic Dis*. 2018;21(3):411–418.

Koivisto P, Kononen J, Palmberg C, et al. Androgen receptor gene amplification: a possible molecular mechanism for androgen deprivation therapy failure in prostate cancer. *Cancer Res*. 1997;57(2):314–319.

Kolvenbag GJ, Blackledge GR. Worldwide activity and safety of bicalutamide: a summary review. *Urology*. 1996;47(1A Suppl):70–79 [discussion 80–74].

Kolvenbag GJ, Nash A. Bicalutamide dosages used in the treatment of prostate cancer. *Prostate*. 1999;39(1):47–53.

Kruit WH, Stoter G, Klijn JG. Effect of combination therapy with aminoglutethimide and hydrocortisone on prostate-specific antigen response in metastatic prostate cancer refractory to standard endocrine therapy. *Anticancer Drugs*. 2004;15(9):843–847.

Krupski TL, Smith MR, Lee WC, et al. Natural history of bone complications in men with prostate carcinoma initiating androgen deprivation therapy. *Cancer*. 2004;101(3):541–549.

Kuhn JM, Billebaud T, Navratil H, et al. Prevention of the transient adverse effects of a gonadotropin-releasing hormone analogue (buserelin) in metastatic prostatic carcinoma by administration of an antiandrogen (nilutamide). *N Engl J Med*. 1989;321(7):413–418.

Kwak C, Jeong SJ, Park MS, et al. Prognostic significance of the nadir prostate specific antigen level after hormone therapy for prostate cancer. *J Urol*. 2002;168(3):995–1000.

Labrie F, Dupont A, Belanger A, et al. New approach in the treatment of prostate cancer: complete instead of partial withdrawal of androgens. *Prostate*. 1983;4(6):579–594.

Labrie F, Dupont A, Belanger A, et al. Flutamide eliminates the risk of disease flare in prostatic cancer patients treated with a luteinizing hormone-releasing hormone agonist. *J Urol*. 1987;138(4):804–806.

Lallous N, Volik SV, Awrey S, et al. Functional analysis of androgen receptor mutations that confer anti-androgen resistance identified in circulating cell-free DNA from prostate cancer patients. *Genome Biol*. 2016;17:10.

Lamharzi N, Halmos G, Jungwirth A, et al. Decrease in the level and mRNA expression of LH-RH and EGF receptors after treatment with LH-RH antagonist cetrorelix in DU-145 prostate tumor xenografts in nude mice. *Int J Oncol*. 1998;13(3):429–435.

Lee F, Siders DB, McHug TA, et al. Long-term follow-up of stages T2-T3 prostate cancer pretreated with androgen ablation therapy prior to radical prostatectomy. *Anticancer Res*. 1997;17(3A):1507–1510.

Leuprolide Study G. Leuprolide versus diethylstilbestrol for metastatic prostate cancer. *N Engl J Med*. 1984;311(20):1281–1286.

Levy ME, Perera S, van Londen GJ, et al. Physical function changes in prostate cancer patients on androgen deprivation therapy: a 2-year prospective study. *Urology*. 2008;71(4):735–739.

Li Y, Chan SC, Brand LJ, et al. Androgen receptor splice variants mediate enzalutamide resistance in castration-resistant prostate cancer cell lines. *Cancer Res*.

2013;73(2):483–489.

Lin BJ, Chen KK, Chen MT, et al. The time for serum testosterone to reach castrate level after bilateral orchiectomy or oral estrogen in the management of metastatic prostatic cancer. *Urology*. 1994;43(6):834–837.

Liu C, Lou W, Zhu Y, et al. Niclosamide inhibits androgen receptor variants expression and overcomes enzalutamide resistance in castration-resistant prostate cancer. *Clin Cancer Res*. 2014;20(12):3198–3210.

Loblaw DA, Mendelson DS, Talcott JA, et al. American Society of Clinical Oncology recommendations for the initial hormonal management of androgen-sensitive metastatic, recurrent, or progressive prostate cancer. *J Clin Oncol*. 2004;22(14):2927–2941.

Loprinzi CL, Goldberg RM, O'Fallon JR, et al. Transdermal clonidine for ameliorating post-orchiectomy hot flashes. *J Urol*. 1994;151(3):634–636.

Loprinzi CL, Barton DL, Carpenter LA, et al. Pilot evaluation of paroxetine for treating hot flashes in men. *Mayo Clin Proc*. 2004;79(10):1247–1251.

Loprinzi CL, Dueck AC, Khoyratty BS, et al. A phase III randomized, double-blind, placebo-controlled trial of gabapentin in the management of hot flashes in men (N00CB). *Ann Oncol*. 2009;20(3):542–549.

Lu-Yao GL, Albertsen PC, Moore DF, et al. Survival following primary androgen deprivation therapy among men with localized prostate cancer. *J Am Med Assoc*. 2008;300(2):173–181.

Maatman TJ, Gupta MK, Montie JE. Effectiveness of castration versus intravenous estrogen therapy in producing rapid endocrine control of metastatic cancer of the prostate. *J Urol*. 1985;133(4):620–621.

Mahler C, Verhelst J, Denis L. Clinical pharmacokinetics of the antiandrogens and their efficacy in prostate cancer. *Clin Pharmacokinet*. 1998;34(5):405–417.

Marumo K, Baba S, Murai M. Erectile function and nocturnal penile tumescence in patients with prostate cancer undergoing luteinizing hormone-releasing hormone agonist therapy. *Int J Urol*. 1999;6(1):19–23.

McHugh DJ, Root JC, Nelson CJ, et al. Androgen-deprivation therapy, dementia, and cognitive dysfunction in men with prostate cancer: how much smoke and how much fire? *Cancer*. 2018;124(7):1326–1334.

McLeod DG, Iversen P, See WA, et al. Bicalutamide 150 mg plus standard care vs standard care alone for early prostate cancer. *BJU Int*. 2006;97(2):247–254.

Melton LJ 3rd, Alothman KI, Khosla S, et al. Fracture risk following bilateral orchiectomy. *J Urol*. 2003;169(5):1747–1750.

Messing EM, Manola J, Sarosdy M, et al. Immediate hormonal therapy compared with observation after radical prostatectomy and pelvic lymphadenectomy in men with node-positive prostate cancer. *N Engl J Med*. 1999;341(24):1781–1788.

Messing EM, Manola J, Yao J, et al. Immediate versus deferred androgen deprivation treatment in patients with node-positive prostate cancer after radical prostatectomy and pelvic lymphadenectomy. *Lancet Oncol*. 2006;7(6):472–479.

Miller JI, Ahmann FR, Drach GW, et al. The clinical usefulness of serum prostate specific antigen after hormonal therapy of metastatic prostate cancer. *J Urol*. 1992;147(3 Pt 2):956–961.

Miyamoto H, Messing EM, Chang C. Androgen deprivation therapy for prostate cancer: current status and future prospects. *Prostate*. 2004;61(4):332–353.

Moffat SD, Zonderman AB, Metter EJ, et al. Longitudinal assessment of serum free testosterone concentration predicts memory performance and cognitive status in elderly men. *J Clin Endocrinol Metab*. 2002;87(11):5001–5007.

Mohler JL, Gregory CW, Ford OH 3rd, et al. The androgen axis in recurrent prostate cancer. *Clin Cancer Res*. 2004;10(2):440–448.

Moilanen AM, Riikonen R, Oksala R, et al. Discovery of ODM-201, a new-generation androgen receptor inhibitor targeting resistance mechanisms to androgen signaling-directed prostate cancer therapies. *Sci Rep*. 2015;5:12007.

Montgomery RB, Mostaghel EA, Vessella R, et al. Maintenance of intratumoral androgens in metastatic prostate cancer: a mechanism for castration-resistant tumor growth. *Cancer Res*. 2008;68(11):4447–4454.

Morgans AK, Smith MR, O'Malley AJ, et al. Bone density testing among prostate cancer survivors treated with androgen-deprivation therapy. *Cancer*. 2013;119(4):863–870.

Moschini M, Briganti A, Murphy CR, et al. Outcomes for patients with clinical lymphadenopathy treated with radical prostatectomy. *Eur Urol*. 2016;69(2):193–196.

Moyad MA. Complementary/alternative therapies for reducing hot flashes in prostate cancer patients: reevaluating the existing indirect data from studies of breast cancer and postmenopausal women. *Urology*. 2002;59(4 Suppl 1):20–33.

Nead KT, Gaskin G, Chester C, et al. Association between androgen deprivation therapy and risk of dementia. *JAMA Oncol*. 2017;3(1):49–55.

Neri RO, Monahan MD, Meyer JG, et al. Biological studies on an anti-androgen (SH 714). *Eur J Pharmacol*. 1967;1(5):438–444.

Nesbit RM, Baum WC. Serum phosphatase determinations in diagnosis of prostatic cancer; a review of 1,150 cases. *J Am Med Assoc*. 1951;145(17):1321–1324.

Nieh PT. Withdrawal phenomenon with the antiandrogen casodex. *J Urol*. 1995;153(3 Pt 2):1070–1072 [discussion 1072–1073].

Nishiyama T, Kanazawa S, Watanabe R, et al. Influence of hot flashes on quality of life in patients with prostate cancer treated with androgen deprivation therapy. *Int J Urol*. 2004;11(9):735–741.

Oefelein MG, Feng A, Scolieri MJ, et al. Reassessment of the definition of castrate levels of testosterone: implications for clinical decision making. *Urology*. 2000;56(6):1021–1024.

Palmer CB. A puzzle for future archaeologists. *Science*. 1893;21(535):246.

Parys BT, Hamid S, Thomson RG. Severe hepatocellular dysfunction following cyproterone acetate therapy. *Br J Urol*. 1991;67(3):312–313.

Penson DF, Armstrong AJ, Concepcion R, et al. Enzalutamide versus bicalutamide in castration-resistant prostate cancer: the STRIVE Trial. *J Clin Oncol*. 2016;34(18):2098–2106.

Pfitzenmeyer P, Foucher P, Piard F, et al. Nilutamide pneumonitis: a report on eight patients. *Thorax*. 1992;47(8):622–627.

Ponder BA, Shearer RJ, Pocock RD, et al. Response to aminoglutethimide and cortisone acetate in advanced prostatic cancer. *Br J Cancer*. 1984;50(6):757–763.

Pont A. Long-term experience with high dose ketoconazole therapy in patients with stage D2 prostatic carcinoma. *J Urol*. 1987;137(5):902–904.

Potosky AL, Knopf K, Clegg LX, et al. Quality-of-life outcomes after primary androgen deprivation therapy: results from the Prostate Cancer Outcomes Study. *J Clin Oncol*. 2001;19(17):3750–3757.

Potosky AL, Haque R, Cassidy-Bushrow AE, et al. Effectiveness of primary androgen-deprivation therapy for clinically localized prostate cancer. *J Clin Oncol*.

2014;32(13):1324–1330.

Poulsen MH, Rasmussen J, Edenbrandt L, et al. Bone Scan Index predicts outcome in patients with metastatic hormone-sensitive prostate cancer. *BJU Int*. 2016;117(5):748–753.

Quella SK, Loprinzi CL, Sloan J, et al. Pilot evaluation of venlafaxine for the treatment of hot flashes in men undergoing androgen ablation therapy for prostate cancer. *J Urol*. 1999;162(1):98–102.

Rathkopf DE, Morris MJ, Fox JJ, et al. Phase I study of ARN-509, a novel antiandrogen, in the treatment of castration-resistant prostate cancer. *J Clin Oncol*. 2013;31(28):3525–3530.

Rathkopf DE, Smith MR, Ryan CJ, et al. Androgen receptor mutations in patients with castration-resistant prostate cancer treated with apalutamide. *Ann Oncol*. 2017;28(9):2264–2271.

Reese DM. Choice of hormonal therapy for prostate cancer. *Lancet*. 2000;355(9214):1474–1475.

Rizzo M, Mazzei T, Mini E, et al. Leuprorelin acetate depot in advanced prostatic cancer: a phase II multicentre trial. *J Int Med Res*. 1990;18(Suppl 1):114–125.

Rodrigues NA, Chen MH, Catalona WJ, et al. Predictors of mortality after androgen-deprivation therapy in patients with rapidly rising prostate-specific antigen levels after local therapy for prostate cancer. *Cancer*. 2006;107(3):514–520.

Rodriguez-Vida A, Bianchini D, Van Hemelrijck M, et al. Is there an antiandrogen withdrawal syndrome with enzalutamide? *BJU Int*. 2015;115(3):373–380.

Rubin MA, Putzi M, Mucci N, et al. Rapid (“warm”) autopsy study for procurement of metastatic prostate cancer. *Clin Cancer Res*. 2000;6(3):1038–1045.

Ruzicka L, Wettstein A. Synthesis of the testicular hormone (testosterone) (androstene 3-on-17-ol). *Helv Chim Acta*. 1935;18:1264–1275.

Ryan CJ, Small EJ. Early versus delayed androgen deprivation for prostate cancer: new fuel for an old debate. *J Clin Oncol*. 2005;23(32):8225–8231.

Ryan CJ, Smith MR, de Bono JS, et al. Abiraterone in metastatic prostate cancer without previous chemotherapy. *N Engl J Med*. 2013;368(2):138–148.

Saigal CS, Gore JL, Krupski TL, et al. Androgen deprivation therapy increases cardiovascular morbidity in men with prostate cancer. *Cancer*. 2007;110(7):1493–1500.

Sanford EJ, Drago JR, Rohner TJ Jr, et al. Aminoglutethimide medical adrenalectomy for advanced prostatic carcinoma. *J Urol*. 1976;115(2):170–174.

Schally AV, Arimura A, Baba Y, et al. Isolation and properties of the FSH and LH-releasing hormone. *Biochem Biophys Res Commun*. 1971;43(2):393–399.

Schellhammer PF, Davis JW. An evaluation of bicalutamide in the treatment of prostate cancer. *Clin Prostate Cancer*. 2004;2(4):213–219.

Scher HI, Kelly WK. Flutamide withdrawal syndrome: its impact on clinical trials in hormone-refractory prostate cancer. *J Clin Oncol*. 1993;11(8):1566–1572.

Scher HI, Sawyers CL. Biology of progressive, castration-resistant prostate cancer: directed therapies targeting the androgen-receptor signaling axis. *J Clin Oncol*. 2005;23(32):8253–8261.

Scher HI, Buchanan G, Gerald W, et al. Targeting the androgen receptor: improving outcomes for castration-resistant prostate cancer. *Endocr Relat Cancer*. 2004;11(3):459–476.

Scher HI, Fizazi K, Saad F, et al. Increased survival with enzalutamide in prostate cancer after chemotherapy. *N Engl J Med*. 2012;367(13):1187–1197.

Scher HI, Lu D, Schreiber NA, et al. Association of AR-V7 on circulating tumor cells as a treatment-specific biomarker with outcomes and survival in castration-resistant prostate cancer. *JAMA Oncol*. 2016;2(11):1441–1449.

Scholz M, Jennrich R, Strum S, et al. Long-term outcome for men with androgen independent prostate cancer treated with ketoconazole and hydrocortisone. *J Urol*. 2005;173(6):1947–1952.

Schroder FH, Collette L, de Reijke TM, et al. Prostate cancer treated by anti-androgens: is sexual function preserved? EORTC Genitourinary Group. European Organization for Research and Treatment of Cancer. *Br J Cancer*. 2000;82(2):283–290.

Schroder FH, Kurth KH, Fossa SD, et al. Early versus delayed endocrine treatment of T2-T3 pN1-3 M0 prostate cancer without local treatment of the primary tumour: final results of European Organisation for the Research and Treatment of Cancer protocol 30846 after 13 years of follow-up (a randomised controlled trial). *Eur Urol*. 2009;55(1):14–22.

Schulze H, Senge T. Influence of different types of antiandrogens on luteinizing hormone-releasing hormone analogue-induced testosterone surge in patients with metastatic carcinoma of the prostate. *J Urol*. 1990;144(4):934–941.

See W, Iversen P, Wirth M, et al. Immediate treatment with bicalutamide 150 mg as adjuvant therapy significantly reduces the risk of PSA progression in early prostate cancer. *Eur Urol*. 2003;44(5):512–517 [discussion 517–518].

See WA, Wirth MP, McLeod DG, et al. Bicalutamide as immediate therapy either alone or as adjuvant to standard care of patients with localized or locally advanced prostate cancer: first analysis of the early prostate cancer program. *J Urol*. 2002;168(2):429–435.

Seidell JC, Bjorntorp P, Sjostrom L, et al. Visceral fat accumulation in men is positively associated with insulin, glucose, and C-peptide levels, but negatively with testosterone levels. *Metabolism*. 1990;39(9):897–901.

Seidenfeld J, Samson DJ, Hasselblad V, et al. Single-therapy androgen suppression in men with advanced prostate cancer: a systematic review and meta-analysis. *Ann Intern Med*. 2000;132(7):566–577.

Shahinian VB, Kuo YF, Freeman JL, et al. Risk of fracture after androgen deprivation for prostate cancer. *N Engl J Med*. 2005;352(2):154–164.

Shahinian VB, Kuo YF, Freeman JL, et al. Determinants of androgen deprivation therapy use for prostate cancer: role of the urologist. *J Natl Cancer Inst*. 2006;98(12):839–845.

Shahinian VB, Kuo YF, Gilbert SM. Reimbursement policy and androgen-deprivation therapy for prostate cancer. *N Engl J Med*. 2010;363(19):1822–1832.

Sharifi N, Gulley JL, Dahut WL. Androgen deprivation therapy for prostate cancer. *J Am Med Assoc*. 2005;294(2):238–244.

Shore ND, Chowdhury S, Villers A, et al. Efficacy and safety of enzalutamide versus bicalutamide for patients with metastatic prostate cancer (TERRAIN): a randomised, double-blind, phase 2 study. *Lancet Oncol*. 2016;17(2):153–163.

Siddiqui SA, Boorjian SA, Inman B, et al. Timing of androgen deprivation therapy and its impact on survival after radical prostatectomy: a matched cohort study. *J Urol*. 2008;179(5):1830–1837 [discussion 1837].

Small EJ, Srinivas S. The antiandrogen withdrawal syndrome. Experience in a large cohort of unselected patients with advanced prostate cancer. *Cancer*. 1995;76(8):1428–1434.

Small EJ, Halabi S, Dawson NA, et al. Antiandrogen withdrawal alone or in combination with ketoconazole in androgen-independent prostate cancer patients: a phase III trial (CALGB 9583). *J Clin Oncol*. 2004;22(6):1025–1033.

Smith JA Jr. A prospective comparison of treatments for symptomatic hot flushes following endocrine therapy for carcinoma of the prostate. *J Urol*. 1994;152(1):132–134.

Smith MR. Osteoporosis and obesity in men receiving hormone therapy for prostate cancer. *J Urol*. 2004;172(5 Pt 2):S52–S56 [discussion S56–57].

Smith MR, Finkelstein JS, McGovern FJ, et al. Changes in body composition during androgen deprivation therapy for prostate cancer. *J Clin Endocrinol Metab*. 2002;87(2):599–603.

Smith MR, Lee WC, Brandman J, et al. Gonadotropin-releasing hormone agonists and fracture risk: a claims-based cohort study of men with nonmetastatic prostate cancer. *J Clin Oncol*. 2005;23(31):7897–7903.

Smith MR, Boyce SP, Moyneur E, et al. Risk of clinical fractures after gonadotropin-releasing hormone agonist therapy for prostate cancer. *J Urol*. 2006;175(1):136–139 [discussion 139].

Smith MR, Bae K, Efstathiou JA, et al. Diabetes and mortality in men with locally advanced prostate cancer: RTOG 92-02. *J Clin Oncol*. 2008;26(26):4333–4339.

Smith MR, Saad F, Egerdie B, et al. Sarcopenia during androgen-deprivation therapy for prostate cancer. *J Clin Oncol*. 2012;30(26):3271–3276.

Smith MR, Antonarakis ES, Ryan CJ, et al. Phase 2 study of the safety and antitumor activity of apalutamide (arn-509), a potent androgen receptor antagonist, in the high-risk nonmetastatic castration-resistant prostate cancer cohort. *Eur Urol*. 2016;70(6):963–970.

Smith MR, Saad F, Chowdhury S, et al. Apalutamide treatment and metastasis-free survival in prostate cancer. *N Engl J Med*. 2018;378(15):1408–1418.

Soga N, Kageyama T, Ogura Y, et al. Clinical effect of switching from a luteinizing hormone-releasing hormone agonist to an antagonist in patients with castration-resistant prostate cancer and serum testosterone level >/= 20 ng/dl. *Curr Urol*. 2016;9(1):31–35.

Soloway MS, Pareek K, Sharifi R, et al. Neoadjuvant androgen ablation before radical prostatectomy in cT2bNxMo prostate cancer: 5-year results. *J Urol*. 2002;167(1):112–116.

Spetz AC, Zetterlund EL, Varenhorst E, et al. Incidence and management of hot flashes in prostate cancer. *J Support Oncol*. 2003;1(4):263–266 [269–270, 272–263; discussion 267–268, 271–262].

Stefanopoulou E, Yousaf O, Grunfeld EA, et al. A randomised controlled trial of a brief cognitive behavioural intervention for men who have hot flushes following prostate cancer treatment (MANCAN). *Psychooncology*. 2015;24(9):1159–1166.

Strum SB, McDermed JE, Scholz MC, et al. Tisman G. Anaemia associated with androgen deprivation in patients with prostate cancer receiving combined hormone blockade. *Br J Urol*. 1997;79(6):933–941.

Studer UE, Whelan P, Albrecht W, et al. Immediate or deferred androgen deprivation for patients with prostate cancer not suitable for local treatment with curative intent: European Organisation for Research and Treatment of Cancer (EORTC) Trial 30891. *J Clin Oncol*. 2006;24(12):1868–1876.

Sun M, Choueiri TK, Hamnvik OP, et al. Comparison of gonadotropin-releasing hormone agonists and orchiectomy: effects of androgen-deprivation therapy. *JAMA Oncol*. 2016;2(4):500–507.

Suzuki H, Akakura K, Komiya A, et al. Codon 877 mutation in the androgen receptor gene in advanced prostate cancer: relation to antiandrogen withdrawal syndrome. *Prostate*. 1996;29(3):153–158.

Sweeney CJ, Chen YH, Carducci M, et al. Chemohormonal therapy in metastatic hormone-sensitive prostate cancer. *N*

Engl J Med. 2015;373(8):737–746.

Tannock IF, de Wit R, Berry WR, et al. Docetaxel plus prednisone or mitoxantrone plus prednisone for advanced prostate cancer. *N Engl J Med*. 2004;351(15):1502–1512.

Taplin ME, Bubley GJ, Shuster TD, et al. Mutation of the androgen-receptor gene in metastatic androgen-independent prostate cancer. *N Engl J Med*. 1995;332(21):1393–1398.

Taplin ME, Rajeshkumar B, Halabi S, et al. Androgen receptor mutations in androgen-independent prostate cancer: Cancer and Leukemia Group B Study 9663. *J Clin Oncol*. 2003;21(14):2673–2678.

Taplin ME, Rajeshkumar B, Halabi S, et al. Androgen receptor mutations in androgen-independent prostate cancer: Cancer and Leukemia Group B Study 9663. *J Clin Oncol*. 2003;21(14):2673–2678.

Tay MH, Kaufman DS, Regan MM, et al. Finasteride and bicalutamide as primary hormonal therapy in patients with advanced adenocarcinoma of the prostate. *Ann Oncol*. 2004;15(6):974–978.

The Medical Research Council Prostate Cancer Working Party Investigators Group. Immediate versus deferred treatment for advanced prostatic cancer: initial results of the Medical Research Council Trial. *Br J Urol*. 1997;79(2):235–246.

Thole Z, Manso G, Salgueiro E, et al. Hepatotoxicity induced by antiandrogens: a review of the literature. *Urol Int*. 2004;73(4):289–295.

Thorpe SC, Azmatullah S, Fellows GJ, et al. A prospective, randomised study to compare goserelin acetate (Zoladex) versus cyproterone acetate (Cyprostat) versus a combination of the two in the treatment of metastatic prostatic carcinoma. *Eur Urol*. 1996;29(1):47–54.

Tomera K, Gleason D, Gittelman M, et al. The gonadotropin-releasing hormone antagonist abarelix depot versus luteinizing hormone releasing hormone agonists leuprolide or goserelin: initial results of endocrinological and biochemical efficacies in patients with prostate cancer. *J Urol*. 2001;165(5):1585–1589.

Tomic R. Some effects of orchiectomy, oestrogen treatment and radiation therapy in patients with prostatic carcinoma. *Scand J Urol Nephrol Suppl*. 1983;77:1–37.

Touijer KA, Mazzola CR, Sjoberg DD, et al. Long-term outcomes of patients with lymph node metastasis treated with radical prostatectomy without adjuvant androgen-deprivation therapy. *Eur Urol*. 2014;65(1):20–25.

Trachtenberg J, Pont A. Ketoconazole therapy for advanced prostate cancer. *Lancet*. 1984;2(8400):433–435.

Trachtenberg J, Halpern N, Pont A. Ketoconazole: a novel and rapid treatment for advanced prostatic cancer. *J Urol*. 1983;130(1):152–153.

Trachtenberg J, Gittleman M, Steidle C, et al. A phase 3, multicenter, open label, randomized study of abarelix versus leuprolide plus daily antiandrogen in men with prostate cancer. *J Urol*. 2002;167(4):1670–1674.

Tran C, Ouk S, Clegg NJ, et al. Development of a second-generation antiandrogen for treatment of advanced prostate cancer. *Science*. 2009;324(5928):787–790.

Tsai HK, D'Amico AV, Sadetsky N, et al. Androgen deprivation therapy for localized prostate cancer and the risk of cardiovascular mortality. *J Natl Cancer Inst*. 2007;99(20):1516–1524.

Tsushima T, Nasu Y, Saika T, et al. Optimal starting time for flutamide to prevent disease flare in prostate cancer patients treated with a gonadotropin-releasing hormone agonist. *Urol Int*. 2001;66(3):135–139.

Tyrrell CJ, Kaisary AV, Iversen P, et al. A randomised comparison of ‘Casodex’ (bicalutamide) 150 mg monotherapy versus castration in the treatment of metastatic and locally advanced prostate cancer. *Eur Urol*. 1998;33(5):447–456.

Tyrrell CJ, Payne H, Tammela TL, et al. Prophylactic breast irradiation with a single dose of electron beam radiotherapy (10 Gy) significantly reduces the incidence of bicalutamide-induced gynecomastia. *Int J Radiat Oncol Biol Phys*. 2004;60(2):476–483.

van Londen GJ, Levy ME, Perera S, et al. Body composition changes during androgen deprivation therapy for prostate cancer: a 2-year prospective study. *Crit Rev Oncol Hematol*. 2008;68(2):172–177.

von Klot CA, Kramer MW, Boker A, et al. Is there an anti-androgen withdrawal syndrome for enzalutamide? *World J Urol*. 2014;32(5):1171–1176.

Vanuytsel L, Ang KK, Vantongelen K, et al. Ketoconazole therapy for advanced prostatic cancer: feasibility and treatment results. *J Urol*. 1987;137(5):905–908.

Verhagen PC, Wildhagen MF, Verkerk AM, et al. Intermittent versus continuous cyproterone acetate in bone metastatic prostate cancer: results of a randomized trial. *World J Urol*. 2014;32(5):1287–1294.

Visakorpi T, Hyytinen E, Koivisto P, et al. In vivo amplification of the androgen receptor gene and progression of human prostate cancer. *Nat Genet*. 1995;9(4):401–406.

Vitolins MZ, Griffin L, Tomlinson WV, et al. Randomized trial to assess the impact of venlafaxine and soy protein on hot flashes and quality of life in men with prostate cancer. *J Clin Oncol*. 2013;31(32):4092–4098.

Walsh PC, Siiteri PK. Suppression of plasma androgens by spironolactone in castrated men with carcinoma of the prostate. *J Urol*. 1975;114(2):254–256.

Walsh PC, Swerdloff RS, Odell WD. Feedback regulation of gonadotropin secretion in men. *J Urol*. 1973;110(1):84–89.

Walsh PC, DeWeese TL, Eisenberger MA. A structured debate: immediate versus deferred androgen suppression in prostate cancer-evidence for deferred treatment. *J Urol*. 2001;166(2):508–515 [discussion 515–506].

Waxman HJ, Hendry WF, Whitfield HN, et al. A long term follow-up of patients with advanced prostatic cancer treated with buserelin. *Prog Clin Biol Res*. 1985;185A:271–277.

Weckermann D, Harzmann R. Hormone therapy in prostate cancer: LHRH antagonists versus LHRH analogues. *Eur Urol*. 2004;46(3):279–283 [discussion 283–274].

Wei JT, Gross M, Jaffe CA, et al. Androgen deprivation therapy for prostate cancer results in significant loss of bone density. *Urology*. 1999;54(4):607–611.

White JWI. The surgery of the hypertrophied prostate. *Ann Surg*. 1893;17(1):70–75.

Whitley GS, Nussey SS, Johnstone AP. SGHTL-34, a thyrotrophin-responsive immortalised human thyroid cell line generated by transfection. *Mol Cell Endocrinol*. 1987;52(3):279–284.

Widmark A, Fossa SD, Lundmo P, et al. Does prophylactic breast irradiation prevent antiandrogen-induced gynecomastia? Evaluation of 253 patients in the randomized scandinavian trial SPCG-7/SFUO-3. *Urology*. 2003;61(1):145–151.

Wilkinson S, Chodak G. An evaluation of intermediate-dose ketoconazole in hormone refractory prostate cancer. *Eur Urol*. 2004;45(5):581–584 [discussion 585].

Wirth M, Tyrrell C, Wallace M, et al. Bicalutamide (Casodex) 150 mg as immediate therapy in patients with localized or locally advanced prostate cancer significantly reduces the risk of disease progression. *Urology*. 2001;58(2):146–151.

Wirth MP, See WA, McLeod DG, et al. Bicalutamide 150 mg in addition to standard care in patients with localized or locally advanced prostate cancer: results from the second analysis of the early prostate cancer program at median followup of 5.4 years. *J Urol*. 2004;172(5 Pt 1):1865–1870.

Witjes WP, Schulman CC, Debruyne FM. Preliminary results of a prospective randomized study comparing radical prostatectomy versus radical prostatectomy associated with neoadjuvant hormonal combination therapy in T2-3 N0 M0 prostatic carcinoma. The European Study Group on Neoadjuvant Treatment of Prostate Cancer. *Urology*. 1997;49(3A Suppl):65–69.

Wright AS, Douglas RC, Thomas LN, et al. Androgen-induced regrowth in the castrated rat ventral prostate: role of 5alpha-reductase. *Endocrinology*. 1999;140(10):4509–4515.

Wyatt AW, Azad AA, Volik SV, et al. Genomic alterations in cell-free DNA and enzalutamide resistance in castration-resistant prostate cancer. *JAMA Oncol*. 2016;2(12):1598–1606.

Yuzurihara M, Ikarashi Y, Noguchi M, et al. Involvement of calcitonin gene-related peptide in elevation of skin temperature in castrated male rats. *Urology*. 2003;62(5):947–951.

Zacho HD, Gade M, Mortensen JC, et al. Bone scan index is an independent predictor of time to castration-resistant prostate cancer in newly diagnosed prostate cancer: a prospective study. *Urology*. 2017;108:135–141.

Zhang XZ, Donovan MP, Williams BT, et al. Comparison of subcapsular and total orchiectomy for treatment of metastatic prostate cancer. *Urology*. 1996;47(3):402–404.

Treatment of Castration-Resistant Prostate Cancer

Emmanuel S. Antonarakis MD, Michael A. Carducci MD

During the past several decades, endocrine manipulations developed to inhibit hormone-sensitive prostate cancer growth and differentiation have constituted the basic strategy for the systemic control of prostate cancer. Suppression of gonadal testosterone is the central principle of androgen deprivation therapy (ADT), and this represents one of the most effective systemic treatments known for solid tumors. Although the therapy is extremely effective initially, almost all patients eventually develop biochemical and clinical evidence of treatment resistance. The outcomes with conventional endocrine therapy have changed significantly but only modestly during the past few decades. Progression-free and overall survival figures of patients with metastatic disease with various methods of ADT have ranged from 12 to 20 months and 24 to 36 months, respectively (Crawford et al., 1989; Denis et al., 1993; Eisenberger et al., 1998; Leuprolide Study Group, 1984). Whereas somewhat longer survival times are reported in the more recent studies, this is most likely because of a “lead time” effect observed in contemporary populations of patients. The development of ADT resistance (i.e., cancer progression despite castrate levels of serum testosterone) is a universal state that affects all patients treated with ADT. Undoubtedly, further improvement in the outcome of patients with metastatic castration-resistant prostate cancer (mCRPC) rests on the use of nonhormonal approaches that can effectively control the growth of the disease. However, recent understandings of the biology of castration-resistant prostate cancer (CRPC) have also led to the development of next-generation androgen receptor (AR)–targeting therapies, and some of these have also led to substantial clinical benefits.

During recent years, clinical investigations testing nonhormonal approaches have shown that systemic chemotherapy improves survival and quality of life in patients with castration-resistant disease. Advances in the understanding of the biology of prostate cancer and the characterization of key molecular pathways have added an important new dimension for treatment and the opportunity to design disease-specific targeted treatment approaches. Evolving data suggest that targeted approaches may play an important role in the treatment of prostate cancer that may improve the outcome in patients.

Progress in cell and molecular biology during the past decade has also enhanced our understanding of the mechanisms involved in the progression of prostate cancer, and this may provide the opportunity for rational planning of the appropriate timing of systemic therapeutic intervention with the objective of preventing or delaying progression of disease to lethal proportions. Cancer cells demonstrating the castration-resistant phenotype can be identified during the early stages of development of prostate cancer. Somatic alterations of the AR are frequently observed in patients with evidence of disease progression after androgen deprivation. It has also been demonstrated that during cancer progression, in the absence of androgens, a molecularly altered AR can still undergo ligand-dependent activation by other hormones such as estrogens and progestational agents, as well as non–ligand-dependent activation by growth factors and cytokines (Feldman and Feldman, 2001; Gelmann, 2002; Nelson et al., 2003). The observation that the AR can still be activated even after long-term gonadal ablation suggests that it continues to play an important role in prostate cancer growth and may indeed be a reasonable target for treatment in patients with castration-resistant disease, as exemplified by success with abiraterone and enzalutamide.

In the presence of androgens, prostatic cancer growth is based on a cell proliferation rate that exceeds that of cell death (Isaacs et al., 1992). Androgen ablation primarily affects the cell death rate by inducing a swift apoptotic cascade. As the tumor progresses, the threshold of apoptosis progressively rises to a point at which cell proliferation exceeds cell death (Berges et al., 1995). This results in the accumulation of endocrine-independent cells that eventually dominate the biologic behavior of prostate cancer in late stages.

Preclinical data suggest that the relatively low growth fraction expressed by prostate cancer cells (compared with other common adenocarcinomas) may be a determining factor to explain the relative insensitivity to conventional cytotoxic chemotherapy. The proliferation rate of prostate cancer cells, which is directly proportional to the growth fraction, appears to increase with tumor progression especially after androgen ablation. Cell proliferation antigens, such as Ki-67 expressed by cycling cells, may have important prognostic and therapeutic implications, because most of the conventional cytotoxic chemotherapeutic agents available are usually more effective in tumors with high proliferative rates such as lymphomas, small cell lung carcinomas, and germ cell tumors.

Changes in differentiation pathways in prostate cancer have been increasingly emphasized, particularly in the form of neuroendocrine/anaplastic cells (diSant'Agnese, 1995). Evolving experience suggests that this aggressive clinical entity may be responsive to treatment regimens frequently used for comparable tumors at other sites with similar phenotypic characteristics, such as small cell carcinoma of the lung. There is strong evidence to support the relationship between prostate cancer growth and various peptide growth factors (Djakiew et al., 1991; Hofer et al., 1995; Kaplan et al., 1999; Nelson et al., 2003; Steiner, 1993). Peptide growth factors may also exert their effects through the activation of the AR. Androgens are capable of inducing stromal production of various growth factors that could replace the androgen requirements for cell growth and differentiation (Lee, 1996). In addition, cytokines released primarily by stromal cells, such as interleukin-6, may also be important in the pathogenesis of prostate cancer. Indeed, small molecule inhibitors and other modalities of treatment (e.g., monoclonal antibodies) are being actively designed to target intracellular pathways associated with the expression of various growth factors and their receptors. Such strategies have involved inhibition of receptor tyrosine kinase activity and other intracellular molecular pathways of signal transduction as well as other critical pathways of cell growth and survival.

Clinical Considerations

Disease Assessment and Prognostic Considerations

Conventional staging criteria, such as the tumor, node, metastases (TNM) staging system, do not describe the extent of disease beyond a simple anatomic classification, and they are not very helpful in the management of patients with recurrent or advanced prostate cancer. Treatment practices have resulted in the creation of different disease states as described by Scher et al. (2008). This system of “clinical states” allows classification of patients into a more relevant fashion and is increasingly being used throughout the literature. Fig. 162.1 illustrates the natural history of prostate cancer relative to treatment practices and identifies the various clinical states according to the response status to different therapies. Throughout this chapter, prognostic and therapeutic considerations are largely based on the concepts proposed by this classification model.

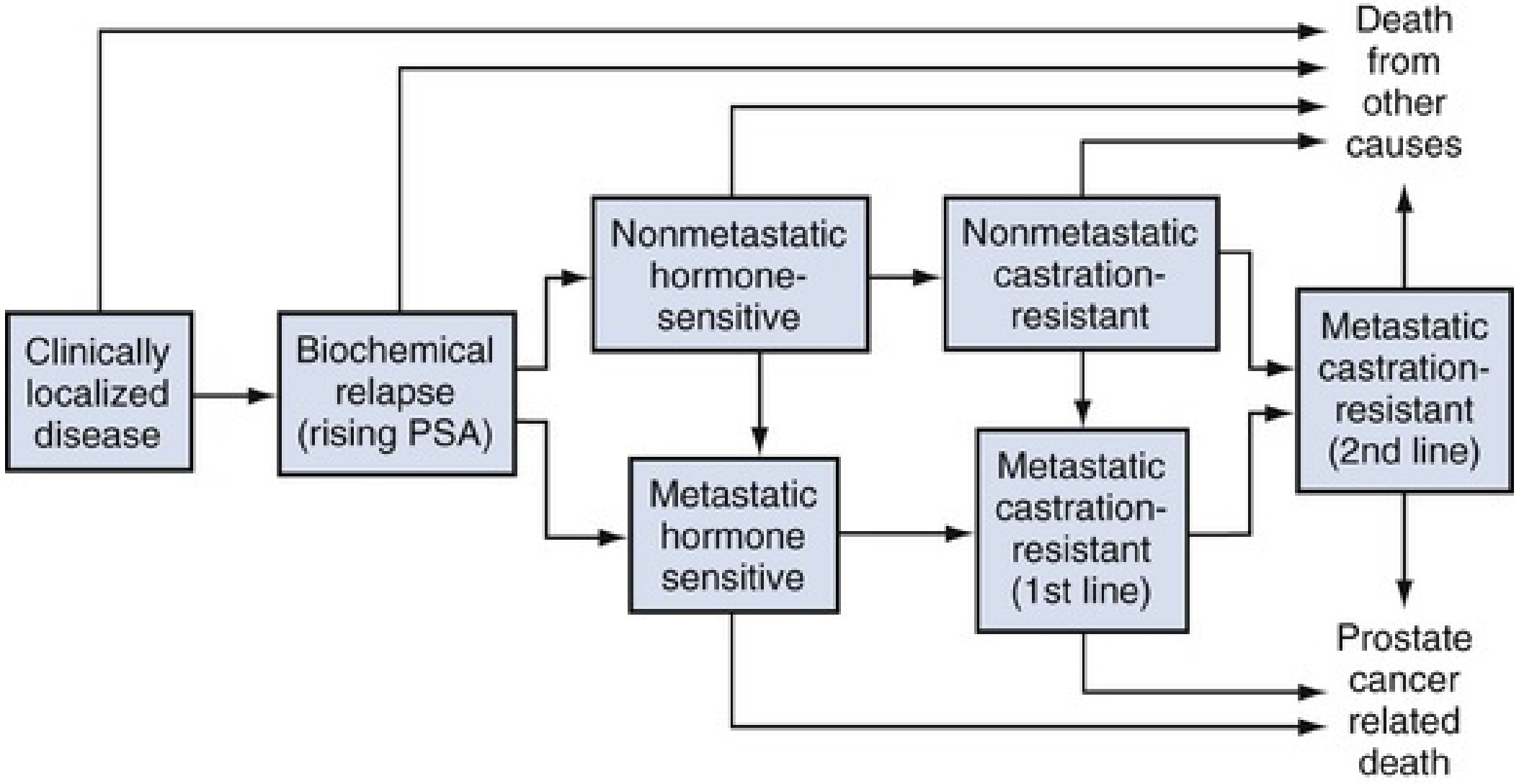
Death from other causes
Nonmetastatic hormone-sensitive
Nonmetastatic castration-resistant
Clinically localized disease
Biochemical relapse (rising PSA)
Metastatic castration-resistant (2nd line)
Metastatic hormone sensitive
Metastatic castration-resistant (1st line)
Prostate cancer related death

FIG. 162.1 Prostate cancer clinical states. *PSA,* Prostate-specific antigen. (Modified from Scher HI, Halabi S, Tannock I, et al.: Design and end points of clinical trials for patients with progressive prostate cancer and castrate levels of testosterone: recommendations of the Prostate Cancer Clinical Trials Working Group. *J Clin Oncol* 26:1148–1159, 2008.)

A complete disease evaluation is required to estimate the prognosis and to make therapeutic decisions. Critical baseline components should also be considered, including extent of disease, mode and site of progression (rising prostate-specific antigen [PSA] level alone, new bone metastasis, visceral and nodal metastasis), presence or absence of symptoms including bone pain, and response to previous endocrine treatment. Regular monitoring with serial bone scintigraphs and CT scans together with serum PSA levels provides important information in patients demonstrating evidence of disease progression while they are receiving hormone therapy. Usually the first manifestation of disease progression after hormone therapy is a rising serum PSA level. In patients with metastatic disease, a rise in serum PSA level precedes evidence of advancing disease on the bone scan, and during this time patients may remain relatively asymptomatic (Eisenberger et al., 1995). Routine evaluation of serum testosterone levels may provide important information for the choice of subsequent treatment. This is especially important when there may be reasons to suspect treatment noncompliance or if the choice of previous treatment involved regimens known not to result in a sustained suppression of serum testosterone to castrate levels (e.g., monotherapy with nonsteroidal antiandrogens, low-dose estrogens, or 5α-reductase inhibitors).

For several years, it was postulated that discontinuation of androgen suppression in patients who have not undergone orchiectomy may adversely influence the outcome of their disease in terms of progression and survival (Taylor et al., 1993). Similarly it has been shown that administration of exogenous testosterone and its derivatives may indeed produce a significant clinical flare, resulting in severe pain and neurologic, urologic, and coagulation complications in a small proportion of patients (Fowler and Whitmore, 1981; Manni et al., 1988). In a retrospective analysis of 205 patients with castration-resistant disease treated with chemotherapy, Hussain et al. (1994) evaluated various prognostic variables including orchiectomy. A multivariate analysis failed to indicate a significant correlation between previous orchiectomy and improved progression-free and overall survival. In these patients, all medical forms of androgen deprivation were discontinued at least 4 weeks before initiation of chemotherapy and, contrary to that suggested by Taylor et al. (1993), this did not significantly affect outcomes. Until this issue is resolved, the general consensus is to maintain all patients on luteinizing hormone–releasing hormone (LHRH) agonists or antagonists indefinitely, even during the course of subsequent therapies, including chemotherapy. Indeed almost all clinical trials that test novel therapies for men with castration-resistant prostate cancer (CRPC) mandate the continued suppression of serum testosterone levels, either with chronic ADT or with surgical castration.

Another important management aspect relates to antiandrogen withdrawal effects (Scher and Kelly, 1993; Small et al., 2004). Discontinuation of antiandrogens (steroidal and nonsteroidal) can result in short-term clinical responses expressed by decreases in PSA levels, symptomatic benefits, and (less frequently) objective improvements in soft-tissue and bone metastasis in a small proportion of patients. Because of this phenomenon, it has been recommended that in patients who appear to be progressing while on first-generation antiandrogens in combination with other forms of androgen deprivation (e.g., LHRH agonists), the first step should involve the carefully observed discontinuation of the antiandrogen, including serial monitoring of PSA levels for a period of 4 to 8 weeks before embarking on the next therapeutic maneuver.

The subsequent step is to determine which modality of treatment should be used next, either administration of second-line hormonal manipulation (including novel AR-directed therapies) or cytotoxic chemotherapy. There is an increasing body of data on second-line endocrine therapies, suggesting that there may be a role for this approach before institution of chemotherapy (Ang et al., 2009; Ryan, 2006; Small et al., 2004). Although initial response rates to the second-generation hormonal manipulations range between 20% and 60%, the median duration of such responses is short, ranging between 2 and 4 months. Agents that have been reported to produce some benefit in this setting include diethylstilbestrol (Smith et al., 1986), aminoglutethimide (Sartor and Myers, 1995), ketoconazole (Small et al., 2004), and corticosteroids (Storlie et al., 1995). Since around 2012, additional next-generation AR-targeting therapies have become available (e.g., abiraterone and enzalutamide) and have largely replaced the second-generation endocrine agents listed earlier. In view of the potential higher toxicity profile associated with cytotoxic chemotherapy, a sequential hormonal approach may be a reasonable alternative for those patients with relatively limited metastatic disease who remain asymptomatic at the time of disease progression (e.g., rising serum PSA value without other clinical manifestations or pain).

Another important consideration is the initial clinical assessment of the potential biologic behavior of these tumors when they become castration resistant. Evolving data evaluating the role of PSA dynamics suggest that the PSA doubling time (PSADT) predicts the rapidity of bone scan progression and survival (Armstrong et al., 2007; D'Amico et al., 2005; Robinson et al., 2008). Patients with PSADT shorter than 3 months have a particularly rapid clinical course and should possibly be considered for more aggressive management approaches. Similarly, patients with symptomatic bone pain or visceral-predominant disease may be better served with cytotoxic chemotherapy up front. In addition, poorly differentiated and neuroendocrine tumors usually have a low likelihood of significant and durable responses to further AR-directed therapies. The anaplastic/neuroendocrine phenotype is rare and requires special therapeutic considerations (see later). It has been suggested that systematic biopsies of disease sites in patients with clinically aggressive disease and relatively low serum PSA levels may demonstrate evidence of a neuroendocrine phenotype by immunostaining, which may be of prognostic and therapeutic significance. The usefulness of systematic biopsies in all patients with extensive metastasis and relatively low PSA levels, however, must be better defined before routine clinical application.

Nonmetastatic Castration-Resistant Prostate Cancer

The extraordinary stage migration that has affected all stages of prostate cancer has profoundly modified the spectrum of the clinical presentation of patients with castration-resistant disease. An increasing number of patients now begin ADT at very early stages of their disease course, often at the first sign of a rising PSA after local therapy, before clinical and radiologic evidence of metastasis is present. This group of patients, termed the M0 (nonmetastatic) castrate-resistant subset, is now seen in increasing proportions in the clinic. Given the changes in treatment practices with early initiation of androgen deprivation, it is conceivable that these numbers will continue to increase. At this time data on the natural history of these patients are evolving, but the strongest predictor of metastatic progression appears to be the PSA kinetics (PSA velocity, PSADT).

A number of clinical trials using second-line hormonal manipulations and noncytotoxic interventions (bone-targeted treatments) focusing on time to development of bone metastasis have provided some useful information. A report of 201 patients from a prospective clinical trial comparing the effects of the bisphosphonate zoledronate versus placebo in men with M0 castrate-resistant disease suggested that the time to radiographic metastasis may be very long. At 2 years, only 33% of these patients exhibited evidence of bone metastasis, with a median time to bone metastasis in this group of 30 months. The baseline PSA level (>10 ng/mL) and the PSA velocity independently predicted time to bone metastasis and survival (Smith et al., 2005). In a retrospective review of a similar group of patients who were prescribed ADT before the development of metastatic disease, the median time to clinical metastasis was 9 months. The pretreatment PSA level and the PSA nadir on ADT predicted metastasis-free survival (Dotan et al., 2005). The wide difference observed with these two reports (30 months vs. 9 months for time to bone scan metastasis) underscores the heterogeneity of this group of patients and the need for careful prospective evaluation. Their outcome is dependent on various factors, among which are pre-ADT characteristics (pretreatment PSA level, PSADT, initial stage, Gleason score), as well as differential response to hormonal treatment. However, it is probable that the risk of metastatic progression may be best estimated by PSA kinetics constructs such as PSADT and PSA velocity.

Until recently, there was no consensus regarding the most appropriate management for patients with nonmetastatic CRPC, although the sequential endocrine approach (using first-generation agents; e.g., bicalutamide, ketoconazole) was the most commonly used therapeutic modality. This all changed in February 2018, when the US Food and Drug Administration (FDA) approved the first drug specifically for use in men with nonmetastatic (M0) CRPC, apalutamide. This agent, which is a potent androgen receptor antagonist and is discussed in more detail later, was approved based on its ability to prolong metastasis-free survival compared with placebo in an M0 CRPC patient population (Smith et al., 2018). Apalutamide was the first drug for prostate cancer to receive regulatory approval based on the end point of metastasis-free survival (freedom from radiographic metastasis or death, whichever occurred first), opening the door for a new registrational end point. In July 2018 the FDA also approved enzalutamide (an AR antagonist that is also discussed later) for M0 CRPC based on a similar placebo-controlled trial demonstrating improved metastasis-free survival using this agent (Hussain et al., 2018). Unlike apalutamide that first entered the market in the M0 CRPC space, enzalutamide had previously received FDA approval for metastatic (M1) CRPC several years earlier.

Metastatic Castration-Resistant Prostate Cancer

Patients with mCRPC represent a heterogeneous population with respect to their clinical and disease characteristics at the time of disease progression on ADT. Metastatic prostate adenocarcinoma has an overwhelming predilection to involve the bone. Although the explanation for this unique metastatic pattern has not been completely elucidated, it may reflect the combination of various biologic factors (tumor-specific and host-specific) present at the time of metastatic spread. Circulating prostatic adenocarcinoma cells are arrested in the cortical and medullary bone spaces, where they subsequently adhere to bone surfaces through specific receptors for moieties such as integrins, collagens, laminin, and other bone-derived proteins. Cell growth is subsequently promoted by a number of factors such as hormones, growth factors, and stromal-epithelial interactions, most of which operate in the bone marrow. Expansion of tumor cells in the bone may cause pain, compression of spinal nerves or the spinal cord, or pathological fractures. In addition, extensive bone marrow replacement may cause impairment in hematologic function (most often manifested as myelophthisic anemia and thrombocytopenia).

Clinical involvement of visceral sites (excluding lymph nodes) is less common, even in patients with widespread castration-resistant disease. Even more rare is the occurrence of visceral disease in the absence of any bone involvement. Data from prospective clinical trials involving men with mCRPC suggest that radiographic evidence of visceral metastasis is observed in fewer than 20% of patients, whereas about 30% to 40% have demonstrable soft-tissue nodal disease. Because the majority of tumor burden in metastatic prostate cancer is found in bone, responses to treatment (e.g., tumor shrinkage) in soft-tissue sites alone (e.g., nodal or visceral sites) may not reflect a major treatment benefit because it represents only a small proportion of the overall disease burden. For this reason, the evaluation of “response rate” as the primary end point in clinical trials of mCRPC is discouraged, and “progression-free survival” (PFS) (that takes into account radiographic progression of bone and/or soft-tissue disease) is a much more acceptable trial end point (Scher et al., 2008).

Patients with mCRPC may experience a range of hematologic deficiencies caused primarily by the disease or by its treatment. Anemia is the most common hematologic abnormality, which can be explained by a variety of factors, such as anemia of chronic disease, bone marrow invasion, blood loss, and, rarely, secondary to a microangiopathic hemolytic anemia usually associated with a consumption coagulopathy (disseminated intravascular coagulation). A decrease in the red blood cell count of patients with advanced CRPC commonly results from a combination of factors, such as previous treatment with local irradiation of bone marrow (especially pelvic bones), systemic use of chemotherapy and radiopharmaceuticals, long-term androgen deprivation, as well as from extensive bone marrow invasion by a tumor resulting in substantial decrease in bone marrow reserves. The use of erythropoietin has been popular in the past. However, use of erythropoietin-stimulating agents has fallen out of favor and should be used with caution, because evidence is now mounting that these agents may increase mortality in cancer patients (Bennett et al., 2008). Thrombocytopenia (and, more rarely, leukopenia) is usually a complication of extensive radiation therapy or systemic chemotherapy. As an end-stage process, rapidly growing tumors with bone marrow involvement may result in pancytopenia. Thrombocytosis is also a nonspecific manifestation associated with many neoplastic conditions, including prostate cancer. However, clotting complications associated with thrombocytosis are rarely seen in men with prostate cancer, and treatment is not usually necessary.

Among the most important urologic sequelae of advanced prostate cancer is the development of obstructive uropathy. This complication, usually related to the primary disease or to pelvic/retroperitoneal adenopathy, can be devastating in terms of quality of life, and it may even present major therapeutic implications. In addition to an increased incidence of infection and pain, obstructed kidneys may critically impair renal function to a point at which some chemotherapeutic agents (which depend largely on renal mechanisms for their clearance) cannot be safely used. In general, patients who are otherwise considered candidates for treatment with cytotoxic drugs are best managed by first relieving the obstruction either with placement of internal ureteral stents or by percutaneous nephrostomy tubes.

Finally, one of the greatest emergencies in oncology is the development of spinal cord compression (Sorensen et al., 1990). Because of the frequent involvement of vertebral bodies by metastatic prostate cancer, the incidence of cord compression is of particular concern and requires expeditious management to preserve or reverse neurologic function (see later).

Key Points: Clinical Considerations

- Evaluate the extent and aggressiveness of the disease before contemplating therapy.
- Realize that the critical determinants are presence or absence of

radiographic metastases, biochemical versus clinical progression, and presence or absence of symptoms (e.g., pain).

- Understand that the presentation of metastatic CRPC is heterogeneous in terms of distribution of metastatic sites and disease kinetics.
- Consider the use of apalutamide or enzalutamide in men with nonmetastatic (M0) CRPC, which are FDA approved for this indication, to delay the onset of radiographic metastases.

Cytotoxic Chemotherapy

Evaluation of Treatment Efficacy

Measurement of therapeutic efficacy in the clinical trial setting for patients with advanced prostate cancer may be confounded by significant methodologic challenges. The most common metastatic site in these patients is bone, manifested by diffuse osteoblastic lesions that cannot be measured reliably by current methods (termed “nonmeasurable” disease). Soft-tissue or visceral metastatic sites that allow serial measurements (“measurable” disease) are uncommon and represent only a small fraction of the total metastatic burden of the disease. Selection of bidimensionally measurable disease sites to assess therapeutic efficacy with serial tumor measurements has been the subject of significant criticism, because many patients may only harbor metastases in osseous sites. Furthermore, patients with soft-tissue metastasis (especially visceral metastases) are often considered a subgroup with biologic and clinical features distinct from those with bone-only metastases. As a result of these potential caveats, the evaluation of “response rate” as the primary end point in clinical trials of mCRPC has been discouraged, and the use of PFS (taking into account radiographic progression of bone and/or soft-tissue disease) has become a much more acceptable trial end point in instances in which overall survival is not a feasible end point (Scher et al., 2008).

A number of prognostic models evaluating baseline and post-treatment characteristics have been developed to help dissect the heterogeneity of CRPC in the context of various cytotoxic and noncytotoxic therapies (Armstrong et al., 2007; Halabi et al., 2003, 2013b; Smaletz et al., 2002). Among numerous clinical and laboratory parameters with consistent prognostic significance across a range of therapeutic settings are the patient's functional status (performance status), presence of pain, baseline hemoglobin level, baseline PSA level, baseline alkaline phosphatase, baseline LDH level, extent of bone involvement (number of lesions or pattern/distribution of bone lesions), and presence of visceral disease. Quantitative methods to evaluate circulating tumor cell (CTC) numbers and various PSA constructs (e.g., >30% PSA reduction) are among the post-treatment parameters with the strongest prognostic significance (Armstrong et al., 2007; de Bono et al., 2008; Halabi et al., 2013a; Scher et al., 2004).

Preclinical observations have suggested that some drugs may reduce PSA secretion without affecting tumor growth, whereas other drugs may affect tumor growth without necessarily reducing PSA levels (Eisenberger and Nelson, 1996; Larocca et al., 1991; Seckin et al., 1996). Although these laboratory observations are likely to be clinically relevant, assays used to evaluate a separate drug effect on PSA secretion still require careful validation. A PSA consensus meeting developed by several leading investigators in the field generated initial guidelines with regard to the use of the PSA test for clinical trials in patients with CRPC (Bubley et al., 1999). These guidelines were updated and now also provide a consensus on the use of radiologic end points as well as clinical end points (e.g., pain) for the evaluation of men with advanced CRPC (Scher et al., 2008). Undoubtedly, new biomarkers are needed to enhance our ability to identify rapidly the active treatments for CRPC, and one such marker may be the enumeration of CTCs (at baseline and after a period of treatment) (de Bono et al., 2008). Furthermore, evolving noncytotoxic and targeted therapies may require a new set of end points and identification of drug-specific intermediate biomarkers that reflect mechanism-specific biologic activity.

Chemotherapeutic Agents

Most of the chemotherapeutic agents available in oncologic practice have been used in patients with CRPC, either as single agents or in various combinations. Historical examples have included cyclophosphamide, 5-fluorouracil, estramustine, vinorelbine, etoposide, cisplatin, carboplatin, doxorubicin, mitoxantrone, paclitaxel, and docetaxel (Eisenberger, 1988). With the exception of docetaxel (and the related agent, cabazitaxel) and perhaps mitoxantrone, most other cytotoxic agents are no longer being used with frequency because they have not been associated with either symptomatic improvements or extension of survival. Evolving data with selected chemotherapy agents during the new millennium suggest that the survival of patients with advanced CRPC receiving first-line chemotherapy is now somewhere between 16 and 20 months (Petrylak et al., 2004; Tannock et al., 2004) as opposed to 6 to 12 months as previously described with historical agents (Eisenberger, 1988).

Mitoxantrone

A first step forward in the chemotherapeutic management of CRPC came with mitoxantrone. This agent, a semisynthetic anthracycline, had previously shown modest symptomatic benefits but with minimal evidence of objective antitumor activity (Osborne et al., 1983; Rearden et al., 1995). In addition, mitoxantrone appeared to have its maximal palliative effect in combination with low-dose corticosteroids (Moore et al., 1994). In two seminal prospective randomized trials of mitoxantrone plus prednisone versus prednisone alone (Tannock et al., 1996) or mitoxantrone plus hydrocortisone versus hydrocortisone alone (Kantoff et al., 1999), the combination resulted in significant improvements of various quality-of-life parameters, including pain, but survival was not significantly improved in either trial. These studies provided the justification for the FDA to approve mitoxantrone with prednisone in 1997 for patients with *symptomatic* CRPC. Even though the use of first-line mitoxantrone has dramatically declined with the advent of more effective chemotherapy agents (docetaxel and cabazitaxel; see later), mitoxantrone is still sometimes useful for patients with docetaxel- and cabazitaxel-refractory disease, or in those with a marginal performance status in which the more toxic taxane agents may not be well tolerated.

Docetaxel

The next significant advance in the use of chemotherapy for metastatic CRPC came with docetaxel, a member of the taxane family. This agent acts by inducing apoptosis in cancer cells through TP53-independent mechanisms that are thought to be a result of the inhibition of microtubule depolymerization and the blockade of antiapoptotic signaling. The induction of microtubule stabilization intracellularly through β-tubulin interactions causes guanosine triphosphate-independent polymerization and cell cycle arrest at the G_2M phase. In addition, docetaxel has been found to induce BCL2 phosphorylation in vitro, a process that has been correlated with caspase-3 activation and loss of its normal antiapoptotic activity. Unable to inhibit the proapoptotic molecule BAX, phosphorylated BCL2 may also induce apoptosis through this alternate pathway. However, additional mechanisms may also be important, such as CDKN1B (p27) induction and repression of BCL-XL. Finally, it has emerged that docetaxel may exert part of its therapeutic effect by impairing association of the cytosolic AR to microtubules, thereby disrupting the transport of the ligand-bound AR from the cytoplasm into the nucleus on board the microtubules (Darshan et al., 2011; Zhu et al., 2010).

Early data with docetaxel monotherapy initially suggested that this compound may have significant activity in prostate cancer even as a single agent (Beer, 2004; Friedland et al., 1999; Picus and Schultz, 1999). In 2004 docetaxel became the chemotherapy drug of choice for the treatment of mCRPC based on a large phase III randomized trial, termed TAX 327 (Fig. 162.2), which demonstrated superiority beyond the previous standard: mitoxantrone plus prednisone (Tannock et al., 2004). The TAX 327 study enrolled 1006 patients with no previous chemotherapy treatment and with stable pain scores into one of three study arms (all with concomitant prednisone 5 mg twice daily): mitoxantrone 12 mg/m^2 intravenously every 21 days; docetaxel 75 mg/m^2 intravenously every 21 days; or docetaxel 30 mg/m^2 intravenously every 7 days. Patients remained on androgen suppression (e.g., LHRH agonists or orchiectomy), but all other second-line hormonal agents were discontinued. The anticipated treatment duration was 30 weeks (i.e., 10 cycles of therapy) in all study arms, although more patients completed treatment in the every-3-week docetaxel group than in the mitoxantrone group because of differences in disease progression rates (46% vs. 25%). After a median follow-up of 20.7 months, overall survival in the every-3-week docetaxel group was 18.9 months (with a pain response rate of 35% and a PSA response of 45%), compared with weekly docetaxel at 17.3 months (and 31% and 48%), respectively. This translated into a 24% relative reduction in the risk of death (95% confidence interval [CI] 6% to 48%, P = 0.0005) using every-3-week docetaxel (see Fig. 162.2). Meanwhile, patients on the mitoxantrone arm experienced a median survival of 16.4 months, a pain response of 22%, and a PSA response of 32%. The conclusion of the TAX 327 trial was that every-3-week docetaxel was superior to weekly docetaxel and every-3-week mitoxantrone. This was a landmark study, because it showed for the first time that chemotherapy could improve survival in mCRPC patients.

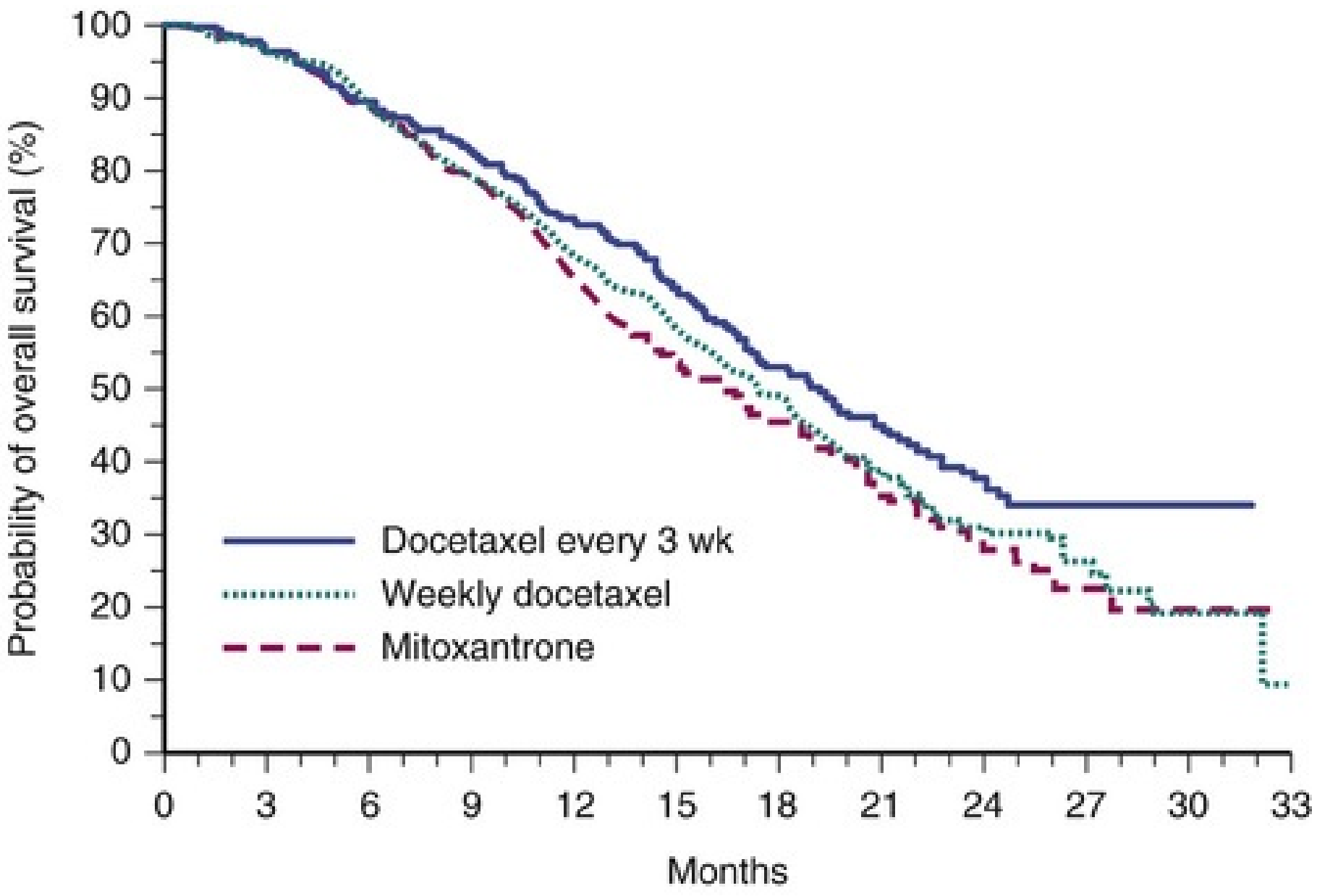

No. at risk						
Docetaxel every 3 wk	335	296	217	104	37	5
Weekly docetaxel	334	297	200	105	29	4
Mitoxantrone	337	297	192	95	29	3

FIG. 162.2 Overall survival in the TAX 327 study. (Data from Tannock I, DeWit R, Berry W, et al.: Docetaxel plus prednisone or mitoxantrone plus prednisone for advanced prostate cancer. *N Engl J Med* 351:1502–1512, 2004.)

Toxicity in the every-3-week versus weekly docetaxel groups was notable because of an increase in hematologic events in the every-3-week group (3% neutropenic fever vs. 0; 32% grade 3/4 neutropenia vs. 1.5%) but slightly lower rates of nausea and vomiting, fatigue, nail changes, hyperlacrimation, and diarrhea. Neuropathy was slightly more common in the every-3-week group (grade 3/4 neuropathy in 1.8% vs. 0.9% in the weekly group). Quality-of-life responses as measured by the FACT-P instrument did not differ significantly between the two docetaxel schedules but were more favorable than in the mitoxantrone group.

The Southwest Oncology Group (SWOG) 9916 study was the second large phase III trial (Fig. 162.3) to evaluate docetaxel (Petrylak et al., 2004). In this study, 770 patients with progressive CRPC were randomly assigned to oral estramustine (280 mg three times daily) plus docetaxel (60 mg/m^2 IV every 21 days) versus mitoxantrone (12 mg/m^2 IV every 21 days) plus prednisone. Median overall survival in the SWOG 9916 study was longer in the docetaxel-estramustine group than in the mitoxantrone-prednisone group (17.5 vs. 15.6 months, $P = 0.02$), with a corresponding hazard ratio (HR) for death of 0.80

(95% CI 0.67–0.97) (see Fig. 162.3). Because of the high rate of thromboembolic events with estramustine, prophylactic low-dose warfarin and aspirin were added to that study arm. Similarly, 20% and 15%, respectively, of patients in the docetaxel-estramustine arm had grade 3/4 gastrointestinal and cardiovascular toxicities. Although comparisons between the docetaxel arms across these two seminal trials may not be appropriate because of differences in schedule, patient populations, and docetaxel dosing (60 mg/m^2 in SWOG 9916 and 75 mg/m^2 in TAX 327), it was concluded that estramustine is unlikely to add significantly to the activity of single-agent docetaxel. For this reason, and because of its thromboembolic toxicities, estramustine is currently only a historic remnant and is no longer generally used in the United States.

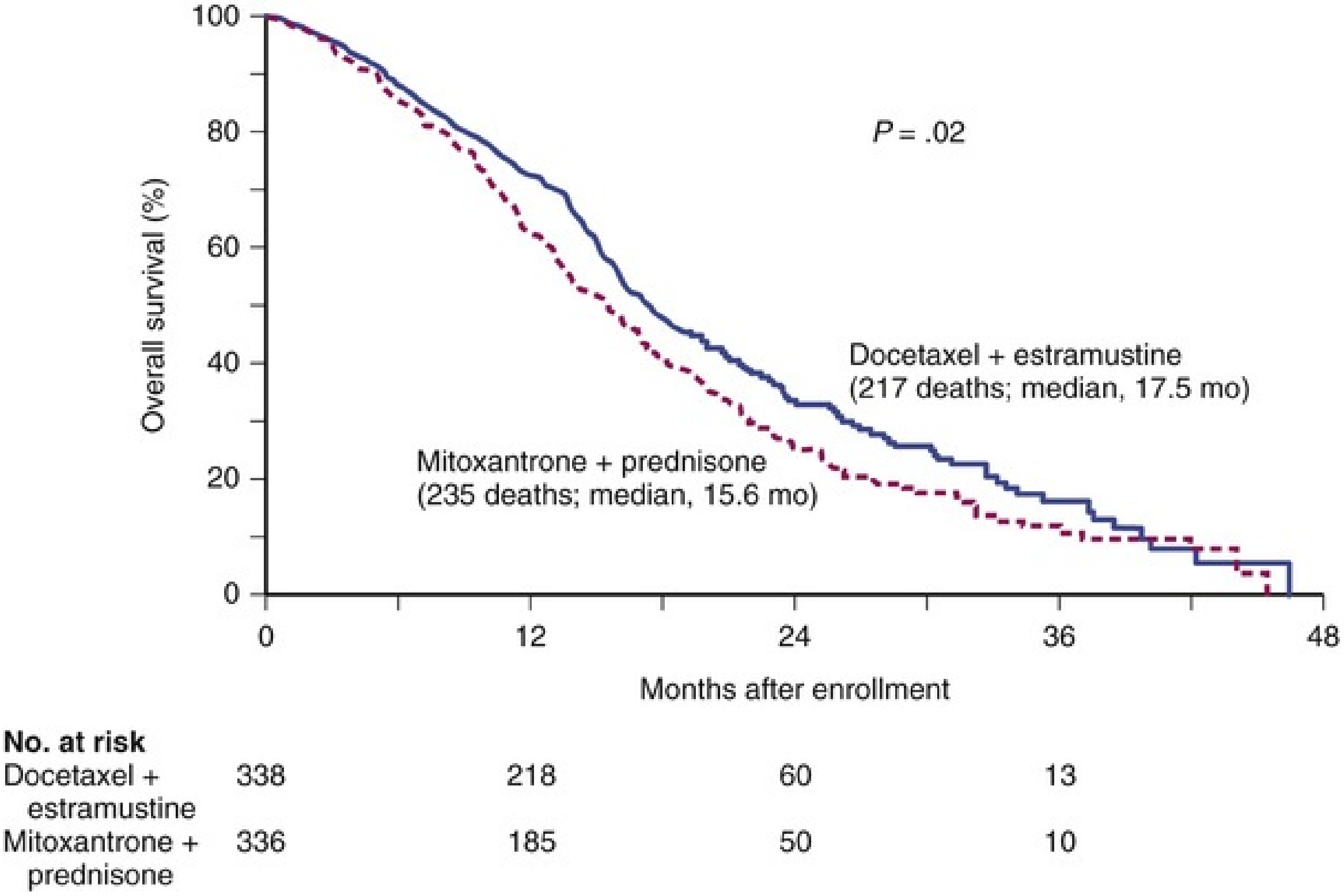

No. at risk				
Docetaxel + estramustine	338	218	60	13
Mitoxantrone + prednisone	336	185	50	10

FIG. 162.3 Overall survival in the Southwest Oncology Group 9916 study. (Data from Petrylak DP, Tangen CM, Hussain MH, et al.: Docetaxel and estramustine compared with mitoxantrone and prednisone for advanced refractory prostate cancer. *N Engl J Med* 351:1513–1520, 2004.)

A number of experimental agents have been investigated in combination with docetaxel in an attempt to improve on the efficacy of single-agent docetaxel. However, the results of most phase III trials of docetaxel-based combination therapy have been disappointing. Although serum vascular endothelial growth factor (VEGF) levels correlate inversely with survival, antiangiogenic agents (bevacizumab, aflibercept, and lenalidomide) combined with docetaxel have not improved overall survival. Combinations of bone-targeted agents such as atrasentan, zibotentan, and dasatinib with docetaxel have also produced disappointing results. Finally, high-dose vitamin D (calcitriol) combined with weekly docetaxel also demonstrated no survival advantage beyond docetaxel alone. Potential reasons for the failure of docetaxel-based combination therapies include marginal activity of the agents that were combined with docetaxel, lack of well-conducted randomized phase II trials before initiating phase III studies, as well as dose reductions of docetaxel that were often required as a result of overlapping drug toxicities (Antonarakis and Eisenberger, 2013).

Cabazitaxel

Until 2010 effective life-prolonging therapies for men with docetaxel-refractory prostate cancer were lacking. This changed with the advent of cabazitaxel, a second-generation taxane agent that was FDA approved in 2010 for the treatment of docetaxel-pretreated mCRPC based on the results of a pivotal randomized phase III (TROPIC) trial (Fig. 162.4). Cabazitaxel is a novel tubulin-binding taxane that differs from docetaxel and paclitaxel because of its poor affinity for P-glycoprotein, the adenosine triphosphate–dependent drug efflux pump (Paller and Antonarakis, 2011). In preclinical studies using cancer cell lines and mouse xenograft models, cabazitaxel was shown to be active in docetaxel-sensitive tumors as well as in those with primary or acquired docetaxel resistance (Attard et al., 2006). The first hint of cabazitaxel's safety and efficacy in men with prostate cancer came during phase I testing, in which cabazitaxel was administered by intravenous infusion every 3 weeks at escalating doses of 10 to 25 mg/m^2 (Mita et al., 2009). In that study, the principal dose-limiting toxicity (DLT) was neutropenia. Given the lack of cross-resistance between this agent and docetaxel, and based on early reports of favorable responses in men with CRPC from this phase I trial, a phase III trial was launched to evaluate its activity.

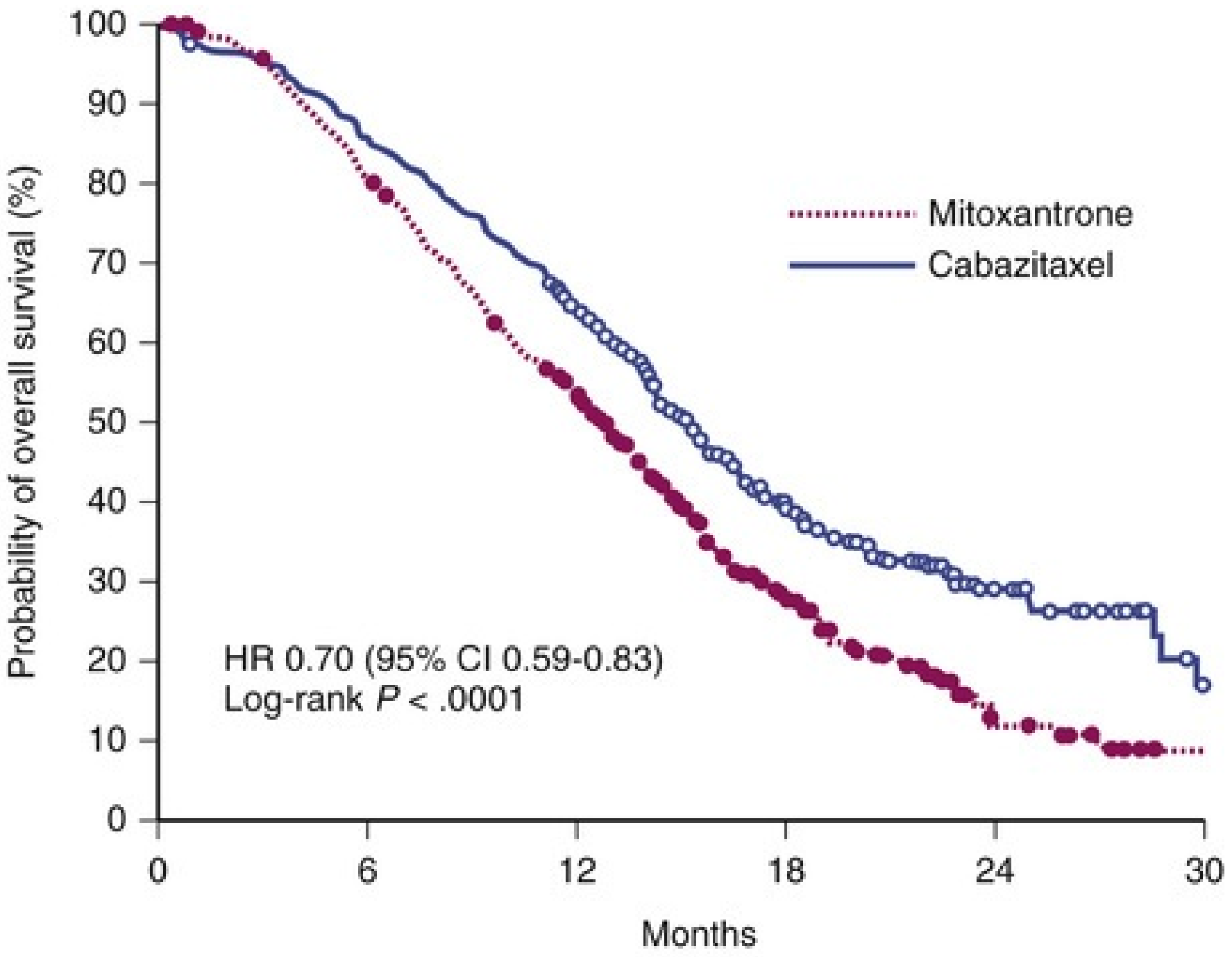

Number at risk						
Mitoxantrone	377	300	188	67	11	1
Cabazitaxel	378	321	231	90	28	4

FIG. 162.4 Overall survival in the TROPIC study. *CI,* Confidence interval; *HR,* hazard ratio. (From de Bono JS, Oudard S, Ozguroglu M, et al.: Prednisone plus cabazitaxel or mitoxantrone for metastatic castration-resistant prostate cancer progressing after docetaxel treatment: a randomised open-label trial. *Lancet* 376:1147–1154, 2010.)

The safety and efficacy of cabazitaxel in patients with advanced prostate cancer were definitively evaluated in the TROPIC trial conducted in 146 institutions across 26 countries, which recruited 755 men with mCRPC who had progressed after docetaxel-based chemotherapy (de Bono et al., 2010). Of these, 377 patients were randomized to receive mitoxantrone 12 mg/m^2 intravenously every 3 weeks (with oral prednisone 10 mg daily), and 378 patients were assigned to receive cabazitaxel 25 mg/m^2 intravenously every 3 weeks (plus prednisone). After a median follow-up of 12.8 months, overall survival in men receiving cabazitaxel was 15.1 months compared with 12.7 months in men receiving mitoxantrone (HR 0.70, $P < 0.0001$) (see Fig. 162.4) (de Bono et al., 2010). Compared with mitoxantrone, cabazitaxel also significantly lengthened PFS (2.8 months vs. 1.4 months, $P < 0.0001$), extended time to PSA progression (6.4 months vs. 3.1 months, $P = 0.001$), increased radiographic tumor response rates (14.4% vs. 4.4%, $P = 0.0005$), and increased PSA response rates (39.2% vs. 17.8%, $P = 0.0002$). There were no differences between the two treatment arms with respect to pain responses or time to pain progression. The results of this study formed the basis for the FDA's approval of cabazitaxel plus prednisone in June 2010 for the second-line treatment of docetaxel-refractory mCRPC.

In subset analyses, the survival advantage of cabazitaxel persisted regardless of whether patients experienced measurable disease or pain, or whether progression had occurred while receiving docetaxel or after a treatment holiday. In addition, cabazitaxel's survival benefit was most pronounced for men with Eastern Cooperative Oncology Group (ECOG) performance status 0 to 1 (vs. 2), and for patients with disease progression within less than 3 months of docetaxel initiation (vs. ≥3 months of docetaxel initiation) (de Bono et al., 2010). The last observation implies that cabazitaxel may be effective even in men with truly docetaxel-refractory disease, providing clinical evidence that there may not be significant cross-resistance between docetaxel and cabazitaxel.

The most common serious adverse events related to cabazitaxel were hematologic, including grade 3 to 4 neutropenia in 82% of patients (febrile neutropenia in 8%). Patients older than 65 years experienced a 6.6% higher rate of grade 3 neutropenia than younger patients. This degree of myelosuppression begs the question of whether a lower dose of cabazitaxel (e.g., 20 mg/m^2) may have been more appropriate; a randomized phase III trial (PROSELICA) comparing the safety and efficacy of these two doses of cabazitaxel (25 mg/m^2 vs. 20 mg/m^2 every 3 weeks) has answered this question (Eisenberger et al., 2017). That study, which was designed as a noninferiority trial in the post-docetaxel population, demonstrated that overall survival was no worse in the 20 mg/m^2 compared with the 25 mg/m^2 dose group (upper 95% confidence limit was 1.18, with the noninferiority margin set at <1.21), whereas grade 3 or 4 adverse events were less frequent at the lower cabazitaxel dose (40% vs. 55%, respectively). Based on the PROSELICA trial, the FDA modified the package insert in September 2017 to recommend a dose of 20 mg/m^2 in most mCRPC patients, although the 25 mg/m^2 dose is still a reasonable choice in select patients who are at lower risk of neutropenia. The option to use either dose of cabazitaxel is reflected in several national guidelines (Mohler et al., 2016). Other nonhematologic toxicities of cabazitaxel include grade 3 to 4 diarrhea (6%) and grade 3 to 4 fatigue (5%). Diarrhea is more common in patients older than 65 as well as in those with a history of previous radiation therapy. Encouragingly, although peripheral neuropathy (all grades) is observed in 14% of patients receiving cabazitaxel, only 1% of men develop grade 3 neuropathy (de Bono et

al., 2010).

Given the favorable activity of cabazitaxel in docetaxel-pretreated patients, it was logical to evaluate cabazitaxel as first-line chemotherapy in men with mCRPC. To this end, an international randomized phase III trial (FIRSTANA) of docetaxel versus cabazitaxel (20 mg or 25 mg/m^2) in chemotherapy-untreated patients was recently reported (Oudard et al., 2017). Unfortunately, that trial failed to show superior overall survival of either dose-level of cabazitaxel compared with standard docetaxel in the chemotherapy-naive mCRPC setting, even though objective tumor response rates were numerically higher using cabazitaxel 25 mg/m^2 compared with docetaxel 75 mg/m^2. At the current time, therefore, cabazitaxel is not recommended or FDA approved for use as a first-line chemotherapy agent in mCRPC.

Platinum Agents

Although platinum-containing drugs (e.g., cisplatin, carboplatin) are generally not widely used (nor FDA approved) in unselected patients with mCRPC, there may be certain populations that benefit preferentially from these compounds. One such group are the patients with small cell neuroendocrine prostate cancer (discussed further, later), also sometimes called aggressive-variant prostate cancers. A limited number of clinical trials have shown that such patients with small cell or aggressive-variant prostate cancer may respond favorably, albeit for a short duration, to combination regimens consisting of cisplatin-etoposide or docetaxel-carboplatin (Aparicio et al., 2013). Recent molecular data have revealed that these small cell neuroendocrine prostate cancers are characterized by at least 2 out of 3 of the following parameters: *PTEN* loss, *TP53* mutation, and *RB1* loss (Aparicio et al., 2016). To this end, a recent randomized phase II trial comparing cabazitaxel versus cabazitaxel-carboplatin confirmed this molecular signature and showed longer PFS with the combination regimen in aggressive-variant mCRPC but not in usual-type mCRPC, potentially suggesting that aggressive-variant prostate cancer is a platinum-sensitive tumor (Aparicio et al., 2017). Finally, emerging data suggest that another potential platinum-sensitive mCRPC population may be those patients harboring DNA repair deficiency mutations. One example pertains to patients with germline *BRCA2* mutations, who appear to respond better to docetaxel-carboplatin than to docetaxel alone (Pomerantz et al., 2017). The full spectrum of platinum-sensitivity in mCRPC is an active area of investigation and has yet to be fully defined.

Key Points: Cytotoxic Chemotherapy

- Docetaxel is the standard first-line chemotherapy for mCRPC. It prolongs progression-free and overall survival, ameliorates pain, and improves quality of life.
- Toxicity of docetaxel includes myelosuppression, fatigue, peripheral edema, neurotoxicity, hyperlacrimation, and nail dystrophy.
- Cabazitaxel is as a second-line chemotherapy option for patients with mCRPC who have had progressive disease during or after docetaxel treatment. Both doses (20 mg/m^2 or 25 mg/m^2 every 3 weeks) are acceptable, and the lower dose has less toxicity.
- Side effects with cabazitaxel include neutropenia (including febrile neutropenia) and diarrhea but generally not neuropathy.
- Although it does not prolong survival, mitoxantrone has been approved to palliate symptoms associated with metastatic disease. It is sometimes used in patients who have previously received docetaxel and/or cabazitaxel or in those who would not tolerate these agents.
- Platinum agents are indicated in patients with small cell prostate cancer and perhaps in other subsets of mCRPC patients (e.g., those with combined *TP53* and *PTEN* inactivation or DNA repair deficiency mutations).

Next-Generation Hormonal Therapies

CYP17 Inhibition: Abiraterone and Other Agents

It has been recognized that the AR and ligand-dependent AR signaling commonly remain active and upregulated in men with castrate levels of testosterone (i.e., <50 ng/dL) (Debes and Tindall, 2004). Standard hormonal therapies such as LHRH agonists/antagonists inhibit gonadal androgenesis but do not affect androgen synthesis from adrenal or other extragonadal sources that may account for up to 10% of total androgen production. It has also been suggested that CRPC may produce intratumoral androgens autonomously (Mostaghel et al., 2007). In addition, overexpression of CYP17 has been demonstrated in tumors of men with CRPC (Stigliano et al., 2007). All of this laboratory evidence suggests that CRPC is not androgen independent and often remains hormone driven, implying that further suppression of nongonadal androgen sources may yield therapeutic gains.

Abiraterone acetate is an oral selective inhibitor of cytochrome P450 isoform 17 (CYP17), an enzyme that has 17,20-lyase and 17α-hydroxylase activity, and is a key regulator of extragonadal androgen synthesis. Phase I/II studies using abiraterone in men with CRPC (before and after docetaxel) showed a substantial number of PSA responses (PSA declines ≥50%) and also some partial radiologic responses in men with bony and soft-tissue metastases (Attard et al., 2008; Danila et al., 2010). Furthermore, abiraterone retains its activity even in patients with previous ketoconazole treatment (a weak CYP17 inhibitor) (Ryan et al., 2010). Common side effects of abiraterone include hypokalemia, hypertension, and pedal edema. These effects are explained by a syndrome of secondary mineralocorticoid excess, which improves with use of the mineralocorticoid receptor antagonist eplerenone or with the addition of prednisone, which blunts the ACTH drive. Importantly, patients receiving abiraterone must also continue treatment with an LHRH agonist/antagonist, whereas the clinical activity of single-agent abiraterone is largely unknown.

To evaluate conclusively the efficacy and safety of abiraterone in men with CRPC, a pivotal multicenter placebo-controlled blinded randomized phase III trial (COU-AA-301) was conducted in men with docetaxel-pretreated ketoconazole-naive mCRPC (de Bono et al., 2011). This trial randomized men (2

: 1) to receive either abiraterone 1000 mg daily plus prednisone 10 mg daily (*n* = 797) or placebo plus prednisone (*n* = 398). The trial met its primary end point, demonstrating a median overall survival of 14.8 months in the abiraterone arm and 10.9 months in the placebo arm (HR 0.65, $P < 0.0001$) (Fig. 162.5). In addition, when compared with placebo, abiraterone prolonged radiographic PFS (5.6 vs. 3.6 months, $P < 0.0001$), improved time to PSA progression (10.2 vs. 6.6 months, $P < 0.0001$), and produced more PSA responses (38% vs. 10%, $P < 0.0001$). Further analysis showed that abiraterone had significant benefits compared with placebo in terms of pain relief, patient-reported fatigue, delaying pain progression, and prevention of skeletal-related events (Fizazi et al., 2012; Logothetis et al., 2012). Based on the results of the COU-AA-301 study, the FDA approved abiraterone plus prednisone in April 2010 for the treatment of patients with mCRPC who have received previous docetaxel chemotherapy. The recommended dose of abiraterone is 1000 mg daily by mouth.

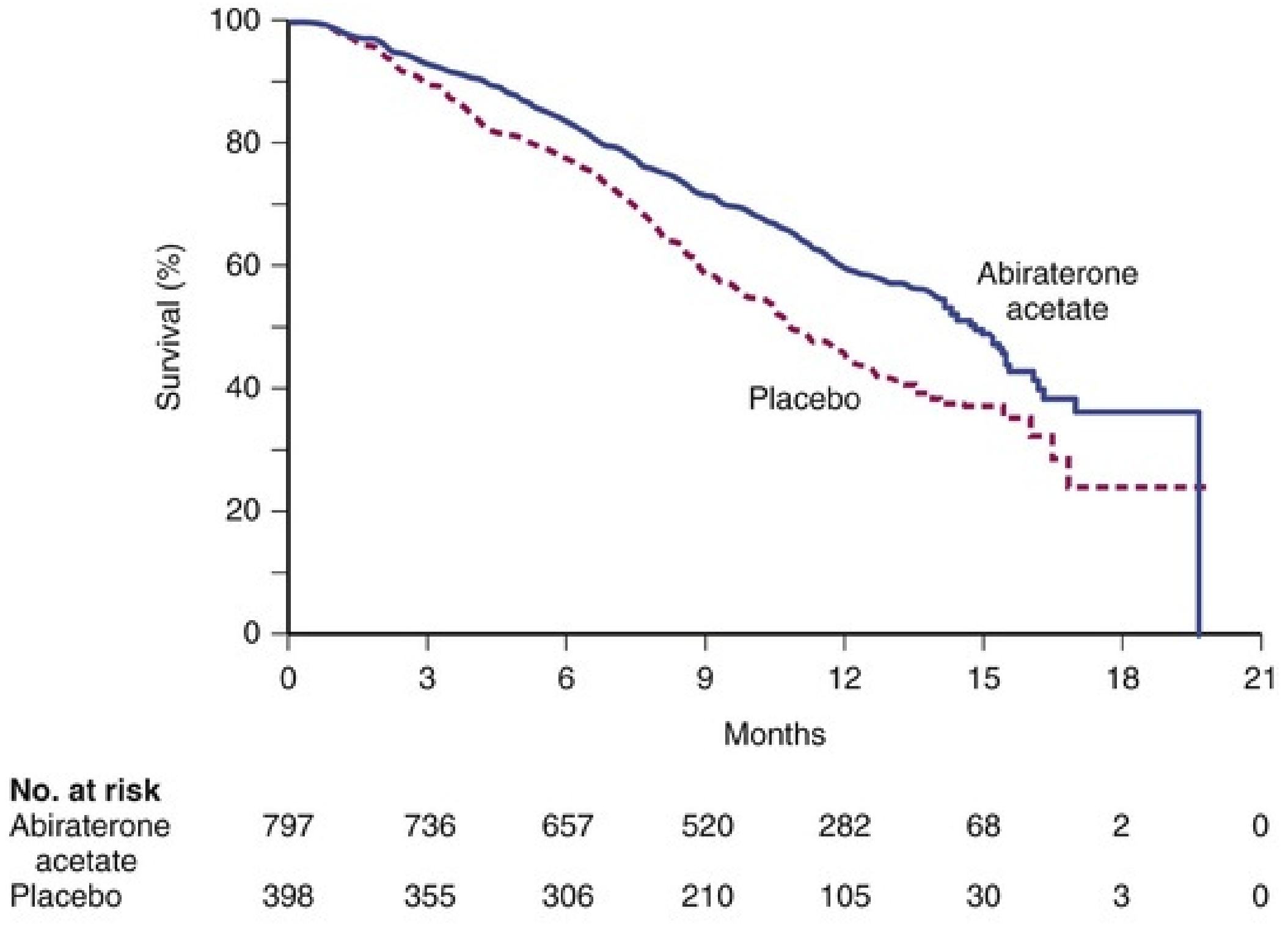

FIG. 162.5 Overall survival in the COU-AA-301 study. (Data from de Bono JS, Logothetis CJ, Molina A, et al.: Improved survival from metastatic prostate cancer with abiraterone acetate. *N Engl J Med* 364:1995–2005, 2011.)

Because of the success of abiraterone in the post-docetaxel setting, a second randomized phase III trial (COU-AA-302) targeting men with docetaxel-naive CRPC was undertaken. This double-blind placebo-controlled study recruited asymptomatic or mildly symptomatic chemotherapy-naive patients with mCRPC and randomized them (1 : 1) to receive abiraterone (1000 mg) and prednisone (10 mg daily) or placebo and prednisone. The coprimary end points of this trial were radiographic PFS and overall survival. The study demonstrated a statistically significant difference in PFS in favor of the abiraterone arm (HR 0.43, 95% CI 0.35–0.52, $P < 0.0001$), representing a 57% reduction in the risk of radiographic progression with abiraterone (Ryan et al., 2013). The study also showed a strong trend toward improved overall survival and significantly delayed initiation of cytotoxic chemotherapy (26.5 months vs. 16.8 months). Importantly, in the final analysis, overall survival was significantly improved in the abiraterone arm (HR 0.81, 95% CI 0.70– 0.93, $P = 0.003$), reflecting a 19% reduction in the risk of death and meeting the prespecified significance level set by the O'Brien-Fleming rule (that required a P value of < 0.038) (Ryan et al., 2015). Once again, abiraterone produced additional benefits in the predocetaxel setting, including improved patient-reported quality-of-life outcomes (Basch et al., 2013). Based on the results of the COU-AA-302 trial, the FDA expanded the label for abiraterone to encompass all patients with mCRPC (i.e., including those who have not received docetaxel chemotherapy). Abiraterone is not currently approved for patients with nonmetastatic (M0) CRPC, a setting in which enzalutamide and apalutamide are approved.

Other agents that target the androgen signaling pathway through CYP17 inhibition are also in clinical development but have had less success thus far. Orteronel (TAK-700) has a similar mechanism of action to abiraterone; it is a nonsteroidal CYP17 inhibitor with potentially greater 17,20 lyase selectivity (i.e., impairing androgen synthesis preferentially over corticosteroid synthesis). Orteronel has been evaluated in two large placebo-controlled phase III trials (with prednisone in both arms) in men with mCRPC who were either chemotherapy naive or docetaxel pretreated. In the international ELM-PC5 (post-docetaxel) trial, although orteronel produced a significant improvement in PFS (HR 0.76, 95% CI 0.65–0.89, $P = 0.0004$), the study did not meet its primary survival end point (HR for survival: 0.89, 95% CI 0.74–1.06, $P = 0.19$) (Dreicer et al., 2014) and orteronel did not gain FDA approval. Interestingly, in countries where abiraterone was not available post-progression, survival was significantly improved with orteronel; whereas in countries where abiraterone was already approved; survival was not affected probably because of subsequent treatment with abiraterone. The phase III pre-chemotherapy (ELM-PC4) study had a similar fate. This study, which was a randomized trial of orteronel/prednisone versus placebo/prednisone in chemotherapy-untreated mCRPC patients, also failed to demonstrate an improvement in overall survival (HR 0.92, 95% CI 0.79–1.08; $P = 0.31$) (Saad et al., 2015). Therefore, although orteronel is now being tested in a phase III trial of up-front androgen deprivation plus orteronel vs. androgen deprivation alone for metastatic hormone-sensitive prostate cancer, it does not have an FDA-approved indication for any setting.

Androgen Receptor Modulation: Enzalutamide, Apalutamide, and Other Agents

A slightly different AR-directed approach has focused on the development of next-generation antiandrogens that include advantages beyond the established agents in this class (bicalutamide, nilutamide, flutamide). One such drug is enzalutamide, a potent oral nonsteroidal AR antagonist (Chen et al., 2009). Importantly, enzalutamide remains a strong antagonist of the AR in the castration-resistant state, even in the setting of overexpressed or constitutively activated AR (Watson et al., 2010). Unlike other antiandrogens that may also function as partial AR agonists, enzalutamide does not exhibit any measurable agonistic activity. In addition to acting as an AR blocker, enzalutamide also disrupts the translocation of the AR from the cytoplasm (where it is inert) into the nucleus (where it acts as a transcription factor), while also impairing binding of the AR to the transcriptional complex at the androgen-response elements of DNA (Tran et al., 2009). One potential advantage of enzalutamide over abiraterone is the lack of a requirement for concurrent corticosteroid administration. In fact, data suggest that enzalutamide may potentially be less active if administered together with prednisone, perhaps because of promiscuous activation of AR by prednisone or by direct agonism of the glucocorticoid receptor (Scher et al., 2013).

A pivotal placebo-controlled double-blind phase III study (AFFIRM), randomizing 1199 patients with docetaxel-pretreated ketoconazole-naive CRPC to enzalutamide ($n = 780$) or placebo ($n = 390$), was conducted to examine the effect of enzalutamide on overall survival. Patients receiving up to 2 previous lines of chemotherapy (one of which must have contained docetaxel) were the target population. The trial showed a 4.8-month improvement in median survival with enzalutamide compared with placebo (18.4 months vs. 13.6 months, HR 0.63, *P* < 0.0001) (Fig. 162.6; Scher et al., 2012). A survival benefit was observed in all prespecified subgroups, although less benefit was seen in those with ECOG performance status of 2, similar to what was observed in the abiraterone trials. Confirmed PSA declines of more than 50% were seen in 54.0% compared with 1.5% (*P* < 0.0001) of patients receiving enzalutamide and placebo, respectively. Median time to progression was 8.3 compared with 3.0 months in the two arms (HR 0.25, *P* < 0.0001). Side effects were minimal and included fatigue, diarrhea, and hot flashes. Seizures were observed in about 1% of enzalutamide-treated patients. Based on the results of the AFFIRM trial, the FDA approved enzalutamide in August 2012 for the treatment of mCRPC in patients who have previously received docetaxel-containing chemotherapy.

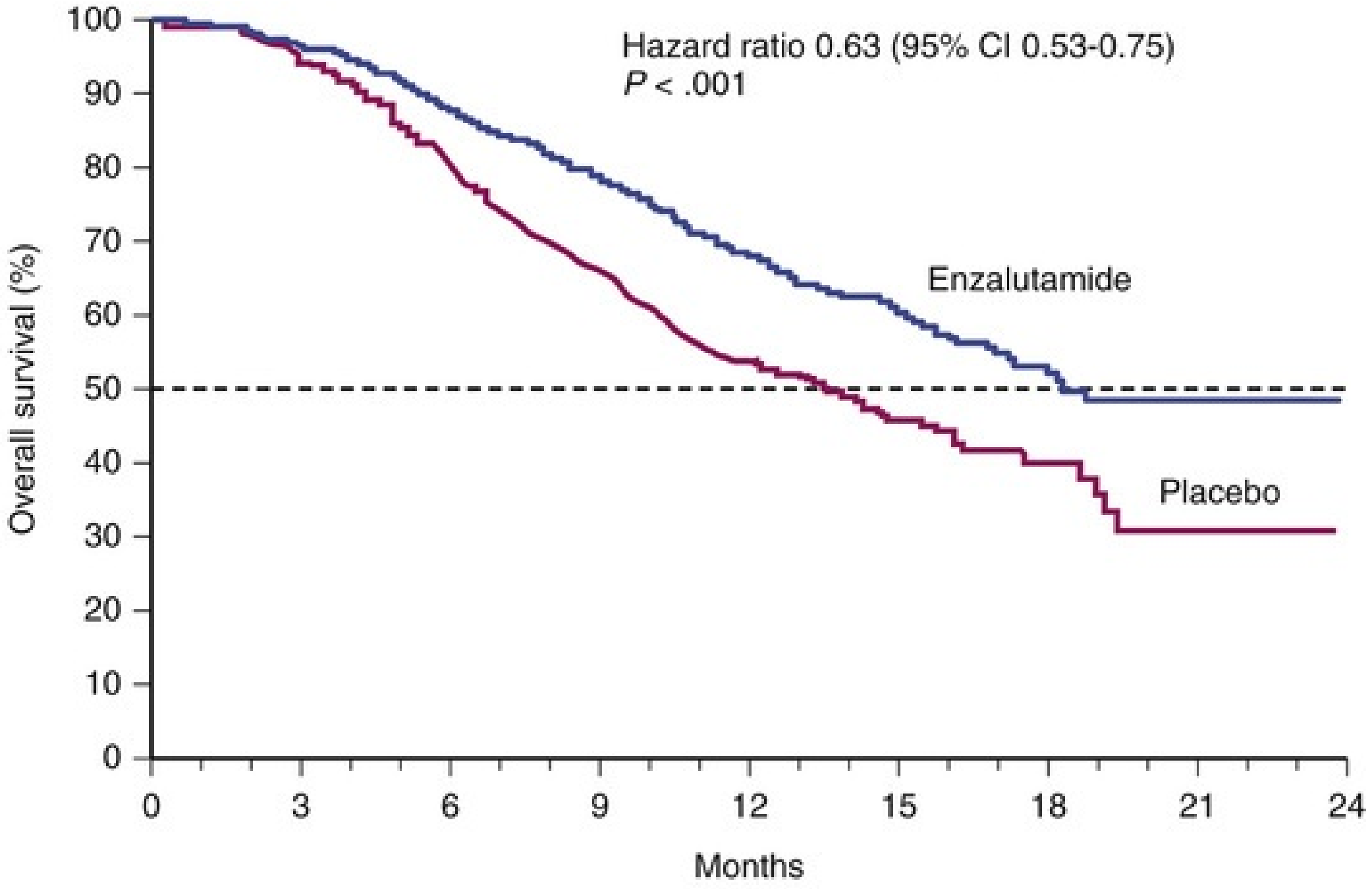

No. at risk									
Enzalutamide	800	775	701	627	400	211	72	7	0
Placebo	399	376	317	263	167	81	33	3	0

FIG. 162.6 Overall survival in the AFFIRM study. (Data from Scher HI, Fizazi K, Saad F, et al.: Increased survival with enzalutamide in prostate cancer after chemotherapy. *N Engl J Med* 367:1187–1197, 2012.)

To evaluate the efficacy of enzalutamide in the pre-chemotherapy setting, the PREVAIL study was designed. This was a phase III double-blind placebo-controlled trial in 1717 chemotherapy-naive patients with asymptomatic or minimally symptomatic mCRPC who were randomized (1 : 1) to oral enzalutamide or placebo. At the time of an interim analysis, the study met its coprimary end points of radiographic PFS and overall survival. Compared with placebo, treatment with enzalutamide in the pre-chemotherapy setting resulted in a 29% reduction in the risk of death (HR 0.71, 95% CI 0.60–0.84, $P < 0.0001$) and an 81% reduction in the risk of radiographic progression (HR 0.19, 95% CI 0.15–0.23, $P < 0.0001$) (Beer et al., 2014). Based on the results of the PREVAIL trial, the FDA expanded its label to allow use of enzalutamide in all patients with mCRPC, regardless of whether they have received prior docetaxel.

Finally, the most recent pivotal trial of enzalutamide was the PROSPER study, a phase III trial of enzalutamide vs. placebo in men with nonmetastatic (M0) CRPC with a PSADT of less than 10 months. In that study, enzalutamide was shown to dramatically improve metastasis-free survival, the primary endpoint of the trial, by an impressive 71% (HR 0.29, 95% CI 0.24–0.35; $P < 0.001$) (Hussain et al., 2018). Overall survival was also numerically improved, although not statistically greater, in the enzalutamide rather than the placebo arm. Based on the positive outcome of the PROSPER trial, the FDA label of enzalutamide was expanded again in July 2018 to include any patients with CRPC, regardless of whether they have radiographic metastases identified. This is the broadest label for an antiandrogen drug that the FDA has granted.

Another next-generation AR signaling inhibitor is apalutamide (formerly ARN-509). This is a novel antiandrogen (similar to enzalutamide) that also functions as a pure antagonist of the AR, while also inhibiting AR nuclear translocation and DNA binding (Clegg et al., 2012). Apalutamide may include potential advantages over enzalutamide in that it does not cross the blood-brain barrier and it has not been associated with seizures. Early evidence of clinical activity was obtained from a phase I study in 30 patients with progressive CRPC who received continuous daily oral apalutamide at doses between 30 and 480 mg; a maximum efficacious dose of 240 mg daily was selected for phase II testing (Rathkopf et al., 2013). Adverse events with apalutamide included fatigue (47%), diarrhea (30%), headache (20%), and hot flashes (13%). A phase II study of apalutamide was then conducted, which enrolled three separate patient cohorts: men with nonmetastatic CRPC, men with mCRPC, and men with abiraterone-pretreated mCRPC (Rathkopf et al., 2012). In all three cohorts, a significant proportion of PSA responses gave evidence to clinical activity (although these responses were less frequent in each successive cohort as a result of more advanced disease).

This agent was then studied in the pivotal SPARTAN trial, a multicenter blinded randomized phase III study for patients with nonmetastatic CRPC, in which metastases-free survival was selected as the primary end point. In that study, patients with M0 CRPC and a PSADT of less than 10 months were randomized (2 : 1) to either apalutamide or placebo. Notably, the SPARTAN trial met its primary end point of delaying metastasis-free survival by an impressive 72% (HR 0.28, 95% CI 0.23–0.35; $P < 0.001$) (Smith et al., 2018), with a similar trend in overall survival. Time to symptomatic progression was also longer with apalutamide than with placebo (HR 0.45, 95% CI 0.32–0.63, $P < 0.001$). The rate of adverse events leading to drug discontinuation was 10.6% in the apalutamide group and 7.0% in the placebo group. Side effects that occurred more commonly in the apalutamide arm included rash (24% vs. 6%), hypothyroidism (8% vs. 2%), falls (16% vs. 9%), and fractures (12% vs. 6%). Based on the impressive efficacy and favorable toxicity profile, the FDA approved apalutamide in February 2018 for the treatment of M0 CRPC, the first approval of its kind for this disease space. However, it must be remembered that apalutamide does not have approval for use in metastatic prostate cancer at this time.

AR-V7: A Potential Treatment-Selection Marker

One molecular biomarker that may aid appropriate selection of therapy (i.e., AR-directed therapy vs. taxane chemotherapy) for patients with CRPC is the presence of androgen receptor splice variant 7 (AR-V7) in circulating tumor cells (CTCs) (Antonarakis et al., 2016). AR-V7 is a splicing variant of the androgen receptor that lacks the ligand-binding domain yet remains constitutively active as a transcription factor in a ligand-independent manner. Lack of response of men with CRPC to abiraterone and enzalutamide was associated with detection of AR-V7 mRNA in CTCs using an mRNA-based polymerase chain reaction (PCR) assay (Antonarakis et al., 2014). However, AR-V7 presence did not preclude clinical benefit from taxane chemotherapies (docetaxel and cabazitaxel) (Antonarakis et al., 2015). Men with AR-V7(+) CTCs exhibited superior PFS with taxanes compared with novel hormonal therapies (abiraterone and enzalutamide); however, the two classes of agents resulted in comparable PFS in men with AR-V7(–) CTCs. A confirmatory study used a different CTC assay that detected nuclear-localized AR-V7 protein using an immunofluorescence approach. Men with AR-V7(+) CTCs in that study had superior overall survival with taxanes versus abiraterone or enzalutamide, whereas survival was not different between the two classes of agents among patients with AR-V7(–) CTCs (Scher et al., 2016). These data perhaps suggest that men with AR-V7(+) mCRPC may respond more favorably to taxane agents, whereas those with AR-V7(–) mCRPC may benefit equally from AR-directed agents or taxane chemotherapies.

These single-center clinical experiences suggest that AR-V7 assays are promising predictors of abiraterone and enzalutamide resistance (and not taxane resistance), but they have not yet been validated prospectively and externally. Furthermore, the prevalence of AR-V7 positivity is only 3% to 10% in patients who have not yet received treatment with enzalutamide, abiraterone, or taxanes (Antonarakis et al., 2017; Scher et al., 2016), so the authors believe that AR-V7 detection may not be useful to inform treatment decisions in the treatment-naive CRPC setting. On the other hand, the prevalence of AR-V7 positivity is higher after progression on abiraterone or enzalutamide (20% to 40%) (Antonarakis et al., 2017; Scher et al., 2016), and therefore the clinical utility of this biomarker may be best demonstrated in this clinical setting (where the choice between sequential AR-directed therapies or switching to taxane chemotherapies is being entertained). Several prospective trials aiming to validate the AR-V7 biomarker are underway.

Key Points: Next-Generation Hormonal Therapies

- There is mounting evidence that CRPC is not androgen-independent and continues to rely on androgen/AR signaling.
- Abiraterone is a CYP17 inhibitor that depletes adrenal and intratumoral androgens. It is approved for the treatment of mCRPC before and after chemotherapy (but not for nonmetastatic CRPC).
- Enzalutamide is an AR signaling inhibitor that antagonizes the AR and prevents nuclear translocation and DNA binding. It was shown to improve survival in men with mCRPC in the prechemotherapy and postchemotherapy settings and to improve metastasis-free survival for men with M0 CRPC. Enzalutamide is approved for any patient with CRPC, regardless of metastatic status.

- Apalutamide is a second AR signaling inhibitor that has shown superiority to placebo in men with nonmetastatic (M0) CRPC and has received approval for this indication. Apalutamide is not approved for use in metastatic CRPC.
- Additional CYP17-inhibiting agents (e.g., orteronel) and AR-targeting agents (e.g., darolutamide) are in clinical development.
- AR-V7 is a blood-based biomarker that may be used to aid in the choice of therapy for mCRPC patients. AR-V7(+) patients may benefit more from taxane chemotherapy, whereas AR-V7(–) men may benefit similarly from either AR-directed therapy or chemotherapy.

Immunotherapy

An alternative or complementary strategy for the treatment of prostate cancer involves the use of immune-active agents. Cancer immunotherapy refers generally to approaches that attempt to treat cancer by activating immune responses against malignant cells while overcoming tumor-induced tolerance (Drake, 2010). Although not traditionally considered a disease amenable to immune-directed therapies, prostate cancer may in fact be an ideal target for immunologic attack because it is a slow-growing disease (allowing a stimulated immune system the time to generate an antitumor response), and it produces several tissue-specific proteins that may serve as tumor antigens: these include PSA, prostatic acid phosphatase (PAP), and others.

Entraining the immune system to overcome tumor-induced tolerance is the goal of nearly every cancer vaccine program, and active immunotherapy with vaccination against tumor-specific antigens has been pursued in many different cancer models including prostate cancer. A variety of approaches have been used, including dendritic cell–based therapies, adjuvants such as granulocyte-macrophage colony-stimulating factor (GM-CSF), viral carriers, single-antigen or whole-cell vaccines, genetically modified tumor cell vaccines, and DNA plasmid vaccines. More recently, strategies incorporating costimulatory molecules, cytotoxic T-lymphocyte antigen–4 (CTLA-4) blockade, PD-1 blockade, and intracellular viral or bacterial mediators have also been developed (Blattman et al., 2002; Drake, 2010; Harzstark and Small, 2009; Mapara and Sykes, 2004; Webster et al., 2005).

In prostate cancer, several of these immunologic approaches have been under clinical investigation, the most important of which is sipuleucel-T (an autologous PAP-loaded dendritic cell vaccine), which has gained FDA approval for patients with asymptomatic or minimally symptomatic mCRPC. Other immunotherapies that have entered late-phase clinical development include the GVAX allogeneic recombinant whole-cell vaccine (which failed to meet its primary end point in phase III trials), the ProstVac-VF recombinant poxviral PSA vaccine (currently in phase III testing), and CTLA-4 inhibitory approaches including ipilimumab (also in phase III testing).

Sipuleucel-T

Sipuleucel-T (Provenge) is a personalized vaccine that is derived from autologous CD54+ dendritic cells, the major class of antigen-presenting cells, which are apheresed from individuals and processed with a recombinant fusion protein composed of PAP and GM-CSF. PAP was chosen based on its prostate cell membrane localization and the success of preclinical models using it to generate prostate-specific immune responses and autoimmune prostatitis. Mixed activity was initially reported in early-phase trials using sipuleucel-T in patients with CRPC. In a randomized phase II/III trial comparing sipuleucel-T against placebo in 127 asymptomatic men with mCRPC, there was no significant difference in time to disease and pain progression ($P = 0.052$), which was the primary study end point (Small et al., 2006). However, patients randomized to placebo could cross over to receive the active vaccine at the time of progression, whereas those initially randomized to receive the active vaccine were treated at their physician's discretion at the time of progression. A 3-year update of this trial suggested a statistically significant improvement in overall survival for those patients assigned to receive sipuleucel-T initially ($P = 0.01$). Post hoc analyses also suggested that the benefits of sipuleucel-T may be limited to the subgroup of men with tumor Gleason sums of 7 or lower. Although preparation and production of large-scale quantities of individually tailored vaccine can be challenging, this vaccine was well tolerated, with minimal infusion-related fevers and rigors being the predominant adverse events (Small et al., 2006).

A second phase II/III trial that randomized 98 men with asymptomatic CRPC to either sipuleucel-T or placebo also failed to show a statistically significant improvement in time to progression (the primary end point of this study). However, post hoc pooled analyses of these two trials ($n = 225$) did show an overall survival advantage, with median survival being 18.9 months in the placebo group and 23.2 months in the sipuleucel-T group (HR 0.67, 95% CI 0.49–0.91, $P = 0.01$) (Higano et al., 2009). However, because overall survival was not the primary end point in either of these two trials, the FDA (justifiably) did not grant approval of this treatment at that time.

To evaluate definitively the clinical usefulness of sipuleucel-T in a larger patient population, a pivotal multicenter double-blind placebo-controlled randomized phase III trial (IMPACT) was conducted in men with asymptomatic or minimally symptomatic mCRPC (Kantoff et al., 2010a), finally leading to the FDA approval of this agent in April 2010. In this trial, 512 patients were randomized (2 : 1) to sipuleucel-T or to placebo, and the study was powered to detect an overall survival advantage. Notably, this study did not enroll men with visceral metastases or those taking narcotics for cancer pain, and most patients (85%) were chemotherapy naive. Impressively, median overall survival was 25.8 months in the sipuleucel-T group versus 21.7 months in the placebo group (HR 0.78, $P = 0.03$) (Fig. 162.7), despite 64% of patients on placebo crossing over to receive salvage sipuleucel-T at the time of disease progression. In the subset of patients with previous chemotherapy exposure, overall survival trended in favor of sipuleucel-T, but this effect was not statistically significant. Therefore, although this immunotherapy is approved for all patients with asymptomatic or minimally symptomatic CRPC, it will likely provide its largest impact in the pre-chemotherapy setting. In addition, it should not be used in patients with visceral disease or in those requiring narcotic analgesics for cancer-related pain.

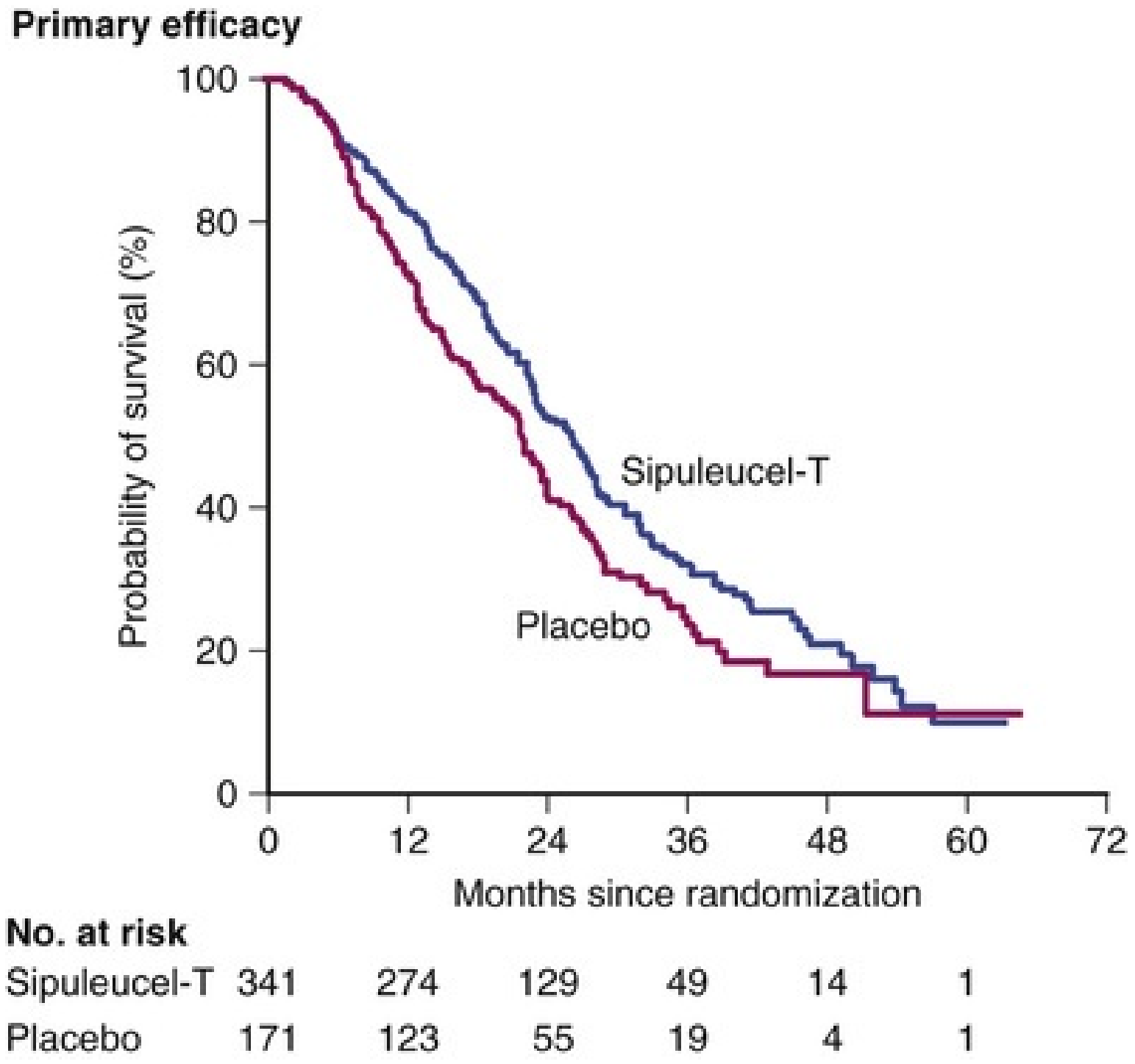

FIG. 162.7 Overall survival in the IMPACT study. (Data from Kantoff PW, Higano CS, Shore ND, et al.: Sipuleucel-T immunotherapy for castration-resistant prostate cancer. *N Engl J Med* 363:411–422, 2010.)

Similar to previous studies with sipuleucel-T, the IMPACT study detected no difference in PFS or PSA/radiographic response rates between the two treatment arms. Some investigators attribute the discord between progression-free and overall survival to a possible class effect of immunotherapy agents relating to their mechanism of action, which is distinct from cytotoxic therapies.

Problematic end points such as PFS in CRPC (which may be confounded by bone scan flare or delayed-onset effects) may perhaps be better addressed by revised guidelines using outcomes that are tailored to immunologic agents (Hoos et al., 2010). These new immune-related response criteria may help in the future development of additional immunotherapy agents for prostate cancer and other malignancies.

Because of the notion that immunotherapies are likely to have their biggest impact in the early disease setting, sipuleucel-T has also been tested in combination with ADT in men with nonmetastatic biochemically recurrent prostate cancer (Antonarakis and Kibel, 2013). Although the immunologic data from this trial appear encouraging, the mature clinical results are still awaited. In addition, other trials are currently testing the combination of sipuleucel-T with other AR-directed therapies. For example, one trial is examining the combination and sequencing of sipuleucel-T with abiraterone in men with mCRPC. Another trial is evaluating the optimal combination and sequencing of sipuleucel-T with enzalutamide. Both of these studies have not yet produced mature results. However, it is likely that immunotherapies will be combined routinely with other standard prostate cancer therapies moving forward so as to maximize clinical outcomes, especially if these agents do not have overlapping toxicities.

ProstVac-VF

ProstVac-VF is a PSA-targeted poxviral-based vaccine approach that has been developed through a series of iterative preclinical and clinical studies. The final version uses a heterologous prime-boost strategy (vaccinia prime, fowlpox boost) and incorporates a DNA plasmid containing the PSA gene plus three costimulatory molecules serving to increase PSA-specific immune responses (Madan et al., 2009). This particular vaccine is not a personalized product, is relatively inexpensive to synthesize, and is administered by repeated subcutaneous injections throughout several months. Similar to the clinical experience with sipuleucel-T, a randomized phase II study using this immunotherapy product demonstrated improved overall survival (a secondary end point) among men with mCRPC who received ProstVac-VF compared with those receiving an empty-vector placebo (25.1 vs. 16.6 months, HR 0.56, P = 0.006), whereas there was no impact on the primary end point of PFS (Kantoff et al., 2010b).

After from these encouraging results, and recognizing that this class of agents may produce a survival benefit without altering radiographic progression, a multinational randomized phase III trial (PROSPECT) was launched in which 1297 men with chemotherapy-naive asymptomatic or minimally symptomatic mCRPC were allocated (1 : 1 : 1) to one of three treatment arms: ProstVac-VF administered alone, ProstVac-VF plus subcutaneous GM-CSF, or double-placebo. The primary end point of this pivotal trial was overall survival. Unfortunately, the final results of this trial were recently presented and there was no survival advantage observed for either of the ProstVac-VF–containing arms over placebo (Gulley et al., 2018). There were also no differences seen in any of the secondary efficacy end points.

However, there has been considerable interest in combining ProstVac-VF with other standard prostate cancer therapies in earlier disease settings. In a completed phase II study involving 42 men with nonmetastatic CRPC, patients were randomized to ProstVac-VF, followed by nilutamide versus nilutamide, followed by ProstVac-VF (Madan et al., 2008). This study suggested a potential improvement in overall survival in men receiving ProstVac-VF before nilutamide rather than the opposite sequence (6.2 vs. 3.7 years, $P = 0.04$). Another randomized phase II trial currently compares the combination of ProstVac-VF plus enzalutamide versus enzalutamide alone in men with biochemically recurrent prostate cancer. Finally a separate randomized phase II study compares ProstVac-VF plus enzalutamide versus enzalutamide alone in men with mCRPC. These studies may help to elucidate the role of combination immunohormonal therapy in various prostate cancer clinical states, although the fate of ProstVac-VF is uncertain.

Immune Checkpoint Blockade

Because of ongoing host immunologic pressures on evolving tumors, cancers have developed mechanisms to escape immune surveillance, effectively inducing a state of immune tolerance (Drake et al., 2006). One way to inhibit immunologic evasion by tumor cells is through the blockade of the immune checkpoint molecule CTLA-4 (cytotoxic T lymphocyte-associated antigen-4), thus preventing the normal attenuation of antitumor T-cell responses (Hodi, 2007). In murine prostate cancer models, CTLA-4 inhibition has been shown to potentiate T-cell effects and to induce tumor rejection including at metastatic sites (Kwon et al., 1999).

Several clinical trials using the monoclonal anti–CTLA-4 antibody, ipilimumab, have been conducted in men with mCRPC. These include phase I and II studies of ipilimumab monotherapy or therapy in combination with radiation (Small et al., 2007), as well as a phase I study combining ipilimumab with GM-CSF (Fong et al., 2009). Encouragingly, across a broad range of phase I and II studies, greater than or equal to 50% of PSA reductions have been observed in about 10% to 20% of prostate cancer patients, and radiologic tumor responses were seen in about 5% of men (Slovin et al., 2013), which is particularly noteworthy given that PSA and tumor responses were rarely reported in the immunotherapy trials with sipuleucel-T or other therapeutic vaccines. Common side effects of ipilimumab include fatigue (42%), nausea (35%), pruritus (24%), constipation (21%), and rash (19%). In addition, because CTLA-4 normally attenuates autoimmunity, immunologic toxicities resulting from an unchecked immune response may occur. Such immune-related adverse events include colitis (15% to 20%), hepatitis (5%), adrenal insufficiency and other endocrinopathies (2%), dermatitis/vitiligo (2%), and even hypophysitis (1%) (Dillard et al., 2010; Drake et al., 2014).

Based on these encouraging phase II data, ipilimumab entered phase III testing in the pre- and post-chemotherapy settings. The first trial to be completed was a placebo-controlled phase III study in 799 men with mCRPC who had previously received docetaxel-based chemotherapy: all patients received a low dose of immune-stimulatory radiotherapy to a bone metastasis (8 Gy) followed by treatment allocation to either ipilimumab (administered intravenously every 3 weeks for 12 weeks, and then every 12 weeks thereafter) or matching placebo. In this trial, although treatment with ipilimumab was associated with superior PSA response rates (13.1% vs. 5.3%, $P = 0.001$) and improved PFS (HR 0.70, 95% CI 0.61–0.82, $P < 0.0001$), there was no statistically significant improvement in overall survival although there was a strong trend favoring the ipilimumab arm (HR 0.85, 95% CI 0.72–1.00, $P = 0.053$) (Drake et al., 2014). Patients without visceral disease experienced the greatest benefit from ipilimumab, as well as those patients with normal hemoglobin and alkaline phosphatase levels. A second pre-docetaxel placebo-controlled phase III study that enrolled 600 patients was also recently reported. In this trial, men with asymptomatic or minimally symptomatic CRPC were randomized to ipilimumab or placebo; overall survival was the primary end point. Unfortunately, this study also failed to show an improvement in patient lifespan among those receiving ipilimumab versus placebo (HR 1.11, 95% CI 0.88–1.39, $P = 0.37$) (Beer et al., 2017), although PFS was prolonged with ipilimumab and there were several patients who achieved PSA responses and objective tumor responses. This suggests that a subset of mCRPC patients may benefit from ipilimumab treatment, although the unselected population as a whole does not derive benefit.

Pembrolizumab for Microsatellite Instability-High Cancers

In May 2017 the FDA approved the use of the anti–PD-1 antibody, pembrolizumab, for treatment of patients with “unresectable or metastatic microsatellite instability-high (MSI-H) or mismatch repair-deficient (dMMR) solid tumors who have progressed on prior treatments and who have no satisfactory alternative treatment options” (Keytruda, 2017). The recommended adult dosage of pembrolizumab for this indication is 200 mg given intravenously once every 3 weeks. Approval was based on the treatment of 149 patients across 5 clinical studies involving MSI-H or dMMR colorectal (n = 90) or non-colorectal (n = 59) cancers, demonstrating an objective response rate of 40% (59/149) (Keytruda, 2017). All patients received at least 1 prior systemic regimen. Among the non-colorectal cohorts, 2 patients had metastatic CRPC: one achieved a partial objective response with pembrolizumab, and the other achieved stable disease for more than 9 months.

A total of 11 additional patients with metastatic CRPC treated with pembrolizumab have been reported (Graff et al., 2016; Le et al., 2017). In one study, only 1 patient had dMMR prostate cancer (Le et al., 2017). He had treatment-refractory, progressive, mCRPC and experienced a complete response with pembrolizumab. In the other study, 10 patients with mCRPC and biopsiable metastases (bone = 7; lymph nodes = 2; bone and liver = 1) who had disease progression on enzalutamide were treated with pembrolizumab and concurrent enzalutamide (Graff et al., 2016). Three of the 10 patients showed a near-complete PSA response. Two of these 3 patients had radiographically measurable disease and also achieved a partial radiographic response (including a response in liver metastases). Genetic analysis of biopsy tissue revealed that one responder had a dMMR/MSI-H tumor, whereas the other responder and the non-responders did not.

The most common adverse events from pembrolizumab are fatigue, pruritus, diarrhea, anorexia, constipation, nausea, rash, fever, cough, dyspnea, and musculoskeletal pain. Pembrolizumab also may be associated with immune-mediated side effects, which include colitis, hepatitis, endocrinopathies, pneumonitis, and nephritis.

Based on the available data, the authors support the use of pembrolizumab in patients with MSI-H or dMMR metastatic CRPC whose disease has progressed through at least one line of systemic therapy for mCRPC (e.g., abiraterone or docetaxel). The prevalence of MMR deficiency in metastatic CPRC is estimated at 2% to 5% (Le et al., 2017; Robinson et al., 2015), and testing for MSI-H or dMMR can be performed using next-generation DNA sequencing or immunohistochemistry for the MMR proteins (MSH2, MSH6, MLH1, and PMS2). If a tumor is found to have MSI-H and/or dMMR, the authors also recommend referral to genetic counseling for consideration of germline testing for Lynch syndrome (hereditary non-polyposis colorectal cancer).

Key Points: Immunotherapy

- Sipuleucel-T was the first therapeutic vaccine to be approved by the FDA for the treatment of any cancer, and it is indicated for men with asymptomatic or minimally symptomatic mCRPC without visceral metastases or cancer-related pain requiring narcotics.
- ProstVac-VF is a poxviral-based PSA-directed prostate cancer vaccine that is administered by subcutaneous injection. The phase III PROSPECT trial failed to show an improvement in survival, calling into question the role of this immunotherapy.
- Ipilimumab did not show prolongation in survival either in the post-docetaxel or the pre-docetaxel settings and did not receive FDA approval for use in mCRPC, although some patients achieved objective tumor responses suggesting a potential benefit in a small subset of patients; ipilimumab should not be used routinely in clinical practice.
- Pembrolizumab is a PD-1 inhibitor that is indicated for mCRPC patients with a MSI-high and/or MMR-deficient phenotype, although this may only reflect 2% to 5% of prostate cancers.
- The future of prostate cancer immunotherapies is likely to involve their use in the early disease setting or in combination with other standard prostate cancer therapeutics (hormone therapy, chemotherapy, or radiotherapy).

Targeted Treatments

Rational Target Overview

An understanding of the basic biology involved in the pathogenesis and progression of prostate cancer provides the opportunity to identify potential therapeutic targets for this disease. In general terms, the first therapeutic opportunity is the demonstration of a mutation or functional dysregulation of a target. Simply targeting overexpressed proteins has been less effective than the specific targeting of mutations that drive the bulk of the tumor growth. However, with the exception of the AR, this scenario is rare in prostate cancer. The second goal is identifying target causality, indicating the importance of the target alone or in combination with other aberrations in reproducing the phenotypic findings of prostate cancer. Finally there should be evidence from preclinical models that inhibition of the target leads to tumor regression or quiescence, not just growth restriction.

In prostate cancer, the AR is one potential therapeutic target, although there are many others. Given the molecular complexity of the prostate cancer cell and the relatively poor understanding of the role of non-AR pathways in prostate cancer progression and metastasis, the simultaneous inhibition of multiple pathways remains a common strategy to induce sustained and clinically meaningful patient responses. In addition, although a prostate cancer stem cell has yet to be conclusively demonstrated, prostate cancer clearly progresses from an androgen-dependent tumor (with features similar to the luminal differentiated glands of the prostate) to an AR-independent tumor (that has features of adult stem cells, including antiapoptotic mechanisms, chemotherapy resistance, and reliance on non-AR–related pathways).

To this end, candidate pathways currently under evaluation as targets for prostate cancer treatment include phosphatidylinositol 3-kinase (PI3K)/Akt/mammalian target of rapamycin (mTOR) signaling, epidermal growth factor receptor (EGFR) signaling, mitogen-activated protein kinase (MAPK) signaling, angiogenesis signaling, apoptosis signaling, hedgehog signaling, insulin-like growth factor receptor (IGF-1R) signaling, Src kinase signaling, endothelin signaling, and several others (Wozney and Antonarakis, 2014). However, therapeutic approaches targeting these pathways have been largely unsuccessful, with few exceptions. Here we outline some of the most promising efforts relating to therapies targeting the Akt/mTOR pathway, angiogenesis, and MET signaling, as well as apoptotic pathways. This section provides an overview of these select pathways as they pertain to prostate cancer rational targets and the approaches that are currently being developed for therapeutic purposes.

PI3K/Akt/mTOR Pathway

The PI3K/Akt/mTOR pathway is an important signaling cascade present in many different types of human cancer. This pathway has been linked to cell survival, differentiation, proliferation, growth, metabolism, migration, and angiogenesis. Normally, signaling via this pathway begins with the binding of a growth factor to a receptor tyrosine kinase resulting in downstream activation of PI3K. Alternatively, PI3K activation can occur via Ras through G-protein–coupled receptors. PI3K phosphorylates its substrate, phosphatidylinositol 4,5-bisphosphate (PIP2) to produce phosphatidylinositol 3,4,5-triphosphate (PIP3). PIP3 can proceed to bind to various signaling proteins and can initiate downstream signaling via Akt. This pathway is negatively regulated by the protein tyrosine phosphatase (PTEN) (often deleted in prostate cancer), which dephosphorylates PIP3 to PIP2, thereby terminating further signaling (Courtney et al., 2010; Engelman, 2009). The PI3K/Akt signaling cascade promotes cell survival and resistance to apoptosis through several different mechanisms, including interactions with the Bcl-2 family members BAD and BAX, nuclear factor-κB (NF-κB), and Mdm2. Also downstream of this pathway is the mTOR protein. Activation of mTOR leads to increased protein synthesis through phosphorylation of ribosomal proteins and translation elongation factors. In this fundamental way, mTOR is an important modulator of cell growth. Multiple feedback loops and regulators control mTOR signaling, and the pathway integrates inputs from various metabolic, growth factor, and survival pathways (Dancey, 2010).

Laboratory data have provided compelling foundations for studying the role of inhibitors of PI3K and its downstream targets in prostate cancer. Taylor et al. (2010) performed genomic profiling of 218 primary or metastatic prostate cancers, integrating information about DNA copy number, mRNA expression profiles, and exon sequencing. A core pathway analysis showed that altered signaling in the PI3K pathway was present in nearly half of all primary prostate tumors and in virtually all metastatic tumors tested. About 40% of all cases demonstrated loss-of-function of PTEN through deletion, inactivating mutation, or reduced expression. In contrast to many other cancers, activating mutations in the *PIK3CA* gene were rare. However, loss-of-function mutations in the regulatory subunits PIK3R1 and PIK3R3 were prevalent, suggesting another mechanism for constitutive activation of PI3K in prostate cancer (Taylor et al., 2010).

Despite these telling observations, attempts to target segments of the PI3K/Akt/mTOR pathway in prostate cancer patients have been modest. Studies of the mTOR inhibitors rapamycin, everolimus, and temsirolimus as single agents and in combination with the AR antagonist bicalutamide failed to demonstrate significant clinical activity in mCRPC (Amato et al., 2008; Armstrong et al., 2013; Nakabayashi et al., 2012). Nevertheless, based on preclinical data showing that mTOR inhibition can reverse chemotherapy resistance in PTEN-deficient prostate cancer cell lines, ongoing trials are examining the efficacy of combined treatment with mTOR inhibitors and docetaxel (Duran et al., 2012; Grunwald et al., 2002). Other novel mTOR inhibitors and combination therapies are also under investigation.

One possible explanation for the failure of single-agent mTOR inhibitors to show efficacy in prostate cancer is the hypothesis that mTOR blockade leads to feedback-driven upregulation of signaling molecules upstream in the PI3K pathway. Studies by Carver et al. (2011) have demonstrated the existence of bidirectional crosstalk between PI3K signaling and AR signaling. For example, in a preclinical model, inhibition of the PI3K pathway resulted in activation of AR signaling in PTEN-deficient prostate cancer cells. Similarly, the AR antagonist enzalutamide appeared to upregulate Akt signaling by reducing levels of the regulatory phosphatase PHLPP (PH domain leucine-rich repeat protein phosphatase). Combined blockade with the dual PI3K/mTOR inhibitor, BEZ235, and enzalutamide led to reductions in tumor size in human prostate cancer xenograft models (Carver et al., 2011). This work provides a sound rationale for simultaneous targeting of both pathways.

Under this premise, BEZ235 currently is being studied in combination with abiraterone in men with advanced CRPC. A first-in-human phase I study (which enrolled patients with various solid tumors) showed that BEZ235 was tolerable because no DLTs were observed in the doses tested. Frequently reported side effects were fatigue and gastrointestinal symptoms. A few tumor responses were seen; patients whose tumors demonstrated activated PI3K pathway signaling were the most likely to respond to treatment with BEZ235. Because of pharmacokinetic variability, the drug was reformulated to improve bioavailability, which initially delayed clinical development of this agent (Burris et al., 2010; Maira et al., 2008).

Efforts to develop the potent and specific Akt inhibitor, MK2206, are also seeking to capitalize on the preclinical observations that simultaneous AR blockade and PI3K pathway inhibition may be synergistic. Previous phase II studies of another putative inhibitor of Akt, perifosine, had been disappointing. However, correlative pharmacodynamic studies were not performed in perifosine-treated patients, and therefore it is unclear whether target inhibition was actually achieved in these studies (Chee et al., 2007; Posadas et al., 2005). Conversely, pharmacodynamic correlates to the phase I study that established the safety profile and maximum tolerated dose of MK2206 have confirmed its ability to target and inhibit Akt in humans. The most frequent side effects of MK2206 are hyperglycemia, nausea, diarrhea, skin rash, and stomatitis (Yap et al., 2011). Another Akt inhibitor, ipatasertib, is currently being studied in combination with abiraterone (de Bono et al., 2019). To this end, in the phase III IPATential150 trial, 1100 patients with mCRPC and PTEN deficiency will be randomized to abiraterone alone or in combination with oral ipatasertib; the primary end point of this trial is to improve radiographic PFS. The most common adverse events associated with ipatasertib include diarrhea, nausea, vomiting, asthenia, rash, decreased appetite, and hyperglycemia.

Angiogenesis

Therapeutic strategies aimed at preventing the growth of tumor vasculature have yielded clinical benefits for patients with several types of cancers, most notably renal cell carcinoma. There is a strong preclinical basis for studying inhibitors of angiogenesis in prostate cancer because this process appears to play an important role in prostate carcinogenesis and maintenance. One of the key factors in angiogenesis is hypoxia-induced factor-1α (HIF-1α), a transcription factor whose expression is regulated by oxygen levels and growth factor signaling. HIF-1α controls expression of various genes, including many that are involved in angiogenesis, such as VEGF. VEGF acts directly on endothelial cells to stimulate proliferation and to increase vascular permeability, forming the matrix on which neovascularization can occur. In this manner, hypoxia-dependent and hypoxia-independent mechanisms can induce angiogenesis (Semenza, 2003). In prostate cancer, neovascularization is triggered not only by the hypoxic tumor microenvironment but also by aberrant growth factor signaling. For example, prostate cancer cells may aberrantly express the VEGF receptor and ligand. This suggests a dual role for this pathway, involving paracrine signaling, which promotes angiogenesis, and autocrine signaling, which stimulates cell growth and proliferation (Ferrer et al., 1997, 1999).

Many drugs that inhibit VEGF signaling have been tested in prostate cancer, including several that have been FDA approved for treatment of other solid tumors. The best known is bevacizumab, a humanized monoclonal antibody to VEGF. Bevacizumab was evaluated in a phase III cooperative group trial in patients with mCRPC. Participants were treated with docetaxel and either bevacizumab (15 mg/kg IV every 21 days) or placebo. More than 1050 patients were enrolled in the study. PFS improved in the bevacizumab arm (9.9 vs. 7.5 months, $P < 0.001$), but overall survival did not differ significantly between arms (22.6 vs. 21.5 months, $P = 0.18$) (Kelly et al., 2012). Grade-3 or higher toxicities were more common in the bevacizumab arm, as was treatment-related mortality. Serious adverse events attributed to bevacizumab included hypertension, gastrointestinal perforation/hemorrhage, mucositis, and pneumonitis. Based on the “negative” results of this study, the FDA has not approved bevacizumab for use in patients with advanced prostate cancer. Ongoing studies are evaluating its role in conjunction with a short course of ADT in the PSA-recurrent/nonmetastatic setting. It is also being studied in mCRPC patients in combination with the mTOR inhibitors everolimus and temsirolimus.

An alternative antiangiogenic strategy involves the use of the VEGF-trap molecule aflibercept. Aflibercept is a decoy receptor that binds circulating VEGF ligand, thereby preventing its association with cellular VEGF receptors. The drug was studied in a multinational phase III trial in symptomatic mCRPC patients. More than 1200 patients were randomized to receive docetaxel plus either aflibercept or placebo. In this trial, there were no significant differences in progression-free or overall survival, and toxicities were higher in the aflibercept arm (Tannock et al., 2013). The increase in toxicities in the interventional arm mimicked the higher rate of adverse events with the docetaxel-bevacizumab combination. Because of these negative findings, no further studies of aflibercept are planned in patients with prostate cancer.

Attempts to target VEGF signaling with small molecule inhibitors in men with prostate cancer have shown some promise in phase II studies, but only one of these agents (sunitinib) has entered phase III testing. Sunitinib is a promiscuous tyrosine kinase inhibitor that blocks VEGFR2 and platelet-derived growth factor-β. A phase III study was conducted in patients with mCRPC who progressed after docetaxel chemotherapy. In this trial, more than 870 men were randomized to single-agent sunitinib or placebo. Although PFS was superior for sunitinib (5.6 vs. 4.1 months, $P < 0.001$), there was no significant difference in overall survival compared with placebo (13.1 vs. 11.8 months, $P = 0.17$) (Michaelson et al., 2014). The results of this study also raise the question of whether an overall survival benefit may have been observed if sunitinib had been continued beyond radiographic progression in patients who were tolerating the drug well. This agent is not FDA approved for prostate cancer.

Despite the disappointing results from the aforementioned phase III trials, several drugs targeting angiogenesis in novel ways remain in clinical development. Perhaps the most promising of these is tasquinimod, a second-generation quinolone-3-carboxamide analogue. Tasquinimod inhibits angiogenesis by preventing the upregulation of HIF-1α and the resultant aberrant VEGF expression. It also appears to induce expression of an endogenous antiangiogenesis factor, thrombospondin-1. Through an alternative or complementary mechanism of action, the drug also inhibits S100A9, a protein involved in differentiation and cell cycle progression. Inhibition of S100A9 also prevents recruitment of myeloid-derived suppressor cells (MDSCs), which are important players in the tumor microenvironment. MDSCs may participate in immune escape and other mechanisms by which tumors evade immunologic attack (Isaacs, 2010). A phase II study of tasquinimod was conducted in men with mCRPC who had not received chemotherapy. The primary end point was radiographic PFS at 6 months. More than 200 men were randomized (2 : 1) to receive tasquinimod or placebo. Median PFS was 7.6 months with tasquinimod versus 3.3 months with placebo ($P = 0.004$). The drug had minimal effects on PSA kinetics, and few men achieved a significant reduction in PSA. Common side effects of tasquinimod were fatigue, nausea, constipation, and anorexia. Grade-3 and higher toxicities included asymptomatic elevations in the lipase and amylase levels, anemia, and venous thrombosis (Pili et al., 2011). Based on these results, tasquinimod advanced to a placebo-controlled randomized phase III trial for patients with similar characteristics to those in the phase II study. Unfortunately, this agent was also unable to improve survival in the pivotal placebo-controlled trial (Sternberg et al., 2016), resulting in cessation of its development in prostate cancer.

c-Met Signaling

The c-Met receptor tyrosine kinase has received considerable attention as a potential therapeutic target for many solid tumors, including prostate cancer. c-Met is the cell surface receptor for the hepatocyte growth factor (HGF). In normal tissues, stromal cells produce HGF, and signaling through c-Met occurs largely via paracrine mechanisms. HGF/c-Met signaling is thought to be important for many physiologic processes, including embryogenesis, organogenesis, angiogenesis, wound healing, and repair of organ damage (Scagliotti et al., 2013; Trusolino et al., 2010). Activation of c-Met can lead to signaling via multiple signal transduction pathways, including Src kinase and the PI3K/Akt/mTOR and MAPK cascades. These pathways activate many cellular processes relevant to cancer, including proliferation, survival, and resistance to apoptosis. HGF/c-Met signaling also promotes invasiveness, motility, and metastasis through changes in the structure of the cytoskeleton and altered integrin expression (Peters and Adjei, 2012).

Abnormal c-Met expression has been observed in a variety of human malignancies, including prostate cancer. Mechanisms responsible for aberrant c-Met signaling include gene amplification and chromosomal rearrangement. Activating mutations and alternative splice variants can also lead to overactive c-Met signaling (Jeffers et al., 1997; Peters and Adjei, 2012; Scagliotti et al., 2013). In prostate cancer, paracrine mechanisms are believed to be predominantly responsible for increased c-Met signaling (Knudsen and Edlund, 2004). High c-Met expression exists in approximately 50% of primary prostate tumors at diagnosis and has been universally observed in bone metastases (Knudsen et al., 2002). In vitro, many CRPC cell lines also express high levels of c-Met mRNA and protein, and they are responsive to HGF in a concentration-dependent manner (Knudsen and Edlund, 2004). Therefore the relationship between AR signaling and c-Met expression has been investigated. To this end, the AR appears to regulate negatively c-Met expression by interfering with Sp1, a transcription factor that binds to the promoter region of the *c-MET* gene. In support of this hypothesis, high c-Met expression has been observed in castration-resistant xenograft models. These findings have led to the conclusion that expression of c-Met and signaling via the HGF/Met axis may be important for the progression of prostate cancer to the castration-resistant state (Verras et al., 2007).

In addition, the presumed importance of c-Met signaling in prostate cancer and its widespread expression in osseous metastases has led investigators to study inhibitors of this signaling pathway in patients with advanced prostate cancer. Although several Met-targeting strategies have been used, cabozantinib (XL184) is the most promising c-Met inhibitor in clinical development for the treatment of prostate cancer. It is an oral tyrosine kinase inhibitor that potently inhibits c-Met and VEGFR2 (as well as RET). In phase I testing, side effects with cabozantinib were manageable and included diarrhea, fatigue, decreased appetite, and rash. The main DLTs of this agent were hand-foot syndrome, mucositis, and elevations of liver enzymes (aspartate aminotransferase [AST] and alanine aminotransferase [ALT]) as well as lipase elevations. Clinical benefit was seen in a broad range of tumor types (Kurzrock et al., 2011).

Based on the responses seen in this phase I study, an international phase II randomized-discontinuation trial was conducted in nine tumor types simultaneously, including a cohort of men with mCRPC. The dose selected for this phase II study was 100 mg daily. All patients received open-label treatment with cabozantinib during a 12-week lead-in stage, and the trial then randomized patients with stable disease at 12 weeks to cabozantinib or placebo. The study oversight committee suspended randomization after the lead-in stage after the accrual of 122 patients, because unprecedented improvements were seen on bone scans across multiple tumor types (including prostate cancer). At that point, median PFS in CRPC patients with cabozantinib was 23.9 weeks compared with 5.9 weeks with placebo (Smith et al., 2013). Ultimately, the study enrolled a total of 171 patients with mCRPC, almost half of whom had previously received chemotherapy. Although the partial radiographic response rate was only 5%, an additional 75% of patients had stable disease. As before, cabozantinib appeared particularly active in treating bone metastases, with 12% of patients showing complete resolution of disease on technetium-99 bone scan. Reductions in pain scores and narcotic use were also observed in a significant proportion of patients. Importantly, PSA changes did not correlate with the favorable results seen on imaging studies or other signs of clinical benefit; some patients exhibited rising PSA levels despite reductions in the size of soft-tissue lesions or bone metastases. The toxicity profile of cabozantinib in this study was similar to that reported in the phase I trial, although higher rates of grade-3 hypertension were seen (Smith et al., 2013).

Cabozantinib was studied in two phase III trials in men with mCRPC with progressive disease after treatment with docetaxel and a novel AR-directed agent (abiraterone or enzalutamide). The first study (COMET-1) evaluated the efficacy of single-agent cabozantinib versus placebo, with a primary end point of overall survival. The second study (COMET-2) investigated the effect of cabozantinib versus mitoxantrone on quality-of-life measures and pain control; the primary end point of that study was the frequency of durable pain responses lasting at least 12 weeks (whereas overall survival was a secondary end point). These trials were considered the registrational studies for cabozantinib in advanced mCRPC. However, both studies failed to meet their primary end points (Smith et al., 2016).

Apoptosis Pathway

Another rational therapeutic approach for multiple cancer types including prostate cancer is the induction of tumor cell apoptosis. To this end, clusterin is a stress-induced antiapoptotic chaperone protein expressed in various cancers including prostate cancer (Zoubeidi et al., 2010), and it has received renewed attention because of the development of an antisense inhibitor to this protein. Importantly, expression of clusterin in prostate tumors increases after treatment with androgen ablation or chemotherapy (July et al., 2002; Miyake et al., 2000), conferring a more resistant phenotype. Custirsen is a novel intravenously administered antisense oligonucleotide moiety that inhibits clusterin at the mRNA level, increasing sensitivity to androgen deprivation as well as chemotherapy in prostate cancer cell lines and in xenograft models (Gleave and Miyake, 2005; Sowery et al., 2008).

In a randomized phase II trial of docetaxel administered with or without custirsen in 82 patients with mCRPC, PSA responses (58% vs. 54%) as well as PFS (7.3 vs. 6.1 months) were similar in both arms. However, there was a trend in overall survival favoring the combination arm (23.8 vs. 16.9 months, $P = 0.06$), although survival was not the primary end point of this study, and confidence intervals around these estimates were wide and potentially confounded by subsequent therapies (Chi et al., 2010). Adverse events associated with custirsen in that trial included fatigue (48%), fever (30% to 50%), rigors (40% to 60%), diarrhea (40% to 60%), and rash (20% to 40%).

Finally, two registrational placebo-controlled phase III trials of custirsen are underway. The first study (SYNERGY) randomized 1022 patients with chemotherapy-naive mCRPC to receive standard docetaxel versus the combination of docetaxel plus open-label custirsen; overall survival was chosen as the primary end point in this trial. This study failed to meet its primary end point (Chi et al., 2017). The second study (AFFINITY) randomized 630 patients with docetaxel-pretreated CRPC to either cabazitaxel alone or cabazitaxel plus custirsen; the primary end point of this study was also overall survival. Unfortunately, that study also failed to achieve its primary end point, calling into question the future development of custirsen in prostate cancer (Beer et al., 2017b).

Targeting DNA Repair

A new class of agents being explored for the treatment of metastatic CRPC are the poly–ADP-ribose polymerase (PARP) inhibitors (Christenson et al., 2018). PARP is an enzyme that is involved in multiple aspects of DNA repair, particularly single-strand DNA repair, and may rescue cells with deficiencies in homologous recombination (which is the primary mechanism of double-strand DNA repair). In several different cancers in which homologous recombination is impaired, pharmacologic inhibition of PARP may result in “synthetic lethality” and apoptosis of cancer cells (Farmer et al., 2005). PARP inhibitors have proven particularly effective in ovarian and breast cancer patients harboring germline and/or somatic mutations in *BRCA1* or *BRCA2* and have already received FDA approvals in advanced breast and ovarian cancers with inherited *BRCA1/2* deficiencies.

Although PARP inhibitors do not appear to be effective in unselected patients with advanced prostate cancer, the drugs may have better activity in tumors harboring somatic and/or germline mutations in DNA repair genes, especially inactivating mutations of homologous recombination genes (e.g., *BRCA1/2, ATM*, *PALB2*, *FANCA* and other Fanconi anemia genes). The prevalence of somatic DNA repair gene mutations in metastatic CRPC appears to as high as 20% to 25% (Robinson et al., 2015). To this end, olaparib (400 mg twice daily) was recently tested in a study of men with heavily pretreated metastatic CRPC (Mateo et al., 2015). Although the response rate to olaparib was only 33% in the unselected population, an 88% response rate was observed in men with germline or somatic mutations in one or more DNA repair genes. In addition, PFS and overall survival were superior with olaparib in the biomarker-positive patients compared with biomarker-negative patients. Based on the results of this study, the FDA has granted olaparib “breakthrough therapy” status for the treatment of metastatic CRPC with germline and/or somatic mutations in *BRCA1/2* or *ATM*. Randomized studies of olaparib versus second-generation hormonal therapy in metastatic CRPC patients with mutated *BRCA1/2* or *ATM* genes (e.g., the PROFOUND trial) are currently underway. A number of other PARP inhibitors are also being tested in advanced prostate cancer, including rucaparib, niraparib, and talazoparib (Christenson et al., 2018). Toxicities of PARP inhibitors include nausea, fatigue, myelosuppression, and a 1% risk of myelodysplastic syndrome or acute myeloid leukemia.

Key Points: Targeted Treatments

- Despite often promising phase II results, phase III trials have failed to demonstrate the clinical utility of angiogenesis inhibition in advanced prostate cancer.
- Because of the reciprocal interactions between the PI3K/Akt/mTOR pathway and AR signaling, dual inhibition of both pathways concurrently will likely represent the most fruitful therapeutic strategy. This is exemplified by the ongoing phase III trial combining the Akt inhibitor, ipatasertib, with abiraterone in mCRPC patients.
- Cabozantinib is a novel small molecule inhibitor of c-Met and VEGFR2 with significant activity on CRPC bone metastases, but it failed to meet its primary end points in the COMET-1 and COMET-2 pivotal trials.
- Custirsen is an antisense oligonucleotide against clusterin mRNA, which may play a role in reversing resistance to taxane chemotherapies, but phase III trials were negative, calling into question its role in the treatment of mCRPC.
- PARP inhibitors (e.g., olaparib, rucaparib, niraparib) are being explored in mCRPC patients with germline or somatic mutations that result in inactivation of homologous recombination DNA repair, which is present in about 20% to 25% of advanced prostate cancers. PARP inhibitors are not currently FDA approved for any prostate cancer indication.

Palliative Management

Pain and Spinal Cord Compression

As in other disseminated malignancies, palliation of symptoms and maintenance of adequate quality of life represent the most important objectives in the management of advanced prostate cancer. Cancer-related pain is undoubtedly the most debilitating symptom associated with advanced-stage metastatic prostatic carcinoma. Prompt recognition of the various pain syndromes associated with this disease is critical to accomplish effective control of this devastating symptom. The most common pain syndromes and their respective therapeutic considerations are summarized in Table 162.1. Focal bone pain in patients with CRPC can be well controlled using external-beam localized radiation therapy. In general, it is also recommended that painful areas that are shown to be abnormal on bone scintigraphy should be evaluated with plain radiographs or CT imaging to exclude the presence of osteolytic lesions or pathological fractures. Such considerations become even more important when the painful areas affect extremities and weight-bearing sites.

TABLE 162.1

Common Pain Syndromes in Metastatic Castration-Resistant Prostate Cancer

PAIN SYNDROME	INITIAL MANAGEMENT	OTHER THERAPEUTIC ALTERNATIVES
Localized bone pain	Pharmacologic pain management	Surgical stabilization of pathological fractures or extensive bone erosions
	Localized radiotherapy (special attention to weight-bearing areas, lytic metastasis, and extremities)	Epidural metastasis and cord compression should be evaluated in all patients with focal back pain
		Radiopharmaceuticals should be considered if local radiation

		therapy fails
Diffuse bone pain	Pharmacologic pain management	Corticosteroids
	“Multispot” or wide-field radiotherapy	Bisphosphonates or RANK ligand inhibitors
	Radiopharmaceuticals	Calcitonin
		Chemotherapy
Epidural metastasis and cord compression	High-dose corticosteroids	Pharmacologic pain management
	Radiation therapy	Physical therapy for recovery of neurologic function
	Surgical decompression and stabilization is indicated in high-grade epidural compressions, extensive bone involvement, or recurrence after irradiation	
Nerve plexopathies caused by direct tumor extension or previous therapy (rare)	Pharmacologic pain management	Tricyclic antidepressants (amitriptyline)
	Radiation therapy (if not previously used)	Anticonvulsants (gabapentin, pregabalin)
	Neurolytic procedures (nerve blocks)	
Miscellaneous neurogenic causes: postherpetic neuralgia, peripheral neuropathies	Complete neurologic evaluation	Tricyclic antidepressants (amitriptyline)
	Pharmacologic pain management	Anticonvulsants (gabapentin, pregabalin)
	Discontinuation of neurotoxic drugs: docetaxel, platinum compounds	
Other uncommon pain syndromes: extensive skull metastasis with cranial nerve/skull base involvement, extensive painful liver metastasis, or pelvic masses	Radiation therapy	Chemotherapy
	Pharmacologic pain management	Intrathecal chemotherapy may ameliorate symptoms of meningeal involvement
	Corticosteroids (cranial nerve involvement)	

RANK, Receptor activator of nuclear factor-κB.

Epidural metastasis is fairly common and is a potentially devastating complication of systemic cancer. In view of the propensity for prostate cancer to metastasize to the vertebrae and paravertebral regions, the incidence of epidural cord compression is particularly high in this disease. Early diagnosis and treatment of epidural metastasis is critical in preserving ambulation and bowel and bladder function and aids in the management of back pain (Gabriel and Schiff, 2004; Grossman and Lossignol, 1990). Epidural cord compressions arising from vertebral bodies account for the majority of spinal cord compressions; less frequently they are associated with soft-tissue masses involving the paravertebral region. Most of these patients have abnormalities on bone scintigraphs and/or abnormal findings on radiography at the time of diagnosis. However, a deficit on neurologic examination may be the only finding in patients who exhibit soft-tissue epidural metastasis in the paravertebral region.

Spinal magnetic resonance imaging (MRI) is used routinely to exclude the possibility of significant epidural disease, and it has almost entirely replaced other methods such as CT myelography and conventional myelography. The first therapeutic intervention in patients with suspected or documented cord compression should include the administration of high doses of intravenous glucocorticoids. Dexamethasone at doses ranging from 16 to 100 mg daily is most commonly used. Patients are often administered an intravenous “loading dose” of 10 mg of dexamethasone followed by 4 to 10 mg every 6 hours; the optimal steroid dose remains relatively undefined. On improvement of symptoms, which can be accomplished promptly with glucocorticoids, the steroid dose may be tapered down throughout a 2-week to 3-week period.

Radiation therapy is often the mainstay of definitive treatment. However, reports suggest that decompressive surgery followed by radiation therapy may be superior to radiation therapy alone (Patchell et al., 2005). To this end, surgery should be considered in patients who have evidence of progressive signs and symptoms during radiation therapy, develop or are seen initially with unstable pathological fractures that require stabilization, or experience recurrence after radiotherapy. In addition, the overall prognosis of the underlying disease should be considered during the treatment selection. Chemotherapy is rarely used to treat epidural cord compression during the acute management of this complication.

Bone-Targeted Approaches

The pathogenesis of bone metastases in prostate cancer remains a subject of major study. Alterations in the normal process of bone absorption and formation, which usually follow an orderly and sequential path, appear to be a key determining factor in the development of bone metastasis associated with most malignant neoplasms (Roodman, 2004). Under normal physiologic conditions the process of bone remodeling is initiated by an increase in osteoclastic activity followed by an increase in osteoblastic differentiation and maturation, which results in the formation of new bone and the repair of the initial absorption caused by osteoblasts. Bone loss associated with prostate cancer can result from an enhanced osteoclastic activity associated with long-term androgen suppression, which in turn can cause excessive resorption of bone mineral and organic matrix. Tumor cells may also cause mineral release and matrix resorption in the areas involved by metastatic disease (Galasko, 1986). In addition, various cytokines, growth factors, tumor necrosis factors, and bone morphogenic proteins have been shown in preclinical studies to play a major role in the induction of osteoclastic and osteoblastic activity (Reddi and Cunningham, 1990). In prostate cancer, bone metastases are predominantly blastic, which reflects a predominance of osteoblastic activity in the process of bone remodeling (Roodman, 2004). This phenomenon may be a result of specific growth factor secretion that is responsible for the induction of osteoblasts. Unlike other bone-tropic malignancies, hypercalcemia is rare in metastatic prostate cancer. In fact, a significantly elevated serum calcium concentration is most frequently a result of the neuroendocrine prostate cancer (see later) and is mediated through parathyroid hormone–related protein (PTHrP) (diSant'Agnese, 1995; Nelson et al., 2007).

Bisphosphonates

Bisphosphonates have become an integral part of the management of metastatic prostate cancer involving the bones (Van den Wyngaert et al., 2009). These compounds reduce bone resorption by inhibiting osteoclastic activity and proliferation. Zoledronate is a potent intravenous bisphosphonate first approved for the treatment of hypercalcemia and decreased bone mineral density in postmenopausal women (Green and Rogers, 2002). In patients with progressive CRPC and bone metastases, zoledronate was shown to reduce the incidence of skeletal-related events (e.g., pain, fractures) compared with placebo in a prospective randomized trial of 422 patients (Saad et al., 2004). In addition, zoledronate and pamidronate have also been shown to increase bone mineral density in patients with nonmetastatic prostate cancer receiving long-term androgen deprivation (Smith et al., 2001, 2003).

At present, zoledronate is indicated for the treatment of patients with progressive CRPC with evidence of bone metastasis, and it is administered at a dose of 4 mg intravenously repeated at intervals of 4 weeks for several months. Side effects of this agent include fatigue, myalgias, fever, anemia, and mild elevation of serum creatinine. Hypocalcemia has been described with the use of zoledronate, and concomitant administration of oral calcium supplements (1000 mg/day) and vitamin D (800 units/day) is often recommended. An unusual complication of zoledronate is the development of severe jaw pain associated with osteonecrosis of the mandibular bone (called osteonecrosis of the jaw [ONJ]). The cause of this phenomenon is not well understood. However, it is most frequently seen in patients undergoing dental work or those with a history of poor dentition and chronic dental disease. Zoledronate should not be administered to patients with these problems. Other bisphosphonates have also been evaluated in prostate cancer, including alendronate, etidronate, ibandronate, and clodronate; however, their benefit has not been conclusively established in prospective randomized clinical trials (Berry et al., 2006; Van den Wyngaert et al., 2009).

RANK Ligand Inhibitors

Interactions between tumor cells and the bone marrow microenvironment have been postulated as an additional important mechanism in the pathogenesis of bone metastasis. Tumor-associated cytokines have been shown to induce the expression of the receptor activator of nuclear factor-κB ligand (RANKL) that binds and activates RANK, which is found in osteoclasts (Brown et al., 2001). Inhibition of the RANKL system has been the focus of much research and represents an evolving bone-targeted strategy. Among the approaches used are monoclonal antibodies to RANKL and the use of recombinant osteoprotegerin (the natural decoy receptor of RANKL), both of which significantly inhibit osteoclastic function in vitro and in vivo (Schwarz and Ritchlin, 2007). Denosumab, a fully human monoclonal antibody against RANKL, was the first agent to enter clinical trials in patients with prostate cancer, as well as breast cancer. In a phase II randomized study evaluating 50 patients with metastatic prostate cancer, denosumab (administered subcutaneously every 4 weeks) produced a reduction in bone resorption beyond that of zoledronate, as indicated by a lowering of urinary *N*-telopeptide levels, and it also resulted in fewer skeletal-related events (Fizazi et al., 2009).

Following from these encouraging results, a pivotal multicenter phase III double-blind randomized study was conducted comparing denosumab against zoledronate for the prevention of skeletal-related events in patients with bisphosphonate-naive mCRPC. In that trial of 1904 patients, compared with men receiving zoledronate ($n = 951$), men receiving denosumab ($n = 950$) showed an improved time-to-first skeletal-related event (20.7 vs. 17.1 months, $P = 0.008$) and a longer time to first-and-subsequent skeletal-related events (HR 0.82, $P = 0.004$) (Fizazi et al., 2011). Notably, there was no difference in overall survival or PFS between study arms. Based partially on the results of this study (and partially on two other large randomized studies in metastatic breast cancer and other solid metastatic tumors), the FDA approved denosumab in November 2010 for the prevention of skeletal-related events in patients with bone metastases from solid tumors. Common toxicities of denosumab include fatigue, nausea, hypophosphatemia, and hypocalcemia (grade ≥3 in 5% of patients). ONJ also occurs in about 2% to 4% of patients, and prophylactic use of calcium and vitamin D supplementation is strongly encouraged. Therefore denosumab is a reasonable alternative to zoledronate for the prevention of skeletal-related events in patients with mCRPC, and it also includes an advantage in that it does not require dose adjustment or monitoring for renal impairment. The recommended dose of denosumab is 120 mg administered by subcutaneous injection every 4 weeks.

Radium-223 and Other Radiopharmaceuticals

The introduction of “bone-seeking” radiopharmaceuticals has provided a useful resource for the management of diffuse bone pain from widespread prostate cancer metastases (Pandit-Taskar et al., 2004), and it may even improve survival (Parker et al., 2013a). Historically the most commonly used compounds were the beta emitters strontium-89 (^{89}Sr) (Porter et al., 1993) and samarium-153 (^{153}Sm) (Sartor et al., 2004), although these agents will largely be replaced by the alpha emitter radium-223 (^{223}Ra). Initial studies with ^{89}Sr showed palliation of bone pain in 25% to 65% of patients with CRPC and diffuse bone pain (Jager et al., 2000). The pharmacokinetics of ^{89}Sr vary considerably according to the extent of bone involvement, but the half-life is generally 4 to 5 days. The retention of this isotope is significantly longer in patients with diffuse osteoblastic metastases compared with those with relatively limited bone involvement. It is important to recognize this factor because it affects the degree and duration of myelotoxicity associated with this radioactive compound (its most significant toxicity). The clinical experience with ^{153}Sm suggests that this isotope is associated with a lower incidence of myelotoxicity, probably because of its shorter half-life of 2 days. Encouraging results were reported by Sartor et al. (2004) in a phase III trial comparing radioactive ^{153}Sm and nonradioactive ^{152}Sm, indicating that a dose of ^{153}Sm of 1 mCi/kg is safe and effective palliation for patients with CRPC and severe bone pain. However, although ^{89}Sr and ^{153}Sm are FDA approved for the palliative management of castration-resistant bone metastases, neither compound was demonstrated to provide a survival advantage. To this end, the novel alpha-emitting agent radium-223 will probably replace these beta emitters because of its capacity not only to palliate bone pain but also to improve overall survival in this setting.

Radium-223 is a novel alpha-emitting radiopharmaceutical that has received significant attention. Alpha particles are approximately 7000 times heavier than beta particles, and as few as one or two hits can be sufficient to cause cell death, in comparison with hundreds or thousands of hits required from beta particles. In addition, alpha particles have a very short path length (<100 μm), which may spare surrounding healthy bone marrow, thereby limiting hematologic toxicities (Henriksen et al., 2003). A series of phase I and II trials demonstrated the safety of radium-223, together with evidence of biologic activity in terms of serum markers of bone turnover and PSA changes, and raised the possibility that treatment with radium-223 may improve overall survival (Nilsson et al., 2005, 2007, 2012; Parker et al., 2013b).

These promising early phase data led to the design of the phase III ALSYMPCA trial (Parker et al., 2013a), as a result of which radium-223 gained FDA approval for use in mCRPC patients with symptomatic bone metastases. This was an international, randomized, double-blind, placebo-controlled phase III study comparing best standard care plus radium-223 versus best standard care plus placebo in men with mCRPC who were chemotherapy-refractory or chemotherapy-ineligible. Enrollment was restricted to men with symptomatic bone metastases in the absence of known visceral disease or bulky lymph-node metastases. Radium-223 was administered at a dose of 50 kBq/kg (intravenously) every 4 weeks for a total of 6 doses. The primary end point of this trial was overall survival, which was improved by radium-223 compared with placebo (HR 0.70, 95% CI 0.58–0.83, $P < 0.001$); this translated into a median survival benefit of 3.6 months beyond placebo (Fig. 162.8; Parker et al., 2013a). In addition, all of the secondary efficacy end points were also met, with a 6-month delay in median time-to-first symptomatic-skeletal event (HR 0.66, 95% CI 0.52–0.83, $P < 0.001$), and a significant improvement in quality of life measured using the FACT-P scale. Remarkably, the incidence of adverse events and serious adverse events was lower in the radium-223 group than in the placebo group. Diarrhea was the most common side effect in ^{223}Ra-treated patients. Hematologic toxicity was rare (e.g., grade 3/4 thrombocytopenia was seen in 6% of men receiving radium-223 vs. 2% for placebo). Based on the results of the ALSYMPCA trial, radium-223 would be a reasonable treatment choice for any patient with symptomatic bone-mCRPC without visceral or bulky nodal metastases. This agent may be used in docetaxel-refractory patients and in those who are ineligible or uninterested in receiving chemotherapy.

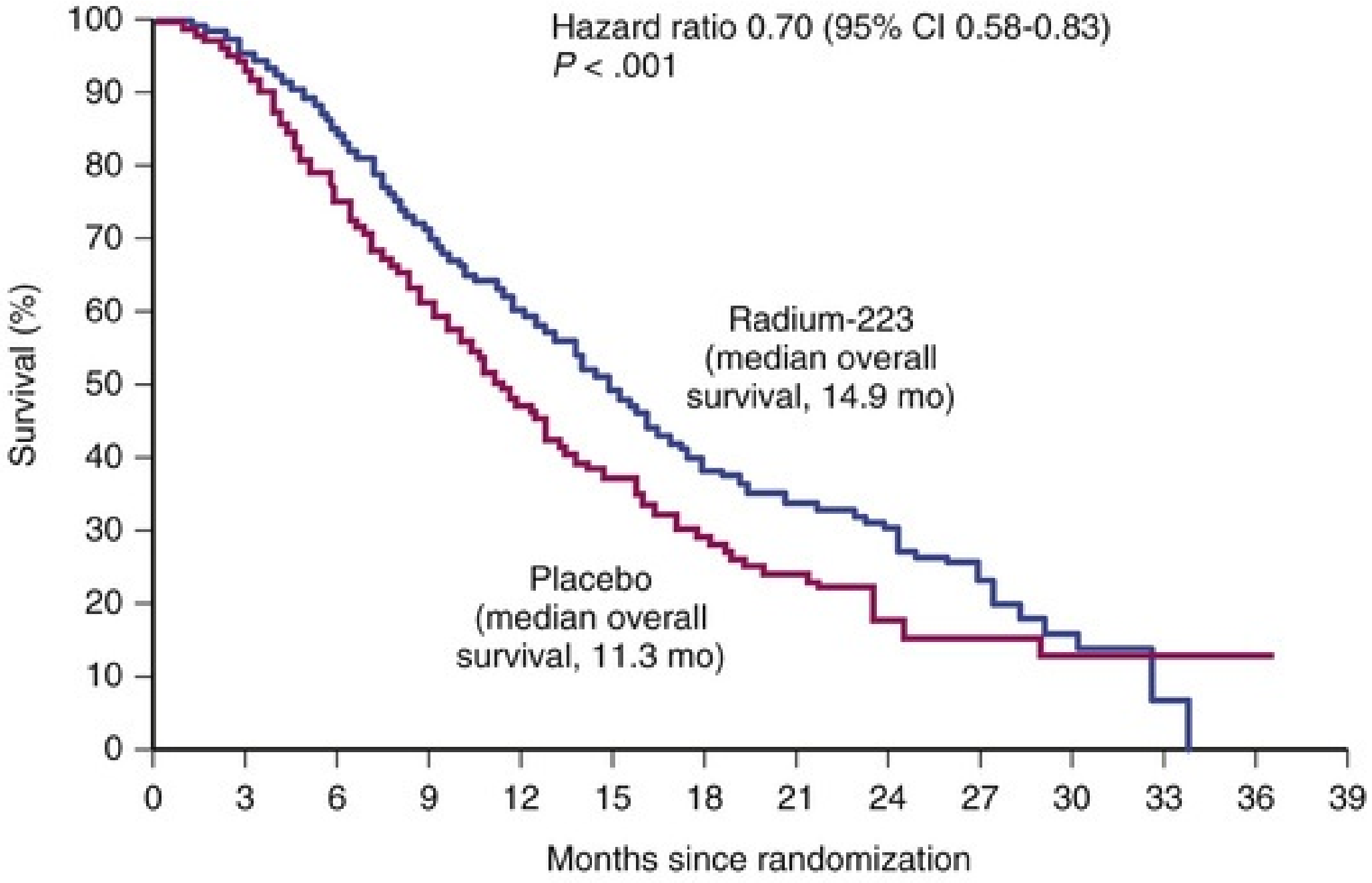

No. at risk														
Radium-223	614	578	504	369	274	178	105	60	41	18	7	1	0	0
Placebo	307	288	228	157	103	67	39	24	14	7	4	2	1	0

FIG. 162.8 Overall survival in the ALSYMPCA study. (Data from Parker C, Nilsson S, Heinrich D, et al.: Alpha emitter radium-223 and survival in metastatic prostate cancer. *N Engl J Med* 369:213–223, 2013.)

Key Points: Palliative Management

- Patients with back pain and a history of bone metastases should be evaluated for spinal cord compression. This clinical syndrome often includes one of the following signs and symptoms: back pain, focal neurologic deficit (motor, sensory), or changes in bladder or bowel control.
- Initial management of suspected cord compression includes immediate MRI of the spine and initiation of high-dose intravenous corticosteroids. Definitive treatment should include radiation therapy, surgical decompression, or both.
- Zoledronic acid and denosumab are both reasonable treatment options for the prevention of skeletal-related events in patients with castration-resistant bone metastases. Denosumab may include the advantage of not requiring renal dosing. Both agents can (rarely) cause ONJ.
- Radium-223 is a novel alpha-emitting radiopharmaceutical that has received FDA approval for the treatment of symptomatic bone metastases in CRPC patients without visceral metastases or bulky lymph node disease.

Neuroendocrine Prostate Cancer

Laboratory and clinical evidence indicate that alterations in the differentiation pathway of prostate cancer can be seen in a small proportion of patients with advanced-stage disease, giving rise to a neuroendocrine/anaplastic transformation (diSant'Agnese, 1995; Nelson et al., 2007). The therapeutic implications of this finding are of significance because tumors demonstrating this phenotype usually represent an inherently endocrine-resistant subtype and, in view of their different clinical and biologic properties compared with the usual adenocarcinoma of the prostate, these tumors also require different treatment strategies.

Such tumors possess a number of biologic characteristics unique to neuroendocrine tumors that can also arise from other organs, most commonly the lung. Among these are the expression of receptors to various neuroendocrine peptide growth factors, such as somatostatin, chromogranin A, and serotonin, as well as PTHrP and *TP53* mutations. These tumors have an uncharacteristic clinical behavior (compared with the usual metastatic prostate cancer), reflected by frequent visceral involvement and rapidly growing soft-tissue metastases. Patients frequently have subacute and often dramatic changes in their disease pattern characterized primarily by a rapidly growing soft-tissue mass (frequently involving the primary site but also with retroperitoneal masses), rapid development of visceral (especially liver) infiltration, osteolytic (as opposed to osteoblastic) bone metastasis, and a high incidence of parenchymal brain involvement (Fig. 162.9). Histologic evaluation is strongly encouraged. This frequently culminates with the demonstration of a small cell variant or a poorly differentiated neoplasm on pathology with the presence of neuroendocrine markers on immunostaining (diSant'Agnese, 1995; Nelson et al., 2007). Interestingly, patients with this tumor phenotype either stop expressing PSA in the presence of major tumor progression or even have undetectable PSA levels at the time of this transformation.

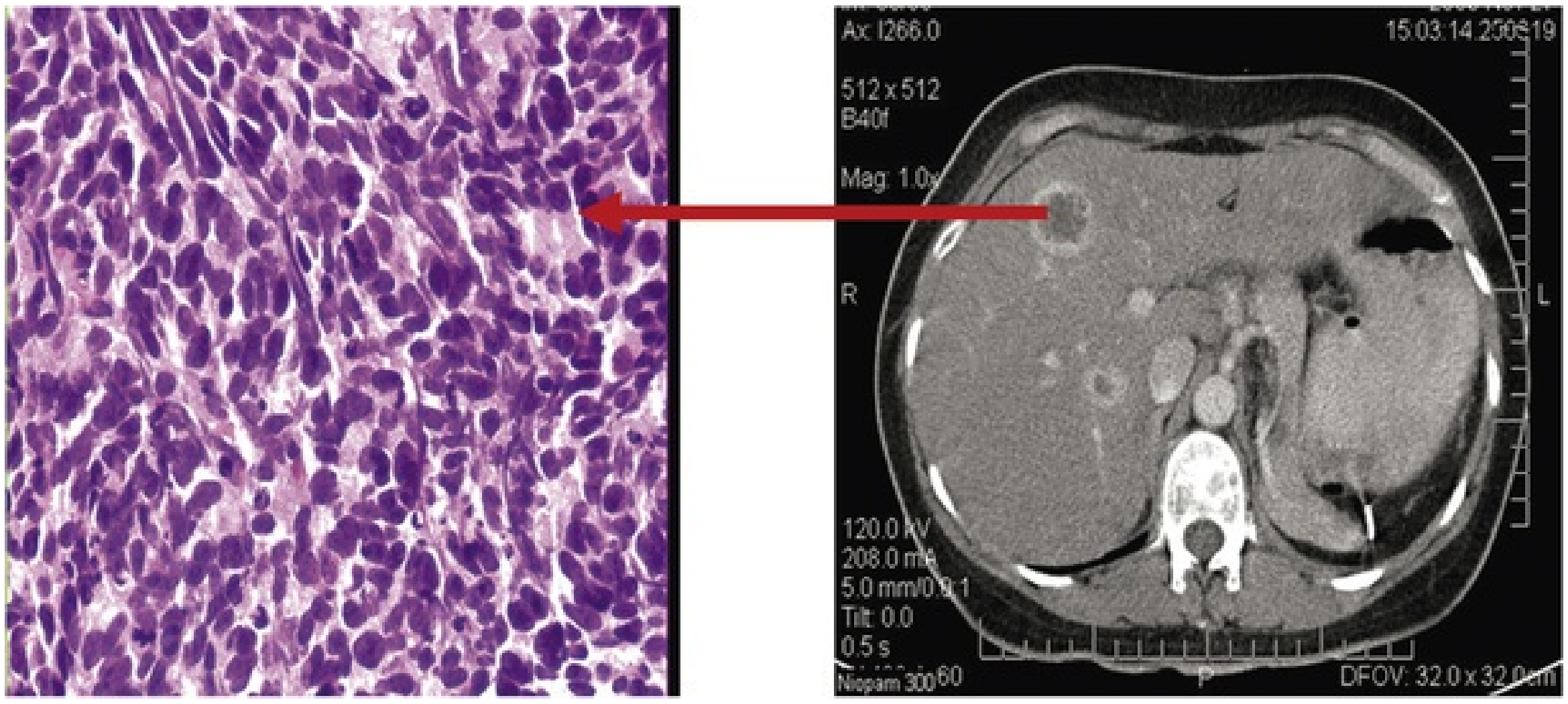

FIG. 162.9 Neuroendocrine/anaplastic carcinoma of the prostate: clinical and pathological features. Red arrow shows histologic section from liver mass biopsy. *PSA,* Prostate-specific antigen.

Treatment of the neuroendocrine/anaplastic phenotype is often similar to that of patients with other neuroendocrine tumors (e.g., small cell carcinoma of the lung) and usually includes combinations of cisplatin and etoposide (Frank et al., 1995), or the combination of a taxane plus carboplatin (Aparicio et al., 2013, 2017) (please also see the section on Platinum agents, earlier). One group has also reported doxorubicin-containing combinations as modestly efficacious (Papandreou et al., 2002). Radiation therapy is effective and should be considered in cases with bulky disease, with brain metastasis, or when local disease control in critical areas may have a positive impact on quality of life (pain, potential pathological fractures, and bladder outlet obstruction). A combined chemotherapy and radiation therapy approach is frequently necessary to accomplish maximal disease control. Despite high initial response rates with chemotherapy and radiation treatment, the prognosis of these patients remains poor and is dependent on various factors, including extent and location of metastases. In general, survival is less than 12 months.

Key Points: Neuroendocrine Prostate Cancer

- Rapidly growing disease with the following clinical characteristics should prompt evaluation for the neuroendocrine subtype: pelvic masses, visceral involvement, osteolytic metastasis with hypercalcemia (associated with high serum PTHrP), and parenchymal brain metastasis.

- PSA is most commonly undetectable (or levels are low/declining) despite evidence of rapid disease progression. Serum chromogranin A and urine serotonin metabolites may be detectable but are not necessary for diagnosis.
- These tumors are invariably unresponsive to hormonal manipulations but are transiently sensitive to radiation therapy and chemotherapy, including platinum-etoposide combinations or platinum-taxane combinations.

Conclusion

With more drugs at our fingertips for the treatment of CRPC than ever before and an increasing number of novel therapeutic targets being discovered every day, we are still left with several challenges and unanswered questions. First we must determine how these approved and experimental therapies should ideally be sequenced in individual patients with CRPC to maximize the therapeutic benefit. Second, we need to develop strategies to combine these drugs optimally in a rational manner, taking advantage of our understanding of negative feedback loops and alternative pathway activation to overcome resistance to monotherapies. Only prospective trials incorporating biomarker-driven hypotheses will ultimately be able to address these key clinical questions. Thus the collection of tumor biopsy specimens or correlative samples may be essential in identifying novel targets or developing enrichment strategies moving forward. Third, we must design smarter trials with the goal of quickly yet reliably identifying agents that do not hold promise, while enabling those that do to move swiftly to registrational studies. Finally we must select our patients more carefully based on clinical or molecular characteristics (e.g., AR-V7, DNA repair mutations) so as to identify the subset most likely to benefit from a particular therapy. Meanwhile several active agents are currently in phase III development, and some of these therapies are also likely to further expand our therapeutic arsenal in the near future for men with mCRPC.

Suggested Readings

Antonarakis ES, Eisenberger MA. Expanding treatment options for metastatic prostate cancer. *N Engl J Med*. 2011;364:2053–2056.

Armstrong AJ, Eisenberger M, Halabi S, et al. Biomarkers in the management and treatment of men with metastatic castration-resistant prostate cancer. *Eur Urol*. 2012;61:549–559.

Cha E, Fong L. Immunotherapy for prostate cancer: biology and therapeutic approaches. *J Clin Oncol*. 2011;29:3677–3685.

Christenson ES, Antonarakis ES. PARP inhibitors for homologous recombination-deficient prostate cancer. *Expert Opin Emerg Drugs*. 2018;23(2):123–133.

de Bono JS, Logothetis CJ, Molina A, et al. Improved survival from metastatic prostate cancer with abiraterone acetate. *N Engl J Med*. 2011;364:1995–2005.

de Bono JS, Oudard S, Ozguroglu M, et al. Prednisone plus cabazitaxel or mitoxantrone for metastatic castration-resistant prostate cancer progressing after docetaxel treatment: a randomised open-label trial. *Lancet*. 2010;376:1147–1154.

Drake CG. Prostate cancer as a model for tumour immunotherapy. *Nat Rev Immunol*. 2010;10:580–593.

Fizazi K, Carducci M, Smith M, et al. Denosumab versus zoledronic acid for treatment of bone metastases in men with castration-resistant prostate cancer: a randomized double-blind study. *Lancet*. 2011;377:813–822.

Hussain M, Fizazi K, Saad F, et al. Enzalutamide in men with nonmetastatic, castration-resistant prostate cancer. *N Engl J Med*. 2018;378(26):2465–2474.

Kantoff PW, Higano CS, Shore ND, et al. Sipuleucel-T immunotherapy for castration-resistant prostate cancer. *N*

Engl J Med. 2010;363:411–422.

Le DT, Durham JN, Smith KN, et al. Mismatch repair deficiency predicts response of solid tumors to PD-1 blockade. *Science*. 2017;357:409–413.

Mateo J, Carreira S, Sandhu S, et al. DNA-repair defects and olaparib in metastatic prostate cancer. *N Engl J Med*. 2015;373:1697–1708.

Parker C, Nilsson S, Heinrich D, et al. Alpha emitter radium-223 and survival in metastatic prostate cancer. *N Engl J Med*. 2013;369:213–223.

Petrylak DP, Tangen CM, Hussain MH, et al. Docetaxel and estramustine compared with mitoxantrone and prednisone for advanced refractory prostate cancer. *N Engl J Med*. 2004;351:1513–1520.

Rubin MA, Maher CA, Chinnaiyan AM. Common gene rearrangements in prostate cancer. *J Clin Oncol*. 2011;29:3659–3668.

Ryan CJ, Smith MR, de Bono JS, et al. Abiraterone in metastatic prostate cancer without previous chemotherapy. *N Engl J Med*. 2013;368:138–148.

Ryan CJ, Tindall DJ. Androgen receptor rediscovered: the new biology and targeting the androgen receptor therapeutically. *J Clin Oncol*. 2011;29:3651–3658.

Sartor O, de Bono JS. Metastatic prostate cancer. *N Engl J Med*. 2018;378(7):645–657.

Scher HI, Fizazi K, Saad F, et al. Increased survival with enzalutamide in prostate cancer after chemotherapy. *N Engl J Med*. 2012;367:1187–1197.

Scher HI, Halabi S, Tannock I, et al. Design and end points of clinical trials for patients with progressive prostate cancer and castrate levels of testosterone: recommendations of the Prostate Cancer Clinical Trials Working Group. *J Clin Oncol*. 2008;26:1148–1159.

Scher HI, Lu D, Schreiber NA, et al. Association of AR-V7 on circulating tumor cells as a treatment-specific biomarker with outcomes and survival in castration-resistant prostate cancer. *JAMA Oncol*. 2016;2:1441–1449.

Scher HI, Morris MJ, Basch E, et al. End points and outcomes in castration-resistant prostate cancer: from clinical trials to clinical practice. *J Clin Oncol*. 2011;29:3695–3704.

Seruga B, Tannock IF. Chemotherapy-based treatment for castration-resistant prostate cancer. *J Clin Oncol*. 2011;29:3686–3694.

Smith MR, Saad F, Chowdhury S, et al. Apalutamide treatment and metastasis-free survival in prostate cancer. *N Engl J Med*. 2018;378(15):1408–1418.

Tannock I, DeWit R, Berry W, et al. Docetaxel plus prednisone or mitoxantrone plus prednisone for advanced prostate cancer. *N Engl J Med*. 2004;351:1502–1512.

Tannock I, Osoba D, Stockler MR, et al. Chemotherapy with mitoxantrone plus prednisone or prednisone alone for symptomatic hormone-resistant prostate cancer: a Canadian randomized trial with palliative endpoints. *J Clin Oncol*. 1996;14:1753–1755.

References

Amato RJ, Jac J, Mohammad T, et al. Pilot study of rapamycin in patients with hormone-refractory prostate cancer. *Clin Genitourin Cancer*. 2008;6:97–102.

Ang JE, Olmos D, de Bono JS. CYP17 blockade by abiraterone: further evidence for frequent continued hormone-dependence in castration-resistant prostate cancer. *Br J Cancer*. 2009;100:671–675.

Antonarakis ES, Armstrong AJ, Dehm SM, et al. Androgen receptor variant-driven prostate cancer: clinical implications and therapeutic targeting. *Prostate Cancer Prostatic Dis*. 2016;19:231–241.

Antonarakis ES, Eisenberger MA. Phase III trials with docetaxel-based combinations for metastatic castration-resistant prostate cancer: time to learn from past experiences. *J Clin Oncol*. 2013;31:1709–1712.

Antonarakis ES, Kibel AS, Adams G, et al. A randomized phase II study evaluating the optimal sequencing of sipuleucel-T and androgen deprivation therapy (ADT) in biochemically-recurrent prostate cancer. *J Clin Oncol*. 2013;31(Suppl) [abstract 5016].

Antonarakis ES, Lu C, Luber B, et al. Androgen receptor splice variant 7 and efficacy of taxane chemotherapy in patients with metastatic castration-resistant prostate cancer. *JAMA Oncol*. 2015;1:582–591.

Antonarakis ES, Lu C, Luber B, et al. Clinical Significance of Androgen Receptor Splice Variant-7 mRNA Detection in circulating tumor cells of men with metastatic castration-resistant prostate cancer treated with first- and second-line abiraterone and enzalutamide. *J Clin Oncol*. 2017;35(19):2149–2156.

Antonarakis ES, Lu C, Wang H, et al. AR-V7 and resistance to enzalutamide and abiraterone in prostate cancer. *N Engl J Med*. 2014;371:1028–1038.

Aparicio A, Xiao L, Tapia ELN, et al. The aggressive variant prostate carcinoma molecular signature and platinum-sensitivity in castration resistant prostate cancer. *J Clin Oncol*. 2017;35(15_suppl) [abstract 5013].

Aparicio AM, Harzstark AL, Corn PG, et al. Platinum-based chemotherapy for variant castrate-resistant prostate cancer. *Clin Cancer Res*. 2013;19:3621–3630.

Aparicio AM, Shen L, Tapia EL, et al. Combined tumor suppressor defects characterize clinically defined aggressive variant prostate cancers. *Clin Cancer Res*. 2016;22(6):1520–1530.

Armstrong AJ, Garrett-Mayer ES, Yang YC, et al. A contemporary prognostic nomogram for men with hormone-refractory metastatic prostate cancer: a TAX327 study analysis. *Clin Cancer Res*. 2007;13:6396–6403.

Armstrong AJ, Shen T, Halabi S, et al. A phase II trial of temsirolimus in men with castration-resistant metastatic prostate cancer. *Clin Genitourin Cancer*. 2013;11:397–406.

Attard G, Greystoke A, Kaye S, et al. Update on tubulin-binding agents. *Pathol Biol*. 2006;54:72–84.

Attard G, Reid AH, Yap TA, et al. Phase I clinical trial of a selective inhibitor of CYP17, abiraterone acetate, confirms that castration-resistant prostate cancer commonly remains hormone driven. *J Clin Oncol*. 2008;26:4563–4571.

Basch E, Autio K, Ryan CJ, et al. Abiraterone acetate plus prednisone versus prednisone alone in chemotherapy-naive men with metastatic castration-resistant prostate cancer: patient-reported outcomes from a randomised phase 3 trial. *Lancet Oncol*. 2013;14:1193–1199.

Beer TM, Armstrong AJ, Sternberg CN, et al. Enzalutamide in men with chemotherapy-naïve metastatic prostate cancer (mCRPC): results of the phase 3 PREVAIL study. *J Clin Oncol*. 2014;32(Suppl) [abstract 1].

Beer TM, Hotte SJ, Saad F, et al. Custirsen (OGX-011) combined with cabazitaxel and prednisone versus cabazitaxel and prednisone alone in patients with metastatic castration-resistant prostate cancer previously treated with docetaxel (AFFINITY): a randomised, open-label, international, phase 3 trial. *Lancet Oncol*. 2017;18(11):1532–1542.

Beer TM, Kwon ED, Drake CG, et al. Randomized, double-blind, phase iii trial of ipilimumab versus placebo in asymptomatic or minimally symptomatic patients with metastatic chemotherapy-naive castration-resistant prostate cancer. *J Clin Oncol*. 2017;35(1):40–47.

Beer TM. Advances in systemic therapy for prostate cancer: chemotherapy for androgen-independent prostate cancer. *Proc Am Soc Clin Oncol*. 2004;23:225–232.

Bennett CL, Silver SM, Djulbegovic B, et al. Venous thromboembolism and mortality associated with recombinant erythropoietin and darbepoetin administration for the treatment of cancer-associated anemia. *J Am Med Assoc*. 2008;299:914–924.

Berges R, Vukanovic J, Epstein J, et al. Implications of cell kinetic changes during the progression of human prostatic cancer. *Clin Cancer Res*. 1995;1:473–480.

Berry S, Waldron T, Winquist E, et al. The use of bisphosphonates in men with hormone-refractory prostate cancer: a systematic review of randomized trials. *Can J Urol*. 2006;13:3180–3188.

Blattman JN, Antia R, Sourdive DJ, et al. Estimating the precursor frequency of naïve antigen-specific CD8 T cells. *J Exp Med*. 2002;195:657–664.

Brown JM, Corey E, Lee ZD, et al. Osteoprotegerin and rank ligand expression in prostate cancer. *Urology*. 2001;57:611–616.

Bubley GJ, Carducci M, Dahut W, et al. Eligibility and response guidelines for phase II clinical trials in androgen independent prostate cancer: recommendations from the Prostate-Specific Antigen Working Group. *J Clin Oncol*. 1999;17:3461–3467.

Burris H, Rodon J, Sharma S, et al. First-in-human phase I study of the oral PI3K inhibitor BEZ235 in patients with advanced solid tumors. *J Clin Oncol*. 2010;28(Suppl) [Abstract 3005].

Carver BS, Chapinski C, Wongvipat J, et al. Reciprocal feedback regulation of PI3K and androgen receptor signaling in PTEN-deficient prostate cancer. *Cancer Cell*. 2011;19:575–586.

Chee KG, Longmate J, Quinn DI, et al. The AKT inhibitor perifosine in biochemically recurrent prostate cancer: a phase II California/Pittsburgh cancer consortium trial. *Clin Genitourin Cancer*. 2007;5:433–437.

Chen Y, Clegg NJ, Scher HI. Anti-androgens and androgen-depleting therapies in prostate cancer: new agents for an established target. *Lancet Oncol*. 2009;10:981–991.

Chi KN, Higano CS, Blumenstein B, et al. Custirsen in combination with docetaxel and prednisone for patients with metastatic castration-resistant prostate cancer (SYNERGY trial): a phase 3, multicentre, open-label, randomised trial. *Lancet Oncol*. 2017;18(4):473–485.

Chi KN, Hotte SJ, Yu EY, et al. Randomized phase II study of docetaxel and prednisone with or without OGX-011 in patients with metastatic castration-resistant prostate cancer. *J Clin Oncol*. 2010;28:4247–4254.

Christenson ES, Antonarakis ES. PARP inhibitors for homologous recombination-deficient prostate cancer. *Expert Opin Emerg Drugs*. 2018;23(2):123–133.

Clegg NJ, Wongvipat J, Joseph JD, et al. ARN-509: a novel antiandrogen for prostate cancer treatment. *Cancer Res*. 2012;72:1494–1503.

Courtney KD, Corcoran RB, Engelman JA. The PI3K pathway as drug target in human cancer. *J Clin Oncol*. 2010;28:1075–1083.

Crawford E, Eisenberger M, McLeod D, et al. A controlled randomized trial of leuprolide with and without flutamide in prostatic cancer. *N Engl J Med*. 1989;321:419–424.

D'Amico A, Moul J, Carroll PR, et al. Surrogate end point for prostate cancer specific mortality in patients with nonmetastatic hormone refractory prostate cancer. *J Urol*. 2005;173:1572–1576.

Dancey J. mTOR signaling and drug development in cancer. *Nat Rev Clin Oncol*. 2010;7:209–219.

Danila DC, Morris MJ, de Bono JS, et al. Phase II multicenter study of abiraterone acetate plus prednisone therapy in patients with docetaxel-treated castration-resistant prostate cancer. *J Clin Oncol*. 2010;28:1496–1501.

Darshan MS, Loftus MS, Thadani-Mulero M, et al. Taxane-induced blockade to nuclear accumulation of the androgen receptor predicts clinical responses in metastatic prostate cancer. *Cancer Res*. 2011;71:6019–6029.

de Bono JS, De Giorgi U, Nava Rodrigues D, et al. Randomized phase II study of Akt blockade with or without ipatasertib in abiraterone-treated patients with metastatic prostate cancer with and without PTEN loss. *Clin Cancer Res*. 2019;25(3):928–936.

de Bono JS, Logothetis CJ, Molina A, et al. Improved survival from metastatic prostate cancer with abiraterone acetate. *N Engl J Med*. 2011;364:1995–2005.

de Bono JS, Oudard S, Ozguroglu M, et al. Prednisone plus cabazitaxel or mitoxantrone for metastatic castration-resistant prostate cancer progressing after docetaxel treatment: a randomised open-label trial. *Lancet*. 2010;376:1147–1154.

de Bono JS, Scher HI, Montgomery RB, et al. Circulating tumor cells predict survival benefit from treatment in metastatic castration-resistant prostate cancer. *Clin Cancer Res*. 2008;14:6302–6309.

Debes JD, Tindall DJ. Mechanisms of androgen-refractory prostate cancer. *N Engl J Med*. 2004;351:1488–1490.

Denis L, Carneiro de Moura JL, Bono A, et al. Goserelin acetate and flutamide versus bilateral orchiectomy: a phase III EORTC study (30853). *Urology*. 1993;42:119–130.

Dillard T, Yedinak CG, Alumkal J, et al. Anti–CTLA-4 antibody therapy associated autoimmune hypophysitis: serious immune related adverse events across a spectrum of cancer subtypes. *Pituitary*. 2010;13:29–38.

diSant'Agnese P. Neuroendocrine differentiation in prostatic carcinoma: recent findings and new concepts. *Cancer*. 1995;75:1850–1859.

Djakiew D, Delsite R, Pflug B, et al. Regulation of growth factor–like protein which modulates paracrine interactions between a neoplastic epithelial cell line and stromal cells of the human prostate. *Cancer Res*. 1991;51:3304–3310.

Dotan ZA, Bianco FJ, Rabbani F, et al. Pattern of PSA failure dictates the probability of a positive bone scan in patients with increasing serum PSAs after radical prostatectomy. *J Clin Oncol*. 2005;23:1962–1968.

Drake CG, Jaffee E, Pardoll DM. Mechanisms of immune evasion by tumors. *Adv Immunol*. 2006;90:51–81.

Drake CG, Kwon ED, Fizazi K, et al. Results of subset analyses on overall survival (OS) from study CA184-043: ipilimumab versus placebo in post-docetaxel metastatic castration-resistant prostate cancer (mCRPC). *J Clin Oncol*. 2014;32(Suppl) [abstract 2].

Drake CG. Prostate cancer as a model for tumour immunotherapy. *Nat Rev Immunol*. 2010;10:580–593.

Dreicer R, Jones R, Oudard S, et al. Results from a phase 3, randomized, double-blind, multicenter, placebo-controlled trial of orteronel (TAK-700) plus prednisone in patients with metastatic castration-resistant prostate cancer that has progressed during or following docetaxel-based therapy (ELM-PC5 trial). *J Clin Oncol*. 2014;32(Suppl) [abstract 7].

Duran I, Montagut C, Calvo E, et al. Overcoming docetaxel resistance in advanced castration-resistant prostate cancer (CRPC): a phase I/II trial of the combination of temsirolimus and docetaxel. *J Clin Oncol*. 2012;30(Suppl) [abstract 250].

Eisenberger M, Hardy-Bessard AC, Kim CS, et al. Phase III study comparing a reduced dose of cabazitaxel (20 mg/m2) and the currently approved dose (25 mg/m2) in postdocetaxel patients with metastatic castration-resistant prostate cancer-PROSELICA. *J Clin Oncol*. 2017;35(28):3198–3206.

Eisenberger MA, Blumenstein BA, Crawford ED, et al. Bilateral orchiectomy with or without flutamide in metastatic prostate cancer. *N Engl J Med*. 1998;339:1036–1042.

Eisenberger MA, Crawford E, McLeod D, et al. The prognostic significance of prostate specific antigen in stage D2 prostate cancer: interim evaluation of Intergroup 0105. *Proc Am Soc Clin Oncol*. 1995;14 [abstract 613].

Eisenberger MA, Nelson WG. How much can we rely on PSA as an endpoint for clinical trials in prostate cancer? a word of caution. *J Natl Cancer Inst*. 1996;88:779–780.

Eisenberger MA. Chemotherapy for prostate carcinoma. *NCI Monogr*. 1988;7:151–163.

Engelman JA. Targeting PI3K signaling in cancer: opportunities, challenges and limitations. *Nat Rev Cancer*. 2009;9:550–562.

Farmer H, McCabe N, Lord CJ, et al. Targeting the DNA repair defect in BRCA mutant cells as a therapeutic strategy. *Nature*. 2005;434:917–921.

Feldman BJ, Feldman D. The development of androgen independent prostate cancer. *Nat Rev Cancer*. 2001;1:34–45.

Ferrer FA, Miller LJ, Andrawis RI, et al. Vascular endothelial growth factor (VEGF) expression in human prostate cancer: in situ and in vitro expression of VEGF by human prostate cancer cells. *J Urol*. 1997;157:2329–2333.

Ferrer FA, Miller LJ, Lindquist R, et al. Expression of vascular endothelial growth factor receptors in human prostate cancer. *Urology*. 1999;54:567–572.

Fizazi K, Carducci M, Smith M, et al. Denosumab versus zoledronic acid for treatment of bone metastases in men with castration-resistant prostate cancer: a randomized double-blind study. *Lancet*. 2011;377:813–822.

Fizazi K, Lipton A, Mariette X, et al. Randomized phase II trial of denosumab in patients with bone metastases from prostate cancer, breast cancer, or other neoplasms after intravenous bisphosphonates. *J Clin Oncol*. 2009;27:1564–1571.

Fizazi K, Scher HI, Molina A, et al. Abiraterone acetate for treatment of metastatic castration-resistant prostate cancer: final overall survival analysis of the COU-AA-301 randomised, double-blind, placebo-controlled phase 3 study. *Lancet Oncol*. 2012;13:983–992.

Fong L, Kwek SS, O'Brien S, et al. Potentiating endogenous antitumor immunity to prostate cancer through combination immunotherapy with CTLA4 blockade and GM-CSF. *Cancer Res*. 2009;69:609–615.

Fowler J Jr, Whitmore W Jr. The response of metastatic adenocarcinoma of the prostate to exogenous testosterone. *J Urol*. 1981;126:372–375.

Frank S, Amsterdam A, Kelly W, et al. Platinum-based chemotherapy for patients with poorly differentiated hormone-refractory prostate cancer: response and pathologic considerations. *Proc Am Soc Clin Oncol*. 1995;14:232.

Friedland D, Cohen J, Miller R, et al. A phase II trial of docetaxel (Taxotere) in hormone refractory prostate cancer: correlation of antitumor effect to phosphorylation of Bcl-2. *Semin Oncol*. 1999;26:19–23.

Gabriel K, Schiff D. Metastatic spinal cord compression by solid tumors. *Semin Neurol*. 2004;24:375–383.

Galasko C. Mechanisms of bone destruction in the development of skeletal metastasis. *Nature*. 1986;263:507–508.

Gelmann EP. Molecular biology of the androgen receptor. *J Clin Oncol*. 2002;20:3001–3015.

Gleave M, Miyake H. Use of antisense oligonucleotides targeting the cytoprotective gene, clusterin, to enhance androgen- and chemo-sensitivity in prostate cancer. *World J Urol*. 2005;23:38–46.

Graff JN, Alumkal JJ, Drake CG, et al. Early evidence of anti-PD-1 activity in enzalutamide-resistant prostate cancer. *Oncotarget*. 2016;7:52810–52817.

Green JR, Rogers MJ. Pharmacologic profile of zoledronic acid: a highly potent inhibitor of bone resorption. *Drug Dev Res*. 2002;55:210–224.

Grossman S, Lossignol D. Diagnosis and treatment of epidural metastasis. *Oncology*. 1990;4:47–54.

Grunwald V, DeGraffenried L, Russel D, et al. Inhibitors of mTOR reverse doxorubicin resistance conferred by PTEN status in prostate cancer cells. *Cancer Res*. 2002;62:6141–6145.

Gulley JL, Borre M, Vogelzang NJ, et al. Results of PROSPECT: a randomized phase 3 trial of PROSTVAC-V/F (PRO) in men with asymptomatic or minimally symptomatic metastatic, castration-resistant prostate cancer. *J Clin Oncol*. 2018;36(15_suppl) [abstract 5006].

Halabi S, Armstrong AJ, Sartor O, et al. Prostate-specific antigen changes as surrogate for overall survival in men with metastatic castration-resistant prostate cancer treated with second-line chemotherapy. *J Clin Oncol*. 2013;31:3944–3950.

Halabi S, Lin CY, Small EJ, et al. Prognostic model predicting metastatic castration-resistant prostate cancer survival in men treated with second-line chemotherapy. *J Natl Cancer Inst*. 2013;105:1729–1737.

Halabi S, Small EJ, Kantoff PW, et al. Prognostic model for predicting survival in men with hormone refractory metastatic prostate cancer. *J Clin Oncol*. 2003;22:1232–1237.

Harzstark AL, Small EJ. Immunotherapeutics in development for prostate cancer. *Oncologist*. 2009;14:391–398.

Henriksen G, Fisher DR, Roeske JC, et al. Targeting of osseous sites with alpha-emitting ^{223}Ra: comparison with the beta-emitter ^{89}Sr in mice. *J Nucl Med*. 2003;44:252–259.

Higano CS, Schellhammer PF, Small EJ, et al. Integrated data from 2 randomized, double-blind, placebo-controlled, phase 3 trials of active cellular immunotherapy with sipuleucel-T in advanced prostate cancer. *Cancer*. 2009;115:3670–3679.

Hodi FS. Cytotoxic T-lymphocyte-associated antigen-4. *Clin Cancer Res*. 2007;13:5238–5242.

Hofer DR, Sherwood ER, Bromberg WD, et al. Autonomous growth of androgen independent human prostatic carcinoma cells: role of transforming growth factor-α. *Cancer Res*. 1995;51:2780–2785.

Hoos A, Eggermont AM, Janetzki S, et al. Improved endpoints for cancer immunotherapy trials. *J Natl Cancer Inst*. 2010;102:1388–1397.

Hussain M, Fizazi K, Saad F, et al. Enzalutamide in men with nonmetastatic, castration-resistant prostate cancer. *N Engl J Med*. 2018;378(26):2465–2474.

Hussain M, Wolf M, Marshall E, et al. Effects of continued androgen deprivation therapy and other prognostic factors on response and survival in phase-II chemotherapy trials for hormone-refractory prostate cancer. *J Clin Oncol*. 1994;12:1868–1875.

Isaacs JT, Lundmo PI, Berges R, et al. Androgen regulation of programmed cell death of normal and malignant prostatic cells. *J Androl*. 1992;13:457–464.

Isaacs JT. The long and winding road for the development of tasquinimod as an oral second-generation quinolone-3-carboxamide antiangiogenic drug for the treatment of prostate cancer. *Expert Opin Investig Drugs*. 2010;19:1235–1243.

Jager PL, Kooistra A, Piers DA. Treatment with radioactive ^{89}strontium for patients with bone metastases from prostate cancer. *BJU Int*. 2000;86:929–934.

Jeffers M, Schmidt L, Nakaigawa N, et al. Activating mutations for the met tyrosine kinase receptor in human cancer. *Proc Natl Acad Sci USA*. 1997;94:445–450.

July LV, Akbari M, Zellweger T, et al. Clusterin expression is significantly enhanced in prostate cancer cells following androgen withdrawal therapy. *Prostate*. 2002;50:179–188.

Kantoff PW, Halabi S, Conaway M, et al. Hydrocortisone with or without mitoxantrone in men with hormone-refractory prostate cancer: results of the cancer and leukemia group B 9182 study. *J Clin Oncol*. 1999;17:2506–2513.

Kantoff PW, Higano CS, Shore ND, et al. Sipuleucel-T immunotherapy for castration-resistant prostate cancer. *N Engl J Med*. 2010;363:411–422.

Kantoff PW, Schuetz TJ, Blumenstein BA, et al. Overall survival analysis of a phase II randomized controlled trial of a poxviral-based PSA-targeted immunotherapy in metastatic castration-resistant prostate cancer. *J Clin Oncol*. 2010;28:1099–1105.

Kaplan P, Mohan S, Cohen P, et al. The insulin-like growth factor axis and prostate cancer: lessons from the transgenic adenocarcinoma of mouse prostate model. *Cancer Res*. 1999;59:2203–2209.

Kelly WK, Halabi S, Carducci M, et al. Randomized, double-blind, placebo-controlled phase III trial comparing docetaxel and prednisone with or without bevacizumab in men with metastatic castration-resistant prostate cancer. *J Clin Oncol*. 2012;30:1534–1540.

Knudsen BS, Edlund M. Prostate cancer and the met hepatocyte growth factor receptor. *Adv Cancer Res*. 2004;91:31–67.

Knudsen BS, Gmyrek GA, Inra J, et al. High expression of the Met receptor in prostate cancer metastasis to bone. *Urology*. 2002;60:1113–1117.

Kurzrock R, Sherman SI, Ball DW, et al. Activity of XL184 (cabozantinib), an oral tyrosine kinase inhibitor, in patients with medullary thyroid cancer. *J Clin Oncol*. 2011;29:2660–2666.

Kwon ED, Foster BA, Hurwitz AA, et al. Elimination of residual metastatic prostate cancer after surgery and adjunctive cytotoxic T lymphocyte-associated antigen 4 (CTLA-4) blockade immunotherapy. *Proc Natl Acad Sci USA*. 1999;96:15074–15079.

Larocca RV, Danesi R, Cooper MR, et al. Effect of suramin on human prostate cancer cells in vitro. *J Urol*. 1991;145:393–398.

Le DT, Durham JN, Smith KN, et al. Mismatch repair deficiency predicts response of solid tumors to PD-1 blockade. *Science*. 2017;357:409–413.

Lee C. Role of androgen in prostate growth and regression: stromal-epithelial interaction. *Prostate*. 1996;6:52–56.

Leuprolide Study Group. Leuprolide versus diethylstilbestrol for metastatic prostate cancer. *N Engl J Med*. 1984;311:1281–

1289.

Logothetis CJ, Basch E, Molina A, et al. Effect of abiraterone acetate and prednisone compared with placebo and prednisone on pain control and skeletal-related events in patients with metastatic castration-resistant prostate cancer: exploratory analysis of data from the COU-AA-301 randomised trial. *Lancet Oncol*. 2012;13:1210–1217.

Madan RA, Arlen PM, Mohebtash M, et al. ProstVac-VF: a vector-based vaccine targeting PSA in prostate cancer. *Expert Opin Investig Drugs*. 2009;18:1001–1011.

Madan RA, Gulley JL, Schlom J, et al. Analysis of overall survival in patients with nonmetastatic castration-resistant prostate cancer treated with vaccine, nilutamide, and combination therapy. *Clin Cancer Res*. 2008;14:4526–4531.

Maira SM, Stauffer F, Brueggen J, et al. Identification and characterization of BEZ235, a new orally available dual phosphatidylinositol 3-kinase/mammalian target of rapamycin inhibitor with potent in vivo antitumor activity. *Mol Cancer Ther*. 2008;7:1851–1863.

Manni A, Bartholomew M, Caplan R. Androgen priming and chemotherapy in advanced prostate cancer: determinants of clinical outcome. *J Clin Oncol*. 1988;6:1456–1466.

Mapara MY, Sykes M. Tolerance and cancer: mechanisms of tumor evasion and strategies for breaking tolerance. *J Clin Oncol*. 2004;22:1136–1151.

Mateo J, Carreira S, Sandhu S, et al. DNA-repair defects and olaparib in metastatic prostate cancer. *N Engl J Med*. 2015;373:1697–1708.

Michaelson MD, Oudard S, Ou YC, et al. Randomized, placebo-controlled, phase III trial of sunitinib plus prednisone versus prednisone alone in progressive, metastatic, castration-resistant prostate cancer. *J Clin Oncol*. 2014;32:76–82.

Mita AC, Denis LJ, Rowinsky EK, et al. Phase I and pharmacokinetic study of XRP6258 (RPR 116258A), a novel taxane, administered as a 1-hour infusion every 3 weeks in patients with advanced solid tumors. *Clin Cancer Res*. 2009;15:723–730.

Miyake H, Nelson C, Rennie PS, et al. Acquisition of chemoresistant phenotype by overexpression of the antiapoptotic gene testosterone-repressed prostate message-2 in prostate cancer xenograft models. *Cancer Res*. 2000;60:2547–2554.

Mohler JL, Armstrong AJ, Bahnson RR, et al. Prostate cancer, Version 1.2016. *J Natl Compr Canc Netw*. 2016;14(1):19–30.

Moore M, Osoba D, Murphy K, et al. Use of palliative endpoints to evaluate the effects of mitoxantrone and low-dose prednisone in patients with hormonally resistant prostate cancer. *J Clin Oncol*. 1994;12:689–694.

Mostaghel EA, Page ST, Lin DW, et al. Intraprostatic androgens and androgen-regulated gene expression persist after testosterone suppression: therapeutic implications for castration-resistant prostate cancer. *Cancer Res*. 2007;67:5033–5041.

Nakabayashi M, Werner L, Courtney KD, et al. Phase II trial of RAD001 and bicalutamide for castration-resistant prostate cancer. *BJU Int*. 2012;110:1729–1735.

Nelson EC, Cambio AJ, Yang JC, et al. Clinical implications of neuroendocrine differentiation in prostate cancer. *Prostate Cancer Prostatic Dis*. 2007;10:6–14.

Nelson WG, DeMarzo AM, Isaacs WB. Prostate cancer. *N Engl J Med*. 2003;349:366–381.

Nilsson S, Franzen L, Parker C, et al. Bone-targeted radium-223 in symptomatic, hormone-refractory prostate cancer: a randomised, multicentre, placebo-controlled phase II study. *Lancet Oncol*. 2007;8:587–594.

Nilsson S, Larsen RH, Fossa SD, et al. First clinical experience with alpha-emitting radium-223 in the treatment of skeletal metastases. *Clin Cancer Res*. 2005;11:4451–4459.

Nilsson S, Strang P, Aksnes AK, et al. A randomized, dose-response, multicenter phase II study of radium-223 chloride for the palliation of painful bone metastases in patients with castration-resistant prostate cancer. *Eur J Cancer*. 2012;48:678–686.

Osborne C, Drelichman A, Von Hoff D, et al. Mitoxantrone: modest activity in a phase II trial in advanced prostate cancer. *Cancer Treat Rep*. 1983;67:1133–1135.

Oudard S, Fizazi K, Sengeløv L, et al. Cabazitaxel versus docetaxel as first-line therapy for patients with metastatic castration-resistant prostate cancer: a randomized Phase III trial-FIRSTANA. *J Clin Oncol*. 2017;35(28):3189–3197.

2017. *KEYTRUDA (pembrolizumab), package insert*. [Whitehouse Station, NJ; Merck & Co. (website)] https://www.accessdata.fda.gov/drugsatfda_docs/label/2017/1 2017.

Paller CJ, Antonarakis ES. Cabazitaxel: a novel second-line treatment for metastatic castration-resistant prostate cancer. *Drug Des Devel Ther*. 2011;5:117–124.

Pandit-Taskar N, Batraki M, Divgi CR. Radiopharmaceutical therapy for palliation of bone pain from osseous metastases. *J Nucl Med*. 2004;45:1358–1365.

Papandreou CN, Daliani DD, Thall PF, et al. Results of a phase II study with doxorubicin, etoposide, and cisplatin in patients with fully characterized small-cell carcinoma of the prostate. *J Clin Oncol*. 2002;20:3072–3080.

Parker C, Nilsson S, Heinrich D, et al. Alpha emitter radium-223 and survival in metastatic prostate cancer. *N Engl J Med*. 2013;369:213–223.

Parker C, Pascoe S, Chodacki A, et al. A randomized, double-blind, dose-finding, multicenter, phase 2 study of radium chloride (Ra-223) in patients with bone metastases and castration-resistant prostate cancer. *Eur Urol*. 2013;63:189–197.

Patchell RA, Tibbs PA, Regine WF, et al. Direct decompressive surgical resection in the treatment of spinal cord compression caused by metastatic cancer: a randomized trial. *Lancet*. 2005;366:643–648.

Peters S, Adjei AA. MET: a promising anticancer therapeutic target. *Nat Rev Clin Oncol*. 2012;9:314–326.

Petrylak DP, Tangen CM, Hussain MH, et al. Docetaxel and estramustine compared with mitoxantrone and prednisone for advanced refractory prostate cancer. *N Engl J Med*. 2004;351:1513–1520.

Picus J, Schultz M. Docetaxel (Taxotere) as monotherapy in treatment of hormone-refractory prostate cancer: preliminary results. *Semin Oncol*. 1999;26(Suppl 17):14–18.

Pili R, Haggman M, Stadler WM, et al. Phase II randomized, double-blind, placebo-controlled study of tasquinimod in men with minimally symptomatic metastatic castrate-resistant prostate cancer. *J Clin Oncol*. 2011;29:4022–4028.

Pomerantz MM, Spisák S, Jia L, et al. The association between germline BRCA2 variants and sensitivity to platinum-based chemotherapy among men with metastatic prostate cancer. *Cancer*. 2017;123(18):3532–3539.

Porter AT, McEwan AJ, Powe JE, et al. Results of a randomized phase III trial to evaluate the efficacy of strontium-89 adjuvant to local field external beam irradiation in the management of endocrine resistant metastatic prostate cancer. *Int J Radiat Oncol Biol Phys*. 1993;25:805–813.

Posadas EM, Gulley J, Arlen PM, et al. A phase II study of perifosine in androgen independent prostate cancer. *Cancer Biol Ther*. 2005;4:1133–1137.

Rathkopf DE, Morris MJ, Fox JJ, et al. Phase I study of ARN-

509, a novel antiandrogen, in the treatment of castration-resistant prostate cancer. *J Clin Oncol*. 2013;31:3525–3530.

Rathkopf DE, Shore N, Antonarakis ES, et al. A phase II study of the androgen signaling inhibitor ARN-509 in patients with castration-resistant prostate cancer (CRPC). *J Clin Oncol*. 2012;30(Suppl) [abstract TPS4697].

Rearden T, Small E, Valone F, et al. Phase II study of mitoxantrone for hormone refractory prostate cancer. *Proc Am Soc Clin Oncol*. 1995;14 [abstract 688].

Reddi A, Cunningham N. Bone induction by osteogenic and bone morphogenic proteins. *Biomaterials*. 1990;11:33–34.

Robinson D, Sandblom G, Johansson R, et al. PSA kinetics provide improved prediction of survival in metastatic hormone-refractory prostate cancer. *Urology*. 2008;72:903–907.

Robinson D, Van Allen EM, Wu YM, et al. Integrative clinical genomics of advanced prostate cancer. *Cell*. 2015;161:1215–1228.

Roodman GD. Mechanisms of bone metastasis. *N Engl J Med*. 2004;350:1655–1664.

Ryan CJ, Smith MR, de Bono JS, et al. Abiraterone in metastatic prostate cancer without previous chemotherapy. *N Engl J Med*. 2013;368:138–148.

Ryan CJ, Smith MR, Fizazi K, et al. Abiraterone acetate plus prednisone versus placebo plus prednisone in chemotherapy-naive men with metastatic castration-resistant prostate cancer (COU-AA-302): final overall survival analysis of a randomised, double-blind, placebo-controlled phase 3 study. *Lancet Oncol*. 2015;16(2):152–160.

Ryan CJ, Smith MR, Fong L, et al. Phase I clinical trial of the CYP17 inhibitor abiraterone acetate demonstrating clinical activity in patients with castration-resistant prostate cancer who received prior ketoconazole therapy. *J Clin Oncol*.

2010;28:1481–1488.

Ryan CJ. Secondary hormonal manipulations in prostate cancer. *Hematol Oncol Clin North Am*. 2006;20:925–934.

Saad F, Fizazi K, Jinga V, et al. Orteronel plus prednisone in patients with chemotherapy-naive metastatic castration-resistant prostate cancer (ELM-PC 4): a double-blind, multicentre, phase 3, randomised, placebo-controlled trial. *Lancet Oncol*. 2015;16(3):338–348.

Saad F, Gleason DM, Murray R, et al. Long-term efficacy of zoledronic acid for the prevention of skeletal complications in patients with metastatic hormone-refractory prostate cancer. *J Natl Cancer Inst*. 2004;96:879–882.

Sartor O, Myers C. The influence of aminoglutethimide and corticosteroids on the therapeutic benefits of flutamide withdrawal. *Proc Am Soc Clin Oncol*. 1995;14:245.

Sartor O, Reid RH, Hoskin PJ, et al. Samarium-153–lexidronam complex for treatment of painful bone metastases in hormone-refractory prostate cancer. *Urology*. 2004;63:940–945.

Scagliotti GV, Novello S, von Pawel J. The emerging role of MET/HGF inhibitors in oncology. *Cancer Treat Rev*. 2013;39:793–801.

Scher HI, Eisenberger M, D'Amico AV, et al. Eligibility and outcomes reporting for clinical trials for patients in the state of a rising PSA: recommendations from the Prostate-Specific Antigen Working Group. *J Clin Oncol*. 2004;22:537–556.

Scher HI, Fizazi K, Saad F, et al. Impact of on-study corticosteroid use on efficacy and safety in the phase III AFFIRM study of enzalutamide, an androgen receptor inhibitor. *J Clin Oncol*. 2013;31(Suppl 6) [abstract 6].

Scher HI, Fizazi K, Saad F, et al. Increased survival with enzalutamide in prostate cancer after chemotherapy. *N Engl J Med*. 2012;367:1187–1197.

Scher HI, Halabi S, Tannock I, et al. Design and end points of clinical trials for patients with progressive prostate cancer and castrate levels of testosterone: recommendations of the Prostate Cancer Clinical Trials Working Group. *J Clin Oncol*. 2008;26:1148–1159.

Scher HI, Kelly KW. Flutamide withdrawal syndrome: its impact on clinical trials in hormone refractory prostate cancer. *J Clin Oncol*. 1993;11:1566–1572.

Scher HI, Lu D, Schreiber NA, et al. Association of AR-V7 on circulating tumor cells as a treatment-specific biomarker with outcomes and survival in castration-resistant prostate cancer. *JAMA Oncol*. 2016;2:1441–1449.

Schwarz EM, Ritchlin CT. Clinical development of anti-RANKL therapy. *Arthritis Res Ther*. 2007;9(Suppl):S7.

Seckin B, Anthony CT, Murphy B, et al. Can prostate-specific antigen be used as a valid end point to determine the efficacy of chemotherapy for advanced prostate cancer? *World J Urol*. 1996;14:S26–S29.

Semenza GL. Targeting HIF-1 for cancer therapy. *Nat Rev Cancer*. 2003;3:721–732.

Slovin SF, Higano CS, Hamid O, et al. Ipilimumab alone or in combination with radiotherapy in metastatic castration-resistant prostate cancer: results from an open-label, multicenter phase I/II study. *Ann Oncol*. 2013;24:1813–1821.

Smaletz O, Scher H, Small EJ, et al. Nomogram for survival of patients with progressive metastatic prostate cancer after castration. *J Clin Oncol*. 2002;20:3972–3982.

Small EJ, Halabi S, Dawson NA, et al. Antiandrogen withdrawal alone or in combination with ketoconazole in androgen independent prostate cancer: a phase III trial (CALGB 9583). *J Clin Oncol*. 2004;22:1025–1033.

Small EJ, Schellhammer PF, Higano CS, et al. Placebo-controlled phase III trial of immunologic therapy with sipuleucel-T (APC8015) in patients with metastatic, asymptomatic hormone refractory prostate cancer. *J Clin Oncol*. 2006;24:3089–3094.

Small EJ, Tchekmedyian NS, Rini BI, et al. A pilot trial of CTLA-4 blockade with human anti–CTLA-4 in patients with hormone-refractory prostate cancer. *Clin Cancer Res*. 2007;13:1810–1815.

Smith DC, Smith MR, Sweeney C, et al. Cabozantinib in patients with advanced prostate cancer: results of a phase II randomized discontinuation trial. *J Clin Oncol*. 2013;31:412–419.

Smith M, De Bono J, Sternberg C, et al. Phase III study of cabozantinib in previously treated metastatic castration-resistant prostate cancer: COMET-1. *J Clin Oncol*. 2016;34(25):3005–3013.

Smith MR, Eastham J, Gleason D, et al. Randomized controlled trial of zoledronic acid to prevent bone loss in men receiving androgen deprivation therapy for nonmetastatic prostate cancer. *J Urol*. 2003;169:2008–2012.

Smith MR, Kabbinavar F, Saad F, et al. Natural history of rising serum PSA in men with castrate nonmetastatic prostate cancer. *J Clin Oncol*. 2005;23:2918–2925.

Smith MR, McGovern FJ, Zietman AL, et al. Pamidronate to prevent bone loss during androgen-deprivation therapy for prostate cancer. *N Engl J Med*. 2001;345:948–955.

Smith MR, Saad F, Chowdhury S, et al. Apalutamide treatment and metastasis-free survival in prostate cancer. *N Engl J Med*. 2018;378(15):1408–1418.

Smith PH, Suciu S, Robinson MRG, et al. A comparison of the effect of diethylstilbestrol with low dose estramustine phosphate in the treatment of advanced prostatic cancer: final analysis of a phase III trial of the European Organization for Research on Treatment of Cancer. *J Urol*. 1986;136:619–623.

Sorensen PS, Borgensen SE, Rohde K. Metastatic epidural spinal cord compression: results of treatment and survival. *Cancer*. 1990;65:1502–1510.

Sowery RD, Hadaschik BA, So AI, et al. Clusterin knockdown using the antisense oligonucleotide OGX-011 resensitizes docetaxel-refractory prostate cancer PC-3 cells to chemotherapy. *BJU Int*. 2008;102:389–397.

Steiner MS. Role of peptide growth factors in the prostate. *Urology*. 1993;42:99–110.

Sternberg C, Armstrong A, Pili R, et al. Randomized, double-blind, placebo-controlled Phase III study of tasquinimod in men with metastatic castration-resistant prostate cancer. *J Clin Oncol*. 2016;34(22):2636–2643.

Stigliano A, Gandini O, Cerquetti L, et al. Increased metastatic lymph node 64 and CYP17 expression are associated with high stage prostate cancer. *J Endocrinol*. 2007;194:55–61.

Storlie J, Buckner J, Wiseman G, et al. Prostate specific antigen levels and clinical response to low dose dexamethasone for hormone-refractory metastatic prostate carcinoma. *Cancer*. 1995;76:96–100.

Tannock I, DeWit R, Berry W, et al. Docetaxel plus prednisone or mitoxantrone plus prednisone for advanced prostate cancer. *N Engl J Med*. 2004;351:1502–1512.

Tannock I, Fizazi K, Ivanov S, et al. Aflibercept versus placebo in combination with docetaxel and prednisone for treatment of men with metastatic castration-resistant prostate cancer (VENICE): a phase III, double-blind randomized trial. *Lancet Oncol*. 2013;14:760–768.

Tannock I, Osoba D, Stockler MR, et al. Chemotherapy with mitoxantrone plus prednisone or prednisone alone for symptomatic hormone-resistant prostate cancer: a Canadian randomized trial with palliative endpoints. *J Clin Oncol*. 1996;14:1753–1755.

Taylor BS, Schultz N, Hieronymus H, et al. Integrative genomic profiling of human prostate cancer. *Cancer Cell*. 2010;18:11–22.

Taylor CD, Elson P, Trump DL. Importance of continued testicular suppression in hormone-refractory prostate cancer. *J Clin Oncol*. 1993;11:2167–2172.

Tran C, Ouk S, Clegg NJ, et al. Development of a second-generation antiandrogen for treatment of advanced prostate cancer. *Science*. 2009;324:787–790.

Trusolino L, Bertotti A, Comoglio PM. MET signaling: principles and functions in development, organ regeneration and cancer. *Nat Rev Mol Cell Biol*. 2010;11:834–848.

Van den Wyngaert T, Huizing MT, Fossion E, et al. Bisphosphonates in oncology: rising stars or fallen heroes. *Oncologist*. 2009;14:181–191.

Verras M, Lee J, Xue H, et al. The androgen receptor negatively regulates the expression of c-Met: implications for a novel mechanism of prostate cancer progression. *Cancer Res*. 2007;67:967–975.

Watson PA, Chen YF, Balbas MD, et al. Constitutively active androgen receptor splice variants expressed in castration-resistant prostate cancer require full-length androgen receptor. *Proc Natl Acad Sci USA*. 2010;107:16759–16765.

Webster WS, Small EJ, Rini BI, et al. Prostate cancer immunology: biology, therapeutics, and challenges. *J Clin Oncol*. 2005;23:8262–8269.

Wozney JL, Antonarakis ES. Growth factor and signaling pathways and their relevance to prostate cancer therapeutics. *Cancer Metastasis Rev*. 2014;33(2–3):581–594.

Yap TA, Yan L, Patnaik A, et al. First-in-man clinical trial of the oral pan-AKT inhibitor MK-2206 in patients with advanced solid tumors. *J Clin Oncol*. 2011;29:4688–4695.

Zhu ML, Horbinski CM, Garzotto M, et al. Tubulin-targeting chemotherapy impairs androgen receptor activity in prostate cancer. *Cancer Res*. 2010;70:7992–8002.

Zoubeidi A, Chi K, Gleave M. Targeting the cytoprotective chaperone, clusterin, for treatment of advanced cancer. *Clin Cancer Res*. 2010;16:1088–1093.

Index

Page numbers followed by “*f*” indicate figures, “*t*” indicate tables, “*b*” indicate boxes, and “*e*” indicate online content.

A

AAST, American Association for Surgery of Trauma

Abdomen

- clinical staging of, TGCTs and, 1689, 1689*f*
- exiting of
  - after laparoscopic and robotic surgery, 218–219
  - complications related to, 230
- hostile, 463

Abdominal aorta, 1669, 1669.e1*f*, 1671*f*, 1672*t*

Abdominal distention, 383, 387*b*

Abdominal incisions, in urologic surgery, 135–136

- Gibson incision, 135–136, 138*f*
- midline incision, 135, 136*f*–137*f*
- Pfannestiel incision, 135, 138*f*

Abdominal leak point pressure (ALPP)

- measurement of, 2561–2562, 2562*f*
- for sling procedure, 2833

Abdominal mesh removal, 2887

Abdominal obesity, 1418–1419

Abdominal paravaginal repair, for pelvic organ prolapse, 2780*t*, 2787, 2788*f*

Abdominal pressure, increased, urinary incontinence during, 2516

Abdominal sacrocolpopexy, for apical pelvic organ prolapse repair, 2798–2809
- complications of, 2804, 2806*t*
- cost of, 2809
- laparoscopic
  - comparison with, 2806, 2807*t*
  - *versus* robotic-assisted, 2806–2809, 2808*t*
  - *versus* robotic-assisted colpopexy, 2809
  - technique for, 2802*f*–2803*f*, 2803–2804
- learning curve in, 2809
- open, technique for, 2798–2800, 2800*f*–2801*f*
- results of, 2804–2806, 2805*t*
- robotic-assisted laparoscopic, 2800–2803, 2801*f*–2803*f*

Abdominal sacrohysteropexy, 2822–2823, 2824*t*

Abdominal surgery, operative team placement for
- retroperitoneal procedures, 207, 207*f*
- transperitoneal procedures, 206, 206*f*, 206.e1*f*
  - complication of, 223*t*

Abdominal testis, surgical management of, 967–968
- Fowler-Stephens orchidopexy, 967–968
- laparoscopic orchidopexy, 967–968
- open transabdominal orchidopexy, 967

Abdominal wall
- closure of, for classic bladder exstrophy, 545–548, 546*f*–548*f*
- defects, in bladder exstrophy, 533
- lower
  - inguinal canal, 2445–2447, 2448*f*
  - internal surface of, 2447–2448, 2448*f*
  - musculature of, 2444–2445, 2447*f*–2448*f*
  - skin and subcutaneous fascia, 2444, 2446*f*
- posterior, 1658–1665
  - flank muscles of, 1658–1665, 1662*f*–1664*f*, 1664*t*
- in prune-belly syndrome, 585–586, 586*f*–587*f*
- reconstruction of, for prune-belly syndrome, 594–595

Abdominal wall defects, 410

Abdominal wall related complications, after robot-assisted cystectomy, 3272

Abdominoperineal resection (APR), LUTD after, 2620–2621

Abdominoscrotal hydroceles, 889, 892–893

Abiraterone, 3677–3678, 3677*f*, 3693–3695, 3694*f*

Ablation

- adjuvants to, 3638
- approach of, 3624
- brachytherapy, 3632–3638
- cryotherapy, 3624–3628, 3625*f*, 3627*t*
- follow up, 3638
- high-intensity focused ultrasonography, 3628, 3629*t*–3630*t*, 3631*f*–3632*f*
- irreversible electroporation, 3628–3632, 3635*f*, 3636*t*
- laser, 3628, 3633*f*, 3634*t*, 3635*f*
- other modalities, 3638
- types, 3624, 3624*f*
- vascular-targeted photodynamic therapy, 3632, 3637*t*

Ablative therapy

- adrenal surgery, 2424–2425
- failure of, laparoscopic radical nephrectomy after, 2298
- laparoscopic ablation *versus*, 2318
- laparoscopic kidney, 2304–2305
- for renal tumors, 2309, 2322
    - new modalities of, 2319–2323, 2323*b*

Abnormal adrenal function disorders, 2383–2384

Absorbable gelatin matrix agents, 147

Absorbable stapling techniques, for cutaneous continent urinary diversion, 3227–3228

- right colon pouch, 3228, 3229*f*
- stapled sigmoid reservoir, 3228, 3230*f*
- W-stapled reservoir, 3228–3229, 3231*f*

Absorbable sutures, 149–150

Absorbed dose, 28

Absorbent products

  - for bladder emptying/storage failure, 2904
  - for urinary incontinence, in geriatric patients, 2920.e6

Absorption, of ultrasound waves, 71, 72*f*

Absorptive hypercalciuria (AH), 2019

ACC, Adrenal cortical carcinoma

Access needles, 169–170, 170*f*

Accreditation, for ultrasonography, 89–90

Acellular human dermis, allograft slings and, 2834–2835

^{11}C-acetate positron emission tomography scan, 3662, 3662*f*

Acetazolamide, in stone formation, 2033

Acetylcholine (ACh)
  - in bladder function, 2474–2475
  - botulinum toxins and, 2512, 2720.e3
  - for detrusor underactivity, 2660–2661
  - mechanism of action of, 2681
  - in ureteral function, 1887

Acid-base balance, filtrate transport, 1911–1912, 1912*f*, 1912*b*

Acid-base metabolic, pneumoperitoneum effects on, 222

Acid-base physiology, 461

Acidosis
  - after augmentation cystoplasty, 698
  - requiring treatment, with intestinal anastomoses, 3180*t*

Acontractile detrusor, 2521, 2565

Acoustical shadow, 71, 71*f*

Acquired curvatures of penis, 1837–1838

Acquired diverticula, 525

Acquired immunodeficiency syndrome (AIDS), lower urinary tract dysfunction and, 2625

Acquired renal cystic diseases (ARCD), 772–774, 774*b*

  - clinical features of, 772
  - etiology of, 772
  - evaluation of, 773
  - histopathology of, 772–773, 773*f*
  - treatment of, 773–774

Acquired renal scars, 499–500

Acquired scarring, pathophysiology of, 500–501, 500*f*–501*f*
  - age, 500
  - bacterial virulence, 500
  - host susceptibility and response, 500
  - hypertension, 501
  - papillary anatomy, 500
  - renal failure and somatic growth, 501
  - renal growth, 501

Acrosome, 1442.e1

ACTH-dependent Cushing syndrome, 2361, 2361*f*
  - Cushing disease, 2361
  - ectopic ACTH syndrome, 2361, 2362*f*, 2362*t*, 2366
  - treatment of, 2365–2366, 2366*f*

ACTH-independent bilateral macronodular adrenal hyperplasia, 2362

ACTH-independent Cushing syndrome, 2362, 2366–2367

Actin, in thin filaments, 2471

Actinomyosin cross-bridge cycling, 2472–2473, 2472*b*, 2473*f*

Action potentials
  - of smooth muscles, of bladder, 2473–2474, 2474*f*
  - of ureteral muscle cells, 1879–1881, 1879*f*–1880*f*

Active surveillance
  - barriers to, of prostate cancer
    - economics, 3546
    - nomenclature, 3546
  - complementary roles of focal therapy and, 3620
  - of prostate cancer, 3537–3547, 3539*b*

        - barriers to, 3545–3546
        - management of men on, 3541–3542
        - outcomes of, 3540–3542, 3540*t*, 3540*b*
        - patient selection in, 3540–3541, 3541*t*
        - research questions in, 3546–3547
        - watchful waiting, 3541
    - for RCC, 2173, 2173*t*

Activin, 1390, 1391*f*

Activities of daily living (ADLs), of geriatric urology patient, 2909

Activity product ratio, 2010

Acupuncture, for PE, 1572.e3

Acute adenolymphangitis (ADL), as filariasis clinical manifestation, 1329

Acute chest syndrome, 451

Acute disseminated encephalomyelitis (ADEM), lower urinary tract dysfunction and, 2625–2626

Acute epididymitis, 1202–1223

Acute focal or multifocal bacterial nephritis, 1171.e1, 1171.e1*f*

Acute interstitial nephritis (AIN), AKI caused by, 1925, 1925*t*

Acute kidney injury (AKI), 1921–1927, 1927*b*
    - in children, 353–354, 353*t*, 353*b*–354*b*
        - prerenal, 353–354
    - definition of, 1921, 1922*t*
    - differential diagnosis of, 1925–1926, 1926*t*
    - epidemiology and classification of, 1922
        - postrenal, 1923
        - prerenal, 1922–1923
    - management of, 1926–1927, 1927*t*
    - staging of, 1922*t*

Acute orchitis, 1218–1219

Acute post-streptococcal glomerulonephritis, 346

Acute pyelonephritis, 1168–1171, 1168*f*–1169*f*, 1170*t*

Acute renal injury, fractional excretion of sodium for, 777

Acute schistosomiasis, 1324

Acute scrotum, 893–899, 893*b*

- epididymitis, 898–899
- MRI, 414
- pain causes of, 899, 899*b*
- spermatic cord torsion, 893–897
- torsion of appendix testis and epididymis, 897–898, 898*f*
- ultrasonography of, 410–411, 411*f*–412*f*, 412*b*

Acute transverse myelitis, lower urinary tract dysfunction with, 2617

Acute tubular necrosis, resulting from ischemic injury, 1923

Acute upper respiratory tract infection (URTI), 450

Acute urinary retention (AUR)

- age and, 3337, 3337*f*
- with benign prostatic hyperplasia, 3336–3339, 3337*f*–3339*f*, 3337*t*–3338*t*, 3400–3401, 3400*t*
- epidemiology
  - of analytical, 3337–3339
  - of descriptive, 3336, 3337*t*
- lower urinary tract symptoms with, 3337–3338, 3338*t*
- management of, 3400–3401, 3401*f*
- prevention with medical therapy, 3401, 3401*b*
- prostate volume in, 3338–3339, 3338*f*–3339*f*
- serum PSA in, 3338–3339, 3338*f*–3339*f*
- urodynamic parameters of, 3338, 3338*f*

AD, Atopic dermatitis

Adalimumab, for BPS/IC oral therapy, 1243

Adaptive immune system, 1334–1336, 1335*f*

ADEM, Acute disseminated encephalomyelitis

Adenine, 1346.e1, 1346.e2*f*

Adenocarcinoma

- of bladder, 3090, 3090*f*
  - in pediatric patients, 1118
- of nonurothelial malignant lesions, 2189

  - of rete testis, 1708
  - of Skene gland, urethral diverticula differentiated from, 2986, 2986*f*

Adenomas
  - as benign lesions, 2362, 2389–2391, 2390*f*, 2391*b*
  - metanephric, 2128–2129, 2129*f*, 2129*b*
  - papillary, of kidney, 2128, 2128*b*
  - prostatic, enucleation of
    - retropubic simple prostatectomy for, 3451–3452, 3451*f*–3452*f*
    - in robot-assisted laparoscopic simple prostatectomy, 3455
    - suprapubic prostatectomy for, 3453, 3453*f*

Adenomatoid tumors, of testicular adnexa, 1709

Adenosine, and ED, 1499

Adenosine triphosphate (ATP), urothelium release of, 2469

Adenylyl cyclase pathway, in ED, 1498

ADHD, Attention-deficit/hyperactivity disorder

Adherence, 428–429

Adhesins, 428–429

Adjuvant androgen deprivation
  - with radiation therapy, for locally advanced prostate cancer, 3653–3654
  - with radical prostatectomy, for locally advanced prostate cancer, 3652

Adjuvant chemotherapy
  - for muscle-invasive bladder cancer, 3120–3125
    - randomized trials of, 3121–3123, 3121*t*
  - for penile cancer, 1798–1800

Adjuvant intravesical topical chemotherapy, after nephroureterectomy, 2220

Adjuvant radiation therapy
  - after radical prostatectomy, for locally advanced prostate cancer, 3650–3652, 3651*t*
  - for biochemical recurrence after radical prostatectomy, salvage radiation therapy *versus*, 3664–3665

Adjuvant therapy, in lymph node metastatic prostate cancer, 3684

Adjuvant topical therapy, for UTUC, 2220

ADL, Acute adenolymphangitis

ADLs, Activities of daily living

ADPKD, Autosomal dominant polycystic kidney disease

Adrenal adenomas
- as benign lesions, 2362, 2393–2394, 2393*f*, 2394*b*
- MRI and, 51–52

Adrenal cancer, in nuclear medicine, 43

Adrenal cortex, physiology of, 2356–2357, 2357*f*, 2357*t*–2358*t*

Adrenal cortical carcinoma (ACC)
- malignant lesions, 2362, 2384–2388, 2384*f*, 2385*t*, 2386*f*, 2386*b*, 2387*t*, 2388*b*
- MRI and, 52
- pediatric, 2388
- surgery, 2408–2409, 2408*b*–2409*b*

Adrenal cyst, as benign lesion, 2393–2394, 2393*f*, 2394*b*

Adrenal disorders, 2354–2404
- of abnormal adrenal function, 2383–2384
- anatomy and, 2355*f*, 2356, 2356*b*
- benign lesions, 2389–2394
  - adenoma, 2362, 2389–2391, 2390*f*, 2391*b*
  - adrenal cyst, 2393–2394, 2393*f*, 2394*b*
  - ganglioneuromas, 2392–2393, 2393*b*
  - myelolipoma, 2392, 2392*f*, 2392*b*
  - oncocytoma, 2391, 2392*b*
  - pheochromocytoma, Pheochromocytoma
- of decreased adrenal function, 2380–2383, 2383*b*
  - clinical characteristics, 2381–2382, 2382*t*
  - diagnostic tests, 2382
  - overview and epidemiology, 2380–2381
  - pathophysiology, 2381, 2381*f*
  - prognosis, 2383
  - treatment, 2382–2383, 2383*t*
- embryology and, 2354–2356, 2356*b*
- histology and, 2355*f*, 2356
- historical background, 2354
- of increased adrenal function, 2360–2380
  - Cushing syndrome, Cushing syndrome
  - pheochromocytoma, Pheochromocytoma

    - primary aldosteronism, Primary aldosteronism
  - malignant lesions, 2384–2388
    - adrenal cortical carcinoma, 2384–2388, 2384*f*, 2385*t*, 2386*f*, 2386*b*, 2387*t*, 2388*b*
    - malignant pheochromocytomas, 2373, 2375, 2389
    - metastases, 2388–2389, 2389*f*, 2390*b*
    - neuroblastoma, Neuroblastoma
    - pheochromocytomas, 2373, 2375, 2389
  - physiology and, 2356–2360, 2360*b*
    - adrenal cortex, 2356–2357, 2357*f*, 2357*t*–2358*t*
    - adrenal medulla, 2358–2360, 2358*f*, 2359*t*–2360*t*

Adrenal glands, 2345–2354, 2346*f*, 2353*b*
  - anatomic relationships in, 2345
  - anatomy, 2355*f*, 2356, 2356*b*, 2405–2406
  - embryology, 2345–2351, 2351*f*, 2354–2356, 2356*b*
  - histology, 2351–2352, 2351*f*, 2355*f*, 2356
  - nerves, 2345, 2350*f*
  - physiology, 2356–2360, 2360*b*
    - adrenal cortex, 2356–2357, 2357*f*, 2357*t*–2358*t*
    - adrenal medulla, 2358–2360, 2358*f*, 2359*t*–2360*t*
  - radiology, 2352–2353, 2352*f*
  - surgical landmarks, 2345, 2347*f*–2348*f*
  - vasculature, 2345, 2348*f*–2349*f*, 2355*f*, 2356, 2405–2406, 2406*f*

Adrenal incidentalomas
  - adrenal surgery for, 2409*b*
  - evaluation of, 2394, 2394*t*

Adrenal lesions, 54, 57*t*

Adrenal magnetic resonance imaging, 51–54

Adrenal medulla, physiology of, 2358–2360, 2358*f*, 2359*t*–2360*t*

Adrenal sex steroid hypersecretion, in evaluation of adrenal masses, 2401–2402

Adrenal surgery, 2405–2426, 2426*b*
  - ablative therapy, 2424–2425
  - complications, 2423–2424, 2423*b*–2424*b*
  - for Conn syndrome, 2409–2410, 2409*b*
  - for Cushing syndrome, 2409*b*, 2410
  - evolution of, 2405

- future of, 2425–2426
- hand-assisted, 2419
- indications, 2403, 2403*f*, 2404*b*, 2406–2407, 2406*f*, 2407*b*
- laparoendoscopic single-site, 2419–2420
- laparoscopic adrenalectomy, 2407–2409, 2407*b*
    - left, 2414–2415, 2415*f*–2416*f*, 2417–2418
    - outcomes, 2421–2423
    - retroperitoneal approach, 2417–2418, 2418*f*, 2422
    - right, 2415–2416, 2417*f*–2418*f*, 2418
    - transperitoneal approach, 2414–2417, 2415*f*–2417*f*, 2422
- natural orifice transluminal endoscopic surgery, 2421
- open adrenalectomy, 2410–2414
    - anterior transabdominal approach, 2412–2413, 2412*f*–2413*f*
    - flank retroperitoneal approach, 2410–2411, 2410*f*–2411*f*
    - left, 2412–2413, 2412*f*–2413*f*
    - outcomes, 2421–2423
    - posterior lumbodorsal approach, 2411–2412, 2411*f*–2412*f*
    - thoracoabdominal approach, 2413–2414, 2413*f*–2414*f*
- partial adrenalectomy, 2421, 2421*b*
- perioperative management for, 2409–2410
- for pheochromocytoma, 2409, 2409*b*
- preoperative and perioperative management for, 2409–2410, 2409*b*
- robot-assisted, 2418–2419, 2419*f*–2420*f*, 2422–2423
- surgical anatomy, 2405–2406, 2406*f*

Adrenal tumors
- ablative therapy for, 2424–2425
- Cushing syndrome and, 2362
- evaluation of, 2394–2403
    - adrenal incidentalomas, 2394, 2394*t*
    - assessment of function, 2399–2403, 2400*b*, 2401*f*, 2402*t*, 2403*b*
    - biopsy, 2398–2399, 2399*f*, 2399*b*
    - imaging, 2394–2398, 2396*f*–2397*f*, 2397*b*
    - size and growth, 2397–2398, 2398*f*, 2398*b*, 2408
    - surgical indications, 2403, 2403*f*, 2404*b*

α-Adrenergic agonists, 1888
- for stress urinary incontinence in women, 2714

β-Adrenergic agonists
- for stress urinary incontinence in women, 2714

  ureteral response to, 1885

Adrenergic agonists, for stress urinary incontinence, 2501

β_3-Adrenergic agonists, for OAB, 2647

α_1-Adrenergic antagonists, for PE, 1572.e1

α-Adrenergic antagonists, 1534

β-Adrenergic antagonists

  to facilitate bladder filling and urine storage, 2682*t*, 2698–2699

    with antimuscarinics, 2706

  for stress urinary incontinence in women, 2714

  ureteral response to, 1888

α-Adrenergic blockers

  and ED, 1506

  for OAB, 2647

α1-Adrenergic blockers

  adverse events with, 3369

  for benign prostatic hyperplasia, 3355–3356

  cardiovascular diseases with, 3369–3370

  classification of, 3356–3357, 3356*t*

  comparison of, 3367–3369, 3368*t*

  complications associated with, 3370–3371

  in elderly, 3370

  hemodynamic side effects of, 3369, 3369*f*

  intraoperative floppy iris syndrome, 3370

  nonselective, 3356

  5α-reductase inhibitors and, 3385, 3386*f*

  safety profile of, 3369

  selective, 3356–3357

  sexual function and, 3370

β-Adrenergic blockers, and ED, 1506

α-Adrenergic receptor antagonists, for bowel-bladder dysfunction, 657–658

Adrenergic receptors

  pharmacology of, 2500–2501, 2501*b*

    - α-adrenergic receptors, 2500–2501, 2501*f*
    - β-adrenergic receptors, 2500
  - in ureteral function, 1888

Adrenogenital syndrome, testicular “tumor” of, 1708

α-Adrenoreceptor antagonists
  - for detrusor underactivity, 2661
  - to facilitate bladder emptying, 2719–2720
  - to facilitate bladder filling and urine storage, 2682*t*, 2697–2698
    - with 5α-Reductase inhibitors, 2707

ADT, Androgen deprivation therapy

Advance TOT sling, 2887–2888

Advanced imaging, for pediatric urology, 390–391
  - computed tomography, 390–391
  - magnetic resonance imaging, 390

Advancement flap, laparoscopic or robotic, 3031, 3032*f*

Advancement procedures, for hypospadias, 918–920
  - M inverted V glansplasty, 920, 922*f*
  - meatal advancement glanuloplasty, 920, 921*f*
  - urethral, 920, 922*f*
  - urethromeatoplasty, 918

AdvaSeal-S, 215.e2

Aerobactin, 429

Aerobic glycolysis, 96

Afferent arterioles, 1869

Afferent neuropeptides, lower urinary tract and, 2501–2502
  - endothelins, 2502
  - prostanoids, 2502
  - tachykinins, 2501–2502, 2501*t*

Afferent pathways
  - in detrusor underactivity, 2653–2655, 2655*f*
  - in lower urinary tract, 2481–2486, 2487*b*
    - cannabinoids, 2486

        - functional properties of, 2482–2483, 2483*f*
        - modulators of, 2483–2484
        - neuromodulation of, 2511
        - nitric oxide in, 2484, 2484*f*
        - pelvic organ interactions with, 2486, 2486*f*
        - properties of, 2481
        - purinergic signaling, 2484–2485, 2485*f*
        - spinal cord pathways of, 2481–2482, 2481*t*, 2482*f*
        - transient receptor potential cation channels, 2485
    - in overactive bladder and detrusor overactivity, 2641–2642
- AFFINITY study, 3702
- AFFIRM study, 3695, 3695*f*
- Aflibercept, 3700
- African plum, for benign prostatic hyperplasia, 3398
- Age
    - acute urinary retention and, 3337, 3337*f*
    - and aging, 2922*b*
        - biology and principles of, 2905–2906
        - demographics of, 2906–2908, 2907*f*–2908*f*
        - detrusor muscle and, 2653, 2654*f*
        - geriatric urology and, 2905–2923
        - lower urinary system and, 2906
        - lower urinary tract dysfunction and, 652, 2509–2510, 2510*b*, 2633
        - orthoptic urinary diversion and, 3237
        - physiologic, 2905–2906
        - prevalence of OAB and, 2639
        - renal calculi and, 2089–2090
        - ureter physiology effects of, 1900, 1901*f*
        - and urinary incontinence, 2582–2583
        - urinary incontinence and
            - conservative interventions for, 2735
        - UTUC variations and, 2185
    - colposuspension and, 2756
    - prostate cancer diagnosis and, 3459
    - renal calculi and, 2006
- Age-based self-assessment pain tools, 448–449, 448*f*
- Agency for Healthcare Research and Quality (AHRQ), 101
- Agenesis, 949

Aging
- hypothalamic-pituitary-gonadal axis and, 1392
- Peyronie's disease and, 1600

β3-Agonist (Mirabegron)
- for benign prostatic hyperplasia, 3381–3393
- indication, efficacy, and safety profile of, 3381–3382

AH, Absorptive hypercalciuria

AHRQ, Agency for Healthcare Research and Quality

AIDS, Acquired immunodeficiency syndrome

AIN, Acute interstitial nephritis

Air-charged catheters, for urodynamic studies, 2558

Air embolism, vena caval thrombectomy causing, 2277

AirSeal System, 211, 211.e3*f*

AKI, Acute kidney injury

Albumin, 1436

Albuminuria
- in CKD, 1928, 1928*t*
- in urine, during pregnancy, 283

Albuterol (Ventolin), for contrast media reaction treatment, 30–31

Alcohol
- consumption, prostate cancer and, 3465
- and ED, 1509
- use, benign prostatic hyperplasia and, 3322

Aldosterone hypersecretion, in evaluation of adrenal masses, 2401, 2401*f*

Aldosterone receptor antagonists, and ED, 1507

Alfuzosin
- for benign prostatic hyperplasia, 3361–3363, 3362*t*
- to facilitate bladder emptying, 2682*t*, 2720.e1

Alfuzosin, Finasteride and Combination study, 3385

Aligning catheters, for PFUIs, 1828

Alkali agents, for pediatric kidney stone disease, 869

Alkalosis, after augmentation cystoplasty, 698.e1

Allantois, 319*f*, 330*f*

Allergic dermatitis

- atopic dermatitis, 1275–1276, 1276*f*
- contact dermatitis, 1276–1277, 1277*f*
- differential diagnosis, 1275*b*
- erythema multiforme and Stevens-Johnson syndrome, 1277–1278, 1278*f*

Allergy

- contrast media and, 32
- patient history of, 8

Allogeneic hematopoietic stem cell transplantation, for RCC, 2331, 2331*t*

Allograft, for pubovaginal sling, 2834–2835

- outcomes of, 2841–2843, 2841*t*–2842*t*

Allopurinol

- for chronic scrotal pain syndrome, 1216
- for pediatric kidney stone disease, 870

Alpha hemolysin, 429

5-Alpha reductase inhibitors, for nocturia, 2674

Alpha/beta ratio, 3593

Alpha-blockers, for chronic scrotal pain syndrome, 1215

Alport syndrome, 347

ALPP, Abdominal leak point pressure

Alprostadil, 1535

ALSYMPCA trial, 3704, 3705*f*

Alternative hormone treatments, in ED, 1530

Alternative therapies, for ED, 1537–1538

Alveolar RMS, 1111, 1112*f*, 1113*b*

Alzheimer disease, and ED, 1502

Amantadine, for delayed ejaculation, 1579

Ambiguous genitalia, 386, 998–1018, 999*f*, 999*b*

Ambulatory urodynamics, 2571–2574, 2574*b*

- clinical utility of, 2571–2574
- monitoring, 484–485

Amebiasis, of genitourinary tract, 1332

American Academy of Pediatrics Guidelines, for febrile urinary tract infection diagnosis and management in young children, 507, 508*t*

American Association for Surgery of Trauma (AAST), Organ Injury Severity Scale for Kidney, 1992*t*

American Joint Committee on Cancer and Union International Control Cancer (AJCC and UICC) staging systems, for penile squamous cell carcinoma, 1748–1750

American Joint Committee on Cancer (AJCC) staging system, for UTUC, 2194, 2195*t*

American Society of Anesthesiologists Classification and Risk, in urologic surgery, 119, 120*t*, 120*b*

American Society of Anesthesiologists Task Force Recommendation, on the prevention of peripheral neuropathies, 146*t*

American Urological Association (AUA)

- best practice statement
    - on antibiotic, prophylaxis, 188
    - on use of VTE prophylaxis, 231
- Guideline for the Surgical Management of Stress Urinary Incontinence, 2875–2876
- RCC management guidelines of, 2162–2163, 2163*f*
- Symptom Score, 109

American Urological Association Symptom Index (AUASI), for benign prostatic hyperplasia, 3344

γ-Aminobutyric acid (GABA), 1494, 1495*t*

- in efferent pathways to bladder, 2488

  - in inhibition of micturition, 2704
- Aminoglutethimide, 3677
- Aminoglycosides
  - prophylaxis with, for uncomplicated urologic procedures, 1194*t*–1196*t*
  - for UTIs, 1150*t*–1153*t*, 1154, 1155*f*
- Aminopenicillins, for UTIs, 1154
- Aminophylline, for ureteral relaxation, 1899
- Amitriptyline (Elavil)
  - for BPS/IC oral therapy, 1241–1242, 1241*t*
  - urethral function effects of, 1903
- Ammonium acid urate stones, 2066
  - in renal calculi, 2032
- Amniotic fluid, 404
  - pulmonary development and, 716–717
- Amoxicillin, for UTIs, 1151*t*–1153*t*, 1154, 1187*t*
- Ampicillin, for UTIs, 1151*t*–1153*t*, 1154, 1170*t*, 1187*t*
- Amplatz dilators, 171, 171*f*
- Amplitude-coded color Doppler sonography, 389
- Ampulla, 335
- Amputation
  - penile, traumatic, 3050–3051
  - of penis, for penile cancer, 1752–1753
- Amyloidosis
  - lower urinary tract dysfunction and, 2632
  - of urethra, reconstructive surgery for, 1810
- Anaerobes, in urinary tract, 1133
- Anal perineum, female, 2435, 2436*f*
- Anal sphincter, 2435
- Anal triangle

- female, 2434
- male, 2449–2450

Analgesia
- for pediatric patients, 447*b*
  - children of Jehovah's Witnesses, 448
  - children with asthma, 447–448
  - children with spina bifida, 452
- for prostate biopsy, 3496–3497

Analgesics, UTUC risk and, 2187

Anaplastic Wilms tumor, 1100

Anastomosis, excision and primary, for transmen, 3071

Ancillary procedures, in pediatric kidney stone disease, 861

Androgen, 1390
- for benign prostatic hyperplasia, manipulation of, 3371–3379
  - aromatase inhibitors for, 3377
  - cetrorelix, 3377
  - chlormadinone acetate, 3377
  - dutasteride, 3374–3376, 3374*f*, 3375*t*, 3376*f*
  - finasteride, 3371–3374, 3373*t*
  - flutamide, 3376–3377
  - literature interpretation for, 3371
  - literature review for, 3371
  - pharmacological classification for, 3371, 3372*t*
  - rationale for, 3371
  - 5α-reductase inhibitors and sexual dysfunction, 3378
  - selective estrogen and androgen receptor modulators, 3377
  - summary for, 3379
  - tolerability and safety of, 3378
  - zanoterone, 3376
- lower urinary tract and, 2503
- in nuclear matrix, 3294–3295
- plasma binding proteins of, 3282*f*, 3284
- in prostate cancer, 3462, 3466, 3467*f*
- in prostate growth, 3282–3283, 3283*f*
  - metabolism of, 3286–3287, 3286*f*, 3287*t*
  - regulation of, 3285–3286, 3285*f*
- role in benign prostatic hyperplasia, 3306–3308, 3306*t*
- sources of, 3673, 3674*t*, 3674*b*

- stromal-epithelial interaction regulation by, 3287
- synthesis inhibition, 3677–3678

Androgen axis
- androgen sources in, 3673, 3674*t*, 3674*b*
- blockade mechanisms for, 3673–3678, 3679*b*
  - response to, 3679–3680
- molecular biology of, 3672–3673, 3672*f*, 3673*t*, 3673*b*

Androgen-binding protein, 1396–1398

Androgen deprivation therapy (ADT), 3687
- for biochemical recurrence after radiation therapy, 3668–3670
- for biochemical recurrence after radical prostatectomy, 3665
  - salvage radiation therapy with, 3663–3664
- continuous, 3683–3684
- intermittent *versus* continuous, 3684–3685
- for localized prostate cancer, immediate *versus* delayed, 3684
- for locally advanced prostate cancer, 3655–3656, 3656*b*
  - intermittent, 3656
  - quality of life, 3656

Androgen receptor (AR), 3293*b*
- in benign prostatic hyperplasia, 3307
- chaperonin binding, 3289
- defects of, 1013–1014
- dimerization of, 3291
- DNA-binding domain, 3289–3290
- function of, 3295*b*
- ligand-binding domain, 3290–3291
- modulation of, for castration-resistant prostate cancer, 3695–3696, 3695*f*
- nuclear localization of, 3291
- post-translational modifications of, 3291
- in prostate cancer, 3472
- in prostate growth regulation, 3288–3292, 3289*f*–3290*f*
- structure of, 3295*b*
- transcriptional activation domains, 3291–3292, 3291*b*, 3292*f*

Androgen receptor-associated biomarkers, 3685–3686

Androgen receptor-dependent chromatin remodeling, in prostate growth regulation, 3293–3295

Androgen receptor splice variant 7 (AR-V7), 3696

Androgen receptor splice variants, 3685

Androgen suppression, combined with radiation, 3600–3602, 3602*b*
- background and potential mechanisms of, 3600
- localized disease and, 3600–3602, 3601*t*
- locally advanced disease and, 3602
  - benefit of, 3602
- optimal duration of, 3602

Andropause, 1392

Androstenedione, 3283, 3283*f*

Anejaculation, 1451
- causes of, 1574, 1574*t*
- and neurologic disorders, 1576–1577
- treatment of, 1578–1579, 1579*t*

Anemia
- in CKD, 355
- hormonal therapy and, 3682

Anesthesia
- acute perioperative events, 452–453
  - nonspecific fever, 453
  - sepsis, 452, 453*b*
  - trauma, 452–453
  - URTIs, 453
  - UTI, 453
- children with asthma, 447–448
- comorbidities, 450–453
- disposal of unused narcotics, 456, 457*t*
- ERAS protocols, 453–455
- in geriatric urology patient, 2912
- intraoperative considerations, 453–454
  - anaphylaxis, 454–455
  - fluid management, 454

    - malignant hyperthermia, 454–455
    - pain management, 455
    - preoperative antibiotics, 453–454, 454*t*
- for laparoscopic and robotic surgery, complications related, 228
- for laparoscopic kidney surgery, 2279
- laparoscopic procedures, 455–456
- for laparoscopic radical prostatectomy, 3568–3570
- for pediatric kidney stone disease, 861
- for pediatric patients, 447, 447*b*
- for percutaneous nephrolithotomy, 2104
- perioperative home, 447, 457*b*
- perioperative planning and postoperative considerations, 450–453, 452*b*
    - acute upper respiratory tract infection (URTI), 450
    - anaphylaxis, 454–455, 455*b*
    - for asthma and pulmonary disease, 450
    - for cardiovascular anomalies, 450–451
    - chemotherapy and, 451
    - congenital adrenal hyperplasia, 452
    - fluid management, 454
    - hematologic disorders, 451
    - oncologic disorders, 451–452
    - pheochromocytoma, 451–452
    - for premature infants, 450
    - for renal abnormalities, 451
    - spina bifida, 452
- post care unit and pain management, 456
- postoperative management, 455–456
    - immediate, 455–456
    - inpatient, 456
    - outpatient, 456
- and potential neurocognitive effects, 447
- preoperative assessment
    - department of social services, 448
    - diabetes and metabolic disorders, 449–450
    - enteral tube feeds, 449
    - fasting times, 449
    - for Jehovah's witness, 448
    - ketogenic diet, 449
    - medication administration, 450
    - NPO status, 449, 449*t*
    - pain assessment tools, 448–449

- risk, 447–448
- setting, 448
- special, 448
- preoperative studies, 450
  - chest X-ray, 450
  - laboratory tests, 450
  - pulmonary function testing, 450
  - urine evaluation, 450
- preparation for surgery, risk, 447–448
- pubovaginal sling procedure, 2836–2837
- for retropubic radical prostatectomy, 3551–3552, 3551*f*
- for simple prostatectomy, 3450
- for vasectomy, 1850

Aneurysm
- as laparoscopic and robotic surgery contraindication, 204
- in penile implant, 1593, 1593*f*

Angioembolization
- indications for, 1072–1073
- of isolated renal segment, 1072
- for renal injuries, 1986, 1986*f*

Angiogenesis
- in castration-resistant prostate cancer, 3700–3701
- in RCC, 2146
- in UTUC, 2197

Angiography
- in adrenal radiology, 2353
- interventional, for priapism, 1560–1561, 1561*f*
- of renal artery, 179*f*
- renovascular hypertension, screening tests for, MRA, 1917–1918, 1918*b*
- for renovascular hypertension screening, 1917–1918, 1918*b*

Angiokeratomas of Fordyce, 1302, 1303*f*

Angiomyolipoma (AML), 293
- in pediatric patients, 1110, 1110*f*
- renal, 2125–2128, 2128*b*
  - diagnosis of, 2125–2126, 2126*f*

        - epidemiology of, 2125
        - management of, 2126–2128, 2127*f*
        - pathophysiology of, 2125

Angiotensin, urethral function effects of, 1902

Angiotensin II (AT2)
- renal vascular tone control by, 1913
- in tubulointerstitial fibrosis, 788
- type 1 receptor antagonists, and ED, 1507

Angiotensin receptor blockers (ARBs), AKI caused by, 1922

Angiotensin-converting enzyme (ACE), 788

Angiotensin-converting enzyme (ACE) inhibitors
- AKI caused by, 1922
- and ED, 1506–1507

Anhydrous ethanol, for prostatic injections, 3447

Animal bites, of penis, 3050

Animal models, laparoscopic training with, 232

Animal protein
- in pediatric kidney stone disease, 869
- for urinary lithiasis, 2047–2048, 2048*b*

Annexin A3, as prostate cancer biomarker, 3487

Anogenital distance, 305

Anorectal defects
- in bladder exstrophy, 533
- urinary fistula with, 622–623, 622*f*

Anorectal malformation, 386, 644–645, 650*b*
- pathogenesis of, 645
- presentation of, 644–645, 646*f*
- specific recommendations for, 645

Anorgasmia, patient history of, 6

ANP, Atrial natriuretic peptide

Antegrade endoscopic evaluation, for UTUC, 2191

Antegrade injection, of male stress urinary incontinence, 2896–2897

Antegrade nephroureteroscopy, for UTUC, 2212–2219

- biopsy and definitive therapy in, 2216–2217, 2216*f*–2217*f*
- consideration for urinary diversions, 2219
- establishment of nephrostomy tract, 2215–2216, 2215*f*
- result of, 2217–2219, 2218*t*
- second-look nephroscopy in, 2217

Antegrade pyelography

- for genitourinary tuberculosis diagnosis, 1312–1313
- for ureterovaginal fistula, 2943
- for urinary tract obstruction, 781

Antegrade ureterography, of ureteral injuries, 1995

Antenatal urinary incontinence, 2726

Anterior approaches, for open kidney surgery, 2252–2253

- chevron incision, 2253
- midline, 2252–2253, 2253.e1*f*
- subcostal, 2253

Anterior colporrhaphy, for pelvic organ prolapse

- complications of, 2782–2783
- results with, 2779–2782, 2780*t*
- technique for, 2779, 2779*f*

Anterior compartment prolapse, 2587

Anterior cutaneous perforating nerves, 136*f*

Anterior extraperitoneal approach, to laparoscopic pyeloplasty, 1956

Anterior labial commissure, 1627.e1

Anterior pituitary, in HPG axis, 1390–1391, 1391*f*

Anterior-posterior renal pelvic diameter, in perinatal urology, 359–360, 360*t*

Anterior transabdominal approach, to open adrenalectomy, 2412–2413, 2412*f*–2413*f*

Anterior trunk, 2451*t*, 2452

Antiandrogens, 3674–3676, 3675*f*

- and ED, 1508, 1509*t*
- nonsteroidal, 3674–3676
- for priapism, 1553
- steroidal, 3674
- withdrawal syndrome, 3676

Antibiotic prophylaxis, in urologic surgery, 127–128, 127*b*

Antibiotic Prophylaxis and Recurrent Urinary Tract Infection in Children (PRIVENT) study, 516

Antibiotics

- for BPS/IC oral therapy, 1243
- for hypospadias, preoperative, 916–918
- for inguinal lymphadenectomy, 1801
- before inguinal node dissection, 1800–1801
- pediatric stone disease and, 867
- for percutaneous nephrolithotomy, 2104
- prophylaxis with, for cystourethroscopy, 188, 189*t*
- for prostate biopsy, 3496, 3496*t*
- for renal calculi, pretreatment, 2071
- urethral function effects of, 1904
- for vesicovaginal fistula surgery, 2934

Anticholinergic medication

- detrusor underactivity and, 2657
- for urinary incontinence, in geriatric patients, 2919.e1

Anticholinergic receptor blockers, for benign prostatic hyperplasia, 3389–3393, 3390*t*, 3392*f*

Anticholinergics, Antimuscarinic agents

- for bowel-bladder dysfunction, 657
- for enuresis, 665

Anticholinesterases, ureteral response to, 1887–1888

Anticoagulants, for vena caval thrombectomy, 2266–2267

Anticoagulated patient
  holmium laser enucleation of prostate and, 3438
  monopolar transurethral resection of prostate in, 3416
  photoselective vaporization of prostate and, 3441
Anticoagulation
  for inguinal lymphadenectomy, 1801
  before inguinal node dissection, 1801
Anticonvulsants, and ED, 1508
Antidepressants
  and ED, 1507–1508
  to facilitate bladder filling and urine storage, 2682*t*, 2702–2703
Antiglomerular basement membrane (Anti-GBM) disease, 347
Antihistamines
  for BPS/IC oral therapy, 1242
  for contrast media reaction treatment, 31
Antihypertensive agents
  and ED, 1506–1507, 1509*t*
  effect on sexual function, 1507*t*
Antihypertensive and Lipid-Lowering Treatment to Prevent Heart Attack Trial (ALLHAT), 3369–3370
Anti-inflammatory therapy, for chronic scrotal pain syndrome, 1215
Antimicrobial formulary, for UTIs, 1150–1155, 1150*t*–1151*t*, 1155*f*
Antimicrobial prophylaxis
  for common urologic procedures, 1193–1201, 1193*b*, 1194*t*–1196*t*, 1201*t*, 1201*b*
    for lower tract endoscopy, 1198
    for open and laparoscopic surgery, 1199–1200
    principles of, 1193–1197, 1193*b*, 1194*t*–1196*t*
    for shock wave lithotripsy, 1198
    special considerations, 1200–1201, 1201*t*
    for transurethral resection of prostate and bladder, 1198–1199
    for TRUSP biopsy, 1197–1198
    for upper tract endoscopy, 1199
    for urethral catheterization and removal, 1193*b*, 1194*t*–1196*t*, 1197
    for urodynamics, 1197

for UTIs, 1130, 1162–1163

Antimicrobial selection, for uncomplicated cystitis, 1156–1157

Antimicrobial suppression, for UTIs, 1130

Antimicrobial therapy, for UTIs

- antimicrobial formulary for, 1150–1155, 1150*t*–1153*t*, 1155*f*
- bacterial resistance to, 1144–1146, 1145*t*–1146*t*, 1147*b*
- duration of, 1155
- principles of, 1149–1155, 1155*f*, 1155*b*
- prophylaxis, 1130
- selection of agents in, 1155–1157
- suppression, 1130

Antimuscarinic agents

- adverse effects of, 2683–2684
- clinical use of, 2683
- to facilitate bladder filling and urine storage, 2681–2684, 2682*t*, 2697*b*
  - with 5α-reductase inhibitors, 2707
  - with α-adrenoreceptor antagonists, 2704–2706
  - atropine sulfate, 2684
  - with β_3-adrenoreceptor agonist, 2706
  - combinations of, 2706–2707
  - darifenacin hydrobromide, 2684–2685
  - fesoterodine fumarate, 2685–2687
  - flavoxate hydrochloride, 2696
  - imidafenacin, 2687
  - oxybutynin chloride, 2693
  - propantheline bromide, 2688
  - propiverine hydrochloride, 2695–2696
  - solifenacin succinate, 2688–2689
  - tolterodine tartrate, 2689–2691
  - trospium chloride, 2691–2692
- mechanism of action of, 2681–2682, 2681*f*
- for neuromuscular dysfunction of lower urinary tract, 633–634
- nocturnal polyuria and, 2668–2669
- pharmacologic properties of, 2682–2683
- for urinary incontinence
  - in geriatric patients, 2920.e3
  - urgency, 2544

Anti-neutrophil cytoplasmic antibodies (ANCA)-associated glomerulonephritis, 347

Antioxidant therapy, for calcium oxalate precipitation, 2020

Anti-PD-1 approved therapies, 2223

Anti-PD-L1 approved therapies, 2223–2224

Antiproliferative factor (APF), in BPS/IC etiology, 1232.e7, 1232.e8*b*

Antipsychotics, and ED, 1507

Antireflux procedure
- for classic bladder exstrophy, 554–556, 555*f*–556*f*
- for urinary tract reconstruction, 683–685, 685*b*
  - with intestinal segments, 683–685
  - psoas hitch for, 683, 684*f*
  - single ureteral reimplant for, 683
  - transureteroureterostomy for, 683, 683*f*

Antiretroviral agents
- and ED, 1509
- in stone formation, 2032–2033

Antiseptics, for cystourethroscopy, 189

Antisperm antibodies, 1398–1399

Antithrombotic therapy, in urologic surgery, 32–34, 57*t*

Antituberculosis drugs, 1311*t*, 1315–1317, 1315*t*–1316*t*

Anuria, 386, 461

Anxiety
- contrast media and, 32
- prostatitis and, 1210

Anxiolytics, and ED, 1508

Aorta, 1669, 1669.e1*f*, 1671*f*, 1672*t*
- in radical nephrectomy, 2258, 2258*f*, 2258.e1*f*
- reconstruction of, RPLND with, 1719

Aortic aneurysm, as laparoscopic and robotic surgery contraindication, 204

Aortic replacement, in retroperitoneal tumors, 2243

Apalutamide, 3676, 3695–3696

Aphallia, 876–877, 877*f*

Aphthous ulcers, 1286–1287, 1287*f*

Apical mesh complications, 2886–2887

Apical prolapse, 2587

Apoptosis
- after renal obstruction, 790
- as evolutionarily conserved process, 1365–1366
- in GU cancers, 1365–1367, 1367*b*
  - alternative regulators of, 1366–1367
  - extrinsic pathway, 1366.e1*f*–1366.e2*f*, 1366.e2
  - global defects in, 1366–1367
  - intrinsic pathway, 1366.e1, 1366.e1*f*
  - TP53 role in, 1366
- pathway, in castration-resistant prostate cancer, 3701–3702
- regulation of, 783–784
  - in benign prostatic hyperplasia, 3309
- in UTUC, 2197

Apparent diffusion coefficient maps, 63–64, 64*f*

Appendicovesicostomy, 708, 708*f*

Appendix
- for continent urinary diversions, 707–708
- in ileocecocystoplasty, 694

Appendix epididymis, 319*f*

Appendix testis, 319*f*

APR, Abdominoperineal resection

Aprepitant, to facilitate bladder filling and urine storage, 2713.e4

Aquaporin 2 (AQP2), 793

Aquaporins (AQPs), 793

AR, Androgen receptor

ARBs, Angiotensin receptor blockers

ARCD, Acquired renal cystic diseases

Arcuate arteries, 1869

Arcus tendineus fascia pelvis (ATFP), 2427, 2429*f*, 2438

Arcus tendineus levator ani (ATLA), 2427, 2429*f*

Area under the curve (AUC), 3479

Areflexia, 2565

- in detrusor underactivity, 2650

L-Arginine

- for BPS/IC oral therapy, 1241*t*, 1243
- for female sexual arousal disorders, 1650

Arginine vasopressin (AVP), in water regulation, 2668, 2670*f*

Argon beam coagulator

- for laparoscopic and robotic surgery, 215.e1
- for monopolar electrosurgery, 235

Aristolochic acid nephropathy, in UTUC, 2187

Aromatase inhibitors, for benign prostatic hyperplasia, 3377

Arousal, female sexual dysfunction and, 1637

ARPKD, Autosomal recessive polycystic kidney disease

Arsenic, UTUC risk and, 2187

Arterial revascularization, in ED, 1537

Arterial supply, to male pelvis, 2451–2452, 2451*t*

Arterial system, 1807.e9

- of retroperitoneum, 1669–1672, 1669.e1*f*–1669.e2*f*, 1671*f*, 1671.e1*f*, 1672*t*

Arterial system, surgical anatomy of, 3548, 3549*f*

Arterioureteral fistulas, 1993

Arteriovenous fistulas (AVFs), renal, 737

Artifacts, of ultrasonography images, 71–73, 72*f*–73*f*

Artificial somatic-autonomic reflex pathway procedure, for neuromuscular dysfunction of lower urinary tract, 638

Artificial urinary sphincter (AUS), 2546–2547

- for bladder neck reconstruction, 687–688
    - results with, 687–688
    - technique for, 687.e1
- complications with, 3005–3008, 3008*b*
    - mechanical failure, 3007
    - sling, 3008
    - special circumstances of, 3007–3008
    - urethral atrophy, 3007
    - urethral erosion, 3006–3007
    - urinary retention, 3005
- evaluation of persistent incontinence after, 2997–2998
- history and development of, 2994, 2994*f*
- implantation technique, 3000, 3001*f*, 3003*f*
    - bladder neck, 3003–3004, 3005*b*
    - control pump placement, 3000, 3002*f*
    - making connections, 3000, 3002*f*
    - outcomes of, 3003*t*
    - pressure-regulating balloon, 3000
    - tandem cuff, 3000–3002, 3003*f*
    - transcorporal, 3002, 3004*f*
    - trans-scrotal, 3002–3003, 3003*f*
- infection, 3005–3006
- long-term results with, 3008, 3009*b*
- for neuromuscular dysfunction of lower urinary tract, 637

AR-V7, Androgen receptor splice variant 7

As low as reasonably achievable (ALARA) principle, 78, 403, 403*b*

ASB, Asymptomatic bacteriuria

Ascending route of infection, 1131

Ascent anomaly, 339, 339*f*

Ascites

- laparoscopic and robotic surgery causing, 231.e1
- as laparoscopic and robotic surgery contraindication, 204

Ask-Upmark kidney, 744, 744*f*

Aspiration
  of gastric contents, during laparoscopic and robotic surgery, 228.e1
  of testis, technique of, 1847–1848
Assisted reproduction, 1445–1452, 1445.e3, 1445.e3*t*
Asthma
  contrast media and, 32
  preoperative care for pediatric patients with, 447–448
Asymmetrical unit membrane (AUM), of urothelium of bladder, 2462, 2463*f*
Asymptomatic bacteriuria (ASB), 434–435
  in elderly, 1147–1149, 1147*t*
  in geriatric patients, 2920.e10–2920.e11
  in pregnancy, 1185
Atamestane, for benign prostatic hyperplasia, 3377
ATFP, Arcus tendineus fascia pelvis
Atherosclerotic renal artery stenosis, 1930–1933
  arterial physiology, concepts in, 1930–1931, 1930*f*–1931*f*
  clinical features of, 1931–1932
  diagnostic evaluation of, 1931–1932
  hypertension in, pathophysiology of, 1930–1931
  ischemic nephropathy, pathophysiology of, 1931
  laboratory features of, 1932
  radiographic assessment of, 1932–1933
  therapeutic options for, 1933
    medical management, 1933
    procedural management, 1933
ATLA, Arcus tendineus levator ani
Atopic dermatitis (AD), 1275–1276, 1276*f*
ATP, Adenosine triphosphate
Atrial natriuretic peptide (ANP)
  in bilateral ureteral obstruction, 791–792
  renal vascular tone control by, 1913, 1913*f*

Atropine, ureteral response to, 1888

Atropine sulfate, to facilitate bladder filling and urine storage, 2682*t*, 2684

Attention Deficit Hyperactivity Disorder scale, 477

Attention-deficit/hyperactivity disorder (ADHD)

- lower urinary tract dysfunction and, 2633
- and priapism, 1545

Attenuation mechanisms, in ultrasonography, 71, 71*f*–72*f*

Attribution bias, 103–104

“Atypical suspicious for carcinoma,”, 3506

AUA, American Urological Association

AUASI, American Urological Association Symptom Index

AUC, Area under the curve

Audiovisual and vibratory stimulation, in ED, 1526

Augmentation cystoplasty, 2889–2890

- approach to, 701
- bladder capacity after, 2889–2890
- bladder compliance after, 697–698, 697*f*, 2889
- bladder level after, 2889–2890, 2890*b*
- capacity of, 2889
- cecocystoplasty for, 694
- complications of, 635–636, 696–701
    - calculi, 699
    - delayed spontaneous bladder perforation, 700–701, 700*f*
    - metabolic, 698
    - mucus, 698
    - urinary tract infection, 699
- contraindications to, 2890
- detrusor overactivity and, 2889–2890
- gastrocystoplasty for, 695
- gastrointestinal effects of, 696–697
- historical perspective on, 2889
- ileocecocystoplasty for, 694, 694*f*–695*f*

ileocystoplasty for, 692–693, 693*f*

ileovesicostomy for, 702, 702*b*

indications for, 2889–2890

intestinal segment management for, 692

native bladder management for, 692, 692*f*

necessity of, 701–702

for neuromuscular dysfunction of lower urinary tract, 635–636

postoperative management of, 695–696

early, 695

late, 696

pregnancy and, 701

quality of life and, 702

in renal transplantation, 1058

results with, 696–701

segment choice for, 701

sigmoid cystoplasty for, 694–695, 696*f*

techniques for, 2890

for urinary tract reconstruction, in pediatric patients, 691–706, 702*b*

Augmented anastomosis, for urethral stricture disease, 1821–1823, 1826*f*–1827*f*

Augmented bladders

renal transplantation and, 1057–1058

tumors of, in pediatric patients, 1118

Augmented valved rectum, 3209

AUM, Asymmetrical unit membrane

AUR, Acute urinary retention

AUS, Artificial urinary sphincter

Autoaugmentation

for augmentation cystoplasty, 703–705, 704*f*

for neuromuscular dysfunction of lower urinary tract, 636

Autoimmunity, BPS/IC etiology and, 1232.e2–1232.e3, 1232.e3*b*

Autologous graft, for pubovaginal sling, 2834

outcomes of, 2839–2841, 2840*t*

Autonomic dysreflexia
- lower urinary tract dysfunction with, 2614–2615
- symptoms of, 2614
- treatment of, 2614–2615

Autonomic nervous system
- and ED, 1527
- in retroperitoneum, 1674–1675, 1676*f*–1677*f*

Autonomic pathways, penile erection and, 1490, 1490*f*

Autonomy, definition of, 115

Autosomal dominant polycystic kidney disease (ADPKD), 349–350, 405, 750–755, 755*b*
- clinical features of, 752
- emerging therapeutics for, 755
- evaluation of, 753–754, 753*f*–754*f*
- extrarenal manifestations of, 752–753
- genetics of, 750–751
- histopathology of, 753, 753*f*
- pathogenesis of, 751–752
- prognosis of, 754–755
- renal cell carcinoma association with, 753
- renal cell carcinoma in, 2158
- treatment of, 754–755

Autosomal recessive polycystic kidney disease (ARPKD), 349, 405, 746–749, 751*b*
- clinical features of, 748
- evaluation of, 748–749, 749*f*–750*f*
- genetics of, 748
- histopathology of, 748, 748*f*
- treatment of, 749

Autotransplantation
- ureteral injuries, upper, 1997
- for ureteral stricture disease, 1975

AVFs, Arteriovenous fistulas

Avitene Microfibrillar Collagen Hemostat, 215.e2

AVP, Arginine vasopressin

Avulsion

- injury, ureteral, with ureteroscopy, 2002
- in ureteroscopic stone management, 2109

Axial flaps, for urethral and penile reconstruction, 1807, 1807*f*–1808*f*

Axial resolution, of ultrasonography images, 70, 70*f*

Axitinib, for RCC, 2179*t*–2180*t*, 2336–2337, 2337*t*

Azathioprine derivatives, for BPS/IC oral therapy, 1241*t*, 1243

Azoospermia, 1445.e1

Azotemia, with benign prostatic hyperplasia, 3336

Aztreonam, for UTIs, 1151*t*–1153*t*, 1154–1155

B

Bacille Calmette-Guérin (BCG)

- in bladder cancer, 1333, 1334*f*, 1338–1339, 1339*f*
- for non-muscle-invasive bladder cancer, 3099–3100
    - carcinoma treatment in situ with, 3100
    - contraindications to, 3102*b*
    - mechanism of action of, 3100
    - prophylaxis to prevent recurrence, 3100–3101
    - residual tumor treatment, 3100
    - toxicity management of, 3102*b*

Baclofen

- drug delivery of, 2720.e2
- to facilitate bladder emptying, 2720.e2–2720.e3
- to facilitate bladder filling and urine storage, 2682*t*, 2704
- for priapism, 1553–1554

Bacteremia, 427, 428*f*

- UTIs and, 1182–1187, 1184*b*

Bacteria

- cell wall components, in septic shock, 1183
- mesh complication with, 2878
- urease production by, 2030–2031, 2031*t*
- in urine, 23, 24*f*
- urothelial cancer and, 3099

Bacterial adherence, 1134–1135

Bacterial adhesins, 1134

Bacterial fimbriae, 428–429

Bacterial nephritis, 435, 435*f*

Bacterial persistence, in recurrent UTIs, 1160–1161

Bacterial “relapse,” renal infection from, 1177.e1

Bacterial resistance, to UTI antimicrobial therapy, 1144–1146, 1145*t*–1146*t*, 1147*b*

Bacterial type 1 (mannose-sensitive) pili, 1134

Bacterial vaginosis, 1271–1272, 1272*t*

Bacteriology, sepsis and, 1184

Bacteriuria
- after augmentation cystoplasty, 699
- catheter-associated, 1190, 1191*b*
- in elderly, 1188–1190, 1190*b*
  - asymptomatic, 1147–1149, 1147*t*, 1147*b*–1149*b*
  - diagnosis, 1188–1189
  - epidemiology, 1188
  - management, 1189–1190, 1189*t*
  - pathogenesis, 1188
  - screening for, 1188
- in pregnancy, 1184–1185, 1188*b*
  - anatomic and physiologic changes and, 1185–1186, 1185*t*, 1186*f*
  - complications of, 1186–1187
  - management of, 1186–1187, 1187*t*
  - pathogenesis, 1185
- UTIs and, 1129, 1159

Bacteroides fragilis, infection after mid-urethral sling surgery, 2870–2871

Baden-Walker classification, of PFDs, 2529–2530

Baden-Walker Halfway Scoring System, 2588

Balanitis
- infection, 1288
- pseudoepitheliomatous, keratotic, and micaceous, 1299–1300, 1300*f*
- urethral reconstructive surgery for, 1811
- Zoon, 1302, 1303*f*

Balanitis xerotica obliterans (BXO), 875–876, 876*f*, 939, 940*f*

Balanoposthitis, 1288, 1289*f*

Ballistic lithotripsy, 2111–2112, 2112*f*

Balloon catheters, 173

Balloon dilation
    for achieving extraperitoneal access and developing extraperitoneal space, 209, 210*f*
    for ureteral stricture disease
        antegrade, 1967–1968
        results with, 1968
        retrograde, 1966–1967, 1967*f*–1968*f*
    for ureteroenteric strictures, 1977
Balloon dilators, 171–172, 171*f*–172*f*
Balloon incision, cautery wire, for ureteroenteric strictures, 1977
Barotrauma, during laparoscopic and robotic surgery, 225
Barrier function, of urothelium of bladder, 2467–2468, 2468*f*
Barrington nucleus, 2493
Bartter syndrome, 349, 2019
Basal cell carcinoma (BCC)
    as neoplastic condition, 1297–1298, 1300*f*
    of penis, 1772
Basal cells
    epididymis, 1374–1375, 1403–1404
    of prostate, 3278, 3278*f*
Base excision repair (BER), 1351.e1, 1351.e1*f*
Baseline urinary function, localized prostate cancer and, 3524
Bashful bladder
    detrusor underactivity and, 2659
    lower urinary tract dysfunction and, 2628–2629
Basic Laparoscopic Urologic Surgery (BLUS), 471
“Bayesian” problem, 3543
BBD, Bladder and bowel dysfunction
BCC, Basal cell carcinoma
BCG, Bacille Calmette-Guérin
BCI, Bladder contractility index

BCR, Bulbocavernosus reflex

BD, Behçet disease

BDL, Biomarker Development Laboratory

Beckwith-Wiedemann syndrome (BWS), genomic alterations in, 1098, 1354*t*

Behavior, norms of, masculinity and, 1416

Behavioral modification, for bowel-bladder dysfunction, 656

Behavioral therapy (BT)
- for enuresis, 663, 664*f*
- for OAB, 2647
- for urinary incontinence, in geriatric patient, 2920.e3

Behavioral training
- levels of evidence and recommendations for, 2722.e1*b*, 2722.e4*b*
- with urge suppression, 2727–2729, 2728*f*

Behavioral treatment programs, for urinary incontinence, 2722–2738, 2738*b*
- adherence to, 2734–2735
- assessment for, 2722–2723, 2723.e1*f*–2723.e2*f*, 2724*f*
- bladder training, 2728*f*, 2730–2732, 2730.e1*t*
- common, 2722, 2723*f*
- conditions benefitting from, 2722.e1*t*
- indications for, 2722
- levels of evidence and recommendations for, 2722.e1*b*, 2722.e4*b*
- lifestyle modifications as, 2722, 2722.e1*b*
- models of delivery, 2737–2738, 2737.e1*f*
- patient education for, 2723
- for pelvic floor dysfunction, 2732–2735
- pelvic floor muscle electrical stimulation, 2729–2730
- pelvic floor muscle training for, Pelvic floor muscle training
- for prevention, 2735–2736
- role of biofeedback in, 2727.e1*f*, 2729
- vaginal and urethral mechanical devices, 2736–2737

Behçet disease (BD), 1286–1287, 1287*f*

Bell-shaped curve, 480

Beneficence, definition of, 115

Benign bounce phenomenon, brachytherapy and, 3608

Benign cutaneous diseases, of external genitalia, of male genitalia

- angiokeratomas of Fordyce, 1302, 1303*f*
- ectopic sebaceous glands, 1303*f*, 1304
- median raphe cysts, 1304
- pearly penile papules, 1302, 1303*f*
- sclerosing lymphangitis, 1302–1304
- Zoon balanitis, 1302, 1303*f*

Benign disease, bladder surgery for, 3010–3047

- anatomy of, 3010
- bladder stones, 3043–3046
- diverticulectomy, 3010–3019, 3011*f*, 3011*b*, 3046*b*–3047*b*
- enterocystoplasty, 3034–3038
- foreign-body removal, 3043–3046
- partial cystectomy, 3038–3043
- psoas hitch and Boari flap, 3026–3034
- surgical considerations of, 3010
- urachal surgery, 3038–3043
- ureteral reimplantation, 3019–3026

Benign idiopathic urethrorrhagia, 401

Benign joint hypermobility syndrome, lower urinary tract dysfunction and, 2633

Benign lesions, adrenal, 2389–2394

- adenoma, 2362, 2389–2391, 2390*f*, 2391*b*
- adrenal cyst, 2393–2394, 2393*f*, 2394*b*
- ganglioneuromas, 2392–2393, 2393*b*
- myelolipoma, 2392, 2392*f*, 2392*b*
- oncocytoma, 2391, 2392*b*
- pheochromocytoma, Pheochromocytoma

Benign multilocular cyst, 765–766, 765*f*, 766*b*, 767*f*

Benign oncocytomas, 98

Benign prostatic hyperplasia (BPH), 3063, 3305–3342

acute urinary retention with, 3400–3401, 3400*t*
    as complication of, 3336–3339, 3337*f*–3339*f*, 3337*t*–3338*t*
α1-adrenergic blockers for, 3355–3356
    adverse events with, 3369
    alfuzosin, 3361–3363, 3362*t*
    anticholinergic receptor blockers with, 3389–3393, 3390*t*, 3392*f*
    cardiovascular diseases with, 3369–3370
    classification of, 3356–3357, 3356*t*
    comparison of, 3367–3369, 3368*t*
    complications associated with, 3370–3371
    doxazosin for, 3359–3361, 3360*t*–3361*t*
    in elderly, 3370
    hemodynamic side effects of, 3369, 3369*f*
    hypertension with, 3369–3370
    intraoperative floppy iris syndrome, 3370
    literature review for, 3357–3367
    naftopidil, 3365–3367, 3367*t*
    nonselective, 3356
    phosphodiesterase type 5 inhibitors with, 3393, 3394*t*
    rationale for, 3355–3356, 3355*f*
    safety profile of, 3369
    selective, 3356–3357
    sexual function and, 3370
    silodosin, 3365, 3365*f*, 3366*t*
    summary for, 3371
    tamsulosin, 3363–3365, 3363*f*, 3364*t*
    terazosin for, 3357–3359, 3357*t*–3358*t*, 3359*f*
α-adrenergic receptors in, 2500
β3-agonist (Mirabegron) for, 3381–3393
    indication, efficacy, and safety profile, 3381–3382
    phosphodiesterase type 5 inhibitors, 3382
alcohol use and, 3322
anatomic features of, 3313–3314, 3313*f*–3314*f*
androgen manipulation for, 3371–3379
    aromatase inhibitors for, 3377
    cetrorelix, 3377
    chlormadinone acetate, 3377
    dutasteride, 3374–3376, 3374*f*, 3375*t*, 3376*f*
    finasteride, 3371–3374, 3373*t*
    flutamide, 3376–3377
    literature interpretation for, 3371
    literature review for, 3371
    pharmacological classification for, 3371, 3372*t*

rationale for, 3371
5α-reductase inhibitors and sexual dysfunction, 3378
selective estrogen and androgen receptor modulators, 3377
summary for, 3379
tolerability and safety of, 3378
zanoterone, 3376
anticholinergic receptor blockers for
α-adrenergic blockers with, 3389–3393, 3390*t*, 3392*f*
β_3-agonists, 3393
autopsy prevalence of, 3317, 3317*f*
bladder obstruction in
measures of, 3320
response to, 3315–3316
body mass index and, 3324, 3325*t*
clinical prevalence of, 3317, 3318*f*
combination therapy for, 3385
α-adrenergic blockers and 5α-reductase inhibitors, 3385, 3386*f*
Combination of Avodart and Tamsulosin Study, 3386–3389, 3389*f*, 3389*t*
Medical Therapy of Prostatic Symptoms Trial, 3385–3386, 3387*f*–3388*f*, 3387*t*
complications of, 3335–3339
acute urinary retention with, as complication of, 3336–3339, 3337*f*–3339*f*, 3337*t*–3338*t*
bladder decompensation, 3335
bladder stones, 3335
hematuria, 3336
mortality, 3335
upper urinary tract deterioration and azotemia, 3336
urinary incontinence, 3335
urinary tract infections, 3336
cystourethrogram for, 3348
cystourethroscopy for, 3348
diagnostic evaluation of, 3343–3351, 3351*b*
diet and, 3324, 3325*t*
epidemiology of, 3316–3335, 3341*b*
analytical studies, 3320–3327
definitions for, 3316–3317
descriptive studies for, 3317–3320
parameter correlations, 3324–3327, 3326*f*–3327*f*, 3327*t*
etiology of, 3305–3313, 3316*b*
androgen receptors in, 3307
androgen role, 3306–3308, 3306*t*
cytokines, 3311, 3312*f*

  - dihydrotestosterone in, 3307–3308, 3308*f*
  - estrogen role in, 3308–3309, 3308*t*
  - familial factors in, 3311–3312, 3311*t*
  - genetic factors in, 3311–3312, 3311*t*
  - growth factors, 3309–3310, 3310*f*
  - hyperplasia, 3305–3306
  - inflammatory pathways in, 3311, 3312*f*
  - programmed cell death regulation, 3309
  - prolactin, 3313
  - signaling pathways in, 3310–3311
  - steroid 5α-reductase in, 3307–3308, 3308*f*
  - stromal-epithelial interaction, 3309

filling cystometry for, 3347

frequency-volume charts and bladder diaries of, 3344–3345

future directions for, 3401–3402, 3402*f*

health-related quality of life and, 3319

histologic features of, 3314–3315, 3314*f*

histologic prevalence of, 3317, 3317*f*

hypertension and, 3322

imaging for, 3347

instrumental investigations of, 3346–3351

laboratory tests of, 3345–3346

liver cirrhosis and, 3322

lower urinary tract function and, 2528

in lower urinary tract symptoms, 3305, 3306*f*

management of lower urinary tract symptoms caused by, 3351–3371
  - conservative, 3351, 3352*f*–3353*f*
  - lifestyle and dietary modifications, 3351–3353
  - watchful waiting, 3351

medical history for, 3343

medications and, 3324
  - effects of, 3404

metabolic syndrome and, 3324, 3325*t*

muscarinic receptor antagonists for, 3379–3381
  - efficacy of, 3379–3381, 3380*t*
  - rationale and indication for, 3379, 3379*t*
  - summary for, 3381
  - tolerability and safety profile of, 3381

natural history of, 3316–3335

obesity and, 3324, 3325*t*

pathology of, 3313–3315

pathophysiology of, 3313–3316, 3313*f*

phosphodiesterase type 5 inhibitors for, 3382, 3382*f*, 3383*t*–3384*t*, 3385*f*

- α1-adrenergic blockers with, 3393, 3394*t*

physical activity and, 3324, 3325*t*

physical examination for, 3344

phytotherapy for, 3393–3399

- current role of, 3395
- extract composition of, 3394, 3394*t*–3395*t*
- *Hypoxis rooperi* (South African star grass), 3398
- lycopene, 3398–3399
- mechanism of action, 3394–3395, 3395*t*
- origin of agents for, 3394, 3394*t*
- *Pygeum africanum* (African plum), 3398
- *Serenoa repens* (saw palmetto berry), 3395–3398, 3396*f*, 3397*t*
- summary for, 3399

postvoid residual volume for, 3346

pressure-flow study for, 3347

prostate and bladder imaging for, 3348

prostate size and, 3320, 3320*f*, 3404

prostate-specific antigen in, 3345

religion and, 3320–3321

serum creatinine measurement for, 3345–3346

sexual activity and, 3322, 3322*f*, 3323*t*

smoking and, 3324

smooth muscle in, 3315, 3315*f*

socioeconomic factors in, 3321, 3321*t*

surgery for, 3321, 3339–3340, 3340*f*

surgical treatment for, 3403–3404

symptom of

- assessment of, 3343–3344
- severity and frequency of, 3317–3319, 3319*f*

untreated, natural history of, 3327–3328

- baseline symptom severity in, 3331–3332
- clinical parameters of, 3328, 3328*t*
- disease progression in, 3332, 3332*f*–3333*f*, 3334*t*
- longitudinal population-based studies, 3333–3335, 3334*f*, 3334*t*–3335*t*
- outcomes of interest with, 3328, 3328*t*

        - perception of improvement, 3333
        - placebo control groups in, 3331, 3331*t*
        - placebo/sham effect in, 3331–3332
        - sham control groups in, 3331
        - study methods for, 3328–3335, 3329*t*
        - watchful waiting studies for, 3329–3330, 3330*f*, 3330*t*
    - upper-tract imaging for, 3347–3348
    - upper urinary tract in, deterioration of, 3336
    - urinalysis for, 3345
    - urodynamics for, 3347
    - uroflowmetry for, 3346–3347, 3346*f*
    - vasectomy and, 3322, 3322*f*, 3323*t*
- Benign prostatic obstruction (BPO), bladder outlet obstruction and, 2566
- Benign renal tumors, 2121–2132, Renal cysts
    - angiomyolipoma, 2125–2128, 2126*f*–2127*f*, 2128*b*
    - cystic nephroma, 2129–2130, 2129*f*
    - diagnosis of, 2121
    - leiomyoma, 2131, 2131*f*, 2131*b*
    - metanephric adenoma, 2128–2129, 2129*f*, 2129*b*
    - mixed epithelial and stromal, 2130, 2130*f*, 2130*b*
    - mixed mesenchymal and epithelial, 2129–2130, 2129*f*
    - oncocytoma, 2123–2125, 2124*f*, 2125*b*
    - other, 2131–2132, 2132*b*
    - papillary adenoma, of kidney, 2128, 2128*b*
- Benign urethral tumors, 1776
    - FEPs, 1776
    - hemangiomas, 1776
    - leiomyomas, 1776
- Benzodiazepines, to facilitate bladder emptying, 2720.e2
- BER, Base excision repair
- Berger disease, 17
- Beta-blockers, contrast media and, 32
- Bethanechol (Urecholine)
    - administration of, 2717

  for detrusor underactivity, 2660–2661
  efficacy of, 2718
  to facilitate bladder emptying, 2716–2717
  side effects of, 2718
  supersensitivity test, 2565
  ureteral response to, 1887

Bevacizumab, 1358, 3700
  for RCC, 2146, 2333–2334, 2333*t*

BEZ235, 3700

BF, Biofeedback

Bicalutamide, 3675

Bicarbonate reabsorption, in neonate, 342

Bicycle riding, long-distance, penile implants and, 1596, 1597*f*

Bifid pelvis, 737, 738*f*

Bifid scrotum, 886, 887*f*

Bifid ureters, 820–821

BII, BPH Impact Index

Bilateral anterior subcostal approach, for open kidney surgery, 2253

Bilateral renal agenesis (BRA), 714–717
  amniotic fluid production and, 716–717
  diagnosis of, 717
  gross pathologic description of, 715, 716*f*
  incidence of, 714
  mammalian kidney organogenesis in, 714–715
  phenotypic features associated with, 715–716, 717*f*
  postnatal radiographic evaluation of, 717
  prognosis of, 717
  renal embryology and possible etiology of, 714

Bilateral vanishing testes syndrome, 1005–1006

Bilirubin, in urine, 20

Binary survival outcomes, 104–105

Biochemical evaluation, of pheochromocytoma, 2376, 2377*f*, 2377*t*

Biochemical recurrence

- after radiation therapy, 3665–3670
    - androgen deprivation therapy after, 3668–3670
    - biopsy, 3666
    - imaging for, 3666–3667
    - natural history, 3666
    - prostate-specific antigen bounce, 3666
    - prostate-specific antigen recurrence, 3665–3666
    - salvage brachytherapy, 3668
    - salvage cryotherapy, 3667–3668, 3669*t*
    - salvage high-intensity focused ultrasound, 3668
    - salvage radical prostatectomy, 3667, 3667*t*
- after radical prostatectomy, 3659–3665
    - adjuvant radiation therapy, 3664–3665
    - androgen deprivation therapy, 3665
    - androgen deprivation therapy with salvage radiation therapy for, 3663–3664
    - definition of, 3659
    - imaging of, 3661–3662, 3662*f*
    - natural history of, 3660–3661
    - prediction of, 3659–3660, 3660*t*
    - salvage radiation therapy dose response, 3663
    - salvage radiation therapy for, 3662–3663
    - ultrasensitive prostate-specific antigen for, 3661
    - whole-pelvis *versus* prostatic bed radiation therapy, 3664, 3664*f*–3665*f*
- of prostate cancer, management strategies for, 3659–3670, 3670*b*

Bioethics, 115

Biofeedback (BF)

- for bowel-bladder dysfunction, 656–657
- for genito-pelvic pain-penetration disorder, 1653
- with PFMT, 2727.e1*f*, 2729, 2729*f*, 2729.e1*f*–2729.e2*f*

Biofilm, 434

- formation, 430, 434

BioGlue, 215.e2

Biologic grafts, for posterior compartment repair, 2829

Biologic therapies, for neuroblastoma, 1095–1096

Biologically active agents, 148

Biomarker Development Laboratory (BDL), 3478–3479

Biomarker Reference Laboratories (BRL), 3478–3479

Biomarkers
- for non-muscle-invasive bladder cancer, 3109, 3109*f*
- for penile cancer, 1759, 1759*t*
- telomerase activity as, 1364
- for testicular tumors, in pediatric patients, 1122, 1122*f*

Biopsy
- bladder, for RMS, 1113
- prostate, after radiotherapy for biochemical recurrence, 3666
- renal
  - laparoscopic, 2292, 2292*f*
  - ultrasound guidance of, 79–80
- for renal tumor ablation, 2314
- in retrograde ureteroscopic, 2212
- testis, 1454–1456
  - aspiration, percutaneous, 1455
  - complications of, 1456
  - indications of, 1454–1455
  - open testis biopsy: microsurgical technique for, 1455, 1456*f*
  - percutaneous, 1455
- in transurethral resection of bladder tumor, for non-muscle-invasive bladder cancer, 3096

Biopsy-based lesion identification, for focal therapy for prostate cancer, 3621

Biosyn suture, 149

Biothesiometry, 1527

Bipolar electrocautery, 466

Bipolar electrosurgical devices, 237
- for laparoscopic and robotic surgery, 214

Bipolar resectoscope, 172

Bipolar transurethral resection of the prostate (B-TURP), 3418–3420
- complications with, 3419
  - intraoperative, 3419

    - perioperative, 3419
    - postoperative, 3419
  - concept for, 3418–3419
  - conclusion for, 3419–3420
  - outcomes with, 3419
    - comparative studies, 3419
    - single-cohort studies, 3419
  - technique for, 3419
- Birmingham Reflux Study (Birmingham Reflux Study Group 1987), 515
- Birt-Hogg-Dubé (BHD) syndrome, genomic alterations in, 1354*t*, 1358, 2142*t*, 2144–2145
- BISF-W, Brief Index of Sexual Function for Women
- Bisphosphonates, for castration-resistant prostate cancer, 3703–3704
- Bites, animal and human, penile, 3050
- Bladder, 315*f*, 324*f*
  - afferent pathways in, 2481–2486, 2487*b*
    - cannabinoids, 2486
    - in detrusor underactivity, 2653–2655, 2655*f*
    - functional properties of, 2482–2483, 2483*f*
    - modulators of, 2483–2484
    - nitric oxide in, 2484, 2484*f*
    - pelvic organ interactions with, 2486, 2486*f*
    - properties of, 2481
    - purinergic signaling, 2484–2485, 2485*f*
    - spinal cord pathways of, 2481–2482, 2481*t*, 2482*f*
    - transient receptor potential cation channels, 2485
  - aging and, 2509–2510
  - anatomy of, 2461–2513, 2462*f*, 3010
    - lamina propria of, 2462–2463
    - smooth muscle of, 2465, 2465*f*
    - stroma of, 2463
    - urothelium of, 2461–2462, 2462*f*–2463*f*, Urothelium, of bladder
    - vasculature of, 2462–2463, 2464*f*
  - capacity of
    - nocturnal, 661–662
    - pharmacologic therapy to increase, 2679–2700
    - reconstruction and, 681–682
  - cells, receptivity in UTIs, 1136–1137, 1137*f*

changes, during pregnancy, 1185
closure of, for classic bladder exstrophy, 545–548, 546*f*–548*f*
contractility of
  bladder emptying and, 2716–2718
  pharmacologic therapy to inhibit, 2679–2700
contraction of
  muscarinic receptors and, 2679–2681
  normal, in voiding, 2515–2516
decompensation, in benign prostatic hyperplasia, 3335
defects in, in bladder exstrophy, 535–537, 536*f*–537*f*
defunctionalized, lower urinary tract dysfunction and, 2632–2633
development of, 329–333, 333*b*
dynamics of, 681–682
dysfunction of, 680–681
  with posterior urethral valves, 616–619
efferent pathways to, 2487–2493, 2487*f*
  adrenergic, 2488
  in detrusor underactivity, 2653, 2655*f*
  glutamate in, 2488, 2489*f*
  glycine and γ-aminobutyric acid in, 2488
  purinergic, 2488–2489
  reflex circuitry, 2489–2493, 2490*f*
  serotonin in, 2488–2489
  terminal nerve fibers, 2487–2488
  transmitters in, 2488, 2490*b*, 2491*f*–2492*f*, 2491*t*
emptying failure of, 2903–2904, 2903*b*–2904*b*
  absorbent products for, 2904
  catheterization for, 2900–2902, 2900*f*
  external collecting devices for, 2903–2904
  intravesical pressure increases for, 2902–2903
emptying of
  benign prostatic hyperplasia and, 3354–3355
  failure of, 2518–2519
  reconstruction and, 682
  therapy to facilitate, 2520*b*
  urodynamic studies of, 2564–2566
estrogens and, 2503
filling of, Continence
  abnormalities of, 2516–2519, 2516*b*–2517*b*, 2518*t*
  bladder response during, 2514–2515
  mechanics of, 2478–2479

    - outlet response to, 2515
    - smooth muscles in, 2478
    - urodynamic studies of, 2552*t*–2553*t*, 2559
- in genitourinary tuberculosis, 1309
- glycosaminoglycan layer, 1232.e5–1232.e7, 1232.e7*b*
- high-pressure, spinal cord injury with, host defense mechanisms in UTIs and, 1140
- injuries of, 3054–3057, 3055*b*–3056*b*
    - clinical signs and symptoms of, 3056
    - complications with, 3057
    - diagnosis of, 3055–3056
    - etiology of, 3054–3055
    - with holmium laser enucleation of prostate, 3438
    - management of, 3056–3057, 3056.e1*f*
    - outcomes with, 3057
    - radiographic imaging of, 3055–3056, 3055*f*
- male
    - circulation of, 2456
    - innervation of, 2456
    - relationship with, 2448*f*
    - trigone, 2455–2456, 2456*f*
    - ureterovesical junction of, 2455–2456, 2456*f*
- mesh perforation of, in midurethral sling, 2868–2870, 2868*f*, 2869*t*, 2870*b*
- natural defenses of, 1138–1139
- necrosis of, with transurethral vaporization of prostate, 3426
- neoplasia in, 1360–1361
- neural tube defects and, early intervention for, 628, 628*f*
- obstruction of
    - response to, 3315–3316
    - RMS causing, 1113
- overactive, Overactive bladder
- paralytic, 2522
- perforation of
    - after augmentation cystoplasty, 700–701, 700*f*
    - in transurethral resection of bladder tumor, 3135, 3135*f*
- pharmacology of, 2497–2503
    - adrenergic mechanisms, 2500–2501, 2501*f*, 2501*b*
    - muscarinic mechanisms, 2497–2500, 2499*t*, 2500*b*
    - sex steroids, 2502–2503
- physical examination for, 10, 10*f*–11*f*
- in prune-belly syndrome, 582–583, 584*f*

- pudendal nerve stimulation and, 2511
  - inhibitory and excitatory frequencies for, 2511
- reconstruction of, 690–691
  - after RMS treatment, 1116
- regeneration of, for augmentation cystoplasty, 706
- sensation of
  - altered, filling/storage failure due to, 2517–2518
  - detrusor underactivity and, 2659
  - terminology for, 2581
- sensory input of, pharmacologic therapy to decrease, 2679–2700
- smooth muscle of, 1185, 2465, 2465*f*
- storage failure of, 2517–2518, 2903–2904, 2904*b*
  - absorbent products for, 2904
  - augmentation cystoplasty for, 2889–2890
  - external collecting devices for, 2903–2904
- storage function of
  - after retropubic suspension surgery, 2770
  - pharmacologic therapy to facilitate, 2679–2716
  - urinary incontinence and, 2581
  - urodynamic studies of, 2552*t*–2553*t*, 2559
- suburothelial interstitial cells of, 2470, 2470*f*
- surgical considerations of, 3010
- transabdominal pelvic ultrasonography, 80–81, 80*f*–81*f*
- transurethral resection of, 1198–1199
- trigone of, 2455–2456, 2456*f*
- tumors of, Bladder tumors
- underactive, 2506–2507, 2650
  - parasympathomimetics for, 2660–2661
  - pediatric, 660
- unstable, 2637
- UPEC persistence in, 1136–1137, 1138*f*
- urothelium of, genetic alterations in, 1360–1361
- voiding of, Micturition
  - bashful bladder, 2628–2629
  - mechanics of, 2479

Bladder advancement flap, laparoscopic or robotic, 3031, 3033*f*

Bladder and bowel dysfunction (BBD), 397–399, 495
- conservative management of, 656

  - neuromodulation for, 658, 659*t*
  - in pediatric patients, 654
  - pharmacotherapy for, 657–658
  - treatment for, 655–656
  - urotherapy for, 655–656

Bladder anomalies, in children, 518–527
  - acquired, 525–526, 527*b*
    - inflammatory, 526
    - noninflammatory, 525–526
  - congenital, 518–525, 523*b*
    - embryology of urinary bladder, 518
    - normal and abnormal antenatal sonographic findings of bladder, 518–525

Bladder augmentation, pharmacologic therapy in, to facilitate bladder filling and urine storage, 2718

Bladder calculi
  - after renal transplantation, 2117
  - bladder outlet obstruction with bladder lithiasis, 2115–2116
  - etiopathogenesis of, 2114–2115
  - lithotripsy
    - for EHL, 241
    - pneumatic, 244.e4
  - medical management of, 2066–2067
  - in patients with spinal cord injury, 2116–2117
  - in urinary diversions and augmented bladder, 2116

Bladder cancer
  - BCG in, 1333, 1334*f*, 1338–1339, 1339*f*
  - bladder diverticula with, 2969–2971, 3011
  - chronic inflammation role in, 1336–1338, 1337*f*–1338*f*
  - diminished bladder capacity and, 2671
  - DNA methylation in, 1349
    - *CDH1* and *RASSF1A* genes, 1350
    - hypermethylation, 1350
    - hypomethylation, 1350
    - *INK4A* gene, 1350
  - genomic alterations in, 1358–1360
    - alterations in normal and benign urothelium, 1360–1361

    - detection and surveillance using, 1361
    - before neoplasia, 1360–1361
  - in geriatric patients, 2920.e12–2920.e13
  - hereditary, 3076
  - immune checkpoint blockade in, 1342
  - immunotherapy for, 1333
  - long-term indwelling catheterization and, 2616
  - metastatic
    - chemotherapy for, 3127*t*
    - FDA-approved agents and future directions for, 3130
    - first-line, immune checkpoint inhibitor therapy, 3130
    - immune checkpoint inhibitor therapy, 3129–3130
    - management of, 3112–3132, 3131*b*
    - multiagent, second-line chemotherapy for, 3129
    - randomized trials in, 3127–3128, 3127*t*
    - second-line, immune checkpoint inhibitor therapy, 3130
    - second-line chemotherapy for, 3128, 3128*t*
    - single agent, second-line chemotherapy for, 3128–3129, 3129*t*
    - targeted therapy for, 3130–3131
  - minimally invasive, 3144
  - as non-AIDS-defining urologic malignancy, 1268
  - in nuclear medicine, 43
  - screening for, molecular genetics-based assays for, 1361
  - UTUC after, 2192–2193
- Bladder cancer, pediatric
  - in augmented bladders, 1118
  - carcinoma, 1118
  - TCC, 1117–1118
  - urachal carcinoma, 1118
- Bladder coil, 174*f*
- Bladder compliance (C), 2478
  - after augmentation cystoplasty, 697–698, 697*f*
  - impaired, urodynamic studies of, 2560–2561, 2560*f*–2561*f*
- Bladder contractility index (BCI), 2567, 2567*f*, 2659
- Bladder cooling reflex, 2485
- Bladder cuff

  - management, 2200
  - open distal ureterectomy with excision of, 2204

Bladder diary, 3
  - for behavioral treatment programs, 2723, 2724*f*
  - for benign prostatic hyperplasia (BPH), 3344–3345
  - Questionnaire-Based Voiding Diary, 2723, 2723.e1*f*–2723.e2*f*
  - for urinary incontinence, male, 2541, 2541*f*

Bladder diverticula, 509–510, 509.e1*f*, 2964–2972, 2965*f*–2966*f*
  - associated conditions, 2969–2971
    - bladder outlet obstruction, 2969
    - endoscopic examination, 2969, 2970*f*
    - ipsilateral vesicoureteral reflux, 2971
    - malignancy, 2969–2971
  - classification of, 2964–2965
  - diagnosis of, 2965–2969, 2971*b*
    - evaluation of, 2965–2967, 2966*f*
    - imaging of, 2965*f*, 2967, 2968*f*–2969*f*
    - presentation of, 2965–2967, 2966*f*
    - urodynamics of, 2967–2969
  - etiology of, 2964–2965
  - malignancy, 3011
  - management of, 2971–2972, 2972*b*, 2973*f*
    - endoscopic, 2972
    - indications for intervention, 2972
    - observation and nonsurgical, 2972
  - nonsurgical management of, 2972
  - pathophysiology of, 2964–2965
  - surgical management of, laparoscopic and robotic diverticulectomy, 2972
  - techniques for repair, complication with, 2991, 2991*f*

Bladder diverticulectomy, 3010–3019, 3011*f*, 3011*b*, 3046*b*–3047*b*
  - complications of, 3018–3019
  - evaluation of, 3011–3012, 3012*f*
  - laparoscopic and robotic techniques, 3015–3018, 3016*f*–3017*f*
  - outcomes of, 3018–3019
  - postoperative care of, 3018–3019
  - surgical indications, 3011–3012, 3012*f*
  - surgical technique of, 3012–3018, 3012*f*

Bladder duplication, 521–522, 521*f*

Bladder dysfunction, after pediatric renal transplantation, 1063

Bladder epithelial grafts, 1806

Bladder exstrophy, 330, 379–380, 381*f*

- recommendations for, 379–380

Bladder filling, ureteral function effects of, 1893

Bladder function

- localized prostate cancer and, 3524
- in prune-belly syndrome, 596–600

Bladder functional assessment, for ureteral anomalies, 806

Bladder health promotion research, for LUTS prevention, 2735–2736

Bladder hemangiomas, 525

Bladder imaging, for benign prostatic hyperplasia, 3348

Bladder infections, 1166*b*

- complicated, 1158–1159, 1158*f*, 1158*t*
- emphysematous cystitis, 1158–1159
- recurrent UTIs, 1159–1166, 1160*t*, 1160*b*
    - bacterial persistence, 1160–1161
    - cranberry, 1163–1164, 1164*f*
    - D-mannose, 1166
    - estrogen, 1164–1165, 1164*f*
    - immunoactive prophylaxis, 1166
    - low-dose continuous prophylaxis for, 1162–1163
    - management, 1161–1166, 1161*f*
    - methenamine, 1165–1166, 1165*t*
    - non-antibiotic management, 1163
    - probiotics, 1165
- uncomplicated cystitis, 1155–1158
    - antimicrobial selection for, 1156–1157
    - clinical presentation, 1156
    - follow-up, 1157–1158
    - laboratory diagnosis, 1156
    - management, 1156–1157, 1157*f*
    - risk factors, 1156*b*
- unresolved UTIs, 1159, 1159*b*

Bladder injury
  complications of seminal vesicle surgery, 1863
  and intraoperative consultation, 299–300, 303*b*
    diagnosis/recognition, 300
    incidence, 299, 299*t*
    management, 300
    mechanisms, 299–300, 300*t*
  during laparoscopic and robotic surgery, 230.e1
  perforation/extrusion and, 2882–2883, 2882*f*
Bladder mobilization, for ureteral reimplantation, 3021, 3021*f*
Bladder mucosa, in vesicovaginal fistula repair, 2940, 2941*f*
Bladder neck, 1807.e4*f*, 1807.e8
  division of, 690
  in laparoscopic radical prostatectomy
    identification and transection of, 3573, 3573*f*
    reconstruction of, 3577
  mesh perforation/extrusion at, 2883, 2883*b*, 2884*f*–2885*f*
  in neuromuscular dysfunction of lower urinary tract, 637
  in retropubic radical prostatectomy
    division of, 3559–3560, 3560*f*–3561*f*
    reconstruction and anastomosis of, 3560–3562, 3561*f*–3562*f*
Bladder neck closure
  in classic bladder exstrophy
    failure of, 563–564, 564*b*
    outcomes and results of, 558–559, 559*t*, 559*b*, 560*f*
  for vesicoureteral reflux, 2615
Bladder neck contracture
  after photoselective vaporization of prostate, 3441
  after retropubic radical prostatectomy, 3564
  with bipolar transurethral resection of prostate, 3419
  with holmium laser enucleation of prostate, 3438
  with monopolar transurethral resection of prostate, 3417
Bladder neck dysfunction, 2519
  lower urinary tract dysfunction and, 2627–2628
  videourodynamics for, 2570, 2570*f*

Bladder neck reconstruction

- artificial urinary sphincter for, 687–688
- bladder neck division for, 690
- bulking agents for, 687
- fascial sling for, 686–687
- Pippi Salle procedure for, 690, 691*f*
- urethral lengthening for, 688–690, 689*f*
- in urinary tract reconstruction, 685–690, 690*b*
- Young-Dees-Leadbetter repair for, 685–686

Bladder neck slings, for neuromuscular dysfunction of lower urinary tract, 637

Bladder neck stenosis, after transurethral microwave therapy, 3430

Bladder neck stricture, in robotic prostatectomy, 3580

Bladder outlet

- closure of, 2898, 2899*f*
- overactivity of, emptying/voiding failure from, 2519
- response of, to filling, 2515
- storage failure at, 2890–2898, 2898*b*
  - adjustable continence therapy, 2895, 2895*f*
  - adverse events of, 2893
  - bladder outlet closure, 2898, 2898*b*, 2899*f*
  - cell-based therapy, 2895–2898
  - complications of, 2895
  - human studies, 2896
  - injectable agents for male stress urinary incontinence, 2896–2897
  - injection techniques of, 2891–2893, 2892*f*
  - outcomes of, 2895
  - patient selection, indications, and contraindications, 2891
  - periprocedure care of, 2893
  - urethral bulking agents, 2890–2895
- surgery of, for detrusor underactivity, 2662–2663
- underactivity of
  - emptying/voiding failure from, 2518–2519
  - filling/storage failure from, 2518
- ureteroceles and, 806–807, 807*f*–808*f*

Bladder outlet obstruction (BOO)

- after pubovaginal sling procedure, 2845–2848, 2848*b*
  - surgical management of, 2846–2848, 2847*t*

- in benign prostatic hyperplasia, medical treatment and, 3354
- with bladder diverticula, 2964–2965
- detrusor underactivity and, 2655–2656, 2657*b*
- emptying/voiding failure from, 2519
- in geriatric patients, 2920.e7
- mechanisms of, 2505–2506, 2506*b*
- in mesh complication, 2880
- nocturia and, 2671–2673
- urodynamic studies of
  - in men, 2566–2567, 2567*f*
  - in women, 2567–2568
- videourodynamic studies of
  - in women, 2570, 2570*f*
- in women, lower urinary tract dysfunction and, 2628

Bladder output relation (BOR), 2566, 2566*f*

Bladder pain syndrome (BPS), 2517–2518
- female sexual dysfunction and, 1657
- overactive bladder distinguished from, 2637, 2638*f*
- terminology for, 2637

Bladder pain syndrome and interstitial cystitis (BPS/IC), 1224–1250
- definition of, 1224, 1225*f*–1226*f*, 1226*b*
- diagnosis of, 1225*b*, 1233, 1234*t*, 1235*f*, 1236*b*, 1239*b*
  - markers in, 1238
  - potassium chloride test, 1238–1239
- epidemiology of
  - associated disorders, 1230–1231, 1230*t*, 1231*f*, 1231*b*
  - natural history, 1228–1229, 1230*b*
  - prevalence, 1226, 1227*t*–1228*t*, 1229*b*
- etiology of, 1231–1232, 1232*f*, 1232.e11*b*
  - animal models, 1232.e1
  - antiproliferative factor, 1232.e7, 1232.e8*b*
  - autoimmunity and inflammation, 1232.e2–1232.e3, 1232.e3*b*
  - bladder glycosaminoglycan layer and epithelial permeability, 1232.e5–1232.e7, 1232.e7*b*
  - genetics, 1232.e10
  - infection, 1232.e1–1232.e2
  - mast cells and histamine, 1232.e4–1232.e5, 1232.e5*b*
  - neurobiology, 1232.e7–1232.e9, 1232.e9*b*
  - nitric oxide metabolism, 1232.e9

    - other potential causes, 1232.e10–1232.e11
    - pelvic organ cross-sensitization, 1232.e9, 1232.e9*b*
    - urine abnormalities, 1232.e9–1232.e10
  - historical perspective of, 1224–1225, 1225*b*
  - mechanisms of, 2507–2509, 2509*b*
  - nomenclature, 1224
  - pathology, 1232–1235, 1233*b*
  - surgical therapy for, 1247–1248, 1249*b*
    - historical procedures, 1247–1248
    - for Hunner lesion, 1248
    - hydrodistention, 1247
    - major procedures, 1248
    - surgical considerations, 1247
  - taxonomy, 1224, 1225*f*
  - treatment of, 1239*b*
    - conservative therapies, 1239–1240
    - diet, 1240–1241, 1240*b*
    - intravesical therapies, 1241*t*, 1244–1247, 1245*b*
    - neuromodulation, 1246–1247, 1247*b*
    - oral therapies, 1241–1244, 1241*t*, 1244*b*
    - surgical therapy, 1247–1248, 1249*b*
  - urgency, 1225–1226, 1226*f*, 1226*b*
  - urine studies
    - biopsy, 1236–1238, 1237*f*
    - clinical assessment and research, 1235.e1, 1235.e1*b*
    - office cystoscopy, 1236, 1237*f*
    - urodynamic evaluation, 1235–1236
    - voiding diary, 1235
- Bladder recurrence, UTUC after, 2193
- Bladder retraining, types of, 3352
- Bladder RMS, 1111
  - biopsy of, 1113
  - epidemiology and syndromic associations of, 1111
  - imaging evaluation of, 1113–1114
  - pathology and molecular biology of, 1111–1113, 1112*f*, 1113*b*
  - presenting symptoms and examination of, 1113–1117, 1113*t*, 1113*b*
  - staging and COG risk group assignment of, 1113–1114, 1114*t*
  - treatment of, 1115*b*

        - COG multimodal approaches to, 1114–1115
        - European Cooperative Group approaches to, 1115
        - evolution of multimodal, 1114
        - late effects of, 1116–1117
        - outcomes of, 1116
        - surgical reconstruction, 1116
        - for very young children, 1116

Bladder spasm, 932

Bladder sphincter function, effects of sex reassignment surgery on, 3062–3063

Bladder stones, 243.e1, 244.e3–244.e4, 3043–3046

    - with benign prostatic hyperplasia, 3335
    - complications of, 3046
    - endourologic approach to, 2115, 2116*f*
    - evaluation of, 3043–3044
    - laparoscopic and robotic technique, 3044–3045, 3045*f*–3046*f*
    - management of, 2115
        - medical, 2115
    - open surgery for, 2115
    - open technique of, 3044, 3045*f*
    - percutaneous, 3045–3046
    - postoperative care of, 3046
    - presentation of, 2115
    - surgical indication of, 3043–3044
    - surgical technique of, 3044–3046

Bladder surgery, for genitourinary tuberculosis treatment, 1317–1318

Bladder training

    - evidence for, 2730
    - for urinary incontinence, 2722.e2*b*–2722.e4*b*, 2728*f*, 2730, 2730.e1*t*

Bladder tumor antigen (BTA) assay, of bladder tumor, 3079–3081

Bladder tumors, 3073–3090, 3078*b*

    - benign, 3010–3047
        - anatomy of, 3010
        - bladder stones, 3043–3046
        - diverticulectomy, 3010–3019, 3011*f*, 3011*b*, 3046*b*–3047*b*
        - enterocystoplasty, 3034–3038
        - foreign-body removal, 3043–3046

      - partial cystectomy, 3038–3043
      - psoas hitch and Boari flap, 3026–3034
      - surgical considerations of, 3010
      - urachal surgery, 3038–3043
      - ureteral reimplantation, 3019–3026
  - benign, pediatric, 1119
  - nonurothelial malignancy, 3089–3090, 3089*f*
      - prostatic urethral cancer, 3084
      - sarcomas, Sarcomas, of bladder
  - during pregnancy, and urologic malignancy, 293

Bladder urinary diversion, rectal, 3209–3211
  - augmented valved rectum, 3209
  - folded rectosigmoid bladder, 3209
  - hemi-Kock pouch procedures with valved rectum, 3209–3210
  - Mainz II pouch, 3210–3211
  - sigma-rectum pouch, 3210–3211
  - T pouch procedures with valved rectum, 3209–3210, 3210*f*

Bladder wall
  - collagen of, 2463–2464
  - elastin of, 2464
  - matrix of, 2464
  - stroma of, 2463

Bladder wall thickness (BWT), 3348

Blake drains, 148

Bland thrombus, IVC filtration and permanent interruption for, 2277

Bleeding
  - after midurethral sling, 2874
  - during anterior colporrhaphy, 2782
  - complication of scrotal surgery, 1855
  - in monopolar transurethral resection of prostate, 3415
  - with prostate biopsy, 3499
  - at the sheath site, 226–227, 227*f*

Bleomycin, for penile cancer, 1771

Bleomycin-etoposide-cisplatin (BEP), for seminomas, 1705

Blind access, 169

Blind trocar placement, complications related to, 225–226

α-Blockade, for pheochromocytoma, 2378, 2379*f*

β-Blockade, for pheochromocytoma, 2378, 2379*f*

α-Blockers

- for nocturia, 2674
- transurethral microwave therapy *versus*, 3429

Blockers of inhibition, to facilitate bladder emptying, 2719

Blood-based biomarkers, for prostate cancer, 3480–3485

Blood-epididymis barrier, 1404

Blood/hematuria, 16

- differential diagnosis and evaluation of, 16

Blood loss/transfusion, in robotic prostatectomy, 3580

Blood pressure, anesthesia-related changes in, during laparoscopic and robotic surgery, 228.e1

Blood products

- transfusions, preoperative considerations for, for laparoscopic and robotic surgery, 204
- for urologic surgery, 147–148

Blood-testis barrier, 1373, 1398–1399, 1399*f*

Blood tests, for male urinary incontinence, 2543

“BLUE stent,”, 834–835, 834*f*

Blunt dissection instrumentation, for laparoscopic and robotic surgery, 218

Blunt trauma

- renal, 1982
  - imaging of, 1984
  - nonoperative management of, 1986–1987
  - renal artery thrombosis with, 1990
- ureteral, 1992, 1992*t*
  - diagnosis of, 1992–1993

BLUS, Basic Laparoscopic Urologic Surgery

BMI, Body mass index

Boari flap, 3026–3034

- with bladder advancement flap, 3031
- complications with, 3032
- evaluation for, 3026
- laparoendoscopic single-site, 3031
- laparoscopic or robotic, 3030–3031, 3030*f*–3031*f*
- for lower ureteral injuries, 1999, 2000*f*
- with mega-Boari flap, 3033*f*
- outcomes with, 3033–3034
- postoperative care of, 3032
- surgical indication for, 3026
- surgical technique for, 3027–3028, 3028*f*
- with ureteroneocystostomy, 1973

Body habitus, hormonal therapy and, 3681

Body mass index (BMI)

- benign prostatic hyperplasia and, 3324, 3325*t*
- in bladder tumor, 3076
- male SUI and, 2540–2541
- prostate cancer and, 3465, 3465*f*
- urinary incontinence and, 2582

Body weight, renal calculi and, 2027–2028

Bone mineralization, renal regulation of, 1914, 1914*f*

Bone morphogenic protein-7 (BMP-7), in tubulointerstitial fibrosis, 787

Bone scan, for localized prostate cancer, 3527

Bone scan index, 3679

Bone-anchored porcine single-incision sling, 2843

Bone-anchored sling, history and development of, 2994

Bony pelvis

- female, 2427, 2428*f*
- male, 2444

BOO, Bladder outlet obstruction

BOR, Bladder output relation

Bors-Comarr classification, of voiding dysfunction, 2522–2523, 2523*b*

Bosniak category IV lesions, 770

Bosniak classification, for renal cystic lesions, 2122, 2122*f*, 2122*t*, 2137, 2137*t*

Botox, for chronic scrotal pain syndrome, 1221

Bottleneck technique, 1845, 1847*f*

Botulinum toxin (BoNT), OnabotulinumtoxinA

- adverse effects of, 2709
- for bowel-bladder dysfunction, 658
- clinical use of, 2708
- for detrusor underactivity, 2662
- efficacy of, 2709
- to facilitate bladder emptying, 2720.e3
- to facilitate bladder filling and urine storage, 2682*t*, 2707–2709
- mechanism of action of, 2707–2709
- for neuromuscular dysfunction of lower urinary tract, 634–635
- for OAB, 2647
- for Parkinson disease, 2606
- for prostatic injections, 3447

Botulinum-A toxin, for PE, 1572.e3

Bowel cleansing, before inguinal node dissection, 1801

Bowel disorders, normal *versus* abnormal, 667, 668*t*

Bowel dysfunction, in geriatric patients, 2920.e9

Bowel entrapment, during laparoscopic and robotic surgery, 230

Bowel function

- localized prostate cancer and, 3525
- urinary incontinence and, 2734

Bowel injury, 275–281, 276*f*

- duodenal and pancreatic injuries, during nephrectomy, 277, 277*f*

- during laparoscopic and robotic surgery, 228*f*, 229
- laparoscopic kidney surgery causing, 2307, 2307*f*
- lymphoceles, 280–281, 281*f*
- management, 278
- mechanism of, 276–277
- port site hernia, 278, 278*f*–279*f*
- rectal injury, 277–278
- in robotic prostatectomy, 3580
- venous thromboembolism, 278–280, 279*t*–280*t*

Bowel insufflation, during laparoscopic and robotic surgery, 224

Bowel interposition, for ureteral injuries, upper, 1998, 1998*f*

Bowel mobilization, in transurethral resection of bladder tumor, 3137, 3137*f*

Bowel obstruction, 3272
- with intestinal anastomoses, 3180–3181, 3180*t*, 3181*f*

Bowel preparation
- preoperative, for laparoscopic and robotic surgery, 204
- for urinary tract reconstruction, 682
- in urologic surgery, 124–125

Bowel resection, orthoptic urinary diversion and, 3238–3239

Bowen disease, of penis, 1742, 1742.e1*f*

Bowenoid papulosis
- as neoplastic condition, 1296, 1298*f*
- of penis, 1742

BP, Bullous pemphigoid

BPH, Benign prostatic hyperplasia

BPH Impact Index (BII), 110*t*
- for benign prostatic hyperplasia, 3344

BPO, Benign prostatic obstruction

BPS, Bladder pain syndrome

BPS/IC, Bladder pain syndrome and interstitial cystitis

BRA, Bilateral renal agenesis

Brachytherapy, 3632–3638

- benign bounce phenomenon and, 3608
- combined with external irradiation, 3613–3615
- external beam radiation therapy *versus*, 3612–3613, 3614*t*
- outcomes for, 3612
- for penile cancer, 1765–1767, 1767*f*–1768*f*
- for prostate cancer, 3591, 3596–3600, 3600*b*
  - combined with external irradiation, 3599–3600
  - high-dose-rate, 3598–3599
  - low-dose-rate, technique and trends of, 3596, 3597*f*
  - patient selection for, 3599
  - permanent implant quality assessment, 3597–3598, 3597*f*, 3598*t*
  - transrectal ultrasound-guided, 3591–3592, 3592*f*

Bradley classification, of voiding dysfunction, 2524

Brain circuits, in detrusor underactivity, 2653, 2655*f*

Brain metastases, of TGCTs, 1706–1707, 1707*b*

Brain tumor

- lower urinary tract dysfunction with, 2604
- neurogenic bladder with, 648

Brainstem

- bladder modulatory mechanisms of, 2493–2494, 2495*f*
  - neurotransmitters and modulators within, 2495–2496
- neuromuscular lower urinary tract dysfunction at and above, 2602–2607

Brainstem stroke, lower urinary tract dysfunction with, 2603

Branchio-oto-renal syndrome, 336–337

Bricker anastomosis, 3187, 3187*f*

Brief Index of Sexual Function for Women (BISF-W), 112, 112*t*

Brindley system, 2741–2742

Bristol Female Lower Urinary Tract Symptoms (BFLUTS) Questionnaire, 110

Bristol Stool Scale, 473–474, 474*f*, 667–668, 668*f*

BRL, Biomarker Reference Laboratories

Broad ligament, 2430, 2431*f*

Brödel-type orientation, 162, 163*f*

Brushite calculi, surgical management of, 2076

- stone fragility and, 2077.e1

Brushite stone formers, 2011–2012, 2013*f*

Brushite stones, surgical management of, method selection for, 2077.e2

BT, Behavioral therapy

B-TURP, Bipolar transurethral resection of the prostate

Buccal mucosa, in complex penile reconstruction, 946

Bulbar urethra, 1807.e8

Bulbocavernosus reflex (BCR), in pelvic floor disorders, 2530

Bulbospongiosus, 2435

Bulbourethral artery, 1383

Bulbourethral glands, 1383

Bulbous urethra, 1383, 1383*f*, 1807.e2*f*, 1807.e4*f*

Bullous pemphigoid (BP), 1284–1285, 1285*f*

Bumetanide, in stone formation, 2033

Bupropion

- for female sexual arousal disorders, 1650
- for female sexual interest disorder, 1645

Burch colposuspension, 2763–2766, 2766*b*

- Marshall-Marchetti-Krantz procedure *versus*, 2773
- paravaginal repair *versus*, 2766
- prophylactic colposuspension, 2765
- pubovaginal sling *versus*, 2771, 2772*f*
- reoperative surgery, 2765–2766
- results with, 2763–2765
- suspensions in, configuration of, 2758
- technique for, 2763, 2764*f*

    urethral elevation in, 2758

Buried penis, 394, 877–878, 878*f*–879*f*

Burns, of penis, 3053

Buschke-Löwenstein tumor, 1742.e1*f*, 1742.e3

Buspirone, for female sexual interest disorder, 1645

BWS, Beckwith-Wiedemann syndrome

BWT, Bladder wall thickness

BXO, Balanitis xerotica obliterans

Byars flap procedure, 927, 931*f*

Bypass techniques, for vena caval thrombectomy, 2275–2276, 2275*f*–2276*f*, 2275.e1*f*, 2276.e1*f*

C

C3 complement, in prostatic secretions, 3298*t*, 3302

CA, Cryoablation

Cabazitaxel, 3692–3693, 3693*f*

Cabozantinib, 3701
  for RCC, 2337, 2338*f*
C-acetate PET/CT, 43
Cadaveric fascia lata
  allograft slings and, 2834–2835
  for pelvic organ prolapse reconstructive surgery, 2781*t*–2782*t*, 2786, 2786*f*
Cadaveric models, laparoscopic training with, 232
Cadherins, in prostate growth regulation, 3288
Caffeine reduction
  for OAB, 2647
  for urinary incontinence, 2733
CAH, Congenital adrenal hyperplasia
Caiman 5 vessel-sealing system, 214.e1*f*
Cake or lump kidney, 728*f*–729*f*, 729
Calcifying nanoparticles (CNPs), 2011
Calcitonin gene-related peptide (CGRP)
  and ED, 1499
  in ureteral function, 1887
Calcium
  filtrate transport, 1911, 1912*f*
  metabolism of, 2015–2016
  in pediatric kidney stone disease, 869
  in prostate cancer, 3463–3465
  PTH and, 1914, 1914*f*, 2016
  sensitization to, 2472–2473
  in smooth muscle contraction, 2472–2473, 2472*b*, 2473*f*, 2475–2476, 2476*f*
  in ureter physiology
    excitation-contraction coupling and, 1884–1885
    as second messengers, 1885–1887, 1885*f*–1886*f*
  vitamin D and, 1914, 2015
Calcium antagonists

    - to facilitate bladder filling and urine storage, 2682*t*, 2696–2697
    - urethral function effects of, 1903
- Calcium apatite, 2011
- Calcium-based calculi in, 2048–2049, 2049*b*
    - dietary, 2049
- Calcium channel blockers (CCBs)
    - and ED, 1507
    - for pheochromocytoma, 2379–2380, 2379*f*
    - ureteral function effects of, 1900
- Calcium channels, in detrusor muscle, 2474–2475, 2475*f*
- Calcium hydroxylapatite (Coaptite), for female urinary incontinence, 2894–2895
- Calcium-induced calcium release (CICR), 2476
- Calcium oxalate stones
    - of crystal formation, 2010
    - formation of, 2008
    - formers of, 2011–2012
    - homogeneous nucleation, 2011
    - Randall plaques and, 2011, 2012*f*–2013*f*, 2018
    - surgical management of, 2076
        - stone fragility and, 2077.e2
- Calcium stones, in renal calculi, 2018–2026
    - hypercalciuria, 2018–2020
    - hyperoxaluria, 2020–2023, 2021*f*–2022*f*
    - hyperuricosuria, 2023–2024, 2024*f*
    - hypocitraturia, 2024
    - hypomagnesiuria, 2026
- Calculi
    - after augmentation cystoplasty, 699
    - HIV and, 1266
- Caldesmon (CaD), 2472, 2473*f*
- Calicovesicostomy, for ureteropelvic junction obstruction, laparoscopic, 1960

Calyceal diverticula
- percutaneous nephrolithotomy and, 2105, 2105*f*
- renal calculi with, 2034
  - surgical management of, 2077–2078, 2077.e1*f*

Calyceal diverticulectomy, laparoscopic, 2294

Calyceal diverticulum, 737–738, 739*f*, 774, 774*f*

Calyceal fornix, 161, 162*f*

Calyces, 1865.e1*f*
- hydrocalycosis, 738
- megacalycosis, 738–739, 740*f*
- renal, 1869, 1869.e1*f*
  - normal urothelium of, 2188

Cameras, for laparoscopic and robotic surgery, 213

Camey II orthotopic substitute, 3243, 3243*f*

cAMP, Cyclic adenosine monophosphate

Camper fascia, 2444, 2446*f*

Cancer
- chronic inflammation in GU cancers, 1336, 1338*b*
  - bladder cancer, 1336–1338, 1337*f*–1338*f*
  - kidney cancer, 1338
  - prostate cancer, 1338
- female urethral, 1782–1785, 1785*b*
- fertility preservation in, 1452
- immunologic response to, 1333–1345, 1336*b*
  - adaptive immune system, 1334–1336, 1335*f*
  - immune editing hypothesis, 1336, 1337*f*
  - innate immune system, 1333–1334, 1334*f*–1335*f*, 1334*t*–1335*t*
- immunotherapy for, 1333–1345, 1341*b*, 1343*b*
  - BCG in bladder cancer, 1333–1334, 1334*f*, 1338–1339, 1339*f*
  - cancer vaccines, 1339–1340, 1340*f*–1341*f*
  - combination, 1343–1345, 1345*f*
  - immune checkpoint blockade, 1342, 1342*f*
- male urethral, 1776–1782, 1782*b*
- surgery, 2959–2960
- of testis, 1440

  - with urinary intestinal diversion, 3203–3204
  - vaccines for, 1339–1340, 1340*f*
    - for genitourinary tumors, 1341–1342, 1342*f*
    - for kidney cancer, 1340–1341
    - for prostate cancer, 1341, 1341*f*

CancerSEEK test, 3485

Candida albicans, 445

Candidal intertrigo, 1293–1294, 1294*f*

Candidiasis, 1272, 1272*t*

Cannabinoids
  - in bladder afferent pathway, 2486
  - in ED, 1495, 1495*t*
  - to facilitate bladder filling and urine storage, 2713.e2–2713.e3

Cantwell-Ransley procedure, for classic bladder exstrophy repair, modified, 551–552, 552*f*–553*f*

Capacitive coupling, 237

Capillary hemangioma, 1304–1306

Capio suture capturing device, for sacrospinous ligament fixation, 2795

Caprini risk assessment model, 279*t*

Caprosyn suture, 149

Capsaicin
  - to facilitate bladder filling and urine storage, 2682*t*, 2709
  - intravesical, 2709.e1
  - for prostate cancer, 3544
  - ureteral response to, 1889

Capsular invasion, 3507

Capsular penetration, 3507

Capsular perforations
  - with bipolar transurethral resection of prostate, 3419
  - with holmium laser enucleation of prostate, 3438
  - with transurethral incision of prostate, 3435

  - with transurethral vaporization of prostate, 3425–3426
- Capsular polysaccharides, 429
- Carbamylcholine (Carbachol), ureteral response to, 1887
- Carbon dioxide (CO), as insufflant choice, 241
- Carbon monoxide (CO)
  - in ED, 1498
  - renal vascular tone control by, 1913
- Carbon-11 (11C), 91
- Carbon-coated zirconium beads (Durasphere), for female urinary incontinence, 2894
- Carbonic anhydrase inhibitors, in stone formation, 2033
- Carbonic anhydrase IX (CA-IX, MN-9), 98, 2136
- Carboplatin
  - for NSGCTs, 1697
  - for penile cancer, 1771
  - for seminomas, 1704, 1704*t*
- Carcinoid tumors, of kidney, 2181*t*, 2183
- Carcinoma in situ (CIS)
  - of penis, 1742
  - of upper urinary tracts, 2219–2220
  - UTUC association with, 2193
- Cardiac abnormalities, contrast media and, 32
- Cardiac arrest, anesthesia-related, during laparoscopic and robotic surgery, 228.e1
- Cardiac arrhythmias
  - anesthesia-related, during laparoscopic and robotic surgery, 228.e1
  - pneumoperitoneum causing, 221
- Cardiac glycosides, urethral function effects of, 1903–1904
- Cardiac ischemia, during vena caval thrombectomy, 2278
- Cardinal ligament, 2429–2430, 2431*f*

Cardinal veins, retrocaval ureter and, 1963, 1966*b*

Cardiopulmonary bypass (CPB), for vena caval thrombectomy, 2275–2276, 2275*f*–2276*f*, 2276.e1*f*

Cardiovascular disease (CVD)

- α-blocker therapy in patients with, 3369–3370
- and ED, 1504
- erectile dysfunction and, 1425–1426, 1426*b*
- prostatitis and, 1210
- renal calculi and, 2008–2009

Cardiovascular morbidity/mortality, hormonal therapy and, 3681

Cardiovascular system

- abnormalities of, with cloacal exstrophy, 575
- pneumoperitoneum effects on, 220–221
- Wilms tumor treatment effects on, 1108

Carnitine, for PD, 1611, 1616*t*

Carter-Thomason needle-point suture passer, 219, 219*f*

Caruncle, urethral, urethral diverticula differentiated from, 2987, 2987*f*

Casale continent catheterizable stoma, 711, 712*f*

Caspases, in GU cancers, 1365–1366

Castration-resistant prostate cancer

- anaplastic phenotype, 3705
- assessment of, 3687–3689
- bisphosphonates for, 3703–3704
- clinical considerations for, 3687–3690, 3690*b*
- cytotoxic chemotherapy for, 3690–3693, 3694*b*
  - chemotherapeutic agents as, 3690–3693
  - evaluation of treatment efficacy, 3690
  - platinum agents as, 3693
- epidural cord compression in, 3702
- immunotherapy for, 3697–3699, 3699*b*
  - immune checkpoint blockade as, 3698
  - pembrolizumab, 3698–3699
  - ProstVac-VF, 3698

    - sipuleucel-T, 3697–3698, 3697*f*
  - metastatic, 3689–3690
  - neuroendocrine subtype, 3704–3705
  - nonmetastatic, 3689
  - novel hormonal therapies for, 3693–3696, 3696*b*
    - androgen receptor modulation as, 3695–3696, 3695*f*
    - AR-V7 as, 3696
    - CYP17 inhibition as, 3693–3695, 3694*f*
  - palliative management of, 3702–3704, 3705*b*
    - bone-targeted approaches as, 3703–3704
    - pain and spinal cord compression as, 3702, 3703*t*
  - prognostic considerations for, 3687–3689, 3688*f*
  - radiopharmaceuticals for, 3704
  - RANK ligand inhibitors for, 3704
  - targeted treatments for, 3699–3702, 3702*b*
    - angiogenesis, 3700–3701
    - apoptosis pathway in, 3701–3702
    - DNA repair, 3702
    - MET signaling, 3701
    - PI3K/Akt/mTOR pathway in, 3699–3700
  - treatment for, 3687–3706

Casts, in urine, 23, 23*f*–24*f*

Catch bonds, 1135

Catecholamine hypersecretion, in evaluation of adrenal masses, 2402–2403, 2402*t*

Catecholamine synthesis blockade, for pheochromocytoma, 2378–2379, 2379*f*

Catecholamine testing, for pheochromocytoma, 2377

Catecholamines, adrenal medulla physiology and, 2358–2360, 2359*t*–2360*t*

Category I cysts, 769

Category II cysts, 769

Category III cysts, 769–770

Catheter-associated bacteriuria, UTIs and, 1190, 1191*b*

Catheter-associated UTI (CAUTI), 433

Catheter placement, for urodynamics, 2535

Catheterization
- anatomic considerations in, 152
- for bladder emptying failure, 2900–2902, 2900*f*
  - continuous, 2901–2902
- of children, urethral, 153
- difficult, 156–158
- history of, 152
- lower urinary tract, 152–159
  - technique of, 152–155
- in men, urethral, 153
- preparation for, 152–153
- suprapubic, 155–156
- ureteral, 1197
- urethral, antimicrobial prophylaxis for urologic procedures and, 1197
- in women, urethral, 153

Catheterized urine specimens, in urine collection, 1141

Catheters
- air-charged, for urodynamic studies, 2558
- condom, 155
- diagnostic, 154–155, 155*f*
- double-lumen, 154
- drain, 155
- hematuria, 154, 154*f*
- indwelling, in geriatric patients, 2919
- knotting and balloon malfunction, 159
- long-term, bladder cancer and, 2616
- single-lumen, 154
- sizing, 153–154, 154*t*
- types of, 153–155
- water-filled, for urodynamic studies, 2558

Cation transport, urinary tract obstruction and, 794

Cauda equina, 2619

Cauda equina syndrome, 2620

Cauterization, energy modalities for, 235–241
  electrosurgery, 235–241, 236*f*
  ultrasound instrumentation, 237–238
Cautery wire balloon incision, for ureteroenteric strictures, 1977
CAUTI, Catheter-associated UTI
CAVD, Congenital absence of vas deferens
Caveolae, in ED, 1499
Cavernosal nerves, 1378
Cavernosal veins, 1807.e5*f*
Cavernosogram, of penis, 1386, 1387*f*
Cavernous smooth muscle content test, 1525
Cavitation mechanism, in ultrasonography, 77
Cavoplasty, for IVC, 2276, 2277*f*
CBCL, Child Behavior Checklist
CBE, Classic bladder exstrophy
CCBs, Calcium channel blockers
C-choline and F-fluorocholine, 43
CCI, Charlson Comorbidity Index
CCSK, Clear cell sarcoma of kidney
CDC, Centers for Disease Control and Prevention
CDH1 gene, in bladder cancer, 1350
CDKIs, Cyclin-dependent kinase inhibitors
CDKN1B, in UTUC, 2197
Cecil-Culp repair, for hypospadias fistula, 947*f*
Cecocystoplasty, 694
Cecum, proximal, 3211
Celecoxib, urethral function effects of, 1903

Cell adhesion molecules, in prostate growth regulation, 3287–3288, 3288*b*

Cell-based therapy, of male stress urinary incontinence, 2897

Cell cycle deregulation, in GU cancers, 1347–1348, 1349*b*

- CDKIs, 1347.e1, 1347.e1*f*
- cell cycle entry, 1347.e1
- cell cycle progression through S phase, 1347.e2
- cyclin-dependent kinases and cyclins, 1347.e1, 1347.e1*f*
- G_1/S checkpoint, 1347.e2
- G2M checkpoint, 1347.e2–1347.e3
- mitosis, 1347.e2
- mitotic arrest and spindle assembly checkpoint, 1347.e3
- RB1, 1347.e1, 1347.e1*f*
- S phase arrest, 1347.e2
- TP53, 1347.e2, 1347.e2*f*, 1348

Cell cycle markers, in UTUC, 2197

Cell cycle progression, in prostate cancer, 3543

Cell differentiation, in UTUC, 2197

Cell migration and invasion, in UTUC, 2197

Cell proliferation, in UTUC, 2197

Cells, in urine, 21–23, 21*f*–23*f*

CellSearch system, 3484–3485, 3485*f*

Cellular proliferation, 305

Cellules, 2967

Cellulitis, 1288–1289, 1290*f*

- genital skin loss and, 3053

Centers for Disease Control and Prevention (CDC), 1251

Central defect, in pelvic floor support mechanism, 2597–2598

Central perineal tendon, 1807.e10

Central venous pressure, pneumoperitoneum effects on, 221

Cephalad renal ectopia, 724–725, 726*f*

Cephalexin, for UTIs, 1170*t*

Cephalosporins

- prophylaxis with, for uncomplicated urologic procedures, 1194*t*–1196*t*
- for UTIs, 1151*t*–1153*t*, 1154, 1187*t*

Cerebellar ataxia, lower urinary tract dysfunction with, 2604

Cerebral palsy (CP)

- lower urinary tract dysfunction with, 2604–2605
- pathogenesis of, 647–648
- presentation of, 647, 650*b*
- specific recommendations of, 648

Cerebrovascular accident (CVA), lower urinary tract dysfunction and, 2602–2603

Cerebrovascular disease, lower urinary tract dysfunction and, 2602–2603

Cernilton, 3399

- for diminished bladder, 2674

Cervical atresia, 984–985, 985*f*

Cervical myelopathy, lower urinary tract dysfunction with, 2617

Cervical RMS, in pediatric patients, 1120

Cervix, 325, 325*f*

- anatomy of, 2436

Cesarean delivery, urinary incontinence and, 2583

Cetrorelix, for benign prostatic hyperplasia, 3377

CEVC, Clinical Epidemiological Validation Center

CGA, Comprehensive geriatric assessment

cGMP, Cyclic guanosine monophosphate

CGRP, Calcitonin gene-related peptide

Chancroid, 1255*t*, 1259–1260, 1259*f*

Chaperone-usher pathway (CUP), 428–429

Chaperonin, androgen receptor binding of, 3289

Charlson Combined Comorbidity Index, 107–108

Charlson Comorbidity Index (CCI), 2909, 3522

Checkpoint inhibition, in GU cancers, 1367–1368, 1368*b*

Chemical exposure, in workplace, 1416

Chemodenervation, for urinary incontinence, in geriatric patients, 2920.e5

Chemokines, 1333–1334, 1335*f*, 1335*t*

Chemotherapy
- for bladder tumor, 3077
- for castration-resistant prostate cancer, 3690–3693
  - cabazitaxel, 3692–3693, 3693*f*
  - docetaxel, 3690–3692, 3691*f*–3692*f*
  - mitoxantrone, 3690, 3693*f*
- for metastatic bladder cancer, 3125
  - second-line, 3128, 3128*t*
- for metastatic RCC, 2341–2342
- for muscle-invasive bladder cancer, 3121–3123, 3121*t*
  - randomized trials in, 3127–3128, 3127*t*
- for neuroblastoma, 1093*f*, 1095
- at PC-RPLND, 1727
- for penile cancer, 1769–1771, 1772*b*
  - adjuvant, 1771
  - combination, 1770–1771
  - single-agent, 1769–1770
  - surgical consolidation after, 1771
- with radiation therapy, for locally advanced prostate cancer, 3654–3655
- for RCC, resistance to, 2145
- for retroperitoneal tumors, 2245–2247, 2246*t*
- for TGCTs
  - with brain metastases, 1706–1707, 1707*b*
  - NSGCTs, 1695
  - post-salvage, 1701
  - relapsed tumors, 1700
  - residual mass management after, 1698–1700, 1698*t*–1699*t*
  - seminomas, 1704, 1704*t*
  - toxicity of, 1707

- for UTUC, 2222–2223, 2223*f*
- for Wilms tumor, 1100, 1102*f*

Chest, imaging of, for TGCTs, 1690

Chest X-ray, 450

Chevron and subcostal incision, kidney and retroperitoneum approaches, 137–138, 139*f*

Chevron incision, for open kidney surgery, 2253

Chief complaint, in patient history, 1

Child Behavior Checklist (CBCL), 477, 654

Childbearing women, prevention of urinary incontinence and, 2735

Childhood diseases, and male infertility, 1432–1434

Children

- fundamentals of
  - MRI in, 412–413
  - sonography in, 404
- ionizing radiation in, 403
- megaureter in, 849–852, 852*b*
  - cutaneous ureterostomy for, 850–851, 850*f*
  - definition of, 849
  - definitive reconstruction for, 850–851, 850*f*
  - dilatation and stenting for, 852
  - etiology, occurrence, and presentation of, 849
  - excisional tapering for, 851–852, 851*f*
  - Kalicinski plication technique for, 851, 851*f*
  - outcomes with, 852
  - remodeling for, 837*f*–839*f*, 851
  - Starr plication technique for, 851, 851*f*
  - surgical indications for, 849–850
  - surgical management of, 850–852, 850*f*–851*f*
  - ureteral polyps with, 835–836
  - ureteral strictures with, 835
- surgery of ureter in, 826–852
- ureteropelvic junction obstruction in, 826–836
  - associated anomalies, 826
  - clinical presentation of, 826, 827*f*
  - complications with, 832*f*, 835, 835*f*
  - definition of, 826

    - dismembered pyeloplasty, 828, 828*f*–830*f*
    - endoscopic approach to, 830
    - flank approach to, 829
    - laparoscopic pyeloplasty for, 830–834, 833*f*–834*f*
    - lower pole, 826, 827*f*
    - minimally invasive techniques for, 830–835
    - nondismembered pyeloplasty for, 828–829, 829*f*–831*f*
    - outcomes with, 835
    - posterior lumbotomy for, 829, 832*f*
    - secondary, 826
    - surgical approach to, 829
    - surgical indications for, 826–827
    - surgical repair of, 827–828
  - urethral catheterization of, 153
  - UTI in, 426
    - diagnosis of, 426*b*
  - vesicoureteral reflux in, 836–846, 836*b*
    - clinical presentation of, 836
    - Cohen Cross-Trigonal technique for, 840, 841*f*
    - complications of ureteral reimplantation for, 844–846
    - definition of, 836
    - early complications of, 844–846
    - endoscopic treatment of, 846–849
    - extravesical procedures for, 840–842, 842*f*–843*f*
    - Glenn-Anderson technique for, 840, 840*f*
    - incision for, 836, 837*f*–839*f*
    - intravesical procedures for, 836–840
    - long-term complications of, 846
    - minimally invasive procedures for, 842–844
    - Politano-Leadbetter technique for, 837*f*–839*f*, 840
    - postoperative evaluation of, 844
    - reoperative reimplantation for, 846
    - robotic-assisted laparoscopic ureteral reimplantation- extravesical for, 844, 845*f*
    - surgical management of, 836

- Children's Oncology Group (COG)
  - staging systems and risk group assignments of
    - for bladder RMS, 1113–1114, 1114*t*
    - for testicular tumors, 1122, 1122*t*
  - treatment recommendations of, bladder RMS approaches, 1114–1115

- Chills, patient history of, 7

- *Chlamydia*

  - as fastidious organism in UTIs, 1133
  - as nongonococcal urethritis, 1253
  - prostatitis microbiology and, 1205–1206

Chloride absorption, after augmentation cystoplasty, 698

Chlormadinone acetate, for benign prostatic hyperplasia, 3377

Chloroquine derivatives, for BPS/IC oral therapy, 1241*t*, 1243

Cholecalciferol (vitamin D3), 1914

Cholesterol, testosterone synthesis from, 1395–1396

Choline PET/CT, 43

Cholinergic agonists, ureteral response to, 1887

Chondroitin sulfate, in crystal formation, 2014

“Choosing Wisely” campaign, 3527

“Chop-fmru,”, 413

Chordee
  - in classic bladder exstrophy repair, 551
  - without hypospadias, 1836

Choriocarcinoma
  - histology of, 1683–1684, 1683*f*
  - spread of, 1706

Chromatin remodeling
  - androgen receptor-dependent, 3293–3295
  - in prostate cancer, 3470

Chromogranin A testing, for pheochromocytoma, 2377

Chromophobe RCC, pathology of, 2149*t*–2151*t*, 2152–2153, 2154*f*

Chromosomal abnormalities
  - in GU cancers, 1351–1352, 1362*b*
    - bladder cancer, 1358–1360
    - bladder RMS, 1111–1113
    - CNAs, 1354, 1354*t*–1355*t*
    - gross abnormalities, 1351, 1352*b*
    - neuroblastoma, 1087

    - prostate cancer, 1352–1353, 1354*t*
    - renal cancer, 1353, 1354*t*, 1355*f*, 1358
    - testicular cancer, 1121, 1353, 1361–1362
    - Wilms tumor, 1096–1099, 1097*t*, 1354*t*
  - male reproductive physiology and, age-related, 1401–1402
- Chromosomal instability
  - telomerase reversal of, 1364
  - telomeres and, 1362
- Chromosomal recombination, 1401
- Chromosomal sex, 990, 991*f*, 991*b*
- Chromosome abnormalities, association with pathologic stage of prostate cancer, 3642*t*
- Chromosomes, basics of, 1346.e4
- Chronic bacterial prostatitis
  - evaluation of, 1211–1214, 1214*b*
    - assessment, 1211, 1212*f*
    - history, 1211
    - laboratory/office studies, 1213–1214, 1214*b*
    - physical examination, 1211–1213, 1213*f*
    - review of symptoms, 1211
  - histopathology, 1205–1207, 1207*b*
  - symptoms, 1209–1211
    - anxiety and depression, 1210
    - association with other medical diseases, 1210
    - multidisciplinary approach, 1209–1210
    - phenotypic approach to symptoms and symptom clustering, 1210–1211, 1210*f*
    - prevalence, 1209
    - severity, 1210
    - sexual dysfunction, 1210
  - treatment of, 1214–1218, 1218*b*
    - Cochrane review, 1218
    - conservative, 1216
    - minimally invasive therapies, 1216–1217
    - pharmacologic, 1214–1216
    - prostate-specific, 1217
    - summary and approach, 1218
- Chronic constipation, pelvic organ prolapse and, 2591

Chronic diarrhea, ammonium acid urate stones from, 2032

Chronic epididymitis, 1202–1223

- nonmedical therapy for, 1221
- nonradical surgical treatments, 1221
- surgical therapy, 1221–1222

Chronic flank pain, genitourinary trauma and, 1078

Chronic inflammation

- in cancer immune response, 1336, 1338*b*
  - bladder cancer, 1336–1338, 1337*f*–1338*f*
  - kidney cancer, 1338
  - prostate cancer, 1338
- UTUC risk and, 2187

Chronic kidney disease (CKD), 1927–1934, 1934*b*

- bone disease, 355
- in children, 354–355, 354*t*, 355*b*
- definition of, 1927, 1928*f*, 1928*t*
- genitourinary trauma and, 1078
- renal calculi and, 2009

Chronic Kidney Disease Epidemiology Collaboration (CKD-EPI) equation, 777, 1905

Chronic pelvic pain syndrome (CPPS)

- epidemiology, 1202
- evaluation of, 1211–1214, 1214*b*
  - assessment, 1211, 1212*f*
  - history, 1211
  - laboratory/office studies, 1213–1214, 1214*b*
  - physical examination, 1211–1213, 1213*f*
  - review of symptoms, 1211
- historical perspective, 1202
- symptoms in, 1209–1211
  - anxiety and depression, 1210
  - association with other medical diseases, 1210
  - multidisciplinary approach, 1209–1210
  - phenotypic approach to symptoms and symptom clustering, 1210–1211, 1210*f*
  - prevalence, 1209
  - severity, 1210

      - sexual dysfunction, 1210
    - treatment of, 1214–1218, 1218*b*
      - Cochrane review, 1218
      - conservative, 1216
      - minimally invasive therapies, 1216–1217
      - pharmacologic, 1214–1216
      - prostate-specific, 1217
      - summary and approach, 1218

Chronic pyelonephritis, 1176–1177, 1177*f*

Chronic renal failure, and ED, 1511

Chronic scrotal pain
  - complication of scrotal surgery, 1855
  - surgical management of, 1853–1855, 1854*f*

Chronic scrotal pain syndrome, 1219–1220, 1222*b*
  - nonmedical therapy for, 1221
  - nonradical surgical treatments, 1221
  - surgical therapy, 1221–1222, 1223*f*

Chylous ascites
  - after RPLND, 1731, 2244
  - laparoscopic and robotic surgery causing, 231.e1

Chyluria
  - as filariasis clinical manifestation, 1330
  - nephrolysis for, 2294, 2294*f*

CIC, Clean intermittent catheterization

CICR, Calcium-induced calcium release

Cidofovir, for condylomata acuminata, 1742.e3

CIQ-FLUTS, International Consultation on Incontinence Questionnaire Female Lower Urinary Symptoms

Circle nephrostomy tube, 174*f*

Circulating tumor cells (CTCs), as prostate cancer biomarkers, 3484–3485, 3485*f*

Circulating tumor DNA, as prostate cancer biomarkers, 3484–3485, 3485*f*

Circumcision, 393, 872–876, 873*b*
  complications of, 873–874, 874*f*, 876*b*
    urethral reconstructive surgery and, 1811–1812
  female, 987–988, 988*f*
  penile cancer management with, 1752–1753
  for penile carcinoma, prevention of, 1743
  for posterior urethral valves, 615
  for prune-belly syndrome, 593
Circumferential compression mechanism, of stone fragmentation, 2096–2097
CIS, Carcinoma in situ
Cisapride, to facilitate bladder emptying, 2718
Cisplatin
  for penile cancer, 1770
  for TGCTs, toxicity of, 1707
Citrate
  in crystal formation, 2014, 2024
  in pediatric kidney stone disease, 869
Citric acid, in prostatic secretions, 3295
Citrus juices, for hypocitraturia, 2053–2054
CJD, Creutzfeldt-Jakob prion disease
CKD, Chronic kidney disease
Classic bladder exstrophy (CBE), 290–291
  abdominal wall defects in, 533
  anatomic considerations in, 531–537
  anorectal defects in, 533
  antireflux procedure for, 554–556, 555*f*–556*f*
  chordee in, 551
  complete repair for, 544, 544*f*
    continence outcomes with, 560
    technical aspects of, 550, 550*f*
  continence procedure for, 554–556, 555*f*–556*f*
  continence with, 565

continent urinary diversion for, 564–565, 565*b*
epispadias repair for, 550–551
  failure of, 564
evaluation of, at birth, 539–542, 539*f*, 539*b*
female genital defect in, 534–535, 535*f*
fertility, 290–291
genital anatomy, 290
immobilization techniques for, complications of, 542–543, 543*t*, 543*b*
Kelly repair for, 544
  continence outcomes with, 561
  technical aspects of, 549–550, 549*f*
long-term adjustment issues with, 567–568, 568*b*
male genital defect in, 533–534, 533*f*–534*f*
management of, at birth, 539–542, 539*f*
Mitchell repair for, 544, 544*f*
  continence outcomes with, 560
  technical aspects of, 550, 550*f*
mode of delivery, 291
modern staged repair of exstrophy, 545
  bladder, posterior urethral, and abdominal wall closure for, 545–548, 546*f*–548*f*
  combined bladder closure and epispadias repair, 548
  management after, 548–549
osteotomy for, 540–542, 541*f*–542*f*
  complications of, 542–543
outcomes and results of modern initial repair, 556–559
  bladder neck repair, 558–559, 559*t*, 559*b*, 560*f*
  epispadias repair, 557–558
  initial closure, 557
pelvic bone defects in, 531–532, 531*f*
pelvic floor defects in, 532, 532*f*
penile reconstruction for, 551–552, 552*f*–553*f*
penile skin closure for, 552–554
pregnancy, 291
reconstruction failures and complications, 561–565
  epispadias repair, 564
  failed bladder neck repair, 563–564, 564*b*
  failed closure, 561–563, 561*f*–562*f*, 561*t*, 563*b*
Schrott-Erlangen approach to, 545
  continence outcomes with, 560

  - spinal defects in, 531–532
  - surgical options in newborn with, 543–545
    - Mainz repair, 545
  - surgical reconstruction of, 538–556
    - alternative, 564–565
    - female exstrophy, 554
    - patient selection for, 540
    - postoperative care, 556
    - postoperative problems, 554
    - small exstrophy bladder unsuitable for newborn closure, 540
  - ureterosigmoidostomy for, 564
  - urethral reconstruction for, 564
  - urinary defects in, 535–537, 536*f*–537*f*
- Classic Wilms tumor, 1100, 1100*f*
- Classical Cushing syndrome, 2363, 2363*f*, 2364*t*
- Clavien-Dindo scale, 260–261, 261*t*
- Clavien-Dindo System of Classifying Complications, 105–106, 106*t*
- Clean intermittent catheterization (CIC)
  - for bladder emptying failure, 2901
  - for bowel-bladder dysfunction, 657
  - for renal transplantation, 1057
  - for urinary tract infections, 625
- Cleansing enema, for prostate biopsy, 3496
- Clear cell RCC
  - chemotherapy, 2341–2342
  - familial form of, 1354*t*, 1358, 2141–2143, 2143*t*, 2144*f*
  - hormonal therapy, 2342–2343
  - immunologic approaches to, 2329–2332
    - allogeneic hematopoietic stem cell transplantation, 2331, 2331*t*
    - IL-2, 2329–2331, 2330*t*
    - immune checkpoint inhibitors, 2331–2332, 2332*f*
    - interferons, 2329, 2329*t*
  - pathology of, 2149*t*–2151*t*, 2151–2152, 2152*f*
  - targeted molecular therapies for
    - basis of, 2332–2333, 2333*f*
    - combination and sequential therapy with, 2339–2341

        - immune “checkpoint” inhibitor-based combination strategies, 2341, 2342*f*
        - mTOR pathway inhibitors, 2326–2327, 2338–2339, 2340*f*, 2340*t*
        - other, 2341–2343
        - VEGFR-based, 2326–2327, 2333–2337, 2333*t*–2335*t*, 2336*f*, 2337*t*
- Clear cell sarcoma of kidney (CCSK), in pediatric patients, 1108–1109
- Clenbuterol, for stress urinary incontinence in women, 2714
- Climate, renal calculi and, 2007
- Clindamycin, prophylaxis with, for uncomplicated urologic procedures, 1194*t*–1196*t*
- Clinic, in transitional urology, 1047
- Clinical Epidemiological Validation Center (CEVC), 3478–3479
- Clinical question, in urodynamic studies, 2551–2552
- Clinical target volume (CTV), 3590
- Clinical trials, for locally advanced prostate cancer, 3657, 3657*t*–3658*t*
- Clipping devices, for laparoscopic and robotic surgery, 216–217, 217*f*
- Clitoral complex, 1627.e2–1627.e4, 1627.e3*f*
- Clitoris, 1627.e1, 2435, 2436*f*–2437*f*
    - disorders of, 975, 977*b*
        - diminutive clitoris, 975, 976*f*
        - hypertrophied clitoris, 975, 975*f*
- Clitorodynia, sexual pain and, 1651–1652
- Clitoroplasty, initial management, timing, and principles for, 1026, 1026*f*, 1028*f*–1029*f*
- Cloaca, 330*f*
- Cloacal anomalies, 1019–1042
    - classification of, 1019–1025
    - evaluation of, 1021
    - history and physical examination for, 1021–1022, 1022*f*
    - radiographic and endoscopic evaluation of, 1024–1025, 1025*f*
- Cloacal exstrophy, 380, 381*t*, 573–576
    - anatomic considerations for, 574–575

- cardiovascular abnormalities with, 575
- evaluation of, at birth, 576, 576*b*
- failed, 579
- gender assignment for, 576–577, 577*f*
- genitourinary abnormalities with, 575
- intestinal tract abnormalities with, 575
- long-term adjustment issues with, 567–568, 568*b*
- long-term issues in, 580, 580*b*
- management of, at birth, 576, 577*b*
- neurospinal abnormalities with, 574–575, 574*f*
- prenatal diagnosis of, 576
- pulmonary abnormalities with, 575
- sexuality with, male concerns, 566
- skeletal system abnormalities with, 575
- surgical reconstruction of, 576–580
  - immediate, 577–578
- urinary continence creation in, 579–580
- urinary tract reconstruction of, 578–579
  - modern staged, 578, 578*t*
  - osteotomy role in, 578–579
  - single-stage, 579
- variants of, 575*f*, 576

Cloacal malformation, 380–382

Clonidine
- to facilitate bladder emptying, 2720
- suppression testing, for pheochromocytoma, 2377

Clorpactin, for BPS/IC treatment, 1244.e1

Closed access techniques
- for achieving transperitoneal access and establishing pneumoperitoneum, 207–209
- complications related to, 224

“Closing zipper,” in hypospadias, 905

Cloudy urine, cause of, 14

CLPP, Cough leak point pressure

Clusterin, 3701

c-*MET* gene, 2143–2144

  in UTUC, 2198

CMG, Cystometrogram

CMN, Congenital mesoblastic nephroma

CNAs, Copy number alterations

CNF, Congenital nephrotic syndrome of Finnish type

CNPs, Calcifying nanoparticles

CNS, Congenital nephrotic syndrome

Coaxial introducer, 170

Cobb-Ragde needles, in pubovaginal sling placement, 2838–2839

Cocaine, ureteral response to, 1888

Cockcroft-Gault formula, 1905

Coffee, UTUC risk and, 2186

COG, Children's Oncology Group

Cognition, of geriatric urology patient, 2910, 2911*f*

Cognitive function, hormonal therapy and, 3681

Cognitive/mental fusion, 3622

Cohen Cross-Trigonal technique, for vesicoureteral reflux in children, 840, 841*f*

Coherence, 238

Coital alignment technique, for female orgasmic disorder, 1647

Coital incontinence, 2540

Colchicine, for PD, 1611, 1616*t*

Collagen

  of bladder wall, 2463–2464

  of male stress urinary incontinence, 2897

  of urethra, 2468

- Collagen disorders, and PD, 1602
- Collagenase *Clostridium histolyticum*, for PD, 1613, 1617*t*
- Collecting duct RCC
  - pathology of, 2149*t*–2151*t*, 2154
  - systemic therapy for, 2344
- Collecting system, 161–162, 162*f*
  - injury, 179
  - of kidney, 336
  - obstruction, 182
  - radiologic anatomy of, 1872–1873
- Collecting system repair, laparoscopic repair of, 2302, 2303*f*
- Colles fascia, 1807.e9–1807.e10, 2444, 2446*f*
- Collimator, 91
- Collings knives, 172
- Colon
  - pseudo-obstruction of, 3181
  - reflection of, for simple nephrectomy, 2285–2286, 2287*f*
  - selection, 3162
  - for urinary diversion
    - preparation for, 3160–3161, 3161*f*
    - selection of, 3161
- Colon conduit, 3196–3197, 3196*f*, 3198*t*
- Colon isolation, in robot-assisted intracorporeal continent cutaneous diversion, 3269, 3269*f*
- Colon mobilization, in robot-assisted intracorporeal continent cutaneous diversion, 3269, 3269*f*
- Colon pouches
  - creation, in robot-assisted intracorporeal continent cutaneous diversion, 3269
  - right
    - with intussuscepted terminal ileum, 3219–3220
    - for orthoptic urinary diversion, 3246
- Color Doppler ultrasonography, 73, 388

        - transrectal, for prostate biopsy, 3500–3501, 3500*f*–3502*f*
        - for urinary tract obstruction, 778

- Color flow with spectral display ultrasonography, 73–74
- Colpexin sphere, 2726, 2726*f*, 2726.e1*f*
- Colpocleisis, for apical pelvic organ prolapse repair, 2809–2814, 2920.e10
    - partial
        - results with, 2812–2814
        - technique for, 2811–2812, 2811*f*
    - total
        - results with, 2812
        - technique for, 2812, 2813*f*
- Colpoperineorrhaphy, posterior, 2825
- Colpopexy and Urinary Reduction Efforts (CARE) trial, 2535–2536
- Colporrhaphy
    - anterior
        - complications of, 2782–2783
        - results with, 2779–2782, 2780*t*
        - technique for, 2779, 2779*f*
    - posterior, 2825–2829, 2825*f*
        - perineorrhaphy, technique for, 2827–2829
        - results with, 2827–2829, 2828*t*
        - site specific, technique for, 2826–2827, 2826*f*–2827*f*
- Colposuspension
    - Burch, Burch colposuspension
    - definition of, 2757
    - laparoscopic, 2759
    - open retropubic, 2757
    - prophylactic, 2765
    - tension-free vaginal tape procedure compared with, 2773–2774
- Columns of Bertin, 1866
- Combination ballistic and ultrasonic devices, 2112–2113
- Combination of Avodart and Tamsulosin (CombAT) Study, 3386–3389, 3389*f*, 3389*t*
- Combination therapies, in ED, 1537–1538

Combined intracavernosal injection and stimulation, in ED, 1521

Combined intra-extravesical approach, for bladder diverticula, 3015, 3015*f*

Comet tail artifact, 74*f*

Commensal bacteria, 427–428

Common excretory duct, 328

Common iliac arteries, 1873.e1*f*, 1874

Common iliac lymphadenectomy, 3152, 3153*f*–3154*f*

Common penile artery, 1807.e5*f*, 1807.e9

Common Terminology Criteria for Adverse Events (CTCAE), 105, 106*t*

Communicating hydrocele, 889

- epidemiology and pathogenesis of, 889

Comorbidity, definition of, 107–108

Comparative Effectiveness Analysis of Surgery and Radiation (CEASAR) study, 3532

Compensatory renal growth, with urinary tract obstruction, 794–795

Complete repair, for classic bladder exstrophy, 544, 544*f*

- continence outcomes with, 560
- technical aspects of, 550, 550*f*

Complex cystic masses, 50

Complex stones, percutaneous nephrolithotomy and, 2106

Complexed prostate-specific antigen, in prostate cancer, 3518

Compliance number, 2560–2561

Compound calyx, 161

Comprehensive geriatric assessment (CGA), 2913

Compressive dressings and stockings, for inguinal lymphadenectomy, 1801

Computed tomography (CT), 45–51, 46*f*–48*f*, 51*b*, 416–418

- of adrenal glands, 2352, 2352*f*
- in adrenal mass evaluation, 2395–2396, 2396*f*

after orthoptic urinary diversion, 3235, 3235*f*

for biochemical recurrence after radical prostatectomy, 3662

of bladder diverticula, 2967, 2968*f*

of bladder injuries, 3055*f*

of bladder RMS, 1113

of bladder/urethra, 418

for calculus disease, 418

for cysts/masses, 416

fundamentals of, 416

infection and, 418, 418*f*

for inguinal node dissection, 1792

of IVC tumor thrombus, 2175, 2175*f*

of kidney, 1868*f*

for kidney preoperative evaluation, 2248, 2249*f*

for localized prostate cancer, 3527

of male pelvis, 2458, 2458*f*–2459*f*

of matrix stones, 2076, 2076*f*

of neuroblastoma, 1089

obstruction of kidney/ureter, 416

for pediatric genitourinary trauma, 1066

of pediatric stone disease, 854

radiation exposure with, 780

of RCC, 2159–2160, 2160*f*

renal, 390–391

of renal angiomyolipoma, 2125–2126, 2126*f*

of renal calculi, pretreatment assessment, 2071

of renal injuries, 1984–1985, 1984*f*–1985*f*

of renal lymphoma, 2182, 2182*t*

of renal tumor ablation, 2313, 2314*f*

for renal tumor evaluation, 2134–2135, 2136*f*–2137*f*

for renovascular hypertension screening, 1917–1918, 1918*b*

of retrocaval ureter, 1963, 1965*f*

of retroperitoneal fibrosis, 1979, 1979*f*

scrotum/testes/internal genitalia, 418

of seminal vesicles and ejaculatory ducts, 1378

  trauma and, 418
  of ureteral injuries, 1995, 1995*f*
  of ureteropelvic junction obstruction, 1943, 1944*f*–1945*f*
  for ureterovaginal fistula, 2945*f*
  of urinary lithiasis, 2037–2038, 2037*f*, 2037*t*
  of urinary tract obstruction, 779–780
  for UTIs, 1144, 1168, 1169*f*, 1178–1179, 1179*f*
  of UTUC, 2193

Computed tomography angiography (CTA), of kidneys, 1869.e2*f*

Concealed penis, 394

Concentration product (C_p), 2009

Concentration product ratio (CPR), 2010

"Concerning a New Kind of Ray,", 3587

Condom catheters, 155, 156*f*, 2920.e6

Conduction velocity, ureteral, 1883

Condyloma acuminatum, 988

Condylomata acuminata, malignant transformation of, 1742.e2

Congenital absence of vas deferens (CAVD), 903

Congenital adrenal hyperplasia (CAH), 311, 380–382, 1007–1010, 1007*f*–1008*f*, 1007*b*, 1438, 2383–2384
  lower urinary tract dysfunction and, 2633
  postnatal treatment of, 382
  prenatal treatment of, 382

Congenital anomalies, genitourinary trauma and, 1075–1076

Congenital bilateral absence of the vas deferens, 1450

Congenital bladder diverticulum, 3011

Congenital cryptorchidism, 949, 953–954

Congenital curvature of penis, 1836–1837

Congenital defects *versus* acquired scar, 498–499

Congenital disorders, and delayed ejaculation, 1575

Congenital diverticula, 522

  urethral, reconstructive surgery for, 1810

Congenital megacystis, 376–377, 519–521, 519*f*, 520*t*

Congenital mesoblastic nephroma (CMN), in pediatric patients, 1109

Congenital nephrosis, 756

Congenital nephrotic syndrome (CNS), 345

Congenital nephrotic syndrome of Finnish type (CNF), 756

Congenital neurogenic bladder, diagnostic evaluation and follow-up of, 631, 631*f*, 632*t*

Congenital penile curvature, 914, 917*f*

Congenital penile nevi, 883, 883*f*

Congenital strictures, 1815

Congenital unilateral absence of the vas deferens, 1449–1450

Congenital urethral fistula, 883, 883*f*

Conn syndrome, adrenal surgery for, 2409–2410, 2409*b*

Connexin 43, 2476–2477, 2477*f*

Conservative therapies, for BPS/IC treatment, 1239–1240

Constipation, Defecation disorders

Constitutional symptoms, patient history of, 7

Consultation, intraoperative, 296–304, 298*b*

Contact dermatitis, 1276–1277, 1277*f*

Content validity, 109

Contextual features, definition of, 116

CONTILIFE, 111*t*

Continence

  during abdominal pressure increases, 2516

- after creation of neobladder, 3272–3273, 3272*t*
- after orthoptic urinary diversion, 3251–3254, 3252*t*–3253*t*, 3254*b*
- bladder expansion in, 2593, 2593*b*
- bladder outlet in, 2593–2595
- in cloacal exstrophy, 579–580
- estrogens and, 2713
- lower urinary tract neural control in, 2593
- in male epispadias, 569–570, 570*t*
- mechanisms of, 2593–2595
  - development of, 329–333
- medical diagnoses and, 2527
- physiotherapy, role of, in laparoscopic radical prostatectomy, 3579
- procedure, for classic bladder exstrophy, 554–556, 555*f*–556*f*
- promotion and advocacy for, 2920.e9
- reflex circuitry controlling, 2489–2493, 2490*f*
  - somatic to visceral reflexes, 2492
  - sphincter to bladder reflexes, 2490*f*, 2491–2492, 2492*f*
  - storage phase, 2490–2491, 2490*f*–2491*f*, 2491*t*
- sphincteric mechanisms in, 2593–2595
  - female, 2594–2595, 2595*b*
  - male, 2594, 2594*f*, 2595*b*

Continent catheterizable channels, for bladder emptying failure, 2898–2900, 2899*f*

Continent catheterizable stoma, 292

Continent catheterizing pouches, 3211–3226, 3212*f*

- continent ileal reservoir, 3213–3215, 3214*f*
- double T pouch, 3215, 3216*f*–3217*f*
- gastric pouch, 3225–3226, 3225*f*–3226*f*
- general care, 3213
- general procedural methodology, 3212–3213
- Indiana pouch, 3220–3224, 3222*f*–3223*f*
- Mainz pouch I, 3215–3219, 3218*f*–3221*f*
- Penn pouch, 3224–3225, 3224*f*
- right colon pouches with intussuscepted terminal ileum, 3219–3220

Continent ileal reservoir, 3213–3215, 3214*f*

Continent urinary diversions, 191, 3208–3226
  catheterizable stoma for, 706–711
  for classic bladder exstrophy, 564–565, 565*b*
  considerations for, 706
  continent vesicostomy, 710–711
  cutaneous, 3206–3232, 3231*b*
    absorbable stapling techniques in, 3227–3228
    comments on, 3208
    continent catheterizing pouches, 3211–3226, 3212*f*
    cystectomy for, 3206–3208, 3207*f*
    general considerations of, 3206
    operative technique variations for, 3227–3229
    patient preparation of, 3206
    patient selection of, 3206
    postoperative care of, 3208
    quality-of-life assessments, 3226–3227
    rectal bladder urinary diversion, 3209–3211
  flap valves for, 707–709
  hydraulic valves for, 710
  ileocecal valve for, 709–710
  mechanisms for, 706–711, 707*f*
  Mitrofanoff principle for, 707–709
  nipple valves for, 707
  for pediatric patients, 706–713, 711*b*
    considerations to, 706
    results with, 709
    technique for, 708–709, 708*f*
  ureterosigmoidostomy for, 706–707
Continent vesicostomy, 710–711
Continuous incontinence, patient history of, 5
Continuous occlusion test, 2659
Continuous positive airway pressure (CPAP)
  for nocturnal polyuria, 2669
  for obstructive sleep apnea, 2920.e8
Continuous urinary incontinence, 2540, 2581
Continuous wave lasers, 238

Contractile activity, of ureters, 1883–1887, 1883*f*
    calcium and excitation-contraction coupling, 1884–1885
    proteins, 1883–1884, 1883*f*–1884*f*
    second messengers in, 1885–1887, 1885*f*–1886*f*
    urothelial effects on, 1885
Contractile (motor) function, in overactive bladder, 2640
Contractile proteins
    of smooth muscles, 2470–2472, 2471*f*–2473*f*
    of ureters, 1883–1884, 1883*f*–1884*f*
Contractile tissue, epididymal, 1403*f*, 1404
Contralateral internal ring, 892, 892*f*
Contrast agents, in ultrasonography, 76–77
Contrast media, 29–35, 35*b*
    adverse reactions, 29–34, 30*t*
    allergic-like reactions, 30
    considerations, 32–34
    contrast reactions, treatment of, 30–31
    delayed contrast reactions, 32
    magnetic resonance imaging contrast agents, 34–35
    premedication, 31–32, 31*b*
Contrast nephropathy, 1923–1924
Contusion, ureteral, 1996
Convective radiofrequency water vapor thermal therapy, 3421–3422
    complications of, 3422
    conclusion for, 3422
    outcomes with, 3422
        comparative studies, 3422
        single-cohort studies, 3422
    technique for, 3421–3422, 3421*f*–3422*f*
Conventional radiation, 3587
Conventional radiography, 28, 29*f*, 29*b*, 415
    intravenous pyelography, 415

    plain abdominal radiography, 415
    retrograde pyelography, 415
Convergent validity, 109
Cooper ligament, 2444, 2447*f*–2448*f*
Cope catheter, 173, 173*f*
Cope retention mechanism, 173
Copy number alterations (CNAs), in GU cancers, 1354, 1354*t*–1355*t*
Cordonnier and Nesbit techniques, in urinary diversion, 3187
Corpora amylacea, 1203
Corpora cavernosa, 1383–1384
    anatomy of, 1807.e1*f*–1807.e2*f*
Corporal perforation, 1589–1591, 1590*f*
Corpus cavernosum electromyography, and single potential analysis of cavernous electrical activity, 1527
Corpus spongiosum, 1383–1384
    anatomy of, 1807.e1*f*–1807.e3*f*, 1807.e6*f*–1807.e7*f*
Cortical defects, vesicoureteral reflux, 498–501, 500*b*
    acquired renal scars, 499–500
    congenital defects *versus* acquired scar, 498–499
    pathophysiology of acquired scarring, 500–501, 500*f*–501*f*
    reflux-associated renal dysplasia, 499, 499*f*, 499*t*, 499.e1*f*
Cortical microcystic disease, 756–757
Cortical renal scan with DMSA, 440
Cortical sex cords, 319*f*
Corticobasal degeneration, lower urinary tract dysfunction and, 2631
Corticosteroids
    in genitourinary tuberculosis medical therapy, 1316–1317
    and nephrotic syndrome, 345, 348*b*
Corticotropin-releasing factor (CRF), 2495–2496

Cortisol hypersecretion, testing for, 2399–2401

Corynebacterial infection, as cutaneous disease of external genitalia, 1292–1293, 1293*f*

CoSeal, 215.e2

COU-AA-301 study, 3694, 3694*f*

Cough leak point pressure (CLPP), 2562

Council catheters, 153, 173*f*

Cowden syndrome, 2142*t*, 2145

COX-2 inhibitors
  - to facilitate bladder filling and urine storage, 2703
  - urethral function effects of, 1903
  - for urinary tract obstruction, 795

CP, Cerebral palsy

CPAP, Continuous positive airway pressure

CPB, Cardiopulmonary bypass

CPDN, Cystic partially differentiated nephroblastoma

CPPS, Chronic pelvic pain syndrome

CPR, Concentration product ratio

Cranial suspensory ligament (CSL), 318–320

Creatinine
  - GFR and, 777, 1905, 1906*f*
  - serum
    - for benign prostatic hyperplasia, 3345–3346
    - measurement, in AKI, 1921, 1922*t*

Creatinine clearance (CrCl), GFR estimation with, 1905

Credé maneuver, 2902

Creep, ureteral, 1891

Cremasteric artery, 1370–1371, 1372*f*, 1375, 1393

Cremasteric muscle, 1394*f*

Creutzfeldt-Jakob prion disease (CJD), allografts and, 2835

CRF, Corticotropin-releasing factor

Criterion validity, 109

Crossed renal ectopia, 727–728, 727*f*–728*f*, 731*b*

Cross-organ sensitization, 2486, 2508

Cross-sectional imaging, of pheochromocytoma, 2375

Cryoablation (CA)

- for locally advanced prostate cancer, 3655
- for renal tumors, 2309–2310, 2310*b*
    - background and mode of action, 2309–2310
    - complications of, 2318–2319, 2320*f*–2321*f*, 2320*b*
    - duration, 2310
    - follow-up for, 2312–2314, 2314*b*
    - freeze-thaw cycles, 2310
    - laparoscopic, 2304
    - oncologic outcomes of, 2314–2318, 2315*t*–2316*t*, 2318*b*
    - percutaneous, 2312, 2313*f*, 2318
    - RFA *versus*, 2317–2318
    - success of, 2313–2314, 2314*f*
    - treatment temperature, 2310

Cryotherapy, 3624–3628, 3625*f*, 3627*t*

Cryptorchidism, 321, 322*f*–323*f*, 413*f*, 949, 972*b*, 1432–1433, 1440, 1449
- acquired, 949, 954
- adjuvant hormonal therapy for, 965
- associated pathology of, 961–964
  - epididymis anomalies with, 962–963, 962*f*
  - gubernacular anomalies with, 962–963
  - processus vaginalis anomalies with, 962–963
  - testicular anomalies with, 963–964
  - testicular maldevelopment, 961–964
- cancer risk and, 1680
- congenital, 949, 953–954
- definitions for, 949
- diagnosis of, 958–964
  - nonpalpable testes, 959–961, 960*f*
  - palpable testes, 958–959, 959*f*
- diagnostic laparoscopy for, 960–961
- epidemiology of, 953–954
- etiology, diagnosis and management of, 949–958
- examination in, 958, 958*f*
- genetic susceptibility to, 954–955
- hormonal defects of, 950*f*, 956–957
- hormonal evaluation of, 960
- human chorionic gonadotropin for, 964–965
- imaging of, 960
- luteinizing hormone-releasing hormone for, 964–965
- management of, 959*f*, 964
- medical management of, 964–965
- MRI of, 415
- pathogenesis of, 954–958
- prognosis for, 968–972
- surgical management of, 965–968
  - abdominal testis, 967–968
  - palpable testis, 966–967
- syndromic, 957–958
- testicular cancer and, 970–972
- testicular embryology and, 949–953

  - testicular hormone production for, 950–951, 950*f*
  - ultrasonography of, 412, 412*b*

Crystallization
  - inhibitors and promoters of, 2014–2015
  - in urine, 2009

Crystals
  - aggregation of, 2011
  - homogeneous nucleation of, 2011
  - oxidative stress and, 2013–2014
  - retention of, 2011
  - scanning electron micrographs of, 2041, 2042*f*
  - in urine, 23, 24*f*

CSL, Cranial suspensory ligament

CT, Computed tomography

CT urogram (CTU), for genitourinary tuberculosis diagnosis, 1312, 1313*f*

CTA, Computed tomography angiography

CTCAE, Common Terminology Criteria for Adverse Events

“CTC-Chip,”, 3485

CTCL, Cutaneous T-cell lymphoma

CTCs, Circulating tumor cells

CTLA-4, Cytotoxic T-lymphocyte antigen-4

CTV, Clinical target volume

Culp-DeWeerd spiral flap, for ureteropelvic junction obstruction, 1960–1961, 1961*f*

CUP, Chaperone-usher pathway

Curriculum, for men's health center, 1427

Curvatures of penis, 394, 880–881, 881*f*
  - correction of, 306–310, 311*f*
  - reconstructive surgery for, 1836–1838, 1838*b*
    - acquired, 1837–1838

        - congenital, 1836–1837

- Cushing disease, 2361
- Cushing syndrome, 2360–2367, 2367*b*
    - ACTH-dependent, 2361, 2361*f*
        - Cushing disease, 2361
        - ectopic ACTH syndrome, 2361, 2362*f*, 2362*t*, 2366
        - treatment of, 2365–2366, 2366*f*
    - ACTH-independent, 2362, 2366–2367
        - bilateral macronodular adrenal hyperplasia, 2362
    - adrenal surgery for, 2409*b*, 2410
    - adrenal tumors and, 2362
    - clinical characteristics, 2363–2364
        - classical, 2363, 2363*f*, 2364*t*
        - subclinical Cushing syndrome, 2363–2364
    - diagnostic tests, 2364–2365, 2365*f*, 2365*b*, 2400, 2400*b*
    - epidemiology of, 2360
    - exogenous, 2361, 2365
    - increased adrenal function in, 2360–2367, 2361*f*–2363*f*, 2362*t*, 2364*t*, 2365*f*–2366*f*, 2365*b*, 2367*b*, 2400*b*
    - overview of, 2360–2361
    - pathophysiology of, 2360–2362, 2361*f*–2362*f*, 2362*t*
    - primary pigmented nodular adrenocortical disease, 2362
    - prognosis, 2367
    - treatment, 2365–2367, 2409*b*, 2410
- Cutaneous artery, 136*f*
- Cutaneous continent urinary diversion, 3206–3232, 3231*b*
    - absorbable stapling techniques in, 3227–3228
        - right colon pouch, 3228, 3229*f*
        - stapled sigmoid reservoir, 3228, 3230*f*
        - W-stapled reservoir, 3228–3229, 3231*f*
    - comments on, 3208
    - continent catheterizing pouches, 3211–3226, 3212*f*
        - continent ileal reservoir, 3213–3215, 3214*f*
        - double T pouch, 3215, 3216*f*–3217*f*
        - gastric pouch, 3225–3226, 3225*f*–3226*f*
        - general care, 3213
        - general procedural methodology, 3212–3213
        - Indiana pouch, 3220–3224, 3222*f*–3223*f*

        - Mainz pouch I, 3215–3219, 3218*f*–3221*f*
        - Penn pouch, 3224–3225, 3224*f*
        - right colon pouches with intussuscepted terminal ileum, 3219–3220
    - cystectomy for, 3206–3208, 3207*f*
    - general considerations of, 3206
    - operative technique variations for, 3227–3229
        - conduit conversion to continent reservoir, 3227
        - minimally invasive, 3227
    - patient preparation of, 3206
    - patient selection of, 3206
    - postoperative care of, 3208
    - quality-of-life assessments, 3226–3227
    - rectal bladder urinary diversion, 3209–3211
        - augmented valved rectum, 3209
        - folded rectosigmoid bladder, 3209
        - hemi-Kock pouch procedures with valved rectum, 3209–3210
        - Mainz II pouch, 3210–3211
        - sigma-rectum pouch, 3210–3211
        - T pouch procedures with valved rectum, 3209–3210, 3210*f*
- Cutaneous diseases, of external genitalia, 1273–1306, 1306*b*
    - allergic dermatitis
        - atopic dermatitis, 1275–1276, 1276*f*
        - contact dermatitis, 1276–1277, 1277*f*
        - differential diagnosis, 1275*b*
        - erythema multiforme and Stevens-Johnson syndrome, 1277–1278, 1278*f*
    - basic dermatology, 1273, 1274*f*, 1274*t*
    - benign, of male genitalia
        - angiokeratomas of Fordyce, 1302, 1303*f*
        - ectopic sebaceous glands, 1303*f*, 1304
        - median raphe cysts, 1304
        - pearly penile papules, 1302, 1303*f*
        - sclerosing lymphangitis, 1302–1304
        - Zoon balanitis, 1302, 1303*f*
    - common miscellaneous
        - capillary hemangioma, 1304–1306
        - dermatofibroma, 1304, 1305*f*
        - epidermoid cyst, 1304, 1305*f*
        - lentigo simplex, 1304, 1305*f*
        - mole, 1304, 1305*f*
        - neurofibroma, 1304, 1305*f*
        - seborrheic keratosis, 1304, 1305*f*

  - skin tag, 1304
  - vitiligo, 1305*f*, 1306
- dermatologic therapy, 1273–1275, 1275*f*
- infections and infestations
  - balanitis, 1288
  - balanoposthitis, 1288, 1289*f*
  - candidal intertrigo, 1293–1294, 1294*f*
  - cellulitis, 1288–1289, 1290*f*
  - corynebacterial infection (trichomycosis axillaris and erythrasma), 1292–1293, 1293*f*
  - dermatophyte infection, 1294–1295, 1295*f*
  - ecthyma gangrenosum, 1293, 1294*f*
  - erysipelas, 1288–1289
  - folliculitis, 1290–1291, 1291*f*
  - Fournier gangrene, 1289–1290, 1290*f*
  - furunculosis, 1291, 1291*f*
  - genital bite wounds, 1293, 1294*f*
  - hidradenitis suppurativa, 1291–1292, 1292*f*
  - infestation, 1295–1296, 1296*f*–1297*f*
  - STDs, 1288, 1289*f*
- neoplastic conditions
  - basal cell carcinoma, 1297–1298, 1300*f*
  - bowenoid papulosis, 1296, 1298*f*
  - cutaneous T-cell lymphoma, 1302, 1302*f*
  - extramammary Paget disease, 1301–1302, 1301*f*
  - Kaposi sarcoma, 1298–1299, 1300*f*
  - melanoma, 1300–1301
  - pseudoepitheliomatous, keratotic, and micaceous balanitis, 1299–1300, 1300*f*
  - squamous cell carcinoma, 1296, 1299*f*
  - squamous cell carcinoma in situ, 1296, 1298*f*
  - verrucous carcinoma (Buschke-Lowenstein tumor), 1296–1297, 1299*f*
- noninfectious genital ulcers, 1286–1288, 1286*b*
  - aphthous ulcers and Behçet disease, 1286–1287, 1287*f*
  - pyoderma gangrenosum, 1287–1288, 1288*f*
  - traumatic causes, 1288, 1288*f*
- papulosquamous disorders, 1278–1283, 1278*b*
  - fixed drug eruption, 1282, 1283*f*
  - lichen nitidus, 1281
  - lichen planus, 1280–1281, 1281*f*
  - lichen sclerosus, 1281–1282, 1282*f*
  - psoriasis, 1278–1279, 1279*f*
  - reactive arthritis, 1279–1280, 1280*f*
  - seborrheic dermatitis, 1282–1283
- vesicobullous disorders, 1283–1286, 1284*b*

        - bullous pemphigoid, 1284–1285, 1285*f*
        - dermatitis herpetiformis, 1285
        - Hailey-Hailey disease, 1285–1286, 1286*f*
        - linear IgA bullous dermatosis, 1285, 1285*f*
        - pemphigus vulgaris, 1284, 1284*f*

Cutaneous fistulae, 2962

Cutaneous horn, of penis, 1742.e1, 1742.e1*f*

Cutaneous lesions, penile premalignant, 1742

- Buschke-Löwenstein tumor, 1742.e1*f*, 1742.e3
- non-human papillomavirus-related, 1742.e1–1742.e2
- virus-related, 1742.e2–1742.e3, 1743*b*

Cutaneous T-cell lymphoma (CTCL), as neoplastic condition, 1302, 1302*f*

“Cut-to-the-light” procedure, 3059

CVA, Cerebrovascular accident

CVD, Cardiovascular disease

CxBladder, of bladder tumor, 3081

CyberWand, 245

Cyclic adenosine monophosphate (cAMP), in ureteral contractions, 1885

Cyclic guanosine monophosphate (cGMP), in ureteral contractions, 1885

Cyclic guanosine monophosphate-signaling pathway, 1497–1499

Cyclin D2, 3616

Cyclin-dependent kinase inhibitors (CDKIs), in GU cancers, 1347.e1, 1347.e1*f*

Cyclin-dependent kinases, in GU cancers, 1347.e1, 1347.e1*f*

Cyclins, in GU cancers, 1347.e1, 1347.e1*f*

Cyclooxygenase (COX) inhibitors

- to facilitate bladder filling and urine storage, 2703
- urethral function effects of, 1903

Cyclooxygenase-2 (COX-2), in UTUC, 2198

Cyclosporine, for BPS/IC oral therapy, 1241*t*, 1242–1243

CYP17 inhibition, 3693–3695, 3694*f*

Cyproheptadine, for delayed ejaculation, 1579

Cyproterone acetate, 3674

Cystadenomas, of testicular adnexa, 1709

Cystatin C, GFR estimation with, 1905

Cystectomy

- for cutaneous continent urinary diversion, 3206–3208, 3207*f*
- for non-muscle-invasive bladder cancer, 3106–3107, 3107*b*
- oncologic outcomes following, radical, 3118–3119
- partial, 3038–3043
  - evaluation for, 3038–3040
  - extraperitoneal approach to, 3040–3041
  - open, 3040
  - outcomes with, 3042–3043
  - surgical indications for, 3038–3040
  - surgical technique for, 3040–3041
  - transperitoneal approach to, 3041–3042, 3042*f*–3043*f*
- with pelvic lymph node dissection, radical
  - anatomic extent of, 3115–3116
  - bilateral, 3115
  - density of, 3117
  - distal urethra management, 3118
  - extracapsular nodal extension, 3117
  - intraoperative decision making, 3117–3118
  - intraoperative frozen sections of ureter, 3117–3118
  - managing female urethra in, 3118
  - for muscle-invasive bladder cancer, 3114–3119
  - number removed in, 3125
  - oncologic outcomes following, 3118–3119, 3118*t*

Cystic and solid renal masses, CT and, 48–50, 50*f*, 52*f*

Cystic dysplasia of rete testis, 899

Cystic fibrosis transmembrane conductance regulator, 1450

- mutation assessment, for male infertility, 1443

Cystic lymphangioma, retroperitoneal tumors and, 2237, 2237*f*

Cystic masses, retroperitoneal tumors and, 2236–2237

Cystic mesothelioma, retroperitoneal tumors and, 2238

Cystic nephroma, 765–766, 765*f*, 766*b*, 767*f*, 2129–2130, 2129*f*

Cystic partially differentiated nephroblastoma (CPDN), in pediatric patients, 1109

Cystic renal disease, 339, 349–350

Cystine stones, in renal calculi, 2029–2030, 2029*f*

Cystinuria, 859, 2029, 2060–2068, 2063*b*
  - ammonium acid urate stones, 2066
  - bladder calculi, medical management of, 2066–2067
  - clinical considerations of, 2060–2061
  - compliance and quality of life, 2062–2063
  - conservative strategies of, 2061
  - drug-containing calculi, 2065–2066, 2066*t*
  - follow-up of, 2062
  - infection calculi, 2063–2065, 2063*f*, 2064*t*, 2065*b*
  - medical therapy for, 2061–2062
  - metabolic stone formation, 2066
  - miscellaneous and drug-induced stones, 2065, 2065*b*

Cystitis
  - definition of, 1129
  - diminished bladder capacity and, 2671
  - mechanosensitive afferent sensitization with, 2508
  - spinal cord chemical changes with, 2507
  - with spinal cord injury, 2467

Cystitis cystica, 526
  - of bladder, 3082, 3082*f*

Cystitis glandularis, of bladder, 3082, 3082*f*

Cystocele, 2526, 2587, 2589*f*

Cystography
  - after modern staged repair of exstrophy, 548–549
  - of bladder injuries, 3055*f*–3056*f*

Cystolithotripsy
  EHL for, 241.e2
  laser, 244.e4
Cystometrogram (CMG), in urodynamic studies, 2556, 2557*f*
Cystometry, in urodynamic studies, 2556, 2557*f*
Cystoplasty
  reduction, for prune-belly syndrome, 592
  sigmoid, 694–695, 696*f*
Cystoscopy, 156, 2443, 2443*f*
  after modern staged repair of exstrophy, 548–549
  antimicrobial prophylaxis for, 1198
  of bladder tumor, 3078–3079
  in diagnostic of hematuria, 250–251
  for genitourinary tuberculosis diagnosis, 1313–1314, 1314*f*
  for non-muscle-invasive bladder cancer, 3096
    surveillance, 3108
  for partial cystectomy, 3038
  for pelvic floor disorder assessment, 2534
  in pubovaginal sling placement and fixation, 2838–2839
  in retropubic midurethral sling, 2853
  for sphincteric urinary incontinence, 2996–2997, 2997*f*
  for transurethral resection of bladder tumor, 3133
  for urothelial cancer, 3091
  for UTUC, 2190
Cystourethoscopy, 26, 26*t*
Cystourethrogram
  for benign prostatic hyperplasia, 3348
  for striated sphincter dyssynergia, 2611*f*
Cystourethroscopy
  for benign prostatic hyperplasia, 3348
  equipment for, 186–187, 186*t*, 188*f*–189*f*, 188*t*
  indications for, 185–186, 186*t*, 191*b*
  patient preparation for, 187–190, 189*t*

- special circumstances in
    - continent urinary diversions, 191
    - suprapubic cystostomy, 190–191
- technique for, 190, 190*f*
- for urethral diverticula, 2982, 2982*f*

Cysts
- of Gartner duct, urethral diverticula differentiated from, 2986, 2986*f*
- of prostate, on transrectal ultrasonography, 3493, 3493*f*
- of scrotal wall, excision of, 1844
- simple, 766–770, 770*b*
    - classification of, 768–770, 769*b*, 770*f*
    - clinical features of, 766
    - evaluation of, 768, 768*f*–769*f*
    - histopathology of, 766–768
    - prognosis of, 770, 770*f*
    - treatment of, 770, 770*f*
- of Skene gland, urethral diverticula differentiated from, 2974, 2986*f*
- vestibular, 976–977, 977*f*

Cytochrome P450 oxidoreductase deficiency, 1011

Cytokine regulation, 788

Cytokines, 1333–1334, 1335*f*, 1335*t*
- in benign prostatic hyperplasia, 3311, 3312*f*
- septic shock and, 1183
- in tubulointerstitial fibrosis, 787–788

Cytoreductive androgen deprivation therapy (ADT), for localized prostate cancer, 3524

Cytoreductive nephrectomy
- laparoscopic, 2298
- for metastatic RCC, 2325–2328, 2326*f*–2327*f*, 2327*t*, 2328*b*

Cytosine, 1346.e1, 1346.e2*f*

Cytosolic free calcium, 1495

Cytotoxic T-lymphocyte antigen-4 (CTLA-4), 2146

D

da Vinci robotic platform, 467

da Vinci Robotic System, 211, 212.e2*f*
  instrumentation for, 218, 218*f*
  virtual reality training for, 231.e2, 233.e1*f*

da Vinci Surgical System, 2822–2823

DA-8031, for PE, 1572.e2

Danish Prostatic Symptom Score (DAN-PSS), 110*t*, 3344

DAN-PSS, Danish Prostatic Symptom Score

Dantrolene, to facilitate bladder emptying, 2720.e3

Dapoxetine, and PE, 1571

Darifenacin hydrobromide, to facilitate bladder filling and urine storage, 2682*t*, 2684–2685

Darkfield examination, syphilis test, 1258

Dartos pouch procedure, 1855

Data Management and Coordinating Center (DMCC), 3478–3479

Davis and Trattner Diagnostic Foley catheters, 154

Daytime urinary incontinence, bladder dysfunction and, 655–660, 660*b*

DBD, Diabetes-induced bladder dysfunction

DDR, DNA damage response

De novo detrusor overactivity, as complication of anterior colporrhaphy, 2782

Debulking nephrectomy, for metastatic RCC, 2325–2328, 2326*f*–2327*f*, 2327*t*, 2328*b*

Decipher assay, 3488

Decipher biopsy test, 3542–3543

Decipher test, 3521

Decision making, in intraoperative consultation, 296–297, 297*f*

Decreased adrenal function disorders, 2380–2383, 2383*b*
  - clinical characteristics, 2381–2382, 2382*t*
  - diagnostic tests, 2382
  - overview and epidemiology, 2380–2381
  - pathophysiology, 2381, 2381*f*
  - prognosis, 2383
  - treatment, 2382–2383, 2383*t*

De-differentiated liposarcomas, in retroperitoneum, 2230

Deep brain stimulation, for Parkinson disease, 2606

Deep perineal space, 1807.e10

Deep venous thrombosis (DVT)
  - after laparoscopic and robotic surgery, 231
  - after retropubic radical prostatectomy, 3563
  - prophylaxis, after laparoscopic radical prostatectomy, 3579

Defecation disorders, 667–679, 667*b*
  - classification of, 667–671, 668*t*
  - disimpaction for, 672
  - epidemiology of, 667–671, 668*t*
  - evaluation of, 667–669, 668.e1*f*, 669*t*, 671*b*
  - imaging studies of, 669–671, 669*f*–670*f*, 669.e1*f*, 670.e1*f*
  - large bowel/rectum washout for, 672
  - maintenance therapy for, 672–673
  - management of, 671–678, 671*f*, 673*b*, 679*b*
  - nonpharmacologic interventions, 671–673
  - prognosis of, 673
  - surgical management of, 673–678, 673*f*
    - enema regimen for, 677–678, 678*f*
    - operative technique for, 674–677, 675*f*–677*f*
    - outcomes with, 678, 678*f*, 678*t*
    - patient selection and preparation for, 674
  - urinary tract and, 667, 668*f*

Deferential artery, 1370–1371, 1372*f*, 1375, 1393, 1394*f*

Definitive perineostomy, for transmen, 3072, 3072*f*

Deflazacort, for ureteral stone passage, 1900

Defunctionalized bladder, lower urinary tract dysfunction and, 2632–2633

Dehydroepiandrosterone (DHEA), 3281, 3283*f*

Delayed contrast reactions, in contrast media, 32

Delayed ejaculation, 1572–1579, 1579*b*

- causes of, 1574, 1574*t*
- and congenital disorders, 1575
- and endocrinopathy, 1575
- epidemiology of, 1574
- evaluation of, 1577–1578, 1577*t*, 1578*f*
- iatrogenic causes of, 1575
- and infective disorders, 1575
- and neurologic disorders, 1576–1577
- psychological, 1574–1575
- terminology and definition of, 1573–1574
- treatment of, 1578–1579
  - pelvic cancers, 1575–1576
  - pharmacotherapy, 1578–1579, 1579*t*
  - psychological strategies, 1578

Delayed orchiectomy, 1712

Delayed spontaneous bladder perforation, after augmentation cystoplasty, 700–701, 700*f*

Delayed voiding, 2732

Delirium, 2914

Delivery

- sphincter function and, 2596
- urinary incontinence and, 2583

Dementia, lower urinary tract dysfunction with, 2603–2604

Dénes technique, 595, 598*f*–600*f*

Denosumab, 3704

Dent disease, 349

Depression
  - in geriatric urology patient, 2910
  - prostatitis and, 1210

Dermal grafts, for urethral and penile reconstruction, 1805–1806

Dermatitis herpetiformis, 1285

Dermatofibroma, 1304, 1305*f*

Dermatophyte infection, 1294–1295, 1295*f*

Dermoid cysts, testicular, 1708

Derogatis Interview for Sexual Functioning (DISF), 112, 112*t*

Desmoid tumor, retroperitoneal tumors and, 2234, 2234*f*

Desmopressin (DDAVP)
  - in children, 2711
  - efficacy of, 2712
  - for enuresis, 664
  - to facilitate bladder filling and urine storage, 2682*t*, 2710–2712
  - gender and, 2712
  - for nocturia, 2672*t*, 2920.e8–2920.e9
  - for nocturnal enuresis, 2712
  - for nocturnal polyuria, 2669–2670, 2673*t*
  - in nocturnal polyuria, 2713*b*

Desperation RPLND, 1728, 1728*t*

Desperation surgery, for NSGCTs, 1701

Detection bias, 105

Detrusor contractility, impaired, in detrusor underactivity, 2650

Detrusor contraction assessment
  - duration, 2659
  - speed, 2659
  - strength, 2657–2659, 2658*f*

Detrusor failure, in detrusor underactivity, 2650

Detrusor hyperactivity with impaired contractility (DHIC), 2651

- in geriatric patients, 2919.e2

Detrusor hyperreflexia, 2637

Detrusor leak point pressure (DLPP), 485–486
- urodynamic studies of, 2561*f*, 2562

Detrusor muscle, 2465, 2465*f*
- acontractile, 2521, 2565
- actinomyosin cross-bridge cycling, 2472–2473, 2472*b*, 2473*f*
- action potentials of, 2473–2474, 2474*f*
- aging and, 2509–2510, 2653, 2654*f*
- areflexia of, 2521
  - after CVA, 2602
  - after traumatic brain injury, 2604
  - with cerebellar ataxia, 2604
  - with lumbar disk protrusion, 2619–2620
  - with MS, 2608
  - with Parkinson disease, 2605–2606
  - urodynamic classification of, 2521–2522, 2522*b*
- calcium signaling in, 2475–2476, 2476*f*
- contractile proteins, 2470–2472, 2471*f*–2473*f*
- contraction of
  - electrical stimulation and, 2729
  - muscarinic receptors and, 2680
- electrical response propagation, 2476–2477, 2477*f*
- excitation-contraction coupling in, 2474–2475, 2475*f*
- interstitial cells of, 2477–2478, 2478*f*
- involuntary contractions of, 2559
- membrane electrical properties of, 2473–2474, 2474*f*
- motor sensory network in, 2479–2480, 2479*f*
- normal function of, 2564
- overactivity, neurogenic, 2521–2522

Detrusor overactivity (DO), 496, 2833
- afferent mechanisms in, 2642
- after CVA, 2602
- benign prostatic hyperplasia and, 3355
- with brain tumor, 2604
- with cerebellar ataxia, 2604

- herpesvirus infection and, 2621–2622
- hypothesis of, 2642
- idiopathic, 2560
- interstitial cells and, 2477–2478, 2478*f*
- with MS, 2608
- neurogenic, 2560
- neuromodulation for, rationale for, 2510, 2510*f*
- nocturnal, 2671
- with Parkinson disease, 2605
- pharmacologic therapy for, 2682*t*
  - antimuscarinic agents, 2681
- spinal cord injury and, 2504–2505, 2505*b*
- stress-induced, urodynamic studies of, 2563, 2563*f*
- with suprasacral spinal cord injury, 2610
- test induced, 2560
- with traumatic brain injury, 2604
- urodynamic studies of, 2560–2561, 2560*f*–2561*f*
- vasculature in, 2463

Detrusor overactivity incontinence (DOI), 2543, 2581
- cough-induced, 2543

Detrusor sphincter dyssynergia (DSD), 2521
- with autonomic dysreflexia, 2614
- lower urinary tract dysfunction and, 2627
- with Parkinson disease, 2605
- urinary incontinence and, 2595–2596

Detrusor underactivity (DUA), 2521, 2565, 2650
- definition of, 2650, 2651*f*, 2652*b*
- diagnosis of, 2657–2659, 2658*t*, 2659*b*
  - ambulatory urodynamics, 2659
  - bladder sensation, 2659
  - detrusor contraction duration, 2659
  - detrusor contraction speed, 2659
  - detrusor contraction strength, 2657–2659, 2658*f*
- epidemiology of, 2650–2652, 2652*t*, 2653*f*
- etiopathogenesis of, 2653–2657, 2654*f*–2655*f*, 2657*b*
  - bladder outlet obstruction, 2655–2656, 2657*b*

        - diabetes mellitus, 2656–2657, 2657*b*
        - myogenic factors, 2653
        - neurogenic factors, 2653–2655
        - neurologic disease or injury, 2657, 2657*b*
        - specific factors, 2655–2657, 2656*b*
    - in geriatric patients, 2919.e2
    - management of, 2659–2663, 2660*f*, 2663*b*
        - bladder outlet surgery for, 2662–2663
        - botulinum toxin, 2662
        - conservative, 2660
        - electrical stimulation, 2661–2662
        - initial assessment for, 2656*b*, 2660
        - pharmacotherapies for, 2660–2661
        - reconstructive surgery for, 2663
        - urinary diversion for, 2663
    - prevalence of, 2652*t*
    - regenerative medicine for, 2663
    - symptoms of, 2650, 2651*f*, 2652*b*
    - terminology for, 2650, 2652*b*
    - treatment of, 2719*b*
- Detrusor wall thickness (DWT), 3348
- Developmental disorders, and male infertility, 1449–1450
- Dexamethasone sodium sulfate, for contrast media, 32
- Dextroamphetamine, for BPS/IC oral therapy, 1243
- DGN, Dorsal genital nerve
- DHEA, Dehydroepiandrosterone
- DHIC, Detrusor hyperactivity with impaired contractility
- DHT, Dihydrotestosterone
- Diabetes-induced bladder dysfunction (DBD), 2656–2657
- Diabetes insipidus, 2678
- Diabetes mellitus
    - detrusor underactivity and, 2656–2657, 2657*b*
    - ED and, 1510, 1510*t*–1511*t*
    - hormonal therapy and, 3681

- host defense mechanisms in UTIs and, 1139
- hyperoxaluria and, 2059–2060
- low urine pH and, 2027–2028
- lower urinary tract dysfunction and, 2622–2624, 2624*b*
- Peyronie's disease and, 1600, 1601*f*
- renal calculi and, 2008
- ureteral function effects of, 1900

Diabetic cystopathy, 2623, 2656–2657

Diacylglycerol (DG), in ureteral contractions, 1885

Diagnosis, of UTIs, 1141–1143, 1141*b*, 1142.e1*t*, 1143*f*

Diagnostic and Statistical Manual of Mental Disorders (DSM-5), and premature ejaculation, 1567

Diagnostic catheters, 154–155, 155*f*

Diagnostic evaluation, in ED, 1517–1519, 1528*b*

- cardiovascular risk assessment tools for, 1519
- laboratory tests, 1519
- medical history, 1518
- physical examination for, 1519
- psychosocial history, 1519
- questionnaires and sexual function symptom scores, 1519, 1520*f*
- sexual history, 1518, 1518*t*

Dialysis, in renal transplantation, 1058

Diameter, of ureters, 1891

Diaphragm, anatomy of, 2448–2449, 2449*f*

DIAPPERS acronym, 2526*t*, 2539

Diarrhea, with bowel preparation, 3165, 3166*t*

Diclofenac, urethral function effects of, 1903

Diet

- after laparoscopic radical prostatectomy, 3579
- benign prostatic hyperplasia and, 3324, 3325*t*
- bladder cancer and, 3077–3078

  - for BPS/IC treatment, 1240–1241, 1240*b*
  - and exercise, for metabolic syndrome, 1422
  - prostate cancer and, 3464–3465, 3544
  - urinary incontinence and, 2586

Dietary calcium, 2049

Dietary hyperoxaluria, 2023

Dietary supplements, bladder cancer and, 3078

Differentiation, in urinary tract obstruction, 784–786, 785*f*

Diffuse mesangial sclerosis (DMS), 756

Diffuse pelvic floor hypertonicity, 2881

Diffusion-weighted imaging (DWI), 61, 63–64, 64*f*

Diffusion-weighted imaging magnetic resonance imaging (DWI-MRI), for biochemical recurrence after radiotherapy, 3666–3667

Digital palpation, for PFM function assessment, 2723

Digital rectal examination (DRE)
  - for pelvic floor disorders, 2530
  - physical examination for, 11–12
  - for prostate cancer, 3515
    - tumor extent prediction with, 3519
  - for simple prostatectomy, 3450

Digital ureteroscopes, 195, 195*f*, 196*t*
  - care and sterilization of, 195–197

Digoxin, and ED, 1508–1509

Dihydrotestosterone (DHT), 1391, 3371
  - in benign prostatic hyperplasia, 3307–3308, 3308*f*
  - epididymal function and, 1406
  - in prostate, 3280–3281, 3282*t*
    - cancer, 3466, 3467*f*
  - in vas deferens, 1407

Dihydroxyadenine stones, in renal calculi, 2031–2032

1,25-Dihydroxycholecalciferol (Calcitriol), 1914 in calcium metabolism, 2015

Dilated bladder, 519–521

Dilation devices, for ureteroscopy, 197

Dilators and insertion, for genito-pelvic pain-penetration disorder, 1653

Dimercaptosuccinic acid (DMSA), 92, 796

Dimerization, of androgen receptors, 3291

Dimethyl sulfoxide (DMSO), 1244

  to facilitate bladder filling and urine storage, 2703–2704

Diminished bladder capacity

  causes of, 2671

  management of, 2671–2674, 2675*t*–2677*t*

  nocturia and, 2667, 2668*t*, 2671–2674

  nocturnal polyuria and, 2674–2678

Diminutive clitoris, 975, 976*f*

Diode lasers, 240

Diphallia, 877, 877*f*

Dipsogenic polydipsia, 2678

Dipstick test, 15

Dipstick urinalysis, 479

Direct cutaneous artery, 136*f*

Direct neocystostomy, 2207, 2209*f*

Direct visualization, 459

Directed masturbation, for female orgasmic disorder, 1647

Disc kidney, 728*f*, 729

Disease-specific mortality, 103–104

DISF, Derogatis Interview for Sexual Functioning

Disimpaction, 672

Disk disease, lower urinary tract dysfunction with, 2619–2620

Disk prolapse, lower urinary tract dysfunction with, 2619
Dismembered pyeloplasty, 1952–1953
  indications for, 1952–1953
  technique of, 1953, 1953*f*–1954*f*
  for ureteropelvic junction obstruction, 1945–1946, 1953*f*–1954*f*
    in children, 828, 828*f*–830*f*
    results of, 1957–1958, 1959*t*
Disorders of sex development (DSD), 990–1018, 1449
  ambiguous genitalia, 998–1018, 999*f*, 999*b*
  of gonadal differentiation and development, 1000–1007
    46,XX males, 1000–1001
    bilateral vanishing testes syndrome, 1005–1006
    embryonic testicular regression, 1005–1006
    Klinefelter syndrome and variants, 1000
    syndromes of gonadal dysgenesis, 1001–1005
  ovotesticular, 999*f*, 1006–1007
  testicular tumors associated with, 1122–1124, 1123*t*
  46,XX, 1007–1011
    congenital adrenal hyperplasia, 1007–1010, 1007*f*–1008*f*, 1007*b*
    secondary to maternal androgens and progestins and maternal tumors, 1010–1011
  46,XY, 1011–1017
    androgen receptor and postreceptor defects, 1013–1014
    Leydig cell aplasia, 1011
    Mayer-Rokitansky-Küster-Hauser syndrome, 1017
    persistent Müllerian duct syndrome, 1016–1017, 1016*f*
    5α-reductase deficiency, 1014–1016, 1015*f*
    testosterone biosynthesis disorders, 1011–1013
Disorders of sexual differentiation, 908
Disposable probes, 245
Disruptive Behavior Disorders Rating instrument, 477
Dissection, energy modalities
  for electrosurgery, 235–241, 236*f*
  ultrasound instrumentation, 237–238
Dissemination of disease, of UTUC, 2193
Dissertatio de Arthritide: Mantissa Schematica: De Acupunctura, 2749

Distal hypospadias, repair of, 918

Distal renal tubular acidosis
    type 1, 2025–2026, 2025*f*
        causes of, 2055*b*
        chronic diarrheal states, 2055–2056
    type 4, 2026

Distal ureter
    stone localization and, 2086, 2086*t*
    surgery of, 3010

Distal ureterectomy
    with bladder psoas muscle hitch/Boari flap, 2207, 2209*f*
    laparoscopic or robotic, reimplantation and, 2208, 2209*t*

Distal vagina, 980, 1627, 1627.e1

Distraction injuries, urethral, ED with, 3059

Diuresis
    postobstructive, 796
    ureteral function effects of, 1893

Diuretic renal scintigraphy, 419–423, 419*f*–424*f*

Diuretic renography, 390
    for UPJO and reflux differentiation, 1943
    for ureteropelvic junction obstruction, 1944, 1946*f*
    for urinary tract obstruction, 779

Diuretic scintigraphy, 41–42, 41*f*–42*f*

Diuretics
    and ED, 1506
    for pediatric kidney stone disease, 869

Divergent validity, 109

Diverticulectomy
    bladder, 3010–3019, 3011*f*, 3011*b*, 3046*b*–3047*b*
        complications of, 3018–3019
        evaluation of, 3011–3012, 3012*f*
        laparoscopic and robotic techniques, 3015–3018, 3016*f*–3017*f*

        - outcomes of, 3018–3019
        - postoperative care of, 3018–3019
        - surgical indications, 3011–3012, 3012*f*
        - surgical technique of, 3012–3018, 3012*f*
    - bladder outlet, 2971–2972
    - calyceal, 2294
    - laparoscopic, 3012–3013
    - urethral, 2989*b*, 2991–2992, 2991*t*

DLPP, Detrusor leak point pressure

DMCC, Data Management and Coordinating Center

DMS, Diffuse mesangial sclerosis

DMSA, Dimercaptosuccinic acid

DMSA renal cortical scintigraphy, 418

DMSO, Dimethyl sulfoxide

DNA
- basics of, 1346.e1–1346.e4, 1346.e2*f*
- damage and repair of, 1350–1351, 1351*b*
    - DSB repair, 1351.e1*f*–1351.e2*f*, 1351.e2
    - mechanisms, 1351.e1, 1351.e1*f*

DNA-binding domain, of androgen receptors, 3289–3290

DNA damage response (DDR), 1350–1351

DNA hypermethylation, in prostate cancer, 3470

DNA methylation, 1348–1350, 1350*b*
- in bladder cancer, 1349
- in prostate cancer, 1349

DO, Detrusor overactivity

Docetaxel
- for castration-resistant prostate cancer, 3690–3692, 3691*f*–3692*f*
- cisplatin, and 5-fluorouracil (TPF), for penile cancer, 1770
- for non-muscle-invasive bladder cancer, 3105

Documentation
- in intraoperative consultation, 297–298

surgical time out, 298, 298*t*

ultrasonography, 76, 77*f*

DOI, Detrusor overactivity incontinence

Domestic station, patient history of, 9

Donabedian, Avedis, 101

Donabedian model, 101

Dopamine

- agonists, for female sexual arousal disorders, 1650
- in ED, 1494, 1495*t*
- in ejaculatory response, 1564
- in PD, 2605

Dopaminergic agonists, 1534

Doppler ultrasound, 73–74

- for urinary tract obstruction, 778

Dorsal artery, of penis, 1385*f*, 1387*f*, 1807.e5*f*

Dorsal genital nerve (DGN), electrical stimulation of, 2752

Dorsal lithotomy, 467*f*

Dorsal lumbotomy

- approach, for open kidney surgery, 2251, 2251*f*
- urologic surgery, 141–142, 141*f*–142*f*

Dorsal nerve

- conduction velocity, 1527
- of penis, 1386

Dorsal plication, 912, 912*f*

Dorsal rhizotomy, 2741–2742

- clinical results of, 2743, 2744*t*
- effect of, 2742–2743
- goal of, 2742–2743
- patient selection for, 2742
- post-stimulus voiding in, technique of, 2742
- stimulator of, 2741–2742, 2742*f*

    - surgical implantation technique of, 2742–2743, 2743*f*

Dorsal segmental artery, 136*f*

Dorsal shortening technique, 912–913, 915*f*

Dorsal vein, of penis, 1384–1385, 1807.e5*f*

Dorsal vein complex (DVC)

- division of, in retropubic radical prostatectomy, 3553–3554, 3554*f*
- ligation of
    - in laparoscopic radical prostatectomy, 3572–3573, 3573*f*
    - in retropubic radical prostatectomy, 3553–3556, 3553*f*

Dose-volume histogram (DVH), 3587–3588, 3588*f*

Double dye test, for ureterovaginal fistula, 2943

Double T pouch, 3215, 3216*f*–3217*f*

Double-lumen catheters, 154

Double-strand breaks (DSBs), repair of, 1351.e1*f*–1351.e2*f*, 1351.e2

Dovitinib, for RCC, 2337–2338

Down training, 2732

Doxazosin

- for benign prostatic hyperplasia, 3359–3361, 3360*t*–3361*t*
- for diminished bladder, 2674, 2675*t*–2677*t*
- to facilitate bladder emptying, 2720.e1
- to facilitate bladder filling and urine storage, 2682*t*
- ureteral response to, 1888

Doxepin, to facilitate bladder filling and urine storage, 2702

Doxorubicin (Adriamycin), for non-muscle invasive bladder cancer, 3103–3104

Doyen rib stripper, 140

Drain catheters, 155

Drainage, renal, for urinary tract obstruction, 795

DRE, Digital rectal examination

Dribble-Stop, 2546

Dromedary hump, 1865

Drug-containing calculi, 2065–2066, 2066*t*

Drug-induced erectile dysfunction, 1506–1509

Drug-resistant tuberculosis, 1318

Drug toxicity, AKI caused by, 1924–1925, 1924*t*

Drugs

- lower urinary tract function and, 2528, 2528*t*
- renal calculi induced by, 2032
- transport of, prostatic secretions and, 3303–3304, 3304*b*

Dry matrix agents, 147

DSBs, Double-strand breaks

DSD, Disorders of sex development

DSM-5, Diagnostic and Statistical Manual of Mental Disorders

DSNB, Dynamic sentinel node biopsy

DUA, Detrusor underactivity

Dual-modality lithotripters, 244–246, 245*f*, 246*b*

- LithoClast Ultra, 244–245

Dual-source CT (DSCT), 45

Ductuli efferentes, 1393

Ductus (vas) deferens, physiology of, 1406–1407, 1408*b*

- absorption and secretion and, 1407
- cytoarchitecture, 1406
- functions of, 1406
- gross architecture, 1406
- sperm transport and, 1406–1407

Duke Activity Status Index, 120, 121*t*

Duloxetine

- to facilitate bladder filling and urine storage, 2682*t*, 2702–2703
- for stress urinary incontinence, 2504, 2546

in men, 2716
in women, 2715–2716
Duodenum, 1668, 1668.e2*f*, 1669*f*–1670*f*
injury of, during radical nephrectomy, 2261
Duplex Doppler ultrasonography, 388
or renovascular hypertension screening, 1917–1918, 1918*b*
Duplex kidney, genitourinary trauma and, 1076
Duplex ultrasonography, in ED, 1521–1523, 1522*f*
Duplicated collecting system, ureteral calculi with, surgical management of, 2087
Duplicated urethra, 310
Duplication anomaly, 333
Dutasteride, for benign prostatic hyperplasia, 3374–3376, 3374*f*, 3375*t*, 3376*f*
DVC, Dorsal vein complex
DVH, Dose-volume histogram
DVISS, Dysfunctional Voiding and Incontinence Scoring System
DVSS, Dysfunctional Voiding Symptom Score
DVT, Deep venous thrombosis
DWI, Diffusion-weighted imaging
DWI-MRI, Diffusion-weighted imaging magnetic resonance imaging
DWT, Detrusor wall thickness
Dye testing, for pelvic floor disorders, 2533
Dynamic contrast-enhanced magnetic resonance imaging, 64, 65*f*
Dynamic dosimetry, 3598
Dynamic infusion cavernosometry and cavernosography, in ED, 1523, 1523*f*–1524*f*
Dynamic pressure perfusion studies, for ureteropelvic junction obstruction, 1944–1945

Dynamic renal imaging, 92–93

  with Technetium-99m Mercaptoacetyltriglycine (^{99}mTc-MAG3), 92–93, 94*f*

Dynamic sentinel node biopsy (DSNB)

  of inguinal nodes, for penile cancer, 1760–1761

  for penile cancer, 1793

Dysfunctional elimination syndrome, 432

Dysfunctional voiding, 2568–2569

Dysfunctional Voiding and Incontinence Scoring System (DVISS), 476

Dysfunctional Voiding Symptom Score (DVSS), 476, 653

Dyslipidemia, 1419

Dyspareunia

  female sexual dysfunction and, 1637

  genito-pelvic pain-penetration disorder and, 1652

Dysplastic lesion, of upper tract urothelium, 2188

Dysuria

  after photoselective vaporization of prostate, 3440

  after transurethral needle ablation of prostate, 3433

  patient history of, 3–4

  of urethral diverticula, 2980

E

Early detection research network (EDRN), 3478

Eastern Cooperative Oncology Group (ECOG) Scale, 107, 107*t*

Echelon Flex, 216, 216*f*

Echinococcosis, of genitourinary tract, 1332

Economics

  of metabolic evaluation of urinary lithiasis, 2044–2045, 2045*b*

  prostate cancer and, 3546

  of ureteral calculi surgical management, 2088.e1

ECRS, Extracorporeal renal surgery

Ecthyma gangrenosum, 1293, 1294*f*

Ectoderm, 305

Ectodermal ingrowth theory, 905

Ectopic ACTH syndrome, 2361, 2362*f*, 2362*t*, 2366

Ectopic corticotropin-releasing hormone, 2361–2362

Ectopic kidney, 177

- genitourinary trauma and, 1076, 1077*f*

Ectopic scrotum, 886–887, 888*f*

Ectopic sebaceous glands, 1303*f*, 1304

Ectopic ureter, 333, 798

- anatomic description of, 798*b*, 799*f*
- ureterostomy for, 819

Ectopic ureteral insertion, 977, 978*f*

ED, Erectile dysfunction

EDCs, Endocrine-disrupting chemicals

Edging artifact, in ultrasonography, 72, 73*f*

EDRN, Early detection research network

Education

- for female orgasmic disorder, 1647
- for genito-pelvic pain-penetration disorder, 1653

EEC, Exstrophy-epispadias complex

Effective dose, 28

Efferent pathways, to bladder, 2487–2493, 2487*f*

- adrenergic, 2488
- in detrusor underactivity, 2653, 2655*f*
- glutamate in, 2488, 2489*f*
- glycine and γ-aminobutyric acid in, 2488
- purinergic, 2488–2489

- reflex circuitry, 2489–2493, 2490*f*
- serotonin in, 2488–2489
- terminal nerve fibers, 2487–2488
- transmitters in, 2488, 2490*b*, 2491*f*–2492*f*, 2491*t*

“Eggplant deformity,” with penile fracture, 3048, 3048.e1*f*

EHL, Electrohydraulic lithotripsy

Ehlers-Danlos syndrome, lower urinary tract dysfunction and, 2631

Ehrlich technique, 595

Eight edition TNM penile staging system, 1748–1750, 1750*t*

Ejaculation

- delayed, 1572–1579, 1579*b*
  - causes of, 1574, 1574*t*
  - and congenital disorders, 1575
  - and endocrinopathy, 1575
  - epidemiology of, 1574
  - evaluation of, 1577–1578, 1577*t*, 1578*f*
  - iatrogenic causes of, 1575
  - and infective disorders, 1575
  - and neurologic disorders, 1576–1577
  - pharmacotherapy, 1578–1579, 1579*t*
  - psychological, 1574–1575
  - psychological strategies, 1578
  - terminology and definition of, 1573–1574
  - treatment of, 1578–1579
  - and treatment of pelvic cancers, 1575–1576
- disorders, α_1-blocker therapy associated with, 3370
- failure, patient history of, 6
- premature, 1564–1572, 1572*b*
  - and assessment of erectile function, 1570
  - causes of, 1568–1569
  - classification of, 1564–1565
  - definition of, 1565–1567, 1565.e1, 1566*t*
  - and determination of intravaginal ejaculation latency time, 1569
  - diagnosis of, 1569
  - evaluation of, 1569
  - patient-reported outcome measures, 1569–1570
  - physical examination of, 1570, 1570*f*
  - prevalence of, 1567–1568, 1567*f*
  - treatment of, 1570–1572

Ejaculatory anhedonia, 1580

Ejaculatory ductal obstruction, 1450–1451
  delayed ejaculation and, 1575

Ejaculatory ducts, 315*f*, 1407, 1408*f*, 1408*b*
  anatomy of, 1454

Ejaculatory dysfunction
  after monopolar transurethral resection of prostate, 3418
  after retroperitoneal tumors management, 2243–2244
  after RPLND, 1729–1730
  after transurethral microwave therapy, 3430
  after transurethral needle ablation of prostate, 3433
  in male infertility, 1450–1451

Elastin, of bladder wall, 2464

Elderly
  α1-adrenergic blockers in, 3370
  bacteriuria in, 1188–1190, 1190*b*
    asymptomatic, 1147–1149, 1147*t*, 1147*b*–1149*b*
    diagnosis, 1188–1189
    epidemiology, 1188
    management, 1189–1190, 1189*t*
    pathogenesis, 1188
    screening for, 1188
  for laparoscopic kidney surgery, 2279
  mid-urethral sling outcomes in, 2862–2863, 2863*b*
  mistreatment of, 2921–2922
  sexual health in, 2920–2921
  in urologic surgery, 121–122

Electrical activity, of ureters
  action potentials, 1879–1881, 1879*f*–1880*f*
  pacemaker potentials and pacemaker activity, 1881–1882, 1882*f*
  propagation, 1882–1883
  resting potential, 1878–1879, 1879*f*, 1881, 1881*b*

Electrical stimulation, 2739–2755, 2755*b*
  constant *versus* intermittent, 2754–2755

- current and future perspectives for, 2743–2746
- for detrusor underactivity, 2661–2662
- for genito-pelvic pain-penetration disorder, 1653
- history of, 2739–2740
- levels of evidence and recommendations for, 2722.e2*b*–2722.e4*b*
- neurophysiology of, 2740–2741, 2741*f*
- of pelvic floor muscle, 2729–2730
- rechargeable neurostimulator of, 2755
- sacral anterior root stimulation, 2741–2742, 2742*f*
- sacral dorsal rhizotomy, 2741–2742, 2742*f*
  - clinical results of, 2743, 2744*t*
  - goal and effect of, 2742–2743
  - patient selection in, 2742
  - surgical implantation technique of, 2742–2743, 2743*f*
- techniques of, 2747–2754
  - dorsal genital nerve, 2752
  - intravesical, 2747–2748
  - percutaneous tibial nerve, 2748–2751, 2749*f*
  - pudendal nerve, 2751–2752
  - sacral nerve, 2752–2754
  - transcutaneous, 2748
- types of, 2729
- working mechanism of, 2746–2747, 2746*f*–2747*f*

Electrocardiogram, 450

Electrohydraulic (spark gap) generator, 2094, 2095*f*

Electrohydraulic lithotripsy (EHL), 197, 241*f*, 241*b*, 2109–2110, 2110*f*
- for bladder stones, 241
- chemical stone composition and, 241
- physics and mechanism of action of, 241
- tissue effects, 243
- ureteroscopy with, 243.e1

Electrolyte abnormalities
- in CKD, 355
- with urinary intestinal diversion, 3199–3201, 3199*t*, 3200*f*

Electromagnetic generator, 2094, 2095*f*

Electromotive drug administration (EMDA), 1614, 1617*t*

Electromyography (EMG)

- for PFM function assessment, 2723
- in urodynamic studies, 2557, 2559
- for urodynamics, 2535

Electrostimulation, for neuromuscular dysfunction of lower urinary tract, 637

Electrosurgery

- devices for laparoscopic and robotic surgery, 214
- safety of, 236–237
- tissue dissection and cauterization with, 235–237, 236*f*

Electrotonic spread, in ureteral cells, 1882

Elephantiasis, as filariasis clinical manifestation, 1330, 1330*f*

11p15 locus, in Wilms tumor, 1097*t*, 1098

Elocalcitol, to facilitate bladder filling and urine storage, 2713.e1

EM, Erythema multiforme

Embolization

- before kidney surgery, 2248, 2248.e1*f*
- of prostate, 3445–3446
- for renal injuries, 1986, 1986*f*
- for renal tumors, targeted, 2323

Embolotherapy, 903, 903.e1*f*

Embryology, 799–800, 801*b*

- of exstrophy-epispadias complex, 530, 530*f*
- of female genitalia, 973–974, 974*f*, 974*b*
- of neuroblastoma, 1087–1088
- of prune-belly syndrome, 581
- of supernumerary kidney, 721
- of testis, 949–953
- of thoracic kidney, 725–726
- of unilateral renal agenesis, 718, 719*f*
- of vagina, 973–974, 974*f*, 974*b*

Embryonal carcinoma (EC), histology of, 1682–1683, 1683*f*

Embryonal RMS, 1111, 1112*f*, 1113*b*

Embryonic testicular regression, 1005–1006

EMDA, Electromotive drug administration

Emergency situations, 118

EMG, Electromyography

Emphysema, subcutaneous, during laparoscopic and robotic surgery, 225

Emphysematous cystitis, 1158–1159

Emphysematous pyelonephritis, 1171–1172, 1171*f*

Empirical treatment, in male infertility, 1452

EMT, Epithelial-mesenchymal transition

En bloc hilar vessel stapling, in laparoscopic radical nephrectomy, 2297

Encephalitis, and ED, 1502

Endo Close, 219

Endo Stitch, 215

EndoAvitene, 215.e2

Endocarditis, antimicrobial prophylaxis for uncomplicated urologic procedures and, 1200

Endocrine, concepts of, basic, for HPG axis, 1390, 1391*f*

Endocrine-disrupting chemicals (EDCs), cryptorchidism and, 949

Endocrine evaluation, and male infertility, 1436–1438

Endocrinology, of prostate, 3280–3295, 3281*f*

- adrenal androgens, 3282–3283, 3283*f*
- androgen-binding proteins in plasma, 3282*f*, 3284
- androgen production by testes, 3281–3282, 3282*f*–3283*f*, 3282*t*
- estrogens in male, 3282*t*, 3283–3284

End-of-life care, 2922

Endometriosis, of bladder, 3039, 3040*f*

Endopelvic fascia, 2850
    incision of, in retropubic radical prostatectomy, 3552, 3552*f*
Endopyeloplasty, percutaneous, for ureteropelvic junction obstruction, 1949
Endopyelotomy, for ureteropelvic junction obstruction, 191–192
Endoscopic incision (direct vision internal urethrotomy), for transmen, 3071
Endoscopic inguinal lymphadenectomy, for penile cancer, 1794
Endoscopic surgery, 145
    complications, of seminal vesicle surgery, 1863
Endoscopy, 185–202
    of bladder diverticula, 2969, 2970*f*
        management of, 2972
    of cloacal anomalies, 1024–1025, 1025*f*
    equipment and video-endoscopic systems for, 185, 186*f*–187*f*
    female pelvis anatomy for, 2443, 2443*f*, 2443*b*
    in genitourinary tuberculosis treatment, 1317
    history of, 185
    kidney anatomy for, 1865.e2*f*
    for male urinary incontinence, 2543
    of ureteral anomalies, 799*f*–800*f*, 808, 808*f*–809*f*
    of urogenital sinus abnormalities, 1023*f*–1024*f*
Endothelial dysfunction, 1420
Endothelins (ETs)
    lower urinary tract and, 2502
    renal vascular tone control by, 1913
    urethral function effects of, 1903–1904
Endothelium, ED and, 1506
Endoureterotomy, for ureteral stricture disease, 1968–1969
    antegrade approach to, 1969
    combined retrograde and antegrade approach, 1969
    results with, 1969
    retrograde ureteroscopic approach to, 1968–1969, 1969*f*

Endourologic management
- of upper tract urothelial cancer, 2210–2224
  - antegrade nephroureteroscopic, 2212–2219, 2215*f*–2217*f*, 2218*t*
  - basic attributes, 2210–2211, 2210*f*
  - lymph node-positive and metastatic disease treatment, 2222–2224, 2223*f*
  - positive upper tract urinary cytology and carcinoma in situ management, 2219–2222, 2219*f*, 2221*f*, 2221*t*
  - retrograde ureteroscopic, 2211–2212, 2211*f*, 2213*f*, 2214*t*, 2215*f*
- for ureteral stricture disease, 1966–1969, 1971*b*
- for ureteroenteric anastomotic stricture, 1977, 1978*f*
- for ureteropelvic junction obstruction, 1947, 1952*b*

Endourology, rise of, 2069.e2–2069.e3

Endovascular stents, for renovascular injuries, 1990

EndoWrist instruments, 218, 218*f*

End-stage renal disease (ESRD)
- in children, 355–357
- in CKD, 1929–1930
- neural tube defects and, early intervention for, 629

Enema
- cleansing, for prostate biopsy, 3496
- for defecation disorders, 677–678, 678*f*

Energetic harmony, 2749

Energy modalities in urologic surgery, for tissue dissection and cauterization
- electrosurgery, 235–241, 236*f*
- ultrasound instrumentation, 237–238

Enhanced recovery after surgery (ERAS), 453–455, 3165–3169, 3167*t*–3168*t*, 3170*t*–3174*t*

Enteral nutrition, 122

Enteral tube feeds, 449

Enteric hyperoxaluria, 2022–2023, 2022*f*, 2056
- medical therapy for, 2057

Enterobiasis, of genitourinary tract, 1332

Enterocele, 2526, 2587, 2589*f*

Enterococcus, 442

Enterocystoplasty, 3034–3038

- complications with, 3036–3038
- evaluation for, 3034–3035
- laparoscopic and robotic techniques, 3036, 3037*f*
- outcomes with, 3037–3038
- postoperative care of, 3036–3038
- seromuscular, 705–706, 705*f*
- surgical indication of, 3034–3035
- surgical technique for, 3035–3036, 3035*f*

Enucleation, for small renal tumors, 2263, 2264*f*

Enuresis

- alarm for, 663–664
- alternative therapies for, 665
- background on, 660–661
- behavioral therapy for, 663, 664*f*
- combination therapy for, 665
- epidemiology of, 661, 661*f*
- evaluation of, 662–663
- genetics of, 661
- natural history of, 661, 661*f*
- nocturnal, 2539, 2581
- pathophysiology of, 661–662, 662*f*
- patient history of, 6
- pediatric, 660–665, 665*b*
- pharmacotherapy for, 664
- terminology for, 660–661
- treatment of, 663–664, 2547

Enuresis risoria, 658–660

Environmental factors, UTUC variations and, 2186–2188

Environmental pollution, bladder cancer and, 3077

Enzalutamide, 3676, 3695–3696, 3695*f*

Eosinophilic cystitis, 526, 526*f*

EP, Etoposide-cisplatin

EPD, Extramammary Paget disease

Ephedrine

- in stone formation, 2033
  - surgical management of, 2077.e2–2077.e3
- for stress urinary incontinence in women, 2714

Epidemiology of Lower Urinary Tract Symptoms (EpiLUTS) II, 2734

Epidermal growth factor receptor (EGFR) therapy, for metastatic bladder cancer, 3131

Epidermoid cysts, 1123, 1304, 1305*f*

- testicular, 1708

Epididymal appendix, 391–392, 392*f*

Epididymal cysts, 903

Epididymal tumor excision, 1850

Epididymal/vasal injury, complication of scrotal surgery, 1856

Epididymectomy, 1853

- for chronic scrotal pain syndrome, 1222

Epididymis, 319*f*, 1850

- acute, 1853
- anatomy of, 1376*b*
  - arterial supply, 1375
  - blood supply of, 1454, 1454*t*
  - gross structure, 1374, 1374*f*–1375*f*
  - innervation in, 1403
  - lymphatic supply, 1375
  - microanatomic architecture, 1374–1375
  - nerve supply, 1375
  - vascular and lymph supply, 1402–1403
  - venous drainage, 1375
- anomalies of, 903
  - cryptorchidism and, 962–963, 962*f*
- appendix, torsion of, 897–898
- chronic, 1853
- in genitourinary tuberculosis, 1309
- HIV and, 1266
- imaging of
  - magnetic resonance imaging, 1376
  - ultrasound, 1375–1376, 1376*f*
- palpable abnormalities of, 1853
- physiology of, 1402–1406, 1406*b*
  - cytoarchitecture, 1403–1404

        - gross architecture in, 1402–1403, 1403*f*
        - regulation of, 1405–1406

Epididymitis, 898–899
    - after photoselective vaporization of prostate, 3441
    - as STD, 1255

Epididymo-orchitis, 392, 410–411

Epidural cord compression, in castration-resistant prostate cancer, 3702, 3703*t*

Epigenetic anomalies, and male infertility, 1446

Epigenetic changes, male reproductive physiology and, age-related, 1402

Epigenetic events, in prostate cancer, 3470

Epigenetic modifications, as prostate cancer biomarkers, 3487–3489

Epispadias, 568–572, 572*b*, 1449
    - female, 570–572, 571*f*–572*f*
        - associated anomalies, 571
        - operative techniques for, 571, 573*f*
        - surgical objectives for, 571
        - surgical results for, 571–572
    - male, 568–570, 568*f*
        - associated anomalies, 568–569
        - genital reconstruction in, 569
        - surgical management of, 569–570
        - urethral reconstruction in, 569
        - urinary continence in, 569–570, 570*t*
    - repair of, 550–551
        - failure of, 564
        - outcomes and results with, 557–558

Epithelial cell receptivity, in UTIs
    - bladder cells, 1136–1137, 1137*f*
    - vaginal cells, 1135–1136, 1135*f*
    - variation in, 1136

Epithelial-mesenchymal transition (EMT), 789

Epithelial metaplasia, of bladder, 3081

Epithelial permeability, bladder glycosaminoglycan layer and, 1232.e5–1232.e7, 1232.e7*b*

Epithelial spread, of UTUC, 2194

Epithelial stem cells, of prostate, 3278*f*, 3279

Epithelium, epididymal, 1403–1404, 1403*f*

EPO, Erythropoietin

Epoöphoron, 319*f*

Epstein criteria, of localized prostate cancer, 3526–3527

EQUIL 2, 2010

ERAS, Enhanced recovery after surgery

Erbium:YAG (Er:YAG) laser lithotripsy, basic physics of, 244

Erectile bodies, of penis, 1807.e6*f*–1807.e7*f*

Erectile dysfunction (ED), 1425–1426

- after laparoscopic radical prostatectomy, 3579
- after photoselective vaporization of prostate, 3442
- after retropubic radical prostatectomy, 3564
- after robotic radical prostatectomy, 3582–3583, 3582*f*
- arteriogenic, 1504–1505
- cardiovascular disease and, 1425–1426, 1426*b*
- causes of
  - arteriogenic, 1505
  - cavernous (venogenic), 1505*t*
  - drug-induced, 1506–1509
- classification of, 1502*b*
- corporal structural defects and, 1505–1506
- endocrinologic, 1503–1504
- epidemiology of, 1513–1514
- evaluation and management of, 1513–1538
  - diagnostic evaluation, 1517–1519, 1518*f*
  - historical perspective, 1513, 1514*t*
  - management principles, 1515–1517, 1515*t*, 1516*f*
  - public health significance, 1513–1514
  - specialized evaluation and testing, 1519–1529, 1521*t*
  - treatment considerations, 1529–1538
- HIV and, 1267
- hormonal therapy and, 3681

intraoperative troubleshooting, 1588–1591, 1592*b*
    crural crossover, 1589–1591, 1590*f*
    fibrotic corpora, 1588–1589, 1589*f*
metabolic syndrome and, 1422
neurogenic, 1502–1503
pathophysiology of, 1500–1512, 1512*b*
    incidence and epidemiology of, 1500–1512
patient history of, 6, 8*t*
and PD, 1600–1601
perspectives on, 1512
postoperative complications of, 1591–1596, 1596*b*
    cylinder aneurysm as, 1593, 1593*f*
    cylinder erosion as, 1594, 1595*f*
    cylinder extrusion as, 1593–1594, 1594*f*–1595*f*
    infection as, 1591–1593, 1592*f*, 1593*b*
    penile necrosis after implant placement, 1595–1596, 1595*f*
    visceral erosion of the reservoir, 1594–1595, 1595*f*
preoperative preparation for, 1583–1584
    device placement for, 1585–1588, 1585*f*–1587*f*, 1588*b*
    incision for, 1584–1585, 1585*f*
    reservoir placement, 1586–1588, 1587*f*–1588*f*
primary, 1511–1512
prostate cancer and, 3606
psychogenic, 1501–1502
risk factors for, 1501, 1502*f*
surgery for, 1582–1598
    device placement for, 1585–1588, 1585*f*–1587*f*
    incision for, 1584–1585, 1585*f*
    informed consent for, 1582–1583, 1584*b*
    patient and partner satisfaction for, 1597–1598
    postoperative care for, 1596–1597
    in special situations, 1596
    types of implants for, 1582, 1583*f*
with transurethral vaporization of prostate, 3426
with urethral distraction injury, 3060
vascular, 1505
Erectile Dysfunction Inventory of Treatment Satisfaction, 111
Erectile prosthesis, testicular implants and, 3069, 3070*f*

Erector spinae, 1658, 1662*f*–1665*f*, 1664*t*

Ergot alkaloids, with RPF, 1978

Erlotinib, for RCC, 2343–2344

Erosion, in penile implant, 1594, 1595*f*

Erysipelas, 1288–1289

Erythema multiforme (EM), 1277–1278, 1278*f*

Erythromycin, in pregnancy, 1187*t*

Erythroplasia of Queyrat, 1742

Erythropoiesis, renal regulation of, 1914

Erythropoietin (EPO), 1914

Escherichia coli, 428, 429*f*

ESRD, End-stage renal disease

Established urinary incontinence, in geriatric patients, 2919

Estradiol, 1391, 1434, 1437

Estrogens, 1390, 1394

- benign prostatic hyperplasia role of, 3308–3309, 3308*t*
- bladder and, 2503
- continence mechanism and, 2713
- to facilitate bladder filling and urine storage, 2682*t*
- and female sexual response, 1627.e5
- in male, 3282*t*, 3283–3284
- for overactive bladder, 2709–2710
- in prostate cancer, 3462–3463
- for stress urinary incontinence in women, 2713–2714
- supplementation of, for vesicovaginal fistula surgery, 2934
- urethra and, 2503
- for urgency urinary incontinence, 2709–2710
- for UTIs, 1164–1165, 1164*f*

ESWL, Extracorporeal shock wave lithotripsy

ESWT, Extracorporeal shock wave therapy

Ethics, 115–118
  medical, 115–116
Ethnicity
  renal calculi and, 2006
  urinary incontinence and, 2583–2585
Etoposide-cisplatin (EP), for seminomas, 1705
ETs, Endothelins
ETS family gene fusions, 3469
European Cooperative Groups, bladder RMS treatment approaches of, 1115
Everolimus, for RCC, 2337, 2338*f*
Evicel, 215.e2
Ewing sarcoma, retroperitoneal tumors and, 2232–2233, 2233*f*
Ewing-like sarcoma, retroperitoneal tumors and, 2232–2233, 2233*f*
Excisional tapering, for megaureter in children, 851–852, 851*f*
Excitation-contraction coupling
  in detrusor muscle, 2474–2475, 2475*f*
  in ureters, 1884–1885
Excretory urography
  ureter anatomy on, 1873–1874
  of ureteropelvic junction obstruction, 1943, 1944*f*
  of urinary tract obstruction, 780
Excurrent ducts, of testis, 1454
Exercise, for prostate cancer, 3543–3544
Exercise-induced hematuria, 18
Exogenous Cushing syndrome, 2361, 2365
Expressed prostatic secretions, 24, 25*f*
Exstrophy
  in perinatal urology, 379–382
  in transitional urology, 1049–1050

        - female with, 1051–1052
        - long-term reconstructive outcomes, 1049
        - urologic, 1049–1050
- Exstrophy-epispadias complex (EEC), 528–580, 529*f*, 531*b*
    - adolescents with, 565
    - adults with, 565
    - embryology of, 530, 530*f*
    - fertility with
        - female patient, 567
        - male patient, 566
    - historical aspects of, 528
    - incidence of, 528–530
    - inheritance of, 528–530
    - long-term adjustment issues with, 567–568, 568*b*
    - prenatal diagnosis of, 538, 538*b*
    - pseudoexstrophy, 537
    - quality of life with, 567
    - sexuality with
        - female concerns, 566–567
        - male concerns, 565–566
    - split symphysis variant of, 538
    - variants of, 537–538, 538*f*
- Extended-core biopsy techniques, 3497, 3498*f*
- Extended pelvic lymphadenectomy
    - common iliac, 3152, 3153*f*–3154*f*
    - external iliac, 3148–3149, 3151*f*
    - hypogastric, 3149–3152, 3153*f*
    - obturator, 3149, 3152*f*
    - presacral, 3152, 3154*f*
- Extended sentinel lymph node dissection, for penile cancer, 1760
- Extensively drug-resistant tuberculosis, 1318
- External beam hypofractionation, outcomes for, 3611–3612, 3611*t*, 3612*b*, 3613*t*
- External-beam radiation therapy, for penile cancer, 1765, 1766*t*
- External beam radiation treatment, for prostate cancer, 3593–3596, 3596*b*

    brachytherapy *versus*, 3612–3613, 3614*t*
    fractionation, 3593
    heavy particle beams/proton therapy, 3594–3596, 3594*f*, 3595*t*
    high dose rate as a boost with, 3599
    outcomes for, 3609–3610, 3610*t*
    radiobiologic basis for hypofractionation, 3593, 3593*t*
    stereotactic body radiation therapy, 3593–3594
    tumor control after, 3611*b*
External collecting devices, 2903–2904
External compression (Credé), 2902
External genitalia, 312*b*
    male, development of, 1392, 1392*f*
External iliac lymphadenectomy, 3148–3149, 3151*f*
External irradiation, brachytherapy combined with, 3599–3600
External sphincter
    damage, orthoptic urinary diversion and, 3238
    male sphincteric mechanisms and, 2594
    urodynamic studies of, 2568–2569
Extracellular matrix, in obstructive nephropathy, 788–790
Extracorporeal renal surgery (ECRS), 2254–2257, 2256*f*
    preoperative considerations for, 2254–2255
    surgical procedure for, 2255–2257
Extracorporeal shock wave lithotripsy (ESWL), 2094–2103, 2103*b*, 2115
    adjuncts to improve, 2102, 2102*b*
    bioeffects of, 2097–2100
        acute renal injury as, 2098–2099, 2098*f*–2099*f*, 2099*b*
        chronic renal injury as, 2099–2100, 2099*t*
        extrarenal damage as, 2097–2098, 2097*f*
    combination of ultrasonography and fluoroscopy for, 2095
    fluoroscopy for, 2094–2095
    future direction in, 2102–2103, 2103*f*
    generator types for, 2094
        electrohydraulic (spark gap), 2094, 2095*f*

    - electromagnetic, 2094, 2095*f*
    - piezoelectric, 2094, 2096*f*
  - imaging systems for, 2094–2095
  - methods and physical principles, 2094–2097
  - optimization of, 2100–2102, 2100*b*, 2101*f*, 2102*b*
  - stone fragmentation in, 2095–2097, 2096*f*
  - tissue injury from, 2100
  - ultrasonography for, 2095

Extracorporeal shock wave therapy (ESWT), and PD, 1614, 1617*t*

Extraction, in laser lithotripsy, 2111

Extragenital skin harvest, for hypospadias, 945

Extramammary Paget disease (EPD), as neoplastic condition, 1301–1302, 1301*f*

Extraperitoneal approach
  - anterior, to laparoscopic pyeloplasty, 1956
  - operative team placement for, 211

Extrapituitary endocrine modulators, 1448

Extraprostatic extension, 3507, 3511

Extratesticular endocrine dysfunction, male infertility and, 1448–1449

Extravaginal spermatic cord torsion, 897, 897*f*

Extravasation of contrast material, contrast media and, 32

Extrinsic apoptotic pathway, 1366.e1*f*–1366.e2*f*, 1366.e2

Extrusion, in penile implant, 1593–1594, 1594*f*–1595*f*

Eyeball UDS, 2534

Eye-of-the-needle technique, 166–167, 167*f*

F

F antigens, 428–429

FAAH, Fatty acid amide hydrolase

Fabry disease, 1302, 1303*f*

Facility setup, for urodynamic studies, 2552–2553

Factors, additional, in urodynamic studies, 2554

Failed epispadias repair, reconstructive surgery for, 1813

Failed hypospadias repair, reconstructive surgery for, 1812–1813

Fallopian tubes
- anatomy of, 2436–2437
- for continent urinary diversions, 709

Falls, nocturia and, 2666

Familial benign prostatic hyperplasia, 3311–3312, 3311*t*

Familial hypomagnesemia with hypercalciuria and nephrocalcinosis (FHHNC), 2019

Familial hypoplastic glomerulocystic kidney disease, 756–757

Familial papillary RCC, molecular genetics of, 1354*t*, 1358

Familial RCC, 2141–2145, 2142*t*–2143*t*, 2144*f*
- treatment of, 2173–2174, 2174*f*

Familial Wilms tumor, 1098

Family history, 9
- prostate cancer and, 3542

Fanconi syndrome, 348

Fascia lata, 2834
- harvest of, 2837

Fasciae
- of anterior abdominal wall, 2429*f*
- of lower abdominal wall, 2444, 2446*f*
- pelvic
  - female, 2427, 2429*f*
  - male, 2448*f*, 2449, 2452*f*
- of perineum and perineal body, 2449, 2450*f*

Fascial closure
- after laparoscopic and robotic surgery, 218–219

- techniques, 150–151

Fascial sling

- for bladder neck reconstruction, 686–687
- results with, 686–687
- technique for, 686

FAST, Focused assessment with sonography for trauma

Fast spin-echo (FSE), 412–413

Fast-twitch fibers, of urethral striated muscle, 2466

Fatty acid amide hydrolase (FAAH), 2713.e2

Febrile child, 426

Fecal diversion, for radiation fistula, 2956

Fecal impaction, transient urinary incontinence and, 2919.e1

Fecal incontinence (FI)

- in geriatric patients, 2920.e9
- ultrasound for, 2439, 2440*f*

Female circumcision, 987–988, 988*f*

Female external genitalia, 2435–2436, 2436*f*–2437*f*

- abnormalities of
  - acquired, 986–988
  - cervical atresia, 984–985, 985*f*
  - clitoris, 975, 977*b*
  - congenital, 975–986
  - lateral fusion, 985–986
  - management of, 973–989
  - structural, 974
  - vagina, 978–986, 982*b*
  - vertical fusion, 979–981
  - vestibule, 975–977, 977*b*
- acquired disorders of, 986–988, 988*b*
  - condyloma acuminatum, 988
  - female circumcision, 987–988, 988*f*
  - labial adhesions, 986–987, 987*f*
- defect of, in bladder exstrophy, 534–535, 535*f*
- development of, 307*f*, 310–311, 311*f*–313*f*

  - embryology of, 973–974, 974*f*, 974*b*
  - evaluation and classification of, 974, 975*f*

Female genital-pelvic pain dysfunction, 1636

Female orgasmic disorder, 1646, 1648*b*
  - assessment for, 1646–1647
  - with desire and arousal problem, 1647–1648
  - medical treatment for, 1647–1648
  - medication-induced, 1648
  - psychosocial treatment for, 1647
  - sexual enhancement products, 1647

Female pelvis
  - anatomy of, 2427–2443, 2439*b*
    - anal perineum of, 2435
    - bony pelvis, 2427, 2428*f*
    - external genitalia of, 2435–2436, 2436*f*–2437*f*
    - fascia of, 2427, 2429*f*
    - innervation of, 2433–2434
    - ligaments of, 2428–2430, 2430*f*–2432*f*
    - lymphatic drainage of, 2433, 2434*f*
    - muscles of pelvic floor, 2430–2432, 2432*f*
    - organ support of, 2438, 2438*f*
    - organs of, 2436–2438, 2437*f*
    - perineum of, 2434–2435, 2435*f*
    - peritoneum of, 2427, 2429*f*
    - urethra, 2438–2439, 2439*f*, 2465–2466, 2466*f*
    - vasculature of, 2432–2433, 2433*f*
  - endoscopic anatomy of, 2443, 2443*f*, 2443*b*
  - radiographic anatomy of, 2439–2443
    - fluoroscopy, 2442–2443, 2442*f*
    - magnetic resonance imaging, 2440–2442, 2440*f*–2442*f*
    - ultrasound, 2439, 2440*f*

Female persistent genital arousal disorders, 1650, 1650*t*
  - psychosocial characterization and etiologic factors, 1650
  - treatment targets for, 1650

Female radical cystectomy, 3155–3157, 3157*f*–3158*f*

Female reproductive system, pediatric tumors of, 1121*b*
  - cervical or uterine RMS, 1120

    - ovarian, 1120–1121
    - vaginal RMS, 1119–1120, 1119*f*
    - vulvar RMS, 1119
- Female reproductive tract, development of, 324–327, 324*f*–325*f*
- Female sexual arousal disorders, 1648–1649, 1651*b*
    - interview assessment for, 1649, 1649*t*
    - pharmacotherapy for, 1649–1650
        - hormonal therapy, 1649–1650
        - nonhormonal therapy, 1650
    - potential treatments for, 1649
- Female sexual arousal dysfunction, 1636
- Female sexual dysfunction
    - epidemiology of, 1636–1637, 1637*b*
    - lower urinary tract dysfunction and, 1654–1655, 1657*b*
        - clinical signs and investigations for, 1655
        - epidemiology of, 1654
        - etiology and classification of, 1654–1655
        - links and treatments, 1655–1657
        - self-image/body image connected to, 1657
        - sexual lifestyle and communication and, 1654–1655, 1654*t*
- Female Sexual Function Inventory (FSFI), 112, 112*t*
- Female sexual interest-arousal disorders, 1635–1636
- Female sexual interest disorder, 1640–1648, 1646*b*
    - definition of, 1640–1641
    - evaluation of, 1641–1643, 1642*t*–1643*t*
    - pathophysiology of, 1641, 1641*f*
    - treatment for, 1643, 1644*f*
        - medical, 1643–1646
        - psychological, 1643
- Female sexual organs, anatomy and physiology of, 1627, 1627*b*
- Female sexual response
    - hormonal regulators of, 1627.e5–1627.e6
    - neurogenic mediators of, 1627.e5
- Female stress urinary incontinence, use of injectable agents for, 2890–2891

Female urethra, 152
- catheterization of, 153

Female urethral cancer, 1782–1785, 1785*b*
- anatomy and pathology of, 1782–1785, 1783*f*
- epidemiology, etiology, and clinical presentation of, 1782
- evaluation and staging of, 1783
- prognosis of, 1783–1784
- recurrence after cystectomy, 1787–1789, 1789*b*
- treatment of, 1784–1785

Females, with exstrophy, 1051–1052
- fertility, 1051
- pregnancy and delivery, 1051–1052
- procedentia repair, 1051
- reconstruction of genitalia, 1051
- sexual function, 1051

Female-to-male transexuals, Transmen

Female-to-male transgender, reconstructive surgery for, 1841–1842, 1842*b*

Femoral nerve, 2453*t*

Fenretinide, for neuroblastoma, 1096

FEPs, Fibroepithelial polyps

Fertility
- after RPLND, 1729
- with cryptorchidism, 969–970
- with exstrophy-epispadias complex
  - female patient, 567
  - male patient, 566
- in prune-belly syndrome, 600
- RMS treatment effects on, 1116–1117
- sperm, 1405, 1405*f*
- urologic surgery and, 288
- Wilms tumor treatment effects on, 1108

Fesoterodine

  - for diminished bladder, 2675, 2675*t*–2677*t*
  - to facilitate bladder filling and urine storage, 2682*t*, 2685–2687
  - for urinary incontinence, in geriatric patients, 2920.e4

Fetal cystoscopy, in urinary tract dilation, 364–365

Fetal magnetic resonance imaging, 358, 359*f*

Fetal myelomeningocele closure, outcomes for, 382

α-Fetoprotein (AFP), in pediatric patients, 1122, 1122*f*

Fetus, fundamentals of, 404
  - MRI in, 412–413

Fever
  - evaluation and management of, 426–433, 427*f*
  - patient history of, 7
  - UTI diagnosis and, 1143

^{18}F-FACBC, 99

F-FDG PET/CT, 43

FFP, Fresh frozen plasma

FG, Fournier gangrene

FGF, Fibroblast growth factors

FH gene, systemic therapy targeting, 2343

FHHNC, Familial hypomagnesemia with hypercalciuria and nephrocalcinosis

FI, Fecal incontinence

Fibrin-based glue, for laparoscopic and robotic surgery, 215.e2

Fibrin sealants, 148

Fibroblast growth factor receptor therapy, for metastatic bladder cancer, 3131

Fibroblast growth factors (FGF), in prostate development, 3276

Fibroblasts, in tubulointerstitial fibrosis, 782*f*, 789

Fibrocystin, 748

Fibroepithelial polyps (FEPs), 526

- of ureter, 821–822, 821*f*–822*f*
- of urethra, 1776

Fibrosis
- mechanisms of, 788–790
- in obstructive nephropathy, 788–790
- PC-RPLND findings of, survival outcomes associated with, 1726, 1727*t*
- pelvic, as laparoscopic and robotic surgery contraindication, 203

Fibrotic corpora, 1588–1589, 1589*f*

Fibrotic gene expression, and PD, 1606

Fibrous dysplasia, 1933–1934, 1934*f*

Filariasis, of genitourinary tract, 1328–1331, 1332*b*
- diagnosis, 1330
- epidemiology, 1328–1329
- organisms, 1328, 1328*f*
- pathology and clinical manifestations, 1329–1330, 1329*f*–1330*f*
- prevention and control, 1331
- treatment, 1330–1331

Filling cystometry, for benign prostatic hyperplasia, 3347

Filtrate transport, 1906–1913
- acid-base balance, 1911–1912, 1912*f*, 1912*b*
- calcium, 1911, 1912*f*
- potassium, 1909–1910, 1910*b*
- sodium, 1906–1909, 1907*f*–1910*f*, 1909*b*
- solutes, 1912–1913
- water, 1910–1911, 1911*f*, 1911*b*

Fimbria, 319*f*, 324*f*

Finasteride
- for benign prostatic hyperplasia, 3371–3374, 3373*t*
- for diminished bladder, 2674, 2675*t*–2677*t*

Fine-needle aspiration cytology, for penile cancer, 1760

FIRSTANA trial, 3693

First-morning void, 2667

FISH, Fluorescence in situ hybridization

Fistula obstruction, 3272

Fistulae

- classification of, 2930–2931, 2931*f*
- complex, of posterior urethra, 1835–1836, 1836*b*
- cutaneous, 2962
- with intestinal anastomoses, 3179–3180
- other urinary, 2962, 2962*b*
- radiation, 2960–2962
  - chemotherapy of, 2961–2962
  - combination therapies of, 2962
  - diversion procedures for, 2961
  - interpositional grafts for, 2961
  - management approaches for, 2961
  - recommendations for, 2961
  - repair techniques for, 2961
- urethral, 883, 883*f*
- urethrocutaneous, 935–937, 936*f*–937*f*
- urinary tract, 2924–2963, 2924*b*
  - after renal preservation surgery, 2962
  - after renal transplantation, 2962
  - general considerations of, 2924
  - management of, 2925*b*
  - other, 2962, 2962*b*
  - surgical repair of, 2925*b*
- urocutaneous, 2962
- uroenteric, 2952–2953
  - pyeloenteric, 2953–2955, 2953*f*
  - vesicoenteric, 2953*t*
- urogynecologic, 2946
  - ureterovaginal, 2942, 2942*b*
  - urethrovaginal, 2947–2951
  - vesicouterine, 2946–2947, 2947*b*
  - vesicovaginal, 2924–2926
- urovascular, 2958
  - pyelovascular, 2958
  - renovascular, 2958
  - ureterovascular, 2958–2959

Fixed drug eruption, as papulosquamous disorder, 1282, 1283*f*

Fixed particle growth theory, 2011

FLA, Focal laser ablation

Flank approaches

- for open kidney surgery, 2249–2251
  - subcostal, 2249–2250, 2249.e1*f*, 2250*f*–2251*f*, 2250.e1*f*
  - supracostal, 2250–2251, 2251.e1*f*
- to ureteropelvic junction obstruction in children, 829

Flank incision, kidney and retroperitoneum approaches, 138–140

- 12th rib supracostal and 11th rib transcostal, 140, 140*f*
- true flank incision, 139–140, 140*f*

Flank muscles, of posterior abdominal wall, 1658, 1662*f*–1664*f*, 1664*t*

Flank pain, 400

- UTI diagnosis and, 1143

Flank retroperitoneal approach, in open adrenalectomy, 2410–2411, 2410*f*–2411*f*

Flap urethroplasty, for transmen, 3071

Flaps

- for continent urinary diversions, 707–709, *see also* specific flaps
- for penile transplantation, 1838–1842, 1840*f*, 1842*b*
- for ureteropelvic junction obstruction, 1960–1962
  - Culp-DeWeerd spiral flap, 1960–1961, 1961*f*
  - Foley Y-V plasty, 1960, 1960*f*
  - intubated ureterotomy, 1961–1962, 1963*f*
  - salvage procedures, 1963
  - Scardino-Prince vertical flap, 1961, 1962*f*
- for urethral and penile reconstruction, 1807, 1807*f*
  - axial, 1807, 1807*f*–1808*f*
  - island, 1807
  - peninsular, 1807
  - random, 1807, 1807*f*
- for urethral stricture disease, 1823–1827, 1824*f*–1825*f*

Flavoxate hydrochloride, to facilitate bladder filling and urine storage, 2682*t*, 2696

Flexible cystourethroscopes, 186–187, 189*t*

Flexible laser lithotripsy, 244.e4

Flexible lithotripters, 2109–2111

Flexible ureteroscopes, 194*f*–195*f*, 195, 196*t*

- care and sterilization of, 195–197, 197*f*
- technique, 201

Flibanserin, for female sexual interest disorder, 1645–1646

Flip-flap technique (Mathieu), 924, 924*f*

FloSeal, 148, 215.e2

- for renal trauma, 1990, 1990*f*

FLS, Fundamentals of Laparoscopic Surgery

Fluid intake, for pediatric kidney stone disease, 868–869

Fluids

- bladder cancer and, 3077
- intake of, renal calculi and, 2009
- management of, 2732–2733
  - evidence for, 2733
  - excessive, 2732–2733
  - inadequate, 2733
  - timing of, 2733

Fluorescence in situ hybridization (FISH), of bladder tumor, 3079

Fluorine-18 (^{18}F), 91

(^{18}F)fluoro-D-glucose (18F-FDG), 96, 97*f*, 100*b*

- for bladder cancer, 97
- for kidney cancer, 97–98
- for penile cancer, 100
- for prostate cancer, 98–100
- for testis cancer, 100

Fluoroquinolones

- prophylaxis with
  - for cystourethroscopy, 189
  - for uncomplicated urologic procedures, 1194*t*–1196*t*
- for UTIs, 1151*t*–1153*t*, 1153–1154, 1156, 1187*t*

Fluoroscopic-guided access, 166–169, 166*f*–167*f*

Fluoroscopic imaging, for urodynamics, 2535

Fluoroscopy, 389
  - of female pelvis, 2442–2443, 2442*f*
  - of male pelvis, 2457–2458
  - of pediatric stone disease, 861
  - ureteroscopy, 199

5-Fluorouracil
  - for condylomata acuminata, 1742.e3
  - for penile cancer, 1770

Flurbiprofen, to facilitate bladder filling and urine storage, 2682*t*, 2703

Flush stoma, 3182–3183

Flutamide
  - for benign prostatic hyperplasia, 3376–3377
  - for prostate cancer, 3674

Focal ablative therapy, for locally advanced prostate cancer, 3655
  - cryoablation, 3655
  - high-intensity focused ultrasound, 3655

Focal extraprostatic extension, 3511

Focal laser ablation (FLA), 3628, 3633*f*, 3634*t*, 3635*f*

Focal segmental glomerulosclerosis (FSGS), 345

Focal therapy, for prostate cancer, 3616–3639, 3639*b*
  - ablation patterns and current technologies of, 3624–3638
    - ablation approach, 3624
    - ablation types, 3624, 3624*f*
    - adjuvants to, 3638
    - brachytherapy, 3632–3638
    - cryotherapy, 3624–3628, 3625*f*, 3627*t*
    - follow up, 3638
    - high-intensity focused ultrasonography, 3628, 3629*t*–3630*t*, 3631*f*–3632*f*
    - irreversible electroporation, 3628–3632, 3635*f*, 3636*t*
    - laser, 3628, 3633*f*, 3634*t*, 3635*f*
    - other modalities, 3638
    - vascular-targeted photodynamic therapy, 3632, 3637*t*

- advanced imaging techniques in, 3621–3622
  - MRI-targeted/fusion biopsy, 3622
  - multiparametric magnetic resonance imaging, 3621–3622
- biologic basis for, 3616–3620
  - multifocality of, *versus* index lesion hypothesis, 3617–3620, 3619*t*, 3620*f*
  - using cancer grade as indication of aggressiveness, 3616–3617, 3617*f*
- clinical applications of, 3620
  - complementary roles and active surveillance, 3620
  - index lesion treatment, 3620
- concepts of, 3616
- future research for, 3638–3639
- historical perspective of, 3616
- patient selection for, 3620–3621
  - biopsy-based lesion identification, 3621
- promising imaging modalities of, 3622–3624
  - contemporary patient selection criteria, 3622–3624, 3623*t*
  - multiparametric ultrasonography, 3622
  - positron emission tomography, 3622

Focused assessment with sonography for trauma (FAST), of upper urinary tract, 1066

Focused ultrasound, for renal tumor ablation, 2319–2321

Folded rectosigmoid bladder, 3209

Foley catheters, 173, 484

Foley Y-V plasty, for ureteropelvic junction obstruction, 1960, 1960*f*

Follicle cells, 319*f*

Follicle-stimulating hormone (FSH), 1390, 1391*f*, 1437

Folliculitis, 1290–1291, 1291*f*

Foods, bladder cancer and, 3078

Force-length relations, of ureters, 1890, 1890*f*

Force-velocity relations, of ureters, 1890–1891, 1891*f*

Foregut, 318*f*

Foreign-body removal, bladder, 3043–3046
- complications of, 3046

    evaluation of, 3043–3044
    laparoscopic and robotic technique, 3044–3045, 3045*f*–3046*f*
    open technique of, 3044, 3045*f*
    percutaneous, 3045–3046
    postoperative care of, 3046
    surgical indication of, 3043–3044
    surgical technique of, 3044–3046

Formation product (K_f), 2009

46,XX DSD, 1007–1011

46,XX males, 1000–1001

46,XY complete, 998*t*, 1004–1005, 1005*f*

46,XY DSD, 1011–1017

Fosfomycin, for UTIs, 1151*t*–1153*t*, 1153

Fosfomycin trometamol, for UTIs, 1156

Fossa navicularis, 1383, 1383*f*–1384*f*, 1807.e2*f*, 1807.e4*f*, 1807.e8

Four-Box framework, 116, 117*t*

Fourchette, 1627.e2

Fournier gangrene (FG), 1289–1290, 1290*f*
    genital skin loss and, 3053

Four-principles framework, 115

Four-way catheter, 154*f*

Fowler syndrome, 2629, 2720.e3

Fowler-Stephens orchidopexy, 967–968

fPSA, Free prostate-specific antigen

12-Fr Cope nephrostomy tube, 181, 181*f*

Fractional excretion of sodium (FENa), urinary tract obstruction and, 777

Fractionation, in radiation therapy, 3593

Fracture

  of penis, 3048–3049, 3048.e1*f*, 3049*f*–3050*f*, 3049.e1*f*
  of testis, 3051–3053

Fragmentation, in laser lithotripsy, 2111

Frailty, 2913–2914, 2913*f*
  definition of, 108

Frank hematuria, 247

Frasier syndrome, 998*t*, 1004

Free crystal particle growth, 2011

Free graft urethroplasty, for transmen, 3071

Free prostate-specific antigen (fPSA), 3481–3482, 3481*t*, 3482*f*, 3517–3518
  isoforms, 3483–3484, 3483*f*

Free water loss, 341–342

Frequency-volume chart, 2666
  for benign prostatic hyperplasia, 3344–3345
  nocturia classification with, 2667, 2668*t*

Frequently-relapsing nephrotic syndrome (FRNS), 345

Fresh frozen plasma (FFP), transfusion with, 147

Fresh prostatic cancer tissues, genomic research on, 3586

FRNS, Frequently-relapsing nephrotic syndrome

Fructose, in prostatic secretions, 3295–3296

FSE, Fast spin-echo

FSFI, Female Sexual Function Inventory

FSGS, Focal segmental glomerulosclerosis

FSH, Follicle-stimulating hormone

Fuhrman's classification system, for RCC, 2148, 2148*t*

Full-thickness skin grafts, for urethral and penile reconstruction, 1805, 1806*f*

Functional acute kidney injury, in children, 353

Functional capacity, 120

Functional imaging
  in adrenal mass evaluation, 2396–2397
  of pheochromocytoma, 2375–2376, 2376*f*
Functional incidental training, in toileting programs, 2730.e1*t*
Functional incontinence, patient history of, 6
Functional phase. of dynamic renal imaging, 93
Functional profile length, 2563
Functional status
  assessment of, 107
  definition of, 106–107
Fundamentals of Laparoscopic Surgery (FLS), 471
Funguria, 445
Funiculoepididymitis, as filariasis clinical manifestation, 1329
Furosemide
  for nocturnal polyuria, 2673*t*
  in stone formation, 2033
Furunculosis, 1291, 1291*f*
Fusion anomalies, genitourinary trauma and, 1076, 1077*f*
Future business plan, for men's health center, 1427

G

G_1/S checkpoint, deregulation of, in GU cancers, 1347.e2
G2M checkpoint, deregulation of, 1347.e2–1347.e3
Gabapentin, to facilitate bladder filling and urine storage, 2713.e3
^{67}Ga-citrate, 96
Gadolinium, for contrast media, 34
Gadolinium-based contrast media (GBCM), contrast media and, 32–33
Galdakao-modified supine position, 165

Gallium-68 (^{68}Ga), 91, 92*t*

Ganglioneuroblastomas, in retroperitoneum, 2234, 2235*f*

Ganglioneuroma
  as benign lesion, 2392–2393, 2393*b*
  in retroperitoneum, 2234

GAP, Glans approximation procedure

^{68}Ga-PSMA PET scans, 3667

Gardasil, 1262

Gartner duct cysts, 319*f*, 977, 977*f*
  urethral diverticula differentiated from, 2986, 2986*f*

GAS, Gender-affirmation surgery

Gas embolism
  during laparoscopic and robotic surgery, 224–225
  vena caval thrombectomy causing, 2277

Gasless laparoscopic transperitoneal approach, 2416–2417, 2417*f*

Gastric contents, aspiration of, during laparoscopic and robotic surgery, 228.e1

Gastric pouch, for cutaneous continent urinary diversion, 3225–3226, 3225*f*–3226*f*

Gastrocystoplasty, 695

Gastroenterologic changes, with aging, 2906

Gastrointestinal cystoplasty, alternatives to, 702–706, 706*b*
  autoaugmentation, 703–705, 704*f*
  bladder regeneration, 706
  seromuscular enterocystoplasty, 705–706, 705*f*
  ureterocystoplasty, 703, 703*f*

Gastrointestinal injury
  during laparoscopic and robotic surgery, 225–226
  laparoscopic kidney surgery causing, 2307, 2307*f*
  during radical nephrectomy, 2261

Gastrointestinal tract

    abnormalities of, with cloacal exstrophy, 575
    after augmentation cystoplasty, 696–697
    in prune-belly syndrome, 587–588, 587*f*

Gastrointestinal viscera, in retroperitoneum, 1668–1669, 1668.e2*f*, 1669*f*–1670*f*, 1674*b*

Gastroparesis, lower urinary tract dysfunction and, 2630

GBCM, Gadolinium-based contrast media

GBS, Guillain-Barré syndrome

GC, Genomic classifier

GCTs, Germ cell tumors

GD, Gender dysphoria

GEARS, Global Evaluative Assessment of Robotic Skills

GelPort, 212, 212*f*

Gemcitabine, for non-muscle-invasive bladder cancer, 3105

Gender
    assignment of
        for cloacal exstrophy, 576–577, 577*f*
        in newborn, 1000
    desmopressin and, 2712
    lower urinary tract dysfunction and, 652
    renal calculi and, 2005–2006
    UTUC variations and, 2185

Gender-affirmation surgery (GAS), 3062

Gender dysphoria (GD), 3062

Gender identity, 3062
    role, and orientation, 996–997

Gender nonconforming youths, urologic issues in, 3062

Gender reassignment surgery (GRS), 3062

Gene amplification, androgen receptor and, 3685–3686

Gene fusions, in prostate cancer, 3468–3470 as biomarkers for, 3486

Gene rearrangements

  in prostate cancer, 1352–1353, 1354*t*

  in renal cancer, 1353, 1354*t*

  in testicular cancer, 1353

General anesthesia

  for laparoscopic and robotic surgery, complications related to, 228

  in urologic surgery, 132

General appearance, physical examination for, 9–10

Genes

  oncogenes, 1346–1347, 1347*b*

  structure of, 1346.e4

  tumor suppressor, 1346–1347, 1347*f*, 1347*b*

Genetic factors, in pelvic organ prolapse, 2591

Genetic mutations, male reproductive physiology and, age-related, 1402

Genetic predisposition, UTUC variations and, 2185, 2186*f*

Genetic syndromes, male infertility and, 1445–1446

Genetic testing, for evaluation of pediatric stone disease, 351

Genetics

  of autosomal dominant polycystic kidney disease, 750–751

  of autosomal recessive polycystic kidney disease, 748

  of benign prostatic hyperplasia, 3311–3312, 3311*t*

  of bladder tumor, 3076

  in BPS/IC etiology, 1232.e10

  of clear cell RCC, 2141–2143, 2143*t*, 2144*f*

  of enuresis, 661

  of hernia and hydroceles, 889

  of juvenile nephronophthisis, 755

  of lower urinary tract function, 2528

  of neuroblastoma, 1096–1099

  overview of, 741

  of prune-belly syndrome, 581

  - of tuberous sclerosis complex, 757, 759*f*

Genital bite wounds, 1293, 1294*f*

Genital burns, 3054

Genital lymphedema, 884–885

Genital Perception Score (GPS), 942–943

Genital ridges, 318*f*

Genital ulcers
  - noninfectious, 1286–1288, 1286*b*
    - aphthous ulcers and Behçet disease, 1286–1287, 1287*f*
    - pyoderma gangrenosum, 1287–1288, 1288*f*
    - traumatic causes, 1288, 1288*f*
  - STDs, 1255–1261, 1255*t*
    - chancroid, 1255*t*, 1259–1260, 1259*f*
    - diagnosis of, 1256
    - granuloma inguinale, 1260
    - herpes, 1255*t*
    - HPV, 1261, 1262*f*
    - lymphogranuloma, 1255*t*, 1260–1261, 1260*f*
    - *Molluscum contagiosum*, 1261, 1261*f*
    - pediculosis pubis, 1271
    - presentation of, 1256, 1256*f*
    - scabies, 1271
    - syphilis, 1255*t*, 1257, 1257*f*–1258*f*, 1257*t*
    - treatment of, 1256–1257, 1256*t*
    - vaginitis, 1271–1272, 1272*t*

Genitalia
  - ambiguous, 998–1018, 999*f*, 999*b*
  - external, development of, 305–310, 307*f*–310*f*, 312*f*
    - masculinization of, 305

Genitalia of female, external, 395–398
  - bladder and bowel dysfunction, 397–398
  - development of, 307*f*, 310–311, 311*f*–313*f*
  - foreign body, 398
  - hymenal disorders, 395, 396*f*
  - hymenal skin tags, 395
  - interlabial masses, 395

  - labial adhesions, 395, 396*f*
  - paraurethral cyst, 395, 397*f*
  - prolapsing ureterocele, 395, 397*f*
  - urethral prolapse, 395, 397*f*
  - vaginal discharge, 397
  - vaginal rhabdomyosarcoma, 397
- Genitalia of male, external, 391–395
  - abnormal penile orientation, 394
    - hypospadias, 394
    - parameatal urethral cyst, 394
    - penile curvature, 394
    - penile torsion, 394
    - priapism, 394–395
  - penile conditions, 393–395
    - buried penis, 394
    - circumcision, 393
    - concealed penis, 394
    - foreskin, 393
    - inconspicuous penis, 394
    - paraphimosis, 393
    - phimosis, 393
    - smegma pearl, 393–394
    - smegmoma, 393–394, 393*f*
    - webbed penis, 394
  - scrotal conditions, 391–393
    - epididymo-orchitis, 392
    - hernia, 392
    - hydrocele, 392
    - scrotal and testicular pain, 391
    - scrotal mass, 392
    - testicular torsion, 391
    - testicular tumor, 392–393
    - torsion of testicular, 391–392
    - undescended testicle, 391
    - varicocele, 392
- Genitocerebral evoked potential, 1527
- Genitofemoral nerve, 1372–1373, 2447*f*–2448*f*, 2453, 2453*t*
- Genitography, 390
- Genito-pelvic pain-penetration disorder, 1636, 1651–1653, 1653*b*

  - clinical presentation of, 1652, 1652*f*
  - clitoris and clitorodynia, 1651–1652
  - pain and sex, 1651
  - provoked vestibulodynia, 1651
  - treatment for, 1653

- Genitourinary malignancies, 1940–1941, 1941*b*
  - bladder cancer, 1941
  - molecular imaging of, 96–100
  - prostate cancer, 1941
  - renal cell carcinoma, 1940–1941, 1940*f*
- Genitourinary problem index (GUPI), 1211, 1212*f*
- Genitourinary region, pediatric, 391–402
  - external
    - of female, 395–398
    - of male, 391–395
  - sexual abuse, 398, 400
  - urinary tract, 398–402
    - infection of, 398–399, 402*b*
    - pyelonephritis, 398–399
    - urinary incontinence, 399–400
    - vesicoureteral reflux, 399
- Genitourinary surgery, genito-pelvic pain-penetration disorder and, 1652–1653
- Genitourinary tract
  - abnormalities of, with cloacal exstrophy, 575
  - embryology of, 305–340, 306*f*–307*f*
    - external genitalia, development of, 305–310, 307*f*–310*f*
    - female external genitalia, 307*f*, 310–311, 311*f*–313*f*
    - gonads, development of, 317–322, 318*f*
    - human seminal vesicle, development of, 317
    - kidneys, 333–340, 333*f*–334*f*, 339*b*
    - Müllerian structures, 322–329, 323*f*, 327*b*
    - ureter, development of, 329–333, 332*f*, 332*t*
- Genitourinary trauma
  - genitourinary malignancies, 2920
  - in geriatric patients, 2920.e11
- Genitourinary tuberculosis (GUTB), 1307–1319

- clinical manifestations and pathologic features of, 1308–1309
    - bladder, 1309
    - epididymis, vas deferens, testes, and scrotum, 1309
    - kidney, 1308–1309
    - prostate and seminal vesicles, 1309
    - ureter, 1309
    - urethra and penis, 1309
- development of, 1308
- diagnosis of, 1309–1314
    - culture, 1310
    - histopathology, 1310
    - nucleic acid amplification tests, 1310
    - radiography, 1311–1313, 1311*f*–1313*f*
    - screening tests, 1310–1311
- management, in special situations, 1318–1319
- relapse, 1318
- transmission and host immune response, 1307–1308
- treatment of, 1315–1318
    - medical therapy, 1311*t*, 1315–1317, 1315*t*–1316*t*
    - surgical therapy, 1317–1318

Genome, GU cancer alterations in, 1351–1362, 1362*b*
- bladder cancer, 1358–1360
- bladder RMS, 1111–1113
- CNAs, 1354, 1354*t*–1355*t*
- gross chromosomal abnormalities, 1351–1352, 1352*b*
- prostate cancer, 1352–1353, 1354*t*, 1355*f*
- renal cancer, 1353, 1354*t*, 1358
- testicular cancer, 1121, 1353, 1361–1362
- Wilms tumor, 1096–1099, 1097*t*, 1354*t*

Genomic assessment, in male infertility, 1442–1443

Genomic classifier (GC), of prostate cancer, 3542–3543

Genomic expression profiles, as prostate cancer biomarkers, 3488

Genomic predictors, hormonal therapy and, 3680

Genomic prostate score (GPS), 3543

Genomic sequence assessment, for male infertility, 1443

Genomic tests, for localized prostate cancer, 3529

Geography

- renal calculi and, 2006–2007, 2007*f*
- in transitional urology, 1047

Geriatric patients, in urinary incontinence, 2917–2920

- absorbent products for, 2920.e6
- behavioral therapies for, 2920.e3
- clinical evaluation of, 2920
- costs of, 2918
- established, 2919
- history for, 2920.e1
- laboratory testing for, 2920.e2
- negative impacts of, 2918–2919
- pharmacotherapies for, 2920.e3–2920.e4
- physical examination for, 2920.e1
- PVR assessment, 2920.e1
- risk factors of, 2918
- surgical therapies for, 2920.e4–2920.e6
- transient, 2919
- treatment of, 2920
- urine containment for, 2920.e6
- urodynamic studies for, 2920.e2
- voiding diaries, 2920.e1–2920.e2

Geriatric syndromes, 2913–2917

- asymptomatic bacteriuria, 2920.e10–2920.e11
- bladder outlet obstruction, 2920.e7
- delirium, 2914
- falls, 2915
- fecal incontinence, 2920.e9
- frailty, 2913–2914, 2913*f*
- genitourinary malignancies, 2920
- genitourinary trauma, 2920.e11
- hematuria, 2920.e11
- medication optimization, 2915–2917, 2916*t*–2917*t*

- neurogenic bladder, 2920.e7–2920.e8
- nocturia, 2920.e8–2920.e9
- pelvic organ prolapse, 2920.e9–2920.e10
- polypharmacy, 2915–2917
- pressure ulcers, 2915
- underactive bladder, 2920.e7–2920.e8
- urinary incontinence, 2917–2920
- urinary retention, 2920.e7–2920.e8
- urinary tract infections, 2920.e10–2920.e11

Geriatric urology patient
- care coordination of, 2921
- clinical evaluation of, 2908–2922, 2909*f*
  - activities of daily living, 2909
  - cognition of, 2910, 2911*f*
  - comprehensive geriatric assessment, 2913
  - depression in, 2910
  - functional assessment, 2909–2910
  - instrumental activities of daily living, 2909
  - mobility of, 2909–2910
- discharge planning for, 2921
- end-of-life care, 2922
- palliative care of, 2922
- surgical risk and medical optimization in, 2911–2913, 2911*b*–2912*b*
  - anesthesia, 2912
  - prehabilitation, 2912–2913

Germ cell neoplasia in situ, 1692–1693, 1693*b*

Germ cell tumors (GCTs)
- in female pediatric patients, 1120
- retroperitoneal tumors and, 2227–2229

Germ cell/gonadal origins, retroperitoneal tumors and, 2227

Germ cells
- in spermatogenesis, 1396, 1399, 1401
- of testis, 1398, 1398*f*

Gerota fascia, 1667–1668, 1667*f*–1668*f*, 1668*b*, 1865–1866, 1865.e4*f*

GETUG-16 trial, 3663–3664

GFR, Glomerular filtration rate

Giant condyloma acuminatum, of penis, 1742.e1*f*, 1742.e3

Gibson incision, of abdomen, 135–136, 138*f*

Giggle incontinence, 658–660, 2540

Gitelman syndrome, 349

Glans approximation procedure (GAP), 907*f*, 920–921

Glans dehiscence, 937, 938*f*

Glans meatus and penile shaft (GMS) score, 907–908, 908*f*

Glans penis, 1383–1384

Glanular adhesions, of penis, 874–875, 874*f*

Glanular urethra, 305

Gleason grading system, 3507–3508, 3508*f*, 3509*b*, 3510–3511

Gleason scoring system, of localized prostate cancer, 3526

Glenn-Anderson technique, for vesicoureteral reflux in children, 840, 840*f*

Glial-derived neurotrophic factor (Gdnf)/RET, vesicoureteral reflux and, 491.e1

Global Action Plan Prostate Cancer Active Surveillance (GAP3), 3545

Global Evaluative Assessment of Robotic Skills (GEARS), 470

Global Objective Assessment of Laparoscopy (GOALS), 470

Global polyuria, 2667, 2668*t*

Glomerular capillary tuft, 335–336

Glomerular disease, 258–259

- in children, 344–348, 344*b*
  - nephrotic syndrome, 344–345

Glomerular filtration rate (GFR), 341, 1905–1914

- aging and, 2905
- in AKI, 1921, 1922*t*
- clinical assessment of, 1905, 1906*f*
- determinants of, 1905

- developmental changes in, 342
- filtrate transport, 1906–1913
- nephron anatomy, 1906, 1906*f*–1907*f*, 1907*b*
- preoperative evaluation of, 2248
- renal hormone effects, 1913–1914
- urinary tract obstruction and
  - in bilateral ureteral obstruction, 791–792
  - renal blood flow and, 791
  - renal vascular resistance and, 791
  - in unilateral ureteral obstruction, 791

Glomerular hematuria, 16–17, 16*t*, 17*f*

Glomerulonephritis, 345–346
- in CKD, 1929

Glomerulosclerosis, with urinary tract obstruction, 781, 782*f*

Glucocorticoid-induced hypercalcemia, 2020

Glucocorticoids
- in adrenal cortex physiology, 2357, 2358*t*
- hypercalcemia induced by, 2020

Glucose
- homeostasis, 2665–2666
- in urine, 19–20

Glucosuria, 479

Glue, for laparoscopic and robotic surgery, 215.e2

Glutamate, in efferent pathways to bladder, 2488, 2489*f*

Glutaraldehyde cross-linked (GAX) bovine collagen (Contigen), for female urinary incontinence, 2893–2894, 2894*f*

Gluteal compartment syndrome, 262

Glycine, in efferent pathways to bladder, 2488

Glycosaminoglycans
- for BPS/IC treatment, 1244–1245
- in crystal formation, 2014
- in crystal matrix, 2015

layer, of bladder urothelium, 2467–2468

GnRH, Gonadotropin-releasing hormone

GnRH analogues, for priapism, 1553

GOALS, Global Objective Assessment of Laparoscopy

Goldman's cardiac risk index, 120*t*

Gonadal descent, 318–322

Gonadal dysfunction, opioid abuse and, 1426–1427

Gonadal dysgenesis, 1001–1005

- mixed, 998*t*, 1002–1004, 1003*f*, 1003*b*, 1004*t*
- partial, 1004
- 46,XX “pure,”, 998*t*, 1002
- 46,XY complete, 998*t*, 1004–1005, 1005*f*

Gonadal stage of differentiation, 993–994, 994*f*, 994*b*

Gonadal stromal tumors, in male pediatric patients, 1124, 1124*f*

Gonadal veins, 1672–1673

- dissection of, for RPLND, 1716

Gonadoblastomas, 1708

Gonadotropin-releasing hormone (GnRH), 1390, 1391*f*, 1391*t*

Gonadotropin-releasing hormone (GnRH) antagonists, to facilitate bladder filling and urine storage, 2713.e3

Gonads, development of, 317–322, 318*f*, 321*f*–322*f*, 322*b*

Goniometer, 912

Gonocytes, 951, 1399

Goodpasture syndrome, 347

GPS, Genital Perception Score

Grading systems, in perinatal urology, 358–361

Graduated introducer, 170

Grafts
  for pelvic organ prolapse reconstructive surgery, 2776
    anterior compartment, 2783, 2785*f*
    biologics *versus* mesh, 2787
    cadaveric fascia, 2781*t*–2782*t*, 2786, 2786*f*
    polypropylene mesh, 2781*t*–2782*t*, 2783–2786, 2786*f*
    porcine dermis, 2781*t*–2782*t*, 2786–2787, 2787*f*
    posterior compartment, 2829
  for pubovaginal sling, 2834–2835
    harvest for, 2837, 2837*f*
  for renal transplantation, 1058, 1058.e2*f*
  for urethral and penile reconstruction, 1805–1807, 1806*f*
    dermal, 1805–1806
    full-thickness skin, 1805, 1806*f*
    oral mucosa, 1806, 1806*f*
    split-thickness skin, 1805
    vein, 1806
  for urethral stricture disease, 1821*f*–1823*f*
Granuloma inguinale, 1260
Granulomatous disease
  hypercalcemia in, 2020
  hypercalciuria in, 2050
Granulomatous orchitis, 1219
Granulomatous prostatitis, histopathology, 1203
Granulosa cell tumors, of testis, 1708
Grasping instrumentation, for laparoscopic and robotic surgery, 218
Gray-scale ultrasound, 73
Greater omentum, in vesicovaginal fistula repair, 2940
Groin pain, 2880
  in mesh complication, 2881–2882
Gross hematuria, 252–253, 400–401
Gross tumor volume (GTV), 3590
Growth

    - impairment, and chronic kidney disease, 354–355
    - in prune-belly syndrome, 600
    - regulation, in urinary tract obstruction, 783–784
- Growth factors
    - in benign prostatic hyperplasia, 3309–3310, 3310*f*
    - in tubulointerstitial fibrosis, 787–788
- GRS, Gender reassignment surgery
- Grynfeltt lumbar triangle, 169
- GTV, Gross tumor volume
- Guaifenesin, in stone formation, 2033
    - surgical management of, 2077.e2–2077.e3
- Guanine, 1346.e1, 1346.e2*f*
- Guanylyl cyclase pathway, in ED, 1498
- Guarding reflex, in bladder filling, 2515
- Gubernacular anomalies, cryptorchidism and, 962–963
- Gubernaculum
    - anomalies of, cryptorchidism and, 962–963
    - development of, testis descent and, 951–952, 952*f*
- Guidewires, 170
    - for ureteroscopy, 197
- Guillain-Barré syndrome (GBS), lower urinary tract dysfunction with, 2624
- Gunshot wounds
    - penile, 3049–3050
    - renal, 1982
        - nonoperative management of, 1986–1987
    - ureteral, 1995–1996
        - diagnosis of, 1995–1996
- GUPI, Genitourinary problem index
- Gut, 324*f*
- GUTB, Genitourinary tuberculosis

Gynecologic history, pelvic floor disorders and, 2527–2528

Gynecologic laparoscopy, ureteral injuries after, 1993

Gynecomastia, hormonal therapy and, 3681–3682

H

Habit training, 2730.e1*t*, 2731

Hailey-Hailey disease, 1285–1286, 1286*f*

Hald-Bradley classification, of voiding dysfunction, 2523–2524, 2523*b*

HALN, Hand-assisted laparoscopic nephrectomy

Haloperidol, for delirium, 2914

Hammock anastomosis, in urinary diversion, 3189

Hammock hypothesis, of urinary incontinence, 2466, 2518, 2596, 2597*b*

Hand-assist devices, for laparoscopic and robotic surgery, 212, 212*f*

Hand-assisted adrenal surgery, 2419

Hand-assisted laparoscopic nephrectomy (HALN), 2296–2297, 2296*f*

Hand-assisted laparoscopy, for kidney, 2281–2282, 2283*f*

Hand port access, for transperitoneal access, 209

Harmonic Scalpel, 466, 466*f*

Harmonic scanning ultrasound, 74, 75*f*

Hasson technique, 271–272, 464
  for achieving extraperitoneal access and developing extraperitoneal space, 209–210, 210*f*
  for achieving transperitoneal access and establishing pneumoperitoneum, 209, 209*f*
  complications related to, 224

Hautmann pouch, for orthoptic urinary diversion, 3245, 3246*f*

Hawthorne effect, 484–485

Hayflick “limit,” aging and, 2905

HBOT, Hyperbaric oxygen therapy

hCG, Human chorionic gonadotropin

HDCT, High-dose chemotherapy

HDRB, High-dose rate brachytherapy

Headache, orgasmic, 1580–1581

Health, norms of, masculinity and, 1416

Health care, global implications for, 2907–2908

Health issues, in geriatric patients, 2920.e13

Health policy, in ED, 1514, 1515*b*

Health-related quality of life (HRQoL), 108

- benign prostatic hyperplasia and, 3319
- pelvic floor disorders and, 2532*t*–2533*t*

Health services, outcomes research and, 101

Heart, 318*f*

- in prune-belly syndrome, 586

Heart and Estrogen/Progestin Replacement Study (HERS), 2710

Heart disease, nocturia and, 2665

Heart rate variability and sympathetic skin response test, 1527

Heavy particle beams, 3594–3596, 3594*f*, 3595*t*

Hedgehog signaling pathway, in prostate development, 3276

Heineke-Mikulicz principle, of urethromeatoplasty, 918, 921*f*

Heineke-Mikulicz procedure, for lower ureteral injuries, 1999

Heineke-Mikulicz urethroplasty, urethral reconstruction and, 3071

Helium, as insufflant choice, 220

Hemangiomas

- congenital, 888
- renal, 2131–2132
- subcutaneous, 888
- urethral, 1776

        - reconstructive surgery for, 1808

Hemangiopericytomas, in retroperitoneum, 2232, 2233*f*

Hematogenous route of infection, 1131.e1

Hematogenous spread, of UTUC, 2194

Hematologic dyscrasias, priapism and, 1542, 1542*b*

Hematoma

- after midurethral sling, 2874
- postoperative, complication of scrotal surgery, 1855
- urinoma compared with, 1988

Hematopoietic stem cell transplantation, for RCC, 2331, 2331*t*

Hematospermia

- patient history of, 6–7
- prostate biopsy and, 3499

Hematuria, 1936

- after transurethral microwave therapy, 3430
- with benign prostatic hyperplasia, 3336
- in children, 342–343, 343*b*
    - cause of, 342*b*, 343
- classification of, 247
- CT and, 50–51
- evaluation of, 247–259
    - for urothelial cancer, 3078
- in geriatric patients, 2920.e11
- gross, 252–253, 386–387, 386*t*
- hemorrhagic cystitis, 253–255, 253*b*, 255*b*
- management of, 247–259
- microscopic, 247–250, 250*b*
- patient history of, 3
- in pregnant, 283–284
- prostatic origin, 255–257, 256*f*, 257*b*
- in renal injuries, 1982–1983
- timing of, 247
- upper tract imaging in diagnostic evaluation of, 248*t*, 251

- upper urinary tract, 258–259, 258*b*–259*b*
- in ureteral injuries, 1995
- urethral bleeding, 257–258, 258*b*
- urinary biomarkers, 248*t*, 252
- urine cytology for, 248*t*, 252
- UTUC causing, 2189–2190

Hematuria catheter, 154, 154*f*

Hematuria-dysuria syndrome, after augmentation cystoplasty, 698.e1

Hemi-Kock pouch

- for orthoptic urinary diversion, 3243–3244, 3244*f*
- procedure for with valved rectum, 3209–3210

Heminephrectomy, laparoscopic, 2299

Hemodynamics

- changes in, with urinary tract obstruction, 791–792, 793*b*
- during laparoscopic and robotic surgery, approach and patient position effects on, 222

Hemoglobinopathies, 451

Hem-o-Lock clips, 216–217, 217*f*, 217*b*, 467

Hemolysin, 429

Hemolytic uremic syndrome (HUS), 347–348

Hemorrhage

- with holmium laser enucleation of prostate, 3438
- with intestinal anastomoses, 3181
- laparoscopic kidney surgery causing, 2306–2307
- with monopolar transurethral resection of prostate, 3417
- partial nephrectomy causing, 2265–2266
- with percutaneous antegrade endopyelotomy, 1949
- tray, for laparoscopic surgery, 226*b*
- during vena caval thrombectomy, 2278

Hemorrhagic cystitis, 253–255, 253*b*, 255*b*, 526

- management of, 254–255, 254*f*

Hemostasis

  - instrumentation, for laparoscopic and robotic surgery, 214–215, 218
  - for monopolar transurethral resection of prostate, 3410–3415

Henoch-Schönlein purpura (HSP), 346–347, 899

Heparin
  - for vena caval thrombectomy, 2266
  - VTE prophylaxis with for laparoscopic and robotic surgery, 231

Heparin sulfate, in crystal formation, 2014

Hepatic cysts, 752

Hepatic dysfunction, during vena caval thrombectomy, 2278

Hepatic function, aging and, 2906

Hepatic resections, RPLND with, 1719–1720

Hepatitis, allografts and, 2835

Hepatitis B, STDs and, 1268–1269, 1269*t*

Hepatitis C, STDs and, 1270

Hepatobiliary evaluation, 121

Hepatorenal ligament, 1865

Hereditary hypophosphatemic rickets with hypercalciuria (HHRH), 2019

Hereditary leiomyomatosis and RCC (HLRCC) syndrome, 1358, 2142*t*, 2144
  - systemic therapy for, 2343

Hereditary nonpolyposis colorectal cancer, genomic alterations in, 1354*t*

Hereditary papillary RCC (HPRCC) syndrome
  - genomic alterations in, 1354*t*, 1358, 2142*t*, 2143–2144
  - systemic therapy for, 2343–2344, 2344*f*

Hereditary pheochromocytoma, 2373, 2374*t*, 2375, 2380

Hereditary prostate cancer (HPC), genomic alterations in, 1354–1355, 1354*t*, 1355*f*

Hereditary renal malignancy, in partial nephrectomy, 2262–2263

Hereditary spastic paraplegia (HSP), lower urinary tract dysfunction and, 2624–2625

Herlyn-Werner-Wunderlich syndrome, 985–986, 986*f*

Hernia, 392, 888–893, 892*b*

- after laparoscopic and robotic surgery, 231
- definitions for, 889, 889*f*
- diagnosis of, 889–890
- embryology of, 888–889
- epidemiology and pathogenesis of, 889
- genetics of, 889
- with intestinal anastomoses, 3180*t*
- as laparoscopic and robotic surgery contraindication, 204
- physical examination of, 890, 890*f*
- radiologic imaging of, 890, 890*f*

Herpes, genital ulcers, 1255*t*

Herpesvirus infection, lower urinary tract dysfunction with, 2621–2622

HERS, Heart and Estrogen/Progestin Replacement Study

HGPIN, High-grade prostatic intraepithelial neoplasia

HHRH, Hereditary hypophosphatemic rickets with hypercalciuria

Hidden incision endoscopic surgery (HIdES), 458, 459*f*

HIdES, Hidden incision endoscopic surgery

Hidradenitis suppurativa (HS), 1291–1292, 1292*f*

HIFU, High-intensity focused ultrasound ablation

High-dose chemotherapy (HDCT), for NSGCTs, 1697–1698

High-dose rate brachytherapy (HDRB), 1767, 3668

- for prostate cancer, 3598–3599
  - as boost with external beam radiation therapy, 3599
  - monotherapy, 3599

High-dose-rate monotherapy, 3599

High-energy linear accelerators, 3587

High-grade prostatic intraepithelial neoplasia (HGPIN), 3506, 3507*f*

High-intensity focused ultrasonography, 3628, 3629*t*–3630*t*, 3631*f*–3632*f* for locally advanced prostate cancer, 3655

High-intensity focused ultrasound ablation (HIFU), for renal tumor ablation, 2319–2321

High-pressure bladder, spinal cord injury with, host defense mechanisms in UTIs and, 1140

Hillier, Thomas, 160

Hindgut, 318*f*

Hinge region, of urothelium of bladder, 2462, 2463*f*

Hippocratic oath, 115, 116*b*

Histamine

in BPS/IC etiology, 1232.e4, 1232.e5*b*

urethral function effects of, 1901–1902

Histamine antagonists, urethral function effects of, 1901–1902

Histamine H_2 receptor antagonists, and ED, 1509

Histology, adrenal, 2351–2352, 2351*f*, 2355*f*, 2356

Histone post-translational modifications, in prostate cancer, 3470

History, Patient history

History of present illness, 1–7

HIV, Human immunodeficiency virus

H-line measurement, 2441–2442, 2442*f*

HO, Hyperbaric oxygen

Hodson-type kidney, 162, 163*f*, 164

HoLEP, Holmium laser enucleation of prostate

Holmium laser

for bladder mesh perforation, 2868–2869

use of, 168–169

Holmium laser enucleation of prostate (HoLEP), 3436

in anticoagulated patient, 3438

- complications with, 3438
  - intraoperative, 3438
  - perioperative, 3438
  - postoperative, 3438
- conclusion for, 3438
- introduction and concept for, 3436
- open prostatectomy *versus*, 3437
- outcomes with, 3437–3438
  - comparative series, 3437–3438
  - single-cohort series, 3437
- technique for, 3436
  - intraoperative, 3436
  - postoperative, 3436
  - preoperative, 3436
- thulium laser *versus*, 3442–3443
- transurethral resection of prostate *versus*, 3437

Holmium:YAG (Ho:YAG) laser, 240, 245*b*

- basic physics of, 244

Homeobox gene, 317

Homogeneous nucleation, 2011

HOPE, Hypospadias Objective Penile Evaluation

Hormonal evaluation, and ED, 1527–1529

Hormonal therapy

- for benign prostatic hyperplasia, 3371
- for ED, 1529
- for metastatic RCC, 2342–2343
- for priapism, 1553
- for prostate cancer, 3671–3686
  - androgen axis molecular biology and, 3672–3673, 3672*f*, 3673*t*, 3673*b*
  - androgen blockade mechanisms, 3673–3678, 3679*b*
  - androgen blockade response in, 3679–3680
  - androgen synthesis inhibition, 3677–3678
  - anemia, 3682
  - antiandrogens, 3674–3676, 3675*f*
  - body habitus changes with, 3681
  - cardiovascular morbidity and mortality, 3681
  - with chemotherapy, 3683

        - clinical follow-up on, 3679–3682, 3680*b*
        - cognitive function and, 3681
        - combination therapy, 3682–3683, 3683*b*
        - combined androgen blockade, 3682
        - complications of, 3680–3682, 3682*b*
        - diabetes and, 3681
        - gynecomastia, 3681
        - historical overview of, 3671–3672
        - hot flashes, 3680–3681
        - metabolic syndrome and, 3681
        - osteoporosis and, 3680
        - with radiation therapy, 3682
        - with radical prostatectomy, 3682
        - sexual dysfunction and, 3681
        - timing of, 3683–3686
    - urinary incontinence and, 2585

- Hormones
    - for female orgasmic disorder, 1648
    - for female sexual interest disorder, 1643–1645
    - of HPG axis
        - anterior pituitary, 1390–1391, 1391*f*
        - hypothalamus, 1390, 1391*f*
        - testis, 953, 1391–1392, 1391*f*
    - laparoscopic and robotic surgery effects on, 222
    - renal
        - bone mineral regulation by, 1914, 1914*f*
        - erythropoiesis regulation by, 1914
        - red blood cell production, 1914
        - vasoconstriction, 1913
        - vasodilation, 1913

- Horseshoe kidneys, 177, 177*f*, 731–733, 733*b*, 1869.e2*f*
    - anomalies of, 731–732, 732*f*
    - description for, 731
    - diagnosis and radiographic appearance of, 732, 732*f*
    - incidence of, 731
    - percutaneous nephrolithotomy and, 2105–2106
    - prognosis of, 732–733
    - renal calculi and, 2034
        - surgical management of, 2078–2081, 2079*f*
    - symptoms of, 732

HOSE, Hypospadias Objective Scoring Evaluation

Host defense mechanisms, alterations in, in UTI pathogenesis, 1139–1140

- diabetes mellitus, 1139
- HIV, 1140
- obstruction, 1139
- pregnancy, 1140
- RPN, 1139–1140, 1139*b*
- spinal cord injury with high-pressure bladders, 1140
- underlying disease, 1139
- vesicoureteral reflux, 1139

Hostile Abdomen Index Scoring Table, 463*t*

Hot flashes, hormonal therapy and, 3680–3681

Hounsfield units, 46–48

24-hour voiding frequency, 3345

Hox homeobox genes, 317

HPC, Hereditary prostate cancer

HPV, Human papillomavirus

HRQoL, Health-related quality of life

HS, Hidradenitis suppurativa

HSP, Henoch-Schönlein purpura

HTN, Hypertension

Human bites, of penis, 3050

Human chorionic gonadotropin (hCG), in TGCTs, 1686

Human herpesvirus 8, penis, tumors of, 1742.e5

Human immunodeficiency virus (HIV)

- allografts and, 2835
- circumcision protection against, 1812
- genitourinary tuberculosis management and, 1318
- host defense mechanisms in UTIs and, 1140
- occupational exposure to, 1264–1265

  - penis tumors related to, 1742.e5
  - as STD, 1264–1268
    - diagnosis, 1264
    - erectile dysfunction and, 1267
    - interactions with other STDs, 1257, 1264–1268
    - Kaposi sarcoma, 1267–1268
    - male circumcision, 1264
    - malignancy, 1267
    - nephrolithiasis, 1266
    - non-AIDS-defining urologic malignancies, 1268
    - nonulcerating skin infections and, 1265
    - postexposure prophylaxis, 1264–1265
    - pre-exposure prophylaxis, 1265
    - prostatitis and, 1266
    - renal dysfunction and, 1266–1267
    - renal infections, 1266
    - testis, epididymis, seminal vesicles and, 1266
    - urologic manifestations of, 1265–1268, 1265*f*
    - UTI and, 1265–1266
    - voiding dysfunction and, 1267
  - vaccine, 1262–1263

Human kallikrein 2 (hK2)
  - as prostate cancer biomarkers, 3484
  - in prostate cancer diagnosis, 3518
  - in prostatic secretions, 3298, 3298*t*

Human kallikrein 11 (hK11), in prostatic secretions, 3298*t*, 3299

Human kallikrein 14 (KLK14), in prostatic secretions, 3298*t*, 3299

Human kallikrein L1, in prostatic secretions, 3298–3299, 3298*t*

Human papillomavirus (HPV)
  - as genital ulcers, 1261, 1262*f*
  - penis tumors and
    - carcinoma, 1743–1744
    - premalignant lesions, 1742

Human prostate, 311–317, 313*f*–316*f*, 315*t*, 317*t*, 317*b*

Human seminal vesicle, development of, 317

Hunner lesion, surgery for, 1248

HUS, Hemolytic uremic syndrome

Hutch diverticula, bladder, 3011

Hydraulic valves, for continent urinary diversions, 710

Hydrocalycosis, 738

Hydrocele, 392, 1394

- as filariasis clinical manifestation, 1329–1330, 1330*f*
- recurrence, complication of scrotal surgery, 1856

Hydrocelectomy, 1845

Hydroceles, 888–893, 892*b*

- abdominoscrotal, 889, 892–893
- communicating, 889
- definitions for, 889, 889*f*
- diagnosis of, 889–890
- embryology of, 888–889
- genetics of, 889
- noncommunicating, 889
- physical examination of, 890, 890*f*
- radiologic imaging of, 890, 890*f*
- scrotal, 889
- of spermatic cord, 889
- surgical repair of, 891

Hydrocephalus, normal-pressure

- lower urinary tract dysfunction with, 2604
- transient urinary incontinence and, 2919.e1

Hydrodistention, for BPS/IC treatment, 1247

Hydrogen ions, transport of, urinary tract obstruction and, 793–794

Hydrogen sulfide, in ED, 1498

Hydronephrosis

- after pediatric renal transplantation, 1062–1063, 1063*f*
- Color Doppler ultrasonography for, 778
- *versus* cystic renal diseases, 404, 404*f*, 408*f*
- infected, 1174
- neonatal diagnosis of, 1943

- prevalence of, 776
- retroperitoneal fibrosis with, 1978
- urinary tract obstruction and, 776–777
- UTUC with, 2196–2197

Hydrothorax, 180

Hydroureter, urinary tract obstruction and, 776

Hydroureteronephrosis of pregnancy, 1900

25-Hydroxycholecalciferol (Calcidiol), 1914

17α-Hydroxylase deficiency, 1012

3β-Hydroxysteroid dehydrogenase deficiency, 1011–1012

17β-Hydroxysteroid oxidoreductase deficiency, 1012–1013

Hymen, imperforate, 327, 328*f*, 978–979, 979*f*

Hymen vaginae, 1627.e2

Hymenal disorders, 395

- imperforate hymen, 395

Hymenal skin tags, 395, 978–979, 979*f*

Hyperbaric oxygen (HO), 945

Hyperbaric oxygen therapy (HBOT), 255

Hypercalcemia

- glucocorticoid-induced, 2020
- in granulomatous disease, 2020
- malignancy-associated, 2020
- in RCC, 2156
- in sarcoidosis, 2020

Hypercalcemic-induced hypercalciuria, 2020

Hypercalciuria, 350, 857–858, 858*t*, 2050–2053

- absorptive, 2019
- calcium stone formation associated with, 2018–2020
- calcium supplementation, 2050–2051
- clinical considerations of, 2050

- conservative strategies for, 2051
- hypercalcemic-induced, 2020
- idiopathic, 2050, 2051*b*
- medical therapy for, 2051–2053, 2053*b*
- renal, 2019–2020
- resorptive, 2020, 2050, 2050*b*
- in sarcoidosis and granulomatous disease, 2050

Hypercapnia, 461

Hyperfiltration injury, in partial nephrectomy, 2262

Hyperkalemia, 353

Hyperlipidemia, and ED, 1504

Hypermobile glans penis, 1591, 1591*f*

Hypermobility, in stress urinary incontinence, 2757, 2834

Hypernatremia, 353

Hyperoxaluria, 350, 858, 858*t*, 2056–2060, 2057*b*

- calcium stone formation, 2020–2023, 2021*f*–2022*f*, 2057–2058
- causes of, 2021
- clinical considerations of, 2056
- conservative strategies for, 2056–2057, 2057*b*
- diabetes, obesity, and metabolic syndrome, 2059–2060
- dietary, 2023
- enteric, 2022–2023, 2056
- hypomagnesuric calcium nephrolithiasis, 2058*t*
- idiopathic, 2023
- medical therapy for, 2057
- primary, 2021–2022, 2021*f*, 2056–2057
- uric acid stones, 2058–2059

Hyperparathyroidism, primary, with resorptive hypercalciuria, 2020

Hyperprolactinemia treatments, 1530–1532

Hypertension (HTN), 1419–1420

- after renal injury, 1992

  - benign prostatic hyperplasia and, 3322
    - with α1-adrenergic blockers, 3369–3370
  - in children, 351–353, 352*b*
  - and ED, 1504–1505
  - genitourinary trauma and, 1077–1078
  - nocturia and, 2665
  - in RCC, 2156
  - renal calculi and, 2008
  - with renovascular injuries, 1990
  - staging of, 351–352
  - with urinary tract obstruction, 794

Hypertensive emergency, 351–352

Hyperthyroidism
  - contrast media and, 32
  - lower urinary tract dysfunction and, 2630

Hypertrophied clitoris, 975, 975*f*

Hyperuricemia, and ED, 1511

Hyperuricosuria, 858*t*, 859
  - in calcium stone formation, 2023–2024
  - in uric acid stone formation, 2029

Hyperuricosuric calcium oxalate nephrolithiasis, 2057–2058

Hypoactive sexual desire dysfunction, 1636

Hypocitraturia, 858–859, 2053–2056, 2054*b*, 2055*f*
  - calcium stone formation associated with, 2024
  - clinical considerations of, 2053
  - conservative strategies for, 2053–2054
  - distal renal tubular acidosis (type 1) in, 2055–2056, 2055*f*
  - medical therapy for, 2054
  - thiazide-induced hypocitraturia, 2056

Hypofractionation, radiobiologic basis for, 3593, 3593*t*

Hypogastric artery, 2432, 2433*f*, 2452

Hypogastric lymphadenectomy, 3149–3152, 3153*f*

Hypogastric plexus, 2434

Hypogonadism, 1430

- and ED, 1504
- and PD, 1602

Hypogonadotropic hypogonadism, 1447–1448

Hypohedonic orgasm, 1636

Hypokalemic metabolic alkalosis, 349

Hypomagnesiuria, in calcium stone formation, 2026

Hypomagnesuric calcium nephrolithiasis, 2058, 2058*t*

Hypomethylation, in bladder cancer, 1350

Hyponatremia, 353

- with desmopressin, 2711
- as effect of desmopressin, 2670

Hypoplastic glomerulocystic disease, 756–757

Hypospadias, 306, 310*f*, 394, 905–948, 1449

- advancement procedures for, 918–920
  - M inverted V glansplasty, 920, 922*f*
  - meatal advancement glanuloplasty, 920, 921*f*
  - urethral, 920, 922*f*
  - urethromeatoplasty, 918
- anatomic imaging of, 941
- assessment and management for
  - intraoperative, 911, 911*b*
  - preoperative, 932–934
- complications of, 934–941
  - balanitis xerotica obliterans, 939, 940*f*
  - glans dehiscence, 937, 938*f*
  - meatal stenosis, 937–938
  - recurrent penile curvature, 939–941, 940*f*
  - skin, 941
  - urethral diverticulum, 938–939, 939*f*
  - urethral stricture, 938
  - urethrocutaneous fistula, 935–937, 936*f*–937*f*
- diagnosis of, 905–908, 907*f*
- disorders of sexual differentiation in, 908

embryology of, 905, 905*b*, 906*f*
etiology of, 908–909, 909*b*
improving outcomes for, 941
outcome assessment for, 942–943
outcomes after, 941–947
  sexual function, 942
  urinary stream, 942
patient-reported outcomes in, 942–943
postoperative management for, 932–934
  dressing, 918, 920*f*
  medications, 932
  urinary diversion, 932
preoperative androgen stimulation for, 910–911
proximal, 925–932, 925*b*, 948*f*
pudendal nerve block for, 911
reoperations for, 943–947, 945*b*, 948*b*
  buccal mucosa, 946
  dorsal inlay graft, 934*f*, 946
  tubularized, incised plate procedure, 916–918, 922–924
repair of, failure of, reconstructive surgery for, 1812–1813
surgical assessment for, 909–918
surgical repair for
  Byars flaps, 927, 931*f*
  comments on, 932, 932*b*, 935*f*
  distal, 918
  general considerations of, 916–918, 918*b*, 919*f*
  graft or flap, 932, 934*f*
  one-stage, 925–926
  preputial flaps, 926*f*, 938–939
  proximal, 925–932, 925*b*
  scrotoplasty, 941
  technical aspects of, 925–926, 926*f*
  two-stage, 926–927
  two-stage with free graft, 927, 929*f*
  two-stage with pedicle flap, 927–932, 931*f*
in transitional urology, 1049
tubularization techniques for, 920–941
  flip-flap technique, 924, 924*f*
  glans approximation procedure, 907*f*, 920–921
  island onlay flap procedure, 924–925, 926*f*
  slitlike adjusted Mathieu procedure for, 924, 925*f*

    - Thiersch Duplay repair, 921–922, 923*f*
  - urethral plate formation for, 905
  - urethroplasty for
    - algorithm for, 912*f*, 914
    - complications with, 936*t*
    - distal tubularized incised plate, 923*f*
    - hair-bearing skin, 918
    - proximal tubularized incised plate, 928*f*
  - ventral penile curvature and, 911–914, 916*b*
    - artificial erection for, 911–912
    - dorsal shortening technique for, 912–913, 915*f*
    - goniometer for, 912
    - significance of, 911
    - ventral corporal lengthening procedures for, 913, 915*f*–916*f*
- Hypospadias Objective Penile Evaluation (HOPE), 942–943, 943*t*, 944*f*
- Hypospadias Objective Scoring Evaluation (HOSE), 942–943
- Hypothalamic-pituitary-adrenal axis physiology, normal, 2360–2361, 2361*f*
- Hypothalamic-pituitary-gonadal (HPG) axis, 1390–1402, 1393*b*
  - aging and, 1392
  - basic endocrine concepts for, 1390, 1391*f*
  - components of, 1390–1392
    - anterior pituitary, 1390–1391, 1391*f*
    - hypothalamus, 1390, 1391*f*
    - testis, 1391–1392, 1391*f*
  - development of, 1392, 1392*f*
  - and ED, 1503
- Hypothalamus
  - in HPG axis, 1390, 1391*f*
  - micturition control by, 2496
- Hypothermia
  - anesthesia-related, during laparoscopic and robotic surgery, 228.e1
  - for laparoscopic partial nephrectomy, 2302
  - for partial nephrectomy, 2262
  - in urologic surgery, 125, 145
- Hypothermic arrest, for vena caval thrombectomy, 2275–2276

Hypoxia-induced factor-1α (HIF-1α), 3700

Hypoxis rooperi (South African star grass), for benign prostatic hyperplasia, 3398

Hysterectomy, 3063–3064

- laparoscopic, ureteral injuries after, 1993
- lower urinary tract dysfunction after, 2621
- pelvic organ prolapse and, 2591
- vaginal, with McCall culdoplasty technique, 2814–2815, 2815*f*

Hysteresis, ureteral, 1890, 1890*f*

Hysteropexy, 2815–2823

- minimally invasive sacrohysteropexy, 2822–2823, 2824*t*
- minimally invasive uterosacral, 2820–2822, 2821*t*
- open abdominal sacrohysteropexy, 2822–2823, 2824*t*
- sacrospinous, 2817–2820
- transvaginal uterosacral ligament, 2817, 2819*t*

I

IADLs, Instrumental activities of daily living

Iatrogenic factors, in UTUC etiology, 2187–2188

Iatrogenic fistulae, 2926–2942, 2927*f*

Iatrogenic priapism

- ADHD and, 1545
- intracavernous injections for, 1544–1545

Iatrogenic urethral strictures, 1815

IBS, Irritable bowel syndrome

Ibuprofen, 932–934

ICAs, Intracranial aneurysms

Ice-water test, 2485, 2505

ICI, International Consultation on Incontinence

ICIQ, International Consultation on Incontinence Questionnaire

ICIQ-BD, International Consultation on Incontinence Questionnaire Bladder Diary

ICIQ-MLUTS, International Consultation on Incontinence Questionnaire Male Lower Urinary Tract Symptoms

ICIQ-Nocturia Quality of Life Question (ICIQ-Nqol), 110*t*

ICIQ-UI-SF, International Consultation on Incontinence Questionnaire Urinary Incontinence Short Form

ICS, International Continence Society

ICSmale Questionnaire, 110*t*

IDC-P, Intraductal carcinoma of the prostate

IDCs, Involuntary detrusor contractions

Idiopathic detrusor overactivity (IDO), 2504

- resiniferatoxin in, 2709.e1

Idiopathic hypercalciuria, 2018

Idiopathic hyperoxaluria, 2023

Idiopathic hypocitraturic calcium nephrolithiasis, 2054

Idiopathic scrotal edema, 899

Idiopathic strictures, 1815

IDO, Idiopathic detrusor overactivity

IFIS, Intraoperative floppy iris syndrome

IFNs, Interferons

Ifosfamide, for NSGCTs, 1697

IGCCCG, International Germ Cell Cancer Collaborative Group

IGFs, Insulin-like growth factors

IGRAs, Interferon-gamma release assays

IIEF, International Index of Erectile Function

IIQ, Incontinence Impact Questionnaire

Ileal conduit, 3193–3196, 3194*f*–3195*f*, 3195*t*

- in minimally invasive urinary diversion, 3261–3262

Ileal neobladder, for orthoptic urinary diversion, 3245, 3246*f*

Ileal reservoirs

- continent, 3213–3215, 3214*f*
- for orthoptic urinary diversion, 3243

Ileal ureteral replacement, 2208, 2209*f*

Ileal ureteral substitution

- minimally invasive, for ureteral stricture disease, 1973–1975
- for ureteral stricture disease, 1973–1975, 1974*f*

Ileal vesicostomy, 3197–3198

Ileocecal conduit, colon conduit and, 3196, 3198*t*

Ileocecal valve

- for continent urinary diversions, 709–710
- in ileocecocystoplasty, 694
- imbricating, in robot-assisted intracorporeal continent cutaneous diversion, 3269

Ileocecocystoplasty, 694, 694*f*–695*f*

Ileocolic anastomosis, in robot-assisted intracorporeal continent cutaneous diversion, 3269, 3269*f*

Ileocystoplasty, 692–693, 693*f*

Ileostomy bowel diversions, ammonium acid urate stones from, 2032

Ileovesicostomy, 702, 702*b*

Ileum

- selection, 3162
- tapering of, in robot-assisted intracorporeal continent cutaneous diversion, 3269

Ileus, after RPLND, 1731

Iliac aneurysm, as laparoscopic and robotic surgery contraindication, 204

Iliac arteries, 2451–2452, 2451*t*

Iliac crests, 2428*f*

Iliac lymph nodes, 2433

Iliac spines, 2428*f*, 2445*f*

Iliac veins, 2452

Iliacus, 1658, 1662*f*–1665*f*, 1664*t*

Iliococcygeus muscle, 2430–2432, 2432*f*

Iliococcygeus suspension, for apical pelvic organ prolapse repair, 2797–2798, 2799*f*

Iliohypogastric nerve, 2447*f*–2448*f*, 2453, 2453*t*

Ilioinguinal nerve, 2447*f*–2448*f*, 2453, 2453*t*

Illicit drug use, patient history of, 9

ILND, Inguinal lymphadenectomy

IMA, Inferior mesenteric artery

Image guidance, to prostate cancer, 3589

Image-guided radiation therapy, for prostate cancer, 3589–3590, 3591*f*–3592*f*

Image storage, ultrasonography, 76, 77*f*

Imaging
  - in adrenal mass evaluation, 2394–2398, 2396*f*–2397*f*, 2397*b*
  - for benign prostatic hyperplasia, 3347
  - for male urinary incontinence, 2543
  - for pediatric urology, 388–391
    - prenatal ultrasonography, 389
    - renal bladder ultrasound, 388–389
    - ultrasonography, 388–389
  - of pheochromocytoma, 2375, 2376*f*
  - techniques, for UTIs, 1143–1144, 1144*b*
    - CT and MRI, 1144
    - indications, 1144*b*
    - radionuclide studies, 1144.e1
    - ultrasonography, 1144
    - voiding cystourethrogram, 1144

Imidafenacin, to facilitate bladder filling and urine storage, 2682, 2682*t*

Imipramine (Tofranil)

- to facilitate bladder filling and urine storage, 2682*t*, 2702
- for nocturnal polyuria, 2668, 2673*t*
- for stress urinary incontinence in women, 2714–2715
- ureteral response to, 1888

Imiquimod cream, for condylomata acuminata, 1742.e3

Immune checkpoint blockade, 1342, 1342*f*

- in bladder cancer, 1342
- in kidney cancer, 1343
- in prostate cancer, 1343

Immune editing hypothesis, 1336, 1337*f*

Immune response, pathogen recognition, 1138–1139

ImmunoCyt, of bladder tumor, 3081

Immunoglobulin A (IgA) nephropathy, 346

Immunoglobulins, in prostatic secretions, 3298*t*, 3302

Immunologic effects, of laparoscopic and robotic surgery, 223

Immunologic function, aging and, 2906

Immunology, immune response in GU cancers, 1333–1345, 1336*b*

- adaptive immune system, 1334–1336, 1335*f*
- immune editing hypothesis, 1336, 1337*f*
- inflammation effects in, 1336, 1337*f*–1338*f*, 1338*b*
- innate immune system, 1333–1334, 1334*f*–1335*f*, 1334*t*–1335*t*

Immunomodulator drugs, for BPS/IC oral therapy, 1241*t*, 1242–1243

Immunosuppressed patients, penile implants for, 1596

Immunosuppression, in end stage renal disease, 357

Immunotherapy

- for castration-resistant prostate cancer, 3697–3699, 3699*b*
- for GU cancers, 1333–1345, 1341*b*, 1343*b*
  - BCG in bladder cancer, 1333, 1334*f*, 1338–1339, 1339*f*

        - cancer vaccines, 1339–1340, 1340*f*–1341*f*
        - combination, 1343–1345, 1345*f*
        - immune checkpoint blockade, 1342, 1342*f*
    - for non-muscle-invasive bladder cancer, 3099–3103, 3103*b*
        - Bacille Calmette-Guérin, 3099–3100
        - interferon, 3102–3103
        - investigational, 3103
    - for UTUC, 2223–2224
- IMPACT study, 3697, 3697*f*
- Impedance, in ultrasonography, 71, 71*f*
- Imperforate hymen, 395, 396*f*, 978–979, 979*f*
- Implants, for ED, 1582
    - inflatable, 1582, 1583*f*
    - semirigid rods, 1582, 1583*f*, 1584*t*
- IMT, Inflammatory myofibroblastic tumor
- IMV, Inferior mesenteric vein
- In vitro fertilization, 1428, 1445.e3
- Incidental urolithiasis, 402
- Incidentalomas, adrenal
    - adrenal surgery for, 2409*b*
    - evaluation of, 2394, 2394*t*
- Incision instrumentation, for laparoscopic and robotic surgery, 214–215
- Incisional hernia, after laparoscopic and robotic surgery, 231
- Inclusion cysts, 882–883, 882*f*
- Inconspicuous penis, 394, 872*t*, 877–879, 879*f*
- Incontinence Impact Questionnaire (IIQ), 110, 111*t*
- Incontinence Quality of Life Instrument (I-QOL), 111*t*
- Incontinence Symptom Index (ISI-P), 477
- Incontinent urinary diversion, for neuromuscular dysfunction of lower urinary tract, 636–637

Increased through transmission, in ultrasonography, 72, 72*f*

Index lesion hypothesis, multifocality of prostate cancer *versus*, 3617–3620, 3619*t*, 3620*f*

Index of Premature Ejaculation (IPE), 112*t*

Indiana pouch, 3220–3224, 3222*f*–3223*f*

Indigo carmine, toxicity of, 1994

Indinavir sulfate (Crixivan), in stone formation, 2032–2033

Indirect inguinal hernia, 889

Indirect medical risk factors, in bladder tumor, 3077

Indium-111 (^{111}In), 91, 92*t*

- capromab pendetide scanning, for biochemical recurrence after radical prostatectomy, 3661

Indomethacin

- to facilitate bladder filling and urine storage, 2682*t*, 2703
- urethral function effects of, 1902

Induction process, 785–786, 786*f*

Indwelling catheters, for urinary incontinence, in geriatric patients, 2920.e5

Indwelling orthopedic hardware, antimicrobial prophylaxis for uncomplicated urologic procedures and, 1201

Infected hydronephrosis and pyonephrosis, 1174, 1174*f*

Infection

- after midurethral sling, 2870–2871
- after prostate biopsy, 3499
- with artificial urinary sphincter, 3005–3006
- in BPS/IC etiology, 1232.e1–1232.e2
- complicated, 1129, 1130*b*
- complication of scrotal surgery, 1856
- from cutaneous diseases of external genitalia
    - balanitis, 1288
    - balanoposthitis, 1288, 1289*f*
    - candidal intertrigo, 1293–1294, 1294*f*
    - cellulitis, 1288–1289, 1290*f*

        - corynebacterial infection (trichomycosis axillaris and erythrasma), 1292–1293, 1293*f*
        - dermatophyte infection, 1294–1295, 1295*f*
        - ecthyma gangrenosum, 1293, 1294*f*
        - erysipelas, 1288–1289
        - folliculitis, 1290–1291, 1291*f*
        - Fournier gangrene, 1289–1290, 1290*f*
        - furunculosis, 1291, 1291*f*
        - genital bite wounds, 1293, 1294*f*
        - hidradenitis suppurativa, 1291–1292, 1292*f*
        - infestation, 1295–1296, 1296*f*
        - STDs, 1288, 1289*f*
    - host factors increasing risk of, 1193*b*
    - and inflammation, and male infertility, 1432
    - with intestinal anastomoses, 3180
    - penile implant and, 1591–1593, 1592*f*, 1593*b*
    - with percutaneous antegrade endopyelotomy, 1949
    - preoperative care for pediatric patients with, 447–448
    - prostate cancer and, 3461, 3462*f*
    - prostatitis and, 1207
    - renal transplantation and, 1056–1057, 1061
    - ureteral anomalies and, 801–802
    - ureteral function effects of, 1899
    - with urinary intestinal diversion, 3198–3205, 3205*b*
    - UTUC risk and, 2187

Infection calculi, 2063–2065, 2063*f*, 2064*t*, 2065*b*

Infection stones, 2030–2031
    - bacteriology of, 2030–2031, 2031*t*
    - epidemiology of, 2031
    - pathogenesis of, 2030, 2030*f*

Infectious granulomatous nephritis
    - malacoplakia, 1179–1181, 1180*f*
    - renal echinococcosis, 1181.e1, 1181.e2*f*
    - XGP, 1177–1179, 1178*f*–1179*f*

Infective disorders, and delayed ejaculation, 1575

Inferior epigastric artery, 136*f*

Inferior mesenteric artery (IMA), in radical nephrectomy, 2261

Inferior mesenteric vein (IMV), in radical nephrectomy, 2261

Inferior vena cava (IVC)

- filtration and permanent interruption of, 2277
- patching, replacing, and interrupting of, 2276–2277, 2277*f*
- in radical nephrectomy, 2258, 2258*f*, 2258.e1*f*
- RCC involvement of, 2174–2176, 2175*f*–2176*f*, 2298
- resection of, RPLND with, 1718–1719
- in retroperitoneum, 1672

Inferior vesical artery, 1380, 1380*f*

Infertility

- ligation with resulting, complication of scrotal surgery, 1856
- male, 1428–1452
    - abdominal, imaging of, 1444, 1445*f*
    - assisted reproduction, 1445–1452, 1445.e3, 1445.e3*t*
    - causes of, 1446–1447
    - and childhood diseases, 1432–1434
    - and chromosomal numerical disorders, 1445–1446
    - cranial, imaging of, 1444–1445, 1445*f*
    - developmental disorders and, 1449–1450
    - diagnoses and therapies for, 1445, 1452*b*
    - and ejaculatory dysfunction, 1450–1451
    - epidemiology of, 1428
    - epigenetic anomalies and, 1446
    - and extratesticular endocrine dysfunction, 1448–1449
    - and genetic syndromes, 1445–1446
    - and genetics, 1433
    - and genomic assessment, 1442–1443
    - history of, 1428–1434, 1429*t*, 1434*b*
    - and hypogonadotropic hypogonadism, 1447–1448
    - imaging of, 1443–1445, 1445*b*
    - and infections and inflammation, 1432
    - laboratory evaluation of, 1436–1443, 1443*b*
    - and microductal obstruction, 1447, 1447*f*
    - and pediatric surgery, 1432
    - physical examination of, 1434–1436, 1436*b*
    - and pituitary dysfunction, 1447–1448
    - and spermatogenic dysfunction, 1446
    - and steroidogenic dysfunction, 1447
    - structural chromosomal anomalies and, 1446

- and structural sperm abnormalities, 1451–1452
- testicular dysgenesis hypothesis, and childhood diseases, 1433
- testis histopathology and, 1445, 1445.e1*f*–1445.e2*f*, 1445.e2*b*
- vasography for, 1444
- venography for, 1444

TGCT and, 1690

Infestation, as cutaneous disease of external genitalia, 1295–1296, 1296*f*–1297*f*

Infibulation, 987–988, 988*f*

Inflammation
- in BPS/IC etiology, 1232.e2–1232.e3, 1232.e3*b*
- in cancer immune response, 1336, 1338*b*
- pathways of, in benign prostatic hyperplasia, 3311, 3312*f*
- prostate cancer and, 3461, 3462*f*
- prostatitis and, 1207
- triggers for, 3477*b*

Inflammatory bowel disease, ammonium acid urate stones from, 2032

Inflammatory cell infiltration, in tubulointerstitial fibrosis, 787

Inflammatory myofibroblastic tumor (IMT), in pediatric patients, 1119

Inflammatory strictures, 1815

Informed consent, 115–118
- elements of, 117–118
- for erectile dysfunction, surgery for, 1582–1583, 1584*b*
- exception to, requirement, 118
  - emergency situations, 118
  - patients without decision-making capacity, 118
  - pediatric patients, 118
- history of, 116–117
- quality of, 118

Infraumbilical, 135

Infundibulopelvic stenosis, 739–740, 740*f*

Inguinal canal, anatomy of, 2445–2447, 2448*f*

Inguinal hernia
- epidemiology and pathogenesis of, 889

- female, 988
- surgical repair of, 890–891
    - complications with, 891
    - laparoscopic, 891–892
    - scrotal approach to, 891
    - standard, 891

Inguinal incisions, in urologic surgery, 140–141
- inguinal ligament, incision above, 140–141, 141*f*
- and pelvic lymphadenectomy, in penile cancer, 141, 141*f*

Inguinal ligament, incision above, 140–141, 141*f*

Inguinal lymph nodes, 1386
- anatomy of, 1790, 1791*f*

Inguinal lymphadenectomy (ILND), 1753–1756
- in clinically negative groins
    - DSNB, 1760–1761
    - laparoscopic and robotic ILND, 1761
    - modified complete ILND, 1761
    - sentinel lymph node biopsy, 1760
    - superficial inguinal node dissection, 1761
- complications of, 1801–1802
- indications for
    - expectant management of, 1759–1760, 1760*t*
    - modified procedures, 1760–1762
    - traditional procedures, 1761–1762
    - watchful waiting, 1759
- palpable adenopathy in selection for, 1753–1756
- for penile cancer
    - immediate *versus* delayed, 1756
    - indications for modified procedures, 1760–1762
    - indications for traditional procedures, 1761–1762
    - indications for watchful waiting, 1759
    - molecular prognostic markers for, 1759, 1759*t*
    - morbidity *versus* benefit, 1756–1757, 1756*t*, 1757*f*
    - palpable adenopathy in selection for, 1753–1756
    - prognostic significance of metastatic disease, 1753, 1754*t*–1755*t*
    - tumor histology in selection for, 1757–1759, 1758*t*
- postoperative care after, 1801
    - antibiotics for, 1801
    - anticoagulation for, 1801

    - bed rest in, 1801
    - compressive dressings and stockings for, 1801
    - dietary considerations of, 1801
    - drainage, 1801
  - prognostic significance of metastatic disease, 1753, 1754*t*–1755*t*
- Inguinal node dissection, 1790–1803, 1803*b*
  - anatomic considerations for
    - inguinal anatomy, 1790–1791, 1791*f*
    - penile lymphatics, 1790
    - urethral lymphatics, 1790
  - endoscopic anatomy of, 1791
  - follow-up after, 1802–1803, 1802*t*
  - imaging evaluation of, 1791–1792
  - oncologic control after, 1802, 1802*t*
  - patient before surgery, preparation of, 1800–1801
    - antibiotics, 1800–1801
    - anticoagulation, 1801
    - bowel cleansing, 1801
  - for penile cancer, 1792, 1792*b*
    - nonpalpable inguinal adenopathy, 1792–1796
    - palpable inguinal adenopathy or positive inguinal lymph nodes, 1796–1800
    - surgical management of, 1792
- Inguinal nodes
  - palpable adenopathy in selection for, 1753–1756
  - penile cancer metastasis to
    - imaging studies for, 1747–1748
    - risk-based management for, 1762–1765, 1763*f*–1764*f*
  - treatment of, for penile cancer, 1753–1765, 1762*b*
    - palpable adenopathy in selection for, 1753–1756
    - prognostic significance of metastatic disease, 1753, 1754*t*–1755*t*
- Inguinal orchiopexy, 966–967
- Inherited genetic markers, as prostate cancer biomarkers, 3488–3489
- Inhibin, 1390, 1391*f*
- Inhibitors, of crystal formation, 2014–2015
- Injection therapy
  - for bladder neck reconstruction, 687

- for female stress urinary, in geriatric patients, 2920.e5
- for prostate, 3446–3447

Injuries, of bladder, 3054–3057, 3055*b*–3056*b*

INK4A gene (p16), in bladder cancer, 1350

Innate immune system, 1333–1334, 1334*f*–1335*f*, 1334*t*

- cytokines and chemokines, 1333–1334, 1335*f*, 1335*t*

Innervation

- of bladder, 2456
- of labium majus, 2436
- motor nerve, of bladder smooth muscle, 2465, 2465*f*, 2480, 2480*f*
- of pelvis
  - female, 2433–2434
  - male, 2447*f*–2448*f*, 2453, 2453*f*, 2453*t*, 2454*b*
- of vagina, 2438

Innominate bones, 2444

Inositol 1,4,5-trisphosphate (IP3), in ureteral contractions, 1885

In-oxine, 96

Insemination, intrauterine, 1445.e3

Insensible urinary incontinence (IUI), 2540, 2581

- overactive bladder and, 2637
- pathophysiology of, 2597

INSS, International Neuroblastoma Staging System

Instillation therapy, 2220, 2221*f*

Institutional support, in transitional urology, 1045

Instrument development, 108

Instrumental activities of daily living (IADLs), of geriatric urology patient, 2909

Instrumentation, for visualization, 213, 213.e1*f*

Insufflant, for laparoscopic and robotic surgery, 220

Insufflation, for laparoscopic and robotic surgery, complications related to, 224–225

Insulin resistance, low urine pH and, 2027–2028

Insulin-like growth factor-3, 1392

Insulin-like growth factors (IGFs)

- in compensatory renal growth, 794–795
- in prostate cancer, 3463

Integral theory, 2596, 2597*b*, 2831

Integrated endoscopy systems, for laparoscopic surgery, 205–206, 205.e1*f*

Intensity-modulated radiation therapy, for prostate cancer, 3588–3589, 3589*f*, 3589*t*

Interaortocaval lymph nodes, 1372

Inter-α-trypsin, in crystal formation, 2015

Intercellular communication, penile erection and, 1500

Interference, of ultrasound waves, 71, 71*f*

Interferon alfa-2b (IFNs), for PD, 1612–1613, 1617*t*

Interferon-gamma release assays (IGRAs), for genitourinary tuberculosis, 1311

Interferons (IFNs)

- for clear cell RCC, 2329, 2329*t*
- for condylomata acuminata, 1742.e3
- for metastatic RCC, 2326, 2326*f*, 2327*t*
- for non-muscle-invasive bladder cancer, 3102–3103
- for RCC, 2178–2179

Interlabial masses, 395, 398*b*

Interleukin-2 (IL-2), for metastatic RCC, 2326, 2329–2331, 2330*t*

Interleukin-18 (IL-18), in tubulointerstitial fibrosis, 788

Interleukins, 1334, 1335*f*, 1335*t*

Interlobar arteries, 1869

Interlobular arteries, of kidney, 1869, 1870.e1*f*

Interlobular veins, of kidney, 1869–1870

Intermediate cells, of prostate, 3278*f*, 3279

Intermediate junctions, ureteral, 1877, 1883

Intermediate stratum, 2427, 2429*f*

Intermittent testicular torsion, 1855

Internal genitalia, male, development of, 1392, 1392*f*

Internal iliac arteries, 1873.e1*f*, 1874

Internal iliac lymph nodes, 1381

Internal iliac veins, 1381, 1874

Internal pudendal artery, 1381, 1807.e4*f*

Internal spermatic artery, 1393, 1394*f*

Internal sphincter
  male sphincteric mechanisms and, 2594
  urodynamic studies of, 2569

Internal urethrotomy, for urethral stricture disease, 1818

International Association for the Study of Pain, 448

International Classification of Vesicoureteral Reflux, 498*t*

International Consultation on Incontinence (ICI)
  Oxford guidelines
    for behavior therapy, 2722.e4*b*
    to facilitate bladder filling and urine storage, 2681*t*
  pelvic floor disorder questionnaires, 2531, 2532*t*–2533*t*

International Consultation on Incontinence Modular Questionnaire-male LUTS (ICIQ-MLUTS), 3344

International Consultation on Incontinence Questionnaire (ICIQ), 111*t*

International Consultation on Incontinence Questionnaire Bladder Diary (ICIQ-BD), 2541, 2541*f*

International Consultation on Incontinence Questionnaire Female Lower Urinary Symptoms (ICIQ-FLUTS), 111*t*

International Consultation on Incontinence Questionnaire Male Lower Urinary

Tract Symptoms (ICIQ-MLUTS), 2541, 2541.e1*f*–2541.e2*f*

International Consultation on Incontinence Questionnaire Urinary Incontinence Short Form (ICIQ-UI-SF), 2541, 2542*f*

International Continence Society (ICS)

- classification of voiding dysfunction, 2517, 2521*b*
- nocturia definition of, 2664
- transient incontinence causes, 2525, 2526*t*

International Germ Cell Cancer Collaborative Group (IGCCCG), risk classification for advanced GCTs, 1690, 1691*t*

International Index of Erectile Function (IIEF), 112*t*

International Neuroblastoma Staging System (INSS), 1090*t*–1091*t*, 1091

International Prostate Symptom Score (IPSS), 4*t*–5*t*, 109, 110*t*

- for benign prostatic hyperplasia, 3344
- for male urinary incontinence, 2541
- for nocturia, 2664
- for pelvic floor disorders, 2531

International Reflux Study in Children, 515

International Society for Sexual Medicine, and Premature ejaculation, 1565–1567

- rationales for, 1567.e1–1567.e2

International Society of Urological Pathology, Gleason grading system, 3511

Interpolar calyx, 166

Interposition material, in urethrovaginal fistulae, 2951

Interrupted-shaped curve, 480

Interstitial cells

- bladder outlet obstruction and, 2506
- of detrusor muscle, 2477–2478, 2478*f*

Interstitial cystitis, female sexual dysfunction and, 1657

Interstitium, of testis, 1394–1396

- in testosterone synthesis, 1394

Interventional angiography, for priapism, 1560–1561, 1561*f*

Intestinal anastomoses, in urinary intestinal diversion, 3169–3184, 3184*b*
- abdominal stomas with, 3182–3183
  - complications of, 3183–3184, 3186*t*
  - flush, 3182–3183
  - loop end ileostomy, 3183, 3183*f*
  - nipple (rosebud), 3182, 3182*f*–3183*f*
- with biofragmentable ring, 3179
- complications of, 3179–3181
  - bowel obstruction, 3180–3181, 3180*t*, 3181*f*
  - fistulas, 3179–3180
  - hemorrhage, 3181
  - infection, 3180
  - intestinal stenosis, 3181, 3181*f*
  - pseudo-obstruction, 3181
  - sepsis, 3180
- complications of isolated intestinal segment, 3181–3182
  - intestinal stricture, 3181
  - segment elongation, 3181–3182, 3182*f*
- compression, 3179
- laparoscopic and robotic, 3178–3179, 3178*f*–3179*f*
- stapled, 3176–3178
  - ileal-ileal, 3177–3178, 3178*f*
  - ileocolonic end-to-end, 3176, 3176*f*
  - ileocolonic with circular device, 3177, 3177*f*
- types of, 3174–3176
  - end-to-side ileocolic, 3175–3176, 3176*f*
  - ileocolonic end-to-end, 3176, 3176*f*
  - single-layer suture, 3175, 3175*f*
  - two-layer suture, 3174–3175, 3175*f*

Intestinal antireflux valves, in urinary intestinal diversion, 3189–3191
- intussuscepted ileal valve, 3190–3191, 3191*f*
- intussuscepted ileocecal valve, 3189–3190, 3191*f*
- nipple valve, 3191, 3192*f*

Intestinal motility
  pneumoperitoneum effects on, 222
  urinary intestinal diversion and, 3203
Intestinal neobladders, pharmacologic therapy in, to facilitate bladder filling and urine storage, 2712–2713
Intestinal segments
  for antireflux procedure, 683–685
  in augmentation cystoplasty, 692
    effects of, 696–697
  neuromechanical aspects of, 3204–3205
  used in urinary diversion, minimally invasive, 3268
Intestinal stenosis, with intestinal anastomoses, 3181, 3181*f*
Intestinal stricture, with intestinal anastomoses, 3181
Intestinal tract abnormalities, with cloacal exstrophy, 575
Intimal fibroplasia, 1916, 1916*f*
Intra-abdominal pressure, for laparoscopic and robotic surgery, 220–221
Intra-abdominal vessels, injury of, during laparoscopic and robotic surgery, 226
Intracavernosal injection, in ED, 1534–1535, 1535*t*
Intracorporeal lithotripsy, 2109–2113
  ballistic lithotripsy, 2111–2112, 2112*f*
  combination ballistic and ultrasonic devices in, 2112–2113
  commonly used, 242*t*
  electrohydraulic lithotripsy, 2109–2110, 2110*f*
  laser lithotripsy, 2110–2111
  pneumatic, 243*b*
    basic physics of, 243
    for percutaneous nephrolithotomy, 243.e1
    tissue effects of, 243
    ureteroscopy with, 243.e1
  ultrasonic lithotripsy, 2112, 2112*f*
Intracorporeal neobladder, in minimally invasive urinary diversion, 3262–3273, 3263*t*

Intracranial aneurysms (ICAs), 752

Intradetrusor therapies, for BPS/IC treatment, 1245–1246

Intraductal carcinoma of the prostate (IDC-P), 3506

Intralabial masses, in female, 386

Intraluminal lithotripsy, ureteroscopic

- devices for, 197
- retropulsion prevention devices for, 198, 198*f*
- stone retrieval devices, 198
- ureteral access sheaths for, 199, 199*f*, 199*t*

Intramural ureter, tumor confined to, 2211–2212, 2213*f*, 2215*f*

Intraoperative consultation, 296–304, 298*b*

- bladder injury, 299–300, 303*b*
- decision making, 296–297, 297*f*
- documentation, 297–298
- ethical considerations, 296
  - patient-physician relationship, 296
- placental cases, 303–304
- renal injury, 302–303
- ureteral injury, 300–302
- urethral injury, 298–299

Intraoperative floppy iris syndrome (IFIS), α1-adrenergic blockers and, 3370

Intraoperative management, in urologic surgery, 125–134

- anesthetic considerations, 130–132
- antibiotic prophylaxis, 127–128, 127*b*
- pain management, 134
- patient management, 125
- patient positioning, 126–127, 126*b*, 128*b*
- patient safety, 126
- skin preparation, 132–133
- transfusion considerations, 133
- venous thromboembolic prophylaxis, 128–130, 129*t*–131*t*, 131*b*

Intraoperative obturator nerve injury, 262

Intraoperative planning, 3596

Intraoperative urethral injury, 2883

Intraoperative vascular complications, 269–270

Intraperitoneal urine leak, in robotic prostatectomy, 3580

Intraprostatically injected drugs, to facilitate bladder filling and urine storage, 2713.e2–2713.e3

Intrarenal schwannoma, 2132

Intrarenal vasculature, 162–164, 163*f*

Intrascrotal pain, surgical management of, 1853–1855

Intratesticular varicocele, 901–902

Intratubular germ cell neoplasia (ITGCN), 1680

Intraurethral valve-pump, for women with impaired detrusor contractility, 2902–2903

Intrauterine insemination, 1445.e3, 1445.e3*t*

Intravaginal devices, for urinary incontinence, 2736–2737, 2736.e1*f*, 2737*f*, 2737.e1*f*

Intravaginal slingplasty, 2831, 2851

Intravascular volume management, for pheochromocytoma, 2379*f*, 2380

Intravenous general anesthesia, 132

Intravenous pyelography, 415, 806, 807*f*

- of ureteral injuries, 1995–1996, 1996*f*

Intravenous urography (IVU), 35, 36*f*

- for genitourinary tuberculosis diagnosis, 1312, 1312*f*–1313*f*
- for ureterovaginal fistula, 2929, 2944*f*
- for vesicovaginal fistula, 2929

Intravesical approach, for bladder diverticula, 3013–3015, 3013*f*–3014*f*

Intravesical chemotherapy, for non-muscle invasive bladder cancer, 3103–3105, 3104*t*, 3105*b*

- combination therapy, 3105

- doxorubicin, 3103–3104
- mitomycin C, 3104–3105
- novel agents, 3103
- to prevent implantation, 3103–3105
- thiotepa, 3103
- valrubicin, 3104

Intravesical electrotherapy (IVE), for detrusor underactivity, 2661–2662

Intravesical pressure, increasing
- external compression for, 2902–2903
  - to facilitate bladder emptying, 2716–2718
- to facilitate bladder emptying, 2902–2903
- intraurethral valve-pump for women with impaired detrusor contractility, 2902–2903
- reflex contraction promotion or initiation, 2902
- stimulated myoplasty, 2903

Intravesical prostatic protrusion (IPP), 3348

Intravesical stimulation, 2747–2748

Intravesical therapies, for BPS/IC treatment, 1241*t*, 1244–1247, 1245*b*
- Clorpactin, 1244.e1
- DMSO, 1244
- glycosaminoglycans, 1244–1245
- intradetrusor therapies, 1245–1246
- silver nitrate, 1244.e1

Intrinsic apoptotic pathway, 1366.e1, 1366.e1*f*

Intrinsic kidney injury, 1923

Intrinsic renal disease, AKI due to, 1923

Intrinsic sphincter dysfunction, 2518

Intrinsic sphincteric deficiency (ISD), 2518
- causes of, 2595–2596
- midurethral sling for, outcomes of, 2859–2860
- quantification of, 2562
- sling procedure and, 2834
- stress urinary incontinence and, 2597, 2757

  - urinary incontinence and, 2595–2596

Introitus, 1627.e1

Intubated ureterotomy, for ureteropelvic junction obstruction, 1961–1962, 1963*f*

Intussuscepted ileal valve, 3190–3191, 3191*f*

Intussuscepted ileocecal valve, 3189–3190, 3191*f*

Inverse treatment planning, 3588

Inverted papilloma, of bladder, 3081

Involuntary detrusor contractions (IDCs), 2560

Iodinated intravenous contrast agents, 292

Iodine-123 (^{123}I), 91

Iodine-124 (^{124}I), 91

Ion channels
  - in detrusor muscle, 2474, 2474*f*
  - in ED, 1499

Ionic transport, across bladder urothelium, 2469

Ionizing radiation, technique of, 403, 403*b*

IPE, Index of Premature Ejaculation

Ipilimumab, 2146
  - for RCC, 2332

IPP, Intravesical prostatic protrusion

Ipsilateral vesicoureteral reflux, bladder diverticula with, 2971

IPSS, International Prostate Symptom Score

I-QOL, Incontinence Quality of Life Instrument

IRE, Irreversible electroporation

Irinotecan, for penile cancer, 1770

Irreversible electroporation (IRE), 3628–3632, 3635*f*, 3636*t*
  - for renal tumors, 2322

Irritable bowel syndrome (IBS), cross-organ sensitization in, 2486

Irritative lower urinary tract symptoms, patient history of, 3

Isaacs syndrome, lower urinary tract dysfunction and, 2630

Ischemic nephropathy, 1915, 1921–1935

Ischemic priapism, 1539, 1540*f*

  epidemiology and pathophysiology of, 1541–1545, 1543*f*

  penile implants in, 1596

Ischial spine, 2427, 2428*f*

Ischiococcygeus muscle, 2432*f*, 2434

Ischiorectal fossa, 2435

ISD, Intrinsic sphincteric deficiency

ISI-P, Incontinence Symptom Index

Island flaps, for urethral and penile reconstruction, 1807

Island onlay flap procedure (OIF), 924–925, 926*f*

Isoproterenol, ureteral response to, 1885, 1888

Isovolumetric pressure, 2659

ITGCN, Intratubular germ cell neoplasia

IUI, Insensible urinary incontinence

IV pyelography (IVP)

  of renal injuries, 1985, 1995–1996, 1996*f*

  for renal tumor evaluation, 2134

IVC, Inferior vena cava

IVC filters, for vena caval thrombectomy, 2266–2267

IVE, Intravesical electrotherapy

IVU, Intravenous urography

J

Jaboulay (Winkelman) technique, 1845, 1847*f*

Jackson-Pratt drains, 148

Jehovah's Witnesses

- anesthesia preoperative considerations for, 448
- blood transfusion and, 133

Jejunal conduit, 3195–3196, 3196*t*

Jejunum, selection, 3162

JESS, Joint Expert Speciation System

Joint Expert Speciation System (JESS), 2010

Justice, definition of, 115

Juvenile granulosa cell tumors, 1120–1121

Juvenile nephronophthisis, 747*t*, 755–756, 756*f*, 756*b*

- clinical features of, 755–756
- evaluation of, 756, 756*f*
- genetics of, 755
- treatment of, 756

Juvenile xanthogranuloma, 883

Juxtaglomerular cell tumor, 2132

K

K antigens, 429

Kalicinski plication technique, for megaureter in children, 851, 851*f*

Kaposi sarcoma (KS)

- HIV and, 1267–1268, 1298–1299, 1300*f*
- as neoplastic condition, 1298–1299, 1300*f*
- of penis, 1742.e5

Karnofsky Performance Scale (KPS), 107, 107*t*

Karyotype, for male infertility, 1442

Kaye nephrostomy tamponade balloon, 178*f*

KDIGO, Kidney Disease: Improving Global Outcomes

Kegel's exercises, 2833

Kelly repair, for classic bladder exstrophy, 544

- continence outcomes with, 561
- technical aspects of, 549–550, 549*f*

Ketoconazole, 3677

Ketogenic diet, 449

Ketones, in urine, 19–20

Ketorolac, for urinary tract obstruction, 795

Kidney, 324*f*, 333–340, 333*f*–334*f*, 339*b*

- deterioration of, in urinary intestinal diversion, 3192–3193, 3193*b*
- early events in, 334
- molecular mechanisms of, 336

Kidney and retroperitoneum anterior approaches, 136–138, 138*f*, 139*t*

- Chevron and subcostal incision, 137–138, 139*f*
- thoracoabdominal incision, 136–137

Kidney cancer

- in geriatric patients, 2920.e13
- in nuclear medicine, 42

Kidney Disease: Improving Global Outcomes (KDIGO)

- AKI definition by, 1921, 1922*t*
- CKD classification by, 1927, 1928*f*

Kidney disease, nocturia and, 2665

Kidney infections, 1181*b*

- infectious granulomatous nephritis
  - malacoplakia, 1179–1181, 1180*f*
  - renal echinococcosis, 1181.e1, 1181.e2*f*
  - XGP, 1177–1179, 1178*f*–1179*f*
- renal infection (bacterial nephritis), 1166–1181
  - acute focal or multifocal bacterial nephritis, 1171.e1, 1171.e1*f*
  - for acute pyelonephritis, 1168–1171, 1168*f*–1169*f*, 1170*t*
  - bacterial “relapse,”, 1177.e1

    - chronic pyelonephritis, 1176–1177, 1177*f*
    - emphysematous pyelonephritis, 1171–1172, 1171*f*
    - infected hydronephrosis and pyonephrosis, 1174, 1174*f*
    - pathology, 1166–1168, 1167*f*–1168*f*
    - perinephric abscess, 1174–1176, 1175*f*
    - renal abscess, 1172–1174, 1172*f*–1173*f*

Kidney surgery, 2248–2278, 2278*b*

- approaches used in, 2248–2253
    - anterior, 2252–2253, 2253.e1*f*
    - dorsal lumbotomy, 2251, 2251*f*
    - flank, 2249–2251, 2249.e1*f*, 2250*f*–2251*f*, 2250.e1*f*, 2251.e1*f*
    - thoracoabdominal, 2251–2252, 2252*f*–2253*f*, 2252.e1*f*
- for benign diseases, 2253–2257
    - extracorporeal renal surgery, 2254–2257, 2256*f*
    - open nephrectomy, 2254, 2254.e1*f*
    - partial nephrectomy, 2254, 2255*f*
    - simple nephrectomy, 2253–2254, 2253.e2*f*, 2254*f*
- historical perspective, 2248
- for malignancy, 2257–2278
    - partial nephrectomy, 2261–2266, 2262*f*–2266*f*, 2263.e1*f*–2263.e2*f*, 2264.e1*f*
    - radical nephrectomy, 2257–2261, 2257*f*–2260*f*, 2258.e1*f*, 2259.e1*f*, 2260.e1*f*
    - vena caval thrombectomy, Vena caval thrombectomy
- preoperative evaluation and preparation for, 2248, 2248.e1*f*, 2249*f*
    - prophylactic measures, 2248
    - surgical instruments, 2248

Kidneys, 1865–1872, 1868*b*

- AAST Organ Injury Severity Scale for, 1992*t*
- anatomy of, 1865–1876
    - congenital anomalies in, 1869, 1869.e1*f*–1869.e2*f*
    - gross and microscopic, 1866–1868, 1866.e1*f*–1866.e2*f*, 1867*f*
    - innervation, 1872, 1872.e1*f*
    - lymphatic drainage, 1870–1871, 1870.e1*f*
    - radiologic, 1868–1869, 1868*f*, 1868.e1*f*, 1869*b*, 1869.e1*f*–1869.e2*f*
    - surface anatomy and relationships, 1865–1866, 1865.e1*f*–1865.e4*f*, 1866*f*
    - vasculature, 1869–1870, 1869.e2*f*–1869.e3*f*, 1870*f*–1871*f*, 1871*b*
- anatomy of, changes during pregnancy, 1185–1186, 1185*t*
- Ask-Upmark, 744, 744*f*
- cake or lump, 728*f*
- calcium absorption in, 2016
- collecting system of, 794

  cystic disease of, 741–775
  developing, pathological changes in, with urinary tract obstruction, 781–786
  disc, 728*f*
  drainage of, for urinary tract obstruction, 795
  ectopic
    inferior, 729
    superior, 728*f*, 729–731
  functional imaging of, 91–96
    ^{99}TC-MAG3 and ^{99}mTC-DTPA for, 92–93
    dosing and pharmacokinetics in, 92
    image acquisition and interpretation in, 92–93
    patient preparation for, 92
    relevant renal physiology of, 91–92
    Technetium-99m diethyltriaminepentaacetic acid (^{99}mTC-DTPA) for, 92
    Technetium-99m dimercaptosuccinic acid (^{99}mTC-DMSA) for, 92
    Technetium-99m mercaptoacetyltriglycine (^{99}mTC-MAG3) for, 92
  in genitourinary tuberculosis, 1308–1309
  growth regulation of, 783, 783*t*–784*t*
  horseshoe, 731–733, 733*b*
  localization, in UTI diagnosis, 1142.e1*t*, 1143
  L-shaped, 728*f*
  mature, pathological changes in, with urinary tract obstruction, 781, 782*f*
  organoneogenesis of
    molecular mechanisms of, 721
    new advances in, 714–715
  physical examination for, 10–12, 10*f*
  in prune-belly syndrome, 581, 582*f*
  sigmoid, 728*f*
  size of, with spina bifida, 629
  solitary, upper urinary tract calculi and, 2089
  supernumerary, 721–722, 722*f*–723*f*
  thoracic, 725–727, 726*f*
  urine egress from, in urinary tract obstruction, 794
Kidney-ureter-bladder (KUB) radiograph, kidney anatomy, 1868
King's Health Questionnaire, 111*t*
Kinins, urethral function effects of, 1902

Kisspeptin protein, 1392

Klinefelter syndrome and variants, 1000

Klippel-Trénaunay-Weber syndrome, 888

“The Knack, 2725, 2725.e1*t*

Kocher maneuver, for radical nephrectomy, 2258, 2258*f*

Kock ileal reservoir, for orthoptic urinary diversion, 3243–3244, 3244*f*

Kock pouch, 3213–3215, 3214*f*

KPS, Karnofsky Performance Scale

KS, Kaposi sarcoma

KUL-7211, ureteral response to, 1888–1889

L

LABD, Linear IgA bullous dermatosis

Labia majora, 1627.e1, 2435, 2436*f*–2437*f*

Labia minora, 1627.e1

Labial adhesions, 395, 396*f*, 986–987, 987*f*

Labioplasty, initial management, timing, and principles for, 1026, 1026*f*, 1028*f*–1029*f*

Labor, vesicovaginal fistulae with, 2925

Lactate dehydrogenase (LDH)

- in prostatic secretions, 3302
- in TGCTs, 1686

Lamina propria, 2462–2463

Laminectomy, LUT function and, 2620

Laparoendoscopic single-site surgery (LESS), 458, 466, 2419–2420

- access devices for, 212
- Boari flap, 3031
- instrumentation for, 218

- for kidney surgery
    - clinical experience of, 2305–2306, 2305*f*
    - robotic, 2306
    - surgical approaches and access for, 2284–2285, 2285*f*, 2286*t*
- pyeloplasty, for ureteropelvic junction obstruction, 1956–1957, 1957*f*

Laparoscopes, for laparoscopic and robotic surgery, 213, 213.e1*f*

Laparoscopic adrenalectomy, 2407–2409, 2407*b*

- left, 2414–2415, 2415*f*–2416*f*, 2417–2418
- outcomes, 2421–2423
- retroperitoneal approach, 2417–2418, 2418*f*, 2422
- right, 2415–2416, 2417*f*–2418*f*, 2418
- transperitoneal approach, 2414–2417, 2415*f*–2417*f*, 2422

Laparoscopic and robotic surgery, in children

- acid-base physiology during, 461
- advantages in postoperative pain control after, 459
- approach to, 465, 465*b*
    - retroperitoneal, 465
    - transperitoneal, 465
    - vesicoscopic, 465
- cardiovascular changes during, 460
- comparative effectiveness of access technique for, 465
- equipment and instrumentation for, 465–467, 468*b*
    - clips, 467
    - hemostatic devices, 466
    - laparoscopic ports, 465–466
    - robotic-assisted surgery, 467
    - single-site surgery, 466
    - staplers, 466
    - suture assistance, 467
- intracranial pressure during, 461
- learning curves for, 460
- minimally invasive surgery, 458–460
- open access for, 464, 464*f*
- pneumoperitoneum during
    - physiology of, 460–461, 462*b*
    - stress response to, 461
- principles of, 458–472

  - pulmonary changes during, 460–461
  - renal physiology during, 461
  - Veress needle access for, 463, 464*f*
  - visual obturator access for, 464–465
- Laparoscopic calicovesicostomy, for ureteropelvic junction obstruction, 1960
- Laparoscopic carts, 205, 205.e1*f*
- Laparoscopic colposuspension, 2759
- Laparoscopic dismembered tubularized flap pyeloplasty, for ureteropelvic junction obstruction, 1960
- Laparoscopic heminephrectomy, 2299
- Laparoscopic hysterectomy, ureteral injuries after, 1993
- Laparoscopic ILND, for penile cancer, 1761
- Laparoscopic kidney surgery, 2279–2308, 2308*b*
  - ablative techniques, 2304–2305, 2318
  - biopsy for medical renal disease, 2292, 2292*f*
  - calyceal diverticulectomy, 2294
  - complications of, 2306–2308, 2307*f*
  - laparoendoscopic single-site surgery
    - clinical experience of, 2305–2306, 2305*f*
    - robotic, 2306
    - surgical approaches and access for, 2284–2285, 2285*f*, 2286*t*
  - nephrolysis, 2294, 2294*f*
  - nephropexy, 2292–2294, 2293*f*
    - procedure for, 2293*f*
    - results of, 2293–2294
  - partial nephrectomy, Laparoscopic partial nephrectomy
  - patient evaluation and preparation for, 2279
  - radical nephrectomy, Laparoscopic radical nephrectomy
  - for renal cystic disease, 2291–2292, 2291*f*
    - procedure for, 2291, 2291*f*
    - results of, 2291–2292
  - simple nephrectomy, 2285–2291
    - dissection of ureter, 2287, 2287*f*
    - identification of renal hilum, 2287–2288, 2288*f*
    - organ entrapment and extraction, 2289, 2289*f*–2290*f*

- postoperative management for, 2289
- reflection of colon, 2285–2286, 2287*f*
- results of, 2291
- securing of renal blood vessels, 2288, 2288*f*
- upper pole dissection, 2288, 2288*f*

surgical approaches and access for, 2279–2285

- hand-assisted laparoscopy, 2281–2282, 2283*f*
- laparoendoscopic single-site surgery and natural orifice transluminal endoscopic surgery, 2284–2285, 2285*f*, 2286*t*
- retroperitoneal, 2279–2281, 2282*f*
- robotic-assisted laparoscopy, 2282–2284, 2284*f*–2285*f*
- transperitoneal, 2279, 2280*f*–2281*f*

Laparoscopic live-donor nephrectomy, 270

Laparoscopic partial nephrectomy (LPN), 2298–2304

indications for, 2298–2300, 2299*f*

- central and hilar tumors, 2299
- clinical stage T1b and greater tumors, 2299
- laparoscopic heminephrectomy, 2299
- multiple tumor management, 2300
- repeat, 2300
- tumors in solitary kidneys, 2299–2300

positive surgical margins in, 2304

procedure for, 2300–2304

- collecting system repair, 2302, 2303*f*
- hemostasis, 2301–2302, 2302*f*
- renal hypothermia, 2302
- retroperitoneal approach, 2300
- robotic-assisted, 2300
- transperitoneal approach, 2300
- tumor localization and excision, 2300–2301, 2301*f*
- warm ischemia and hilar control, 2303–2304

results of, 2304

Laparoscopic Prostatectomy Robot Open (LAPPRO) study, 3581

Laparoscopic pyelolithotomy, for pediatric kidney stone disease, 868–870

Laparoscopic pyeloplasty

technique of, 832–834, 833*f*

for ureteropelvic junction obstruction

- anterior extraperitoneal approach to, 1956
- in children, 830–834, 833*f*–834*f*
- with concomitant pyelolithotomy, 1958–1960
- dismembered tubularized flap for, 1960

    - indications and contraindications for, 1955
    - results of, 1957–1958, 1959*t*
  - retroperitoneal approach to, 1956
  - robotic-assisted, 1956, 1957*f*
  - single-site surgery approach, 1956–1957
  - techniques for, 1955–1957
  - transmesenteric modification of transperitoneal approach to, 1956
  - transperitoneal approach to, 1955–1956, 1955*f*
  - vascular transposition for, 1956

Laparoscopic radical nephrectomy (LRN), 2294–2298
- hand-assisted, 2296–2297, 2296*f*
- retroperitoneal approach to, 2295–2296
- special considerations for, 2297–2298
  - cytoreductive nephrectomy, 2298
  - en bloc hilar vessel stapling, 2297
  - large tumors, 2297
  - local recurrence, 2298, 2298*f*
  - lymphadenectomy, 2297–2298
  - port-site recurrence, 2297
  - renal vein and caval tumor thrombus, 2298
  - specimen extraction, 2297
  - surgical salvage after failed ablative therapies, 2298
  - tumor seeding, 2297
- transperitoneal approach to, 2294–2295, 2295*f*

Laparoscopic radical nephroureterectomy, for UTUC, 2202–2205
- indications of, 2202
- results of, 2205
- robot-assisted, 2205, 2205*f*
- transperitoneal laparoscopic nephroureterectomy, 2203–2204, 2203*f*–2204*f*

Laparoscopic radical prostatectomy (LRP)
- abdominal access in, 3570, 3571*f*
- anesthesia for, 3568–3570
- apical dissection, 3576–3577, 3577*f*
- bladder neck in, identification and transection of, 3573, 3573*f*
- bladder neck reconstruction, 3577
- blood loss/transfusion with, 3580
- bowel preparation for, 3567
- contraindications for, 3566–3567

deep dorsal venous complex litigation in, 3572–3573, 3573*f*

evolution of, 3566

extraperitoneal approach to, 3570–3571, 3571*f*

  transperitoneal approach *versus*, 3571

hospital stay with, 3581

indications for, 3566–3567

informed consent for, 3567–3568

instrumentation for, 3567, 3568*b*, 3570*b*

insufflation in, 3570, 3571*f*

intraoperative inspection of prostate, 3577

neurovascular bundle preservation in, 3575–3576, 3575*f*–3576*f*

operating room personnel for, 3568, 3569*f*

outcomes with, functional, 3581–3583

pain management, 3578–3579

patient positioning for, 3568, 3569*f*

patient selection for, 3566–3567, 3570*b*

postoperative complications of, 3580–3581

postoperative management for, 3578–3580

preoperative preparation for, 3567–3570, 3570*b*

prostate and rectum plane development in, 3574–3575, 3574*f*

prostatic pedicle control in, 3575, 3575*f*

return to normal activity, 3579

robotic-assisted *versus*, 3570

role of continence physiotherapy in, 3579

seminal vesicle dissection in, 3573–3574, 3574*f*

space of Retzius development for, 3571–3572, 3572*f*

specimens

  delivery in, 3578

  entrapment in, 3577

technique of, 3578*b*

transperitoneal approach to, 3570

  extraperitoneal approach *versus*, 3571

trocar placement in, 3570, 3571*f*

vasa deferentia dissection in, 3573–3574, 3574*f*

vesicourethral anastomosis, 3577–3578, 3578*f*

  posterior support of, 3577, 3578*f*

Laparoscopic removal, of kidney down to mid-ureter, 2203–2204, 2203*f*–2204*f*

Laparoscopic retroperitoneal lymph node dissection, for testicular tumors, 1734–1741, 1741*b*

- bilateral, 1738
- complications of, 1739–1740, 1739*t*
- duplication of, 1735
- postoperative care after, 1738–1739
- prospective nerve-sparing techniques for, 1739
- rationale and evolution of, 1734
- results and current status of, 1740–1741, 1740*t*
- staging, 1734–1735
- surgical technique for, 1735–1738
    - approach for, 1735
    - left-sided dissection, 1736–1738
    - patient positioning and port placement for, 1735–1736, 1735*f*–1736*f*
    - right-sided dissection, 1736, 1736*f*

Laparoscopic retropubic suspension surgery, 2768–2769, 2769*b*

Laparoscopic sacrocolpopexy, for apical pelvic organ prolapse repair, 2802*f*–2803*f*, 2803–2804

Laparoscopic surgery, 145

- access technology for hand-assist devices, 212, 212*f*
    - trocars, 211, 211*f*
- common urologic procedures, antimicrobial prophylaxis for, 1199–1200
- complications and troubleshooting, 223–231, 232*b*
    - anesthesia-related, 228
    - early postoperative, 230–231
    - equipment-related, 223–224
    - exit-related, 230
    - late postoperative, 231
    - during learning curve, 223
    - pneumoperitoneum-related, 224
    - of seminal vesicle surgery, 1864
- equipment placement for, 205–207, 205.e1*f*
- instrumentation used in
    - for da Vinci Robotic System, 218, 218*f*
    - for grasping and blunt dissection, 218
    - for incising and hemostasis, 214–215

  - for LESS, 218
  - for morcellation, 218
  - for NOTES, 218
  - for port site closure, 219
  - for retraction, 218
  - for specimen entrapment, 217–218, 217*f*
  - for stapling and clipping, 216–217, 216*f*
  - surgical pharmaceuticals, 215
  - for suturing and tissue anastomosis, 215–216, 215.e3*f*
  - for visualization, 213, 213.e1*f*
- operative team placement for
  - retroperitoneal upper abdominal procedures, 207, 207*f*
  - transperitoneal upper abdominal procedures, 206, 206*f*
- for partial nephrectomy, 811–813, 814*f*
- physiologic considerations in, 223*b*
  - hemodynamic effects related to approach and patient position, 222
  - hormonal and metabolic effects during surgery, 222–223
  - immunologic effects, 223
  - insufflant choice, 220
  - pneumoperitoneum pressure choice, 220
- preoperative preparation for, 204*b*
  - blood products, 204
  - bowel preparation, 204
  - operating room setup, 205, 205*b*
  - patient positioning, 205*f*
  - patient selection and contraindications, 203–204
  - prophylaxis, 205
- procedure for, 219*b*
  - abdomen exit, 218–219
  - achieving extraperitoneal access and developing extraperitoneal space, 210–211
  - achieving retroperitoneal access and developing retroperitoneal space, 209–210
  - achieving transperitoneal access and establishing pneumoperitoneum, 209
  - hand-assist device placement, 212
  - initial incision, 207
  - port removal and fascial closure, 218–219
  - port site closure, 219
  - skin closure, 219
  - trocar placement, 212–213
- training and practicing for, 231–233
  - equipment for, 232
  - formal programs for, 233
- ureteral injuries with, 1993

Laparoscopic training boxes, 232, 232*f*, 232.e1*f*

Laparoscopic ureterocalicostomy, for ureteropelvic junction obstruction, 1958

Laparoscopic ureterolysis, for retroperitoneal fibrosis, 1980

Laparoscopic ureteroneocystostomy, for ureteral stricture disease, 1972, 1972*f*

- with Boari flap, 1973
- with psoas hitch, 1972–1973

Laparoscopic ureteroureterostomy, for ureteral stricture disease, 1972

Lapides classification, of voiding dysfunction, 2522–2523, 2522*b*

Lapides Diagnostic Foley catheter, 154

Lapra-Ty clips, 215, 215*f*

Laser ablation, for penile cancer, 1752

Laser cystolithotripsy, 244.e4

Laser instrumentation

- for laparoscopic and robotic surgery, 214
- for tissue dissection and cauterization
  - CO2 laser, 241
  - delivery systems for, 238–241
  - diode laser, 240
  - Ho:YAG laser, 240
  - KTP laser, 239
  - LBO laser, 239–240
  - light-tissue interaction, 238–239
  - Nd:YAG laser, 239
  - pulsed and continuous wave lasers, 238
  - soft tissue applications, 238–241
  - Thu:YAG laser, 240–241

Laser lithotripsy, 2110–2111

- Ho:YAG and Er:YAG,basic physics of, 244

Laser treatments, for benign prostatic hyperplasia, 3435–3438, 3443*b*

- safety for, 3435–3436

Lasers, for urethral stricture disease, 1818–1828

Late-night salivary cortisol, in evaluation of adrenal masses, 2400

Late relapse RPLND, 1728*t*, 1729

Latent pacemakers, ureteral, 1882

Latent stress incontinence, 2563

Latent syphilis, 1257–1258

Lateral cutaneous nerve, 136*f*

Lateral decubitus position, 146

Lateral defect, in pelvic floor support mechanism, 2597–2598

Lateral fusion abnormalities, 985–986, 985*f*

- inguinal hernias, 988
- rhabdomyosarcoma, 986, 986*f*
- uterus and cervix duplication, 985–986, 986*f*

Lateral plexuses, 2452

Lateral resolution, of ultrasonography images, 70, 70*f*

Lax suspensory ligament, penile implants and, 1596, 1596*f*

Laxative abuse, ammonium acid urate stones from, 2032

LDH, Lactate dehydrogenase

Le Duc technique, in urinary diversion, 3189, 3189*f*

Leadbetter and Clarke technique, in urinary diversion, 3185, 3185*f*, 3186*t*

Lead-time bias, 102, 103*f*

Leak point pressures, urodynamic studies of, 2561–2563

- abdominal, 2561, 2562*f*
- detrusor, 2561*f*, 2562

Left adrenalectomy

- laparoscopic, 2414–2415, 2415*f*–2416*f*, 2417–2418
- open, 2412–2413, 2412*f*–2413*f*

Leiomyoma

- bladder, 3038, 3039*f*
- renal, 2131, 2131*f*, 2131*b*
- of urethra, 1776

Leiomyosarcoma
    of kidney, 2181
    retroperitoneal tumors and, 2231, 2231*f*
Length-time bias, 103, 103*f*
Lentigo simplex, 1304, 1305*f*
Lenvatinib, for RCC, 2337–2338
Leptin, 1392
    in prostate cancer, 3463
Lesion
    measurable, 104
    target, 104–105
LESS, Laparoendoscopic single-site surgery
Leucine aminopeptidase, in prostatic secretions, 3302
Leukemia
    of kidney, 2181–2183, 2182*t*
    testicular metastases of, 1124–1125, 1709
Leukocyte esterase, 437
    in urine, 20–21, 20*f*
Leukoplakia, of bladder, 3082
Levator ani muscle, 2430–2432, 2432*f*
    complex, 2597
Levator plate, 2430–2432, 2432*f*
Leydig cell aplasia, 1011
Leydig cell tumors, 1124, 1124*f*, 1707–1708
Leydig cells, 305, 1370
    testis cytoarchitecture and, 1394
    testosterone production by, 3280–3281
    testosterone synthesis in, 1394
        control of, 1395–1396
LGPIN, Low-grade prostatic intraepithelial neoplasia

LGV, Lymphogranuloma venereum

LH, Luteinizing hormone

Libido, loss of

- hormonal therapy and, 3681
- patient history of, 6

Lichen nitidus (LN), as papulosquamous disorder, 1281

Lichen planus (LP), as papulosquamous disorder, 1280–1281, 1281*f*

Lichen sclerosus (LS)

- male, 1742.e1–1742.e2
  - reconstructive surgery for, 1808–1810, 1809*f*
- as papulosquamous disorder, 1281–1282, 1282*f*

Lichen sclerosus et atrophicus, in male, circumcision and, 875, 876*f*

Lidocaine, for cystourethroscopy, 189–190

Lifestyle modifications

- for ED, 1529
- for urinary incontinence, 2732–2734
  - bowel function, 2734
  - caffeine reduction, 2733
  - dietary irritants, 2733–2734
  - fluid management, 2732–2733
  - levels of evidence and recommendations, 2722.e1*b*
  - obesity and weight reduction, 2734

Ligaments, of female pelvis, 2428–2430, 2430*f*–2432*f*

Ligand-binding domain, of androgen receptors, 3290–3291

LigaSure device, 466

LigaSure vessel-sealing system, 214

Ligation, of ureter, 2000–2001, 2001*f*

Light-tissue interaction, 238–239, 239*f*

Likelihood ratio (LR), 3479–3480

Likert scales, 108–109

Linea alba, 2444, 2447*f*–2448*f*

Linear IgA bullous dermatosis (LABD), 1285, 1285*f*

Linear-quadratic formula, 3593

Lipomeningocele, 639–641, 642*b*

- pathogenesis of, 639–641, 641*f*
- presentation of, 639, 639*t*, 640*f*–641*f*
- recommendations for, 641, 642*f*

Lipopolysaccharide (LPS), 1138

Liposarcoma

- of kidney, 2181
- retroperitoneal tumors and, 2229–2230, 2230*f*
- of testicular adnexa, 1709

Lipotoxicity, 2028–2029

Lithium triborate (LBO) laser, 239–240

LithoClast Ultra, 244–245

Lithotomy position, 146

Lithotripsy

- dual-modality, 244–246, 245*f*
- holmium:YAG and Erbium: YAG laser, 244
- intracorporeal, 2109–2113
  - ballistic lithotripsy, 2111–2112, 2112*f*
  - combination ballistic and ultrasonic devices in, 2112–2113
  - electrohydraulic lithotripsy, 2109–2110, 2110*f*
  - laser lithotripsy, 2110–2111
  - ultrasonic lithotripsy, 2112, 2112*f*
- pneumatic, 243, 243*b*
  - basic physics of, 243
  - tissue effects, 243
- ultrasonic, 243, 244*b*
  - basic physics of, 243
  - tissue effects of, 243

Live animal models, laparoscopic training with, 232

Liver cirrhosis, benign prostatic hyperplasia and, 3322

Liver injury, during radical nephrectomy, 2261

LN, Lichen nitidus

Localization, in UTI diagnosis, 1142.e1*t*, 1143

Localized prostate cancer

- active management strategies for, 3522–3536
- androgen deprivation therapy for, 3683–3684
- host evaluation of, 3522–3529
  - bladder function, 3524
  - bowel function and other conditions affecting treatment choice, 3525
  - longevity assessment and competing risks for mortality, 3522–3524, 3523*f*
  - patient preference and biases, 3525
  - sexual function, 3524–3525
- patient counseling of, 3532–3535, 3532*f*
  - observation *versus* active treatment, 3532–3534, 3533*t*–3534*t*
  - partial gland *versus* whole gland treatment, 3534–3535
  - surgery *versus* radiation *versus* whole-gland ablation, 3535
  - treatment delivery type, 3535
- risk assessment of, 3525–3529
  - Epstein criteria, 3526–3527
  - genomic tests for risk stratification, 3529
  - Gleason scoring and grade groups, 3526
  - low, intermediate, and high risk definition, 3525–3526, 3526*t*
  - nomograms for prediction of stage, 3527–3528
  - prostate magnetic resonance imaging in, 3528–3529
  - staging, 3527
  - stratification nomograms, 3528, 3528*f*
  - tools for risk stratification, 3525
- treatment selection of, 3529–3532
  - comparative population-based studies, 3529–3531, 3530*f*
  - functional outcomes, 3531–3532
  - oncologic outcomes, 3529–3532

Locally advanced prostate cancer

- androgen deprivation for, 3655–3656, 3656*b*
  - intermittent, 3656
  - quality of life, 3656
- clinical trials for, 3657, 3657*t*–3658*t*
- contemporary risk assessment for, 3640–3641, 3640*b*
- definition of, 3640–3643
- focal ablative therapy for, 3655
  - cryoablation, 3655

        - high-intensity focused ultrasound, 3655
    - imaging modalities for, 3641–3642, 3641*f*–3642*f*
    - immediate *versus* delayed ADT in, 3684
    - incidence trends of, 3643–3644, 3643*b*
    - management of delayed sequelae, 3657
    - natural history of, 3644–3645, 3645*f*, 3645*t*
    - novel markers for, 3642–3643, 3642*t*
    - radiation therapy for, 3652–3655, 3653*t*
        - adjuvant androgen deprivation with, 3653–3654
        - chemotherapy with, 3654–3655
        - neoadjuvant androgen deprivation with, 3652–3653, 3654*b*
    - radical prostatectomy for, 3645–3652, 3648*b*
        - adjuvant androgen deprivation with, 3652
        - adjuvant radiation therapy, 3650–3652, 3651*t*, 3652*b*
        - for clinical stage T3, 3645–3652, 3646*t*
        - neoadjuvant androgen deprivation, 3648–3649, 3648*t*–3649*t*
        - neoadjuvant chemotherapy and chemotherapy-hormonal therapy, 3649–3650, 3650*t*
        - outcomes of, 3646–3647, 3647*f*
        - pathologic findings in, 3643, 3643*t*
    - treatment, 3640–3658
        - trends of, 3643–3644, 3643*b*, 3644*f*

LOCM, Low-osmolality contrast media

Loop diuretics, in stone formation, 2033
    - surgical management of, 2077.e3

Loop end ileostomy, 3183, 3183*f*

Loopography, 38, 39*f*

Lord plication, 1845, 1847*f*

Lost stone, in ureteroscopic stone management, 2109

Low-dose continuous prophylaxis, for recurrent UTIs, 1162–1163

Low-dose rate brachytherapy, 1765–1767
    - for prostate cancer, 3596, 3597*f*

Lower extremity compartment syndrome, 262, 263*f*

Lower motor neuron (LMN) lesion, voiding dysfunction after, 2522, 2523*b*

Lower pole renal calculi, surgical management of, 2081–2084, 2081*f*, 2082*t*, 2083*f*

Lower tract endoscopy
- antimicrobial prophylaxis for, 1198
- cystoscopy, antimicrobial prophylaxis for, 1198

Lower tract urinary complications, 267–269
- bladder injuries, 267
- urine leaks, after radical prostatectomy, 267–269, 268*f*–269*f*

Lower urinary system, aging and, 2906

Lower urinary tract, assessment of, 503–505
- cystographic imaging, 503–504, 504*f*
- cystoscopy and the positioning of the instillation of contrast cystogram, 504–505

Lower urinary tract (LUT)
- afferent pathways in, 2481–2486, 2487*b*
  - cannabinoids, 2486
  - functional properties of, 2482–2483, 2483*f*
  - modulators of, 2483–2484
  - nitric oxide in, 2484, 2484*f*
  - pelvic organ interactions with, 2486, 2486*f*
  - properties of, 2481
  - purinergic signaling, 2484–2485, 2485*f*
  - spinal cord pathways of, 2481–2482, 2481*t*, 2482*f*
  - transient receptor potential cation channels, 2485
- anatomy of, 2461, 2462*f*
  - bladder, Bladder, anatomy of
  - urethra, Urethra, anatomy of
- efferent pathways of, 2487–2493, 2487*f*, 2489*f*–2492*f*, 2490*b*, 2491*t*
- electrical stimulation of, techniques of, 2747–2754
  - dorsal genital nerve, 2752
  - intravesical, 2747–2748
  - percutaneous tibial nerve, 2748–2751, 2749*f*
  - pudendal nerve, 2751–2752
  - sacral nerve, 2752–2754
  - transcutaneous, 2748
- function of, 2679
  - mechanisms underlying two phases of, 2514
  - normal, 2514–2516
  - sensory aspects of, 2516
  - two-phase concept of, 2514–2516

- neural control of, 2480–2497, 2593
  - parasympathetic pathways, 2480, 2480*f*
  - peripheral nervous system, 2480–2497, 2480*f*
  - somatic pathways, 2480*f*–2481*f*, 2481
  - supraspinal pathways, 2493–2497, 2495*f*–2496*f*
  - sympathetic pathways, 2480, 2480*f*
- overview of, 2580
- pharmacology of, 2497–2503
  - adrenergic mechanisms, 2500–2501, 2501*f*, 2501*b*
  - afferent neuropeptides, 2501–2502, 2501*t*
  - muscarinic mechanisms, 2497–2500, 2499*t*, 2500*b*
  - sex steroids, 2502–2503
  - urethral tone in women, 2501
- posterior urethral valves and, 603–604, 605*f*–606*f*
- supraspinal pathways in, 2493–2497
  - additional regions in, 2496–2497
  - bladder modulatory mechanisms, 2493–2494, 2495*f*
  - brain-bladder control model, 2497, 2498*f*
  - central circuitry regulation of, 2494–2495
  - cerebral control of voiding, 2496
  - human brain imaging studies in, 2496, 2496*f*
  - modulators in, 2495–2496
  - neurotransmitters in, 2495–2496
  - pontine micturition center, 2493–2494, 2495*f*
- transabdominal pelvic ultrasonography of, 80–81, 80*f*, 82*f*
- trauma and, 2527

Lower urinary tract calculi, 2114–2120, 2120*b*
- bladder calculi
  - after renal transplantation, 2117
  - bladder outlet obstruction with bladder lithiasis, 2115–2116
  - etiopathogenesis of, 2114–2115
  - in patients with spinal cord injury, 2116–2117
  - in urinary diversions and augmented bladder, 2116
- bladder stones
  - endourologic approach to, 2115, 2116*f*
  - management of, 2115
  - open surgery for, 2115
  - presentation of, 2115
- history of, 2114
- in special situations, 2115–2117
- unusual, 2118–2120

- preputial calculi, 2118–2119
- prostatic calculi, 2119–2120, 2119*f*

urethral calculi, 2117–2120

- clinical presentation and evaluation of, 2117–2118
- pathogenesis and composition of, 2117
- primary, 2117
- treatment of, 2118, 2119*f*

Lower urinary tract catheterization, 152–159, 159*b*

complications of, 158–159

- erosion, 159
- iatrogenic trauma, 159
- infection, 158–159, 159*b*
- malignancy, 159
- stricture, 159

contraindications of, 152

diagnostic, 152

difficulty with, 156–158, 158*f*

- abnormal anatomy, 157–158
- artificial urinary sphincter, 158
- bladder neck reconstruction, 158
- bladder replacement, 157
- continent urinary reservoir, 157–158
- obesity, 157
- posterior urethral valves, 157
- prostatic obstruction, 156–157
- reconstruction of, 157
- urethral stricture, 157
- urethral trauma, 157
- urinary conduit, 158

indications for, 152, 155*b*

technique of, 152–155

therapeutic, 152

types of, 153–155

Lower urinary tract complications, 1939–1940

benign prostatic hyperplasia, 1939

transplant, small bladder after, 1939

urine incontinence, 1939–1940

voiding dysfunction, 1939

Lower urinary tract dysfunction (LUTD), 2503–2512, Urinary incontinence,

Voiding dysfunction

- aging and, 2509–2510, 2510*b*
- bladder outlet obstruction, 2505–2506, 2506*b*
- bladder pain syndrome and interstitial cystitis, 2507–2509, 2509*b*
- bowel dysfunction, 654
- bowel function, 473–474
- in children, 473–488
- clinical aids, 474–475
- clinical evaluation of, 473–479
- detrusor underactivity and, 2651–2652
- evaluation strategies for specific, 486–488
    - anorectal malformations, 487
    - cerebral palsy, 487
    - non-neurogenic, 486–487
    - pelvic tumors, 487
    - posterior urethral valves, 487
    - sacral agenesis, 487
    - spinal cord injury, 487
    - spinal dysraphism, 487
    - transverse myelitis, 488
- and female sexual dysfunction, 1654–1655, 1657*b*
    - clinical signs and investigations for, 1655
    - epidemiology of, 1654
    - etiology and classification of, 1654–1655
    - links and treatments, 1655–1657
    - self-image/body image connected to, 1657
    - sexual lifestyle and communication and, 1654–1655, 1654*t*
- future research for, 2512–2513
- genitourinary malignancies, 2920
- history of, 473–477, 479*b*
- idiopathic detrusor overactivity, 2504
- infections, 475–476
- laboratory testing, 479–480
    - additional, 479–480
    - urinalysis, 479, 480*b*
    - urine culture, 479
- neurologic diseases and
    - acute disseminated encephalomyelitis, 2625–2626
    - AIDS, 2625
    - hereditary spastic paraplegia, 2624–2625

    - Lyme disease, 2624
    - reflex sympathetic dystrophy, 2626
    - schistosomal myelopathy, 2626
    - syringomyelia, 2626
    - systemic lupus erythematosus, 2626
    - tropical spastic paraparesis, 2625
    - tuberculosis, 2626–2627
- neurologic function, 476
- neuromodulation, 2510–2512
    - to inhibit OAB, rationale for, 2511, 2511*f*
    - inhibitory and excitatory stimulation frequencies, 2511
    - onabotulinumtoxinA, 2512
    - pudendal nerve stimulation, 2511
    - sacral, mechanism of action, 2510
    - somatic afferents activation, in foot, 2511–2512
    - for voiding, rationale for, 2510, 2510*f*
- nocturia, 2505
- overactive bladder, 2504
- pathophysiology and classification of, 2514–2524
- pediatric, 652
    - clinical significance of, 652
    - comorbidities with, 653–654, 655*b*
    - epidemiology of, 652, 655*b*
    - giggle incontinence, 658–660
    - pollakiuria, 660
    - quality-of-life and, 652–653, 655*b*
    - self-esteem and, 652–653
    - terminology of, 654–655
    - underactive bladder, 660
    - urinary incontinence and, 655–660, 660*b*
    - vaginal reflux, 660
- physical examination, 477–479, 479*b*
    - abdominal, 478
    - of female, 479
    - genital, 478–479
    - of male, 479
    - neurologic examination, 477–478, 478*f*, 478*t*
    - vital signs, 477
- psychological associations with, 654
- signs and symptoms of, 2580
- spinal cord injury and neurogenic detrusor overactivity, 2504–2505
- storage symptoms of, 473

- stress urinary incontinence, 2504
- terminology of, 2580–2581, 2581*t*
- urinary tract infections and, 653
- urodynamic evaluation, 480–486, 486*b*
  - formal, 483–486
  - frequency, 486
  - interpretation of studies, 485–486
  - noninvasive testing, 480–483, 483*b*
  - patch electromyography, 483
  - in pediatric setting, 485
  - pelvic ultrasonography, 482–483, 482*f*
  - unique considerations in pediatric, 484–485
  - uroflowmetry, 480–481
  - video, 485
- validated questionnaires, 476–477
- vesicoureteral reflux and, 653–654
- voiding symptoms of, 473, 474*f*

Lower urinary tract obstruction, 375–377, 376*f*–377*f*, 384
- congenital megacystis, 376–377
- posterior urethral valve, 375, 377*f*
- prune belly syndrome/megalourethra, 375
- recommendations for, 377, 377*f*
- urethral stenosis/atresia, 376

Lower urinary tract symptoms (LUTS), 109
- with acute urinary retention, 3337–3338, 3338*t*
- aging and, 2643
- benign prostatic hyperplasia in, 3305, 3306*f*
- bias associated with trials on medical treatment of, 3355
  - adverse events, 3355
  - sample size, 3355
- classification of, 2540*t*
- clinical end points of, 3354
- clinical indications for, 3354
- in detrusor underactivity, 2650, 2651*f*
- drugs used in treatment of, 2682*t*, 2708*b*
- management of, 3351–3371, 3353*b*
  - conservative, 3351, 3352*f*–3353*f*
  - lifestyle and dietary modifications, 3351–3353

            - watchful waiting, 3351
        - medical therapy of, 3353–3354
            - impact and trends of, 3354
        - metabolic syndrome and, 1421
        - outcome measures for, 3354–3355
        - with Parkinson disease, 2605
        - patient history of, 3–6, 4*t*–5*t*
        - practical flowchart for evaluation of patients with, 3349–3351, 3349*f*–3350*f*
        - prevalence of, 2650, 2681
        - prognosis of patients receiving medical treatment for, 3399–3400, 3399*b*
        - questionnaires for, 2532*t*–2533*t*
        - related to overactive bladder, 2638–2639
        - result of, 2681
        - review of literature on currently approved α_1-blockers for treatment of, 3357–3367
            - alfuzosin, 3361–3363, 3362*t*
            - doxazosin, 3359–3361, 3360*t*–3361*t*
            - naftopidil, 3365–3367, 3367*t*
            - silodosin, 3365, 3365*f*, 3366*t*
            - tamsulosin, 3363–3365, 3363*f*, 3364*t*
            - terazosin, 3357–3359, 3357*t*–3358*t*, 3359*f*
        - symptoms of, 3354
        - terminology of, 2580–2581, 2581*t*
        - urodynamic observations of, 2580
        - urodynamic studies of, 2550–2579
            - evidence-based review of, 2574–2578
        - videourodynamics for, 2570, 2571*f*
- Low-grade prostatic intraepithelial neoplasia (LGPIN), 3506
- Low-osmolality contrast media (LOCM), 30
- Lowsley retractor, 156
- LP, Lichen planus
- LPN, Laparoscopic partial nephrectomy
- LPS, Lipopolysaccharide
- LR, Likelihood ratio
- LRN, Laparoscopic radical nephrectomy

LRP, Laparoscopic radical prostatectomy

LS, Lichen sclerosus

L-shaped kidney, 728*f*, 729

Lumbar notch, 169, 170*f*

Lumbar vein, 1869–1870

Lumbodorsal fascia, in retroperitoneum, 1665–1666, 1666*f*, 1666.e1*f*

Lumbosacral plexus, 1675–1676, 1675.e1*f*, 1677*f*–1678*f*, 1679*t*, 2447*f*–2448*f*, 2453, 2453*f*, 2453*t*

Lumbosacral trunk, 2453*t*

Luminal epithelial cells, 3278, 3278*f*

Lungs

- development of, amniotic fluid and, 716–717
- in prune-belly syndrome, 586–587

LUT, Lower urinary tract

LUTD, Lower urinary tract dysfunction

Luteinizing hormone (LH), 1390, 1391*f*, 1395–1396, 1429, 1437

Luteinizing hormone receptor abnormality, 1011

Luteinizing hormone-releasing hormone agonists, 3676

Luteinizing hormone-releasing hormone antagonists, 3676–3677

LUTS, Lower urinary tract symptoms

LVI, Lymphovascular invasion

17,20-Lyase deficiency, 1012

Lycopene, for benign prostatic hyperplasia, 3398–3399

Lyme disease, lower urinary tract dysfunction and, 2624

Lymph node metastases, 3511

Lymph node-positive, treatment of, 2222–2224, 2223*f*

Lymph nodes

- counts, RPLND outcomes and, 1729
- iliac, 2433
- number of identified, 3116–3117, 3116*f*

Lymphadenectomy
- common iliac, 3152, 3153*f*–3154*f*
- external iliac, 3148–3149, 3151*f*
- hypogastric, 3149–3152, 3153*f*
- inguinal
  - antibiotics for, 1801
  - anticoagulation for, 1801
  - bed rest in, 1801
  - complications of, 1801–1802
  - compressive dressings and stockings for, 1801
  - dietary considerations of, 1801
  - drainage, 1801
  - postoperative care after, 1801
- laparoscopic radical nephrectomy with, 2297–2298
- obturator, 3149, 3152*f*
- patient positioning and port placement for, 1736, 1737*f*–1738*f*
- presacral, 3152, 3154*f*
- for RCC, 2177, 2177*f*, 2260, 2260*f*, 2260.e1*f*
- in retropubic radical prostatectomy, 3551–3552, 3551*f*
- for UTUC, 2205–2207, 2206*f*

Lymphangiomas, renal, 2132

Lymphatic complications, after RPLND, 2244

Lymphatic drainage
- of bladder, 2456
- of kidneys, 1870–1871, 1870.e1*f*
- of pelvis
  - female, 2433, 2434*f*
  - male, 2452–2453
- of retroperitoneum, 1674, 1675*f*
- of ureters, 1870–1871, 1870.e1*f*
- of uterus, 2436–2437
- of vulva, 2436

Lymphatic spread

of infection, 1131.e1

of UTUC, 2193–2194

Lymphedema

as filariasis clinical manifestation, 1329

genital, 884–885

Lymphocele, 280–281, 280*t*, 281*f*, 1938–1939
  after RPLND, 1731, 2244
  diagnosis of, 1939
  laparoscopic and robotic surgery causing, 231.e1
  treatment of, 1939
Lymphogranuloma venereum (LGV), 1255*t*, 1260–1261, 1260*f*
Lymphoma
  of kidney, 2181–2183, 2182*t*
  prostatic, 3513
  retroperitoneal tumors and, 2236, 2237*f*
  testicular metastases of, 1124–1125, 1709
Lymphovascular invasion (LVI), UTUC with, 2197

M

M inverted V glansplasty (MIV), 920, 922*f*
M region, 2493
MACE, Malone antegrade continence enema
Machado-Joseph (MJ) disease, lower urinary tract dysfunction and, 2632
Macrohematuria, 247
Magnesium
  in calcium stone formation, 2017
  in crystal formation, 2014
  metabolism of, 2016
  transport of, urinary tract obstruction and, 794
Magnetic resonance angiography (MRA), for renovascular hypertension screening, 1917–1918, 1918*b*
Magnetic resonance fusion-guided prostate biopsy, 66–67
Magnetic resonance imaging (MRI), 51–67, 61*t*, 67*b*, 390, 412–415
  of acute scrotum, 414
  adrenal, 51–54

of adrenal glands, 2352
for adrenal mass evaluation, 2395–2396
for biochemical recurrence after radical prostatectomy, 3662
of bladder RMS, 1113
of bladder/urethra, 414
cranial, 1444–1445, 1445*f*
of cyst/masses/stones, 413–414
for differences of sex development, 415
and ED, 1528
of epididymis, 1375–1376
of female pelvis, 2440–2442, 2440*f*–2442*f*
fundamentals of, 412–413
for genitourinary tuberculosis diagnosis, 1313
for infection, 414
for inguinal node dissection, 1792
of IVC tumor thrombus, 2175
of kidney/ureter, 413–414, 1866.e2*f*
    hydronephrosis, 413
for locally advanced prostate cancer, 3641, 3641*f*
of male pelvis, 2458–2460, 2459*f*–2460*f*
with nanotechnology, for inguinal node dissection, 1792
for neuroblastoma, 1089, 1089*f*–1090*f*
for other congenital malformations, 414
for pelvic organ prolapse, 2589*f*, 2597
of penis, 1386, 1388*f*
of posterior urethral valves, 607, 608*f*
in pregnant, 284
of prostate, 61–63, 1380–1381, 1381*f*
    for localized prostate cancer, 3527–3529
for prostate cancer, 3542–3543, 3543*b*
protocol of, 412–413
for radiation therapy for prostate cancer, 3590–3591
renal, 390
of renal calculi, pretreatment assessment, 2071
for renal tumor ablation, 2313, 2314*f*
for renal tumor evaluation, 2135, 2138*f*

  - for retroperitoneal fibrosis, 1979, 1979*f*
  - for sedation in child, 413
  - of seminal vesicles and ejaculatory ducts, 1378, 1378*f*
  - of testis, 1373–1374
  - for TGCTs, 1686
  - for undescended testis, 415
  - for ureteral anomalies, 805, 805*f*–806*f*
  - for urethral diverticula, 2983, 2985*f*
- Magnetic resonance imaging-targeted/fusion biopsy, for prostate cancer, 3622
- Magnetic resonance spectroscopic imaging (MRSI), for biochemical recurrence after radiotherapy, 3666
- Magnetic resonance spectroscopy, 64
- Magnetic resonance urography (MRU), 412–413
  - for urinary tract obstruction, 780
- MAGPI, Meatal advancement glanuloplasty
- Mainz II pouch, 3210–3211
- Mainz III, for orthoptic urinary diversion, 3246, 3248*f*
- Mainz pouch I, 3215–3219, 3218*f*–3221*f*
- Mainz repair, for classic bladder exstrophy, 545
- Major vascular reconstruction, RPLND with, 1718–1719, 1719*f*
- Malacoplakia, 1179–1181, 1180*f*
- Male, 1050–1051
  - fertility, 1051
  - penile concerns and management, 1050, 1050*f*
  - sexual function, 1050–1051
- Male apical dissection, 3155
- Male climacteric, 1392
- Male external genitalia, 871.e1*t*, 871.e2*f*
  - anomalies of, 871–886
    - acute scrotum, 893–899
    - epididymal and vasal, 903

    - hernia, 888–893
    - hydrocele, 888–893
    - penile, 871–886
    - scrotal, 886–888
    - varicocele, 899–903
    - vascular lesions of, 888
  - benign cutaneous diseases of
    - angiokeratomas of Fordyce, 1302, 1303*f*
    - ectopic sebaceous glands, 1303*f*, 1304
    - median raphe cysts, 1304
    - pearly penile papules, 1302, 1303*f*
    - sclerosing lymphangitis, 1302–1304
    - Zoon balanitis, 1302, 1303*f*
  - defect of, in bladder exstrophy, 533–534, 533*f*–534*f*
  - embryology of, 871
  - injuries of, 3048–3054, 3054*b*
  - management of abnormalities of, 871–904
  - normal, 871
  - penile reconstruction of, 3054
  - skin loss from, 3053–3054, 3053*f*–3054*f*
  - surgical repair of, 890–892
  - ultrasonography of, 871, 871.e2*f*

- Male infertility, 1428–1452
  - assisted reproduction, 1445–1452, 1445.e3, 1445.e3*t*
  - causes of, 1446–1447
  - and childhood diseases, 1432–1434
    - testicular dysgenesis hypothesis, 1433
  - and chromosomal numerical disorders, 1445–1446
  - developmental disorders and, 1449–1450
  - diagnoses and therapies for, 1445, 1452*b*
  - and ejaculatory dysfunction, 1450–1451
  - epidemiology of, 1428
  - epigenetic anomalies and, 1446
  - and extratesticular endocrine dysfunction, 1448–1449
  - and genetic syndromes, 1445–1446
  - and genetics, 1433
  - and genomic assessment, 1442–1443
  - history of, 1428–1434, 1429*t*, 1434*b*

  - and hypogonadotropic hypogonadism, 1447–1448
  - imaging of, 1443–1445, 1445*b*
    - abdominal, 1444, 1445*f*
    - cranial, 1444–1445, 1445*f*
  - and infections and inflammation, 1432
  - laboratory evaluation of, 1436–1443, 1443*b*
  - and microductal obstruction, 1447, 1447*f*
  - and pediatric surgery, 1432
  - physical examination of, 1434–1436, 1436*b*
  - and pituitary dysfunction, 1447–1448
  - and spermatogenic dysfunction, 1446
  - and steroidogenic dysfunction, 1447
  - structural chromosomal anomalies and, 1446
  - and structural sperm abnormalities, 1451–1452
  - surgical management of, 1453–1484
    - electroejaculation, 1472
    - orchiopexy in adults, 1483–1484, 1483*f*
    - sperm retrieval techniques, 1472–1476
    - surgery of epididymis, 1467–1471, 1468*f*–1469*f*, 1468*t*
    - surgical anatomy in, 1453–1454
    - testis biopsy, 1454–1456
    - transurethral resection of ejaculatory ducts, 1471–1472, 1472*f*
    - varicocelectomy, 1476–1483, 1476*f*, 1476*t*
    - vasography, 1457–1460, 1457*f*–1459*f*
    - vasovasostomy, 1460–1467, 1461*f*–1462*f*, 1463*t*
  - testis histopathology and, 1445, 1445.e1*f*–1445.e2*f*, 1445.e2*b*
  - vasography for, 1444
  - venography for, 1444

Male lichen sclerosus, 1742.e1–1742.e2

Male lumpectomy, 3616

Male menopause, 1392

Male mesh slings, 2887–2888, 2887*b*–2888*b*, 2888*f*

Male orgasm and ejaculation, disorders of, 1564–1581
  - anatomy and physiology of ejaculatory response, 1564, 1565*f*
  - delayed ejaculation, anejaculation, and anorgasmia, 1572–1579
  - painful ejaculation, 1581

    postorgasmic illness syndrome, 1581
    premature ejaculation, 1564–1572
    retrograde ejaculation, 1579
Male Overactive Bladder in Veterans (MOTIVE) study, 2727
Male pelvis
    anatomy of, 2444–2460, 2449*b*
        arterial supply, 2451–2452, 2451*t*
        bladder, 2448*f*, 2455, 2456*f*
        bony pelvis of, 2444
        innervation of, 2447*f*–2448*f*, 2453, 2453*f*, 2453*t*, 2454*b*
        lower abdominal wall, 2444–2448, 2445*f*–2448*f*
        lymphatics, 2452–2453
        musculature of, 2448–2449, 2449*f*
        pelvic fascia of, 2449, 2452*f*
        pelvic ureter, 2456, 2456*f*
        perineum, 2450*f*–2451*f*, 2451*b*
        perineum and perineal body fasciae, 2449–2450, 2450*f*–2451*f*
        rectum, 2450*f*, 2454, 2455*f*
        soft tissues of, 2448–2449, 2449*f*
        urethra, 2465, 2465*f*
        vasculature of, 2451–2452, 2451*t*
        venous supply, 2452
        viscera, 2454–2456, 2457*b*
    endoscopic anatomy of, 2456–2457, 2457*f*, 2460*b*
        CT, 2458, 2458*f*–2459*f*
        magnetic resonance imaging, 2458–2460, 2460*f*
        radiographs and fluoroscopy, 2457–2458
Male reproductive system
    pediatric tumors of, paratesticular RMS, 1126–1127, 1127*b*
    physiology of, 1390–1410
        ductus (vas) deferens, 1406–1407
        seminal vesicle and ejaculatory ducts, 1407–1408
        testis, 1392–1394, 1393*f*–1394*f*
Male reproductive system anatomy
    epididymis, 1374, 1374*f*–1376*f*, 1376*b*
    penis, 1383–1386, 1387*b*, 1807, 1807.e1*f*–1807.e7*f*
    prostate, 1378–1381, 1379*f*–1381*f*, 1381*b*
    scrotum, 1387–1389, 1388*f*, 1389*b*
    seminal vesicles and ejaculatory ducts, 1377–1378, 1378*f*, 1378*b*

- testis, 1370–1374, 1371*f*–1373*f*, 1374*b*
- urethra, 1381–1383, 1381*f*–1384*f*, 1384*b*, 1807, 1807.e1*f*–1807.e7*f*, 2465, 2465*f*
- vas deferens, 1376–1377, 1376*f*–1377*f*, 1377*b*

Male stress incontinence, 3009

Male stress urinary incontinence, injectable agents for, 2896–2897

- after urinary diversion, 2897–2898
- injection techniques, 2896–2897

Male urethra, 152

- catheterization of, 153

Male urethral cancer, 1776–1782, 1782*b*

- anterior, 1777–1781
- carcinoma of penile urethra, 1778–1780, 1779*f*–1780*f*
- epidemiology, etiology, and clinical presentation of, 1776–1777
- evaluation and staging of, 1777, 1778*f*, 1778*t*
- pathology of, 1777, 1777*f*, 1777*t*
- posterior, 1781–1782, 1782*t*
- recurrence after cystectomy, 1786*t*, 1789*b*
- treatment of, 1778, 1779*t*

Malecot catheters, 155, 155*f*, 173, 174*f*

Male-to-female transexuals, Transwomen

Malignancy, PC-RPLND findings of, survival outcomes associated with, 1726–1727, 1727*t*

Malignancy-associated hypercalcemia, 2020

Malignant fibrous histiocytoma/undifferentiated pleomorphic sarcoma, retroperitoneal tumors and, 2231, 2232*f*

Malignant lesions

- adrenal, 2384–2388
    - adrenal cortical carcinoma, 2384–2388, 2384*f*, 2385*t*, 2386*f*, 2386*b*, 2387*t*, 2388*b*
    - malignant pheochromocytomas, 2373, 2375, 2389
    - metastases, 2388–2389, 2389*f*, 2390*b*
    - neuroblastoma, Neuroblastoma
- of bladder, 3083–3084, 3083*f*–3084*f*

Malignant peripheral nerve sheath tumors, in retroperitoneum, 2235–2236

Malignant pheochromocytomas, 2373, 2375, 2389

Malone antegrade continence enema (MACE), 673, 674*f*–675*f*, 678*t*

Malrotation, of kidney, 1869, 1869.e1*f*

Mammalian target of rapamycin (mTOR)

- inhibitors, for metastatic RCC, 2326–2327, 2338–2339, 2340*f*, 2340*t*
- in RCC, 2145, 2145*t*

Management principles, of ED

- cardiac risk assessment, 1516–1517, 1517*f*
- early detection, 1515, 1515*t*
- follow-up care, 1517
- goal-directed management, 1516
- role of partner interview, 1516
- shared decision making and treatment planning, 1515–1516
- specialist referral, 1517
- step-care approach, 1516

Manchester procedure, in uterine sparing, 2816–2817, 2819*t*

Mannose-sensitive adhesin, 429

Manometry, for PFM activity measurement, 2729

Manual dexterity, orthoptic urinary diversion and, 3238

Manual dilation, for achieving retroperitoneal access and developing retroperitoneal space, 210

Manual therapy, for genito-pelvic pain-penetration disorder, 1653

Margins, 3511

Marionette stitch, for minimally invasive urinary diversion, 3261–3262, 3261*f*

Marshall-Marchetti-Krantz (MMK) procedure, 2762–2763, 2763*b*

- Burch colposuspension *versus*, 2773
- results with, 2762–2763
- technique for, 2762, 2762*f*

Martius flap

- in urethrovaginal fistulae, 2950
- in vesicovaginal fistula repair, 2940, 2949*f*

Martius labial fat pad graft, 2866–2868

Masked hypertension, 352

Mast cells, in BPS/IC etiology, 1232.e4–1232.e5, 1232.e5*b*

Mastectomy, 3063–3064

Maternal anemia, from bacteriuria in pregnancy, 1186.e1

Maternal-fetal ultrasound, 358, 359*f*

Matrix

- of bladder wall, 2464
- renal calculi and, 2015

Matrix GLA protein (MGP), in crystal formation, 2015

Matrix stones

- composition of, 2076–2077, 2076*f*
- imaging of, 2076, 2076*f*
- in renal calculi, 2032

Matrix substance A, 2015

Maturation arrest, 1445.e1, 1445.e2*f*

Maximum birth weight, pelvic organ prolapse and, 2591

Maximum urethral closure pressure (MUCP), 2563, 2757

- for sling procedure, 2831, 2833

Maximum urethral pressure (MUP), 2563

Maximum voided volume (MVV), 2667

Mayer-Rokitansky-Küster-Hauser syndrome (MRKH), 720, 1017

McCall culdoplasty technique, vaginal hysterectomy with, 2814–2815, 2815*f*

MCDK, Multicystic dysplastic kidney

McGuire's technique, for pubovaginal sling, modified, 2834

MCKD, Medullary cystic kidney disease

MDSC, Microsurgical denervation of the spermatic cord

Meatal advancement glanuloplasty (MAGPI), 920, 921*f*

Meatal retrusion, 938

Meatal stenosis, 875, 875*f*, 937–938

- urethral, reconstructive surgery for, 1811

Meatotomy, urethral reconstruction and, 3071

Mechanical assistants, for laparoscopic and robotic surgery, 218.e2

Mechanical bowel preparation, in urologic surgery, 125

Mechanical index (MI), in ultrasonography, 78

Mechanical injury, during laparoscopic and robotic surgery, 229

Mechanical properties, of ureters, 1890–1891

- force-length relations, 1890, 1890*f*
- force-velocity relations, 1890–1891, 1891*f*
- pressure-length-diameter relations, 1891

Mechanical reliability, repair for, 1597, 1597*f*

Medial fibroplasia, 1915, 1915*f*

Medial hyperplasia, 1916

Median raphe cysts, 882, 882*f*, 1304

Median umbilical ligament, 330–333

Medical conditions

- in bladder tumor, 3076–3077
- urinary incontinence and, 2586

Medical devices, in ED, 1536–1537

Medical ethics, 115–116, 118*b*

- in clinical practice, 115–116
- four-principles of, 115
- history of, 115

Medical expulsive therapy (MET), for ureteral calculi

- in megaureter, 2087

  stone localization and, 2085

Medical history, adrenal surgery and, 2407–2408

Medical indications, 116

Medical management, in schistosomiasis treatment, 1326–1327

Medical therapy

  for adrenal cortical carcinoma, 2387–2388

  for genitourinary tuberculosis treatment, 1311*t*, 1315–1317, 1315*t*–1316*t*

Medical Therapy of Prostatic Symptoms (MTOPS) Trial, 3385–3386, 3387*f*–3388*f*, 3387*t*

Medication change, for ED, 1529

Medication optimization, in geriatric patient, 2915–2917, 2916*t*–2917*t*

Medication-related stones

  in renal calculi, 2032–2033

  surgical management of, 2077.e2–2077.e3

Medications

  benign prostatic hyperplasia and, 3324

  patient history of, 7–8

  transient urinary incontinence and, 2919.e1

Medullary cystic kidney disease (MCKD), 747*t*, 755–756, 756*f*, 756*b*

  clinical features of, 755–756

  evaluation of, 756, 756*f*

  genetics of, 755

  treatment of, 756

Medullary sex cord, 319*f*

Medullary sponge kidney (MSK), 771–772, 771*f*, 772*b*

  clinical features of, 771

  diagnosis of, 771

  histopathology of, 771

  prognosis of, 771–772

  renal calculi and, 2034–2035

  treatment of, 771–772

Megacalycosis, 738–739, 740*f*

Megacystis microcolon intestinal hypoperistalsis syndrome (MMIHS), 520–521

Megacystis-megaureter association, 510

Megaureter

- in children, 849–852, 852*b*
  - cutaneous ureterostomy for, 850–851, 850*f*
  - definition of, 849
  - definitive reconstruction for, 850–851, 850*f*
  - dilatation and stenting for, 852
  - etiology, occurrence, and presentation of, 849
  - excisional tapering for, 851–852, 851*f*
  - Kalicinski plication technique for, 851, 851*f*
  - outcomes with, 852
  - remodeling for, 837*f*–839*f*, 851
  - Starr plication technique for, 851, 851*f*
  - surgical indications for, 849–850
  - surgical management of, 850–852, 850*f*–851*f*
  - ureteral polyps with, 835–836
  - ureteral strictures with, 835
- ureteral calculi in, surgical management of, 2087
- ureterovesical junction obstruction, 374–375
  - recommendations for, 374–375

Meiosis, testis germ cells and, 1400–1401, 1401*t*

Melanocortin-receptor agonists, 1534

Melanocortins, in ED, 1494, 1495*t*

Melanoma, as neoplastic condition, 1300–1301

Melatonin, 1392

MELD score, in assessment of perioperative mortality, 121

Membrane potential, of smooth muscles, of bladder, 2473–2474, 2474*f*

Membranoproliferative glomerulonephritis (MPGN), 346

Membranous glomerulonephritis (MGN), with RPF, 1978

Membranous nephropathy (MN), 345

Membranous urethra, 1382, 1382*f*–1383*f*, 1807.e4*f*, 1807.e8

Memorial Sloan-Kettering Cancer Center (MSKCC) penile rehabilitation program, 3579

MEN, Multiple endocrine neoplasia

Menopause

- genito-pelvic pain-penetration disorder and, 1652
- pelvic organ prolapse and, 2591

Men's health, integrated, 1411–1427

- cardiovascular risk, and testosterone therapy, 1424–1425, 1425*b*
- health centers for, 1427
- mental health and opioid abuse in men, 1426–1427, 1427*b*
- metabolic syndrome and, 1417–1424, 1424*b*
- rationale for, 1411–1417, 1417*b*
  - gender longevity gap, 1411, 1412*t*–1415*t*, 1415*f*
  - global men's health movement, 1417
  - health and wellness gap by gender, 1411, 1415*t*
  - poorer health of men, explanation of, 1411–1416
  - targets and effective interventions, 1416–1417

Mental illness, in men, 1426

Mepartricin, for chronic scrotal pain syndrome, 1216

Meperidine (Demerol), urethral function effects of, 1902

Mesenchymal condensation, 3275–3276

Mesenchymal-epithelial conversion, 338

Mesenchymal tumors, of prostate, 3512

Mesenteric blood flow, pneumoperitoneum effects on, 222

Mesh complications, 2877–2888, 2878*b*

- among three slings, 2880–2887
- apical, 2886–2887
- exposure, treatment of, 2886–2887, 2886*f*
- male, 2887–2888, 2887*b*–2888*b*, 2888*f*
- materials for, 2877
- in midurethral sling, 2877
  - bladder, perforation of, 2868–2870, 2868*f*, 2869*t*, 2870*b*
  - contraction of, 2877

- exposure of, 2864–2866, 2864*f*, 2865*t*, 2866*b*, 2877, 2878*f*
- extrusion of, 2877
- perforation of, 2877, 2879*f*
- prominence of, 2877
- risk factors for, 2879–2880
- for stress urinary incontinence, 2879
- urethra, perforation of, 2866–2868, 2867*t*, 2870*b*

prolapse, treatment of, 2885

and properties, 2877–2878

surgical removal, 2885–2886, 2886*b*

surrounding, 2877

transvaginal (anterior and posterior wall), 2883–2885

Mesoderm, 305

Mesodermal origins, retroperitoneal tumors and, 2229

Mesonephric duct, 324*f*

degenerating, 319*f*

ureteral development from, 1877

Mesonephric tubules, 319*f*, 324*f*

Mesonephros, 324*f*, 334–335, 334*f*

Mesotheliomas, of testicular adnexa, 1709

Mesovarium, 2437–2438

MESTs, Mixed epithelial and stromal tumors

MET, Medical expulsive therapy

MET gene, systemic therapy targeting, 2343, 2344*f*

MET signaling, in castration-resistant prostate cancer, 3701

Metabolic changes, with aging, 2906

Metabolic syndrome (MetS)

benign prostatic hyperplasia and, 3324, 3325*t*

bladder cancer, 1421

definition of, 1417–1418, 1417*f*, 1418*t*

and ED, 1510–1511

hormonal therapy and, 3681

  - hyperoxaluria and, 2059–2060
  - novel strategy for, 1422
    - diet and exercise, 1422
    - metformin, 1422
    - statins, 1422
    - testosterone therapy, 1422
  - physiology of, 1418–1420, 1419*f*
    - abdominal obesity, 1418–1419
    - dietary factors, 1420
    - dyslipidemia, 1419
    - endothelial dysfunction, 1420
    - genetics, 1420
    - glucocorticoid and stress-response mediators, 1420
    - hypercoagulable state, 1420
    - hypertension, 1419–1420
    - insulin resistance, 1419
    - obstructive sleep apnea, 1420
  - prevalence and predictors of, 1418
  - renal calculi and, 2008
  - sleep duration and, 2665–2666
  - urologic disorders and, 1420–1422
    - bladder cancer, 1421
    - erectile dysfunction, 1422
    - low testosterone and erectile dysfunction, 1422
    - lower urinary tract symptoms, 1421
    - overactive bladder, 1421
    - prostate cancer, 1421–1422
    - renal insufficiency, 1420
    - renal stones, 1420–1421
    - tumor, 1421

Metabolomics, for prostate cancer biomarkers, 3479

Metanephric adenofibroma, in pediatric patients, 1109

Metanephric adenoma, of kidney, 2128–2129, 2129*f*, 2129*b*

Metanephric mesenchyme, ureteric bud outgrowth, 336–338, 337*f*

Metanephrine testing, for pheochromocytoma, 2377, 2377*f*

Metanephros, 335–336, 335*f*

Metaplastic lesion, of upper tract urothelium, 2188

Metastasectomy, in advanced RCC, 2328, 2328*b*

Metastasis
- adrenal disorder, 2388–2389, 2389*f*, 2390*b*
- after renal tumor ablation, 2317
- MRI and, 53–54
- neuroblastoma with, 1089
- of penile cancer
  - primary tumor histology in prediction of, 1757–1759, 1758*t*
  - prognostic significance of, 1753, 1754*t*–1755*t*
  - risk-based management for, 1762–1765, 1763*f*–1764*f*
- from prostate, castration-resistant, 3689–3690
- renal, 2181*t*, 2183
- testicular, 1124, 1709

Metastatic bladder cancer
- chemotherapy for, 3127*t*
- FDA-approved agents and future directions, 3130
- immune checkpoint inhibitor therapy, 3129–3130
  - first-line, 3130
  - second-line, 3130
- management of, 3112–3132, 3131*b*
- randomized trials in, 3127–3128, 3127*t*
- second-line chemotherapy for, 3128, 3128*t*
  - multiagent, 3129
  - single agent, 3128–3129, 3129*t*
- targeted therapy for, 3130–3131

Metastatic disease, treatment of, 2222–2224, 2223*f*

Metastatic potential, of UTUC, 2193–2194

Metastatic prostate cancer, castration-sensitive, phase III clinical trials for, 3678*t*

Metastatic RCC, 2177
- treatment of, 2325–2328
  - advanced, immunologic approaches, 2329–2332, 2329*t*–2331*t*, 2332*f*
  - chemotherapy, 2341–2342
  - debulking or cytoreductive nephrectomy, 2325–2328, 2326*f*–2327*f*, 2327*t*, 2328*b*
  - hormonal therapy, 2342–2343
  - palliative surgery, 2328, 2328*b*
  - prognostic factors and, 2324–2325, 2325*f*, 2325*t*
  - resection of metastases, 2328, 2328*b*
  - systemic therapy for non-clear cell variants, 2343–2344, 2344*f*

targeted molecular agents in, 2324, 2333–2341, 2333*t*–2335*t*, 2336*f*, 2337*t*

Metastatic restaging, in UTUC, 2225

Metformin, 449

and gadolinium, contrast media and, 34

and iodinated contrast, contrast media and, 33–34

for metabolic syndrome, 1422

for prostate cancer, 3545

in prostate cancer prevention, 3475

Methacholine (Mecholyl), ureteral response to, 1887

Methenamine, for UTIs, 1165–1166, 1165*t*

Methotrexate

for BPS/IC oral therapy, 1241*t*, 1243

for penile cancer, 1770

Methoxamine, for stress urinary incontinence in women, 2714

α-Methylacyl coenzyme A racemase *(AMACR)* gene, as prostate cancer biomarker, 3487

Methylene blue

for pelvic floor disorder testing, 2533

toxicity of, 1994

ureteral response to, 1886

Methylprednisolone sodium succinate, for contrast media, 32

Methysergide (Sansert), with RPF, 1978

Meticulous padding, 164–165, 165*f*

Metoclopramide, to facilitate bladder emptying, 2718

Metoidioplasty, 3068–3069

Metronidazole, prophylaxis with, for uncomplicated urologic procedures, 1194*t*–1196*t*

MetS, Metabolic syndrome

Meyers scale, 473–474, 474*f*

MGN, Membranous glomerulonephritis

MGP, Matrix GLA protein

MHCs, Myosin heavy chains

MI, Mechanical index

Mic-Key button, for bladder emptying, 711

Microbiology, TB, 1307

Microbiome, in GU cancers, 1368–1369, 1369*b*

Microductal aplasia, 1449–1450

Microductal obstruction, 1447, 1447*f*

Microfibrillar collagen (Avitene), 147

Microhematuria, 401

Microlithiasis, testicular, in pediatric patients, 1124–1125

Micromotions, 2642

Micronutrients, for prostate cancer, 3544

Micropapillary urothelial carcinoma (MPUC), 3088

Micropenis, 872*t*, 879–880, 880*f*, 880.e1*b*, 881*b*

Microphthalmia-associated transcription factor-associated cancer syndrome, 2145

Microporous polysaccharide spheres (Arista), 147

MicroRNA (miRNA), as prostate cancer biomarker, 3487

Microsatellite instability, in UTUC, 2197

Microscopic hematuria, 247–250, 250*b*, 252*b*, 479

- American Urologic Association (AUA) guideline panel define, 247
- causes of, 247, 248*b*, 249*t*
- criteria for diagnosis of, 247, 248*t*
- cystoscopy in diagnostic evaluation of, 250–251
- guideline-based evaluation of, 250–252, 251*f*
- natural history, in patients with negative evaluation, 252
- requirement for, 247
- screening for, 250

selection of patient, for evaluation of, 247–250, 248*t*

symptomatic, 252

Microsurgical denervation of the spermatic cord (MDSC), 1853–1855, 1854*f*–1855*f*

Microsurgical epididymal sperm aspiration, in sperm retrieval, 1473–1474, 1473*f*–1474*f*

Microwave ablation (MWA), for renal tumors, 2322

Micturating cystourethrogram, 415–416

Micturition

- brainstem modulatory mechanisms of, 2493–2494, 2495*f*
- cerebral control of, 2496
- charts, 3344
- mechanics of, 2479
- neuromodulation for, rationale for, 2510, 2510*f*
- nitric oxide and, 2484
- physiology of, 2564, 2564*f*
- pontine micturition center in, 2493–2494, 2495*f*
- reflex circuitry controlling, 2489–2493, 2490*f*
    - emptying phase, 2490*f*, 2491*t*, 2492
    - urethra to bladder reflexes, 2492–2493, 2492*f*–2494*f*

Micturition cycle, 2516

- abnormalities of, 2600
- bladder emptying/voiding in
    - failure of, pathophysiology of, 2516
    - urodynamic studies of, 2564–2566
- bladder filling/storage in
    - failure of, pathophysiology of, 2516
    - urodynamic studies of, 2552*t*–2553*t*, 2559
- phases of, mechanisms underlying, 2514

Micturitional urethral pressure profile (MUPP), 2567

Midline incision, of abdomen, 135, 136*f*–137*f*

Midodrine, for stress urinary incontinence in women, 2714

Mid-ureter, stone localization and, 2086*t*

Midurethral sling (MUS), 2849–2851
- age of, 2831–2832
- anatomy of, 2850, 2851*b*
- complications of, 2863–2866, 2864.e1*t*–2864.e2*t*
  - bleeding after, 2874
  - infection and pain after, 2870–2871
  - management of SUI after, 2874
  - mesh exposure in, 2864–2866, 2864*f*, 2865*t*, 2866*b*
  - mesh perforation of bladder, 2868–2870, 2868*f*, 2869*t*, 2870*b*
  - mesh perforation of urethra, 2866–2868, 2867*t*, 2870*b*
  - regulatory and legal issues related to, 2874–2876
  - serious, 2874
  - sexual dysfunction after, 2873
  - trocar injury to urinary tract, 2866–2873
  - urethral perforation during placement, 2866–2868, 2866*f*, 2867*t*
  - voiding dysfunction after, 2871–2873, 2872*t*, 2873*b*
- evolution of, 2830–2831
- materials for, 2851, 2851*b*
- mechanics of, 2849–2850, 2851*b*
- mesh complications of, 2877
  - among three slings, 2880–2887
  - contraction of, 2877
  - exposure of, 2877, 2878*f*
  - extrusion of, 2877
  - perforation of, 2877, 2879*f*
  - prominence of, 2877
  - risk factors for, 2879–2880
  - for stress urinary incontinence, 2879
- operative procedures for, 2851–2863
  - anesthesia for, 2851–2854
  - patient counseling for, 2851
  - positioning for, 2851–2854
  - preparation for, 2851–2854
- outcomes of
  - for elderly women, 2862–2863, 2863*b*
  - for intrinsic sphincteric deficiency, 2859–2860
  - for mixed urinary incontinence, 2858–2859
  - for obese patients, 2863, 2863*b*
  - for pelvic organ prolapse, 2861–2862
  - for predominantly SUI, 2854
  - for recurrent SUI, 2860–2861, 2861*b*
- retropubic

- anatomy of, 2850
- complications of, 2863–2866
- outcomes for, 2854–2856, 2855*t*
- removal of, 2870
- surgical approach to, 2851–2853, 2852*f*–2853*f*

retropubic, complications of, 2880

single-incision
- anatomy of, 2851
- complications of, 2863–2866, 2879
- outcomes for, 2857–2858
- surgical approach to, 2854, 2855*f*

for stress urinary incontinence, 2879

transobturator
- anatomy of, 2850–2851
- complications of, 2863–2866
- inside-out, surgical approach for, 2853–2854, 2854*f*
- outcomes for, 2856–2857, 2857*t*
- outside-in, surgical approach for, 2853

Mild androgen insensitivity syndrome, 1014

Milnacipran hydrochloride, to facilitate bladder filling and urine storage, 2702

Mindfulness, for female orgasmic disorder, 1647

Mineral metabolism, 2017*b*

Mineralocorticoids, in adrenal histology, 2356, 2357*t*

Mini balloon button, for bladder emptying, 711

Mini Mental State Examination (MMSE), 2910

Mini-Cog, 2910, 2911*f*

Minimally invasive and endoscopic management of benign prostatic hyperplasia, 3403–3448

defining outcomes for, 3405–3407
- comparing to other treatments, 3407, 3408*t*
- response rates, 3405–3407
- secondary procedures, 3407

epidemiology of, 3403–3404, 3404*b*

failed, failing, and future directions for, 3443–3447
- aquablation (aquabeam), 3444–3445, 3445*f*
- prostate embolization, 3445–3446
- prostate stents, 3443–3444

    - prostatic injections, 3446–3447
    - Temporary Implantable Nitinol Device, 3444
  - increasing age and, 3404
  - laser treatments, 3435–3438
    - safety for, 3435–3436
  - marketshare, 3403–3404, 3404*b*
  - non-laser options for, 3409–3443, 3422*b*, 3435*b*
  - presurgical factors for, 3407–3409, 3409*b*
    - antibiotic coverage for, 3409
    - histologic specimen for, 3409
    - matching treatment with patient, 3409
    - treatment indications, 3407–3409
  - workup for, 3404–3405, 3405*f*–3406*f*
- Minimally invasive ileal ureteral substitution, for ureteral stricture disease, 1973–1975, 1974*f*
- Minimally invasive pelvic lymph node dissection, 3584–3586
  - complications of, 3585–3586, 3586*b*
  - future of, 3586
  - indications for, 3584
  - surgical technique of, 3584–3585, 3585*f*
- Minimally invasive surgery (MIS)
  - access, 463–465, 465*b*
    - comparative effectiveness of, 465
    - open, 464, 464*f*
    - Veress needle, 463, 464*f*
    - visual obturator, 464–465
  - additional benefit of, 459
  - advantages and disadvantages of, 458–459, 459*f*, 459*t*, 460*b*
  - approach to, 465, 465*b*
    - retroperitoneal, 465
    - transperitoneal, 465
    - vesicoscopic, 465
  - assessment, 470
  - complications of, 468–469, 469*b*
    - incisional hernia, 468–469, 469*f*
    - pulmonary air embolus, 469
    - vascular injury, 468, 469*f*
    - visceral injury, 468

cost of, 460
drawbacks of, 460
learning curves, 472
length-of-stay benefits for selected, 458–459, 459*t*
patient selection for, 462–463, 463*b*
pediatric urologic procedures, 462*t*
simulation training and evaluation of, 469–472, 470*f*–471*f*, 472*b*
skills acquisition, stages of, 470*t*
training, 470
in urologic practice, 2308
warm-up, 471–472

Minimally invasive urinary diversion, 3258–3273
- anatomic considerations in
  - men, 3260–3261, 3260*f*
  - women, 3261
- complications of, 3270, 3271*t*
- Florin: Florence robotic intracorporeal neobladder, 3267
  - configuration and setup, 3267, 3267*f*
  - uretero-neobladder anastomosis, 3267
- functional outcomes with, 3272–3273
- future direction for, 3273
- hospital stay for, 3259
- ileal conduit, 3261–3262
  - bowel restoration, 3262
  - bowel segment isolation, 3262
  - bowel selection for, 3261
  - left ureter transfer for, 3261
  - marionette stitch, 3261–3262, 3261*f*
  - pre-stoma preparation, 3262, 3262*b*
  - ureteroileal anastomosis, 3262
- intracorporeal *versus* extracorporeal, 3273
- learning curve for, 3270
- modified Studer neobladder: Karolinska Institute Technique, 3263*t*, 3264–3265
  - bowel detubularization, 3264
  - closure of neobladder, 3265
  - configuration and setup, 3264, 3264*f*
  - neobladder creation, 3264
  - neobladder-urethral anastomosis, 3264
  - uretero-neobladder anastomosis, 3264

- modified Studer neobladder: The USC Institute of Urology Technique, 3265
    - configuration and setup, 3265, 3265*f*
    - neobladder-urethral anastomosis and cross-folding of pouch, 3265
    - rotation of pouch, 3265
    - uretero-neobladder anastomosis, 3265
- modified “W” Hautmann neobladder: The Roswell Park Comprehensive Cancer Center Technique, 3267–3269
    - configuration and setup, 3267–3268, 3268*f*
    - neobladder creation, 3268
    - uretero-neobladder anastomosis, 3268–3269
- modified Y neobladder: The Clinique Saint-Augustin Technique, 3266
    - configuration and setup, 3266, 3266*f*
    - neobladder creation, 3266
    - uretero-neobladder anastomosis, 3266
- operative time for, 3270
- outcomes with, 3270
- Padua neobladder, 3266–3267
    - configuration and setup, 3266–3267, 3267*f*
    - uretero-neobladder anastomosis, 3267
- patient position for, 3259–3260, 3259*f*, 3260*b*
- patient selection for, 3258
- port placement for, 3259–3260, 3259*f*, 3260*b*
- postoperative care for, 3269–3270
- preoperative care for, 3259, 3259*b*
- pyramid neobladder: The University College London Hospital technique, 3265–3266
    - configuration and setup, 3265, 3266*f*
    - formation of, 3265–3266
    - uretero-neobladder anastomosis, 3266
- surgeon choice in, 3258–3259

Mi-Prostate Score (MiPS), 3486

MiPS, Mi-Prostate Score

Mirabegron, 2500, 2544
- adverse effects of, 2700
- for benign prostatic hyperplasia, 3381–3393
- for diminished bladder, 2674, 2675*t*–2677*t*
- efficacy of, 2699–2700
- to facilitate bladder filling and urine storage, 2682*t*, 2699–2700
    - with antimuscarinics, 2706

  - indication, efficacy, and safety profile of, 3381–3382
  - for OAB, 2647
  - pharmacokinetics of, 2699
  - tolerability of, 2700
  - for urinary incontinence, in geriatric patients, 2920.e4

MIS, Minimally invasive surgery

Mismatch repair (MMR), 1351.e1, 1351.e1*f*

Misoprostol, for BPS/IC oral therapy, 1241*t*, 1243

Mitchell repair, for classic bladder exstrophy, 544, 544*f*
  - continence outcomes with, 560
  - technical aspects of, 550, 550*f*

Mitomycin C (MMC), for non-muscle-invasive bladder cancer, 3104–3105

Mitosis
  - deregulation of, in GU cancers, 1347.e2
  - in UTUC, 2197–2198

Mitotic arrest, deregulation of, 1347.e3

Mitoxantrone, 3690, 3693*f*

Mitrofanoff principle, for continent urinary diversions, 707–709

MIV, Minverted V glansplasty

Mixed epithelial and stromal tumors (MESTs), of kidney, 2130, 2130*f*, 2130*b*

Mixed fiber mesh, for anterior compartment repair, 2781*t*–2782*t*

Mixed gonadal dysgenesis, 998*t*, 1002–1004, 1003*f*, 1003*b*, 1004*t*

Mixed mesenchymal and epithelial tumors, renal, 2129–2130, 2129*f*

Mixed urinary incontinence (MUI)
  - definition of, 2539, 2581
  - midurethral sling for, outcomes of, 2858–2859
  - overactive bladder and, 2637
  - patient history of, 5
  - pubovaginal sling for, outcomes of, 2844–2845
  - treatment of, 2547

MK2206, 3700

MLCs, Myosin light chains

M-line measurement, 2441–2442, 2442*f*

MMC, Mitomycin C

MMIHS, Megacystis microcolon intestinal hypoperistalsis syndrome

MMR, Mismatch repair

MMSE, Mini Mental State Examination

MN, Membranous nephropathy

Modafinil, for PE, 1572.e2–1572.e3

Modern staged reconstruction, of cloacal exstrophy, 578, 578*t*

Modern staged repair of exstrophy (MRSE), 545

- bladder, posterior urethral, and abdominal wall closure for, 545–548, 546*f*–548*f*
- combined bladder closure and epispadias repair, 548
- management after, 548–549, 549*b*

Modified Cantwell-Ransley repair, for classic bladder exstrophy, 551–552, 552*f*–553*f*

Modified cardiac risk index, 120*t*

Modified complete ILND, for penile cancer, 1761

Modified inguinal lymph node dissection, for penile cancer, 1794

Modified supine positioning, 467*f*

Modified Young-Dees-Leadbetter bladder neck reconstruction, 555*f*–556*f*

Modulators, within brainstem networks, 2495–2496

Mohs micrographic surgery, for penile cancer, 1752

Mole, 1304, 1305*f*

Molecular genetics of GU cancers, 1346–1369, 1346.e1–1346.e4

- apoptosis, 1365–1367, 1367*b*
  - extrinsic pathway of, 1366.e1*f*–1366.e2*f*, 1366.e2
  - intrinsic pathway of, 1366.e1, 1366.e1*f*
- basic concepts for

    chromosomes and gene structure, 1346.e4
    DNA, 1346.e1–1346.e4, 1346.e2*f*
    protein synthesis, 1346.e3–1346.e4, 1346.e3*f*–1346.e4*f*
    transcription, 1346.e3, 1346.e3*f*
cell cycle deregulation, 1347–1348, 1349*b*
    CDKIs, 1347.e1, 1347.e1*f*
    cell cycle entry, 1347.e1
    cell cycle progression through S phase, 1347.e2
    cyclin-dependent kinases and cyclins, 1347.e1, 1347.e1*f*
    G_1/S checkpoint, 1347.e2
    G2M checkpoint, 1347.e2–1347.e3
    mitosis, 1347.e2
    mitotic arrest and spindle assembly checkpoint, 1347.e3
    RB1, 1347.e1, 1347.e1*f*
    S phase arrest, 1347.e2
    TP53, 1347.e2, 1347.e2*f*, 1348
checkpoint inhibition, 1367–1368, 1368*b*
DNA damage and repair, 1350–1351, 1351*b*
    DSB repair, 1351.e1*f*–1351.e2*f*, 1351.e2
    mechanisms, 1351.e1, 1351.e1*f*
DNA methylation, 1348–1350, 1350*b*
genomic alterations, 1351–1362, 1362*b*
    in bladder cancer, 1358–1360
    bladder RMS, 1111–1113
    CNAs, 1354, 1354*t*–1355*t*
    gross chromosomal abnormalities, 1351–1352, 1352*b*
    in prostate cancer, 1352–1353, 1354*t*, 1355*f*
    in renal cancer, 1353, 1354*t*, 1358
    in testicular cancer, 1121, 1353, 1361–1362
    in Wilms tumor, 1096–1099, 1097*t*, 1354*t*
microbiome, 1368–1369, 1369*b*
oncogenes, 1346–1347, 1347*b*
stem cells, 1367, 1368*b*
telomerase, 1362–1365, 1363*f*, 1365*b*
    chromosome stabilizing activity of, 1364
    as potential diagnostic marker, 1364
    therapies based on, 1365
telomeres, 1362–1365, 1365*b*
    cancers and premalignant lesions with short, 1363–1364
    chromosomal instability and, 1362
    prostate cancer prognosis using, 1364–1365
    as tumor suppressive mechanism, 1363, 1363*f*

    - terminology for, 1346.e1*b*–1346.e2*b*
    - tumor suppressor genes, 1346–1347, 1347*f*, 1347*b*
- Molecular imaging, 91
- Molecular oxygen, penile erection and, 1500
- *Molluscum contagiosum*, 1261, 1261*f*
- Monfort technique, 595, 596*f*–597*f*
- Monopolar electrocautery, 466
- Monopolar electrosurgery
    - argon beam coagulator, 215.e1
    - devices for, 237
        - in laparoscopic and robotic surgery, 214
    - generator settings for, 235–236
    - physics of, 235, 236*f*
    - safety of, 236–237
- Monopolar thermal energy, 468
- Monopolar transurethral resection of the prostate (M-TURP), 3409–3418
    - in anticoagulated patient, 3416
    - complications of, 3416–3418
        - intraoperative, 3416–3417
        - perioperative, 3416–3417
        - postoperative, 3417–3418
    - conclusion for, 3418
    - outcomes with, 3416
    - technique for, 3410–3416
        - intraoperative, 3410–3415, 3411*f*–3414*f*, 3414*f*–3415*f*
        - postoperative, 3415–3416
        - preoperative, 3410
- Monosymptomatic enuresis (MSE), 660
- Mons pubis, 1627.e1, 2435, 2436*f*–2437*f*
- Montelukast, for BPS/IC oral therapy, 1241*t*, 1242
- Monti procedure, for ureteral injury, upper, 1998
- Morbid obesity, in urologic surgery, 122

Morcellation instrumentation, for laparoscopic and robotic surgery, 218

Morphine, urethral function effects of, 1902

Mortality
  after RPLND, 1731
  with benign prostatic hyperplasia, 3335
  definition of, 102
  early, nocturia and, 2664–2666
  in locally advanced prostate cancer, 3644, 3645*f*
  prostate cancer, rates of, 3457, 3458*f*
    global, 3458–3459
    screening effect of, 3459–3460
  rate, 102

Motility, sperm, 1404–1405, 1405*f*

Motor nerve innervation, in detrusor muscle, 2465, 2465*f*, 2480, 2480*f*

Motor paralytic bladder, 2522

MPGN, Membranoproliferative glomerulonephritis

MPUC, Micropapillary urothelial carcinoma

MRA, Magnetic resonance angiography

MRI, Magnetic resonance imaging

MRKH, Mayer-Rokitansky-Küster-Hauser syndrome

MRSE, Modern staged repair of exstrophy

MRSI, Magnetic resonance spectroscopic imaging

MRU, Magnetic resonance urography

MS, Multiple sclerosis

MSA, Multiple system atrophy

MSE, Monosymptomatic enuresis

MSK, Medullary sponge kidney

^{99}mTc hexamethylpropyleneamine oxine (^{99}mTc-HMPAO), 96

mTOR, Mammalian target of rapamycin

M-TURP, Monopolar transurethral resection of the prostate

Mucinous cystadenoma, retroperitoneal tumors and, 2237

Mucosal glands, 315*f*

Mucosal plexus, 2463

MUCP, Maximum urethral closure pressure

Mucus, after augmentation cystoplasty, 698

MUI, Mixed urinary incontinence

Müllerian Aplasia, 980–981, 981*f*

Müllerian duct, 324*f*

Müllerian-inhibiting substance (MIS), 317–318, 1392, 1392*f*

Müllerian tubercle, 324, 776

Multichannel UDS, 2536, 2565*f*

Multicystic dysplastic kidney (MCDK), 339–340, 349, 350*b*, 377–378, 378*f*, 401, 405, 762–765, 762*f*, 765*b*

- clinical features of, 762
- duplex anomaly, recommendation of, 379, 381*f*
- duplication anomalies/ureterocele/ectopic ureter, 378–379, 379*f*–380*f*
- etiology of, 762
- evaluation of, 763, 763*f*–764*f*
- histopathology of, 762–763, 763*f*
- prognosis of, 763–765
- recommendations for, 378
- treatment of, 763–765

Multidetector computed tomography urography (CTU), for urinary tract obstruction, 779–780

Multidisciplinary approach, to pelvic pain study, 1209–1210

Multidisciplinary team, in transitional urology, 1045

Multidrug-resistant tuberculosis, 1318

Multimodal physical therapy, for genito-pelvic pain-penetration disorder, 1653

Multiparametric magnetic resonance imaging, 66, 66*f*–67*f*, 66*t*
  of prostate, 3502–3504, 3502*t*–3503*t*, 3502*b*, 3504*f*
  for prostate cancer, 3621–3622
Multiparametric ultrasonography, 77*f*
  prostate, 3502
  for prostate cancer, 3622
Multiple endocrine neoplasia (MEN), genomic alterations in, 1354*t*–1355*t*
Multiple malformation syndromes with renal cysts, 747*t*, 757–761
  tuberous sclerosis complex, 757–759
  von Hippel-Landau disease, 759–761
Multiple sclerosis (MS)
  cause of, 2607
  lower urinary tract dysfunction and, 2607–2608
  overview of, 2607
  treatment for, 2608
Multiple system atrophy (MSA), lower urinary tract dysfunction with, 2606–2607, 2607*b*
MUP, Maximum urethral pressure
MUPP, Micturitional urethral pressure profile
MUS, Midurethral sling
Muscarinic receptor antagonists, for benign prostatic hyperplasia, 3379–3381
  efficacy of, 3379–3381, 3380*t*
  rationale and indication for, 3379, 3379*t*
  summary for, 3381
  tolerability and safety profile of, 3381
Muscarinic receptors
  in bladder function, 2470
    contraction, 2679–2681
  distribution of, 2680*t*
  pharmacology of, 2497–2500, 2499*t*, 2500*b*
    for detrusor underactivity, 2661
    selectivity of, 2499

Muscle-invasive bladder cancer
  adjuvant chemoradiation for, 3122
  adjuvant chemotherapy for, 3120–3125
    randomized trials of, 3121–3123, 3121*t*
  bladder preservation with, 3122–3123
    partial cystectomy, 3124–3125
    radiation monotherapy, 3124
    radical transurethral resection, 3124
    single modality treatment for, 3124–3125
    trimodal therapy for, 3123, 3123*t*
    trimodality therapy for, 3123–3124
  clinical presentation of, 3112–3114
  clinical staging for, 3112–3113, 3113*t*
  diagnosis of, 3112–3114
  grossly positive nodes and, 3117
  histology of, 3112
  management of, 3112–3132, 3131*b*
  natural history of, 3112
  neoadjuvant chemotherapy for, 3119–3120, 3120*t*
  pathologic staging for, 3113–3114, 3114*t*
  prognostic nomograms for, 3125–3127, 3126*f*
  radical cystectomy and pelvic lymph node dissection for, 3114–3119
Muscles
  of abdominal wall, lower, 2444–2448, 2447*f*–2448*f*
  of pelvic floor
    female, 2430–2432, 2432*f*
    male, 2449, 2449*f*
  in prune-belly syndrome, 587, 600
Musculocutaneous artery, 136*f*
Mutation, androgen receptor and, 3685–3686
Mutations (SPOP, FOXA1, IDH1), tumors defined by, 3470–3472, 3470*f*
MVV, Maximum voided volume
MWA, Microwave ablation
Myasthenia gravis
  contrast media and, 32

lower urinary tract dysfunction and, 2630

Mycobacterium tuberculosis, 1133

Mycophenolate mofetil (CellCept), for BPS/IC oral therapy, 1243

Mycoplasma genitalium, 1253–1254

Myelodysplasia

early intervention in, 628

renal dysfunction in, 629

sexuality and, 629–630

Myelolipoma

as benign lesions, 2392, 2392*f*, 2392*b*

MRI and, 52–53, 53*f*–56*f*, 58*f*

Myelomeningocele

closure, prenatal counseling for prenatal surgery for, 362

lower urinary tract dysfunction with, 2617

prenatal closure of, 625

presentation of, 625*f*

urologic surgery and, 288–290

Myofibroblasts, 2470, 2470*f*

and PD, 1605

Myogenic hypothesis, 2642

Myoplasty

for bladder emptying, 2903

stimulated, 2903

Myosin, in thick filaments, 2471, 2471*f*

Myosin heavy chains (MHCs), 2471, 2471*f*

Myosin light chains (MLCs), 2471

Myotonic dystrophy, lower urinary tract dysfunction and, 2631

N

NAATs, Nucleic acid amplification tests

Naftopidil
  for benign prostatic hyperplasia, 3365–3367, 3367*t*
  to facilitate bladder filling and urine storage, 2682*t*
  for ureteral stone passage, 1900

Naloxone, to facilitate bladder emptying, 2719

Narcotic considerations, patient history of, 2–3

Narrow band imaging (NBI), for non-muscle invasive bladder cancer, 3097–3098

NASA TLX, National Aeronautics and Space Administration Task Load Index assessment

National Aeronautics and Space Administration Task Load Index assessment (NASA TLX), 471

National Institutes for Clinical Excellence Guidelines, 507

Natriuretic peptides, in ED, 1498

Natural orifice transluminal endoscopic surgery (NOTES), 2421
  instrumentation for, 218
  for kidney surgery, 2284–2285, 2285*f*, 2286*t*

NBCi, Nocturnal bladder capacity index

NBI, Narrow band imaging

NCCT, Noncontrast computed tomography

NDO, Neurogenic detrusor overactivity, Nocturnal detrusor overactivity

Nd:YAG, Neodymium:yttrium-aluminum-garnet

Near-infrared spectroscopy (NIRS), for benign prostatic hyperplasia, 3349

Necrosis
  PC-RPLND findings of, survival outcomes associated with, 1726
  penile, implant for, 1595–1596, 1595*f*

Needle biopsy
  for prostate adenocarcinoma, 3509–3510, 3510*b*
  for prostate cancer, 3519–3520

Needle drivers, for laparoscopic and robotic surgery, 215, 215.e3*f*

Needle suspension repair, retropubic suspension surgery *versus*, 2771

Negative feedback, in HPG axis, 1390, 1391*f*

Neoadjuvant androgen deprivation

- with radiation therapy, for locally advanced prostate cancer, 3652–3653, 3654*b*
- with radical prostatectomy, for locally advanced prostate cancer, 3648–3649, 3648*t*–3649*t*

Neoadjuvant chemotherapy, for muscle-invasive bladder cancer, 3119–3120, 3120*t*

Neoadjuvant chemotherapy-hormonal therapy, with radical prostatectomy, for locally advanced prostate cancer, 3649–3650, 3650*t*

Neobladder-urethral anastomosis

- maneuvers facilitating, 3268–3269
- for minimally invasive urinary diversion, 3264

Neodymium:yttrium-aluminum-garnet (Nd:YAG), 239

Neonatal urologic emergencies, 382–383

Neonates

- hydronephrosis diagnosis in, 1943
- with UPJO, 1943

Neoplasia, of bladder, 1360–1361

Neoplastic conditions, of cutaneous diseases of external genitalia

- basal cell carcinoma, 1297–1298, 1300*f*
- bowenoid papulosis, 1296, 1298*f*
- cutaneous T-cell lymphoma, 1302, 1302*f*
- extramammary Paget disease, 1301–1302, 1301*f*
- Kaposi sarcoma, 1298–1299, 1300*f*
- melanoma, 1300–1301
- pseudoepitheliomatous, keratotic, and micaceous balanitis, 1299–1300, 1300*f*
- squamous cell carcinoma, 1296, 1299*f*
- squamous cell carcinoma in situ, 1296, 1298*f*
- verrucous carcinoma, 1296–1297, 1299*f*

Neostigmine, ureteral response to, 1887–1888

Nephrectomy, 444
  for genitourinary tuberculosis treatment, 1317
  history of, 2133
  for metastatic RCC, 2325–2328, 2326*f*–2327*f*, 2327*t*, 2328*b*
  open, technique of, 2254, 2254.e1*f*
  renal bleeding and, 1988–1989
  in renal transplantation, 1058
  for renal trauma
    partial, 1989–1990, 1989*f*
    total, 1991
  for retroperitoneal tumors, 2243
  RPLND with, 1718, 1718*t*
  segmental, for large polar tumors, 2263–2264, 2263.e1*f*–2263.e2*f*, 2264.e1*f*, 2265*f*
  for ureteral anomalies
    laparoscopic partial, 811–813, 814*f*
    open partial, 811, 812*f*–814*f*
    upper pole partial, 811–813, 812*f*, 814*b*
  for ureteral injuries, upper, 1998
  for ureteropelvic junction obstruction, 1946–1947
Nephric ducts, formation of, 336
Nephroblastomatosis, 1101, 1101*f*
Nephrocalcin
  in crystal formation, 2014
  in crystal matrix, 2015
Nephrogenic adenoma, 526
  of bladder, 3082
    in pediatric patients, 1119
Nephrogenic rests, 1100–1101, 1101*f*
Nephrogenic systemic fibrosis (NSF), 773
  contrast media and, 34–35

Nephrolithiasis, 400, 1939, Urinary lithiasis
  child with, 854–856, 855*f*–856*f*
  HIV and, 1266
  treatment of, 1939
Nephrolithotomy
  percutaneous, 243.e1, 244.e3
    for bladder stones, 244.e3–244.e4
    ShockPulse-SE, 245–246
  for ureteropelvic junction obstruction, percutaneous antegrade endopyelotomy simultaneous with, 1949
Nephrolysis, laparoscopic, 2294, 2294*f*
Nephron, 1866–1868, 1867*f*
  anatomy, 1906, 1906*f*–1907*f*, 1907*b*
  hydrogen ion transport in, urinary tract obstruction and, 793
  sodium transport in, urinary tract obstruction and, 793
Nephronophthisis, 350
Nephron-sparing surgery, for RCC, 2173–2174, 2174*f*
Nephropathy, aristolochic acid, 2196
Nephropexy, laparoscopic, 2292–2294, 2293*f*
  procedure for, 2293*f*
  results of, 2293–2294
Nephropleural fistula, 180
Nephrostomy tract, establishment of, in antegrade nephroureteroscopic, for UTUC, 2215–2216, 2215*f*
Nephrostomy tube, for pediatric genitourinary trauma, 1072
Nephrotic syndrome, in children, 344–345
Nephroureteral stent, 173, 174*f*, 176*b*
Nephroureterectomy
  for posterior urethral valves, 615
  radical, 2199–2202
    distal ureter and bladder cuff management, 2200

- indications of, 2199
- laparoscopic, 2202–2205
- open, 2199–2200, 2200*f*
- total laparoscopic technique in, 2202, 2203*f*
- traditional open distal ureterectomy in, 2200–2201, 2200*f*–2201*f*
- transurethral resection of ureteral orifice, 2201–2202, 2202*f*
- transvesical ligation and detachment technique in, 2201, 2201*f*

robot-assisted, 2205, 2205*f*

transperitoneal, 2203–2204, 2203*f*–2204*f*

NER, Nucleotide excision repair

Nerve growth factor (NGF)
- in bladder outlet obstruction, 2506
- in bladder pain syndrome and interstitial cystitis, 2508
- in detrusor overactivity, 2505
- in overactive bladder, 2504

Nerve injury, during laparoscopic and robotic surgery, 230

Nerve sheath tumors, retroperitoneal tumors and, 2235–2236, 2236*f*

Nerves, adrenal, 2345, 2350*f*

Nerve-sparing RPLND, 2241–2242, 2242*f*

Nervous system
- of lower urinary tract, peripheral nervous system, 2480–2497, 2480*f*
- of retroperitoneum, 1674–1679
  - autonomic nervous system, 1674–1675, 1676*f*–1677*f*
  - somatic nervous system, 1675–1679, 1675.e1*f*, 1677*f*–1678*f*, 1679*t*
- in ureteral function
  - parasympathetic, 1887–1888
  - purinergic, 1889–1890
  - sensory innervation and peptidergic agents, 1889
  - sympathetic, 1888–1889

Nested variant, of urothelial cancer, 3088

Neural injury, in robotic prostatectomy, 3580

Neural tube defects (NTD), 624–631, 626*b*
- early intervention for, 628–629, 629*b*
- epidemiology of, 624
- findings with, 626–628

- pathogenesis of, 624, 626*t*
- perinatal concerns with, 625
- postnatal management of
  - congenital neurogenic bladder, 631, 631*f*, 632*t*
  - initial, 626
  - neurogenic bowel dysfunction, 631
- prenatal closure of, bladder function after, 625
- prevention of, 290
- risk factors for, 624
- upper urinary tract deterioration with, 626–628, 627*f*

Neurobiology, in BPS/IC etiology, 1232.e7–1232.e9, 1232.e9*b*

Neuroblastoma, 1087–1096, 1096*b*, 2388

- clinical presentation and pattern of spread of, 1088–1089, 1089*f*
- diagnosis of
  - imaging, 1089, 1089*f*–1090*f*
  - laboratory evaluation, 1089
  - screening, 1089–1090
  - staging, 1090–1091, 1090*t*–1091*t*
- epidemiology and genetics of, 1087
- pathology of, 1088, 1088*f*–1089*f*
- prognosis of, 1091–1092
  - biologic variables affecting, 1092
  - clinical variables affecting, 1091–1092
- in retroperitoneum, 2234
- spontaneous regression of, 1087–1088
- treatment of
  - biologic therapies, 1095–1096
  - chemotherapy, 1093*f*, 1095
  - radiotherapy, 1096
  - spinal cord decompression, 1096
  - surgery, 1092–1095, 1093*f*

Neuroendocrine cells, of prostate, 3278*f*, 3279

Neurofibroma, 1304, 1305*f*

- in retroperitoneum, 2235

Neurogenic acontractile detrusor, 2565

Neurogenic bladder

  - autonomous, 2522
  - with CNS tumors, 648
  - diminished bladder capacity and, 2671
  - reflex, 2522
  - renal transplantation and, 1057–1058
  - sensory, 2522
  - uninhibited, 2522

Neurogenic bladder dysfunction, 2964

Neurogenic bowel dysfunction, management of, with spina bifida, 631

Neurogenic detrusor overactivity (NDO), 2521
  - capsaicin for, 2709.e1
  - detrusor underactivity and, 2521
  - resiniferatoxin in, 2709.e1
  - urinary incontinence and, 2595

Neurogenic lower urinary tract dysfunction (NLUTD)
  - urodynamic studies, evidence-based review of, 2577–2578
  - videourodynamics for, 2569–2570

Neurogenic origins, retroperitoneal tumors and, 2234

Neuroimaging, in ED, 1526

Neurologic complications, after RPLND, 1731, 2244

Neurologic conditions, pelvic floor disorders and, 2527

Neurologic disease
  - detrusor underactivity and, 2657, 2657*b*
  - prostatitis and, 1210

Neurologic examination
  - for pelvic floor disorders, 2530
  - physical examination for, 12, 12*f*

Neuromodulation, Electrical stimulation
  - for bowel-bladder dysfunction, 658, 659*t*
  - for BPS/IC treatment, 1246–1247, 1247*b*
  - for chronic scrotal pain syndrome, 1221

- for lower urinary tract dysfunction, 2510–2512
    - to inhibit OAB, rationale for, 2511, 2511*f*
    - inhibitory and excitatory stimulation frequencies, 2511
    - onabotulinumtoxinA, 2512
    - pudendal nerve stimulation, 2511
    - somatic afferents activation, in foot, 2511–2512
    - for voiding, rationale for, 2510, 2510*f*
- for neuromuscular dysfunction of lower urinary tract, 637–638
- sacral, mechanism of action, 2510
- for urinary incontinence, in geriatric patients, 2920.e5

Neuromuscular complication, in urologic surgery, 261–262

Neuromuscular dysfunction of lower urinary tract, 624–651, 2600–2636, Voiding dysfunction

- acquired immunodeficiency syndrome and, 2625
- acute disseminated encephalomyelitis and, 2625–2626
- aging and, 2633
- amyloidosis, 2632
- amyotrophic lateral sclerosis and, 2624
- attention-deficit/hyperactivity disorder, 2633
- bashful bladder, 2628–2629
- benign joint hypermobility syndrome, 2633
- bladder neck dysfunction, 2627–2628
- bladder outlet obstruction in women, 2628
- in children
    - anorectal malformation, 644–645
    - causes of, 624, 625*t*
    - management principles for, 632–638, 632*t*–633*t*, 633*b*
    - medical management for, 633–634, 633*t*, 638*b*
    - neuromodulation for, 637–638
    - renal function assessment with, 629–631
    - surgical management of, 635–638, 638*b*
    - vesicoureteral reflux in, 638–639, 638*f*, 639*b*
- congenital adrenal hyperplasia, 2633
- corticobasal degeneration, 2631
- defunctionalized bladder, 2632–2633
- detrusor sphincter dyssynergia and, 2627
- distal to spinal cord, 2619–2624
    - childbirth, 2621

  - diabetes mellitus, 2622–2624, 2624*b*
  - disk disease, 2619–2620
  - Guillain-Barré syndrome, 2624
  - herpesvirus infection, 2621–2622
  - hysterectomy, 2621
  - radical pelvic surgery, 2620–2621
  - spinal stenosis, 2620
- dysfunctional voiding, 2627
- Ehlers-Danlos syndrome, 2631
- Fowler syndrome, 2629
- gastroparesis, 2630
- hereditary spastic paraplegia and, 2624–2625
- hyperthyroidism, 2630
- Isaacs syndrome, 2630
- Lyme disease and, 2624
- Machado-Joseph disease, 2632
- myasthenia gravis, 2630
- myotonic dystrophy, 2631
- neuroplasticity and, 2600–2602
- at or above brainstem, 2602–2607
  - brain tumor, 2604
  - brainstem stroke, 2603
  - cerebellar ataxia, 2604
  - cerebral palsy, 2604–2605
  - cerebrovascular disease, 2602–2603
  - dementia, 2603–2604
  - multiple system atrophy, 2606–2607, 2607*b*
  - normal-pressure hydrocephalus, 2604
  - Parkinson disease, 2605–2606
  - progressive supranuclear palsy, 2607
  - traumatic brain injury, 2604
- patterns of, 2600–2602, 2601*t*
- radiation, 2632
- reflex sympathetic dystrophy and, 2626
- sacrococcygeal teratoma, 2631
- schistosomal myelopathy and, 2626
- schizophrenia, 2630
- spinal cord involvement in, 2607–2619
  - acute transverse myelitis, 2617

        - autonomic dysreflexia, 2614–2615
        - bladder cancer and, 2616
        - cervical myelopathy, 2617
        - follow-up for, 2616–2617
        - multiple sclerosis, 2607–2608
        - neurologic and urodynamic correlation, 2612–2614
        - neurospinal dysraphism, 2617–2619
        - pernicious anemia, 2619
        - poliomyelitis, 2619
        - sacral injury, 2611–2612, 2613*f*, 2613*b*
        - spinal cord injury, 2609–2617, 2609*b*
        - spinal shock, 2610
        - subacute combined degeneration, 2619
        - suprasacral injury, 2610–2611, 2611*f*–2612*f*, 2612*b*
        - tabes dorsalis, 2619
        - urinary tract infection, 2615
        - vesicoureteral reflux, 2615
        - in women, 2615–2616
    - syringomyelia and, 2626
    - systemic lupus erythematosus and, 2626
    - systemic sclerosis, 2631
    - treatment of, 2634–2635, 2634*b*
    - tropical spastic paraparesis and, 2625
    - tuberculosis and, 2626–2627
    - urinary retention, postoperative, 2629–2630
    - Wernicke encephalopathy, 2631
    - Williams-Beuren syndrome, 2631–2632
- Neuroplasticity, in lower urinary tract dysfunction, 2600–2602
- Neurospinal abnormalities, with cloacal exstrophy, 574–575, 574*f*
- Neurospinal dysraphism, lower urinary tract dysfunction with, 2617–2619
- Neurotransmitters, within brainstem networks, 2495–2496
- Neurovascular bundle (NVB)
    - injury, complications of seminal vesicle surgery, 1864
    - preservation of, in laparoscopic radical prostatectomy, 3575–3576, 3575*f*–3576*f*
    - in retropubic radical prostatectomy, 3555–3556
        - high anterior release of, at apex, 3557–3558, 3558*f*–3559*f*
        - identification of, 3556–3558
        - preservation of, 3556–3557, 3556*f*–3557*f*

wide excision of, 3558, 3559*f*

Neutrons, 3594

NGF, Nerve growth factor

NHCT, Noncontrast helical computed tomography

Nicardipine, for PD, 1612, 1617*t*

Nicotinic agonists, ureteral response to, 1887

Nifedipine

- for BPS/IC oral therapy, 1241*t*, 1243
- for ureteral relaxation, 1900

Nighttime, definition of, 2666

Nilutamide, 3675–3676

Nintedanib, for RCC, 2337–2338

Nipple (rosebud) stoma, 3182, 3182*f*–3183*f*

Nipple valve, 3191, 3192*f*

- for continent urinary diversions, 707

NIRS, Near-infrared spectroscopy

Nitric oxide (NO)

- bladder afferent pathway and, 2484, 2484*f*
- in ED, 1494, 1495*t*, 1497–1498
- to facilitate bladder emptying, 2720.e1
- metabolism of, in BPS/IC etiology, 1232.e9
- and PD, 1605
- renal vascular tone control by, 1913
- ureteral response to, 1886, 1886*f*
- urothelium release of, 2469

Nitrite, 437

Nitrite tests, in urine, 20–21, 20*f*

Nitrofurantoin, 441

- for UTIs, 1150–1153, 1151*t*–1153*t*, 1156, 1163, 1187*t*

Nitrous oxide, as insufflant choice, 220

NK_1-receptor antagonists, to facilitate bladder filling and urine storage, 2713.e4

Nkx3.1, 3276

NLUTD, Neurogenic lower urinary tract dysfunction

NMIBC, Non-muscle-invasive bladder cancer

NO, Nitric oxide

No drainage tube, 176

Nocturia, 2581, 2664–2678, 3345

- behavioral therapy with urge suppression for, 2727
- bladder capacity and, 2667, 2668*t*, 2671–2674
- classification of, 2667, 2668*t*, 2669*f*
- definition of, 2664, 2665*t*
- degree of bother of, 2664
- drug effects causing, 2671*b*
- evaluation of, 2666–2667, 2667*b*, 2678*b*
- in geriatric patients, 2920.e8–2920.e9
- mechanisms of, 2505
- mortality, early and, 2664–2666
- nocturnal polyuria and, 662, 2667–2668, 2668*t*
- overactive bladder and, 2637
- polyuria and, 2667–2668, 2668*t*
- prevalence of, 2461, 2664
- rationale for evaluation and management of, 2664–2666, 2666*b*
- societal costs of, 2666
- treatment algorithm for, 2669*f*

Nocturia Quality of Life (N-QoL) score, 2669

Nocturnal bladder capacity index (NBCi), 2667

Nocturnal detrusor overactivity (NDO), 2671

Nocturnal enuresis, 2539, 2581

- desmopressin for, 2712
- treatment of, 2547

Nocturnal polyuria

- diminished bladder capacity and, 2674–2678
- epidemiology and causes of, 2667–2668, 2670*f*
- management of, 2668–2671, 2673*t*
- nocturia and, 662, 2667–2668, 2668*t*
- with obstructive sleep apnea, 2668

Nocturnal polyuria index (NPi), 2667

Nocturnal urine volume (NUV), 2667

Node-positive disease, outcomes of prostatectomy for, 3647–3648

Nonabsorbable sutures, 150

Non-AIDS-defining urologic malignancies, 1268

Nonatherosclerotic renal artery diseases, 1933–1934

Noncommunicating hydroceles, epidemiology and pathogenesis of, 889

Noncontrast computed tomography (NCCT), of urinary calculi, 2037, 2037*f*

Noncontrast helical computed tomography (NHCT), for urinary tract obstruction, 779

Nondilated or absent bladder, 518–519
- bladder agenesis, 518–519
- bladder hypoplasia, 519
- cloacal and bladder exstrophy, 519

Nondismembered pyeloplasty, for ureteropelvic junction obstruction in children, 828–829, 829*f*–831*f*

Nonfilarial parasitic infections, of genitourinary tract
- amebiasis, 1332
- echinococcosis, 1332
- enterobiasis, 1332
- trichomoniasis, 1332

Nonfocal extraprostatic extension, 3511

Nonglomerular hematuria, 17–18

Nongonococcal urethritis, 1253, 1254*f*
- *Chlamydia*, 1253

- *Mycoplasma genitalium*, 1253–1254
- recurrent and persistent, 1254
- *Trichomatis vaginalis*, 1254

Noninfectious genital ulcers, 1286–1288, 1286*b*
- aphthous ulcers and Behçet disease, 1286–1287, 1287*f*
- pyoderma gangrenosum, 1287–1288, 1288*f*
- traumatic causes, 1288, 1288*f*

Nonionizing radiation, technique of, 403, 403*b*

Nonmaleficence, definition of, 115

Nonmonosymptomatic enuresis, 660

Non-muscle-invasive bladder cancer (NMIBC), 3075
- Bacille Calmette-Guérin for, 3099–3100
  - carcinoma treatment in situ with, 3100
  - contraindications to, 3102*b*
  - mechanism of action of, 3100
  - prophylaxis to prevent recurrence, 3100–3101
  - residual tumor treatment, 3100
  - toxicity management of, 3102*b*
- biology of, 3092–3094
- early cystectomy for, 3106–3107, 3107*b*
- endoscopic surgical management of, 3094–3098, 3099*b*
  - confocal laser endomicroscopy for, 3097–3098
  - fluorescence cystoscopy for, 3097–3098, 3098*f*
  - laser resection for, 3097
  - narrow band imaging for, 3097–3098
  - office-based, 3097
  - optical coherent tomography for, 3097–3098
- immunotherapy for, 3099–3103, 3103*b*
  - Bacille Calmette-Guérin, 3099–3100
  - interferon, 3102–3103
  - investigational, 3103
- intravesical chemotherapy for, 3103–3105, 3104*t*, 3105*b*
  - combination therapy, 3105
  - doxorubicin, 3103–3104
  - mitomycin C, 3104–3105
  - novel agents, 3103
  - to prevent implantation, 3103–3105
  - to prevent tumor implantation, 3100*b*

- thiotepa, 3103
- valrubicin, 3104
- intravesical immunotherapy for, 3099–3103
  - Bacille Calmette-Guérin, 3099–3100
- intravesical therapy of, 3098–3105
- management strategies for, 3091–3111
- pathology of, 3092*t*, 3094*b*
  - characteristics by stage, 3094, 3094*t*
- perioperative intravesical therapy for, 3098–3099
- prevention of
  - secondary, 3110
  - surveillance for, 3107–3110, 3108*t*, 3111*b*
- refractory high-grade disease, 3105–3107
  - alternative options for, 3106
  - management of, 3106, 3107*b*
- surveillance for, 3108–3109
  - cystoscopic, 3108–3109
  - extravesical, 3110
  - tumor markers, 3109–3110, 3109*f*
  - urine cytology, 3109
- transurethral resection for
  - complications of, 3096
  - repeat, 3096–3097

Non-rapid eye movement (NREM), 2665

Nonrefluxing ureteral reimplantation, 3021–3022, 3022–3025, 3022*f*–3024*f*

Nonselective α_1-blockers, 3356

Nonseminoma germ cell tumors (NSGCTs), 2227–2229
- chemotherapy for, 1695, 1696*t*, 1697
- clinical stage I tumors, 1693–1696, 1694*t*
  - retroperitoneal lymph node dissection, 1694–1695, 1695*t*
  - risk assessment, 1693
  - surveillance, 1693–1694, 1694*t*
  - treatment selection for, 1695–1696
- clinical stage IIA and IIB, 1696–1697
- clinical stage IIC and III tumors, 1697–1700
- clinical stage IS, 1696
- genomic alterations in, 1361
- relapse after, 1701–1702

  - residual mass management after, 1698–1700, 1698*t*–1699*t*
  - treatment of, 1692, 1692*b*, 1702*b*

Nonstaghorn renal calculi, 2069–2070
  - stone burden of
    - between 1 and 2 cm, 2073–2074, 2073*f*
    - greater than 2 cm, 2074
    - up to 1 cm, 2072–2073, 2072*b*

Nonsteroidal antiandrogens, 3674–3676

Nonsteroidal anti-inflammatory drugs (NSAIDs)
  - RI and, 778
  - for urinary tract obstruction, 795

Nonsurgical focal therapy, of renal tumors, 2309–2323
  - complications, 2318–2319, 2320*f*–2321*f*, 2320*b*
  - cryoablation, 2309–2310, 2310*b*, Cryoablation (CA), for renal tumors
  - new ablation modalities, 2319–2323, 2323*b*
  - oncologic outcomes, 2314–2318, 2315*t*–2316*t*, 2318*b*
  - radiofrequency ablation, 2310–2312, 2312*b*
  - surgical technique, 2312
  - treatment success and follow-up protocol after tumor ablation, 2312–2314, 2314*b*

Nontreponemal syphilis tests, 1258

Nontuberculous mycobacteria, 1133

Nonulcerating skin infections, HIV and, 1265

Nonurothelial malignant lesions, 2189
  - adenocarcinoma, 2189
  - other, 2189
  - squamous cell carcinoma, 2189

Norephedrine, for stress urinary incontinence in women, 2714

Norepinephrine
  - in ED, 1494, 1495*t*
  - renal vascular tone control by, 1913
  - ureteral response to, 1888

Normal compliance, 2560–2561

Normal detrusor function, 2565

Normal-pressure hydrocephalus, lower urinary tract dysfunction with, 2604

Normal scrotal position, 949

Normocomplemententemic glomerulonephritis, 346–348

Normothermia, definition of, 145

North American and International Finasteride trial, 3372

Nosocomial UTIs, 433

NOTES, Natural orifice transluminal endoscopic surgery

Novel markers, for locally advanced prostate cancer, 3642–3643, 3642*t*

NPi, Nocturnal polyuria index

NPO guidelines, 449, 449*t*

- enteral tube feeds, 449
- ketogenic diet, 449
- special, 449

NR0B1 gene, 992*f*, 992*t*, 993

NR5A1 gene, 992–993, 992*f*, 992*t*

NREM, Non-rapid eye movement

NS-398, urethral function effects of, 1903

NSAIDs, Nonsteroidal anti-inflammatory drugs

NSF, Nephrogenic systemic fibrosis

NSGCTs, Nonseminoma germ cell tumors

NTD, Neural tube defects

Nuclear cystography, 389–390

Nuclear imaging, 806, 806*f*

Nuclear localization, of androgen receptors, 3291

Nuclear matrix, androgens in, 3294–3295

Nuclear medicine

  basic principles of, 91–100
  imaging agents in, 91
  in urologic oncology, 42–44

Nuclear renography, for urinary tract obstruction, 779

Nuclear scintigraphy, 40–44, 44*b*

Nucleation, 2011

Nucleic acid amplification tests (NAATs), for genitourinary tuberculosis, 1310

Nucleotide excision repair (NER), 1351.e1, 1351.e1*f*

Nucleotides, 1346.e1, 1346.e2*f*

Numeric pain rating scale, 448*f*

Nurses' Health Study, 2710

Nursing Home Setting, urinary incontinence in, 2919–2920

Nutcracker syndrome, 1869–1870

Nutrition, urinary intestinal diversion and, 3203

Nutritional status, in urologic surgery, 122–123

NUV, Nocturnal urine volume

NVB, Neurovascular bundle

NX-1207, to facilitate bladder filling and urine storage, 2713.e2

O

OAB, Overactive bladder

Obesity, 1418–1419
  abdominal, 1418–1419
  benign prostatic hyperplasia and, 3324, 3325*t*
  and ED, 1504
  hyperoxaluria and, 2059–2060
  as laparoscopic and robotic surgery contraindication, 203
  laparoscopic kidney surgery and, 2279
  midurethral sling outcomes with, 2863, 2863*b*

- morbid, percutaneous nephrolithotomy and, 2106–2107
- orthotopic urinary diversion and, 3238
- prostate cancer and, 3465, 3465*f*, 3544
- in retropubic suspension surgery, 2756
- upper urinary tract calculi and, 2089
- urinary incontinence and, 2585–2586, 2734

Objective structured assessment of technical skills (OSATS) tool, 470

Obstetric fistulae, 2925–2926, 2926*f*

Obstetric history, pelvic floor disorders and, 2527–2528

Obstructed hemivagina and ipsilateral renal agenesis (OHVIRA) syndrome, 327, 328*f*

Obstructed labor injury complex, 2925

Obstruction
- bladder
  - response to, 3315–3316
  - RMS causing, 1113
- of seminal vesicles and ejaculatory ducts, 1407
- ureteropelvic junction, Ureteropelvic junction obstruction
- urinary tract, Urinary tract obstruction
- in UTI host defense mechanisms, 1139

Obstructive sleep apnea (OSA), 1420
- metabolic syndrome and, 1420
- nocturnal polyuria with, 2668
- treatment of, 2920.e8

ObTape, 2851

Obturator internus, 2448–2449, 2449*f*

Obturator lymph node, 1380

Obturator lymphadenectomy, 3149, 3152*f*

Obturator nerve, 2453*t*

OBTX, OnabotulinumtoxinA

Occult spinal dysraphism, 389

“Occult” stress urinary incontinence, 2591–2592

Occupation

- patient history of, 9
- renal calculi and, 2007–2008

Occupational exposures, UTUC risk and, 2186

Occupational risk, in bladder tumor, 3076, 3076*t*

Odd-skipped related 1 *(Osr1)*, vesicoureteral reflux and, 491.e1

ODS, Output display standard

Off-clamp partial nephrectomy, 2303

Ogilvie syndrome, with intestinal anastomoses, 3181

Olaparib, 3702

Older women, prevention of urinary incontinence and, 2735

Oligohydramnios, prenatal sonogram for, 409*f*

Oligomeganephronia, 742–744, 743*f*

Oliguria, 386, 461

Omental herniation, 468–469

OnabotulinumtoxinA (OBTX), 286

- to facilitate bladder filling and urine storage, 2707–2708
- neuromodulation with, 2512
- in surgical management of voiding dysfunction, 2848
- for UUI, 2546

Oncocytoma, 2391, 2392*b*

- renal, 2123–2125, 2125*b*
    - epidemiology and etiology of, 2123
    - evaluation of, 2124
    - management of, 2124–2125
    - pathophysiology of, 2123–2124, 2124*f*

Oncogenes, 1346–1347, 1347*b*

Oncologic fistulae, 2959

Oncology

- chronic inflammation in GU cancers, 1336, 1338*b*
    - bladder cancer, 1336–1338, 1337*f*–1338*f*
    - kidney cancer, 1338
    - prostate cancer, 1338
- immunologic response in GU cancers, 1333–1345, 1336*b*
    - adaptive immune system, 1334–1336, 1335*f*
    - immune editing hypothesis, 1336, 1337*f*
    - innate immune system, 1333–1334, 1334*f*–1335*f*, 1334*t*–1335*t*
- immunotherapy for GU cancers, 1333–1345, 1341*b*, 1343*b*
    - BCG in bladder cancer, 1333, 1334*f*, 1338–1339, 1339*f*
    - cancer vaccines, 1339–1340, 1340*f*–1341*f*
    - combination, 1343–1345, 1345*f*
    - immune checkpoint blockade, 1342, 1342*f*
- molecular genetics in, Molecular genetics
- pediatric, Pediatric oncology

Oncotype DX Prostate Cancer Test, 3488, 3521

One-kidney, one-clip model, of renovascular hypertension, 1917, 1918*f*

One-port catheters, 153

On-table intravenous pyelography, for pediatric genitourinary trauma, 1073–1074

Open access techniques
- for achieving extraperitoneal access and developing extraperitoneal space, 210–211
- for achieving retroperitoneal access and developing retroperitoneal space, 209–210
- for achieving transperitoneal access and establishing pneumoperitoneum, 209, 209*f*
- complications related to, 224

Open adrenalectomy, 2410–2414
- anterior transabdominal approach, 2412–2413, 2412*f*–2413*f*
- flank retroperitoneal approach, 2410–2411, 2410*f*–2411*f*
- left, 2412–2413, 2412*f*–2413*f*
- outcomes, 2421–2423
- posterior lumbodorsal approach, 2411–2412, 2411*f*–2412*f*
- thoracoabdominal approach, 2413–2414, 2413*f*–2414*f*

Open cystotomy, 156, 156*f*

Open distal ureterectomy with excision of bladder cuff, 2204

Open flank incision, 459*f*

Open nephrectomy, technique of, for benign diseases, 2254, 2254.e1*f*

Open prostatectomy, robotic prostatectomy *versus*, 3532

Open radical prostatectomy, 3548–3565

Open reconstruction, for urethral stricture disease, 1819–1828

Open segmental ureterectomy, 2207, 2208*f*–2209*f*

Open simple prostatectomy, 3450

- incision for, 3450
- patient positioning for, 3450
- space of Retzius development for, 3450

Open surgery, common urologic procedures, antimicrobial prophylaxis for, 1199–1200

Open transabdominal orchidopexy, 967

Operating room setup, for laparoscopic and robotic surgery, 205, 205*b*

Operative nerve injury, 262

Operative team placement, for laparoscopic and robotic surgery

- retroperitoneal upper abdominal procedures, 207, 207*f*
- transperitoneal upper abdominal procedures, 206*f*, 206.e1*f*

Opiates, and ED, 1509

Opioid-receptor antagonists, to facilitate bladder emptying, 2719

Opioids

- abuse, in men, 1426
- and ED, 1494–1495, 1495*t*
- for urinary tract obstruction, 795

Oral mucosa grafts, for urethral and penile reconstruction, 1806, 1806*f*

Oral therapies, for BPS/IC treatment, 1241–1244, 1241*t*, 1244*b*

Orchalgia, 1219–1220

- nonmedical therapy for, 1221
- nonradical surgical treatments, 1221

surgical therapy, 1221–1222

Orchidopexy

Fowler-Stephens, 967–968

laparoscopic, 967–968

open transabdominal, 967

for prune-belly syndrome, 593–594

transscrotal, 967, 967*f*

Orchiectomy, 3674

castration-resistant prostate cancer and, 3688

for chronic scrotal pain syndrome, 1222

delayed, 1712

evaluation after, 1712

partial, Partial orchiectomy

radical, Radical orchiectomy

simple, 1848

technique of, 1848, 1849*f*

for TGCTs, 1686

Orchiopexy, in adults, 1483–1484, 1483*f*

Orchitis, 1440

acute, 1202–1223

Orciprenaline, ureteral response to, 1888

Organ Injury Severity Scale for Kidney, of AAST, 1992*t*

Organ ischemia, during vena caval thrombectomy, 2278

Organ preservation, in penile cancer management, 1751

Organ transplantation, Transplantation

Organomegaly, as laparoscopic and robotic surgery contraindication, 204

Organ-sparing therapy, UTUC after, 2220

Orgasm, female sexual dysfunction and, 1637

Orgasmic headache, 1580–1581

Orteronel, 3695

Orthophosphate, for hypercalciuria, 2052–2053

Orthostatic proteinuria, 343–344

Orthotopic Mainz pouch, for orthotopic urinary diversion, 3246, 3248*f*

Orthotopic neobladder, 3178

Orthotopic urinary diversion, 3233–3257

- basic principles of, 3234–3235, 3235*b*
- bladder substitution in
    - bowel segment selection for, 3241–3249, 3242*b*
    - reflux prevention in, 3241–3242, 3242*b*
- complications of, 3249–3257
- continence mechanism in, 3239, 3241*b*
- continence preservation in
    - anterior apical dissection in male patient, 3239–3240
    - urethra preservation in female patient, 3240–3241, 3240*f*
- follow-up for, 3255, 3255*b*
- general perioperative management for, 3242–3243
- history of, 3233–3234, 3234*f*, 3234*b*
- oncologic factors for, 3235–3237, 3237*b*
    - locally advanced tumor stage, 3237
    - urethral recurrence risk in men, 3235–3236
    - urethral recurrence risk in women, 3236
- patient selection for, 3235–3239, 3235*f*
    - patient-related factors, 3237–3239, 3239*b*
- quality of life after, 3255–3257, 3256*t*, 3257*b*
- results with, 3249–3257
    - continence in, 3251–3254, 3252*t*–3253*t*, 3254*b*
    - urinary retention with, 3254, 3254*b*
- surgical techniques for, 3243–3246
    - Camey II, 3243, 3243*f*
    - colon and ileocolic pouches, 3246–3248
    - ileal neobladder, 3245, 3246*f*
    - ileal reservoirs, 3243
    - Kock ileal reservoir, 3243–3244, 3244*f*
    - minimally invasive, 3248–3249
    - orthotopic Mainz pouch, 3246, 3248*f*
    - Padua pouch, 3248, 3250*f*
    - right colon pouch, 3246
    - serous-lined extramural tunnel, 3244–3245, 3245*f*

        - sigmoid pouch, 3248, 3249*f*
        - Studer pouch, 3245, 3247*f*
        - T pouch modification, 3245–3246, 3247*f*

OSA, Obstructive sleep apnea

Osmolality, 15

Osmotic effect, of urothelium of bladder, 2467

Osteogenic sarcoma, of kidney, 2181

Osteomalacia, with urinary intestinal diversion, 3201–3202

Osteopontin, in crystal formation, 2011, 2014–2015

Osteoporosis, hormonal therapy and, 3680

Osteotomy

- for classic bladder exstrophy, 540–542, 541*f*–542*f*
    - complications of, 542–543
- in urinary tract reconstruction, of cloacal exstrophy, 578–579, 579*f*

Ouabain, urethral function effects of, 1903

Outcomes research, 101

- binary survival, 104–105
- definition of, 101
- disease progression, 104–105
- disease-specific mortality in, 103–104
- health services and, 101
- health-related quality of life, 112–113, Health-related quality of life
- measure, 101–102
- overall mortality in, 102–103
- proxy endpoints, 104
- recurrence, 104–105
- sexual dysfunction, 110–112
- short-term, 105–108

Outflow resistance, 682

Output display standard (ODS), in ultrasonography, 78

Ovarian formation, 318

Ovarian tumors, in pediatric patients, 1120

Ovariectomy, 3063–3064

Ovaries
- anatomy of, 324*f*, 2437–2438
- function of, 995
- ligament of, 321

Overactive bladder (OAB), 1421, 2637–2649, 2915
- afferent mechanisms in, 2641–2642
- after retropubic suspension surgery, 2770
- clinical assessment of, 2643–2646, 2646*b*
  - advanced evaluation, 2645–2646, 2645*f*–2646*f*
  - initial evaluation, 2643–2645, 2644*t*
  - laboratory examination, 2645
  - physical examination, 2645
- costs of, 2640
- definitions for, 2637, 2638*f*, 2638*t*, 2639*b*
- detrusor overactivity with, 2640
- economics of, 2638–2640
- epidemiology of, 2638–2640, 2639*t*
- estrogens for, 2709–2710, 2713–2714
- etiology of, 2643, 2643*b*
- female sexual dysfunction and, 1655–1656
- health burden of, 2639–2640
- incidence and progression of, 2639
- management of, 2646–2649, 2649*b*
  - approach, 2647–2649, 2648*f*
  - first-line therapy, 2646–2647
  - fourth-line therapy, 2647
  - second-line therapy, 2647
  - third-line therapy, 2647
- mechanisms of, 2504, 2713.e4*b*
- metabolic syndrome and, 1421
- neuromodulation for, 2510
  - rationale for, 2511, 2511*f*
- nocturnal bladder capacity and, 661–662
- pathophysiology of, 2517, 2640–2643, 2640*f*–2641*f*, 2643*b*

- pelvic organ prolapse and, 2591
- pharmacologic therapy for, 2682*t*, 2704*b*
  - antimuscarinic agents, 2681, 2681*f*
- prevalence of, 2591, 2638–2639
- questionnaires for, 2532*t*–2533*t*
- sacral nerve stimulation for, 2752–2753
- terminology for, 2637, 2638*f*, 2638*t*, 2639*b*
  - bladder pain syndrome distinguished from, 2637, 2638*f*
  - mixed symptoms incorporating urinary urgency, 2637, 2638*f*
- urgency urinary incontinence with, 2539

Overactive Bladder Questionnaire (OAB-Q), 111*t*

Overflow incontinence, patient history of, 5–6

Overflow proteinuria, 18

Overnight low-dose dexamethasone suppression test, in evaluation of adrenal masses, 2400

Overnight water deprivation test (OWDT), 2678

Ovotesticular disorder of sexual development, 322, 323*f*, 999*f*, 1006–1007

OWDT, Overnight water deprivation test

Oxalate

- in calcium stone formation, 2020
- foods containing, 2057*b*
- metabolism of, 2016–2017

Oxalobacter formigenes, 2017

Oxford guidelines

- for behavior therapy, 2722.e4*b*
- to facilitate bladder filling and urine storage, 2681*t*

Oxidative stress, stone disease and, 2013–2014

Oxidized regenerated cellulose agents, 147

Oxybutynin, 2498, 2499*t*, 3381

- for urinary incontinence, 657

Oxybutynin chloride

effects on cognition of, 2695
extended release, 2693–2694
to facilitate bladder filling and urine storage, 2682, 2682*t*
with α-adrenoreceptor antagonists, 2705
with other antimuscarinics, 2693
immediate-release, 2693
intravesical administration of, 2695
rectal administration of, 2695
topical gel, 2694
transdermal, 2694

Oxygen free radicals and oxidative stress, and PD, 1605

Oxytocin
in ED, 1494, 1495*t*
for female orgasmic disorder, 1648
for female sexual arousal disorders, 1650

Oxytocin antagonists, for PE, 1572.e2

P

P (mannose-resistant) pili, 429, 1134–1135

p16, INK4A gene

Pacemaker activity, 1881–1882, 1882*f*

Pacemaker potentials, 1881–1882, 1882*f*

Packed red blood cells, for urologic surgery, 147

Paclitaxel, for non-muscle-invasive bladder cancer, 3105

Paclitaxel, ifosfamide, and cisplatin (TIP)
for NSGCTs, 1700
for penile cancer, 1770

Pad tests
for male urinary incontinence, 2541–2543
for pelvic floor disorders, 2531–2533
use of, 109–110

PADAM, Partial androgen deficiency in aging male

Padua pouch, for orthotopic urinary diversion, 3248, 3250*f*

Pagano technique, in urinary diversion, 3186–3187, 3187*f*

Pain

- after laparoscopic and robotic surgery, 230–231
- after midurethral sling, 2870–2871
- in castration-resistant prostate cancer, 3702, 3703*t*
- definition of, 448
- intensity of, 448*f*
- management of, Analgesia
  - after laparoscopic radical prostatectomy, 3578–3579
  - in urinary tract obstruction, 795
- patient history of, 2–3
- ureteral anomalies and, 802

Painful orgasm, 1636

Paired box gene 2 *(PAX2),* vesicoureteral reflux and, 491.e1

Palliative care, 2922

Palliative surgery, for metastatic RCC, 2328, 2328*b*

Palpable testis, surgical management of, 966–967

- inguinal orchiopexy, 966–967
- transscrotal orchidopexy, 967, 967*f*

Pampiniform plexus, 1372, 1372*f*–1373*f*, 1393

Pancreas, 1668, 1668.e2*f*, 1669*f*–1670*f*

Pancreatic injury

- during laparoscopic and robotic surgery, 230.e1
- during radical nephrectomy, 2261

Panurothelial disease, UTUC, 2194

Papaverine, 1535

Papillary adenoma, of kidney, 2128, 2128*b*

Papillary necrosis, hematuria and, 18

Papillary RCC
  molecular genetics of, 1354*t*, 1358
  pathology of, 2149*t*–2151*t*, 2152, 2153*f*
Papillary urothelial neoplasm of low malignant potential (PUNLMP), 3083–3084, 3083*f*, 3092
Papilloma
  of bladder, 3081, 3081*f*
  of upper urinary tract, 2188
Papulosquamous disorders, 1278–1283, 1278*b*
  fixed drug eruption, 1282, 1283*f*
  lichen nitidus, 1281
  lichen planus, 1280–1281, 1281*f*
  lichen sclerosus, 1281–1282, 1282*f*
  psoriasis, 1278–1279, 1279*f*
  reactive arthritis, 1279–1280, 1280*f*
  seborrheic dermatitis, 1282–1283
Paracolpium, 2438
Paradoxical incontinence, Overflow incontinence
Paraganglioma
  of adrenal gland, 2235, 2235*f*
  of bladder, 3038–3039, 3039*f*
Paraganglionic system tumors, retroperitoneal tumors and, 2235, 2235*f*
Parameatal urethral cyst, 394, 882, 882*f*
Parametrium, 2438
Paraneoplastic syndromes, in RCC, 2156
Paranephric fat, 1865–1866
Parapelvic cyst, 775, 775*f*
Paraphimosis, 393, 871–872, 872*f*
Paraphimosis, urethral reconstructive surgery for, 1811
Pararenal space, anterior, 1668, 1668.e1*f*–1668.e2*f*

Parasites, in urine, 24, 25*f*

Parasitic infections, of genitourinary tract, 1319–1332

- filariasis, 1328–1331, 1332*b*
    - diagnosis, 1330
    - epidemiology, 1328–1329
    - organisms, 1328, 1328*f*
    - pathology and clinical manifestations, 1329–1330, 1329*f*–1330*f*
    - prevention and control, 1331
    - treatment, 1330–1331
- nonfilarial
    - amebiasis, 1332
    - echinococcosis, 1332
    - enterobiasis, 1332
    - trichomoniasis, 1332, Trichomoniasis
- schistosomiasis, 1319–1328, 1328*b*
    - biology and life cycle, 1319, 1320*f*–1321*f*
    - clinical manifestations, 1324
    - diagnosis, 1325–1326, 1325*f*–1326*f*
    - epidemiology, 1319–1321
    - history, 1319
    - pathogenesis and pathology, 1321–1324, 1321*f*, 1323*f*
    - prevention and control, 1327–1328
    - prognosis, 1327
    - treatment, 1326–1327

Parasympathetic blocking agents, ureteral response to, 1888

Parasympathetic decentralization, LUTD and, 2620–2621

Parasympathetic nervous system

- in retroperitoneum, 1675
- in ureteral function, 1887–1888

Parasympathetic pathways, of lower urinary tract, 2480, 2480*f*

Parasympathetic transmission, in neural control of LUT, 2593

Parasympathomimetics

- for detrusor underactivity, 2660–2661
- to facilitate bladder emptying, 2716–2718

Paratesticular cancer, RMS in pediatric patients, 1126–1127, 1127*b*

- outcomes of, 1126–1127

- presentation and staging of, 1126
- RPLND role in, 1126
- treatment of, 1126

Parathyroid hormone (PTH)
- in calcium metabolism, 2016
- in renal hypercalciuria, 2019
- renal regulation of, 1914, 1914*f*
- in resorptive hypercalciuria, 2020

Paraureteral congenital diverticula, 522, 522*f*

Paraureteral diverticula, 525

Paraurethral cysts, 394*f*, 395, 397*f*, 976–977, 977*f*

Paravaginal repair procedures
- for female incontinence, 2766–2767, 2767*b*
  - Burch colposuspension *versus*, 2773
  - results with, 2766–2767
  - suspensions in, configuration of, 2758
  - technique for, 2766, 2767*f*
  - tissue approximation in, 2759
  - urethral elevation in, 2758
- for pelvic organ prolapse
  - abdominal, 2779, 2780*t*
  - vaginal, 2780*t*, 2783, 2784*f*–2785*f*

Parenchymal compression, for laparoscopic partial nephrectomy, 2303–2304

Parental counseling for fetal intervention, 362

Parity, urinary incontinence and, 2583

Parkinson disease (PD)
- detrusor underactivity and, 2657
- diagnosis of, 2605
- in ED, 1502
- lower urinary tract dysfunction with, 2605–2606
- pathophysiology of, 2605
- treatment for, 2605

Paroxetine hydrochloride, to facilitate bladder filling and urine storage, 2702

Partial adrenalectomy, 2421, 2421*b*

Partial androgen deficiency in aging male (PADAM), 1392

Partial colpocleisis, for apical pelvic organ prolapse repair

- results with, 2812–2814
- technique for, 2811–2812, 2811*f*–2812*f*

Partial cystectomy, 3038–3043

- evaluation for, 3038–3040
- extraperitoneal approach to, 3040–3041
- for muscle-invasive bladder cancer, 3124–3125
- open, 3040
- outcomes with, 3042–3043
- surgical indications for, 3038–3040
- surgical technique for, 3040–3041
- transperitoneal approach to, 3041–3042, 3042*f*–3043*f*
- with transurethral resection of bladder tumor, 3143, 3144*f*

Partial gonadal dysgenesis, 1004

Partial nephrectomy (PN)

- for benign diseases, 2254, 2255*f*
- laparoscopic, Laparoscopic partial nephrectomy
- for malignancy, 2261–2266, 2262*f*
  - complications of, 2265–2266
  - enucleation for small cortical tumors, 2263, 2264*f*
  - preoperative considerations for, 2262–2263, 2262*f*–2263*f*, 2263.e1*f*
  - segmental nephrectomy for large polar tumors, 2263–2264, 2263.e1*f*–2263.e2*f*, 2264.e1*f*, 2265*f*
  - wedge resection for large cortical tumors, 2263, 2265*f*
- for RCC, local recurrence after, 2164–2169, 2165*b*, 2167*t*, 2169*f*
- for renal injuries, 1989–1990, 1989*f*
- for Wilms tumor, 1107–1108

Partial orchiectomy, 1712

- technique for, 1712
- for TGCT, 1686–1688

Partial prostate ablation, 3624

Partial scrotectomy, 1844–1845, 1846*f*

Partial transection, for lower ureteral injuries, 1999

Partial ureteral obstruction (PUO), hemodynamic changes with, 792

Partial urogenital mobilization (PUM), 1033–1034, 1034*f*–1036*f*

Partin tables, 3527–3528

Past surgical history, 7

Patch cavoplasty, for IVC, 2276, 2277*f*

Patch electromyography, 483

Patent urachus, 523–525, 524*f*

Pathogenesis

- of bacteriuria in pregnancy, 1185
- UTI, 1131–1140, 1140*b*
    - alterations in host defense mechanisms, 1139–1140
    - bacterial virulence factors, 1133–1134
    - early events in UPEC pathogenesis, 1134–1135, 1134*f*
    - epithelial cell receptivity, 1135–1137
    - fastidious organisms, 1133
    - natural defenses of urinary tract against, 1137–1139
    - phase variation of bacterial pili in vivo, 1135.e1, 1135.e1*f*
    - routes of infection, 1131
    - urinary pathogens, 1132, 1133*f*

Patient, Geriatric patients, Pediatric patients

Patient biases, of localized prostate cancer, 3525

Patient counseling, of localized prostate cancer, 3532–3535, 3532*f*

Patient decision making, 118, 118*f*

Patient growth, after augmentation cystoplasty, 698

Patient history, 1–9

- chief complaint, 1
- medical history, 7–9
- overview, 1
- physical examination, 9–12
- of present illness, 1–7
- special populations, 12–13

Patient positioning, 205
  for laparoscopic and robotic surgery, 205*f*
    hemodynamic effects related to, 222
  for laparoscopic kidney surgery, 2279–2285
    hand-assisted laparoscopy, 2281–2282, 2283*f*
    laparoendoscopic single-site surgery and natural orifice transluminal endoscopic surgery, 2284–2285, 2285*f*, 2286*t*
    retroperitoneal, 2279–2281, 2282*f*
    robotic-assisted laparoscopy, 2282–2284, 2284*f*–2285*f*
    transperitoneal, 2279, 2280*f*–2281*f*
  for laparoscopic radical prostatectomy, 3568, 3569*f*
  for open simple prostatectomy, 3450
  for prostate biopsy, 3497
  for robot-assisted laparoscopic simple prostatectomy, 3454
Patient preparation
  for cystourethroscopy, 187–190, 189*t*
  for surgery, Preoperative care
  for ureteroscopy, 199–200
  for urodynamic studies, 2552
Patient safety, in ultrasonography, 77–78
Patient selection
  for brachytherapy, 3599
  for focal therapy for prostate cancer, 3620–3621
  for prostate cancer, 3540–3541
Patient-physician relationship, in intraoperative consultation, 296
Patient-reported outcome measures, for male urinary incontinence, 2541, 2541.e1*f*–2541.e2*f*, 2542*f*
Patient-reported outcomes, 108–113, 110*t*, 476
  methods of assessing, 108–109
  selecting an appropriate, 477
  tools for use in females with sexual dysfunction, 112*t*
  tools for use in men with sexual dysfunction, 112*t*
  tools for use primarily in women with urinary incontinence, 111*t*
Pazopanib, for RCC, 2179*t*–2180*t*, 2335–2336
PBR, Peripheral benzodiazepine receptor

PBS, Prune-belly syndrome

PCA3, Prostate cancer antigen 3

PCI, Protein C inhibitor

PCN, Percutaneous nephrostomy

PCPT, Prostate Cancer Prevention Trial

PCr, Plasma creatinine

PC-RPLND, Postchemotherapy retroperitoneal lymph node dissection

PCS, Post-chemotherapy surgery

PD-1, Programmed death-1

PDE5-I, Phosphodiesterase type 5 inhibitors

PDT, Photodynamic therapy

Pearly penile papules, 1302, 1303*f*

Pectus excavatum, 587*f*, 600

Pediatric ACC, 2388

Pediatric catheters, size of, 153*t*

Pediatric genitourinary trauma, 1065–1086

- assessment of
    - computed tomography for, 1066
    - focused assessment with sonography for trauma, 1066
    - renal trauma grading system for, 1066–1072, 1067*f*–1069*f*, 1067*t*, 1069*t*
    - renal ultrasonography for, 1066
- bladder injuries, 1080–1083, 1080*t*, 1083*b*
    - imaging of, 1080
    - management, 1080–1081
    - pelvic fracture of, 1080
    - presentation of, 1080
- blunt *versus* penetrating, 1069
- genital injury in, 1083–1086, 1086*b*
- indications for renal imaging for, 1065, 1066*t*
- management of, 1069–1070
    - angioembolization of isolated renal segment, 1072
    - chronic flank pain, 1078

        - chronic kidney disease, 1078
        - congenital anomalies and renal injuries, 1075–1076
        - control of renal vasculature, 1074
        - early repeat imaging, 1070
        - follow-up and activities with solitary kidney, 1078
        - follow-up and long-term issues, 1076, 1078*b*
        - fusion anomalies and ectopic kidney, 1076, 1077*f*
        - hypertension, 1077–1078
        - late repeat imaging and assessment of renal function, 1077
        - nephrostomy tube, 1072
        - nonoperative, 1070, 1073*b*
        - on-table intravenous pyelography or ultrasonography, 1073–1074
        - operative, 1073–1078, 1076*b*
        - percutaneous drain, 1071–1072, 1072*f*
        - persistent urine leak, 1070, 1071*f*
        - reconstruction *versus* nephrectomy, 1074
        - renal arterial laceration, 1074
        - renal arterial occlusion, 1074
        - renal exploration, 1073
        - renal exploration with repair of urine leak, 1072
        - renal pelvis rupture, 1075
        - ureteral stent, 1071
        - ureteropelvic junction disruption, 1074–1075, 1075*f*
        - ureteropelvic junction obstruction, 1076, 1076*f*
    - penile, 1083–1084, 1083*t*
    - persistent or delayed bleeding of, 1072–1073
    - scrotal, 1084, 1084*t*, 1085*f*
    - ureteral, 1078–1079, 1080*b*
        - American Association for Surgery of Trauma Classification, 1079, 1079*t*
        - distal ureteral injury surgical repair, 1079
        - epidemiology of, 1078
        - follow-up imaging, 1079
        - imaging findings of, 1079
        - lengthy ureteral injuries, 1079
        - management of, 1079
        - presentation of, 1078–1079
        - proximal or mid-ureteral injury surgical repair, 1079
    - urethral, 1081–1083, 1081*t*, 1083*b*
        - evaluation of, 1081
        - in females, 1083
        - management of, 1081–1083, 1082*f*
    - vaginal, 1084–1086, 1085*t*
- Pediatric kidney stone disease

conservative management of, 865*b*

evaluation of, 854–856, 859*b*

extrarenal manifestations of, 853–859, 854*b*

goals of therapy for, 860–861

laparoscopic and robotic-assisted pyelolithotomy for, 868–870

management of, 853–870, 854*f*

medical expulsion therapy for, 859–860

medical history in, 856–857

medications for, 869–870

metabolic investigations in, 856–857, 857*t*

percutaneous nephrolithotomy, 865–868, 866*t*, 868*b*

- complications, 868
- planning for, 867
- technique for, 867–868, 867*f*–868*f*

physical examination for, 856–857

secondary prevention for, 868–869

shock wave lithotripsy for, 864–865, 865*b*

- limitations and concerns with, 865
- stone size, location, and composition, 864–865
- technique for, 865

surgical management of, 860, 860*t*

ureteroscopic management of, 861–863, 864*b*

- equipment for, 863, 863*f*
- indications for, 861, 862*t*
- limitations and complications of, 864
- technique for, 863–864, 863*f*

urinary metabolic abnormalities of, 857–858

- cystinuria, 859
- hypercalciuria, 857–858, 858*t*
- hyperoxaluria, 858, 858*t*
- hyperuricosuria, 858*t*, 859
- hypocitraturia, 858–859
- primary hyperoxaluria, 858
- secondary hyperoxaluria, 858–859

Pediatric nephrology, urologic aspects of, 341–357
- acute kidney injury, 353–354, 353*t*, 353*b*–354*b*
- chronic kidney disease, 354–355, 354*t*, 355*b*
- cystic renal disease, 349–350
- end-stage renal disease, 355–357
- fluid and electrolyte homeostasis, 341–342
- glomerular disease, 344–348, 344*b*
- hematuria, 342–343, 343*b*
- hypertension, 351–353, 352*b*
- proteinuria, 343–344, 344*b*
- renal function, 341–342
- tubulopathies, 348–349
- urolithiasis, medical management, 350–351, 351*b*

Pediatric oncology, 1087–1127
- adrenal tumors, neuroblastoma, Neuroblastoma
- bladder tumors
  - adenocarcinoma and squamous cell carcinoma, 1118
  - in augmented bladders, 1118
  - benign, 1119
  - RMS, Bladder RMS
  - TCC, 1117–1118
  - urachal carcinoma, 1118
- female genital tract tumors, 1121*b*
  - cervical or uterine RMS, 1120
  - ovarian, 1120–1121
  - vaginal RMS, 1119–1120, 1119*f*
  - vulvar RMS, 1119
- male reproductive tumors
  - paratesticular RMS, 1126–1127, 1127*b*
  - testicular, Testicular tumors
- renal tumors
  - angiomyolipoma, 1110, 1110*f*
  - CCSK, 1108–1109
  - CMN, 1109
  - CPDN, 1109
  - metanephric adenofibroma, 1109
  - RCC, 1109–1110
  - RTK, 1109
  - solitary multilocular cyst nephroma, 1109

    - Wilms tumor, Wilms tumor

Pediatric patients
  - bladder and bowel dysfunction, Bladder and bowel dysfunction
  - bladder anomalies in, Bladder anomalies, in children
  - imaging of, *see specific imaging modalities*
  - kidneys of, 1065
  - lower urinary tract dysfunction in, 652
    - clinical significance of, 652
    - comorbidities with, 653–654, 655*b*
    - enuresis, Enuresis
    - epidemiology of, 652, 655*b*
    - giggle incontinence, 658–660
    - pollakiuria, 660
    - quality-of-life and, 652–653, 655*b*
    - self-esteem and, 652–653
    - terminology of, 654–655
    - underactive bladder, 660
    - urinary incontinence and, 655–660, 660*b*
    - vaginal reflux, 660
  - neuromuscular dysfunction of lower urinary tract in, Neuromuscular dysfunction of lower urinary tract, in children
  - transitional urology for, Transitional urology
  - ureteral anomalies in, Ureteral anomalies
  - urinary tract reconstruction in
    - antireflux, 683–685, 685*b*
    - augmentation cystoplasty for, 691–706, 702*b*, Augmentation cystoplasty
    - bladder neck reconstruction, 685–690, 690*b*
    - continent urinary diversions, 706–713, 711*b*, Continent urinary diversions
    - patient evaluation for, 681–682, 683*b*
    - patient preparation for, 682–683, 683*b*
    - summary for, 713
    - urodynamics for, 681–682

Pediatric Penile Perception Score (PPS), 942–943, 942*f*

Pediatric renal transplantation, 1054–1064
  - bladder preparation for
    - capacity, 1056, 1056*f*
    - clean intermittent catheterization, 1057
    - general issues, 1054–1055
    - hypertonicity, 1055–1056
    - infections, 1056–1057

    - complications with, 1060–1064, 1061*t*, 1064*b*
        - bladder dysfunction, 1063
        - hydronephrosis, 1062–1063, 1063*f*
        - infection, 1061
        - obstruction, 1062–1063, 1062*f*–1063*f*
        - reflux, 1062, 1062*f*
        - stones, 1063–1064
        - urine leaks, 1060–1061, 1061*f*, 1061.e1*f*
    - cutaneous stomas for, 1058
    - defunctionalized bladder, 1057–1058
        - augmentation decision, 1057–1058
        - neuropathic, 1057
        - non-neuropathic, 1057
    - native kidney management, 1059, 1059.e4*f*–1059.e5*f*
    - nephrectomy with, 1059
    - pretransplant assessment for, 1054, 1054*b*, 1055*f*
    - pretransplant preparation for, 1054–1059, 1057*b*
    - reconstruction strategies for, 1058–1059, 1059*b*
        - dialysis issues, 1058
        - enterocystoplasty, 1058–1059, 1058.e1*f*
        - graft placement, 1058, 1058.e2*f*
        - native nephrectomy, 1059, 1059.e2*f*–1059.e4*f*
        - timing of, 1058
    - ureteral anastomosis, 1060, 1060*b*, 1060.e1*f*–1060.e4*f*
    - ureteral stenting, 1060
- Pediatric sepsis, 452
- Pediatric Urinary Incontinence Quality of Life Score (PinQ), 476–477, 653
- Pediatric urogenital imaging, 403–425
    - computed tomography for, 416–418
    - conventional radiography for, 415
    - DMSA renal cortical scintigraphy, 418
    - magnetic resonance imaging for, 412–415
    - technique of, 403
        - ionizing, 403, 403*b*
        - nonionizing, 403, 403*b*
    - ultrasonography for, 404–412
    - voiding cystourethrography (VCUG), 415–416
- Pediatric urology, 395*b*

- advanced imaging for, 390–391
    - computed tomography, 390–391
    - magnetic resonance imaging, 390
- flank pain in, 400
- imaging for, 388–391
    - prenatal ultrasonography, 389
    - renal bladder ultrasound, 388–389
    - ultrasonography, 388–389
- overview of, 388
- presentations by genitourinary region, 391–402
- renal scintigraphy for, 390
    - diuretic renography, 390
    - renal cortical scintigraphy, 390
- triage of common, 389*t*
- urodynamic testing, 390
- voiding cystourethrogram, 389–390
    - fluoroscopy, 389
    - genitography, 390
    - nuclear cystography, 389–390

Pedicle effect, 468

Pediculosis pubis
- infestation, 1295–1296, 1296*f*
- as STD, 1271

PEKMB, Pseudoepitheliomatous, keratotic, and micaceous balanitis

Pelvic abscesses, after mid-urethral sling surgery, 2870

Pelvic arterial ischemia, detrusor inactivity and, 2657

Pelvic autonomic plexus, 2453–2454, 2454*f*–2455*f*

Pelvic bone defects, in bladder exstrophy, 531–532, 531*f*

Pelvic cystic lesion, and distended bladder, 385

Pelvic drain, after laparoscopic radical prostatectomy, 3579

Pelvic examination
- in female, physical examination for, 12
- for PFDs, 2528

Pelvic fascia

  - female, 2427, 2429*f*
  - male, 2449, 2452*f*
  - surgical anatomy of, 3549–3550, 3550*f*

- Pelvic fibrosis, as laparoscopic and robotic surgery contraindication, 203
- Pelvic floor
  - defects in
    - in bladder exstrophy, 532, 532*f*
    - prostatitis and, 1208, 1208*f*
  - female, 2427, 2428*f*
    - muscles of, 2430–2432, 2432*f*
  - genitourinary malignancies, 2920
  - support mechanism of, 2597–2598, 2598*f*
- Pelvic floor disorders (PFDs)
  - diagnostic evaluation of, 2525–2528
    - benign prostatic hyperplasia and, 2528
    - general considerations for, 2525–2526, 2526*t*, 2526*b*, 2527*f*
    - genetics and, 2528
    - history for, 2526, 2528*b*
    - history of present illness, 2527
    - male incontinence, 2528
    - medications and, 2528, 2528*t*
    - past medical and surgical history, 2527–2528
  - impact of, 2525
  - management of, 2537–2538
    - for incontinence, 2537
    - for pelvic prolapse, 2537–2538
  - physical examination for, 2528–2530, 2529*f*–2530*f*, 2529*t*–2530*t*, 2530*b*
  - supplemental evaluation of, 2530–2537, 2531*t*, 2533*b*
    - cystoscopy, 2534
    - dye testing, 2533
    - magnetic resonance imaging, 2536–2537
    - pad tests, 2531–2533
    - postvoid residual, 2534
    - quality of life instruments for, 2531, 2532*t*–2533*t*
    - questionnaires for, 2531, 2532*t*–2533*t*
    - radiographic imaging, 2536
    - ultrasonography, 2536
    - urinalysis, 2534
    - urodynamics, 2534–2536, 2536*b*
    - voiding diaries for, 2530

  symptom quantification instruments for, 2531
  terminology of, 2526*t*

Pelvic floor muscle (PFM)
  assessment of, for PFMT, 2723–2725
  contraction of, to prevent stress incontinence, 2540, 2725
  dysfunction of, behavioral training for, 2732–2735
  electrical stimulation of, 2729–2730
  female, 2430–2432, 2432*f*
  for SUI, 2540
  teaching control of, 2725

Pelvic floor muscle exercise (PFME), for urinary incontinence, in geriatric patients, 2919.e2

Pelvic floor muscle training (PFMT), 2723–2727
  assessment of PFMF, 2723–2725
  biofeedback for, 2729, 2729*f*, 2729.e1*f*–2729.e2*f*
  evidence for, 2725–2726
  exercise regimens for, 2725, 2725.e1*t*
  handout for, 2725.e1*t*
  levels of evidence and recommendations for, 2722.e1*b*–2722.e4*b*
  as nonsurgical treatment option, 2833
  for prevention of stress incontinence, 2725
  teaching of, 2725
  vaginal cones for, 2726, 2726.e1*f*

Pelvic floor physiotherapy
  for chronic scrotal pain syndrome, 1221
  for detrusor underactivity, 2660

Pelvic fracture, bladder injuries with, 3057

Pelvic fracture urethral injuries (PFUIs), 1828–1834
  evaluation of, 1829
  postoperative management of, 1832–1834, 1834*f*
  repair of, 1829–1832, 1830*f*–1833*f*

Pelvic inlet, female, 2427, 2428*f*

Pelvic lymphadenectomy (PLND)
  extended
    common iliac, 3152, 3153*f*–3154*f*
    external iliac, 3148–3149, 3151*f*
    hypogastric, 3149–3152, 3153*f*
    obturator, 3149, 3152*f*
    presacral, 3152, 3154*f*
  in laparoscopic radical prostatectomy, 3577
  for penile cancer, 1761–1762
  for prostate cancer staging, 3521
  radical cystectomy with
    anatomic extent of, 3115–3116
    bilateral, 3115
    density of, 3117
    distal urethra management, 3118
    extracapsular nodal extension, 3117
    intraoperative decision making, 3117–3118
    intraoperative frozen sections of ureter, 3117–3118
    managing female urethra in, 3118
    for muscle-invasive bladder cancer, 3114–3119
    number of lymph nodes identified, 3116–3117, 3116*f*
    oncologic outcomes following, 3118–3119, 3118*t*
    prostatic urothelial carcinoma and, 3118
  with transurethral resection of bladder tumor, 3137–3138, 3138*f*–3139*f*
Pelvic muscle electromyography (EMG), 2557
Pelvic muscle training device, 2727*f*
Pelvic nerve afferents, 2481–2482, 2481*t*, 2482*f*
Pelvic node dissection, in robotic prostatectomy, 3580–3581
Pelvic organ cross-sensitization, in BPS/IC etiology, 1232.e9, 1232.e9*b*
Pelvic organ prolapse (POP), Pelvic floor disorders
  classification of, 2526, 2527*f*, 2587–2589, 2589*b*
    systems for, 2529–2530, 2529*f*, 2530*t*
  conditions associated with, 2592*b*
  consequences of, 2592–2593, 2592*b*
  definition of, 2587–2589, 2589*b*
  epidemiology of, 2590–2591, 2591*b*
  female sexual dysfunction and, 1656–1657

- financial impact of, 2593
- in geriatric patients, 2920.e9–2920.e10
- history of, 2528
- imaging of, 2441–2442, 2442*f*
- incidence of, 2590
- midurethral sling outcomes for, 2861–2862
- pathophysiology of, 2598–2599, 2599*b*
- physical examination of, 2588–2589, 2588*f*–2589*f*
- prevalence of, 2590
- on quality of life, 2592–2593
- questionnaires for, 2532*t*–2533*t*
- reconstructive surgery for, 2776–2829
    - in anterior compartment, 2778–2790, 2790*b*
        - abdominal paravaginal repair, 2780*t*–2782*t*, 2787, 2788*f*
        - anterior colporrhaphy, 2778–2783, 2779*f*, 2780*t*
        - with cadaveric fascia, 2781*t*–2782*t*, 2786, 2786*f*
        - with grafts, 2783, 2785*f*
        - with polypropylene mesh, 2781*t*–2782*t*, 2783–2786, 2786*f*
        - with porcine dermis, 2781*t*–2782*t*, 2786–2787, 2787*f*
        - with sling, 2788–2790, 2789*f*
        - vaginal paravaginal repair, 2780*t*, 2783, 2784*f*–2785*f*
    - in apical compartment, 2790–2809
        - abdominal sacrocolpopexy, 2798–2809, 2800*f*–2801*f*
        - colpocleisis, 2809–2814, Colpocleisis, for apical pelvic organ prolapse repair
        - comparison of procedures of, 2809–2823
        - hysteropexy, 2815–2823
        - iliococcygeus suspension, 2797–2798, 2799*f*
        - sacrospinous ligament fixation, 2793–2797, Sacrospinous ligament fixation (SSLF), for pelvic organ prolapse repair
        - uterine prolapse, 2814
        - uterine sparing, 2815–2823
        - uterosacral ligament suspension, 2790–2793
        - vaginal hysterectomy with McCall culdoplasty technique, 2814–2815, 2815*f*
    - in apical vaginal compartment
        - colpocleisis, Colpocleisis, for apical pelvic organ prolapse repair
        - sacrospinous ligament fixation, Sacrospinous ligament fixation
    - approach to, 2778*t*
    - mesh for, 2776–2778, 2778*t*
        - complications from, 2787
    - in posterior compartment, 2823–2829, 2829*b*
        - interposition graft repairs of, 2829
        - posterior colporrhaphy, 2825–2829, 2825*f*
    - preoperative counseling for, 2776, 2777*b*
    - preparation for, 2776, 2777*b*
- risk factors for, 2590–2591
- social impact of, 2592
- societal costs of, 2592
- symptoms of, 2587–2588
- urinary incontinence and, 2591–2592, 2592*b*

Pelvic Organ Prolapse Quantification (POPQ), 2529–2530, 2529*f*, 2530*t*, 2588, 2589*f*

Pelvic organs, female, 2436–2438, 2437*f*

Pelvic pain, 2988

  in mesh complication, 2881

Pelvic plexus, for retropubic radical prostatectomy, 3548, 3549*f*

Pelvic plexus injury, LUTD after, 2620–2621

Pelvic resections, RPLND with, 1720

Pelvic sidewalls, female, 2430, 2432*f*

Pelvic surgery, 645–647

  medical diagnoses and, 2528

  operative team placement for, transperitoneal and extraperitoneal procedures, 207, 208*f*

  pathogenesis for, 647

  presentation for, 645–647

  specific recommendations for, 647

Pelvic ultrasonography, 482–483, 482*f*

  bladder wall thickness, 482, 483*f*

  postvoid residual, 482

  rectal diameter, 482

  transabdominal, Transabdominal pelvic ultrasonography

  urinary debris, 482

Pelvicalyceal system, anatomy of, 1872–1873, 1872*f*

  endoscopic, 1875–1876, 1875*b*, 1875.e1*f*

Pelvis

  clinical staging of, TGCTs and, 1689, 1689*f*

  female, Female pelvis

  male, Male pelvis

Pembrolizumab, for microsatellite instability-high cancers, 3698–3699

Pemphigus vulgaris, 1284, 1284*f*

Pendulous urethra, Penile urethra

Penectomy, for penile cancer, 1752

Penetrating trauma
  bladder, 3055
  penile, 3049–3051
  renal, 1982
    imaging of, 1984
    nonoperative management of, 1987
  scrotal, 3051
  ureteral, 1992, 1992*t*
    diagnosis of, 1992–1993

Penile angiography, 1523, 1524*f*

Penile anomalies, 871–886
  abnormal number, 876–877
    aphallia, 876–877, 877*f*
    diphallia, 877, 877*f*
  abnormal orientation, 880–882
    curvature, 880–881, 881*f*
  accessory urethral openings, 883–884
    congenital urethral fistula, 883, 883*f*
    urethral duplication, 883–884, 884*f*
  genital lymphedema, 884–885
  inconspicuous penis, 872*t*, 877–879, 879*f*
    buried penis, 877–878, 878*f*–879*f*
    webbed penis, 878–879, 879*f*
  masses, 882–883
    congenital penile nevi, 883, 883*f*
    inclusion cysts, 882–883, 882*f*
    juvenile xanthogranuloma, 883
    median raphe cysts, 882, 882*f*
    parameatal urethral cyst, 882, 882*f*
  micropenis, 872*t*, 879–880, 880*f*, 880.e1*b*, 881*b*
  penoscrotal transposition, 885–886, 886*f*
  prepuce, 871–876
    circumcision, 872–876
    phimosis and paraphimosis, 871–872, 872*f*
  priapism, 885, 885*b*
  torsion, 881–882, 881*f*

Penile blood flow, historical and investigational studies of, 1523–1525

Penile brachial pressure index, 1523

Penile cancer

- chemotherapy for, 1769–1771, 1772*b*
  - adjuvant, 1771
  - combination, 1770–1771, 1770*t*
  - single-agent, 1769–1770
  - surgical consolidation after, 1771
- inguinal lymph node dissection for, Inguinal lymphadenectomy
- as non-AIDS-defining urologic malignancy, 1268
- nonpalpable inguinal adenopathy, 1792–1796, 1792*b*
  - dynamic sentinel lymph node biopsy, 1793
  - endoscopic inguinal lymphadenectomy, 1794
  - follow-up, 1793
  - modified inguinal lymph node dissection, 1794
  - robotic inguinal lymphadenectomy, 1794
  - sentinel lymph node biopsy, 1792–1793
  - superficial inguinal lymph node dissection, 1793–1794
  - surgical technique, 1794–1796, 1795*f*, 1797*f*–1798*f*
  - technique of, 1793
- nonsquamous neoplasms, 1771–1775, 1775*b*
  - adenosquamous carcinoma, 1774
  - basal cell carcinoma, 1772
  - extramammary Paget disease, 1774
  - lymphoreticular malignant neoplasm, 1774
  - melanoma, 1772, 1773*f*
  - metastases, 1774–1775
  - sarcomas, 1772–1774
- palpable inguinal adenopathy or positive inguinal lymph nodes, 1796–1800
  - adjuvant chemotherapy, 1798–1800
  - curative purposes, surgery for, 1796
  - palliative purposes, surgery for, 1800
  - radical inguinal lymph node dissection, 1796–1798, 1799*f*–1800*f*
- radiation therapy for, 1765–1769, 1769*b*
  - adverse effects of, 1767–1768
  - inguinal areas, 1768–1769, 1769*f*
  - primary lesion, 1765–1768
- risk-based management of inguinal region in, 1762–1765, 1763*f*–1764*f*
  - bulky adenopathy and fixed nodal metastasis, 1765
  - high-risk patients, 1762–1765
  - low- to intermediate-risk patients, 1762

- very low-risk patients, 1762
- surgical management of, 1753*t*, 1753*b*, 1792
  - amputation, 1752–1753

Penile elephantiasis, as filariasis clinical manifestation, 1330

Penile erection, 1485–1512, Erectile dysfunction

- physiology of, 1485–1500, 1490*b*, 1495*b*
  - functional anatomy of, 1485–1487, 1486*f*–1488*f*, 1486*t*
  - hemodynamics and mechanism of erection and detumescence, 1487–1489, 1489*f*, 1490*t*
  - historical context of, 1485
  - neuroanatomy and neurophysiology of, 1489–1495, 1490*f*, 1491*t*–1492*t*
  - smooth muscle, 1495–1500, 1496*f*–1497*f*, 1500*b*, 1501*f*

Penile imaging, in priapism, 1549–1550, 1550*f*, 1550*b*

Penile incisions, in urologic surgery, 143–144, 143*f*

Penile magnetic resonance imaging, 1524

Penile near infrared spectrophotometry, 1524–1525

Penile pain, patient history of, 2

Penile plethysmography, 1524

Penile prosthesis

- for Peyronie's disease
  - indications for, 1624
  - techniques for, 1624–1625, 1625*t*
- surgery, 1537

Penile rehabilitation, role of, in laparoscopic radical prostatectomy, 3579

Penile revascularization surgery, 1537

Penile thermal sensory testing, 1527

Penile torsion, 394

Penile traction, and PD, 1614–1615, 1617*t*

Penile transplantation, 1838–1842, 1840*f*, 1842*b*

- after trauma, 1841

Penile tumescence and rigidity monitoring, 1525–1526, 1525*f*

Penile urethra, 1383, 1383*f*, 1807.e4*f*, 1807.e8

- carcinoma of, 1780–1781, 1781*f*

Peninsular flaps, for urethral and penile reconstruction, 1807

Penis

- amputation of
  - for penile cancer, 1752–1753
  - traumatic, 3050–3051
- anatomy of, 1387*b*, 1485–1487, 1486*t*, 1807.e8–1807.e9, 1807.e10*b*
  - arterial supply, 1384–1385, 1386*f*, 1807.e5*f*
  - arteries, 1487, 1487*f*
  - blood supply, 1807.e8–1807.e9
  - corpora cavernosa, corpus spongiosum, and glans penis, 1485–1486
  - lymphatics, 1386, 1807.e9
  - nerve supply, 1386, 1387*f*, 1807.e9
  - reconstructive surgery and, 1807, 1807.e1*f*–1807.e7*f*
  - sphincteric, 1807.e8
  - structure, 1383–1384, 1385*f*–1386*f*
  - urethral, 1807.e8
  - venous drainage, 1385, 1487, 1488*f*, 1807.e5*f*
- curvatures of, Curvatures of penis
- in genitourinary tuberculosis, 1309
- imaging of
  - cavernosogram, 1386, 1387*f*
  - Doppler ultrasound, 1386, 1387*f*
  - magnetic resonance imaging, 1386, 1388*f*
- injuries and trauma of, 3048–3051
  - amputation, 3050–3051
  - animal and human bites, 3050
  - burns, 3053
  - with circumcision, 874*f*, 875
  - fracture, 3048–3049, 3048.e1*f*, 3049*f*–3050*f*, 3049.e1*f*
  - gunshot wounds, 3049–3050
  - microvascular, 3050
  - penetrating, 3049–3051
  - strangulation, 3051
  - total reconstruction after, 1841
  - zipper, 3051
- length of, 871, 872*t*
- nerve supply of, 305–306
- neuroanatomy and neurophysiology of
  - neurotransmitters and, 1492–1495, 1495*t*
  - spinal centers and peripheral pathways, 1489–1491, 1490*f*, 1491*t*

  - supraspinal pathways and centers, 1491–1492, 1491*t*–1493*t*
- physical examination for, 10–11
- physiology of
  - corpora cavernosa, 1488–1489, 1489*f*
  - corpus spongiosum and glans penis, 1489, 1490*t*
- preservation of, in penile cancer management, 1751
- reattachment of, 3051*b*
- reconstructive surgery of, 1804–1842, 1805*b*, 1813*b*, 3054
  - for amyloidosis, 1810
  - anatomy of, 1807, 1807.e1*f*–1807.e7*f*
  - balanitis xerotica obliterans, 939, 940*f*
  - for balanitis xerotica obliterans, 939, 940*f*
  - for circumcision complications, 1811–1812
  - in classic bladder exstrophy, 551–552, 552*f*–553*f*
  - for curvatures of penis, 1836–1838, 1838*b*
  - for failed epispadias repair, 1813
  - for failed hypospadias repair, 1812–1813
  - for female-to-male transgender, 1841–1842, 1842*b*
  - for fistulae of posterior urethra, 1835–1836, 1836*b*
  - for glans dehiscence, 937, 938*f*
  - for LS, 1808–1810, 1809*f*
  - in male epispadias, 569
  - for meatal stenosis, 937–938, 1811
  - for paraphimosis, balanitis, and phimosis, 1811
  - penile transplantation, 1838–1842, 1840*f*, 1842*b*
  - for PFUIs, 1828–1834, 1830*f*–1834*f*
  - principles of, 1804–1807, 1806*f*–1807*f*, 1808*b*
  - for recurrent penile curvature, 939–941, 940*f*
  - for urethral diverticulum, 938–939, 939*f*, 1810–1811
  - for urethral stricture, 938, 1814–1828, 1814*f*, 1828*b*
  - for urethrocutaneous fistula, 935–937, 936*f*–937*f*, 1810
  - for vesicourethral distraction defects, 1834*b*, 1835, 1836*b*
- skin complications of, 874
- tumors of, 1742–1775
  - malignant, Penile cancer
  - premalignant cutaneous lesions, 1742
    - Buschke-Löwenstein tumor (giant condyloma acuminatum), 1742.e1*f*, 1742.e3
    - carcinoma in situ (penile intraepithelial neoplasia), 1742
    - non-human papillomavirus-related, 1742.e1–1742.e2
    - virus-related, 1742.e2–1742.e3, 1743*b*
  - squamous cell carcinoma, 1743–1751, Squamous cell carcinoma
  - surgical management of, 1751–1753, 1753*t*, 1753*b*
    - circumcision and limited excision strategies, 1752–1753
    - contemporary penile amputation, 1752–1753
    - laser ablation, 1752
    - Mohs micrographic surgery, 1752

organ preservation, 1751

ultrasonography of, 85–88, 86*f*

Penn pouch, 3224–3225, 3224*f*

Penoscrotal transposition, 886*f*

Penrose drains, 148

Pentosan polysulfate, for chronic scrotal pain syndrome, 1216

Pentoxifylline, for PD, 1611, 1616*t*

Peptide hormones, of reproductive axis, 1390, 1391*f*

Peptidergic agents, in ureteral function, 1889

PERC Mentor, 176, 177*f*

Percutaneous antegrade endopyelotomy, for ureteropelvic junction obstruction, 1947

complications with, 1949

indications and contraindications for, 1947, 1947*f*

patient preparation for, 1947

postoperative care for, 1948

results with, 1949

technique of, 1947–1948

Percutaneous drain, for pediatric genitourinary trauma, 1071–1072, 1072*f*

Percutaneous endopyeloplasty, for ureteropelvic junction obstruction, 1949

Percutaneous epididymal sperm aspiration, in sperm retrieval, 1474, 1474*f*

Percutaneous nephrolithotomy (PCNL), 243.e1, 2103–2107, 2105*b*

anesthesia for, 2104

antibiotics for, 2104

calyceal diverticula and, 2105, 2105*f*

clinical use of, 246

complications of, 2107

CyberWand, 245

horseshoe kidney and, 2105–2106

laser fragmentation, 244.e3

morbid obesity and, 2089, 2106–2107

- old age and frailty and, 2089–2090
- patient preparation, 2103–2104
- pediatric, 865–868, 866*t*, 868*b*
    - complications, 868
    - planning for, 867
    - technique for, 867–868, 867*f*–868*f*
- prior renal surgery and, 2090
- for renal calculi
    - in calyceal diverticula, 2078
    - in horseshoe kidneys, 2080
    - lower pole calculi, 2081, 2081*f*, 2082*t*, 2083*f*
    - in renal ectopia, 2080, 2081*f*
    - stone composition and, 2076, 2076*f*
    - stone localization and, 2075
- renal function and, 2088–2089
- renal transplants and, 2091
- ShockPulse-SE, 245–246
- solitary kidney and, 2089
- spinal deformity or limb contractures and, 2090
- for staghorn calculi, 2074
- staghorn calculi or complex stones and, 2106
- stone burden and
    - between 1 and 2 cm, 2073
    - greater than 2 cm, 2074
    - up to 1 cm, 2072–2073
- stone removal in, 2104–2105
- tissue effects, 246
- transplantation and pelvic kidneys and, 2106, 2106*f*
- uncorrected coagulopathy and, 2090
- for ureteral calculi
    - duplicated collecting system and, 2087
    - in megaureter, 2087
    - outcome of, 2091–2093
    - stone composition and, 2087
    - stone localization and, 2085–2086, 2086*t*
- urinary diversion and, 2091
- urinary tract infection and, 2088

Percutaneous nephrostomy drains, 288

Percutaneous nerve evaluation test, for sacral neuromodulation, 2754

Percutaneous posterior tibial nerve stimulation (PTNS), for UUI, 2546

Percutaneous procedures, antimicrobial prophylaxis for, 1199

Percutaneous pyelolithotomy, 160

Percutaneous renal access and drainage, 160–182

- anatomic considerations of, 160–164
  - collecting system, 161–162, 162*f*
  - intrarenal vasculature, 162–164, 163*f*
  - perirenal anatomy, 160–161, 161*f*
  - renal parenchyma, 161–162
- anesthetic considerations for, 165
- complications, 178–182, 182*b*
  - acute hemorrhage, 178
  - death, 182
  - delayed hemorrhage, 178–179
  - fever and sepsis, 181
  - loss of renal function, 182
  - metabolic and physiologic, 181
  - neuromusculoskeletal, 181–182
  - pleural injury, 180–181
  - venous thromboembolism, 182
  - visceral injury, 179–180
- history of, 160
- image guidance for puncture, 166–169
- indications of, 160
  - diagnostic studies, 160
  - percutaneous renal surgery, 160
  - simple drainage, 160
  - therapeutic instillations, 160
- obtaining, 169*b*
- postprocedural drainage, 173–176
  - general considerations of, 174–175
- special situations, 177–178
  - horseshoe kidney, 177
- surgical technique, 164–176
  - advanced guidance techniques, 169–172
  - antimicrobial prophylaxis, 164
  - choice of calyx for access, 165
  - diagnostic imaging, 164

        - interpolar calyx, 166
        - lower pole calyx, 166
        - management of anticoagulation, 164
        - obtaining access, 164
        - patient positioning, 164
        - prone position, 164–165, 165*f*
        - supine position, 165
        - upper pole calyx, 165–166, 166*f*
    - training for, 176

Percutaneous renal tumor ablation, 2312, 2313*f*, 2318

Percutaneous Shunting in Lower Urinary Tract Obstruction (PLUTO) trial, 364

Percutaneous stone removal, 2069.e2

Percutaneous surgery, 243.e2

Percutaneous tibial nerve stimulation (PTNS), 2748–2751, 2749*f*
- clinical results of, 2749–2750
- compared with other treatments, 2750
- history of, 2749
- implantable, 2750–2751, 2751*f*
- prognostic factors for, 2750
- technique of, 2749, 2750*f*

Perforating artery, 136*f*

Perforation
- of bladder, in transurethral resection of bladder tumor, 3135*f*
- with monopolar transurethral resection of prostate, 3417
- ureteral, ureteroscopic, 2002
- in ureteroscopic stone management, 2108

Perfusion phase, 92–93

Perfusion studies, for UPJO, 1944–1945

Perinatal neuroblastoma, surgical treatment of, 1093

Perinatal testicular torsion, 897, 897*f*

Perinatal urology, 358–387
- congenital adrenal hyperplasia, 382, 383*f*
- exstrophy, 379–382

- grading systems, 358–361
- key conditions, 372–375
- kidney anomalies, 377–379
- lower urinary tract obstruction, 375–377, 376*f*–377*f*
- perinatal urgencies/emergencies, 382–387
- postnatal evaluation and management, 366–370, 367*b*, 370*b*
  - imaging, 367–370
  - magnetic resonance urography, 369–370
  - renal scintigraphy, 367–369, 369*f*–370*f*
  - renal ultrasound/resolution of urinary tract dilation, 367, 368*f*
  - voiding cystourethrogram, 367
- postnatal urinary tract dilation, management recommendations for, 370–372
- prenatal imaging, 358, 358*b*
- prenatal multidisciplinary consultations, 361–362, 362*b*
- urinary tract dilation, 362–366
- urogenital sinus, 382, 382*b*, 383*f*

Perineal body, 1807.e10, 2434
- fasciae of, 2449, 2450*f*–2451*f*
- female sexual organs, 1627.e2

Perineal bone-anchored slings, 2887

Perineal incisions, in urologic surgery, 144

Perineal membrane, 2434

Perineal pain, after transurethral needle ablation of prostate, 3433

Perineal ultrasonography, of penis and male urethra, 85, 87*f*

Perineal urethrostomy, for urethral stricture disease, 1827–1828

Perineorrhaphy, posterior colporrhaphy with, for pelvic organ prolapse repair, 2827–2829

Perinephric abscess
- after renal injury, 1992
- as renal infection, 1174–1176, 1175*f*

Perinephric fat, 1865

Perineum
- fasciae of, 2449, 2450*f*–2451*f*

- female, 2434–2435, 2435*f*
- Fournier gangrene and, 1289–1290, 1290*f*
- male, 2450*f*–2451*f*, 2451*b*
  - anatomy of, 1807.e9–1807.e10, 1807.e10*b*

Perineural invasion, 3512

Perioperative intravesical therapy, for non-muscle-invasive bladder cancer, 3098–3099

Peripheral benzodiazepine receptor (PBR), 1394–1395

Peripheral (or modified-peripheral) loading, 3596

Peripheral nervous system, of lower urinary tract, 2480–2497, 2480*f*

- afferent pathways in, 2481–2486, 2481*t*, 2482*f*–2486*f*, 2487*b*
- efferent pathways to, 2487–2493, 2487*f*, 2489*f*–2492*f*, 2490*b*, 2491*t*
- parasympathetic pathways, 2480, 2480*f*
- somatic pathways, 2480*f*–2481*f*, 2481
- supraspinal pathways, 2493–2497, 2495*f*–2496*f*
- sympathetic pathways, 2480, 2480*f*

Peripheral neuropathy, 146

Periprostatic plexus, 1380

Perirenal anatomy, 160–161, 161*f*

Peristalsis, of ureters

- cellular, 1877
- contractile activity, 1883–1887, 1883*f*–1886*f*
- development of, 1877–1878, 1878*f*
- drug effects on, 1901–1903
- electrical activity, 1878–1883, 1879*f*–1880*f*
- mechanical properties, 1890–1891, 1890*f*–1891*f*
- nervous system function in, 1887–1890
- urine transport, 1891–1894, 1892*f*–1893*f*

Peritoneal dialysis, in children, 356, 357*b*

Peritoneal flap, for vesicovaginal fistula repair, 2940, 2940*f*

Peritoneum

  - female, 2427, 2429*f*
  - male, 2448*f*, 2449

Peritubular tissue, 1398, 1398*f*

Periureteral fascia, 1865

Periurethral abscess, 1182, 1182*b*

Periurethral bulking agents
  - as alternative treatment for slings, 2833
  - for neuromuscular dysfunction of lower urinary tract, 637
  - urethral diverticula differentiated from, 2987

Periurethral glands, 2439
  - urethral diverticula and, 2976

Periurethral region, natural defenses of, 1137

Periurethral technique, injection, 2892

Perivascular epithelioid cell tumor, retroperitoneal tumors and, 2234

Permeability, of urothelium of bladder, 2461–2462, 2467, 2468*f*

Pernicious anemia, lower urinary tract dysfunction with, 2619

Persistent genital arousal disorder, 1636

Persistent Müllerian duct syndrome (PMDS), 322, 323*f*, 1016–1017, 1016*f*

Persistent penile erection, with monopolar transurethral resection of prostate, 3417

Pessaries
  - continence, 2736, 2736*f*, 2736.e1*f*
  - for pelvic organ prolapse, 2920.e9–2920.e10

PET, Positron emission tomography

Peyronie's disease (PD)
  - and aging, 1600
  - and collagen disorders, 1602
  - and combination therapy, 1615
  - curvatures of penis associated with, 1837–1838
  - and diabetes, 1600, 1601*f*

- diagnosis and management of, 1599–1626
  - epidemiology, 1599–1602, 1602*b*
  - etiology, 1604–1606, 1606*b*
  - evaluation of patient, 1607–1609, 1607*f*–1609*f*, 1609*b*
  - general considerations with, 1599, 1600*b*
  - natural history of, 1599
  - nonsurgical treatment, 1610–1616, 1616*b*
  - penile anatomy, 1602–1604, 1603*f*–1604*f*
  - surgical, 1616–1625
  - symptoms, 1606–1607
  - treatment protocols, 1609–1610
- and electromotive drug administration, 1614
- erectile dysfunction and, 1600–1601
- etiology of, 1604–1606, 1606*b*
- and extracorporeal shock wave therapy, 1614
- and fibrotic gene expression, 1606
- and hypogonadism, 1602
- and impact of wound healing, 1603–1604
- incidence of, 1599–1600
- intralesional injections for, 1612–1613, 1617*t*
- oral medications for, 1610–1612, 1616*t*
- and penile traction, 1614–1615
- and psychological aspects, 1601–1602
- and radiation therapy, 1615–1616
- and radical prostatectomy, 1602
- and role of myofibroblasts, 1605
- and role of nitric oxide, 1605
- and role of oxygen free radicals and oxidative stress, 1605
- and role of transforming growth factor-β1, 1605–1606
- surgical management of, 1616–1625, 1626*b*
  - indications, 1616–1618, 1618*b*, 1619*t*
  - penile prosthesis, 1624–1625
  - tunica lengthening procedures, 1621–1624
  - tunical shortening procedures, 1618–1621, 1620*f*–1621*f*, 1622*t*
- topical drug application for, 1613–1614
- and vacuum therapy, 1615

Pezzer tube, 155, 155*f*

Pfannenstiel incision, of abdomen, 135, 138*f*

PFDs, Pelvic floor disorders

P fimbriae, 431

PFM, Pelvic floor muscle

PFME, Pelvic floor muscle exercise

PFMT, Pelvic floor muscle training

PFUIs, Pelvic fracture urethral injuries

PG, Pyoderma gangrenosum

PGI-I, Post-operative Patient Global Impression of Improvement

pH, of urine, 15–16
- low
    - in calcium stone formation, 2024–2025
    - in uric acid stone formation, 2027–2029, 2028*f*

Phallic urethra, 3068, 3069*f*

Phalloplasty, 3068

Pharmacologic therapy
- in ED, 1532–1536, 1533*b*, 1538*b*
    - future directions for, 1538
    - intracavernosal injection, 1534–1535, 1535*t*
    - intraurethral suppositories, 1535–1536
    - oral, 1532–1534
    - transdermal/topical, 1536
- to facilitate bladder emptying, 2716–2720
    - by bladder contractility, 2716–2718
    - by decreasing outlet resistance, 2719–2720, 2720*b*
    - by increasing intravesical pressure, 2716–2718
- to facilitate bladder filling and urine storage, 2679–2716, 2682*t*
    - α-adrenoreceptor antagonists, 2682*t*, 2697–2698
    - β-adrenoreceptor antagonists, 2682*t*, 2698–2699
    - antidepressants, 2682*t*, 2702–2703
    - antimuscarinic agents, 2681–2684, 2682*t*, 2697*b*, Antimuscarinic agents, to facilitate bladder filling and urine storage
    - in augmented or intestinal neobladders, 2712–2713
    - botulinum toxins, 2682*t*, 2707–2709
    - cannabinoids, 2713.e2–2713.e3
    - centrally acting drugs, 2713.e3–2713.e4
    - combinations for, 2704–2707

        - cyclooxygenase inhibitors, 2682*t*, 2703
        - desmopressin for, 2710–2712
        - dimethyl sulfoxide, 2703–2704
        - estrogens for, 2709–2710, 2713–2714
        - future possibilities of, 2713
        - gabapentin, 2713.e3
        - gonadotropin-releasing hormone antagonists, 2713.e3
        - guidelines for, 2681*t*
        - by increasing outlet resistance, 2713–2716
        - by inhibiting bladder contractility, 2679–2700
        - intraprostatically injected drugs, 2713.e2–2713.e3
        - membrane channel activity, 2682*t*, 2696–2697
        - mirabegron, 2699–2700
        - muscarinic receptors in, 2679–2681, 2680*t*
        - NK_1-receptor antagonists, 2713.e4
        - phosphodiesterase inhibitors, 2682*t*, 2700–2702
        - prostanoid-receptor agonists and antagonists, 2713.e1–2713.e2
        - toxins, 2707–2709
        - tramadol, 2713.e3–2713.e4
        - transient receptor potential channel antagonists, 2713.e1
        - vanilloids for, 2709
        - vitamin D_3-receptor analogues, 2713.e1
    - for hypospadias, 945
    - for lower urinary tract, 2497–2503
        - adrenergic mechanisms, 2500–2501, 2501*f*, 2501*b*
        - afferent neuropeptides, 2501–2502, 2501*t*
        - muscarinic mechanisms, 2497–2500, 2499*t*, 2500*b*
        - sex steroids, 2502–2503
        - urethral tone in women, 2501
- Phenazopyridine, for pelvic floor disorder testing, 2533
- Phenotypic gender development, 1390
- Phenotypic sexual differentiation, 995–996, 995*f*–997*f*
- Phenoxybenzamine
    - to facilitate bladder emptying, 2720.e1
    - ureteral response to, 1888
- Phentolamine (Regitine), 1535
    - ureteral response to, 1888
- Phenylephrine
    - in priapism, 1551

  - ureteral response to, 1888

Phenylpropanolamine (PPA), for stress urinary incontinence in women, 2714

Pheochromocytoma, 451–452
  - clinical characteristics, 2373–2375, 2375*t*
  - contrast media and, 32
  - diagnostic tests, 2375–2378, 2376*f*–2378*f*, 2377*t*, 2402, 2402*t*
  - hereditary, 2373, 2374*t*, 2375, 2380
  - increased adrenal function in, 2373–2380, 2373*f*, 2374*t*–2375*t*, 2376*f*–2379*f*, 2377*t*
  - malignant, 2373, 2375, 2380
  - MRI and, 54
  - overview and epidemiology, 2373, 2373*f*
  - pathophysiology, 2373
  - prognosis, 2380
  - surgery, 2409, 2409*b*
  - treatment, 2378, 2379*f*, 2409, 2409*b*

Phimosis, 393, 871–872, 872*f*
  - urethral reconstructive surgery for, 1811

Phosphate
  - in crystal formation, 2014
  - transport of, urinary tract obstruction and, 794

Phosphatidylinositol 3-kinase (PI3K) pathway, in prostate cancer, 3469

Phosphaturia, in urine, 14

Phosphodiesterase
  - in ED, 1498–1499
  - for PE, 1572

Phosphodiesterase inhibitors
  - for BPS/IC oral therapy, 1243
  - to facilitate bladder filling and urine storage, 2682*t*, 2700–2702

Phosphodiesterase type 5 inhibitors (PDE5-I)
  - for benign prostatic hyperplasia, 3382, 3393, 3394*t*
  - for chronic scrotal pain syndrome, 1216
  - for ED, 1532–1534, 1532*t*

- for female orgasmic disorder, 1648
- for female sexual arousal disorders, 1650
- for PD, 1611–1612
- for priapism, 1554
- rationale and efficacy of, 3382–3385, 3382*f*, 3383*t*–3384*t*, 3385*f*

Phosphorus, metabolism of, 2016

Phosphorylcholine, in prostatic secretions, 3296

Photodynamic therapy (PDT), for refractory high-grade non-muscle-invasive bladder cancer, 3106

Photon, 238

Photoselective vaporization of prostate (PVP), 3438–3442
- in anticoagulated patients, 3441
- complications with, 3441–3442
  - intraoperative, 3441
  - perioperative, 3441
  - postoperative, 3441–3442
- concept and introduction for, 3438–3439
- conclusion for, 3442
- outcomes with, 3440–3441
  - comparative studies, 3440–3441
  - single-cohort studies, 3440
- technique for, 3439–3440
  - intraoperative, 3439
  - postoperative, 3439–3440
  - preoperative, 3439

Phototherapy, for chronic scrotal pain syndrome, 1216

Physical activity, benign prostatic hyperplasia and, 3324, 3325*t*

Physical examination, 1434–1436, 1436*b*
- bladder, 10, 10*f*–11*f*
- of male reproductive system, 1435–1436
  - phallus, examination of, 1436
  - prostate and seminal vesicles, 1436
  - scrotum, examination of, 1435
  - spermatic cord, examination of, 1435–1436
  - testis and epididymis, examination of, 1435, 1435*f*

  - penis, 10–11
  - scrotum, 11, 11*f*
  - in urinalysis, 14

Physiologic hydronephrosis, of pregnancy, 284

Physostigmine, ureteral response to, 1887–1888

Phytotherapy

  - for benign prostatic hyperplasia, 3393–3399
  - current role of, 3395
  - extract composition of, 3394, 3394*t*–3395*t*
  - mechanism of action, 3394–3395, 3395*t*
  - origin of agents for, 3394, 3394*t*

PI3K/Akt/mTOR pathway, in castration-resistant prostate cancer, 3699–3700

PIA, Proliferative inflammatory atrophy

Piezoelectric generator, 2094, 2096*f*

Pigment-related kidney injury, 1924

Pigtail drains, 148

Pili, 428–429

  - bacterial type 1 (mannose-sensitive), 1134
  - classification of, 429
  - P (mannose-resistant), 1134–1135

PIN, Prostatic intraepithelial neoplasia

Pioglitazone, bladder cancer and, 3077

Pippi Salle procedure, for bladder neck reconstruction, 690, 691*f*

PIRADS, Prostate Image Reporting and Data System

Pituitary tumors, 1448

Pivmecillinam, for UTIs, 1155–1156

PIVOT, 3530–3531

Placenta accreta, 294, 303

Placental abnormality, urologic management of, 294–295, 295*b*

Plain abdominal radiography, 35–36, 36*f*–37*f*, 415

Planning target volume (PTV), 3590

Plaques, of urothelium of bladder, 2462

Plasma creatinine (PCr), GFR estimation with, 1905, 1906*f*

Plasma free metanephrines, in evaluation of adrenal masses, 2402, 2402*t*

Plasma markers, GFR estimation with, 1905, 1906*f*

Plasmacytoma, retroperitoneal tumors and, 2236

Plateau-shaped curve, 480

Platelet transfusion, 147

Platinum agents, 3693

Pleomorphic liposarcoma, retroperitoneal tumors and, 2230–2231

PLESS, Proscar Long-Term Efficacy and Safety Study

PLISSIT Model, for female sexual function, 1628–1629, 1628*t*–1629*t*

PLND, Pelvic lymphadenectomy

Ploidy-flow cytometry, in UTUC, 2198

PNET, Primitive neuroectodermal tumor

Pneumatic compression stockings, VTE prophylaxis with, for laparoscopic and robotic surgery, 231

Pneumatic lithotripsy, 243, 243*b*

- basic physics, 243
- tissue effects of, 243

Pneumaturia, patient history of, 7

Pneumomediastinum, during laparoscopic and robotic surgery, 225

Pneumopericardium, during laparoscopic and robotic surgery, 225

Pneumoperitoneum

- for laparoscopic and robotic surgery
  - acid-base metabolic effects of, 222
  - cardiovascular effects of, 220–221
  - complications related to, 224

        - mesenteric blood flow and intestinal motility effects of, 222
        - pressure of, 220
        - renal effects of, 221
        - respiratory effects of, 221
    - physiology of, 460–461, 462*b*
    - stress response to, 461
- Pneumothorax, during laparoscopic and robotic surgery, 225
- Podophyllin, for condylomata acuminata, 1742.e3
- Poiseuille's law, 932, 935*f*
- Polaris Loop stent, 176*f*
- Pole calyx
    - lower, 166, 166.e1*f*
    - upper, 165–166, 166*f*, 166.e1*f*
- Poliomyelitis, lower urinary tract dysfunction with, 2619
- Politano-Leadbetter technique, for vesicoureteral reflux in children, 837*f*–839*f*, 840
- Political support, in transitional urology, 1045
- Pollakiuria, 660
- Poly-ADP-ribose polymerase (PARP) inhibitors, 3702
- Polyamide (Nylon), 150
- Polyamines, in prostatic secretions, 3296
- Polyanion macromolecules, in crystal formation, 2014
- Polycythemia, in RCC, 2156
- Polydioxanone suture, 150
- Polyductin, 748
- Polyester (Mersilene), 150
- Polyglactin 910 suture, 149–150
- Polyglactin mesh, for anterior compartment repair, 2781*t*–2782*t*
- Polyglyconate (Maxon) suture, 150

Polyorchidism, 963

Polypharmacy, 2915–2917

Polypropylene (Prolene), 150

Polypropylene mesh, for pelvic organ prolapse reconstructive surgery, 2781*t*–2782*t*, 2783–2786, 2786*f*

Polyuria
- etiology of, 2678
- management of, 2678
- nocturia and, 2667, 2668*t*, 2678
- transient urinary incontinence and, 2919.e1

Pontine micturition center, 2493–2494, 2495*f*

Pontine tegmentum, 2493

POPQ, Pelvic Organ Prolapse Quantification

Population trends, aging and, 2906–2907

Porcine dermis, anterior repair with, for pelvic organ prolapse reconstructive surgery, 2781*t*–2782*t*, 2786–2787, 2787*f*

Porcine origin, of xenograft sling material, 2835

Port removal, after laparoscopic and robotic surgery, 218–219

Port site closure, after laparoscopic and robotic surgery, 219

Portal vein, 1673–1674, 1673*f*

Port-site hernias, 468–469

Port-site recurrence, of renal malignancy, 2297

Positional complication, in urologic surgery, 261–262

Positional nerve injury, in urologic surgery, 261–262

Positioning, Patient positioning

Position-related neuropathy, 146

Positive upper tract urinary cytology, 2219–2222, 2219*f*

Positron emission tomography (PET), 42

- for biochemical recurrence after radical prostatectomy, 3662, 3662*f*
- degree of radiotracer of, 91
- degree of visual conspicuity of, 91
- for inguinal node dissection, 1792
- physical characteristics of, 92*t*
- principles of, 91
- for prostate cancer, 3622
- radionuclides in, 91

Positron emission tomography magnetic resonance imaging, 44, 45*t*

Postchemotherapy retroperitoneal lymph node dissection (PC-RPLND), 2241
- adjuvant chemotherapy at, 1727
- auxiliary procedures for, 1717–1720, 1721*b*
  - hepatic resection, 1719–1720
  - major vascular reconstruction, 1718–1719, 1719*f*
  - nephrectomy, 1718, 1718*t*
  - pelvic resection, 1720
  - supradiaphragmatic disease, management of, 1720
- clinical complete remission to induction chemotherapy, 1721–1722, 1722*t*
- in high-risk populations
  - desperation RPLND, 1728, 1728*t*
  - late relapse RPLND, 1728*t*, 1729
  - reoperative RPLND, 1728*t*, 1729
  - salvage RPLND, 1727–1728, 1728*t*
- histologic findings at, survival outcomes and, 1726–1727, 1727*t*, 1727*b*

Post-chemotherapy surgery (PCS)
- for NSGCTs, 1698–1700, 1698*t*–1699*t*
- for seminomas, 1705–1706

Postcoital syndrome, 1636

Postcontrast acute kidney injury, contrast media and, 32–33

Posterior colpoperineorrhaphy, 2825

Posterior colporrhaphy, for pelvic organ prolapse repair, 2825–2829, 2825*f*
- perineorrhaphy, technique for, 2827–2829
- results with, 2827–2829, 2828*t*
- site specific, 2826–2827, 2826*f*–2827*f*

Posterior compartment prolapse, 2587

Posterior labial commissure, 1627.e1

Posterior lumbodorsal approach, to open adrenalectomy, 2411–2412, 2411*f*–2412*f*

Posterior lumbosacral incision, in urologic surgery, 141–142, 141*f*–142*f*

Posterior lumbotomy, for ureteropelvic junction obstruction in children, 829, 832*f*

Posterior pararenal space, 1666–1667, 1667*f*

Posterior pedicle dissection, ureteral control and, 3152–3157, 3155*f*–3156*f*

Posterior urethral valves, 375, 377*f*, 1053, 1053*b*

- sexual function and fertility, 1053

Posterolateral and multiple congenital diverticula, 522, 523*f*

Postexposure prophylaxis, for HIV treatment, 1264–1265

Posthysterectomy vesicovaginal fistulae, 2926–2927

Postmicturition leakage or dribble, 2540

- treatment of, 2547

Postnatal detection, incidental, of ureteral anomalies, 801

Postobstructive diuresis, 796

Postoperative care

- for laparoscopic simple nephrectomy, 2289
- for RPLND, 1717

Postoperative complications, adrenal surgery, 2424, 2424*b*

Postoperative management, for pheochromocytoma, 2380

Post-operative Patient Global Impression of Improvement (PGI-I), 2531

Postoperative urinary retention, lower urinary tract dysfunction and, 2629–2630

Postorgasmic illness syndrome (POIS), 1564, 1581, 1581.e1*b*, 1636

Postpartum, urinary incontinence and, PFMT for, 2726

Post-prostatectomy, vesicourethral region, 2993

Postprostatectomy incontinence (PPI), 2596

- PFMT for, 2726

Postrenal kidney injury, 1923

Post-SSRI sexual dysfunction, 1580

Post-translational modifications, of androgen, 3291

Post-void dribbling, for transmen, 3072

Postvoid residual (PVR), 482

- measurement in urinary incontinence, in men, 2543
- pelvic floor disorders and, 2534
- for sling procedure, 2832
- urinary flow rate with, 2565
- in urinary incontinence, in geriatric patients, 2920.e1
- in urodynamic studies, 2556

Postvoid residual volume, in benign prostatic hyperplasia, 3346

Potaba, for PD, 1610, 1616*t*

Potassium

- filtrate transport, 1909–1910, 1910*b*
- in kidney, of neonate, 342, 342*b*
- transport of, urinary tract obstruction and, 794

Potassium channel openers

- to facilitate bladder filling and urine storage, 2682*t*, 2697
- urethral function effects of, 1903

Potassium channels, in detrusor muscle, 2474, 2474*f*

Potassium chloride test, for BPS/IC diagnosis, 1238–1239

Potassium titanyl phosphate (KTP) laser, 239

Pouch calculi, with intestinal anastomoses, 3180*t*

Pouch of Douglas, 2427–2428

Power Doppler ultrasonography, 74

- transrectal, for prostate biopsy, 3500–3501, 3500*f*–3502*f*

PPNAD, Primary pigmented nodular adrenocortical disease

Practice accreditation, for ultrasonography, 89–90

Prazosin

- to facilitate bladder filling and urine storage, 2682*t*, 2720.e1
- ureteral response to, 1888

Precalyceal canalicular ectasia, 771

Precipitancy, 2919.e2

PRECISION trial, 3503–3504

Precoital pseudoephedrine, for delayed ejaculation, 1579

Precursor malignant lesions, of bladder, 3082–3083, 3083*f*

Pre-exposure prophylaxis, for HIV, 1265

Pregnancy
- augmentation cystoplasty and, 701
- bacteriuria in, 1184–1185, 1188*b*
  - anatomic and physiologic changes and, 1185–1186, 1185*t*, 1186*f*
  - complications of, 1186–1187
  - management of, 1186–1187, 1187*t*
  - pathogenesis, 1185
  - renal insufficiency and, 1187.e1
- classic bladder exstrophy, 290–291
- with congenital urologic conditions, 288–291, 291*b*
  - fertility, 288
  - mode of delivery, 289–290
  - myelomeningocele, 288–290
- considerations for imaging in, 284–285
- functional and anatomic urologic concerns during, 291–292
  - continent catheterizable stoma, 292
  - intermittent catheterization, 291
  - urinary diversion, 291–292
  - urinary tract infection and urinary diversion, 292
- genitourinary tuberculosis management during, 1318
- host defense mechanisms in UTIs and, 1140
- as laparoscopic and robotic surgery contraindication, 204
- neural tube defects, prevention of, 290
- PFMT during, 2726
- physiologic changes during, 282–284
  - cardiovascular, 282
  - hematologic, 282–283
  - hematuria, 283–284
  - renal and urinary tract, 283
  - respiratory, 282
  - urine chemistries during, 283
- physiologic hydronephrosis of, 284
- reflux and, 510–511, 511*b*
- renal calculi in, 2035
- RMS treatment effects on, 1116–1117
- surgical management of, 285
- ureter physiology effects of, 1900–1901
- urinary incontinence and, 2583
  - conservative interventions for, 2735

  - urinary tract infections in, management of, 293–294
  - urolithiasis in, 286–288, 288*b*
  - urologic considerations in, 282–295
  - urologic malignancy during, 292–293
  - urologic medication administration during, 285–286
  - in urologic surgery, 122
  - Wilms tumor treatment effects on, 1108

- Premature ejaculation, 1564–1572, 1572*b*
  - and assessment of erectile function, 1570
  - causes of, 1568–1569
    - acquired premature ejaculation, 1568
    - comorbid erectile dysfunction, 1568
    - hyperthyroidism and, 1568–1569
    - lifelong premature ejaculation, 1568
    - prostate disease, 1568
    - sexual performance anxiety, psychological or relationship problems and, 1568
  - classification of, 1564–1565
  - definition of, 1565–1567, 1565.e1, 1566*t*
  - and determination of intravaginal ejaculation latency time, 1569
  - diagnosis of, 1569
  - evaluation of, 1569
    - medical history in, 1569, 1569*t*
  - patient history of, 6
  - patient-reported outcome measures, 1569–1570
    - index of premature ejaculation, 1570.e1
    - premature ejaculation diagnostic tool, 1570.e1
    - premature ejaculation profile, 1570.e1
  - physical examination of, 1570, 1570*f*
  - prevalence of, 1567–1568, 1567*f*
  - treatment of, 1570–1572
    - pharmacologic, 1571–1572, 1573*t*
    - psychosexual therapy, 1571
- Prematurity, from bacteriuria in pregnancy, 1186
- Prenatal detection, of ureteral anomalies, 801
- Prenatal hydronephrosis, 401
- Prenatal imaging, and perinatal urology, 358, 358*b*

Prenatal mortality, from bacteriuria in pregnancy, 1186

Prenatal multidisciplinary consultations, 361–362, 362*b*

Prenatal ultrasonography, for pediatric urology, 389

Prenatal urinary tract dilation, etiology of, 372, 372*t*

Preoperative cardiovascular evaluation, 119–120

- clinical markers, 120
- functional capacity, 120
- surgery-specific cardiac risk, 120

Preoperative care

- for adrenal surgery, 2409–2410, 2409*b*
- evaluation
  - for kidney surgery, 2248, 2248.e1*f*, 2249*f*
  - for laparoscopic kidney surgery, 2279
- for laparoscopic and robotic surgery
  - blood products, 204
  - bowel preparation, 204
  - operating room setup, 205, 205*b*
  - patient positioning, 205, 205*f*
  - patient selection and contraindications, 203–204
  - prophylaxis, 205
- for minimally invasive urinary diversion, 3259, 3259*b*
- preparation for surgery
  - for kidney surgery, 2248, 2248.e1*f*, 2249*f*
  - for laparoscopic kidney surgery, 2279

Preoperative evaluation, 119

Preoperative management, for pheochromocytoma, 2378–2380

Preoperative multiparametric magnetic resonance imaging, use of, 3567

Preputial calculi, 2118–2119

Prerenal kidney injury, 353–354, 1922–1923

Presacral lymphadenectomy, 3152, 3154*f*

Prespermatogonia, 951

Pressure effects, for laparoscopic and robotic surgery, 221*t*

Pressure transmission theory, 2597*b*

Pressure ulcers, 2915

Pressure-flow study

- for benign prostatic hyperplasia, 3347
- in urodynamic studies, 2557

Presurgical testing, 119

- American Society of Anesthesiologists Classification and Risk, 119, 120*t*, 120*b*

Preureteral iliac artery, 824

Preureteral vena cava, 822–824, 823*f*, 824*b*

PREVAIL study, 3696

Prevesical space, 2427, 2429*f*, 2850

PRF, Retroperitoneal fibrosis

Priapism, 394–395, 885, 885*b*, 1539–1563

- causes of, 1542*b*
- classifying, 1539
- definition of, 1539, 1540*b*
- epidemiology and pathophysiology
  - in children, 1546
  - etiology of ischemic priapism (veno- occlusive, low-flow), 1541–1545, 1543*f*
  - etiology of nonischemic (arterial, high- flow), 1546, 1546*b*
  - etiology of stuttering (intermittent), 1545–1546, 1545*b*
- epidemiology of, 1540–1546
- evaluation and diagnosis of, 1547–1550
  - history of, 1547, 1548*f*, 1548*b*
  - laboratory testing in, 1548–1549, 1549*f*, 1549*t*
  - penile imaging in, 1549–1550, 1550*f*, 1550*b*
  - physical examination for, 1548, 1549*t*
- historical perspectives of, 1539–1540
- interventional angiography, 1560–1561, 1561*f*
- ischemic, 1539, 1540*f*
  - penile implants in, 1596
- medical treatments for, 1550–1554, 1552*b*, 1554*b*
  - ischemic priapism, 1550–1552, 1551*f*, 1552*b*
  - stuttering, 1553–1554

    - molecular basis of, 1547
    - nonischemic priapism, 1539, 1541*f*
    - sickle cell disease and, 1544, 1547*b*
    - stuttering priapism, 1539
    - surgical management of arterial, 1561, 1562*f*–1563*f*, 1562*b*
    - surgical management of ischemic, 1554–1560, 1558*b*
        - immediate implantation of penile prosthesis, 1558–1560, 1560*f*, 1560*b*
        - shunting, 1554–1558, 1555*f*–1559*f*, 1556*b*

- Primary aldosteronism
    - clinical characteristics, 2368
    - diagnostic tests, 2368–2372, 2369*b*–2370*b*, 2370*f*–2371*f*
    - increased adrenal function in, 2367–2372, 2367*f*–2368*f*, 2369*b*–2370*b*, 2370*f*–2371*f*, 2372*b*
    - overview and epidemiology, 2367
    - pathophysiology, 2367–2368, 2367*f*–2368*f*
    - treatment and prognosis, 2372, 2409*b*
- Primary ciliary dyskinesia, 1452
- Primary cutaneous lesions, 1273, 1274*t*
- Primary erectile dysfunction, causes of
    - micropenis, 1511
    - vascular abnormalities, 1511–1512
- Primary hyperoxaluria, 858, 2056–2057
    - medical therapy for, 2057
- Primary hyperoxalurias (PHs), 350, 2021–2022, 2021*f*
- Primary nephrotic syndrome, in children, 344
- Primary pigmented nodular adrenocortical disease (PPNAD), 2362
- Primary syphilis, 1255*t*, 1257, 1257*f*–1258*f*
- Primary urethral calculi, 2117
- Primary vestibulodynia, 1651
- Primitive neuroectodermal tumor (PNET), of kidney, 2181*t*, 2183
- Primordial germ cells, 318*f*
- Principal cells, epididymis, 1374–1375, 1403–1404

Pringle maneuver, in vena caval thrombectomy, 2273, 2273.e1*f*

Prior surgery, as laparoscopic and robotic surgery contraindication, 203

Probiotics, for UTIs, 1165

Processus vaginalis, 318–320

- cryptorchidism and, 962–963

Procidentia repair, 1051

Programmed cell death, Apoptosis

Programmed death-1 (PD-1), 2146

Progression, disease, 104–105

Progressive renal dysfunction, urinary tract obstruction and, 776, 777*f*

Projected isovolumetric pressure (PIP), 2658, 2658*f*

Prolactin, 1391, 1391*f*

- in benign prostatic hyperplasia, 3313
- in ED, 1494, 1495*t*

Prolapsed ureterocele, 395, 397*f*, 977, 978*f*

Prolaris test, 3488, 3521

Proliferative inflammatory atrophy (PIA), prostate cancer and, 3461

Promoters, of crystal formation, 2014–2015

Prompted voiding, 2730.e1*t*, 2731–2732

Prone position, 164–165, 165*f*

- modifications to, 165

Prone position for percutaneous nephroscopy, 146–147

Pronephros, 334–335, 334*f*

Propagation, electrical, in ureteral cells, 1882–1883

Propantheline bromide, to facilitate bladder filling and urine storage, 2682*t*, 2688

Prophylactic antibiotics, for UTI, 371–372

Prophylactic colposuspension, 2765

Prophylactic pelvic nodal treatment, for prostate cancer, 3602–3603, 3603*b*

Propiverine hydrochloride, to facilitate bladder filling and urine storage, 2682*t*, 2695–2696

- with α-adrenoreceptor antagonists, 2704

Propranolol (Inderal), ureteral response to, 1888

Proscar Long-Term Efficacy and Safety Study (PLESS), 3332, 3372–3373

PROSELICA trial, 3692–3693

Prospective European Doxazosin and Combination Therapy (PREDICT) study, 3385

PROSPER study, 3696

Prospermatogonia, 951

Prostaglandins (PGs)

- to facilitate bladder emptying, 2718–2719
- for female sexual arousal disorders, 1650
- in prostatic secretions, 3296
- urethral function effects of, 1902–1903
- urothelium release of, 2469–2470

Prostanoid-receptor agonists and antagonists, to facilitate bladder filling and urine storage, 2713.e1–2713.e2

Prostanoids

- for detrusor underactivity, 2661
- lower urinary tract and, 2502

Prostate

- anatomy of, 1381*b*
  - arterial supply, 1380, 1380*f*
  - gross structure, 1378–1379, 1379*f*
  - lymphatic drainage, 1380
  - microanatomic architecture, 1379–1380
  - nerve supply, 1380
  - ultrasonographic, 3490, 3491*f*–3492*f*
  - venous drainage, 1380
- cell types of, 3277*t*, 3278–3279, 3278*f*, 3279*b*
  - basal cells, 3278, 3278*f*

    epithelial stem cells, 3278*f*, 3279
    intermediate cells, 3278*f*, 3279
    luminal epithelial, 3278
    neuroendocrine cells, 3278*f*, 3279
development of, 311–317, 313*f*–316*f*, 315*t*, 317*t*, 317*b*, 3274–3280, 3277*t*, 3278*b*
    budding induction, 3274–3276
    budding of, 3274, 3275*f*
    cytodifferentiation, 3274
    epithelial budding, 3276
    fibroblast growth factors, 3276
    hedgehog signaling pathway, 3276
    molecular features of, 3274–3277
    Nkx3.1 and Sox9, 3276
    regional differentiation, 3274
    transforming growth factor-β superfamily, 3276–3277
    Wnt signaling pathway, 3276
    zonal and lobar anatomy, 3277, 3277*t*
endocrine control of growth of, 3280–3295, 3281*f*, 3284*b*
    adrenal androgens, 3282–3283, 3283*f*
    androgen production by testes, 3281–3282, 3282*f*–3283*f*, 3282*t*
    androgen-binding proteins in plasma, 3282*f*, 3284
    estrogens in male, 3282*t*, 3283–3284
fate of, in transwomen, 3063
in genitourinary tuberculosis, 1309
growth regulation of
    androgen action at cellular level, 3285–3286, 3285*f*
    androgen metabolism in, 3286–3287, 3286*f*, 3287*t*
    androgen receptor in, 3288–3292, 3289*f*–3290*f*
    androgen receptor-dependent chromatin remodeling, 3293–3295
    cell adhesion molecules, 3287–3288, 3288*b*
    at molecular level, 3288–3292
    protein growth factors in, 3284–3285, 3284*f*
    5α-reductase metabolism in, 3286–3287, 3286*f*, 3287*t*
    steroid receptors, 3288–3292
    steroids in, 3284–3285, 3284*f*
    stromal-epithelial interactions, 3287
localization studies, 1143
MRI of, T2-weighted, 1380–1381, 1381*f*
in prune-belly syndrome, 583–584, 584*f*
secretions of, Prostatic secretions
size of, benign prostatic hyperplasia and, 3320, 3320*f*, 3404
stents for, 3443–3444

- stroma of, 3280
- tissue matrix of, 3280
- transabdominal pelvic ultrasonography of, 80–81, 82*f*
- transrectal ultrasound of, 88–89, 89*f*, 1380, 1380*f*, 3493, 3493*f*, Transrectal ultrasonography, of prostate
- transurethral resection of, 1198–1199
- volume of
  - in acute urinary retention, 3338–3339, 3338*f*–3339*f*
  - transurethral microwave therapy and, 3426

Prostate adenocarcinoma, 3506–3512

- Gleason grading of, 3507–3509, 3508*f*, 3509*b*
- location of, 3507
- needle biopsy of, 3509–3510, 3510*b*
- radical prostatectomy specimens for, 3510–3512
- spread of, 3507
- staging classification for, 3506–3507
- subtypes of, 3512–3513
  - malignant tumors, 3513
  - mesenchymal, 3512
  - urothelial carcinoma, 3512–3513
- transurethral resection specimens for, 3510
- treatment effect and, 3512
- volume of, 3507

Prostate biopsy, 3494–3500, 3504*b*

- for adenocarcinoma, 3509–3510, 3510*b*
- advanced techniques for, 3500–3504
- after radiotherapy, for biochemical recurrence, 3666
- analgesia for, 3496–3497
- antibiotic prophylaxis for, 3496, 3496*t*
- bleeding with, 3499
- cleansing enema for, 3496
- complications of, 3499–3500
- contraindications to, 3495
- extended-core techniques, 3497, 3498*f*
- indications for, 3494–3495, 3495*b*
- infections after, 3499

- investigational techniques for, 3500–3504
- needle, 3519–3520
- patient positioning for, 3497
- patient preparation for, 3495–3497
- postradiation therapy, 3608
  - imaging and sampling error, 3609
  - interpretation of, 3608–3609, 3609*b*
  - timing of, 3608–3609
- PSA triggers for, 3516–3517
- repeat, 3497–3498
- risks of, 3499–3500
- saturation, 3497–3498
- sextant, 3497
- transperineal, 3498–3499
- transrectal techniques, 3497–3498
- transurethral, 3499

Prostate cancer, 1421–1422, 3063

- abiraterone for, 3677–3678, 3677*f*
- adenocarcinoma, Prostate adenocarcinoma
- African-Americans *versus* Caucasians, 3472, 3472*f*
- aminoglutethimide for, 3677
- androgen receptor in, 3472
- androgens, influence of, 3462, 3466, 3467*f*
- bicalutamide for, 3675
- biomarkers for, 3478–3489, 3489*b*, 3542–3543
  - annexin A3, 3487
  - blood-based, 3480–3485
  - cell cycle progression, 3543
  - circulating tumor cells, 3484–3485, 3485*f*
  - development of, 3478–3479
  - epigenetic modifications, 3487–3489
  - gene fusions, 3486
  - genomic classifier, 3542–3543
  - genomic expression profiles, 3488
  - genomic prostate score, 3543
  - human kallikrein 2, 3484
  - inherited genetic markers, 3488–3489
  - metabolomics, 3479
  - α-methylacyl coenzyme A racemase gene, 3487

    - microRNA, 3487
    - performance assessment, 3479–3480
    - prostate cancer antigen 3, 3485–3486, 3485*f*
    - prostate-specific membrane antigen, 3484
    - tissue-based, 3487–3489
    - urine-based, 3485–3487
- The Cancer Genome Atlas and, 3467–3468, 3469*f*
- castration-resistant, Castration-resistant prostate cancer
- chemoprevention of, 3473, 3477*b*
    - metformin, 3475
    - pharmacologic agents for, 3473–3475
    - Prostate Cancer Prevention Trial on, 3473–3475, 3474*f*
    - rationale for, 3470*f*, 3473
    - 5α-reductase inhibitors for, 3473–3475
    - Reduction by Dutasteride of Prostate Cancer Events Trial, 3475
    - selenium, 3476, 3476*f*
    - soy, 3476
    - statins, 3475
    - toremifene citrate, 3475
    - tumorigenesis model for, 3472–3473
    - vitamin E, 3476, 3476*f*
- chronic inflammation role in, 1338
- and delayed ejaculation, 1575–1576
- diagnosis of, 3514–3518, 3521*b*
    - age at, 3459
    - digital rectal examination for, 3515
    - prostate cancer gene 3, 3518
    - prostate-specific antigen for, 3515–3517
    - stage at, 3459
- DNA methylation in, 1349
- DNA repair defects and, 3472
- enzalutamide for, 3676
- epidemiology of, 3457–3460, 3477*b*
    - molecular, 3461–3462, 3477*b*
- epigenetic changes in, 3470–3472, 3471*f*
- etiology of, 3465–3473, 3477*b*
- flutamide for, 3674
- focal therapy for, Focal therapy, for prostate cancer
- gene fusions in, 3468–3470
- genomic alterations in
    - gene rearrangements, 1352–1353, 1354*t*

    HPC, 1354–1355, 1354*t*, 1355*f*
    sporadic prostate cancer, 1355–1358
in geriatric patients, 2920.e12
hereditary, Hereditary prostate cancer
hormonal therapy for, Hormonal therapy, for prostate cancer
immune checkpoint blockade in, 1343
incidence of, 3457, 3458*f*, 3458*t*
    global, 3458–3459
    screening effect of, 3459–3460
ketoconazole for, 3677
lifestyle management of, 3543–3544
    diet, 3544
    exercise, 3543–3544
    micronutrients, 3544
    smoking cessation, 3543
    weight control, 3544
localized, Localized prostate cancer
locally advanced, Locally advanced prostate cancer
magnetic resonance imaging of, 3542–3543, 3543*b*
management strategies for biochemical recurrence of, 3659–3670
metabolic syndrome and, 1421–1422
molecular genetics of, 3465–3473, 3477*b*
mortality rates of, 3457, 3458*f*
    global, 3458–3459
    screening effect of, 3459–3460
mutations (SPOP, FOXA1, IDH1) in, 3470–3472, 3470*f*
natural history of, 3537–3539
    molecular genetics of Gleason pattern 3 *versus* patterns 4 and 5, 3538–3539, 3538*t*
nilutamide for, 3675–3676
as non-AIDS-defining urologic malignancies, 1268
in nuclear medicine, 43
overdiagnosis and overtreatment of, 3537
pharmacologic intervention of, 3544–3545
phosphatidylinositol 3-kinase pathway, 3469
prognostic value of telomere length for, 1364–1365
prostate-specific antigen, Prostate-specific antigen
psychological aspects of, 3543
racial differences and, 3457–3458

RB1 in, 1348
risk factors for, 3460–3465, 3542
  alcohol consumption, 3465
  androgens, 3462
  calcium, 3463–3465
  diet, 3464–3465
  estrogens, 3462–3463
  familial, 3460–3461, 3460*t*, 3461*f*, 3477*b*
  family history, 3542
  genetic, 3460–3461, 3460*t*, 3461*f*, 3477*b*
  infection, 3461, 3462*f*, 3477*b*
  inflammation, 3461, 3462*f*, 3477*b*
  insulin-like growth factor axis, 3463
  leptin, 3463
  monitoring, 3542
  obesity, 3465, 3465*f*
  race, 3542
  sexual activity, 3463–3464
  sexually transmitted disease, 3463–3464
  smoking, 3464
  vasectomy, 3464
  vitamin D, 3463–3465
  vitamin D receptor, 3463–3465
screening for, 3514–3515
  general concepts of, 3514
  randomized trials for, 3514
  specialty group recommendations for, 3514–3515
SPOP mutations in, 3470–3472
sporadic, 1355–1358
staging of, 3518–3521, 3521*b*
  classifications for, 3519, 3519*t*
  clinical *versus* pathologic, 3518–3519
  combined pretreatment parameters in, 3520
  general concepts of, 3518–3519
  imaging for, 3520
  molecular, 3520–3521
  needle biopsy, 3519–3520
  pelvic lymphadenectomy, 3521
  tumor extent prediction, 3519
stem cells in, 3466, 3468*f*
summary for, 3545
tissue-based genomics of, 3543

  - *TP53* gene in, 3469
  - tumor initiation and progression in, somatic mutations associated with, 3466–3467, 3469*f*
  - vaccines for, 1341, 1341*f*

Prostate cancer antigen 3 (PCA3), as prostate cancer biomarker, 3485–3486, 3485*f*, 3518

Prostate cancer imaging
  - imaging studies with metastatic, 100*f*
  - PET radiotracers for, 99*t*

Prostate Cancer Intervention *versus* Observation Trial (PIVOT), 3539

Prostate Cancer Outcomes Study, 3531

Prostate Cancer Prevention Trial (PCPT), 3473–3475, 3474*f*

Prostate D90, 3597

Prostate embolization, 3445–3446

Prostate HistoScanning, 3501–3502

Prostate Image Reporting and Data System (PIRADS), 3502, 3502*t*–3503*t*, 3502*b*, 3622

Prostate imaging, for benign prostatic hyperplasia, 3348

Prostate Intervention Versus Observation Trial (PIVOT), 3620

Prostate stem cell antigen (PSCA), in prostatic secretions, 3298*t*, 3300–3301

Prostate surgery
  - lower urinary tract function and, 2528
  - orthotopic urinary diversion and, 3238–3239

Prostate Testing for Cancer and Treatment (ProtecT), 3531

Prostate V100, 3597

Prostatectomy
  - holmium laser enucleation of prostate *versus*, 3437
  - radical, Radical prostatectomy
  - simple, 3449–3456, 3456*b*
    - anesthesia for, 3450
    - complications with, 3455
    - contraindications for, 3450

        - indications for, 3449–3450
        - open, 3450
        - operating day preparation for, 3450
        - postoperative management for, 3454–3455
        - preoperative evaluation for, 3450
        - retropubic, 3450–3452, 3451*f*–3452*f*
        - robotic-assisted laparoscopic, 3454–3455
        - summary for, 3455–3456
        - suprapubic, 3452–3454, 3452*f*–3454*f*
        - surgical technique for, 3450–3454
    - SUI following, 2546
    - urinary incontinence and, conservative interventions for, 2735
- Prostate-specific antigen (PSA), 25, 3679, 3688
    - in acute urinary retention, 3338–3339, 3338*f*–3339*f*
    - in benign prostatic hyperplasia, 3345
    - in biochemical recurrence
        - after radiation therapy, 3665–3666
        - after radical prostatectomy, 3661
    - free, 3481–3482, 3481*t*, 3482*f*
        - isoforms of, 3483–3484, 3483*f*
    - measurement of, for urine incontinence, 2543
    - in prostate cancer, 3515–3517
        - as biomarker, 3480–3484, 3480*f*–3481*f*
        - biopsy triggers, 3516–3517
        - clinical use for, 3516, 3516*t*
        - complex, 3518
        - derivatives and molecular forms of, 3517–3518
        - factors influencing, 3515–3516
        - free, 3517–3518
        - isoforms, 3518
        - multiplex tests, 3518
        - tumor extent prediction with, 3519
        - velocity of, 3517
        - volume-based parameters of, 3517
    - in prostatic secretions, 3297, 3298*t*
        - derivatives of, 3297–3298, 3298*t*
    - radiation therapy and, 3606–3607
        - doubling time, 3607–3608
        - failure and, 3606–3607
        - nadir value significance, 3607–3608
        - neoadjuvant hormones, 3608
        - time to nadir of, 3607

Prostate-specific membrane antigen (PSMA), 99, 3622
  - as prostate cancer biomarker, 3484
  - in prostatic secretions, 3298*t*, 3300

Prostate-specific protein 94 (PSP-94), in prostatic secretions, 3298*t*, 3301–3302

Prostate-specific transglutaminases, in prostatic secretions, 3298*t*, 3299–3303

Prostatic abscess, histopathology, 1205, 1205*f*

Prostatic acid phosphatase, in prostatic secretions, 3298*t*, 3301

Prostatic calculi, 2119–2120, 2119*f*
  - clinical presentation of, 2119
  - etiopathogenesis and composition of, 2119
  - evaluation and management of, 2119–2120

Prostatic epithelial squamous metaplasia, 316

Prostatic injections, 3446–3447

Prostatic intraepithelial neoplasia (PIN), 3506, 3507*f*, 3513*b*
  - high-grade, 3506, 3507*f*
  - low-grade, 3506

Prostatic lymphoma, 3513

Prostatic neoplasia, pathology of, 3506–3513

Prostatic obstruction, 156–157

Prostatic pain, patient history of, 2

Prostatic secretions, 3295–3304
  - drug transport and, 3303–3304, 3304*b*
  - nonpeptide components of, 3295–3297
    - citric acid, 3295
    - fructose, 3295–3296
    - phosphorylcholine, 3296
    - polyamines, 3296
    - prostaglandins, 3296
    - zinc, 3296–3297
  - proteins in, 3297–3303, 3298*t*–3299*t*, 3299*b*
    - C3 complement, 3302
    - human kallikrein 2, 3298
    - human kallikrein 11, 3299

- human kallikrein 14, 3299
- human kallikrein L1, 3298–3299
- immunoglobulins, 3302
- lactate dehydrogenase, 3302
- leucine aminopeptidase, 3302
- prostate stem cell antigen, 3300–3301
- prostate-specific antigen, 3297
- prostate-specific antigen derivatives, 3297–3298
- prostate-specific membrane antigen, 3300
- prostate-specific protein 94, 3301–3302
- prostate-specific transglutaminases, 3299–3303
- prostatic acid phosphatase, 3301
- protein C inhibitor, 3302
- semenogelins I and II, 3300
- seminal vesicle secretory proteins, 3303
- transferrin, 3302
- zinc α_2-glycoprotein, 3302–3303

Prostatic urethra, 1382, 1382*f*, 1807.e4*f*, 1807.e8

Prostatic urethral lift (PUL), 3420–3421, 3420*f*
- complications of, 3421
- conclusion for, 3421
- outcomes with, 3420–3421
  - comparative studies, 3421
  - single-cohort studies, 3420–3421

Prostatic utricle, 1382

Prostatitis, 1202–1223
- chronic bacterial, 1205–1207, 1207*b*, Chronic bacterial prostatitis
- current classification, 1202, 1205*b*
- epidemiology, 1202
- etiology, 1207–1209, 1209*b*
  - abnormal sensory processing, 1209
  - endocrine abnormalities, 1208
  - genetics, 1208–1209
  - infection, 1207
  - inflammation, 1207
  - neurologic causes, 1207–1208
  - pelvic floor dysfunction, 1208, 1208*f*
  - psychosocial factors, 1208
- granulomatous, 1203
- histopathology, 1202–1203, 1203*f*

  historical perspective, 1202
  HIV and, 1266
  microbiology, 1204
  prostatic abscess, 1205, 1205*f*
  in transwomen, 3063
ProstVac-VF, 1341, 1341*f*, 3698
Protein C inhibitor (PCI), in prostatic secretions, 3302
Protein kinase G (PKG), in ED, 1498
Protein malnutrition, and chronic kidney disease, 354
Protein synthesis, basics of, 1346.e3–1346.e4, 1346.e3*f*–1346.e4*f*
Proteins
  androgen-binding, in plasma, 3282*f*, 3284
  of bladder urothelium
    tight junction, 2467, 2468*f*
    uroplakins, 2462
  connexin 43, 2476–2477, 2477*f*
  contractile, of smooth muscles, 2470–2472, 2471*f*–2473*f*
  RhoA, 2473, 2473*f*
Proteinuria, 15*t*, 18–19, 19*f*
  in children, 343–344, 344*b*
  in urine, during pregnancy, 283
Proteolytic balance, dysregulation of, 782*f*, 789
Proton beams, 3594–3595
Proton therapy, 3594–3596, 3594*f*, 3595*t*
Provoked vestibulodynia, genito-pelvic pain-penetration disorder, 1651
Proximal renal tubular acidosis, 348, 2026
Proximal ureter, stone localization and, 2085–2086, 2086*t*
Proximal ureteronephrectomy, 2204, 2204*f*
Proxy endpoints, 104
Prune-belly syndrome (PBS), 375, 410*f*, 581–601

adult presentation of, 590

clinical features of, 581–588, 583*b*, 588*b*

  abdominal wall defect, 585–586, 586*f*–587*f*

  bladder, 582–583, 584*f*

  cardiac anomalies, 586

  extragenitourinary abnormalities, 585–588, 585*t*

  gastrointestinal abnormalities, 587–588, 587*f*

  genitourinary anomalies, 581–585

  kidneys, 581, 582*f*

  oral abnormalities, 588

  orthopedic abnormalities, 588, 588*f*

  prostate, 583–584, 584*f*

  pulmonary anomalies, 586–587

  sex organs, 583–584

  testes, 584–585, 585*f*

  ureters, 581–582, 582*f*–583*f*

  urethra, anterior, 584, 585*f*

description of, 581

embryology of, 581

evaluation of, 590–595

female syndrome, 590

genetics of, 581

incidence of, 581

incomplete, 590

long-term outlook with, 595–600, 600*b*

management of, 590–595, 591*b*

neonatal presentation of, 589

prenatal, diagnosis and management of, 588–589, 589*f*

presentation of, 588–590

spectrum of, 589–590, 589*t*

surgical management of, 591–595, 595*b*

  abdominal wall reconstruction, 594–595

  cutaneous vesicostomy, 592, 592*f*

  Dénes technique, 595, 598*f*–600*f*

  Ehrlich technique, 595

  Furness technique, 595

  internal urethrotomy, 592

  Monfort technique, 595, 596*f*–597*f*

  orchidopexy, 593–594, 594*f*

  Randolph technique, 595

  reduction cystoplasty, 592

    - supravesical urinary diversion, 591–592
    - ureteral reconstruction, 592
    - urethral reconstruction, 592–593, 593*f*

PRX302, 3447
  - to facilitate bladder filling and urine storage, 2713.e2

PSA, Prostate-specific antigen

PSCA, Prostate stem cell antigen

Pseudoaneurysm, 274–275

Pseudoepitheliomatous, keratotic, and micaceous balanitis (PEKMB), 1299–1300, 1300*f*, 1742.e1

Pseudoexstrophy, 537

Pseudoincontinence, patient history of, 5

Pseudomembranous enterocolitis, with bowel preparation, 3165, 3166*t*

Pseudomonas aeruginosa, 442

Pseudo-obstruction of colon, with intestinal anastomoses, 3181

Pseudoureterocele, 801

PSMA, Prostate-specific membrane antigen

Psoas, 1658, 1662*f*–1665*f*, 1664*t*

Psoas hitch, 3026–3034
  - evaluation for, 3026
  - laparoscopic and robotic technique of, 3028–3029, 3029*f*
  - for lower ureteral injuries, 1998–1999, 1999*f*
  - surgical indication for, 3026
  - surgical technique for, 3026–3027, 3027*f*
  - with ureteroneocystostomy, 1973
  - for urinary tract reconstruction, 683, 684*f*

Psoas syndrome, 262

Psoriasis, as papulosquamous disorder, 1278–1279, 1279*f*

Psychological evaluation, in ED, 1526

Psychological Impact of Erectile Dysfunction (PIED) scale, 112*t*

Psychological screening, 477

Psychometric analysis, 108

Psychophysiologic evaluation, in ED, 1525–1526

Psychosexual development, 996–997, 997*b*

Psychosexual therapy, for ED, 1529

Psychotropic medication, and ED, 1507–1508, 1509*t*

PTH, Parathyroid hormone

PTNS, Percutaneous tibial nerve stimulation

Puberty, 1392

Pubic lice, Pediculosis pubis

Pubic rami, 2427

Pubic tubercles, 2428*f*

Public health notification, from USFDA Center for Devices and Radiological Health, 2777

Pubococcygeal line (PCL), 2537

Pubococcygeus muscle, 2430–2432, 2432*f*

Puboprostatic ligaments, division of, in retropubic radical prostatectomy, 3552, 3552*f*

Pubovaginal sling (PVS), 2833–2835

- allograft
    - materials for, 2834–2835
    - outcomes of, 2841–2843, 2841*t*–2842*t*
- anatomy for, 2834
- autologous graft
    - materials for, 2834
    - outcomes of, 2839–2841, 2840*t*
- complications of, 2848–2849, 2849*b*
    - nonurologic, 2849
    - perforation and exposure, 2848–2849
- evolution of, 2830
- materials for, 2834–2835, 2836*b*

- mechanics of, 2834
- operative procedure for, 2836–2839, 2839*b*
    - anesthesia for, 2836–2837
    - counseling, 2836
    - graft harvest for, 2837, 2837*f*
    - patient positioning for, 2836–2837
    - postoperative care for, 2839
    - preparation for, 2836–2837
    - sling placement and fixation in, 2838–2839, 2838*f*–2839*f*
    - vaginal dissection for, 2837–2838, 2838*f*
- outcomes of, 2839–2844, 2845*b*
    - for mixed urinary incontinence, 2844–2845
    - for urethral reconstruction, 2845
- retropubic suspension surgery *versus*, 2771–2773, 2772*f*
- synthetic prosthetic
    - materials for, 2835, 2836*t*
    - outcomes of, 2843
- voiding dysfunction after, 2845–2848, 2848*b*
    - surgical management of, 2846–2848, 2847*t*
- xenograft
    - materials for, 2835
    - outcomes of, 2843–2844, 2844*t*

Pubovesical ligaments, 2429–2430, 2438

Pudendal arteries, 1807.e4*f*
- preservation of, in retropubic radical prostatectomy, 3552, 3552*f*

Pudendal nerve, 2434
- stimulation of, 2511, 2751–2752
    - inhibitory and excitatory stimulation frequencies, 2511

Pulmonary abnormalities, with cloacal exstrophy, 575

Pulmonary complications
- after RPLND, 1730
- of radical nephrectomy, 2261–2266

Pulmonary embolism
- after laparoscopic and robotic surgery, 231
- after retropubic radical prostatectomy, 3563
- vena caval thrombectomy and, 2266–2267, 2277

Pulmonary evaluation, 120–121

Pulmonary hypoplasia, with posterior urethral valves, 610–611, 610*f*

Pulsed radiofrequency, for chronic scrotal pain syndrome, 1221

Pulsed wave lasers, 238

PUM, Partial urogenital mobilization

PUNLMP, Papillary urothelial neoplasm of low malignant potential

PUO, Partial ureteral obstruction

Purinergic nervous system, in ureteral function, 1889–1890

Purinergic signaling

- in bladder afferent pathway, 2484–2485, 2485*f*
- in bladder pain syndrome and interstitial cystitis, 2508

PVP, Photoselective vaporization of prostate

PVR, Postvoid residual

PVS, Pubovaginal sling

Pyeloenteric fistulae, 2953–2955, 2953*f*–2954*f*

Pyelogenic cyst, 774, 774*f*

Pyelography

- antegrade, Antegrade pyelography
- intravenous, Intravenous pyelography
- for pediatric genitourinary trauma, 1073–1074
- retrograde, Retrograde pyelography

Pyelolithotomy, laparoscopic pyeloplasty with, for ureteropelvic junction obstruction with, 1958–1960

Pyelolymphatic backflow, 38

Pyelonephritis, 398–400, 1129

- acute, 1168–1171, 1168*f*–1169*f*, 1170*t*
- chronic, 1176–1177, 1177*f*
- emphysematous, 1171–1172, 1171*f*
- with ureterointestinal anastomoses in urinary intestinal diversion, 3180*t*, 3192

  - XGP, 1177–1179, 1178*f*–1179*f*

Pyeloplasty, 836*b*
  - with concomitant pyelolithotomy, 1958–1960
  - dismembered, Dismembered pyeloplasty
  - laparoscopic, Laparoscopic pyeloplasty
  - laparoscopic dismembered tubularized flap, 1960
  - nondismembered, Nondismembered pyeloplasty
  - open surgery, 1953
  - for prune-belly syndrome, 592
  - results of, 1957–1958, 1959*t*
  - salvage procedures for, 1963

Pyelopyelostomy, for retrocaval ureter, 1963, 1965*f*

Pyelosinus backflow, 38

Pyelotubular backflow, 38

Pyeloureterostomy, for ureteral anomalies, 816–817, 817*b*

Pyelovascular fistulae, 2958

Pygeum africanum (African plum)
  - for benign prostatic hyperplasia, 3398
  - for nocturia, 2674

Pyoderma gangrenosum (PG), 1287–1288, 1288*f*

Pyonephrosis, 435
  - infected, 1174, 1174*f*

Pyridium, for pelvic floor disorder testing, 2533

Pyridoxine, for pediatric kidney stone disease, 870

Pyrophosphate, in crystal formation, 2014

Pyuria, 14, 426, 1129

Q

Qmax, 480–481, 481*t*

QOL-MED, 112*t*

Q-tip test, for urethral mobility, 2529

Quadratic fixation

- mechanisms of action of, 2995, 2995*f*
- mechanisms of continence of, 2995

Quadratus lumborum, 1658, 1662*f*–1665*f*, 1664*t*

Quadruple ureters, 821

Quality of care, definition of, 101

Quality of life, Health-related quality of life

- after androgen deprivation therapy, 3656
- after orthotopic urinary diversion, 3255–3257, 3256*t*, 3257*b*
- augmentation cystoplasty and, 702
- with cutaneous continent urinary diversion, 3226–3227
- cystinuria and, 2062–2063
- definition of, 116
- with exstrophy-epispadias complex, 567
- lower urinary tract dysfunction and, in pediatric patients, 652–653, 655*b*
- nocturia and, 2664
- with posterior urethral valves, 620, 623*b*
- in prune-belly syndrome, 595

Quality-of-life questionnaires

- for male urinary incontinence, 2541, 2541.e1*f*–2541.e2*f*, 2542*f*
- for pelvic floor disorders, 2531, 2532*t*–2533*t*

Quercetin, for BPS/IC oral therapy, 1241*t*, 1243

Questionnaire-Based Voiding Diary (QVD), 2723, 2723.e1*f*–2723.e2*f*

Quick flicks, 2730

Quiescent intracellular reservoir (QIR), 429

QVD, Questionnaire-Based Voiding Diary

R

RAA, Renal artery aneurysm

Race

- pelvic organ prolapse and, 2591
- urinary incontinence and, 2583–2585
- UTUC variations and, 2185

Race, prostate cancer and, 3457–3458, 3542

Rad, 28

Radiation

- for adrenal cortical carcinoma, 2387
- bladder cancer and, 3077
- in pediatric kidney stone disease, 861
- for retroperitoneal tumors, 2245

Radiation exposure, 28

- with CT, 780
- lower urinary tract dysfunction and, 2632
- medical diagnoses and, 2527

Radiation fistulae, 2959–2962

- chemotherapy of, 2961–2962
- combination therapies of, 2962
- diversion procedures for, 2961
- interpositional grafts for, 2961
- management approaches for, 2961
- recommendations for, 2961
- repair techniques for, 2961

Radiation therapy

- adjuvant, *Adjuvant radiation therapy*
- after partial orchiectomy, 1712
- biochemical recurrence after, Biochemical recurrence, after radiation therapy
- brachytherapy, Brachytherapy
- definitive, 3665–3666
- external beam, External beam radiation treatment
- for locally advanced prostate cancer, 3652–3655, 3653*t*
  - adjuvant androgen deprivation with, 3653–3654
  - chemotherapy with, 3654–3655
  - neoadjuvant androgen deprivation with, 3652–3653, 3654*b*

for muscle-invasive bladder cancer, 3122
for neuroblastoma, 1096
in non-muscle-invasive bladder cancer, 3106
for PD, 1615–1616, 1617*t*
for penile cancer, 1765–1769, 1769*b*
    adverse effects of, 1767–1768
    inguinal areas, 1768–1769, 1769*f*
    primary lesion, 1765–1768
for prostate cancer, 3587–3615
    androgen suppression combined with, 3600–3602, 3602*b*
        background and potential mechanisms of, 3600
        localized disease and, 3600–3602, 3601*t*
        locally advanced disease and, 3602
        optimal duration of, 3602
    CT-based treatment planning and three-dimensional conformal radiotherapy, 3587–3588, 3588*f*
    evaluating response to, 3606–3609, 3609*b*
    high-energy linear accelerators, 3587
    in high-risk or locally advanced disease, 3611
    historical perspective on, 3587–3592, 3592*b*
    hormonal therapy with, 3682
    image-guided radiation therapy and treatment margins, 3589–3590, 3591*f*–3592*f*
    intensity-modulated radiation therapy, 3588–3589, 3589*f*, 3589*t*
    multiparametric magnetic resonance imaging in, 3590–3591
    postradiation therapy biopsy, 3608
        imaging and sampling error, 3609
        interpretation of, 3608–3609, 3609*b*
        timing of, 3608–3609
    prostate-specific antigen and, 3606–3607
        doubling time, 3607–3608
        failure and, 3606–3607
        nadir value significance, 3607–3608
        neoadjuvant hormones, 3608
        time to nadir of, 3607
    role of prophylactic pelvic nodal treatment, 3602–3603, 3603*b*
    technological advances of, 3587–3592, 3592*b*
    transrectal ultrasound-guided brachytherapy, 3591–3592, 3592*f*
    treatment morbidity and quality-of-life outcomes of, 3603–3606, 3604*t*–3605*t*, 3606*b*
        erectile dysfunction and management, 3606
        rectal toxicity and management, 3603–3604
        rectal-sparing strategies, 3604, 3604*f*
        urinary toxicity and management, 3604–3606
for renal tumor ablation, 2321–2322
salvage, Salvage radiation therapy
for seminomas, 1702–1703, 1703*t*
stereotactic body, 3593–3594
for TGCTs, 1692
in uroradiology, 28–29, 29*t*

        - radiation protection, 28–29
        - relative radiation levels, 28, 29*t*

Radiation Therapy Oncology Group (RTOG), 3594

Radical cystectomy
    - continence preservation in
        - anterior apical dissection in male patient, 3239–3240, 3241*b*
        - urethra preservation in female patient, 3240–3241, 3240*f*
    - history of, 3133
    - indications for, 3144
    - oncologic outcomes of, 3118–3119, 3133
    - with pelvic lymph node dissection
        - anatomic extent of, 3115–3116
        - bilateral, 3115
        - density of, 3117
        - distal urethra management, 3118
        - extracapsular nodal extension, 3117
        - intraoperative decision making, 3117–3118
        - intraoperative frozen sections of ureter, 3117–3118
        - managing female urethra in, 3118
        - for muscle-invasive bladder cancer, 3114–3119
        - number removed in, 3125
        - oncologic outcomes following, 3118–3119, 3118*t*
    - robotic, Robotic radical cystectomy
    - with transurethral resection of bladder tumor
        - female, 3141–3143, 3142*f*–3143*f*
        - male, 3138–3141, 3139*f*–3141*f*

Radical inguinal lymph node dissection, for penile cancer, 1796–1798, 1799*f*–1800*f*

Radical nephrectomy
    - laparoscopic, Laparoscopic radical nephrectomy
    - for malignancy, 2257–2261, 2257*f*
        - complications of, 2261
        - regional lymphadenectomy with, 2260, 2260*f*, 2260.e1*f*
        - surgical procedure for, 2257–2260, 2258*f*–2259*f*, 2258.e1*f*, 2259.e1*f*
        - wound closure for, 2261
    - for RCC, local recurrence after, 2164–2165, 2165–2166, 2165*b*, 2166*f*, 2167*t*, 2168*f*

Radical nephroureterectomy, for UTUC, 2199–2202
    - distal ureter and bladder cuff management, 2200

- indications of, 2199
- laparoscopic, 2202–2205
- open, 2199–2200, 2200*f*
- total laparoscopic technique in, 2202, 2203*f*
- traditional open distal ureterectomy in, 2200–2201, 2200*f*–2201*f*
- transurethral resection of ureteral orifice, 2201–2202, 2202*f*
- transvesical ligation and detachment technique in, 2201, 2201*f*

Radical orchiectomy, 1711
- technique for, 1711–1712
- for TGCTs, 1686

Radical pelvic irradiation, localized prostate cancer and, 3525

Radical prostatectomy
- biochemical recurrence after, 3659–3665, Biochemical recurrence, after radical prostatectomy
- for locally advanced prostate cancer, 3645–3652, 3648*b*
    - adjuvant androgen deprivation with, 3652
    - adjuvant radiation therapy, 3650–3652, 3651*t*, 3652*b*
    - for clinical stage T3, 3645–3652, 3646*t*
    - neoadjuvant androgen deprivation, 3648–3649, 3648*t*–3649*t*
    - neoadjuvant chemotherapy and chemotherapy-hormonal therapy, 3649–3650, 3650*t*
    - outcomes of, 3646–3647, 3647*f*
- pathologic findings with, 3643, 3643*t*
- and PD, 1602
- for prostate adenocarcinoma, 3510–3512
- for prostate cancer, hormonal therapy with, 3682
- retropubic, Retropubic radical prostatectomy
- salvage, Salvage radical prostatectomy
- urinary incontinence after
    - prevalence of, 2587
    - risk factors for, 2587
    - sphincteric function and, 2596

Radiofrequency ablation (RFA)
- for RCC, 2171
- for renal tumors, 2310–2312, 2312*b*
    - background and mode of action, 2310–2312
    - CA *versus*, 2317–2318
    - complications of, 2318–2319, 2320*f*–2321*f*, 2320*b*
    - equipment variations, 2311

    - follow-up for, 2312–2314, 2314*b*
    - intraoperative monitoring, 2311–2312
    - laparoscopic, 2304–2305
    - oncologic outcomes of, 2314–2318, 2315*t*–2316*t*, 2318*b*
    - percutaneous, 2312, 2313*f*, 2318
    - treatment temperature, 2311

Radiography
  - of bladder injuries, 3055–3056
  - of cloacal anomalies, 1024–1025
  - of defecation disorders, 669–670, 669*f*–670*f*
  - for genitourinary tuberculosis, 1311–1313, 1311*f*–1313*f*
  - intravenous urography, Intravenous urography
  - loopography, Loopography
  - of male pelvis, 2457–2458
  - of neuroblastoma, 1089
  - retrograde pyelography, Retrograde pyelography
  - retrograde urethrography, Retrograde urethrography
  - static cystography, Static cystography
  - for ureteropelvic junction obstruction, 1943, 1944*f*
  - of urethral diverticula, 2982–2983, 2983*f*–2984*f*
  - of urinary lithiasis, 2038
  - of urogenital sinus abnormalities, 1023–1024
  - voiding cystourethrogram, Voiding cystourethrogram

Radioisotopic penography, 1524

Radiologic imaging
  - of pediatric urology, 388
  - for UTUC, 2191–2192

Radionuclide cystography, 423, 424*f*–425*f*

Radionuclide renal scan, for posterior urethral valves, 608

Radionuclide studies, for UTIs, 1144.e1

Radionuclide testicular scanning, 423

Radiopharmaceuticals
  - for castration-resistant prostate cancer, 3704
  - for nuclear imaging of kidneys, 96*b*

Radiotherapy and Androgen Deprivation in Combination after Local Surgery (RADICALS), 3663–3664

Radiotracers, 91

Radium-223, for castration-resistant prostate cancer, 3704

RAE, Renal artery embolization

RaLPN, Robotic-assisted laparoscopic partial nephrectomy

RALRP, Robotic-assisted laparoscopic radical prostatectomy

Randall plaques, 2011, 2012*f*–2013*f*, 2018

Randolph technique, 595

Random flaps, for urethral and penile reconstruction, 1807, 1807*f*

Randomized Intervention for Management of Vesicoureteral Reflux (RIVUR) study, 515–516

RANK ligand inhibitors, for castration-resistant prostate cancer, 3704

Rapid eye movement (REM), 2665

RAS, Renal artery stenosis

RASSF1A gene, in bladder cancer, 1349

RAVES (Radiotherapy-Adjuvant Versus Early Salvage) trial, 3664–3665

RAZOR trial, of robotic cystectomy, 3144

RBF, Renal blood flow

RCC, Renal cell carcinoma

RCCT, Renal concentrating capacity test

Reactive arthritis

- as papulosquamous disorder, 1279–1280, 1280*f*
- urethral involvement in, reconstructive surgery for, 1808
    - for reactive arthritis, 1808
    - for urethral hemangioma process, 1808

Real-time CT fluoroscopy, 45

Real-time elastography (RTE), 74, 75*f*

- of scrotum, 84

Real-time or ultrasound dosimetry, 3598

Reanastomosis, for urethral stricture disease, 1819–1820, 1819*f*–1820*f*

Reboxetine, for delayed ejaculation, 1579

Reconstructive surgery

- after bladder RMS treatment, 1116
- for cloacal anomalies, 1037–1041, 1040*b*
  - definitive, 1039–1041, 1039*f*
  - gastrointestinal tract decompression for, 1038
  - genitourinary tract decompression for, 1038–1039, 1038*f*
  - initial management, timing, and principles for, 1037–1038
  - obstructive urinary repair, 1039
  - results of, 1040–1041, 1041*t*
- for detrusor underactivity, 2663
- for disorders of sex development and urogenital sinus
  - current operative techniques for, 1028–1034, 1029*f*
  - high vaginal confluence: with or without clitoral hypertrophy, 1030–1033, 1031*f*–1033*f*
  - initial management, timing, and principles, 1025–1028, 1026*f*
  - low vaginal confluence: clitoral hypertrophy, 1028–1030, 1030*f*, 1030*b*
  - results of, 1034–1037
  - total and partial urogenital mobilization, 1033–1034, 1034*f*–1036*f*
- microvascular, 3050
- penile and urethral, 1804–1842, 1805*b*, 1813*b*
  - for amyloidosis, 1810
  - anatomy of, 1807, 1807.e1*f*–1807.e7*f*
  - for balanitis xerotica obliterans, 939, 940*f*
  - for circumcision complications, 1811–1812
  - in classic bladder exstrophy, 551–552, 552*f*–553*f*
  - for curvatures of penis, 1836–1838, 1838*b*
  - for failed epispadias repair, 1813
  - for failed hypospadias repair, 1812–1813
  - female-to-male transgender, 1841–1842, 1842*b*
  - for fistulae of posterior urethra, 1835–1836, 1836*b*
  - for glans dehiscence, 937, 938*f*
  - for LS, 1808–1810, 1809*f*
  - in male epispadias, 569
  - for meatal stenosis, 937–938, 1811
  - for paraphimosis, balanitis, and phimosis, 1811
  - penile transplantation, 1838–1842, 1840*f*, 1842*b*
  - for PFUIs, 1828–1834, 1830*f*–1834*f*

    - principles of, 1804–1807, 1806*f*–1807*f*, 1808*b*
    - for reactive arthritis, 1808
    - for recurrent penile curvature, 939–941, 940*f*
    - for urethral diverticulum, 938–939, 939*f*, 1810–1811
    - for urethral hemangioma process, 1808
    - for urethral stricture, 938, 1814–1828, 1814*f*, 1828*b*
    - for urethrocutaneous fistula, 935–937, 936*f*–937*f*, 1810
    - for vesicourethral distraction defects, 1834*b*, 1835, 1836*b*

Rectal bladder urinary diversion, 3209–3211
  - augmented valved rectum, 3209
  - folded rectosigmoid bladder, 3209
  - hemi-Kock pouch procedures with valved rectum, 3209–3210
  - Mainz II pouch, 3210–3211
  - sigma-rectum pouch, 3210–3211
  - T pouch procedures with valved rectum, 3209–3210, 3210*f*

Rectal carcinoma, and delayed ejaculation, 1576

Rectal fascia, 2427, 2429*f*

Rectal injury
  - bowel injury and, 277–278
  - complications of seminal vesicle surgery, 1864

Rectal mucosal grafts, 1807

Rectal toxicity, prostate cancer and, 3603–3604

Rectocele, 2526, 2587
  - repair of, 2825

Rectourethral fistulae (RUF), 2955–2958, 2956*f*, 2958*b*

Rectouterine pouch, 2427–2428, 2429*f*

Rectovaginal space, 2427, 2429*f*

Rectovesical pouch, bladder, 3010

Rectum, anatomy of, 2449, 2450*f*, 2454, 2455*f*

Rectus abdominis, 136*f*, 2447, 2447*f*–2448*f*

Rectus muscle flap, in urethrovaginal fistulae, 2950

Rectus sheath, 2444, 2447*f*–2448*f*

Recurrent cryptorchidism, 949

Recurrent infection, in bladder tumor, 3077

Recurrent penile curvature, 913*f*–914*f*, 939–941, 940*f*

Recurrent stenosis, after urethral injury, 3060

Recurrent uric acid stone formation, ammonium acid urate stones from, 2032

Recurrent UTIs, 1159–1166, 1160*t*, 1160*b*

- ammonium acid urate stones from, 2032
- bacterial persistence and, 1160–1161
- cranberry, 1163–1164, 1164*f*
- D-mannose, 1166
- estrogen, 1164–1165, 1164*f*
- immunoactive prophylaxis, 1166
- low-dose continuous prophylaxis for, 1162–1163
- management, 1161–1166, 1161*f*
- methenamine, 1165*t*, 1166
- non-antibiotic management, 1163
- probiotics, 1165

REDUCE, Reduction by Dutasteride of Prostate Cancer Events

5α-Reductase

- in benign prostatic hyperplasia, 3307–3308, 3308*f*
- prostate metabolism, 3286–3287, 3286*f*, 3287*t*

5α-Reductase deficiency, 1014–1016, 1015*f*

5α-Reductase inhibitors
- α-adrenergic blockers and, 3385, 3386*f*
- for benign prostatic hyperplasia, 3378
- for chemoprevention of prostate cancer, 3473–3475
- for chronic scrotal pain syndrome, 1215
- to facilitate bladder filling and urine storage
  - with α-adrenoreceptor antagonists, 2707
  - with antimuscarinic agents, 2707
- for priapism, 1553
- prostate-specific antigen and, 3515

5α-Reductase-specific antibodies (5ARIs), in prostate cancer, 3544

Reduction by Dutasteride of Clinical Progression Events in Expectant Management of Prostate Cancer (REDEEM) study, 3544

Reduction by Dutasteride of Prostate Cancer Events (REDUCE), 3475

Re-entry catheter, 173, 174*f*

Reflection, of ultrasound waves, 71, 71*f*

Reflex circuitry
- controlling continence, 2489–2493, 2490*f*
  - somatic to visceral reflexes, 2492
  - sphincter to bladder reflexes, 2490*f*, 2491–2492, 2492*f*
  - storage phase, 2490–2491, 2490*f*–2491*f*, 2491*t*
- controlling micturition, 2489–2493, 2490*f*
  - emptying phase, 2490*f*, 2491*t*, 2492
  - urethra to bladder reflexes, 2492–2493, 2492*f*–2494*f*

Reflex contraction, promotion or initiation of, 2902

Reflex sympathetic dystrophy (RSD), lower urinary tract dysfunction and, 2626

Reflux nephropathy, 742

Reflux-associated renal dysplasia, 499, 499*f*, 499*t*, 499.e1*f*

Refluxing ureteral reimplantation, 3023–3026, 3023*f*

Refractory urinary storage symptoms, after urethrolysis, 2848

Regional anesthesia, in urologic surgery, 131–132

Regions of interest (ROI), 3587–3588

Regitine, Phentolamine

Reiter syndrome, Reactive arthritis

Relapse, tumors
- NSGCTs, 1700–1702
- seminomas, 1706

Relative jet frequency (RJF), 778

Relative saturation ratio (RSR), 2010

Reliability, definition of, 109

Religion, benign prostatic hyperplasia and, 3320–3321

REM, Rapid eye movement

Renal abscess, 1172–1174, 1172*f*–1173*f*

Renal agenesis, 741–742
- unilateral, Unilateral renal agenesis

Renal anomalies, 510

Renal arterial clamping, for laparoscopic partial nephrectomy, 2303

Renal arterial laceration, for pediatric genitourinary trauma, 1074

Renal arterial occlusion, for pediatric genitourinary trauma, 1074

Renal arteries, 1671–1672
- occlusion of, Ischemic nephropathy, Renovascular hypertension
- in radical nephrectomy, 2258, 2258*f*, 2258.e1*f*
- in simple nephrectomy, 2288, 2288*f*

Renal arteriovenous fistula, 737

Renal artery aneurysm (RAA), 736–737

Renal artery embolization (RAE), before kidney surgery, 2248, 2248.e1*f*

Renal artery stenosis (RAS)
- diagnosis of, 1916–1918, 1917*f*–1918*f*, 1918*b*
- incidence and etiology of, 1914*b*
- management of, 1918–1919

- medical therapy, 1918
- percutaneous intervention, 1918–1919, 1919*f*
- surgical, 1919, 1920*b*

pathophysiology of, 1915–1916, 1915*f*–1916*f*, 1915*t*, 1916*b*

- one-kidney, one-clip model of, 1917, 1918*f*
- two-kidney, one-clip model of, 1917, 1917*f*

in renovascular hypertension, 1915

screening tests for

- angiography, 1917–1918, 1918*b*
- CT, 1917–1918, 1918*b*
- duplex Doppler ultrasonography, 1917–1918, 1918*b*
- MRA, 1917–1918, 1918*b*

Renal artery thrombosis (RAT), 387

Renal bladder ultrasound, for pediatric urology, 388–389

Renal bleeding

nephrectomy and, 1988–1989

with renal injury, 1991

Renal blood flow (RBF), 1905, 1906*b*

aging and, 2905

urinary tract obstruction and

- in bilateral ureteral obstruction, 791–792
- GFR and, 791
- renal vascular resistance and, 791
- in unilateral ureteral obstruction, 791

Renal calculi, 2069.e1, 2084*b*

ammonium acid urate stones in, 2032

anatomic predisposition to, 2033–2035

- caliceal diverticula, 2034
- horseshoe kidneys, 2034
- medullary sponge kidney, 2034–2035
- ureteropelvic junction obstruction, 2034

calcium stones in, 2018–2026

- hypercalciuria, 2018–2020
- hyperoxaluria, 2020–2023, 2021*f*–2022*f*
- hyperuricosuria, 2023–2024, 2024*f*
- hypocitraturia, 2024
- hypomagnesiuria, 2026

classification of, 2017–2018, 2017*t*–2018*t*

clinical factors of, 2088–2091, 2091*b*
  duration, 2091
  morbid obesity and, 2089
  old age and frailty, 2089–2090
  prior renal surgery, 2090
  renal function, 2088–2089
  renal transplants, 2091
  solitary kidney, 2089
  spinal deformity or limb contractures, 2090
  uncorrected coagulopathy, 2090
  urinary diversion, 2091
  urinary tract infection and, 2088
composition of, treatment decision based on, 2076
cystine stones in, 2029–2030, 2029*f*
dihydroxyadenine stones in, 2031–2032
epidemiology of, 2005–2009, 2009*b*
  age, 2006
  cardiovascular disease, 2008–2009
  chronic kidney disease, 2009
  climate, 2007
  gender, 2005–2006
  geography, 2006–2007, 2007*f*
  obesity, diabetes, and metabolic syndrome, 2008
  occupation, 2007–2008
  race and ethnicity, 2006
  water intake, 2009
infection stones in, 2030–2031
  bacteriology of, 2030–2031, 2031*t*
  epidemiology of, 2031
  pathogenesis of, 2030, 2030*f*
matrix stones in, 2032
medication-related stones in, 2032–2033
mineral metabolism and, 2015–2017, 2017*b*
  calcium, 2015–2016
  magnesium, 2016
  oxalate, 2016–2017
  phosphorus, 2016
natural history of, 2069–2070
nonmedical management of, 2069–2093
  anatomic factors in, 2077–2084
  in calyceal diverticula, 2077–2078, 2077.e1*f*
  factors affecting, 2070*b*

    - imaging for, 2071
    - laboratory tests for, 2071
    - lower pole calculi, 2081–2084, 2081*f*, 2082*t*, 2083*f*
    - medical history for, 2071
    - pretreatment assessment for, 2070–2071
    - in renal ectopia, 2080–2081, 2081*f*
    - stone burden and treatment decision, 2072–2074, 2072*b*, 2073*f*
    - stone composition and, 2076
    - stone localization and, 2075–2076
    - treatment algorithm for, 2069, 2070*f*
    - in ureteropelvic junction obstruction, 2077
  - nonstaghorn, Nonstaghorn renal calculi
  - pathophysiology of, 2017–2035, 2035*b*
  - physicochemistry of, 2009–2015, 2015*b*
    - inhibitors and promoters, 2014–2015
    - matrix of, 2015
    - nucleation and crystal growth, 2010–2014, 2012*f*–2013*f*
    - saturation state in, 2009–2010, 2010*f*–2011*f*
  - in pregnancy, 2035
  - staghorn, Staghorn calculi
  - technical factors of, 2088
  - uric acid stones in, 2026–2029, 2027*f*–2028*f*
    - hyperuricosuria, 2029
    - low urinary volume, 2029
    - low urine pH, 2027–2029, 2028*f*
  - with urinary intestinal diversion, 3180*t*, 3195–3196
  - in urinary tract obstruction, 778
  - xanthine stones in, 2031–2032
- Renal calyces, 1869, 1869.e1*f*
- Renal cell carcinoma (RCC)
  - autosomal dominant polycystic kidney disease association with, 753, 2158
  - clear cell type, 55
  - clinical associations of, 2156–2158
  - clinical presentation of, 2155–2156, 2156*t*, 2156*b*
  - etiology of, 2140–2141, 2141*b*
  - familial, 2141–2145, 2142*t*–2143*t*, 2144*f*
    - treatment of, 2173–2174, 2174*f*
  - historical considerations for, 2133
  - incidence of, 2138–2140

metastatic, Metastatic RCC

as non-AIDS-defining urologic malignancy, 1268

pathology of, 2148–2155, 2148*t*–2151*t*, 2153*b*

- chromophobe RCC, 2149*t*–2151*t*, 2152–2153, 2154*f*
- classification systems, 2149–2151, 2149*t*–2151*t*
- clear cell RCC, 2149*t*–2151*t*, 2151–2152, 2152*f*
- collecting duct RCC, 2149*t*–2151*t*, 2154
- papillary RCC, 2149*t*–2151*t*, 2152, 2153*f*
- renal medullary RCC, 2149*t*–2151*t*, 2154–2155
- sarcomatoid and rhabdoid differentiation, 2149*t*–2151*t*, 2155, 2155*f*
- unclassified, 2149*t*–2151*t*, 2155

in pediatric patients, 1109–1110

prognosis of, 2160–2162, 2161*t*

screening for, 2156–2158, 2157*t*

staging of, 2158–2160, 2158*t*–2159*t*, 2160*f*, 2160*b*

treatment of advanced, 2325–2328

- chemotherapy, 2341–2342
- debulking or cytoreductive nephrectomy, 2325–2328, 2326*f*–2327*f*, 2327*t*, 2328*b*
- hormonal therapy, 2342–2343
- palliative surgery, 2328, 2328*b*
- prognostic factors and, 2324–2325, 2325*f*, 2325*t*
- resection of metastases, 2328, 2328*b*
- systemic therapy for non-clear cell variants, 2343–2344, 2344*f*
- targeted molecular agents in, 2324, 2333–2341, 2333*t*–2335*t*, 2336*f*, 2337*t*

treatment of localized, 2162–2174

- active surveillance, 2173, 2173*t*
- AUA guidelines for, 2162–2163, 2163*f*
- nephron-sparing surgery in, 2173–2174, 2174*f*
- partial nephrectomy, 2164–2169, 2165*b*, 2167*t*, 2169*f*
- radical nephrectomy, 2164–2165, 2165–2166, 2165*b*, 2166*f*, 2167*t*, 2168*f*
- risk stratification and renal mass biopsy, 2163–2164, 2164*f*, 2164*b*
- thermal ablative therapies, 2171–2173, 2171*f*, 2172*t*
- tumor enucleation, 2170–2171, 2170*f*

treatment of locally advanced, 2174–2180, 2174*b*

- adjuvant therapy, 2178–2180, 2178*b*
- IVC involvement, 2174–2176, 2175*f*–2176*f*, 2298, Vena caval thrombectomy
- local recurrence, 2178, 2178*b*
- locally invasive, 2176–2177
- lymph node dissection, 2177–2178, 2177*f*, 2177*t*, 2260, 2260*f*, 2260.e1*f*

with tuberous sclerosis complex, 758

tumor biology clinical implications in, 2145–2148

- angiogenesis and targeted pathways, 2146, 2148

    - cancer genome research, 2146–2148
    - immunobiology and immune tolerance, 2145–2146, 2147*f*
    - resistance to cytotoxic therapy, 2145, 2145*t*

Renal clearance, 1905

Renal concentrating capacity test (RCCT), 2678

Renal cortex, 1866, 1866.e1*f*

Renal cortical scintigraphy, 390

Renal cystic diseases, 745–746, 746*f*
- acquired, Acquired renal cystic diseases
- benign multilocular cyst, 765–766, 765*f*, 766*b*, 767*f*
- classification of, 745–746, 745*b*
- congenital nephrosis, 756
- familial hypoplastic glomerulocystic kidney disease, 756–757
- inheritable, 745*b*, 746
- medullary, 747*t*, 755–756, 756*f*, 756*b*
- medullary sponge kidney, 771–772, 771*f*, 772*b*
- multicystic dysplastic kidney, 762–765, 762*f*, 765*b*
- multiple malformation syndromes, 747*t*, 762*b*
- polycystic, 751*t*
    - autosomal dominant, 750–755, 755*b*
    - autosomal recessive, 746–749, 751*b*

Renal cysts, 401–402, 405, 2121–2123, 2123*b*
- epidemiology, etiology, and pathophysiology of, 2121
- evaluation of, 2122, 2122*f*, 2122*t*
- laparoscopic surgery for, 2291–2292, 2291*f*
    - procedure for, 2291, 2291*f*
    - results of, 2291–2292
- management options of, 2123, 2123*f*
- multiple malformation syndromes with, Multiple malformation syndromes with renal cysts
- natural history of, 2121–2122
- papillary adenoma, of kidney, 2128, 2128*b*

Renal descensus, for ureteral stricture disease, 1973

Renal drainage, for urinary tract obstruction, 795

Renal dysfunction, HIV and, 1266–1267

Renal dysplasia, 741–742, 741*b*
  definition of, 741, 742*f*
  etiology of, 741–742, 742*f*–743*f*
Renal echinococcosis, 1181.e1, 1181.e2*f*
Renal ectopia, 1869, 1869.e1*f*
  cephalad, 724–725, 726*f*
  crossed, 727–728, 728*f*, 731*b*
  simple, 724*f*–725*f*
Renal exploration
  for pediatric genitourinary trauma, 1073
  for renal injuries, 1988–1989, 1988*f*
Renal (Gerota) fascia, 1865
Renal function
  after RCC surgery, 2164–2169, 2165*b*, 2167*t*, 2169*f*
  aging and, 2905
  orthotopic urinary diversion and, 3237–3238
  in posterior urethral valves, 619, 620*b*
  in prune-belly syndrome, 595–596
  upper urinary tract calculi and, 2088–2089
Renal functional assessment
  for benign prostatic hyperplasia, 3345–3346
  for ureteral anomalies, 806, 806*f*
Renal hilum, 1865, 1869
  identification of, for simple nephrectomy, 2287–2288, 2288*f*
Renal hypercalciuria, 2019–2020
Renal hypodysplasia, 742–745, 745*b*
Renal hypoplasia, 742–745, 745*b*
Renal infection (bacterial nephritis), 1166–1177
  acute focal or multifocal bacterial nephritis, 1171.e1, 1171.e1*f*
  for acute pyelonephritis, 1168–1171, 1168*f*–1169*f*, 1170*t*
  bacterial “relapse,”, 1177.e1

- chronic pyelonephritis, 1176–1177, 1177*f*
- emphysematous pyelonephritis, 1171–1172, 1171*f*
- HIV and, 1266
- infected hydronephrosis and pyonephrosis, 1174, 1174*f*
- pathology, 1166–1168, 1167*f*–1168*f*
- perinephric abscess, 1174–1176, 1175*f*
- renal abscess, 1172–1174, 1172*f*–1173*f*

Renal injuries, 1982–1992, 1992*b*

- angioembolization for, 1986, 1986*f*
- classification of, 1983–1986, 1983*f*, 1983*t*
- damage control for, 1991
- genitourinary trauma and, 1075–1076
- hematuria in, 1982–1983
- history for, 1982–1983
- imaging of
  - CT, 1984–1985, 1984*f*–1985*f*
  - indications for, 1984, 1984*f*
  - IVP, 1985
- in intraoperative consultation, 302–303
  - diagnosis/recognition, 302–303
  - incidence, 302
  - management, 303
  - mechanisms, 302
- nonoperative management of, 1986–1988, 1987*f*
- operative management of, 1988–1991
  - complications with, 1991–1992
  - indications for, 1991
  - partial nephrectomy, 1989–1990, 1989*f*
  - renal exploration for, 1988–1989, 1988*f*
  - renal reconstruction, 1989–1991, 1989*f*–1990*f*
  - renorrhaphy, 1989, 1989*f*
  - for renovascular injuries, 1990–1991, 1990*f*–1991*f*
  - total nephrectomy, 1991
- pediatric, 1065
- presentation of, 1982–1983
- renal trauma grading system for, 1066–1072, 1067*f*–1069*f*, 1067*t*, 1069*t*

Renal insufficiency, 1921–1935

- bacteriuria in pregnancy and, 1187.e1

- metabolic syndrome and, 1420
- partial nephrectomy causing, 2266

Renal ischemia, Ischemic nephropathy, Renovascular hypertension
- for laparoscopic partial nephrectomy, 2303–2304
- for partial nephrectomy, 2262, 2262*f*

Renal magnetic resonance imaging, 55–67, 59*f*–60*f*

Renal malignancies, 2133–2184, 2134*t*
- chronic inflammation role in, 1336
- classification of, 2133–2134, 2137*t*
- genomic alterations in, 1353, 1354*t*, 1358
- hereditary, Hereditary leiomyomatosis and RCC syndrome, Hereditary papillary RCC syndrome
- historical considerations for, 2133
- immune checkpoint blockade in, 1343
- lymphoma and leukemia, 2181–2183, 2182*t*
- metastases, 2181*t*, 2183
- other, 2181*t*, 2183–2184
- port-site recurrence of, 2297
- radiographic evaluation of, 2134–2138, 2135*t*, 2136*f*
  - CT, 2134–2135, 2136*f*, 2174*f*
  - for cystic lesions, 2137–2138, 2139*f*–2140*f*
  - MRI, 2135, 2138*f*
  - ultrasonography, 2135
- RCC, 2138–2162, Renal cell carcinoma
- sarcomas, 2180–2181, 2181*t*, 2182*f*
- surgical techniques for, Kidney surgery
- vaccines for, 1339–1340

Renal medulla, 1866, 1866.e1*f*–1866.e2*f*, 1867*f*

Renal medullary RCC, pathology of, 2149*t*–2151*t*, 2154–2155

Renal morphogenesis, 341

Renal osteodystrophy, 355

Renal pain, patient history of, 2

Renal papilla, 1866, 1866.e1*f*–1866.e2*f*

Renal papillary necrosis (RPN), host defense mechanisms in UTIs and, 1139–

1140, 1139*b*

Renal parenchyma, 161–162

radiologic anatomy of, 1868–1869, 1868*f*, 1868.e1*f*, 1869*b*, 1869.e1*f*–1869.e2*f*

Renal pelvic perforation, 179, 180*f*

Renal pelvis

normal upper tract urothelium, 2188

physiology of, 1877–1904

rupture of, for pediatric genitourinary trauma, 1075

urothelial neoplasms, 2188–2189

Renal physiology, 1905–1920

hormonal, renal hormone effects, 1913–1914, 1913*f*–1914*f*, 1914*b*

vascular

blood flow, Renal blood flow

glomerular filtration, Glomerular filtration rate

Renal preservation surgery, urinary leak after, 2962

Renal rotation, anomalies of, 733–735, 735*b*

description for, 733

diagnosis of, 734, 735*f*

dorsal position in, 733

incidence of, 733

lateral position in, 733–735

prognosis of, 735

symptoms of, 734

ventral position in, 733

ventromedial position in, 733

Renal scintigraphy, 367–369, 369*f*–370*f*, 390

diuretic renography, 390

renal cortical scintigraphy, 390

Renal sinus, 1865

cyst of, 775, 775*f*

Renal stones, 406

metabolic syndrome and, 1420–1421

- Renal threshold, 19–20
- Renal transplantation
  - evaluation, 94–95
  - genitourinary tuberculosis management and, 1318–1319
  - pediatric, Pediatric renal transplantation
  - in posterior urethral valves, 619–620
  - urinary leak after, 2962
  - urologic complications of, 1936–1941
    - genitourinary malignancies, 1940–1941, 1941*b*
      - bladder cancer, 1941
      - prostate cancer, 1941
      - renal cell carcinoma, 1940–1941, 1940*f*
    - hematuria, 1936
    - lower urinary tract complications, 1939–1940
      - benign prostatic hyperplasia, 1939
      - transplant, small bladder after, 1939
      - urine incontinence, 1939–1940
      - voiding dysfunction, 1939
    - lymphocele, 1938–1939
    - nephrolithiasis, 1939
    - ureteral leak, 1937, 1937*b*
    - ureteral stent management, 1936, 1936*b*
    - ureteral structure, 1937–1938, 1937*t*, 1938*b*
    - vesicoureteral reflux, 1938
- Renal trauma, Renal injuries
- Renal tubular acidosis (RTA)
  - in calcium stone formation, 2025–2026, 2025*f*
  - type 1 (distal), 2025–2026, 2025*f*
  - type 2 (proximal), 2026
  - type 4 (distal), 2026
- Renal tubular disorders, 348, 349*b*
- Renal tubules
  - apoptosis in, 790
  - urinary tract obstruction and, 791
- Renal tumors, 402
  - benign, 2121–2132, Renal cysts
    - angiomyolipoma, 2125–2128, 2126*f*–2127*f*, 2128*b*
    - cystic nephroma, 2129–2130, 2129*f*
    - diagnosis of, 2121

- leiomyoma, 2131, 2131*f*, 2131*b*
- metanephric adenoma, 2128–2129, 2129*f*, 2129*b*
- mixed epithelial and stromal, 2130, 2130*f*, 2130*b*
- mixed mesenchymal and epithelial, 2129–2130, 2129*f*
- oncocytoma, 2123–2125, 2124*f*, 2125*b*
- other, 2131–2132, 2132*b*
- papillary adenoma, of kidney, 2128, 2128*b*

imaging and clinical risk stratification of, 2133–2134, 2135*t*

malignant, Renal malignancies

nonsurgical focal therapy of, 2309–2323

- complications, 2318–2319, 2320*f*–2321*f*, 2320*b*
- cryoablation, 2309–2310, 2310*b*, Cryoablation (CA), for renal tumors
- new ablation modalities, 2319–2323, 2323*b*
- oncologic outcomes, 2314–2318, 2315*t*–2316*t*, 2318*b*
- radiofrequency ablation, 2310–2312, 2312*b*
- surgical technique, 2312
- treatment success and follow-up protocol after tumor ablation, 2312–2314, 2314*b*

pediatric

- angiomyolipoma, 1110, 1110*f*
- CCSK, 1108–1109
- CMN, 1109
- CPDN, 1109
- metanephric adenofibroma, 1109
- neuroblastoma, Neuroblastoma
- RCC, 1109–1110
- RTK, 1109
- solitary multilocular cyst nephroma, 1109
- Wilms tumor, Wilms tumor

radiologic evaluation of, 2134–2138, 2135*t*, 2136*f*

- CT, 2134–2135, 2136*f*, 2174*f*
- for cystic lesions, 2137–2138, 2139*f*–2140*f*
- MRI, 2135, 2138*f*
- ultrasonography, 2135

surgical techniques for, Kidney surgery

Renal ultrasonography

for acute pyelonephritis, 1168

indications for, 78

limitations of, 80

normal findings in, 78–79, 79*f*

procedural applications of, 79–80

technique of, 78

Renal vascular development, 338–340

Renal vascular hypertension, evaluation of, 94

Renal vasculature

- anomalies of, 735–736, 737*b*
  - aberrant, accessory, or multiple vessels, 735–736, 736*f*
  - renal arteriovenous fistula, 737
  - renal artery aneurysm, 736–737
- hormonal, renal hormone effects, 1913–1914, 1913*f*–1914*f*, 1914*b*

Renal vein thrombosis, AKI caused by, 1925

Renal vein tumor thrombus, laparoscopic radical nephrectomy for, 2298

Renal veins, 1673, 1869–1870

- in radical nephrectomy, 2258, 2258*f*, 2258.e1*f*
- in simple nephrectomy, 2288, 2288*f*

Renal/abdominal solid masses, 405–406

Renin-angiotensin system (RAS), erectile dysfunction and, 1493

Reninoma, 2132

Renography

- diuretic, Diuretic renography
- normal curve of, 779
- nuclear, for urinary tract obstruction, 779
- in transitional urology, 1048

Renomedullary interstitial cell tumors, 2132

Renorrhaphy, for renal injuries, 1989, 1989*f*

Renovascular fistulae, 2958

Renovascular hypertension, 1915–1919

- diagnosis of, 1916–1918, 1917*f*–1918*f*, 1918*b*
- incidence and etiology of, 1914*b*
- management of, 1918–1919
  - medical therapy, 1918
  - percutaneous intervention, 1918–1919, 1919*f*
  - surgical, 1919, 1920*b*
- pathophysiology of, 1915–1916, 1915*f*–1916*f*, 1915*t*, 1916*b*

    - one-kidney, one-clip model of, 1917, 1918*f*
    - two-kidney, one-clip model of, 1917, 1917*f*
  - screening tests for
    - angiography, 1917–1918, 1918*b*
    - CT, 1917–1918, 1918*b*
    - duplex Doppler ultrasonography, 1917–1918, 1918*b*
    - MRA, 1917–1918, 1918*b*

Renovascular injuries, operative management of, 1990–1991, 1990*f*–1991*f*

Reoperative RPLND, 1728*t*, 1729

Replantation, of penis, 3050–3051

Reports, ultrasonography, 76–77

Reproductive system
  - female, Female reproductive system
  - male, Male reproductive system

Residual tumor, after treatment
  - NSGCTs with, 1698–1700, 1698*t*–1699*t*
  - seminomas with, 1705–1706

Resiniferatoxin, 2485
  - to facilitate bladder filling and urine storage, 2682*t*, 2709
  - in idiopathic detrusor overactivity, 2709.e1
  - in neurogenic detrusor overactivity, 2709.e1
  - urgency and, 2709.e1

Resistance, to chemotherapy, RCC with, 2145, 2145*t*

Resolution, of ultrasonography images, 70–71, 70*f*

Resorptive hypercalciuria, 2020

Respiratory system
  - aging and, 2906
  - pneumoperitoneum effects on, 221

Response Evaluation Criteria In Solid Tumors (RECIST), 104, 105*t*

Resting membrane potential (RMP), of ureteral muscle cells, 1878–1879, 1879*f*, 1881, 1881*b*

Restriction point, RB1 and, 1347.e1, 1347.e1*f*

Rete testis, 1393
  adenocarcinoma of, 1708
  cystic dysplasia of, 899
Retention sutures, 151
Retinoblastoma susceptibility protein (RB1), in GU cancers, 1347.e1, 1347.e1*f*
13-*cis*-Retinoic acid, for neuroblastoma, 1095–1096
Retractile testis, 949, 1855
Retraction instrumentation, for laparoscopic and robotic surgery, 218
Retrocaval ureter
  etiology and diagnosis of, 1963, 1965*f*, 1966*b*
  operative intervention for, 1963–1965, 1965*f*
    laparoscopic surgical intervention, 1963–1965
Retrocrural disease, resection of, 1720, 1721*f*
Retrograde ejaculation, 1451
  after transurethral needle ablation of prostate, 3433
  with holmium laser enucleation of prostate, 3438
  with transurethral incision of prostate, 3435
  treatment of, 1579, 1580*b*
Retrograde injection, of male stress urinary incontinence, 2896, 2897*f*
Retrograde intrarenal surgery, Ureterorenoscopy
Retrograde pyelography, 36–38, 415
  complications, 38, 38*f*
  for genitourinary tuberculosis diagnosis, 1312–1313
  indications, 37
  limitations, 37
  technique, 36–37, 37*f*
  of urinary tract obstruction, 780–781
Retrograde renal access drainage, 182–184, 184*b*
  guide wire placement of, 183, 183*f*
  history, 182
  indications, 182

    - stent placement of, 183, 183*f*
    - stent tolerance, 184
    - stent varieties of, 183–184
        - design, 183–184, 184*f*
        - materials, 183
    - surgical technique of, 182–183
- Retrograde ureterography, of ureteral injuries, 1995
- Retrograde ureteroscopic endopyelotomy, for ureteropelvic junction obstruction, 1949–1950
    - complications of, 1950
    - indications and contraindications for, 1950
    - other, 1950
    - results with, 1950
    - technique for, 1950, 1951*f*–1952*f*
- Retrograde ureteroscopic endoureterotomy, for ureteral stricture disease, 1968–1969, 1969*f*
    - antegrade approach combined with, 1969
- Retrograde urethrography, 38, 39*f*
- Retroiliac ureter, 824
- Retroperitoneal approach, 832
    - to laparoscopic adrenalectomy, 2417–2418, 2418*f*, 2422
    - for laparoscopic and robotic surgery, 1956
        - operative team placement for, 207, 207*f*
    - to laparoscopic kidney surgery, 2279–2281, 2282*f*
    - to laparoscopic partial nephrectomy, 2300
- Retroperitoneal cancer of unknown primary origin, retroperitoneal tumors and, 2238
- Retroperitoneal fibrosis (RPF), 1981*b*
    - evaluation of, 1978–1979
    - management of
        - initial, 1979
        - medical, 1979–1980
        - surgical, 1980, 1981*f*
    - presentation and etiology of, 1977–1978

Retroperitoneal incision, for renal exploration, 1988, 1988*f*

Retroperitoneal lymph node dissection (RPLND), 1713–1717, 1713*f*, 2240–2241, 2241*f*, 2241*t*

- auxiliary procedures for, 1717–1720, 1721*b*
  - hepatic resection, 1719–1720
  - major vascular reconstruction, 1718–1719, 1719*f*
  - nephrectomy, 1718, 1718*t*
  - pelvic resection, 1720
  - supradiaphragmatic disease, management of, 1720
- complications of, 1730–1731, 1730*t*
  - chylous ascites, 1731
  - ileus, 1731
  - lymphocele, 1731
  - mortality, 1731
  - neurologic, 1731
  - pulmonary, 1730
  - VTE, 1731
- high-risk
  - desperation, 1728, 1728*t*
  - late relapse, 1728*t*, 1729
  - reoperative, 1728*t*, 1729
  - salvage, 1727–1728, 1728*t*
- laparoscopic, Laparoscopic retroperitoneal lymph node dissection
- management of clinical complete remission to induction chemotherapy, 1721–1722, 1722*t*
- for NSGCTs, 1694–1695, 1695*t*
- outcomes and functional considerations of
  - fertility, 1729–1730
  - lymph node counts, 1729
- in paratesticular RMS, 1126
- preoperative planning for, 1713–1714
- robotic, Robotic-assisted retroperitoneal lymph node dissection
- surgical technique for, 1714–1717
  - closure and postoperative care, 1717
  - gonadal vein dissection, 1716
  - interaortocaval packet, 1715–1716, 1716*f*
  - left para-aortic packet, 1714–1715
  - nerve sparing, 1716–1717, 1717*f*
  - retroperitoneum exposure, 1714, 1714*f*
  - right paracaval packet, 1716
  - split and roll technique, 1714, 1715*f*

  - template use in, 1722–1723, 1723*f*, 1723*t*
  - TGCT staging with, 1689–1690
  - in unique situations, 1731–1733, 1733*b*
    - for seminoma, 1731–1732
    - for sex cord stromal tumors, 1732–1733

Retroperitoneal tumors (RPTs), 2226–2247
  - anatomic considerations of retroperitoneum, 2226, 2226*b*
  - differential diagnosis of, 2227–2238, 2228*t*, 2238*b*
    - cystic change of solid retroperitoneal tumors, 2238
    - cystic lymphangioma, 2237, 2237*f*
    - cystic masses, 2236–2237
    - cystic mesothelioma, 2238
    - desmoid tumor, 2234, 2234*f*
    - Ewing and Ewing-like sarcoma, 2232–2233, 2233*f*
    - germ cell tumor, 2227–2229
    - germ cell/gonadal origins, 2227
    - hematologic conditions/lymphomas of retroperitoneum, 2236
    - leiomyosarcoma, 2231, 2231*f*
    - liposarcoma, 2229–2230, 2230*f*
    - lymphomas, 2236, 2237*f*
    - malignant fibrous histiocytoma/undifferentiated pleomorphic sarcoma, 2231, 2232*f*
    - mesodermal origins, 2229
    - mucinous cystadenoma, 2237
    - nerve sheath tumors, 2235–2236, 2236*f*
    - neurogenic origins, 2234
    - paraganglionic system tumors, 2235, 2235*f*
    - perivascular epithelioid cell tumor, 2234
    - plasmacytoma, 2236
    - pleomorphic liposarcoma, 2230–2231
    - retroperitoneal cancer of unknown primary origin, 2238
    - sex cord stromal tumor, 2229
    - solitary fibrous tumor, 2232, 2233*f*
    - sympathetic ganglia tumors, 2234–2235, 2235*f*
    - synovial sarcoma, 2231–2232, 2232*f*
    - unclassified sarcomas, 2233
  - disease-specific neoadjuvant and adjuvant therapies for, 2245–2247, 2246*t*, 2247*b*
  - initial evaluation of, 2226–2227, 2227*b*
  - surgical management of, 2238–2245, 2245*b*
    - auxiliary procedures for, 2242–2243
    - complications of, 2243–2244
    - modifications for, 2240–2243
    - postoperative care in, 2244–2245

    preoperative considerations, 2238
    technique for, 2238–2240
    template considerations for management of metastatic germ cell tumors, 2240–2242, 2241*f*, 2241*t*
    vascular reconstruction in, 2243

Retroperitoneum
  anatomic considerations of, 2226, 2226*b*
  anatomy of, 1658–1679, 1659*f*–1661*f*, 1659*t*, 1661*b*, 1666*b*
    10th, 11th, and 12th ribs, 1658–1665, 1658.e1*f*, 1665*f*
    arterial system, 1669–1672, 1669.e1*f*–1669.e2*f*, 1671*f*, 1671.e1*f*, 1672*t*
    body surface landmarks, 1658, 1662*f*
    fasciae and spaces, 1666–1668, 1666.e1*f*, 1667*f*–1668*f*, 1668*b*, 1674*b*
    gastrointestinal viscera, 1668–1669, 1668.e2*f*, 1669*f*–1670*f*, 1674*b*
    lumbodorsal fascia, 1665–1666, 1666*f*, 1666.e1*f*
    lymphatic system, 1674, 1675*f*
    nervous structures, 1674–1679, 1679*b*
    posterior abdominal wall, 1658, 1662*f*–1664*f*, 1664*t*
    psoas, iliacus, quadratus lumborum, and erector spinae, 1658, 1662*f*–1665*f*, 1664*t*
    spine, 1658, 1658.e1*f*
    vasculature, 1669–1674
    venous system, 1672–1674, 1672.e1*f*
  approach to, 2239–2240
  exposure of, 2239, 2239*f*
  exposure of, for RPLND, 1714, 1714*f*
  interaortocaval region in, 2240
  left para-aortic region in, 2239–2240
  right paracaval region in, 2240
  split-and-roll technique for, 2239, 2239*f*

Retropubic mid-urethral slings
  anatomy of, 2850
  complications of, 2863–2866
  outcomes for, 2854–2856, 2855*t*
  surgical approach to, 2851–2853, 2852*f*–2853*f*

Retropubic radical prostatectomy (RRP)
  accessory pudendal artery preservation in, 3552, 3552*f*
  anesthesia for, 3551–3552, 3551*f*
  bladder neck division, 3559–3560, 3560*f*–3561*f*
  bladder neck reconstruction and anastomosis, 3560–3562, 3561*f*–3562*f*
  complications with, 3563–3564

        - bladder neck contracture, 3564
        - erectile dysfunction, 3564
        - intraoperative, 3563
        - postoperative, 3563–3564
        - thromboembolic events, 3563
        - urinary incontinence, 3564
    - dorsal vein complex division, 3553–3554, 3554*f*
    - dorsal vein complex ligation, 3553–3556, 3553*f*
    - endopelvic fascia incision for, 3552, 3552*f*
    - exposure for, 3552
    - incision for, 3551–3552, 3551*f*
    - instruments for, 3551
    - lateral pedicles division in, 3558–3559, 3560*f*
    - lymphadenectomy in, 3551–3552, 3551*f*
    - neurovascular bundle in, 3555–3556
        - high anterior release of, at apex, 3557–3558, 3558*f*–3559*f*
        - identification of, 3556–3558
        - preservation of, 3556–3557, 3556*f*–3557*f*
        - wide excision of, 3558, 3559*f*
    - posterior dissection in, 3558–3559, 3560*f*
    - postoperative management for, 3562–3563
    - preoperative preparation for, 3550–3551
    - puboprostatic ligament division for, 3552, 3552*f*
    - seminal vesicle excision in, 3559–3560, 3560*f*–3561*f*
    - surgical anatomy of, 3548–3550, 3564*b*–3565*b*
        - pelvic fascia, 3549–3550, 3550*f*
        - pelvic plexus, 3548, 3549*f*
        - striated urethral sphincter, 3549, 3549*f*–3550*f*
        - venous and arterial, 3548, 3549*f*
    - surgical technique for, 3550–3563
    - urethra division and suture placement, 3554–3555, 3555*f*
- Retropubic simple prostatectomy, 3450–3452
    - adenoma enucleation for, 3451–3452, 3451*f*–3452*f*
    - hemostatic maneuvers in, 3451, 3451*f*
    - prostate exposure for, 3450, 3451*f*
- Retropubic space, bladder, 3010
- Retropubic suspension surgery, for incontinence in women, 2756–2775

- comparisons with, 2771–2774
    - anterior repair, 2771, 2771*b*
    - needle suspension, 2771, 2771*b*
    - pubovaginal sling, 2771–2773, 2772*f*, 2773*b*
    - between techniques, 2773
    - tension-free vaginal tape procedure, 2773–2774, 2774*b*
- complications of, 2769–2771, 2771*b*
    - bladder overactivity, 2770
    - postoperative voiding difficulty, 2770
    - vaginal prolapse, 2770–2771
- hypermobility in, 2757
- indications for, 2759–2761, 2760*f*
- intrinsic sphincter deficiency
    - contribution, 2757
    - issues of, 2759
- key points for, 2775*b*
- laparoscopic, 2768–2769, 2769*b*
- outcomes, assessment for
    - cure, definition of, 2759
    - follow-up, duration of, 2759
    - patient's *versus* physician's perspective, 2759
- potential contraindications for, 2760
- surgical procedures for, 2756–2757, 2757–2759, 2757*b*
    - Burch colposuspension, 2757–2758, 2758*f*, Burch colposuspension
    - Marshall-Marchetti-Krantz procedure, 2757–2758, 2758*f*, Marshall-Marchetti-Krantz procedure
    - paravaginal defect repair, 2757–2758, 2758*f*, Paravaginal repair
    - vagino-obturator shelf repair, 2757–2758, 2758*f*, Vagino-obturator shelf repair
- technical issues for, 2761–2762
    - bladder drainage for, 2761
    - dissection for, 2761
    - drains for, 2762
    - suture material for, 2761
- technique, choice of, 2757–2759
- therapeutic options for, 2756–2757, 2757*b*
- use of synthetic mesh in, 2774
- vaginal surgery *versus*, 2760–2761, 2761*b*

Retropulsion prevention devices, for ureteroscopic intraluminal lithotripsy, 198, 198*f*

Retrorectal space, 2427, 2429*f*

Reverberation artifact, in ultrasonography, 73, 73*f*–74*f*

Review of systems, patient history of, 9

RFA, Radiofrequency ablation

Rhabdoid differentiation, 2149*t*–2151*t*, 2155, 2155*f*

Rhabdoid tumor of kidney (RTK), in pediatric patients, 1109

Rhabdomyolysis, after laparoscopic and robotic surgery, 231

Rhabdomyosarcoma (RMS), 986, 986*f*

- bladder, Bladder RMS
- cervical or uterine, in pediatric patients, 1120
- paratesticular, in pediatric patients, 1126–1127, 1127*b*
- perineal, 1127, 1127*f*
- of prostate, 3512
- of testicular adnexa, 1709
- vaginal, in pediatric patients, 1119–1120, 1119*f*
- vulvar, in pediatric patients, 1119

Rhabdosphincter, 2467

- male sphincteric mechanisms and, 2594

Rho kinase signaling pathway, 1495, 1497*f*

RhoA, 2473, 2473*f*

Rhythmic suprapubic manual pressure, 2902

Ribs, in retroperitoneum, 1658–1665, 1658.e1*f*, 1665*f*

Right adrenalectomy

- laparoscopic, 2415–2416, 2417*f*–2418*f*, 2418
- open, 2413, 2413*f*

Right colon pouches

- with intussuscepted terminal ileum, 3219–3220
- operative technique variations for, 3228, 3229*f*

Rigid cystourethroscopes, 186, 188*f*–189*f*, 188*t*

Rigid lithotripters, 2111–2112

Rigid metal dilators, 171, 171*f*

RIVUR study, Randomized Intervention for Management of Vesicoureteral Reflux (RIVUR) study

RJF, Relative jet frequency

R-LESS, Robotic laparoscopic single-site surgery

RMS, Rhabdomyosarcoma

RNA

- in transcription, 1346.e3, 1346.e3*f*
- in translation, 1346.e3, 1346.e3*f*–1346.e4*f*

Robot-assisted adrenalectomy, 2418–2419, 2419*f*–2420*f*, 2422–2423

Robot-assisted approach, incorporation of, in minimally invasive urinary diversion, 3258, 3258*b*

Robot-assisted intracorporeal continent cutaneous diversion, 3269–3270, 3269*f*, 3270*b*

Robotic inguinal lymphadenectomy, for penile cancer, 1761, 1794

- background of, 1794
- surgical technique for, 1761

Robotic laparoscopic single-site surgery (R-LESS), for kidney surgery, 2306

Robotic machine failure, in robotic prostatectomy, 3580

Robotic partial nephrectomy, 811–813, 814*f*

Robotic port site incisions, 459*f*

Robotic prostatectomy, open prostatectomy *versus*, 3532

Robotic radical cystectomy, 3143–3157, 3159*b*

- anterior vascular pedicle dissection, 3148, 3149*f*–3150*f*
- extended pelvic lymphadenectomy, 3148–3152
- instrumentation of, 3146, 3146*t*
- lateral space of Retzius, 3148, 3149*f*–3150*f*
- patient positioning of, 3145, 3145*f*
- patient selection of, 3144–3145
- port and assistant placement of, 3145–3146, 3145*f*
- posterior dissection of, 3146, 3146*t*, 3147*f*–3148*f*

- reoperation after, 3270–3273
- sigmoid release of, 3146, 3146*t*, 3147*f*
- ureteral control and posterior pedicle dissection, 3152–3157, 3155*f*–3156*f*

Robotic surgery, 203
- access technology for
  - hand-assist devices, 212
  - LESS devices, 212, 212.e2*f*
  - trocars, 211, 211*f*, 212.e2*f*
- complications and troubleshooting in, 223–231, 232*b*
  - anesthesia-related, 228
  - early postoperative, 230–231
  - equipment-related, 223–231
  - exit-related, 230
  - late postoperative, 231
  - during learning curve, 223
  - pneumoperitoneum-related, 224
  - seminal vesicle surgery, 1864
- equipment placement for, 205–207, 205.e1*f*
- instrumentation used in
  - abdomen exit, 218–219
  - for da Vinci Robotic System, 218, 218*f*
  - for grasping and blunt dissection, 218
  - for incising and hemostasis, 215–216, 215.e3*f*
  - for LESS, 218
  - for morcellation, 218
  - for NOTES, 218
  - for port site closure, 219
  - for retraction, 218
  - for specimen entrapment, 217–218, 217*f*
  - for stapling and clipping, 216–217
  - surgical pharmaceuticals, 215
  - for suturing and tissue anastomosis, 215–216
- operative team placement for
  - retroperitoneal upper abdominal procedures, 207, 207*f*
  - transperitoneal and extraperitoneal pelvic procedures, 207
  - transperitoneal upper abdominal procedures, 206.e1*f*, 207.e1*f*
- physiologic considerations in, 223*b*
  - hemodynamic effects related to approach and patient position, 222
  - hormonal and metabolic effects during surgery, 222–223
  - immunologic effects, 223
  - insufflant choice, 220
  - pneumoperitoneum pressure choice, 220

- preoperative preparation for, 204*b*
  - blood products, 204
  - bowel preparation, 204
  - operating room setup, 205, 205*b*
  - patient positioning, 205, 205*f*
  - patient selection and contraindications, 203–204
  - prophylaxis, 205
- procedure for, 219*b*
  - abdomen exit, 218–219
  - hand-assist device placement, 212
  - port removal and fascial closure, 218–219
  - port site closure, 219
  - pre-incision checklist, 207
  - skin closure, 219
  - trocar placement, 212–213
- training and practicing for, 231–233, 233*b*
  - equipment for, 232
  - formal programs for, 233
- ureteral injuries with, 1993

Robotic systems, 206, 206.e1*f*

Robotic-assisted laparoscopic partial nephrectomy (RaLPN), 2300

Robotic-assisted laparoscopic radical prostatectomy (RALRP)

- complications of, 3580, 3583*b*
- evolution of, 3566
- outcomes of, 3579–3580, 3583*b*
  - oncologic, 3583
- pure laparoscopic *versus*, 3570
- quality-of-life outcomes after, 3581
- technique of, 3578*b*

Robotic-assisted laparoscopic sacrocolpopexy, for apical pelvic organ prolapse repair, 2800–2803, 2801*f*–2803*f*

Robotic-assisted laparoscopic simple prostatectomy, 3454–3455

- abdominal access, insufflation, and trocar placement for, 3454–3455
- adenoma enucleation in, 3455
- adenoma extraction and closure for, 3455
- bladder neck incision for, 3455
- hemostasis and vesicourethral anastomosis, 3455

  - patient positioning for, 3454
  - space of Retzius development for, 3455

Robotic-assisted laparoscopic surgery
  - bladder diverticulectomy, Bladder diverticulectomy
  - Boari flap, Boari flap
  - for kidney, 2282–2284, 2284*f*–2285*f*
  - pyelolithotomy, for pediatric kidney stone disease, 868–870
  - pyeloplasty, for ureteropelvic junction obstruction, 1956
  - pyelopyelostomy, for retrocaval ureter, 1963
  - ureteral reimplantation, Ureteral reimplantation
  - ureteroureterostomy, for ureteral stricture disease, 1972
  - for vesicovaginal fistula, Vesicovaginal fistula

Robotic-assisted pyeloplasty, 832
  - techniques of, 832–834, 833*f*

Robotic-assisted retroperitoneal lymph node dissection, 1734–1741, 1741*b*
  - complications of, 1739–1740, 1739*t*
  - postoperative care for, 1738–1739
  - prospective nerve-sparing techniques for, 1739
  - rationale and evolution of, 1734
  - results and current status for, 1740–1741
  - surgical technique for, 1735–1738
    - port placement and technique, 1738, 1738*f*
    - preoperative patient preparation and technical considerations for, 1735

Roentgen, Wilhelm Conrad, 3587

Rolipram, for ureteral relaxation, 1899

Rome IV criteria, for functional constipation in children, 474, 474*t*, 475*f*

RON, in UTUC, 2198

Rosebud stoma, 3182, 3182*f*–3183*f*

Round ligament, 2430, 2431*f*

RPLND, Retroperitoneal lymph node dissection

RPTs, Retroperitoneal tumors

RRP, Retropubic radical prostatectomy

RSD, Reflex sympathetic dystrophy

RSPO1 gene, 992*f*, 992*t*, 993

RSR, Relative saturation ratio

RTA, Renal tubular acidosis

RTE, Real-time elastography

RTK, Rhabdoid tumor of kidney

RUF, Rectourethral fistulae

S

S phase, deregulation of progression through, in GU cancers, 1347.e1

S phase arrest, deregulation of, in GU cancers, 1347.e2

Saccules, 2967

SACD, Subacute combined degeneration

Sacral agenesis, 487, 641–644, 644*b*
- pathogenesis of, 642–643
- presentation of, 641–642, 643*f*–644*f*
- specific recommendations for, 643–644

Sacral arteries, 2451–2452, 2451*t*

Sacral dorsal rhizotomy, 2741–2742, 2742*f*
- clinical results of, 2743, 2744*t*
- goal and effect of, 2742–2743
- patient selection in, 2742
- surgical implantation technique of, 2742–2743, 2743*f*

Sacral evoked response: bulbocavernosus reflex latency, 1527

Sacral nerve stimulation (SNS), 2510, 2752–2754
- current indications for, 2752
- implantation procedure for, 2753–2754
  - percutaneous nerve evaluation test, 2754
  - staged implant procedure, 2754, 2754*f*
- indications for, 2753, 2753*f*

  - for nonobstructive chronic underactive bladder, 2753
  - for OAB with or without urinary continence, 2752–2753
  - outcomes for, 2752
  - patient selection for, 2753–2754

- Sacral neuromodulation (SNM), 2739
  - for detrusor underactivity, 2662
  - for neuromuscular dysfunction of lower urinary tract, 637–638
  - for OAB, 2647
  - for UUI, 2546
- Sacral plexus, 2433
  - neuromodulation of, 2510
- Sacral spinal cord injury
  - lower urinary tract dysfunction with, 2611–2612, 2613*f*
  - management with, 2613*b*
- Sacrococcygeal teratoma, lower urinary tract dysfunction and, 2631
- Sacrocolpopexy, abdominal, for apical pelvic organ prolapse repair, 2798–2809
  - complications of, 2804, 2806*t*
  - cost of, 2809
  - laparoscopic
    - comparison with, 2806, 2807*t*
    - *versus* robotic-assisted, 2806–2809, 2808*t*
    - *versus* robotic-assisted colpopexy, 2809
    - technique for, 2802*f*–2803*f*, 2803–2804
  - learning curve in, 2809
  - open, technique for, 2798–2800, 2800*f*–2801*f*
  - results of, 2804–2806, 2805*t*
  - robotic-assisted laparoscopic, 2800–2803, 2801*f*–2803*f*, 2810*t*–2811*t*
- Sacrohysteropexy
  - minimally invasive, 2822–2823, 2824*t*
  - open abdominal, 2822–2823, 2824*t*
  - results with, 2823
- Sacroiliac ligaments, 2428–2429
- Sacrospinous ligament colposuspension, 2433

Sacrospinous ligament fixation (SSLF), for pelvic organ prolapse repair, 2793–2797
  - complications with, 2797
  - results of, 2795–2797, 2796*t*–2797*t*
  - surgical anatomy for, 2794–2795, 2795*f*
  - technique for, 2795, 2796*f*

Sacrospinous ligaments, 2428–2429

Sacrotuberous ligaments, 2428–2429

Sacrum, 2427, 2428*f*, 2444

Salbutamol, to facilitate bladder filling and urine storage, 2682*t*

Saline drop test examination, for bowel injury, 276

Salvage brachytherapy, for biochemical recurrence after radiation therapy, 3668

Salvage cryotherapy, for biochemical recurrence after radiation therapy, 3667–3668, 3669*t*

Salvage high-intensity focused ultrasound, for biochemical recurrence after radiation therapy, 3668

Salvage radiation therapy, for biochemical recurrence after radical prostatectomy, 3662–3663
  - adjuvant radiation therapy *versus*, 3664–3665
  - androgen deprivation therapy (ADT), 3663–3664
  - dose response, 3663
  - whole-pelvis *versus* prostatic bed radiation therapy, 3664, 3664*f*–3665*f*

Salvage radical prostatectomy, for biochemical recurrence after radiation therapy, 3667, 3667*t*

Salvage robotic-assisted radical prostatectomy, 3583–3584
  - technique of, 3584

Salvage RPLND, 1727–1728, 1728*t*

Sansert, Methysergide

Saphenous hiatus, 1791

Sarcoidosis

  - hypercalcemia in, 2020
  - hypercalciuria in, 2050

Sarcomas
  - of bladder
    - adenocarcinoma, 3090, 3090*f*
    - small cell carcinoma, 3089, 3089*f*
    - squamous cell cancer, 3089–3090, 3089*f*
    - urachal adenocarcinoma, 3090, 3090*b*
  - of kidney, 2180–2181, 2181*t*, 2182*f*
  - of prostate, 3512
  - of testicular adnexa, 1709

Sarcomatoid differentiation, in RCC, 2149*t*–2151*t*, 2155, 2155*f*

Saw palmetto berry, for benign prostatic hyperplasia, 3395–3398, 3396*f*, 3397*t*

Scabies
  - infestation, 1295–1296, 1297*f*
  - as STD, 1271

Scalpels, for laparoscopic and robotic surgery, 214

Scandinavian Prostate Cancer Group Study Number 4 (SPCG-4), 3529–3530, 3539

Scanning electron microscope (SEM)
  - of bladder blood vessels, 2464*f*
  - of urothelium, 2462, 2463*f*

Scardino-Prince vertical flap, for ureteropelvic junction obstruction, 1961, 1962*f*

Scarpa fascia, 2444, 2446*f*

Scattering, of ultrasound waves, 71, 71*f*

SCC, Squamous cell carcinoma

SCCis, Squamous cell carcinoma in situ

SCD, Sickle cell disease

Scheduled voiding regimens, Toileting programs

Schistosomal myelopathy, lower urinary tract dysfunction and, 2626

Schistosomiasis

  - in bladder tumor, 3077
  - of genitourinary tract, 1319–1328, 1328*b*
    - biology and life cycle, 1319, 1320*f*–1321*f*
    - diagnosis, 1325–1326, 1325*f*–1326*f*
    - epidemiology, 1319–1321, 1321–1324, 1321*f*, 1323*f*
    - history, 1319
    - prevention and control, 1327–1328
    - prognosis, 1327
    - treatment, 1326–1327
      - surgical management in, 1327

Schizophrenia, lower urinary tract dysfunction and, 2630

Schrott-Erlangen approach, for classic bladder exstrophy, 545
  - continence outcomes with, 560

Schwannomas
  - intrarenal, 2132
  - in retroperitoneum, 2235

SCI, Spinal cord injury

Sciatic nerve injury, 261–262

Scintillation crystal, 91

Scissors, for laparoscopic and robotic surgery, 214

Scleroderma, lower urinary tract dysfunction and, 2631

Sclerosing lymphangitis, 1302–1304

Sclerotherapy, 903, 903.e1*f*, 1845–1847, 1848*t*

Screening tests, for genitourinary tuberculosis, 1310–1311

Scrotal agenesis, 887, 887.e1*f*

Scrotal anomalies, 886–888
  - bifid scrotum, 886, 887*f*
  - ectopic scrotum, 886–887, 888*f*
  - scrotal agenesis, 887, 887.e1*f*
  - scrotal hypoplasia, 887
  - scrotoschisis, 887–888, 888.e1*f*

Scrotal elephantiasis, as filariasis clinical manifestation, 1330, 1330*f*

Scrotal engulfment, 885–886, 886*f*

Scrotal hydrocele, 889

Scrotal incision, in urologic surgery, 142–143

Scrotal mass, 392

- in neonate, 387, 387*t*

Scrotal pain, patient history of, 2

Scrotal reconstruction, 3054, 3054.e1*f*

Scrotal ultrasonography, for pediatric urology, 389

Scrotal wall, 1843

Scrotectomy, 1844–1845, 1846*f*

Scrotoplasty, 941, 3068

Scrotum, 1843

- access into, 1844
- acute, Acute scrotum
- anatomy of, 1389*b*, 1843, 1844*f*
  - arterial supply, 1387–1389
  - gross structure, 1387–1389, 1388*f*
  - lymphatic drainage, 1389
  - nerve supply, 1389
  - venous drainage, 1389
- in genitourinary tuberculosis, 1309
- penetrating injuries to, 3051
- physical examination for, 11, 11*f*
- surgeries of, 1843–1864
  - approaches to, 1844, 1850*b*, 1855*b*
  - complications of, 1855–1856
  - innervation, 1843
  - preoperative considerations of, 1843–1844
  - reconstruction, 1845, 1847*f*
  - vasectomy, Vasectomy
- ultrasonography of, 81–84, 1373
  - for GCTs, 1685–1686, 1685*f*
  - indications for, 82
  - normal findings in, 82–83, 83*f*–85*f*
  - procedural applications of, 83

    - sonoelastography, 84
    - technique of, 82

SCSTs, Sex cord-stromal tumors

SDHRCC, Succinate dehydrogenase RCC

Sealants, for laparoscopic and robotic surgery, 215.e2

Seborrheic dermatitis (SD), as papulosquamous disorder, 1282–1283

Seborrheic keratosis, 1304, 1305*f*

Second malignancies
- after bladder RMS treatment, 1117
- after Wilms tumor treatment, 1108

Second messengers, in ureteral contractions, 1885–1887, 1885*f*–1886*f*

Secondary cryptorchidism, 949

Secondary cutaneous lesions, 1273, 1274*t*

Secondary hyperoxaluria, 858–859

Secondary paraureteral diverticula, 525

Secondary syphilis, 1257, 1258*f*

Secondary therapy, receipt of, 105

Secondary vestibulodynia, 1651

Second-look nephroscopy, in antegrade nephroureteroscopic, for UTUC, 2217

Sedation, 484

Segmental hypoplasia, 744, 744*f*

Segmental nephrectomy, for large renal tumors, 2263–2264, 2263.e1*f*–2263.e2*f*, 2264.e1*f*, 2265*f*

Segmental pyelonephritis, 388–389

Segmental ureteral resection, for UTUC, 2207–2210
- ileal ureteral replacement, 2208, 2209*f*
- laparoscopic or robotic distal ureterectomy and reimplantation, 2208, 2209*t*
- open segmental ureterectomy, 2207, 2208*f*–2209*f*
- results of, 2208–2210

SELECT, Selenium and Vitamin E Cancer Prevention Trial

Selective α_1-blockers, 3356–3357

Selective androgen receptor modulators, for benign prostatic hyperplasia, 3377

Selective estrogen receptor modulators (SERMs), for benign prostatic hyperplasia, 3377

Selective serotonin reuptake inhibitors, and PE, 1571–1572

Selective tissue estrogenic activity regulator, for female sexual arousal disorders, 1649–1650

SelectMDx test, 3486

Selenium, in prostate cancer prevention, 3476, 3476*f*

Selenium and Vitamin E Cancer Prevention Trial (SELECT), 3476, 3476*f*

Self-care practices, for bowel function, 2734

Self-catheterization, orthotopic urinary diversion and, 3238

Self-styled dilators, for achieving extraperitoneal access and developing extraperitoneal space, 210

SEM, Scanning electron microscope

Semen
  coagulation and liquefaction of, 3303, 3304*b*
  density of, 896–897
  evaluation of, in male infertility, 1438–1442
    acrosome reaction, 1442
    bulk semen parameters, 1438–1440, 1438*t*
    comet assay, 1441–1442
    computer-assisted semen analysis, 1440.e2
    denatured sperm DNA assays, 1442
    pyospermia assays, 1440–1441
    reactive oxygen species, 1442
    secondary semen assays, 1440–1441
    semen volume, 1439
    sperm density, 1439
    sperm DNA integrity assays, 1441
    sperm fluorescence in situ hybridization, 1442
    sperm morphology, 1439–1440
    sperm motility, 1439
    sperm mucus interaction, 1442
    sperm ovum interaction, 1442
    sperm ultrastructural assessment, 1442
    sperm vitality, 1440
    tertiary and investigational sperm assays, 1441–1442
    TUNEL assay, 1441, 1441*f*
Semenogelins I and II, in prostatic secretions, 3298*t*, 3300
Seminal vesicle and ejaculatory ducts, physiology of, 1407–1408, 1408*b*
  gross architecture and cytoarchitecture, 1407
  unit function, 1407
Seminal vesicle cysts (SVCs), management of, 1862–1863
Seminal vesicle invasion, 3511
Seminal vesicle secretory proteins, in prostatic secretions of, 3303
Seminal vesicles
  anatomy of, 1378*b*, 1856, 1856*f*–1858*f*
    arterial supply, 1377
    gross structure, 1377
    lymphatic drainage, 1378
    microanatomic architecture, 1377
    nerve supply, 1378

        - venous drainage, 1378
    - development of, 3280
    - dissection of, in laparoscopic radical prostatectomy, 3573–3574, 3574*f*
    - embryology of, 1856, 1856*f*–1858*f*
    - in genitourinary tuberculosis, 1309
    - HIV and, 1266
    - imaging
        - CT, 1378
        - MRI, 1378, 1378*f*
        - transrectal ultrasound, 1378
    - in retropubic radical prostatectomy, excision of, 3559–3560, 3560*f*–3561*f*
    - surgeries of, 1843–1864, 1863*b*
        - anterior approach to, 1856–1857, 1859*f*–1861*f*
        - complications of, 1863–1864
        - perineal approach to, 1857
        - posterior approach to, 1857–1862, 1862*f*
        - preoperative considerations of, 1843–1844
        - scrotal wall procedures, 1844–1845
        - testis, 1845–1850
        - transrectal ultrasound-guided aspiration, 1863
        - transurethral endoscopic treatments, 1863
        - tumor excision, 1863
- Seminiferous epithelium, 1445.e1, 1445.e2*f*
- Seminiferous tubules, 1370, 1371*f*, 1373, 1393, 1393*f*, 1396–1398
- Seminomas, 1680, 1702–1706, 1706*b*
    - genomic alterations in, 1353, 1361
    - histology of, 1682, 1683*f*
    - treatment of, 1692, 1692*b*
        - clinical stage I tumors, 1702–1704
        - clinical stage IIA and IIB tumors, 1704–1705
        - clinical stage IIC and III tumors, 1705–1706
        - relapsed tumors, 1706
    - treatment of, RPLND, 1731–1732
- Seminomatous GCTs, 2227
- Semirigid ureteroscopes, 192, 192*f*, 193*t*
    - care and sterilization of, 195–197
    - technique for, 199–201, 201*f*

Senior-Loken syndrome, 756

Sensate focus, for female orgasmic disorder, 1647

Sensation, bladder
  altered, filling/storage failure due to, 2517–2518
  detrusor underactivity and, 2659
  terminology for, 2581

Sensorineural deafness, 347

Sensor-transducer function, of bladder urothelium, 2469–2470

Sensory innervation, in ureteral function, 1889

Sensory nerve (afferent) signaling, in overactive bladder, 2640

Sentinel lymph node biopsy
  of inguinal nodes, for penile cancer, 1760
  for penile cancer, 1792–1793

Sepsis
  with intestinal anastomoses, 3180
  UTIs and, 1182–1187, 1183*b*–1184*b*

Septic shock, UTIs and, 1182–1187, 1184*b*

Serenoa repens (saw palmetto berry), for benign prostatic hyperplasia, 3395–3398, 3396*f*, 3397*t*

Serlopitant, to facilitate bladder filling and urine storage, 2713.e4

Serology, syphilis tests, 1258

Seromuscular enterocystoplasty, 705–706, 705*f*

Serotonin (5-HT)
  in ED, 1494, 1495*t*
  in efferent pathways to bladder, 2488–2489
  in ejaculatory response, 1564
  urethral function effects of, 1902

Serotonin-noradrenaline uptake inhibitors, for stress urinary incontinence in women, 2714–2716

Serotonin-receptor effectors, 1534

Serous-lined extramural tunnel, for orthotopic urinary diversion, 3244–3245, 3245*f*

Sertoli cell tumors, 1124, 1708

Sertoli cell-only syndrome, 1445.e1, 1445.e1*f*

Sertoli cells, 1392, 1437

- testis physiology and, 1396–1398, 1397*f*

Serum gonadotropin measurements, 1528

Serum laboratory studies, in urine, 25

Serum prolactin measurement, 1528

Serum testosterone measurements, 1527–1528

Serum tests, for UTIs, 438

Serum thyroid function tests, 1528–1529

Severe bilateral urinary tract dilation, considerations for, 371

Sex cord-stromal tumors (SCSTs), 1707–1708

- retroperitoneal tumors and, 2229
- treatment of, RPLND, 1732–1733

Sex determination, 1392

Sex hormone-binding globulin, 1434, 1436–1437, 1437*b*

Sex reassignment surgery (SRS), 3062

Sex steroids, lower urinary tract and, 2502–2503

Sextant biopsy, of prostate, 3497

Sexual activity

- benign prostatic hyperplasia and, 3322, 3322*f*, 3323*t*
- prostate cancer and, 3463–3464

Sexual development, 990–997

- disorders of, Disorders of sex development
- gender identity, role, and orientation, 996–997
- gonadal function, 994–995, 994*b*
    - ovary, 995

      - testis, 994, 995*f*
  - gonadal stage of differentiation, 993–994, 994*f*, 994*b*
  - normal genotypic development, 990–993
    - additional genes in, 991–993, 992*f*, 992*t*
    - chromosomal sex, 990, 991*f*, 991*b*
    - SRY, 990, 991*f*–992*f*
  - normal phenotypic development, 993–994
  - phenotypic, 995–996, 995*f*–997*f*
  - psychosexual development, 996–997, 997*b*

Sexual dysfunction, Erectile dysfunction
  - after mid-urethral slings, 2873
  - after transurethral needle ablation of prostate, 3433
  - benign prostatic hyperplasia and, 3378
  - of female
    - arousal dysfunction, 1636
    - definitions of, 1635, 1637*b*
    - DSM-5 definitions of, 1635–1636, 1635*t*
    - epidemiology, 1636–1637, 1637*b*
    - female sexual interest-arousal disorder, 1635–1636
    - genital-pelvic pain dysfunction, 1636
    - genito-pelvic pain-penetration disorder, 1636
    - hypoactive sexual desire dysfunction, 1636
    - hypohedonic orgasm, 1636
    - orgasmic disorder, 1636
    - painful orgasm, 1636
    - persistent genital arousal disorder, 1636
    - postcoital syndrome, 1636
    - sexual arousal dysfunction, 1636
  - hormonal therapy and, 3681
  - patient history of, 6
  - prostatitis and, 1210

Sexual function
  - α1-adrenergic blockers and, 3370
  - of female
    - evaluation of sexual wellness, 1627–1637
    - female sexual physiology, 1627.e4
    - female sexual response, 1627.e4–1627.e5, 1627.e4*f*
    - international consultation on sexual medicine, 1636
    - mental aspects of sexual response, 1627.e6
    - physiologic measures of, 1634, 1634*t*

        - PLISSIT model for, 1628–1629, 1628*t*–1629*t*
        - in special populations, 1637–1640, 1640*b*
            - fertility in transgender people, 1638–1639
            - gender dysphoria and hormonal treatment, 1638, 1639*t*
            - in LGBTQ, 1637–1638, 1638*t*
            - malignancies in female transgender patients, 1639–1640
            - sexuality and disability, 1640
    - localized prostate cancer and, 3524–3525
    - pelvic organ prolapse and, 2593
    - in prune-belly syndrome, 600
    - transurethral microwave therapy and, 3430

Sexual health, in elderly, 2920–2921

Sexual Health Inventory for Men (SHIM), 112*t*

Sexual history, and male infertility, 1433–1434

Sexual intercourse, penile fracture with, 3048

Sexual maturation, 1390

Sexual Quality of Life for Men (SQOL-M), 112*t*

Sexual relations, patient history of, 9

Sexual wellness in women, evaluation of, 1627–1637, 1635*b*
- history, 1627–1629, 1628*t*–1630*t*
- laboratory tests for, 1633–1634
- partner, 1629
- physical examination in, 1629–1633, 1632*f*–1633*f*
- questionnaires for, 1629, 1630*t*–1632*t*

Sexuality
- with exstrophy-epispadias complex
    - female concerns, 566–567
    - male concerns, 565–566
- neural tube defects and, 629–631

Sexually transmitted diseases (STDs), 1251–1272, 1272*b*
- CDC screening recommendations for, 1251–1252
- cutaneous infections and infestations from, 1288, 1289*f*
- epidemiology of, 1251–1252, 1252*t*
- epididymitis, 1255
- genital ulcers, 1255–1261, 1255*t*

  - chancroid, 1255*t*, 1259–1260, 1259*f*
  - diagnosis of, 1256
  - granuloma inguinale, 1260
  - herpes, 1255*t*
  - HPV, 1261, 1262*f*
  - lymphogranuloma, 1255*t*, 1260–1261, 1260*f*
  - *Molluscum contagiosum*, 1261, 1261*f*
  - pediculosis pubis, 1271
  - presentation of, 1256, 1256*f*
  - scabies, 1271
  - syphilis, 1255*t*, 1257, 1257*f*–1258*f*, 1257*t*
  - treatment of, 1256–1257, 1256*t*
  - vaginitis, 1271–1272, 1272*t*
- gonococcal infections, 1252
- HIV, 1264–1268
  - diagnosis, 1264
  - erectile dysfunction and, 1267
  - interactions with other STDs, 1257, 1264–1268
  - Kaposi sarcoma, 1267–1268
  - male circumcision, 1264
  - malignancy, 1267
  - nephrolithiasis, 1266
  - non-AIDS-defining urologic malignancies, 1268
  - nonulcerating skin infections and, 1265
  - postexposure prophylaxis, 1264–1265
  - pre-exposure prophylaxis, 1265
  - prostatitis and, 1266
  - renal dysfunction and, 1266–1267
  - renal infections, 1266
  - testis, epididymis, seminal vesicles and, 1266
  - urologic manifestations of, 1265–1268, 1265*f*
  - UTI and, 1265–1266
  - voiding dysfunction and, 1267
- nongonococcal urethritis, 1253, 1254*f*
  - chlamydia, 1253
  - *Mycoplasma genitalium*, 1253–1254
  - recurrent and persistent, 1254
  - *Trichomonas vaginalis*, 1254
- prostate cancer and, 3463–3464
- reportable, 1252
- urethritis, 1252–1254
- viral hepatitis and, 1268–1271, 1269*t*
- Zika virus, 1263–1264

Shared decision making, in localized prostate cancer, 3525

Sharp dissectors, for laparoscopic and robotic surgery, 214

Shear stress mechanism, of stone fragmentation, 2097

Shear wave elastography (SWE), 74, 76*f*

Shock wave lithotripsy (SWL), 2094–2103, 2103*b*

- adjuncts to improve, 2102, 2102*b*
- attenuation values and, 2077.e2
- bioeffects of, 2097–2100
  - acute renal injury as, 2098–2099, 2098*f*–2099*f*, 2099*b*
  - chronic renal injury as, 2099–2100, 2099*t*
  - extrarenal damage as, 2097–2098, 2097*f*
- combination of ultrasonography and fluoroscopy for, 2095
- contraindications to, 2072*b*
- extracorporeal, 2069.e2–2069.e3
- factors negatively affecting success of, 2072*b*
- fluoroscopy for, 2094–2095
- future direction in, 2102–2103, 2103*f*
- generator types for, 2094
  - electrohydraulic (spark gap), 2094, 2095*f*
  - electromagnetic, 2094, 2095*f*
  - piezoelectric, 2094, 2096*f*
- imaging systems for, 2094–2095
- methods and physical principles, 2094–2097
- morbid obesity and, 2089
- old age and frailty and, 2089–2090
- optimization of, 2100–2102, 2100*b*, 2101*f*, 2102*b*
- pediatric, 864–865, 865*b*
  - limitations and concerns with, 865
  - stone size, location, and composition, 864–865
  - technique for, 865
- prior renal surgery and, 2090
- for renal calculi
  - in calyceal diverticula, 2078
  - in horseshoe kidneys, 2079
  - lower pole calculi, 2081, 2081*f*, 2082*t*, 2083*f*
  - in renal ectopia, 2081
  - stone composition and, 2076, 2076*f*

        - stone localization and, 2075
    - renal function and, 2088–2089
    - renal transplants and, 2091
    - solitary kidney and, 2089
    - spinal deformity or limb contractures and, 2090
    - for staghorn calculi, 2074
    - stone burden and
        - between 1 to 2 cm, 2073
        - greater than 2 cm, 2074
        - up to 1 cm, 2072
    - stone fragmentation in, 2095–2097, 2096*f*
    - tissue injury from, 2100
    - ultrasonography for, 2095
    - uncorrected coagulopathy and, 2090
    - for ureteral calculi
        - duplicated collecting system and, 2087
        - in megaureter, 2087
        - outcome of, 2091
        - stone burden and, 2087
        - stone composition and, 2087
        - stone localization and, 2085–2086, 2086*t*
        - with ureteral stricture or stenosis, 2087–2088
    - urinary diversion and, 2091
    - urinary tract infection and, 2088
- ShockPulse-SE, 245–246
- Short bowel, urinary intestinal diversion and, 3203
- Short Screening Instrument for Psychological Problems in Enuresis (SSIPPE), 477
- Shunting, for ischemic priapism, 1554–1558, 1555*f*–1559*f*, 1556*b*
- Shy-Drager syndrome, lower urinary tract dysfunction with, 2606
- Sickle cell disease (SCD), 451
    - and priapism, 1544, 1547*b*
- Sickle cell trait and disease, contrast media and, 32
- Siderophore aerobactin, 429
- Sigma-rectum pouch, 3210–3211

Sigmoid colon, colon conduit and, 3196, 3197*f*, 3198*t*

Sigmoid cystoplasty, 694–695, 696*f*

Sigmoid kidney, 728*f*, 729

Sigmoid pouch, for orthotopic urinary diversion, 3248, 3249*f*

Signal transduction cascade, 429, 430*f*

Signal transmission, in urodynamic studies, 2558

Sildenafil (Viagra)

- to facilitate bladder filling and urine storage, 2682*t*, 2701
- for ureteral relaxation, 1899

Silicate stones, 2033

Silicone catheters, 152

Silicone microimplants (Macroplastique), 2894, 2894*f*

- for female urinary incontinence, 2894
- of male stress urinary incontinence, 2897

Silk suture, 150–151

Silodosin

- for benign prostatic hyperplasia, 3365, 3365*f*, 3366*t*
- to facilitate bladder emptying, 2720.e1
- to facilitate bladder filling and urine storage, 2682*t*
- ureteral response to, 1888

SILS Port, 212.e1, 212.e1*f*

Silver nitrate, for BPS/IC treatment, 1244.e1

Simple cysts, 766–770, 770*b*

- classification of, 768–770, 769*b*, 770*f*
- clinical features of, 766
- evaluation of, 768, 768*f*–769*f*
- histopathology of, 766–768
- prognosis of, 770, 770*f*
- treatment of, 770, 770*f*

Simple nephrectomy

- laparoscopic, 2285–2291
    - dissection of ureter, 2287, 2287*f*
    - identification of renal hilum, 2287–2288, 2288*f*
    - organ entrapment and extraction, 2289, 2289*f*–2290*f*
    - postoperative management for, 2289
    - reflection of colon, 2285–2286, 2287*f*
    - results of, 2291
    - securing of renal blood vessels, 2288, 2288*f*
    - upper pole dissection, 2288, 2288*f*
- open, 2253–2254, 2253.e2*f*, 2254*f*

Simple orchiectomy, 1848
- technique of, 1848, 1849*f*

Simple prostatectomy, nocturia and, 2671–2673

Simple renal ectopia, anomalies of, 723–724, 724*f*–725*f*
- description for, 723–724
- diagnosis of, 724
- incidence of, 723
- prognosis of, 724

Sims-Huhner test, 1442.e2

Simulation, 3587–3588

Single-incision mid-urethral slings
- anatomy of, 2851
- complications of, 2863–2866
- outcomes for, 2857–2858
- surgical approach to, 2854, 2855*f*

Single-lumen catheters, 154

Single-photon emission computed tomography (SPECT), 91, 440

Single photon imaging
- physical characteristics of, 92*t*
- principles of, 91
- three-dimensional images in, 91

Sinovaginal bulbs, 325–326, 776

Sipuleucel-T, 1341, 3697–3698, 3697*f*

Skeletal muscle, smooth muscles compared with, 2471*t*

Skeletal system abnormalities, with cloacal exstrophy, 575

Skene gland, cysts of, urethral diverticula differentiated from, 2974, 2986*f*

Skin, of external genitalia, loss of, 3053–3054, 3053*f*–3054*f*

Skin bridge, of penis, 874–875, 874*f*

Skin closure, 150–151

- after laparoscopic and robotic surgery, 219

Skin tag, 1304

Skin tags

- hymenal, 978–979, 979*f*

SLE, Systemic lupus erythematosus

Sleep

- enuresis and, 662
- nocturia effect on, 2664–2665
- states of, 2665

Sleep efficiency, definition of, 2664–2665

Sleep latency, definition of, 2664–2665

Slings, 2830–2876

- alternative treatment options to, 2833
- evolution of, 2830–2831, 2832*b*
- mid-urethral, Midurethral sling
- for pelvic organ prolapse, anterior compartment, 2788–2790, 2789*f*
- preoperative assessment for, 2832–2833, 2833*b*
- pubovaginal, Pubovaginal sling
- for urinary incontinence, in geriatric patients, 2920.e5

Slitlike adjusted Mathieu (SLAM) procedure, 924, 925*f*

Slow-twitch fibers

- male sphincteric mechanisms and, 2594
- of urethral striated muscle, 2467

Slow-wave sleep (SWS), glucose homeostasis and, 2665–2666

SMA, Superior mesenteric artery

Small bowel, for urinary diversion, 3160

Small bowel anastomosis

- tunneled, 3188
- in urinary diversion, 3187–3189
  - Bricker anastomosis, 3187, 3187*f*
  - Hammock anastomosis, 3189
  - Le Duc technique, 3189, 3189*f*
  - split-nipple technique, 3188–3189, 3188*f*
  - tunneled, 3188, 3188*f*
  - ureteral dipping technique, 3189
  - ureteral-small bowel, 3189, 3190*f*
  - Wallace technique, 3187–3188, 3188*f*

Small cell carcinoma

- of bladder, 3089, 3089*f*
- of kidney, 2181*t*, 2183

Small cell neuroendocrine prostate cancer, 3693

Smegma pearl, 393–394

Smegmoma, 393–394, 393*f*

Smoking

- benign prostatic hyperplasia and, 3324
- in bladder tumor, 3076
- and ED, 1509
- penile cancer and, 1744
- prostate cancer and, 3464, 3543
- urinary incontinence and, 2586
- UTUC risk and, 2186

Smooth muscles

- in benign prostatic hyperplasia, 3315, 3315*f*
- of bladder, 2465, 2465*f*
  - actinomyosin cross-bridge cycling, 2472–2473, 2472*b*, 2473*f*
  - action potentials of, 2473–2474, 2474*f*
  - calcium signaling in, 2475–2476, 2476*f*
  - contractile proteins, 2470–2472, 2471*f*–2473*f*
  - electrical response propagation, 2476–2477, 2477*f*

    - excitation-contraction coupling in, 2474–2475, 2475*f*
    - during filling, 2478
    - interstitial cells of, 2477–2478, 2478*f*
    - membrane electrical properties of, 2473–2474, 2474*f*
    - motor sensory network in, 2479–2480, 2479*f*
    - physiology of, 2470–2478, 2478*b*
    - during voiding, 2479
  - of penis, physiology of, 1495–1500
    - cytosolic calcium, and calcium sensitization pathway, 1495
    - intracavernous tissue architecture and erectile response, 1500, 1501*t*
    - modulation of antitumescence pathways by protumescence pathways, 1496–1500
    - molecular pathways that directly modulate intracellular free calcium and, 1495
    - molecular pathways that indirectly modulate intracellular free calcium and, 1495–1496
  - skeletal muscle compared with, 2471*t*
  - of urethral sphincter, 2467
    - CVA and, 2603

Smooth sphincter, decreasing outlet resistance at, to facilitate bladder emptying, 2719–2720

Smooth sphincter dyssynergia, 2521–2522
  - with autonomic dysreflexia, 2614

SMV, Superior mesenteric vein

SNM, Sacral neuromodulation

SNS, Sacral nerve stimulation

Social history, 8–9

Social Security Administration (SSA), 102

Society for Fetal Urology classification, 404, 405*f*

Society for Fetal Urology grading system, 360–361, 360*f*

Socioeconomic factors, in benign prostatic hyperplasia, 3321, 3321*t*

Sodium
  - filtrate transport, 1906–1909, 1907*f*–1910*f*, 1909*b*
  - fractional excretion of, urinary tract obstruction and, 777
  - hypercalciuria and, 2051
  - in kidney, of neonate, 342, 342*b*
  - in pediatric kidney stone disease, 869

    - transport of, urinary tract obstruction and, 793
- Sodium cellulose phosphate, for hypercalciuria, 2053
- Sodium pentosan polysulfate, for BPS/IC oral therapy, 1242
- Soft tissue sarcomas, in retroperitoneum, 2229
- Solid retroperitoneal tumors, cystic change of, retroperitoneal tumors and, 2238
- Solid/cystic renal masses, 384–385
- Solifenacin
  - for diminished bladder, 2668–2669, 2675*t*–2677*t*
  - to facilitate bladder filling and urine storage, 2682, 2682*t*
    - with β-adrenoreceptor antagonists, 2700
- Solitary fibrous tumor
  - of kidney, 2132
  - retroperitoneal tumors and, 2232, 2233*f*
- Solitary multilocular cyst nephroma, in pediatric patients, 1109
- Solubility product, 2009–2010, 2010*f*
- Solutes, filtrate transport, 1912–1913
- Somatic nervous system
  - and ED, 1527
  - in retroperitoneum, 1675–1679, 1675.e1*f*, 1677*f*–1678*f*, 1679*t*
- Somatic pathways
  - of lower urinary tract, 2480*f*–2481*f*, 2481
  - penile erection and, 1490–1491
- Sonic Hedgehog protein, ED and, 1506
- Sonoelastography
  - limitations of, 84, 85*f*
  - mode of, 74–75
  - of scrotum, 84
- Sonography, 403, 405*b*
  - prenatal, 404, 407*f*
- Sorafenib, 1358

    - for RCC, 2179*t*–2180*t*, 2334, 2334*t*

South African star grass, for benign prostatic hyperplasia, 3398

Southwest Oncology Group (SWOG), 3691, 3692*f*

SOX9 gene, 992*f*, 992*t*, 993, 3276

Soy, in prostate cancer prevention, 3476

Space of Retzius, 2850

- development of
  - for laparoscopic radical prostatectomy, 3571–3572, 3572*f*
  - of open simple prostatectomy, 3450
  - of robot-assisted laparoscopic simple prostatectomy, 3455

Spall fracture mechanism, of stone fragmentation, 2095–2096

Spallation, of stone fragmentation, 2095–2096

SPARTAN trial, 3696

Spatial compounding ultrasonography, 74

Specialist nurse, in transitional urology, 1046–1047

Specific gravity, of urine, 15

Specimen collection, for urinalysis, 14

Specimen entrapment instrumentation, for laparoscopic and robotic surgery, 217–218, 217*f*

Speckling, in ultrasonography, 71, 72*f*

SPECT, Single-photon emission computed tomography

Sperm cryopreservation, for TGCT patients, 1690

Sperm granuloma, complication of scrotal surgery, 1856

Sperm production, age-related decrease in, 1392

Sperm retrieval

- in anejaculation, 1580
- surgical techniques for, 1472–1476, 1473*t*
  - microsurgical epididymal sperm aspiration, 1473–1474, 1473*f*–1474*f*
  - percutaneous epididymal sperm aspiration, 1474, 1474*f*
  - postmortem, 1476

        - testicular sperm extraction, 1474–1475, 1474*f*–1475*f*, 1475*t*

Spermatic cord, 1393

Spermatic cord dissection, patient positioning and port placement for, 1736, 1736*f*, 1738

Spermatic cord torsion, 893–897

- acute intravaginal, 893–894
    - clinical presentation of, 894
    - diagnostic studies of, 894, 895*f*
    - management and surgical treatment of, 894–896, 896*f*
    - predisposing factors for, 893–894
    - prognosis for, 896–897
- extravaginal, 897, 897*f*
- intermittent intravaginal, 897

Spermatic vessel ligation, for prune-belly syndrome, 594

Spermatids, 1398, 1398*f*

Spermatoceles, excision of, 1850

Spermatocytes, 1396, 1397*f*–1398*f*, 1400–1401

Spermatocytic tumors, histology of, 1682

Spermatogenesis, 1399–1402

- cycle of, 1399, 1399*f*
- genetics of, 1401
    - paternal age and, 1401–1402, 1402*b*
- germ cells in, 1396, 1401
- meiosis, 1401
- Sertoli cells in, 1396, 1401
- spermiogenesis, 1401
- testis stem cell migration, 1399
- testis stem cell proliferation, 1400
- testis stem cell renewal, 1400, 1400*f*

Spermatogonia, 1396

Spermatotoxicity, 1429–1432

- medications and
    - antibiotics, 1430

    - antihypertensives, 1430
    - anti-inflammatory agents, 1431
    - antipsychotics, 1430
    - cytotoxic chemotherapeutics, 1430–1431
    - endocrine modulators, 1429
    - environmental toxicants, 1431
    - opioids, 1430
    - phosphodiesterase V inhibitors, 1431
    - radiation, 1431–1432
    - recreational drugs, 1430
    - thermal toxicity, 1431

Spermatozoa, 1408–1410, 1409*f*, 1410*b*
  - epididymal function and, 1404–1406
    - maturation, 1404–1405
    - storage of, 1404
    - transport of, 1404
  - maturation of
    - biochemical changes, 1405
    - fertility, 1405, 1405*f*
    - motility, 1404–1405, 1405*f*
  - production of, Spermatogenesis
  - vas deferens function and, 1406–1407

Sphincteric urinary incontinence
  - cause of, 2993
  - classification of, 2993–2998
  - diagnosis of, 2995–2998
  - etiology of, 2993–2998
  - evaluation of, 2995–2998, 2996*f*, 2998*b*
    - cystoscopy for, 2996–2997, 2997*f*
    - history for, 2995
    - laboratory of, 2996
    - patient-reported measures, 2995–2996
    - physical examination for, 2996
    - urodynamics for, 2997
  - history and development of devices, 2993–2994, 2994*f*
  - implantation device technique, 3000–3005
    - artificial urinary sphincter, 3000, 3001*f*, 3003*f*
    - four-arm sling, 3005, 3005*b*
    - operative preparation of, 3000
    - transobturator bulbourethral sling, 3005, 3006*f*

- improving quality of evidence, 3009
- indications for surgery, 2998–2999, 2999*b*
- innovations and emerging concepts in device design, 2994–2995
- mechanisms of continence with surgical devices, 2995
- pathophysiology of, 2993–2998
- training paradigms of, 3009

Spina bifida (SB)

- kidney size with, 629
- lower urinary tract dysfunction with, 2617
- neuropathic bladder, 1052–1053
    - changes in function and continence, 1052
    - preparation for pregnancy, 1052–1053
    - renal and urologic concerns, 1052
    - sex and sexuality, 1052

Spinal cord

- abnormalities of, with cloacal exstrophy, 574–575
- cystitis and, chemical changes with, 2507
- neuromuscular lower urinary tract dysfunction involvement of, 2607–2619
- segment numbering for, 2609

Spinal cord compression, neuroblastoma causing, 1096

Spinal cord injury (SCI)

- bladder calculi in patients with, 2116–2117
- cystitis with, 2467
- and delayed ejaculation, 1576–1577, 1576*t*
- epidemiology of, 2609, 2609*b*
- general concepts of, 2609, 2609*b*
- with high-pressure bladders, host defense mechanisms in UTIs and, 1140
- lower urinary tract dysfunction with, 2609–2617, 2609*b*
    - autonomic dysreflexia, 2614–2615
    - bladder cancer and, 2616
    - follow-up for, 2616–2617
    - neurologic and urodynamic correlation, 2612–2614
    - sacral, 2611–2612, 2613*f*, 2613*b*
    - spinal shock, 2610
    - suprasacral, 2610–2611, 2611*f*–2612*f*, 2612*b*
    - urinary tract infection, 2615
    - vesicoureteral reflux, 2615

        - in women, 2615–2616
    - morbidity of, 2609, 2609*b*
    - neurogenic detrusor overactivity and, 2504–2505
    - traumatic, 648–649, 650*b*
        - pathogenesis of, 648
        - presentation of, 648, 648*f*
        - specific recommendations for, 649
    - urothelium and, 2467

Spinal cord pathways, in lower urinary tract, 2481–2482, 2481*t*, 2482*f*

Spinal defects, in bladder exstrophy, 531–532

Spinal dysraphism, 487
- lower urinary tract dysfunction with, 2617–2619
- occult, 644, 645*t*

Spinal shock, lower urinary tract dysfunction with, 2610

Spinal stenosis, lower urinary tract dysfunction with, 2620

Spinal ultrasound, 389

Spindle assembly checkpoint, deregulation of, 1347.e3

Spine, anatomy of, in retroperitoneum, 1658, 1658.e1*f*

Splenic injury
- during laparoscopic and robotic surgery, 230.e1
- during radical nephrectomy, 2261

Splenogonadal fusion, 963, 963*f*

Splenorenal ligament, 1865

Split onlay skin flap (SOS) hypospadias repair technique, 946*f*

Split symphysis variant of exstrophy-epispadias complex, 538

Split-and-roll technique, for RPLND, 2239, 2239*f*

Split-nipple technique, in urinary diversion, 3188–3189, 3188*f*

Split-thickness skin grafts, for urethral and penile reconstruction, 1805

SPOP mutations, in prostate cancer, 3470–3472

Sporadic glomerulocystic kidney disease (GCKD), 772

Sporadic prostate cancer, 1355–1358

Spread-out Bragg peak, 3594, 3594*f*

Squamous cell carcinoma (SCC)

- of bladder, 3089–3090, 3089*f*
  - in pediatric patients, 1118
- as neoplastic condition, 1296, 1299*f*
- of penis, 1743–1751
  - biopsy for, 1746, 1747*b*
  - delay in, 1745
  - diagnosis of, 1745–1751
  - differential diagnosis of, 1751
  - etiology of, 1743–1744, 1745*b*
  - examination for, 1745–1746
  - histologic features of, 1746, 1747*b*
  - invasive, 1743
  - invasive carcinoma, 1743
  - laboratory studies of, 1746–1747
  - natural history of, 1745, 1746*b*
  - presentation of, 1745, 1746*b*
  - prevention of, 1744, 1745*b*
  - radiologic studies of, 1747–1748, 1748*b*
  - signs of, 1745
  - staging of, 1748–1751, 1748*t*–1749*t*, 1750*f*, 1751*t*, 1751*b*
  - symptoms of, 1745
- of upper urinary tract, 2189

Squamous cell carcinoma in situ (SCCis), as neoplastic condition, 1296, 1298*f*

Squeezing-splitting mechanism, of stone fragmentation, 2096–2097

SRY gene, 990, 991*f*–992*f*, 1392

SSIGN score, Stage, Size, Grade and Necrosis (SSIGN) score

SSIPPE, Short Screening Instrument for Psychological Problems in Enuresis

SSIs, Surgical site infections

SSLF, Sacrospinous ligament fixation

Stab wounds

- renal, 1982
  - nonoperative management of, 1986–1987
- ureteral, 1995–1996

diagnosis of, 1995–1996

Staccato-shaped curve, 480

Stage, Size, Grade and Necrosis (SSIGN) score, 2162

Staged implant procedure, for sacral neuromodulation, 2754

Staged tubularized autograft (STAG) repair, 927, 930*f*

Staghorn calculi, 2070, 2070*f*

- epidemiology of, 2031
- percutaneous nephrolithotomy and, 2106
- surgical treatment selection for, 2074–2075

Stamey incontinence grading system, 2893*t*

Stamey needles, in pubovaginal sling placement, 2838–2839

Standardized uptake value (SUV), 91

Stapled sigmoid reservoir, for cutaneous continent urinary diversion, 3228, 3230*f*

Staplers, 466

Stapling devices, for laparoscopic and robotic surgery, 216, 216*f*

StAR, Steroid acute regulatory protein

Starr plication technique, for megaureter in children, 851, 851*f*

States of saturation, renal calculi and, 2009–2010, 2010*f*–2011*f*

Static cystography, 39, 40*f*

Statins

- and ED, 1509
- for metabolic syndrome, 1422
- for prostate cancer, 3544–3545
- in prostate cancer prevention, 3475

Stauffer syndrome, 2156

STDs, Sexually transmitted diseases

Stem cell transplantation, for RCC, 2331, 2331*t*

Stem cells

- in GU cancers, 1367, 1368*b*

- in prostate cancer, 3466, 3468*f*
- testis
  - migration of, 1399
  - proliferation of, 1400
  - renewal of, 1400, 1400*f*

Stenosis, urethral, reconstructive surgery for, 1811

Stents
- endovascular, for renovascular injuries, 1990
- for prostate, 3443–3444
- ureteral, Ureteral stents
- for ureteroenteric strictures, 1977
- for ureteropelvic junction obstruction, 834–835
  - in percutaneous antegrade endopyelotomy, 1948
- for urethral stricture disease, 1818–1819

Stepper, 3592

Stereotactic body radiation therapy, 3593–3594

Sterilization, of ureteroscopes, 195–197

Steroid acute regulatory protein (StAR), 1394–1395
- deficiency of, 1011

Steroid hormones, of male reproductive system, 1390, 1391*f*

Steroid-dependent nephrotic syndrome (SDNS), 345

Steroidogenic dysfunction, 1447

Steroid-resistant nephrotic syndrome (SRNS), 345

Steroids
- for retroperitoneal fibrosis, 1980
- sex, lower urinary tract and, 2502–2503

Steroid-sensitive nephrotic syndrome (SSNS), and nephrotic syndrome, 345

Stevens-Johnson syndrome, 1277–1278, 1278*f*

Stimulated myoplasty, 2903

Stoma
- for intestinal anastomoses in urinary intestinal diversion, 3161*f*

        - complications of, 3180*t*
        - flush, 3182–3183
        - loop end ileostomy, 3183, 3183*f*
        - nipple (rosebud), 3182, 3182*f*–3183*f*
    - in minimally invasive urinary diversion, preparation of, 3262, 3262*b*

Stomach
    - selection, 3162
    - for urinary diversion, 3160

Stone breakage mechanism, of stone fragmentation, 2097

Stone clearance, 861

Stone composition, after shock wave lithotripsy, 865

Stone disease, Calculi

Stone fragility, 2077.e1–2077.e2

Stone location, after shock wave lithotripsy, 865

Stone removal
    - laparoscopic and robotic, 2113
    - in percutaneous nephrolithotomy, 2104–2105

Stone retrieval devices, for ureteroscopic, intraluminal lithotripsy, 198

Stone size, after shock wave lithotripsy, 864–865

Stones, Calculi

Stop test, 2659

“Straddle fractures,” urethral injuries with, 3057, 3057.e1*f*

Straight ureteral catheter, 166.e1*f*

Streak gonad, 321–322, 323*f*

Stress Incontinence Surgical Treatment Efficacy Trial (SISTEr), 2840–2841

Stress relaxation, ureteral, 1885, 1885*f*

Stress strategies, 2725, 2725.e1*t*

Stress urinary incontinence (SUI)
    - adrenergic agonists for, 2501
    - with bipolar transurethral resection of prostate, 3419

  - BMI and, 2540–2541
  - cause of, 2834
  - definition of, 2539, 2581
  - estrogens for, 2713–2714
  - female
    - algorithm for management of, 2760*f*
    - drugs used for treatment of, 2713–2716
    - urodynamic studies, evidence-based review in, 2574–2576
    - use of injectable agents for, 2890–2891
  - genuine, 2518
  - hypermobility in, 2757, 2834
  - male
    - drugs used for treatment for, 2716
    - injectable agents for, 2896–2897
      - after urinary diversion, 2897–2898
      - injection techniques, 2896–2897
  - mechanisms of, 2504
  - occult, urodynamic studies of, 2563
  - pathophysiology of, 2517, 2596–2597, 2597*b*
    - intrinsic sphincteric deficiency in, 2597, 2757, 2834, 2859–2860
    - urethral support and, loss of, 2596–2597, 2596*f*
  - patient history of, 4
  - pelvic floor muscle training for, 2540, 2723
  - recurrent, midurethral sling outcomes for, 2860–2861, 2861*b*
  - treatment for
    - choice of, 2757
    - in men, 2546–2547, 2546*t*, 2547*b*
    - midurethral sling, Midurethral sling
    - pharmacologic, 2683*t*, 2713, 2717*b*
    - pubovaginal sling for, Pubovaginal sling
    - surgical, 2574
  - urethral collagen and, 2467
  - urethral slings for, 2831
- Striated muscles, of urethral sphincter, 2466–2467
  - fiber types of, 2466–2467
- Striated sphincter, decreasing outlet resistance at, to facilitate bladder emptying, 2720
- Striated sphincter dyssynergia, 2521–2522

  after CVA, 2603
  baclofen for, 2720.e2–2720.e3
  with cerebellar ataxia, 2604
  cystourethrogram of, 2611*f*
  with MS, 2608
  with suprasacral spinal cord injury, 2610
  with traumatic brain injury, 2604

Striated urethral sphincter, surgical anatomy of, 3549, 3549*f*–3550*f*

Strickler technique, in urinary diversion, 3186, 3186*t*, 3187*f*

Stricture
  ureteral, Ureteral strictures
  with ureterointestinal anastomoses, in urinary intestinal diversion, 3192
  in ureteroscopic stone management, 2108
  urethral, Urethral strictures

Stroke
  and ED, 1502
  lower urinary tract dysfunction and, 2602–2603

Stroma
  of bladder wall, 2463
  of prostate, 3280
  of urethra, 2468

Stromal-epithelial interactions
  in benign prostatic hyperplasia, 3309
  in prostate growth, 3287

Structural chromosomal anomalies, male infertility and, 1446

Structural sperm abnormalities, in male infertility, 1451–1452

Structure, definition of, 101

Studer neobladder, modified, for minimally invasive urinary diversion, 3263*t*, 3264–3265

Studer pouch, for orthotopic urinary diversion, 3245, 3247*f*

Subacute combined degeneration (SACD), lower urinary tract dysfunction and, 2619

Subclinical Cushing syndrome, 2363–2364

Subclinical filariasis, 1329

Subcostal artery, 136*f*

Subcostal flank approach, for open kidney surgery, 2249–2250, 2249.e1*f*, 2250*f*–2251*f*, 2250.e1*f*

Subcutaneous emphysema, during laparoscopic and robotic surgery, 225

Subcutaneous tissue expansion, for hypospadias, 945

Subepithelial plexus, 2463

Submucosal stone, in ureteroscopic stone management, 2109

Substance P, in ureteral function, 1889

Suburethral hammock, 2831

Suburethral slings, 2830

Suburothelial interstitial cells, 2470, 2470*f*

Succinate dehydrogenase RCC (SDHRCC), 2142*t*, 2144

Sudeck's point, 3161

SUI, Stress urinary incontinence

Sunitinib, 3700
- for RCC, 2179*t*–2180*t*, 2334–2335, 2335*t*, 2336*f*

Superficial bladder cancer, Non-muscle-invasive bladder cancer

Superficial fascia, 136*f*

Superficial inguinal lymph node dissection, for penile cancer, 1761, 1793–1794

Superficial perineal space, 1807.e10

Superior ectopic kidney, 728*f*, 729–731
- anomalies of, 729–730, 730*f*
- diagnosis of, 730–731
- prognosis of, 731
- symptoms of, 730, 730*f*

Superior lumbar triangle, 169

Superior mesenteric artery (SMA), 1869–1870

- in radical nephrectomy, 2261

Superior mesenteric vein (SMV), in radical nephrectomy, 2261

Superior vesical artery, 1377

Supernumerary kidney, 721–722, 722*f*–723*f*

Supernumerary renal arteries, 1869

Supine hypotensive syndrome, in pregnant, 282

Supine position, 146, 165

- modifications to, 165

Suplatast tosilate, for BPS/IC oral therapy, 1241*t*, 1243

Supracostal flank approach, for open kidney surgery, 2250–2251, 2251.e1*f*

Supradiaphragmatic tumors, testicular tumors with, 1720

Suprapubic aspiration, 437

- in urine collection, 1141

Suprapubic catheterization, 155–156

- techniques of, 156
    - placement with a guidewire and Seldinger technique, 156

Suprapubic cystostomy, 190–191

- for posterior urethral injury, 3058, 3058*f*

Suprapubic simple prostatectomy, 3452–3454

- adenoma enucleation for, 3453, 3453*f*
- closure for, 3453–3454, 3454*f*
- hemostatic maneuvers for, 3452*f*, 3453
- prostate exposure for, 3452–3453, 3452*f*

Suprasacral spinal cord injury

- lower urinary tract dysfunction with, 2610–2611, 2611*f*–2612*f*
- management with, 2612*b*

Supraspinal pathways, in lower urinary tract, 2493–2497

- additional regions in, 2496–2497

    - bladder modulatory mechanisms, 2493–2494, 2495*f*
    - brain-bladder control model, 2497, 2498*f*
    - central circuitry regulation of, 2494–2495
    - cerebral control of voiding, 2496
    - human brain imaging studies in, 2496, 2496*f*
    - modulators in, 2495–2496
    - neurotransmitters in, 2495–2496
    - pontine micturition center, 2493–2494, 2495*f*
- Supravesical urinary diversion, for prune-belly syndrome, 591–592
- Surface electrode electromyography (sEMG), for PFM activity measurement, 2729
- Surgery
    - adrenal, Adrenal surgery
    - in ED, 1537
    - for genito-pelvic pain-penetration disorder, 1653, 1653.e1*f*
    - for hypospadias
        - Byars flap, 927, 931*f*
        - distal, 918
        - general considerations of, 916–918, 918*b*
        - graft or flap, 932, 934*f*
        - one-stage, 925–926
        - preputial flaps, 926*f*, 938–939
        - proximal, 925–932, 925*b*
        - scrotoplasty, 941
        - technical aspects of, 925–926, 926*f*
        - two-stage, 926–927
        - two-stage, with free graft, 927, 929*f*
        - two-stage, with pedicle flap, 927–932, 931*f*
    - kidney, Kidney surgery
    - for Peyronie's disease (PD), 1616–1625, 1626*b*
        - indications, 1610*f*, 1616–1618, 1618*b*, 1619*t*
        - penile prosthesis, 1624–1625
        - tunica lengthening procedures, 1621–1624
        - tunical shortening procedures, 1618–1621, 1620*f*–1621*f*, 1622*t*
    - postoperative care for, Postoperative care
    - preoperative care for, Preoperative care
    - preparation for, 123–125
        - antithrombotic therapy, 32–34

        bowel preparation, 124–125
        medication management, 32
Surgery-specific cardiac risk, 120
Surgical antimicrobial prophylaxis, in pediatric kidney stone disease, 861
Surgical castration, 3371
Surgical history, adrenal surgery and, 2407–2408
Surgical landmarks, of adrenal glands, 2345, 2347*f*–2348*f*, 2405–2406, 2406*f*
Surgical mesh removal, 2885–2886, 2886*b*
Surgical neurotomy, cryoablation, and neuromodulation, of dorsal penile nerve, 1572.e3
Surgical outcomes, assessment of, 101–114
Surgical pharmaceuticals, for laparoscopic and robotic surgery, 215
Surgical site infections (SSIs), 453–454
    risk of, 145
Surgical wounds
    classification of, 1201*t*
    of radical nephrectomy, closure of, 2261
Surgiflo, 148
Surveillance
    active, for RCC, 2173, 2173*t*
    for NSGCTs, 1693–1694, 1694*t*
    for penile cancer, 1757
    for seminomas, 1703–1704, 1703*t*
Suturing instrumentation, for laparoscopic and robotic surgery, 215–216, 216*f*
SWE, Shear wave elastography
Swedish Reflux Study, 515
SWL, Shock wave lithotripsy
Swyer syndrome, 998*t*, 1004–1005, 1005*f*
Sympathetic ganglia tumors, retroperitoneal tumors and, 2234–2235, 2235*f*

Sympathetic nervous system
  in retroperitoneum, 1675
  in ureteral function, 1888–1889
Sympathetic pathways, of lower urinary tract, 2480, 2480*f*
Sympathetic transmission, in neural control of LUT, 2593
Sympathomimetic agents, for neuromuscular dysfunction of lower urinary tract, 634, 634*f*
Symptom Impact Index (SII), 111*t*
Symptom Severity Index (SSI), 111*t*
Symptomatic microscopic hematuria, 252
Symptoms Management After Reducing Therapy (SMART) trial, 3389
Syndrome of complete androgen insensitivity, 1013–1014
Syndrome of partial androgen resistance, 1014
Syndromic cryptorchidism, 957–958
SYNERGY study, 3702
Synovial sarcoma, retroperitoneal tumors and, 2231–2232, 2232*f*
Synthetic mesh, for posterior compartment repair, 2829
Synthetic prosthetic materials, for pubovaginal sling, 2835, 2836*t*
  outcomes of, 2843
Syphilis
  diagnosis, 1258–1259
  as genital ulcers, 1255*t*, 1257, 1257*f*–1258*f*, 1257*t*
  treatment, 1259, 1259*t*
Syringomyelia, lower urinary tract dysfunction and, 2626
Systemic chemotherapy, for UTUC, 2222
Systemic lupus erythematosus (SLE), lower urinary tract dysfunction and, 2626
Systemic sclerosis, lower urinary tract dysfunction and, 2631
Systemic therapies, for retroperitoneal tumors, 2245–2247

T

T pouch

  for orthotopic urinary diversion, 3245–3246, 3247*f*

  with valved rectum, 3209–3210, 3210*f*

T2-weighted imaging, 63, 63*f*

Tabes dorsalis, lower urinary tract dysfunction with, 2619

Tachykinins

  lower urinary tract and, 2501–2502, 2501*t*

  in ureteral function, 1889

Tadalafil

  for benign prostatic hyperplasia, 3385

  to facilitate bladder filling and urine storage, 2682*t*, 2701

  for ureteral relaxation, 1899

  for urinary incontinence, 2544–2546

Tamm-Horsfall protein

  in crystal formation, 2014

  in crystal matrix, 2015

Tamoxifen, for PD, 1611, 1616*t*

Tamsulosin

  for benign prostatic hyperplasia, 3363–3365, 3363*f*, 3364*t*

  for detrusor underactivity, 2661

  for diminished bladder capacity, 2675*t*–2677*t*

  to facilitate bladder emptying, 2720.e1

  to facilitate bladder filling and urine storage, 2682*t*

    with antimuscarinic agent, 2704

  for nocturia, 2671–2673

  ureteral response to, 1888

Tanner classification, 871, 872*t*

“Taqaandan,” penile fracture with, 3048

Targeted angioembolization, for renal tumors, 2323

Targeted molecular therapies, for advanced RCC

  basis of, 2332–2333, 2333*f*
  combination and sequential therapy with, 2339–2341
  immune “checkpoint” inhibitor-based combination strategies, 2341, 2342*f*
  mTOR pathway inhibitors, 2326–2327, 2338–2339, 2340*f*, 2340*t*
  VEGFR-based, 2326–2327, 2333–2337, 2333*t*–2335*t*, 2336*f*, 2337*t*
Tasquinimod, 3700–3701
TAX 327 study, 3691, 3691*f*
TCC, Transitional cell carcinoma
^{99m}Tc-DMSA, Technetium-99m dimercaptosuccinic acid
^{99m}TC-DTPA, TECHNETIUM-99M-DIETHYLENETRIAMINE PENTAACETIC ACID
^{99m}Tc-MAG3, Technetium-99m-mercaptoacetyl triglycine
TCS, Tethered cord syndrome
^{99m}Tc-sestamibi, 98, 98*f*
Tea, UTUC risk and, 2186
Technetium-99m (^{99}mTc), 91, 92*t*
Technetium-99m dimercaptosuccinic acid (^{99m}Tc-DMSA), 92, 96*b*
  for imaging infections of kidney, 96
  renal cortical imaging with, 95–96
Technetium-^{99m}-diethylenetriamine pentaacetic acid (^{99m}Tc-DTPA), 41, 92, 96*b*
  dynamic renal scintigraphy with, 94–95
  scintigraphy, 94–95
Technetium-99m-mercaptoacetyl triglycine (^{99m}Tc-MAG3), 41, 41*f*, 92, 94*f*, 96*b*
  additional applications of, 94–95
  dynamic renal imaging with, 92–93
  dynamic renal scintigraphy with, 94–95
  renogram, 95*f*
Telomerase, in GU cancers, 1362–1365, 1363*f*, 1365*b*
  chromosome stabilizing activity of, 1364
  as potential diagnostic marker, 1364
  therapies based on, 1365

Telomere shortening, 2905

Telomeres, in GU cancers, 1362–1365, 1365*b*

  cancers and premalignant lesions with short, 1363–1364

  chromosomal instability and, 1362

  prostate cancer prognosis using, 1364–1365

  as tumor suppressive mechanism, 1363, 1363*f*

Temperature, epididymal function and, 1406

Temporal lobe epilepsy, and ED, 1502

Temsirolimus (Torisel), 2148

  for RCC, 2338–2339, 2339*t*–2340*t*, 2340*f*

Tension-free vaginal tape (TVT) procedure

  colposuspension compared with, 2773–2774

  evolution of, 2831

Teratomas, 1122

  histology of, 1683*f*, 1684

  PC-RPLND findings of, survival outcomes associated with, 1726, 1727*t*

Terazosin

  for autonomic dysreflexia, 2615

  for benign prostatic hyperplasia, 3357–3359, 3357*t*–3358*t*, 3359*f*

  for diminished bladder, 2674, 2675*t*–2677*t*

  to facilitate bladder emptying, 2682*t*, 2720.e1

Terbutaline, to facilitate bladder filling and urine storage, 2682*t*, 2714

Terminal ileum, right colon pouches with intussuscepted, 3219–3220

Tertiary or late syphilis, 1258

Testicular adnexa, tumors of, 1709

Testicular anomalies, cryptorchidism and, 963–964

Testicular artery, 1370–1371, 1372*f*–1373*f*, 1375

Testicular cancer, Paratesticular cancer

  and delayed ejaculation, 1576

  genomic alterations in, 1361–1362

    - gene rearrangements, 1353
  - in geriatric patients, 2920.e13
  - non-germ cell, 1707–1709
    - adenocarcinoma of rete testis, 1708
    - dermoid and epidermoid cysts, 1708
    - secondary metastases, 1709
    - sex cord-stromal tumors, 1707–1708
  - in nuclear medicine, 43–44, 44*f*
  - pediatric, 1121–1125, 1125*b*
    - biomarkers for, 1122, 1122*f*
    - epidemiology of, 1121
    - gonadal stromal tumors, 1124, 1124*f*
    - leukemia and lymphoma metastases, 1124–1125
    - management algorithms for, 1125, 1125*f*
    - microlithiasis, 1124–1125
    - pathogenesis and molecular biology of, 1121
    - presentation of, 1121–1122
    - sexual development disorders associated with, 1122–1124, 1123*t*
    - staging of, 1122, 1122*t*
    - testis-sparing surgery technique for, 1125
    - ultrasonography of, 1122
  - staging of, 1687*t*–1688*t*
- Testicular dysgenesis syndrome (TDS), 909, 955–956
- Testicular fixation, with suture, 1855
- Testicular formation, 317–318, 319*f*, 320*t*

Testicular germ cell tumors (TGCTs), 1680–1707, 1681*t*, 1684*b*, 1688*b*
- clinical staging of, 1687*t*–1688*t*, 1689–1690, 1691*b*
  - chest imaging and, 1690
  - imaging studies, 1689
  - prognostic classification of advanced germ cell tumor, 1690, 1691*t*
  - serum tumor markers in, 1690
  - sperm cryopreservation, 1690
- diagnosis delay, 1685
- diagnostic testing and initial management of, 1685–1688
  - contralateral testis biopsy, 1688
  - partial orchiectomy, 1686–1688
  - radical inguinal orchiectomy, 1686
  - scrotal ultrasound, 1685–1686, 1685*f*
  - serum tumor markers, 1686
  - for suspected extragonadal GCTs, 1688
- differential diagnosis of, 1685
- epidemiology of, 1680
- genomic alterations in, 1122*t*, 1361
- histologic classification of, 1682–1684
  - choriocarcinoma, 1683–1684, 1683*f*
  - EC, 1682–1683, 1683*f*
  - germ cell tumor neoplasia in situ, 1682
  - seminoma, 1682, 1683*f*
  - spermatocytic tumor, 1682
  - teratoma, 1683*f*, 1684
  - YSTs, 1683*f*, 1684
- initial presentation of, 1684–1685
- pathogenesis and biology of, 1681–1682
- physical examination for, 1685
- risk factors for, 1680–1681
- signs and symptoms of, 1684–1685
- suspected, 1688
- treatment of, 1691–1693
  - brain metastases, 1706–1707, 1707*b*
  - NSGCTs, 1692, 1692*b*
  - relapse after, 1700–1702
  - residual mass management after, 1698–1700, 1698*t*–1699*t*
  - seminomas, 1692, 1692*b*
  - sequelae of, 1707, 1707*b*
  - therapeutic principles, 1691–1692

Testicular hypotrophy, 900–901

Testicular injury

- complications with, 3053
- diagnosis of, 3051–3052, 3052*f*
- etiology of, 3051
- management of, 3052–3053, 3052*f*
- outcome of, 3053

Testicular maldevelopment, cryptorchidism and, 961–964

Testicular microlithiasis, 971–972, 971*f*

- in pediatric patients, 1124–1125

Testicular prosthesis placement, 1848–1850, 1849*f*

Testicular retraction, 949

Testicular rupture, 899

Testicular sperm extraction, 1474–1475, 1474*f*–1475*f*, 1475*t*

Testicular torsion, 387, 391–392, 392*f*, 1432

- perinatal, 897, 897*f*

Testicular tumors, 392–393

- laparoscopic retroperitoneal lymph node dissection, 1734–1741, 1741*b*
  - bilateral, 1738
  - complications of, 1739–1740, 1739*t*
  - duplication of, 1735
  - postoperative care after, 1738–1739
  - prospective nerve-sparing techniques for, 1739
  - rationale and evolution of, 1734
  - results and current status of, 1740–1741, 1740*t*
  - staging, 1734–1735
  - surgical technique for, 1735–1738
- malignant, Testicular cancer
- management of, 1711–1712
- as non-AIDS-defining urologic malignancies, 1268
- robotic-assisted retroperitoneal lymph node dissection, 1734–1741, 1741*b*
  - complications of, 1739–1740, 1739*t*
  - postoperative care for, 1738–1739
  - prospective nerve-sparing techniques for, 1739
  - rationale and evolution of, 1734

- results and current status for, 1740–1741
- surgical technique for, 1735–1738

surgery of, 1711–1733, 1712*b*
- delayed orchiectomy, 1712
- evaluation after, 1712
- in high-risk populations, 1727–1729, 1728*t*, 1729*b*
- histologic findings and survival outcomes of, 1726–1727, 1727*t*, 1727*b*
- history, and physical examination, ultrasonography, and preorchiectomy evaluation, 1711–1712
- outcomes, functional considerations, and complications of, 1729–1731, 1732*b*
- for seminoma, 1731–1732
- for sex cord stromal tumors, 1732–1733

surgical decision making for, 1721–1726, 1726*b*
- adjuvant chemotherapy for primary RPLND, 1724–1726
- in cases of clinical complete remission to induction chemotherapy, 1721–1722, 1722*t*
- template use in PC-RPLND, 1723–1724, 1724*f*, 1725*t*
- template use in primary RLND, 1722–1723, 1723*f*, 1723*t*

Testis

anatomy of, 1374*b*
- arterial supply to, 1370–1371, 1372*f*, 1393
- blood supply of, 1453–1454, 1454*t*
- gross structure, 1370, 1371*f*
- lymphatic supply, 1372, 1373*f*
- microanatomic architecture, 1370, 1371*f*
- nerve supply, 1372–1373
- venous drainage, 1372, 1372*f*–1373*f*

androgen production by, 3281–3282, 3282*f*–3283*f*, 3282*t*

anomalies of, cryptorchidism and, 963–964

appendix, torsion of, 897–898, 898*f*

descent of
- gubernacular development and, 951–952, 952*f*
- regulation of, 952–953

differentiation of, 949–950

embryology of, 949–953

function of, 994, 995*f*

in genitourinary tuberculosis, 1309

HIV and, 1266

hormones of, 950–951, 1391–1392, 1391*f*

imaging of
- magnetic resonance imaging, 1373–1374
- scanning electron micrograph, 1393*f*

      - ultrasound, 1373, 1373*f*–1374*f*
  - inflammation of, Orchitis
  - injuries of, 3051–3053
  - magnetic resonance imaging, 1373–1374
  - neoplasms of, 1680–1710, 1681*t*
  - physiology of, 1392–1394, 1402*b*
    - cytoarchitecture, 1394–1399, 1395*f*–1396*f*
    - gross architecture in, 1392–1394, 1393*f*–1394*f*
    - in HPG axis, 1391–1392, 1391*f*
  - in prune-belly syndrome, 584–585, 585*f*
  - ultrasonography of, 82, 1373, 1373*f*–1374*f*
    - indications for, 82
    - normal findings in, 78*f*, 82–83, 83*f*–84*f*
    - procedural applications of, 83
    - sonoelastography, 84
  - undescended, Cryptorchidism
  - vanishing, 959–960, 960*f*

Testis stem cell

  - migration of, 1399
  - proliferation of, 1400
  - renewal of, 1400, 1400*f*

Testis-sparing surgery

  - for pediatric tumors, 1125
  - for TGCT, 1686–1688

Testosterone

  - aging effects on, 1392
  - biosynthesis disorders of, 1011–1013
  - cycles of, 1396, 1396*f*
  - epididymal function and, 1406
  - for female sexual arousal disorders, 1649–1650
  - for female sexual response, 1627.e5–1627.e6
  - in HPG axis, 1391
  - lower urinary tract and, 2503
  - in prostate cancer, 3466, 3467*f*
  - sources of, 3673
  - synthesis of, 1394–1395, 3280–3281, 3283*f*

control of, 1395–1396

Testosterone therapy, 1529–1532, 1531*t*

- buccal, 1530
- cardiovascular risk of, 1424–1425
- intramuscular, 1530
- for metabolic syndrome, 1422
- oral, 1530
- subcutaneous, 1530
- transdermal, 1530

Tethered cord syndrome (TCS), lower urinary tract dysfunction with, 2618

TGCTs, Testicular germ cell tumors

The Cancer Genome Atlas (TGCA), 3467–3468, 3469*f*

Theophylline, for ureteral relaxation, 1899

Thermal ablative therapies, for RCC, 2171–2173, 2171*f*, 2172*t*

“Thermal dose,”, 3426

Thermal index (TI), in ultrasonography, 78

Thermodynamic solubility product (K_{sp}), 2009

Thiazide-induced hypocitraturia, 2056

Thiazides

- for hypercalciuria, 2051–2052, 2052*t*
- in stone formation, 2033

Thick filaments, 2471, 2471*f*

Thiersch Duplay (TD) repair, 921–922, 923*f*

Thigh pain, in mesh complication, 2881

Thin filaments, 2470–2471

Thiol-containing agents, for pediatric kidney stone disease, 869–870

Thiotepa, for non-muscle-invasive bladder cancer, 3103

Thoracic kidney, 725–727, 726*f*

- anomalies of, 726

- description for, 726
- diagnosis of, 726, 726*f*
- embryology of, 725–726
- incidence of, 725
- prognosis of, 727
- symptoms of, 726

Thoracoabdominal approach
- for kidney surgery, 2251–2252, 2252*f*–2253*f*, 2252.e1*f*
- to open adrenalectomy, 2413–2414, 2413*f*–2414*f*

Thoracoabdominal incision, kidney and retroperitoneum approaches, 136–137

Thoracostomy, 181

Three-dimensional conformal radiotherapy, for prostate cancer, 3587–3588, 3588*f*

Three-dimensional laparoscopic systems, 213

Three-dimensional scanning, in ultrasonography, 75, 77*f*

Three-port catheters, 153

Thrombectomy, vena caval, 2266–2278, 2278*b*
- bypass techniques for, 2275–2276, 2275*f*–2276*f*, 2275.e1*f*, 2276.e1*f*
- IVC filtration and permanent interruption for bland thrombus, 2277
- level I, right-sided tumor technique, 2267–2269, 2267.e1*f*, 2269.e1*f*, 2270*f*
- level II, left-sided tumor technique, 2269–2270, 2269.e1*f*, 2271*f*
- level III-IV
  - combined intra-abdominal and intrathoracic approach, 2274–2275, 2274*f*, 2274.e1*f*
  - intra-abdominal approach technique, 2270–2274, 2271*f*–2274*f*, 2273.e1*f*
- patching, replacing, and interrupting of IVC in, 2276–2277, 2277*f*
- perioperative complications, 2277–2278
- preoperative considerations for, 2266–2267, 2267*t*, 2268*f*–2269*f*

Thromboembolic events, after retropubic radical prostatectomy, 3563

Thulium laser, 3442–3443
- complications with, 3443
  - intraoperative, 3443
  - perioperative, 3443
  - postoperative, 3443

    - concept and introduction for, 3442
    - conclusion for, 3443
    - holmium laser enucleation of prostate *versus*, 3442–3443
    - outcomes with, 3442–3443
        - comparative series, 3442–3443
        - single-cohort series, 3442
    - technique for, 3442
    - transurethral resection of prostate *versus*, 3442

Thulium:YAG (Thu:YAG) laser, 240–241

Thymine, 1346.e1, 1346.e2*f*

Tibial nerve stimulation, for OAB, 2647

Tight junction (TJ) proteins, in bladder urothelium, 2467, 2468*f*

Time activity curve (TAC), 92–93, 93*f*

Timed Up and Go (TUG) test, 2910

Timed voiding, 2730.e1*t*, 2731

Tisseel VH Fibrin Sealant, 215.e2

Tissue adhesives (Bioglue), 148

Tissue anastomosis instrumentation, for laparoscopic and robotic surgery, 215–216

Tissue banking, genomic research on, 3586

Tissue matrix, of prostate, 3280

Tissue transfer, principles of, 1805

Tissue-based biomarkers, 3487–3489

Tissue-based genomics, caveats of, 3543

TMP, Trimethoprim

TMP-SMX, Trimethoprim-sulfamethoxazole

TNF-α, Tumor necrosis factor-α

TNM staging, Tumor, nodes, and metastases (TNM) staging

Tofranil, Imipramine

Toileting programs
  bladder training, 2728*f*, 2730, 2730.e1*t*
  caregiver-administered, challenges of, 2732.e1
  delayed voiding, 2732
  habit training, 2730.e1*t*, 2731
  prompted voiding, 2730.e1*t*, 2731–2732
  timed voiding, 2730.e1*t*, 2731
  understanding, 2730.e1*t*
  for urinary incontinence, 2730–2731
Tolterodine, 2498, 2499*t*
  for diminished bladder, 2674, 2675*t*–2677*t*
  to facilitate bladder filling and urine storage, 2682, 2682*t*
    with α-adrenoreceptor antagonists, 2697–2698
    with other antimuscarinics, 2685
Tonsil clamps, in pubovaginal sling placement, 2838–2839
TOOKAD Soluble, 3632
Top-down approach (TDA), 439
Topical local anesthetics, for PE, 1572
Topical therapy, for genito-pelvic pain-penetration disorder, 1653
Topical thrombin agents, 148
Topiramate, in stone formation, 2033
Toremifene citrate, in prostate cancer prevention, 3475
Torisel, Temsirolimus
Toronto group, 3540
Torsion of appendix testis and epididymis, 897–898
Torulopsis glabrata, 445
Total colpocleisis, for apical pelvic organ prolapse repair
  results with, 2812
  technique for, 2812, 2813*f*
Total laparoscopic technique, in nephroureterectomy, for UTUC, 2202, 2203*f*

Total nephrectomy, for renal injuries, 1991

Total parenteral nutrition (TPN), 122

Total scrotectomy, 1844–1845, 1846*f*

Total urogenital mobilization (TUM), 1033–1034, 1034*f*–1036*f*

Tower-shaped curve, 480

Toxins, to facilitate bladder filling and urine storage, 2682*t*, 2707–2709, 2709*b*

- botulinum toxins, 2707–2709
- capsaicin, 2709
- resiniferatoxin, 2709

TP53

- in apoptosis, 1366
- in GU cancers, 1347.e2, 1347.e2*f*, 1348
- in prostate cancer, 3469
- in Wilms tumor, 1098

TPE, Tropical pulmonary eosinophilia

Tract dilation, 170–172

Tract sealants, 176

Traditional open distal ureterectomy, in UTUC, 2200–2201, 2200*f*–2201*f*

Tramadol

- to facilitate bladder filling and urine storage, 2713.e3–2713.e4
- for PE, 1572.e1

Trans Tasman Radiation Oncology Group (TROG), 3600–3602

Transabdominal pelvic ultrasonography

- indications for, 80
- limitations of, 81
- normal findings in, 80–81, 80*f*, 82*f*
- procedural applications of, 81
- technique of, 80

Transcolonic technique of Goodwin, in urinary diversion, 3185–3186, 3186*f*

Transcription, basics of, 1346.e3, 1346.e3*f*

Transcriptional activation domains, of androgen receptors, 3291–3292, 3291*b*, 3292*f*

Transcutaneous electrostimulation, 2748

- sacral dermatome, 2748
- tibial nerve, 2748

Transducers, in urodynamic studies, 2558

Transection, of ureter, delayed recognition, 2001–2002

Transepithelial resistance (TER), 2467

Transferrin, in prostatic secretions, 3298*t*, 3302

Transforming growth factor-β superfamily, in prostate development, 3276–3277

Transforming growth factor-β1 (TGF-β1)

- and PD, 1605–1606
- in tubulointerstitial fibrosis, 787

Transfusion protocol, massive, 147

Transgender, Transmen, Transwomen

- female-to-male, 1841–1842, 1842*b*
- special urologic considerations in, 3062–3072, 3072*b*
  - early postoperative care of, 3069–3070

Transient receptor potential (TRP) channels

- antagonists of, to facilitate bladder filling and urine storage, 2713.e1
- in bladder afferent pathway, 2485

Transient urinary incontinence

- in geriatric patients, 2919.e1
- with holmium laser enucleation of prostate, 3438

Transient urinary tract dilation, 372–373, 373*f*

Transitional cell carcinoma (TCC), Urothelial cancer

- pediatric, 1117–1118, 1123–1124, 1124*f*
- upper tract and lower tract magnetic resonance imaging for, 61, 62*f*

Transitional urology, 1043–1053

- barriers to, 1045–1047
  - expanding numbers and management of service long-term, 1046

        - importance of specialist nurses, 1046–1047
        - institutional, 1045–1046
        - patients, 1046
        - professional, 1046
    - clinical delivery to, 1047
        - geography, 1047
    - clinical practice:major diagnosis of, 1047–1050, 1050*b*
        - blood tests, 1049
        - exstrophy, 1049–1050
        - flow rates, 1048
        - functional assessment of reconstructed urinary tract, 1047–1048
        - hypospadias, 1049
        - renography, 1048
        - ultrasonography, 1048–1049
        - video-urodynamics, 1048, 1048*f*
    - definitions for, 1043–1045
        - failure of transition, 1044
        - models for transition, 1044–1045
        - transfer, 1044
        - transition, 1043–1045, 1044*t*
    - patient population to, 1045
    - patient/parent preparation for, 1047, 1047*b*
    - setting up a service of, 1045
        - institutional and political support, 1045
        - multidisciplinary team, 1045
        - training, 1045

Translation, basics of, 1346.e3, 1346.e3*f*–1346.e4*f*

Transmen
- transurethral catheterization in, 3070
- urethral complications in, 3070–3071
- urologic issues in, 3063–3069
    - diagnosis of, 3063
    - genitoperineal transformation, 3066–3068
    - metoidioplasty, 3068–3069
    - phallic urethra, 3068
    - phalloplasty, 3068
    - preoperative care of, 3063
    - removal of female anatomic structures, 3063–3066
    - scrotoplasty, 3068
    - sex reassignment surgery, 3063
    - testicular implants and erectile prosthesis, 3069, 3070*f*

Transmural cystotomy, nonrefluxing ureteral reimplantation and, 3021–3022

Transneuronal tracing, 2494–2495

Transobturator AdVance sling, long-term results with, 3008

Transobturator bulbourethral slings
- implantation technique for, 3005
- outcomes with, 3003*t*

Transobturator mid-urethral slings
- anatomy of, 2850–2851
- complications of, 2863–2866
- outcomes for, 2856–2857, 2857*t*
- surgical approach for
  - inside-out, 2853–2854, 2854*f*
  - outside-in, 2853

Transobturator slings
- history and development of, 2994
- mechanisms of continence, 2995

Transperineal prostate biopsy, 3498–3499

Transperineal ultrasound, 85, 87*f*–88*f*

Transperitoneal approach
- to laparoscopic adrenalectomy, 2414–2417, 2415*f*–2417*f*, 2422
- to laparoscopic kidney surgery, 2279, 2280*f*–2281*f*
- to laparoscopic partial nephrectomy, 2300
- to laparoscopic radical nephrectomy, 2294–2295, 2295*f*
- robot-assisted, 2418–2419, 2419*f*–2420*f*

Transperitoneal laparoscopic nephroureterectomy, 2203–2204, 2203*f*–2204*f*

Transplant kidney, 177–178

Transplantation
- hematopoietic stem cell, for RCC, 2331, 2331*t*
- percutaneous nephrolithotomy and, 2106, 2106*f*
- renal, Renal transplantation

Transport, of sperm

    - by epididymis, 1404
    - by vas deferens, 1406–1407
- Transrectal prostate biopsy, 3497–3498
- Transrectal ultrasonography (TRUS), 1444
  - of locally advanced prostate cancer, 3641, 3641*f*
  - of prostate, 88–89, 89*f*, 1380, 1380*f*, 3490
    - after treatment, 3493–3494
    - anatomy of, 3490, 3491*f*–3492*f*
    - cancer, 3493, 3493*f*
    - color Doppler, 3500–3501, 3500*f*–3502*f*
    - cystic lesions, 3493, 3493*f*
    - elastography, 3501, 3502*f*
    - gray-scale, 3490–3494, 3494*b*
    - investigational techniques for, 3501–3504
    - machine setting for, 3491
    - other malignancies and, 3494
    - power Doppler, 3500–3501, 3500*f*–3502*f*
    - probe manipulation in, 3491–3492, 3492*f*
    - Prostate HistoScanning, 3501–3502
    - techniques for, 3491–3492
    - volume calculations in, 3492–3493
  - of seminal vesicles and ejaculatory ducts, 1378
- Transrectal ultrasound-guided aspiration, 1863
- Transrectal ultrasound-guided brachytherapy, for prostate cancer, 3591–3592, 3592*f*
- Transrectal ultrasound-guided prostate (TRUSP) biopsy, antimicrobial prophylaxis, 1197–1198
- Transscrotal orchidopexy, 967, 967*f*
- Transumbilical approach, 464
- Transureteroureterostomy (TUU)
  - for midureteral injuries, 1998
  - for urinary tract reconstruction, 683, 683*f*
  - for vesicoureteral reflux, 2615
- Transurethral endoscopic treatments, 1863
- Transurethral incision (TUI), for ureteroceles, 817–819, 818*f*–819*f*, 819*b*

- reflux outcomes after, 819

Transurethral incision of prostate (TUIP), 3434–3435
- complications with, 3435
  - intraoperative, 3435
  - perioperative, 3435
  - postoperative, 3435
- introduction and concept of, 3434
- outcomes with, 3434–3435
  - comparative studies, 3434–3435
  - single-cohort studies, 3434
- summary for, 3435
- technique for, 3434, 3434*f*
- transurethral resection of prostate *versus*, 3434–3435

Transurethral microwave therapy (TUMT), 3426–3430
- α-blocker *versus*, 3429
- complications with, 3430
  - intraoperative, 3430
  - perioperative, 3430
  - postoperative, 3430
- conclusion for, 3430
- contraindications to, 3427–3428
- introduction and concept of, 3426, 3427*f*
- mechanism of action of, 3426–3427
  - morphology changes, 3427
  - nerve degeneration/sensory changes, 3426–3427
- outcomes with, 3428–3430
  - comparative studies for, 3429
  - prediction of, 3428
  - single-cohort studies, 3428–3429
- sham *versus*, 3429
- technique for, 3427–3428
  - intraoperative, 3428, 3428*f*
  - postoperative, 3428
  - preoperative, 3427–3428, 3428*f*
- transurethral resection of prostate *versus*, 3429–3430

Transurethral needle ablation (TUNA), 3430–3434
- complications with, 3433
  - intraoperative, 3433

    - perioperative, 3433
    - postoperative, 3433
  - conclusion for, 3433–3434
  - introduction and concept of, 3430–3431, 3431*f*
  - other minimally invasive surgical techniques *versus*, 3433
  - outcomes with, 3432–3433
    - comparative studies, 3433
    - single-cohort studies, 3432–3433
  - technique for, 3431–3432
    - intraoperative, 3431–3432, 3432*f*
    - postoperative, 3432
    - preoperative, 3431
  - transurethral resection of prostate *versus*, 3433

- Transurethral prostate biopsy, 3499
- Transurethral resection (TUR), 1454
  - of diverticular neck, for bladder diverticula, 2972
  - of ureteral orifice, in UTUC, 2201–2202, 2202*f*
- Transurethral resection of bladder tumor (TURBT), 3133–3135, 3134*f*, 3159*b*
  - bladder perforation with, 3135, 3135*f*
  - challenges with, 3134–3135
  - cystoscopy for, 3133
  - goal of, 3134
  - history of, 3133
  - of muscle-invasive bladder cancer, radical, 3124
  - of non-muscle-invasive bladder cancer, 3096–3097
    - complications of, 3096
    - repeat, 3096–3097
  - partial cystectomy with, 3143, 3144*f*
  - patient preparation for, 3135–3136
  - pelvic lymphadenectomy with, 3137–3138, 3138*f*–3139*f*
  - physical examination and, 3113
  - physical examination of, 3133
  - postoperative care for, 3157
  - radical cystectomy
    - female, 3141–3143, 3142*f*–3143*f*
    - male, 3138–3141, 3139*f*–3141*f*

    - surgical technique for, 3136–3137, 3136*f*–3137*f*
- Transurethral resection of ejaculatory ducts (TURED), 1454, 1471–1472
    - complications of, 1471–1472
        - epididymitis, 1471
        - reflux, 1471
        - retrograde ejaculation, 1471–1472
    - diagnosis for, 1471
    - results for, 1472
    - technique for, 1471, 1472*f*
- Transurethral resection of prostate (TURP)
    - for adenocarcinoma, 3510
    - bipolar, Bipolar transurethral resection of the prostate
    - holmium laser enucleation of prostate *versus*, 3437
    - for localized prostate cancer, 3524
    - monopolar, Monopolar transurethral resection of the prostate
    - for nocturia, 2671–2673
    - thulium laser *versus*, 3442
    - transurethral incision of prostate *versus*, 3434–3435
    - transurethral microwave therapy *versus*, 3429–3430
    - transurethral needle ablation of prostate *versus*, 3433
    - urinary incontinence after, risk factors for, 2587
- Transurethral technique, injection, 2892–2893, 2893*f*
- Transurethral vaporization of prostate (TUVP), 3422–3426
    - comparative studies for, 3425
        - bipolar studies, 3425
        - monopolar studies, 3425
    - complications of, 3425–3426
        - intraoperative, 3425–3426
        - perioperative, 3425–3426
        - postoperative, 3426
    - conclusion for, 3426
    - electrode for, 3423, 3423*f*
    - introduction and concept of, 3422–3424, 3423*f*
    - outcomes with, 3424–3425
        - animal/in vitro studies, 3424
        - single-cohort studies, 3424–3425

technique for, 3424
    intraoperative, 3424
    postoperative, 3424
    preoperative, 3424

Transvaginal uterosacral ligament hysteropexy, 2817, 2819*t*

Transversalis fascia, 1666–1667, 1667*f*, 2427, 2429*f*, 2447*f*–2448*f*

Transverse colon, colon conduit and, 3196

Transverse myelitis, 649–650, 650*b*
  pathogenesis of, 650
  presentation of, 649–650, 650*f*
  specific recommendations for, 650

Transverse preputial island flap (TPIF), 925, 927*f*

Transverse testicular ectopia (TTE), 963–964

Transverse vaginal septum, 327, 979–980, 979*f*–980*f*

Transverse vesical fold, bladder, 3010

Transversus abdominus, 136*f*

Transvesical ligation and detachment technique, in nephroureterectomy, in UTUC, 2201, 2201*f*

Transwomen
  fate of prostate in, 3063
  urologic issues in, 3062–3063
  vaginoplasty in, 3062

Trauma
  of external genitalia, 3048–3054, 3054*b*
    genital skin loss, 3053–3054, 3053*f*–3054*f*
    penile reconstructions, 3054
    penis, 874*f*, 875, 3048–3049, 3048.e1*f*, 3049*f*–3050*f*, 3049.e1*f*
  genital and lower urinary tract, 3048–3061, 3061*b*
  LUT function and, 2527
  noninfectious genital ulcers caused by, 1288, 1288*f*
  renal, Renal injuries
  spinal cord, Spinal cord injury

- testis, 3051–3053
- ureteral, Ureteral injuries

Traumatic brain injury, lower urinary tract dysfunction with, 2604

Traumatic urethral strictures, 1815

Treatment margins, for prostate cancer, 3589–3590, 3591*f*–3592*f*

Trendelenburg position, 146–147, 460–461

Treponemal syphilis tests, 1258–1259

Triamterene

- in stone formation, 2033
- in stone formation, surgical management of, 2077.e3

Triangulation, 218.e3, 218.e3*f*

- technique, 167, 168*f*

Trichloroacetic acid, for condylomata acuminata, 1742.e3

Trichomonas vaginalis, 1254

Trichomoniasis, 1272, 1272*t*

- of genitourinary tract, 1332

Tricyclic antidepressants (TCAs)

- for BPS/IC oral therapy, 1241*t*, 1242
- for enuresis, 664–665
- to facilitate bladder filling and urine storage, 2702
- and PE, 1571–1572

Trigone of bladder, 2455–2456, 2456*f*

- formation of, 328–329, 331*f*

Trimethoprim (TMP), for UTIs, 1156, 1187*t*

Trimethoprim-sulfamethoxazole (TMP-SMX)

- prophylaxis with
  - for common urologic procedures, 1156, 1162, 1170*t*, 1194*t*–1196*t*
  - for cystourethroscopy, 189
- for UTIs, 1153

TriPort, 212.e1, 212.e1*f*

Trocars
  for laparoscopic and robotic access, 211, 211*f*, 211.e2*f*
    complications related to placement of, 225–226
  for laparoscopic kidney surgery, 2279–2285
    hand-assisted laparoscopy, 2282, 2283*f*
    laparoendoscopic single-site surgery and natural orifice transluminal endoscopic surgery, 2284–2285, 2285*f*, 2286*t*
    retroperitoneal, 2280–2281, 2282*f*
    robotic-assisted laparoscopy, 2282–2284, 2284*f*–2285*f*
    transperitoneal, 2279, 2280*f*–2281*f*
  in midurethral sling, injury to urinary tract with, 2866–2873
TROPIC study, 3692, 3693*f*
Tropical pulmonary eosinophilia (TPE), as filariasis clinical manifestation, 1330
Tropical spastic paraparesis, lower urinary tract dysfunction and, 2625
Tropomyosin (TM), 2472, 2473*f*
Trospium chloride
  for diminished bladder, 2674, 2675*t*–2677*t*
  to facilitate bladder filling and urine storage, 2682*t*, 2683
    with other antimuscarinics, 2691–2692
TRP channels, Transient receptor potential (TRP) channels
TRPA1, 2485
TRPM8, 2485
TRPV4, 2485
True flank incision, 139–140, 140*f*
TRUS, Transrectal ultrasonography
TRUSP biopsy, Transrectal ultrasound-guided prostate (TRUSP) biopsy
TSC, Tuberous sclerosis complex
Tubeless percutaneous procedure, 175–176
Tubercular epididymitis, 1221
Tuberculin skin test (TST), 1310
Tuberculosis (TB), 1307–1332, 1319*b*
  drug-resistant, 1318

- epidemiology, 1307
- genitourinary, Genitourinary tuberculosis
- history, 1307
- lower urinary tract dysfunction and, 2626–2627
- microbiology, 1307
- relapse, 1318

Tuberous sclerosis complex (TSC), 757–759, 757*f*–758*f*, 2125, 2142*t*, 2145
- clinical features of, 757–758
- genetics of, 757, 759*f*
- radiographic evaluation of, 758–759, 758*f*
- renal cell carcinoma in, 758, 2157–2158
- treatment of, 759

Tubular function, 341–342
- developmental changes in, 342

Tubular proteinuria, 18

Tubularization techniques, for hypospadias, 920–941
- flip-flap, 924, 924*f*
- glans approximation procedure, 907*f*, 920–921
- island onlay flap procedure, 924–925, 926*f*
- slitlike adjusted Mathieu procedure for, 924, 925*f*
- Thiersch Duplay repair, 921–922, 923*f*

Tubularized incised plate urethroplasty
- distal, 923*f*
- proximal, 928*f*
- for reoperation, 916–918, 922–924, 923*f*

Tubulogenesis, 338

Tubulointerstitial fibrosis, 786–790, 790*b*

Tubulopathies, 348–349

TUI, Transurethral incision

TUIP, Transurethral incision of prostate

TUM, Total urogenital mobilization

Tumor, nodes, and metastases (TNM) staging, 3084, 3085*t*, 3086*f*
    for RCC, 2158–2159, 2159*t*
    of urethral cancer, 1777, 1778*f*, 1778*t*
    for UTUC, 2194, 2195*t*, 2198*b*
Tumor enucleation, for RCC, 2170–2171, 2170*f*
Tumor lysis syndrome (TLS), 1924
Tumor necrosis factor-α (TNF-α), in tubulointerstitial fibrosis, 787
Tumor suppressor genes, 1346–1347, 1347*f*, 1347*b*
Tumor syndromes, 1354, 1354*t*
    in prostate cancer, 1354–1355, 1354*t*, 1355*f*
    in renal cancer, 1354*t*, 1358
Tumor thrombectomy, in retroperitoneal tumors, 2243
Tumor volume, 3511
Tumorigenesis model, for prostate cancer, 3472–3473
Tumors, Malignancy, Oncology, *specific tumors*
    formation of, augmentation cystoplasty and, 699–700
    renal, metabolic syndrome and, 1421
TUMT, Transurethral microwave therapy
TUNA, Transurethral needle ablation
Tunica albuginea, 317, 1370, 1371*f*, 1374*f*, 1392–1393, 1599
    anatomy of, 1486–1487, 1486*f*
    in penile fracture, 3048
Tunica lengthening
    graft materials for, 1622–1623
    grafting surgical technique for, 1623–1624
    postoperative management for, 1624
Tunica vaginalis grafts, 1807
Tunical shortening, procedures for, 1618–1621, 1620*f*–1621*f*, 1622*t*
TUR, Transurethral resection

TURBT, Transurethral resection of bladder tumor

TURED, Transurethral resection of ejaculatory ducts

Turner syndrome, 1001–1002, 1001*f*–1002*f*, 1002*b*

TURP, Transurethral resection of prostate

TUU, Transureteroureterostomy

TUVP, Transurethral vaporization of prostate

TVT procedure, Tension-free vaginal tape (TVT) procedure

Two-kidney, one-clip model, of renovascular hypertension, 1917, 1917*f*

Two-port catheters, 153

Two-stage urethroplasty, for transmen, 3071

Tyramine, ureteral response to, 1888

Tyrosine kinase inhibitors, for RCC, 2167–2168

U

UA, Urinalysis

UCLA Integrated Staging System (UISS), for RCC, 2162

UCSF and the Cancer of the Prostate Risk Assessment (CAPRA) score, 3528

UDS, Urodynamic studies

UISS, UCLA Integrated Staging System

Ulaanbaatar repair, 927–932, 933*f*

Ulcers, Genital ulcers

Ulnar nerve injury, 261–262

Ultrafiltration, in end stage renal disease, 356

Ultrasensitive prostate-specific antigen (uPSA), for biochemical recurrence after radical prostatectomy, 3661

Ultrasonic lithotripsy, 243, 244*b*, 2112, 2112*f*

- basic physics of, 243

- tissue effects of, 243

Ultrasonography, 68–90, 90*b*, 391*b*, 404–412
- abdominal wall defects, 410
- of adrenal glands, 2352
- in adrenal mass evaluation, 2395
- bladder tumors, 408–409
- bladder/urethra, 408–412, 409*f*–410*f*
  - obstruction of, 408
- clinical urologic
  - penis and male urethra, 85–88, 86*f*
  - renal, 78–80, 79*f*
  - scrotum, 81–84, 83*f*–85*f*
  - transabdominal pelvic, 80–81, 80*f*–82*f*
  - TRUS of prostate, 88–89, 89*f*
- contrast agents in, 76–77
- for cysts/masses/stones, 405–406, 406*b*, 407*f*, 411–412
  - abdominal solid, 405–406
  - renal, 405
  - renal stones, 406
  - ureteral stones, 406
- of defecation disorders, 669–670, 670*f*, 670.e1*f*
- for differences of sex development, 412
- documentation and image storage in, 76, 77*f*
- Doppler, Doppler ultrasound
- of epididymis, 1375–1376, 1376*f*
- of exstrophy-epispadias complex, 538, 539*f*
- of female pelvis, 2439, 2440*f*
- with fine-needle aspiration cytology, for inguinal node dissection, 1791–1792
- fundamental of, in fetus and child, 404
- history of, 68, 69*f*
- infection and, 406–407, 408*b*, 409
- of kidney/ureter, 404–407, 1868, 1868.e1*f*
- of male external genitalia, 871, 871.e2*f*
- midline pelvic cysts, 408–409
- modes of
  - Doppler, 73–74
  - gray-scale, 73
  - harmonic scanning, 74, 75*f*

    - sonoelastography, 74–75
    - spatial compounding, 74
    - three-dimensional scanning, 75, 77*f*
- noncontrast voiding, 406–407
- obstruction, of kidney/ureter, 404–405, 405*b*
    - dilated ureters, 404
    - functional interpretation of, 404–405
    - hydronephrosis *versus* cystic renal diseases, 404
- of other congenital malformation, 407, 410
- patient safety in, 77–78
- pediatric
    - genitourinary trauma, 1073–1074
    - stone disease, 854–856, 855*f*
    - urology, 388–389
- of penile fracture, 3048–3049, 3049*f*
- of penis, 1386, 1387*f*
- for PFM function assessment, 2723
- physical principles of, 68–73, 69*f*
    - artifacts, 71–73, 72*f*
    - attenuation mechanisms, 71, 71*f*–72*f*
    - image generation, 70, 70*f*
    - resolution, 70–71, 70*f*
- of posterior urethral valves, 607, 607*f*
- practice accreditation for, 89–90
- in pregnant, 284
- prenatal, 389
- renal bladder, 388–389
- for renal calculi, 778–779
    - pretreatment assessment, 2071
- for renal tumor evaluation, 2135
- for renovascular hypertension screening, 1917–1918, 1918*b*
- scrotal, 389, 1373, 1443–1444, 1444*f*
    - for GCTs, 1685–1686, 1685*f*
- of testis, 1373, 1373*f*–1374*f*
    - injury to, 3052, 3052*f*
- in transitional urology, 1048–1049
- transrectal, Transrectal ultrasonography
- for trauma, 407, 408*b*
    - scrotum, acute, 410–411, 411*f*–412*f*, 412*b*

  - of undescended testis, 412, 412*b*
  - of ureteral anomalies, 803–805, 804*f*–805*f*
  - ureteral anomalies, imaging interpretation of, 804*f*, 806
  - for ureteral calculi, 778–779
  - for ureteropelvic junction obstruction, 1943
  - urethral, 1384*f*
  - of urethral diverticula, 2983
  - of urinary lithiasis, 2038, 2038*f*–2039*f*
  - for urinary tract obstruction, 778–781
  - for UTIs, 1144, 1168, 1169*f*
  - Wilms tumor screening with, 1098–1099, 1099*f*

Ultrasound instrumentation
  - for laparoscopic and robotic surgery, 214–215
  - for tissue dissection and cauterization, 237–238

Ultrasound-guided access, 169, 169*f*

Umbrella cells, 2461–2462, 2463*f*, 2467

UMN bladder, in Bors-Comarr classification system, 2523

Unclassified RCC, 2149*t*–2151*t*, 2155

Unclassified sarcomas, retroperitoneal tumors and, 2233

Uncomplicated cystitis, 1155–1158
  - antimicrobial selection for, 1156–1157
  - clinical presentation, 1156
  - follow-up, 1157–1158
  - laboratory diagnosis, 1156
  - management, 1156–1157, 1157*f*
  - risk factors, 1156*b*

Underactive bladder, Bladder, underactive

Underactive detrusor, Detrusor underactivity (DUA)

Undescended testis, 391, 949–972, Cryptorchidism

Unilateral levator hypertonicity, 2881

Unilateral renal agenesis (URA), 717–721

    - anomalies of other organ systems and, 720
    - associations with, 718
    - current concepts regarding prognosis in adults with, 720–721
    - diagnosis of, 720
    - embryology of, 718, 719*f*
    - genitourinary and adrenal anomalies with, 718–719
        - in female, 719–720
        - in male, 719
    - incidence of, 718
    - prognosis of, 720
    - special considerations in, 720
- Unilateral renal cystic disease, 770
- Unilateral ureteral obstruction (UUO)
    - hemodynamic changes with, 791, 791*f*
    - renal recovery after, 795
    - tubular function with, 792–793
- Unresolved UTIs, 1159, 1159*b*
- Unstable bladder, 2637
- Up training, 2732
- UPEC, Uropathogenic *E. coli*
- UPJ, Ureteropelvic junction
- UPP, Urethral pressure profile
- Upper abdominal surgery, operative team placement for
    - retroperitoneal procedures, 207, 207*f*
    - transperitoneal procedures, 206, 206*f*, 206.e1*f*
- Upper motor neuron (UMN) lesion, voiding dysfunction after, 2522, 2523*b*
- Upper respiratory infections (URIs), perioperative care for pediatric patients with, 447–448
- Upper tract endoscopy
    - antimicrobial prophylaxis for, 1199
    - equipment for, 192–199, 192*f*, 193*t*, 195*f*, 196*t*, 199*f*, 199*t*
    - indications for, 191–192

    - percutaneous procedures, antimicrobial prophylaxis for, 1199
    - technique, 199–201, 201*f*
    - ureteroscopy, antimicrobial prophylaxis for, 1199

- Upper tract urothelial cancer (UTUC), 2185–2199
  - diagnosis of, 2189–2192, 2192*b*, 2199
    - cystoscopy for, 2190
    - uretero-renoscopic evaluation for, 2190–2191, 2190*f*
    - ureteroscopic evaluation and biopsy for, 2199
  - endourologic management of, 2210–2224
    - antegrade nephroureteroscopic, 2212–2219, 2215*f*–2217*f*, 2218*t*
    - basic attributes, 2210–2211, 2210*f*
    - lymph node-positive and metastatic disease treatment, 2222–2224, 2223*f*
    - positive upper tract urinary cytology and carcinoma in situ management, 2219–2222, 2219*f*, 2221*f*, 2221*t*
    - retrograde ureteroscopic, 2211–2212, 2211*f*, 2213*f*, 2214*t*, 2215*f*
  - epidemiology of, 2185, 2185*b*
    - incidence of, 2185
    - mortality rate of, 2185
    - variations by gender, race, and age, 2185
  - follow-up in, 2224–2225, 2224*f*
  - histopathology of, 2188–2189, 2189*b*
    - micropapillary variant of, 2188
    - normal upper tract urothelium, 2188
    - urothelial carcinoma, 2188, 2189*f*
  - natural history of, 2192–2194
    - panurothelial disease, 2194
  - prognosis of, 2194–2198
    - histologic grading of, 2194
    - postoperative factors, 2195–2197
    - preoperative factors, 2194–2195
    - surgical margins, 2197–2198
  - prognostic factors of
    - age-sex-ethnicity, 2194–2195
    - lymph node involvement, 2197
    - lymphovascular invasion, 2197
    - molecular markers, 2197–2198
    - predictive tools, 2198
    - risk stratification, 2198, 2198*f*
    - surgical delay, 2195
    - tobacco consumption, 2195
    - tumor location, 2195
    - tumor stage and grade, 2195–2197, 2196*f*

- risk factors of, 2185–2188, 2188*b*
    - environmental factors, 2186–2188
    - genetic predisposition, 2185, 2186*f*
- staging of, 2192–2194, 2194*b*
- surgical management of, 2199–2210
    - distal ureter and bladder cuff management, 2200
    - ileal ureteral replacement, 2208, 2209*f*
    - intussusception (stripping) technique in, 2202, 2202*f*
    - laparoscopic or robotic distal ureterectomy and reimplantation, 2208, 2209*t*
    - laparoscopic radical nephroureterectomy, 2202–2205
    - lymphadenectomy, 2205–2207, 2206*f*
    - open radical nephrectomy in, 2199–2200, 2200*f*
    - open segmental ureterectomy, 2207, 2208*f*–2209*f*
    - robot-assisted laparoscopic nephroureterectomy, 2205, 2205*f*
    - segmental ureteral resection, 2207–2210
    - total laparoscopic technique in, 2202, 2203*f*
    - traditional open distal ureterectomy in, 2200–2201, 2200*f*–2201*f*
    - transperitoneal laparoscopic nephroureterectomy, 2203–2204, 2203*f*–2204*f*
    - transurethral resection of ureteral orifice, 2201–2202, 2202*f*
    - transvesical ligation and detachment technique in, 2201, 2201*f*
- treatment algorithm for, 2199, 2200*b*
- ureter compared with collecting system, 2192

Upper urinary tract

- anomalies of, 714–740
    - collecting system, Upper urinary tract collecting system, anomalies of
    - renal vasculature, Renal vasculature, anomalies of
    - rotation of, 733–735, 735*b*
- anomalies of ascent of, 722–727, 727*b*
    - cephalad renal ectopia, 724–725
    - simple renal ectopia, 722–724
    - thoracic kidney, 725–727
- anomalies of form and fusion of, 727–733
    - cake or lump kidney, 728*f*–729*f*, 729
    - crossed renal ectopia, 727–728, 727*f*–728*f*, 731*b*
    - disc kidney, 728*f*, 729
    - horseshoe kidney, 731–733
    - inferior ectopic kidney, 729
    - L-shaped kidney, 728*f*, 729
    - sigmoid kidney, 728*f*, 729
    - superior ectopic kidney, 728*f*, 729–731
- anomalies of number of, 714–722, 722*b*, 734*t*
    - bilateral renal agenesis, Bilateral renal agenesis

    - supernumerary kidney, 721–722
    - unilateral renal agenesis, Unilateral renal agenesis
  - assessment of, 505–507
    - controversies in usage of invasive investigations, 506
    - rationale for serial assessment of upper tracts, 505
    - renal scintigraphy, 505–506, 506*f*
    - renal scintigraphy and the top-down approach, 506–507
    - renal sonography, 505
  - defects in, in bladder exstrophy, 535–537
  - deterioration of
    - with benign prostatic hyperplasia, 3336
    - early intervention for, 628
    - with neural tube defects, 626–628, 627*f*
  - dysfunction of, 680
  - posterior urethral valves and, 604–605, 606*f*
  - urothelium of, abnormal, 2188

- Upper urinary tract bleeding, 258*b*–259*b*
  - lateralizing essential hematuria evaluation of, 259
  - vascular condition affecting, 259

- Upper urinary tract calculi, 2094–2113
  - extracorporeal shock wave lithotripsy, 2094–2103, 2103*b*
    - bioeffects of, 2097–2100
    - future direction in, 2102–2103, 2103*f*
    - methods and physical principles, 2094–2097
    - techniques to optimize outcome of, 2100–2102, 2100*b*, 2101*f*, 2102*b*
  - intracorporeal lithotripsy for, 2109–2113
    - ballistic lithotripsy, 2111–2112, 2112*f*
    - combination ballistic and ultrasonic devices in, 2112–2113
    - electrohydraulic lithotripsy, 2109–2110, 2110*f*
    - laser lithotripsy, 2110–2111
    - ultrasonic lithotripsy, 2112, 2112*f*
  - nonmedical management of, 2069–2093
  - percutaneous nephrolithotomy for, 2103–2107, 2105*b*
    - anesthesia for, 2104
    - antibiotics for, 2104
    - calyceal diverticula and, 2105, 2105*f*
    - complications of, 2107
    - horseshoe kidney and, 2105–2106
    - morbid obesity and, 2106–2107
    - patient preparation, 2103–2104

        - staghorn calculi or complex stones and, 2106
        - stone removal in, 2104–2105
        - transplantation and pelvic kidneys and, 2106, 2106*f*
    - ureteroscopic stone management, 2107–2109
        - avulsion in, 2109
        - perforation in, 2108
        - stricture in, 2108
        - submucosal stone and lost stone in, 2109

Upper urinary tract collecting system, anomalies of, 737–740, 740*b*
    - bifid pelvis, 737, 738*f*
    - calyceal diverticulum, 737–738, 739*f*
    - hydrocalycosis, 738
    - infundibulopelvic stenosis, 739–740, 740*f*
    - megacalycosis, 738–739, 740*f*

Upper urinary tract drainage, fundamentals of, 160–184

Upper urinary tract obstruction, 383–384, 384*f*
    - evaluation of, 1942
    - management of, 1942–1981
    - retrocaval ureter, Retrocaval ureter
    - retroperitoneal fibrosis, Retroperitoneal fibrosis
    - ureteroenteric anastomotic stricture, Ureteroenteric anastomotic stricture
    - ureteropelvic junction obstruction, Ureteropelvic junction obstruction

Upper urinary tract tumors, benign
    - others, 2189
    - papillomas, 2188
    - von Brunn nests, 2188

Upper-tract imaging, for benign prostatic hyperplasia, 3347–3348

Urachal abnormalities, of bladder, 3039–3040, 3041*f*

Urachal adenocarcinoma, of bladder, 3090, 3090*b*

Urachal anomalies, 330–333, 522–525, 524*f*, 525*b*

Urachal carcinoma, in pediatric patients, 1118

Urachal cyst, 525

Urachal diverticulum, 525

Urachal sinus, 525

Urachus

- anatomy of, 2448*f*, 2455
- surgery of, 3038–3043
  - complications with, 3042
  - evaluation for, 3038–3040
  - laparoscopic and robotic techniques, 3043*f*
  - outcomes with, 3042–3043
  - postoperative care of, 3042
  - surgical indications for, 3038–3040
  - surgical technique for, 3041

Uracil, 1346.e1, 1346.e2*f*

UraTape, 2851

Ureaplasma infection, 1253

Urease, bacteria production by, 2030–2031, 2031*t*

Uresta, 2736–2737, 2737*f*

Ureter, 324*f*

- access of, for ureteroscopy, 200, 200*f*
- anatomy of, 1865–1876, 1872*f*, 1873.e1*f*
  - arteries, veins, and lymphatic drainage of, 1873.e1*f*, 1874, 1874*b*
  - cellular, 1877
  - endoscopic, 1875–1876, 1875*b*, 1875.e1*f*
  - microscopic, 1875, 1875.e1*f*
  - nerve supply of, 1874
  - pelvic, 2456, 2456*f*
  - radiologic, 1873–1874, 1874*b*
- aperistaltic segment of, 1942, 1943*f*
- development of, 329–333, 332*f*, 332*t*
- dissection of, for simple nephrectomy, 2287, 2287*f*
- distal
  - dissection of, 2204, 2204*f*
  - management, 2200
- in genitourinary tuberculosis, 1309
- herniation of, 824
- muscle-invasive bladder cancer involvement, 3119–3120, 3120*t*
- normal urothelium of, 2188

- pharmacology, 1877–1904
- physiology of, 1877–1904
    - cellular, 1877
    - contractile activity, 1883–1887, 1883*f*–1886*f*
    - development of, 1877–1878, 1878*f*
    - drug effects on, 1901–1903
    - electrical activity, 1878–1883, 1879*f*–1880*f*
    - mechanical properties, 1890–1891, 1890*f*–1891*f*
    - nervous system function, 1887–1890
    - urine transport, 1891–1894, 1892*f*–1893*f*
- in prune-belly syndrome, 581–582, 582*f*–583*f*
- in renal transplantation, 1060
- vascular anomalies involving, 822–824
- vascular obstruction of, 824

Ureteral access sheaths, for ureteroscopy, 199, 199*f*, 199*t*

Ureteral anomalies, 798–825, 822*b*

- anatomic assessment of, 803
- classification and anatomic description of, 798–801
    - ectopic ureter, 798, 798*b*, 799*f*
    - ureterocele, 798–799, 799*f*, 800*b*
- clinical management of, 808–820
    - fetal, 810
    - general, 810
    - goals for, 808–809, 811*b*
    - historical perspective on, 809–810
    - neonatal, 810
    - observational, 810–811
    - summary for, 819–820, 819*f*, 820*t*
- clinical presentation of, 801–802, 802*b*
- ectopic ureter, Ectopic ureter
- embryology and etiology of, 799–800, 801*b*
- endoscopic evaluation of, 799*f*–800*f*, 808, 808*f*–809*f*
- evaluation of, 802–808, 809*b*
    - magnetic resonance imaging, 805, 805*f*–806*f*
    - physical examination, 803, 803*f*–804*f*
    - ultrasonography, 803–805, 804*f*–805*f*
- functional assessment of, 805–807
    - bladder, 806
    - renal, 806, 806*f*
    - voiding cystourethrogram for, 805

- general patterns of, 798
- imaging of, 801
- incontinence and, 802
- infection and, 801–802
- late presentation of, 802
- lower tract reconstruction for, 813–816
- nonurgent management of, 810
- of number, 820–821
- pain and, 802
- of position, 822–824
- prolapse of, 802, 803*f*
- pyeloureterostomy for, 816–817, 817*b*
  - laparoscopic, 817, 817*f*
- total reconstruction for, 811
- upper pole partial nephrectomy for, 811–813, 812*f*, 814*b*
  - complications with, 813
  - laparoscopic, 811–813, 814*f*
  - open, 811, 812*f*–814*f*
  - outcomes with, 813
- ureteral clipping of, 813
- ureteral-trigonal-renal development and, 800–801
- ureteroceles, Ureteroceles
- ureteroureterostomy for, 816–817, 817*f*, 817*b*
  - laparoscopic, 817, 817*f*
  - open, 816–817
- urgent management of, 810

Ureteral calculi, 2069.e1

- clinical factors of, 2088–2091, 2091*b*
  - duration, 2091
  - morbid obesity and, 2089
  - old age and frailty, 2089–2090
  - prior renal surgery, 2090
  - renal function, 2088–2089
  - renal transplants, 2091
  - solitary kidney, 2089
  - spinal deformity or limb contractures, 2090
  - uncorrected coagulopathy, 2090
  - urinary diversion, 2091
  - urinary tract infection and, 2088

    - residual fragments, assessment and fate of, 2091–2093, 2093*b*
    - spontaneous passage of, 2085, 2085*t*
    - surgical management of, 2084–2093, 2084*b*, 2088*b*
        - anatomic factors, 2087–2088
        - duplicated collecting system and, 2087
        - megaureter and, 2087
        - natural history of, 2084–2085
        - pretreatment assessment for, 2085
        - stone burden in, 2087
        - stone composition and, 2087
        - stone factors for, 2085–2087
        - stone location in, 2085–2087, 2086*t*
        - treatment algorithm, 2084*f*
        - ureteral stricture or stenosis, 2087–2088
    - technical factors of, 2088
    - ureteral function effects of, 1899–1900
    - in urinary tract obstruction, 778–779
- Ureteral catheterization, UTI diagnosis and, 1142.e1*t*, 1143
- Ureteral development, 313*f*, 327, 329*f*
- Ureteral dipping technique, in urinary diversion, 3189
- Ureteral duplication, 508–509, 508.e1*f*
- Ureteral function
    - age effects on, 1900, 1901*f*
    - effect of calculi and stents on, 1899–1900
    - effect of diabetes on, 1900
    - effect of infection on, 1899
    - effects of obstruction on, 1894–1898, 1894*f*–1897*f*
        - physiologic methodologies for, 1897–1898, 1898*f*
    - pathologic processes affecting, 1894–1900, 1894*f*–1899*f*, 1901*f*
    - pregnancy effects on, 1900–1901
    - vesicoureteral reflux and, 1898–1899, 1899*f*

Ureteral injuries, 264–267, 1992–2002
  cause of, 1992–1995
  complications of seminal vesicle surgery, 1864
  diagnosis of, 1995–1996
    hematuria, 1995
    intraoperative recognition, 1995
  external trauma, 1992–1993, 1992*t*
    contusion, 1996
    management for, 1996–1999
  imaging of, 1995–1996
    antegrade ureterography, 1995
    computed tomography, 1995, 1995*f*
    intravenous pyelography, 1995–1996, 1996*f*
    retrograde ureterography, 1995
  incidence and anatomic landmarks, 264–265
  in intraoperative consultation, 300–302
    diagnosis/recognition, 300–301
    grade 1 and 2 injury, 301–302
    grade 3 to 5 distal ureteral injury, 302
    grade 3 to 5 mid-and proximal ureteral injury, 302
    grade 5 injury, 302
    incidence, 300, 300*t*
    management, 301
    mechanisms, 300, 301*t*
    principles of repair, 301
    ureteral catheters, 302
    ureteroscopic avulsion injury, 302
  intraoperative management, 265, 266*f*
  key points of, 2002*f*–2003*f*, 2002*b*
  during laparoscopic and robotic surgery, 230.e1
  lower, 1998–1999
    Boari flap for, 1999, 2000*f*
    partial transection for, 1999
    psoas bladder hitch for, 1998–1999, 1999*f*
    ureteroneocystostomy for, 1998
  management of, 1996–2002, 1996*f*
    damage control, 1999
    general principles of, 1996, 1997*f*
  mechanisms of, 265
  midureteral, 1998

  - with monopolar transurethral resection of prostate, 3417
  - presentation of unrecognized, 265–266
  - in robotic prostatectomy, 3580
  - strictures, 267
  - surgical, 1993–1994, 1999–2002
    - avoidance and detection of, 1993–1994, 1994*f*
    - delayed recognition of, 2001–2002
    - immediate recognition of, 2001
    - ligation, 2000–2001, 2001*f*
    - robotic and laparoscopic, 1993
    - tenuous ureteral blood supply, 1994
    - timing of repair of, 1999–2002
    - with vascular surgery, 1993
  - upper, 1996–1998
    - autotransplantation for, 1997
    - bowel interposition for, 1998, 1998*f*
    - monitoring after repair, 1998
    - nephrectomy for, 1998
    - ureterocalicostomy for, 1997
    - ureteroureterostomy for, 1996–1997, 1997*f*
  - ureteroscopic, 1994–1995, 2002
    - avulsion, 2002
    - perforation, 2002
  - ureterovaginal fistula, 266–267

Ureteral leak, 1937, 1937*b*
  - diagnosis of, 1937
  - treatment of, 1937

Ureteral mobilization, for ureteral reimplantation, 3020–3021, 3021*f*

Ureteral obstruction
  - partial, hemodynamic changes with, 792
  - ureteral stenting for, 795

Ureteral pain, patient history of, 2

Ureteral polyps, with megaureter in children, 835–836

Ureteral reconstruction, for prune-belly syndrome, 592

Ureteral reimplantation, 3019–3026
  - complications with, 3025

- evaluation of, 3019, 3019*f*–3020*f*
- laparoscopic and robotic techniques of, 3023–3024, 3024*f*
- nonrefluxing, 3021–3022, 3022–3025, 3022*f*–3024*f*
- outcomes of, 3025–3026
- postoperative care of, 3025
- refluxing, 3023–3026, 3023*f*
- surgical indications of, 3019, 3019*f*–3020*f*
- surgical technique for, 3020–3021

Ureteral stents
- management of, 1936, 1936*b*
  - diagnosis and treatment of, 1936, 1937*f*
  - prevention of, 1936
  - retained, 1936
  - timing of, 1936
- for pediatric genitourinary trauma, 1071
- for ureteral obstruction, 795
- for ureterovaginal fistula, 2945, 2945*f*

Ureteral stones, 406

Ureteral strictures, 1937–1938, 1937*t*, 1938*b*
- autotransplantation for, 1975
- balloon dilation for
  - antegrade, 1967–1968
  - results with, 1968
  - retrograde, 1966–1967, 1967*f*–1968*f*
- buccal mucosa grafting, 1975
- diagnosis of, 1937–1938
- diagnostic studies of, 1966
- endoureterotomy for, 1968–1969
  - antegrade approach to, 1969
  - combined retrograde and antegrade approach, 1969
  - results with, 1969
  - retrograde ureteroscopic approach to, 1968–1969, 1969*f*
- etiology of, 1965–1966, 1966*b*
- intervention for
  - endourologic, 1966–1969, 1967*f*–1970*f*
  - indications for, 1966
  - surgical, 1969–1975, 1970*t*, 1976*b*

    - management algorithm for, 1969*f*
    - with megaureter in children, 835
    - minimally invasive ileal ureteral substitution for, 1973–1975, 1974*f*
    - psoas hitch, 1972–1973
    - renal descensus for, 1973
    - transureteroureterostomy for, 1973
    - treatment of, 1938, 1938*f*
    - ureteral stent placement for, 1966
    - ureteroneocystostomy for, 1972
    - ureteroscopy for, 191–192
    - ureteroureterostomy for, 1970–1972
        - open approach, 1970–1972, 1971*f*
        - postoperative care, 1972
- Ureteral surgery, for genitourinary tuberculosis treatment, 1317–1318
- Ureteral tapering, 1897–1898
- Ureteral tumors, benign
    - other, 2189
    - papilloma, 2188
    - von Brunn nests, 2188
- Ureteric bud branching, 335*f*, 337–338
- Ureteric fistulae, 2942–2946, 2946*b*
    - diagnosis of, 2943–2946, 2943*f*, 2945*f*
    - etiology of, 2942–2943, 2942*b*
    - management of, 2943–2946, 2943*f*, 2945*f*
    - presentation of, 2942–2943
- Ureterocalicostomy
    - for ureteral injuries, upper, 1997
    - for ureteropelvic junction obstruction
        - laparoscopic and robotic-assisted, 1958
        - for UPJ reconstruction, 1962, 1964*f*
- Ureteroceles, 333, 798–825, Ureteral anomalies
    - anatomic description of, 798–799, 799*f*
    - bladder outlet and, 806–807, 807*f*–808*f*
    - excision of, and common-sheath reimplantation, 813–816, 815*f*–816*f*, 817*b*

- prolapsed, 802, 803*f*, 977, 978*f*
- transurethral incision for, 817–819, 818*f*–819*f*, 819*b*
  - reflux outcomes after, 819
- voiding dysfunction and, 820

Ureterocolonic anastomosis
- in robot-assisted intracorporeal continent cutaneous diversion, 3269
- in urinary diversion, 3185–3187
  - complications of, 3191–3192
    - stricture, 3192
    - urinary fistula, 3191–3192
  - Cordonnier and Nesbit techniques, 3187
  - intestinal antireflux valves, 3189–3191
    - intussuscepted ileal valve, 3189–3190, 3191*f*
    - intussuscepted ileocecal valve, 3189–3190, 3191*f*
  - Leadbetter and Clarke technique, 3185, 3185*f*
  - Pagano technique, 3186–3187, 3187*f*
  - Strickler technique, 3186, 3186*t*, 3187*f*
  - transcolonic technique of Goodwin, 3185–3186, 3186*f*

Ureterocystoneostomy, for prune-belly syndrome, 592

Ureterocystoplasty, 703, 703*f*

Ureteroenteric anastomotic stricture, 1977*b*
- evaluation of, 1976
- incidence and etiology of, 1975–1976
- intervention for
  - endourologic, 1976–1977, 1978*f*
  - initial management and, 1976–1977

Uretero-enteric strictures, 3272

Ureteroileal anastomosis, for minimally invasive urinary diversion, 3262

Ureterointestinal anastomosis, for urinary diversion, 3184–3192
- complications of, pyelonephritis, 3180*t*
- intestinal antireflux valves, nipple valve, 3191, 3192*f*
- small bowel anastomoses, 3187–3189
  - Bricker anastomosis, 3187, 3187*f*
  - Hammock anastomosis, 3189
  - Le Duc technique, 3189, 3189*f*
  - split-nipple technique, 3188–3189, 3188*f*
  - tunneled, 3188, 3188*f*
  - ureteral dipping technique, 3189

- ureteral-small bowel, 3189, 3190*f*
- Wallace technique, 3187–3188, 3188*f*

ureterocolonic anastomoses, 3185–3187

- Cordonnier and Nesbit techniques, 3187
- Leadbetter and Clarke technique, 3185, 3185*f*
- Pagano technique, 3186–3187, 3187*f*
- Strickler technique, 3186, 3186*t*, 3187*f*
- transcolonic technique of Goodwin, 3185–3186, 3186*f*
- ureterocolonic anastomoses, 3185–3187

Ureterolysis, for retroperitoneal fibrosis, outcomes of, 1980

Ureteroneocystostomy

- with a bladder psoas muscle hitch or Boari flap, 2207, 2209*f*
- for ureteral stricture disease, 1972

Ureteronephrectomy, proximal, 2204, 2204*f*

Ureteropelvic junction (UPJ)

- disruption of, for pediatric genitourinary trauma, 1074–1075, 1075*f*
- flap procedures of, 1960–1962
  - Culp-DeWeerd spiral flap, 1960–1961, 1961*f*
  - Foley Y-V plasty, 1960, 1960*f*
  - intubated ureterotomy, 1961–1962, 1963*f*
  - Scardino-Prince vertical flap, 1961, 1962*f*
  - ureterocalicostomy for, 1962, 1964*f*
- injury of, 1992–1993
- surgical exposure to, 1953, 1953*f*–1954*f*
- urine transport and, 1891, 1892*f*

Ureteropelvic junction obstruction (UPJO), 400, 507–508, 509*f*, 1942–1963, 1952*b*

- acquired, 1943
- calicovesicostomy for, laparoscopic, 1960
- congenital, 1942, 1943*f*
- diagnosis of, 1942
- dismembered pyeloplasty, 1952–1953
- flap procedures for, 1960–1962
  - Culp-DeWeerd spiral flap, 1960–1961, 1961*f*
  - Foley Y-V plasty, 1960, 1960*f*
  - intubated ureterotomy, 1961–1962, 1963*f*
  - salvage procedures, 1963

    - Scardino-Prince vertical flap, 1961, 1962*f*
    - ureterocalicostomy for, 1962, 1964*f*
- genitourinary trauma and, 1076, 1076*f*
- interventions for, 1947
    - endourologic management of, 1947, 1952*b*
    - historical notes on, 1951–1952
    - indications for, 1945–1963
    - management of complications for, 1963
    - nephrectomy for, 1946–1947
    - operative, 1951–1953
    - options for, 1947–1950
    - postoperative care for, 1963
- intrinsic, 1942
- nephrolithotomy for, percutaneous antegrade endopyelotomy simultaneous with, 1949
- pathogenesis of, 1942–1943, 1943*f*
- patient presentation and diagnostic studies for, 1943–1945, 1944*f*–1946*f*
- pattern of dilation, 373–374
    - recommendations for, 373–374
- in pediatric patients, 826–852
    - associated anomalies, 826
    - clinical presentation of, 826, 827*f*
    - complications with, 832*f*, 835, 835*f*
    - definition of, 826
    - dismembered pyeloplasty, 828, 828*f*–830*f*
    - endoscopic approach to, 830
    - flank approach to, 829
    - laparoscopic pyeloplasty for, 830–834, 833*f*–834*f*
    - lower pole, 826, 827*f*
    - minimally invasive techniques for, 830–835
    - nondismembered pyeloplasty for, 828–829, 829*f*–831*f*
    - outcomes with, 835
    - posterior lumbotomy for, 829, 832*f*
    - secondary, 826
    - surgical approach to, 829
    - surgical indications for, 826–827
    - surgical repair of, 827–828
- percutaneous antegrade endopyelotomy for, 1947, 1947*f*–1948*f*
    - nephrolithotomy simultaneous with, 1949
- percutaneous endopyeloplasty for, 1949
- postoperative care and complications, 1957
- pyeloplasty for
    - dismembered, 1945–1946, 1953*f*–1954*f*

        - laparoscopic and robotic intervention, 1953–1955, 1960*b*
        - laparoscopic dismembered tubularized flap, 1960
        - open surgery, 1953
        - with pyelolithotomy, 1958–1960
        - salvage procedures for, 1963
    - renal calculi with, surgical management of, 2077
    - results of, 1957–1958, 1959*t*
        - minimally invasive approaches, 1957–1958
        - open approach, 1957
    - retrograde ureteroscopic endopyelotomy for, 1949–1950, 1951*f*–1952*f*
    - surgical approaches to, 1953–1958
    - ureterocalicostomy for, laparoscopic and robotic-assisted, 1958
    - ureteroscopy for, 191–192
- Ureteropelvic surgery, for genitourinary tuberculosis treatment, 1317–1318
- Ureteroplasty, for prune-belly syndrome, 592
- Ureteropyeloscopy, 2211, 2211*f*
- Ureterorenoscopy (URS), 2069.e2
    - morbid obesity and, 2089
    - old age and frailty and, 2089–2090
    - prior renal surgery and, 2090
    - for renal calculi
        - in calyceal diverticula, 2078
        - in horseshoe kidneys, 2079
        - in renal ectopia, 2081
        - stone composition and, 2076, 2076*f*
        - stone localization and, 2075
    - renal function and, 2088–2089
    - solitary kidney and, 2089
    - spinal deformity or limb contractures and, 2090
    - stone burden and
        - between 1 and 2 cm, 2073
        - greater than 2 cm, 2074
        - up to 1 cm, 2072
    - uncorrected coagulopathy and, 2090
    - for ureteral calculi, 2087–2088
        - duplicated collecting system and, 2087
        - in megaureter, 2087
        - outcome of, 2091–2093

        - stone burden and, 2087
        - stone composition and, 2087
        - stone localization and, 2085–2086, 2086*t*
    - urinary diversion and, 2091
    - urinary tract infection and, 2088

Ureteroscopic endoureterotomy, retrograde, for ureteral stricture disease, 1968–1969, 1969*f*

Ureteroscopic stone management, 2107–2109
- avulsion in, 2109
- perforation in, 2108
- stricture in, 2108
- submucosal stone and lost stone in, 2109

Ureteroscopic-assisted fluoroscopic access, 168–169, 168*f*

Ureteroscopy, 202*b*, 2211, 2211*f*
- antimicrobial prophylaxis for, 1199
- common supplies for, 200*t*
- dual-modality lithotripters, 244–246
- EHL with, 243.e1
- equipment for, 192, 192*f*, 193*t*, 195*f*, 196*t*, 198*f*–199*f*, 199*t*
- flexible, 244.e2
- fragmentation, 243.e2
- for genitourinary tuberculosis diagnosis, 1313–1314, 1314*f*
- indications for, 191–192
- intracorporeal lithotripters used in, 244.e4*f*
- laser fragmentation, 244.e2
- technique, 199–201, 201*f*
- ultrasonic lithotripsy, 243.e2
- ureteral injuries with, 1994–1995, 2002
    - avulsion, 2002
    - perforation, 2002

Ureterosigmoidostomy
- for classic bladder exstrophy, 564
- for continent urinary diversions, 706–707
- history of, 3233
- tumor formation and, 699

Ureterostomy
- cutaneous, for megaureter in children, 850–851, 850*f*
- for ectopic ureter, 819

Ureterotomy, intubated, for ureteropelvic junction obstruction, 1961–1962, 1963*f*

Ureteroureterostomy, 2207, 2208*f*
- laparoscopic, 817
- open, 816–817
- for ureteral anomalies, 816–817, 817*f*, 817*b*
- for ureteral injuries, upper, 1996–1997, 1997*f*
- for ureteral stricture disease, 1970–1972
  - laparoscopic or robotic approach, 1972
  - open approach, 1970–1972, 1971*f*
  - postoperative care, 1972

Ureterovaginal fistula (UVF), 266–267, 2942, 2942*b*

Ureterovascular fistulae, 2958–2959

Ureterovesical junction (UVJ), 1873, 1877, 2455–2456, 2456*f*
- with epispadias, 569
- physiology of, 1891, 1892*f*

Ureters
- bifid, 820–821
- quadruple, 821
- triplication of, 821

Urethra, 315*f*
- α-adrenergic receptors in, 2500–2501, 2501*f*
- anatomy of, 2461, 2462*f*
  - common to both genders, 2466
  - female, 2438–2439, 2439*f*, 2465–2466, 2466*f*, 2974–2975, 2974*f*, 3010
  - male, 1381–1383, 1381*f*–1384*f*, 1384*b*, 1807.e2*f*, 1807.e4*f*, 2465, 2465*f*
  - tone, 2468–2469
- caruncle of, urethral diverticula differentiated from, 2987, 2987*f*
- closure of, for classic bladder exstrophy, 545–548, 546*f*–548*f*
- distraction injuries of, 1807.e2*f*
- division of, in retropubic radical prostatectomy, 3554–3555, 3555*f*

duplication of, 310, 883–884, 884*f*

estrogens and, 2503

female, 152, 1627.e2

  in orthotopic urinary diversion, 3240–3241, 3240*f*

  radical cystectomy and, 3118

function of

  during filling/storage, 2521

  during voiding, 2521

in genitourinary tuberculosis, 1309

  treatment, 1318

hypermobility of, filling/storage failure due to, 2518

instability of, filling/storage failure due to, 2518

localization studies, 1143

male, 152

  anatomy of, 1381–1383, 1381*f*–1384*f*, 1384*b*, 1807.e2*f*, 1807.e4*f*, 2465, 2465*f*

  ultrasonography of, 85–88, 86*f*, 1384*f*

mesh perforation/extrusion at, 2883, 2883*b*, 2884*f*–2885*f*

  in midurethral sling, 2866–2868, 2867*t*, 2870*b*

mobility of, Q-tip test for, 2529

necrosis of, with transurethral vaporization of prostate, 3426

prolapse of, urethral diverticula differentiated from, 2986–2987

in prune-belly syndrome, 584, 585*f*

reconstructive surgery of, 1804–1842, 1805*b*, 1813*b*

  for amyloidosis, 1810

  anatomy of, 1807, 1807.e1*f*–1807.e7*f*

  for balanitis xerotica obliterans, 939, 940*f*

  for circumcision complications, 1811–1812

  for curvatures of penis, 1836–1838, 1838*b*

  for failed epispadias repair, 1813

  for failed hypospadias repair, 1812–1813

  for female-to-male transgender, 1841–1842, 1842*b*

  for glans dehiscence, 937, 938*f*

  for LS, 1808–1810, 1809*f*

  for meatal stenosis, 937–938, 1811

  for paraphimosis, balanitis, and phimosis, 1811

  penile transplantation, 1838–1842, 1840*f*, 1842*b*

  for PFUIs, 1828–1834, 1830*f*–1834*f*

  principles of, 1804–1807, 1806*f*–1807*f*, 1808*b*

  for reactive arthritis, 1808

  for recurrent penile curvature, 939–941, 940*f*

  for urethral diverticulum, 938–939, 939*f*, 1810–1811

        - for urethral hemangioma process, 1808
        - for urethral stricture, 938, 1814–1828, 1814*f*, 1828*b*
        - for urethrocutaneous fistula, 935–937, 936*f*–937*f*, 1810
        - for vesicourethral distraction defects, 1834*b*, 1835, 1836*b*
    - stroma of, 2468
    - support mechanisms, stress urinary incontinence and, 2596–2597, 2596*f*
    - tone of, in women, 2501
- Urethra Resistance Factor (URA), 2566
- Urethral advancement procedure, 920, 922*f*
- Urethral atresia, 620–621, 621*f*
- Urethral atrophy, with artificial urinary sphincter, 3007
- Urethral bleeding, 257–258
- Urethral calculi, 2117–2120
    - clinical presentation and evaluation of, 2117–2118
    - pathogenesis and composition of, 2117
    - primary, 2117
    - treatment of, 2118
- Urethral cancer
    - female, 1782–1785, 1785*b*
        - anatomy and pathology of, 1782–1785, 1783*f*
        - epidemiology, etiology, and clinical presentation of, 1782
        - evaluation and staging of, 1783
        - prognosis of, 1783–1784
        - recurrence after cystectomy, 1787–1789, 1789*b*
        - treatment of, 1784–1785
    - male, 1776–1782, 1782*b*
        - anterior, 1777–1781
        - carcinoma of penile urethra, 1778–1780, 1779*f*–1780*f*
        - epidemiology, etiology, and clinical presentation of, 1776–1777
        - evaluation and staging of, 1777, 1778*f*, 1778*t*
        - pathology of, 1777, 1777*f*, 1777*t*
        - posterior, 1781–1782, 1782*t*
        - recurrence after cystectomy, 1785–1787, 1786*t*, 1789*b*
        - treatment of, 1778, 1779*t*
- Urethral caruncle, 2920.e10
- Urethral catheterization

    - after laparoscopic radical prostatectomy, 3579
    - antimicrobial prophylaxis for urologic procedures and, 1193*b*, 1194*t*–1196*t*, 1197
- Urethral closure pressure profile (UCP), 2563
- Urethral compressor, 2438–2439
- Urethral dilation
    - in mesh complication, 2880
    - for neuromuscular dysfunction of lower urinary tract, 637
    - as surgical technique
        - for detrusor underactivity, 2663
        - for urethral stricture disease, 1817–1818
    - for transmen, 3071
- Urethral discharge, patient history of, 7
- Urethral diverticula (UD), 2966*f*, 2975–2992
    - anatomy and histology of, 2977, 2978*f*, 2978*t*–2980*t*
    - classification of, 2987
    - differential diagnosis of, 2983–2987
        - Gartner duct abnormalities, 2986, 2986*f*
        - periurethral bulking agents, 2987
        - Skene gland abnormalities, 2984–2986, 2986*f*
        - urethral caruncle, 2987
        - urethral mucosal prolapse, 2986–2987
        - vaginal leiomyoma, 2983–2984, 2985*f*
        - vaginal wall cysts, 2986, 2986*f*
    - etiology of, 2975–2976, 2975*f*
    - evaluation and diagnosis of, 2981–2982
        - cystourethroscopy, 2982, 2982*f*
        - history and physical examination, 2981–2982, 2981*f*
        - urine studies, 2982
        - urodynamics, 2982
    - female, 2972–2975, 2974*f*, 2987*b*
    - imaging of, 2982–2987, 2983*f*
    - management of, 2992*b*
    - pathophysiology of, 2975–2976, 2975*f*
    - presentation of, 2980–2981, 2981*b*
    - prevalence of, 2976–2977
    - reconstructive surgery for, 1810–1811

- stress urinary incontinence and, 2988–2992, 2988*f*
- surgical repair of, 2987–2988
  - alternative techniques for, 2989
  - indications for, 2987–2988
- urethral calculi within, 2977, 2977*f*
- urethral diverticulectomy for
  - complications of, 2991, 2991*f*, 2991*t*
  - excision and reconstruction, 2989, 2989*b*
  - persistence of symptoms following, 2991–2992
  - postoperative care for, 2991
  - preoperative preparation for, 2989
  - procedure for, 2989–2991, 2990*f*
  - techniques for, 2989–2992, 2989*b*

Urethral diverticulectomy, 2989*b*, 2991–2992, 2991*t*

Urethral diverticulum, 938–939, 939*f*

Urethral duplication, 621–622, 621*f*–622*f*

Urethral erosion, with artificial urinary sphincter, 3006–3007

Urethral fistula, for transmen, 3070

Urethral hair growth, for transmen, 3072

Urethral hemangioma, reconstructive surgery for, 1808

Urethral injection therapy, for female stress urinary incontinence, 2893

Urethral injury, 3057–3061
- anterior, 3060–3061, 3060.e1*f*
  - initial management of, 3060
- delayed reconstruction of, 3060–3061
  - posterior, 3059, 3059*f*
- distraction, ED with, 3059
- gunshot wounds, 3049–3050
- initial, primary realignment for, 3058–3059, 3058*f*
- and intraoperative consultation, 298–299
  - diagnosis, 299
  - incidence, 298
  - management, 299
  - mechanisms, 298–299
- with penile fracture, 3048

posterior, 3057–3060
    diagnosis of, 3057, 3057*f*
    endoscopic treatment, 3059
    etiology of, 3057, 3057.e1*f*
    immediate open, 3056
    initial management of, 3057–3059
    suprapubic cystostomy, 3057–3058
    surgical reconstruction, 3059–3060
    urethrography for, 3057, 3058*f*

Urethral instability, filling/storage failure due to, 2518

Urethral lengthening
  for bladder neck reconstruction, 688–690
  results with, 689–690
  technique for, 688–689, 689*f*

Urethral meatus, 1807.e8
  location of, 907, 907*f*–908*f*

Urethral obstruction, after pediatric renal transplantation, 1062–1063, 1062*f*–1063*f*

Urethral orifice, 1627.e2

Urethral polyp, 976, 976*f*

Urethral pressure, during bladder filling, 2515

Urethral pressure profile (UPP)
  micturitional, 2567
  in urodynamic studies, 2557

Urethral pressure profilometry
  urodynamic studies of, 2563–2564, 2564*f*

Urethral prolapse, 395, 397*f*, 975–976, 976*f*

Urethral reconstruction
  in classic bladder exstrophy, 564
  in male epispadias, 569
  for prune-belly syndrome, 592–593, 593*f*
  pubovaginal sling for, outcomes of, 2845
  for transmen, 3071–3072

Urethral region, natural defenses of, 1137

Urethral slings, stress urinary incontinence and, 2831

Urethral sphincter

- coordination of, urodynamic studies of, 2568–2569, 2569*f*–2570*f*
- CVA and, 2603
- deficiency of, intrinsic, 2518
  - quantification of, 2562
- development of, 2466
- disk disease and, 2620
- dynamics of, 682
- female, 2465–2466, 2466*f*
- male, 2465*f*
- mechanisms of, urinary incontinence and, 2596–2597, 2596*f*
- micturition and, 2494
- neurospinal dysraphism and, 2618
- obstruction of, nonrelaxing, 2521
- with Parkinson disease, 2605
- tone of, 2466

Urethral stenosis/atresia, 376

Urethral strictures, 157, 938, 1814–1828, 1814*f*, 1828*b*

- after photoselective vaporization of prostate, 3441
- after transurethral microwave therapy, 3430
- anatomic considerations for, 1814
- with bipolar transurethral resection of prostate, 3419
- decision making, 1817
- diagnosis and evaluation of, 1815–1817, 1816*f*–1817*f*
- etiology of, 1814–1815
- with holmium laser enucleation of prostate, 3438
- with monopolar transurethral resection of prostate, 3417–3418
- orthotopic urinary diversion and, 3238
- prior pelvic radiation and, 3238
- for transmen, 3070–3071, 3071*f*
- treatment, 1817–1818, 1828*b*
  - augmented anastomosis, 1821–1823, 1826*f*–1827*f*

    - dilation, 1817–1818
    - excision and reanastomosis, 1819–1820, 1819*f*–1820*f*
    - flap onlay, 1823–1827, 1824*f*–1825*f*
    - graft onlay, 1821*f*–1823*f*
    - internal urethrotomy, 1818
    - lasers, 1818–1828
    - open reconstruction, 1819–1828
    - perineal urethrostomy, 1827–1828
    - vessel-sparing technique, 1820, 1820*f*–1821*f*

- Urethral tumors, 1776–1789
  - benign, 1776
    - FEPs, 1776
    - hemangiomas, 1776
    - leiomyomas, 1776
  - malignant, Urethral cancer

- Urethral valves
  - anterior, 620
  - posterior, 602–623
    - antenatal management of, 608–610, 610*b*
    - bladder dysfunction with, 616–619
    - circumcision for, 615
    - clinical presentation of, 608–611
    - delayed presentation of, 611
    - description of, 602, 603*f*
    - diagnosis of, 607–608, 608*b*
    - epidemiology of, 602–603, 603*b*
    - initial management of, 608–611
    - laboratory studies for, 608
    - lower urinary tract and, 603–604, 605*f*–606*f*
    - nephroureterectomy, 615
    - pathophysiology of, 603–606, 604*t*, 606*b*
    - postnatal management of, 610–611, 611*b*
    - pulmonary hypoplasia with, 610–611, 610*f*
    - quality of life with, 620, 623*b*
    - radionuclide renal scan for, 608
    - renal function prognostic indicators in, 619, 620*b*
    - surgical intervention for, 611–615, 615*b*
    - transplantation in, 619–620
    - ultrasonography of, 607, 607*f*
    - upper tract diversion, 613–614, 615*f*
    - upper urinary tract and, 604–605, 606*f*
    - urinomas with, 611, 611*f*
    - valve ablation for, 611–615, 612*f*

- valve bladder syndrome with, 617–619, 617*f*–618*f*
- vesicostomy for, 612–613, 613*f*–614*f*
- vesicoureteral reflux and dysplasia, 606, 606*b*, 607*f*
- vesicoureteral reflux in, 615–616, 619*b*
- voiding cystourethrography for, 608, 609*f*

Urethrectomy
- after cutaneous diversion, 1787, 1788*f*
- after orthotopic diversion, 1787

Urethritis, 258, 436, Nongonococcal urethritis
- in differential diagnosis, 1140–1141
- as STD, 1252–1254

Urethrocutaneous fistula, 935–937, 936*f*–937*f*
- reconstructive surgery for, 1810

Urethrography, for posterior urethral injury, 3057, 3058*f*

Urethrolysis, for voiding dysfunction after pubovaginal sling, 2846, 2847*t*

Urethromeatoplasty, 918

Urethroplasty
- algorithm for, 912*f*, 914
- complications of, 934–941, 936*t*
  - balanitis xerotica obliterans, 939, 940*f*
  - glans dehiscence, 937, 938*f*
  - meatal stenosis, 937–938
  - recurrent penile curvature, 939–941, 940*f*
  - skin, 941
  - urethral diverticulum, 938–939, 939*f*
  - urethral stricture, 938
  - urethrocutaneous fistula, 935–937, 936*f*–937*f*
- genitoperineal transformation, 3066–3068
- hair-bearing skin for, 918
- outcome assessment for, 942–943
- for posterior urethral injury, 3059, 3059.e1*f*
- tubularized incised plate
  - distal, 923*f*
  - proximal, 928*f*

Urethrorrhagia, 622

Urethroscopy, for posterior urethral injury, 3057

Urethrostomy, perineal, for urethral stricture disease, 1827–1828

Urethrotomy, internal, for prune-belly syndrome, 592

Urethrovaginal fistulae, 2868, 2947–2951, 2953*b*

- diagnosis of, 2948–2950, 2949*f*–2950*f*
- etiology of, 2947–2948
- presentation of, 2947–2948, 2948*f*–2949*f*
- treatment of, 2950–2951
    - abdominal approach for, 2951
    - complications, 2951
    - follow-up, 2951
    - labial flaps, 2950–2951
    - neourethra, 2950–2951
    - operative technique for, 2951, 2952*f*
    - posterior approach for, 2951
    - vaginal approach for, 2950
    - vaginal flaps, 2950–2951

Urge suppression, behavioral training with, 2727–2729, 2728*f*

Urge-Incontinence Impact Questionnaire (U-IIQ), 111*t*

Urgency urinary incontinence (UUI)

- behavioral therapy with urge suppression for, 2727–2729, 2728*f*
- definition of, 2539, 2581, 2637, 2638*f*
- estrogens for, 2709–2710, 2711*b*
- in mesh complication, 2880
- patient history of, 4–5
- percutaneous tibial nerve stimulation for, 2750
- treatment of, 2544–2546, 2547*b*

Urge-Urinary Distress Inventory (U-UDI), 111*t*

Uric acid

- in calcium stone formation, 2023–2024
- in uric acid stone formation, 2026–2029, 2027*f*–2028*f*

Uric acid stones, 2058–2059, 2060*b*

- clinical considerations of, 2058–2059
- diagnosis of, 2060

- low urine pH, 2059, 2059*f*
- prevention of
  - conservative, 2060
  - medical treatment for, 2060
- in renal calculi, 2026–2029, 2027*f*–2028*f*
  - hyperuricosuria, 2029
  - low urinary volume, 2029
  - low urine pH, 2027–2029, 2028*f*

Uricase, 2026

Urinalysis (UA), 14, 437
- for benign prostatic hyperplasia, 3345
- color of, 14, 15*t*
- for pelvic floor disorder assessment, 2534
- physical and gross examination, 14
- for RCC, 2157
- for renal calculi, pretreatment assessment, 2070–2071
- specimen collection of, 14
- for sphincteric urinary incontinence, 2995
- turbidity, 14
- for urinary incontinence, in men, 2541
- for urinary tract obstruction, 777
- for UTI diagnosis, 1142

Urinary acidification
- in neonate, 342
- urinary tract obstruction and, 793–794

Urinary ascites, 384

Urinary bladder, surgery of, 3010

Urinary catheters, falls and, 2915

Urinary complications, 262–263

Urinary continence
- after robotic radical prostatectomy, 3581–3582, 3581*f*–3582*f*
- physiology of, 2593–2595

Urinary dipstick, sensitivity of, 16

Urinary diversion
  in antegrade nephroureteroscopic, for UTUC, 2219
  cutaneous continent, Cutaneous continent urinary diversion
  for detrusor underactivity, 2663
  for hypospadias postoperative management, 932
  minimally invasive, Minimally invasive urinary diversion
  for neuromuscular dysfunction of lower urinary tract, 636–637
  orthotopic, Orthotopic urinary diversion
  for posterior urethral valves, 613–614, 615*f*
  for urinary incontinence, in geriatric patients, 2920.e5

Urinary fistula
  with anorectal malformation, 622–623, 622*f*
  partial nephrectomy causing, 2265
  with ureterointestinal anastomoses in urinary intestinal diversion, 3186*t*, 3191–3192

Urinary flow rate, with postvoid residual, 2565

Urinary fractionated metanephrines, in evaluation of adrenal masses, 2402–2403, 2402*t*

Urinary free cortisol (UFC) evaluation, in evaluation of adrenal masses, 2400–2401

Urinary hesitancy, 4

Urinary incontinence (UI), 109–110, 399–400, 1083, 2580–2599, Pelvic floor disorders
  after retropubic radical prostatectomy, 3564
  aging and, 2582–2583
  anogenital herpes and, 2622
  associated with chronic retention, 2540
  with benign prostatic hyperplasia, 3335
  with brain tumor, 2604
  causes of, 2526
  classification of, 2580
  coital, 2540
  conservative management of, 2722–2738
    adherence to, 2734–2735

  - assessment for, 2722–2723
  - behavioral training with urge suppression, 2727–2729, 2728*f*
  - biofeedback for, 2727.e1*f*, 2729, 2729*f*, 2729.e1*f*–2729.e2*f*
  - bladder training, 2728*f*, 2730–2732, 2730.e1*t*
  - indications for, 2722
  - lifestyle modifications, 2722, 2722.e1*b*
  - patient education for, 2723
  - for pelvic floor dysfunction, 2732–2735
  - pelvic floor muscle electrical stimulation, 2729–2730
  - pelvic floor muscle training for, Pelvic floor muscle training
  - for prevention, 2735–2736
  - toileting programs for, 2730–2731, 2730.e1*t*
- continuous, 2540, 2581
- CVA and, 2602
- daytime, Bladder and bowel dysfunction
- definition of, 2539, 2580
- diagnosis of, 2526
- diet and, 2586
- epidemiology of, 2581–2582
- female
  - retropubic suspension surgery for, Retropubic suspension surgery
  - urethra and, 2466
  - use of injectable agents for, 2890–2891, 2891*t*
- female sexual dysfunction and, 1655–1656
- general comments on, 2581–2582
- in geriatric patients, 2917–2920
  - absorbent products for, 2920.e6
  - behavioral therapies for, 2920.e3
  - clinical evaluation of, 2920
  - costs of, 2918
  - established, 2919
  - history for, 2920.e1
  - laboratory testing for, 2920.e2
  - negative impacts of, 2918–2919
  - pharmacotherapies for, 2920.e3–2920.e4
  - physical examination for, 2920.e1
  - PVR assessment, 2920.e1
  - risk factors of, 2918
  - surgical therapies for, 2920.e4–2920.e6
  - transient, 2919
  - treatment of, 2920
  - urine containment for, 2920.e6

  - urodynamic studies for, 2920.e2
  - voiding diaries, 2920.e1–2920.e2
- giggle, 2540
- hammock hypothesis of, 2466, 2518, 2596, 2597*b*
- herpesvirus infection and, 2621–2622
- hormonal therapy and, 2585
- incidence of, 2582, 2582*b*
- insensible, 2540
- lower urinary tract dysfunction and, 655–660, 660*b*
- male, 2539–2549, 2539*b*
  - cause of, 2993
  - classification of, 2993–2998
  - diagnosis of, 2995–2998
  - epidemiology of, 2587
  - etiology of, 2993–2998
  - evaluation of, 2540–2544, 2544*b*, 2995–2998, 2996*f*, 2998*b*
  - first-line investigations for, 2540–2544
  - history and development of devices, 2993–2994, 2994*f*
  - history for, 2540
  - implantation device technique, 3000–3005
  - improving quality of evidence, 3009
  - incidence of, 2587
  - indications for surgery, 2998–2999, 2999*b*
  - innovations and emerging concepts in device design, 2994–2995
  - management of, 2544–2547, 2545*f*, 2548*f*–2549*f*
  - mechanisms of continence with surgical devices, 2995
  - pathophysiology of, 2993–2998
  - physical examination for, 2540
  - prevalence of, 2587
  - principal methods in, 2544
  - remission rates of, 2587
  - risk factors for, 2587
  - sphincteric, 2993–3009, Sphincteric urinary incontinence
  - training paradigms of, 3009
- mechanical devices for, 2736–2737
  - intravaginal, 2736–2737, 2736.e1*f*, 2737*f*, 2737.e1*f*
- medical conditions and, 2586
- mixed, 2539, 2581
  - treatment of, 2547
- neurospinal dysraphism and, 2618
- nocturnal enuresis, 2539, 2581

    - treatment of, 2547
  - in nursing home setting, 2919–2920
  - obesity and, 2585–2586
  - pathophysiology of, 2595–2596
    - bladder storage and, 2595
    - sphincteric function, 2595–2596
  - patient history of, 4–6, 8*t*
  - pelvic organ prolapse and, 2591–2592, 2592*b*
  - physiology of, 2593–2595
  - postmicturition leakage or dribble, 2540
    - treatment of, 2547
  - postpartum, PFMT for, 2726
  - pregnancy and, 2583
  - prevalence of
    - in adult women, 2581–2582, 2583*f*
    - urinary urge incontinence, 2585*f*
    - worldwide, 2584*f*
  - questionnaires for, 2532*t*–2533*t*, 2582
  - race and ethnicity and, 2583–2585
  - radiation therapy and, 3606
  - remission of, 2582, 2582*b*
  - risk factors for, 2582–2586, 2586*b*
  - signs and symptoms of, 2580
  - smoking and, 2586
  - social impact of, 2592, 2592*b*
  - societal costs of, 2592, 2592*b*
  - stress, Stress urinary incontinence (SUI)
  - terminology of, 2580–2581, 2581*t*
  - types of, 2539–2540
  - ureteral anomalies and, 802
  - urethral diverticula and, 2982
  - urgency, 2539, 2581, 2637, 2638*f*
    - treatment of, 2544–2546
  - urodynamic observations of, 2580
  - in women, 2581–2582

Urinary intestinal diversion

- bowel preparation for, 3162–3169, 3169*b*
  - antibiotic, 3164–3165, 3164*t*–3165*t*
  - diarrhea and pseudomembranous enterocolitis with, 3165, 3166*t*
  - mechanical, 3163–3164, 3163*t*
- complications of, urinary fistula, 3186*t*, 3191–3192
- conduit urinary diversion types, 3193–3198, 3198*b*
  - colon conduit, 3196–3197, 3196*f*, 3198*t*
  - ileal conduit, 3193–3196, 3194*f*–3195*f*, 3195*t*
  - ileal vesicostomy, 3197–3198
  - jejunal conduit, 3195–3196, 3196*t*
  - management of, 3195*f*, 3198
- intestinal anastomoses for, Intestinal anastomoses, in urinary intestinal diversion
- intestinal segments in, 3160–3205
- metabolic problems of, 3198–3205, 3205*b*
  - altered sensorium, 3201
  - cancer, 3203–3204
  - drug absorption abnormalities, 3201
  - electrolyte abnormalities, 3199–3201, 3199*t*, 3200*f*
  - growth and development, 3202
  - infection, 3202
  - intestinal motility, 3203
  - nutritional problems, 3203
  - osteomalacia, 3201–3202
  - short bowel, 3203
  - stones, 3202
- neuromechanical aspects of intestinal segments in, 3204–3205
  - motor activity, 3204–3205, 3204*f*
  - volume-pressure considerations, 3204, 3204*f*
- postoperative recovery of, 3162–3169, 3169*b*
- renal deterioration in, 3180*t*, 3192–3193, 3193*b*
- selection for, 3161–3162, 3162*b*
- surgical anatomy for, 3160–3161, 3161*b*
  - of colon, 3160–3161, 3161*f*
  - of small bowel, 3160
  - of stomach, 3160
- ureterointestinal anastomoses, 3184–3192, Ureterointestinal anastomosis, for urinary diversion

Urinary lithiasis, Renal calculi
- calcium-based calculi in, 2048–2049, 2049*b*
  - dietary, 2049
- classification of, 2046–2048
  - animal protein for, 2047–2048, 2048*b*

    - fluid recommendation for, 2047
    - general recommendation for, 2047–2048
- cystinuria in, 2060–2068, 2063*b*
    - ammonium acid urate stones, 2066
    - bladder calculi, medical management of, 2066–2067
    - clinical considerations of, 2060–2061
    - compliance and quality of life, 2062–2063
    - conservative strategies of, 2061
    - drug-containing calculi, 2065–2066, 2066*t*
    - follow-up of, 2062
    - infection calculi, 2063–2065, 2063*f*, 2064*t*, 2065*b*
    - medical therapy for, 2061–2062
    - metabolic stone formation, 2066
    - miscellaneous and drug-induced stones, 2065, 2065*b*
- distal renal tubular acidosis (type 1) in, 2055–2056, 2055*f*
    - causes of, 2055*b*
    - chronic diarrheal states, 2055–2056
- epidemiology and morbidity from, 2036, 2036*b*
- evaluation of, 2036–2068
- hypercalciuria in, 2050–2053
    - calcium supplementation, 2050–2051
    - clinical considerations of, 2050
    - conservative strategies for, 2051
    - idiopathic, 2051*b*
    - medical therapy for, 2051–2053, 2053*b*
    - resorptive, 2050, 2050*b*
    - in sarcoidosis and granulomatous disease, 2050
- hyperoxaluria, 2056–2060, 2057*b*
    - calcium stone formation, 2057–2058
    - clinical considerations of, 2056
    - conservative strategies for, 2056–2057, 2057*b*
    - diabetes, obesity, and metabolic syndrome, 2059–2060
    - enteric, 2056
    - hypomagnesuric calcium nephrolithiasis, 2058*t*
    - medical therapy for, 2057
    - primary, 2056–2057
    - uric acid stones, 2058–2059
- hypocitraturia in, 2053–2056, 2054*b*, 2055*f*
    - clinical considerations of, 2053
    - conservative strategies for, 2053–2054
    - distal renal tubular acidosis (type 1) in, 2055–2056, 2055*f*
    - medical therapy for, 2054
    - thiazide-induced hypocitraturia, 2056

  - imaging for, 2036–2039, 2039*b*
    - computed tomography, 2037–2038, 2037*f*, 2037*t*
    - modalities, 2038–2039
    - radiography, 2038
    - ultrasound, 2038, 2039*f*
  - medical management of, 2036–2068
    - follow-up considerations in, 2067–2068, 2067*f*
  - metabolic evaluation for, 2039–2045
    - 24-hour urine collection, 2043–2044, 2044*f*
    - economics of, 2044–2045, 2045*b*
    - of first-time stone former, 2039
    - for high-risk and recurrent stone formers, 2042–2043, 2043*b*
    - of high-risk stone former, 2040*b*, 2043*b*
    - in newly diagnosed stone formers, 2040–2041, 2040*b*–2041*b*, 2041*t*, 2042*f*
    - patient selection for, 2040*b*
  - stone analysis in, 2045–2046, 2045*t*, 2046*f*, 2046*b*

Urinary markers, 25–26
  - for urothelial cancer, 3109

Urinary metabolic abnormalities, of pediatric kidney stone disease, 857–858
  - cystinuria, 859
  - hypercalciuria, 857–858, 858*t*
  - hyperoxaluria, 858, 858*t*
  - hyperuricosuria, 858*t*, 859
  - hypocitraturia, 858–859
  - primary hyperoxaluria, 858
  - secondary hyperoxaluria, 858–859

Urinary oxalate, 2010

Urinary prothrombin fragment 1 (F1), in crystal formation, 2015

Urinary retention, 384, 385*f*, 2980
  - after CVA, 2602
  - after monopolar transurethral resection of prostate, 3418
  - after orthotopic urinary diversion, 3254, 3254*b*
  - with artificial urinary sphincter, 3005
  - with botulinum toxins, 2709
  - with brain tumor, 2604
  - detrusor underactivity and, 2657

    - in geriatric patients, 2920.e7–2920.e8
    - with herpesvirus infections, 2621–2622
    - lower urinary tract dysfunction and, 2629
    - neuromodulation for, 2510
    - postoperative, lower urinary tract dysfunction and, 2629–2630
    - risk factors for, 2880
    - with spinal cord injury, 648–649
    - with spinal shock, 2610
    - with subacute combined degeneration, 2619–2620
    - with transurethral incision of prostate, 3435
- Urinary sediment, in urinalysis, 21
- Urinary sheaths, 2920.e6
- Urinary sphincter, artificial
    - complications with, 3005–3008, 3008*b*
    - evaluation of persistent incontinence after, 2997–2998
    - history and development of, 2994, 2994*f*
    - implantation technique, 3000, 3001*f*, 3003*f*
    - infection, 3005–3006
    - long-term results with, 3008, 3009*b*
- Urinary storage symptoms
    - after monopolar transurethral resection of prostate, 3418
    - after photoselective vaporization of prostate, 3441
- Urinary toxicity, prostate cancer and, 3604–3606
- Urinary tract
    - anaerobes in, 1133
    - anatomic and physiologic changes during pregnancy, 1185–1186
    - defecation disorders and, 667, 668*f*
    - defects in, in bladder exstrophy, 535–537
    - dysfunction of, 680–681
    - fistulae of, Fistulae
    - functional, 680–681
        - active voiding phase, 680
        - passive storage phase, 680
    - functional assessment of, 1047–1048

lower, Lower urinary tract

natural defenses against UTIs, 1137–1139

bladder, 1138–1139

periurethral and urethral region, 1137

urine, 1137

trocar injury to, in midurethral sling, 2866–2873

upper, Upper urinary tract

Urinary tract dilation, 358, 362–366

fetal cystoscopy, 364–365

grading system, 361, 361*f*, 362*b*

lower urinary tract obstruction, prenatal intervention for, 362–364, 363*t*, 365*f*–366*f*

P1 (lower risk), 370, 371*b*

P2 (intermediate risk), 370–371

P3 (high risk), 371

prenatal management, 362–366

risk stratification and management for prenatal urinary tract dilation, 362, 363*f*–364*f*

vesicoamniotic shunt placement *versus* fetal cystoscopy, 365–366, 367*f*

Urinary tract imaging, 28–67, 91–100

conventional radiography, 28

infection imaging, 96

radiation management, in uroradiology, 28–29

Urinary tract infections (UTIs), 371–372, 372*f*, 372*b*, 398–399, 402*b*, 475–476, 1129–1201
- adherence in, 428–429
- after augmentation cystoplasty, 699
- after mid-urethral sling surgery, 2873–2874
- after photoselective vaporization of prostate, 3441
- antimicrobial prophylaxis for common urologic procedures and, 1193–1201, 1193*b*, 1194*t*–1196*t*, 1201*t*, 1201*b*
    - for lower tract endoscopy, 1198
    - for open and laparoscopic surgery, 1199–1200
    - principles of, 1193–1197, 1193*b*, 1194*t*–1196*t*
    - for shock wave lithotripsy, 1198
    - special considerations, 1200–1201, 1201*t*
    - for transurethral resection of prostate and bladder, 1198–1199
    - for TRUSP biopsy, 1197–1198
    - for upper tract endoscopy, 1199
    - for urethral catheterization and removal, 1193*b*, 1194*t*–1196*t*, 1197
    - for urodynamics, 1197
- antimicrobial therapy for
    - agent selection in, 1155–1157, 1186–1187, 1187*t*
    - antimicrobial formulary for, 1150–1155, 1150*t*–1153*t*, 1155*f*
    - bacterial resistance to, 1144–1146, 1145*t*–1146*t*, 1147*b*
    - duration of, 1155
    - principles of, 1149–1155, 1155*f*, 1155*b*
    - prophylaxis, 1130, 1162–1163
    - suppression, 1130
- bacteremia and, 1182–1187, 1184*b*
- bacterial factors of, 430*b*
- bacteriuria in elderly, 1188–1190, 1190*b*
    - asymptomatic, 1147–1149, 1147*t*, 1147*b*–1149*b*
    - diagnosis, 1188–1189
    - epidemiology, 1188
    - management, 1189–1190, 1189*t*
    - pathogenesis, 1188
    - screening for, 1188
- bacteriuria in pregnancy, 1184–1185, 1188*b*
    - anatomic and physiologic changes and, 1185–1186, 1185*t*, 1186*f*
    - complications of, 1186–1187
    - management of, 1186–1187, 1187*t*
    - pathogenesis, 1185
    - renal insufficiency and, 1187.e1

with benign prostatic hyperplasia, 3336
bladder infections, 1155–1166
catheter-associated bacteriuria, 1190, 1191*b*
clean intermittent catheterization and, 625
definitions of, 426, 1129–1131, 1130*f*, 1131*b*
Escherichia coli causing, 428, 429*f*
evaluation, 1140–1143, 1140*b*, 1143*b*
    diagnosis, 1141–1143, 1141*b*, 1142.e1*t*, 1143*f*
    symptoms and signs, 1140–1141
Fournier gangrene, 1182, 1182*b*
genitourinary malignancies, 2920
in geriatric patients, 2920.e10–2920.e11
HIV and, 1265–1266
imaging techniques, 1143–1144, 1144*b*
    CT, 1144, 1168
    indications, 1144*b*
    MRI, 1144
    radionuclide studies, 1144.e1
    ultrasonography, 1144, 1168, 1168*f*
    voiding cystourethrogram, 1144
incidence and epidemiology, 1131, 1131*b*, 1132*f*
kidney infections, Kidney infections
management of, during pregnancy, 293–294
pathogenesis, 426–430, 1131–1140, 1140*b*
    alterations in host defense mechanisms, 1139–1140
    bacterial virulence factors, 1133–1134
    early events in UPEC pathogenesis, 1134–1135, 1134*f*
    epithelial cell receptivity, 1135–1137
    fastidious organisms, 1133
    natural defenses of urinary tract against, 1137–1139
    phase variation of bacterial pili in vivo, 1135.e1, 1135.e1*f*
    routes of infection, 1131
    urinary pathogens, 1132, 1133*f*
in pediatric patients, 426–446, 653
    antibiotics for, 434
    bacterial factors leading to, 427–428
    classification of, 433–435, 435*b*
        acute renal abscess, 435
        asymptomatic bacteriuria, 434–435
        bacterial nephritis, 435, 435*f*
        pyonephrosis, 435
    complicated, 433

  - diagnosis of, 426*b*, 435–440, 438*b*
    - catheter insertion for, 436–437
    - computed tomography, 440
    - laboratories for, 436–438, 438*b*
    - magnetic resonance imaging, 440
    - physical examination, 436
    - radiographic imaging for, 438–440, 439*t*, 440*b*
    - serum tests for, 438
    - symptoms of, 435–436, 438*b*
    - ^{99m}Tc-Dimercaptosuccinic acid, 440
    - ultrasound for, 439
    - urinalysis for, 437
    - urine collection methods for, 436–437
    - urine culture, 437–438
    - urine dipstick tests, 437
    - urine microscopic examination, 437
    - voiding cystourethrogram, 439–440
  - host risk factors leading to, 430–433, 433*b*
    - age, 430
    - anatomic abnormalities, 432
    - bladder and bowel dysfunction, 432, 443–444
    - circumcision, 431
    - fecal and perineal bacterial colonization, 431–432
    - gender, 430
    - genetics, 431
    - iatrogenic factors, 433
    - immune status, 433
    - neurogenic bladder, 432–433
    - race, 430–431
    - sexual activity, 432
    - vesicoureteral reflux, 432
  - management of, 440–442
    - after, 442–444
    - antibiotic duration for, 441
    - antibiotic selection, 441–442, 441*t*–442*t*
    - antibiotic treatment for, 440–441
    - inpatient, 441
    - outpatient, 441
    - prophylactic antibiotics, 443
    - vesicoureteral reflux, 444
  - nosocomial, 433
  - pathogenesis of, 426–430
  - recurrent, 434
  - sequelae of, 444–445, 445*b*
    - long-term, 444–445
    - renal scarring, 444
    - xanthogranulomatous pyelonephritis (XGP), 444
  - uncommon, 445
    - funguria, 445
    - viral cystitis, 445
  - uncomplicated, 433
  - upper, 433–434
- periurethral abscess, 1182, 1182*b*
- recurrent, 434
- renal calculi and, 2088
- in renal transplantation, 1059
- risk factors, 1156*b*

- sepsis and, 1182–1187, 1183*b*–1184*b*
- septic shock and, 1182–1187, 1184*b*
- sexual activity and, 432
- with spinal cord injury, 2615
  - management of, 1191–1192, 1192*b*
- symptoms of, 435–436, 438*b*
- transient urinary incontinence and, 2919.e1
- typical, 427
- uncomplicated, 428*f*
- unresolved, 1159, 1159*b*
- urethritis and, 436
- virulence factors of, 428

Urinary tract injury, during laparoscopic and robotic surgery, 230.e1

Urinary tract obstruction

- cation transport and, 794
- clinical impact of, 794–795, 794*b*
- clinical presentation in, 776
  - children, 776
- compensatory renal growth with, 794–795
- congenital
  - antegrade pyelography for, 781
  - retrograde pyelography for, 780–781
  - Whitaker test for, 780
- definition of, 776–777
- diagnostic imaging for, 778–781, 781*b*
  - computed tomography, 779–780
  - excretory urography, 780
  - magnetic resonance urography, 780
  - nuclear renography, 779
  - ultrasonography, 778–779
- emerging therapeutic options for, 790
- hemodynamic changes with, 791–792, 793*b*
  - bilateral ureteral obstruction, 791–792, 792*f*
  - glomerular filtration and, 791
  - partial ureteral obstruction, 792
  - renal blood flow, 791–792
  - renal vascular resistance, 791–792
  - unilateral ureteral obstruction, 791, 791*f*

hydrogen ion transport and, 793–794
hypertension with, 794
laboratory studies for, 777–778
  biomarkers of, 778
  fractional excretion of sodium, 777
  renal function assessment, 777–778
  urinalysis, 777
pathological changes of, 781–786
pathophysiology of, 776–797
postobstructive diuresis after, 796
prevalence of, 776
progressive renal dysfunction and, 776, 777*f*
renal recovery after, 795–796
sodium transport and, 793
treatment of, 795–796, 797*b*
  pain management, 795
  renal drainage, 795
  surgical intervention for, 796
tubular function effects of, 792–794
tubulointerstitial fibrosis with, 786–790, 790*b*
urinary acidification and, 793–794
urinary concentration ability with, 793
urine egress from kidney in, 794
Whitaker test for, 780

Urinary tract reconstruction
for cloacal exstrophy, 578–579
  modern staged, 578, 578*t*
  osteotomy role in, 578–579, 579*f*
  single-stage, 579
in pediatric patients
  antireflux, 683–685, 685*b*
  augmentation cystoplasty for, 691–706, 702*b*, Augmentation cystoplasty
  bladder neck reconstruction, 685–690, 690*b*
  continent urinary diversions, 706–713, 711*b*, Continent urinary diversions
  patient evaluation for, 681–682, 683*b*
  patient preparation for, 682–683, 683*b*
  summary for, 713
  urodynamics for, 681–682

Urinary tract trauma, upper, 1982–2004

Urinary urgency

- with holmium laser enucleation of prostate, 3438
- patient history of, 3–4

Urine

- abnormalities, in BPS/IC etiology, 1232.e9–1232.e10
- acidification of, urinary tract obstruction and, 793–794
- analysis, Urinalysis
- chemical examination of, 15–27, 25*b*–27*b*
    - additional serum studies, 26
    - bacteria, 23, 24*f*
    - Berger disease, 17
    - bilirubin and urobilinogen, 20
    - blood/hematuria, 16
    - casts, 23, 23*f*–24*f*
    - cells, 21–23, 21*f*–23*f*
    - crystals, 23, 24*f*
    - CT and MRI, 27
    - cystometrography and multichannel urodynamic studies, 26–27
    - cystourethroscopy, 26
    - expressed prostatic secretions, 24, 25*f*
    - glomerular hematuria, 16–17, 16*t*, 17*f*
    - glucose and ketones, 19–20
    - intravenous pyelogram, and plain radiographs, 27
    - leukocyte esterase and nitrite tests, 20–21, 20*f*
    - microscopy technique, 21
    - nonglomerular hematuria, 17–18
    - office diagnostic procedures, 26
    - parasites, 24, 25*f*
    - pH, 15–16
    - prostate-specific antigen, 25
    - proteinuria, 15*t*, 18–19
    - radiologic imaging, 27
    - serum laboratory studies, 25
    - specific gravity and osmolality, 15
    - ultrasonography, 27
    - urinary markers, 25–26
    - urinary sediment, 21
    - uroflowmetry and ultrasound, for postvoid residual, 26
    - yeast, 22*f*, 23
- concentration of, with urinary tract obstruction, 793

crystallization in, 2009
culture, for UTI diagnosis, 1142–1143, 1143*f*
egress from kidney, in urinary tract obstruction, 794
natural defenses of, 1137
pH, low
    in calcium stone formation, 2024–2025
    in uric acid stone formation, 2027–2029, 2028*f*
physical and gross examination of, 14
volume of, low, in uric acid stone formation, 2029

Urine containment, for urinary incontinence, in geriatric patients, 2920.e6

Urine culture, 437–438
reconstruction and, 682

Urine cytology
of bladder tumor, 3079, 3079*f*, 3080*t*
endoscopic evaluation and collection of, 2211
for non-muscle-invasive bladder cancer surveillance, 3109
for UTUC diagnosis, 2192

Urine dipstick tests, 437

Urine flow rate, male urinary incontinence and, 2543

Urine leaks
after partial nephrectomy, 263–264
after upper tract urologic surgery, 263–264
indications for intervention for, 1071
with intestinal anastomoses, 3180*t*
management, 263–264, 264*f*–265*f*
persistent, 1070
renal exploration with repair of, 1072
risk factors and diagnosis, 263, 264*f*

Urine microscopic examination, 437

Urine transport, 1891–1894
bladder filling and neurogenic vesical dysfunction effects on, 1893
diuresis effects, 1893
ureteropelvic junction, physiology of, 1891, 1892*f*

- ureterovesical junction, physiology of, 1893–1894
- urinary bolus propulsion in, 1892–1893, 1893*f*

Urine-based biomarkers, 3485–3487

Urinoma
- hematoma compared with, 1988
- for pediatric genitourinary trauma, 1071, 1071*f*
- with posterior urethral valves, 611, 611*f*

Urobilinogen, in urine, 20

Urocutaneous fistulae, 2962

Urodynamic catheters, 155

Urodynamic observations, of urinary incontinence, 2580

Urodynamic stress incontinence (USI), 2543

Urodynamic stress test, 2562

Urodynamic studies (UDS), 2550–2579
- of acute urinary retention, 3338, 3338*f*
- after radical pelvic surgery, 2620–2621
- ambulatory, 2571–2574
  - clinical utility of, 2571–2574
- analysis and interpretation in, 2559–2569, 2569*b*
- antimicrobial prophylaxis for, 1197
- for benign prostatic hyperplasia, 3347
- of bladder diverticula, 2967
- clinical applications of, evidence-based, 2574–2578
  - guidelines, 2574
  - in lower urinary tract symptoms, 2576–2577
  - in neurogenic lower urinary tract dysfunction, 2577–2578
  - in stress incontinence in women, 2574–2576
- in clinical practice, 2550–2551, 2551*b*
- components of, 2556–2557, 2557*f*
- conduction of, 2551–2554
- cystometrogram in, 2556, 2557*f*
- definition of, 2550
- of detrusor underactivity, 2650, 2651*f*

electromyography in, 2557, 2559

equipment for, 2557–2559, 2559*b*

eyeball, 2534

of filling and storage phase, 2552*t*–2553*t*, 2559

- detrusor overactivity and impaired compliance, 2560–2561, 2560*f*–2561*f*
- leak point pressures, 2561–2563, 2562*f*–2563*f*
- normal, 2559–2560, 2559*f*
- occult stress incontinence, 2563
- stress-induced detrusor overactivity, 2563, 2563*f*
- urethral pressure profilometry, 2563–2564, 2564*f*

guidelines for, 2550

key points of, 2578*b*

for male urinary incontinence, 2543–2544

of MS, 2607

multichannel, 2536, 2565*f*

neurologic injury and, 2612–2614

in overactive bladder, 2645

Parkinson disease and, 2605

for pelvic floor disorders assessment, 2534–2536, 2536*b*

postvoid residual in, 2556

preparation for, 2551–2554, 2554*b*–2556*b*

pressure-flow studies in, 2557

room for, 2552–2553

rules for, 2551

signal transmission and transducers for, 2558

of sphincteric urinary incontinence, 2997

terminology for, 2554*b*–2556*b*

of urethral diverticula, 2982

urethral pressure profile in, 2557

of urinary incontinence, in geriatric patients, 2920.e2

for urinary tract reconstruction, in pediatric patients, 681–682

uroflowmetry in, 2556, 2557*f*, 2558–2559

video, Videourodynamics

of voiding and emptying phase, 2564–2566

- bladder outlet obstruction in men, 2566–2567, 2567*f*
- bladder outlet obstruction in women, 2567–2568
- normal, 2564–2565, 2564*f*–2565*f*

    - sphincter coordination, 2568–2569, 2569*f*–2570*f*
    - voiding pressure-flow studies, 2565–2566, 2566*f*
  - of voiding dysfunction, functional classification and, 2551

Urodynamic systems, 2557–2558

Urodynamic testing
  - setup, 480–486, 480*f*
  - in urine, 26

Uroenteric fistulae, 2952–2953
  - pyeloenteric, 2953–2955, 2953*f*
  - urethrovaginal, Urethrovaginal fistulae
  - vesicoenteric, 2953*t*, Vesicoenteric fistulae

Uroflow, 942

Uroflowmetry
  - for benign prostatic hyperplasia, 3346–3347, 3346*f*
  - test equipment, 480–481, 480*f*–481*f*
  - in urodynamic studies, 2556, 2557*f*, 2558–2559

Urogenital Distress Inventory, 110, 111*t*

Urogenital hiatus, 2434

Urogenital imaging, pediatric, 403–425
  - computed tomography for, 416–418
  - conventional radiography, 415
  - DMSA renal cortical scintigraphy, 418
  - magnetic resonance imaging for, 412–415
  - technique of, 403
    - ionizing, 403, 403*b*
    - nonionizing, 403, 403*b*
  - ultrasonography for, 404–412

Urogenital sinus, 380–382
  - abnormalities of, 1019*b*
    - classification of, 1019–1025, 1020*f*–1021*f*
    - evaluation of, 1019–1021, 1022*b*
    - history and physical examination for, 1021–1022
    - outcomes of reconstruction, 1037*b*
    - radiographic and endoscopic evaluation of, 1023–1025, 1023*f*–1024*f*

    - urogenital mobilization, 1036*b*
  - formation of, 320*t*, 328, 330*f*–331*f*
  - surgical reconstruction of, Reconstructive surgery, for disorders of sex development and urogenital sinus

- Urogenital triangle
  - female, 2434
  - male, 2450, 2451*f*
- Urogynecologic fistulae, 2946
  - ureterovaginal, 2942, 2942*b*
  - urethrovaginal, 2947–2951
  - vesicouterine, 2946–2947, 2947*b*
  - vesicovaginal, 2924–2926
- Urolithiasis
  - CT and, 48, 49*f*
  - lithotripsy for, Lithotripsy
  - medical management, 350–351, 351*b*
  - in pregnancy, 286–288, 288*b*
    - etiology, 286
    - evaluation, 286–288
  - ureteroscopy for, 191
- Urologic cancer, in geriatric patients, 2920.e13
- Urologic considerations, in pregnancy, 282–295
- Urologic disorders, and metabolic syndrome, 1420–1422
  - bladder cancer, 1421
  - low testosterone and erectile dysfunction, 1422
  - lower urinary tract symptoms, 1421
  - overactive bladder, 1421
  - prostate cancer, 1421–1422
  - renal insufficiency, 1420
  - renal stones, 1420–1421
  - tumor, 1421
- Urologic evaluation of child, 388–402
- Urologic malignancy, during pregnancy, 292–293

- angiomyolipoma, 293
- bladder tumors, 293
- renal tumors, 292–293

Urologic oncology, nuclear medicine in, 42–44

Urologic patient, evaluation of, 1–27, 13*b*, 27*b*

Urologic surgeon, 145

Urologic surgery
- adverse events during, 145
- blood products for, 147–148
  - biologically active agents, 148
  - component therapy, 147
  - dry matrix agents, 147
  - hemostatic agents, 147
  - massive transfusion protocol, 147
  - packed red blood cells, 147
- complications of, 260–281, 281*b*
  - bowel injury, 275–281, 276*f*
  - classification of, 260–261
  - Clavien-Dindo scale, 260–261, 261*t*
  - lower tract urinary, 267–269
  - neuromuscular, 261–262
  - physiologic, 261
  - positional, 261–262
  - ureteral injury, 264–267
  - urinary, 262–263
  - urine leaks, after upper tract urologic surgery, 263–264
  - vascular, 269–275, 270*f*
- drains during, 148
  - Blake, 148
  - Jackson-Pratt, 148
  - Penrose, 148
  - pigtail, 148
- hypothermia during, 145
- incision closure for, 148–151
  - fascial closure techniques, 150–151
  - retention sutures, 151
  - skin closure, 150–151
- lithotomy position during, 146
- patient environment during, 145–147

- patient positioning in, 146–147
- patient safety during, 145
- patient temperature during, 145
- physiologic complication in, 261
- preventable injuries during, 145
- principles of, 119–151, 134*b*, 144*b*, 151*b*
  - abdominal incisions, 135–136
  - flank incision, 138–140
  - hepatobiliary evaluation, 121
  - incisions for specific surgeries, 141–144
  - inguinal incisions, 140–141
  - intraoperative management, 125–134
  - kidney and retroperitoneum anterior approaches, 136–138, 138*f*, 139*t*
  - preoperative evaluation, 119
  - preparation, 123–125
  - presurgical testing, 119
  - pulmonary evaluation, 120–121
  - special populations, 121–123
- skin preparation in, 145
- suture material for, 148–151, 149*t*
  - absorbable, 149–150
  - Biosyn, 149
  - Caprosyn, 149
  - nonabsorbable, 150
  - plain gut and chronic gut, 149
  - poliglecaprone, 149
  - polyamide (Nylon), 150
  - polydioxanone, 150
  - polyester (Mersilene), 150
  - polyglactin 910, 149–150
  - polyglyconate, 150
  - polypropylene (Prolene), 150
  - silk, 150–151

Urology

- assessing surgical complications in, 105–106, 106*t*
  - pain in, 108
  - risk of, 106–108
- commonly assessed short-term outcomes in, 105–108
- conceptual framework for assessing the effectiveness of treatment and improving care in, 101–102
- geriatric syndromes and, 2913–2917
  - asymptomatic bacteriuria, 2920.e10–2920.e11

        - bladder outlet obstruction, 2920.e7
        - delirium, 2914
        - falls, 2915
        - fecal incontinence, 2920.e9
        - frailty, 2913–2914, 2913*f*
        - genitourinary malignancies, 2920
        - genitourinary trauma, 2920.e11
        - hematuria, 2920.e11
        - medication optimization, 2915–2917, 2916*t*–2917*t*
        - neurogenic bladder, 2920.e7–2920.e8
        - nocturia, 2920.e8–2920.e9
        - pelvic organ prolapse, 2920.e9–2920.e10
        - polypharmacy, 2915–2917
        - pressure ulcers, 2915
        - underactive bladder, 2920.e7–2920.e8
        - urinary incontinence, 2917–2920
        - urinary retention, 2920.e7–2920.e8
        - urinary tract infections, 2920.e10–2920.e11
    - health care costs, 114, 114*b*
    - health-related quality of life in, 112–113, 113*t*
    - long-term disease outcomes commonly assessed in, 102–105
    - outcomes of interest in, 113–114
    - patient satisfaction, 113
    - patient-reported outcomes in, 108–113
    - specific symptom scales, 109–113
- UroLume stent, for urethral stricture disease, 1819
- Uropathogenic bacteria, 427–428, 430*f*
- Uropathogenic *E. coli* (UPEC), 1132
    - pathogenesis, early events in, 1134–1135, 1134*f*
    - persistence, in bladder, 1136–1137, 1138*f*
- Uroplakin III, vesicoureteral reflux and, 491.e1
- Uroplakins, of bladder urothelium, 2462
- Uropontin, in crystal formation, 2014–2015
- Uroradiology, radiation management in, 28–29, 29*t*
- Uroselectivity, 2680–2681
- Urothelial cancer, Bladder tumors

- detection of, 3078–3081, 3081*b*, 3092
- direct extension of, 3084
- with divergent differentiation, of urothelial cancer, 3088–3089
- economic impact of, 3075
- epidemiology of, 3073–3075, 3074*f*–3075*f*
  - gender, racial, and age differences, 3073–3075
  - incidence of, 3073
  - mortality of, 3073
  - prevalence of, 3073
- histologic variants of, 3087–3090, 3088*b*
  - clear cell, 3087–3088
  - micropapillary, 3088, 3088*f*
  - nested variant, 3088, 3089*f*
  - plasmacytoid, 3088
  - sarcomatoid, 3088
- pathological grading of, 3092, 3092*f*–3093*f*
- pathological staging of, 3091–3092
- pathology of, 3076*t*, 3081–3087, 3091–3094, 3092*t*
  - cystitis cystica, 3082, 3082*f*
  - cystitis glandularis, 3082, 3082*f*
  - epithelial metaplasia, 3081
  - inverted papilloma, 3081
  - leukoplakia, 3082
  - malignant lesions, 3083–3084, 3083*f*–3084*f*
  - molecular biology of, 3084–3087, 3087*f*
  - nephrogenic adenoma, 3082
  - papilloma, 3081, 3081*f*–3082*f*
  - precursor malignant lesions, 3082–3083, 3083*f*
  - staging, 3084, 3085*t*–3086*t*, 3086*f*
- prevention of, 3107–3110, 3108*t*
- of prostate, 3512–3513
- recurrence, 3118
- risk factors of, 3075–3078

Urothelial cell carcinoma, genomic alterations in, 1359

Urothelial malignant lesions, of upper tract urothelium, 2188

Urothelium
- of bladder, 2461–2462, 2462*f*–2463*f*
  - asymmetrical unit membrane (AUM), 2462, 2463*f*
  - barrier function of, 2467–2468, 2468*f*

        - glycosaminoglycan layer of, 2467–2468
        - hinge region of, 2462, 2463*f*
        - ionic transport of, 2469
        - permeability of, 2461–2462, 2467, 2468*f*
        - physiology of, 2467–2470, 2470*b*
        - plaques of, 2462
        - sensor-transducer function of, 2469–2470
        - suburothelial interstitial cells, 2470, 2470*f*
        - umbrella cells, 2461–2462, 2463*f*, 2467
    - genetic alterations in, 1358–1359
    - idiopathic OAB and, 2504
    - of upper urinary tract, normal, 2188
    - of ureters, contractile activity and, 1885
- Urothelium-based hypothesis, 2642
- Urothelium-derived inhibitory factors, 2470
- Urotherapy, for bowel-bladder dysfunction, 655–656
- Urovascular fistulae, 2958, 2959*b*
    - pyelovascular, 2958
    - renovascular, 2958
    - ureterovascular, 2958–2959
- USI, Urodynamic stress incontinence
- Uterine artery, 2432, 2433*f*, 2436
- Uterine body, anatomy of, 2436
- Uterine procidentia, 2526
- Uterine prolapse, 2814
    - exstrophy-epispadias complex and, 567
    - hysteropexy, 2815–2823
        - minimally invasive sacrohysteropexy, 2822–2823, 2824*t*
        - minimally invasive uterosacral, 2820–2822, 2821*t*
        - open abdominal sacrohysteropexy, 2822–2823, 2824*t*
        - sacrospinous, 2817–2820
        - transvaginal uterosacral ligament, 2817, 2819*t*
    - uterine sparing and, 2815–2823, 2816*t*
- Uterine RMS, in pediatric patients, 1120

Uterine tube, 324–325, 324*f*–325*f*

Uterosacral fold, 2427–2428, 2429*f*

Uterosacral hysteropexy, minimally invasive, 2820–2822, 2821*t*

Uterosacral ligament, 2429–2430, 2431*f*

- surgical anatomy of, 2789*f*, 2790, 2791*f*

Uterosacral ligament suspension, for apical vaginal vault prolapse repair, 2790–2793

- abdominal approach to, 2791, 2793*f*
- high suspension, 2790–2791, 2792*f*
- results of, 2792–2793, 2794*t*

Uterovaginal canal, 324*f*

Uterus

- anatomy of, 2436
- imaging of, 2440–2441, 2441*f*–2442*f*
- round ligament of, 321

Uterus corpus, 325, 325*f*

Uterus didelphys, 327

UTIs, Urinary tract infections

Utricle, 315*f*

UTUC, Upper tract urothelial cancer

UUI, Urgency urinary incontinence

UVF, Ureterovaginal fistula

UVJ, Ureterovesical junction

V

Vaccination, for GU cancers, 1339–1340, 1340*f*

- genitourinary tumors, 1341–1342, 1342*f*
- kidney cancer, 1340–1341
- prostate cancer, 1341

Vacuum therapy, and PD, 1615, 1617*t*

Vagina, 325–327, 326*f*–327*f*

- anatomy of, 2438
- disorders of, 978–986, 982*b*
  - associated findings, 981–982
  - hymenal skin tags, 978–979, 979*f*
  - imperforate hymen, 978–979, 979*f*
  - transverse vaginal septum, 979–980, 979*f*–980*f*
  - vaginal agenesis, 980–981, 981*f*
  - vaginal atresia, 980
  - vertical fusion, 979–981
- embryology of, 973–974, 974*f*, 974*b*
- leiomyoma of, urethral diverticula differentiated from, 2983–2984, 2985*f*

Vaginal agenesis, 327, 980–981, 981*f*

Vaginal atresia, 980

Vaginal birth, urinary incontinence and, 2583

Vaginal cells, receptivity of, in UTIs, 1135–1136, 1135*f*

Vaginal cones

- for pelvic floor muscle training, 2722.e2*b*–2722.e4*b*, 2726, 2726.e1*f*
- for urinary incontinence, in geriatric patient, 2920.e3

Vaginal delivery, for congenital urologic conditions, 290

Vaginal discharge, 397

Vaginal hysterectomy, for uterine prolapse, 2814

Vaginal mesh

- exposure
  - after mid-urethral sling surgery, 2864, 2864*f*
  - complications from, 2880, 2881*f*
- removal, complications from, 2882, 2882*b*

Vaginal pain, in mesh complication, 2881

Vaginal paravaginal repair, for pelvic organ prolapse, 2780*t*, 2783, 2784*f*–2785*f*

Vaginal prolapse, after retropubic suspension surgery, 2770–2771

Vaginal pull-down maneuver, 974, 975*f*

Vaginal reflux, pediatric, 660

Vaginal replacement surgery, 982–984, 985*b*

  intestinal neovagina creation for, 983–984, 983*f*–984*f*

  skin neovagina creation for, 982–983, 982*f*

Vaginal rhabdomyosarcoma, 397

Vaginal RMS, in pediatric patients, 1119–1120, 1119*f*

Vaginal wall cysts, urethral diverticula differentiated from, 2986, 2986*f*

Vaginectomy, 3064–3066, 3064*f*–3068*f*

Vaginismus, female sexual dysfunction and, 1637

Vaginitis, 1140, 1271–1272, 1272*t*

Vagino-obturator shelf (VOS) repair, 2767–2768

  results with, 2768

  suspensions in, configuration of, 2758

  technique for, 2767–2768, 2767*f*

  tissue approximation in, 2759

  urethral elevation in, 2758

Vaginoplasty, 3062

  initial management, timing, and principles for, 1026, 1026*f*, 1028*f*–1029*f*

Valid surrogate end point, 104

Validated questionnaires, 476–477

Validity, definition of, 109

Valrubicin, for non-muscle-invasive bladder cancer, 3104

Valsalva leak point pressure (VLPP), 2562, 2597

Valsalva maneuver, 2902

Valve bladder syndrome, 617–619, 617*f*–618*f*

Vancomycin

  prophylaxis with, for uncomplicated urologic procedures, 1194*t*–1196*t*

  for UTIs, 1150*t*–1151*t*

Vanilloids, to facilitate bladder filling and urine storage, 2709

Vanillylmandelic acid testing, for pheochromocytoma, 2377

Vanishing testis, 959–960, 960*f*

Vardenafil (Levitra)
- to facilitate bladder filling and urine storage, 2682*t*, 2701
- for ureteral relaxation, 1899

Varicocele, 899–903, 900*b*, 1440, 1450
- associated pathologic processes, 900–901
- diagnosis and classification of, 900, 900*t*
- epidemiology of, 899–900
- hormonal function, 901
- intratesticular, 901–902
- pathogenesis of, 899–900
- sclerotherapy or embolotherapy for, 903, 903.e1*f*
- semen quality in, 901
- surgical repair of, 902, 902*t*
- testicular histology, 901
- treatment for, 902–903
- varicocelectomy for
  - retroperitoneal or laparoscopic, 902–903, 903*f*
  - subinguinal or inguinal microsurgical, 902

Varicocelectomy, 1855
- complications of, 1482
  - hydrocele, 1482
  - testicular artery injury, 1482
  - varicocele recurrence, 1482
- laparoscopic, 902–903, 903*f*, 1477
- microsurgical inguinal and subinguinal operations for, 1477–1481
  - anesthesia for, 1477
  - approaches for, 1478, 1478*f*–1479*f*, 1478*t*
  - delivery of testis, 1478*t*, 1480–1481, 1481*f*
  - dissection of cord, 1479–1480, 1479*f*–1481*f*
- radiographic occlusion technique for, 1481–1482
- results for, 1482–1483
- retroperitoneal, 902–903, 903*f*, 1476–1477, 1476*f*
- scrotal operations for, 1476
- subinguinal or inguinal microsurgical, 902

Vas deferens, 1850–1853
  anatomy of, 1377*b*
    arterial supply, 1377
    gross structure, 1376, 1376*f*–1377*f*
    lymphatic drainage, 1377
    microanatomic architecture, 1376–1377
    nerve supply, 1377
    venous drainage, 1377
  anomalies of, 903
  blood supply of, 1454, 1454*t*
  dissection of, in laparoscopic radical prostatectomy, 3573–3574, 3574*f*
  in genitourinary tuberculosis, 1309
  imaging of
    transrectal ultrasound, 1444.e3
    vasogram, 1377
Vas isolation, methods of, 1850
Vascular anomaly, 338–339
Vascular changes, with aging, 2906
Vascular complications, after RPLND, 2244
Vascular complications, of urologic surgery, 269–275
  access technique, comparison of, 271–272
  diagnosis of, 274–275, 275*f*
  epigastric vessels, injury of, 272
  injury, mechanisms of, 271
  major vessels, injury of, 272–273, 273*f*
  management, 270, 270*f*
    intraoperative vascular complications, 269–270
  postoperative vascular complications, 274
  stapler malfunction, 273–274, 274*f*
  vascular incidents, management of, 272, 272*f*
  vascular injury, during abdominal access, 271
Vascular endothelial growth factor (VEGF)
  inhibitors of
    for metastatic bladder cancer, 3130–3131
    for metastatic RCC, 2326–2327, 2333–2337, 2333*t*–2335*t*, 2336*f*, 2337*t*

  - in RCC, 2146

Vascular evaluation, in ED, 1521–1523

Vascular injury
  - during abdominal access, 271
  - during laparoscopic and robotic surgery, 229–230
  - laparoscopic kidney surgery causing, 2306–2307
  - during radical nephrectomy, 2261

Vascular invasion, 3512

Vascular malformations, 888, 888*f*

Vascular reconstruction, RPLND with, 1718–1719, 1719*f*

Vascular surgery, ureteral injuries with, 1993

Vascular transposition, for laparoscopic pyeloplasty, 1956

Vascular-targeted photodynamic (VTP) therapy, 3632, 3637*t*

Vasculature
  - adrenal, 2345, 2348*f*–2349*f*, 2355*f*, 2356, 2405–2406, 2406*f*
  - of bladder, 2455, 2456*f*, 2462–2463, 2464*f*
  - of epididymis, 1375
  - of pelvis
    - female, 2432–2433, 2433*f*
    - male, 2451–2452, 2451*t*
  - of penis, 1807.e4*f*
  - of prostate, 1380, 1380*f*
  - renal, 1869–1870
  - of scrotum, 1843
  - of testis, 1370–1371, 1372*f*
  - of urethra, 2438–2439, 2439*f*
  - of uterus, 2436
  - of vagina, 2438

Vasectomy, 1440, 1850–1853, 1853*b*
  - conventional technique for, 1850–1851
  - failure, complication of scrotal surgery, 1856
  - minimally invasive, 1851, 1851*f*

  - no-scalpel technique for, 1851–1853, 1852*f*
  - prostate cancer and, 3464
  - reversal, 1853

Vasoactive drugs, for PE, 1572.e2

Vasoactive intestinal polypeptide, 1535

Vasoconstriction, renal hormone effects, 1913

Vasodilation, renal hormone effects, 1913

Vasoepididymostomy, 1467–1471
  - indications for, 1468
  - intussusception, 1469–1470, 1470*f*
  - long-term follow-up evaluation and results, 1471
  - techniques for, and microsurgical end-to-side, 1468–1469, 1468*f*–1469*f*, 1468*t*
  - varicocelectomy and, 1470

Vasoepididymostomy, for chronic scrotal pain syndrome, 1221

Vasogram, of vas deferens, 1377

Vasography, 1457–1460
  - complications of, 1458–1459
    - hematoma, 1459
    - injury to vasal blood supply, 1459
    - sperm granuloma, 1459
    - stricture, 1458–1459
  - fine-needle, 1459–1460
  - in male, 1444
  - techniques, and interpretation of findings, 1457–1458, 1457*f*–1459*f*
  - transrectal and seminal vesiculography, 1459–1460

Vasopressin, renal vascular tone control by, 1913

Vasovasostomy, 1460–1467
  - and anastomosis in convoluted, 1465–1466, 1466*f*
  - anastomotic techniques for, 1463–1464
  - anesthesia for, 1460
  - for chronic scrotal pain syndrome, 1221
  - crossed, 1466
    - technique for, 1466, 1466*f*

    - long-term follow-up evaluation for, 1467
    - and microsurgical multilayer microdot method, 1464–1465, 1464*f*–1465*f*
    - and multiple vasal obstructions, 1462
    - postoperative complications of, 1467
    - postoperative management for, 1467
    - preoperative evaluation for, 1460
        - laboratory tests, 1460
        - physical examination, 1460
    - preparation of vasa, 1461, 1461*f*–1462*f*
    - set-up for, 1464
    - surgical approaches for
        - inguinal, 1460–1461
        - scrotal, 1460, 1461*f*
    - and transposition of testis, 1466, 1467*f*
    - and varicocelectomy, 1462–1463
    - and vasoepididymostomy, 1461–1462, 1463*t*
    - wound closure, 1466–1467
- VCUG, Voiding cystourethrogram
- VDR, Vitamin D receptor
- VEGF, Vascular endothelial growth factor
- Vein grafts, for urethral and penile reconstruction, 1806
- Velocity of sound, 70*f*
- Vena caval replacement, 2276–2277, 2277*f*
- Vena caval resection, in retroperitoneal tumors, 2243
- Vena caval thrombectomy, 2266–2278, 2278*b*
    - bypass techniques for, 2275–2276, 2275*f*–2276*f*, 2275.e1*f*, 2276.e1*f*
    - IVC filtration and permanent interruption for bland thrombus, 2277
    - level I, right-sided tumor technique, 2267–2269, 2267.e1*f*, 2269.e1*f*, 2270*f*
    - level II, left-sided tumor technique, 2269–2270, 2269.e1*f*, 2271*f*
    - level III-IV
        - combined intra-abdominal and intrathoracic approach, 2274–2275, 2274*f*, 2274.e1*f*
        - intra-abdominal approach technique, 2270–2274, 2271*f*–2274*f*, 2273.e1*f*
    - patching, replacing, and interrupting of IVC in, 2276–2277, 2277*f*
    - perioperative complications, 2277–2278

    preoperative considerations for, 2266–2267, 2267*t*, 2268*f*–2269*f*

Veneficus, 427–428

Venereal warts, Condylomata acuminata

Venography, 1444, 1444.e1

Venous drainage, 1807.e8–1807.e9

Venous flow, pneumoperitoneum effects on, 220–221

Venous gas embolism, 181

Venous reconstruction, in ED, 1537

Venous supply, to male pelvis, 2452

Venous system

    of retroperitoneum, 1672–1674, 1672.e1*f*

    surgical anatomy of, 3548, 3549*f*

Venous thromboembolism (VTE), 278–280, 279*t*–280*t*

    after RPLND, 1731

    prophylaxis for, in urologic surgery, 128–130, 129*t*–131*t*, 131*b*

Venous tumor thrombus

    laparoscopic radical nephrectomy for, 2298

    in RCC, 2160

    surgery for, Vena caval thrombectomy

Venovenous bypass (VVB), for vena caval thrombectomy, 2275, 2275*f*, 2275.e1*f*

Ventral corporal lengthening procedures, 913, 915*f*–916*f*

Ventral penile curvature, 911–914, 916*b*

    artificial erection for, 911–912

    assessment and management of, 911–914

    dorsal shortening technique for, 912–913, 915*f*

    goniometer for, 912

    significance of, 911

    ventral corporal lengthening procedures for, 913, 915*f*–916*f*

Ventriculoperitoneal (VP) shunts, 461

Verapamil, for PD, 1612, 1617*t*

Veress needle, 463, 464*f*
  for achieving transperitoneal access and establishing pneumoperitoneum, 207–209
  complications related to, 224
  vascular injury, 469*f*
Verrucous carcinoma (Buschke-Lowenstein tumor)
  as neoplastic condition, 1296–1297, 1299*f*
  of penis, 1742.e1
Vertebral column abnormalities, with cloacal exstrophy, 575
Vertical fusion, abnormalities of, 979–981
Verumontanum, 315*f*, 1382, 1382*f*–1383*f*
Vesicle pain, patient history of, 2
Vesicoamniotic shunt placement *versus* fetal cystoscopy, 365–366, 367*f*
Vesicobullous disorders, 1283–1286, 1284*b*
  bullous pemphigoid, 1284–1285, 1285*f*
  dermatitis herpetiformis, 1285
  Hailey-Hailey disease, 1285–1286, 1286*f*
  linear IgA bullous dermatosis, 1285, 1285*f*
  pemphigus vulgaris, 1284, 1284*f*
Vesicoenteric fistulae, 2953*t*, 2955*b*
  etiology of, 2952–2953, 2953*t*
  presentation of, 2952–2953, 2953*t*
Vesicopelvic ligament, 2429–2430
Vesicostomy
  continent, 710–711
  cutaneous, 690–691
    for posterior urethral valves, 612–613, 613*f*–614*f*
    for prune-belly syndrome, 592, 592*f*
Vesicoureteral reflux (VUR), 330, 374, 374*f*–375*f*, 399, 489–517, 836–846, 836*b*, 1139, 1938
  after pediatric renal transplantation, 1062, 1062*f*
  assessment of, 95
  associated anomalies and conditions, 507–511

  - bladder diverticula, 509–510, 509.e1*f*
  - megacystis-megaureter association, 510
  - other anomalies, 510
  - pregnancy and reflux, 510–511, 511*b*
  - renal anomalies, 510
  - ureteral duplication, 508–509, 508.e1*f*
  - ureteropelvic junction obstruction, 507–508, 509*f*
- causes of, 495–497
  - clinical correlates, 496–497, 497*f*
  - primary reflux, 495
  - secondary reflux, 495–496, 496*f*
- clinical presentation of, 836
- Cohen Cross-Trigonal technique for, 840, 841*f*
- complications of ureteral reimplantation for, 844–846
  - contralateral reflux, 844
  - obstruction, 844–846
  - persistent reflux, 844
- controversies in usage of invasive investigations, 507
  - American Academy of Pediatrics Guidelines for febrile urinary tract infection diagnosis and management in young children, 507, 508*t*
  - National Institutes for Clinical Excellence Guidelines, 507
- cortical defects, 498–501, 500*b*
  - acquired renal scars, 499–500
  - congenital defects *versus* acquired scar, 498–499
  - pathophysiology of acquired scarring, 500–501, 500*f*–501*f*
  - reflux-associated renal dysplasia, 499, 499*f*, 499*t*, 499.e1*f*
- defecation disorders and, 667, 667.e1*f*
- definition of, 836
- demographics, 489–490, 490*b*
  - age, 490, 490*t*
  - prevalence, 489
  - race, 490
  - reflux in the fetus, 490
  - sex, 489–490
- diagnosis and evaluation of, 501–503, 502*b*, 1938
  - confirmation of urinary tract infection, 501–502
  - evaluating urinary tract infection, 502–503, 503*f*
- early complications of, 844–846
- embryology of ureterovesical junction, 493
- endoscopic treatment of, 846–849
  - follow-up for, 847–848
  - injection technique, 846–847, 847*f*

  - materials used for, 848
  - recurrence after, 848–849
- with epispadias, 569
- extravesical procedures for, 840–842, 842*f*–843*f*
- functional anatomy of the antireflux mechanism, 493–495, 494*f*, 494*t*, 495*b*
- Glenn-Anderson technique for, 840, 840*f*
- grading of, 497–498, 498*f*, 498*t*
- historical perspective, 489
- incision for, 836, 837*f*–839*f*
- inheritance and genetics, 490–492, 492*b*
  - genes involved, 491–492, 492*f*–493*f*
  - sibling reflux, 490–491
- intravesical procedures for, 836–840
  - ureter mobilization, 836–840, 837*f*–839*f*
- long-term complications of, 846
  - obstruction, 846
  - recurrent or persistent reflux, 846
- lower urinary tract, assessment of, 503–505
  - cystographic imaging, 503–504, 504*f*
  - cystoscopy and the positioning of the instillation of contrast cystogram, 504–505
- minimally invasive procedures for, 842–844
- natural history and management, 511–517, 516*b*
  - antibiotic controversies and potential new approaches, 514–515
  - individualizing patient care, 516–517, 517*f*
  - landmark studies, 515–516
  - medical management: continuous antibiotic prophylaxis, 513–514, 513*t*
  - principles, 512–513
  - resolution by age, 512, 512*f*
  - resolution by grade, 511
  - spontaneous resolution, 511
- neural tube defects and, early intervention for, 628
- in neuromuscular dysfunction of lower urinary tract, 638–639, 638*f*, 639*b*
- in pediatric patients, 653–654
- Politano-Leadbetter technique for, 837*f*–839*f*, 840
- with posterior urethral valves, 615–616, 619*b*
- postoperative evaluation of, 844
- recommendations for, 374
- reoperative reimplantation for, 846
- robotic-assisted laparoscopic ureteral reimplantation- extravesical for, 844, 845*f*

- surgical management of, 836
- treatment of, 1938
- upper urinary tract, assessment of, 505–507
  - controversies in usage of invasive investigations, 506
  - rationale for serial assessment of upper tracts, 505
  - renal scintigraphy, 505–506, 506*f*
  - renal scintigraphy and the top-down approach, 506–507
  - renal sonography, 505
- ureteral function relation with, 1898–1899, 1899*f*
- ureteropelvic junction obstruction with, 1943
- urinary tract dysfunction with, 2615
- urinary tract infection and, 497, 497*b*
- Valsalva maneuver and, 2902

Vesicoureteral reflux and dysplasia (VURD), posterior urethral valves and, 606, 606*b*, 607*f*

Vesicourethral distraction defects, 1834*b*, 1835, 1836*b*

Vesicouterine fistulae, 2946–2947, 2947*b*

- diagnosis of, 2946–2947, 2946*f*–2947*f*
- etiology of, 2946
- management of, 2946–2947
- presentation of, 2946

Vesicouterine pouch, 2427–2428, 2429*f*

- bladder, 3010

Vesicovaginal fistula (VVF), 2924–2926, 2925*f*, 2925*b*, 2942*b*

- abdominal techniques for, 2937
  - suprapubic intraperitoneal or extraperitoneal, 2937, 2937*f*–2938*f*
  - transvesical, 2937
  - vaginal *versus*, 2933–2934, 2933*t*
- adjuvant procedures in repair of, 2939–2942
  - greater omentum, 2940
  - Martius flap, 2939–2940, 2939*f*
  - other flap and graft techniques, 2940, 2941*f*
  - peritoneal flap, 2940, 2940*f*
- causes of, 2927*b*
- conservative and minimally invasive therapy for, 2931–2932, 2932*f*
- etiology of, 2925, 2925*f*, 2925*b*

- history of, 2929
- intraoperative risk factors for, 2927–2930
  - cystoscopy for, 2929, 2929*f*
  - diagnosis of, 2928
  - evaluation of, 2928
  - imaging for, 2929, 2930*f*–2931*f*
  - physical examination of, 2928–2929, 2928*f*
  - presentation of, 2928
  - urine studies for, 2929–2930
- laparoscopic approaches to, 2937–2939, 2939*t*
  - transabdominal transvesical, 2940
- posthysterectomy, 2926–2927
- prevalence of, 2925
- robotic approaches to, 2937–2939
- surgery for
  - abdominal *versus* vaginal approach, 2932–2933, 2933–2934, 2933*t*
  - adjuvant flaps or grafts, 2934
  - antibiotics, 2934
  - estrogen supplementation, 2934
  - excision *versus* no excision, 2934
  - immediate *versus* delayed, 2933
  - indications for, 2934–2935
  - outcomes of, 2942
  - postoperative drainage, 2934
  - preoperative counseling for, 2934–2935
- treatment for, 2931–2942
- urinary diversion and, 2940–2942
- vaginal techniques for, 2935–2937
  - abdominal *versus*, 2933–2934, 2933*t*
  - complications with, 2936–2937
  - other transvaginal techniques, 2937
  - vaginal flap or flap-splitting technique, 2935–2936, 2935*f*–2936*f*

Vesicovaginal space, 2427, 2429*f*

Vesiculodeferential artery, 1377

Vessel-sparing technique, for urethral stricture disease, 1820, 1820*f*–1821*f*

Vestibular cysts, 976–977, 977*f*

Vestibule, 1627.e1
- disorders of, 975–977, 977*b*
  - ectopic ureteral insertion, 977, 978*f*

- prolapsed ureterocele, 977, 978*f*
- urethral polyp, 976, 976*f*
- urethral prolapse, 975–976, 976*f*
- vestibular cysts, 976–977, 977*f*

Veterans Affairs Cooperative Study, 3385

VHL, von Hippel-Lindau disease

VHL gene, 2141–2143, 2143*t*, 2144*f*, 2332–2333, 2333*f*

Viagra, Sildenafil

Vicryl suture, 149–150

Video-endoscopic systems, 185, 186*f*–187*f*

Videourodynamics (VUDS), 1048, 1048*f*, 2569–2571, 2571*b*, 2572*f*

- for benign prostatic hyperplasia, 3347
- for bladder neck dysfunction, 2570, 2570*f*
- for BOO diagnosis in women, 2570, 2570*f*
- for LUTS in men, 2570, 2571*f*
- methods of, 2570
- for neuropathic voiding dysfunction, 2573*f*
- for pelvic floor disorders, 2535
- for voiding phase dysfunction, 2570

Vinblastine-ifosfamide-cisplatin (VeIP), for NSGCTs, 1697

Vincristine, for penile cancer, 1771

Viral hepatitis, STDs and, 1268–1271, 1269*t*

Virchow triad, in pregnancy, 283

Virtual reality trainers, for laparoscopic and robotic surgery, 232–233

Virtue Quadratic male sling, 2887

Virulent bacteria, 427–428

Virus-related tumors, of penis, 1742.e2–1742.e3, 1743*b*

- Bowenoid papulosis, 1742.e2
- HPV, 1742.e5
- Kaposi sarcoma, 1742.e5

Visceral injury

  - during laparoscopic and robotic surgery, 224
  - laparoscopic kidney surgery causing, 2307, 2307*f*

Visible hematuria, 247

Visual estimation targeting (VET), 3622

Visual obturator access, 464–465

Vital signs, 9

Vitamin D
  - in absorptive hypercalciuria, 2019
  - in calcium metabolism, 2015
  - in prostate cancer, 3463–3465
  - renal regulation of, 1914, 1914*f*

Vitamin D receptor (VDR), 2019
  - in prostate cancer, 3463–3465

Vitamin D_3-receptor analogues, to facilitate bladder filling and urine storage, 2713.e1

Vitamin E
  - for PD, 1611, 1616*t*
  - in prostate cancer prevention, 3476, 3476*f*

Vitiligo, 1305*f*, 1306

VLPP, Valsalva leak point pressure

Voided urine specimens, in urine collection, 1141

Voiding, Micturition
  - bashful bladder, 2628–2629
  - with normal bladder contraction, 2515–2516
  - therapy to facilitate, 2520*b*

Voiding cystourethrogram (VCUG), 39–40, 40*f*, 367, 389–390, 404–405, 406*f*, 414*f*, 415–416
  - bladder, 3011
  - of bladder diverticula, 2965*f*
  - for bladder/urethra, 415–416
    - cysts/masses, 415

        - infection, 415
        - obstruction of, 415, 416*f*
    - for differences of sex development, 416, 417*f*
    - fluoroscopy, 389
    - fundamentals of, 415
    - genitography, 390
    - of kidney/ureter, 415
        - cysts/masses, 415
        - infection, 415
        - obstruction of, 415
    - nuclear cystography, 389–390
    - of posterior urethral valves, 608, 609*f*
    - for scrotum/testes/internal genitalia, 416
    - trauma and, 415–416, 417*f*
    - for ureteral anomalies, 805
    - for vesicovaginal fistula, 2929, 2930*f*
- Voiding diaries, 476*f*
    - for PFDs evaluation, 2531
    - for urinary incontinence, in geriatric patients, 2920.e1–2920.e2
- Voiding dysfunction
    - after mid-urethral sling, 2871–2873, 2872*t*, 2873*b*
        - management of, 2871–2873
    - after pubovaginal sling procedure, 2845–2848, 2848*b*
        - surgical management of, 2846–2848, 2847*t*
    - behavioral treatment for, 2732
    - benign prostatic hyperplasia in, 3305, 3306*f*
    - classification of
        - functional, 2551
    - classification systems of, 2519–2524
        - Bors-Comarr, 2522–2523, 2523*b*
        - Bradley, 2524
        - functional, 2516*b*–2517*b*, 2518*t*, 2519*b*–2521*b*, 2520–2521
        - Hald-Bradley, 2523–2524, 2523*b*
        - International Continence Society, 2517, 2521*b*
        - Lapides, 2522–2523, 2522*b*
        - urodynamic, 2521–2522, 2522*b*
    - electrical stimulation in, 2746–2747, 2746*f*–2747*f*
    - HIV and, 1267

    - lower urinary tract dysfunction and, 2627
    - neurogenic, 2967
    - neuropathic
        - patterns of, 2600–2602
        - videourodynamics for, 2573*f*
    - postoperative, after retropubic suspension surgery, 2770
    - ureterocele and, 820
    - urodynamic studies of, functional classification, 2551
    - videourodynamics for, 2570

- von Brunn nests, of upper urinary tract, 2188
- von Hippel-Lindau disease (VHL), 759–761
    - classification of, 760, 760*t*
    - clinical features of, 760
    - etiology of, 760
    - evaluation of, 761
    - histopathology of, 760–761
    - screening for, 761, 761*t*
    - targeted molecular therapies for
        - basis of, 2332–2333, 2333*f*
        - combination and sequential therapy with, 2339–2341
        - mTOR pathway inhibitors, 2326–2327, 2338–2339, 2340*f*, 2340*t*
        - VEGFR-based, 2326–2327, 2333–2337, 2333*t*–2335*t*, 2336*f*, 2337*t*
    - treatment of, 761
- von Hippel-Lindau syndrome
    - genomic alterations in, 1354*t*, 1358, 2141–2143, 2143*t*, 2144*f*
    - RCC screening for, 2158
    - treatment of RCC in, 2173–2174, 2174*f*
- VOS repair, Vagino-obturator shelf (VOS) repair
- VTE, Venous thromboembolism
- VUDS, Videourodynamics
- Vulva, 1627.e1–1627.e2, 1627.e1*f*, 2436, 2436*f*–2437*f*
- Vulvar RMS, in pediatric patients, 1119
- VUR, Vesicoureteral reflux

VVB, Venovenous bypass

VVF, Vesicovaginal fistula

W

Wallace technique, in urinary diversion, 3187–3188, 3188*f*

Warburg effect, 96

WAS, Water avoidance stress

Watchful waiting, Surveillance
- for benign prostatic hyperplasia, studies on, 3329–3330, 3330*f*, 3330*t*
- for lower urinary tract symptoms, 3351
- for prostate cancer, 3541

Water
- filtrate transport, 1910–1911, 1911*f*, 1911*b*
- intake of, renal calculi and, 2009
- urothelium permeability to, 2467

Water avoidance stress (WAS), bladder pain syndrome and interstitial cystitis and, 2508

Water imbalance, diabetes insipidus, 2678

Water-filled catheters, for urodynamic studies, 2558

Watts factor (WF), 2658

Wavelength, 70*f*

WBS, Williams-Beuren syndrome

Webbed penis, 394, 878–879, 879*f*

Wedge resection, for large renal tumors, 2263, 2265*f*

Weight control, for prostate cancer, 3544

Weight loss, for OAB, 2647

Weight reduction, for urinary incontinence, 2734

Well differentiated liposarcomas, in retroperitoneum, 2229–2230

Wernicke encephalopathy, lower urinary tract dysfunction and, 2631

WHI, Women's Health Initiative

Whitaker test, 160
  for urinary tract obstruction, 780

White blood cell, priapism and, 1542

White coat hypertension, 352

White line of Toldt, 1866

Whole-body bone scan, 42

Williams-Beuren syndrome (WBS), lower urinary tract dysfunction and, 2631–2632

Wilms tumor, 402, 1096–1110, 1110*b*, 2181*t*, 2183
  biology and genetics of, 1096–1099, 1097*t*, 1354*t*
  epidemiology of, 1096
  pathology of, 1099–1101
    after preoperative chemotherapy, 1100
    anaplasia, 1100
    favorable histology, 1100, 1100*f*
    nephrogenic rests, 1100–1101, 1101*f*
  preoperative evaluation of, 1101–1103, 1103*t*
  screening for, 1098–1099, 1099*f*, 1099*t*
  treatment of
    chemotherapy, 1106–1108, 1107*f*
    late effects of, 1108–1110
    partial nephrectomy, 1107–1108
    surgical considerations of, 1103–1104, 1105*f*

Window technique, 1845

Wisconsin Stone Quality of Life (WiSQoL) questionnaire, 175

Wnt signaling pathway, 3276

WNT4 gene, 992*f*, 992*t*, 993

Wolffian duct (WD), 324*f*, 334–335, 714

Women's Health Initiative (WHI), 2710

Wong-Baker FACES, 448*f*

World Health Organization, RCC classification system of, 2148*t*

Wound, Surgical wounds

  genital bite, 1293, 1294*f*

Wound dressing, 151

Wound healing, and PD, 1603–1604

Wound infections, Surgical site infections

  after laparoscopic and robotic surgery, 231

W-stapled reservoir, for cutaneous continent urinary diversion, 3228–3229, 3231*f*

WT1 gene, 991–992, 992*f*, 992*t*, 1097, 1097*t*

WTX gene, 1097–1098, 1097*t*

X

Xanthine stones

  in renal calculi, 2031–2032

  surgical management of, 2077.e3

Xanthogranulomatous pyelonephritis (XGP), 444, 1177–1179, 1178*f*–1179*f*

Xenograft, for pubovaginal sling, 2835

  outcomes of, 2843–2844, 2844*t*

XGP, Xanthogranulomatous pyelonephritis

Y

Y chromosome microdeletion testing, for male infertility, 1442–1443

Yang-Monti technique, 709, 710*f*

Yeast, in urine, 22*f*, 23

Yellowfins stirrups, 3580

Yerba mate, UTUC risk and, 2186

Yoga, for female orgasmic disorder, 1647

Yolk sac, 318*f*

Yolk sac tumors (YSTs)

- in female pediatric patients, 1120
- testicular
  - histology of, 1683*f*, 1684
  - in pediatric patients, 1123–1124, 1124*f*

Young-Dees-Leadbetter bladder neck reconstruction, 685–686

- modified, 555*f*–556*f*
- results with, 685–686
- technique for, 685

YSTs, Yolk sac tumors

Z

Zanoterone, for benign prostatic hyperplasia, 3376

Zika virus, STD and, 1264–1268

Zinc, in prostatic secretions, 3296–3297

Zinc α_2-glycoprotein, in prostatic secretions, 3302–3303

Zipper injuries, to penis, 3051

Zoledronate, 3703

Zona fasciculata, in adrenal cortex physiology, 2357, 2357*f*, 2358*t*

Zona glomerulosa, in adrenal cortex physiology, 2356–2357

Zona reticularis, in adrenal cortex physiology, 2357

Zonal anatomy, prostate, 1379*f*–1380*f*, 1380–1381

Zonisamide, in stone formation, 2033

Instructions for online access

Thank you for your purchase. Please note that your purchase of this Elsevier eBook also includes access to an online version. Please click here (or go to http://ebooks.elsevier.com) to request an activation code and registration instructions in order to gain access to the web version.